PREP XI RR

STUDY NOTES

# PATHOLOGY

22
VIDEOS

252
PAGES

PREMIUM STUDY MATERIAL

PREP XI RR

Table of Contents follows on next page

YOURWISH

## RR Reignite


| # | Topic / Video Name | Pages |
|---|---|---|
| 1 | Cell Injury Part 1 | 3 – 10 |
| 2 | Cell Injury Part 2 | 11 – 15 |
| 3 | Cell Injury Part 3 | 16 – 24 |
| 4 | Inflammation | 25 – 37 |
| 5 | Genetics Pathology | 38 – 56 |
| 6 | Neoplasia | 57 – 71 |
| 7 | Immunity | 72 – 82 |
| 8 | Central Nervous System Pathology | 83 – 89 |
| 9 | Cardiac Pathology | 90 – 100 |
| 10 | Vascular Pathology | 101 – 109 |
| 11 | Lung Pathology. | 110 – 118 |
| 12 | Gastrointestinal Pathology. | 119 – 135 |
| 13 | Hepatobiliary Pathology. | 136 – 144 |
| 14 | Renal Pathology. | 145 – 164 |
| 15 | Male Genital System Pathology | 165 – 170 |
| 16 | Female Genital System Pathology | 171 – 181 |
| 17 | Breast/Bone/Skin/Soft Tissue Pathology | 182 – 196 |
| 18 | Endocrine Pathology | 197 – 203 |
| 19 | Red Blood Cells | 204 – 221 |
| 20 | White Blood Cells | 222 – 237 |
| 21 | Platelets | 238 – 244 |
| 22 | Blood Banking and Transfusion Medicine | 245 – 254 |

# 1. CELL INJURY PART 1

## BIG QUESTION 1: What are the key facts regarding causes and sensitivity of cell injury?

**Broad Answer:** The most common cause of cell injury is hypoxia, with ischemia being the most common cause of hypoxia. Different cell types vary in their sensitivity to hypoxia.

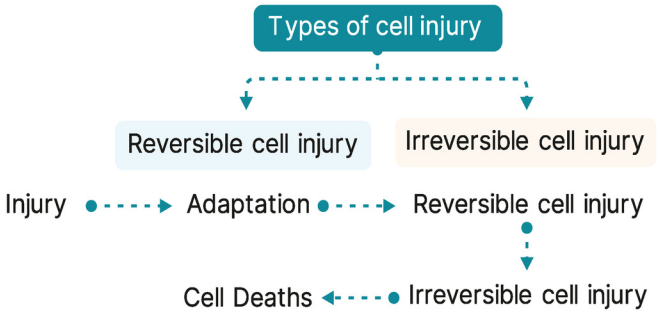


## DETAILED QUESTIONS

### Q1.1: What is the most common cause of cell injury?

**Answer:** Hypoxia.

### Q1.2: What is the most common cause of hypoxia?

**Answer:** Ischemia.

### Q1.3: Which cell is most sensitive to hypoxia and how long can it withstand it?

**Answer:**

- Neurons / Brain tissue.
- Can withstand hypoxia for 3-5 minutes.

### Q1.4: Which cell is most resistant to hypoxia and how long can it withstand it?

**Answer:**

- Fibroblasts.
- Can withstand up to 60 minutes of hypoxia.

## BIG QUESTION 2: What are the key features and mechanisms of reversible cell injury?

**Broad Answer:** Reversible cell injury is the earliest stage of cellular damage, characterised by mitochondrial dysfunction and disturbance in membrane ion pumps, particularly the $Na^+/K^+$ ATPase. These changes can reverse if the damaging stimulus is removed.

PYQ: FMGE 2023 PYQ: AIIMS 2019

↓ $O_2$
↓
Mitochondrial dysfunction
↓
↓ATP
↓
$Na^+$ - $K^+$ ATPase pump failure
↓
Water influx
↓
Cellular swelling - Hydropic change
↓
Cell finally burst - Myelin figures

↓$O_2$
↓
Anaerobic glycolysis
↓
Lactic acid production
↓
Acidic pH
↓
Nuclear chromatin clumping

Rough endoplasmic reticulum - makes protein (It is rough due to the presence of ribosomes)
↓
Ribosomes detach
↓
Protein synthesis goes down

## DETAILED QUESTIONS

### Q2.1: What is the first change seen in reversible cell injury?

**Answer:** Mitochondrial dysfunction.

### Q2.2: What happens to the $Na^+/K^+$ ATPase during reversible cell injury?

**Answer:** The $Na^+/K^+$ ATPase fails.

### Q2.3: What is the normal function of the $Na^+/K^+$ ATPase?

**Answer:**

- Mnemonic: **NOKIa**
- **$Na^+$ Out, $K^+$ In**
- Specifically:
  - 3 sodium ions go out.
  - 2 potassium ions come in.

### Q2.4: What are Myelin figures and when are they seen?

**Answer:**

- Composed of phospholipids and calcium (phospholipid >>> calcium)
- Seen in:
  - Reversible cell injury.
  - Irreversible cell injury (more enhanced).
- Under the microscope:
  - Appear as **lamellated concretions** under electron microscopy.

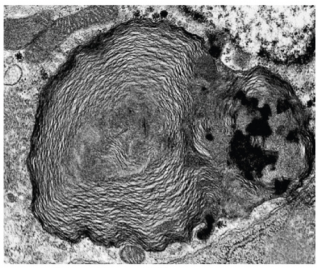
Electron Microscope

### BIG QUESTION 3: What are the key features of irreversible cell injury and the different types of cell death?

**Broad Answer:** Irreversible cell injury occurs when membrane damage and intracellular derangements become so severe that the cell cannot recover, leading to cell death. Cell death can occur through necrosis, apoptosis, necroptosis, or pyroptosis.



YOURWISH

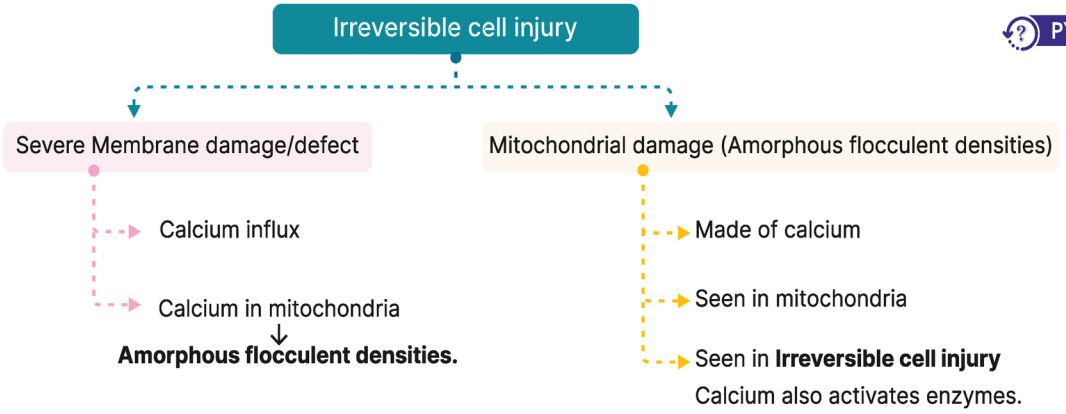


PYQ: FMGE 2019

## DETAILED QUESTIONS

### Q3.1: What is the earliest ultrastructural change seen in irreversible cell injury?

**Answer:** Severe membrane damage/defect.

### Q3.2: What is seen in mitochondria during irreversible cell injury?

**Answer:**

- Amorphous flocculent densities composed of calcium.
- These are a hallmark of irreversible cell injury.

### Q3.3: What causes nuclear changes during irreversible cell injury?

**Answer:** Nucleases.

### Q3.4: What are the types of nuclear changes seen in irreversible cell injury?

PYQ: AIIMS 2019

**Answer:**

- **Pyknosis:** Nuclear shrinkage and condensation.
- **Karyorrhexis:** Nuclear fragmentation.
- **Karyolysis:** Complete nuclear dissolution.

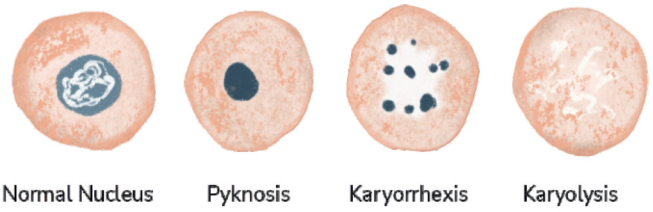


### Q3.5: What are the types of cell death?

**Answer:**

**Mnemonic:** P -> K -> K

- Necrosis
- Apoptosis
- Necroptosis
- Pyroptosis

### BIG QUESTION 4: What is necrosis and what are its different types?

**Broad Answer:** Necrosis is a form of pathological cell death characterised by cell swelling, membrane damage, enzymatic digestion, and inflammation. It occurs in different forms depending on the tissue involved and the nature of the injurious stimulus.

## DETAILED QUESTIONS

### Q4.1: What is necrosis?

**Answer:**

- Necrosis is pathological cell death.
- It is always associated with inflammation.

### Q4.2: What are the types of necrosis?

**Answer:**

1. Coagulative necrosis
2. Liquefactive necrosis
3. Caseous necrosis
4. Fat necrosis
5. Fibrinoid necrosis
6. Gangrenous necrosis
7. Zenker's Degeneration

## BIG QUESTION 5: What is Coagulative Necrosis and where is it seen?

**Broad Answer:** Coagulative necrosis is the most common type of necrosis. It occurs predominantly in solid organs due to ischaemia or infarction, except in the brain and pancreas. It is characterised by preserved tissue architecture, loss of cellular details, and denaturation of structural proteins.

## Detailed Questions:

### Q5.1: What is the most common type of necrosis?

**Answer:** Coagulative necrosis.

- Cause infarction in the organs
- Mechanism of action: Denaturation of proteins.

### Q5.2: Where is coagulative necrosis commonly seen?

**Answer:**

- Solid organs:
  - Kidney
  - Heart (most common)
  - Liver
- **Exceptions:**
  - Brain → Shows liquefactive necrosis.
  - Pancreas → Shows liquefactive necrosis.

### Q5.3: What is the characteristic microscopic appearance of coagulative necrosis?

**Answer:**

- **Ghost Cells:**
  - **Outline of cells is preserved.**
  - **Loss of cellular details.**
- Multiple Ghost Cells: **Tombstone appearance**

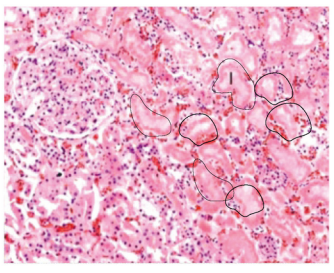

- **Tissue architecture is initially maintained.**
- This is due to denaturation of structural proteins and enzymes, preventing immediate enzymatic digestion.

**Q5.4: A 61-year-old female patient presents with left-sided chest pain radiating to the left arm and jaw. The patient explains that the pain has increased severely over the past 40 minutes. She was immediately rushed to the hospital. Cardiac enzymes are elevated. The patient was admitted and started on thrombolytic therapy. However, on the fifth day of observation, she suddenly collapses and dies. Which of the following necrosis are you most likely to find in the heart of this patient?**

A. Liquefactive Necrosis
B. Coagulative Necrosis
C. Fat Necrosis
D. Fibrinoid Necrosis

**Answer:** B. Coagulative Necrosis
This is a case of Myocardial infarction → In any solid organ, the type of necrosis is Coagulative Necrosis.

## BIG QUESTION 6: What is Liquefactive Necrosis and where is it seen?

**Broad Answer:** Liquefactive necrosis is a type of necrosis characterised by enzymatic digestion of dead cells, leading to transformation of tissue into a liquid viscous mass. It occurs commonly in the central nervous system (CNS) and pancreas (rich in Hydrolytic Enzymes)

## DETAILED QUESTIONS

### Q6.1: What is liquefactive necrosis?

**Answer:** A type of necrosis where enzymatic digestion of dead cells leads to transformation of tissue into a liquid viscous mass.

### Q6.2: Where is liquefactive necrosis commonly seen?

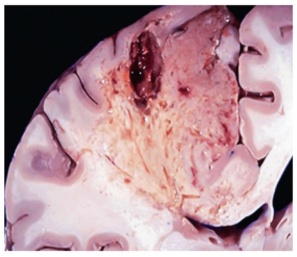

**Answer:**

- **CNS (Central Nervous System)** – following infarction.
- **Pancreas** – due to enzymatic destruction.

## BIG QUESTION 7: What is Caseous Necrosis and where is it seen?

PYQ: FMGE 2019

**Broad Answer:** Caseous necrosis is a form of tissue necrosis with a cheese-like (caseous) gross appearance. It is most characteristically seen in tuberculosis and fungal infections. Microscopically, it shows amorphous, granular, eosinophilic debris surrounded by inflammatory cells.

## DETAILED QUESTIONS

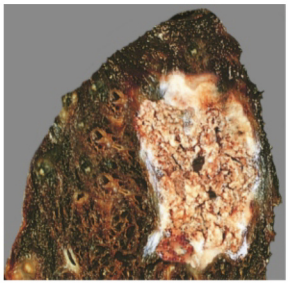

### Q7.1: What is caseous necrosis?

**Answer:** A combination of Coagulative Necrosis (more common) + Liquefactive Necrosis.

- Cheese-like, soft, white gross appearance.
- A type of necrosis with a cheese-like, soft, white gross appearance.



YOURWISH

### Q7.2: Where is caseous necrosis commonly seen?

**Answer:**

- Tuberculosis.
- Fungal infections(histoplasmosis, coccidioidomycosis)

### Q7.3: What is the microscopic appearance of caseous necrosis?

**Answer:**

- Amorphous, granular, eosinophilic debris.
- Surrounded by a border of inflammatory cells.

## BIG QUESTION 8: What is Fat Necrosis and where is it seen?

**Broad Answer:** Fat necrosis is a type of necrosis that involves the destruction of fat cells, typically seen in acute pancreatitis and traumatic injuries to fat tissue. It is characterised by chalky white deposits due to saponification.

## DETAILED QUESTIONS

### Q8.1: What is fat necrosis?

**Answer:**

- Necrosis involving the destruction of adipose (fat) tissue.
- Associated with enzymatic digestion of fat and saponification.

### Q8.2: Where is fat necrosis commonly seen?

**Answer:**

- Acute pancreatitis.
- Traumatic fat injury (e.g., breast trauma).

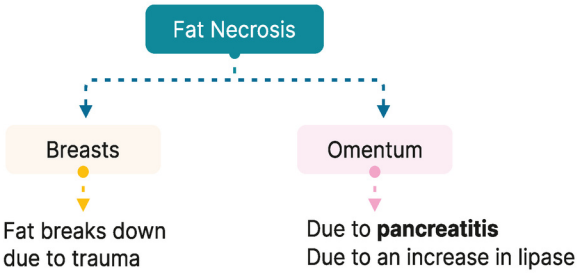


### Q8.3: What is the gross appearance of fat necrosis?

**Answer:**

- Chalky white deposits.
- Result from saponification (combination of fatty acids with calcium).

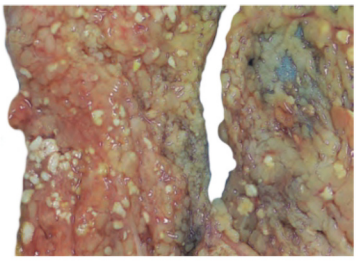

## BIG QUESTION 9: What is Fibrinoid Necrosis and where is it seen?

**Broad Answer:** Fibrinoid necrosis is a type of necrosis associated with antigen-antibody reactions involving blood vessels, characterised by immune complex deposition and fibrin leakage into vessel walls, giving them a fibrin-like appearance under microscopy.

## DETAILED QUESTIONS

### Q9.1: What is fibrinoid necrosis?

**Answer:** A type of necrosis involving immune complex deposition and fibrin leakage into vessel walls.



YOURWISH

YOURWISH

### Q9.2: Where is fibrinoid necrosis commonly seen?

**Answer:**

- **Polyarteritis Nodosa (PAN)**
- **Rheumatic Heart Disease (RHD)** → Seen in Aschoff bodies
- **Systemic Lupus Erythematosus (SLE)**
- **Malignant Hypertension (HTN)**

### Q9.3: What is the characteristic microscopic appearance of fibrinoid necrosis?

**Answer:** Bright pink, amorphous, fibrin-like material is seen in vessel walls on H&E staining.

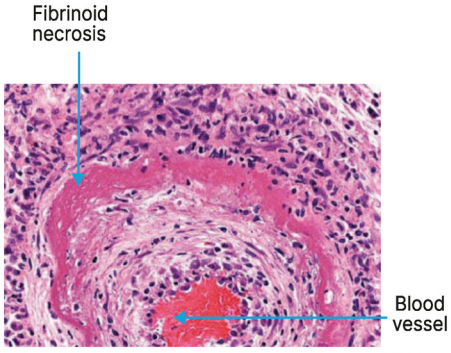

Blood vessel showing fibrinoid necrosis - in PAN

## BIG QUESTION 10: What is Gangrenous Necrosis and what are its types?

**Broad Answer:** Gangrenous necrosis is a clinical variant of coagulative necrosis typically affecting extremities due to loss of blood supply. It may occur as dry gangrene or progress to wet gangrene if superimposed bacterial infection develops.

## DETAILED QUESTIONS

### Q10.1: What is gangrenous necrosis?

**Answer:**

- A clinical variant of coagulative necrosis affecting extremities, particularly due to ischaemia.
- May be complicated by bacterial infection, converting it to wet gangrene.

### Q10.2: What are the types of gangrenous necrosis?

**Answer:**

- **Dry gangrene:**
  - Due to ischaemia.
  - Typically affects limbs.
  - Coagulative necrosis
- **Wet gangrene:**
  - Dry gangrene, complicated by bacterial infection.
  - Superadded liquefactive necrosis.
- **Gas gangrene:**
  - Caused by Clostridium species.
  - Produces gas within tissues.


Dry G Wet G

## BIG QUESTION 11: What is Zenker's Degeneration and where is it seen?

**Broad Answer:** Zenker's degeneration is a severe form of muscle injury classified as hyaline or waxy degeneration. It occurs specifically in skeletal muscles, especially in the rectus abdominis during enteric fever.

## DETAILED QUESTIONS

### Q11.1: What type of degeneration is Zenker's degeneration?

**Answer:**

- A type of Coagulative Necrosis.
- A form of hyaline degeneration
- Also called waxy degeneration

### Q11.2: Where is Zenker's degeneration seen?

**Answer:**

- Skeletal muscles (eg: Rectus Abdominis, Diaphragmatic Muscle)
  - Occurs in typhoid

### Q11.3: A 45-year-old female patient complained of being hit in the chest by a football while passing by a garden 4 weeks back. Initially, her left breast was tender and swollen. But over the weeks, the tenderness has subsided. However, she now notices a lump in the periareolar region, which is firm and hard in consistency. Radiological investigations reveal calcific deposits. Which of the following best describes the phenomenon above?

A. Liquefactive necrosis
B. Coagulative necrosis
C. Fat necrosis
D. Fibrinoid necrosis

**Answer:** C. Fat necrosis
This is a case of traumatic fat necrosis in the breast.

# 2. CELL INJURY PART -2

## BIG QUESTION 1: What is Apoptosis and what are its key features?

**Broad Answer:**

Apoptosis is a form of programmed cell death characterised by cell shrinkage, membrane blebbing, chromatin condensation, and formation of apoptotic bodies without inflammation. It can be physiological or pathological.

## DETAILED QUESTIONS:

### Q1.1: What is apoptosis?

PYQ: AIIMS 2018, 2019

**Answer:**

- A form of **programmed cell death** → Caspase Dependent Programmed Cell Death
- Occurs with preservation of plasma membrane integrity.
- Results in formation of **apoptotic bodies**.
- Does **not cause inflammation**.

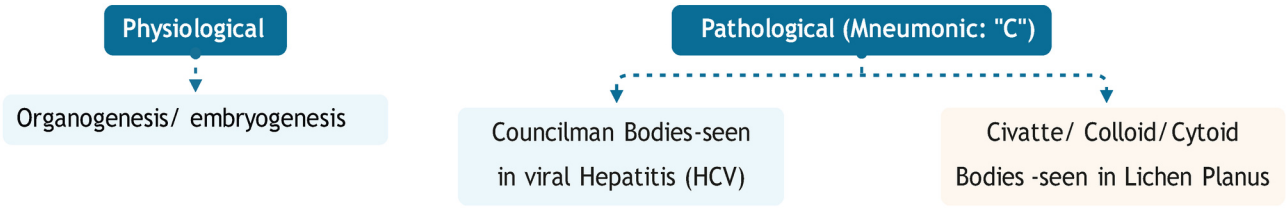


### Q1.2: What are the morphological features of apoptosis?

**Answer:**

- **Cell shrinkage.**
- **Chromatin condensation.**
- **Cytoplasmic blebbing.**
- Formation of **apoptotic bodies.**
- No inflammation.

### Q1.3: What are the two pathways of apoptosis?

**Answer:**

- Intrinsic (Mitochondrial) pathway.
- Extrinsic (Death receptor) pathway.

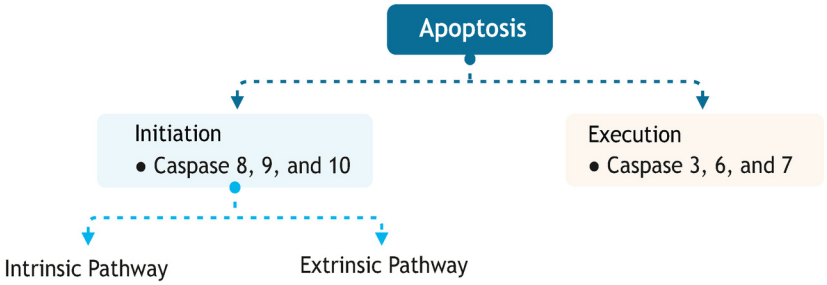




YOURWISH

### Q1.4: What is the intrinsic (mitochondrial) pathway of apoptosis?

**Answer:**

PYQ: AIIMS 2019

- Caspase 9
- Occurs when cells are under stress (like UV ray)
- Stress sensors: BIM, BID, BAD, NOXA and PUMA
- Sensor: Increases pro-apoptotic factors; Decreases anti-apoptotic factors.
- Send a signal to mitochondria
- Mitochondria release SMAC/DIABLO and cyt C
- Cyt combines with Apaf 1 → Forms apoptosome → Activates Procaspase 9 into Caspase 9.

### Q1.5: What is the extrinsic (death receptor) pathway of apoptosis?

PYQ: AIIMS 2019

**Answer:**

- Caspase 8, 10
- Site: Outside the cell
- Cell has CD95/Fas
- T cell has CD95 Ligand/Fas Ligand
- Binding leads to Trimerization of CD95/Fas
- FADD will activate Procaspase 8, 10 into Caspase 8, 10.
- Process is inhibited by FLIP (anti-apoptotic molecule.)

### Q1.6: What is the final execution phase of apoptosis?

**Answer:**

- Apoptotic bodies: Cells go off in bits and pieces as membrane bound organelles (with or without a piece of nucleus)
- Efferocytosis (eat me signal): Apoptotic bodies send signals to macrophages by flipping of phosphatidylserine.
- Macrophages then phagocytose the cells.

### Q1.7: What are the pro-apoptotic and anti-apoptotic factors regulating apoptosis?

**Answer:**

| Pro-apoptotic factors | Anti-apoptotic factors |
|---|---|
| P53 | BCL 2 |
| BAX | BCL XL |
| BAK | MCL 1 |
| BCL XS | |

- **Pro-apoptotic factors:** Promote mitochondrial outer membrane permeabilisation, leading to cytochrome c release and activation of the intrinsic pathway.
- **Anti-apoptotic factors:** Preserve mitochondrial membrane integrity, preventing cytochrome c release and inhibiting apoptosis.

### Q1.8: What is the hallmark of apoptosis?

**Answer:** **Nuclear chromatin condensation.**



YOURWISH

YOURWISH

### Q1.9: What are the diagnostic markers of apoptosis?

**Answer:**

1. **Annexin V**
   - Also called **Apoptosis-Annexin Penta**.
   - Binds to phosphatidylserine exposed on the outer leaflet of the plasma membrane in apoptotic cells.
2. **Annexin a1**
   - Seen in **Hairy Cell Leukemia**.
3. **Molecular Marker:**
   - **Cd95 / Fas**

### Q1.10: What is seen on microscopy in apoptosis?

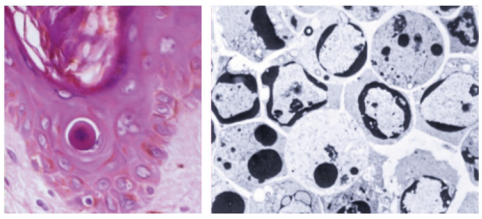

**Answer:**

- Cell shrinkage.
- Nuclear chromatin condensation (blue nucleus).
- Cytoplasmic blebbing.
- Apoptotic body formation.
- Pink cytoplasm.

### Q1.11: What stain is used to detect apoptosis?

**Answer:**

- **TUNEL stain (Terminal deoxynucleotidyl transferase dUTP Nick End Labelling):**
  - Positive in apoptosis.
  - Negative in necrosis.

### Q1.12: What are the DNA gel electrophoresis findings in apoptosis?

**Answer:**

DNA gel electrophoresis can show:

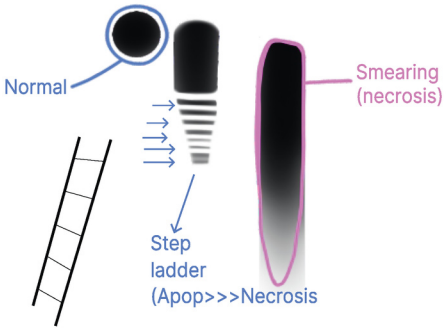


- **Step ladder pattern:**
  - Seen due to internucleosomal DNA fragmentation.
  - Classically associated with apoptosis.
  - Can also be seen in some cases of necrosis.
- **Smearing pattern:**
  - Indicates random DNA degradation.
  - Can be seen in both necrosis and late-stage apoptosis.

## BIG QUESTION 2: What are the newer forms of cell death apart from necrosis and apoptosis?

**Broad Answer:** In addition to classical necrosis and apoptosis, several newer forms of regulated cell death have been described, including necroptosis, pyroptosis, and ferroptosis, each with distinct molecular pathways and features.

## DETAILED QUESTIONS

### Q2.1: What is necroptosis?

**Answer:**

- A regulated form of necrosis.

- Also called **programmed necrosis.**
- Features:
  - o Morphologically resembles necrosis.
  - o Mechanistically resembles apoptosis.
- Mediated by:
  - o **RIPK1** and **RIPK3** (Receptor-interacting protein kinases).

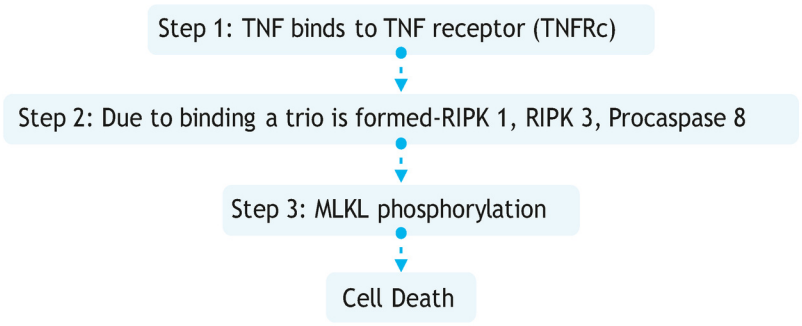


- No caspase activation.

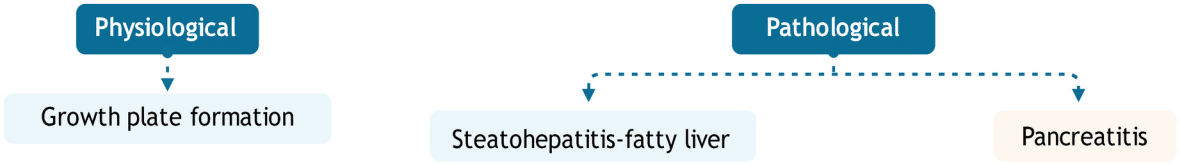


**Q2.2: What is pyroptosis?**

**Answer:**

- Pyro means Fever + Apoptosis means cell death.
- Associated with bacteria like Shigella and salmonella.
- Caspase 1 activates Interleukin 1 (IL-1) - causing fever.

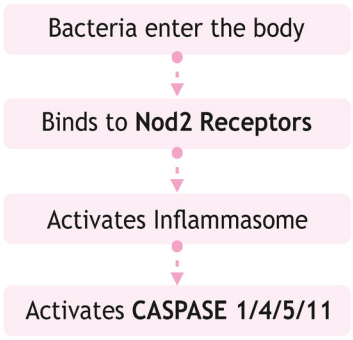


**Q2.3: Choose the incorrect statement about Necroptosis.**

A) It is a caspase-independent cell death
B) RIP 1&3 complex is formed.
C) Caspase 8 is formed.
D) Growth plate formation follows necroptosis.

**Answer:** C. Caspase 8 is formed.

- Procaspase 8 is used
- It is caspase-independent programmed cell death.

**Q2.4: Choose the incorrect statement about pyroptosis**

A) Seen in response to Shigella.
B) TLR is used.
C) Caspase 1 is required.
D) IL1 activated.

**Answer:** B. TLR is used → It uses NOD 2 receptor

**Q2.5: What is the origin and function of the term "caspase"?**

**Answer:**

- C - Cysteine residues
- ASP - Aspartic acid
  - o Breaks after aspartic acid
- Ase - For enzyme

**Q2.6: The following gel electrophoresis pattern of the patient is seen in:**

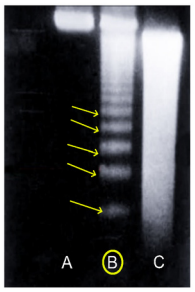


A) Necrosis

B) Apoptosis

C) Both

D) None

**Answer:** C) Both

- The observed gel electrophoresis pattern is characteristic of both necrosis and apoptosis.

# 3. CELL INJURY PART 3

## BIG QUESTION 1: What are the types and mechanisms of cellular adaptations in response to injury?

**Broad Answer:** The main types of cellular adaptations include **hypertrophy**, **hyperplasia**, **atrophy**, and **metaplasia**. These adaptations occur in response to stress, hormones, or pathological stimuli and involve changes in cell size, number, or type.

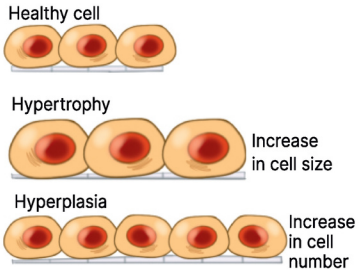


PYQ: FMGE 2021

## DETAILED QUESTIONS

### Q1.1: What is hypertrophy and how does it occur?

**Answer:**

- Increase in the **size** of cells
- Associated with an increase in **transcription factors:**
  - GATA
  - NFAT
  - MEF2

### Q1.2: What is hyperplasia and how does it occur?

**Answer:**

- Increase in the **number** of cells
- Associated with an increase in **mitosis**

### Q1.3: In what conditions are both hypertrophy and hyperplasia seen?

**Answer:**

- Gravid uterus (pregnant uterus
  - Hypertrophy >>> Hyperplasia
- Breast
  - Puberty
  - Pregnancy

    → Hyperplasia >>> Hypertrophy

### Q1.4: What are examples where only hyperplasia is seen?

**Answer:**

| Sex | Condition | Hormone |
|---|---|---|
| Females | Endometrial hyperplasia | Estrogen |
| | → May lead to **Endometrial Cancer Type 1** | |
| Males | Nodular hyperplasia of prostate | Testosterone → DHT |
| | Enzyme: 5α-reductase type 2 | |
| | Inhibited by: **Finasteride** (treatment)<br>Testosterone —5α reductase type 2→ Dihydrotestosterone (DHT) → Nodular hyperplasia prostate<br>↑ inhibits<br>Finasteride (treatment) | |



YOURWISH

### Q1.5: What is atrophy and what are its causes?

**Answer:**

- Decrease in **size and number of cells**
- Mechanism: **Ubiquitin Proteasome Pathway (UPP)**
- Types:
  a. **Disuse Atrophy** - e.g., Muscle atrophy after fracture
  b. **Malnutrition**
  c. **Ischemic Atrophy**
  d. **Denervation Atrophy**
  e. **Endometrial Atrophy**
  - **Postmenopausal**
  - Can lead to **Endometrial Cancer Type 2 (worse prognosis)**

### Q1.6: Which conditions show hypertrophy alone?

**Answer:**

- **Body builders (skeletal muscle hypertrophy)**
- **Proximal to obstruction (obstruction in urinary bladder due to stone → remaining tissue adapts by hypertrophy).**

## BIG QUESTION 2: What is metaplasia and how does it differ from other cellular adaptations?

**Broad Answer:** Metaplasia refers to the **reversible** transformation of one differentiated cell type to another, often in response to chronic irritation. It can involve epithelial or mesenchymal tissues and is caused by **reprogramming of stem cells.**

## DETAILED QUESTIONS

### Q2.1: What are the types of metaplasia?

**Answer:**

- One **epithelium** to another epithelium
- One **mesenchymal tissue** to another mesenchymal tissue
- It is **100% reversible**

### Q2.2: What is the mechanism behind metaplasia?

**Answer:**

- **Reprogramming of stem cells**

### Q2.3: What is the most common type of metaplasia?

**Answer:**

- **Squamous metaplasia**
  - Seen in **chronic smokers** or **Vitamin A deficiency/excess**
  - **Pseudostratified ciliated columnar epithelium → Squamous epithelium**
  - Terminology is based on the **end result**

### Q2.4: What is Barrett's Esophagus?

PYQ: NEET PG 2020

**Answer:**

- A type of metaplasia due to **GERD (Gastroesophageal Reflux Disease)**
- **Squamous epithelium (normal) → Columnar epithelium with goblet cells (hallmark)**
- Contains **acidic mucin**
- **Alcian blue positive** staining

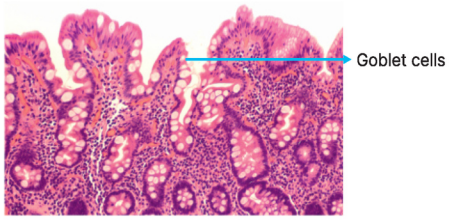


### Q2.5: What is mesenchymal metaplasia?

**Answer:**

- **Myositis ossificans:** Muscle transforms into bone
- Occurs due to **trauma**

### Q2.6: What is the histopathological difference between Barrett's epithelium and gastric mucosa?

A. Barrett's mucosa is acidic and stains alcian blue positive.

B. Barrett's is alkaline and stains Prussian blue positive.

C. Barrett's alcian blue negative because it's negative.

D. The gastric mucosa is alkaline and stains alcian blue positive.

**Answer:** A. Barrett's mucosa is acidic and stains alcian blue positive

## BIG QUESTION 3: What are intracellular accumulations and their types?

**Broad Answer:** Cells may accumulate various substances including **pigments, lipids, proteins, glycogen, and calcium** due to metabolic disturbances, genetic disorders, or exposure to harmful agents.

## DETAILED QUESTIONS

### Q3.1: What are the different types of pigments that can accumulate in cells?

PYQ: AIIMS 2020

**Answer:**

- **Lipofuscin**
  - Seen in **senile atrophy**
  - Known as **wear and tear pigment**
  - Indicator of **free radical injury**
  - Product of **lipid peroxidation**
  - **Stains:**
    - → **Oil Red O**
    - → **ZN stain**
  - Appears as **brown-colored perinuclear pigment**
- **Hemosiderin**
  - Associated with **hemorrhage/hematoma**
  - **Stains:**
    - → **Perl's stain**
    - → **Prussian blue stain**

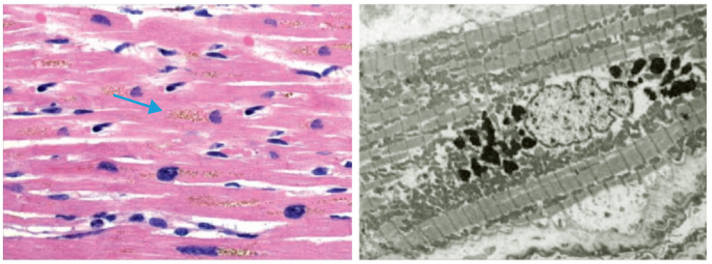

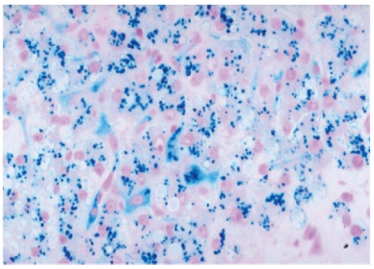

**Iron-related → Perl's stain.**

- **Melanin**
  - Found in:
    - → **Hair**
    - → **Eyes**
    - → **Skin**
    - → **Brain (Substantia nigra)**
  - **Stains:**
    - → **Masson Fontana** (Mnemonic: TAN - SKIN)
    - → **SCHMORL stain** (Mnemonic: SCHMORL-MOLE)
  - **Enzyme: Dopa oxidase** (Most important)
  - **IHC Markers: HMB-45, S100**
  - Present in the **stratum basale** layer of skin
  - Melanin localization is often visualized via **Masson Fontana stain**

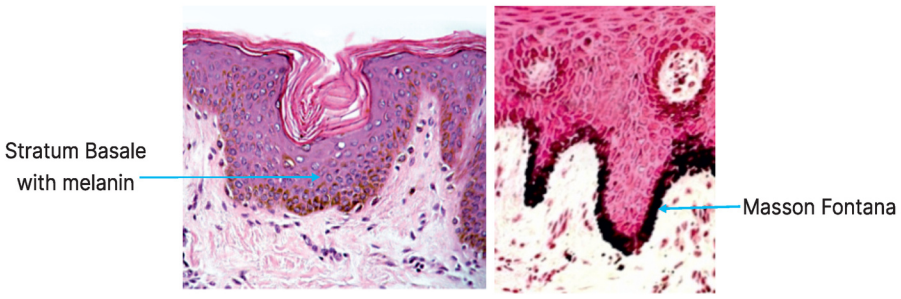


### Q3.2: Incorrect about the pigment shown?

A. Defined as yellow - brown in appearance
B. Formed due to lipid peroxidation
C. Can be positive for oil red O
D. Seen more commonly in infants

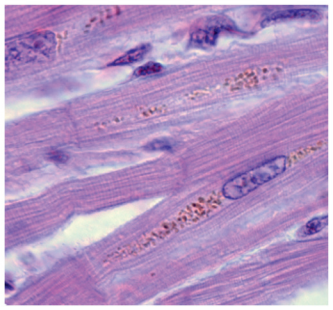

**Answer:** D. Seen more commonly in infants

**Explanation**

- The pigment described is **lipofuscin**, a **perinuclear pigment**
- Seen in the **elderly** (senile atrophy)
- Hence, **D is incorrect**

### Q3.3: What is anthracotic pigment and where is it found?

**Answer:**

- Caused by **carbon deposits**
- Leads to **black-colored lungs**

### Q3.4: What are the stains used for copper accumulation and related disease?

**Answer:**

- **Disease:** Wilson disease
- **Stains:**
  - **Rhodanine stain**
  - **Rubeanic acid stain**
  - Mnemonic: **RhodaMine-MTB**

### Q3.5: How is glycogen accumulation identified?

**Answer:**

- **PAS stain** → pink-colored
- **DS:** diastase-sensitive
- Found in:
  - **Glycogen storage diseases**

- **Diabetes mellitus (DM)**
  - → In kidney: **Armani Ebstein lesion**
  - → **Glycogen in Proximal Convulated Tubule (PCT)**

### Q3.6: What are the types and stains for lipid accumulation?

**Answer:**

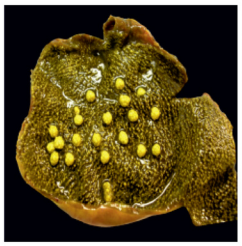

Strawberry gallbladder

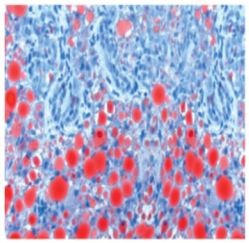

**OIL RED O**

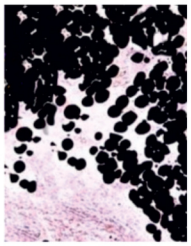

**Sudan Black B**

| Organ | Feature | Stains |
|---|---|---|
| Liver | Fatty liver | Oil Red O, Sudan Black B |
| Heart | Tigered/tabby cat appearance | Sudan IV (orange color) |
| Gallbladder | Cholesterolosis (Strawberry GB) | Oil Red O |

### Q3.7: How is fat identified in histopathology?

**Answer:**

- **Technique:** Frozen section
- **Process:**
  - Tissue is frozen without chemical processing
  - Advantage: **Fat is preserved**
- **Stain used: Oil Red O**

### Q3.8: What are the types of pathological calcifications?

**Answer:**

1. **Dystrophic Calcification** (Mnemonic: **DDD**)
   - Occurs in **Dead and Degenerating tissue**
   - Examples:
     - → **Dead parasite**
     - → **Tuberculosis (TB)**
     - → **Atheroma**
   - **Serum calcium level is normal**
   - Special Case:
     - → **Monckeberg's sclerosis**
       - – Also known as **calcific medial degeneration**
       - – Affects **tunica media**
       - – Seen in **old age**

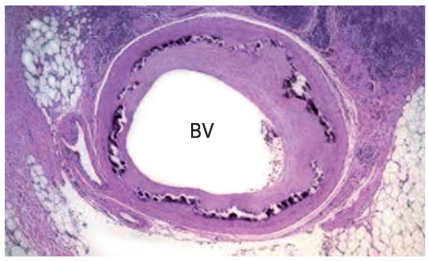


MONCKEBERG ↓aka CALCIFIC (Dystrophic) SCLEROSIS MEDIAL (T.media) DEGENERATION (old age)

   - **Psammoma Bodies (Mnemonic: PSM)** seen in:



YOURWISH

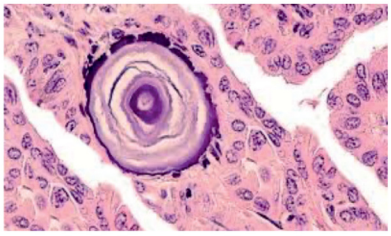

- → Papillary Carcinoma of the **thyroid**, **ovary**, **kidney**, etc.
- → **Prolactinoma**
- → **Somatostatinoma**
- → **Serous ovarian tumor**
- → **Meningioma**
- → **Mesothelioma**

2. **Metastatic Calcification**
   - o **Serum calcium is high**
   - o Calcium gets deposited in **normal tissues**
   - o **Most commonly affected organ: Lungs**
   - o Causes include:
     - → **Hyperparathyroidism**
     - → **Sarcoidosis** (↑ calcium)
     - → **Increased Vitamin D**
     - → **Milk-alkali syndrome**

### Q3.9: What is the first site of calcium deposition in cells?

**Answer:**

- **Mitochondria**
- **In kidneys**, deposition occurs in the **basement membrane**

### Q3.10: What are the stains used to detect calcium accumulation?

**Answer:**

- **Von Kossa stain** - Black (Mnemonic: C/AL/CIUM)
- **Calcein**
- **Alizarin Red S** - Detects even minute amounts (Mnemonic: ZARA = ZARIN)

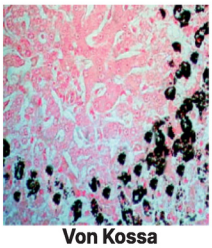

Von Kossa

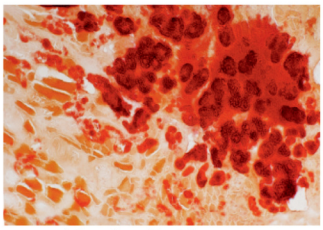

Alizarin - Red S

## BIG QUESTION 4: What are the key processes and mechanisms in cellular aging and free radical injury?

**Broad Answer:** Cellular aging involves progressive functional decline of cells driven by mechanisms such as telomere shortening, oxidative stress, and impaired autophagy. Free radical injury (ROS) contributes to aging and cellular damage through oxidative reactions.

## DETAILED QUESTIONS

### Q4.1: What is autophagy and its significance?




**Answer:**

- **Self-eating / self-cannibalism** mechanism
- Discovered by **Yoshinori Ohsumi** (Nobel Prize 2016)
- **Marker**: LC3 (Light Chain 3)
- **Gene**: ATG 1
  - o **ATG 5 mutation** → Risk of **Tuberculosis**
  - o **ATG 16L mutation** → Associated with **Inflammatory Bowel Disease (IBD)**

### Q4.2: What are the causes and mechanisms of cellular aging?

**Answer:**

- **Most common cause: Free radical injury**
- Other causes:
  - **Telomere shortening**
  - **Insulin resistance**

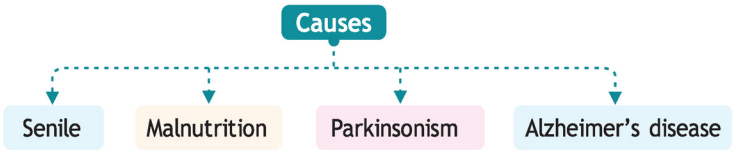


### Q4.3: What is telomere shortening and how does it contribute to aging?

**Answer:**

- Telomeres are the **terminal ends of chromosomes**
- Sequence: **TTAGGG**
- With each division, telomeres shorten → leads to aging
- **Prevented by telomerase**
  - Telomerase = **RNA-dependent DNA polymerase (RdDP)**
  - Known as the **Immortality Gene**
- **Hayflick limit:** Normal cells divide ~**60-70 times**

### Q4.4: How can lifespan be prolonged via sirtuins?

**Answer:**

- **Sirtuins:** SIRT1-SIRT7
- Function: **Histone deacetylases**
- Benefits (Mnemonic: ACD):
  - Anti-aging
  - Cancer treatment
  - Diabetes management (↑ insulin sensitivity)
- Boosting Sirtuins:
  - **Calorie deficit**
  - **Red wine**

### Q4.5: What are progeroid syndromes and their causes?

**Answer:** Progeria → Premature aging

| Syndrome | Defect | Alias |
|---|---|---|
| **Werner Syndrome** | **DNA Helicase defect** | Adult Progeria |
| **Hutchinson-Gilford Syndrome** | **LMNA (Lamin A) gene** | Laminopathy / Paa movie reference |



### Q4.6: Werner Syndrome is a defect in?

A. DNA Helicase
B. NER genes
C. MMR genes
D. All of the above

**Answer:** A. DNA Helicase

- Werner syndrome: Progeroid syndrome
- Wermer syndrome: MEN I syndrome (Mnemonic:M-M)

**Q4.7: Hutchinson-Gilford Progeria syndrome is due to the mutation in**

A. Keratin A

B. Keratin B

C. Lamin A

D. Lamin B

**Answer:** C. Lamin A

**Q4.8: What is free radical injury and how does it occur?**

**Answer:**

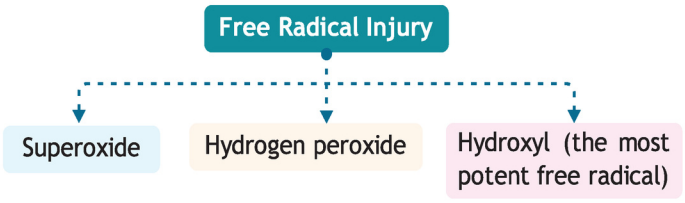


- Also known as **ROS (Reactive Oxygen Species)**
- Examples:
  - **Superoxide ($O_2^-$)**
  - **Hydrogen peroxide ($H_2O_2$)**
  - **Hydroxyl radical ($OH^-$)** - Most potent
- **Sources:**
  - Environmental toxins
  - Reperfusion injury
  - Inflammation

**Q4.9: What enzymes protect against free radical injury?**

**Answer:**

| Enzyme | Function |
|---|---|
| **Superoxide dismutase** | • Converts superoxide ▫ $H_2O_2$; mutations cause ALS (Amyotrophic Lateral Sclerosis)<br>• Forms free radicals and helps in breaking them as well<br>• SOD forms hydrogen peroxide which can then be broken down into many other things |
| **Catalase** | Breaks $H_2O_2 \rightarrow H_2O + O_2$ |
| **Glutathione peroxidase** | Acts on both $H_2O_2$ and hydroxyl radicals |

- ALS (Amyotrophic Lateral Sclerosis) = **SOD1 mutation**
- ALS involves both **UMN + LMN signs**

**Q4.10: Q. All of the following enzymes may contribute to generating free oxygen radicals within neutrophils to kill intracellular bacteria, except?**

A. Superoxide dismutase

B. Fenton's ration

C. NADPH oxidase

D. Glutathione peroxidase

**Answer:** D. Glutathione peroxidase



YOURWISH

### Q4.11: What is the function of Glutathione peroxidase?

**Answer:**

- Breaks down **free radicals**
- Acts on both **Hydrogen Peroxide ($H_2O_2$)** and **Hydroxyl radicals ($Oh^-$)**

### Q4.12: What is ferroptosis?

**Answer:**

- **Iron (Fe)-induced cell death**
- **Morphologically similar to necrosis**
- Master regulator: **GPX4 (Glutathione peroxidase type 4)**

### Q4.13: What is Fenton's Reaction?

**Answer:**

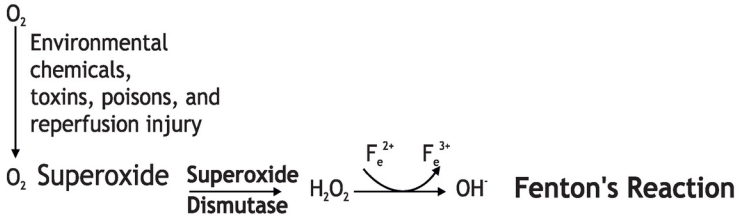


### Q4.14: What pigment serves as a tell-tale sign of free radical injury?

**Answer:** Lipofuscin pigment.



YOURWISH

# 4. INFLAMMATION

## BIG QUESTION 1: How is inflammation classified?

**Broad Answer:**

- Inflammation can be classified based on fluid type or duration.
- Each type has characteristic exudates and clinical examples.

## DETAILED QUESTIONS

### 1.1: How is inflammation classified based on fluid type?

**Answer:**

- **Serous Inflammation:** Watery fluid
- **Fibrinous Inflammation:** Thready fluid
  - *Example:* Sero-Fibrinous Pericarditis in RHD (Bread & Butter appearance) → Watery and Thready fluid (Serous and Fibrinous inflammation) is visible.
- **Purulent Inflammation:** Pus
  - *Example:* Abscess
- **Catarrhal Inflammation:** Mucus + water
  - Most common
  - *Example:* Common cold

### Q1.2: How is inflammation classified based on duration?

PYQ: FMGE 2020

**Answer:**

| Type | Features |
|---|---|
| **Acute** | • Immediate onset - ↑ Neutrophils/PMC<br>• Exception: Typhoid → Relative Lymphocytosis |
| **Chronic** | • Delayed onset - ↑ Lymphocytes, macrophages, plasma cells<br>• Exception: Chronic Pseudomonas → Neutrophils |

## BIG QUESTION 2: What are the vascular events in acute inflammation?

**Broad Answer:**

- Acute inflammation begins with vascular changes, including vasoconstriction, vasodilation, and increased permeability.
- These events lead to fluid exudation and tissue swelling.

## DETAILED QUESTIONS

### Q2.1: What are the initial vascular events in acute inflammation?

**Answer:**

- **Vasoconstriction:**
  - First event
  - Transient, lasts seconds
  - Reflex action
- **Vasodilation:**
  - Mediated by Histamine & Serotonin

### Q2.2: What is increased vascular permeability and its hallmark significance?

PYQ: INICET 2022

**Answer:**

- Fluids and cells exit vessels → swelling (tumor)
- Hallmark event of acute inflammation
- Most commonly in post-capillary venules

### Q2.3: What mechanisms cause increased vascular permeability?

PYQ: FMGE 2022

**Answer:**

- **Endothelial cell retraction (gap formation):**
  - Most common
  - Mediators: Histamine, Serotonin
  - Immediate transient response
  - Endothelial cells are Cd34+
- **Direct endothelial injury:**
  - Immediate sustained or delayed prolonged response
  - Examples: Sunburn (delayed), sepsis (immediate sustained)
- **Transcytosis:**
  - Via Vesiculo-Vacuolar Organelles (VVO)
  - Mediators: Histamine, VEGF
- **Angiogenesis**
  - Leaky Channels: Formation of immature new blood vessels
  - Mediators: Histamine, VEGF

### Q2.4: What is stasis in acute inflammation?

**Answer:**

- Plasma loss → ↑ RBC concentration → ↑ viscosity → sluggish blood flow

## BIG QUESTION 3: What are the cellular events in acute inflammation?

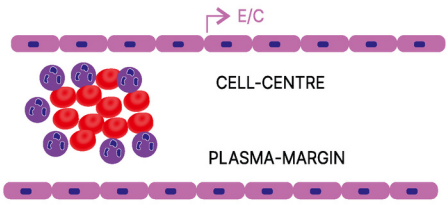


**Broad Answer:**

- Cellular events involve white blood cells leaving circulation and migrating to the site of injury.
- This process follows seven steps summarized by the mnemonic MRATCOP.

## DETAILED QUESTIONS

PYQ: NEET PG 2021

### Q3.1: What does MRATCOP stand for in acute inflammation?

**Answer:**

- Margination

- **R**olling & weak adhesion
- **A**dhesion (strong)
- **T**ransmigration (Diapedesis)
- **C**hemotaxis
- **O**psonization
- **P**hagocytosis

### Q3.2: What occurs during margination and rolling?

**Answer:**

- **Margination:** WBCs move to vessel margin
- **Rolling:** Mediated by selectins:
  - **P-selectin:** Platelets, endothelium → binds Sialyl Lewis X
  - **E-selectin:** Endothelium → binds Sialyl Lewis X
  - **L-selectin:** Leukocytes → binds GlyCAM, MadCAM, Cd34

### Q3.3: What molecules are involved in strong adhesion?

**Answer:**

- Integrins on leukocytes:
  - $\beta_1$ integrins → bind VCAM
  - $\beta_2$ integrins (LFA/MAC/CD11/18) → bind ICAM

### Q3.4: What mediates transmigration (diapedesis)?

**Answer:**

- **PECAM/CD31** mediates passage between endothelial cells
- Basement membrane degraded by **MMP (Zn dependent)**

### Q3.5: What are key mediators of chemotaxis?

**Answer:**

- **Exogenous:** bacterial products
- **Endogenous:**
  - L → LTB4
  - I → IL-8
  - C → C5a

### Q3.6: What is opsonization and which opsonins are important?

**Answer:**

- Coating bacteria to enhance phagocytosis
- Major opsonins:
  - IgG
  - C3b

### Q3.7: What are the mechanisms of phagocytosis?

**Answer:**

- **Oxygen-dependent killing:**
  - $H_2O_2$-MPO-halide system

- NADPH oxidase (PHOX gene) → crucial enzyme
- **Oxygen-independent killing:**
  - MBP from eosinophils → parasitic infections

## BIG QUESTION 4: What are NETs and Emperipolesis in inflammation?

**Broad Answer:**

- NETs (Neutrophil Extracellular Traps) and Emperipolesis are specialized processes in inflammation, involved in defense and unique cell interactions.

## DETAILED QUESTIONS

### Q4.1: What are NETs and why are they called beneficial suicide?

**Answer:**

- NETs = nuclear chromatin released outside cell → traps bacteria
- Occur in severe infections (e.g., sepsis)
- Cell dies → **"beneficial suicide"**
- Amino acid involved: Arginine
- NETs → extracellular killing; phagocytosis → intracellular
- NETs → possible source of ANA → SLE

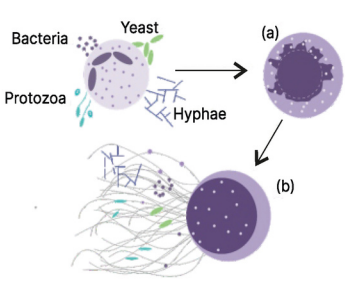


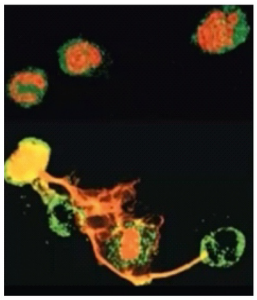

### Q4.2: What is emperipolesis?

**Answer:**

- Cell-within-a-cell phenomenon (no killing)
- Seen in:
  - **M** → MDS/MPN
  - **A** → AIH
  - **R** → Rosai-Dorfman disease
  - **C** → CLL

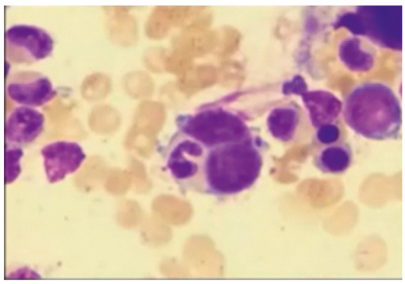

## BIG QUESTION 5: What are the clinical correlations in inflammation?

**Broad Answer:**

- Several genetic or acquired disorders affect inflammation processes, leading to recurrent infections and other complications.

## DETAILED QUESTIONS

### Q5.1: What are types and features of Leukocyte Adhesion Deficiency (LAD)?

**Answer:** LAD (Leukocyte Adhesion Defect)

- All of them are autosomal recessive defects.
- Repeated infections observed
- Bombay blood group: All antigens (H, A, B) absent; All antibodies present.

| Type | Defect | Key Features |
|---|---|---|
| LAD 1 | $\beta_2$ integrin | Delayed separation of umbilical cord |



YOURWISH

| | | |
|---|---|---|
| LAD 2 | Sialyl Lewis X | Bombay blood group |
| LAD 3 | FermT3 gene | Bleeding tendency |

### Q5.2: What is Bruton's Hypogammaglobulinemia?

**Answer:**

- X-linked B-cell defect (most commonly seen in boys)
- Defective BTK gene
- Defect in IgG → Defective opsonization

### Q5.3: What is Chediak-Higashi Syndrome?

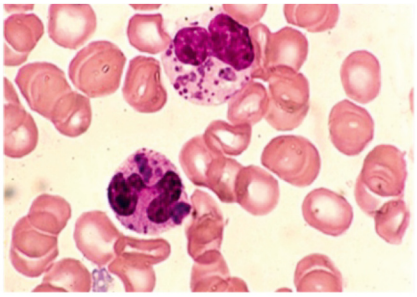

**Answer:**

- LYST gene defect (lysosomal trafficking)
- Clinical mnemonic "C-H-E-D-I-A-K":
  - C - CNS/neurological abnormalities
  - HE - Hemorrhage
  - DI - Decreased Immunity
  - A - Albinism- silvery gray hair
  - K - Coarse cytoplasmic granules

### Q5.4: What is Chronic Granulomatous Disease?

**Answer:**

- NADPH oxidase defect (PHOX gene)
- Susceptibility → catalase-positive organisms
- Diagnosis:
  - Screening: NBT (Nitroblue Tetrazolium) test
  - Confirmatory: DHR (Dihydrorhodamine) by flow cytometry

### Q5.5: A 4-year-old male has recurrent infections, neutrophilia, and Bombay blood group. What's the defect?

A. LAD 1
B. LAD 2
C. Bruton's Hypogammaglobulinemia
D. SCID

**Answer: B. LAD 2**

- Defect in Sialyl Lewis X, associated with Bombay blood group.

## BIG QUESTION 6: What are the mediators of inflammation and their functions?

**Broad Answer:**

- Inflammation involves preformed and newly synthesized mediators, each playing distinct roles in vasodilation, permeability, chemotaxis, and pain.

## DETAILED QUESTIONS

### Q6.1: What are preformed mediators of inflammation?

**Answer:**

- **Histamine:**

- Source: Mast cells (richest source), basophils
- Precursor: Histidine

- **Serotonin (5HT):**
  - Source: Platelets, EC cells (richest source)
  - Precursor: Tryptophan
- Both cause:
  - Vasodilation
  - Increased vascular permeability
  - Bronchoconstriction

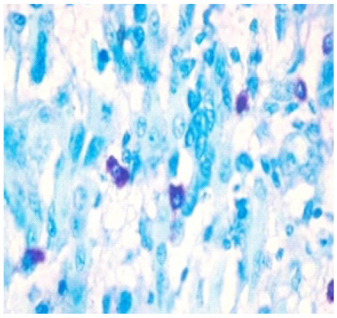

### Q6.2: What stain identifies mast cells and basophils?

**Answer:**

- Toluidine blue stain

### Q6.3: What are lysosomal granule enzymes?

**Answer:**

- These enzymes come from granules in neutrophils.
- There are three granules:

| Granule Type | Contents |
|---|---|
| Primary (Azurophilic) | • Acid Hydrolase<br>• Bacteria killing Myeloperoxidase (MPO)<br>• Collagenase, Cathepsin<br>• Defensin<br>• Elastase<br>(Mneumonic: ABCDE) |
| Secondary (Specific) | Collagenase IV, lactoferrin (Mneumonic: Specific-specific Lac2ferrin) |
| Tertiary (C-particle) | Gelatinase (Mneumonic: C → G) |

### Q6.4: What are newly synthesized mediators?

**Answer:**

- **NO:** Vasodilation, anti-platelet
- **PAF:** Platelet aggregation, vasoconstriction
- **Chemokines:** C = Cysteine ; X = Any amino acid

| | CX3C | CXC-α | CC-β |
|---|---|---|---|
| Examples | Fractalkine | Interleukin 8 (IL8) | Eotaxin<br>MCP<br>Rantes |
| Attracts | T-cells<br>Monocytes | Neutrophils | Eosinophil<br>Monocytes<br>T-cells |

### Q6.5: What are major cytokines and functions?

**Answer:**

- IL (Interleukins)
- TNF a
- Interferons

| Cytokine | Function |
|---|---|
| IL-1, IL-6, TNFα | Fever |
| TNFα | Appetite loss, septic shock |
| IL-4, IL-6 | Pro/anti-inflammatory |
| IL-10, TGFβ | Anti-inflammatory |
| IL-7 | T-cell maturation |
| IL-5 | Eosinophil activation |
| IL-8 | Neutrophil recruitment |
| IL-6 | Regulates APR (e.g. CRP ↑) |

### Q6.6: What are the types, sources, and functions of interferons?

**Answer:**

| | IFN-α | IFN β | IFN-γ |
|---|---|---|---|
| **Sources (Mnemonic: LFT)** | Leukocyte (Macrophages) | Fibroblast | TH 1 |
| **Function (Mnemonic: αβγ)** | Antiviral properties | Treatment of Brain disease<br>• Multiple sclerosis | • Granular formation<br>• Treatment of Chronic granular disease |

### Q6.7: What are acute phase reactants (APRs) and how are they regulated?

**Answer:**

- APRs are proteins whose plasma levels change significantly in response to inflammation.
- Regulated mainly by **IL-6.**
- **Functions:**
  - o Limit tissue damage.
  - o Assist in pathogen clearance.
  - o Modulate immune responses.

**Classification of APRs:**

| Positive APRs (Increase in blood) | Negative APRs (Decrease in blood) (TTTAAN) |
|---|---|
| • CRP<br>• Ferritin<br>• Hepcidin<br>• Haptoglobin<br>• Fibrinogen<br>• Procalcitonin (marker of sepsis)<br>• Serum Amyloid A (SAA) | • Albumin<br>• Transferrin<br>• Transthyretin<br>• Transcortin<br>• Antithrombin |



YOURWISH

- **IL-6** is also linked to **anemia of chronic disease** via its regulatory role on APRs.

## Q6.8: What are key AA metabolites in inflammation?

PYQ: NEET PG 2023

**Answer:**

- **COX pathway:**
  - COX-1 → gastroprotective
  - COX-2 → inflammation; inhibited by celecoxib
- **Prostaglandins:** $PGE_2$ causes pain
- **LOX pathway:**
  - Target for Zileuton (5-LOX inhibitor)
    → Used for asthma → But it also inhibits chemotaxis → Leukotriene receptor antagonists can be given
  - Montelukast → Leukotriene receptor antagonists (only inhibit LTC4, D4, E4).

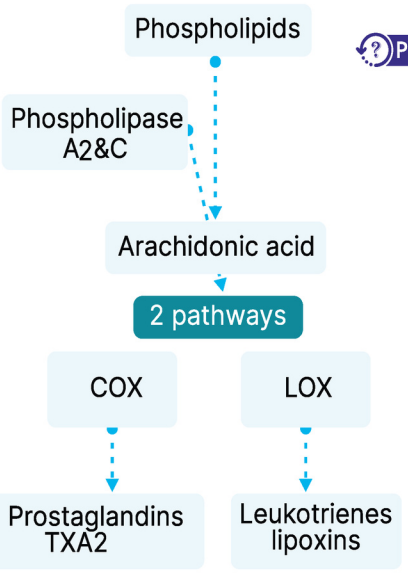


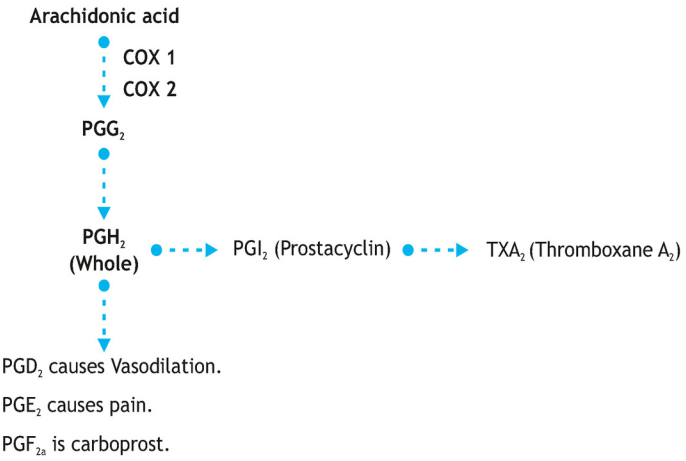


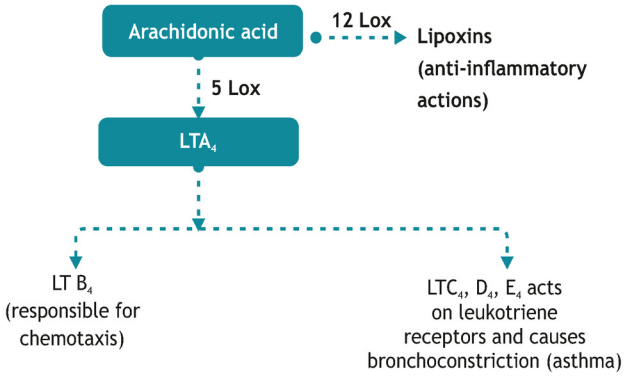


## Q6.9: How does the complement system work in inflammation?

**Answer:**

- 3 pathways:
  - Classical → immune complex (IgM, IgG)
  - Alternative → IgA
  - Mannose → microbial triggers
- Most critical step = C3
- Forms **MAC (C5b-9)** → bacterial lysis
- Deficiency:
  - C2 → most common
  - C1,2,4 → SLE
  - MAC (C5b-C9) → Capsulated organism → Eg: Meningococcus
  - C1 inhibitor → hereditary angioedema

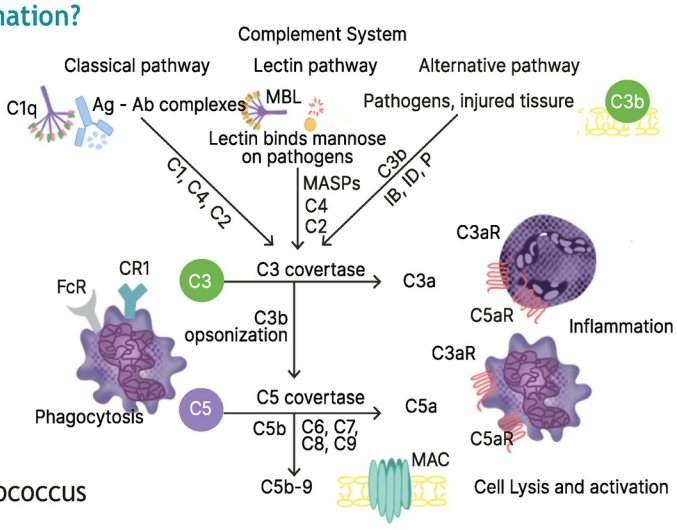


## Q6.10: Gelatinase is released from which granules?

A. Primary granules



YOURWISH

B. Specific granules
C. C particle
D. Azurophilic granules

Answer: **C. C particle**

### Q6.11: C-C chemokines include which of the following?

A. IL-8
B. Eotaxin
C. Fractalkine
D. Lymphotactin

Answer: **B. Eotaxin**

## BIG QUESTION 7: What are the features and mechanisms of chronic inflammation and granulomas?

### Broad Answer:

- Chronic inflammation involves macrophages, lymphocytes, and plasma cells, often forming granulomas with distinct cellular structures.
- Types of Cells:
  - Lymphocytes
  - Macrophages (most important)
  - Plasma cells

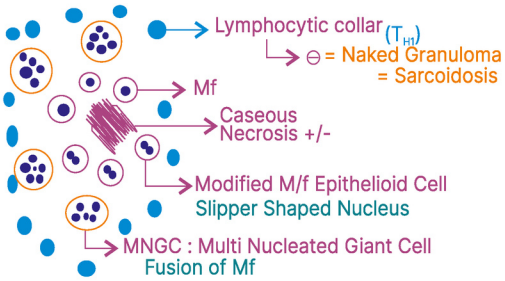


## DETAILED QUESTIONS

### Q7.1: What are macrophage names in various organs? (Size 10, Bold)

Answer:

| Organ | Organ |
|---|---|
| Brain | Microglia |
| Lung | Dust cells / Alveolar Macrophages |
| Liver | Kupffer cells |
| Kidney | Mesangial cells |
| Spleen | Littoral cells |
| Placenta | Hoffbauer cells (residence of Zika virus) |
| Bone | Osteoclasts |
| Synovium | Type A synoviocytes |

### Q7.2: What are the components of granuloma?

Answer:

- **Caseous necrosis (at centre)**
  - Present: Caseating granuloma
  - Absent: Non-caseating granuloma

- Both caseating and non-caseating granuloma: TB (caseating more common), sarcoidosis (non-caseating more common)

- **Lymphocytic collar (at periphery)**
  - TH1 lymphocyte: IFNγ
  - Absent: Naked granuloma (sarcoidosis).
- **Nuclei of cells surrounding caseous necrosis:**
  - Round nucleus - Macrophages
  - Slipper-shaped nucleus - Modified macrophages or Epithelioid cells (most important cells of granuloma)
- MNGC or multinucleated giant cells.
  - Fusion of macrophages.

### Q7.3: What are types of multinucleated giant cells?

PYQ: FMGE 2020,2022

**Answer:**

| Giant Cell Type | |
|---|---|
| Langhans 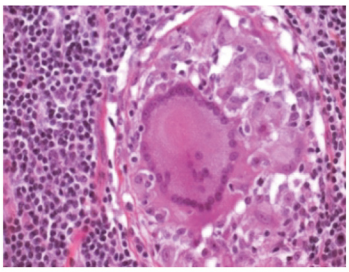 | • Nuclei arranged in the form of a horse shoe<br>• Seen in TB |
| Touton 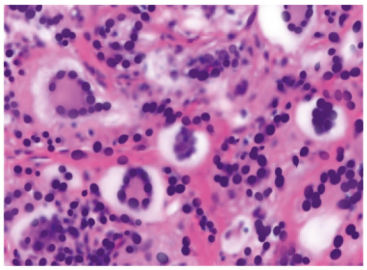 | • Nuclei arranged in a round fashion<br>• Wreath like nuclei<br>• Seen in Xanthoma (lipid disorder) |
| Foreign body 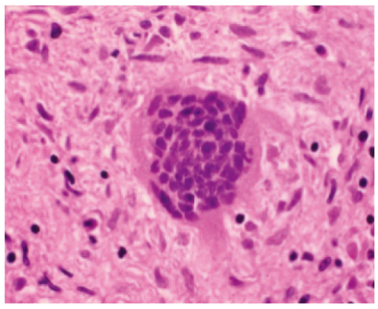 | • Haphazard nuclei<br>• Seen in foreign bodies like talcum powder, suture material |
| Warthin-Finkeldey 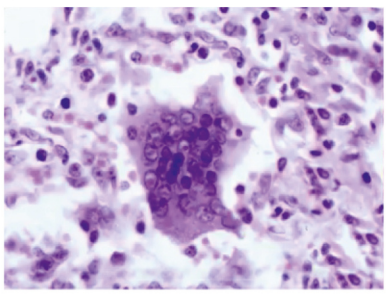 | • Intranuclear inclusions<br>• Intracytoplasmic inclusions<br>• Seen in measles |

| | |
|---|---|
| Reed-Sternberg<br>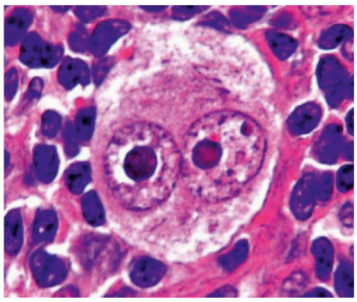 | • The owl eye appearance has eosinophilic inclusions<br>• Seen in hodgkin's lymphoma |
| Basophilic Owl eye<br>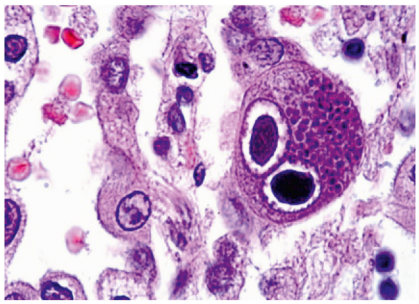 | • Seen in CMV |
| HSV giant cells<br>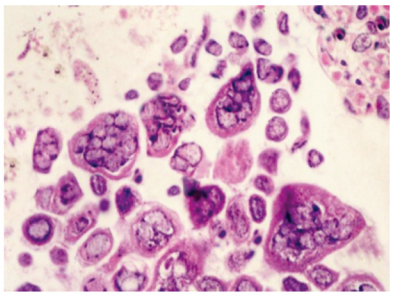 | • Multinucleated<br>• Moulding of nuclei<br>• Margination of the nucleus |

## Q7.4: What special types of granulomas exist?

PYQ: INICET 2023

**Answer:**

- Stellate → cat scratch, LGV (lymphogranuloma venereum)

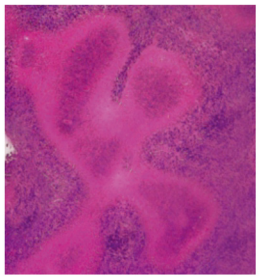

- Doughnut → Q fever, allopurinol

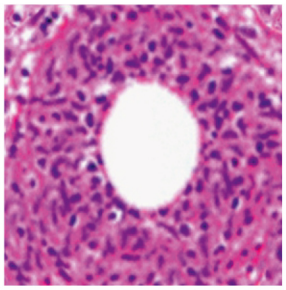

- Durck → Cerebral malaria (Plasmodium falciparum), Field stain (special stain)

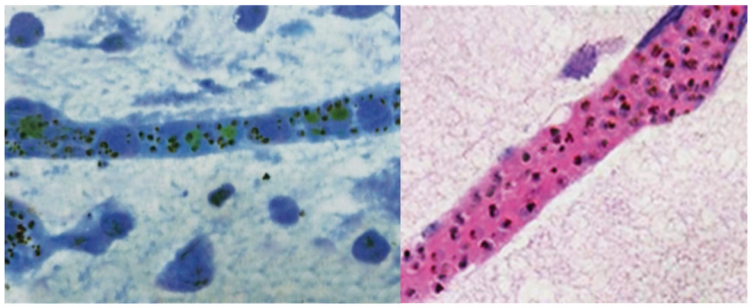

## BIG QUESTION 8: What are the mechanisms and stages of wound healing?

**Broad Answer:**

- Wound healing progresses through inflammation, granulation tissue formation, collagen deposition, and remodeling.
- It can also produce excessive scars like keloids.

## DETAILED QUESTIONS

### Q8.1: What are events in wound healing by days?

**Answer:**

| Day | Event |
|---|---|
| 0 | Platelets, fibrin clot |
| 1 | Blood clot remains, Neutrophils (acute inflammation) |
| 2 | Blood clot remains, Neutrophils (acute inflammation), Thin epithelium forms |
| 3 | • Chronic inflammation starts<br>• Macrophages<br>• Granulation tissue begins to form (blood vessel formation starts)- hallmark of repair<br>• Collagen formation starts (margins) |
| 5 | Maximum granulation tissue (neovascularization), Collagen bridging starts |
| 21 (Week 3) | Maximum collagen |

### Q8.2: What collagen types change during healing?

**Answer:**

- Start: Type III collagen
- End: Type I collagen (strongest)
- Ratio Type III: Type I = 1:4
- 100% wound strength: Never

### Q8.3: What factors affect wound healing?

**Answer:**

- Vitamin C, zinc essential



YOURWISH

- Infection → most common cause of delayed healing
- Other causes: DM, steroids

### Q8.4: What is wound contraction and what cell causes it?

**Answer:**

- Wound contraction by **myofibroblasts**

### Q8.5: What characterizes excessive wound healing?

PYQ: FMGE 2020,2021 PYQ: NEET PG 2021

**Answer:**

- **Proud Flesh:**
  - Red in color
  - Excessive granulation tissue
- **Excessive scar formation**
  - Either keloid or hypertrophic scar



| Feature | Keloid | Hypertrophic Scar |
|---|---|---|
| |  |  |
| Site | Sternum common | Variable |
| Collagen | Thick, haphazard | Thin, orderly |
| Treatment | Intralesional steroids | Often regresses |

### Q8.6: Describe Masson trichome stain

- **Masson trichrome stain:**

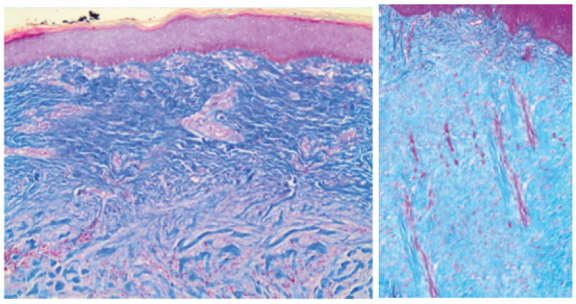

  - Used for microscopic visualization of keloid and hypertrophic scars
  - Differentiates tissue types:
    → Muscle → red
    → Collagen → blue

### Q8.7: What does the Masson-Fontana stain specifically highlight or identify in tissue samples?

**Answer:** Melanin

# 5. GENETICS PATHOLOGY

## BIG QUESTION 1: What are the classifications and types of genetic disorders?

**Broad Answer:**

- Genetic disorders are broadly classified based on inheritance patterns, chromosomal abnormalities, and complex multifactorial causes.
- These categories include
  - Mendelian disorders (single-gene defects with predictable inheritance),
  - Non-Mendelian disorders (not following classical Mendelian laws),
  - Chromosomal disorders (numerical or structural anomalies), and
  - Multifactorial disorders (resulting from genetic and environmental interactions).

## DETAILED QUESTIONS

### Q1.1: What are the main categories of genetic disorders?

**Answer:**

- Genetic disorders are categorized as:
  - **Mendelian Disorders**
    - → Caused by mutations in single genes
    - → Follow Mendelian inheritance patterns (AD, AR, XLR, XLD)
  - **Non-Mendelian Disorders**
    - → Do not follow classic Mendelian laws
    - → Examples:Mitochondrial inheritance, trinucleotide repeat disorders, genomic imprinting, gonadal mosaicism
  - **Chromosomal Disorders**
    - → Result from numerical or structural chromosomal abnormalities
    - → Examples: Trisomies, monosomies, structural deletions or duplications
  - **Multifactorial Disorders**
    - → Involve multiple genes and environmental factors
    - → Examples: Diabetes, hypertension

### Q1.2: What defines Mendelian disorders?

**Answer:**

- Involve single gene mutations
- Inheritance is predictable and follows Mendel's laws
- Can be Autosomal Dominant, Autosomal Recessive, X-Linked Recessive, or X-Linked Dominant
- Often affect structural proteins (AD) or enzymes (AR)

### Q1.3: What are Non-Mendelian disorders?

**Answer:**

- Genetic conditions that **do not strictly obey Mendelian inheritance**
- Include:
  - Mitochondrial inheritance (maternal only)
  - Trinucleotide repeat expansions
  - Genomic imprinting (gene silencing via methylation)
  - Gonadal mosaicism (post-zygotic mutations in germ cells)

### Q1.4: What characterizes chromosomal disorders?

**Answer:**

- Result from abnormal **number or structure of chromosomes**
- Types:
  - **Numerical disorders:** Trisomy (extra chromosome) or monosomy (missing chromosome)
  - **Structural disorders:** deletions, duplications, translocations
- Often cause syndromic features, congenital anomalies, or intellectual disability

### Q1.5: What defines multifactorial disorders?

**Answer:**

- Caused by **interaction of multiple genes and environmental factors**
- Do **not follow simple Mendelian inheritance**
- Examples:
  - Hypertension
  - Diabetes mellitus
  - Schizophrenia
  - Cleft lip and palate

## BIG QUESTION 2: How do Mendelian disorders manifest and what are their examples?

**Broad Answer:**

- Mendelian disorders arise from mutations in single genes and are inherited in predictable patterns:
  - Autosomal dominant (AD),
  - Autosomal recessive (AR),
  - X-linked recessive (XLR), or
  - X-linked dominant (XLD).
- Each pattern has characteristic inheritance features and disease examples.

## DETAILED QUESTIONS

PYQ: NEET PG 2020
PYQ: AIIMS 2020
PYQ: FMGE 2023

### Q2.1: What defines autosomal dominant (AD) disorders?

**Answer:**

- Most common Mendelian inheritance pattern for **structural protein defects**
- Only one mutated allele is needed for disease expression
- Features:
  - Vertical transmission (seen in multiple generations)
  - Often affects structural proteins or receptors
  - Variable expressivity and reduced penetrance possible

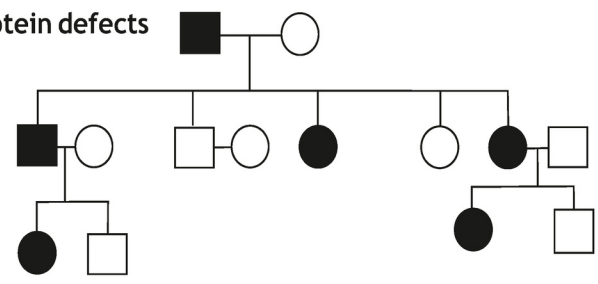

**Examples:**

- He- Hereditary Spherocytosis, Hereditary Telangiectasia, Hereditary Non-Polyposis Colon Cancer (HNPCC / Lynch Syndrome- Colon, endometrial and ovarian cancers)
- Has - Huntington's Disease, Hypertrophic Cardiomyopathy
- A - Autosomal Dominant Polycystic Kidney Disease (AD PKD)
- Very-Von Willebrand Disease (VWD), Von Hippel Lindau Syndrome (VHL Syndrome- chromosome 3p deleted)
- Dominant- Muscle Dystonia, Osteogenesis Imperfecta, Marfan's Syndrome, Intermittent Porphyria, NF 1 & NF 2, Achondroplasia, Noonan Syndrome, Tuberous Sclerosis.
- Powerful - Pseudohypoparathyroidism
- Father- Familial Adenomatous Polyposis (FAP), Li Fraumeni Syndrome (mutation in p53), Familial hypercholesterolemia.

### Q2.2: What are key features of Marfan's syndrome?

**Answer:**

- Defect: Chromosome 15, Fibrillin-1 gene (FBN1)
- Affected protein: Fibrillin-1
- Clinical features:
  - **Mitral Valve Prolapse (most common cardiac abnormality)**
  - Aortic dissection (common cause of death)
  - Retinal detachment
  - Freely moveable joints (esp. thumb)
  - Arachnodactyly (spider fingers)
  - High-arched palate
  - Tall stature, long limbs
  - Pigeon chest deformity
  - Ectopia Lentis (lens dislocation superotemporal)
    → Opposite: inferior nasal in homocystinuria
  - Skeletal abnormalities (most common manifestation overall)



- **Diagnostic tests:**
  - Steinberg Sign: thumb tip extends from palm when fist is closed





YOURWISH

- Walker Sign: thumb and little finger overlap when encircling wrist
- Revised Ghent's criteria:
  - → Family history
  - → Clinical features
  - → Fibrillin-1 gene analysis



### Q2.3: What defines autosomal recessive (AR) disorders?

PYQ: FMGE 2018

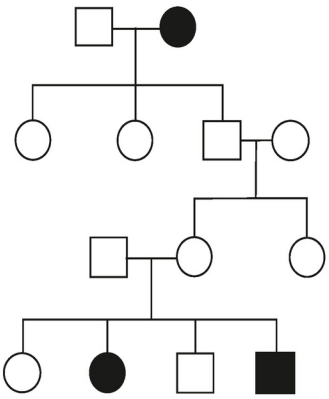

**Answer:**

- Most common mode of inheritance in **inborn errors of metabolism**
- Requires mutations in both alleles
- Skips generations
- Mostly enzyme defects
- **Examples (Mnemonic: Pasta Fried Chawal / Big Fax):**
  - P - Phenylketonuria (Phenylalanine Hydroxylase deficiency, mousy urine odor)
  - A - Alkaptonuria (black urine due to homogentisic acid oxidase deficiency)



Black urine on standing



Cartilage



Nails

  - S - Sickle Cell Anemia
  - Ta - Thalassemia
  - Fried - Friedreich's Ataxia
  - C - Cystic Fibrosis
  - H - Hemophilia C, Homocystinuria, Hemochromatosis
  - A - Alpha 1 Antitrypsin Deficiency
  - W - Wilson Disease
  - A - Albinism, Congenital Adrenal Hyperplasia
  - L - Lysosomal Storage Disease, Glycogen Storage Disease
  - Big - Bloom Syndrome
  - Fa - Fanconi Anemia
  - Ataxia Telangiectasia
  - X - Xeroderma Pigmentosum
- *Note*: All the Lysosomal storage disorders are AR except Fabry's and Hunter's disease which is XLR
- This (Big FAX) is also known as set DNA repair defects.

## Q2.4: What are examples of lysosomal storage disorders?

**Answer:**

| Disorder | Deficiency | Key Features |
|---|---|---|
| Tay Sachs Disease | Hexosaminidase A deficiency | Onset: Childhood<br>Cherry red spot in the Macula of the eye.<br>Spleen not palpable.<br>Balloon neurons (contain fat).<br>Electron microscopy: Onion skinning in the Lysosome. |
| 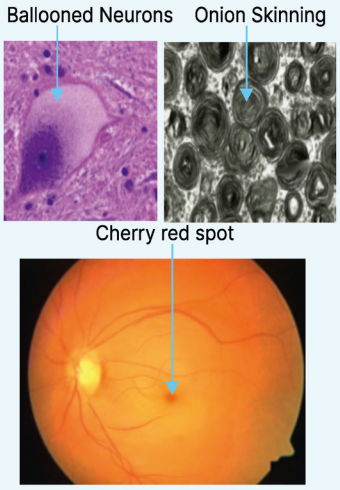 | | |
| Gaucher's Disease<br>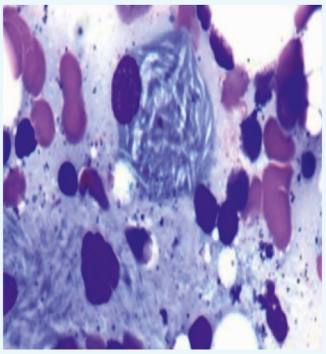 | Beta-glucocerebrosidase deficiency | Crumpled tissue paper appearance in Gaucher's cells, bone pain |
| Niemann-Pick Disease<br>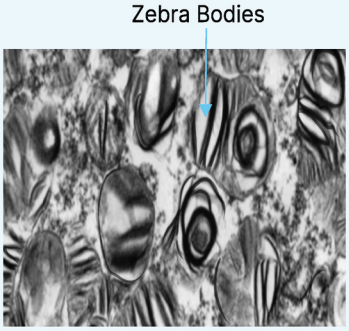 | Sphingomyelinase deficiency | Palpable spleen<br>Light Microscopy: Foamy cells<br>E/M: Zebra bodies<br>Rest same as Tay Sach's Disease |

## Q2.5: What defines X-linked recessive (XLR) and X-linked dominant (XLD) disorders?

PYQ: FMGE 2018

**Answer:**

- **XLR Disorders:**
  - Males affected, females are carriers

- Examples (Mnemonic: Wise ABCDEFGH)
  - → Wise- Wiskott Aldrich Syndrome.
  - → AB- Haemophilia A, B
  - → B- Bruton's Hypogammaglobulinemia.
  - → C- Chronic Granulomatous Disease Oxidase deficiency), Red Green Color Blindness, Ocular albinism is X-Linked recessive , whereas Albinism is Autosomal recessive.
  - → D- DMD (Duchenne muscle dystrophy), BMD (Becker's Muscular Dystrophy): Dystrophy Gene is on the X chromosome.
  - → E- Lesch Nyhan Syndrome (HGPRT deficiency).
  - → F- Fabry Disease, Fragile X Syndrome (XLR >> XLD).
  - → G- G6PD Deficiency Anemia
  - → H- Hunter Disease

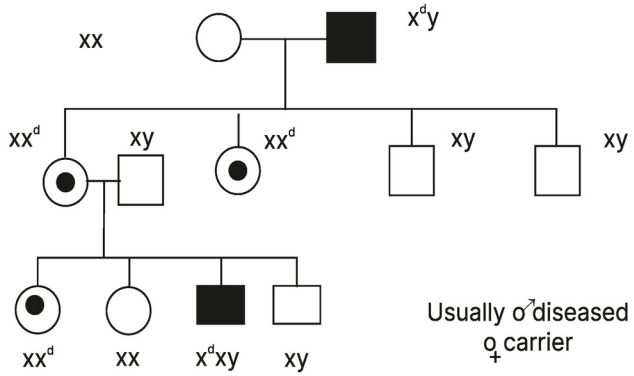




- **XLD Disorders:**
  - Females and males affected, but often milder in females
  - Dad transmits XLD disorders to **all daughters** but no sons
  - From the Daughter (mother) to 50% of their offspring.

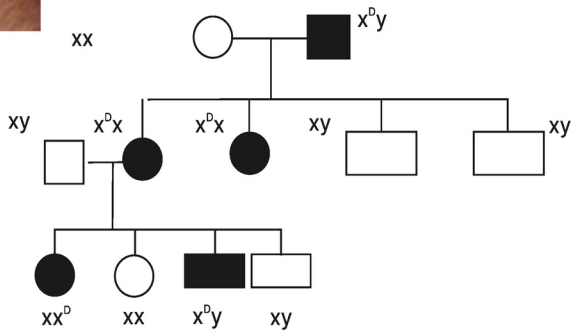


  - Examples (Mnemonic: RAVI):
    - → Rett's Syndrome
    - → Alport Syndrome (AD, AR, XLR, XLD—all forms exist; XLD most common)
    - → Vitamin D-resistant Rickets (X linked Hypophosphatemia)
    - → Incontinentia Pigmenti

### Q2.6:What is Y-linked (Holandric) inheritance?

**Answer:**

- Only affects males
- Passed strictly from father → son
- Example: Hypertrichosis (hairy ears)

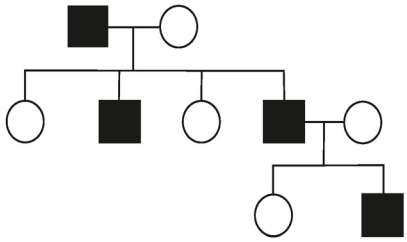

### Q2.7: Sickle Cell Anemia is:

A. AD
B. AR
C. XLR
D. XLD

**Answer: B. AR**

- Sickle Cell Anemia is autosomal recessive.



YOURWISH

**Q2.8: Haemophilia C is:**

A. AD
B. AR
C. XLR
D. XLD

**Answer: B. AR**

- Hemophilia A, B = XLR
- Hemophilia A, C = AR
- Ocular Albinism = XLR
- Albinism = AR

**Q2.9: A 22-year-old man features an arm span greater than height, subluxated lenses, and a flattened and dilated aortic bulb. Which gene is likely mutated?**

A. FBN 1
B. FBN 2
C. FBN 3
D. FBN R

**Answer: A. FBN 1**

- Seen in Marfan's syndrome.

**Q2.10: Crumpled tissue paper appearance is seen in:**

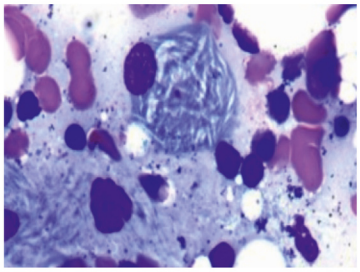

A. Tay Sachs Disease
B. Gaucher's Disease
C. Niemann Pick disease
D. Fabry Disease

**Answer: B. Gaucher's Disease**

- Due to accumulation of lipid in macrophages.

**Q2.11: Father has an XLD disorder. How many percent of daughters will be affected?**

A. 0%
B. 50%
C. 75%
D. 100%

**Answer: D. 100%**

- All daughters inherit the affected X from the father.

## BIG QUESTION 3: What are the types and features of Non-Mendelian genetic disorders?

**Broad Answer:**

- Non-Mendelian genetic disorders do not follow classical Mendelian inheritance.
- They include mitochondrial inheritance, trinucleotide repeat disorders, genomic imprinting, and gonadal mosaicism.
- These disorders involve unique inheritance patterns, variable expression, and specific clinical manifestations.



YOURWISH

YOURWISH

## DETAILED QUESTIONS

PYQ: AIIMS 2019

### Q3.1: What is mitochondrial inheritance and its clinical implications?

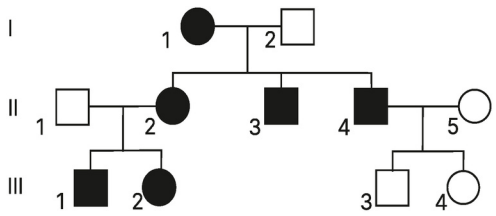


**Answer:**

- Mitochondrial DNA (mtDNA) is inherited exclusively from the mother.
- Maternal mtDNA defects → transmitted to all offspring.
- Paternal mtDNA defects → transmitted to none.

- **Common Mitochondrial Disorders:**
  - **MELAS (Mitochondrial Encephalopathy, Lactic Acidosis, Stroke-like episodes)**
    → Most common mitochondrial disorder overall.
  - **CPEO (Chronic Progressive External Ophthalmoplegia)**
    → Most common mitochondrial muscle-related disease.
  - **LHON (Leber's Hereditary Optic Neuropathy)**
  - **NARP (Neurogenic Ataxia, Retinitis Pigmentosa)**
- **Rare Mitochondrial Disorders:**
  - Leigh's syndrome
  - Pearson syndrome
  - Kearns-Sayre syndrome
  - MERRF (Myoclonus Epilepsy with Ragged Red Fibers)
    → Red ragged fibers: Abnormal mitochondria accumulated in muscle.
    → Stain: Gomori trichrome stain.
    → Appear as phonographic record or parking lot under microscopy.

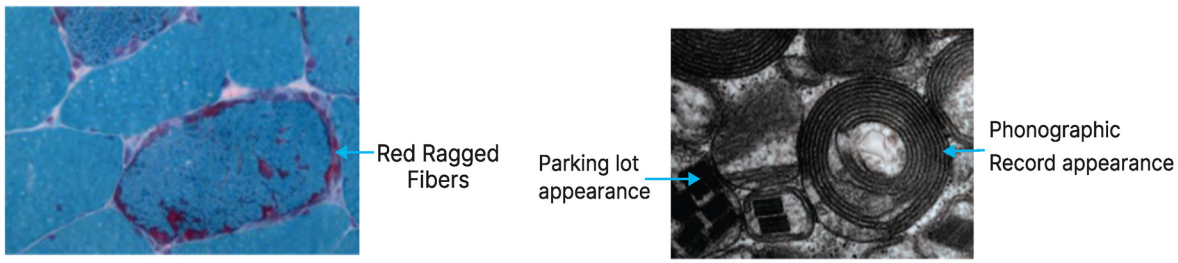


Muscle biopsy

### Q3.2: What are trinucleotide repeat disorders, and how are they classified?

**Answer:**

- Trinucleotide repeat disorders result from expansions of specific 3-nucleotide sequences.

| Region | Disorders | Repeat Type |
|---|---|---|
| Intron (Non-coding) | Fragile X syndrome | CGG |
| | Myotonic dystrophy | CTG |
| | Friedreich's Ataxia | GAA |
| Exon (Coding)<br>Mnemonic: **Kennedy is hunting in a CAGe** | Huntington's disease | CAG (Chromosome 4 is affected) |
| | Kennedy disease | CAG |

### Q3.3: What are the clinical features of Fragile X syndrome?

PYQ: NEET PG 2019

**Answer:**

- Involves Xq chromosome.
- Gene: FMR1 (Familial Mental Retardation Gene).
- CGG repeat expansion:

| Repeats | Description |
|---|---|
| <55 | Normal |
| 55-200 | Premutation → Fragile X tremors, ataxia |
| 200-4000 | Full mutation → Fragile X Syndrome |

- Sherman's Paradox/Anticipation: disease severity and repeat number increase across generations.
- Occurs primarily in males; females are carriers.
- **Clinical Features:**
  - Macro-orchidism (large testes) → most characteristic feature.
  - Large jaw/mandible.
  - Large ears.
  - Long face.
  - Mental retardation (IQ 20-60).
  - Female carriers: Premature ovarian failure (<40 yrs).



- **Diagnosis:**
  - Test of choice → PCR.
  - If PCR fails → Southern blot.
  - **Molecular Techniques:**
    - → Eastern → post-translational modifications.
    - → Northern (Roti) → RNA detection.
    - → Southern (Dosa) → DNA detection.
    - → Western (Pizza) → protein detection.

PYQ: NEET PG 2018

### Q3.4: What are the features of Myotonic Dystrophy?

**Answer:**

- CTG trinucleotide repeat disorder.
- Clinical features:
  - Inability to relax grip (myotonia).
  - "Hatchet facies."

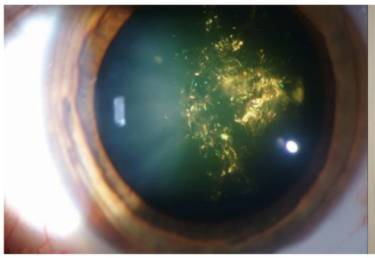

Christmas tree Cataract

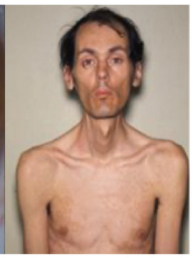

Hatchet Facies

### Q3.5: Find the incorrect match about disease and trinucleotide repeat:

A. Fragile X Syndrome - CGG
B. Myotonic Dystrophy - CTG
C. Huntington disease - CAA
D. Friedreich's Ataxia - GAA

**Answer:** C. Huntington disease - CAA

### Q3.6: What is genomic imprinting, and what syndromes are associated?

**Answer:**

- Gene silencing via DNA methylation (silences genes).

- DNA acetylation → activates genes.
- **Associated Syndromes:**
  - Prader-Willi syndrome
  - Angelman syndrome ("Happy puppets")

PYQ: AIIMS 2021

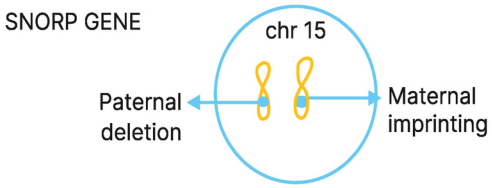


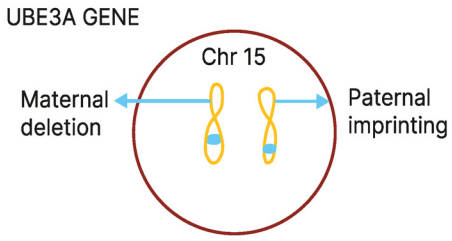


PRADER WILLI SYNDROME
- Maternal imprinting
- Paternal deletion
- Maternal disomy of chromosome 15

ANGELMANN SYNDROME
- Maternal deletion
- Paternal imprinting
- Paternal disomy of chromosome 15

| Prader-Willi syndrome | Angelman syndrome |
|---|---|
| • MR (Maternal Retardation)<br>• Short Stature<br>• Obesity/hyperphagia (because of an increase in the hormone called Ghrelin) | • Seizures<br>• Ataxia<br>• Mental Retardation (MR)<br>• Inappropriate laughter (Mnemonic: SARI) |

### Q3.7: What is gonadal mosaicism?

**Answer:**

- Post-zygotic mutation in germ cells.
- Parents appear normal.
- Can result in only one child being affected in a family.
- Examples:
  - Osteogenesis imperfecta
  - Tuberous sclerosis

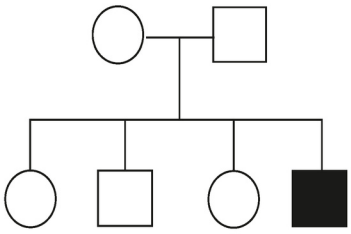

## BIG QUESTION 4: What are chromosomal numerical disorders and their clinical manifestations?

**Broad Answer:**

- Chromosomal numerical disorders involve an abnormal number of chromosomes, resulting in trisomies or monosomies.
- Common examples include **Down's syndrome (Trisomy 21)**, **Edward's syndrome (Trisomy 18)**, **Patau syndrome (Trisomy 13)**, **Klinefelter syndrome (47,XXY)**, and **Turner's syndrome (45,X0)**.
- These syndromes manifest with characteristic physical, developmental, and systemic abnormalities.

## DETAILED QUESTIONS

### Q4.1: What is the most common monosomy and trisomy compatible with life?

**Answer:**

- **Monosomy: Turner's Syndrome = 45 X0**
- Trisomy: Down's syndrome (Trisomy 21)



YOURWISH

- Most cases due to meiotic non-disjunction in the ovum
- Strong association with advanced maternal age.

### Q4.2: What are the clinical features and complications of Down's syndrome?

**Answer:**

- **Clinical Features:**
  - Mental retardation (most common cause)
  - **Facial features:**
    - → Mongoloid facies
    - → Oblique palpebral fissures
    - → Flat nasal bridge (nasal bone hypoplasia)
    - → Open mouth
    - → Micrognathia (small chin)
    - → Macroglossia
    - → Brushfield spots (iris)



Mongoloid Facies

  - **Limb features:**
    - → Single palmar crease (Simian crease)
    - → Sandal toe gap
    - → Short little finger with single crease

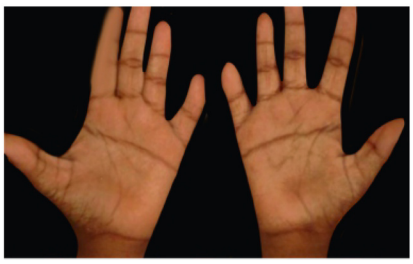



Sandal toe

- **Complications:**
  - **Hematology:**
    - → ALL (most common leukemia)
    - → AML-M7 (most common <3 yrs)
    - → Transient abnormal myelopoiesis (TAM) → Most common hematological abnormality
  - **CNS:**
    - → Presenile Alzheimer's disease (in 30s)
  - **Cardiac:**
    - → Endocardial cushion defects > VSD
  - **GI:**
    - → Duodenal atresia, annular pancreas, Hirschsprung disease

### Q4.3: What are the screening and confirmatory tests for Down's syndrome?

PYQ: NEET PG 2019

**Answer:**

- **Screening:**
  - **Ultrasound (USG):**
    - → Increased nuchal translucency
    - → Nasal bone hypoplasia
  - **Triple Marker (2nd trimester):**
    - → ↑ β-hCG
    - → ↓ AFP
    - → ↓ Estriol
  - **Quadruple Marker (3rd trimester):**
    - → ↑ β-hCG, ↑ Inhibin A
    - → ↓ AFP, ↓ Estriol



YOURWISH

YOURWISH

- **Confirmatory:**
  - **Karyotyping**

### Q4.4: What are Edward's and Patau syndromes?

**Answer:**

| Syndrome | Trisomy | Clinical Features |
|---|---|---|
| **Edward's**<br>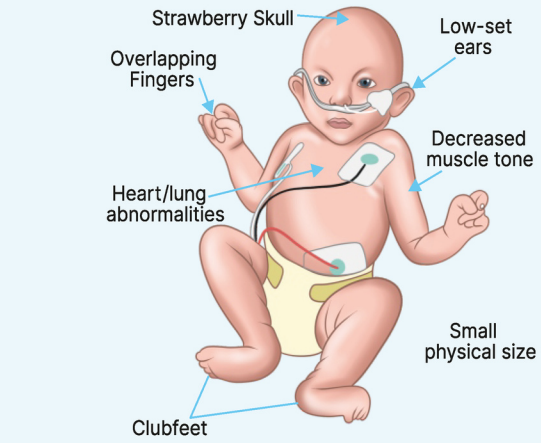<br> | 18 | • Maternal origin<br>• Mental retardation<br>• PDA<br>• VSD<br>• Rocker bottom feet<br>• Horse-shoe kidney<br>• Overlapping fingers<br>• Strawberry skull Skull (means small chin & Prominent Occiput back side of the head) |
| **Patau**<br>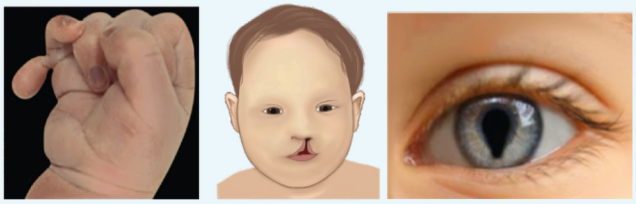 | 13 | • Maternal origin<br>• Mental retardation<br>• PDA<br>• VSD<br>• Rocker bottom feet<br>• Polydactyly<br>• Cleft lip/palate<br>• Coloboma (keyhole iris) |

### Q4.5: What are the clinical features and complications of Klinefelter syndrome?

**Answer:**

- **Genotype:** 47,XXY (can be more, e.g., 48,XXXY)
- **Origin:** Most commonly maternal
- **Features:**
  - Mental retardation (↑ with more X chromosomes)
  - Hypogonadism
  - Decreased secondary sexual characteristics
  - Tall stature
- **Complications:**
  - Male breast cancer
  - Extragonadal germ cell tumors (teratoma, seminoma)
  - Mitral valve prolapse
  - Associated with **SLE**
  - **Hormonal profile:** ↓ Testosterone, ↑ LH, ↑ FSH

### Q4.6: What is Turner's syndrome and how is it diagnosed? PYQ: FMGE 2019 PYQ: AIIMS 2018 PYQ: NEET PG 2021

**Answer:**

- **Genotype:** 45,X0 (monosomy) or 46,X,r(X) (ring chromosome)
- **IQ:** Normal
- **Cardiac risk:** Higher in patients with webbed neck
- **Clinical Features:**
  - Short stature
  - Low posterior hairline
  - Webbed neck (due to cystic hygroma)
  - Bicuspid aortic valve > Coarctation of aorta
  - Widely spaced nipples
  - Rudimentary/streak ovaries → no menstruation
  - Most common cause of **primary amenorrhea**

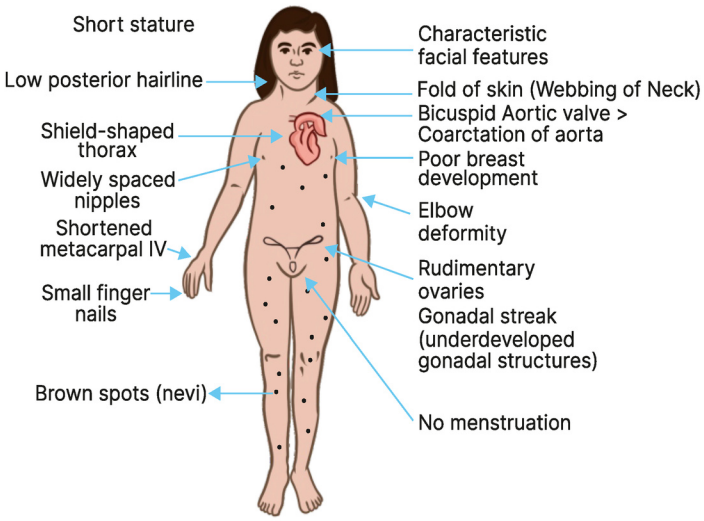


## BIG QUESTION 5: What are the molecular diagnostic techniques used in genetic pathology?

**Broad Answer:**

- Molecular diagnostic techniques analyze genetic material to detect mutations, chromosomal abnormalities, or gene expression patterns.
- Methods like **karyotyping, FISH, PCR, CGH**, and advanced sequencing technologies help diagnose genetic disorders, cancers, and infectious diseases.

## DETAILED QUESTIONS

### Q5.1: What is karyotyping, and how is it performed?

**Answer:**

- **Study of chromosomes**
- Steps involved:

| Step | Details |
|---|---|
| Sample collection | Pregnant women: Amniocentesis (14-16 weeks), Chorionic villus sampling (10 weeks)<br>Others: Blood lymphocytes (preferred), skin fibroblasts (painful). |
| Arrest | Metaphase arrest using colchicine |
| Fixative | Carnoy fixative (Methanol : Glacial acetic acid = 3:1) |
| Staining/banding | • Q-banding (quinacrine fluorescence)<br>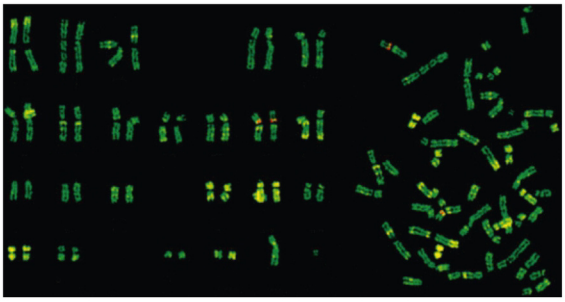 |

| | |
|---|---|
| | • G-banding (Giemsa, most common)<br>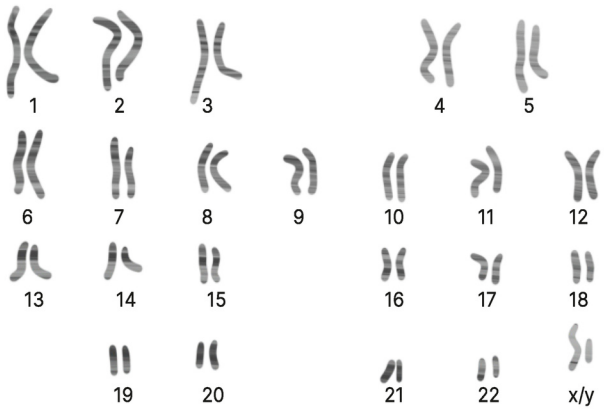<br><br>Normal Karyotype |
| Arrangement | Chromosomes ordered by length; chromosome 21 is shortest |

- **Findings examples:**
  - Trisomy 21 → Down's syndrome

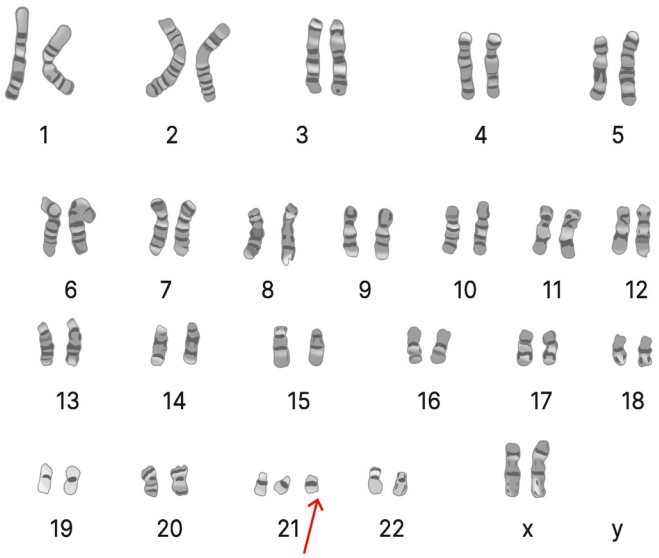


  - Trisomy 18 → Edward's syndrome

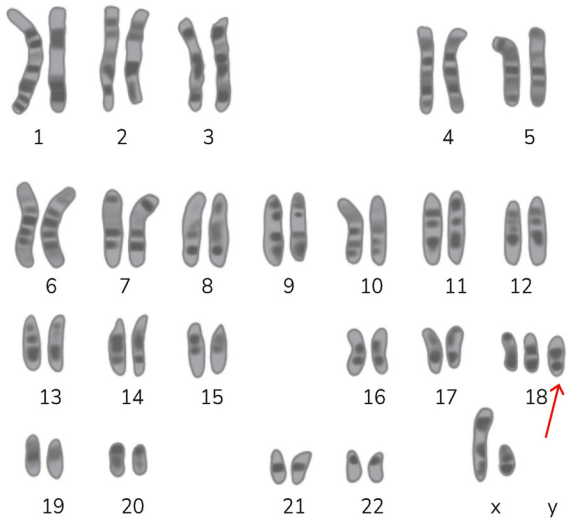




YOURWISH

### Q5.2: What is FISH, and what abnormalities does it detect?

PYQ: AIIMS 2018

**Answer:**

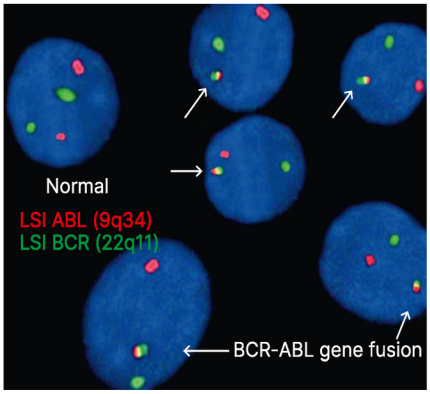


- **Full name:** Fluorescent in situ hybridization
- **Cells are arrested at:** Interphase (not metaphase)
- Detects:
  - Amplifications
  - Deletions
  - Translocations
- **Principle:**
  - Probes labeled with fluorescent dyes bind specific DNA sequences.
  - Fusion signals reveal translocations.
  - Absence of signals suggests deletions.
  - For a 2-color FISH, the chromosome that doesn't have a pair is identified as abnormal.

### Q5.3: FISH technique is used in the diagnosis of all of the following except?

A. Amplification
B. Deletion
C. Translocation
D. Point mutation

**Answer:** D. Point mutation

- FISH cannot detect single-base changes.

### Q5.4: What are the steps and types of PCR?

**Answer:**

- **Steps in PCR:**
  - Denaturation: DNA strands separate at ~94°C
  - Annealing: Primers bind at ~54°C
  - Extension: DNA synthesis at ~72°C
  - Stop cycle: Dideoxy nucleotides terminate elongation
- **Types of PCR:**

| Type | Use |
|---|---|
| Sanger sequencing | Gold standard for mutation detection |
| SBPE (Single Base Primer Extension) | For known locus mutations, e.g. BRAF V600 in hairy cell leukemia |
| RFLP (Restriction Fragment Length Polymorphism) | For unknown loci, inheritance studies |
| Amplicon Length Analysis | For repeat expansions like Fragile X |
| RT-PCR (Reverse Transcription PCR) | For RNA viruses |
| qPCR (Quantitative/Real-time PCR) | Viral load in COVID, CML |
| GWAS (Genome-Wide Association Study) | Research for complex diseases like diabetes, hypertension |
| Pyrosequencing | Detects mutations in low tumor yield samples; alternative: NGS |

| | |
|---|---|
| Nested PCR | Higher specificity using two primers |
| Droplet PCR | High sensitivity; splits sample into multiple droplets for absolute quantification |
| Multiplex PCR | Simultaneous amplification of multiple targets |

**Q5.5: A 54-year-old female has presented with a breast lump measuring 9×7 cm in the upper outer quadrant. The lump is firm to hard in consistency and seems to be fixed to the underlying muscle. A trucut biopsy is done, revealing infiltrating ductal carcinoma. Further tumor cells are sent for genetic testing. However, the number of tumor cells constitutes only 8% of biopsies. The rest is stromal fat and ducts. Which of the following techniques is best suited?**

A. Sanger sequencing
B. SBPE
C. Pyrosequencing
D. Amplicon Length Analysis

**Answer: C. Pyrosequencing**

- Pyrosequencing (or NGS) works well when tumor content is low.

**Q5.6: What is Comparative Genomic Hybridization (CGH)?**

**Answer:**

- Compares patient DNA to normal DNA to detect gains/losses in genome.
- Technique:
  - Label patient DNA (red), normal DNA (green)
  - Hybridize both onto a microarray
  - Interpretation:
    - → Red signal → gain of genetic material
    - → Green signal → loss
    - → Yellow signal → normal
- Used for:
  - Tumor analysis
  - Detecting chromosomal imbalances



**Q5.7: What stains or fixatives are important in genetic techniques?**

**Answer:**

- **Carnoy fixative:** Used in karyotyping
- **Special stains:**
  - Quinacrine → Q-banding
  - Giemsa → G-banding

**Q5.8 Which of the following is associated with karyotyping?**

A. Carnay fixative
B. Carnoy fixative
C. Sacchomano fixative
D. Formalin

**Answer:** B. Carnoy fixative

**Q5.9: What method is commonly used for detecting COVID-19 that combines qPCR and reverse transcriptase techniques?**

**Answer:** The method is real-time reverse transcriptase PCR (rRT-PCR), which combines reverse transcription of viral RNA into DNA followed by quantitative PCR to detect the presence of SARS-CoV-2.

## BIG QUESTION 6: What are key cytogenetic and inheritance principles relevant to genetic pathology?

**Broad Answer:**

- Cytogenetic principles and inheritance patterns such as Barr bodies, co-dominance, the Davidson body, and analysis rules like the 2G rule help clinicians diagnose genetic diseases, interpret pedigrees, and understand chromosomal abnormalities.

## DETAILED QUESTIONS

**Q6.1: What is a Barr body, and how is it calculated?**

**Answer:**

- The inactive X chromosome in females is called the **Barr body**, also known as the Davidson body in certain contexts.

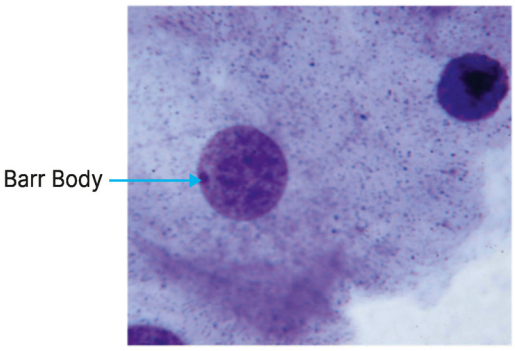


- **Locations:**
  - Buccal smear → dot-like structure at nuclear periphery
  - Peripheral smear → drumstick-like projection from neutrophil nucleus (Davidson body)
- **Formula:** No. of Barr bodies = No. of X chromosomes – 1

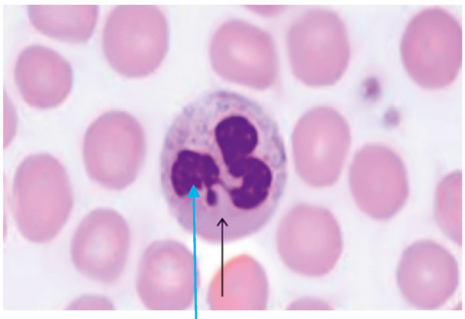


| Condition | Barr Body Count |
|---|---|
| Normal female (46XX) | 1 |
| Normal male (46XY) | 0 |
| Klinefelter male (47XXY) | 1 |
| Klinefelter male (48XXXY) | 2 |
| Turner's syndrome (45XO) | 0 |

**Q6.2: What is co-dominance, and give examples?**

**Answer:**

- Co-dominance refers to simultaneous expression of both alleles in a heterozygous state.
- **Examples:**
  - ABO blood group → Both A and B antigens expressed on red cells
  - HLA gene expression

**Q6.3: What are the core rules for analyzing pedigrees in genetic inheritance?**

**Answer:**

- **Autosomal dominant:** No gender bias; multiple generations affected.

- **Autosomal recessive:** No gender bias; can skip generations.
- **X-linked recessive:** Males affected, females carriers.
- **X-linked dominant:** Affected fathers → all daughters affected.
- **Y-linked (Holandric):** Only males affected, transmitted father to son.
- **Mitochondrial inheritance:** Mother to all offspring.
- **Gonadal mosaicism:** Single child affected, normal parents.

### Q6.4: What is the 2G rule for determining inheritance patterns?

**Answer:**

- **G1:** Check for gender discrimination
  - o X-linked recessive → males affected; females carriers.
- **G2:** Check for generation discrimination
  - o Autosomal disorders (AD, AR) → assess presence across generations.

### Q6.5: What symbols are used in pedigree charts, and what do they represent?

**Answer:**

| Symbol | Meaning |
|---|---|
|  | Male |
|  | Female |
|  | Unknown gender |
|  | Diseased |
| 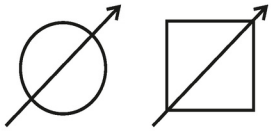 | Death due to disease |
|  | X-linked carrier |
|  | Carrier |
| 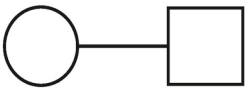 | Marriage |
| 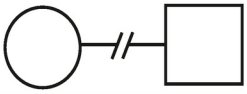 | Divorced |

| | |
|---|---|
| 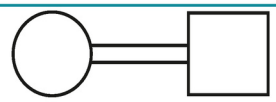 | Consanguineous marriage |
| 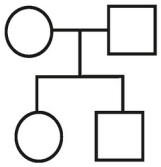 | Offspring |
| 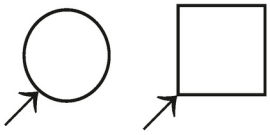 | Proband (index case) |
| 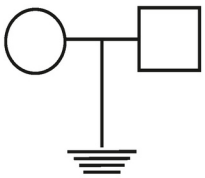 | Infertility |
| 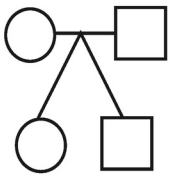 | Dizygotic Twins |
| 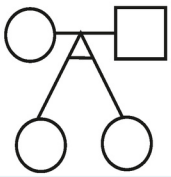 | Monozygotic Twins |



YOURWISH

# 6. NEOPLASIA

## BIG QUESTION 1: How are neoplasms classified and what are their histological variants?

**Broad Answer:** Neoplasms are classified into benign or malignant tumors, with specific nomenclature patterns and structural features. Some tumors defy naming conventions, while others originate from multiple germ layers or show mixed components.

## DETAILED QUESTIONS

### Q1.1: How are benign tumors named and what are exceptions to the naming rule?

**Answer:**

- Benign tumors usually end with the suffix **"-oma"**
- **Exceptions** (though malignant):
  - **Lymphoma**
  - **Melanoma**
  - **Seminoma**
  - **Chloroma** (AML in soft tissue like orbit)

### Q1.2: What distinguishes carcinomas from sarcomas?

**Answer:**

- Both are **malignant tumors**
- **Carcinomas**: arise from **epithelial** tissue
- **Sarcomas**: arise from **mesenchymal** tissue

### Q1.3: What is a teratoma and its types?

PYQ: FMGE 2021

**Answer:**

- Tumor derived from **2 or more germ layers**
- Types:
  - **Mature teratoma**: Benign
  - **Immature teratoma**: May be **malignant**
- Example: **Dermoid cyst** = Mature cystic teratoma



Dermoid cyst: Mature cystic teratoma.

### Q1.4: What is a mixed tumor and give an example?

**Answer:**

- Tumor with **epithelial and mesenchymal components**
- Example: **Pleomorphic adenoma** (benign mixed tumor)

### Q1.5: What is a hamartoma?

**Answer:**

- **Haphazard proliferation** of **native tissue**
- Example: **Pulmonary hamartoma**






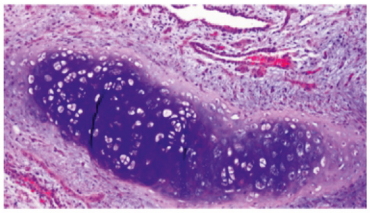

- Pathology: Presence of **cartilage**
- Radiology signs:
  - **Coin lesions**
  - **Popcorn calcification**

### Q1.6: What is a choristoma?

**Answer:**

- **Ectopic** tissue in an abnormal location
- Example: **Pancreatic tissue in the stomach**

### Q1.7: What is anaplasia and what does it indicate?

PYQ: NEET PG 2018
PYQ: FMGE 2018

**Answer:**

- Hallmark of **malignancy**
- **Anaplasia** = **Loss of differentiation** in cells

## BIG QUESTION 2: What are the key features distinguishing benign from malignant tumors?

**Broad Answer:** Malignant tumors differ from benign ones in growth rate, invasion, and ability to metastasize. Invasion through the basement membrane and distant spread are hallmarks of malignancy.

## DETAILED QUESTIONS

### Q2.1: What is the difference between dysplasia and anaplasia regarding basement membrane involvement?

**Answer:**

| Feature | Basement Membrane Status |
|---|---|
| **Dysplasia** | Intact |
| **Anaplasia** | **Breached** |

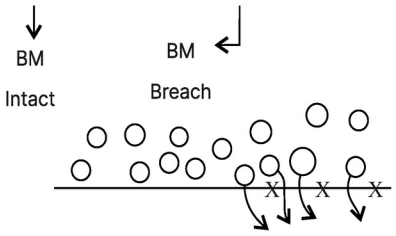


### Q2.2: How does the rate of growth compare between benign and malignant tumors?

**Answer:**

- **Malignant tumors** grow **faster** than benign tumors

### Q2.3: What is the second most reliable sign of malignancy?

**Answer:**

- **Local invasion**

### Q2.4: What is the most reliable sign of malignancy?

**Answer:**

- **Metastasis** (spread to distant sites)
- **Exceptions** (malignant but **do not metastasize**):
  - **Basal cell carcinoma**
  - **Brain tumors (gliomas)**

## BIG QUESTION 3: What are the pathways of metastasis?

**Broad Answer:** Tumors can spread by hematogenous, lymphatic, or trans-coelomic routes. Each type is associated with certain cancers and mechanisms of dissemination.

## DETAILED QUESTIONS

### Q3.1: Which tumors spread via the hematogenous route?

**Answer:**

- **All sarcomas** (except: rhabdomyosarcoma, synovial sarcoma) → Lymphatic spread
- **Veins** are more commonly affected than **arteries**

### Q3.2: Which tumors spread by lymphatics?

**Answer:**

- Common in **carcinomas**
- Exceptions:
  - Renal cell carcinoma
  - Hepatocellular carcinoma
  - Follicular carcinoma thyroid

  } Hematogenous spread

### Q3.3: What is direct seeding (trans-coelomic spread) and which tumors use it?

**Answer:**

- Spread into **body cavities** like **peritoneum**
- Seen in:
  - **Pseudomyxoma peritonei**: mucin-secreting tumors of appendix or ovary
  - **Krukenberg tumor**: stomach cancer to ovary via **retrograde lymphatic spread**, not true trans-coelomic. No peritoneal cavity involvement.

### Q3.4: Which tumors commonly metastasize to bone?

**Answer:**

Mnemonic: **PuBLIK Toilet**

| Tumor Origin | Cancer Type |
|---|---|
| P | Prostate cancer |
| B | Breast cancer |
| L | Lung cancer |
| I | Intestine cancer |
| K | Kidney cancer |
| T | Thyroid cancer |

## BIG QUESTION 4: What are the bone metastasis patterns associated with different cancers?

**Broad Answer:** Tumors may metastasize to bone with different effects: some stimulate new bone formation (osteoblastic), others destroy bone (osteolytic), while a few do both.



YOURWISH

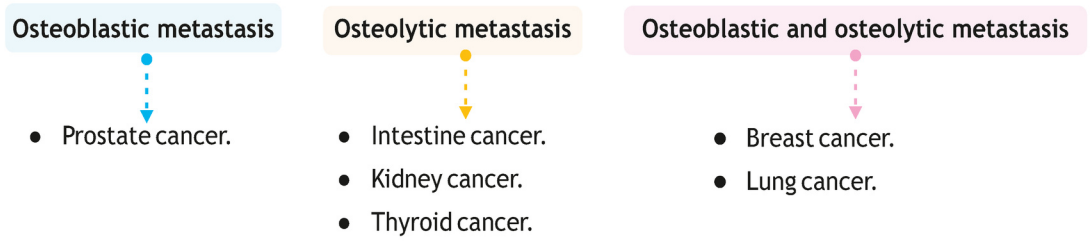


## DETAILED QUESTIONS

### Q4.1: Which cancer causes osteoblastic metastasis?

**Answer:**

- **Prostate cancer**

### Q4.2: Which cancers cause osteolytic metastasis?

**Answer:**

- **Intestine cancer**
- **Kidney cancer**
- **Thyroid cancer**

### Q4.3: Which cancers cause both osteoblastic and osteolytic metastasis?

**Answer:**

- **Breast cancer**
- **Lung cancer**

## BIG QUESTION 5: What are the fundamental hallmarks and mechanisms of neoplasia?

**Broad Answer:** Neoplastic cells acquire multiple capabilities that allow them to survive, proliferate uncontrollably, and invade. These include genetic and metabolic adaptations that promote tumor progression and immune evasion.

## DETAILED QUESTIONS

### Q5.1: What are the key hallmarks of neoplasia?

PYQ: AIIMS 2019

PYQ: NEET PG 2022

**Answer:**

- **Self-sufficiency in growth signals**
- **Inactivation of tumor suppressor genes**
- **Limitless replicative potential**
- **Evasion from apoptosis**
- **Angiogenesis**
- **Invasion and metastasis**
- **DNA repair defects**
- **Warburg effect** (aerobic glycolysis)
- **Immune surveillance escape**



YOURWISH

YOURWISH

**Q5.2: What are examples of mutations leading to self-sufficiency in growth signals?**

**Answer:**

| Gene | Cancer | |
|---|---|---|
| PDGF β | Brain tumor (astrocytoma). | |
| PDGFR β | Brain tumor (astrocytoma). | |
| HST | Osteosarcoma. | |
| HGF | Hepatocellular carcinoma. | **This is also known as the Scatter factor.** |
| EGFR1 | Adenocarcinoma of the lung. | |
| EGFR2 | Breast carcinoma. | Also known as HER2NEU. |
| RET<br>**Mnemonic:** RET TEN MED MEN | Medullary carcinoma of the thyroid. | Chromosome **10.**<br>Associated with **MEN 2a** and **2b.** |
| Ckit | **Mnemonic:** GAMES<br>• G - Gastrointestinal stromal tumor.<br>• A - Acute myeloid leukemia.<br>• M - Mastocytosis.<br>• E - Melanoma.<br>• S - Seminoma. | Also known as CD 117. |
| ALK | • Adenocarcinoma of the lung.<br>• Anaplastic large cell lymphoma.<br>• Inflammatory myofibroblastic tumor. | |
| KRAS<br>**(K a P i L)** | • Colon cancer.<br>• Pancreatic cancer.<br>• Lung cancer. | |
| HRAS | • Renal cell carcinoma.<br>• Urinary bladder cancer.<br>• Pituitary carcinoma. | |
| NRAS | Acute myeloid leukemia.<br>Melanoma. | |
| Cmyc | Burkitt's lymphoma. | |
| Lmyc | Small cell lung cancer. | |
| Nmyc | Neuroblastoma | |
| Abl | Chronic myeloid leukemia. | BcR-Abl fusion seen in translocation t (9:22). |
| BRAF | • Hairy cell leukemia. (HCL)<br>• Langerhans cell histiocytosis. (LCH)<br>• Papillary carcinoma of the thyroid.<br>• Juvenile pilocytic astrocytoma.<br>• Colon cancer.<br>• Melanoma. | |
| Cyclin D | Mantle cell lymphoma. | |

## Q5.3: What are key tumor suppressor gene mutations and their associated diseases?

**Answer:**

| Gene | Chromosome |
|---|---|
| P53 | 17p13 |
| RB | 13q14 |
| NF1 - Neurofibromatosis | 17 |
| NF2 - Neurofibromatosis | 22 |
| BRCA1 | 17 |
| BRCA2 | 13 |
| WT1 - Wilms tumor | 11p |
| WT2 - Wilms tumor | 11p |
| APC - Familial Adenomatous polyposis | 5q21 |
| PTEN | 10 |
| CDH1 | E-cadherin, 16 |

| Gene | Associations / Notes |
|---|---|
| p53 | - Mutation leads to **Li-Fraumeni syndrome** (autosomal dominant) - Follows **Chompret criteria** - p73 is considered the "**big brother**" of p53 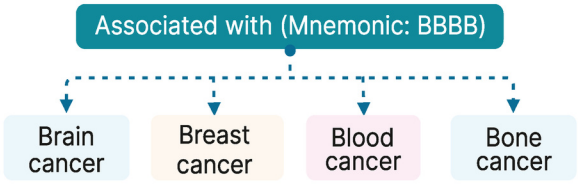  |
| RB | - Known as the "**Governor gene**" - Located on **chromosome 13q14** - Functions when **hypophosphorylated** - Mutation causes **Retinoblastoma** - Explains **Knudson's two-hit hypothesis** - **Trilateral RB**: Bilateral RB + **Pinealoblastoma** 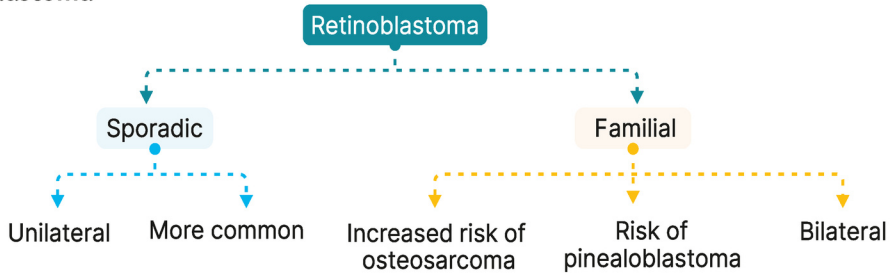  |
| PTEN | - Located on **chromosome 10** - Associated with **Cowden syndrome** - Increases risk for **endometrial carcinoma**<br>• **Cowden syndrome.(PTEN)**<br>o Endometrial carcinoma.<br>o Thyroid tumor.<br>o Trichilemmoma.<br>o Intestinal polyps.<br>o Breast cancer. |

- **CD117 (c-KIT)** related tumors (**Mnemonic: GAMES**):
  - **G** - Gastrointestinal stromal tumor (GIST)
  - **A** - Acute myeloid leukemia (AML)
  - **M** - Mastocytosis
  - **E** - Melanoma
  - **S** - Seminoma

### Q5.4: What tumors are associated with CDH1 (E-cadherin) mutations?

**Answer:**

- CDH1 gene loss → **Loss of E-cadherin (cell-cell adhesion)**
- Associated tumors:
  - **Diffuse gastric cancer**
  - **Invasive lobular carcinoma of the breast**

### Q5.5: How do tumors achieve limitless replicative potential?

**Answer:**

- By **increasing telomerase** activity

### Q5.6: How do tumors evade apoptosis?

**Answer:**

- By **increasing anti-apoptotic factors**, e.g., **Bcl-2**

### Q5.7: What are key DNA repair defect syndromes?

**Answer:**

| Type of DNA Repair | Syndrome / Cancer Type | Inheritance |
|---|---|---|
| **Nucleotide excision repair** | **Xeroderma pigmentosum** → SCC, BCC | Autosomal recessive |
| **Mismatch repair defect** | **HNPCC (Lynch syndrome)** → colon, endometrial, ovarian | Autosomal dominant |
| **Homologous recombination** | Mnemonic: **Big FAX**<br>- **Fanconi anemia**<br>- **Bloom syndrome**<br>- **Ataxia telangiectasia** | Autosomal recessive |

### Q5.8: What is the Warburg effect and its clinical use?

**Answer:**

- **Warburg effect** = **aerobic glycolysis** (↑ glucose uptake despite oxygen availability)
- Tumor cells become **glucose-hungry**
- Basis of **18FDG-PET scans**
  - Inject **fluorodeoxyglucose (FDG)**
  - Uptake visualized → indicates presence of tumor



YOURWISH

**Q5.9: A 62-year-old woman presents with a breast lump that she discovered 6 days ago. A breast biopsy shows lobular carcinoma in situ. Compared to normal epithelial cells of the breast lobule, these malignant cells would most likely show decreased expression of which of the following proteins?**

A. Desmin.
B. E-cadherin.
C. P-selectin.
D. Telomerase.

**Answer:** B. E-cadherin.

## BIG QUESTION 6: How is the cell cycle regulated and what is its relevance to radiosensitivity?

**Broad Answer:** The cell cycle is governed by cyclins, CDKs, and checkpoints. These mechanisms determine cell progression, DNA repair, and sensitivity to radiotherapy. Some tumors and cells exhibit distinct radiosensitivity.




## DETAILED QUESTIONS

**Q6.1: What are the key points in the cell cycle and their radiosensitivity?**

**Answer:**

| Feature | Phase |
|---|---|
| Point of no return | S phase |
| Most radiosensitive phase | G2 and M phases |
| Least radiosensitive phase | S phase |
| Most radiosensitive tumor | Ewing's sarcoma |
| Most radiosensitive testicular tumor | Seminoma |
| Most radiosensitive cell | Lymphocyte |
| Least radiosensitive cell | Platelet |

**Q6.2: What are the cyclins and their associated CDKs in cell cycle progression?**

**Answer:**

Mnemonic: **Dhoni Ek Accha Batsman**

| Cyclin | CDK Partner |
|---|---|
| Cyclin D | CDK4, CDK6 |



YOURWISH

| | |
|---|---|
| Cyclin E | CDK2 |
| Cyclin A | CDK2 |
| Cyclin B | CDK1 |

### Q6.3: What are the checkpoints in the cell cycle and their key regulators?

Answer:

| Checkpoint | Location | Key Genes | |
|---|---|---|---|
| **First** | Between G1 and S | **p53**, **RB** (Governor gene) | |
| **Second** | Between G2 and M | **p53** only | - **CD117 (c-KIT)** related tumors (**Mnemonic: GAMES**): |

- **G** - Gastrointestinal stromal tumor (GIST)
- **A** - Acute myeloid leukemia (AML)
- **M** - Mastocytosis
- **E** - Melanoma
- **S** - Seminoma

### Q6.4: Which of the following describes the correct order of cyclins in cell cycle progression?

A. A/D/E/B.

B. D/E/A/B.

C. B/E/A/D.

D. D/E/B/A.

Answer: B. D/E/A/B.

## BIG QUESTION 7: What are the etiological agents associated with cancer development?

**Broad Answer:** Cancer can result from exposure to radiation, chemicals, and infectious agents. These carcinogens act by damaging DNA, promoting mutations, and evading normal cellular controls.

## DETAILED QUESTIONS

### Q7.1: What cancers are associated with ionizing radiation?

Answer:

- **UV-B is associated with cancer**
- **Most common: Acute myeloid leukemia (AML)**
- **Most common thyroid cancer: Papillary carcinoma of the thyroid**
- **Never associated with radiation: Chronic lymphocytic leukemia (CLL)**

### Q7.2: What are common chemical carcinogens and their associated cancers?

PYQ: NEET PG 2021

Answer:

| Chemical Agent | Associated Cancer(s) |
|---|---|
| **Alcohol** | Hepatocellular carcinoma |
| **Tobacco** | Oral cancer, Lung cancer, Renal cell carcinoma |
| **Asbestos** | Most common: **Adenocarcinoma of lung** - Most specific: **Mesothelioma** |
| **DES (diethylstilbestrol)** | Clear cell carcinoma of female genital tract (in daughters) |
| **Vinyl chloride** | **Angiosarcoma of the liver** (PVC exposure) |
| **Arsenic** (Found in **pesticides**) | Angiosarcoma of the liver |
| **Thorotrast** (Contrast dye) | Angiosarcoma of the liver |
| **Estrogen** | Endometrial cancer |
| **OCP** | Cervical cancer |

### Q7.3: What is the Ames test?

Answer:

- Used to determine **mutagenic potential** of a chemical
- Assesses whether a substance can cause **mutation and cancer**

### Q7.4: What are micro-organism related carcinogens and their effects?

Answer:

| Microbial carcinogenesis | |
|---|---|
| H. pylori | • Adenocarcinoma of the stomach.<br>• Maltoma of the stomach. |
| • Aflatoxin<br>o Aspergillus flavus<br>o Peanut contamination. | • Mutation of p53 at codon 249.<br>• Hepatocellular carcinoma. |
| Schistosoma hematobium | Squamous cell carcinoma of the urinary bladder. |
| Clonorchis sinensis | Cholangiocarcinoma |
| HPV - Human papilloma virus | • Cervical cancer.<br>• Penile cancer.<br>• Anal cancer.<br>• Esophageal cancer.<br>• Larynx cancer |
| EBV- Ebstein Barr virus | • Gastric cancer.<br>• Nasopharyngeal carcinoma.<br>• Hodgkin's lymphoma. |

| | |
|---|---|
| | • Non-Hodgkin's lymphoma.<br>o Burkitt's lymphoma.<br>o Diffuse large B cell lymphoma.<br>• Leiomyosarcoma. |
| HHV 8 | • Kaposi sarcoma.<br>• Primary effusion lymphoma.<br>• Castleman disease. |
| HTLV - Human T cell leukemia/lymphoma virus | Adult T-cell leukemia/lymphoma. |

**Q7.5: What are the special stains used for H.pylori diagnosis?**

**Answer:**

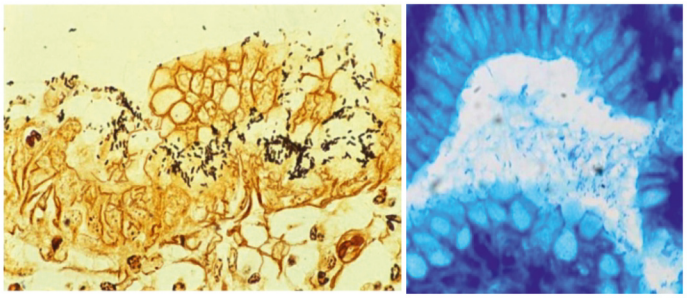

- Warthin starry silver stain.- Black color
- Modified Giemsa stain.

**Q7.6: What are koilocytes?**

**Answer:**

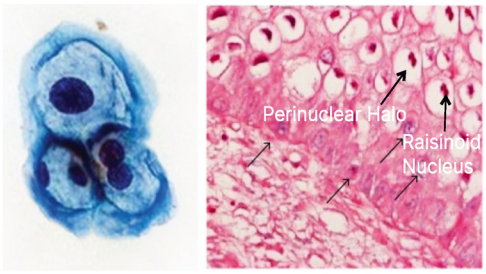


Pap smear Cervical biopsy

Koilocyte cells: Raisinoid nucleus with a perinuclear halo.

**Q7.7: What are the various HPV proteins, and their role in causing cancers?**

**Answer:**

- HPV is associated with multiple proteins, i.e., L1, E2, E4/E5, E6, and E7.
  - o L1 - **Vaccine preparation.**
  - o E2 - Controller.
  - o E4/E5 - Koilocyte production.
  - o E6 - **Inactivation of the p53 gene.**
  - o E7 - **Inactivation of the RB gene.**

### Q7.8: What are the features and cancers caused by EBV?

**Answer:**

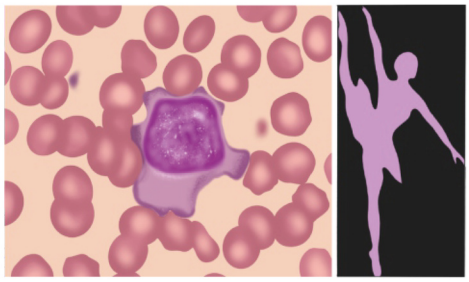

- EBV enters B cells.
  - **Via receptors CD21/CR2.**
- Release LMP1, EBNA2, and IL-10 - responsible for cancer
- Causes infectious mononucleosis or kissing disease.
- The **most common cancer** associated with EBV is **gastric cancer.**
- Carcinoma, lymphoma, and sarcoma.
- Infectious mononucleosis: **Downey cells.**
  - **Ballerina skirt appearance.**
  - **CD 8 T** cells.

### Q7.9: What are the cancers caused by HTLV?

**Answer:**

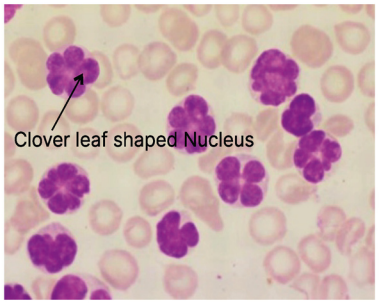


- Human T-cell leukemia/lymphoma virus.
- Causes Adult T-cell leukemia-lymphoma.
  - Microscopically shows Clover leaf cells.
  - Regulated by the TAX gene

### Q7.10: What are the features of HHV8 in carcinogenesis?

**Answer:**

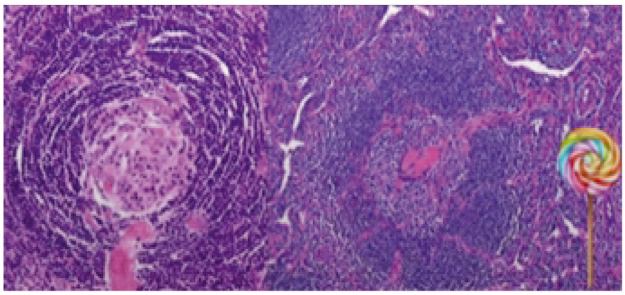

- Human herpesvirus 8.
- Kaposi sarcoma.
- Primary effusion lymphoma.
- Castleman disease.
  - Onion skin pattern of the lymph node.
  - Lollipop follicle.

## BIG QUESTION 8: What are the various pathological diagnostic tests available for the diagnosis of cancers?

**Broad answer:** Tumor diagnosis relies on cytological (FNAC), histopathological (biopsy), and molecular techniques. Tumor markers aid in detection and monitoring, while immunohistochemistry (e.g., cytokeratin) helps identify tumor origin—especially in carcinomas.

## DETAILED QUESTIONS

### Q8.1: What are the various tumor markers used for the diagnosis of neoplastic conditions?

**Answer:**

| | |
|---|---|
| β-HCG | Choriocarcinoma |
| Calcitonin | Medullary carcinoma of the thyroid. |
| Catecholamines | Pheochromocytoma |
| 5HIAA | Carcinoid tumor |



YOURWISH

| | |
|---|---|
| AFP - Alpha feto protein | • Yolk sac tumor.<br>• Hepatocellular carcinoma.<br>• Hepatoblastoma |
| CEA - Carcinoembryonic antigen | Colon cancer |
| PSA - Prostate-specific antigen,<br>PAP - Prostatic acid phosphatase | Prostate cancer |
| Ig | Multiple myeloma |
| NSE - Neuron specific enolase | • Neuroendocrine tumors.<br>• Neuroblastoma. |
| CA 125 | Ovarian cancer (surface epithelial tumors). |
| CA 19-9 | Pancreatic cancer |
| CA 15-3 | Breast cancer |
| NMP 22 | Recurrent urinary bladder cancer. |

**Q8.2: CA 19-9 is a tumor marker of?**

A. Stomach cancer
B. Pancreatic cancer
C. Colon cancer
D. Lung cancer

**Answer:** B. Pancreatic cancer

**Q8.3: What is FNAC, and which cancer cannot be diagnosed from FNAC?**

**Answer:**

- Fine needle aspiration cytology
- Franzen handle
- Pitfall
  - Cannot diagnose **follicular thyroid carcinoma (biopsy is required).**



Ultrasound-guided FNAC.




**Q8.4: Which is the gold standard investigation for diagnosing cancers?**

**Answer:** Biopsy

**Q8.5: What are the features of immunohistochemistry?**

**Answer:**

- Brown color stain.
  - Diaminobenzidine (DAB).
- Note:
  - Benzene exposure can cause AML
  - Benzidine exposure can cause urinary bladder cancer.

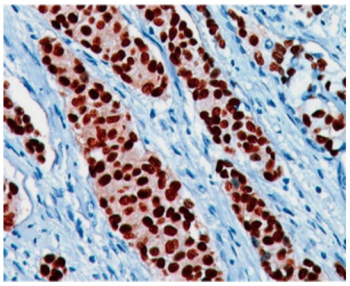

**Q8.6: What are the various immunohistochemistry markers used for diagnosis?**

**Answer:**

| Marker | Tumor |
|---|---|
| Cytokeratin | Carcinoma. |
| Vimentin | Sarcoma |
| LCA/CD 45 | Lymphoma |
| HMB 45 | Melanoma |
| CD 1a | Langerhans cell histiocytosis. |
| CD99 | Granulosa cell tumor, ovary |
| CD99/MIC 2 | Ewing's sarcoma. |

**Q8.7: What is the role of cytokeratins in diagnosing cancers?**

**Answers:**

**CK7+ CK20+**

- Bladder carcinoma.
- Ovarian mucinous tumor.

**CK7+ CK20-**

- In females and above the colon.
  - Breast cancer.
  - Endometrial cancer.
  - Ovarian cancer.
  - Lung adenocarcinoma
  - Salivary gland cancer.
  - Thyroid cancer.

**CK7- CK20+**

- Colorectal carcinoma.
- Merkel cell carcinoma.

**CK7- CK20-**

- Renal cell carcinoma.
- Squamous cell carcinoma of the lung.
- Hepatocellular carcinoma.
- Small cell carcinoma of the lung.

## BIG QUESTION 9: What are paraneoplastic syndromes, and how do they manifest in association with malignancies?

**Broad Answer:** Paraneoplastic syndromes are systemic effects of cancer unrelated to direct tumor invasion or metastasis. They result from ectopic hormone production, immune cross-reactivity, or cytokine release. These syndromes can affect various systems—endocrine, neurologic, dermatologic, and hematologic.

## DETAILED QUESTIONS

**Q9.1: What are the various paraneoplastic cancers associated with cancers?**

**Answer:**

| PNS | Tumor |
|---|---|
| Hypercalcemia | Squamous cell carcinoma of the lung. |
| Cushing syndrome | Small cell carcinoma of the lung.<br>Renal cell carcinoma. |
| SIADH | Small cell carcinoma of the lung. |
| Hypoglycemia | Fibrosarcoma |
| Hyperglycemia | Bone tumors |
| Acanthosis nigricans | Gastric cancer |
| Lambert Eaton syndrome | Small cell carcinoma of the lung. |
| Myasthenia gravis | Thymoma PYQ: FMGE 2019 |
| Pure red cell aplasia | Thymoma |
| Migratory thrombophlebitis/<br>Trousseau phenomenon | Adenocarcinoma of the lung. |
| Osteomalacia | Phosphaturic mesenchymal tumor. |

**Q9.2: A 65-year-old man complains of muscle weakness and a dry cough for 4 months. He has smoked two packs of cigarettes daily for 45 years. A chest X-ray shows a 4cm central left lung mass. Laboratory studies reveal hyperglycemia and hypertension. A transbronchial biopsy is diagnosed as small cell carcinoma. Metastases to the liver are detected by a CT scan. Which of the following might account for the development of hyperglycemia and hypertension in this patient?**

A. Diabetes mellitus
B. Paraneoplastic syndrome
C. Pituitary adenoma
D. Pituitary metastases

Answer: B. Paraneoplastic syndrome

**Explanation:**

Small cell carcinoma can produce ectopic ACTH, leading to Cushing's syndrome, which causes hyperglycemia and hypertension—classic features of a paraneoplastic endocrine effect.



YOURWISH

# 7. IMMUNITY

## BIG QUESTION 1: What are the major immune cell types and their surface markers?

**Broad Answer:** The immune system is composed of various cell types including NK cells, T cells, and B cells. Each has distinct surface markers, functions, and interactions in immune defense and regulation.

## DETAILED QUESTIONS

### Q1.1: What are the key features of NK (Natural Killer) cells?

PYQ: FMGE 2019

**Answer:**

- **Inhibitory arm:** Recognizes **MHC I** on self cells
- **Activating arm:** Recognizes **NKG2D** on virus-infected or cancer cells
- **Cytokines involved:** IL-2, IL-12, IL-15
- **Surface markers:** CD16, CD56, CD94

### Q1.2: What are the important surface markers and types of T cells?

**Answer:**

- CD1 to CD8, CD28
- **Signal transduction:** CD3 (also the **pan-T cell marker**)
- **Helper T cells:** CD4
- **Cytotoxic T cells:** CD8
- TCR types:
  - 95% are **αβ TCR**
  - 5% are **γδ TCR**
- **CD4:CD8 ratio** = 2:1
  - **Decreases** in **HIV**
  - **Increases** in **Sarcoidosis**

### Q1.3: What are the subtypes and functions of T helper cells?

**Answer:**

| T Cells | | |
|---|---|---|
| $CD_4 \rightarrow T_H$ cells | | $CD_8 \rightarrow$ T cytotoxic cells (Cell killing) |
| Th1 | • IL2<br>o TH1 release IL2<br>o IL2 will stimulate TH1<br>o NK stimulation<br>• IFN γ - Granuloma formation | • CD95 (Apoptosis)<br>• Perforin Granzyme pathway |
| TH2 | • IL4 - Isotype switch<br>• IL5 - Eosinophil activation<br>• IL13 - Mucus production | |
| TH17 | • IL 17 | |



YOURWISH

### Q1.4: What are the surface markers and functions of B cells?

**Answer:**

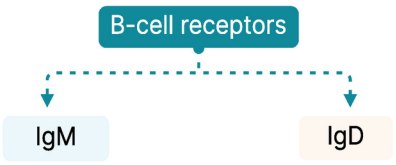


- Surface markers: CD10, CD19, CD20, CD21, CD22, CD23, CD40, CD79a, Cd79b
- **Pan-B cell marker**: CD19
- **Signal transduction**: CD79a and Cd79b
- **EBV receptor**: CD21

### Q1.5: How do B and T cells interact to promote antibody isotype switching?

**Answer:**

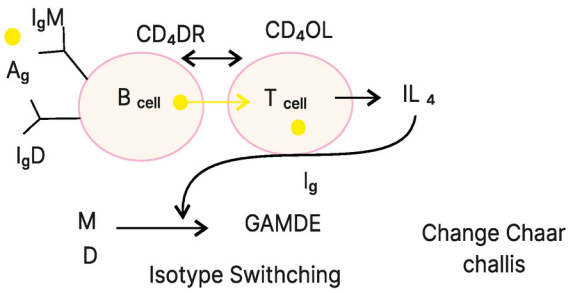


- **B cells** express **CD40 receptor**
- **T cells** express **CD40 ligand (CD40L)**
- Interaction induces **IL-4** release from T cells
- IL-4 triggers **isotype switching**:
  - From **IgM/IgD** → to **IgG, IgA, IgE**

## BIG QUESTION 2: How do antigen-presenting cells and MHC molecules mediate immune activation?

**Broad Answer:** Immune activation begins when antigen-presenting cells (APCs) present antigens to T cells using MHC molecules. These interactions determine immune specificity and tolerance, leading to hypersensitivity reactions if dysregulated.

## DETAILED QUESTIONS

### Q2.1: What are the types of antigen-presenting cells (APCs)?

**Answer:**

| Type | Examples |
|---|---|
| Professional | Dendritic cells, B cells, Macrophages |
| Non-professional | Thymic epithelial cells, Endothelial cells, Fibroblasts |

### Q2.2: How do APCs activate T cells?

**Answer:**

- APCs capture and process antigens
- Present the processed antigens to **T cells** using **MHC molecules**

### Q2.3: Where is the HLA (MHC) gene located?

**Answer:**

- Located on the **short arm of chromosome 6p**

### Q2.4: What are the different parts of the HLA gene and their contents?

**Answer:**

| HLA Gene Part | Includes |
|---|---|
| Class I | HLA-A, HLA-B, HLA-C |
| Class II | HLA-DP, HLA-DQ, HLA-DR |
| Class III | Complement proteins (C2, C4), HSPs, TNFα |

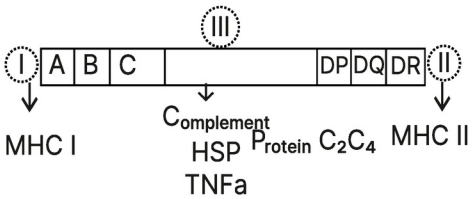

### Q2.5: What is the structure and function of MHC Class I and II molecules?

**Answer:**

| Characteristic | MHC I | MHC II |
|---|---|---|
| Structure | 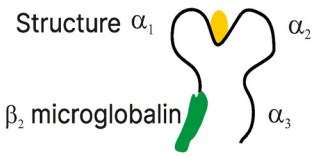 |  |
| | • α1<br>• α2<br>• α3<br>• β2-microglobulin | • α1<br>• α2<br>• β1<br>• β2 |
| Antigen binding cleft | α1-α2 junction | α1-β1 junction |
| Present on cells | • All nucleated cells.<br>• Platelets.<br>• Red blood cells and sperm cells lack MHC I. | Antigen-presenting cells. |
| Present to cells | CD8 T cells. | CD4 T cells. |

## BIG QUESTION 3: What are the types and examples of hypersensitivity reactions?

**Broad Answer:** Hypersensitivity reactions are immune responses that cause tissue damage and disease. They are classified into four main types (I-IV) based on the underlying mechanism and examples, with some sources recognizing a fifth type involving antibody-mediated receptor effects.

PYQ: AIIMS 2021 PYQ: NEET PG 2020 PYQ: FMGE 2020, 2021, 2023

| Type I | Type II | Type III | Type IV |
|---|---|---|---|
| Anaphylaxis | Cytotoxicity | Immune complex | Delayed type |

## DETAILED QUESTIONS

### Q3.1: What are the features and examples of Type I hypersensitivity?

PYQ: FMGE 2019

**Answer:**

- **Mechanism:** IgE-mediated, immediate allergic reaction
- **Mnemonic:** ABCD
- **Examples:**
  - Allergic dermatitis
  - Allergic rhinitis
  - Allergic conjunctivitis
  - Atopy (genetic predisposition, Chromosome 5)
  - Bronchial asthma
  - Casoni test (Echinococcus granulosus)
  - Drug allergies
  - Positive PK (Prausnitz-Küstner) reaction
  - Theobald-Smith phenomenon

### Q3.2: What are the features and examples of Type II hypersensitivity?

PYQ: NEET PG 2020

**Answer:**

- **Mechanism:** Antibody-mediated cytotoxicity
- **Mnemonic:** My Blood Group Is Rh Positive
- **Examples:**
  - Myasthenia gravis
  - Blood transfusion reactions
  - Goodpasture syndrome
  - Graves' disease
  - Immune hemolytic anemia
  - Immune thrombocytopenic purpura (ITP)
  - Rh incompatibility
  - Rheumatic heart disease
  - Pemphigus (bullous)
  - Pernicious anemia

### Q3.3: What is Type V hypersensitivity and what are examples?

PYQ: INICET 2021, 2022

**Answer:**

- **Mechanism:** Antibodies against **cellular receptors**
- **Examples:**
  - **Myasthenia gravis** (anti-acetylcholine receptor)
  - **Graves' disease** (anti-TSH receptor)

### Q3.4: What are the features and examples of Type III hypersensitivity?

**Answer:**

- **Mechanism:** Immune complex-mediated
- **Mnemonic:** SHARP
- **Examples:**
  - **S**LE
  - **S**erum sickness
  - **S**chick test (Corynebacterium diphtheriae)
  - **H**enoch-Schönlein purpura (IgA vasculitis in children)
  - **A**rthus reaction (localized)
  - **R**aji assay
  - **R**eactive arthritis
  - **P**ost-streptococcal GN (cola-colored urine)
  - **P**olyarteritis nodosa (PAN)

### Q3.5: What are the features and examples of Type IV hypersensitivity?

**Answer:**

- **Mechanism:** T-cell mediated (delayed type)
- **Examples:**
  - Granulomas
  - Skin tests: Mantoux (TB), Lepromin test

- Inflammatory bowel disease (Crohn's)
- Multiple sclerosis
- Contact dermatitis
  - → Due to poison ivy (global)
  - → In India: detergents, artificial jewelry (nickel, cadmium)

### Q3.6: What diseases involve mixed or multiple hypersensitivity types?

**Answer:**

| Condition | Hypersensitivity Types Involved |
|---|---|
| Rheumatoid arthritis | Type III and IV |
| Hypersensitivity pneumonitis | Type III and IV |
| SLE | Type II and IV |
| Transplant rejection | Hyperacute: Type II; Acute: Type II + IV; Chronic: Type IV |

## BIG QUESTION 4: What are the diagnostic antibodies and patterns in autoimmune diseases?

**Broad Answer:** Autoimmune diseases are diagnosed using specific autoantibodies and immunofluorescence staining patterns. These markers help distinguish between conditions such as SLE, Sjogren's, and scleroderma, and also identify drug-induced variants.

## DETAILED QUESTIONS

### Q4.1: What are the key antibodies in systemic lupus erythematosus (SLE)?

**Answer:**

- **Anti-dsDNA**: Specific and sensitive for SLE
- **Anti-Ro (SSA)**: Seen in **neonatal lupus**
- **Anti-ribosomal P**: Associated with **psychosis in SLE**
- **Most sensitive :** ANA (antinuclear antibody)
- **Most specific :** ASA (anti-Smith antibody)

### Q4.2: What antibody is seen in drug-induced lupus and what are the drugs involved?

**Answer:**

- **Anti-histone antibody**
- Mnemonic: **SHIP-D**
  - **S**ulfonamides
  - **H**ydralazine
  - **I**soniazid
  - **P**rocainamide
  - **D**apsone

### Q4.3: What are the key antibodies in Sjogren's syndrome?

**Answer:**

- **Anti-SS-A (Anti-Ro) - most sensitive**
- **Anti-SS-B (Anti-La) - most specific**



YOURWISH

### Q4.4: What are the diagnostic markers for scleroderma?

**Answer:**

| Type | Antibody |
|---|---|
| Limited scleroderma | Anti-centromeric antibody |
| Diffuse scleroderma | Anti-topoisomerase (Anti-Scl70) |

### Q4.5: What are the patterns and targets in immunofluorescence (ANA testing)?

PYQ: AIIMS 2023

**Answer:**

| Pattern | Antibody Target | Associated Disease |
|---|---|---|
| Homogeneous | Anti-chromatin, anti-histone, anti-nuclear | SLE |
| Peripheral/Rim | Anti-dsDNA | SLE |
| Nucleolar | RNA-related antibodies | Scleroderma |
| Speckled (most common) | Anti-Smith (SLE), Anti-Ro/La (Sjogren's) | SLE, Sjogren's syndrome |
| Centromeric | Anti-centromeric antibody | Limited scleroderma |

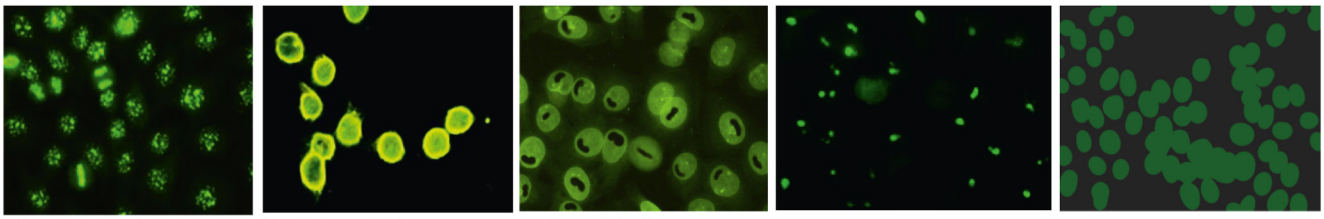

Centromeric pattern | Peripheral/rim pattern | Speckled pattern | Nucleolar pattern | Homogeneous pattern

## BIG QUESTION 5: What are the major types and causes of immunodeficiency disorders?

**Broad Answer:** Immunodeficiencies may be congenital or acquired and can affect B cells, T cells, or both. Many follow X-linked or autosomal recessive inheritance and are characterized by specific gene mutations and clinical presentations.

## DETAILED QUESTIONS

### Q5.1: What are the causes of Severe Combined Immunodeficiency (SCID)?

PYQ: AIIMS 2019

**Answer:**

- **X-linked recessive:** Defect in **γ (gamma) subunit** of cytokine receptors
- **Autosomal recessive:**
  - **ADA deficiency** (most common in AR)
  - **JAK3 gene defect**
  - **RAG1, RAG2 gene defects**
- **Features:** Morbilliform rash, recurrent infections

### Q5.2: What are the features of Bruton's agammaglobulinemia?

**Answer:**

- **BTK gene defect**

- Affects **boys** (X-linked)
- **B cell deficiency**
- Low **IgG levels**
- **Defective opsonization**

### Q5.3: What are the features of DiGeorge syndrome?

PYQ: FMGE 2021

**Answer:**

- **22q11 deletion**
- **No thymus → T cell defect**
- **Parathyroid deficiency → Hypocalcemia**
- Craniofacial anomalies:
  - Cleft lip, cleft palate, abnormal facies
- Associated congenital heart disease:
  - **Tetralogy of Fallot**

### Q5.4: What is Hyper IgM syndrome?

**Answer:**

- Defect in **CD40 receptor** or **CD40 ligand**
- Recurrent infections, e.g., **Pneumocystis jirovecii pneumonia**

### Q5.5: What is Hyper IgE syndrome (Job syndrome) and its mnemonic?

**Answer:**

- **STAT3 gene defect**
- Mnemonic: **FATE**
  - **F**: Coarse **Facies**
  - **A**: Cold **Abscesses** (Staph)
  - **T**: **Teeth retention** (primary)
  - **E**: **Elevated IgE**, **Eczema**

### Q5.6: What is Isolated IgA deficiency and its implication in transfusion?

**Answer:**

- **IgA deficiency**
- May cause anaphylaxis during transfusion
- Use **washed red blood cells**

### Q5.7: What are the features of Wiskott-Aldrich syndrome?

**Answer:**

- **WASP gene defect** (X-linked)
- Classic triad:
  - Thrombocytopenia (small platelets → bleeding)
  - **Infections**
  - **Skin eczema**
- **IgM ↓, IgA/IgE ↑**

### Q5.8: What is the defect seen in Bare lymphocyte syndrome?

**Answer:** MHC II missing

### Q5.9: What is the most common inheritance pattern seen in SCID?

**Answer:** Overall, the X-linked recessive pattern is the most common defect in severe combined immunodeficiency.

### Q5.10: What is the most common defect in autosomal recessive severe combined immunodeficiency?

**Answer:** ADA deficiency.

## BIG QUESTION 6: What are the different types of grafts in transplant immunology?

**Broad Answer:** Transplants are categorized based on genetic relationship between donor and recipient. They are important in understanding graft acceptance, rejection, and immune tolerance.

## DETAILED QUESTIONS

### Q6.1: What are the types of grafts?

PYQ: FMGE 2018,2019, 2020 PYQ: NEET PG 2018, 2020

**Answer:**

| Type | Definition |
|---|---|
| Autograft | From self |
| Isograft | Between genetically **identical** individuals (e.g., twins) |
| Allograft | Between **same species**, genetically **non-identical** |
| Xenograft | Between **different species** |

## BIG QUESTION 7: What are the types and mechanisms of transplant rejection?

**Broad Answer:** Transplant rejection can occur at different times post-transplant and involve distinct immune mechanisms—ranging from preformed antibodies to cellular immune responses. Each type shows characteristic histopathology and timing.

## DETAILED QUESTIONS

### Q7.1: What are the types of transplant rejection and their mechanisms?

**Answer:**

| Type | Hypersensitivity | Mechanism | Notes |
|---|---|---|---|
| Hyperacute | Type II | Preformed antibodies | Seen in multiparous women, multiple transfusions, <48hours." |
| Acute | Type II & IV | Humoral + Cellular | Most common, days to weeks |
| Chronic | Type IV | Cellular rejection, fibrosis | Long-term rejection, weeks to months |

### Q7.2: What are the histological findings in different types of rejection?

PYQ: FMGE 2018, 2022

**Answer:**

- **Hyperacute rejection:**
  - **Fibrinoid necrosis** of vessels
  - **Coagulative necrosis** in kidney
- **Acute rejection:**
  - **Humoral:** Marker is **C4d, rejection vasculitis**
  - **Cellular: Tubulitis, Endotheliitis**
- **Chronic rejection:**
  - **Glomerular BM duplication**
  - **Obliterative vasculopathy**
  - **Tubular atrophy, interstitial fibrosis**

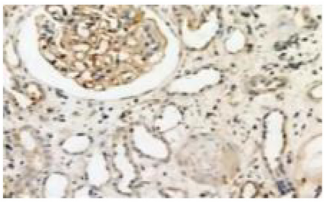

### Q7.3: What is Graft-versus-Host Disease (GVHD) and when does it occur?

PYQ: AIIMS 2021

**Answer:**

- Occurs when **graft is immunocompetent** and **recipient is immunocompromised**

| | Acute GVHD | Chronic GVHD |
|---|---|---|
| Duration | < 100 days | > 100 days |
| Skin | Rash. | |
| Intestine | Diarrhea. | |
| Liver | Jaundice. | |

## BIG QUESTION 8: What are the types and causes of amyloidosis?

**Broad Answer:** Amyloidosis is the deposition of abnormal protein aggregates and is classified by the protein type involved. It may arise from chronic inflammation, cancer, or genetic mutations.

## DETAILED QUESTIONS

### Q8.1: What are the different amyloids deposited in different disease processes?

**Answer:**

| Disease | Amyloid |
|---|---|
| Chronic inflammation<br>Except for chronic bronchitis | AA |
| Cancers | AA |
| Familial Mediterranean fever | AA |
| Medullary carcinoma thyroid | Acal (calcitonin) |
| Systemic senile amyloidosis | ATTR (Increased quantity) |
| Familial amyloidotic polyneuropathy | ATTR (Mutant) |
| Alzheimer's disease | Aβ |



YOURWISH

| | |
|---|---|
| Hemodialysis PYQ: AIIMS 2023 | Aβ2 |
| Diabetes mellitus | IAPP |
| Multiple myeloma | AL |

AL - Amyloid light chain, AA - Amyloid-associated proteins, ACal - Amyloid calcitonin, Aß - Amyloid ß plaques, Aß2 - Amyloid ß2 microglobulin, ATTR - Amyloid transthyretin

### Q8.2: What are the common sites of amyloid deposition?

**Answer:**

| Organ | Site |
|---|---|
| **Kidney**<br>• **Most common organs are affected** | Mesangium |
| **Heart**<br>• **The most common organ is affected in the elderly** | Subendocardial |
| Liver | Space of Disse |
| Spleen red pulp | Lardaceous spleen |
| Spleen white pulp | Sago spleen |
| Skin | Pinch purpura |
| GIT | Organomegaly |
| Joints | Carpal tunnel syndrome at the wrist joint. |
| Blood vessels | Subendothelial |

### Q8.3: What is the gross appearance of Amyloidosis?

**Answer:**

- All organs look waxy.
- Diffuse organomegaly.
- Except for the kidneys, which shrink in later stages.
- Gross stain
  - o Lugol's iodine
  - o Mahogany brown color

### Q8.4: What are the microscopic stains and appearance of amyloidosis?

**Answer:**

| Detection | Feature |
|---|---|
| Gross stain | Lugol's iodine<br>Mahogany brown color |
| Microscopic stains | |
| Congo red PYQ: AIIMS 2019 | Apple green birefringence on **polarizing** microscopy.<br>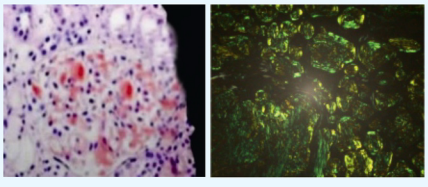 |

| | |
|---|---|
| Thioflavin T | UV light. |
| Miscellaneous stains | Methyl violet, Crystal violet, PAS |
| Electron microscopy | 7.5-10 nm diameter. |
| X-ray crystallography | ß pleated sheets. PYQ: AIIMS 2019 |

**Q8.5: What is the most common site of sample collection?**

**Answer:** Abdominal fat aspiration>>Rectal biopsy.

**Q8.6: Which imaging modality is used to assess the extent of amyloidosis in the body?**

**Answer:** Scintigraphy.

# 8. CENTRAL NERVOUS SYSTEM PATHOLOGY

## BIG QUESTION 1: What are the key cellular components and pathological findings in CNS histology?

**Broad Answer:**

The central nervous system includes specialized cells like astrocytes and microglia that support neuronal function and respond to injury or infection. Neurodegenerative diseases such as Alzheimer's are characterized by distinctive genetic mutations and histological findings.

## DETAILED QUESTIONS

### Q1.1: What are astrocytes and what is their function in the CNS?

**Answer:**

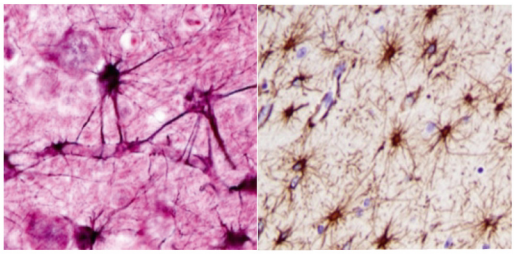

- **Star-shaped glial cells**
- Help in forming the **blood-brain barrier**
- On **immunohistochemistry**, they stain **brown**
- Marker: **GFAP positive** (Glial Fibrillary Acidic Protein)

### Q1.2: What are microglia and what roles do they play?

**Answer:**

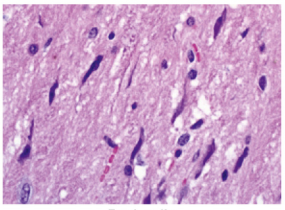

Rod cells

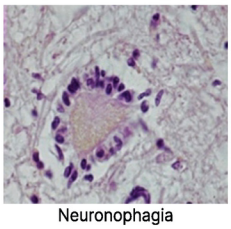

Neuronophagia

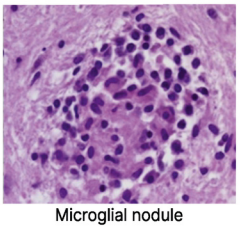

Microglial nodule

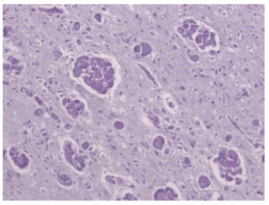

Globoid bodies

- **Resident macrophages of the brain**
- Appear **elongated** - referred to as **Rod cells**
- Seen in **Neurosyphilis**
- Phagocytose infected or damaged neurons → called **neuronophagia**
  - Seen in **Polio** and **Rabies**
- Form **microglial nodules** in **HIV-positive patients**
- **Globoid bodies** seen in **Krabbe's disease**

### Q1.3: What is the typical onset and symptom of Alzheimer's disease?

**Answer:**

PYQ: NEET PG 2019
PYQ: AIIMS 2020
PYQ: FMGE 2023

- Onset: **Senile old age**, typically after **70 years**
- Symptom: **Memory loss**

### Q1.4: What are the key genetic factors associated with Alzheimer's disease?

**Answer:**

| Gene/Protein | Chromosome | Notes |
|---|---|---|
| APP (Amyloid Precursor Protein) | 21 | Overexpressed in **Trisomy 21 (Down syndrome)** → early-onset AD 30 years |
| PS1 (Presenilin 1) | 14 | Increases **gamma-secretase** activity |
| PS2 (Presenilin 2) | 1 | Also influences **gamma-secretase** activity |
| APOE4 | – | Mutation causes **early-onset Alzheimer's** |

### Q1.5: What is the histological stain used to visualize Alzheimer's pathology?

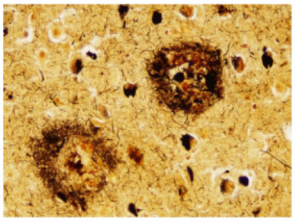

**Answer:**

- **Bielschowsky stain** - gives a **blackish-brown** appearance under microscope

## BIG QUESTION 2: What are the key pathological findings in common neurodegenerative diseases?

**Broad Answer:**

Neurodegenerative disorders such as Alzheimer's, Parkinson's, Huntington's, and ALS are characterized by distinct pathological proteins and neuronal degeneration patterns, each with specific histological markers.

## DETAILED QUESTIONS

### Q2.1: What are the main microscopic findings in Alzheimer's disease?

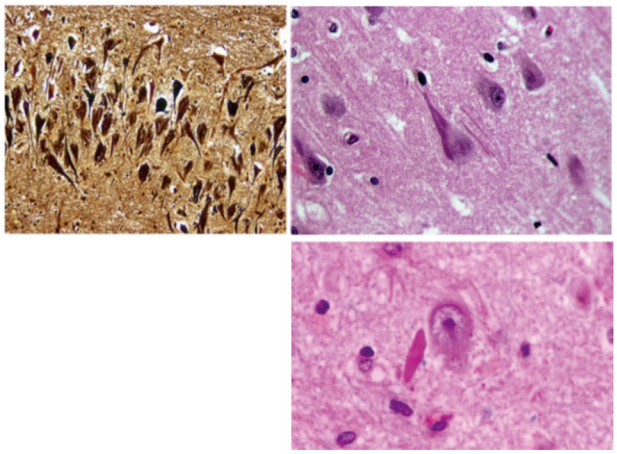

**Answer:**

- **Neuritic plaques**
  - Center: **Aß amyloid**
  - Periphery: **Degenerating neurons → Neuritic plaque**
- **Neurofibrillary tangles (NFT)**
  - Appear **flame-shaped**
  - Composed of **hyperphosphorylated tau protein**
- **Hirano bodies**
  - Needle-shaped, made of **actin**
- **Cerebral amyloid angiopathy**
  - Amyloid deposition in blood vessels
- **Granulovacuolar degeneration**

### Q2.2: What is the primary pathology in Parkinson's disease?

PYQ: FMGE 2019,2020,2021 PYQ: NEET PG 2022,2023 PYQ: INICET 2022,2023

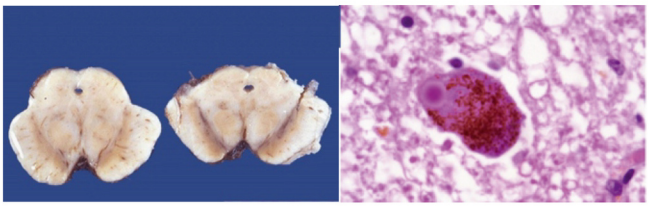

**Answer:**

- **Loss of dopaminergic neurons** in the **substantia nigra**
- Substantia nigra becomes **pale** due to loss of **melanin**
  **(Normally, brown in color- d/t melanin)**
- **Lewy bodies** present:
  - Round structures, **dark center with lighter periphery**
  - Composed of **alpha-synuclein**

### Q2.3: What is the genetic basis of Huntington's disease?

PYQ: NEET PG 2020

**Answer:**

- Caused by **CAG trinucleotide repeats**
- Located on **chromosome 4**
- Increased levels of:
  - **Huntingtin protein**
  - **Ubiquitin**
- Changes localized in the **caudate nucleus**



YOURWISH

### Q2.4: What is Amyotrophic Lateral Sclerosis (ALS)?

PYQ: NEET PG 2021

PYQ: FMGE 2019

**Answer:**

- Involves both **upper and lower motor neurons**
- Characterized by **Bunina bodies** (diagnostic inclusion bodies)

## BIG QUESTION 3: What are the pathological features and genetic markers of primary brain tumors?

**Broad Answer:**

Primary brain tumors such as pilocytic astrocytoma, glioblastoma, and oligodendroglioma each exhibit distinct age distribution, morphology, prognosis, and genetic markers. Histopathology and radiology help classify them into prognostic grades.

## DETAILED QUESTIONS

### Q3.1: What are the features of pilocytic astrocytoma (juvenile)?

PYQ: FMGE 2022

**Answer:**

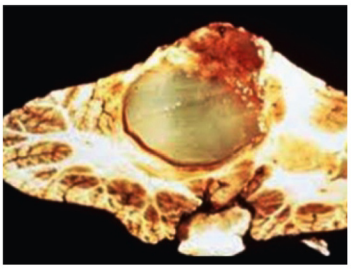

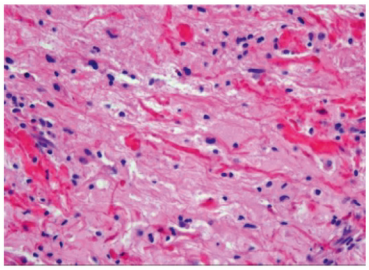

- Seen in **children**
- **Cystic tumor**
- Located in the **cerebellum**
- Caused by **BRAF mutations:**
  - **BRAF-KIAA fusion**
  - **BRAF V600E mutation**
- **Grade 1 tumor** → good prognosis
- Treatment: **Surgical removal**
- Microscopy: **Rosenthal fibers** (thin pink fibers)

### Q3.2: What are the features of glioblastoma?

PYQ: FMGE 2022

**Answer:**

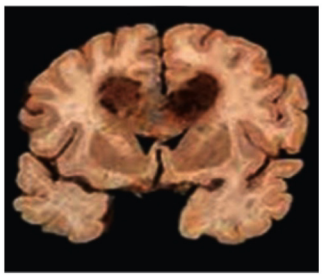

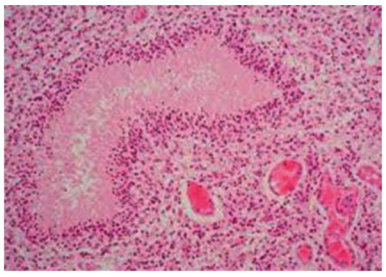

- Occurs in **adults**
- **Grade IV tumor** → very poor prognosis
- Features:
  - **Butterfly glioma**
  - **Serpentine necrosis**
  - **Pseudopalisading of tumor cells**
  - **Glomeruloid bodies**
- Gene: **IDH mutation**
  - **IDH wild-type**: 90%
  - **IDH mutant**: 10%

### Q3.3: What are the features of oligodendroglioma?

**Answer:**

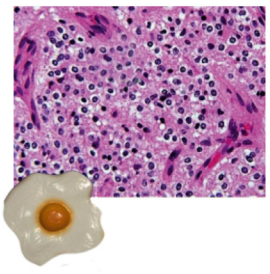

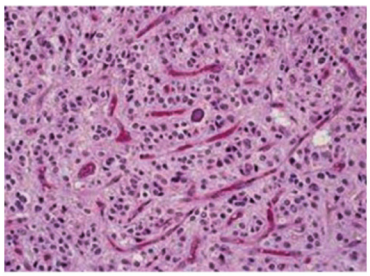

- Caused by **IDH mutations**
- Associated with **1p/19q co-deletion**
  (which means that 1 chromosome p is shorter, 19 chromosome q means longer)
- Response: **Good to chemotherapy**

- Microscopy:
  - o **Fried egg appearance** (nucleus with white halo)
  - o **Chicken wire blood vessels**
- Radiology: **Calcification**

**NOTE:** IDH mutations Enchondroma, Glioblastoma, Oligodendroglioma (: Mnemonic: I am EGOtistical)

### Q3.4: What other tumors show calcification or "fried egg" appearance?

**Answer:**

| Context | Appearance/Pattern | Tumor/Entity |
|---|---|---|
| Brain | Fried egg | Oligodendroglioma |
| BMB | Fried egg | Hairy Cell Leukemia |
| Testes/Ovary | Fried egg | Seminoma / Dysgerminoma |
| Microbiology | Fried egg colony | Mycoplasma, Malassezia furfur |
| Radiology | Calcification | Craniopharyngioma, Oligodendroglioma, Meningioma |
| Histology | Chicken wire calcification | Chondroblastoma |
| Blood vessels | Chicken wire vessels | Oligodendroglioma, Mucinous carcinoma (breast) |
| Fibrosis | Chicken wire fibrosis | Alcoholic liver disease (ALD) |

## BIG QUESTION 4: What are the features, variants, and patterns of other major brain tumors?

**Broad Answer:**

Ependymomas, medulloblastomas, and meningiomas are common CNS tumors with distinct age, site, histological features, genetic markers, and imaging findings. Variants like RELA fusion and patterns like pseudorosettes help in diagnosis.

## DETAILED QUESTIONS

### Q4.1: What are the features of ependymoma?

**Answer:**

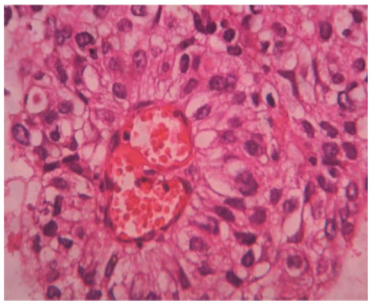

- Derived from **ependymal cells** of the **ventricle**
- **Most common site in children: Fourth ventricle** (infratentorial)
- In **adults:** More common in the **spinal cord**
- Microscopy:
  - o Shows **perivascular pseudorosettes**
  - o Central blood vessel surrounded by tumor cells
- Variant: **RELA fusion ependymoma**
  - o Associated with **chromosome 11**
  - o Found in **supratentorial** location

### Q4.2: What are the features of medulloblastoma?

PYQ: FMGE 2019

**Answer:**

- Occurs in **children**
- Located in the **cerebellum**

- **Grade 4 tumor** → poor prognosis
- **Not cystic**
- Microscopy:
  - o **Homer Wright pseudorosettes (Fake rosette)**
    → Center: **pink fibrillary material**
    → Seen in:
      - **Medulloblastoma**
      - **Ewing's sarcoma**
      - **Neuroblastoma**
      - **Retinoblastoma**
  - o **Flexner-Wintersteiner rosettes** (true rosettes)
    → Center: **white and empty**

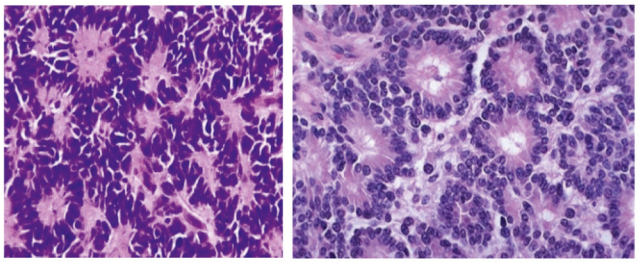

### Q4.3: What are the features of meningioma?

PYQ: FMGE 2020

**Answer:**

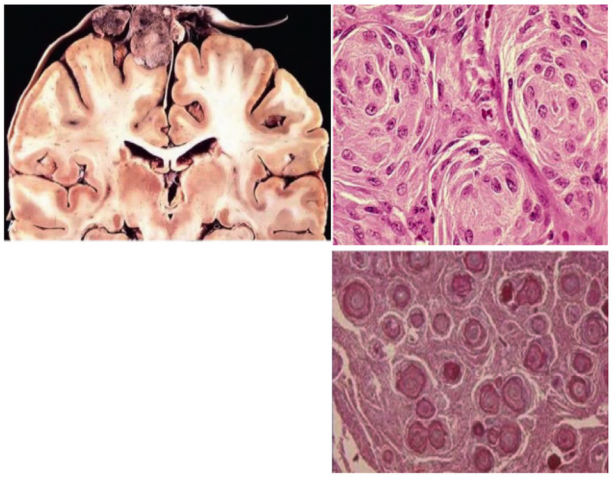

- More common in **females**
- Linked with **pregnancy or menstruation**
- **Progesterone receptor positive** → hormone responsive
- Associated with **NF2**
- Origin: **Meninges**
- Radiology: **Dural-tail / Sandwich sign**
- Pathology:
  - o **Whorled arrangement** of tumor cells
  - o Presence of **Psammoma bodies** (calcified structures)

## BIG QUESTION 5: What are the features of miscellaneous and aggressive brain tumors?

**Broad Answer:**

Various rare and aggressive brain tumors, including schwannomas, lymphomas, and gliomas, display distinct histological, genetic, and staining features. Some are associated with specific mutations (e.g., INI1, H3K27M), while others have diagnostic patterns such as palisading or angiocentric arrangements.

## DETAILED QUESTIONS

### Q5.1: What are the features of atypical teratoid/rhabdoid tumors (AT/AR)?

**Answer:**

- Mutations in the **SNF/INI gene**

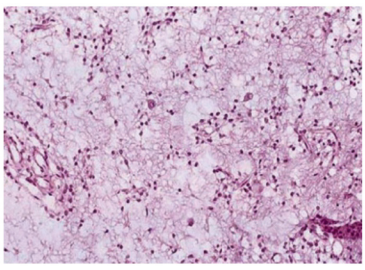

### Q5.2: What is DNET and its identifying feature?

**Answer:**

- **Dysembryoplastic neuroepithelial tumor (DNET)**
- Shows **floating neurons in pools of mucin**

### Q5.3: What are the features of schwannomas?

**Answer:**

- Associated with **NF2**
- Microscopy:
  - **Antony A areas**: Hypercellular
  - **Antony B areas**: Hypocellular
  - **Verocay bodies**: Rows of **palisading nuclei** with cytoplasm in center

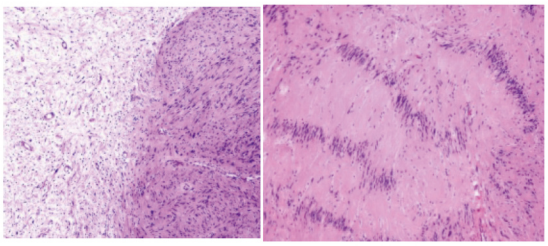

### Q5.4: Which brain tumors are associated with NF2?

**Answer:**

1. **Multiple inherited Schwannomas**
2. **Meningioma**
3. **Ependymoma**

### Q5.5: What are the features of primary CNS lymphoma?

**Answer:**

- Seen in **HIV-positive** patients
- Histology:
  - **Diffuse large B-cell lymphoma (DLBCL)**
  - **Angiocentric pattern**: Lymphoma cells arranged around blood vessels
  - **Hooping pattern**: Reticulin fibers encasing tumor cells

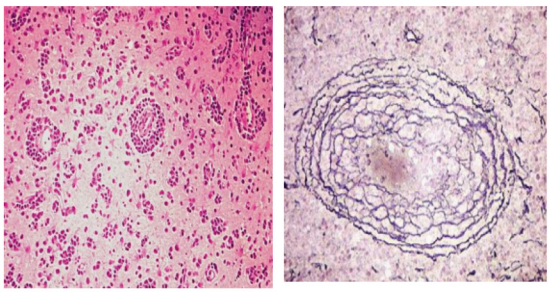

### Q5.6: What are the features of diffuse midline glioma?

**Answer:**

- Located in the **midline** of brain
- **Highly invasive** - spreads diffusely
- **Poor prognosis**
- Mutation: **H3K27M** (Histone H3 variant)

### Q5.7: What are the features of prion diseases like kuru?

**Answer:**

- Also called **Transmissible Spongiform Encephalopathy (TSE)**
- **Transmissible**, affects **brain** (encephalopathy)
- Microscopy:
  - Shows **vacuolations** (spongiform changes)
  - Characteristic **kuru plaque**
- Stains:
  - **Congo red positive**
  - **PAS positive**

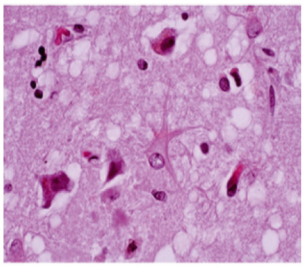

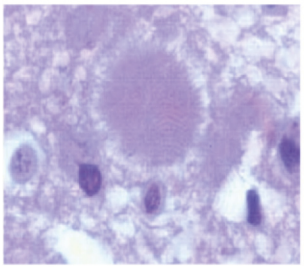

## BIG QUESTION 6: What are the diagnostic features of craniopharyngioma?

**Broad Answer:**

Craniopharyngioma is a pediatric brain tumor located in the suprasellar region. It presents with characteristic histological and anatomical findings, and may be identified intraoperatively by the release of a distinctive fluid.



YOURWISH

## DETAILED QUESTIONS

### Q6.1: Where is craniopharyngioma located and what are its clinical symptoms?

Answer:

- Located in the **suprasellar region**
- Tumor often sits on the **optic chiasm**
- Common symptoms:
  - **Vision defects**
  - **Headaches**

### Q6.2: What is the typical age of onset for craniopharyngioma?

Answer:

- Usually occurs in **children (young age)**

### Q6.3: What are the key histological features of craniopharyngioma?

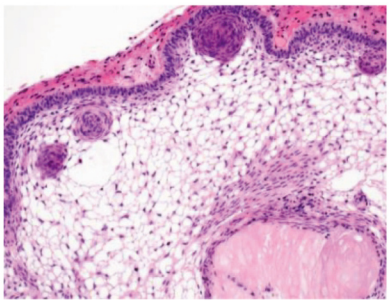

Answer:

- **Peripheral palisading** of cells
- Presence of **stellate reticulum** (loose cells)
- **Wet keratin**:
  - Pink material seen under microscope
  - On surgical removal, tumor releases **brown, machine-oil-like fluid**

# 9. CARDIAC PATHOLOGY

## BIG QUESTION 1: What are the biochemical markers and laboratory findings relevant to myocardial infarction?

**Broad Answer:**

- In myocardial infarction (MI), various cardiac enzymes and markers help diagnose, time, and monitor heart muscle injury.
- Key markers include myoglobin, troponins, CK-MB, AST/SGOT, and LDH, each rising and falling at characteristic times.
- Additional markers aid in detecting reinfarction and early ischemic injury.

## DETAILED QUESTIONS

### Q1.1: Which cardiac enzymes are elevated in myocardial infarction?

PYQ: FMGE 2019

**Answer:**

- Myoglobin (non-specific)
- Troponin T
- Troponin I (more important)
- CK-MB
- AST (SGOT)
- LDH-1

### Q1.2: What is the significance of the LDH-1 to LDH-2 ratio in MI?

**Answer:**

- Normally, LDH-2 > LDH-1
- In MI, the ratio reverses → **LDH-1 > LDH-2** (called "flipping" of LDH ratio)

### Q1.3: What are the timing characteristics (start, peak, fall) of cardiac enzymes in MI?

**Answer:**

| Cardiac Enzyme | Start | Peak | Fall |
|---|---|---|---|
| Myoglobin | 2 hrs | - | 24 hrs |
| Troponin | 2-4 hrs | 48 hrs | 7-10 days |
| CK-MB | 2-4 hrs | 24 hrs | 48-72 hrs |
| AST/SGOT | <12 hrs | 48 hrs | 4-5 days |
| LDH1 | 24 hrs | 4-5 days | After 10 days |

### Q1.4: What markers are useful for detecting reinfarction or early ischemia?

**Answer:**

- Marker of reinfarction: Troponin T, Troponin I
- Earlier markers than myoglobin:
  - Ischemia Modified Albumin (IMA)
  - Heart fatty acid binding protein (HFABP)

## BIG QUESTION 2: What are the morphological and histological changes observed in myocardial infarction?

**Broad Answer:**

- Morphological changes in MI progress through specific stages visible under gross and microscopic examination.
- Early ultrastructural changes occur within minutes. Special stains like TTC identify infarcts grossly.
- Reperfusion injury can produce distinctive contraction band necrosis due to sudden calcium influx after restoring blood flow.

## DETAILED QUESTIONS

### Q2.1: What is the earliest change seen in myocardial infarction?

PYQ: FMGE 2023

**Answer:**

- Earliest change: Relaxation of myofibrils and mitochondrial swelling
- Seen on electron microscopy
- Occurs in < 30 minutes

### Q2.2: What is the first change visible on light microscopy in MI?

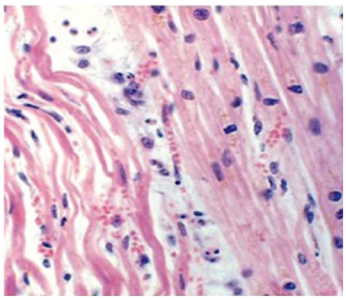

**Answer:**

- Seen between **30 minutes - 4 hours**
- Findings:
  - **Waviness** of cardiac muscle fibers
  - **Vacuolization** of muscle fibers

### Q2.3: When does the first gross change appear in MI, and what does it look like?

**Answer:**

- Occurs **> 4 hours** after infarction
- Appearance: **Occasional mottling** of the myocardium

### Q2.4: What type of necrosis occurs in MI, and what stain is used for gross diagnosis?

**Answer:**

- Necrosis type: **Coagulative necrosis**
- Gross stain: **Triphenyl tetrazolium chloride (TTC)**
  - TTC stains **LDH1**
  - Normal myocardium → brick red
  - Infarcted area → pale
  - Useful for infarcts older than **4 hours**
- Pearly white scar = old myocardial infarction

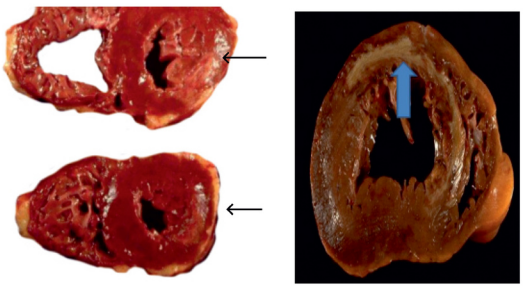

### Q2.5 What tissue change occurs around day 7 of healing, leading eventually to scar formation?

**Answer:**

- Granulation of tissue starts on the 7th day.
- These are rich in blood vessels.
- After 10 days, scar formation starts.
  - o Stain: Masson Trichrome
  - o Red: Muscle
  - o Blue: Collagen

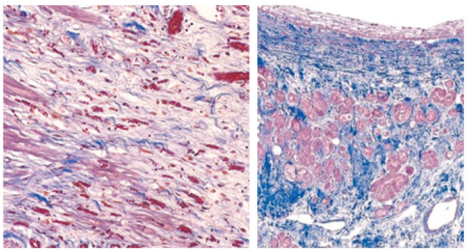

**Q2.6: What is reperfusion injury, and what histological change is seen?** PYQ: NEET PG 2020

**Answer:**

- Occurs when blood flow is restored after a clot is removed
- Mechanism:
  - o Generation of free radicals
  - o Sudden influx of calcium → hypercontracture of myocytes
- Histological finding: **Contraction band necrosis**

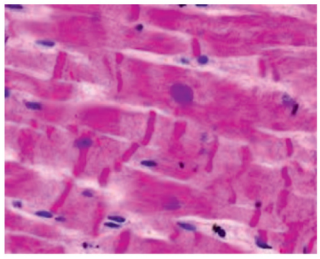

**Q2.7: Autopsy diagnosis of myocardial infarction can be confirmed using which stain?** PYQ: FMGE 2020

A. Triphenyl tetrazolium chloride
B. 100% alcohol
C. Orcein stain
D. Crystal violet

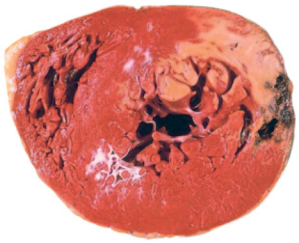

**Answer: A. Triphenyl tetrazolium chloride**

- Infarcted tissue → pale
- Normal tissue → brick red

**Q2.8: A 61-year-old female patient presents with left-sided chest pain and radiation to the left arm and jaw. The patient explains that the pain has increased severely over the past 40 minutes. She is immediately rushed to the hospital. Cardiac enzymes are elevated. The patient was admitted and started on thrombolytic therapy. However, on the 5 day of observation, she suddenly collapses and dies. Which of the following necrosis are you most likely to find in this patient's heart?**

A. Liquefactive necrosis
B. Coagulative necrosis
C. Fat necrosis
D. Fibrinoid necrosis

**Answer: B. Coagulative necrosis**

## BIG QUESTION 3: What are the different types and features of carditis?

**Broad Answer:**

- Carditis refers to inflammation of different layers of the heart, including the pericardium, myocardium, and endocardium.
- Each type has specific causes, pathological features, and clinical associations such as infections, autoimmune disorders, and systemic diseases.

## DETAILED QUESTIONS

**Q3.1: What are the features of pericarditis?**



YOURWISH

YOURWISH

**Answer:**

- Serofibrinous pericarditis is also known as bread-and-butter pericarditis.
- It is seen in rheumatic heart disease.
- Analogy:
  - Two pieces of bread = pericardium
  - Butter = fluid between them

### Q3.2: What are the causes of myocarditis?

PYQ: AIIMS 2021

**Answer:**

- Viral infections: Coxsackievirus, Herpes virus
- Parasitic infections: Trichinella spiralis

### Q3.3: What are the causes and types of endocarditis?

**Answer:**

- Rheumatic heart disease (Group A ß-hemolytic streptococcus)
- Infective endocarditis:
  - Streptococcus viridans
  - Staphylococcus species
  - Coagulase-negative Staphylococcus → associated with prosthetic heart valves
- Non-bacterial thrombotic endocarditis (NBTE) / marantic endocarditis:
  - Seen in AML M3
  - Associated with lung and pancreatic cancers
- Libman-Sacks endocarditis:
  - Seen in systemic lupus erythematosus (SLE)

### Q3.4: What are the features of vegetations in different types of endocarditis?

**Answer:**

PYQ: INICET 2023 PYQ: NEET PG 2021 PYQ: FMGE 2020,2021,2022

| Type of Endocarditis | Vegetation Characteristics | Embolization | Sterility |
|---|---|---|---|
| Rheumatic Heart Disease | Small, warty; along lines of valve closure  | - | Sterile |

| | | | |
|---|---|---|---|
| Infective Endocarditis | Large, bulky; extends downward, damaging chordae tendineae/papillary muscles  | +/- | Non-sterile (bacterial) |
| NBTE / Marantic | Small, friable  | +++ | Sterile |
| Libman-Sacks Endocarditis (LSE) | Vegetations present on both valve surfaces, more commonly lower surface  | - | Sterile |

**Q3.5: What are key clinical criteria for diagnosing infective endocarditis?**

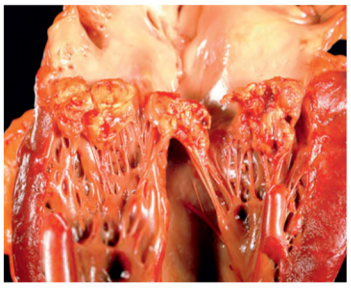

**Answer:** Modified dukes criteria of Infective endocarditis

- Major criteria:
  - Blood culture positive (2 cultures taken 12 hours apart)
- Minor criteria:
  - Fever
  - Immunological phenomena:

- Roth spots (retinal emboli)
- Osler nodes (painful subcutaneous nodules)
- Microbiological evidence
- Vascular phenomena:
- Janeway lesions (seen on palms and soles)
- Predisposing factors, e.g. IV drug abuse

PYQ: FMGE 2022 PYQ: AIIMS 2023 PYQ: NEET PG 2020

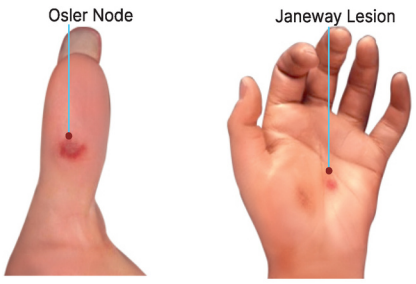


- Diagnostic criteria:
  - 2 Major OR
  - 1 Major + 3 Minor OR
  - 5 Minor
- Most commonly affected valve:
  - Mitral valve (left-sided disease)
- IV drug abusers:
  - More commonly affects right-sided valves

## BIG QUESTION 4: What are the pathological features and complications of rheumatic heart disease (RHD)?

**Broad Answer:**

- Rheumatic heart disease (RHD) is a consequence of rheumatic fever caused by Group A β-hemolytic streptococcal infection.
- It affects multiple heart valves, producing characteristic lesions and complications including valve deformities, heart failure, and systemic effects.

## DETAILED QUESTIONS

### Q4.1: Which valves are most and least commonly involved in RHD?

**Answer:**

- Most commonly involved valve: Mitral valve
- Least commonly involved valve: Pulmonary valve

### Q4.2: What are the differences between acute and chronic RHD?



**Answer:**

- Acute RHD:
  - Main lesion: Mitral regurgitation
  - Characteristic feature:
  - Posterior wall of the left atrium shows irregular area called Maccallum patch
- Chronic RHD:
  - Main lesion: Mitral stenosis
  - Characteristic appearance:
  - Fish mouth or buttonhole valve
- ***Note*:** "Fish mouth vertebrae" is a term used in osteoporosis and sickle cell anemia, not related to RHD valves.

### Q4.3: What is the most characteristic histological lesion in RHD?

**Answer:**

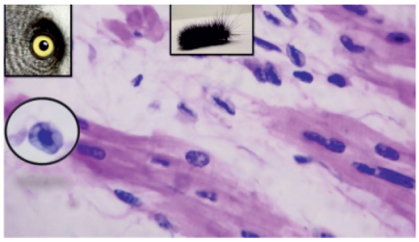

- **Aschoff bodies:**
  - Fibrinoid necrosis surrounded by **Anitschkow cells**
  - Anitschkow cells may appear:
  - Like a caterpillar (elongated chromatin)
  - Or as an owl-eye appearance
- Distribution:
  - Found in all three layers of the heart
  - Maximum presence in the myocardium

### Q4.4: What is the Maccallum patch in RHD?

**Answer:**

- Maccallum patch:
  - Irregular endocardial thickening in the posterior wall of the left atrium
    Resulting from regurgitant jet injury in acute RHD

### Q4.5: What are complications associated with RHD?

**Answer:**

- Chronic valve deformities → Heart failure
- Thromboembolism
- Infective endocarditis superimposed on damaged valves

## BIG QUESTION 5: What are the types and pathological features of cardiomyopathies?

**Broad Answer:**

- Cardiomyopathies are diseases of the heart muscle, classified as dilated, hypertrophic, restrictive, or arrhythmogenic types.
- They vary in etiology, genetic associations, and pathological changes affecting heart chambers, muscle fibers, and overall cardiac function.

## DETAILED QUESTIONS

### Q5.1: What are the key features of Dilated Cardiomyopathy (DCM)?

**Answer:**

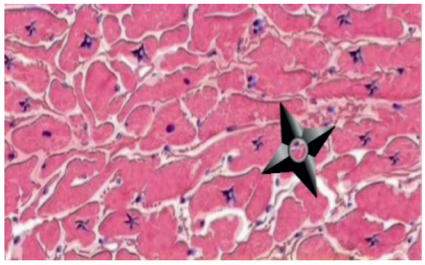

- Chambers: All four chambers dilated
- Most common cause:
  - Idiopathic
  - Alcohol
  - Titin gene mutation
- Microscopic:
  - "Ninja star" nucleus in Titin gene mutation
- ***Note***:
  - Titin is the largest protein in the body



YOURWISH

## Q5.2: What is Takotsubo Cardiomyopathy and its features?

PYQ: NEET PG 2019

**Answer:**

- Also known as Broken Heart Syndrome
- Triggered by emotional stress → rise in catecholamines
- Only the left ventricle is dilated

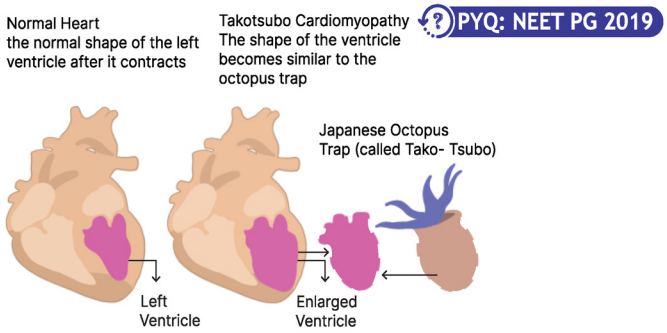


## Q5.3: What are the pathological features of Hypertrophic Cardiomyopathy (HDCM)?

PYQ: FMGE 2020

**Answer:**

- Genetic:
  - Autosomal dominant inheritance
  - Mutation in β-myosin heavy chain (β MHC)
- Pathology:
  - Hypertrophy of the interventricular septum
  - Left ventricle becomes narrowed
- Clinical:
  - Sudden cardiac death in young athletes
  - Family history common
- Gross:
  - Banana-shaped heart
- Microscopic:
  - Helter-skelter (disorganized) arrangement of cardiac fibers

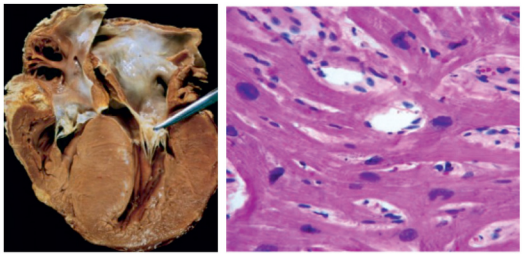

## Q5.4: What is Arrhythmogenic Right Ventricular Cardiomyopathy (ARVCM)?

**Answer:**

- Mutation in desmosomes
- Right ventricle pathology:
  - Yellow fat infiltration
  - Thinned ventricular wall
- Syndrome:
  - Naxos syndrome (Plakoglobin gene defect)
  - Wooly hair
  - Palmoplantar keratosis
  - ARVCM

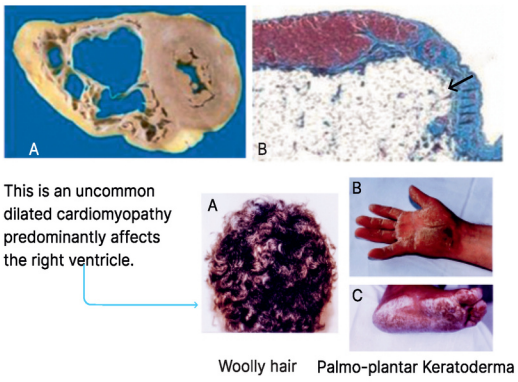


## Q5.5: What are features of Restrictive Cardiomyopathy?

**Answer:**

- Characterized by diastolic dysfunction
- Most common cause: Amyloidosis
- Hemochromatosis:
  - Can cause both dilated and restrictive cardiomyopathy
  - Dilated cardiomyopathy more common than restrictive in hemochromatosis

**Q5.6: A 19-year-old college basketball player suddenly collapses on the court. A cardiac monitor shows ventricular tachycardia and then ventricular fibrillation. He is successfully resuscitated and hospitalized. The patient's history indicates that his father died suddenly at 38 years of age. The boy's echocardiogram reveals a thickened left ventricular wall with a small slit-like chamber. The interventricular septum is also markedly thickened. Five years later, the patient expires suddenly. Histologic examination of the heart muscle at autopsy is shown in the image. Which of the following is the most likely diagnosis?**

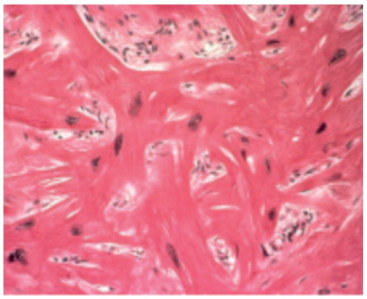

A. Amyloidosis
B. Cardiac myxoma
C. Dilated cardiomyopathy
D. Hypertrophic cardiomyopathy

**Answer:** D. Hypertrophic cardiomyopathy

- The helter-skelter disarray of myocardial fibers and family history point toward HDCM.

## BIG QUESTION 6: What are the types and key features of cardiac tumors?

**Broad Answer:**

- Cardiac tumors may be primary (originating in the heart) or secondary (metastases from other sites).
- Primary tumors are rare and may be benign or malignant, with differing predilections for age groups and cardiac chambers.
- The most common cardiac tumor overall is metastatic involvement.

## DETAILED QUESTIONS

**Q6.1: What is the most common cardiac malignancy?**

**Answer:**

- Metastasis (tumors spreading to the heart from other organs)

**Q6.2: What is the most common primary cardiac tumor in adults and children?**

**Answer:**

| | Adults | Children |
|---|---|---|
| **Benign** | Myxoma | Rhabdomyoma |
| **Malignant** | Angiosarcoma | Rhabdomyosarcoma |

**Q6.3: What is the most common primary cardiac valve tumor?**



**Answer:**

- Papillary fibroelastoma
  - Appearance: Sea anemone-like projections

**Q6.5: What are the features of cardiac myxoma and rhabdomyoma?**

**Answer:**

PYQ: NEET PG 2019 PYQ: FMGE 2020

| Feature | Myxoma | Rhabdomyoma |
|---|---|---|
| Age group | Adults | Children |
| Chamber | Left atrium | Left ventricle |
| Cell type | Lepidic cells 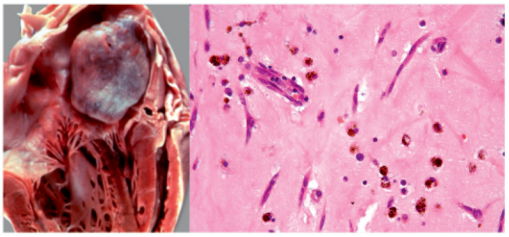 | Spider cells with glycogen, PAS+ 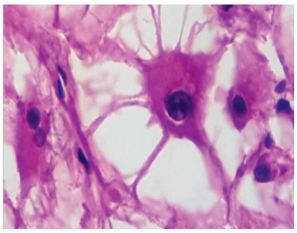 |
| Associated syndrome | Carney complex (GNAS mutation) | Tuberous sclerosis |

## BIG QUESTION 7: What are the pathological features of heart failure?

**Broad Answer:**

- Heart failure pathology differs between left-sided and right-sided failure.
- Left-sided failure leads to pulmonary congestion, while right-sided failure affects systemic organs such as the liver and spleen.
- Characteristic histological findings include heart failure cells in the lungs and nutmeg liver in chronic venous congestion.

## DETAILED QUESTIONS

### Q7.1: What are heart failure cells and where are they found?

**Answer:**

- Seen in the lungs due to left-sided heart failure
- They are hemosiderin-laden macrophages
- Stain used: Perl's/Prussian blue stain



### Q7.2: What organs are affected in right-sided heart failure?

**Answer:**

- Liver → chronic venous congestion → Nutmeg liver
- Spleen → congestion → Gamma Gandy bodies

### Q7.3: What is nutmeg liver and how does it appear histologically?

**Answer:**

- Appearance due to chronic venous congestion of the liver
- Histological findings:
  - Dilated and congested hepatic venules
  - Centrilobular hemorrhagic necrosis of hepatocytes
  - Light areas → fatty change
  - Dark areas → hemorrhagic necrosis



YOURWISH

### Q7.4: What are gamma Gandy bodies?

**Answer:**

- Seen in spleen in chronic congestion
- Represent fibrous nodules with hemosiderin deposition

### Q7.5: What differences exist between left and right heart failure regarding congestion?

**Answer:**

| Aspect | Left-sided HF | Right-sided HF |
|---|---|---|
| Main effect | Pulmonary congestion | Systemic venous congestion |
| Histological feature | Heart failure cells (lungs) | Nutmeg liver, gamma Gandy bodies |
| Organs commonly involved | Lungs | Liver, spleen |



YOURWISH

# 10. VASCULAR PATHOLOGY

## BIG QUESTION 1: What are the structural and cellular components of blood vessels?

**Broad Answer:**

- Blood vessels are lined by endothelial cells which have specific markers and organelles relevant to vascular function.

## DETAILED QUESTIONS

### Q1.1: What lines the inside of blood vessels and what marker identifies it?

**Answer:**

- Blood vessels are lined by **endothelial cells.**
- Endothelial cells are **CD34 positive.**

### Q1.2: What unique structures are present in endothelial cells?

**Answer:**

- Endothelial cells contain **Weibel-Palade bodies.**
- Weibel-Palade bodies contain:
  - **Von Willebrand Factor (VWF)**
  - **P-selectins**

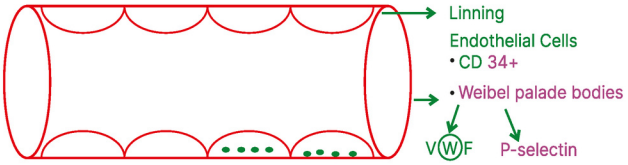


## BIG QUESTION 2: What are the types and features of large vessel vasculitis?

**Broad Answer:**

- Large vessel vasculitis includes **Temporal Arteritis** and **Takayasu Arteritis**, both involving granulomatous inflammation of major arteries with age-specific and vessel-specific involvement.

## DETAILED QUESTIONS

### Q2.1: What are the two major types of large vessel vasculitis?

**Answer:**

- Temporal Arteritis (Giant Cell Arteritis)
- Takayasu Arteritis (Aorto Arteritis / Pulseless Disease)

### Q2.2: What are the key features of Temporal Arteritis?

PYQ: FMGE 2020

**Answer:**

- Age: >50 years
- Vessel involved: **Superficial temporal artery**
- Most common symptom: **Localized unilateral throbbing headache**
- Most specific symptom: **Jaw claudication**
- Most dangerous symptom: **Loss of vision**

- On exam: Nodular, tender superficial temporal artery
- Microscopy: **Granuloma with multinucleated giant cells**, fragments of **internal elastic lamina**
- Special stain: **VVG stain** for elastic lamina
- **Steroids should be started immediately** to prevent vision loss


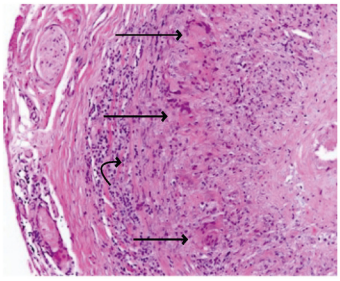
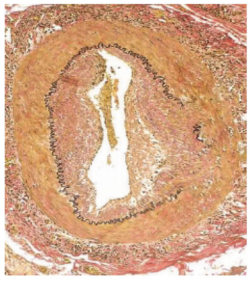

### Q2.3: What are the key features of Takayasu Arteritis?

PYQ: NEET PG 2021 PYQ: FMGE 2021

**Answer:**

- Age: <50 years
- Vessel involved: **Subclavian artery** (most common)
- Clinical: **Pulselessness** (e.g., radial pulse absent, femoral normal)
- Pathology: **Intimal thickening**, **narrowed lumen** on cross-section
- Also called: **Aorto arteritis / Pulseless disease**

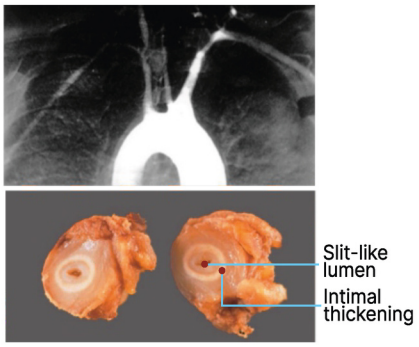


## BIG QUESTION 3: What are the types and features of medium vessel vasculitis?

**Broad Answer:**

- Medium vessel vasculitis affects medium-sized arteries and includes **Polyarteritis Nodosa (PAN), Kawasaki Disease, and Buerger's Disease**, each with distinct clinical and pathological features.

## DETAILED QUESTIONS

### Q3.1: What are the medium vessel vasculitis diseases?

**Answer:**

- Polyarteritis Nodosa (PAN)
- Kawasaki Disease (Mucocutaneous lymph node syndrome)
- Buerger's Disease (Thromboangiitis obliterans)

### Q3.2: What are the features of Polyarteritis Nodosa (PAN)?

PYQ: NEET PG 2019

**Answer:**

- Affects medium vessels
- Most commonly involves **renal vessels** → flea-bitten kidney
- Spares pulmonary circulation → **no glomerulonephritis**
- Associated with **Hepatitis B surface antigen (HBsAg)** in 30% of cases
- Microscopy: **Fibrinoid necrosis**

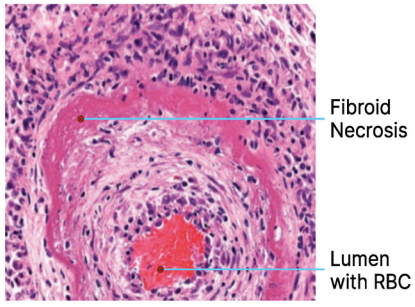

### Q3.3: What are the features of Kawasaki Disease?

PYQ: NEET PG 2020

**Answer:**

- Also known as **Mucocutaneous lymph node syndrome**
  - Age: Mostly <5 years old
  - Diagnostic criteria: **Fever plus ≥4 of CREAM criteria:**
    - Conjunctivitis (non-purulent)
    - Rash
    - Edema
    - Adenopathy (mostly unilateral cervical)
    - Mucosal involvement (**Strawberry tongue**)
  - **Strawberry tongue** seen in Kawasaki disease and Scarlet fever
  - Pathogenesis: **Anti-endothelial cell antibodies** positive
  - Lab: **Thrombocytosis** (↑ platelets)
  - Most significant complication: **Coronary artery aneurysm → myocardial infarction**
  - Vasculitis causing the most deaths in children.



Strawberry Tongue

### Q3.4: What are the features of Buerger's Disease?

**Answer:**

- Also called **Thromboangiitis obliterans**
- Strongly associated with **smoking**
- Involves arteries, veins, and nerves → **obliteration**
- Symptoms:
  - **Intermittent claudication**
    (pain on exertion due to vessel involvement)
  - **Pain at rest** (d/t gradual involvement of nerves)
- Causes **thrombosis → blocked blood flow**
- Lymphatic channels **not affected**
- Treatment: **Smoking cessation**
- Buerger's = vasculitis; **Berger's = IgA nephropathy**

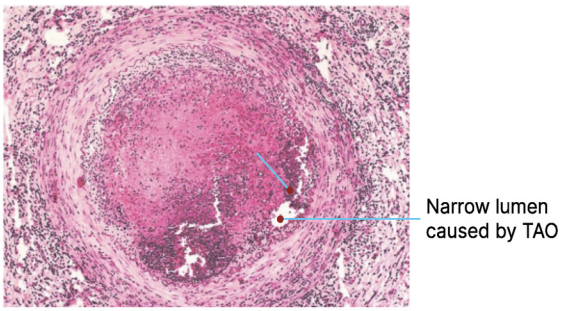


## BIG QUESTION 4: What are the types and features of small vessel vasculitis?

**Broad Answer:**

- Small vessel vasculitis includes **Henoch-Schönlein Purpura (HSP)** and various **ANCA-associated vasculitides**, each with unique causes, clinical manifestations, and microscopic findings.

## DETAILED QUESTIONS

### Q4.1: What are the main types of small vessel vasculitis?

PYQ: FMGE 2023

**Answer:**

- Henoch-Schönlein Purpura (HSP)
- Wegener's Granulomatosis (Granulomatosis with polyangiitis)
- Microscopic polyangiitis
- Churg-Strauss syndrome (Eosinophilic granulomatosis with polyangiitis)

### Q4.2: What are the features of Henoch-Schönlein Purpura (HSP)?

**Answer:**

- IgA-mediated vasculitis
- Occurs mostly in **children**
  - Most common vasculitis in children
- Platelet count: **Normal or increased**
- Clinical features (**PAARPura mnemonic**):
  - **P**urpura (rash, usually lower limbs)
  - **A**rthralgia
  - **A**bdominal pain
  - **R**enal involvement (**hematuria**) → Most commonly affected organ

### Q4.3: What are the features of Wegener's Granulomatosis (Granulomatosis with polyangiitis)?

**Answer:**

- Involves two triads:
- **First triad:**
  - Kidneys (**RPGN III**)
  - Blood vessels
  - Lungs
- **Second triad:**
  - Otitis media (ear)
  - Nasal septal perforation (nose)
  - Strawberry gums (throat)
- Associated with **C-ANCA (PR3 ANCA)** predominantly




### Q4.4: What are the features of Microscopic Polyangiitis?

**Answer:**

- Also called **leukocytoclastic vasculitis**
- Considered the **opposite of PAN**:
  - No Hepatitis B association
  - **Pulmonary vessels involved**
  - **Glomerulonephritis present**
  - No granulomas
- Microscopy: Shows **leukocytoclastic vasculitis**

### Q4.5: What are the features of Churg-Strauss Syndrome?

**Answer:**

- Also known as **Eosinophilic Granulomatosis with polyangiitis**
- Marked **eosinophilia in blood**
- Causes **cardiac complications** (common cause of death)

## BIG QUESTION 5: What is the role of ANCA and how is ANCA-associated vasculitis classified?

**Broad Answer:**

- ANCA (Anti-Neutrophil Cytoplasmic Antibodies) are autoantibodies directed against proteins in neutrophil



YOURWISH

granules. ANCA-associated vasculitis, also known as pauci-immune vasculitis, involves small vessel inflammation without significant immune complex deposition.

- There are two major types of ANCA patterns and associations with specific diseases.

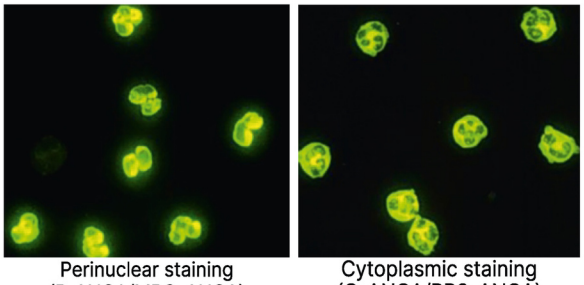

Perinuclear staining (P-ANCA/MPO-ANCA) | Cytoplasmic staining (C-ANCA/PR3-ANCA)

## DETAILED QUESTIONS

### Q5.1: What does ANCA stand for and what is its significance?

**Answer:**

- **ANCA = Anti-Neutrophil Cytoplasmic Antibodies**
- They are autoantibodies directed against cytoplasmic components of neutrophils and monocytes.
- Important in diagnosing and classifying certain types of small vessel vasculitis.

### Q5.2: What are the types of ANCA and their full forms?

**Answer:**

- **C-ANCA:** Cytoplasmic ANCA → now known as **PR3 ANCA**
- **P-ANCA:** Perinuclear ANCA → now known as **MPO ANCA** *(Mnemonic: CPR)*

### Q5.3: Which vasculitis is associated with C-ANCA predominantly?

**Answer:**

- Wegener's Granulomatosis (Granulomatosis with Polyangiitis)
- ***Note***: Wegener's can show both P-ANCA and C-ANCA, but **C-ANCA is more common.**

### Q5.4: In which gastrointestinal diseases is P-ANCA seen?

**Answer:**

- **Ulcerative colitis >> Crohn's disease**

### Q5.5: Where is P-ANCA seen in liver disease?

**Answer:**

- **Primary Sclerosing Cholangitis**

### Q5.6: Why is ANCA-associated vasculitis called pauci-immune?

**Answer:**

- Because these conditions feature minimal or no immune complex deposition in vessel walls, differentiating them from immune-complex vasculitis.

## BIG QUESTION 6: What are the various types of sclerosis and atherosclerosis in vascular pathology?

**Broad Answer:**

- Sclerosis refers to stiffening or thickening of blood vessels and tissues.
- It has multiple forms, including hyaline, hyperplastic, Monckeberg's sclerosis, and atherosclerosis.
- Atherosclerosis involves lipid deposition, inflammation, and plaque formation within arterial walls, leading to significant vascular complications.

## DETAILED QUESTIONS

### Q6.1: What is hyaline arteriolosclerosis, and where is it seen?

**Answer:**

- Blood vessels appear **pink and glassy** under microscopy.
- Seen in **benign hypertension** and **diabetes mellitus**.

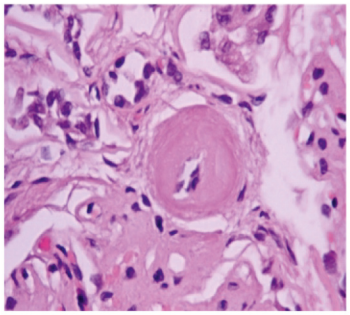

### Q6.2: What characterizes hyperplastic arteriolosclerosis?

**Answer:**

- Shows **onion-skin appearance** under the microscope.
- Due to increased smooth muscle and fibroblasts.
- Seen in **malignant hypertension**.

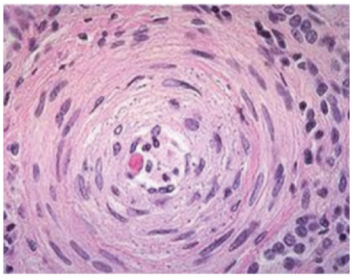

### Q6.3: Describe Monckeberg's sclerosis.

**Answer:**

- Also called **Calcific Medial Degeneration**.
- Characterized by **dystrophic calcification** in the **tunica media**.
- Occurs with **old age**.
- No significant clinical consequences.

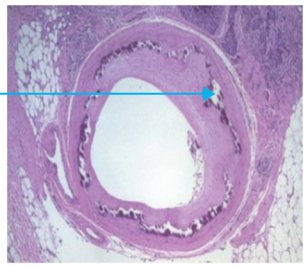


### Q6.4: What infections are linked with the development of atherosclerosis?

**Answer:**

- Chlamydia
- CMV (Cytomegalovirus)
- Herpes virus

### Q6.5: What is the sequence of lesions in atherosclerosis?

**Answer:**

- **First lesion:** Fatty streaks (1-2 mm)
- **Second lesion:** Atheromatous plaques composed of cholesterol and triglycerides.

### Q6.6: Where in the arterial wall are atheromatous plaques found?

**Answer:**

- Located **subintimally** (under the intimal layer of the vessel wall).

### Q6.7: What cells are seen microscopically in atherosclerosis?

**Answer:**

- **Foam cells** (lipid-laden macrophages)
- Stain **positive with Oil Red.**

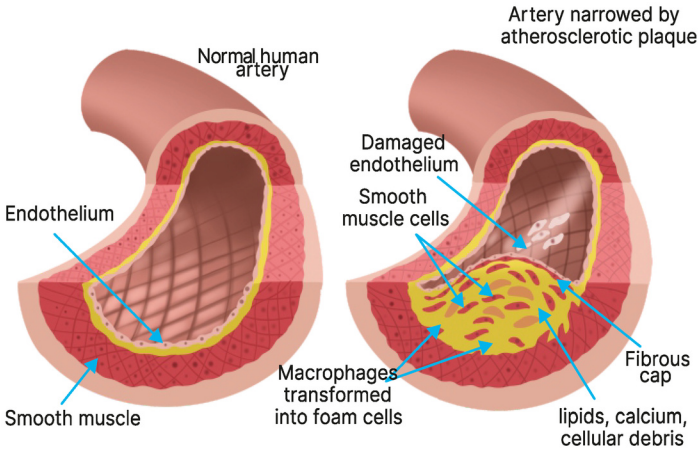


### Q6.8: List complications of atherosclerosis.

**Answer:**

*(Mnemonic: ACUTE)*

- **A:** Aneurysm
- **C:** Calcification
- **U:** Ulceration
- **T:** Thrombosis
- **E:** Embolism

### Q6.9: Which vessels are most commonly affected in atherosclerosis?

**Answer:**

- **A:** Abdominal aorta → most common
- **C:** Coronary arteries
- **P:** Popliteal arteries
- **Delhi Traffic:** Descending thoracic aorta
- **Is:** Internal carotid arteries
- **Cute:** Circle of Willis → least common

## BIG QUESTION 7: What are the different types of vascular tumors and their key features?

**Broad Answer:**

- Vascular tumors are classified into benign, intermediate, and malignant types.
- They vary in clinical presentation, microscopic features, and associated syndromes or infections.
- Correct identification is crucial for diagnosis and treatment.

## DETAILED QUESTIONS

### Q7.1: Which tumors are included under benign vascular tumors, and what are their features?

**Answer:**

- **Capillary hemangiomas:**
  - Superficial sites (skin, mucosa)
  - Composed of small blood vessels.



YOURWISH

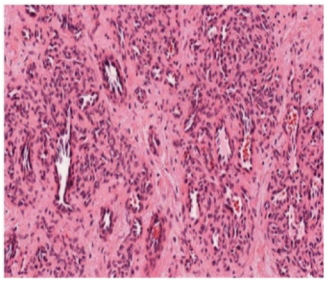

- **Cavernous hemangiomas:**
  - Deep-seated (organs, liver, deep tissue)
  - Large, dilated blood vessels.
  - Associated with **Von Hippel Lindau (VHL) syndrome.**

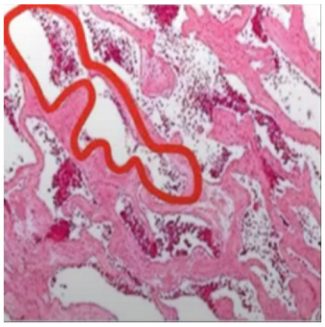

- **Pyogenic granuloma (Granuloma gravidarum/Pregnancy tumor):**
  - Lobular capillary hemangioma.
  - Common in **oral cavity, fingers.**



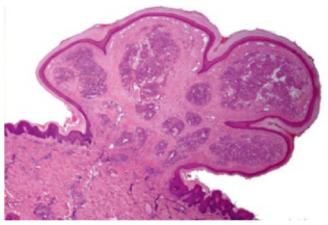

- **Lymphangioma:**
  - Tumor of lymphatic channels.
  - When present in the neck → **Cystic hygroma.**
  - Seen in **Turner's syndrome (45,X0).**
- **Glomus tumor:**
  - Arises in **subungual region (nail bed).**
  - **Extremely painful.**
  - Originates from glomus bodies.



- **Bacillary angiomatosis:**
  - Caused by **Bartonella henselae.**
  - Positive for **Warthin-Starry Silver Stain (WSSS).**
  - Bartonella also causes **cat scratch disease.**



**Q7.2: What is Kaposi sarcoma, and what are its key features?**

**Answer:**

- An **intermediate vascular tumor.**
- Caused by **HHV-8 virus.**
- Associated with **HIV/AIDS.**
- Immunohistochemistry (IHC): Positive for **LANA (Latency-associated nucleic acid).**

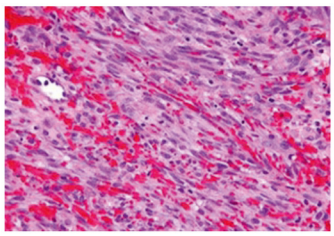



YOURWISH

YOURWISH

- Most common site: **Cutaneous purple lesions** on lower limbs.
- Second most common site: **Lymph nodes.**
- Microscopy: Presence of **spindle cells.**

**Q7.3: Describe angiosarcoma.**

**Answer:**

- A **malignant vascular tumor.**
- Seen in **liver** due to exposure to:
  - Vinyl chloride (PVC)
  - Arsenic (pesticides)
  - Thorotrast (thorium contrast dye)

**Q7.4: What is hemangiopericytoma and its unique microscopic appearance?**

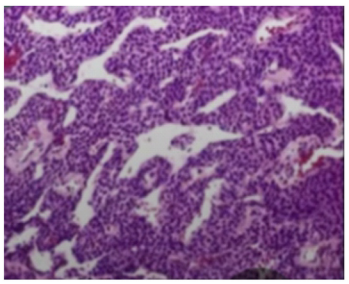

**Answer:**

- Malignant tumor.
- Blood vessels appear as **horns of a deer** → described as **stag horn/fish hook blood vessels.**

**Q7.5: A 45-year-old male patient presents with a subungual mass of 1×1 cm. Patient complains of excruciating pain. What is the most likely diagnosis?**

A. Pyogenic granuloma
B. Glomus tumour
C. Hemangiopericytoma
D. Bacillary angiomatosis

**Answer: B. Glomus tumour**

- Extremely painful, arises under the nail bed (subungual).
- Different from pyogenic granuloma, which is linked to pregnancy.
- Hemangiopericytoma shows stag horn vessels.
- Bacillary angiomatosis is associated with Bartonella henselae.

# 11. LUNG PATHOLOGY

## BIG QUESTION 1: What are the types, features, and pathology of Obstructive Lung Diseases?

**Broad Answer:** Obstructive lung diseases involve increased airway resistance and difficulty in exhaling air.

- Major types include COPD (Emphysema and Chronic Bronchitis), Asthma, and Bronchiectasis, each with unique causes, pathological features, and clinical findings.

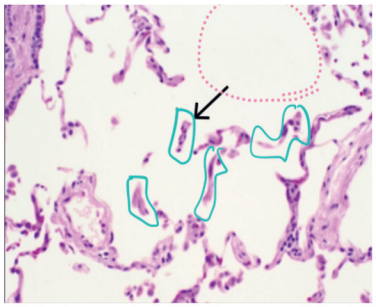

The image shows walls are not joined -floating septa

## DETAILED QUESTIONS

### Q1.1: What are the types and features of Chronic Obstructive Pulmonary Disease (COPD)?

**Answer:**

- Includes Emphysema (pink puffers) and Chronic Bronchitis blue bloaters.
- Common cause: Smoking.
- Permanent damage to airways distal to terminal bronchioles:
  - Respiratory Bronchiole
  - Alveolar duct
  - Alveolar sac

### Q1.2: What are the types and differences among emphysema patterns?

PYQ: NEET PG 2019

**Answer:**

| Type | Etiology | Location | Structures Affected | Clinical |
|---|---|---|---|---|
| **Centriacinar**  | Smoking | Upper lobes | Respiratory bronchiole<br>The Alveoli duct and sac are saved | Most common clinically |
| **Panacinar** 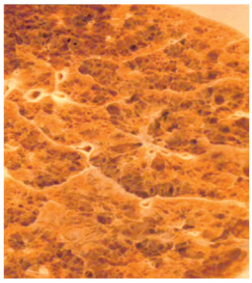 | α-1 antitrypsin deficiency | Lower lobes | All alveolar structures damaged | |

| | | | | |
|---|---|---|---|---|
| **Distal Acinar (Paraseptal)** 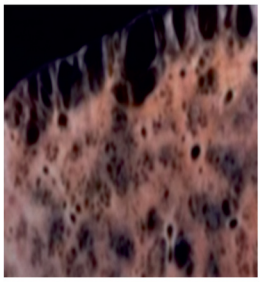 | Spontaneous pneumothorax | - | Alveolar duct & sac damaged; Respiratory bronchiole spared | |
| **Irregular** | Scarring | - | Variable | Most common histologically |

- Emphysema clinical features:
  - Associated with cor pulmonale.
  - Radiologically: Flattening of diaphragm.
  - Pink puffers.

**Q1.3: What defines Chronic Bronchitis, and what are its pathological features?** PYQ: FMGE 2022,2023

**Answer:**

- Productive cough:
  - For at least 3 months in 2 consecutive years.
- Smoking-related:
  - ↑Mucus production.
  - Increased risk of infections (e.g. H. influenzae).
- **Reid index:**
  - Ratio of submucosal gland thickness to wall thickness.
  - Normal value: 0.4
  - Increase in REID index in chronic bronchitis
- Associated with cor pulmonale.

**Q1.4: What are the key features and sputum findings in Asthma?** PYQ: FMGE 2019

**Answer:**

- Type I hypersensitivity.
- Sputum microscopy:
  - **Curschmann spirals:** mucus spirals.
  - **Creola bodies:** epithelial cell clusters.
  - **Charcot-Leyden crystals:** galectin-10 from eosinophils.

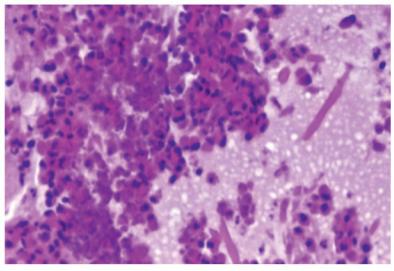

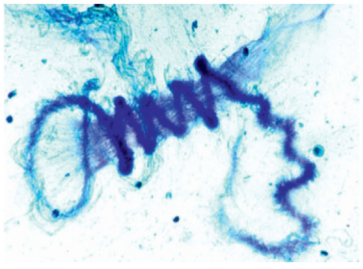

**Airway remodelling (Chronic Asthma):**

- Thickened mucosa:
  - ↑ Goblet cells.
  - ↑ Basement membrane thickness.
  - ↑ Eosinophils in lamina propria.
  - ↑ Muscularis mucosae.
- ↑ Submucosal glands.

### Q1.5: What is Bronchiectasis, its causes, and diagnostic features?

PYQ: NEET PG 2022

**Answer:**

- Definition:
  - Dilatation of bronchi and bronchioles.
- Causes:
  - **Genetic:** Kartagener syndrome:
    - → Dynein defect of cilia.
    - → Triad:
      - – Sinusitis.
      - – Bronchiectasis.
      - – Situs inversus.
    - → Associated with male and female infertility.
  - **Acquired:** Obstruction or sepsis.
- Most common location: Left lower lobe.
- **Investigation of choice (IOC):** HRCT.
  - "Tram-track appearance."
- ***Note*:** Tram-track appearance also seen microscopically in:
- MPGN Type I (Membranoproliferative Glomerulonephritis).

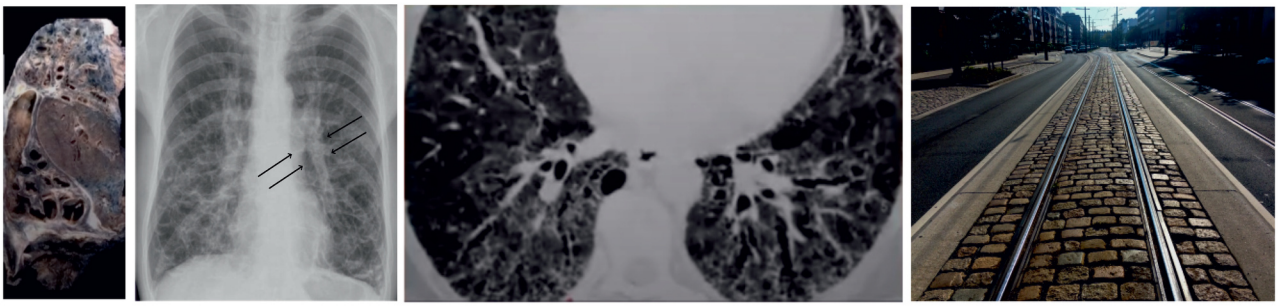

## BIG QUESTION 2: What are the types, features, and pathology of Restrictive Lung Diseases?

**Broad Answer:** Restrictive lung diseases are characterized by reduced lung expansion and decreased total lung capacity.

- They include interstitial lung diseases such as sarcoidosis and pneumoconioses, which involve fibrosis, granulomas, and specific occupational exposures.

## DETAILED QUESTIONS

### Q2.1: What are the features, organs involved, and diagnostic clues in Sarcoidosis?

PYQ: FMGE 2019,2023

**Answer:**

- Cause: Unknown.



YOURWISH

- Multi-organ disorder; **most commonly affects lungs.**
- Lymph nodes = "Potato nodes."
- Gland involvement = Mikulicz disease.
- Can cause non-infectious hepatitis.
- Skin lesions common.
- **Löfgren syndrome:**
  - Lymphadenopathy.
  - Joint pain.
  - Fever.
  - Erythema nodosum.
- **Granulomas:**
  - Non-caseating (most common).
  - Naked granuloma (lacks lymphocytic collar).

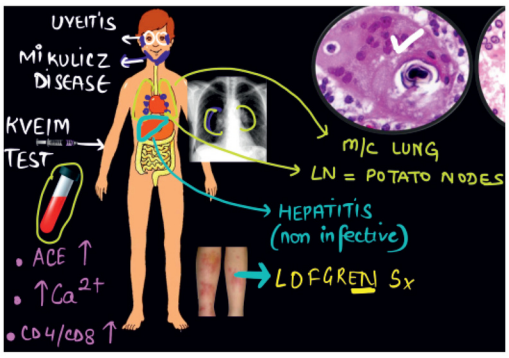


**Diagnosis:**

- Skin test: Kveim test.
- Blood tests:
  - ↑Calcium.
  - ↑ACE levels.
  - ↑CD4 and Cd8.

**Asteroid body appearance:**

- In sarcoidosis → inside giant cells.
- In sporotrichosis → extracellular.

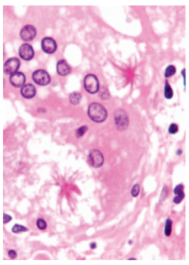
Asteroid bodies (looks like stars)

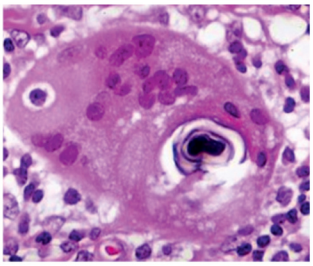
Schaumann bodies (made of calcium look round)

PYQ: INICET 2022

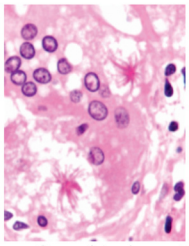
Sarcoidosis

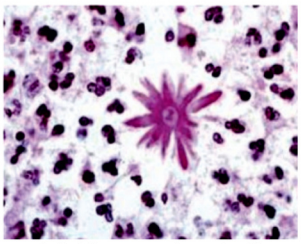
Sporothrix/ Rose gardener's disease

## Q2.2: What are the types, exposures, and findings in Pneumoconioses?

**Answer:** PYQ: NEET PG 2019,2022,2023 PYQ: FMGE 2020,2021,2023 PYQ: AIIMS 2018,2020 PYQ: INICET 2022,2023

| Type | Exposure/Industry | Lung Pathology | Other Findings |
|---|---|---|---|
| **Silicosis (Most common)** | Glass industry | Nodular fibrosis | Eggshell calcification in lymph nodes. ↑ TB and cancer risk. |
| **Coal Workers Pneumoconiosis (CWP)** | Coal dust | 1. Anthracosis (Black lungs)<br>2. Simple CWP (Centriacinar emphysema)<br>3. Complicated CWP (Fibrosis) | Caplan syndrome = CWP + RA. |
| **Asbestosis** | Shipyard, cement industry<br>Forms<br>1. Amphibole/ Crocidolite<br>2. Serpentine/Crysotile | Only pneumoconiosis that affects the lower lobes | Pleural plaques → nodules → cancer. |

## Q2.3: What is the pathology and cancer association in Asbestosis?

**Answer:**

- Pleural nodule = Asbestos / Ferruginous bodies.
  - Dumbbell-shaped.
  - Iron deposition → Prussian blue (Perl's stain) positive.

- Most common cancer = **Adenocarcinoma.**
- Most specific cancer = **Mesothelioma.**

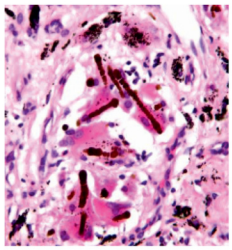
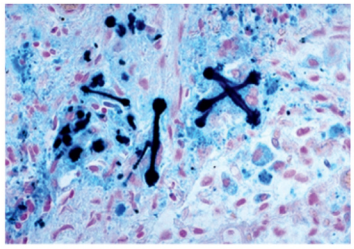


**Q2.4: What dumbbell-shaped structures are notable in pathology?**

**Answer:**

| Field | Dumbbell-shaped Structure |
|---|---|
| Lungs | Asbestos body. 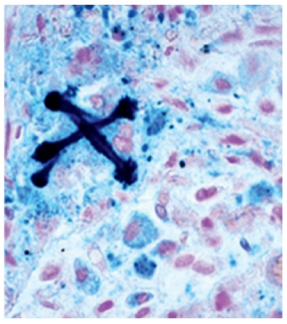 |
| Radiology | Schwannoma (spine). 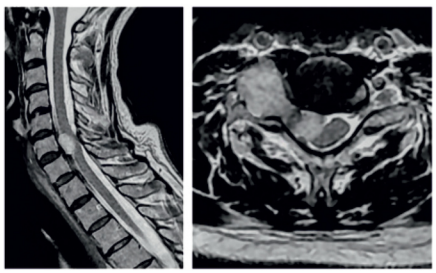 |
| Urine crystals | Calcium oxalate monohydrate. (Mnemonic: "Mona is dumb.") 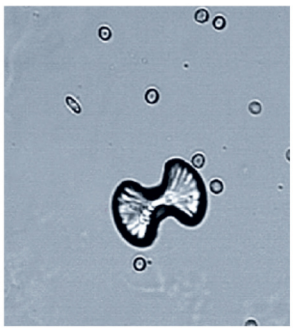 |
| Microbiology | Pox virus DNA 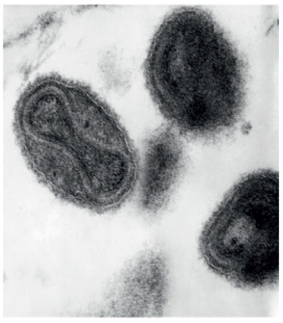 |

### Q2.5: What other diseases are caused by occupational dust exposures?

**Answer:**

| Disease | Exposure |
|---|---|
| Byssinosis | Cotton/organic dust. |
| Bagassosis | Sugarcane dust. |
| Berylliosis | Beryllium; causes non-caseating granuloma. |
| Baritosis | Barium |
| Stannosis | Tin/lead |
| Siderosis | Iron |

## BIG QUESTION 3: What are the types, features, and pathology of Lung Tumors?

**Broad Answer:**

- Lung tumors can be benign or malignant.
- The most common benign tumor is pulmonary hamartoma.
- Lung carcinoma includes squamous cell carcinoma, adenocarcinoma, small cell carcinoma, and large cell carcinoma, each with unique histologic, immunohistochemical, and paraneoplastic features.

## DETAILED QUESTIONS

### Q3.1: What is the most common benign lung tumor and its features?

**Answer:**

- Most common benign tumor: **Pulmonary Hamartoma.**
- Radiologic finding:
  - **Coin lesion.**
  - **Popcorn calcification.**

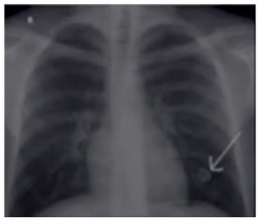

Coin lesion



Popcorn calcification

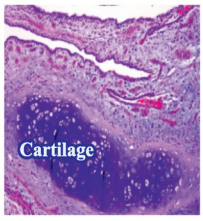


### Q3.2: What are the main types of primary lung carcinoma and their features?

**Answer:** PYQ: NEET PG 2023 PYQ: AIIMS 2022

| Tumor Type | Smoking Association | Location | Genetics | Precancerous Lesion |
|---|---|---|---|---|
| Squamous Cell Carcinoma | Yes | Central | p53 | Positive |
| Adenocarcinoma | | Peripheral | EGFR 1, KRAS, ALK | Positive |
| Small Cell Carcinoma | Yes | Central | Loss of chromosome 3p, L-Myc amplification | Positive, most aggressive |
| Large Cell Carcinoma | | Peripheral | | Positive |

### Q3.3: What are key microscopic and immunohistochemical (IHC) markers for lung carcinomas?

**Answer:**



YOURWISH

| Tumor Type | Tumor Type | IHC Markers | Paraneoplastic Syndromes |
|---|---|---|---|
| Squamous Cell Carcinoma | Keratin pearls 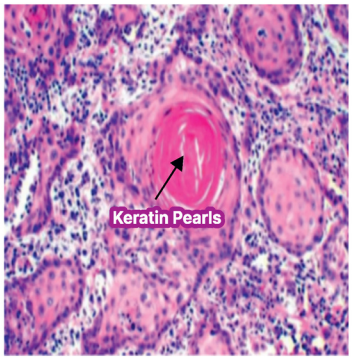  | p40 (best), p63 | Hypercalcemia |
| Adenocarcinoma | Gland formation 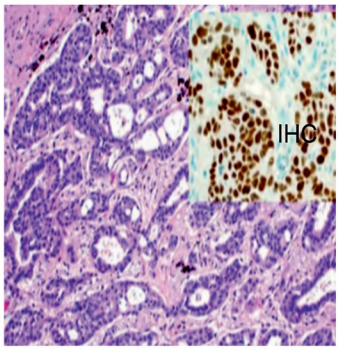  | NAPSIN A, MUC1, TTF-1 | Migratory thrombophlebitis (Trousseau) |
| Small Cell Carcinoma | Azzopardi effect, salt & pepper chromatin, neurosecretory granules on EM 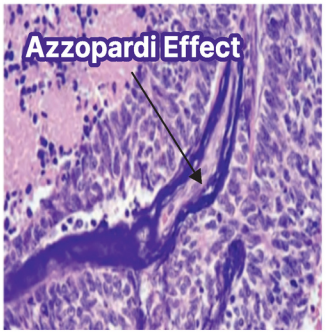  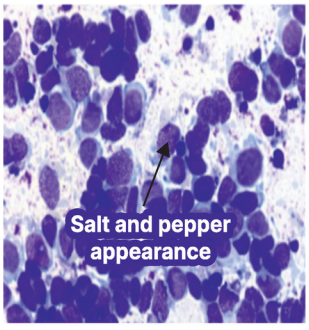  | Synaptophysin, chromogranin, bombesin, CD56, CD57, NSE | SIADH, Cushing, Lambert-Eaton |



YOURWISH

| | | | |
|---|---|---|---|
| | 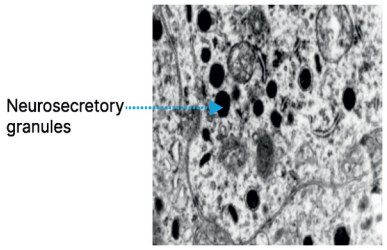 | | |
| Large Cell Carcinoma | Poorly differentiated | | |

### Q3.4: What is adenocarcinoma in situ (AIS) and its features?

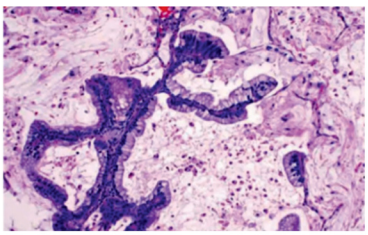

**Answer:**

- Previously called **Bronchioalveolar carcinoma.**
- **Lepidic pattern** (butterfly on the fence appearance).
- No invasion into surrounding stroma.

### Q3.5: What is the nuclear marker for neuroendocrine tumors?

**Answer:**

- Nuclear marker for neuroendocrine tumors:
  - o **INSM1** (Insulinoma-associated protein 1).
    - → Mnemonic: **IN = Intra-nuclear.**

### Q3.6: How does mesothelioma differ from adenocarcinoma?

**Answer:**

| Feature | Mesothelioma | Adenocarcinoma |
|---|---|---|
| Microvilli | Long 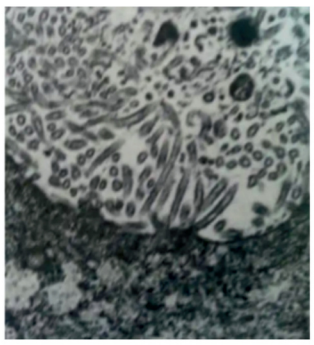 | Non-branching 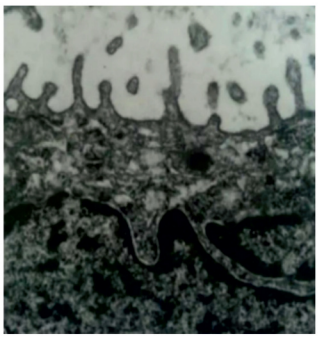 |
| Marker (IHC) | Calretinin (positive) | TTF-1, NAPSIN A (positive) |
| Association | Asbestosis | Asbestosis |

### Q3.7: Which of these is used as a marker in mesothelioma?

A. Calretinin

B. TTF-1

C. CK-8/9

D. Glypican

**Answer:** A. Calretinin

**Q3.8: What is the marker of small cell cancer of the lung?**

A. Chromogranin
B. Cytokeratin
C. Desmin
D. Vimentin

**Answer:** A. Chromogranin

# 12. GASTROINTESTINAL PATHOLOGY

## BIG QUESTION 1: What are the layers of the Gastrointestinal tract, and what are its specific characteristics in different parts of GIT?

**Broad Answer:** The gastrointestinal (GI) tract is composed of four main concentric layers. From innermost to outermost, these are: mucosa, submucosa, muscularis externa, and serosa/adventitia. Each layer plays a vital role in digestion, absorption, and motility. Their structure and function vary slightly along different parts of the GI tract.

## DETAILED QUESTIONS

### Q1.1: What are the layers of the Gastrointestinal tract?

**Answer:**

**From innermost to outermost:**

1. Mucosa
2. Submucosa (Gall bladder does not have Submucosa)
3. Muscularis Propria
4. Serosa (Esophagus doesn't have Serosa)

### Q1.2: Describe the normal histology of the gastrointestinal tract.

**Answer:**

- **Mucosa -** Innermost layer with epithelium, lamina propria, and muscularis mucosae; specialized for secretion and absorption.
- **Submucosa -** Dense connective tissue containing blood vessels, lymphatics, and the Meissner's (submucosal) plexus.
- **Muscularis propria (externa) -** Typically has inner circular and outer longitudinal smooth muscle layers, with Auerbach's (myenteric) plexus in between.

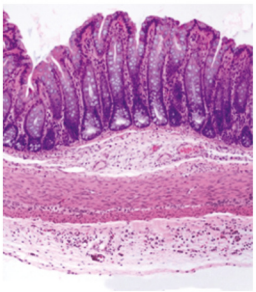


- **Serosa/Adventitia -** Outermost layer; serosa is a smooth mesothelial covering (in intraperitoneal parts), while adventitia is fibrous connective tissue (in retroperitoneal parts).

### Q1.3: What are the pacemaker cells of the GI tract?

**Answer:** The pacemaker cells of the GI tract are the Interstitial cells of Cajal.

### Q1.4: What is the neoplasm arising from interstitial cells of Cajal?

**Answer:** Gastrointestinal stromal tumor (GIST)

## BIG QUESTION 2: Describe the pathogenesis, Clinical manifestations, and management of Achalasia cardia.

**Broad Answer:** Achalasia cardia is a primary esophageal motility disorder characterized by impaired relaxation of the lower esophageal sphincter and absent peristalsis. It commonly presents with progressive dysphagia, regurgitation, and weight loss. Diagnosis involves a combination of imaging and functional studies. Management is aimed at reducing outflow resistance at the gastroesophageal junction.

## DETAILED QUESTIONS

### Q2.1: What is the pathogenesis of Achalasia cardia?

**Answer:**

- Achalasia is caused by the degeneration of inhibitory neurons in the myenteric plexus, leading to failure of LES (lower esophageal sphincter) relaxation.
- Loss of Nitric Oxide and VIP (which usually relaxes the esophagus)

### Q2.2: What are the causes of Achalasia?

**Answer:**

- Idiopathic
- Trypanosoma cruzi (Chagas disease)

### Q2.3: What are the clinical features of Achalasia?

**Answer:**

- Dysphagia (liquid > solids)
- Regurgitation
- Weight loss

### Q2.4: How is Achalasia diagnosed?

PYQ: FMGE 2021

PYQ: NEET PG 2023




**Answer:**

- Diagnosis can be made using barium swallow, manometry, or endoscopy.
- On barium swallow- Bird-beak appearance

### Q2.5: What are the treatment options for Achalasia cardia?

**Answer:**

- Injection of botulinum toxin decreases the activity of acetylcholine
- Heller's myotomy
- Pneumatic dilatations

## BIG QUESTION 3: What are the various Alcohol-induced lacerations seen in the GI tract, and what are their features?

**Broad Answer:** Gastrointestinal lacerations due to forceful vomiting or retching are often seen with chronic alcohol use. These can present as Mallory-Weiss tears (mucosal) or the more severe Boerhaave syndrome (transmural), the latter classically associated with Mackler's triad.



YOURWISH

## DETAILED QUESTIONS

### Q3.1: What is Mallory-Weiss syndrome?

PYQ: FMGE 2021

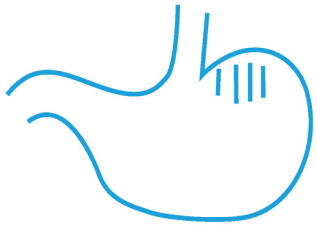

**Answer:**

- Mallory-Weiss syndrome is a mucosal tear/ superficial tear below the Gastroesophageal junction.
- It is Alcohol- induced due to forceful vomiting or retching
- It is a longitudinal tear.

### Q3.2: What are the features of Boerhaave syndrome?

**Answer:**

- It is a full-thickness tear/ transmural tear
- Above the gastroesophageal junction (2.5 cm)
- Classically associated with Mackler's triad

### Q3.3: What are the components of Mackler's triad?

**Answer:**

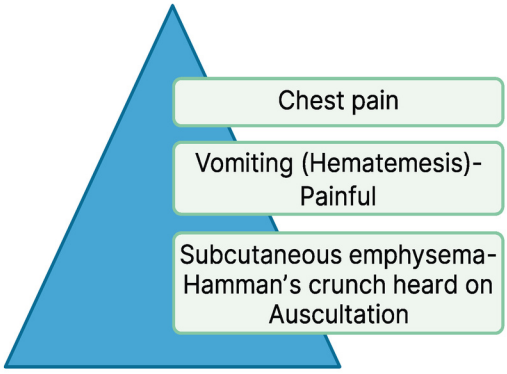


## BIG QUESTION 4: What is Barret's esophagus and what are its consequences?

**Broad Answer:** Barrett's esophagus is a condition where the normal esophageal lining is replaced by intestinal-type epithelium due to chronic acid exposure. It carries a risk of progression to dysplasia and eventually esophageal adenocarcinoma.

## DETAILED QUESTIONS

### Q4.1: What is the pathological process that causes Barrett's esophagus?

**Answer:**

In Barrett's esophagus,

- Squamous epithelium (normal) → Intestinal columnar Epithelium (Goblet cells)
- This process is known as Metaplasia**: Intestinal metaplasia**

### Q4.2: What is the trigger for the intestinal metaplasia of the esophagus?

**Answer:** GERD (Gastroesophageal reflux disease)

PYQ: NEET PG 2022, 2023 PYQ: FMGE 2020, 2021 PYQ: INICET 2021, 2023

### Q4.3: Describe the histopathological features of Barrett's esophagus.

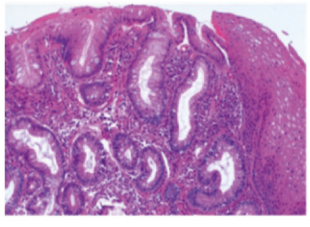

**Answer: The histological features of Barrett's esophagus are:**

- Intestinal metaplasia with replacement of squamous epithelium by non-ciliated, columnar epithelium.
- Presence of goblet cells, which are considered the hallmark of Barrett's esophagus.

### Q4.4: What stain is used for Goblet cells?

**Answer:**

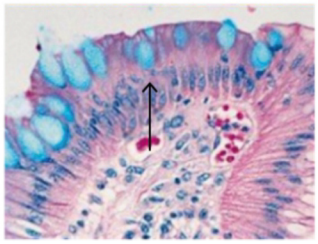

Alcian blue stains acidic mucin in goblet cells, resulting in a blue color.

### Q4.5: What are the endoscopic findings seen in Barrett's esophagus?

**Answer:**

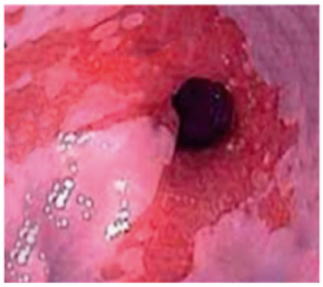

Endoscopy characteristically shows "red velvety mucosa"

### Q4.6: What are the complications of Barrett's esophagus?

**Answer:**

- Dysplasia (low-grade or high-grade)
- Esophageal adenocarcinoma

## BIG QUESTION 5: What are the risk factors of esophageal cancers and their histological features?

**Broad Answer:** Esophageal cancer is broadly classified into squamous cell carcinoma and adenocarcinoma. The risk factors vary with each type. Squamous type typically arises in the upper/mid esophagus and adenocarcinoma in the lower esophagus. Histologically, SCC is characterized by the presence of keratin pearls, whereas adenocarcinoma shows glandular formations.

## DETAILED QUESTIONS

### Q5.1: What are the risk factors for Squamous cell carcinoma of the esophagus?

**Answer:**

**Risk Factors of Squamous Cell Carcinoma**

- Alcohol
- Smoking
- Hot beverages
- Celiac disease
- Drugs/radiation
- Epidermolysis bullosa
- Human papilloma virus
- Tylosis palmaris et plantaris (Thickening of palms and soles)
- Plummer Vinson syndrome/ Sideropenic dysphagia
    - IDA - Iron Deficiency Anemia
    - Esophageal webs
    - Atrophic Glossitis

### Q5.2: What are the main risk factors for the development of esophageal adenocarcinoma?

**Answer:** Barrett's esophagus

### Q5.3: What is the most common esophageal cancer?

**Answer:**

- Overall, Squamous cell carcinoma is the most common
- Most common location- The upper 2/3rds of the esophagus

### Q5.4: What are the histological features seen in SCC of the esophagus?

**Answer:** Keratin pearls are diagnostic

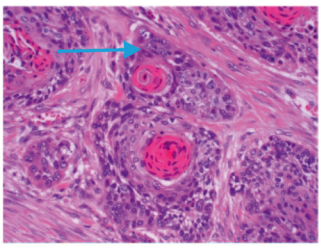

Keratin pearls

### Q5.5: What are the histopathological features of adenocarcinoma of esophagus?

**Answer:** Gland formation

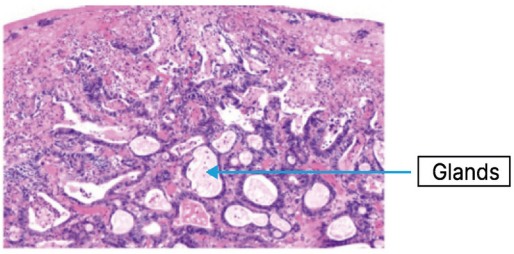


Barrett's esophagus

## BIG QUESTION 6: What are the features of Helicobacter pylori, and its clinical implications?

**Broad Answer:** Helicobacter pylori is a gram-negative bacterium that colonizes the gastric mucosa, especially in the antrum. It plays a key role in the pathogenesis of gastritis and peptic ulcer disease and has associations with gastric adenocarcinoma and MALT lymphoma. Its presence alters the gastric environment and mucosal defenses. Recognition and eradication of H. pylori have important clinical implications in preventing recurrence and malignant transformation.

## DETAILED QUESTIONS




### Q6.1: What is the important biochemical test for H. pylori?

**Answer:** Urease test (H.pylori has the highest urease activity)

- When a gastric biopsy containing H. pylori is placed in a medium with urea and a pH indicator such as phenol red, the bacterial urease rapidly hydrolyzes urea to ammonia. This raises the pH and produces a color change from yellow to pink or red, indicating a positive result

### Q6.2: What are the special stains for H.pylori?

**Answer:**

- Warthin-Starry silver stain - H. pylori stains black
- Modified Giemsa Stain - H. pylori stains blue

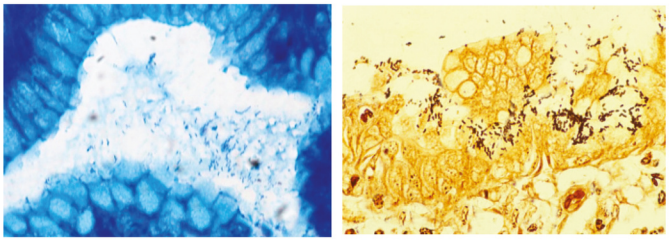

### Q6.3: What are the virulence factors of H.pylori?

**Answer:**

- CagA
- VacA

### Q6.4: What are the complications of H.pylori infection?

**Answer:**

- Chronic gastritis
- Peptic ulcer disease (especially duodenal and gastric ulcers)
- Gastric adenocarcinoma
- MALToma (mucosa-associated lymphoid tissue lymphoma)

PYQ: NEET PG 2021
PYQ: FMGE 2020




### Q6.5: What are the features of MALToma?

**Answer:**

- Bacteria: H. Pylori
- Genetics: Translocation (11:18)
- Microscopically Examined: Lymphoepithelial lesions (LEL)
- Lymphoma cells are invading the glands.

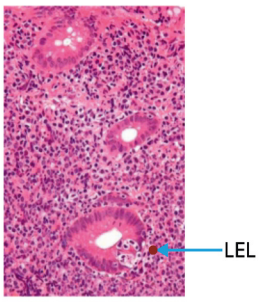


## BIG QUESTION 7: What are the stress gastric ulcers, what are their causes, and what are their differentiating features?

**Broad Answer:** Stress gastric ulcers are acute erosions of the stomach lining that occur in response to severe physiological stress, such as trauma, burns, or neurological injury. They result from mucosal ischemia and impaired protective mechanisms.

## DETAILED QUESTIONS

### Q7.1: What are the features of Curling's ulcer?

**Answer:**

- They are associated with severe burns (especially over large body surface areas)
- M/C site: Duodenum
- They are superficial ulcers
- This can lead to upper GI bleeding

### Q7.2: What are the features of Cushing's ulcers?

**Answer:**

- Cause: Increased intracranial pressure (e.g., head trauma, brain surgery, tumors)
- Mechanism: Vagal stimulation $\rightarrow \uparrow$ ACh $\rightarrow \uparrow$ gastric acid secretion
- Sites: Stomach
- They are deep ulcers
- Complication: High risk of perforation and bleeding



YOURWISH

### Q7.3: Summarise important features of Stress ulcers.

PYQ: FMGE 2020

**Answer:**

| | Curling ulcer | Cushing ulcer |
|---|---|---|
| **Cause** | Burning | Increase intracranial tension |
| **Site** | Duodenum | Stomach |
| **Type** | Superficial ulcer | Deep ulcer |

## BIG QUESTION 8: What is the pathology of Gastric adenocarcinoma?

**Broad Answer:** Gastrointestinal carcinomas arise due to a combination of chronic inflammation, dietary factors, infections (like H. pylori), and genetic mutations. Risk factors vary by site but commonly include smoking, alcohol, obesity, and certain infections. Grossly, tumors may appear as ulcerative, infiltrative, or polypoid masses, and histologically, most are adenocarcinomas showing gland formation. These cancers are typically spread by local invasion, lymphatics, and hematogenous routes, often reaching the liver or peritoneum.

## DETAILED QUESTIONS

### Q8.1: What are the important risk factors for Gastric adenocarcinoma?

**Answer:**

- Alcohol
- Smoking
- Hot beverages
- Smoked and salted food
- Pernicious anemia (Most common site: Fundus)
- Adenomatous polyps
- Blood group A
- H. Pylori
- Menetrier's Disease

### Q8.2: What are the features of Menetrier's Disease?

**Answer:**

- Gender: More common in males
- Cause: Increase of TGF α (Gastric pathology)
- Clinical: Protein-losing enteropathy (intermittent edema)
- Gross: Cerebriform Rugae
- Microscopy: Foveolar cell hyperplasia



### Q8.3: What is the most common site of gastric adenocarcinoma?

**Answer:** Most common site: Antrum

### Q8.4: What are the microscopic types of Gastric cancer?

**Answer:**

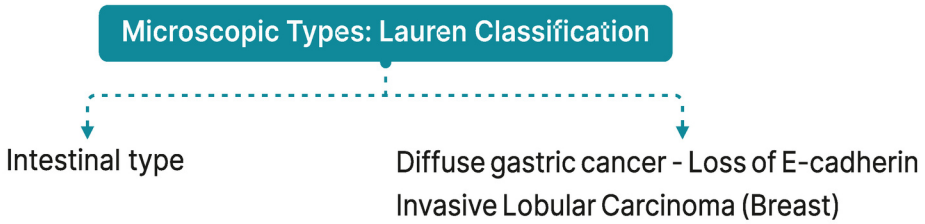

### Q8.5: What is the gross appearance of diffuse gastric cancer?

**Answer:** Linitis Plastica / Leather bottle appearance of the stomach (stomach becomes like a leather bottle)

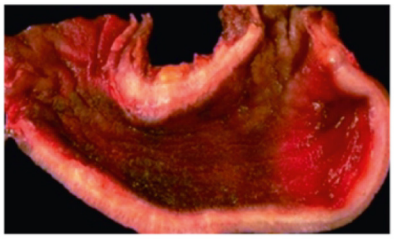



Linitis plastica → LEATHER BOTTLE

PYQ: NEET PG 2020, 2021

PYQ: FMGE 2021

### Q8.6: What are the histopathological features of diffuse gastric cancer?

**Answer:**

- Signet Ring cells (Nucleus is at the periphery, and inside is mucin)
- Also seen in Invasive Lobular Carcinoma Breast and Krukenberg tumor

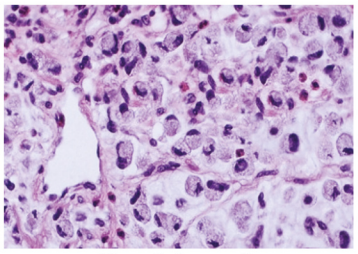

Signet ring cells

### Q8.7: What are the different ways of the spread of gastric cancer?

**Answer:**

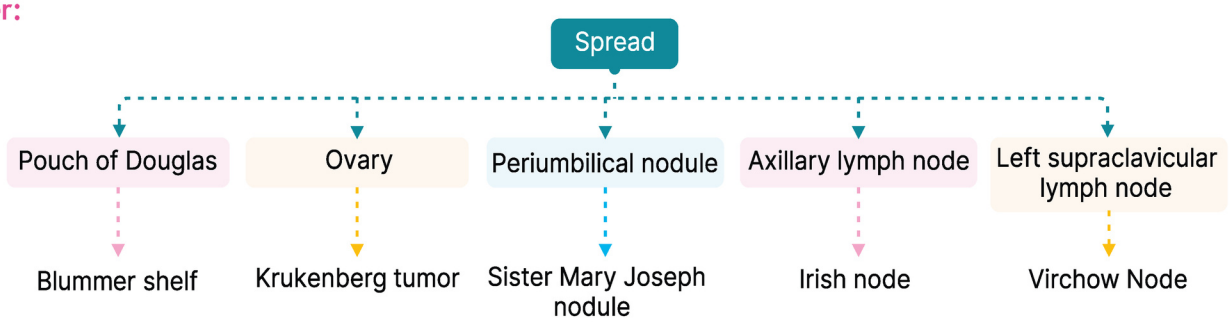


## BIG QUESTION 9: What is GIST? Explain its pathogenesis, features, and management.

**Broad Answer:** Gastrointestinal stromal tumors (GISTs) are mesenchymal tumors arising in the GI tract. They originate from the interstitial cells of Cajal and are driven by mutations that promote abnormal cell growth. Clinically, they may present with nonspecific symptoms like bleeding or mass effect. Diagnosis is based on imaging and histology, and treatment often involves surgery and targeted therapy.

## DETAILED QUESTIONS

### Q9.1: What are the mutations seen in GIST?

**Answer:**

- CD117/CKIT- Increase in Tyrosine Kinase
- PDGFRA mutations
- SDH (succinate dehydrogenase) mutation = Pediatric GIST

### Q9.2: What is the most common site of GIST

**Answer:** GIST is commonly seen in the stomach.

### Q9.3: What are the markers of GIST?

**Answer:**

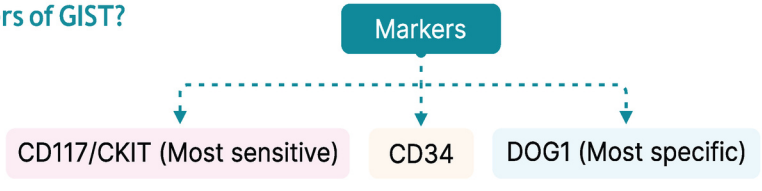

### Q9.4: How is GIST managed?

**Answer:**

**Treatment**

- Surgical resection
- Tyrosine Kinase Inhibitor - IMATINIB
- Used in GIST and CML

## BIG QUESTION 10: What are the various malabsorption syndromes? Describe their features in detail.

**Broad Answer:** Malabsorption syndrome refers to impaired absorption of nutrients from the gastrointestinal tract, leading to symptoms like diarrhea, weight loss, and nutritional deficiencies. It can result from mucosal damage, enzyme deficiencies, or infections. Common causes include celiac disease, tropical sprue, Whipple's disease, and protozoal infections like Giardia lamblia and Cryptosporidium. The underlying mechanisms and presentations vary, but all share a disruption in normal digestive and absorptive processes.

## DETAILED QUESTIONS

### Q10.1: What are the clinical features of malabsorption syndrome?

**Answer:**

- Impaired absorption
- Hallmark feature:
  - Steatorrhea- Impaired absorption of fats
  - Patients typically report bulky, frothy, foul-smelling stools that are difficult to flush

### Q10.2: What is the causative agent of Whipple's disease?

**Answer:** Tropheryma Whipple (Gram +ve)

### Q10.3: What are the histology features of Whipple's disease?

**Answer:**

- Foam cells are macrophages
- Diagnosis - PAS stain-positive macrophages in the Lamina Propria

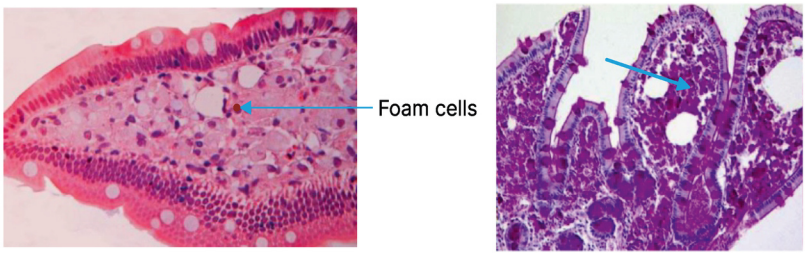


### Q10.4: How to differentiate Whipple's disease and TB?

**Answer:**

- In Whipple's → Foam cells: PAS +ve, but ZN stain -ve
- In TB → Foam cells: ZN stain +ve

### Q10.5: What is the etiopathogenesis of Celiac disease?

**Answer:**

- Also known as Gluten-Sensitive Enteropathy

PYQ: NEET PG 2021
PYQ: FMGE 2021

- Sensitive to Gluten foods: Barley, Rye, Oats, and Wheat - contain alpha-gliadin, a small molecule
- Over 95% of individuals with celiac disease possess the HLA-DQ2 or HLA-DQ8 alleles. These genes encode molecules on antigen-presenting cells, which are essential for presenting gluten-derived peptides to T cells in the intestinal mucosa
- CD4T and CD8T both are involved
- Gluten (BROW) consumption → Antibody formed → Attack Duodenal

### Q10.6: What are the antibodies seen in Celiac disease?

**Answer:**

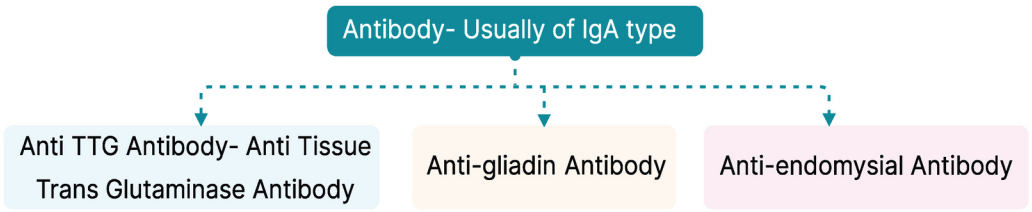


### Q10.7: What is the classification system used for celiac disease?

**Answer:** Marsh classification: Describes the histological changes in the small intestinal mucosa seen in celiac disease, based on the severity of mucosal damage.

### Q10.8: What are the histopathological features of Celiac disease?

**Answer:**

- Antibodies attack villi- Villous Atrophy.
- Crypt hyperplasia occurs
- Intraepithelial lymphocytes (CD8 T cells) are present

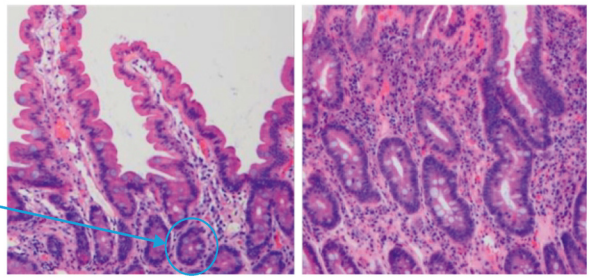


### Q10.9: What is the treatment of Celiac disease?

**Answer:**

- Avoid BROW foods
- Replace BROW with rice and maize
- Steroids

### Q10.10: Which cancer is associated with Celiac disease?

**Answer:** These patients have a risk of Enteropathy-associated T-cell lymphoma

### Q10.11: Summarise the features of celiac disease.

**Answer:**

Diarrhea

Duodenum (Iron absorption hampered)

Dermatitis Herpetiformis (IgA)

Dapsone drug for the treatment of dermatitis

### Q10.12: What are the features of tropical sprue?

**Answer:**

- Also known as environmental Enteropathy
- Cause - E. coli



YOURWISH

- Intestine affected - Duodenum, Ileum, Jejunum
  - Iron deficiency - Iron deficiency anemia
  - B12, folic acid deficiency - Megaloblastic anemia
- Treatment - Antibiotics
- Risk of cancer: No

**Q10.13: Where in the intestinal epithelium are Cryptosporidium organisms typically found?**

**Answer:** Organisms are present along the brush border.

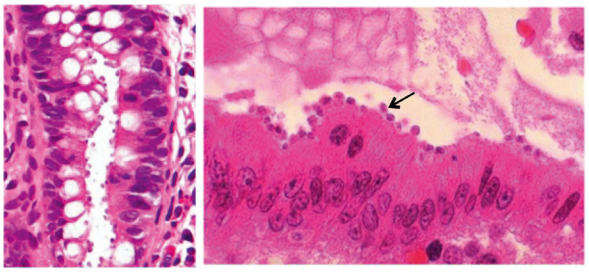

**Q10.14: What are the histological features seen in Giardia infection?**

**Answer:**

- Causative agent: Giardia Lamblia
- Pear or sickle-shaped organism
  - Located in the intestinal lumen, often adherent to the surface of duodenal and jejunal mucosa
  - Falling leaf motility

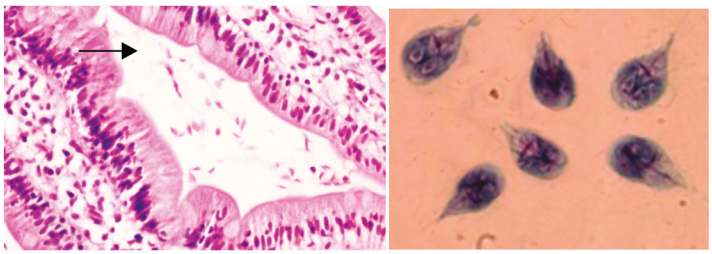

**BIG QUESTION 11: Compare and contrast the key features of tubercular, typhoid, and amoebic ulcers in the gastrointestinal tract.**

**Broad Answer:** Ulcerative disorders of the intestine are conditions characterized by mucosal erosion due to infection or inflammation. Common causes include intestinal tuberculosis, typhoid fever, and amoebiasis, each affecting different segments of the bowel with distinct patterns of ulceration. These lesions can lead to bleeding, perforation, or chronic complications if untreated.

## DETAILED QUESTIONS

PYQ: FMGE 2023

**Q11.1: What are the features of tubercular ulcers?**

**Answer:**

- Commonly involves the ileocecal region.
- Ulcers are transverse, irregular, and often multiple.
- Associated with caseating granulomas and strictures.
- May lead to obstruction, perforation, or fistula formation.



TB ulcer

**Q11.2: What are the features of typhoid ulcers?**

**Answer:**

- Typically involves the Peyer's patches in the ileum.
- Ulcers are longitudinal, oval, and arranged along the long axis of the bowel.
- Caused by Salmonella typhi invading the lymphoid tissue.
- Risk of bleeding and perforation during the 2nd to 3rd week of illness.



Typhoid ulcer

### Q11.3: What are the features of amoebic ulcers?

**Answer:**

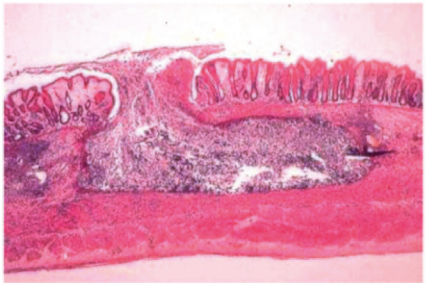

- Caused by Entamoeba histolytica infection of the colon.
- Ulcers are flask-shaped, with a narrow neck and broad base.
- Typically seen in the cecum and ascending colon.
- May lead to toxic megacolon, perforation, or liver abscess if spread occurs.

## BIG QUESTION 12: What are the major types, clinical features, complications, and pathological differences in inflammatory bowel disease?

**Broad Answer:** Inflammatory bowel disease (IBD) is a chronic inflammatory condition of the gastrointestinal tract with a fluctuating course of remission and relapse. It primarily includes ulcerative colitis and Crohn's disease, each with distinct pathological patterns. The exact cause is unclear but involves immune dysregulation, genetics, and environmental triggers. Diagnosis relies on a combination of investigations. Management typically includes long-term medical therapy, with surgery reserved for select cases.

PYQ: NEET PG 2022, 2023
PYQ: FMGE 2020, 2021
PYQ: INICET 2023

## DETAILED QUESTIONS

### Q12.1: What are the lesions seen in Crohn's disease?

**Answer:**

- Most common in the Ileum
- Skip lesions- Cobblestone appearance on the inside of the intestine.

PYQ: FMGE 2019, 2020

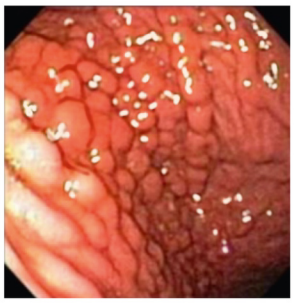

- Skin nodules
- Full thickness, the entire wall is affected → Results in Fissures or Fistulas
- The rectum is spared
- Aphthous Ulcer (first lesion)

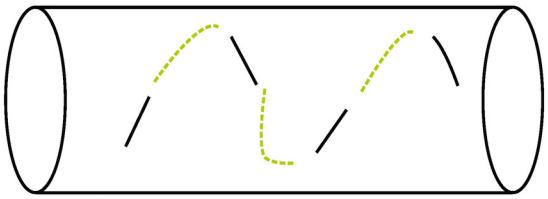

Progressing: Serpiginous ulcers

- Creeping Fat: Outside of the intestine

PYQ: FMGE 2020, 2021



**Q12.2: What is the histological feature seen in Crohn's disease?**

**Answer:**

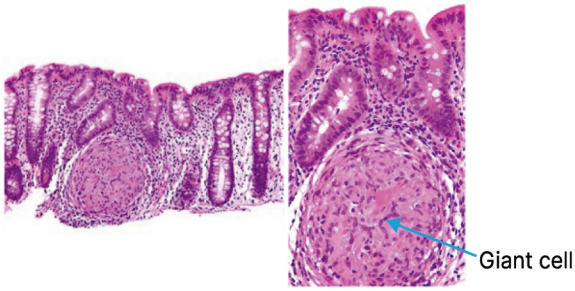


Microscopy shows non-caseating granuloma.

**Q12.3: What is the antibody seen with Crohn's disease?**

**Answer:** Associated with Saccharomyces cerevisiae (ASCA+)

**Q12.4: What are the radiological features of Crohn's disease?**

**Answer:** String sign of Kantor

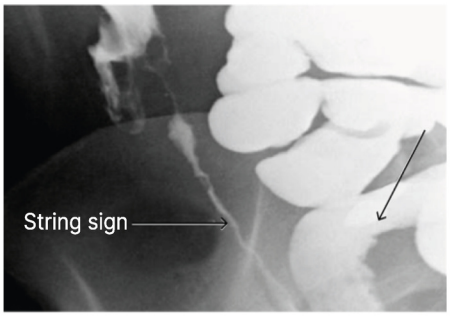


**Q12.5: What is the key pro-inflammatory cytokine involved in the pathogenesis of Crohn's disease?**

**Answer:**

- TNF-α (Tumor Necrosis Factor-alpha)
- Overproduction of TNF-α drives chronic intestinal inflammation.

**Q12.6: What is the treatment of Crohn's disease?**

**Answer:** Infliximab (Anti-TNF alpha)

**Q12.7: What are the lesions seen in ulcerative colitis?**

**Answer:**

- Often rectum involved
  - o Retrograde involvement
  - o Backwash Ileitis
- Continuous lesion
- Ulcers with Pseudopolyp -Regenerating mucosa

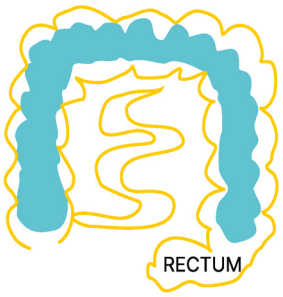


**Q12.8: What has a protective role in ulcerative colitis?**

**Answer:** Smoking

**Q12.9: Which antibody is detected in ulcerative colitis?**

**Answer:** p-ANCA positive (PSC also is p-ANCA positive)

**Q12.10: What radiological feature is seen in Crohn's disease?**

**Answer:** Lead pipe appearance → Toxic megacolon



**Q12.11: What are the complications of ulcerative colitis?**

**Answer:**

- Toxic Megacolon
- Increased risk of cancer

**Q12.12: How is ulcerative colitis managed?**

**Answer:** Medical management of UC includes: 5ASA and 6MP

- 5ASA: Aminosalicylates eg. Mesalamine, sulfasalazine
- Use: Used as first-line therapy for mild to moderate disease, especially for induction and maintenance of remission.
- Immunomodulators: 6-mercaptopurine (6-MP), azathioprine.
- Use:Used for maintenance of remission, particularly in steroid-dependent patients or those with frequent relapses.

**Q12.13: What are the characteristic antibodies associated with Crohn's disease and ulcerative colitis in inflammatory bowel disease?**

**Answer:**

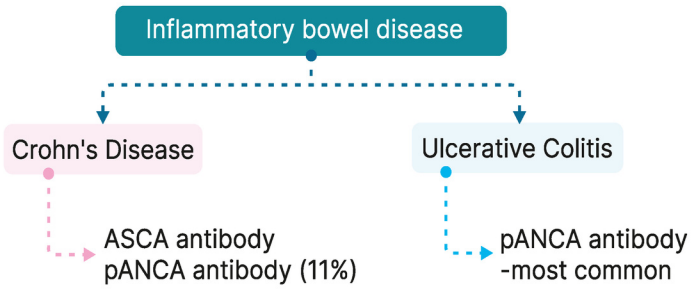


**BIG QUESTION 13: What are the different types of gastrointestinal (GI) polyps, and what clinical syndromes are associated with them?**

**Broad Answer:** Gastrointestinal polyps can be broadly classified based on their origin and histological features. Some are non-neoplastic, like hyperplastic polyps, while others may have malignant potential, such as serrated adenomas or adenomatous polyps. Additionally, several genetic syndromes are associated with multiple types of hamartomatous polyps, each with characteristic clinical and histological findings.



YOURWISH

YOURWISH

## DETAILED QUESTIONS

### Q13.1: How are GI polyps classified?

Answer:

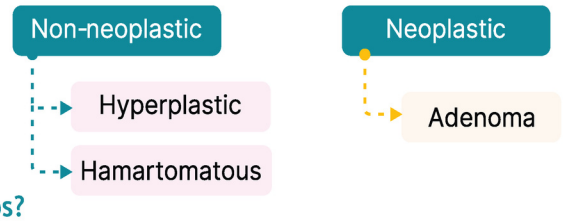


### Q13.2: How do hyperplastic polyps differ from sessile serrated polyps?

Answer:

| Hyperplastic polyp | Sessile serrated adenoma |
|---|---|
| • Do not cause cancer<br>• The lumens of crypts at the bottom are round<br>• The lumen of crypts at the top is irregular<br>• Serrations along the upper part<br>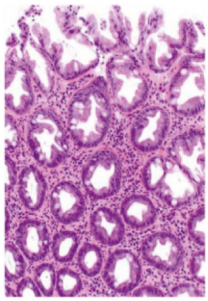 | • Precancerous<br>• Serrations throughout<br>• Boot-shaped crypts<br>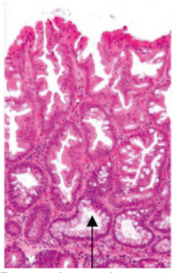<br>Boot-shaped crypts |

### Q13.3: What are the genetic defects and key features of Juvenile rectal polyposis?

Answer:

PYQ: INICET 2019, 2021 | PYQ: FMGE 2019, 2021 | PYQ: NEET PG 2021, 2022, 2023

| Defect | Features | Histopathology |
|---|---|---|
| • SMAD 2<br>• SMAD 4<br>• BMPR 1 | • < 5 yrs<br>• Bleeding PR<br>• Digital clubbing | 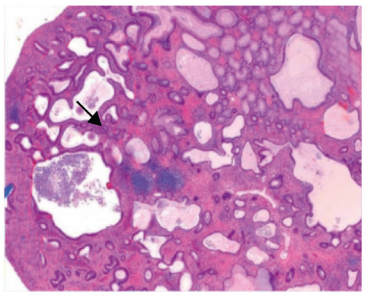<br>Cystically dilated glands on microscopy |

### Q13.4: What are the genetic associations and clinical features of Peutz-Jeghers syndrome?

Answer:

- **Gene defect:** STK11/LKB1
- **Key features:**
  - o Jejunal polyps
  - o Shows pigmentation
- **Histology**
  - o Arborizing / Christmas tree polyp - smooth muscles





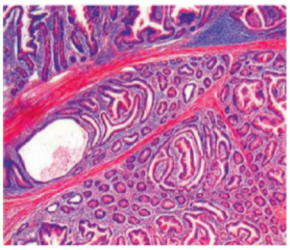

**Q13.5: List the gene mutations and characteristic clinical manifestations of Cowden syndrome, Bannayan-Ruvalcaba-Riley syndrome, Tuberous sclerosis, and Cronkhite-Canada syndrome.**

**Answer:**

| Syndromes | Defects | Features |
|---|---|---|
| Cowden Syndrome | • PTEN (Chromosome 10) | • Polyp cancer<br>• Endometrial cancer<br>• Thyroid cancer, Trichillemoma<br>• Breast cancer |
| Banayan Ruvalcaba Riley syndrome | • PTEN | • Polyps<br>• Mental retardation |
| Tuberous Sclerosis | • TSC 1 (Chromosome 9)<br>• TSC 2 (Chromosome 16) | • Rhabdomyoma |
| Cronkhite Canada Syndrome | • Non-hereditary | • Polyps<br>• Hair loss<br>• Skin pigmentation<br>• Nail atrophy |

**Q13.6: How are adenomas classified, and what are their key histological features?** PYQ: INICET 2020

**Answer:**

| Adenoma types | Features |
|---|---|
| Tubular adenoma | • Circular rings |
| Villous adenoma | • Finger-like villi - the risk of intestinal cancer |
| Tubulo villous adenoma | |
| FAP (Familial Adenomatous Polyposis) | • Risk of Cancer 100%<br>• APC gene on chromosome 5q<br>• Minimum 100 polyps |
| Classical FAP | • Polyps and Congenital Hypertrophy of Retinal Pigment Epithelium |
| Turcot syndrome | • FAP (colon) and Brain tumors (Medulloblastoma, Glioblastoma) |
| Gardner syndrome | • FAP + Sebaceous cyst<br>• Fibroma<br>• Osteoma<br>• Supernumerary teeth |

**BIG QUESTION 14: What is the etiopathogenesis & diagnosis of Intestinal carcinoma?**

**Broad Answer:** Intestinal carcinoma develops through a well-defined multistep sequence starting from normal epithelium to carcinoma, involving progressive mutations at different stages. This transformation is accompanied by specific genetic alterations. Diagnosis can be confirmed radiologically and via tumor markers or stool tests.

## DETAILED QUESTIONS

### Q14.1: What is the stepwise sequence of changes in the development of intestinal cancer?

**Answer:** This is multistep carcinogenesis

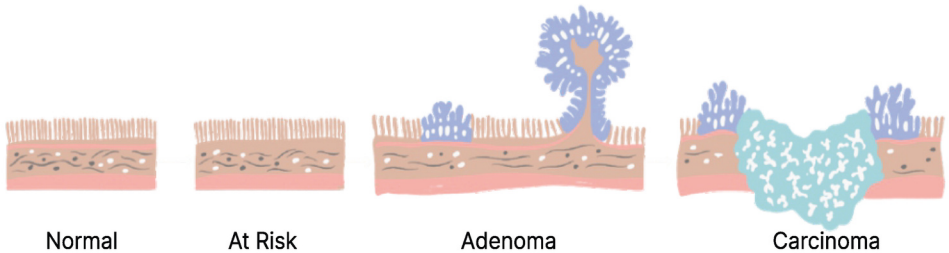


Adenoma Carcinoma Sequence

### Q14.2: What mutations are involved in the adenoma-carcinoma sequence?

**Answer:**

APC gene mutation ⇢ KRAS mutation ⇢ p53, SMAD 2 and SMAD 4

### Q14.3: What is the radiological feature of Colorectal cancer?

**Answer:** On barium enema, there is an apple core deformity

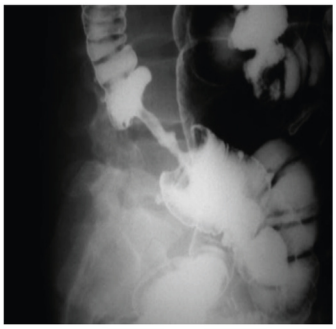

### Q14.4: What is the tumor marker for colorectal carcinoma?

**Answer:** CEA (Carcinoembryonic antigen)

PYQ: NEET PG 2021, 2022
PYQ: FMGE 2020, 2021

### Q14.5: What is the Guiauc test?

**Answer:**

- The Guaiac test is a chemical test used to detect the presence of hidden (occult) blood in stool samples.
- The guaiac test card contains a chemical called guaiac, which reacts with the heme component of blood
- When a small sample of stool is smeared onto the test card, and hydrogen peroxide is added, the presence of blood catalyzes the oxidation of guaiac, causing a rapid blue color change indicating the presence of occult blood in stool.

# 13. HEPATOBILIARY PATHOLOGY

## BIG QUESTION 1: What are the key histological components and cell types of the hepatobiliary system?

**Broad Answer:** The liver is organized into structural units between the central vein and the portal triad. Blood from the sinusoids supplies hepatocytes, with several unique cell types playing distinct roles in liver function and regeneration. The space of Disse is a key anatomical location between hepatocytes and sinusoids involved in pathological and physiological processes.

## DETAILED QUESTIONS

### Q1.1: Where are hepatocytes located, and how do they receive blood?

**Answer:**

- Hepatocytes are present between the central vein and the portal triad.
- They receive blood supply from sinusoids (blood vessels)

### Q1.2: What are the cells present inside the sinusoids of the liver?

**Answer:**

- Sinusoids contain Kupffer cells in their walls
- They are macrophages of the liver.

### Q1.3: What is the space of Disse, and what is its significance?

**Answer:**

- The space of Disse is the area between the sinusoids and hepatocytes
- Amyloid deposition in the liver occurs here

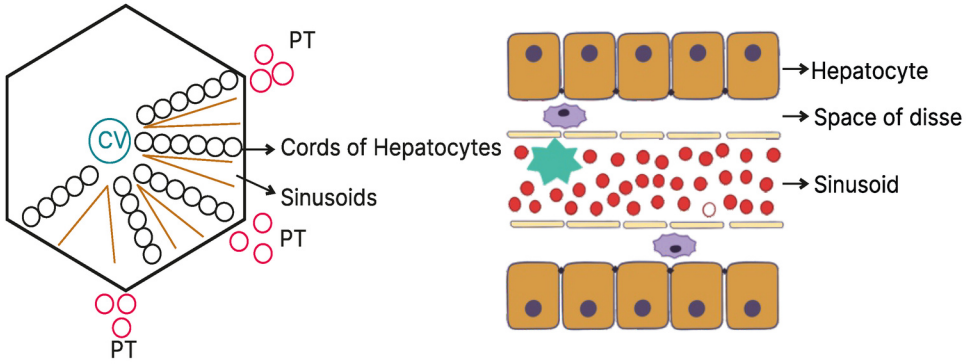


### Q1.4: Which specialized cells are found in the space of Disse?

**Answer:**

- Ito/Stellate cells are present in the space of Disse.
- Although anatomically the same, Ito and stellate cells have different functions.

### Q1.5: What are the functions of Ito and Stellate cells?

**Answer:**

- Ito cells → Responsible for vitamin A storage
- Stellate cells → Involved in collagen formation (Hyperactive Ito cells)



YOURWISH

### Q1.6: What is the role of Stem or oval cells in the liver?

**Answer:**

- Present in the canal of Hering
- Involved in the regeneration of the liver

## BIG QUESTION 2: What are the different types and causes of hyperbilirubinemia?

**Broad Answer:** Hyperbilirubinemia is classified based on the type of bilirubin that is elevated—unconjugated or conjugated. Different inherited syndromes and enzyme defects contribute to these patterns, affecting bilirubin conjugation or excretion.

## DETAILED QUESTIONS

### Q2.1: What are the two types of bilirubin, and how are they classified?

PYQ: NEET PG 2018

**Answer:**

- Indirect bilirubin (Unconjugated)
- Direct bilirubin (Conjugated)
- Increase in indirect bilirubin → Unconjugated hyperbilirubinemia
- Increase in direct bilirubin → Conjugated hyperbilirubinemia.

### Q2.2: Which disorders are associated with unconjugated hyperbilirubinemia?

**Answer:**

- Crigler-Najjar Syndrome
- Gilbert Syndrome

### Q2.3: Which disorders are associated with conjugated hyperbilirubinemia?

**Answer:**

- Dubin-Johnson Syndrome
- Rotor Syndrome

### Q2.4: What is the cause of unconjugated hyperbilirubinemia?

**Answer:**

- Conjugation has not occurred
- The enzyme responsible: UGT (UDP glucuronyl Transferase)

### Q2.5: How do Crigler-Najjar Syndromes type 1 and 2, and Gilbert Syndrome differ?

**Answer:**

| Crigler-Najjar Syndrome Type 1 | Crigler-Najjar Syndrome Type 2 | Gilbert Syndrome |
|---|---|---|
| • Complete deficiency of UGT<br>• 100% Fatal (Intra-uterine death) | • Partial deficiency of UGT<br>• Rx: Phenobarbitone (Increases UGT) | • Very mild deficiency of UGT<br>• Asymptomatic<br>• Manifests in stress (Fever, Pregnancy) |

### Q2.6: What is conjugated hyperbilirubinemia?

**Answer:**

- UGT levels are normal
- There is an excretion defect → Increase in levels of conjugated bilirubin

### Q2.7: What are the features of Dubin-Johnson and Rotor syndrome?

**Answer:**

| Dubin-Johnson Syndrome | Rotor Syndrome |
|---|---|
| • MRP protein defect<br>• Darkly pigmented liver | • ATP Family protein defect<br>• Non-pigmented liver |

### Q2.8: What is the composition of the pigment seen in Dubin-Johnson Syndrome?

**Answer:** The pigment in Dubin-Johnson Syndrome is derived from epinephrine metabolites.

### Q2.9: What is the inheritance pattern of these syndromes?

**Answer:**

- All are autosomal recessive,
  - Except for Crigler-Najjar Type 2, which is autosomal dominant
  - Sometimes, Gilbert Syndrome can also be autosomal dominant

### Q2.10: What type of hyperbilirubinemia is seen in hemolytic anemia?

**Answer:** Hemolytic Anemia → RBC breakdown → Excess heme → Elevated levels of unconjugated bilirubin

### Q2.11: What are other causes of conjugated hyperbilirubinemia?

**Answer:**

- Obstructive conditions:
  - Stones
  - Strictures
  - Cancer
  - Clonorchis sinensis (parasite)
- Biliary diseases:
  - Primary Biliary Cirrhosis (PBC)
  - Primary Sclerosing Cholangitis (PSC)

### Q2.12: What are the features of Primary biliary cirrhosis?

**Answer:** PYQ: INICET 2022, 2023 PYQ: NEET PG 2021, 2022 PYQ: FMGE 2020, 2021, 2022

- Age - 50 years
- More common in females
- Associated with AMA(anti-mitochondrial antibody), ANA(anti-nuclear antibody)
- Associated with Sjögren's Syndrome
- Intrahepatic bile ducts are affected

### Q2.13: What are the features of Primary Sclerosing Cholangitis?

**Answer:**

- Age - 30 years
- More common in males
- Associated with p-ANCA
- Radiology - Shows Pruning of bile ducts and beading of large bile ducts

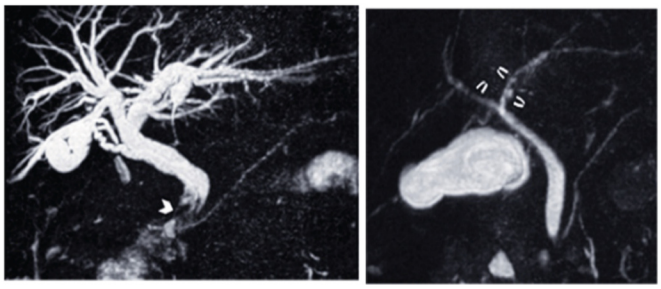

- Pathology - Onion skinning of the Bile duct

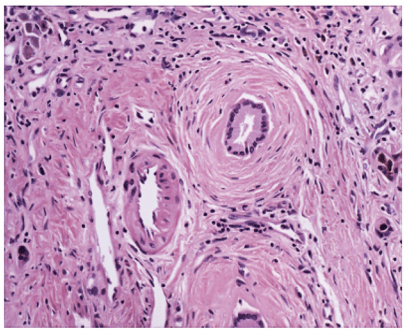

- Intrahepatic and Extrahepatic bile ducts are affected
- Associated with Ulcerative Colitis

## BIG QUESTION 3: What is cirrhosis, and what are the pathological changes seen in cirrhosis?

**Broad Answer:** Cirrhosis is the final common pathway of many chronic liver diseases. It is characterized by nodule formation, fibrosis, and specific histopathological changes that differ based on the underlying cause.

## DETAILED QUESTIONS

PYQ: AIIMS 2021

### Q3.1: What is cirrhosis, and how are nodules classified based on size?

**Answer:**

- Cirrhosis = nodule formation occurs in the liver
- Nodules can be:
  - Micronodular: < 3 mm in size
  - Macronodular: > 3 mm in size

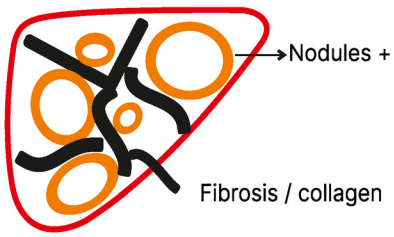


### Q3.2: What is the type of collagen laid down in cirrhosis?

**Answer:**

- Type of collagen laid down → Type I and Type III
- Cells that lay down collagen →Stellate cells

**Q3.3: How is cirrhosis classified based on the size of nodules, and what are the conditions associated with each type?**

**Answer:**

| Macronodular Cirrhosis | Micronodular Cirrhosis |
|---|---|
| Seen in:<br>• Viral Hepatitis<br>• Wilson disease<br>• ALD (common for both)<br>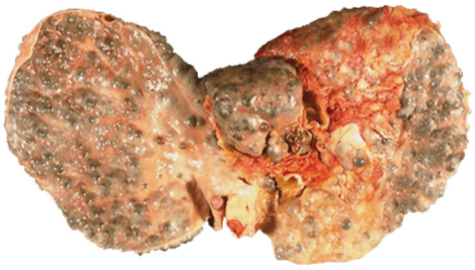 | Seen in:<br>• ICD (Indian Childhood Cirrhosis)<br>• Hemochromatosis<br>• PBC (Primary Biliary Cholangitis)<br>• ALD (common for both)<br> |

**Q3.4: What stain is used to detect fibrosis in cirrhosis, and how does it appear under the microscope?**

**Answer:**

- Masson Trichrome stain is used to detect fibrosis and collagen.
  - Muscle appears Red
  - Collagen appears Blue

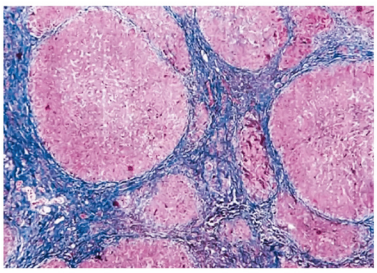

**BIG QUESTION 4: What are the various causes of cirrhosis, and their characteristic pathological features?**

**Broad Answer:** Cirrhosis can result from a wide range of etiologies, including infections, genetic conditions, autoimmune disorders, drug-induced injury, metabolic diseases, and vascular conditions. These causes can be broadly classified based on their pathophysiological mechanism and associated clinical disorders.

## DETAILED QUESTIONS

**Q4.1: What is the basic pathological process in alcoholic liver disease (ALD)?**

**Answer:** ALD involves fatty liver / steatosis due to the accumulation of fat in the liver

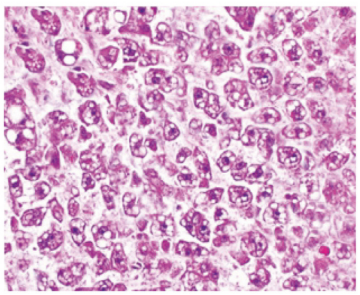

**Q4.2: What are the two types of steatosis seen in ALD, and what are their causes?**

**Answer:**

- Microvesicular steatosis → Small fat droplets on the liver
  - Causes: Fatty liver of pregnancy, HELLP Syndrome, Reye's Syndrome

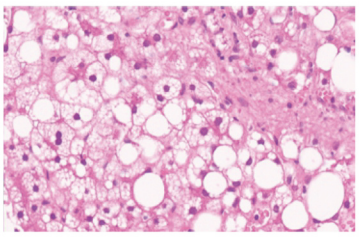

- Macrovesicular steatosis → Big fat droplets on the liver
  - Causes: Obesity, DM, Starvation, Total Parenteral Nutrition, Hepatitis C
- Both microvesicular and macrovesicular steatosis are seen in ALD



YOURWISH

YOURWISH

### Q4.3: What is steatohepatitis, and when does it occur?

**Answer:**

- Steatohepatitis occurs after chronic alcohol consumption, where fat accumulation is accompanied by inflammation.

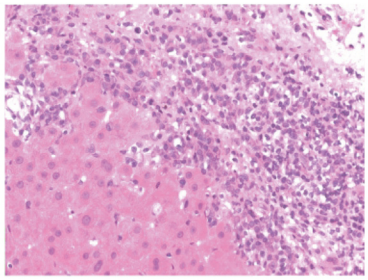

### Q4.4: What are the microscopic features seen in ALD?

**Answer:**

- Mallory hyaline / Mallory Denk bodies
- Chicken wire fibrosis

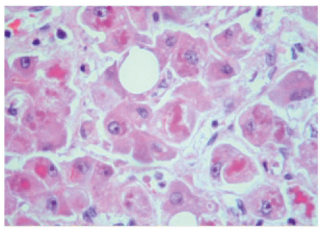

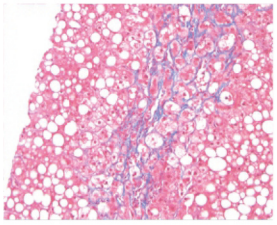

### Q4.5: What is the progression sequence of Alcoholic Liver Disease?

**Answer:** Steatohepatitis → Cirrhosis →Scarring → Laennec's cirrhosis (End stage)

### Q4.6: What are the features of autoimmune hepatitis?

**Answer:**

- AIH occurs due to the intake of a drug, causing an antibody to act against the liver.
- Associated antibody: Anti-LKM-2 antibody
- Key microscopic features:
  - Interface hepatitis → Hepatocytes (Pink colored liver cells) end near the portal triad → High level of inflammation (blue) found in the junction of hepatocytes and portal triad
  - Emperipolesis → Big cell (Hepatocyte) eating small cell (Lymphocyte)
  - Hepatic Rosettes → Hepatocytes are arranged in a round fashion

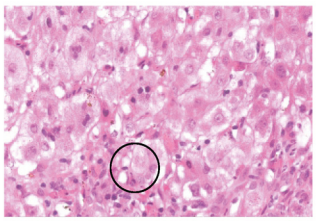

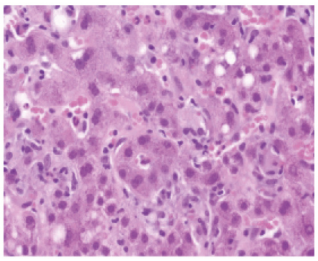

### Q4.7: What is the enzyme deficiency leading to cirrhosis, and what are its key features?

**Answer:**

**Alpha 1 antitrypsin deficiency**

- Chromosome 14 (codes for this enzyme)
- Inheritance: Autosomal recessive
- Onset: Childhood
- Genotypes:
  - PiMM: Normal (has α1-antitrypsin)
  - PiZZ: Disease (no α1-antitrypsin)
  - PiMZ: Mixed; carrier state
- Organs affected:
  - Lung: Panacinar emphysema
  - Liver: Cirrhosis
- Histological stain: PAS-positive, diastase-resistant inclusions

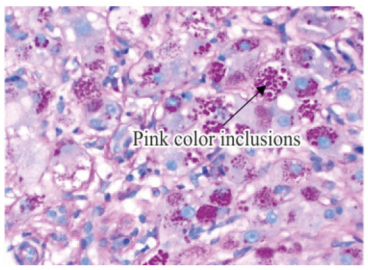


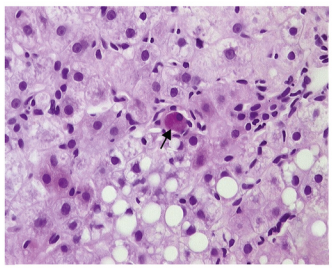

## Q4.8: What are the histopathological features of hepatitis?

**Answer:**

Apoptotic body, i.e, Councilman Body→ seen in Viral Hepatitis/Hepatitis C

PYQ: FMGE 2019

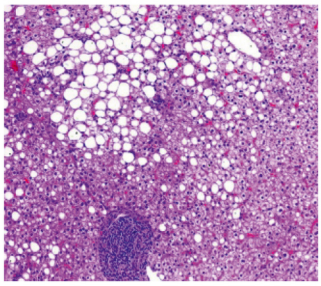

Macrovesicular steatosis and Large coloured Lymphocytes seen in Hepatitis C

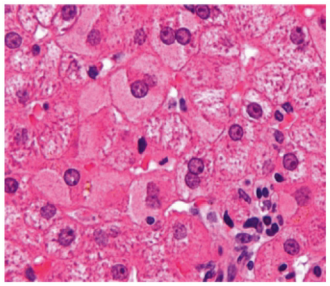

Ground glass hepatocyte (hazy appearance) seen in Hepatitis B

## Q4.9: What are the features of hemochromatosis?

**Answer:**

- Also known as Bronze diabetes → Iron Overload
- **Genetic factors:**
  - HFE gene (chromosome 6)
  - HJV (hemojuvelin) gene (juvenile HC)
- **Acquired causes:** Thalassemia → Increased BT → Increased Iron overload
- **Clinical features:**
  - Liver → cirrhosis
  - Skin → Bronze discolouration (caused by melanin>>>>hemosiderin)
  - Pancreas → DM (Iron accumulation → Hampers insulin production)
- **Treatment of choice:** (Therapeutic blood donation) Phlebotomy
- **Drug of choice:** Fe Chelators (Desferrioxamine)

PYQ: FMGE 2021, 2022

PYQ: NEET PG 2019

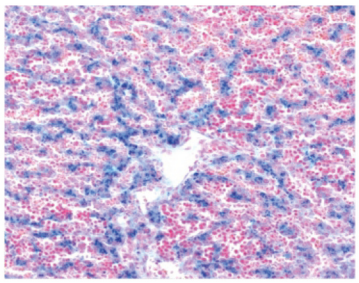

## Q4.10: What are the features of Wilson's disease?

**Answer:**

- Wilson disease → Copper overload
- Genetic factor: ATP 7B gene mutation on chromosome 13
  - Note: ATP 7A's gene mutation → Menke's disease
- Clinical features:
  - Liver → Cirrhosis
  - Eye → Kayser Fleischer ring (Copper accumulates in the Descemet membrane of the cornea)
  - Brain → (can accumulate in the putamen, basal ganglia), causing Psychosis, Parkinsonism-like features
- Treatment: Cu chelators (Trientine)

PYQ: NEET PG 2021, 2022, 2023

PYQ: FMGE 2020, 2021

PYQ:INICET 2022, 2023

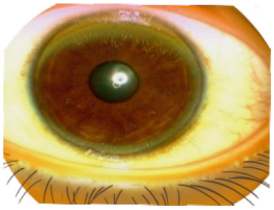

### Q4.11: What are some other causes of cirrhosis listed in the notes?

**Answer:**

- **Biliary diseases** - PBC, PSC
- **Cryptogenic cirrhosis** - NALD due to obesity, DM, ↑ cholesterol/triglycerides
- **Drug-induced cirrhosis** - Also associated with anti-LKM-2 antibodies

### Q4.12: What is the composition of Mallory hyaline/ Denk bodies?

**Answer:** CK 8/18 (Cytokeratin 8/18/Intermediate filaments)

### Q4.13: In which conditions are Mallory hyaline bodies seen?

**Answer:**

- NALD, ALD
- ICD (Indian Childhood Cirrhosis)
- Wilson disease
- Alpha antitrypsin deficiency
- Tumors of the liver (HCC)
- Cholestasis in the liver
- Primary hepatic/biliary diseases
  - Not seen in Hemochromatosis and Secondary hepatic/biliary diseases

## BIG QUESTION 5: What are the types, features, and tumor markers associated with liver tumors?

**Broad Answer:** Liver tumors are commonly malignant, with hepatocellular carcinoma (HCC) being the most frequent type. HCC has classical and fibrolamellar variants, each with distinct features, modes of spread, and tumor markers. Newer tumor markers have also been identified recently for improved diagnosis.

## DETAILED QUESTIONS

### Q5.1: What is the most common liver malignancy?

**Answer:** Metastasis is the most common liver malignancy.

### Q5.2: Compare the features of Classical HCC and the fibrolamellar variant HCC.

**Answer:**

| Features | Classical HCC | Fibrolamellar Variant HCC |
|---|---|---|
| Age | > 40 yrs | 19 - 20 yrs |
| Gender | More common in males | Equal Male and Female occurrence |
| Associated with Hepatitis | Hepatitis B & C | • Not associated with Hepatitis<br>• Associated with the Deletion of Chromosome 19 |
| Tumor Marker | Alpha fetoprotein → Elevation of AFP | • AFP: Normal<br>• Neurotensin is the tumor marker |
| Spread | Hematogenous spread | Lymphatic spread |
| Prognosis | Bad prognosis | Good prognosis |



YOURWISH

## Q5.3: What are the new (updated) tumor markers for HCC?

**Answer**

- Arginase 3
- Hep-PAR1
- Glypican3



YOURWISH

# 14. RENAL PATHOLOGY

## BIG QUESTION 1: Describe the structure and functional components of the glomerulus and Bowman's capsule.

**Broad Answer:** Urine formation begins in the renal corpuscle, which consists of the glomerulus and Bowman's capsule. These structures work together to initiate blood filtration. The filtration membrane, located at their interface, plays a crucial role in determining what substances enter the nephron.

## DETAILED QUESTION

### Q1.1: What is the functional unit of the kidney?

**Answer:** The nephron.

### Q1.2: What is the structure of the Glomerulus?

PYQ: INICET 2022

**Answer:**

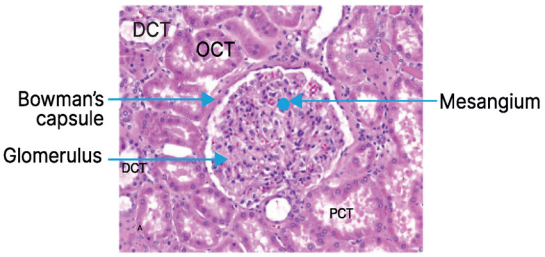


- Outer membrane: Bowman's capsule.
- An arteriole called the afferent arteriole enters the Glomerulus.
- It comes in and makes a tuft of capillaries, which is the Glomerulus.
- Some cells are present between the capillaries, known as mesangial cells, which are similar in function to macrophages and provide structural support.
  - Note: In certain diseases, such as amyloidosis, abnormal proteins (amyloid) can be deposited in the mesangium of the kidney, leading to damage.
- Then the remaining blood goes out as an efferent arteriole.

### Q1.3: What is the structure of the Bowman's capsule?

**Answer:**

- Bowman's Capsule surrounds the Glomerulus
- It has 2 layers:
  - Outer layer: Parietal Epithelial Layer
  - Inner layer: Visceral Epithelial Layer(Podocytes)
- The space created by both layers is known as Bowman's Space. It is where urine accumulates and goes to the other parts of the kidney.

### Q1.4: What constitutes the filtration membrane?

**Answer:**

- The filtration membrane is the site where urine formation begins, located between the glomerular capillaries and the visceral layer (podocytes) of the Bowman's capsule.

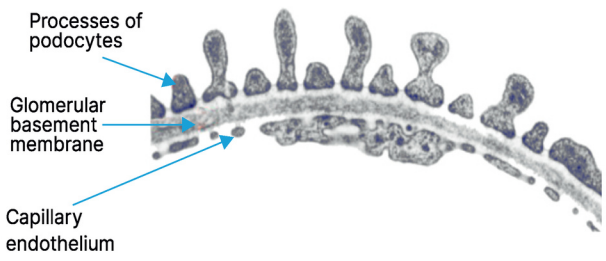

- This membrane is **trilaminar**
- Made primarily of **Type IV collagen.**

## BIG QUESTION 2: What are the various gross appearances of the kidney and their pathological associations?

**Broad Answer:** Kidneys can exhibit distinct gross morphologies based on underlying pathological processes, including infections, hypertension, immune disorders, amyloidosis, and congenital conditions. Recognising these appearances aids in identifying the associated disease.

## DETAILED QUESTIONS

### Q2.1: What is a Putty kidney, and what clinical feature is associated with it?

**Answer:** Putty kidney presents with sterile pyuria.

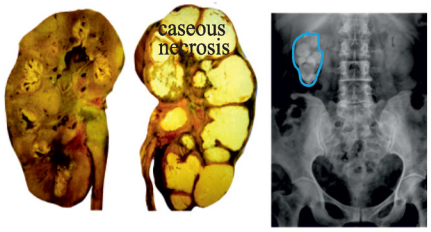


### Q2.2: What is a Leather grain kidney, and in which condition is it seen?

**Answer:** Leather grain kidney is seen in Benign Hypertension (benign nephrosclerosis).



### Q2.3: What is a Symmetrically contracted kidney?

**Answer:** It refers to bilateral kidney shrinkage, as seen in chronic conditions like benign nephrosclerosis, malignant Hypertension, and chronic pyelonephritis.

### Q2.4: What is a flea-bitten kidney, and where is it seen?

**Answer:**

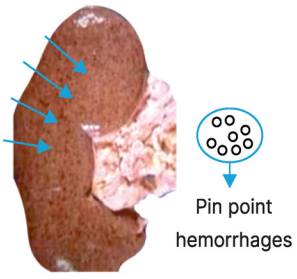


- Flea-bitten kidney is seen in Malignant Hypertension (malignant nephrosclerosis).
- Red dark dots are present on the kidney's surface, known as pinpoint haemorrhages.
- Other causes of pinpoint haemorrhages:
  - Wegener's Granulomatosis
  - HSP (Henoch-Schönlein purpura)
  - HUS/TTP
  - PSGN (Post-streptococcal glomerulonephritis)
  - PAN (Polyarteritis nodosa)
  - SLE (Systemic lupus erythematosus)
  - SABE (Subacute bacterial endocarditis)
  - Malignant HTN

### Q2.5: What is a Waxy kidney, and what condition is it seen in?

**Answer:**

- Waxy kidney is seen in Amyloidosis.
- The kidney appears like candle wax.



### Q2.6: What are the key gross and microscopic features of Chronic Pyelonephritis (CPN)?

**Answer:**

- It is a tubular disorder.
- Tubules undergo atrophy and are filled with pink material: Thyroidization of Tubules.
- The scars lead to periglomerular fibrosis around the glomerulus.

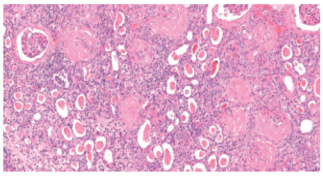

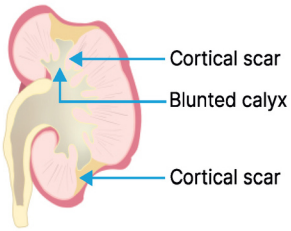


### Q2.7: What is Malakoplakia, and what are its characteristic features?

PYQ: FMGE 2021 PYQ: NEET PG 2022

**Answer:**

- A phagolysosome defect is present.
- Yellow-white mucosal plaques mimic cancer.
- Macrophages try to eat E. coli but fail due to the defect in phagolysosomes.
- Calcium deposits around E. coli form Michaelis-Gutmann bodies.
- The entire macrophage containing this is called a Von Hansemann Cell.




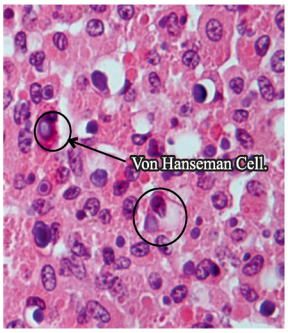


### Q2.8: What are the types and features seen in Polycystic Kidney Disease?

PYQ: NEET PG 2022
PYQ: FMGE 2019
PYQ: AIIMS 2019

**Answer:**

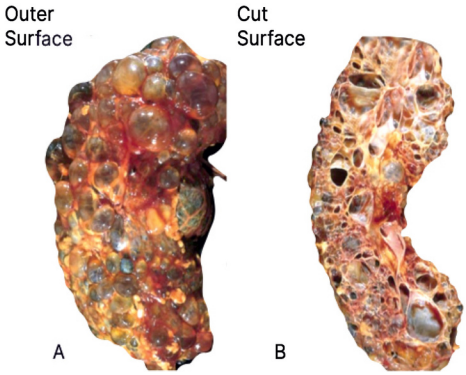


| In ADPKD disease | In ARPKD disease |
|---|---|
| • Cysts are shown at both outer and Inner surfaces.<br>• Adult Onset<br>• Chromosomes number: 16 and 4<br>• The affected Gene is PKD- 1, 2.<br>• The affected protein is polycystin.<br>• Causes: aortic dissection, > in boys, increased BP, Increased blood in urine, berry aneurysm, colonic diverticula, cysts | • The outer surface looks normal and cysts are shown on the inner surface.<br>• Childhood Onset<br>• Chromosomes number: 6<br>• The affected Gene is PKHD<br>• The affected protein is fibrocystin.<br>• Congenital Hepatic Fibrosis is present in these cysts. |

## BIG QUESTION 3: What are the different types of urinary crystals and casts, and what do they indicate clinically?

**Broad Answer:** Urine may contain various crystals and casts whose shapes, compositions, and associations provide key diagnostic clues about underlying metabolic, infectious, or renal diseases. Identifying these elements helps differentiate between normal findings and pathological conditions.

## DETAILED QUESTIONS

PYQ: FMGE 2023

### Q3.1: What is the shape of Cystine crystals?

**Answer:** Hexagonal



### Q3.2: What is the shape of Tyrosine crystals?

**Answer:** Thin needles

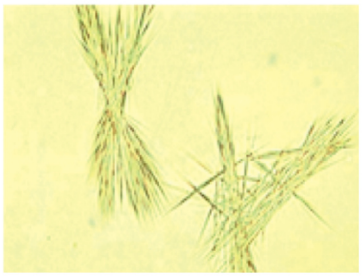

### Q3.3: What is the appearance of Bilirubin crystals?

**Answer:** Pigmented thin needles

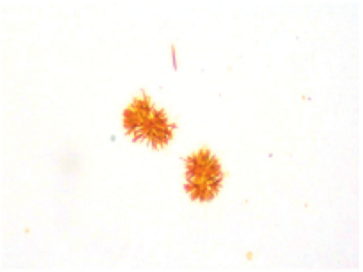

### Q3.4: What is the characteristic feature of Ammonium biurate crystals, and where are they seen?

**Answer:**

- Apple thorn appearance
- Seen in laxative abuse

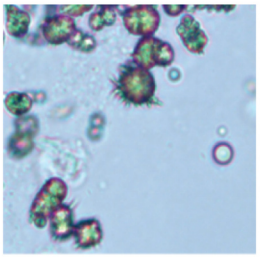

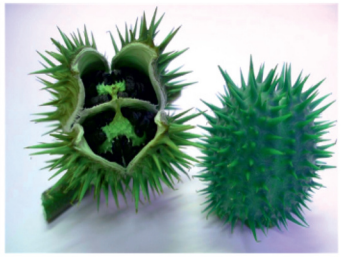

### Q3.5: What is the appearance of Leucine crystals?

**Answer:** Lamellated appearance



**Q3.6: What is the shape of Calcium carbonate crystals?**

**Answer:** Round wheel



**Q3.7: What is the appearance of Calcium oxalate monohydrate crystals?**

PYQ: FMGE 2020

**Answer:** Dumbbell-shaped

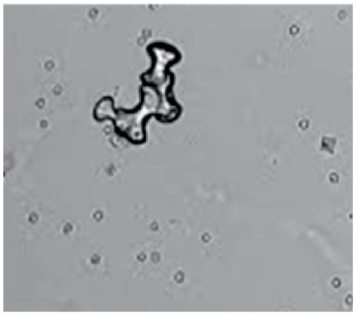

**Q3.8: What is the appearance of Calcium oxalate dihydrate crystals?**

**Answer:** Envelope-shaped

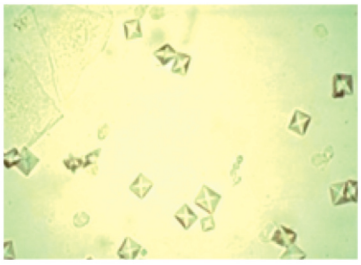

**Q3.9: What is the appearance and significance of Triple phosphate (Struvite) crystals?**

**Answer:**

- Coffin lid appearance
- Can terminate into staghorn calculus (deer/antler appearance)
- Associated with Proteus infection
- Proteus functions in alkaline urine







**Q3.10: What are the features of Uric acid crystals?**

**Answer:**

- Shapes: Rhombus, triangle, parallelogram, etc.
- They are radiolucent

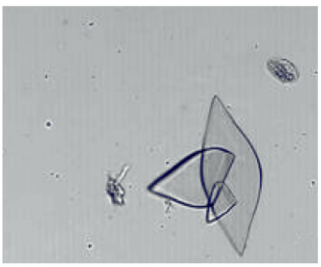

**Q3.11: What is the appearance of Cholesterol crystals?**

**Answer:** Broken chips



**Q3.12: What is a Hyaline cast, and what is it composed of?**

PYQ: FMGE 2023

**Answer:**

- Cylindrical shape
- Made up of **Tamm-Horsfall protein**
- Tamm-Horsfall protein originates from the loop of Henle
- Seen in routine exams, fever, dehydration, and pregnancy

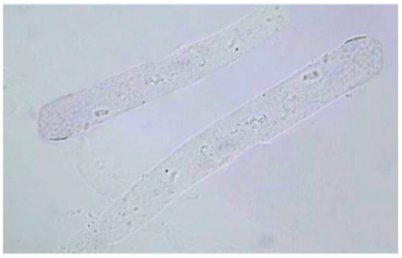

**Q3.13: What is a Red cast, and where is it seen?**

**Answer:**

- Tamm-Horsfall protein gets along with RBCs
- Seen in glomerulonephritis

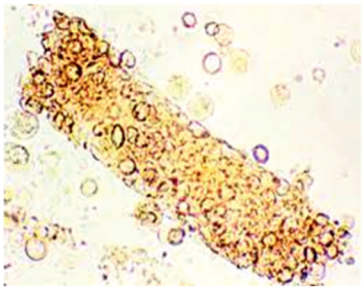

**Q3.14: What is a WBC cast, and where is it seen?**

**Answer:**

- Tamm-Horsfall protein gets along with WBCs
- Associated with a rise in eosinophils
- Seen in chronic pyelonephritis (CPN) and interstitial nephritis

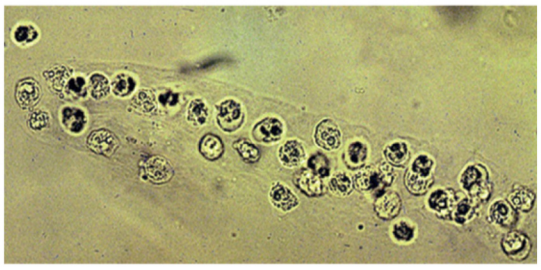

**Q3.15: What is a Granular cast?**

**Answer:** Degenerated cast



**Q3.16: What is a Muddy brown cast, and where is it seen?**

**Answer:**

- Seen in acute tubular necrosis (ATN)
- Example: Toxin abuse, such as ethylene glycol (used as antifreeze)

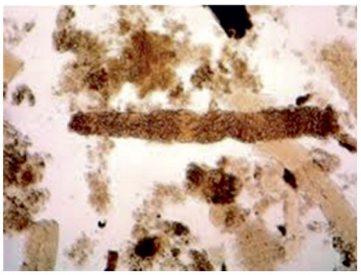

### Q3.17: What is a Broad waxy cast, and in which condition is it seen?

**Answer:** Seen in Chronic Renal Failure (CRF)

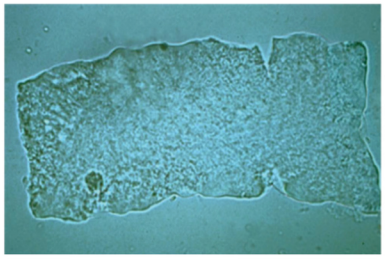

## BIG QUESTION 4: What are the key differences between Nephritic and Nephrotic syndromes, and what are the features of PSGN AND IgA nephropathy?

**Broad Answer:** Nephritic and nephrotic syndromes differ in their clinical presentation and underlying pathology. Nephritic syndrome is characterised mainly by hematuria, while nephrotic syndrome features massive proteinuria. Among the nephritic types, Post-Streptococcal Glomerulonephritis is the most common in children, whereas IgA Nephropathy is most common in adults and globally.

## DETAILED QUESTIONS

PYQ: INICET 2020, 2021
PYQ: FMGE 2020, 2021
PYQ: NEET PG 2022

### Q4.1: What are the differences between Nephrotic Syndrome and Nephritic Syndrome?

**Answer:**

| Nephrotic Syndrome | Nephritic Syndrome |
|---|---|
| Massive proteinuria (>3.5gm/24-hour urine sample) | Mild proteinuria (<1gm/ 24-hour sample) |
| Lipiduria | **H** - HTN (hypertensive) |
| Hypoalbuminemia | **O** - Oliguria (Less urine output): <400ml/day |
| Edema (causes are sodium water retention and hypoalbuminemia) | **H** - Hematuria (blood in urine): >3 RBC/HPF |
| Thrombotic events (removal of ATIII through urine) | **A** - Azotemia (Increase in blood urine nitrogen levels): Increase in BUN |

### Q4.2: What is the difference between Nephritic and Nephrotic Syndrome based on urine appearance?

**Answer:**

- Cola-colour urine → indicates hematuria, characteristic of Nephritic Syndrome.
- Frothy urine → indicates the presence of protein and fat, characteristic of Nephrotic Syndrome.



Frothy urine



Blood/Cola-color

### Q4.3: What is the most common cause of Nephritic Syndrome in children and adults?

**Answer:**

- Most common pediatric cause: Post-Streptococcal Glomerulonephritis (PSGN)
- Most common adult cause:
  - IgA Nephropathy / Berger's Disease
  - The most common cause of nephritic syndrome worldwide



YOURWISH

### Q4.4: What is the etiology of Post-Streptococcal Glomerulonephritis (PSGN)?

**Answer:**

- PSGN is a type III hypersensitivity reaction
- Also known as:
  - Post-Infectious Glomerulonephritis
  - Acute Proliferative Glomerulonephritis
- Caused by Streptococcus pyogenes (Group A β-hemolytic streptococcus)
- Common strains: 12, 4, 1

### Q4.5: What are the clinical features of PSGN?

**Answer:**

- Sore throat (13-14 days before)
- Followed by cola-colored urine (hematuria)

### Q4.6: What is the blood test finding in PSGN?

**Answer:**

- Transient Hypocomplementemia
- Presence of C3 is noted

### Q4.7: What are the gross and microscopic findings in PSGN?

PYQ: NEET PG 2023

PYQ: FMGE 2023

**Answer:**

- Gross Finding: Flea-bitten appearance

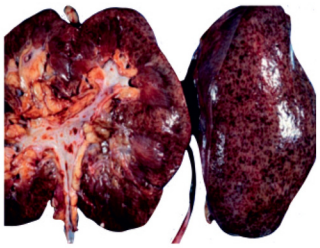

- Immunofluorescence: Starry sky appearance

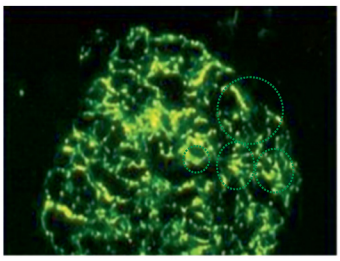

- Electron Microscopy: Subepithelial humps

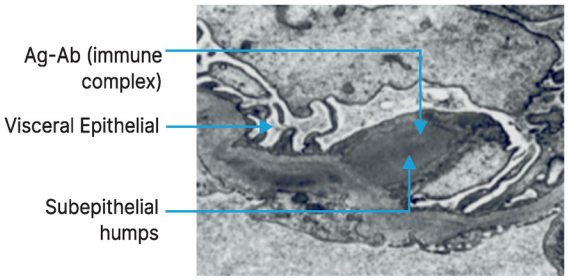


### Q4.8: How is PSGN treated?

**Answer:** It is a self-limiting disorder



YOURWISH

### Q4.9: What is IgA Nephropathy/Berger's Disease and its features?

**Answer:**

- Most common in adults
- Most common nephritic syndrome worldwide
- Pathogenesis:
  - o Antibodies are produced against IgA1
  - o Forms immune complexes → Deposited in the kidney
  - o Leads to mesangial deposition in the kidney

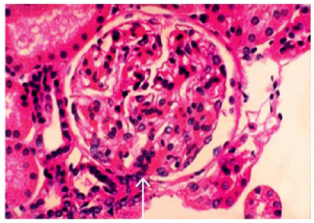

IgA1 immunocomplex getting deposited in mesangial cells

### Q4.10: What are the symptoms of IgA Nephropathy?

**Answer:**

- Sore throat (3-4 days before) in adults
- Followed by recurrent hematuria

### Q4.11: What can IgA Nephropathy progress into?

**Answer:** It can progress into Rapidly Progressive Glomerulonephritis (RPGN)

## BIG QUESTION 5: What are the key features of Rapidly Progressive Glomerulonephritis (RPGN)?

**Broad Answer:** RPGN is a severe and rapidly progressing form of glomerulonephritis marked by crescent formation in the glomeruli and a poor prognosis. It is also known as crescentic glomerulonephritis and has a characteristic composition and prognostic indicators.

## DETAILED QUESTIONS

### Q5.1: What is another name for Rapidly Progressive Glomerulonephritis?

PYQ: NEET PG 2020

**Answer:** Crescentic Glomerulonephritis

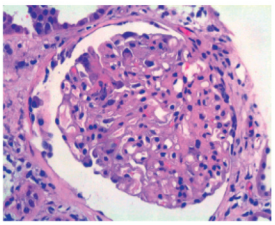

### Q5.2: What is the cellular composition of the crescents in RPGN?

**Answer:**

- Fibrin
- Leukocytes
- Parietal epithelial cells (most common)
- Visceral epithelial cells (least common) (Mnemonic: FLaP)

### Q5.3: What are the types of RPGN?

PYQ: NEET PG 2019
PYQ: FMGE 2018

**Answer:**

| Feature | RGPN I | RGPN II | RGPN III (Most Common) |
|---|---|---|---|
| Includes | Goodpasture Syndrome (Anti Glomerular Basement Membrane Disease) | PSGN, IgA, SLE, HSP (antigen-antibody complex) | Microscopic polyangiitis, |

| | | | |
|---|---|---|---|
| | | | Wegener's Granulomatosis (Pauci Immune Vasculitis) |
| IF | Linear (Ribbon Pattern) | Lumpy/ Bumpy/ Granular/ Starry Sky (Garland Pattern) | Nil |
| | 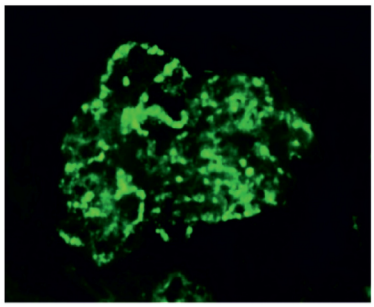 | 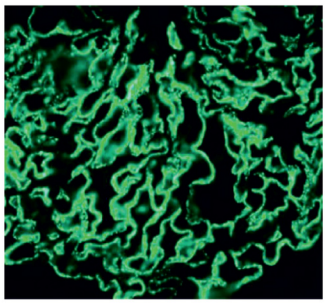 | |
| EM | **Common:** R R R (**R**GPN causing **R**upture and wrinkling of basement membrane) | | |

**Q5.4: What is the electron microscopy finding seen in RPGN?**

**Answer:** Rupture and wrinkling of the basement membrane

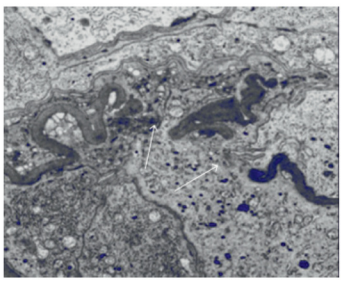

**Q5.5: What is the prognostic significance of crescents in RPGN?**

**Answer:** An increased number of crescents is associated with poor prognosis.

## BIG QUESTION 6: What are the distinguishing features of Goodpasture Syndrome, Thin Basement Membrane Disease, and Alport Syndrome?

These three conditions are glomerular diseases involving defects or antibodies directed against specific chains of Type IV collagen, and are key causes of nephritic syndrome. They are differentiated by the specific α-chain involved, mode of inheritance, clinical presentation, and microscopic features.

## DETAILED QUESTIONS:

**Q6.1: What type of RPGN is Goodpasture Syndrome classified as?**

**Answer:** Type I RPGN

**Q6.2: What is the pathogenesis of Goodpasture Syndrome?**

**Answer:**

- Type II Hypersensitivity reaction
- Antibody against the α3 chain of Type IV collagen
- NOTE: Mnemonic- 1234

- 1. Type I RGPN
- 2. Type II Hypersensitivity reaction
- 3. Ab against Alpha α3 chain of
  ↓
- 4. Type IV collagen

### Q6.3: What are the clinical features of Goodpasture Syndrome?

**Answer:**

- Hemoptysis (due to lung involvement)
- Hematuria (due to kidney involvement)
- The most common cause of death in Goodpasture Syndrome: Uremia

### Q6.4: What is the characteristic immunofluorescence pattern seen in Goodpasture Syndrome?

**Answer:** Linear Immunofluorescence

### Q6.5: What are the features of thin basement membrane disease?

**Answer:**

- AKA Benign Familial Hematuria
- Defect in the α4 chain of Type IV collagen.
- Thickness of the basement membrane in Thin Basement Membrane Disease: <200 nm

### Q6.6: What is the pathogenesis of Alport Syndrome?

**Answer:**

- Defect in the α5 chain of Type IV collagen
- All modes of inheritance are possible
  - Autosomal Dominant (AD)
  - Autosomal Recessive (AR)
  - X-linked Recessive (XLR)
  - X-linked Dominant (XLD - Most Common)

### Q6.7: What are the clinical features and management of Alport syndrome?

**Answer:**

- Clinical triad:
  - Kidneys: Hematuria
  - Eyes: Anterior lenticonus
  - Ears: Sensorineural hearing loss

### Q6.8: What is the electron microscopy finding in Alport Syndrome?

PYQ: FMGE 2019

**Answer:**

- Basket Weave appearance
- Due to multiple holes in the lamina densa of the basement membrane
- Gold Standard for diagnosis

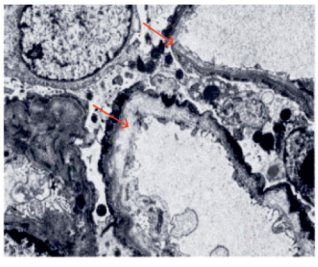

### Q6.9: Summarise the defects seen in Nephritic syndrome.

**Answer:**

| Type IV Collagen Chain | Disease |
|---|---|
| α3 | Goodpasture Syndrome (GPS) |
| α4 | Thin Basement Membrane Disease (BFH) |
| α5 | Alport Syndrome |

## BIG QUESTION 7: How are the various types of Nephrotic Syndrome classified based on age, causes, histological findings, and associated mutations?

**Broad Answer:** Nephrotic Syndrome presents differently across age groups. It is most commonly caused by Minimal Change Disease in children, FSGS in adults, and Membranous GN in the elderly. Diagnosis depends on age, clinical features like selective proteinuria and oedema, histopathology (light microscopy, IF, EM), and specific markers or genetic mutations. Treatment and prognosis vary depending on the underlying cause.

## DETAILED QUESTIONS

### Q7.1: What are the common causes of Nephrotic Syndrome?

**Answer:**

- M/C in children: Minimal Change Disease (MCD)
- M/C Adults: Focal Segmental Glomerulosclerosis
- M/C Elderly Population: Membranous Glomerular Nephropathy

### Q7.2: What are the key features of Minimal Change Disease (MCD)?

**Answer:**

- Also known as Lipoid Nephrosis or Nil Deposit Disease
- **Age:** Common in children between 2-6 years
- **Cause:** Poorly understood; associated with atopy, Hodgkin's lymphoma, ↑ lymphokines
- **Clinical features:** Selective proteinuria (albumin loss) and oedema episodes

### Q7.3: What are the histological findings in MCD?

**Answer:**

- Gross: Normal kidney
- Light Microscopy: Normal glomerulus, lipid in PCT (→ Lipoid nephrosis)
- IF (Immunofluorescence): Nil deposits
- EM (Electron Microscopy): Effacement of foot processes (Gold standard)

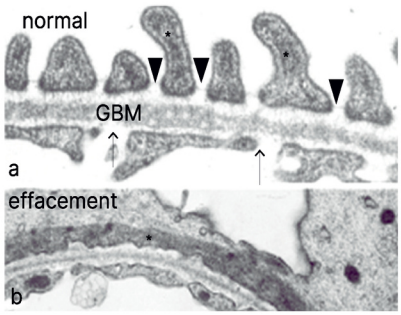


### Q7.4: What is the treatment response in MCD?

**Answer:** Shows excellent (100%) steroid response

### Q7.5: What defines Focal Segmental Glomerulosclerosis (FSGS)?

**Answer:**

- Focal = Few glomeruli affected.



YOURWISH

- Segmental = Only part of the glomerular segment affected
- Leads to segmental sclerosis

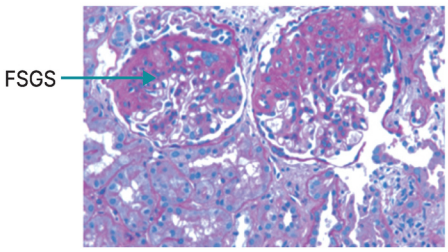


### Q7.6: What are the types and causes of FSGS?

**Answer:**

- Primary type: Idiopathic
- Secondary causes:
  - HIV
  - Hypertension
  - Heroin abuse
  - Reflux nephropathy
  - Renal tissue loss
  - Sickle cell anaemia

### Q7.7: What is the Columbia Classification of FSGS?

**Answer:**

1. FSGS NOS (Not Otherwise Specified) - Most common
2. FSGS, Glomerular Tip - Best prognosis
3. FSGS, Collapsing Type - Worst prognosis, seen in HIVAN
4. Perihilar type
5. Cellular type

### Q7.8: What are the genetic mutations associated with Congenital Nephrotic Syndrome and FSGS?

**Answer:**

| Gene | Protein | Disease |
|---|---|---|
| NPHS1 | Nephrin | Congenital NS (Finnish type) |
| NPHS2 | Podocin | AR FSGS |
| Alpha Actinin 4 | Actin | AD FSGS |
| CD2AP | - | No disease |
| TRPC6 | - | Adult-onset FSGS |
| APOL1 polymorphism | - | Associated with HIVAN |

### Q7.9: What are the causes of Membranous Glomerular Nephropathy (MGN)?

**Answer:**

- Primary / Idiopathic:
  - Ab against PLA2 receptor (PLA2Rc)
  - Ab against THSD7A (Thrombospondin)
  - Ab against CD10 (neural endopeptidase)
- Secondary causes:
  - Drugs: Gold, NSAIDs, Penicillamine

- Infections: HBV, HCV, Syphilis, Schistosoma, Malaria, Leprosy
- Cancers: Colon, Lung, Melanoma
- Systemic Diseases: DM, SLE

### Q7.10: What are the antigen-antibody targets in humans and animals for MGN?

**Answer:**

- Humans: Ab against PLA2Rc
- Rats/mice (Heymann Nephritis): Ab against Megalin

### Q7.11: What is the electron microscopy finding in MGN?

**Answer:**

- Subepithelial deposits
- Leads to "spike and dome" pattern formation

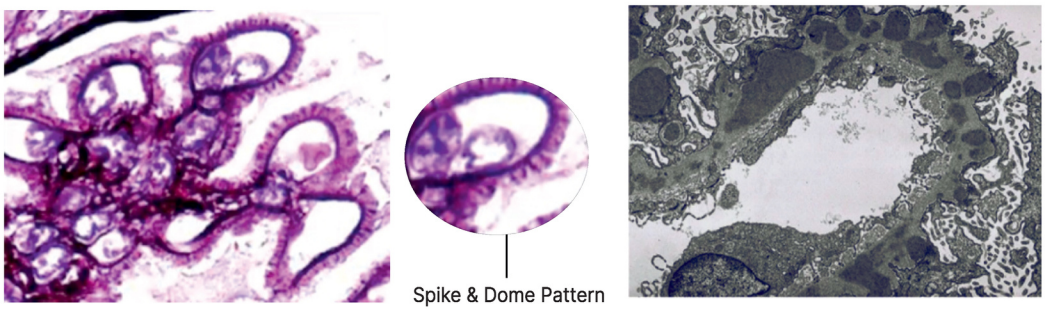


### Q7.12: What are the types and features of MPGN (MembranoProliferative Glomerulonephritis)?

**Answer:**

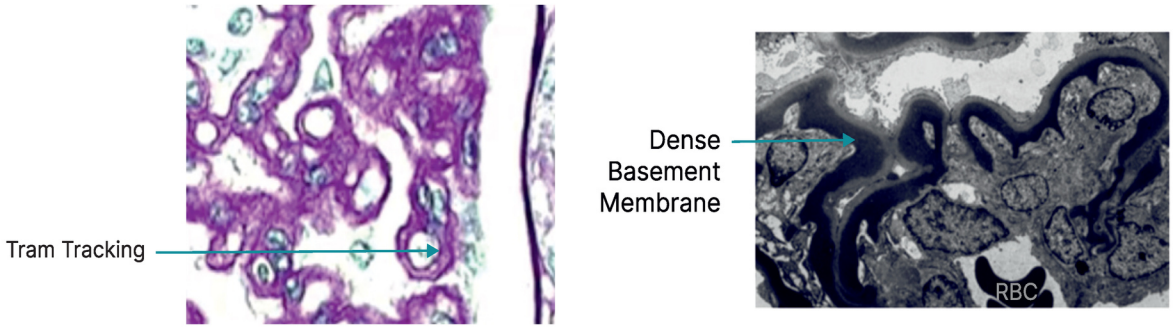


- MPGN (MembranoProliferative Glomerulonephritis)/ (Mesangiocapillary Glomerulonephritis)
- **MPGN I**
  - Primary: Idiopathic
  - Secondary: AATD (alpha1 antitrypsin deficiency), Hep B, Hep C, HIV, Schistosoma. Cryoglobulinemia, CLL.
  - Tram Tracking (splitting of basement membrane).
- **MPGN II**
  - C3 nephritic factor (C3NeF) that binds the alternative pathway C3 convertase.
  - This favours persistent C3 activation and hypocomplementemia.
- E/M: DDD Dense Deposit Disease- Intramembranous disease.

### Q7.13: What are the different sites of immune complex deposition in glomerular diseases?

**Answer:**

| Site | Disease |
|---|---|
| Subepithelial | PSGN, MGN |
| Mesangial | Berger's Disease |
| Intramembranous | Dense Deposit Disease (MPGN II) |
| Subendothelial | MPGN I, SLE (Wire loop lesions) |

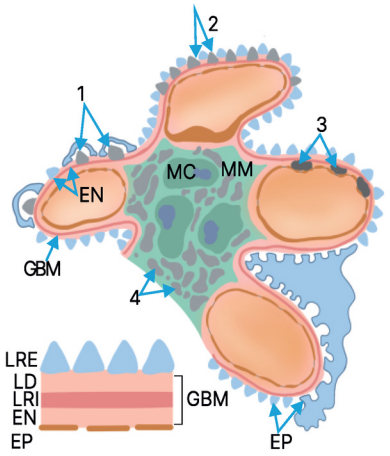


**Q7.14: Which infection is most strongly associated with cryoglobulinemia and MGN?**

**Answer:** Hepatitis C Virus (HCV): Cryoglobulinemia >> MGN

## BIG QUESTION 8: What are the characteristic renal findings in Systemic Lupus Erythematosus (SLE), particularly in lupus nephritis?

**Broad Answer:** Lupus nephritis shows distinct histopathological features across classes, with hallmark immune complex depositions and specific patterns seen on immunofluorescence and electron microscopy. These include wire loop lesions, subendothelial deposits, and the "Full House" pattern on IF.

## DETAILED QUESTIONS

**Q8.1: What are the characteristic lesions seen in lupus nephritis under light microscopy?** PYQ: NEET PG 2020

**Answer:**

- Wire Loop Lesions are observed in Class III, IV, and V lupus nephritis.
- These are due to subendothelial immune complex deposition.

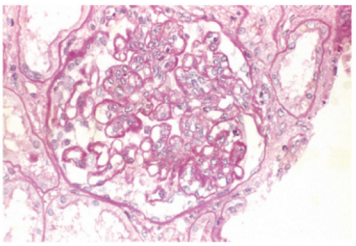

**Q8.2: What is seen on electron microscopy (E/M) in lupus nephritis?**

**Answer:** Thumbprint appearance is observed on electron microscopy.



**Q8.3: What is the immunofluorescence (IF) finding in lupus nephritis?**

**Answer:**

- Full House Effect is seen, with deposits of:
  - IgG, IgA, IgM, C1, C3
- All these components get deposited in the kidney.

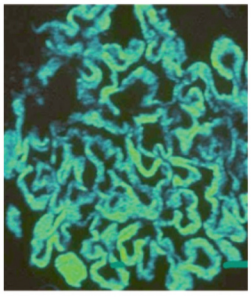

## BIG QUESTION 9: What are the key pathological features of diabetic nephropathy?

**Broad Answer:** Diabetic nephropathy presents with thickened basement membranes, vascular and glomerular changes, and characteristic lesions such as the Kimmelstiel-Wilson nodule. These findings result from non-enzymatic glycosylation and manifest in both glomerular and tubular structures.

## DETAILED QUESTIONS

### Q9.1: What vascular change is commonly seen in diabetic nephropathy?

PYQ: FMGE 2019 PYQ: AIIMS 2018

**Answer:**

- Thickening of Capillary Basement Membrane.
- Hyaline arteriosclerosis, seen in both benign hypertension and diabetes mellitus.

### Q9.2: What is an Armani abstain lesion?

**Answer:** Armani Abstain lesion - refers to glycogen deposition in the proximal convoluted tubule (PCT).

### Q9.3: What are the glomerular lesions in diabetic nephropathy?

**Answer:**

- Diffuse glomerulosclerosis
- Fibrin Cap
- Capsular Drop
- Nodular glomerulosclerosis – specifically the Kimmelstiel-Wilson (KW) lesion

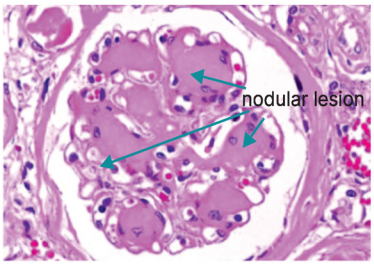


### Q9.4: What is the most characteristic lesion of diabetic nephropathy?

**Answer:**

- Kimmelstiel-Wilson (KW) lesion, also called nodular glomerulosclerosis.
- Non-enzymatic glycosylation end products are the underlying cause.
- PAS-positive.

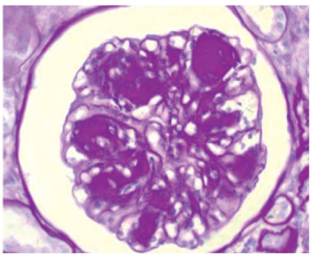

PAS staining

## BIG QUESTION 10: How are renal tumours classified in adults and children, and what are the distinguishing features of the benign tumours?

**Broad Answer:** Renal tumours are classified based on age and behaviour into benign and malignant types. Some tumours, like oncocytomas, show specific histological and staining patterns, while angiomyolipomas have distinct tissue components and immunohistochemical markers.

## DETAILED QUESTIONS

### Q10.1 What are the benign renal tumours seen in adults?

**Answer:**

- Renal papillary adenoma (Carries risk of RCC)
- Oncocytoma
- Angiomyolipoma



YOURWISH

**Q10.2: What is the malignant renal tumour seen in adults?**

PYQ: INICET 2022

**Answer:** Renal Cell Carcinoma (RCC)

**Q10.3: What is the renal tumour typically seen in children?**

PYQ: NEET PG 2020, 2021

PYQ: FMGE 2022, 2023

**Answer:** Wilms tumor

**Q10.4: What are the histological and structural features of renal oncocytoma?**

**Answer:**

- Increase in mitochondria
- Origin: Collecting duct of the kidney
- Colour: Mahogany brown
- Centre: Central stellate scar
- H&E stain: Diffusely pink cells observed
- Electron microscope: Shows a lot of mitochondrial structures

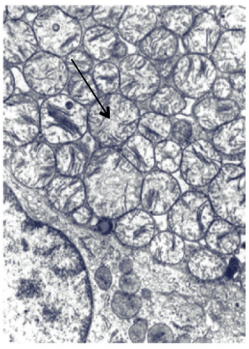

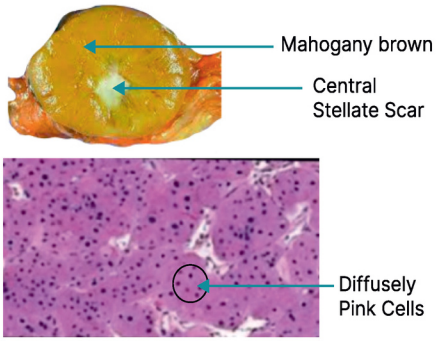


**Q10.5: What are the other conditions where a central stellate scar is seen?**

**Answer:**

| Central Stellate Scar | |
|---|---|
| Parts | Tumors |
| Kidney | Oncocytoma, Chromophobe RCC |
| Liver | FNH, Fibrolamellar, Carcinoma Liver |
| Pancreas | Serous Cystadenocarcinoma Pancreas |
| Breast | Radial Scar |

**Q10.6: What is the significance of the mahogany brown colour in renal pathology?**

**Answer:**

- Oncocytoma appears mahogany brown
- Also seen in Lugol's $I_2$ stain used on amyloidosis specimens

**Q10.7: What other cells or organs also have an abundance of mitochondria like oncocytoma?**

**Answer:**

- Hepatocytes (liver cells)
- Hurthle cells (thyroid)

**Q10.8: What are the features of angiomyolipoma (AML)?**

**Answer:**

- Circular blood vessels, muscle, and fat
- Origin: PEComa (Perivascular Epithelioid Cell tumour)
- PEComa in other organs:
  - Lung tumour: Sugar tumour
  - Kidney tumour: AML (Angiomyolipoma)

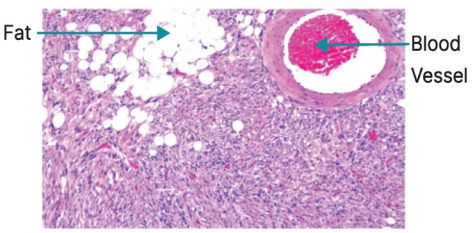

### Q10.9: What immunohistochemical marker is angiomyolipoma positive for?

**Answer:** HMB45

## BIG QUESTION 11: What are the key pathological subtypes, features, and genetic associations of Renal Cell Carcinoma (RCC)?

**Broad Answer:** Renal Cell Carcinoma (RCC), also called Grawitz Tumour or Hypernephroma, occurs primarily in adults and consists of several histological types, each with distinct genetic mutations, microscopic characteristics, and clinical associations. RCC types include clear cell, papillary, chromophobe, collecting duct, medullary, and pediatric RCC. Some types are linked with hereditary syndromes such as VHL and Birt-Hogg-Dube. Diagnosis involves histopathology, cytogenetics, and special stains, with grading done by the Fuhrman nuclear grading system.

## DETAILED QUESTIONS:

### Q11.1: What is another name for Renal Cell Carcinoma (RCC)?

**Answer:** RCC is also known as Grawitz Tumour or Hypernephroma.

### Q11.2: What is the most common type of RCC and its genetic basis?

**Answer:** The most common type is Clear Cell RCC.

- It is associated with the deletion of chromosome 3p, leading to VHL (Von Hippel-Lindau) syndrome.
- VHL can cause bilateral clear RCC affecting both kidneys.

### Q11.3: What are the microscopic and gross features of Clear Cell RCC?

**Answer:**

- 00ss: Tumour appears golden yellow due to fat content.

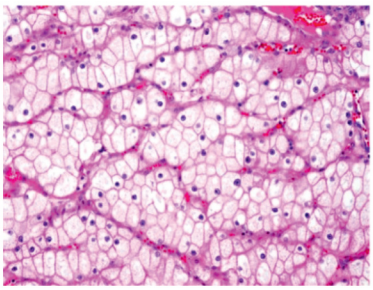

### Q11.4: Which type of RCC is associated with dialysis, and what are its genetic associations?

**Answer:**

- Papillary RCC is seen in dialysis/hemodialysis patients
- Genetic associations:
  - Trisomy 7 (extra C-MET gene; hereditary)
  - Trisomy 17
  - Loss of Y chromosome
  - HPRCC (Hereditary Papillary RCC): Trisomy 7
  - HLRCC (Hereditary Leiomyomatosis Papillary RCC): Fumarate Hydratase mutation
    → Features: Multiple leiomyomatosis lesions
  - Renal papillary adenoma can lead to papillary RCC.

### Q11.5: What microscopic finding is commonly seen in Papillary RCC?

**Answer:** Psammoma bodies

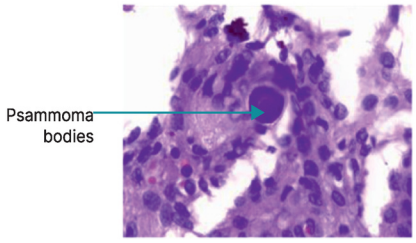


### Q11.6: What are the features of Chromophobe RCC and its associated syndrome?

**Answer:**

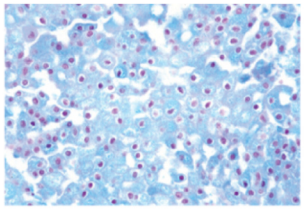

- Genetics: Multiple chromosomal losses
- Associated Syndrome: Birt-Hogg-Dube syndrome
- Microscopy:
  - Cells resemble plant cells
  - Well-defined outlines
  - Dark, irregular nucleus: "Raisinoid nucleus"
  - Perinuclear Halo
- Special stain: Hale's colloidal iron positive
- Prognosis: Best among all RCCs

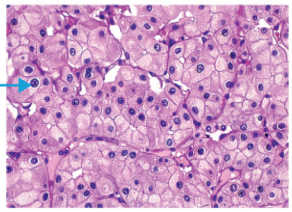


### Q11.7: Which RCC subtype has the worst prognosis, and what are its microscopic features?

**Answer:**

- Bellini/Collecting duct RCC
- Microscopy: Presence of hobnail cells

### Q11.8: Which RCC subtype is associated with Sickle Cell Trait?

**Answer:**

- Medullary RCC occurs in patients with Sickle Cell Trait (HbAS)
- Not associated with Sickle Cell Anaemia (HbSS)

### Q11.9: What are the features of Pediatric RCC?

**Answer:**

- Associated with the translocation of Xp
- Involves TFE3 gene

### Q11.10: What grading system is used for Renal Cell Carcinoma?

**Answer:** Fuhrman Nuclear Grade is used for microscopic grading of RCC.

## BIG QUESTION 12: What is Wilms' Tumour and what are its key histological features and clinical implications?

**Broad Answer:** Wilms' Tumour, also called nephroblastoma, is a pediatric renal tumour characterised by a triphasic histological pattern comprising epithelial, mesenchymal, and blastemal elements. The presence of anaplasia in the tumour indicates a p53 mutation and is associated with resistance to chemotherapy.

## DETAILED QUESTIONS:

### Q12.1: What is another name for Wilms' tumour?

**Answer:** Wilms' tumour is also known as nephroblastoma.

### Q12.2: Why is Wilms' tumour called a triphasic tumour?

**Answer:** It is called triphasic because it consists of three components:

- Epithelial component: Abortive glomeruli/tubules
- Mesenchymal component: Spindle cells
- Blastemal component: Blue-colored primitive cells

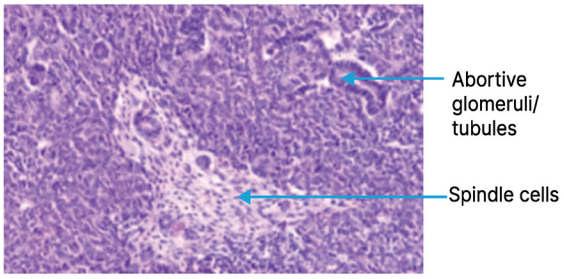


### Q12.3: What histological change is seen in Wilm's Tumour with anaplasia?

**Answer:** Wilm's tumour with anaplasia shows:

- p53 mutation
- Resistance to chemotherapy



YOURWISH

# 15. MALE GENITAL SYSTEM PATHOLOGY

## BIG QUESTION 1: What is Cryptorchidism, its clinical implications, and what are its microscopic features?

**Broad Answer:** **Cryptorchidism** is the failure of one or both testes to descend into the scrotum. The inguinal canal is the most common site where the testis may get arrested during its descent. This condition is clinically important because affected individuals have an increased risk of testicular cancer and infertility due to impaired spermatogenesis. To minimize these risks, corrective surgery (orchiopexy) is recommended within the first 18 months of life.

## DETAILED QUESTIONS

### Q1.1: What is the most common site of arrest?

**Answer:**

The inguinal canal.

### Q1.2: What are the primary risks associated with cryptorchidism, and by what age should corrective orchiopexy ideally be performed?

**Answer:**

- **Risks:** Patients are at increased risk of testicular cancer and infertility
- **Corrective Procedure:** Corrective orchiopexy should be done within 18 months.

PYQ: AIIMS 2018

### Q1.3: Describe the key microscopic findings in cryptorchidism.

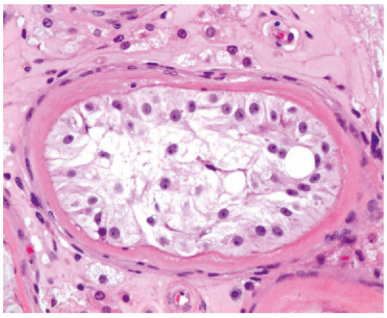

**Answer:**

- Sertoli cells
- Spermatids and spermatogonia are absent due to lack of spermatogenesis
- Thick basement membrane
- Leydig cell hyperplasia

### Q1.4: A surgeon suspecting testicular carcinoma in a patient asks the intern to send the sample for histopathology. What is the fluid in which the intern should send the sample to the pathologist?

A. Bouin solution

**B. 10% formalin**

C. 95% ethanol

D. Alcohol

**Answer:** **10% formalin**

- If the reason for testing is suspected infertility, a Bouin solution is used.
- Bouin solution is a picric acid-based solution.
- If the reason for testing is suspected carcinoma, the tumor is sent in 10% neutral buffered formalin (NBF).

## BIG QUESTION 2: What are the associations, precursors, and main classifications of testicular tumors?

**Broad Answer:** Testicular tumors are associated with chromosomal abnormalities and specific genetic syndromes.

They largely arise from a precancerous germ cell neoplasia in situ, with distinct exceptions. These tumors are broadly classified into germ cell and non-germ cell categories, each with important subtypes.

## DETAILED QUESTIONS

### Q2.1: What are the genetic and clinical conditions associated with testicular tumors?

Answer: **Associations:**

- Isochromosome 12p.
- Klinefelter syndrome.
- Cryptorchidism.

### Q2.2: What is the precursor (precancerous condition) for most testicular germ cell tumors, and which specific types are exceptions to this derivation?

Answer:

- **Precursors (precancerous condition):** ITGCN/GCNIS (Germ cell neoplasia in situ).
- **Derivatives:** All testicular germ cell tumors except teratoma and spermatocytic seminoma arise from ITGCN.

PYQ: FMGE 2020,2021

### Q2.3: How are testicular tumors broadly classified, and what are the specific subtypes within each major category?

| | |
|---|---|
| Germ cell tumors | • **Seminomatous tumors**<br>o Seminoma/Dysgerminoma<br>o Spermatocytic seminoma<br>• **Non-seminomatous tumors**<br>o Choriocarcinoma<br>o Yolk sac tumor<br>o Teratoma<br>o Embryonal carcinoma (CD30+) |
| Non-germ cell tumors | • **Sex cord-stromal tumors**<br>o Sertoli cell tumors<br>o Leydig cell tumors<br>• **Others**<br>o Lymphoma |

## BIG QUESTION 3: What are the key tumor markers, gross, and microscopic features of seminoma?

Broad Answer: Seminoma is a type of germ cell tumor with specific tumor marker profiles, including common positivity for LDH and PLAP, and occasional positivity for HCG, but always negative for AFP.

## DETAILED QUESTIONS

### Q3.1: Which tumor markers are typically associated with Seminoma, and how do HCG and AFP levels relate to it?

Answer:

- **Markers:** LDH and PLAP.
- **HCG:** 15-20% can be HCG positive.
- **AFP:** AFP negative.

**Q3.2: Describe the typical gross and microscopic appearances of seminoma.**

PYQ: NEET PG 2021

Answer:

- **Gross:** Cut potato appearance.
- **Microscopy:** Fried egg appearance.

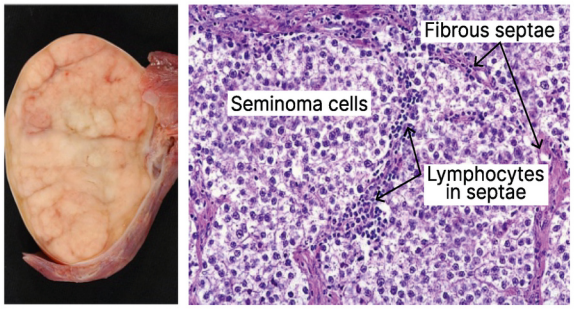


## BIG QUESTION 4: What are the characteristic patient demographics, genetic features, metastatic potential, prognosis, and microscopic findings of Spermatocytic Seminoma?

**Broad Answer:** Spermatocytic Seminoma typically affects older males and is characterized by a specific chromosomal gain.

### DETAILED QUESTIONS

**Q4.1: In what age group is Spermatocytic Seminoma typically seen, and what specific chromosomal gain is associated with it?**

Answer:

- **Age:** Above 65 years.
- **Genetic Feature:** Gain of chromosome 9.

**Q4.2: Does Spermatocytic Seminoma commonly metastasize, and what is its typical prognosis?**

Answer:

- **Metastasis:** Does not typically metastasize.
- **Prognosis:** Excellent prognosis.

**Q4.3: What are the distinct cell types observed on microscopic examination of Spermatocytic Seminoma?**

Answer:

- 3 types of cells: Small, medium, and large multinucleated cells.

## BIG QUESTION 5: What are the key clinical and pathological characteristics of Testicular Lymphoma, including patient age, presentation, most common subtype, and prognosis?

**Broad Answer:** Testicular Lymphoma predominantly affects older males, often presents bilaterally, generally carrying a poor prognosis.

### DETAILED QUESTIONS

**Q5.1: What are the characteristic features of Testicular Lymphoma?**

Answer: **Mnemonic: B/B/B/B**

- **Big:** Above 60 years.
- **Bilateral:** Bilateral presentation.

- **M/c:** Diffuse large **B** cell lymphoma (DLBCL).
- **Prognosis: B**ad prognosis

**Q5.2: Why is FNAC contraindicated in testicular tumors, and what characteristic feature is seen in FNAC from a lymph node in testicular tumor?**

**Answer:**

- **FNAC is contraindicated in testicular tumors:** The insertion of the needle can create a path for spread of the tumor.
- **FNAC from a lymph node in testicular lymphoma** shows a **tigroid background** (looks like dark and white stripes of a tiger).

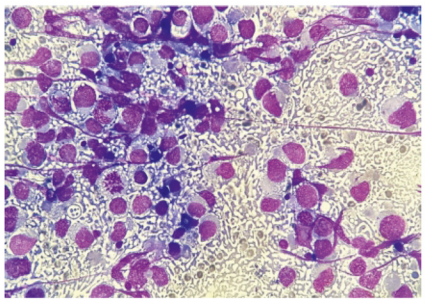


## BIG QUESTION 6: What are the characteristic histological patterns used in Gleason grading for prostate cancer?

**Broad Answer:** Gleason grading for prostate cancer relies on histologic patterns of glandular differentiation.

PYQ: AIIMS 2019

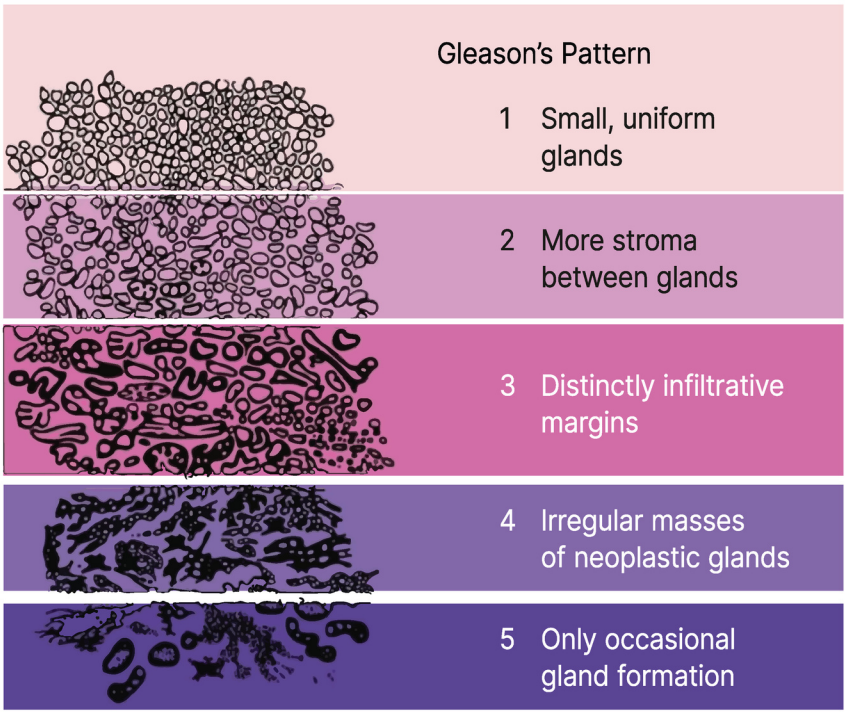


## DETAILED QUESTIONS

**Q6.1: Describe the histological features associated with Gleason Pattern 1.**

**Answer:** Small, uniform glands.



YOURWISH

YOURWISH

**Q6.2: What are the key features of Gleason Pattern 2 regarding glands and stroma?**

**Answer:** More stroma between glands.

**Q6.3: What is the defining characteristic of Gleason Pattern 3 regarding its margins?**

**Answer:** Distinctly infiltrative margins.

**Q6.4: How are Gleason Pattern 4 tumors characterized regarding glandular arrangement, and what two specific patterns are included within it?**

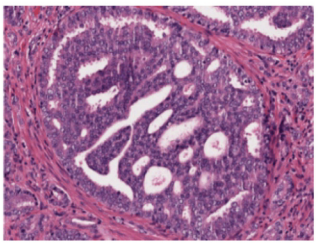

**Answer:** Irregular masses of neoplastic glands.

- **Specific Patterns**
  - Cribriform pattern
  - Hypernephroid pattern

**Q6.5: Describe the key features of Gleason Pattern 5, including gland formation, cell arrangement, and necrosis type.**

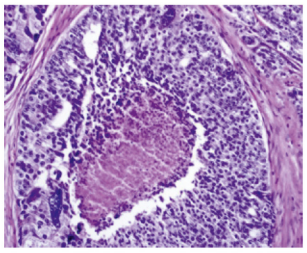

**Answer:**

- There is only occasional gland formation.
- Single cells.
- Comedonecrosis pattern.

**Q6.6. What are the scoring and grade patterns used in Gleason grading for prostate cancer**

**Answer:**

- **Score:** Sum of primary + secondary patterns (range 2-10)

| Two patterns given |
|---|
| • Predominant pattern is pattern number 1.<br>• Minor pattern is pattern number 2.<br>• The predominant pattern is cribriform (4), and the minor pattern is comedonecrosis (5).<br>• Therefore, the score is 4+5 = 9. |
| **One pattern given** |
| • Double the pattern.<br>• Only cribriform (4) pattern seen.<br>• Therefore, score is 4+4 = 8. |
| **Three patterns given** |
| • Predominant/primary pattern considered.<br>• Higher pattern between the second or third pattern is considered.<br>• Example: 80% - cribriform pattern (4), 15% - comedonecrosis pattern (5), and 5% - uniform pattern (1).<br>• Score is 4+5 = 9. |

- **Grade Groups: 1 to 5**

| Gleason score | Grade Group |
|---|---|
| ≤ 6 | I |
| 3 + 4 = 7 | II |
| 4 + 3 = 7 | III |

| | |
|---|---|
| 8 | IV |
| 9 to 10 | V |

**Q6.7: A 69-year-old male is found on rectal examination to have a hard, irregular nodule within his prostate. PSA levels are 100 ng/ml. TRUS-guided biopsy shows the presence of tumor cells without any glandular formation. Cribriform pattern is seen in 10% of the tumor pattern. What is the Gleason grade?**

A. Grade 2
B. Grade 3
C. Grade 4
**D. Grade 5**

**Answer:**

- Pattern:
  - Primary pattern: Single cells - Gleason pattern 5
  - Secondary pattern: Cribriform - Gleason pattern 4
- Score: 2 patterns:
  - Primary + Secondary = 5 + 4 = 9
- Grade: Grade 5

**Q6.8:Prostate biopsy shows the presence of adenocarcinoma predominantly in a cribriform pattern followed by a crowded pattern but separate glands and a minor component (5%) of single cell infiltration. What is the Gleason grade?**

A. Grade 2
B. Grade 3
C. Grade 4
D. Grade 5

**Answer:** Grade 5
**Explanation:**

- Pattern:
  - Primary pattern: Cribriform - pattern 4
  - Secondary pattern: Crowded pattern but separate glands - Pattern 2
  - Tertiary pattern: Single cell - pattern 5
- Score: When there are 3 patterns:
  - Primary + Higher pattern = 4 + 5 = 9
- Grade: Grade 5

# 16. FEMALE GENITAL SYSTEM PATHOLOGY

## BIG QUESTION 1: Write briefly about Pap smear.

**Broad Answer:** The **Pap smear** (Papanicolaou test) is a screening procedure used to detect **precancerous and cancerous changes in the cervix**, especially for **cervical cancer**. It involves collecting cells from the cervix and examining them microscopically for abnormalities.

## DETAILED QUESTIONS

### Q1.1: What are the 2 methods of Pap smear testing?

**Answer:**

1. Conventional PAP smear
2. Liquid-based cytology (LBC)

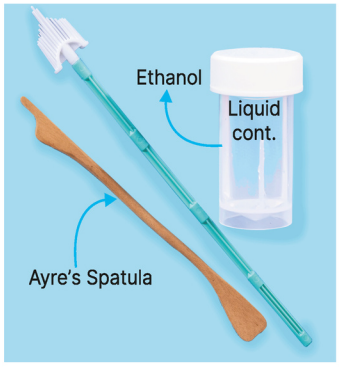


### Q1.2: Write a short note on Conventional PAP smear.

**Answer:**

- The sample is taken using a wooden or plastic spatula known as Ayre's spatula.
- The sample is then brushed or painted over a slide.

### Q1.3: What are the characteristics of Liquid-based cytology (LBC)?

PYQ: AIIMS 2020

**Answer:**



- Newer technique - better, more advanced.
- Liquid and a brush are used in this technique.
- In this technique, the sample is applied to the slide in a circular area.

### Q1.4: What are the 2 types of Liquid-based cytology (LBC)?

**Answer:**




- SurePath LBC: It has a smaller circle (diameter = 13mm)
- ThinPrep LBC: It has a bigger circle (diameter = 20mm)

### Q1.5: What is the fixative used for the PAP stain?

**Answer:**

95% Ethanol

### Q1.6: What is the Composition of PAP Stain?

**Answer:**

**Mnemonic: HOPE**

- **H:** Hematoxylin
- **O:** OG6 (Orange and green)
- **P:** PAP stain
- **E:** EA 50 (Eosin Azure), which includes Eosin, Light green, Bismarck brown

### Q1.7: What are the Adequacy Criteria for PAP Smear?

**Answer:**

Given by the Bethesda Group for reporting:

| | Conventional | LBC |
|---|---|---|
| Epithelial cells | 8,000-12,000/10 hpf | >5,000/10 hpf |
| Endocervical cells | ≥ 10 | ≥ 10 |

### Q1.8: What are the Normal Cells seen on a PAP Smear?

**Answer:**

1. Squamous Epithelial Cells (Ectocervix)
2. Endocervical Cells
3. Endometrial Cells

### Q1.9: What are the three types of squamous epithelial cells found in a Pap smear?

**Answer:**

- Comprises of 3 cells:
  - Superficial epithelial cells: Pink, Polygonal, and Pyknotic nuclei
  - Intermediate cells: Blue-colored cells
  - Parabasal cells: Round cells in a cluster

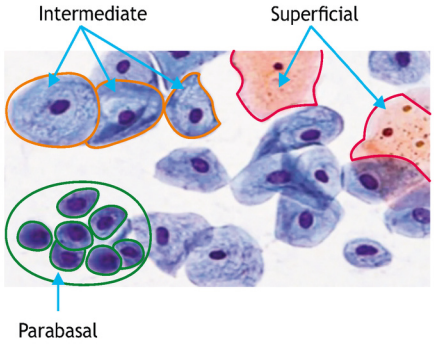


### Q1.10: What are the characteristic appearances of endocervical cells in a Pap smear?

**Answer:**

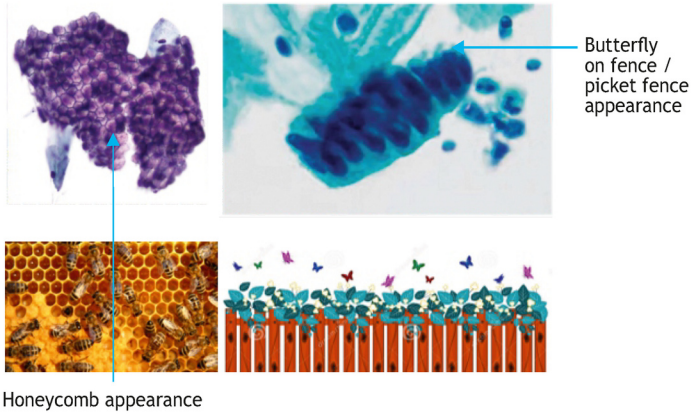


- It is a tall columnar cell that has a Butterfly on fence/ picket fence appearance.
- From the top view, it has a Honeycomb appearance.



YOURWISH

YOURWISH

### Q1.11: When are endometrial cells typically observed and shed during the menstrual cycle?

**Answer:**

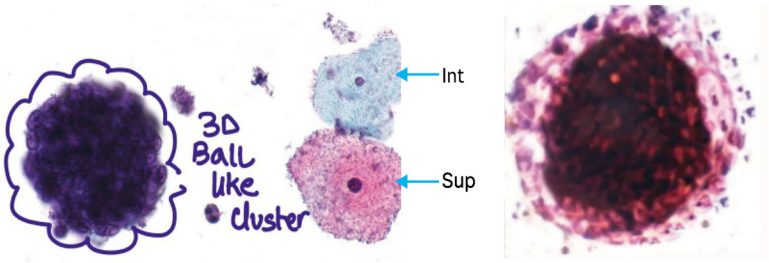


- Endometrial cells are seen when the female is menstruating (day 5).
- Endometrial cells shed off from Day 6 to Day 10 - Exodus.

## BIG QUESTION 2: Name a few different cervical pathologies most commonly seen in the reproductive age group.

**Broad Answer:** The most common cervical infections in the reproductive age group are trichomoniasis, candidiasis, bacterial vaginosis, actinomycosis and HPV infection.

## DETAILED QUESTIONS

### Q2.1: What are the clinical presentations and microscopic findings of trichomoniasis?

PYQ: FMGE 2021

**Answer:**

Caused by Trichomonas.

- Presents with:
  - Greenish discharge
  - Strawberry cervix



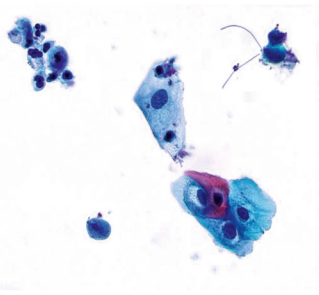

- Microscopy:

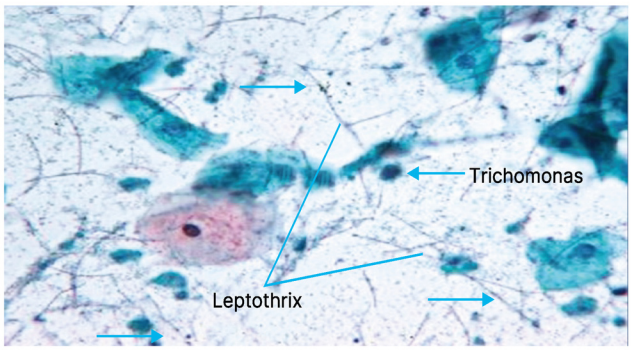


  - Pear/kite-shaped organism.
  - Leptothrix and Trichomonas are found together, exhibiting a "spaghetti and meatball" appearance.

## Q2.2: What are the characteristic findings of candidiasis?

PYQ: NEET PG 2020

PYQ: FMGE 2020

**Answer:**

- Presents with a curdy white discharge.

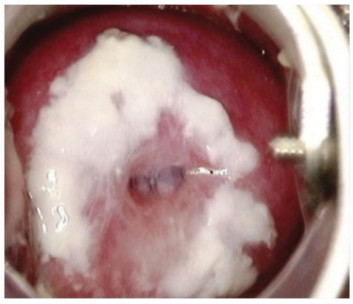

- Microscopy: Sheesh kabab appearance.

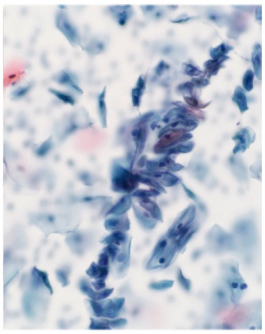

## Q2.3: What are the key characteristics, microscopic findings, and diagnostic criteria for bacterial vaginosis?

PYQ: NEET PG 2021, 2022

PYQ: INICET 2021

PYQ: FMGE 2021

**Answer:**

- Caused by Gardnerella vaginalis, a coccobacillus.
- Microscopy: Clue cells and Filmy background are seen.

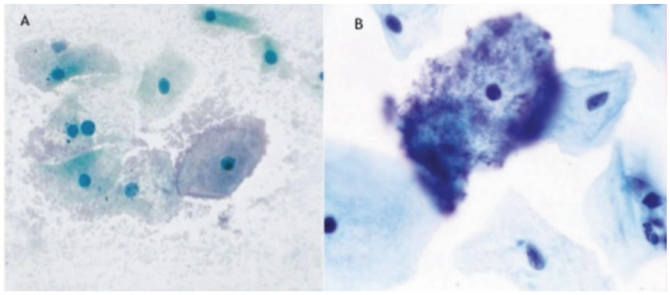


- Criteria for bacterial vaginosis - Amsel's criteria.

## Q2.4: Write a short note on Actinomycosis.

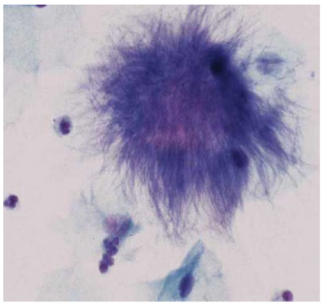

**Answer:**

- IUCD users are at risk of Actinomyces infection.
- Actinomyces: It is a filamentous organism.
- Appearances: Cotton ball/ Woolly ball/ Dust bunnies/ Gupta bodies.

## Q2.5: What are the characteristics of koilocytes on a Pap smear and biopsy?

**Answer:**

- Seen in HPV.
- PAP Smear:
  - Raisinoid nucleus

- Perinuclear halo

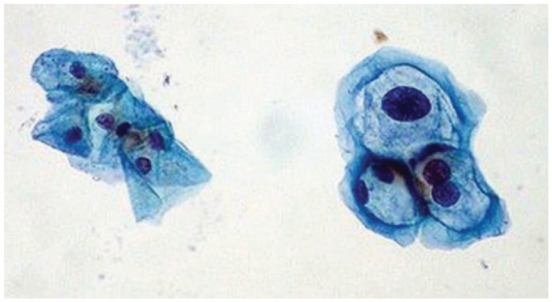

- Biopsy:

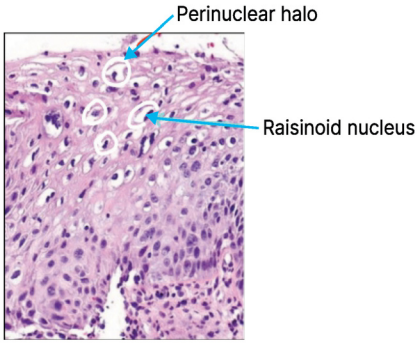


### Q2.6: What are tadpole cells?

**Answer:**

- They have a huge head and a tiny tail.
- Indicative of Squamous cell carcinoma.

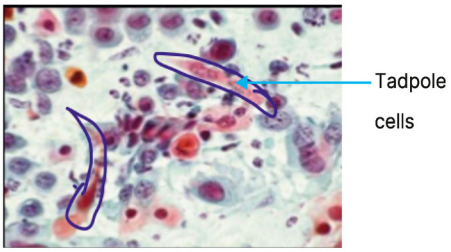


## BIG QUESTION 3: Write briefly about endometriosis and adenomyosis.

**Broad Answer:** **Endometriosis** is a condition where endometrial tissue grows outside the uterus, commonly on the ovaries, pelvic peritoneum, or bowel, leading to **pelvic pain, dysmenorrhea, and infertility**. **Adenomyosis** involves the presence of endometrial tissue within the **myometrium (uterine muscle wall)**, causing **heavy menstrual bleeding and a uniformly enlarged, tender uterus.**

## DETAILED QUESTIONS

### Q3.1: What is the criteria for endometriosis?

**Answer:**

- Criteria for endometriosis:
  - The normal endometrial glands, stroma and hemosiderin should be seen outside the uterus.

### Q3.2: What is the most common site of endometriosis?

**Answer:**

The most common site: Ovary - Chocolate cyst.

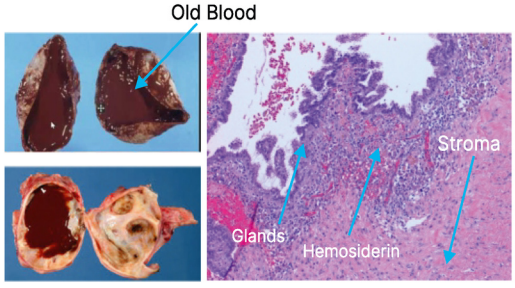


### Q3.3: What is adenomyosis?

**Answer:**

It is a condition where endometrial glands and stroma migrate into the myometrium.

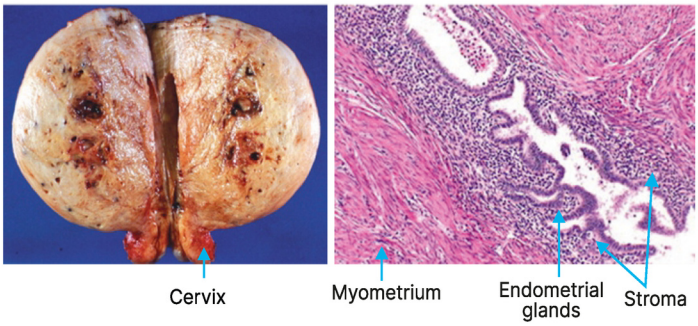


## BIG QUESTION 4: Write briefly about leiomyoma and leiomyosarcoma.

**Broad Answer:** **Leiomyoma**, also known as a uterine fibroid, is a **benign smooth muscle tumor** of the uterus, commonly causing **heavy menstrual bleeding, pelvic pressure, or infertility**. In contrast, **leiomyosarcoma** is a **rare malignant tumor** arising from smooth muscle, often presenting with **rapidly enlarging pelvic mass, postmenopausal bleeding**, and may metastasize early.

## DETAILED QUESTIONS

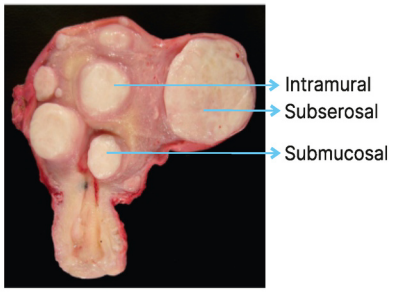


### Q4.1: What are the types of leiomyoma?

**Answer:**

- Leiomyoma is a benign tumor of smooth muscle.
- May be submucosal, intramural or subserosal.

### Q4.2: Which subtype of leiomyoma has the Maximum risk of bleeding?

**Answer:**

The maximum risk of bleeding is in submucosal leiomyoma.

### Q4.3: Which gene mutation is seen in leiomyoma?

**Answer:**

MED 12 gene mutation.

### Q4.4: Name the other tumours showing MED12 gene mutation?

**Answer:**

- Fibroid → Uterus
- Fibroadenoma → Breast
- Phyllodes tumour → Breast

### Q4.5: What are the histological features of leiomyoma?

**Answer:**

- The characteristic histological features of leiomyoma include whorling of smooth muscle tumor cells and elongated, cigar-shaped nuclei.
- Other conditions where **cigar nuclei** are also seen:
  - Normal smooth muscle
  - Leiomyosarcoma

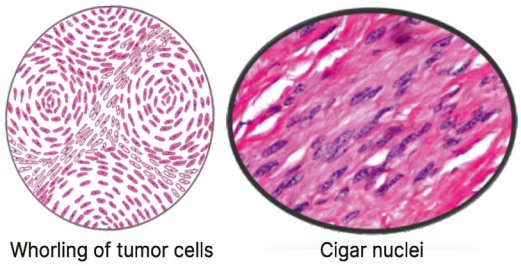




YOURWISH

YOURWISH

**Q4.6: What are the 3 types of degeneration seen in fibroids? Write briefly about the red degeneration of fibroid.**

**Answer:**

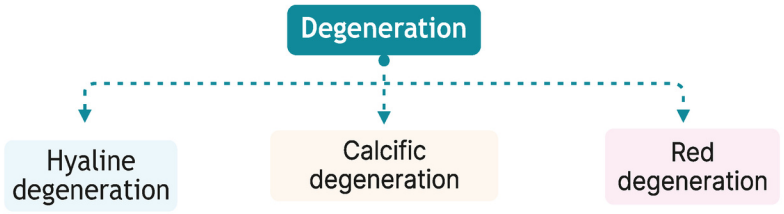


- **Red degeneration:**
  - Beefy red colour.
  - Seen in pregnancy presenting with pain and fever due to **Aseptic Thrombosis** of the blood vessels which supply the fibroid.

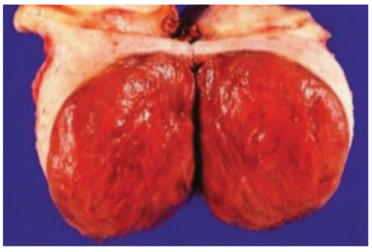

**Q4.7: What is the most important criterion and finding in Leiomyosarcoma?**

**Answer:**

- The most important criterion is mitotic count.
  - Cut-off: ≥ 10/10 hpf.
- Findings:
  - Cigar nuclei- smooth muscle

## BIG QUESTION 5: Classify ovarian tumours.

**Broad Answer:**

PYQ: INICET PG 2022, 2023 | PYQ: NEET PG 2021, 2023 | PYQ: FMGE 2020, 2021, 2023

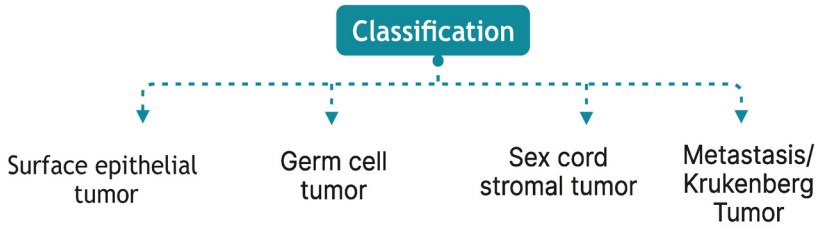


## DETAILED QUESTIONS

**Q5.1: Classify the various types of Surface Epithelial Tumors.**

**Answer:**

| Tumor | Gross findings | Microscopy | Tumor markers | Extra |
|---|---|---|---|---|
| Serous ovarian tumor | • Single cyst  • Serous/Watery fluid. | • Psammoma bodies • Ciliated epithelium 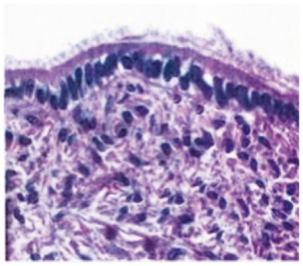 | CA 125 | Bilateral |

| | | | | |
|---|---|---|---|---|
| Mucinous ovarian tumor | • Multiple cysts<br><br>• Mucinous fluid | • Mucinous epithelium<br>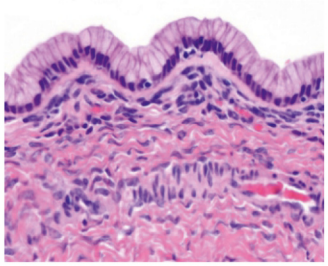 | CA 125 | Unilateral |
| Brenner's tumor | | • Transitional epithelium (bladder epithelium)<br>• Coffee bean nuclei<br>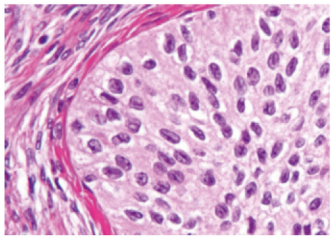 | CA 125 | |
| Clear cell tumor | | | CA 125 | The associated drug is Diethylstilbestrol (DES) |
| Endometrioid tumors | | | CA 125 | It is associated with Endometriosis |

**Q5.2: Classify the various types of Germ Cell tumours.**

**Answer:**

| Tumor | Gross findings | Microscopy | Tumor markers |
|---|---|---|---|
| Dysgerminoma [Dysgerminoma, In testes → Seminoma] | • Cut potato appearance | • Fried egg appearance<br>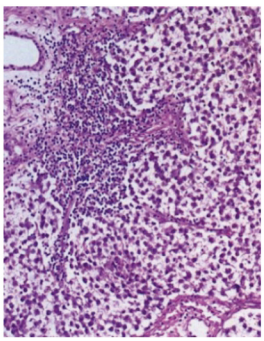<br>• Lymphoplasmacytic inflammation | LDH<br>PLAP |

| | | | |
|---|---|---|---|
| Yolk sac tumor/Endodermal sinus tumor | | • Schiller Duval body/Glomeruloid body<br>o Blood vessel in the center<br>o 2 rows of tumor cells with space<br>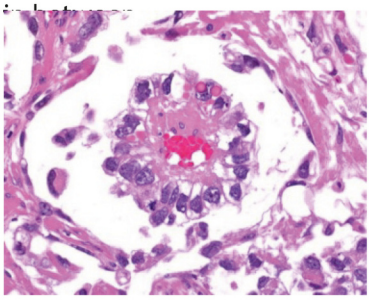 | αFP<br>α1-Anti-Trypsin |
| Choriocarcinoma | • Hemorrhage<br>• Necrosis<br>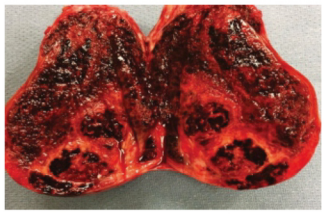 | • Cytotrophoblast - single nuclei<br>• Syncytiotrophoblast- multiple nuclei<br>• No villi formation<br>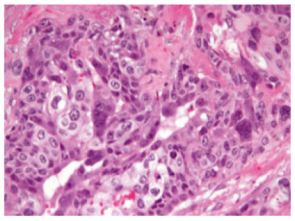<br>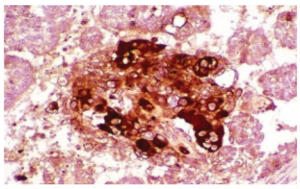 | β-HCG |
| Teratoma | • Rokitansky protuberance (Foci of cancer)<br>• Hair, teeth, bone<br> | | |

**Q5.3: Classify the different types of Teratoma**

**Answer:**

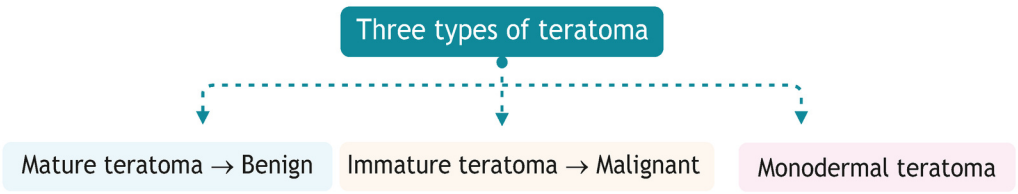




YOURWISH

**Q5.4: What are the characteristics distinguishing a teratoma from a monodermal teratoma, and what is an example of a monodermal teratoma?**

**Answer:**

- Teratoma has at least 2 germ layers.
- Monodermal teratoma has only one germ layer.
  - o Struma ovarii (thyroid in the ovary).
  - o Functional thyroid follicles are present in the ovary.
  - o Hyperthyroidism

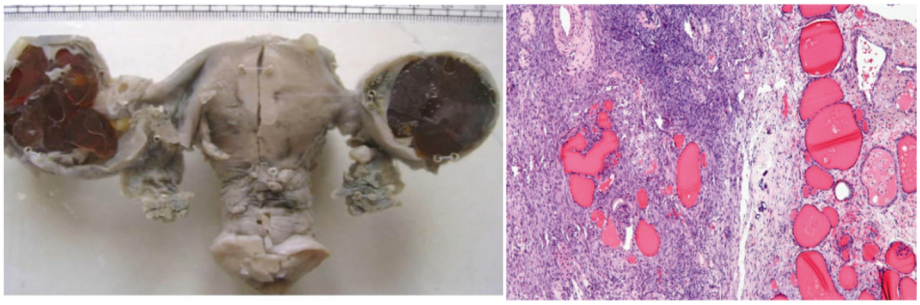

Thyroid (colloid)

**Q5.5: Classify the different types of Sex Cord Stromal Tumours.** PYQ: FMGE 2020

**Answer:**

| Tumor | Features | Microscopy | Tumor markers |
|---|---|---|---|
| 1. Sertoli-Leydig tumor<br>2. Pure Leydig tumor | | · Reinke's crystalloids in Leydig cells 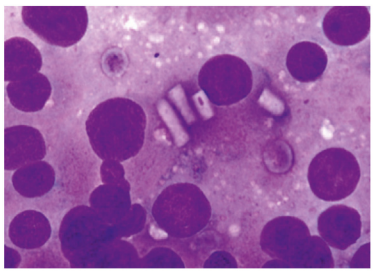 | |
| 3. Fibroma<br>4. Thecoma | • White<br>• Yellow | • Spindle cells<br>• Vacuolated cells | Vimentin<br>Oil red O |
| 5. Granulosa cell tumor | • Post-menopausal female<br>• Hyperestrogenism | • Call-Exner bodies 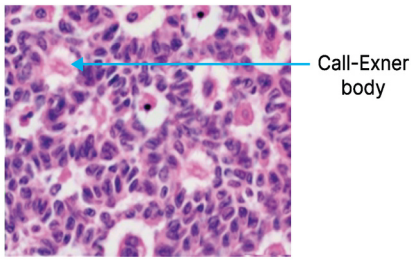 <br>• Coffee bean nuclei 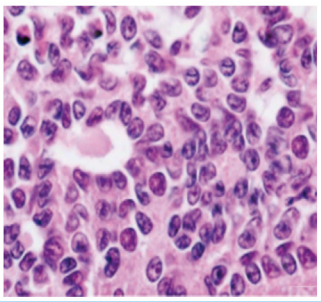 | CD99<br>Inhibin |



YOURWISH

YOURWISH

### Q5.6: What are the syndromes associated with fibroma?

**Answer:**

- Fibromas are associated with MEIG's syndrome and Gorlin syndrome.
- Meigs' syndrome:
  - Fibroma in the ovary
  - Ascites in the abdomen
  - Right-sided hydrothorax
- Gorlin syndrome:
  - Bilateral fibroma
  - Basal cell carcinoma
  - Desmoplastic medulloblastoma in the brain

### Q5.7: What are the key features of Krukenberg tumor?

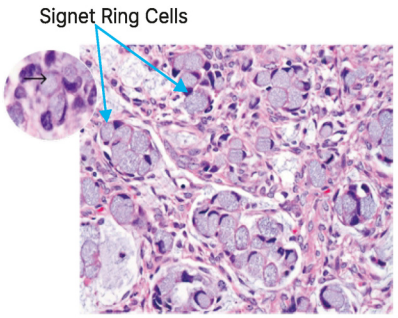


**Answer:**

- Metastasis of breast, stomach, and colon cancer to the ovary
- The most common metastasis is stomach cancer.
- Signet ring cells.
  - Mucin accumulation with the nucleus at the periphery.

### Q5.8: What is a Hydatidiform mole, and what are its features and types?

PYQ: NEET PG 2019 PYQ: FMGE 2020

**Answer:**

- It is a gestational trophoblastic disease.
- Features: Grape-like vesicles.
- Microscopy: Hydropic villi.
- 2 types:
  - Partial mole
    - → Fetal parts are present
    - → p57 positive
  - Complete mole:
    - → Fetal parts are absent
    - → P57 negative

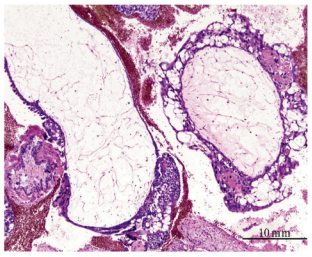
HYDROPIC VILLI

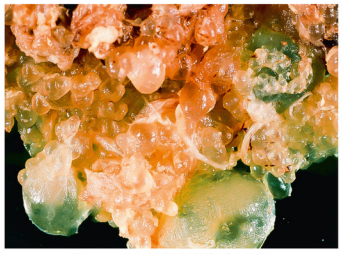
GRAPE LIKE VESICLES

# 17. BREAST/BONE/SKIN/SOFT TISSUE PATHOLOGY

## BIG QUESTION 1: Name some of the diseases affecting the breast

**Broad Answer:**

- Fibrocystic disease
- Radial scar
- Fibroadenoma
- Phyllodes tumour
- Ductal carcinoma in situ
- Mucinous or colloid carcinoma
- Inflammatory breast carcinoma
- Invasive lobular carcinoma
- Paget's disease

## DETAILED QUESTIONS

### Q1.1: What is fibrocystic disease, its gross and histological appearance

**Answer:**

- Fibro: Fibrosis
- Cystic: Cyst
- Gross- The cyst is filled with a fluid, due to which it appears like a blue dome cyst
- Histological- Apocrine cells with snouts- Pinkish-coloured cells with secretions

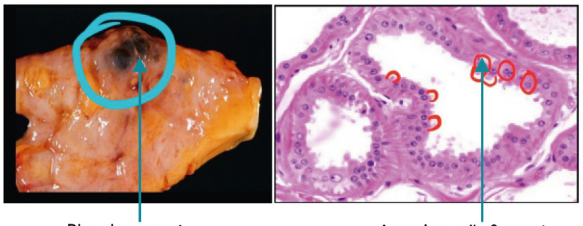


### Q1.2: What is a Radial scar and its microscopic appearance?

**Answer:**

- A Premalignant whitish scar is present at the centre (central stellate scar)
- Microscopically shows starry projection

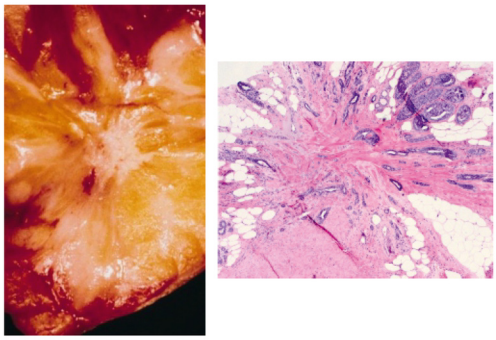

### Q1.3: What are the radiological features of Fibroadenoma?

**Answer:**

- Shows Breast mouse: The lump is mobile and slippery, hence called breast mouse
- Popcorn calcification

### Q1.4: What are the FNAC findings in Fibroadenoma?

PYQ: FMGE 2021

**Answer:**

- Staghorn clusters of cells: Deerhorn-like cells
- Bare nuclei: Empty, naked cells

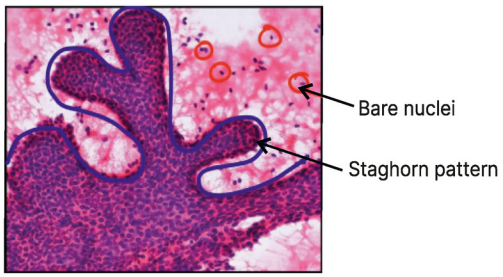


### Q1.5: Name the types of Fibroadenoma and their biopsy findings with prognosis.

**Answer:**

| Intracanalicular Fibroadenoma | Pericanalicular Fibroadenoma |
|---|---|
| • Ducts are compressed 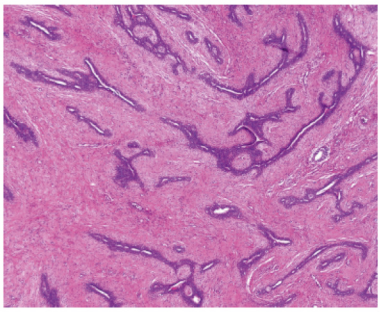 | • Ducts are open 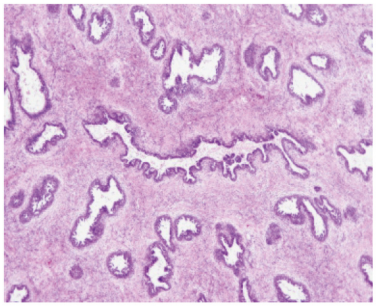 |

- Prognosis remains the same for both findings

### Q1.6: What is the microscopic appearance of a Phyllodes tumour?

**Answer:**

- Phyllodes means phylum, which appears as a leaf-like structure microscopically

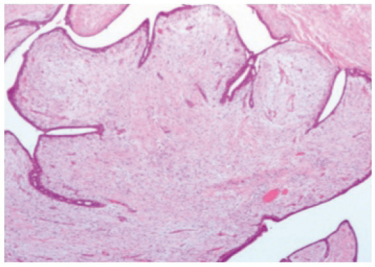

### Q1.7: How do you categorize Phyllodes tumour as benign, borderline & malignant?

**Answer:**

| Criteria | Benign | Borderline | Malignant |
|---|---|---|---|
| Mitoses/10 high power fields - definitive criteria | < 5 Mitosis | 5 to 9 Mitosis | > or = 10 hpf |

### Q1.8: What is Ductal carcinoma in situ and its types?

**Answer:**

- Ductal carcinoma in situ is a precancerous condition with basement membrane affecting the breast. Types of Ductal carcinoma in situ are:
  - o Cribriform
  - o Comedo-necrosis

### Q1.9: How to identify Cribriform and Comedo-necrosis types of Ductal carcinoma in situ microscopically?

**Answer:**

| Cribriform | Comedo-necrosis |
|---|---|
| • Cribriform means sieves- The duct contains holes within it 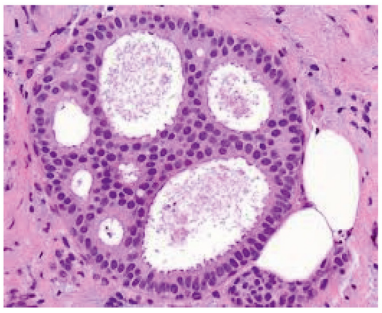 | • Comedo-necrosis has necrosis in the middle of the duct, just like the dirt that comes out from the acne 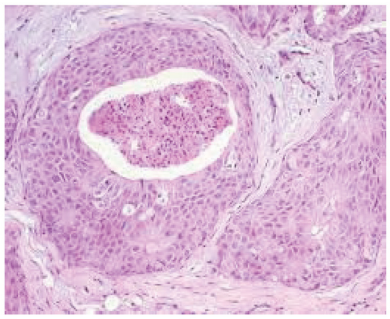 |

### Q1.10: What are the FNAC and biopsy findings in mucinous or colloid carcinoma?

PYQ: AIIMS 2018

**Answer:**

- **FNAC:** Shows chicken wire blood vessels
- **Biopsy:** Shows pools of mucin with tumor cells floating

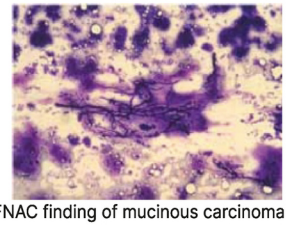
FNAC finding of mucinous carcinoma

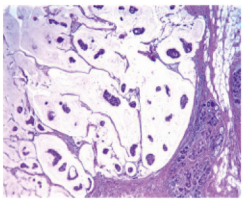
Biopsy findings

### Q1.11: How does Inflammatory breast carcinoma appear, and what is the reason for the appearance?

PYQ: INICET 2021 PYQ: FMGE 2021 PYQ: NEET PG 2022

**Answer:**

- Looks like an inflammation
- Skin has a Peau de' Orange appearance (dimpling) due to the infiltration of subdermal lymphatics




### Q1.12: Which protein is responsible for Invasive lobular carcinoma?

**Answer:**

- Decreased levels of E-cadherin protein is responsible for Invasive lobular carcinoma

### Q1.13: What is the microscopic appearance of Invasive lobular carcinoma?

**Answer:**

- Tumour cells in Invasive lobular carcinoma are present back to back, just like the army men, hence, called the Indian file pattern.

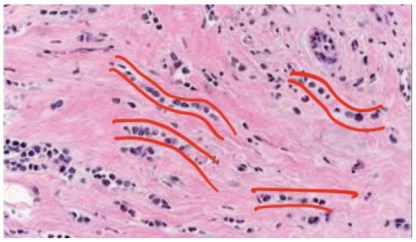

### Q1.14: Molecular classification of Breast cancer is based on?

**Answer:**

- Initially Molecular classification of Breast cancer was based on gene expression profiling
- Later, to make it simple, the basis changed to estrogen (ER) or progesterone (PR) receptors and HER2neu.



YOURWISH

### Q1.15: How do you identify the estrogen (ER) or progesterone (PR) and HER2neu on Immunohistochemistry?

**Answer:**

- Immunohistochemistry, used as a staining technique, gives a brown color
  - o In ER and PR, the nucleus becomes brown
  - o In Her2neu, the membrane becomes brown

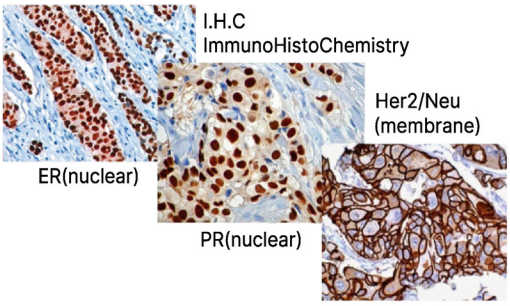


### Q1.16: Based on what scoring systems, the ER & PR and HER2neu are determined positive or negative?

**Answer:**

- For ER and PR, ALLRED scoring is done
  - o Even if 1% brown cells- positive test
- For HER2neu
  - o 0 and 1+→ Negative
  - o 2+→ Equivocal (not negative, not positive)-FISH is performed
  - o 3+→ Positive, Her2amplified- treated with Trastuzumab

### Q1.17: What is the status of ER, PR and HER2neu in different subtypes of Breast cancer?

**Answer:**

PYQ: INICET 2023, 2024 PYQ: FMGE 2021, 2022 PYQ: NEET PG 2022, 2023

| Luminal A | Luminal B | Her2 rich | Triple-negative or basal |
|---|---|---|---|
| ER- positive | ER - positive | ER - negative | ER - negative |
| PR - positive | PR - positive | PR - negative | PR - negative |
| Her2neu - negative | Her2neu - negative<br>• Sometimes Her2neu is positive.<br>• Also called triple positive. | Her2neu - positive | Her2neu - negative |

### Q1.18: What is Ki67 and its use in Breast cancer?

**Answer:**

- Ki67 is MIB1 labeling index
- It is a proliferating marker used to differentiate luminal A from luminal B type of Breast cancer
  - o Ki67 <14%- luminal A
  - o Ki67>14%- luminal B

### Q1.19: How are histological types of Breast cancer classified based on subtypes?

**Answer:**

| Luminal A | Luminal B | HER2 rich | Triple-negative |
|---|---|---|---|
| • Tubular carcinoma<br>• Mucinous carcinoma<br>• Papillary carcinoma<br>• Low-grade ILC | High-grade ILC | • Apocrine carcinoma<br>• Mnemonic: H APOcrine carcinoma. | • Medullary carcinoma<br>• Metaplastic carcinoma |

### Q1.20: Write briefly about Paget's disease.

**Answer:**

- Paget's disease of the breast and vulva are similar but differ from Paget's disease of the bone.
- Associated with a lump underneath the breast → Ductal carcinoma in situ or cancerous lump.

### Q1.21: What are the findings associated with Paget's disease?

**Answer:**

- Dermatological lesions seen is crusting in the nipple and areola
- Biopsy findings show Clear cells called Paget's cells

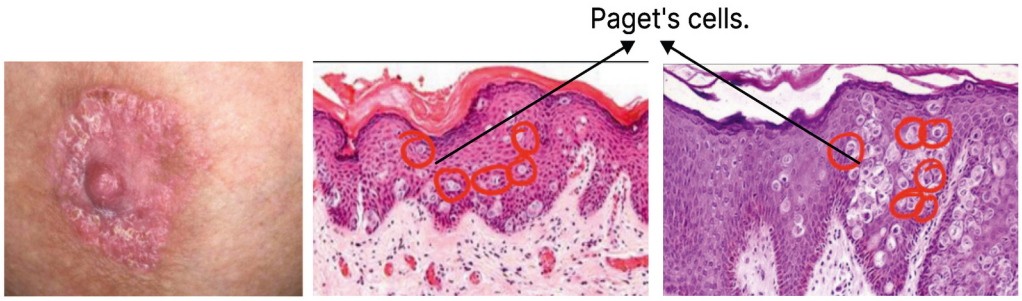


## BIG QUESTION 2: Name some of the diseases affecting the bone

**Broad Answer:**

- Bone-forming tumour: Osteosarcoma
- Cartilage-forming tumours: Enchondroma & Chondrosarcoma
- Ewing's sarcoma
- Giant cell tumour
- Chordoma
- Fibrous dysplasia
- Aneurysmal bone cyst

## DETAILED QUESTIONS

### Q2.1: What are the radiological features of Osteosarcoma?

PYQ: INICET 2022

**Answer:**

- Radiologically shows Codman Triangle
  - Shaft of the bone on one side
  - Periosteum is lifted because of the tumor- A triangle is formed when joining these two lines
- New bone formation- Sun ray or sunburst appearance

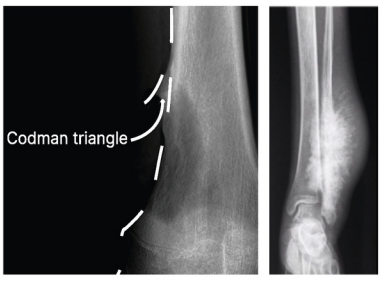


### Q2.2: What is the hallmark of Osteosarcoma?

**Answer:**

- **Osteoid** is the hallmark of Osteosarcoma
- It is a thin, pink, lacy, and glassy unmineralized bone

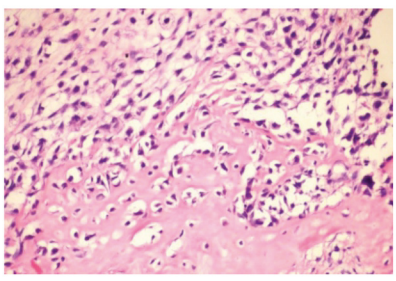

### Q2.3: What are the types of cartilage-forming bone tumours?

**Answer:**

- Benign tumor: Enchondroma
- Malignant tumor: Chondrosarcoma

### Q2.4: What are the mutations seen in the Enchondroma?

**Answer:**

- Mutations in Enchondroma are:
  - Isocitrate dehydrogenase 1 (IDH1)
  - Isocitrate dehydrogenase 2 (IDH2)

### Q2.5: IDH mutations are seen in which conditions?

**Answer:**

- Enchondroma
- Glioblastoma
- Oligodendroglioma

### Q2.6: What is the difference between Enchondroma & Chondrosarcoma?

**Answer:**

| Enchondroma | Chondrosarcoma |
|---|---|
| • Small bones<br>• Permeation is not seen in this<br>• Speckled calcification present<br>• Benign cartilage<br>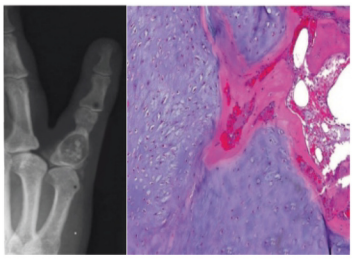 | • Occurs in axial skeleton<br>• Permeation is seen<br>• Malignant cartilage<br>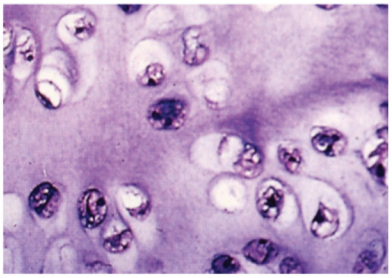 |

### Q2.7: What are the mutations seen in Osteochondroma/Exostosis?

**Answer:**

- Mutations in Osteochondroma/Exostosis are:
  - EXT 1
  - EXT 2

### Q2.8: What are the radiological and gross findings of Osteochondroma/Exostosis?

**Answer:**

- **Radiologically:** Mushroom-shaped growth.
- **Gross:** A cartilage cap is present over the bone (cortex, medulla, marrow)

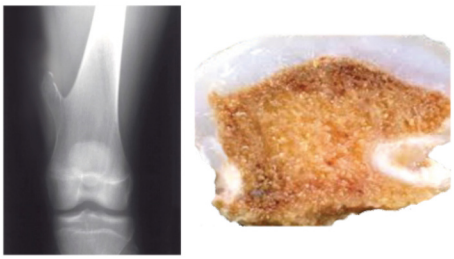



YOURWISH

## Q2.9: Write briefly about the location, histological appearance of Chondroblastoma.

**Answer:**

- Also known as Codman tumour
- Location: Epiphyseal
- Histology
  - o Giant cells are present
  - o Coffee bean nucleus appearance
  - o Chicken wire calcification is present

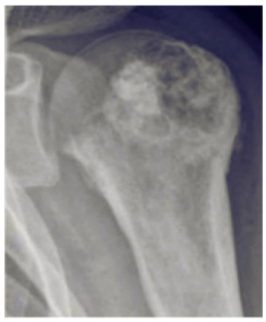

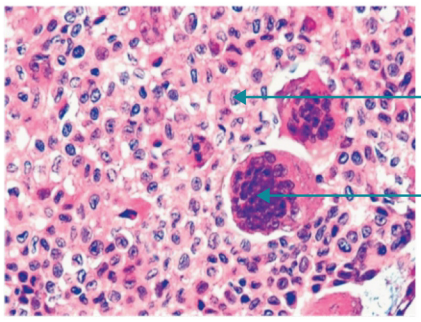


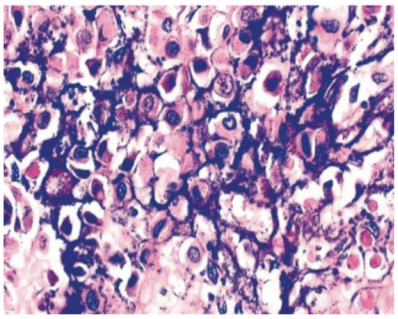

## Q2.10: Chicken wire appearance is observed in which conditions?

**Answer:**

| | |
|---|---|
| **Chicken wire blood vessels FNAC:** Mucinous carcinoma breast | 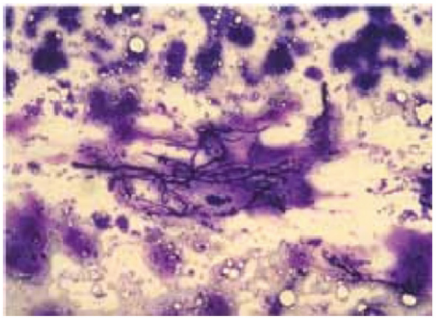 |
| **Chicken wire blood vessels biopsy:** Oligodendroglioma | 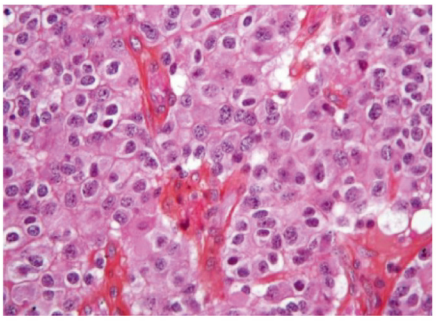 |
| **Chicken wire calcification:** Chondroblastoma | 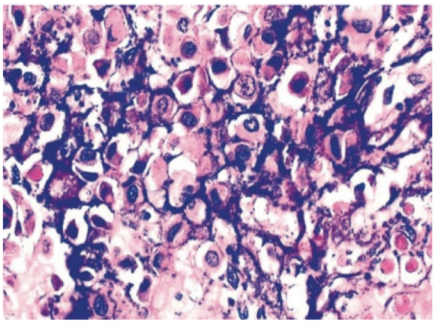 |



YOURWISH

| | |
|---|---|
| **Chicken wire fibrosis:** Alcoholic liver disease | 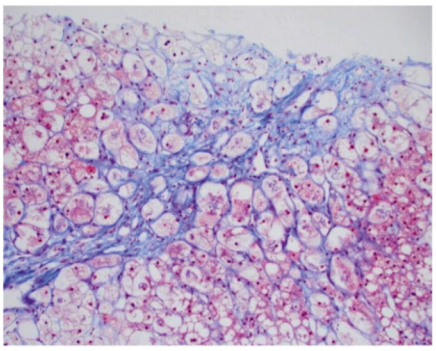 |

### Q2.11: What is the age of presentation and mutation seen in Ewing's sarcoma?

**Answer:**

- Age: Adolescent
- Mutation: T(11:22) EWS-FLI fusion

### Q2.12: What are the clinical, radiological & histological features of Ewing's sarcoma?

PYQ: FMGE 2019

**Answer:**

- Clinical features: Pain and swelling in the knee and fever
  - o Mimics osteomyelitis
- X-ray: Onion peel appearance (periosteal reaction)
- Histology shows: Homer Wright pseudorosette

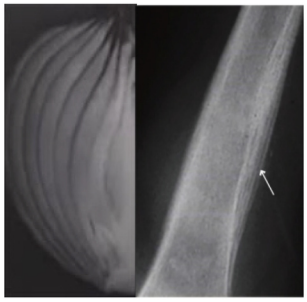

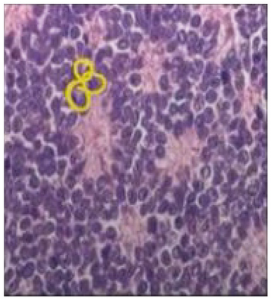

### Q2.13: In which conditions Homer Wright pseudorosette is seen

**Answer:**

- Medulloblastoma
- Neuroblastoma
- Retinoblastoma
- Ewing's sarcoma

### Q2.14: What stain is used in the diagnosis of Ewing's sarcoma?

**Answer:**

- Stain: PAS + (contains glycogen) - pink

### Q2.15: What are the markers used in diagnosis of Ewing's sarcoma?

**Answer:**

- Markers: CD99/Mic-2 Positive/t (11,22)

### Q2.16: Write in brief about gross, radiological & histological features along with treatment options of Giant cell tumour.

**Answer:**

- Grossly, hemorrhage is present
- On X-ray, soap bubble appearance due to hemorrhage
- On histology, the mononuclear cell is the tumor part & multinucleated giant cell is just the reaction to a tumor

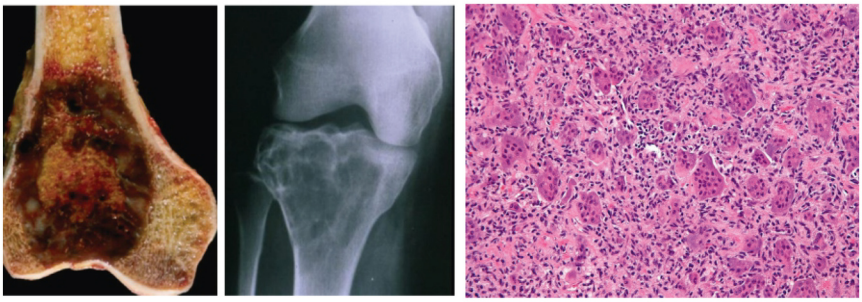

- Treatment: Surgery/Denosumab

**Q2.17: Write in brief about the origin, site, microscopic features, gene involved, and immunohistochemistry of Chordoma.**

**Answer:**

- Origin: Notochord
- Site: Clivus, Sacrococcygeal region
- Microscopically: Bubbly cells or physaliferous cells
- Genetics: Brachyury Gene
- IHC: Brachyury

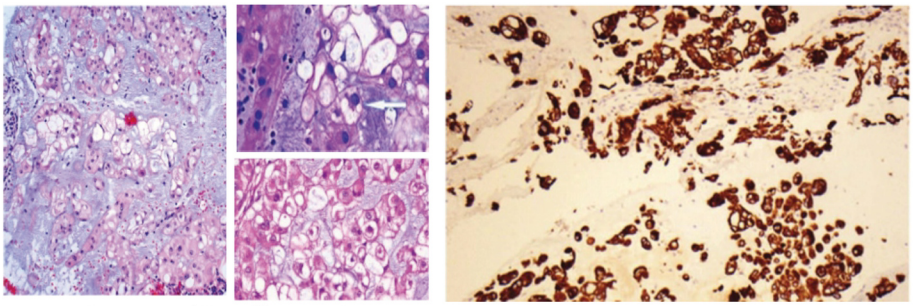

Bubbly cells/Physaliferous cells

**Q2.18: What are the radiological and histological features of Fibrous dysplasia?**

**Answer:**

- On X-ray: Shepherd crook deformity & Ground glass appearance
- On Microscopy: Chinese letter bony trabeculae appearance

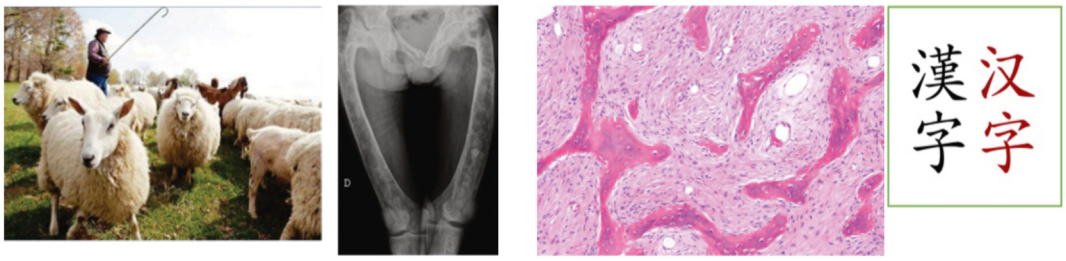


**Q2.19: Non-ossifying fibroma also has Chinese letter appearance on histology. How do you differentiate features between Non-ossifying fibroma and Fibrous dysplasia?**

**Answer:**

- Osteoblastic rimming is present in Non-ossifying fibroma, but absent in Fibrous dysplasia

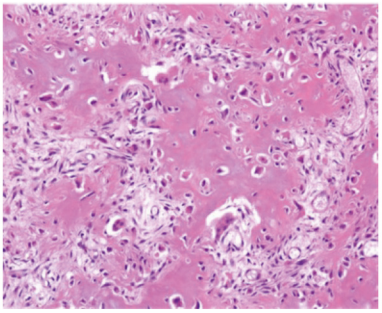

### Q2.20: Write in brief about Aneurysmal bone cyst.


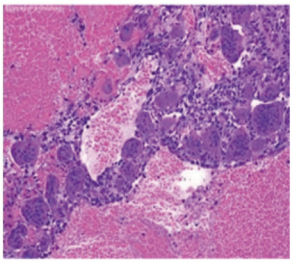

**Answer:**

- Haemorrhage +
- Radiolucent
- Blood channels lined by giant cells

### Q2.21: How do you classify bone tumours based on their location?

**Answer:**

| Epiphyseal | Metaphyseal | Diaphyseal |
|---|---|---|
| • E: Epiphyseal<br>• C<br>o Chondroblastoma<br>o Clear Cell<br>o Chondrosarcoma<br>• G - GCT | • S - Simple Bone Cyst<br>• O - Osteosarcoma<br>• F - Fibrous Dysplasia<br>• A - ABC<br>• Chair - Osteochondroma | • M - Multiple Myeloma<br>• A - Adamantinoma<br>• L - Leukemia<br>• E - Ewing's Sarcoma<br>• Officer - Osteoid Osteoma |

## BIG QUESTION 3: Name some of the diseases affecting the skin

**Broad Answer:**

- Psoriasis
- Lichen planus
- Molluscum contagiosum
- Bullous disorders- Pemphigus vulgaris, Pemphigus foliaceus, Bullous pemphigoid, Epidermolysis bullosa acquisita, Dermatitis herpetiformis
- Basal cell carcinoma

## DETAILED QUESTIONS

### Q3.1: What are the gross and microscopic features of psoriasis?

PYQ: INICET 2022,2023

**Answer:**

- This condition will have silvery scales
- Underneath the scales, a reddish appearance can be seen
- Microscopically
  - o Hyperkeratosis: Keratin production is more
  - o Parakeratosis: The nucleus is present in the stratum corneum
  - o Collection of inflammatory cells in the stratum corneum - Munro's microabscess


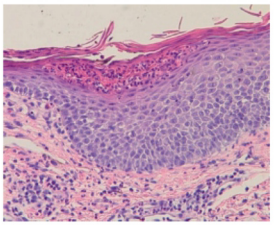

### Q3.2: In which condition is Pautrier's microabscess seen?

**Answer:**

- Mycosis fungoides (cutaneous TNHL)

### Q3.3: What is the gross and microscopic features of Lichen planus?

PYQ: NEET PG 2012

**Answer:**

- Gross- Lichen planus shows **Wickham striae**
- Microscopic-
  - **Saw tooth of rete ridges** can be seen
  - The entire band of blue color dot cells are seen, indicating - band-like lymphocytic infiltrate at the dermo-epidermal junction
  - Inflammation will cause damage to the cells, and cells will start breaking off
  - These cells are called the colloid body/Civatte body or the cytoid body
  - Apoptotic bodies are seen in the case of Lichen planus
  - The dead cell will be removed, and the area will become white, called **Max Joseph space.**



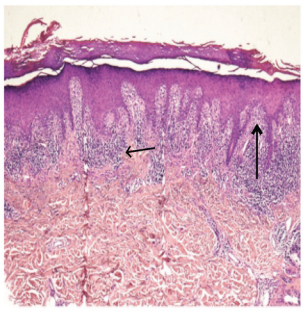

Lichen planus's microscopy

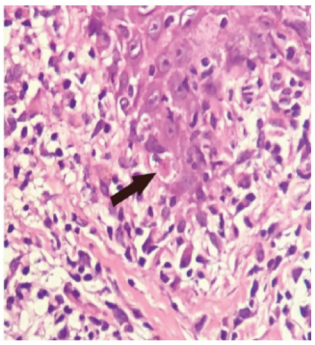

### Q3.4: What is a causative agent for Molluscum contagiosum, and what is the stain used in diagnosis?

**Answer:**

- Caused by Pox virus (DNA VIRUS)
- Phloxine tartrate stain is used for Molluscum Contagiosum

### Q3.5: What are the gross and microscopic features of Molluscum contagiosum?

**Answer:**

- Molluscum Contagiosum presents with Umbilicated lesions
  - Umbilicated means there will be a dot in the center (depression/crater)
  - When it is pressed, some cheesy, curdy material comes out
- Microscopically, these lesions have a classical cup shape
  - These cups are filled with pink color bodies called **HP (Henderson Patterson) bodies**



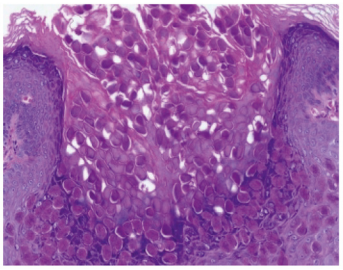



### Q3.6: What is the character of the bulla in Pemphigus?

**Answer:**

- Bulla is flaccid in Pemphigus

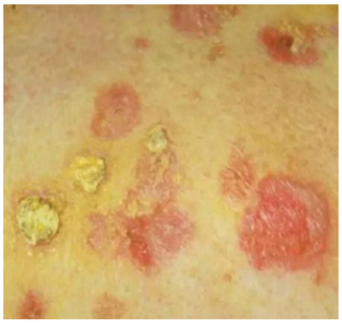

YOURWISH

**Q3.7: What are the antibodies involved and the microscopic features of Pemphigus vulgaris?**

Answer:

- Antibodies against Desmoglein (dsg) 1 and 3 will both be involved
- Involvement will be against the skin and the oral cavity
- Microscopy-
  - In Pemphigus Vulgaris, there is a suprabasal split
  - The layer left is the basal layer: **Row of tombstone-appearance**

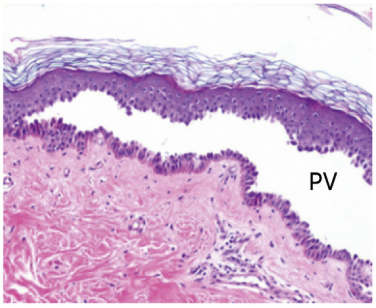


**Q3.8: Write briefly about the antibodies involved, the microscopic features, and the IHC of Pemphigus foliaceus.**

Answer:

- Antibodies against desmoglein 1
- Only skin is involved
- Microscopy: In Pemphigus foliaceus, the split will be in the first layer- the sub-corneal split
- Immunofluorescence: **Fishnet** is seen

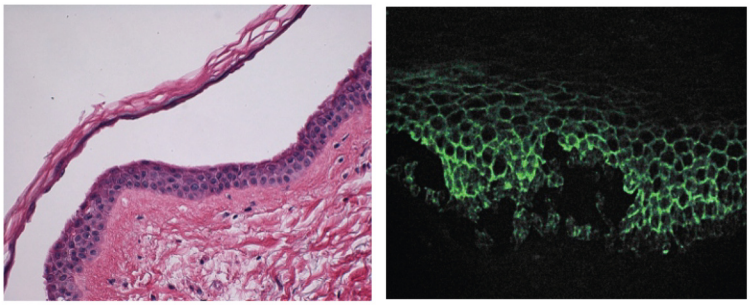

Pemphigus Vulgaris/Pemphigus Foliaceous

**Q3.9: Write briefly about the character of the bulla, antibodies involved, microscopic features, and IHC of Bullous Pemphigoid.**

Answer:

- Character of bullae: Well-formed and tense
- Microscopy: A subepidermal split is seen
- Antibodies are against hemidesmosomes E.g.: BPAG (Bullous pemphigoid antigen)
- Under Immunofluorescence
  - Linear Immunofluorescence at the roof of the bulla
  - Ribbon candy appearance

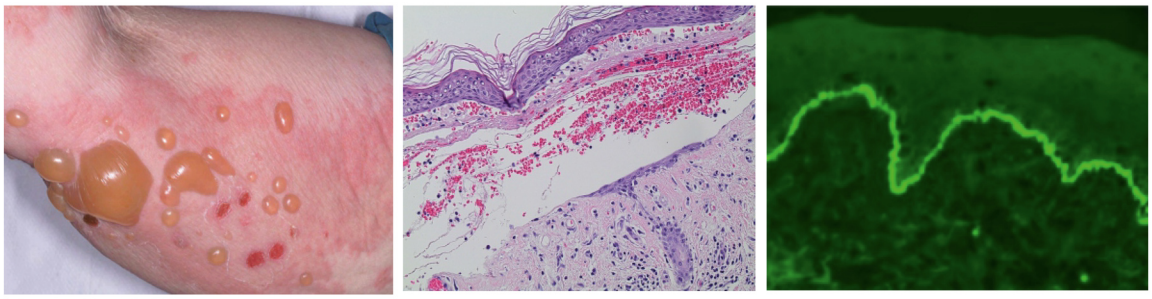

**Q3.10: At which layer is the split seen in Epidermolysis bullosa acquisita and what are the IHC findings?**

Answer:

- Split is seen in this subepidermal because of the collagen 7 defect
- Immunofluorescence will be on the floor of the bulla

### Q3.11: Difference between Bullous pemphigoid and EBA

**Answer:**

| Bullous pemphigoid | EBA |
|---|---|
| • Subepidermal split<br>• Linear appearance: Roof of the bulla<br>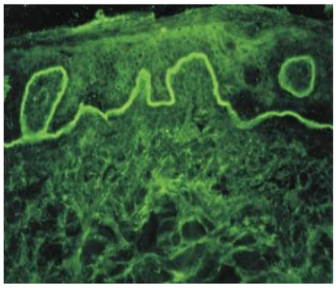 | • Subepidermal split<br>• Linear appearance: Floor of the bulla<br>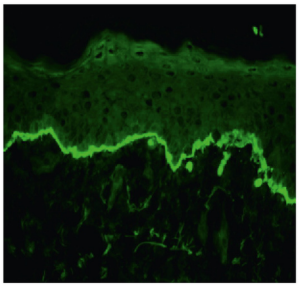 |

### Q3.12: Write briefly about the split of layer, antibodies involved and associated disorder in Dermatitis Herpetiformis

PYQ: FMGE 2023

**Answer:**

- Split is in the subepidermal layer
- Due to IgA (Immunoglobulin A) antibody → Tip lesions
- Associated with a disorder of the intestine called Celiac disease

### Q3.13: Write in brief about Basal cell carcinoma.

PYQ: FMGE 2021

**Answer:**

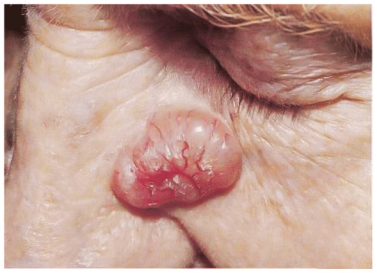

- AKA Rodent's ulcer
- Associated with Gorlin Syndrome
- Occurs on the face, medial canthus
- Defined as pearly white lesions with rolled margins
- Associated with telangiectatic blood vessels

### Q3.14: What is the histopathology of Basal cell carcinoma?

**Answer:**

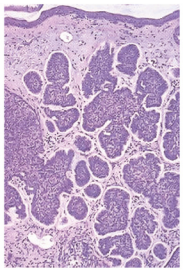

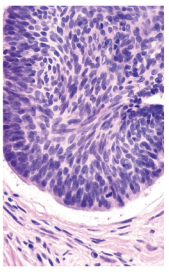

- Tumor cells are arranged in peripheral palisading
- Whitish color spaces are seen: Retraction artefact

## BIG QUESTION 4: Name some diseases that affect the soft tissue

**Broad Answer:**

- Fibrosarcoma
- Smooth muscle tumour: Leiomyosarcoma, Leiomyoma
- Skeleton muscle tumour: Rhabdomyosarcoma

## DETAILED QUESTIONS

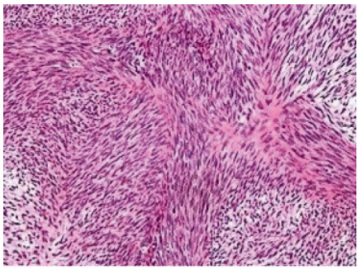

### Q4.1: What is the pattern seen on histology in Fibrosarcoma?

**Answer:**

- Herring bone pattern

### Q4.2: What is the shape of the nucleus in Leiomyosarcoma & Leiomyoma?

**Answer:**

- Leiomyosarcoma (malignant): Cigar-shaped nuclei
- Leiomyoma (benign): Cigar-shaped nuclei

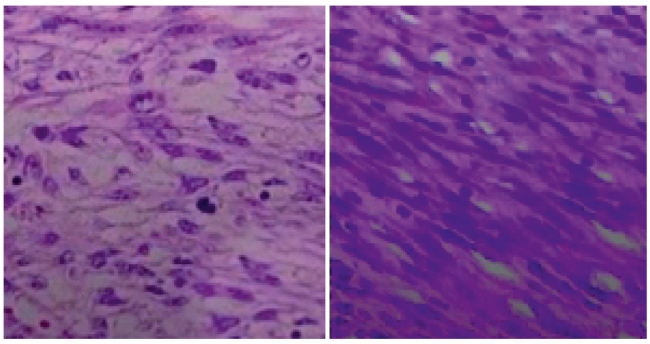

### Q4.3: What are the IHC findings in smooth muscle tumours?

**Answer:**

- IHC findings in smooth muscle tumors are:
  - Vimentin+
  - Smooth muscle actin+

### Q4.4: Write briefly about Rhabdomyosarcoma

**Answer:**

- It is a skeletal muscle tumour
- **Types**
  - Sarcoma Botryoids (grape-like)
  - Embryonal RMS
- Microscopy
  - The cambium layer has so many cells
    - → Strap cell
    - → Tennis racket appearance
  - Below the cambium layer, hypocellularity is present
  - Stain: Phosphotungstic Acid Hematoxylin
  - IHC:Vimentin+, Desmin+, MyoD1+

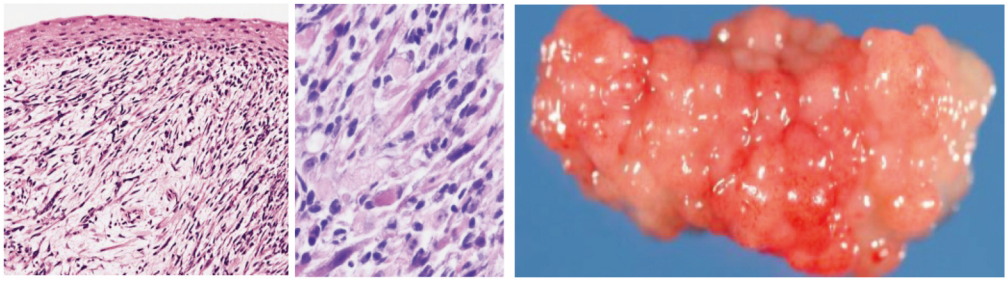

### Q4.5: What are the conditions with Tennis racket appearance on histology?

**Answer:**

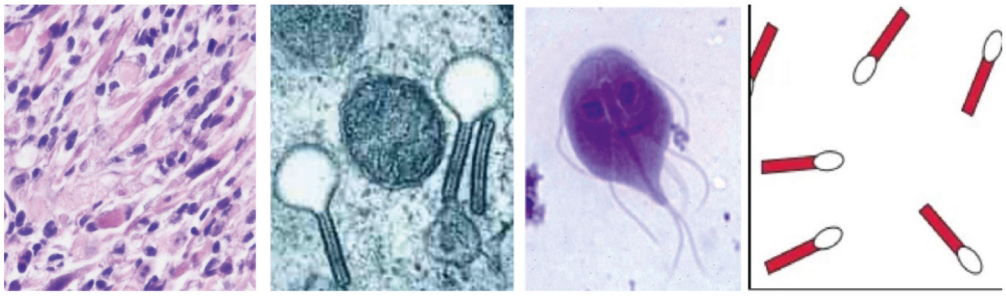

RMS LCH Giardia Lamblia Clostridium Tertium



YOURWISH

## Q4.6: What are the differences between Gout and Pseudo gout?

**Answer:**

PYQ: INICET 2023, 2024 | PYQ: FMGE 2021, 2022 | PYQ: NEET PG 2022, 2023

| Features | Gout | Pseudogout |
|---|---|---|
| Crystal | Uric Acid | CPPD: Calcium Pyrophosphate Deposition |
| Shape | Needle Like  | Rhomboid 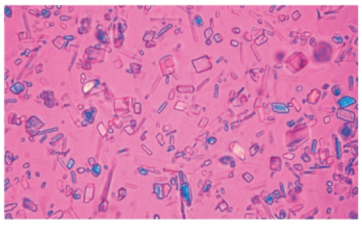 |
| Birefringence<br>Polarizing microscopy | Negative | Weakly positive |

# 18. ENDOCRINE PATHOLOGY

## BIG QUESTION 1: How is FNAC used in evaluating thyroid lesions, and what are the pathological features of different types of thyroiditis?

**Broad Answer:** Fine-needle aspiration cytology (FNAC) is a key diagnostic tool in evaluating thyroid lesions. The Bethesda system outlines criteria for sample adequacy. Various forms of thyroiditis (Hashimoto's, De Quervain's, Subacute lymphocytic, and Riedel's) typically cause hypothyroidism, each with distinct histological and clinical characteristics.

## DETAILED QUESTIONS

### Q1.1: What are the adequacy criteria for FNAC in thyroid evaluation?

PYQ: NEET PG 2020

**Answer:**

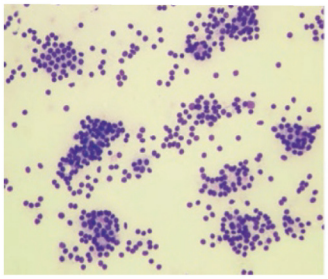

- As per the Bethesda system:
  - At least six groups of cells or follicles
  - Each group must have at least ten cells
- Exceptions (number is irrelevant):
  - Colloid goiter
  - Cancerous changes
  - Inflammatory conditions (e.g., Hashimoto's thyroiditis)

### Q1.2: What are the pathological and clinical features of Hashimoto's thyroiditis?

**Answer:** Also known as lymphocytic thyroiditis

- Autoimmune disease with HLA-DR3 and DR5 association
- Microscopy:
  - Dense lymphocytic infiltration
  - Formation of lymphoid follicles with germinal centres
  - Hurthle cells (eosinophilic, pink-staining cells) — hallmark feature

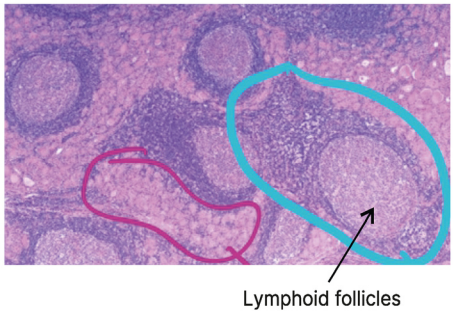


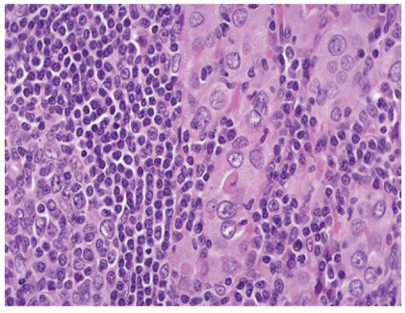

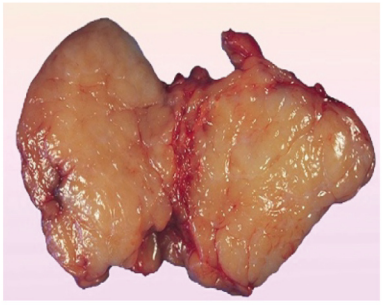

- Gross: Homogeneous, diffusely enlarged thyroid
- Antibodies: Anti-TPO, Anti-TG
- Risk: Papillary thyroid carcinoma, MALT lymphoma

### Q1.3: What are the key features of De Quervain's thyroiditis?

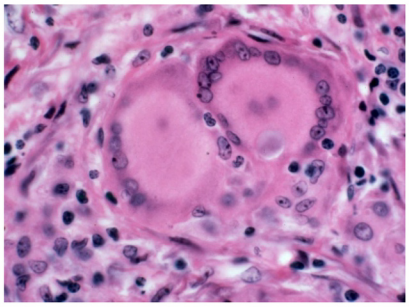

**Answer:**

- Also called granulomatous thyroiditis
- Painful thyroid
- Typically follows viral infections (e.g., mumps, adenovirus)
- Histology: Presence of granulomas and giant cells

### Q1.4: What defines subacute lymphocytic thyroiditis?

**Answer:**

- Painless thyroiditis
- Occurs postpartum

### Q1.5: What are the features of Riedel's thyroiditis?

**Answer:**

- Stony hard thyroid
- Extensive fibrosis
- Can mimic carcinoma
- Part of IgG4-related disease

| Thyroiditis | Features | |
|---|---|---|
| Hashimoto's Thyroiditis/ Lymphocytic thyroiditis | Risk of papillary carcinoma thyroid, Maltoma (Lymphoma) | Anti-TPO, Anti TG, HLA DR3, 5 |
| De Quervain Thyroiditis/ Granulomatous thyroiditis | Painful thyroiditis | Post-viral infection (mumps or adenovirus) |
| Subacute Lymphocytic Thyroiditis | Painless | Postpartum |
| Reidles Thyroiditis | • Stony hard<br>• Fibrosis<br>• **Mimics cancer** | • IgG4 related disease<br>• All the fibrosing conditions are put under this category |

## BIG QUESTION 2: What are the key features and diagnostic findings in Graves' disease ?

**Broad Answer:** Graves' disease, also called Basedow disease, is the most common cause of hyperthyroidism due to autoantibodies that stimulate thyroid hormone production. It presents with characteristic gross and cytological changes, including scalloped colloid and fire flares on FNAC.

## DETAILED QUESTIONS

### Q2.1: What is the pathophysiology of Graves' disease?

**Answer:**

- Thyroid-stimulating immunoglobulin (TSI) binds to TSH receptors
- Stimulates excessive production of T3 and T4
- Results in hyperthyroidism

### Q2.2: What are the gross features of the thyroid gland in Graves' disease?

PYQ: FMGE 2021

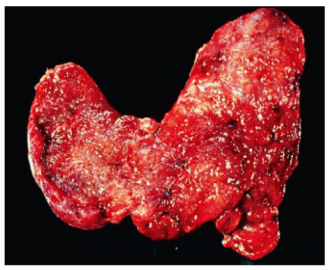

**Answer:**

- Beefy red appearance of the thyroid gland
- Occurs due to hyperactivity

### Q2.3: What are the cytological findings on FNAC in Graves' disease?

**Answer:**

- Scalloping of colloid
- Appearance of fire flares

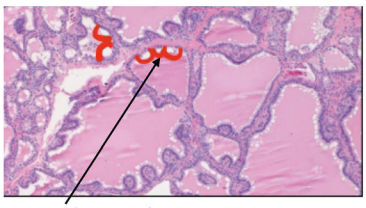

Scalloping colloid

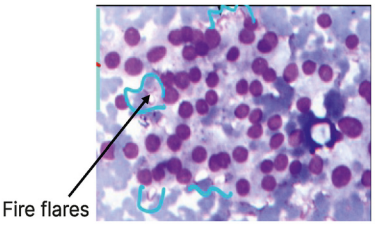

Fire flares

## BIG QUESTION 3: What are the histopathological types, risk factors, and diagnostic features of thyroid carcinomas?

**Broad Answer:** Thyroid carcinomas include papillary, follicular, medullary, and anaplastic types. Each has distinct molecular markers, microscopic features, and clinical behaviors. Papillary carcinoma is the most common and has an excellent prognosis, while anaplastic carcinoma is aggressive with a poor outcome. Diagnosis is made through FNAC and histopathology, with some features unique to biopsy or cytology.

## DETAILED QUESTIONS

### Q3.1: What are the key features of papillary carcinoma of the thyroid (PTC)?

PYQ: FMGE 2020

**Answer:**

- Most common thyroid malignancy
- Risk factors:
  - Radiation exposure
  - Hashimoto thyroiditis
  - BRAF mutation
  - RET-PTC fusion
- Prognosis: Excellent; nearly 100% survival
- Histology:
  - True papillae (finger-like projections)
  - Orphan Annie eye nucleus (formalin artifact)
  - Intranuclear cytoplasmic inclusions
  - Coffee bean nucleus
  - Psammoma bodies
- FNAC finding: Chewing gum colloid (sticky colloid)

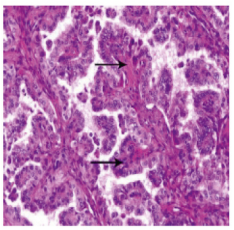

Papillae

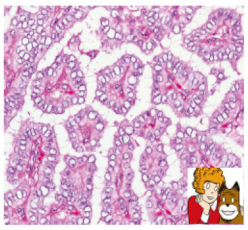

Orphan Annie eye nucleus

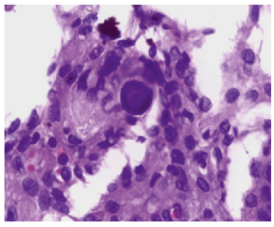

Psammoma body

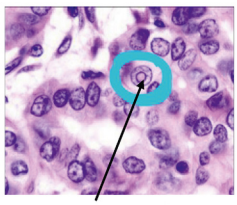

Intranuclear cytoplasmic inclusion

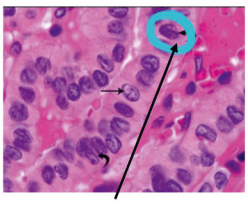

Coffee bean nucleus



Chewing gum colloid

### Q3.2: What are the important variants of papillary carcinoma?

**Answer:**

1. Lindsay tumor:
   - Solid, encapsulated, follicular variant of papillary carcinoma

2. Tall cell variant:
   - Cells are three times taller than wide
   - Must constitute >30% of the tumor
   - Associated with BRAF mutation

### Q3.3: What are the features and spread pattern of follicular carcinoma?

PYQ: NEET PG 2022 PYQ: FMGE 2021

**Answer:**

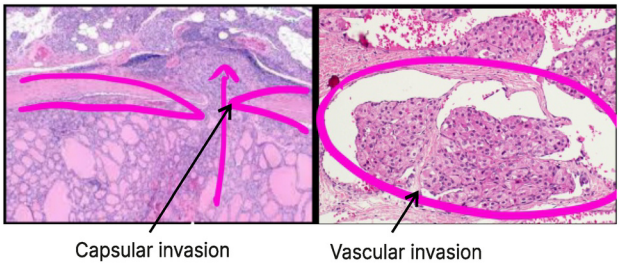


- Risk factors/mutations:
  - RAS mutation (most common)
  - PTEN, PPI3K, PAX8-PPARγ mutations
- Only thyroid carcinoma that spreads hematogenously
- Histological features:
  - Capsular invasion
  - Vascular (angio-) invasion

### Q3.4: What are the features of medullary carcinoma of the thyroid?

PYQ: NEET PG 2022 PYQ: NEET PG 2022

**Answer:**

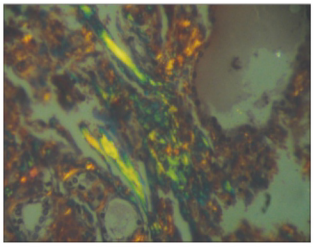

- Associated gene: RET (on chromosome TEN)
- Seen in MEN 2A and MEN 2B syndromes
- Tumor marker: Calcitonin
- Histology:
  - Amyloid deposits from calcitonin → called Acal
  - Stains with Congo red
  - Shows apple green birefringence under polarized light

### Q3.5: What are the characteristics of anaplastic carcinoma of the thyroid?

**Answer:**

- Rare
- Most aggressive type
- Very poor prognosis due to rapid progression and death

## BIG QUESTION 4: What are the features, markers, and prognostic factors of adrenal gland tumors - pheochromocytoma and neuroblastoma?

**Broad Answer:** Adrenal gland tumors primarily include pheochromocytoma and neuroblastoma. Pheochromocytoma is a neuroendocrine tumor often diagnosed using histological features and catecholamine metabolites. Neuroblastoma is a common childhood malignancy with distinct histopathological features and genetic markers that determine prognosis.

## DETAILED QUESTION

### Q4.1: What are the key features and rules associated with pheochromocytoma?

PYQ: FMGE 2028, 2021

**Answer:**

- Known for the Rule of 10s:
  - 10% are bilateral
  - 10% occur in children



YOURWISH

- 10% are extra-adrenal (called paragangliomas)
- 10% are malignant
- 10% do not cause hypertension

- Clinical features:
  - Hypertension, sweating, increased heart rate due to catecholamine release
- Genetic associations:
  - RET, EPAS1, VHL, Nf1, SDH B, C, D
- 25% cases are familial

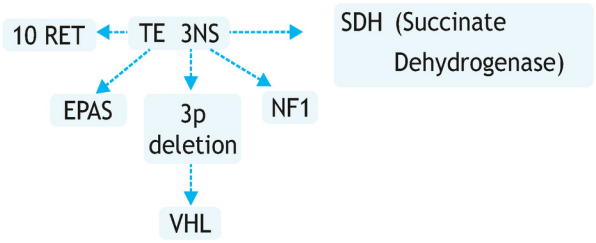


## Q4.2: What are the histological and immunohistochemical features of pheochromocytoma?

**Answer:**

- Microscopy:
  - Zellballen (nesting) pattern:
    - → Central chief cells: True neuroendocrine cells
    - → Peripheral sustentacular cells

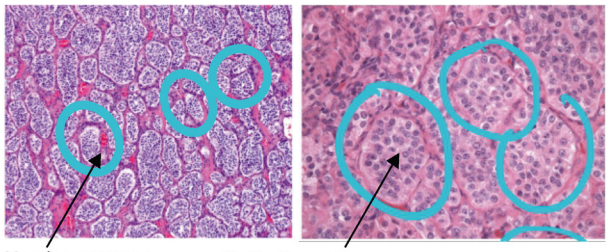


- Immunohistochemistry will show a brown color stain

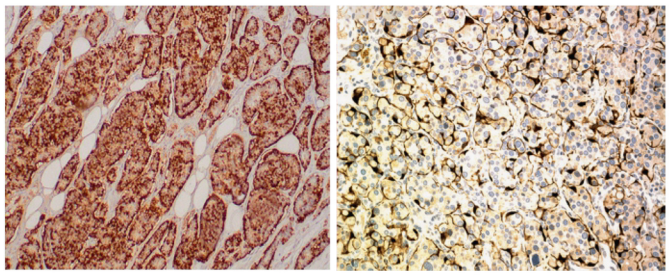

- Markers:
  - Chief cells: Positive for neuroendocrine markers (brown stain)
  - Sustentacular cells (supportive cells): Positive for S-100
- Ultrastructure (E/M):
  - Presence of neurosecretory granules
- Tumor Marker:
  - Metanephrines (catecholamine metabolites)

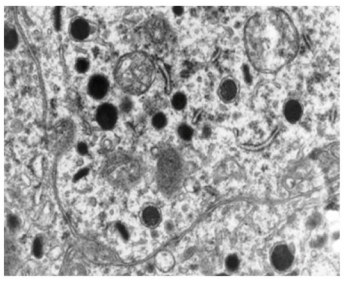
Neurosecretory Granules

## Q4.3: What are the histological features and associations of neuroblastoma?

**Answer:**

- Shows Homer Wright pseudorosettes
  - Also seen in:
    - → Medulloblastoma
    - → Ewing's sarcoma
- Genetic marker:
  - NMYC amplification – indicates poor prognosis

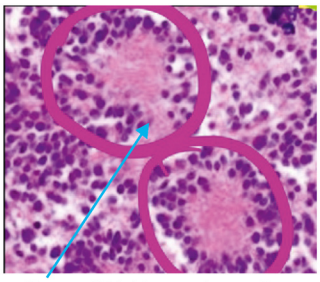
Homer Wright pseudorosettes

### Q4.4: What are the prognostic factors for neuroblastoma?

**Answer:**

| Prognostic factors | Good | Bad |
|---|---|---|
| Age | Less than 18 months | Older than 18 months |
| Differentiation | Gangliocytic or shwannian | |
| MKI | Less than 200/5000 cells | More than 200/5000 cells |
| DNA PLOIDY | Hyperdiploid | Hypodiploid |
| TRK A (Mnemonic - Acha) | **Good** | |
| TRK B | | **Bad** |
| Chromosome 1p loss, 11q loss | | Bad |
| NMYC | | Bad |

## BIG QUESTION 5: What are the genetic mutations and syndromic associations related to the pituitary gland and MEN syndromes?

**Broad Answer:** Pituitary tumors and associated endocrine neoplasias have distinct genetic mutations. These include somatic activating mutations like *GNAS*, *USP8*, and *HRAS*, and germline inactivating mutations such as *AIP*, *CDKN1A*, and *PRKAR1A*. Additionally, Multiple Endocrine Neoplasia (MEN) syndromes involve different gene defects with overlapping tumor profiles and diagnostic relevance in endocrine pathology.

## DETAILED QUESTIONS

### Q5.1: What are the key genetic mutations in various pituitary tumors?

**Answer:**

- Pituitary carcinoma: HRAS mutation (important in kidney cancers)
- Pituitary blastoma: DICER1 mutation
- Corticotroph adenoma: CDKN1A, USP8 (Mnemonic: C-C-U)
- Somatotroph adenoma: PRKAR1A, AIP, GNAS
- Lactotroph adenoma: PRKAR1A, AIP

### Q5.2: What is the classification of mutations based on their function?

**Answer:**

- Somatic activating mutations:
  - HRAS
  - USP8
  - GNAS
- Germline inactivating mutations:
  - CDKN1A
  - AIP
  - PRKAR1A

## Q5.3: What are the genetic defects and clinical features in MEN syndromes?

Answer:

PYQ: INICET 2022 PYQ: NEET PG 2021

| MEN 1 | MEN 2a | MEN 2b | MEN 4 |
|---|---|---|---|
| MENIN gene | RET gene problem | | CDKN1B gene |
| Also known as Wermer Syndrome | Also known as Sipple Syndrome (Mnemonic-**Pa**pa give **me** the **phe**es) | (Mnemonic - **Muma** give **me** the **phe**es) | |
| **P**ituitary **A**denoma | **Pa**rathyroid hyperplasia | • **Mu**cosal Neuroma<br>• **Ma**rfanoid Habitus | Pituitary Adenoma |
| **Pa**rathyroid hyperplasia | **Me**dullary carcinoma thyroid | **Me**dullary carcinoma thyroid | Parathyroid hyperplasia |
| **Pa**ncreatic Tumor | **Phe**ochromocytoma | **Phe**ochromocytoma | Pancreatic Tumor |
| | | | • MEN1 &MEN 4 have similar features<br>• Only genetics is different from MEN1. |



YOURWISH

# 19. RED BLOOD CELLS

## BIG Question 1: What are the key features of bone marrow aspiration and biopsy procedures?

**Broad Answer:**

Bone marrow aspiration and biopsy are essential procedures in evaluating hematological conditions. Aspiration involves collecting marrow fluid using specialized needles like Salah or Klima, while biopsy involves removing a bone core using a Jamshidi needle. Site selection varies with age and patient habitus, and interpretation includes assessing the cell-to-fat ratio.

## DETAILED QUESTIONS

PYQ: FMGE 2021

### Q1.1: What needles are used for bone marrow aspiration, and what are their distinguishing features?

**Answer:**

- Salah needle: Has a side screw
- Klima needle: Has a longitudinal screw that moves along the axis



Salah Needle.



Kilma Needle.

### Q1.2: What is the needle used for bone marrow biopsy, and what are its characteristics?

**Answer:**

- Needle used: Jamshidi needle
- Material: Previously stainless steel, now disposable
- Shape: T-shaped



Jamshidi Needle

### Q1.3: What are the common sites for bone marrow biopsy and aspiration?

**Answer:**

- Most common sites for bone marrow biopsy:
- Adults: Posterior superior iliac spine or iliac crest
- Obese individual (fat in gluteal region): Anterior superior iliac spine.
- Children (preferred site): Anteromedial part of the tibia.

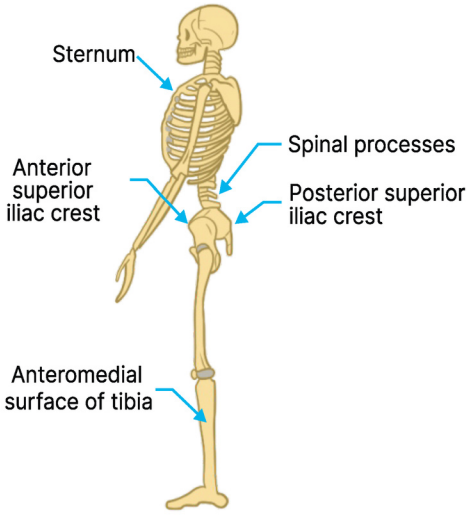




YOURWISH

### Q1.4: What is the typical appearance and cellularity of adult bone marrow?

**Answer:**

- Bone marrow contains both cells and fat
- The cell-to-fat ratio in adults is 1:1

### Q1.5: What features are seen in a peripheral smear, and which stains are

**Answer:**

- Red dots: Red Blood Cells
- White blood cells
- Platelets
- Stains (Romanowsky family):
  - Giemsa
  - Leishman
  - Wright, Jenner, Field (used in 90% cases)
  - Special stain for Plasmodium falciparum: Field stain

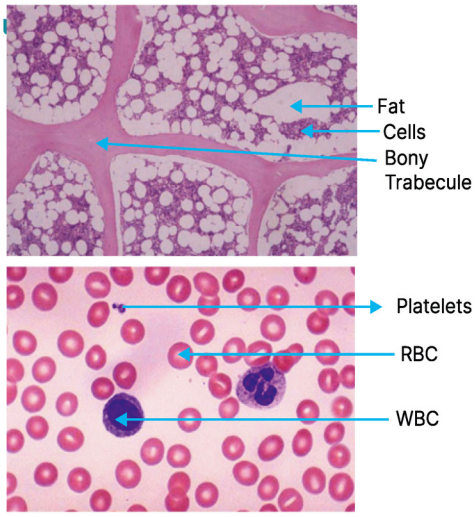


## BIG QUESTION 2: What are the stages of red blood cell development, and how are RBC parameters assessed in clinical practice?

**Broad Answer:** Red blood cells (RBCs) develop through multiple stages, starting in the bone marrow and ending in the peripheral blood as mature erythrocytes. Reticulocytes are immature RBCs with residual RNA, identifiable using supravital stains. RBC indices such as MCV, MCH, and MCHC help assess red cell morphology and anemia types.

## DETAILED QUESTIONS

### Q2.1: What are the stages of erythropoiesis and their characteristics?

**Answer:**

- Bone Marrow Stages (nucleus present):
  - Pronormoblast
  - Early normoblast (basophilic normoblast)
  - Intermediate normoblast (polychromatophilic normoblast)
  - Late normoblast (orthochromic normoblast)

PYQ: FMGE 2019

- Peripheral Blood Stages (nucleus absent):
  - Reticulocyte
  - Erythrocyte (mature RBC)

### Q2.2: What is a reticulocyte, and how is it identified?

**Answer:**

- A reticulocyte is an immature RBC containing a reticulum of RNA

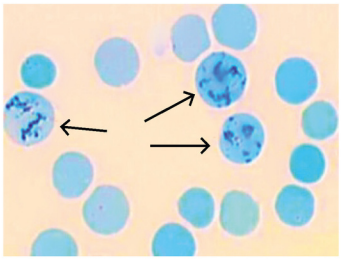

**RNA Staining:**

- Visible only if stained in a living condition

- Only stained by Supravital staining
  - o New methylene blue (best supravital stain)
  - o Brilliant cresyl blue.

### Q2.3: What is the normal reticulocyte count, and how is the corrected count calculated in anemia?

**Answer:**

- Normal Reticulocyte Count: 0.5% - 2.0%
- Corrected Reticulocyte Count (CRC):
  - o Formula:
    - → CRC = Reticulocyte Count × Hb of the patient / Hb of a normal person
  - o Example:
    - → Retic count = 6%, Hb = 5 g/dL
    - → CRC = 6 × 5 / 15 = 2%

### Q2.4: What is hematocrit, and how is it measured?

**Answer:**

- PCV/Haematocrit: The proportion of RBCs packed at the bottom of a blood sample
- **Measured using**:
- Wintrobe Tube:
  - o Sample: Collected and filled in the entire tube.
  - o Gives: PCV, ESR
  - o Westergren pipette: Measures only ESR, not PCV

### Q2.5: What are the red blood cell indices and their normal ranges?

**Answer:**

- MCV (Mean Corpuscular Volume): 80-100 fL (RBC size)
- MCH (Mean Corpuscular Hemoglobin): 27-32 pg (Hemoglobin content)
- MCHC (Mean Corpuscular Hemoglobin Concentration): 33-37 g/dL (Hemoglobin concentration)
- RDW (Red Cell Distribution Width): 11.5-14.5% (variation in RBC size)
- PCV/Haematocrit: Normal = 45%

### Q2.6: How does the Westergren pipette differ from the Wintrobe tube?

**Answer:**

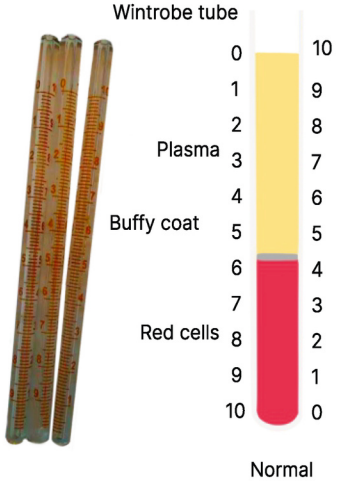


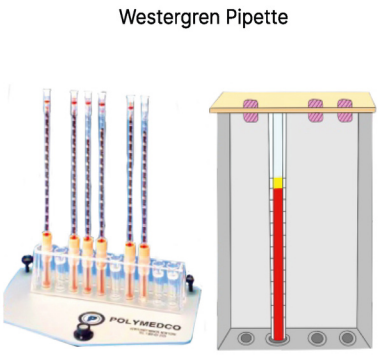


- The Westergren pipette is a longer tube
- It is used only for ESR measurement

- It does not provide PCV information

## BIG QUESTION 3: What are the causes, pathophysiology, diagnosis, and management of microcytic hypochromic anemia, particularly iron deficiency anemia?

**Broad Answer:** Microcytic hypochromic anemia can result from various causes, including iron deficiency, thalassemia, lead poisoning, anemia of chronic disease, and sideroblastic anemia. Iron metabolism involves conversion between Fe3+ and Fe2+, absorption in the duodenum, and transport via transferrin. Iron deficiency anemia is the most common form in India, characterized by specific clinical features and lab findings. Diagnosis involves an iron profile and bone marrow evaluation; treatment includes iron supplementation.

## DETAILED QUESTIONS

### Q3.1: What are the causes of microcytic hypochromic anemia?

**Answer:**

Mnemonic: SITAL

- Sideroblastic anemia
- Iron deficiency anemia
- Thalassemia
- Anemia of chronic diseases
- Lead poisoning
  - It is a type of sideroblastic anemia

### Q3.2: What is the most common cause of microcytic hypochromic anemia in India?

**Answer:** Iron deficiency anemia is the most common cause in India

### Q3.3: Where and how is iron absorbed in the body?

**Answer:**

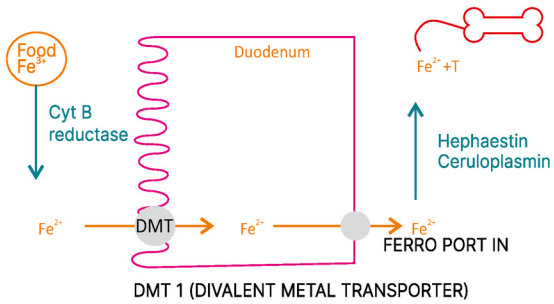


- Site of absorption: Duodenum
- Dietary form: $Fe^{3+}$ (Ferric)
- Absorbed form: $Fe^{2+}$ (Ferrous)
- Conversion:
  - $Fe^{3+} \rightarrow Fe^{2+}$ by cytochrome B reductase
- Transport across the enterocyte:
  - By DMT1 (Divalent Metal Transporter 1)
- Export into blood:
  - Via Ferroportin
  - Then $Fe^{2+}$ is converted to $Fe^{3+}$ by hephaestin and ceruloplasmin
  - $Fe^{3+}$ binds to transferrin for transport to the bone marrow

### Q3.4: What is the function and regulation of hepcidin in iron metabolism?

**Answer:**

- Source: Liver
- Function:
  - Inhibits iron absorption
  - Inhibits the release of iron from ferritin stores
  - Acts by inhibiting ferroportin
- Role: Master regulator of iron metabolism



YOURWISH

### Q3.5: What is the transport and storage form of iron in the body?

**Answer:**

- Transport form: $Fe^{3+}$ bound to transferrin
  - Normal transferrin saturation: 33%
- Storage form: Ferritin

### Q3.6: What are the clinical features and causes of iron deficiency anemia?

**Answer:**

- **Clinical sign**: Koilonychia (spoon-shaped nails)
- **Causes**:
  - Dietary deficiency
  - Blood loss: RTA, trauma, PUD, menorrhagia, occult GI bleeding (e.g., colon cancer)
  - Hookworm infestation
  - Chronic disease anemia

PYQ: NEET PG 2021
PYQ: FMGE 2022

### Q3.7: What are the characteristic blood smear findings in iron deficiency anemia?

**Answer:**

- Microcytic hypochromic RBCs
- Anisocytosis: Variation in RBC size
- Poikilocytosis: Variation in RBC shape (e.g., pencil cells)

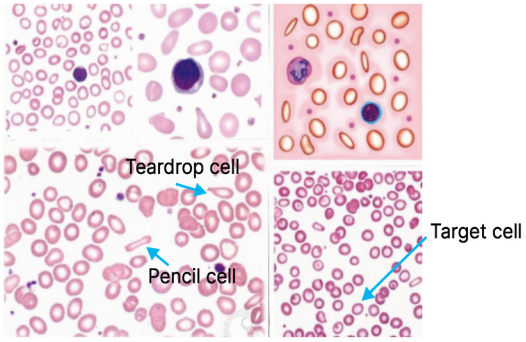


### Q3.8: What is the iron profile seen in iron deficiency anemia?

**Answer:**

- Serum iron: ↓
- Transferrin saturation: ↓
- Ferritin: ↓
- Total iron binding capacity (TIBC): ↑

### Q3.9: What is the most definitive diagnostic test for iron deficiency anemia?

**Answer:**

- Bone marrow aspirate with Pearl stain (for iron):
  - Shows zero staining → Confirms iron deficiency

### Q3.10: What is the treatment of iron deficiency anemia?

**Answer:** Iron supplements

### Q3.11: What are the lab findings in iron deficiency anemia?

**Answer:**

- Hb ↓
- MCV ↓
- MCH ↓
- MCHC ↓
- RDW ↑



YOURWISH

YOURWISH

## BIG QUESTION 4: How do Anemia of Chronic Disease and Sideroblastic Anemia differ in etiology, lab findings, and diagnostic features?

**Broad Answer:** Anemia of Chronic Disease (AOCD) and Sideroblastic Anemia are two distinct causes of anemia with different underlying mechanisms. AOCD is commonly associated with chronic inflammation, such as rheumatoid arthritis, and involves IL-6-induced hepcidin upregulation. In contrast, sideroblastic anemia is due to defects in heme synthesis enzymes. Their iron profiles, peripheral smear findings, and bone marrow appearances help in differentiation and diagnosis.

## DETAILED QUESTIONS

### Q4.1: What is an example and pathophysiology of anemia of chronic disease (AOCD)?

**Answer:**

- Example: Rheumatoid arthritis
- Mechanism:
  - IL-6 stimulates the liver to increase hepcidin production
  - Hepcidin inhibits iron absorption and iron release from storage

### Q4.2: How do iron study parameters differ between IDA and AOCD?

**Answer:**

| IDA | Features | AOCD |
|---|---|---|
| ↓ | Serum iron | ↓ |
| ↓ | Transferrin saturation | ↓ |
| ↓ | ferritin | ↑ |
| ↑ | TIBC | ↓ |

TIBC: Increased on top in IDA; Decreased to bottom in AOCD.

Mnemonic: TIBC (Total Iron Binding Capacity)

- T - Top
- I - IDA
- B - Bottom
- C - Chronic Disease

### Q4.3: What is the treatment approach for anemia of chronic disease?

**Answer:** Treat the underlying cause of the chronic disease (e.g., infection, inflammation, autoimmune disease)

### Q4.4: What is the key difference between sideroblastic anemia and iron deficiency anemia?

**Answer:**

PYQ: INICET 2023 PYQ: FMGE 2023,2022 PYQ: NEET PG 2022,2023

- IDA: Iron is missing
- Sideroblastic anemia: Protoporphyrin is missing
  - Caused by a deficiency of ALA synthase and ALA dehydratase

| Features | IDA | Sideroblastic Anaemia |
|---|---|---|
| Serum iron | ↓ | ↑ |

| | | |
|---|---|---|
| Transferrin saturation | ↓ | ↑ |
| Ferritin | ↓ | ↑ |
| TIBC | ↑ | ↓ |

### Q4.5: What are the peripheral smear findings in sideroblastic anemia?

**Answer:**

- Pappenheimer bodies (iron-laden mitochondria)

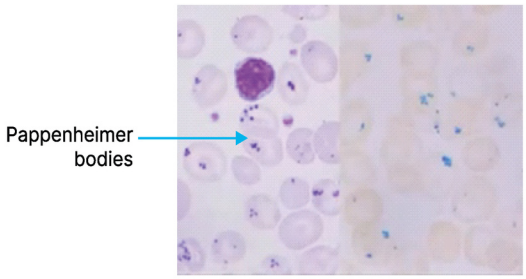


### Q4.6: What is seen on bone marrow biopsy in sideroblastic anemia?

**Answer:**

- Ringed sideroblasts
  - Criteria:
    - → At least five granules per cell
    - → Granules covering >1/3 of the nucleus circumference
  - Stain used: Pearl's or Prussian blue

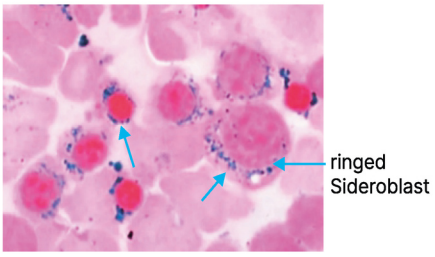


### Q4.7: Which toxic exposures and nutritional deficiencies are linked to sideroblastic anemia?

**Answer:**

- Vitamin B6 deficiency
- Alcohol intoxication
- Lead poisoning

## BIG QUESTION 5: What are the causes, clinical features, biochemical findings, and diagnostic indicators of megaloblastic anemia?

**Broad Answer:** Megaloblastic anemia is a macrocytic anemia caused primarily by deficiencies in vitamin B12 and folic acid. Vitamin B12 absorption requires intrinsic factor from gastric parietal cells and occurs in the terminal ileum, while folic acid is absorbed in the jejunum. Neurological features are seen only in B12 deficiency due to impaired myelin synthesis. Diagnosis is supported by blood tests, peripheral smear findings, and in some cases, the Schilling test to determine the cause. Elevated bilirubin and LDH, along with characteristic smear findings like macro-ovalocytes, Howell-Jolly bodies, and hypersegmented neutrophils, support the diagnosis.

## DETAILED QUESTIONS

### Q5.1: What are the main causes of megaloblastic anemia, and where are they absorbed?

**Answer:**

- Causes: Deficiency of vitamin B12 and folic acid
- B12 absorption site: Terminal ileum

- Requires intrinsic factor (released by parietal cells of the stomach)
- Folic acid absorption site: Jejunum

### Q5.2: What is pernicious anemia, and how does it affect B12 absorption?

**Answer:**

- Cause: Autoantibodies against parietal cells
- Effect: ↓ Intrinsic factor → ↓ B12 absorption → Megaloblastic anemia
- Pathogenesis is autoimmune, not dietary

### Q5.3: What are the clinical features of megaloblastic anemia?



**Answer:**

- Common: Fatigue, pallor
- Skin changes: Hyperpigmentation of knuckles and phalanges
- Dietary factor: Seen in pure vegetarians not consuming dairy products

### Q5.4: What neurological manifestations are associated with B12 deficiency?

**Answer:**

- Symptoms of B12 deficiency are not associated with folic Acid deficiency.
- SACD (Subacute Combined Degeneration):
  - Sensory-motor loss
  - Degeneration of spinal cord tracts

### Q5.5: What metabolic reactions require vitamin B12?

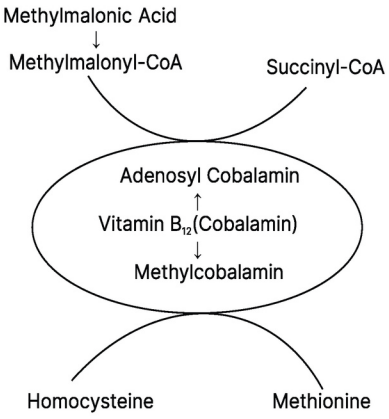


**Answer:**

- Conversion of methyl malonyl-CoA → Succinyl-CoA
- Conversion of homocysteine → Methionine
- Deficiency results in:
  - ↑ Homocysteine
  - ↑ Methyl malonyl-CoA
  - ↓ Succinyl-CoA → ↓ Myelin → Neurological symptoms (major reason: SACD).

### Q5.6: What are the biochemical findings in megaloblastic anemia?

**Answer:**

- ↑ Serum bilirubin
- ↑ LDH
- ↓ Vitamin B12
- ↓ Folic acid
- ↑ Homocysteine
- ↑ Methyl malonyl-CoA
- Anti-intrinsic factor antibody: Positive in pernicious anemia
- FIGLU (Formamino Glutamic acid): Folic acid test in urine sample



YOURWISH

### Q5.7: What is the Schilling test, and when is it used?

**Answer:**

- Purpose: To determine the cause of megaloblastic anemia
- It is not used for the diagnosis of megaloblastic anemia

### Q5.8: What are the key peripheral smear findings in megaloblastic anemia?

**Answer:**

1. Macrocytic anemia
2. Macro-ovalocytes
3. Howell-Jolly bodies:
   - o DNA remnants
   - o Single, round bodies
   - o Also seen post-splenectomy
4. Cabot rings:
   - o Arginine-rich mitotic spindles
   - o Often figure-of-eight shaped
5. Fine basophilic stippling:
   - o Made of RNA
   - o Seen in megaloblastic anemia and thalassemia
     - → Coarse basophilic stippling is seen in Lead poisoning.
6. Hypersegmented neutrophils:
   - o 5% with five lobes each
   - o Even one neutrophil with ≥6 lobes is diagnostic

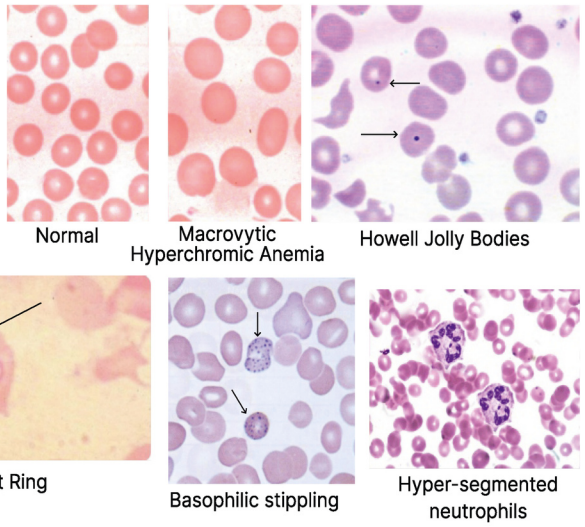


### Q5.9: What urinary test is used to assess folic acid deficiency?

**Answer:** FIGLU test (Formamino Glutamic acid test) using a urine sample

### Q5.10: What infection is associated with B12 deficiency?

**Answer:** Diphyllobothrium latum (fish tapeworm)

### BIG QUESTION 6: What are the key membrane defects in hemolytic anemias?

**Broad Answer:** Hemolytic anemias can be caused by structural defects in the red blood cell membrane.

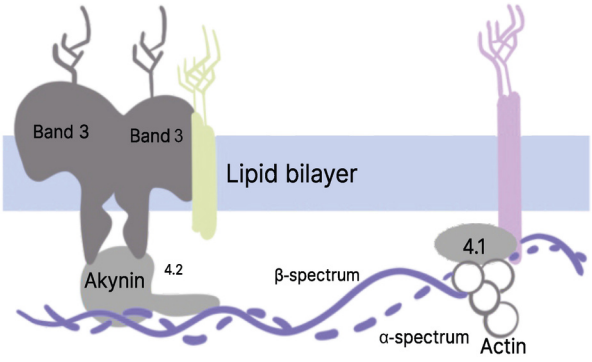




YOURWISH

| | |
|---|---|
| The Protein responsible for the biconcave shape | Spectrin maintains the shape |
| The most common mutation seen in Hereditary Spherocytosis (Autosomal dominant >Autosomal recessive) | Ankyrin |
| Spectrin mutation | Hereditary Spherocytosis (severe) autosomal recessive |
| Most abundant protein? | Glycophorin A |
| Protein never mutated in Hereditary Spherocytosis.? | Glycophorin A |
| BAND 3 defect 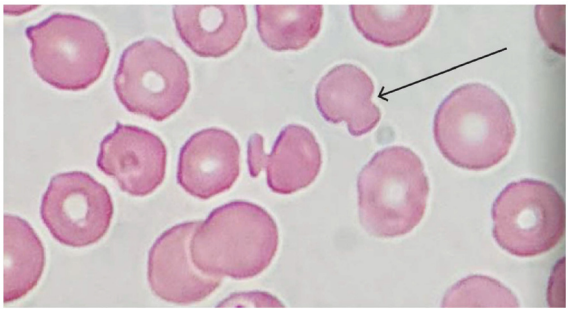 | Pincer cells are seen with band 3 defect. |

## DETAILED QUESTIONS

### Q6.1: What confirmatory test is used to detect membrane defects in hereditary spherocytosis?

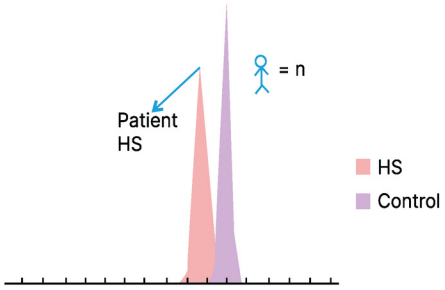


**Answer:**

- EMA (Eosin-5-maleimide) test
  - A fluorescent dye-based test
  - Performed using flow cytometry

### Q6.2: What are the most common genetic mutations in hereditary spherocytosis?

**Answer:**

- Ankyrin mutation: Most common; autosomal dominant inheritance
- Spectrin mutation (most severe): Autosomal recessive

### Q6.3: What is the inheritance pattern of hereditary spherocytosis?

**Answer:**

- Autosomal dominant > Autosomal recessive

### Q6.4: Which protein is the most abundant on the RBC membrane and never mutated in hereditary spherocytosis?

**Answer:**

- Glycophorin A
  - Most abundant membrane protein
  - Never mutated in hereditary spherocytosis

### Q6.5: What RBC shape abnormality is seen with Band 3 defects?

**Answer:**

- Pincer cells are observed in Band 3 defects

### Q6.6: What are the clinical features of hereditary spherocytosis (HS)?

**Answer:**

- Extravascular hemolysis (EVH): Occurs in the spleen
- RBC breakdown leads to:
  - Jaundice
  - Splenomegaly
  - Pigment gallstones

### Q6.7: What happens to RBC indices in hereditary spherocytosis?

**Answer:**

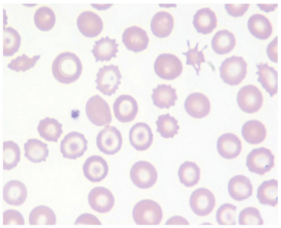

- Reticulocyte count: ↑
- MCV (Mean Corpuscular Volume): ↓
- MCHC (Mean Corpuscular Hemoglobin Concentration): ↑
- RDW (Red cell Distribution Width): ↑
- Small, hyperchromic spherocytes are characteristic

### Q6.8: What is aplastic crisis, and what causes it in HS patients?

**Answer:**

- Sudden cessation of RBC and WBC production
- Cause: Infection with Parvovirus B19

### Q6.9: What is the screening and confirmatory test for HS?

**Answer:**

- Screening test: Osmotic fragility test
- Confirmatory test: EMA (Eosin 5 maleimide) testing via flow cytometry

### Q6.10: How does the osmotic fragility test differentiate HS from thalassemia?

PYQ: FMGE 2022

**Answer:**

- Graph axes:
  - X-axis: NaCl concentration
  - Y-axis: % RBC lysis
- Normal RBCs: Break from 0.5% to 0.3% NaCl
- HS RBCs: High fragility → Break at 0.7% NaCl → Right shift

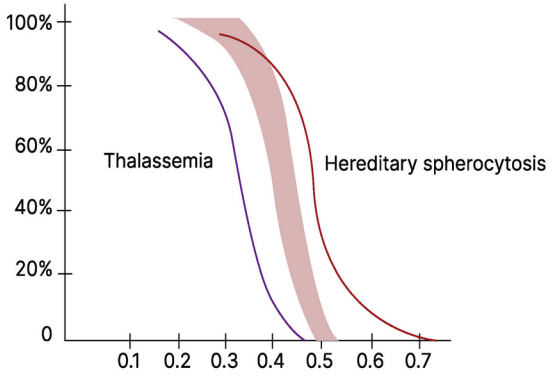


### Q6.11: What is the treatment for hereditary spherocytosis?

**Answer:**

- Splenectomy – removes the site of extravascular hemolysis

## BIG QUESTION 7: What are the diagnostic features and blood cell morphologies associated with G6PD deficiency and other RBC shape abnormalities?

**Broad Answer:** G6PD deficiency is an X-linked enzymopathy characterized by intermittent hemolysis, primarily

extravascular, triggered by oxidative stress. It presents without splenomegaly and shows unique blood smear findings such as Heinz bodies and bite cells. Screening and confirmatory tests help in diagnosis. Other RBC shape abnormalities, such as acanthocytes and echinocytes, are associated with specific clinical settings like abetalipoproteinemia, burns, or artifact from anticoagulants like EDTA.

## DETAILED QUESTIONS

### Q7.1: What are acanthocytes, and where are they seen?

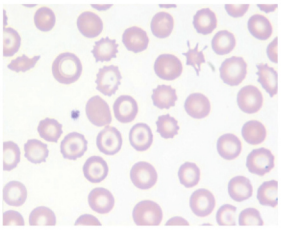

**Answer:**

- Also called spur cells or spike cells
- Seen in abetalipoproteinemia

### Q7.2: What are echinocytes, and what conditions are they associated with?

**Answer:**

- Also called burr cells
- Seen in:
  - Burns
  - Uremia
  - EDTA-induced changes (in vitro artifact)

### Q7.3: What triggers hemolysis in G6PD deficiency?

**Answer:**

- Oxidative stress
- Precipitating factors:
  - Fava beans
  - Antimalarial drugs

### Q7.4: What type of hemolysis is more prominent in G6PD deficiency, and what is the clinical pattern?

**Answer:**

- EVH > IVH (Extravascular hemolysis predominates)
- Intermittent disorder
- No splenomegaly

### Q7.5: What are the characteristic blood smear findings in G6PD deficiency?

PYQ: NEET PG 2021

**Answer:**

- Heinz bodies:
  - Composed of denatured hemoglobin
  - Not seen with Romanowsky stains
  - Stained with crystal violet
- Bite cells (Degmacytes):
  - Seen on microscopic examination

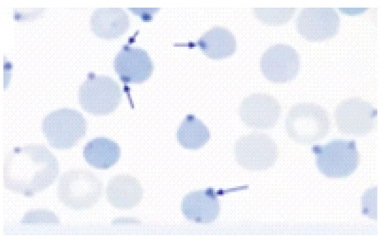

Heinz Bodies

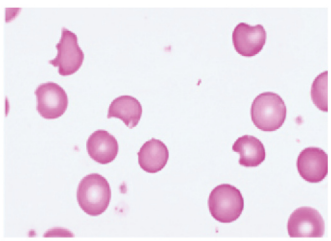

Bite cells



YOURWISH

### Q7.6: What are the screening tests and confirmatory tests for G6PD deficiency?

**Answer:**

- Screening tests:
  - Fluorescent spot test
  - Methemoglobin reduction test
- Confirmatory test:
  - G6PD assay

## BIG QUESTION 8: What is Paroxysmal Nocturnal Hemoglobinuria (PNH), and how is it diagnosed and managed?

**Broad Answer:** Paroxysmal Nocturnal Hemoglobinuria (PNH) is the only acquired red blood cell membrane defect that leads to intravascular hemolysis, resulting in hemoglobinuria, especially noticeable in the morning. It is caused by a somatic mutation in the PIGA gene, which impairs GPI anchor formation, leading to the absence of protective surface proteins CD55 (DAF) and CD59 (MIRL). Diagnosis includes screening tests like Ham's test and gel card test, with flow cytometry and FLAER assay being confirmatory.

## DETAILED QUESTIONS

### Q8.1: What makes PNH unique among red blood cell disorders?

**Answer:**

- It is the only acquired RBC membrane defect (not inherited)
- Causes intravascular hemolysis → leads to hemoglobinuria

### Q8.2: What gene is mutated in PNH, and what does it affect?

**Answer:**

- PIGA gene defect
  - Leads to the absence of GPI anchors
- GPI anchors are required to attach proteins like:
  - CD55 (DAF: Decay Accelerating Factor)
  - CD59 (MIRL: Membrane Inhibitor of Reactive Lysis)

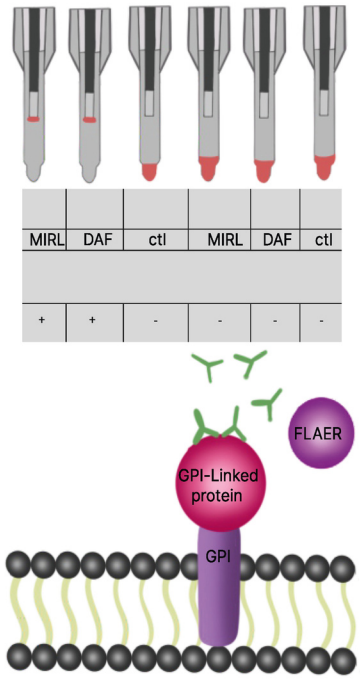


### Q8.3: What are the screening tests used for PNH?

**Answer:**

- Ham's acidified serum test
- Sucrose lysis test
- Gel card test
  - Top line is positive.
  - Bottom line is negative (CD 55 and CD 59 are negative)
  - MIRL: CD 59 are line is seen
  - DAF: CD 55

### Q8.4: What are the confirmatory tests for PNH?

**Answer:**

- Flow cytometry: Detects the absence of CD55 and CD59
- FLAER test: Detects absence of GPI anchors



YOURWISH

### Q8.5: What complications are associated with PNH?

**Answer:**

- Thrombosis, especially:
  - Hepatic vein thrombosis (HVT)
  - Cerebral vein thrombosis (CVT)
- Aplastic anemia
- Acute leukemia

### Q8.6: What is the treatment of choice for PNH?

**Answer:**

- Eculizumab
  - A monoclonal antibody that inhibits complement-mediated hemolysis

### Q8.7: Can you provide images of Howell-Jolly bodies, Pappenheimer bodies, and Heinz bodies?

**Answer:**

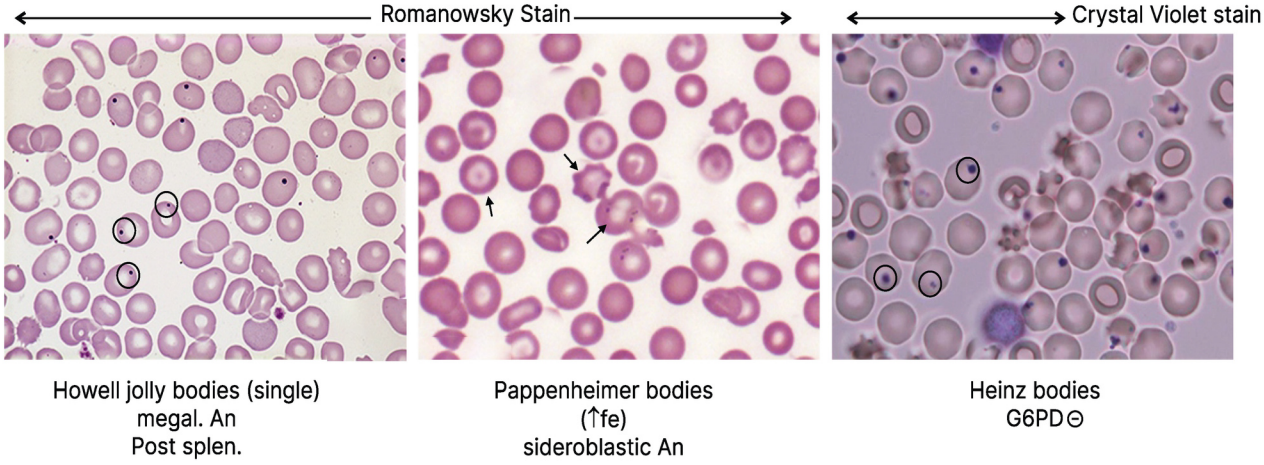


## BIG QUESTION 9: What are the key types, mutations, clinical features, and diagnostic tests of hemoglobinopathies such as Sickle Cell Disease, Thalassemia, and HbC Disease?

**Broad Answer:** Hemoglobinopathies are inherited disorders of hemoglobin structure or production. These include Sickle Cell Disease, Thalassemias, and HbC Disease, each with characteristic genetic mutations and clinical presentations. Diagnosis involves peripheral smear, sickling **tests**, **Hb electrophoresis**, and **HPLC**. Some forms lead to severe anemia, skeletal deformities, and splenic complications. Understanding mutation patterns and differentiating features is essential for diagnosis and management.

## DETAILED QUESTIONS

### Q9.1: What is the molecular mutation in Sickle Cell Disease and its key morphological feature?

**Answer:**

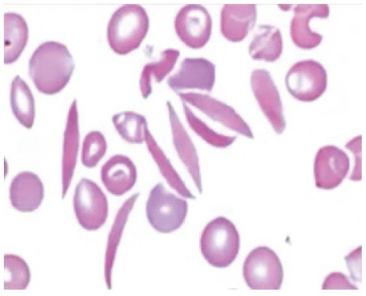

- At the β6 position, valine replaces glutamic acid
- Leads to the formation of Drepanocytes (sickle cells)
- Cells stick to each other, causing vascular occlusion

### Q9.2: What are the clinical features of Sickle Cell Disease?

**Answer:**

- Crew cut skull appearance
- Fish mouth vertebrae
- Auto-splenectomy

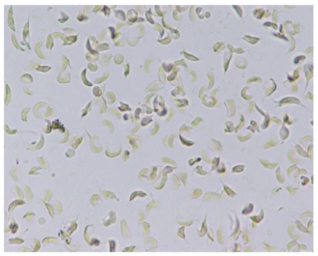

### Q9.3: What tests are used to diagnose Sickle Cell Disease?

**Answer:**

- Peripheral smear: Shows sickle cells
- Sickling test: Uses 2% sodium metabisulfite

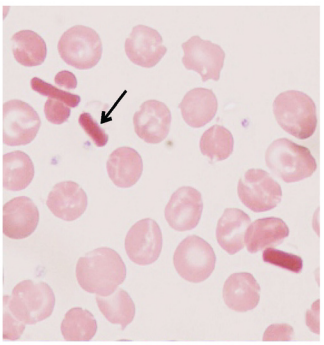

### Q9.4: What is the mutation in HbC disease?

**Answer:**

- At the ß6 position, lysine replaces glutamic acid
- HbC crystals are the classical finding

### Q9.5: What is the gold standard test for hemoglobinopathies, and how does electrophoresis work?

**Answer:**

- HPLC is the gold standard
- Hb Electrophoresis:
  - Anode (+) side: Hb H, A, F, S (S overlaps with D)
  - Cathode (-) side: Hb C, $A_2$, O, E

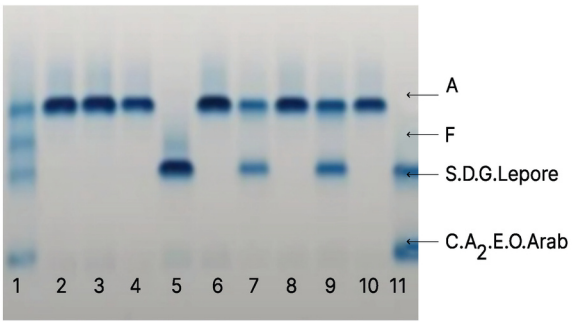


### Q9.6: What is the mechanism of action of hydroxyurea in sickle cell anemia?

**Answer:**

- Increases fetal hemoglobin (HbF)
- HbF has more oxygen affinity, preventing sickling

### Q9.7: What are the deletion patterns and outcomes in Alpha Thalassemia?

**Answer:**

| Alpha Gene Deletion | α gene deletion |
|---|---|
| AA/AA | Normal Person |
| AA/A- | 1. Deletion = asymptomatic |
| AA/- - | 2. Deletions = α thalassemia trait |

| | |
|---|---|
| A -/ - - | 3. Deletions<br>o Hbh disease (β4 tetramers)<br>o Golf Ball Inclusion<br>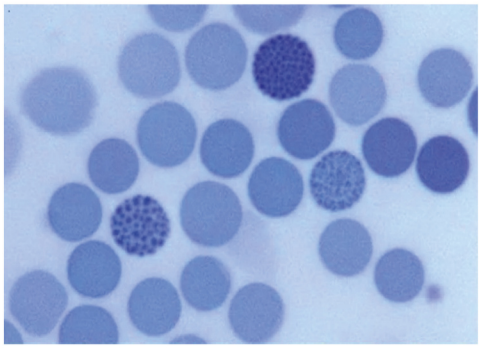 |
| -/- | 4. Deletion: Intra Uterine disease<br>o **Hb Barts Disease:** Fetus dies in uterine<br>o γ4 tetramer |

### Q9.8: What are the common mutations in Beta Thalassemia seen in India?

**Answer:**

- Splicing mutation: IVS 1-5 G→C (most common)
- Frameshift mutations: +8/9 and +41/42
- Deletion: 619 bp deletion

### Q9.9: How is Beta Thalassemia classified clinically?

**Answer:**

| Features | Thalassemia. Major | Thalassemia. Intermedia | Thalassemia. Minor/Trait |
|---|---|---|---|
| Beta Chain Production | • Cooley Anaemia<br>• Transfusion dependent | - | - |
| Clinically | • Pallor<br>• Jaundice<br>• Splenomegaly | • Pallor<br>• Jaundice<br>• Splenomegaly | Asymptomatic |
| Hb | 3-5 | 5-8 | >8 |
| Iron Profile | Increased | Normal | Normal |
| Hb electrophoresis and HPLC | • Increased Hbf<br>• More than 90% of Hbf | Both increased | HbA2 > 3.5% |

### Q9.10: What are the morphological features of Beta Thalassemia on imaging and smear?

**Answer:**

PYQ: FMGE 2021 PYQ: NEET PG 2022

- Crew cut/hair-on-end skull
- Chipmunk facies
- Target cells (Codocytes)

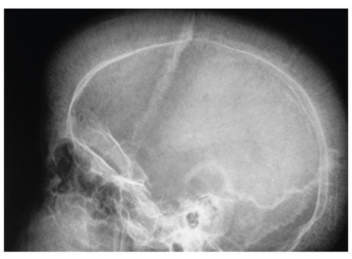



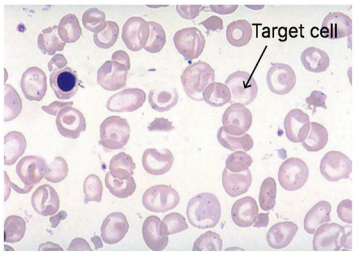

### Q9.11: How can you differentiate IDA from Beta Thalassemia Minor?

**Answer:**

| IDA | Features | Thalassemia minor |
|---|---|---|
| If more than 13 | Mentzer Index<br>MCV / RCB | Less than 13 (ThaLESSemia) |
| Elevated | RDW - a variation of size | Normal |
| | HbA2 Confirmation | HbA2> 3.5 % |

### Q9.12: What is the NESTROFT test and its principle?

**Answer:**

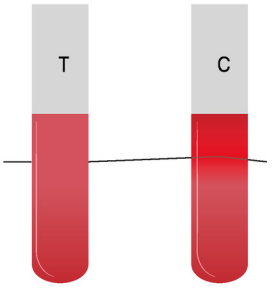


- Naked Eye Single Tube Red Cell Osmotic Fragility Test
- Principle: Thalassemic cells are tough and resist lysis in hypotonic saline
  - o Lines visible = Positive (RBCs lysed)
  - o Lines absent = Thalassemia (cells intact)

## BIG QUESTION 10: What are the different types, mechanisms, and features of Autoimmune Hemolytic Anemia (AIHA) and schistocyte-associated hemolysis?

**Broad Answer:** Autoimmune Hemolytic Anemia (AIHA) is a condition where antibodies target RBCs, causing hemolysis. It is classified based on the temperature at which the antibodies are active: Warm AIHA (IgG at 37°C) and Cold AIHA (IgM or IgG at 4°C). Hemolysis may be intravascular or extravascular, depending on the mechanism and condition. Schistocytes (fragmented RBCs) are seen in mechanical damage or microangiopathic processes, and some viral infections, like Parvovirus B19, can lead to characteristic morphologic changes.

PYQ: NEET PG 2019

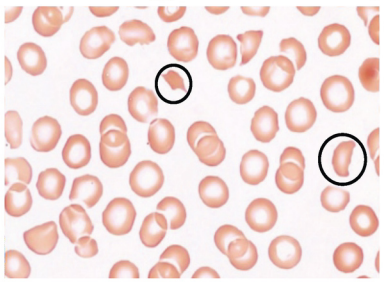

## DETAILED QUESTIONS

### Q10.1: What causes schistocytes (fragmented RBCs) on peripheral smear?

**Answer:**

- Caused by microangiopathic and macroangiopathic hemolytic anemias
- Macroangiopathic hemolysis:
  - o Seen in prosthetic heart valves
- Microangiopathic hemolysis:
  - o Hemolytic Uremic Syndrome (HUS)
  - o Thrombotic Thrombocytopenic Purpura (TTP)
  - o Disseminated Intravascular Coagulation (DIC)

### Q10.2: What are the key features of Warm Autoimmune Hemolytic Anemia (Warm AIHA)?

**Answer:**

- IgG antibodies are active at 37°C
- Leads to extravascular hemolysis
- Example: CLL

### Q10.3: What are the types and features of Cold AIHA?

**Answer:**



YOURWISH

- Cold Agglutinin Disease:
  - IgM antibodies are active at 4°C
  - Causes RBC agglutination
- Cold Hemolysin Disease
  - At 4°C
  - P - Paroxysmal
  - C - Cold
  - H - Hemoglobinuria
  - IgG works at 4°C
  - Donath Landsteiner antibody

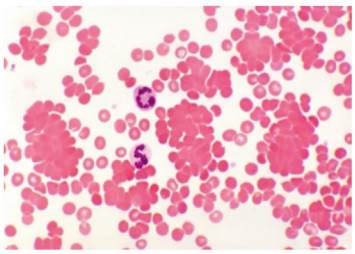

### Q10.4: Which types of hemolysis are seen in various anemias?

**Answer:**

| Extravascular hemolysis | Intravascular hemolysis |
|---|---|
| • Hereditary spherocytosis<br>• Sickle cell anemias<br>• Thalassemia | • Paroxysmal nocturnal Hemoglobinuria<br>• Paroxysmal cold Hemoglobinuria |
| G6PD Deficiency shows both EVH and IVH | |

### Q10.5: What is the significance of 'dog ear projections' in RBCs?

**Answer:**

- Dog ear projections are seen in Parvovirus B19 infection
- Parvovirus binds to the P antigen on RBCs

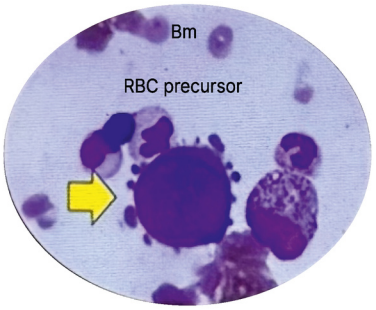

# 20.WHITE BLOOD CELLS

## BIG QUESTION 1: What are WBCs, and the different cells categorized under them?

**Broad Answer:**

- White blood cells, also known as **leukocytes**, are a critical component of the immune system.
- TLC falls between the range of 4000-11000 cells/mm3. The five different cells are as follows (Arranged in the order from the maximum number to the least number of cells (Never Let Monkey Eat Bananas):
  - Neutrophil- **Never**
  - Lymphocyte- **Let**
  - Monocyte- **Monkey**
  - Eosinophil- **Eat**
  - Basophil- **Bananas**

## DETAILED QUESTIONS

PYQ: FMGE 2021

### Q1.1: How to identify the different WBCs on a microscope?

**Answer:**

- Neutrophil- 3-5 lobes
- Lymphocyte- Large dark-stained nuclei
- Monocyte- Kidney-shaped nucleus
- Eosinophil- Orange granules, spectacle nucleus.
- Basophil- Blue-black granules

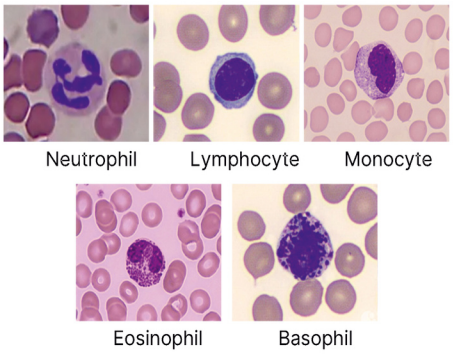


### Q1.2: What are Dohle bodies?

**Answer:**

- Dohle bodies are inclusion bodies made up of dilated endoplasmic reticulum
- They are seen in cases of severe sepsis

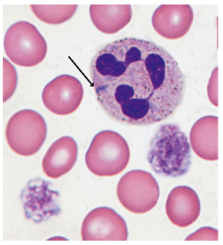

### Q1.3: What is the special stain used for Basophils?

**Answer:** The stain for Basophils/Mast cells is Toluidine Blue

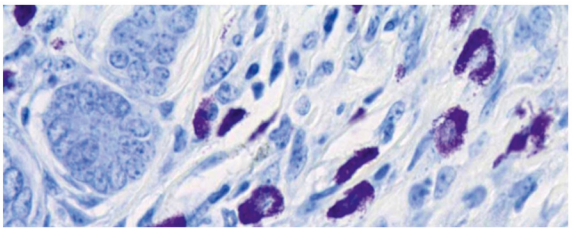

### Q1.4: What are blasts, and what are the types of blasts?

**Answer:**

- **Blasts** are **immature precursor cells** found in the **bone marrow** that develop into mature blood cells.
- The five mature cells come from the bone marrow

- The types of blasts are
  - Lymphoblast
  - Myeloblast
  - Monoblast

### Q1.5: Write briefly about lymphoblast

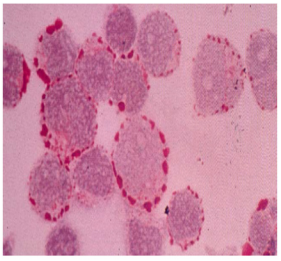

**Answer:**

- Lymphoblasts give rise to Lymphocytes
- Pink - PAS (Block Positivity)
- T- Lymphoblasts- Acid phosphatase positive

### Q1.6: Myeloblasts give rise to which cells?

**Answer:**

- Neutrophils
- Eosinophils
- Basophils

### Q1.7: How to identify Myeloblasts microscopically and which stains are they positive for?

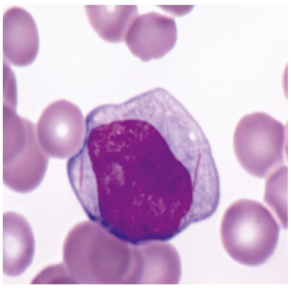

**Answer:**

- Myeloblasts are characterized by the presence of **Auer rods** on microscopy and are positive for:
  - MPO (Myeloperoxidase)
  - Sudan Black B
  - CAE (Chloroacetate Esterase)

### Q1.8: Monoblast gives rise to which cell, and what stain is it positive for?

**Answer:**

- Monoblasts give rise to Monocytes
- Positive for Non-Specific Esterase

### Q1.9: Elaborate on the process of Myelopoiesis

**Answer:**

Myeloblast (Contains Auer Rods)
↓
Promyelocyte (Biggest cell)
↓
**Myelocyte (D-shaped nucleus)**
↓
Metamyelocyte (Indented nucleus)
↓
Band/stab Form
↓
Neutrophils/basophils/eosinophils

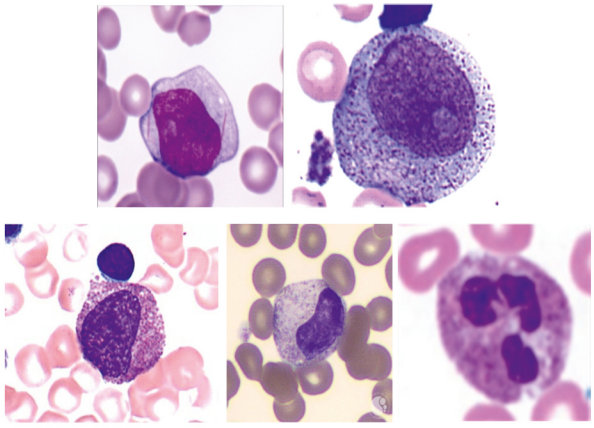

- Myelocytes decide whether there will be the formation of neutrophils, basophils, or eosinophils (critical step)



YOURWISH

### Q.1.10: What are some conditions or diseases associated with an increased count of specific types of white blood cells?

**Answer:**

- Lymphocyte count is increased in Tuberculosis
- Monocytes are increased in Malaria
- Eosinophils are increased in allergy, Asthma, parasitic infections
- Basophils are increased in CML

## BIG QUESTION 2: How is ALL defined and classified?

**Broad Answer:**

- ALL (Acute lymphoblastic leukemia) is condition in which there is > 20% Blasts in the bone marrow.
- It is classified based on:
  - FAB
  - WHO

## DETAILED QUESTIONS

### Q2.1: How is ALL classified based on FAB?

**Answer:**

- FAB (French-American-British) classification
  - L1 - Most common and best prognosis in children
  - L2
  - L3 - Least common and worst prognosis
    - → Oil Red O +ve (they contain fats)
    - → Shows cytoplasmic vacuolation

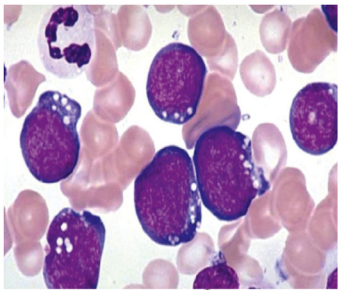

### Q2.2: How is ALL classified according to WHO?

**Answer:**

- WHO classification of ALL
  - B-ALL
  - T-ALL
    - → Goes into tissue infiltration (CNS/Mediastinum/Testes)
    - → Bad prognosis

### Q2.3: Based on genetics, which type of ALL has a good and bad prognosis?

**Answer:**

| Good prognosis | Bad prognosis |
|---|---|
| • Mnemonic: ALL has alphabets 3. Anything that comes up with 3 is good<br>• Hyperdiploidy >2n<br>• Trisomy 4, 7, 10<br>• Translocation (12;21) (1+2=3) | • Hypodiploidy < 2n<br>• T(9:22) |

## BIG QUESTION 3: How is AML defined and classified?

**Broad Answer:**

- AML (Acute myeloid leukemia) is a condition in which there are >20% Blasts in the bone marrow.



YOURWISH

YOURWISH

- AML is classified based on FAB classification- M0, M1, M2, M3, M4, M5, M6, and M7

### Q3.1: What are the key morphological features of M0 to M1 subtypes AML?

**Answer:**

- M0
  - AML undifferentiated
  - MPO (-)ve
- M1
  - AML without maturation

### Q3.2: What are the key morphological and genetic features of the M2 subtype of AML?

**Answer:**

- It is AML with maturation
- The most common type of AML
- Genetic abnormality- Translocation (8:21)

### Q3.3: What are the key morphological, genetic, and microscopic features of the M3 subtype of AML?

**Answer:**

PYQ: NEET PG 2021

- M3- APML (Acute Promyelocytic Leukemia
- It is the only leukemia associated with DIC
- Genetic abnormality- t(15:17) leading to PML:RARA fusion
- Microscopic feature- Faggot cells AML M3
  - Crisscross Auer Rods (Many Auer rods are seen)

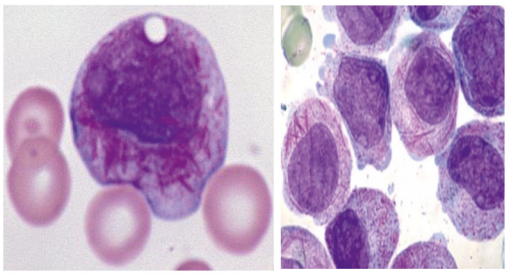

### Q3.4: How is the M3 subtype of AML treated?

**Answer:**

- ATRA (All-Trans Retinoic Acid)
- Arsenic trioxide
- Chemotherapy is not given

### Q3.5: What are the key morphological and genetic features of the M4 subtype of AML?

**Answer:**

- Genetic abnormality- Inversion 16
- Myeloblasts and monoblasts are seen in this condition
- Tissue infiltration (gums, skin) is seen

### Q3.6: What are the key morphological features of the M5 subtype of AML?

**Answer:**

- Tissue Infiltration (gums, skin) is seen
- Only monoblasts are seen

### Q3.7: What are the key morphological and genetic features of the M6 and M7 subtypes of AML?

**Answer:**

- M6-Pure Erythroid Leukemia

- M7-Acute Megakaryoblastic Leukemia
  - It is associated with Down Syndrome

### Q3.8: What are the stains used in the diagnosis of AML, and which subtypes show positive stains?

**Answer:**

- Stains used to diagnose AML are:
  - PAS (Periodic Acid-Schiff) stain
  - MPO (Myeloperoxidase) stain
  - CAE (Chloroacetate esterase) stain
  - NSE (Non-Specific Esterase) stain

| |
|---|
| AML M0 - No stain is positive |
| AML M1 - MPO, CAE is positive |
| AML M2 - MPO, CAE is positive |
| AML M3 - PAS is positive |
| AML M4 - MPO, CAE, NSE is positive |
| AML M5 - NSE is positive |
| AML M6 - PAS is positive |
| AML M7 - PAS is positive |

### Q.3.9: Dual Esterase (CAE & NSE +ve) positive is seen in?

**Answer:**

- It is shown in AML M4
- Myelomonocytic Leukaemia

## BIG QUESTION 4: Write in brief about CLL- Genetics, incidence.

**Broad Answer:**

- Chronic Lymphocytic Leukemia (CLL) is a clonal malignancy of mature B lymphocytes
- Most commonly seen in elderly people
- Genetic abnormality- Deletion of 13q
- Not associated with any radiation

## DETAILED QUESTIONS

### Q4.1: What are the criteria to diagnose CLL?

**Answer:**

- Blood sample: Absolute lymphocyte count > 5000/ $mm^3$
- Bone marrow: Lymphocyte > 30%
- Flow Cytometry: CD5 / CD23 / CD200 are positive

### Q4.2: What are the peripheral smear findings in CLL?

**Answer:**

- Smudge cells/Basket cells/Parachute cells
  - Artefacts: When pressure is applied, these will break due to loss of vimentin
- Also called the Convent School Girl Appearance

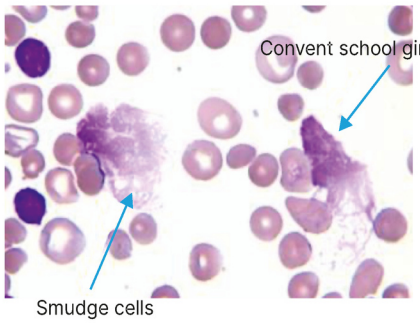

### Q4.3: What are the conditions associated with CLL?

PYQ: FMGE 2021

**Answer:**

- Evan's Syndrome (Mnemonic- Everyone is affected): AIHA (Autoimmune Hemolytic Anemia) + CLL + ITP (RBC + WBC + Platelets)
- Richter Syndrome: CLL/SLL → Diffuse Large B Cell Lymphoma

## BIG QUESTION 5: Write in brief about CML

**Broad Answer:** Chronic Myeloid Leukemia (CML) is a **myeloproliferative neoplasm** characterized by the **clonal proliferation of mature and maturing granulocytes** (neutrophils, basophils, eosinophils) due to a **BCR-ABL fusion gene** formed by the **Philadelphia chromosome.**

## DETAILED QUESTIONS

### Q5.1: What is the genetic abnormality causing CML?

**Answer:**

- Genetic abnormality: t (9:22) ABL-BCR fusion involving Philadelphia chromosome
  - o Increase in tyrosine kinase
  - o Weight of proteins formed

### Q5.2: What is the weight of proteins formed in ALL, CML, and CNL due to t (9:22) ABL-BCR fusion?

**Answer:**

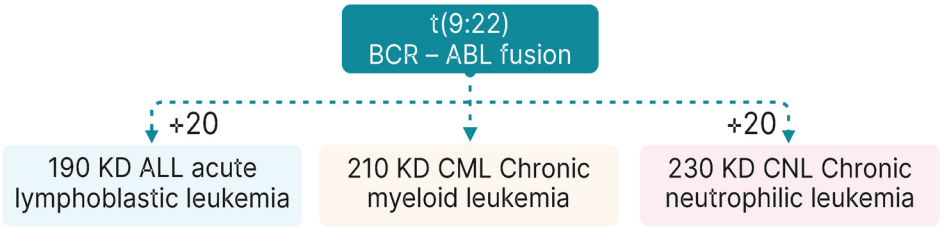


### Q5.3: Elaborate on the phases of CML and their features

**Answer:**

| | |
|---|---|
| Chronic | • Blast count is less than 10% |
| Accelerated | • Blast count is 10-19%<br>• Basophils >20%<br>• Total leukocyte counts are high/Platelet count is either high or very low<br>• Massive splenomegaly<br>• Unresponsive to treatment |
| Blast Crisis | • Blast count > 20%<br>• CML → AML >ALL<br>• College girl appearance / Garden party appearance<br>o Different types of cells including immature myeloid series of cells, eosinophils, basophils, mature neutrophils giving colourful appearance 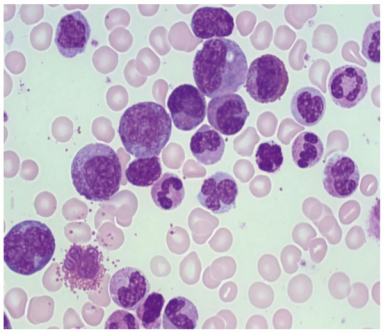 |

### Q5.4: Write briefly regarding clinical features, screening test score, and treatment of CML.

**Answer:**

- Clinical features: Massive Splenomegaly- Dragging Sensation
- Screening test- The LAP/NAP score is low.
- Treatment of CML- Tyrosine kinase Inhibitor: Imatinib (also used in GIST)

### Q5.5: What are LAP and NAP scores, and in which conditions are their levels high and low?

**Answer:**

- Leukocyte Alkaline Phosphatase (LAP) and Neutrophil Alkaline Phosphatase (NAP) are used to assess the activity of the alkaline phosphatase enzyme in white blood cells (leukocytes), specifically neutrophils
- Normal score: 40-100

| Low LAP score | High LAP score |
|---|---|
| • CML<br>• PNH | **Mnemonic**: Lakes Ponds<br>• **Lakes**- Leukemoid reaction<br>• **P** - Pregnancy<br>• **O** - OCP<br>• **N** - Neutrophilia<br>• **Ds** - Down's Syndrome |

### Q5.6: What is the investigation of choice used in the diagnosis of CML?

PYQ: NEET PG 2021

**Answer:**

- Fish-Philadelphia- To identify T(9:22) BCR- ABL fusion

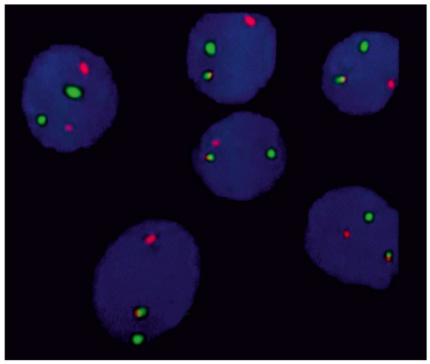

## BIG QUESTION 6: What is lymphoma, and name some of the different types of lymphoma.

**Broad Answer:**

- Lymphoma is a group of malignant neoplasms of the lymphoid tissue, arising from B cells, T cells, or NK cells.
- Some of the lymphomas are: CLL, SLL, Mantle cell lymphoma, Follicular lymphoma, Burkitt's lymphoma, Diffuse large B cell lymphoma, Hodgkin's lymphoma

## DETAILED QUESTIONS

### Q6.1: Explain the origin of lymphomas.

**Answer:**

- The first cell is a Naive B cell
- When it enters the lymph node, it first goes into



YOURWISH

YOURWISH

the Mantle zone, which is an unchallenged zone

- It then enters the Germinal Center, where all the actual exposures to antigens will occur
- After coming out of the germinal center, it becomes a post-germinal center
- It then goes into the marginal zone
- After going through all these, it either retains its memory (memory B cell) or forms a plasma cell

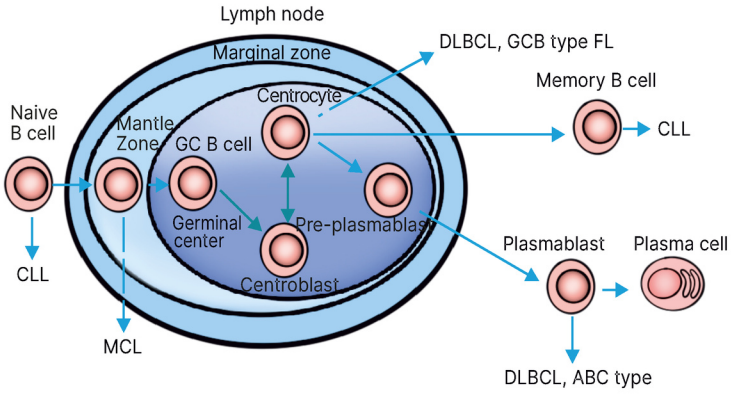


### Q6.2: What is the origin of various lymphomas?

**Answer:**

| Origin | Type of lymphoma |
|---|---|
| Naive B cell | • CLL / SLL |
| Mantle cell/unchanged zone | • Mantle cell lymphoma |
| Germinal centre | • Follicular lymphoma<br>• Burkitt's lymphoma<br>• Diffuse large B-cell lymphoma |
| Post-germinal centre B cell | • Hodgkin's lymphoma |
| Marginal zone | • Marginal Zone Lymphoma |
| Memory cells | • Hairy-cell leukemia |
| Plasma cells | • Multiple myeloma |

### Q6.3: What are the types of hodgkin's lymphoma?

**Answer:**

- Hodgkin's lymphoma is classified into:
  - o Classical- Nodular sclerosis, Mixed cellularity, Lymphocytic rich, Lymphocyte depleted
  - o Non-classical- Nodular Lymphocyte Predominant Hodgkin's Lymphoma

### Q6.4: Write in detail about the classical variety of Hodgkin's lymphoma- RS cell, features, prognosis

**Answer:**

PYQ: FMGE 2021, 2022

| HL - Hodgkin's Lymphoma | RS Cell | Extra | Prognosis |
|---|---|---|---|
| Classical HL | CD 15, 30 (Most sensitive), PAX 5 (Most Specific) 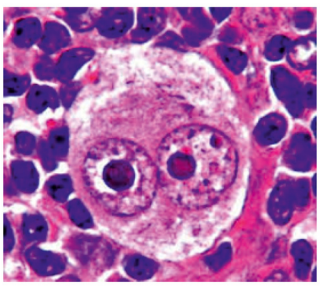 | Epstein-Barr Virus Association | |

| | | | |
|---|---|---|---|
| 1. Nodular Sclerosis | Lacunar RS Cells 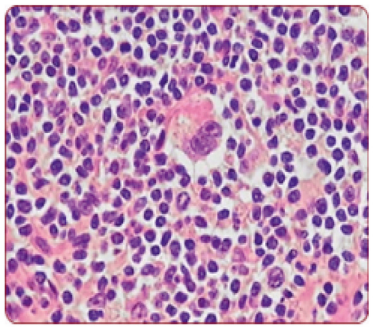 | Most common in the world | The best prognosis in classical HL |
| 2. Mixed Cellularity | Classical RS Cells | Most common in India<br>Most common with EBV and HIV | |
| 3. Lymphocyte Rich | Mononuclear Cells | | |
| 4. Lymphocyte Depleted | Mummified RS Cell | Immunodeficiency-associated: HIV | Worst prognosis |

**Q6.5: Write in detail about the classical variety of Non-Hodgkin's lymphoma- RS cell, features, prognosis**

**Answer:**

| HL - Hodgkin's Lymphoma | RS Cell | Extra |
|---|---|---|
| Non-classical HL<br>NLPHL | CD20, CD45, EMA, Bcl6 | • **Not associated with Epstein Barr virus**<br>• **Not associated with CD15/30** |
| Nodular Lymphocyte Predominant Hodgkin's Lymphoma | POPCORN /L&H RS cell 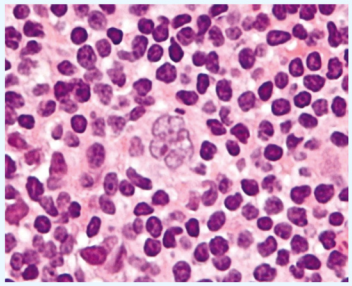 | Best prognosis **overall** |

**Q6.6: What are the types and subtypes of Non-Hodgkin's lymphoma?**

**Answer:**

| Types | Subtypes |
|---|---|
| B-NHL | • Follicular lymphoma- Best prognosis<br>• Diffuse large B-cell lymphoma- Most common and worst prognosis<br>• Burkitt's lymphoma<br>• CLL/SLL<br>• Mantle cell lymphoma<br>• Marginal zone lymphoma/MALToma<br>• Hairy-cell leukemia |
| T-NHL | • Anaplastic Large Cell Lymphoma<br>• Mycosis Fungoides |

### Q6.7: What are the genetic abnormalities of various B-NHL subtypes?

**Answer:**

| Type of B-NHL | Genetic abnormality |
|---|---|
| Follicular lymphoma | • t(14:18) |
| Burkitt's lymphoma | • Mnemonic- t(8:Even no)<br>• t(8:22)<br>• t(8:14)<br>• t(2:8) |
| Mantle cell lymphoma | • t (11:14)<br>• Cyclin D1+<br>• SOX 11+ |
| Marginal zone lymphoma/MALToma | • t(11:18) |

### Q6.8: What are the genetic CD markers of various subtypes of B-NHL?

**Answer:**

| Type of B-NHL | Genetic CD markers |
|---|---|
| CLL/SLL | • CD 5+<br>• CD 23+<br>• CD 200+ |
| Mantle cell lymphoma | • CD 5+<br>• CD 23-<br>• CD 200 - |
| Marginal zone lymphoma/MALToma | • CD 5-<br>• CD 23-<br>• CD 200- |
| Hairy-cell leukemia | • BRAF mutation<br>• Annexin A1<br>• TRAP positivity gives red staining on cytochemical staining |

### Q6.9: Elaborate on the endemic variety of Burkitt's lymphoma with an example.

PYQ: NEET PG 2022

**Answer:**

- Endemic variety of Burkitt's lymphoma is associated with Epstein-Barr virus
- E.g. an African child (Epstein-Barr virus) with a jaw swelling
  - Africa is endemic to EBV
  - The starry sky's appearance shows that the sky represents tumour cells, and the white colour of twinkling stars represents macrophages
  - Vacuolations with Oil Red O+


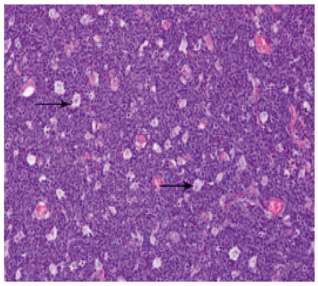
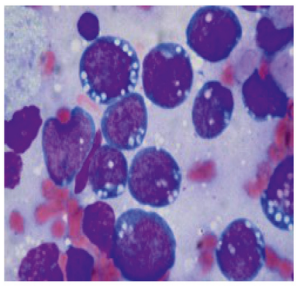

**Q6.10: Write briefly about hairy cell leukemia- clinical features, associated infections, peripheral smear, bone marrow aspiration, and biopsy.**

PYQ: FMGE 2022

**Answer:**

- Most common in boys
- Clinical feature- Massive splenomegaly (Red Pulp is affected)
- Associated Infections - Opportunistic infections such as Mycobacterium avium complex (MAC)
- PS - Pancytopenia
- Bone marrow aspirate - Dry tap
- BM Biopsy - Fried egg appearance
- Hairy cells (because of their projections) are seen on a phase contrast microscope
- Hairy Cell Leukaemia is also important for CD11C, CD25, CD103, and DBA44 markers


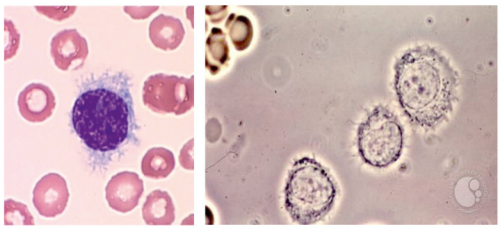

PYQ: NEET PG 2020

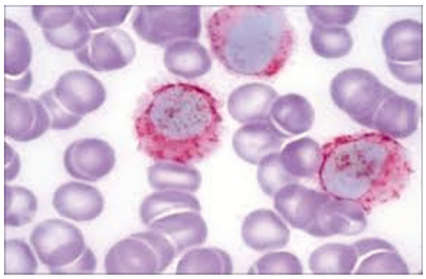

**TRAP**: It gives **red colors** to the cell.

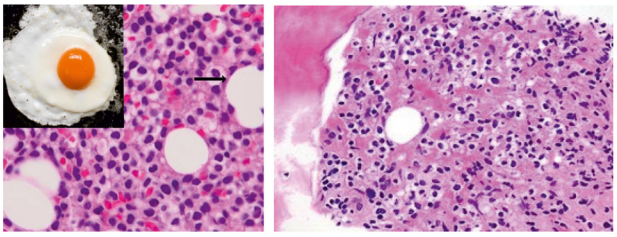

**Bone Marrow Biopsy:**
Fried Egg appearance is seen, i.e., white areas around it.

**Q6.11: What are the types of T-NHL and explain in brief about them.**

**Answer:**

| TNHL | Extra |
|---|---|
| **Anaplastic Large Cell Lymphoma** (CD30+) | 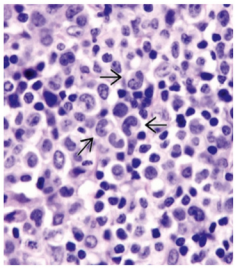 Hallmark Cells 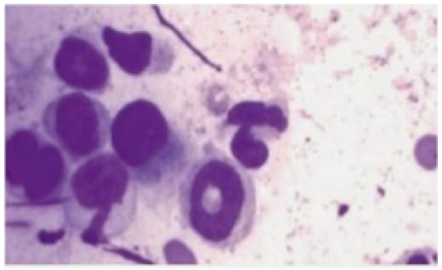 Doughnut Cells |



YOURWISH

YOURWISH

| | | |
|---|---|---|
| **Mycosis Fungoides** | • Cutaneous TNHL- Cancer cells male clusters called Pautrier's Micro abscess on skin<br>• **Cerebriform Sezary cells in blood (spill in blood) -** Sezary Syndrome | 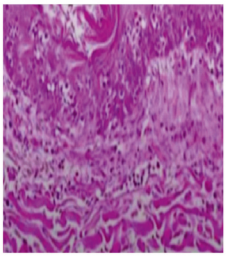 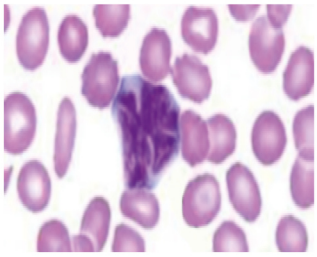 |

**Q6.12: Which specific microabscesses are associated with Psoriasis and Mycosis Fungoides, respectively?**

**Answer:**

- Munro's microabscess is seen in Psoriasis
- Pautrier's microabscess is seen in Mycosis Fungoides

## BIG QUESTION 7: Explain briefly about multiple myeloma

**Broad Answer:** PYQ: FMGE 2020, 2021 PYQ: NEET PG 2022 PYQ: INICET 2023

- Multiple myeloma is a malignant proliferation of plasma cells in the bone marrow, leading to the overproduction of monoclonal immunoglobulins (M-protein) and associated organ damage

## DETAILED QUESTIONS

**Q7.1: Explain briefly regarding a normal plasma cell.**

**Answer:**

- In a plasma cell, the nucleus will always be on one side; Eccentric nucleus
- Around the nucleus, there is a white area called Perinuclear Halo which contains Golgi Apparatus for making antibodies
- The nucleus shows cartwheel chromatin
- Plasma cells are present in the bone marrow
- Bone marrow can have Osteoblasts which looks like a plasma cell
  - The nucleus is eccentric
  - Paranuclear halo (located away from the nucleus)

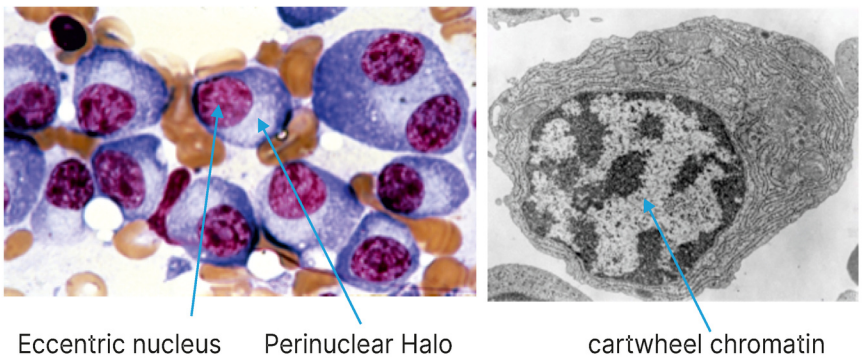


**Q7.2: What are the diagnostic criteria for Multiple myeloma?**

**Answer:**

- Bone marrow plasma cells > 10%
- Immunoglobulin (Most common - IgG) >3gm/dl
- Myeloma Defining Events: classified under CRAB & SLIM

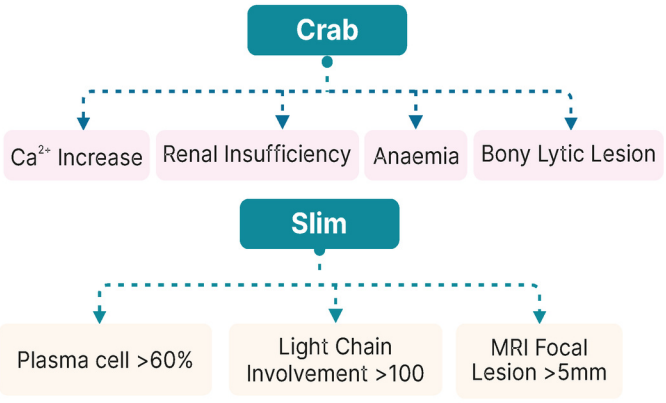


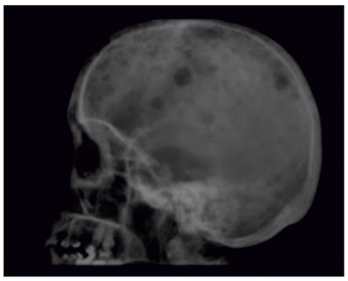

**Q7.3: What are the findings observed in the blood in the case of Multiple myeloma?**

**Answer:**

- Red Blood Cells show a stack of coin formations known as the Rouleaux Formation.

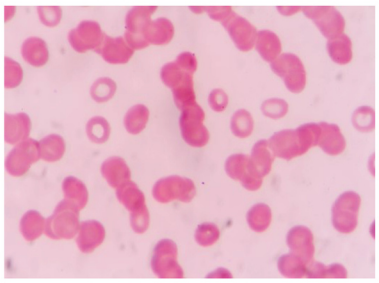

**Q7.4: What are the bone marrow aspirate findings noticed in Multiple myeloma?**

**Answer:**

- Plasma cells show intracytoplasmic bodies known as Russel bodies in the cytoplasm
- In the nucleus, these bodies are called intranuclear bodies or the Dutcher Bodies
- When the bodies give the appearance of mulberry, they are called Mulberry / Mott cells
- A cell looking like a flame is called a Flame Cell
  - Flame cells are most commonly associated with IgA increase (Mnemonic: IgA causes Aag)
- All these cell compositions are Immunoglobulins
  - The most common immunoglobulin is IgG

i 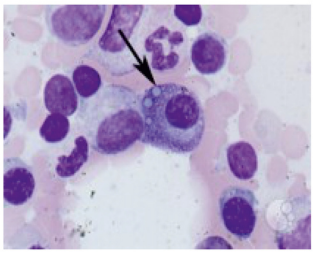 ii 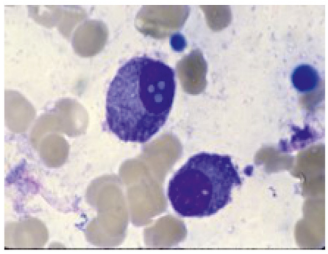 iii 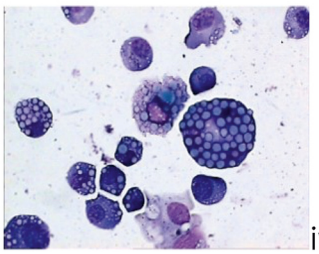 iv 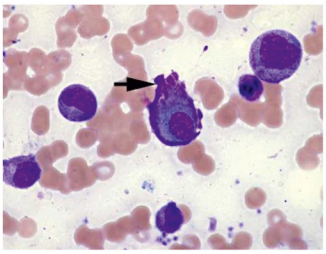

**Q7.5: What are the bone marrow biopsy findings in Multiple myeloma?**

**Answer:**

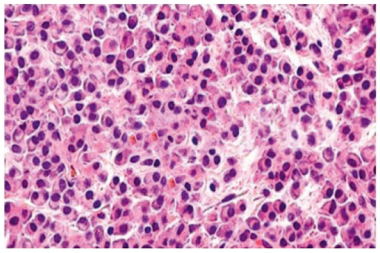

Sheets of plasma cells with peripheral nuclei

**Q7.6: How is the electrophoresis test used to diagnose Multiple myeloma?**

**Answer:**

- Test for antibodies

- Normally, the maximum protein in the blood is albumin, followed by a-1, a-2, b protein and g protein
- Presence of M spike indicates IgG spike
  - o M spike indicates myeloma spike/Monoclonal spike

PYQ: FMGE 2022

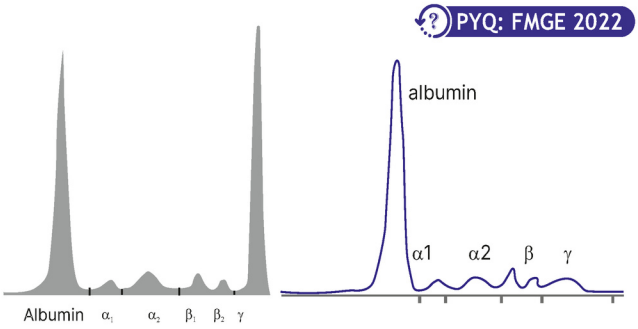


### Q7.7: What are the criteria for diagnosing plasma cell leukemia?

**Answer:** Plasma cell leukemia is a condition in which the peripheral blood contains >20% plasma cells

### Q7.8: What are the markers of a plasma cell?

**Answer:**

| Cells | CD45 (WBC) | CD19 (B Cells) | CD38 (Plasma cells) | CD138 (Plasma cells) | Ig |
|---|---|---|---|---|---|
| Normal Plasma Cells | + | + | + | + | + |
| Malignant Plasma Cells | - | - | + | + | + |

### Q7.9: Write briefly about Waldenstrom Macroglobulinemia

**Answer:**

- AKA: Lymphoplasmacytic Lymphoma
- Cells: Lymphocytes, Plasma Cells, and Mast Cells are seen
- Genetics: MYD88 Mutation
- Clinical Features- Since IgM is elevated, it causes Hyperviscosity syndromes (Hyperviscosity symptoms such as hypertension and visual disturbances) and no lytic bone lesions unlike MM

## BIG QUESTION 8: What is flow cytometry, and what are its uses?

**Broad Answer:** Flow cytometry is a technique used to analyze and identify cells based on their size, granularity, and surface or intracellular markers using fluorescent-labeled antibodies. It is especially useful in diagnosing leukemias, lymphomas, and other blood cancers, as it helps determine the type and maturity of cells (e.g., B cells, T cells, blasts) by detecting CD markers

## DETAILED QUESTIONS

### Q8.1: What samples can be used to perform flow cytometry?

**Answer:**

- Samples can be blood, bone marrow aspirate, CSF, or Pleural fluid sample (Anything that is fluid can be taken)

### Q8.2: How does hydrodynamic focusing work?

**Answer:**

- Cells fall one by one
- As the cells fall, they are hit by a blue-colored light
- The wavelength of the light is 488 nm
- Some of the light goes forward, and some goes sideways

### Q8.3: Explain forward scatter & side scatter.

**Answer:**



Forward Scatter | Side Scatter

- The forward one is called FSC (Forward scatter)
  - Forward scatter measures the size of the cell
  - If the cell is small, then the light scattered is small, and if the cell is bigger, the light scattered is bigger
  - Forward scatter is indicative of the size of cells i.e., the larger the size of the cell, the larger the forward scatter.
- The side one is called SSE (Side scatter)
  - Side scatter depends on the complexity or granularity of the cells, i.e., the more the granularity of the cell, the more will be side scatter
- Dyes: FITC (Fluoro Iso Thio Cyanate), and this dye gives green colour

### Q8.4: How to interpret flow cytometry

**Answer:**

**Histogram**

- It is used for a test called EMA
- EMA is a dye
- EMA is a confirmatory test for Hereditary spherocytosis

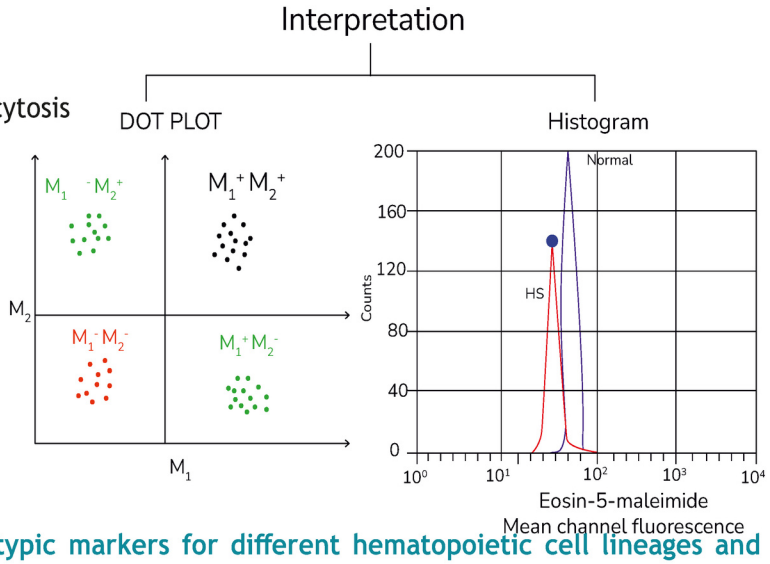


**Dot Plot analysis**

- Cells will be shown in the form of dots
- X axis is the marker 1 and Y axis indicates Marker 2
- M1 and M2 are negative → Double negative
- M1 and M2 are positive → Double positive
- M1 is +ve and M2 is -ve → M1 positive
- M1 is -ve and M2 is +ve → M2 positive

### Q8.5: What are the characteristic immunophenotypic markers for different hematopoietic cell lineages and related hematological malignancies?

**Answer:**

| Lineage | Markers |
|---|---|
| Blasts | TdT, HLA DR, CD 34 |
| LCA (Leukocyte common antigen) | CD 45 |
| T Cells | CD 1-8, 28, Pan T cell marker is **CD 3** |
| B cells | CD10 (CALLA), CD 19-23, CD40, CD 79 a and b, Pan B cell marker is **CD 19** |
| NK cells | CD 16, 56, 94 |
| Myeloid cells | **MPO**, CD13, CD33 |
| Monocytic lineage | CD11, CD14, CD64 |
| Megakaryocytic lineage | M416, CD41, CD42, CD61 |
| CLL/SLL | CD5+ CD23+ CD200+ |
| Mantle cell lymphoma | CD5+ CD23- CD200- |
| Marginal zone lymphoma/Maltoma | CD5- CD23- CD200- |



YOURWISH

| | |
|---|---|
| PNH | CD 55- CD59- |
| Plasma cells (normal) | CD45+ CD 19+ CD38 + CD138+ |
| Multiple myeloma (cancer) | CD45- CD19- CD38+ CD138 + |

**Q8.6: What is the most likely diagnosis of the below dot plot analysis on flow cytometry?**

A. MZL

B. MCL

**C. CLL**

D. AML

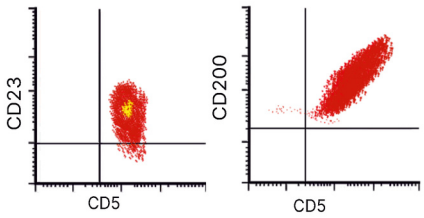


**Answer:**

- When CD 5, CD 23 and CD 200 are positive, it becomes a case of CLL

**Q8.7: Which hematological malignancies are associated with the following flow cytometry marker profiles?**

**Answer:**

- TdT + /CD3+ → T-ALL
- TdT+/ CD19+ → B-ALL
- HLADR+/MPO+ → AML
- HLA DR+/ MPO+/CD 3+ → Biphenotypic Leukemia

# 21. PLATELETS

**BIG QUESTION 1: Write briefly about the precursor cell of platelets, its key morphological characteristics, functions of platelets, and the normal count.**

**Broad Answer:** The precursor cell of platelets is the **megakaryocyte**. Megakaryocytes are **large, multinucleated cells** found in the **bone marrow**, as shown in the image. Platelets play an important role in clot formation and support the coagulation cascade. Normal count of platelets is 1.5 to 4.5 lakhs/mm

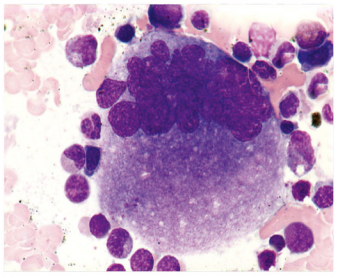

Megakaryocyte bone marrow aspiration

## DETAILED QUESTIONS

**Q1.1: Name the defects of Megakaryocytes.**

**Answer:**

- Staghorn megakaryocyte
- Pawn ball megakaryocyte
- Cloud-like megakaryocyte
- Dwarf Megakaryocyte

**Q1.2: How does the nucleus appear in a Staghorn megakaryocyte, and in what condition is it seen in?**

**Answer:**

- The nucleus of megakaryocytes is in the form of a deer horn
- Seen in ET: Essential Thrombocythemia

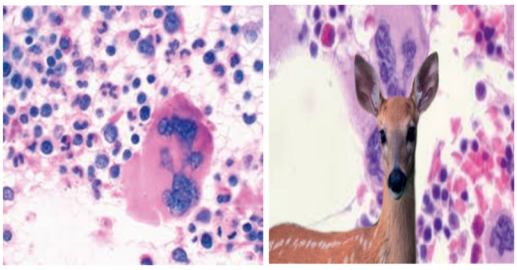

Staghorn megakaryocytes

**Q1.3: How does the nucleus appear in a Pawn ball megakaryocyte, and in what condition is it seen in?**

**Answer:**

- 3 nuclei are present just as a pawnball outside the gold buying shops in the UK
- Seen in myelodysplastic syndrome (MDS)

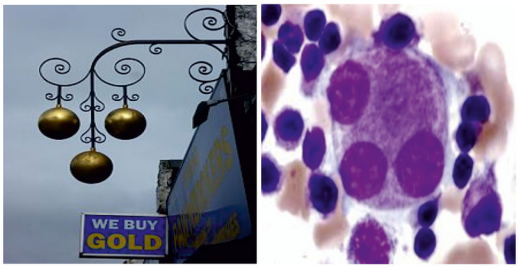


Pawn ball megakaryocyte

**Q1.4: How does the nucleus appear in a Cloud-like megakaryocyte, and in what condition is it seen in?**

**Answer:**

- The nucleus in a megakaryocyte looks like a cloud
- Seen in Primary myelofibrosis

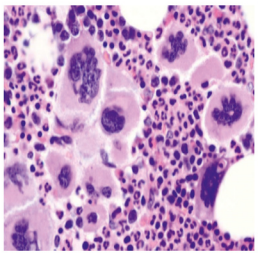

Cloud like megakaryocyte

### Q1.5: How does the nucleus appear in a Dwarf megakaryocyte, and in what condition is it seen in?

**Answer:**

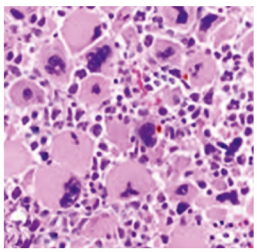

dwarf megakaryocyte

- Megakaryocytes become small
- Seen in CML

## BIG QUESTION 2: What are the steps involved in clot formation?

**Broad Answer:**

- Clot formation includes 3 steps
  - Platelet adhesion (1st step in clot formation)
  - Platelet secretion
  - Platelet aggregation

## DETAILED QUESTIONS

### Q2.1: Explain the mechanism of platelet adhesion

PYQ: NEET PG 2021

**Answer:**

- Important factors required for platelet adhesion are Gp1b/9 & Von Willebrand factor (VWF)

Blood vessels are lined by endothelial cells, which contain Von Willebrand factor

↓

If there is any injury, endothelial cells are damaged, and bleeding occurs

↓

Platelets come to the bleeding site

↓

Contains Gp1b/9 on its surface and binds with VWF

↓

Platelet adhesion occurs

### Q2.2: What are the contents of alpha and delta granules in platelets?

**Answer:**

- Alpha and delta granules are two types of storage compartments found within platelets, which are essential for blood clotting

| | |
|---|---|
| Alpha granules from: | • P-Selectin<br>• PF4 (Platelet factor 4)<br>• PDGF (Platelet-Derived Growth Factor)<br>• Factor 5, 8<br>• Fibrinogen |

| Delta granules (dense granules) give: | • Adenosine diphosphate<br>• Adenosine triphosphate<br>• Serotonin<br>• Serum calcium<br>• Epinephrine |
|---|---|

- This is how alpha and delta granules are secreted

### Q2.3: How does platelet aggregation occur?

**Answer:**

- Platelet aggregation occurs between Gp2b/3a and fibrinogen

Platelets contain Gp2b/3a on their surface

↓

Two platelets with Gp2b/3a are attached by Fibrinogen

↓

All Platelets get aggregated

### Q2.4: How are the clotting factors activated during the formation of the primary hemostatic plug?

**Answer:**

- Platelet adhesion, Platelet secretion, & Platelet aggregation are essential to form the primary hemostatic plug

Flipping of phosphatidylserine

↓

Gives a negative charge to the platelets inside the body

↓

This negative charge activates the clotting pathway

## BIG QUESTION 3: What are the two clotting pathways, and when are they activated

**Broad Answer:**

- The two clotting pathways are:
  - o Intrinsic pathway- Activated with the presence of a negative charge
  - o Extrinsic pathway- Activated when there is any tissue injury

## DETAILED QUESTIONS

### Q3.1: What are the factors activated in the Intrinsic and Extrinsic pathways?

**Answer:**

| Intrinsic pathway | Extrinsic pathway |
|---|---|
| • Factor 12<br>• Factor 11<br>• Factor 9<br>• Factor 8<br>• All these 4 activate factor 10 | • Releases tissue factor - Factor 3<br>• Factor 3<br>• Factor 7<br>• Both these factors activate Factor 10 |



YOURWISH

YOURWISH

### Q3.2: Elaborate on the common pathway followed by the Intrinsic and extrinsic pathways.

**Answer:**

**Common pathway:** Follows the rule of half

- Factor 10 in the presence of factor 5 activates factor 2
  - Prothrombin to Thrombin
- Activated factor 2a activates factor 1
  - Fibrinogen to Fibrin
  - This Fibrin is the blood clot
  - Blood clot is stabilised by F13 /Fibrin stabilising factor, also called the Laki Lorand factor
- Factor 4 (calcium) - Needed at the junction points
  - In the activation of factor 10 by factor 8 in the intrinsic pathway
  - In the activation of factor 10 in the extrinsic pathway

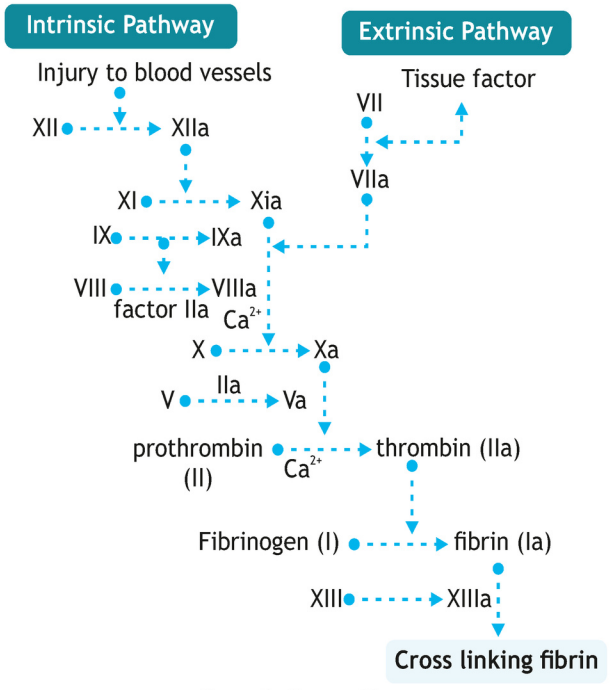


**Coagulation pathways**

### Q3.3: What are the vitamin K-dependent factors?

**Answer:**

- Factor 2
- Factor 7
- Factor 9
- Factor 10

### Q3.4: What are BT, CT, PT, APTT, and TT & their normal values?

**Answer:**

- **Bleeding Time (BT):** Measure of the Platelets (2 to 9 minutes)
- **Clotting Time (CT):** Time required for clot formation (8 to 15 minutes)
- **Prothrombin time (PT):** Measure of the extrinsic pathway (11- 16 seconds)
- **APTT:** Measure of intrinsic pathway (25-35 seconds)
- **Thrombin time(TT):** Measure of fibrinogen (factor 1)

### Q3.5: What is the Urea clot solubility test?

**Answer:** Urea clot solubility test is a diagnostic test used to identify factor 13 (Laki lorand factor)

## BIG QUESTION 4: What are platelet defects and it's types?

**Broad Answer:**

- Platelet defects refer to conditions where platelets, the blood cells responsible for clotting, are either too low in number or don't function properly
- The two types of platelet defects are:
  - Functional defects
  - Quantitative defects

## DETAILED QUESTIONS

### Q4.1: Identify the functional platelet defects and the diseases caused by them.

**Answer:**

PYQ: NEET PG 2022 PYQ: FMGE 2021,2022

| Defect | Disease |
|---|---|
| Gp1b/9 | Bernard Soulier syndrome (shows big-sized platelets) |
| Von Willebrand factor | Von Willebrand disease |
| Alpha granules | Gray platelet syndrome (aged platelets) |
| Delta granules | Hermansky pudlak syndrome (oculocutaneous syndrome) |
| Gp2b/3a | Glanzmann thrombasthenia |

### Q4.2: Write briefly about Idiopathic / immune Thrombocytopenia purpura (ITP)

**Answer:**

- ITP is a type of quantitative platelet defect
- In this, the platelet count decreases
- In ITP, antibodies are produced against Gp1b/9 and Gp2b/3a
- Types
  - Acute ITP
  - Chronic ITP

### Q4.3: What are the differences between acute ITP and chronic ITP?

**Answer:**

| Features | Acute ITP | Chronic ITP |
|---|---|---|
| Age | Child | Adult |
| History of viral infection | Present | Absent |
| Platelet count | < 50,000 | Very low platelet count |
| Resolution | Normal within 6 months | > 6 months |
| Treatment | Supportive treatment | • Steroids (1st line)<br>• If not respond: a splenectomy can be done |

## BIG QUESTION 5: Name some clotting factor defects.

**Broad Answer:**

- **Clotting factor defects** refer to a group of disorders characterized by impaired blood coagulation due to the deficiency or dysfunction of one or more clotting factors. Some of the clotting factor defects are:
  - o Hemophilia
  - o Von Willebrand disease

## DETAILED QUESTIONS

### Q5.1: Write in detail about the two types of Hemophilia.

PYQ: INICET 2022, 2023

**Answer:**

| Hemophilia A | Hemophilia B/Christmas disease |
|---|---|
| • Factor 8 deficiency.<br>• Intrinsic pathway defect.<br>• APTT is elevated.<br>• BT, PT, and TT are normal.<br>• Factor 8 assay is done to detect factor 8 deficiency.<br>• Cryoprecipitate is given | • Factor 9 deficiency.<br>• Intrinsic pathway defect.<br>• APTT is elevated.<br>• BT, PT and TT are normal.<br>• Factor 9 assay is done to detect factor 9 deficiency.<br>• Fresh frozen plasma (FFP) is given. |

### Q5.2: What is Von Willebrand disease, and write briefly about VWF.

**Answer:**

- Von Willebrand Disease is caused by a deficiency or dysfunction of VWF. It involves both platelet and coagulation factor defects
- VWF helps bind to Gp1b/9 and helps in platelet adhesion
- It is also a carrier for factor 8
- A defect in VWF causes the elevation of APTT

### Q5.3: What are the classical features of Von Willebrand disease?

**Answer:**

- **BT-** High
- **PT-** Normal
- **APTT-** High

### Q5.4: Elaborate on conditions that show varied levels of platelet count, BT, PT, and APTT.

**Answer:**

PYQ: NEET PG 2021 PYQ: FMGE 2022, 2023

| Disease | Platelet Count | BT | PT | APTT |
|---|---|---|---|---|
| Bernard Soulier syndrome- Qualitative | Normal | **Elevated** | Normal | Normal |
| Glanzmann thrombasthenia- Qualitative | Normal | **Elevated** | Normal | Normal |
| ITP | Low | **Elevated** | Normal | Normal |
| Hemophilia A- Factor 8 defect | Normal | Normal | Normal | **Elevated** |
| Hemophilia B- Factor 9 defect | Normal | Normal | Normal | **Elevated** |
| VWD- Platelet and factor 8 defect | Normal | **Elevated** | Normal | **Elevated** |



YOURWISH

**Q5.5: Based on what parameters, one can differentiate between a platelet disorder and a clotting factor disorder**

**Answer:**

- **Defect in Platelets:** Problem in bleeding time
- **Defect with clotting factors:** Problem in APTT and PT



YOURWISH

# 22. BLOOD BANKING AND TRANSFUSION MEDICINE

**BIG QUESTION 1: Describe the genetic basis of blood groups, types of blood group classification including special types like Bombay blood group, various methods of blood grouping, and the principles and procedures of blood donation and transfusion including safety protocols.**

**Broad Answer:** The ABO blood group system is determined by genes on chromosome 9, while the H gene (chromosome 19) is essential for antigen expression, and the Rh system is on chromosome 1. The Bombay blood group lacks all antigens (A, B, H) and has all corresponding antibodies. Blood grouping methods include slide, tube, ELISA plate (96 wells), gel card, and automated systems, using antisera like Anti-A, B, D. In emergencies, O group RBCs and AB plasma are safest for transfusion. Blood donation requires age 18-65 years, Hb >12.5 g/dL, and weight >45 kg, using biomixers and pre-donation bags. Blood is separated into components and screened mandatorily for HIV, HBV, HCV, malaria, and syphilis. Leukoreduction removes WBCs to prevent febrile reactions and CMV transmission. Anticoagulants like CPD-A (35 days) and CP-SAGM (42 days) help preserve blood.

## DETAILED QUESTIONS

### Q1.1 Who gave the A, B blood grouping system?

**Answer:** Landsteiner.

### Q1.2 What are the chromosome locations for blood group genes?

**Answer:**

- H gene → Chromosome 19
- A, B, O genes → Chromosome 9
- Rh/D gene → Chromosome 1

### Q1.3 What antigen is common to all blood groups?

**Answer:** H antigen

### Q1.4 Short note on blood group classification

| | Group A | Group B | Group AB | Group O |
|---|---|---|---|---|
| Red blood cell type | A  | B  | AB  | O  |

| Antibodies in plasma | Anti-B | Anti-A | None | Anti-A and Anti-B |
|---|---|---|---|---|
| |  |  | | 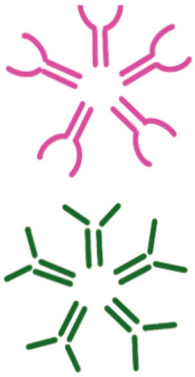 |
| **Antigens in red blood cells** | **A antigen** | **B antigen** | **A and B antigen** | **None** |
| |  |  |  | |

**Q1.5 What antigens and antibodies are present in Bombay blood group?**

**Answer:**

- Absent antigens: H, A, B
- Present antibodies: anti-H, anti-A, anti-B

**Q1.6 Bombay blood group is associated with which immunodeficiency?**

**Answer:**

- Leukocyte Adhesion Defect Type II

**Q1.7 What is the safest blood group to transfuse in emergencies?**

**Answer:**

- **Blood:** Group O (no antigens = universal donor)
- **Plasma:** Group AB (no antibodies)

**Q 1.8 What are the methods for blood grouping?**

**Answer:**

- Slide method
- Tube method
- Gel card
- Automated machines

**Q1.9 What does a positive test with Anti-A and Anti-D indicate?**

**Answer:** Blood group is A+

**Q1.10 What does it mean if all tubes including the control are clotted?**

**Answer:** Invalid test — control should always be clean (no clotting)

### Q1.11 How to read results in blood grouping? PYQ: AIIMS 2018

**Answer:**

- If clotting is seen with anti-A and Anti-D, the blood
- group is A+
- If clotting is only seen with anti-A, it is A-
- If clotting is seen with anti-B and Anti-D, it is B+
- If clotting is only seen with anti-B, it is B-
- If clotting is seen with Anti-A, Anti-B, and Anti-D, it is AB+
- If clotting is seen with Anti-A, Anti-B, and not in Anti-D, it is AB-
- If clotting is not seen only in Anti-D, it is O+
- When no clotting is seen in any, it is O-
- When everything with control comes positive, it becomes invalid because control can never come +ve it is always clean

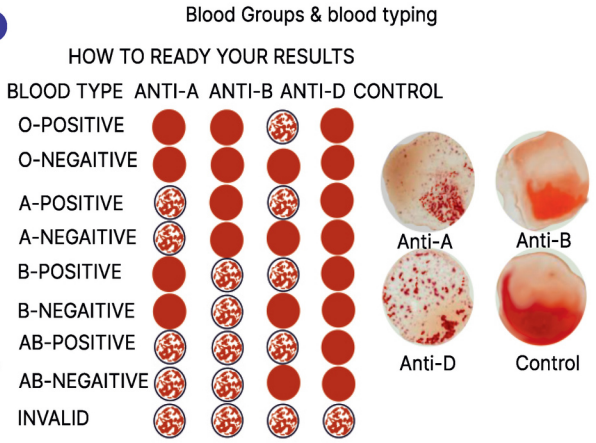


### Q1.12 How many wells are there in a standard ELISA plate?

**Answer:**

- ELISA plate has 8 wells vertically and 12 wells horizontally.
- Total wells are 12×8 = 96 Wells
- In this plate, we can test 20-30 people.



### Q1.13 In Gel Card technique, what does the line at the top vs. bottom indicate?

**Answer:**

- Top line → Positive
- Bottom line → Negative

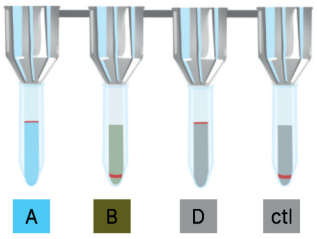

A+ blood group

### Q1.14 What are the eligibility criteria for blood donation?

**Answer:**

- Age: 18-65 years
- Weight:
  - o >45 kg (minimum)
  - o 45-55 kg → 350 ml
  - o >55 kg → 450 ml
- Hb: >12.5 g/dL

### Q1.15 What is the first bag blood goes into during donation?

**Answer:**

- Mother bag (contains whole blood)

### Q1.16 What are the blood components separated from whole blood?

**Answer:**

- PRBC (Packed Red Blood Cells)
- Platelet-rich Plasma
- Fresh Frozen Plasma

### Q1.17 What is a PDB (Pre-donation bag)?

**Answer:**

- First 10-30 ml collected to remove contamination (skin flora, antiseptics, etc.)

### Q1.18 Why is leukoreduction done?

**Answer:**

- To reduce febrile non-hemolytic transfusion reactions (due to cytokines)
- Prevent CMV transmission

### Q1.19 Briefly describe Biomixer



**Answer:**

- Machine: Biomixer
  - o It displays weight.
  - o It has an auto clamp, which means it will automatically close the tube as soon as the set limit is achieved.
  - o It is needed to mix the blood with anticoagulants.

### Q1.20 What are penta bags used for?

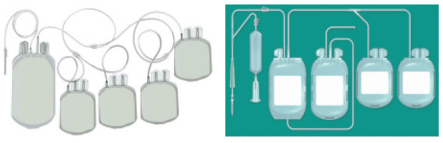

**Answer:**

- Pediatric blood transfusion – 4 small bags of ~100-120 ml

### Q1.21 What are the mandatory TTI screenings in India?



**Answer:**

- HIV (Type 1 and 2)
- HBV
- HCV
- Malaria
- Syphilis

### Q1.22 What anticoagulants are used in blood storage and their shelf life?

**Answer:**

| Anticoagulant | Shelf Life | Notes |
|---|---|---|
| ACD- Acid citrate dextrose | **21 days (3 weeks)** | Older method |
| **CPD- Citrate phosphate dextrose** | **21 days (3 weeks)** | Similar to ACD |
| **(CPD-A) Citrate phosphate dextrose adenine** | **35 days (5 weeks)** | **Most commonly used** |
| **(CP-SAGM) Citrate phosphate saline adenine Glucose Mannitol** | **42 days (6 weeks)** | Longest shelf life |

### Q1.23: What are the different types of blood bag tubing configurations?

**Answer:**

- When all the tubings are on the top - TAT bag - top & top bag.
- From the mother bag, two tubes go: TAB bag - Top and Bottom bag.

## BIG QUESTION 2: Discuss the various blood components used in transfusion medicine

**Broad Answer:**

| Component | Temperature | Shelf |
|---|---|---|
| **Whole blood / PRBC** | 2-6 degree Celsius | 21 d (ACB/CPD)<br>35 d (CPDA)<br>42 d (SAGM) |



YOURWISH

| | | |
|---|---|---|
| **Platelets rich plasma** | 20-24 degree Celsius | 5 days of agitation |
| **Random Donor platelets** (collected from multiple donors) | | |
| **Single donor platelets** (collected from a single person) | | |
| **Fresh frozen plasma**<br>• Poor in factor 5 and factor 8 | Less than - 18 degrees Celsius | 1-year |
| **Cryoprecipitate**<br>• Factor 8 present<br>• Von Willebrand factor (VWF)<br>• 1st - factor fibrinogen<br>• last factor F13 | | |

## DETAILED QUESTIONS

### Q2.1 What are the storage temperatures and durations for Whole Blood and Packed RBCs (PRBC)?

**Answer:**

- Stored at 2-6°C
- Shelf-life depends on anticoagulant:
  - ACD/CPD → 21 days
  - CPDA → 35 days
  - CP-SAGM → 42 days

### Q2.2 What is the ideal storage condition for platelet-rich plasma?

**Answer:**

- Temperature: 20-24°C
- Duration: 5 days with continuous gentle agitation

### Q2.3 What are Random Donor Platelets and Single Donor Platelets?

**Answer:**

- Random Donor Platelets (RDP): Collected from multiple donors
- Single Donor Platelets (SDP): Collected from one donor using apheresis

### Q2.4 How is Fresh Frozen Plasma (FFP) stored and what are its characteristics?

**Answer:**

- Stored at < -18°C
- Shelf-life: 1 year
- Poor in Factor V and VIII

### Q2.5 What are the components of Cryoprecipitate?

**Answer:**

Cryoprecipitate is rich in:

- Factor VIII

- Von Willebrand Factor (vWF)
- Fibrinogen (Factor I)
- Factor XIII

### Q2.6 Describe briefly platelet agitators

**Answer:**



- Platelets are kept in it
- Constantly moving left and right
- If the machine is working, the shelf life of platelet-rich plasma is properly 5 days, and if it stops, it is only 1 day
- If the fresh frozen plasma melts or thawing occurs, then the shelf life is one day

### Q2.7 Describe briefly Apheresis machine

**Answer:**

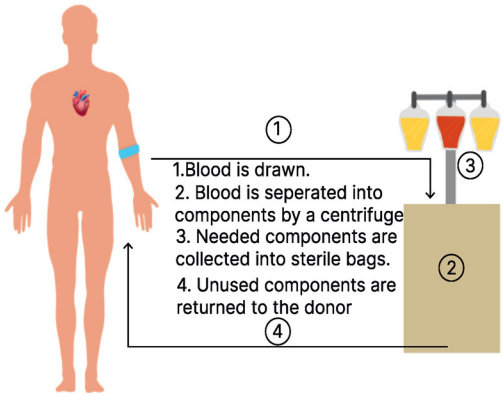




- Donor gives blood, and then the blood goes into the Apheresis machine.
- It has bags hanging because it has a live process going on.
- After entering, the blood is separated into
  - RBC
  - Platelets
  - Fresh frozen plasma
- Separated because whatever component is needed is kept.
- Then, the other parts of the blood are returned to the donor.
- Naming is done based on components the blood bank has taken
  - E.g., Platelet Apheresis - Blood bank has kept the platelets
  - Plasma Apheresis - Plasma was taken to procure antibodies.

## BIG QUESTION 3: Discuss the color coded vacutainers used in blood collection

**Broad Answer:** Color-coded vacutainers are essential for accurate blood sample analysis. Each color represents specific additives and uses:

- Purple/Lavender: EDTA → for CBC, HbA1c, ESR (Wintrobe).
- Light Blue: Trisodium citrate → PT, aPTT, ESR (Westergren).
- Grey: Sodium fluoride + Potassium oxalate → glucose tests (FBS, RBS, GTT).
- Green: Heparin (Lithium/Sodium) → ABG analysis.
- Red/Yellow/Orange: No anticoagulant; used for serum-based tests (LFT, KFT, hormones).
- Pink: Crossmatch; Royal Blue: Trace elements (Cu, Zn); White: PCR.

## DETAILED QUESTIONS

### Q3.1 Write a short note on EDTA vacutainers

**Answer:**

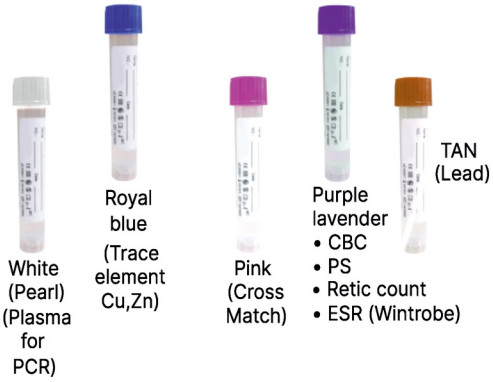


- Di potassium EDTA is the of EDTA (K2 EDTA) best
- The colors include:
  - White: Plasma for polymerization chain reaction (PCR)
  - Royal blue: Tests for trace elements (Cu, Zn, etc.)
  - Pink: Crossmatch
  - Purple/Lavender
  - Tan: Lead in cases of lead poisoning

  (Mnemonic: WHITE princess belonging to a ROYAL family needs a sunTAN and her favorite colors are PINK and PURPLE)
- The tests in Purple include routine tests
  - CBC
  - Peripheral smear
  - Reticulocyte count
  - ESR (Wintrobe)
  - HbA1c



### Q3.2 Describe color coding of various other vacutainers and clinical significance

**Answer:**

| | |
|---|---|
| Grey Top Vacutainer | • Gray top for glucose estimators<br>o FBS<br>o PPBS<br>o RBS<br>o GTT |
| Heparin Vacutainers  | • These are containers green<br>o Light green - Contains Lithium heparin (Light for Lithium)<br>o Dark green - Contains Sodium heparin<br>• These are used for Arterial Blood gas (ABG) analysis |
| Light Blue Top Vacutainer  | • Anticoagulant: Trisodium Citrate 3.2% PYQ: INICET 2023<br>o Inverted for 3-4 times<br>o Anticoagulant: Blood ratio<br>→ 1:9 → coagulation studies ( T, aPTT)<br>→ 1:4 → ESR (Westergren) |
| Black Top Vacutainer  | • Anticoagulant is Trisodium Citrate<br>o Used for Automated ESR test |

| | |
|---|---|
| Orange Vacutainer  | • Contains based activator gel Thrombin PYQ: INICET 2022<br>o Clotting time is 5 mins only<br>o Inverted for 5-6 times<br>• Number of times mixed<br>o Purple (EDTA), Gray, Green - 8 times<br>o Light blue - 3-4 times<br>o Serum separator tubes - 5-6 times |
| Coagulating Vacutainers 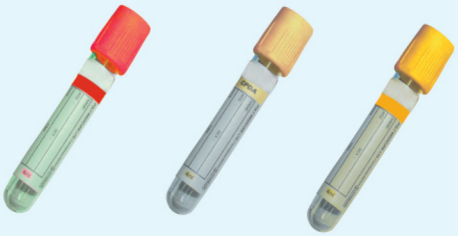 | • Used to separate serum(Serum separator tubes)<br>• Preferred for hormone profile tests like<br>o Serum T3, T4, TSH<br>o HCG<br>o Prolactin, LH, FSH, Testosterone<br>o KFT<br>o LFT<br>• Also used for enzymes and antibodies<br>• Inverted for 5-6 times |

### Q3.3 Describe the types of coagulating vacutainers

**Answer:**

1. Red Vacutainer
   - Clotting time is 60 mins
   - Clot activator is added
   - Gel is not added
2. Golden Yellow Vacutainer
   - Clotting time is 30 mins
   - Clot activator is added
   - Gel is added clot faster that makes clot faster

### Q3.4 How is HbA1c estimation done ?

**Answer:**

For HbA1c, as it estimates glycated hemoglobin rather than glucose alone, a Purple/lavender vial is used.

- The anticoagulant Potassium Oxalate used is
- Additive Sodium fluoride is (NaF) Added to inhibit Enolase, which ultimately inhibits glycolysis
- Scenario: For a patient who has to perform FBS, samples are collected early, and the sample may reach the lab late. In this meantime, glycolysis occurs and when the sample is tested for fasting glucose, it may show false reports. Hence, an additive is added to prevent glycolysis

### Q3.5 Which vacutainer is used in the Wintrobe method for ESR?

**Answer:** Purple/Lavender vacutainer with EDTA.

### Q3.6 Which vacutainer is used in the Westergren method?

**Answer:** Light blue vacutainer with 3.2% trisodium citrate.



YOURWISH

YOURWISH

### Q3.7 Which vacutainer is used in automated ESR?

**Answer:** Black (Trisodium citrate)

### Q3.8 Write about the correct order of draw during venipuncture and its clinical relevance.

**Answer:** Order of blood collection minimizes cross-contamination of additives:

1. Sterile (Light Yellow) - For blood culture.
2. Light Blue - Coagulation studies (PT, aPTT).
3. Red - For serum tests (no additive).
4. Yellow (SST) - Serum with gel separator.
5. Green - Heparin for ABG.
6. Lavender/Purple - EDTA for CBC, ESR.
7. Grey - NaF for glucose estimation.
   (Mnemonic: S L R S G L G Stop Light is Red. Stay Green Light says Go)

## BIG QUESTION 4: Explain the principles and components of manual blood cell counting and hemoglobin estimation using the Improved Neubauer chamber and Sahli's Hemoglobinometer

**Broad Answer:**

- The Improved Neubauer chamber is a hemocytometer used to manually count blood cells. The chamber has grids designed for different cell types: 4 peripheral large squares for WBC count, a central grid for RBCs, and the same central grid (excluding the middle green line) for platelets. Rees & Ecker fluid is used for platelet dilution. RBC and WBC pipettes differ: RBC pipette has red bead, markings 0.5, 1, 101, and uses Hayem or Dacie fluid; WBC pipette has white bead, markings 0.5, 1, 11, and uses Turk's fluid.
- Sahli's hemoglobinometer estimates Hb using a comparator with brown glass, a graduated tube, and N/10 HCl to form acid hematin. The blood is diluted until the color matches the standard, indicating hemoglobin concentration

## DETAILED QUESTIONS

### Q4.1 Describe the grid layout and counting principles of the Improved Neubauer chamber.

**Answer:**




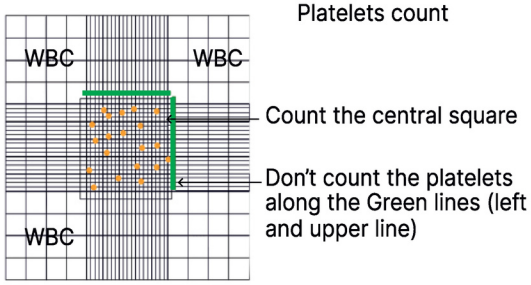


**The Neubauer chamber has:**

- WBC count: 4 large squares at the corners.
- RBC count: Central grid (1 large square) containing 5 small squares (4 corners +center).
- Platelets: Entire central grid excluding green line. Each area corresponds to a known volume to calculate cell concentration.



### Q4.2 Explain the working of Sahli's hemoglobinometer.

**Answer:**

- Blood is added to N/10 HCl in a Sahli tube, forming brown acid hematin.

Dilution continues with distilled water until the color matches the standard brown glass. The hemoglobin value is then read from the graduations.

### Q4.3 Differentiate between RBC and WBC pipettes.

| | RBC pipette | WBC pipette |
|---|---|---|
| Bead, mouthpiece color | Red | White |
| Markings | 0.5, 1, 101 | 0.5, 1, 11 |
| Cells counted | Lakhs | Thousands |
| Dilution range | 0.5-101 times | 0.5-11 times |
| Fluid | Hayem & Dacie fluid | Turk fluid |

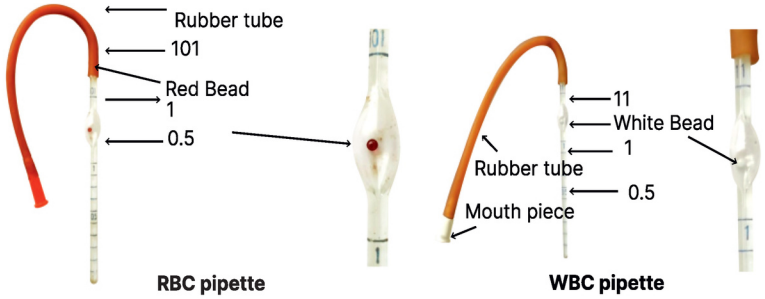


### Q4.4 What is the role of Rees and Ecker fluid in platelet estimation?

**Answer:**

- Rees and Ecker fluid preserves and stains platelets, suppressing RBCs, making platelet counting easier in the Neubauer chamber.

### Q4.5: What are the components of Sahli's hemoglobinometer?

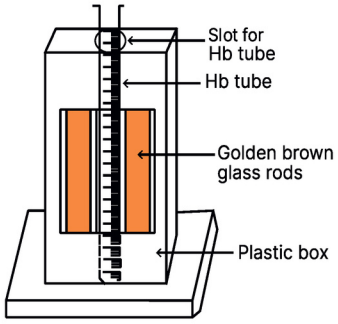


Comparator with a brown glass standard




Sahli's graduated hemoglobin tube

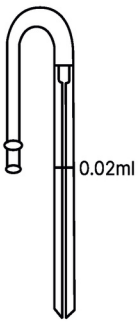


Hemoglobin pipette



Stirrer
Thin glass rod.