PREP XI RR

STUDY NOTES

DERMATOLOGY

17
VIDEOS

190
PAGES

PREMIUM STUDY MATERIAL

PREP XI RR

Table of Contents follows on next page

RR Reignite

#	Topic / Video Name	Pages
1	Basics of Dermatology	3 – 12
2	Viral Infections of Skin	13 – 23
3	Bacterial Infections of Skin	24 – 30
4	Cutaneous Tuberculosis and Leprosy	31 – 41
5	Fungal Infections of Skin	42 – 51
6	Sexually Transmitted Infections	52 – 71
7	Papulosquamous Disorders	72 – 86
8	Immunobullous Disorders	87 – 98
9	Systemic Diseases and Skin	99 – 111
10	Pigmentary Disorder	112 – 124
11	Eczemas	125 – 131
12	Parasitic Infestations/Adverse Drug Reactions	132 – 142
13	Skin Tumours	143 – 149
14	Genodermatoses	150 – 161
15	Disorders of Glands	162 – 170
16	Hair and Nail Disorders	171 – 182
17	Miscellaneous Topics	183 – 192

1. BASICS OF DERMATOLOGY

BIG QUESTION 1: What are the basic layers of the skin, their structure, functions, and pathological findings in dermatology?

Broad Answer: The skin has three main components: epidermis, dermis, and subcutaneous tissue, with muscle beneath. The epidermis consists of five layers: Stratum corneum, lucidum, granulosum, spinosum, and basale, arranged from superficial to deep. Cell differentiation proceeds from basal to corneal layer, with progressive loss of nuclei, flattening, dehydration, and death. Each layer has distinct roles in protection, barrier function, and regeneration, and is associated with characteristic pathological changes.

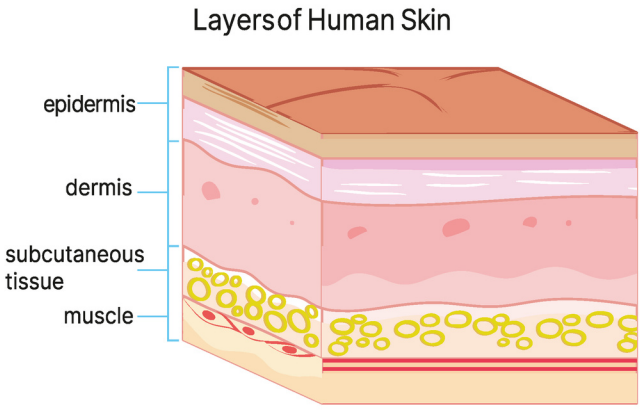

DETAILED QUESTIONS

Q1.1: What are the layers of the epidermis? PYQ: AIIMS 2019

Answer: The epidermis has five layers, remembered by the mnemonic "Come Let's Get Sun Burnt":

- Stratum **C**orneum (**C**ome)
- Stratum **L**ucidum (**L**et's)
- Stratum **G**ranulosum (**G**et)
- Stratum **S**pinosum (**S**un)
- Stratum **B**asale (**B**urn).

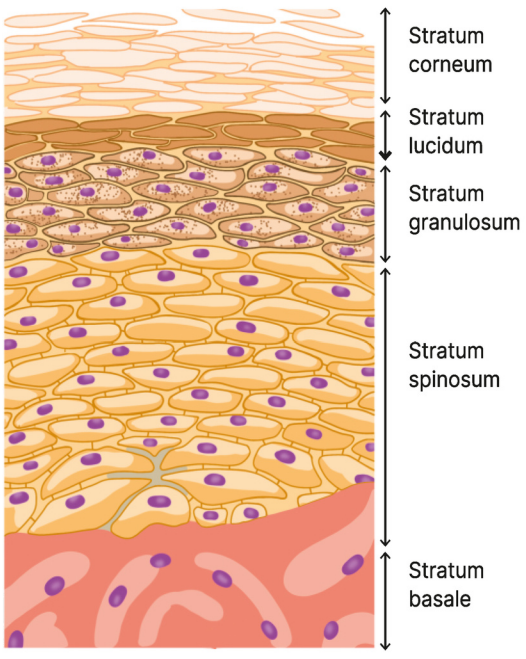

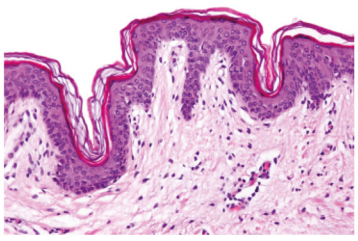

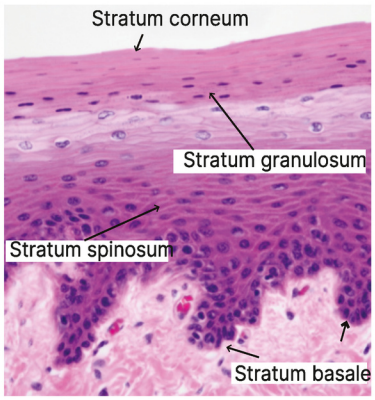

YOURWISH

Q1.2: What is the normal cell kinetics of the epidermis, and how is it altered in psoriasis?

Answer: Normal epidermal turnover time: 52-75 days (average 56 days)

- **Psoriasis** → Reduces drastically to 36 hours to 4 days, leading to immature keratinocyte accumulation and plaque formation.

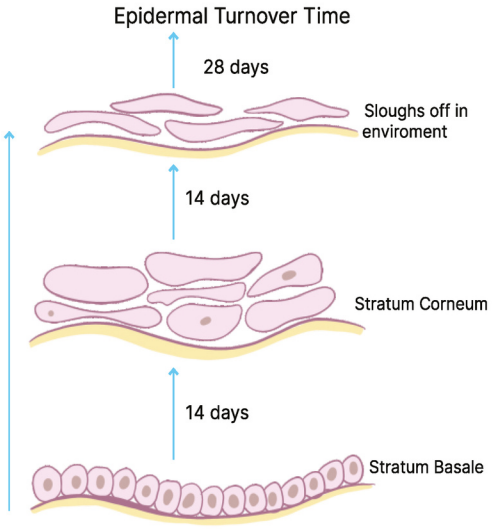

Q1.3: What is cell differentiation?

Answer: Cell differentiation occurs from the basal layer to the corneal layer,

- The following changes are seen:
  - Cell loses nuclei
  - Cell becomes flattened
  - It results in loss of mitosis, and cells are dead
  - The surface area increases
  - Finally, cells become dehydrated

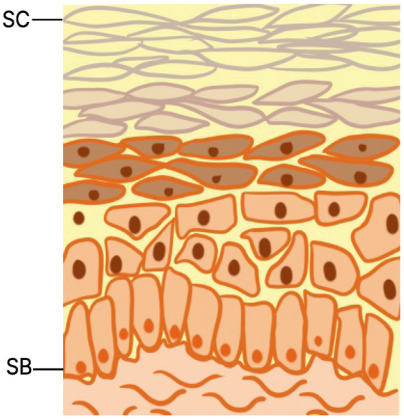

Q1.4: In a preterm infant, which epidermal layer is absent and why?

Answer: The stratum corneum is absent because keratinocyte differentiation has not yet reached the final corneal stage, leaving the skin immature and more permeable

Q1.5: What is the relevance of the stratum corneum?

Answer:

- Acts as a barrier (major importance)
- Has dead keratinocytes

Histopathology Findings	Reasons	Physiological findings	Pathological Findings (PEAS2)
Parakeratosis 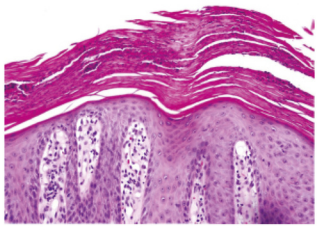	Retention of Nuclei in Stratum Corneum	Mouth and Vagina	Psoriasis, Eczema, Squamous Cell Carcinoma, Actinic Keratosis, Seborrheic Dermatitis, SCC

YOURWISH

Hyperkeratosis 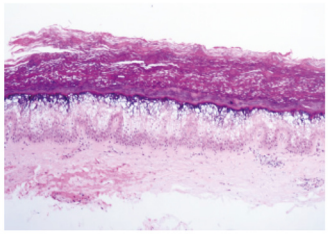	Increased thickness of Stratum Corneum	NA	Lichen Planus, Psoriasis

Q1.6: Where is the stratum lucidum present, and why is it called the clear cell layer?

Answer:

- Stratum lucidum is found in Palms and Soles only
- Skin is thick on these parts
- It is also called the clear cell layer due to the presence of Refractile Granules of Eleidin

Q1.7: Where is the composition of the stratum granulosum layer?

Answer:

- As the name suggests, this layer is mainly made up of granules → The two most important granules of this layer are:

Types of Granules present in Stratum Granulosum	
Keratohyalin Granules	**Lipid Coating Granules**
• Responsible for forming Profilaggrin • Profilaggrin forms Filaggrin	• Responsible for providing moisture. • Odland bodies/ Lamellar Bodies

Q1.8: Which pathologies are associated with the stratum granulosum layer?

Answer:

- Profilaggrin (filament-aggregating protein) → forms Filaggrin → forms KIF (stratum corneum) → barrier functioning
  - o Defect: **Icthyosis Vulgaris**
- Defects in Odland bodies: **Asteatotic Eczema**
- Thickness of granular layer: 1-2 cell layers
  - o Hypergranulosis: Increased layer thickness → **Lichen Planus**
  - o Agranulosis: Absence of layer → **Psoriasis**
  - o Dyskeratosis: Abnormal keratinization
    - → Benign: **Hailey Hailey, Darier's disease**
    - → Malignant: **BCC, SCC, Paget's disease**

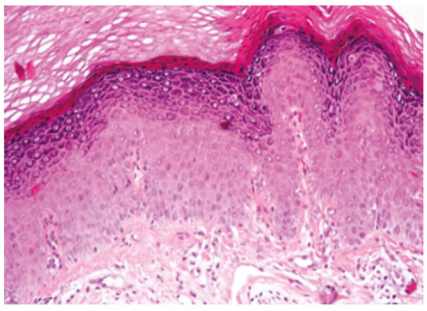

Q1.9: Which is the thickest layer of the epidermis?

Answer:

- Stratum Spinosum/Prickle cell layer is the thickest layer of the epidermis and is boldly visible
- Keratinocytes present in this layer are connected through Desmosomes
- It looks like spines assembled architecturally.

Q1.10: Which pathological findings can be seen in the prickle cell layer?

Answer: Cells have an interlinking fluid:

- Spongiosis: Intercellular Edema (occurs between the cells)
- Ballooning: Intracellular Edema (occurs inside the cells)
  - Both intercellular and intracellular → Acute eczema
- Acanthosis occurs when the Stratum Spinosum thickens → Chronic eczema
- Malpighian Layer: Mitotically active layer of epidermis → Composed of the Stratum Basale and the Stratum Spinosum.

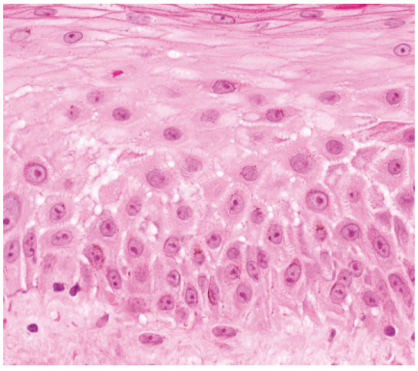

Q1.11: Which pathological findings can be seen in the Stratum Basale layer?

Answer:

- Stratum Basale is a single cell layer that provides an extra layer of thickness
- It is the mitotically active/germinative layer
- Pathological Findings:
  - **Acantholysis:** Separation of keratinocytes → Pemphigus group and Herpes infection
  - **Basal cell degeneration:** Inflammation infiltrate → Lichen planus and LE

Q1.12: What are the types of microabscesses in dermatology, and where are they found?

Answer: Microabscesses are a collection of inflammatory cells in different cell layers.

Type	Associated Structure	Associated Condition
Munro's microabscess	Stratum corneum	Psoriasis
Papillary abscess	Dermal papilla (IgA + neutrophils)	Dermatitis herpetiformis
Kogoj's Spongiform Pustules	Stratum Spinosum	Psoriasis
Eosinophilic	Dermo-Epidermal junction (Eosinophils)	Bullous Pemphigoid
Pautrier's	Stratum corneum	Mycosis Fungoides

Q1.13: Differentiate between the types of cells found in the layers of epidermis.

Answer: Keratinocytes: Present in 90% of Epidermis, present in all layers

	Keratinocyte	Langerhan's cell	Melanocyte	Markel cell
Layer of skin	All layers	Stratum spinousum	Stratum Basale	Stratum Basale
Derived from	Ectoderm	Mesenchyme	Neural crest	Ectoderm > Neural crest
Major Function	Epidermis structure formation by Keratin intermediate filament	Antigen presenting cells.	Pigment forming	Slow adaptive type 1 touch receptor
Special feature		Birbeck granules CD1A, CD207, S100		

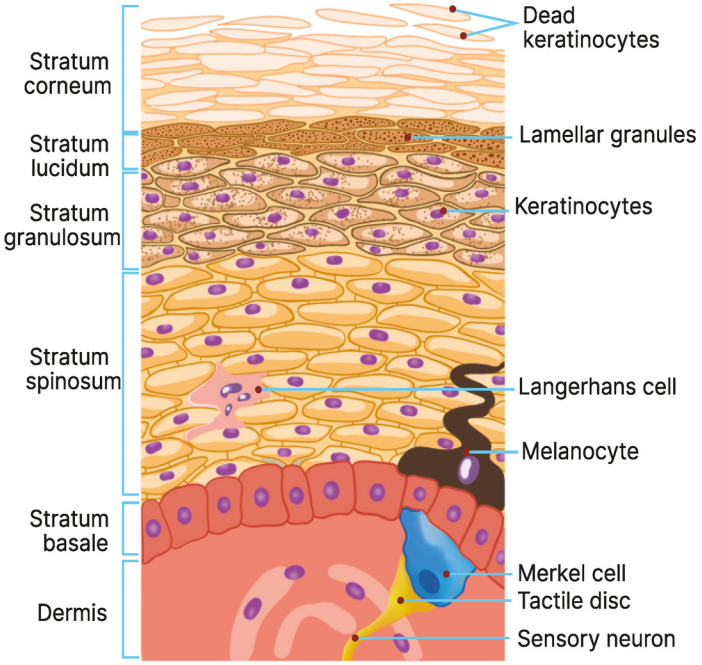

Q1.14: What is the Epidermal Melanin Unit?

Answer: One melanocyte will transfer melanosomes to 36 Keratinocytes, known as **Epidermal Melanin Unit.**

- Melanocytes (dendritic cells) are responsible for forming uniform skin color.

BIG QUESTION 2: What is the structure and function of the dermo-epidermal junction?

Broad Answer: The dermo-epidermal junction (DEJ), also known as the basement membrane zone, connects the epidermis and dermis, providing adhesion and signaling, with Type IV collagen as a key structural component.

DETAILED QUESTIONS

Q2.1: What are the structural features of the dermo-epidermal junction (DEJ) and its main function?

Answer: **DEJ:** Junction between the epidermis and dermis, also called the basement membrane zone (BMZ) → Consists mainly of Type IV collagen

- Rete ridges: Downward extensions of epidermis into dermis
- Dermal papillae: Upward projections of dermis into epidermis
- Function: Provides strong adhesion between epidermis and dermis and acts as a signaling interface important for cell communication

Q2.2: What are the important molecular components of the basement membrane zone (BMZ)?

Answer:

- Keratin 5 & 14 → anchor epidermal keratinocytes
- Hemidesmosomal proteins: Plectin, Integrin
- BP antigen 1 (BP230) and BP antigen 2 (BP180, Collagen XVII)
- Laminin (anchoring filaments) → in lamina lucida
- Type IV collagen → in lamina densa.
- Type VII collagen (anchoring fibrils) → in sublamina densa.

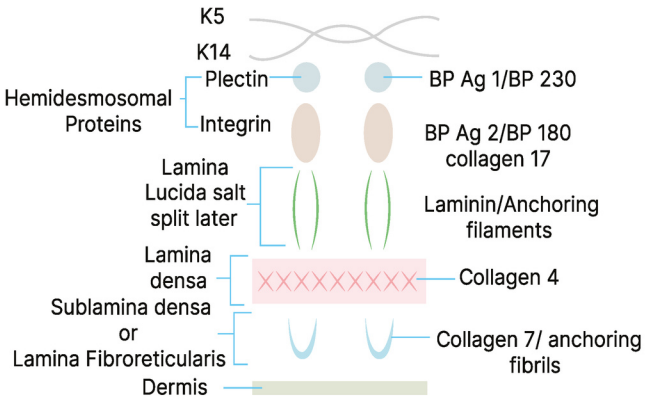

YOURWISH

Q2.3: What are the layers of the dermis and their composition?

Answer: Dermis → next to the epidermis → consists of various cells, Nerve Endings, fibers, Blood vessels, hair follicles, and a lot of ground substances.

- **Layers:**
  - Papillary Dermis
  - Reticular Dermis
- **Key dermal components:**
  - Ground substance: Hyaluronic acid
  - Fibers: Collagen (most abundant), elastic fibers
  - Cells: Fibroblasts (most abundant), mast cells, macrophages, dermal dendrocytes

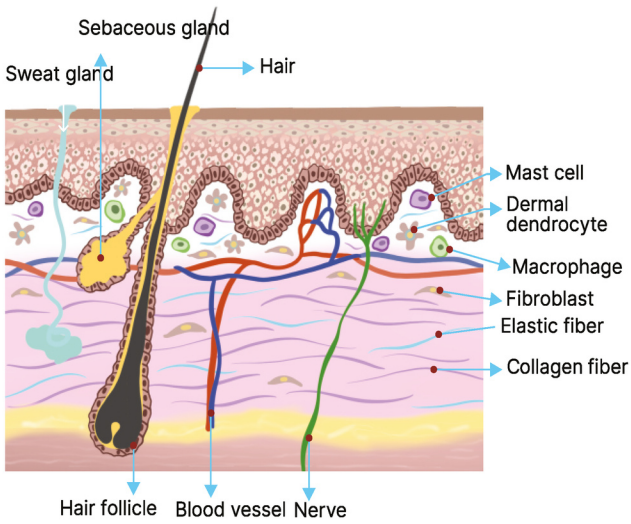

Q2.4: What are the sensory receptors present in the dermis?

Answer: Meissner's corpuscles: Touch receptors

Q2.5: What is the histopathology of dermis?

Answer:

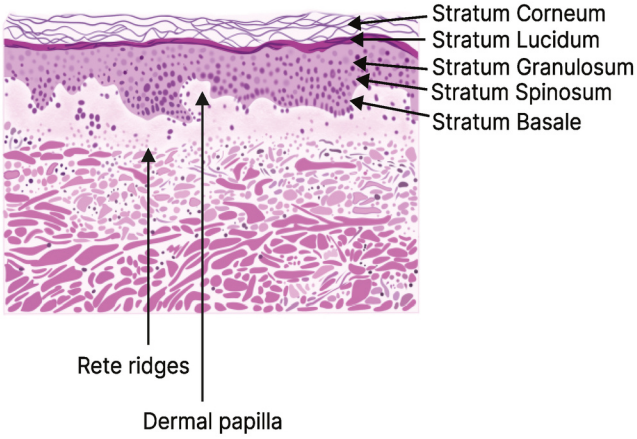

BIG QUESTION 3: What are the types of skin lesions, and how are they classified into primary, secondary, and special types?

Broad Answer: Skin lesions are classified as primary, secondary, or special. Primary lesions are the first to appear in a disease (e.g., macules, papules, vesicles). Secondary lesions result from changes in primary ones (e.g., crusts, scales, erosions). Special lesions are characteristic of specific dermatological disorders.

DETAILED QUESTIONS

Q3.1: What are the three main categories of skin lesions?

Answer:

- Primary lesions: First to appear in a disease (e.g., macule, papule, vesicle)
- Secondary lesions: Develop from changes in primary lesions (e.g., scales, crusts, ulcers)
- Special lesions: Pathognomonic for certain conditions (e.g., herald patch in pityriasis rosea, target lesion in erythema multiforme)

Q3.2: What are macules and patches?

Answer:

- Flat, circumscribed color changes in the skin
- Not raised or depressed, hence better seen than felt
- Size criteria:
  - Macule: <0.5 cm
  - Patch: >0.5 cm
- Example: Vitiligo patches, freckle macules

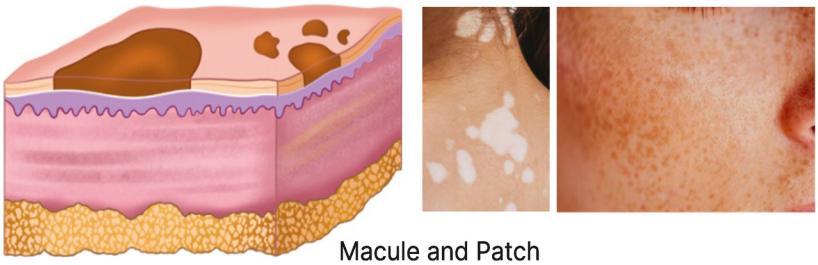

Macule and Patch

Q3.3: What is the difference between a papule, a plaque, and a nodule?

Answer:

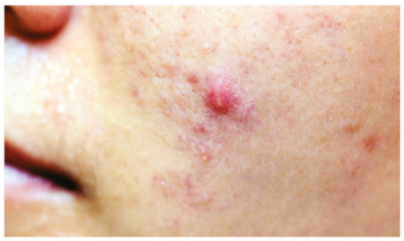

Papule

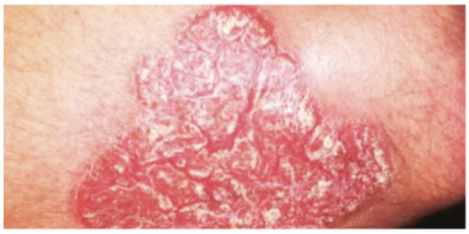

Pustule

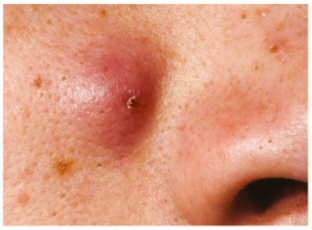

Nodule

- **Papule:** Circumscribed, solid, elevated lesion < 0.5 cm
- **Plaque:** Solid lesion > 0.5 cm in diameter, broader than tall (change in texture)
- **Nodule:** Solid lesion > 0.5 cm with more depth than height, better felt than seen

Q3.4: What are vesicles and bullae?

Answer: Fluid-filled lesions:

- Vesicle: < 0.5 cm (tiny blister)
- Bulla: > 0.5 cm (large blister)



Vesicles



Bullae

Q3.5: What are pustules and abscesses?

Answer:

- Pustule: Pus-filled lesion
  - It can be:
    - → Primary pustular lesion (primary lesion)
    - → Secondary pustular lesion (infected vesicle)

- Abscess: A Collection of pus in tissue, larger and deeper than pustule

Pustule:Pustule can be primary or secondary

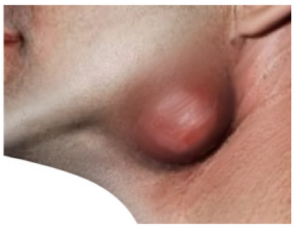



Q3.6: What are petechiae, purpura, and ecchymoses?

Answer: All result from extravasation of RBCs into the skin, usually due to vascular or clotting disorders.

- They are non-blanchable
- Size criteria:
  - Petechiae: 1-2 mm
  - Purpura: >3 mm
  - Ecchymosis: 1-2 cm




PYQ: AIIMS 2020 PYQ: NEET PG 2018

BIG QUESTION 4: What are the different types of secondary skin lesions and their key features?

Broad Answer: Secondary skin lesions are morphological changes that occur when primary lesions evolve, get infected, or undergo chronic irritation. They include scales, crusts, erosions, ulcers, fissures, and lichenification, each with distinct clinical and pathological features important for diagnosis.

DETAILED QUESTIONS

Q4.1: What are scales, and what are their types?

Answer:

- Scales are visible exfoliations of the stratum corneum
- They occur due to abnormal keratinization and shedding of epidermal cells
- Examples:
  - Silvery-white scale
  - Fish-like scale
  - Greasy scale


Silvery white: Psoriasis


Greasy looking: Seborrhoeic dermatitis


Fish like scale: IV


Collarette of scales: P. rosea


Branny Scales: P. versicolor

PYQ:FMGE 2021

Q4.2: What are crusts, and what is their clinical significance?

Answer: Crusts are dried exudates on the skin surface

- Exudate may consist of serum, pus, or blood
- Example: Honey-colored crust → Non-bullous impetigo.




Q4.3: What is the difference between erosions, ulcers, and fissures?

Answer:

- Erosion: Superficial breach involving epidermis and superficial dermis
- Ulcer: Deeper breach involving epidermis + deep dermis, may extend into subcutaneous tissue; has base and margins
- Fissure: Linear crack in the skin.

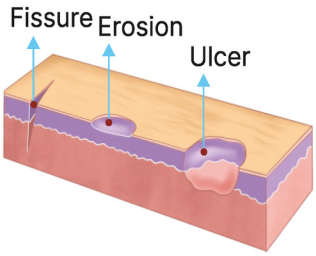





Q4.4: What is lichenification, and how does it appear clinically?



Answer: Lichenification occurs due to chronic scratching/itching

- Pathology: Acanthosis (epidermal thickening)
- Clinical features:
  - o Hyperpigmentation
  - o Increased skin markings (exaggerated lines)
  - o Thickened skin

BIG QUESTION 5: What are special skin lesions and their clinical significance?

Broad Answer: Special skin lesions are unique morphological patterns with diagnostic and surgical importance. Examples include burrows (scabies), comedones (acne), target lesions (erythema multiforme), Blaschko's lines (embryonic development), and Langer's lines (orientation of collagen and muscle fibers).

DETAILED QUESTIONS

Q5.1: In which condition is a burrow seen?



Answer: Scabies

Q5.2: What are comedones seen as?



Answer: Acne

Q5.3: Where is a target lesion seen?



Answer: Erythema multiforme

Q5.4: What is the difference between Blaschko's lines and Langer's lines?

Answer:

Blaschko's Lines	Langer's Lines
PYQ: NEET PG 2022	PYQ: INICET 2023
• They are the lines of **embryonic development.** • They are the lines along which keratinocytes migrate. • These lines are **constant.** • They have a strict midline demarcation. 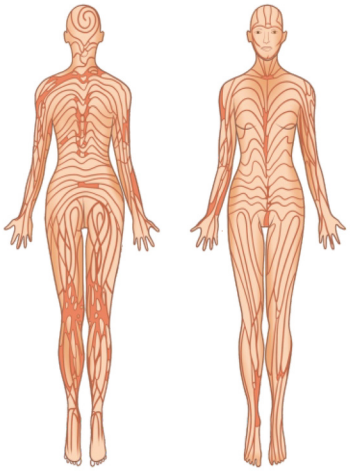	• They are the lines of the **orientation of collagen and muscle fibers** in our body. • Not constant • No midline demarcation • Help in giving surgical incision • They are relaxed skin tension lines 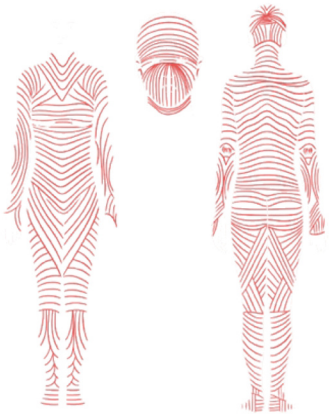

2. VIRAL INFECTIONS OF SKIN

BIG QUESTION 1: What are the important viral infections of the skin, their causative agents, characteristic features, and management?

Broad Answer: Viral skin infections are caused by various DNA and RNA viruses, including Molluscipox virus, Parapoxvirus, HPV, Herpesviruses (HSV, VZV, EBV, HHV-6, 7, 8), Parvovirus B19, and Enteroviruses. They present with lesions such as umbilicated papules, warts, vesicles, or exanthems. Diagnosis involves histopathology showing Henderson-Patterson bodies, koilocytes, or multinucleated giant cells. Treatment ranges from self-resolution and physical/chemical removal to antivirals like acyclovir or symptomatic care.

DETAILED QUESTIONS

Q1.1: What are the causative organisms and types of Molluscum Contagiosum?

Answer:

- **Causative Organism:** Molluscipox virus or MCV (Family: Poxvirus → Largest known DNA viruses)
- **Types**
  - MCV 1: Seen in children
  - MCV 2: Seen in adults

Q1.2: What are the clinical features of Molluscum Contagiosum?

PYQ: AIIMS 2018 PYQ: FMGE 2019

Answer: **Characteristic features:**

- Asymptomatic **umbilicated papule**
- Site: Anywhere on the body, most commonly present on the face.
- **Pseudo-Koebner's phenomena:** Positive
  - Molluscum micro-organism gets seeded along the line of trauma (scratching) Leads to the development of molluscum lesion along the line of trauma.
- Family history might be present.



Umbilicated papules with central indentation

Q1.3: What is Histopathology of Molluscum Contagiosum?

Answer:

- Intracytoplasmic eosinophilic inclusion bodies are present known as Henderson - Patterson Bodies

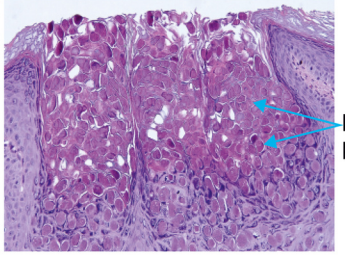

Q1.4: What is the treatment of molluscum contagiosum?

Answer: Treatment

- Self-resolution
- Chemical /physical method
- Systemic: Levamisole, cemetidine

Chemical method	Physical method
• Trichloroacetic acid: TCA • KOH	• Needle extirpation • Electrocautery • Radiofrequency • Cryotherapy

Q1.5: What is Ecthyma contagiosum?

Answer:

- Zoonotic infections - Transferred by animals (Sheep)
- Parapoxvirus / ORF virus



Ecthyma Contagiosum

Q1.6: What is Milker's nodule cow?

Answer:

- Seen in cow handlers.
- Causative organism: Pseudopox virus



Milker's nodule

BIG QUESTION 2: What are the type of Human Papillomavirus?

PYQ: NEET PG 2018,2022

Broad Answer: HPV has>200 subtypes of Viral Infection, a few of which are

- Deep plantar wart: HPV 1
- Superficial plantar warts: HPV 2
- Plane warts: HPV 3
- Common warts: HPV 4, 2, 27
- EDV: Epidermodysplasia Verruciformis: HPV 5
- Anogenital warts: HPV6
- Butcher's warts: HPV 7
- Mnemonic: DSP Come Eat A Burger
- **Few Additional Sub Types**
  - EDV - is also caused by HPV-8
  - Common warts - HPV 4,2,27

- Anogenital warts:
  - → **Low-risk HPV: 6,11**
  - → **High risk HPV: 16, 18, 31, 33, 45**
- Plane warts: HPV 3, 10

Q2.1: What is Verruca Vulgaris?

Answer:

- Asymptomatic
- Caused by 4, 2, 27
- Painless verrucous/Hyperkeratotic growths
- Pseudo Koebner's phenomenon positive

Q2.2: What are Plane warts?

Answer: Also known as **Verruca Plana**



- Plane-topped papules
- Commonly seen in the face
- Causative organism: HPV 3,10
  - Seen in HIV patients and immunocompromised patients.
  - Seen in Kidney transplant patients.
  - Seen in a patient on Chemotherapy.

Q2.3: What are Plantar warts?

Answer:

- Superficial: HPV2- Mosaic pattern
- Deep: HPV 1 - Myrmecia



Mosaic



Myrmecia

Q2.4: What are the key features of Epidermodysplasia Verruciformis?

Answer:

- **HPV 5, 8**
- Genetic tendency to widespread HPV infection
- Autosomal recessive
- Increased Risk of squamous cell carcinoma
- EDV Presents with 3 Ps
  - **Plane warts lesion**
  - **P. Versicolor-like lesions**
  - **Reddish plaques**



YOURWISH

Q2.5: What are the key features of Anogenital warts?

PYQ: FMGE 2020,2021,2023

Answer:



- Associated with sexually transmitted infections.
- Also called Condyloma Accuminata
  - o Accuminata means pointed.
  - o Condyloma means soft.
- **Low risk: HPV - 6, 11**
- **High risk: HPV 16, 18, 31, 35**
  - o High-risk HPV are predisposed to malignancy.
- When the lesions are large, this leads to giant condyloma accuminata: **Buschke-Lowenstein Tumor**

Q2.6: What is the Histopathology of human papillomavirus (HPV) infections?

Answer:

- Koilocytes: **Clear-looking cells with perinuclear halo**
- Transformation of keratinocytes

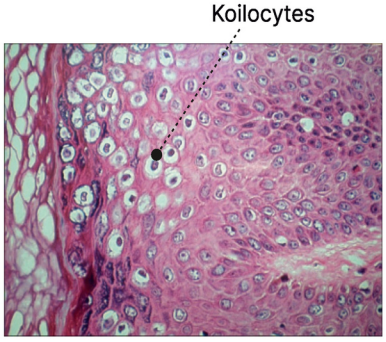

Q2.7: What is the treatment of human papillomavirus (HPV) infection warts?

PYQ: INICET 2020

Answer: Different physical and chemical methods are used.

- Major therapy: Destroying the virus.
- Treatment of choice in case of
  - o Genital lesions: Podophyllin, imiquimod, TCA
  - o Pregnancy: **Cryotherapy, Trichloroacetic acid (TCA)**

Chemical methods	Physical methods
• TCA • Topical 5-FU - 5-fluorouracil • Imiquimod - TLR7 agonist o Toll-like receptor • Podophyllotoxin and podophyllin (genital warts) o Plant derived. • Salicylic acid (plantar warts)	• Electrocautery • Radiofrequency • Cryotherapy • Surgical excision

Q2.8: Give an image of common warts?

Answer:



YOURWISH

YOURWISH

BIG QUESTION 3: What are the key features of Herpes Simplex Virus?

Broad Answer: Herpes Simplex Virus (HHV-1 and 2:)

- Causes primary, recurrent, and latent lesions
  - Primary lesions → More severe than recurrent infections.
- Stay latent in the **Dorsal root ganglion.**
- Passed on to partners in the inactive state
  - **HSV-1: Above waist infections**
  - **HSV-2: Below waist infections**

Q3.1: What are the key features of Herpetic Gingivostomatitis?

Answer:

- Causes painful, Coalescing erosions in oral mucosa, lymphadenopathy, and constitutional symptoms.
- Oral mucosa → Herpetic Gingivostomatitis
  - Most common cause of gingivostomatitis in children
- It's usually a primary infection.

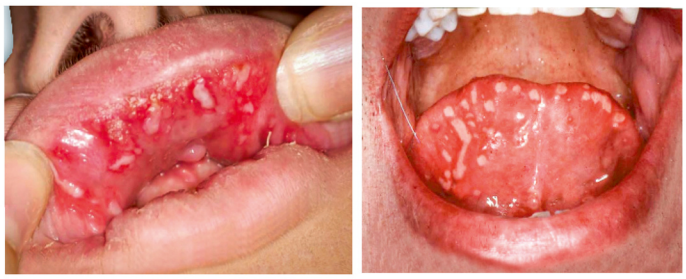

Q3.2: What are the key features of Herpes Labialis?

PYQ: NEET PG 2020

Answer:

- Cold sore
- Viruses may stay latent and cause secondary infection.
- Very mild infection, very recurrent
- Coalescent vesicles, present on the vermillion border of lips
- Slightly painful - mild discomfort
- Aggravating factors for HSV:
  - Fever
  - Stress
  - Menstrual cycle
  - Surgery
- The virus stays Latent in the **trigeminal ganglion.**
- **Treatment:** Topical anti-microbial

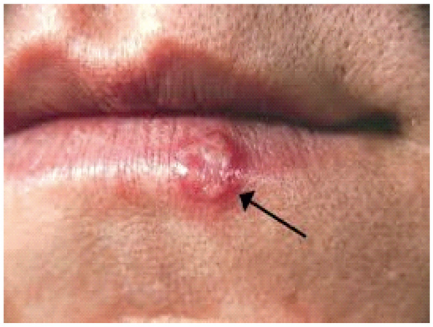

Q3.3: What are the key features of Genital Herpes?

Answer:

- Causative organism: HSV-2
- Shows primary, recurrent, and subclinical shedding.
- Associated with painful vesicles → Rupture and lead to coalescing polycyclic erosions.
- Associated with B/L painful lymphadenopathy.


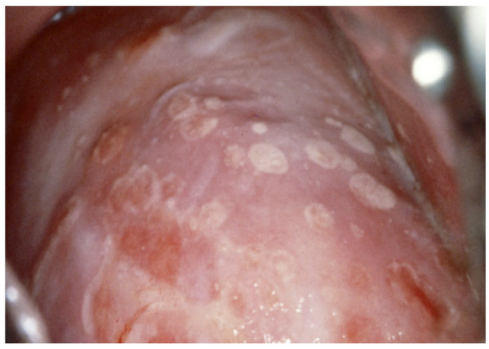

Q3.4: What are key features of Herpetic Whitlow?

Answer: Herpes on the tip of the Finger

- Usually seen in anatomists and pathologists (work with cadavers or samples)



Q3.5: How to Diagnose HSV?

Answer:

- **Tzanck smear for** → Acantholytic cells and Multinucleated giant cell

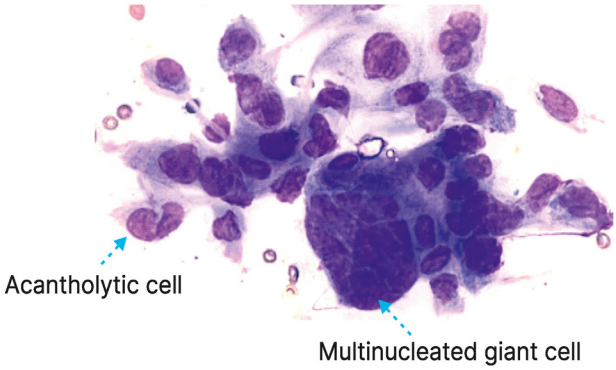

Q3.6: What is the Treatment of HSV?

Answer:

Antiviral	• Primary • 7 - 10 days	• Recurrence • 5 days	• Suppressive • 6-month - 1 yr
Acyclovir	200 mg 5 times /day	400 mg TID	400 mg BD
Valacyclovir	1 gm BD	500 mg BD	500 - 1000 mg BD
Famciclovir	250 mg TID	125 mg BD	250 mg BD

- **Acyclovir-resistant cases:** Foscarnet and Cidofovir

Q3.7: What are the Complications of HSV?

Answer:

- Erythema multiforme seen with drugs (10%) and HSV (90%)
- Eczema Herpeticum / Kaposi Varicelliform Eruption

Q3.8: What are the key features of Erythema Multiforme?

Answer:

- Erythema multiforme seen with drugs (10%) and HSV (90%)
- The most common infectious cause of EM: HSV
- Characteristic lesion: Target lesion with Multiple zones:
  - Central zone of necrosis
  - Second zone of edema
  - Third zone of erythema

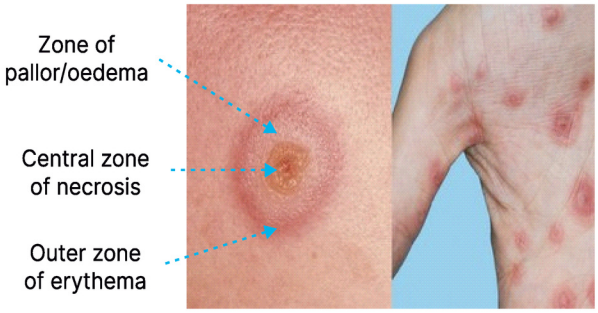

Q3.9: What is Eczema Herpeticum?

Answer: Also known as **Kaposi Varicelliform Eruption**

- **Preexisting dermatosis** → Mostly **Atopic Dermatitis / Darier's / Pemphigus**
  - Patient develops an HSV infection, with numerous painful vesicular lesions/crusts and also develops constitutional symptoms.
- **Treatment:** Acyclovir



Q3.10: What are the types of infections caused by Varicella zoster virus?

Answer: Causes two types of infection

- **Chickenpox: In children**
- **Herpes Zoster: In adults**

Q3.11: What are the key features of Chicken Pox?

PYQ: NEET PG 2018 PYQ: AIIMS 2019 PYQ: FMGE 2023 PYQ: INICET 2023

Answer: **Also known as varicella**

- Usually in children
- Incubation period: 2-3 weeks
- There is a prodrome of:
  - Fever, sore throat
  - Malaise
- Polymorphic morbilliform rash → Centripetal distribution (mostly seen in the trunk).
  - Starts as a vesicle → Turns into a crust → Heals with the pigmentation.
- Characteristic lesion → **Dew drop on a Rose Petal appearance**
- Itching/discomfort
- **Treatment:** Symptomatic treatment

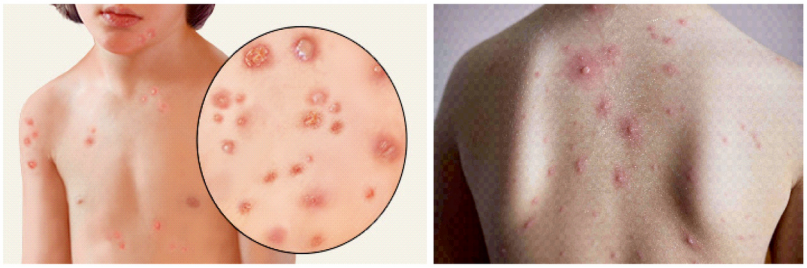



Q3.12: What are the key features of Herpes Zoster?

PYQ: INICET 2021,2022 PYQ: FMGE 2019,2023

Answer: **Herpes zoster** → Reactivation of the varicella-zoster virus → Stays latent in the **dorsal root ganglion** and may get activated later in life.

PYQ: NEET PG 2019

- Seen in
  - Elderly
  - Immunocompromised Patients with HIV
  - Also, in healthy adults
- **Dermatomal Distribution with midline demarcation** → Vesicles & erythema associated with severe pain on a dermatomal distribution.
  - **Most common dermatome - thorax > cervical > trigeminal > lumbosacral**
- **Treatment: Acyclovir** 800mg 5 times a day and **Valaciclovir** 1gm 3 times a day


Thoracic dermatomal distribution

Q3.13: What are the Complications of Herpes Zoster?

Answer:

- Herpes zoster ophthalmicus · Hutchinson's Sign
- Ramsay Hunt Syndrome
- Postherpetic Neuralgia.

Q3.14: What is Hutchinson's Sign?

Answer:

- Vesicles on the ala of the nose → High chance of ophthalmic involvement.
- **Nasociliary nerve** (branch of the **Ophthalmic division of the trigeminal nerve)** → Lesion in the tip of the Nose → May further develop **Herpes Zoster Ophthalmicus.**



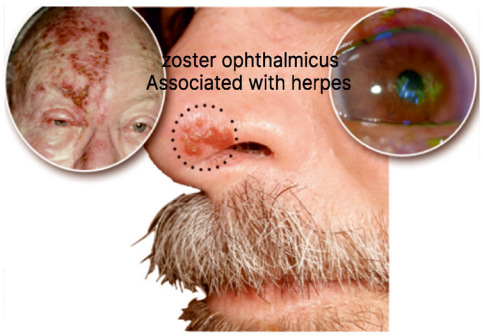

YOURWISH

Q3.15: What are the key features of Ramsay Hunt Syndrome?

Answer:

- Geniculate ganglion
- Trigeminal and facial nerve
  - Vesicles on tympanic membrane → ear pain, tinnitus
  - Facial palsy, vesicles on tongue

Q3.16: What is Postherpetic Neuralgia?

Answer:

- Pain persists for a long duration of time (>3 months after herpes zoster infection).
- Symptoms: Pain, paresthesia, tingling, and heaviness.
- **Treatment:** Gabapentin and Pregabalin

BIG QUESTION 4: What are the key features of Epstein-Barr Virus?

Broad Answer: Causes **Infection Mononucleosis (Glandular fever /kissing disease).**

- Presents with Exanthem, Fever, sore throat, and lymphadenopathy.
- It can be confused with a bacterial condition → Symptoms like fever, sore throat, and lymphadenopathy.
  - Given antibiotics for treatment (amoxicillin, ampicillin) leads to the development of a rash called **Ampi Rash.**

Q4.1: What is Oral Hairy Leukoplakia?

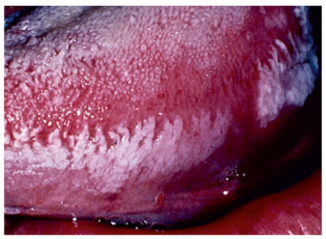

Answer:

- **Causative organism:** EBV
- Presents with a corrugated whitish appearance on the lateral border of the tongue.
- Seen in HIV patients.

Q4.2: What are the key features of HHV 6 & 7?

Answer:

- Causes Pityriasis rosea (PR)
- Trigger factor for LP - lichen planus
- Leads to an infection called Roseola infantum

Q4.3: What is Roseola Infantum?



Answer: Also known as **Exanthem Subitum**

- Caused by HHV 6&7
- Seen in infants <2 years
- Abrupt fever → As soon as the Fever subsides → Sudden appearance of red rose color rashes on the trunk of the body

Q4.4: What is Pityriasis Rosea?

PYQ: INICET 2022,2023

Answer:

- Causative organism: **HHV 6 and 7**
- First lesion → **Herald Patch**
  - Erythematous plaques with collar of scales.
- Characteristic feature: **Collarette of Scales**

- Lesions are present on the trunk, in a **Christmas Tree/Fir Tree pattern** along the lines of cleavage.
- Self-limiting condition and heals on its own.



Q4.5: What are the key features of Kaposi Sarcoma?



Answer:

- Causative organism: HHV-8
- Vascular tumor of the Endothelial cell
- Commonly seen in HIV patients
- **Present on Legs, Mucosa, or in any internal organs.**
- Deep red/bluish papules and nodules.

PYQ: INICET 2023

Q4.6: What are the key features of Parvovirus B19?



Slapped cheek appearance

Answer:

- Causes: **Erythema infectiosum**
- Presents with **Slapped cheek appearance**
- Child is usually well, with no fever
- Presents with Reticular exanthem on the trunk.

Q4.7: What are the Major Diseases Caused by parvovirus B19?

Answer:

Major Disease Caused by parvovirus B19		
Disease	Acute or Chronic	Host
Fifth disease	Acute	Normal children
Arthropathy	Acute or chronic	Normal adults
Transient aplastic crisis	Acute	Patient with increased erythropoiesis
Persistent anemia	Chronic	Immunodeficient and Immunocompromised patients
Hydrops fetalis and congenital anemia	Acute or chronic	Fetus

BIG QUESTION 5: What are key Enteroviral Disease?

Broad Answer:

- Hand, Foot, and Mouth Disease
- Herpangina

Q5.1 What are the key features of Hand Foot and Mouth Disease?

PYQ: AIIMS 2019

Answer:

- **Causative agent: Coxsackie A16 and Enterovirus 71**

- Present with vesicles with erythematous borders on the Hand, Foot, and Mouth
- Associated with Constitutional symptoms



Q5.2: What are the key features of Herpangina?

Answer:

- Causative agent: **Enterovirus 71**
- Vesicles are present on the oral mucosa of the **palate.**

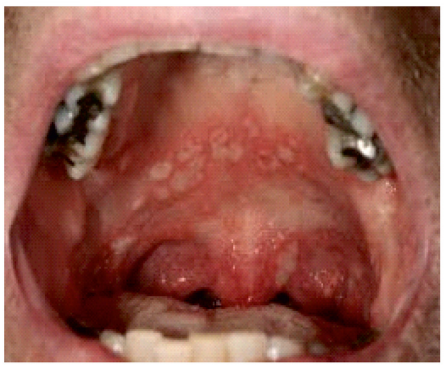

3. BACTERIAL INFECTIONS OF SKIN

BIG QUESTION 1: Describe bacterial skin infections and their types.

Broad Answer: Bacterial skin infection known as pyoderma is further divided into **follicular** and **non-follicular** infections.

- **Follicular infections**
  - Superficial folliculitis
  - Deep folliculitis
  - Furuncle
  - Carbuncle
- **Non-follicular infections**
  - **Impetigo** (most common in children, on the face).
  - **Types:** Non-bullous Vs Bullous impetigo
  - **Erysipelas**
  - **Acute Lymphangitis.**

DETAILED QUESTIONS

Q1.1: What is impetigo?

Answer:

PYQ: FMGE 2018

- Impetigo is the most common bacterial infection, which is usually seen in children on the face.
- It is of two types:
  - Non-bullous impetigo (Impetigo contagiosum) - more common
  - Bullous impetigo



Bullous



Non-bullous impetigo

Q1.2: What is the difference between bullous and non-bullous impetigo?

Answer:

	Bullous impetigo	Non-bullous impetigo /IC
Age group	Usually seen in newborn	Usually seen in preschoolers/toddlers
Organism	Staph aureus	Both by strep and staph • Staph is more commonly seen in developed nations. • Strep is more commonly seen in developing nations. **If both are in option one should mark strep**
C.F/type of crust	Golden crust	Crusted erosions covered by **honey-colored crust.**

YOURWISH

	Superficial bulla • Sometimes fluid-filled, settles down due to gravity, and appears half-moon. o Also called hypopyon	
Complication	These patients may end up with **Staphylococcal scalded skin syndrome (SSSS).**	The common complication is **post-streptococcal glomerulonephritis (PSGN)**

Q1.3. What structure is affected in Bullous Impetigo (BI)?

Answer: **BI-DSG-1** → The target, cleaved by the exfoliative toxin of *Staphylococcus aureus*.

Q1.4. What is the treatment of Impetigo?

Answer: **Topical antibiotics** such as **Mupirocin** and **Fusidic acid** are first-line.

Q1.5: What is the difference between erysipelas and cellulitis?

Answer:



Gp A b-hemolytic strep



staph/strep

Feature	Erysipelas	Cellulitis
Type	Superficial soft tissue infection	Deeper soft tissue infection
Site of involvement	Superficial dermis & lymphatics	Subcutaneous tissue
Lesion characteristics	Warm, red, indurated plaques	
Margins	Well-defined	Ill-defined
Systemic symptoms	Fever, constitutional symptoms	
Treatment	Oral antibiotics, leg elevation, NSAIDs	

Q1.6: What is acute lymphangitis, and how is it characterized?

Answer:



- Acute lymphangitis is a **streptococcal infection of the lymphatic vessels** in the subcutaneous tissue.
- It is characterized by an **erythematous, linear streak** of varying width that extends from the local lesion towards the regional lymph nodes, which are tender and enlarged.
- **Treatment:** Oral antibiotics.

BIG QUESTION 2: What are follicular bacterial infections?

Broad Answer:

- Follicular bacterial infections, or pyodermas, are classified based on the depth of the infection within the hair follicle.
- **Folliculitis** can be either **superficial** (affecting the superficial part of the hair follicle) or **deep**.
- A severe, deep infection of a single hair follicle is called a **furuncle**, while a **carbuncle** involves multiple contiguous hair follicles.

DETAILED QUESTIONS

Q2.1: What is the classification of follicular infections?

Answer: Follicular infections are classified as **superficial folliculitis** (superficial part of the hair follicle) or **deep folliculitis** (deep just around the hair follicle).

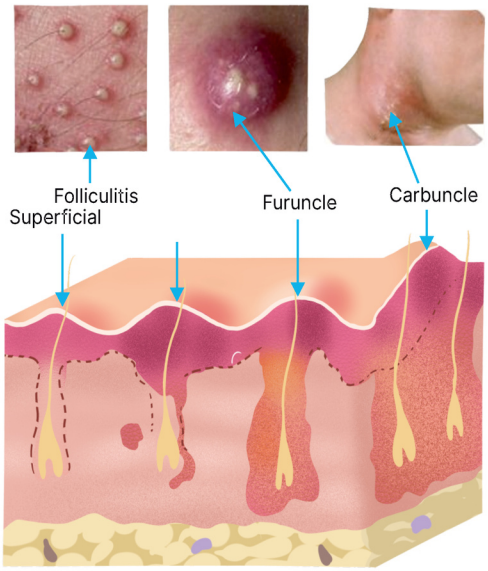

Q2.2: What are furuncles and carbuncles, and how are they related to folliculitis?

Answer:

- **Furuncle:** A severe infection involving the peri-follicular area of a single hair follicle.
- **Carbuncle:** A more extensive infection involving multiple, contiguous hair follicles.
- Both are severe forms of deep folliculitis.

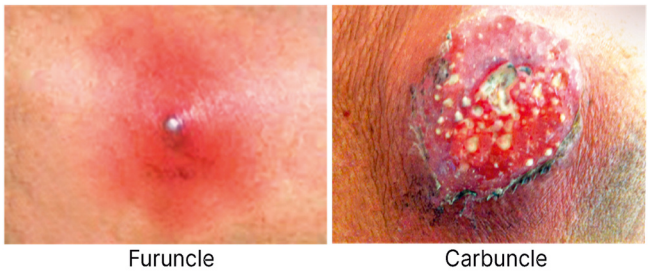
Furuncle Carbuncle

Q2.3: What are the features of superficial folliculitis?

Answer: Superficial folliculitis is characterized by superficial lesions located around the hair margin. A very superficial pustular form is called **Bockhart's impetigo**.



Q2.4: What are the features of deep folliculitis?

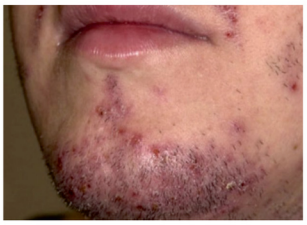
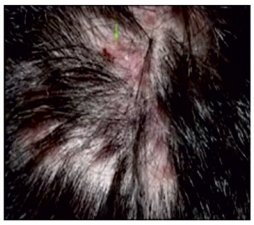

Answer: Deep Folliculitis seen in the beard area called sycosis barbae.

- It can affect the scalp called dissecting cellulitis of the scalp
- Misnomer; sycosis means a fungus, but it is a bacterial infection usually seen in the beard area.
- It is differentiated from Tinea barbae, which is usually itchy and has a KOH positivity.
- They appear like a fig tree, a fig-like appearance

Q2.5: What is the recommended treatment for follicular infections?

Answer:

- **Topical antibiotics** → superficial folliculitis.
- **Oral antibiotics** → deep folliculitis, furuncles, and carbuncles.

BIG QUESTION 3: What is bacterial toxin-mediated dermatoses?

PYQ: FMGE 2019



Broad Answer: **Staphylococcal Scalded Skin Syndrome (SSSS)** is a toxin-mediated dermatosis typically seen in newborns.

- It is caused by **exfoliative toxin 1** from *Staphylococcus aureus* infections, which binds to **desmoglein-1** causing an intraepidermal split (at the granular layer) and a positive Nikolsky sign.
- The condition presents with a newborn with a fever and constitutional symptoms.
- The primary focus of infection can be the eyes, nose, or ears.

DETAILED QUESTIONS AND ANSWERS

Q3.1: List the cutaneous infections caused by Staphylococcus aureus and Streptococcus pyogenes?

Answer: All follicular infections are caused by Staphylococcus.

Staphylococcus aureus	Streptococcus Pyogenes
• Impetigo follicular infections, e.g. superficial folliculitis, deep folliculitis (sycosis barbae and sycosis nuchae), furuncles and carbuncles • Ecthyma (strep > staph) • SSSS, TSS	• NBI • Ecthyma • Erysipelas • Acute lymphangitis, cellulitis • Necrotising fasciitis • TSS, Scarlet fever

Q3.2: What are the main clinical features of SSSS?

Answer:

- SSS is typically seen in **newborns** and presents with a fever and constitutional symptoms.
- The skin appears scalded and has a **positive Nikolsky sign**, where the outer layer of the skin peels away with slight pressure.
- The primary infection site is often the eyes, nose, or ears.

BIG QUESTION 4: Describe the skin infections caused by *Corynebacterium* species.

Broad Answer: Resident flora that can become pathogens by increasing in quantity.

- **Etiology:**
  - Healthy adults
  - Hot and humid climates
  - Asymptomatic/pruritic
- **Site (Most common):** Toe webs > groin crease.
- **Three infections:**
  - Erythrasma
  - Pitted keratolysis
  - Trichomycosis axillaris

DETAILED QUESTIONS

Q4.1: What are the three main infections caused by *Corynebacterium* species?

PYQ: INICET 2023

Answer: **Erythrasma, Pitted Keratolysis, and Trichomycosis axillaris.**

Q4.2: What are the diagnostic features of Erythrasma?

Answer:

- Erythrasma is caused by ***Corynebacterium minutissimum***.
- Well-demarcated, non-itchy, mildly scaly lesions, most commonly affecting the interdigital areas, axilla, and groin.
- Differentiated from tinea (a fungal infection) by Wood's lamp.
- Diagnostic feature → Lesions show a **coral-red fluorescence** under a Wood's lamp → bacteria's production of **coproporphyrin III**.



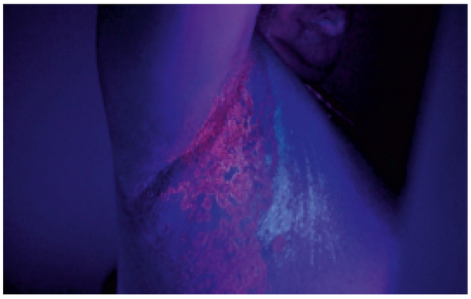

Q4.3: What is the treatment of erythrasma?

Answer: Treatment options include topical therapies like **fusidic acid, clindamycin, or erythromycin**, and oral options such as **clarithromycin or erythromycin**.

Q4.4: What are the features of Pitted Keratolysis?

Answer:

- Keratolysis caused by Micrococcus sedentarius
- Present with Pits in feet.
- Seen in individuals who have:
  - Wet work
  - Swimmers
- Associated with maceration and hyperhidrosis



YOURWISH

BIG QUESTION 5: Describe Anthrax and Pseudomonas skin infections.

Broad Answer:

- **Anthrax** is a zoonotic disease caused by ***Bacillus anthracis*** and is primarily seen in livestock handlers.
- The cutaneous form, known as a **malignant pustule**, is a misnomer because it's neither malignant nor a true pustule. It presents as a papule that crusts over and is surrounded by edema and erythema.
- **Pseudomonas** skin infections, caused by ***Pseudomonas aeruginosa***, have several distinct manifestations.
- They can cause **Green Nail Syndrome**, **Hot Tub Folliculitis**, and **Ecthyma Gangrenosum** (seen in immunocompromised patients).

DETAILED QUESTIONS

Q5.1: What is the causative organism of Anthrax?

Answer:

- Anthrax is caused by the bacterium ***Bacillus anthracis***.
- It is a zoonotic disease, and the main risk factor is contact with infected animals, making it most common in **livestock handlers**.

Q5.2: Describe the clinical features of cutaneous Anthrax and explain.



Answer:

- Cutaneous Anthrax presents as a **raised papule** that progresses to an ulcer and then gets a central black crust (eschar), surrounded by edema and erythema.
- The term **"malignant pustule"** is a misnomer because the lesion is **neither malignant** (cancerous) **nor a pustule** (a pus-filled blister).

Q5.3: What are the skin infections caused by *Pseudomonas aeruginosa*?



Answer:

- *Pseudomonas aeruginosa* can cause several skin infections:
  - **Green Nail Syndrome:** A greenish discoloration of the nail.
  - **Hot Tub Folliculitis:** Monomorphic Erythematous papules on the trunk (H/o taking baths in Jacuzzi or contaminated swimming pools).
  - **Ecthyma Gangrenosum:** A painful, gangrenous ulcer with a central eschar, typically seen in immunocompromised patients.

Q5.4: Explain the diagnosis of Green Nail Syndrome?

Answer: Green Nail Syndrome is diagnosed by a **Wood's test**, which shows a characteristic **greenish fluorescence**.

Q5.5: What are the classifications of Ecthyma?

Answer:

- Three types of Ecthyma:
  - Ecthyma Contagiosum: Orf virus
  - Ecthyma Infectiosum: Streptococcus
  - Ecthyma Gangrenosum: Pseudomonas (eschar)

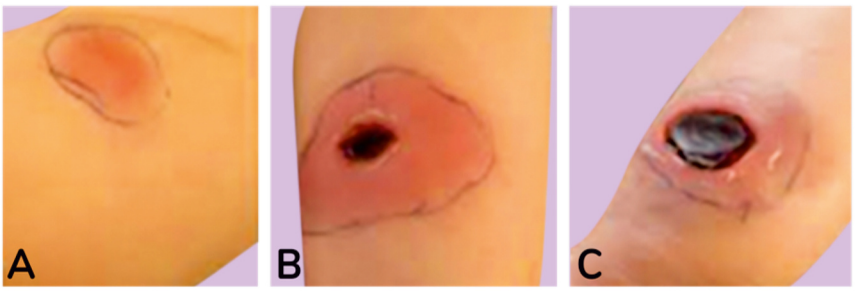

Q5.6: What is the treatment of Pseudomonas skin infections?

Answer:

- Common topical agents include **bacitracin, fusidic acid, mupirocin, and retapamulin** (new agent)
- Oral agents include **cloxacillin, erythromycin, amoxicillin, and cephalosporins.**

4. CUTANEOUS TUBERCULOSIS AND LEPROSY

BIG QUESTION 1: What is cutaneous tuberculosis infection?

Broad Answer: An extrapulmonary form of tuberculosis caused by ***Mycobacterium tuberculosis*** (causes TB and Leprosy). Broadly classified into **exogenous** (from an external source) and **endogenous** (from an internal source) forms.

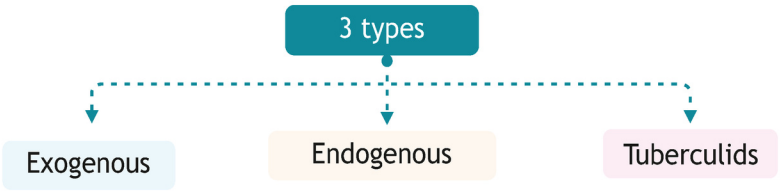

DETAILED QUESTIONS

Q1.1: Describe the key features of TB Chancre?

Answer: **TB Chancre / Primary Inoculation TB**

- Analogous to Ghon's focus on pulmonary TB → Primary inoculation TB. ·
- An ulcer with undermined edges



TB chancre

Q1.2: Describe the key features of Tuberculous Verrucous Cutis (TBVC).

Answer: **Tuberculous Verrucous Cutis (TBVC), also called Post-Primary Cutaneous TB, Anatomists or Pathologists wart**

- Occurs in the skin and appears as verrucous (exogenous source).
  - o Verrucous plaque shows induration associated with some discharge or crusting on the exposed surface (no pain)
- Secondary infection (high immunity against TB bacteria)
- **Predisposing population**
  - o Healthcare workers
  - o Farmers
  - o Children: On buttocks



Verrucous plaque

Q1.3: What are the characteristic features of Lupus Vulgaris?

Answer: Most common form of cutaneous TB in adults in India

- A plaque-type TB
  - o Erythematous plaque → Expanding lesion with peripheral extension and central scarring
- **Endogenous TB:**
  - o Hematogenous spread (common)
  - o Lymphatic spread
  - o Auto inoculation
- Most common sites: Head and neck, Arms, Legs, Buttocks



Lupus vulgaris plaque

YOURWISH

- Associated malignancy: Squamous Cell Carcinoma (SCC), Basal Cell Carcinoma (BCC)

Q1.4: What are "apple jelly nodules"?

Answer:

- **Apple jelly nodules** are a key feature of Lupus Vulgaris.
- They are the yellowish/brownish discolorations of the granuloma seen upon **diascopy** (a diagnostic technique where pressure is applied to the lesion with a glass slide).



Diascopy picture

Q1.5: Which cutaneous TB is painful?

Answer: Any type of cutaneous TB is typically **painless**, with the sole exception being **Orificial TB**.

Q1.6: What are the three ulcers with undermined edges in dermatology?

Answer: The three ulcers with undermined edges are: TB Chancre, Chancroid, and Pyoderma gangrenosum.

Q1.7: What is the causative agent and the primary mode of transmission for Scrofuloderma?

Answer:

- **Causative agent:** *Mycobacterium tuberculosis*.
- **Primary mode of transmission:** Contiguous spread from an underlying focus of infection.

Q1.8: What is the epidemiology of Scrofuloderma?

Answer: The most common form of cutaneous tuberculosis seen in **children**.

Q1.9: What are the common underlying foci of infection for Scrofuloderma?

Answer: **Lymph nodes**: Cervical > Axillary > Pre and Post-auricular lymph nodes

- Other Sites: **Bone** and **lacrimal glands**.

Q1.10: What are the typical clinical signs and symptoms of Scrofuloderma?

Answer: Ulcerating lesions, sinus tract formation, underlying lymph node enlargement, and is usually painless, though discharge may occasionally be present.



BIG QUESTION 2: What are tuberculids? Describe their key diagnostic criteria and the pathogenesis?

Broad Answer: Tuberculids are Type IV hypersensitivity (type of Id reaction → hypersensitivity reaction to the underlying microbe) skin reactions to *Mycobacterium tuberculosis* from a distant focus. They show a positive Mantoux test but negative AFB and culture. Types include Lichen Scrofulosorum (non-scarring lichenoid papules in children), Papulonecrotic Tuberculid (scarring necrotic papules in adults), and Erythema Induratum of Bazin (painful nodules on calves in middle-aged women, healing with scars). All are treated with a standard 6-month anti-tuberculosis therapy (ATT).

DETAILED QUESTIONS

Q2.1: What are tuberculids, and what are the key criteria for their diagnosis?

Answer: **Tuberculids** are skin lesions caused by a **Type IV hypersensitivity reaction** to ***Mycobacterium tuberculosis*** or

its remnants spreading from an internal primary focus.

- The diagnostic criteria include:
  - The presence of a primary focus of TB elsewhere in the body.
  - Positive Mantoux test.
  - Negative culture test and AFB (acid-fast bacilli) test from the skin lesion.
  - Histological findings consistent with a tuberculid on biopsy.
  - Response to anti-tuberculosis therapy (ATT) → Primary focus is improved, CMI decreases.

Q2.2: What are the features of Papulonecrotic Tuberculid?

Answer:

- Necrotic papules appear on the extremities.
- Most commonly found in adults.
- Heals with scarring.
- Biopsy: Obliterative vasculitis (vascular inflammation) and Thrombosis



Papulonecrotic Tuberculid

Q2.3: Describe the key features of Erythema Induratum of Bazin.

Answer:

- Facultative tuberculid (MTB is one of the causes)
- Most common in middle-aged females.
- It occurs in the posterior calves.
- Nodular lesions heal with scarring.
- Painful deep dermal nodules with crusting and scarring.
- **Biopsy:** Lobular panniculitis and vasculitis.
- The induration is deep till the fat cells.

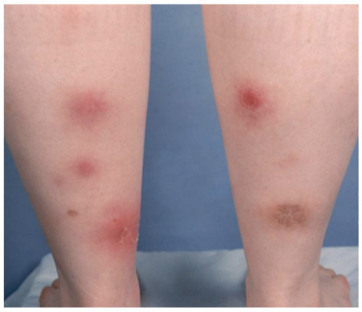

Q2.4: What is the management protocol for all forms of cutaneous TB?

Answer: All forms of cutaneous TB are treated with a standard 6-month course of **anti-tuberculosis therapy (ATT)**.

- The treatment is divided into two phases:
  - **Intensive phase (2 months): HRZE** (Isoniazid, Rifampicin, Pyrazinamide, and Ethambutol).
  - **Maintenance phase (4 months): HRE** (Isoniazid, Rifampicin, and Ethambutol).
    → **HERZ:** Isoniazid, Ethambutol, Rifampicin and Pyrazinamide

Q2.5: What is the Pathogenesis of Tuberculids?

Answer:

Mycobacterium tuberculosis infects the person - primary focus.
↓
MTB or its remnants enter the blood from the primary focus
↓
Initiates cell-mediated immune response (CMI) - delayed-type hypersensitivity reaction
↓
Leads to tuberculids

Q2.6: What are the features of Lichen Scrofulosorum?

Answer:

- Contains grouped lichenoid papules on the trunk. (micropapular)

- Lesions are mainly perifollicular.
- Most common in children.
- Heals without scarring.
- **Biopsy:** Superficial Dermal Granuloma.

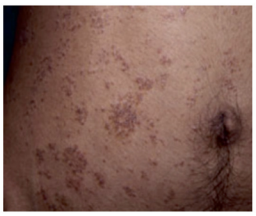


Q2.7: What are the features of Erythema nodosum?

Answer:

- MTB is one of the causes of infection.
- No surface changes, crusting, or scaling.
- Never heals with scarring.
- Present on the Anterior part of the shin.

BIG QUESTION 3: Discuss the different forms of leprosy and their management.

Broad Answer: Leprosy, caused by *Mycobacterium leprae*, is diagnosed by sensory loss in skin lesions, thickened nerves, and acid-fast bacilli on skin smear. It's classified by the Ridley-Jopling system (TT to LL) or WHO criteria (PB vs. MB). The Morphological Index (MI) tracks treatment response. Clinical features range from isolated lesions in TT to widespread nodules and Leonine facies in LL. Reactions (Type 1 & 2) are managed with steroids and continued MDT.

DETAILED QUESTIONS

Q3.1: What are the three cardinal signs and diagnosis of leprosy?

PYQ: FMGE 2023

Answer:

- **Cardinal signs:**
  - Diminished or total loss of sensation in an atypical skin lesion.
  - Enlargement and tenderness in a peripheral nerve.
  - Finding of acid-fast bacilli on a slit skin smear.
- **Detection of bacteria**
  - Slit skin- AFB
  - Culture- cannot be cultured, can grow in a mouse foot pad or a nine-banded armadillo
  - Serology

Q3.2: Explain the procedure for a slit skin smear.

Answer: A slit skin smear is performed by taking a 15 mm blade and making an incision 5 mm long and 3 mm deep → Rotate the blade and scrape out of the tissue → Smear the tissue and do ZN staining → Acid-fast bacilli appear pink on a blue background (do not get colorized).

- **Identification criteria**
  - Site: Ear lobe
  - The density of bacilli in tissue: 10^4 bacilli/ gm

Q3.3: What are the types of bacteria ?

Answer: 3 Types of bacilli

- Solid M. leprae: Living bacilli
- Fragmented: Dead bacilli
- Granular: Dead bacilli

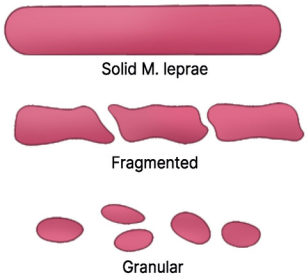



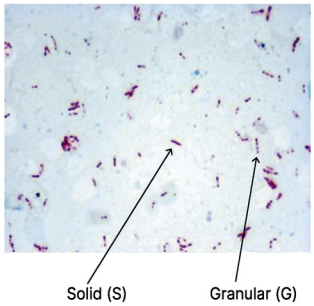

Q3.4: What is the Morphological Index (MI) ?

Answer: It is the percentage of solid-stained (living) bacilli among 200 singly lying bacilli. The MI is the most useful index for **monitoring treatment response** and detecting drug resistance, unlike the Bacteriological Index (BI) which includes dead bacilli.

Q3.5: What is the Bacteriological Index (BI) ?

Answer: Density or concentration of bacilli, living and dead bacilli → Not useful in monitoring treatment.

1-10 bacilli in 100 fields	1+
1-10 bacilli in 10 fields	2+
1-10 bacilli per field	3+
10-100 bacilli per field	4+
100-1000 bacilli per field	5+
>1000 bacilli per field	6+

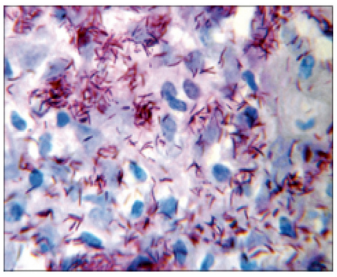

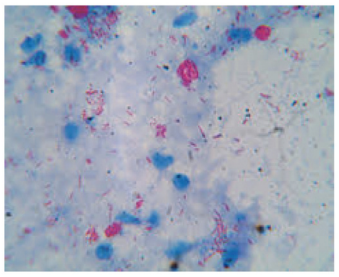

Q3.6: What are the two poles of leprosy?

Answer:

Tuberculoid	Lepromatous
• Here, the immune system is good, • possible to curtail the bacilli. • CMI or Cell-Mediated Immunity is protective against M.leprae of TH1 type. • It has a TH1 response	• Here, the immune system is not good, • It is not possible to curtail the bacilli. • The number of bacilli is more. • Skin lesions will be more. • It is more of a TH2 response. • TH2 is protective of bacteria and not against an individual. • There will be more antibodies.

Q3.7: Nerve damage happens in which pole?

Answer: Nerve damage happens in both poles.

Tuberculoid Pole	Lepromatous Pole
• Nerve damage is localized • Body's immune response targets the nerves as a bystander effect (nerve abscess, tenderness)	• Nerve involvement is bilateral and symmetrical. • Nerve damage is due to the infiltration of bacilli into the nerve (glove and stocking anesthesia)

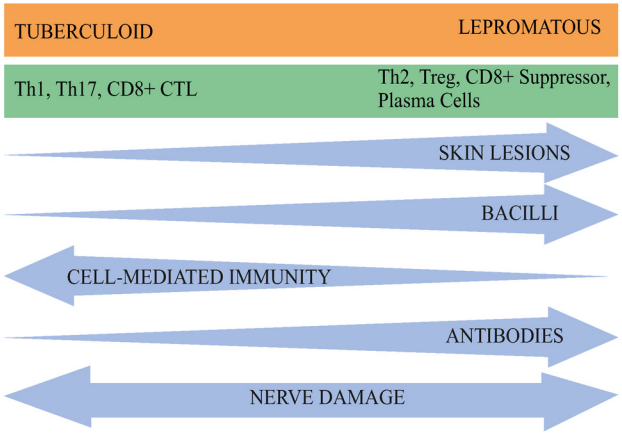

YOURWISH

Q3.8: Describe the Ridley-Jopling classification of leprosy

Answer: Considered the **most scientific classification** of leprosy.

- Based on **4 key parameters:**
  - Clinical features
  - Bacteriological findings
  - Immunological response
  - Histopathology
- Tuberculoid (TT) → Stable, Borderline Tuberculoid (BT), Mid-Borderline (BB), Borderline Lepromatous (BL), Lepromatous (LL) → Stable
- *(TT and LL are stable poles, while BT, BB, BL are immunologically unstable and may shift depending on treatment/disease progression.)*

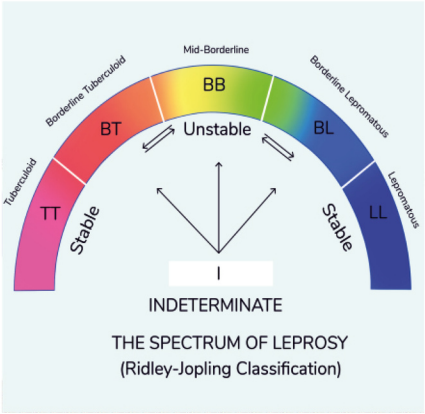

Q3.9: Which type of leprosy is not included in the Ridley-Jopling classification of leprosy?

Answer: Indeterminate and Pure Neuritic Hansen

Q3.10: Describe the WHO classification of leprosy?

PYQ: INICET 2022

Answer:

	MB (Multibacillary)	PB(Paucibacillary)
Skin lesions	> 5	1-5
Nerve involvement	≥ 1	0
AFB	+	-

- According to NLEP: National Leprosy Eradication Programme
  - If there is 1 nerve involvement → PB
  - If >1 nerve involvement → MB

PYQ: INICET 2021

Q3.11: What are the features of Indeterminate Leprosy?

Answer:



- The Most Common form of leprosy in India.
- Endemicity: Jharkhand, UP, Bihar.
- Site: Face or extremities
- Clinical feature:
  - Infiltration: Ill-defined hypopigmented lesions that are single with no loss of sensation and no infiltration.
  - On HPE: Periappendageal granulomas.
- Management: Observation
- **Differentiating from Pityriasis ALBA**
  - Pityriasis Alba → Multiple hypopigmented lesions, scaling, spongiosis (on HPE), negative slit skin smear.

BIG QUESTION 4: Discuss the different determinate forms of leprosy.

PYQ: NEET PG 2021

Broad Answer: Leprosy ranges from Tuberculoid (TT) with few, well-defined lesions and sensory loss, to Lepromatous (LL) with numerous, ill-defined lesions, leonine facies, and glove-and-stocking anesthesia. Borderline forms (BT, BB, BL) show mixed features; BT is most common, BB most unstable, and BL has symmetrical "inverted saucer" lesions. Histoid leprosy is a rare LL variant with firm papules from dapsone monotherapy. Pure neuritic Hansen's affects only nerves, common in India.

YOURWISH

DETAILED QUESTIONS

Q4.1: What are the features of Tuberculoid (TT) leprosy?

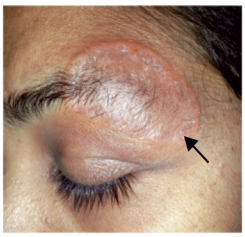



Answer:

- This is a **polar, stable form** with **high immunity**.
- It has a low number of lesions (1-5), which are **well-defined and scaly, large (<10 cm)**, dry, and scaly.
- There is **100% loss of sensation** in these lesions.
- The saucer right way up: Lesion

Q4.2: Describe the "saucer right way up" appearance and the "inverted saucer" appearance.

Answer:

- The **"saucer right way up"** appearance: **TT leprosy**.
  - o Well-defined lesion that is elevated, with a clear border.
- The **"inverted saucer"** appearance: **BL leprosy**.
  - o Lesions with central invasion and ill-defined margins, where the bacilli are invading the surrounding area.
  - o Referred to as annular, punched-out, or dome-shaped lesions.

Q4.3: What are the key clinical features of BT form of leprosy ?



Answer:

- **Most common determinate form of Hansen's disease**
- Immunity is preserved but not as strong as in **tuberculoid leprosy**.
- Lesions are **well to ill-defined**.
- Typically, **10-20 lesions** are present, each measuring about **10-20 cm** in size.
- Lesions start extending outward → **pseudopodia**.
- Smaller surrounding lesions → **satellite lesions** → indicates **disease spread**.
- **Marked sensory loss**, but it is **not complete (not 100%)**.
- **Nerve to patch correlation** will be present.

Q4.4: What are the key clinical features of BL form of leprosy ?





INVERTED SAUCER

Answer:

- **Number:** Numerous small lesions with ill-defined margins, usually symmetrical.
- **Margin:** Lesions have ill-defined borders.
- **Symmetry:** Multiple lesions show a tendency toward symmetry.
- **Sensory loss:** Glove and stocking anesthesia is typically seen.
- **Inverted saucer appearance:** Bacilli invade the surrounding tissue, producing central clearing with raised edges → inverted saucer lesion.
- **Differentiation from BB (Borderline Borderline):**
  - o **Punched-out / Swiss cheese lesions** are more characteristic of **BB** than BL.

Q4.5: What are the key clinical features of the BB form of leprosy?

Answer:

- **Stability:** Most unstable form of leprosy in the Ridley-Jopling spectrum.

- **Number of lesions:** More than 20 lesions, distributed widely across the body.
- **Type of lesions:**
  - o Punched-out lesions: sharply demarcated with central clearing.
  - o Map-like (geographical) lesions: irregular, spreading, and merging in shape.
- **Spread:** Lesions tend to spread extensively all over the body.

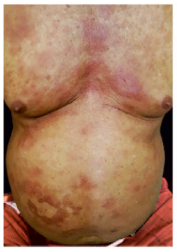


Q4.6: What are the key clinical features of the LL form of leprosy?

Answer:

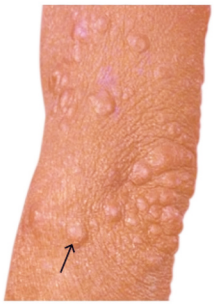


- Immunity: Very low or absent cell-mediated immunity against *Mycobacterium leprae*.
- Number & type of lesions:
  - o Numerous lesions: papules, nodules, and macules.
  - o Lesions are small, symmetric, shiny, and ill-defined.
- Surface: Shiny appearance of lesions.
- Hair & skin changes:
  - o Leprous alopecia: loss of hair over lesions, especially eyebrows (madarosis).
  - o Leonine facies: thickened skin folds of the face producing a lion-like appearance.
- Neurological features:
  - o Anaesthesia: glove and stocking type sensory loss.
- Investigations:
  - o Slit skin smear: Positive for abundant acid-fast bacilli.
    Lepromin test: Negative (reflecting poor immunity).

Q4.7: Describe the specific features of "Leonine Facies" and the "Sanctuary/Safe Sites" in leprosy.

Answer:

- **Leonine Facies**: Includes madarosis (loss of eyebrows and eyelashes), a saddle nose due to cartilage destruction, a sagging face, and enlarged "Buddha's ears" with a collapsed pinna.
- **Sanctuary/Safe Sites** → Include the warmer areas like the axilla, groin, scalp, as well as the CNS, female reproductive tract, posterior chamber of the eye, and lower respiratory tract.


Leonine facies

Q4.8: What are the characteristics of Histoid leprosy?

Answer

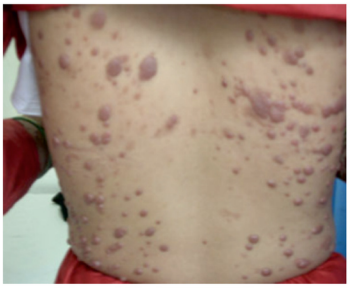

- Unusual form of lepromatous leprosy
- Due to focal loss of immunity.
- AFB is longer and slender.
- Cause: Dapsone monotherapy.
- Clinically: firm papules or nodules on clinically normal skin
- Very high BI and MI
- Spindle-shaped cells in histopathology (biopsy of lesion)

Q4.9: What are the characteristics of Pure Neuritic Hansen?

PYQ: AIIMS 2018

Answer

- Only nerve involvement and no skin lesions

- Endemic to India
- Neurological sensation loss
- Slit skin smear: Negative.
- Absence of other causes of nerve involvement
- **Nerve biopsy:** Take the nerves from purely sensory nerves, which are radial cutaneous nerves, sural nerve.

BIG QUESTION 5: Describe the nerve involvement in leprosy.

Broad Answer: In leprosy, nerve involvement is a hallmark feature, usually presenting with sensory loss that progresses in the order of temperature, then fine touch, and finally pain. The ulnar nerve is most commonly affected among peripheral nerves, while the facial and trigeminal are the most frequent cranial nerves involved. Typical nerve palsies include high ulnar and low median palsy, and enlargement of the greater auricular nerve—often more visible than palpable—is a key diagnostic sign.

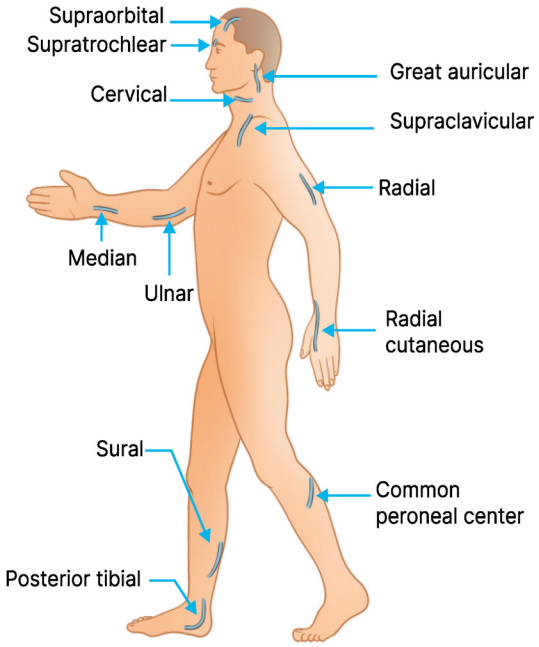

Surface marking of nerves commonly affected in leprosy



DETAILED QUESTIONS

Q5.1: What is the nature of nerve involvement in leprosy, and what is the order of sensory loss?

Answer:

- Nerve involvement in leprosy is **specific, paralytic, and sensory**.
- The most common abnormality is sensory loss,
- Loss of temperature > fine touch > pain
- Deep touch, vibration, and proprioception are generally not affected.

Q5.2: What are the most common peripheral and cranial nerves involved in leprosy?

Answer:

- The most common peripheral nerve involved is the **ulnar nerve**.
- The most common cranial nerves involved are the **facial and trigeminal nerves**.

Q5.3: What type of nerve palsy is characteristic of leprosy?

Answer:

- Leprosy typically causes a **high ulnar palsy** and a **low median palsy**.
- The **greater auricular nerve** is a key nerve to examine, as it is often enlarged due to inflammation and is described as being "better seen than felt."

BIG QUESTION 6: Differentiate between Type 1 and Type 2 reactions.

Broad Answer:

	Type 1	Type 2
Hypersensitivity reaction	Type 4 hypersensitivity reaction	Type 3 hypersensitivity reaction
Spectrum	Upper	The lower end of the spectrum
Predisposing factor	Happens after initiation of MDT	Stress, infection, and pregnancy bring down the immune system further.
Clinical feature	Exacerbation of existing lesions- swelling, redness, tender	• New crops of lesions, along with the evening rise in temperature • Constitutional + systemic symptoms
Nerve involvement	Tenderness, abscess formation	Not seen much here.

DETAILED QUESTIONS

PYQ: INICET 2022

Q6.1: What are the two types of leprosy reactions?

Answer: The two types are **Type 1 reaction** (or reversal reaction) and **Type 2 reaction** (or Erythema Nodosum Leprosum - ENL).

- Type 1 is a **Type 4 hypersensitivity reaction** (cell-mediated).
- Type 2 is a **Type 3 hypersensitivity reaction** (immune complex-mediated).





Q6.2: What are the nerve involvements in Type 1 and Type 2 reactions?

Answer:

- Nerve involvement is a prominent feature of **Type 1 reactions**, presenting as nerve tenderness and the potential for **nerve abscess formation**.
- Nerve involvement is **not as common** in Type 2 reactions.

Q6.3: What is the treatment for Type 1 and Type 2 leprosy reactions?

Answer: Management:

- For both reactions, **MDT must be continued**.

Type 1 Reaction	Type 2 Reaction
• Continue MDT + Oral steroids • Mild: NSAID, aspirin • Neuritis: Steroids • Nerve abscess: Steroids > drain the abscess o Alternative drugs: AZA, cyclosporine, MTX, HCQS	• Oral Steroids and MDT • Thalidomide o Second-line treatment for type 2. o Use:Resistant to steroids or cannot be given medicine. o Multiple crops of new lesions are associated with fever → Arise in the evening and settle in 24 to 48 hours with PIH → Evanescent lesions.

YOURWISH

YOURWISH

Q6.4: What is the management of leprosy in pregnant patients?

Answer: **Pregnancy:** The **same MDT protocol** is continued.

Q6.5: What is the management of leprosy in patients with concomitant TB?

Answer: **Concomitant TB:** The patient receives standard anti-tuberculosis therapy (ATT), and the MDT is continued without Rifampicin to avoid drug interactions and toxicity.

Q6.6: What is the Treatment of leprosy?

PYQ: NEET PG 2021

Answer:

- MB: 12 months
- PB: 6 months



MB-MDT for MB cases			
	Dapsone	Rifampicin	Clofazimine
Adult 50-70 kg	100 mg given daily	600 mg given once a month under supervision	50 mg daily and 300 mg given once a month under supervision
Child 10-14 years	50 mg given daily	450 mg given once a month under supervision	50 mg alternate day and 150 mg given once a month under supervision

5. FUNGAL INFECTIONS OF SKIN

Big Question 1: What are the causes, clinical features, and treatment options for Pityriasis Versicolor, a common skin condition affecting adolescents and adults?

Broad Answer:

- Pityriasis Versicolor is a superficial fungal infection caused by Malassezia species that overgrows in warm, humid climates or in oily skin conditions.
- It presents with asymptomatic hypo- or hyperpigmented, finely scaly macules, most often on the chest, back, and upper arms, sometimes with mild pruritus. '
- Diagnosis is usually clinical, with KOH mount showing "spaghetti and meatball" appearance of hyphae and spores.
- Treatment includes topical antifungals (azoles, selenium sulfide, zinc pyrithione) for localized disease, while systemic azoles like itraconazole or fluconazole are used for extensive or recurrent cases.

DETAILED QUESTIONS

Q1.1: What's the etiology of Pityriasis Versicolor?

PYQ: INICET 2022, 2023

Answer:

- It is also known as Tinea Versicolor - Misnomer
- Organism: Malassezia.
- The species are Globosa (MC), furfur, and sympodialis
- Superficial fungal infection
- They occur in Seborrheic areas.
- It mostly occurs in the hot, humid season.
- It affects adolescents and adults.
- It relapses every year.

Q1.2: How does Pityriasis Versicolor present?

Answer:

- Pityriasis means scaly, and versi means various.
- Presented as asymptomatic hypo/hyperpigmented scaly macules on the trunk
- Scales are very fine, called Branny scales.
- Hypopigmentation is due to the production of carboxylic acid and azelaic acid.
- Hyperpigmentation is due to the production of giant melanosomes.



Q 1.3: How does Malassezia appear on KOH smears and on the wood lamp?

Answer:

KOH smear shows:	• **Spaghetti(hyphae) and meatball(yeast form) appearance,** also called banana and grapes appearance	• Wood's lamp shows **yellowish fluorescence**





Q 1.4: What are the treatment options for Pityriasis Versicolor?

Answer:

- Topicals
- Azoles
- Zinc pyrithione, selenium sulfide, sulfur
- Oral: given only if recurrence is there
- Azoles: Itraconazole or fluconazole are given if the infection is severe.

Big question 2: What are the characteristics and types of Piedra, a fungal infection affecting hair shafts?

Broad Answer: Piedra is a superficial fungal infection of the hair shaft, characterized by nodular concretions along hair. It is classified into Black Piedra, caused by Piedraia hortae, producing hard black nodules on scalp hair, and White Piedra, caused by Trichosporon species, forming soft white to brown nodules on beard, axillary, or pubic hair. The condition is often asymptomatic but causes cosmetic concerns and hair fragility. Management includes shaving affected hairs and use of topical or systemic azoles in persistent cases.

DETAILED QUESTION

Q2.1: What are the causative organism and their clinical presentation of Black Piedra?

Answer:

Black Piedra

- It is caused by Piedra Hortae
- It is presented as:
  - Hard gritty nodules.
  - Appears on the hair shaft, of the scalp.



Q2.2: What are the causative organism and their clinical presentation of White Piedra?

Answer:

White Piedra

- It is caused by **Trichosporon Asahii/Trichomycosis Nodosa.**
- It is presented as:
  - Soft white nodules.
  - Appears on other hair bearing areas.

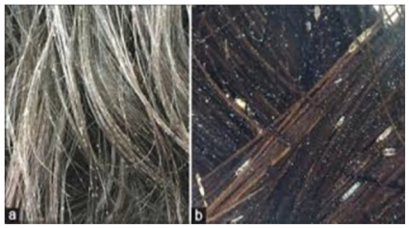

Big question 3: What are the characteristics, types, and treatment options for Dermatophytosis (Tinea), a common fungal infection affecting skin, hair, and nails?

Broad Answer:

- Dermatophytosis is caused by keratinophilic fungi (*Trichophyton*, *Epidermophyton*, *Microsporum*), spreading by direct contact, fomites, or animals.
- It presents in varied forms depending on site: Tinea corporis (ringworm of trunk/limbs), Tinea cruris (groin), Tinea pedis (athlete's foot), Tinea capitis (scalp), and Tinea unguium (nails).
- Characteristic features include annular erythematous plaques with central clearing, scaling, itching, or brittle discolored nails.
- Diagnosis is made by KOH mount showing septate hyphae and fungal culture.
- Treatment ranges from topical antifungals (azoles, allylamines) for limited disease to systemic therapy (terbinafine, itraconazole, griseofulvin) for extensive, hair, or nail involvement.

DETAILED QUESTIONS

Q 3.1: What are the species that cause Tinea infection?

PYQ: INICET 2021, 2023

Answer:

- Dermatophytosis/Tinea:
- Species that cause the infection are:
  - Trichophyton: It affects skin, hair, and nails.
  - Epidermophyton: It affects the skin and nails.
  - Microsporum: It affects skin and hair.

Q 3.2: Define Tinea, and what are the various forms of tinea?

Answer: A classical tinea lesion is an annular lesion with central clearing and showing peripheral activity



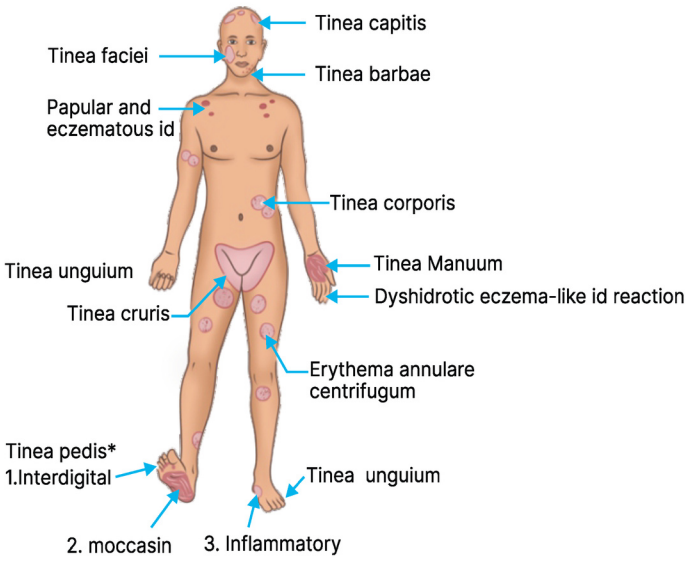

Q3.3: What are the inflammatory types of tinea capitis?

PYQ: NEET PG 2021

Answer: Inflammatory: There will be scarring.

YOURWISH

YOURWISH

Kerion	Favus
• Shows painful boggy swelling studded with pustules with broken hair. • Lymphadenopathy • Organism: **T. ferrugineum, and verrucosum.** • KOH and wood's lamp test will be negative. • Most severe form • Result in scarring 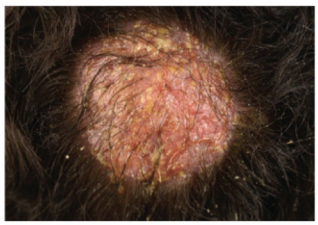	• Cup-shaped crusts, also called scutula. • It is caused by **T. Schoenleinii** • Wood's lamp will be positive with dull green fluorescence 

- Note: M.Ferrugineum will show no fluorescence

Q3.4: What are the non-inflammatory types of tinea capitis?

Answer: Non-inflammatory: There will be a non-scarring circular patch of alopecia.

Gray patch	Black dot
• Ectothrix infection. • These scales are fungal colonies which are evident on surface. 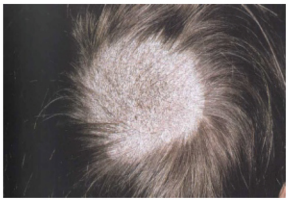 • Causative Organism: M.canis /M.audonii • Positive woods lamp fluorescence. • Responsible for outbreaks in schools	• Endothrix infection • Swollen hair shaft • Does not show woods lamp fluorescence • Organism: T.violaceum and T.sodounies 

Q3.5: What's the management of Tinea capitis?

Answer:

- Griseofulvin (Doc)
- Terbinafine
- Itracaonazole

Q 3.6: Describe Tinea corporis, Tinea circinata, Tinea pedis, and Tinea cruris?

Answer:

- **Tinea corporis**
  - o Organism: T.mentagrophytes (mc)



- **T.circinata**: T.corporis in a concentric pattern known as T.circinata, caused by T.concentricum



- **Tinea pedis**
  - o It affects the Dorsal aspect of the feet.
  - o It is also called the Athlete's foot.
  - o **Interdigital:** It is the most common type of Tinea Pedis, it most commonly affects the 4th web space.



- **Tinea cruris** PYQ: AIIMS 2018
  - o Tinea cruris involves crural folds.
  - o This is also called Dhobi's Itch or Jogger's itch because it happens due to a lot of sweating.
  - o It shows less scaling, due to maceration.



Q3.7: What's steroid-modified tinea?

Answer:

- Tinea incognito is called steroid-modified Tinea.
- It is caused by the excessive use of Corticosteroids on tinea.
- There is no central clearing or scaling in tinea incognito.
- There is the presence of plaque with small pustules and nodules



KOH positive

Q3.8: What is Tinea unguium, and what are the various types of it?

PYQ: NEET PG 2020

Answer:

- It is a type of onychomycosis.
- When a Dermatophytic organism affects the nail, it is called Tinea unguium

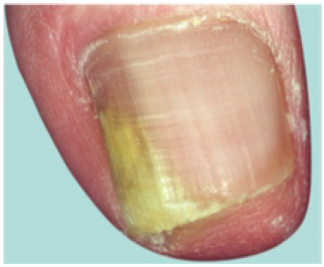

(M/C) Distal lateral Subungual Onychomycosis





Total dystrophic onychomycosis



Superficial white Onychomycosis

- There are various types of tinea unguium:
  1. DLSO: Distal lateral subungual onychomycosis- The commonest
  2. PSO: Proximal subungual onychomycosis
  3. SWO: Superficial white onychomycosis, superficial white plaques that can be scraped off.
  4. TDO: Total dystrophic onychomycosis. The whole nail is destroyed.

Q3.9: What's the difference between onychomycosis and psoriatic nail?

Answer :

- Psoriasis is more common on fingers, and onychomycosis is more common on toes.
- Pitting and salmon or oil drop sign is positive in psoriatic nails and negative in onychomycosis
- KOH is negative for psoriasis, whereas it is positive in onychomycosis.

Q3.10: What are the various treatment options for tinea unguium?

Answer:

- Topical treatment:
  - Nail lacquers
    - → Cyclopiroxolamine is applied daily.
    - → Amorolfine, which is applied weekly.
    - → Luliconazole.
- Systemic treatment:
  - Terbinafine (250 mg OD, 6 weeks for fingernails and 12 weeks for Toenails)
  - Itraconazole (100 mg BD 2 months for fingernails and 3 months for toenails)
- Pulse therapy:
  - Itraconazole 200 mg BD 1 week every month.
  - 2-3 pulses in fingernails
  - 4-5 pulses in toenails

Q3.11: What are the drugs used to treat Dermatophytosis and their mechanism of action?

PYQ: AIIMS 2018

Answer:

- The types of treatment that are most preferably adopted are:
  - Topical
  - Systemic
- The most common type of drug that is being used is
  - Griseofulvin: Inhibits the microtubule system.
  - Azoles: They inhibit the conversion of ergosterol to lanosterol by inhibiting 14 alpha demethylase
    - → Itraconazole
    - → Fluconazole
  - Allylamines: They inhibit the conversion of lanosterol to squalene by inhibiting squalene epoxidase.

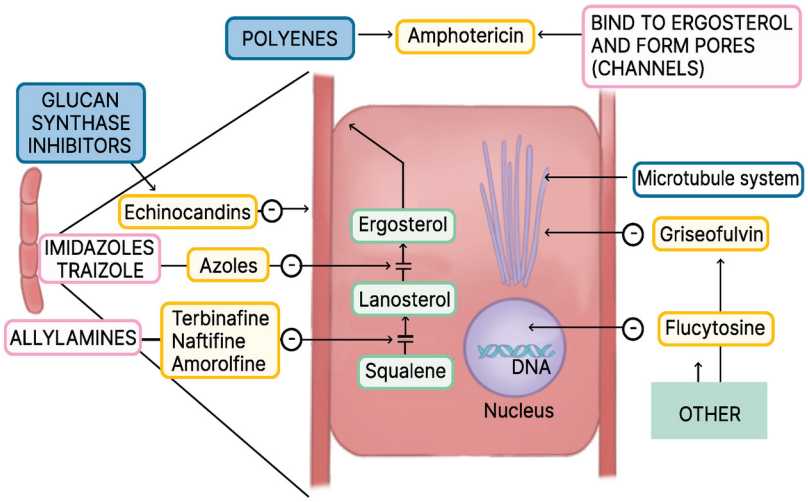

Big question 4: What are the causes, clinical features, and treatment options for candidiasis, a fungal infection caused by Candida species?

Broad Answer:

- Candidiasis is an opportunistic fungal infection by *Candida albicans* and related species, favored by immunosuppression, diabetes, pregnancy, broad-spectrum antibiotics, or moisture.

YOURWISH

- It manifests as oral candidiasis (thrush with white curd-like plaques), cutaneous intertrigo, paronychia, vulvovaginal candidiasis (pruritus with curdy discharge), and systemic candidiasis in severe cases.
- Diagnosis is supported by a KOH mount showing budding yeast with pseudohyphae and confirmed with culture.
- Treatment includes topical azoles or nystatin for mucocutaneous disease, and systemic agents like fluconazole or echinocandins for resistant or disseminated cases.

DETAILED QUESTIONS

Q 4.1: What are the key characteristics and risk factors associated with candidiasis, a fungal infection caused by Candida species?

Answer:



- Candidiasis is caused by Candida.
- The most common Candida species that causes candidiasis is Candida albicans.
- Candida affects the skin, mucosa, and nails.
- Candida presents with budding yeasts on the KOH mount
- It does not affect the hair.
- Candidal infections are more common in immunocompromised, diabetic patients and pregnant females.

Q4.2: What are the characteristics of Oral Candidiasis, and what is the most common form of this condition?

Answer

PYQ: FMGE 2023

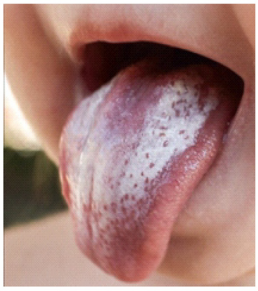

- Oral Candidiasis is of various types
- The most common type of oral candidiasis is oral thrush or acute pseudomembranous candidiasis.
- It is also called acute pseudomembranous candidiasis because these white deposits can be scraped off

Q4.3: Describe chronic plaque, antibiotic sore mouth, denture stomatitis, perleche, and candidal balanoposthitis

Answer:

• **Chronic Plaque** also called Candidal leukoplakia. These cannot be scraped off and are considered pre-malignant. 	• **Antibiotic sore mouth**: Here sore erythematous plaques can be seen on the tongue usually after antibiotic use. 
• **Denture stomatitis / chronic erythematous candidiasis:** This type of candidiasis is seen in patients wearing dentures.	• **Angular cheilitis/perleche:** Candida is the most common infectious cause of angular cheilitis.

YOURWISH

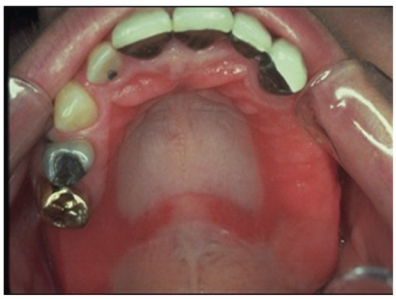



- **Candidial balanoprosthitis:** Seen in uncircumscribed and diabetes patients. Candida affects the glans and causes **satellite pustules and erosions with frayed edges.**
- It is also associated with itching
- In females, it can lead to vulvovaginal candidiasis



Q 4.4: What are the characteristics and manifestations of Candida infections in skin folds and nails?

Answer:

PYQ: NEET PG 2019

Intertrigo



- Candida can also lead to intertrigo or inflammation of the mammary folds and the groin area
  - o These infections occur in the areas of moisture.
  - o It also shows a concave surface of infection.
  - o The candidal lesion shows a satellite lesion and a frayed peeling edge.
- Candida can affect the nails, leading to candidal onychomycosis, and it may also cause paronychia.

Q4.5: What are the clinical investigations and treatment for Candida?

Answer:

Clinical investigation

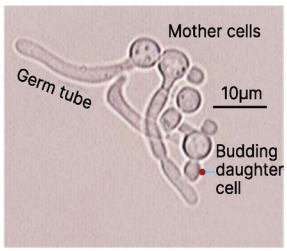

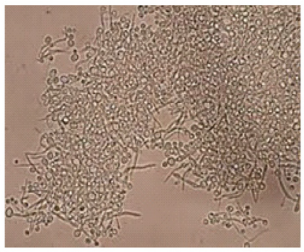



- Germ tube test:
- It is specific for Candida albicans
- KOH test: Budding yeast cells are seen.
- Culture: Creamy white colonies are seen

Treatment :

- Azoles

Big question 5: What are the characteristics, clinical features, and treatment options for subcutaneous fungal infections like Sporotrichosis, Mycetoma, and Chromoblastomycosis?

Broad Answer:

- Subcutaneous mycoses are chronic localized infections acquired by traumatic implantation of fungi from soil or vegetation.

- Sporotrichosis ("rose gardener's disease," Sporothrix schenckii) presents as nodular lymphangitis with linear spread along lymphatics.
- Mycetoma (Madura foot, caused by fungi or actinomycetes) manifests with painless swelling, multiple discharging sinuses, and characteristic colored granules.
- Chromoblastomycosis (caused by dematiaceous fungi) produces slowly progressive verrucous or cauliflower-like pigmented plaques.
- Diagnosis relies on microscopy, culture, and demonstration of characteristic structures (e.g., sclerotic bodies in chromoblastomycosis).
- Treatment varies: itraconazole or saturated solution of potassium iodide for sporotrichosis, surgical excision or antifungals for mycetoma, and prolonged antifungal therapy (itraconazole, terbinafine) with adjunctive surgery for chromoblastomycosis.

DETAILED QUESTIONS

Q5.1: What is Sporotrichosis, and what are its characteristic clinical features and common occupations associated with it?

PYQ: INICET 2020

Answer:

- Sporotrichosis is also called the Rose Gardener's disease.
- Most commonly in farmers and rose gardeners.
- The causative agent for this infection is the Sporothrix schenckii
- The characteristic lesion of sporotrichosis is linear dermal nodules.
- They are erythematous nodules/papules that are linearly arranged along the lymphatics, called a sporotrichoid pattern.



Q 5.2 What is Histopathology and the treatment options of sporotrichosis?

Answer:

Histopathology

- On histopathology, asteroid bodies are seen, which are eosinophilic bodies showing peripheral radiation from a central body

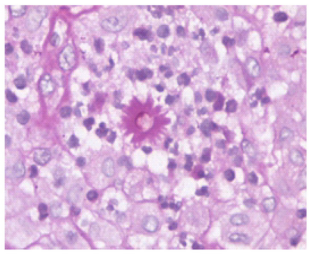

- Star-shaped bodies called asteroid bodies: **Splendor Hoeppli phenomenon**

Pas stain

- On PAS staining **cigar-shaped bodies** can be seen
- Treatment:
  - Itraconazole
  - Potassium iodide
  - Terbinafine

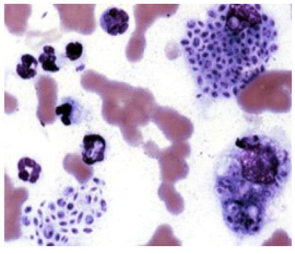

Q 5.3 What are the causative organisms for Mycetoma?

PYQ: FMGE 2021 PYQ: NEET PG 2022

Answer:

- Mycetoma is also called Madura Foot or Maduramycosis
- Mycetoma can be caused by fungi/bacteria:
  - If Mycetoma is caused by bacteria, it is called Actinomycetoma
  - If Mycetoma is caused by a fungus, it is called Eumycetoma.



Q5.4: What are the characteristics of mycetoma?

Answer:

- Usually seen in farmers
- It is a painless infection.
- It shows painless swelling.
- The mycetoma triad:
  - Tumefaction
  - Sinuses
  - Grains: chalky material coming out of the sinuses
- Differentiation of eumycetoma has to be done from actinomycetoma
- Actinomycetoma is caused by bacteria, spreads very rapidly, and is associated with less deformity.
- Eumycetoma, caused by a fungus, spreads very slowly, is invasive, and is associated with a lot of deformity.

Q 5.5: What are the treatment options for mycetoma?

Answer:

- Actinomycetoma: Dapsone + Streptomycin, Cotrimoxazole + Streptomycin
- 2nd line: Rifampicin
- Eumycetoma:
  - Itraconazole
  - Surgical intervention- because of associated deformities

Q 5.6: What are the characteristics and diagnostic features of Chromoblastomycosis, a type of fungal infection?

Answer: PYQ: NEET PG 2022

- Chromo means color, and blasto means vegetative.
- Pigmented verrucous plaque on the feet, caused by a pigmented fungus called Phialophora verrucosa.
- PAS stain: On PAS stain, these fungi are arranged in all planes and appear like sclerotic bodies, copper penny bodies, or Muriform bodies.



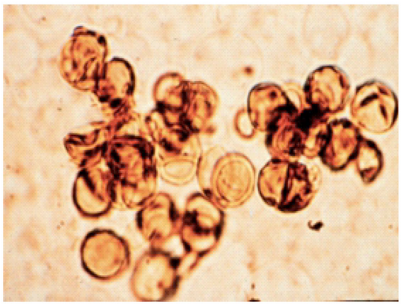

6. SEXUALLY TRANSMITTED INFECTIONS

BIG QUESTION 1: What are the key types of genital ulcer diseases, and how can they be clinically differentiated based on their presentation?

Broad Answer: Genital ulcer diseases include Syphilis, Chancroid, Herpes genitalis, Donovanosis, and LGV. They differ in incubation period, number of ulcers, pain, base characteristics, lymph node involvement, and systemic symptoms. For example, syphilitic ulcers are single, painless, and indurated with bilateral painless lymphadenopathy. Proper identification is crucial for diagnosis and treatment

DETAILED QUESTIONS

Q1.1: What are the main types of Genital Ulcer Diseases?

Answer:

- Syphilis
- Chancroid
- Herpes genitalis
- Donovanosis
- LGV

Q1.2: How can different types of Genital Ulcer Diseases be differentiated based on clinical features?

Answer: PYQ: NEET PG 2023 PYQ: INICET 2023 PYQ: FMGE 2023

	Syphilis	Chancroid	HSV	Donovanosis	LGV
Incubation period	9-90 days	2-5 days	2-7 days	8-80 days	3-30 days
Ulcer number	Single	Multiple	Multiple	Single	Single
Pain	No	Yes	Yes	No	No
Base	clean	Covered with greyish slough	Erosion	Granulomatous	-
Edges	Rubbery	Undermined	Polycyclic	Overhanging granules	-
Induration	Present	Not present	Not present	Ulcer may be firm	-
Bleeds on touch	No	Yes	Yes	Yes very easily	-
Lymph nodes					
Laterality	Shotty	Unilateral	Bilateral	Pseudo Bubo	Bilateral
Pain	No	Yes	Yes	No	Yes

Q1.3: What is the causative organism of Syphilis?

Answer: Treponema Pallidum

YOURWISH

Q1.4: What happens if Syphilis is left untreated?

Answer: It can stay in the body for 10-40 years

Q1.5: What is the incubation period of primary syphilis?

Answer: 10-90 days

Q1.6: How does a genital ulcer present in the primary stage of syphilis?

Answer: Chancre/ Hunterian chancre/ Hard chancre



Q1.7: What are the typical features of the ulcer seen in primary syphilis?

Answer:



- Single
- Painless (hence go into the second stage)
- Well-defined ulcer
- Rubbery margins
- Clean base
- Serous discharge
- Button sign: Base of the ulcer is indurated
- Lymph nodes

Q1.8: How does lymph node involvement manifest in primary syphilis?

Answer:

- Bilateral
- Painless
- Enlarged
- Shotty lymphadenopathy

Q1.9: What is secondary syphilis referred to as?

Answer: The great imitator

Q1.10: What are the typical characteristics of skin lesions in secondary syphilis?

Answer:

- Bilaterally symmetrical
- Asymptomatic
- Polymorphic
- Does **not** present with vesicles and bullae
- Ham/rose color
- Macular/ roseola syphilide
- Papular Lesion





Q1.11: What is macular or roseola syphilide in secondary syphilis?

Answer: First rose-colored rash

Q1.12: What are papular lesions in secondary syphilis?

Answer: These papules are present like a crown on the forehead → Corona Veneris



Q1.13: What skin changes occur on the palms and soles in secondary syphilis?

Answer: Hyperpigmented plaques are seen



Q 1.14: What is the Buschke-Ollendorff sign?

Answer: Tenderness on firm pressure (endarteritis obliterans)

Q1.15: What are condyloma lata in secondary syphilis, and why do they often become macerated?

Answer: Condyloma lata means broad and flat → get macerated due to friction

Q1.16: Where are papular syphilides typically found in secondary syphilis?

Answer:

- On flexors like the perirectal area and vaginal area
- Moist papules present in flexural areas
- These are highly contagious.

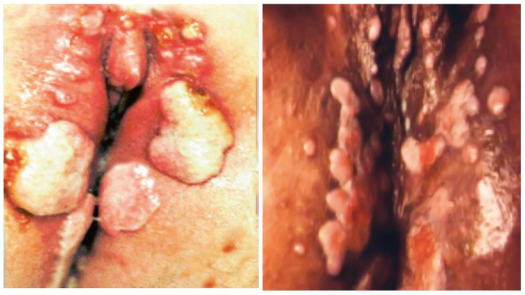

Q1.17: What follows after condyloma lata, which are teeming with spirochetes?

Answer:

- Teaming with spirochetes - very, very infectious
- Covered with greyish slough, which is rich in spirochetes

Q1.18: What are the crusted necrotic plaques seen in severe secondary syphilis called?

Answer: Lues Maligna



Q1.19: Which types of skin lesions are absent in secondary syphilis?

Answer: Vesicles and bullae

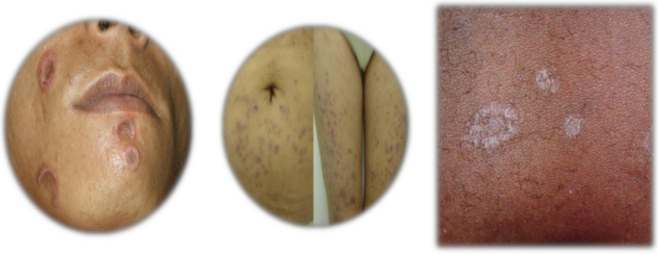

Q1.20: What type of hair loss is seen in secondary syphilis?

Answer:

- Moth-eaten alopecia with circular patches
- Non-scarring alopecia → different from alopecia areata



Q1.21: What are the characteristics of mucosal lesions in secondary syphilis?

Answer:

- Secondary syphilis can lead to mucosal lesions → Mucosal patches or snail track ulcers
- Well-defined, painless erosion is present on the mucosal surface



Q1.22: What type of lymphadenopathy is characteristic of secondary syphilis?

Answer: Bilateral, Symmetrical, painless, wide-spread lymphadenopathy → Epitrochlear Lymphadenopathy (specific for secondary syphilis).



Q1.23: How is latent syphilis present and diagnosed?

Answer: Asymptomatic

- No clinical signs or symptoms, but if you do a serology, it will be positive → **VDRL and TPHA**

Q1.24: What are the telltale signs for latent syphilis?

Answer: Healed ulcers and lymphadenopathy are present

Q1.25: How is latent syphilis classified based on duration?

Answer:

- Early latent syphilis: <1 year or <2 years
- Late latent syphilis: >1 year or >2 years

Q1.26: What is Monorecedive (Chancre redux) in syphilis?

Answer: Lesions develop at the site of the primary chancre; relapsing lesions will appear

Q1.27: What proportion of late latent syphilis cases progress to tertiary syphilis?

Answer: 1/3rd of late latent syphilis patients will go into the tertiary stage (2/3rd patients will recover)

Q1.28: What is the nature and typical time frame for the development of tertiary syphilis?

Answer:

- Non-infective stage
- Develops after 10-40 years

Q1.29: What causes tertiary syphilis?

Answer: Hypersensitivity reaction → reminiscence of the spirochetes

Q1.30: What are the three types of manifestations seen in tertiary syphilis?

Answer:

Benign	It can involve skin, bones and lymph nodes.
CVS	Aortitis and aortic aneurysms, ascending aorta
CNS	General paresis of insane associated with psychiatric + affective issues. • Tabes dorsalis • Charcot joints

Q1.31: What are the characteristics of skin lesions in tertiary syphilis?

Answer: Skin lesions of tertiary syphilis are called gumma

- Gummy consistency: Rubbery, well-defined margins
- Deep, dusky, red papules and nodules
- Heal with scars





Q 1.32: What are the key manifestations observed in primary, secondary, and tertiary syphilis? PYQ: AIIMS 2019

Answer:

YOURWISH

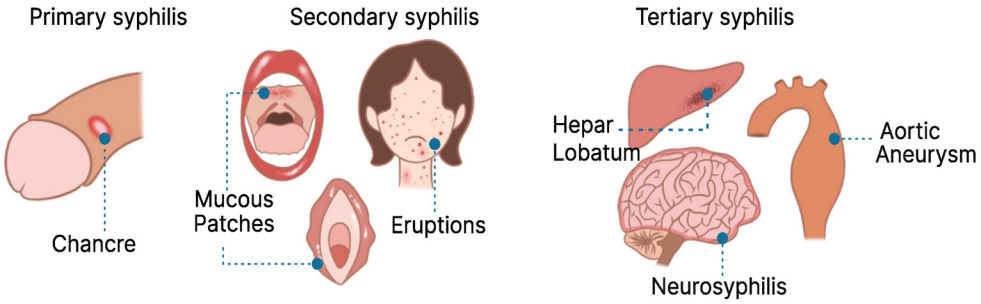

BIG QUESTION 2: What are the key features, stages, clinical manifestations, and diagnostic methods of congenital syphilis, and how is it treated and What is Chancroid?

Broad Answer:

- Congenital syphilis is transmitted after 20 weeks, with early (infective) and late (non-infective) stages. Early signs include nasal discharge and skin vesicles. Diagnosis uses serology and microscopy. Treatment is intravenous penicillin.
- Chancroid causes multiple painful, soft ulcers with ragged edges and unilateral painful lymph nodes (bubo). Diagnosis by Gram stain; treated with a single dose of azithromycin or ceftriaxone.

DETAILED QUESTIONS

Q 2.1: How is congenital syphilis transmitted?

Answer: Transmitted from the mother to the child after 20 weeks

Q 2.2: What are the 2 stages of congenital syphilis?

Answer:

- **Early congenital syphilis**
  - Usually manifests at >2 years
  - Infective
- **Late congenital syphilis**
  - Usually manifests after two years
  - Present with stigmata
  - Not infective

Q 2.3: What is 'snuffles' in congenital syphilis and why is it clinically significant?

Answer:

- Snuffles is the nasal discharge seen in early congenital syphilis
- Discharge is teaming up with spirochetes, making it very infective

Q 2.4: What are key early clinical features of congenital syphilis

Answer:

- Saddle nose or fleur de lis nose
- In the skin, the rash of syphilis presents as vesicles and bullae - early congenital syphilis
- Infants can have vesicles and bullae - Syphilitic pemphigus in infants



Q 2.5: What are the stigmata of late congenital syphilis?

Answer:

- Frontal bossing is seen
- The scapula thickens → Higoumenakis sign



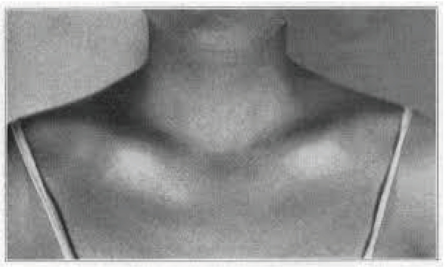

Q 2.6: What is Hutchinson's Triad in congenital syphilis?

Answer:

- Mnemonic: ENT (Eye, Nerve, Teeth)
  - o Hutchinson's teeth: Abnormal permanent upper central incisors that are peg-shaped and notched
  - o Interstitial keratitis
  - o 8th nerve deafness



Q 2.7: What is the specific feature of congenital syphilis?

Answer: Mulberry molars



Q 2.8: How is an organism identified for congenital syphilis?

PYQ: NEET PG 2022

Answer: **Dark ground microscopy**

- Used for an organism that cannot be stained
- Reflects the light transmitted by the organisms
- Treponema pallidum appears spiral wavy slender fluorescent organism
- Dark ground microscopy of chancre



Q 2.9: What are the different serological tests for syphilis?

Answer:

Serological tests	
Treponemal / Specific test	Non-Treponemal/ Reagin Test
• They become positive first • They stay positive, not helping in regular monitoring	• Become positive later • They become negative and help in monitoring
TPHA, FTA-ABS, TPI, TPPA, EIA, latex agglutination	VDRL, RPR, WASSERMAN, TRUST, RST, UST

Q2.10: What is the most specific test for diagnosing syphilis?

Answer: Dark Ground Microscopy

Q2.11: Which blood tests are considered the most specific for syphilis detection?
Answer: FTA-ABS, TPHA

Q2.12: Which test becomes positive earliest in syphilis infection?
Answer: IgM Capita (rarely done) > FTA-ABS

Q2.13: What are the most sensitive tests in syphilis treatment?
Answer: IgM Captia > FTAABS

Q2.14: What are the preferred screening tests for syphilis?
Answer: VDRL, RDR

Q2.15: What is the test of choice (IOC) for primary, secondary, tertiary, and neurosyphilis?
Answer:

- Primary syphilis - Dark ground microscopy
- Secondary syphilis - FTAABS
- Tertiary syphilis - EIA
- Neurosyphilis - CSF EXAM

Q2.16: What is the preferred field-based screening test for syphilis?
Answer: RPR card

Q2.17: Which test is used to monitor treatment response and disease activity in syphilis?
Answer: VDRL

Q2.18: What is the standard treatment for syphilis?
Answer: Injection Benzathine Penicillin

- Dosage: 2.4 million IU Intramuscular (1.2 MU deep IM in each buttock)
- Two divided doses after a test dose

Q2.19: What is the Benzathine Penicillin dosing regimen for different stages of syphilis
Answer:

- Primary, secondary, or early latent syphilis → only one dose is given
- Late latent or tertiary syphilis (benign CVS) → 3 doses at weekly interval
- For children: 50,000 units/kg IM up to the adult dose of 2.4 million units in a single dose

Q2.20: Why is Benzathine Penicillin not used in neurosyphilis and congenital syphilis treatment?
Answer: It cannot cross the blood-brain barrier

Q2.21: What antibiotics are used to treat neurosyphilis and congenital syphilis?
Answer:

- Aqueous crystalline penicillin- Intravenous
- Procaine penicillin + Probenecid

YOURWISH

Q2.22: How is syphilis treated in patients allergic to penicillin?
Answer: Desensitize the patient because penicillin is the most effective drug

Q2.23: What is the causative organism of chancroid?
Answer: *Haemophilus ducreyi*

Q2.24: Why is chancroid called a "soft chancre"?
Answer: Because these are non-indurated

Q2.25: What is the typical incubation period of chancroid?
Answer: 3-7 days

Q2.26: What are the characteristic features of chancroid ulcers?

PYQ: NEET PG 2021

Answer:



- Multiple ulcers
- Painful
- Non indurated
- Ragged undermined edges
- Floor covered with yellow necrotic tissue → bleeds on touch

Q2.27: What are the typical lymph node findings in chancroid?
Answer:

- Unilateral, painful LN
- Suppurative lymphadenopathy is called 'BUBO'

Q2.28: What is the characteristic finding on Gram stain in chancroid?
Answer: Gram-negative bacilli are arranged in chains, also called railway tracks or schools of fish appearance.

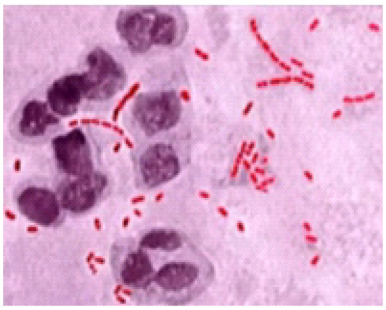

Q2.29: What culture medium is used to grow Haemophilus ducreyi in chancroid?
Answer: Mueller Hinton Agar supplemented with chocolate horse blood

Q2.30: What is the recommended treatment for chancroid?
Answer:

- Azithromycin 1 g orally in a single dose
- Ceftriaxone 250 mg intramuscular in a single dose

BIG QUESTION 3: What is Herpes Genitalis, Donovanosis & Lymphogranuloma Venereum & how do these present clinically, and how is it diagnosed and treated?
Broad Answer:

- Herpes Genitalis is a viral STI caused mainly by HSV-2, presenting with multiple painful vesicles and bilateral

YOURWISH

tender lymphadenopathy. Diagnosis is via Tzanck smear/ELISA, and treatment is Acyclovir for 5-10 days.

- Donovanosis is a painless, beefy red ulcer-causing STI with Donovan bodies on smear; treated with Azithromycin or Doxycycline for ≥3 weeks
- Lymphogranuloma Venereum (LGV) is caused by *Chlamydia trachomatis* (L1-L3), presenting with transient ulcers and painful lymphadenopathy with groove sign. Treatment: Doxycycline 100 mg twice daily for 21 days.

DETAILED QUESTIONS

Q3.1: What is the most common causative organism of Herpes Genitalis?

Answer: HSV 2 > HSV 1

Q3.2: What is the incubation period of Herpes Genitalis?

Answer: 2-7 days

Q3.3: How does Herpes Genitalis typically present clinically?

Answer:

- Presents as primary, recurrent stage, latent infection
- Multiple painful vesicles
- They rupture to form coalescing vesicles or polycyclic erosions



Q3.4: What are the characteristic lymph node findings in Herpes Genitalis?

Answer: Bilateral and tender Lymphadenopathy

Q3.5: What are the key investigations used to diagnose Herpes Genitalis?

Answer:

- Tzanck Smear: Multinucleated giant cells
- Serology: ELISA: Ag- HSV glycoprotein

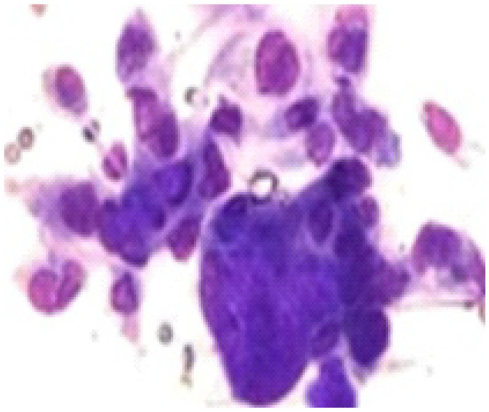

Q3.6: What is the treatment regimen for Herpes Genitalis infections?

Answer:

- Acyclovir: 200 mg 5 times a day
- Acyclovir: 400 mg 3 times a day
- 7-10 days for primary infection
- 5 days for secondary infection

Q3.7: Where does Herpes Simplex Virus (HSV) remain latent in the body?
Answer: Dorsal root ganglion

Q3.8: What is Donovanosis also known as?
Answer: Granuloma venereum (STD) or Granuloma Inguinale

Q3.9: What is the causative organism of Donovanosis (Granuloma Inguinale)?
Answer: Calymmatobacterium granulomatis/Klebsiella granulomatis

Q3.10: What is the incubation period of Donovanosis (Granuloma Inguinale)?
Answer: 3 days to 3 months

Q3.11: How does Donovanosis typically present?
Answer: Beefy red granulomatous ulcer → bleeds very easily on touch



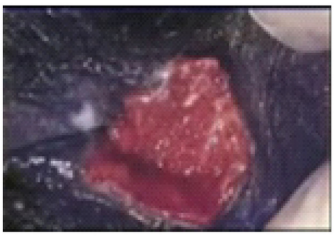


Q3.12: What is the characteristic lymph node involvement in Donovanosis?
Answer: Lymph nodes are not involved in Donovanosis, but groin lesions may resemble lymph nodes before rupture, called "pseudo bubo."

Q3.13: How is Donovanosis diagnosed?
Answer:

- Crushed smear (Wright Giemsa stain)
- Donovan bodies are seen
- Safety pin appearance
- Test: NAAT - Nucleic Acid Amplification Test **(IOC)** or CFT

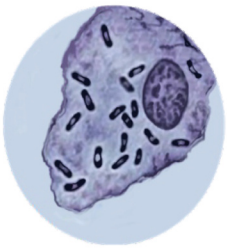
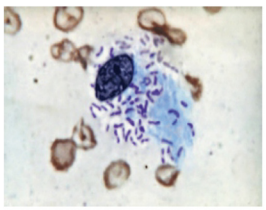

Q3.14: What is the treatment for Donovanosis?
Answer:

- Azithromycin: 1 g orally once per week or 500 mg daily for at least 3 weeks until all lesions are completely healed
- Alternative regimes
  - Doxycycline 100 mg orally twice a day for at least 3 weeks and until all lesions have completely healed

Q3.15: What is a key clinical feature of Lymphogranuloma Venereum (LGV)?
Answer: Lymphatic involvement present

Q3.16: What are the other names for Lymphogranuloma Venereum?
Answer: Climactic BUBO, lymphogranuloma inguinale

Q3.17: What is the causative organism of Lymphogranuloma Venereum?
Answer: Chlamydia Trachomatis → Serovars L1, L2, L3 (L1 is most common)

Q3.18: What is the incubation period of Lymphogranuloma Venereum?

Answer: 10-30 days

Q3.19: What are the clinical stages of Lymphogranuloma Venereum (LGV)?

Answer:

- **Primary stage:** Transient ulcer
- **Secondary stage:** Inguinal syndrome
- **Tertiary:** Genito Acro Crural Syndrome

Q3.20: What are the key features of Lymphogranuloma Venereum (LGV)?

Answer:

- Suppurative lymphadenopathy
- Painful
- Multilocular
- Discharging sinus
- Climactic BUBO



Q3.21: What is the Groove sign of Greenblatt?

Answer: When both the femoral node and inguinal node are involved, it appears taut and forms a groove → Groove sign of Greenblatt



Q3.22: What is another name for the inguinal ligament?

Answer: Poupert's ligament

Q3.23: What characterizes the third stage of lymphogranuloma venereum?

Answer: There is excessive lymphatic involvement

Q3.24: How does the penis appear in males during the tertiary stage of lymphogranuloma venereum (LGV)?

Answer: Saxophone or ramus penis

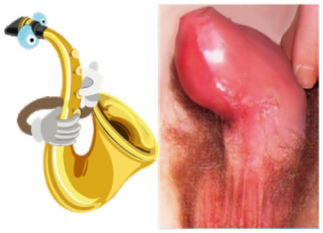

Q3.25: How does vulva appear in females in lymphogranuloma venereum (LGV)?

Answer: Vulva may become enlarged, which is called Esthiomene



Q3.26: What are the key investigations used to diagnose lymphogranuloma venereum (LGV)?

Answer:

- NAAT: Nucleic Acid Amplification Test
- CFT: Complement Fixation Test

Q3.27: What is the standard treatment for lymphogranuloma venereum (LGV)?

Answer:

- Doxycycline 100 mg orally twice a day for 21 days
- Alternative regime
  - Erythromycin base 500 mg orally four times a day for 21 days

BIG QUESTION 4: What are the main causes, clinical features, investigations, and treatments of sexually transmitted infections (STIs) causing urethral or cervical discharge, and how do gonococcal and non-gonococcal urethritis differ?

Broad Answer:

- STIs causing urethral/cervical discharge include gonococcal (Neisseria gonorrhoeae) with thick purulent discharge and fever, and non-gonococcal (Chlamydia, Mycoplasma) with scanty discharge and no fever.
- Diagnosis: Gram stain for gonococcal, NAAT for non-gonococcal. Treatment: ceftriaxone + azithromycin for gonococcal, azithromycin or doxycycline for non-gonococcal

DETAILED QUESTIONS

Q4.1: What are the two broad types of STDs causing discharge?

Answer:

- Gonococcal urethritis
- Non-gonococcal urethritis

Q4.2: What are the causative organisms of Gonococcal and Non-Gonococcal urethritis?

Answer:

- Gonococcal urethritis: *Neisseria gonorrhoeae*
- Non-Gonococcal urethritis: *Chlamydia trachomatis* (D-K, most common), *Mycoplasma*, *Ureaplasma*, *HSV*, *Adenovirus*, *Trichomonas vaginalis*

Q4.3: What are the disease names for urethritis caused by gonococcal and non-gonococcal organisms?

Answer:

- **Gonococcal:** Gonococcal urethritis/cervicitis (GU/GC)
- **Non-Gonococcal:** Nongonococcal urethritis/cervicitis (NGU/NGC)

Q4.4: What is the incubation period for gonococcal and non-gonococcal urethritis?

Answer: Both have an incubation period of 3-5 days

Q4.5: How do constitutional symptoms differ between gonococcal and non-gonococcal urethritis?

Answer:

- Gonococcal urethritis - Have fever
- Non-gonococcal urethritis - No fever

YOURWISH

YOURWISH

Q4.6: How do urinary symptoms help differentiate between gonococcal and non-gonococcal urethritis?

Answer:

- Gonococcal - Urinary symptoms present
- Non- gonococcal urethritis - Urinary symptoms absent

Q4.7: What are the clinical features present in gonococcal urethritis?

Answer:

- Penis: Thick, copious, purulent discharge




- Cervix: Thick, copious, purulent discharge
- Cervix is friable



Q4.8: What are the clinical features of non-gonococcal urethritis?

Answer:

- Penis: Thin watery scanty, clear-looking discharge



- Cervix: Thin, watery, scanty, clear-looking discharge
- Cervix is friable



Q4.9: What are the investigation findings in gonococcal urethritis and non-gonococcal urethritis (NGU)?

Answer:

Investigations	
• Gram stain o Gram -ve diplococci o Bean or kidney-shaped cells o May be intracellularly/ extracellularly. o Seen inside the Polymorphonucleocytes (PMNs) o Remember: PMNs are +ve (>5/HPF)	• Gram stain o No diplococci o Only PMNs are seen. o Culture test: No culture test. o Nucleic acid amplification test **(NAAT)** is performed.

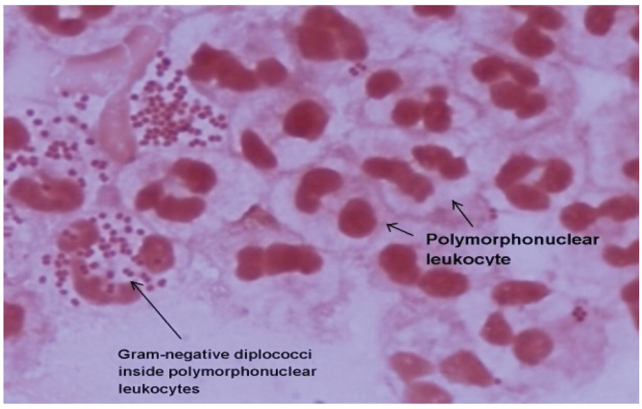

- Culture test: **Thayer Martin Medium**
- Nucleic acid amplification test **(NAAT)** is performed.

Q4.10: What are the complications of gonococcal urethritis?

Answer:

Category	Complications
Male	• Prostate urethritis • Prostatitis • Perianal abscess • Epididymitis • Testis are not involved.
Female	• Salpingitis (Chlamydia causes PID → Secondary infertility) • PID • Bartholin gland abscess
Infant	• Ophthalmia neonatorum

Q4.11: What are the complications of non-gonococcal urethritis?

Answer:

- High chances of
  - o Arthritis
  - o Perihepatitis: Fitzhugh-Curtis syndrome
- Complications are more common with non-gonococcal infections

Q4.12: What is the treatment for gonococcal urethritis?

Answer:

- **Treatment of choice:** Inj. Ceftriaxone 250 mg IM stat + Azithromycin 1 gm
- Ceftriaxone not available: Cefixime 400 mg (oral) + Azithromycin 1 gm

Q4.13: What is the treatment for non-gonococcal urethritis?

Answer:

- **Treatment of choice:** Azithromycin 1 gm stat
- Azithromycin is not available: Doxy 100 mg BD 7 days

Q4.14: Q: Why is Azithromycin given along with treatment for gonococcal urethritis (GU)?

Answer: As there is always a chance that NGU is also present in GU → So, for all GU we give NGU treatment as well.

BIG QUESTION 5: What are the major causes, distinguishing features, and treatments of physiological and pathological vaginal discharge?

Broad Answer:

- Physiological discharge is most common; pathological causes include Candida (curdy white discharge, pruritus), Trichomonas (green frothy discharge, strawberry cervix), and Gardnerella (thin white discharge, fishy odor).
- Diagnosis uses pH, microscopy, and the whiff test.
- Treatment: azoles for Candida, metronidazole/secnidazole for Trichomonas and BV; partner treatment is needed for all STIs except BV

DETAILED QUESTIONS

Q5.1: What is the most common cause of vaginal discharge?

Answer: Physiological

Q5.2: What is the most common pathological cause of vaginal discharge?

Answer: Bacterial vaginosis

Q5.3: What are the three major causes of pathological vaginal discharge?

Answer:

- Vulvovaginal candidiasis
- Trichomonal vaginalis
- Bacterial vaginosis

Q5.4: What are the causative organisms of vulvovaginal candidiasis, trichomonal vaginitis, and bacterial vaginosis?

Answer: **Causative agents are:**

Vulvovaginal candidiasis	Trichomonal vaginalis	Bacterial vaginosis
Candida albicans (fungus)	Trichomonas vaginalis (protozoa)	• Gardnerella vaginalis • Mycoplasma hominis • Ureaplasma • Reduced concentration of lactobacilli

Q5.5: Which populations are more commonly affected by vulvovaginal candidiasis, trichomonal vaginitis, and bacterial vaginosis?

Answer: **Most common affected populations are:**

Vulvovaginal candidiasis	Trichomonal vaginalis	Bacterial vaginosis
More common in diabetics and immunocompromised individuals	Adverse pregnancy outcome	• Not an STD • Nuns • It is an STI in which partner treatment is not done

YOURWISH

Q5.6: In which cases is partner treatment necessary for vaginal infections, and what is the exception?

Answer: Partner treatment is done in all STIs **except Bacterial vaginosis**

Q5.7: What are the common symptoms and pH changes seen in vulvovaginal candidiasis, trichomonal vaginitis, and bacterial vaginosis?

Answer:

Feature	Vulvovaginal candidiasis	Trichomonal vaginalis	Bacterial vaginosis
Symptom	Pruritis	Pruritis	May or may not be symptomatic
pH	Acidic	Basic	Basic

Q5.8: What are the characteristic types of vaginal discharge seen in vulvovaginal candidiasis, trichomonal vaginitis, and bacterial vaginosis?

Answer:

Vulvovaginal candidiasis	Trichomonal vaginalis	Bacterial vaginosis
• Curdy white cheesy discharge • Premenstrual flare • Vulva is red and sore	• Green frothy, foul-smelling discharge • Strawberry cervix	• Thin, homogenous, white discharge • Coating vaginal walls
	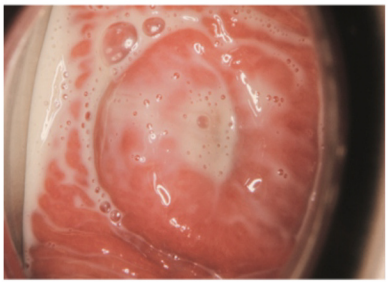	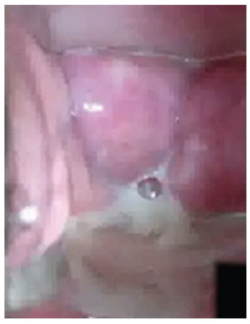

Q5.9: How are vulvovaginal candidiasis, trichomonal vaginitis, and bacterial vaginosis diagnosed and treated?

Answer:

Vulvovaginal candidiasis	Trichomonal vaginalis	Bacterial vaginosis
Diagnosis - Smear Investigation		
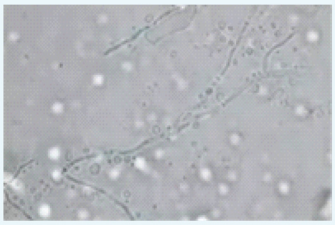	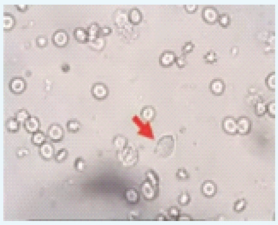	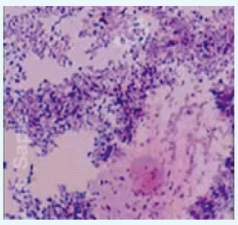
• KOH smear • Pseudo hyphae & budding yeast cells	• Wet mount • Motile, pear-shaped bodies	• Gram stain • Clue cells (>20%) • Stippled appearance of vaginal squamous cells

YOURWISH

Management		
• Azoles	• Secnidazole 2g stat • Tinidazole 2g stat	• Secnidazole 2g stat · • Metronidazole 500 mg TDS 7 days

Q5.10: Strawberry cervix is a feature of?

Answer: Trichomonas vaginalis

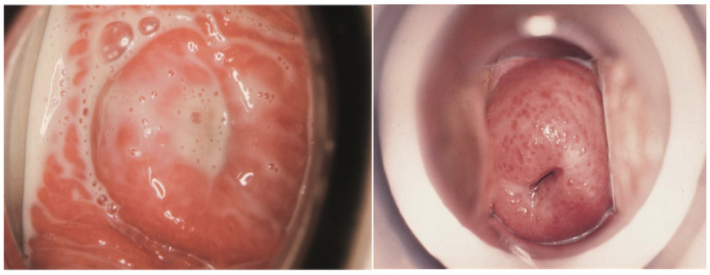

Q5.11: What are Amsel's criteria used to diagnose bacterial vaginosis?

Answer: Three symptoms or signs:

- Grey/white, homogenous, thin, scanty discharge that smoothly coats the vaginal walls
- Clue cells (e.g., vaginal epithelial cells studded with adherent coccobacilli) on microscopic examination, at least 20%
- pH of vaginal fluid >4.5
- A fishy Odor of vaginal discharge before or after the addition of 10% KOH (i.e., the whiff test)

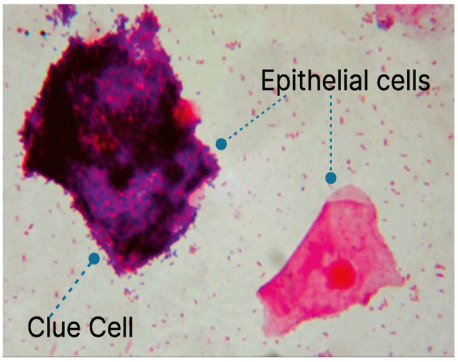

Q5.12: What is shown in the following image?

Answer: Anogenital wart

- Condyloma acuminata - Bushke-Lowenstein tumor



Q5.13: What are the 7 kits used for STD syndromes?

PYQ: AIIMS 2019

Answer: These 7 kits for STD syndromes - mnemonic: Great girls will buy red-yellow bags.

Clinical Condition	Kit to be prescribed	Drugs included	Image
Urethral, or Anorectal, or Cervical discharge	KIT 1: Gray	• Tab Azithromycin 1 g (1 tab) • Tab Cefixime 400 mg (1 tab)	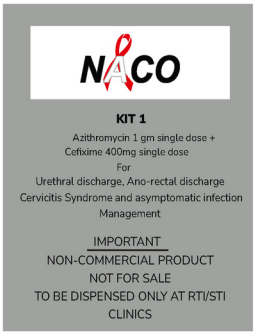
Vaginal Discharge (Vaginitis)	KIT 2: Green	• Tab Secnidazole 2g (1 tab) • Tab Fluconazole 150 mg (1 tab)	
Genital Ulcer Disease (Non Herpitic)	KIT 2: White	• Inj. Benzathine penicillin 2.4 MU (1 vial) + Tab Azithromycin 1g (Kit also contains 10 ml disposable syringe +21 gauge needle + 1 vial of 10 ml sterile water)	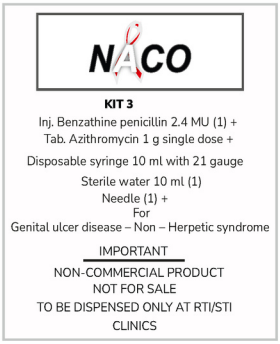
Genital ulcer disease (Nonherpetic) in patient allergic to penicillin	KIT 4: Blue	• Tab Doxycycline 100 mg (1tab BD for 14 days) • Tab Azithromycin 1g x 1 tab	
Genital ulcer disease (Herpetic)	KIT 5: Red	• Tab acyclovir 400 mg x 1 tab • TDS x 7 days	

Lower abdominal pain (pelvic inflammatory disease)	KIT 6: Yellow	• Tab Cefixime 400 mg x 1 tab • Tab Metronidazole 400 mg x (1 DB 14 days) Tab Doxycycline Ig (1 BD 14 days)	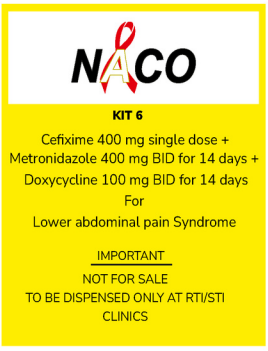
Inguinal Bubo	KIT6: Black	• Tb Doxycycline 100 mg (1 BD x 21 days) • Tab Azithromycin 1g x 1 tab	

YOURWISH

7. PAPULOSQUAMOUS DISORDERS

BIG QUESTION 1: Describe psoriasis.

Broad Answer: Psoriasis is a chronic immune-mediated skin disorder linked to genetics (HLA-Cw6, HLA-B27), environmental triggers (UV exposure, infections, smoking, stress), and Th1/Th17-driven inflammation (TNF-α, IL-17, IL-22). Reduced epidermal turnover (4 vs. 56 days) leads to keratinocyte hyperproliferation and vasodilation. Histology shows hyperkeratosis, parakeratosis, Munro's abscesses, Kogoj's pustules, acanthosis, and elongated rete ridges. Clinically, it presents as symmetrical, salmon-colored plaques with silvery scales on extensor surfaces, winter flares, and Woronoff's ring. Diagnostic signs include candle sign, Berkley's membrane, and Auspitz sign. Koebner's phenomenon may be true (psoriasis, vitiligo), pseudo (warts), or occasional (Darier's).

DETAILED QUESTIONS

Q1.1: What are papulosquamous disorders?

Answer: Disorders with scaly papules and plaques.

Q1.2: What is psoriasis?

Answer: An immune-mediated chronic disorder characterized by a relapsing-remitting course.

Q1.3: What are the factors leading to chronic inflammation in psoriasis?

Answer: Factors that lead to systemic chronic inflammation are:

- Genetic factors (heredity)
- Immune factors
- Environmental factors.

Q1.4: Which genetic factors are associated with psoriasis?

Answer:

- HLA Cw6: Early onset disease, positive family history
- HLA B27: Psoriatic arthritis, nail changes
- PSORS1

Q1.5: What are the major triggers for psoriasis?

Answer: UV, infection, smoking, drinking, stress.

Q1.6: What are the major inflammatory cells and cytokines in psoriasis?

Answer: Epidermal and dermal inflammatory cells include neutrophils, macrophage, dendritic cells, and T cells (Th1, Th17, Th22).

- Important cytokines: IL-2, IL-23, IFN-γ, TNF-α, IL-17, IL-22.

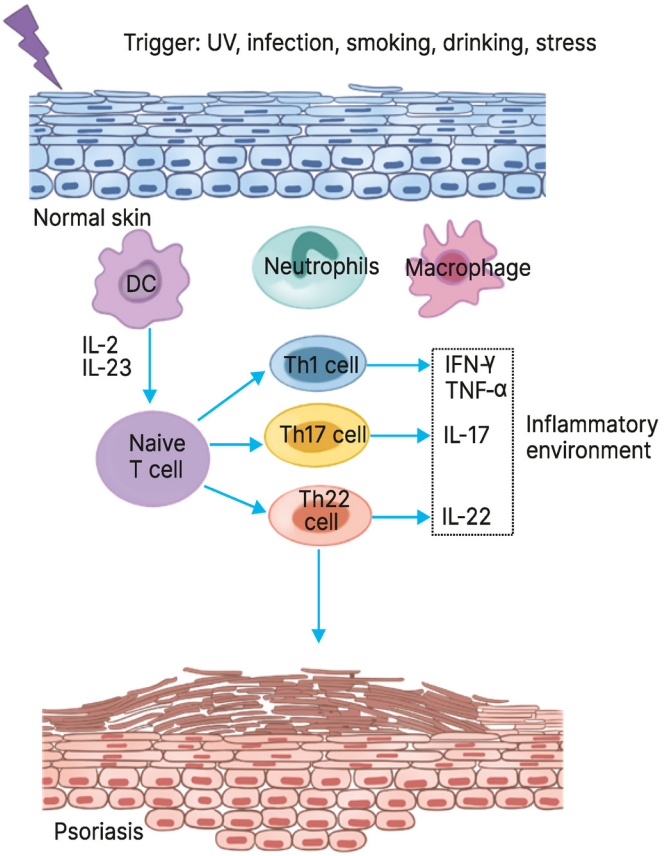

Q1.7: What happens to epidermal turnover time in psoriasis?

Answer: Reduced epidermal turnover time to 4 days (normal 56 days), leading to hyperproliferation of keratinocytes.

Q1.8: What is the vascular change in psoriasis?

Answer: Angiogenesis/vasodilation leading to increased blood flow.

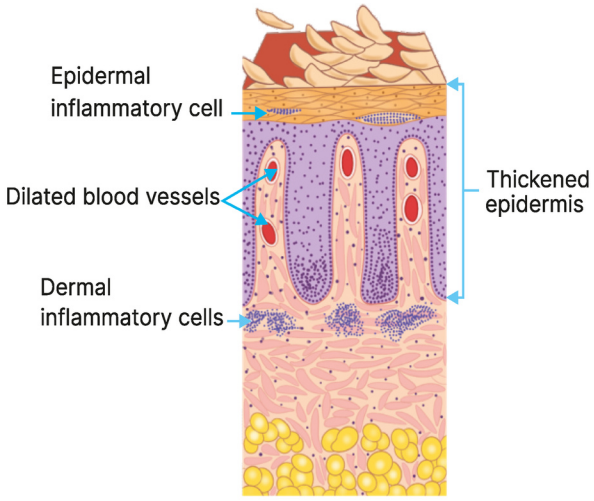

Q1.9: What is the predominant immune response in psoriasis?

Answer: Inflammation: a TH-1 type of response is generated, a predominant TH-1 response, with other inflammatory infiltrates → IFN-γ, TNF-α, TH-17 (IL-17), TH-22 (IL-22).

Q1.10: What happens due to inflammation in psoriasis?

Answer: Inflammation causes vasodilatation, and targets hyperproliferation in keratinocytes.

Q1.11: Do dermal or epidermal changes develop first in psoriasis?

Answer: Dermal changes precede epidermal changes.

Q1.12: What are the main features of psoriatic histopathology?

PYQ: FMGE 2022

Answer:

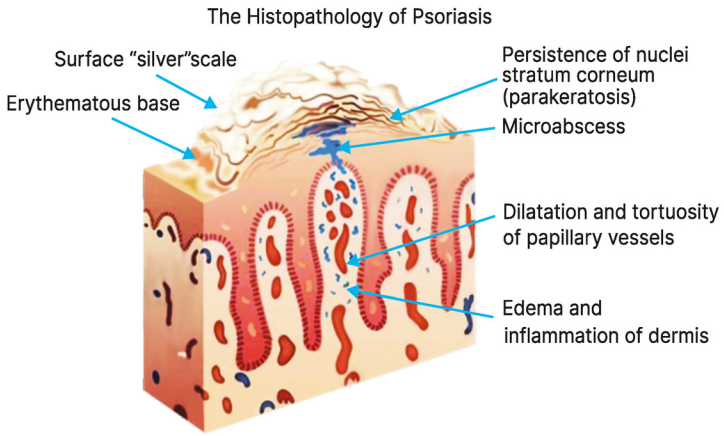

Q1.13: Describe histopathological changes in different layers of skin.

Answer:

Stratum corneum	• **Hyperkeratosis** (thickening of corneum) • **Parakeratosis** (retention of nuclei in Stratum corneum) • **Munro's microabscess** (collection of neutrophils) 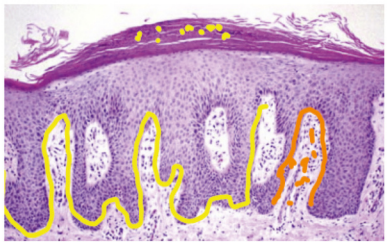
Stratum Granulosum	**Agranulocytosis/ Agranulosis** (absent granular layer)
Malpighian layer (Stratum Spinosum and Basale)	• **Acanthosis** (increased thickness) of Stratum Spinosum • **Kogoj's Spongiform pustules** (collection of neutrophils)
Rete ridges	They are elongated and club-shaped (**Camel foot appearance**). 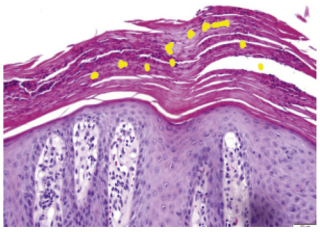
Dermis	• **Suprapapillary thinning** • Dilated tortuous blood vessels • Inflammation

Q1.14: Differentiate histopathological changes of psoriasis from normal skin.

Answer: In psoriasis, we see elongated Rete ridges with Hyperkeratosis and Parakeratosis.

Q1.15: What are the symptoms of psoriasis?

Answer: No itching and winter exacerbation; **Site:** Extensors of the body.

Q1.16: Describe the lesion seen in psoriasis.



Answer: Lesions in psoriasis are:

- **Symmetry of lesions:** Bilaterally symmetrical
- **Color of lesions:** Salmon colored, due to increased inflammation and vasodilatation
- **Texture of lesions:**
  - Well-defined plaques and papules
  - Erythematous (red)
  - Scaly (silvery white scale)
  - Indurated (thickened).

Q1.17: What is Woronoff's ring?



Answer: Around the psoriatic plaque a zone of pallor occurs due to the inability to synthesize PGE2.

Q1.18: Describe the tests and signs of psoriasis.

Answer:

- **Bedside tests:** Done with a blunt object scraping on the psoriatic skin. Continuous scraping produces:
  - **Grattage test/ Candle sign:** Accentuation of scaling.
  - **Berkley's membrane:** Thin translucent membrane
  - **Auspitz sign:** Pinpoint bleeding points
- The 3 tests are combined, called the **Auspitz tests**

Signs of Psoriasis

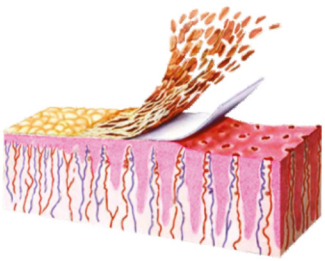



1 Candle sign



2 Sign of the last hautchen



3 Auspitz sign

Q1.19: What is Koebner's phenomenon in psoriasis?

PYQ: FMGE 2020 PYQ: NEET PG 2020



Answer: In Koebner's phenomenon:

- Psoriatic lesions develop along the lines of trauma.
- Isomorphic response (similar morphology lesions are developed)
- All or none phenomenon

Q1.20: What conditions are in each Koebnerization category?

Answer:

- Category 1 (True koebnerization): Psoriasis, Lichen planus, Vitiligo
- Category 2 (Pseudo koebnerization): Warts, Molluscum (autoinoculation or seeding of microbes)
- Category 3 (Occasional koebnerization): Darier disease, Erythema multiforme

- Category 4 (Dubious association with trauma): Pemphigus vulgaris, Lupus erythematosus

BIG QUESTION 2: How to classify and treat psoriasis?

Broad Answer: Psoriasis is classified by site and form. **Scalp psoriasis** crosses the hairline (unlike seborrheic dermatitis), **flexural psoriasis** affects folds with little scaling, **palmo-plantar** shows hyperkeratosis/fissures, and **nail psoriasis** has pitting, onycholysis, salmon patches, leukonychia, and subungual hyperkeratosis (POLISH). **Psoriatic arthritis** (HLA-B27) involves DIP joints, classified as oligoarthritis, polyarthritis, DIP, mutilans, or axial. Other types include **guttate** (post-streptococcal, children), **erythrodermic** (>90% BSA), **pustular** (Von Zumbusch, sterile pustules), and **impetigo herpetiformis** in pregnancy. Severe cases need ICU care; oral steroids are avoided.

Treatment: Topical (emollients, steroids, vitamin D analogues, retinoids, coal tar, anthralin, calcineurin inhibitors), phototherapy (NB-UVB preferred, PUVA, excimer laser), systemic (methotrexate, acitretin, cyclosporine), and biologics (anti-TNF, IL-12/23, IL-17A, alefacept).

DETAILED QUESTIONS

Q2.1: How do we classify psoriasis based on site?

Answer: Based on the site, psoriasis can be differentiated into:

- Scalp psoriasis (Scalp)
- Pityriasis amiantacea (Scalp)
- Inverse/Flexural psoriasis (Flexures)
- Palmo-plantar psoriasis (Palms and soles)
- Nail psoriasis (Nail)
- Psoriatic arthritis (Joint)



Q2.2: How does scalp psoriasis present?

Answer: Scalp psoriasis presents as erythematous scaly plaques that cross the hairline, extend onto the forehead, are not itchy, and do not cause alopecia.

Q2.3: How does scalp psoriasis differ from seborrheic dermatitis?

Answer:

- Seborrheic dermatitis does not cross the hairline and itches.
- Scalp psoriasis crosses the hairline and is not itchy.

Q2.4: What is pityriasis amiantacea?

Answer: Pityriasis amiantacea are thick, asbestos-like scaling which are seen in psoriasis, infections, and Lichen simplex.



Q2.5: What is inverse/flexural psoriasis?

Answer: Inverse or flexural psoriasis affects areas like the axilla, groin, and inframammary folds, presenting as bilaterally symmetrical, non-itchy lesions with little induration and no scaling.



Q2.6: What is palmo-plantar psoriasis?



Answer: Palmo-plantar psoriasis presents with hyperkeratosis and painful fissuring on the palms and soles.

Q2.7: Describe the different nail findings in nail psoriasis.

Answer: Nail psoriasis is associated with Psoriatic Arthritis.

- **Pitting** (shallow depressions) is the most common finding.
  Pits are typically irregular, deep, random, and large.
- **Onycholysis** is the separation of nail plate from bed.
  - This appears white due to air and hyperkeratotic (**subungual hyperkeratosis**) materials.
- **Salmon patch (Oil drop sign)** is the most specific manifestation of Nail psoriasis:
  - Translucent yellow-red discolouration in the nail bed proximal to onycholysis.
- Nail bed parakeratosis and psoriasiform hyperplasia

PYQ: FMGE 2022, 2023
PYQ: NEET PG 2022
PYQ: INICET 2022



Q2.8: How to remember major findings in nail psoriasis?

Answer: Major findings in Nail psoriasis, **POLISH**:

- **P**its
- **O**nycholysis
- **L**eukonychia
- **S**almon patch
- Subungual **H**yperkeratosis

Q2.9: What is psoriatic arthritis?

Answer: Psoriatic arthritis is a seronegative arthritis associated with the HLA-B27 gene, most commonly affecting the distal interphalangeal (DIP) joints.

Q2.10: What is the Moll and Wright classification of psoriatic arthritis?

PYQ: FMGE 2021, 2023

Answer:

Moll and Wright classification of Psoriatic arthritis	
Clinical pattern of presentation	Percentage of patients
Asymmetrical oligoarthritis (MC)	50
Symmetrical polyarthritis	40

Distal interphalangeal arthritis	5
Arthritis mutilans	5
Spinal column or axial involvement	40

Q2.11: How does psoriatic nail differ from onychomycosis?

Answer:

Psoriatic nails	Onychomycosis
Fingernails	Toenails
All the fingers	Few fingers
Pits and oil drops	No pits and oil drops
KOH: Negative	KOH: Positive

Q2.12: How do we classify psoriasis based on morphology?

Answer: Based on morphology, psoriasis can be classified as:

- Guttate Psoriasis
- Unstable Psoriasis
  - o Erythrodermic psoriasis
  - o Pustular psoriasis

Q2.13: What is guttate psoriasis?

PYQ: FMGE 2022

Answer: Guttate psoriasis:



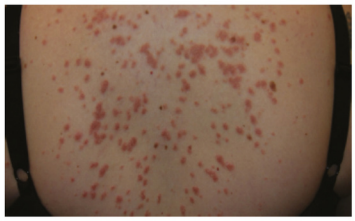

- **Raindrop**-like appearance
- Commonly seen in **children**.
- Preceded by streptococcal infection.
- **Small erythematous scaly plaques** on the trunk.
- **Investigations: ASLO** swab, Throat culture
- **Treatment with antibiotics:** Penicillin, Amoxicillin
  - o Recurrent episode → **Tonsillectomy** is done.

Q2.14: What are constitutional and generalized symptoms of unstable psoriasis?

Answer: Constitutional symptoms:

- Fever
- Malaise
- Pain
- Tenderness

Q2.15: What are the aggravating factors of unstable psoriasis?

Answer: Aggravating factors:

- Withdrawal of steroids
- Coal tar
- Pregnancy
- Stress
- Infections
- Hypocalcemia

Q2.16: What are the types of unstable psoriasis?

Answer: There are 2 types of unstable psoriasis:

Erythrodermic psoriasis	Pustular psoriasis
• Erythema, scaling of > 90% of the BSA. • Red scaly skin 	• Presence of visible Sterile pustules (collection of neutrophils) • Generalized or localized

Q2.17: What is generalized unstable psoriasis?

PYQ: AIIMS 2019

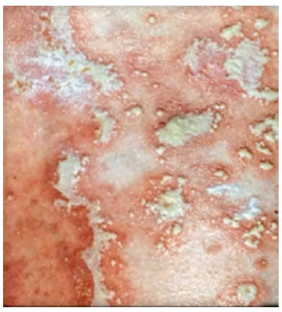

Answer: Acute generalized psoriasis, **Von Zumbusch**

- Erythematous plaques studded with sterile pustules
- Lakes of pus
- Treatment: Acitretin

Q2.18: Describe Impetigo herpetiformis.



Answer: Impetigo herpetiformis is a pustular psoriasis of pregnancy, typically in the last trimester, associated with adverse fetal outcomes such as low birth weight and mortality. It often recurs in subsequent pregnancies and is treated with steroids.

Q2.19: How to manage unstable psoriasis?

Answer: Management of unstable psoriasis:

- Admit in ICU
- Fluid, temperature monitoring
- Avoid aggravating factors

Q2.20: What important considerations should be kept in mind regarding the use of oral steroids in unstable psoriasis and during pregnancy?

Answer: Oral steroids are completely contraindicated in unstable psoriasis because they may lead to a rebound phenomenon. However, in pregnancy, steroids are considered the treatment of choice, and in pregnancy, cyclosporine is considered as the second line of choice.

Q2.21: How to treat psoriasis with topical medications?

PYQ: INICET 2020, 2022

Answer: Topical Treatment of psoriasis:

- <10% BSA
- <10 PASI (Psoriasis Area Severity Index)

Topical treatment of choice:

- **Emollients**, moisturization and hydration of scaly skin ,
- **Corticosteroids** are given topically, but not systematically.
- **Topical Retinoids:** Tazarotene, improve proliferation or keratinization.
- **Vitamin D analogues:** Calcipotriol, for keratinization.
- Coal tar (**Goeckerman's regimen**)
- Anthralin (**Ingram's regimen**)
- Salicylic acid
- Calcineurin inhibitors(**Tacrolimus, Pimecrolimus**) for face and flexures.

Q2.22: What are the steps involved in Goeckerman's and Ingram's regimens for psoriasis?

Answer:

- **Goeckerman's regimen** → applying coal tar paste to the affected areas and phototherapy is performed the next day.
- **Ingram's regimen** → applying Anthralin paste to the affected areas, and phototherapy is performed the next day.

Q2.23: Why are calcineurin inhibitors used instead of long-term steroids?

Answer: Steroids in long use can cause atrophy, hence Calcineurin inhibitors are given.

Q2.24: How to treat psoriasis with phototherapy/light therapy?

Answer: In phototherapy, UV-A and UV-B are used.

- The most used phototherapy is NB (Narrow Band) UVB therapy.
- Wavelength: 311-313 nm

PUVA (Psoralen + UVA) phototherapy	• Psoralens are Topical and Oral forms • Longer exposure may lead to: o **Cataracts, due to their deposition.** o **Skin cancers (SCC and BCC)** • Usually, 300 treatments are to be done using phototherapy for PUVA. • UVB is preferred over UVA, due to the adverse effects of UVA on longer exposure.
Targeted phototherapy	• Excimer lasers/ lamps, 308 xenon-chloride excimer laser • Targeted UVB therapy consists of a noble gas and halide.

Q2.25: What are systemic drugs for psoriasis?

Answer:

Main Drugs	• **Methotrexate (MTX)** o Dihydrofolate (DHFA) reductase inhibitor o 7.5-25 mg once a week o Treatment of choice in: → Chronic plaque psoriasis → Psoriatic arthritis → Erythrodermic psoriasis

YOURWISH

YOURWISH

	• **Acitretin** o Vitamin A analogue o Retinoids, two types: → Isotretinoin (Acne) → Acitretin (Psoriasis) o **Treatment of choice in:** → Pustular psoriasis → HIV → Immunosuppression • **Cyclosporin** o Inhibits Il2 o Crisis drugs → only used to control severe acute episodes o Not used for long-term
Biological drugs	• Anti-TNF-alpha drugs: Etanercept, Infliximab, Adalimumab • IL 12/23 inhibitor: Ustekinumab • LFA-1: Alefacept • IL 17A inhibitor (More commonly used): Secukinumab, Ixekizumab

Q2.26: What are the side effects of Cyclosporin?

Answer:

Side Effects of Cyclosporin	
Involved Organs and System	**Adverse Effects**
Metabolism and nutrition disorders	**Hyperlipidemia**
Nervous system disorders	Tremor, Headache, Paresthesia
Cardiovascular disorders	**Hypertension**
Gastrointestinal disorders	• Nausea • Vomiting • Abdominal pain • Diarrhea • **Gingival hyperplasia**
Hepatobiliary disorders	Abdominal hepatic function
Skin and subcutaneous tissue disorders	**Hypertrichosis**
Musculoskeletal disorders	Muscle cramps myalgia
Renal disorders	**Renal dysfunction**

BIG QUESTION 3: Describe pityriasis rubra pilaris.

Broad Answer: Pityriasis rubra pilaris (PRP) is a papulosquamous dermatitis of unknown cause, presenting with scaly red follicular papules or plaques and erythema between lesions, with characteristic islands of sparing. Palms and soles show hyperkeratosis and red plaques ("PRP sandals"), and knuckles may have nutmeg crater papules. Histology reveals a checkerboard pattern of alternating hyperkeratosis and parakeratosis. PRP is classified into six types, including classical adult (type 1) and HIV-related (type 6). Treatment includes topical agents, methotrexate, and acitretin. Treatment options include topical agents, such as those used for psoriasis, and oral medications like methotrexate and acitretin.

DETAILED QUESTIONS

Q3.1: What is pityriasis rubra pilaris?

Answer: Pityriasis rubra pilaris is a papulosquamous dermatitis of unknown cause, which is characterised by scaly red follicular papules or plaques.

Q3.2: What are the histopathological findings in pityriasis rubra pilaris?

Answer:

- Checkerboard pattern, alternate hyperkeratosis and parakeratosis.
- Erythema is seen between the papules.
- Islands of sparing, which differs from psoriasis.
- Palms and soles have hyperkeratosis and erythematous plaques.which appears to be as a person wearing PRP sandal.
- Erythematous, scaly plaque on knuckles are known as plaque **Nutmeg crater papules.**






Q3.3: What are the different types of pityriasis rubra pilaris (PRP)?

Answer:

- Classical adult-onset PRP (type 1)
- Atypical adult onset PRP (type 2)
- Classical juvenile onset PRP (type 3)
- Circumscribed juvenile PRP (type 4)
- Atypical juvenile PRP (type 5)
- HIV- related PRP (type 6)
  - HIV- related PRP (type-6) is seen in HIV patients.

Q3.4: How to treat pityriasis rubra pilaris (PRP)?

Answer:

- Topical agents (same as psoriasis)
- Oral agents: Methotrexate (MTX) and Acitretin

BIG QUESTION 4: Describe lichen planus.

Broad Answer: Lichen planus is a T-cell-mediated autoimmune disorder affecting skin, mucosa, nails, and hair, often triggered by hepatitis B/C or certain drugs. It presents with the 5 P's—pruritic, purplish, polygonal, plane-topped papules/plaques—on wrist and ankle flexors, showing post-inflammatory hyperpigmentation and positive Koebner's phenomenon. Oral lesions display Wickham's striae, with variants such as reticular (most common), erosive, atrophic, and ulcerative (premalignant). Key features include pterygium in nails, trachyonychia, and cicatricial alopecia.

- Histopathology shows hyperkeratosis, wedge-shaped hypergranulosis, acanthosis with saw-tooth rete ridges, basal cell degeneration with Civatte bodies, Max Joseph spaces, and a band-like lymphocytic infiltrate (interface dermatitis).
- Treatment involves topical corticosteroids, calcineurin inhibitors, antihistamines, and local anesthetics for oral lesions; intralesional steroids for hypertrophic forms; and systemic therapy with corticosteroids, dapsone, HCQS, azathioprine, mycophenolate, or phototherapy (NB-UVB).

DETAILED QUESTIONS

Q4.1: What is lichen planus?

PYQ: FMGE 2021

Answer: Lichen planus is a T-cell-mediated autoimmune disorder that targets the basement membrane zone, affecting the skin, nails, mucosa, and hair. Its etiology is unknown, but it may be triggered by infections such as hepatitis B or C or by certain drugs.

Q4.2: Which drugs can cause lichen planus?

Answer: Drugs causing lichen planus are:

- Antibacterials
- Anti-Tubercular Drugs
- Antihypertensives
- Antimalarials
- Anticonvulsants
- Heavy metals like gold and lithium
- Dental Amalgams

Q4.3: What are the clinical features of lichen planus?

Answer:

- Lichen planus is a papulosquamous disorder that affects:
  - Skin
  - Mucosa
  - Hair and nails.
- It is pruritic and affects Flexures.
- The characteristic lesion of Lichen Planus is the 5 p's
  - Purplish
  - Plane topped
  - Pruritic
  - Polygonal
  - Papules and Plaque.
- The common sites are flexors of the wrist or ankle.





Q4.4: Describe the different types of lesions seen in Lichen Planus.

PYQ: FMGE 2023

Answer:

Type	Description	Image
Post-inflammatory Hyperpigmentation	The Lichen Planus hilled with hyperpigmentation. Hyperpigmented Macules → **Hilled lesions of Lichen Planus.**	
Koebner's phenomenon	**Positive Koebner's phenomenon:** Papules developed along the line of trauma.	
Wickham's Striae	On-hand lens → **Whitish streaks** on a lesion of Lichen Planus → **hypergranulosis.**	
Oral lesions	• **Pain & burning sensation** on eating hot spicy food. • On examination: **Lacy reticular white pattern** on the mucosa.	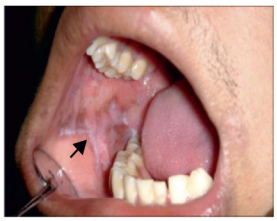
Dental amalgam	Other mucosa affected by Lichen Planus are the **genital or rectal mucosa.**	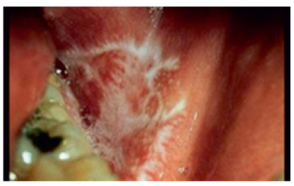 Dental Amalgam
Variants in oral mucosa	• **Reticular (most common)** • Erosive • Atrophic • Ulcerative • **Ulcerative is a premalignant condition**	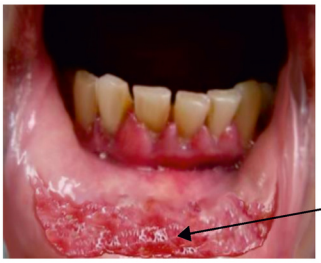 Ulcerative lesion
Trachyonychia	**Longitudinal ridging of nails** (most common finding).	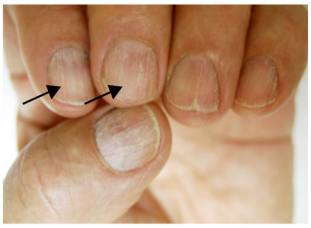

YOURWISH

YOURWISH

Pterygium	• Most specific finding • A wing-shaped extension of the proximal nail fold on the nail plate. • Tenting of nails.	
Cicatricial / Scarring alopecia	• Lichen Planus is an important cause of **Scarring alopecia.** • The hair follicles are destroyed. • Scarring occurs with no growth of hair. • This is **irreversible.**	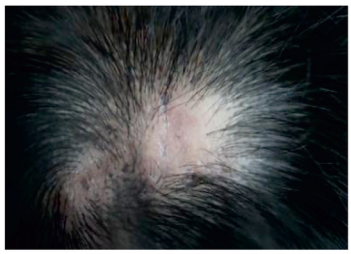 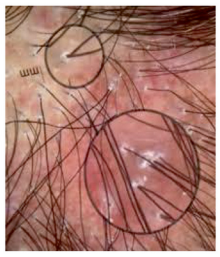

Q4.5: Describe the histopathology of lichen planus.

Answer:

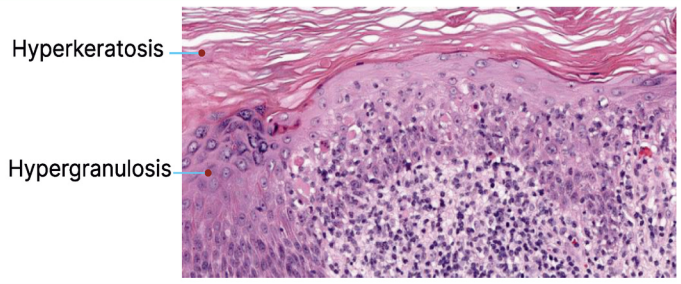

Stratum Corneum	Hyperkeratosis (increased thickening) 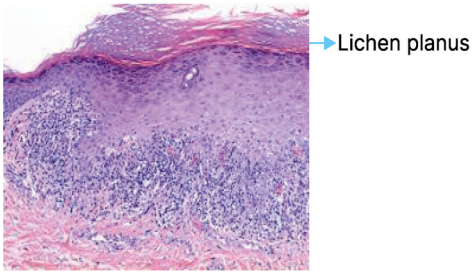
Stratum Granulosum	Typically, focal, wedge-shaped hypergranulosis is seen. 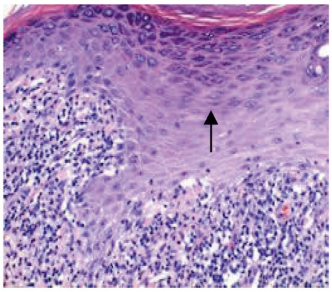
Stratum Spinosum	Acanthosis
Stratum Basale	Basal Cell Degeneration → apoptotic bodies (Civatte bodies)

Rete Ridges	Saw-toothed rete ridges 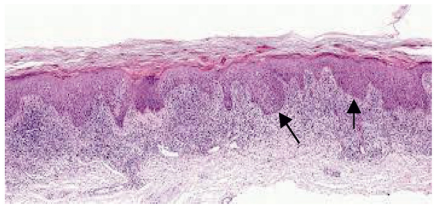
Between epidermis and dermis	Max Joseph Space
Dermis	Band-like infiltrate of lymphocytes

The basal cell degeneration and infiltrate in the dermis are together referred to as Interface dermatitis.

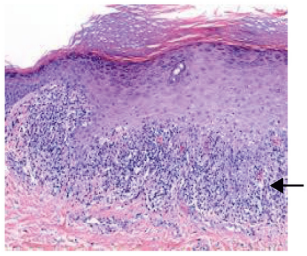

Q4.6: What are the treatment options for lichen planus?

Answer:

Topical	• Corticosteroids • Calcineurin Inhibitors (Tacrolimus, Pimecrolimus) → Applied on the face, flexure regions, and mucosa. • Antihistamine • Oral mucosa affected → Need to give local anesthetics.
Intralesional	• Hypertrophic lesions: Intralesional injections of Corticosteroid.
Systemic	• For more severe forms. • Commonly used systemic agents are: o Oral Corticosteroid o Dapsone o HCQS o Azathioprine o MMF (Mycophenolate Forfeited)
Phototherapy	• NB-UVB Phototherapy. • Used especially in children who have a lot of lesions in the body.

8. IMMUNOBULLOUS DISORDERS

BIG QUESTION 1: What are Immunobullous Disorders, their types, pathogenesis, and antigenic targets

Broad Answer:

- Two main categories: Pemphigus (Intraepidermal split) & Pemphigoid (Subepidermal split)
- Caused by autoantibodies against adhesion proteins in epidermis or basement membrane.
- Pathogenesis: Autoantibodies → loss of keratinocyte adhesion → blister formation.
- Major proteins: Desmosomes (Pemphigus) & Hemidesmosomes/BM zone proteins (Pemphigoid).
- Examples: Pemphigus vulgaris, foliaceus, vegetans, IgA pemphigus, paraneoplastic pemphigus.

Q1.1: What are the two broad categories of Immunobullous Disorders?

Answer:

- Pemphigus group - Intraepidermal split
- Pemphigoid group - Subepidermal split



Q1.2: What is the pathogenesis of Pemphigus group of disorders?

Answer:

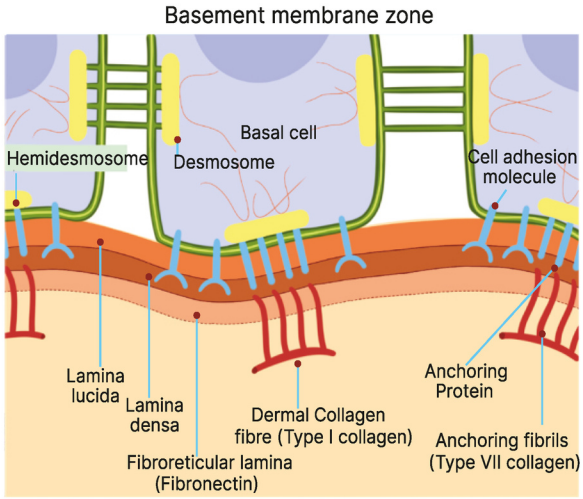

Ag-Ab complexes may form at the Keratinocytes or at Adhesions between Keratinocytes

↓

This will create an empty space between Keratinocytes

↓

The empty space will get filled with tissue fluids

↓

Leads to more separation of Keratinocytes (Acantholysis)

↓

This progresses to form a lesion filled with fluid: Vesicle or Bullae

Q1.3: What are the intraepidermal Immunobullous Disorders?

Answer: **Target Protein:** Desmosomes (cementing substance between keratocytes)

- Pemphigus vulgaris
- Pemphigus foliaceus
- Pemphigus vegetans
- IgA pemphigus
- Paraneoplastic pemphigus

YOURWISH

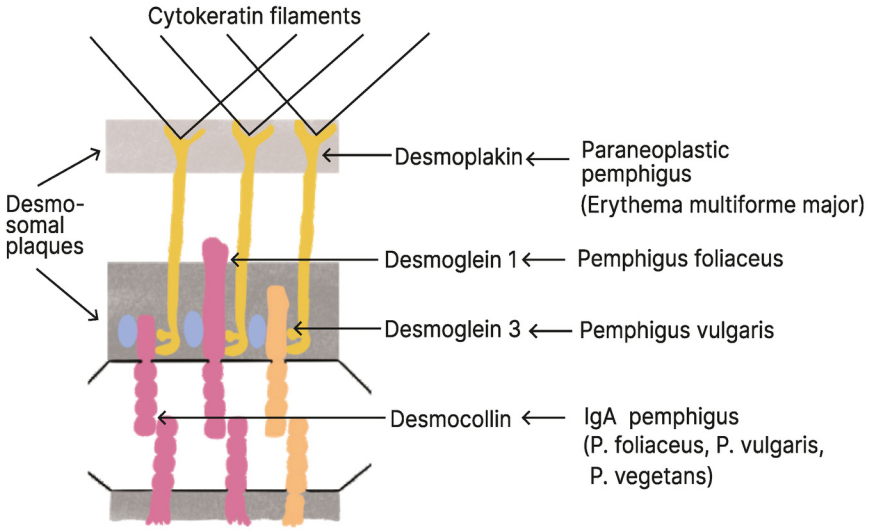

Structure and components of desmosomes

Q1.4: What is the Desmoglein Compensation Theory?

Answer: DSG-1 & DSG-3 compensate for each other.

- **Skin:**
  - DSG-1 → Throughout the skin (Concentration decreases from top to bottom).
  - DSG-3 → Lower layers of skin (Maximum concentration is at stratum basale and spinosum).
- **Mucous Membrane**
  - DSG-1 → Only on the superficial layers.
  - DSG-3 → Throughout the membrane.

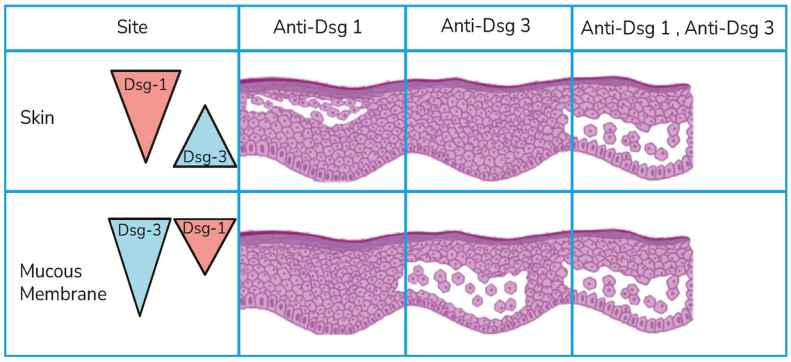

Q1.5: What are the target antigens in Pemphigus variants?

Answer:

Target Antigen	Type
Desmoglein-1 (DSG-1)	Pemphigus foliaceus
Desmoglein-3 (DSG-3)	Pemphigus Vulgaris
Desmocollin	IgA type pemphigus
Desmoplakin	Paraneoplastic pemphigus

Q1.6: How do DSG-1 and DSG-3 autoantibodies affect mucosa and skin?

Answer: PYQ: AIIMS 2018, 2019 | PYQ: INICET 2023 | PYQ: NEET PG 2021

DSG-1 is Targeted	DSG-3 is Targeted	DSG-1 and DSG-3 Both are Targets
• Produces DSG-1 Antibodies. • Mucosa is not affected **(DSG-3 compensates for DSG-1).** • Skin is affected (The upper layer is affected as more DSG-1 is present). • Split is subcorneal • Seen in: **Pemphigus foliaceus.**	• Produces DSG-3 Antibodies. • Skin is not affected **(DSG-1 compensates for DSG-3).** • Mucosa is affected (as DSG-3 is major). • Seen in **Pemphigus vulgaris.**	• Both skin and mucosa are affected. • Seen in **Pemphigus vulgaris (DSG-3 >> DSG-1).**

YOURWISH

YOURWISH

BIG QUESTION 2: What are the key features of Pemphigus Vulgaris and Pemphigus Foliaceus?

Broad Answer:

- Target/Antigen: Desmosomes - PV: DSG-3 > 1; PF: DSG-1.
- Level of split: PV → Suprabasal; PF → Subcorneal.
- Clinical:
  - PV: Painful mucosal erosions + flaccid bullae (trunk/flexures).
  - PF: No mucosal lesions, superficial crusted erosions at seborrheic sites.
- Diagnostic signs: Nikolsky (+), Bulla spread, Asboe-Hansen; False Nikolsky (subepidermal), Pseudo Nikolsky (SJS-TEN).
- Investigations: Tzanck smear (acantholytic cells), HPE (PV: tombstone row; PF: subcorneal split), DIF → Fishnet pattern.

Q2.1: In which populations is Pemphigus Vulgaris more common, and what is its target?

Answer: More common in Ashkenazi Jews, Mediterranean, Iranians

Target Structure	• Desmosome
Target Antigen	• DSG-1 and DSG-3 (3>>1)
Split	• Supra basal.
Layer	• Stratum spinosum

Q2.2: What are the clinical features of Pemphigus Vulgaris?

Answer:

- Involve mucosa (oral, vaginal, esophageal, rectal) and skin.
- **Mucosa:** Non-healing, Painful, erythematous erosions with a tendency to spread peripherally and yellowish slough.


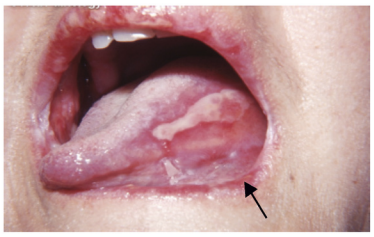

- **Skin: Vesicle → Flaccid Bulla → Ruptures (in 3-4 days) → Crusted erosions → Heal without scarring. Erosions spread peripherally.**
- Most commonly affects the trunk and the flexures.
- Pemphigus vulgaris, bullae rupture in 2 - 3 days

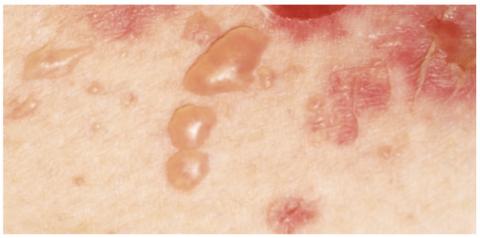



Q2.3: What are the features of Pemphigus Foliaceus?

Answer:

Antigen	• Desmoglein 1
Split	• Sub corneal layer (Stratum Granulosum)
Site	• Seborrheic sites (face, scalp, upper trunk)
Clinical features	• No mucosal lesions (Desmoglein 3 compensates mucosa) • Vesicles and bullae are hardly present. • Superficial vesicles and bullae rupture within a **few hours** which results in **crusted erosions in seborrheic distribution.**  

Q2.4: How do Pemphigus Vulgaris and Foliaceus differ?

Answer

	PV	PF
Antigen	Desmoglein 3>1	Desmoglein 1
Split	Suprabasal	Subcorneal
Skin	Vesicles and flaccid bullae rupture in a few days, seen in the trunk, face, limbs	Crusted erosions in seborrheic distribution
Mucous membrane	++	Absent

Q2.5: What is Nikolsky's sign and its importance?

Answer: **Nikolsky's sign** (Bedside test or sign) → Development of bulla or erosion when a shearing force is applied on the skin surrounding a vesicle or bulla.

- **Importance:**
  - Deals with the severity and activity of the disease.
  - Tells about the treatment's response.
  - Differentiate b/w intraepidermal (+ve) and subepidermal disorders (-ve).
  - Positive in SSSS.
- **False Nikolsky's sign:**
  - Subepidermal cleavage occurring in perilesional skin.
  - Seen in subepidermal disorders.
  - Pulling of the peripheral remnant of the roof of a ruptured blister → extending the erosion on the surrounding normally appearing skin.
- **Pseudo Nikolsky sign:**
  - Pseudo necrosis of epidermal cells and not acantholysis
  - Seen in SJS-TEN.

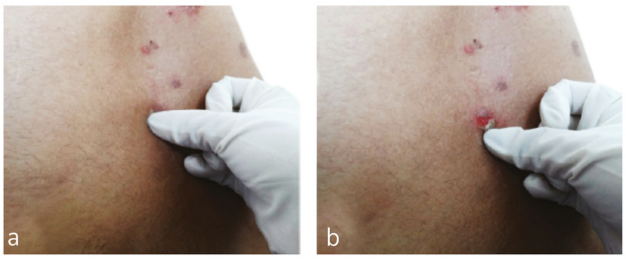

Q2.6: What are other bedside signs in Pemphigus?

Answer: **Bulla spread sign:** Bulla spreads over its margin when pressure is applied laterally. (Angular in intraepidermal lesions and dome-shaped in subepidermal disorders)

- **Importance:**
  - → Deals with the activity of the disease.
  - → Differentiate b/w intraepidermal (angular spread) and subepidermal disorders (circular spread)
- **Asboe Hansen sign:** The pressure is applied from the top for small bulla or vesicles.



Q2.7: What is the role of Tzanck smear in Pemphigus?

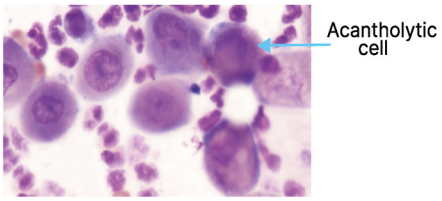

Answer:

- Test: Tissue smear from vesicle
- Findings (Acantholytic cells/ Tzanck cells):
  - Round/oval (not keratinocyte-like)
  - Large nuclei (⅞ of cell)
  - Peripheral cytoplasmic condensation
- Also positive in Herpes (acantholytic cells + multinucleated giant cells)

Q2.8: What are the histopathological features of Pemphigus?

Answer:

Histopathological features	
Two samples are taken: • Lesional sample: H&E staining • Perilesional sample: Direct immunofluorescence 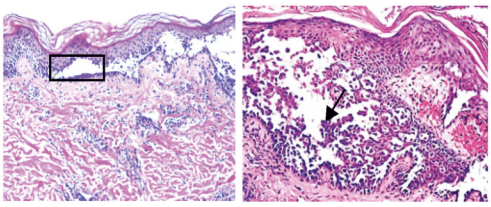	
Pemphigus Vulgaris	**Pemphigus foliaceus**
• Split: Suprabasal • Row of tombstones • Acantholytic cells 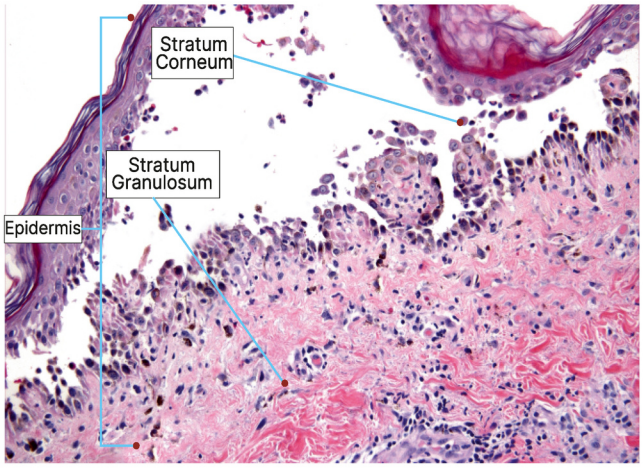	• Split: Subcorneal 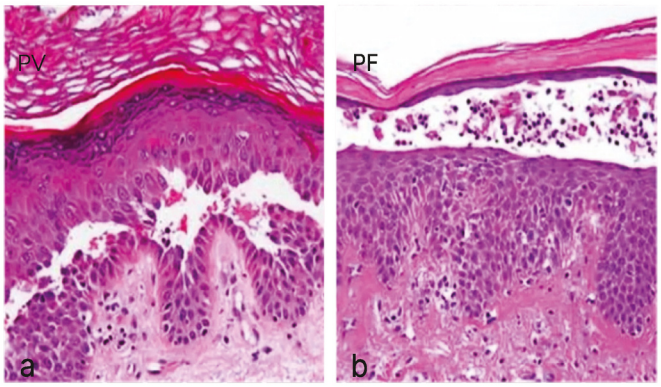

Q2.9: What are the direct immunofluorescence (DIF) findings in Pemphigus?

PYQ: INICET 2021

Answer:

- Gold standard test

YOURWISH

- Demonstrate the presence of Ag-Ab complexes
- Principle of DIF
  - Fluorescent-labeled antibodies bind to antigens.
  - Fluorescence is seen under UV light.
- Fluorescence passes between keratinocytes: Fishnet pattern (characteristic of Pemphigus group)
- Fluorescence is more in the suprabasal area: PV
- Fluorescence is more in the Stratum corneum: PF.

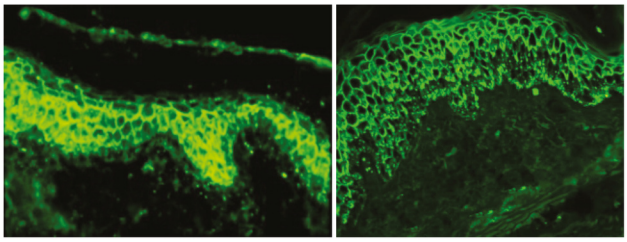

BIG QUESTION 3: What are the variants of Pemphigus and how is it treated?

Broad Answer:

- Variants include Endemic PF (Fogo Selvagem), Paraneoplastic Pemphigus, and IgA Pemphigus.
- Endemic PF: Brazil/Columbia, blackfly bite, flaccid bullae, mucosa spared
- Paraneoplastic Pemphigus: Multiple antigens, lymphoma association, polymorphic, severe mucosal disease.
- IgA Pemphigus: Desmocollin antigen, IgA antibody, circinate lesions in children.
- Treatment: Topical & systemic corticosteroids (1-2 mg/kg, tapered).
- Adjuvants: Immunosuppressants (AZA, MMF, Cyclophosphamide), Rituximab (anti-CD20), Dapsone (for IgA).

Q3.1: What are the features of Endemic Pemphigus Foliaceus (Fogo Selvagem)?

Answer:

- Endemic in Brazil and Colombia
- Common in children and young adults
- Risk factor: Arthropod bite (Blackfly - Simuliidae)
- Initial lesions: Flaccid bullae
- Nikolsky sign: Positive
- First sites involved: Head and neck
- "Fogo selvagem" (Portuguese for wildfire) → burnt appearance & burning sensation
- Mucous membranes not involved

Q3.2: What are the antigens and associations of Paraneoplastic Pemphigus?

Answer:

- **Antigens:**
  - DSG 1 and DSG 3
  - Desmoplakin 1 and 2
  - Envoplakin
  - Periplakin
  - 230 kDa bullous pemphigoid (BP) antigen 1
- **Association:** Underlying neoplasms
- **Commonest:** Non-Hodgkin's lymphoma and B-cell lymphomas
- **Diagnostic Criteria:** Anhalt's criteria

Q3.3: What are the clinical features of Paraneoplastic Pemphigus?

Answer:

- Polymorphic
- Intra and subepidermal bullae

YOURWISH

YOURWISH

- Lichenoid
- Severe mucosal involvement
- Paraneoplastic Pemphigus is the most severe type of Pemphigus

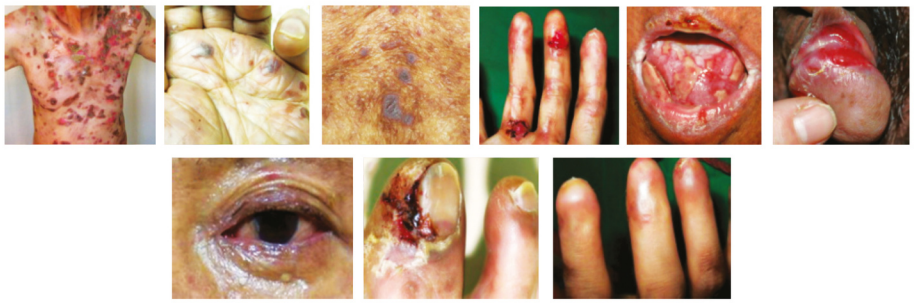

Q3.4: What are the features of IgA Pemphigus?

Answer:

- Antigen: Desmocollin
- Antibody: IgA
- Children
- Circulate/Circinate lesions

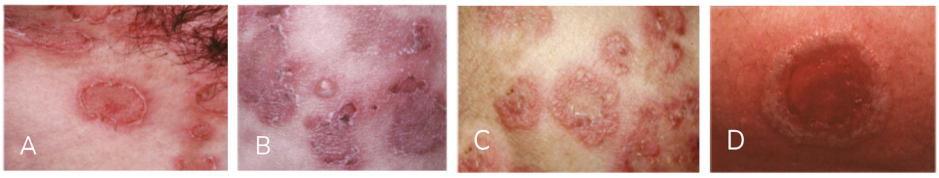

Q3.5: What are the topical and systemic treatment options for Pemphigus?

Answer:

- **Topical:** Topical corticosteroids
- **Systemic:**
  - TOC is Corticosteroids + Immunosuppressants (Azathioprine, Mycophenolate mofetil, Cyclophosphamide)
  - Steroids → daily therapy or pulse therapy.
  - Dosage of corticosteroids: 1-2 mg/kg body weight.
  - Corticosteroids → given for 4-8 weeks and then tapered off.

Q3.6: What are the roles of biological agents and special drugs in Pemphigus treatment?

Answer:

- **Biological agents (Rituximab)**
  - Anti-CD 20 molecule
  - Intravenous agent
  - Given at 0 and 15th day
- **Immunosuppressants :**
  - Azathioprine (AZA)
  - Mycophenolate Mofetil (MMF)
  - Cyclophosphamide
  - AZA, MMF, and Cyclophosphamide are preferred along with corticosteroids.
  - Dapsone → IgA pemphigus.

BIG QUESTION 4: What are Subepidermal Disorders?

Broad Answer:

- Target: Basement membrane zone (Dermo-epidermal junction).
- Types: Pemphigoid group, Dermatitis Herpetiformis.
- Bullae: Tense (thick roof), hemorrhagic, persist for few days, Nikolsky sign negative.

- Bulla in the Pemphigus group is Flaccid (Old grape or balloon).

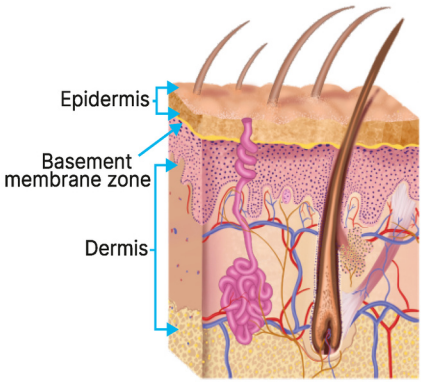

Q4.1 What are the components of the Basement Membrane Zone?

Answer: Lamina lucida: Weakest layer

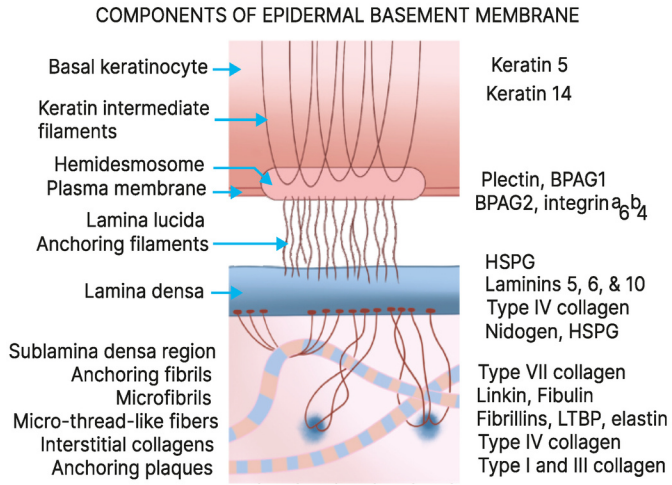

Q4.2 What is the Salt-Split Technique and its importance?

Answer:

- Splits the lamina lucida (BMZ) by adding 1M NaCl.
- Used to differentiate BP and EBA.
- In BP → Immunofluorescence above the split (roof).
- In EBA → Immunofluorescence below the split (floor).

Q4.3 What are the target antigens in subepidermal disorders?

Answer:

Disease	Target antigens
Bullous pemphigoid	BP 180 (BP Ag2), BP 230 (BPAg 1) PYQ: INICET 2023
Pemphigoid gestationis	BP 180, BP 230
Linear IgA bullous dermatosis (LABD)	BP 180 (LAD1)
Epidermolysis bullosa acquisita	Collagen VII
Bullous lupus erythematosus	Collagen VII
Cicatricial pemphigoid	BP 180, laminin, α 4 and β 6 subunits of integrin

MMP (Mucous Membrane Pemphigoid)	BP 180, laminin 332
Linear IgA	LAD1
DH (Dermatitis Herpetiformis)	Epidermal Transglutaminase (not from basement membrane) PYQ: AIIMS 2020

Q4.4: What is the correct sequence of autoimmune blistering disorders arranged in sequence based on the order of split/antigen?

Answer:

- PF
- PV
- BP
- Cicatricial/MMP
- EBA/Bullous SLE

Q4.5: What are the basic features of Bullous Pemphigoid?

Answer:

- Antigen: BPAG1 (230 kDa), BPAG2 (180 kDa)
- Antibody: IgG
- Pathogenesis: Complement activation, eosinophil recruitment
- Age: Elderly (60-80 years)
- Associations: Neurological, autoimmune, psychiatric disorders
- Triggers: Trauma, drugs
- Common sites: Trunk, near umbilicus

Q4.6: What are the clinical features of Bullous Pemphigoid?

PYQ: FMGE 2021 PYQ: NEET PG 2022

Answer:

- **Prebullous stage**
  - Itchy urticarial lesions
  - Refractory to treatment
- **Bullous stage**
  - Tense, hemorrhagic, subepidermal bullae
  - Rupture in few days → crusted erosions
  - Heal with milia formation
  - No scarring, no tendency to spread
  - Mucosa: Rarely involved

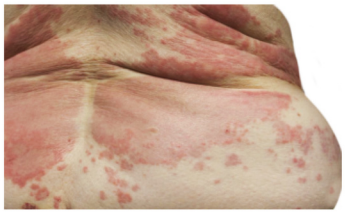





Q4.7: What are the signs and diagnostic findings in Bullous Pemphigoid?

Answer:

- **Signs :**
  - Nikolsky sign: Negative
  - Bulla spread sign: Positive (round spread)
- **Diagnosis :**
  - Tzanck smear: No acantholytic cells, inflammatory cells seen
  - Histopathology: Subepidermal split with eosinophils
  - Direct immunofluorescence: Linear deposition of IgG and C3 at dermo-epidermal junction

YOURWISH

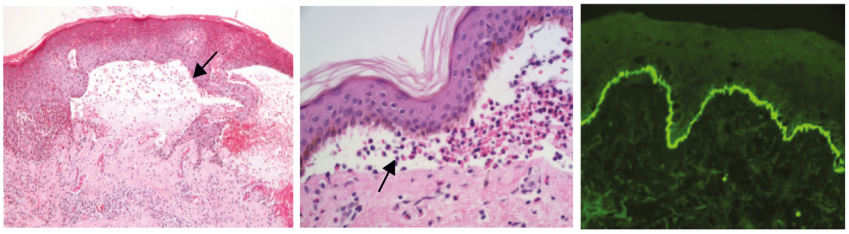

Q4.8: What is the treatment of Bullous Pemphigoid?

PYQ: INICET 2020

Answer:

- **Mild cases:** Topical corticosteroids
- **Severe cases:**
  - Oral corticosteroids
  - Dapsone
  - Nicotinamide
  - Tetracyclines
  - Other immunosuppressants

Q4.9: What are the features of Pemphigoid Gestationis?

Answer: **Also called Herpes Gestationis**

Variant	• Bullous pemphigoid in pregnancy.
Affected	• Pregnant females (3rd trimester), rarely develop trophoblastic tumors.
Antibody	• Circulating complement-fixing IgG1 (HG factor) to BP180. • C3 > IgG
Clinical	• Starts in the periumbilical area • Periumbilical itchy urticarial plaques → tense vesicles.
Treatment	• Mild → Topical steroids • Severe → Oral steroids *In pregnancy, other drugs like dapsone, and immunosuppressants are toxic.*

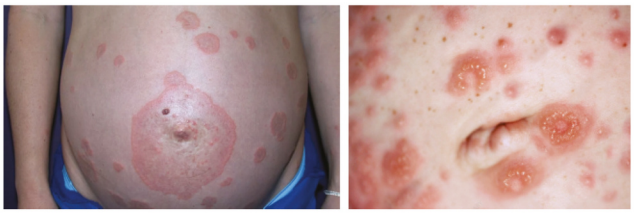

Q4.10: What are the features of Linear IgA Disease (LABD)?

Answer:

Antigen	• LAD1, BP180.
Antibody	• IgA
Age	Bimodal • Children (Chronic bullous disease of childhood-CBDC) • Adults (LAD).

YOURWISH

Site	• Adults → Trunk • Children → Perioral
Clinical	• Vesicles and tense bullae are in the form of rings(Cluster of jewels)/String of pearls 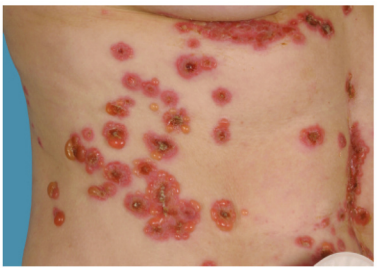 • Perioral distribution
Histopathology	• Subepidermal split.
DIF	• Linear IgA deposits.
Treatment	• Mild → Topical corticosteroids. • Severe → Oral CS, Dapsone, Nicotinamide, Tetracyclines, Immunosuppressants

Q4.11:What are the basic features and associations of Dermatitis Herpetiformis?

Answer:

Type:

- Subepidermal immunobullous disorder

Associations:

- Gluten-sensitive enteropathy (diarrhea, bloating, distension)
- HLA-DQ2, HLA-B8
- Iodine can provoke disease

Antigen:

- Epidermal Transglutaminase

Q4.12 What are the clinical features of Dermatitis Herpetiformis?

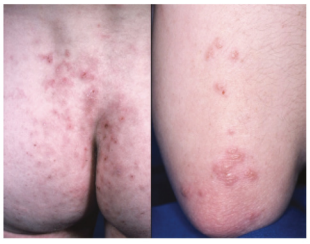

Answer:

- Lesions on extensors and trunk
- Itchy, excoriated papulo-vesicular lesions
- No bullae/vesicles

Q4.13 What are the histopathological and immunofluorescence findings in Dermatitis Herpetiformis?

Answer:

- **Histopathology:**
  - Papillary tip microabscesses with neutrophils
  - Neutrophilic infiltration targets Epidermal Transglutaminase
- **Direct Immunofluorescence (DIF):** Papillary tip immune fluorescence

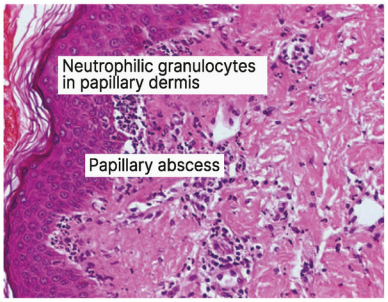

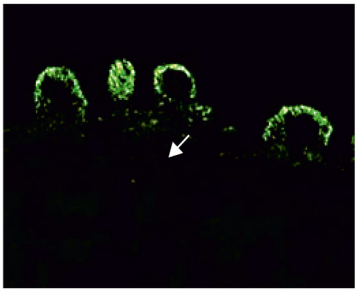

Q4.14 What is the treatment of Dermatitis Herpetiformis?

Answer:

- Dapsone
- Gluten-free diet: Avoid wheat, barley, rye, oats;
- Eat maize, rice

Q4.15 Compare Pemphigus and Pemphigoid.

Answer:

Features	Pemphigus	Pemphigoid
1. Age of onset	40-60 years	60-80 yrs
2. Bullae	Flaccid (Painful erosion)	Tense
3. Mucosal involvement 4. Intraepidermal bullae 5. Nikolsky sign 6. Acanthocytes 7. Row of tombstone	Present	Absent
8. Bullae spread sign	Present	Present

9. SYSTEMIC DISEASES AND SKIN

BIG QUESTION 1: Describe connective tissue disorders.

Broad Answer: Connective tissue disorders are autoimmune, with skin, organ, and antibody involvement. LE spectrum: ACLE (SLE with malar rash sparing nasolabial folds), SCLE, and DLE (discoid lesions with carpet tack sign, cicatricial alopecia). Autoantibodies: ANA, Anti-Smith, Anti-dsDNA. Neonatal LE (Ro/SSA+) shows raccoon sign and congenital heart block. Dermatomyositis causes proximal weakness with Gottron's papules, heliotrope rash, V-sign, shawl sign, holster-sign, calcinosis, mechanic's hand; tests include ANA, anti-Jo-1, CK; treated with steroids, methotrexate, HCQS. Systemic sclerosis has tight skin, Raynaud's, dysphagia, lung disease, mask-like facies; limited type (anticentromere Ab) vs diffuse (anti-Scl-70+). CREST: Calcinosis, Raynaud's, Esophageal dysfunction, Sclerodactyly, Telangiectasias.

DETAILED QUESTIONS

Q1.1: What are the main features of connective tissue disorders?

Answer: Connective tissue disorders are a group of disorders that have:

- Autoimmune inflammation
- Skin manifestations
- Internal organ manifestations
- Autoantibodies on laboratory investigations.

Q1.2: What does the LE spectrum consist of?

Answer:

- Acute cutaneous LE (ACLE)
- Subacute cutaneous LE
- Chronic cutaneous LE/DLE.

Q1.3: What is ACLE?

PYQ: FMGE 2019, 2021

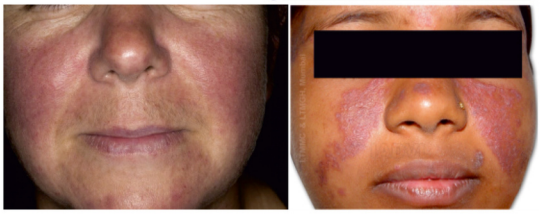

Answer: ACLE is associated with Systemic Lupus Erythematosus (SLE)

- Occurs in a middle-aged female presenting with malar rash/butterfly rash associated with photosensitivity.
- Presents on the cheeks with sparing of nasolabial folds

Q1.4: What is Chronic Cutaneous LE?



Answer: It is also known as DLE (Discoid Lupus Erythematosus) because of discoid lesions.

- Discoid lesions are characterised by three zones:
  - Central atrophic area
  - Middle activity- scaling, which is perifollicular in nature
  - Zone of hyperpigmentation

Q1.5: What are the characteristic signs of DLE?

Answer: Signs of DLE:

- Carpet Tack or Tin Tack Sign, also called Cat's tongue → characteristic of DLE
  - Because of perifollicular scaling
- DLE causes Cicatricial alopecia.

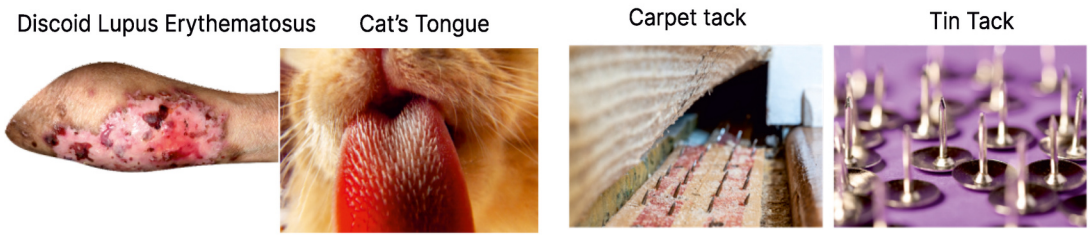

Q1.6: What autoantibodies are positive in lupus erythematosus?

Answer:

- ANA positive: Sensitive test
- Anti-Smith (Anti-SM) antibody: More specific and less commonly done
- Anti-DS DNA: Specific

Q1.7: What is the treatment for LE spectrum?

Answer:

- Sun protection
- Antimalarials (HCQS: Hydroxy Chloroquine Sulphates) **(Drug of choice).**

Q1.8: Describe neonatal LE?



Answer: Neonatal LE is caused by the transplacental passage of maternal antibodies.

- Erythematous, slightly scaly eruption on the face, particularly on the periorbital skin (**racoon sign/owl eye/eye mask**)
- These kids are prone to congenital heart blocks also.
- These patients have positive Ro/SSA antibodies.

Q1.9: What are the characteristics of dermatomyositis? PYQ: INICET 2021, 2022 PYQ: FMGE 2023

Answer: Dermatomyositis is characterized by skin manifestations and muscle symptoms

- Proximal muscles are the group of muscles involved:
  - Difficulty when the patient tries to get up from chair
  - Difficulty when the patient tries to remove his clothes
  - Difficulty when the patient tries to walk upstairs
- Proximal muscle myopathy along with skin manifestations are seen

Q1.10: Name pathognomonic lesions of dermatomyositis.

Answer: Gottron's Papule and Gottron's Sign.

Q1.11: Describe Gottron's Papule.



Gottron's Papule

Answer: Erythematous to violaceous raised papules on the interphalangeal joint, distal interphalangeal joint, and Metacarpophalangeal joint.

Q1.12: Describe Gottron's Sign.

Answer: Gottron's sign refers to confluent, bilateral violaceous macular erythema seen over the interphalangeal spaces and dorsum of the hands.

YOURWISH



Gottron's sign

Q1.13: What other typical skin signs are seen in dermatomyositis?

Answer: CMVE is seen over other body parts also





- Around eyelids: Heliotrope rash
- At the neck, it is called V-sign.
- On the back, it is called Shawl sign
- On the thigh: Holster sign
- Apart from this, Calcinosis & Mechanic's hand are also present

Q1.14: How do we investigate for dermatomyositis?

Answer: Investigations:

- Serology: ANA is positive
- Myositis-specific antibody called anti-synthetase or anti-Jo-1 is positive.
- Tests done for Proximal muscle weakness would be positive
  - Creatine kinase test
  - EMG
  - MRI

Q1.15: What is important age-related information about dermatomyositis?

Answer: Dermatomyositis is bimodal in the age group:

- It affects children and adults
- In Children: Good prognosis

Q1.16: What is the treatment for dermatomyositis?

Answer: Corticosteroids, methotrexate, and HCQS.

Q1.17: What skin changes occur in systemic sclerosis?

Answer: In systemic sclerosis, the skin becomes bound down, thickened, sclerosed, and inelastic, making it impossible to pinch.

Q1.18: What are the types of systemic sclerosis?

Answer: Limited cutaneous systemic scleroderma and diffuse cutaneous systemic scleroderma.

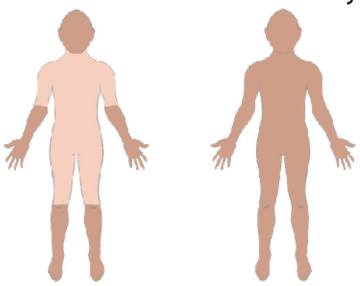

Limited cutaneous systemic Diffuse cutaneous systemic

Q1.19:Differentiate between limited cutaneous systemic sclerosis and diffuse cutaneous systemic sclerosis.

Answer:

Limited cutaneous Systemic sclerosis	Diffuse cutaneous Systemic sclerosis
• It affects area of skin below elbow and below knee • It affects the distal parts of the body • Anticentromere antibody to be positive	• It affects the proximal parts of the body • Anti Scl-70 positivity

Q1.20: What clinical features are present in systemic sclerosis?

Answer:

- Raynaud's phenomenon- positive
- Dysphagia/reflux
- Sclerosis of skin
- Internal organ involvement: GI/Pulmonary
  - Interstitial lung diseases (patient gives history of breathlessness while climbing up the stairs)
- Mask-like appearance
  - Loss of wrinkling
  - Skin appears shiny
  - Restricted mouth opening
  - Central incisors become more prominent
  - Telangiectasias
  - Furrowing along the oral commissure
- On the hands, bound down skin is present that leads to deformities like Sclerodactyly
- Sclerodactyly: Fingers get sclerosed



Q1.21: What is CREST syndrome?

PYQ: FMGE 2022

Answer: CREST syndrome is a localized form of Scleroderma (Mnemonic - **CREST**):

Calcinosis	Calcium deposits in the skin	

Raynaud's phenomenon	Spasm of blood vessels in response to cold or stress	
Esophageal dysfunction	Acid reflux and decrease in motility of esophagus	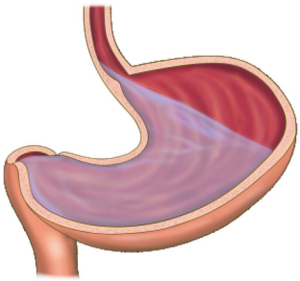
Sclerodactyly	Thickening and tightening of the skin on the fingers and hands	
Telangiectasias	Dilation of capillaries → red marks on the surface of the skin	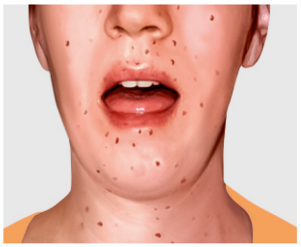

Q1.22: Differentiate the clinical features of connective tissue disorders?

Answer: Clinical features of CREST syndrome:

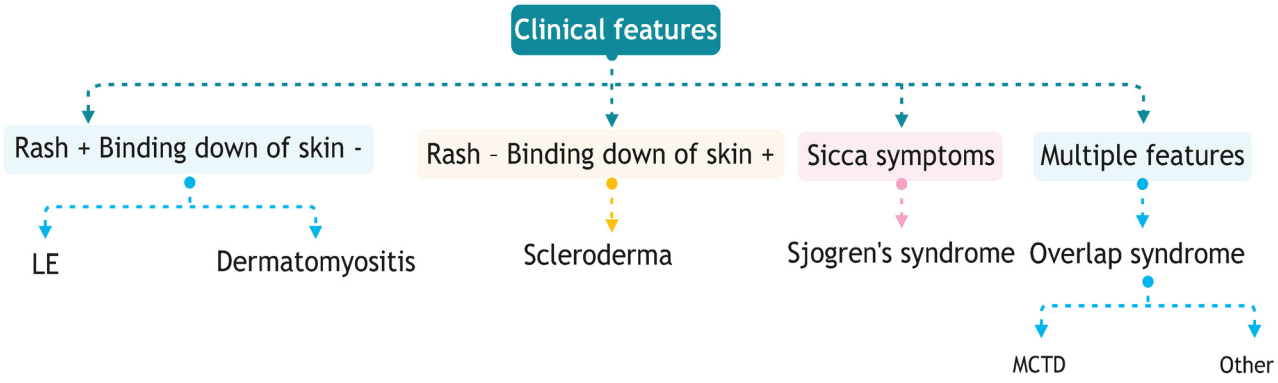

BIG QUESTION 2: Describe nutritional disorders.

Broad Answer: Nutritional disorders:

- **Vitamin A deficiency:**
  - Earliest sign: **Night blindness**; earliest skin change: **Dryness**.
  - **Phrynoderma (Toad skin):** Dry, rough, hyperkeratotic papules on elbows/knees due to deficiency of **Vit A, B, C, EFAs**.

- **Vitamin B3 (niacin) deficiency:**
  - Causes **Pellagra** in chronic maize eaters.
  - **4 Ds:** Dermatitis, Diarrhoea, Dementia, Death.
  - **Dermatitis:** Hyperkeratotic, lichenified eczema on photo-exposed areas (V of neck, dorsum of hands), forming **Cassal's necklace**.
  - **Treatment:** Niacin/Nicotinamide.
- **Acrodermatitis enteropathica (Zinc deficiency):**
  - Features: **Dermatitis, Diarrhoea, Alopecia**.
  - **Congenital:** AR, defective **ZIP4**, onset after 6 months.
  - **Acquired:** Chronic alcoholics.
  - **Dermatitis: Periorificial and acral**.
  - **Treatment:** Zinc supplements.

DETAILED QUESTIONS

Q2.1: Describe Vitamin A deficiency.

PYQ: NEET PG 2020

PYQ: FMGE 2020, 2021

Answer: Vitamin A deficiency:



- Earliest sign: Night blindness
- Earliest skin manifestation: Dryness.
- Phrynoderma (Toad skin):
  - Dry, rough, hyperkeratotic papules on elbows and knees, and other joint areas
  - Due to a deficiency of essential fatty acids, Vitamin B, C, A

Q2.2: Describe Vitamin B3 deficiency.

PYQ: FMGE 2021

PYQ: NEET PG 2022

Answer: Vitamin B3 (Nicotinic Acid, Nicotinamide, Niacin) deficiency:

- Vitamin B3 deficiency causes Pellagra
- Predisposing population: Chronic Maize eaters
- Pellagra leads to 4 Ds
  - **D**ermatitis
    - → Subacute eczema seen on photo exposed areas (V area of neck, dorsum of hands).
    - → Hyperkeratotic lichenified eczematous patches present
    - → On neck → Appears like a necklace- **Cassal's necklace**





  - **D**iarrhoea
  - **D**ementia
  - **D**eath
- **Treatment:** Vitamin B3 or Nicotinamide

Q2.3: Describe Acrodermatitis Enteropathica.

PYQ: FMGE 2021

Answer: **Acro** = Acral dermatitis, and **Enteropathic** = something related to gut/diarrhoea

- **Clinical features:**
  - Dermatitis
  - Diarrhoea
  - Alopecia
  - These patients have Zinc deficiency: Congenital/acquired

YOURWISH

YOURWISH

→ **Congenital:** Autosomal recessive trait → ZIP4 transporter protein is defective → After 6 months of age (Weaning of the child) → Mother's milk helps in Zinc absorption.

→ **Acquired:** Chronic alcoholics

- Dermatitis: Periorificial and Acral dermatitis is a classical feature

- **Treatment:** Zinc supplementation



BIG QUESTION 3: Describe metabolic diseases.

Broad Answer:

- **Granuloma Annulare:**
  - Granulomatous disorder, often in diabetes and hypothyroidism.
  - Asymptomatic annular lesions with a clear center, no scaling/crusting, smooth surface, and raised periphery.
  - Sites: Dorsum of hands and feet.
  - Histopathology: Necrobiotic granuloma (collagen degeneration).
- **Sarcoidosis:**
  - Multisystem granulomatous disorder affecting lungs, lymph nodes, skin, and eyes (uveitis).
  - Biopsy: Sarcoidal (naked) granulomas, Schaumann, and Asteroid bodies.
  - Cutaneous lesions:
    - → Nonspecific: Erythema nodosum.
    - → Specific: Red-brown papules, apple jelly nodules on diascopy.
    - → Lupus pernio: Red papules on the nose/cheeks with telangiectasias.
    - → Angiolupoid: Erythema and telangiectasias onthe face.
  - Treatment: Steroids, HCQS.

DETAILED QUESTIONS

Q3.1: What is Granuloma Annulare?



Answer: Granuloma annulare is a granulomatous disorder that presents with annular lesions

- It is common in patients with diabetes and Hypothyroidism.
- Symptoms: Asymptomatic.
- Sites: Dorsal of hands and feet.

Q3.2: What are the clinical features of Granuloma Annulare?

Answer: The patient may present with:

- Annular lesions with normal, clear centre
- No scaling/crusting
- Smooth overlying surface
- Periphery is raised due to granulomas

Q3.3: What investigation do we use for the diagnosis of Granuloma Annulare?

Answer: **HPE:** Necrobiotic granuloma (Degeneration of collagen).

Q3.4: Describe sarcoidosis.

Answer: Sarcoidosis is a granulomatous disorder that affects the skin and various systems

Organs affected	• Pulmonary • Peripheral lymph nodes • Skin • Eyes: Uveitis
Biopsy	• Sarcoidal granulomas: Naked granulomas (Surrounded by sparse lymphocytic infiltrate). • A biopsy is easily done when the patient presents with lesions on skin • Schaumann bodies and Asteroid bodies

Q3.5: What types of cutaneous lesions do we see in sarcoidosis?

PYQ: FMGE 2019

PYQ: NEET PG 2020

Answer: 2 types of cutaneous lesions are seen in sarcoidosis:

- **Nonspecific:** Erythematous Nodusum
- **Specific:** Sarcoidal granuloma on biopsy are seen.
  - o Red-brown papule with normal surface.
  - o Diascopy: Apple jelly nodules on the skin.
  - o If present on the face:

Lupus pernio	Angiolupoid
Red papules with normal surface present on nose and cheeks along with Telangiectasias.	Erythema and Telangiectasias limited to the face.
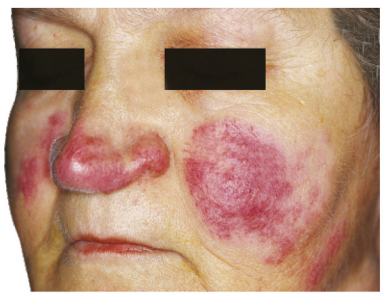	

Q3.6: What is the treatment of sarcoidosis?

Answer: Steroids and antimalarials (HCQS)

BIG QUESTION 4: Describe paraneoplastic dermatoses.

Broad Answer: Certain skin findings can indicate underlying malignancy. Acanthosis nigricans presents as velvety, hyperpigmented skin in body folds; the malignant form has rapid, widespread onset and may include tripe palms and the Sign of Leser-Trelat (sudden seborrheic keratoses), often linked to GI adenocarcinoma. Erythema gyratum repens shows concentric, migrating red bands and is associated with lung cancer. Necrolytic migratory erythema, seen in glucagonoma, causes painful, migrating rashes on the trunk and groin. Henoch-Schönlein purpura is an IgA vasculitis with purpura, GI, joint, and kidney involvement, usually self-limiting in children.

DETAILED QUESTIONS

Q4.1: What is Paraneoplastic Dermatoses?

Answer: These are skin manifestations that may point towards an underlying malignancy.

Q4.2: What is Acanthosis Nigricans?

PYQ: FMGE 2020, 2021

Answer: The term Acanthosis nigricans is a misnomer because acanthosis is not seen on biopsy.

- Velvety hyperpigmented texture of skin on neck, axilla, and groin
- It is associated with skin tags
- Pathogenesis: Increased production of IGF-1 (Insulin-like growth factor 1).
- Commonly seen in associated conditions like:
  - DM
  - Obesity
  - Metabolic syndrome
  - OCP
  - Insulin resistance

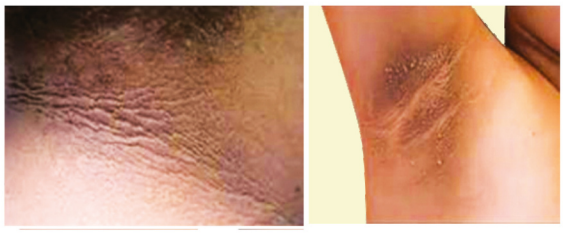

Q4.3: What are the types of Acanthosis Nigricans?

Answer: There are 2 types of Acanthosis nigricans:

- Benign
- Malignant (Paraneoplastic dermatosis):
  - Rapid in onset.
  - Generalised.
  - Bilaterally symmetrical.
  - Tripe palms, sign of Leser-Trelat
  - Associated with Adenocarcinoma of GIT

Q4.4: What is the sign of Leser-Trelat?

Answer: Sudden eruption of seborrheic keratosis on the trunk/face of the patient

- It is associated with:
  - Adenocarcinoma of GIT.
  - Carcinoma of breast.



Q4.5: What are the 2 types of Migratory Erythema?

Answer: 2 types of Migratory Erythema are:

- Erythema Gyratum Repens (EGR)
- Necrolytic Migratory Erythema (NME)

Q4.6: Describe Erythema Gyratum Repens (EGR)?

Answer: It is seen on trunk

- It has wood trunk appearance
- It is mobile, concentric, often palpable, erythematous, and wave-like bands.
- Migrate from day to day, about 1 cm daily.
- Associated with lung cancer.



YOURWISH

Q4.7: Describe Necrolytic Migratory Erythema (NME)?

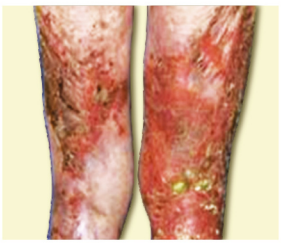


Answer: It is widespread, painful, polycyclic, and inflammatory migratory rash

- It is present on the anogenital region and trunk.
- Associated with a glucagon-secreting alpha-cell tumour of the pancreas.

Q4.8: Differentiate EGR from NME.

Answer:

EGR (Erythema Gyratum Repens)	NME (Necrolytic Migratory Erythema)
• It is seen on trunk • It has wood trunk appearance • It is mobile, concentric, often palpab erythematous, wave-like bands. • Migrate from day to day, about 1 cm da • Associated with lung cancer. 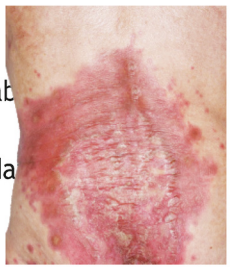	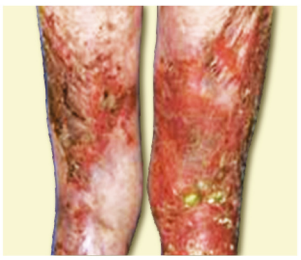 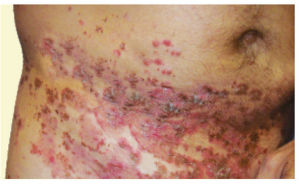 • Widespread painful polycyclic inflammatory migratory rash • It is present on the anogenital region and trunk. • Associated with glucagon-secreting alpha-cell tumour of the pancreas.

Q4.9: Describe Henoch Schonlein Purpura (HSP).




Answer: Also known as Systemic small vessel vasculitis.

- Usually seen in children.
- Aetiology: Infections, drugs.
- On biopsy
  - o IgA-containing immune complexes are seen.
  - o Features of leukocytoclastic manifestations

Q4.10: Which organs are affected by Henoch Schonlein Purpura (HSP)?

Answer:

- **Skin:** Palpable purpura on lower legs and buttocks, which are usually painful.
- **GIT:** Abdominal pain and diarrhoea
- **Joints:** Joint pains: Arthralgias.
- **Kidneys:** Haematuria, Proteinuria, and RBC casts in the urine

Q4.11: How to treat Henoch Schonlein Purpura (HSP)?

Answer:

- Child: Self-limiting.
- Colchicine and steroids
- Dapsone

Q4.12: How can we differentiate between palpable and non-palpable purpurae?

Answer:

- Palpable purpura → feature of Vasculitis

YOURWISH

- Non-palpable purpura → feature of Thrombocytopenia, Bleeding and Clotting disorders

BIG QUESTION 5: What are neutrophilic dermatoses?

Broad Answer: Neutrophilic dermatoses are a group of conditions marked by neutrophilic infiltration on biopsy and often in blood. They include pyoderma gangrenosum (painful ulcers with undermined edges and cribriform scars, linked to IBD, RA, and blood cancers), Sweet's syndrome (acute febrile dermatosis with red, edematous papules/plaques, often in women, treated with steroids), and Behçet's disease (systemic vasculitis with oral/genital ulcers, uveitis, arthritis, and positive pathergy). Erythema nodosum, the most common panniculitis, presents as tender nodules on the shins and is triggered by infections or systemic diseases; it is self-limiting and managed by treating the cause.

DETAILED QUESTIONS

Q5.1: What are neutrophilic dermatoses?

Answer: Neutrophilic dermatoses are a group of conditions that are characterized by neutrophilia on biopsy and peripheral cell count.

- It includes:
  - Pyoderma gangrenosum
  - Behçet's disease
  - Sweet's syndrome

Q5.2: What is Pyoderma Gangrenosum?

Answer: Pyoderma Gangrenosum is an ulceration of the skin associated with an underlying systemic disorder.

- **Association:** IBD, Rheumatoid arthritis, haematological malignancy or monoclonal gammopathy.
- It is a diagnosis of exclusion: No characteristic histopathology feature, no laboratory evaluation evidence.

Q5.3: What are the clinical features of Pyoderma Gangrenosum?



Answer: Painful ulcers with an undermined margin.

- It heals with cribriform scarring

Q5.4: What is Sweet Syndrome?

Answer: Sweet syndrome is an acute febrile neutrophilic dermatosis.

- More common in females.
- Biopsy and Peripheral blood: Neutrophilic infiltrate is seen.

Q5.5: What are the clinical features of Sweet Syndrome?



Answer:

- Fever
- Sudden appearance of erythematous papules and plaques → on the trunk and limbs
- Papules and plaques are oedematous - Pseudo vesiculation (Appearance - Fluid-filled papules, but no fluid is present in actual).

Q5.6: What is the treatment for Sweet Syndrome?

Answer: Corticosteroids and Potassium Iodide

Q5.7: What is Behcet's Disease and its clinical features?

Answer: Also known as Behcet's syndrome → A systemic vasculitis

- **Clinical features:**
  - It is characterized by:
    - → Relapsing uveitis → mainly posterior uveitis
    - → Recurrent genital ulcers
    - → Recurrent Oral ulcers
  - These ulcers are painful and appear like aphthae
  - **Joint:** Non-erosive, asymmetrical seronegative oligoarthritic (MC-knee).
  - **Multi-system Involvement:** Pulmonary, cardiac, GI, and neurological involvement can also be seen.
  - Pathergy is positive

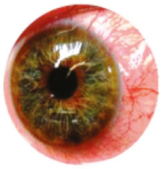

Relapsing uveitis



Recurring genital ulcers



Recurring oral ulcers

Painful Ulcers

Necrotic center ····●◀···· Red rim



Q5.8: What is the treatment for Behcet's Disease?

Answer: We give **corticosteroids** for the treatment of Behcet's disease.

Q5.9: What is Erythema Nodosum?

Answer: Most common panniculitis (Inflammation of the fat layer of the skin/panniculus)

- Acute onset and self-limited course, but it can recur.
- Cutaneous reactive processes are triggered by a wide variety of infectious and inflammatory disorders.

Q5.10: What are the most common triggers for erythema nodosum?

Answer: Tuberculosis, Sarcoidosis, and Crohn's disease

Q5.11: What are the clinical features and differential diagnosis for erythema nodosum?

Answer: **Clinical features:**

- Erythematous, tender papules and nodules on the anterior parts of the leg
- Normal overlying surface
- No scaling, crusting, ulcerations
- **Differential diagnosis:** Erythema induratum of bazin
  - It is present in the posterior calves
  - Associated with overlying ulceration and crusting
  - It is a form of Tuberculid

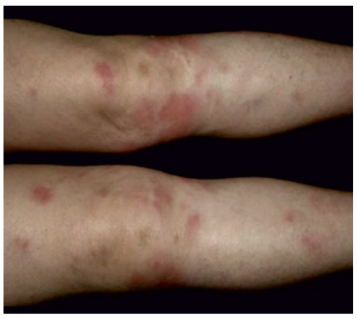

Q5.12: What are the HPE findings and treatment of erythema nodosum?

Answer:

- **On HPE:**
  - Septal panniculitis (Septae are inflamed) is present without vasculitis.

- Miescher radial granulomas are seen.
- **Course:**
  - Spontaneous resolution
  - Tendency to recur
- **Treatment:**
  - Anti inflammatory
  - Find out the underlying cause

BIG QUESTION 6: Describe Reactive Arthritis.

Broad Answer: Reactive Arthritis (Reiter's Disease):

- **Assoc.:** HLA-B27, B51. Triggered by GI infection, HIV, or non-gonococcal urethritis (SARA).
- **Triad:** Polyarthritis (non-suppurative, lower limbs), urethritis, conjunctivitis.
- **Skin signs:**
  - **Keratoderma blennorrhagicum:** Hyperkeratotic papules on palms/soles.
  - **Circinate balanitis:** Superficial erosions on the glans penis.

DETAILED QUESTIONS

Q6.1: What is Reactive Arthritis and its triggers?

Answer: Reactive arthritis is also known as Reiter's disease.

- It is different from Ritter's disease - A Staphylococcal Scalded Skin Syndrome.
- HLA association: HLA B27, B51.
- **Triggers:**
  - GI infection
  - HIV: Commonly seen.
  - NGU-SARA:
    - → Non-gonococcal urethritis
    - → It is called sexually acquired reactive arthritis.

Q6.2: What are the clinical features of Reactive Arthritis?

Answer:

- SARA can show a triad of symptoms:
  - Polyarthritis (Of over a month's duration following gastrointestinal or lower genital infection) - Non-suppurative, lower limbs.
  - Urethritis.
  - Non-gonococcal conjunctivitis (Caused by Chlamydia)
- Reactive arthritis has two manifestations in the skin.
  - **Keratoderma Blennorrhagicum**
    - → Hyperkeratotic papules are present on the palms and soles
  - **Circinate Balanitis**
    - → Superficial erosions on the glans and penis of the patients.





10. PIGMENTARY DISORDER

BIG QUESTION 1: Describe pigmentary disorders.

Broad Answer:

- Pigmentary disorders include all disorders that are associated with pigmentation
- **Hyperpigmentary disorder:** Increase in pigmentation.
- **Hypopigmentary disorder:** Decrease in pigmentation or little loss of pigmentation
- **Depigmentation:** complete absence of pigmentation or no pigmentation

DETAILED QUESTIONS

Q1.1: What are pigmentary disorders?

Answer: Pigmentary disorders include all disorders that are associated with pigmentation.

Q1.2: How are pigmentary disorders classified?

Answer: Pigmentary disorders are classified into 3 categories:

- **Hyperpigmentary disorder:** Increase in pigmentation.
- **Hypopigmentary disorder:** Decrease in pigmentation or little loss of pigmentation
- **Depigmentation:** Complete absence of pigmentation or no pigmentation

BIG QUESTION 2: How is the skin colour classified? Describe the pigment responsible for skin pigmentation.

Broad Answer:

- Skin colour is classified using the Fitzpatrick scale, which grades skin types as I, II, III, IV, V, and VI.
- **Melanin**, responsible for skin color, has two types: **eumelanin** (brown-black, protective) and **pheomelanin** (orange-yellow, non-protective, common in light skin). Melanocytes transfer melanin to keratinocytes via melanosomes, forming the epidermal melanin unit. Skin color varies by melanin type, melanosome number, and distribution—not melanocyte count. Darker skin has larger, individual melanosomes; lighter skin has smaller, clustered ones.

DETAILED QUESTIONS

Q2.1: Describe the Fitzpatrick scale.

Answer: Fitzpatrick grades skin types as 1,2,3,4,5,6

- Type I → Very fair → Tends to burn but never tans
- Type 6 → Black → Always tans but never burns

Fitzpatrick classification of the skin type					
					
I-Very Fair	II-Fair	III-Medium	IV-Olive	V-Brown	VI-Black
Always burns, never tans	Usually burns, tans with difficulty	Sometimes burns, sometime tans	Rarely burn, tans easily	Very rarely burns, tans very easily	Never burns, always tans

YOURWISH

Q2.2: What are the types of melanin?

Answer: Melanin is of two types:

- Eumelanin
- Pheomelanin.



Q2.3: Describe eumelanin.

Answer: A protective brownish to blackish in colour pigment which helps in tan formation and protects from sunburns.

Q2.4: Describe pheomelanin.

Answer: **Pheomelanin (Pheo: Fake):** A non-protective, orangish-yellowish coloured pigment which is seen more in lighter skin types.

Q2.5: What is the epidermal melanin unit?

Answer: Melanocytes transfer their Melanin through melanosomes to 36 keratinocytes around it, which is known as the epidermal melanin unit.

Q2.6: Does skin color depend on melanocyte number?

Answer: The epidermal melanin unit is fixed → Skin colour does not depend on Melanocytes (melanocytes are transferring Melanosomes to fixed Keratinocytes).

Q2.7: What determines skin color?

Answer: Skin color depends on:

- Type of Melanin: Whether there is more of Eumelanin or Pheomelanin
- Number of melanosomes
- Distribution of Melanosomes.

Q2.8: How do melanosome clusters differ in light vs. dark skin?

Answer: Lightly pigmented skin tends to contain melanocytes with clusters of two or three melanosomes, while darkly pigmented skin tends to contain individual melanosomes that are larger.

BIG QUESTION 3: What are Cafe Au Lait Macules?

Broad Answer: Café au lait, meaning “coffee with milk,” refers to hyperpigmented skin lesions that may be single or multiple, usually present at birth, and characterized by serrated borders. Commonly called CALMs, they are of two types: those with regular, well-demarcated margins (“coast of California,” seen in NF1) and those with irregular margins (“coast of Maine,” seen in segmental pigmentary disorders). Pathologically, they show increased melanosomes and are also associated with conditions such as Leopard syndrome, tuberous sclerosis, and neurofibromatosis type 1.

DETAILED QUESTIONS

Q3.1: What does Café Au Lait mean?

Answer: Café Au Lait means coffee with milk.

Q3.2: What are the clinical features of Cafe Au Lait Macules?



Answer: Cafe Au Lait Macules are commonly called CALM'S → Single or multiple hyperpigmented lesions with serrated borders at birth.

Q3.3: What are the types of CALMs?

Answer: CALMs are of two types:

- Regular and clearly demarcated margins ("coast of California"-NF1)
- Irregular margin ("coast of Maine") - segmental pigmentary disorders.

Q3.4: What is the pathology of CALM'S?

Answer: Increased melanosomes.

Q3.5: Which disorders are CALMs seen in?

Answer: Leopard syndrome, Tuberous Sclerosis, and Neurofibromatosis-1 (NF-1).

BIG QUESTION 4: Describe acquired melanocytic nevi.

Broad Answer: Acquired melanocytic nevi, commonly known as moles, result from the proliferation of nevus cells in the epidermis. They are classified into three types: junctional nevi, where cells proliferate at the dermoepidermal junction, appearing flat, black, and with a higher risk of melanoma; dermal nevi, located in the dermis, usually skin-colored or lightly pigmented; and compound nevi, with cells in both the junction and dermis, appearing raised and hyperpigmented but less dark than junctional nevi.

DETAILED QUESTIONS

Q4.1: What is the cause of acquired melanocytic nevi?



Answer: Acquired melanocytic nevi (moles) → A defective proliferation of nevus cells in the epidermis that leads to the development of moles.

Q4.2. What are the types of acquired melanocytic nevi?

Answer: Acquired Melanocytic nevi are of three types:

Junctional nevus	• When the nevus cells are proliferating at the dermoepidermal junction • These are black in colour and more flat • They have higher tendency to turn into Melanoma
Dermal nevus	• When the nevus cells are at the dermis • They are skin colored or lightly colored
Compound nevus	• When the nevus cells are present at the both junction and dermis • They are raised,hyperpigmented but no as black as junctional nevus

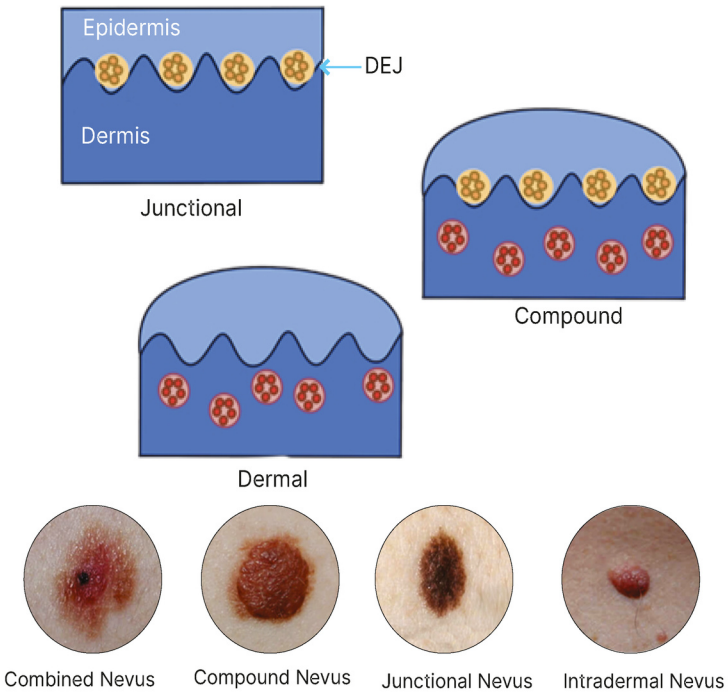

Q4.3. What is a junctional nevus?

Answer: Junctional nevi are the nevus cells which are proliferating at the dermoepidermal junction. These are black in colour and more flat. They have a higher tendency to turn into Melanoma.

Q4.4. What is a dermal nevus?

Answer: Dermal nevi are the nevus cells at the dermis. They are skin colored or lightly colored.

Q4.5. What is a compound nevus?

Answer: Compound nevi are the nevus cells that are present at both the junction and dermis. They are raised, hyperpigmented, but not as black as a junctional nevus.

BIG QUESTION 5: What are congenital melanocytic nevi, their features, and malignant potential?

Broad Answer: Congenital melanocytic nevi are single pigmented lesions present at birth, often associated with hypertrichosis and rugosities. Unlike Becker's nevus, where hypertrichosis appears later, it is present from birth in congenital nevi. In some cases, these nevi may cover part or the entire trunk, termed bathing trunk or garment nevi, which carry an increased risk of developing into melanoma.

DETAILED QUESTIONS

Q5.1: What are congenital melanocytic nevi?

PYQ: FMGE 2021

Answer: Congenital melanocytic Nevi is a single lesion present at birth associated with hypertrichosis and rugosities.



Q5.2: Where else can we see Hypertrichosis other than congenital melanocytic nevi?

Answer: Becker's nevi (but it is not present at birth in this condition).

Q5.3: What are bathing trunk/garment nevi?



Answer: Sometimes congenital nevi can cover the whole or part of the trunk → **Bathing trunk/Garment nevi** → Tendency to develop into a Melanoma.

BIG QUESTION 6: Describe Dermal Melanocytic Nevi.

Broad Answer: Dermal melanocytic nevi include three types: Mongolian spots, nevus of Ota, and nevus of Ito. Mongolian spots are bluish lesions present at birth, commonly in Mongoloid races, usually on the sacral area, and resolve spontaneously; their blue color is due to the Tyndall effect. Nevus of Ota (nevus fuscoceruleus ophthalmomaxillaris) presents as unilateral bluish pigmentation along the ophthalmic and maxillary branches of the trigeminal nerve with scleral deposits, most common in Japanese individuals. Nevus of Ito (nevus fuscoceruleus acromioclavicularis) occurs along the acromial and clavicular nerve distribution over the shoulders and upper back. Both nevus of Ota and Ito are asymptomatic and treated with pigment-specific lasers such as ruby, alexandrite, or Q-switched Nd: YAG.

DETAILED QUESTIONS

Q6.1: What are the types of dermal melanocytic nevi?

Answer: Dermal melanocytic nevi are of 3 types:

- Mongolian spots
- Nevus of Ota
- Nevus of Ito

Q6.2: Describe Mongolian spots.



Answer: Mongolian spots:

- Present at birth
- Usually seen in Mongoloid races
- Bluish spots seen in sacral areas
- Spontaneously resolve
- No treatment is done for this lesion

Q6.3: Why are dermal pigments bluish?

Answer: Dermal pigments appear bluish because of the Tyndall effect.

- Since the pigment is deeper, smaller wavelengths are reflected back → Lesions appear indigo/bluish.

Q6.4: Describe Nevus of Ota.



Answer: **Nevus of Ota (Nevus Fuscoceruleus Ophthalmomaxillaris)**

- Scleral deposits are seen
- Most commonly seen in Japanese people
- They are unilateral and develop along the ophthalmic and maxillary divisions of the trigeminal nerve.
- Asymptomatic lesions

YOURWISH

Q6.5: Describe Nevus of Ito.



Answer: **Nevus of Ito:**

- Common in Japanese people
- Unilateral Bluish pigmented lesions
- It is also called nevus fuscoceruleus acromioclavicularis.
  - Present along the distribution of the acromial and clavicular nerves (branches of the brachial nerve).
- These are present on the shoulders/upper back
- Asymptomatic lesions

Q6.6: What is the treatment for Nevus of Ota and Ito?

Answer: Lasers used are Ruby lasers, Alexandrite lasers and Qs Nd Yag lasers.

- These are pigment-specific lasers used for dermal melanocytic nevi.

BIG QUESTION 7: Describe melasma.

Broad Answer: Melasma is a hyperpigmentation disorder triggered by sun exposure, pregnancy (called chloasma), oral contraceptives, or hypothyroidism, caused by hyperactive melanocytes that produce excess melanin. It presents as asymptomatic hyperpigmented macules on photo-exposed areas and is classified as centrofacial, malar, or mandibular, and further as epidermal, dermal (bluish), or mixed types, distinguishable by Wood's lamp. Treatment includes sun protection, topical agents (hydroquinone, glycolic acid, kojic acid, arbutin), Kligman's triple combination (hydroquinone, tretinoin, hydrocortisone), oral or topical tranexamic acid, chemical peels, and Q-switched Nd: YAG laser therapy.

DETAILED QUESTIONS

Q7.1: What predisposes to melasma?

Answer: A person is predisposed to melasma by:

- Sun exposure
- Post-pregnancy
- OCP
- Hypothyroidism.

Q7.2: What is melasma called post-pregnancy?

Answer: Chloasma.

Q7.3: What is the defect in melasma?

Answer: Melasma occurs due to hyperactive melanocytes that are larger and more dendritic, resulting in increased melanin production.

Q7.4: What is the clinical presentation of Melasma?



Answer: Melasma appears as asymptomatic hyperpigmented macules, typically localized to sun-exposed or photo-exposed areas.

Q7.5: What are the types of melasma?

PYQ: FMGE 2022

Answer: Types of Melasma:

- Centrofacial
- Malar
- Mandibular
- It can also be divided as:
  - Epidermal
  - Dermal (bluish)
  - Mixed Melasma

These can be differentiated by Wood's lamp.

Q7.6: What is the treatment of melasma?

Answer:

- Sun protection by using sunscreen
- **Topical:** Hydroquinone, glycolic acid, kojic acid, arbutinin
- Triple combination cream using Kligman's formula:
  - Hydroquinone (depigmenting agent)
  - Tretinoin (Exfoliating agent)
  - Hydrocortisone (to care of the inflammation generated by Tretinoin)
- **Oral:** Tranexamic acid (also used topically)
- **Peels:** Glycolic acid peel, Lactic acid peel
- **Lasers:** Qs Nd Yag lasers

BIG QUESTION 8: Describe the Depigmentary/Hypopigmentary Disorders.

Broad Answer: There are 2 Depigmentary/Hypopigmentary Disorders:

Nevus depigmentosus	Nevus anemicus
Presents as a stable, congenital hypopigmented macule that does not enlarge beyond normal body growth, is usually single, localized, asymptomatic, and often mistaken for vitiligo.	Known as a pharmacological nevus, appears as pale depigmented lesions due to capillary hyper-responsiveness to catecholamines, causing vasoconstriction.
The two can be differentiated by diascopy: in nevus anemicus, blanching causes margins to merge with normal skin, while in nevus depigmentosus the margins remain unchanged.	

DETAILED QUESTIONS

Q8.1: What is nevus depigmentosus?

Answer: Nevus depigmentosus is a stable (does not increase in size), congenital, and asymptomatic lesion.

Q8.2: How does nevus depigmentosus present clinically?

Answer: Nevus depigmentosus is an asymptomatic lesion that presents as a stable, congenital depigmented to hypopigmented macule that does not enlarge beyond normal body growth.



Q8.3: How are nevus depigmentosus and vitiligo differentiated?

Answer:

- Nevus depigmentosus: Does not increase in size.
- Vitiligo: Single, localised, and grows only in proportion to body growth.

Q8.4: What is Nevus anemicus?



Answer: Nevus anemicus, known as a pharmacological nevus, appears as pale depigmented lesions due to capillary hyper-responsiveness to catecholamines, causing vasoconstriction and pale appearance of the lesions.

Q8.5: What test differentiates nevus depigmentosus and nevus anemicus?

Answer: **Diascopy:** A glass slide is used to blanch the lesion:

- Nevus anemicus → margins merge with the normal surroundings (pharmacological nevus - further vasoconstriction occurs on blanching the lesion)
- Nevus depigmentosus → margins do not change (not dependent on Vasoconstriction).

Nevus depigmentosus	Nevus Anemicus
	
Margins do not change.	Margins will merge with the normal surroundings

BIG QUESTION 9: Describe albinism.

Broad Answer: Albinism is a congenital universal absence of eumelanin synthesis in skin, hair, and eyes. It occurs as ocular albinism (X-linked recessive) affecting only the eyes, or oculocutaneous albinism (OCA) (autosomal recessive) affecting both skin and eyes, commonly called "albino kids." OCA is of two types: tyrosinase-negative (TNA), with complete absence of tyrosinase enzyme leading to no pigmentation, and tyrosinase-positive (TPA), with partial enzyme activity causing gradual pigmentation of skin, hair, and eyes with age. At birth, both types appear similar with complete pigment loss. Patients with OCA are highly prone to sunburns, seborrheic keratoses, skin cancers, and malignancies.

DETAILED QUESTIONS

Q9.1: What is albinism?

Answer: Albinism is an autosomal recessive genetic disorder that shows congenital universal absence of eumelanin synthesis in the skin, hair follicles, and eyes. Kids having albinism are known as Albino kids.

Q9.2: What are the types of albinism?

Answer: Types of Albinism:

- **Ocular albinism:** XLRI (X-linked recessive in nature)
- **Oculocutaneous albinism (OCA):** Affects skin and eyes.

Q9.3: What are the subtypes of OCA?



Answer: OCAs are of 2 types:

- **Tyrosinase negative OCA (TNA):** No tyrosinase synthesized, no pigmentation;
- **Tyrosinase positive OCA (TPA):** Some tyrosinase activity present.

Q9.4: What is the role of the tyrosinase enzyme?

Answer: Tyrosinase is an important enzyme needed for Eumelanin synthesis.

Q9.5: How do OCA1 and OCA2 present?

Answer: At birth, OCA1 & OCA2 both show complete loss of pigment from hair, eyes, and skin.

- **OCA 1** → There will be no pigmentation on hair, skin and eyes (Tyrosinase negative)
- **OCA 2** → Gradually, with age, starts showing some pigmentation on hair, skin, and eyes (Tyrosinase positive).

Q9.6: What complications do OCA patients face?

Answer: OCA patients are also prone to Sunburns, Seborrheic keratosis, Skin cancers, and Malignancies.



Q9.7: How to treat albinism?

Answer: There is no known treatment for Albinism.

BIG QUESTION 10: Describe piebaldism.

Broad Answer: An autosomal dominant disorder caused by KIT gene mutations on chromosome 14, presenting as congenital pie-shaped leukoderma with poliosis and islands of normal pigmentation, usually in the median or paramedian area with a distinct ventral midline pattern. It must be differentiated from **Waardenburg syndrome**, which shows similar skin changes but is associated with dystopia canthorum (lateral displacement of inner canthi with normal interpupillary distance), heterochromia of the irides, and congenital cochlear deafness.

DETAILED QUESTIONS

Q10.1: What is piebaldism?

Answer: An autosomal dominant disease occurring due to mutations in the KIT gene on chromosome 4.

Q10.2: What are the clinical features of piebaldism?



Answer: Clinical features of Piebaldism (to be differentiated from Waardenberg syndrome):

- Isolated congenital leukoderma (white skin), which is pie-shaped, along with Poliosis (white hair) with some islets of normal pigmentation
- Typically present in the median and paramedian area
- Distinct ventral midline pattern

Q10.3: What are the features of Waardenberg syndrome?

Answer:

- Skin lesions resembling piebaldism
- Lateral displacement of the inner canthi and lower lacrimal puncta (dystopia canthorum) with normal interpupillary distance
- Irides show partial or total heterochromia
- Cochlear deafness

BIG QUESTION 11: Describe Vogt-Koyanagi-Harada syndrome (VKH syndrome).

Broad Answer: Vogt -Koyanagi -Harada syndrome (VKH syndrome) usually begins in the third or fourth decade and progresses through three phases: first, a meningo-encephalitic phase with seizures and neurological symptoms; second, bilateral uveitis with choroiditis, optic neuritis, eye damage, and cochlear deafness; and third, within about three months or as uveitis subsides, cutaneous findings such as poliosis (90%), leukoderma (63%), and alopecia (73%).

DETAILED QUESTIONS

Q11.1: What are the phases of VKH syndrome?

Answer: VKH syndrome usually begins in the third or fourth decade and progresses through three phases:

- Meningo-encephalitic phase: Characterized by encephalitic or meningitic symptoms (Seizures)
- Bilateral uveitis with choroiditis and optic neuritis followed by eye damage, cochlear deafness.
- The third phase usually occurs within the first three months or as the uveitis starts subsiding.

Q11.2: What skin changes develop in VKH syndrome?

Answer: Poliosis (90%), leukoderma (63%), and Alopecia(73%)

BIG QUESTION 12: Describe vitiligo.

Broad Answer: Vitiligo is a T-cell-mediated autoimmune disorder causing melanocytopenia, with a 20-30% family history and associations like Hashimoto's thyroiditis, pernicious anemia, and type 1 diabetes. Pathogenesis involves genetic (catalase defect), immune, neural (segmental type), and autotoxic/free-radical mechanisms. It presents as totally depigmented macules with leukotrichia and positive Koebner's phenomenon. **Segmental vitiligo** appears in childhood along dermatomes, is stable, shows leukotrichia, lacks Koebner's, and needs surgery due to poor medical response. **Non-segmental vitiligo** may be focal, mucosal, generalized, vitiligo vulgaris, acrofacial, or universalis (>80%, treated with depigmentation). Treatment includes avoiding trauma, topical steroids/calcineurin inhibitors, phototherapy (NB-UVB, PUVA, excimer), systemic agents (steroids, immunosuppressants, JAK inhibitors), and surgery.

DETAILED QUESTIONS

PYQ: FMGE 2018, 2021, 2022

PYQ: INICET 2021, 2023

Q12.1: What is vitiligo?

Answer: Vitiligo is an autoimmune disorder mediated by T cells, leading to melanocytopenia → Due to defective Melanocytopenia → Family history: 20-30%.



Q12.2: What are the common associations of Vitiligo?

Answer: It is associated with Hashimoto's thyroiditis (coomon), pernicious anemia, and type 1 diabetes mellitus.

Q12.3: What are the theories of vitiligo pathogenesis?

Answer

- Genetic factors: catalase gene
- Immune hypothesis: Autoimmune disorder
- Neural hypothesis: certain neurotransmitters are released, which causes Melanocytopenia. This is responsible for segmental vitiligo.
- Autotoxic self-destructive or free radical hypothesis:
  - In the pathway of pigmentation, the products that are formed self-destruct themselves leading to loss of pigmentation.

Q12.4: How does vitiligo present clinically?

Answer: Vitiligo patients present with:

- Totally depigmented and asymptomatic macules
- Leukotrichia (white hair)




Q12.5: Differentiate between trichrome and quadrichrome vitiligo.

Answer:

Trichrome vitiligo	Quadrichrome vitiligo
	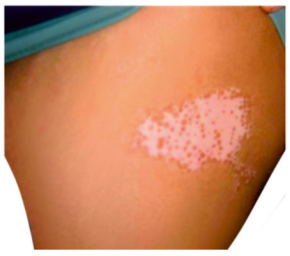
• Three zones are there • Center zone is of depigmentation • Surrounding is the zone of hypopigmentation • Again surrounding it is the zone of hyperpigmentation	• Four zones are present in this condition • Peri follicular pigmentation is seen

Q12.6: Is Koebner's phenomenon present in vitiligo?

Answer: Vitiligo shows positive Koebner's phenomenon: True Koebner's/Isomorphic phenomena.



Q12.7: What is the difference between segmental and non-segmental vitiligo?

Answer:

- Segmental vitiligo
- Non-segmental vitiligo (More common)

Segmental Vitiligo	Non segmental Vitiligo
 • Depigmented lesions along a segment/dermatome • It is usually present early in childhood • Relatively stable course • Frequent association of leukotrichia • Absence of Koebner's phenomenon. • Not responsive to medical treatment hence surgical treatment is required.	 • Not along the segment, it can be focal (limited to one area) 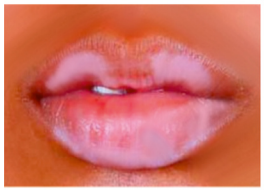 • Mucosal vitiligo • Generalised vitiligo

Q12.8 What is meant by Vitiligo vulgaris, Acrofacial vitiligo, and Vitiligo universalis?

Answer:

Type	Description	Image
Vitiligo vulgaris	• Bilateral, symmetrical depigmented lesions	
Acrofacial vitiligo	• Lesion on acral and facial areas • Poor prognosis →does not respond to treatment very well.	
Vitiligo universalis	• >90% of the body surface area is depigmented **Management:** • Difficult to repigment 90% of BSA • Rest 10% is depigmented → Monobenzyl ether of hydroquinone (MBEH) - Reverse treatment.	 

YOURWISH

Q12.9: What are the treatment options for vitiligo?

Answer:

- **General:** Avoid traumas, rubber chappals
- **Medical:**

Topical	Systemic	Surgical
• Topical corticosteroids • Topical calcineurin inhibitors • Topical Phototherapy -NBUVB, PUVA, PUVAsol, EXCIMER	• Steroids • Cyclophosphamide • Azathioprine • Levamisole • JAK kinase inhibitors -Tofacitinib	-

BIG QUESTION 13: Describe chemical leukoderma.

Broad Answer: Chemical leukoderma occurs due to chemical exposure, producing depigmented patches at contact sites. In rubber, **monobenzyl ether of hydroquinone** is the cause. In women who wear bindis, the adhesive often contains **para-tert-butyl phenol (PTBP)**, which leads to leukoderma and bindi dermatitis. Similarly, **hair dyes** may cause skin and hair changes—**paraphenylene diamine (PPD)** leads to hair dye dermatitis, while **para-tertary butyl catechol** in the dye can cause hair dye-induced depigmentation.

DETAILED QUESTIONS

Q13.1: What causes chemical leukoderma?

PYQ: NEET PG 2019

Answer: Depigmented patches occur because of chemical exposure.



Rubber chappals dermatitis caused by MBEH

Q13.2: What causes rubber chappal dermatitis?

Answer: Along the site of contact of rubber, depigmented macules are seen. Monobenzyl ether of hydroquinone in rubber causes depigmentation.

Q13.3: What causes Bindi dermatitis?

Answer: The adhesive used in bindis contains **Para Tertiary Butyl Phenol (PTBP)**, which can cause leukoderma and bindi dermatitis.



Bindi dermatitis caused by para tertiary butyl phenol

Q13.4: What causes hair dye dermatitis and hair dye-induced depigmentation?

Answer: Paraphenylene diamine (PPD) causes hair dye dermatitis, while Para-tertiary butyl catechol causes hair dye-induced depigmentation.



Hair dye dermatitis caused by PPD (Para phenylenediamine) and para tertiary butyl catechol

YOURWISH

11. ECZEMAS

BIG QUESTION 1: What are Exogenous Eczemas, their types, clinical features, diagnosis, and management?

Answer:

- Definition: Eczemas caused by external/environmental agents (irritants, allergens, light, plants).
- Types: Irritant contact dermatitis (ICD), Allergic contact dermatitis (ACD), Photodermatitis, Phytodermatitis.
- Clinical features: Localized eczematous lesions on exposed sites, itchy, subacute eczema in airborne ACD (Parthenium). Nose tip spared (Nose-tip sign).
- Diagnosis → Patch test (48-96 hrs), Photopatch for photoallergy.
- Management → Avoid irritants, topical steroids, systemic steroids, immunosuppressants (azathioprine, cyclosporine); Retinoids contraindicated.

DETAILED QUESTION

Q1.1: How is deczema broadly classified?

Answer: A type of dermatitis

Exogenous Eczemas	Endogenous Eczemas
• Irritant dermatitis • Allergic contact dermatitis • Photodermatitis • Phytodermatitis	• Atopic dermatitis • Pityriasis alba • Seborrheic dermatitis • Discoid eczema • Hand eczema • Asteatotic eczema • Gravitational eczema • Lichen simplex chronicus • Prurigo nodularis

Q1.2: What are the differences between Irritant Contact Dermatitis (ICD) and Allergic Contact Dermatitis (ACD)?

Answer:

PYQ: NEET PG 2019, 23 PYQ: AIIMS 2018, 2020

ICD (Irritant Contact Dermatitis)	ACD (Allergic Contact Dermatitis)
Onset: Immediate **Reason:** Non-immunological in nature.	**Onset: Not Sudden (within a few hours or days).** **Reason:** Immunological in nature **(Type-IV hypersensitivity).**
Occurrence: First contact	**Occurrence:** Subsequent exposure to antigens (in the first exposure, memory T Cells are formed).
It depends on the concentration and nature of the substance, so it is localized.	It depends on the body's immune response.

Q1.3: What are the common allergens causing ACD and their sources?

Answer:

Allergens	Sources
Nickel, cobalt	Artificial jewelry, jean buttons
Chromium	Cement, Painting
Potassium dichromate	Leather, detergents, paint
Epoxy resins, phenols	Plastics
Parthenium	Plants
Propylene glycol	Cosmetics, medicaments
PPD - *Paraphenylenediamine*	Hair dyes
Neomycin, gentamycin	Topical medications
Latex/ rubber	Gloves, shoes, belts
PTBP - Para tertiary butyl phenol	Bindi

Q1.4: What are the special associations of ACD with daily items?

Answer:

- Artificial jewelry and belt buttons have **Nickel,** which can cause ACD.



- Hair dyes have PPD **(Para Phenylenediamine)**, which can cause ACD.



- Bindi has PTBP (Para Tertiary Butylphenol) as an adhesive, which acts as an allergen.



Q1.5: What is Parthenium dermatitis?

Answer: **Referred to as Airborne contact dermatitis (ABCD)**

- Most common cause in India: Parthenium hysterophorus
- Allergen: Sesquiterpene lactone (SQL)
- Population affected: Mostly farmers, field workers
- Other names: Wild grass, Congress grass

Q1.6: What are the clinical features of Parthenium dermatitis?

Answer:

- Subacute eczema (most common presentation)
- Itchy dermatitis
- Exposed parts: face, neck, upper chest, upper back, flexures
- Nose spared → Nose tip sign
- Airborne exposure → also called Airborne Contact Dermatitis (ABCD)



Q1.7: What is the diagnostic test for Allergic Contact Dermatitis?

PYQ: AIIMS 2019, 2020

Answer: Patch Test

Indications	• Identify allergen • Confirm if dermatitis is ACD
Principle	Simulates the elicitation phase of ACD
Hypersensitivity type	Type IV (delayed)
Site	Patient's back
Reading	Best at 48 hrs and 96 hrs (for delayed reactors)



Q1.8: What is the diagnostic test for Photoallergic Dermatitis?

Answer: Photopatch Test

- Antigen patches applied in duplicate
- One patch covered (opaque), the other patch exposed to UVA at 48 hrs



INTERPRETATION

Reaction on non-irradiated side	Reaction on the irradiated side	Interpretation
Negative	Negative	No allergy, no photoallergy
Negative	Positive	Pure photoallergy
Positive	Negative	Allergy, no photoallergy
Positive	Positive	Allergy with photo-exacerbation

Q1.9: How is dermatitis managed?

Answer:

- Avoid irritants → Most important / Treatment of choice
- Topical steroids
- Oral steroids
- Azathioprine
- Cyclosporine
- Retinoids are avoided (cause dryness → increases irritation)

BIG QUESTION 2: What are the types, clinical features, diagnosis and management of Endogenous Eczemas?

Answer : Chronic relapsing eczemas are caused by genetic, immune, and barrier defects. Types include atopic dermatitis (AD), pityriasis alba, seborrheic dermatitis, pompholyx, asteatotic eczema, and lichen simplex chronicus. AD involves barrier defects (↓ filaggrin), Th2 activation (↑ IgE, IL-4/13), and ↑ TEWL. It presents as facial/extensor lesions in infants, flexural in children, and hand/foot in adults. Other variants show hypopigmented patches, dandruff, vesicles, dry cracks, or lichenified plaques. Diagnosis is clinical (±↑ IgE), with Hanifin & Rajka criteria for AD. Treatment includes trigger avoidance, moisturizers, topical steroids/calcineurin inhibitors, systemic immunosuppressants, and newer agents like dupilumab.

Q2.1: What is Atopic Dermatitis (AD)?

Answer:

Definition	Itchy, chronic or chronically relapsing inflammatory skin condition.
Other name	"Itch that rashes / itch is a disease."
Atopic Triad	• Atopic dermatitis • Asthma • Allergic rhinitis (hay fever).

Q2.2: What is the pathogenesis of Atopic Dermatitis?

PYQ: AIIMS 2019, 20

Answer:

AD Pathogenesis		
Epidermal Barrier Dysfunction • Filaggrin gene impairment • ↑ Skin pH • ↓ S. aureus resistance • ↑ Allergen susceptibility • ↓ Ceramides • ↓ Hydration	**Immunological Abnormalities** • Calcineurin-mediated Th2 cell activation • ↑ TEWL • ↓ IL-4, IL-13 production • ↑ Serum IgE • ↓ PDE-4 activation	**Aggravating Factors** • Dry skin • Harsh soaps, detergents, wool • Seasonal changes • Heat • Sweating • Infections • Stress • Food allergies

Q2.3: What are the clinical features of Atopic Dermatitis?

Answer: **Types:**

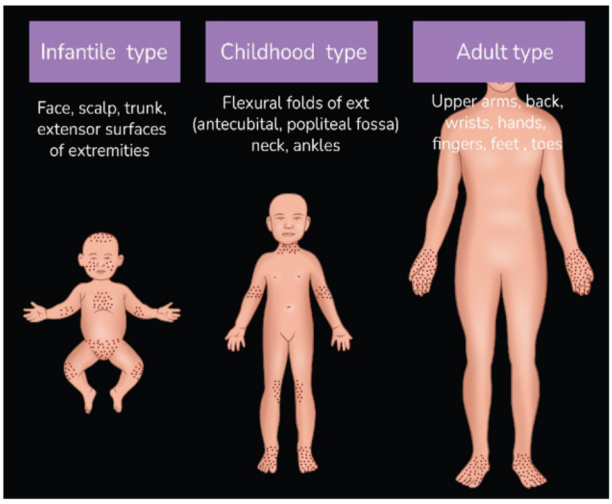

YOURWISH

Infants	Adolescent (childhood type)	Adult type
• 3 months to 2 years • As they crawl, they come in contact with external factors • **Locations:** Face, scalp, trunk, diaper area, and extensor surfaces of extremities. 	• 2 to 12 years.  • Allergens deposit on the flexural folds. • **Locations:** Antecubital fossa, popliteal fossa, neck, and ankles.	• >12 years. • Indulge in a lot of work • **Locations:** Hands, feet, and flexural folds. 

Q2.4: What are the other associated features of atopic dermatitis?



Answer:

- **Associated features:**
  - Keratosis pilaris
  - Hyperlinear palms & soles
  - White dermographism
- Dennie-Morgan fold (extra fold on lower eyelid).

Q2.5: How is Atopic Dermatitis diagnosed?

Answer:

- Mainly clinical
- Raised IgE
- **Hanifin & Rajka criteria (≥3 major):**
  - Pruritus
  - Typical morphology & distribution
  - Infants/children → face/extensors
  - Adults → flexural lichenification
  - Chronic or relapsing course
  - Personal/family history of atopy (asthma, AR, AD)

Q2.6: How is Atopic Dermatitis managed?

Answer:

Environmental factors	• Remove triggers
Barrier repair	• Hydration, moisturizers
Immunological treatment	• Topical: Corticosteroids, Calcineurin inhibitors • Oral: Corticosteroids, Cyclosporine, Azathioprine
Newer drugs	• Crisaborole: PDE-4 inhibitor (topical) • Dupilumab: IL-4 receptor alpha antagonist (systemic) • Apremilast: PDE-4 inhibitor (oral)

Q2.7: What is Pityriasis Alba?

Answer:

Definition	• Pityriasis = scaly; Alba = white
Seen in	• Atopic children
Clinical	• Multiple, hypopigmented, ill-defined, asymptomatic macules/patches on face with mild scaling. 
Histopathology	• Spongiosis
Differential diagnosis	• Indeterminate Hansen (solitary lesion, no scaling, not episodic, periappendageal infiltrate).
Treatment	• Moisturizers • Topical corticosteroids • Topical calcineurin inhibitors.

Q2.8: What is Seborrheic Dermatitis?

Answer:

Definition	• Chronic inflammatory papulosquamous disease.
Pathogenesis	• ↑ Sebum, Malassezia globosa infection.
Age	• Infants <3 months (maternal hormones) • After puberty.
Sites	• Scalp, face, chest, upper back, upper trunk.
Clinical features	• Infants: "Cradle cap" = greasy scales of scalp ± face • Adults: Dandruff; greasy scales + inflammation around nasolabial folds, eyes, behind ears
Management	• Topical ketoconazole shampoo, topical/oral antifungals, mild topical corticosteroids, avoid oil application





Q2.9: What is Pompholyx Eczema?

Answer:

Definition	• Recurrent vesicular endogenous eczema of hands/feet.
Clinical	• Bilaterally symmetrical • Deep-seated itchy vesicles ("sago grain vesicles") • Relapsing-remitting pattern  
Treatment	• Moisturizers and topical corticosteroids o Oral corticosteroids, Cyclosporine and Azathioprine.

Q2.10: What is Asteatotic Eczema?

Answer:

Definition	• "No fat rash."
Seen in	• Elderly, atopics (usually lower legs)
Pathogenesis	• ↓Odland bodies (lipid granules) → less fat and dry skin.
Season	• Winters/dry season.
Clinical	• Cracked skin → Cracked porcelain / crazy paving / dried riverbed pattern. 
Other names	• Eczema craquele, Winter eczema.
Treatment	• Moisturizers, topical steroids, and antihistamines.

Q2.11: What is Lichenification (Lichen Simplex Chronicus)?

Answer:

Definition	Form of neurodermatitis
Pathogenesis	**Itch-scratch cycle** • Severe itching → destroys skin barrier → more itching.
Clinical features	Very itchy lichenified plaques with: • ↑ Pigmentation • ↑ Skin markings • Thickened skin 
Histopathology	Acanthosis

YOURWISH

12. PARASITIC INFESTATIONS/ADVERSE DRUG REACTIONS

BIG QUESTION 1: What is scabies?

PYQ: FMGE 2021

Broad Answer: Scabies is a parasitic skin infestation caused by Sarcoptes scabiei var. hominis, commonly transmitted through fomites and often found in overcrowded settings. It causes intense night-time itching, papules, and burrows, mainly in areas like finger webs, axillae, and groin ("Circle of Hebra"). Diagnosis is typically clinical or via skin scrapings, and treatment involves the use of scabicides (with repeat applications), hygiene of clothing and bedding, and treating all contacts.

DETAILED QUESTIONS

Q1.1: What is the causative agent for scabies?

Answer: Humanus variety of Sarcoptes scabei

Q1.2: How is scabies transmitted, and which populations are most commonly affected?

Answer: Transmission occurs through fomites. It is seen mostly in people who live in overcrowded areas.

Q1.3: Describe the biology and behaviour of the scabies mite.

Answer: Female mites infest the skin and form tunnels called burrows, starting at the stratum corneum and going deeper into the stratum Malpighi, laying eggs at the end of these tunnels.

Q1.4: Identify the scabies mite.

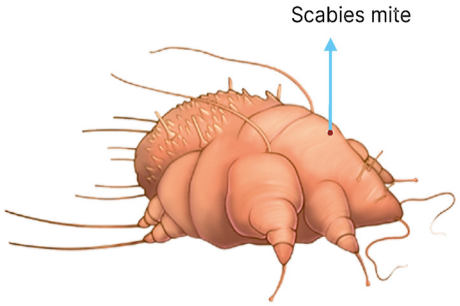

Q1.5: What is the usual number of mites found in a typical scabies patient?

Answer: Usually, there are 10-12 mites per patient.

Q1.6: What is the path the scabies mite takes on the skin?

Answer: The mite tunnels in the skin, starting from the stratum corneum down into the stratum Malpighi.

Q1.7: Illustrate the burrow of scabies mite.

Answer:

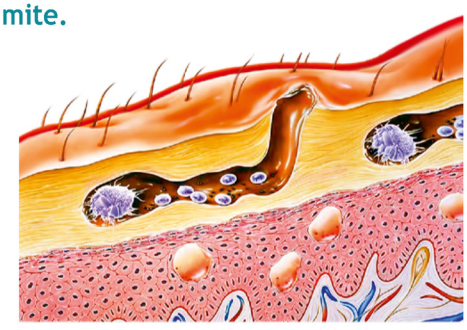

YOURWISH

YOURWISH

Q1.8: Where does the scabies mite lay its eggs?

Answer: Eggs are laid at the end of the burrow tunnels.

Q1.9: Provide a diagram illustrating the skin with the burrow formed by a scabies mite.

Answer:

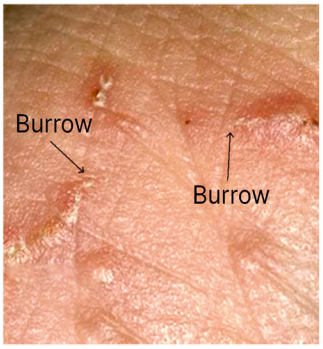

Q1.10: What are the key clinical features and symptoms of scabies?

Answer:

- Positive family history
- Nocturnal itching (more at night)
- Excoriated papules
- Secondary infections
- Burrows.

Q1.11: What is the "Circle of Hebra" and how is it relevant to scabies?

Answer: Mites affect body in the form of an imaginary circle called as Circle of Hebra

- Interweb spaces
- Axilla
- Mammary areas
- Groin
- Flexor areas of wrist

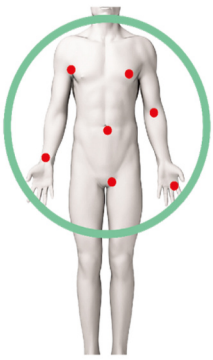

Q1.12: Could you display how scabies appears on the skin?

Answer:



Q1.13: How is scabies diagnosed?

Answer:

- Clinical examination (most common)
- Microscopic: Slide preparation → Smear from the burrow shows female mites, eggs and fecal material called Scybala.

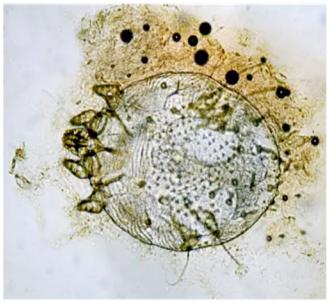

Q1.14: What are the general precautions to prevent the transmission of scabies?

Answer:

- Treat all family members regardless of symptoms
- Treat fomites (linen, bedding, and clothes).

Q1.15: Why is it important to treat all family members in scabies outbreaks regardless of symptoms?

Answer: To avoid transmission, as asymptomatic carriers can spread mites.

Q1.16: How should fomites be managed in scabies control?

Answer: Linen, bedding, and clothes should be treated to prevent reinfestation.

Q1.17: Why is the repeat application of scabicidal drugs necessary?

Answer: Because medications kill mites but not their eggs, which hatch later.

Q1.18: What is the drug of choice for scabies?

Answer: **5% Permethrin**

- MOA: Inhibits sodium gated channels in the mites
- Adults and children: Face is not involved (infants can have)
- Application: Applied from neck to the toes and left overnight and washed --> Repeat the application **after 1 week.**

Q1.19: What medications are used to treat scabies?

Answer:

- 5% Permethrin (DOC)
- Precipitated sulphur (for < 2 months age)
- 3. 1% GBHC (Gamma benzene hexa chloride)
- Malathion
- Benzyl benzoate
- Ivermectin (Oral - Dose of 200 mcg per kg)

Q1.20: Why is 1% Gamma Benzene Hexachloride (GBHC) no longer recommended for scabies treatment?

Answer: Now the use is discontinued because it cannot be used in:

- Pregnant females
- Children
- Individuals with neurological disorders

BIG QUESTION 2: What defines crusted scabies, its clinical features, and treatment?

Broad answer: Crusted scabies, or Norwegian scabies, is a severe form seen in patients with neurological disorders, Down syndrome, or in institutional settings. Due to an inability to itch, burrows accumulate, leading to thick, crusted, hyperkeratotic lesions, especially on the hands and feet, with millions of mites present. Treatment includes topical scabicides, oral ivermectin, keratolytics, and repeated applications.

DETAILED QUESTIONS

Q2.1: What is crusted scabies?

Answer: Crusted scabies is the most severe form of scabies seen mainly in patients with neurological disorders, Down syndrome, and in institutional settings.

Q2.2: How does the inability to itch contribute to the severe presentation of crusted scabies?

Answer: Itching normally serves a protective role by disrupting burrows.

- Inability to itch --> Burrows accumulate --> Leading to the formation of thick, heaped-up crusts (crusted scabies).

Q2.3: Describe the clinical appearance of crusted scabies lesions and their distribution on the body.

Answer: Hyperkeratotic crusted lesions all over the body, predominantly on hands and feet (millions of mites present).

Q2.4: Display the skin manifestations of crusted scabies?

Answer:



Q2.5: What are the treatment approaches for crusted scabies?

Answer: Topical treatment, oral ivermectin, and keratolytics

- Treatment needs to be repeated.

BIG QUESTION 3: What are the types of atypical scabies and their distinguishing features?

Broad answer:

- Infantile scabies
- Animal scabies
- Genital scabies
- Nodular scabies

DETAILED QUESTIONS

Q3.1: What is infantile scabies and how does it differ from typical scabies regarding site involvement?

Answer: Infantile scabies affects the face, unlike adult scabies where the face is usually spared.

Q3.2: Why is the face affected in infantile scabies?

Answer: Infants lack sebum on the face, which normally protects against mites.

Q3.3: What type of lesions are seen in infantile scabies, and why?

Answer: Vesicular lesions occur because infants cannot itch.

Q3.4: What are the characteristics of animal scabies?

Answer: They show no burrows but can transmit scabies.

Q3.5:What is the route of transmission of genital scabies?

Answer: **Considered as a Sexually transmitted Infection**

Q3.6: Describe nodular scabies including common sites and pathophysiology.

Answer:

- Seen in Axilla and groin
- Nodular lesions are developed (antigenic hypersensitivity reaction)
- Persistent nodules are seen.

BIG QUESTION 4: What are the causes, types, clinical presentations, and treatments of pediculosis?

Broad Answer: Pediculosis is caused by Pediculus humanus (capitis and corporis) and Phthirus pubis. P. humanus affects the scalp and body, while Phthirus pubis (pubic lice) is shorter, stout, and characterized by claw-like pincers.

DETAILED QUESTIONS

Q4.1: What organisms cause pediculosis?

Answer: Pediculosis is caused by *Pediculus humanus* and *Phthiriasis pubis*.

Q4.2: Illustrate the organisms responsible for causing pediculosis.

Answer:



Pediculus humanus Phthiriasis pubis

Q4.3: How is Pediculus humanus classified?

Answer: *Pediculus humanus* has two types:

- Pediculus humanus capitis (head lice)
- Pediculus humanus corporis (body lice).

Q4.4: What distinguishes Pediculus humanus capitis from Pediculus humanus corporis?

Answer: Capitis infests the scalp, corporis infests seams of clothing.

Q4.5: Describe the morphology and special features of Phthiriasis pubis.

Answer: Phthiriasis pubis is more stout than head lice and also has clawed hands.

Q4.6: What are the clinical manifestations of Pediculosis capitis in school-going children?

Answer:



- Seen in school-going children
- Lice and nits, along with itching in the scalp
- Severe itching leads to secondary infections → Crusting → Matting of hair (Plica Polonica)
- Recurrent cervical lymphadenopathy
- Recurrent folliculitis

Q4.7: What is “vagabond's disease” and what type of pediculosis does it refer to?

Answer: Vagabond's disease is another name for pediculosis corporis → Seen in homeless or destitute individuals.

YOURWISH

Q4.8: Describe the clinical signs of pediculosis corporis.





Answer:

- Seen in destitutes/homeless individuals
- Mites are present in seams of clothing → Act at night → Causes itching
- Itchy lesions on the trunk and Morbus errorum.

Q4.9: What is Morbus errorum in the context of pediculosis corporis?

Answer: Post-inflammatory hyperpigmentation left after mite bites.

Q4.10: What features characterize pediculosis pubis?

Answer: Sexually transmitted infection with nits and itching on genital hair.



Q4.11: What is macula ceruleae and how does it form?

Answer:

- Macula cerulea - Bluish macules are on genital area
- Blood meal is taken → Extravasation of blood (turns blue) → Leaves behind bluish macules in the genital area.

Q4.12: Which other hair-bearing areas can be affected by nits?

Answer: Eyelashes and axilla.

Q4.13: How is pediculosis pubis treated?

Answer: Pediculosis pubis is treated by manual removal, 1% permethrin, and oral ivermectin.

BIG QUESTION 5: What are the causes, clinical features, and characteristics of fixed drug eruption?

Broad Answer: Fixed drug eruption, commonly triggered by NSAIDs, cotrimoxazole, and fluoroquinolones, often presents with a history of symptoms like headache or stomachache after drug intake. It appears as well-defined erythematous macules or plaques, typically in the genital area, and is a type IV hypersensitivity reaction. Lesions heal with pigmentation, with lip hyperpigmentation being a characteristic feature.

DETAILED QUESTIONS

Q5.1: Which drugs commonly cause fixed drug eruption?

Answers: NSAIDs, cotrimoxazole, fluoroquinolones.

Q5.2: What symptoms might a patient report before skin lesions develop in fixed drug eruption?

Answer: H/o headache and stomachache after drug intake.

Q5.3: Describe the typical clinical appearance of fixed drug eruption lesions.

Answer: Well-defined erythematous macules and plaques on the genital region.

Q5.4: What type of hypersensitivity reaction causes fixed drug eruption?
Answer: Type 4 hypersensitivity.

Q5.5: What is a characteristic healing feature of fixed drug eruption?
Answer: Fixed drug eruption heals with pigmentation

Q5.6: What classical features appear on the lips in fixed drug eruption?
Answer: Hyperpigmentation.

PYQ: FMGE 2022 PYQ: INICET 2021 PYQ: NEET PG 2021






BIG QUESTION 6: What are Stevens-Johnson Syndrome and Toxic Epidermal Necrolysis?

Broad Answer: Stevens-Johnson Syndrome (SJS) and Toxic Epidermal Necrolysis (TEN) are severe drug-induced skin reactions. SJS involves less than 10% and TEN more than 30% of body surface area. Patients develop fever, rash, and painful mucosal erosions. Complications include eye damage, infections, and septic shock. Mortality risk is assessed using the SCORTEN (SCORe for Toxic Epidermal Necrolysis) scale. Treatment is mainly supportive, including fluids, antipyretics, and wound care in a hospital.

DETAILED QUESTIONS

Q6.1: What body surface area (BSA) involvement differentiates between SJS, TEN, and SJS-TEN overlap?
Answer:

PYQ: NEET PG 2022
PYQ: FMGE 2020, 2021

Body surface area <10% - SJS
Body surface area > 30% - TEN
Body surface area - 10-30% SJS-TEN

Q6.2: What is another name for TEN?
Answer: Lyell's disease.

Q6.3: Describe the extent of skin, mucosa, and systemic involvement in SJS/TEN.
Answer: Involves skin and mucosa with systemic symptoms.

Q6.4: How many mucosal sites are usually involved in SJS/TEN?
Answer: ≥2 mucosal sites involved.

Q6.5: What are typical prodromal symptoms seen in SJS/TEN patients?
Answer:

- Fever, malaise, constitutional symptoms.
- Purpuric lesions on trunk, limbs, hands, feet.



Q6.6: How does the of purpuric lesions and sheets of erythema appears after prodromal symptoms?

Answer:

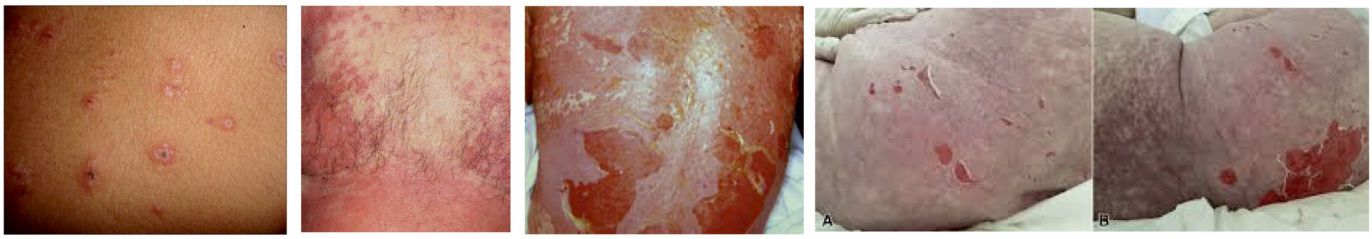

Q6.7: Why is SJS/TEN a dermatological emergency?

Answer: Due to severe skin and mucosal involvement, risk of complications, and high mortality.

Q6.8: What mucosal areas are commonly affected in SJS/TEN?

Answer: Lips, genital mucosa, ocular mucosa.

Q6.9: How does the mucosal involvement appears in SJS/TEN?

Answer:

- ≥2 mucosal involvement
- Lips, genital mucosa, ocular mucosa
- Severe crusting and erosions



Q6.10: Name some acute complications associated with SJS/TEN.

Answer: Hypothermia, hypocalcemia, septic shock, ocular complications.

- High mortality rate

Q6.11: What is the SCORTEN score and what parameters does it include to predict mortality?

Answer: It predicts mortality using certain parameters mentioned:

Scorten Parameters	Score
Age years > 40 years	1
Malignancy	1
Tachycardia	1
Initial surface of epidermal detachment	1
Serum urea	1
Serum glucose	1
Bicarbonate	1

YOURWISH

Q6.12: How does mortality risk change with increasing SCORTEN score?

Answer: Mortality ranges from 3.2% (0-1 score) to 90% (>5 score).

Q6.13: What biochemical parameters are considered while assessing severity in SJS/TEN?

Answer: Serum urea, serum glucose, and bicarbonate.

Q6.14: What are the main components of treatment and supportive care in SJS/TEN?

Answer:

- Admission to the dermatology emergency ward,
- IV fluids
- Antipyretics
- Dressings
- Mostly conservative management is followed

BIG QUESTION 7: Which drugs cause pigmentation, and what type of pigmentation do they cause?

Broad Answer:

- **Minocycline:** Black-blue pigmentation on scars.
- **Hydroquinone:** Ochronosis (deep bluish pigmentation on the malar area)
- **Hydroxychloroquine:** Slate blue pigmentation on the shins.
- **Bleomycin:** Flagellate pigmentation on the body.
- **Zidovudine:** Pigmentation of nails and skin creases on hands.
- **Clofazimine:** Ichthyosis and reddish brown pigmentation on the skin
- **Amiodarone:** Pigmentation on photo-exposed parts (face, dorsum of hands).

DETAILED QUESTIONS

Q7.1: Name some drugs known to cause pigmentation changes in the skin.

Answer:

- Minocycline (acne patients)
- Hydroquinone (melasma patients)
- Hydroxychloroquine (arthritis patients)
- Bleomycin (anticancer therapy patients)
- Zidovudine (HIV positive patients)
- Clofazimine (leprosy patients)
- Amiodarone (tachycardia and arrhythmia patients).

Q7.2: What type of pigmentation and skin reaction can minocycline cause?

Answer: Black/blue pigmentation on scars due to iron chelate deposition; may cause lupus-like reaction.



YOURWISH

YOURWISH

Q7.3: Describe the pigmentation effect caused by hydroquinone and the mechanism involved.

Answer: Ochronosis with deep bluish pigmentation on malar area due to inhibition of homogentisic acid oxidase leading to ochre body deposition.



Q7.4: What pigmentation is associated with hydroxychloroquine use?

Answer: Slate blue pigmentation on the shins.



Q7.5: What is flagellate pigmentation and which drug causes it?

Answer: Flagellate pigmentation (linear streaks) on the body caused by bleomycin.



Q7.6: How is pigmentation caused by zidovudine?

Answer: Causes pigmentation of nails and skin creases on hands.



Q7.7: What pigmentation and skin changes are caused by clofazimine?

Answer: Reddish brown pigmentation and ichthyosis due to crystal deposition in the skin.



YOURWISH

Q7.8: Describe the pigmentation caused by amiodarone and the areas affected.

Answer: Pigmentation on photo-exposed parts such as face and dorsum of hands.



13. SKIN TUMOUR

BIG QUESTION 1: What are the types of Benign Skin Tumours?

Broad Answer: Benign skin tumours include:

- Skin tags
- Syringoma
- Dermatofibroma (Benign Fibrous Histiocytoma)

DETAILED QUESTIONS

Q1.1: What are Skin Tags?

Answer: Skin tags are benign growths composed of loose fibrous tissue covered by skin, appearing as small, soft, pedunculated lesions that commonly occur on the neck, axilla, and other skin folds.



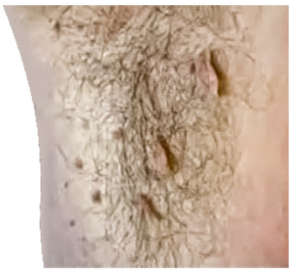

Q1.2: A young woman presents with multiple grouped, shiny, asymptomatic papules around the eyelids with angular borders. What is the most likely diagnosis?

Answer: Syringoma

- **Origin**: Benign tumour of acrosyringium of eccrine sweat glands
- **Site**: Periorbital area

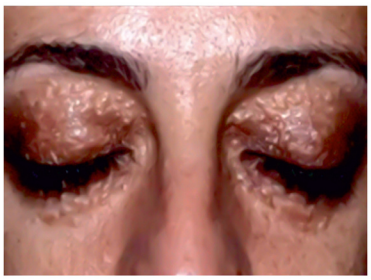

Q1.3: What are the clinical features of Syringoma?

Answer:

- Grouped shiny asymptomatic lesions
- Filled with watery fluid
- Angular borders

Q1.4: What is the histopathology of Syringoma?

Answer: Tadpole/comma-shaped cells

Q1.5: What is Dermatofibroma also called?

Answer: Benign Fibrous Histiocytoma

Q1.6: What are the clinical features of Dermatofibroma?

Answer:

- Solitary
- Hyperpigmented.
- Round
- Oval or targetoid papule, plaque, or nodule
- Common on lower legs



- **Central Dimple sign**: Dimpling in centre on stretching

Q1.7: What are the histopathological features of Dermatofibroma?

Answer:

- Storiform, cartwheel, or whorled pattern
- Spindle cells with elongated nuclei radiating from a central point

Q1.8: In which conditions is this histopathology seen?

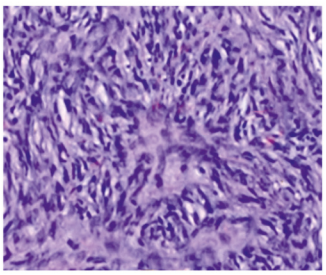

Answer: The storiform or cartwheel pattern of spindle cells with elongated nuclei radiating from a center point is seen in:

- **Dermatofibroma (Benign Fibrous Histiocytoma):** A common benign lesion that usually presents as a solitary, firm, hyperpigmented papule or nodule on the lower legs, often showing the central dimple sign.
- **Dermatofibrosarcoma Protuberans (DFSP):** A rare, locally aggressive, low-grade malignant tumor that also shows a storiform pattern but has greater infiltrative growth and recurrence potential compared to dermatofibroma.

BIG QUESTION 2: What are Non-Melanoma Skin Cancers?

Broad Answer:

- Non-Melanoma Skin Cancers are a group of malignant skin tumors other than melanoma.
- They commonly affect elderly, fair-skinned, photo-exposed individuals.
- Major types include SCC (and its precursors) and BCC.

DETAILED QUESTIONS

Q2.1: How are Non-Melanoma Skin Cancers classified?

PYQ: FMGE 2021

PYQ: FMGE 2019

Answer:

- **Squamous cell carcinoma (SCC) and its precursors:**
  - Actinic keratosis
  - Bowen's disease
  - Keratoacanthoma
- **Basal cell carcinoma (BCC)**

Q2.2: An elderly farmer presents with rough scaly papules on the lower lip that bleed on crust removal. What is the likely diagnosis?



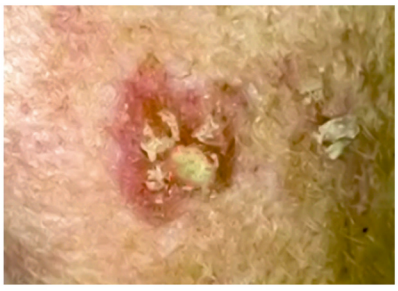

Answer: **Actinic Keratosis**

- Actinic = Sun; Keratoses = Keratotic lesions
- Seen in elderly, white, photo-exposed individuals
- **Clinical features:**
  - Papules with rough scaly surface
  - Adherent yellowish crust
  - Pinpoint bleeding on removal

Q2.3: A white elderly woman develops a plaque with adherent crust on her lower leg, but no bleeding points are seen. What is the diagnosis?

YOURWISH

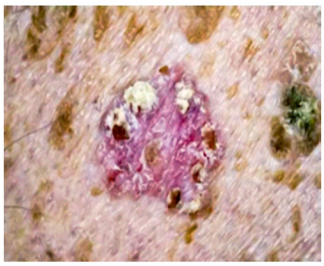


Answer: The diagnosis is Bowen's disease, an intraepidermal (in situ) squamous cell carcinoma that commonly occurs on the lower leg of elderly UV-exposed females, presenting as a plaque with adherent crust but without bleeding.

Q2.4: What are the features of Squamous Cell Carcinoma (SCC)?

PYQ: NEET PG 2021

Answer: Squamous cell carcinoma is a malignant tumor arising from epidermal keratinocytes or their appendages, and it is the second most common skin cancer after basal cell carcinoma, with a relatively low rate of local, regional, and distant spread. It is the most common skin tumor in immunocompromised individuals (HIV, Renal transplants).

Features:

Papule, nodule, plaque, or ulcer with crusting. Occurs on photo-exposed areas	Biopsy: Keratin pearls
 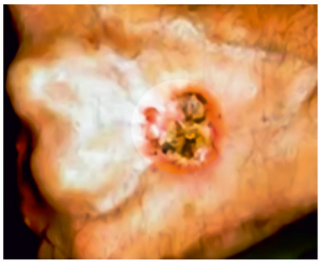	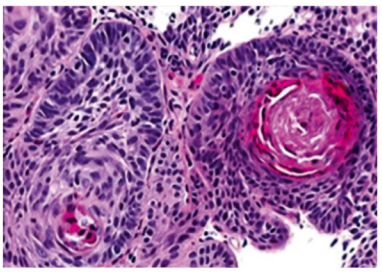

Q2.5 A dome-shaped nodule with central keratin plug is seen on the face. What is the diagnosis?

Answer: **Keratoacanthoma**

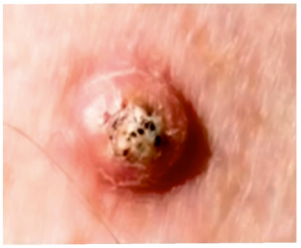

- Well-differentiated SCC type, good prognosis
- **Site:** Face > hands
- **Phases:** Growth → Maturation → Resolution
- **Clinical features:**
  - Start as a papule.
  - Develops to a Dome shaped nodule with Central keratin plug
  - Outer epidermal lining everts to surrounding skin
  - Plug falls off.
  - Lesion disappears.
- **Histopathology**: Epidermal lipping, central keratotic plug

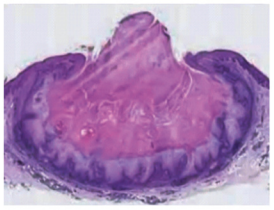
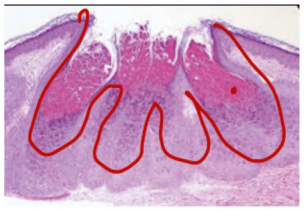

Q2.6: Which skin cancer is known as a "rodent ulcer," and what are its features?

PYQ: INICET 2022

Answer: Basal Cell Carcinoma (BCC), AKA Basalioma, Rodent ulcer. The most common human cancer, slow-growing, locally invasive, rarely metastasizes.

Origin	Basal epidermal cells/follicular structures
Clinical	• Ulcer with overhanging thready margins • Telangiectasia • Bleeds on touch
Sites	Inner canthus of eye, lateral border of nose
Treatment	• Medical (low-risk, small): Imiquimod, 5-FU, PDT, intralesional IFN-α2b, Vismodegib • Surgery: For large or recurrent lesions




BIG QUESTION 3: What are the diagnostic features, prognostic factors, and treatment of Malignant Melanoma?

Broad Answer: Malignant melanoma is a highly aggressive tumor arising from melanocytes with high risk of metastasis. It is diagnosed clinically using the ABCDE rule, confirmed with biopsy, and staged by Breslow depth. Prognosis depends on histopathological markers. Treatment is primarily surgical excision with appropriate margins.

DETAILED QUESTIONS

Q3.1: Define malignant melanoma and mention its major features and predisposing factors.

PYQ: FMGE 2019, 2021, 2023
PYQ: NEET PG 2023

Answer:

- Malignant melanoma is a malignant tumor arising from melanocytes
- Metastasis is seen

Predisposing factors:

- Precursor lesions
- UV radiation (controversial)
- Genetic mutation in Cyclin-Dependent Kinase Inhibitor 2A (CDKN2A) gene

Q3.2: A 45-year-old man presents with a rapidly enlarging mole that has become dark, irregular, and occasionally bleeds. Which rule helps in assessing malignant potential?

Answer: **(ABCDE rule)**

A	**Asymmetry:** Moles that have asymmetrical appearance 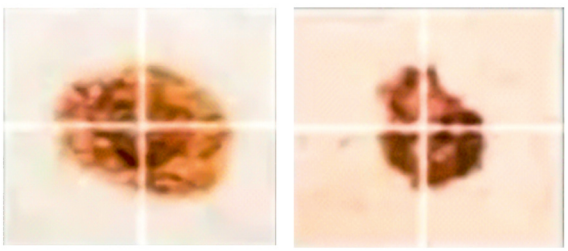 Symmetrical Asymmetrical
D	**Diameter:** Moles with a diameter larger than a pencil eraser (6mm or ¼ inch) 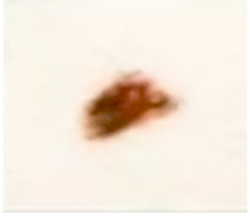 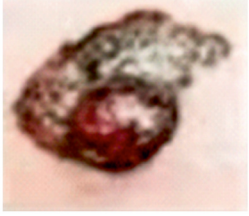 Smaller than 6 mm/0.2 in Bigger than 6 mm/0.2 in

B	**Border:** A mole that has blurry and/or jagged edges 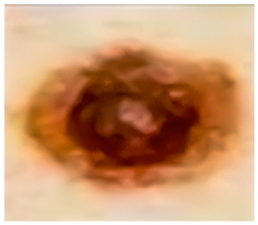 Smooth borders 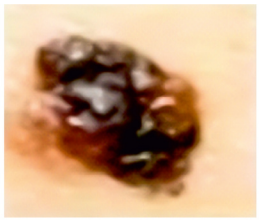 Irregular borders
E	**Evolution:** A mole that has gone through sudden changes in size. Shape or color 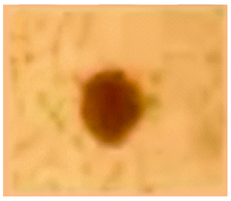 No changes 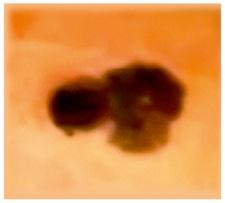 Some changes
C	**Color:** A mole that has more than one color 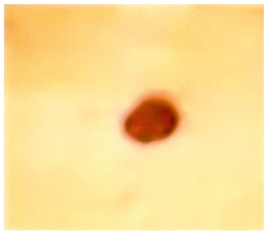 Single Color 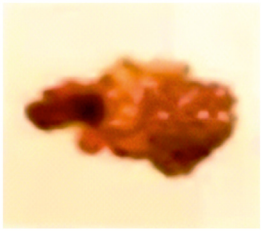 Multicolor

Q3.3 : What are the precursor lesions for melanoma?

Answer:

Precursor lesions	2. Common Nevi	3. Dysplastic/Atypical Nevi
1. CMN: Large CMN (>20 cm) o More often located on the trunk and present with satellites 	o Risk of transformation very low o Highest risk is with junctional nevi  Common Nevia	o Atypical on histopathology

Q3.4 : A biopsy from a suspected melanoma shows invasion depth of 2.2 mm, ulceration, and increased mitotic rate. Which pathological marker is most important for prognosis?

Answer: **Breslow depth**: Most important prognostic marker, measures vertical thickness of tumor in mm from epidermis to deepest cell

- **Other prognostic markers:**
  - Ulceration
  - Mitotic rate
  - Sentinel lymph node status

YOURWISH

Q3.5: What is the standard treatment of malignant melanoma?

Answer:

- Wide local excision: Margins determined by Breslow depth
- Sentinel lymph node biopsy: Indicated if Breslow depth >1.0 mm
- Adjuvant therapy (advanced cases): Immunotherapy (checkpoint inhibitors), targeted therapy, chemotherapy

BIG QUESTION 4: What are the clinical stages and management of Mycosis Fungoides?

Broad Answer: Mycosis fungoides is a cutaneous T-cell lymphoma that progresses slowly through patch, plaque, and tumor stages, with erythroderma in advanced disease. It is diagnosed by clinical features, histology (epidermotropism, Pautrier's microabscess), and Sezary cell detection. Treatment is stage-dependent, ranging from topical therapy to systemic chemotherapy.

DETAILED QUESTIONS

Q4.1: A patient presents with red scaly patches and plaques on the trunk that later progressed to tumors and widespread redness. What is the likely diagnosis?

Answer: Mycosis fungoides (most common variant of cutaneous T-cell lymphoma)

- It is a tumor of skin-homing T-cells (loss of mature T-cell antigens in the skin and other involved organs).
- Caused by monoclonal proliferation of CD4+/CD45RO+ helper T-cells

Q4.2: What are the common clinical features of Mycosis fungoides?

Answer: **Site:** Trunk and central part of the body

Presents in various forms

- Patches
- Plaques
- Tumours
- Erythroderma

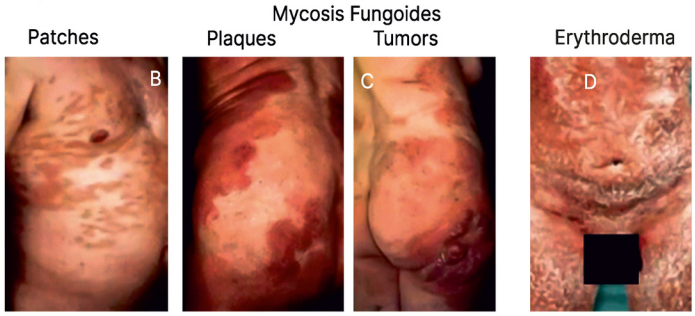

Q4.3: What is Sezary syndrome and its triad?

Answer: **Triad of Sezary Syndrome:**

- **Erythroderma**: Generalized redness and scaling of skin
- **Peripheral lymphadenopathy**: Enlarged lymph nodes
- **Sezary cells**
  - Atypical lymphocytes with a grooved or cerebriform nuclei seen both in tissue and blood
  - >20% of total lymphocyte count or a total sezary count of >1000 cells /cm^3)

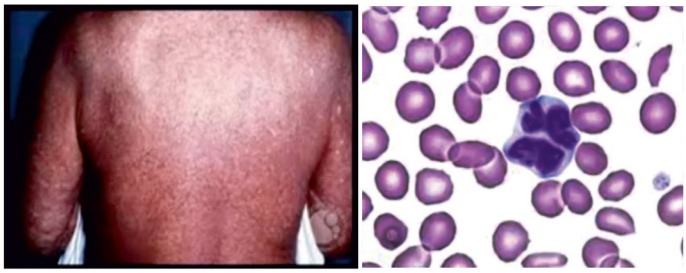

Q4.4: A histology slide shows epidermotropism of lymphocytes with Pautrier's microabscess. Which skin lymphoma is this characteristic of?

Answer: **Mycosis fungoides**

- **Histology features:**
  - Epidermotropism (lymphocytes migrating into epidermis)

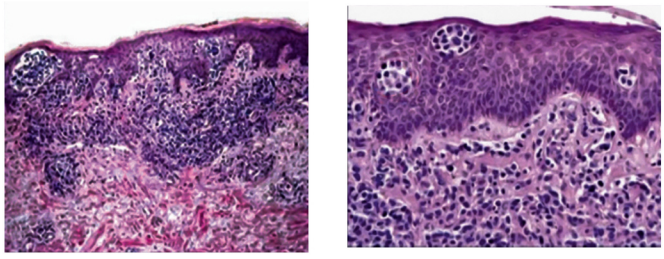

YOURWISH

YOURWISH

- Pautrier's microabscess (clusters of atypical T-cells in epidermis)

Q4.5: How is Mycosis fungoides treated in different stages?

Answer: **Mycosis Fungoides Management**

Patch stage	Topical steroids, Nitrogen mustard (mechlorethamine), Carmustine (BCNU), Bexarotene gel, PUVA, UVB
Plaque stage	Total skin electron beam therapy (TOC), Interferon-alpha, Oral retinoids
Nodal/visceral stage	Aggressive chemotherapy (**CHOP regimen**: Cyclophosphamide, doxorubicin, vincristine, prednisolone)
Newer therapies	Denileukin diftitox, ADAB389-IL-2 fusion toxin, Histone deacetylase inhibitors

14. GENODERMATOSES

BIG QUESTION 1: Describe Neurofibromatosis 1.

Broad Answer: Neurofibromatosis 1, also known as Von Reckling Hausen's disease, follows autosomal dominant inheritance and arises from mutations in the NF1 gene on chromosome 17, which encodes neurofibromin proteins.

A diagnosis of NF1 can be made in an individual with 2 or more of the following
• ≥ 6 cafe au lait macules (> 5 mm in greatest dimensions for prepubertal and > 15 mm in post-pubertal persons) • Axillary and inguinal freckles • ≥ 2 neurofibromas (any types) or plexiform 1 neurofibromas optic glioma • ≥ 2 Lisch nodules • Sphenoid dysplasia, tibial pseudarthrosis, or other distinctive bone lesion • First-degree relative with a diagnosis of NF1
Abbreviation: NF1, neurofibromatosis type 1

DETAILED QUESTIONS

Q1.1: What is Genodermatoses?

Answer: Genetic disorders of the skin are called Genodermatoses.

Q1.2: What is another name and inheritance pattern of Neurofibromatosis 1?

Answer: Neurofibromatosis 1 is also known as Von Reckling Hausen's disease which has an Autosomal dominant inheritance.

Q1.3: On which chromosome is the NF1 gene located?

Answer: NF-1 gene is located on chromosome 17

Q1.4: What protein does the NF1 gene encode?

Answer: NF-1 gene codes for the Neurofibromin protein

Q1.5: How many café-au-lait macules are required for an NF1 diagnosis, and what size criteria apply pre- versus post-puberty?

Answer: ≥ 6 café-au-lait macules (> 5 mm prepubertal, > 15 mm post-pubertal).

Q1.6: What freckling sites count toward an NF1 diagnosis?

Answer: Axillary and inguinal freckles.

Q1.7: How many neurofibromas or plexiform neurofibromas must be present?

Answer: ≥ 2 neurofibromas (any type) or ≥ 1 plexiform neurofibroma or optic glioma.

Q1.8: How many Lisch nodules are diagnostic of Neurofibromatosis type 1?
Answer: ≥ 2 Lisch nodules.

Q1.9: Which bone lesions are considered as distinctive NF1 findings?
Answer: Sphenoid dysplasia, tibial pseudarthrosis, or other distinctive bone lesion.

Q1.10: What family history is required for diagnosis?
Answer: First-degree relative with a diagnosis of NF1.

Q1.11: What does the acronym "CAFES" stand for in Neurofibromatosis type 1?
Answer: CAFES:

- **C**-Café-au-lait spots
- **A**-Axillary/inguinal freckling
- **F**-Fibromas/plexiform neurofibroma
- **E**-Eye hamartomas
- **S**-Skeletal abnormalities

Q1.12: What are the CNS features seen in NF1?
Answer: Epilepsy and low intelligence

Q1.13: What malignancies are seen in NF1?
Answer: Gliomas and Astrocytoma

Q1.14: What are neurofibromas?
Answer: Neurofibromas are soft pedunculated skin growths → 2 neurofibromas should be present.



Q1.15: What is the button-hole sign?
Answer: Buttonhole sign is one plexiform neurofibroma along the nerve.

Q1.16: What are CALMs?
Answer: CALM refers to cafe au lait macules (coffee on milk), which present as hyperpigmented macules on the trunk.

Q1.17: How to diagnose NS1 on the basis on CALMs?
Answer: Diagnosis of NF1 → >6 CALM's should be present, which are >5mm in size in pre-pubertal and >15mm in post-pubertal individuals



Q1.18: What is Crowe's sign?
Answer: Crowe's sign is freckling in the axillary or inguinal areas.

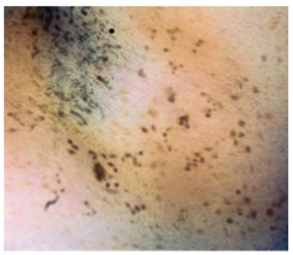

YOURWISH

Q1.19: Where and how are Lisch nodules found?

Answer: Lisch nodules are iris hamartomas seen on slit lamp, not affecting vision.

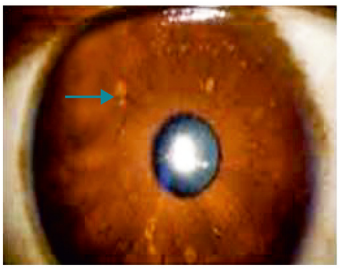

Lisch nodules

BIG QUESTION 2: Describe Tuberous Sclerosis Complex

Broad Answer: Tuberous sclerosis complex (Bourneville's disease/Epiloia) is an autosomal dominant disorder due to TSC1/2 mutations encoding hamartin and tuberin, characterized by hamartomas in the brain, heart, kidneys, eyes, and skin. Key cutaneous signs include facial angiofibromas (adenoma sebaceum), ash leaf macules, shagreen patches, Koenen's tumors, gingival fibromas, dental pits, and confetti macules. Systemic features include cortical tubers, subependymal giant cell astrocytomas, rhabdomyomas, renal angiomyolipomas, lymphangioleiomyomatosis, and polycystic kidneys.

DETAILED QUESTIONS

Q2.1: What is Tuberous Sclerosis Complex?

Answer: Also known as Bourneville's Disease or Epiloia (Epilepsy, low intelligence, Adenoma sebaceum)

- Autosomal dominant inheritance
- Defect in chromosomes 9 and 16
- Genes involved: TSC 1 and TSC 2

Q2.2: What proteins do TSC1 and TSC2 encode?

Answer: Tuberin and Hamartin proteins.

Q2.3: List the hamartomas and systemic findings associated with TSC.

Answer: **Mnemonic: Hamartomas:**

- **H -** Hamartoma
- **A -** Adenoma sebaceum
- **M -** Mental retardation
- **A -** Ash leaf spots
- **C -** Cortical tubers
- **R -** Rhabdomyoma
- **T -** Tubers
- **O -** Optic hamartomas (phakomas)
- **M -** Mitral regurgitation
- **A -** Astrocytoma
- **S -** Seizures

Q2.4: What is adenoma sebaceum?

Answer: Adenoma sebaceum is a misnomer for a cutaneous angiofibroma, a growth of bblood vessels and fibers.

Q2.5: What are the symptoms of adenoma sebaceum?

Answer: Asymptomatic red soft papules on cheeks, nose, nasolabial folds, and chin that appear at 3-4 years of age and increase during puberty (seen in butterfly distribution).

YOURWISH



Q2.6: How does adenoma sebaceum differ from acne?

Answer: No comedones or pustules are present in Adenoma sebaceum, and this differentiates it from acne.

Q2.7: What are ash-leaf macules and shagreen patches?

Answer: Ash leaf macules are hypopigmented leaf-shaped macules on the trunk, which is often the first manifestation. Shagreen patches are collagenomas on the trunk.



Q2.8: What are Koenen's tumours?

Answer: Koenen's tumours are periungual fibromas.



Q2.9: Name other mucocutaneous and dental findings.

Answer:

- Gingival fibromas
- Dental pits
- CALM
- Hypopigmented to depigmented → Confetti-like macules- CLM





Cafe au lait spots





Gingival fibroma

Q2.10: List the ocular, neurological, pulmonary, cardiac, renal, and other organ manifestations.

Answer:

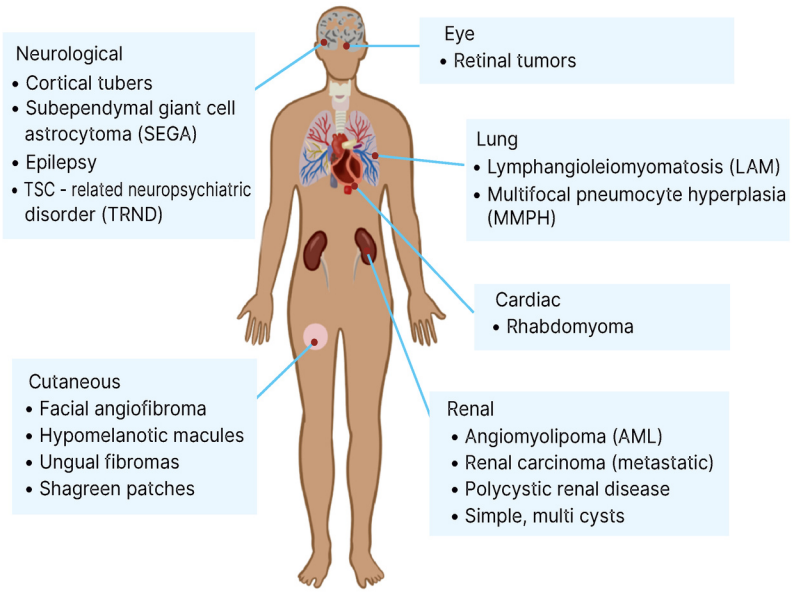

BIG QUESTION 3: Describe Peutz-Jeghers Syndrome and Xeroderma Pigmentosum

Broad Answer:

- Peutz-Jeghers syndrome is an autosomal dominant hamartomatous polyposis disorder caused by SPINK5 mutation, marked by early-onset periorificial lentigines and a family history of gastrointestinal polyposis or gastric cancer, necessitating regular endoscopic monitoring.
- Xeroderma pigmentosum is an autosomal recessive defect in nucleotide excision repair leading to photosensitivity with dry, pigmented skin, persistent erythema, xerosis, diffuse freckles, telangiectasia, atrophic lesions, photophobia, conjunctivitis, and neurological deficits such as cognitive impairment. Patients are prone to benign skin tumors (keratoacanthoma, actinic keratosis), malignant skin cancers (BCC, SCC, melanoma), and systemic malignancies like medulloblastoma and astrocytoma.

DETAILED QUESTIONS

Q3.1: Describe Peutz-Jeghers Hamartomatous.

Answer: Peutz-Jeghers Hamartomatous is an Autosomal dominant condition occurring with a positive family history → SPINK 5 gene is affected in this condition

PYQ: NEET PG 2019, 2020

Q3.2: How does Peutz-Jeghers Hamartomatous present?



Answer: Presents early in life with periorificial lentiginosis and a positive history of gastric cancer or lentiginosis.

Q3.3: What preventive measures are taken for GI adenomatous polyposis symptoms?

Answer: Regular checkup with endoscopy → rule out any symptoms of GI adenomatous polyposis.



Q3.4: What are the features of Xeroderma Pigmentosum?

Answer: Dry, pigmented skin with photosensitivity, oculocutaneous pigmentation, and early neoplasia (DNA damaged and accumulated in the body).

Q3.5: What inheritance pattern and DNA repair defect underlie Xeroderma Pigmentosum?

Answer:

- Inheritance: Autosomal recessive
- Defect: nucleotide excision repair defect

Q3.6: What are the features of Xeroderma Pigmentosum?

Answer:

- Normal at birth
- Photosensitivity
- Persistent erythema
- Acute sunburn
- Xerosis
- Diffuse freckling
- Telangiectasia
- Atrophic lesions
- Eyes: Extreme photophobia, conjunctivitis
- Neurological: MR, Low intelligence.

Q3.7: What malignancies are seen in Xeroderma Pigmentosum?

Answer:

- **Benign:** Keratoacanthoma, AK
- **Malignant:** BCC, SCC, Malignant melanoma
- **Systemic malignancies:** Solid organ malignancies- medulloblastoma, astrocytoma,

BIG QUESTION 4: Describe Epidermolysis Bullosa.

Broad Answer: Also known as mechanobullous disorders → Classified into:

- **EB Simplex** (epidermal basal cell blister; intraepidermal split) - KRT5/14 defect; AD
- **Junctional EB** (lamina lucida blister) - laminin 5 defect; AR
- **Dystrophic EB** (lamina densa/anchoring fibrils) - collagen VII defect; AD/AR
- **Acquired EBA** - collagen 7 defect

Develops at trauma-prone sites with a family history of skin fragility, affecting the trunk in infancy and mainly the extremities in older children, sometimes with mucosal involvement. Diagnosis is made by skin biopsy to identify the level of split and confirmed by electron microscopy, while DIF is not useful. Management is symptomatic or via gene therapy.

DETAILED QUESTIONS

Q4.1: What is another name for Epidermolysis Bullosa?

Answer: Mechanobullous disorders

Q4.2: How is Epidermolysis Bullosa classified?

Answer: Epidermolysis Bullosa is classified as:

- Acquired - EBA defects of collagen 7
- Congenital:
  - EB distrophicans

YOURWISH

- o EB junctionalis
- o EB simplex

Q4.3: Describe levels of blister formation in epidermolysis bullosa at the dermo-epidermal junction.

Answer:

- EB simplex—epidermal basal cell
- EB junctionalis—lamina lucida
- EB dystrophic—lamina densa (anchoring fibrils)

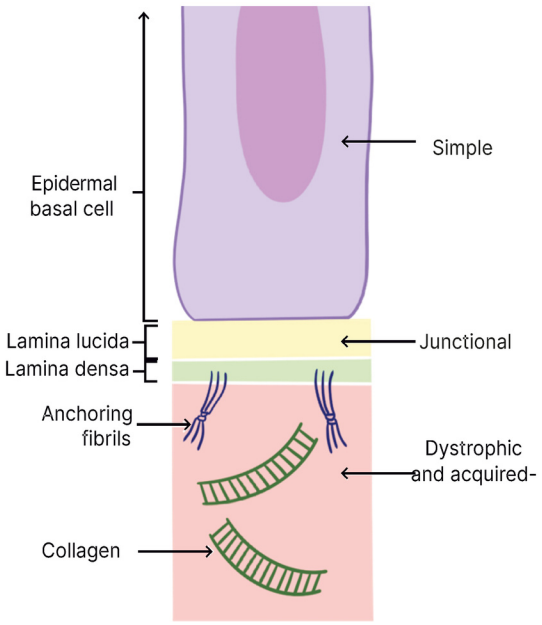

Levels of blister formation in epidermolysis bullosa at the demo - epidermal junction.

Q4.4: Differentiate the 3 types of congenital defects of EB

Answer:

	EBS(Simplex)	EBJ(Junctionalis)	EBD(Dystrophic)
Defect	KRT 5 and 14	Laminin 5	Collagen VII
Split	Intra epidermal split	Sub epidermal bulla	Sub epidermal bulla
Inheritance	AD	AR	AD/AR

Q4.5: How do bullae form and where?

Answer: Bullae form at trauma-prone sites from minor touch or pressure.

Q4.6: How does Epidermolysis Bullosa present clinically?

Answer:

- Baby → even minor trauma or pressure can cause skin splitting, often seen on the trunk
- Older children → appears on the feet at trauma sites, with mucosal involvement varying.



YOURWISH

YOURWISH

Q4.7: How is Epidermolysis Bullosa diagnosed?

Answer:

- Skin biopsy: Split
- Electron microscopy is diagnostic
- DIF has no role.

Q4.8: What is the treatment for Epidermolysis Bullosa?

Answer: Gene therapy/symptomatic treatment.

BIG QUESTION 5: Compare and differentiate between Darier's Disease and Hailey-Hailey Disease

Broad Answer:

- **Darier's Disease** is an autosomal dominant disorder caused by ATP2A2 (SERCA-2 Ca^{2+} ATPase) mutation, typically starting in late childhood and aggravated by summer or monsoon. It presents with rough, greasy, hyperkeratotic papules in seborrheic areas, nail changes like erythro-leukonychia (red-white longitudinal bands) and distal V-notching, and histology showing acantholysis with dyskeratosis characterized by corps ronds and grains.
- **Hailey-Hailey Disease** (familial benign chronic pemphigus) is an autosomal dominant disorder caused by ATP2C1 (Golgi Ca^{2+} ATPase) mutation, presenting with recurrent flaccid vesicles and erosions in intertriginous areas, often macerated, with a chronic relapsing course and no mucosal involvement. Histology shows partial suprabasal acantholysis, giving a "dilapidated brick wall" appearance.

DETAILED QUESTIONS

Q5.1: Which diseases are considered Inherited Acantholytic Disorders?

Answer: Hailey-Hailey disease and Darier's disease

Q5.2: How can we differentiate between Darier's disease and Hailey-Hailey disease?

Answer:

PYQ: NEET PG 2022

Feature	Darier's Disease	Halley-Halley's Disease
Inheritance	Autosomal Dominant	Autosomal Dominant
Defect	Ca^{2+} ATPase	Ca^{2+} ATPase
Gene	ATP 2A2	ATP 2C1
Site	**Seborrheic areas** 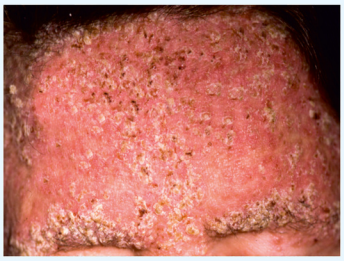	**Intertriginous areas** (skin folds) like axilla, groin & inframammary folds
Lesions	**Verrucous** (warty lesion), greasy with sand paper feel	**Recurrent, flaccid, vesicular** (may rupture causing erosions)

Histology	Acantholysis, dyskeratosis with **corps ronds, corps grains**	Acantholysis, dyskeratosis with **dilapidated brick wall appearance** 
		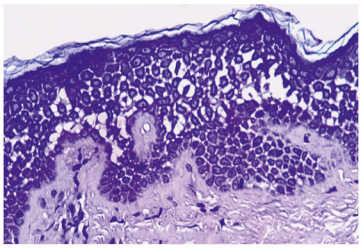 Dilapidated brick wall appearance

Q5.3: Describe Darier's disease.

Answer:

- Inheritance: Autosomal dominant
- Defect: ATP2A2 gene defect- responsible for SERCA-2 type calcium bound
- Onset: Late childhood to early adulthood
- Season: Summer and Monsoon

Q5.4: What are the skin manifestations of Darier's disease?

Answer: Rough hyperkeratotic, greasy-looking, associated with discomfort and itchiness in seborrheic areas

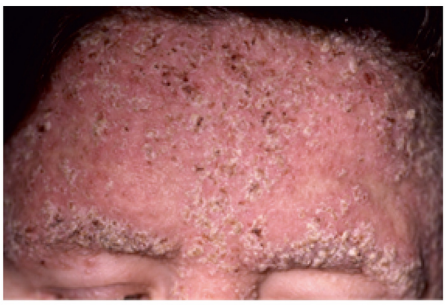


Q5.5: What are the other features of Darier's disease?

Answer:

- On the nails: Longitudinal lines called **Erythro leukonychia**- alternate longitudinal white and red bands
- Distal notching: **V sign on nails**



Q5.6: Describe the feature of Hailey-Hailey disease.

Answer: Hailey-Hailey disease is also known as familial benign chronic pemphigus.

- Recurrent vesicular eruption
- Intertriginous areas
- Maceration
- Exacerbations and remissions




- Chronic course
- No mucosal involvement
- Genetically inherited

Q5.7: What is the histopathological finding of Hailey-Hailey disease?

Answer: Dilapidated brick wall appearance with partial suprabasal acantholysis.



BIG QUESTION 6: Describe ichthyosis

Broad Answer: Ichthyosis is scaly, dry, rough skin with persistent scaling.

Congenital Ichthyosis:

- **Ichthyosis Vulgaris**: an autosomal dominant filaggrin defect, appears after 3 months with fine grey scales on extensor surfaces, worsens in winter, is linked to atopy, and is managed with keratolytics (retinoids avoided).
- **X-Linked Recessive Ichthyosis:** due to steroid sulfatase deficiency, starts at birth with dirty adherent scales in flexural/preauricular areas sparing palms/soles, may involve corneal opacities and cryptorchidism, and is treated with keratolytics, retinoids, or liarozole.
- **Lamellar Ichthyosis:** an autosomal recessive transglutaminase defect, presents as a collodion baby at birth with large plate-like scales, ectropion, and eclabion, managed with keratolytics and retinoids.

Acquired Ichthyosis: It is due to infections (leprosy, HIV), drugs (clofazimine), malignancies (lymphomas), nutritional, hypothyroidism, and sarcoidosis.

DETAILED QUESTIONS

Q6.1: What defines ichthyosis?

Answer: Ichthyosis is scaly, dry, rough skin with persistent scaling.

Q6.2: What are the congenital and acquired subtypes of Ichthyosis?

Answer:

Types	
Congenital	**Acquired**
Ichthyosis Vulgaris	Infections (leprosy), HIV
X- Linked Ichthyosis	Drugs (Clofazimine)
Lamellar Ichthyosis	Malignancies (Lymphomas)
	Nutritional
	Hypothyroidism
	Systemic diseases (Sarcoidosis)

Q6.3: Differentiate between 3 types of congenital ichthyosis.

Answer:

	IV	XLRI	LI
Inheritance	AD	XLR (male manifests)	AR
Defect	Filaggrin	Steroid sulfatase	Transglutaminase
Onset	After 3 months	Not at birth	At birth
Type of Scales	Fine gray, upturned at the edges	Dirty looking adherent	Fish/plate-like scales
Area Affected	Extensors, winter exacerbation	• Flexural, pre auricular • Palms and soles spared	• Erythroderma • Lower legs
Associations	Atopy, KP, PP hyper linearity	Comma-shaped corneal opacities, cryptorchidism	Collodion baby, ectropion, eclabion
Treatment	Keratolytics, No retinoids	Keratolytics, retinoids, liarozole	Keratolytics, retinoids

Q6.4: What are the features of Ichthyosis vulgaris?

Answer:

- Grey fine scales upturned at the edge
- Very dry skin associated with atopy



Q6.5: What are the features of X-linked recessive Ichthyosis?

Answer:

- Scales are dirtier-looking.
- Present in the preauricular area and flexors more than the extensors
- Palms and soles spared.

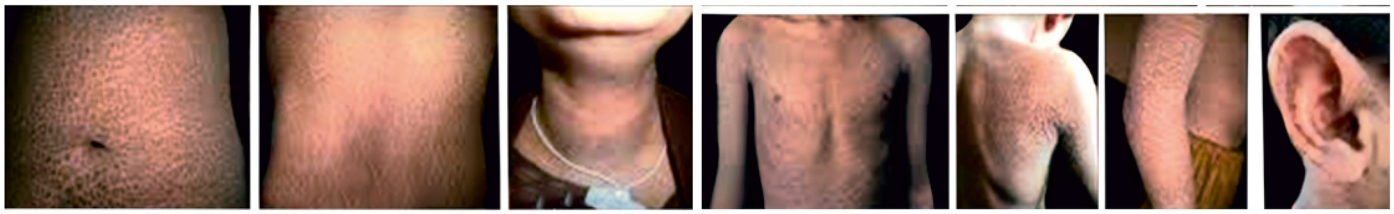

Q6.6: What are the features of Lamellar Ichthyosis?

Answer:

- Born as a collodion baby
- Baby covered in Taut and shiny glistening membrane.
- Ectropion, eclabium- eyes and averted mouth.
- Patients are born with erythroderma, it can present with fish-like or plate-like scales on the lower legs

YOURWISH

YOURWISH



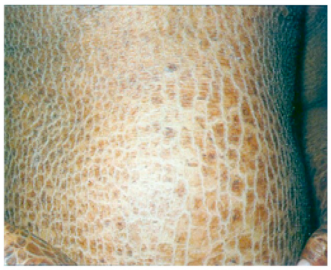

BIG QUESTION 7: Describe Incontinentia Pigmenti

Broad Answer: Incontinentia Pigmenti (Bloch-Sulzberger syndrome) is an X-linked dominant disorder.

- Males die in utero, and females present with NEMO gene mutations.
- Its three phases are:
  - Vesicular (0-2 weeks): vesicular lesions along Blaschko's lines
  - Verrucous (2-6 weeks): hyperkeratotic verrucous lesions
  - Pigmented (12-16 weeks): whorled hyperpigmented macules along Blaschko's lines, the most common presenting phase in children.

DETAILED QUESTIONS

Q7.1: What is Incontinentia Pigmenti?

Answer: Incontinentia Pigmenti is a defect along the dermatome/Blaschko's line and is also called Bloch-Sulzberger syndrome.

Q7.2: What is the inheritance pattern of Incontinentia Pigmenti?

Answer: X-linked dominant inheritance - NEMO gene is defective.

Q7.3: In which gender does Incontinentia Pigmenti present?

Answer: Males will die in utero, and Females will present with this defect

Q7.4: What are the three phases of Incontinentia Pigmenti?

Answer:

Vesicular	• 0-2 weeks persists for 2 months- in utero • Vesicular lesions present along blaschko's line
Verrucous	2 weeks - 6 weeks
Pigmentation	• Hyperpigmented macules • Present as whorls along Blaschko's line. This is the most common presenting phase in a child


0- 2 weeks


2 weeks-6 weeks


12-16 weeks

15. DISORDERS OF GLANDS

BIG QUESTION 1: What are the types of glands in the skin, their features, and related disorders?

Broad Answer: Skin glands include sweat glands (eccrine, apocrine) and sebaceous glands. They differ in location, secretion type, innervation, function, and onset of activity. Disorders include miliaria (eccrine origin), Fox-Fordyce disease, and hidradenitis suppurativa (apocrine origin).

DETAILED QUESTIONS

Q1.1: What are the main types of glands in the skin?

Answer:

- Sweat glands - Eccrine & Apocrine
- Sebaceous glands

Q1.2: What are the modes of secretion of eccrine, apocrine, and sebaceous glands?

Answer:

Gland	Secretion Name	Description
Eccrine	Merocrine secretion	Vesicles are formed and fused to the cell membrane
Apocrine	Apocrine secretion	The apical part of the gland is pinched off
Sebaceous	Holocrine secretion	Whole gland cell ruptures and dies

Q1.3: What are the differences between eccrine and apocrine glands?

Answer:

Criteria	Eccrine Gland	Apocrine Gland
Location	All over the body (more on palms and soles)	Axilla, groin, mammary area/areola
Type of Secretion	Merocrine	Apocrine
Opening	Directly into skin	Into hair follicle
Innervation	Cholinergic	Adrenergic
Secretion	Clear and Watery	Viscous
Role	Thermoregulation	Body odor
Onset of Activity	By birth	Adolescent (Androgen dependent)

Q1.4: Which skin structures represent eccrine and apocrine glands?

Answer:

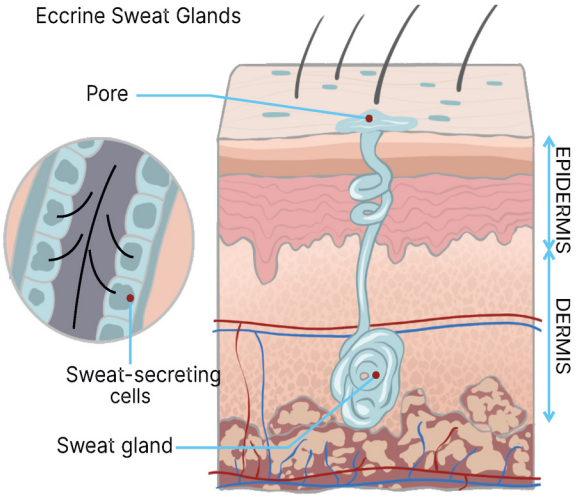

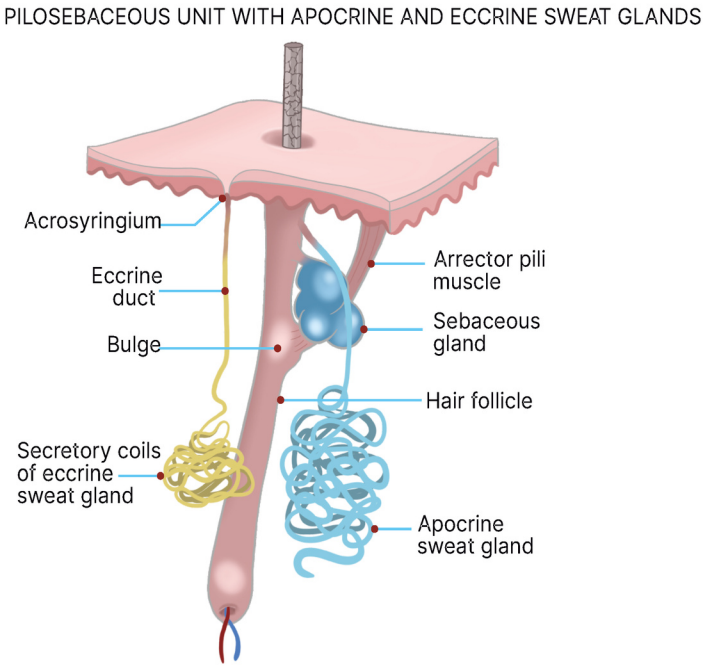

Q1.5: What is miliaria and what glands are affected?

Answer:

- Most common sweat gland disorder.
- Involves eccrine glands.
- Defect: Blockage of the intraepidermal part of sweat duct.

Q1.6: What are the types of miliaria and their level of blockage?

Answer:

- Miliaria crystallina: Stratum corneum.
- Miliaria rubra: Intraepidermal.
- Miliaria profunda: Dermo-epidermal junction.

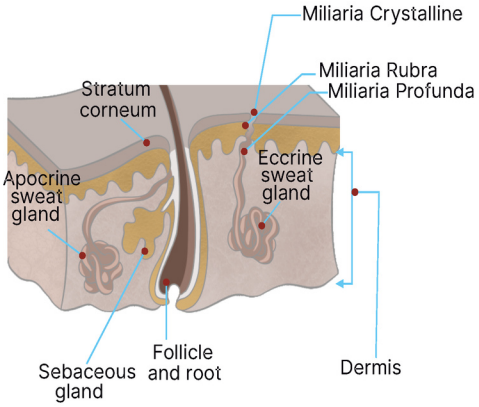

Q1.7: What are the clinical features of miliaria crystallina and rubra?

Answer:

Miliaria Crystallina	Miliaria Rubra
• Usually, infants • Numerous • Clear fluid-filled thin vesicles 	• Other name: Prickly heat • Pruritic Erythematous papules • On Trunk • Itching and irritation 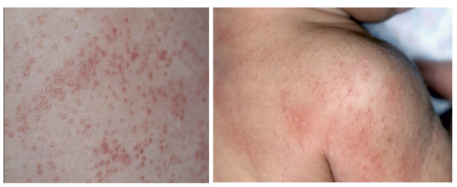

Q1.8: What is Fox-Fordyce disease, and how does it present?

Answer:

- Apocrine miliaria resulting from obstruction of the apocrine gland opening.

YOURWISH

- Common in adolescent females.
- Sites: Axilla, groin, nipples.
- Clinical: Pruritic skin-colored papules.



Q1.9: What is hidradenitis suppurativa, and what are its key features?

Answer:

- Chronic relapsing inflammatory disorder of apocrine glands.
- Other name: Acne inversa.
- Sites: Axilla, groin, mammary areas.
- Age: Post-puberty.
- Risk factors: Obesity, smoking, diabetes, and metabolic syndrome.

Q1.10: What are the clinical findings in hidradenitis suppurativa?

Answer:

Inflammation of apocrine glands
↓
Secondary infection
↓
Development of papules, pustules, boils and cyst (rupture)

- Papules, pustules, and painful nodules.
- **Severe:**
  - Painful cysts and abscess
  - Multiple discharge sinuses
  - Heals with scarring (Bridging/ rope scars)
- Healing with bridging/rope-like scars.
- Comedones: Polyporus comedones (blocked sebaceous ducts)


Polyporus comedones

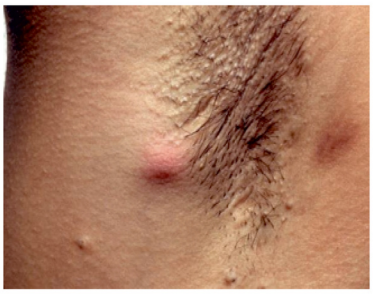
Tender pustules and papules


Cyst and abscesses


Bridging/ Rope Scars

Q1.11: What are the essential diagnostic criteria of hidradenitis suppurativa?

Answer:

Essential criteria for a diagnosis of hidradenitis suppurative to be made	
Typical lesions	Deep-seated painful nodules, abscesses, draining sinuses, bridged scars, and paired or multiheaded open pseudo comedones
Typical topography	Axillae, groin, perineal and perianal region, buttocks, infra-and intermammary folds
Presence and recurrence of lesions	

YOURWISH

Q1.12: What is the treatment of hidradenitis suppurativa?

Answer:

Lifestyle:	Weight reduction, diet, and stop smoking.
Medical:	Analgesics, antibiotics, anti-inflammatory agents, retinoids, and biological agents.
Surgical:	For recurrent or severe disease

BIG QUESTION 2: What are the disorders of sebaceous glands, their types, and features of acne vulgaris?

Broad Answer :

- Sebaceous glands are holocrine glands located mainly in seborrheic areas, opening into hair follicles.
- They may show ectopic modifications, like Meibomian glands and Fordyce spots.
- Their major disorder is acne vulgaris, characterized by comedones, papules, pustules, and scarring due to androgen-driven sebum overproduction, follicular blockage, bacterial colonization, and inflammation.

DETAILED QUESTIONS

Q2.1: What are the general features of sebaceous glands?

Answer:

Location	Seborrheic areas - scalp, face, upper back.
Opening	Into the hair follicle.
Development	Adolescence (androgen-dependent).
Type of secretion	Holocrine

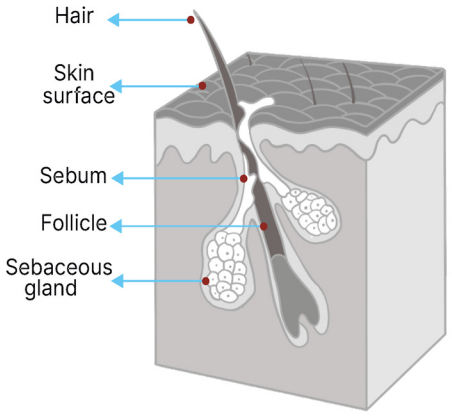

Q2.2: What are ectopic sebaceous glands and their modifications?

Answer: Sebaceous glands that open directly into the skin.

Examples:

Eye	Meibomian glands
Lips	Fordyce spots
Areola of nipple	Montgomery's tubercles
Penis (prepuce)	Tyson's glands

Q2.3: What are Fordyce's spots?

Answer:

- Yellowish, asymptomatic papules
- Seen on oral mucosa, lips, and buccal mucosa



Q2.4: What is acne vulgaris and when does it occur?

Answer:

- A disorder of the sebaceous glands.
- Usually occurs post-puberty.
- Presents with polymorphic lesions - papules, pustules, comedones.
- Common sites: Face, upper chest, back.

Q2.5: What is the pathophysiology of acne vulgaris?

PYQ: NEET PG 2023
PYQ: FMGE 2023
PYQ: INICET 2021

Answer:

Androgen
↓
Increased sebum production
↓
Sebaceous hyperplasia
↓
Altered follicular differentiation (Keratinization) leads to Blockage of sebaceous gland opening.
↓
Colonization of bacteria (Commonly Propionibacterium Acnes)
↓
Inflammation

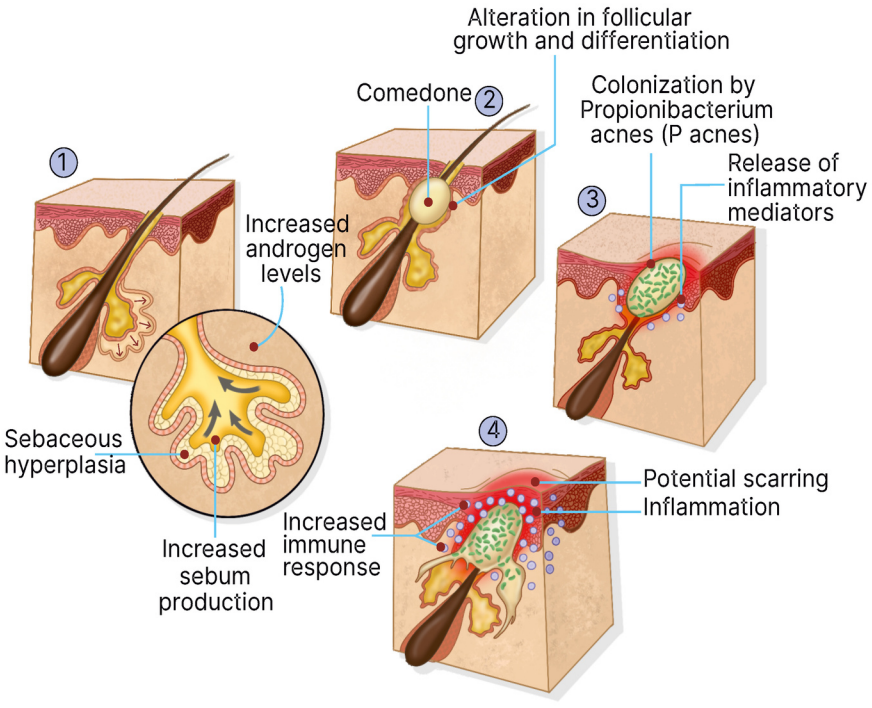

Q2.6: What are the clinical features of acne vulgaris?

Answer:

- Seborrhoea (increased sebum).
- Comedones (blocked pilosebaceous duct - characteristic feature).
- Papules and pustules due to bacterial colonization.
- Scarring due to inflammation.

Q2.7: What are the other factors involved in the pathogenesis of acne and what is the key clinical presentation?

Answer: **Other Factors:**

- IGF-1 (Insulin-like Growth Factor-1) → mTORC1 pathway.
- Inflammation → first stage in acne (not just a late result).
- Additional contributors → Dietary lipids, bacterial antigens, smoking, regulatory neuropeptides

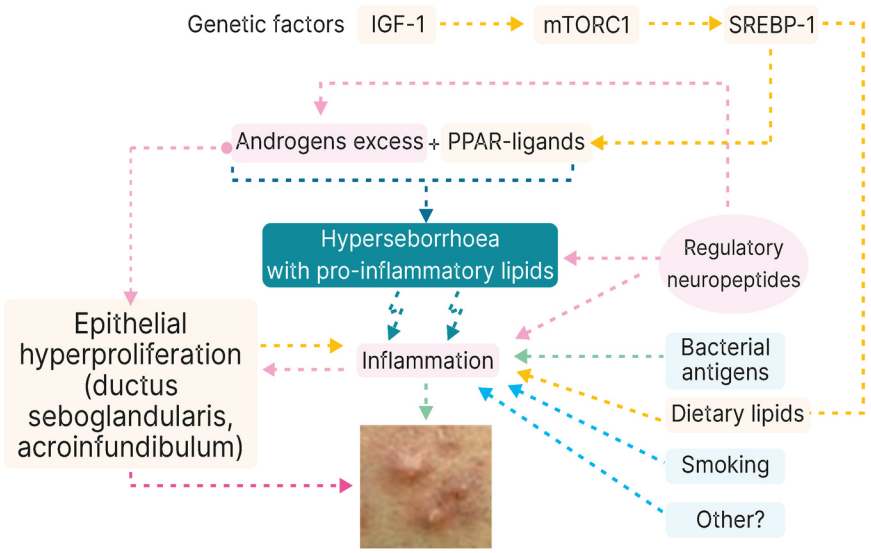

Q2.8: What is the difference between open and closed comedones?

Answer: Comedones are characteristic of acne vulgaris → represent blocked pilosebaceous ducts → Can be open (blackheads) or closed (whiteheads).

Open Comedone	Closed Comedone
• Also called **black comedones** • It is open to the skin surface • **Keratin** that is blocking the gland **will get oxidized** and become black	• Also called **white comedones** • There is a layer of skin over blocked duct

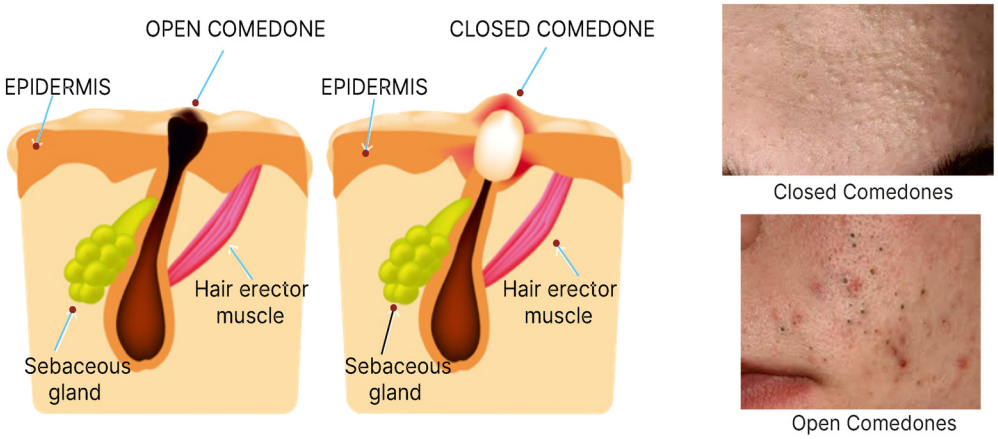

YOURWISH

Q2.9: What other lesions can be seen in acne vulgaris?

Answer:

Polymorphic lesions


Corredone


Nodules/cysts


Papules


Papules and Pustules


Acne scares

BIG QUESTION 3: What are the acne variants, grading, and Rosacea?

Broad Answer: **Acne Variants:** Hormonal acne, Acne Conglobata, Drug-induced acne, Acne Excoriee.

- **Grading:**
  - I → Comedones.
  - II → I + few papules/pustules.
  - III → Multiple papules/pustules.
  - IV → Nodulocystic acne.
- **Rosacea:** Adult misnomer, flushing, no comedones, 4 subtypes (ETTR, PPR, Phymatous, Ocular).

DETAILED QUESTION

PYQ: NEET PG 2023

Q3.1: How does Hormonal Acne present and what is its treatment?

Answer :



- Seen in females, mainly lower face.
- Associated with hyperandrogenism signs: hirsutism, seborrhoea, androgenetic alopecia.
- Rule out PCOS & other causes.
  - **Hair-An:** Hyperandrogenism with insulin resistance with Acanthosis Nigricans
  - **Saha:** Seborrhoea, Acne, Hirsutism, and Androgenetic Alopecia,
- **Treatment:** Hormonal therapy.

Q3.2 Which features define Acne Conglobata, and how is it managed?

Answer:

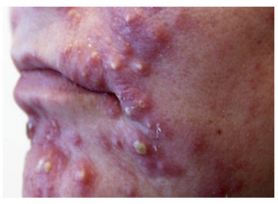



- Most severe form of acne.
- Seen in males, affecting trunk.
- **Lesions:** Predominant nodules, abscesses, intercommunicating sinuses.
- **Treatment:** Oral retinoids + Short-course steroids.

Q3.3 How can you identify Drug-Induced Acne?

Answer:



- Acneiform eruption without comedones.
- Monomorphic papules, mainly trunk.
- **Drugs:** Steroids, Antituberculars, Anticonvulsants.

YOURWISH

YOURWISH

Q3.4 What characterizes Acne Excorie clinically?



Answer:

- Occurs in patients with psychiatric illness.
- ↑ 17-OHP may be seen.
- Patients scratch lesions excessively → multiple scars.

Q3.5: How is Acne graded, and what are the treatment options at each stage?

Answer: PYQ: AIIMS 2018 PYQ: FMGE 2019 PYQ: INICET 2023

Grade-01	• **Comedones** • **Treatment:** Topical Retinoids
Grade-02	• **Comedones + Inflammatory papules and few pustules** **Treatment** • Topical Retinoids + Topical Antibiotics • If necessary, Benzoyl peroxide can be given
Grade-03	• **Comedones + Multiple Inflammatory papules and pustules** • **Treatment:** Topical Retinoids + Topical Antibiotics + Oral Antibiotics
Grade-04	• Nodulocystic acne **(Nodules + cysts)** • Most severe form • **Treatment:** Oral Isotretinoin

Q3.6 Which topical and systemic drugs are used in acne therapy?

Answer:

Topical	• Retinoids (S/E - Irritation, Gram-negative folliculitis) • Benzoyl peroxide (S/E - Staining of clothes, irritation) • Clindamycin
Oral	**Antibiotics** • Minocycline • Doxycycline • Lymecycline.
	Retinoids • Isotretinoin → **Treatment of choice** o Dose is 0.5-1 mg/kg o Cumulative dose 120 - 150 mg/kg o Use: Grade IV acne and in severe acne · o Acts on all pathogenetic mechanisms

Q3.7 What adverse effects should be monitored with Isotretinoin?

Answer:

- Teratogenicity (Not given in pregnancy)
  - o 2 UPTs should be negative if given in the childbearing age group
  - o Contraception advice should be given
  - o Stop 3 months prior to conception
- Dryness

- Cheilitis
- Gram-negative folliculitis
- Rarely psychiatric disturbances

Q3.8: What is Rosacea?

Answer: Also known as **Acne rosacea** (misnomer → not related to Acne)

- Predominantly seen in adults
- Affected areas are Convexities of the face, sparing nasolabial fold.
- Flushing
  - o When exposed to heat or spicy foods Inflammation and vascular hyperactivity Sudden redness and discomfort.

Q3.9 How can Rosacea be differentiated from Acne vulgaris?

Answer :

- No comedones
- Flushing
- Telangiectasia.

Q3.10 What are the four subtypes of Rosacea?

Answer:

<table>
<tr>
<td>Subtype 1
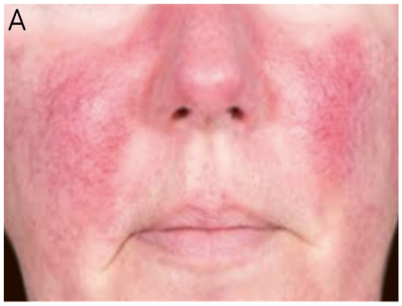

• Erythematotelangiectatic rosacea (ETTR)
• Erythema and telangiectasia (Dilated blood vessels) are seen</td>
<td>Subtype 2
• Papulopustular rosacea (PPR)

• Papules and pustules are seen
• No comedones are seen
• Flushing is seen</td>
<td>Subtype 3
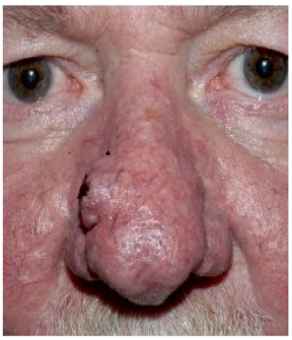
• Granulomatous / Phymatous rosacea (PR)
• Granulomatous lesion - Potato nose</td>
</tr>
<tr>
<td colspan="3">Subtype 4
• Ocular rosacea</td>
</tr>
</table>

Q3.11 How is Rosacea treated?

Answer:

- Topical Metronidazole
- Oral Ivermectin (Demodex mite is one of the cause)
- Doxycycline and other antibiotics → papulopustular stage
- Low-dose isotretinoin.

16. HAIR AND NAIL DISORDERS

BIG QUESTION 1: Describe the structure of hair, types of hair, and the hair cycle.

Broad Answer: Hair has an upper part (sheaths, glands, shaft, muscles, dermal elements) and a lower part (bulb, supra-bulbar area) separated by Adamson's fringe. Types include lanugo (fetal), vellus (fine, short), and terminal (long, pigmented, androgen-dependent). Growth cycles through anagen (2-3 years, 90%), catagen (2-3 weeks, 1%), and telogen (2-3 months, 9%), with normal daily loss of 50-100 hairs (anagen:telogen = 9:1).

DETAILED QUESTIONS

Q1.1: What is the structure of hair?

Answer:

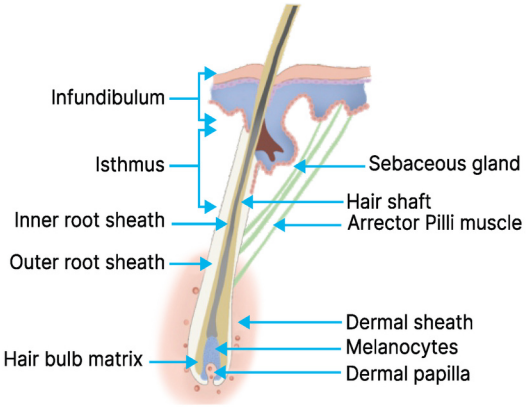

Q1.2: What are the parts of the upper constant part of the hair?

Answer: Infundibulum and isthmus

Q1.3: Where is the infundibulum located?

Answer: Above the sebaceous gland.

Q1.4: What defines the isthmus?

Answer: The region from the origin of the sebaceous gland to the insertion of the Arrector Pili Muscle.

Q1.5: What is the lower (not constant) part of the hair?

Answer: Bulb and suprabulbar area.

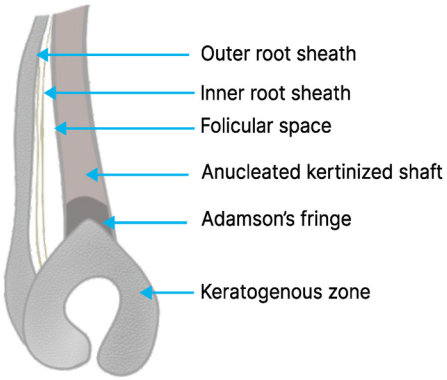

YOURWISH

Q1.6: What is Adamson's fringe and its significance?

Answer: Located above the bulb, it differentiates between the keratogenous (lower) and non-keratogenous (upper) parts and prevents the spread of infection to the bulbar area.

Q1.7: List the three types of hair.

Answer: Lanugo hair, Vellus hair, Terminal hair.



Q1.8: Describe lanugo hair.

Answer: Soft, unmedullated, unpigmented hair, present in utero and in premature babies.

Q1.9: Describe vellus hair.

Answer: Hair on face and forehead, soft, unmedullated, less pigmented, < 2cm long, present till adolescence, coarser.

Q1.10: Describe terminal hair.

Answer: Coarser, longer, medullated and pigmented hair in the bearded and pubic area → Present in androgen-dependent areas with hormones.

Q1.11: What are the phases of the hair growth cycle in the correct order of occurrence?

Answer: Hair growth is not constant and goes through various phases of growth.

- Anagen (growth phase) → Responsible for the length of hair
- Catagen (transition phase)
- Telogen (falling phase) → Responsible for daily hair fall

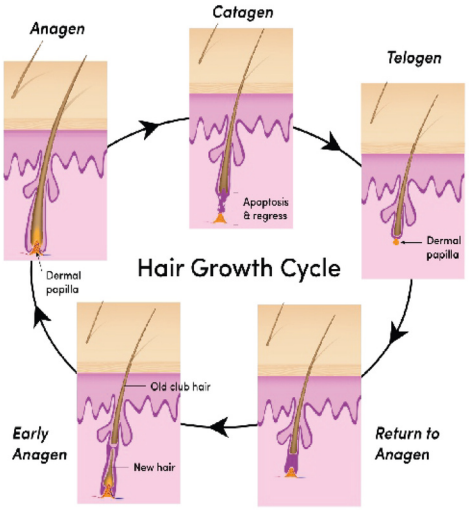

Q1.12: How long does each phase last and what percent of scalp hair are in each phase?

PYQ: NEET PG 2023 PYQ: FMGE 2022

Answer:

- Anagen: 2-3 years, 90% of total hairs
- Catagen: 2-3 weeks, 1%

YOURWISH

- Telogen: 2-3 months, 9% of total hairs
- Anagen:Telogen = 9:1

Q1.13: How many hairs normally fall per day?
Answer: 50-100 hairs.

Q1.14: What are the broad types of hair disorders?
Answer:
- Hair fall (Alopecia)
- Hair growth (Hirsutism/Hypertrichosis)

BIG QUESTION 2: Discuss the different types of alopecia and their classifications.

Broad Answer: Alopecia is hair loss, while hirsutism/hypertrichosis is excess growth. Non-cicatricial alopecia allows regrowth and includes androgenetic alopecia, effluvium, alopecia areata, trichotillomania, tinea capitis, and syphilitic moth-eaten alopecia. Cicatricial alopecia is irreversible from bulb damage, seen in lichen planus, discoid lupus, and pseudopelade of Brocq with "footprints in snow" appearance.

DETAILED QUESTIONS

Q2.1: What are the types of alopecia?
PYQ: INICET 2022, 2023
PYQ: FMGE 2021
Answer: Non Cicatricial alopecia and Cicatricial alopecia.

Q2.2: What defines non cicatricial alopecia?
Answer: No damage to the hair bulb → chances of regrowth are high.

Q2.3: What defines cicatricial alopecia?
Answer: Damage to bulb or stem cells → regrowth is not possible.

Q2.4: What are the types of non cicatricial alopecia?
Answer:
- **Patterned:** Androgenetic Alopecia
- **Diffuse:** Effluvium
- **Patchy:**
  - Alopecia Areata
  - Trichotillomania
  - Tinea capitis (KOH positive, scales+)
  - Moth-eaten alopecia (secondary syphilis, VDRL+).

BIG QUESTION 3: Summarise the mechanism, classification, patterns, and management of androgenetic alopecia

Broad Answer: Androgenetic alopecia, which is due to polygenic inheritance and DHT converting terminal hairs to vellus, presents as male-pattern baldness (Norwood-Hamilton) or female diffuse thinning (Ludwig Types I-III). Management includes counselling, minoxidil, anti-androgens (finasteride/dutasteride in men; cyproterone/spironolactone in women), and options like hair transplant or PRP.

Q3.1: What causes androgenetic alopecia?

Answer: Androgen + Genetic susceptibility (polygenic inheritance).

Q3.2: In males, what is the pattern and grading system?

Answer: Male Androgenetic Alopecia: Frontotemporal recession → vertex balding

- Graded by Norwood-Hamilton classification.

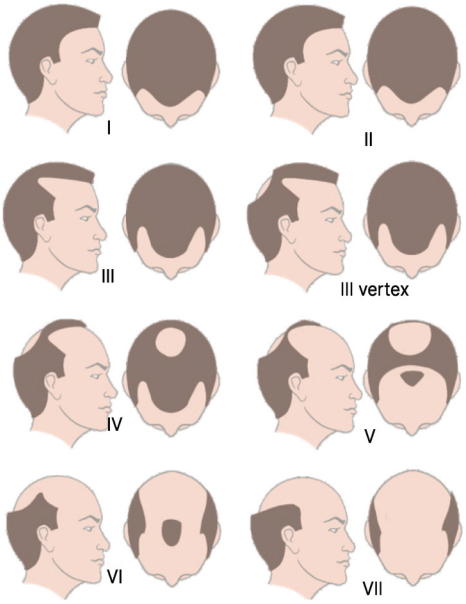



Q3.3: In females, what is the pattern and grading system?

Answer: Female Androgenetic Alopecia: Widening of central parting and loss of density

- Three divisions: Type I, II, III (Christmas tree pattern) → Given by Ludwig.

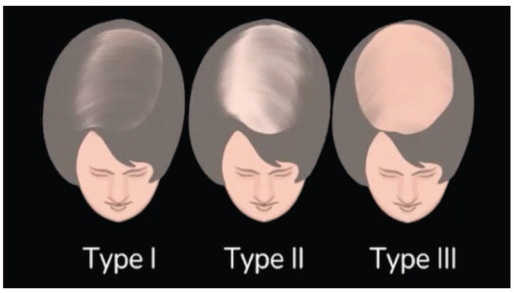

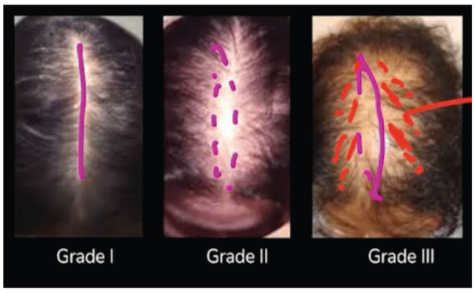

Q3.4: What is the role of hormones and enzymes in androgenetic alopecia?

Answer: Testosterone is converted to dihydrotestosterone (DHT) by 5 alpha-reductase, causing terminal hair to convert into vellus hair.

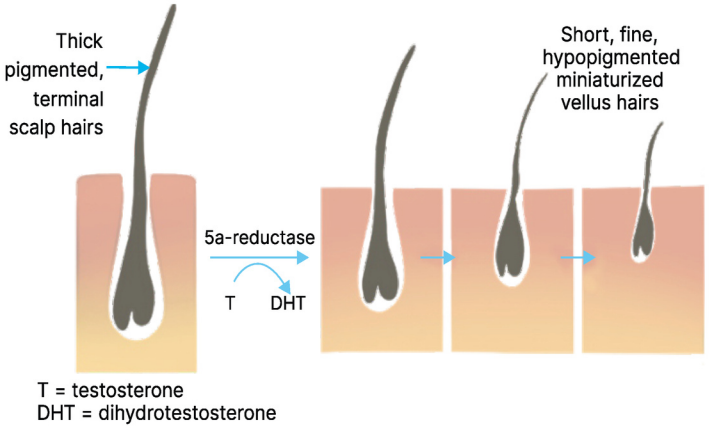

Q3.5: What are the management options for Alopecia?

Answer: **Management:**

- Counselling (long treatment)

Topical management	Systemic management
• Minoxidil o Potassium channel opener o Increase in blood flow • 2% Minoxidil: Female pattern hair loss • 5% Minoxidil: Male pattern hair loss	• Anti-androgens: 5 alpha-reductase inhibitors in males o Finasteride: Type 2 5 alpha-reductase inhibitors o Dutasteride: Type 1 & 2 inhibitor. • For females o Oral anti-androgens: → Cyproterone acetate, →Spironolactone
Surgical management	
• Hair transplantation • Platelet-rich plasma therapy	

BIG QUESTION 4: Describe effluvium, alopecia areata, and trichotillomania.

Broad Answer: Effluvium is diffuse shedding from chemo or stress, managed with counselling and supplements. Alopecia areata is autoimmune patchy loss with exclamation hairs, nail pitting, and variants, treated with steroids, immunotherapy, or JAK inhibitors. Trichotillomania is hair-pulling causing irregular patches, managed with CBT and psychiatric drugs.

DETAILED QUESTIONS

Q4.1: What is effluvium?

PYQ: NEET PG 2022

Answer: Diffuse hair shredding → disorder of the hair cycle.

Q4.2: Differentiate anagen and telogen effluvium.

Answer:

- Anagen Effluvium: Global alopecia, seen in chemotherapy patients
- Telogen Effluvium:
  - Acute TE
  - Chronic TE (hypothyroidism, anemia)

Q4.3: What is the acute telogen effluvium?

Answer: Increase in telogen shedding due to premature anagen phase termination

- Stress prematurely converts Anagen into Telogen.
- Almost 50% of hair is in the telogen phase
- Hair stays in telogen for 2-3 months and falls
- History of insult 2-3 months prior
- Hair pull test positive.

Q4.4: What is the treatment of acute telogen effluvium?

Answer: Counselling and hair supplements like biotin.

Q4.5: What are the stressors for acute telogen effluvium?

Answer:

- **Physical stress:** Prolonged illness: Dengue, COVID-19, TB, Chikungunya, CAD, Stroke.
- **Emotional stress:** Exam, loss of family member.
- **Physiological stress:** Pregnancy

Q4.6: Describe alopecia areata.

PYQ: FMGE 2021

PYQ: NEET PG 2019





Answer: Also called **Pelade**.

- Autoimmune, patchy hair loss
- Associated with Down syndrome, thyroid disorders & pernicious anemia

Q4.7: What is the surface of the patch in alopecia areata?

Answer: Single or multiple patches of hair loss → Smooth, with no scales and no itching.

Q4.8: Where can alopecia areata present apart from scalp?

Answer: Eyebrows and beard area (terminal hairs)





Q4.9: What is turning grey syndrome?

Answer: All pigmented hairs fall off, resulting in grey patches.

- Alopecia areata does not affect grey hair

Q4.10: What are the different variants of alopecia areata?

Answer:

- Alopecia Universalis: Complete hair loss from all over the body
- Alopecia Totalis: Complete hair loss over the scalp
- Ophiasis: Band of Alopecia Areata occurs in the occipital area



Ophiasis



Alopecia Universalis

Q4.11: What are classic findings of alopecia areata on trichoscopy and histopathology?

Answer:

- Exclamation mark hair on trichoscopy
- Swarm of bees appearance (intense lymphocytic infiltrate) on histopathology.

Q4.12: What are exclamation mark hairs?

Answer: Exclamation mark hair are the broken hair present on periphery of the patch because the immune cells target the Spura bulbar area.

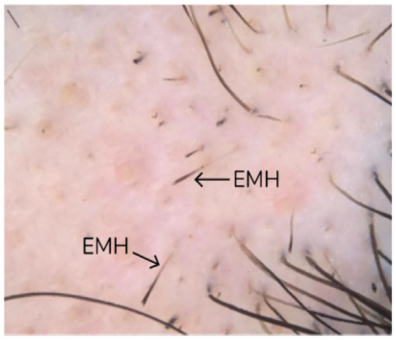

Q4.13: What nail findings are seen?

Answer:

- Pits (superficial, fine, geometric, regular)
- Trachyonychia.

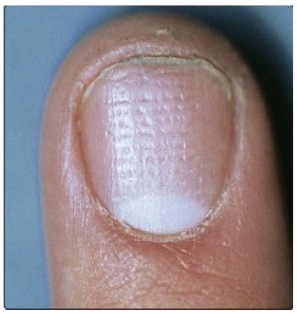
Pits


Trachyonychia

Q4.14: What is the treatment of Alopecia areata?

Answer:

- May spontaneously resolve (children with a single patch)
- Intralesional steroids (ILS) → **Treatment of choice**
- Oral corticosteroids (if >6-8 patches)
- Contact immunotherapy
  - Di-nitrochlorobenzene (DNCB)
  - Squaric acid dibutyl ester (SADBE)
  - Diphencyprone (DPCP)
- JAK kinase inhibitors (Tofacitinib, Baricitinib, Abrocitinib)
- Oral (Levamisole, Cyclosporine, Mini-pulse).

Q4.15: How does Diphencyprone (DPCP) work?

Answer: Apply a slight concentration on the patch. These agents act as contact irritants, triggering an irritant reaction that diverts T cells, freeing the hair follicle and promoting improvement.

Q4.16: What is trichotillomania?

PYQ: FMGE 2021

Answer: Psychiatric disorder of pulling hair, classified in DSM-4.



Q4.17: What is the typical history and presentation of trichotillomania?

Answer:

- History will not be given by patients →others will give hints
- History of psychiatric disturbance like the child is withdrawn, socially inactive
- Patchy hair loss with broken hairs of variable lengths
- Perifollicular hemorrhages (trauma)
- Trichophagia, trichobezoar, GI obstruction (patients may also eat hair)
- **Friar Tuck sign** (Alopecia with various lengths of hair)

Q4.18: What is seen on biopsy in trichotillomania?

Answer: Empty cast, perifollicular hemosiderin.

Q4.19: What is the treatment of trichotillomania?

Answer:

- Cognitive behavioral therapy (CBT)
- Antipsychotics like SSRIs, paroxetine, or N-acetyl cysteine (NAC).

Q4.20: What happens in cicatricial alopecia?

Answer: Damaged hair bulb → Leads to permanent hair loss.

Q4.21: What are the causes of cicatricial alopecia?

Answer: Lichen planus, DLE, and pseudopelade of BROCQ.

Q4.22: Describe follicular Lichen planus in cicatricial alopecia.

Answer: Violaceous, itchy papules on the periphery of the patch leading to cicatricial alopecia.




Q4.23: Describe DLE in cicatricial alopecia.

Answer:

- Adherent scales and perifollicular erythema are present
- DLE → Leads to cicatricial alopecia
- Acute cutaneous LE (ACLE) causes non-cicatricial alopecia

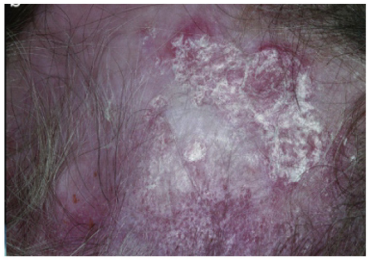
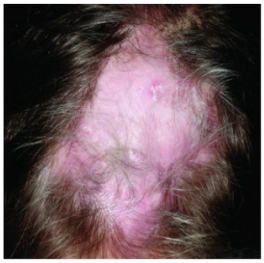

Q4.24: Describe pseudopelade of BROCQ.

Answer: Pseudopelade of BROCQ is an idiopathic condition.

- No inflammation, no scaling, no erythema in biopsy
- It is patchy cicatricial alopecia
- Footprint in the snow appearance
- It is chronic and slowly progressive.



BIG QUESTION 5: Describe hirsutism.

Broad Answer: Hirsutism is excessive terminal hair growth in androgen-dependent areas of females due to conversion of vellus to terminal hair, commonly caused by hyperandrogenic states like PCOS, CAH, or virilizing tumors, and may occur in SAHA syndrome or idiopathically. Diagnosis uses the Ferriman-Gallwey score with investigations including LH, FSH, DHEAS, 5-DHT, TSH, and prolactin. Management includes topical eflornithine, anti-androgens (spironolactone, cyproterone acetate), OCPs for PCOS, and physical methods like laser hair reduction.



DETAILED QUESTIONS

Q5.1: What is hirsutism?

Answer: Excessive hair growth in androgen-dependent sites in females (Growth of terminal hair in the beard area)

Q5.2: What is the pathophysiology of hirsutism?

Answer: Vellus hair is converted to terminal hair.

Q5.3: What causes hirsutism?

Answer: Any cause of hyperandrogenism can cause hirsutism

- PCOS
- Congenital Adrenal Hyperplasia (CAH)
- Virilizing tumours
- SAHA syndrome (4 components)
- Idiopathic.

Q5.4: What is the scoring system used in hirsuitism?

Answer: Ferriman and Galway scoring

Q5.5: What investigations are needed for hirsutism?

Answer:

- PCOS: LH, FSH, DHEA
- Adrenals: 5 DHT levels
- TSH
- Prolactin.

Q5.6: What treatments are used for hirsutism?

Answer:

- **Topical agent:** Eflornithine
- **Antiandrogens:**
  - Spironolactone
  - OCPs if the patient has PCOS
  - Cyproterone acetate
- **Physical method:**
  - Laser hair reduction
  - Diode and long-pulsed Nd Yag

BIG QUESTION 6: Explain the structure of the nail, types of changes seen in systemic diseases, and diagnostic features.

Broad Answer: The nail includes the plate, folds, cuticle, lunula, matrix, and bed. Systemic changes include Beau's lines (illness/MI), leukonychia (Mees' lines in arsenic/chemo), Muehrcke's bands (hypoalbuminemia), Lindsay's half-and-half nails (renal failure/chemo), and Terry's lines (cirrhosis, CHF, diabetes). Trachyonychia (rough nails) occurs in alopecia areata or lichen planus, usually self-limiting, while pterygium (wing-like fold extension) is seen in lichen planus.

DETAILED QUESTIONS

Q6.1: List the anatomical parts of the nail described.

Answer: Nail plate, lateral nail folds, proximal nail fold, cuticle, lunula, nail matrix, nail bed.

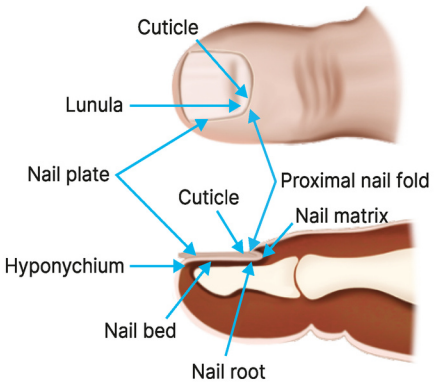

Q6.2: What is the function of the cuticle?

Answer: Connects the proximal nail fold to the nail plate, and is whitish.

Q6.3: What is the lunula?

Answer: The semi-circular portion, which is slightly pink or red.

Q6.4: Where is the nail matrix?

Answer: Located below the proximal nail fold and lunula.

Q6.5: What is the nail bed?

Answer: The skin beneath the nail plate.

Q6.6: What are Beau's lines?



Answer: Beau's lines are transverse grooves

- Helps to judge the duration of the insult and how long ago the insult happened.
- Seen in illness, surgery, and MI.

Q6.7: What do Beau's lines indicate?

Answer: Beau's lines indicates a temporary arrest of nail production.

Q6.8: What is leukonychia?



Answer: White spots or white lines on the nails.

Q6.9: What are the types of leukonychia?

Answer:

- **True leukonychia**
  - Due to matrix involvement
  - Transverse lines (Mees' lines) → Arsenic poisoning, chemotherapy
- **False leukonychia**
  - Due to nail bed involvement
  - **Types:**
    - → Muehrcke's paired bands in hypoalbuminemia
    - → Lindsay/half and half nails in chemotherapy/renal failure
    - → Terry's lines in cirrhosis/CHF/DM)

YOURWISH

Q6.10: Describe true leukonychia?

Answer: Transverse lines called **Mees' lines,** which are seen in Arsenic poisoning and Chemotherapy.

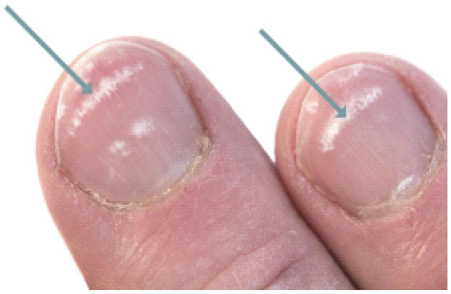

Q6.11: Describe different types of False leukonychia.

Answer: False leukonychia is of 3 types:

Type	Description	Image
Muehrcke's paired white bands	• Paired white lines • Seen in hypoalbuminemia	
Terry's lines	• Proximally white and distally normal nails • Seen in Cirrhosis, CHF and DM	
Lindsay Nails or half and half nails	• Proximal white zone and distal brownish sharp demarcation • Seen in chemotherapy and chronic renal failure	

Q6.12: Describe trachyonychia?

Answer: Roughening of the nail plate

- TND (twenty nail dystrophy)
- Sandblasted nails
- Grey roughened surface
- Causes: idiopathic
- Seen in alopecia areata (most common) and lichen planus
  - o Usually seen in children.



Q6.13: How is trachyonychia treated?

Answer:

- Self-resolves
- Topical vitamin D or topical steroids
- Oral or IM corticosteroids in adults.

Q6.14: What is pterygium ?

Answer: Pterygium is wing extension from proximal nail fold to distal nail plate which is een in lichen planus.



BIG QUESTION 7: Define paronychia and ingrown toenail.

Broad Answer: Paronychia is inflammation of the nail folds, presenting acutely with painful, red, swollen, pus-filled folds due to bacterial infection, or chronically in wet workers (e.g., homemakers, maids) where cuticle damage causes recurrent swelling, redness, and cuticle loss. An ingrown toenail results from improper nail cutting, with the nail edge growing into the lateral fold, leading to redness, tenderness, swelling, and inflammation.

DETAILED QUESTIONS

Q7.1: What is paronychia?

PYQ: NEET PG 2021
PYQ: FMGE 2019, 2020

Answer: Paronychia is an Inflammation of the nail folds.

Q7.2: What are the different types of paronychia?

Answer:

Type	Description	Image
Acute Paronychia	Bacterial infection of nail folds, which leads to accumulation of pus, redness, tenderness and swelling.	
Chronic Paronychia	• Commonly seen in wet workers, homemakers, and maids • Cuticles gets damaged → leading to recurrent paronychia • Complete loss of cuticle • Swollen, red, and itchy folds.	

Q7.3: What is an ingrown toenail?

Answer: Ingrown toenails are swollen, irritated, tender, and red nail folds due to Improper cutting of the nail. Instead of growing straight, the nail gets into the lateral nail fold, leading to inflammation of the lateral nail fold.



17. MISCELLANEOUS TOPICS

BIG QUESTION 1: What are the important Pediatric Dermatoses, their clinical features, and treatments?

Broad Answer: Includes Verrucous epidermal nevus, ILVEN, Becker's nevus, Infantile hemangiomas, Salmon patch, Port wine stain, and Urticaria pigmentosa.

- Differ by age of onset, distribution, morphology, inheritance, and management.

DETAILED QUESTIONS

Q1.1 What are the features of Verrucous Epidermal Nevi?

Answer:



- Present along Blaschko's lines.
- Appear soon after birth or later.
- Clinical: Verrucous plaques, asymptomatic.
- Treatment: Lasers.

Q1.2 What are the features of ILVEN (Inflammatory Linear Verrucous Epidermal Nevus)?

Answer:



- Synonym: Eczematous epidermal nevus (Erythema + Itching
- Papules are skin-colored (not hyperpigmented).
- Blaschko's lines start ~6 months.
- Resistant to usual treatment.
- **Treatment:** Topical steroids (symptomatic relief only).

Q1.3 What are the features of Becker's Nevus?

PYQ: NEET PG 2018

Answer:



- Synonyms: Becker's melanosis / Pigmented hairy epidermal nevus.
- Onset: Adolescence.
- Starts as a hyperpigmented patch → later, hypertrichosis develops.
- Androgen-dependent.
- Must not be confused with Congenital melanocytic nevus (present at birth).

Q1.4 What are the stages and clinical features of Infantile Hemangiomas?

PYQ: FMGE 2023

Answer: Stages

Stages	Age
Growth	3 months
Maturation	3 - 9 months
Resolution	9 months



- Capillary proliferation
- Leaves telangiectasias after resolution.
- Clinical: Erythematous vascular plaques with telangiectasias (anywhere on body)
- Nasal lesion → Pinocchio/Cyrano nose.
- Usually self-resolving; treatment required if:
  - Present over vital organs
  - Bleeding +
  - Ulceration
- Treatment: Systemic steroids, Propranolol.

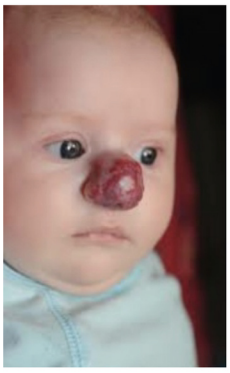

Q1.5 What are the features of Salmon Patch?

Answer:



- Capillary malformation, Autosomal dominant.
- Synonyms: Stork bite, Erythema nuchae.
- **Clinical:**
  - Superficial, reddish pink or salmon coloured, irregular flat areas with telangiectasias
  - Nape of the neck, upper eyelid, forehead, and glabella areas.
- Resolves by 1 year, no treatment needed.

Q1.6 What are the features and associations of Port Wine Stain?

PYQ: FMGE 2021 PYQ: NEET PG 2019

Answer:





- Synonym: Nevus flammeus.
- Capillary malformation, non-resolving → stable course.
- Unilateral, strict midline demarcation; common on face > trunk.
- **Clinical:** Sharp erythematous vascular plaques.
- **Treatment:** Pulse dye laser (PDL).
- Associated with Sturge-Weber Syndrome

Q1.7: What is Sturge-Weber Syndrome?

Answer: Sturge-Weber Syndrome:

- Port wine stain → Present in the trigeminal distribution of facial nerve
- Ipsilateral Leptomeningeal angiomatosis → Convulsions, Behavioural problems, Subnormal intelligence
- Ocular complications because of Choroidal hemangioma → Ipsilateral glaucoma, Buphthalmos, Congestion, Strabismus, Loss of vision.

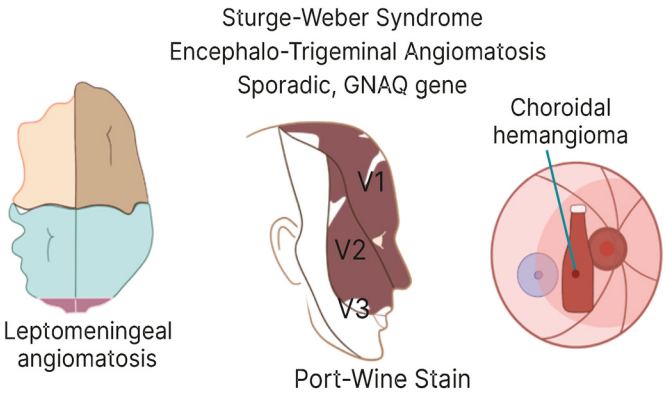

YOURWISH

YOURWISH

Q1.8: What are the radiological findings in Nevus Flammeus?

Answer: S-shaped intracranial calcifications on CT scan and X-rays

Q1.9 What are the features of Urticaria Pigmentosa?



Answer:

- A type of cutaneous mastocytosis (not true urticaria).
- Seen in <2 years of age
- Clinical: Itchy urticarial wheals on trunk → heal with hyperpigmentation.
- No systemic involvement
- **Darier's sign:** Stroke the skin with a pen or key → linear urticarial wheals along the stroking line (release of histamine from mast cell granules) → Not seen in Darier's disease.



BIG QUESTION 2: What are Urticaria, Angioedema, and Hereditary Angioedema, their causes, clinical features, and treatments?

PYQ: NEET PG 2021

Answer:

- Urticaria: Transient, itchy, erythematous papules/plaques due to mast cell degranulation and histamine release
- Angioedema: Deeper, painful, ill-defined swelling of skin/mucosa
- Hereditary Angioedema: Bradykinin-mediated, autosomal dominant, due to C1 inhibitor deficiency or dysfunction

DETAILED QUESTIONS

Q2.1 What are the features and pathogenesis of Urticaria?

Answer:

- Erythematous, edematous, evanescent, itchy papules and plaques
- Lesions disappear within a few hours (evanescent)
- Due to ↑IgE → mast cell degranulation → histamine release → axon reflex

Q2.2 What are the types of Urticaria and their causes?

Answer:

Acute Urticaria	Chronic Urticaria
• Duration is less than 6 weeks.	• Duration is more than 6 weeks.
Causes: (5 Is) Infections (40%)- Viral infections • Drugs (Injections: 9%)- Penicillin, sulfa • Food items (Ingestions) (1%)- Additives • Inhalation- Pollen • Idiopathic (50%)	Causes • Chronic spontaneous urticaria (autoimmune, pseudo allergic, infection, and idiopathic) - 65% • Physical/ inducible urticaria (35%) - Physical force, sun, cold • Urticarial vasculitis (5%).

Q2.3 What are the types of Physical Urticaria and eliciting factors?

Answer:

- Dermographism (Dermographic Urticaria) - Most common physical urticaria.
  - Derma = skin; Graphism = writing → "Writing on skin".
- Cause: Physical force.
- Clinical feature: Linear itchy wheals appear on the skin on stroking.

Type of Physical Urticaria	Eliciting Factors
• Urticaria factitial/ dermographism • Most common type, red, itchy, linear wheal appearing immediately after light stroking of the skin.	• Mechanical shearing forces (wheals arising within 1-5 mins)
• Cold contact urticaria	• Cold objects, air, fluids, wind
• Heat contact urticaria	• Localized heat
• Solar urticaria	• UV and / or visible light
• Delayed pressure urticaria (appear at site of pressure on the skin, painful rather than itchy last for more than 24 hours, poor prognosis)	• Vertical pressure (wheals arise with 3-12 hours latency)
• Aquagenic	• Water
• Cholinergic	• Increase in core body temperature by exercise or spicy food




Q2.4 How is Urticaria managed?

Answer:

- 2nd generation H1 antihistamines - standard dose
- If no response → increase dose up to 4-fold
- If still unresponsive → add Omalizumab (IgE blocker), Montelukast, Cyclosporine, and even 1st generation antihistamines

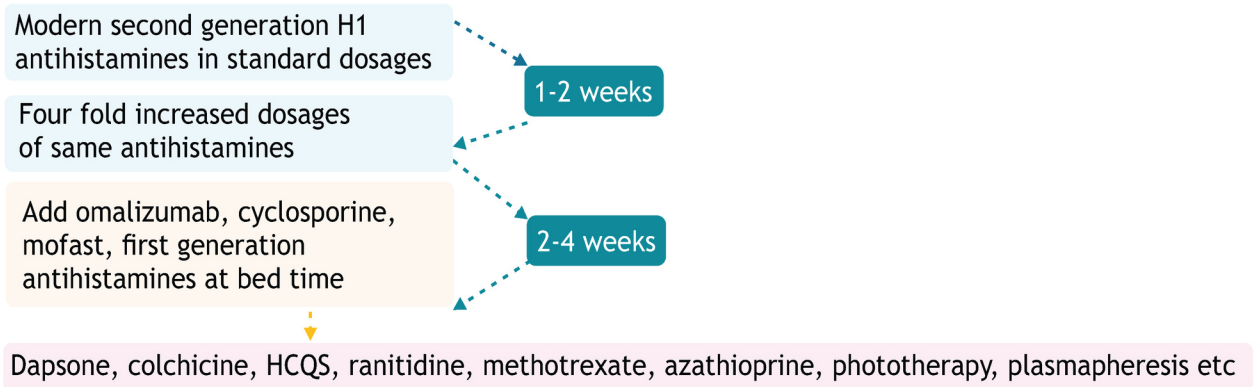

Q2.5 What are the features of Urticarial Vasculitis?



Answer:

- Type of vasculitis,
- Biopsy → leukocytoclastic vasculitis
- Associated with connective tissue diseases, hematological malignancies
- Clinical: Urticarial wheals persisting >24-48 hrs, tender > itchy, heal with pigmentation

Q2.6 What are the features of Angioedema?



Answer:

- Swelling of skin/mucosa, deeper than urticaria
- Less well defined, painful > itchy, less erythematous
- Involves submucosa + hypodermis
- Clinical: Swollen lips, eyes, difficulty in speech,
- Resolves >24 hrs

Q2.7 What are the types of Angioedema?

Answer:

- **Mast Cell-Mediated Angioedema**
  - o Presents with urticaria
  - o Treated the same as urticaria
- **Bradykinin-mediated Angioedema**
  - o Only angioedema present
  - o Not mast cell-mediated

Q2.8 What are the features of Hereditary Angioedema (HAE)?

Answer:

- Also called Quincke's disease
- Autosomal dominant inheritance
- Bradykinin mediated
- C1 inhibitor deficiency/dysfunction → complement consumption

Q2.9: What are the types of Hereditary Angioedema (HAE)?

Answer:

HAE Type I	Low C1 inhibitor protein
HAE Type II	Low C1 inhibitor function
HAE Type III	Normal C1 inhibitor

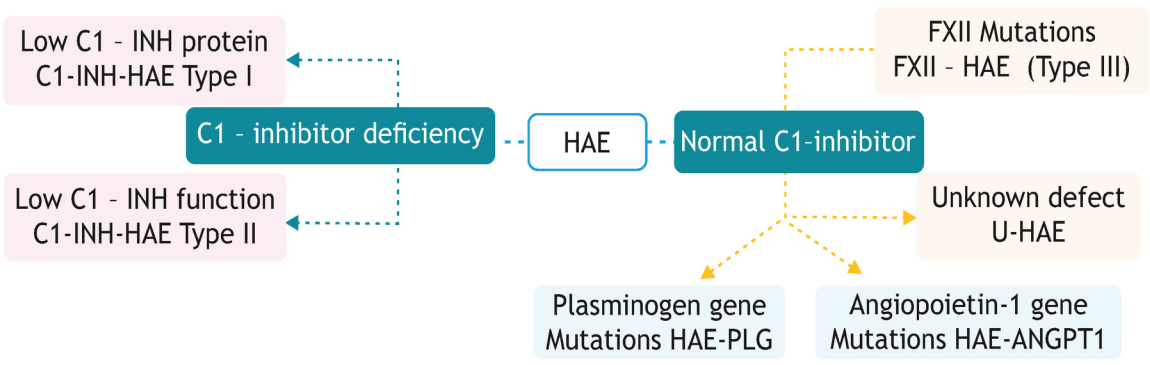

YOURWISH

Q2.10: What are the clinical features and investigations of Hereditary Angioedema (HAE)?

Answer: Clinical: recurrent angioedema, laryngeal edema, colicky abdominal pain, family history +

Investigations:

- Low C4 = screening test
- Low C1 inhibitor = specific test

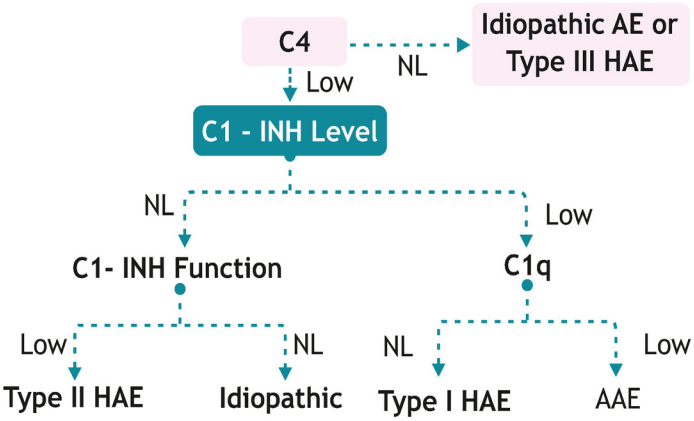

Q2.11: How is Hereditary Angioedema managed?

Answer:

- Acute airway obstruction:
  - o Airway management
  - o Icatibant, a bradykinin receptor 2 antagonist
  - o Ecallantide, a kallikrein inhibitor
  - o Fresh frozen plasma, containing C1INH
- Prophylaxis:
  - o Plasma-derived C1INH replacement therapy
  - o Tranexamic acid
  - o Anabolic steroids (Danazol, Stanozolol)

BIG QUESTION 3: What are the important Vector-Borne Diseases and their types?

PYQ: INICET 2021

Answer :

- Leishmaniasis: Protozoal, sandfly vector → Cutaneous (Old world, New world), Mucocutaneous (Espundia), Visceral (Kala azar → PKDL).
- Lyme disease (ECM): Borrelia via Ixodid tick → Expanding annular rash with central clearing.

DETAILED QUESTIONS

Q3.1: What is Leishmaniasis?

Answer: A Protozoal disease → Caused by Leishmania → Vector: Sandfly

Q3.2: How is Leishmaniasis classified?

Answer:

- Cutaneous: Old world & New world
- Mucocutaneous
- Visceral (Kala Azar → PKDL or Post Kala Azar Dermal Leishmaniasis)

YOURWISH

YOURWISH

Q3.3 Why is Old World Cutaneous Leishmaniasis also called Delhi boil/Baghdad boil/Oriental sore?

Answer: Endemic to India (NE states, Rajasthan)

- Species - ***Mnemonic MAIT*: L. major, L. aethiopica, L. infantum, L. tropica**
- Seen in exposed areas
- Clinical: erythematous papules, ulcer, annular lesion with central crusting



Q3.4 Which species and lesions are characteristic of New World Cutaneous Leishmaniasis?

Answer:

- Species: L. mexicana
- Seen in Mexico
- Chronic ear cartilage ulcer (Chiclero's ulcer)



Q3.5 How does Mucocutaneous Leishmaniasis (Espundia) present?

Answer: Destruction of the nasal cartilage and oral mucosa



Q3.6 How does Post Kala Azar Dermal Leishmaniasis (PKDL) develop and present?

Answer: A consequence of the visceral form of Leishmaniasis

- History of Kala Azar → Prolonged fever, Hepatosplenomegaly, Lesions of PKDL → Occur many years later
- Species → *L.Infantum, L.Chagasi, L.Donovani*
- Endemic → North-eastern areas of India
- **Clinical features:** (Confused with Leprosy)
  - Raindrops like hypopigmented lesions on trunk
  - Succulent erythematous papules and nodules present on muzzle area of face
  - Loss of sensations that are not seen in Kala azar



Q3.7 How is PKDL diagnosed and treated?

PYQ: FMGE 2018 PYQ: INICET 2021

Answer:

- **Diagnosis:** Slit skin smear → Leishman Donovan bodies (amastigotes in macrophages)
- **Treatment:** Parenteral antimonials (most successful but toxic), Lipid Amphotericin B, Miltefosine

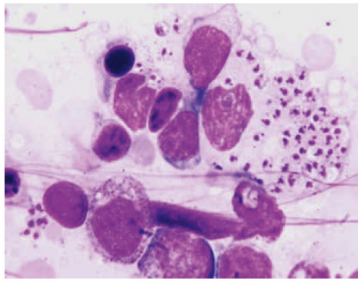

Q3.8 What are the clinical features of Erythema ECM (Erythema Chronicum Migrans)?

Answer: Characteristic of Lyme disease



- Caused by Borrelia burgdorferi (spirochete), vector: Ixodid ticks
- Chronic migrating red rash
- Expands centrifugally from the bite site
- Clears centrally within a week, leaving a red 1 to 2 cm ring that advances for days or weeks → May reach up to 50 cm in diameter.

BIG QUESTION 4: What are the important dermatological tests and investigations, and what are their applications?

Answer :

- Diascopy → glass slide pressed on skin → differentiate purpura vs erythema, nevus depigmentosus vs anemicus, apple jelly nodules.
- Wood's Lamp → low-output mercury lamp with Wood's filter (barium silicate + 9% nickel oxide), emits 320-450 nm (peak 365 nm) → used in tinea capitis (green), pityriasis versicolor (yellow), erythrasma (coral red), vitiligo, melasma, porphyria (red).
- Skin biopsy → diagnostic tool; types = incision, shave, punch, excision (malignancy suspected).

DETAILED QUESTIONS

Q4.1 What is Diascopy and what are its uses?

Answer: Glass slide pressed against skin

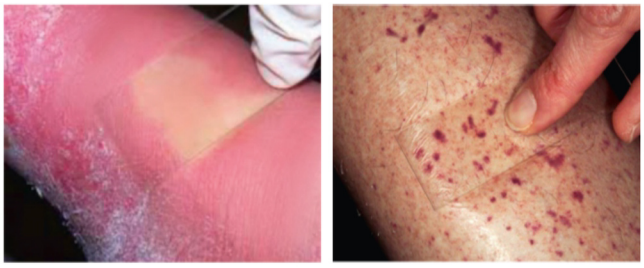

- **Uses:**
  - Differentiates Purpura (non-blanchable, e.g. vasculitis, thrombocytopenia) and Erythema (blanchable)

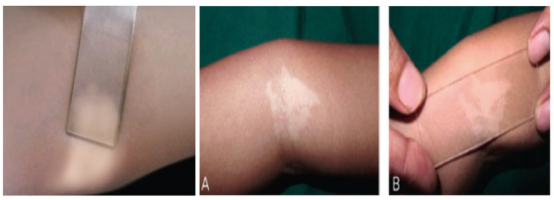

  - Differentiate nevus depigmentosus vs nevus anemicus
  - Detects apple jelly nodules in granulomatous disorders



Q4.2 What is Wood's Lamp and how does it work?

PYQ: INICET 2022 PYQ: INICET 2022

Answer:

- Low-output mercury arc lamp with Wood's filter:
- Barium silicate
- 9% nickel oxide
- Emits light: 320-450 nm, peak 365 nm

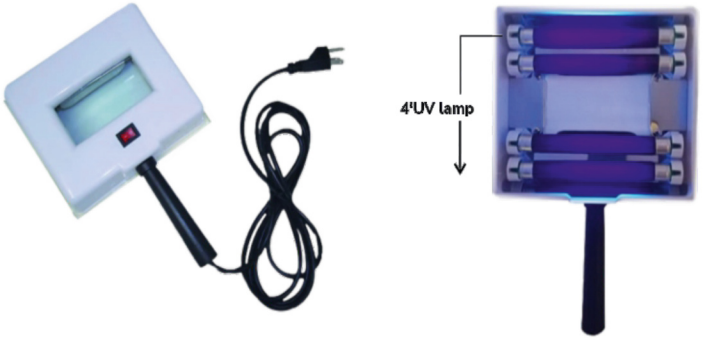

Q4.3 What are the clinical applications of Wood's Lamp?

Answer:

Condition	Interpretation	Image
Fungal infections	• Pityriasis versicolor → yellowish fluorescence • Tinea capitis → greenish fluorescence	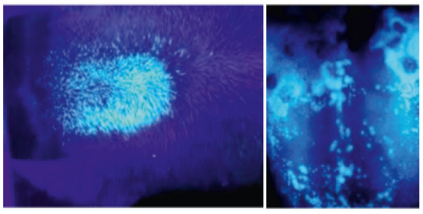
Bacterial infection	• Erythrasma → coral red fluorescence	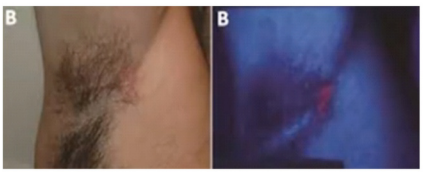
Pigmentary disorders	• Vitiligo → accentuated • Melasma → differentiate epidermal vs dermal	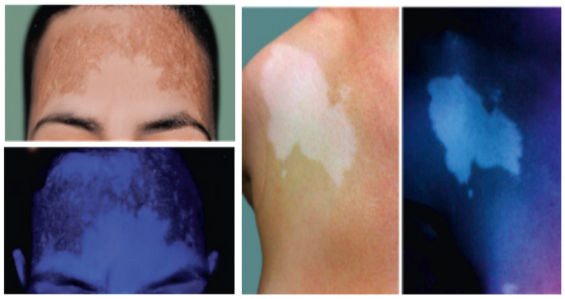
Porphyrias	Congenital erythropoietic porphyria → reddish fluorescence	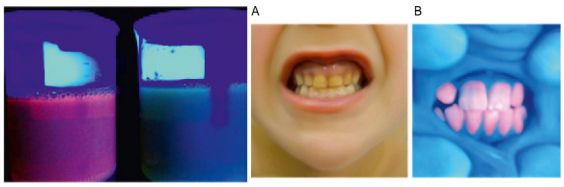

Q4.4 What is a skin biopsy and what are its types?

Answer: Diagnostic for cutaneous disorders

Types	Description
Incision biopsy	Small part of lesion is incised out
Shave biopsy	Seborrheic keratosis, actinic keratosis
Punch biopsy	Most commonly performed; Different punches (various sizes) are used; Circular punch; lesion is taken out - area sutured.
Excision biopsy	Whole lesion removed (malignancy suspected)

YOURWISH

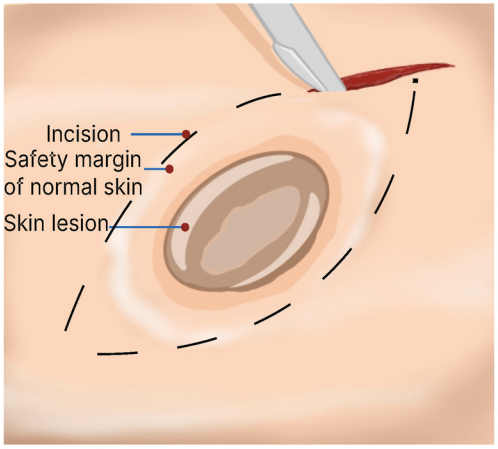

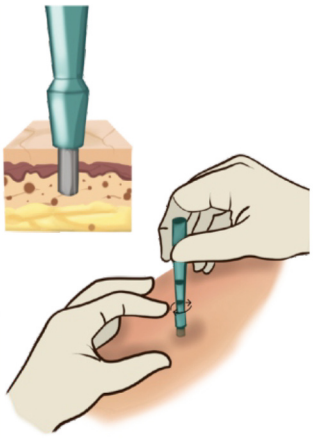

YOURWISH