PREP XI RR

STUDY NOTES

# ENT

15
VIDEOS

171
PAGES

PREMIUM STUDY MATERIAL

PREP XI RR

Table of Contents follows on next page

# TABLE OF CONTENTS

ENT


| # | Topic / Video Name | Pages |
|---|---|---|
| | **RR Reignite** | |
| 1 | Anatomy of Ear | 3 – 19 |
| 2 | Physiology Assessment of Hearing | 20 – 35 |
| 3 | External Ear Diseases | 36 – 41 |
| 4 | Middle Ear Diseases | 42 – 57 |
| 5 | Inner Ear Diseases and Facial Nerve | 58 – 68 |
| 6 | Anatomy of Nose & Para-nasal Sinuses | 69 – 84 |
| 7 | Congenital Anomalies/ Nasal Polyps/Rhinitis/Sinusitis | 85 – 103 |
| 8 | Complications of Sinusitis and Epistaxis | 104 – 110 |
| 9 | Fractures of Facial Skeleton and Tumors of Nose and PNS | 111 – 117 |
| 10 | Anatomy of Pharynx | 118 – 124 |
| 11 | Pharyngeal Spaces | 125 – 130 |
| 12 | Diseases of Pharynx | 131 – 142 |
| 13 | Anatomy of Larynx | 143 – 152 |
| 14 | Congenital, Benign & Inflammatory Lesions of Larynx/ Voice & Speech Disorders | 153 – 166 |
| 15 | Laryngeal Carcinoma | 167 – 173 |

# 1. ANATOMY OF EAR

## BIG QUESTION 1: What are the anatomical components and features of the human ear?

**Broad Answer:** The human ear is anatomically divided into three main parts: the external ear, middle ear, and inner ear. Each part has specific structures that play roles in hearing and balance. The external ear includes the pinna, external auditory canal, and tympanic membrane. The middle ear involves air-filled cavities, ossicles, and the Eustachian tube, while the inner ear consists of the bony and membranous labyrinth involved in hearing and equilibrium.

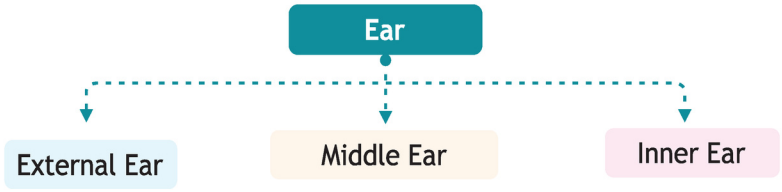


## DETAILED QUESTIONS

### Q1.1: What are the three parts of the external ear?

PYQ: NEET PG 2020
PYQ: FMGE 2021

**Answer:**

1. Pinna
2. External auditory canal (EAC)
3. Tympanic membrane

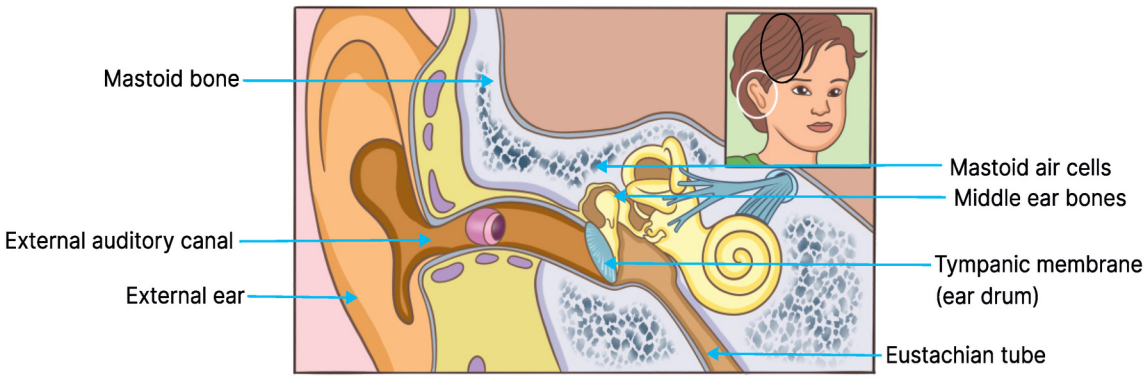


Ear anatomy and mastoid bone

### Q1.2: What are the anatomical features of the pinna?

**Answer:**

- Made up of **elastic cartilage**
- Areas **devoid of cartilage:**
  - **Incisura terminalis** (space between tragus and helix)
  - **Ear lobule**



### Q1.3: What is the external auditory canal (EAC) and what are its features?

**Answer:**

- Continuation of the pinna
- Length: **24 mm**



YOURWISH

- **Two parts:**
  1. **Cartilaginous part** (outer third) → 8 mm
  2. **Bony part** (inner two-thirds) → 16 mm
- **Shape:** S-shaped

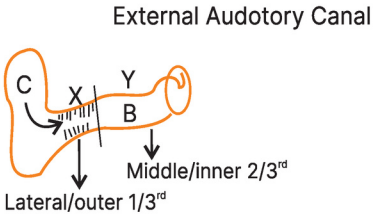


### Q1.4: Differentiate between the cartilaginous and bony parts of the external auditory canal.

**Answer:**

| Cartilaginous part | Bony part |
|---|---|
| It is the lateral or outer part. | It is the medial or inner part. |
| It accounts for 1/3rd length of EAC i.e., 8mm. | It accounts for 2/3rd length of EAC i.e., 16mm |
| Hair follicles, sebaceous glands and ceruminous are present | Hair follicles, sebaceous glands and ceruminous are absent |
| Otitis externa or folliculitis (staphylococcus infection) are seen | Not seen |

### Q1.5: What is the clinical relevance of the Incisura terminalis?

**Answer:**

- It is the **site of incision** in **endaural surgery**
- The incision is called the **Lempert endaural incision**

### Q1.6: How is the EAC examined in different age groups?

**Answer:**

- **Adults:** Pinna is pulled **upwards, backwards, and outwards**
- **Children:** Pinna is pulled **downwards and backwards** (bony part not fully developed)

### Q1.7: What are the communications between the EAC and the parotid gland?

**Answer:**

| Communication | Location |
|---|---|
| **Fissure of Santorini** | Between **cartilaginous part** of EAC and parotid gland |
| **Foramen of Huschke** | Between **bony part** of EAC and parotid gland |

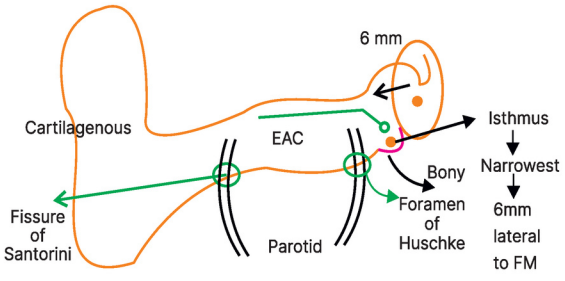


- These allow **infection to spread** between the **parotid gland and EAC**
- They usually **disappear by age 5-7 years**

### Q1.8: What is the tympanic membrane and its features?

**Answer:**

- Separates **external ear** from **middle ear**
- **Obliquely placed** at **45°** to EAC

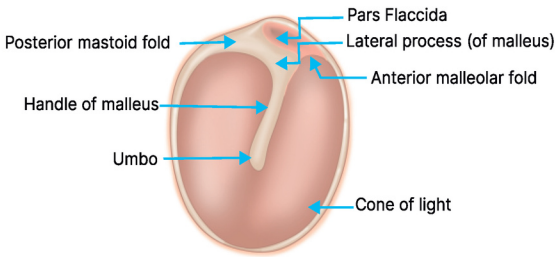




YOURWISH

YOURWISH

- **Shape:** Oval
- **Dimensions:**
  - Height: **10 mm**
  - Width: **9 mm**
  - **Total surface area (TSA):** 90 $mm^2$ (10 × 9)
  - **Thickness:** 0.1 mm
  - **Effective vibrating area:** ½ of TSA → **45 $mm^2$**
    → The vibrating area of TM is the peripheral portion (Because, in the center, the handle of the malleus rests on TM medially, which prevents vibrations)

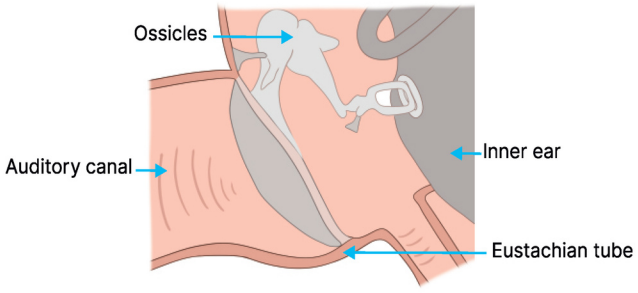


### Q1.9: What are the parts of the tympanic membrane?

**Answer:**

1. **Pars tensa**
   - Tense, tight
   - **Annulus:** Present
   - **Layers:** 3
     → Outer epithelial
     → Middle fibrous
     → Inner endothelial
   - **Umbo:** Centre
   - **Cone of light:** Present in **anteroinferior quadrant**
2. **Pars flaccida**
   - Loose, lax
   - **Annulus:** Absent
   - **Layers:** 2 (outer epithelial and inner endothelial)

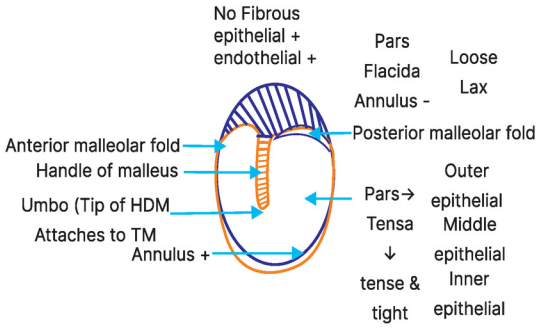


### Q1.10: What is the point called where the tip of the handle of the malleus attaches to the tympanic membrane?

**Answer:**

- The point where the **tip of the handle of the malleus** attaches to the tympanic membrane is called the **umbo.**

### Q1.11: Which malleolar fold is shorter in the tympanic membrane, anterior or posterior?

**Answer:**

- There are two malleolar folds in the tympanic membrane:
  - **Anterior malleolar fold** → shorter
  - **Posterior malleolar fold** → longer

### Q1.12: How is the pars tensa divided and what is the significance of the cone of light?

**Answer:**

- Two **imaginary lines** (horizontal through umbo, vertical through handle of malleus) divide pars tensa into **4 quadrants:**
  - **Anterosuperior**
  - **Anteroinferior**
  - **Posterosuperior**
  - **Posteroinferior**
- **Cone of light:** Present in **anteroinferior quadrant**

**Q1.13: How can you differentiate the right and left tympanic membranes based on the position of the cone of light?**

**Answer:**

- **Right tympanic membrane:** Cone of light at **3 to 6 o'clock**
- **Left tympanic membrane:** Cone of light at **6 to 9 o'clock**

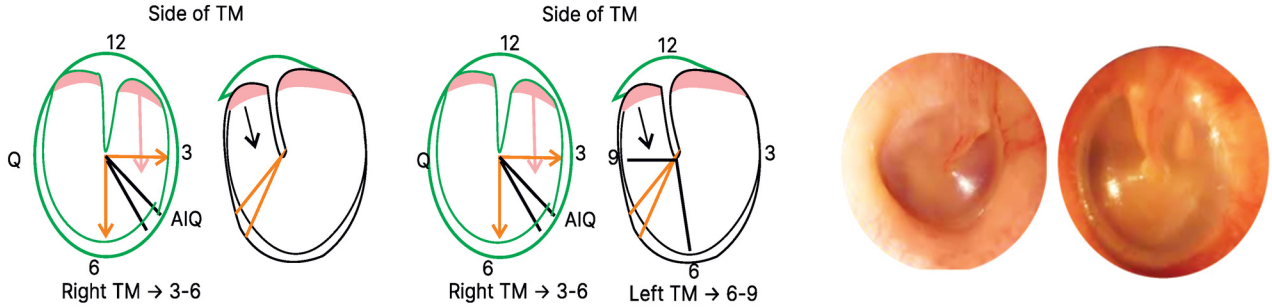


## BIG QUESTION 2: What is the anatomy and ventilatory pathway of the middle ear cleft?

**Broad Answer:** The middle ear cleft is an air-filled system whose chief role is to ventilate and equalise pressure within the middle ear. It extends from the nasopharynx to the mastoid air-cell system and is organised into five interconnected spaces that allow inspired air to pass sequentially from front to back.

## DETAILED QUESTIONS

**Q2.1: What is the primary function of the middle ear cleft?**

**Answer:** Primary function: Ventilation of the middle ear

**Q2.2: What are the five components of the middle ear cleft?**

PYQ: NEET PG 2022

**Answer:**

1. **Eustachian tube** (anterior) - connects the middle ear to the nasopharynx
2. **Middle ear proper** (mesotympanum and hypotympanum)
3. **Attic** (epitympanum)
4. **Aditus** - communication between the attic and the antrum
5. **Mastoid air cells** (posterior)

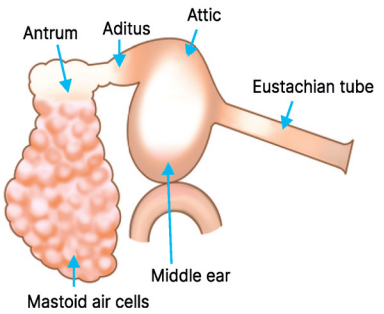


**Q2.3: What is the full ventilatory pathway through the cleft?**

**Answer:** Nose → Nasopharynx → **Eustachian tube** → **Middle ear proper** → **Attic** → **Aditus** → **Antrum** → Rest of the **mastoid air-cell system**

**Q2.4: Which mastoid air cell is the largest?**

**Answer:** The **antrum** is the **largest mastoid air cell.**

**Q2.5: What is the shape of the middle ear proper, and what are its antero-posterior dimensions?**

**Answer:**

- **Shape:** Hour-glass
- **Anteroposterior dimensions:**
  - **Attic:** 4 mm
  - **Mesotympanum:** 2 mm
  - **Hypotympanum:** 6 mm

## BIG QUESTION 3: What are the six walls of the middle ear cavity and their anatomical relations?

**Broad Answer:** The middle ear cavity is a box-shaped air-filled space with **six walls**: roof, floor, anterior, posterior, medial, and lateral. Each wall has important anatomical relationships with nearby neurovascular structures and neighbouring compartments of the skull. Understanding these is essential for ear surgeries and to avoid complications like nerve injury or vascular damage.

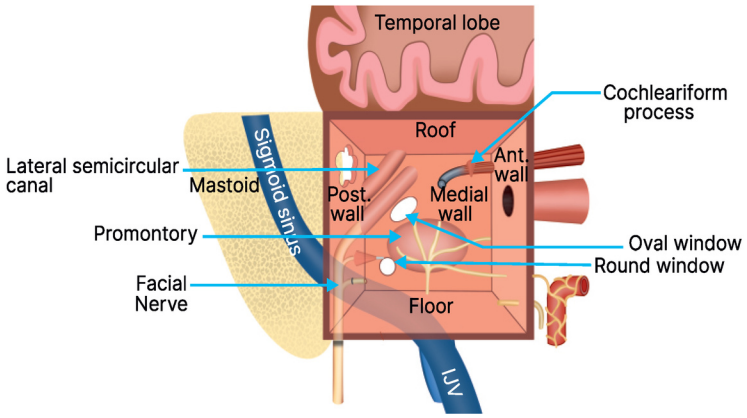


## DETAILED QUESTIONS

### Q3.1: What forms the roof of the middle ear and what does it separate?

**Answer:**

- Formed by: **Tegmen tympani**
- Function: **Separates** the middle ear from the **middle cranial fossa**

### Q3.2: Which structure forms the floor of the middle ear, and what separates it from the jugular bulb?

**Answer:**

- The floor of the middle ear is related to the internal jugular vein, and it is separated from the jugular bulb by a thin bony plate.

### Q3.3: What structures are associated with the anterior wall of the middle ear?

**Answer:**

- Communication with the **Eustachian tube** (ET)
- Bony separation from the **internal carotid artery** (ICA)
- **Canal for the tensor tympani muscle** also runs through this wall

### Q3.4: What are the features of the posterior wall?

**Answer:** Contains:

- **Pyramidal eminence**
- **Aditus**
- **Antrum**

### Q3.5: What forms the lateral wall of the middle ear?

**Answer:**

- **Tympanic membrane**
- **Outer attic wall** called the **scutum**

### Q3.6: What are the features of the medial wall of the middle ear?

**Answer:**

- Impression of the lateral semicircular canal
- Promontory: Impression of the basal turn of the cochlea, and has a tympanic plexus (made of glossopharyngeal nerve and sympathetic plexus around the carotid)
- Oval window
- Round window
- The facial nerve passes between the semicircular canal and the promontory
- Processus cochleariformis

### Q3.7: What are the structural and developmental features of the external, middle, and inner ear?

**Answer:**

| Feature | External Ear |
|---|---|
| Composition | Cartilage - Elastic |
| Cartilage-free areas | Lobule and Incisura terminalis |
| Length of Eustachian tube | 24 mm |
| ET parts | 1/3$^{rd}$ Cartilaginous<br>2/3$^{rd}$ Bony |
| Fissure of Santorini | Present in cartilaginous part of EAC |
| Foramen of Huschke | Present in bony part of EAC |

### Q3.8: What are the anatomical boundaries of each wall in the middle ear?

**Answer:**

| Wall | Middle Ear Structures |
|---|---|
| Roof | Tegmen tympani |
| Floor | Internal jugular vein |
| Posterior wall | Pyramid / Aditus |
| Anterior wall | Eustachian tube / Tensor tympani / Internal carotid artery |
| Lateral wall | Tympanic membrane |
| Medial wall | Promontory, Lateral semicircular canal, Oval window, Round window, Facial nerve, Processus cochleariformis |

### Q3.9: What are the locations of sensory neuroepithelium in the inner ear?

**Answer:**

- Vestibule: Maculae
- Semicircular canals (SCC): Cristae
- Cochlea: Organ of Corti



YOURWISH

## BIG QUESTION 4: What is the nerve supply of the external, middle, and inner ear?

**Broad Answer:** The ear receives complex innervation from cranial and cervical nerves. The **external ear** is supplied by branches of cranial nerves V, VII, X and cervical nerves C2 and C3. The **middle ear** is primarily supplied by the glossopharyngeal nerve (CN IX), and the **inner ear** receives sensory innervation via the vestibulocochlear nerve (CN VIII).

## DETAILED QUESTIONS

### Q4.1: What are the nerves supplying the pinna?

PYQ: INICET 2022

**Answer:**

- Mnemonic: **LAG 7 & 10**
  - Lesser occipital nerve
  - Auriculotemporal nerve
  - Greater auricular nerve
  - 7th and 10th cranial nerves (Facial and vagus nerve)

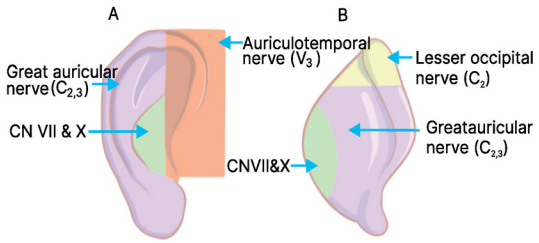


### Q4.2: Which nerve supplies the greater surface area of the pinna?

**Answer:** Greater auricular nerve

### Q4.3: What are the intricate sensory distributions on the lateral surface of the external ear (pinna)?

**Answer:**

| Area | Nerve Supply |
|---|---|
| Lower half | Greater auricular nerve |
| Upper half anterior 2/3 | Auriculotemporal nerve |
| Upper half posterior 1/3 | Lesser occipital nerve |
| Concha | CN VII and X (Arnold's nerve) |

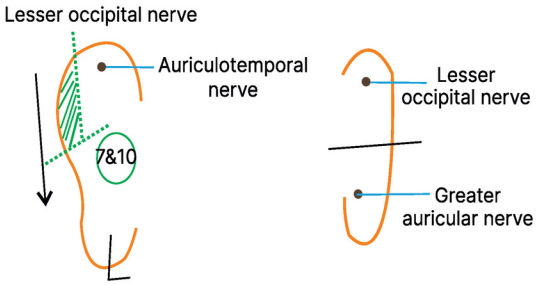


### Q4.4: What is the nerve supply of the external auditory canal (EAC)?

**Answer:**

| Area of EAC | Nerve Supply |
|---|---|
| Anterior wall and roof | **Auriculotemporal nerve** (branch of CN V3) |
| Posterior wall and floor | **Arnold's nerve** (Auricular branch of CN X) |

**Q4.5: What is the nerve supply of the middle ear (ME)?**
**Answer:** **Glossopharyngeal nerve** (CN IX)

**Q4.6: What is the nerve supply of the inner ear (IE)?**
**Answer:** **Vestibulocochlear nerve** (CN VIII)

**Q4.7: Which nerves supply the cochlea and semicircular canals specifically?**
**Answer:**

| Structure | Nerve |
|---|---|
| Cochlea | Cochlear nerve |
| Semicircular canals | Vestibular nerve |

**Q4.8: Give a summary of the nerve supply of the external ear, middle ear, and inner ear.**
**Answer:**

| External ear | Middle ear | Inner ear |
|---|---|---|
| • **L** - Lesser occipital nerve<br>• **A** - Auriculo temporal nerve<br>• **G** - Greater auricular nerve<br>• **7** - Sensory supply<br>• **10** - Arnolds nerve | 9th nerve | **8th nerve:** Vestibulo cochlear nerve<br>• Cochlea: Cochlear nerve<br>• SCC and vestibule- Vestibular nerve |

## BIG QUESTION 5: What are the anatomical features and visible structures in a perforated tympanic membrane?

**Broad Answer:** A **perforated tympanic membrane (TM)** is a breach in the integrity of the eardrum, commonly due to infection or trauma. Its extent and location determine visibility of middle ear structures. A **subtotal perforation** spares the annulus and allows direct visualisation of multiple ossicles and inner wall landmarks.

## DETAILED QUESTIONS

**Q5.1: What is a subtotal perforation of the tympanic membrane?**
**Answer:** A perforation that includes **all four quadrants** of the pars tensa **except the annulus.**

**Q5.2: Which structures are visible through a subtotal perforation?**
**Answer:**

- **Ossicles:**
  - Handle of malleus
  - Long process of incus
  - Head of stapes
  - Stapedial crura
  - Footplate of stapes
- **Muscle:**
  - Stapedius muscle
- **Promontory**
- **Windows:**



- **Oval window**: seen **above**
- **Round window**: seen **below**, in the **posteroinferior quadrant**

- **Eustachian tube opening**:
  - Seen in the **anteroinferior quadrant**
- **Ossicle location**:
  - Ossicles are best visualised in the **posterosuperior quadrant**

## BIG QUESTION 6: What are the intratympanic muscles and the role of the tympanic plexus?

**Broad Answer:** The middle ear contains two key muscles: **tensor tympani** and **stapedius**, both derived from different embryological arches and innervated accordingly. They function to dampen sound vibrations to protect the inner ear. The **tympanic plexus**, located on the promontory, provides sensory innervation to the middle ear mucosa and is derived from the glossopharyngeal nerve.

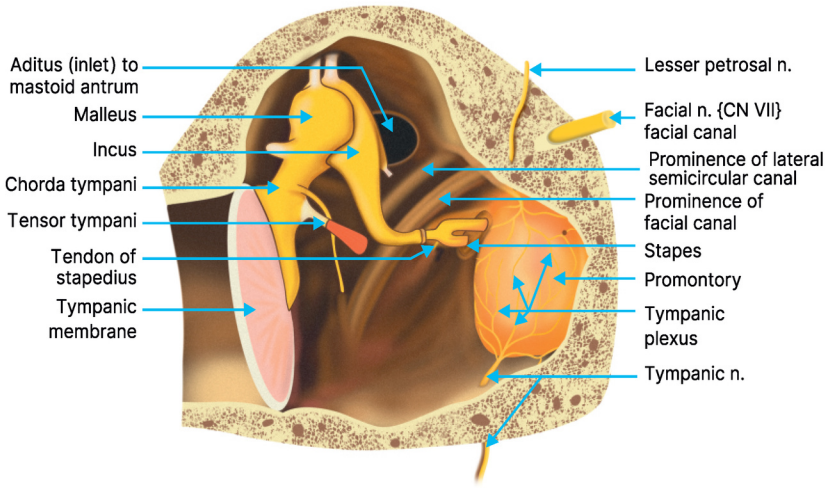


## DETAILED QUESTIONS

### Q6.1: What are the two intratympanic muscles of the middle ear?

**Answer:**

1. **Tensor tympani**
2. **Stapedius**

### Q6.2: What is the embryological origin, innervation, and attachment of the tensor tympani?

**Answer:**

- **Derived from**: 1st embryological arch
- **Nerve supply**: Mandibular branch of the **trigeminal nerve (CN V3)**
- **Attachment**: To the **neck of the malleus**

### Q6.3: What is the embryological origin, innervation, and attachment of the stapedius muscle?

**Answer:**

- **Derived from**: 2nd embryological arch
- **Nerve supply**: **Facial nerve (CN VII)**
- **Attachment**: To the **neck of the stapes**

### Q6.4: What is the function of the intratympanic muscles?

**Answer:** They **dampen loud sound** vibrations and **protect the inner ear** from acoustic trauma.

## BIG QUESTION 7: What are the important facial nerve landmarks within the middle ear?

**Broad Answer:** The **facial nerve (CN VII)** passes through the middle ear in a characteristic path marked by two **genu (bends)** and is associated with crucial surgical landmarks such as the **geniculate ganglion**, **pyramid**, and **facial recess.** A deep understanding of these relations is critical during otologic surgeries, especially cochlear implantation.

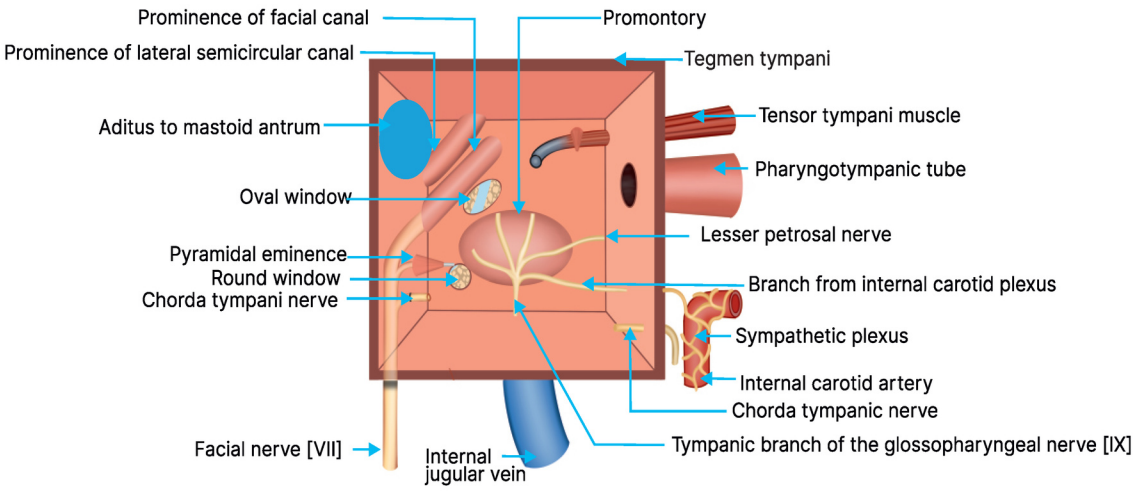


## DETAILED QUESTIONS

### Q7.1: How does the facial nerve course through the middle ear?

**Answer:**

| | Facial nerve | Landmark |
|---|---|---|
| Comes from the inner ear and makes its first turn. | 1st genu / geniculate ganglion | Cochleariform process |
| Continues horizontally in the medial wall of the middle ear and takes a vertical turn to continue in the posterior wall finally exiting through the stylomastoid foramen | 2nd genu | Pyramid |
| In the medial wall of the middle ear | Horizontal segment | It lies above the oval window and below the lateral semicircular canal |

### Q7.2: What are the boundaries and significance of the facial recess?

**Answer:**

- **Boundaries:**
  - **Lateral:** Vertical segment of the **facial nerve**
  - **Medial: Chorda tympani**
  - **Superior: Fossa incudis** (space below incus)
- **Clinical importance:**
  - Approach to reach the middle ear through the posterior route or mastoid route in posterior tympanostomy
  - Posterior tympanotomy done in cochlear implant surgery



YOURWISH

YOURWISH

### Q7.3: What is the sinus tympani, and why is it clinically important?

**Answer:**

- Also called **infra-pyramidal recess**
- It is a **hidden space** behind the promontory and medial to the facial nerve
- **Clinical point:**
  - Most common site for **residual cholesteatoma** after surgery

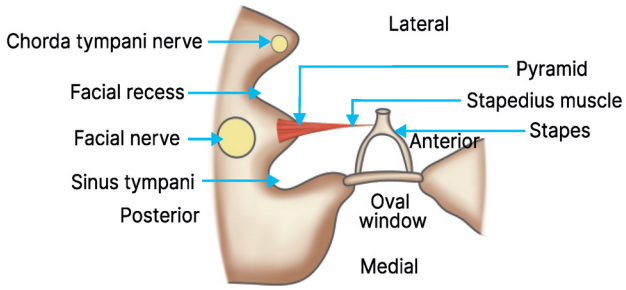


## BIG QUESTION 8: What is the anatomical structure and organisation of the inner ear?

**Broad Answer:** The **inner ear**, also called the **labyrinth**, consists of two major components:

1. **Bony labyrinth** - the outer rigid casing
2. **Membranous labyrinth** Content within bony labyrinth.

## DETAILED QUESTIONS

### Q8.1: What are the two main structural divisions of the inner ear?

**Answer:**

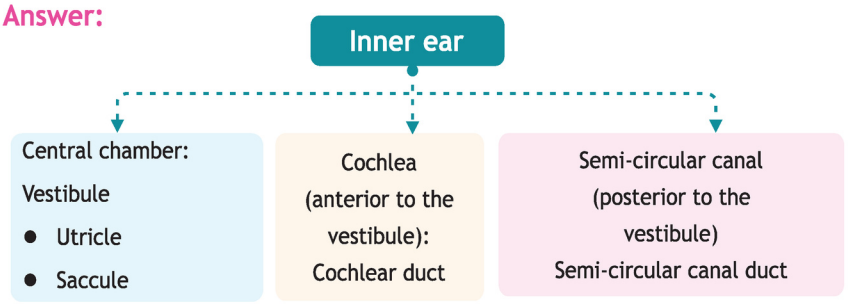


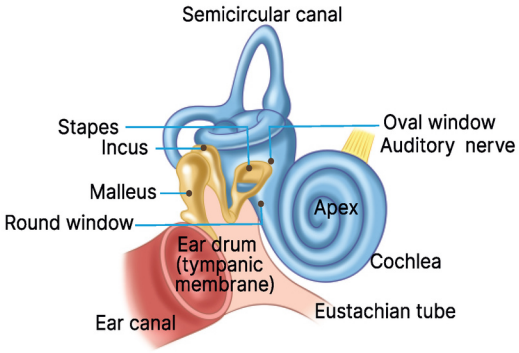


### Q8.2: What are the features of the vestibule?

**Answer:**

- Contains two recesses:
  - **Spherical recess** → contains **saccule**
  - **Elliptical recess** → contains **utricle**
- Belongs to:
  - Recesses = **Bony labyrinth**
  - Utricle and saccule = **Membranous labyrinth**
- **Neurosensory epithelium** = **Maculae** (in saccule and utricle)
  - Function: Responsible for **balance and linear acceleration**
- **Connections:**
  - Saccule connects to cochlear duct anteriorly
  - Utricle connects to semicircular canals



### Q8.3: What are the features of the semicircular canals (SCC)?

**Answer:**

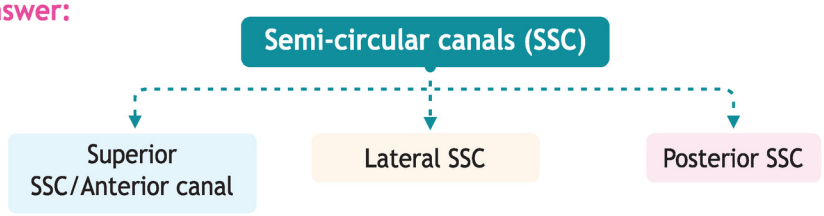


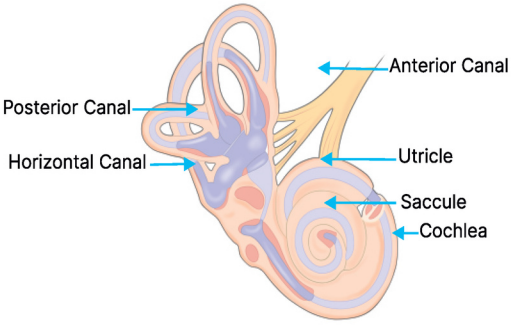

- Each semicircular canal contains its own **semicircular duct**
- Each canal has:
  - o One **dilated end (ampulla)**
  - o One **non-dilated end**
- Each canal contributes **2 openings** to the utricle
  - o Expected: 6 total openings
  - o Actually: **Only 5** openings because:
    - → The **non-ampullated ends of superior and posterior canals fuse** to form the **crus commune**
- So, total:
  - o 3 **ampullated ends**
  - o 2 **non-dilated ends**
  - o 1 **common crus** = **5 openings**

### Q8.4: What is the crista ampullaris, and what is its function?

**Answer:**

- **Crista ampullaris** is the **neurosensory epithelium** present in the **ampullated end** of each SCC
- Function: Detects **angular or rotatory motion**

## BIG QUESTION 9: What is the anatomy and organisation of the cochlear duct?

**Broad Answer:** The **cochlear duct** (scala media) is the functional unit of hearing located within the cochlea of the inner ear. It spirals around a central bony axis called the **modiolus** and is filled with **endolymph**, separated from surrounding perilymphatic compartments by thin membranes. It houses the **Organ of Corti**, the primary sensory structure for sound transduction.

## DETAILED QUESTIONS

### Q9.1: What is the cochlear duct and how is it positioned?

**Answer:**

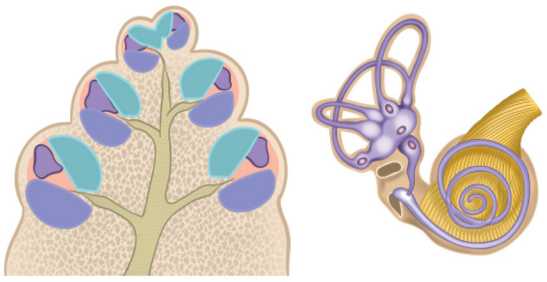

- Also called **scala media**
- It is a **spiral-shaped structure** resembling a snail shell
- It rotates around a central bony core called the **modiolus**
- **Turns:** 2½ to 2¾ turns around the modiolus

### Q9.2: What are the surrounding compartments of the cochlear duct?

**Answer:**

| Compartment | Position | Fluid |
|---|---|---|
| Scala vestibuli | **Above** duct | **Perilymph** |
| Scala media (duct) | **Middle** | **Endolymph** |
| Scala tympani | **Below** duct | **Perilymph** |

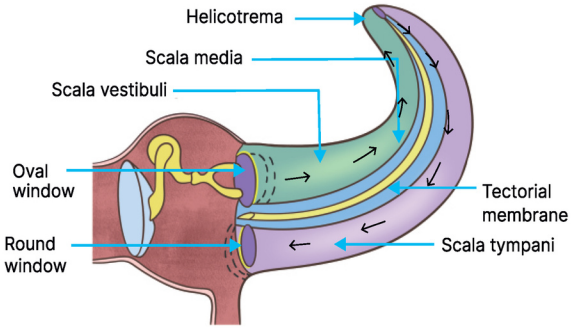


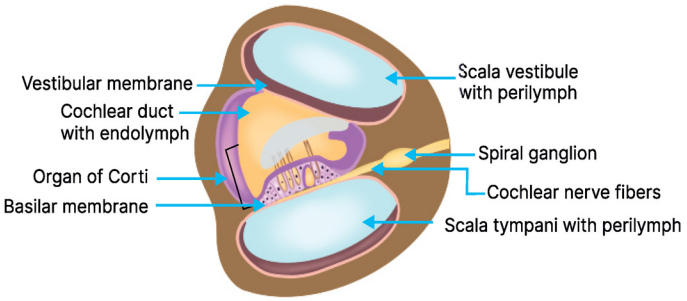


### Q9.3: What are the membranes that separate the cochlear compartments?

**Answer:**

| | |
|---|---|
| **Vestibular/reissners membrane** | Separates scala vestibuli & scala media |
| **Basilar membrane** | Separates scala media from scala tympani |
| **Organ of Corti** | • Neurosensory epithelium responsible for hearing<br>• Present on the basilar membrane in scala media |
| **Aqueduct of cochlea:** | • Communication between scala tympani & subarachnoid space. |

### Q9.4: What is the fluid composition of perilymph and endolymph?

**Answer:**

- **Perilymph:**
  - Found in scala vestibuli and scala tympani
  - **Ultrafiltrate of CSF**
  - **Rich in sodium ($Na^+$)**
  - Communicates with CSF via **aqueduct of cochlea**
- **Endolymph:**
  - Found in scala media (cochlear duct)
  - **Produced and reabsorbed** by **stria vascularis**
  - **Rich in potassium ($K^+$)**

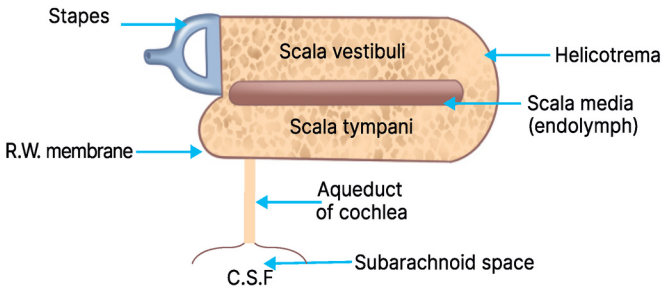


### Q9.5: What are the parts included in the bony labyrinth?

**Answer:**

- Semi-Circular Canals
- Elliptical and spherical recess
- Scala vestibuli and tympani

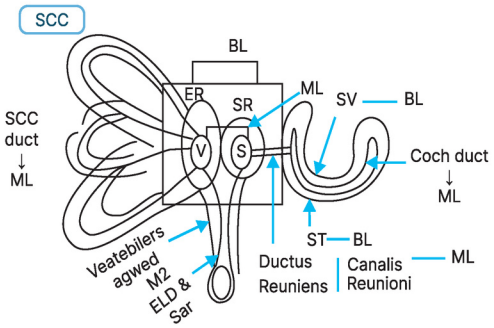


### Q9.6: What are the parts included in the membranous labyrinth?

**Answer:**

- Semi-Circular Canals ducts
- Utricle and Saccule
- Ductus reuniens
- The endolymphatic duct and sac belong to the membranous labyrinth

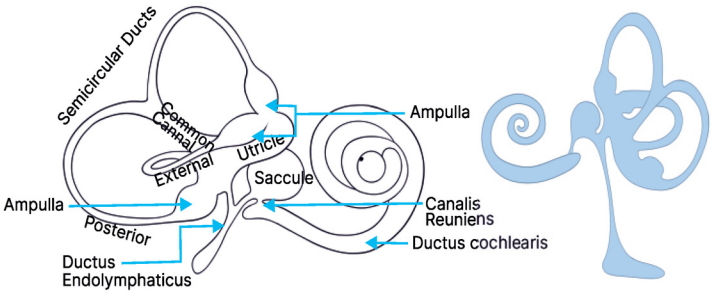




YOURWISH

**Q9.7: Describe the connections of the cochlear duct with the vestibular system and the structures related to endolymph drainage.**

**Answer:**

| Structure | Function |
|---|---|
| **Ductus reuniens (Canalis reuniens)** | Connects the cochlear duct to the saccule |
| **Saccular and utricular ducts** | Unite to form the endolymphatic duct, which continues into the endolymphatic sac |
| **Vestibular aqueduct** | Bony canal enclosing the endolymphatic duct |

## BIG QUESTION 10: What is the surgical landmark for locating the endolymphatic sac?

**Broad Answer:** The **endolymphatic sac** lies in the posterior part of the petrous bone and plays a crucial role in endolymph absorption. During surgical procedures such as endolymphatic sac decompression, it is identified using an imaginary anatomical line known as **Donaldson's line.**

## DETAILED QUESTIONS

**Q10.1: What is Donaldson's line, and how is it defined anatomically?**

**Answer:**

- It is an **imaginary line** that:
  - Starts from the **lateral semicircular canal (LSCC)**
  - Passes **posteriorly**, bisecting the **posterior semicircular canal (PSCC)**

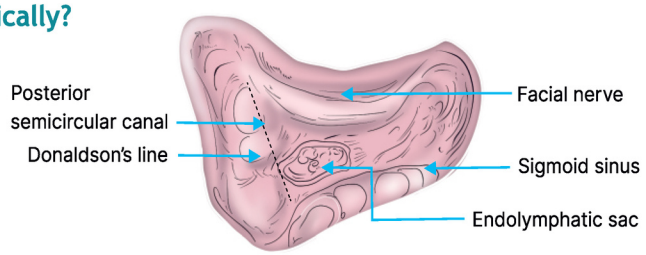


**Q10.2: What is the relationship between Donaldson's line and the endolymphatic sac?**

**Answer:**

- The **endolymphatic duct** lies **along Donaldson's line**
- The **endolymphatic sac** is located **inferior** to Donaldson's line

## BIG QUESTION 11: What is the embryological origin and development of the structures of the ear?

**Broad Answer:** The ear develops from the **first and second pharyngeal arches**, **clefts**, and **pouches**, along with the **otic placode**. The structures of the external, middle, and inner ear each arise from specific germ layers and embryological components. This developmental origin determines their nerve supply, anatomical position, and clinical correlates.

## DETAILED QUESTIONS

**Q11.1: How is the pinna formed embryologically?**

**Answer:**

- Formed from **mesoderm** of the **1st and 2nd pharyngeal arches**
- Six swellings called the **hillocks of Hi**
  - **1st hillock → Tragus**
  - Remaining hillocks fuse to form the **rest of the pinna**



YOURWISH

### Q11.2: How does the middle ear and Eustachian tube develop?

**Answer:**

- Formed from the **fusion of the 1st pharyngeal pouch and 2nd arch**
- Creates the **tubotympanic recess** → gives rise to:
  - **Middle ear cavity**
  - **Eustachian tube**

### Q11.3: What is the embryological derivation of the tympanic membrane?

**Answer:**

- Formed from **all three germ layers:**
  - **Ectoderm** → from 1st cleft
  - **Endoderm** → from 1st pouch
  - **Mesoderm** → from intervening mesenchyme

### Q11.4: What are the embryological origins of the ossicles?

**Answer:**

| Structure | Embryological Source |
|---|---|
| **Malleus** | Mesoderm of **1st arch** |
| **Incus** | Mesoderm of **1st arch** |
| **Stapes (superstructure)** | Mesoderm of **2nd arch** |
| **Stapes (footplate)** | **Otic capsule** (otic placode) |

### Q11.5: What is the final summary of embryological layers and sources for ear structures?

**Answer:**

| Ear Part | Germ Layer / Structure |
|---|---|
| **Pinna** | Mesoderm - 1st & 2nd pharyngeal arches |
| **External auditory canal** | Ectoderm - 1st pharyngeal cleft |
| **Tympanic membrane** | All three layers: ectoderm, mesoderm, endoderm |
| **Middle ear cleft** | Endoderm - tubotympanic recess from 1st pouch |
| **Malleus & Incus** | Mesoderm - 1st arch |
| **Stapes (superstructure)** | Mesoderm - 2nd arch |
| **Stapes (footplate)** | Otic capsule |
| **Mastoid** | Mesoderm - squamous & petrous temporal bone |

## BIG QUESTION 12: What are the frequently asked one-liner MCQs related to ear anatomy?

**Broad Answer:** These short-format recall questions test specific anatomical facts about the ear relevant to NEET PG, INICET, and FMGE exams. They focus on structure identification, clinical anatomy, embryology, and innervation.

## DETAILED QUESTIONS

**Q12.1: What is the part of the pinna between the ascending crest of the helix and the tragus called?**
**Answer:** Incisura terminalis

**Q12.2: Which nerve supplies the major part of the skin of the pinna?**
**Answer:** Greater auricular nerve

**Q12.3: Arnold's nerve is a branch of which cranial nerve?**
**Answer:** Vagus nerve (CN X)

**Q12.4: In newborns, which part of the external auditory canal is absent?**
**Answer:** Bony part

**Q12.5: Fissures of Santorini are found in which part of the EAC?**
**Answer:** Cartilaginous part

**Q12.6: Cough response while cleaning the ear canal is due to stimulation of which cranial nerve?**
**Answer:** Auricular branch of the vagus nerve (Arnold's nerve)

**Q12.7: The tympanic membrane forms an angle of how many degrees with the EAC?**
**Answer:** 45 degrees

**Q12.8: Körner's septum is a persistence of which suture?**
**Answer:** Petrosquamous suture (Clinical point: may obscure identification of mastoid antrum)

**Q12.9: What is the space between the pars flaccida and the neck of the malleus called?**
**Answer:** Prussak's space

**Q12.10: What is the area of the middle ear around the tympanic orifice of the Eustachian tube called?**
**Answer:** Protympanum

**Q12.11: What is the site of exit of chorda tympani from the middle ear?**
**Answer:** Canal of Huguier

**Q12.12: Scutum is part of which wall of the attic?**
**Answer:** Outer wall

**Q12.13: Patulous Eustachian tube is commonly seen in which conditions?**
**Answer:** Rapid weight loss and post-pregnancy

**Q12.14: Electrodes of a cochlear implant are placed into which part of the cochlea?**
**Answer:** Scala tympani (via round window)

**Q12.15: Endolymph is present in which part of the ear?**
**Answer:** **Membranous labyrinth** (Rich in $K^+$)

**Q12.16: What is the length of the Eustachian tube?**
**Answer:** 36 mm

**Q12.17: Which structure is responsible for endolymph secretion?**
**Answer:** Stria vascularis

**Q12.18: Which duct connects the cochlea with the subarachnoid space?**
**Answer:** Aqueduct of cochlea

**Q12.19: What forms the endolymphatic duct?**
**Answer:** Utricular and saccular ducts

**Q12.20: What is the cochlear duct also known as?**
**Answer:** Scala media

**Q12.21: Cochlear duct is connected to the saccule via which duct?**
**Answer:** Ductus reuniens

**Q12.22: Which membrane separates scala media from scala tympani?**
**Answer:** Basilar membrane

**Q12.23: Which membrane separates scala media from scala vestibuli?**
**Answer:** **Reissner's membrane** (Vestibular membrane)



YOURWISH

# 2. PHYSIOLOGY ASSESSMENT OF HEARING

**BIG QUESTION 1: Describe the mechanism of hearing, and how sound is transmitted through the ear?**

**Broad Answer:** The mechanism of hearing involves mechanical conduction of sound in the external and middle ear, transduction of mechanical energy into electrical impulses in the cochlea, and conduction of these electrical impulses to the brain. Sound waves travel from the environment through the EAC, tympanic membrane, ossicles (malleus, incus, stapes), oval window, and cochlea, then impulses are sent to the brain via the 8th cranial nerve.

## DETAILED QUESTIONS

### Q1.1: What are the three main parts involved in the mechanism of hearing?

**Answer:**

- Mechanical Conduction of the sound in the conductive apparatus (External ear and Middle ear).
- Transduction of mechanical energy into electrical impulses by a sensory system of the cochlea.
- Conduction of electrical impulses to the brain (inner ear to the brain: Sensorineural pathway).

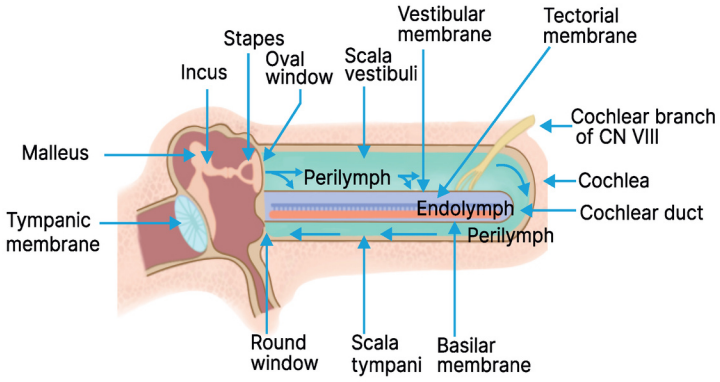


### Q1.2: Trace the path of sound transmission from the environment to the brain.

**Answer:**

- Sound waves from the environment → EAC → Tympanic Membrane → Malleus → Incus → Stapes and its Footplate → Oval window → Scala vestibuli of the cochlea → Scala tympani → Round window → impulses are carried out from the cochlea to the brain (via 8th cranial nerve).

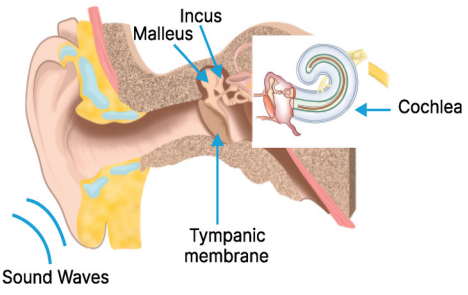


### Q1.3: What is the "Impedance Matching Mechanism," and why is it necessary in the ear?

**Answer:**

- It is the process by which the middle ear amplifies sound intensity to compensate for the decrease in amplitude when sound travels from air (middle ear) to fluid (inner ear), converting low-pressure, high-amplitude sound to high-pressure, low-amplitude vibration to increase its power to penetrate the inner ear fluid. Only 0.1% of sound energy would otherwise enter the inner ear.



YOURWISH

YOURWISH

**Q1.4: Describe the two mechanisms by which sound becomes more powerful as it travels through the middle ear.**

**Answer:**

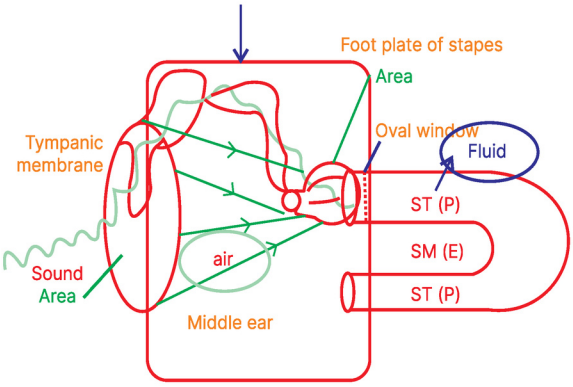


- **Mechanism I (Areal Ratio):**
  - Sound travels from the larger surface area of the tympanic membrane (Effective vibrating area = 45-55 $mm^2$) to the smaller surface area of the stapes footplate (Area = 3.2 $mm^2$). This condensation of energy makes the sound approximately 14 times stronger (Areal ratio = 14:1).
  - Areal ratio = Effective vibrating area / Area of the footplate of stapes
- **Mechanism II (Lever Ratio):**
  - The handle of the malleus is 1.3 times longer than the incus (sound energy goes from the bigger ossicle to the smaller ossicle) → submissive effect. The ratio between malleus to incus (M: I= 1.3:1) is called the Lever ratio

**Q1.5: What is the "Total transformer ratio," and what does it indicate about sound amplification in the middle ear?**

**Answer:**

- Total transformer ratio = Areal ratio × Lever ratio = 14 × 1.3 = 18.
- This means the sound becomes approximately 18 times more powerful when it travels from the middle ear to the inner ear.

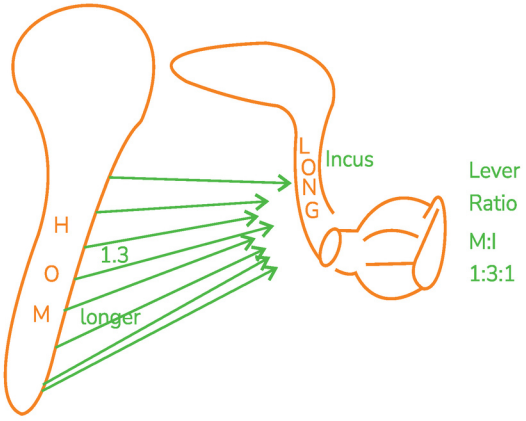


| | |
|---|---|
| Effective vibratory area | 45$mm^2$ / 55$mm^2$ |
| Footplate area | 3.2 $mm^2$ |
| Areal ratio | 14.1/17.1 |
| Lever ratio | 1.3:1 |
| Total transformer ratio | 14 x 1.3 = 18.1<br>17 x 1.3 = 22.1 |

**Q1.6: What happens inside the inner ear when the Basilar membrane vibrates? How is mechanical energy converted into electrical energy?**

**Answer:**

- The Organ of Corti, with numerous hair cells (receptors of hearing) on the Basilar membrane, vibrates.
- These hair cells vibrate against the tectorial membrane, and the friction converts mechanical energy into electrical energy.

**Q1.7: Which type of hair cells on the Organ of Corti are afferent, what neurotransmitter do they secrete, and what is the term for the conversion of mechanical energy to electrical energy?**

**Answer:**

- Type 1 hair cells are afferent.
- They secrete an excitatory neurotransmitter called glutamate, which stimulates the $8^{th}$ nerve.
- This conversion is called Transduction.

### Q1.8: What is the "Auditory Pathway"? List the structures in the order of the Auditory Pathway.

**Answer:**

PYQ: INICET 2019, 2020, 2022, 2023
PYQ: FMGE 2023

- The entire pathway from the cochlea to the 8th nerve to the brain is called the Auditory pathway. ( mnemonic is **ECOLI MA**)
  - **E**- Eight nerve (8th)
  - **C**- Cochlear Nucleus
  - **O**- Superior Olivary complex
  - **L**- Lateral Lemniscus
  - **I**- Inferior Colliculus
  - **M**- Medial Geniculate Body
  - **A**- Auditory Cortex

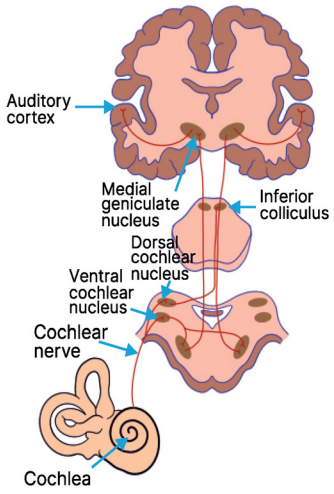


### Q1.9: What functions are associated with the Cochlea, Cochlear nerve, and Higher auditory centers, respectively?

**Answer:**

| Part of pathway | Function |
|---|---|
| Pitch or Frequency | Cochlea |
| Amplitude or intensity | Cochlear nerve |
| Feature detection | Higher auditory centres |
| Localization of sound | Higher auditory centres |

## BIG QUESTION 2:What are the main types of hearing assessment tests?

**Broad Answer:**

- Tuning Fork Tests (512 Hz)
- Pure Tone Audiometry
- Impedance Audiometry
- Speech Audiometry
- Special tests like OAE, BERA, Ecog

## DETAILED QUESTIONS

PYQ: AIIMS 2020
PYQ: FMGE 2020, 2021
PYQ: INICET 2022, 2023

### Q2.1: Write the correct order of examination for assessing hearing using tuning fork and audiometric tests.

**Answer:**

- Tuning Fork Tests (512 Hz)
  - Rinne test
  - Weber test
  - Absolute bone conduction test
- Pure Tone Audiometry
- Impedance Audiometry
- Speech Audiometry

- Special Tests
  - Otoacoustic Emissions (OAE)
  - Brainstem Evoked Response Audiometry (BERA)
  - Electrocochleography (ECog)

**Q2.2: What is considered the first test done for every patient with hearing loss?**

**Answer:** Tuning Fork Tests.

**Q2.3: Define the "Conductive pathway" and the "Sensory neural pathway" in the ear.**

**Answer:**

- **Conductive pathway:** The pathway from the pinna to the footplate of the stapes.
- **Sensory neural pathway:** The pathway from the cochlea to the brain (i.e., the cochlear and the retro cochlear pathway together).

**Q2.4: How is "Air conduction" different from "Bone conduction" in terms of pathways involved?**

**Answer:**

- **Air conduction (AC):** Conductive pathway + Sensory neural pathway.
- **Bone conduction (BC):** Sensory neural pathway.

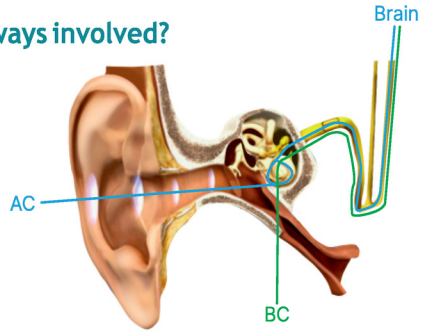


**Q. 2.5: Describe the air conduction pathway**

**Answer:** Air conduction = Conductive pathway + Sensory neural pathway

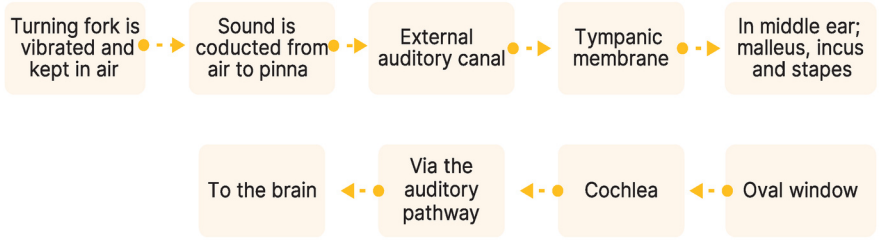


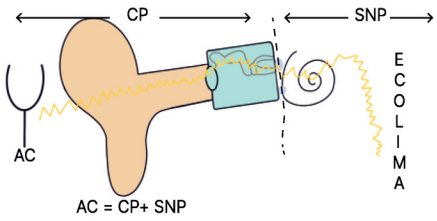


**Q. 2.6: Describe the Bone conduction pathway**

**Answer:** Bone conduction = Sensory neural pathway

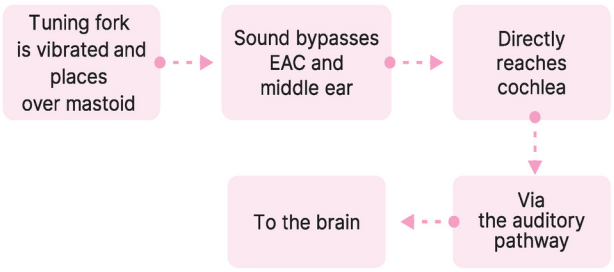


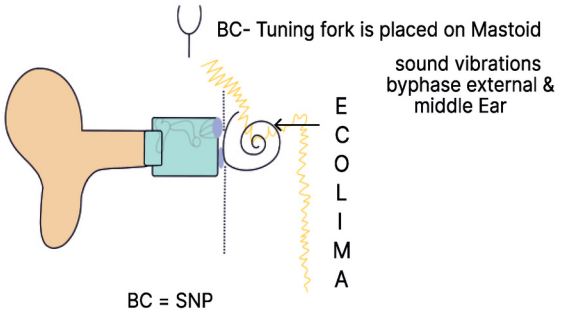


**Q2.7: Interpret the Rinne Test results for a normal ear, conductive hearing loss (CHL), and sensorineural hearing loss (SNHL).**

PYQ: NEET PG 2023

**Answer:**

- **Normal ear:** AC > BC → RINNE positive (AC is longer/louder than BC).
- **Conductive hearing loss:** AC < BC → RINNE negative (due to affected conductive pathway in AC).
- **Sensorineural hearing loss (SNHL):** AC > BC → RINNE positive (both pathways affected, but BC affected more than AC).



YOURWISH

**Q2.8: What is a "False negative Rinne," what are its characteristics, and in what condition is it seen?**

**Answer:**

- False negative Rinne means AC < BC, resulting in a RINNE negative interpretation. It is seen in unilateral (U/L) severe to profound SNHL.

**Q2.9: In which two conditions is a "Rinne positive" result observed?**

**Answer:**

- Normal ear and SNHL.

**Q.2.10: How do the results of the Rinne test, when performed with different tuning fork frequencies (256 Hz, 512 Hz, 1024 Hz), help in estimating the degree of conductive hearing loss (CHL)?**

**Answer:**

| 256 Hz | 512 Hz | 1024 Hz | Amount of HL |
|---|---|---|---|
| - | + | + | 15-30 dB CHL |
| - | - | + | 30-45dB |
| - | - | - | > 45 dB |

**Q2.11: Describe how the Weber Test is performed and how sound lateralization is interpreted for normal hearing, conductive hearing loss, and sensorineural hearing loss.**

**Answer:**

- A vibrated tuning fork is placed on the midline of the head.
  - **Normal:** Sound is felt in the head's center (equal sound distribution).
  - **Conductive hearing loss:** Sound is lateralized towards the diseased ear.
  - **Sensorineural hearing loss:** Sound is lateralized towards the normal ear.
- At least 5dB difference is needed for lateralization

**Q2.12: What are the prerequisites for performing the Absolute Bone Conduction (ABC) Test?**

**Answer:**

- Examiner's hearing should be normal, and the patient's air conduction pathway should be occluded.

**Q2.13: How is the ABC Test performed and interpreted to determine if hearing is normal or if SNHL is present?**

**Answer:**

- A vibrating tuning fork is placed on the patient's mastoid bone while their external ear canal is occluded.
- The patient is asked to signal when they can no longer hear the sound.
- The examiner then listens to the tuning fork to compare their own hearing duration to the patient's.
  - Normal Hearing: The patient and examiner hear the sound for a similar duration.
  - Sensorineural Hearing Loss (SNHL): The patient hears the sound for a shorter duration than the examiner.

**Q2.14: What is Pure Tone Audiometry, what is produced, and what is the resulting graph called?**

PYQ: FMGE 2018

**Answer:**

- Pure Tone Audiometry produces pure tones from an audiometer, testing both AC and BC.
- The charted graph is called an audiogram.
- The intensity of the pure tone is increased or decreased in 5db.



Audiometer Testing room



YOURWISH

- The degree of hearing loss can also be measured accurately.
- The patient is made to sit in a soundproof room.

**Q2.15: What does Pure Tone Audiometry confirm and measure accurately?**

**Answer:**

- It confirms the type of hearing loss (Conductive / Sensorineural / Mixed) and accurately measures the degree of hearing loss.

**Q2.16: How are the right and left ears typically depicted in an audiogram using colors?**

**Answer:** The right ear is depicted in red color, and the left ear in blue color.

**Q2.17: What are the symbols used in an audiogram for AC unmasked, AC masked, BC unmasked, and BCmasked for both right and left ears?**

**Answer:**

| | Right Ear | Left Ear |
|---|---|---|
| AC unmasked | 0 | X |
| AC masked | Δ | [] |
| BC unmasked | < | > |
| BC masked | [ | ] |
| No responses |  |  |

**Q2.18: How is a "Normal Audiogram" characterized based on decibel range and the relationship between AC and BC curves?**

**Answer:**

- The lowest point of hearing for all frequencies of AC and BC lies between 0 to 25 decibels. There is no gap between AC and BC curves, or if there is a gap, it is less than 20dB.

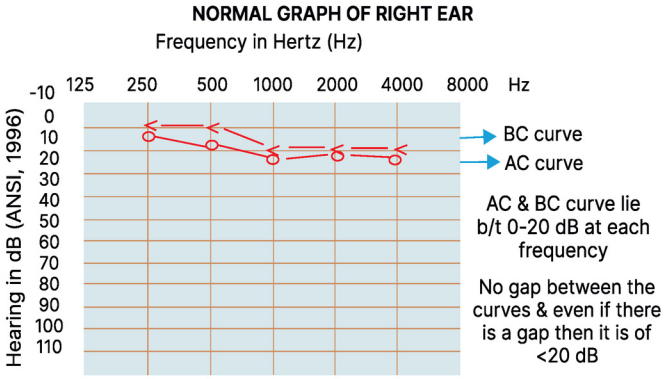


**Q2.19: How is an "Audiogram of Conductive Hearing Loss" characterized? What is considered a significant air-bone gap?**

**Answer:**

- The BC curve is in the normal range, and the AC curve is in the abnormal range, with a significant air-bone gap. An A-B gap of more than 20 decibels is considered very significant.

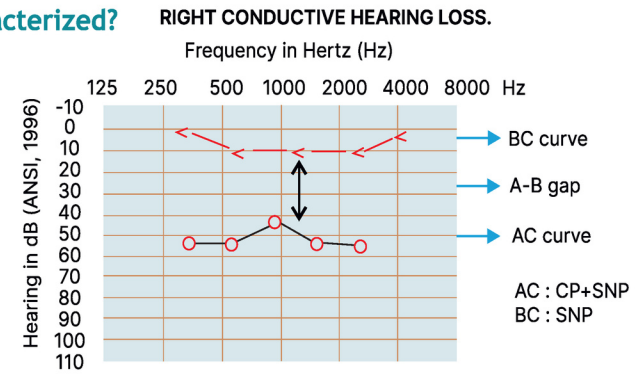

## Q2.20: How is an "Audiogram of Sensorineural Hearing Loss" characterized?

**Answer:**

- The air conduction is abnormal, and the bone conduction is also abnormal, with no significant AB gap present.

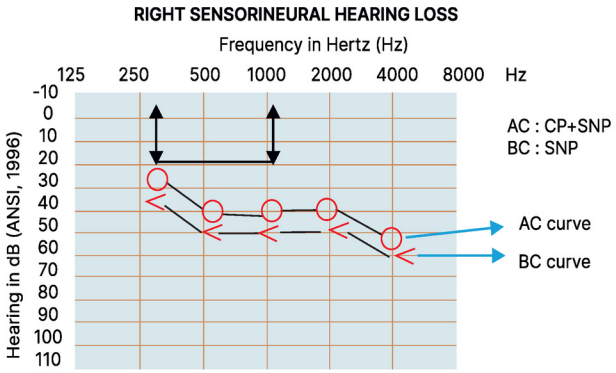


## Q2.21: What is Presbyacusis, and what is its specific audiogram characteristic?

**Answer:**

- Presbyacusis is an age-related SNHL.
- Its audiogram shows abnormal AC and BC with no A-B gap, and a down-sloping graph is very specific in presbyacusis.

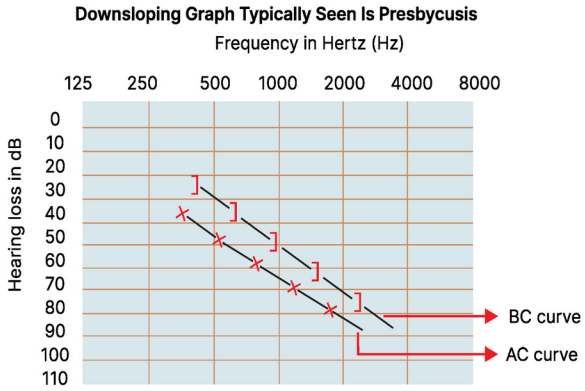


## Q2.22: What is Meniere's Disease, and what are the specific audiogram characteristics that suggest it?

**Answer:**

- Meniere's disease is a cochlear type of pathology resulting in SNHL. Its audiogram shows abnormal AC and BC with no A-B gap, and a higher amount of hearing loss can be seen at low frequencies, with an up-sloping graph being specific for Meniere's disease.

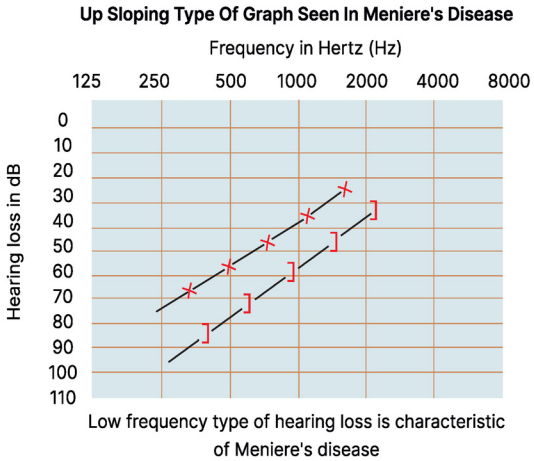


## Q2.23: What are the specific audiogram features noted in Otosclerosis?

**Answer:**

- Otosclerosis is characterized by an abnormal AC curve and a normal BC range, but a typical dip is seen at 2000Hz, called Carhart's Notch.

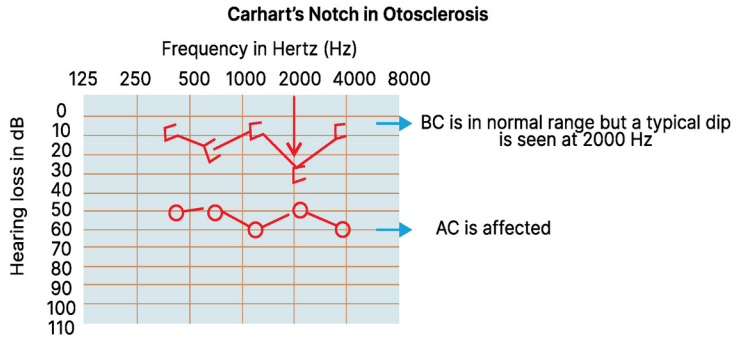


### Q2.24: What is Noise-Induced Hearing Loss (NIHL), and what specific audiogram feature is seen in it?

**Answer:**

- NIHL is characterized by abnormal AC and BC curves in the right ear (SNHL), with a dip in both AC and BC at 4000 Hz, called the boiler's notch, which is specific to NIHL.

PYQ: FMGE 2021

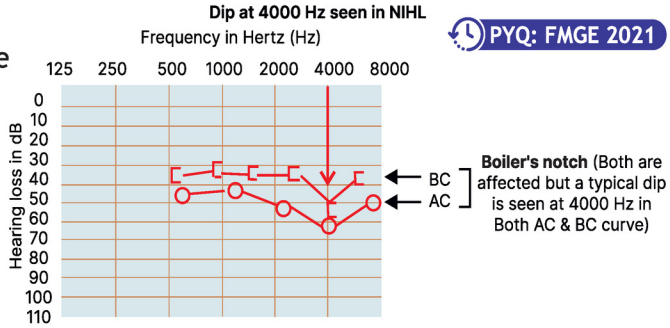


## BIG QUESTION 3: What are the types of tests for hearing?

**Broad Answer:**

- Objective tests include Impedance audiometry, Otoacoustic emissions, BERA, and Electrocochleography.
- Subjective tests include tuning fork tests, Pure tone audiometry, Recruitment, Tone decay, and Speech audiometry.

## DETAILED QUESTIONS

### Q3.1: What two components comprise Impedance Audiometry, and is it an objective or subjective test?

**Answer:**

- Impedance audiometry comprises acoustic reflex and tympanometry.
- It is an objective test.

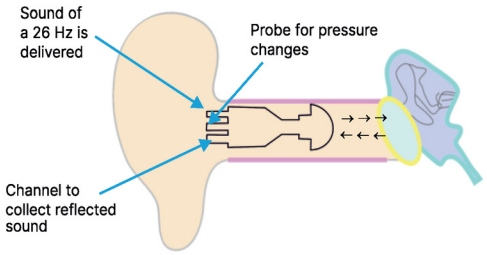


### Q3.2: Describe the five main types of Tympanometry graphs (A, As, Ad, B, C) and the conditions they indicate.

**Answer:**

- When the peak is almost at 0 and occupies almost half of the Y-Axis. This is called A type of graph.
- When the peak of the curve is at 0 but covering the lesser than half of the Y-axis, it is called As type of graph.
- A graph with ascending and descending curves with no peak. This is called an AD type of graph.
- A single flat line is called the B type of graph.
- When an A type of graph is formed on the negative side is called a C type of graph.

| | |
|---|---|
| A type | This type of graph is seen in the Normal condition. |
| $A_D$ type | This type of graph is seen in an Ossicular discontinuity |
| $A_S$ type | This type of graph is seen in Otosclerosis and Tympanosclerosis. |
| B type | This type of graph is seen in the Fluid in the middle ear. |
| C type | This type of graph is seen in the negative middle ear pressure which is seen in Eustachian tube dysfunction. |

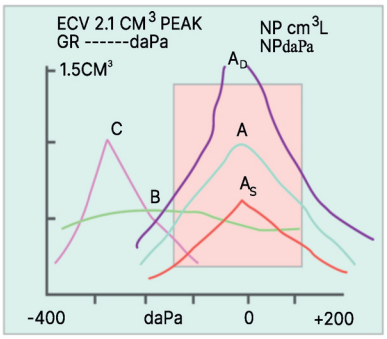




YOURWISH

**Q3.3: What is the Stapedial Reflex (Acoustic Reflex), and what does its presence or absence indicate about 8th vs. 7th nerve pathology? Is it an objective or subjective test?**

**Answer:**

- A loud sound on one side causes contraction of the bilateral stapedius muscle.
- It is an objective test.
- **Bilateral loss:** 8th nerve pathology or cochlear pathology.
- **Unilateral loss:** 7th nerve pathology.

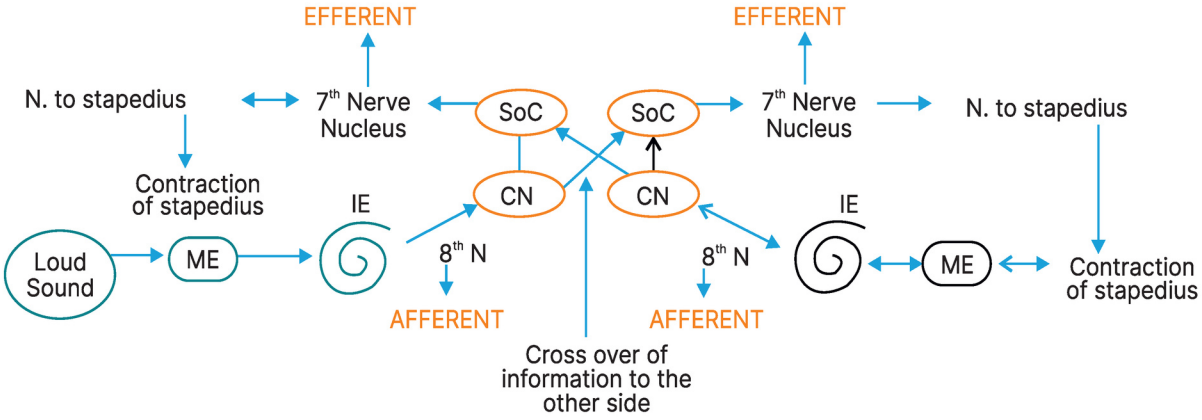


**Q3.4: What are the two tests included in Speech Audiometry, and are they objective or subjective?**

**Answer:**

- Speech Reception Threshold and Speech Discrimination Score.
- Both are subjective tests.

**Q3.5: Define "Speech Reception Threshold" (SRT).**

**Answer:**

- It is a threshold at which 50% of the words spoken are repeated correctly.

**Q3.6: Define "Speech Discrimination Score" (SDS) and what a score below 50% suggests.**

**Answer:**

- It is the ability of a patient to correctly identify phonetically balanced words like box and fox. A score <50% means the patient has some retrocochlear hearing loss, and SDS is affected.

**Q3.7: What does Electrocochleography (ECoG) measure, and where is the electrode placed?**

**Answer:**

- It measures the potentials in the cochlea and the 8th nerve in the first 5 minutes of auditory stimulation.
- The electrode is placed transtympanic over the promontory.

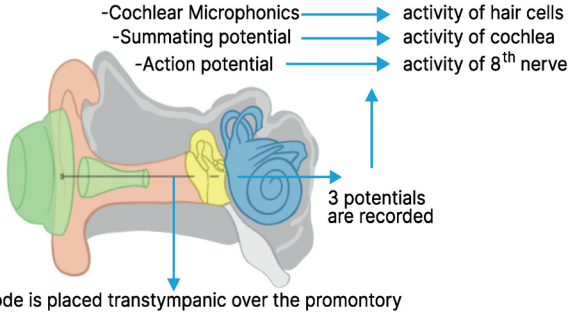


**Q3.8: What is the normal SP/AP ratio, and what SP/AP ratio in ECoG is suggestive of Meniere's disease?**

**Answer:**

- Normal SP/AP is <30% or <0.3
- If SP/AP (Summating Potential / Action Potential) is >30% or >0.3, it is suggestive of Meniere's disease.
- Electrocochleography is the investigation of choice to diagnose Meniere's disease.



YOURWISH

### Q3.9: What is Brainstem Evoked Response Audiometry (BERA) used to assess?

Answer:



- It is a test to assess the auditory pathway from the 8$^{th}$ nerve to the brainstem.
- It's a non-invasive and objective test.
- The test aims to recognize the response coming from the brainstem.

### Q3.10: What stimuli are used to elicit a response in BERA, and how many electrical waves are normally generated? What does each wave represent?

Answer:

- Clicks and tone bursts are used. In a normal person, 5-7 electrical waves are generated. Each wave represents a particular area on the auditory pathway.

| | Mnemonic |
|---|---|
| **These seven waves produced in first 10 mins represents** | |
| • Wave I - Distal part of **E**ighth nerve | **E** |
| • Wave II - Proximal part of **E**ighth nerve near the brainstem | **E** |
| • Wave III - **C**ochlear nucleus | **C** |
| • Wave IV - Superior **O**livary complex | **O** |
| • Wave V - **L**ateral lemniscus | **L** |
| • Wave VI and VII - Inferior Colliculus | **I** |

### Q3.11: List the key uses of BERA.

Answer:

- Confirming hearing loss in infants, non-organic hearing loss, differentiating cochlea from retro cochlea hearing loss, best audiometric test for acoustic neuroma (delay in wave 5 is suggestive), and objective test for hearing.

### Q3.12: What are Otoacoustic Emissions (OAEs), and which hair cells generate them? What are the two types of hair cells in the cochlea and their general functions?



Answer:

- Otoacoustic emissions are generated by the outer hair cells of the cochlea.
- **Outer hair cells:** Generally efferent.
- **Inner hair cells:** Generally afferent.

### Q3.13: What are spontaneous otoacoustic emissions and how are they detected?

Answer:

- Spontaneous otoacoustic emissions are sound waves generated by outer hair cells in the cochlea that travel towards the external auditory canal without any external sound stimulation.
- They are detected by placing an ultra-high-sensitivity probe connected to a handheld recording device in the ear canal, which captures these emissions.

### Q3.14: When is an OAE test considered "passed," and what is indicated if stimulations are absent?

Answer:

- If emissions are recorded with or without sound stimulation, the patient is said to have passed the test.
- If stimulations are absent, refer the patient for further testing, but hearing loss is not confirmed.

### Q3.15: List the uses of OAEs.

**Answer:**

- Best audiometric test for screening hearing loss in neonates, infants, and children
- Can differentiate cochlea from retro cochlea hearing loss
- Useful for early detection of noise-induced hearing loss.

### Q3.16: What is "Recruitment," what is it a test for, and what conditions is it seen in?

**Answer:**

- It's a phenomenon of abnormal growth in the loudness of the sound, where sounds of low intensity is heard as loud sounds. It is a test for cochlear pathology and is seen in lesions affecting the cochlea like Meniere's and presbycusis.




### Q3.17: What is the principle of the SISI (Short Increment Sensitivity Index) test, and what does it help differentiate?

**Answer:**

- Patients with cochlear pathology are able to appreciate small changes in sound intensity more than those with retrocochlear lesions or individuals with normal hearing.
- This test differentiates cochlear from retrocochlear pathology.

### Q3.18: What is the principle of the Threshold Tone Decay Test, and what type of pathology is it a test for?

**Answer:**

- A normal person hears a tone continuously for 60 sec, while patients with retro cochlear pathology stop hearing earlier due to fatigue of the auditory nerve.
- It's a test for retrocochlear pathology.

### Q3.19: Which tests are used for cochlear pathologies versus retrocochlear pathologies?

**Answer:**

| Cochlear Tests | Retrocochlear Tests |
|---|---|
| • Oto acoustic emissions<br>• Recruitment (SISI/ABLB)<br>• Electrocochleography | • BERA<br>• Tone decay test |

**Q3.20: What is High-frequency audiometry done for?**
**Answer:** Done in NIHL/Ototoxicity.

**Q3.21: Which nerves mediate the stapedial reflex?**
**Answer:** The 8th and 7th nerves.

**Q3.22: What do high auditory centers determine?**
**Answer:** Localization and discrimination.

**Q3.23: What structures sense angular movements?**
**Answer:** SCC (semicircular canal) ducts - Cristae.

**Q3.24: What is the screening test for hearing loss, and what is the confirmatory test?**
**Answer:** The screening test is Otoacoustic emissions; the confirmatory test is BERA.

**Q3.25: What are the objective tests for hearing?**
**Answer:** Impedance audiometry, Oto acoustic emissions, BERA, and Electrocochleography

**Q3.26: What are the subjective tests for hearing?**
**Answer:** Tuning fork tests, Pure tone audiometry, Recruitment, Tone decay, and Speech audiometry

**Q3.27: Summarize the key diagnostic interpretations for tuning fork tests, audiometry, and tympanometry findings**
**Answer:**

| Tuning fork tests | Audiometry | Tympanometry |
|---|---|---|
| • Rinnes positive: N/SNHL<br>• Rinnes Negative: CHL<br>• Webers test: N-equal<br>CHL- Decreased<br>SNHL- Opposite | • AC and BC affected -SNHL<br>• Upsloping graph- Meniers disease<br>• Downsloping graph-Presbyacusis<br>• CHL-BC is normal and AC is in the abnormal range<br>• Dip in BC curve at 2000Hz- Otosclerosis<br>• The dip in both the AC and BC curves at 4000Hz is NIHL | • A- Normal<br>• As- Otosclerosis<br>• Ad- Ossicle discontinuity<br>• B-Fluid presence<br>• C-Eustachian tube dysfunction. |

## BIG QUESTION 4: How is the vestibular system organized, and what are the principles and procedures of tests used to assess its function?

**Broad Answer:** The vestibular system, comprising the saccule and utricle within the central vestibule, receives impulses from semicircular canals via superior and inferior vestibular nerves, which then reach the vestibular nucleus. Induced nystagmus is assessed via tests like Dix-Hallpike , Caloric Test, and Fistula Test

### DETAILED QUESTIONS

**Q4.1: How is the central vestibule organized concerning the saccule and utricle, and what parts of the vestibular system send impulses to the superior versus inferior vestibular nerves?**



YOURWISH

**Answer:**

- The central vestibule contains elliptical and spherical recesses.
- The spherical recess holds the saccule; the elliptical recess holds the utricle.
- **Superior vestibular nerve:** Receives impulses from the utricle, Superior, and Lateral semi-circular canals.
- **Inferior vestibular nerve:** Receives impulses from the saccule and Posterior semi-circular canal.Impulses from both nerves reach the vestibular nucleus via the vestibular nerve.

**Q4.2: Differentiate between Peripheral Nystagmus and Central Nystagmus based on latency, duration, direction, fatigability/intensity of vertigo, and incidence.**

**Answer:**

| | Peripheral | Central |
|---|---|---|
| Latency | 2-20 sec | No latency |
| Duration | Less than a minute | More than 1 minute |
| Direction of nystagmus | Fixed, towards the undermost ear | Direction keeps changing |
| Fatigability intensity of Vertigo | Fatigable severe | Non-Fatigable Mild |
| Incidence | Common | Rare |

**Q4.3: What three types of changes can induce nystagmus?**

**Answer:**

- Position, Pressure, Temperature.

**Q4.4: What is the "Dix-Hallpike Test" primarily used to diagnose, and what is its principle?**

**Answer:**

- It is a diagnostic test for benign paroxysmal positional vertigo (BPPV).
- Its principle is that putting the head in a particular position causes displacement of the otolith into the semicircular canal, stimulating the labyrinth and resulting in nystagmus.

**Q4.5: Describe the steps involved in performing the Dix-Hallpike Test.** PYQ: INICET 2022 PYQ: AIIMS 2018

**Answer:**

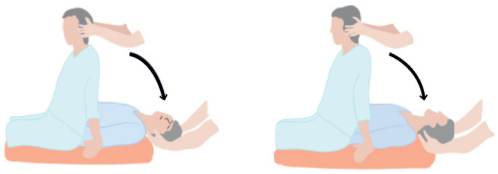

- The patient is made to sit at a table.
- Their head is rotated by 45° either to the right or to the left.
- Then, the patient is taken down in that position with the head hanging from the edge of the table (at a 30° angle).
  - In this position, there is a displacement of the otolith into the semicircular canal causing stimulation of the labyrinth.
  - Responses from the semicircular canal → goes to vestibular nucleus → medial longitudinal fasciculus → results in nystagmus

**Q4.6: Which semicircular canal is commonly stimulated in the Dix-Hallpike test, and what is the direction of the nystagmus observed?**

**Answer:**

- The posterior semicircular canal is commonly stimulated.



YOURWISH

- The direction of nystagmus is towards the undermost ear, with a torsional component being present.

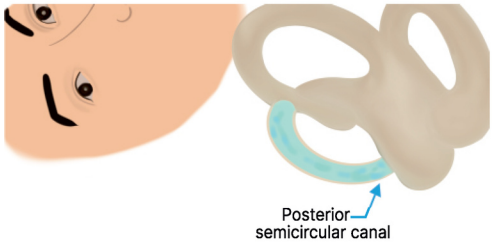


**Q4.7: What is inferred from a positive versus a negative Dix-Hallpike Test?**

**Answer:**

- **Positive:** Diagnosis is BPPV.
- **Negative:** Patient is normal, with no displacement of the otolith.

**Q4.8: What is the "Caloric Test," and what is its principle? Which semicircular canal does it primarily stimulate?**

**Answer:**

- The Caloric Test assesses labyrinthine function by inducing nystagmus via thermal changes in the external auditory canal.
- Warm or cold water induces convection currents in the middle ear, stimulating the lateral semicircular canal.
- Vestibular carries impulses to the ocular motor nucleus and causes nystagmus.

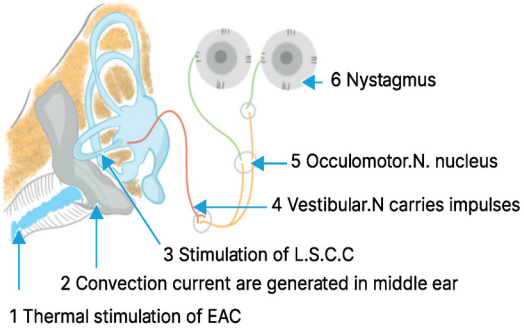


**Q4.9: Describe the patient's position for the Caloric Test and procedure?**

**Answer:**

- Patient position: Supine with a 30° head tilt forward or sitting with a 60° head tilt backward.
- The canal is irrigated with 5 ml of cold water or warm water, constantly for 60 seconds.

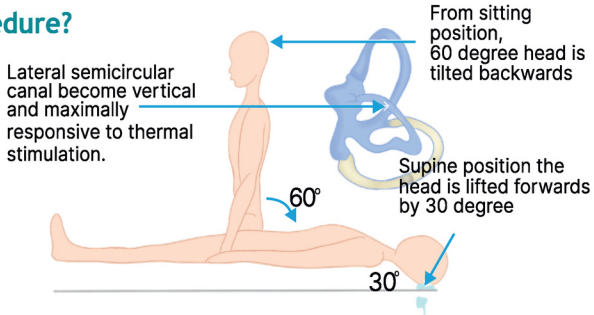


**Q4.10: How are the results of the Caloric Test interpreted regarding nystagmus presence, hypofunctional, and non-functional labyrinths?**

**Answer:**

- **Nystagmus happens:** Normal.
- **Nystagmus at higher volume:** Hypofunctional labyrinth (requires larger stimulation).
- **No nystagmus even at 40 ml:** Non-functional labyrinth/dead labyrinth.
- Mnemonic: **COWS**
  - Cold water will induce nystagmus towards the **O**pposite side.
  - Warm water will induce nystagmus towards the **S**ame side.

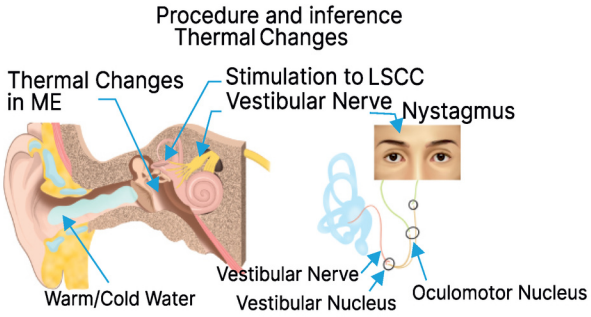


**Q4.11: What are the Modified Kobrak's Test and the Fitzgerald-Hallpike test in relation to the Caloric Test? What are the temperature definitions for cold and warm water?**

**Answer:**

- **Modified Kobrak's Test:** Only cold water is used in the Caloric test.
- **Fitzgerald-Hallpike test:** Both cold and warm water are used.
- **Cold water:** Temperature 7° below 37°C.
- **Warm water:** Temperature 7° above 37°C.

### Q4.12: In what conditions can the Caloric test not be done? What alternative tests are used in these situations?

**Answer:**

- Cannot be done in perforated tympanic membrane and congenital absence of pinna.
- **Perforated tympanic membrane hinders caloric test for vestibular function.**
- **Dundas Grant tube test: Air used for labyrinthine function assessment**
- **Congenital absence of pinna:** Barany's rotational chair test (rotatory movements stimulate crista for angular motion; VR glasses monitor nystagmus).

### Q4.13: What is the "Fistula Test," and what does a positive /negative result indicate?

**Answer:**

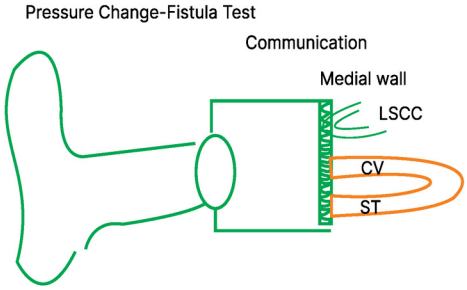


- The Fistula Test checks for an abnormal connection between the middle ear and the inner ear (a fistula).
- The middle and inner ear are normally separated.
- Pressure changes in the middle ear does not impact inner ear and no vertigo or nystagmus normally.
- A positive test means such a communication is present (e.g., a hole in the semicircular canal allows pressure changes from the middle ear to impact the inner ear, causing vertigo/nystagmus).
- A negative fistula test means no communication between the middle ear and the internal ear.

### Q4.14: Describe the procedure for the Fistula Test.

**Answer:**

- Siegel's speculum is kept in the external auditory canal, and pressure in the canal increases pressure in the middle ear.
- Normally no connection between the middle and internal ear so no nystagmus/vertigo.
- When an abnormal connection between the inner ear and the middle ear, e.g., a Hole in the semicircular canal.
- Allows pressure changes in the middle ear to the inner ear, resulting in vertigo/nystagmus.
- Then the Fistula test is positive.

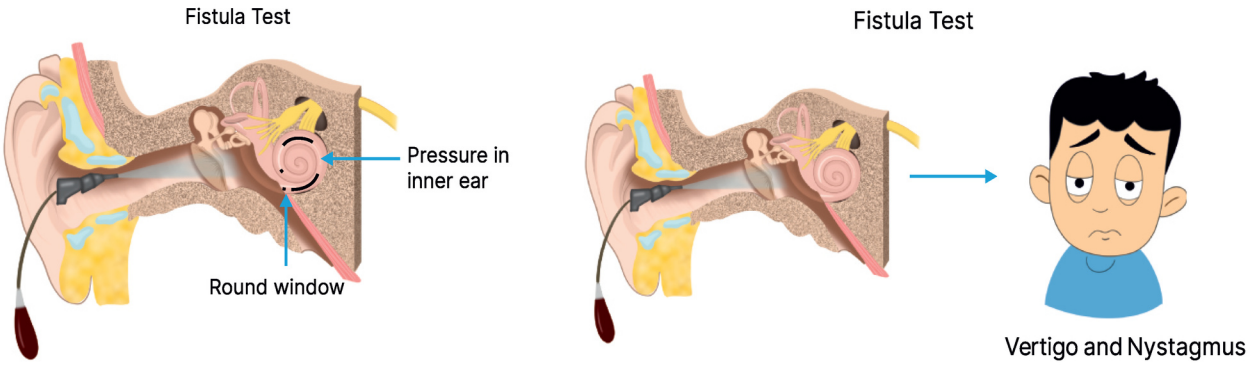


### Q4.15: What are "False positive fistula" and "False negative fistula" tests, and what conditions are they seen in?

**Answer:**

- **False positive fistula (Hennebert's test):** Seen in congenital syphilis.
- **False negative fistula test:** Seen in patients with a dead labyrinth.

**Q4.16: Describe the three efferents of the vestibular nucleus?**

**Answer:**

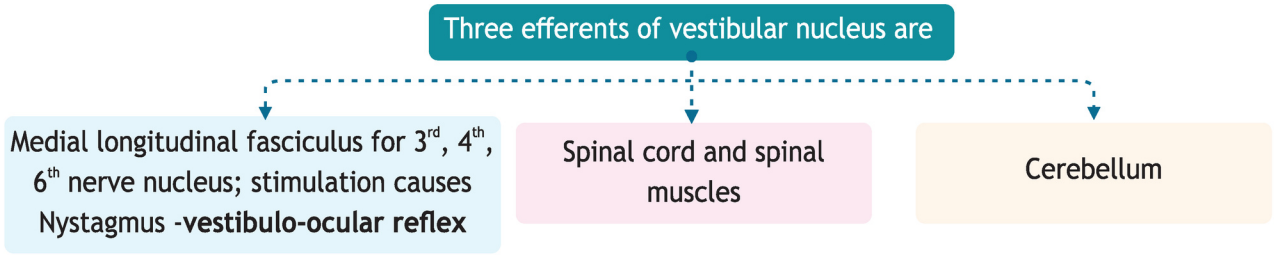




YOURWISH

# 3. EXTERNAL EAR DISEASES

## BIG QUESTION 1: What are the congenital abnormalities of the pinna, and how are they related to its embryological development?

**Broad Answer:** The external ear (pinna or auricle) develops from six mesenchymal hillocks. Any disruption in the normal development, fusion, or migration of these hillocks can result in congenital anomalies. Common abnormalities include anotia, microtia, and pre-auricular sinus. These conditions may occur in isolation or as part of syndromes.

## DETAILED QUESTIONS

### Q1.1: How is Pinna developed?

**Answer:**

- Pinna develops from the mesoderm of the first and second arches
- They form 6 projections, which are called as Hillocks of His
- These 6 projections fuse to form the ear pinna

### Q1.2: What is a Pre-auricular sinus?

**Answer:**

- Occurs due to incomplete fusion of the Hillocks of His
- It may present as a small opening.
- If it gets infected, recurrent purulent discharge is seen along with a swelling (representing the sac)
- To track/identify the sac, methylene blue can be injected, and the preauricular sinus can be excised



Preauricular Sinus

### Q1.3: What is Anotia?

**Answer:** Absence of the ear pinna

### Q1.4: What is Microtia?

**Answer:** The size of the ear pinna is small.



Microtia

### Q1.5: What are the principles behind reconstructive techniques of the pinna?

**Answer:**

- For reconstruction, rib cartilage is required (graft)
  - Rib cartilage develops by 5-7 years of age
  - Hence, correction of microtia/anotia is done at 5-7 years of age
- Another reason for waiting till 5-7 years for reconstruction is to allow the complete development of the normal pinna to take the impression of the normal pinna for symmetric reconstruction

## BIG QUESTION 2: What are the acquired abnormalities of the pinna, their features, and management?

**Broad Answer:** Acquired abnormalities of the pinna include conditions resulting from trauma, infections, or environmental exposure. Common examples are auricular hematoma, chondritis, and keloid formation. These may lead to deformity, pain, or cosmetic issues requiring medical or surgical management.



YOURWISH

## DETAILED QUESTIONS

### Q2.1: What is hematoma auris?

PYQ: AIIMS 2020

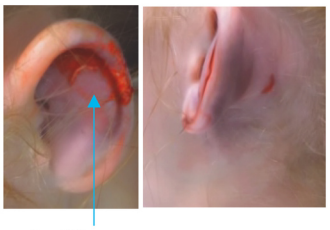


**Answer:**

- Accumulation of blood following trauma between the cartilage and the overlying perichondrium
- Also called **boxer's ear/wrestler's ear.**
- Has to be drained as it can get infected, including the underlying cartilage, leading to necrosis and resulting in a deformity called cauliflower ear

### Q2.2: What are the features of Perichondritis?

**Answer:**

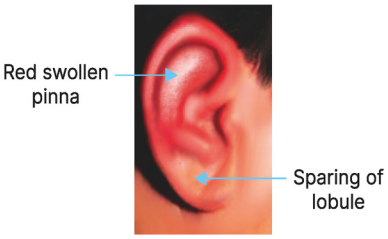


- Sparing of the lobule is seen, suggestive of the cartilaginous part of the pinna being involved, as the lobule only has fat.
- Redness, inflammation, and pain are seen.
- Can also be associated with relapsing polychondritis (laryngeal cartilage, nasal cartilage, and costal cartilage can be involved)

### Q2.3: What are the features and management of keloid?

**Answer:**

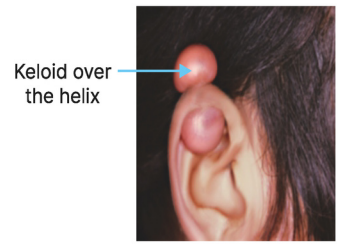


- Abnormal proliferation of the epithelium during healing
- Usually occurs at the site of incision/ site of trauma
- High chance of recurrence even after excision
- Intralesional steroids are given to prevent recurrence
- A short course of radiotherapy can also be given

## BIG QUESTION 3: What are the acquired abnormalities of the external auditory canal, their presentation, and their management?

**Broad Answer:** Acquired abnormalities of the external auditory canal are commonly due to infections, trauma, or foreign materials. Furunculosis is a painful boil caused by Staphylococcus aureus in the lateral canal. Diffuse otitis externa is a widespread bacterial inflammation often seen in swimmers. Malignant otitis externa, a severe necrotizing infection, typically affects diabetic or immunocompromised individuals. Otomycosis refers to a fungal infection, usually due to Aspergillus or Candida. Foreign bodies in the ear canal are common in children and can lead to irritation or infection. Keratosis obturans involves the accumulation of desquamated epithelium, causing canal widening. Herpes zoster oticus (Ramsay Hunt syndrome) presents with painful vesicles and facial palsy. Traumatic perforation of the tympanic membrane may occur due to slap injury, barotrauma, or instrumentation. These conditions often require medical or surgical intervention, depending on severity.

## DETAILED QUESTIONS

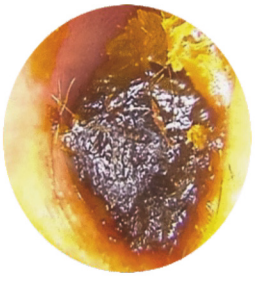

### Q3.1: What is the most common cause of conductive hearing loss in adults?

**Answer**

- Dark pile of sebaceous secretions- wax
- Wax in the EAC is the most common cause of conductive hearing loss in adults

### Q3.2: What is the clinical presentation and treatment of Furunculosis?


Infected hair follicles

**Answer:**

- Infection of the hair follicles is known as furunculosis
- Swelling in the ear with hair follicles is seen
- **Causative organism:** Staphylococcus
- Presents with pain that increases on chewing/ jaw movements
- Treatment:
  - Antibiotics
  - Ichthammol glycerin packs
  - Topical antibiotics

### Q3.3: Write briefly about clinical presentation, mode of infection, causative organism, and treatment of diffuse otitis externa?

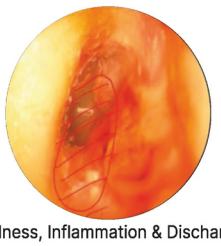
Redness, Inflammation & Discharge in the entire length of EAC

**Answer:**

- Also known as telephonist ear/swimmers' ear/ Singapore ear
- Diffuse inflammation of the external ear
- **Causative organism:** Pseudomonas
- **Mode of infection:** Contaminated water
- Generally, the pH of EAC is acidic. On exposure to water or a humid environment, it becomes alkaline, which favors the growth of bacteria
- Presents with pain that increases on chewing/ jaw movements
- **Treatment:**
  - Antibiotics
  - Ichthammol glycerin packs
  - Topical antibiotics

### Q3.4: What organism causes malignant otitis externa and what are its clinical features?

**Answer:**

- Seen in patients with uncontrolled diabetes, immunosuppressed
- **Caused by:** Pseudomonas infection
- **Symptoms:** Excruciating pain increases on chewing/ jaw movements
- Pseudomonas infection involves the bones: The Base of the skull, along with the facial nerve, is involved
- Later, lower cranial nerves (9th ,10th ,11th) are also involved
- Symptoms due to cranial nerve involvement are also seen
- Locally invasive, aggressive infection

### Q3.5: How is malignant otitis externa diagnosed?

**Answer:**

- Culture: +
- Tc 99 and gallium 67 scan:
  - Tc-99 is a dye that is taken up by osteoclasts and osteoblasts
  - When there is an infection, initially, osteoclast activity leads to bone resorption
  - Osteoclasts will take up the dye, and areas of infection are visualized
  - Hence, used for early diagnosis
  - Osteoblastic activity will continue even after the infection has subsided due to the bony remodeling.

- Hence, this test cannot specify the endpoint of therapy
- Gallium 67 scan: Gallium is taken up by neutrophils (cells of acute inflammation)
- After treatment, the gallium scan will be negative. Hence, it specifies the endpoint of therapy

- **MRI:** When an intracranial complication is suspected
- **CT:** Done to identify any bony erosion

### Q3.6: What management modalities are used for malignant otitis externa?

**Answer:**

- Anti-pseudomonal antibiotics:
  - Piperacillin
  - azobactam
  - Ciprofloxacin
- Debridement of dead tissue

### Q3.7: What are the clinical features and management of Otomycosis?

**Answer:**

- Fungal infection of the EAC
- **Cause:** Aspergillus niger > Candida > Aspergillus fumigatus
- Seen in immunocompromised/ immunocompetent patients
- Most common presenting symptom: itching
- Appearance: Wet, newspaper-like appearance
- **Treatment:**
  - Aural toileting
  - Topical antifungals
  - Systemic antifungals

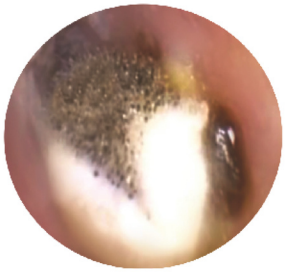

Whitish discharge with black spores

### Q3.8: What are the features of a foreign body in the ear, and how is it removed?

**Answer:**

- Usually seen in children
- Unilateral foul smelling discharge
- Method of removal:
  - If inorganic (beads/ pellets): Foreign body probe/ hook
  - If graspable/ non living: Crocodile forceps is used
  - If living insect: Anesthetize the insect using oil or local anesthetic drops like 4% xylocaine which makes the insect hypoxic and paralyzes it so that removal is easier
  - If organic button batteries: Never do syringing as it may swell or leak
    → Remove with probe/hook/forceps

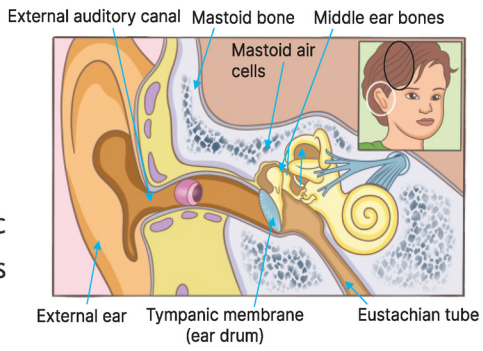


Ear anatomy and mastoid bone

### Q3.9: Describe keratosis obturans with its etiology, pathogenesis, clinical effects, complications, and treatment.

PYQ: NEET PG 2019

**Answer:**

- Ciliary motility disorder in the external auditory canal
- Normally cilia will vibrate pushing all the dead epithelium towards the external auditory canal, in ciliary motility disorder, epithelium gets trapped layer by layer forming a plug of dead desquamated mass- onion skin lamellar arrangement

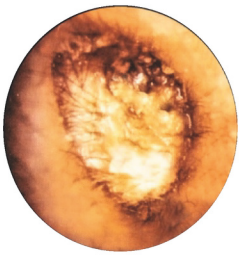

Plug of keratin

- Overlying bone gets widened and ballooning of overlying bone is seen
- Rarely, 7th nerve palsy can also occur
- **Treatment:** Remove the mass after giving keratolytics to soften the mass

**Q3.10: Elaborate on the its pathogenesis, clinical features, and treatment of Herpes zoster oticus (Ramsay Hunt syndrome).**

PYQ: FMGE 2023

**Answer:**



Vesicles



Facial nerve palsy

- Herpes zoster oticus/ Ramsay hunt syndrome
- Reactivation of herpes zoster virus
- The virus remains latent in the **geniculate ganglion**
- Vesicles in the area of distribution of facial nerve is seen
- LMN facial palsy
- Sensorineural hearing loss also can also be present
- **Treatment:**
  - Antiviral therapy: Acyclovir, Valacyclovir
  - Topical agents and lotions for vesicles
  - Steroids +/-

**Q3.11: Describe the causes, features, and management of traumatic perforation of the tympanic membrane.**

**Answer:**

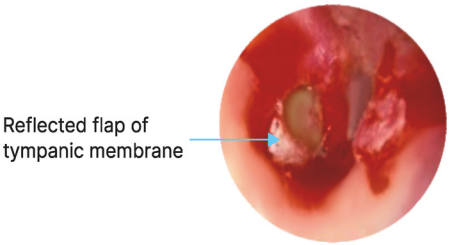


- Cause: trauma like fall or slap
- At the area of perforation, flap can be seen
- Approximation of flap is tried
- Wait for 4-6 weeks as it heals spontaneously
- If it does not heal spontaneously, myringoplasty should be done

**Q3.12: Which fungus is most commonly responsible for causing Otomycosis?**

**Answer:** The fungus causing otomycosis most commonly is Aspergillus niger

**Q3.13: What is the etiological agent causing myringitis bullosa?**

**Answer:**

- Myringitis bullosa is caused by viral infection/ Haemophilus influenzae
- It is a condition where bullous vesicles are seen on the tympanic membrane

**Q3.14: Which organism is the most common cause of otitis externa?**

**Answer:** Malignant otitis externa is caused by Pseudomonas

**Q3.15: What is the characteristic clinical presentation of malignant otitis externa?**

**Answer:** Malignant otitis externa is characterized by excruciating pain which increases on chewing and jaw movement

**Q3.16: What is the hallmark of malignant otitis externa?**

**Answer:** The hallmark of malignant otitis externa includes granulation tissue in the bony cartilaginous junction

**Q3.17: When a patient presenting with painful ear discharge, edema of external auditory canal and facial palsy not responding to antibiotics, what is the most likely diagnosis ?**

**Answer:** Malignant otitis externa

**Q3.18: What is the drug of choice for rapidly spreading infection of the EAC with bone involvement ?**

**Answer:** The drug of choice for rapidly spreading infection of the EAC with bone involvement and granulation tissue is Anti pseudomonal antibiotics:

- Piperacillin
- Tazobactam

**Q3.19: Name 3 conditions in ENT with facial nerve palsy?**

**Answer:** Malignant otitis externa/ Ramsay hunt syndrome/ Keratosis obturans

**Q3.20: What characteristic finding is seen in keratosis obturans?**

**Answer:** Keratosis obturans is characterized by onion ring appearance

**Q3.21: Which condition shows chalky white tympanic membrane on otoscopic examination?**

**Answer:** Chalky white tympanic membrane is seen in tympanosclerosis

# 4. MIDDLE EAR DISEASES

## BIG QUESTION 1: What are the stages, clinical features, complications, and management principles of Acute Suppurative Otitis Media (ASOM)?

**Broad Answer:** ASOM is a bacterial infection of the middle ear, seen commonly in children, and progresses through distinct clinical stages from congestion to perforation and resolution. Each stage has characteristic symptoms like ear pain, fever, and hearing loss. The condition may lead to complications such as mastoiditis or intracranial spread if untreated. Diagnosis is clinical, often confirmed with otoscopy, and treatment includes antibiotics, analgesics, and myringotomy in selected cases. Prompt recognition and stage-wise management are key to preventing chronicity.

## DETAILED QUESTIONS

### Q1.1: What is the most common cause and predisposing factors for Acute Suppurative Otitis Media (ASOM), and why is it common in children?

PYQ: AIIMS 2020
PYQ: NEET PG 2022

**Answer:**

- **Cause:** Streptococcus pneumoniae
- **Predisposing factor:**

URTI, disease affecting the nose/ nasopharynx
↓
Eustachian tube functions are compromised.
↓
Middle ear effusion
↓
Infection → ASOM

- Common in children because their Eustachian tube is shorter, straighter, and more horizontal, making dysfunction more likely.

### Q1.2: What are the stages of ASOM?

**Answer:**

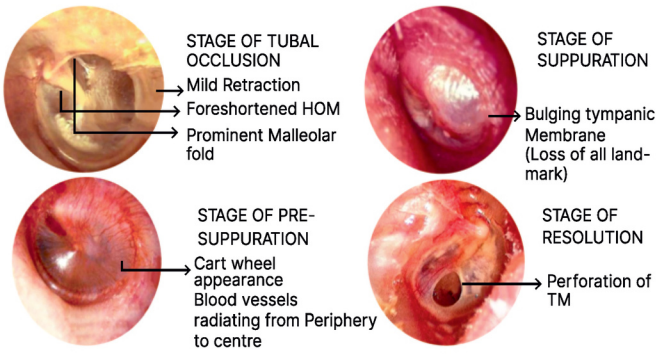


- **Tubal occlusion**
  - o Mild pain and hearing loss
  - o Retracted tympanic membrane:
    - → Prominent malleolar fold
    - → Foreshortened hand of the malleus
    - → Distorted cone of light
- **Pre-suppuration**
  - o Cart-wheel appearance: Blood vessels are radiating from the periphery to the center
  - o High-grade fever
- **Suppuration**
  - o Bulging tympanic membrane: Loss of all landmarks
    - → Pulsatile otorrhea
    - → Light house sign: When the pus reflects light

- **Resolution**
  - Perforation of TM, mostly in the anteroinferior quadrant
  - Resolves on its own
  - Symptoms subside

### Q1.3: What are the clinical features of ASOM?

**Answer:**

- Pain
- Conductive hearing loss
- Fever

### Q1.4: How is ASOM diagnosed?

**Answer:** Diagnosis is based on history and examination

### Q1.5: How is ASOM treated?

**Answer:**

- **Medical therapy:**
  - Antibiotics for at least 8-10 days
  - Nasal/ oral/ topical decongestants
  - Anti-inflammatory drugs
  - Analgesics
- Myringotomy is done as a curvilinear incision in the postero-inferior quadrant (as a cone of light is present in the anteroinferior quadrant)

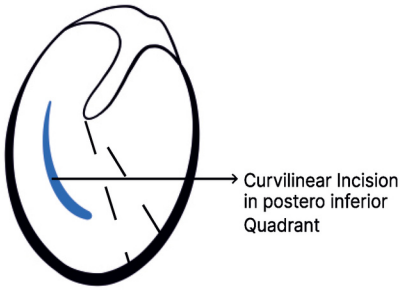


### Q1.6: What are the indications of myringotomy?

**Answer:**

- ASOM not responding to antibiotics
- Persistent effusion beyond 12 weeks
- ASOM and facial palsy
- Excruciating pain, on examination, a bulging tympanic membrane

## BIG QUESTION 2: What are the causes, clinical features, diagnosis, and management of Serous Otitis Media (SOM) in children and adults?

**Broad Answer:** Serous Otitis Media (SOM), also called Otitis Media with Effusion (OME), is a non-suppurative condition characterized by the presence of fluid in the middle ear without signs of acute infection. It is commonly seen in children due to Eustachian tube dysfunction and may follow an upper respiratory infection or episode of ASOM. Patients usually present with hearing loss, aural fullness, or speech delay in children. Diagnosis involves otoscopy and impedance audiometry. Management includes observation, treatment of nasal allergy or infection, and, in chronic cases, myringotomy with grommet insertion.

## DETAILED QUESTIONS

### Q2.1: What are the causes and predisposing factors of SOM?

**Answer:**

- Cause: ET dysfunction
- Predisposing conditions:
  - Nasal cause: URTI
  - Nasopharyngeal cause: Adenoid hypertrophy- MC cause of B/L SOM in children
  - U/L SOM in juvenile age group: JNA
  - U/L SOM in older age group: Nasopharyngeal carcinoma
  - Palatal infection

### Q2.2: What are the openers of ET, and how are they responsible for SOM?

**Answer:**

- The Eustachian tube has two openers: the Tensor veli palatini and the levator veli palatini
- In ET pathologies, the two openers are weak, and ET can not be opened, and middle ear ventilation gets affected.

### Q2.3: What are the characteristics of effusion in SOM?

**Answer:**

- The effusion in the middle ear is sterile, unlike ASOM, i.e, there is no bacterial etiology.
- Also known as non-suppurative otitis media/ otitis media with effusion/ glue ear/ secretory otitis media

### Q2.4: What are the clinical features of SOM?

**Answer:**



- **Age:** Younger age group
- **Symptoms: Conductive hearing loss**
- **Signs:**
  - Tympanic membrane- thick/ thin/ dull/ lusterless
  - Absent light reflex.
  - Retracted tympanic membrane with decreased mobility
  - Presence of an air fluid level with air bubbles

### Q2.5: How is SOM diagnosed?

**Answer:**

- **Tuning fork tests:**
  - Rinne's test: Negative
  - Weber's disease: Lateralized to the affected side
  - Absolute bone conduction test: No role
- **Audiometry:** Shows conductive hearing loss
- **Tympanometry** (IOC): 'B' type of graph- suggesting presence of fluid in the middle ear

### Q2.6: What is the treatment of SOM?

**Answer:**

- Initially, wait and watch till 12 weeks
- If no resolution, Myringotomy along with grommet insertion
- Treat the underlying cause

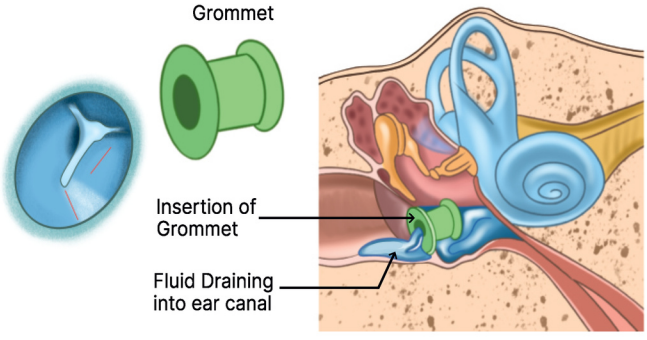




YOURWISH

YOURWISH

- Note: A Grommet is a ventilating tube that allows ventilation between the external auditory canal and the middle ear
- In SOM, myringotomy is done in the anteroinferior quadrant
- Incision: Radial

### Q2.7: What are the differences between ASOM and SOM?

**Answer:**

| ASOM | SOM PYQ: NEET PG 2018 |
|---|---|
| Infective (S. pneumoniae) | Non infective |
| Pain, fever, CHL | CHL |
| • Retraction of tympanic membrane<br>• Cartwheel appearance<br>• Pulsatile otorrhea<br>• Light house sign<br>• Perforation | • Air fluid level<br>• Air bubbles |
| No specific investigations | • Tunic fork test<br>• Audiometry<br>• Tympanometry (IOC) |
| • Medical therapy<br>• Surgery only when indicated<br>o Myringotomy: posteroinferior quadrant/ curvilinear incision | • Wait and watch for 12 weeks<br>• If not resolved, surgery is done<br>o Myringotomy + grommet<br>o Treat the underlying cause<br>o Myringotomy: Anteroinferior quadrant/ radial incision |

## BIG QUESTION 3: What is Chronic Suppurative Otitis Media (CSOM), and how is it classified?

**Broad Answer:** Chronic Suppurative Otitis Media (CSOM) is a long-standing middle ear infection characterized by persistent ear discharge (otorrhea) through a perforated tympanic membrane. It is broadly classified into tubotympanic (safe type) and atticoantral (unsafe type) disease. CSOM may present with hearing loss, foul-smelling discharge, and complications such as mastoiditis or intracranial spread in an unsafe type.

## DETAILED QUESTIONS

### Q3.1: What is the duration of CSOM?

**Answer:**

- CSOM stands for Chronic Suppurative Otitis Media.
- Chronic: Disease lasts for more than 12 weeks.

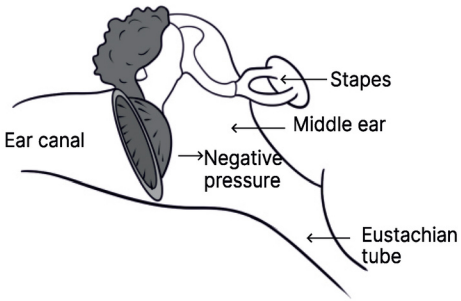


### Q3.2: What are the types of CSOM?

**Answer:**

- Two types of CSOM:
  - o Tubotympanic type/ Mucosal type
  - o Atticoantral type/ Squamous type

### Q3.3: What are the features of Tubotympanic perforation?

**Answer:**

**Tubotympanic Perforation:**

- The disease begins at the eustachian tube and goes to the middle ear cavity.
- Seen in younger age groups.
- Due to nasal or nasopharyngeal pathology
- Anteroinferior part of the middle ear gets affected.
- Discharge: large/ profuse
- Non foul smelling
- Non-blood stained
- Perforation in pars flaccida

### Q3.4: What are the characteristics of Atticoantral perforation?

**Answer:**

**Atticoantral Perforation**

- The disease begins in the atticoantral and goes posteriorly into the mastoid air cells.
- Seen in older people.
- Occurs secondary to cholesteatoma
  Posterosuperior part of the middle ear gets affected.
- Scanty discharge
- Cholesteatoma is an erosive disease, hence:
  - Foul smell
  - Granulation: Blood stain
- Perforation in pars tensa
- High risk of complications like:
  - Ossicular erosion
  - Tegmen erosion
  - Intracranial complications
  - Red fleshy polyps

### Q3.5: What are the differences between Tubotympanic and Atticoantral otitis media?

**Answer:**

| | Tubotympanic | Atticoantral |
|---|---|---|
| Cause | ET: Nasal/ Nasopharyngeal | Cholesteatoma |
| Area involved | Antero inferior | Postero superior |
| Age | Children/ young adults | Older |
| Discharge | Profuse | Scanty/foul smell/blood stain |
| Perforation | Pars tensa | Pars flaccida |
| Hearing loss | + | ++++ (ossicular erosion) |
| Risk of complication | Lesser | Higher |
| Treatment | Treat primary cause followed by tympanoplasty or mastoidectomy | Ear surgery |
| |  |  |

## BIG QUESTION 4: What is cholesteatoma, and how does it develop, present clinically, and what are its complications and general principles of treatment?

**Broad Answer:** Cholesteatoma is an abnormal, non-neoplastic collection of keratinizing squamous epithelium in the middle ear and/or mastoid, often associated with chronic otitis media. It may be congenital or acquired, with acquired types usually resulting from eustachian tube dysfunction and tympanic membrane retraction. Clinically, it presents with foul-smelling otorrhea, hearing loss, and sometimes complications like bone erosion or facial nerve palsy. Its complications can be both extracranial and intracranial. Treatment is primarily surgical, typically involving mastoidectomy.

## DETAILED QUESTIONS

### Q4.1: What is cholesteatoma?

**Answer:**

- Normally, the EAC has stratified squamous epithelium, and the middle ear has cuboidal epithelium.
- The presence of stratified squamous epithelium in the middle ear is Cholesteatoma.

### Q4.2: What is the most common site of origin of cholesteatoma?

**Answer:** **Prussak's space**- it is the space between the pars flaccida and the neck of the malleus.

### Q4.3: What is the most common site of recurrence of cholesteatoma?

**Answer:** **Sinus tympani**- infra pyramidal space

**Q4.4: What is the most common site of erosion?**

**Answer:** Lateral semicircular canal

**Q4.5: What is the most common ossicle to be eroded?**

**Answer:** Long process of incus (lenticular process)

**Q4.6: What is the cause of erosion?**

**Answer:** Production of proteolytic enzymescollagenase, alkaline phosphatase, and acid phosphatase.

**Q4.7: What are the types of cholesteatoma?**

**Answer:**

- Congenital: Entrapment of ectodermal cells in the middle ear during development
- Acquired

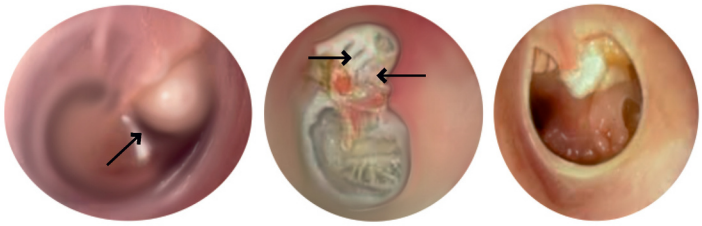

Congenital Acquired

**Q4.8: What is the criteria used for diagnosing congenital cholesteatoma?**

**Answer:**

- Levinson's criteria is used for diagnosing congenital cholesteatoma
  - Presence of a whitish mass behind an intact TM: Congenital cholesteatoma
  - No prior ear disease/ surgery

**Q4.9: What are the features of acquired cholesteatoma?**

**Answer:**

- Epithelial invasion
- Metaplasia
- Basal cell hyperplasia
- Keratin flakes in the attic or posterosuperior quadrant are the hallmark of acquired cholesteatoma.

**Q4.10: What are the symptoms of cholesteatoma?**

**Answer:**

- CHL
- Mild ear discharge
- Foul smell from the ear

**Q4.11: What are the common sites of spread of cholesteatoma?**

**Answer:**

- Cholesteatoma can spread
  - Via tegmen to the middle cranial fossa
  - Medially to the inner ear

YOURWISH

- Laterally to the external auditory canal
- Posteriorly to the mastoid

**Q4.12: How is cholesteatoma diagnosed?**

**Answer:**

- Keratin flakes on otoscopy
- Examination under a microscope
- CT scan to determine the extent of the disease
- Audiological tests

**Q4.13: What is the treatment of cholesteatoma?**

**Answer:** Surgery: MRM (Modified Radical Mastoidectomy)

**Q4.14: What are the types of mastoidectomy?**

**Answer:**

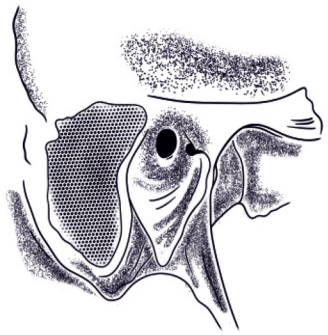

| Modified radical mastoidectomy | Cortical mastoidectomy |
|---|---|
| Canal wall down surgery | Canal wall up surgery/ intact canal wall mastoidectomy/ schwartz surgery |
| Posterior canal wall along with entire mastoid air cells is removed and made into a single cavity | • All the air cells are opened and the entire mastoid is made into a single cavity<br>• Posterior canal wall is kept intact- intact canal wall mastoidectomy |

**Q4.15: What are the features of tubercular otitis media?** PYQ: NEET PG 2020,2021

**Answer:** Multiple tympanic perforations



**Q4.16: What are the key characteristics used to differentiate between ASOM, SOM, Otosclerosis, and the two types of CSOM (tubotympanic and atticoantral)?**

**Answer:**

- Child + ear pain + fever + hearing loss = ASOM
- Child + hearing loss +/- additional features = SOM
- Middle age + female + hearing loss = Otosclerosis
- Ear discharge (profuse, non-foul smell, non-blood stained) +/- pain + hearing loss + discharge increases with URTI = tubotympanic CSOM
- Ear discharge (scanty, foul-smelling, blood-stained) + hearing loss = atticoantral CSOM

**BIG QUESTION 5: What are the complications of Chronic Suppurative Otitis Media (CSOM), and how do they impact patient outcomes?**

**Broad Answer:** CSOM can lead to a range of serious complications due to persistent infection and bone erosion. These are broadly classified into extracranial (such as mastoiditis, facial nerve palsy, labyrinthitis, and hearing loss) and intracranial complications (including brain abscess, meningitis, and lateral sinus thrombosis). Prompt diagnosis and management of these complications are essential to prevent long-term morbidity or mortality.

## DETAILED QUESTIONS

### Q5.1: What are the complications of ASOM and CSOM?

**Answer:**

| Extracranial | Intracranial |
|---|---|
| Mastoiditis | Meningitis |
| Labyrinthitis | Extradural abscess |
| Facial nerve palsy | Subdural abscess |
| Petrositis | Brain abscess |
| Osteomyelitis | Lateral sinus thrombophlebitis |
| Septicemia | Otitic hydrocephalus |
| 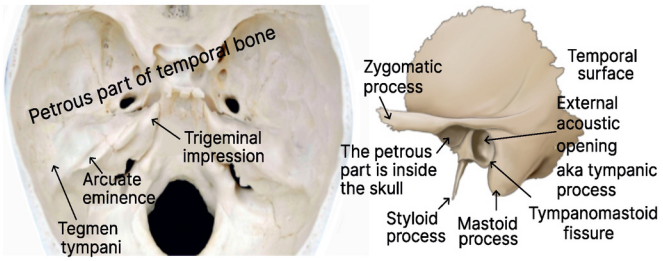 | 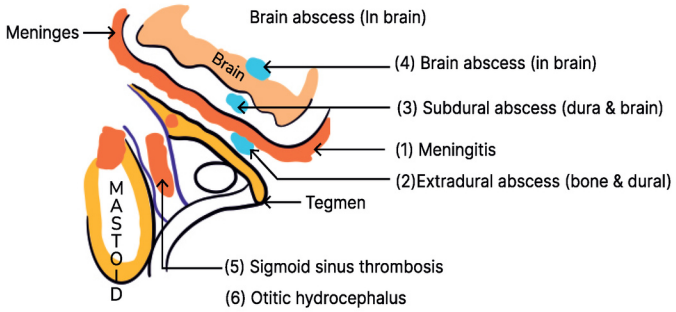 |

**NOTE:** The Internal auditory canal is seen in the petrous part of the temporal bone

### Q5.2: What are the extracranial complications of CSOM?

**Answer:**

| | |
|---|---|
| **Acute mastoiditis** | Through aditus disease in the middle ear goes posteriorly to the mastoid bone. |
| **Labyrinthitis** | The disease goes from middle ear to inner ear. |
| **Facial nerve palsy** | The disease goes towards internal auditory meatus or anywhere along the course of facial nerve results in facial nerve palsy. |
| **Petrositis** | Infection goes towards the apex of the petrous bone and cause petrositis. |
| **Osteomyelitis** | Involvement of squamous temporal bone. |
| **Septicemia** | Blood spread will result in septicemia. |

### Q5.3: What are the intracranial complications of CSOM?

**Answer:**

- Inflammation of the meninges is known as Meningitis
- Localization of pus between the bone and dura is known as an Extradural abscess
- Localization of pus between the dura and brain is known as a subdural abscess, and it extends into the brain parenchyma, known as a Brain abscess.
- The posterior border of the mastoid is in relation to the sigmoid sinus, which can cause thrombosis called Sigmoid sinus thrombosis.

## BIG QUESTION 6: What is acute mastoiditis secondary to CSOM, and what are its clinical features, complications, and management principles?

**Broad Answer:** Acute mastoiditis is an extracranial complication of CSOM caused by infection spreading from the middle ear to the mastoid air cells. It presents with postauricular pain, swelling, ear discharge, and protrusion of the pinna. If not promptly treated, it can lead to abscess formation or intracranial extension. Management involves IV antibiotics and mastoidectomy in severe or unresponsive cases.

## DETAILED QUESTIONS

### Q6.1: What is the etiology of acute mastoiditis?

PYQ: INICET 2019 PYQ: FMGE 2020

**Answer:**

- The most common extracranial complication of acute otitis media
- Spread of middle ear infection to the mastoid air cells
- Organisms/symptoms are similar to a middle ear infection

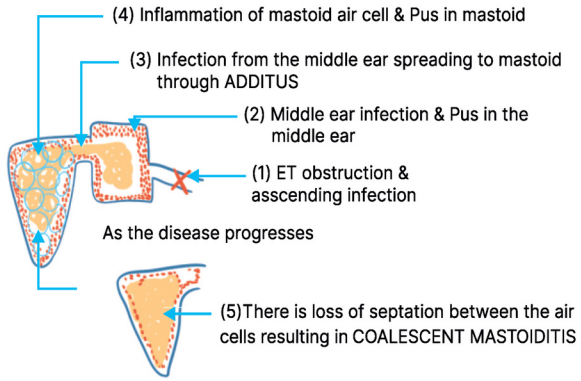


### Q6.2: What are the signs and symptoms of acute mastoiditis?

**Answer:**

- Symptoms will be exaggerated, along with pain and redness beyond the ear
- Pulsatile otorrhea: the lighthouse sign, where pus reflects light
- Ironed out appearance of the mastoid- first sign
- Positive reservoir sign- immediate reappearance of discharge after mopping: specific sign
  - o If it doesn't reappear- ASOM

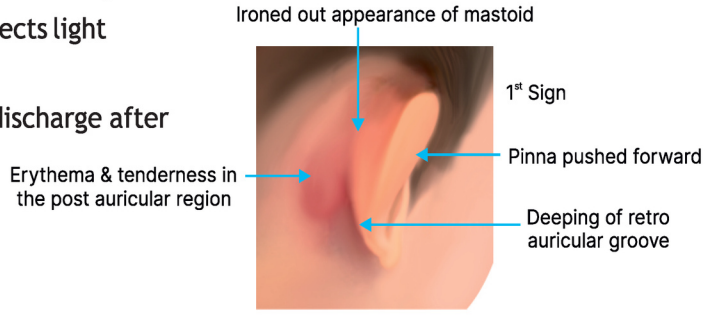


### Q6.3: How is acute mastoiditis diagnosed?

**Answer:**

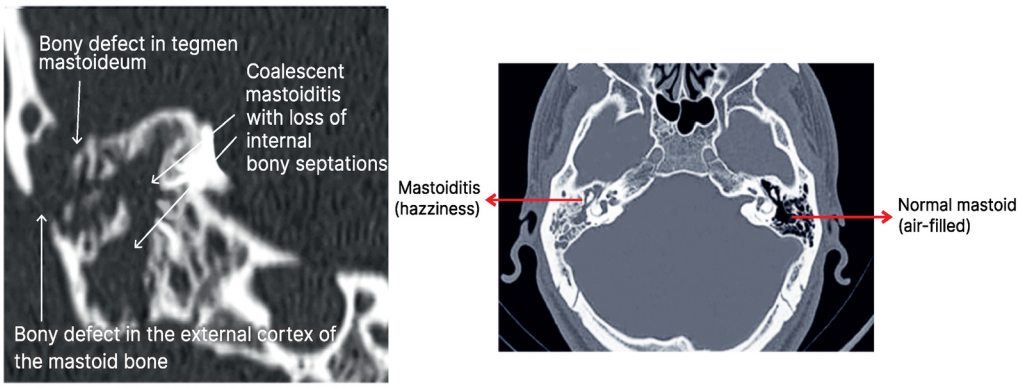

- On X-ray: Hazy mastoid air cells
  - Erosion of bone
- On CT: Diseased region appears gray

### Q6.4: How is acute mastoiditis managed?

**Answer:** Cortical mastoidectomy + IV antibiotics

### Q6.5: What are the various abscesses related to the mastoid?

**Answer:**

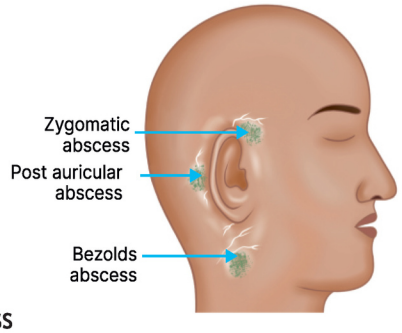


- Pus can break the outer cortex of the mastoid: Post auricular abscess (most common abscess).
- Pus tracks into the sternocleidomastoid muscle: Bezold's abscess
- Abscess into the posterior belly of the digastric muscle: Citelli's abscess
- Pus extends into the external auditory meatus: Luc's abscess · Zygomatic abscess

## BIG QUESTION 7: What are the other intracranial and inner ear complications associated with Chronic Suppurative Otitis Media (CSOM), excluding mastoid abscesses?

**Broad Answer:** CSOM can lead to several serious complications beyond mastoid involvement. These include petrositis (infection of the petrous part of the temporal bone), labyrinthitis (inflammation of the inner ear presenting with vertigo and sensorineural hearing loss), brain abscess (especially temporal lobe or cerebellar), and lateral sinus thrombophlebitis (a vascular complication involving thrombosis of the lateral sinus). These conditions often present with systemic signs and neurological symptoms, requiring urgent imaging and management.

## DETAILED QUESTIONS

### Q7.1: What are the features of petrositis?

**Answer:**

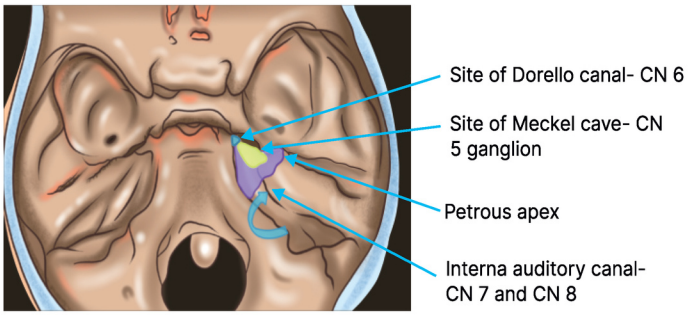


- Inflammation of the petrous apex
- At the petrous apex, there are two cranial nerves
  - $6^{th}$ cranial nerve: Lateral rectus palsy
  - $5^{th}$ cranial nerve: Retro-orbital pain

### Q7.2: What is the Gradenigo triad?

**Answer:** Gradenigo triad is the classic triad seen in petrositis.

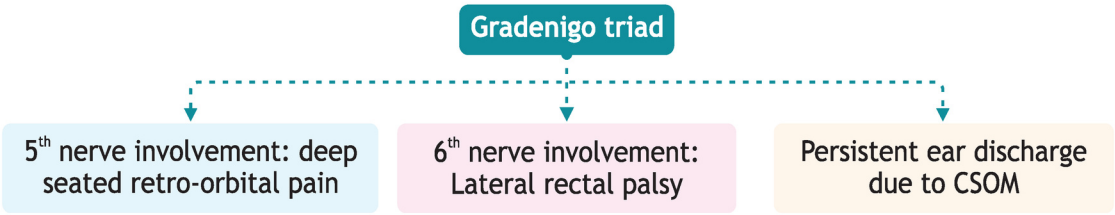


### Q7.3: What are the features of Labyrinthitis?

**Answer:**

- Inflammation of the labyrinth
- It is of three types:
  - Circumscribed- localized to only one part of the labyrinth



YOURWISH

- Diffuse serous- no infection, but sterile fluid in the entire inner ear
- Diffuse suppurative- pus in the inner ear

- Leads to SNHL, vertigo, tinnitus

**Q7.4: What are the distinguishing features of each type of labyrinthitis?**

**Answer:**

| | Circumscribed | Diffuse serous | Diffuse suppurative |
|---|---|---|---|
| **Pathology** | Thinning or erosion of bony capsule of labyrinth | Diffuse inflammation of labyrinth without pus | Pus or infection of labyrinth |
| | Labyrinth is exposed to external stimuli | Labyrinth is inflamed and irritable | Lost vestibular and cochlear functions |
| **Reversibility** | | Reversible | Irreversible |
| **Fistula test** | Positive | Negative | Negative |
| **Nystagmus** | Positive pressure: nystagmus to the same side. Negative pressure nystagmus to opposite side | Nystagmus to same side | Nystagmus to opposite side |
| | Transient vertigo on applying pressure to tragus | Vestibular and cochlear symptoms | Toxic + severe symptoms of serous labyrinthitis |

**Q7.5: Patient presents with h/o ear discharge, foul-smelling, blood stained. Presently complains of headache, projectile vomiting. The MRI image is given above. What is the probable diagnosis?** PYQ: NEET PG 2021

**Answer:** Diagnosis: Brain abscess

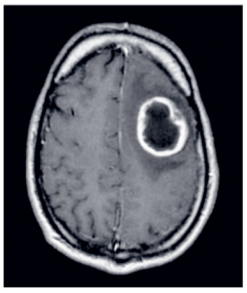

- A space-occupying lesion with a central hypo-dense area with an enhancing ring on the outside is suggestive of a brain abscess.
- This abscess is located on the temporal lobe of the bone- MC abscess secondary to CSOM.
- Organism: Aerobic, anaerobic, or mixed infection
- Infection breaks the tegmen and spreads to the middle cranial fossa
- Treatment: Drainage of the abscess, antibiotics, MRM

**Q7.6: How does lateral sinus thrombophlebitis occur, and what are its key pathological consequences?**

**Answer:**

- Infection spreads from the middle ear to the mastoid sinus
- The posterior border of the mastoid has the sigmoid sinus
- Infection results in thrombosis of the sigmoid sinus
- Leads to intermittent emboli in the bloodstream, producing rigor and a hectic 'picket-fence' type of fever that does not return to baseline.

**Q7.7: What is the Griesinger sign?**

**Answer:**

- Obstruction of mastoid emissary vein drainage into the sigmoid sinus causes edema and bluish discoloration of the mastoid, known as Griesinger sign.
- Cranial circulation cannot drain into the sigmoid sinus- raised ICP- manifests as papilledema- dilatation of the optic disc.



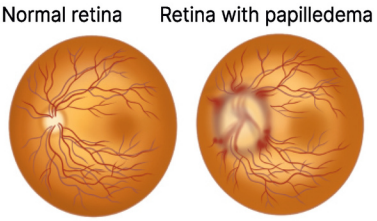


**Q7.8: What are the tests used to diagnose lateral sinus thrombophlebitis?** PYQ: FMGE 2018,2020

**Answer:**

- **Tobey-Ayer's test:** Compression of the IJV on the healthy side produces a rise in CSF pressure.
- **Crowe-Beck test:** Pressure of the IJV on the healthy side produces engorgement of the retinal veins.

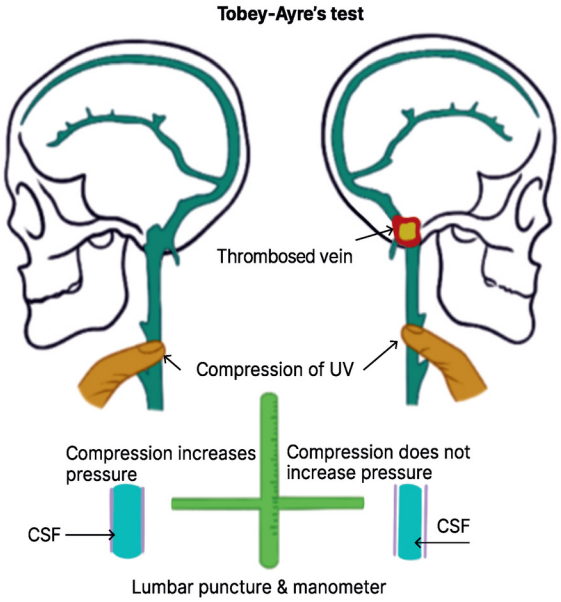


**Q7.9: What are the imaging findings seen in lateral sinus thrombophlebitis?**

**Answer:** Contrast-enhanced CT/MRI shows the Delta sign or the Empty delta sign.

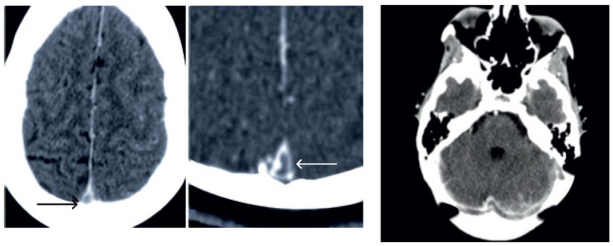

**Q7.10: What are the treatment options available for lateral sinus thrombophlebitis?**

**Answer:**

- Thrombolytics- based on the length of sigmoid sinus thrombosis
- Excision

**BIG QUESTION 8: What is Otosclerosis, what are its clinical features, and management principles?**

**Answer:** Otosclerosis is a primary localized disease of the bony labyrinth, particularly involving abnormal bone remodeling around the stapes footplate. It typically affects young to middle-aged adults and is more common in females. The most common clinical presentation is progressive conductive hearing loss due to stapes fixation, although sensorineural hearing loss may also occur if the cochlea is involved (cochlear otosclerosis). Tinnitus is a common associated symptom, and the tympanic membrane usually appears normal on otoscopy. The classic sign seen in some cases is Schwartze's sign (a reddish hue over the promontory). The condition is often bilateral and can have a hereditary pattern. Treatment options include hearing aids and stapedectomy/stapedotomy.

## DETAILED QUESTIONS

PYQ: FMGE 2022

### Q8.1: What is otosclerosis?

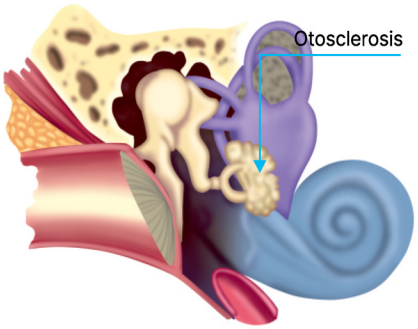


**Answer:**

- Oto: Ear
- Sclerosis: Excessive bone deposition.
- This disease affects the stapes footplate.

### Q8.2: What are the types of otosclerosis?

**Answer:**

- **Stapedial type of otosclerosis-** results in the footplate of the stapes becoming fixed, which does not allow conduction of sound
  - Most common
  - CHL
  - Most common site: Fissula ante fenestram (anterior to the foot plate)
- **Cochlear type of otosclerosis-** the round window is affected
  - SNHL
  - Less common

### Q8.3: Compare the symptoms between Stapedial and Cochlear Otosclerosis.

**Answer:**

| | Stapedial | Cochlear |
|---|---|---|
| Incidence | Common | Less common |
| Hearing loss | Conductive | Sensorineural |
| Tinnitus, Vertigo | Rare | Common |
| Paracusis willisii | Common | No |

### Q8.4: What is Paracusis willisii?

**Answer:** Paracusis willisii is a condition where the patient hears better in a noisy environment as compared to in a silent environment

### Q8.5: What is the etiology of otosclerosis?

**Answer:**

- **Hereditary:** Autosomal dominant with incomplete penetrance
- **Sex:** F > M, but in India, male predominant
- **Age of onset:** 20-40 years
- **Hormonal:** Increases in pregnancy and during menopause.

### Q8.6: What are the syndromes associated with otosclerosis?

**Answer:**

**Vander Hoeve Syndrome**

- Osteogenesis Imperfecta
- Otosclerosis
- Blue sclera



### Q8.7: What are the signs seen in otosclerosis?

**Answer:**

- Tympanic membrane is normal (90%)
- The tympanic membrane is mobile.
- Schwartz Sign (10%): Active lesions show a flamingo-pink hue on the promontory, visible through an intact tympanic membrane (Schwartz sign, seen in ~10% of cases).

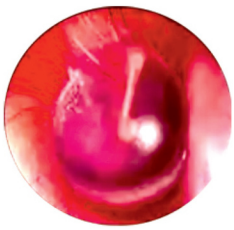

Normal tympanic membrane

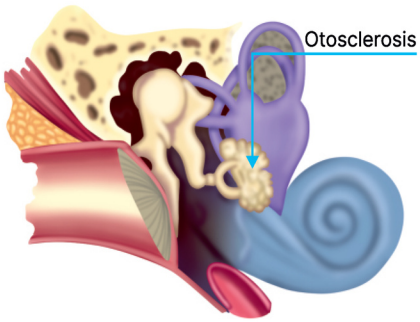


### Q8.8: What are the tests done for stapedial otosclerosis?

PYQ: AIIMS 2018 PYQ: INICET 2019

**Answer:**

| Test | Inference |
|---|---|
| Rinne | Negative |
| Weber | Lateralised to abnormal ear |
| Absolute bone conduction | Normal |
| Gelles test | Negative |
| Tympanometry | As-Type graph |
| Stapedial reflex | Absent |
| Pure tone audiometry | Carhart's notch |

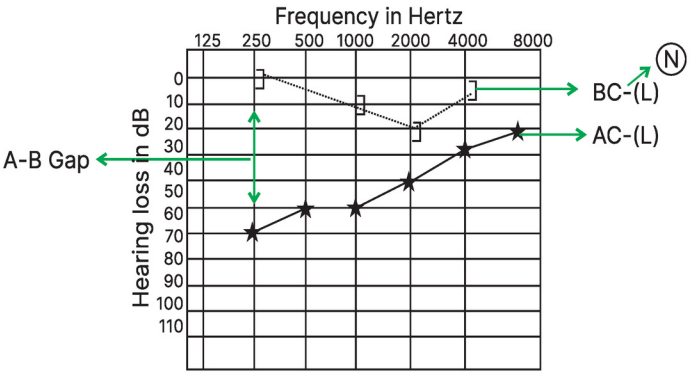


### Q8.9: What is Carhart's notch?

**Answer:**

- Notch in the bone conduction curve at 2000 Hz
- Specific to otosclerosis

### Q8.10: What is the treatment of otosclerosis?

**Answer:**

- Medical
  - Hearing aid
  - Sodium fluoride- given only if there is an active focus that needs to be arrested.

### Q8.11: What is the mechanism of action, indications, and contraindications of sodium fluoride?

**Answer:**

- **Mechanism of action:**
  - Inhibits osteoclastic resorption of bone and osteoblastic new bone deposition, preventing further progression of the disease
  - Cannot reverse the disease process



YOURWISH

- **Indication:**
  - Only in active focus
- **Contraindication**
  - Pregnancy and lactation
  - Renal disease
  - Rheumatoid arthritis
  - Skeletal fluorosis

### Q8.12: What is the surgical management of otosclerosis?

**Answer:**

- Stapedotomy with placement of prosthesis- treatment of choice
- Stapedectomy and placement of a prosthesis
- Stapes mobilization
- Lempert's fenestration operation

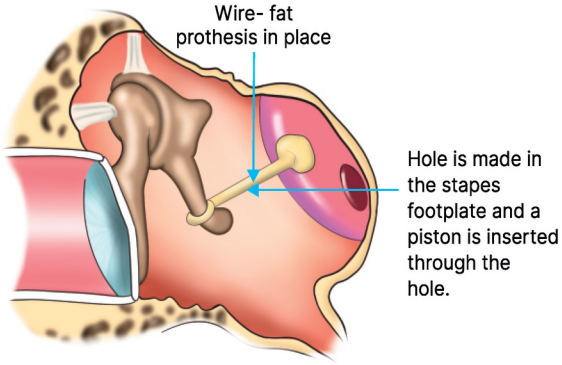


### Q8.13: What is stapedectomy?

**Answer:**

- The entire stapes is removed and replaced by a piston
- Piston: Teflon
- The piston is anchored between the incus and the oval window

### Q8.14: What is stapedotomy?

**Answer:**

- A hole is made on the footplate, and the piston is anchored from the incus to the hole created, while the stapes is intact, or the Suprastructure is removed, and the footplate is kept as it is
- A hole is made in the footplate, and the piston is anchored.

# 5. INNER EAR DISEASES AND FACIAL NERVE

## BIG QUESTION 1: What are glomus tumors, and how do they present clinically?

**Broad answer:** Glomus tumors are benign but locally invasive paragangliomas arising from the paraganglionic cells in the middle ear, associated with the sympathetic plexuses near blood vessels like the internal jugular vein and carotid artery. Two types include glomus tympanicum (from tympanic plexus) and glomus jugulare (from jugular bulb plexus). They commonly cause conductive hearing loss, pulsatile tinnitus, and cranial nerve palsies. Classic signs include the rising sun appearance on otoscopy and Brown's sign. Diagnosis is confirmed with CECT, MRI, and angiography, while treatment involves embolization followed by surgery.

## DETAILED QUESTIONS

### Q1.1: What are the D/D of vertigo ?

PYQ: FMGE 2019,2020,2022

**Answer:**

| | Meniere's | BPPV | Labyrinthitis (inflammation of labyrinth) | Vestibular neuronitis (inflammation of vestibular nerve) |
|---|---|---|---|---|
| Vertigo | Few minutes to hours | Few seconds to few minutes | Single long episode lasting for days to weeks | Single long episode lasting for days to weeks |
| Associated hearing loss | • SNHL: Low frequency type<br>• Diplacusis: Double hearing | No hearing loss as only semicircular canals are involved | SNHL- high frequency | No hearing loss as cochlear nerve is not involved |
| Type of hearing loss | Fluctuating | | Constant | |
| Tinnitus | + | - | + | - |
| Positional change causing vertigo | - | + | - | - |
| IOC | Electrocochleography- SP/AP > 30% | Dix hallpike test | - | - |
| Treatment | Intra tympanic steroids → intratympanic gentamicin → surgery | • Epley's maneuver<br>• 5 step: Rehabilitating maneuver | • Steroids<br>• Antibiotics<br>• Antiviral therapy | • Steroids<br>• Antibiotics<br>• Antiviral therapy |

### Q1.2: What is the benign tumor of the middle ear that arises from paraganglionic cells, and what is its site of origin?

PYQ: FMGE 2021

**Answer:**

- Glomus tumour- Benign, locally invasive, slow growing tumour
- Glomus tumor originates from paraganglionic cells

- Cells of sympathetic nervous system which secrete catecholamines- epinephrine, norepinephrine, dopamine
- Usually present across major blood vessels like internal carotid artery, internal jugular vein
- In the middle ear, floor is related to the internal jugular vein and on the promontory (formed by the basal turn of ganglia), a plexus is formed- tympanic plexus- formed by glossopharyngeal nerve and sympathetic plexus of carotid
- From these sympathetic plexus and the sympathetic plexus covering the internal jugular vein the tumor arises

**Q1.3: What is the difference between Glomus juglare and Glomus tympanicum ?**

**Answer:**

- Glomus juglare: Arising from the sympathetic plexus covering the internal jugular vein
- Glomus tympanicum: Arising from the tympanic plexus

**Q.1.4: What is the pattern all paragangliomas have on HPE ?**

**Answer:**

- Typically, all paragangliomas have a pattern on HPE, known as Zellballen pattern

**Q.1.5: What are the symptoms of glomus tumor?**

**Answer:**

- Sweating, flushing, headache, tachycardia (due to excess catecholamines)
- Conductive hearing loss - gradually progressive type(due to the mass growing)
- Pulsatile tinnitus (resembles the heartbeat)
- Pain + bleeding (as tumor lacks tunica media/ smooth muscle layer). Hence, probe test, biopsy, FNAC shouldn't be done th th th o
- If it involves the jugular foramen, it can cause 9 , 10 , 11 nerve palsies
- It can also cause Horner's syndrome

**Q.1.6: Describe the signs of Glomus tumor**

**Answer:**

- Signs:
  - Reddish hue from the floor of the middle ear: Rising sun appearance
  - Seen on otoscopy
  - Browns sign: When the pressure on the EAC is increased, tumor vibrates vigorously and then becomes pale
  - Salt and pepper appearance- seen on a contrast enhanced MRI
  - Phelps sign- seen on a CT scan: Tumor eroding the bone between the carotid artery and jugular vein

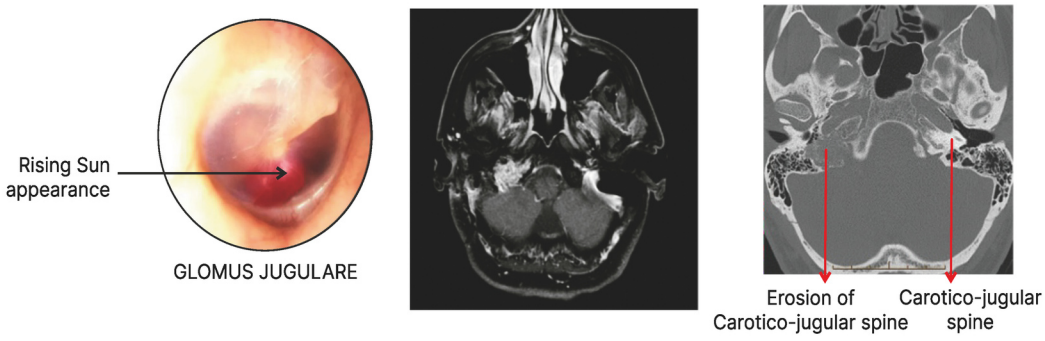


**Q1.7: What is the IOC for glomus tumors?**

**Answer:**

- IOC: CECT
  - MRI can be done to check for intracranial spread
  - Angiography to identify the feeding vessel

### Q1.8: What is the treatment of glomus tumor? Name the classification of glomus tumor

**Answer:**

- Treatment
  - Angiography and embolize the feeding vessel
  - Surgical excision
- Classification of glomus tumors: FISCH classification

### Q1.9: Describe the anatomy of the facial nerve

**Answer:**

- 7th cranial nerve that exits from pons
- Facial nerve nucleus is present in the brain stem
- Supranuclear palsy: Any lesion above the level of pons
- Infranuclear palsy: Any lesion below the level of pons
- Forehead is spared as it receives its innervation from bilateral cerebral cortex
- It is a mixed nerve having sensory root (nerve of Wrisberg), motor root and secretomotor root
- Course of facial nerve is divided into 3 parts:
  - Intracranial
  - Intratemporal
  - Extracranial

### Q.1.10: Describe the Intracranial route of facial nerve

**Answer:**

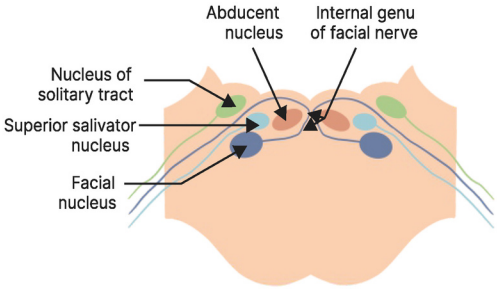


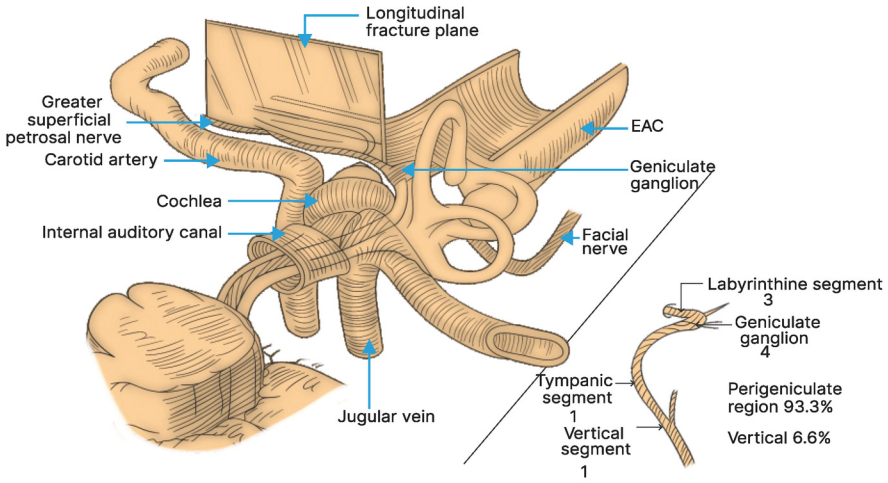


- Facial nerve exits from its nucleus takes a turn around the nucleus of 6th nerve (facial colliculus) and emerges outside and enters the internal auditory canal

### Q.1.11: What is the Intratemporal route of facial nerve ?

**Answer:**

- Once the facial nerve enters the internal auditory canal, it travels to the inner ear, middle ear and to the mastoid
- Longest portion



YOURWISH

- Only nerve which runs in most of its course through a bony canal (Fallopian canal- absent in 50% of population)
- Most common site of dehiscence is the horizontal part

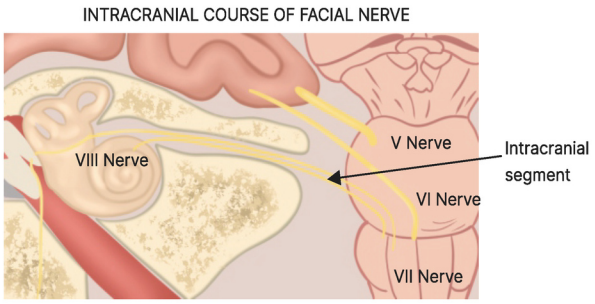


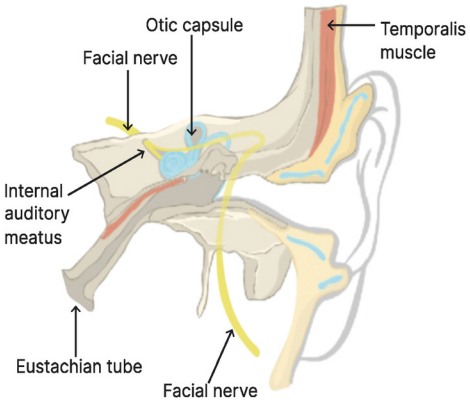


## Q.1.12: Explain Extracranial route of facial nerve

**Answer:**

- Enters parotid gland and gives rise to five terminal branches

## Q1.13: What are the various segments of the intratemporal part of the facial nerve?

**Answer:**

- Intratemporal portion is further divided into:
  - Meatal segment: Lies in the internal auditory meatus
  - Labyrinthine segment: Inner ear
  - Tympanic segment: Middle ear
  - Mastoid segment: Mastoid

## Q.1.14: Explain Meatal segment of intratemporal part of the facial nerve

**Answer:**

- Meatal segment (8-10mm):
  - In the internal acoustic meatus there is a vertical crest of bone called as the Bills bar
  - A horizontal crest of bone called falciform crest
  - In the antero superior quadrant lies the facial nerve
  - In the anteroinferior quadrant lies the cochlear nerve
  - In the posterosuperior quadrant lies the superior vestibular nerve
  - In the posteroinferior quadrant lies the inferior vestibular nerve

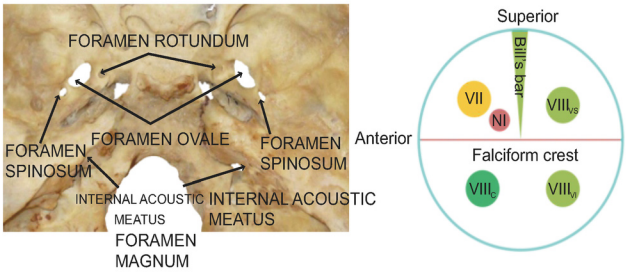


## Q.1.15: Explain Labyrinthine segment of intratemporal part of the facial nerve

**Answer:**

- Labyrinthine segment:
  - In the inner ear, facial nerve travels above the vestibule

- Anteriorly: Cochlea
- Posteriorly: Semicircular canals
- Shortest and narrowest segment
- Most prone to ischemia and edema (Bell's palsy)

## Q.1.16: Explain Tympanic segment of intratemporal part of the facial nerve

**Answer:**

- Tympanic segment (11mm horizontal segment and 13mm vertical segment):
  - 1st genu/ Geniculate ganglion: Turn which the nerve makes while passing from inner ear to the medial wall of the middle ear
  - Landmark for geniculate ganglion: Cochleariform process
  - Runs horizontally on the medial wall of the middle ear above a window (oval window) and below a canal (lateral semicircular)
  - Continues from the medial wall to the posterior wall and taking a turn: 2nd genu nd
  - Landmark for 2nd genu: Pyramid

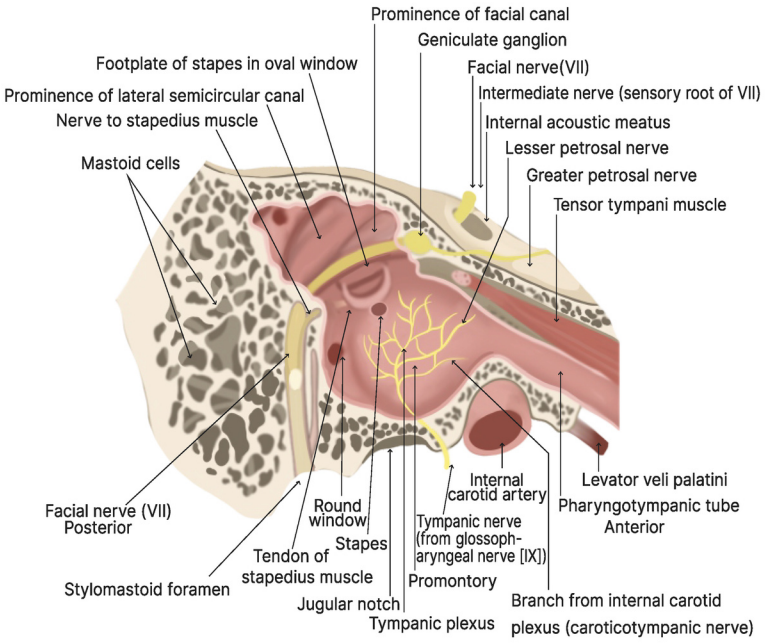


**Right medial wall of the middle ear**

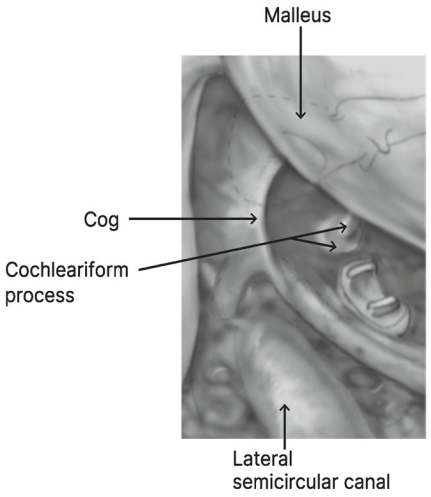


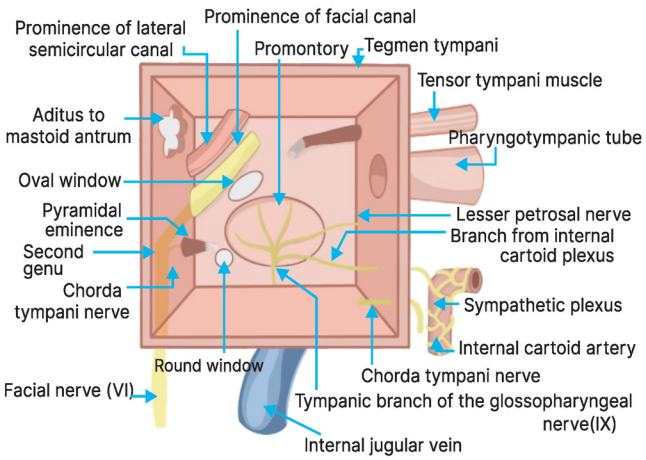

## Q1.17: Explain Mastoid segment of intratemporal part of the facial nerve

**Answer:**

- Mastoid segment
  - Vertical segment of facial nerve
  - In the mastoid bone
  - Exits from stylo mastoid foramen

## Q1.18: What are the branches of facial nerve and clinical test to identify the lesions of facial nerve?

**Answer:**

- Greater superficial petrosal nerve (from 1 genu)
- Nerve to stapedius (from 2 genu)
- Chorda tympani and sensory auricular branch to pinna and EAC (from vertical segment)
- Branches to submandibular and sublingual salivary glands (before exiting from styloid foramen)
- Terminal branches:
  - Temporal
  - Zygomatic
  - Buccal
  - Marginal mandibular
  - Cervical

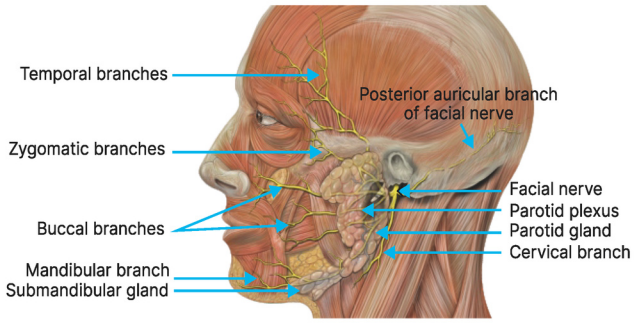


### Topodiagnosis

- Identifying lesions by performing clinical tests

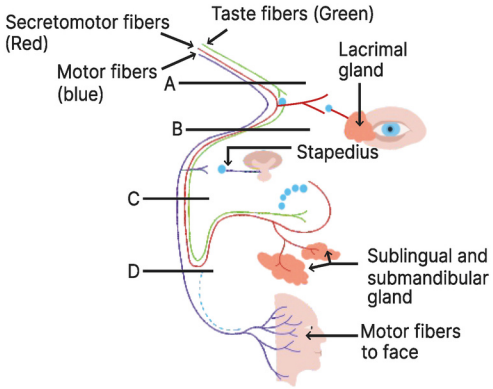


| | Supra Geniculate lesion | Infra Geniculate lesion |
|---|---|---|
| Schirmer's test | - | + |
| Stapedial reflex | - | - |
| Taste | - | - |
| Sub mandibular | - | - |
| LMN Palsy | - | - |

## Q1.19: What are the features of Bell's palsy?

PYQ: FMGE 2019,2023

PYQ: NEET PG 2023

**Answer:**

- Idiopathic facial nerve palsy
- Seen in pregnancy, diabetics
- Usually associated with EBV, HSV

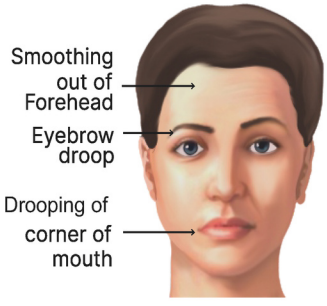


### Clinical features

- Deviation of angle of mouth
- Loss of nasolabial fold
- Sagging of eyebrow
- Hyperacusis: Normal sounds are heard as loud sounds



YOURWISH

### Q1.20: What is the triad of Melkerson' Rosenthal syndrome ?

PYQ: FMGE 2022

**Answer:**

**Triad:**

- Recurrent facial nerve palsy
- Swelling of lips
- Fissured tongue



Swelling of lips



Fissured tongue

### Q1.21: What are the clinical features of Ramsay Hunt Syndrome?

**Answer:**

- Vesicles in the area of distribution of facial nerve
- LMN type of facial palsy
- SNHL due to 8th nerve involvement

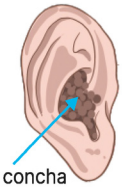

Vesicles in the concha



LMN type facial palsy

### Q1.22: Differentiate between Longitudinal and Transverse fractures of temporal bone

**Answer:**

| Longitudinal fracture | Transverse fracture |
|---|---|
| • Fracture line runs **parallel** to the long axis of the petrous bone<br>• **More common type**<br>• TM perforation is common<br>• Risk of facial nerve palsy is less.<br>• **Conductive hearing loss is common**<br>• Risk of SNHL is no or less.<br>• **CSF otorrhea is common** | • Fracture line runs **perpendicular** to the long axis of the petrous bone<br>• **Less common type**<br>• TM perforation in not common<br>• **High risk of facial nerve palsy**<br>• Conductive hearing loss is not common<br>• High risk of SNHL<br>• **CSF rhinorrhea where there is fluid accumulation in the middle ear- presents as paradoxical CSF rhinorrhea** |

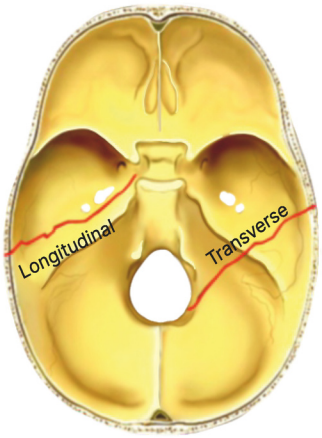


### Q1.23: What is the significance of electrophysiological test in facial palsy and what are the 2 types of electrophysiological test?

**Answer:**

**Significance:**

- To understand the extent of nerve damage and need of treatment

**Types:**

| Electroneuronography | Electromyography |
|---|---|
| • Measure the conduction capacity of the nerve.<br>• Comparing function of normal side v/s paralyzed side | • Measures muscle potentials during rest and voluntary movement. |
| • Procedure<br>• If >90 % decrease in CMAP within 14 days of paralysis, then chances of spontaneous recovery is negligible- consider surgical decompression | • Procedure Interpretation- if **motor unit potentials** are present then it means that the nerve is regenerating.<br>• If **fibrillation potential** is present then chances of spontaneous recovery is negligible and surgical decompression may be considered<br>• No electric output then facial reanimation may be considered. |



YOURWISH

YOURWISH

**Q1.24: What are the consequences of faulty reinnervation of facial nerves?**

**Answer:**

**Crocodile tears**

- If injury is before geniculate ganglion, reinnervating fibers can anastomose with chorda tympani nerve.
- Whenever the patient eat, lacrimation is seen

**Frey's Syndrome**

- Gustatory sweating in the angle of mandible.
- This occurs because of faulty innervation of the auriculotemporal nerve with facial nerve.

**Q1.25: Name the first branch of facial nerve**

**Answer:** GSPN

**Q1.26: Which nerve is e involved in hyperacusis ?**

**Answer:** Nerve to stapedius

**Q1.27: Lacrimination is affected at which level of injury to the facial nerve?**

**Answer:** Above the level of 1st genu

**Q1.28 Which is the most common cause of facial nerve palsy?**

**Answer:** Idiopathic > Traumatic

**Q1.29: What causes iatrogenic facial nerve palsy?**

**Answer:** Mastoidectomy

**Q1.30: Which segment of the facial nerve is affected first in ischemia and edema?**

**Answer:** Labyrinthine segment

**Q1.31: Which segment of facial nerve is affected in iatrogenic trauma ?**

**Answer:** Vertical/mastoid segment

**Q1.32: Which fracture of petrous bone is responsible for facial injury ?**

**Answer:** Transverse fracture

**Q1.33: At which site of facial nerve involvement is taste affected?**

**Answer:** Mastoid segment of facial nerve

**Q1.34: What is the cause of crocodile tears syndrome in facial nerve lesions?**

**Answer:** Crocodile tears occur due to faulty innervation with chorda tympani nerve

## BIG QUESTION 2: What is acoustic neuroma and how does it present clinically and radiologically?

**Broad Answer:** Acoustic neuroma, also called vestibular schwannoma, is a benign tumor originating most commonly from the inferior vestibular nerve in the internal auditory canal, later extending into the cerebellopontine angle. It causes unilateral sensorineural hearing loss (SNHL) and retrocochlear symptoms like tinnitus and imbalance. On MRI, it shows the ice cream cone sign. Bilateral tumors are a hallmark of NF-2. Histologically, it features Antoni A/B areas and Verocay bodies. Treatment depends on size: <3 cm → stereotactic radiosurgery, >3 cm → surgical excision.

## DETAILED QUESTIONS

PYQ: NEET PG 2021

### Q2.1: What are the salient features of acoustic neuroma?

**Answer:**

- It is also known as vestibular schwannoma
- Present in the internal auditory canal
- From internal auditory canal, it grows towards cerebello pontine region
- Most commonly originates from inferior vestibular nerve
- Most common: Unilateral acoustic neuroma
- Bilateral acoustic neuroma is seen in neurofibromatosis type 2

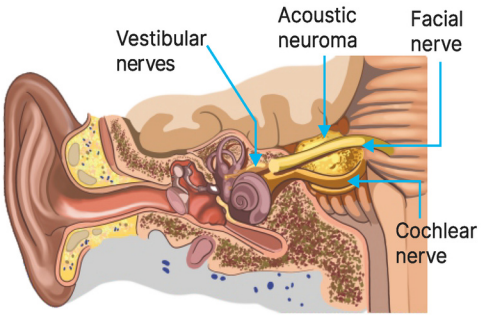


Acoustic neuroma on vestibulocochlear nerve puts pressure on facial nerve

### Q2.2: What are the features seen on HPE of acoustic neuroma?

**Answer:**

- Antoni type A/B
- Verocay body

### Q2.3: Describe the symptoms of acoustic neuroma.

**Answer:**

- Transient vertigo- compensated from the opposite side (due to involvement of inferior vestibular nerve)
- Compresses the cochlear nerve in the canal- unilateral SNHL
- Retro cochlear type of hearing loss
- Tinnitus absent th o Involvement of $5^{th}$ nerve results in absent corneal reflex
- **Hitzelberger sign**: The sensory fibers are affected first, which results in loss of sensation in the concha- occurs due to th involvement of $7^{th}$ nerve
- Sensory fibers of facial nerve are affected first, later motor fibers can also get affected
- Dysphagia, palatal paralysis, speech difficulty indicated involvement of $9^{th}$ , $10^{th}$ ,$11^{th}$ cranial nerves

### Q.2.4: What is the IOC for acoustic neuroma ?

**Answer:**

- MRI with contrast- Ice cream cone appearance

### Q2.5: What is the treatment of choice for acoustic neuroma?

**Answer:**

- If < 3cm - radio surgery- stereotactic radiation
- If > 3 cm - surgical excision

### Q2.6: What is the indication for cochlear implant?

PYQ: FMGE 2019,2021 PYQ: NEET PG 2018

**Answer:**

- Done for patients with bilateral severe to profound SNHL

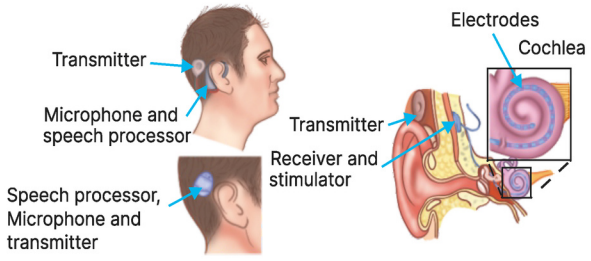


### Q2.7: What are the components of cochlear implant?

**Answer:**

- An external device
- An internal device
- Implant- inserted into the cochlea in scala tympani via round window

### Q2.8: Which approach is used for cochlear implant placement?

**Answer:** Approach: Facial recess approach

### Q2.9: What is BAHA? Describe briefly

**Answer:**

- The screw is placed in the temporal bone screw
- Once the screw gets integrated with the surrounding bone, and is placed over it abutment processor
- This will capture the surrounding sound and through the bone it is conducted to the inner ear
- Used when external/middle ear abnormality is seen, where a hearing aid cannot be used
- Can also be used in unilateral severe to profound SNHL

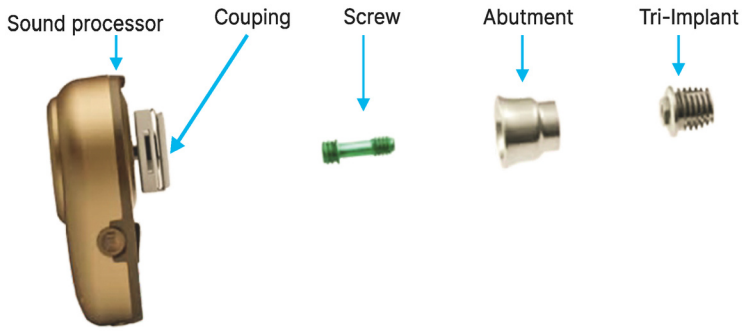


### Q2.10: What is the indication and components of the auditory brainstem implant?

**Answer:**

- In patients with 8$^{th}$ nerve palsy, external, middle and inner ear is bypassed and implant electrode is placed in the brainstem

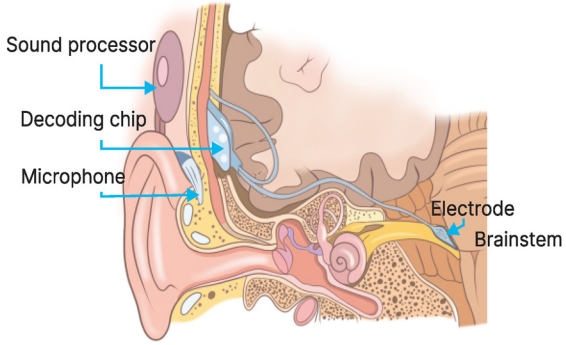


### Q2.11: What is the indication of hearing aid?

**Answer:**

- This can be used in patients with mild to moderate hearing loss

### Q2.12: What is the the best method to rehabilitate in a case of bilateral profound hearing loss ?

**Answer:**

- Cochlear implant

### Q2.13: A 3-year-old child has been diagnosed with bilateral moderate SNHL. What is the best way to rehabilitate ?

**Answer:**

- Hearing aid

### Q2.14: What is the ideal time for treatment of hearing loss in infants ?

**Answer:**

- As early as possible

**Q2.15: Cochlear implant is contraindicated in which of the following?**

A. Scheibe dysplasia

B. Mondini'sdysplasia

C. Alexandersdysplasia

D. Michel aplasias

**Answer:** D. Michel aplasias

| | |
|---|---|
| Scheibe dysplasia | Saccular and cochlear dysplasia |
| Mondini's dysplasia | Cochlea takes only 1- 1.5 turns instead of 2.5 turns |
| Alexander's dysplasia | Basal turn has not developed |
| Michel aplasias | No cochlea |

**Q2.16: In what condition is BAHA used?**

**Answer:** BAHA is used in external/middle ear disease/unilateral SNHL

**Q2.17: What is the principle of action of a cochlear implant?**

**Answer:** A cochlear implant converts mechanical sound energy into electrical impulses.



YOURWISH

# 6. ANATOMY OF NOSE & PARA-NASAL SINUSES

## BIG QUESTION 1: Give a brief description of the anatomy of the Nose.

**Broad Answer:**

- The nose is divided into external and internal nose. The external nose has a bony part and a cartilaginous part. Key landmarks include the nasion and rhinion. The internal nose extends from the inlet to the outlet and includes a roof, floor, medial wall, and lateral wall.

## DETAILED QUESTIONS

### Q1.1: What are the structural components of the external nose?

**Answer:**

- The external nose is divided into:
  - Upper 1/3rd instead made up of the Bony part
  - Lower 2/3rd instead made up of the Cartilaginous part

### Q1.2: Elaborate on the bony structures of the external nose.

PYQ:INICET 2022

**Answer:**

- Bony structures of the external nose is made of 2 paired bones and 1 unpaired bones
  - Paired bones of the external nose are:
    - → 2 nasal bones
    - → 2 ascending process of the maxilla
  - Unpaired bones (from above) of the external nose are:
    - → Frontal bone

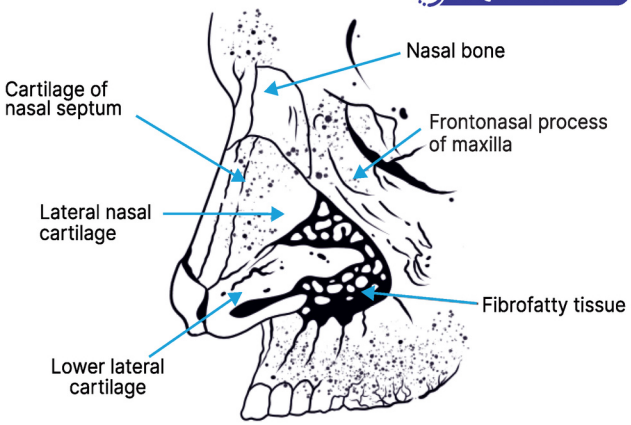


### Q1.3: Elaborate on the Cartilaginous structures of the external nose.

**Answer:**

- Cartilaginous structures of the external nose is made of 3 paired cartilages and 1 unpaired cartilage
  - Paired cartilages
    - → Upper lateral cartilage
    - → Lower lateral cartilage
    - → Sesamoid cartilage
  - Unpaired cartilage
    - → Septum

### Q1.4: What is the Nasion?

**Answer:**

- The point where the Frontal bone meets the nasal bone in the midline

### Q1.5: What is the Rhinion?

**Answer:**

- The point where the nasal bone meets the upper lateral cartilage in the midline

### Q1.6: How is the linea nasii formed, and what is its significance?

**Answer:**

- Limen Nasii is formed by the lower border of upper lateral cartilage
- It forms one of the boundaries of Internal Nasal Valve which is the narrowest portion nasal cavity

### Q1.7: What are the inlet and outlet of the internal nose called?

**Answer:**

- Internal nose (nasal cavity proper) has an inlet called vestibule and an outlet called choana

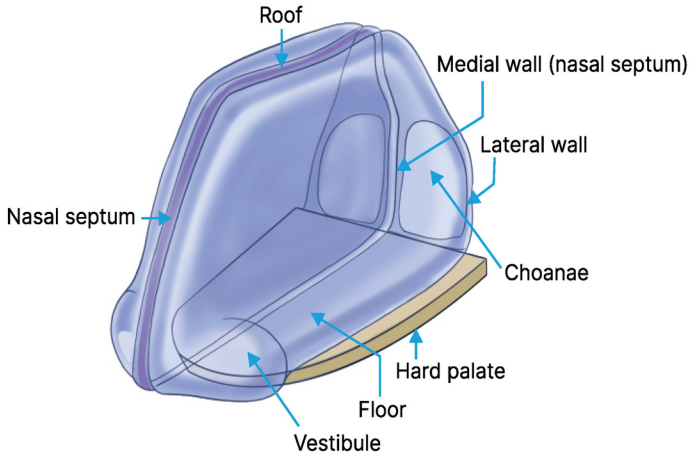


### Q1.8: What is the choana and what does it communicate with?

**Answer:**

- Chona is the communication between the nasal cavity and the nasopharynx (behind choana there is nasopharynx)

### Q1.9: What are the main walls and structures inside the nasal cavity?

**Answer:**

- The nasal cavity has a roof, floor, a medial wall formed by the nasal septum (dividing it into right and left halves), and a lateral wall which contains three bony projections called turbinates or conchae

PYQ:INICET 2019 PYQ:FMGE 2021

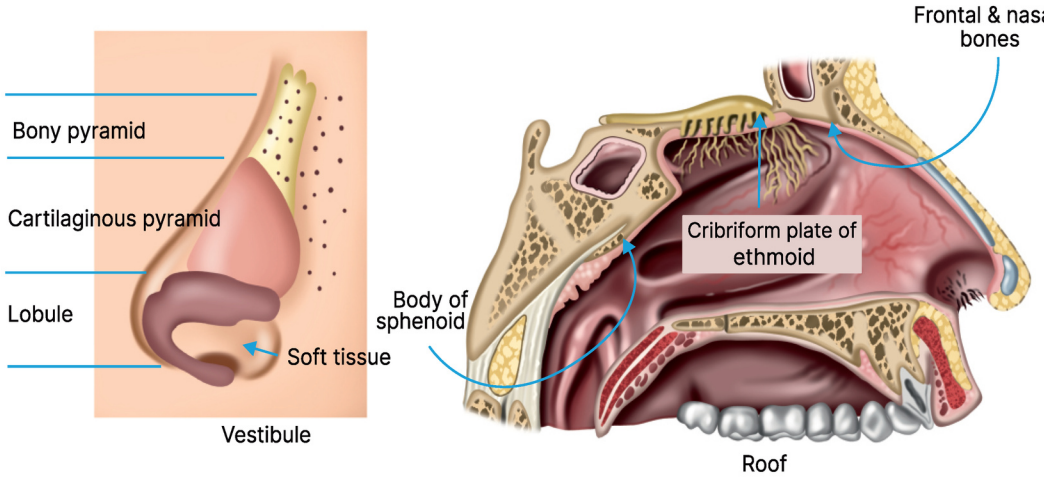

### Q1.10: Which part of the nose is lined by stratified squamous epithelium?

**Answer:**

- The vestibule is the only part of the nose lined by stratified squamous epithelium and contains hair follicles. The rest of the nasal cavity is lined by respiratory epithelium (pseudostratified ciliated columnar epithelium)

### Q1.11: Where is the olfactory epithelium located in the nose?

**Answer:**

- The olfactory epithelium is located in the olfactory cleft, which lies in the roof of the nasal cavity

### Q1.12: What are the boundaries of the internal nasal valve?

**Answer:**

- Internal nasal valve which lies at the level of the vestibule is bounded by:
  - Medially - Septum
  - Superiorly - Limen Nasii
  - Laterally - Head of inferior turbinate

### Q1.13: Which is the narrowest part of the nasal cavity?

**Answer:**

- Internal nasal valve

### Q1.14: What is the normal angle of the internal nasal valve and what happens in DNS?

**Answer:**

- The internal nasal valve normally forms an angle of 10-15 degrees. In cases of Deviated Nasal Septum (DNS), this angle can become further narrowed, especially at the level of the vestibule, leading to nasal obstruction

### Q1.15: What is the communication between the nose and the nasopharynx?

**Answer:**

- Choana (outlet of the internal nose)

### Q1.16: Which bones form the roof of the nasal cavity and what does it separate?

**Answer:**

- The roof of the nasal cavity is formed by three bones and separates the nasal cavity from the anterior cranial fossa (frontal lobe of the brain):
  - Anterior 1/3rd - Frontal bone
  - Middle 1/3rd - Cribriform plate of the ethmoid bone
  - Posterior 1/3rd - Body of the sphenoid bone

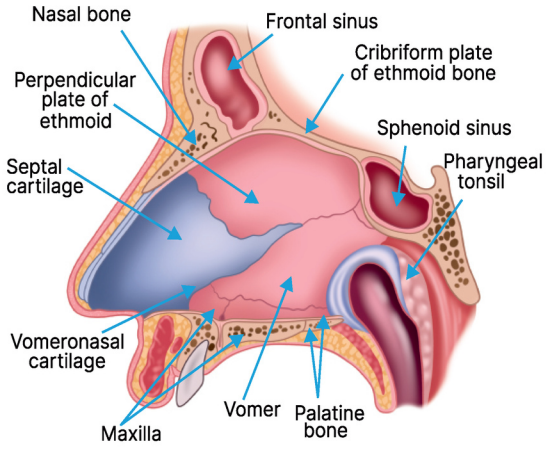


### Q1.17: Which bones form the floor of the nose?

**Answer:**

- Floor of the nose is formed by 2 bones
  - Anteriorly- Crest of the Maxilla
  - Posteriorly- Crest of the Palatine bone



YOURWISH

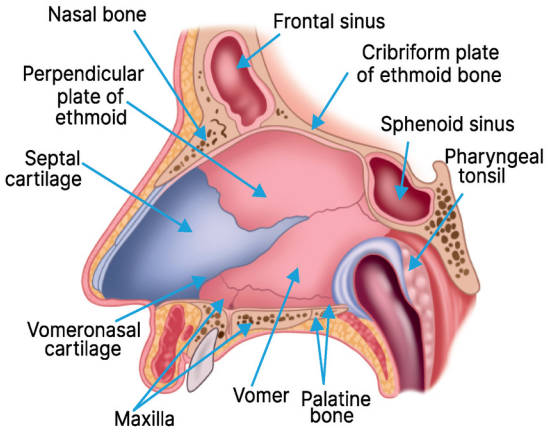


## Q1.18: What forms the medial wall of the nasal cavity (nasal septum)?

**Answer:**

- The medial wall of the nasal cavity is formed by the nasal septum, which has:
- Anterior cartilaginous part: Septal (quadrangular) cartilage
- Posterior bony part:
  - Perpendicular plate of the ethmoid bone (superiorly)
  - Vomer bone (inferiorly)
- It also receives minor contributions from:
  - Nasal spine of the frontal bone
  - Rostrum of the sphenoid
  - Crest of the maxilla
  - Crest of the palatine bone

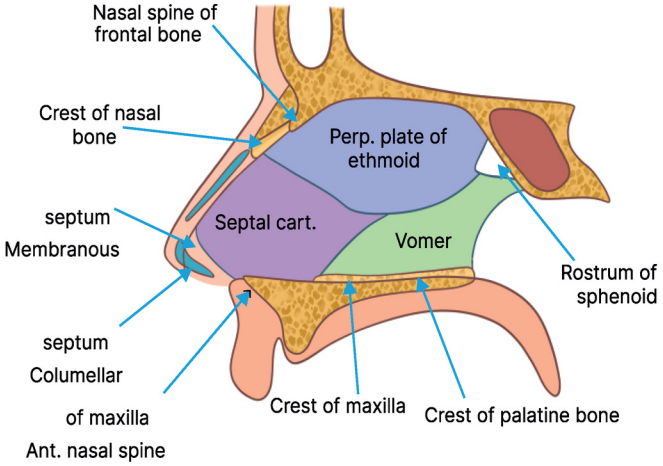


## Q1.19: What is the blood supply of upper half of the septum?

**Answer:**

| | |
|---|---|
| **Upper half of the septum** | • Receives blood supply from Internal Carotid Artery (ICA)<br>• ICA gives off a branch → Ophthalmic Artery<br>• Ophthalmic artery gives off 2 branches:<br>o Anterior Ethmoidal Artery (AEA) supplies anterosuperior portion of septum<br>o Posterior Ethmoidal Artery (PEA) supplies posterosuperior portion of septum |

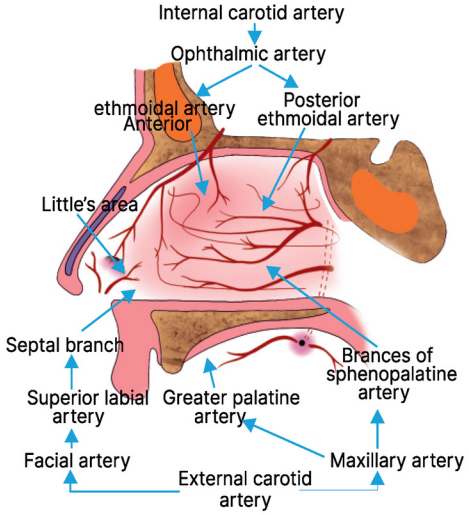




YOURWISH

YOURWISH

### Q1.20: What is the blood supply of lower half of the septum?

**Answer:**

| | |
|---|---|
| **Lower half of the septum** | • Receives blood supply from External Carotid Artery (ECA)<br>• ECA gives off 2 branches<br>o Facial artery gives rise to Superior labial artery whcih supplies anteroinferior portion of septum<br>o Internal maxillary artery gives rise to Sphenopalatine artery and Greater palatine artery which supply posteroinferior portion of septum |

### Q1.21: What is the clinical significance of blood supply of the septum?

**Answer:**

- All the arteries supplying the septum meet in the anteroinferior portion of septum where they form an anastomosis (except Posterior ethmoidal artery), a Arterial Plexus called **Kiesselbach's Plexus/Little's area**
- In posteroinferior portion of septum, a Venous plexus called Woodruff's Plexus is formed
- Any bleeding in Little's area → Anterior Epistaxis
- Any bleeding in Woodruff's plexus → Posterior Epistaxis

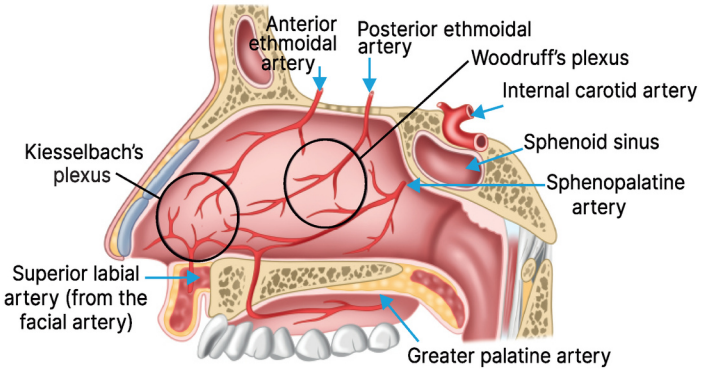


### Q1.22: What are the turbinates in the nasal cavity and what are their origins?

PYQ:INICET 2020, 2021

**Answer:**

- Turbinates or Concha are bony projections originating from the lateral wall of the nose
  - o Inferior turbinate - an independent bone
  - o Middle turbinate - derived from the ethmoid bone
  - o Superior turbinate - derived from the ethmoid bone
  - o Occasionally, a fourth turbinate, called the supreme turbinate, may also be present

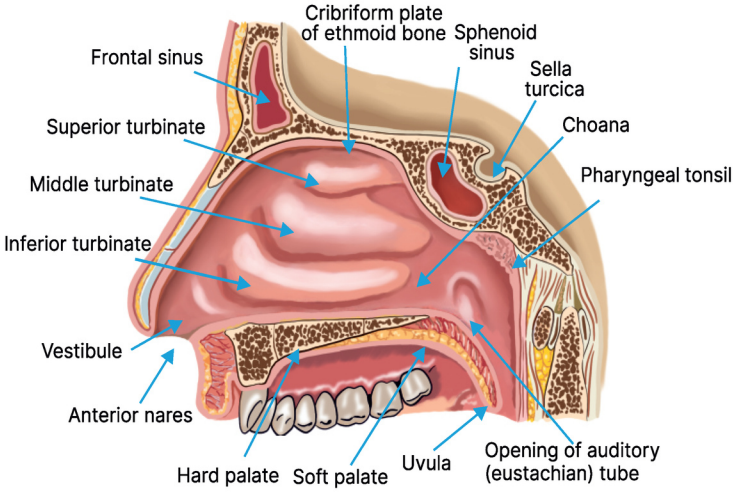

### Q1.23: What are the spaces below the nasal turbinates called?

**Answer:**

- The spaces located below each turbinate in the nasal cavity are called meatuses:
  - Below the inferior turbinate : Inferior meatus
  - Below the middle turbinate : Middle meatus
  - Below the superior turbinate : Superior meatus

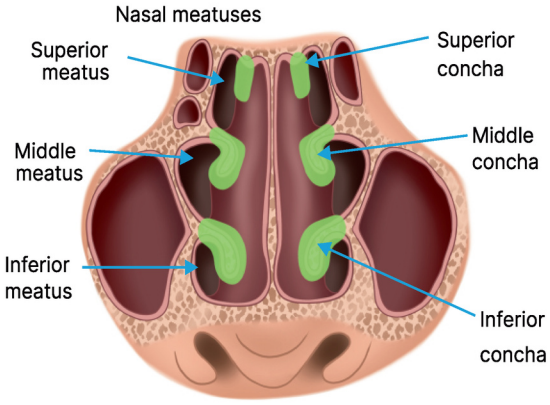


### Q1.24: What structure drains in to the inferior meatus and what is its clinical significance?

**Answer:**

- Nasolacrimal duct opens into Inferior meatus and is guarded by Valve of Hasner
- Direction of nasolacrimal duct → Downwards, Backwards and Laterally (DBL)
  - Inflammation of Lacrimal Sac→ Dacrocystitis → Obstruction → Tears can't drain → sac swells up → Infected → make an opening for drainage → approach trans-nasally and open sac into nasal cavity → Endonasal dacryocystorhinostomy
- Location of lacrimal sac → Medial wall
- Location of Lacrimal gland → Junction of roof and lateral wall of orbit

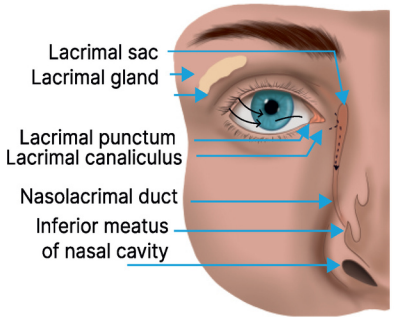


### Q1.25: Which sinuses drain into the middle meatus and what is the role of the osteomeatal complex?

**Answer:**

- The middle meatus receives drainage from the frontal, maxillary, and anterior ethmoidal sinuses (anterior group).
- Hiatus semilunaris, located between the uncinate process (Boomerang shaped bone) and bulla ethmoidalis (big ethmoidal air cell), leads to the infundibulum.
- Maxillary sinus drains into the infundibulum, while the frontal and anterior ethmoidal sinuses drain into the hiatus semilunaris.
- All these drain into the osteomeatal complex
- Blockage of the osteomeatal complex leads to retention of secretions causing sinusitis

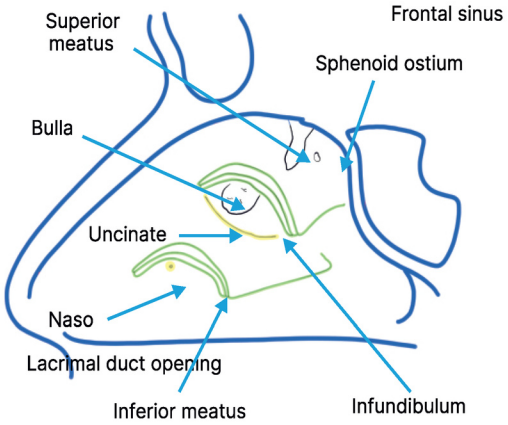


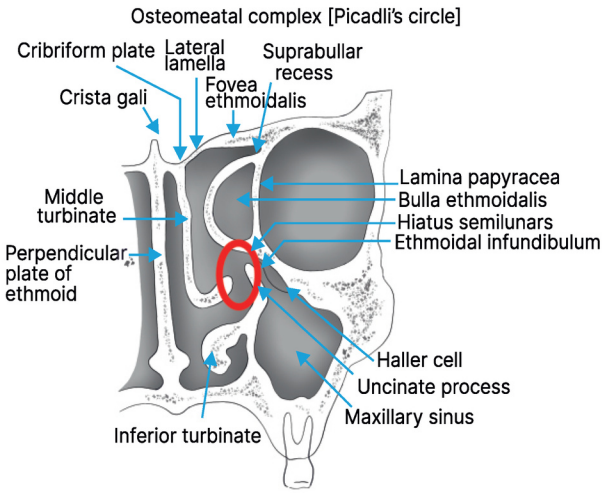


### Q1.26: Which sinuses drain into the Superior meatus?

**Answer:**

- Posterior ethmoidal sinus drains into it Superior meatus

### Q1.27: Which speculums used in Anterior rhinoscopic examination?

**Answer:**

- Thudicum's nasal speculum: Non-self-retaining; more commonly used
- Killian's Nasal speculum: Self-Retaining Nasal Speculum

### Q1.28: What are the structures examined in Anterior rhinoscopic examination?

**Answer:**

- Structures seen
  - Inferior Turbinate
  - Middle turbinate (some portion)
  - Septum, and floor of the nose

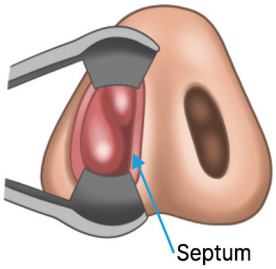


### Q1.29: What is the instrument used in Diagnostic nasal endoscopy and what are the structures seen?

**Answer:**

- Diagnostic nasal endoscopy is performed using a 0-degree nasal endoscope (Hopkins's rod) to visualize the inside of the nose.
- Structures seen are:
  - Medially - septum
  - Laterally - Inferior turbinate
  - Above - Middle Turbinate



## BIG QUESTION 2: What are the different groups of paranasal sinuses, and what are their anatomical features, drainage pathways, and clinical significance?

**Broad Answer:**

- 4 group of Paranasal sinuses are:
  - Maxillary sinus
  - Frontal sinus
  - Ethmoid sinus
  - Sphenoid sinus

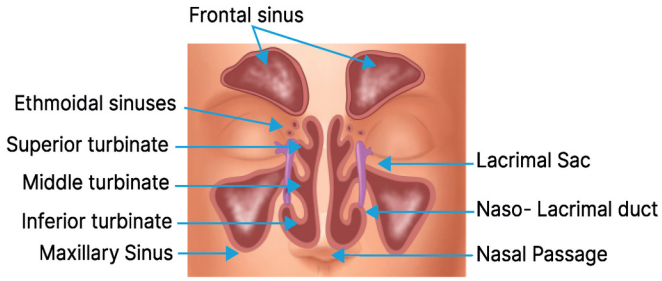


- These paranasal sinuses are air-filled cavities in the skull. They lighten the skull, aid in resonance of voice, and drain into the nasal cavity through specific pathways.

## DETAILED QUESTIONS

### Q2.1: What are the distinguishing features of Maxillary sinus?

**Answer:**

- Also called as Antrum of Highmore
- It's the Largest sinus
- 1st sinus to develop
- 1st sinus to be visible radiologically

### Q2.2: What are the anatomical relations of the maxillary sinus?

**Answer:**

- Base - separates the sinus from the lateral wall of the nose

- Apex - it is present at level of Zygoma
- Roof - it is situated in relation to floor of orbit
- Floor - It is related to 2nd premolar and 1st molar teeth

### Q2.3: What is the clinical important of floor of the maxillary sinus?

**Answer:**

- Floor of maxillary sinus is related to the roots of the 2nd premolar and 1st molar teeth, making it clinically important:
  - Dental infections can lead to maxillary sinusitis
  - Tooth extraction may cause an oroantral fistula
  - Tooth caries can spread to the sinus causing sinusitis

### Q2.4: What are the anatomical and vascular relations of the posterior wall of the maxillary sinus?

**Answer:**

- The posterior wall of the maxillary sinus is related to the Pterygopalatine fossa, which lies behind it.
- The Internal maxillary artery passes through this fossa and gives off:
  - Sphenopalatine artery - enters the sinus via the Sphenopalatine foramen, located 8 mm behind the Middle turbinate
  - Greater palatine artery - descends downward

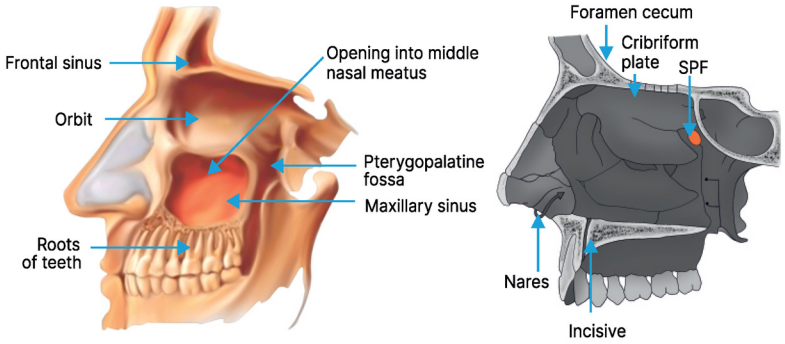


### Q2.5: What structures are related to the anterior wall of the Maxillary sinus

**Answer:** Skin and subcutaneous tissue

### Q2.6: Where is the frontal sinus located and what are its boundaries?

**Answer:**

- The frontal sinus is an air-filled cavity present within the frontal bone, lying between two bony layers:
  - Anterior boundary - formed by the anterior table of the frontal bone
  - Posterior boundary - formed by the posterior table

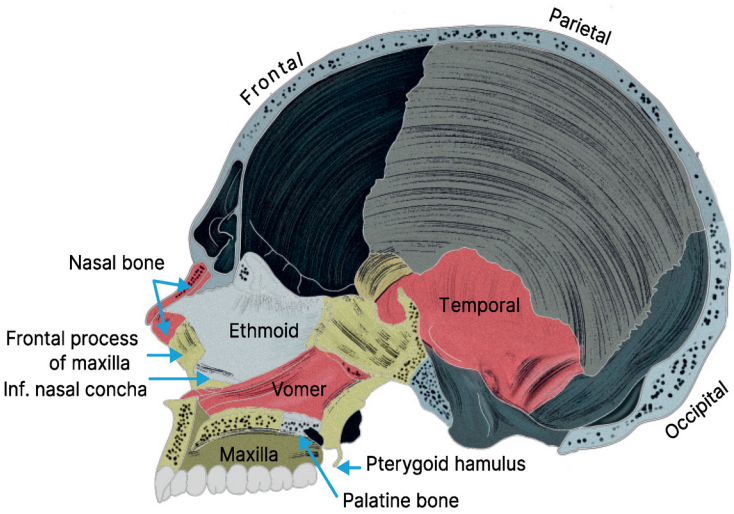


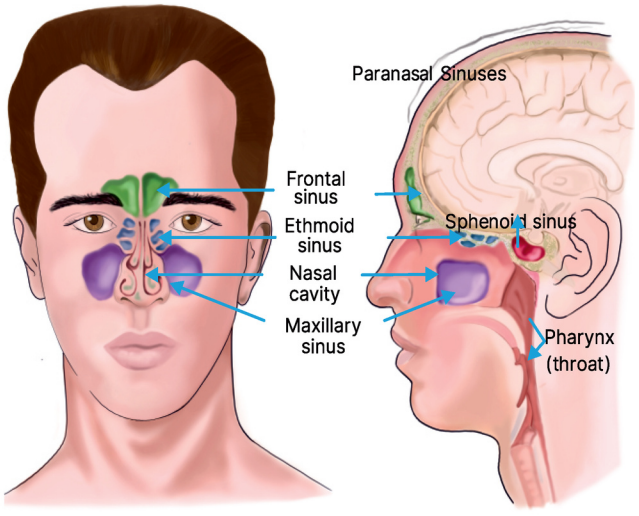




YOURWISH

### Q2.7: What is a serious complication of frontal sinusitis involving the posterior table?

**Answer:**

- In frontal sinusitis, the infection can spread through the posterior table of the frontal bone and reach the frontal lobe of the brain, causing a frontal lobe abscess or intracranial infection

### Q2.8: What are the anatomical features and developmental facts about the frontal sinus?

**Answer:**

- Floor of the Frontal sinus is related to the roof of the orbit
- The right and left sinuses do not communicate due to the midline septum
- It is the last sinus to develop and is absent at birth
- Anterior wall is formed by outer table of frontal bone
- Posterior wall separates it from the cranial cavity
- Floor separates it from the orbit

### Q2.9: What are the anatomical relations of the ethmoidal sinuses?

**Answer:**

- The ethmoidal sinuses are air-filled ethmoidal (pneumatic) cells located between the frontal sinus (anteriorly) and sphenoid sinus (posteriorly)
- Medially: Related to the middle turbinate
- Laterally: Related to the medial wall of the orbit
- Superiorly: Related to the fovea ethmoidalis, which separates the sinus from the anterior cranial fossa

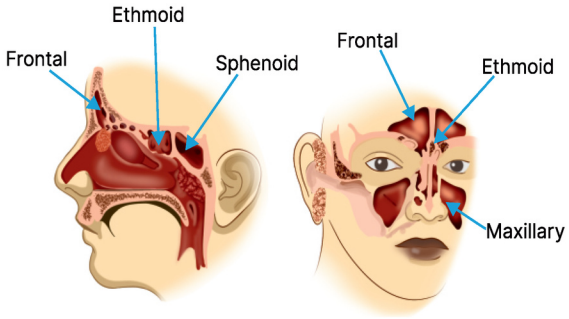


### Q2.10: How are the ethmoid air cells divided, and what anatomical structure separates them?

**Answer:**

- The ethmoid air cells are divided into anterior and posterior ethmoidal cells by the basal lamella, i.e., the Bend of the middle turbinate

### Q2.11: What are the named ethmoidal air cells and their clinical significance?

**Answer:**

- Ethmoid air cells are (most pneumatized at birth):-
  - Agar nasi- Anterior most ethmoidal air cell
  - Haller cell- It is related to the floor of the orbit i.e., inferomedial to the orbit
  - Bulla ethmoidalis- Big ethmoidal cell situated behind agar nasi
  - Onodi cells- Posterior ethmoidal air cell extending into the sphenoid sinus; Related to Optic nerve and Internal Carotid Artery
  - Kuhn cells- These are Anterior ethmoidal air cells that extend/pneumatizes into the frontal sinus → Frontoethmoidal cells → their existence narrows the frontal sinus drainage → prone to develop frontal sinusitis

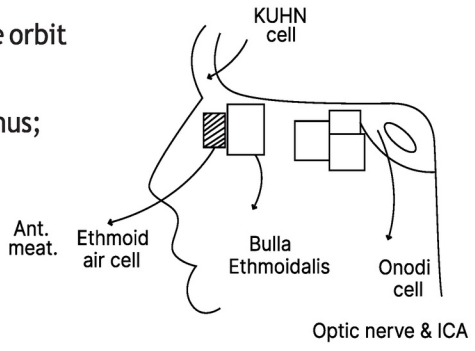


### Q2.12: What are the anatomical features and relations of the sphenoid sinus?

**Answer:**

- Posterior most sinus among the paranasal sinuses

YOURWISH

- Depression in roof of the sinus→ Sella turcica →Lodges the pituitary gland
- Optic nerve passes very closely to the sphenoid sinus (at level of pituitary stalk they form the optic chiasm)

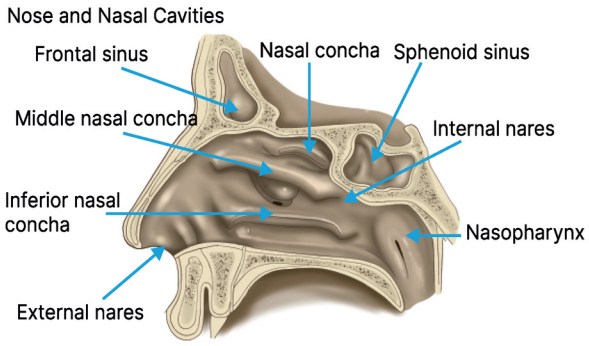


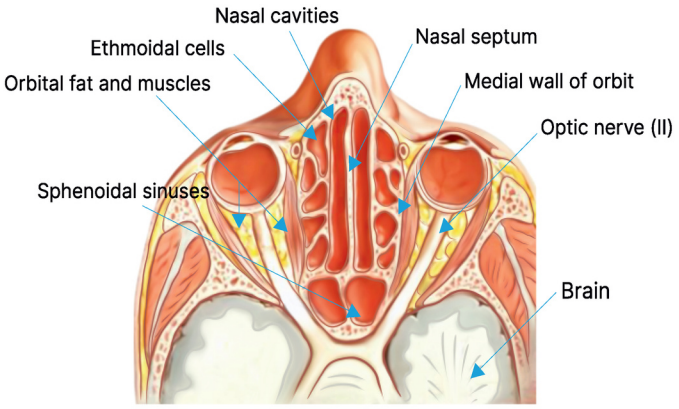


**Q2.13: What important structures are related to the roof and lateral wall of the sphenoid sinus?**

**Answer:**

- Roof:- Optic Nerve
- Lateral wall:- Cavernous sinus
  - CN III
  - CN IV
  - CN V
  - CN VI
  - ICA

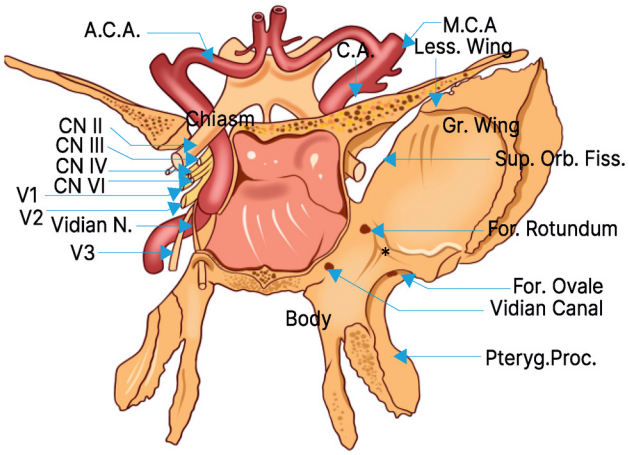


**Q2.14: Identify the marked foramina (purple marked) in the image given below?**

**Answer:**

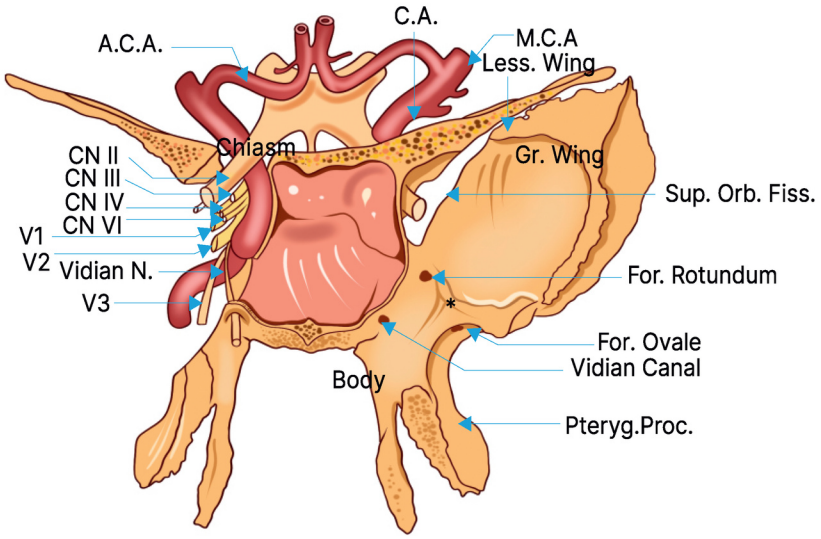


- The one above is Foramen Rotundum
- The one below is Vidian Canal, where Vidian Nerve passes through

### Q2.15: What are the types of sphenoid sinus and their clinical significance?

**Answer:**

| | |
|---|---|
| **Conchal type**<br>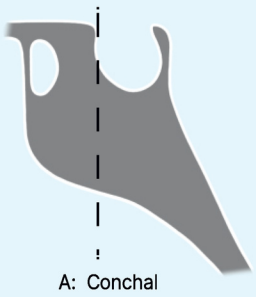<br>A: Conchal | • A bony type of sphenoid<br>• It has a small air filled pneumatized cavity<br>• Difficult to access the pituitary gland by drilling through the sinus |
| **Presellar type**<br>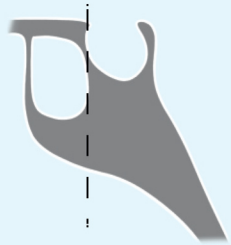<br>B: Presellar | • Less pneumatization/air filled sphenoid compared to Sellar type |
| **Sellar type**<br>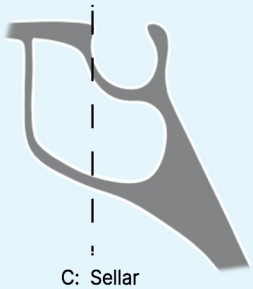<br>C: Sellar | • More pneumatization/ air filled sphenoid → easier access to pituitary gland (Endonasal/Transnasal approach through sphenoid sinus)<br>• Pituitary surgery to be done for Pituitary macroadenoma (Transcranial approach can also be done (less preferred) |

## BIG QUESTION 3: What types of lining membranes are found in different parts of the nose?

**Broad Answer:** The lining membrane of the nose varies in different parts of the nasal cavity, reflecting their specialized functions-such as conditioning inspired air in most regions and detecting smell in the olfactory area.

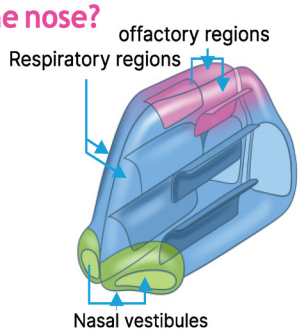


## DETAILED QUESTIONS

### Q3.1: What type of epithelium lines the vestibule of the nose?

**Answer:** The vestibule of the nose is lined by stratified squamous epithelium.

### Q3.2: What type of epithelium lines the rest of the nasal cavity?

**Answer:** The rest of the nasal cavity is lined by respiratory epithelium (pseudostratified ciliated columnar epithelium with goblet cells).

### Q3.3: Which part of the nose contains the olfactory cleft, and what type of epithelium lines it?

**Answer:** The roof of the nasal cavity contains the olfactory cleft, which is lined by olfactory epithelium

### Q3.4: What are the boundaries of Olfactory cleft?

**Answer:**

- Medially- Upper part of the Septum
- Laterally- Superior Turbinate
- Roof- Cribriform of ethmoidal plate

## BIG QUESTION 4: What is the venous drainage of the nose, and what is its clinical significance?

**Broad Answer:**

- The venous drainage of the nose primarily occurs through veins that drain into the facial vein, which then connects to the pterygoid venous plexus. From there, blood can drain into the cavernous sinus (main pathway)

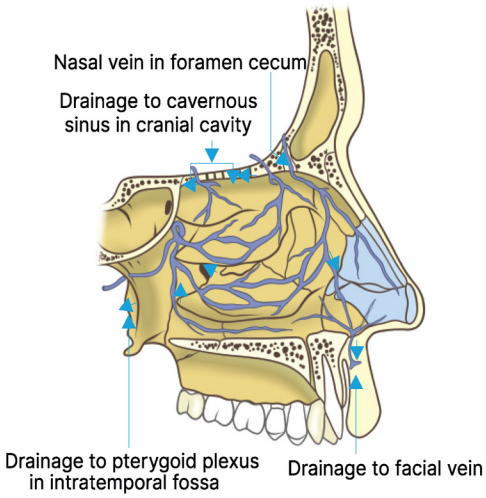


## DETAILED QUESTIONS

### Q4.1: What is the danger triangle of the face and why is it clinically important?

**Answer:**

- The danger triangle of the face is the area between the nasion and the angles of the mouth.
- Infections here can spread to the cavernous sinus because the connecting veins are valveless and can lead to cavernous sinus thrombosis
- Most common route of spread: Deep facial vein → Pterygoid venous plexus → Cavernous sinus
- Infection may also spread via ophthalmic veins

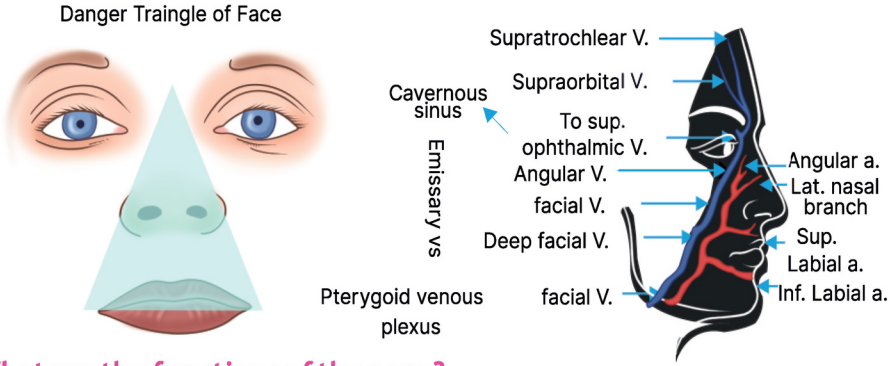


## BIG QUESTION 5: What are the functions of the nose?

**Broad Answer:**

- The **nose** plays a vital role in **breathing, smell (olfaction), filtering and humidifying air**, and contributes to **voice resonance**. It also serves as a **drainage pathway for lacrimal secretions** and protects the **lower respiratory tract** by trapping dust and pathogens



YOURWISH

## DETAILED QUESTIONS

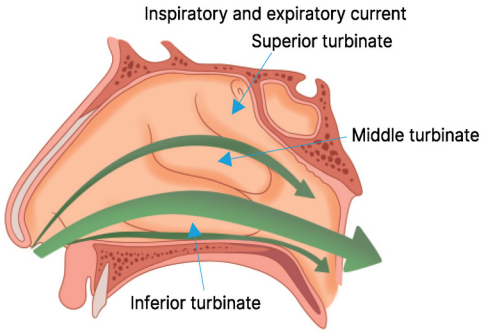


### Q5.1: What are the main functions of the nose?

**Answer:**

- Nasal respiration
- Protection of the lower respiratory tract
- Vocal resonance
- Olfaction (sense of smell)
- Drainage outlet for lacrimal secretions
- Airflow dynamics:
  - Maximum airflow during inspiration occurs in the middle meatus in a parabolic curve
  - Sinus ventilation primarily happens during expiration

### Q5.2: What are the different types of olfactory (smell) disorders and how are they defined?

**Answer:**

- Hyposmia - Decreased perception of smell
- Anosmia - No perception of smell
- Presbyosmia - Age related decrease in perception of smell
- Parosmia/Cacosmia/Dysosmia
  - Cacosmia → everything smells bad
  - Dysosmia → altered perception of smell (not necessarily foulsmelling)
- Phantosmia - No source for smell, but the patient perceives the smell

### Q5.3: How many bones and cartilages form the external nose?

**Answer:**

- Bony structure of external nose has 2 paired bones and 1 unpaired bones
- Cartilaginous structure of external nose has 3 paired cartilages and 1 unpaired cartilages

### Q5.4: What is the other name of the pseudostratified columnar epithelium of nose?

**Answer:**

- Schneiderian membrane

### Q5.5: What are the anatomical landmarks of the external nose?

**Answer:**

- Nasion is Frontal bone with nasal bone in midline
- Rhinion is Nasal bone with upper lateral cartilage in midline
- Limen Nasi is Lower border of upper lateral cartilage

### Q5.6: Which turbinate is not a part of the Ethmoid bone?

**Answer:**

- Inferior turbinate

### Q5.7: What are the drainage pathways of the paranasal sinuses?

**Answer:**

- Sinus draining into hiatus semilunaris is Frontal sinus and Anterior ethmoidal sinus
- Sinus draining into infundibulum is Maxillary sinus

- Sinus draining in superior meatus is Posterior ethmoid sinus
- Sphenoid sinus drains into the sphenoethmoidal recess

**Q5.8: Which paranasal sinus is absent at birth?**

**Answer:** Frontal sinus

**Q5.9: Which paranasal sinus develops in association with the eruption of secondary dentition?**

**Answer:** Maxillary sinus

**Q5.10: Which paranasal sinus is the earliest to develop and visible radiologically?**

**Answer:** Maxillary sinus

**Q5.11: Which is the largest paranasal sinus?**

**Answer:** Maxillary sinus

**Q5.12: Which is the last paranasal sinus to develop?**

**Answer:** Frontal sinus

**Q5.13: Which is the most common sinusitis in children and in adults?**

**Answer:**

- Most common sinusitis in children is Ethmoidal sinusitis
- Most common sinusitis in adults is Maxillary sinusitis

**Q5.14: What is the marked structure, and which foramina are related to it?**

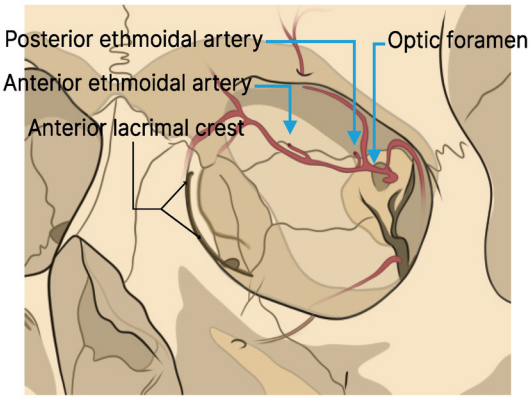


**Answer:**

- Near the nose → medial wall of orbit
- Crest of bone in medial wall of orbit → Anterior Lacrimal Crest
- 24 mm behind from the anterior lacrimal crest → Anterior ethmoidal foramen
- 12 mm behind from anterior ethmoidal foramen → Posterior ethmoidal foramen
- 6 mm behind from posterior ethmoidal foramen → Optic Canal

**Q5.15: A 27-year-old female patient presents to the hospital with amenorrhea and a whitish fluid expressed from both nipples. The patient reports that has been taking cabergoline at its maximum dose for several months for a benign brain tumor. The surgeon decides to remove the tumor. Which sinus would give access to the tumor for removal?**

A. Maxillary sinus
B. Frontal sinus
C. Ethmoid sinus
D. Sphenoidal sinus

**Answer:**

- **D. Sphenoidal sinus**
- The tumor described is a prolactinoma/pituitary adenoma, and the trans-sphenoidal route is the surgical approach for removal.

**Q5.16: 20 year-old male comes to the emergency department with the complaint of bleeding from his nose for the past hour. Nasal inspection via speculum shows a bleeding site located along the nasal floor in the anterior part of septum. The terminal branches of the source of the bleeding in this patient are derived from what vessel?**

A. Superior labial artery
B. Anterior ethmoidal artery
C. Internal maxillary artery
D. Sphenopalatine artery

**Answer:**

- **A. Superior labial artery**
- It is a branch of Facial Artery
- Supplies anteroinferior part of septum and floor of the nose, hence is the answer

**Q5.17: 25-year-old man is admitted for sphenoethmoidal air cell (Onodi cell) operation. In surgical planning, the clinician considers the important head and neck structures in the region. What is the blood supply of the structure at high risk for intra-operative injury during the procedure?**

A. Middle cerebral artery
B. Superficial temporal artery
C. Central retinal artery
D. Facial artery

**Answer:**

- **C. Central retinal artery**
- The structure at high risk is Optic nerve
- Blood supply of optic nerve is Central retinal artery

**Q5.18: The foramen shown is**

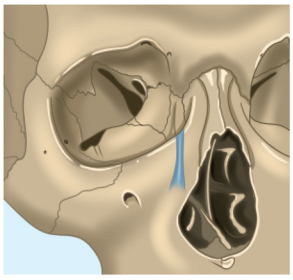

A. Superior orbital fissure
B. Inferior orbital fissure
C. Optic canal
D. Anterior ethmoidal canal

**Answer:**

- **C. Optic canal**



YOURWISH

**Q5.19: The foramen shown is:**

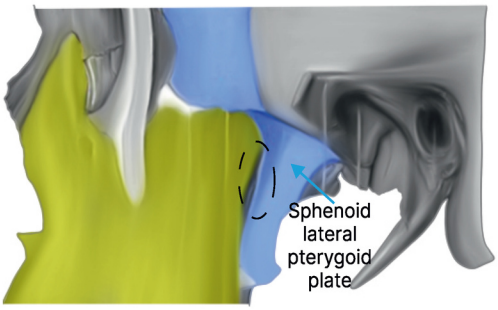


A. Sphenopalatine foramen
B. Greater palatine foramen
C. Inferior orbital fissure
D. None

**Answer:**

- **A. Sphenopalatine foramen**
- Sphenopalatine artery (artery of epistaxis) passes through this foramen

**Q5.20: The artery that is present this fossa is:**

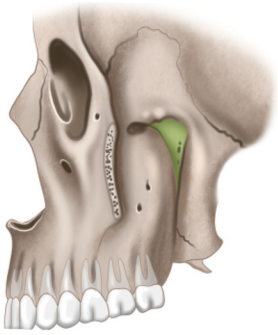

A. Ethmoidal artery
B. Internal maxillary artery
C. External carotid artery
D. Facial artery

**Answer:**

- **B. Internal maxillary artery**
- Pterygopalatine fossa is shown here; and the artery passing through it is Internal Maxillary Artery

**Q5.21: The arrow represents**

PYQ:FMGE 2020,2021

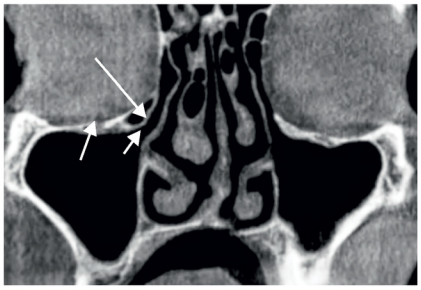

A. Aggar nasi
B. Onodi cell
C. Haller cell
D. Bulla ethmoidalis

**Answer:**

- **C. Haller cell**
- Cell inferomedial to the orbit → Haller cell



YOURWISH

# 7. CONGENITAL ANOMALIES/ NASAL POLYPS/RHINITIS/SINUSITIS

## BIG QUESTION 1: What is Choanal Atresia, its types, and clinical presentations?

**Broad Answer:**

- Choanal atresia is the congenital absence of communication between the nasal cavity and nasopharynx.
- Types
  - Bony
  - membranous
- It can be unilateral/bilateral.
- Associated with CHARGE syndrome

PYQ: FMGE 2023

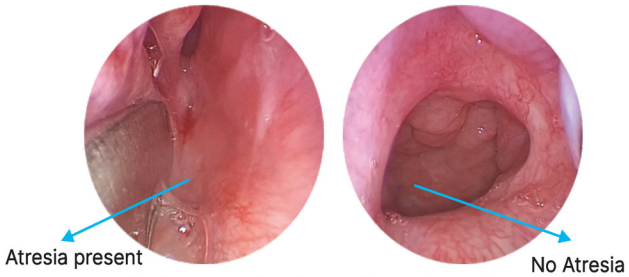


Endoscopy showing unilateral atresia

## DETAILED QUESTIONS

### Q1.1: What is the cause of Choanal Atresia?

**Answer:**

- It occurs due to the persistence of a membrane called the bucconasal membrane.

### Q1.2: What are the two types of choanal atresia?

**Answer:**

- Bony and Membranous.

### Q1.3: Is choanal atresia always symmetrical?

**Answer:** No, it can be unilateral or bilateral.

### Q1.4: With which congenital syndrome is choanal atresia associated? List the components of this syndrome.

**Answer:**

- It is associated with '**CHARGE**' syndrome:
  - **C** - Coloboma Iridis
  - **H** - Heart defects (ASD/VSD)
  - **A** - Atresia (referring to choanal atresia here)
  - **R** - Retardation (Growth/mental)
  - **G** - Genital malformations (Hypospadias)
  - **E** - Ear abnormalities

### Q1.5: Explain "Cyclical Cyanosis" in the context of choanal atresia. Why does cyanosis disappear on crying?

**Answer:**

- Cyclical cyanosis is cyanosis at rest that disappears on crying.
- In bilateral choanal atresia, infants (who are obligate nose breathers until 3 months) cannot breathe from their nose or mouth when at rest, leading to cyanosis.
- When the child cries, the negative intrathoracic pressure pulls air inside, and as a result, cyanosis disappears.
- This is seen only in bilateral choanal atresia.

### Q1.6: Why is bilateral choanal atresia considered an emergency? What immediate intervention is recommended?

**Answer:**

- It is an emergency because infants are obligate nose breathers, and blockage of both choanae obstructs breathing.
- The immediate intervention is to introduce a nipple with an oral airway and a feeding nipple (McGovern nipple).
- McGovern nipple has to be followed through with tracheostomy



McGovern's technique

### Q1.7: When is the surgical correction of bilateral choanal atresia typically performed, and why is it not done at birth?

**Answer:**

- Correction is typically done at 1.5-2 years.
- It cannot be done at birth because the nasal cavity at birth is small, and the child's weight is less.

### Q1.8: Why is unilateral choanal atresia not considered an emergency? How does it typically present, and at what age?

**Answer:**

- It is not an emergency as the child can still breathe through the patent nostril.
- It is typically not present at birth and presents with constant nasal discharge or unilateral rhinorrhea.

### Q1.9: What are the diagnostic methods for unilateral choanal atresia?

**Answer:**

- Diagnosis involves feeling resistance when an infant's feeding tube is inserted, and an X-ray after the introduction of radio-opaque dye.
- The absence of an air bubble in nasal discharge can also be a sign.
- CT scan

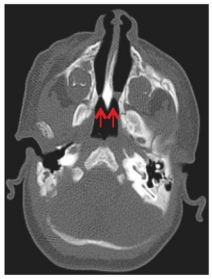
CT showing Choanal atresia

### Q1.10: What is the best time to operate on unilateral choanal atresia?

**Answer:**

- it can be operated at any time.

## BIG QUESTION 2: Describe Meningocele, Glioma, and Dermoid swellings

**Broad Answer:**

| | Meningocele | Glioma | Dermoid |
|---|---|---|---|
| Cause | Improper fusion of bones of base of skull or roof of nasal cavity | No fusion → herniation → delayed fusion | Hamartoma: A congenital anomaly |
| Consistency of swelling | Soft/ Cystic | Firm | Variable |
| Compressibility test | Positive | Negative | Positive |
| Reducibility test | Positive | Negative | Negative |
| Cough impulse test | Positive | Negative | Negative |
| Transillumination test | Positive | Negative | Negative |
| Treatment | Excision + Reconstruction | Excision | Excision |

## DETAILED QUESTIONS

**Q2.1: What is Meningocele?**

**Answer:** Herniation of meninges +/- brain tissue (meningoencephalocele) into the nasal cavity

**Q2.2: What are the bones forming the roof of the nose from anterior to posterior?**

**Answer:** Frontal bone (Anteriorly), Cribriform plate (Middle), Sphenoid bone (Posteriorly).

**Q2.3: Explain the cause of a Meningocele. What happens during development?**

**Answer:**

- It is caused by improper fusion of bones of the base of the skull or roof of the nasal cavity.
- During development, if there is a deficient or dehiscent area in the bones, herniation of meninges (and sometimes brain tissue, meningoencephalocele) can occur through this gap into the nasal cavity.

**Q2.4: Describe the consistency and the results of compressibility, reducibility, cough impulse, and transillumination tests for a Meningocele.**

**Answer:**

- Consistency: Soft/Cystic
- Compressibility test: Positive
- Reducibility test: Positive
- Cough impulse test: Positive
- Transillumination test: Positive

**Q2.5: What is the treatment for a Meningocele?**

**Answer:** Excision of the herniated mass and reconstruction of the defect.

**Q2.6: What is Glioma?**

**Answer:** A condition in which there is presence of glial cells outside the central nervous system

**Q2.7: Explain the cause and formation of a Glioma in the nasal cavity.**

**Answer:** Initially, there is improper fusion of bones in the roof of the nose, leading to herniation of cranial contents into the nose. Later, delayed fusion of bones separates the cranial cavity from the nasal cavity. During this process, CNS tissue (glial cells) gets left behind in the nasal cavity.



YOURWISH

- Nasal immune cells then identify the glioma as foreign, causing an antigen-antibody reaction and subsequent fibrosis.

**Q2.8:Describe the consistency and the results of compressibility, reducibility, cough impulse, and transillumination tests for a Glioma.**

**Answer:**

- Consistency: Firm
- Compressibility test: Negative
- Reducibility test: Negative
- Cough impulse test: Negative
- Transillumination test: Negative

**Q2.9: What is the treatment for a Glioma?**

**Answer:** Excision of the glioma without any reconstruction.

**Q2.10: What is the cause of a Dermoid swelling, and what type of congenital anomaly does it belong to? What layers and materials can it contain?**

**Answer:**

- Dermoids are congenital swellings that occur at the line of fusion of bones.
- They belong to a subset of hamartoma.
- They contain all three germ layers (Ectoderm, Endoderm, Mesoderm) and can form teeth, hair follicles, or cheesy sebaceous material, leading to variable consistency.

**Q2.11:Describe the consistency and the results of compressibility, reducibility, cough impulse, and transillumination tests for a Dermoid.**

**Answer:**

- Consistency: Variable
- Compressibility test: Positive
- Reducibility test: Negative (as most dermoids do not communicate with the cranial cavity)
- Cough impulse test: Negative
- Transillumination test: Negative

**Q2.12: What is the treatment for a Dermoid?**

**Answer:** Excision.

## BIG QUESTION 3: What is a Deviated Nasal Septum (DNS)

**Broad Answer:**

- Deviated Nasal Septum (DNS) is when the nasal septum is not in the midline, manifesting in various forms.
- Surgery for DNS is indicated only when symptomatic, causing nasal obstruction, headache, sinusitis, etc.
- Cottles line and test help guide management and assess internal nasal valve patency.

## DETAILED QUESTIONS

**Q3.1: Describe some common types of deviations.**

**Answer:**



YOURWISH

- Common types include
  - Concave DNS
  - Convex DNS
  - S-shaped septum
  - Sharp bony projection (spur)
  - Anterior dislocation.

**Q3.2: What are the key indications for surgery?**

**Answer:**

- Surgery is indicated only when DNS is associated with symptoms such as nasal obstruction, difficulty in breathing, headache, facial pain, sinusitis, external deformity of the nose, smell disturbance, or reduced ventilation via the Eustachian tube causing middle ear diseases.

**Q3.3: What are the two main surgical procedures for DNS?**

**Answer:**

- Septoplasty and SMR (Submucous Resection).

**Q3.4: What is "Cottles line," and how does it influence the choice of surgical procedure for DNS?**

**Answer:**

- Cottles line is an imaginary line drawn from the frontal spine to the anterior nasal spine. Deviations in front of Cottles line are treated only by septoplasty.
- Deviations behind Cottles line are treated either by septoplasty or with SMR.

**Q3.5: What is the "Cottles test," what anatomical structures bound the internal nasal valve, and how is the test performed to identify obstruction?**

**Answer:**

- Cottle's test is done to identify the patency of the internal nasal valve.
- The internal nasal valve is bounded medially by the septum, superiorly by the lower border of the upper lateral cartilage, and laterally by the head of the inferior turbinate, forming an angle of 10-15 degrees. In the test, the patient breathes in and out to identify the side of obstruction. On the obstructed side, the cheek is pulled away, and the patient breathes in and out. Improvement in breathing suggests an obstruction at the internal nasal valve.

**Q3.6: Compare Septoplasty and SMR-based on flap elevation, anterior deviation , risk of complication and recurrence**

**Answer:**

- Septoplasty: Conservative surgery
  - In septoplasty, flap on the septum is elevated only on one side, deviation is corrected, and the flap is replaced back
- SMR: Radical surgery
  - In SMR, flap is elevated on both sides of the septum, deviation is corrected by removing almost complete cartilage and complete bone and mucosa is replaced back

| | Septoplasty | SMR |
|---|---|---|
| Children | +<br>Conservative | -<br>Radical |
| Elevation of flap | Only on one side | Both the sides |
| Anterior deviation | + | - |
| Risk of complication | Lower | Higher |
| Risk of recurrence | Higher | Lower |

**Q3.7: Why are septal surgeries generally avoided in children under 17-18 years of age?**

**Answer:**

- Septal surgeries are avoided till 17-18 years of age because the nasal bones can still grow, and early surgery may lead to recurrence of the deviation.

## BIG QUESTION 4: Describe Septal Abscess and Septal Hematoma?

**Broad Answer:**



- Septal Abscess is a collection of pus caused by trauma/infection, presenting with bilateral nasal obstruction, headache, fever, and lymphadenopathy
- Septal Hematoma is a collection of blood due to trauma, presenting with bilateral nasal obstruction and headache, but typically without fever or lymphadenopathy
- Presentation for both septal abscess and septal hematoma is same
  - Swelling on either side of septum

## DETAILED QUESTIONS

**Q4.1: What are the typical causes of a Septal Abscess versus a Septal Hematoma?**

**Answer:**

- **Septal Abscess:** Trauma, nasal infection, iatrogenic, nasal picking.
- **Septal HematomAnswer:** Trauma (direct, surgical, iatrogenic).

**Q4.2: How do the clinical presentations of Septal Abscess and Septal Hematoma differ, particularly regarding headache, lymphadenopathy, and fever?**

**Answer:**

| | Septal abscess | Septal hematoma |
|---|---|---|
| Presentation | • H/O trauma +/-<br>• B/L nasal obstruction | • H/O trauma +<br>• B/L nasal obstruction |
| Headache | + | +/- |
| Lymphadenopathy | + | - |
| Fever | + | - |

### Q4.3: Why is early intervention more crucial for a Septal Abscess compared to a Septal Hematoma?

**Answer:**

- Early intervention is more crucial for a septal abscess because it is located in the danger triangle of the face (between the nasion and angle of the lips), meaning infection can spread to the cavernous sinus, leading to cavernous sinus thrombosis.

### Q4.4: What is the treatment for a Septal Abscess, and what is the treatment for a Septal Hematoma?

**Answer:**

- **Septal Abscess:** Incision and drainage + Intravenous (I.V.) antibiotics.
- **Septal Hematom:** Incision and drainage + Pressure packing.

### Q4.5: Compare Septal Abscess and Septal Hematoma regarding risk of complications and recurrence.

**Answer:**

- **Septal Abscess:** Higher risk of complication, higher risk of recurrence.
- **Septal Hematoma:**Lower risk of complication, lower risk of recurrence.

## BIG QUESTION 5:Describe septal perforation based on its location ? What are the presenting symptoms and the treatment options?

**Broad Answer:**

- Septal perforation can occur in the cartilaginous septum, bony septum or total septum
- Small perforations cause a whistling sound, while large ones lead to nasal obstruction, crusting, and discharge.
- Treatment includes septal buttons or reconstruction

## DETAILED QUESTIONS

### Q5.1: List the common causes of septal perforation, specifically in the cartilaginous septum.

**Answer:**

- Trauma, drug abuse, nose picking, inhalation of gases (like mustard gas, asbestos gas), following a septal abscess, and infections like TB.

### Q5.2: What is the cause of perforation of the bony septum?

**Answer:**

- Syphilis.

### Q5.3: What specific condition is associated with perforation of the total septum?

**Answer:**

- Wagener's granulomatosis.

### Q5.4: How do the symptoms of a small septal perforation differ from those of a large septal perforation?

**Answer:**

- **Small perforation:** Patient presents with a whistling sound.
- **Large perforation:** Patient presents with nasal obstruction, crusting, and discharge of blood.



YOURWISH

### Q5.5: When is treatment typically indicated for septal perforation?

**Answer:**

- Treatment is indicated only when symptoms prohibit the patient from performing daily activities or if there is a large bleed.

### Q5.6: What are the treatment options for septal perforation?

**Answer:**

- Treatment includes septal button or reconstruction of the septum.

## BIG QUESTION 6: Differentiate between Antrochoanal and Ethmoidal polyps

**Broad Answer:** PYQ: FMGE 2020 PYQ: INICET 2022

| | AC polyp | Ethmoidal polyp |
|---|---|---|
| Age | Young | Older |
| Etiology | Infection | Allergy |
| Number | Single | Multiple |
| Laterality | U/L | B/L |
| Origin | Maxillary antrum | Ethmoidal air cells |
| Growth | Posteriorly towards choana | Anteriorly towards vestibule of the nose |
| Medical treatment | No role | Yes |
| Surgery | FESS | FESS |
| Recurrence | Low | High |

## DETAILED QUESTIONS

### Q6.1: Describe the origin, laterality, and typical number of Antrochoanal polyps. What is their primary etiology and typical age group?

PYQ: FMGE 2023

**Answer:**

- They originate from the maxillary antrum and extends posteriorly from the choana
- Greyish white massgrows into nasal cavity reaching the nasopharynx
- They are single/unilateral and occur due to infection in the maxillary sinus.
- They are seen in young age groups and are male-predominant.

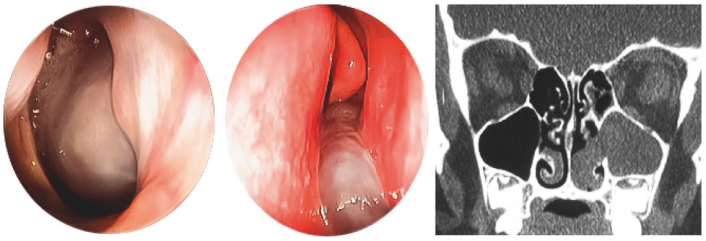

### Q6.2: What organism is responsible for infection causing antrochoanal polyps?

**Answer:**

- Streptococcus pneumoniae.



YOURWISH

**Q6.3: What is "Dodd's sign," and what does it suggest?**

**Answer:**

- Dodd's sign is a blackish shadow between the mass and the posterior pharyngeal wall, suggestive of an antrochoanal polyp seen on an X-ray.

**Q6.4: What are the symptoms associated with an Antrochoanal polyp?**

**Answer:**

- Unilateral nasal obstruction, difficulty in breathing, headache, sinusitis, smell disturbance, and foul smell in the nose.

**Q6.5: What is the treatment for an Antrochoanal polyp? Is medical therapy effective?**

**Answer:**

- There is no role for medical therapy.
- The treatment is surgery, specifically FESS (Functional Endoscopic Sinus Surgery).
- A CT scan is done prior to surgery to identify the origin and extension.

**Q6.6: Describe the origin, laterality, and typical number of Ethmoidal polyps. What is their primary etiology and typical age group?**

**Answer:**

- These are polyps arising from ethmoidal air cells.
- Their etiology is mainly allergic.
- They are seen in adults, are bilateral, and multiple, often appearing like a "bunch of grapes."

**Q6.7: Describe ethmoidal polyps with their etiology, features, and appearance.**

**Answer:**

- Origin: Arise from ethmoidal air cells
- Etiology: Mainly allergic
- Age Group: Seen in adults
- Laterality & Number: Bilateral, multiple
- Appearance> Bunch of grapes
- Growth> Grows anteriorly

**Q6.8: What are the symptoms of Ethmoidal polyps, and how do they compare to Antrochoanal polyps?**

**Answer:**

- Symptoms are similar to antrochoanal polyps but are bilateral.

**Q6.9: What conditions are commonly associated with Ethmoidal polyps? List and briefly describe them.**

**Answer:** Chronic rhinosinusitis, Ciliary motility disorder, Asthma, Cystic fibrosis, Kartagener's syndrome (Bronchiectasis, sinusitis, situs inversus), Young syndrome (Sinopulmonary syndrome, azoospermia), Churg-Strauss syndrome (Asthma, fever, eosinophilia, vasculitis, granuloma).

**Q6.10: What is "Sampter's triad," and what mnemonic is used for it?**

PYQ: NEET PG 2022

PYQ: FMGE 2023

**Answer:**

- Sampter's triad (Mnemonic: **AAP**) consists of

- Asthma
- Aspirin intolerance
- Nasal Polyp

### Q6.11: How are Ethmoidal polyps diagnosed?

**Answer:**

- Diagnosis is done via anterior rhinoscopy, showing multiple grape-like masses in the nasal cavity that do not bleed on touch.

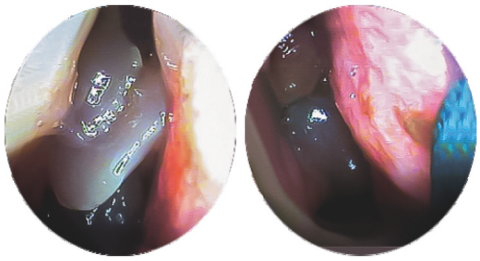

- A CT scan can also be done.

### Q6.12: What are the conservative and surgical treatment options for Ethmoidal polyps?

**Answer:**

- **Conservative:** Antihistamines, steroids, nasal decongestants.
- **Surgery:** FESS (Functional Endoscopic Sinus Surgery) if the polyp doesn't shrink on conservative treatment.

### Q6.13: Case: A Patient with asthma presents with b/l nasal obstruction. On examination, multiple grape-like masses in the nasal cavity are seen. What is the drug to avoid in this patient?

**Answer:** Aspirin has to be avoided as the patient has ian ntolerance to it.

## BIG QUESTION 7: Briefly describe Rhinosporidiosis and Rhinoscleroma

**Broad Answer:**

- Rhinosporidiosis is caused by the aquatic protozoan Rhinosporidium seeberi, presenting as red, fleshy "strawberry" masses with whitish dots and epistaxis, diagnosed by HPE showing sporangia, and treated by excision and cauterization.
- Rhinoscleroma is caused by Klebsiella rhinoscleromatis, endemic to North India, progressing through atrophic, granulomatous (woody hard Hebra nose), and cicatrisation (tapir nose) stages, diagnosed by HPE showing Mikulicz cells/Russel bodies and culture, treated with antibiotics and debridement.

## DETAILED QUESTIONS

### Q7.1: What is the causative agent of Rhinosporidiosis, and how is the infection typically acquired?

**Answer:** It is caused by the aquatic protozoan Rhinosporidium seeberi. Infection occurs through contaminated water.

### Q7.2: What is the causative agent of Rhinoscleroma, and what type of bacteria is it?

**Answer:** It is caused by the Gram-negative bacteria Klebsiella rhinoscleromatis (Frisch bacillus).

### Q7.3: What are the endemic regions for Rhinosporidiosis and Rhinoscleroma in India?

**Answer:**

- **Rhinosporidiosis:** South India.
- **Rhinoscleroma:** North India.

### Q7.4: Describe the characteristic symptoms and signs of Rhinosporidiosis.



**Answer:**

- **Symptoms:** Water-borne infection, nasal obstruction, difficulty in breathing, sinusitis.
- **Signs:** Red, fleshy mass (due to proliferation in the dermal layer) with whitish dots on the surface in the anterior part of the nose, leading to Epistaxis. Often described as a "Strawberry mass."

### Q7.5: Describe the symptoms and signs of Rhinoscleroma across its different stages.



**Answer:**

- **Atrophic stage:** Symptoms: Airborne, Dryness, crusting, foul smell. Signs: Crusting, foul smell.
- **Granulomatous stage:** Symptoms: Antigen-antibody reaction. Signs: Formation of granuloma, described as "Woody hard granuloma" (Hebra nose).
- **Stage of cicatrisation:** Signs: Narrowing/stenosis, leading to "Tapir nose" or "fibrous nose."

### Q7.6: How is Rhinosporidiosis diagnosed microscopically, and can it be cultured?

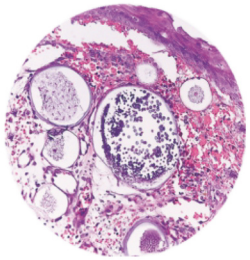

**Answer:**

- Diagnosis is by HPE (Histopathology) showing Sporangia with multiple spores.
- It **cannot** be cultured.

### Q7.7: How is Rhinoscleroma diagnosed microscopically and via culture?

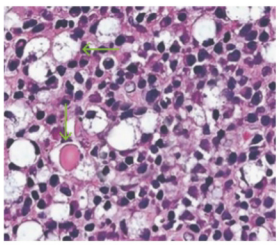

**Answer:**

- Diagnosis is by HPE showing Mikulicz cells and Russel bodies.
- It **can** be cultured on McConkey agar.

### Q7.8: What is the treatment for Rhinosporidiosis?

**Answer:**

- Excision of the mass and cauterization of the base.

### Q7.9: What is the treatment for Rhinoscleroma, including antibiotic regimen and duration?

**Answer:**

- Treatment includes Streptomycin, Tetracycline, and Rifampicin for 6 weeks.
- Treatment is stopped after two negative cultures.
- If any culture is positive, treatment must be continued even beyond 6 weeks.
- Debridement of dead tissue is also performed.

## BIG QUESTION 8: Differentiate between Allergic Rhinitis and Non-Allergic (Vasomotor)

**Broad Answer:**

- Allergic Rhinitis is IgE-mediated, presenting with itching, sneezing, watery discharge, and specific signs like allergic shiners, diagnosed by IgE levels/skin tests, and treated medically.
- Non-allergic rhinitis is due to an autonomic imbalance, with similar symptoms but normal IgE, diagnosed by exclusion, treated medically with possible surgery.

## DETAILED QUESTIONS

**Q8.1: Differentiate between Allergic Rhinitis and Non-Allergic Rhinitis (Vasomotor Rhinitis) based on Serum IgE levels.**

Answer:

- **Allergic Rhinitis:** Serum IgE is Elevated.
- **Non-Allergic Rhinitis:** Serum IgE is Normal.

**Q8.2: What are the typical symptoms of Allergic Rhinitis? With what other condition can it be associated?**

Answer:

- Itching, sneezing, watery nasal discharge, smell disturbances.
- It can be associated with bronchial asthma.

**Q8.3: What are the underlying causes of symptoms in Non-Allergic Rhinitis? List its typical symptoms.**

Answer:

- Symptoms occur due to an imbalance between the sympathetic and parasympathetic nervous systems, specifically parasympathetic hyperactivity and sympathetic hypoactivity.
- Symptoms include itching, sneezing, watery nasal discharge, and smell disturbances.

**Q8.4: List and describe the specific signs observed in Allergic Rhinitis.**

Answer:

- **Darrier line:** Dark line on the dorsum of the nose.



- **Allergic shiners:** Dark circles under the eyes.
- **Dennie morgan fold:** Edema/fold under the eyelid.



- **Salute sign:** Due to constant habit of rubbing the nose.



### Q8.5: How is Allergic Rhinitis diagnosed?

**Answer:**

- Diagnosis involves Serum IgE (does not specify what the patient is allergic to), Skin prick test, Radioallergosorbent test (RAST), and Absolute eosinophil count.

### Q8.6: How is Non-Allergic Rhinitis diagnosed and mention the signs?

**Answer:**

- It is a diagnosis of exclusion.
- Signs
  - **Hypertrophy of inferior turbinate.**
  - **Mulberry appearance of turbinate.**

### Q8.7: What are the treatment options for Allergic Rhinitis?

**Answer:**

- Medical management
  - Antihistamines, decongestants, intranasal and systemic steroids.
- Monoclonal antibodies like Omalizumab and Dupilumab are used.
- There is no role of surgery.

### Q8.8: What are the treatment options for Non-Allergic Rhinitis?

**Answer:**

- **Medical:** Antihistamines, decongestants, intranasal and systemic steroids.
- **Surgery (if medical therapy fails):** Reduction of inferior turbinates, Vidian neurectomy (if surgery fails).

### Q8.9: What is "Rhinitis medicamentosa," and what causes it? What is its primary symptom?

**Answer:**

- It is caused by the abuse of alpha-adrenergic agonists like xylometazoline/oxymetazoline. It leads to rebound nasal congestion.

### Q8.10: What is the treatment for Rhinitis medicamentosa?

**Answer:**

- Stop the offending drug, and use intranasal and systemic steroids (short course).

### Q8.11: Provide examples of drugs that can cause "Drug induced rhinitis" as a side effect.

**Answer:**

- Neostigmine, Guanethidine, Propranolol, and Beta-blockers.

### Q8.12: What is "Atrophic Rhinitis," and what are its characteristic pathological changes? What is its main causative organism?

PYQ: NEET PG 2022

**Answer:**

- Atrophic rhinitis involves atrophy of all structures of the nose, i.e., nasal mucosa, sinus mucosa, and olfactory fibers.
- It is primarily caused by a Gram-negative bacteria, Klebsiella ozaenae (Perez bacillus).

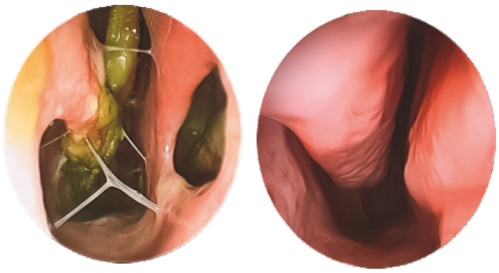

**Q8.13: List other potential etiologies for Atrophic Rhinitis.**

**Answer:**

- It can also be hereditary, endocrinal, nutritional deficiency (vitamin D, vitamin B12, iron), racial, and autoimmune.

**Q8.14: Describe the characteristic signs of Atrophic Rhinitis, including "Merciful anosmia."**

**Answer:**

- Wide roomy nasal cavity, dry nose, crusty nose (greenish foul-smelling). "Merciful anosmia" is a sign where the patient cannot smell the foul smell coming from his nose.

**Q8.15: What are the medical treatment options for Atrophic Rhinitis?**

**Answer:**

- Alkaline nasal douching solution
  - (Sodium chloride (2), sodium bicarbonate (1), sodium borate (1) mixed in 280 ml of water)
- Glycerol
- Glucose in glycerin
- Kemicetine antiozena solution (Chloromycetin, estradiol, placental extracts).

**Q8.16: What are the surgical treatment options for Atrophic Rhinitis if medical therapy fails? Briefly describe each.**

**Answer:**

- **Young's operation:** Complete closure of the nasal cavity where mucosa is elevated from the vestibule of the nose on the lateral, medial, and floor, and sutured together.
- **Modified Young's surgery.**
- **Lautenslager surgery:** Medialization of the lateral wall of the nose, reducing the size of the nasal cavity.

**Q8.17: What is "Rhinitis sicca," and how does it differ from Atrophic Rhinitis in terms of affected area? What causes it?**

**Answer:**

- In Rhinitis sicca, only the anterior 1/3$^{rd}$ of the nose is involved. It is seen in bakers or people continuously exposed to hot and humid air.

**Q8.18: What are the signs and management of Rhinitis sicca ?**

**Answer:**

- Signs include dry nose and crusting of the nose, seen only in the anterior 1/3$^{rd}$ of the nose.
- Medical management: Alkaline nasal douching solution, Glycerol, Glucose in glycerin, Kemicetine antiozena solution
- Surgical management is not required.

## BIG QUESTION 9: Define Sinusitis and its classifications.

**Broad Answer:**

- Sinusitis is inflammation of the sinus mucosa, classified as acute, subacute , or chronic.
- Acute sinusitis is primarily treated medically, with FESS for refractory cases.
- Chronic sinusitis is managed with antibiotics and antral irrigation, or FESS if medical therapy fails.

## DETAILED QUESTIONS

### Q9.1: Describe acute, subacute, and chronic sinusitis

**Answer:**

- Acute (< 4 weeks)
- Subacute (between 4 - 12 weeks).
- Chronic (> 12 weeks)

### Q9.2: Identify the most common sinus affected in adults versus children, and the least common sinus affected overall.

**Answer:**

- **Most common in adults:** Maxillary sinus.
- **Most common in children:** Ethmoidal sinus (as it is most developed in children).
- **Least common:** Sphenoid sinus (as it is the posterior-most sinus).

### Q9.3: List the "exciting factors" and "predisposing factors" for sinusitis.

**Answer:**

- **Exciting factors:** Nasal infection, swimming and diving, trauma, dental infection (especially maxillary sinus, 2$^{nd}$ premolar and 1$^{st}$ molar).
- **Predisposing factors:** Obstruction (due to polyp, edema, congenital abnormalities, uncinate process, airway block) of drainage of sinuses, leading to retention of secretions.

### Q9.4: What are the most common bacteria causing sinusitis? Which organisms are common in sinusitis of dental origin?

**Answer:**

- The most common is Streptococcus pneumoniae.
- Sinusitis of dental origin often involves anaerobic organisms and mixed infections.

### Q9.5: What criteria (major and minor symptoms) are used for the clinical diagnosis of sinusitis?

**Answer:**

- For diagnosis, 2 major symptoms or 1 major and 2 minor symptoms should be present.

| Major | Minor |
|---|---|
| • Nasal obstruction<br>• Facial pain or pressure | Headache |
| Purulent nasal discharge | Cough |
| Fever | Halitosis |



YOURWISH

| | |
|---|---|
| Nasal congestion | Ear pain and pressure |
| Hyposmia or anosmia | Dental pain |
| Facial congestion or fullness | - |

**Q9.6: Describe the typical location of headache and presence of tenderness/redness/edema for Maxillary, Frontal, Ethmoid, and Sphenoid sinusitis.**

**Answer:**

| | Maxillary | Frontal | Ethmoid | Sphenoid |
|---|---|---|---|---|
| Headache | Usually seen over the cheek and forehead and can be confused with frontal sinusitis | Localized to frontal sinus above the medial canthus<br>**Office Headache-** severe headache when the patient wakes up in the morning(due to retention of secretions when patient is in the anti gravity position), decreases as he progresses the day (due to gravity dependent drainage) | Localized over bridge of nose, medial and deep to the eye | Occiput or vertex |
| Tenderness | Cheek | Over frontal sinus | Bridge of nose | Nil |
| Redness and edema | Cheek<br>Lower eyelid puffiness | Upper eyelid puffiness | Both eyelids become puffy | Nil |
| Site of nasal discharge | Middle meatus | Middle meatus | • Anterior ethmoids- middle meatus<br>• Posterior ethmoids- superior meatus | Spheno-ethmoidal recess |

**Q9.7: What is the "Postural test," and how is it used to differentiate between maxillary, frontal, and anterior ethmoidal sinusitis?**

**Answer:**

- The postural test is done to differentiate these types of sinusitis. Discharge in the middle meatus is mopped, and the patient is asked to lie in the opposite direction.
  - o **Reappearance of pus:** Suggestive of maxillary sinusitis.
  - o **No reappearance of pus:** Either frontal or ethmoidal sinusitis.

**Q9.8: What is the first investigation for acute sinusitis? What is the definitive investigation (gold standard)? When is a CT scan indicated?**

**Answer:**

- **First investigation:** X-ray.
- **Definitive investigation (gold standard):** Sinus puncture and bacterial culture.
- **CT scan:** Indicated in immunocompromised patients or when anticipating complications.



YOURWISH

### Q9.9: What is the investigation of choice (IOC) for chronic sinusitis?

**Answer:**

- Non-contrast CT scan.

### Q9.10: What is the medical and surgical treatment for Acute Sinusitis?

**Answer:**

- **Medical:** Antibiotics + decongestants + analgesics + hot fomentation.
- **Surgical:** FESS, if not responsive to medical therapy.

### Q9.11: How long does Chronic Sinusitis last? What is its typical cause and most commonly involved sinus?

**Answer:**

- It lasts for > 12 weeks due to the failure of resolution of acute infection. Maxillary sinus is the most commonly involved.

### Q9.12: How does chronic sinusitis present?

**Answer:** Purulent nasal discharge is the most common and nasal obstruction

### Q9.13: What are the medical and surgical treatment options for Chronic Sinusitis?

**Answer:**

- **Medical:** Antibiotics with antral irrigation.
- **Surgical:** FESS, if medical therapy fails.

## BIG QUESTION 10: Describe fungal sinusitis and its types

**Broad Answer:**

- Fungal sinusitis is broadly classified into non-invasive and invasive forms.
  - Non-invasive types include Fungal Ball and Allergic Fungal Rhinosinusitis (AFRS), typically caused by Aspergillus
  - Invasive forms, such as Invasive Aspergillosis and Invasive Mucormycosis (Mucor being the causative organism for the latter), are often seen in immunocompromised patients,

## DETAILED QUESTIONS

### Q10.1: List the two types of non-invasive fungal sinusitis mentioned.

**Answer:** Fungal ball and Allergic fungal rhinosinusitis (AFRS).

### Q10.2: What is the common causative organism for non-invasive fungal sinusitis?

**Answer:**

- Aspergillus.

### Q10.3: In which patient populations is non-invasive fungal sinusitis typically seen?

**Answer:** It can be seen in both immunocompetent and immunocompromised patients.



### Q10.4: What specific CT scan sign is characteristic of Allergic Fungal Rhinosinusitis (AFRS)?

**Answer:**

- "Double density sign."

### Q10.5: List the "Bent and Kuhn criteria" used for diagnosing AFRS.

**Answer:**

- Serum IgE (Elevated)
- KOH mount (Positive)
- Greenish nasal discharge
- Polyposis
- CT scan (Double density sign).

### Q10.6: What are the primary treatment modalities for non-invasive fungal sinusitis?

**Answer:**

- FESS (Functional Endoscopic Sinus Surgery) and antifungal therapy (e.g., Itraconazole).

### Q10.7: What is the causative organism for Invasive Mucormycosis, and how does it typically spread?

**Answer:**

- The causative organism is *Mucor*.
- Its mode of spread is through the blood.

### Q10.8: What characteristic clinical sign is associated with Mucormycosis, and why does it occur?

**Answer:**

- Mucormycosis presents with a "blackish eschar."
- This occurs because it is angioinvasive, forming a fungal thrombus that inhibits circulation to the tissue, leading to necrosis.

PYQ: FMGE 2021

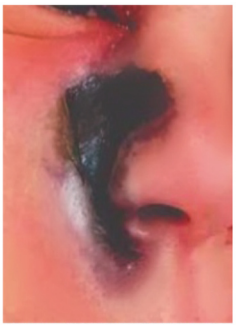

### Q10.9: What specific sign is observed on MRI in cases of invasive fungal sinusitis, particularly Mucormycosis?

**Answer:**

PYQ: INICET 2021

- "Black turbinate sign."

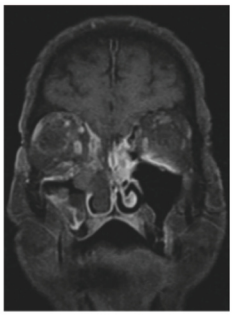

### Q10.10: What is the Investigation of Choice (IOC) for invasive fungal rhinosinusitis? What role does a CT scan play in its diagnosis?

**Answer:**

- The IOC is Contrast-enhanced MRI.
- CT helps to identify bony spread and involvement.

### Q10.11: What are the key components of treatment for invasive fungal rhinosinusitis?

**Answer:**

- Extensive debridement of tissue and the Liposomal form of Amphotericin B.

# 8. COMPLICATIONS OF SINUSITIS AND EPISTAXIS

**BIG QUESTION 1: What are the complications of sinusitis, and what are their clinical features and management?**

**Broad Answer:**

- Complications of Sinusitis occur due to the disease extending into local areas
  - o Intracranial, mainly to the Anterior cranial fossa
  - o Orbital
  - o Sinus-related local
  - o Descending infections

## DETAILED QUESTIONS

### Q1.1: What are the localized sinus-related complications of sinusitis?

**Answer:**

- These complications are limited to the sinuses
  - o Retention cyst: Cystic transformation of the mucosal lining within the sinus
  - o Mucocele
    - → Obstruction to drainage of the sinus causes retention of secretion.
    - → Due to edema, inflammation, polyp, trauma
    - → Most common- Frontal sinus (drainage is very narrow)
    - → Least common- Sphenoid sinus
  - o Pyocoele: Infection of mucocele
  - o Osteomyelitis

PYQ: FMGE 2023

### Q1.2: What are the key characteristics, symptoms, radiological findings, and treatment options for a frontal sinus mucocele?

**Answer:**

| | |
|---|---|
| Site | • Superomedial quadrant of orbit |
| Symptoms | • The eye is displaced forward, downward, and laterally (proptosis) |
| Swelling | • Cystic, non-tender, eggshell cracking |
| X-ray | • Loss of scalloped margin |
| Treatment | • Frontoethmoidectomy to promote drainage of the frontal sinus |



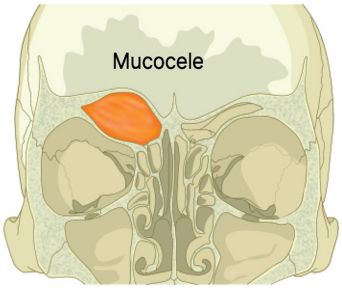




YOURWISH

YOURWISH

### Q1.3: What is Pott's Puffy Tumor, and how does it relate to frontal sinus infection?

**Answer:**

- Infection of the frontal sinus can spread to the overlying bone, causing a subperiosteal abscess
- Osteomyelitis of the frontal bone, known as Pott's puffy tumor

PYQ: FMGE 2021



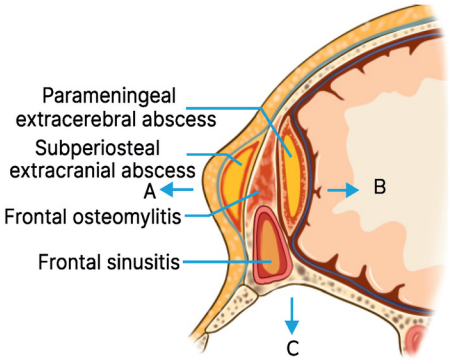


### Q1.4: What is pneumosinus?

**Answer:**

- Pneumosinus of frontal bone is the presence of an air-filled frontal sinus within the frontal bone. Normally, the frontal sinus develops within the diploic space of the frontal bone during adolescence. Sometimes, it may be abnormally enlarged due to trauma, obstruction of drainage, or idiopathic causes.



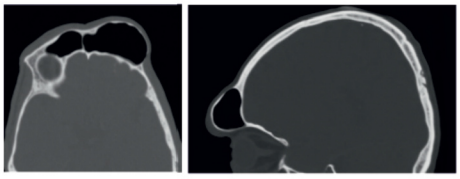

Pneumosinus of frontal bone - air-filled cavity

### Q1.5: What is Chandler's classification of orbital complications of sinusitis?

**Answer:** Pre-septal cellulitis → Orbital cellulitis → Subperiosteal abscess → Orbital abscess → Cavernous sinus thrombosis

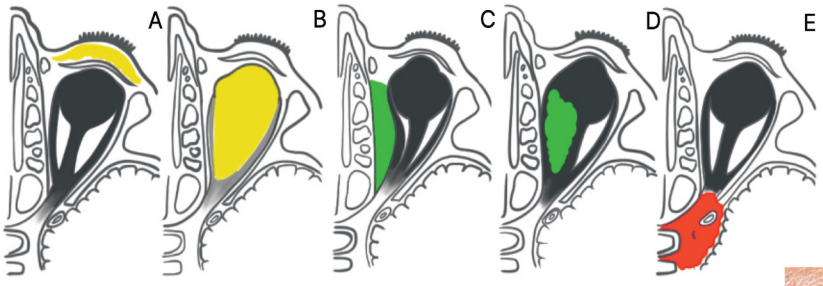


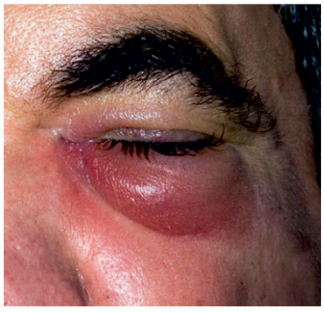

### Q1.6: Which specific complication is particularly common with ethmoid sinusitis?

**Answer:**

- Orbital cellulitis is particularly common in ethmoid sinusitis
  - o Swelling of both upper and lower eyelids

### Q1.7: How does Sinusitis cause intracranial complications?

**Answer:**

- Infection of the Frontal sinus and Ethmoidal sinus breaks into the anterior cranial fossa, and infection of the sphenoidal sinus breaks into the middle cranial fossa

### Q1.8: What are the various types of intracranial complications that can arise from sinusitis, and what are the common clinical features associated with them?

**Answer:**

- Intracranial Complications of Sinusitis
  - Extradural/ Epidural abscess - localization of pus between bone and dura
  - Subdural abscess - localization of pus between dura and brain parenchyma
  - Meningitis - inflammation of the meninges
  - Encephalitis
  - Brain abscess - infection of the brain
  - Cavernous sinus thrombosis of the sinuses, especially the sphenoidal sinus
- Clinical Features of Intracranial Complications of Sinusitis
  - History of sinusitis
  - Personality/behavioral change

## BIG QUESTION 2: What is epistaxis, what are its common types and causes, and from which anatomical sites do these types usually arise?

**Broad Answer:**

- Epistaxis refers to bleeding from the nose, commonly known as a nosebleed. It occurs due to rupture of blood vessels in the nasal mucosa. It can be anterior (more common, from Kiesselbach's plexus) or posterior (from Woodruff's plexus, more severe).
- Causes include trauma, dry air, infections, hypertension, bleeding disorders, or nasal tumors.

## DETAILED QUESTIONS

### Q2.1: How is the blood supply of the nose divided?

**Answer:**

PYQ: FMGE 2019, 2021, 2023

- An imaginary line divides the septum into two halves
  - Blood supply of the upper half of the septum
  - Blood supply of the lower half of the septum

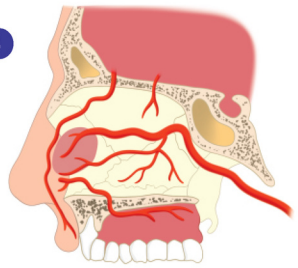

### Q2.2: What is the blood supply of the upper half of the septum?

**Answer:**

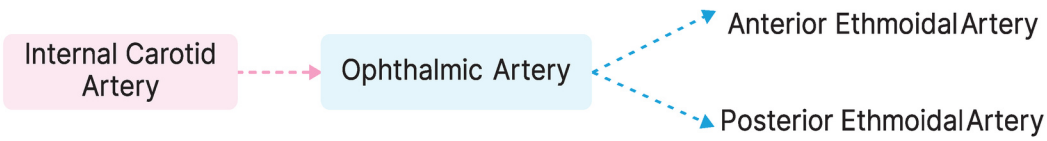

**Q2.3: What is the blood supply of the lower half of the septum?**

**Answer:**

External carotid artery
- Facial artery → Superior labial artery: (Inferior septum via septal branch).
- Internal maxillary artery
  - Sphenopalatine artery: supplies posteroinferior part of septum
  - Greater palatine artery: supplies posteroinferior part of septum

**Q2.4: Which arteries form the Kiesselbach's plexus?**

**Answer:**

- All the arteries supplying the septum will form a plexus in the anteroinferior portion of the septum, except the Posterior Ethmoidal artery. This is called the little area, also called the Kiesselbach plexus
- It is an arterial plexus

**Q2.5: What is Woodruff's plexus, and where is it located?**

**Answer:**

- Corresponding to the arteries supplying the septum, some veins drain the Posterior inferior part of the Septum
- This venous plexus is called Woodruff's plexus

**Q2.6: What are the key differentiating characteristics between Kiesselbach's Plexus and Woodruff's Plexus?**

**Answer:**

PYQ: AIIMS 2020

| | Kiesselbach's Plexus | Woodruff's Plexus |
|---|---|---|
| Composition | Arterial plexus | Venous plexus |
| Location | Anteriorly | Posteriorly |
| Type of epistaxis | Anterior epistaxis | Posterior epistaxis |
| Common age group affected | Common in children | Common in adults |
| Severity of bleeding | Mild | Severe |
| Most common cause | Trauma | Hypertension |

**Q2.7: Where are the anterior and posterior ethmoidal arteries typically ligated, and what are the key anatomical locations for ligation of the internal maxillary artery and sphenopalatine artery?**

**Answer:**

- Anterior and posterior ethmoidal arteries are ligated near the medial wall of the orbit
- The Internal maxillary artery lies in the Pterygopalatine fossa, where it is ligated
- Ligation of the Sphenopalatine artery is done in the Sphenopalatine foramen near the posterior wall of the maxillary sinus, 8-10 mm behind the posterior end of the middle turbinate

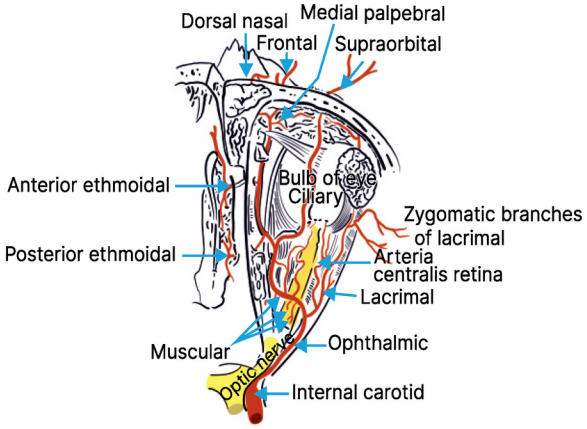


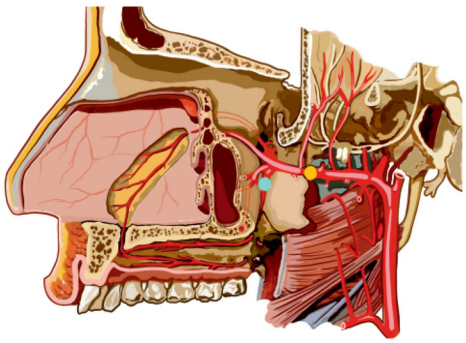



YOURWISH

### Q2.8: What are the causes of Epistaxis?

**Answer:**

| Local Causes | General Cause | Idiopathic |
|---|---|---|
| • Trauma<br>• Infection<br>• Foreign body<br>• Neoplasm of the nose and paranasal sinus<br>• Deviated nasal septum | • Hypertension - most common<br>• Disorders of Blood vessels<br>• Liver disease<br>• Renal disease | • No attributable cause |

- Mediastinal tumors can cause elevation of venous pressure and bleeding from the nose

### Q2.9: What are the distinguishing characteristics between anterior and posterior epistaxis?

**Answer:**

| | Anterior Epistaxis | Posterior Epistaxis |
|---|---|---|
| Incidence | More common | Less common |
| Site | Little's area | Woodruff's plexus |
| Age | Children | After 40 years of age |
| Cause | Trauma | HTN |
| Bleeding | Mild can be controlled by local pressure or anterior pack | The bleeding is severe, and requires hospitalization and a postnasal pack |

### Q2.10: What is the step-by-step management protocol for epistaxis?

**Answer:**

Hippocrates maneuver - pinch the nose and bend forward

↓

Initial medical review and resuscitation - history, IV fluid, blood investigation

↓

Prepare for nasal endoscopy (4% xylocaine + adrenaline)

↓

Nasal endoscopy

↓

Single bleeding point - cauterize with silver nitrate or electrical cautery, radiofrequency

↓

Diffuse bleeding point or no endoscopy - Anterior nasal packing

↓

If fails

↓

Posterior nasal packing

↓

If fails

↓

Ligate the artery



YOURWISH

### Q2.11: What is the order of ligation in the management of epistaxis?

**Answer:**

1. Sphenopalatine Artery- Artery of epistaxis
2. Internal Maxillary Artery
3. External carotid artery
4. Ethmoidal Artery

### Q2.12: How is anterior nasal packing done?

**Answer:**

- The nasal cavity is packed from the roof of the nose to the floor of the nose to the vestibule anteriorly to the choana posteriorly
- The nasopharynx is not packed

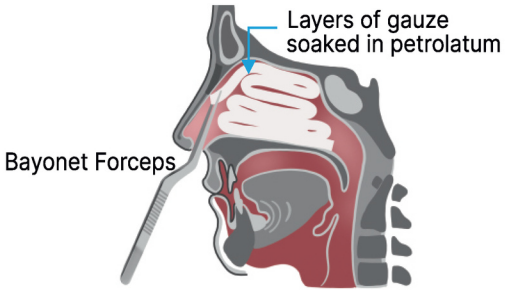


### Q2.13: What is the procedure for performing a posterior nasal packing in the management of epistaxis?

**Answer:**

- An infant feeding tube is passed from the nasal cavity and pulled out through the oral cavity
- A gauze piece is attached to the end, pulled out from the oral cavity
- Retract the nasal end
- The gauze pack is placed in the nasopharynx
- Anterior nasal packing is done

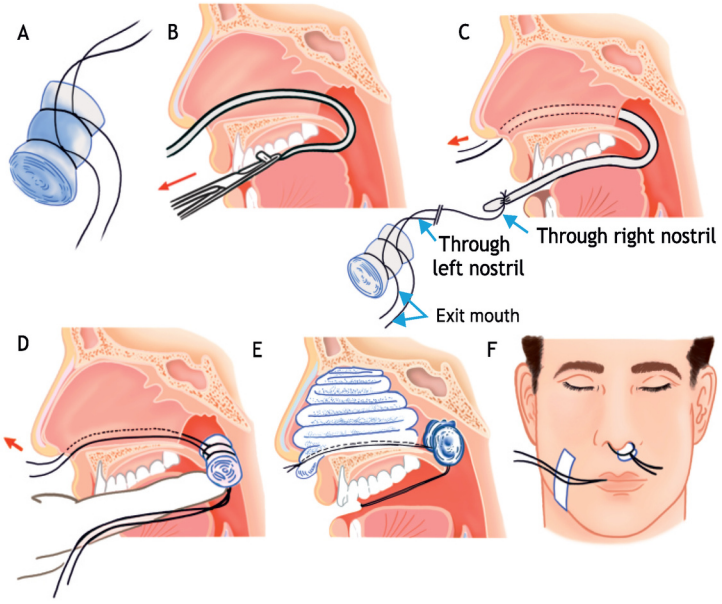


### Q2.14: What is the most common cause of epistaxis?

**Answer:**

- Trauma

### Q2.15: What is the most common cause of epistaxis in children?

**Answer:**

- Nasal picking

### Q2.16: What is the most common cause of epistaxis with foul-smelling nasal discharge?

**Answer:**

- Foreign body (unilateral- seen in children)

### Q2.17: What is the most common cause of recurrent unprovoked profuse epistaxis in adolescent males?

**Answer:**

- Juvenile Nasopharyngeal Angiofibroma

**Q2.18: What is the most common site of epistaxis?**

**Answer:**

- Little's area, AKA Kiesselbach plexus

**Q2.19: From which specific vein does anterior epistaxis originate if it is venous?**

**Answer:**

- Retrocolumellar vein

**Q2.20: Which artery is commonly referred to as the "artery of epistaxis"?**

**Answer:**

- Sphenopalatine artery

**Q2.21: From which plexus does posterior epistaxis originate?**

**Answer:**

- Woodruff's plexus

**Q2.22: What does TESPAL stand for?**

**Answer:**

- Transnasal endoscopic sphenopalatine artery ligation

# 9. FRACTURES OF FACIAL SKELETON AND TUMORS OF NOSE AND PNS

## BIG QUESTION 1: How are the facial skeleton fractures classified?

**Broad Answer:**

- Facial skeleton fractures are classified into
  - Upper
  - Middle: nasal bone fractures are most common
  - Lower

## DETAILED QUESTIONS

### Q1.1: What are the types of nasal bone fractures?

**Answer:**

| | |
|---|---|
| Class 1 | Chevallet fracture |
| Class 2 | Jarjaway fracture |
| Class 3 | Naso-orbito-ethmoid fracture |

### Q1.2: Which type of fracture is most common in the middle third of the facial skeleton?

**Answer:**

- Fractures of the nose.
- A zygomatic fracture is the second most common fracture after the nasal bone fracture.

### Q1.3: Describe the characteristic deformity and risk associated with Naso-orbito-ethmoid (NOE) fracture.

**Answer:**

- "Pig nose deformity," where the orbit and ethmoid bone are depressed, and the rest of the dorsum of the nose gets pushed in an upward direction.
- There is a high chance of CSF leakage because the fracture is very close to the cribriform plate of the ethmoid.

### Q1.4: Differentiate between class 1 and class 2 fractures based on direction of blow and fracture.

**Answer:**

| | Jarjaway fracture (Class 2) | Chevallet fracture (Class 1) |
|---|---|---|
| Direction of blow | From front | From below |
| Direction of fracture | Horizontal 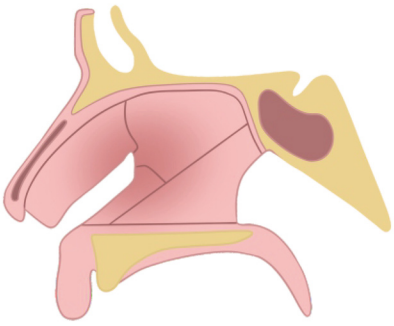 | Vertical 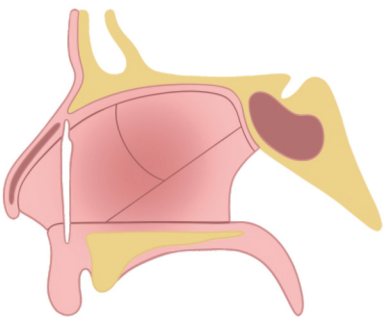 |

**Q1.5: Name the two specific forceps for reducing nasal and septal fractures?**

**Answer:**

- ASH Septum Forceps (for reducing septum fractures)

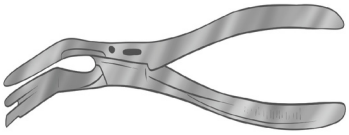

Asch's Forceps

- Walsham Forceps (for reducing nasal bone fractures)



Walsham Forceps

**Q1.6: Why is a Zygomatic fracture also known as a "tripod fracture"? List the three fracture lines associated with it.**

**Answer:**

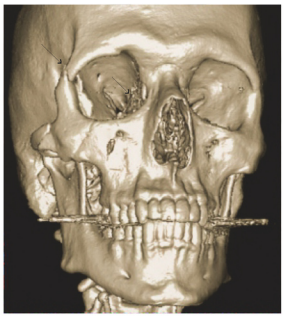

- It is called a tripod fracture because there are three fracture lines:
  - Zygomaticofrontal fracture
  - Zygomaticotemporal fracture
  - Zygomaticomaxillary fracture

**Q1.7: Which nerve is commonly involved in Zygomatic fractures, and why?**

**Answer:** The Infraorbital nerve is involved because it exits from the floor of the orbit, an area often affected by zygoma displacement.

**Q1.8: What visible deformity is characteristic of a Zygomatic fracture?**

**Answer:** Step deformity because of the displacement of the cheekbone.

**Q1.9: Describe fracture of floor of orbit ?** PYQ: NEET PG 2019

**Answer:**

- It is also known as a "Blow-out fracture." Contents of the orbit may herniate into the maxillary sinus because the sinus is air-filled, offering no resistance.
- The floor of the orbit is more susceptible than the medial wall of the orbit.

**Q1.10: What is the classic radiological sign for a Blow-out fracture of the orbit?**

**Answer:** "Teardrop sign."




**Q1.11: Which nerve is commonly involved in fracture of orbital floor, and why?**

**Answer:** Infraorbital nerve is involved as it exits from the floor of the orbit

**BIG QUESTION 2: Describe the LeFort maxillary fractures.** PYQ: FMGE 2019-20

**Broad Answer:**

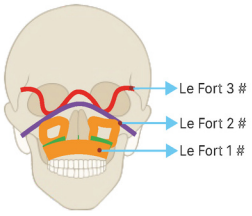


- LeFort I (horizontal) involves the floor of the nose/maxillary sinus
- LeFort II (pyramidal) extends from the nasion to the maxilla
- LeFort III (craniofacial disjunction) separates the midface from the cranium,

involving the nasion, orbits, and zygoma

## DETAILED QUESTIONS

### Q2.1: Describe the fracture line and hallmark features of a LeFort 1 fracture. What is “Guerin's sign"?

**Answer:**

- The fracture line runs horizontally from the floor of the nose and the floor of the maxillary sinus.
- Hallmark features are a "hanging palate" and "hanging teeth."
- Guerin's sign is bluish discoloration of the palate due to greater palatine artery rupture.

### Q2.2: What is another name for a LeFort 2 fracture? Describe its fracture line and hallmark feature.

**Answer:**

- It is also called a "Pyramidal fracture."
- The fracture line goes from the nasion, medial wall of the orbit, the floor of the orbit, then to the maxilla.
- The hallmark feature is "Hanging maxilla."

### Q2.3: Is CSF rhinorrhea always associated with a LeFort 2 fracture?

**Answer:** CSF rhinorrhea may or may not be associated with a LeFort 2 fracture.

### Q2.4: What is another name for a LeFort 3 fracture? Describe its fracture line and its key characteristic in terms of facial skeleton separation.

**Answer:**

- It is also called "craniofacial disjunction."
- The fracture line goes from the nasion, medial wall of the orbit, lateral wall of the orbit, floor of the orbit, and zygoma.
- It signifies a complete separation of the midface from the cranium.

### Q2.5: Which LeFort fracture has a high risk of CSF rhinorrhea? Which LeFort fracture is not typically associated with CSF rhinorrhea?

**Answer:**

- LeFort 3 has a high risk of CSF rhinorrhea.
- LeFort 1 is *not* a feature of CSF rhinorrhea.

### Q2.6. Floating palate/ floating teeth are seen in ?

**Answer:** Lefort 1 fracture

### BIG QUESTION 3: Describe the main types of mandibular fractures and the concept of contrecoup injury.

**Broad Answer:**

- 2 types
  - o Subcondylar fracture
  - o Guardsman fracture
- Contrecoup injury can cause a fracture on the opposite side of trauma (e.g., right-side blow causing left subcondylar fracture).

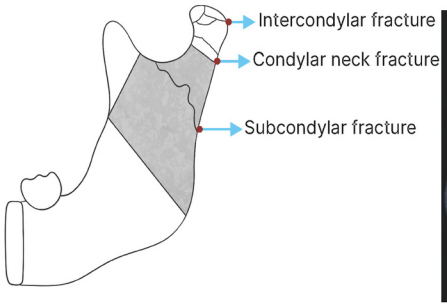

## DETAILED QUESTIONS

**Q3.1: What is the most common site for mandibular fractures, and why is it considered the weakest site?**
**Answer:** The Subcondylar fracture is the most common site and the weakest site of the mandible.

**Q3.2: Explain the concept of "contrecoup injury" in the context of mandibular fractures, providing an example.**
**Answer:**

- When trauma occurs on one side (e.g., the right side), the energy transfers to the opposite side due to contrecoup injury.
- Hence, the fracture can be seen on the opposite side, commonly in the subcondylar region of the mandible.

**Q3.3: What is a "Guardsman fracture" (or "Parade Ground fracture")? What causes it?**
**Answer:** A Guardsman fracture (or Parade Ground fracture) is a bilateral subcondylar region fracture resulting from trauma on the symphysis menti.

**Q3.4: What is the maximum recommended duration for mandibular immobilization after a closed reduction, and why is this limit important?**
**Answer:** Immobilization should not be done for more than 4 weeks because it can result in TMJ (Temporomandibular Joint) ankylosis, leading to permanent difficulty in opening the mouth.

## BIG QUESTION 4: Define CSF rhinorrhea and describe its typical presentation

**Broad Answer:**

- CSF rhinorrhea is the leakage of cerebrospinal fluid into the nasal cavity, most commonly caused by trauma, particularly at the cribriform plate of the ethmoid bone.
- It typically presents as unilateral watery nasal discharge.

## DETAILED QUESTIONS

**Q4.1: What is CSF rhinorrhea? What is its most common cause and the most common anatomical site of leakage?**
**Answer:**

- CSF rhinorrhea involves a leak of CSF into the nasal cavity.
- The most common cause is trauma, and the most common site is the cribriform plate of the ethmoid (thin perforating bone).

**Q4.2: What is the most common presentation of CSF rhinorrhea? When might it be bilateral?**
**Answer:**

- The most common presentation is unilateral watery nasal discharge.
- It can be bilateral in cases of allergy.

**Q4.3: What are the two definitive biochemical diagnostic tests for CSF, and which one is considered the Investigation of Choice (IOC)?**
**Answer:**

- β-2 Transferrin Test (Investigation of choice): Positive test indicates 100% CSF
- β-Trace Protein

### Q4.4: Write briefly on the causes of CSF rhinorrhea.

**Answer:**

- Traumatic causes: 95%.
- Non-traumatic causes (spontaneous)- raised intracranial pressure
  - o Idiopathic intracranial hypertension, space-occupying lesions, obesity

### Q4.5: Name and briefly describe four clinical tests/signs that can suggest the presence of CSF rhinorrhea.

**Answer:**

PYQ: FMGE 2021

- **Halo Sign / Target Sign / Double Ring Sign:** In traumatic CSF rhinorrhea, a drop of fluid on filter paper will show an outer ring and an inner ring, indicating CSF. (Not conclusive alone).
- **Sniff Test:** Nasal fluid can be sniffed back, but CSF cannot be sniffed back. (Not conclusive alone).
- **Handkerchief Test:** In CSF rhinorrhea, there is no stiffening of the handkerchief, unlike a common cold. (Not conclusive alone).
- **Reservoir Sign / Teapot Sign:** In a supine position, CSF collects in the nasal cavity and paranasal sinuses. When the patient is propped up and bends forward, dripping of CSF will be noticed. (Not conclusive alone).

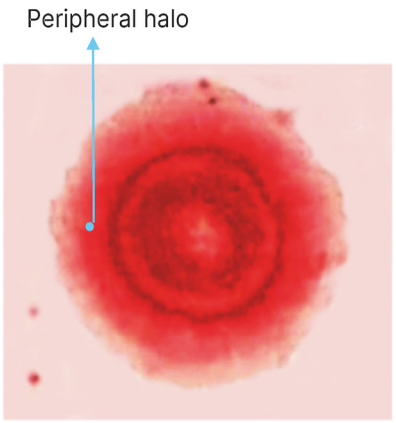


### Q4.6: How does Valsalva maneuver affect CSF leakage in CSF rhinorrhea?

**Answer:** On doing Valsalva, intracranial pressure is increased, and thus the CSF leak will also increase.

### Q4.7: What is the Investigation of Choice (IOC) for determining the site of a CSF leak?

**Answer:** HRCT (High-Resolution CT) of the temporal bone.



### Q4.8: Describe the procedure and purpose of CT Cisternography in diagnosing CSF rhinorrhea.

**Answer:**

- It helps to identify the exact site of an active CSF leak.
- A lumbar puncture is done, CSF is mixed with a fluorescent dye, reinjected, and the dye will go through the active leaking site, which can then be tracked by CT.

### Q4.9: Why might an MRI be chosen for CSF rhinorrhea diagnosis, and what is its limitation?

**Answer:** MRI can be done if the patient does not want the risk of radiation. However, it isn't very specific in detecting the CSF.

### Q4.10: What are the two general treatment approaches for CSF rhinorrhea?

**Answer:** Endoscopic endonasal closure and Craniotomy.

## BIG QUESTION 5: Describe Osteoma, Inverted Papilloma, and Maxillary Sinus Carcinoma

**Broad Answer:**

- Osteoma is the most common benign PNS tumor associated with Gardner's syndrome, treated by excision .

- Inverted Papilloma is a benign yet locally invasive, pre-malignant tumor from the lateral nasal wall.
- Maxillary Sinus Carcinoma's prognosis is assessed by Ohngren's line (above line = poor, below = good) and Lederman's classification; it presents with dull pain, epiphora, and blood-stained discharge.

## DETAILED QUESTIONS

**Q5.1: What is the most common benign tumor of the paranasal sinuses? What is its most common site?**
**Answer:** Osteoma, Its most common site is the frontal sinus.

**Q5.2: What genetic syndrome is associated with osteomas?**
**Answer:** Gardner's syndrome, which consists of osteomas and intestinal polyposis.

**Q5.3: What is the histological pattern of Osteoma?**
**Answer:** Loss of trabecular pattern

**Q5.4: What is the primary treatment for Osteoma? Why is the external approach often preferred for its removal?**
**Answer:**

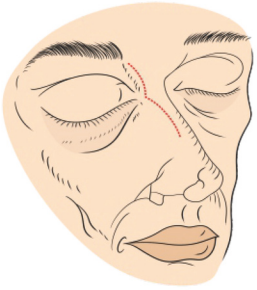

- Excision
- It is difficult to remove bony tumors endonasally, so an external approach (e.g., External fronto-ethmoidectomy via Lynch Howarth incision) is often preferred.
  - From the medial end of the eyebrow to the medial canthus to the nasofacial sulcus

**Q5.5: Inverted Papilloma is also known as?**
**Answer:** Transitional cell papilloma, Ringertz tumor, Schneiderian papilloma.

PYQ: INICET 2022

**Q5.6: What is the nature of Inverted Papilloma as a tumor?**
**Answer:** It is locally invasive, benign, premalignant tumout, but in 10-15% of cases, it is associated with malignancy.

**Q5.7: Describe the characteristic histopathological feature of Inverted Papilloma**
**Answer:** The tumor has finger-like projections that don't grow towards the surface but grow towards the stroma in the reverse direction, hence "inverted."

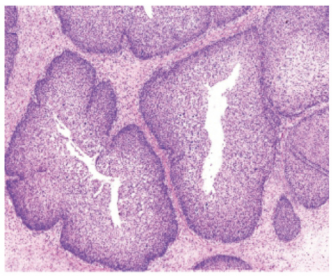

**Q5.8: What are the typical clinical presentations and examination findings of Inverted Papilloma? From where does it typically arise?**
**Answer:**

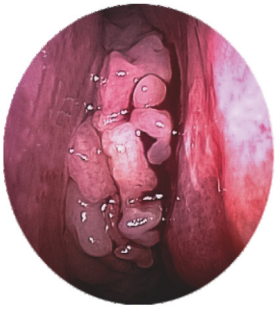

- History of blood stains in the nasal discharge/nasal obstruction.
- On clinical examination, tiny finger-like projections are seen arising from the lateral wall of the nose.
- Diagnosis by examination and histopathology

**Q5.9: What is the surgical treatment for Inverted Papilloma? What structures are removed during this procedure?**
**Answer:**

- Medial Maxillectomy.



YOURWISH

- The lateral wall of the nose and medial wall of the maxilla are removed.

**Q5.10: What is "Ohngren's Line," and what is its significance in Maxillary Sinus Carcinoma?** PYQ: FMGE 2022

**Answer:**

- Ohngren's Line is an imaginary line drawn from the medial canthus to the angle of the mandible.
- This line is used for prognostication
- Any malignancy above this line will have a poor prognosis, while any malignancy below this line will have a good prognosis.

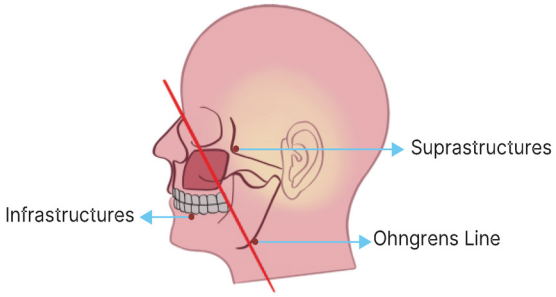


**Q5.11: Briefly explain Lederman's Classification and its purpose in Maxillary Sinus Carcinoma.**

**Answer:**

- Lederman's Classification also used for prognosis. It involves drawing two imaginary vertical lines (passing through the medial wall of each orbit) and two horizontal lines (one from the floor of the orbit, one from the floor of the maxillary sinus).
- Higher malignancy (more superiorly located) will have a poor prognosis, while lower malignancy will have a better prognosis.

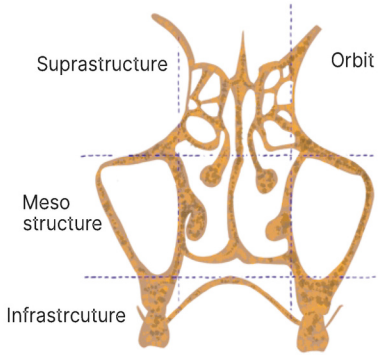


**Q5.12: What are the clinical features of Maxillary Sinus Carcinoma?**

**Answer:**

- Dull pain over the maxillary sinus
- Ipsilateral epiphora
- Blood-stained nasal discharge
- Nasal obstruction and toothache.

**Q5.13: What are the main steps in the treatment approach for Maxillary Sinus Carcinoma? What structures are typically removed in a "Total Maxillectomy"?**

**Answer:**

- Biopsy to confirm diagnosis, radiological studies to assess spread.
- **Surgical:** Total Maxillectomy, where the maxilla, maxillary sinuses, lateral wall of the nose, ethmoid sinus, ipsilateral palate, and ipsilateral eyeball are removed.
- **Adjuvant therapies:** Chemotherapy and Radiotherapy.

# 10. ANATOMY OF PHARYNX

## BIG QUESTION 1: What are the subdivisions of the pharynx, their boundaries, and their clinical relevance ?

**Broad Answer:** The pharynx is divided into three parts:

- Nasopharynx (behind nasal cavity): Bounded superiorly by the base of the skull and inferiorly by the soft palate; it contains the Fossa of Rosenmuller, the most common site of nasopharyngeal carcinoma.
- Oropharynx (behind oral cavity): Extends from soft palate to tip of epiglottis; includes the palatine tonsils and vallecula, a common site for foreign body lodgement.
- Laryngopharynx (behind larynx): From epiglottis to lower border of cricoid cartilage (C6); common site for hypopharyngeal cancers and aspiration-related pathology.

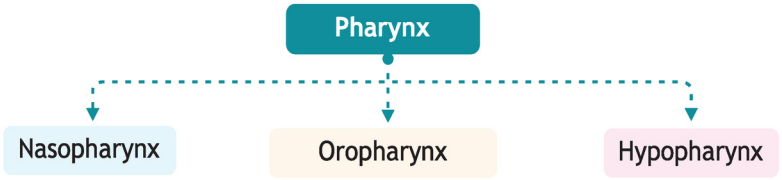


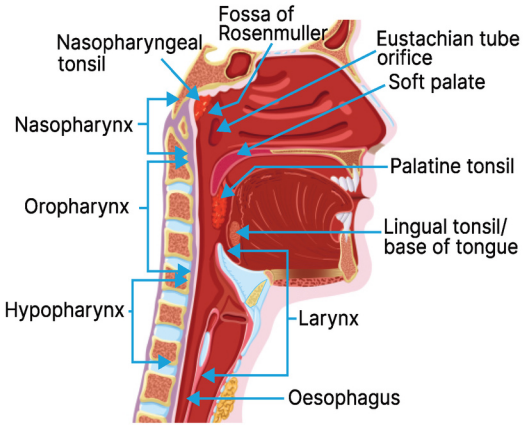


## DETAILED QUESTIONS

### Q1.1 What is the extent of pharynx?

**Answer:**

PYQ: FMGE 2019, 2020, 2021, 2023

- Pharynx is a continuous tube
  - Superiorly border: Base of skull
  - Inferior border: Lower border of cricoid cartilage corresponding to C6 vertebrae

### Q1.2 What are the boundaries of nasopharynx?

**Answer:**

| | |
|---|---|
| Anterior | The nasopharynx connects with the nasal cavity through the choanae. |
| Superior/ roof | It is formed by the base of the sphenoid sinus. |
| Posterior | It is related to the C1 vertebrae. |
| Inferior | It is formed by the imaginary line passing through the palate. |

- The **roof and the posterior wall** are continuous with each other.
  - Basisphenoid + C1 vertebrae
- The **inferior imaginary line** separates the nasopharynx above from the oropharynx below.
  - The nasopharynx is separated from the oropharynx below while deglutition by the fibers of the palatopharyngeus muscle, also called the Passavant's ridge.
  - Avoids the passage of food to the nasal cavity while deglutition.
- On **the lateral wall of the nasopharynx**, there is an opening of the eustachian tube.
  - Eustachian tube is covered by a cushion-like structure known as the torus tubarius.

- Formed by Salpingopharyngeus muscle.
- Behind the torus tubarius is a recess known as the **Fossa of Rosenmuller**

PYQ: NEET PG 2023

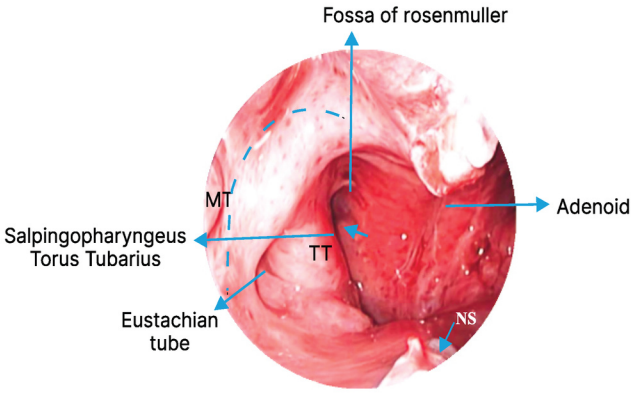


**Q1.3 Which single lymphoid tissue is located in the midline of the nasopharynx?**

**Answer:** Adenoid

**Q1.4 Where is the opening of the Eustachian tube present?**

**Answer:** 1cm behind the posterior end of inferior turbinate in the lateral wall of nasopharynx.

**Q1.5 Which is the most common site of origin of Nasopharyngeal carcinoma?**

**Answer:** Fossa of Rosenmuller

**Q1.6 When is biopsy indicated in case of nasopharyngeal carcinoma?**

**Answer:**

- Biopsy is indicated in those with:
  - Unilateral serous otitis media
  - Older age group
  - Cervical lymphadenopathy

**Q1.7 What is the endoscopic grading of adenoid hypertrophy?**

**Answer:**

- The adenoid hypertrophy is endoscopically graded according to the degree of choanal space occupied.
  - The entire choanal aperture
  - Divide them into 4 quadrants
  - Each part constitutes 25% of the airway space.

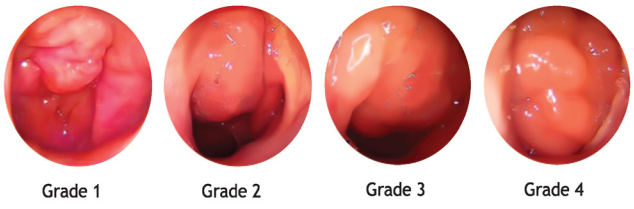


| | |
|---|---|
| Grade I | Adenoid occupies **0- 25%** of the airway space. |
| Grade II | Adenoid occupies **25-50%** of the airway space. |
| Grade III | Adenoid occupies **50-75%** of the airway space. |
| Grade IV | Adenoid occupies > **75%** of the airway space. |



YOURWISH

## Q1.8 What are the boundaries of oropharynx?

**Answer:**

| | |
|---|---|
| **Superior** | An imaginary line passing through the palate. |
| **Inferior** | An imaginary line passing through the tip of the epiglottis. |
| **Anterior** | It communicates to the oral cavity by oropharyngeal isthmus. |
| **Posterior** | Related to the C2 vertebrae. |
| **Lateral** | • Formed by anterior (palatoglossus muscle) and posterior pillars (palatopharyngeus muscle).<br>• The lymphoid tissue present between the two pillars is the **palatine tonsils.** |

- The uvula with anterior pillar is known as the oropharyngeal isthmus.
  - o It separates the oral cavity from the oropharynx
- The base of the tongue (posterior 1/3 portion) is also present in the oropharynx.
  - o Has a fold in the midline from the tongue to the epiglottis: Median glossoepiglottic fold.
  - o Laterally: Lateral glossoepiglotic fold.
  - o Between the median and lateral fold, a depression is present: Vallecula



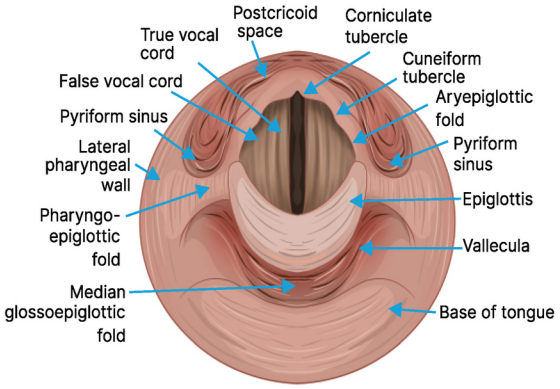


## Q1.9 What are the divisions of tongue?

**Answer:**

- The tongue is divided into two parts: Anterior ⅔ and Posterior ⅓

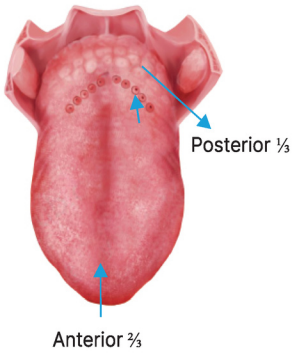


| Anterior ⅔ | Posterior ⅓ |
|---|---|
| • The mesoderm of the arch I give rise to 3 thickenings<br>o **2 lingual swellings**<br>o **1 tuberculum impar**<br>• These three thickenings fuse and form the anterior ⅔ of the tongue. | • The mesoderm of arch III and IV gives rise to a midline swelling called the **hypobranchial eminence.**<br>• The hypobranchial eminence is divided into<br>o **Cranial (arch III)**<br>→ Gives rise to the **posterior ⅓ of the tongue**<br>o **Caudal (arch IV)**<br>→ Gives rise to the **posterior-most part of the tongue.** |

## Q1.10 Describe the nerve supply of tongue

**Answer:**



YOURWISH

| Anterior ⅔ | Posterior ⅓ |
|---|---|
| • Sensory innervation by the lingual branch of the mandibular nerve | • Cranial (arch III): Glossopharyngeal nerve<br>• Caudal (arch IV): Vagus nerve |
| • Taste- by chorda tympani nerve | • Taste- by glossopharyngeal nerve |

- General Sensory supply: Lingual nerve, glossopharyngeal nerve, and vagus nerve
- Motor supply by hypoglossal nerve

### Q1.11 What are the boundaries of hypopharynx ?

**Answer:**

- The boundaries of the hypopharynx are as follows:
  - Superior: An imaginary line passing through the tip of the epiglottis/ hyoid bone
  - Inferior: An imaginary line through the lower border of the cricoid cartilage anteriorly and the C6 vertebrae posteriorly.
  - Posteriorly: Hypopharynx lies opposite the 3rd , 4th , 5th and 6th cervical vertebrae.
  - Anterior: It communicates with the larynx.

PYQ: FMGE 2021

### Q1.12 What are the subdivisions of hypopharynx?

**Answer:**

| | |
|---|---|
| Pyriform fossa | • These are two depressions on the lateral sides of the **aryepiglottic folds.**<br>• Paired structure.<br>• They are also known as the **smuggler's pouch.** |
| Post cricoid region | • It is a depression in the midline below the arytenoids.<br>• Unpaired<br>• Cricopharyngeal sphincter - helps in the passage of food. |
| Posterior pharyngeal wall | • It is a continuous wall of the hypopharynx. |

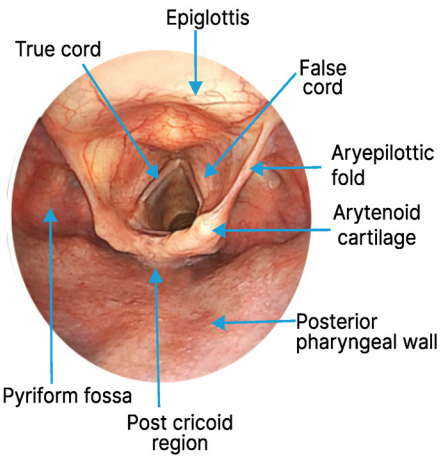


### Q1.13 What are the salient features of Waldeyer's ring?

**Answer:**

- It is formed by the lymphoid tissues present in the upper aerodigestive tract.
- These lymph nodes protect the respiratory tract and digestive tract.
- Protects until 3 - 5 years of age.
  - Mainly the adenoid and palatine tonsil

### Q1.14 What are the lymphoid tissues in Waldeyer's ring?

**Answer:**

| | |
|---|---|
| Adenoids | • It is present in the nasopharynx in the midline.<br>• These are also called **Luschka's tonsils.** |
| Tubal tonsil | • These are present around the eustachian tube that opens in the nasopharynx.<br>• They are a paired structure.<br>• They are also called **Gerlach's tonsils.** |
| Palatine tonsils | • These are paired structures present laterally in the oropharynx.<br>• Also known as faucial tonsil. |
| Lingual tonsil | • It is present in the oropharynx in the midline over the base of the tongue. |

### Q1.15 What are the layers of the pharyngeal wall?

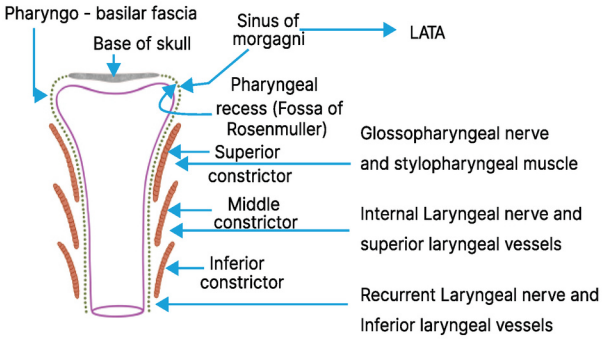


**Answer:** From inside to outside

- Mucosal layer
- Pharyngo-basilar fascia - Capsule of the tonsil.
- 3 constrictor muscles (superior, middle, inferior)
- Outermost layer: bucco-pharyngeal fascia.
- Inferior constrictor: It is made up of the oblique fibers of the thyropharyngeus and the horizontal fibers of the cricopharyngeus.
  - As a result, between these two types of fibers, there is a triangular area of dehiscence in the midline, which is known as Killian's dehiscence.
  - Any outpouching of mucosa from this dehiscence is called a pharyngeal pouch or Zenker's diverticulum.

### Q1.16 What is sinus of morgagni and, what are the structures passing through it ?

**Answer:**

- Space between the base of the skull superiorly and superior constrictor.
- Structures passing
  - Levator veli palatini
  - Auditory tube/eustachian tube
  - Tensor veli palatini
  - Ascending palatine artery

### Q1.17 From which pharyngeal arches are the contents of the sinus of Morgagni derived?

**Answer:** Arch I and II

### Q1.18 What structures passes through the Space between the superior and the middle constrictor muscles?

**Answer:**

- Glossopharyngeal nerve
- Stylopharyngeal muscle
- Derived from 3rd arch

### Q1.19 What are the structures passing through the Space between middle and inferior constrictor muscle?

**Answer:**

- Internal laryngeal nerve

- Superior laryngeal vessels
- Derived from 4th arch

**Q1.20 What structures passes through the Space below the inferior constrictor muscle ?**

**Answer:**

- Recurrent laryngeal nerve
- Inferior laryngeal vessels
- Derived from 6th arch

**Q1.21 Capsule of tonsil is derived from which fascia ?**

**Answer:** Pharyngobasilar fascia

**Q1.22 What is another name for Gerlach's tonsil?**

**Answer:** Tubal tonsil

**Q1.23 In carcinoma of base of tongue, pain is referred via the:**

A. Hypoglossal nerve
B. Facial nerve
C. Glossopharyngeal nerve
D. Lingual nerve

**Answer:** C. Glossopharyngeal nerve

**Explanation:**

- A branch of Glossopharyngeal nerve, Jacobson's nerve causes Ear pain
- Referred otalgia from tonsils.

**Q1.24 Which structures are part of the hypopharynx?**

A. The vallecula
B. The aryepiglottic folds
C. The cricopharyngeus muscle
D. The Choanae

**Answer:** C. The cricopharyngeus muscle

**Explanation:**

The hypopharynx (also called the laryngopharynx) is the part of the pharynx that lies behind and beside the larynx, extending from the hyoid bone to the cricoid cartilage. It includes:

- Pyriform sinuses
- Posterior pharyngeal wall
- Postcricoid area
- Cricopharyngeus muscle (forms the upper esophageal sphincter)

**Q1.25: What is the lower limit of the nasopharynx?**

**Answer:** The lower limit of the nasopharynx is an imaginary line passing through the palate.

### Q1.26: What is the lower limit of the oropharynx?

**Answer:** The lower limit of the oropharynx is an imaginary line passing through the tip of the epiglottis.

### Q1.27: What is the lower limit of the hypopharynx?

**Answer:** The lower limit of the hypopharynx is the lower border of cricoid cartilage/ C6 vertebrae/Upper esophageal sphincter.

### Q1.28: Where is Killian's dehiscence located?

**Answer:** Killian's dehiscence is seen in the inferior constrictor muscles

### Q1.29: Which muscle forms Passavant's ridge?

**Answer:** Passavant's ridge is formed by palatopharyngeus muscle

### Q1.30: Where is the opening of eustachian tube located?

**Answer:** 1cm behind the posterior end of the inferior turbinate in the lateral wall of the nasopharynx.

### Q1.31: What is the lining epithelium of the pharynx?

**Answer:**

- The lining epithelium of the adenoid is Pseudostratified ciliated columnar epithelium.
- The lining epithelium of the tonsil is stratified squamous epithelium.

### Q1.32: How do adenoids feel on palpation?

**Answer:** Bag of worm feel

### Q1.33: Where is hot potato voice seen?

**Answer:** Hot potato voice is seen in Quinsy

### Q1.34: What nerves are responsible for referred otalgia?

**Answer:**

- **Trigeminal nerve (CN V):** Oral cavity lesions
- **Glossopharyngeal nerve (CN IX):** Oropharyngeal lesions
- **Vagus nerve (CN X):** Hypopharyngeal and laryngeal lesions

# 11. PHARYNGEAL SPACES

**BIG QUESTION 1: What are the three major pharyngeal spaces, and why are they clinically important?**

**Broad Answer:** The three main pharyngeal spaces are the parapharyngeal, retropharyngeal, and prevertebral spaces. These are potential spaces in the deep neck that serve as conduits for spread of infections from the oral cavity, tonsils, or pharynx. The parapharyngeal space lies lateral to the pharynx, the retropharyngeal space lies behind the pharynx, and the prevertebral space lies anterior to the vertebral column. Infection can spread inferiorly into the mediastinum, making these spaces critical in deep neck infections.

## DETAILED QUESTIONS

### Q1.1: What are the main pharyngeal spaces?

PYQ: NEET PG 2022
PYQ: FMGE 2019

**Answer:**

- Parapharyngeal space
- Retropharyngeal space
- Prevertebral space

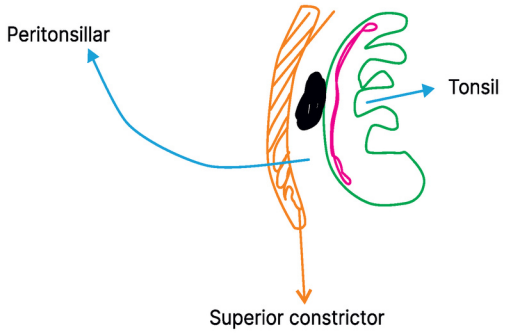


### Q1.2: What is peritonsillar space and, what is its clinical relevance?

**Answer:**

- Peritonsillar space: Space between Capsule of Tonsil and Superior Constrictor Muscle
- Presence of pus in this space → Peritonsillar Abscess / Quinsy
- M/C in adults → Because crypts are deeper in adults → easy spread of infection
- Symptoms: Pain, Sore throat, difficulty in swallowing, Hot Potato Voice
- U/L Enlargement of tonsil → D/D Peritonsillar abscess
- Investigation
  - Clinically Aspirate the abscess → Presence of pus confirms Quincy
  - Radiological Investigation → MRI (better option)/USG
- Incision and Drainage
  - I & D + Tonsillectomy (at the same time) -> Hot Tonsillectomy
  - I & D (Wait for 4-6 weeks afterwards) (Preferred) followed by Interval Tonsillectomy

### Q1.3: Which is the smallest pharyngeal space?

**Answer:**

- Parapharyngeal Space

### Q1.4: What is the shape of parapharyngeal space?

**Answer:**

- Shape of an inverted pyramid (Superiorly → Base of skull; Inferiorly → Hyoid bone)

## Q1.5: What are the boundaries of parapharyngeal space?

**Answer:**

- Bounded Laterally by:
  - o Mandible
  - o Medial Pterygoid Muscle
  - o Parotid Gland
- Bounded Anteromedially: Buccopharyngeal Fascia
- Posteriorly (Relations)
  - o Carotid Sheath
    - → ICA
    - → IJV
    - → CN 9, 10, 11
- Communicates with Retropharyngeal space

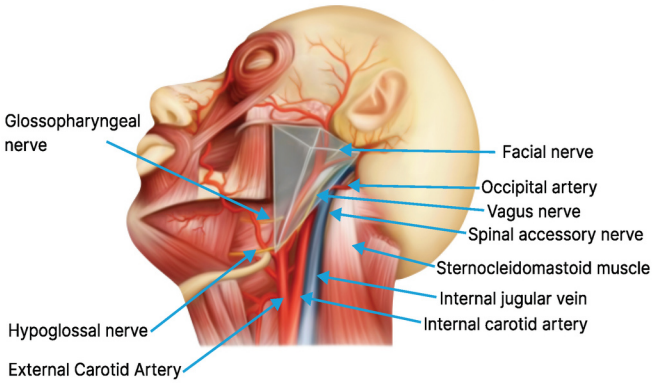


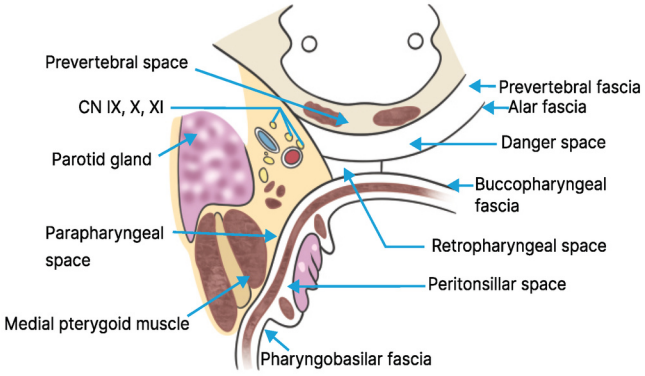


## Q1.6: What are the layers of the pharyngeal wall?

**Answer:** From inside out:

**Layers of pharyngeal wall (from inside out)**

- Mucosa
- Pharyngobasilar fascia (forming capsule of tonsil)
- Superior Constrictor Muscle
- Buccopharyngeal fascia (outermost)

## Q1.7: What are the 2 compartments of parapharyngeal space?

**Answer:**

- Styloid process divides the space into 2 compartments
  - o Pre styloid Compartment (Abscess in this compartment can push the tonsil → U/L Enlargement / Bulge of the tonsil → D/D Prestyloid Parapharyngeal Abscess)
  - o Post styloid Compartment (Abscess in this compartment → Presents as bulge behind the tonsil)

## Q1.8: How is the parapharyngeal space approached?

**Answer:**

- Trans-orally
- Trans-mandibular approach

## Q1.9: What are the boundaries of Retropharyngeal space?

**Answer:**

**Boundaries:**

- Anteriorly: Buccopharyngeal fascia
- Posteriorly: Prevertebral fascia
- Medially: Do not communicate with each other; Septum (Anterior and Posterior fascia fuse at midline)
- Laterally: Communicates with Parapharyngeal space
- Superiorly: Base of Skull
- Inferiorly: Extends up to T4

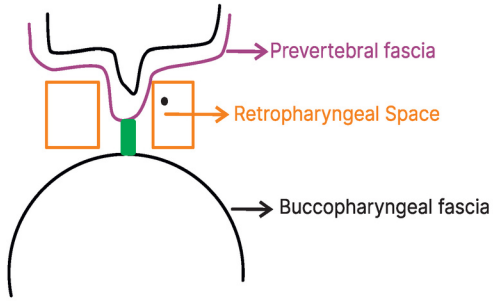


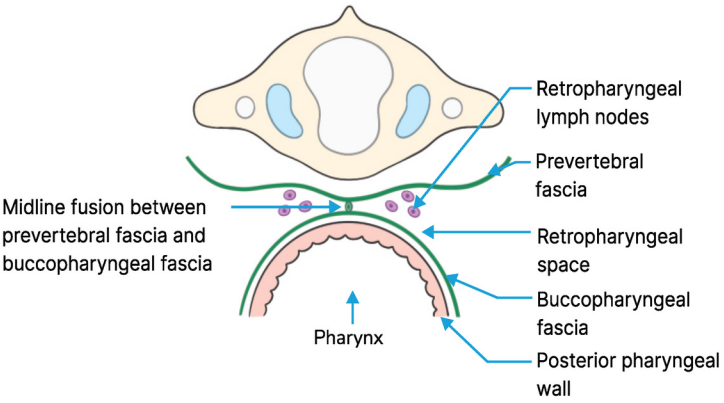


## Q1.10: What are the compartments of the retropharyngeal fascia?

**Answer:**

- Alar fascia divides the retropharyngeal space into

| Anterior Compartment: True Retropharyngeal Space | Posterior Compartment: Danger Space |
|---|---|
| • Contains Node of Ranvier<br>• Extends inferiorly upto T4<br>• Pus/ abscess in this space → Caused by suppuration of Lymph nodes → Secondary to Infection of tonsils/adenoids.<br>• Seen in children<br>• Is an acute condition (Acute Retropharyngeal Abscess) | • Extends upto diaphragm/mediastinum inferiorly.<br>• Abscess in this space → Source is vertebrae<br>• Secondary to TB of spine<br>• Chronic Retropharyngeal abscess<br>• Extends upto mediastinum → Mediastinitis<br>• Danger Space Abscess |

## Q1.11: Describe prevertebral space and what are its boundaries?

**Answer:**

- Space between the prevertebral fascia and body of vertebra
- It is a Midline Space
- It is a Single Space
- Prevertebral Abscess → (Source of infection) Vertebra → TB of spine → Midline Bulge
- Boundaries:
  - Superiorly: Base of skull
  - Inferiorly: Coccyx
  - Anteriorly: Prevertebral fascia
  - Posteriorly: Body of vertebra

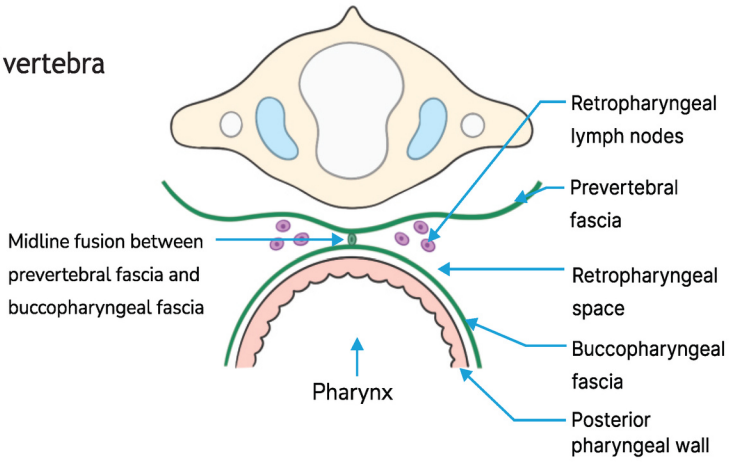




YOURWISH

**Q1.12: What are the differences between abscess of true space, danger space, and Prevertebral abscess?**

**Answer:**

PYQ: FMGE 2020

| | True space abscess (retropharyngeal abscess) | Danger space abscess (retropharyngeal abscess) | Prevertebral abscess |
|---|---|---|---|
| Extent | T4 | Diaphragm | Coccyx |
| Cause | Suppuration of lymph nodes | TB of spine | TB of spine |
| Presentation | Swelling on the side of midline | Swelling on the side of midline | Midline bulge |
| Diagnosis | X-Ray/CT/MRI | X-Ray/CT/MRI | X-Ray/CT/MRI |
| Treatment | Incision & Drainage + Antibiotics | Incision & Drainage + Antibiotics (ATT) | Incision & Drainage + Antibiotics (ATT) |

**Q1.13: What is the space between the capsule of the tonsil and the superior constrictor muscle called?**

**Answer:**

- Peritonsillar space

**Q1.14: What is the most common cause of a parapharyngeal abscess?**

**Answer:**

- Tonsillar infection

**Q1.15: What is the another name of Space of Gillette?**

**Answer:**

- Retropharyngeal space

**Q1.16: All the pharyngeal spaces extend superiorly from which part?**

**Answer:**

- Base of skull

**Q1.17: Trismus is seen in all except**

PYQ: NEET PG 2019

A. Ludwig's angina
B. Quinsy
C. Prevertebral abscess
D. Parapharyngeal abscess

**Answer:**

C. Prevertebral abscess

**Explanation:**

- Trismus is difficulty in opening the mouth
- Parapharyngeal abscess and quincy shows trismus
- Ludwig's angina presents with cellulitis of the submandibular space → Spasm of muscles of mandible
- Not seen in Prevertebral Abscess



YOURWISH

YOURWISH

**Q1.18: Identify:**



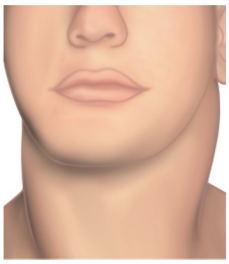

**Answer:**

- Parapharyngeal abscess
- In the image there is U/L enlargement of tonsil with uvula shifted to one side along with neck swelling
  - Quincy → U/L Enlargement → No Neck Swelling
  - Parapharyngeal abscess → U/L Enlargement → Neck swelling present

**Q1.19: Identify:**



**Answer:**

- Retropharyngeal Abscess
  - Swelling on the side of the abscess → retropharyngeal abscess

**Q1.20: Which of the following is not true regarding acute retropharyngeal abscess:**

A. It is common in children
B. Produces difficulty in breathing and suckling
C. It is limited to one side of the midline
D. Incision and drainage is done from outside through carotid sheath
E. It forms due to suppuration in retropharyngeal lymph node

**Answer:** D. Incision and drainage is done from outside through carotid sheath

**Explanation:**

- We do I & D by Trans oral approach → without intubation, preferably do a tracheostomy because the abscess may rupture.

**Q1.21: How is retropharyngeal abscess identified on X-ray?**



**Answer:**

- Air level/ gases seen.
- Reversal of normal cervical lordosis
- Widening
- Retropharyngeal abscess > Parapharyngeal abscess

**Q1.22: In which condition is the Hollman Miller sign observed?**



**Answer:**

- Anterior Bowing of Posterior Wall of Maxillary sinus → Hollman - Miller Sign → JNA ((Juvenile Nasopharyngeal Angiofibroma)

**Q1.23: In which condition is Crescent sign/Dodd's sign observed?**

**Answer:**

- Mass coming from the nose goes into the nasopharynx.

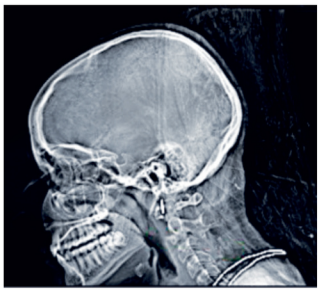

- A column air is present between the mass and posterior pharyngeal wall → Crescent Sign/Dodd's Sign → Antrochoanal Polyp

**Q1.24: What is the inferior extent of the Parapharyngeal space?**

**Answer:**

- Parapharyngeal space extends inferiorly up to Hyoid bone.

**Q1.25: What is the inferior extent of Danger space?**

**Answer:**

- Danger space extends inferiorly up to Diaphragm.

**Q1.26: What is the inferior extent of the Prevertebral space?**

**Answer:**

- Prevertebral space extends inferiorly up to Coccyx.

**Q1.27: What is the smallest pharyngeal space?**

**Answer:**

- Parapharyngeal space

**Q1.28: What is the commonest cause of parapharyngeal abscess?**

**Answer:**

- Tonsillar infection

# 12. DISEASES OF THE PHARYNX

## BIG QUESTION 1: What are the age group, presentation, diagnosis, and management of adenoid hypertrophy?

PYQ: FMGE 2020,2021,2022,2023

**Broad Answer:** Adenoid hypertrophy refers to the pathological enlargement of the nasopharyngeal tonsil (adenoids). Adenoids typically grow during the first decade of life. The primary etiology of adenoid hypertrophy is multifactorial, commonly stemming from recurrent or chronic inflammatory processes. Frequent upper respiratory tract infections (viral or bacterial), chronic rhinosinusitis, and allergic rhinitis are prominent contributing factors.

## DETAILED QUESTIONS

### Q1.1: At what age do Adenoids develop, and how do they differ from Tonsils in their development?

**Answer:**

- Adenoids typically develop between 7 and 15 years of age and then regress and disappear after 15 years of age.
- Tonsils persist with age, unlike Adenoids.

### Q1.2: Elaborate on the clinical presentation of Adenoid hypertrophy.

**Answer:**

- Nasal obstruction/Sinusitis
- Mouth breathing
- Adenoid facies secondary to nasal obstruction
  - Pinched-in nose due to collapse of alar muscles
  - Hitched up upper lip
  - Crowded upper teeth
  - High-arched palate
- Middle ear disease
  - Serous otitis media/glue ear- most common
  - Acute suppurative otitis media
  - Chronic suppurative otitis media
- Obstructive sleep apnea
  - Cessation of breathing for 10 seconds or more during sleep
  - Obstruction due to relaxation of pharyngeal muscles and tongue falling backward
- Rhinolalia clausa
  - Nasal twang in voice due to closure of the upper airway

### Q1.3: Why does adenoid enlargement cause bilateral serous otitis media and hearing loss?

**Answer:**

- Since the adenoid is a midline structure, it causes bilateral serous otitis media, and hearing loss can also be present.



YOURWISH

### Q1.4: What are the investigation modalities to diagnose Adenoid hypertrophy?

**Answer:**

- Post-nasal examination
- Endoscopy (invasive)
- X-ray- Investigation of choice, especially in children

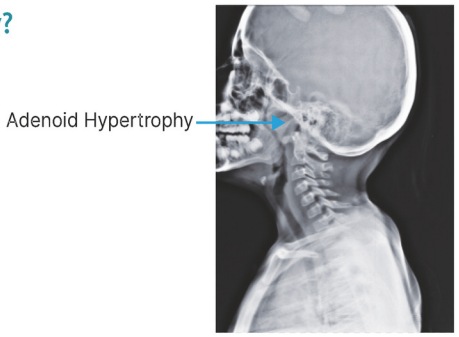


### Q1.5: How is adenoid hypertrophy graded on a lateral X-ray in children, and what are the different grades?

**Answer:**

- On a lateral X-ray
  - Trace an imaginary line on the base of the skull and another imaginary line parallel to it passing through the palate
  - The space between the two lines represents the airway space
  - Now divide this space into four parts horizontally, where each part constitutes 25% of the space

| | |
|---|---|
| Grade I | Adenoid occupies 0- 25% of the airway space. |
| Grade II | Adenoid occupies 25-50% of the airway space. |
| Grade III | Adenoid occupies 50-75% of the airway space. |
| Grade IV | Adenoid occupies 75-100% of the airway space. |

### Q1.6: What are the management approaches for different grades of adenoid hypertrophy?

**Answer:**

- Grade I or II - Conservative
- Grade III or IV with symptoms
  - Surgery: adenoidectomy is done
  - Earlier, adenoidectomy was done using cold instruments like the St. Clair Thompson adenoid curette
  - Now, hot instruments/methods like coblation, radiofrequency, and microdebrider under visualization through endoscopy are used

### Q1.7: What are the indications and contraindications for Adenoidectomy?

PYQ: FMGE 2020

**Answer:**

| Indications | Contraindications |
|---|---|
| 1. Nasal obstruction<br>2. Sinusitis<br>3. Middle ear disease<br>4. Sleep apnoea<br>5. Rhinolalia clausa | 1. Velopharyngeal insufficiency<br>o Seen in Cleft palate.<br>o Causes regurgitation<br>2. Acute adenoiditis. |

### Q1.8: How is adenoid hypertrophy graded on endoscopy?

**Answer:**

- The adenoid hypertrophy is graded according to the degree of choanal space occupied

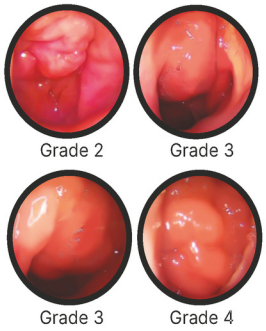




YOURWISH

YOURWISH

| | |
|---|---|
| Grade I | Adenoid occupies 0-25% of the choanal space. |
| Grade II | Adenoid occupies 26-50% of the choanal space. |
| Grade III | Adenoid occupies 51-75% of the choanal space. |
| Grade IV | Adenoid occupies >75% of the choanal space. |

## BIG QUESTION 2: What are the etiology, types, clinical features, diagnosis, and management of tonsillitis?

**Broad Answer:** Tonsillitis is an inflammation of the tonsils, which are two lymphatic tissue pads at the back of the throat. Common symptoms include a sore throat, red and swollen tonsils (sometimes with white spots), difficulty swallowing, and fever. Treatment depends on the cause: rest and antibiotics. In severe or recurrent cases, surgical removal of the tonsils may be considered

## DETAILED QUESTIONS

### Q2.1: Which organism most commonly causes acute tonsillitis, and what complications can arise due to its cross-reactive antigens?

**Answer:**

- Group A β-hemolytic streptococcus is the most common organism causing acute tonsillitis
- This hemolytic streptococcus has a cross-reactive antigen for the myocardium, glomerulus, and joints
- Leading to myocarditis, glomerulonephritis, polyarthritis, and rheumatic fever

### Q2.2: How is tonsillitis classified based on the duration of the disease?

**Answer:**

- Tonsillitis can be divided into two types:
  - Acute: If the disease is present for<4 weeks
  - Chronic: If the disease is present for>12 weeks

### Q2.3: What are the four types of Acute tonsillitis?

**Answer:**

- Acute superficial tonsillitis
- Acute follicular tonsillitis
- Acute parenchymal tonsillitis
- Acute membranous tonsillitis

### Q2.4: What are the characteristics of Acute superficial tonsillitis?

**Answer:**

- In Acute superficial tonsillitis, the infection is limited to the superficial mucosa of the tonsil
- Only redness is seen, and no enlargement of the tonsils

Acute superficial tonsillitis

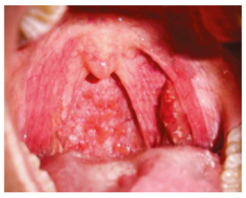

### Q2.5: What are the clinical features of Acute follicular tonsillitis?

**Answer:**

- In Acute follicular tonsillitis, the crypts get blocked with pus
- Whitish yellow dots are seen on the surface of the tonsils

Acute follicular tonsillitis



### Q2.6: What are the features of Acute parenchymal tonsillitis?

Acute parenchymal tonsillitis

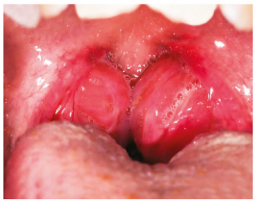

**Answer:**

- In Acute parenchymal tonsillitis, the infection reaches the parenchyma of the tonsils
- The tonsils become red, enlarged, and meet in the midline

### Q2.7: What is the characteristic feature of Acute membranous tonsillitis?

Acute membranous tonsillitis



**Answer:**

- In Acute membranous tonsillitis, a pearly white membrane forms on the tonsils, resulting from all the dead tissues and debris from the tonsils and bacteria

### Q2.8: What are the different types of chronic tonsillitis and their key features?

**Answer:**

| | |
|---|---|
| Chronic follicular tonsillitis | Infection is present in the crypts of the tonsil. It has **enlarged tonsils with yellow pus.** |
| Chronic parenchymatous tonsillitis | Infection is present in the parenchyma of the tonsil. The tonsils are **enlarged.** |
| Chronic fibroid tonsillitis | Due to the antigen-antibody reaction, it leads to fibrosis.<br>The tonsil **decreases in size and becomes firm.** |

### Q2.9: What is the Irwin Moore test?

**Answer:**

- Irwin Moore test: As the tonsil is small in chronic fibroid tonsillitis, it is necessary to differentiate it from a normal tonsil
  - In this test, pressure is applied to the tonsillar crypts with a probe
  - The pus will ooze out of the tonsils, and this is called the Irwin Moore sign

### Q2.10: What are the common symptoms of Tonsillitis?

**Answer:**

- Fever: Very high-grade fever
- Sore throat
- Difficulty in swallowing → drooling of saliva
- Halitosis
- Earache: It is a referred otalgia by the glossopharyngeal nerve

### Q2.11: What are the absolute indications for Tonsillectomy?

**Answer:**

- Obstructive sleep apnea: Huge tonsils cause an oropharyngeal obstruction, which, combined with enlarged adenoids, blocks the airway space

Obstructive sleep apnoea
↓
Chronic hypoxia
↓
Pulmonary hypertension
↓

Right ventricular hypertrophy (RVH)

- This condition is called Cor pulmonale
- The gold standard treatment for children with OSA is adenotonsillectomy

- Malignancy of the tonsil

### Q2.12: What are the relative indications for Tonsillectomy?

**Answer:**

- Recurrent tonsillitis
  - 7 or more episodes of infection in 1 year
  - 5 or more episodes of infection in 2 years
  - 3 or more episodes of infection in 3 years
- Chronic tonsillitis
- 2nd attack of quinsy/ peritonsillar abscess
- If the tonsil has a streptococcal infection, to prevent long-term complications
- Tonsillitis causing febrile seizures, cardiac disease, and IGA nephropathy
- Non-tonsillar indications:
  - Excision of the Styloid process(transoral approach)
  - Glossopharyngeal neuralgia
  - UPPP (Uvulopalatopharyngoplasty)

### Q2.13: What are the complications of Tonsillitis?

**Answer:**

- Streptococcal complication
  - Rheumatic fever
  - Acute glomerulonephritis
  - Subacute bacterial endocarditis
- Abscesses
  - Peritonsillar abscess
  - Parapharyngeal abscess
  - Retropharyngeal abscess

### Q2.14: What are the complications of Tonsillectomy?

**Answer:**

- Primary hemorrhage: Occurs during the surgery due to the peritonsillar vein or tonsillar artery
- Reactionary hemorrhage: This happens after the surgery for up to 24 hours due to a slipped ligature and requires immediate re-exploration
- Secondary hemorrhage: It occurs 24 hours after the surgery and up to 14 days
  - It can happen secondary to infection, so initially, antibiotics are given; if bleeding persists, further exploration is done

### Q2.15: What are the absolute contraindications to Tonsillectomy?

**Answer:**

- Polio epidemic
- Submucous cleft palate (due to velopharyngeal insufficiency)



YOURWISH

**Q2.16: What are the differences between membranous tonsillitis and diphtheria?**

**Answer:**

| Membranous tonsillitis | Diphtheria |
|---|---|
| **True membrane:** Made up of dead tonsillar tissues. | **Pseudomembrane:** It is made up of exotoxin. |
| Pearly white in colour. | Dirty white/greyish in colour. |
| The membrane is limited to the tonsil. | The membrane spreads to the adjacent sites. |
| On peeling, the underlying surface will not bleed. | On peeling, it will bleed. |
| | **Toxic features** and **bull neck** are diagnostic hallmarks of diphtheria. |



Diphtheria

PYQ: FMGE 2021,2022

PYQ: NEET PG 2021

**BIG QUESTION 3: What are the etiology, presentation, investigations, and management of juvenile nasopharyngeal angiofibroma?**

**Broad Answer:** Juvenile Nasopharyngeal Angiofibroma (JNA) is a rare, benign but locally invasive vascular tumor. It commonly presents with recurrent, profuse epistaxis and nasal obstruction. Diagnosis is made using imaging (CT/MRI). The primary treatment is surgical removal, often preceded by preoperative embolization to reduce blood loss. Radiotherapy is reserved for unresectable or recurrent tumors.

## DETAILED QUESTIONS

**Q3.1: What is the nature, common age group, and sex predilection of Juvenile Nasopharyngeal Angiofibroma (JNA)?**

**Answer:**



- Nature: Benign and invasive
- Age of presentation: Juvenile (7-17 years of age)
- Sex: Male (exclusive)

**Q3.2: What is the origin of Juvenile Nasopharyngeal Angiofibroma?**

**Answer:**

- JNA originates from the Sphenopalatine foramen (8-10 mm behind the posterior end of the middle turbinate)
- It can then spread to:
  - Nasopharynx
  - Pterygopalatine fossa
  - Infratemporal fossa



YOURWISH

**Q3.3: What type of bleeding is seen in JNA?**

**Answer:**

- Bleeding is recurrent, unprovoked, and profuse, as it is extremely vascular due to the absence of a tunica media layer in blood vessels.

**Q3.4: Which cranial nerves can be affected by Juvenile Nasopharyngeal Angiofibroma, and why?**

**Answer:**

- Due to the extension into the sphenoid and cavernous sinus, JNA causes cranial nerve palsies of 2,3,4,5,6

**Q3.5: Is the lymphoid tissue affected in JNA?**

**Answer:**

- No

**Q3.6: What is the investigation of choice for Juvenile Nasopharyngeal Angiofibroma, and what is the role of MRI and angiography in its diagnosis and management?**

**Answer:**

- Diagnosis CECT - IOC
- MRI is useful in the recurrence and involvement of the cranial cavity
- Angiography provides information on the specific blood supply of the tumor
  - The most common blood vessel supplying the tumor is the internal maxillary artery
  - It is also used as a treatment with embolization

**Q3.7: How is JNA treated, and what is the role of radiotherapy?**

**Answer:**

- Pre-op embolization and hormone therapy
- Treatment of choice - surgery after 48 hrs of embolization
- Role of Radiotherapy
  - Intracranial involvement
  - Unresectable tumor
  - Multiple recurrences

**Q3.8: What condition should be suspected in a teenage boy presenting with unilateral serous otitis media?**

**Answer:**

- The presence of unilateral serous otitis media in a teenage boy should raise suspicion of nasopharyngeal angiofibroma

**Q3.9: What are the common symptoms of Juvenile Nasopharyngeal Angiofibroma (JNA)?**

**Answer:**

- Bleeding- Recurrent unprovoked profuse epistaxis
- Nasal obstruction and hyponasal speech
- Conductive hearing loss with unilateral serous otitis media
- Frog face deformity: Proptosis, broad nasal bridge, swelling of the cheek
- Involvement of the 2,3,4,5,6 cranial nerve

### Q3.10: What are Holmann Miller's sign and Hondusa's sign?

PYQ: FMGE 2020

**Answer:**

- Holmann Miller sign: Anterior bowing of the posterior wall of the maxillary sinus
- Hondusa's sign: Increased distance between the maxillary sinus and the mandible on CT scan

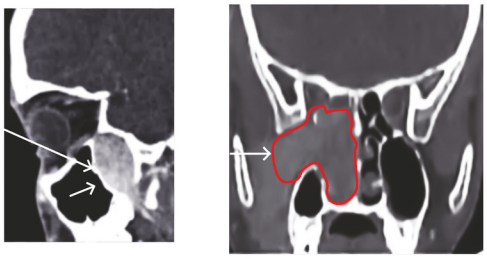

Holmann-Miller Sign Hondusa's sign

### Q3.11: What is the role of carotid angiography in Juvenile Nasopharyngeal Angiofibroma, and which artery most commonly supplies the tumor?

**Answer:**

- Carotid angiography is performed to determine the vascularity of the tumor
- JNA is most commonly supplied by the Internal Maxillary Artery

### Q3.12: What diagnostic modalities are contraindicated in JNA?

**Answer:**

- Biopsy
- FNAC
- Probe test
- Digital palpation

## BIG QUESTION 4: What are the etiopathogenesis, presentation, diagnosis, staging, and management of nasopharyngeal carcinoma?

**Broad Answer:** Nasopharyngeal Carcinoma is a malignant tumor arising from the nasopharyngeal epithelium, commonly associated with Epstein-Barr virus (EBV) infection. It typically presents with neck lymphadenopathy, nasal obstruction, epistaxis, and sometimes serous otitis media due to eustachian tube blockage. Diagnosis is confirmed by nasopharyngeal endoscopy with biopsy, while imaging (CT/MRI) is used to assess local and distant spread. Radiotherapy is the main treatment, often combined with chemotherapy for advanced stages.

## DETAILED QUESTIONS

### Q4.1: What is the nature, common age group, and sex predilection of Nasopharyngeal cancer?

**Answer:**

- Nature: Malignant and invasive
- Age of presentation: In older individuals
- Sex: In both male and female (male > female)

### Q4.2: What is the origin of Nasopharyngeal cancer?

**Answer:**

- Nasopharyngeal cancer originates from the Fossa of Rossenmuller

### Q4.3: What type of bleeding is seen in Nasopharyngeal cancer?

**Answer:**

- Blood-stained discharge is noticed in Nasopharyngeal cancer

### Q4.4: Is the lymphoid tissue affected in Nasopharyngeal cancer?

**Answer:**

- Yes, Cervical lymph node enlargement is present
  - Level 2 lymph nodes in the upper jugular
  - Level 5 lymph nodes in the posterior triangle

### Q4.5: What are the diagnostic modalities for Nasopharyngeal cancer?

**Answer:**

- Biopsy - IOC
- CT /MRI is performed to determine the extent of disease or bony erosion

### Q4.6: How is Nasopharyngeal cancer treated?

**Answer:**

- Radiation Therapy (Intensity-Modulated Radiation Therapy) for early lesions
- Chemo + Radiation Therapy for advanced lesions

### Q4.7: What condition should be suspected in an adult presenting with unilateral serous otitis media?

**Answer:**

- The presence of unilateral serous otitis media in an adult should raise suspicion of nasopharyngeal cancer

### Q4.8: Which lymph nodes are most commonly involved in nasopharyngeal carcinoma?

**Answer:**

- Most common lymph nodes involved in NPC: HO's triangle
  - Medial end of the clavicle
  - Lateral end of the clavicle
  - Junction of the neck with the shoulder

### Q4.9: What are the etiological factors of nasopharyngeal carcinoma, and which serological markers are used for screening and diagnosis?

**Answer:**

- The Chinese have higher genetic susceptibility. In India, it is common in the northeast regions where people are predominantly of mongoloid origin
- Epstein-Barr virus
- Environment
  - Smoking Tobacco, Opium
  - Nitrosamines From Drysalted Fish
- IgA Viral capsid Antigen - highly sensitive (screening tool)
- IgA early antigen (Ig EA) - specific

### Q4.10: What is the most common mode of presentation of Nasopharyngeal carcinoma?

**Answer:**

- Cervical lymph node enlargement
- First node to be involved- Retropharyngeal node

### Q4.11: What are the common routes of spread of Nasopharyngeal carcinoma?

**Answer:**

| | |
|---|---|
| Anteriorly | Nasal cavity |
| Superiorly | Base of skull, cranial cavity |
| Between the superior constrictor and base of skull | Auditory tube, tensor veli palatini, ascending palatine artery |
| Lateral parapharyngeal space | $9^{th}$, $10^{th}$ and $11^{th}$ Cranial nerve |

### Q4.12: Which cranial nerves are commonly involved in Nasopharyngeal carcinoma, and what syndromes can result from their involvement?

**Answer:**

- Nearly all the cranial nerves Can be involved : $2^{nd}$, $3^{rd}$, $4^{th}$, $5^{th}$, $6^{th}$, $9^{th}$, $10^{th}$, $11^{th}$
- Horner's syndrome can also occur due to the involvement of the sympathetic chain
- Jugular foramen syndrome due to involvement of $9^{th}$,$10^{th}$,$11^{th}$ CN in jugular foramen

### Q4.13: What is Trotter's triad, and why is it considered diagnostic of Nasopharyngeal carcinoma?

**Answer:**

- Trotter's Triad is diagnostic of nasopharyngeal carcinoma
  - Unilateral conductive hearing loss- due to compression of the eustachian tube
  - Temporoparietal neuralgia due to $5^{th}$ nerve involvement
  - Palatal paralysis due to $10^{th}$ nerve involvement

### Q4.14: What are the histological variants of nasopharyngeal carcinoma?

**Answer:**

- Well-differentiated variant- Squamous cell carcinoma
- Poor prognostic variant - Verrucous variant and papillary type

## BIG QUESTION 5: What is Ludwig's angina, and what are its key features?

**Broad Answer:**

- Bilateral swelling of the submandibular space
- Presence of serosanguineous fluid
- Infection spreads through tissue spaces
- Submandibular salivary glands are spared

## DETAILED QUESTIONS

### Q5.1: What is the etiology and the source of infection for Ludwig's angina?

**Answer:**

- Etiology - Mixed /Polymicrobial infection



YOURWISH

- The source of infection includes:
  - Dental infections
  - Submandibular or Sublingual infection



### Q5.2: What are the palpatory findings of Ludwig's angina?

**Answer:**

- On palpation, there is a woody hard feeling due to extensive cellulitis a PYQ: FMGE 2019 or of the mouth

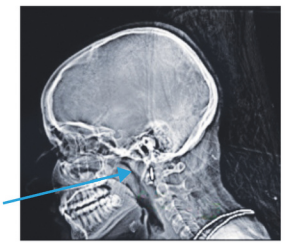


### Q5.3: How is airway obstruction managed in Ludwig's angina?

**Answer:**

- Intubation is done for an impending obstruction
- If the tongue has fallen upwards and backward, a tracheostomy is done

### Q5.4: What is the cause of Vincent's angina?

**Answer:**

- Vincent's angina is caused by Borrelia Vincenti

### Q5.5: How does the mylohyoid muscle divide the submandibular space?

**Answer:**

- The mylohyoid muscle divides the submandibular space into two compartments
  - Above- Sublingual space
  - Below- Submylohyoid space

### Q5.6: What is a Ranula, and how is it treated?

**Answer:**

- Ranula is a cystic swelling in the floor of the mouth arising as an extravasation cyst from the sublingual salivary gland
- The transillumination test is positive
- Treatment: excision with removal of the sublingual gland to prevent recurrence

### Q5.7: What are the X-ray findings of a retropharyngeal abscess, and how is it differentiate l abscess?



**Answer:**

- Retropharyngeal abscess on X-Ray
  - Prevertebral soft tissue shadow is two times more than the size of the vertebra
  - Straightening of the Cervical Spine
  - The presence of air bubbles is seen
- On X-ray, it is usually difficult to differentiate it from a prevertebral abscess. Therefore, an additional CT and MRI are done to confirm the findings

### Q5.8: What is the Crescent sign (Dodd's sign), and in which condition is it seen?

**Answer:**

- Crescent Sign / Dodd's Sign: It refers to the air shadow seen between the mass and the posterior pharyngeal wall on imaging
- Condition: It is typically seen in antrochoanal polyps

## BIG QUESTION 6: What is Zenker's diverticulum (pharyngeal pouch)?

**Broad Answer:**

- Zenker's diverticulum is a pulsion diverticulum of the hypopharynx, occurring through Killian's dehiscence (a weak area between the thyropharyngeus and cricopharyngeus muscles)

## DETAILED QUESTIONS

### Q6.1: What is Killian's dehiscence, and how does it relate to Zenker's diverticulum?

**Answer:**

- The inferior constrictor muscle has oblique fibers of the thyropharyngeus and horizontal fibers of the cricopharyngeus
- Between these two types of fibers is an area of dehiscence known as Killian's dehiscence
- Killian's dehiscence is present posteriorly in the midline
- If there is an outpouching of mucosa through this dehiscence, it is called the pharyngeal pouch or Zenker's diverticulum

### Q6.2: What are the causes of Zenker's diverticulum?

**Answer:**

- Seen in old age due to weakness of muscles
- Due to a tight upper esophageal sphincter or cricopharyngeal sphincter
- Aerophagy
- Allergy
- Acid reflux
  - Acid reflux → UES is exposed to acid → spasm → increased pressure of the hypopharynx → pressure on the inferior constrictor muscle  mucosa will prolapse outwards

### Q6.3: What are the symptoms of Zenker's diverticulum?

**Answer:**

- In the initial few swallows, food enters the wide-mouthed diverticulum preferentially. So, the patient won't be having dysphagia, but food does not enter the stomach - Early symptom
- After a few swallows, the pouch gets filled. Further swallows produce a gurgling sound known as Boyce's sign
- After a few swallows, when the pouch gets filled, it presses on the esophagus, causing dysphagia- a late symptom
- Sleep cough: The contents of the sac regurgitate into the larynx, causing the patient to cough

### Q6.4: How is Zenker's diverticulum diagnosed and treated?

PYQ: NEET PG 2021 PYQ: FMGE 2021

**Answer:**

- Diagnosis by barium swallow
- Treatment:
  - Dohlman's procedure: The partition wall between the esophagus and the pouch is divided by diathermy through an endoscope

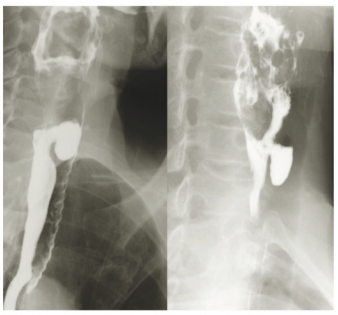

# 13. ANATOMY OF LARYNX

**BIG QUESTION 1: What are the different types of cartilages in the larynx? How is the larynx anatomically divided, and what is the embryological origin of its structures?**

**Broad Answer:** The larynx is made up of several cartilages—some paired, like arytenoid and cuneiform, and some unpaired, like thyroid and cricoid—each playing a structural and functional role. It is divided into supraglottis, glottis, and subglottis based on anatomical landmarks. Developmentally, the larynx arises from the foregut and branchial arches, particularly the 4th and 6th, and undergoes complex morphogenesis to form its adult structure.

## DETAILED QUESTIONS

### Q1.1: What is the larynx made of?

**Answer:**

- Larynx / Voice box of humans
- Made up of cartilages

### Q1.2: What are the types of laryngeal cartilages?

PYQ: FMGE 2020, 2021 PYQ: NEET PG 2021, 2022

**Answer:**

- Unpaired, Paired, Hyaline, Elastic.
- **Unpaired:**
  - Cricoid cartilage: **Hyaline** (Only complete cartilaginous ring in airway)
  - Thyroid cartilage: **Hyaline** (Largest cartilage)
  - Epiglottis cartilage: **Elastic**
- **Paired:**
  - Cuneiform cartilage: **Elastic**
  - Corniculate cartilage: **Elastic**
  - Arytenoid cartilage: **Hyaline**

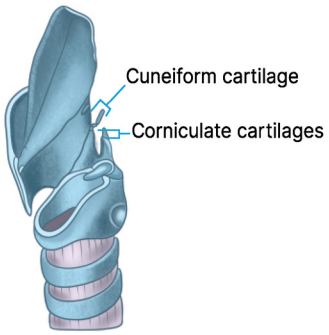


### Q1.3: What is the difference in age-related changes between hyaline and elastic cartilages of the larynx?

**Answer:**

- All hyaline cartilages calcify with age, unlike elastic cartilage.

### Q1.4: What is laryngeal crepitus? What are the conditions where laryngeal crepitus is absent?

**Answer:**

- Laryngeal Crepitus: Caused by the movement of the cricoid cartilage against the vertebrae. **Normally, it is +ve**
- Laryngeal crepitus is absent in post-cricoid carcinoma / Retropharyngeal abscess /Prevertebral abscess → **Moure's Sign or Bocca's Sign.**



YOURWISH

### Q1.5: What are the anatomical features of thyroid cartilage?

**Answer:**

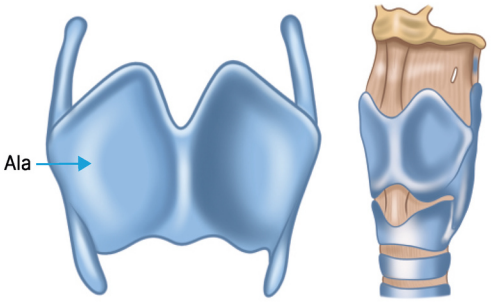


- Largest cartilage
- Butterfly-shaped
- Has 3 parts:
  - Ala
  - Superior horn
  - Inferior horn
- **The 2 Alae meet at an angle of**
  - 90 degree: (causing the Male Adam's apple)
  - 120 degree: Female

### Q1.6: What are the muscles attached to the thyroid cartilage?

**Answer:** Muscles attached to the thyroid cartilages are:

- The oblique line of thyroid cartilage:
  - Sternothyroid muscle
  - Thyrohyoid muscle
  - Thyropharyngeus muscle (part of Inf. constrictors)
- The Inner surface of thyroid cartilage gives attachment to:
  - Epiglottis
  - Vocal cords

### Q1.7: What are the anatomical features of cricoid cartilage?

**Answer:**

- Only signet ring-shaped cartilage
- Anteriorly has a **narrow arch**
- Posteriorly has a **wide lamina**
  - Has a **Superior facet** and **an Inferior facet**
- Superior facet gives attachment to the Arytenoid Cartilage
- The inferior facet gives attachment to the Inferior horn of the thyroid cartilage

### Q1.8: Lesion in the cricoid cartilage leads to what condition?

**Answer:** Subglottic stenosis

### Q1.9: What are the features of Epiglottic cartilage?

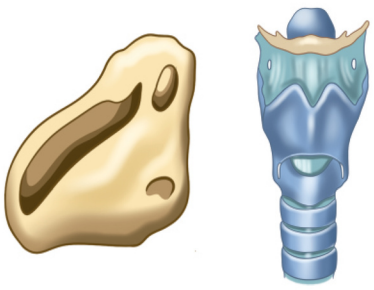

**Answer:**

- Leaf-like structure
- Base: Attached to thyroid cartilage
- Superiorly: Free
- Function: Protection of the airway
- Divided into 2 parts (imaginarily) by the hyoid bone:
  - Suprahyoid Epiglottis (above hyoid)
  - Infrahyoid Epiglottis (below hyoid)
- Has 2 surfaces:



YOURWISH

YOURWISH

- Lingual surface (lined by stratified squamous epithelium.
- Laryngeal surface (Lined by respiratory epithelium)

### Q1.10: What are the features of the arytenoid cartilage?

**Answer:**

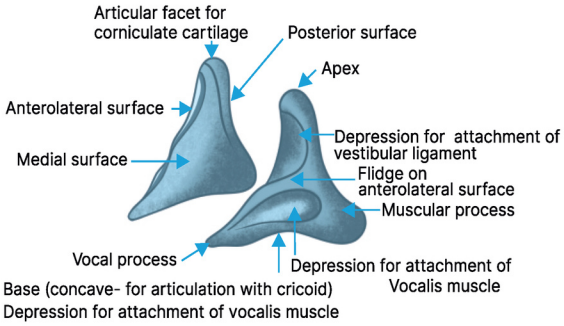


- Pyramid shape
- Its Base rests on the superior surface of the cricoid cartilage.
- Has an Apex over which the Corniculate and Cuneiform cartilages are present.
- Has an Anterior process - Vocal process (vocal cords extend to this)

### Q1.11: What is the extent of the vocal cords?

**Answer:**

- Vocal cords extend from the Thyroid cartilage to the Arytenoid cartilage.
- Has a Muscular process.

### Q1.12: What are the other cartilages of the larynx?

**Answer:**

- Corniculate cartilage: Also known as the Cartilage of Santorini
- Cuneiform cartilage: Also known as the Cartilage of Wrisberg

### Q1.13: What are the divisions of the larynx?

**Answer:** There are 3 divisions of the Larynx.

- **Supraglottis** (Above the level of the vocal cords)
  - Contains:
    - → Epiglottis
    - → Aryepiglottic folds
    - → False cords
    - → Arytenoid cartilage
- **Glottis** (at the level of the vocal cords and 1 cm below)
  - Contains:
    - → Vocal cords
    - → Anterior commissure (vocal cords meet)
    - → Posterior commissure
- **Subglottis** (at 1 cm below the vocal cords to the lower border of the cricoid cartilage)

### Q1.14: How does the larynx develope?

**Answer:**

- Supraglottis: 4$^{th}$ Arch

- Subglottis and glottis: 6th Arch

## BIG QUESTION 2: Describe the anatomical organization of the larynx with reference to its internal divisions, epithelial lining, lymphatic drainage, and supporting membranes.

**Broad Answer:** The larynx is supported by specialized membranes that connect its cartilaginous framework and facilitate both movement and structural stability. Internally, it is divided into key compartments—from the inlet to the lower border of the cricoid—each forming distinct regions that regulate the passage of air and sound. These regions are lined by two main types of epithelium: respiratory epithelium in most parts, and stratified squamous epithelium in high-friction zones like the vocal cords. Finally, lymphatic drainage varies above and below the vocal cords, with upper parts draining to upper deep cervical nodes and lower parts to pre- and paratracheal nodes, playing a vital role in immune defense and the spread of pathology.

## DETAILED QUESTIONS

### Q2.1: What are the membranes of the larynx?

**Answer:**

Membranes of the larynx are of 2 types:

- Extrinsic
- Intrinsic

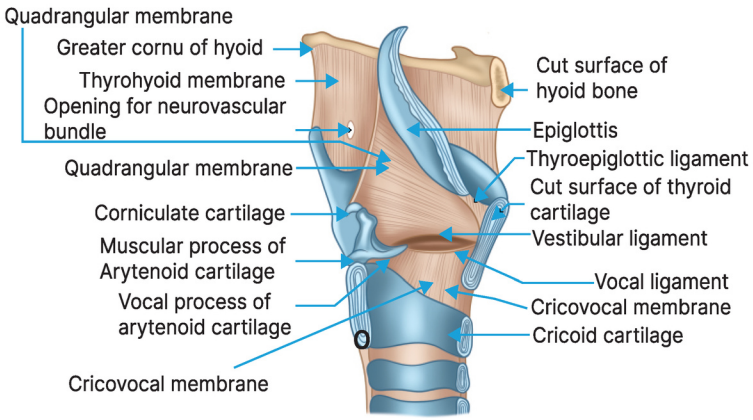


### Q2.2: What are the extrinsic membranes of the larynx?

**Answer:**

Extrinsic membrane: Connects the laryngeal structure to the extra-laryngeal structure.

- Thyrohyoid membrane - has openings for the **Superior laryngeal nerve and vessels** are present.
- Cricotracheal membrane

### Q2.3: What are the intrinsic membranes of the larynx?

**Answer:**

Intrinsic membrane: Connecting 1 part of the larynx to another.

- **Cricovocal membrane/Conus elasticus:** Shape of Cone.
  - Upper fibers form the **Vocal Ligament**, which is part of the **True cords**
- **Quadrangular membrane:** Quadrangular shape.
  - Extends between the Epiglottis, Thyroid cartilage, and Arytenoid cartilage.
  - Upper fibers form the **Aryepiglottic fold.**
  - Lower fibers condense to form the Vestibular ligament, i.e., **False cords.**
- **Cricothyroid membrane:** In an emergency, it is **pierced to make an airway opening, Cricothyrotomy**

### Q2.4: What are the cavities of the larynx?

**Answer:**

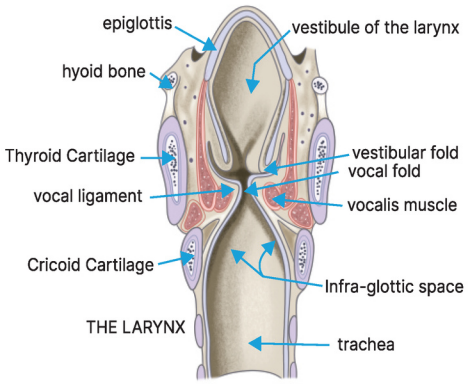


- Begins superiorly, is known as the Inlet of Larynx.
- **Vestibule of larynx:** Present between the 2 Quadrangular membranes.
- Rima Vestibuli: Space between the false cords.
- **Rima Glottidis:** Space between the true cords.
- **Ventricles of Larynx:** Space between false cords(above) and true cords(below).
- Below the Rima glottidis lies the subglottis.

### Q2.5: What is the epithelial lining of the larynx?

**Answer:**

- It is mainly lined by **Respiratory epithelium / Pseudostratified ciliated columnar epithelium.**
- Except in:
  - Lingual surface of the Epiglottis.
  - Upper margin of vocal cords
  - Aryepiglottic folds.
- These are lined by **Stratified squamous epithelium**

### Q2.6: What is the lymphatic drainage of the larynx?

**Answer:**

- **Supraglottis: Upper deep cervical lymph nodes**
- **Subglottis:** Prelaryngeal and pretracheal lymph nodes → **Lower deep cervical lymph nodes** or mediastinal nodes
- **Glottis: No Lymphatics**

## BIG QUESTION 3: Describe the muscular anatomy of the larynx and its functional significance in phonation and airway protection.

**Broad Answer:** The larynx has intrinsic and extrinsic muscles. Intrinsic muscles (like posterior cricoarytenoid, lateral cricoarytenoid, and cricothyroid) control vocal cord movement and tension, aiding phonation and airway protection. The posterior cricoarytenoid is the only abductor of the vocal cords. Extrinsic muscles (like the infrahyoid group) help in elevating or depressing the larynx during swallowing and speech.

## DETAILED QUESTIONS

### Q3.1: What are the muscles of the larynx?

**Answer:**

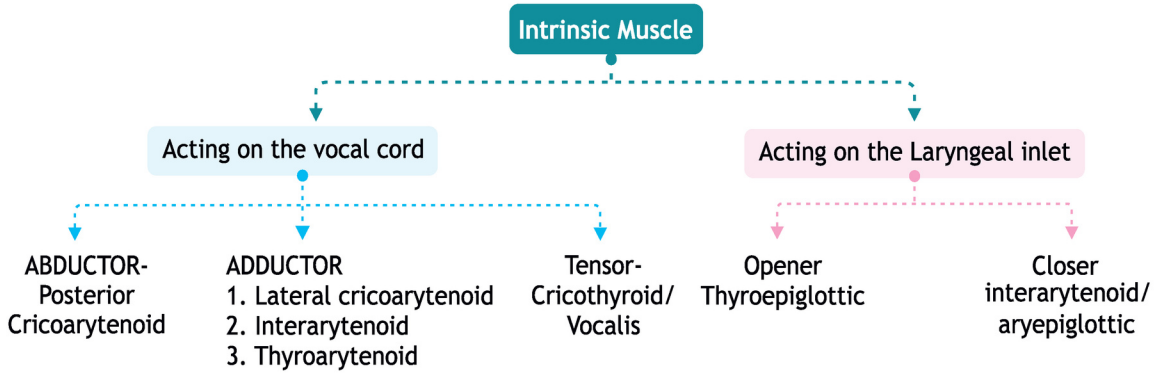




YOURWISH

### Q3.2: What are the features of the cricothyroid muscle?

**Answer:**

- Cricothyroid muscle: The only muscle lying on the **extrinsic surface**
  - Only muscle with 2 bellies
  - Supplied by the External Laryngeal Nerve (a branch of the Superior Laryngeal Nerve)
  - Tensor function

### Q3.3: What are the functions of laryngeal muscles?

**Answer:**

| Muscle | Functions |
|---|---|
| **Thyroarytenoid muscle** (Medial fibers form the **Vocalis**) | • Tensor function |
| **Thyroepiglottic muscle** | • Opener of the Laryngeal inlet |
| **Lateral Cricoarytenoid** | • Adductor of the vocal cord |
| **Posterior Cricoarytenoid** | • Only the Abductor of the Vocal Cord<br>• Respiratory muscle of the larynx<br>• Safety muscle of the larynx |

### Q3.4: Which is the only muscle of the Larynx receiving unpaired dual Innervation?

**Answer:**

Transverse Arytenoid / Interarytenoid muscle

### Q3.5: What is the orientation of the oblique Arytenoid muscle?

**Answer:**

- Apex of arytenoid (origin) → Base of opposite arytenoid (insertion)
- X- shaped arrangement.

### Q3.6: Which nerve innervates the intrinsic muscles of the larynx?

PYQ: FMGE 2022

**Answer:**

All muscles of the larynx are innervated by the Recurrent Laryngeal Nerve, except the Cricothyroid muscle.

## BIG QUESTION 4: Describe the structural organization and clinical relevance of the larynx with respect to its functional roles, age-related anatomical differences, internal spaces, and methods of examination.

**Broad Answer:** The larynx serves crucial functions in phonation, airway protection, and respiration. It contains spaces like the pre-epiglottic and paraglottic spaces, which are important for the spread of infections and tumors. In infants, the larynx is higher, more funnel-shaped, and the epiglottis is omega-shaped, unlike in adults. Examination techniques include indirect laryngoscopy, direct laryngoscopy, and fiberoptic laryngoscopy. Understanding these structural and age-related features is essential for assessing laryngeal pathology.

YOURWISH

## DETAILED QUESTIONS

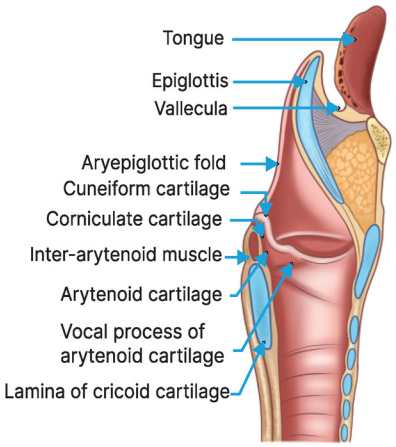


### Q4.1: What are the spaces of the larynx?

**Answer:**

- Pre-epiglottic Space of Boyer
- Paraglottic Space of Tucker
- Reinke's Space

### Q4.2: What are the boundaries of the Pre-epiglottic Space?

**Answer:**

- Pre-epiglottic Space of Boyer (in front of the epiglottis)
- **Boundaries:**
  - o **Anteriorly:** Thyrohyoid membrane
  - o **Superiorly:** Hyoepiglottic ligament
  - o **Posteriorly:** Lingual surface of epiglottis

### Q4.3: What are the boundaries of the Paraglottic Space?

**Answer:**

- Paraglottic Space of Tucker
- **Boundaries:**
  - o **Medially**
    - → Quadrangular membrane with False cords
    - → Cricovocal membrane with True cords
    - → Ventricle Space of Larynx
  - o **Laterally:** Thyroid cartilage

PYQ: INICET 2021

### Q4.4: What is Reinke's Space?

**Answer:**

- Reinke's space is the space between the Epithelium and Superficial Lamina Propria
- Accumulation of edematous tissue in this space → **Reinke's Edema**

### Q4.5: What are the layers of the vocal cords?

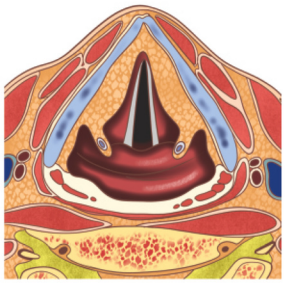

**Answer:**

**4 Layers of Vocal Cords are (Superficial to Deep)**

- Epithelial layer
- Superficial Lamina Propria
- Vocal Ligament (formed by upper fibers of cricovocal membrane)
- Vocalis (formed by median fibers of Thyroarytenoid muscle)

### Q4.6: What are the functions of the larynx?

**Answer:**

- Protection of lower airways
- Phonation

- Respiration
- Fixation of the chest

### Q4.7: What are the differences between the adult and infant larynx?

PYQ: FMGE 2019 PYQ: NEET PG 2020

**Answer:**

| | Infants | Adults |
|---|---|---|
| Position | C2 - C3 | C3, C4, C5, C6 |
| Epiglottis | Curled | Leaf shaped |
| Thyroid Cartilage | Flat | Angulated |
| Narrowest part | Subglottis | Glottis |
| Submucosal tissue | More | Less |
| Cartilages | Soft | Ossified |

**Note:** In Infants, Submucosal tissue is more → Hence, Edema/Inflammation/Infection spreads quickly in the infant.

### Q4.8: How is the larynx examined in clinical practice?

**Answer:**

- **Direct Examination:** By Direct Laryngoscopy with the help of
  - 70-degree Endoscope
  - 90-degree Endoscope
- **Indirect Examination:** By Indirect Laryngoscopic Mirror (IDL) (Reflection of Larynx in Mirror)

### Q4.9: Larynx develops from which arches?

PYQ: FMGE 2019, 2020 PYQ: NEET PG 2020

**Answer:** The larynx develops from the **4$^{th}$ and 6$^{th}$ arches**

### Q4.10: The Supraglottis is derived from which pharyngeal arch?

**Answer:** The supraglottis develops from the **4$^{th}$ arch**

### Q4.11: Which pharyngeal arches give rise to the glottis and subglottis?

**Answer:** Glottis and subglottis develop from the **6$^{th}$ arch**

### Q4.12: What is the location of the larynx in relation to the vertebra?

**Answer:** The larynx lies against the vertebrae **C3-C6**

### Q4.13: How does laryngeal crepitus occur?

**Answer:** Laryngeal crepitus occurs due to the **movement of the Cricoid cartilage against the vertebrae**

### Q4.14: In which conditions is laryngeal crepitus absent?

**Answer:** Laryngeal crepitus is absent in **post-cricoid carcinoma / retropharyngeal abscess/ prevertebral abscess**

### Q4.15: Give examples of hyaline cartilages of the larynx?

**Answer:** Hyaline cartilages in the larynx are the **Thyroid, Cricoid, and Arytenoid.**

**Q4.16: What are the elastic cartilages of the larynx?**

**Answer:** Elastic cartilages in the larynx are the **Epiglottis, Corniculate, and Cuneiform**

**Q4.17: Which is the largest cartilage of the larynx?**

**Answer:** The Largest Cartilage in the larynx is the **Thyroid cartilage**

**Q4.18: Which laryngeal cartilage is signet ring-shaped?**

**Answer:** Signet ring cartilage is the **Cricoid cartilage**

**Q4.19: What is the difference in thyroid angles between males and females?**

**Answer:** The angle at which the thyroid ala meets in males is **90 degrees,** and in females is **120 degrees**

**Q4.20: Which muscles attach to the oblique line of the thyroid?**

**Answer:** The oblique line of the thyroid cartilage gives attachment to the **Sternothyroid, Thyrohyoid, and Thyropharyngeus**

**Q4.21: What are the 2 surfaces of the epiglottis?**

**Answer:** Two surfaces of the epiglottis are the **Lingual and Laryngeal surfaces**

**Q4.22: What are the parts of the epiglottis?**

**Answer:** Parts of the epiglottis are the **Suprahyoid and Infrahyoid epiglottis**

**Q4.23: Which is the only laryngeal cartilage that forms a complete ring?**

**Answer:** The only complete cartilaginous ring in the entire airway is the **Cricoid Cartilage**

**Q4.24: Which is the narrowest part of the larynx in adults and in children?**

**Answer:**The narrowest portion of the adult larynx is the Glottis, but in the pediatric larynx, it is the **Subglottis**

**Q4.25: What are the examples of named laryngeal cartilages?**

**Answer:**

- The cartilage of Santorini is the **Corniculate Cartilage**
- Cartilage of Wrisberg is **Cuneiform Cartilage**

**Q4.26: What is the average length of vocal cords?**

**Answer:** The average length of vocal cords in males is **24 mm** and in females is **18 mm**

**Q4.27: What are the parts of the vocal cord?**

**Answer:** The membranous portion is **Anterior 2/3$^{rd}$,** and the cartilaginous portion is **Posterior 1/3$^{rd}$**

**Q4.28: What is the sinus of Morgagni?**

**Answer:** Sinus of Morgagni of the larynx is the **Ventricle of the larynx**

**Q4.29: What is Rima vestibuli?**

**Answer:** Rima Vestibuli is the **Space between false cords**

**Q4.30: What is Rima glottidis?**

**Answer:** Rima glottidis is the **Space between the true cords**

**Q4.31: What are the named spaces around the larynx?**

**Answer:**

- The space of Tucker is the **Paraglottic space**
- The space of Boyer is the **Pre-epiglottic space**

**Q4.32: Which is the only unpaired muscle of the larynx?**

**Answer:** Only the Unpaired Laryngeal muscle is the **Interarytenoid/ Transverse arytenoid**

**Q4.33: Which is the only laryngeal muscle receiving dual innervation?**

**Answer:** The only muscle that receives dual innervation is the **Interarytenoid / Transverse arytenoid**

**Q4.34: Which is the only muscle of the larynx that performs adduction of the vocal cord?**

**Answer:** Only the Abductor of the vocal cord is the **Posterior Cricoarytenoid**

**Q4.35: Which muscle is the tensor of the vocal cord?**

**Answer:** Tensor of the Larynx is the **Cricothyroid**

YOURWISH

# 14. CONGENITAL, BENIGN & INFLAMMATORY LESIONS OF LARYNX/ VOICE & SPEECH DISORDERS

## BIG QUESTION 1: What are the important congenital anomalies of the larynx, their clinical features, diagnosis, and management?

**Broad Answer:** Congenital anomalies of the larynx usually present in infancy with stridor and respiratory distress of varying severity. They are diagnosed primarily by laryngoscopy and imaging, and managed either conservatively or surgically depending on the degree of airway compromise.

- Most common congenital anomaly - Laryngomalacia
- The second most common congenital anomaly - Congenital vocal cord palsy
- The third most common congenital anomaly - Subglottic stenosis

## DETAILED QUESTIONS

### Q1.1: What is Laryngomalacia, and why does it occur?

**Answer:**

- Malacia means "weakness of tissue'
- In laryngomalacia, excessive flaccidity of the epiglottis or supraglottic structures occurs because the cartilage is immature. With age, the cartilage gradually matures, leading to resolution of the condition.

### Q1.2: What is the characteristic clinical feature of Laryngomalacia, and why does it occur?

PYQ: FMGE 2020

**Answer:** Laryngomalacia presents with Inspiratory stridor (there is no expiratory stridor)

| During Inspiration | During Expiration |
|---|---|
| ↓ | ↓ |
| Air is sucked in | The air is being pushed out |
| ↓ | ↓ |
| Flaccid epiglottis obstructs the laryngeal inlet | Pushes the epiglottis away |
| ↓ | ↓ |
| Inspiratory Stridor | No stridor |

### Q1.3: How does the position of the child affect the stridor in Laryngomalacia?

**Answer:**

| Supine Position | Prone Position |
|---|---|
| The child will have a stridor as the epiglottis covers the laryngeal inlet. | The child will not have stridor as the epiglottis is away from the larynx |

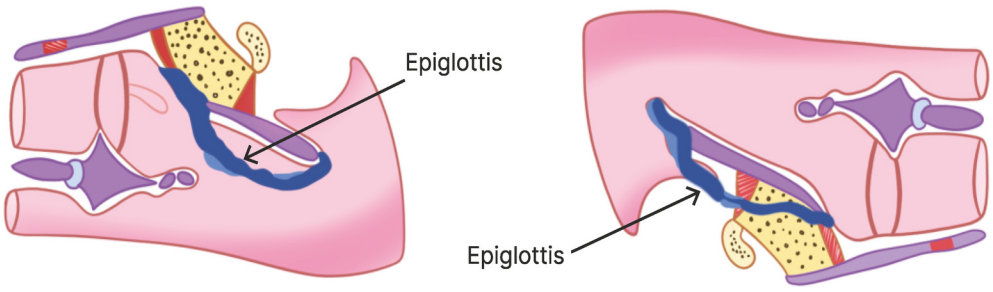

**Q1.4: Why does stridor increase during crying in Laryngomalacia?**

**Answer:**

During crying
↓
A negative intrathoracic pressure builds up in the lung
↓
The epiglottis will be sucked inside, covering the laryngeal inlet
↓
The stridor will increase

**Q1.5: What is the characteristic endoscopic finding in Laryngomalacia?**

**Answer:** On endoscopy, an omega-shaped epiglottis is seen, which appears curled upon itself due to the flaccidity of the tissue

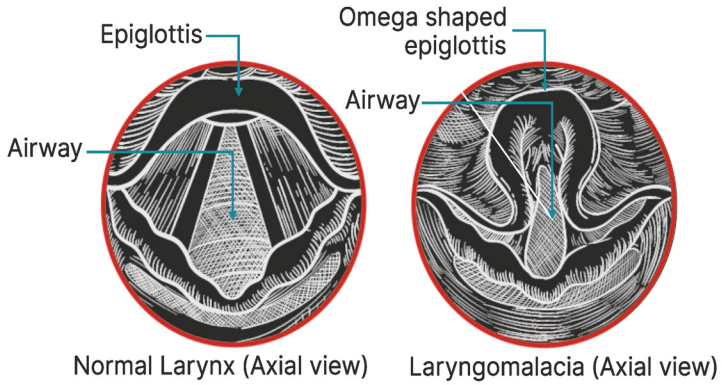


**Q1.6: What is the treatment for Laryngomalacia?**

**Answer:**

- Wait and watch as the epiglottis matures with age
- Epiglottopexy is the surgery done for Laryngomalacia with severe stridor

**Q1.7: What is the most common congenital CNS abnormality causing vocal cord paralysis?**

**Answer:** The most common congenital CNS abnormality causing vocal cord palsy is Arnold-Chiari malformation.

**Q1.8: What are the symptoms of congenital vocal cord paralysis?**

**Answer:**

- Abductor palsy- Disturbance with respiration
  - Bilateral- Stridor
  - Unilateral- Dyspnea
- Adductor palsy- Voice issues, weak cry, aspiration

**Q1.9: What is the treatment for Congenital vocal cord paralysis?**

**Answer:**

- No treatment if no major symptoms
- If stridor is present, tracheostomy followed by laryngeal surgery
  - Laryngeal surgery cannot be done at birth, as it is not well developed

## BIG QUESTION 2: What are the causes, classification, clinical features, and management of subglottic stenosis?

PYQ: NEET PG 2021

**Broad Answer:**

- Subglottic stenosis is a condition characterized by narrowing of the subglottic region of the larynx
- It occurs due to excessive thickening of the cricoid cartilage

## DETAILED QUESTIONS

### Q2.1: What is the narrowest part of the larynx in children, and what subglottic diameter is considered abnormal?

**Answer:**

- The subglottis is the narrowest portion of the larynx in children
- Subglottis diameter <4 mm in full-term neonates and <3.5 mm in a preterm neonate is considered abnormal

### Q2.2: What is the classification system used to classify Subglottic stenosis?

**Answer:**

- The classification system used to classify Subglottic stenosis is called the **Cotton-Meyer Classification**
- It is classified by the amount of narrowing or stenosis of the subglottis

### Q2.3: What are the grades of Subglottic stenosis according to the Cotton-Myer classification?

**Answer:**

| Classification | From | To | Endoscopic Appearance |
|---|---|---|---|
| **Grade I** | No Obstruction | 50% Obstruction | 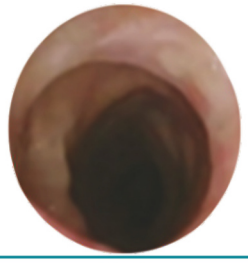 |
| **Grade II** | 51% Obstruction | 70% Obstruction |  |
| **Grade III** | 71% Obstruction | 99% Obstruction | 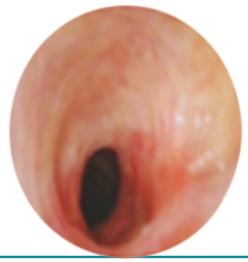 |
| **Grade IV** | No Detectable Lumen | | 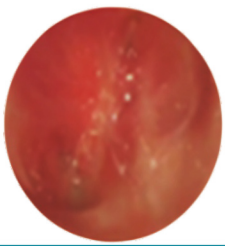 |

### Q2.4: What is the treatment approach for Subglottic stenosis based on grading?



**Answer:**

- Grade I and II
  - Wait and watch if there are no major symptoms
  - Balloon/laser dilatation if symptomatic
- Grade III and IV
  - Laryngotracheal Resection
  - Cricotracheal Reconstruction
  - The Montgomery T-tube is used after the resection of the stenotic segment to keep the airway patent
- Mitomycin C is given to reduce fibrosis after surgery
  - Reduce the possibility of recurrence.

## BIG QUESTION 3: Describe the development, clinical features, and management of laryngeal web.

**Broad Answer:** A laryngeal web is a rare condition characterized by the presence of a membrane-like tissue that partially obstructs the windpipe (trachea) within the voice box (larynx). This web-like tissue can vary in thickness and can make it difficult to breathe normally, and may also affect the voice.

## DETAILED QUESTIONS

### Q3.1: How does a laryngeal web develop, and which branchial arches are involved?

**Answer:**

- Supra glottis develops from the $4^{th}$ arch, glottis, and subglottis from the $6^{th}$ arch, and the two arches fuse to make a complete canal
- It occurs due to the incomplete fusion of the $4^{th}$ and $6^{th}$ arches
- It can be a partial obstruction called a partial web or a complete obstruction called a complete web

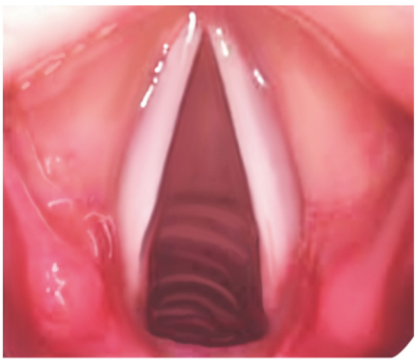

Normal vocal cord

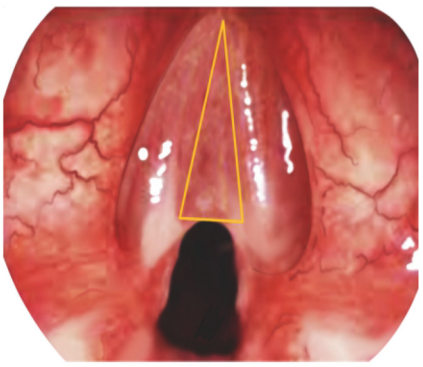

Partial web

### Q3.2: What are the symptoms of a laryngeal web?

**Answer:**

- Symptoms
  - Depends on the location and thickness of the web
  - The most common level is at the level of the glottis
  - Partial obstruction-Dyspnea and weak cry
  - Complete obstruction-Stridor

### Q3.3: How are laryngeal webs managed?

**Answer:** Tracheostomy is done in cases with stridor to release the web



YOURWISH

YOURWISH

## BIG QUESTION 4: What are the inflammatory conditions of the Larynx?

PYQ: FMGE 2021, 22

PYQ: NEET PG 2022, 23

**Broad Answer:**

- Acute Epiglottitis: Inflammation of the Epiglottis or Supraglottis
- Laryngo-Tracheo-bronchitis/Croup: Inflammation of the larynx, trachea, and bronchi
- Both require early recognition and airway management, with antibiotics for epiglottitis and steroids/nebulized adrenaline for severe croup.

## DETAILED QUESTIONS

### Q4.1: What are the causes and clinical features of acute epiglottitis?

PYQ: FMGE 2021

**Answer:**

- Cause: Secondary to bacterial infection - Streptococcus pneumonia (most common)
- Sudden onset
- Rapid progression in children
- Occurs in a child (3-7 years). The child will sit in the tripod position



Tripod posture

### Q4.2: What are the symptoms of Acute epiglottitis?

**Answer:**

- Malaise and fever
- Respiratory: Inspiratory stridor
- Digestive: Dysphagia, Odynophagia, and drooling of saliva
- Phonatory/ voice: No/mild change in voice and no cough
  - Vocal cords are spared

### Q4.3: Why is throat examination avoided in suspected cases of Acute epiglottitis or Laryngotracheobronchitis (Croup) in children?

**Answer:** An examination is avoided in both cases, as they may have laryngeal obstruction

### Q4.4: What is the radiological sign seen in acute epiglottitis?

**Answer:** Lateral View X-ray of the neck: Thumb sign- due to swollen epiglottis



Acute epiglottis thumb sign

### Q4.5: What is the treatment approach for Acute epiglottitis in children?

**Answer:**

- Compulsory hospitalization is required
- Antibiotics with steroids are given to reduce airway edema
- Racemic adrenaline nebulization or injection
  - Reduce airway edema and prevent obstruction
- Hydration is very important
- Intubation or tracheostomy is done in an airway emergency

### Q4.6: What are the etiology and clinical features of laryngotracheobronchitis?

**Answer:**

- Cause: Viral infection- Parainfluenza 1 & 2 (most common)
- Slow onset
- It can progress to obstruction, but slowly
- Occurs in children (3 months to 3 years)

### Q4.7: What are the characteristic symptoms of Laryngotracheobronchitis (Croup) in children?

**Answer:**

- Malaise and fever: Present but low grade or no fever, and the child is not toxic
- Respiratory: Biphasic stridor
- Digestive: Not present or mild
- Phonatory/ voice: Change in voice and cough (barking seal-like cough)

### Q4.8: What is the radiological sign seen in Laryngotracheobronchitis (croup)?

**Answer:** Anteroposterior view of the neck: Steeple sign due to subglottic stenosis



Croup : Steeple sign

### Q4.9: What is the treatment approach for Laryngotracheobronchitis (Croup)?

**Answer:**

- Antibiotics with steroids are given to reduce airway edema
- Racemic adrenaline nebulization
- Voice rest
- Cough suppressant
- Bronchodilator
- Hydration is important
- Intubation or tracheostomy may be required

### Q4.10: In Acute epiglottitis in children, death occurs due to?

A. Atelectasis
B. Aspiration
C. Laryngospasm
D. Airway obstruction

**Answer: D.** Airway obstruction

- Acute epiglottitis (often caused by Streptococcus pneumoniae & Haemophilus influenzae type b) leads to rapid inflammation and swelling of the epiglottis and surrounding tissues, which can quickly block the upper airway and cause fatal respiratory obstruction if not treated emergently. Airway obstruction is the principal life-threatening complication in these cases.

**Q4.11: A 4-year-old child presented with sore throat, difficulty in swallowing, and difficulty in breathing. The child has a high-grade fever with tachypnoea. There is inspiratory stridor with recession of suprasternal and intercostal spaces. No stridor is observed during expiration. The clinical picture is suggestive of:**

A. Bronchopneumonia
B. Lower tracheal obstruction
C. Intrathoracic obstruction
D. Extra thoracic obstruction

**Answer: D.** Extra thoracic obstruction

- The above presentation indicates a case of acute epiglottitis. This condition causes swelling of the epiglottis (an extrathoracic structure), leading to obstruction during inspiration

## BIG QUESTION 5: What are the benign lesions of the vocal cords, their features, diagnosis, and management?

**Broad Answer:**

PYQ: FMGE 2022
PYQ: NEET PG 2020

- Benign lesions of the vocal cord include:
  - Vocal nodule
  - Vocal polyp
  - Reinke's edema
  - Contact Ulcer / Pachyderma Laryngitis / Kissing Ulcer
  - Keratosis of Larynx /Leukoplakia of Vocal Cord

## DETAILED QUESTIONS

**Q5.1: What are the causes, clinical features, and treatment of vocal nodules?**

**Answer:**

| | |
|---|---|
| **Alternate names** | • Singer or screamer's nodule |
| **Cause** | • Chronic vocal abuse<br>• Seen in singers, teachers |
| **Laterality** | • Bilateral or symmetrical |
| **Location** | • Free edge of the vocal cord at the junction of the anterior 1/3$^{rd}$ and the posterior 2/3$^{rd}$. This is the area of maximum vibration of the vocal cord. |
| **Appearance** | • Sessile lesions |
| **Symptoms** | • Hoarseness<br>• Vocal fatigue |
| **Treatment** | • Initially, voice rest.<br>• If it fails, microscopic excision without injuring the vocal ligament. |
| **Endoscopic view** | 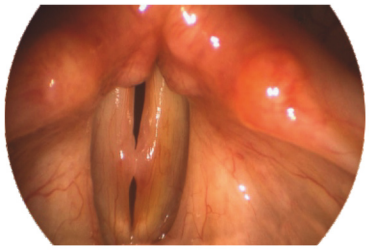<br>Vocal nodule |

**Q5.2: What are the causes, clinical features, and treatment of vocal polyp?**

**Answer:**

| | |
|---|---|
| **Cause** | • Sudden vocal abuse, like shouting |
| **Laterality** | • Unilateral |
| **Location** | • Free edge of the vocal cord at the junction of the anterior 1/3rd and the posterior 2/3rd. This is the area of maximum vibration of the vocal cord |
| **Appearance** | • Pedunculated polyp |
| **Symptoms** | • Hoarseness of voice<br>• Diplophonia: Double voice due to different vibrating frequencies of the two vocal cords |
| **Treatment** | • Microscopic excision |
| **Endoscopic view** | <br>Vocal polyp |

**Q5.3: What is Reinke's edema, and what are its causes and anatomical site of involvement?**

**Answer:**

- Reinke's Oedema is an accumulation of oedematous or myxomatous tissue in Reinke's space
- It involves the anterior 2/3rd, which is the membranous portion of the vocal cord
- Smoking and reflux are the most common causes



Reinke's oedema

**Q5.4: What are the clinical features of Reinke's edema?**

**Answer:**

- Diplophonia or a change in voice is present
- Dyspnea

**Q5.5: How is Reinke's edema treated?**

**Answer:**

- Initially, voice rest, anti-reflux medication, wait and watch
- Stripping of the vocal cord/Decortication
  - o One cord followed by another to prevent adhesions (laryngeal web)

**Q5.6: Describe the features, causes, and histopathological findings of Contact ulcer. How is it managed?**

**Answer:** Contact ulcers are lesions affecting the posterior part of the larynx



YOURWISH

| | |
|---|---|
| Cause | • Voice abuse<br>• Reflux |
| Features | • Hypertrophic epithelium on one side and depression on the other side<br>• There is no true breach in the epithelium; therefore, it is a pseudo-ulcer |
| Differential diagnosis | • Tuberculosis<br>• Carcinoma |
| Histopathological findings | • Hyperkeratosis and Acanthosis are seen |
| Treatment | • Excisional biopsy |
| Endoscopic view | 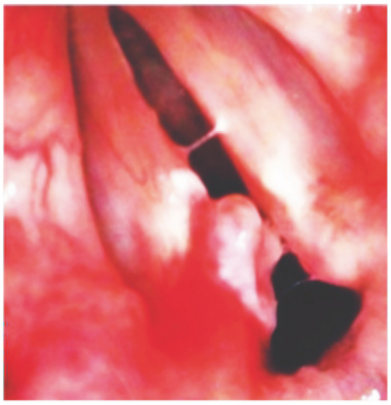 |

### Q5.7: What is keratosis of the larynx? Mention its causes, differential diagnosis, and treatment.

**Answer:**

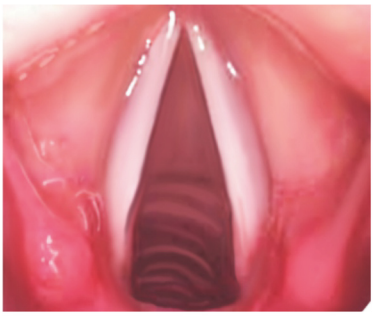

- Keratosis of Larynx /Leukoplakia of Vocal cord is a whiteish plaque-like lesion
- Causes: Smoking(most common), tobacco chewing, excessive voice abuse, and reflux
- Differentiation diagnosis - Candidiasis
- Treatment: Excisional biopsy/Stripping of the vocal cord

## BIG QUESTION 6: What are the key clinical features, diagnosis, and management of tuberculosis of the larynx?

**Broad Answer:**

- Tuberculosis of the Larynx is often associated with pulmonary tuberculosis
- Commonly, the posterior part of the larynx is involved first, and the anterior part is involved last
- It is an extremely painful condition

## DETAILED QUESTIONS

### Q6.1: What are the earliest and last signs of laryngeal tuberculosis?

**Answer:**

- First sign: Hyperaemia of the vocal cord, sluggish movement of the vocal cords
- Mamillated arytenoids (Swollen arytenoids)
- Mouse-bitten or moth-eaten appearance (Discontinuous multiple ulcerations on the vocal cords)
- Last sign: Turban epiglottis (Swollen epiglottis)



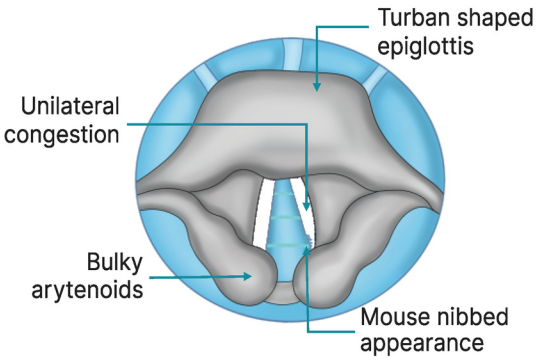


**Q6.2: How is laryngeal tuberculosis diagnosed and treated?**

**Answer:**

- Diagnosis
  - Culture/ histopathology/ gene expert/ molecular methods that we use for TB
- Treatment
  - ATT: Anti-tuberculosis therapy

**Q6.3: Where do vocal nodules and polyps commonly occur on the vocal cord?**

**Answer:** Vocal nodules and polyps occur at the junction of the anterior 1/3$^{rd}$ and the posterior 2/3$^{rd}$

**Q6.4: What is the morphological difference between a vocal nodule and a vocal polyp?**

**Answer:** Sessile is a nodule, and pedunculated is a polyp

**Q6.5: In which vocal cord pathology is diplophonia more commonly observed?**

**Answer:** Diplophonia is seen in a Polyp > Reinke's edema

**Q6.6: What is the treatment of choice for vocal polyps and vocal nodules?**

**Answer:**

- Microlaryngeal surgery is the treatment of choice for vocal polyps
- Voice rest is the treatment of choice for vocal nodules.

**Q6.7: What type of lesions are vocal nodules?**

**Answer:** Vocal nodules are bilateral and symmetrical lesions

**Q6.8: What is the characteristic lesion pattern seen in pachyderma laryngitis?**

**Answer:** An ulcer on one side and heaped-up epithelium on the other side is seen in pachyderma laryngitis

**Q6.9: What is the focal length used in microlaryngeal surgery to excise laryngeal lesions?**

**Answer:** Microlaryngeal surgery involves using a microscope to excise the lesion with a focal length of 400nm

**Q6.10: What part of the vocal cord is involved in Pachyderma laryngitis, and is the ulcer true or pseudo?**

**Answer:**

- Pachyderma laryngitis involves the posterior part of the vocal cord
- Pachyderma laryngitis is not a true ulcer

**Q6.11: What is the most painful condition affecting the larynx?**

**Answer :** TB larynx

**Q6.12: What is the premalignant condition of the larynx?**

**Answer:** Premalignant condition of the larynx is leukoplakia/ keratosis

**Q6.13: What procedure is commonly done in cases of leukoplakia or Reinke's edema?**

**Answer:** Stripping of the vocal cord is done in leukoplakia or Reinke's edema

**Q6.14: What part of the larynx is first involved in Lupus of the larynx?**

**Answer:**

- Lupus of the larynx is a low-grade infection of TB
- Affects the anterior part of the larynx; the epiglottis is first involved

**Q6.15: Elaborate on the differences between TB larynx and Lupus larynx.**

**Answer:**

| | TB larynx | Lupus Larynx |
|---|---|---|
| 1. Pulmonary TB | Yes | No |
| 2. Activity of TB | Active | Low grade |
| 3. Parts affected | Posterior | Anterior |
| 4. Symptomatic | Yes | No |

## BIG QUESTION 7: What are laryngeal papillomas, and what are their types, features, and management?

PYQ: FMGE 2020 PYQ: NEET PG 2020

**Broad Answer:**

- Papilloma means finger-like projections
- Laryngeal papillomas are caused by HPV6 and HPV11
- The two types of papillomas:
  - Juvenile-Onset Laryngeal Papillomatosis
  - Adult-Onset Laryngeal Papillomatosis



## DETAILED QUESTIONS

**Q7.1: Elaborate on the differences between Juvenile-Onset Laryngeal Papillomatosis & Adult-Onset Laryngeal Papillomatosis**

PYQ: FMGE 2021 PYQ: NEET PG 2021

**Answer:**

| | Juvenile-Onset Laryngeal Papillomatosis | Adult-Onset Laryngeal Papillomatosis |
|---|---|---|
| **Age** | Infants and young children | 30-50years |
| **Sex** | | In males, it's twice more common. |
| **mode of transmission** | Mother to child during vaginal delivery | Sexual |
| **Number** | Multiple at multiple sites | Single |
| **Location** | True and false vocal cords, epiglottis, subglottis | The anterior half of the vocal cord or anterior commissure |

| | | |
|---|---|---|
| **Presentation** | Change in voice (initial), airway obstruction, respiratory distress, and stridor | Change in voice (initial), airway obstruction, respiratory distress, and stridor |
| **Aggressive** | Aggressive recurrence is common after excision | Less aggressive does not recur after excision |
| **Treatment** | Antivirals, interferons, excise the papillomas (debrider-assisted resection) | |

## BIG QUESTION 8: What are the voice and speech disorders, their causes, presentations, investigations, and management?

**Broad Answer:**

- Dysphonia Plica Ventricularis
- Spasmodic Dysphonia
- Puberphonia
- Phonasthenia
- Functional aphonia

## DETAILED QUESTIONS

### Q8.1: What is Dysphonia Plica Ventricularis, and how is it managed?

**Answer:**

- Dysphonia Plica Ventricularis is a change in voice characterized by a low-pitched voice.
- Instead of true cords, False cords come in midline and adduct to produce sound
- This condition further leads to hypertrophy of false cords
- Seen in a dubbing artist
- Cause:
  - Organic pathology-True vocal cord pathology compensated by false cords.
  - Functional- No cause
- Treatment - Speech therapy, Reduction of false cords

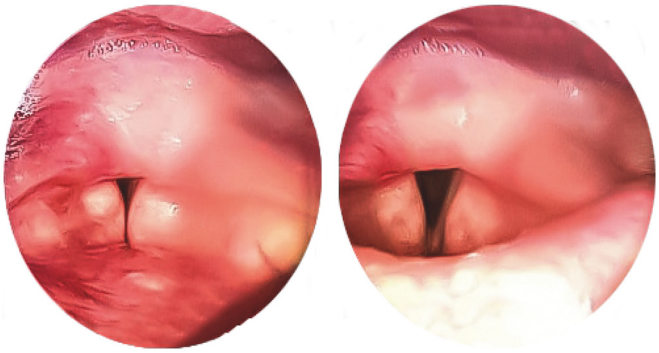

### Q8.2: What is Spasmodic Dysphonia, and with which conditions is it associated?

**Answer:**

- Spasmodic Dysphonia is caused by a spasm of a laryngeal muscle
- Associated with:
  - Certain neurological conditions, like Parkinsonism and Alzheimer's disease
  - Other dystonias include Oromandibular dystonia and blepharospasm



YOURWISH

YOURWISH

### Q8.3: What are the types of Spasmodic Dysphonia?

**Answer:**

- Adductor spasmodic dysphonia: Spasm in the thyroarytenoid muscle
  - o Presents with a strangulated or scratchy, croaky voice
- Abductor spasmodic dysphonia: Spasm in the posterior cricoarytenoid muscle
  - o Presents with a Breathy voice
- Mixed spasmodic dysphonia: It is a combination of both spasmodic dysphonias

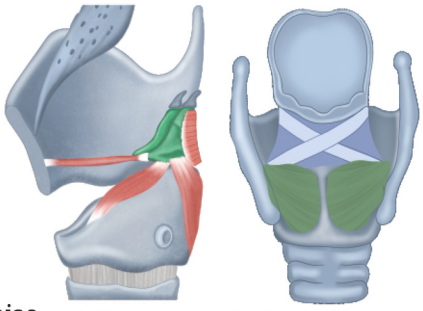

Adductor spasmodic dysphonia

### Q8.4: How is Spasmodic Dysphonia treated?

**Answer:**

- Botulinum injection
  - o In the thyroarytenoid muscle, to treat adductor spasmodic dysphonia
  - o In posterior cricoarytenoid muscle is used to treat abductor spasmodic dysphonia.
- Recurrence is present

### Q8.5: What is Puberphonia, and how does it present?

**Answer:**

- Puberphonia is an inappropriate persistence of adolescent and often female-like voice even after puberty, and is commonly seen in males more than females
- It presents with a high-pitched voice

### Q8.6: What is the purpose of the Gutzmann test, and how is it done?

**Answer:**

- Gutzmann pressure test
  - o Pressure is applied to the thyroid cartilage
  - o The patient is asked to phonate
  - o On application of pressure, if voice quality improves, then the patient is having puberphonia

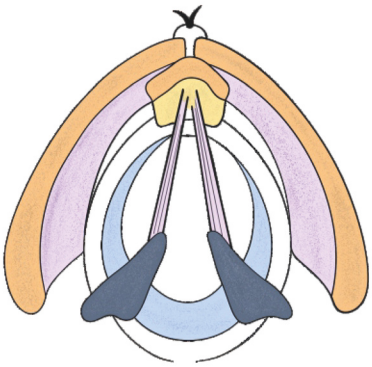

### Q8.7: What is the treatment for Puberphonia?

**Answer:**

- Speech therapy
- Shortening of vocal cords- Type-3 thyroplasty

### Q8.8: What is Phonasthenia, and what are its laryngoscopy findings?

PYQ: NEET PG 2021

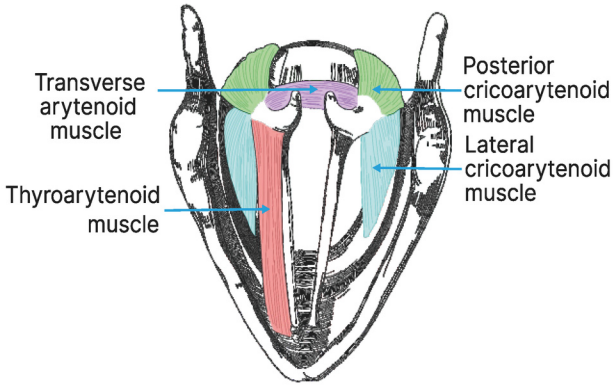


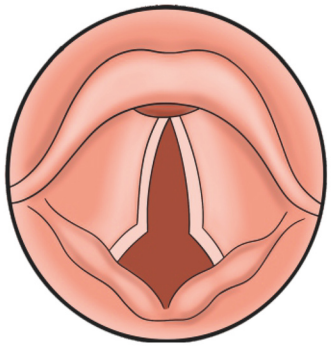

Answer:

- **Phonasthenia is caused by** weakness of the thyroarytenoid muscle and the interarytenoid muscle, leading to bowing of the vocal cords
- Laryngoscopy: Keyhole appearance of the glottis

### Q8.9: What is Functional Aphonia, and how is it diagnosed and managed?

Answer:

- In functional aphonia, the patient is unable to speak
- Cause
  - Emotionally Labile individuals
  - Stress/Anxiety
  - Sudden emotional shock
- No neurological deficit
- Cough test: cough is normal
- Laryngeal examination: Vocal cord adducts on coughing
- Refer the patient to psychologists for counselling.

### Q8.10: Which clinical test is used to assess Puberphonia?

Answer: Gutzmann pressure test

### Q8.11: In which condition is the keyhole appearance of vocal cords seen?

Answer: Phonasthenia

### Q8.12: Which muscles are involved in adductor and abductor spasmodic dysphonia?

Answer:

- Adductor spasmodic dysphonia occurs due to the thyroarytenoid muscle
- Abductor spasmodic dysphonia occurs due to the posterior cricoarytenoid muscle

# 15. LARYNGEAL CARCINOMA

## BIG QUESTION 1: What are the common causes, types, staging principles, and investigative approaches in laryngeal carcinoma?

**Broad Answer:** Laryngeal carcinoma is most commonly linked to tobacco and alcohol use, with chronic irritation playing a significant role. It can be classified based on anatomical location into supraglottic, glottic, and subglottic types, each presenting differently. Staging is guided by the TNM system, which considers tumor size, nodal involvement, and metastasis. Diagnosis relies on endoscopic visualization, biopsy for histopathology, and imaging like CT/MRI for staging and treatment planning.

## DETAILED QUESTIONS

### Q1.1: What is the etiology and incidence of laryngeal carcinoma?

**Answer:**

PYQ: FMGE 2020

- Etiology:
  - Viral infection like HPV
  - Smoking
  - Alcohol
  - Tobacco
  - Genetic factors
- Incidence: Males > Females

### Q1.2: What are the types of laryngeal carcinoma?

**Answer:** According to the site of malignancy, carcinomas can be divided into:

- Supraglottic
- Glottic
- Subglottic

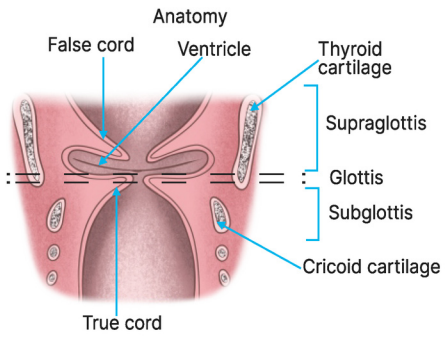


### Q1.3: What is the most common laryngeal carcinoma?

**Answer:**

- The most common carcinoma is glottic carcinoma.
- Glottic carcinoma > supraglottic carcinoma > subglottic carcinoma.

### Q1.4: Compare and contrast the clinical features, morphology, lymphatic spread, and prognosis of supraglottic, glottic, and subglottic laryngeal cancers.

PYQ: FMGE 2021

**Answer:**

| Type of Cancer | Supraglottic | Glottic | Subglottic |
|---|---|---|---|
| Incidence | Intermediate | Most common | Least common |
| Site | Most common in epiglottis | Most commonly at free edge and superior surface of anterior and middle 1/3$^{rd}$ of vocal cord | Most common in midline in anterior half. |



YOURWISH

| | | | |
|---|---|---|---|
| Morphology | • Exophytic or sometimes ulcerative<br>• If the lesion becomes big, it obstructs the airway | Nodule or ulcer | Submucosal Nodule |
| Vocal cord | Vocal cord involvement is very late. So, hoarseness of voice is late. | Vocal cord involvement of voice is early. So, hoarseness of voice is early. But vocal cord fixation is very late. Vocal cord fixation indicates infiltration of thyroarytenoid muscle and is a very bad prognostic sign | Late |
| Lymphatic spread | Upper deep cervical lymph nodes | No lymphatics | Pretracheal and prelaryngeal group of lymph nodes |
| Prognosis | • Bad because symptoms are late as it is silent most of the time.<br>• Early lymphatic metastases because of rich metastases<br>• Anaplastic and highly malignant | • Good because<br>o Presents early with Hoarseness of voice.<br>o No lymphatic metastases<br>o Well differentiated Squamous cell carcinoma | |

### Q1.5: How is laryngeal carcinoma staged?

**Answer:** The TNM classification according to different stages is as follows:

| | |
|---|---|
| Stage 1 | T1 N0 M0 |
| Stage 2 | T2 N0 M0 |
| Stage 3 | T 3 N1 M0 |
| Stage 4a | T 4a N2 M0 |
| Stage 4b | T4b N3 M0 |
| Stage 4c | T4c Any N M1 |

### Q1.6: What is the TNM classification of laryngeal carcinoma?

PYQ: AIIMS 2018 PYQ: FMGE 2022 PYQ: NEET PG 2019, 2020

**Answer:**

| | |
|---|---|
| T1 | Only 1 sub site is involved, and the vocal cords are mobile. |
| T2 | More than 1 sub site is involved, and the vocal cord can be normal/mobile or can have restricted mobility. |
| T3 | More than 1 sub site is involved, vocal cords are fixed, invasion of cartilage (inner perichondrium) of the larynx, and involvement of spaces around the larynx. |
| T4a | It is the local spread. |



YOURWISH

| | |
|---|---|
| T4b | It is a distant spread. |
| N0 | No neck nodes are involved. |
| N1 | The size of the lymph node is <3 cm and it is ipsilateral. |
| N2a | Single ipsilateral node between 3-6 cm. |
| N2b | Multiple ipsilateral nodes between 3-6 cm. |
| N2c | Single or multiple contralateral nodes between 3-6 cm. |
| N3a | The size of the lymph node is >6 cm and there is no extra nodal spread. |
| N3b | The size of the lymph node is >6 cm and there is extra nodal spread. |

### Q1.7: How is laryngeal carcinoma diagnosed?

**Answer:**

| | |
|---|---|
| Investigation of choice | Biopsy |
| First line investigation to identify the extent of disease | Contrast Enhanced CT scan (CECT) |
| Most accurate test to assess cartilage involvement or space involvement | MRI scan |

### Q1.8: Why the radiology done before performing the biopsy of the laryngeal carcinoma?

**Answer:** Imaging studies are performed before a biopsy because the inflammation and swelling from the procedure can make a tumor appear larger or more widespread than it actually is. This can lead to a false-positive result and a misdiagnosis.

## BIG QUESTION 2: What are the main treatment strategies for laryngeal carcinoma, and how is the choice of laryngectomy determined based on disease extent?

**Broad Answer:** Treatment of laryngeal carcinoma depends on the tumor site, stage, and vocal function preservation. Early-stage tumors may be treated with radiation or conservative surgeries like vertical hemilaryngectomy or supraglottic laryngectomy. Advanced lesions often require total laryngectomy with or without neck dissection. Chemoradiation is also used for organ preservation in selected cases. Surgical choices aim to balance oncological clearance with voice and airway maintenance.

## DETAILED QUESTIONS

### Q2.1: What are the treatment options for laryngeal cancer?

**Answer:**

- Radiotherapy
- MLS (Micro laryngeal surgery)
- Conservative surgeries
- Hemi-laryngectomy
- Supraglottic laryngectomy

### Q2.2: What are the treatment options for stage 1 and stage 2 cancers?

**Answer:**

- Stage 1: T1 N0 M0 and T2 N0 M0.

- The treatment of choice is **radiotherapy**, as the aim of the treatment is voice preservation.
- Exception: **Micro laryngeal surgery (MLS)** is done when the carcinoma is in the middle 1/3$^{rd}$ of the vocal cord and amenable small lesion
- Conservative surgeries are done in patients with recurrence of the carcinoma, as radiation therapy failed to treat the primary carcinoma.

### Q2.3: What are the conservative surgeries for laryngeal cancers?

**Answer:** Conservative surgeries are of two types:

| Vertical hemi laryngectomy | Subglottic Laryngectomy |
|---|---|
| 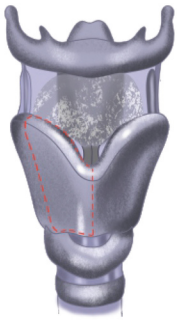 |  |
| • One half of the larynx is removed vertically in this surgery.<br>• **Indication**: Involvement of cancer in the vertical one-half of the larynx with a subglottic extension not more than 1 cm. It is done when there is recurrence. | • In this surgery, the complete larynx is excised above the level of vocal cords.<br>• **Indication**: If the cancer is a supraglottic carcinoma not involving the vocal cords. |

### Q2.4: What is the treatment option for recurrence?

**Answer:**

- For primary carcinoma: Radiotherapy and MLS
- For recurrence: Conservative surgeries (Vertical hemi-laryngectomy and Subglottic laryngectomy)

### Q2.5: How are stage 3 and 4A tumors treated?

**Answer:**

1. Concurrent chemo RT - for stage 3 and early stage 4 (Cisplatin/ Carboplatin/Cetuximab) OR
2. Near Total Laryngectomy: This is for stage 3 or stage 4a with one arytenoid spared

### Q2.6: What are the indications of total laryngectomy?

**Answer:**

- T4a with thyroid cartilage invasion
- Stage 3 and 4a patients who cannot tolerate chemoradiotherapy
- Stage 3 and 4a recurrent tumours
- Bilateral arytenoid involvement
- T4b lesions with distant spread
- The outer cortex of the Thyroid cartilage is involved

### Q2.7: What is the management of laryngeal cancer post-laryngectomy?

**Answer:**

- After a total laryngectomy is done, the patient will have a permanent tracheostomy

- In this case, the patient will breathe from a permanent tracheostomy
- The patient cannot phonate in case of permanent tracheostomy
  - In this case, rehabilitation has to be given to produce speech

**Q2.8: Give a brief summary on the treatment modalities used in laryngeal carcinoma.**

**Answer:**

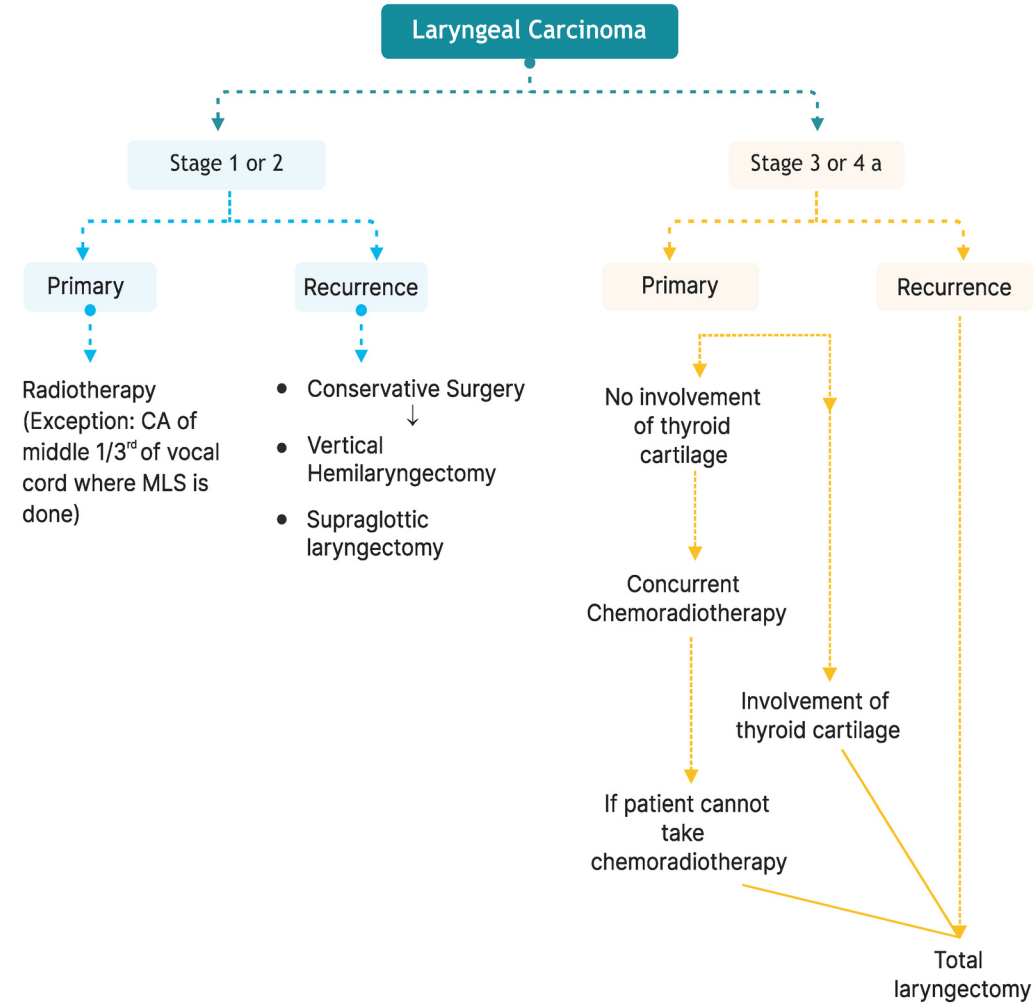


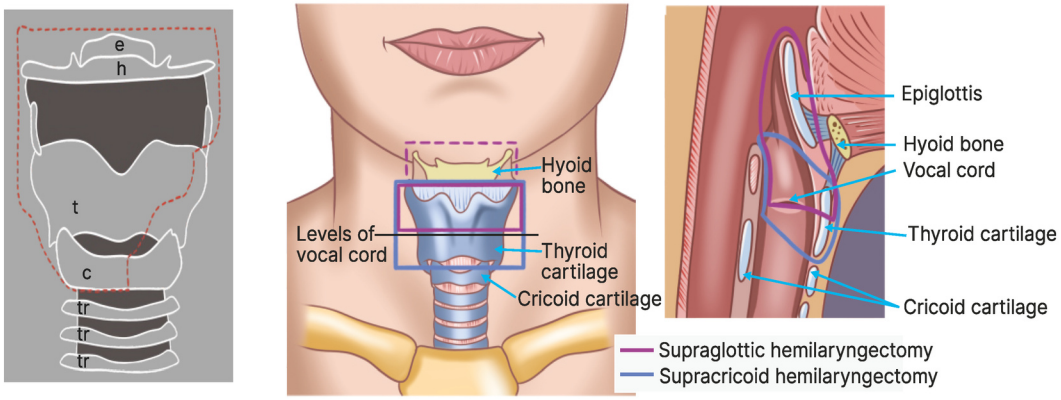


**BIG QUESTION 3: How is voice rehabilitation approached following surgical treatment for laryngeal carcinoma, particularly after total laryngectomy?**

**Broad Answer:** Voice rehabilitation post-laryngectomy aims to restore communication through alternative methods. The main techniques include tracheoesophageal puncture (TEP) with a voice prosthesis, esophageal speech, and electronic larynx devices. TEP is the most effective and commonly used method. Each approach requires patient training and speech therapy to optimize vocal outcomes and improve quality of life after surgery.

## DETAILED QUESTIONS

### Q3.1: What are the various voice rehabilitation methods?

**Answer:**

- Oesophageal speech
- Tracheo-oesophageal speech
- Artificial Larynx:
  - o Electrolarynx
  - o Transoral pneumatic device

### Q3.2: What is esophageal speech?

**Answer:**

In this, the patient is asked to swallow a gulp of air and is held in the oesophagus.

↓

It is held in the oesophagus because the larynx is not present.

↓

Whatever air is swallowed, it goes into the oesophagus via the oropharynx and hypopharynx.

↓

Pressure builds up in the lumen of the oesophagus.

↓

When the patient phonates, these air currents present in the oesophagus go and hit the Upper esophageal sphincter (UES)

↓

UES acts as a vibrator against which the air column will hit and produce acoustic waves

- Acoustic waves, when they go through the articulator, produce speech
- The patient will be able to speak 6-10 words before re-swallowing
- Voice rough but loud and understandable.

### Q3.3: What is Tracheo-Oesophageal Speech?

**Answer:**

- The patient has a permanent tracheostomy
- A hole is made between the trachea and the esophagus, and a prosthesis
- This prosthesis can be a **Bloom single prosthesis** or a **Provox prosthesis**
- In this, the patient is asked to close the tracheostomy with the help of a finger.
- Now the air current in the trachea will get redirected into the oesophagus, which will hit the upper esophageal sphincter and generate acoustic waves that go through the articulators to produce speech
- Now little more quantity of air is present because lung has some residual capacity.
- It resembles normal speech more than esophageal speech. The patient can speak a few long sentences.

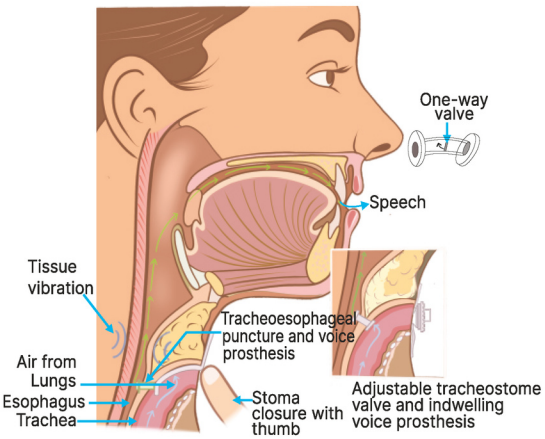




YOURWISH

**Q3.4: How does an electrolarynx help in phonation?**

**Answer:** Here, an artificial sound source or vibrator is used to produce speech.

