Pathology Collection

Question Bank with Answers & Explanations

Generated on April 18, 2026

88 Topics • 1695 Questions

Need help or updates?
■ *Click here to contact the creator of this PDF*

Viewer Guide

Navigation Tips:

- Use the outline/bookmarks pane (left side in most PDF viewers) to jump between sections.
- Click links at the bottom of each question to switch between Part A (questions) and Part B (answers).
- Master Index links take you to topic parts.

Viewer Settings:

- Adobe Reader: View > Show/Hide > Navigation Panes > Bookmarks
- Chrome: Install PDF viewer extension if needed.
- Mobile: Use apps like Adobe Acrobat or Xodo for outline support.

■ *For queries & support: Message @Neet_pg_bot on Telegram*

DIRECTORY EXPLORER

Click a folder below to open it.

» **01_Cell Injury**

» **02_Inflammation**

» **03_Genetics**

» **04_Neoplasia**

» **05_Immunity**

» **06_CVS_ Blood Vessels and Vasculitis**

» **07_Respiratory System**

» **08_Salivary Glands**

» **09_Gastrointestinal Tract**

» **10_Liver_ Biliary System and Pancreas**

» **11_Renal System**

» **12_Genital System**

» **13_Endocrinology**

» **14_Breast Pathology**

» **15_Central Nervous System**

» **16_Skin and Musculoskeletal**

» **17_Hematology_ Red Blood Cells**

» **18_Hematology_ White Blood Cells**

» **19_Platelet and Bleeding Disorders**

» **20_Blood Banking and Transfusion Medicine**

» **21_Bone Disorders**

» **22_Techniques in Pathology**

» **23_Skin Pathology**

» **24_Miscellaneous**

» **25_Platelets and Blood Transfusion**

» 01_Cell Injury

« Back to Parent Directory

Path: 01_Cell Injury

• 001 Cell Injury Free Radical Injury And Er Stress Related	***Questions***	***Answers***
• 002 Cell Death	***Questions***	***Answers***
• 003 Cell Ageing Autophagy And Cellular Adaptations	***Questions***	***Answers***
• 004 Intracellular Accumulations	***Questions***	***Answers***
• 005 Previous Year Questions	***Questions***	***Answers***

» 02_Inflammation

« Back to Parent Directory

Path: 02_Inflammation

• 006 Acute Inflammation	***Questions***	***Answers***
• 007 Chronic Inflammation	***Questions***	***Answers***
• 008 Mediators Of Inflammation	***Questions***	***Answers***
• 009 Previous Year Questions	***Questions***	***Answers***

» 03_Genetics

« Back to Parent Directory

Path: 03_Genetics

• 010 Genetics- Introduction Mendelian Disorders	***Questions***	***Answers***
• 011 Non-Mendelian Disorders	***Questions***	***Answers***
• 012 Diagnosis Of Genetic Disorders And Miscellaneous	***Questions***	***Answers***
• 013 Previous Year Questions	***Questions***	***Answers***

» 04_Neoplasia

« Back to Parent Directory

Path: 04_Neoplasia

• 014 Classification And Features Of Neoplasia	***Questions***	***Answers***
• 015 Etiology Of Neoplasia	***Questions***	***Answers***
• 016 Diagnosis Of Tumors And Paraneoplastic Syndromes	***Questions***	***Answers***
• 017 Fundamentals Of Neoplasia	***Questions***	***Answers***
• 018 Previous Year Questions	***Questions***	***Answers***

» 05_Immunity

« Back to Parent Directory

Path: 05_Immunity

• 019 Types Of Immunity	***Questions***	***Answers***
• 020 Types Of Hypersensitivity Reactions	***Questions***	***Answers***
• 021 Immune Tolerance And Autoimmune Disease	***Questions***	***Answers***
• 022 Immunodeficiency Disorders	***Questions***	***Answers***
• 023 Amyloidosis	***Questions***	***Answers***
• 024 Transplant Immunity	***Questions***	***Answers***
• 025 Previous Year Questions	***Questions***	***Answers***

» 06_CVS_ Blood Vessels and Vasculitis

« Back to Parent Directory

Path: 06_CVS_ Blood Vessels and Vasculitis

• 026 Sclerosis And Vascular Tumors	***Questions***	***Answers***
• 027 Ischemic Heart Disease And Myocardial Infarction	***Questions***	***Answers***
• 028 Rhd And Infective Endocarditis	***Questions***	***Answers***
• 029 Carditis And Cardiac Tumors	***Questions***	***Answers***
• 030 Vasculitis	***Questions***	***Answers***
• 031 Previous Year Questions	***Questions***	***Answers***

» 07_Respiratory System

« Back to Parent Directory

Path: 07_Respiratory System

• 032 Obstructive Lung Disease	***Questions***	***Answers***
• 033 Pulmonary Hypertension And Lung Tumors	***Questions***	***Answers***
• 034 Congenital Anomalies And Lung Infections	***Questions***	***Answers***
• 035 Sarcoidosis And Occupational Lung Diseases	***Questions***	***Answers***
• 036 Previous Year Questions	***Questions***	***Answers***

» 08_Salivary Glands

« Back to Parent Directory

Path: 08_Salivary Glands

• 037 Salivary Gland Pathology	***Questions***	***Answers***
• 038 Previous Year Questions	***Questions***	***Answers***

» 09_Gastrointestinal Tract

« Back to Parent Directory

Path: 09_Gastrointestinal Tract

• 039 Basics Of Git And Esophagus	***Questions***	***Answers***
• 040 Peptic Ulcer Disease Gastric Polyps And Tumors - I	***Questions***	***Answers***
• 041 Intestinal Polyps And Intestinal Carcinoma - I	***Questions***	***Answers***
• 042 Malabsorption Syndrome Celiac Disease And Ibd	***Questions***	***Answers***
• 043 Previous Year Questions	***Questions***	***Answers***

» 10_Liver_ Biliary System and Pancreas

« Back to Parent Directory

Path: 10_Liver_ Biliary System and Pancreas

• 044 Hepatobiliary Pathology-I	***Questions***	***Answers***
• 045 Hepatobiliary Pathology-Ii	***Questions***	***Answers***
• 046 Hepatic Tumors And Pancreas	***Questions***	***Answers***
• 047 Previous Year Questions	***Questions***	***Answers***

» 11_Renal System

« Back to Parent Directory

Path: 11_Renal System

• 048 Basics Of Renal Pathology	***Questions***	***Answers***
• 049 Nephritic And Nephrotic Syndromes	***Questions***	***Answers***
• 050 Renal Urinary Tract Tumors	***Questions***	***Answers***
• 051 Previous Year Questions	***Questions***	***Answers***

» 12_Genital System

« Back to Parent Directory

Path: 12_Genital System

• 052 Pathology Of Male Genital Tract	***Questions***	***Answers***
• 053 Pathology Of Female Genital Tract-I	***Questions***	***Answers***
• 054 Pathology Of Female Genital Tract-Ii	***Questions***	***Answers***
• 055 Previous Year Questions	***Questions***	***Answers***

» 13_Endocrinology

« Back to Parent Directory

Path: 13_Endocrinology

• 056 Thyroid Gland	***Questions***	***Answers***
• 057 Parathyroid Pituitary And Adrenal Glands - I	***Questions***	***Answers***
• 058 Previous Year Questions	***Questions***	***Answers***

» 14_Breast Pathology

« Back to Parent Directory

Path: 14_Breast Pathology

• 059 Benign Breast Lesions	***Questions***	***Answers***
• 060 Malignant Breast Lesions	***Questions***	***Answers***
• 061 Previous Year Questions	***Questions***	***Answers***

» 15_Central Nervous System

« Back to Parent Directory

Path: 15_Central Nervous System

• 062 Cns Pathology	***Questions***	***Answers***
• 063 Previous Year Questions	***Questions***	***Answers***

» 16_Skin and Musculoskeletal

« Back to Parent Directory

Path: 16_Skin and Musculoskeletal

	Questions	*Answers*
• 064 Previous Year Questions		

» 17_Hematology_ Red Blood Cells

« Back to Parent Directory

Path: 17_Hematology_ Red Blood Cells

• 065 Introduction To Hematology	***Questions***	***Answers***
• 066 Hemolytic Anemia-I	***Questions***	***Answers***
• 067 Hemolytic Anemia-Ii	***Questions***	***Answers***
• 068 Microcytic Hypochromic Anemia	***Questions***	***Answers***
• 069 Macrocytic Hypochromic Normocytic Anemia	***Questions***	***Answers***
• 070 Previous Year Questions	***Questions***	***Answers***

» 18_Hematology_ White Blood Cells

« Back to Parent Directory

Path: 18_Hematology_ White Blood Cells

• 071 Cml And Cll	***Questions***	***Answers***
• 072 Plasma Cell Disorders	***Questions***	***Answers***
• 073 Wbc Basics And Instruments	***Questions***	***Answers***
• 074 All And Aml	***Questions***	***Answers***
• 075 Myeloid Disorders	***Questions***	***Answers***
• 076 Hodgkin S And Non-Hodgkin S Lymphoma	***Questions***	***Answers***
• 077 Previous Year Questions	***Questions***	***Answers***

» 19_Platelet and Bleeding Disorders

« Back to Parent Directory

Path: 19_Platelet and Bleeding Disorders

• 078 Platelet And Hemostasis Disorders	***Questions***	***Answers***
• 079 Previous Year Questions	***Questions***	***Answers***

» 20_Blood Banking and Transfusion Medicine

« Back to Parent Directory

Path: 20_Blood Banking and Transfusion Medicine

• 080 Blood Banking And Transfusion Pathology	***Questions***	***Answers***
• 081 Previous Year Questions	***Questions***	***Answers***

» 21_Bone Disorders

« Back to Parent Directory

Path: 21_Bone Disorders

• 082 Bone And Soft Tissue Pathology - I	*Questions*	*Answers*
• 083 Previous Year Questions	*Questions*	*Answers*

» 22_Techniques in Pathology

« Back to Parent Directory

Path: 22_Techniques in Pathology

	Questions	*Answers*
• 084 Previous Year Questions		

» 23_Skin Pathology

« Back to Parent Directory

Path: 23_Skin Pathology

• 085 Skin Pathology	***Questions***	***Answers***
• 086 Previous Year Questions	***Questions***	***Answers***

» 24_Miscellaneous

« Back to Parent Directory

Path: 24_Miscellaneous

	Questions	*Answers*
• 087 Previous Year Questions		

» 25_Platelets and Blood Transfusion

« Back to Parent Directory

Path: 25_Platelets and Blood Transfusion

	Questions	*Answers*
• 088 Previous Year Questions		

Part A — All Questions

• [01_Cell Injury] 001 Cell Injury Free Radical Injury And Er Stress Related

« Back to Folder Directory

[01_Cell Injury] 001 Cell Injury Free Radical Injury And Er Stress Related — Quick Jump

Q1 (p. 30)	*Q2 (p. 30)*	*Q3 (p. 31)*	*Q4 (p. 31)*	*Q5 (p. 31)*	*Q6 (p. 32)*
Q7 (p. 32)	*Q8 (p. 32)*	*Q9 (p. 33)*	*Q10 (p. 33)*	*Q11 (p. 34)*	*Q12 (p. 34)*
Q13 (p. 34)	*Q14 (p. 35)*	*Q15 (p. 35)*	*Q16 (p. 36)*		

Q1: Which of the following are pathological factors that contribute to the development of thrombosis? (Q879510)

A. Endothelial injury, abnormal blood flow, hypercoagulability

B. Increased vascular compliance, reduced platelet activity, and fibrinolysis

C. Decreased vascular tone, enhanced anticoagulant proteins, and vasodilation

D. Smooth muscle hypertrophy, hypocoagulability, and increased tissue perfusion

See Answer in Part B → Q1

@Neet_pg_bot

Q2: What is the most common cause of cell injury? (Q845267)

A. Hypoxia

B. Immunologic reactions

C. Drug-induced

D. Nutritional imbalance

See Answer in Part B → Q2

@Neet_pg_bot

Q3: Identify the correct combination of most and least sensitive cells to hypoxia. (Q845270)

A. Most sensitive - hepatocytes and least sensitive - Lymphocytes

B. Most sensitive - bone marrow cells and least sensitive - nerve cells

C. Most sensitive - retina and least sensitive - adipose tissue

D. Most sensitive - neurons and least sensitive - fibroblasts

See Answer in Part B → Q3

@Neet_pg_bot

Q4: Which among the following is not a feature of reversible cell injury? (Q845271)

A. Large amorphous densities in the mitochondria

B. Decrease in ATP generation

C. Swelling of the endoplasmic reticulum

D. Detachment of ribosomes from granular ER

See Answer in Part B → Q4

@Neet_pg_bot

Q5: Which of the following are features of irreversible cell injury? Increased eosinophilia Pyknosis Decrease in ATP production Small amorphous densities in mitochondria (Q845275)

A. 1, 2

B. 1, 2, 3, 4

C. 1, 2, 4

D. 2, 3

See Answer in Part B → Q5

@Neet_pg_bot

Q6: Match the following descriptions of the nuclear changes in irreversible cell injury. I. Pyknosis a. Nuclear fragmentation II. Karyorrhexis b. Dissolution of nucleus III. Karyolysis c. Shrinking of the nucleus and clumping of nuclear chromatin (Q845280)

A. I-a, II-b, III-c

B. I-b, II-c, III-a

C. I-c, II-a, III-b

D. I-c, II-b, III-a

See Answer in Part B → Q6

@Neet_pg_bot

Q7: Which of the following is the most important electron microscopic finding in irreversible cell injury? (Q845288)

A. Small amorphous densities in the mitochondria

B. Swelling of the endoplasmic reticulum

C. Large amorphous densities in the mitochondria

D. Detachment of ribosomes from the granular endoplasmic reticulum

See Answer in Part B → Q7

@Neet_pg_bot

Q8: Which of the following statements regarding free radical injury is true? (Q845289)

A. Free radicals are highly stable molecules with unpaired electrons that contribute positively to cellular functions.

B. Free radical injury can lead to cell damage through lipid peroxidation, protein oxidation, and DNA strand breaks.

C. Antioxidants play a minor role in protecting cells from free radical damage.

D. Free radicals primarily cause cell death through apoptosis and do not contribute to necrosis.

See Answer in Part B → Q8

@Neet_pg_bot

Q9: Which of the following ultrastructural findings given below can be seen in irreversible cell injury? (Q845292)

A. Swelling of endoplasmic reticulum

B. Formation of myelin figures

C. Disaggregation of granular and fibrillar elements

D. Nuclear fragmentation

See Answer in Part B → Q9

@Neet_pg_bot

Q10: A sample of tissue preparation is subjected to oxidative stress under experimental conditions. Different types of free radicals are generated in the process. However, the researcher wants to work on the most potent and reactive free radicals among the ones generated. Which of the following will he be working on? (Q845294)

A. Hydroxyl radical (OH•)

B. Nitric oxide radical (NO•)

C. Superoxide anion radical (O2•-)

D. Peroxyl radical (ROO•)

See Answer in Part B → Q10

@Neet_pg_bot

Q11: Which of the following is a telltale sign of free radical injury in cells? (Q845295)

A. Increased antioxidant levels in the cell

B. Decreased lipid peroxidation products

C. Generation of Lipofuscin and stress markers such as malondialdehyde (MDA)

D. Enhanced cellular energy production.

See Answer in Part B → Q11

@Neet_pg_bot

Q12: What is the primary function of superoxide dismutase (SOD) in cells? (Q845298)

A. Activation of inflammatory responses.

B. Generation of reactive oxygen species (ROS)

C. Neutralization of superoxide anion radicals (O2•-) into hydrogen peroxide (H2O2)

D. Promotion of lipid peroxidation.

See Answer in Part B → Q12

@Neet_pg_bot

Q13: A 50-year-old male presents with progressive weakness and muscle atrophy, primarily affecting his arms and legs. He reports difficulty with tasks such as buttoning shirts and lifting objects. On examination, you note fasciculations in his upper extremities and decreased muscle strength. His reflexes are brisk, and there is no sensory deficit. Nerve conduction studies show signs of denervation. Genetic testing reveals a mutation in the SOD1 gene. Based on this clinical scenario, what is the most likely diagnosis for this patient? (Q845300)

A. Multiple sclerosis

B. Myasthenia gravis

C. Amyotrophic lateral sclerosis

D. Guillain-Barré syndrome

See Answer in Part B → Q13

@Neet_pg_bot

Q14: Which of the following best describes the primary function of chaperones within the cellular environment? (Q845304)

A. Facilitating the degradation of misfolded proteins

B. Promoting protein folding and preventing misfolding

C. Catalyzing enzymatic reactions by providing a scaffold

D. Transporting proteins across cellular membranes

See Answer in Part B → Q14

@Neet_pg_bot

Q15: A 60-year-old man has been complaining of fatigue, unintentional weight loss, and swelling in his ankles and legs over the past few months. On physical examination, you notice hepatomegaly and proteinuria. Laboratory tests reveal elevated serum creatinine levels and microscopic hematuria. Which of the following types of amyloid is most likely responsible for this patient's presentation? (Q845308)

A. AA amyloidosis

B. AB amyloidosis

C. AL amyloidosis

D. ATTR amyloidosis

See Answer in Part B → Q15

@Neet_pg_bot

Q16: Which cellular pathway is primarily involved in the pathogenesis of Amyotrophic Lateral Sclerosis (ALS)?Which of the following pathways are responsible for the pathogenesis of ALS? (Q845311)

A. Autophagy-lysosome pathway

B. Ubiquitin-proteasome pathway

C. Endocytic pathway

D. Apoptotic pathway

See Answer in Part B → Q16

@Neet_pg_bot

• [01_Cell Injury] 002 Cell Death

« Back to Folder Directory

[01_Cell Injury] 002 Cell Death — Quick Jump

Q1 (p. 37)	*Q2 (p. 37)*	*Q3 (p. 38)*	*Q4 (p. 38)*	*Q5 (p. 38)*	*Q6 (p. 39)*
Q7 (p. 39)	*Q8 (p. 39)*	*Q9 (p. 40)*	*Q10 (p. 40)*	*Q11 (p. 40)*	*Q12 (p. 41)*
Q13 (p. 41)	*Q14 (p. 41)*	*Q15 (p. 42)*	*Q16 (p. 43)*	*Q17 (p. 43)*	*Q18 (p. 43)*
Q19 (p. 44)	*Q20 (p. 44)*	*Q21 (p. 44)*	*Q22 (p. 45)*	*Q23 (p. 46)*	*Q24 (p. 46)*

Q1: A construction worker involved in bridge building reports widespread bone pain. Imaging reveals ischemic necrosis affecting both femoral heads, the left tibia, and the right humerus. Which of the following factors is most likely responsible for this condition? (Q879491)

A. Alterations in ambient pressure

B. Changes in blood viscosity

C. Impaired blood flow

D. Increased coagulability

See Answer in Part B → Q1

@Neet_pg_bot

Q2: Which of the following diseases is primarily attributed to protein misfolding, resulting in cellular dysfunction or apoptosis? (Q879402)

A. Cystic fibrosis

B. Familial hypercholesterolemia

C. Tay-Sachs disease

D. All of the above

See Answer in Part B → Q2

@Neet_pg_bot

Q3: A 65-year-old patient with a neurodegenerative disorder is found to have neuronal death associated with iron accumulation and lipid peroxidation. Which form of cell death is most likely involved? (Q879401)

A. Apoptosis

B. Necrosis

C. Ferroptosis

D. Pyroptosis

See Answer in Part B → Q3

@Neet_pg_bot

Q4: A 30-year-old individual has cells that resist Fas-mediated apoptosis despite Fas ligand binding. Which of the following proteins is most likely responsible for blocking caspase-8 activation in this scenario? (Q879400)

A. Bcl-2

B. FLIP

C. BID

D. FADD

See Answer in Part B → Q4

@Neet_pg_bot

Q5: Which of the following statements about caspases is true? (Q879392)

A. Caspases function independently of apoptotic signaling pathways

B. Caspases cleave at cysteine residues

C. Caspases act on asparagine residues

D. Caspases are cysteine proteases

See Answer in Part B → Q5

@Neet_pg_bot

Q6: Which of the following represents pathological apoptosis rather than physiological apoptosis? (Q879391)

A. Regression of the lactating breast after weaning

B. Elimination of autoreactive T-lymphocytes in the thymus

C. Death of hepatocytes during viral hepatitis

D. Removal of neutrophils after resolution of acute appendicitis

See Answer in Part B → Q6

@Neet_pg_bot

Q7: A pathology slide shows necrotic cells with intense eosinophilic cytoplasm on H&E staining. Which of the following best explains this increased eosinophilia? (Q879390)

A. Loss of glycogen and lipid droplets

B. Accumulation of denatured cytoplasmic proteins that bind eosin

C. Swelling of mitochondria with amorphous densities

D. Presence of intracytoplasmic myelin figures

See Answer in Part B → Q7

@Neet_pg_bot

Q8: Which of the following is true about apoptosis? (Q879389)

A. It is an irreversible type of cell injury

B. It is associated with inflammation

C. It results in nuclear changes such as pyknosis, karyorrhexis, and karyolysis

D. It is an active process

See Answer in Part B → Q8

@Neet_pg_bot

Q9: A pathology student is reviewing the sequence of nuclear and cellular changes that occur during necrosis. Which of the following correctly represents the order of events? 1. Cell swelling 2. Karyolysis 3. Karyorrhexis 4. Pyknosis (Q879387)

A. 1 → 2 → 3 → 4

B. 1 → 4 → 3 → 2

C. 2 → 3 → 4 → 1

D. 4 → 3 → 2 → 1

See Answer in Part B → Q9

@Neet_pg_bot

Q10: Which of the following are involved in the pathogenesis of pyroptosis? (Q845353)

A. Caspase 8 and FADD

B. RIPK3 and MLKL

C. Caspase 1 and inflammasome

D. Iron and glutathione antioxidants

See Answer in Part B → Q10

@Neet_pg_bot

Q11: Which type of cell death prevents metastasis? (Q845357)

A. Necroptosis

B. Pyroptosis

C. Anoikis

D. Necrosis

See Answer in Part B → Q11

@Neet_pg_bot

Q12: Which of the following is true about programmed necroptosis? (Q845354)

A. Caspase-independent programmed cell death.

B. It is non-inflammatory.

C. It is only pathological.

D. It helps kill the Herpes simplex virus.

See Answer in Part B → Q12

@Neet_pg_bot

Q13: Which of the following is true about coagulative necrosis? (Q845314)

A. It is the least common type of necrosis

B. Brain is most likely to undergo coagulative necrosis

C. It causes a wedge-shaped necrosis in the affected organs

D. The tissue architecture is lost

See Answer in Part B → Q13

@Neet_pg_bot

Q14: Which of the following cell deaths is most likely to show pattern B? (Q845352)

A. Apoptosis

B. Necrosis

C. Both

D. None of the above



See Answer in Part B → Q14

@Neet_pg_bot

Q15: Which of the following substances is not a component of ‘eat-me signals’ of efferocytosis? (Q845351)

A. C1q

B. Thrombospondin

C. Phosphatidyl serine

D. Fas Ligand

See Answer in Part B → Q15

@Neet_pg_bot

Q16: Which of the following forms the apoptosome complex? (Q845350)

A. SMAC, DIABLO

B. Cyt C and Apaf

C. Procaspase 9 and Caspase 9

D. Caspase 3, 6, 7

See Answer in Part B → Q16

@Neet_pg_bot

Q17: Arrange the steps of the extrinsic pathway of apoptosis in the correct order. i. Binding of Fas ligand of T cells to Fas ii. Trimerization of Fas iii. Activation of caspase 8, 10. iv. Formation of FADD (Q845349)

A. i>ii>iii>iv

B. iii>i>ii>iv

C. i>ii>iv>iii

D. iv>i>ii>iii

See Answer in Part B → Q17

@Neet_pg_bot

Q18: Match the following apoptotic genes with their functions: 1. BCL2 , MCL1 a. Allows cytochrome c leakage 2. BAX, BAK b. Initiates apoptosis when upregulated 3. BAD, BID, NOXA c. Prevents leakage of cytochrome C from the cytosol (Q845346)

A. 1-b , 2-c , 3-a

B. 1-c , 2-a , 3-b

C. 1-a , 2-b , 3-c

D. 1-b , 2-a , 3-c

See Answer in Part B → Q18

@Neet_pg_bot

Q19: Which of the following statements about apoptosis is false? (Q845342)

A. Characterized by the activation of caspases leading to DNA fragmentation by endonuclease

B. Inflammatory response and release of damage-associated molecular patterns (DAMPs).

C. Chromatin condensation and formation of cytoplasmic blebs.

D. Eliminates cells that are injured beyond repair without eliciting a host reaction.

See Answer in Part B → Q19

@Neet_pg_bot

Q20: Identify the correctly matched pair among the following (Q845340)

A. Coagulative necrosis- Leucocytic enzymes- Brain

B. Liquefactive necrosis- Lysosomal enzymes - Heart

C. Fat necrosis- Pancreatic lipase- Omentum

D. Fibrinoid necrosis- Bacterial enzymes- Leg

See Answer in Part B → Q20

@Neet_pg_bot

Q21: Based on the provided image, which features are indicative of the type of gangrene depicted? {{caption_text}} (Q845334)

A. Presence of gas bubbles in the affected tissue

B. Formation of bullae filled with fluid

C. Dry, shrunken, and mummified appearance with a clear demarcation

D. Presence of foul-smelling discharge and crepitus on palpation



See Answer in Part B → Q21

@Neet_pg_bot

Q22: Which of the following conditions does not involve fibrinoid necrosis? (Q845330)

A. Systemic Lupus Erythematosus.

B. Malignant hypertension

C. Atherosclerosis

D. Polyarteritis Nodosa (PAN)

See Answer in Part B → Q22

@Neet_pg_bot

Q23: A 45-year-old man presents to the clinic with a persistent cough, weight loss, and night sweats. A chest X-ray shows cavitary lesions in the upper lobes of the lungs. Sputum analysis is positive for acid-fast bacilli. A biopsy is taken, and a cut section of the lung is shown below.What type of necrosis is most likely present in this patient's lung tissue? (Q845324)

A. Coagulative necrosis

B. Caseous necrosis

C. Fatty necrosis

D. Liquefactive necrosis

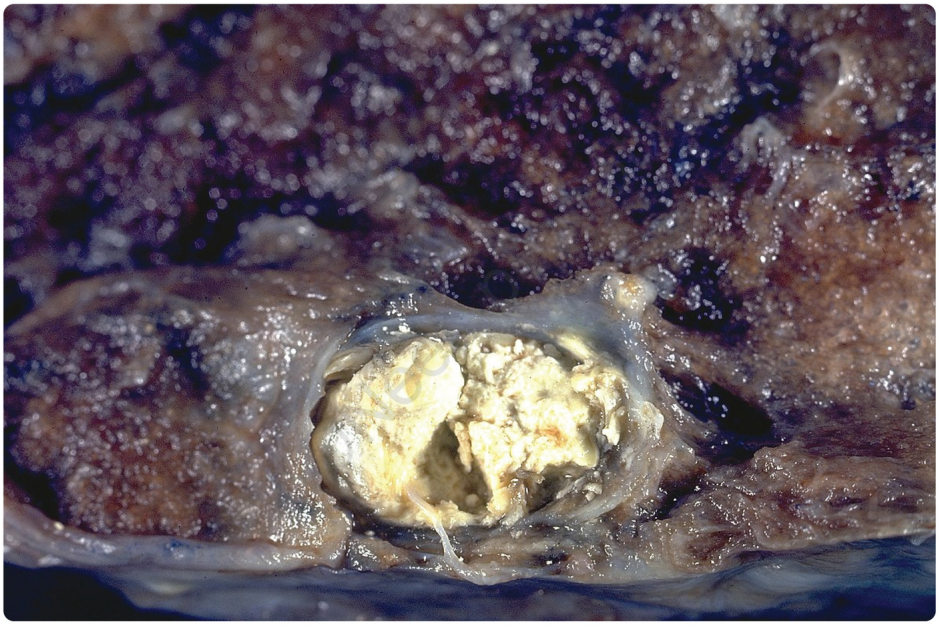

@Neet_pg_bot

See Answer in Part B → Q23

@Neet_pg_bot

Q24: A 65 year male presents with weakness on the right half of his body. He is a known case of atrial fibrillation, not on any treatment. CT angiography shows a complete occlusion of a small branch of the middle cerebral artery. What is the most likely change seen in this pathology? (Q845318)

A. Coagulative necrosis

B. Liquefactive necrosis

C. Apoptosis

D. Fibrinoid necrosis

See Answer in Part B → Q24

@Neet_pg_bot

• [01_Cell Injury] 003 Cell Ageing Autophagy And Cellular Adaptations

« Back to Folder Directory

[01_Cell Injury] 003 Cell Ageing Autophagy And Cellular Adaptations — Quick Jump

Q1 (p. 48)	*Q2 (p. 48)*	*Q3 (p. 49)*	*Q4 (p. 49)*	*Q5 (p. 50)*	*Q6 (p. 50)*
Q7 (p. 51)	*Q8 (p. 52)*	*Q9 (p. 52)*	*Q10 (p. 52)*	*Q11 (p. 53)*	*Q12 (p. 53)*
Q13 (p. 53)	*Q14 (p. 54)*	*Q15 (p. 54)*	*Q16 (p. 55)*	*Q17 (p. 55)*	*Q18 (p. 55)*
Q19 (p. 56)	*Q20 (p. 56)*	*Q21 (p. 56)*	*Q22 (p. 57)*	*Q23 (p. 57)*	*Q24 (p. 58)*
Q25 (p. 58)	*Q26 (p. 58)*				

Q1: Which option best characterizes the cellular phenomenon known as anaplasia? (Q879557)

A. Abnormal increase in cell size

B. Loss of cellular differentiation

C. Replacement of one mature cell type with another

D. Physiological increase in cell number

See Answer in Part B → Q1

@Neet_pg_bot

Q2: Bronchial biopsy in a middle-aged chronic smoker shows replacement of columnar epithelium by squamous epithelium. Deficiency of which vitamin can contribute to this metaplastic change? (Q879553)

A. Vitamin K

B. Vitamin E

C. Vitamin D

D. Vitamin A

See Answer in Part B → Q2

@Neet_pg_bot

Q3: Which of the following conditions is associated with metaplastic transformation into connective tissue? (Q879547)

A. Myositis ossificans

B. Squamous metaplasia of bronchi

C. Barrett’s esophagus

D. Chronic gastric reflux

See Answer in Part B → Q3

@Neet_pg_bot

Q4: The image below is the lining epithelium of a middle-aged man who is a chronic smoker. Which of the following is the correct marking? (Q879540)

A. 1. Normal columnar epithelium 2. Squamous metaplasia

B. 1. Columnar metaplasia 2. Normal squamous epithelium

C. 1. Normal squamous epithelium 2. Columnar metaplasia

D. 1. Normal columnar epithelium 2. Normal squamous epithelium

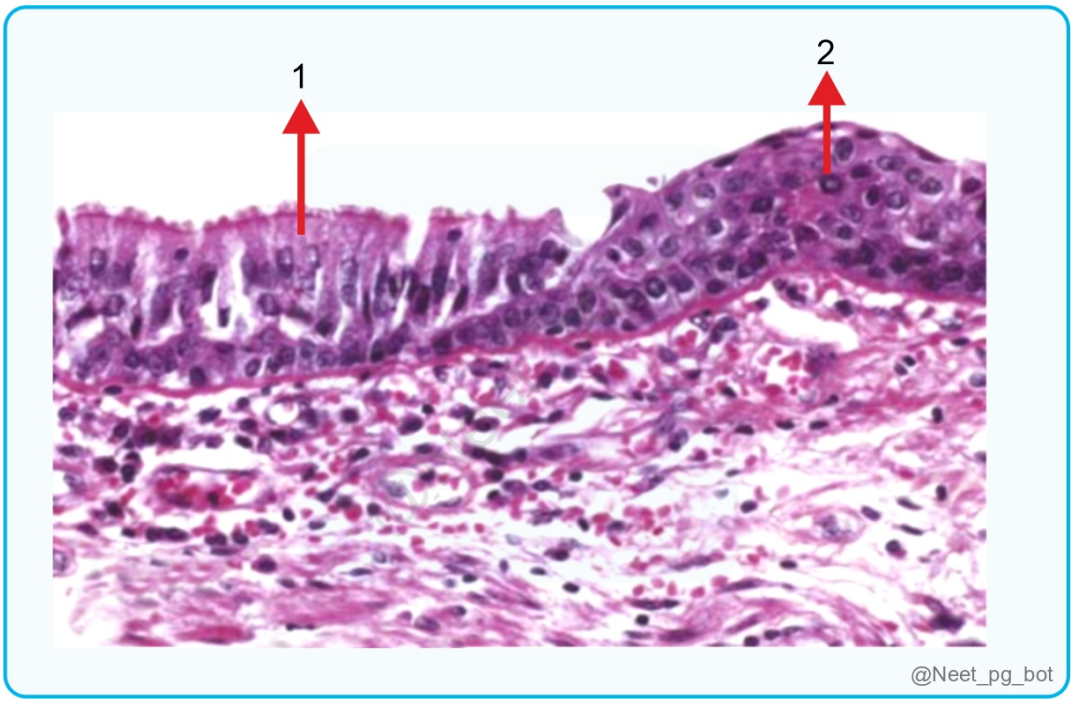

See Answer in Part B → Q4

@Neet_pg_bot

Q5: Which epithelial transformation is encountered most frequently as an example of metaplasia? (Q879538)

A. Replacement of squamous epithelium by columnar epithelium

B. Replacement of squamous epithelium by transitional epithelium

C. Replacement of columnar epithelium by transitional epithelium

D. Replacement of columnar epithelium by squamous epithelium

See Answer in Part B → Q5

@Neet_pg_bot

Q6: Below is the image of a 79-year-old male with a history of long-standing atherosclerosis who presented with progressive cognitive decline and neurological deficits. What type of atrophy is noticed in the image? (Q879536)

A. Nutritional atrophy

B. Neurogenic atrophy

C. Pressure atrophy

D. Ischemic atrophy



See Answer in Part B → Q6

@Neet_pg_bot

Q7: In which of the following scenarios do both physiological hypertrophy and hyperplasia occur? (Q879535)

A. Enlargement of skeletal muscle with exercise

B. Left ventricular thickening in hypertension

C. Uterine growth during pregnancy

D. Enlargement of breast tissue at puberty

See Answer in Part B → Q7

@Neet_pg_bot

Q8: Which of the following organs undergoes only hypertrophy? (Q879516)

A. Breast

B. Heart

C. Liver

D. Uterus

See Answer in Part B → Q8

@Neet_pg_bot

Q9: By which of the following mechanisms does muscle hypertrophy occur? (Q879514)

A. ■-myosin heavy chain is replaced by the ■ form of the myosin heavy chain

B. ■-myosin heavy chain is replaced by the ■ form of the myosin light chain

C. ■-myosin light chain is replaced by the ■ form of the myosin heavy chain

D. ■ form of the myosin light chain is replaced by the ■-myosin heavy chain

See Answer in Part B → Q9

@Neet_pg_bot

Q10: Which of the following statements accurately describes cellular adaptations in response to environmental changes? (Q879512)

A. Hypertrophy refers to an increase in cell number without a change in cell size

B. Hyperplasia is an increase in cell size without an increase in cell number

C. Metaplasia is a reversible change of one differentiated cell type to another

D. Atrophy results from a combination of increased protein synthesis and decreased protein degradation

See Answer in Part B → Q10

@Neet_pg_bot

Q11: A pathology resident is reviewing special stains for detecting tissue deposits. Which of the following stains is not used for demonstrating calcium in histological sections? (Q879411)

A. Congo red

B. Von Kossa stain

C. Alizarin Red S

D. Azan stain

See Answer in Part B → Q11

@Neet_pg_bot

Q12: A 55-year-old man with long-standing hyperlipidemia presents with multiple yellowish nodules over his Achilles tendon and extensor tendons of the hands. Biopsy of one lesion shows foam cells packed with cholesterol and cholesterol esters. Which of the following conditions does this represent? (Q879407)

A. Fabry's disease

B. Xanthoma

C. Niemann-Pick disease type C

D. Strawberry gallbladder

See Answer in Part B → Q12

@Neet_pg_bot

Q13: Which of the following statements regarding metaplasia is true? (Q845260)

A. Metaplasia refers to the abnormal growth of cells, often leading to cancer.

B. It is a reversible change in which one adult cell type is replaced by another adult cell type.

C. Metaplasia is always a pathological process and never occurs in response to normal physiological stimuli.

D. Metaplasia is characterized by the replacement of differentiated cells with undifferentiated stem cells.

See Answer in Part B → Q13

@Neet_pg_bot

Q14: Which of the following statements best describes the role of telomerase in cellular ageing? (Q845194)

A. Telomerase accelerates ageing by reducing the length of telomeres with each cell division

B. Telomerase maintains the constant telomere length in somatic cells throughout their lifespan.

C. Telomerase prevents the shortening of telomeres by adding DNA sequences to the ends of chromosomes, thus potentially extending cell's lifespan.

D. Telomerase is a Ribozyme delaying cell aging.

See Answer in Part B → Q14

@Neet_pg_bot

Q15: Which type of metaplasia characterizes the histological changes observed in Barrett's oesophagus? (Q845257)

A. Transformation of columnar epithelium to squamous epithelium

B. Replacement of squamous epithelium with columnar epithelium containing goblet cells

C. Conversion of glandular epithelium to squamous epithelium

D. Substitution of mesenchymal cells with epithelial cells

See Answer in Part B → Q15

@Neet_pg_bot

Q16: Which type of atrophy is observed in a patient with smaller and weaker muscles who is bedridden for several weeks? (Q845255)

A. Disuse atrophy

B. Neurogenic atrophy

C. Endocrine atrophy

D. Senile atrophy

See Answer in Part B → Q16

@Neet_pg_bot

Q17: Which of the following is an example of physiological atrophy? (Q845254)

A. Testicular atrophy due to hypogonadism

B. Intestinal villi atrophy in malabsorption syndromes

C. Reduction in thymus gland size during ageing

D. Brain atrophy in neurodegenerative diseases

See Answer in Part B → Q17

@Neet_pg_bot

Q18: Which of the following statements about the mechanism of hypertrophy is inaccurate? (Q845250)

A. Activation of G-protein-coupled receptor-initiated pathways

B. Stimulation of growth factor production such as TGF-β and IGF1

C. Inhibition of transcription factors like GATA4, MEF2, NFAT

D. Activation of downstream pathways including the PI3K/AKT pathway

See Answer in Part B → Q18

@Neet_pg_bot

Q19: A 45-year-old female presents with irregular and heavy menstrual bleeding for the past six months. She reports experiencing prolonged periods lasting more than ten days with excessive bleeding, abdominal discomfort, and pelvic pain during her menstrual cycle. On further evaluation, transvaginal ultrasound reveals thickening of the endometrial lining. Endometrial biopsy confirms the presence of abnormal glandular proliferation without cytologic atypia. Which of the following best describes the cellular adaptation observed in this clinical scenario? (Q845248)

A. Physiological hypertrophy

B. Pathological hypertrophy

C. Physiological hyperplasia

D. Pathological hyperplasia

See Answer in Part B → Q19

@Neet_pg_bot

Q20: Which statement accurately distinguishes between hypertrophy and hyperplasia? (Q845245)

A. Hypertrophy involves an increase in cell number, while hyperplasia involves an increase in cell size.

B. Hypertrophy increases tissue mass, while hyperplasia maintains tissue mass.

C. Hypertrophy is irreversible, while hyperplasia is reversible.

D. Hypertrophy results from increased cellular protein production, while hyperplasia involves growth factor-driven proliferation of mature cells.

See Answer in Part B → Q20

@Neet_pg_bot

Q21: Which of the following biomarkers is associated with autophagy? (Q845243)

A. Annexin A1

B. Annexin V

C. Beclin 1

D. LC3

See Answer in Part B → Q21

@Neet_pg_bot

Q22: What is the mechanism by which chaperone-mediated autophagy (CMA) targets misfolded proteins for degradation? (Q845240)

A. Direct uptake by lysosomes via endocytosis

B. Activation of mTOR leading to inhibition of ULK1 complex

C. Selective degradation of damaged or dysfunctional mitochondria

D. Binding of chaperones to misfolded proteins, followed by lysosomal entry via LAMP2A for autophagy

See Answer in Part B → Q22

@Neet_pg_bot

Q23: Which cellular process is primarily responsible for the degradation and recycling of unnecessary or dysfunctional cellular components? (Q845237)

A. Autophagy

B. Necrosis

C. Apoptosis

D. Pyroptosis

See Answer in Part B → Q23

@Neet_pg_bot

Q24: A 36-year-old male presents to the clinic with complaints of bilateral cataracts, short stature, premature greying and loss of hair, and skin changes. He also reports joint stiffness and pain, as well as type 2 diabetes mellitus. On examination, the patient appears older than his stated age, with characteristic "bird-like" facies and a high-pitched voice. Which of the following conditions is most likely to be associated with his presentation? (Q845202)

A. Hutchinson-Gilford Syndrome

B. Werner syndrome

C. Wermer syndrome

D. Cockayne Syndrome

See Answer in Part B → Q24

@Neet_pg_bot

Q25: How do “Sirtuins” contribute to cellular ageing? (Q845198)

A. By accelerating telomere shortening.

B. By enhancing cell repair mechanisms and exerting anti-ageing effects.

C. By functioning as histone acetyltransferases, promoting chromatin condensation.

D. By decreasing insulin sensitivity

See Answer in Part B → Q25

@Neet_pg_bot

Q26: Which of the following statements is correct about the concept of the Hayflick Limit? (Q845196)

A. The ageing of cells is not determined by telomere length.

B. It refers to the age at which cells cease all metabolic activities and undergo apoptosis.

C. A cell typically undergoes 20-40 cell divisions before reaching senescence.

D. It represents the average number of times a cell can divide before experiencing replicative senescence.

See Answer in Part B → Q26

@Neet_pg_bot

• [01_Cell Injury] 004 Intracellular Accumulations

« Back to Folder Directory

[01_Cell Injury] 004 Intracellular Accumulations — Quick Jump

Q1 (p. 60) *Q2 (p. 60)* *Q3 (p. 61)* *Q4 (p. 61)* *Q5 (p. 61)* *Q6 (p. 62)*
Q7 (p. 62) *Q8 (p. 63)* *Q9 (p. 64)* *Q10 (p. 64)* *Q11 (p. 64)* *Q12 (p. 65)*

Q1: Which of the following pathological conditions involves the accumulation of pigments through exogenous sources? (Q845361)

A. Chronic venous insufficiency

B. Vitiligo

C. Obstructive jaundice

D. Coal worker’s pneumoconiosis

See Answer in Part B → Q1

@Neet_pg_bot

Q2: A 83-year-old man presents to his gastroenterologist with complaints of fatigue and discomfort in the upper abdomen. He has a history of hypertension and type 2 diabetes mellitus, for which he takes medications regularly. On physical examination, the liver edge is palpable below the right costal margin, indicating hepatomegaly. Laboratory investigations reveal mildly elevated liver enzymes. Which of the following pigments is most likely responsible for the brown discolouration of the liver observed in this patient? (Q845363)

A. Melanin

B. Glycogen

C. Lipofuscin

D. Bilirubin

See Answer in Part B → Q2

@Neet_pg_bot

Q3: A 45-year-old woman presents with a painless, slow-growing, pigmented lesion on her back with irregular borders and varying shades of brown and black. Excisional biopsy of the lesion is performed, and histopathological examination reveals nests of melanocytes within the dermis, with prominent melanin pigment deposition. Which of the following staining techniques would be most suitable for visualization of the melanin pigment within the melanocytes in this patient's biopsy specimen? (Q845365)

A. Massaon Fontana stain

B. Masson Trichome stain

C. Periodic-Acid-Schiff (PAS) stain

D. Immunohistochemical staining for Melan- A

See Answer in Part B → Q3

@Neet_pg_bot

Q4: A 45-year-old man presents with complaints of fatigue, joint pain, and abdominal discomfort. On examination, he exhibits bronze-coloured skin pigmentation mainly on the face and hands. Laboratory tests reveal elevated serum ferritin levels and transferrin saturation. Which of the following staining techniques would be most appropriate to visualize hemosiderin deposition in tissues in this patient? (Q845368)

A. Perl’s stain

B. Lillie's stain

C. Rhodanine stain

D. Supravital stains

See Answer in Part B → Q4

@Neet_pg_bot

Q5: Which of the following pathological conditions is associated with the 'Tabby cat' effect? (Q845369)

A. Diphtheria myocarditis

B. Xanthomas

C. Cholesterolosis

D. Fatty liver

See Answer in Part B → Q5

@Neet_pg_bot

Q6: Which of the following stains is not typically employed for the detection of lipid accumulation in histological samples? (Q845371)

A. Sudan Black

B. Sudan IV

C. Oil red O

D. Toluidine blue

See Answer in Part B → Q6

@Neet_pg_bot

Q7: A 60-year-old woman presents with bone pain and tenderness over her lower back. Imaging reveals multiple lytic lesions in the vertebral column. Laboratory tests indicate anaemia, elevated serum calcium levels, and monoclonal gammopathy. A bone marrow biopsy confirms plasma cell proliferation. Microscopic examination of the biopsy reveals intracellular inclusions, as shown in the image. What is the composition of the intracellular inclusions marked in the image? {{caption_text}} (Q845373)

A. Aggregates of misfolded proteins

B. Clusters of ribosomes

C. Accumulations of immunoglobulins

D. Vacuoles containing lipids

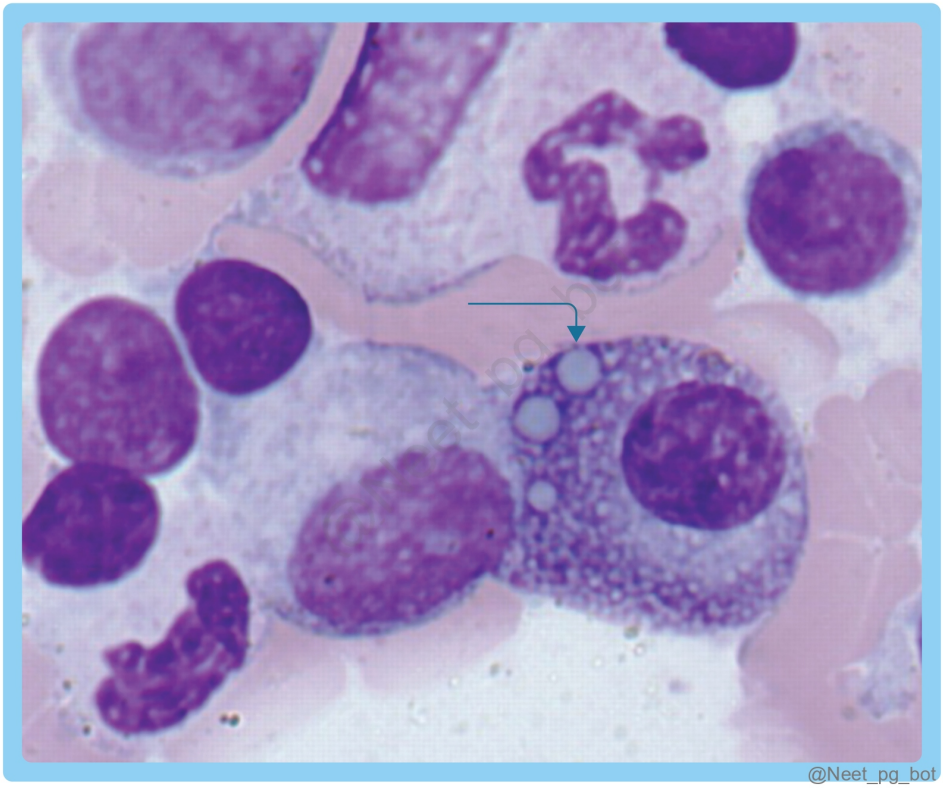

See Answer in Part B → Q7

@Neet_pg_bot

Q8: Following the resection of the pituitary adenoma in a patient with Cushing's disease, which intracellular change is most likely in residual adenoma cells? (Q845374)

A. Mallory-Denk bodies

B. Lewy bodies

C. Crooke hyaline change

D. Civatte bodies

See Answer in Part B → Q8

@Neet_pg_bot

Q9: Which of the following stains would be most appropriate for visualizing glycogen deposits? (Q845375)

A. Hematoxylin and eosin (H&E) stain

B. Periodic acid-Schiff (PAS) stain

C. Masson's trichrome stain

D. Oil Red O stain

See Answer in Part B → Q9

@Neet_pg_bot

Q10: Which of the following statements is incorrect about dystrophic calcification? (Q845376)

A. It occurs in damaged or necrotic tissues.

B. It is characterized by the deposition of calcium salts in normal tissues.

C. It is often seen in areas of chronic inflammation.

D. Serum calcium levels are normal

See Answer in Part B → Q10

@Neet_pg_bot

Q11: Which of the following case scenarios is not indicative of metastatic calcification? (Q845378)

A. A 60-year-old male with a history of chronic renal failure presented with shortness of breath and bilateral lung opacities on chest X-ray.

B. A 45-year-old female with spinal tuberculosis complained of back pain.

C. A 30-year-old male with a long-standing history of heavy milk and calcium carbonate intake now experiencing recurrent kidney stones.

D. A 55-year-old female with sarcoidosis demonstrated elevated levels of serum vitamin D and calcium.

See Answer in Part B → Q11

@Neet_pg_bot

Q12: Which staining technique is commonly used to visualize calcium deposits in tissues and is particularly useful for detecting minute amounts of calcium? (Q845380)

A. Masson's trichrome stain

B. Prussian blue stain

C. Alizarin Red S stain

D. Wright-Giemsa stain

See Answer in Part B → Q12

@Neet_pg_bot

• [01_Cell Injury] 005 Previous Year Questions

« Back to Folder Directory

[01_Cell Injury] 005 Previous Year Questions — Quick Jump

Q1 (p. 66)	*Q2 (p. 66)*	*Q3 (p. 67)*	*Q4 (p. 67)*	*Q5 (p. 67)*	*Q6 (p. 68)*
Q7 (p. 68)	*Q8 (p. 69)*	*Q9 (p. 69)*	*Q10 (p. 70)*	*Q11 (p. 70)*	*Q12 (p. 70)*
Q13 (p. 71)	*Q14 (p. 72)*	*Q15 (p. 72)*	*Q16 (p. 72)*	*Q17 (p. 73)*	*Q18 (p. 73)*
Q19 (p. 74)	*Q20 (p. 74)*	*Q21 (p. 74)*	*Q22 (p. 75)*	*Q23 (p. 75)*	*Q24 (p. 75)*
Q25 (p. 76)					

Q1: Identify the correct statements regarding amyloidosis. Amyloidosis is called so because it looks like the deposition of starch. Beta-pleated sheets are seen. AL is a type of secondary amyloidosis. It is an extracellular protein. (Q857424)

A. 1, 2 and 3

B. 1, 4

C. 2, 3 and 4

D. 1, 2 and 4

See Answer in Part B → Q1

@Neet_pg_bot

Q2: A diabetic male presented with seizures. Radiological examination shows a lesion. Histopathological examination shows liquefactive necrosis. What is the most important mechanism responsible for this? (Q866754)

A. Enzymatic degradation

B. Mechanical

C. Ischemic

D. Pressure

See Answer in Part B → Q2

@Neet_pg_bot

Q3: Which of the following is pro-apoptotic? (Q866665)

A. Bcl-2

B. Bcl-xL

C. Mcl-1

D. Bax

See Answer in Part B → Q3

@Neet_pg_bot

Q4: Which of the following types of cell death involves activation of caspase enzymes? (Q866340)

A. Necrosis and Apoptosis

B. Apoptosis and Pyroptosis

C. Apoptosis and necroptosis

D. Apoptosis only

See Answer in Part B → Q4

@Neet_pg_bot

Q5: Caspase-1 is primarily involved in which type of programmed cell death? (Q865391)

A. Apoptosis

B. Pyroptosis

C. Necroptosis

D. Necrosis

See Answer in Part B → Q5

@Neet_pg_bot

Q6: Apoptotic bodies comprise of? (Q860513)

A. Include cytoplasm + intranuclear material + organelle

B. Cytoplasm + organelle

C. Organelle + intranuclear material

D. Only organelle

See Answer in Part B → Q6

@Neet_pg_bot

Q7: The body of an 82-year-old man has been seen for a post-mortem to determine the cause of death. You are examining a histopathological slide containing a section of his cardiac tissue where you notice some pigmentation. Which is the substance that is seen in the image given below? (Q859859)

A. Melanin

B. Lipofuscin

C. Hemosiderin

D. Iron

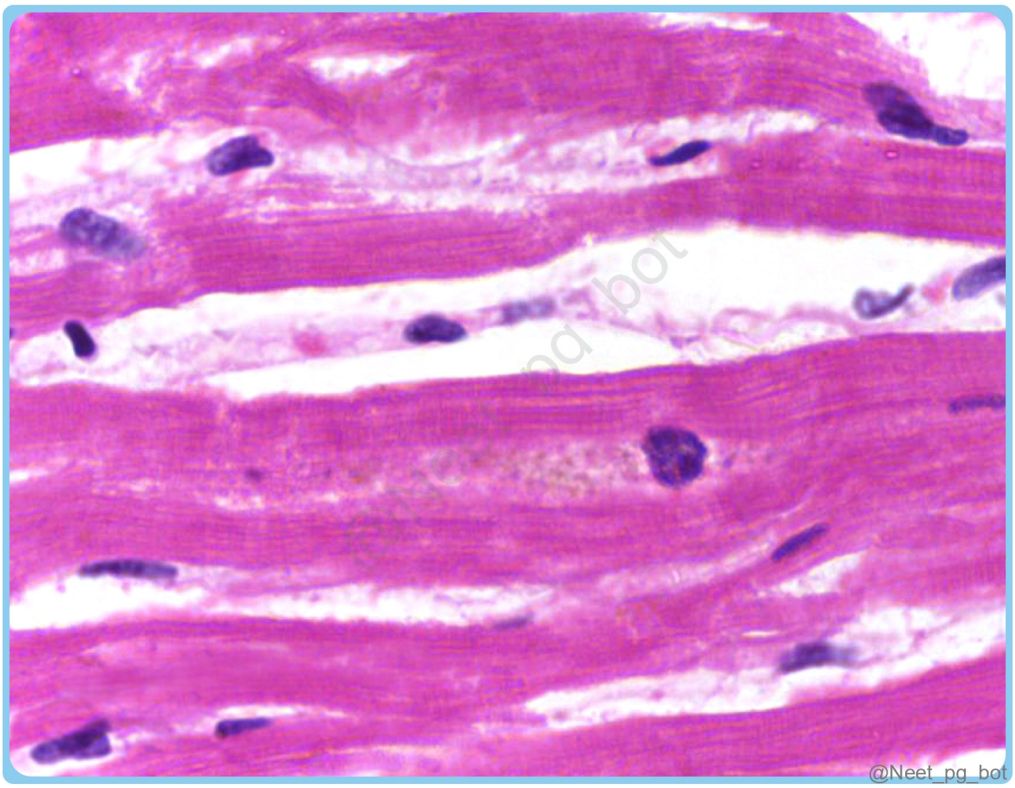

See Answer in Part B → Q7

@Neet_pg_bot

Q8: Among the following, which molecule is required for the presentation of the antigens by the APCs to TH2 cells? (Q859298)

A. NK cells

B. G-protein coupled receptor

C. MHC

D. Lectin receptor

See Answer in Part B → Q8

@Neet_pg_bot

Q9: Supravital stains are used in the identification of all except? (Q857588)

A. Reticulocytes

B. Copper in tissue

C. Heinz bodies

D. Ribosomal RNA

See Answer in Part B → Q9

@Neet_pg_bot

Q10: Which of the following is an anti-apoptotic gene? (Q857450)

A. BAK

B. MCL1

C. PUMA

D. BAD

See Answer in Part B → Q10

@Neet_pg_bot

Q11: Which of the following diseases is caused by abnormal folding of proteins? (Q857433)

A. Creutzfelt Jakob disease

B. Cirrhosis

C. Nephritic syndrome

D. Sickle cell anemia

See Answer in Part B → Q11

@Neet_pg_bot

Q12: Which nuclear change of cell injury is being shown in the image? (Q857432)

A. Pyknosis

B. Karyorrhexis

C. Karyolysis

D. Normal nucleus



See Answer in Part B → Q12

@Neet_pg_bot

Q13: A 24-year-old male was brought to the emergency department after suffering severe injuries in a motorcycle accident. His blood pressure was 80/60 mm Hg, and he was tachycardic with cold, clammy skin. An ultrasound examination revealed a ruptured spleen. Arterial blood gas analysis was suggestive of metabolic acidosis. Which of the following conditions most likely caused the patient to suffer? (Q857122)

A. Cardiogenic shock

B. Septic shock

C. Hypovolemic shock

D. Neurogenic shock

See Answer in Part B → Q13

@Neet_pg_bot

Q14: All of the following are crosslinking fixatives except? (Q856893)

A. Glutaraldehyde

B. Formaldehyde

C. Methanol

D. Osmium tetroxide

See Answer in Part B → Q14

@Neet_pg_bot

Q15: Which of the following caspases binds to Cyt c and the APAF-1 complex? (Q856488)

A. Caspase 1

B. Caspase 8

C. Caspase 9

D. Caspase 4

See Answer in Part B → Q15

@Neet_pg_bot

Q16: A chronic alcoholic patient presented with increasing abdominal girth. On examination, shifting dullness was present, and the liver span was less than 7cm.

Histopathological examination revealed the presence of intracytoplasmic eosinophilic inclusions in hepatocytes. What is the content of these inclusions? (Q856152)

A. Intermediate filaments

B. Actin

C. Microtubules

D. Fibronectin

See Answer in Part B → Q16

@Neet_pg_bot

Q17: A 70-year-old patient presented with cough, fatigue, and weight loss. He was diagnosed with squamous cell carcinoma on bronchoscopy. The resected specimen had a hilar lymph node that was 1 cm in size and showed a black pigment. What is the black pigment likely to be? (Q856097)

A. Anthracotic pigment

B. Melanin

C. Lipochrome

D. Hemosiderin

See Answer in Part B → Q17

@Neet_pg_bot

Q18: Senile atrophy occurs due to which of the following? (Q856024)

A. Denervation

B. Decreased nutrition

C. Decreased workload

D. Reduced blood supply

See Answer in Part B → Q18

@Neet_pg_bot

Q19: Which of the following measures is associated with an increased life span? (Q855961)

A. Regular moderate exercise for 30 min

B. Decrease stress

C. Decreasing calorie intake by 30%

D. Pharmacological intervention with proton pump inhibitors

See Answer in Part B → Q19

@Neet_pg_bot

Q20: Choose the correct statement regarding the telomerase theory of ageing: (Q855914)

A. Telomere stability is associated with ageing

B. Abnormal telomerase activation is associated with ageing

C. Decreased telomere length is associated with ageing

D. Increased telomere length is associated with ageing

See Answer in Part B → Q20

@Neet_pg_bot

Q21: Which of the following is true regarding sirtuins? Increases insulin sensitivity and glucose metabolism Promotes genes that increase longevity They are of 7 types They are one of the types of histone deacetylases (Q855087)

A. 1, 2, 3

B. 1, 2, 3, 4

C. 2, 3

D. 2, 4

See Answer in Part B → Q21

@Neet_pg_bot

Q22: Cell-in-cell appearance is seen in which of the following? (Q855076)

A. Necrosis

B. Apoptosis

C. Necroptosis

D. Entosis

See Answer in Part B → Q22

@Neet_pg_bot

Q23: Which among the following is less related to irreversible cell injury? (Q820573)

A. Blebs formation

B. Karyolysis

C. Amorphous densities

D. Pyknotic nucleus

See Answer in Part B → Q23

@Neet_pg_bot

Q24: Metastatic calcification occurs in all except ? (Q793597)

A. Kidney

B. Fundus of the stomach

C. Pulmonary veins

D. Atheroma

See Answer in Part B → Q24

@Neet_pg_bot

Q25: Which of the following are features describing necrosis? Cell swelling Disrupted cell membrane Induces inflammation Physiological (Q857443)

A. 1 and 2

B. 1, 2 and 4

C. 1, 2 and 3

D. 1 and 3

See Answer in Part B → Q25

@Neet_pg_bot

• [02_Inflammation] 006 Acute Inflammation

« Back to Folder Directory

[02_Inflammation] 006 Acute Inflammation — Quick Jump

Q1 (p. 77)	*Q2 (p. 78)*	*Q3 (p. 78)*	*Q4 (p. 79)*	*Q5 (p. 79)*	*Q6 (p. 80)*
Q7 (p. 80)	*Q8 (p. 80)*	*Q9 (p. 81)*	*Q10 (p. 81)*	*Q11 (p. 82)*	*Q12 (p. 82)*
Q13 (p. 82)	*Q14 (p. 83)*	*Q15 (p. 83)*	*Q16 (p. 84)*	*Q17 (p. 84)*	*Q18 (p. 84)*
Q19 (p. 85)	*Q20 (p. 85)*	*Q21 (p. 86)*	*Q22 (p. 86)*	*Q23 (p. 86)*	*Q24 (p. 87)*
Q25 (p. 87)	*Q26 (p. 88)*				

Q1: A 42-year-old man comes with swelling of both ankles. On examination, pitting oedema is noted. Which of the following alterations in Starling forces could contribute to the development of this condition? Increased capillary hydrostatic pressure Decreased capillary hydrostatic pressure Increased plasma oncotic pressure Decreased plasma oncotic pressure (Q879471)

A. 1 and 3

B. 2 and 3

C. 1 and 4

D. 2 and 4

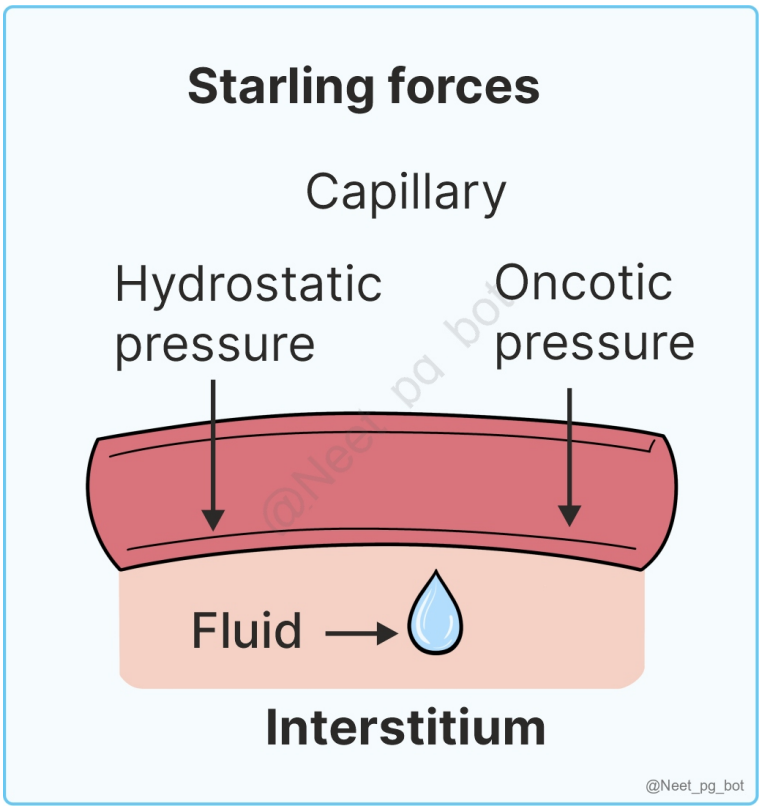

See Answer in Part B → Q1

@Neet_pg_bot

Q2: Which of the following inflammatory cells contains granules rich in major basic protein, toxic to helminths? (Q879443)

A. Neutrophils

B. Eosinophils

C. Basophils

D. Macrophages

See Answer in Part B → Q2

@Neet_pg_bot

Q3: A child presents with recurrent pyogenic infections, partial oculocutaneous albinism, and peripheral neuropathy. Which immunodeficiency is most likely due to defective phagolysosome fusion? (Q879442)

A. Chronic granulomatous disease

B. Chediak-Higashi syndrome

C. Mannose-binding lectin deficiency

D. Glanzmann-Rinicker syndrome

See Answer in Part B → Q3

@Neet_pg_bot

Q4: Which of the following enzymes/proteins is not involved in neutralizing reactive oxygen species? (Q879440)

A. Myeloperoxidase

B. Ceruloplasmin

C. Catalase

D. Glutathione peroxidase

See Answer in Part B → Q4

@Neet_pg_bot

Q5: Which infection is characteristically associated with prolonged neutrophilic infiltration at the site of inflammation, even after 2–3 days? (Q879436)

A. Pseudomonas

B. Staphylococcus

C. Fungal infection

D. Viral infection

See Answer in Part B → Q5

@Neet_pg_bot

Q6: A 40-year-old woman develops acute pyelonephritis. Within the first 2 days of infection, she experiences high fever, flank pain, and dysuria. Urine microscopy reveals abundant pus cells. Which cell type is the main mediator of tissue damage in this stage of inflammation? (Q879435)

A. Neutrophils

B. Eosinophils

C. Macrophages

D. Plasma cells

See Answer in Part B → Q6

@Neet_pg_bot

Q7: Which of the following adhesion molecules does not serve as a ligand for integrins during leukocyte adhesion? (Q879419)

A. CD54 (ICAM-1)

B. CD102 (ICAM-2)

C. CD106 (VCAM-1)

D. CD34

See Answer in Part B → Q7

@Neet_pg_bot

Q8: Which of the following statements regarding selectins are correct? They mediate the initial rolling of leukocytes on the endothelium There are three main types: L-selectin, E-selectin, and P-selectin P-selectin is expressed on endothelial cells and

platelets Selectins mediate firm, high-affinity adhesion of leukocytes (Q879417)

A. 1 and 2 only

B. 1, 2 and 3

C. 2, 3 and 4

D. 1 and 4 only

See Answer in Part B → Q8

@Neet_pg_bot

Q9: During normal laminar blood flow in venules, the phenomenon of axial streaming determines the distribution of blood cells. Which cells predominantly occupy the central axial column? (Q879414)

A. Red blood cells

B. Neutrophils

C. Platelets

D. Lymphocytes

See Answer in Part B → Q9

@Neet_pg_bot

Q10: A 30-year-old female presents to the clinic with complaints of abdominal discomfort and bloating. Upon further evaluation, an abdominal ultrasound reveals a heterogeneous mass within the right ovary. Subsequent histopathological examination of the ovarian mass demonstrates the presence of entotic cells. Which of the following best describes the process observed in the histopathological findings? (Q845364)

A. Phagocytosis of apoptotic cells by neighboring cells

B. Engulfment of live cells by neighboring cells

C. Fusion of lysosomes within a cell leading to autophagy

D. Exocytosis of cellular debris from a damaged cell

See Answer in Part B → Q10

@Neet_pg_bot

Q11: A 6-month-old male infant presents with recurrent bacterial infections, including otitis media and pneumonia. Laboratory investigations reveal markedly reduced levels of all immunoglobulin classes (IgG, IgA, and IgM). Flow cytometry analysis shows a complete absence of mature B cells in peripheral blood. Which of the following gene mutations is most likely responsible for this condition? (Q845372)

A. BTK gene

B. LYST gene

C. WASP gene

D. ADA gene

See Answer in Part B → Q11

@Neet_pg_bot

Q12: Which of the following defects is most likely associated with Leukocyte Adhesion Deficiency Type 1 (LAD)-1? (Q845370)

A. Defective synthesis of β2 integrin

B. Defective synthesis of Sialyl Lewis X modified glycoprotein

C. Defective FERMT3 gene

D. Myeloperoxidase deficiency

See Answer in Part B → Q12

@Neet_pg_bot

Q13: Which condition is characterized by recurrent catalase positive bacterial, and fungal infections, defective nitroblue tetrazolium (NBT) test results, and deficient reactive oxygen species production by phagocytes? (Q845366)

A. Leukocyte Adhesion Deficiency

B. Hyper-IgM Syndrome

C. X-linked Agammaglobulinemia

D. Chronic Granulomatous Disease

See Answer in Part B → Q13

@Neet_pg_bot

Q14: Which among the following is a cardinal sign of inflammation? (Q845313)

A. Prolonged fever

B. Tissue scarring

C. Abrasions

D. Redness

See Answer in Part B → Q14

@Neet_pg_bot

Q15: Which of the following statements is incorrect regarding Emperipolesis and Phagocytosis? (Q845362)

A. Emperipolesis involves engulfment by any cell depending on disease; Phagocytosis involves engulfment by macrophages, neutrophils, and dendritic cells.

B. Emperipolesis doesn’t involve the killing of the cell; phagocytosis results in the degradation of engulfed cells.

C. Emperipolesis maintains internalized cell membrane integrity; Phagocytosis involves the fusion of engulfed material with lysosomes.

D. Emperipolesis is physiological; phagocytosis is pathological.

See Answer in Part B → Q15

@Neet_pg_bot

Q16: A 45-year-old male complains of painless bilateral cervical lymphadenopathy for the past six months. Biopsy of a lymph node reveals sheets of large histiocytes with emperipolesis, surrounded by lymphocytes and plasma cells. What is the most likely diagnosis? (Q845360)

A. Hodgkin lymphoma

B. Sarcoidosis

C. Infectious mononucleosis

D. Rosai-Dorfman disease

See Answer in Part B → Q16

@Neet_pg_bot

Q17: Which of the following statements regarding neutrophil extracellular traps (NETs) is incorrect? (Q845359)

A. NETs are formed in response to infectious pathogens and inflammatory mediators.

B. NETs consist of nuclear chromatin and granule proteins like antimicrobial peptides and enzymes.

C. NET formation is initiated by the release of histones from activated neutrophils.

D. NETs directly phagocytose the invading pathogens.

See Answer in Part B → Q17

@Neet_pg_bot

Q18: A 40-year-old male presents with recurrent bacterial infections. Laboratory tests reveal reduced opsonization activity in his serum. Which of the following processes is primarily affected in this patient? (Q845356)

A. Complement activation

B. Diapedesis

C. Microbial engulfment

D. Leucocyte rolling.

See Answer in Part B → Q18

@Neet_pg_bot

Q19: A 45-year-old man with a history of poorly controlled diabetes presents to the hospital with complaints of fever, productive cough, and chest pain. Chest imaging reveals the presence of multiple cavitary lesions in the lung parenchyma. Microscopic examination of lung tissue obtained via biopsy demonstrates numerous neutrophils and macrophages surrounding fungal hyphae. Which of the following phenomena is most likely associated with the formation of these cavitary lesions? (Q845347)

A. Activation of complement proteins

B. Release of lysozymes from neutrophils

C. Impaired phagocytosis

D. Formation of neutrophil extracellular traps (NETs)

See Answer in Part B → Q19

@Neet_pg_bot

Q20: Which of the following plays a crucial role in mediating firm adhesion of leukocytes during acute inflammation? (Q845345)

A. CD11a/CD18

B. PECAM 1

C. CD31

D. CD44

See Answer in Part B → Q20

@Neet_pg_bot

Q21: A patient presents with fluid accumulation in the pleural cavity. Which of the following characteristics would be consistent with a diagnosis of exudate rather than a transudate? (Q845336)

A. High LDH

B. Low protein concentration

C. Presence of mainly albumin

D. Low specific gravity

See Answer in Part B → Q21

@Neet_pg_bot

Q22: Which of the following is considered the hallmark event of acute inflammation? (Q845332)

A. Vasodilation

B. Increased vascular permeability

C. Stasis

D. Leukocyte extravasation

See Answer in Part B → Q22

@Neet_pg_bot

Q23: Which of the following mechanisms primarily contributed to the increased vascular permeability in this patient's with a right knee injury after fall from stairs? (Q845326)

A. Contraction of endothelial cells resulting in the opening of interendothelial gaps

B. Direct damage to endothelial cells

C. Neutrophil-mediated injury to the endothelium

D. Proliferation of lymphatic vessels

See Answer in Part B → Q23

@Neet_pg_bot

Q24: A 30-year-old male presents to the emergency department with sudden onset right lower abdominal pain, accompanied by nausea and fever. On examination, there is tenderness over McBurney's point, and rebound tenderness is noted. Laboratory investigations reveal leukocytosis. Which type of inflammation is most likely to be associated with the following clinical scenario? (Q845322)

A. Serous inflammation

B. Fibrinous inflammation

C. Purulent inflammation

D. Ulcerative inflammation

See Answer in Part B → Q24

@Neet_pg_bot

Q25: Which of the following features is a characteristic of acute inflammation? (Q845319)

A. Presence of granulomas

B. Proliferation of fibroblasts and angiogenesis

C. The predominance of lymphocytes in the inflammatory infiltrate

D. Accumulation of neutrophils at the site of injury

See Answer in Part B → Q25

@Neet_pg_bot

Q26: A 30-year-old female presents with a history of recent major surgery, deep vein thrombosis (DVT) in the lower extremities, and a family history of thrombotic events. Which of the following components constitute Virchow's triad, predisposing individuals to thrombosis? (Q845316)

A. Endothelial injury, hypercoagulability, and venous stasis

B. Endothelial dysfunction, leukocytosis, and platelet activation

C. Arterial dilation, decreased platelet count, and fibrinolysis

D. Hypothermia, acidosis, and coagulopathy

See Answer in Part B → Q26

@Neet_pg_bot

• [02_Inflammation] 007 Chronic Inflammation

« Back to Folder Directory

[02_Inflammation] 007 Chronic Inflammation — Quick Jump

Q1 (p. 89)	*Q2 (p. 89)*	*Q3 (p. 90)*	*Q4 (p. 90)*	*Q5 (p. 90)*	*Q6 (p. 91)*
Q7 (p. 92)	*Q8 (p. 92)*	*Q9 (p. 92)*	*Q10 (p. 93)*	*Q11 (p. 93)*	*Q12 (p. 94)*
Q13 (p. 94)	*Q14 (p. 95)*	*Q15 (p. 96)*	*Q16 (p. 97)*	*Q17 (p. 97)*	

Q1: A 50-year-old man developed a small purulent abscess on his shoulder. After appropriate drainage and infection control measures, the wound healed well, leaving a healthy scar. During the early stages of tissue repair, which type of collagen predominates in the provisional matrix? (Q879470)

A. Type I

B. Type II

C. Type III

D. Type IV

See Answer in Part B → Q1

@Neet_pg_bot

Q2: A 45-year-old woman undergoes excision of a sebaceous cyst with primary closure of the wound. During the healing process, angiogenesis is initiated early but reaches its maximum on which postoperative day? (Q879468)

A. Day 4

B. Day 3

C. Day 5

D. Day 7

See Answer in Part B → Q2

@Neet_pg_bot

Q3: During healing by primary intention, the initial acute inflammatory response is dominated by neutrophils. On which postoperative day do macrophages typically replace neutrophils as the predominant inflammatory cells at the wound site? (Q879467)

A. Day 1

B. Day 2

C. Day 3

D. Day 7

See Answer in Part B → Q3

@Neet_pg_bot

Q4: Which of the following is NOT true regarding the actions of Transforming Growth Factor Beta (TGF-β)? (Q879464)

A. TGF-β promotes collagen synthesis by fibroblasts

B. TGF-β enhances the breakdown of extracellular matrix proteins

C. TGF-β contributes to tissue fibrosis in organs

D. TGF-β has anti-inflammatory properties

See Answer in Part B → Q4

@Neet_pg_bot

Q5: Which of the following diseases are typically associated with non-caseating granulomas? (Q879462)

A. Leprosy, Sarcoidosis, and Crohn’s disease

B. Tuberculosis and Syphilis

C. Cat-scratch disease only

D. All of the above

See Answer in Part B → Q5

@Neet_pg_bot

Q6: A 30-year-old man presents to the clinic with a raised scar on his chest. He reports that the scar has been gradually increasing in size since he had a minor injury in that area about a year ago. On examination, the scar extends beyond the original wound margins and appears firm and raised. Which of the following is the most likely diagnosis for the scar on the patient's chest? {{caption_text}} (Q845432)

A. Hypertrophic scar

B. Keloid

C. Exuberant granulation tissue

D. Contracture

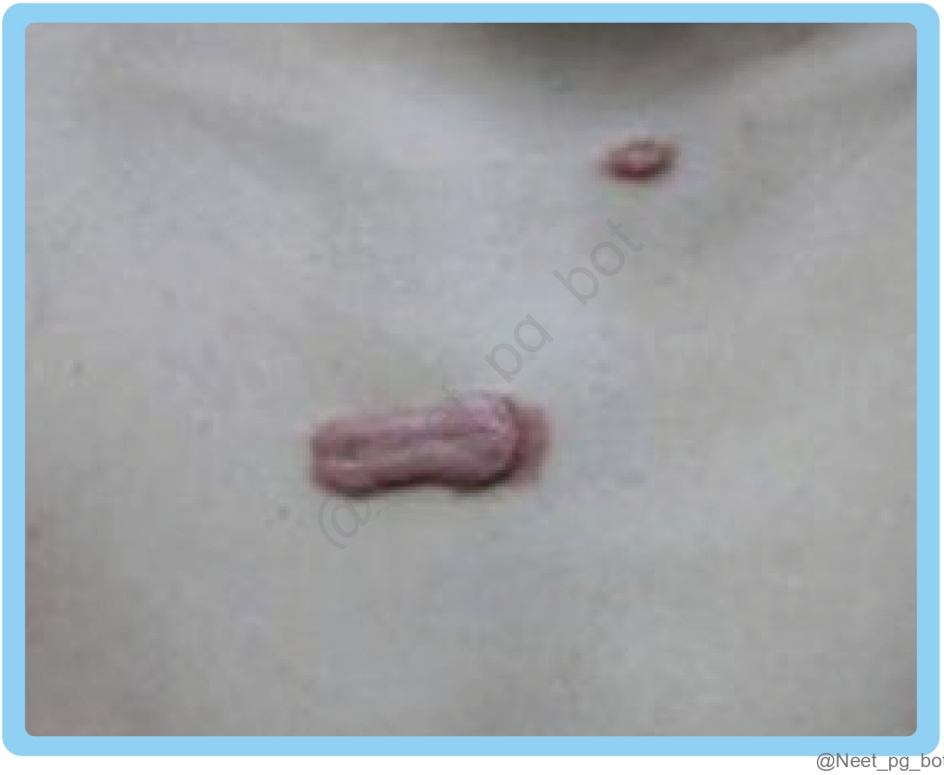

@Neet_pg_bot

See Answer in Part B → Q6

@Neet_pg_bot

Q7: Which of the following statements regarding wound healing is true? (Q847861)

A. The wound regains 20% of its normal strength by 1 week.

B. The wound regains 70-80% of its normal strength by 12 weeks.

C. The wound regains its original strength eventually.

D. The initial collagen formed in the process of wound healing is Type-1 collagen.

See Answer in Part B → Q7

@Neet_pg_bot

Q8: A 55-year-old man undergoes a minor surgical procedure to remove a small skin lesion from his forearm, and the wound is meticulously closed with sutures. Three days after the surgery, he comes to the OPD for review. Which event of the wound healing process is typically observed in this patient? (Q845437)

A. Platelet and fibrin clot formation

B. Neutrophils start to accumulate

C. Replacement of neutrophils by macrophages

D. Collagen bridging initiation

See Answer in Part B → Q8

@Neet_pg_bot

Q9: Which of the following cell types is classified as stable cells in terms of their proliferative capacity and turnover rate? (Q845435)

A. Neurons in the brain

B. Hematopoietic cells in bone marrow

C. Stratified squamous epithelia of the skin

D. Endothelial cells in blood vessels

See Answer in Part B → Q9

@Neet_pg_bot

Q10: Match the following tissue macrophages with respective organs: 1. Kupffer cells a) liver 2. Dust cells b) spleen 3. Hofbauer cells c) lung 4. Littoral cells d) placenta 5. Mesangial cells e) kidney (Q845403)

A. 1-b, 2-a, 3-d, 4-e, 5-c

B. 1-a, 2-c, 3-d, 4-b, 5-e

C. 1-a, 2-d, 3-e, 4-b, 5-c

D. 1-c, 2-e, 3-b, 4-d, 5-a

See Answer in Part B → Q10

@Neet_pg_bot

Q11: A 45-year-old woman undergoes a routine elective surgery for the removal of a benign skin lesion on her forearm. The procedure involves making a small incision, excising the lesion, and closing the wound with sutures. Which of the following statements accurately describes wound healing by primary intention in this scenario? (Q845430)

A. Myofibroblasts play a significant role in wound contraction.

B. The wound is associated with large tissue deficits.

C. Granulation tissue formation is extensive.

D. The wound is expected to heal with minimal inflammatory response.

See Answer in Part B → Q11

@Neet_pg_bot

Q12: A 45-year-old male presents with a persistent subcutaneous nodule on his forearm. Biopsy reveals the presence of multinucleated giant cells within the lesion, as shown in the accompanying HPE image. Further analysis indicates a central zone of lipid-laden macrophages surrounded by a wreath-like arrangement of nuclei. Which type of giant cell is most likely to be observed in this scenario? {{caption_text}} (Q845424)

A. Touton giant cells

B. Reed-Sternberg Cells

C. Warthin-Finkeldey giant cells

D. Foreign body giant cells

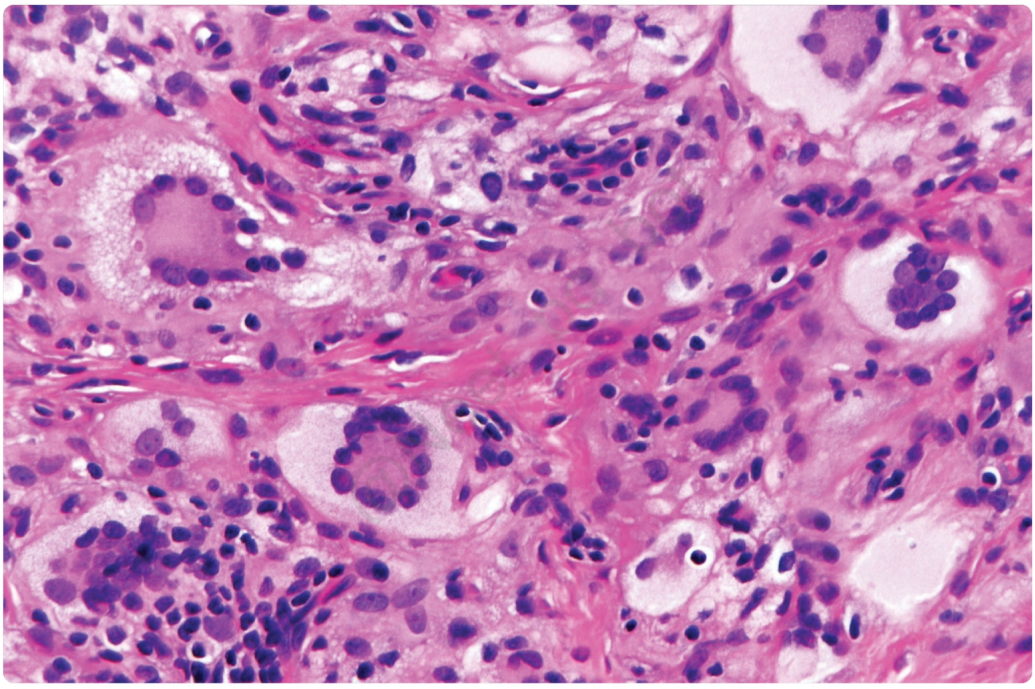

@Neet_pg_bot

See Answer in Part B → Q12

@Neet_pg_bot

Q13: Which of the following is not a physiological giant cell? (Q845413)

A. Osteoclast

B. Syncytiotrophoblast

C. Megakaryocytes

D. Langhans cells

See Answer in Part B → Q13

@Neet_pg_bot

Q14: A 40-year-old woman presents with a persistent dry cough, shortness of breath, and bilateral enlargement of the lymph nodes in her chest, incidentally detected on a routine chest X-ray given below. Physical examination reveals fine crackles in her lung bases. Pulmonary function tests show reduced lung volumes and a decreased diffusion capacity for carbon monoxide. Which type of granuloma is commonly associated with the histopathological findings in this patient? {{caption_text}} (Q845412)

A. Naked granuloma

B. Stellate granuloma

C. Eosinophilic granuloma

D. Durck granuloma

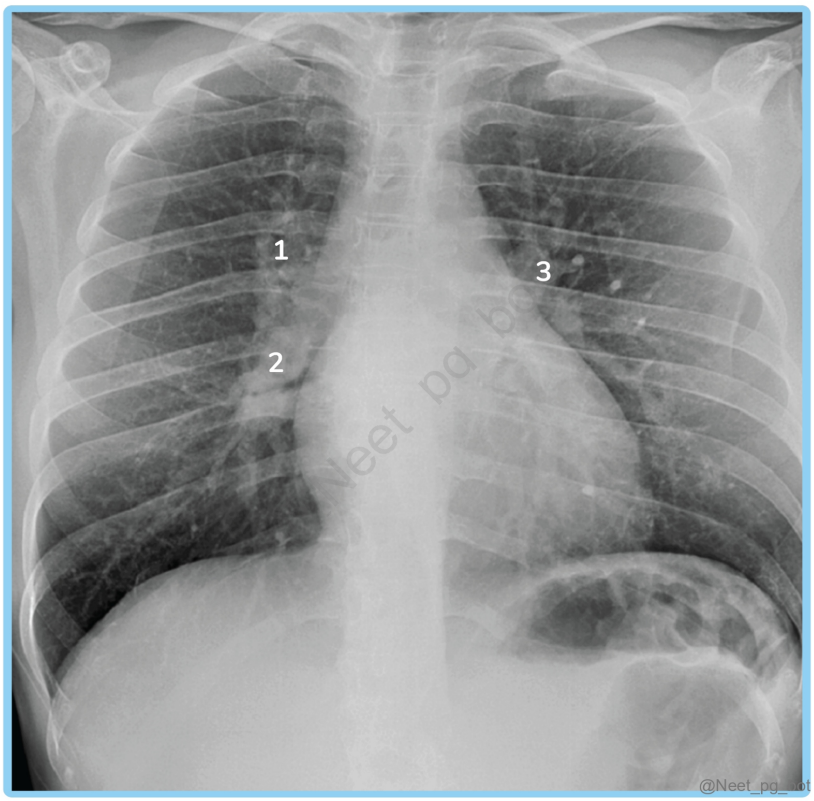

See Answer in Part B → Q14

@Neet_pg_bot

Q15: Which sequence accurately identifies lymphocytes, epithelioid cells, Langhans giant cells, and caseous necrosis in the image given below? (Q845410)

A. b, d, a, c

B. d, b, a, c

C. d, b, c, a

D. b, d, c, a

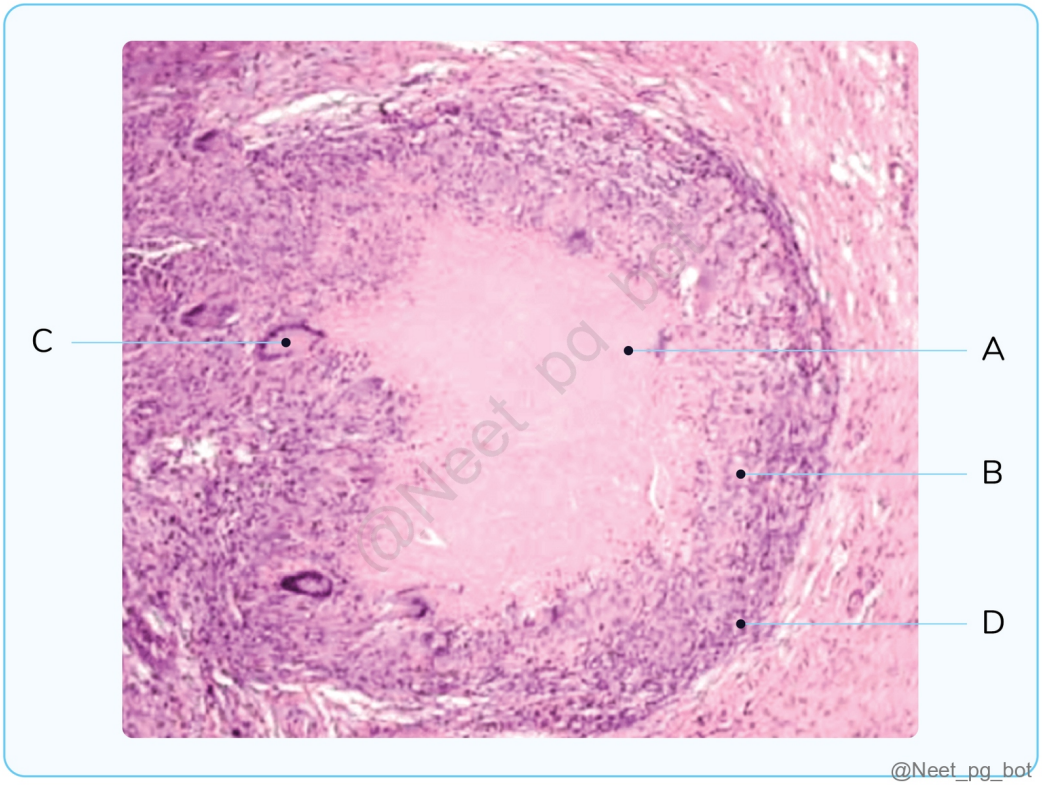

See Answer in Part B → Q15

@Neet_pg_bot

Q16: Which of the following statements about granulomas is incorrect? (Q845408)

A. Granuloma formation is a Type IV hypersensitivity reaction

B. IFN-gamma is an important cytokine involved in this process

C. CD8+ is the type of T lymphocytes involved in this process

D. Epitheloid cells in granuloma are modified macrophages

See Answer in Part B → Q16

@Neet_pg_bot

Q17: Which type of macrophages predominantly contributes to tissue repair and resolution of inflammation in patients with chronic obstructive pulmonary disease

complicated by pneumonia? (Q845406)

A. M1 macrophages

B. M2 macrophages

C. Both M1 and M2 macrophages

D. Resting macrophages

See Answer in Part B → Q17

@Neet_pg_bot

• [02_Inflammation] 008 Mediators Of Inflammation

« Back to Folder Directory

[02_Inflammation] 008 Mediators Of Inflammation — Quick Jump

Q1 (p. 99)	*Q2 (p. 99)*	*Q3 (p. 100)*	*Q4 (p. 100)*	*Q5 (p. 100)*	*Q6 (p. 101)*
Q7 (p. 101)	*Q8 (p. 102)*	*Q9 (p. 102)*	*Q10 (p. 102)*	*Q11 (p. 103)*	*Q12 (p. 103)*
Q13 (p. 103)	*Q14 (p. 104)*	*Q15 (p. 104)*	*Q16 (p. 105)*	*Q17 (p. 105)*	*Q18 (p. 105)*
Q19 (p. 106)	*Q20 (p. 106)*	*Q21 (p. 107)*	*Q22 (p. 107)*	*Q23 (p. 107)*	*Q24 (p. 108)*
Q25 (p. 108)	*Q26 (p. 109)*				

Q1: In some chronic inflammatory reactions, organized lymphoid follicles resembling lymph nodes may form. These are called tertiary lymphoid structures. Which of the following conditions may show these structures? (Q879461)

A. Synovium in long-standing rheumatoid arthritis

B. Thyroid in Hashimoto thyroiditis

C. Infiltrates around some tumors

D. All of the above

See Answer in Part B → Q1

@Neet_pg_bot

Q2: Which of the following mediators is not primarily involved in producing fever during inflammation? (Q879460)

A. IL-1

B. Prostaglandins

C. TNF

D. Histamine

See Answer in Part B → Q2

@Neet_pg_bot

Q3: Which of the following inflammatory mediators are correctly matched with their primary actions? 1. Histamine – arteriolar dilation and ↑ vascular permeability causing hypotension in anaphylaxis 2. Bradykinin – major mediator of pain in inflammation 3. Platelet-activating factor (PAF) – bronchoconstriction via activation of platelets and leukocytes with mediator release 4. Neutrophil lysosomal enzymes – cleavage of C3 and C5 to generate active complement fragments 5. Interleukin-1 (IL-1) mediates vasodilation and bronchoconstriction in asthma (Q879459)

A. 1, 2, 3

B. 1, 3, 5

C. 1, 2, 3, 4

D. 2, 4, 5

See Answer in Part B → Q3

@Neet_pg_bot

Q4: A 39-year-old woman with long-standing rheumatoid arthritis presents with fatigue and pallor. Lab tests reveal anemia of chronic disease. Elevated levels of which of the following acute-phase reactants are primarily responsible for this anemia? (Q879458)

A. Fibrinogen

B. C-reactive protein (CRP)

C. Serum amyloid A (SAA)

D. Hepcidin

See Answer in Part B → Q4

@Neet_pg_bot

Q5: During the acute-phase response in inflammation, which of the following acts as a negative acute-phase reactant by decreasing in serum concentration? (Q879456)

A. Albumin

B. Serum amyloid A (SAA)

C. C-reactive protein (CRP)

D. Fibrinogen

See Answer in Part B → Q5

@Neet_pg_bot

Q6: Fractalkine, a unique chemokine with both membrane-bound and soluble forms, belongs to which chemokine family? (Q879453)

A. C

B. CX3C

C. CXC

D. CC

See Answer in Part B → Q6

@Neet_pg_bot

Q7: Which of the following cytokines primarily exhibits anti-inflammatory activity? (Q879452)

A. IL-1

B. IL-4

C. TNF

D. IFN-γ

See Answer in Part B → Q7

@Neet_pg_bot

Q8: Which of the following statements regarding prostaglandins and related eicosanoids is INCORRECT? (Q879451)

A. Thromboxane A2 (TxA2) is the predominant product of platelets

B. Prostacyclin (PGI2) acts as a vasodilator and inhibits platelet aggregation

C. PGD2 is one of the major prostaglandins released from mast cells

D. Vascular endothelium lacks prostacyclin synthase

See Answer in Part B → Q8

@Neet_pg_bot

Q9: Release of arachidonic acid, the precursor of prostaglandins and leukotrienes, is mainly mediated by which of the following enzymes? (Q879449)

A. Phospholipase A1 and C

B. Phospholipase A2 and C

C. Phospholipase B and C

D. Phospholipase A1 and B

See Answer in Part B → Q9

@Neet_pg_bot

Q10: Which of the following mediators is released immediately during the earliest phase of acute inflammation? (Q879446)

A. Serotonin

B. Interleukins

C. Prostaglandins

D. Bradykinin

See Answer in Part B → Q10

@Neet_pg_bot

Q11: A 25-year-old female presents to the emergency department with sudden-onset swelling of her face, lips, and tongue. She reports a history of similar episodes occurring intermittently since childhood, often triggered by stress or trauma. On examination, she appears anxious and has marked swelling of her lips and tongue, with difficulty speaking and swallowing. There are no signs of urticaria or pruritus. Her vital signs are stable. Which of the following deficiencies is seen in this condition? (Q845600)

A. Deficiency of properdin

B. Deficiency of C1, C2, C3, C4

C. Deficiency of C1 esterase inhibitor

D. Deficiency of C5-C9

See Answer in Part B → Q11

@Neet_pg_bot

Q12: Pain during inflammation is mediated by? (Q845603)

A. Serotonin

B. Leukotrienes

C. Interleukin-1

D. Bradykinin

See Answer in Part B → Q12

@Neet_pg_bot

Q13: Which of the following deficiencies is seen in paroxysmal nocturnal hemoglobinuria? (Q845602)

A. C5-C9

B. CD59

C. C1

D. Factor H

See Answer in Part B → Q13

@Neet_pg_bot

Q14: A 25-year-old female presents to the emergency department with severe allergic reaction symptoms, including urticaria and hypotension, after ingesting a shrimp. How does the vasoactive mediator involved primarily cause hypotension? (Q845563)

A. Vasodilation and increased vascular permeability

B. Enhancing nitric oxide production and vasodilation

C. Inducing the release of other pro-inflammatory cytokines

D. Inhibiting platelet aggregation and causing clotting

See Answer in Part B → Q14

@Neet_pg_bot

Q15: Which of the following is false regarding the alternate complement pathway? (Q845599)

A. Teichoic acid is an initiator of the alternate complement pathway.

B. The first complement protein to be activated is C1.

C. The C3 convertase of the alternate pathway is C3bBb.

D. Properdin is the stabilizer of the alternate pathway.

See Answer in Part B → Q15

@Neet_pg_bot

Q16: Match the following with their correct answers. 1 C3a i Decay accelerating factor 2 C3b ii EBV receptor 3 CR2 iii Anaphylatoxin 4 CD55 iv Opsonin (Q845597)

A. 1-iii, 2-iv, 3-ii, 4-i

B. 1-iii, 2-iv, 3-i, 4-ii

C. 1-iv, 2-iii, 3-i, 4-ii

D. 1-iv, 2-iii, 3-ii, 4-i

See Answer in Part B → Q16

@Neet_pg_bot

Q17: A 45-year-old male presents to the clinic with a high fever, chills, and malaise. He reports feeling unwell for the past few days and has noticed redness and swelling around a cut on his forearm. On examination, the healthcare provider observes a localized area of erythema and induration at the site of the wound. Which of the following events is a crucial step in the activation of the complement system in response to the patient's initial condition? (Q845594)

A. Binding of C1q to antigen-antibody complexes

B. Formation of membrane attack complex

C. Cleavage of C3 into C3a and C3b

D. Cleavage of C5 by C5 convertase

See Answer in Part B → Q17

@Neet_pg_bot

Q18: Select the correct statements about the complement system. 1) The complement system primarily functions by adaptive immunity. 2) Complement proteins are solely produced in the liver. 3) All complement proteins are synthesized in inactive forms and are activated by proteolysis. 4) Complement activation occurs through three pathways. 5) Complements have two equal fragments. (Q845573)

A. 1,2,3

B. 2,4

C. 2,3,5

D. 3,4

See Answer in Part B → Q18

@Neet_pg_bot

Q19: A 20-year-old male is prescribed naproxen for a musculoskeletal injury. What is naproxen's mechanism of action? (Q845572)

A. Lipoxygenase inhibition

B. COX-2 inhibition

C. Cycloxygenase (COX) 1 and COX-2 inhibition

D. Prostaglandin (PG) F2 inhibition

See Answer in Part B → Q19

@Neet_pg_bot

Q20: Which of the following mediators is responsible for cancer cachexia? (Q845571)

A. TNF-alpha

B. IFN-gamma

C. IL-8

D. TGF-beta

See Answer in Part B → Q20

@Neet_pg_bot

Q21: A 35-year-old male presents with a history of chronic obstructive pulmonary disease (COPD) exacerbation. Which of the following chemokines is primarily responsible for recruiting neutrophils to the airways in COPD exacerbations? (Q845570)

A. IL-8

B. MCP-1

C. SDF-1

D. RANTES

See Answer in Part B → Q21

@Neet_pg_bot

Q22: A 30-year-old male presents with symptoms of flu-like illness, including fever, sore throat, and fatigue. Further investigation reveals a positive HIV serology. Which of the following chemokine receptors primarily facilitates the entry of HIV into CD4+ T cells? (Q845569)

A. CX3CL1

B. CCR5 , CXCR4

C. CCL11 , MCP-1

D. CXCL8

See Answer in Part B → Q22

@Neet_pg_bot

Q23: All are chemoattractants among the following except : (Q845568)

A. IL-8

B. C5a

C. LTB4

D. C3b

See Answer in Part B → Q23

@Neet_pg_bot

Q24: Which of the following best describes the mechanism of action of PAF in inducing bronchoconstriction? (Q845567)

A. By binding to seven transmembrane G protein–coupled receptors.

B. Causing smooth muscle constriction by directly stimulating muscarinic receptors

C. Induction of smooth muscle relaxation and bronchodilation

D. Activation of platelets and leukocytes leading to release of inflammatory mediators

See Answer in Part B → Q24

@Neet_pg_bot

Q25: Which of the following is the role of neutrophil lysosomal enzymes in acute inflammation? (Q845566)

A. Cleavage of C3 and C5

B. Inhibition of complement proteins

C. Activation of macrophages

D. Degradation of prostaglandins

See Answer in Part B → Q25

@Neet_pg_bot

Q26: Which type of nitric oxide synthase (NOS) is involved in microbial killing and is induced in macrophages by cytokines or microbial products? (Q845565)

A. Endothelial NOS (eNOS)

B. Neuronal NOS (nNOS)

C. Inducible NOS (iNOS)

D. None of the above

See Answer in Part B → Q26

@Neet_pg_bot

• [02_Inflammation] 009 Previous Year Questions

« Back to Folder Directory

[02_Inflammation] 009 Previous Year Questions — Quick Jump

Q1 (p. 110)	*Q2 (p. 110)*	*Q3 (p. 111)*	*Q4 (p. 111)*	*Q5 (p. 112)*	*Q6 (p. 112)*
Q7 (p. 113)	*Q8 (p. 113)*	*Q9 (p. 113)*	*Q10 (p. 114)*	*Q11 (p. 114)*	*Q12 (p. 114)*
Q13 (p. 115)	*Q14 (p. 116)*	*Q15 (p. 116)*	*Q16 (p. 116)*	*Q17 (p. 117)*	*Q18 (p. 117)*
Q19 (p. 117)	*Q20 (p. 118)*	*Q21 (p. 118)*			

Q1: Which of the following cytokines does not cause the Jarisch-Herxheimer reaction? (Q855911)

A. TNF alpha

B. IL-6

C. IL-8

D. INF-γ

See Answer in Part B → Q1

@Neet_pg_bot

Q2: A patient underwent a cystoscopy, which showed multiple yellow-white plaques in the trigone of the bladder. The histopathology image is given below. What is the diagnosis? (Q855952)

A. Interstitial cystitis

B. Malakoplakia

C. Polypoid cystitis

D. Acute cystitis

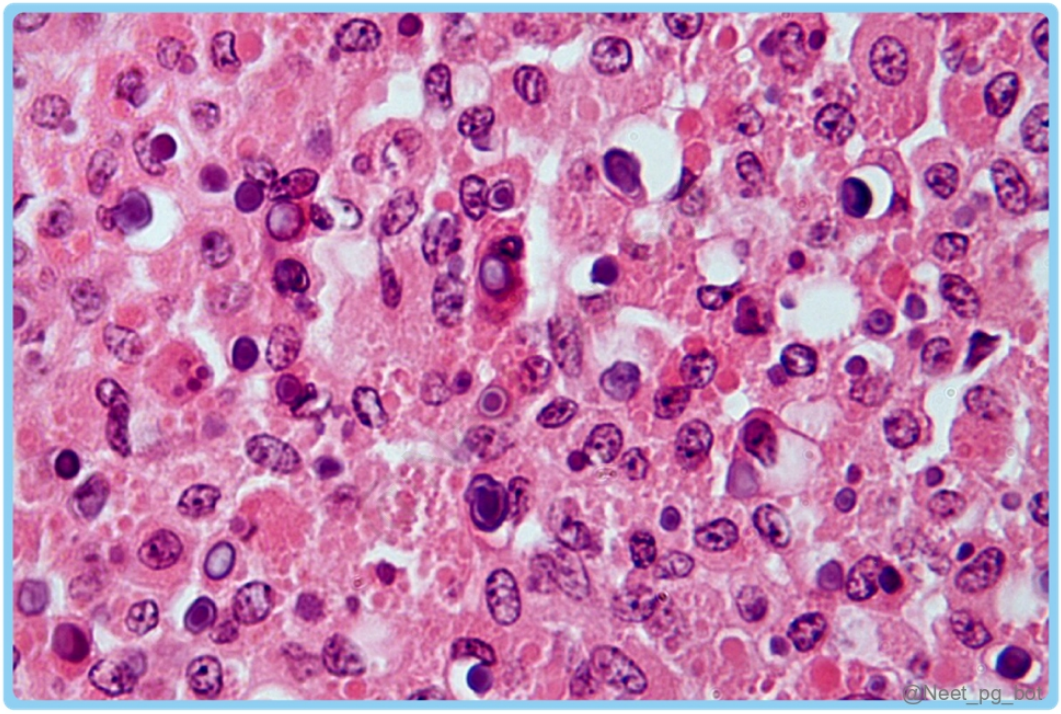

See Answer in Part B → Q2

@Neet_pg_bot

Q3: All of the following statements regarding neutrophil extracellular trapping (NET) are true, except? (Q855938)

A. It is detected in blood during sepsis

B. It is produced in response to bacterial infection

C. Mitochondrial DNA is seen

D. It is chromatin with antibacterial enzymes

See Answer in Part B → Q3

@Neet_pg_bot

Q4: A 12-year-old child presented with 15 days of cough. On examination, cervical lymphadenopathy was noted, and the lymph node biopsy showed caseating granulomas. What is the most probable diagnosis? (Q854881)

A. Tuberculosis

B. Leprosy

C. Sarcoidosis

D. Syphilis

See Answer in Part B → Q4

@Neet_pg_bot

Q5: During acute inflammation, leukocytes exit the bloodstream and migrate toward the site of tissue injury through several coordinated steps. Arrange the following events in the correct chronological order: Chemotaxis Adhesion Opsonization Rolling Phagocytosis Margination Cytokine-mediated integrin activation Transmigration (Q856703)

A. 1, 2, 3, 4, 5, 6, 7, 8

B. 6, 4, 7, 2, 8, 1, 3, 5

C. 4, 6, 2, 1, 3, 7, 8, 5

D. 2, 1, 4, 3, 5, 6, 7, 8

See Answer in Part B → Q5

@Neet_pg_bot

Q6: During wound healing, the cells that appear first, due to chemotaxis, at the site of the wound are: (Q857608)

A. Neutrophils

B. Monocytes

C. Macrophages

D. Lymphocytes

See Answer in Part B → Q6

@Neet_pg_bot

Q7: Which of the following molecules helps in the firm adhesion of the leukocyte to the endothelium during inflammation? (Q857101)

A. P-selectin

B. Platelet-activating factor

C. VCAM-1

D. Complements

See Answer in Part B → Q7

@Neet_pg_bot

Q8: Cyclooxygenase plays a role in which of the following pathways? (Q855125)

A. Kreb’s cycle

B. Prostaglandin

C. Leukotriene

D. Vitamin K

See Answer in Part B → Q8

@Neet_pg_bot

Q9: Match the following cells with their locations: Cells Locations 1. Kupffer cells a. Stomach 2. Parietal cells b. Liver 3. Dust cells c. Alveoli 4. Clara cells d. Bronchioles (Q855088)

A. 1-a, 2-b, 3-c, 4-d

B. 1-c, 2-d, 3-a, 4-b

C. 1-d, 2-a, 3-d, 4-c

D. 1-b, 2-a, 3-c, 4-d

See Answer in Part B → Q9

@Neet_pg_bot

Q10: Match the cytokines with the effector cells 1. IL-4 a. Eosinophils 2. IL-5 b. Mast cells 3. IL-9 c. B cells 4. IL-13 d. Dendritic cells (Q856029)

A. 1-c, 2-a, 3-b, 4-d

B. 1-a, 2-c, 3-d, 4-b

C. 1-b, 2-d, 3-c, 4-a

D. 1-d, 2-b, 3-a, 4-c

See Answer in Part B → Q10

@Neet_pg_bot

Q11: Which of the following molecules helps leukocytes roll over endothelial cells in vessels? (Q856001)

A. Cadherins

B. PECAM-1

C. E-selectin

D. CD11a

See Answer in Part B → Q11

@Neet_pg_bot

Q12: Match the following: 1. IL-5 A. Regulates acute phase reactants 2. IL-6 B. T cell maturation 3. IL-7 C. Neutrophil recruitment 4. IL-8 D. Eosinophils activation (Q860495)

A. 1-B, 2-C, 3-D, 4-A

B. 1-D, 2-A, 3-B, 4-C

C. 1-C, 2-D, 3-B, 4-A

D. 1-D, 2-C, 3-B, 4-A

See Answer in Part B → Q12

@Neet_pg_bot

Q13: A patient presents with complaints of cough, night sweats, and fever. A lung biopsy demonstrates the following histological findings. What is the most likely cytokine involved? (Q854700)

A. Interferon-γ

B. Complement C5a

C. Histamine

D. Bradykinin

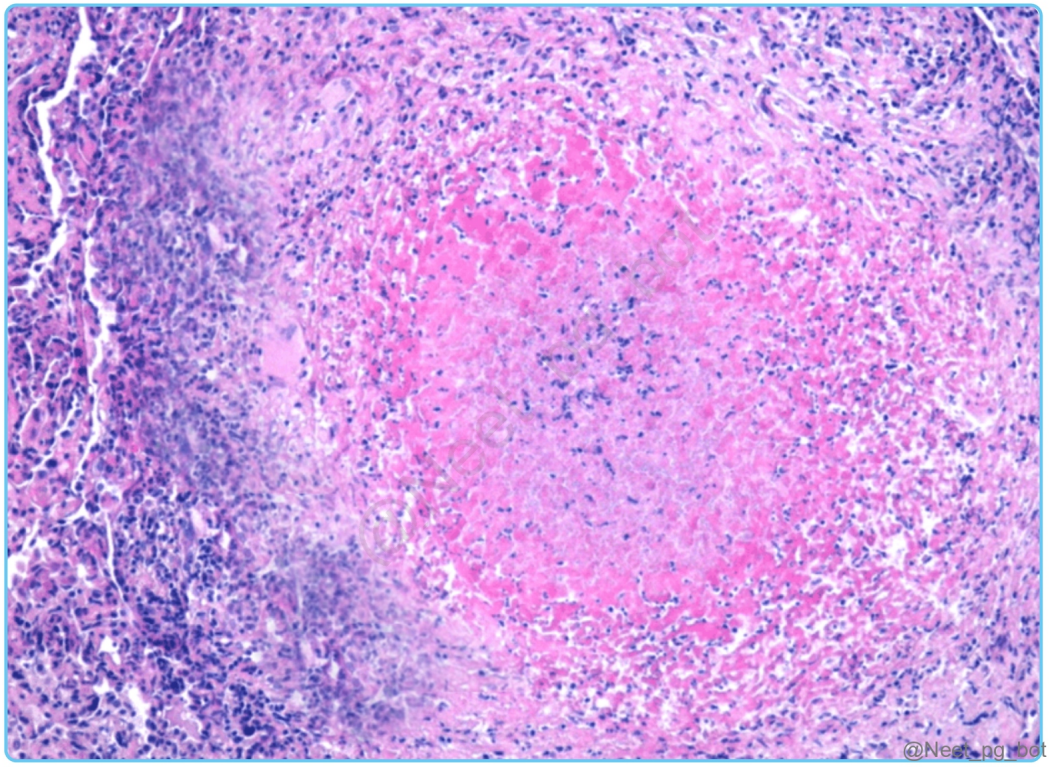

See Answer in Part B → Q13

@Neet_pg_bot

Q14: Which substance plays a role as a mediator in chronic inflammation? (Q830804)

A. IL-1

B. TNF-α

C. TGF-β

D. None

See Answer in Part B → Q14

@Neet_pg_bot

Q15: All of the following are correct about 'Neutrophil extracellular traps' except? (Q860299)

A. May result in SLE

B. Phagocytosis

C. Sepsis

D. Arginine needed

See Answer in Part B → Q15

@Neet_pg_bot

Q16: Match the following: 1. IL-5 A. Regulates acute phase reactants 2. IL-6 B. T cell maturation 3. IL-7 C. Neutrophil recruitment 4. IL-8 D. Eosinophils activation (Q860293)

A. 1-B, 2-C, 3-D, 4-A

B. 1-D, 2-A, 3-B, 4-C

C. 1-C, 2-D, 3-B, 4-A

D. 1-D, 2-C, 3-B, 4-A

See Answer in Part B → Q16

@Neet_pg_bot

Q17: A 50-year-old female presents with cervical lymphadenopathy. A biopsy has revealed granulomatous necrotising inflammation. Which of the following options is correct? (Q860203)

A. Metastatic calcification with normal serum calcium level

B. Dystrophic calcification with normal serum calcium level

C. Metastatic calcification with increased serum calcium level

D. Dystrophic calcification with increased serum calcium level

See Answer in Part B → Q17

@Neet_pg_bot

Q18: Which of the following is the most effective enzyme in Acute inflammation? (Q860193)

A. NADPH oxidase

B. Defensin

C. Catalase

D. MPO

See Answer in Part B → Q18

@Neet_pg_bot

Q19: Which of the following parameters decreases in acute inflammation? (Q860161)

A. CRP

B. Hepcidin

C. Fibrinogen

D. Albumin

See Answer in Part B → Q19

@Neet_pg_bot

Q20: All of the following are growth-promoting proto-oncogenes, except? (Q840061)

A. FGF

B. PDGF

C. TGF-α

D. TGF-β

See Answer in Part B → Q20

@Neet_pg_bot

Q21: All of the following are correct about NETs except? (Q860511)

A. May result in SLE

B. Phagocytosis

C. Sepsis

D. Arginine needed

See Answer in Part B → Q21

@Neet_pg_bot

• [03_Genetics] 010 Genetics- Introduction Mendelian Disorders

« Back to Folder Directory

[03_Genetics] 010 Genetics- Introduction Mendelian Disorders — Quick Jump

Q1 (p. 119) *Q2 (p. 119)* *Q3 (p. 120)* *Q4 (p. 120)* *Q5 (p. 121)* *Q6 (p. 121)*
Q7 (p. 121) *Q8 (p. 122)* *Q9 (p. 122)* *Q10 (p. 123)* *Q11 (p. 123)* *Q12 (p. 123)*
Q13 (p. 124)

Q1: Match the following with their correct terms. 1 Exon i Non-coding region 2 Intron ii One of the alternate forms of a single gene occupying a given position in a chromosome 3 Locus iii Coding region 4 Allele iv Location of a gene on the chromosome (Q845099)

A. 1-iii, 2-i, 3-iv, 4-ii

B. 1-iii, 2-i, 3-ii, 4-iv

C. 1-i, 2-iii, 3-iv, 4-ii

D. 1-i, 2-iii, 3-ii, 4-iv

See Answer in Part B → Q1

@Neet_pg_bot

Q2: A 25-year-old male from a tribal area of Madhya Pradesh presents to the clinic with complaints of fatigue and shortness of breath. On examination, he appears pale, and jaundice is noted. Laboratory investigations reveal low hemoglobin levels and increased reticulocyte count. The peripheral blood smear shows numerous sickle-shaped erythrocytes. What is the most likely molecular mechanism underlying the pathogenesis of this patient's condition? (Q845100)

A. Chromosomal translocation

B. Missense mutation

C. Frameshift mutation

D. Nonsense mutation

See Answer in Part B → Q2

@Neet_pg_bot

Q3: A couple visits a genetics counselor due to concerns about their baby's blood type. The father has blood type A (genotype I A I A), and the mother has blood type B (genotype I B I B). The counselor explains that blood type is determined by codominant alleles, where both alleles contribute equally to the phenotype in the heterozygous condition. Which of the following best describes codominance? (Q845101)

A. One allele completely masks the expression of the other allele

B. The phenotype of the heterozygote is intermediate between the phenotypes of the homozygotes

C. Only one allele is expressed, while the other remains silent

D. Both alleles contribute to the phenotype equally in the heterozygous condition

See Answer in Part B → Q3

@Neet_pg_bot

Q4: A 30-year-old man presents to the clinic with a history of tall stature, long limbs, and joint hypermobility. Upon further examination, he also exhibits features such as a high-arched palate, arachnodactyly (long, slender fingers), and aortic root dilation. His father has a similar appearance. Which of the following statements is true regarding the inheritance pattern seen in this condition? (Q845103)

A. Males are more commonly affected than females.

B. Most mutations lead to reduced production of a gene product or give rise to a dysfunctional or inactive protein.

C. Complete penetrance can be seen

D. The least common mode of inheritance

See Answer in Part B → Q4

@Neet_pg_bot

Q5: A 6-month-old male infant presents to the pediatric clinic with failure to thrive, recurrent respiratory infections, and hepatosplenomegaly. Upon further examination, the infant also displays signs of skeletal abnormalities including bowed legs and frontal bossing. Lab investigations reveal pancytopenia with markedly decreased platelet count. Genetic testing confirms a diagnosis of Gaucher disease. What is the pattern of inheritance and underlying genetic defect leading to this disorder? (Q845104)

A. Autosomal Dominant Inheritance, Mutation in the CFTR Gene

B. X-linked Recessive Inheritance, Mutation in the GBA Gene

C. Autosomal Dominant Inheritance, Mutation in the HEXA Gene

D. Autosomal Recessive Inheritance, Mutation in the GBA Gene

See Answer in Part B → Q5

@Neet_pg_bot

Q6: A 6-month-old infant presents with hepatosplenomegaly, failure to thrive, and hypotonia. The infant has a cherry-red spot on the macula and exhibits poor startle reflexes on physical examination. Further evaluation reveals foam cells in the bone marrow. What is the diagnosis and associated enzyme deficiency? (Q845105)

A. Diagnosis: Niemann-Pick disease type A, Enzyme Deficiency: Acid sphingomyelinase

B. Diagnosis: Tay-Sachs disease, Enzyme Deficiency: Hexosaminidase A

C. Diagnosis: Gaucher disease, Enzyme Deficiency: Glucocerebrosidase

D. Diagnosis: Metachromatic leukodystrophy, Enzyme Deficiency: Arylsulfatase A

See Answer in Part B → Q6

@Neet_pg_bot

Q7: Sarah is a 3-year-old girl who is brought to her pediatrician by her parents due to concerns about her development. Her parents report that Sarah has been experiencing a loss of previously acquired skills, such as hand skills and language, stereotypic hand movements and seizure episodes . What is the mode of inheritance? (Q845106)

A. X-linked dominant

B. X-linked recessive

C. Autosomal recessive

D. Autosomal dominant

See Answer in Part B → Q7

@Neet_pg_bot

Q8: A 25-year-old male presents with severe hypotonia at birth, joint hypermobility, scoliosis, fragile skin, and ocular fragility. Genetic testing reveals mutations in the gene encoding Lysyl Hydroxylase. Which subtype of Ehlers-Danlos Syndrome (EDS) is most likely present in this patient and its mode of inheritance? (Q845107)

A. Classical EDS - Autosomal Dominant

B. Hypermobility EDS - Autosomal Dominant

C. Kyphoscoliotic EDS - Autosomal Dominant

D. Kyphoscoliotic EDS - Autosomal Recessive

See Answer in Part B → Q8

@Neet_pg_bot

Q9: What type of inheritance pattern is associated with hypertrichosis pinnae? (Q845108)

A. Autosomal Dominant

B. Autosomal Recessive

C. X-Linked Dominant

D. Holandric

See Answer in Part B → Q9

@Neet_pg_bot

Q10: A 5-year-old boy is brought to the emergency department due to excessive bleeding after a minor injury. His mother reports that his grandfather also had similar bleeding episodes. Laboratory tests reveal a deficiency in factor IX. What is the mode of inheritance for this condition? (Q845109)

A. Autosomal dominant

B. Autosomal recessive

C. X-linked recessive

D. X-linked dominant

See Answer in Part B → Q10

@Neet_pg_bot

Q11: If the mother and father have the β-thalassemia trait, what percentage of their children are expected to have β-thalassemia major? (Q845110)

A. 25%

B. 50%

C. 75%

D. 100%

See Answer in Part B → Q11

@Neet_pg_bot

Q12: If a mother has sickle cell trait and the father has sickle cell disease , what percentage of their children are expected to have sickle cell disease? (Q845111)

A. 25%

B. 50%

C. 75%

D. 100%

See Answer in Part B → Q12

@Neet_pg_bot

Q13: A 10-year-old boy presents to the clinic with a complaint of bone pain. He does not sustain any trauma. He denies a history of fever. On examination, hepatosplenomegaly and bone tenderness are noted. Biopsy specimen from the spleen shows a crumpled tissue paper appearance. Keeping in view the most likely diagnosis, which of the following substance would most likely accumulate in this disorder? (Q882175)

A. Glucocerebroside

B. SphingomyelinSulfatide

C. Sulfatide

D. Ganglioside

See Answer in Part B → Q13

@Neet_pg_bot

• [03_Genetics] 011 Non-Mendelian Disorders

« Back to Folder Directory

[03_Genetics] 011 Non-Mendelian Disorders — Quick Jump

Q1 (p. 125)	*Q2 (p. 125)*	*Q3 (p. 125)*	*Q4 (p. 126)*	*Q5 (p. 126)*	*Q6 (p. 127)*
Q7 (p. 128)	*Q8 (p. 128)*	*Q9 (p. 129)*	*Q10 (p. 129)*	*Q11 (p. 130)*	*Q12 (p. 131)*
Q13 (p. 131)	*Q14 (p. 131)*	*Q15 (p. 132)*	*Q16 (p. 132)*	*Q17 (p. 132)*	*Q18 (p. 133)*

Q1: Fabry disease is an X-linked lysosomal storage disorder caused by a deficiency of which enzyme? (Q879663)

A. Alpha-galactosidase A

B. Beta-glucocerebrosidase

C. Acid alpha-glucosidase

D. Sphingomyelinase

See Answer in Part B → Q1

@Neet_pg_bot

Q2: Which of the following correctly describes the genetic basis of Myotonic Dystrophy type 1? (Q879658)

A. Autosomal recessive disorder caused by CAG expansion in the HTT gene on chromosome 4

B. Autosomal dominant disorder caused by CTG trinucleotide expansion in the DMPK gene on chromosome 19q13.3

C. X-linked disorder caused by CGG repeat expansion in the FMR1 gene

D. Autosomal dominant disorder caused by GAA trinucleotide expansion in the FXN gene

See Answer in Part B → Q2

@Neet_pg_bot

Q3: A one-month-old infant presents with developmental delays and physical features such as a prominent occiput, low-set ears, clenched hands with overlapping fingers, and a small mouth with a protruding tongue. Heart murmurs and rocker-bottom foot deformity are also noted. Which syndrome is the most likely cause of these features? (Q845124)

A. Noonan syndrome

B. Down syndrome

C. Patau syndrome

D. Edward syndrome

See Answer in Part B → Q3

@Neet_pg_bot

Q4: A 15-year-old boy presents to the clinic with tall stature and long limbs, along with a history of frequent joint dislocations. Upon physical examination, he exhibits long fingers ,sunken chest, and an echocardiogram shows a dilated aortic root. Considering these clinical features, which of the following genes are commonly mutated in this condition? (Q845130)

A. FBN 1

B. FBN 2

C. FBN 3

D. FBN 4

See Answer in Part B → Q4

@Neet_pg_bot

Q5: A 3-year-old boy presents with developmental delay, short stature, a heart murmur, and characteristic facial features, as shown in the image below. What is the most likely diagnosis for this patient? (Q845129)

A. Noonan syndrome

B. Down syndrome

C. Williams syndrome

D. Turner syndrome



See Answer in Part B → Q5

@Neet_pg_bot

Q6: An 18-year-old girl presents to the clinic due to the concern that she hasn't started menstruating yet. The girl has a short stature and a webbed neck. Physical examination reveals a broad chest with widely spaced nipples. What is the most likely diagnosis for this patient? (Q845128)

A. Turner syndrome

B. Mullerian agenesis

C. Congenital adrenal hyperplasia

D. 47, XXX syndrome

See Answer in Part B → Q6

@Neet_pg_bot

Q7: A 30-year-old tall male patient presents to the clinic for fertility treatment. He undergoes testing and is found to have low sperm counts. He has a history of diabetes, and a physical examination reveals gynecomastia, small testes, and minimal facial and body hair. What chromosomal abnormality is most likely causing this condition in the patient? (Q845127)

A. 45,X

B. 47,XXY

C. 47,XXX

D. 47,XYY

See Answer in Part B → Q7

@Neet_pg_bot

Q8: A 6-month-old child has recently passed away after a long ICU stay. Examination reveals microphthalmia and microcephaly. Other known diagnoses included ventricular septal defect, polycystic kidney disease, and omphalocele at birth. What is the chromosome involved? (Q845126)

A. Chromosome 21

B. Chromosome 18

C. Chromosome 13

D. Chromosome Y

See Answer in Part B → Q8

@Neet_pg_bot

Q9: A 2-year-old boy is brought to the pediatrician by his parents for delayed milestones. Upon examination, the pediatrician notices several physical features, including upward-slanting eyes, a flat facial profile, a protruding tongue, and a single palmar crease. Which type of inheritance is definitely not present in this child? (Q845125)

A. Meiotic nondisjunction of chromosome 21.

B. Robertsonian translocation

C. Mitotic non-disjunction

D. Autosomal recessive inheritance

See Answer in Part B → Q9

@Neet_pg_bot

Q10: A young male patient presented with recurrent episodes of acute neurologic dysfunction, cognitive changes, muscle weakness, and lactic acidosis. There is a family history of similar conditions depicted in the pedigree chart below. What is the most likely diagnosis? (Q845115)

A. MELAS

B. MERRF

C. Metachromatic leukodystrophy

D. Adrenoleukodystrophy

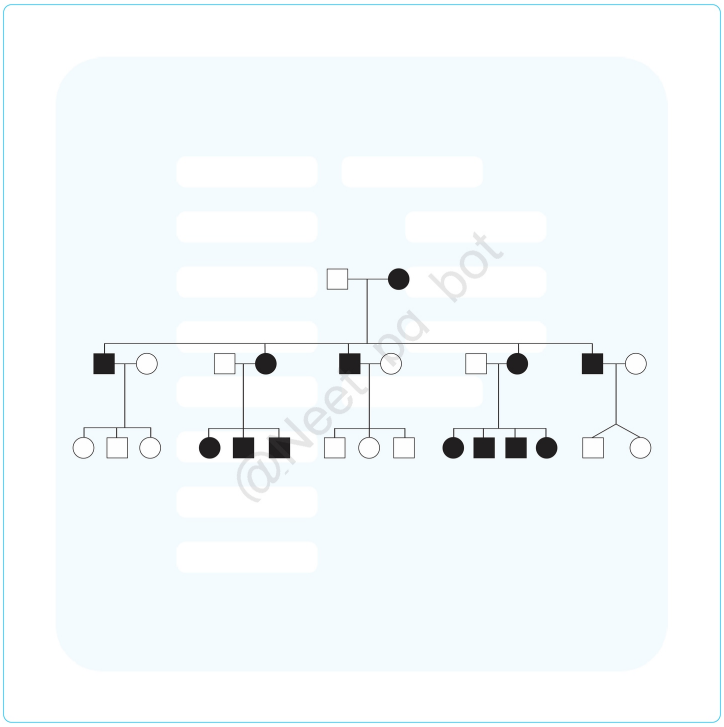

@Neet_pg_bot

See Answer in Part B → Q10

@Neet_pg_bot

Q11: A 50-year-old man presents with intentional tremors, cerebellar ataxia, and intellectual disability. His father had similar symptoms at 60 and died due to aortic dissection. The patient's son started showing tremors and has an intellectual disability and aggressive behavior. Additionally males of the family have large ears and mandibles. What condition is most likely affecting him? (Q845123)

A. Fragile X syndrome

B. Huntington's disease

C. Parkinson's disease

D. Alzheimer's disease

See Answer in Part B → Q11

@Neet_pg_bot

Q12: A group of researchers studying genetic material noticed the presence of both wild-type and mutated mitochondrial genomes in different mitochondria of the same cells. What does this finding indicate? (Q845122)

A. Copy number variation

B. Heteroplasmy

C. Trinucleotide expansion

D. Imprinting

See Answer in Part B → Q12

@Neet_pg_bot

Q13: Which of the following explains a single mutant gene leading to different end effects in sickle cell anemia? (Q845121)

A. Variable expressivity

B. Variable penetrance

C. Pleiotropy

D. Genetic heterogeneity

See Answer in Part B → Q13

@Neet_pg_bot

Q14: A 4-year-old girl is brought to the pediatrician's office for evaluation of developmental delay and seizures. She is very jovial, has microcephaly and is diagnosed with happy puppet syndrome. What is the genetic basis for this child's diagnosis? (Q845120)

A. Imprinting

B. Robertsonian translocation

C. Trinucleotide repeats

D. Monosomy

See Answer in Part B → Q14

@Neet_pg_bot

Q15: A 25-year-old male presents with brief, abrupt, involuntary movements of his arms and face for the last 2 months. A history of Huntington's disease in his father, who was diagnosed at 40 years of age and passed away at the age of 50, is found. What is the mechanism behind this patient's earlier presentation? (Q845119)

A. Anticipation

B. Mosaicism

C. Imprinting

D. Non-penetrance

See Answer in Part B → Q15

@Neet_pg_bot

Q16: Match the following Disease Trinucleotide repeats a. Fragile X syndrome 1. CAG b. Friedreich ataxia 2. CTG c. Myotonic dystrophy 3. GAA d. Huntington disease 4. CGG (Q845118)

A. a-2, b-1, c-4, d-3

B. a-4, b-3, c-2, d-1

C. a-3, b-2, c-1, d-4

D. a-4, b-1, c-3, d-2

See Answer in Part B → Q16

@Neet_pg_bot

Q17: Which of the following does not show the same pattern of inheritance as Leber hereditary optic neuropathy? (Q845117)

A. MERRF

B. MELAS

C. Fragile-X syndrome

D. NARP

See Answer in Part B → Q17

@Neet_pg_bot

Q18: What is the most likely diagnosis of a 5-year-old child with hyperphagia, delayed milestones, and growth retardation? (Q845116)

A. Angelman syndrome

B. Prader-Willi syndrome

C. Fragile X syndrome

D. Patau syndrome

See Answer in Part B → Q18

@Neet_pg_bot

• [03_Genetics] 012 Diagnosis Of Genetic Disorders And Miscellaneous

« Back to Folder Directory

[03_Genetics] 012 Diagnosis Of Genetic Disorders And Miscellaneous — Quick Jump

Q1 (p. 134)	*Q2 (p. 134)*	*Q3 (p. 135)*	*Q4 (p. 135)*	*Q5 (p. 135)*	*Q6 (p. 136)*
Q7 (p. 136)	*Q8 (p. 136)*	*Q9 (p. 137)*	*Q10 (p. 137)*	*Q11 (p. 138)*	*Q12 (p. 139)*
Q13 (p. 139)	*Q14 (p. 139)*	*Q15 (p. 140)*	*Q16 (p. 140)*	*Q17 (p. 141)*	*Q18 (p. 142)*
Q19 (p. 142)					

Q1: Which of the following chromosomal aberrations results in a change in the amount of genetic material? (Q879652)

A. Balanced reciprocal translocation

B. Inversion

C. Deletion

D. Paracentric inversion

See Answer in Part B → Q1

@Neet_pg_bot

Q2: Which of the following chromosomal aberrations and mechanisms is correctly matched? (Q879646)

A. Trisomy – caused by deletion of a chromosome segment.

B. Balanced reciprocal translocation – inversion of a chromosome segment without change in gene copy number.

C. Isochromosome formation – fusion of chromosome ends after breaks.

D. Ring chromosome – breaks at both ends of a chromosome with fusion of the damaged ends.

See Answer in Part B → Q2

@Neet_pg_bot

Q3: In cytogenetic notation, what does Xp21.2 represent? (Q879644)

A. Long arm of the X chromosome, region 21, band 1, sub-band 2

B. Short arm of the X chromosome, region 2, band 1, sub-band 2

C. Short arm of the X chromosome, region 21, band 2, sub-band 1

D. Long arm of the X chromosome, region 1, band 2, sub-band 1

See Answer in Part B → Q3

@Neet_pg_bot

Q4: A 35-year-old pregnant woman presents for prenatal screening due to advanced maternal age. She undergoes amniocentesis, and chromosome analysis is performed on the fetal cells to assess for chromosomal abnormalities . The results indicate Down syndrome. From the below chromosomal analysis, which of the following results is most likely associated with this case? (Q845185)

See Answer in Part B → Q4

@Neet_pg_bot

Q5: Arrange the following steps of karyotyping in the correct sequence: Staining/Banding Sample collection Fixative Arrangement of chromosomes Arrest Interpretation (Q847860)

A. 2, 5, 3, 1, 4, 6

B. 2, 3, 5, 1, 4, 6

C. 1, 2, 3, 5, 4, 6

D. 3, 5, 2, 4, 1, 6

See Answer in Part B → Q5

@Neet_pg_bot

Q6: A researcher wants to analyze gene expression levels in a sample using a PCR technique that quantifies the amount of DNA produced after each amplification cycle. Which type of PCR is most suitable for this purpose? (Q845190)

A. Real-time PCR

B. Nested PCR

C. Reverse Transcription PCR (RT-PCR)

D. Multiplex PCR

See Answer in Part B → Q6

@Neet_pg_bot

Q7: A 35-year-old female undergoes genetic testing due to a family history of Cystic Fibrosis. The test reveals a suspected deletion in the CFTR gene. Which technique is most suitable for confirming large deletions or duplications in the CFTR gene? (Q845189)

A. Polymerase Chain Reaction (PCR)

B. Comparative Genomic Hybridization (CGH)

C. Multiplex Ligation Dependent Probe Amplification (MLPA)

D. Sanger sequencing

See Answer in Part B → Q7

@Neet_pg_bot

Q8: Which technique is specifically designed to detect copy number variations (CNVs) in the genome by comparing patient DNA with a reference DNA sample? (Q845188)

A. PCR

B. Comparative Genomic Hybridization (CGH)

C. DNA sequencing

D. Southern blotting

See Answer in Part B → Q8

@Neet_pg_bot

Q9: Which steps are NOT involved in the Polymerase Chain Reaction (PCR) process? (Q845187)

A. Denaturation

B. Annealing

C. Amplification

D. Ligation

See Answer in Part B → Q9

@Neet_pg_bot

Q10: In a cytogenetics laboratory, a technician is tasked with preparing chromosomes obtained from a patient's blood sample for analysis under a light microscope. The patient has been experiencing unexplained developmental delays, and the physician suspects a potential chromosomal abnormality. To aid in the identification and analysis of individual chromosomes, which technique will the technician employ to produce distinct banding patterns? (Q845186)

A. G-banding

B. C-banding

C. Q-banding

D. R-banding

See Answer in Part B → Q10

Q11: In a community where consanguineous marriages are prevalent, a distant relative couple decide to get married. They later have a child who presents with symptoms of anaemia and requires regular blood transfusions. Further investigation reveals that the child has beta-thalassemia, a genetic disorder prevalent in the region. Which of the following symbols can be anticipated in this couple, which is a risk factor for this disease? (Q845176)

A. A

B. B

C. C

D. D

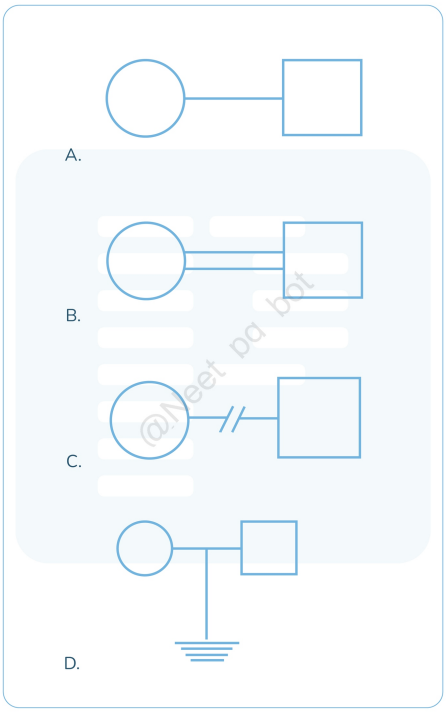

See Answer in Part B → Q11

Q12: A 45-year-old woman has been newly diagnosed with breast cancer. Histopathological analysis of the tumour reveals invasive ductal carcinoma. Given the aggressive nature of her tumour, the oncologist wants to determine if the patient's cancer is HER2-positive. Which diagnostic method is most appropriate for detecting HER2/neu amplification in this patient? (Q845184)

A. Immunohistochemistry (IHC)

B. Fluorescence In Situ Hybridization (FISH)

C. Polymerase Chain Reaction (PCR)

D. Western Blotting

See Answer in Part B → Q12

@Neet_pg_bot

Q13: Which of the following statements regarding gonadal mosaicism is true? (Q845183)

A. It is associated with autosomal recessive disorders.

B. It occurs due to a pre-zygotic mutation during early embryonic development.

C. It can be associated with osteogenesis imperfecta.

D. It follows the laws of Mendelian inheritance.

See Answer in Part B → Q13

@Neet_pg_bot

Q14: A 25-year-old male has been complaining of painless, progressive central vision loss in both eyes over the past few months. He reports a family history of similar visual problems, with his maternal grandfather and maternal uncle experiencing sudden vision loss in their 20s. On examination, the ophthalmologist notes bilateral optic disc pallor and central scotomas on visual field testing. The patient denies any systemic symptoms or significant medical history. What is the inheritance pattern seen in this

condition? (Q845182)

See Answer in Part B → Q14

@Neet_pg_bot

Q15: Hairy pinna is associated with which type of Mendelian inheritance? (Q845181)

A. Autosomal dominant

B. X-linked recessive

C. Mitochondrial inheritance

D. Y-linked inheritance

See Answer in Part B → Q15

@Neet_pg_bot

Q16: In which of the following conditions can you see this pedigree chart? (Q845180)

A. Fabry disease

B. Albinism

C. Reye syndrome

D. Alport syndrome

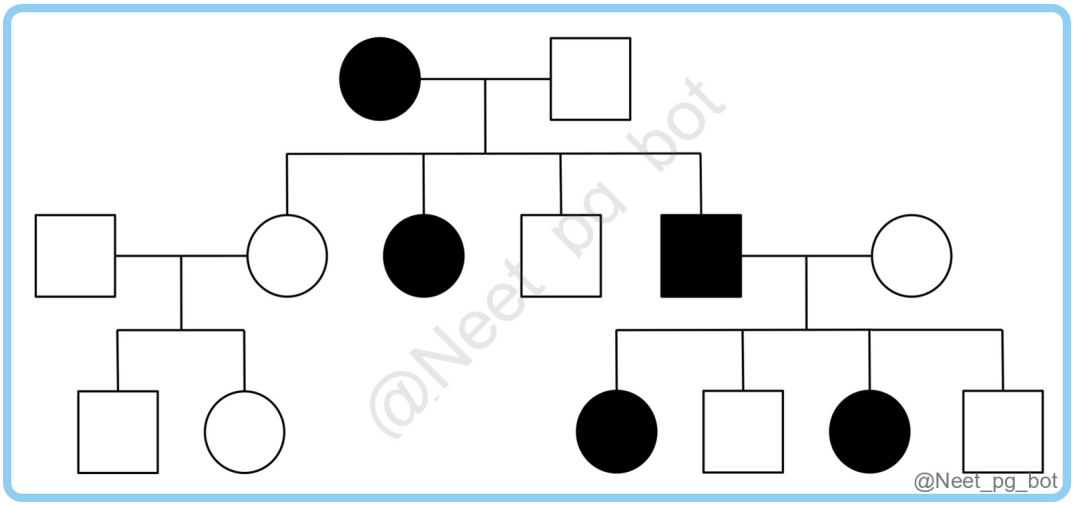

See Answer in Part B → Q16

@Neet_pg_bot

Q17: A 6-year-old boy presents to the clinic with complaints of muscle weakness and difficulty walking. His parents report a family history of similar symptoms. A detailed history was obtained, and a pedigree analysis was done, which is shown below. What is the most likely diagnosis and the inheritance pattern seen in this condition? (Q845179)

A. Dystonia myotonica, autosomal dominant

B. Dystonia myotonica, X-linked recessive

C. Duchenne muscular dystrophy, autosomal recessive

D. Duchenne muscular dystrophy, X-linked recessive

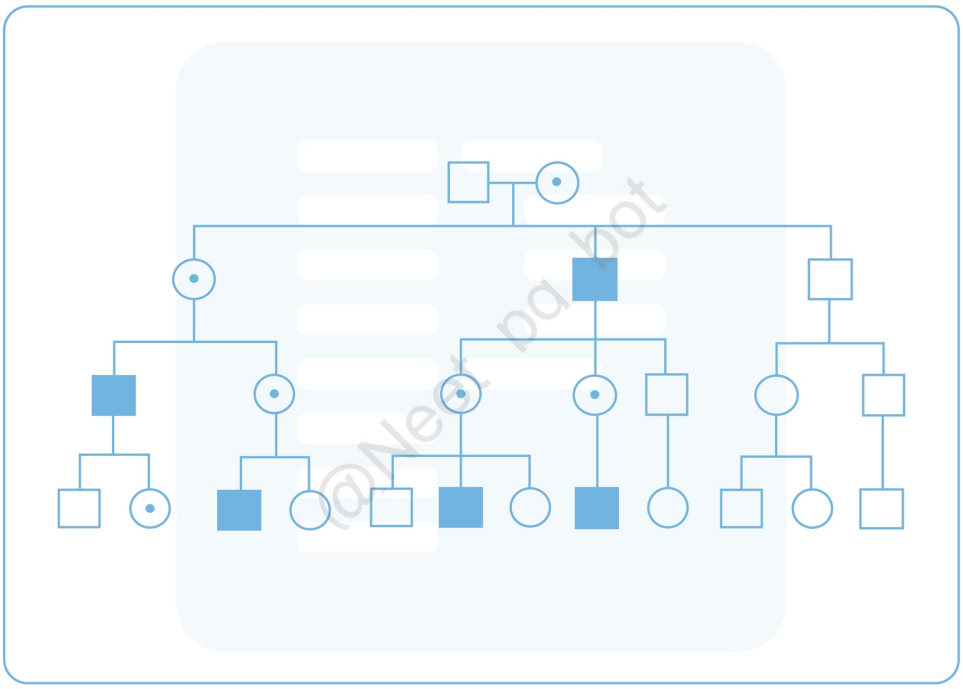

@Neet_pg_bot

See Answer in Part B → Q17

@Neet_pg_bot

Q18: A 10-year-old boy presents to the clinic with complaints of unsteady gait and frequent falls. Upon further inquiry, it is revealed that he has experienced progressive difficulty with coordination and balance over the past few years. His parents report a similar history in his older sister, who is now 15 years old. Interestingly, the parents are both asymptomatic, but the boy's maternal uncle was diagnosed with a similar condition in his late 20s. What is the most likely inheritance pattern seen in this condition? (Q845178)

A. Autosomal Dominant

B. X linked dominant

C. X linked recessive

D. Autosomal Recessive

See Answer in Part B → Q18

@Neet_pg_bot

Q19: A couple seeks medical advice after their daughter presents with frequent nosebleeds and easy bruising. Lab investigations reveal prolonged bleeding time, prolonged aPTT, and a normal PT. A detailed history and a pedigree analysis were obtained, suspecting a genetic disorder. Based on the pedigree chart, what is this condition's most likely inheritance pattern? (Q845177)

A. Autosomal recessive

B. Autosomal dominant

C. X linked recessive

D. X linked dominant

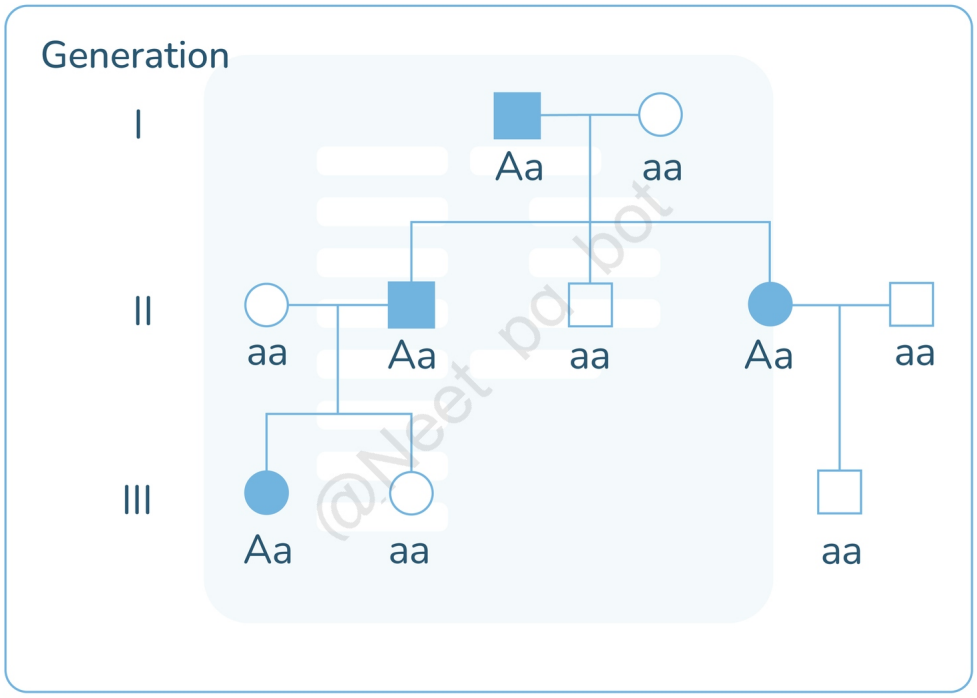

@Neet_pg_bot

See Answer in Part B → Q19

@Neet_pg_bot

• [03_Genetics] 013 Previous Year Questions

« Back to Folder Directory

[03_Genetics] 013 Previous Year Questions — Quick Jump

Q1 (p. 144)	*Q2 (p. 145)*	*Q3 (p. 146)*	*Q4 (p. 147)*	*Q5 (p. 147)*	*Q6 (p. 148)*
Q7 (p. 148)	*Q8 (p. 149)*	*Q9 (p. 149)*	*Q10 (p. 149)*	*Q11 (p. 150)*	*Q12 (p. 151)*
Q13 (p. 151)	*Q14 (p. 151)*	*Q15 (p. 152)*	*Q16 (p. 152)*	*Q17 (p. 152)*	*Q18 (p. 153)*
Q19 (p. 153)	*Q20 (p. 154)*	*Q21 (p. 154)*	*Q22 (p. 154)*	*Q23 (p. 155)*	*Q24 (p. 155)*
Q25 (p. 155)	*Q26 (p. 156)*	*Q27 (p. 157)*	*Q28 (p. 157)*	*Q29 (p. 158)*	*Q30 (p. 159)*
Q31 (p. 160)	*Q32 (p. 161)*	*Q33 (p. 161)*	*Q34 (p. 162)*	*Q35 (p. 162)*	*Q36 (p. 162)*
Q37 (p. 163)	*Q38 (p. 164)*	*Q39 (p. 164)*	*Q40 (p. 165)*	*Q41 (p. 165)*	*Q42 (p. 166)*
Q43 (p. 167)	*Q44 (p. 167)*				

Q1: A karyotyping image is given below. What are the clinical features most likely to be expected in such patients? (Q856714)

A. Gynecomastia and long limbs

B. Flat occiput

C. Webbing of neck and lymphedema

D. Cleft lip and polydactyly

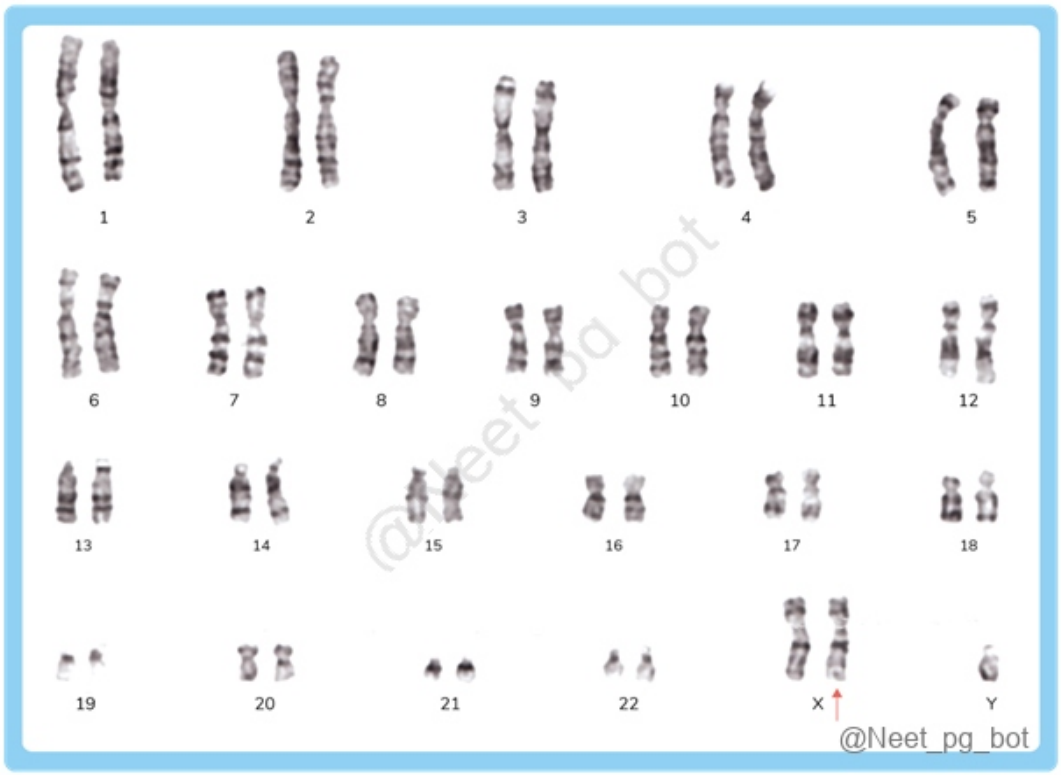

See Answer in Part B → Q1

@Neet_pg_bot

Q2: Identify the type of inheritance? (Q820500)

A. Autosomal Dominant

B. Autosomal Recessive

C. X-linked dominant

D. X-linked recessive

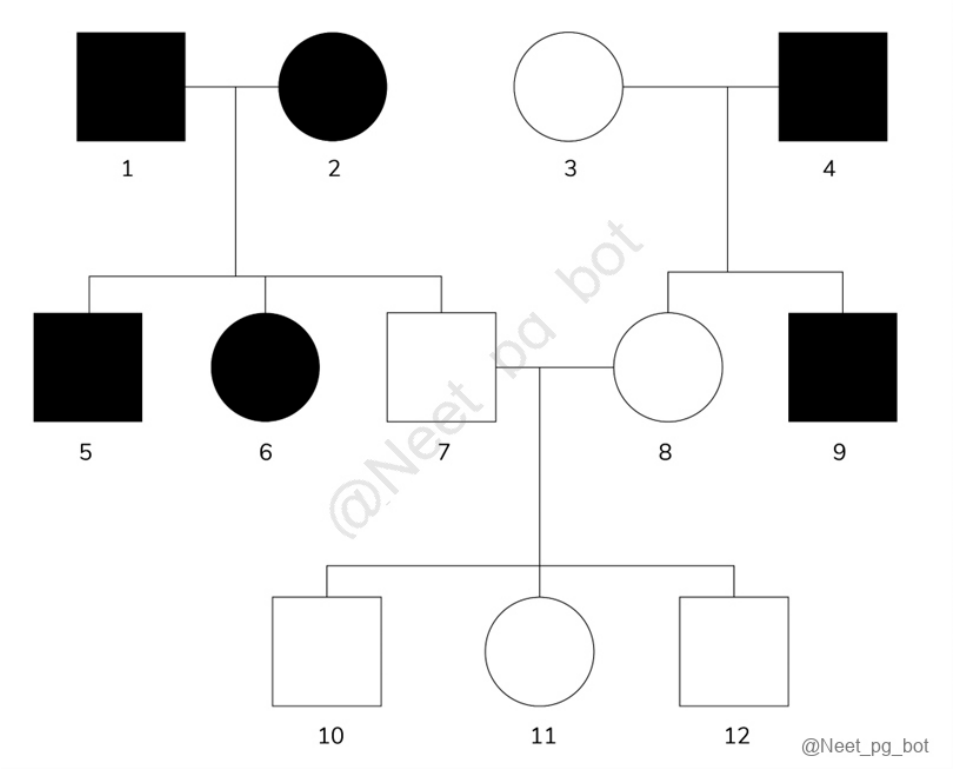

See Answer in Part B → Q2

@Neet_pg_bot

Q3: What is the status of the marked individual? (Q866668)

A. Adopted from another family

B. Has a disease of chronic origin

C. Curable disease

D. Twin

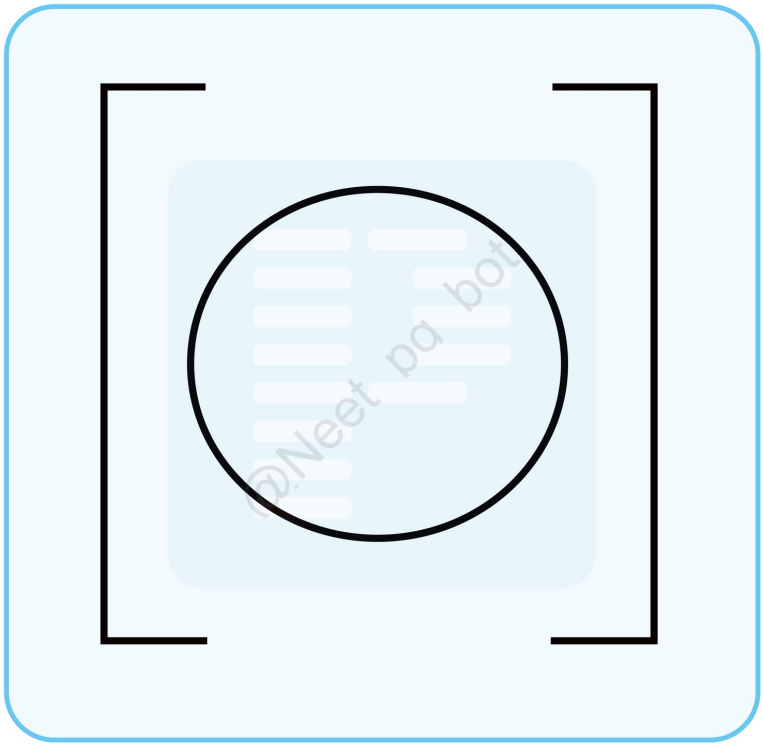

See Answer in Part B → Q3

@Neet_pg_bot

Q4: Which of the following statements regarding Mendelian (single-gene) disorders is correct? (Q855359)

A. X-linked dominant disorders are the most common type of Mendelian disorders.

B. Autosomal recessive disorders always appear in every generation of a family.

C. Y-linked disorders are extremely rare because few genes are present on the Y-chromosome.

D. In autosomal dominant disorders, two defective alleles are required for the disease to manifest.

See Answer in Part B → Q4

@Neet_pg_bot

Q5: A 30-year-old pregnant woman who has the thalassemia trait visits the clinic for genetic counselling. Her husband is also confirmed to have the thalassemia trait. Considering their genetic background, what is the likelihood of their next offspring having thalassemia? (Q858074)

A. 100%

B. 50%

C. 75%

D. 25%

See Answer in Part B → Q5

@Neet_pg_bot

Q6: Which of the following correctly represents the effect of the mutation causing sickle cell anaemia? (Q858078)

A. Glutamate by valine at the 6th position

B. Valine by glutamate at the 6th position

C. Glutamate by valine at the 5th position

D. Valine by glutamate at the 5th position

See Answer in Part B → Q6

@Neet_pg_bot

Q7: B cells express IgM and IgD antibodies at the same time. Which phenomenon is it due to? (Q856008)

A. Somatic hypermutation

B. Alternative RNA splicing

C. Affinity maturation

D. Allelic exclusion

See Answer in Part B → Q7

@Neet_pg_bot

Q8: Differential expression of a gene depending upon the parent of origin is a feature of: (Q855071)

A. Gonadal mosaicism

B. Genomic imprinting

C. Anticipation

D. Incomplete penetrance

See Answer in Part B → Q8

@Neet_pg_bot

Q9: Which of the following disorders is inherited in an X-linked dominant pattern? (Q855075)

A. Rett syndrome

B. Duchenne muscular dystrophy

C. Huntington’s disease

D. Tuberous sclerosis

See Answer in Part B → Q9

@Neet_pg_bot

Q10: In cystic fibrosis, which of the following structures is affected in the pancreas? (Q855391)

A. A

B. B

C. C

D. D

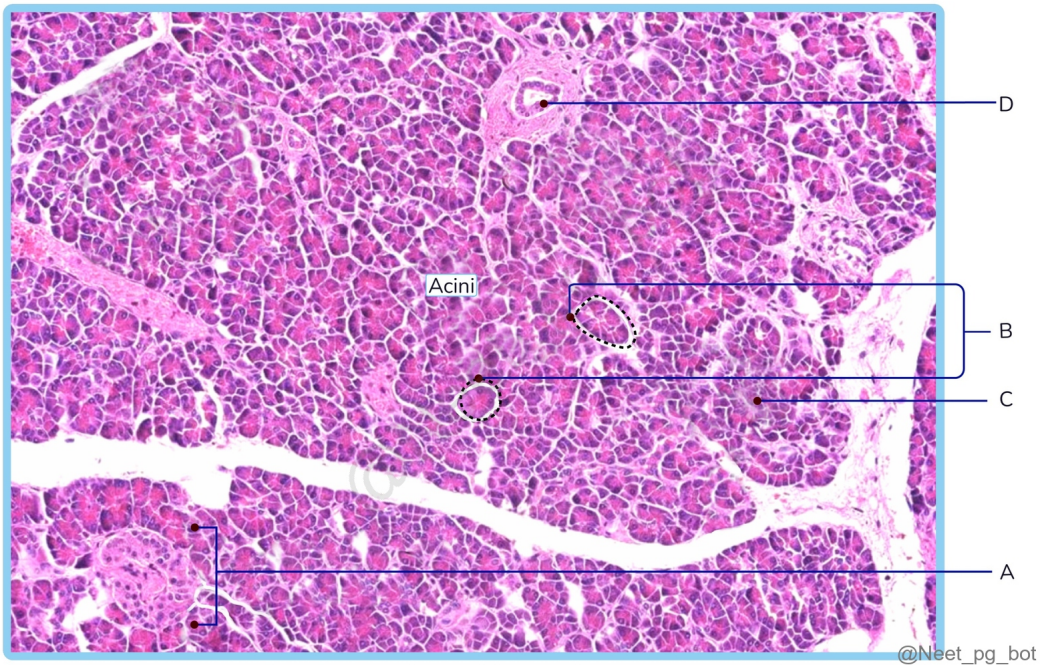

See Answer in Part B → Q10

@Neet_pg_bot

Q11: A 30-year-old pregnant woman who has the thalassemia trait visits the clinic for genetic counseling. Her husband is also confirmed to have the thalassemia trait. Considering their genetic background, what is the likelihood of their next offspring having thalassemia? (Q820511)

A. 100%

B. 50%

C. 75%

D. 25%

See Answer in Part B → Q11

@Neet_pg_bot

Q12: A girl presents with short stature, a webbed neck, thick calves, a shield-shaped chest, swelling of the ankle, and an increased carrying angle. What is the likely diagnosis? (Q856105)

A. Turner syndrome

B. Down syndrome

C. Patau syndrome

D. Edward syndrome

See Answer in Part B → Q12

@Neet_pg_bot

Q13: Which of the following statements is correct about Huntington's chorea? (Q854894)

A. It is a trinucleotide repeat disorder

B. There is a loss of function type of mutation

C. There are abnormal length repeats of CUG

D. Abnormality is seen due to a defect in chromosome 6

See Answer in Part B → Q13

@Neet_pg_bot

Q14: Premature ageing in Werner syndrome is due to: (Q858514)

A. Increased telomerase activity

B. Defects in DNA helicase

C. Increase in length of telomere due to decrease in telomerase activity

D. Decreased telomerase activity

See Answer in Part B → Q14

@Neet_pg_bot

Q15: What is the mode of inheritance in a patient suffering from colour blindness? (Q859300)

A. AD

B. AR

C. XLR

D. XLD

See Answer in Part B → Q15

@Neet_pg_bot

Q16: A female is heterozygous for an autosomal recessive mitochondrial disorder. What does this involve? (Q879194)

A. Skeletal muscle and immune system

B. Skeletal muscle and cardiac muscle

C. Skeletal muscle and neural tissue

D. Gastric and respiratory tissue

See Answer in Part B → Q16

@Neet_pg_bot

Q17: A 3-year-old child presents with unilateral proptosis and leukocoria. Histopathology demonstrates Flexner–Wintersteiner rosettes. Regarding this condition, which of the following statements is false? It is always unilateral Called the guardian of the genome The RB protein is hypophosphorylated in the inactive state Oncogenesis is due to a loss-of-function mutation (Q879199)

A. 1,2,3

B. 1,2,3,4

C. 3,4

D. 2,3

See Answer in Part B → Q17

@Neet_pg_bot

Q18: Which of the following statements regarding Gaucher disease are correct? Enzyme defect: Sphingomyelinase Enzyme defect: β-glucocerebrosidase Presence of foamy macrophages Macrophages exhibit a “crumpled tissue paper” appearance (Q879204)

A. 1, 2, 3

B. 2, 3, 4

C. 1, 2, 4

D. 1, 3, 4

See Answer in Part B → Q18

@Neet_pg_bot

Q19: What are the steps involved in the polymerase chain reaction (PCR)? (Q879217)

A. Denaturation - Annealing - Extension

B. Denaturation - Annealing - Extension - Hybridization

C. Annealing - Extension - Denaturation

D. Extension - Denaturation - Annealing

See Answer in Part B → Q19

@Neet_pg_bot

Q20: A boy with karyotype 46,XY del(15)(q11–13) presents with obesity and elevated ghrelin levels. What is the most likely diagnosis? (Q879225)

A. Prader-Willi syndrome

B. Angelman syndrome

C. Cri du chat syndrome

D. Fragile X syndrome

See Answer in Part B → Q20

@Neet_pg_bot

Q21: An adult tall male presents with subluxation of the lens, long arm span, pectus excavatum, and cardiac abnormalities. What is the most likely protein found to be defective? (Q844234)

A. Elastin

B. Collagen

C. Fibrillin

D. Laminin

See Answer in Part B → Q21

@Neet_pg_bot

Q22: A 25-year-old man presents with headaches, visual disturbances, and hypertension. MRI brain shows a cerebellar hemangioblastoma, and abdominal imaging reveals multiple cysts in the kidneys along with a solid renal mass suggestive of renal cell carcinoma. His father had similar findings and died from a brain tumor in his 40s.Which of the following chromosomal abnormalities is most likely associated with his condition? (Q866733)

A. Deletion on chromosome 13q

B. Deletion on chromosome 17p

C. Deletion on chromosome 3p

D. Trisomy of chromosome 12

See Answer in Part B → Q22

@Neet_pg_bot

Q23: FBN1 gene mutation is seen in which of the following genetic disorders? (Q866750)

A. Ehlers-Danlos syndrome

B. Marfan syndrome

C. Homocystinuria

D. von Hippel-Lindau syndrome

See Answer in Part B → Q23

@Neet_pg_bot

Q24: Which of the following is not an aneuploidy? (Q865426)

A. Bloom syndrome

B. Trisomy 13

C. Trisomy 21

D. Klinefelter syndrome

See Answer in Part B → Q24

@Neet_pg_bot

Q25: A lymphoma characterised by the presence of centrocytes and centroblasts, along with BCL2 positivity and CD10 expression, is most commonly associated with

which chromosomal translocation? (Q866357)

A. t(2;5)

B. t(8;14)

C. t(14;18)

D. t(11;14)

See Answer in Part B → Q25

@Neet_pg_bot

Q26: Which of the following diseases exhibits the inheritance pattern shown? (Q866378)

A. Kearns-Sayre syndrome

B. Williams syndrome

C. Achondroplasia

D. Cystic fibrosis

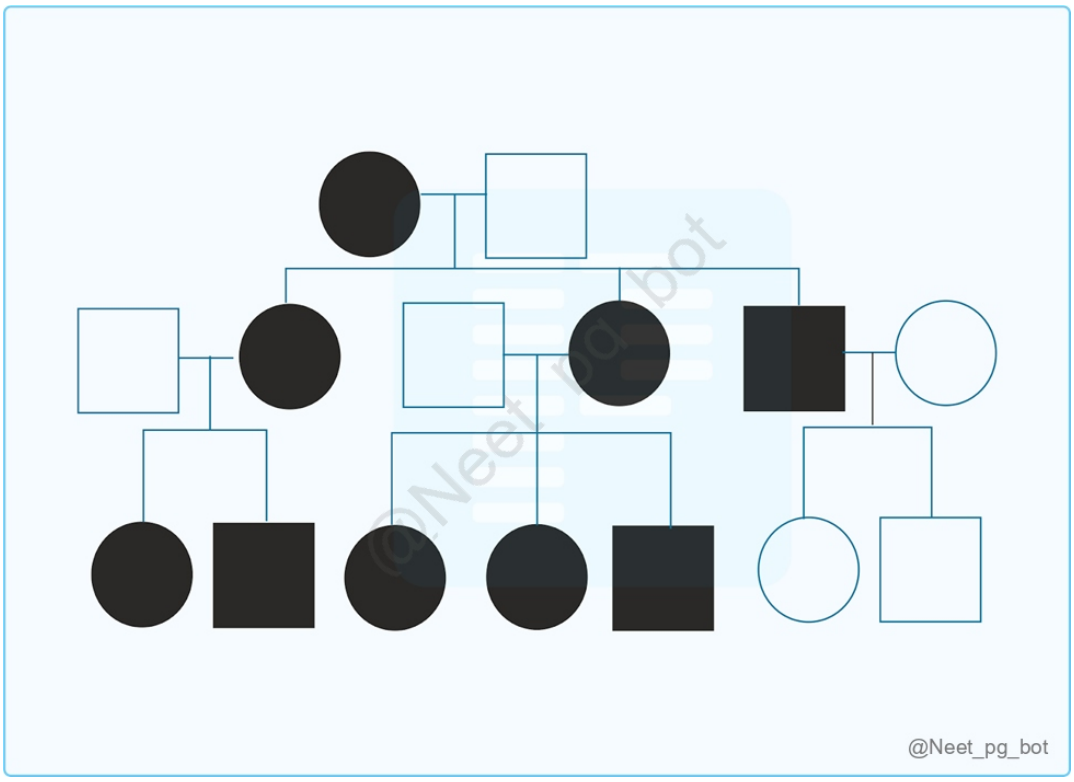

See Answer in Part B → Q26

@Neet_pg_bot

Q27: Match the following with the appropriate disorder. A. Autosomal recessive Kennedy disease B. Mitochondrial 2. Duchenne's muscular dystrophy C. X-linked recessive 3. Leber's disease D. Trinucleotide repeats 4. Cystic fibrosis (Q853376)

A. A-4, B-3, C-1, D-2

B. A-4, B-3, C-2, D-1

C. A-2, B-1, C-3, D-4

D. A-1, B-2, C-4, D-3

See Answer in Part B → Q27

@Neet_pg_bot

Q28: Identify the syndrome associated with the following chromosomal pattern on chromosome number 15 : (Q843980)

A. Angelman syndrome

B. Prader-Willi syndrome

C. Rett syndrome

D. Cri-du-chat syndrome

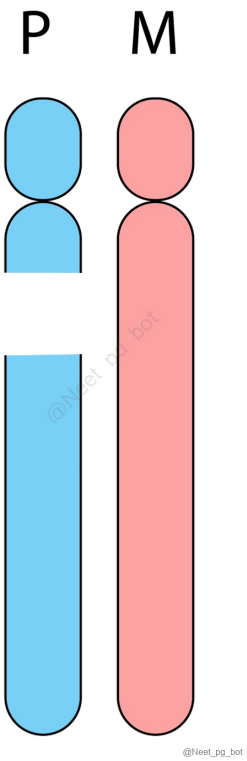

See Answer in Part B → Q28

@Neet_pg_bot

Q29: A 23-year-old female with a height of 4 feet has a karyotype, as shown in the image below. Which of the following conditions is the most likely etiology? (Q844074)

A. Turner syndrome

B. Klinefelter syndrome

C. Mayer-Rokitansky-Küster-Hauser syndrome (MRKHS)

D. Edwards syndrome

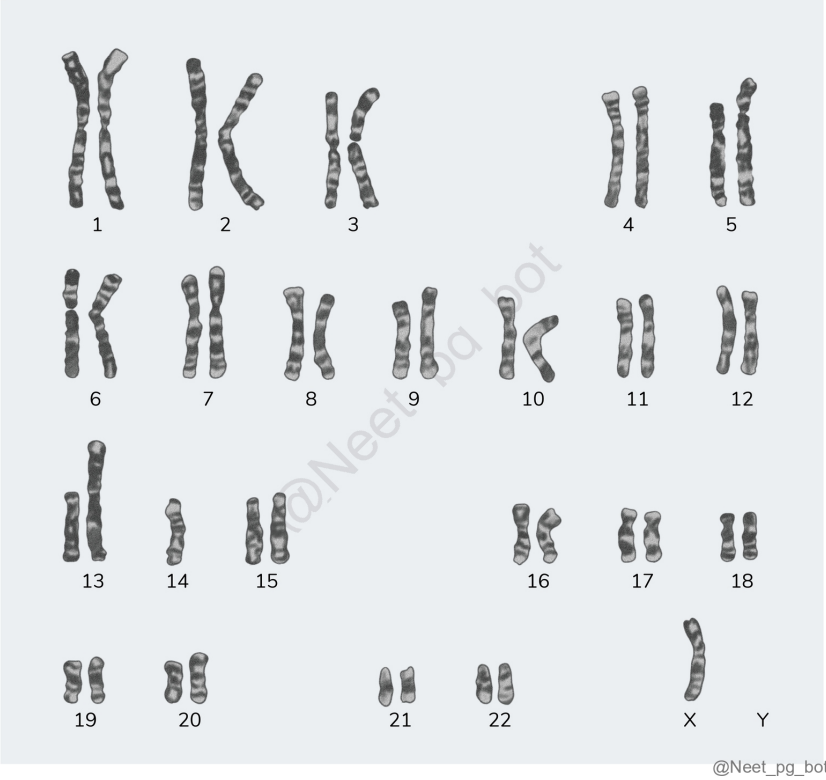

See Answer in Part B → Q29

@Neet_pg_bot

Q30: Identify the disease associated with the image provided: (Q844143)

A. Gaucher's disease

B. Tay-Sachs disease

C. Sandhoff's disease

D. Fabry's disease

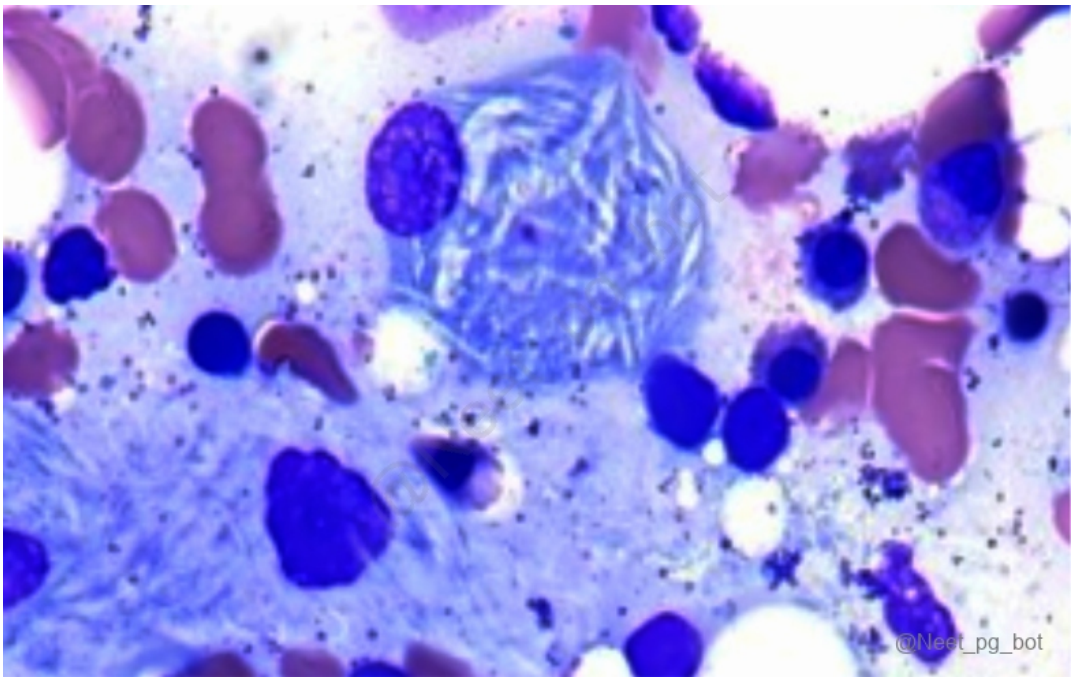

See Answer in Part B → Q30

@Neet_pg_bot

Q31: Which of the following diseases follows the mode of inheritance shown in the image provided? (Q844173)

A. Wiskott-Aldrich syndrome

B. Wilson's disease

C. Prader-Willi syndrome

D. Achondroplasia

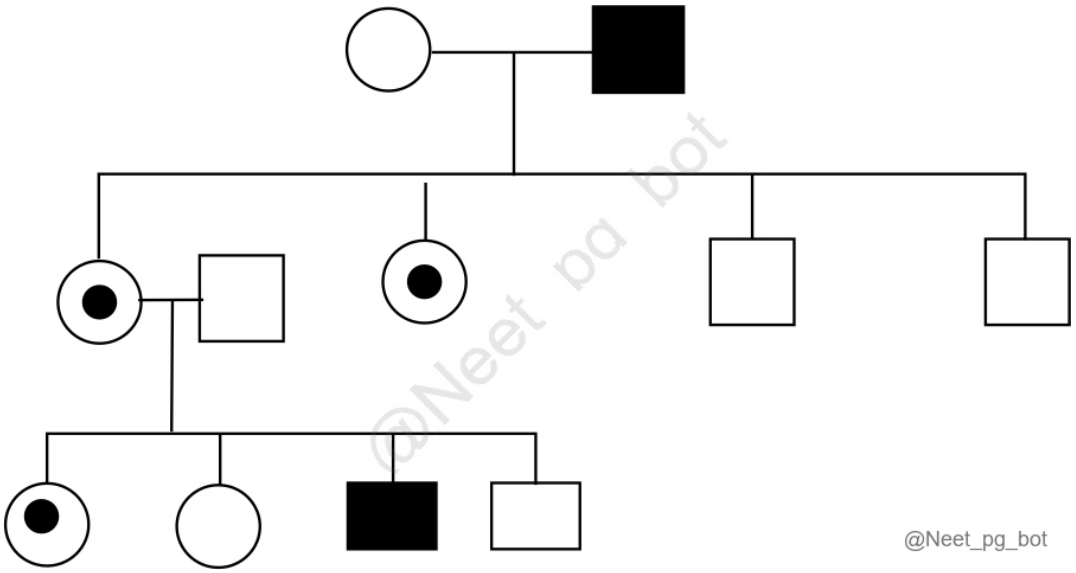

See Answer in Part B → Q31

@Neet_pg_bot

Q32: The SRY gene is present on: (Q857449)

A. Y-chromosome short arm

B. Y-chromosome long arm

C. X-chromosome short arm

D. X-chromosome long arm

See Answer in Part B → Q32

@Neet_pg_bot

Q33: Which mutation is linked to the Philadelphia chromosome? (Q860544)

A. Inversion

B. Deletion

C. Reciprocal translocation

D. Insertion

See Answer in Part B → Q33

@Neet_pg_bot

Q34: A teenager was brought to the OPD with complaints of delayed fertility and primary amenorrhea. Physical examination reveals a webbed neck and widely spaced nipples. Which karyotype is associated with a given condition? (Q860555)

A. 45, X

B. 47, XXY

C. 47, XXX

D. 47, XYY

See Answer in Part B → Q34

@Neet_pg_bot

Q35: Which of the following is not a feature of G6PD deficiency? (Q840016)

A. Males and females are equally affected

B. Oxidative stress

C. Absence of NADPH

D. Presence of Heinz's bodies

See Answer in Part B → Q35

@Neet_pg_bot

Q36: A child with a strawberry skull, mental retardation, and the given karyotype suggests which diagnosis? (Q860199)

A. Patau syndrome

B. Edward syndrome

C. Prader-Willi syndrome

D. Angelman syndrome

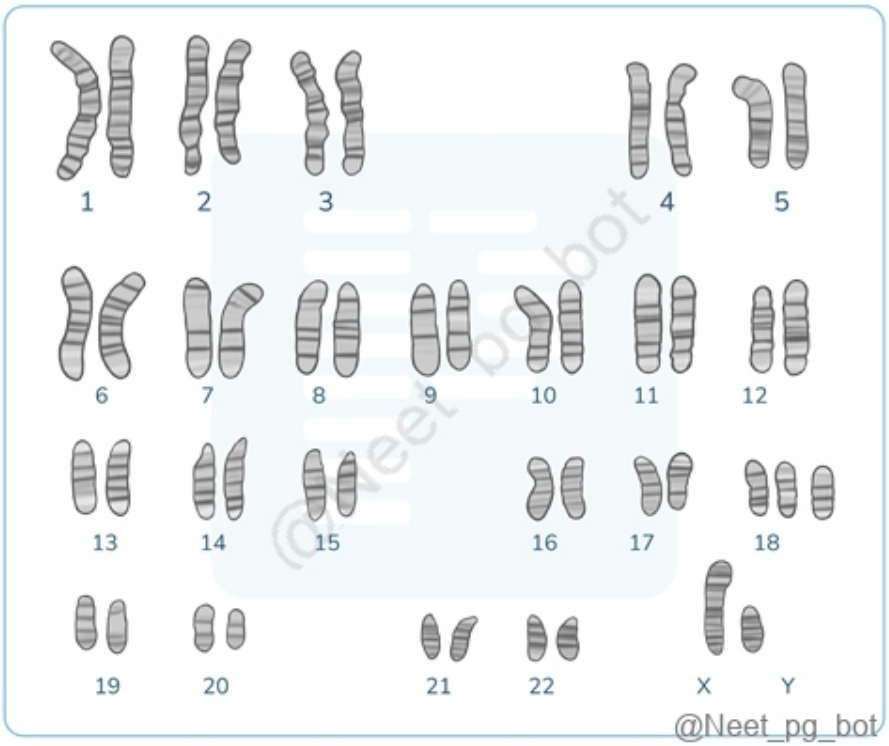

See Answer in Part B → Q36

@Neet_pg_bot

Q37: All of the following are used to detect abnormal gene sequences, except? (Q857421)

A. FISH

B. RFLP analysis

C. Pyrosequencing

D. Flow cytometry

See Answer in Part B → Q37

@Neet_pg_bot

Q38: What is the interpretation of the given pedigree chart? (Q857425)

A. Incomplete penetrance

B. Autosomal dominant

C. Autosomal recessive

D. Pseudo-dominance

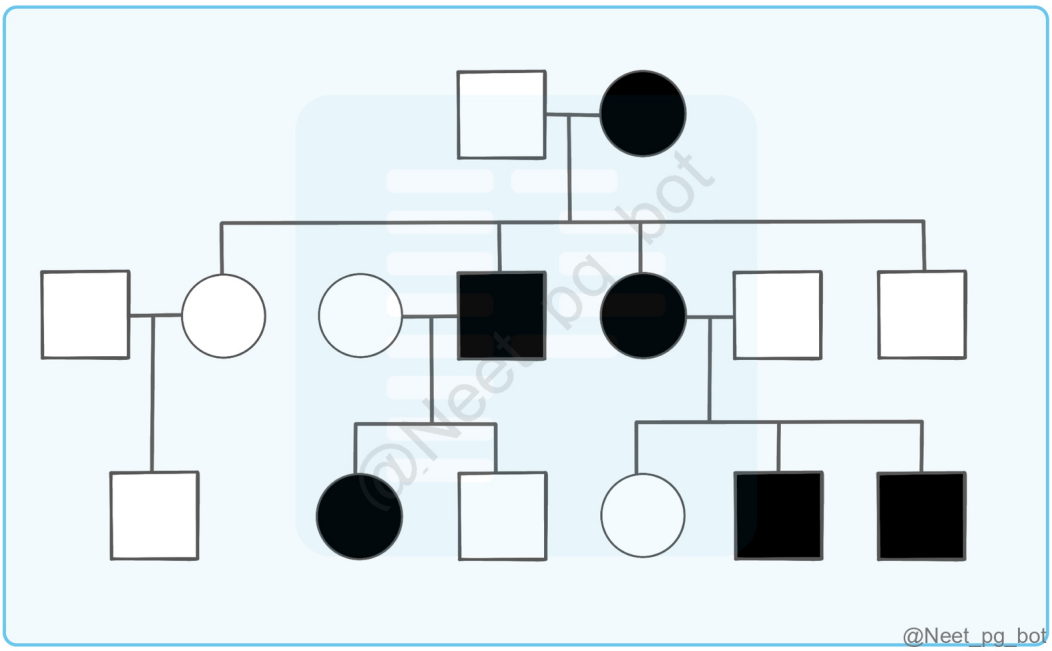

See Answer in Part B → Q38

@Neet_pg_bot

Q39: Match the following genetic abnormalities with their disorders. A. Trinucleotide repeat Patau syndrome B. Trisomy 18 2. Huntington C. Trisomy 13 3. Sickle cell anemia D. Hb beta chain Glu 4. Edward syndrome (Q857437)

A. A-1, B-3, D-4, D-2

B. A-1, B-2, C-3, D-4

C. A-2, B-4, C-1, D-3

D. A-2, B-1, C-4, D-3

See Answer in Part B → Q39

@Neet_pg_bot

Q40: The family pedigree chart is given below. Identify the mode of inheritance of this condition. (Q854889)

A. Autosomal dominant

B. Autosomal recessive

C. X-linked dominant

D. X-linked recessive

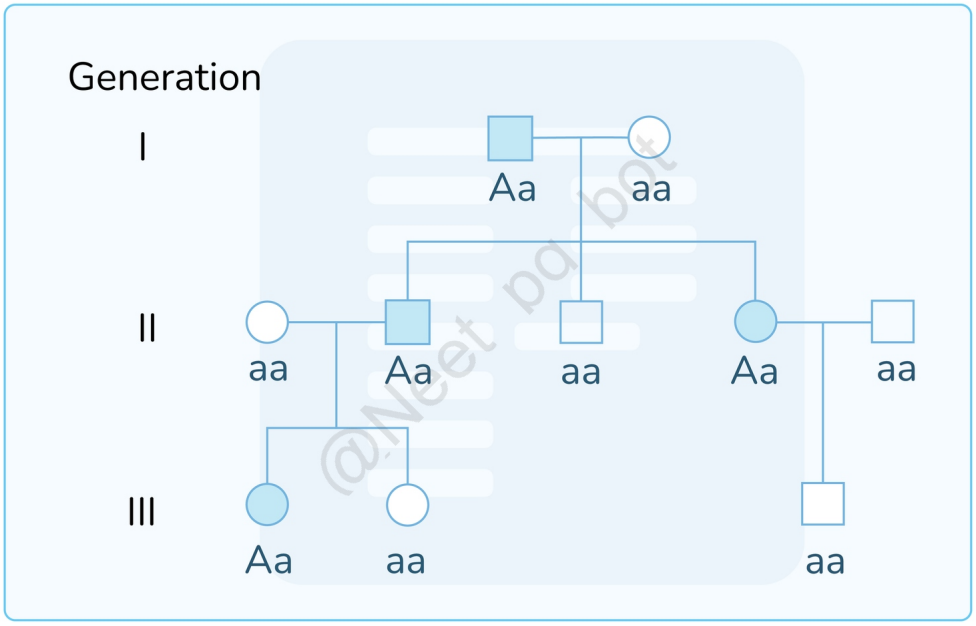

@Neet_pg_bot

See Answer in Part B → Q40

@Neet_pg_bot

Q41: A boy was diagnosed with a medical condition that is believed to have been passed down from his grandmother to his father, and now to him. What is the pattern of inheritance in this case ? (Q793641)

A. X-linked dominant

B. X-linked recessive

C. Autosomal dominant

D. Autosomal recessive

See Answer in Part B → Q41

@Neet_pg_bot

Q42: What does the given pedigree chart indicate? (Q860176)

A. Autosomal Dominant (AD)

B. Autosomal Recessive (AR)

C. Mitochondrial Disorder

D. X-linked Recessive (XLR)

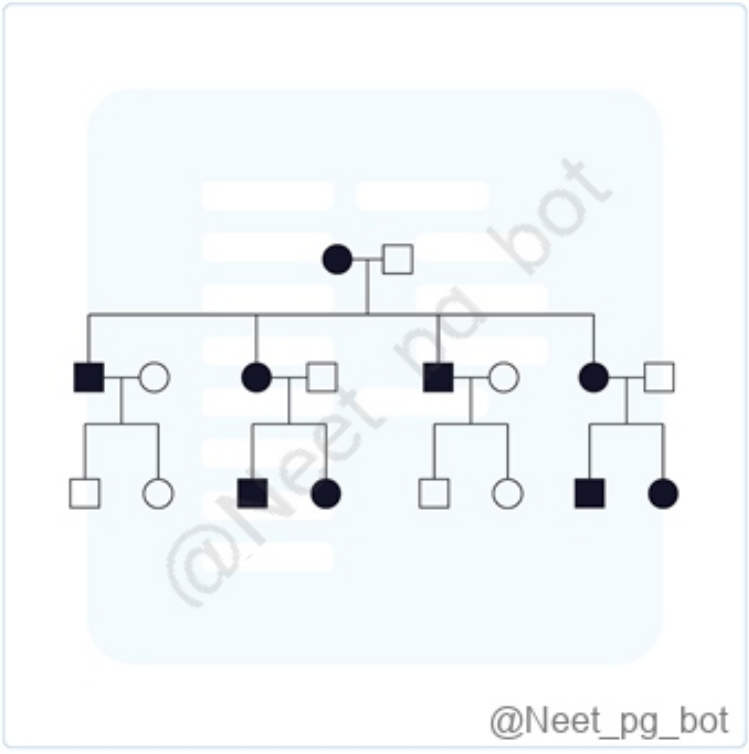

See Answer in Part B → Q42

@Neet_pg_bot

Q43: What is the interpretation of the given pedigree chart? (Q858065)

A. Autosomal dominant

B. Autosomal recessive

C. X-linked recessive

D. X-linked dominant

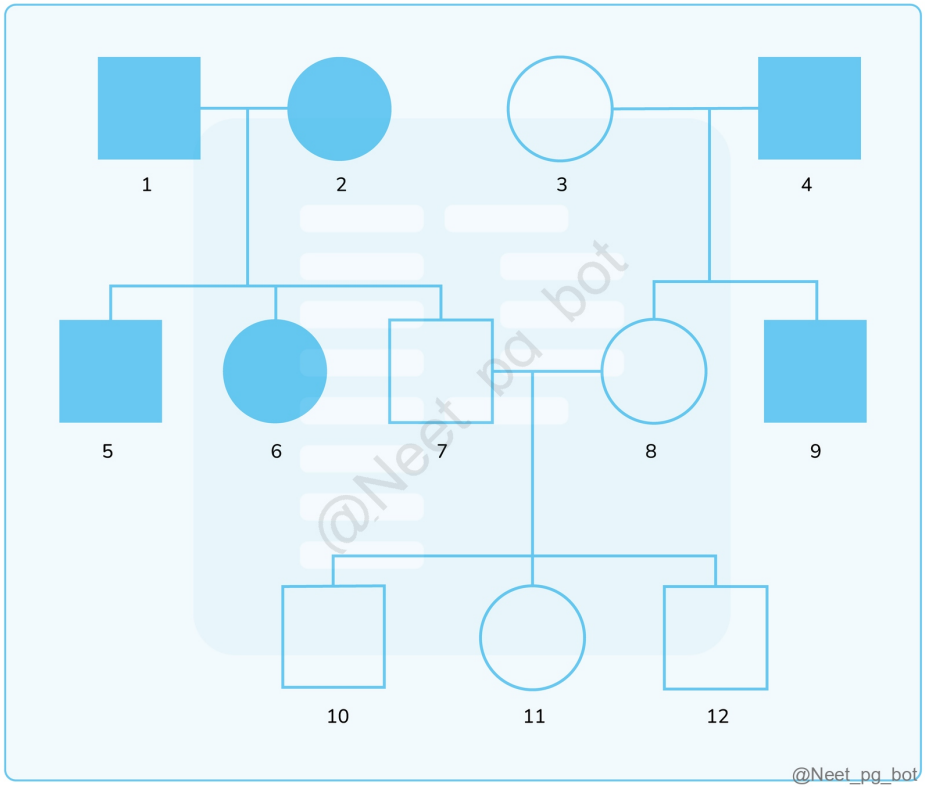

See Answer in Part B → Q43

@Neet_pg_bot

Q44: Match the columns A. Autosomal dominant 1. Duchenne muscular dystrophy B. X-linked recessive 2. Leber hereditary optic neuropathy C. Autosomal recessive 3. Cystic fibrosis D. Mitochondrial 4. Myotonic dystrophy (Q854706)

A. A-1, B-4, C-2, D-3

B. A-2, B-3, C-4, D-1

C. A-1, B-3, C-2, D-4

D. A-4, B-1, C-3, D-2

See Answer in Part B → Q44

@Neet_pg_bot

• [04_Neoplasia] 014 Classification And Features Of Neoplasia

« Back to Folder Directory

[04_Neoplasia] 014 Classification And Features Of Neoplasia — Quick Jump

Q1 (p. 169)	*Q2 (p. 169)*	*Q3 (p. 170)*	*Q4 (p. 170)*	*Q5 (p. 170)*	*Q6 (p. 171)*
Q7 (p. 171)	*Q8 (p. 171)*	*Q9 (p. 172)*	*Q10 (p. 172)*	*Q11 (p. 173)*	*Q12 (p. 173)*
Q13 (p. 173)	*Q14 (p. 174)*	*Q15 (p. 174)*	*Q16 (p. 175)*	*Q17 (p. 175)*	

Q1: A biopsy from a rapidly enlarging thigh mass in a 35-year-old man reveals a malignant tumor composed of spindle-shaped cells arising from mesenchymal tissue. Which of the following is the most appropriate designation for this neoplasm? (Q879697)

A. Adenocarcinoma

B. Lymphoma

C. Sarcoma

D. Papilloma

See Answer in Part B → Q1

@Neet_pg_bot

Q2: Which of the following statements best characterizes a hamartoma? (Q879693)

A. Malignant neoplasm composed of immature, non-native cells

B. Disorganized but benign proliferation of mature, native cells within an organ

C. Developmental cyst always present from birth and never clonal

D. Metastatic lesion that reproduces the normal architecture of the tissue

See Answer in Part B → Q2

@Neet_pg_bot

Q3: A 4-year-old child presents with an abdominal mass. Biopsy shows a poorly differentiated neoplasm composed of uniform, undifferentiated cells with scant cytoplasm and hyperchromatic nuclei, giving a "small round blue cell" appearance. Which of the following tumors is not typically classified under the group of small round blue cell tumors of childhood?' (Q879691)

A. Neuroblastoma

B. Wilms tumor

C. Medulloblastoma

D. Hepatoblastoma

See Answer in Part B → Q3

@Neet_pg_bot

Q4: Which of the following statements about adenomas is correct? (Q879679)

A. Adenoma refers only to benign epithelial tumors that form true glandular structures.

B. Adenoma can refer to benign epithelial tumors of glandular origin, even if they do not form glands

C. Adenoma is a term used for malignant tumors of glandular epithelium

D. Adenoma refers exclusively to tumors of the adrenal cortex

See Answer in Part B → Q4

@Neet_pg_bot

Q5: A 55-year-old patient is diagnosed with a tumor. Histopathology shows uncontrolled proliferation, invasion into adjacent structures, and the presence of cells with variable differentiation. Which of the following features is the most definitive indicator of malignancy in this tumor? (Q879673)

A. Presence of mitotic figures

B. Tissue of origin identifiable as epithelial

C. Ability to invade surrounding tissues

D. Formation of glandular patterns in some areas

See Answer in Part B → Q5

@Neet_pg_bot

Q6: Which of the following types of cancer is least likely to exhibit distant metastasis? (Q845142)

A. Renal cell carcinoma

B. Melanoma

C. Basal cell carcinoma

D. Prostatic carcinoma

See Answer in Part B → Q6

@Neet_pg_bot

Q7: Which of the following is true regarding the Sentinel lymph node? (Q845146)

A. The first lymph node to receive metastasis from a secondary tumour.

B. Also helpful in identifying metastasis in Melanoma.

C. Commonly involved in skip metastasis

D. The presence of cancer cells indicates a good prognosis

See Answer in Part B → Q7

@Neet_pg_bot

Q8: Which of the following tumors do not follow lymphatic route of spread? (Q845145)

A. Rhabdomyosarcoma

B. Krukenberg tumor

C. Follicular thyroid carcinoma

D. Synovial sarcoma

See Answer in Part B → Q8

@Neet_pg_bot

Q9: Which of the following tumours do not typically exhibit direct seeding of body cavities? (Q845144)

A. Pseudomyxoma peritonei

B. Gastric carcinoma

C. Hepatocellular carcinoma

D. Medulloblastoma

See Answer in Part B → Q9

@Neet_pg_bot

Q10: A 45-year-old female presents with a palpable lump in her left breast which is freely mobile and painless. A biopsy of the lump was performed, and a histopathological examination was done. Which feature from the biopsy report is most likely to differentiate between benign and malignant breast lesions? (Q845134)

A. Presence of well-defined glandular structures

B. Evidence of invasion into surrounding tissues

C. Low mitotic rate

D. Presence of fibrous stroma

See Answer in Part B → Q10

@Neet_pg_bot

Q11: Which of the following characteristics distinguishes hemangiomas from other benign tumors? (Q845141)

A. Rapid growth rate

B. Presence of extracellular matrix (ECM) deposited by stromal cells

C. Easily resected by excision

D. Unencapsulated

See Answer in Part B → Q11

@Neet_pg_bot

Q12: Which of the following statements is/are True? The basement membrane remains intact in dysplasia. Dysplasia is always irreversible. Pleomorphism is observed in metaplasia. Myositis ossificans is an example of dysplasia. (Q845140)

A. 1, 3 and 4

B. 1 only

C. 2 and 4

D. 1, 2 and 3

See Answer in Part B → Q12

@Neet_pg_bot

Q13: Which of the following features is not a characteristic of anaplasia? (Q845139)

A. Pleomorphism

B. Loss of polarity

C. Increased nuclear-to-cytoplasmic ratio

D. Intact basement membrane

See Answer in Part B → Q13

@Neet_pg_bot

Q14: A 55-year-old man presents with chronic heartburn and difficulty swallowing. Upon examination, the physician suspects gastroesophageal reflux disease (GERD) and orders an upper GI endoscopic biopsy, which reveals the presence of columnar epithelium in the lower oesophagus, replacing the normal squamous epithelium. Which of the following terms describes the observed cellular change? (Q845138)

A. Metaplasia

B. Dysplasia

C. Anaplasia

D. Desmoplasia

See Answer in Part B → Q14

@Neet_pg_bot

Q15: A 30-year-old female presents with pelvic pain and irregular menstrual cycles. She undergoes surgical resection of the mass, and histopathological examination reveals a tumour composed of mature tissues derived from multiple germ layers, including hair, teeth, and sebaceous material. Based on the histopathological findings described, which of the following tumours is the most likely diagnosis? (Q845137)

A. Teratoma

B. Serous cystadenoma

C. Mucinous cystadenoma

D. Granulosa cell tumour

See Answer in Part B → Q15

@Neet_pg_bot

Q16: What is the most likely diagnosis of a patient with a painless, slowly enlarging mass in the right parotid gland region that is well-defined and heterogeneous, with both epithelial and mesenchymal components present in the biopsy? (Q845136)

A. Pleomorphic adenoma

B. Mucoepidermoid carcinoma

C. Acinic cell carcinoma

D. Warthin tumour

See Answer in Part B → Q16

@Neet_pg_bot

Q17: Which of the following tumour is of mesenchymal origin? (Q845135)

A. Adenoma

B. Papilloma

C. Seminoma

D. Leiomyoma

See Answer in Part B → Q17

@Neet_pg_bot

• [04_Neoplasia] 015 Etiology Of Neoplasia

« Back to Folder Directory

[04_Neoplasia] 015 Etiology Of Neoplasia — Quick Jump

Q1 (p. 176)	*Q2 (p. 176)*	*Q3 (p. 177)*	*Q4 (p. 178)*	*Q5 (p. 178)*	*Q6 (p. 178)*
Q7 (p. 179)	*Q8 (p. 179)*	*Q9 (p. 179)*	*Q10 (p. 180)*	*Q11 (p. 180)*	*Q12 (p. 180)*
Q13 (p. 181)	*Q14 (p. 181)*	*Q15 (p. 182)*	*Q16 (p. 182)*	*Q17 (p. 182)*	*Q18 (p. 183)*
Q19 (p. 183)	*Q20 (p. 184)*	*Q21 (p. 184)*	*Q22 (p. 185)*	*Q23 (p. 186)*	*Q24 (p. 186)*
Q25 (p. 187)	*Q26 (p. 187)*	*Q27 (p. 188)*	*Q28 (p. 188)*	*Q29 (p. 188)*	*Q30 (p. 189)*
Q31 (p. 189)	*Q32 (p. 190)*	*Q33 (p. 190)*	*Q34 (p. 191)*	*Q35 (p. 191)*	

Q1: Which of the following conditions is most likely associated with vinyl chloride exposure? (Q845149)

A. Hepatocellular carcinoma

B. Hepatic angiosarcoma

C. Cholangiocarcinoma

D. Focal nodular hyperplasia

See Answer in Part B → Q1

@Neet_pg_bot

Q2: A 35-year-old man presents with painless enlarged lymph nodes in the neck and intermittent low-grade fever. Laboratory studies show normal peripheral blood counts. A biopsy of the lymph node reveals enlarged follicles with prominent vascular proliferation and increased plasma cells. Which of the following is the most likely diagnosis? (Q879869)

A. Angiolymphoma

B. Hodgkin’s lymphoma

C. IgG4-related disease

D. Castleman disease

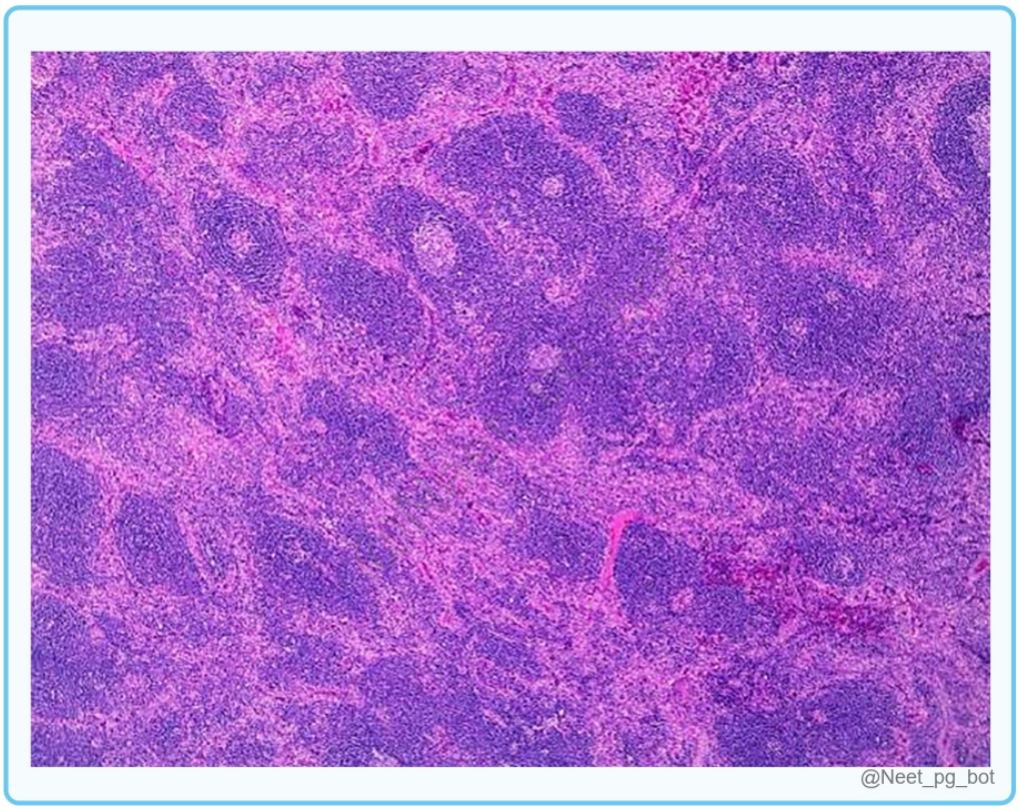

See Answer in Part B → Q2

@Neet_pg_bot

Q3: A teenager is diagnosed with infectious mononucleosis, confirmed by a positive Monospot (heterophile antibody) test. The virus responsible for this condition is also linked to several malignancies. Which of the following cancers is least likely to be associated with this viral infection? (Q879867)

A. Burkitt lymphoma

B. Hodgkin’s lymphoma

C. Nasopharyngeal carcinoma

D. Follicular lymphoma

See Answer in Part B → Q3

@Neet_pg_bot

Q4: Infection with Human T-lymphotropic virus type 1 (HTLV-1) is most strongly associated with which of the following hematologic malignancies? (Q879844)

A. Adult T-cell leukemia/lymphoma

B. Enteropathy-associated T-cell lymphoma

C. Diffuse large B-cell lymphoma

D. B-cell lymphomas

See Answer in Part B → Q4

@Neet_pg_bot

Q5: Which of the following cancers is least likely to be linked to an infectious etiology? (Q879840)

A. Burkitt lymphoma

B. Castleman’s disease

C. Adenocarcinoma of the lung

D. Primary effusion lymphoma

See Answer in Part B → Q5

@Neet_pg_bot

Q6: A 52-year-old construction worker with a history of chronic sun exposure presents for a routine skin examination. Which of the following skin conditions are considered UV-induced premalignant or malignant lesions? 1. Squamous cell carcinoma 2. Basal cell carcinoma 3. Seborrheic keratosis 4. Actinic keratosis (Q879835)

A. 1, 2, 3

B. 2, 3, 4

C. 1, 3, 4

D. 1, 2, 4

See Answer in Part B → Q6

@Neet_pg_bot

Q7: Which of the following compounds acts as a direct-acting carcinogen, meaning it does not require metabolic conversion to become carcinogenic? (Q879831)

A. Cyclophosphamide

B. Benzidine

C. 3-Methylcholanthrene

D. Dimethylaminoazobenzene

See Answer in Part B → Q7

@Neet_pg_bot

Q8: Which of the following neoplasms is considered the prototype for studying the multi-step process of carcinogenesis? (Q879825)

A. Colon carcinoma

B. Melanoma

C. Thyroid carcinoma

D. Breast carcinoma

See Answer in Part B → Q8

@Neet_pg_bot

Q9: Which of the following immune checkpoint interactions is correctly matched with its inhibitory effect on T-cell activation? (Q879809)

A. CTLA-4 binding to B7 molecules on APCs – prevents costimulatory signaling via CD28

B. PD-1 binding to PD-L1/PD-L2 on tumor cells – enhances T-cell cytotoxic activity

C. CD28 binding to B7 molecules on APCs – induces long-lived unresponsiveness of T cells

D. PD-1 blockade – reduces T-cell function in the tumor microenvironment

See Answer in Part B → Q9

@Neet_pg_bot

Q10: Deletion of which microRNAs is most commonly associated with increased BCL2 expression in chronic lymphocytic leukemia? (Q879806)

A. miR-15 and miR-16

B. miR-155 and miR-21

C. miR-34a and miR-200

D. miR-17 and miR-92

See Answer in Part B → Q10

@Neet_pg_bot

Q11: Which of the following genes is most frequently mutated in malignant rhabdoid tumors? (Q879801)

A. SNF5

B. ARID1A

C. PBRM1

D. DNMT3A

See Answer in Part B → Q11

@Neet_pg_bot

Q12: Which type of circulating blood cell shows the greatest resistance to radiation damage? (Q879733)

A. Lymphocytes

B. Granulocytes

C. Platelets

D. Erythrocytes

See Answer in Part B → Q12

@Neet_pg_bot

Q13: Which of the following cancers is most strongly associated with excessive alcohol use? (Q879729)

A. Carcinoma of lip

B. Carcinoma of larynx

C. Carcinoma of pancreas

D. Carcinoma of stomach

See Answer in Part B → Q13

@Neet_pg_bot

Q14: The Notch signaling pathway in angiogenesis is mainly involved in? (Q879725)

A. ECM degradation

B. Vasodilation

C. Regulating sprouting and branching of new vessels

D. Endothelial cell proliferation

See Answer in Part B → Q14

@Neet_pg_bot

Q15: A 60-year-old man who has worked in the zinc mines presents to his urologist with urinary symptoms, including increased frequency, hesitancy, and nocturia. During a digital rectal examination, he is found to have an enlarged prostate with a palpable nodule. Which environmental exposure is most likely associated with his prostate cancer risk? (Q845148)

A. Zinc

B. Benzopyrene

C. Arsenic

D. Cadmium

See Answer in Part B → Q15

@Neet_pg_bot

Q16: A 16-year-old girl presents with a clear-cell vaginal tumour. Upon further inquiry, it was revealed that her mother has a history of taking medication during pregnancy to prevent premature labour. Which medication is most likely associated with the development of this tumour in the daughter? (Q845150)

A. DES (Diethylstilbestrol)

B. Thalidomide

C. Tamoxifen

D. Medroxyprogesterone acetate

See Answer in Part B → Q16

@Neet_pg_bot

Q17: Which of the following is not an indirect-acting carcinogen? (Q845151)

A. Griseofulvin

B. Azo dyes

C. Nitrosoureas

D. Betel nuts

See Answer in Part B → Q17

@Neet_pg_bot

Q18: Which of the following radiations is the most common cause of skin cancer? (Q845152)

A. UV-A radiation

B. UV-B radiation

C. UV-C radiation

D. UV-D radiation

See Answer in Part B → Q18

@Neet_pg_bot

Q19: A 55-year-old female radiology technician with 25 years of occupational exposure to diagnostic X-rays and fluoroscopy presents with a three-month history of increasing fatigue, unintentional weight loss, and frequent infections. Which cancer type is most likely associated with her occupational history? (Q845153)

A. Acute Myeloid Leukemia

B. Pancreatic cancer

C. Medullary thyroid cancer

D. Chronic Lymphocytic Leukemia

See Answer in Part B → Q19

@Neet_pg_bot

Q20: A 35-year-old woman presents for a routine gynaecological examination. Her Pap smear and biopsy reveals abnormal cells suggestive of cervical dysplasia. Further, HPV testing indicates the presence of specific HPV types associated with cervical cancer. Which HPV types are most commonly linked to an increased risk of cervical cancer in this patient? (Q845154)

A. Low-risk 6, 11

B. High-risk 6, 11

C. Low-risk 16, 18

D. High-risk 16, 18

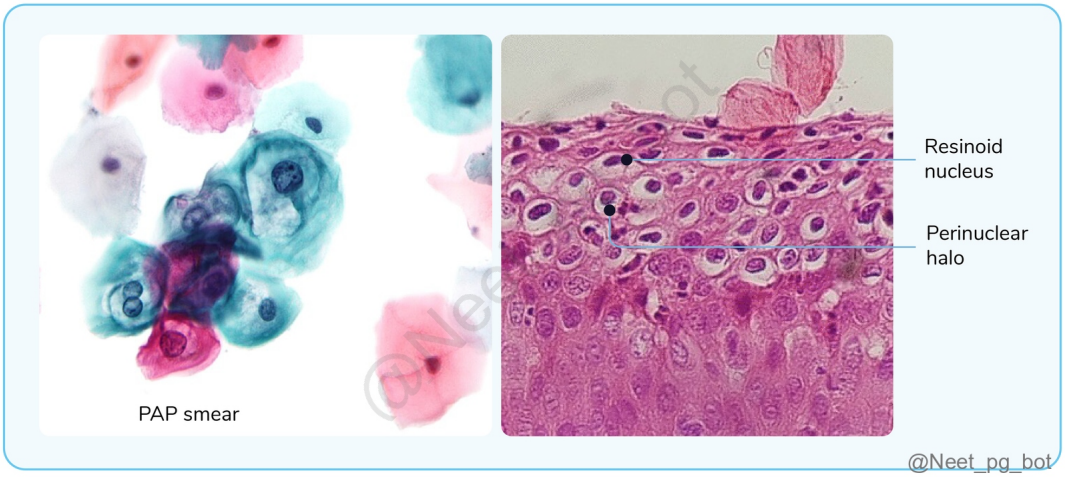

See Answer in Part B → Q20

@Neet_pg_bot

Q21: A 35-year-old woman with regular menstrual cycles undergoes routine Pap smear screening, which reveals a high-grade squamous intraepithelial lesion (HSIL) of the cervix. Further testing confirms infection with high-risk HPV type 16. Which of the following mechanisms regarding the oncogenic activity of E6 and E7 of HPV is correct? (Q845155)

A. E6 protein inhibits the degradation of p53.

B. E6 stimulates the expression of TERT.

C. E7 activates CDK inhibitors.

D. E7 can inactivate cyclins A and E

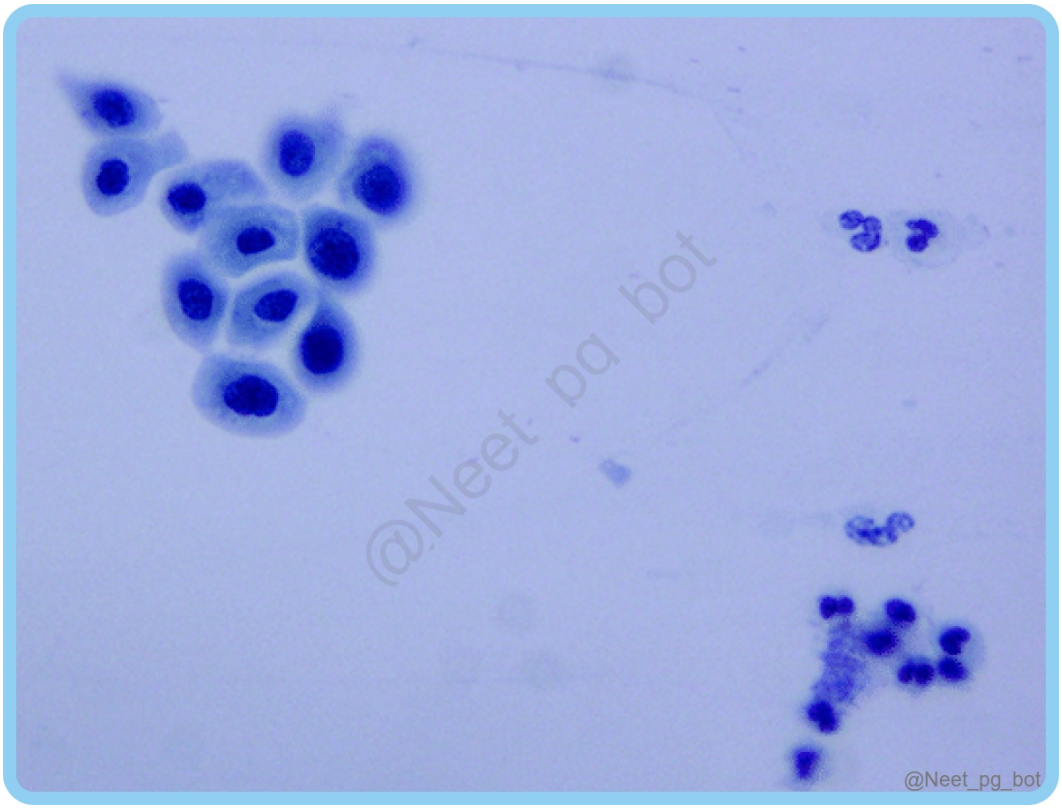

See Answer in Part B → Q21

@Neet_pg_bot

Q22: A 10-year-old girl presents with rapidly growing jaw swelling and pain. Further examination reveals bilateral enlargement of the mandible and maxilla. Biopsy suggests the presence of a starry-sky appearance as shown in the image. Which of the following infectious agents is most commonly associated with the pathogenesis of this malignancy? (Q845156)

A. EBV

B. HTLV-1

C. HHV-8

D. Aspergillus flavus

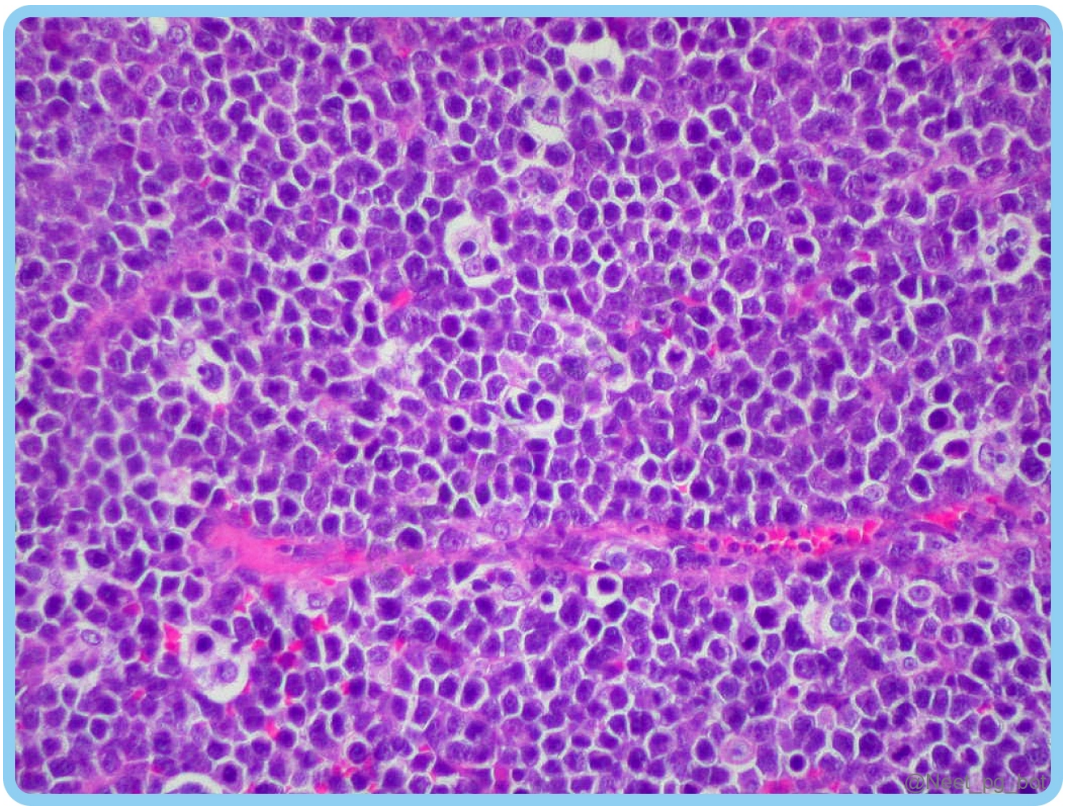

See Answer in Part B → Q22

@Neet_pg_bot

Q23: Infection with Helicobacter pylori is linked to the development of several gastrointestinal diseases. Which of the following conditions is least likely to be associated with H. pylori infection? (Q845158)

A. Peptic ulcer disease

B. Barrett’s esophagus

C. Gastric adenocarcinoma

D. Mucosa-associated lymphoid tissue (MALT) lymphoma

See Answer in Part B → Q23

@Neet_pg_bot

Q24: Match the following carcinogens with the respective cancer risk 1. Azodyes a) Urothelial carcinoma of the bladder 2. Schistosoma haematobium b) AML & ALL 3. Radon c) Squamous cell carcinoma of the bladder 4. Benzene d) Squamous cell carcinoma of the lung (Q845159)

A. 1-a, 2-c, 3- d, 4-b

B. 1-a, 2-c, 3- b, 4-d

C. 1-c, 2-a, 3- d, 4-b

D. 1-c, 2-a, 3- b, 4-d

See Answer in Part B → Q24

@Neet_pg_bot

Q25: A 60-year-old man who has worked in the zinc mines presents to his urologist with urinary symptoms, including increased frequency, hesitancy, and nocturia. During a digital rectal examination, he is found to have an enlarged prostate with a palpable nodule. Which environmental exposure is most likely associated with his prostate cancer risk? (Q845484)

A. Benzene

B. Benzopyrene

C. Arsenic

D. Cadmium

See Answer in Part B → Q25

@Neet_pg_bot

Q26: Which of the following is not an indirect-acting carcinogen? (Q845487)

A. Griseofulvin

B. Azo dyes

C. Nitrosoureas

D. Betel nuts

See Answer in Part B → Q26

@Neet_pg_bot

Q27: Which of the following conditions is most likely associated with vinyl chloride exposure? (Q845485)

A. Hepatocellular carcinoma

B. Hepatic angiosarcoma

C. Cholangiocarcinoma

D. Focal nodular hyperplasia

See Answer in Part B → Q27

@Neet_pg_bot

Q28: A 16-year-old girl presents with a clear-cell vaginal tumour. Upon further inquiry, it was revealed that her mother has a history of taking medication during pregnancy to prevent premature labour. Which medication is most likely associated with the development of this tumour in the daughter? (Q845486)

A. DES (Diethylstilbestrol)

B. Thalidomide

C. Tamoxifen

D. Medroxyprogesterone acetate

See Answer in Part B → Q28

@Neet_pg_bot

Q29: Match the following carcinogens with the respective cancer risk: 1. Azodyes a) Urothelial carcinoma of the bladder 2. Schistosoma haematobium b) Adenocarcinoma of the lung 3. Radon c) Squamous cell carcinoma of the bladder 4. Asbestos d) Squamous cell carcinoma of the lung (Q845494)

A. 1-a, 2-c, 3- d, 4-b

B. 1-a, 2-c, 3- b, 4-d

C. 1-c, 2-a, 3- d, 4-b

D. 1-c, 2-a, 3- b, 4-d

See Answer in Part B → Q29

@Neet_pg_bot

Q30: Which of the following statements regarding H. pylori infection and its association with malignancies is correct ? (Q845493)

A. Gastric lymphomas associated with H. pylori infection are primarily of B-cell origin.

B. H. pylori strains associated with gastric adenocarcinomas contain the cytotoxin-associated B gene.

C. VacA, a toxin from H. pylori, causes gastric cell apoptosis, reducing cancer risk.

D. MALT lymphomas associated with t(11;18) translocation respond to anti-H.Pylori therapy.

See Answer in Part B → Q30

@Neet_pg_bot

Q31: A 10-year-old girl presents with rapidly growing jaw swelling and pain. Further examination reveals bilateral enlargement of the mandible and maxilla. Biopsy suggests the presence of a starry-sky appearance. What is the characteristic chromosomal translocation associated with this tumor? (Q845492)

A. t(8;14)

B. t(15;17)

C. t(9;22)

D. t(11;14)

See Answer in Part B → Q31

@Neet_pg_bot

Q32: A 35-year-old woman with regular menstrual cycles undergoes routine Pap smear screening, which reveals a high-grade squamous intraepithelial lesion (HSIL) of the cervix. Further testing confirms infection with high-risk HPV type 16. Which of the following mechanisms regarding the oncogenic activity of E6 and E7 of HPV is correct? (Q845491)

A. E6 protein inhibits the degradation of p53.

B. E6 stimulates the expression of TERT.

C. E7 activates CDK inhibitors.

D. E7 can inactivate cyclins A and E.

See Answer in Part B → Q32

@Neet_pg_bot

Q33: A 35-year-old woman presents for a routine gynaecological examination. Her Pap smear and biopsy reveals abnormal cells suggestive of cervical dysplasia. Further, HPV testing indicates the presence of specific HPV types associated with cervical cancer. Which HPV types are most commonly linked to an increased risk of cervical cancer in this patient? (Q845490)

A. Low-risk 6, 11

B. High-risk 6, 11

C. Low-risk 16, 18

D. High-risk 16, 18

See Answer in Part B → Q33

@Neet_pg_bot

Q34: A 55-year-old female radiology technician with 25 years of occupational exposure to diagnostic X-rays and fluoroscopy presents with a three-month history of increasing fatigue, unintentional weight loss, and frequent infections. Which cancer type is most likely associated with her occupational history? (Q845489)

A. Acute Myeloid Leukemia

B. Pancreatic cancer

C. Medullary thyroid cancer

D. Chronic Lymphocytic Leukemia

See Answer in Part B → Q34

@Neet_pg_bot

Q35: Which of the following radiations is the most common cause of skin cancer? (Q845488)

A. UV-A radiation

B. UV-B radiation

C. UV-C radiation

D. UV-D radiation

See Answer in Part B → Q35

@Neet_pg_bot

• [04_Neoplasia] 016 Diagnosis Of Tumors And Paraneoplastic Syndromes

« Back to Folder Directory

[04_Neoplasia] 016 Diagnosis Of Tumors And Paraneoplastic Syndromes — Quick Jump

Q1 (p. 192)	*Q2 (p. 192)*	*Q3 (p. 193)*	*Q4 (p. 193)*	*Q5 (p. 193)*	*Q6 (p. 194)*
Q7 (p. 194)	*Q8 (p. 195)*	*Q9 (p. 195)*	*Q10 (p. 196)*	*Q11 (p. 196)*	*Q12 (p. 197)*
Q13 (p. 197)	*Q14 (p. 198)*	*Q15 (p. 198)*	*Q16 (p. 199)*	*Q17 (p. 199)*	*Q18 (p. 200)*
Q19 (p. 200)	*Q20 (p. 200)*	*Q21 (p. 201)*			

Q1: Which of the following best describes the change in the nuclear-to-cytoplasmic ratio seen in malignant cells compared to normal cells? (Q879702)

A. Decreased ratio due to abundant cytoplasm

B. Increased ratio due to larger nuclei and scant cytoplasm

C. No change; ratio remains constant across benign and malignant cells

D. Decreased ratio due to nuclear shrinkage (pyknosis)

See Answer in Part B → Q1

@Neet_pg_bot

Q2: Which of the following markers is not used to identify gastrointestinal stromal tumors (GISTs)? (Q879908)

A. KIT

B. SDH

C. PDGFRA

D. NRG-1

See Answer in Part B → Q2

@Neet_pg_bot

Q3: Which of the following is not classified as an oncofetal tumor marker? (Q879907)

A. Alpha-fetoprotein

B. Carcinoembryonic antigen

C. Prostate-specific antigen

D. Both A and B

See Answer in Part B → Q3

@Neet_pg_bot

Q4: Which of the following tumor markers is most useful for diagnosing pheochromocytoma? (Q879906)

A. Calcitonin

B. Catecholamine

C. Alpha-fetoprotein

D. Carcinoembryonic antigen

See Answer in Part B → Q4

@Neet_pg_bot

Q5: A 48-year-old man develops recurrent, painful, red, tender nodules that appear and disappear on his arms and legs over several weeks. This clinical picture suggests migratory thrombophlebitis. Which of the following cancers is not commonly associated with this condition? (Q879904)

A. Uterine carcinoma

B. Pancreatic carcinoma

C. Bronchogenic carcinoma

D. Bladder carcinoma

See Answer in Part B → Q5

@Neet_pg_bot

Q6: A 55-year-old man presents with headache, dizziness, and blurred vision. He has a ruddy complexion and mild hypertension. Labs show hemoglobin 19.2 g/dL and hematocrit 60%. Secondary polycythemia from ectopic erythropoietin is suspected. Which tumor is least likely to be responsible? (Q879901)

A. Melanoma

B. Renal cell carcinoma

C. Cerebellar hemangioma

D. Hepatocellular carcinoma

See Answer in Part B → Q6

@Neet_pg_bot

Q7: Based on the image and clinical presentation of this 58-year-old obese female, which of the following tumors is not commonly associated with this dermatologic condition? (Q879896)

A. Gastric carcinoma

B. Bladder carcinoma

C. Uterine carcinoma

D. Thymoma



See Answer in Part B → Q7

@Neet_pg_bot

Q8: A 55-year-old patient presents with generalized fatigue, muscle weakness, and bone pain. Laboratory tests reveal a serum calcium level of 14.2 mg/dL. Which type of lung cancer is most commonly associated with this hypercalcemia? (Q879874)

A. Squamous cell carcinoma

B. Small cell carcinoma

C. Adenocarcinoma

D. Large cell carcinoma

See Answer in Part B → Q8

@Neet_pg_bot

Q9: Which subtype of acute myeloid leukemia is characteristically linked to disseminated intravascular coagulation (DIC) as a paraneoplastic syndrome?

(Q879871)

A. AML minimally differentiated

B. Acute promyelocytic leukemia

C. Acute myelomonocytic leukemia

D. Acute megakaryoblastic leukemia

See Answer in Part B → Q9

@Neet_pg_bot

Q10: Choose the correct option regarding tumor invasion and metastasis: Assertion (A): All tumors that show invasive properties eventually metastasize. Reason (R): The ability to invade allows tumor cells to penetrate blood vessels or lymphatics, facilitating spread to distant organs. (Q879708)

A. Both A and R are true, and R correctly explains A

B. Both A and R are true, but R does not explain A

C. A is false, but R is true

D. A is true, but R is false

See Answer in Part B → Q10

@Neet_pg_bot

Q11: A biopsy from a liver mass in a 60-year-old man reveals clusters of malignant epithelial cells forming irregular glands. The surrounding liver architecture is compressed but not invaded by native hepatocytes. Which histological feature most strongly suggests that this mass represents a metastatic carcinoma rather than a primary liver tumor? (Q879705)

A. Presence of malignant epithelial cells with atypia

B. Lack of normal organ-specific architecture within the tumor

C. Presence of mitotic figures in tumor cells

D. Hyperchromatic nuclei with increased nuclear-to-cytoplasmic ratio

See Answer in Part B → Q11

@Neet_pg_bot

Q12: Which of the following is used in immunohistochemical (IHC) staining as a chromogen to diagnose tumours of unknown origin? (Q845495)

A. Diaminobenzidine

B. Congo Red

C. Masson's Trichrome

D. Mucicarmine

See Answer in Part B → Q12

@Neet_pg_bot

Q13: An appendix specimen, whose HPE is shown below, had a 2 cm submucosal nodule identified. Electron microscopy showed numerous neurosecretory granules in the cytoplasm. Twenty-four-hour urine analysis showed an elevation of 5-hydroxy indoleacetic acid (5-HIAA). Which of the following would not be seen in this condition? (Q845506)

A. Flushing

B. Diarrhea

C. Valvular heart disease

D. Bronchodilation

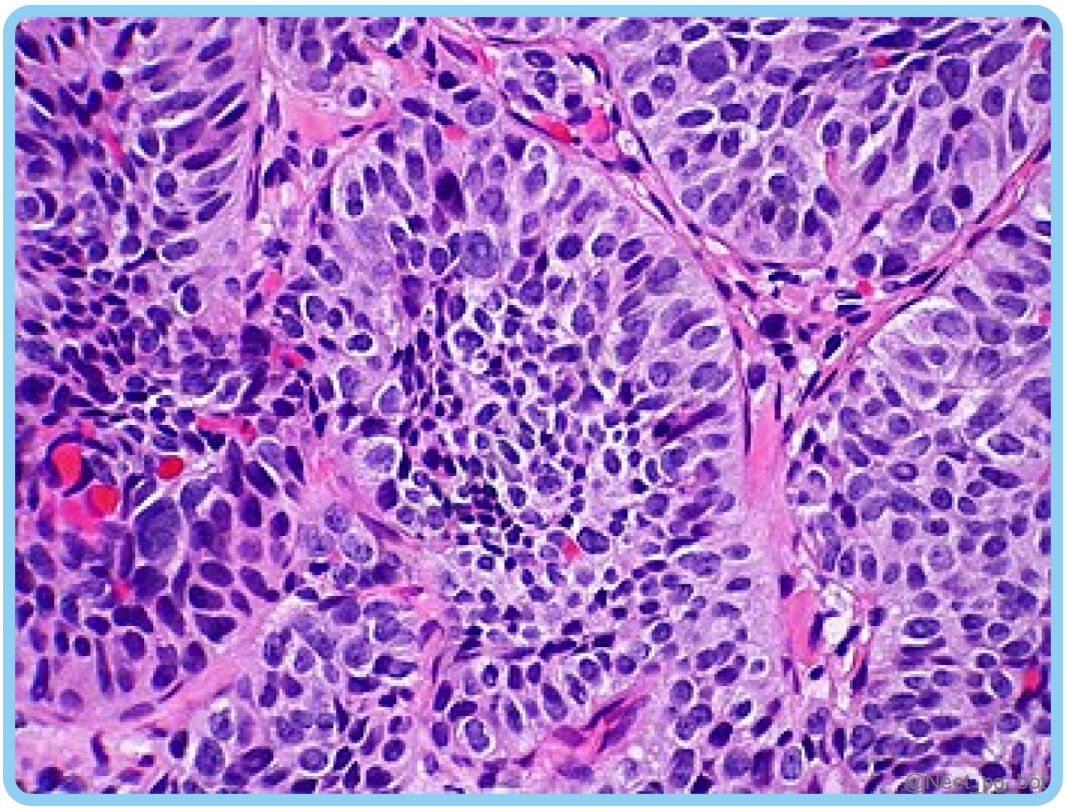

See Answer in Part B → Q13

@Neet_pg_bot

Q14: Which of the following paraneoplastic syndrome is not associated with lung cancer? (Q845504)

A. Dermatomyositis

B. Acanthosis nigricans

C. Myasthenia

D. Red cell aplasia

See Answer in Part B → Q14

@Neet_pg_bot

Q15: A 60-year-old male was diagnosed with a lung malignancy two months ago. He now came with complaints of malaise, abdominal pain, bone pain, lethargy, and confusion. The intern suspects a condition related to lung cancer and decides to send a blood test. Which of the following would be the appropriate test? (Q845503)

A. Erythropoietin

B. Adrenocorticotrophic hormone

C. Parathyroid hormone-related protein

D. Antidiuretic hormone

See Answer in Part B → Q15

@Neet_pg_bot

Q16: Match the given neoplasias with their respective immunohistochemistry markers. 1. Carcinoma A. S100 2. Sarcoma B. Leucocyte common antigen 3. Lymphoma C. Cytokeratin 4. Melanoma D. Vimentin (Q845502)

A. 1-C, 2-A, 3-B, 4-D

B. 1-A, 2-C, 3-B, 4-D

C. 1-C, 2-D, 3-B, 4-A

D. 1-A, 2-D, 3-B, 4-C

See Answer in Part B → Q16

@Neet_pg_bot

Q17: A 45-year-old female presents with a breast lump. On biopsy, the tissue shows anaplastic cells without any differentiation. Immunohistochemistry (IHC) staining is performed to characterise the tumour further. Which marker would be most appropriate to confirm the epithelial origin of the tumour cells in breast cancer? (Q845500)

A. CD20

B. p63

C. TTF-1

D. CK7

See Answer in Part B → Q17

@Neet_pg_bot

Q18: Which of the following conditions is FNAC helpful in establishing diagnosis ? (Q845499)

A. Follicular adenoma of the thyroid

B. Testicular cancer

C. Hydatid cyst

D. Medullary thyroid carcinoma

See Answer in Part B → Q18

@Neet_pg_bot

Q19: What needle size is typically employed for Fine Needle Aspiration Cytology (FNAC) procedures? (Q845498)

A. 18-gauge needle

B. 22-gauge needle

C. 25-gauge needle

D. 30-gauge needle

See Answer in Part B → Q19

@Neet_pg_bot

Q20: Which of the following is used to determine treatment response in patients with colorectal cancer? (Q845497)

A. Alpha-fetoprotein

B. Carcinoembryonic antigen

C. Human Chorionic Gonadotropin

D. Calcitonin

See Answer in Part B → Q20

@Neet_pg_bot

Q21: Which of the following is a marker for breast cancer? (Q845496)

A. CA-19-9

B. CA-125

C. CA-15-3

D. β - HCG

See Answer in Part B → Q21

@Neet_pg_bot

• [04_Neoplasia] 017 Fundamentals Of Neoplasia

« Back to Folder Directory

[04_Neoplasia] 017 Fundamentals Of Neoplasia — Quick Jump

Q1 (p. 202)	*Q2 (p. 202)*	*Q3 (p. 203)*	*Q4 (p. 203)*	*Q5 (p. 203)*	*Q6 (p. 204)*
Q7 (p. 204)	*Q8 (p. 204)*	*Q9 (p. 205)*	*Q10 (p. 205)*	*Q11 (p. 205)*	*Q12 (p. 206)*
Q13 (p. 206)	*Q14 (p. 207)*	*Q15 (p. 207)*	*Q16 (p. 207)*	*Q17 (p. 208)*	*Q18 (p. 208)*
Q19 (p. 208)	*Q20 (p. 209)*	*Q21 (p. 209)*	*Q22 (p. 210)*	*Q23 (p. 210)*	*Q24 (p. 210)*
Q25 (p. 211)	*Q26 (p. 211)*	*Q27 (p. 212)*	*Q28 (p. 212)*		

Q1: What is the consequence of the RB protein being in its hypophosphorylated (active) state? (Q879748)

A. Cell cycle is halted at the G2 phase

B. Cell cycle is arrested at the G1 phase

C. RB protein’s phosphorylation status does not impact the cell cycle

D. Cell cycle continues normally, leading to cell division

See Answer in Part B → Q1

@Neet_pg_bot

Q2: Which of the following disorders is unrelated to defects in homologous recombination-mediated DNA repair pathways? (Q879792)

A. Bloom syndrome

B. Ataxia-telangiectasia

C. Fanconi anemia

D. Li-Fraumeni syndrome

See Answer in Part B → Q2

@Neet_pg_bot

Q3: Which of the following oncogenes, when mutated, can give rise to neoantigens recognized by the immune system? (Q879786)

A. KRAS

B. TP53

C. CDKN2A

D. PTEN

See Answer in Part B → Q3

@Neet_pg_bot

Q4: Which of the following changes does not convert a proto-oncogene into an oncogene? (Q879784)

A. Gene amplification

B. Point mutation

C. Chromosomal translocation

D. Gene deletion

See Answer in Part B → Q4

@Neet_pg_bot

Q5: Which of the following is a receptor tyrosine kinase, rather than a nonreceptor tyrosine kinase? (Q879766)

A. ABL

B. BCR-ABL

C. JAK2

D. EGFR

See Answer in Part B → Q5

@Neet_pg_bot

Q6: Which gene plays a key role in promoting epithelial-mesenchymal transition (EMT) in carcinomas? (Q879764)

A. E-cadherin

B. SNAIL

C. Vimentin

D. Smooth muscle actin

See Answer in Part B → Q6

@Neet_pg_bot

Q7: Which of the following mechanisms is commonly used by cancer cells to evade apoptosis? (Q879763)

A. Overexpression of pro-apoptotic BAX and BAK proteins

B. Loss of TP53 function and overexpression of anti-apoptotic BCL2 family proteins

C. Increased activation of caspase-9

D. Enhanced release of cytochrome c from mitochondria

See Answer in Part B → Q7

@Neet_pg_bot

Q8: Which of the following statements about BRCA mutations is correct? (Q879762)

A. BRCA1 and BRCA2 are involved in DNA repair via homologous recombination

B. BRCA proteins primarily use nonhomologous end-joining (NHEJ) for DNA repair

C. BRCA1 mutations are not associated with ovarian cancer

D. BRCA2 mutations cause only breast cancer

See Answer in Part B → Q8

@Neet_pg_bot

Q9: A 45-year-old man presents with progressive abdominal discomfort and weight loss. Endoscopy reveals a gastric mass, and biopsy confirms diffuse gastric carcinoma. Which protein responsible for maintaining cell-to-cell adhesion and inhibiting cell motility is most likely mutated in this condition? (Q879760)

A. p63

B. p53

C. E-cadherin

D. Integrin

See Answer in Part B → Q9

@Neet_pg_bot

Q10: A 19-year-old woman presents with recurrent episodes of abdominal pain and melena. On physical examination, she has dark-blue to brown macules on her lips and buccal mucosa. Genetic testing reveals germline loss-of-function mutations in the STK11 gene. What is the most likely diagnosis? (Q879758)

A. HNPCC

B. Gorlin syndrome

C. von Hippel-Lindau syndrome

D. Peutz-Jeghers syndrome

See Answer in Part B → Q10

@Neet_pg_bot

Q11: Which of the following is the etiology of Gorlin syndrome? (Q879757)

A. Germline loss-of-function mutation in STK11

B. Germline missense mutation in SDHB

C. Germline loss-of-function mutation in WT1

D. Germline loss-of-function mutation in PTCH1

See Answer in Part B → Q11

@Neet_pg_bot

Q12: A 25-year-old woman experiences progressive balance issues and bilateral sensorineural hearing loss. Imaging reveals tumors affecting both vestibular nerves. This clinical picture is characteristic of a hereditary condition involving a mutation in which protein that plays a role in linking the cytoskeleton to the cell membrane? (Q879756)

A. Neurofibromin

B. Merlin

C. PATCHED

D. RB protein

See Answer in Part B → Q12

@Neet_pg_bot

Q13: A 35-year-old woman presents with multiple trichilemmomas on her face, a history of breast cancer, and the recent discovery of endometrial hyperplasia. She also reports that her father had colon polyps. Germline loss-of-function mutations of which gene are most likely responsible for her condition? (Q879753)

A. CDKN2A

B. SMAD2

C. APC

D. PTEN

See Answer in Part B → Q13

@Neet_pg_bot

Q14: Which of the following statements about p53 is true? (Q879752)

A. p53 is rarely altered in cancers

B. p53 is induced by DNA damage

C. p53 promotes cell cycle progression by downregulating p21

D. p53 inhibits apoptosis by suppressing BAX

See Answer in Part B → Q14

@Neet_pg_bot

Q15: Which of the following statements about Knudson's two-hit hypothesis for retinoblastoma is true? (Q879746)

A. Both familial and sporadic cases require two somatic mutations in the same retinoblast

B. In familial cases, one defective RB allele is inherited in the germline, and the second hit occurs somatically

C. Sporadic cases are caused by inheritance of one defective RB allele and a spontaneous second hit

D. Only one mutation is sufficient to cause retinoblastoma in any case

See Answer in Part B → Q15

@Neet_pg_bot

Q16: Which of the following cancers is typically associated with a translocation involving cyclin D1? (Q879744)

A. Chronic myeloid leukemia

B. Non-Hodgkin's lymphoma

C. Acute lymphoblastic leukemia

D. Mantle cell lymphoma

See Answer in Part B → Q16

@Neet_pg_bot

Q17: Which type of proteins are produced as a result of MYC gene expression? (Q879741)

A. Proteins that control the cell division cycle

B. Proteins that regulate gene activity within the nucleus

C. Proteins involved in transmitting signals inside the cell

D. Proteins that act as receptors for growth-promoting signals

See Answer in Part B → Q17

@Neet_pg_bot

Q18: Which gene mutation is associated with the development of astrocytoma? (Q845511)

A. PDGFB

B. HST1

C. FGF3

D. HGF

See Answer in Part B → Q18

@Neet_pg_bot

Q19: Which of the following genetic events best describes the carcinogenesis mechanism in a patient with retinoblastoma? (Q876253)

A. Balanced translocation

B. Expansion of trinucleotide repeat

C. Gene amplification

D. Loss of heterozygosity

See Answer in Part B → Q19

@Neet_pg_bot

Q20: Which of the following mechanisms is not employed by tumour cells to evade the host immune system? (Q845522)

A. Selective outgrowth of the antigen-negative variants

B. Reduced expression of MHC molecules

C. Secretion of immunosuppressive factors

D. Enhanced antigen presentation to promote T cell activation

See Answer in Part B → Q20

@Neet_pg_bot

Q21: Which of the following is true regarding the Warburg effect? (Q845521)

A. Cancer cells primarily rely on oxidative phosphorylation for ATP production.

B. It involves a shift from glycolysis to oxidative phosphorylation in cancer cells.

C. Cancer cells exhibit increased glucose uptake and preferentially metabolise glucose via glycolysis, even in the presence of oxygen.

D. It is characterised by decreased glucose uptake and utilisation by cancer cells.

See Answer in Part B → Q21

@Neet_pg_bot

Q22: Which of the following statements are true regarding Lynch syndrome? (Q845519)

A. It is autosomal recessive in inheritance.

B. It is also known as hereditary breast and ovarian cancer syndrome.

C. It is caused by mutations in genes involved in nonhomologous end-joining repair.

D. Amsterdam II criteria are used for diagnosis.

See Answer in Part B → Q22

@Neet_pg_bot

Q23: Which of the following diseases is associated with a defect in homologous DNA repair? (Q845517)

A. Trichothiodystrophy

B. Fanconi anemia

C. Endometrial carcinoma

D. Wermer syndrome

See Answer in Part B → Q23

@Neet_pg_bot

Q24: A 9-year-old child presents with multiple freckle-like dark spots on sun-exposed areas such as the face and arms. The child complains of discomfort and pain upon exposure to sunlight, and there is evidence of sunburn even after brief periods outdoors. Upon further questioning, they reveal a family history of skin cancer in relatives who also experienced similar skin issues from a young age. What is the most likely diagnosis and the genetic defect in this condition? (Q845516)

A. Xeroderma pigmentosum, defective homologous repair

B. Cockyane syndrome, nucleotide excision repair

C. Xeroderma pigmentosum, nucleotide excision repair

D. Bloom syndrome, defective homologous repair

See Answer in Part B → Q24

@Neet_pg_bot

Q25: Which of the following cyclin-CDK combinations is incorrectly matched? (Q845515)

A. Cyclin A- CDK 2

B. Cyclin B- CDK 6

C. Cyclin D- CDK 4

D. Cyclin E- CDK 2

See Answer in Part B → Q25

@Neet_pg_bot

Q26: Match the following protooncogenes with their malignancies. Proto-oncogene Malignancy 1. JAK-2 a. Hairy cell leukemia 2. BRAF b. Neuroblastoma 3. N Myc c. Burkitt's lymphoma 4. C Myc d. Polycythemia vera (Q845514)

A. 1-b, 2-a, 3-d, 4-c

B. 1-d, 2-a, 3-b, 4-c

C. 1-c, 2-a, 3-b, 4-d

D. 1-d, 2-b, 3-c, 4-a

See Answer in Part B → Q26

@Neet_pg_bot

Q27: Identify the correctly matched pair of RAS mutation and its associated malignancy. (Q845513)

A. KRAS- Bladder cancer

B. HRAS- Lung cancer

C. KRAS- Kidney cancer

D. NRAS- Melanoma

See Answer in Part B → Q27

@Neet_pg_bot

Q28: A 70-year-old male presented with a persistent cough, weight loss, and shortness of breath. A CT scan of the chest revealed a lesion consistent with adenocarcinoma of the lung. Which of the following growth factor receptor mutations can lead to adenocarcinoma of the lungs? (Q845512)

A. FLT3 and RET

B. ALK and ERBB1

C. RET and KIT

D. KIT and FLT3

See Answer in Part B → Q28

@Neet_pg_bot

• [04_Neoplasia] 018 Previous Year Questions

« Back to Folder Directory

[04_Neoplasia] 018 Previous Year Questions — Quick Jump

Q1 (p. 213)	*Q2 (p. 213)*	*Q3 (p. 214)*	*Q4 (p. 214)*	*Q5 (p. 214)*	*Q6 (p. 215)*
Q7 (p. 216)	*Q8 (p. 216)*	*Q9 (p. 217)*	*Q10 (p. 217)*	*Q11 (p. 217)*	*Q12 (p. 218)*
Q13 (p. 218)	*Q14 (p. 219)*	*Q15 (p. 219)*	*Q16 (p. 219)*	*Q17 (p. 220)*	*Q18 (p. 221)*
Q19 (p. 221)	*Q20 (p. 221)*	*Q21 (p. 222)*	*Q22 (p. 223)*	*Q23 (p. 223)*	*Q24 (p. 224)*
Q25 (p. 224)	*Q26 (p. 224)*	*Q27 (p. 225)*	*Q28 (p. 226)*	*Q29 (p. 226)*	*Q30 (p. 226)*
Q31 (p. 227)					

Q1: Match the malignancies in Column A with the genes in Column B: Column A Column B 1. Pleomorphic adenoma a. Rb 2. Burkitt lymphoma b. N-MYC 3. Neuroblastoma c.C-MYC 4. Retinoblastoma d. PLAG1 (Q855077)

A. 1-c, 2-b, 3-d, 4-a

B. 1-b, 2-c, 3-d, 4-a

C. 1-d, 2-c, 3-b, 4-a

D. 1-b, 2-d, 3-c, 4-a

See Answer in Part B → Q1

@Neet_pg_bot

Q2: Which of the following best describes the mechanism by which mutations in the Ras/MAP kinase gene cause oncogenicity? (Q879232)

A. Constitutive activation of a GTP-binding protein leading to continuous MAP kinase signalling

B. Enhanced DNA repair leading to genomic instability

C. Inactivation of a tumour suppressor gene resulting in loss of cell cycle checkpoint control

D. Increased activity of tyrosine kinase receptors through gene amplification

See Answer in Part B → Q2

@Neet_pg_bot

Q3: All of the following are correct about neuroendocrine tumours except? It has a salt and pepper appearance of chromatin Tumours arising from different organs have different microscopic features Light microscopy reveals secretory granules On microscopic examination, small, round, blue cells forming a rosette pattern are visible (Q879192)

A. 1, 2, and 3

B. Only 3

C. 2, 3, and 4

D. 1, 3, and 4

See Answer in Part B → Q3

@Neet_pg_bot

Q4: Why do neoplastic cells utilise Warburg metabolism? (Q855927)

A. It decreases glucose utilization by neoplastic cells

B. It forms metabolic intermediates which are needed for cell growth and multiplication

C. It provides more energy in the form of increased ATP production

D. It prevents apoptosis and makes the cancer immortal

See Answer in Part B → Q4

@Neet_pg_bot

Q5: A 3-year-old boy was brought by his parents with concerns about being increasingly clumsy for the past 6 months. On examination, there is leukocoria with an absence of the red reflex in the left eye. As further workup reveals a tumour, the eye is enucleated, and the microscopic appearance is as shown in the image. Molecular analysis of the tumour indicates a loss of cell cycle control in the tumour cells. What is

the most likely diagnosis? (Q859874)

A. Wilms tumor

B. Retinoblastoma

C. Ependymoma

D. Neuroblastoma

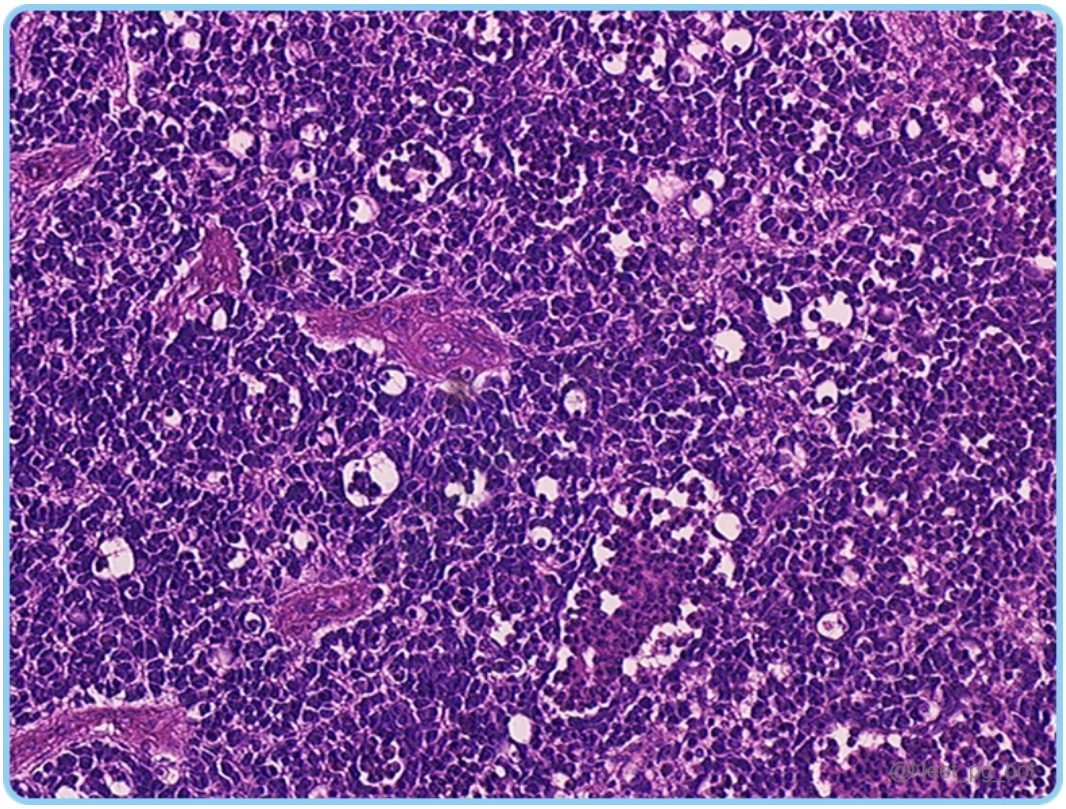

See Answer in Part B → Q5

@Neet_pg_bot

Q6: Which of the following enzymes is responsible for the immortality of cancer cells? (Q859238)

A. Telomerase

B. Topoisomerase

C. Helicase

D. RNA polymerase

See Answer in Part B → Q6

@Neet_pg_bot

Q7: The lining epithelium of the respiratory tract of a middle-aged man who is a chronic smoker shows a change from columnar to stratified squamous epithelium, as depicted in the image below. The change is called what? {{caption_text}} (Q858510)

A. Dysplasia

B. Hypertrophy

C. Atrophy

D. Metaplasia

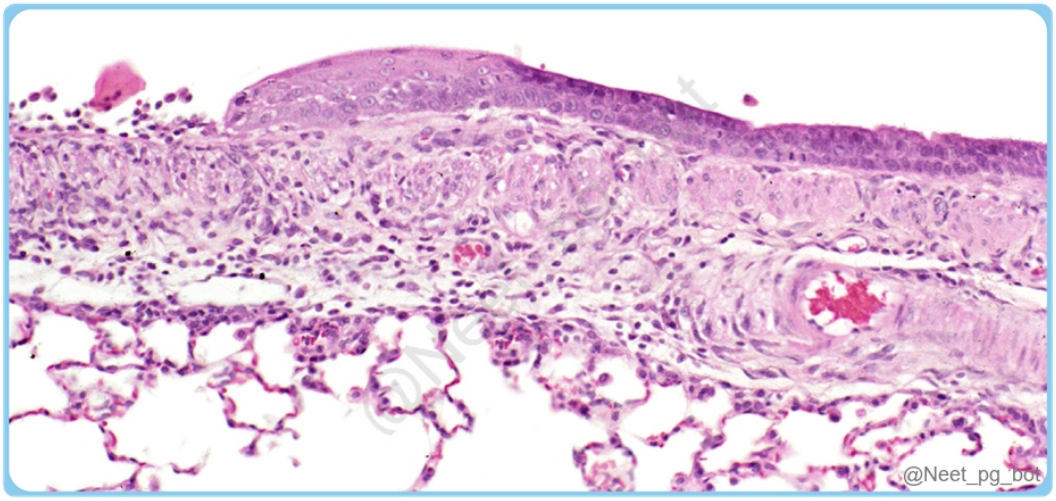

See Answer in Part B → Q7

@Neet_pg_bot

Q8: What is the fixation technique employed to examine fat in histopathology? (Q856484)

A. IHC

B. Frozen section

C. Liquid paraffin

D. Formalin-fixed

See Answer in Part B → Q8

@Neet_pg_bot

Q9: A woman was diagnosed with metastatic liver adenocarcinoma with CK7-, CK20+, and CDX1+ immunohistochemistry (IHC) markers. Which of the following is the most likely primary site of origin for this metastasis? (Q856914)

A. Colon carcinoma

B. Breast carcinoma

C. Pancreatic carcinoma

D. Ovarian carcinoma

See Answer in Part B → Q9

@Neet_pg_bot

Q10: A pap smear taken from a patient revealed hyperchromatic nuclei, irregular nuclear borders, and a low maturation index involving the whole thickness but did not breach the basement membrane. What is the diagnosis? (Q856160)

A. Dysplasia

B. Carcinoma

C. Metaplasia

D. Hyperplasia

See Answer in Part B → Q10

@Neet_pg_bot

Q11: A 65-year-old female patient is diagnosed with pure red cell aplasia and a mediastinal mass. Which of the following is a likely cause? (Q856155)

A. Thymoma

B. Non-Hodgkin lymphoma

C. Bronchogenic carcinoma

D. Germ cell tumour

See Answer in Part B → Q11

@Neet_pg_bot

Q12: A patient with occupational exposure to benzene presents with repeated infections, easy fatigability, weight loss, and an evening rise in temperature. This occupational exposure will predispose him to which of the following cancers? (Q856108)

A. Leukemia

B. Lung cancer

C. Bladder cancer

D. Skin cancer

See Answer in Part B → Q12

@Neet_pg_bot

Q13: Which of the following is true? BRCA1 is an oncogene HER2neu is amplified only in a fraction of breast cancer EGFR+ is seen in non-small cell lung cancer N-MYC is a tumor suppressor gene (Q856708)

A. 1, 2

B. 1, 3

C. 2, 3

D. All of these

See Answer in Part B → Q13

@Neet_pg_bot

Q14: The human papillomavirus inactivates the Rb gene by which of the following proteins? (Q855392)

A. E6

B. E7

C. L1

D. L2

See Answer in Part B → Q14

@Neet_pg_bot

Q15: Which of the following is true about anaplasia? (Q857175)

A. Loss of cohesion between cells

B. Loss of differentiation

C. Change of epithelium type

D. Benign and fully reversible

See Answer in Part B → Q15

@Neet_pg_bot

Q16: Which of the following statements is true about proto-oncogenes? KIT has decreased expression via the tyrosine kinase signalling pathway in GIST. KRAS mutation is more commonly associated with small-cell lung cancer. ERBB2 is overexpressed in association with breast carcinomas. PDGFR-β has suppressed expression in colorectal cancer. (Q855121)

A. 2 only

B. 3 only

C. 1 and 4

D. 2 and 3

See Answer in Part B → Q16

@Neet_pg_bot

Q17: A 25-year-old woman presents with lower abdominal discomfort. The surgical image is given below. What is the most likely diagnosis? (Q866741)

A. Serous cystadenoma

B. Immature teratoma

C. Mature cystic teratoma

D. Endometrioma



See Answer in Part B → Q17

@Neet_pg_bot

Q18: Neurosecretory bodies are seen in all of the following, except: (Q855069)

A. Medullary thyroid carcinoma

B. Pituitary adenoma

C. Paraganglioma

D. Adrenal cortical tumour

See Answer in Part B → Q18

@Neet_pg_bot

Q19: Match the following microscopic appearance and the respective tumour in which they are seen Microscopic appearance Tumor 1. Schiller Duval bodies a. Krukenberg tumor 2. Presence of teeth, hair, etc B. Granulosa cell tumor 3. Signet ring cells C. Yolk sac tumour 4. Call-Exner bodies d. Teratoma (Q855924)

A. 1-c, 2-a, 3-d, 4-b

B. 1-b, 2-c, 3-a, 4-d

C. 1-d, 2-b, 3-c, 4-a

D. 1-c, 2-d, 3-a, 4-b

See Answer in Part B → Q19

@Neet_pg_bot

Q20: The type of cancer that rarely spreads through the lymphatic system is: (Q855915)

A. Squamous cell carcinoma

B. Merkel cell carcinoma

C. Basal cell carcinoma

D. Malignant melanoma

See Answer in Part B → Q20

@Neet_pg_bot

Q21: The following picture shows a lymph node biopsy of a 30-year-old male with cervical lymphadenopathy. The diagnosis is: (Q858133)

A. Acute myeloid leukemia (AML)

B. Hodgkin disease

C. Human papillomavirus (HPV)

D. Chronic lymphocytic leukemia (CLL)

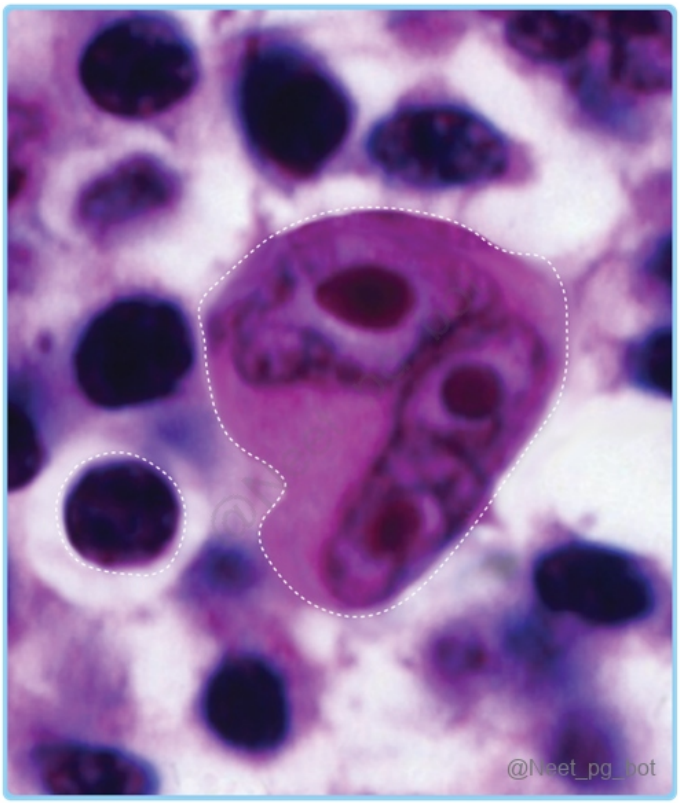

See Answer in Part B → Q21

@Neet_pg_bot

Q22: A 70-year-old male comes with complaints of hip pain. An X-ray of the hip shows lytic lesions and elevated serum calcium levels. Bone marrow plasma cells are 42%, and the cells seen are given in the image below. What is the most likely diagnosis? (Q858126)

A. Multiple myeloma

B. CLL

C. ALL

D. CML

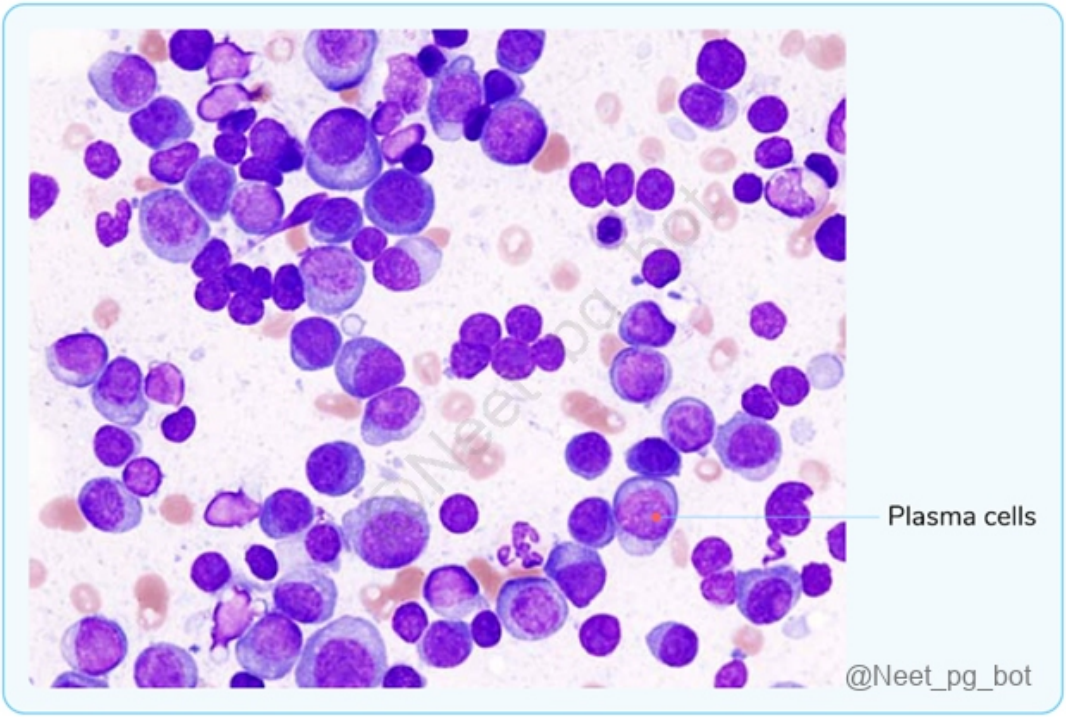

See Answer in Part B → Q22

@Neet_pg_bot

Q23: Asbestos exposure may be associated with which of the following malignancies? (Q858108)

A. Mesothelioma

B. Acute myeloid leukemia

C. Hepatic angiosarcoma

D. Skin carcinoma

See Answer in Part B → Q23

@Neet_pg_bot

Q24: Match the given mutations with the respective cancers: A. K-RAS Myeloproliferative neoplasm B. KIT 2. Adenocarcinoma C. JAK 2 3. Pancreatic cancer D. ALK 4. GIST (Q854690)

A. A-3, B-4, C-1, D-2

B. A-2, B-3, C-4, D-1

C. A-1, B-3, C-2, D-4

D. A-2, B-4, C-3, D-1

See Answer in Part B → Q24

@Neet_pg_bot

Q25: Which of the following features does not distinguish between necrosis and apoptosis? (Q840014)

A. Enzymatic degradation

B. Association with underlying pathology

C. Lipid change

D. Intact membrane

See Answer in Part B → Q25

@Neet_pg_bot

Q26: A 35-year-old male presents with a testicular mass, and a gross image of the mass is provided. What is the most likely diagnosis? (Q860552)

A. Teratoma

B. Seminoma

C. Yolk sac tumour

D. Choriocarcinoma

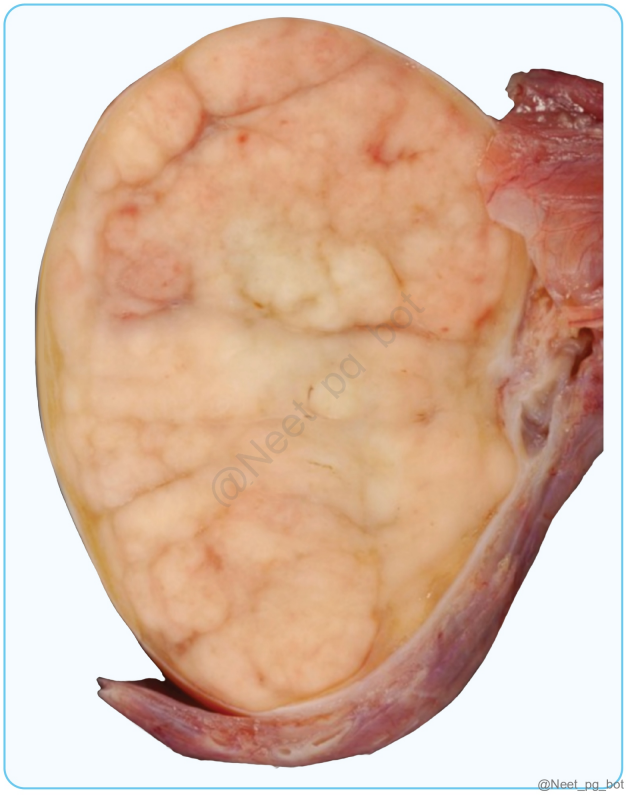

See Answer in Part B → Q26

@Neet_pg_bot

Q27: What is the tumour marker for a carcinoid tumour? (Q860551)

A. Beta-HCG

B. Calcitonin

C. 5-HIAA

D. Alpha-fetoprotein

See Answer in Part B → Q27

@Neet_pg_bot

Q28: Epithelial-mesenchymal transition induced by which pair of transcription factors? (Q853375)

A. TF IIA & TF IIB

B. Cathepsin & MMP 8

C. SNAIL & TWIST

D. STAT-5 & HIF-1 alpha

See Answer in Part B → Q28

@Neet_pg_bot

Q29: Match the following: A. Medullary thyroid cancer i. Catecholamine B. Hepatoblastoma ii. AFP C. Choriocarcinoma iii. Calcitonin D. Pheochromocytoma iv. Beta HCG (Q853373)

A. A-i, B-ii, C-iii, D-iv

B. A-iii, B-ii, C-iv, D-i

C. A-iv, B-iii, C-ii, D-i

D. A-ii, B-i, C-iii, D-iv

See Answer in Part B → Q29

@Neet_pg_bot

Q30: Which of the following is not correct? (Q853368)

A. C- MYC - Burkitts lymphoma

B. Least radiosensitive phase is S phase of cell cycle

C. Least radiosensitive cell is platelet

D. Cyclin E triggers cells to move from G0 to G1 and G1 to S phase

See Answer in Part B → Q30

@Neet_pg_bot

Q31: Which of the following is an incorrect gene-disease association? (Q865377)

A. STK11 - Breast Cancer

B. PTEN - Thyroid Carcinoma

C. TP53 - Mucosal Neuroma

D. BRCA2 - Prostate Carcinoma

See Answer in Part B → Q31

@Neet_pg_bot

• [05_Immunity] 019 Types Of Immunity

« Back to Folder Directory

[05_Immunity] 019 Types Of Immunity — Quick Jump

Q1 (p. 228) *Q2 (p. 228)* *Q3 (p. 228)* *Q4 (p. 229)* *Q5 (p. 229)* *Q6 (p. 230)*
Q7 (p. 230) *Q8 (p. 230)* *Q9 (p. 231)* *Q10 (p. 231)* *Q11 (p. 232)* *Q12 (p. 232)*

Q1: Which of the following is not a feature of innate immunity? (Q845264)

A. Present since birth

B. Made of epithelial barriers, phagocytes, innate lymphoid cells (ILCs) and NK cells

C. Quick, non-specific response

D. Has a lag phase between exposure and response

See Answer in Part B → Q1

@Neet_pg_bot

Q2: A 45-year-old male presents with a fever, sore throat, and swollen lymph nodes. He is diagnosed with a viral infection. Which of the following cells is most likely involved in the early defense against the offending agent in this patient? (Q845266)

A. NK cells

B. T cells

C. Macrophages

D. Histocytes

See Answer in Part B → Q2

@Neet_pg_bot

Q3: A 20-year-old medical student went for a screening health test and was injected with PPD intradermally. Identify the immune cell in the skin that picks up the PPD to present it to T cells. (Q845274)

A. Langhans cells

B. Follicular dendritic cells

C. Langerhans cells

D. Natural killer cells

See Answer in Part B → Q3

@Neet_pg_bot

Q4: Match the following immune cells with their markers. Cells Markers 1. Natural killer cell a. CD 19 2. T lymphocyte b. CD 16 3. B lymphocyte c. CD 11 4. Monocyte d. CD 3 (Q845278)

A. 1-a; 2-d; 3-b; 4-c

B. 1-b; 2-a; 3-c; 4-d

C. 1-b; 2-d; 3-a; 4-c

D. 1-a; 2-c; 3-d; 4-b

See Answer in Part B → Q4

@Neet_pg_bot

Q5: Toll-like receptors are predominantly expressed in which of the following cell types? (Q845386)

A. Macrophages

B. Endothelial cells

C. Natural killer cells

D. All of the above

See Answer in Part B → Q5

@Neet_pg_bot

Q6: An 8-year-old child is brought with complaints of fever and burning micturition. She was diagnosed to have UTI with toxin-producing strains of E.coli. Where are blood-borne antigens trapped in the immune response to these toxins? (Q845387)

A. Lymph nodes

B. Thymus

C. Bone marrow

D. Spleen

See Answer in Part B → Q6

@Neet_pg_bot

Q7: Which of the following HLA gene regions encodes Class II MHC molecules? (Q845389)

A. HLA-A

B. HLA-B

C. HLA-C

D. HLA-D

See Answer in Part B → Q7

@Neet_pg_bot

Q8: A patient presented with a fever and loose stool for one week. He was diagnosed with typhoid infection. Which of the following MHC class is responsible for antigen presentation in this patient? (Q845390)

A. Class I

B. Class II

C. Class III

D. Non-MHC-dependent antigen presentation

See Answer in Part B → Q8

@Neet_pg_bot

Q9: Which component functions as the antigen binding site in MHC complexes 1 and 2, respectively? (Q845404)

A. MHC 1 - beta microglobulin; MCH 2 - alpha 3 domain

B. MHC 1 - alpha 1 and 2; MHC 2 - alpha 1 and beta 1

C. MHC 1 - alpha 1 and beta 1; MHC 2 - alpha 1 and 2

D. MHC 1 - invariant chain; MHC 2 - beta microglobulin

See Answer in Part B → Q9

@Neet_pg_bot

Q10: A newborn delivered by a mother who received no prenatal care is being evaluated. On examination, the baby has severe oedema, icterus, and organomegaly and is in respiratory distress. What immunoglobulin class was responsible for this child's presentation? (Q845407)

A. IgG

B. IgM

C. IgA

D. IgE

See Answer in Part B → Q10

@Neet_pg_bot

Q11: A 65-year-old male presents to the emergency department with a fever, productive cough, and shortness of breath. He is diagnosed with pneumonia. Which of the following cytokines is most likely to be elevated in this patient due to the activation of classical macrophages in response to the infection? (Q845411)

A. Interleukin- 1

B. Interleukin- 2

C. Interleukin- 4

D. Interleukin- 10

See Answer in Part B → Q11

@Neet_pg_bot

Q12: A 10-year-old boy is brought with a history of eating sand. His stool examination showed Ascaris eggs. What type of T-cell is responsible for dealing with this infection? (Q845415)

A. TH1 cells

B. TH2 cells

C. TH17 cells

D. Treg cells

See Answer in Part B → Q12

@Neet_pg_bot

• [05_Immunity] 020 Types Of Hypersensitivity Reactions

« Back to Folder Directory

[05_Immunity] 020 Types Of Hypersensitivity Reactions — Quick Jump

Q1 (p. 233) *Q2 (p. 233)* *Q3 (p. 234)* *Q4 (p. 234)* *Q5 (p. 234)* *Q6 (p. 235)*
Q7 (p. 235) *Q8 (p. 236)* *Q9 (p. 236)* *Q10 (p. 236)* *Q11 (p. 237)* *Q12 (p. 237)*

Q1: A 35-year-old woman presents to the clinic with sudden hives, facial swelling, and difficulty breathing shortly after eating shrimp at a restaurant. She reports similar reactions in the past. She appears anxious, with pronounced facial swelling and wheezing. Which sequence correctly describes the immunological events in this type of reaction? (Q845417)

A. Allergen exposure → Mast cell activation → IgE production → Th2 cell activation → Release of inflammatory mediators

B. Th2 cell activation → Allergen exposure → IgE production → Mast cell activation → Release of inflammatory mediators

C. Allergen exposure → Th2 cell activation → IgE production → Mast cell activation → Release of inflammatory mediators

D. Allergen exposure → Th2 cell activation → Mast cell activation → IgE production → Release of inflammatory mediators

See Answer in Part B → Q1

@Neet_pg_bot

Q2: Which of the following cytokines acts on B cells to stimulate class switching to IgE and promotes the development of additional Th2 cells in type I hypersensitivity reactions? (Q845419)

A. IL-4

B. IL-5

C. IL-13

D. IL-10

See Answer in Part B → Q2

@Neet_pg_bot

Q3: A 45-year-old patient with a history of allergic asthma presents with worsening respiratory symptoms. The sputum sample shows the presence of Charcot-Leyden crystals. Which of the following is NOT typically associated with this phase of hypersensitivity reaction? (Q845420)

A. Recruitment of eosinophils to the site of inflammation by chemokines like eotaxin

B. Production of IL-5 by Th2 cells to activate eosinophils

C. Release of histamine and tryptase by eosinophils

D. Liberation of major basic protein and eosinophil cationic protein by activated eosinophils

See Answer in Part B → Q3

@Neet_pg_bot

Q4: Which of the following is not an example of a Type I hypersensitivity reaction? (Q845421)

A. Graft rejection

B. Vernal Keratoconjunctivitis

C. Casoni test

D. P-K reactions

See Answer in Part B → Q4

@Neet_pg_bot

Q5: Which of the following diseases is not an example of a Type II hypersensitivity reaction? (Q845426)

A. Rheumatic fever

B. Multiple sclerosis

C. Immune thrombocytopenic purpura

D. Pernicious anaemia

See Answer in Part B → Q5

@Neet_pg_bot

Q6: Which of the following statements regarding pernicious anaemia is incorrect? (Q845428)

A. Natural Killer (NK) cells participate in Antibody-dependent cellular cytotoxicity.

B. Opsonisation involves IgG antibodies coating cells, enhancing phagocytosis via Fc receptors.

C. When antibodies deposit in intracellular tissues, the injury is due to inflammation and not phagocytosis or cell lysis.

D. Myasthenia gravis is an example of antibody-mediated cell surface receptor dysfunction.

See Answer in Part B → Q6

@Neet_pg_bot

Q7: An 11-year-old boy presents to the emergency department with swelling in his face and legs, decreased urine output, and dark-colored urine. His parents reported that he had a sore throat about three weeks ago, which resolved without treatment. Urinalysis shows proteinuria and hematuria. Which type of hypersensitivity reaction is associated with this condition? (Q845438)

A. Type I hypersensitivity

B. Type II hypersensitivity

C. Type III hypersensitivity

D. Type IV hypersensitivity

See Answer in Part B → Q7

@Neet_pg_bot

Q8: Which of the following is typically associated with localized immune-complex mediated hypersensitivity? (Q845440)

A. Serum sickness

B. Arthus reaction

C. Membranous glomerulonephritis

D. Reactive arthritis

See Answer in Part B → Q8

@Neet_pg_bot

Q9: A 40-year-old man presents with jaundice and fatigue, recently diagnosed with hepatitis B infection. Further investigation reveals abnormal liver function tests, indicating hepatic injury. Which of the following statements regarding the mechanisms of hypersensitivity involved in this case is true? (Q845442)

A. CD8+ T cells differentiate into Th1 and Th17 cells upon antigen exposure

B. CD4+ T cells differentiate into Th2 cells upon exposure to antigen

C. Cytotoxic T-lymphocytes (CTLs) directly kill virus-infected cells via the Fas-Fas ligand pathway

D. Perforin-granzyme-dependent killing is a mechanism employed by CD4+ T cells

See Answer in Part B → Q9

@Neet_pg_bot

Q10: A 35-year-old woman presents with a history of persistent cough and unintentional weight loss. The physician suspects a TB infection and performs a tuberculin skin test. Which of the following is not an example of the type of hypersensitivity reaction associated with this test? (Q845444)

A. Contact dermatitis from poison ivy exposure.

B. Rheumatoid arthritis.

C. Crohn's disease.

D. Reactive arthritis.

See Answer in Part B → Q10

@Neet_pg_bot

Q11: Which of the following statements accurately describes Type V hypersensitivity? (Q845446)

A. Antibodies bind to cell surface receptors, leading to altered cellular function

B. Immune complexes form and deposit in tissues, triggering localized inflammation and damage.

C. Antibodies target cell surface antigens, resulting in complement activation and cell destruction.

D. IgE antibodies mediate the release of histamine from mast cells, causing immediate allergic reactions.

See Answer in Part B → Q11

@Neet_pg_bot

Q12: Which of the following sequences correctly describes the phases of pathogenesis in Type III hypersensitivity? (Q845447)

A. Formation of immune complexes → Inflammation and tissue injury → Deposition in blood vessels.

B. Deposition of immune complexes → Formation of antibodies → Tissue injury and inflammation.

C. Formation of immune complexes → Deposition in tissues → Inflammation and tissue injury.

D. Antibody production → Immune complex formation → Activation of cytotoxic T cells.

See Answer in Part B → Q12

@Neet_pg_bot

• [05_Immunity] 021 Immune Tolerance And Autoimmune Disease

« Back to Folder Directory

[05_Immunity] 021 Immune Tolerance And Autoimmune Disease — Quick Jump

Q1 (p. 238)	*Q2 (p. 238)*	*Q3 (p. 239)*	*Q4 (p. 239)*	*Q5 (p. 239)*	*Q6 (p. 240)*
Q7 (p. 240)	*Q8 (p. 240)*	*Q9 (p. 241)*	*Q10 (p. 241)*	*Q11 (p. 242)*	*Q12 (p. 242)*
Q13 (p. 242)	*Q14 (p. 243)*	*Q15 (p. 243)*	*Q16 (p. 243)*	*Q17 (p. 244)*	*Q18 (p. 244)*
Q19 (p. 244)	*Q20 (p. 245)*	*Q21 (p. 245)*	*Q22 (p. 245)*	*Q23 (p. 246)*	*Q24 (p. 246)*
Q25 (p. 247)	*Q26 (p. 248)*	*Q27 (p. 248)*	*Q28 (p. 249)*	*Q29 (p. 250)*	*Q30 (p. 251)*
Q31 (p. 251)	*Q32 (p. 252)*				

Q1: In healthy individuals, what is the typical ratio of CD4+ to CD8+ T lymphocytes? (Q890517)

A. 1:2

B. 2:1

C. 1:4

D. 4:1

See Answer in Part B → Q1

@Neet_pg_bot

Q2: Which of the following conditions belongs to the spectrum of IgG4-related disorders? Mikulicz syndrome Riedel thyroiditis Idiopathic retroperitoneal fibrosis Autoimmune pancreatitis Sclerosing cholangitis (Q890556)

A. 1,2

B. 1,2,4

C. 1,4,5

D. All of the above

See Answer in Part B → Q2

@Neet_pg_bot

Q3: Which of the following best describes the cell type that forms the characteristic lupus erythematosus (LE) cell? (Q890555)

A. Monocyte

B. Neutrophil

C. Basophil

D. Lymphocyte

See Answer in Part B → Q3

@Neet_pg_bot

Q4: Which of the following autoantibodies is least likely to cause a homogeneous nuclear staining pattern on immunofluorescence? (Q890554)

A. Anti-histone antibodies

B. Anti-chromatin antibodies

C. Anti-double-stranded DNA antibodies

D. Anti-RNA antibodies

See Answer in Part B → Q4

@Neet_pg_bot

Q5: Which mechanism primarily contributes to the development of autoimmunity in Epstein-Barr virus infection? (Q890553)

A. Molecular mimicry

B. Polyclonal B-cell activation

C. Upregulation of co-stimulatory molecules

D. Cross-reactive antigen recognition

See Answer in Part B → Q5

@Neet_pg_bot

Q6: Which of the following genes is a frequently implicated non-HLA susceptibility gene associated with multiple autoimmune diseases? (Q890552)

A. FOXP3

B. PTPN22

C. NOD2

D. AIRE

See Answer in Part B → Q6

@Neet_pg_bot

Q7: Which of the following autoimmune diseases is predominantly driven by T cell-mediated inflammation, although autoantibodies and immune complexes also contribute to its pathogenesis? (Q890551)

A. Pemphigus vulgaris

B. Pernicious anemia

C. Rheumatoid arthritis

D. Goodpasture syndrome

See Answer in Part B → Q7

@Neet_pg_bot

Q8: Which of the following proteins are encoded by genes in the MHC class III region? Complement component C4 Tumour necrosis factor (TNF) Heat shock proteins β2-microglobulin (Q890532)

A. 2,3

B. 1,3,4

C. 1,2,3

D. 4 only

See Answer in Part B → Q8

@Neet_pg_bot

Q9: Which of the following cytokines is a potent activator of basophils? (Q890529)

A. IL-3

B. IL-2

C. IFN-γ

D. TNF-α

See Answer in Part B → Q9

@Neet_pg_bot

Q10: Which of the following statements about γδ T-cells are correct? They kill extracellular bacteria using granulysin and perforin. They require antigen processing and presentation for recognition. They can directly kill infected macrophages. They protect against mycobacterial infections. (Q890528)

A. 2 only

B. 1,2

C. 2,3,4

D. 1,3,4

See Answer in Part B → Q10

@Neet_pg_bot

Q11: Which of the following cell types shows recirculation? (Q890526)

A. Plasma cells

B. T lymphocytes

C. Plasma cells and T lymphocytes

D. B lymphocytes and plasma cells

See Answer in Part B → Q11

@Neet_pg_bot

Q12: Papain digestion of an immunoglobulin molecule produces which of the following end products? (Q890525)

A. 2 Fc and 1 Fab fragments

B. 1 variable chain and 1 constant chain

C. 1 Fc and 2 Fab fragments

D. 2 Fc and 2 Fab fragments

See Answer in Part B → Q12

@Neet_pg_bot

Q13: Which class of antibodies is primarily produced in response to polysaccharide and lipid antigens? (Q890524)

A. IgG

B. IgM

C. IgD

D. IgA

See Answer in Part B → Q13

@Neet_pg_bot

Q14: Which cytokine primarily stimulates B cells to induce and produce IgE antibodies? (Q890523)

A. IL-1

B. IL-2

C. IL-4

D. IL-6

See Answer in Part B → Q14

@Neet_pg_bot

Q15: On antigen-presenting cells, which of the following molecules provide the necessary costimulatory signals to activate T cells? (Q890521)

A. CD28 and CD86

B. CD80 only

C. CD28 and CD80

D. CD80 and CD86

See Answer in Part B → Q15

@Neet_pg_bot

Q16: Which feature is shared by both natural killer (NK) cells and cytotoxic T lymphocytes (CTLs)? (Q890519)

A. They are restricted by MHC class I molecules

B. They need antibodies to mediate their effect

C. They can target virus-infected cells

D. Their activity is antigen-specific

See Answer in Part B → Q16

@Neet_pg_bot

Q17: A 5-year-old boy presents with severe, chronic diarrhoea, failure to thrive, and a rash. His medical history includes a diagnosis of type 1 diabetes mellitus and thyroiditis. Laboratory tests show elevated levels of anti-enterocyte antibodies. Based on these findings, which mechanism is most likely impaired in this patient's condition? (Q845501)

A. Central tolerance

B. Peripheral tolerance

C. Anergy

D. Hidden antigen

See Answer in Part B → Q17

@Neet_pg_bot

Q18: Activation of NOD-like receptors by gain-of-function mutations is most likely to result in which of the following conditions? (Q890516)

A. Malignancy

B. Granulomatous disease

C. Autoinflammatory syndrome

D. Autoimmune disorders

See Answer in Part B → Q18

@Neet_pg_bot

Q19: Which of the following immune cells are capable of mediating antibody-dependent cellular cytotoxicity (ADCC)? (Q890515)

A. Only macrophages

B. Only natural killer (NK) cells

C. Neutrophils and eosinophils

D. NK cells, neutrophils, and eosinophils

See Answer in Part B → Q19

@Neet_pg_bot

Q20: Which of the following is not a feature of dermatomyositis? (Q845621)

See Answer in Part B → Q20

@Neet_pg_bot

Q21: A 28-year-old female presents with fatigue, joint pain, and a rash. A blood test reveals positive anti-nuclear antibodies. Which of the following fluorescence patterns is most commonly associated with systemic lupus erythematosus (SLE)? (Q845616)

See Answer in Part B → Q21

@Neet_pg_bot

Q22: A 30-year-old woman is being evaluated for proximal muscle weakness. Which of the following is consistent with a diagnosis of polymyositis? (Q845529)

A. CD4+ T cell infiltration in affected tissue

B. Endomysial inflammation

C. Associated with underlying malignancies

D. Vascular injury involved in pathogenesis

See Answer in Part B → Q22

@Neet_pg_bot

Q23: A 32-year-old woman presents with fatigue, muscle weakness, and joint pain. On examination, she has a rash over her cheeks, along with Raynaud's phenomenon and swollen fingers. Laboratory tests reveal positive anti-U1 RNP antibodies. Which of the following conditions is this patient most likely suffering from? (Q845527)

A. Systemic lupus erythematosus

B. Scleroderma

C. Mixed connective tissue disease

D. Sjögren's syndrome

See Answer in Part B → Q23

@Neet_pg_bot

Q24: A 45-year-old woman presents with progressive proximal muscle weakness over the past 6 months. On examination, the hip and shoulder girdle muscles have symmetrical weakness. Laboratory investigations show elevated serum creatine kinase (CK) levels. A muscle biopsy reveals endomysial inflammation with CD8+ T lymphocytes and muscle fiber necrosis. Which of the following is the most likely diagnosis? (Q845525)

A. Dermatomyositis

B. Myasthenia gravis

C. Inclusion body myositis

D. Polymyositis

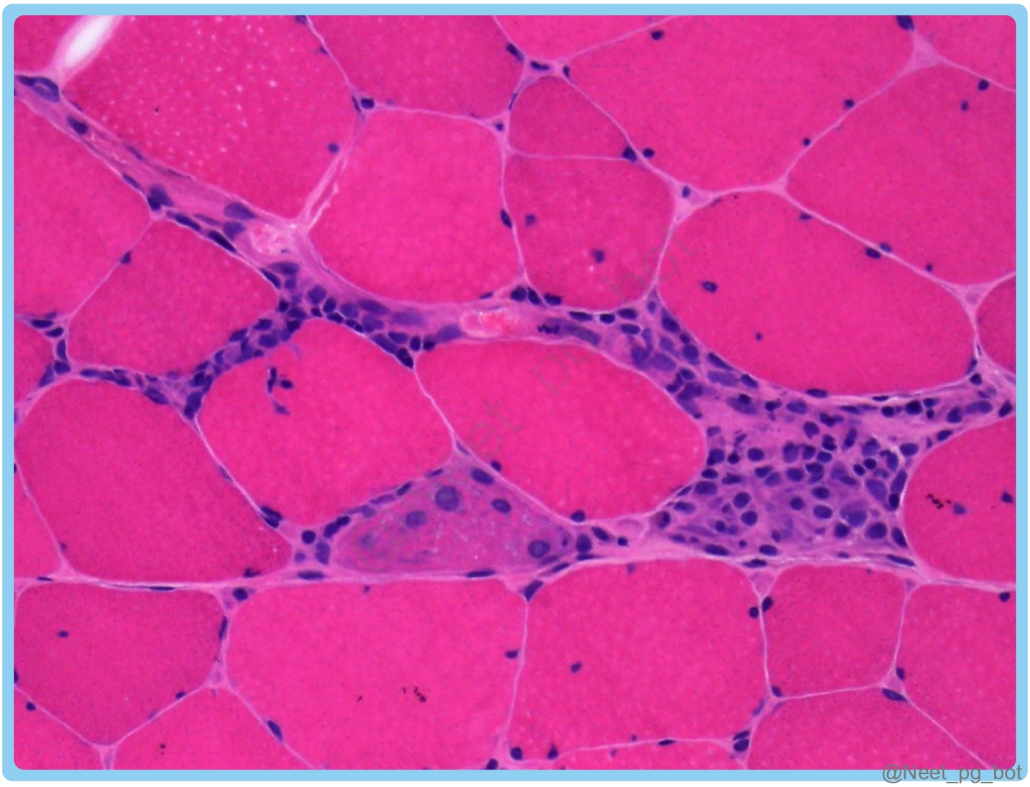

See Answer in Part B → Q24

@Neet_pg_bot

Q25: A 60-year-old woman complains of bilateral hand pain and stiffness, especially in the morning. On examination, you notice diffuse thickening and tightening of the skin all over her body. Echo showed pulmonary hypertension. Laboratory tests show positive Anti-SCL-70 antibodies What is the most likely diagnosis? (Q845523)

A. Rheumatoid arthritis

B. Osteoarthritis

C. CREST syndrome

D. Systemic sclerosis

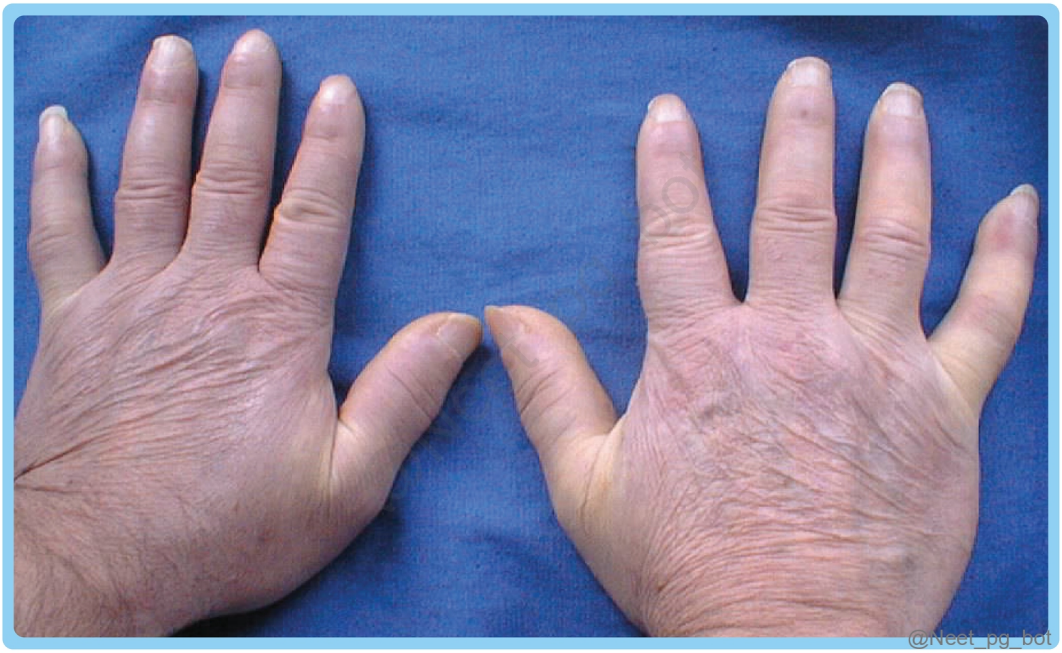

See Answer in Part B → Q25

@Neet_pg_bot

Q26: A 20-year-old female complains of recurrent episodes of her fingers turning symmetrically white, which are associated with pain and a tingling sensation. This is worse when exposed to cold water and is relieved when she dips her fingers in warm water. The autoimmune panel is negative. What is the likely diagnosis? (Q845520)

A. Primary Raynaud phenomenon

B. Dermatomyositis

C. Secondary Raynaud phenomenon

D. Calcinosis cutis

See Answer in Part B → Q26

@Neet_pg_bot

Q27: A 55-year-old woman has had persistent dry eyes and mouth for the past several months. She also reports difficulty in swallowing solid foods and occasional blurred

vision. On examination, she has bilateral parotid gland enlargement. She has a history of rheumatoid arthritis. Which antibodies are specific for this disease? (Q845518)

A. Anti-Sm

B. Anti La

C. Anti-Scl 70

D. Anti-U1 RNP



See Answer in Part B → Q27

@Neet_pg_bot

Q28: A 45-year-old woman with SLE complains of red, frothy urine for the past two months despite being on treatment. Urine analysis shows RBCs and proteins. An image of renal biopsy is given below. Which of the following accurately describes the histopathological findings? (Q845510)

A. Diffuse capillary wall thickening.

B. Wire loop lesions

C. Glomerular crescents

D. Kimmelstiel-Wilson lesion

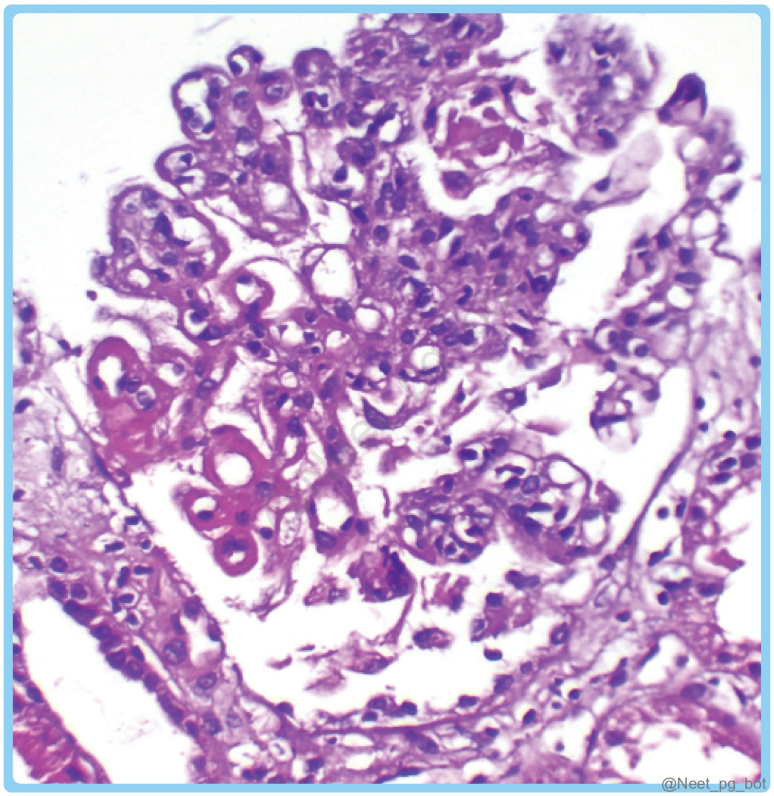

See Answer in Part B → Q28

@Neet_pg_bot

Q29: A 19-year-old woman presents with malaise, joint pain, and fever for the past 3 months. Physical examination shows a malar rash and mouth ulcers. She has significant proteinuria and decreased GFR. Which of the following antibodies are most specific and most sensitive, respectively? (Q845509)

A. ANA, Anti ds DNA

B. Anti-Sm, ANA

C. Anti- Ro, Anti- La

D. Anti-beta-2-glycoprotein, Anticardiolipin

See Answer in Part B → Q29

@Neet_pg_bot

Q30: A 30-year-old woman presents with a history of fatigue, fever, and weight loss. She also reports joint pain, swelling and a rash, as shown below. What is the most likely diagnosis? (Q845508)

A. Dermatomyositis

B. Systemic Lupus Erythematosus

C. Psoriatic Arthritis

D. Ankylosing Spondylitis



See Answer in Part B → Q30

@Neet_pg_bot

Q31: Which of the following is an immune-privileged site? (Q845507)

A. Heart

B. Lung

C. Kidney

D. Testis

See Answer in Part B → Q31

@Neet_pg_bot

Q32: Match the following processes in immune tolerance with their associated regulators. Process Regulators 1. Negative selection a. CD-28 2. Anergy b. FOXP3 3. Deletion by apoptosis c. AIRE 4. Suppression by regulatory T cells d. CD95 (Q845505)

A. 1-c, 2-a, 3-d, 4-b.

B. 1-a, 2-c, 3-d, 4-b.

C. 1-c, 2-b, 3-d, 4-a.

D. 1-a, 2-d, 3-c, 4-b.

See Answer in Part B → Q32

@Neet_pg_bot

• [05_Immunity] 022 Immunodeficiency Disorders

« Back to Folder Directory

[05_Immunity] 022 Immunodeficiency Disorders — Quick Jump

Q1 (p. 253)	*Q2 (p. 253)*	*Q3 (p. 254)*	*Q4 (p. 254)*	*Q5 (p. 254)*	*Q6 (p. 255)*
Q7 (p. 255)	*Q8 (p. 256)*	*Q9 (p. 256)*	*Q10 (p. 256)*	*Q11 (p. 257)*	*Q12 (p. 257)*
Q13 (p. 258)	*Q14 (p. 259)*	*Q15 (p. 259)*	*Q16 (p. 259)*	*Q17 (p. 260)*	*Q18 (p. 260)*
Q19 (p. 261)	*Q20 (p. 261)*	*Q21 (p. 262)*	*Q22 (p. 263)*	*Q23 (p. 263)*	*Q24 (p. 263)*
Q25 (p. 264)	*Q26 (p. 264)*	*Q27 (p. 265)*	*Q28 (p. 265)*	*Q29 (p. 266)*	*Q30 (p. 266)*

Q1: Assertion: Patients with Common Variable Immunodeficiency (CVID) commonly present with recurrent respiratory infections, gastrointestinal issues, and autoimmune disorders. Reason: Defects in the BTK gene lead to impaired B cell signaling, resulting in decreased maturation of B cells from pre-B-cells. (Q845677)

A. Both Assertion and Reason are true, and Reason is the correct explanation for Assertion

B. Both Assertion and Reason are true, but Reason is not the correct explanation for Assertion

C. Assertion is true, but Reason is false

D. Assertion is false, but Reason is true

See Answer in Part B → Q1

@Neet_pg_bot

Q2: A 52-year-old HIV-positive male presents with multiple raised, violaceous plaques and nodules over both legs. The lesions have gradually increased in number over the past few months. Skin biopsy shows a dermal lesion composed of irregular, slit-like vascular spaces lined and surrounded by plump, spindle-shaped cells. The stroma contains extravasated red blood cells, hemosiderin deposits, areas of haemorrhage, and a mixed mononuclear inflammatory infiltrate. Occasional mitotic figures are seen. Which of the following infectious agents is associated with this tumour? (Q890583)

A. Human herpesvirus type 8

B. Epstein-Barr virus

C. Cytomegalovirus

D. Human papillomavirus

See Answer in Part B → Q2

@Neet_pg_bot

Q3: A 30-year-old HIV-positive patient presents with persistent, painless swelling of multiple lymph nodes. A lymph node biopsy is performed. Which of the following histopathological findings is least likely to be observed in this patient? (Q890582)

A. Florid follicular hyperplasia

B. Destruction of germinal centres

C. Hematoxylin bodies

D. Expansion of monocytoid B cells in the sinuses

See Answer in Part B → Q3

@Neet_pg_bot

Q4: In patients with HIV/AIDS, which of the following is the most frequently observed brain tumour? (Q890581)

A. Oligodendroglioma

B. Primary CNS lymphoma

C. Ependymoma

D. Pilocytic astrocytoma

See Answer in Part B → Q4

@Neet_pg_bot

Q5: Which of the following immune cells is least likely to be directly infected by HIV during the course of the disease? (Q890580)

A. Helper T cells (CD4+ cells)

B. Neutrophils

C. Dendritic cells

D. Macrophages

See Answer in Part B → Q5

@Neet_pg_bot

Q6: A 6-year-old boy presents with recurrent eczema, recurrent pneumonia and otitis media since infancy, and easy bruising. Laboratory investigations show thrombocytopenia with small platelets and abnormal immunoglobulin levels. Which of the following statements regarding his condition is correct? Serum IgE is elevated Serum IgA is elevated Serum IgM is normal Serum IgG is normal (Q890569)

A. 2, 3 and 4

B. 1, 2 and 4

C. 2 and 4 only

D. 1, 2 and 3

See Answer in Part B → Q6

@Neet_pg_bot

Q7: In patients diagnosed with common variable immunodeficiency (CVID), which of the following best describes the typical finding in peripheral B-cell numbers? (Q890567)

A. B-cell count is consistently reduced

B. B-cell count is markedly increased

C. B-cells are completely absent

D. B-cell count is usually within the normal range

See Answer in Part B → Q7

@Neet_pg_bot

Q8: Mutation in which of the following is responsible for the development of X-linked lymphoproliferative disorder, characterised by an abnormal immune response to Epstein-Barr virus (EBV)? (Q890564)

A. SLAM-associated protein

B. WAS gene

C. LYST gene

D. FOXP3 gene

See Answer in Part B → Q8

@Neet_pg_bot

Q9: Individuals with selective IgA deficiency most commonly show reduced levels of which IgG subclass? (Q890563)

A. IgG1

B. IgG2

C. IgG3

D. IgG4

See Answer in Part B → Q9

@Neet_pg_bot

Q10: Which of the following genes is not typically associated with the development of severe combined immunodeficiency (SCID)? (Q890562)

A. IL-7Rα

B. RAG1 and RAG2

C. JAK3

D. BTK

See Answer in Part B → Q10

@Neet_pg_bot

Q11: A 7-month-old infant presents with persistent oral thrush and extensive diaper rash. History reveals multiple serious infections since birth, requiring repeated hospital admissions. Oral examination shows easily scrapable white patches. Thymic biopsy demonstrates underdeveloped Hassall's corpuscles. Which of the following statements about this condition is correct? The most common form of SCID is X-linked Adenosine deaminase (ADA) enzyme deficiency is the most common cause Hematopoietic stem cell transplantation is the preferred treatment It is due to defects in both humoral and cell-mediated immune responses (Q890561)

A. 1,2

B. 2,3,4

C. 1,3,4

D. All of the above

See Answer in Part B → Q11

@Neet_pg_bot

Q12: A young adult develops recurrent episodes of facial and lip swelling accompanied by abdominal pain and vomiting following minor stress or trauma. There is no associated urticaria. Which of the following complement deficiencies is most likely responsible? (Q890560)

A. C1 inhibitor

B. C2

C. C3

D. C5,C6, C7, C8, C9

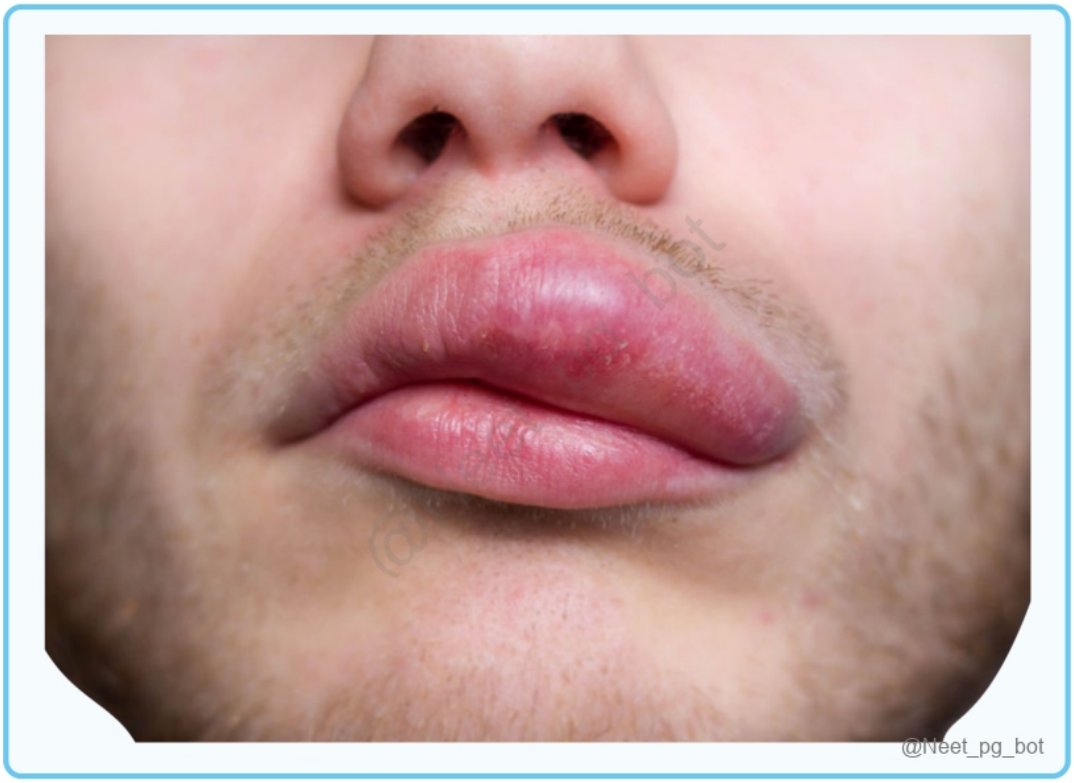

See Answer in Part B → Q12

@Neet_pg_bot

Q13: Which of the following complement deficiencies is correctly matched with its associated disorder? (Q890559)

A. C1 esterase inhibitor - Hereditary angioedema

B. C3 - Recurrent Neisseria infections

C. Factor H - Glomerulonephritis

D. C6-C9 - Hemolytic uremic syndrome

See Answer in Part B → Q13

@Neet_pg_bot

Q14: A 6-month-old infant presents with persistent fever and rapid breathing for 1 week. History reveals multiple previous infections. Blood culture grows Serratia marcescens. Nitroblue tetrazolium (NBT) test is negative. Which of the following statements about this condition is true? (Q890558)

A. It is inherited in an autosomal dominant manner

B. Due to lymphocytic inflammatory reaction

C. Primarily affects the adaptive immune system

D. It is due to defects in leukocytic superoxide production

See Answer in Part B → Q14

@Neet_pg_bot

Q15: In a pediatric clinic, a six-year-old male presents with a history of frequent respiratory and skin infections, eczema flare-ups, and microthrombocytopenia. Given these symptoms, which genetic evaluation method would be the most effective for confirming the suspected diagnosis? (Q845948)

A. WASP gene mutation analysis

B. ANA titer

C. FISH

D. B cell tyrosine kinase activity detection

See Answer in Part B → Q15

@Neet_pg_bot

Q16: In a pediatric clinic, a six-year-old male presents with a history of frequent respiratory and skin infections, eczema flare-ups, and thrombocytopenia. Given these symptoms, which genetic evaluation method would be the most effective for confirming the suspected diagnosis? (Q845648)

A. WASP gene mutation analysis

B. ANA titer

C. FISH

D. B cell tyrosine kinase activity detection

See Answer in Part B → Q16

@Neet_pg_bot

Q17: A 35-year-old male with a known history of selective IgA deficiency receives a blood transfusion during surgery. Shortly after the transfusion, he develops acute allergic reactions, including hives and difficulty breathing. Given his IgA deficiency, which blood products should have been considered to minimize the risk of such complications? (Q845676)

A. Standard red blood cells with no modification

B. Plasma products that are rich in IgA

C. Washed red blood cells

D. Fresh frozen plasma

See Answer in Part B → Q17

@Neet_pg_bot

Q18: A 7-year-old child presents with recurrent skin abscesses and pneumonia. He also has a history of skeletal abnormalities, including scoliosis and delayed shedding of primary teeth. His lab work shows elevated serum IgE levels. What is the most likely diagnosis? (Q845675)

A. Job syndrome

B. Bruton’s Agammaglobulinemia

C. Wiskott-Aldrich syndrome

D. Ataxia-Telangiectasia

See Answer in Part B → Q18

@Neet_pg_bot

Q19: A 4-year-old boy presents with recurrent bacterial infections, including pneumonia and otitis media. He also has a history of chronic diarrhoea. Laboratory tests reveal elevated IgM levels with markedly reduced IgG, IgA, and IgE levels. Flow cytometry shows normal numbers of CD19+ B cells and CD3+ T cells. Genetic testing reveals a mutation in the CD40L gene. Which of the following pathogens is the patient most at risk for developing severe infections with? (Q845674)

A. Streptococcus pneumoniae

B. Haemophilus influenzae

C. Staphylococcus aureus

D. Pneumocystis jirovecii

See Answer in Part B → Q19

@Neet_pg_bot

Q20: A patient presents with autoimmune hemolytic anemia, thrombocytopenia and neutropenia. Based on the flow cytometry findings, what is the most likely diagnosis? (Q845673)

A. Paroxysmal Nocturnal Hemoglobinuria

B. Hyper IgE syndrome

C. Hyper IgM syndrome

D. Glanzmann Thrombasthenia

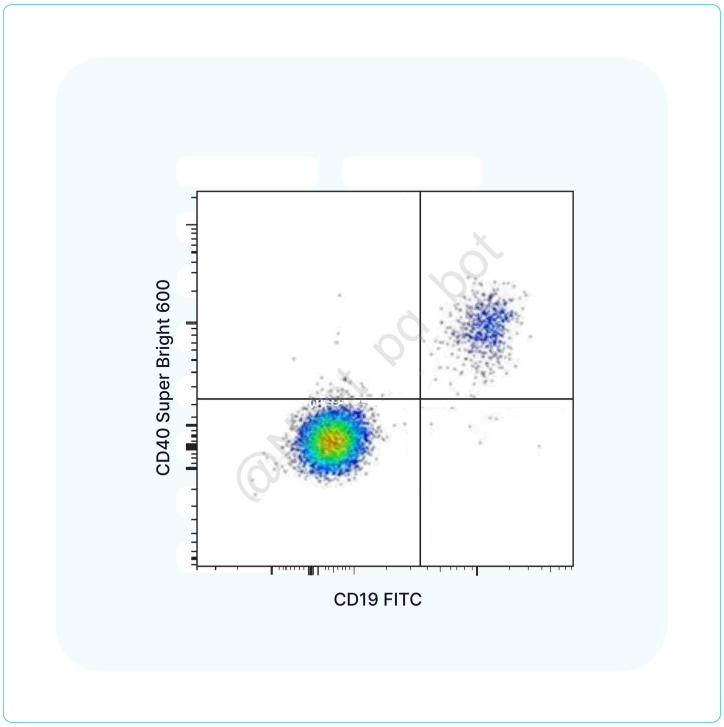

@Neet_pg_bot

See Answer in Part B → Q20

@Neet_pg_bot

Q21: A 7-year-old boy is brought to the pediatric clinic due to recurrent infections, including pneumonia and abscesses. He has a history of photophobia and exhibits partial oculocutaneous albinism. On examination, he has notable nystagmus and ataxia. Genetic testing confirms a defect in the LYST gene. Which of the following laboratory findings would be most characteristic of this patient's condition? (Q845672)

A. Decreased immunoglobulin levels

B. Elevated eosinophil count

C. Presence of giant granules in leukocytes

D. Elevated platelet count

See Answer in Part B → Q21

@Neet_pg_bot

Q22: Match the following. i) X-linked Agammaglobulinemia a) WAS ii) Job syndrome b) LYST iii) Wiskott-Aldrich syndrome c) STAT3 iv) Ataxia Telangiectasia d) BTK v) Chediak-Higashi syndrome e) ATM (Q845671)

A. i-d, ii-c, iii-b, iv-e, v-a

B. i-c, ii-d, iii-a, iv-e, v-b

C. i-d, ii-b, iii-a, iv-e, v-c

D. i-d, ii-c, iii-a, iv-e, v-b

See Answer in Part B → Q22

@Neet_pg_bot

Q23: An 8-month-old male infant presents with a history of severe, recurrent bacterial infections. On physical examination, the tonsils were found to be absent. Peripheral blood examination reveals an absence of B cells, while the T cell count is normal. Additionally, serum analysis reveals undetectable levels of immunoglobulins (IgG, IgA, and IgM). Which of the following most accurately explains the molecular mechanism responsible for this patient's immunodeficiency? (Q845670)

A. BTK gene mutation

B. RAG1/2 gene mutation

C. CD40L deficiency

D. BAFF receptor abnormality

See Answer in Part B → Q23

@Neet_pg_bot

Q24: A 30-year-old female patient presents with a history of recurrent respiratory infections, chronic diarrhoea, and autoimmune manifestations. Laboratory investigations reveal low levels of serum immunoglobulins (IgG, IgA, and IgM). BAFF

gene defect noted. Which of the following immunodeficiency disorders is most likely associated with these clinical findings? (Q845669)

A. X-linked agammaglobulinemia (XLA)

B. Common variable immunodeficiency (CVID)

C. Hyper IgM syndrome

D. Severe Combined Immunodeficiency (SCID)

See Answer in Part B → Q24

@Neet_pg_bot

Q25: A 6-year-old child presents with recurrent bacterial infections, delayed wound healing, and poor pus formation. Genetic testing reveals a mutation in the SLC35C1 gene, leading to a deficiency in Sialyl Lewis X (SLex) synthesis. Which of the following is the most likely consequence of this deficiency? (Q845668)

A. Leukocyte adhesion deficiency II

B. Defective opsonisation

C. Reduced chemokine production

D. Increased neutrophil apoptosis

See Answer in Part B → Q25

@Neet_pg_bot

Q26: A 2-year-old child presents with recurrent bacterial infections, delayed wound healing, and poor pus formation despite having a normal leukocyte count. Upon further investigation, a defect is identified in the integrin-mediated adhesion of leukocytes. Which of the following conditions is most likely responsible for this clinical presentation? (Q845667)

A. Chronic granulomatous disease (CGD)

B. Leukocyte Adhesion Deficiency Type 1 (LAD-1)

C. Hyper IgM syndrome

D. Severe Combined Immunodeficiency (SCID)

See Answer in Part B → Q26

@Neet_pg_bot

Q27: Which of the following disorders is characterised by absent tonsils and lymph nodes, markedly decreased levels of serum immunoglobulins (particularly IgG, IgA, and IgM), and a lack of mature B cells in peripheral blood? (Q845666)

A. Common Variable Immunodeficiency (CVID)

B. Severe Combined Immunodeficiency (SCID)

C. X-linked Agammaglobulinemia (XLA)

D. Hyper-IgM Syndrome

See Answer in Part B → Q27

@Neet_pg_bot

Q28: A 5-year-old male presents with progressive difficulty in coordinating movements, slurred speech, and frequent infections. Physical examination reveals the findings shown in the image below and dysarthria. Laboratory investigations show decreased levels of serum IgA, IgG, and IgE. Which of the following is the most likely diagnosis? (Q845665)

A. Hereditary spastic paraplegia

B. Friedreich ataxia

C. Ataxia Telangiectasia

D. Spinocerebellar ataxia type 1



See Answer in Part B → Q28

@Neet_pg_bot

Q29: An 8-month-old infant is brought to the clinic with a history of persistent, severe respiratory infections since birth. Physical examination reveals failure to thrive and absent tonsils and lymph nodes. The child is diagnosed with adenosine deaminase deficiency; what is the most appropriate diagnosis? (Q845650)

A. DiGeorge Syndrome

B. X-linked Agammaglobulinemia (XLA)

C. Hyper-IgM Syndrome

D. Severe Combined Immunodeficiency (SCID)

See Answer in Part B → Q29

@Neet_pg_bot

Q30: A 4-year-old child presents with recurrent infections, congenital heart defects, and facial dysmorphisms, including a long face with a prominent nasal bridge. Genetic testing reveals a microdeletion on chromosome 22q11. What is the most likely diagnosis? (Q845649)

A. Down syndrome

B. Turner syndrome

C. DiGeorge syndrome

D. Cri-du-chat syndrome

See Answer in Part B → Q30

@Neet_pg_bot

• [05_Immunity] 023 Amyloidosis

« Back to Folder Directory

[05_Immunity] 023 Amyloidosis — Quick Jump

Q1 (p. 268) *Q2 (p. 268)* *Q3 (p. 269)* *Q4 (p. 269)* *Q5 (p. 269)* *Q6 (p. 270)*
Q7 (p. 270) *Q8 (p. 270)* *Q9 (p. 271)* *Q10 (p. 271)* *Q11 (p. 271)* *Q12 (p. 272)*
Q13 (p. 272)

Q1: Which of the following sites is most commonly affected in secondary (AA) amyloidosis? (Q879914)

A. Heart and brain

B. Kidneys and liver

C. Lungs and spleen

D. Skin and skeletal muscle

See Answer in Part B → Q1

@Neet_pg_bot

Q2: A 58-year-old man with end-stage renal disease has been receiving hemodialysis for 6 years. He now presents with joint pain, carpal tunnel syndrome, and shoulder stiffness. Laboratory tests show normal inflammatory markers and no evidence of plasma cell disorder. Which type of amyloid is most likely responsible for his symptoms? (Q879916)

A. AA amyloid

B. AL amyloid

C. Aβ2-m

D. ATTR

See Answer in Part B → Q2

@Neet_pg_bot

Q3: Which type of amyloid is commonly deposited in the pancreas of patients with type 2 diabetes mellitus? (Q879919)

A. AL amyloid

B. AA amyloid

C. Islet amyloid polypeptide (IAPP)

D. β2-microglobulin

See Answer in Part B → Q3

@Neet_pg_bot

Q4: In medullary thyroid carcinoma, amyloid deposits are primarily derived from which of the following? (Q879920)

A. Thyroglobulin

B. Calcitonin

C. Parathyroid hormone

D. Islet amyloid polypeptide

See Answer in Part B → Q4

@Neet_pg_bot

Q5: Which of the following organs is most commonly affected in AL (primary) amyloidosis? (Q879921)

A. Kidneys

B. Liver

C. Heart

D. Pancreas

See Answer in Part B → Q5

@Neet_pg_bot

Q6: In primary (AL) amyloidosis, the typical bone marrow finding is? (Q879936)

A. Extensive osteolytic lesions with >30% plasma cells

B. Modest increase in plasma cells producing monoclonal light chains

C. Normal plasma cell count with no monoclonal proteins

D. Hypercellular marrow with granulocytic predominance

See Answer in Part B → Q6

@Neet_pg_bot

Q7: Which of the following is the preferred initial investigation for suspected systemic amyloidosis? (Q879937)

A. Kidney biopsy

B. Abdominal fat pad aspiration stained with Congo red

C. Bone marrow aspirate

D. Radiolabeled serum amyloid P scintigraphy

See Answer in Part B → Q7

@Neet_pg_bot

Q8: Which of the following stains is most commonly used to detect amyloid deposits in kidney biopsies? (Q879938)

A. Hematoxylin and eosin

B. Congo red

C. Masson’s trichrome

D. Periodic acid–Schiff

See Answer in Part B → Q8

@Neet_pg_bot

Q9: When stained with Congo red and viewed under polarized light, amyloid deposits in tissue typically show? (Q879939)

A. Bright red fluorescence

B. Apple-green birefringence

C. Blue-black metachromasia

D. Orange-red color under light microscope only

See Answer in Part B → Q9

@Neet_pg_bot

Q10: Identify the false statements regarding the amyloid. 1) It is a proteoglycan. 2) It is a misfolded protein seen intracellularly. 3) They show cross-β-pleated sheet conformation in light microscopy. 4) 95% of amyloid consists of fibril proteins. 5) It appears as an amorphous, basophilic, hyaline, extracellular substance. (Q845450)

A. 1,2,3

B. 2,5

C. 3,4

D. 2,3,5

See Answer in Part B → Q10

@Neet_pg_bot

Q11: Match the following. Condition Amyloid protein 1 Chronic inflammation i ATTR 2 Alzheimer's disease ii AA 3 Familial amyloid polyneuropathy iii AIAPP 4 Diabetes mellitus iv Aβ (Q845453)

A. 1-i, 2-ii, 3-iii, 4-iv

B. 1-ii, 2-iv, 3-iii, 4-i

C. 1-ii, 2-iv, 3-i, 4-iii

D. 1-iii, 2-ii, 3-i, 4-iv

See Answer in Part B → Q11

@Neet_pg_bot

Q12: A 65-year-old male with a history of multiple myeloma in remission presents with fatigue, weight loss, and abdominal discomfort. He reports early satiety and a palpable firm mass in the left upper quadrant. Which finding is not associated with this condition? (Q845454)

A. Sago's spleen

B. Lardaceous spleen

C. Carpal tunnel syndrome

D. Nephritic syndrome

See Answer in Part B → Q12

@Neet_pg_bot

Q13: A 60-year-old man with poorly controlled hypertension and diabetes presents with fatigue, shortness of breath, ankle swelling, hepatomegaly, and bilateral lower extremity oedema. Labs show proteinuria and elevated serum creatinine. Which staining technique is most appropriate to confirm the diagnosis? (Q845458)

A. Periodic acid Schiff (PAS) stain

B. Masson trichome stain

C. Congo red stain

D. Oil red O

See Answer in Part B → Q13

@Neet_pg_bot

• [05_Immunity] 024 Transplant Immunity

« Back to Folder Directory

[05_Immunity] 024 Transplant Immunity — Quick Jump

Q1 (p. 274) *Q2 (p. 274)* *Q3 (p. 275)* *Q4 (p. 275)* *Q5 (p. 275)* *Q6 (p. 276)*
Q7 (p. 276) *Q8 (p. 276)* *Q9 (p. 277)* *Q10 (p. 277)*

Q1: Which immune cells primarily mediate acute cellular rejection of a kidney allograft? (Q879941)

A. B cells producing preformed antibodies

B. CD8■ cytotoxic T lymphocytes and CD4■ helper T cells

C. Natural killer (NK) cells only

D. Macrophages without T cell involvement

See Answer in Part B → Q1

@Neet_pg_bot

Q2: A kidney transplant patient develops sudden anuria immediately after reperfusion. The graft is cyanotic and mottled. Biopsy shows fibrinoid necrosis of arteries and thrombi in arterioles, with neutrophilic infiltration. What type of rejection is most likely? (Q879955)

A. Hyperacute rejection

B. Acute cellular (T cell–mediated) rejection

C. Acute antibody-mediated rejection

D. Chronic rejection

See Answer in Part B → Q2

@Neet_pg_bot

Q3: Which of the following organs are primarily affected in acute graft-versus-host disease (GVHD)? (Q879962)

A. Skin, liver (bile ducts), and intestines

B. Heart, lungs, and kidneys

C. Brain, pancreas, and spleen

D. Lymph nodes and bone marrow only

See Answer in Part B → Q3

@Neet_pg_bot

Q4: A 20-year-old girl was diagnosed with acute lymphoblastic leukaemia (ALL). Her medical team has determined that a bone marrow transplant is necessary to achieve remission and prevent disease recurrence. She has an identical twin sister, who is an eligible donor. What type of grafting was done on this patient? (Q845524)

A. Allograft

B. Autograft

C. Isograft

D. Xenograft

See Answer in Part B → Q4

@Neet_pg_bot

Q5: What is the minimum HLA matching that should be achieved to proceed with the transplant in the pediatric population? (Q845526)

A. 4/6

B. 6/6

C. 6/8

D. 8/10

See Answer in Part B → Q5

@Neet_pg_bot

Q6: A 35-year-old woman with end-stage renal disease recently received a compatible donor organ from her brother. The kidney transplant surgery proceeds as planned, but within minutes of reperfusion, the kidney becomes mottled, cyanotic and anuric. What is the cause for this presentation? (Q845528)

A. Preformed antibodies in the donor

B. Preformed antibodies in the recipient

C. Cytotoxic T-lymphocyte-mediated injury

D. CD4+ cells mediated inflammation

See Answer in Part B → Q6

@Neet_pg_bot

Q7: A 45-year-old man, two weeks post-kidney transplant, presents with sudden oliguria, fever, and graft site swelling. Biopsy shows glomerular and peritubular capillary inflammation with complement deposition. What is the most likely diagnosis? (Q845530)

A. Acute humoral rejection

B. Acute calcineurin inhibitor nephrotoxicity

C. Acute cellular rejection

D. BK virus infection

See Answer in Part B → Q7

@Neet_pg_bot

Q8: A 45-year-old male patient presents with a widespread rash, severe diarrhoea, and jaundice. He underwent bonemarrow transplantation for acute myeloid leukaemia and received cells from a matched, unrelated donor. Which is the most likely diagnosis? (Q845531)

A. Acute transplant rejection

B. Chronic transplant rejection

C. Graft-versus-host disease

D. Immune reconstitution inflammatory syndrome

See Answer in Part B → Q8

@Neet_pg_bot

Q9: A 55-year-old male patient who has undergone kidney transplantation is now presenting with signs of renal dysfunction. Which complement activation product is a known histological marker for the diagnosis of antibody-mediated rejection in transplant biopsies? (Q845532)

A. C3d

B. C5a

C. C3b

D. C4d

See Answer in Part B → Q9

@Neet_pg_bot

Q10: A patient presented with oliguria for the last three days. She is a known case of diabetic nephropathy and underwent an allogeneic renal transplant four years ago. The physician suspects a possibility of graft rejection. Which of the following is not true regarding the suspected condition in this patient? (Q845533)

A. Predominantly antibody-mediated reaction

B. Manifests as interstitial fibrosis and narrowing of graft blood vessels

C. HPE shows duplication of the basement membrane

D. Its morphologic correlate in the lung is bronchiolitis obliterans

See Answer in Part B → Q10

@Neet_pg_bot

• [05_Immunity] 025 Previous Year Questions

« Back to Folder Directory

[05_Immunity] 025 Previous Year Questions — Quick Jump

Q1 (p. 279)	*Q2 (p. 279)*	*Q3 (p. 280)*	*Q4 (p. 280)*	*Q5 (p. 280)*	*Q6 (p. 281)*
Q7 (p. 281)	*Q8 (p. 281)*	*Q9 (p. 282)*	*Q10 (p. 282)*	*Q11 (p. 283)*	*Q12 (p. 283)*
Q13 (p. 283)	*Q14 (p. 284)*	*Q15 (p. 284)*	*Q16 (p. 285)*	*Q17 (p. 285)*	*Q18 (p. 285)*
Q19 (p. 286)	*Q20 (p. 286)*	*Q21 (p. 286)*	*Q22 (p. 287)*	*Q23 (p. 288)*	*Q24 (p. 288)*
Q25 (p. 288)	*Q26 (p. 289)*	*Q27 (p. 289)*	*Q28 (p. 289)*	*Q29 (p. 290)*	*Q30 (p. 290)*
Q31 (p. 291)	*Q32 (p. 291)*	*Q33 (p. 291)*	*Q34 (p. 292)*	*Q35 (p. 292)*	*Q36 (p. 293)*
Q37 (p. 293)					

Q1: A 78-year-old male presents with fatigue, breathlessness, and palpitations. On examination, he has pedal oedema, with a pulse rate of 55 bpm, BP of 100/70 mmHg, and oxygen saturation of 94%. ECG is normal, and echocardiography reveals restrictive cardiomyopathy. A cardiac biopsy stained with Congo red shows apple-green birefringence under polarised light. What is the most likely diagnosis? (Q857590)

A. Heart failure

B. Cardiac amyloidosis

C. Hemosiderosis

D. Dystrophic calcification

See Answer in Part B → Q1

@Neet_pg_bot

Q2: In a patient with Bare Lymphocyte Syndrome, graft-versus-host disease (GVHD) does not occur. Which of the following causes it? (Q855987)

A. Complement deficiency

B. Deficiency of CD4 T lymphocytes

C. MHC Class II deficiency in lymphocytes

D. MHC Class I deficiency in lymphocytes

See Answer in Part B → Q2

@Neet_pg_bot

Q3: Which of the following is not a part of innate immunity? (Q855074)

A. Alpha defensins

B. B lymphocytes

C. Gamma delta T lymphocytes

D. Alternate pathway

See Answer in Part B → Q3

@Neet_pg_bot

Q4: Which of the following cytokines is not involved in the Th1 response? (Q855089)

A. IFN gamma

B. IL-2

C. IL-12

D. IL-4

See Answer in Part B → Q4

@Neet_pg_bot

Q5: A person was brought to the emergency department with facial swelling, itching, and hypotension following a bee sting. The mentioned clinical features are due to the increase in which of the following immunoglobulins? (Q857097)

A. IgA

B. IgE

C. IgM

D. IgG

See Answer in Part B → Q5

@Neet_pg_bot

Q6: A Rh-negative mother delivered an Rh-positive baby, and Coomb's test was positive for the baby. What is the mechanism of hypersensitivity seen in this scenario? (Q857100)

A. Antigen-dependent cellular cytotoxicity

B. Antibody-dependent cellular cytotoxicity

C. Antigen-antibody immune complex deposition

D. CD4 T-cell-mediated cytokine release

See Answer in Part B → Q6

@Neet_pg_bot

Q7: Which of the following conditions is associated with hypocalcemia, thymic hypoplasia, cardiac abnormalities, and deletion of chromosome 22q11.2? (Q857124)

A. Williams syndrome

B. Pitt syndrome

C. DiGeorge syndrome

D. Cri-du-chat syndrome

See Answer in Part B → Q7

@Neet_pg_bot

Q8: A 24-year-old female patient presented with a malar rash, recurrent oral ulcers, and multiple joint pains. She has a relevant past history and does not take any medication. Upon further investigations, thrombocytopenia was seen, and the anti-Smith (anti-Sm) antibody was positive. What is the most likely diagnosis? (Q857140)

A. Scleroderma

B. Sjögren syndrome

C. Systemic lupus erythematosus (SLE)

D. Rheumatoid arthritis

See Answer in Part B → Q8

@Neet_pg_bot

Q9: Xenograft is: (Q857173)

A. Graft across species

B. Grafts from the same species

C. Graft from the same individual

D. Graft between genetically identical individuals

See Answer in Part B → Q9

@Neet_pg_bot

Q10: A child, upon disturbing a bee hive, had several stings. After a few minutes, the child developed symptoms of shock, respiratory failure, and vascular collapse. Which of the following is the principal mediator of this reaction? (Q857559)

A. Adrenaline

B. Histamine

C. Dopamine

D. Substance P

See Answer in Part B → Q10

@Neet_pg_bot

Q11: A boy presents with recurrent episodes of melena. On examination, there is eczema of the skin with multiple petechiae. His platelet count is low, with normal RBC and WBC counts. Which of the following is the diagnostic investigation for this patient? (Q855956)

A. WASP gene mutation

B. Anti-platelet antibodies

C. Bone marrow biopsy

D. Electron microscopy

See Answer in Part B → Q11

@Neet_pg_bot

Q12: Which of the following mediators is involved in the early phase of type 1 hypersensitivity? Mast cell Histamine Neutrophils Prostaglandins Leukotrienes (Q855445)

A. 1, 5

B. 1, 2, 3, 4

C. 1, 2, 4, 5

D. 2, 3, 4

See Answer in Part B → Q12

@Neet_pg_bot

Q13: A person was brought to the emergency department with facial swelling, itching, and hypotension following a bee sting. The mentioned clinical features are due to an increase in which immunoglobulin? (Q856690)

A. IgA

B. IgE

C. IgM

D. IgG

See Answer in Part B → Q13

@Neet_pg_bot

Q14: Isotype switching is seen in: (Q856894)

A. Helper T cells

B. Activated B cells

C. Cytotoxic T cells

D. B cells

See Answer in Part B → Q14

@Neet_pg_bot

Q15: B-cells are induced to produce IgE by which of the following? (Q854863)

A. IL-2

B. IL-4

C. IL-1

D. IL-6

See Answer in Part B → Q15

@Neet_pg_bot

Q16: A graft from an identical twin is called: (Q854871)

A. Allograft

B. Autograft

C. Isograft

D. Xenograft

See Answer in Part B → Q16

@Neet_pg_bot

Q17: Graft from an identical twin is called: (Q859849)

A. Allograft

B. Autograft

C. Isograft

D. Xenograft

See Answer in Part B → Q17

@Neet_pg_bot

Q18: A teenager developed swelling of the face, lips, and tongue and also found it difficult to breathe within a few minutes of consuming prawns. What type of hypersensitivity is seen here? (Q859855)

A. Type 1

B. Type 2

C. Type 3

D. Type 4

See Answer in Part B → Q18

@Neet_pg_bot

Q19: Which type of cells are implicated in the development of contact dermatitis in a 12-year-old boy who presented to the emergency department? (Q859906)

A. Helper T cells

B. Neutrophils

C. NK cells

D. Cytotoxic T cells

See Answer in Part B → Q19

@Neet_pg_bot

Q20: A patient with a deficiency of CD40 is most likely to exhibit which of the following immunological abnormalities? (Q857448)

A. Absence of B cells

B. Absence of T cells

C. Elevated IgM levels

D. Elevated IgG levels

See Answer in Part B → Q20

@Neet_pg_bot

Q21: A patient underwent a bone marrow transplant without HLA matching. In which of the following disorders transplant rejection does not occur: (Q865422)

A. Bare lymphocyte syndrome

B. Chediak Higashi syndrome

C. Wishkott Aldrich syndrome

D. Job’s syndrome

See Answer in Part B → Q21

@Neet_pg_bot

Q22: A patient presented to the OPD with hepatosplenomegaly, and his bone marrow showed 22% of plasma cells. Biopsy reveals pinkish acellular material deposition. What is the most likely diagnosis? (Q844184)

A. Myxoid degeneration of the bone marrow

B. Amyloidosis

C. Plasma cell leukemia

D. Hemolytic anemia

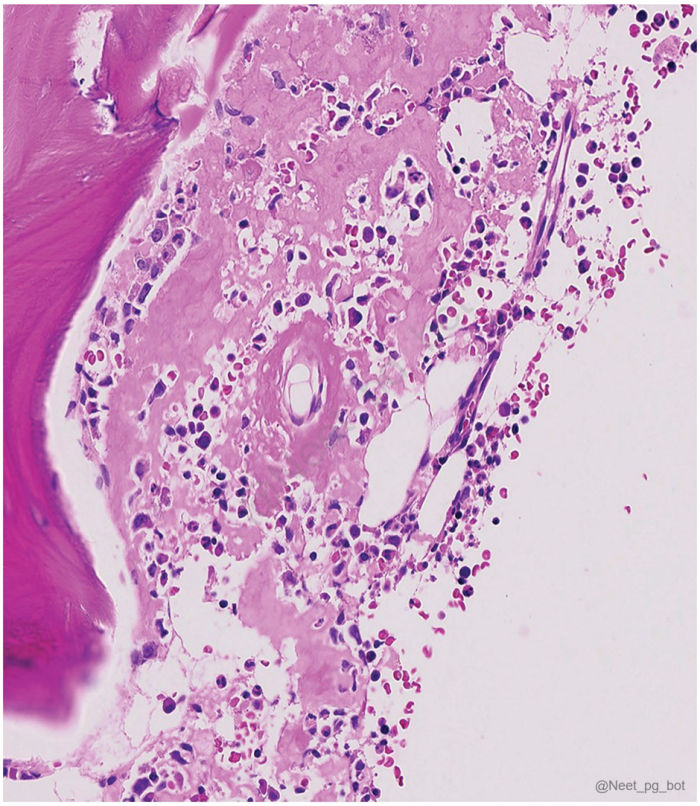

See Answer in Part B → Q22

@Neet_pg_bot

Q23: A child is brought to the OPD by his parents with complaints of recurrent infections. On mediastinal imaging, the thymus gland was found to be absent. Based on further investigation, ADA levels are low. What is the most likely diagnosis? (Q844212)

A. Bruton's hypogammaglobulinemia

B. Bare lymphocyte syndrome

C. DiGeorge syndrome

D. Severe combined immunodeficiency (autosomal recessive)

See Answer in Part B → Q23

@Neet_pg_bot

Q24: A 7-year-old boy presents with a history of recurrent bacterial and fungal infections, particularly involving the skin and respiratory tract. The patient's parents report that he has had multiple abscesses and lymphadenitis. Dihydrorhodamine test results show an abnormal pattern. What is the primary suspicion based on these findings? (Q860539)

A. CGD

B. SCID

C. Sialyl Lewis X

D. LAD

See Answer in Part B → Q24

@Neet_pg_bot

Q25: Which of the following organs is a primary lymphoid organ? (Q860208)

A. Lymph node

B. Spleen

C. Thymus

D. MALT

See Answer in Part B → Q25

@Neet_pg_bot

Q26: Which of the following antibodies is specific for scleroderma? (Q857434)

A. Anti-topoisomerase/Anti-scl 70 antibody

B. Anti-La antibody

C. Anti-Jo-1 antibody

D. Anti-U1 RNP antibodies

See Answer in Part B → Q26

@Neet_pg_bot

Q27: Which of the following genes is responsible for the regulation of T lymphocytes by the thymus? (Q857440)

A. AIRE

B. Notch 1

C. E2A

D. Rag1/2

See Answer in Part B → Q27

@Neet_pg_bot

Q28: Blood transfusion reactions are mediated by which type of hypersensitivity reaction? (Q866752)

A. Type I

B. Type II

C. Type III

D. Type IV

See Answer in Part B → Q28

@Neet_pg_bot

Q29: Which type of hypersensitivity reaction is a type 2 lepra reaction? (Q820565)

A. Type I hypersensitivity

B. Type II hypersensitivity

C. Type III hypersensitivity

D. Type IV hypersensitivity

See Answer in Part B → Q29

@Neet_pg_bot

Q30: After class switching, a particular class of antibody is produced, but IgM and IgD are expressed concomitantly on the surface of a B cell due to which of the following phenomena? (Q854696)

A. Allelic exclusion

B. Alternate RNA splicing

C. Somatic hypermutation

D. Affinity maturation

See Answer in Part B → Q30

@Neet_pg_bot

Q31: What method is employed for the detection of autoantibodies? (Q854704)

A. Direct Immunofluorescence

B. ELISA

C. Indirect Immunofluorescence

D. FISH

See Answer in Part B → Q31

@Neet_pg_bot

Q32: A young person with recurrent seasonal conjunctivitis presents with itchiness and eye-watering. What is the most likely cell involved in the immediate phase of this condition? (Q858100)

A. Eosinophils

B. Mast cells

C. Neutrophils

D. Lymphocytes

See Answer in Part B → Q32

@Neet_pg_bot

Q33: Which of the following is implicated in the pathogenesis of rheumatoid arthritis? (Q858104)

A. IgE-mediated

B. Defective cellular and humoral immunity

C. Autoimmunity

D. Chronic microbial infections

See Answer in Part B → Q33

@Neet_pg_bot

Q34: Which of the following is a marker of natural killer cells? (Q855942)

A. CD68

B. CD3

C. CD25

D. CD94

See Answer in Part B → Q34

@Neet_pg_bot

Q35: The below-given ANA pattern on immunofluorescence (IF) is seen; identify the pattern. (Q857429)

A. Nucleolar

B. Speckled

C. Centromeric

D. Diffuse

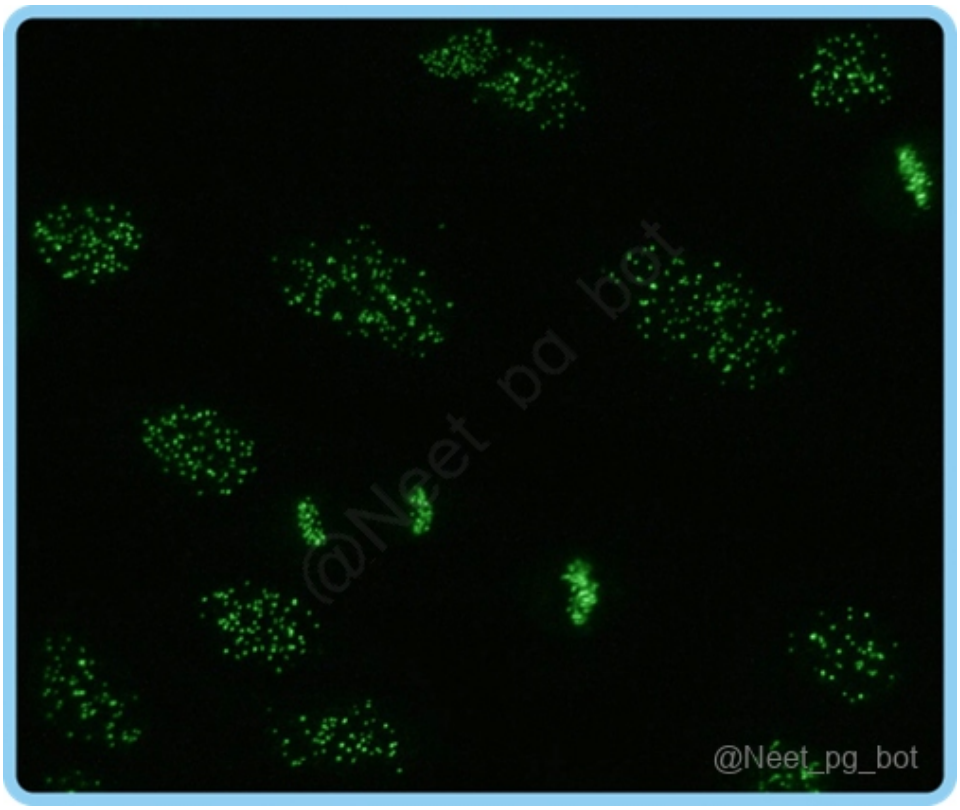

See Answer in Part B → Q35

@Neet_pg_bot

Q36: Which of the following cells is responsible for graft rejection? (Q793603)

A. Macrophages

B. T cells

C. B cells

D. Plasma cells

See Answer in Part B → Q36

@Neet_pg_bot

Q37: The X-ray of a middle-aged man showed multiple lytic lesions , following which a urine examination was done . The sample revealed Bence Jones proteins. Which is the

most common immunoglobulin associated with this condition ? (Q793750)

A. IgA

B. IgD

C. IgG

D. IgM

See Answer in Part B → Q37

@Neet_pg_bot

• [06_CVS_ Blood Vessels and Vasculitis] 026 Sclerosis And Vascular Tumors

« Back to Folder Directory

[06_CVS_ Blood Vessels and Vasculitis] 026 Sclerosis And Vascular Tumors — Quick Jump

Q1 (p. 295) *Q2 (p. 296)* *Q3 (p. 297)* *Q4 (p. 297)* *Q5 (p. 298)* *Q6 (p. 300)*
Q7 (p. 300) *Q8 (p. 301)* *Q9 (p. 301)* *Q10 (p. 302)* *Q11 (p. 302)*

Q1: A 60-year-old male with a chronic history of diabetes, hypertension and hypercholesterolemia came to the clinic for follow-up. His BP has not been under control for many years. He has a vascular lesion similar to the image shown below. What does this image indicate? {{caption_text}} (Q845201)

A. Atheromatous plaques

B. Thick arterial wall due to deposition of pink, hyaline material

C. Onion-skin appearance

D. Lipid deposition within the vessel wall

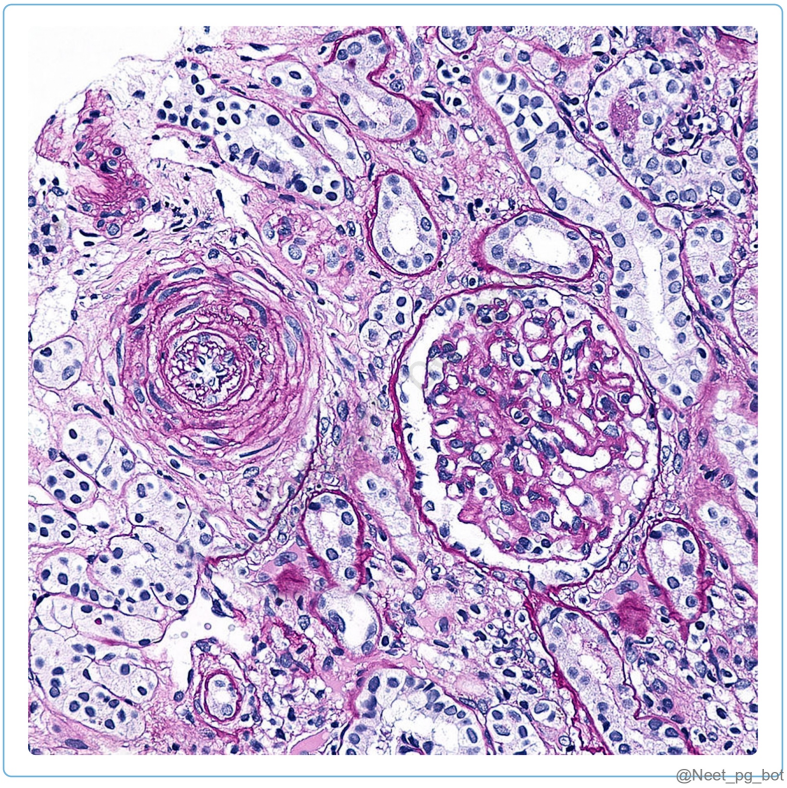

See Answer in Part B → Q1

@Neet_pg_bot

Q2: A 65-year-old male presents with high pulse pressure. Histopathological examination is shown below. The arteries appear thickened, but there is no significant luminal narrowing. Which of the following conditions is the likely cause? {{caption_text}} (Q845207)

A. Atherosclerosis

B. Monckeberg medial calcific sclerosis

C. Hyperplastic arteriosclerosis

D. Hyaline arteriosclerosis

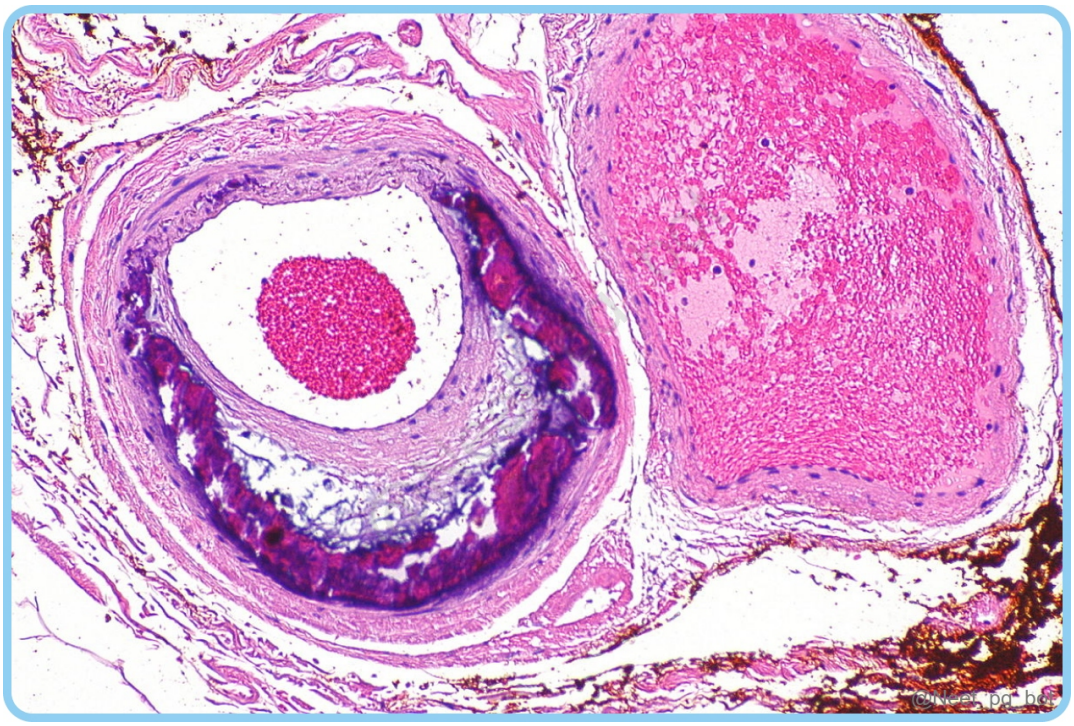

See Answer in Part B → Q2

@Neet_pg_bot

Q3: Arrange the following steps of atherosclerosis formation in the correct order. Endothelial injury and dysfunction Accumulation of lipoproteins Platelet adhesion and factor release Smooth muscle and collagen formation (Q845209)

A. 1>2>3>4

B. 1>2>4>3

C. 2>3>4>1

D. 1>3>2>4

See Answer in Part B → Q3

@Neet_pg_bot

Q4: A 65-year-old male presents with sudden-onset severe abdominal pain radiating to his back. On physical examination, a pulsatile mass is palpated in his abdomen. He

has a history of hypertension, hyperlipidemia, and smoking. Based on the clinical presentation and risk factors, which of the following is the most likely diagnosis? (Q845213)

A. Takayasu's arteritis

B. Diverticulitis

C. Abdominal aortic aneurysm

D. Pancreatitis

See Answer in Part B → Q4

@Neet_pg_bot

Q5: Match the following types of aortic dissections. a. {{caption_text}} 1. Stanford Type A b. {{caption_text}} 2. Debakey type I c. {{caption_text}} 3. Debakey II 4. Debakey III (Q845216)

A. A-2, B-4, C-1

B. A-3, B-1, C-4

C. A-2, B-1, C-4

D. A-4, B-3, C-1







See Answer in Part B → Q5

@Neet_pg_bot

Q6: Which of the following is an intermediate-grade vascular tumour? (Q845224)

A. Kaposi sarcoma

B. Angiosarcoma

C. Hemangiopericytoma

D. Pyogenic granuloma

See Answer in Part B → Q6

@Neet_pg_bot

Q7: A 6-month-old infant is brought to the clinic with a rapidly expanding, clearly defined, bright red lesion on the face. Upon examination, the lesion feels soft, yields to

pressure, and temporarily loses color when pressure is applied. Which of the following is the most likely diagnosis? (Q845227)

A. Pyogenic granuloma

B. Infantile hemangioma

C. Nevus flammeus

D. Venous malformation

See Answer in Part B → Q7

@Neet_pg_bot

Q8: A 30-year-old patient presents with a history of multiple tumours in various organs, including the brain, retina, and kidneys. On examination, retinal angiomas and cerebellar hemangioblastomas are noted. The patient's family history reveals similar manifestations in relatives. Which of the following lesions is commonly associated with this syndrome? (Q845327)

A. Glioblastoma multiforme

B. Adenomatous polyps

C. Capillary hemangioma

D. Cavernous hemangioma

See Answer in Part B → Q8

@Neet_pg_bot

Q9: A 45-year-old individual complains of a throbbing mass on the tip of their index finger. Upon examination, the lesion is bluish and extremely tender to the touch. Which of the following is the most probable diagnosis? (Q845331)

A. Ganglion cyst

B. Bacillary angiomatosis

C. Glomus tumour

D. Cavernous lymphangioma

See Answer in Part B → Q9

@Neet_pg_bot

Q10: A 60-year-old HIV-positive patient presents with multiple reddish-purple nodules on the lower extremities. On examination, the lesions are non-tender, non-pruritic, and do not blanch with pressure. There is also evidence of mucosal involvement in the oral cavity. Which of the following is the most likely diagnosis? (Q845338)

A. Hemangiopericytoma

B. Hemangioendothelioma

C. Kaposi sarcoma

D. Angiosarcoma

See Answer in Part B → Q10

@Neet_pg_bot

Q11: A 28-year-old woman, 20 weeks pregnant, presents with a painful, growing, reddish lump on her gums (as shown below) that bleeds when brushing or eating. The lesion is tender, and she denies any history of trauma or irritation. What is the most likely diagnosis? {{caption_text}} (Q846620)

A. Hemangiopericytoma

B. Kasabach-Merritt Syndrome

C. Angiosarcoma

D. Lobular Capillary Hemangioma



See Answer in Part B → Q11

@Neet_pg_bot

• [06_CVS_ Blood Vessels and Vasculitis] 027 Ischemic Heart Disease And Myocardial Infarction

« Back to Folder Directory

[06_CVS_ Blood Vessels and Vasculitis] 027 Ischemic Heart Disease And Myocardial Infarction — Quick Jump

Q1 (p. 304)	*Q2 (p. 304)*	*Q3 (p. 305)*	*Q4 (p. 305)*	*Q5 (p. 305)*	*Q6 (p. 306)*
Q7 (p. 306)	*Q8 (p. 307)*	*Q9 (p. 307)*	*Q10 (p. 308)*	*Q11 (p. 308)*	*Q12 (p. 309)*
Q13 (p. 310)	*Q14 (p. 310)*	*Q15 (p. 311)*	*Q16 (p. 311)*	*Q17 (p. 312)*	*Q18 (p. 312)*
Q19 (p. 312)	*Q20 (p. 313)*	*Q21 (p. 313)*			

Q1: Which of the following best describes using Triphenyl tetrazolium chloride (TTC) in myocardial infarction? (Q845321)

A. It is used to measure blood flow in coronary arteries

B. It helps visualize viable myocardial tissue after an infarction.

C. It acts as an anticoagulant to prevent clot formation.

D. It assists in the diagnosis of arrhythmias following a heart attack.

See Answer in Part B → Q1

@Neet_pg_bot

Q2: A pathology report of a heart specimen describes "brisk interstitial infiltrate of neutrophils" and "coagulative necrosis with loss of nuclei. What is the most likely age of this infarct? (Q884942)

A. 4-12 hours

B. 1-3 days

C. 7-10 days

D. >2 months

See Answer in Part B → Q2

@Neet_pg_bot

Q3: A 68-year-old woman is admitted with an acute anterior wall myocardial infarction. On hospital day 5, she suddenly develops hypotension and pulseless electrical activity. Bedside echocardiography shows a large pericardial effusion with tamponade physiology. At what time after myocardial infarction does this complication most commonly occur? (Q884940)

A. Within the first 2 days

B. 2-3 weeks

C. 3-7 days

D. After 3 weeks

See Answer in Part B → Q3

@Neet_pg_bot

Q4: A 62-year-old man presents with severe substernal chest pain that began 90 minutes ago. ECG shows ST-segment elevation in the inferior leads. Which of the following events is most likely occurring at this time in ischemic cardiac myocytes? (Q884937)

A. ATP reduced to 50% of normal

B. Loss of contractility

C. Irreversible cell injury

D. Microvascular injury

See Answer in Part B → Q4

@Neet_pg_bot

Q5: Which hormone is associated with an increased risk of myocardial infarction in post-menopausal women? (Q884936)

A. Progesterone

B. Estrogen

C. Prolactin

D. Oxytocin

See Answer in Part B → Q5

@Neet_pg_bot

Q6: A patient with chronic lung disease presents with pedal oedema, raised JVP, and hepatomegaly. He is diagnosed with isolated right heart failure. What is the structural cause of his right-sided heart failure? (Q884935)

A. Left ventricular hypertrophy

B. Right ventricular hypertrophy and dilatation

C. Mitral stenosis

D. Decreased systemic vascular resistance

See Answer in Part B → Q6

@Neet_pg_bot

Q7: Which of the following is a cause of isolated right-sided heart failure? (Q884932)

A. Systemic hypertension

B. Mitral valve stenosis

C. Primary pulmonary hypertension

D. Aortic regurgitation

See Answer in Part B → Q7

@Neet_pg_bot

Q8: A 68-year-old patient presents with exertional dyspnea. Echocardiography shows preserved ejection fraction with impaired left ventricular relaxation. He is diagnosed with left-sided diastolic heart failure (HFpEF). Which of the following is the most common cause of left-sided diastolic heart failure? (Q884931)

A. Hypertension

B. Cardiac amyloidosis

C. Ischemic heart disease

D. Constrictive pericarditis

See Answer in Part B → Q8

@Neet_pg_bot

Q9: A patient with long-standing left-sided heart failure develops progressive dyspnea. Sputum cytology shows findings as shown in the image. What are these cells most appropriately termed? (Q884929)

A. Dust cells

B. Hemosiderin-laden macrophages

C. Foam cells

D. Langhans giant cells

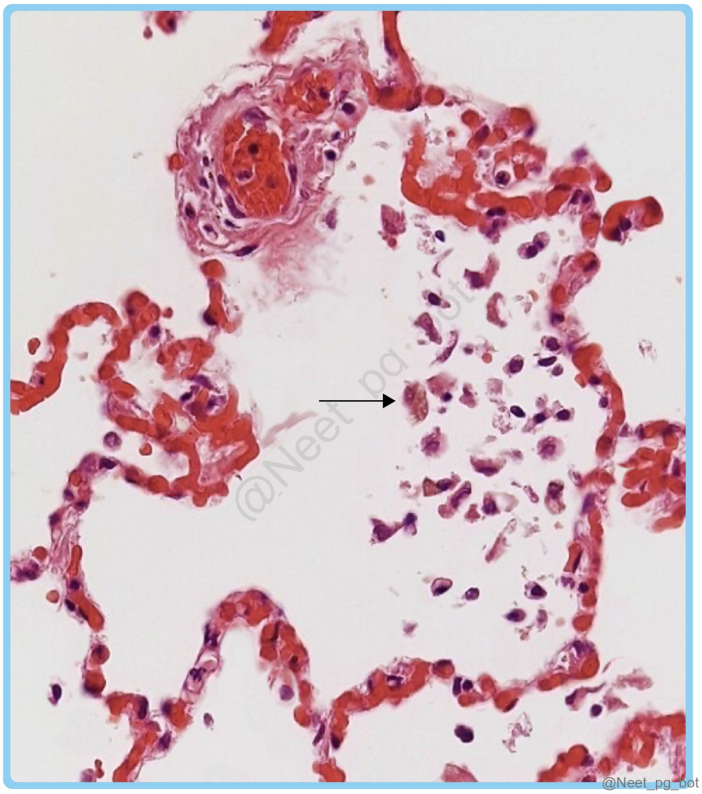

See Answer in Part B → Q9

@Neet_pg_bot

Q10: A histologic examination of the heart in an elderly individual reveals several age-related changes. Which of the following is not typically seen in the ageing heart? (Q884928)

A. Lipofuscin deposition in myocytes

B. Transthyretin amyloid deposition

C. Decreased left atrial cavity size

D. Decreased left ventricular cavity size

See Answer in Part B → Q10

@Neet_pg_bot

Q11: A histologic section of a normal cardiac valve is examined under microscopy. Which of the following correctly lists the layers of a normal cardiac valve? (Q884927)

A. Intima, media, adventitia

B. Fibrosa, spongiosa, ventricularis

C. Endocardium, myocardium, epicardium

D. Tunica interna, tunica externa

See Answer in Part B → Q11

@Neet_pg_bot

Q12: A 65-year-old male with a history of hypertension and coronary artery disease presents with worsening shortness of breath and orthopnea. Chest X-ray reveals pulmonary congestion. Bronchoalveolar lavage shows hemosiderin-laden macrophages, as shown in the image below. What is the most likely diagnosis? {{caption_text}} (Q845258)

A. Right-sided heart failure

B. Left-sided heart failure

C. Pulmonary embolism

D. Acute myocardial infarction

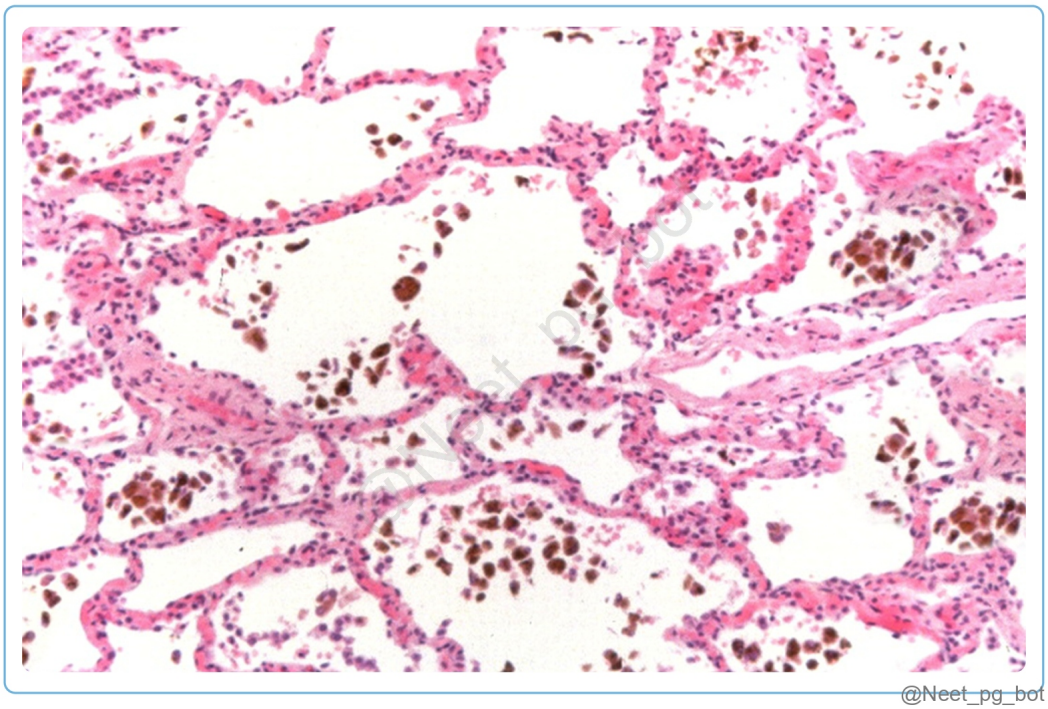

See Answer in Part B → Q12

@Neet_pg_bot

Q13: A 58-year-old male presents with complaints of chest pain and shortness of breath. He had a history of MI one month ago, for which he received appropriate medical management. His vitals are stable, and his physical examination reveals a pericardial rub. An ECG shows diffuse ST-segment elevation. Which of the following is the most likely cause of this condition? (Q845320)

A. Ventricular aneurysm

B. Dressler syndrome

C. Arrhythmia

D. Myocardial rupture

See Answer in Part B → Q13

@Neet_pg_bot

Q14: A 55-year-old male with a history of hypertension and smoking presents with chest pain and shortness of breath. ECG shows ST-segment elevation in inferior leads. He undergoes PCI but, within hours, develops deteriorating cardiac function. What is the most likely primary mechanism of cardiac deterioration in this patient? (Q845317)

A. Oxidative stress

B. Intracellular calcium overload

C. Activation of coagulation cascade

D. Activation of the complement system

See Answer in Part B → Q14

@Neet_pg_bot

Q15: Which histopathological feature would not be expected in the myocardium within the first 24 hours after the infarction onset? (Q845315)

A. Coagulative necrosis

B. Marginal contraction band necrosis

C. Neutrophilic infiltration

D. Neovascularisation

See Answer in Part B → Q15

@Neet_pg_bot

Q16: At what phase of myocardial infarction does the myocardium exhibit Mottling with a yellow-tan infarct center? (Q845303)

A. 4-12 hours

B. 1-3 days

C. 7-10 days

D. 4-8 weeks

See Answer in Part B → Q16

@Neet_pg_bot

Q17: What histopathological changes are typically observed during the reversible phase of myocardial infarction? Mitochondrial swelling Sarcolemmal disruption Relaxation of myofibrils (Q845301)

A. 1, 2, and 3

B. 1 and 3

C. 2 and 3

D. Only 3

See Answer in Part B → Q17

@Neet_pg_bot

Q18: In a patient with acute myocardial infarction, which of the following is a characteristic change in LDH isoenzyme levels indicative of myocardial damage in this patient? (Q845299)

A. Elevated LDH2 levels

B. Decreased LDH1/LDH2 ratio

C. Increased LDH2/LDH1 ratio

D. Increased LDH1/LDH2 ratio

See Answer in Part B → Q18

@Neet_pg_bot

Q19: A 58-year-old man presents to the emergency department with sudden-onset chest pain radiating to his left arm and jaw, along with diaphoresis and anxiety. His vital signs show a blood pressure of 160/90 mmHg, heart rate of 110 bpm, and oxygen

saturation of 94% on room air. An ECG reveals ST-segment elevation in leads II, III, and aVF, suggestive of acute myocardial infarction (MI). Which of the following biomarkers is most reliable for confirming myocardial injury in this condition? (Q845297)

A. Myoglobin

B. CK-MB (Creatine Kinase-MB)

C. Cardiac-specific troponin I (cTn I)

D. Atrial natriuretic peptide (ANP)

See Answer in Part B → Q19

@Neet_pg_bot

Q20: A 50-year-old woman presents to the emergency department with recurrent episodes of chest pain radiating to her left arm and jaw that occur at rest and are not triggered by physical exertion. ECG during an episode shows transient ST-segment elevation. Troponin levels are normal. Which type of angina is most likely responsible for her symptoms? (Q845263)

A. Stable Angina

B. Unstable Angina

C. Silent Angina

D. Prinzmetal Angina

See Answer in Part B → Q20

@Neet_pg_bot

Q21: Which of the following statements is incorrect regarding the pathologic changes in right-sided heart failure? (Q845262)

A. Nutmeg liver appearance.

B. Pretibial oedema is the hallmark of right-sided heart failure.

C. Fibrosis in periportal areas of the liver

D. Congestive splenomegaly due to portal hypertension

See Answer in Part B → Q21

@Neet_pg_bot

• [06_CVS_ Blood Vessels and Vasculitis] 028 Rhd And Infective Endocarditis

« Back to Folder Directory

[06_CVS_ Blood Vessels and Vasculitis] 028 Rhd And Infective Endocarditis — Quick Jump

Q1 (p. 315) *Q2 (p. 315)* *Q3 (p. 316)* *Q4 (p. 316)* *Q5 (p. 317)* *Q6 (p. 317)*
Q7 (p. 318) *Q8 (p. 318)* *Q9 (p. 319)* *Q10 (p. 319)* *Q11 (p. 320)* *Q12 (p. 320)*
Q13 (p. 321)

Q1: Which of the following statements about rheumatic heart disease (RHD) is incorrect? (Q845229)

A. An abnormal immune response to Group A Streptococcus infection causes RHD.

B. RHD commonly affects the pulmonary valve, resulting in valvular stenosis or regurgitation.

C. Chronic inflammation and scarring of heart valves.

D. Prevented with timely treatment of streptococcal infections with antibiotics.

See Answer in Part B → Q1

@Neet_pg_bot

Q2: A 10-year-old child presents to the clinic with complaints of shortness of breath and fatigue. Upon examination, a diastolic murmur along the left sternal border is detected. An echocardiogram reveals mitral valve stenosis and regurgitation, consistent with Rheumatic heart disease (RHD). What is the most common predisposing condition for this patient to develop RHD? (Q845231)

A. Streptococcal pharyngitis

B. Streptococcal skin infections

C. Streptococcal glomerulonephritis

D. All the above

See Answer in Part B → Q2

@Neet_pg_bot

Q3: A 7-year-old child presented to the clinic with fever, joint pain, and rash with a history of sore throat about three weeks ago, which resolved without treatment. Examination reveals a rash characterized by pink to red lesions with well-defined borders and tender, swollen joints. What is the primary mechanism underlying the development of acute rheumatic fever (ARF) in this patient following the untreated sore throat? (Q845232)

A. Direct invasion of tissues by streptococcal bacteria

B. Delayed hypersensitivity reaction to streptococcal exotoxins

C. Cross-reactivity between streptococcal antigens and host proteins

D. Activation of complement by streptococcal toxins

See Answer in Part B → Q3

@Neet_pg_bot

Q4: A 35-year-old male presented with severe dyspnea and a history of recurrent sore throat in childhood. An echocardiogram reveals thickened, immobile, prolapsed mitral valve leaflets. An endomyocardial biopsy reveals characteristic histopathological findings, as shown in the image. Which of the following is not a characteristic histopathological finding in this patient? {{caption_text}} (Q845235)

A. Presence of Anitschkow cells

B. Infiltration of lymphocytes, plasma cells, and macrophages

C. Presence of fibrinoid necrosis

D. Presence of granulation tissue

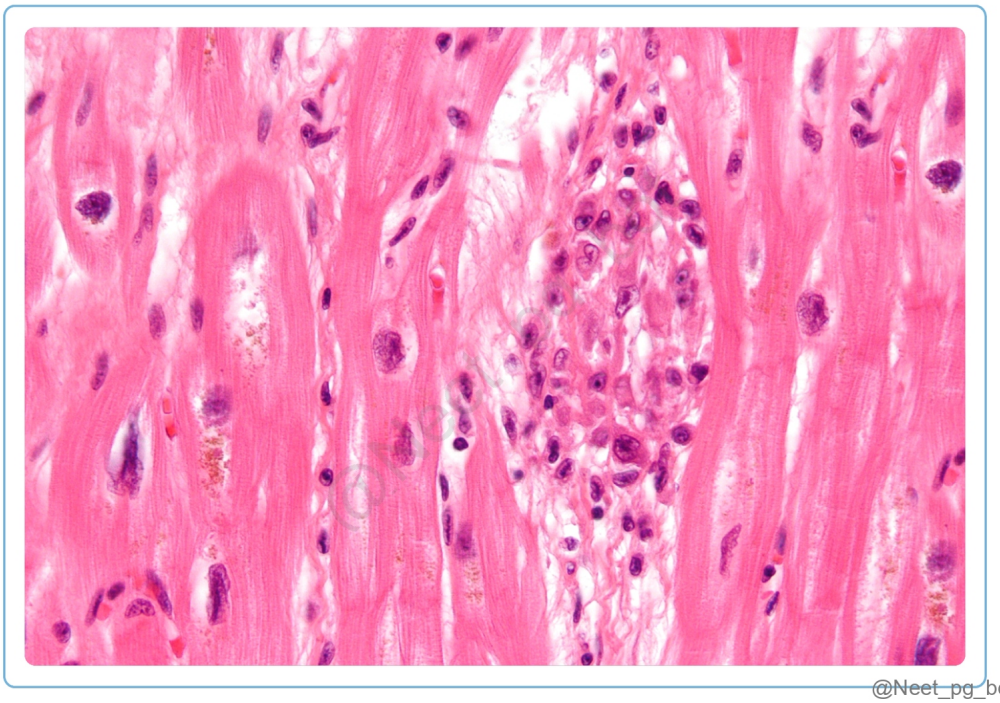

See Answer in Part B → Q4

@Neet_pg_bot

Q5: Which of the following is a major criterion in the Jones criteria for diagnosing acute rheumatic fever (ARF)? (Q845241)

A. Polyarthralgia involving two or more joints

B. Fever (≥38.5°C)

C. Elevated acute phase reactants

D. Subcutaneous nodules over bony prominences

See Answer in Part B → Q5

@Neet_pg_bot

Q6: A 54-year-old man with a history of mitral valve prolapse presents to the clinic with fever and malaise following a recent dental procedure. On examination, a new regurgitant murmur is auscultated. Blood cultures are obtained, and subsequent

testing reveals the presence of gram-positive cocci in chains. Which of the following organisms is most likely responsible for the new onset murmur in this patient? (Q845246)

A. Staphylococcus aureus

B. Streptococcus viridans

C. Staphylococcus epidermidis

D. Enterococci

See Answer in Part B → Q6

@Neet_pg_bot

Q7: Which of the following statements best describes the nature of vegetation in infective endocarditis (IE)? (Q845247)

A. Smooth and non-destructive lesions

B. Typically contain only fibrin and inflammatory cells

C. Prone to embolisation

D. Most commonly found on the tricuspid valve

See Answer in Part B → Q7

@Neet_pg_bot

Q8: A 30-year-old man with a history of intravenous drug use presents with fever, chills, and fatigue for the past week. On examination, the patient has multiple lesions on the palms and soles as shown below. The patient also has a new heart murmur. Blood cultures are positive for Staphylococcus aureus. What are these lesions shown below? {{caption_text}} (Q845249)

A. Splinter hemorrhages

B. Osler nodes

C. Janeway lesions

D. Roth spots



See Answer in Part B → Q8

@Neet_pg_bot

Q9: Which of the following is not a predisposing factor for Nonbacterial Thrombotic Endocarditis (NBTE)? (Q845251)

A. Advanced malignancy

B. Antiphospholipid antibody syndrome

C. Systemic lupus erythematosus

D. Traumatic injury to the heart valves

See Answer in Part B → Q9

@Neet_pg_bot

Q10: Match the following pathologies with the correct pattern of vegetative endocarditis caused by them: 1. Rheumatic Heart Disease a) Small, warty, sterile vegetations along the line of closure of valve leaflets 2. Infective Endocarditis b) Small, bland, sterile vegetation along the line of closure 3.Non-bacterial thrombotic endocarditis (NBTE) c) Small or medium-sized sterile vegetations on both sides of valvular leaflets. 4. Libman-Sacks endocarditis d) Large, bulky, infected, friable, irregular mass along the line of closure or on valvular cusps. (Q845253)

A. 1-a, 2-d, 3-c, 4-b

B. 1-a, 2-d, 3-b, 4-c

C. 1-b, 2-d, 3-c, 4-a

D. 1-d, 2-c, 3-b, 4-a

See Answer in Part B → Q10

@Neet_pg_bot

Q11: Which of the following correctly lists the valves in order from most commonly to least commonly affected in chronic rheumatic heart disease? (Q889827)

A. Mitral > Aortic > Tricuspid > Pulmonary

B. Aortic > Mitral > Tricuspid > Pulmonary

C. Mitral > Tricuspid > Aortic > Pulmonary

D. Pulmonary > Tricuspid > Mitral > Aortic

See Answer in Part B → Q11

@Neet_pg_bot

Q12: A 40-year-old woman with a history of Acute rheumatic fever in childhood had long-standing exertional dyspnea and palpitations. At autopsy, the mitral valve shows findings as shown. Which pathological process is primarily responsible for this deformity? (Q889828)

A. Vegetation formation

B. Myxomatous degeneration

C. Calcification and fibrosis

D. Fibrofatty replacement

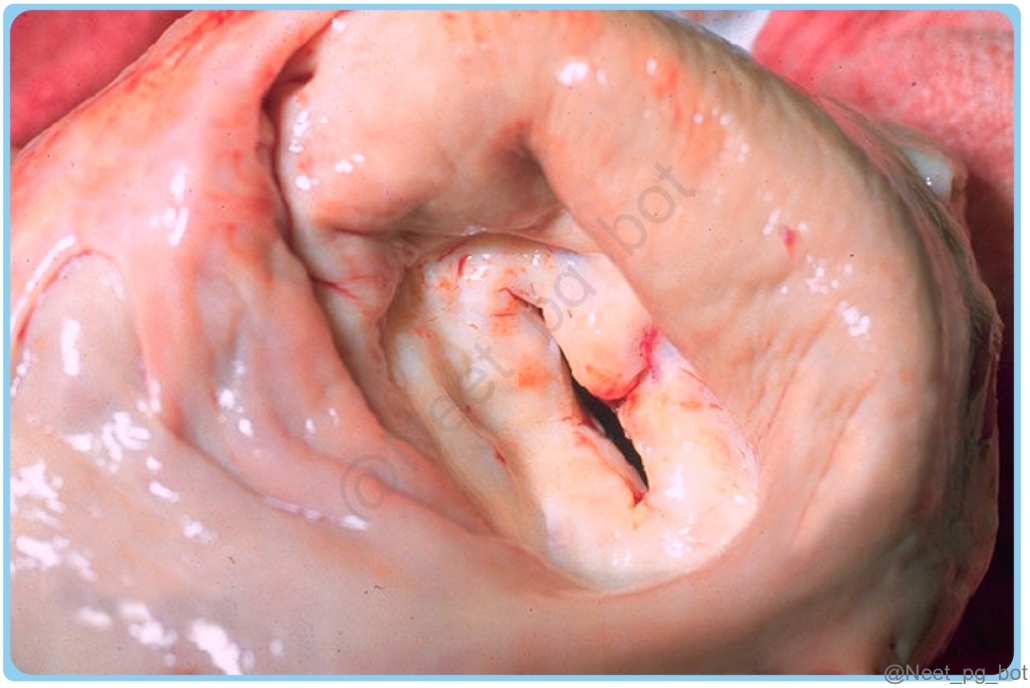

See Answer in Part B → Q12

@Neet_pg_bot

Q13: Which organism is most commonly responsible for infective endocarditis in a previously normal valve? (Q889832)

A. Viridans streptococci

B. Staphylococcus aureus

C. Enterococcus faecalis

D. HACEK organisms

See Answer in Part B → Q13

@Neet_pg_bot

• [06_CVS_ Blood Vessels and Vasculitis] 029 Carditis And Cardiac Tumors

« Back to Folder Directory

[06_CVS_ Blood Vessels and Vasculitis] 029 Carditis And Cardiac Tumors — Quick Jump

Q1 (p. 323)	*Q2 (p. 323)*	*Q3 (p. 324)*	*Q4 (p. 324)*	*Q5 (p. 325)*	*Q6 (p. 325)*
Q7 (p. 325)	*Q8 (p. 326)*	*Q9 (p. 326)*	*Q10 (p. 327)*	*Q11 (p. 327)*	*Q12 (p. 328)*
Q13 (p. 328)	*Q14 (p. 329)*	*Q15 (p. 329)*	*Q16 (p. 330)*	*Q17 (p. 330)*	*Q18 (p. 331)*
Q19 (p. 331)	*Q20 (p. 331)*	*Q21 (p. 332)*	*Q22 (p. 332)*		

Q1: A 30-year-old woman from a rural area presents with progressively worsening dyspnea on exertion and bilateral lower limb swelling for the past few months. She reports a history of recurrent fevers and weight loss over the past year. Physical examination reveals elevated jugular venous pressure, ascites, and hepatomegaly. Chest X-ray shows an enlarged cardiac silhouette. Echocardiography reveals restrictive filling patterns with apical obliteration and thickened endocardium. What is the most likely diagnosis? (Q845431)

A. Hypertrophic cardiomyopathy

B. Dilated cardiomyopathy

C. Endomyocardial fibrosis

D. Constrictive pericarditis

See Answer in Part B → Q1

@Neet_pg_bot

Q2: A 6-month-old infant presents with progressive heart failure. Echocardiography shows diffuse fibroelastic thickening of the left ventricular endocardium with reduced ventricular compliance. There is a history of intrauterine viral exposure. Which infection is most commonly associated with this condition? (Q889821)

A. Rubella

B. Mumps

C. Epstein-Barr virus

D. Cytomegalovirus

See Answer in Part B → Q2

@Neet_pg_bot

Q3: A 32-year-old man presents with progressive dyspnea. Labs show marked eosinophilia. Imaging shows endomyocardial fibrosis with mural thrombus. Which type of cardiomyopathy is most likely? (Q889817)

A. Dilated cardiomyopathy

B. Hypertrophic cardiomyopathy

C. Restrictive cardiomyopathy

D. Arrhythmogenic RV cardiomyopathy

See Answer in Part B → Q3

@Neet_pg_bot

Q4: A 13-year-old boy presents with recurrent syncope and palpitations. He has tightly curled woolly hair since birth and diffuse palmoplantar keratoderma since early childhood. ECG shows T-wave inversion in V1-V3, and echocardiography reveals right ventricular dilatation. What is the most likely diagnosis? (Q889814)

A. Carvajal syndrome

B. Naxos disease

C. Noonan syndrome

D. Isolated ARVC

See Answer in Part B → Q4

@Neet_pg_bot

Q5: Which of the following deficiencies is associated with the development of dilated cardiomyopathy? Thiamine deficiency Selenium deficiency Vitamin B12 deficiency Carnitine deficiency (Q889812)

A. 1, 2 and 4

B. 1 and 3

C. 2 and 3

D. 3 and 4

See Answer in Part B → Q5

@Neet_pg_bot

Q6: A 48-year-old man presents with progressive dyspnea and echocardiographic evidence of dilated cardiomyopathy; which of the following is the most likely risk factor? (Q889810)

A. Hypertension

B. Alcohol abuse

C. Hyperlipidemia

D. Rheumatic fever

See Answer in Part B → Q6

@Neet_pg_bot

Q7: Which of the following is the least common type of cardiomyopathy? (Q889806)

A. Dilated cardiomyopathy

B. Hypertrophic cardiomyopathy

C. Restrictive cardiomyopathy

D. Peripartum cardiomyopathy

See Answer in Part B → Q7

@Neet_pg_bot

Q8: A 28-year-old male presents with palpitations and dizziness during a soccer match. He is diagnosed with ARVC (Arrhythmogenic Right Ventricular Cardiomyopathy). Which of the following statements about this condition is true? Statement 1 - It is an autosomal recessive disorder Statement 2 - Associated with NAXOS syndrome Statement 3 - Marked by fatty infiltration and focal fibrosis within the ventricle Statement 4 - It involves mutation in Plakoglobin (Q846623)

A. 1, 2, 3

B. 1, 3, 4

C. 2, 3, 4

D. 1, 2, 3,4

See Answer in Part B → Q8

@Neet_pg_bot

Q9: A 6-month-old infant presents with cyanosis and respiratory distress. Physical examination reveals a murmur and a palpable liver edge. Echocardiography demonstrates multiple intracardiac masses located primarily in the ventricular walls. What is the most likely diagnosis? (Q845436)

A. Rhabdomyoma

B. Cardiac fibroma

C. Myxoma

D. Metastatic neuroblastoma

See Answer in Part B → Q9

@Neet_pg_bot

Q10: Identify the true statements regarding atrial myxoma. 1) It is the most common primary tumor of the heart in adults. 2) It is a malignant neoplasm. 3) It is associated with mutations in the GNAS1 gene. 4) 90% of these tumors arise from ventricles. 5) Histologically, it contains lepidic cells (Q845434)

A. 1,2,3

B. 1,2,3,4,5

C. 1,3,4

D. 1,3,5

See Answer in Part B → Q10

@Neet_pg_bot

Q11: What is the most likely diagnosis based on the image given below? It is a stained specimen of endomyocardial tissue. {{caption_text}} (Q845433)

A. Hypertrophic cardiomyopathy

B. Dilated cardiomyopathy

C. Cardiac amyloidosis

D. Sarcoidosis



@Neet_pg_bot

See Answer in Part B → Q11

@Neet_pg_bot

Q12: Which viral organism is most commonly associated with myocarditis? (Q845392)

A. Influenza

B. Human immunodeficiency virus (HIV)

C. Coxsackievirus

D. Epstein-Barr virus (EBV)

See Answer in Part B → Q12

@Neet_pg_bot

Q13: Which of the following is not a cause for restrictive cardiomyopathy? (Q845429)

A. Hemochromatosis

B. Amyloidosis

C. Sarcoidosis

D. Alcohol

See Answer in Part B → Q13

@Neet_pg_bot

Q14: A 19-year-old boy collapsed during a football game and was brought dead to the hospital. Suspecting a heart condition, a biopsy was done, which showed asymmetric septal hypertrophy. Which of the following histological findings will not be seen in this condition? (Q845425)

A. Massive myocyte hypertrophy

B. Myofibre disarray

C. Fibrotic narrowing of small intramural arteries

D. Ninja star nuclei

See Answer in Part B → Q14

@Neet_pg_bot

Q15: A 22-year-old man presents to his cardiologist with complaints of exertional chest pain and shortness of breath. His family history is significant for the sudden cardiac death of his brother at the age of 28. Physical examination reveals a harsh systolic murmur and irregular heart sounds. Which of the following genes is most commonly involved in this condition? (Q845423)

A. Titin

B. Beta-myosin heavy chain

C. Troponin T

D. Alpha-tropomyosin

See Answer in Part B → Q15

@Neet_pg_bot

Q16: Which of the following conditions is characterised by transient left ventricular dysfunction, often triggered by emotional or physical stress, presenting with symptoms mimicking acute coronary syndrome but with normal coronary arteries on angiography? (Q845401)

A. Acute Myocardial Infarction (AMI)

B. Takotsubo Cardiomyopathy (TCM)

C. Hypertrophic Cardiomyopathy (HCM)

D. Dilated Cardiomyopathy (DCM)

See Answer in Part B → Q16

@Neet_pg_bot

Q17: A 55-year-old woman presents to the emergency department with sudden-onset chest pain and shortness of breath following the news of death of her son. An electrocardiogram shows ST-segment elevation in the anterior leads, and cardiac biomarkers are elevated. Coronary angiography reveals no significant coronary artery disease. Which of the following is the most likely underlying mechanism in this patient? (Q845400)

A. Excessive release of catecholamines

B. Viral myocarditis

C. Autoimmune response

D. Genetic predisposition

See Answer in Part B → Q17

@Neet_pg_bot

Q18: Which of the following genes is most commonly associated with inherited forms of dilated cardiomyopathy? (Q845398)

A. BRCA1 gene

B. TTN gene

C. CFTR gene

D. SCN5A gene

See Answer in Part B → Q18

@Neet_pg_bot

Q19: A 45-year-old male with a history of intravenous drug abuse, presenting with fever, malaise, and a new-onset heart murmur, reports recent injection site infections. On examination, there are multiple healing scars on the upper extremities, and a grade III/VI holosystolic murmur is auscultated at the left sternal border. His temperature is 38.5°C, heart rate is 110 bpm. Which criterion amongst the following is a major criterion for the condition diagnosed? (Q845397)

A. Fever of unknown origin lasting more than 7 days

B. IV drug abuse

C. Predisposing cardiac condition such as a prosthetic heart valve

D. Positive blood cultures for typical microorganisms persistently isolated from blood cultures

See Answer in Part B → Q19

@Neet_pg_bot

Q20: Which of the following is not a major criterion according to Jones Criteria for Rheumatic Heart Disease? (Q845395)

A. Polyarthritis

B. Carditis

C. Subcutaneous nodules

D. Fever

See Answer in Part B → Q20

@Neet_pg_bot

Q21: Which of the following findings is most likely present in the myocardial biopsy of a Rheumatic Heart disease patient? (Q845394)

A. Fibrous thickening of the endocardium

B. Areas of lymphocytic infiltrates, Anitschkow cells and fibroblasts in all layers of the heart

C. Calcific nodules on the valve leaflets

D. Disruption of the endothelial lining of blood vessels

See Answer in Part B → Q21

@Neet_pg_bot

Q22: Which of the following statements best describes the vegetation found in Infective Endocarditis compared to other conditions? (Q845393)

A. Vegetations in Infective Endocarditis are typically small, friable, sterile and composed of fibrin, and platelets.

B. Vegetations in Infective Endocarditis are large, verrucous, and primarily consist of fibrin, inflammatory cells, and microorganisms.

C. Nonbacterial Thrombotic Endocarditis (NBTE) commonly presents with small, non-sterile vegetations composed mainly of fibrin and platelets.

D. Libman-Sacks Endocarditis is characterised by tiny, marantic vegetations consisting of fibrin and micro-organisms.

See Answer in Part B → Q22

@Neet_pg_bot

• [06_CVS_ Blood Vessels and Vasculitis] 030 Vasculitis

« Back to Folder Directory

[06_CVS_ Blood Vessels and Vasculitis] 030 Vasculitis — Quick Jump

Q1 (p. 333)	*Q2 (p. 333)*	*Q3 (p. 334)*	*Q4 (p. 334)*	*Q5 (p. 334)*	*Q6 (p. 335)*
Q7 (p. 335)	*Q8 (p. 336)*	*Q9 (p. 336)*	*Q10 (p. 336)*	*Q11 (p. 337)*	*Q12 (p. 337)*
Q13 (p. 337)	*Q14 (p. 338)*	*Q15 (p. 338)*	*Q16 (p. 339)*	*Q17 (p. 339)*	*Q18 (p. 340)*

Q1: A 55-year-old female presents with hematuria, hemoptysis, and sinusitis. Renal biopsy reveals pauci-immune necrotising crescentic glomerulonephritis. What is the most likely diagnosis? (Q845459)

A. Wegener's Granulomatosis

B. Goodpasture Syndrome

C. Systemic Lupus Erythematosus (SLE)

D. Microscopic Polyangiitis (MPA)

See Answer in Part B → Q1

@Neet_pg_bot

Q2: A 3-year-old child presents with persistent high fever, bilateral conjunctival erythema, strawberry tongue, erythema of palms and soles, desquamating rash, and cervical lymphadenopathy. This presentation is classically referred to as which of the following? (Q889802)

A. Mucocutaneous lymph node syndrome

B. Polyarteritis nodosa

C. Takayasu arteritis

D. Henoch-Schönlein purpura

See Answer in Part B → Q2

@Neet_pg_bot

Q3: Anti-endothelial cell antibodies are most commonly associated with which of the following conditions? (Q889800)

A. Polyarteritis nodosa

B. Kawasaki disease

C. Takayasu arteritis

D. Granulomatosis with polyangiitis

See Answer in Part B → Q3

@Neet_pg_bot

Q4: A 27-year-old woman presents with fatigue, weak upper limb pulses, and visual disturbances. Imaging reveals narrowing of major branches of the aorta. She is diagnosed with Takayasu arteritis. Which of the following statements is correct? (Q889799)

A. The renal artery is spared

B. It commonly involves the aortic arch

C. B-cell mediated disease

D. It is a medium vessel granulomatous vasculitis

See Answer in Part B → Q4

@Neet_pg_bot

Q5: A 68-year-old woman presents with new-onset temporal headache, jaw claudication, and transient vision loss. ESR is elevated. Which of the following statements is correct regarding this condition? (Q889798)

A. A negative temporal artery biopsy excludes the diagnosis

B. The disease uniformly affects the entire length of the artery

C. A negative biopsy does not exclude the diagnosis

D. The aorta is spared

See Answer in Part B → Q5

@Neet_pg_bot

Q6: A 72-year-old woman presents with temporal headache, scalp tenderness, and transient visual disturbances. ESR is markedly elevated. Temporal artery biopsy confirms Giant cell arteritis. Which of the following statements is incorrect regarding this condition? (Q889797)

A. It commonly affects individuals older than 50 years

B. It is characterised by granulomatous inflammation with giant cells

C. It can also involve veins

D. Risk of vision loss

See Answer in Part B → Q6

@Neet_pg_bot

Q7: A 25-year-old girl with a history of asthma presents with wheezing and rhinitis. Lab reports show eosinophilia and antibodies against neutrophil myeloperoxidase. What is the most likely diagnosis? (Q845462)

A. Churg-Strauss syndrome

B. PAN

C. Buerger's disease

D. Wegener granulomatosis

See Answer in Part B → Q7

@Neet_pg_bot

Q8: A 30-year-old male patient presents with recurrent oral ulcers, genital ulcers, and skin lesions on the lower extremities. He also complains of blurred vision and pain in his right eye. On examination, there are multiple oral and genital ulcers with posterior uveitis evident on ophthalmologic evaluation. Which of the following is false regarding the condition? (Q845461)

A. HLA B27 positivity

B. Painful scarring genital ulcers

C. Erythema nodosum

D. Positive pathergy test

See Answer in Part B → Q8

@Neet_pg_bot

Q9: A 45-year-old female presents with rapidly progressive hematuria, hemoptysis, and peripheral neuropathy. Serological testing reveals the presence of perinuclear anti-neutrophil cytoplasmic antibodies (p-ANCA) targeting myeloperoxidase (MPO). What is the most likely diagnosis based on these serological findings? (Q845460)

A. Microscopic Polyangiitis

B. Granulomatosis with Polyangiitis

C. Eosinophilic Granulomatosis with Polyangiitis

D. Goodpasture Syndrome

See Answer in Part B → Q9

@Neet_pg_bot

Q10: Weibel-Palade bodies consist of which of the following components? (Q845439)

A. Collagen

B. von Willebrand factor (vWF)

C. Platelet-derived growth factor (PDGF)

D. Tumor necrosis factor (TNF)

See Answer in Part B → Q10

@Neet_pg_bot

Q11: A 10-year-old child presents with palpable purpura on the lower extremities, arthralgia, and abdominal pain. Laboratory tests show elevated serum IgA levels and red blood cell casts in urine. What is the most likely diagnosis? (Q845457)

A. Henoch-Schönlein Purpura

B. Systemic Lupus Erythematosus

C. Kawasaki Disease

D. Rheumatic Fever

See Answer in Part B → Q11

@Neet_pg_bot

Q12: Which of the following is a characteristic feature of Buerger disease? (Q845456)

A. Segmental fibrinoid necrosis of the media with focal transmural necrotising lesions

B. Segmental thrombosing vasculitis affecting small and medium-sized arteries

C. Granulomatous inflammation of vessel walls

D. Adventitial mononuclear infiltrates with perivascular cuffing of the vasa vasorum

See Answer in Part B → Q12

@Neet_pg_bot

Q13: A 42-year-old male heavy smoker presents with a history of recurrent episodes of pain and discolouration in his fingers and toes, particularly when exposed to cold temperatures. On examination, you notice superficial migratory thrombophlebitis in his lower extremities. Doppler ultrasound reveals segmental occlusions in the arteries of his lower limbs. Considering his clinical presentation, which of the following is the most likely diagnosis? (Q845455)

A. Thromboangiitis Obliterans

B. Raynaud's Phenomenon

C. Atherosclerosis

D. Giant Cell Arteritis

See Answer in Part B → Q13

@Neet_pg_bot

Q14: A 3-year-old child presents with a high fever persisting for five days, along with bilateral conjunctival injection, strawberry tongue, and rash on the trunk and extremities. There is also swelling and erythema of the hands and feet. What is the most likely diagnosis? (Q845452)

A. Measles

B. Scarlet fever

C. Henoch-Schönlein purpura

D. Kawasaki disease

See Answer in Part B → Q14

@Neet_pg_bot

Q15: A 52-year-old woman presents with a 3-month history of muscle aches, joint pain, and numbness in her hands and feet and blood in stools. She also reports experiencing episodes of abdominal pain and nausea. Physical examination reveals decreased sensation in the distal extremities and decreased peripheral pulses.

Laboratory tests show elevated erythrocyte sedimentation rate (ESR) and C-reactive protein (CRP). Nerve conduction studies indicate peripheral neuropathy. What is the most likely diagnosis? (Q845449)

A. Polyarteritis nodosa (PAN)

B. Wegener's granulomatosis

C. Churg-Strauss syndrome

D. Giant cell arteritis

See Answer in Part B → Q15

@Neet_pg_bot

Q16: A 28-year-old female presents to the outpatient department with complaints of fatigue, weight loss, and intermittent claudication in her upper limbs. On further questioning, she reports occasional headaches and dizziness. Physical examination reveals absent pulses in both brachial arteries and decreased blood pressure in the upper extremities compared to the lower extremities. Laboratory investigations show elevated ESR & CRP, and Doppler ultrasound shows diffuse narrowing and irregularities in the brachial and subclavian arteries. What is the most likely diagnosis? (Q845448)

A. Rheumatoid arthritis

B. Takayasu arteritis

C. Polyarteritis nodosa

D. Microscopic polyangiitis

See Answer in Part B → Q16

@Neet_pg_bot

Q17: An arterial biopsy of an elderly male was performed and is shown below. What is the most likely diagnosis? {{caption_text}} (Q845445)

A. Giant cell arteritis

B. Takayasu arteritis

C. Polyarteritis nodosa

D. Microscopic polyangiitis

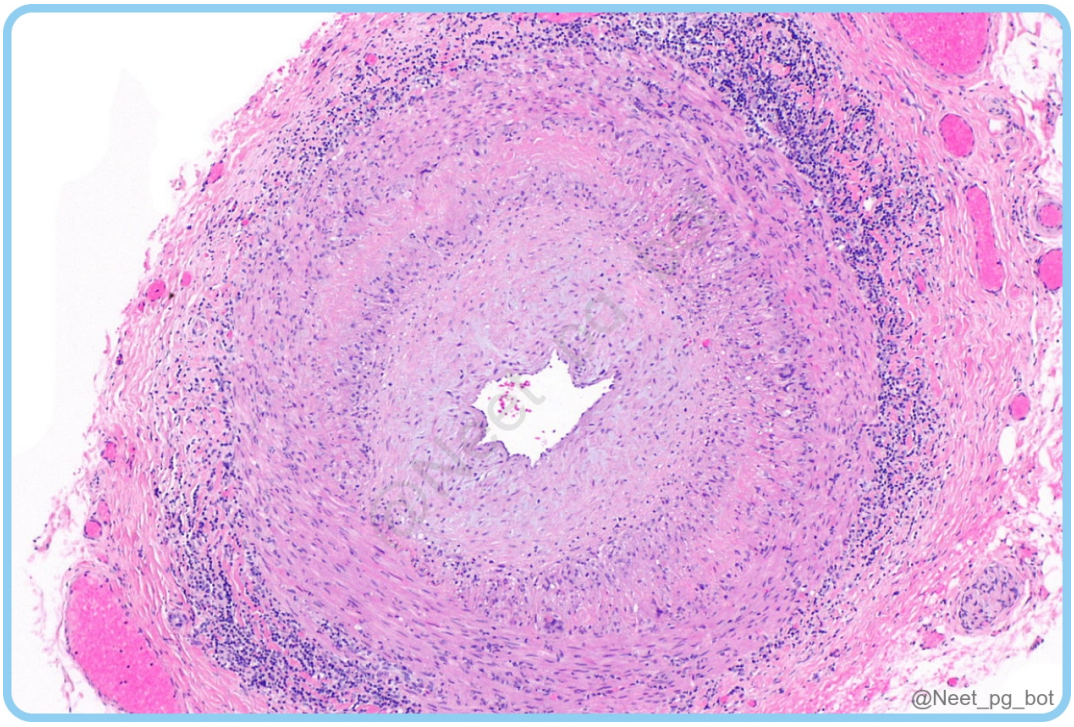

See Answer in Part B → Q17

@Neet_pg_bot

Q18: A 68-year-old woman presents to the emergency department with a three-week history of progressively worsening temporal headaches, jaw pain, and visual disturbances. On examination, her right temporal artery appears swollen and tender to palpation. Which of the following statements regarding this condition are false? (Q845441)

A. Involves large to medium-sized arteries

B. It is the most common cause of vasculitis in adults

C. It occurs as a result of a B cell-mediated immune response

D. It is associated with polymyalgia rheumatica

See Answer in Part B → Q18

@Neet_pg_bot

• [06_CVS_ Blood Vessels and Vasculitis] 031 Previous Year Questions

« Back to Folder Directory

[06_CVS_ Blood Vessels and Vasculitis] 031 Previous Year Questions — Quick Jump

Q1 (p. 342)	*Q2 (p. 342)*	*Q3 (p. 343)*	*Q4 (p. 343)*	*Q5 (p. 343)*	*Q6 (p. 344)*
Q7 (p. 344)	*Q8 (p. 344)*	*Q9 (p. 345)*	*Q10 (p. 346)*	*Q11 (p. 346)*	*Q12 (p. 347)*
Q13 (p. 347)	*Q14 (p. 348)*	*Q15 (p. 349)*	*Q16 (p. 349)*	*Q17 (p. 350)*	*Q18 (p. 350)*
Q19 (p. 351)	*Q20 (p. 352)*				

Q1: Which of the following syndromes can lead to pulmonary hemorrhage in a patient and show p-ANCA positivity? (Q844207)

A. Monckeberg's Sclerosis

B. Microscopic polyangiitis

C. Wegener granulomatosis

D. Polyarteritis nodosa

See Answer in Part B → Q1

@Neet_pg_bot

Q2: Which of the following statements regarding rheumatic fever are correct? (Q879221)

A. Characterized by the presence of Aschoff bodies

B. Caused by Group B β-hemolytic Streptococci

C. Manifests only as myocarditis

D. Associated with aortic valve rupture

See Answer in Part B → Q2

@Neet_pg_bot

Q3: A 65-year-old man was admitted to the emergency ward with severe, sudden-onset chest pain radiating to the left arm and profuse sweating. The ECG showed ST-segment elevation in precordial leads. The person succumbed after 3 hours. During the autopsy, his heart was taken out and immersed in a solution. The normal area of the heart turned brick-red, whereas the infarcted portion turned pale. Which of the following is a likely component of the solution? (Q859250)

A. Formalin

B. Triphenyl tetrazolium chloride

C. Ethanol

D. Glutaraldehyde

See Answer in Part B → Q3

@Neet_pg_bot

Q4: How is thrombosis initiated? (Q858519)

A. Platelet activation

B. Endothelial injury

C. Coagulation cascade

D. Vasoconstriction of vessels

See Answer in Part B → Q4

@Neet_pg_bot

Q5: Which of the following features does the histology of the reperfused myocardium show? (Q854873)

A. Wavy fibres

B. Neutrophils in cardiac muscle

C. Swelling of cells

D. Eosinophilic contraction band

See Answer in Part B → Q5

@Neet_pg_bot

Q6: A 3-year-old child has been brought to the hospital with complaints of fever, rash, and swelling of her hands and feet for the past 5 days. There is desquamative skin rash, edema of hands and feet, erythema of palms and soles, oral erythema, and cervical lymphadenopathy. What is the likely condition? (Q854849)

A. Kawasaki disease

B. Measles

C. Scarlet fever

D. Henoch-Schonlein purpura

See Answer in Part B → Q6

@Neet_pg_bot

Q7: Large, friable, irregular vegetation on heart valves is seen in which condition? (Q854841)

A. Infective endocarditis

B. Rheumatic heart disease

C. Libman-Sacks endocarditis

D. Non-bacterial thrombotic carditis

See Answer in Part B → Q7

@Neet_pg_bot

Q8: A 34-year-old female patient presented to the outpatient department with migratory arthritis, and examination revealed a pan-systolic murmur. An echocardiography was performed, which was suggestive of mitral regurgitation. A biopsy specimen was obtained, and the image is provided below. What is the most likely lesion shown in the histopathology slide? {{caption_text}} (Q856158)

A. Aschoff's bodies

B. Epithelioid granuloma

C. Granulomatous vasculitis

D. Granuloma inguinale

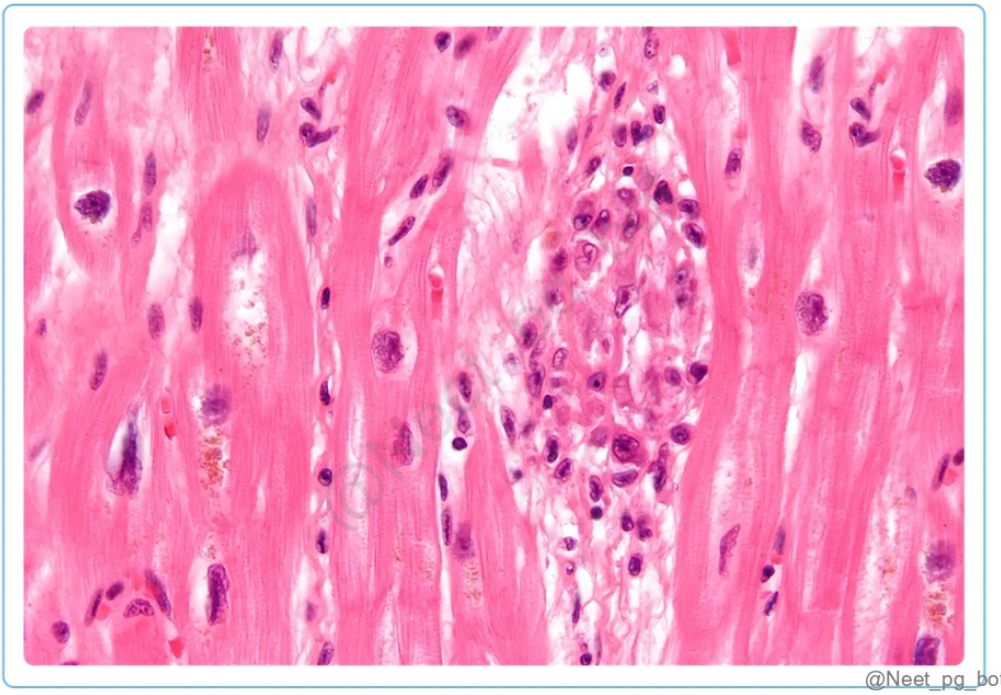

See Answer in Part B → Q8

@Neet_pg_bot

Q9: A child is presenting with palpable blanching purpura, abdominal pain, and pain in the knee joint resulting from arthritis. Urine examination showed hematuria and proteinuria. What is the most likely diagnosis? (Q856146)

A. Immune thrombocytopenic purpura

B. Dengue

C. Churg-Strauss syndrome

D. Henoch-Schonlein purpura

See Answer in Part B → Q9

@Neet_pg_bot

Q10: What is the gold standard investigation for the diagnosis of myocarditis? (Q856719)

A. Endo-myocardial biopsy

B. Magnetic Resonance Imaging

C. Brain Natriuretic Peptide

D. LDH1 to LDH2 ratio

See Answer in Part B → Q10

@Neet_pg_bot

Q11: A patient presented with complaints of dyspnea on exertion for 1 month. Echocardiography showed the presence of mitral stenosis and left ventricular hypertrophy. Identify the histopathological finding given below and the probable diagnosis. (Q855407)

A. Aschoff body; Rheumatic heart disease

B. Calcification of valve; Mitral stenosis

C. Granuloma; Sarcoidosis

D. Non-caseating granuloma; Tuberculosis

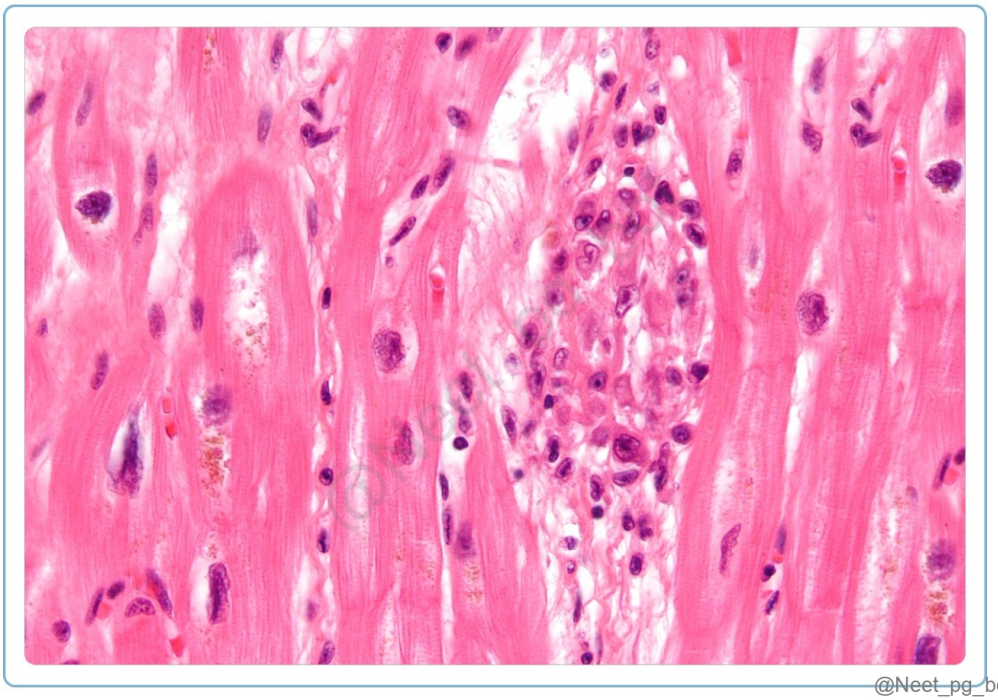

See Answer in Part B → Q11

@Neet_pg_bot

Q12: Which of the following histopathological findings is not seen 12 hours after an ischemic injury to the heart? (Q857177)

A. Karyorrhexis of myocytes

B. Neocapillary invasion of myocytes

C. Hyper-eosinophilia of myocytes

D. Coagulation necrosis of myocytes

See Answer in Part B → Q12

@Neet_pg_bot

Q13: A 65-year-old man dies due to a myocardial infarction. Which stains can be used to see the infarct in the heart while conducting an autopsy? (Q858094)

A. Oil Red O

B. Triphenyl tetrazolium chloride

C. Sudan black B

D. Masson's trichrome

See Answer in Part B → Q13

@Neet_pg_bot

Q14: A 34-year-old female patient presented to the outpatient department with migratory arthritis, and examination revealed a pan-systolic murmur. An echocardiography was performed, which was suggestive of mitral regurgitation. A biopsy specimen was obtained, and the image is provided below. What is the most likely lesion shown in the histopathology slide? (Q858083)

A. Aschoff’s bodies

B. Epithelioid granuloma

C. Granulomatous vasculitis

D. Granuloma inguinale

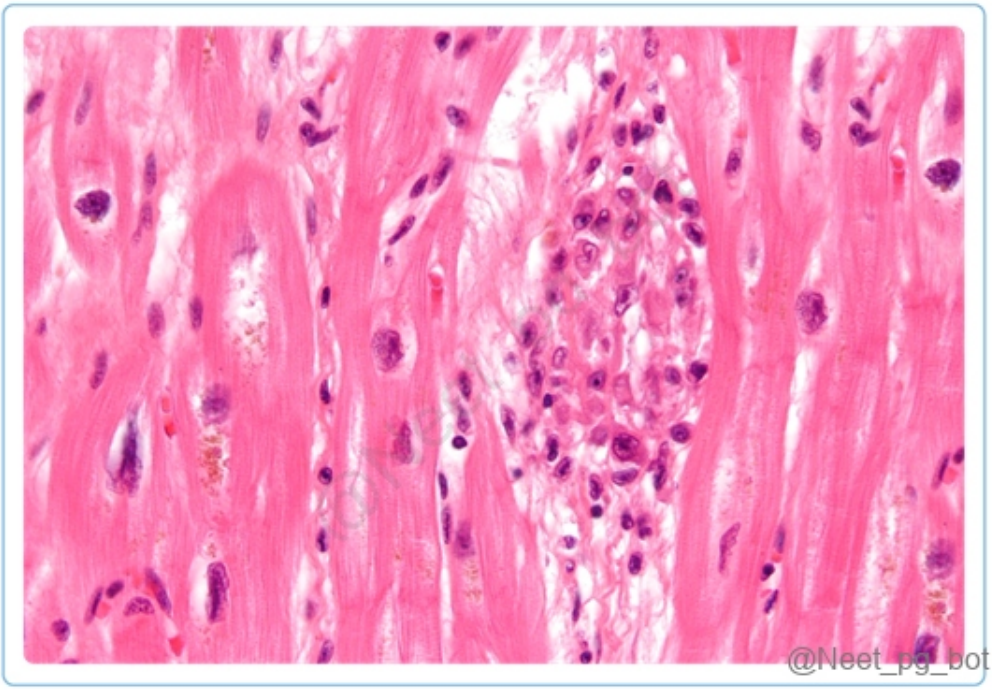

See Answer in Part B → Q14

@Neet_pg_bot

Q15: A 5-year-old child presents with fever, fatigue, and left ventricular dysfunction. An endomyocardial biopsy is shown below. What is the most likely diagnosis? (Q855420)

A. Acute rheumatic fever

B. Chagas cardiomyopathy

C. Pyogenic myocarditis

D. Lymphocytic myocarditis

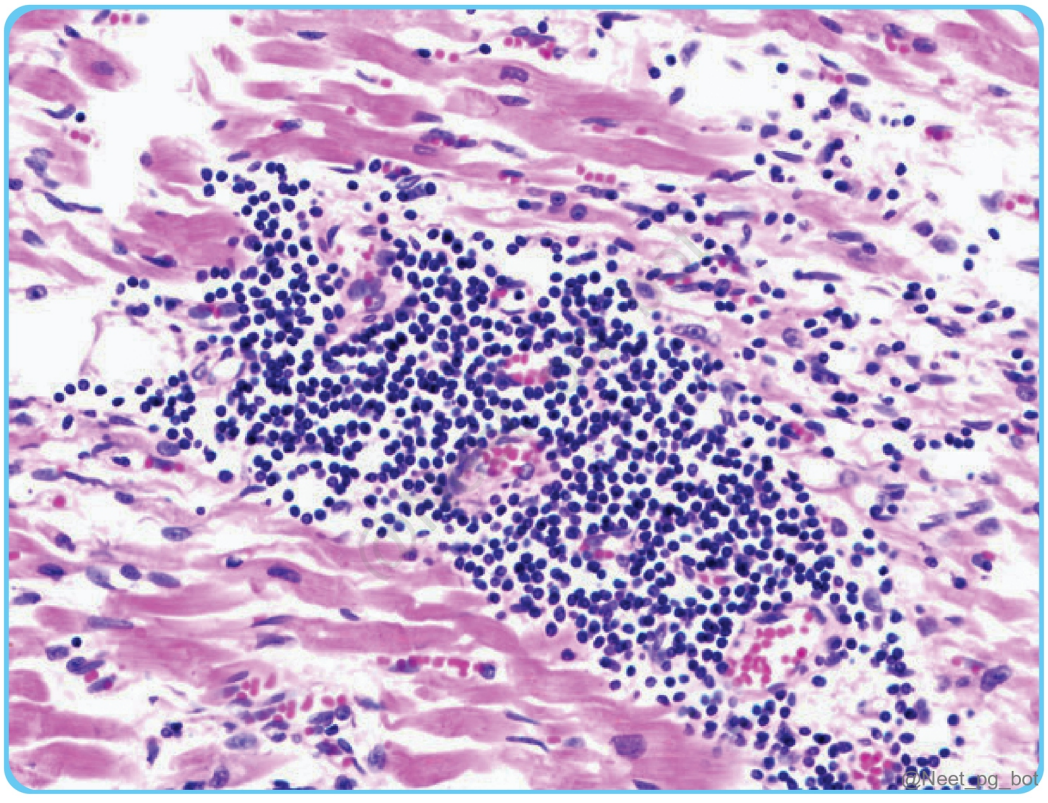

See Answer in Part B → Q15

@Neet_pg_bot

Q16: Which of the following is the earliest marker to rise in a case of myocardial infarction (MI)? (Q860196)

A. CKMB (Creatine Kinase-MB)

B. Troponin

C. LDH

D. Heart fatty acid binding protein

See Answer in Part B → Q16

@Neet_pg_bot

Q17: A 35-year-old patient presents with colicky abdominal pain, joint pain, and palpable purpura. Urinalysis shows only red blood cells with no other significant findings. Which of the following is the likely diagnosis? (Q860153)

A. IgA vasculitis

B. Granulomatosis with polyangiitis

C. Microscopic polyangiitis

D. Behçet's disease

See Answer in Part B → Q17

@Neet_pg_bot

Q18: A 30-year-old football player is brought to the emergency department after he collapsed due to sudden cardiac arrest. Based on the biopsy findings of his cardiac tissue, what is the most likely cause of his death? (Q844091)

A. Hypertrophic obstructive cardiomyopathy

B. Dilated cardiomyopathy

C. Restrictive cardiomyopathy

D. Arrhythmogenic cardiomyopathy

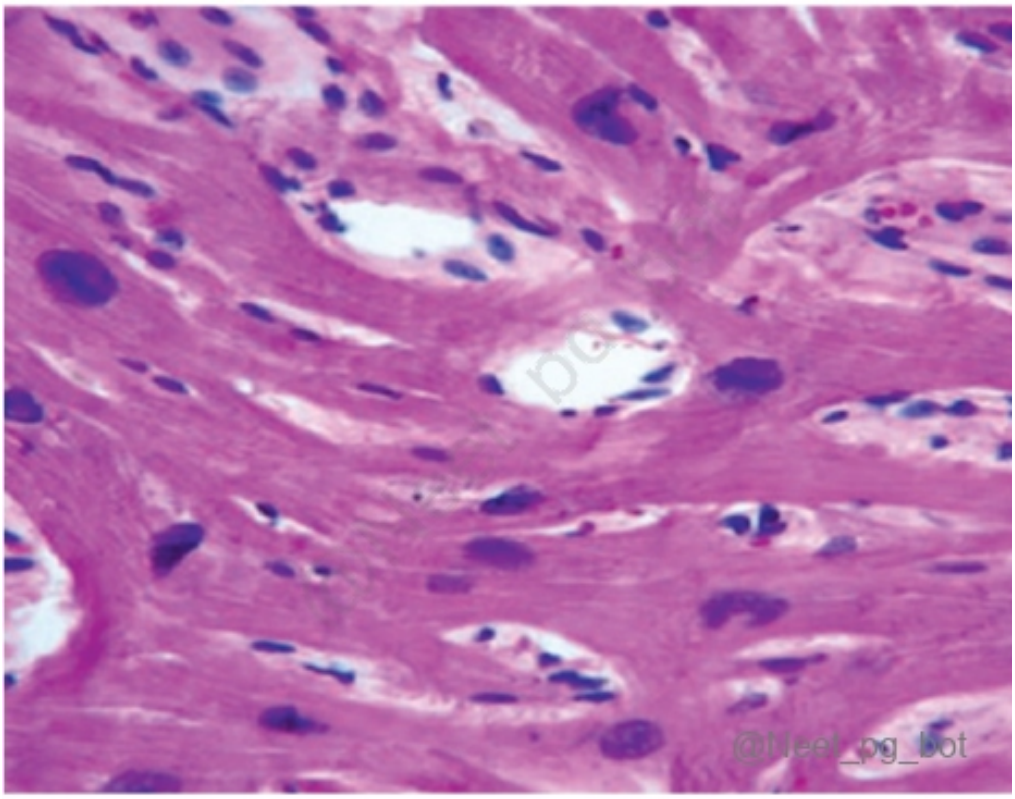

See Answer in Part B → Q18

@Neet_pg_bot

Q19: A 20-year-old athlete suddenly collapsed while playing football and was taken to the hospital, where he was declared dead. His autopsy image is given below. Which of the following is the most likely cause of death? (Q855424)

A. Valvular heart disease due to RHD

B. Sudden cardiac death due to arrhythmia

C. Sudden cardiac death due to hypertrophic cardiomyopathy

D. Sudden cardiac death due to atherosclerosis

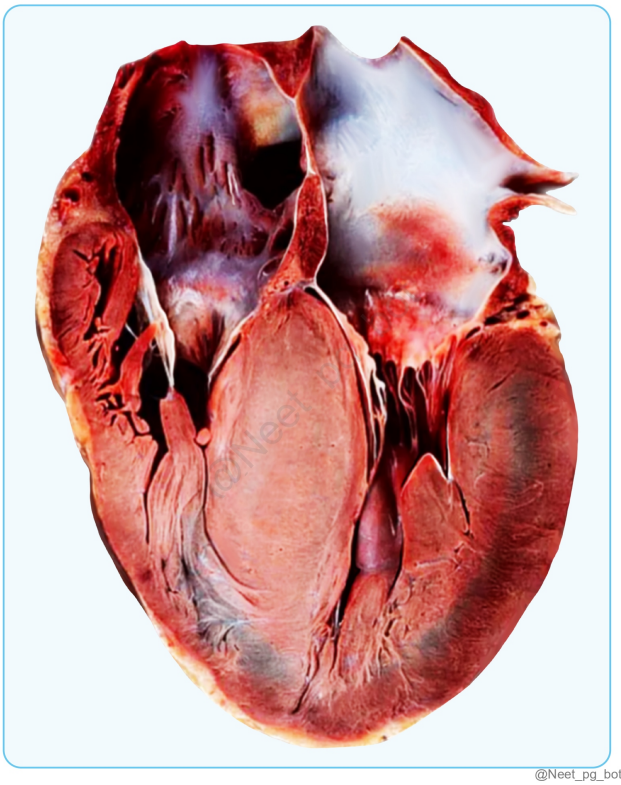

See Answer in Part B → Q19

@Neet_pg_bot

Q20: A 34-year-old female patient presented to the outpatient department with migratory arthritis , and examination revealed a pan-systolic murmur . An echocardiography was performed, which was suggestive of mitral regurgitation . A biopsy specimen was obtained, and the image is provided below. What is the most likely lesion shown in the histopathology slide? (Q799426)

A. Aschoff’s bodies

B. Epithelioid granuloma

C. Granulomatous vasculitis

D. Granuloma inguinale

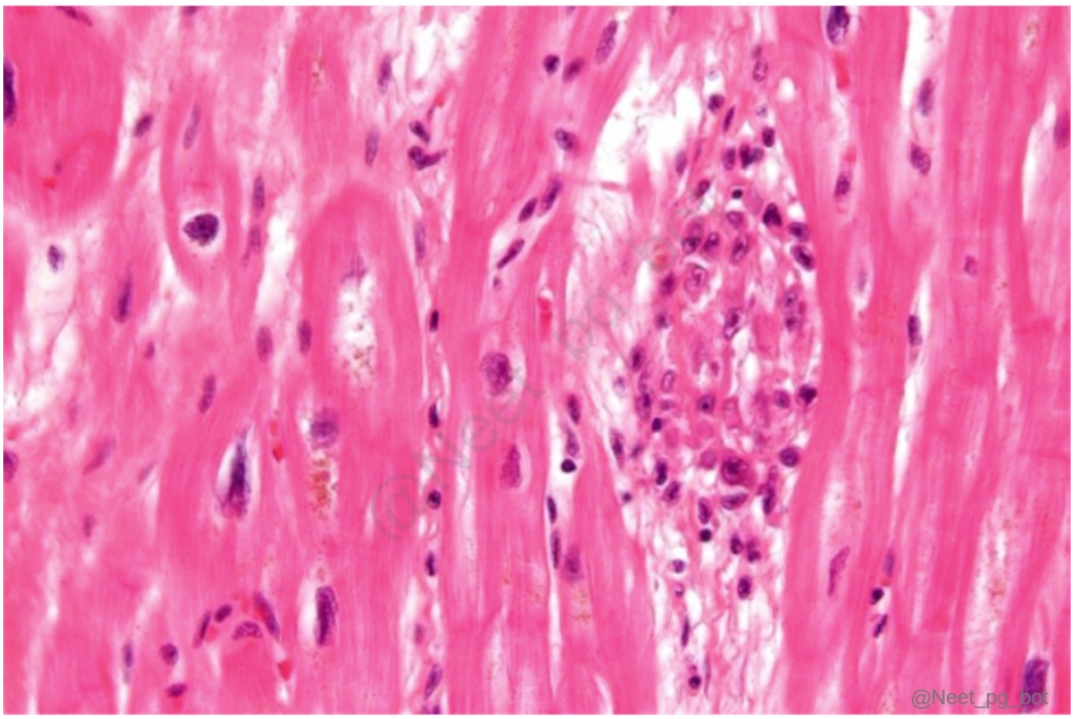

See Answer in Part B → Q20

@Neet_pg_bot

• [07_Respiratory System] 032 Obstructive Lung Disease

« Back to Folder Directory

[07_Respiratory System] 032 Obstructive Lung Disease — Quick Jump

Q1 (p. 354) *Q2 (p. 354)* *Q3 (p. 355)* *Q4 (p. 355)* *Q5 (p. 355)* *Q6 (p. 356)*
Q7 (p. 356) *Q8 (p. 357)* *Q9 (p. 357)* *Q10 (p. 358)* *Q11 (p. 358)* *Q12 (p. 359)*

Q1: A 20-year-old male presented with cough and breathing difficulty and was diagnosed with emphysema after radiographic examination. Which of the following genetic conditions should be suspected as a possible cause? (Q845463)

A. Cystic fibrosis

B. Asthma

C. Alpha-1 antitrypsin deficiency

D. Bronchiectasis

See Answer in Part B → Q1

@Neet_pg_bot

Q2: Match the following types of emphysema with their characteristic features: Types of Emphysema Characteristic Features 1) Centriacinar emphysema A) Uniformly affects the entire acinus, commonly associated with alpha 1 antitrypsin deficiency 2) Panacinar emphysema B) Predominantly involves the upper lobes, often associated with bullae formation. Alveolar ducts and sacs are spared 3) Paraseptal emphysema C) Associated with scarring and fibrosis, often seen in patients with chronic inflammation or recurrent infections 4) Irregular emphysema D) Involves the distal airways and is often associated with spontaneous pneumothorax (Q845464)

A. 1-a, 2-c, 3-b, 4-d

B. 1-b, 2-a, 3-d, 4-c

C. 1-a, 2-b, 3-c, 4-d

D. 1-d, 2-b, 3-a, 4-c

See Answer in Part B → Q2

@Neet_pg_bot

Q3: Which of the following mechanisms is not involved in the development of emphysema? (Q845465)

A. Toxic injury and inflammation leading to variable degrees of parenchymal destruction.

B. Protease-antiprotease imbalance with a relative deficiency of protective antiproteases.

C. The presence of T and B cells in affected parts of the lung indicates a robust adaptive immune response.

D. Oxidative stress induced by substances in tobacco smoke, alveolar damage, and inflammatory cells.

See Answer in Part B → Q3

@Neet_pg_bot

Q4: A 65-year-old man has been a heavy smoker for the past 40 years and presents with complaints of progressive shortness of breath, especially with exertion, and a chronic cough with occasional scanty sputum production. Physical examination reveals a barrel-shaped chest, decreased breathing sounds, and a prolonged expiratory phase. Based on the clinical presentation and history, what is the most likely diagnosis? (Q845466)

A. Chronic bronchitis

B. Emphysema

C. Pulmonary fibrosis

D. Asthma

See Answer in Part B → Q4

@Neet_pg_bot

Q5: A 45-year-old male patient presents with a history of chronic cough, increased sputum production, and shortness of breath. He reports that these symptoms have been present for several years and have gradually worsened over time. The patient is a lifelong smoker, having smoked one pack of cigarettes per day for the past 20 years. What is the likely diagnosis? (Q845469)

A. Emphysema

B. Asthma

C. Chronic bronchitis

D. Lung cancer

See Answer in Part B → Q5

@Neet_pg_bot

Q6: Which of the following is not true regarding chronic bronchitis? (Q845472)

A. Reid index >0.4

B. The most common cause is smoking

C. The most common cause of exacerbation is Haemophilus influenzae.

D. Recurrent, episodic attacks of wheezing, prolonged expiration, dyspnea (shortness of breath), and chest tightness.

See Answer in Part B → Q6

@Neet_pg_bot

Q7: A 32-year-old female presents with recurrent episodes of wheezing, coughing, and shortness of breath. On further testing, a diagnosis of asthma was made. Which of the following best describes the underlying pathophysiological changes seen in this patient's condition? (Q845474)

A. Reduced goblet cell secretion

B. Thinning of the basement membrane

C. Increase in airway inflammation and remodeling

D. Decreased submucosal gland activity

See Answer in Part B → Q7

@Neet_pg_bot

Q8: A 45-year-old male has a history of recurrent wheezing, coughing, and shortness of breath. His sputum microscopy, shown in the image below, reveals the following finding. Which best describes this finding? (Q845476)

A. Extrusion of mucus plugs from the subepithelial mucous gland ducts or bronchioles.

B. Ciliated columnar cells sloughed from the bronchial mucosa.

C. Polypoid plugs of loose organizing connective tissue within the bronchioles.

D. They are composed of Galectin 10.

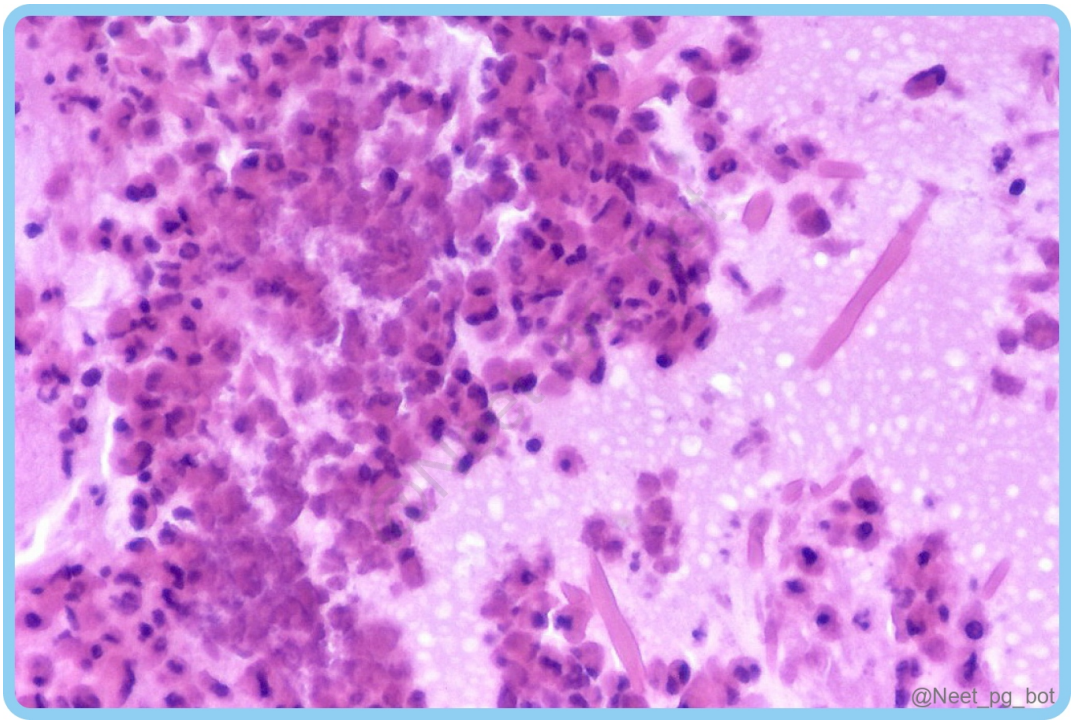

See Answer in Part B → Q8

@Neet_pg_bot

Q9: A 30-year-old patient presents with a history of recurrent wheezing, coughing, and shortness of breath. Upon further investigation, it is found that the patient has a family history of allergies and asthma. Which genetic factor is most likely co-related to the severity of this condition? (Q845477)

A. Variant IL-4 receptor gene

B. IL-13 polymorphism

C. ADAM33 polymorphism

D. YKL40 gene mutation

See Answer in Part B → Q9

@Neet_pg_bot

Q10: A 35-year-old male presents to the emergency department with complaints of chronic cough with production of purulent sputum, intermittent hemoptysis, and recurrent respiratory infections over the past several years. He reports a history of childhood respiratory infections and no significant past medical history. Physical examination reveals coarse crackles and rhonchi on auscultation of the chest. Chest X-ray shows bilateral bronchial wall thickening and tram-line shadows. Which of the following is unlikely to be a cause for this condition? (Q845478)

A. Primary ciliary dyskinesia

B. Bronchial Asthma

C. Cystic fibrosis

D. Kartagener syndrome

See Answer in Part B → Q10

@Neet_pg_bot

Q11: Which of the following statements accurately describes the pathophysiology of Kartagener's syndrome? (Q845479)

A. Mutation in the CFTR gene leading to impaired ciliary function.

B. Autosomal dominant inheritance pattern affecting the cilia in the respiratory tract.

C. The primary defect involves dynein arm proteins, leading to impaired ciliary motility.

D. Characterized by an excess of cilia in the respiratory epithelium.

See Answer in Part B → Q11

@Neet_pg_bot

Q12: A 45-year-old male presents with a chronic cough productive of copious sputum. He reports frequent respiratory infections over the past several years. Physical examination reveals digital clubbing and coarse crackles on auscultation. An HRCT is done and shown below. Which of the following is the most likely diagnosis? (Q845480)

A. Tuberculosis

B. Asthma

C. Chronic obstructive pulmonary disease

D. Bronchiectasis

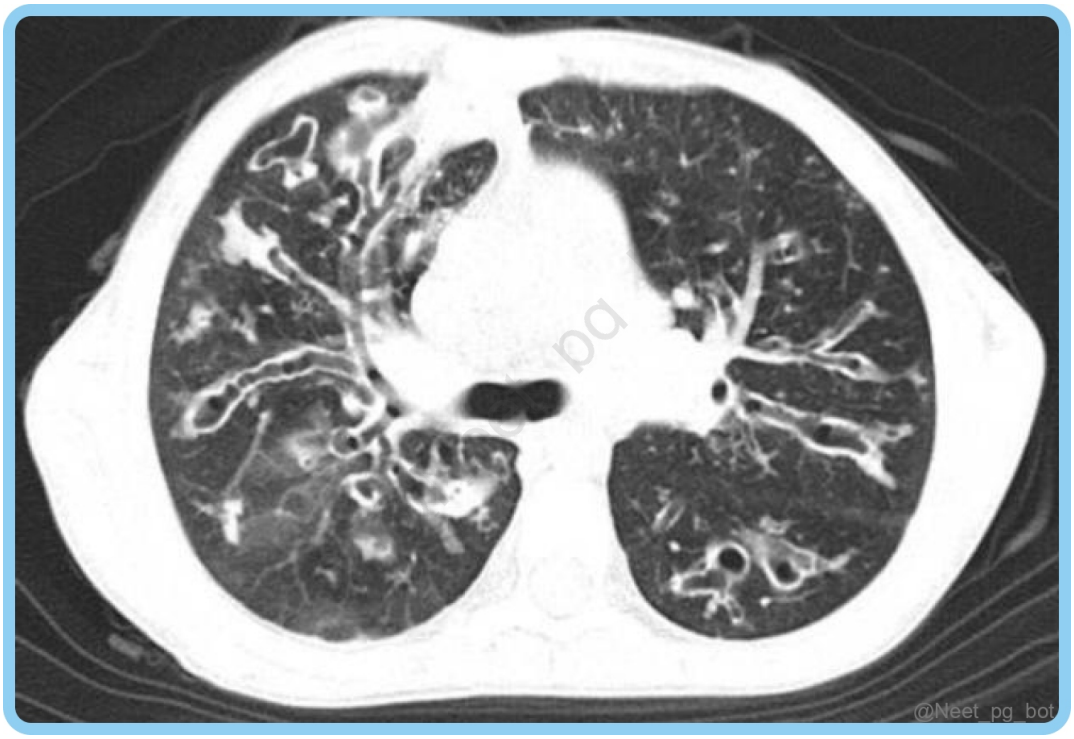

See Answer in Part B → Q12

@Neet_pg_bot

• [07_Respiratory System] 033 Pulmonary Hypertension And Lung Tumors

« Back to Folder Directory

[07_Respiratory System] 033 Pulmonary Hypertension And Lung Tumors — Quick Jump

Q1 (p. 361)	*Q2 (p. 362)*	*Q3 (p. 362)*	*Q4 (p. 363)*	*Q5 (p. 363)*	*Q6 (p. 364)*
Q7 (p. 364)	*Q8 (p. 364)*	*Q9 (p. 365)*	*Q10 (p. 366)*	*Q11 (p. 366)*	*Q12 (p. 367)*
Q13 (p. 367)	*Q14 (p. 368)*	*Q15 (p. 369)*	*Q16 (p. 369)*	*Q17 (p. 370)*	*Q18 (p. 371)*
Q19 (p. 372)	*Q20 (p. 372)*	*Q21 (p. 373)*	*Q22 (p. 373)*		

Q1: A 50-year-old female presents with a chronic cough and recurrent episodes of wheezing. Bronchoscopy reveals a "coat button lesion" within the bronchus, as shown in the image. Biopsy of the lesion shows nesting of cells with uniform round nuclei and moderate eosinophilic cytoplasm. What is the most likely diagnosis based on the described features? (Q845562)

A. Small cell lung carcinoma

B. Squamous cell carcinoma

C. Bronchial carcinoid tumor

D. Adenocarcinoma

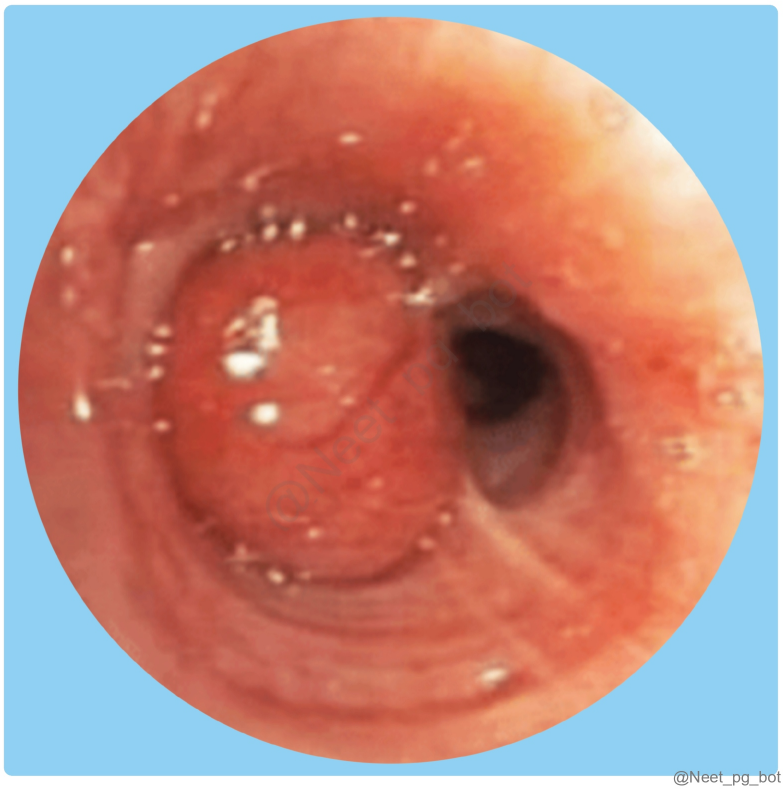

See Answer in Part B → Q1

@Neet_pg_bot

Q2: Which of the following lung cancer subtypes has the highest mutational burden and is the most aggressive? (Q890492)

A. Adenocarcinoma

B. Squamous cell carcinoma

C. Small cell carcinoma

D. Large cell carcinoma

See Answer in Part B → Q2

@Neet_pg_bot

Q3: Which of the following is the most common presenting symptom of lung carcinoma? (Q890491)

A. Cough

B. Hemoptysis

C. Chest pain

D. Weight loss

See Answer in Part B → Q3

@Neet_pg_bot

Q4: Which of the following represents the most common histologic subtype of lung cancer worldwide? (Q890490)

A. Adenocarcinoma > Squamous cell carcinoma > Small cell carcinoma

B. Small cell carcinoma > Large cell carcinoma > Adenocarcinoma

C. Adenocarcinoma > Small cell carcinoma > Squamous cell carcinoma

D. Squamous cell carcinoma > Adenocarcinoma > small cell carcinoma

See Answer in Part B → Q4

@Neet_pg_bot

Q5: What is the diagnosis for a patient who has a history of smoking 24 packs, is currently experiencing breathlessness and chest pain, and is found to have a lung tumor with positive chromogranin staining? (Q882173)

A. Adenocarcinoma

B. Squamous cell carcinoma

C. Mesothelioma

D. Small cell carcinoma

See Answer in Part B → Q5

@Neet_pg_bot

Q6: Which of the following is not an IHC marker for small-cell lung carcinoma? (Q846630)

A. Napsin A

B. Chromogranin

C. NSE

D. CD56

See Answer in Part B → Q6

@Neet_pg_bot

Q7: A 56-year-old male presents with persistent shoulder pain radiating to the ulnar aspect of the forearm and progressive weakness in his right hand. Examination reveals muscle wasting in the right hand. Imaging of the chest shows a mass at the apex of the right lung involving nearby neurovascular structures. Which syndrome is most likely associated with this presentation? (Q845630)

A. Horner syndrome

B. Superior vena cava (SVC) syndrome

C. Caplan syndrome

D. Carcinoid syndrome

See Answer in Part B → Q7

@Neet_pg_bot

Q8: A 55-year-old woman has an incidental finding of a lung mass on imaging. CT scan reveals a well-circumscribed lesion with calcifications. Biopsy revealed spindle

and epithelioid cells with an eosinophilic cytoplasm, perivascular growth, and positive HMB-45 staining. What is the most likely diagnosis? (Q845627)

A. Pulmonary hamartoma

B. Sugar tumour (PEComa)

C. Solitary fibrous tumour

D. Carcinoid tumour

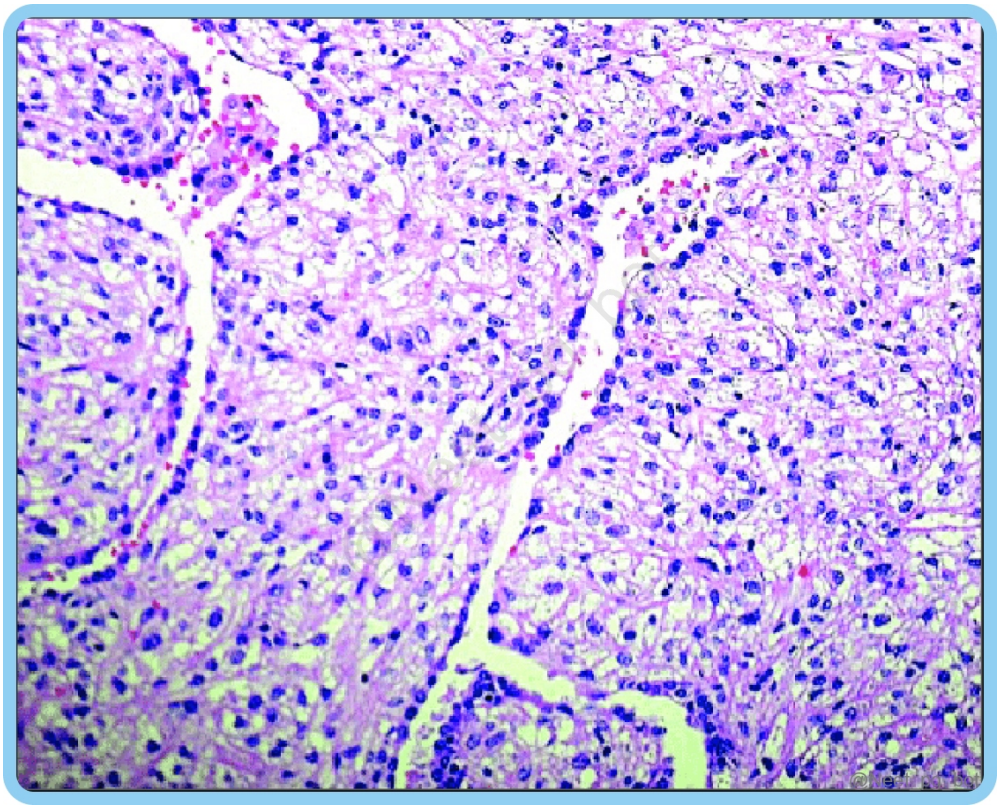

See Answer in Part B → Q8

@Neet_pg_bot

Q9: A 55-year-old former shipyard worker presents with progressive dyspnea and left-sided chest pain for three months. He has a history of occupational asbestos exposure. Physical examination reveals decreased breath sounds over the left lung base. Imaging shows left-sided pleural thickening and effusion. Biopsy confirms mesothelioma. Which of the following statements is not accurate about mesothelioma and adenocarcinoma following asbestos exposure? (Q845595)

A. Adenocarcinoma often has a shorter latency period compared to mesothelioma following asbestos exposure.

B. Mesothelioma under electron microscopy, reveals non-branching microvilli.

C. Mesothelioma often presents with positive staining for calretinin and WT-1.

D. Adenocarcinoma is commonly associated with EGFR mutation.

See Answer in Part B → Q9

@Neet_pg_bot

Q10: A 55-year-old male presents with pleuritic chest pain and a pleural-based mass observed on imaging studies. Histopathological examination of a biopsy from the mass reveals spindle-shaped cells within a collagenous stroma. Which immunohistochemical marker would be most useful in differentiating solitary fibrous tumour (SFT) from mesothelioma? (Q845579)

A. CD34

B. Calretinin

C. WT1

D. TTF-1 (Thyroid transcription factor 1)

See Answer in Part B → Q10

@Neet_pg_bot

Q11: A 45-year-old nonsmoking woman presents with a persistent cough and hemoptysis. Imaging reveals a solitary pulmonary nodule in the right lung. Biopsy shows cells with neuroendocrine features, including round to oval nuclei, stippled chromatin, and abundant granular cytoplasm arranged in nests and trabeculae. Which cell type is most likely involved in the origin of this patient's lung tumour? (Q845564)

A. Type II pneumocytes

B. Clara cells

C. Kulchitsky cells

D. Alveolar macrophages

See Answer in Part B → Q11

@Neet_pg_bot

Q12: A 45-year-old female presents progressive shortness of breath, especially on exertion, fatigue, and ankle swelling. Physical examination reveals elevated jugular venous pressure. Echocardiography shows right ventricular hypertrophy and elevated pulmonary artery pressure. Which of the following conditions can predispose her to this condition? (Q845467)

A. High altitude

B. Recurrent thromboembolic

C. Scleroderma

D. All the above

See Answer in Part B → Q12

@Neet_pg_bot

Q13: A 50-year-old heavy smoker presents with a persistent cough and unintentional weight loss. Imaging shows a right lung mass with mediastinal lymphadenopathy. Biopsy reveals small, round cells with scant cytoplasm and nuclei exhibiting a salt-and-pepper chromatin pattern. Immunohistochemistry (IHC) is positive for neuroendocrine markers. Which of the following features is incorrectly associated with this clinical condition? (Q845561)

A. Both glandular and squamous differentiation are seen

B. Encrustation of tumour cells along the blood vessels with DNA material

C. Presence of dense neurosecretory granules on electron microscopy

D. High proliferative index

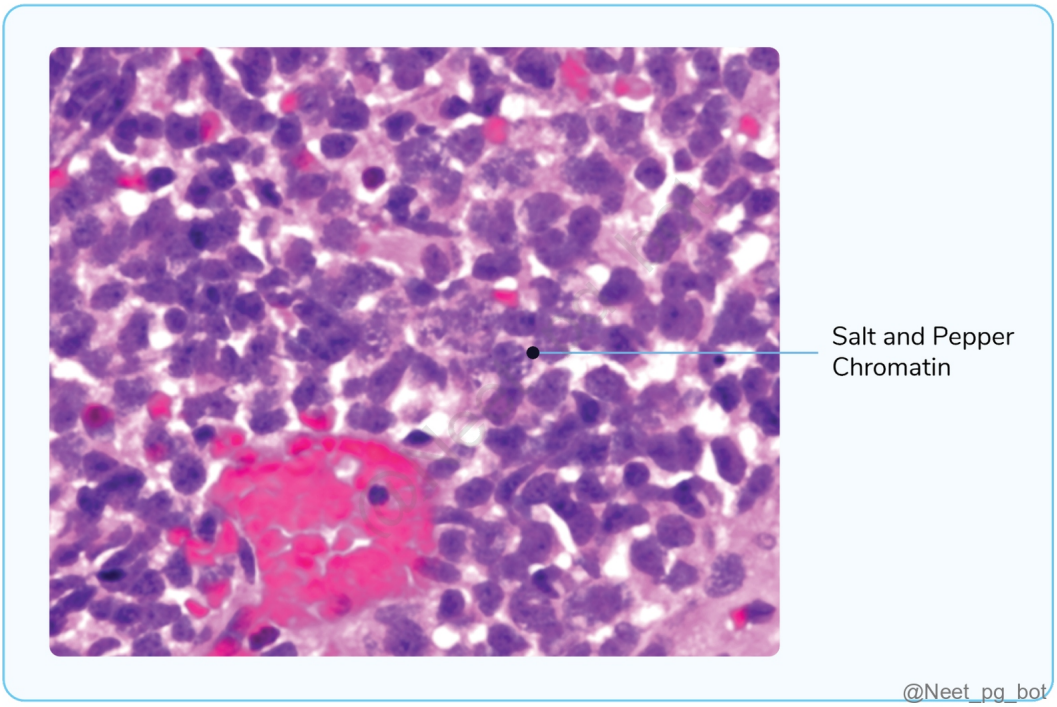

See Answer in Part B → Q13

@Neet_pg_bot

Q14: A 52-year-old male, non-smoker, presents with progressive shortness of breath, persistent dry cough, and chest pain. A CT scan reveals a peripheral mass in the lower lobe of left lung, and a biopsy of the nodule demonstrates a glandular pattern with mucinous differentiation, as shown in the image below. Which of the following markers is least likely to be positive in this patient's lung lesion? (Q845560)

A. TTF-1 (Thyroid Transcription Factor-1)

B. MUC1

C. Napsin A

D. Chromogranin

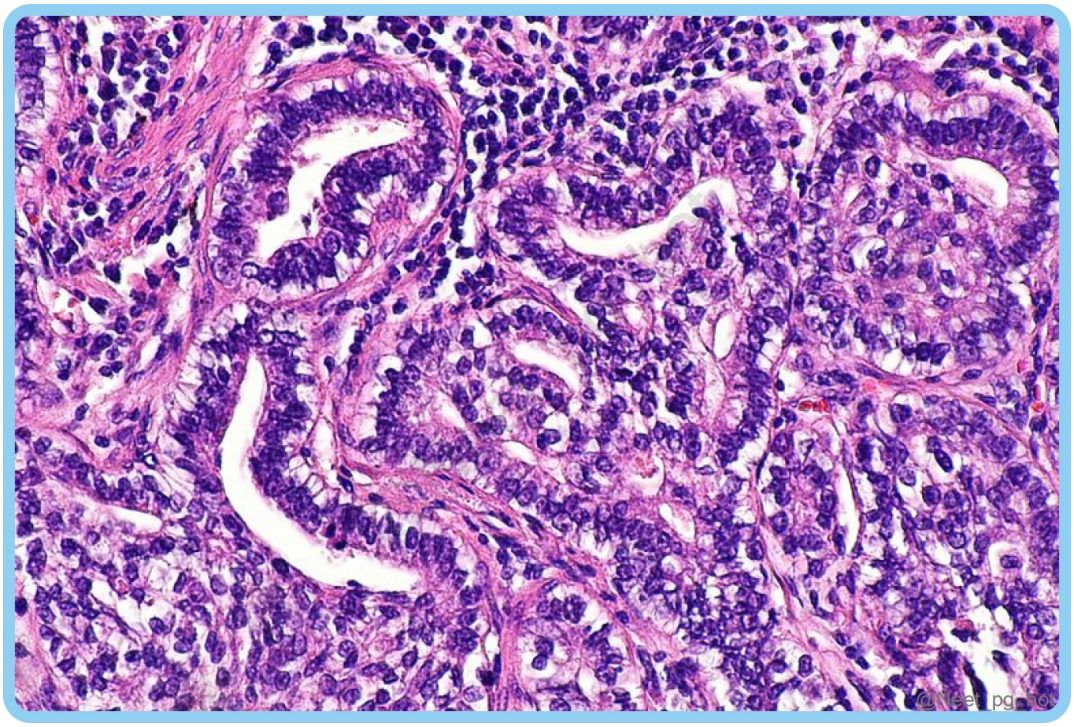

See Answer in Part B → Q14

@Neet_pg_bot

Q15: A 59-year-old heavy smoker presents with loss of appetite and a persistent cough for the past few months. Imaging reveals a central lung mass involving the right bronchus and mediastinal lymph nodes. Immunohistochemical staining of a lung mass biopsy is positive for chromogranin and synaptophysin. Which set of genes is most likely involved in the underlying pathology of this patient's condition? P53 RB L-myc (Q845559)

A. 1, 2

B. 1, 2, 3

C. Only 2

D. 2, 3

See Answer in Part B → Q15

@Neet_pg_bot

Q16: A 57-year-old male smoker with a persistent cough and weight loss is found to have a lung mass on imaging. The biopsy showed keratin pearls and intercellular bridges. Which of the following paraneoplastic syndromes is highly associated with this diagnosis? (Q845558)

A. Hypercalcemia

B. Syndrome of Inappropriate Antidiuretic Hormone Secretion (SIADH)

C. Migratory thrombophlebitis

D. Cushing's syndrome

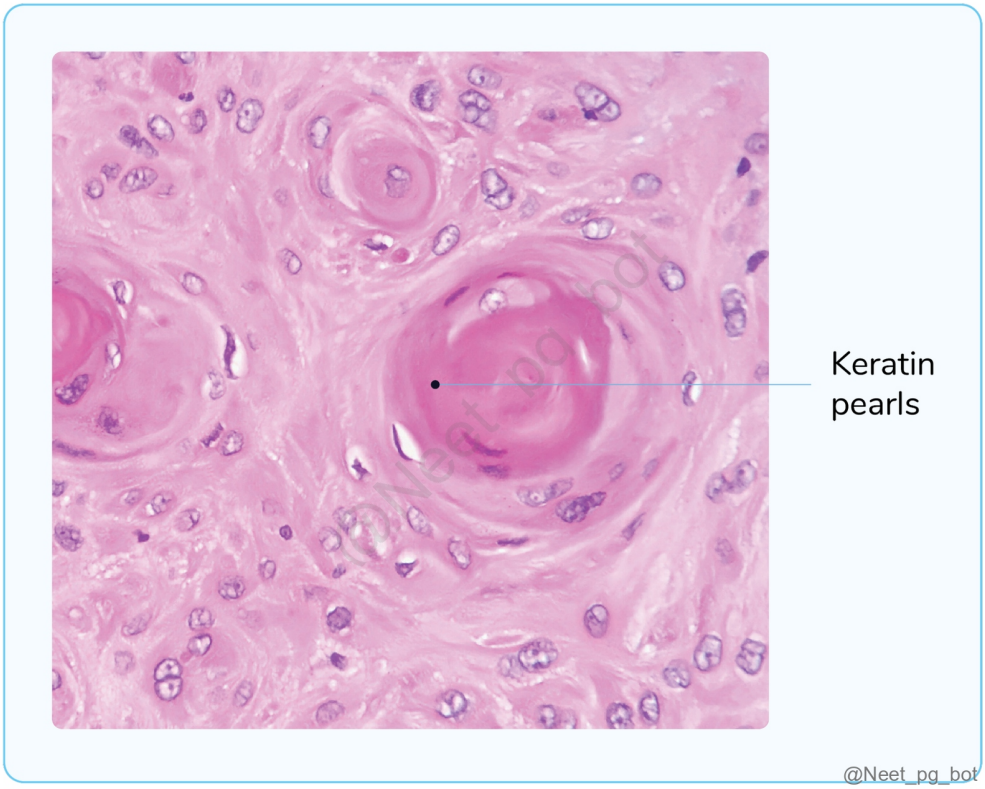

See Answer in Part B → Q16

@Neet_pg_bot

Q17: A 67-year-old male smoker presents with a persistent cough and weight loss. Imaging reveals a lung mass in the upper lobe of the right lung. The biopsy reveals typical features, including keratin pearls, intercellular bridges, and nests of malignant squamous cells with abundant eosinophilic cytoplasm. Based on this scenario, which of

the following statements is incorrect? (Q845557)

A. Keratin pearls are not seen in poorly differentiated squamous cell carcinoma.

B. p40 is the best marker for squamous cell carcinoma.

C. Squamous dysplasia is a precursor lesion of squamous cell carcinoma

D. The squamous cell carcinoma described is likely a peripheral lung lesion.

See Answer in Part B → Q17

@Neet_pg_bot

Q18: A 58-year-old male smoker presents with a persistent cough and mild shortness of breath. Chest imaging reveals a solitary pulmonary nodule. A biopsy is performed, and a histopathological examination of the lung tissue is shown in the image below. What is the most likely diagnosis? (Q845556)

A. Carcinoma in situ

B. Adenomatous hyperplasia

C. Adenocarcinoma in situ

D. Diffuse idiopathic pulmonary neuroendocrine cell hyperplasia

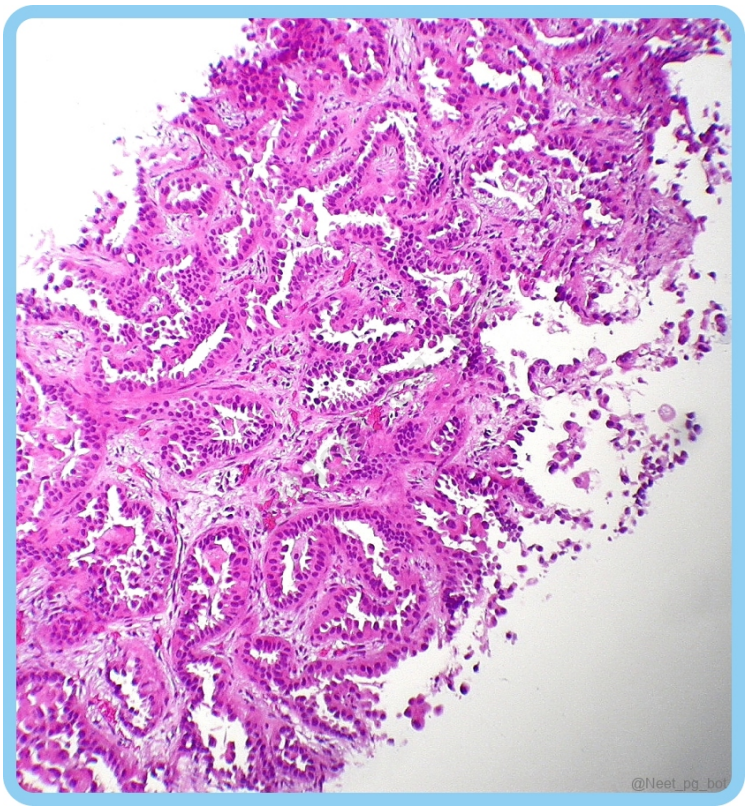

See Answer in Part B → Q18

@Neet_pg_bot

Q19: A 55-year-old male smoker presents to the clinic with chronic cough and hemoptysis. He has been smoking two packs of cigarettes per day for the past 30 years. Upon further evaluation, a biopsy reveals lung carcinoma. Which of the following statements regarding risk factors for lung carcinoma is false? (Q845473)

A. Smoking is a major risk factor for squamous cell carcinoma of the lung.

B. Smoking has no association with adenocarcinoma of the lung.

C. Smoking is a significant risk factor for small-cell lung carcinoma.

D. Asbestosis exposure, along with smoking, multiplies the risk of lung cancer.

See Answer in Part B → Q19

@Neet_pg_bot

Q20: A 55-year-old man presents with severe shortness of breath, cough, and fever after recent bacterial pneumonia. Physical examination shows tachypnea, hypoxia, and diffuse crackles on chest auscultation. Chest X-ray reveals bilateral opacities suggestive of pulmonary oedema. Histopathological examination of lung biopsy shows congested, edematous lungs with inflammation. Which histopathological finding is characteristic of the acute exudative stage in this patient's lung injury? (Q845471)

A. Proliferation of type II pneumocytes

B. Formation of fibrotic thickening in the alveolar septa

C. Presence of waxy hyaline membranes lining the alveolar walls

D. Resolution of granulation tissue in the alveolar spaces

See Answer in Part B → Q20

@Neet_pg_bot

Q21: Which of the following statements regarding the pathogenesis sequence of non-cardiogenic pulmonary oedema (NCPE) and acute respiratory distress syndrome (ARDS) is incorrect? Endothelial activation is the hallmark of pathogenesis. Release of cytokines by alveolar epithelial cells Macrophage activation resulting in the release of IL-8 and TNF Recruitment of lymphocytes by IL-8 (Q845470)

A. 1 and 3

B. 1, 2 and 3

C. 2 and 4

D. 1 and 4

See Answer in Part B → Q21

@Neet_pg_bot

Q22: A 45-year-old woman presents with progressive shortness of breath and fatigue. On examination, she has elevated jugular venous pressure and a loud pulmonary component of the second heart sound. Echocardiography reveals right ventricular

hypertrophy and dilation. Which of the following statements is correct regarding the vascular changes of this condition? (Q845468)

A. BMPR2 mutations result in endothelial and vascular smooth muscle cell apoptosis.

B. Classic atherosclerotic changes are commonly observed in pulmonary arteries.

C. Plexiform lesions are early changes of pulmonary hypertension.

D. Pulmonary arterioles show medial hypertrophy and intimal fibrosis, narrowing the lumens.

See Answer in Part B → Q22

@Neet_pg_bot

• [07_Respiratory System] 034 Congenital Anomalies And Lung Infections

« Back to Folder Directory

[07_Respiratory System] 034 Congenital Anomalies And Lung Infections — Quick Jump

Q1 (p. 375) *Q2 (p. 375)* *Q3 (p. 375)* *Q4 (p. 376)* *Q5 (p. 377)* *Q6 (p. 377)*
Q7 (p. 378) *Q8 (p. 381)* *Q9 (p. 381)* *Q10 (p. 381)*

Q1: Ciliocytophthoria is seen in? (Q845391)

A. Kartagener syndrome

B. Cystic fibrosis

C. Situs inversus

D. Acute respiratory infection

See Answer in Part B → Q1

@Neet_pg_bot

Q2: Which of the following is false regarding extralobular sequestration? (Q845396)

A. It is external to the lung.

B. It most commonly presents as a mass lesion.

C. It most often occurs in older children.

D. It has a separate pleural covering.

See Answer in Part B → Q2

@Neet_pg_bot

Q3: A 65-year-old female presents to the clinic with a productive cough, fever, and fatigue for the past two weeks. She has a history of poorly controlled diabetes mellitus and reports recent hospitalisation for a urinary tract infection. On physical examination, coarse crackles are auscultated over the right lower lung fields. The chest X-ray is shown below. Which of the following is the most common risk factor for developing this condition? (Q845399)

A. Antecedent primary lung infection

B. Aspiration of infective material

C. Septic embolism

D. Neoplasia

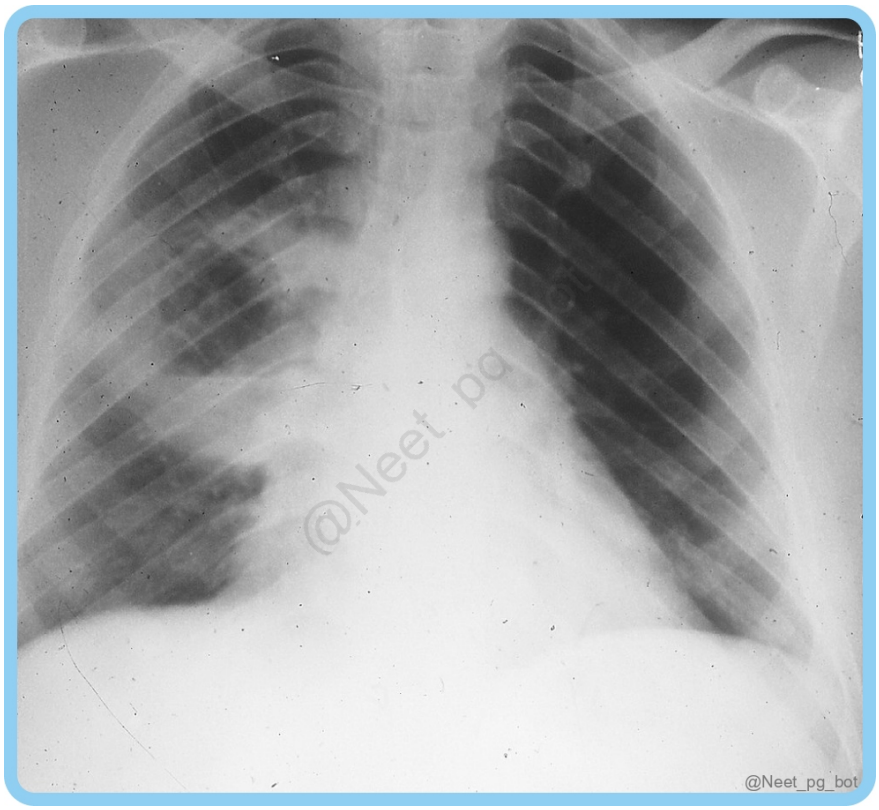

See Answer in Part B → Q3

@Neet_pg_bot

Q4: A 29-year-old previously healthy male presents with a one-week history of progressively worsening dry cough, fever, and shortness of breath. He denies any

recent travel but mentions attending a crowded social gathering a week ago. He is febrile, tachypneic, and has crackles on auscultation. Laboratory investigations reveal leukocytosis. A chest X-ray demonstrates patchy infiltrates in the lower lobes bilaterally. Which of the following features is not associated with this condition? (Q845402)

A. Inflammatory changes are confined to the pulmonary interstitium.

B. Neutrophils are involved in this infection.

C. It is associated with viral infections

D. It is also known as walking pneumonia.

See Answer in Part B → Q4

@Neet_pg_bot

Q5: Red hepatisation of the lungs is seen on which day? (Q845405)

A. 1-2

B. 2-4

C. 5-7

D. Beyond 7 day

See Answer in Part B → Q5

@Neet_pg_bot

Q6: A 55-year-old male with a long-standing history of chronic alcohol abuse presents with a one-week history of high-grade fever, productive cough with thick, mucoid, blood-tinged "currant jelly" sputum, and right-sided pleuritic chest pain. He reports frequent binge drinking episodes and he had several recent episodes of aspiration while intoxicated. On examination, he appears ill, with a temperature of 39.5°C, tachypnea, and signs of consolidation over the right upper lung fields. Laboratory investigations reveal leukocytosis with neutrophilia and elevated inflammatory markers. Chest X-ray shows bulging of right upper lobe fissure consistent with a dense

lobar consolidation. What is the most likely organism implicated in this condition? (Q845409)

A. Mycoplasma pneumoniae

B. Legionella pneumophila

C. Moraxella catarrhalis

D. Klebsiella pneumoniae

See Answer in Part B → Q6

@Neet_pg_bot

Q7: Match the following: 1) Pneumocystis pneumonia a) 2) Blastomycosis b) 3) Aspergillus c) 4) Measles d) (Q845414)

A. 1-b, 2-d, 3-c, 4-a

B. 1-a, 2-d, 3-c, 4-b

C. 1-c, 2-d, 3-b, 4-a

D. 1-b, 2-a, 3-c, 4-d

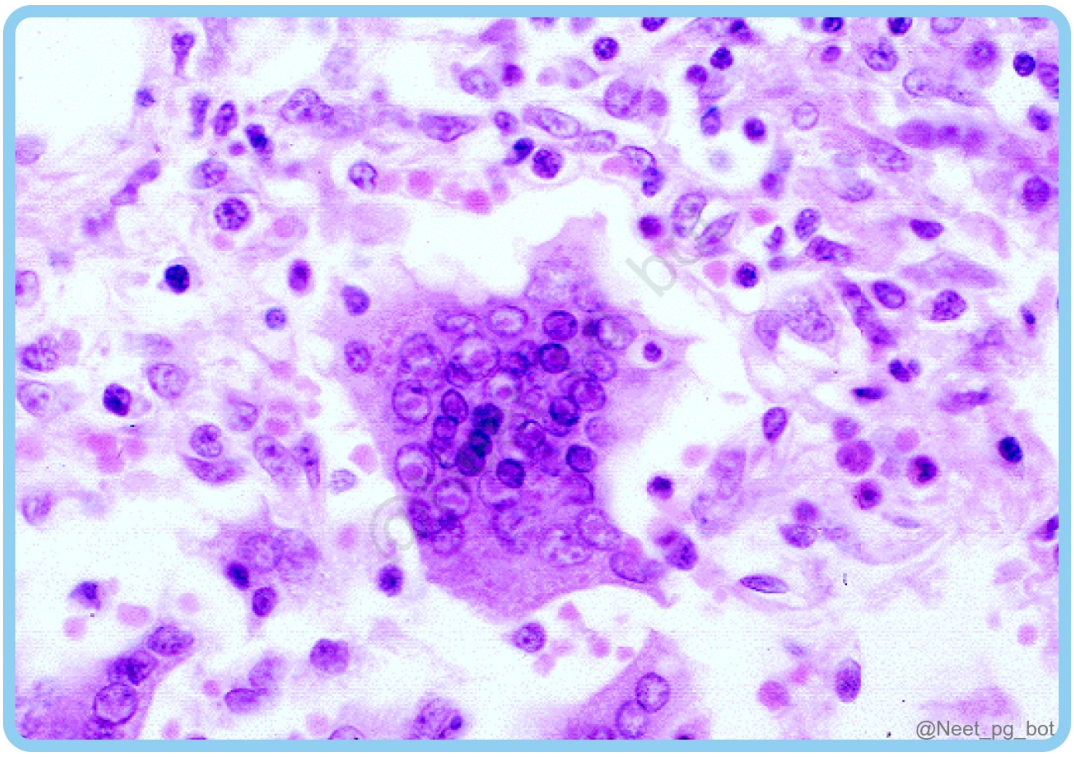
@Neet_pg_bot

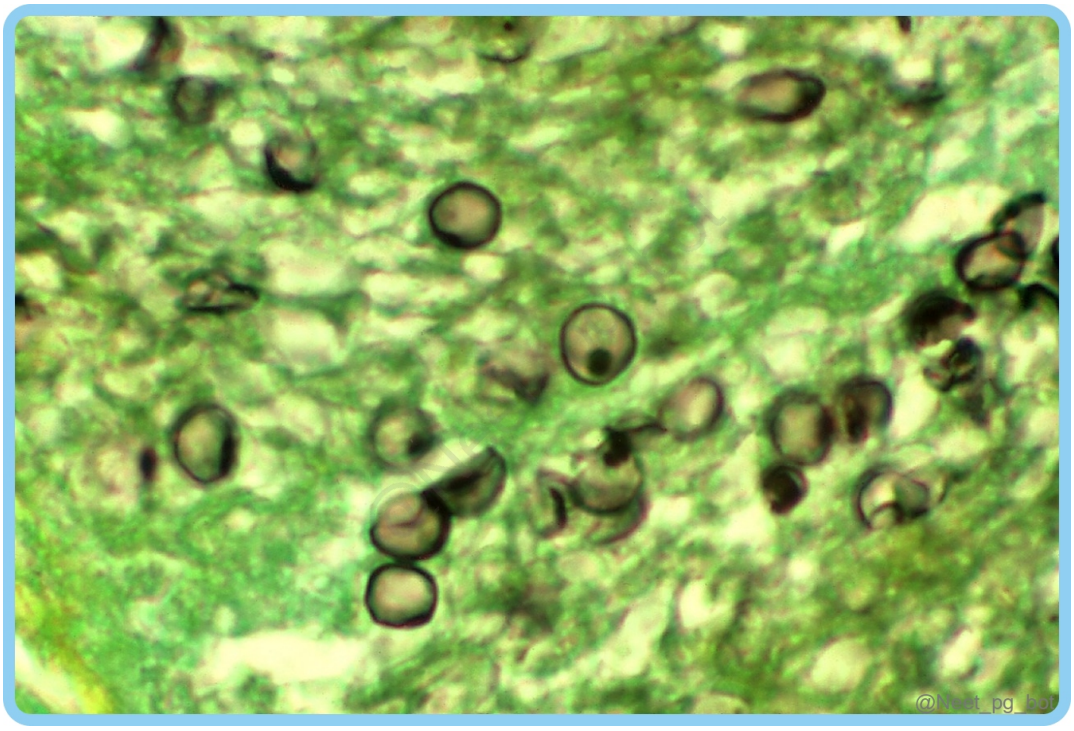
@Neet_pg_bot

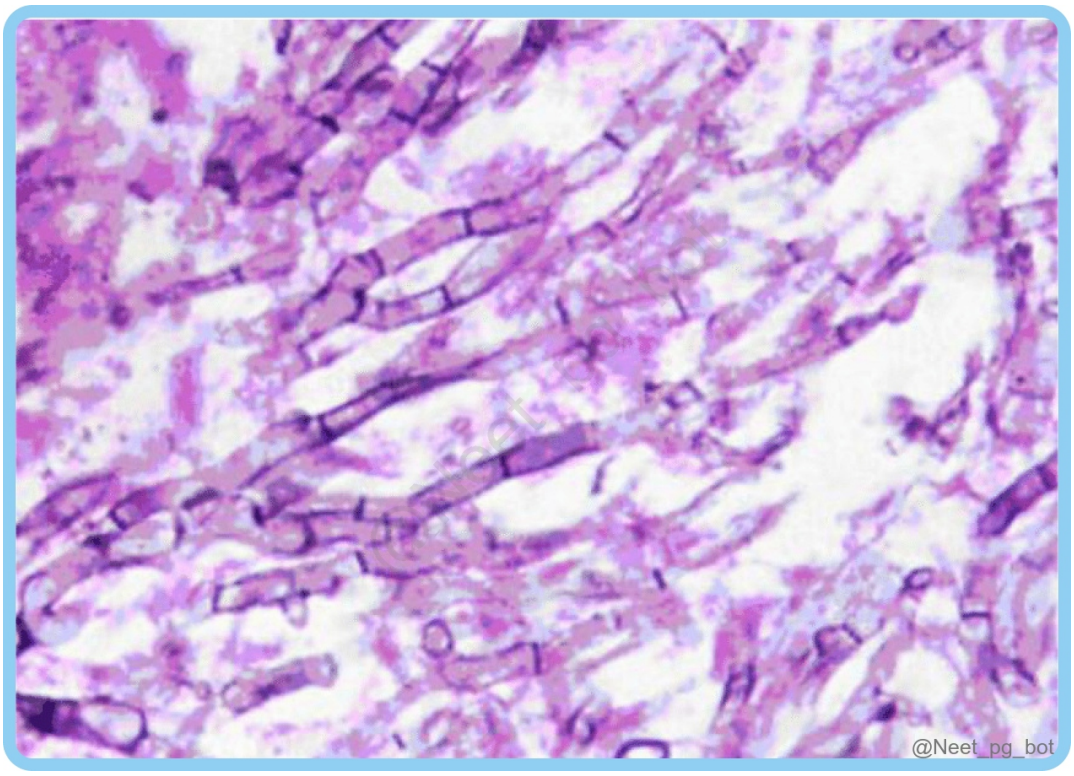

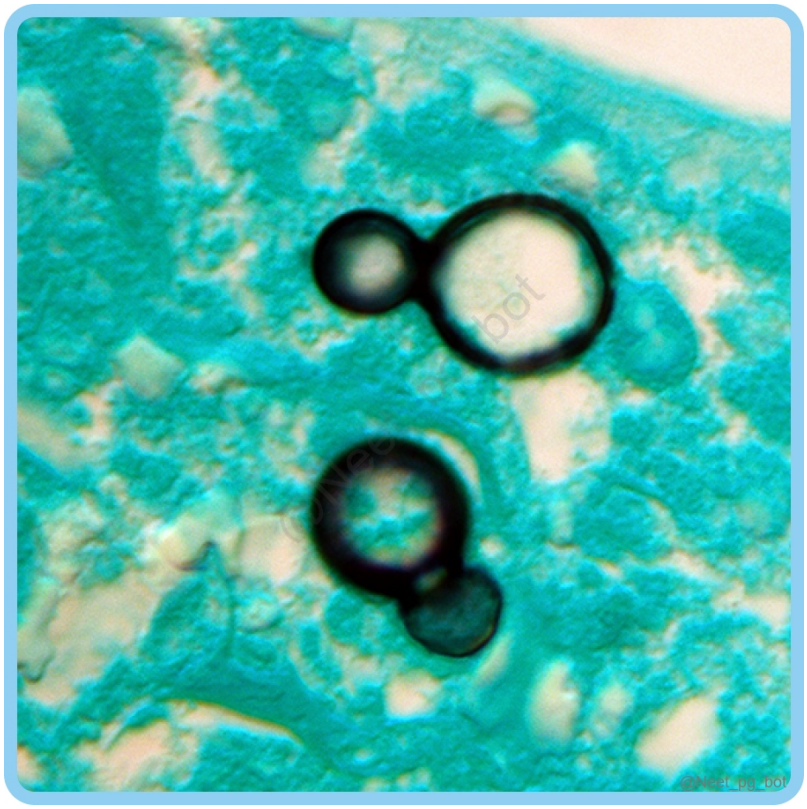

See Answer in Part B → Q7

@Neet_pg_bot

Q8: Which of the following conditions is not associated with aspiration? (Q845418)

A. Mendelson syndrome

B. Lipoid pneumonia

C. Meconium aspiration syndrome

D. Nelson syndrome

See Answer in Part B → Q8

@Neet_pg_bot

Q9: A 45-year-old man presents with a persistent cough, night sweats, and unintentional weight loss. Chest X-ray reveals an infiltrate in the upper lobe of the right lung. Which of the following pathological processes is not seen in this condition? (Q845422)

A. Th2-mediated macrophage activation and killing of bacteria.

B. The bacterium blocks phagolysosome formation.

C. M. tuberculosis is recognised by innate immunity receptors.

D. It causes granulomatous inflammation and damage.

See Answer in Part B → Q9

@Neet_pg_bot

Q10: Match the following lesions with their site of occurrence. Lesion Site 1 Puhl's focus i Lung + Lymph node 2 Simon focus ii Blood vessels 3 Ghon complex iii Supraclavicular region of the lung 4 Weighert focus iv The apex of the lung (Q845427)

A. 1-iii, 2-iv, 3-i, 4-ii

B. 1-iii, 2-iv, 3-ii, 4-i

C. 1-iv, 2-iii, 3-i, 4-ii

D. 1-iv, 2-i, 3-ii, 4-iii

See Answer in Part B → Q10

@Neet_pg_bot

• [07_Respiratory System] 035 Sarcoidosis And Occupational Lung Diseases

« Back to Folder Directory

[07_Respiratory System] 035 Sarcoidosis And Occupational Lung Diseases — Quick Jump

Q1 (p. 383) *Q2 (p. 383)* *Q3 (p. 384)* *Q4 (p. 384)* *Q5 (p. 384)* *Q6 (p. 385)*
Q7 (p. 386) *Q8 (p. 386)* *Q9 (p. 387)* *Q10 (p. 388)* *Q11 (p. 388)*

Q1: Which immunologic abnormalities are observed in the local milieu of sarcoid granulomas? (Q845654)

A. Accumulation of CD8+ T cells and increased CD8/CD4 T-cell ratio

B. Oligoclonal expansion of B-cell subsets

C. Increased levels of Th1 cytokines such as IL-4 and IL-10

D. Accumulation of CD4+ T cells and increased CD4/CD8 T-cell ratios

See Answer in Part B → Q1

@Neet_pg_bot

Q2: A 40-year-old male presents with fever, bilateral hilar lymphadenopathy, erythema nodosum, and acute polyarthritis affecting ankles and knees. He has a history of recurrent uveitis. Laboratory tests show elevated serum angiotensin-converting enzyme (ACE) levels and hypercalcemia. What is the most likely diagnosis? (Q845655)

A. Lupus pernio

B. Lofgren's syndrome

C. Mikulicz syndrome

D. Systemic Lupus Erythematosus

See Answer in Part B → Q2

@Neet_pg_bot

Q3: In a histopathological examination of a lung biopsy from a patient with suspected sarcoidosis, which of the following microscopic features would be most characteristic and supportive of the diagnosis? (Q845656)

A. Macrophages with abundant cytoplasm containing dusty brown pigment

B. Non-necrotizing granulomas with asteroid bodies and Schaumann bodies

C. Coalescent tubercles with central caseation

D. Curschmann spirals and Charcot-Leyden crystals

See Answer in Part B → Q3

@Neet_pg_bot

Q4: A 55-year-old male presents with a chronic cough, dyspnea, and chest tightness. On examination, fine crackles are heard bilaterally. A lung biopsy reveals collections of carbon-laden macrophages within the respiratory bronchioles and alveolar ducts, along with focal fibrosis and occasional small granulomas. Which of the following is not a condition associated with this patient? (Q845657)

A. Anthracosis

B. Simple Coal Worker’s Pneumoconiosis

C. Complicated coal Worker’s pneumoconiosis

D. Psittacosis

See Answer in Part B → Q4

@Neet_pg_bot

Q5: A 50-year-old sandblaster presents with chronic cough, dyspnea, and chest pain. Further investigation reveals a history of prolonged exposure to sandblasting. He has also worked for several years in mines, where he was exposed to chronic asbestos and

beryllium. A chest X-ray was taken, which is shown below. What is the most likely diagnosis? (Q845658)

A. Byssinosis

B. Silicosis

C. Asbestosis

D. Berylliosis



See Answer in Part B → Q5

@Neet_pg_bot

Q6: Which of the following is not a cause of eggshell calcification? (Q845659)

A. Silicosis

B. Sarcoidosis

C. Post-radiation therapy

D. Metastatic lymph nodes

See Answer in Part B → Q6

@Neet_pg_bot

Q7: Which of the following forms of asbestos is more toxic? (Q845660)

A. Serpentine

B. Amphibole

C. Chrysolite

D. Erionite

See Answer in Part B → Q7

@Neet_pg_bot

Q8: A patient has been experiencing dyspnea for the past few weeks. A biopsy of his lungs has revealed the finding given below. What is the characteristic finding shown below in this patient? (Q845661)

A. Creola body

B. Schaumann body

C. Ferruginous body

D. Asteroid body

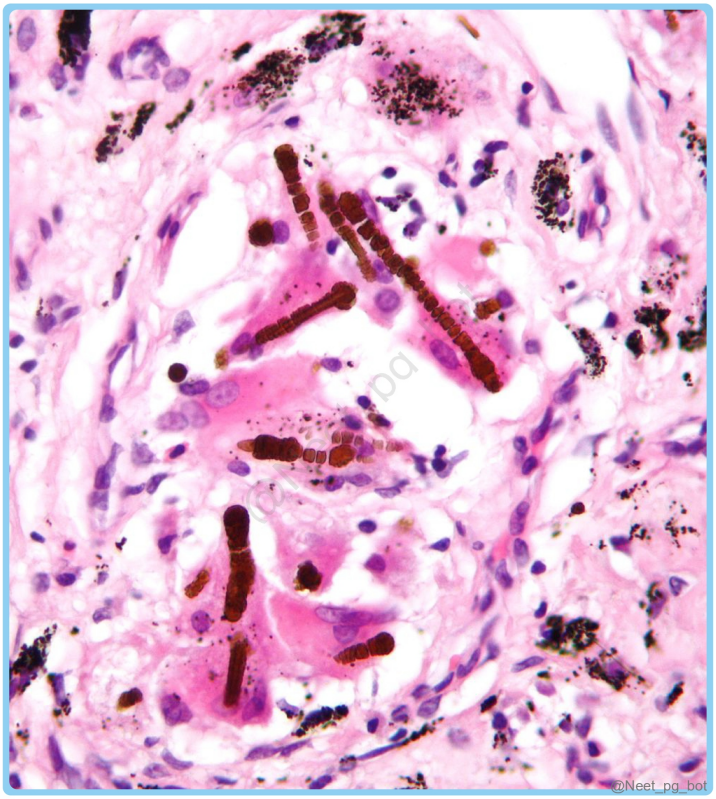

See Answer in Part B → Q8

@Neet_pg_bot

Q9: A 55-year-old male presents to the clinic with complaints of persistent chest pain, shortness of breath, and unexplained weight loss. He was chronically exposed to minerals when he worked as a shipbuilder. Imaging studies revealed a growth that was subjected to needle biopsy. What is the most common lung malignancy associated with his occupational exposure? (Q845662)

A. Squamous cell carcinoma

B. Adenocarcinoma

C. Mesothelioma

D. Small cell cancer

See Answer in Part B → Q9

@Neet_pg_bot

Q10: Match the following occupational lung diseases with their characteristics. A) Byssinosis 1. Iron exposure B) Bagassosis 2. Monday disease C) Siderosis 3. Non-caseating granuloma. D) Berylliosis 4. Sugarcane dust exposure (Q845663)

A. A-4, B-2, C-1, D-3

B. A-2, B-4, C-1, D-3

C. A-3, B-1, C-4, D-2

D. A-2, B-1, C-4, D-3

See Answer in Part B → Q10

@Neet_pg_bot

Q11: Which of the following is incorrect about mesothelioma? (Q846631)

A. Most specific cancer associated with asbestos exposure

B. Can lead to frozen hemithorax

C. Leads to a mediastinal shift

D. Not associated with smoking

See Answer in Part B → Q11

@Neet_pg_bot

• [07_Respiratory System] 036 Previous Year Questions

« Back to Folder Directory

[07_Respiratory System] 036 Previous Year Questions — Quick Jump

Q1 (p. 389)	*Q2 (p. 389)*	*Q3 (p. 390)*	*Q4 (p. 390)*	*Q5 (p. 391)*	*Q6 (p. 391)*
Q7 (p. 392)	*Q8 (p. 392)*	*Q9 (p. 393)*	*Q10 (p. 394)*	*Q11 (p. 395)*	*Q12 (p. 395)*
Q13 (p. 395)	*Q14 (p. 396)*	*Q15 (p. 396)*	*Q16 (p. 397)*	*Q17 (p. 397)*	*Q18 (p. 398)*
Q19 (p. 399)	*Q20 (p. 400)*	*Q21 (p. 401)*	*Q22 (p. 401)*	*Q23 (p. 402)*	*Q24 (p. 402)*
Q25 (p. 403)					

Q1: A chronic smoker who worked in a cement factory for 20 years developed mesothelioma. It is due to? (Q855446)

A. Silicosis

B. Asbestosis

C. Coal worker pneumoconiosis

D. Bagassosis

See Answer in Part B → Q1

@Neet_pg_bot

Q2: Which of the following is a post-mortem finding seen in the lung after the death of a patient from COVID-19 after a week? (Q855970)

A. Fresh and old intra-alveolar hemorrhage

B. Thick layer of fibrin

C. Perivascular cuffing

D. Pulmonary artery hypertrophy with increased resistance

See Answer in Part B → Q2

@Neet_pg_bot

Q3: A 30-year-old woman with a long history of dyspnea, chronic cough with sputum, and wheezing died of respiratory failure following a bout of lobar pneumonia. She was not a smoker or an alcoholic. The lung at autopsy is shown in the image below. Which of the following is most likely to cause the pathological changes shown? (Q854883)

A. Alpha-1 antitrypsin deficiency

B. Cystic fibrosis

C. Mutation in dynein arms

D. Antibodies against type-IV collagen



See Answer in Part B → Q3

@Neet_pg_bot

Q4: A 55-year-old male presents with a chronic cough, shortness of breath, and chest pain. He has a history of working in construction for several decades, where he was exposed to asbestos. Physical examination reveals decreased breath sounds over the

lower lung fields. A chest X-ray shows bilateral, diffuse interstitial opacities. Pulmonary function tests reveal a restrictive pattern. High-resolution computed tomography (HRCT) of the chest demonstrates "honeycombing" in the lung parenchyma. What is the diagnosis? (Q856495)

A. Tuberculosis

B. Chronic Obstructive Pulmonary Disease (COPD)

C. Asbestosis

D. Pneumonia

See Answer in Part B → Q4

@Neet_pg_bot

Q5: The most common lung finding in a COVID-19 infection is: (Q856477)

A. Pulmonary infarction

B. Diffuse alveolar damage

C. Endothelial injury

D. Fibrin clots

See Answer in Part B → Q5

@Neet_pg_bot

Q6: A 42-year-old female patient presents with a cough, a low-grade fever, and hemoptysis. Investigations reveal a cavitary lesion on her right lung apex, which, on biopsy, reveals caseous necrosis. The underlying pathophysiology is: (Q856728)

A. Enzyme degradation

B. Type-4 hypersensitivity reaction

C. Fibrinoid deposition

D. Sudden cut off of blood supply

See Answer in Part B → Q6

@Neet_pg_bot

Q7: A person working in an industry for a long time develops progressive breathlessness. The histopathological image of his lung biopsy is given below. What industry was the person most likely working in? (Q856697)

A. Silica

B. Asbestos

C. Coal dust

D. Cotton

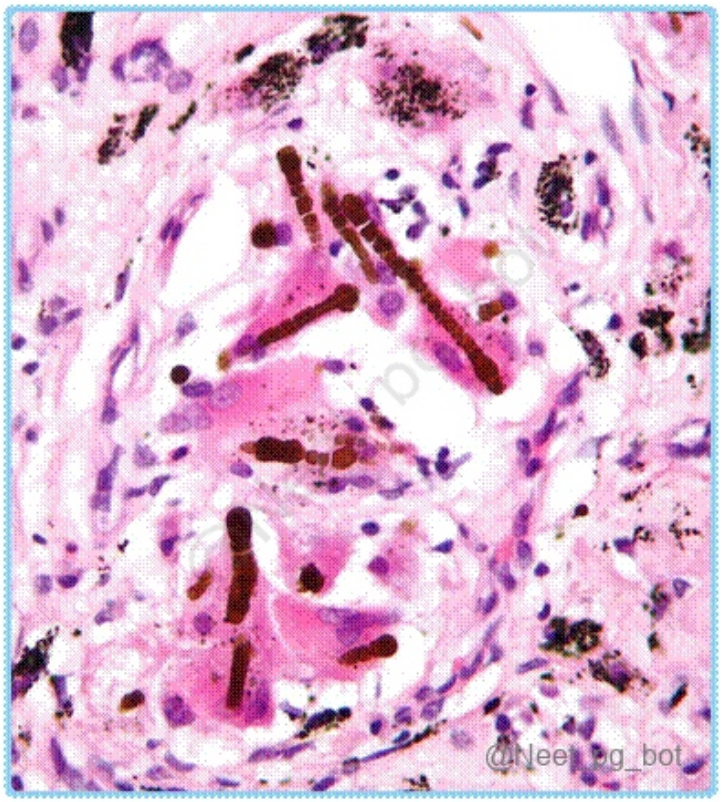

See Answer in Part B → Q7

@Neet_pg_bot

Q8: Below is an electron microscopic image of lung tissue. A patient infected with SARS-CoV2 presents with ARDS. The infection would affect and expand in which of the following labelled layers? (Q855415)

A. B

B. A

C. D

D. None of the above

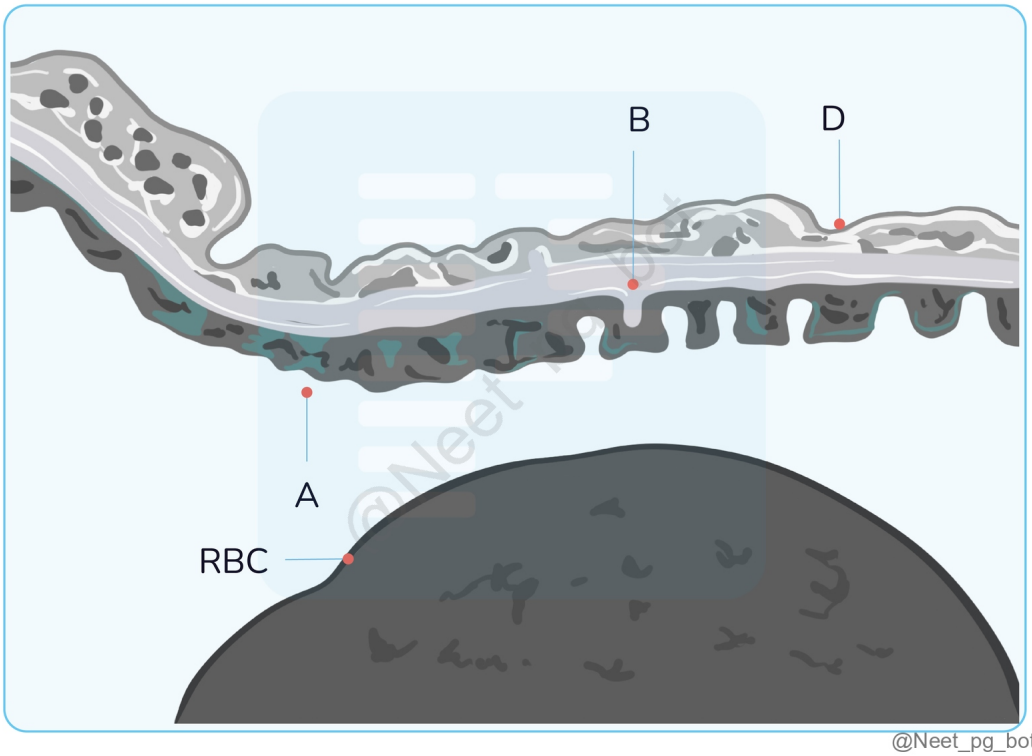

See Answer in Part B → Q8

@Neet_pg_bot

Q9: A 45-year-old patient who has been working in a factory for the past 20 years presents with breathlessness. HRCT of the chest shows pleural thickening and fibrosis. What is the person suffering from? (Q857611)

A. Asbestosis

B. Coal worker pneumoconiosis

C. Silicosis

D. Berylliosis

See Answer in Part B → Q9

@Neet_pg_bot

Q10: A 12-year-old child presents with a persistent cough for 15 days. Upon examination, cervical lymphadenopathy is observed. A lymph node biopsy image is given below. What is the most likely diagnosis? (Q857586)

A. Tuberculosis

B. Leprosy

C. Sarcoidosis

D. Syphilis

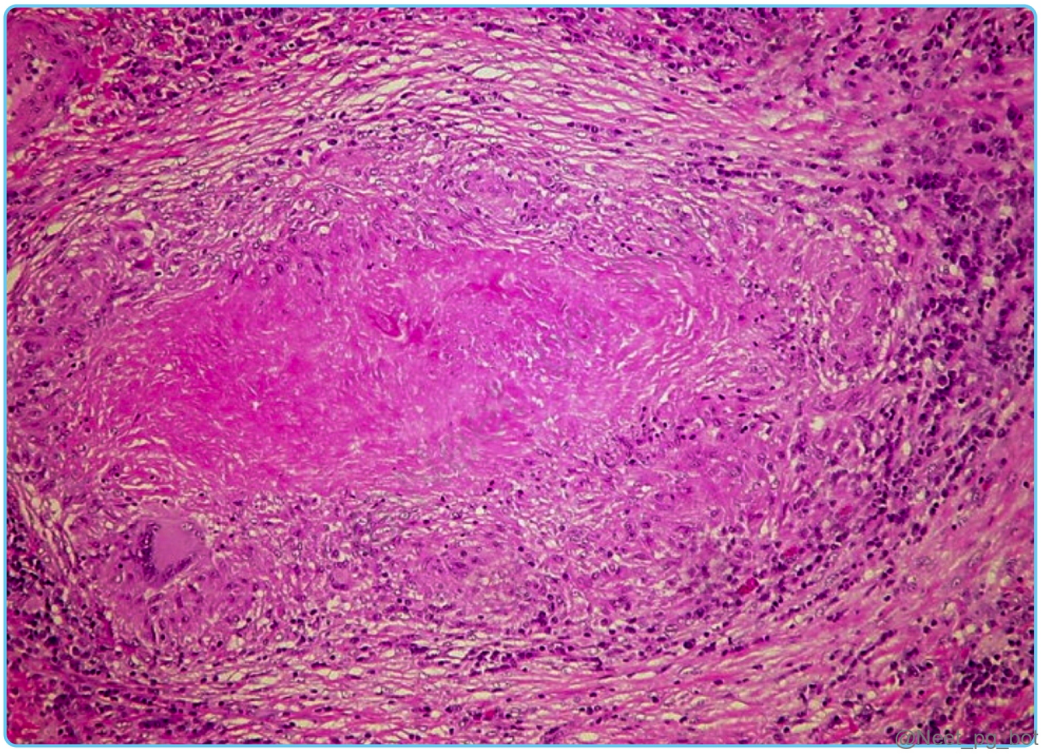

See Answer in Part B → Q10

@Neet_pg_bot

Q11: A middle-aged man working in the sandblasting industry developed hemoptysis and a productive cough. A chest x-ray is suggestive of tuberculosis. Which of the following is associated with the same? (Q857109)

A. Asbestosis

B. Silicosis

C. Anthracosis

D. Siderosis

See Answer in Part B → Q11

@Neet_pg_bot

Q12: What is the diagnosis for a patient with a history of smoking 24 packs, currently experiencing breathlessness and chest pain, and found to have a lung tumour with positive chromogranin staining? (Q855092)

A. Adenocarcinoma

B. Squamous cell carcinoma

C. Mesothelioma

D. Small cell carcinoma

See Answer in Part B → Q12

@Neet_pg_bot

Q13: A chronic smoker who worked in a cement factory for the past 20 years developed mesothelioma. This association is most likely due to? (Q866738)

A. Bagassosis

B. Silicosis

C. Asbestosis

D. Adenocarcinoma

See Answer in Part B → Q13

@Neet_pg_bot

Q14: An elderly male smoker presents with a chronic cough, significant weight loss, and fatigue. The serum calcium level is raised. A lung biopsy reveals large atypical cells with hyperchromasia. What is the probable diagnosis? (Q855423)

A. Large cell neuroendocrine tumour

B. Small cell carcinoma

C. Adenocarcinoma

D. Squamous cell carcinoma

See Answer in Part B → Q14

@Neet_pg_bot

Q15: A 30-year-old patient arrives at the emergency room with complaints of respiratory discomfort. The patient has been experiencing shortness of breath, coughing, and chest pain for the past few weeks. The patient's medical history is unremarkable, and there is no significant smoking history. Upon further investigation, a lung biopsy is performed, and microscopic examination reveals the presence of asteroid bodies. What is the most likely diagnosis for this patient? (Q820569)

A. Sarcoidosis

B. RA

C. Sjogren syndrome

D. SLE

See Answer in Part B → Q15

@Neet_pg_bot

Q16: Match the following: A. Caplan’s syndrome 1. Found first in coal worker B. Asbestosis 2. Crazy pavement C. Mesothelioma 3. Involves lower lobe D. Silicosis 4. Pleural effusion (Q857428)

A. A-1, B-3, C-4, D-2

B. A-2, B-4, C-1, D-3

C. A-3, B-2, C-1, D-4

D. A-4, B-1, C-2, D-3

See Answer in Part B → Q16

@Neet_pg_bot

Q17: What is the most probable diagnosis based on the provided histopathology of the enlarged cervical lymph node? (Q840059)

A. Sarcoidosis

B. Tuberculosis

C. Histoplasmosis

D. Brucellosis

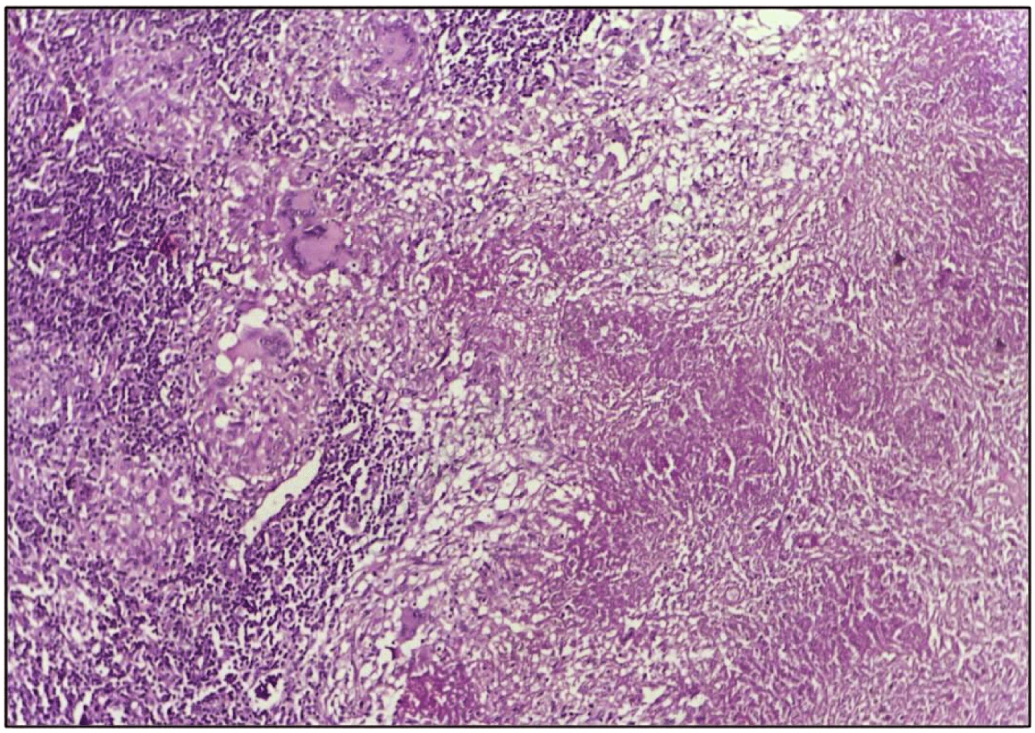

See Answer in Part B → Q17

@Neet_pg_bot

Q18: Based on the biopsy image given below, what is the most probable diagnosis? (Q840057)

A. Adenocarcinoma

B. Squamous cell carcinoma

C. Small cell carcinoma

D. Large cell carcinoma

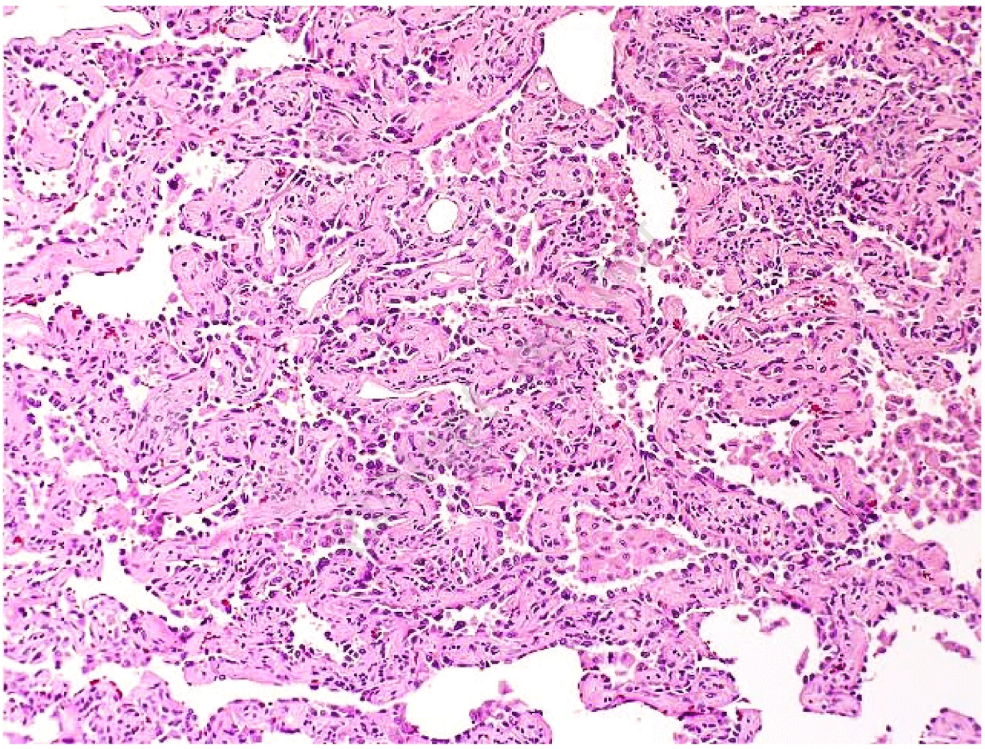

@Neet_pg_bot

See Answer in Part B → Q18

@Neet_pg_bot

Q19: A 65-year-old patient on immunosuppressive therapy presents with a cough, fever, and pneumonia. A biopsy reveals the given findings. Which organism is responsible for the infection? (Q860561)

A. EBV

B. CMV

C. Pox virus

D. Chickenpox

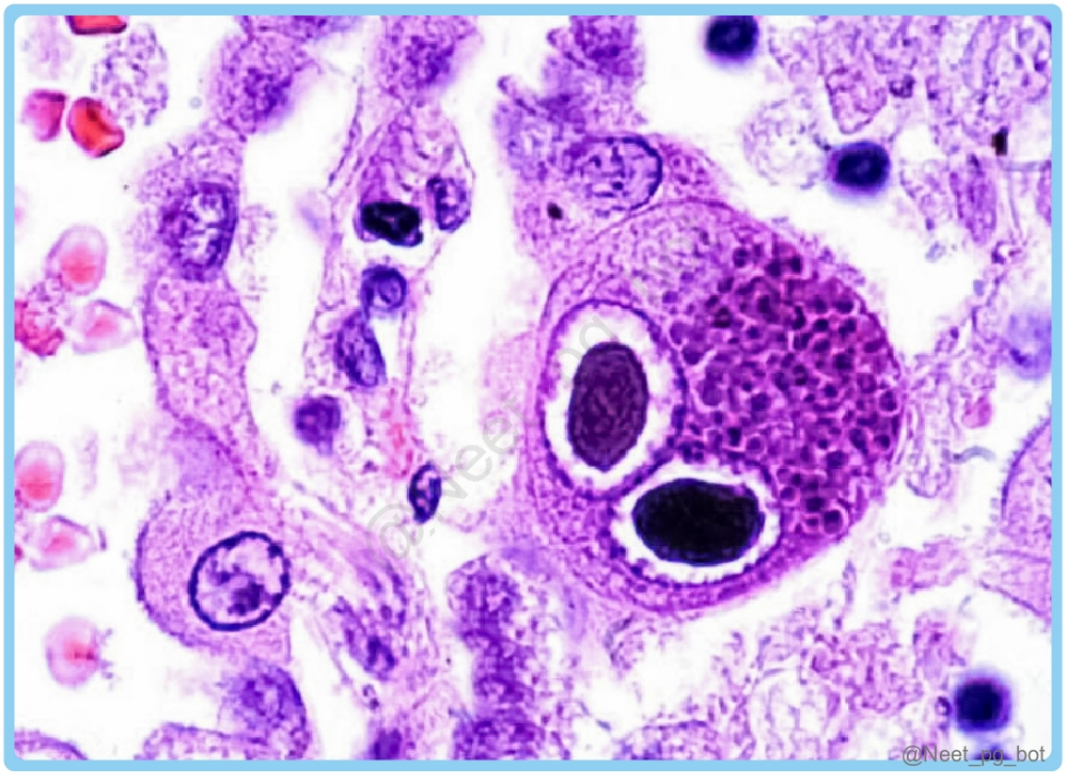

See Answer in Part B → Q19

@Neet_pg_bot

Q20: A patient presented with interstitial lung disease with an occupational history of working in a factory for 20 years and underwent a biopsy. Based on the findings, what is the most likely diagnosis? (Q844241)

A. Stanosis

B. Silicosis

C. Byssinosis

D. Asbestosis

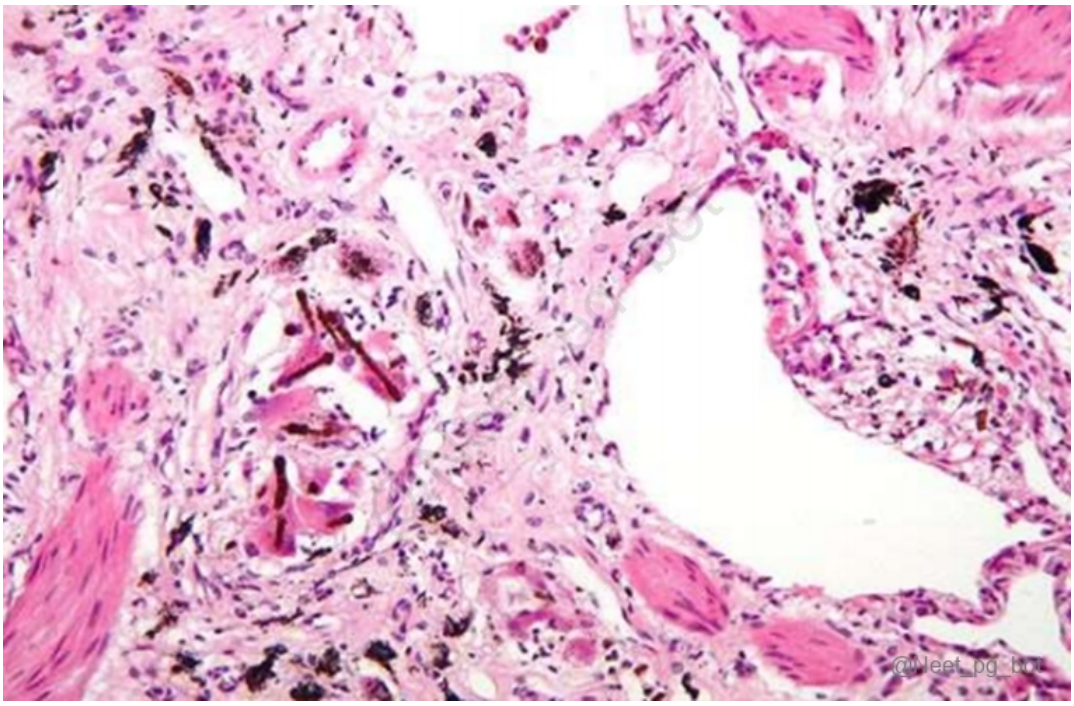

See Answer in Part B → Q20

@Neet_pg_bot

Q21: A patient presents with respiratory distress and is diagnosed with pan-acinar emphysema. Which deficiency is responsible for his condition? (Q844156)

A. Type 1 surfactant

B. Type 2 surfactant

C. Alpha-1 antitrypsin deficiency

D. Albumin

See Answer in Part B → Q21

@Neet_pg_bot

Q22: A male patient is diagnosed with ARDS and is not responding to oxygen therapy. What is the role of IL-8 in ARDS? (Q844145)

A. Endothelial cell activation

B. Neutrophil recruitment

C. Macrophage activation

D. Promotion of surfactant production

See Answer in Part B → Q22

@Neet_pg_bot

Q23: TTF-1 immunohistochemical marker is associated with which of the following cancers? (Q844039)

A. Squamous cell carcinoma

B. Lung adenocarcinoma

C. Small cell carcinoma

D. Large cell carcinoma

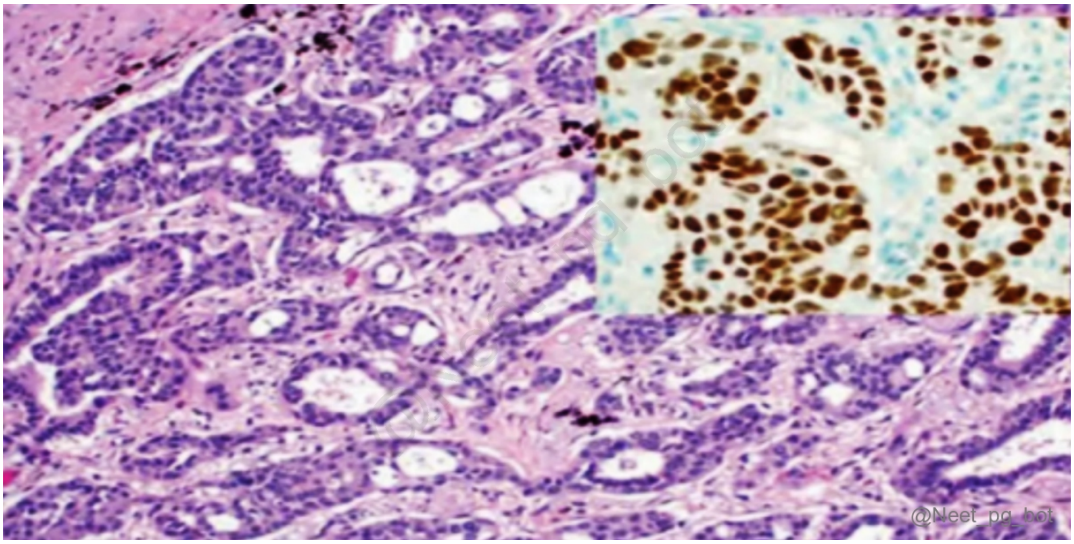

See Answer in Part B → Q23

@Neet_pg_bot

Q24: A 40-year-old female patient presents with skin lesions, respiratory symptoms, and enlarged lymph nodes. Skin lesions appear as raised, erythematous nodules, and a

chest X-ray shows bilateral hilar lymphadenopathy. A biopsy of the affected tissues is performed. Microscopic examination reveals the presence of granulomas without central necrosis. What is the most likely histological finding in this scenario? (Q820587)

A. Caseating granuloma

B. Stellate granuloma

C. Non-caseating granuloma

D. Eosinophilic granuloma

See Answer in Part B → Q24

@Neet_pg_bot

Q25: Which malignancy is most commonly associated with asbestosis? (Q857561)

A. Mesothelioma

B. Anthracosis

C. Hepatocellular carcinoma

D. Renal cell carcinoma

See Answer in Part B → Q25

@Neet_pg_bot

• [08_Salivary Glands] 037 Salivary Gland Pathology

« Back to Folder Directory

[08_Salivary Glands] 037 Salivary Gland Pathology — Quick Jump

Q1 (p. 404) *Q2 (p. 405)* *Q3 (p. 405)* *Q4 (p. 406)* *Q5 (p. 406)* *Q6 (p. 407)*
Q7 (p. 408) *Q8 (p. 408)*

Q1: A 28-year-old female presents with a painless, bluish, fluctuant and translucent swelling on the lower lip that enlarges with eating or pressure, as shown in the image below. She reports a history of accidentally biting her lip frequently. What histopathological feature would be expected on biopsy of the lesion? (Q845534)

A. Mucin-filled cavity surroundedby granulation tissue and chronic inflammatory cells.

B. Proliferation of ductal cells within fibrous connective tissue

C. Epithelial dysplasia and atypical cells.

D. Eosinophilic granuloma with multinucleated giant cells



See Answer in Part B → Q1

@Neet_pg_bot

Q2: A 40-year-old female presents with a slowly growing painless mass in her left parotid gland region that has been present for several months. On examination, a firm, mobile, non-tender mass is palpable in the preauricular area. Fine needle aspiration cytology (FNAC) reveals epithelial and myoepithelial cells in a chondromyxoid background. What is the most likely diagnosis? (Q845535)

A. Pleomorphic adenoma

B. Warthin tumor

C. Mucoepidermoid carcinoma

D. Adenoid cystic carcinoma

See Answer in Part B → Q2

@Neet_pg_bot

Q3: A 45-year-old female presents with a painless, slowly growing mass in her left parotid gland. Examination reveals a firm, mobile mass. Biopsy confirms pleomorphic adenoma with characteristic islands of cartilage and foci of bone in a myxoid stroma. Which of the following is incorrect regarding this condition? (Q845536)

A. Mostly found in the parotid gland

B. Mixed tumours with ductal, myoepithelial and mesenchymal cells

C. Radiation exposure is a risk factor

D. Down-regulation of PLAG1 results in abnormal cell proliferation

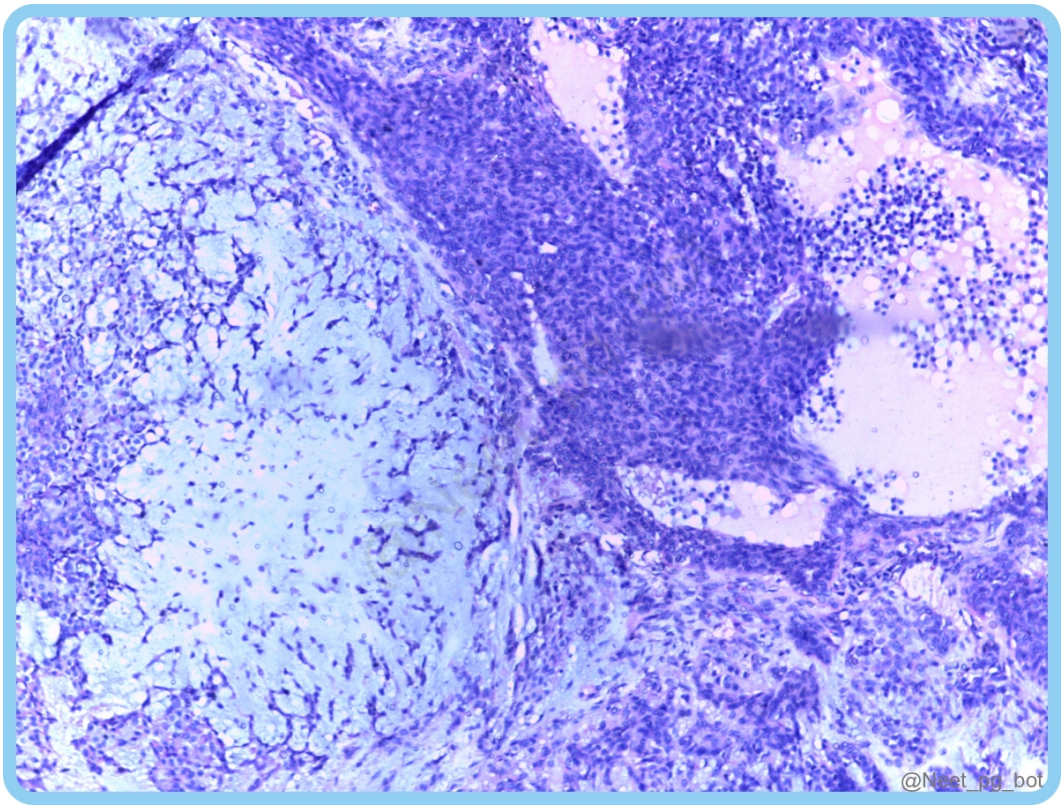

See Answer in Part B → Q3

@Neet_pg_bot

Q4: A 55-year-old male has a painless, slowly enlarging mass in the left parotid gland over several years. Examination reveals a firm, mobile, non-tender mass. Histological findings confirm pleomorphic adenoma. Which factor is associated with an increased risk of malignant transformation in pleomorphic adenomas? (Q845537)

A. Younger age of the patient

B. Larger size of the tumour

C. Increased age of the lesion

D. Presence of hyalinized stroma within the tumour

See Answer in Part B → Q4

@Neet_pg_bot

Q5: A 50-year-old male smoker presents with a painless swelling in the parotid region. Fine needle aspiration cytology (FNAC) reveals murky fluid. Which of the following histopathological features is true regarding this condition? (Q845538)

A. Proliferation of squamous epithelial cells with keratinisation

B. Oncocytic cells with double-layered lining

C. Neuroendocrine differentiation

D. Papillary architecture with psammoma bodies

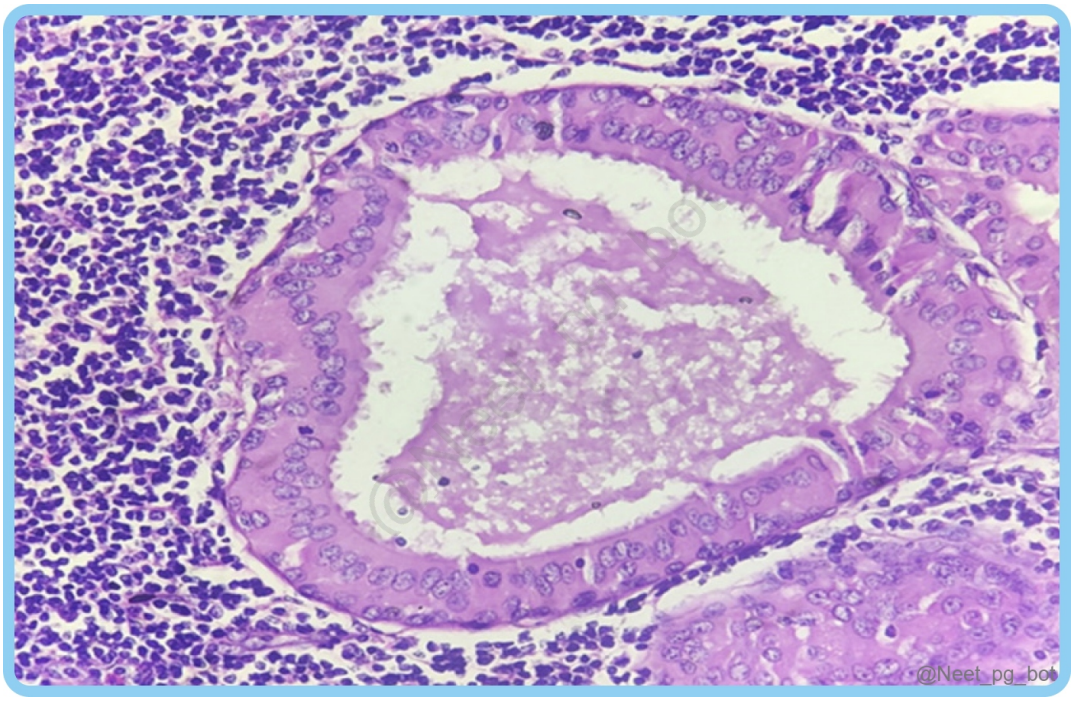

See Answer in Part B → Q5

@Neet_pg_bot

Q6: Which of the following statements about Warthin's tumour is true? (Q845539)

A. It is the most common malignant tumour of the salivary glands.

B. They are typically located in the parotid gland.

C. It is more common in females.

D. Associated with human papillomavirus (HPV) infection.

See Answer in Part B → Q6

@Neet_pg_bot

Q7: A 45-year-old female presents with a slow-growing painless mass in the left submandibular gland region. Imaging studies reveal a solid lesion with cystic components. Fine needle aspiration cytology (FNAC) shows a mixture of mucin-producing, epidermoid, and intermediate cells. A histopathology image is given below. Which of the following features is true regarding this condition? (Q845540)

A. Most commonly found in the sublingual salivary glands.

B. Most are associated with a (11;19) translocation.

C. Encapsulated tumours.

D. Histologically characterized by the presence of spindle cells

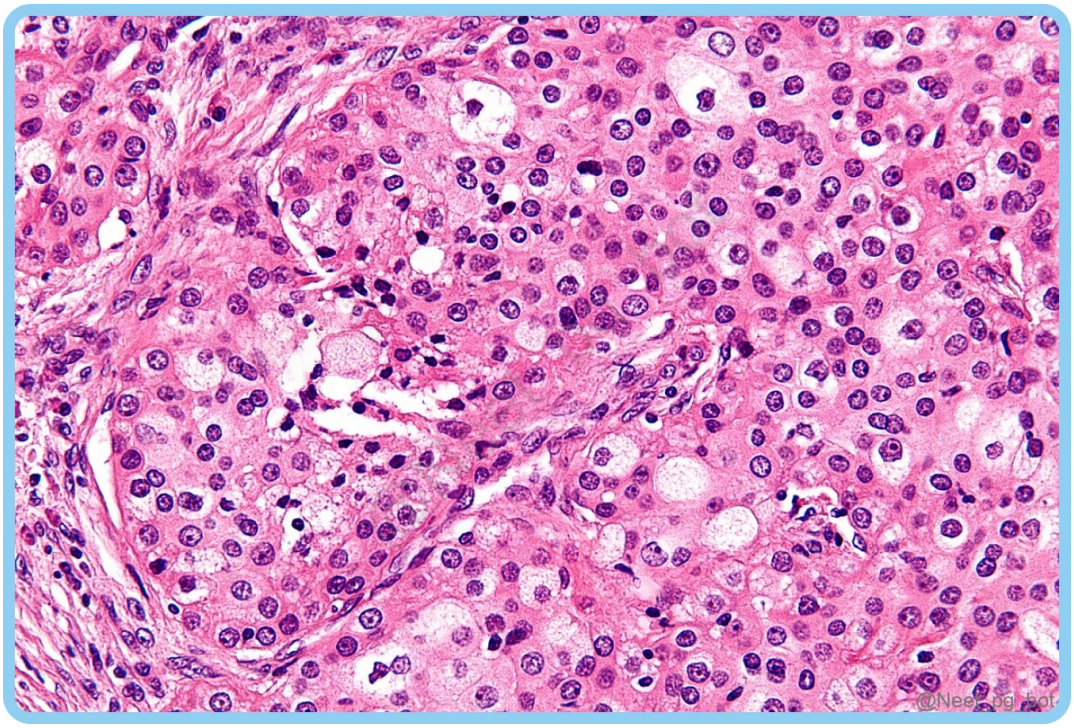

See Answer in Part B → Q7

@Neet_pg_bot

Q8: A 55-year-old male presents with a slowly enlarging painless mass in the right parotid gland region. Imaging studies reveal a solid tumour with a characteristic "Swiss cheese" appearance on MRI. Fine needle aspiration cytology (FNAC) shows basaloid cells with cribriform and tubular patterns. Which of the following statements is true regarding this condition? (Q845541)

A. Most commonly occur in the parotid and submandibular glands.

B. MYB-NFIB gene rearrangements are present in all cases

C. Encapsulated lesions with a smooth surface.

D. Tend to grow rapidly and have a high mitotic rate.

See Answer in Part B → Q8

@Neet_pg_bot

• [08_Salivary Glands] 038 Previous Year Questions

« Back to Folder Directory

[08_Salivary Glands] 038 Previous Year Questions — Quick Jump

Q1 (p. 410) *Q2 (p. 410)* *Q3 (p. 410)*

Q1: A middle-aged woman presents with dry eyes and dry mouth. Laboratory tests reveal positive anti-Ro (SSA) and anti-La (SSB) antibodies. What is the most likely underlying pathological mechanism? (Q866381)

A. Destruction of exocrine glands by neutrophils

B. IgE-mediated hypersensitivity reaction

C. Lymphocytic infiltration and destruction of salivary and lacrimal glands

D. Deposition of amyloid in salivary glands

See Answer in Part B → Q1

@Neet_pg_bot

Q2: Warthin's tumor is also called? (Q820513)

A. Adenolymphoma

B. Pleomorphic adenoma

C. Mucoepidermoid carcinoma

D. Acinic cell carcinoma

See Answer in Part B → Q2

@Neet_pg_bot

Q3: Which of the following features is not observed in pleomorphic adenoma? (Q855079)

A. Myoepithelial cells

B. Keratin pearls

C. Chondroid differentiation

D. Perineural invasion

See Answer in Part B → Q3

@Neet_pg_bot

• [09_Gastrointestinal Tract] 039 Basics Of Git And Esophagus

« Back to Folder Directory

[09_Gastrointestinal Tract] 039 Basics Of Git And Esophagus — Quick Jump

Q1 (p. 412) *Q2 (p. 412)* *Q3 (p. 413)* *Q4 (p. 413)* *Q5 (p. 414)* *Q6 (p. 415)*
Q7 (p. 416) *Q8 (p. 417)* *Q9 (p. 417)* *Q10 (p. 417)* *Q11 (p. 418)* *Q12 (p. 419)*
Q13 (p. 419) *Q14 (p. 420)*

Q1: Which of the following statements regarding the layers of the digestive tract is incorrect? (Q845634)

A. The mucosa is the first layer of the digestive tract.

B. The submucosa is absent in the gallbladder.

C. The muscularis propria is present throughout the GIT.

D. The esophagus lacks the submucosal layer.

See Answer in Part B → Q1

@Neet_pg_bot

Q2: A 58-year-old male presents with chronic heartburn and regurgitation. Upper endoscopy reveals the presence of Barrett's esophagus. What is the primary cellular change seen in this condition? (Q845637)

A. Metaplasia of squamous epithelium

B. Dysplasia of squamous epithelium

C. Hyperplasia of columnar epithelium

D. Hypertrophy of columnar epithelium

See Answer in Part B → Q2

@Neet_pg_bot

Q3: A 50-year-old male presents with chronic heartburn for two years. An endoscopy is performed, and the biopsy of the esophageal specimen stained with special stain is shown below. Which of the following conditions is the patient at an increased risk of? (Q845640)

A. Squamous cell carcinoma

B. Adenocarcinoma

C. Plummer Vinson syndrome

D. MALToma

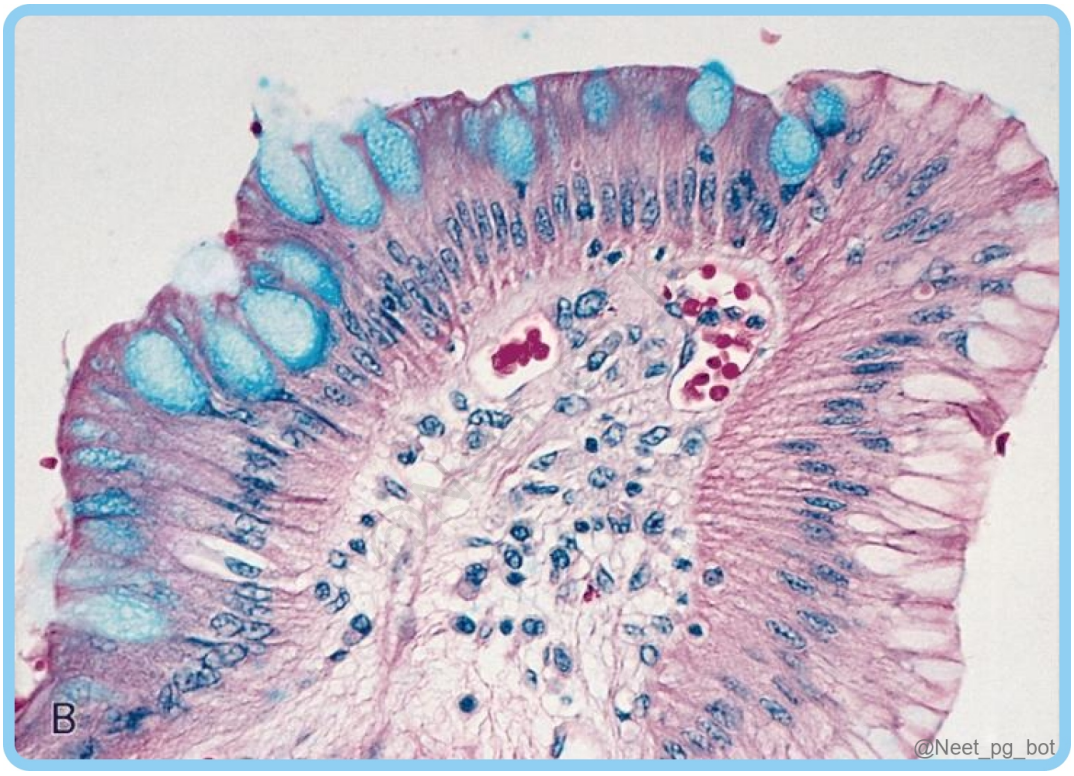

See Answer in Part B → Q3

@Neet_pg_bot

Q4: A woman presented with dysphagia to solids for a month. On examination, there are multiple lesions on the lips. An endoscopy reveals obstructive lesions in the upper oesophagus. Which of the following additional findings can be seen in this patient? (Q845641)

A. Development of GI polyps

B. Degeneration of nitric oxide–producing neurons

C. Iron deficiency anemia

D. Apple core appearance on imaging

See Answer in Part B → Q4

@Neet_pg_bot

Q5: A 45-year-old male presents with complaints of severe odynophagia, retrosternal chest pain, and difficulty in swallowing solids and liquids for the past week. He has a history of untreated HIV infection with a CD4 count of 80 cells/mm^3. An upper gastrointestinal endoscopy image is shown below. What is the most likely diagnosis? (Q845642)

A. CMV esophagitis

B. HSV esophagitis

C. Eosinophilic esophagitis

D. Candida esophagitis

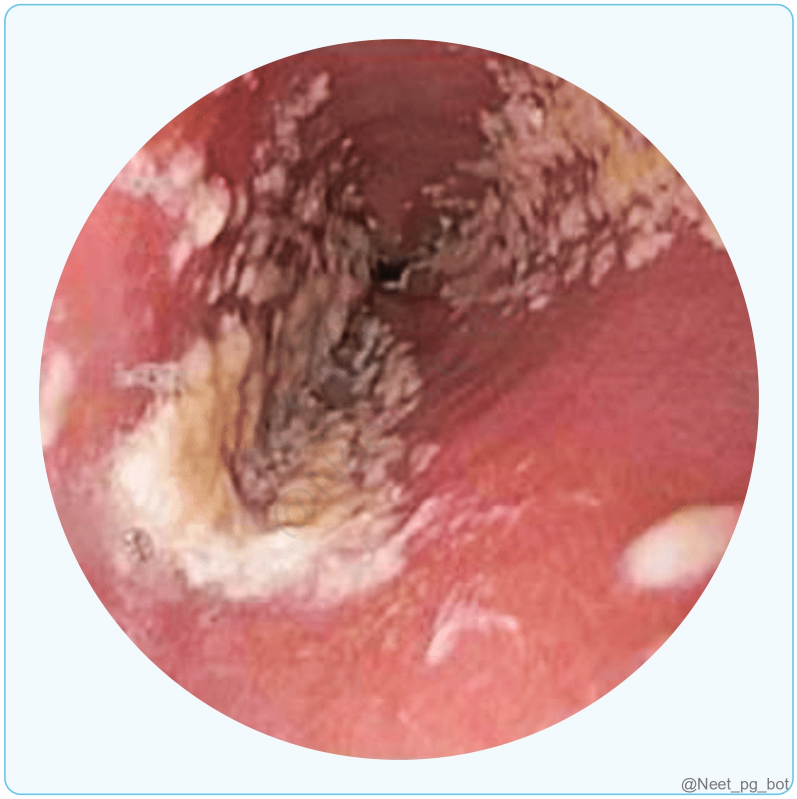

See Answer in Part B → Q5

@Neet_pg_bot

Q6: Which of the following is true regarding the condition shown in the endoscopic image below? (Q845643)

A. Its cause is primarily infectious.

B. Characteristic rat tail appearance.

C. Interleukin 5 has a major role in pathogenesis.

D. Diagnosed by observing at least ten lymphocytes/HPF.

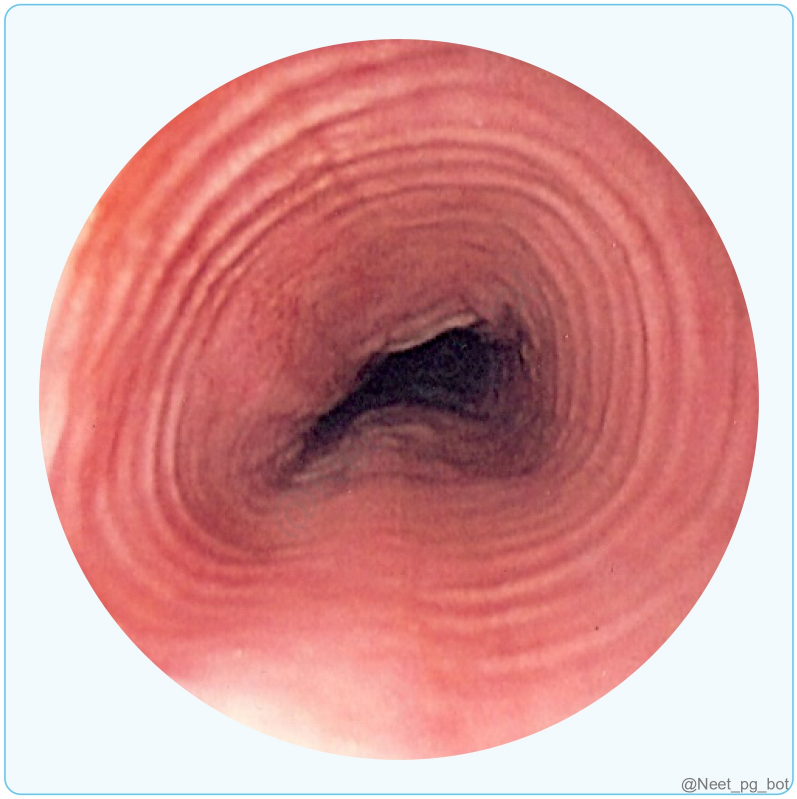

See Answer in Part B → Q6

@Neet_pg_bot

Q7: Identify the correct statement/s regarding carcinoma of the oesophagus SCC is more common in the lower two-thirds of the oesophagus Smoking increases the risk of both SCC and adenocarcinoma H. pylori is associated with a decreased risk of oesophageal adenocarcinoma Adenocarcinoma is the overall most common type SCC is linked to fermented milk- mursik, which contains acetaldehyde (Q845644)

A. 1, 3, 5

B. 2, 3, 5

C. 1, 2, 4

D. 2, 4, 5

See Answer in Part B → Q7

@Neet_pg_bot

Q8: Which of the following is the most common site of fistulization in congenital GI anomalies? (Q890287)

A. Ileum

B. Colon

C. Esophagus

D. Stomach

See Answer in Part B → Q8

@Neet_pg_bot

Q9: Heterotopic (ectopic) gastric mucosa most commonly occurs in which of the following locations? (Q890289)

A. Cervical oesophagus

B. Rectum

C. Ileum (outside Meckel diverticulum)

D. Colon

See Answer in Part B → Q9

@Neet_pg_bot

Q10: A 48-year-old man has intermittent dysphagia to solids with occasional food impaction. Endoscopy shows a thin ring, as shown in the image, at the gastroesophageal junction. What is the diagnosis? (Q890292)

A. Esophageal web

B. Achalasia

C. Schatzki ring

D. Type A ring

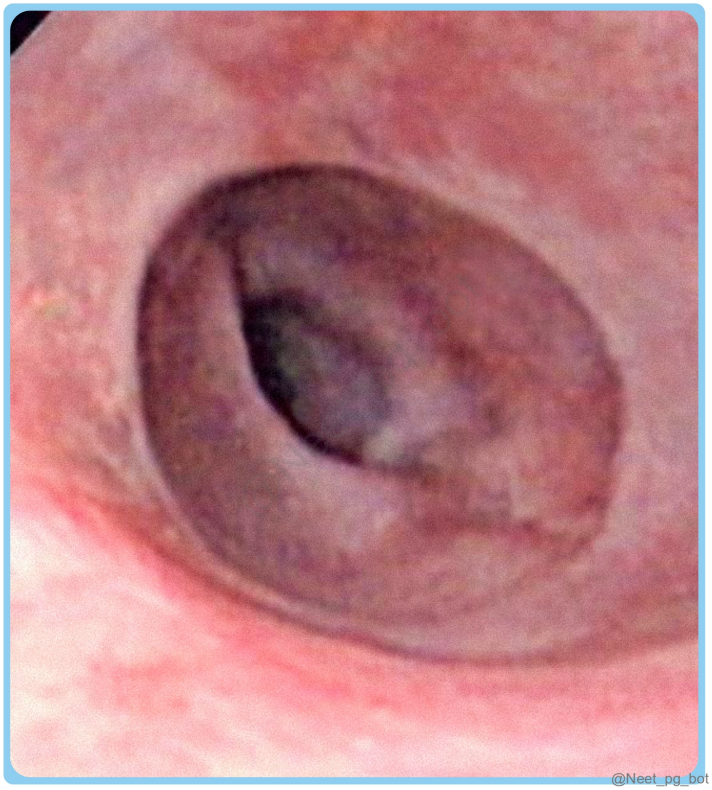

See Answer in Part B → Q10

@Neet_pg_bot

Q11: A 40-year-old man from rural South America presents with progressive dysphagia to solids and liquids and chronic constipation. Imaging shows findings as shown. What is the mechanism of his oesophageal disease? (Q890295)

A. Degeneration of nitric oxide-producing neurons

B. Autoimmune destruction of inhibitory neurons

C. Destruction of the myenteric plexus

D. Smooth muscle fibrosis

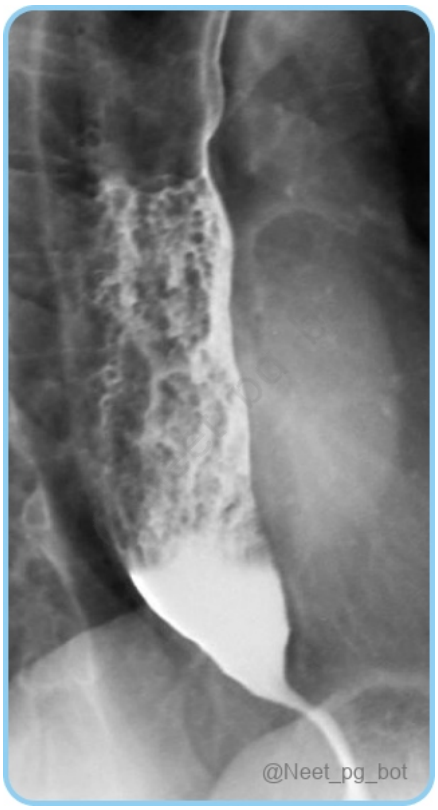

See Answer in Part B → Q11

@Neet_pg_bot

Q12: Which of the following statements regarding primary achalasia is incorrect? (Q890298)

A. Degeneration of nitric oxide-producing inhibitory neurons

B. May involve degeneration of the dorsal motor nucleus of the vagus

C. Not associated with autoimmune conditions

D. Loss of LES relaxation

See Answer in Part B → Q12

@Neet_pg_bot

Q13: Which of the following statements regarding eosinophilic esophagitis is incorrect? (Q890302)

A. Commonly associated with atopic disorders

B. Characterised by superficial intraepithelial eosinophils

C. Strongly associated with Barrett's oesophagus

D. Endoscopic dilation relieves dysphagia but not inflammation

See Answer in Part B → Q13

@Neet_pg_bot

Q14: Which of the following statements regarding Mallory-Weiss tear is incorrect? (Q890305)

A. Usually longitudinal and located near the GEJ

B. Commonly result from severe retching or vomiting

C. Transmural perforation of the oesophageal wall

D. Most cases resolve without surgical intervention

See Answer in Part B → Q14

@Neet_pg_bot

• [09_Gastrointestinal Tract] 040 Peptic Ulcer Disease Gastric Polyps And Tumors - I

« Back to Folder Directory

[09_Gastrointestinal Tract] 040 Peptic Ulcer Disease Gastric Polyps And Tumors - I — Quick Jump

Q1 (p. 421)	*Q2 (p. 422)*	*Q3 (p. 423)*	*Q4 (p. 423)*	*Q5 (p. 423)*	*Q6 (p. 424)*
Q7 (p. 424)	*Q8 (p. 425)*	*Q9 (p. 426)*	*Q10 (p. 426)*	*Q11 (p. 427)*	*Q12 (p. 427)*
Q13 (p. 428)	*Q14 (p. 429)*	*Q15 (p. 429)*	*Q16 (p. 430)*	*Q17 (p. 430)*	*Q18 (p. 431)*
Q19 (p. 431)	*Q20 (p. 431)*	*Q21 (p. 432)*			

Q1: A 45-year-old patient presents with persistent abdominal discomfort, nausea, weight loss, and occasional diarrhoea. He was recently diagnosed with a viral infection. The following gross image of the gastric mucosa is observed upon upper gastrointestinal endoscopy. Which of the following is correct regarding the patient's condition? (Q845222)

A. Associated with excessive secretion of TNF-α.

B. Histopathologically, villous atrophy is observed.

C. Increases the risk of gastric carcinoma.

D. More common in females and can cause protein-losing enteropathy.

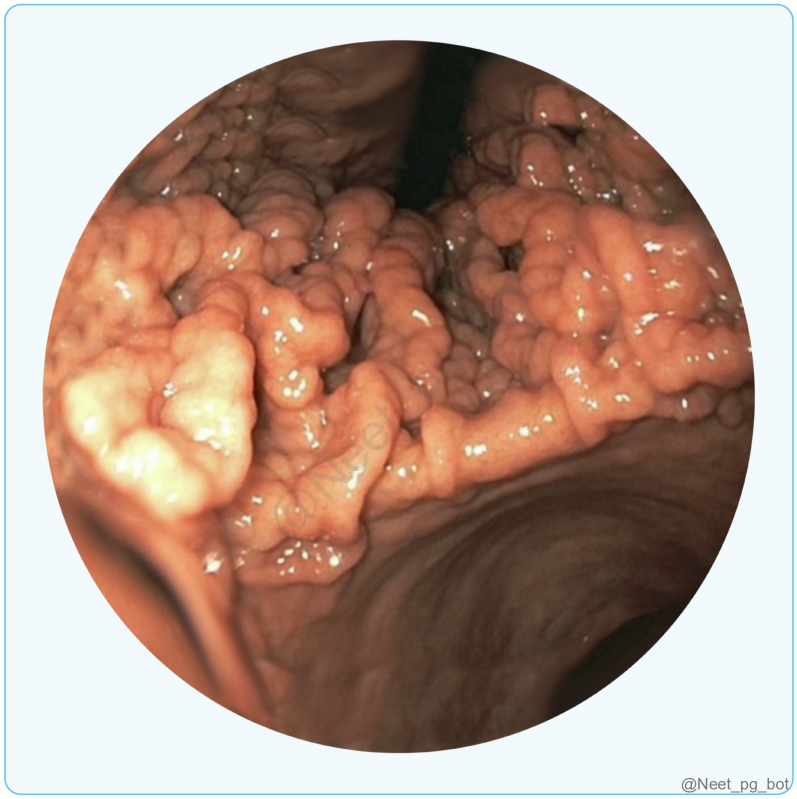

See Answer in Part B → Q1

@Neet_pg_bot

Q2: A 60-year-old man presents with vague abdominal discomfort and early satiety. Imaging reveals a large mass in the gastric fundus. He undergoes surgical resection of the mass, and histopathology confirms a gastrointestinal stromal tumor (GIST). Which of the following factors is a favorable prognostic indicator of this condition? (Q845244)

A. Tumor size > 10 cm

B. Epithelioid cell type

C. Gastric location

D. Intestinal location

See Answer in Part B → Q2

@Neet_pg_bot

Q3: Which of the following markers will help confirm the diagnosis of GIST in C-kit negative cases? (Q845242)

A. CD34

B. DOG1

C. S-100

D. CD117

See Answer in Part B → Q3

@Neet_pg_bot

Q4: Which of the following is the most common mutation found in GIST (Gastrointestinal Stromal Tumor)? (Q845238)

A. KIT mutation

B. PDGFRA mutation

C. SDH mutation

D. BRAF mutation

See Answer in Part B → Q4

@Neet_pg_bot

Q5: A 55-year-old man with intermittent abdominal pain, nausea, and early satiety has a palpable epigastric mass. Imaging shows a well-defined, heterogeneously enhancing stomach mass, and endoscopic biopsy reveals CD117-positive spindle cells. What is the likely origin of this condition? (Q845236)

A. Cajal cells

B. Goblet cells

C. Paneth cells

D. G cells

See Answer in Part B → Q5

@Neet_pg_bot

Q6: A 55-year-old male presents with episodes of flushing, sweating, and colicky abdominal pain. Upper gastrointestinal endoscopy reveals a yellow-tan intramural mass in the stomach. Biopsy revealed sheets of uniform cells with scant granular cytoplasm. What is the most likely diagnosis? (Q845234)

A. Carcinoid tumor

B. Gastric outlet obstruction

C. Hypertrophic pyloric stenosis

D. Crohn's disease

See Answer in Part B → Q6

@Neet_pg_bot

Q7: A 48-year-old female presents with recurrent abdominal pain, bloating, and early satiety for the past few months. Endoscopic biopsy revealed lympho-epithelial lesions with infiltration of small lymphoid cells. Which of the following statements is true regarding this condition? (Q845233)

A. Dense neutrophilic infiltrate

B. Reactive-appearing T-cell follicles seen

C. Plasmacytic differentiation seen

D. Presents as discrete small nodules in the GI tract

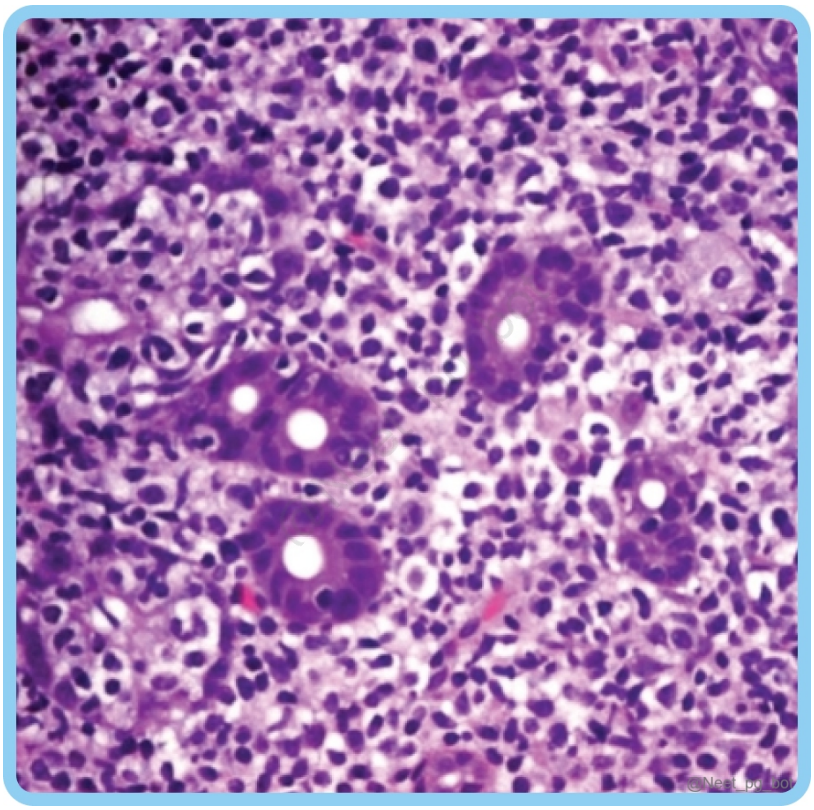

See Answer in Part B → Q7

@Neet_pg_bot

Q8: A 45-year-old female has a history of intermittent epigastric discomfort, nausea, and early satiety. Upper endoscopy reveals gastric wall thickening with a leather bottle appearance. Biopsy of the lesion shows signet ring cells infiltrating the gastric mucosa. What is the most likely diagnosis? (Q845228)

A. Intestinal-type gastric adenocarcinoma

B. Diffuse-type gastric adenocarcinoma

C. Peptic ulcer disease

D. Gastric lymphoma

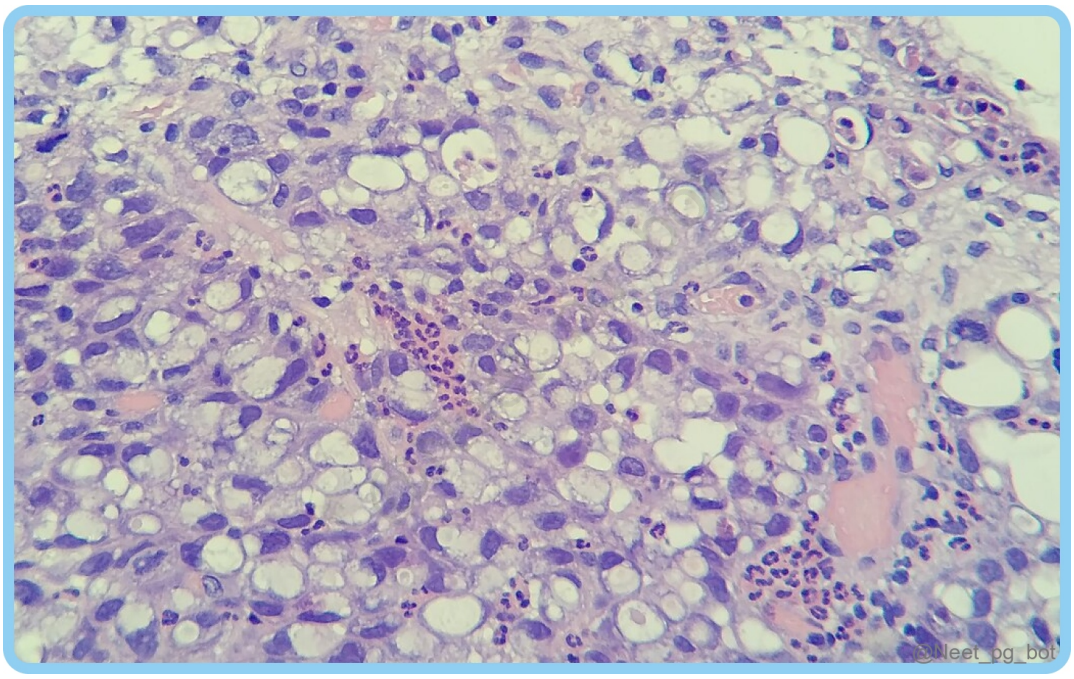

See Answer in Part B → Q8

@Neet_pg_bot

Q9: A 60-year-old male presents with a history of epigastric pain, unintentional weight loss, and early satiety over the past few months. An upper GI endoscopy revealed a nodular mass on the gastric wall, and a biopsy revealed well-differentiated glandular structures with intestinal metaplasia. Which of the following is least likely associated with this condition? (Q845226)

A. Helicobacter pylori (H. pylori) infection

B. APC gene mutation

C. CDH-1 gene mutation

D. High intake of smoked or pickled foods

See Answer in Part B → Q9

@Neet_pg_bot

Q10: Which of the following is NOT a recognised risk factor for gastric adenocarcinoma? (Q845225)

A. Alcohol

B. Hot beverages

C. Blood group O

D. H. pylori

See Answer in Part B → Q10

@Neet_pg_bot

Q11: A 45 y/o male presents with recurrent episodes of abdominal pain and persistent heartburn. Upper gastrointestinal endoscopy reveals multiple duodenal ulcers. Lab investigations show elevated serum gastrin levels (> 1000 pg/ml). Which features are most likely associated with the patient's condition? (Q845223)

A. Presence of gastrin-secreting tumors in the stomach

B. Presence of erosive esophagitis and hiatal hernia

C. Hyperplasia of parietal cells within the stomach

D. Association with MEN2 gene mutation

See Answer in Part B → Q11

@Neet_pg_bot

Q12: Which cells are primarily responsible for secreting neutral mucin that forms a protective layer in the stomach? (Q845197)

A. Parietal cells

B. Chief cells

C. Foveolar cells

D. Enterochromaffin cells

See Answer in Part B → Q12

@Neet_pg_bot

Q13: A 58-year-old female presents with recurrent epigastric discomfort and intermittent nausea. Histopathological examination of gastric biopsy samples reveals irregular, cystically dilated, and elongated foveolar glands. She also has a history of untreated H. pylori infection. What type of lesions is most likely to be associated with these findings? (Q845219)

A. Hyperplastic polyps

B. Gastric adenomas

C. Inflammatory fibroid polyps

D. Juvenile polyps

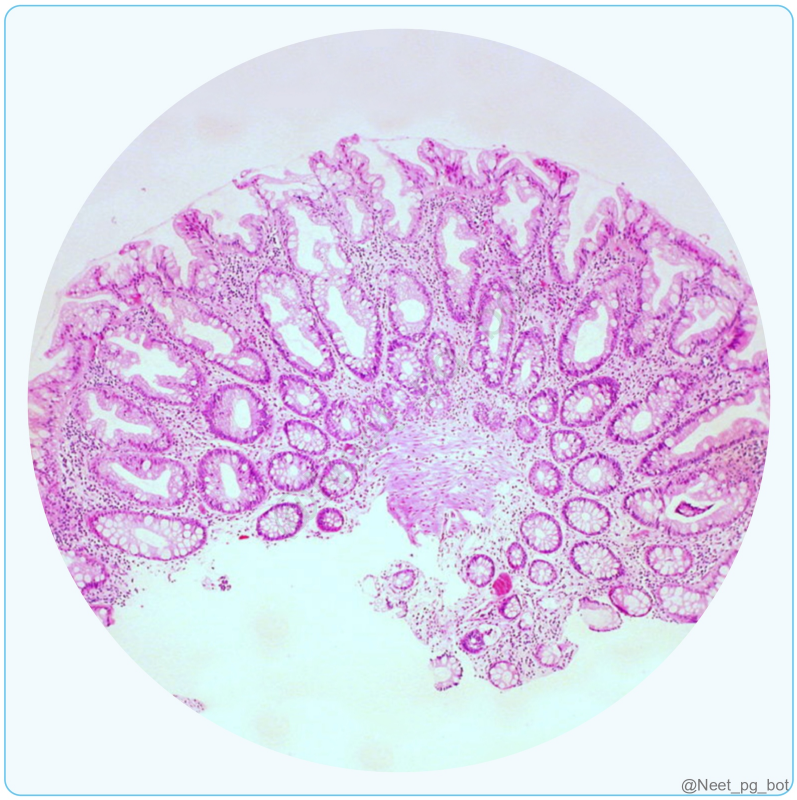

See Answer in Part B → Q13

@Neet_pg_bot

Q14: A 60-year-old man on long-term proton pump inhibitor therapy for acid reflux undergoes an upper gastrointestinal endoscopy for recurrent epigastric discomfort. The endoscopy reveals smooth-surfaced lesions in the gastric body and fundus. Which statement about these findings is likely correct? (Q845215)

A. PPIs decrease gastrin secretion, reducing the risk of fundic gland polyps

B. Fundic gland polyps are commonly associated with H. pylori infection.

C. Composed of cystically dilated glands lined by parietal, chief, and foveolar cells.

D. Sporadic fundic gland polyps carry a significant risk of neoplasia.

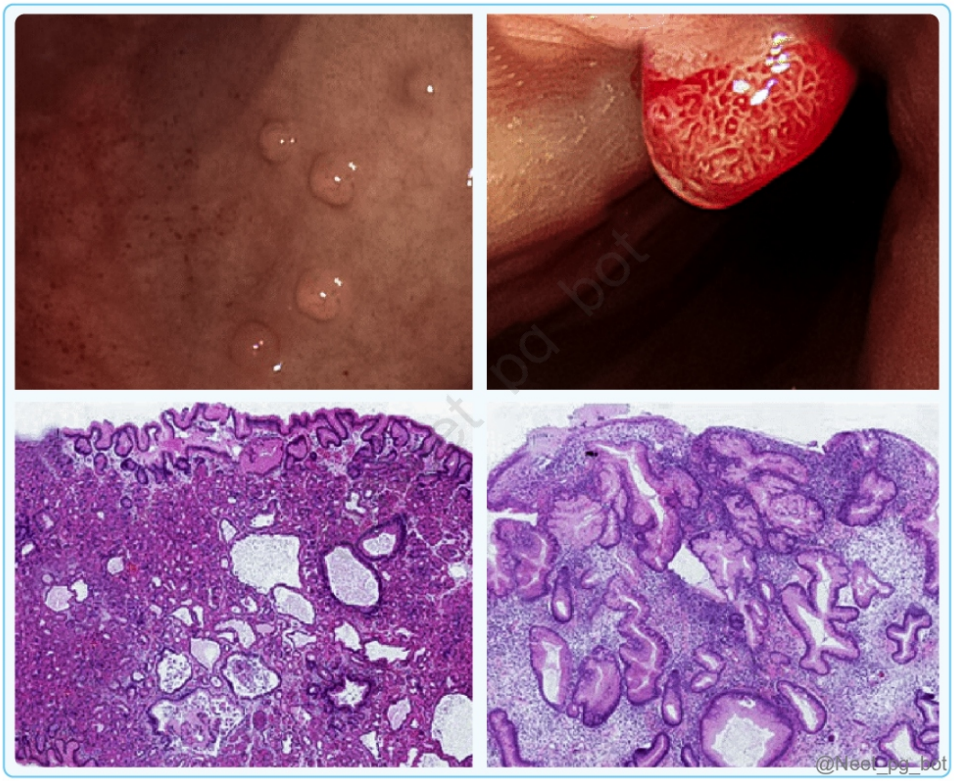

See Answer in Part B → Q14

@Neet_pg_bot

Q15: Which type of gastritis is associated with a distinctive endoscopic appearance characterised by thickened folds, small nodules, and central aphthous ulceration affecting the entire stomach? (Q845214)

A. Eosinophilic gastritis

B. Lymphocytic gastritis

C. Granulomatous gastritis

D. Chemical gastritis

See Answer in Part B → Q15

@Neet_pg_bot

Q16: A 45-year-old female presents with chronic epigastric pain, nausea, and occasional vomiting. Upper gastrointestinal endoscopy reveals diffuse mucosal atrophy. Biopsy confirms chronic gastritis. Which of the following is a characteristic feature of Chronic Gastritis Type A? (Q845212)

A. Predominantly affects the antrum of the stomach

B. Autoimmune destruction of parietal cells

C. Associated with H. pylori infection

D. Increased risk of gastric carcinoma

See Answer in Part B → Q16

@Neet_pg_bot

Q17: A 55-year-old patient presents with recurrent epigastric pain and signs of gastrointestinal bleeding. An upper endoscopy reveals gastric ulcers, and a biopsy is performed for further evaluation. Which stain is best for identifying the causative organism in this condition? (Q845210)

A. Z-N stain

B. Wright stain

C. Modified Giemsa stain

D. Gram stain

See Answer in Part B → Q17

@Neet_pg_bot

Q18: Which of the following is NOT a protective factor against Peptic Ulcer Disease? (Q845208)

A. Mucus

B. Bicarbonate

C. COX-1

D. Pepsin

See Answer in Part B → Q18

@Neet_pg_bot

Q19: A 45-year-old man experiences recurrent upper abdominal pain worsened after meals, unresponsive to over-the-counter antacids. Which of the following is NOT typically a risk factor for the patient's presentation? (Q845206)

A. Helicobacter pylori infection

B. Cocaine use

C. Cigarette smoking

D. Obesity

See Answer in Part B → Q19

@Neet_pg_bot

Q20: A 55-year-old female with traumatic brain injury undergoes emergency craniotomy and is now intubated in the neurosurgical ICU. She suddenly develops hematemesis despite stabilisation. What is the most likely cause of the patient's bleeding? (Q845205)

A. Curling ulcer

B. Cushing ulcer

C. Gastric antral vascular ectasia (GAVE)

D. Dieulafoy lesions

See Answer in Part B → Q20

@Neet_pg_bot

Q21: A 55-year-old male presents to the gastroenterology clinic with complaints of persistent abdominal pain, nausea, and unintentional weight loss over the past three months. His medical history is significant for peptic ulcer disease and he is a former smoker. An upper endoscopy reveals multiple gastric lesions, and a biopsy is taken for histological examination. The results indicate the presence of gastric adenocarcinoma, and positive for Helicobacter pylori. Which protein produced by Helicobacter pylori is primarily associated with this condition? (Q845199)

A. Urease

B. CagA

C. SRC

D. SHP2

See Answer in Part B → Q21

@Neet_pg_bot

• [09_Gastrointestinal Tract] 041 Intestinal Polyps And Intestinal Carcinoma - I

« Back to Folder Directory

[09_Gastrointestinal Tract] 041 Intestinal Polyps And Intestinal Carcinoma - I — Quick Jump

Q1 (p. 433) *Q2 (p. 433)* *Q3 (p. 434)* *Q4 (p. 435)* *Q5 (p. 436)* *Q6 (p. 436)*
Q7 (p. 436) *Q8 (p. 437)* *Q9 (p. 437)* *Q10 (p. 438)* *Q11 (p. 438)* *Q12 (p. 438)*
Q13 (p. 439) *Q14 (p. 439)*

Q1: During a routine colonoscopy of a 60-year-old male, a small polyp is identified in the colon. Subsequent biopsy results confirm the presence of a hyperplastic polyp. Which characteristic is typically associated with this condition? (Q845256)

A. Commonly found in the right colon

B. Pathogenesis involves increased epithelial cell turnover

C. Lacks malignant potential

D. Histologically composed of immature goblet cells

See Answer in Part B → Q1

@Neet_pg_bot

Q2: A 55-year-old man undergoes a routine colonoscopy. During the procedure, a polyp is discovered. Histological examination reveals serrated architecture, as shown in the image. Which of the following is true about this polyp? (Q845259)

A. It has malignant potential

B. Predominantly found in the left colon

C. Serrated architecture is limited to the surface of the lesions

D. Do not require surveillance or follow-up after detection

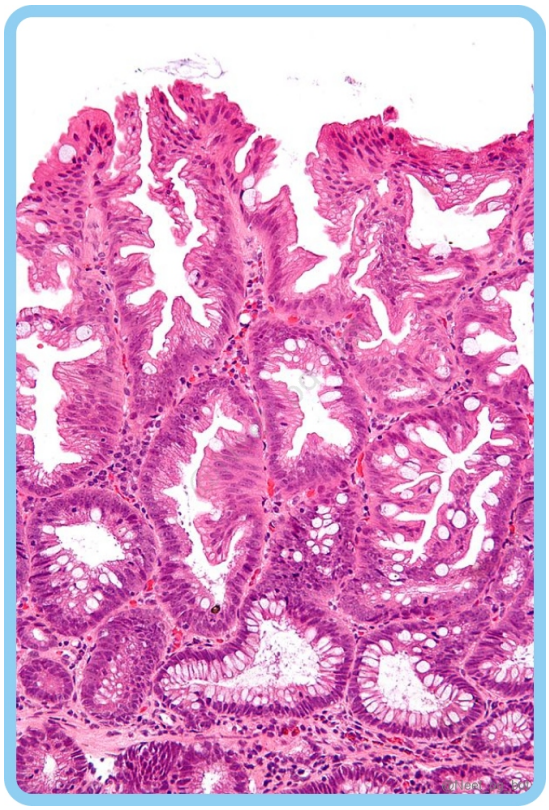

See Answer in Part B → Q2

@Neet_pg_bot

Q3: A 4-year-old girl presents to the OPD with complaints of rectal bleeding and abdominal pain for the past six months. Investigations reveal approximately 40 hamartomatous colon polyps. The biopsy shows cystic spaces with dilated glands filled with mucin and inflammatory debris. What is the most likely diagnosis for this patient? (Q845265)

A. Familial adenomatous polyposis

B. Adenocarcinoma colon

C. Juvenile polyposis syndrome

D. Sessile Serrated Adenoma

See Answer in Part B → Q3

@Neet_pg_bot

Q4: A 13-year-old female presents to the OPD due to abdominal pain and blood in stools. On examination, she had pigmented macules on her lips and oral mucosa. Endoscopy reveals multiple large, pedunculated polyps in the small intestine which shows an arborizing pattern of smooth muscle and glands lined by normal epithelium. Which of the following statements is incorrect about this condition? Autosomal dominant disorder Polyps are more common in the colon Increased risk of developing colon, pancreatic, and breast cancers Gain-of-function mutation in STK11 gene (Q845268)

A. 1 and 2

B. 2 and 4

C. 3 and 4

D. 1 and 3

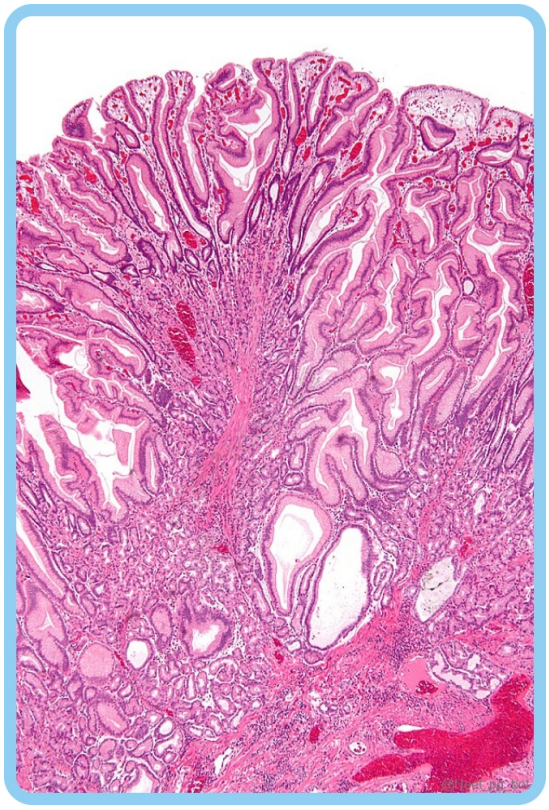

See Answer in Part B → Q4

@Neet_pg_bot

Q5: A 58-year-old female presents with weight loss, nail changes, alopecia, and skin hyperpigmentation. Colonoscopy reveals multiple hamartomatous polyps in the intestine. Family history is negative for intestinal cancers. What is the most likely diagnosis? (Q845281)

A. Tuberous sclerosis

B. Bannayan-Ruvalcaba-Riley Syndrome

C. Cowden syndrome

D. Cronkhite-Canada Syndrome

See Answer in Part B → Q5

@Neet_pg_bot

Q6: A 20-year-old man with a family history of colorectal carcinoma presents with chronic abdominal discomfort and occasional rectal bleeding.Upon further evaluation, a mutation in APC gene is identified leading to a diagnosis of Familial Adenomatous Polyposis. Which of the following statement is true regarding FAP? (Q845282)

A. Mutation in 6th chromosome

B. 50 % risk of colon cancer if untreated

C. Presence of a minimum of 100 polyps

D. Congenital atrophy of the retinal pigment epithelium

See Answer in Part B → Q6

@Neet_pg_bot

Q7: A 28-year-old woman presents with a history of unexplained weight loss along with multiple sebaceous cysts on her face and scalp. She has a family history of colorectal cancer. Upon further examination, she is found to have a bony lesion on her jaw. What is the most likely diagnosis? (Q845283)

A. Turcot syndrome

B. Gardner syndrome

C. Lynch syndrome

D. MUTYH Associated Polyposis (MAP)

See Answer in Part B → Q7

@Neet_pg_bot

Q8: A 6 cm polyp is identified in the descending colon during a routine colonoscopy. Histological examination reveals villous architecture with high-grade dysplasia. Based on this scenario, which factors most strongly correlate with the risk of malignancy in colorectal adenomas? (Q845284)

A. Presence of villous architecture

B. Size of the adenoma

C. Histologic grade of dysplasia

D. Location within the gastrointestinal tract

See Answer in Part B → Q8

@Neet_pg_bot

Q9: A patient underwent genetic testing after being diagnosed with colon cancer. Testing reveals a mutation associated with Hereditary Nonpolyposis Colorectal Cancer (HNPCC). Which of the following genes is defective in this patient? (Q845285)

A. SMAD4, BMPR1

B. STK11

C. APC, MUTYH

D. MLH1, MSH2

See Answer in Part B → Q9

@Neet_pg_bot

Q10: A 55-year-old male presents to the clinic with complaints of recurrent abdominal discomfort and changes in bowel habits over the past few months. Further investigation with colonoscopy confirmed the presence of adenocarcinoma. Which of the following factors is most closely associated with this condition? (Q845286)

A. Use of aspirin

B. Estrogen replacement therapy

C. High intake of unabsorbable vegetable fiber

D. High consumption of red meat

See Answer in Part B → Q10

@Neet_pg_bot

Q11: A 55-year-old female presents with abdominal pain, changes in bowel habits, unintended weight loss. A previous colonoscopy showed a polyp, but a recent one confirmed colorectal adenocarcinoma. Which gene mutations are characteristically associated with development of colorectal adenocarcinoma? (Q845287)

A. APC, TGFBR2, SMAD2, and BAX

B. TP53, BRAF, TGFBR2, and BAX

C. APC, KRAS, SMAD4 and TP53

D. APC, KRAS, TP53, and MYC

See Answer in Part B → Q11

@Neet_pg_bot

Q12: A 45-year-old female presents with abdominal pain, changes in bowel habits, and weight loss. Her mother and aunt were diagnosed with endometrial and ovarian cancer in their 50s. A colonoscopy and a biopsy confirm well-differentiated

adenocarcinoma. Which genetic pathway is most likely associated with adenocarcinoma in this patient? (Q845290)

A. APC/β-catenin pathway

B. TGF-β signaling pathway

C. DNA mismatch repair pathway

D. BAX pathway

See Answer in Part B → Q12

@Neet_pg_bot

Q13: Which of the following is the most common site of metastasis for colon adenocarcinoma? (Q845291)

A. Brain

B. Lungs

C. Bones

D. Liver

See Answer in Part B → Q13

@Neet_pg_bot

Q14: A 60-year-old male presents with abdominal pain, altered bowel habits and 5kg weight loss in one month. A barium enema study showed the following finding. Which of the following statements is true about the patient's condition? (Q845293)

A. Presents asweakness due to iron deficiency anemia

B. Leads to a napkin-ring constriction and luminal narrowing

C. Growth tends to be polypoidal (growth is into the wall of the intestine?)

D. HPE commonly shows signet-ring cells

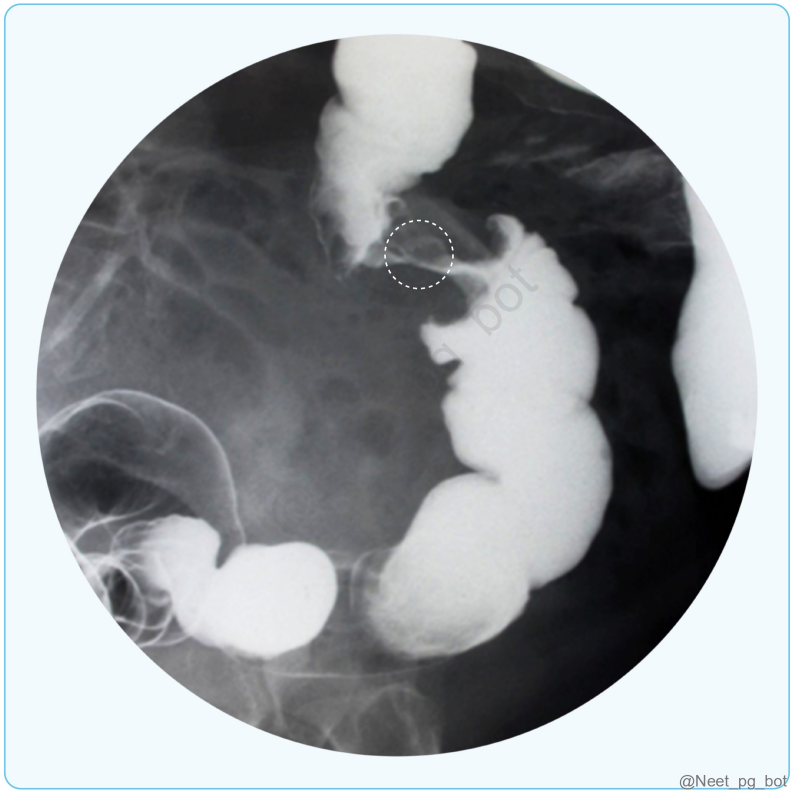

See Answer in Part B → Q14

@Neet_pg_bot

• [09_Gastrointestinal Tract] 042 Malabsorption Syndrome Celiac Disease And Ibd

« Back to Folder Directory

[09_Gastrointestinal Tract] 042 Malabsorption Syndrome Celiac Disease And Ibd — Quick Jump

Q1 (p. 441) *Q2 (p. 441)* *Q3 (p. 442)* *Q4 (p. 443)* *Q5 (p. 443)* *Q6 (p. 444)*
Q7 (p. 445) *Q8 (p. 445)* *Q9 (p. 446)* *Q10 (p. 447)* *Q11 (p. 448)* *Q12 (p. 448)*
Q13 (p. 449) *Q14 (p. 449)*

Q1: A 47-year-old male presents with chronic diarrhoea, unintentional weight loss, joint pain, pallor, and generalised weakness. Upper GI endoscopy and biopsy revealed characteristic histopathological findings suggestive of Whipple's disease. Which of the following histopathological features would have led to the diagnosis? (Q845296)

A. Foamy macrophages filled with PAS-positive granules

B. Villous atrophy and blunting of the small intestinal mucosa

C. Lymphoplasmacytic infiltrate in the lamina propria

D. Presence of caseating granulomas and acid-fast bacilli

See Answer in Part B → Q1

@Neet_pg_bot

Q2: A 35-year-old female presents with chronic diarrhoea, abdominal bloating, and unintended weight loss. She reports discomfort after consuming gluten-containing foods. Laboratory tests show elevated tissue transglutaminase (tTG) and anti-endomysial antibodies (EMA) levels, prompting a small intestinal biopsy via upper endoscopy. Which of the following combinations of histopathological features will be seen in this condition? Intraepithelial CD8+ T Lymphocytes Crypt hyperplasia Villous atrophy Decreased mitotic activity Inflammatory cell infiltration in lamina propria (Q845302)

A. 1, 2, 3

B. 1, 2, 3, 4

C. 2, 4, 5

D. 1, 2, 3, 5

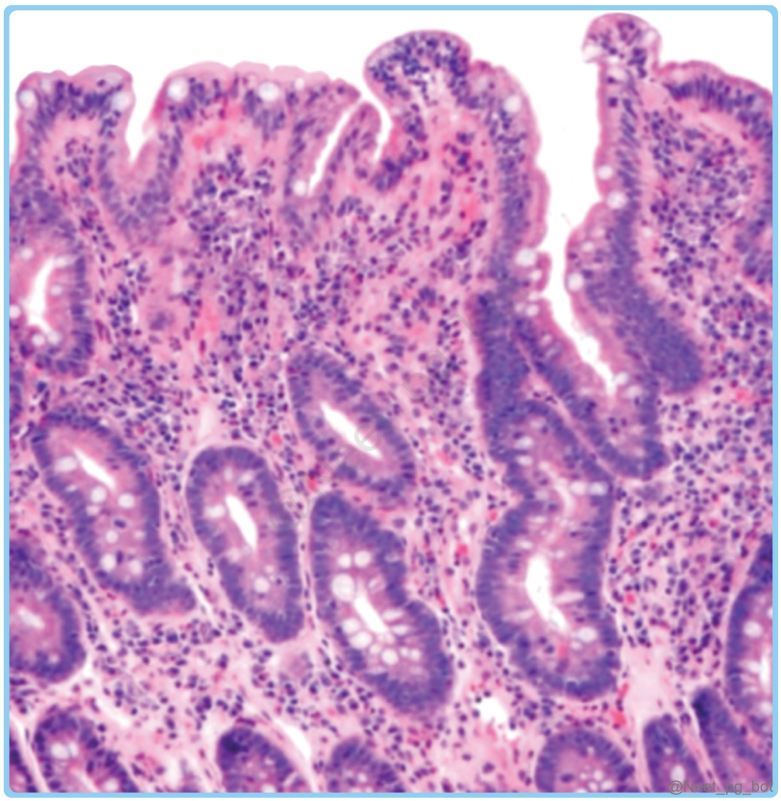

See Answer in Part B → Q2

@Neet_pg_bot

Q3: A 45-year-old woman presents to the clinic with a history of chronic abdominal pain and diarrhoea, worsening notably after consuming wheat-based foods. Physical examination reveals signs suggestive of malabsorption. Considering celiac disease as a possible diagnosis, which of the following statements regarding its pathogenesis is NOT correct? (Q845306)

A. Gliadin peptides in the lamina propria are deamidated by tissue transglutaminase.

B. HLA-DR2 or HLA-DR8 significantly influences celiac disease susceptibility.

C. Gliadin peptides may induce epithelial cells to express IL-15, activating CD8+ lymphocytes.

D. Type 1 diabetes, Sjögren syndrome, and IgA nephropathy are associated with celiac disease.

See Answer in Part B → Q3

@Neet_pg_bot

Q4: A 35-year-old female who recently returned from a tropical region presents with persistent diarrhoea, weight loss, fatigue, anaemia, and vitamin deficiencies, along with a small intestine biopsy findings of villous atrophy and chronic mucosal inflammation. Which part of the gastrointestinal tract is typically NOT affected in this condition? (Q845307)

A. Duodenum

B. Jejunum

C. Ileum

D. Colon

See Answer in Part B → Q4

@Neet_pg_bot

Q5: A 6-month-old infant presents with failure to thrive, chronic diarrhoea, and poor weight gain. A peripheral blood smear revealed a characteristic appearance, as shown in the image below. Biochemical investigations reveal very low levels of triglycerides, cholesterol, and fat-soluble vitamins. Which genetic mutation is most likely responsible for these findings? (Q845309)

A. APOB gene mutation

B. MTTP gene mutation

C. MYO5B gene mutation

D. LPL gene mutation

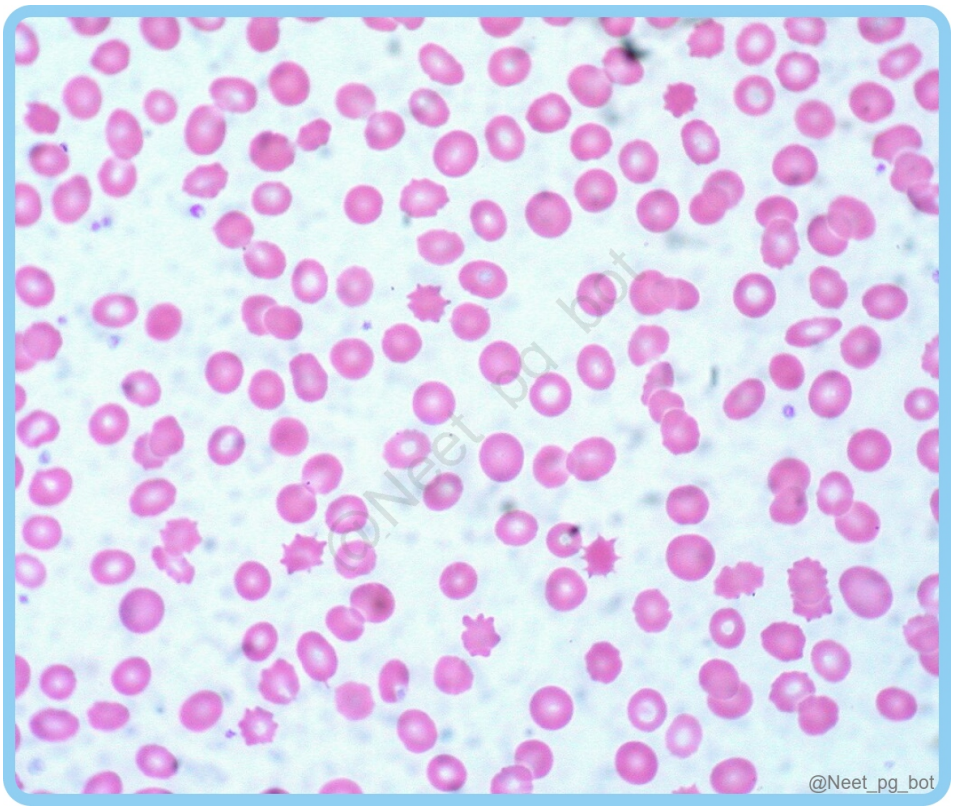

See Answer in Part B → Q5

@Neet_pg_bot

Q6: A 4-week-old infant presents with severe watery diarrhoea and failure to thrive since birth. Stool studies are negative for pathogens. A small bowel biopsy shows villous atrophy, cytoplasmic inclusion bodies within enterocytes, and reduction of microvilli on the enterocyte surface. Which of the following statements is true regarding this condition? (Q845310)

A. It is characterised by the absence of ganglion cells in the distal part of the colon.

B. It is associated with mutations in the MYO5B or STX3 genes.

C. Histological findings include villous atrophy and crypt hyperplasia.

D. It is commonly caused by rotavirus infection, which leads to persistent diarrhoea.

See Answer in Part B → Q6

@Neet_pg_bot

Q7: A 28-year-old female presents with foul-smelling, greasy diarrhoea, bloating, and abdominal cramps following a hiking trip in a remote area. Stool microscopy reveals cysts containing motile trophozoites. A duodenal biopsy shows luminal organisms, as shown in the image, without tissue invasion. Based on the clinical presentation and biopsy findings, what is the most likely causative organism? (Q845312)

A. Cryptosporidium

B. Tropheryma whipplei

C. Entamoeba histolytica

D. Giardia lamblia

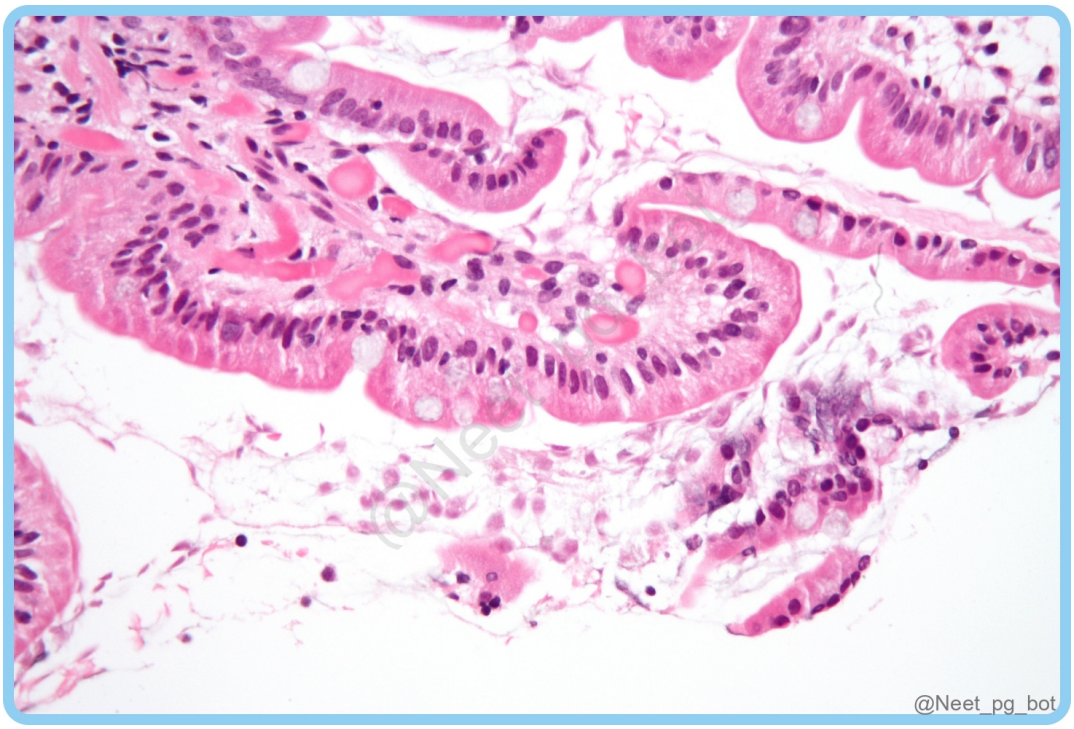

See Answer in Part B → Q7

@Neet_pg_bot

Q8: Which type of ulcer is characterised by flask shaped, multiple punched-out ulcers with undermined edges and necrotic bases on histopathological examination? (Q845325)

A. TB ulcer

B. Typhoid ulcer

C. Amoebic ulcer

D. Peptic ulcer

See Answer in Part B → Q8

@Neet_pg_bot

Q9: A 60-year-old patient presents with severe diarrhoea and abdominal pain after completing a course of broad-spectrum antibiotics for a respiratory infection. Stool studies detect the presence of Clostridioides difficile (C. difficile) toxin. A colonoscopy revealed diffuse yellowish plaques covering the colonic mucosa, as shown in the image. Which inflammatory cell type predominantly infiltrates the lamina propria and surface epithelium in this condition? (Q845329)

A. Lymphocytes

B. Eosinophils

C. Neutrophils

D. Plasma cells



See Answer in Part B → Q9

@Neet_pg_bot

Q10: A 32-year-old man presents with chronic abdominal pain, diarrhoea, weight loss, and occasional blood in the stool. A colonoscopy reveals skip lesions with areas of normal mucosa alternating with segments, cobblestoning and deep linear fissuring ulcers in the patchy terminal ileum and colon. The histopathological findings from the affected area are shown below. What histopathological features are observed in this patient's condition? (Q845333)

A. Presence of noncaseating granulomas

B. Smooth transition between ulcerated and adjacent normal mucosa

C. Absence of metaplastic changes in the epithelium

D. Uniform distribution of inflammation throughout the affected areas

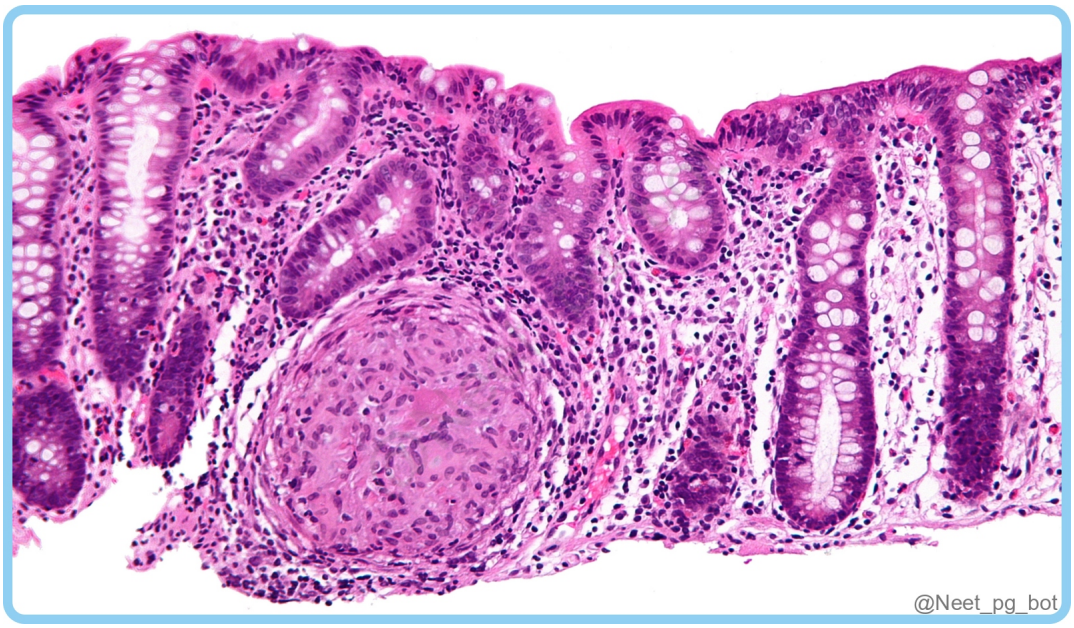

See Answer in Part B → Q10

@Neet_pg_bot

Q11: A 32-year-old male presents with a 6-month history of abdominal pain, diarrhoea, and weight loss. A colonoscopy reveals findings consistent with Crohn's diseaseWhat histological features would you observe in this patient's biopsy? (Q845339)

A. Inflammation is limited superficial layer

B. Fibrosis is not seen

C. Ulcers are limited to mucosa

D. Ulcers can extend beyond the mucosa

See Answer in Part B → Q11

@Neet_pg_bot

Q12: Which statement is true regarding inflammatory bowel disease (IBD) pathogenesis? (Q845341)

A. NOD2 polymorphisms are closely associated with Crohn's disease in Asian populations.

B. ATG16L1 mutation promotes ATG16L1 degradation and enhances autophagy.

C. Dysbiosis is often established at disease presentation in IBD.

D. All of the above

See Answer in Part B → Q12

@Neet_pg_bot

Q13: Which of the following statements regarding ulcerative colitis and Crohn's disease is true? (Q845344)

A. Ulcerative colitis is characterised by skip lesions, whereas Crohn’s disease typically presents with continuous inflammation.

B. Cobblestone appearance is a feature seen in ulcerative colitis and Crohn's disease but is more commonly associated with Crohn's disease.

C. Ulcerative colitis typically begins in the rectum and extends proximally, whereas Crohn's disease can involve any part of the GI tract with rectal sparing.

D. Fistulae, strictures, and abscesses are more commonly seen in ulcerative colitis than in Crohn's disease.

See Answer in Part B → Q13

@Neet_pg_bot

Q14: A 32-year-old male presents to the outpatient clinic with a 5-day history of non-bloody, watery diarrhea. He reports that he recently returned from a hiking trip in a rural area where he drank water from a nearby stream. On examination, he appears dehydrated but is otherwise stable. A stool sample was sent for analysis, which revealed the presence of oocysts. Which of the following is the most likely cause of this patient's gastrointestinal symptoms? (Q846629)

A. Cryptosporidium

B. Microsporidium

C. Giardia lamblia

D. Entamoeba histolytica

See Answer in Part B → Q14

@Neet_pg_bot

• [09_Gastrointestinal Tract] 043 Previous Year Questions

« Back to Folder Directory

[09_Gastrointestinal Tract] 043 Previous Year Questions — Quick Jump

Q1 (p. 451)	*Q2 (p. 451)*	*Q3 (p. 452)*	*Q4 (p. 452)*	*Q5 (p. 453)*	*Q6 (p. 454)*
Q7 (p. 454)	*Q8 (p. 455)*	*Q9 (p. 455)*	*Q10 (p. 456)*	*Q11 (p. 456)*	*Q12 (p. 457)*
Q13 (p. 457)	*Q14 (p. 458)*	*Q15 (p. 459)*	*Q16 (p. 459)*	*Q17 (p. 459)*	*Q18 (p. 460)*
Q19 (p. 460)	*Q20 (p. 460)*	*Q21 (p. 461)*	*Q22 (p. 462)*	*Q23 (p. 462)*	*Q24 (p. 463)*
Q25 (p. 463)	*Q26 (p. 464)*	*Q27 (p. 464)*			

Q1: Which of the following is a sensitive and specific marker of intestinal inflammation? (Q858080)

A. Procalcitonin

B. Fecal lactoferrin

C. Tissue transglutaminase IgA

D. High-sensitivity C-reactive protein

See Answer in Part B → Q1

@Neet_pg_bot

Q2: A 12-year-old boy presents with multiple dark-brown macules around the lips and oral mucosa. Upper GI endoscopy shows numerous hamartomatous polyps in the jejunum. Which of the following statements regarding this condition are correct? Autosomal recessive inheritance Presence of congenital retinal pigmentation (CRPE) Loss-of-function mutation in the STK11 gene. Arborising pattern due to the proliferation of smooth muscle in the polyp histology (Q879201)

A. 1, 2

B. 1, 3, 4

C. 3, 4

D. 2, 3, 4

See Answer in Part B → Q2

@Neet_pg_bot

Q3: Which of the following is a characteristic feature of Barrett's oesophagus? (Q859302)

A. Squamous metaplasia

B. Severe dysplasia

C. Intestinal metaplasia

D. Cuboidal metaplasia

See Answer in Part B → Q3

@Neet_pg_bot

Q4: A 5-year-old child was admitted to the hospital with a history of prolapsing rectal mass and painless rectal bleeding. The histopathological image of the mass is shown below. What is the most likely diagnosis? (Q858520)

A. Peutz-Jegher syndrome

B. Villous adenoma

C. Juvenile polyp

D. Tubular adenoma

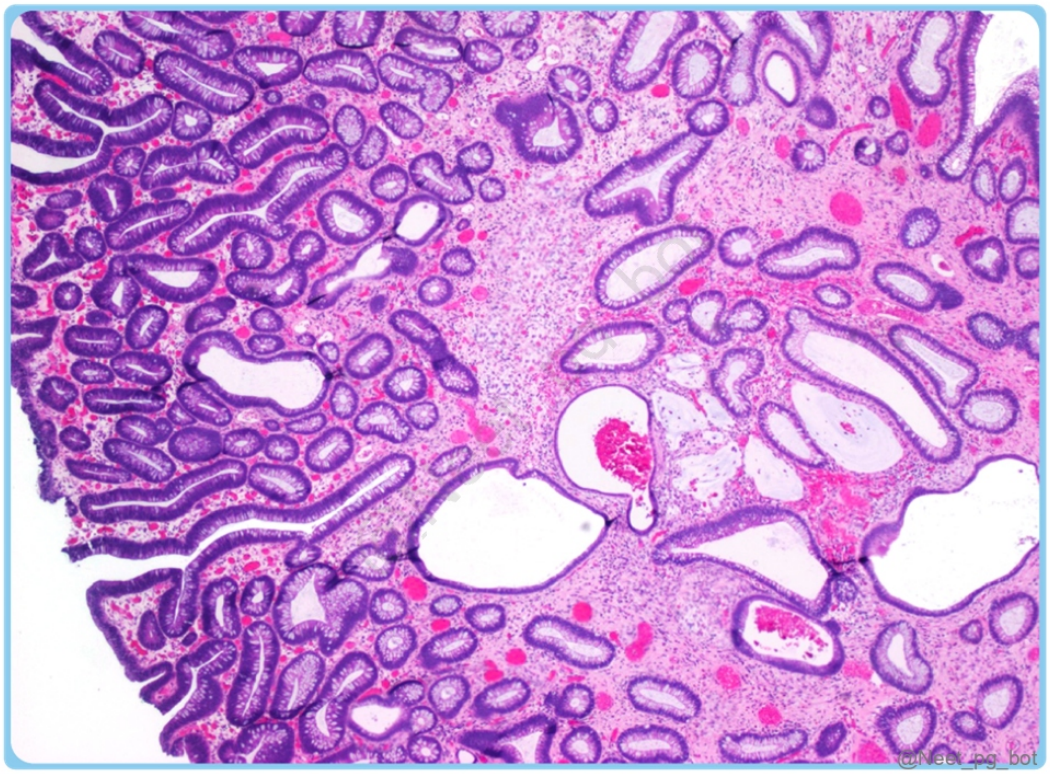

See Answer in Part B → Q4

@Neet_pg_bot

Q5: A 50-year-old man presented with a retroperitoneal mass. A biopsy of the lesion is shown in the image below. Molecular analysis revealed t(12;16). What is the most likely condition? (Q858516)

A. Myxoid liposarcoma

B. Lipoma

C. Spindle lipoma

D. Polymorphic lipoma

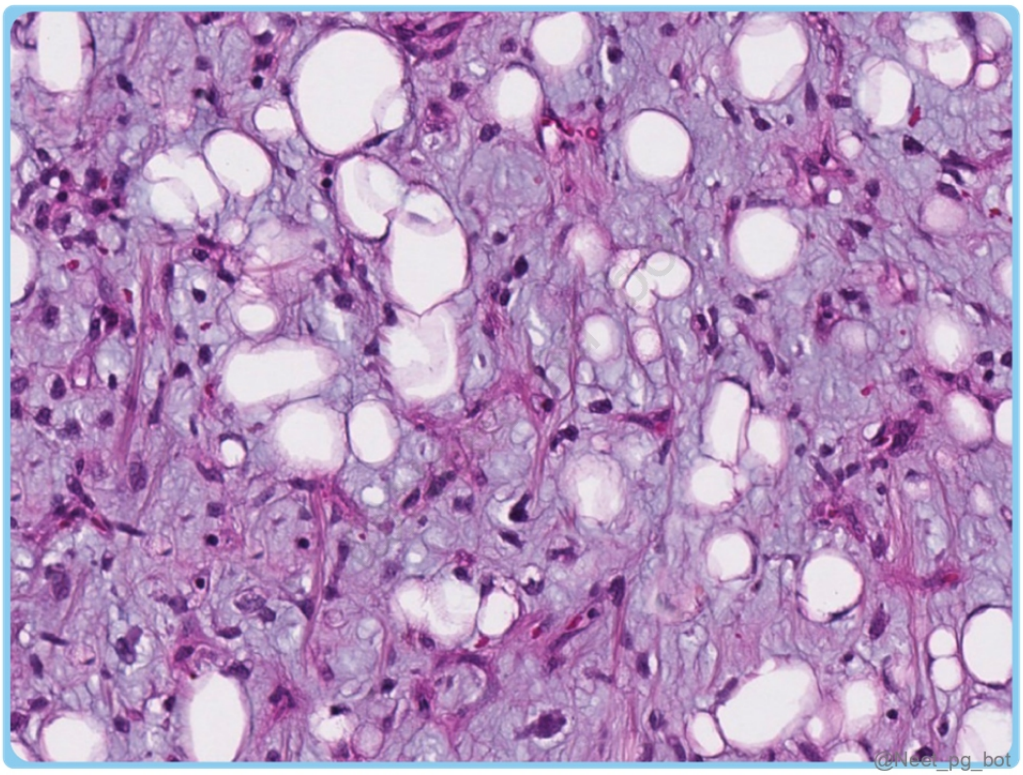

See Answer in Part B → Q5

@Neet_pg_bot

Q6: A 30-year-old female presents with chest pain, recurrent heartburn, and dysphagia. A barium swallow shows a bird beak sign. Which of the following statements is true regarding the condition in this patient? (Q854892)

A. Relaxation of LES

B. Increased peristalsis

C. Decreased release of NO and VIP in the distal esophagus

D. Decreased tone of LES

See Answer in Part B → Q6

@Neet_pg_bot

Q7: Which of the following is true about the pathogenesis of Hirschsprung disease? (Q854856)

A. Failure of migration of neural crest cells

B. Increase in ganglion cells

C. Visceral myopathy

D. Obstruction by inflammatory strictures

See Answer in Part B → Q7

@Neet_pg_bot

Q8: A 20-year-old patient presents with a history of malabsorption, diarrhea, and poor appetite. A duodenal biopsy shows crypt hyperplasia, villi atrophy, and CD8+ cells in the lamina propria. What is the most probable diagnosis? (Q854843)

A. Environmental enteropathy

B. Celiac disease

C. Whipple’s disease

D. Chronic pancreatitis

See Answer in Part B → Q8

@Neet_pg_bot

Q9: Which of the following statements regarding Peutz-Jeghers syndrome is correct? An arborizing pattern of smooth muscle Loss of heterozygosity in STK11 gene Multiple GI polyps Autosomal recessive inheritance Congenital hypertrophy of retinal pigmental epithelium is seen (Q856473)

A. 2, 4, 5

B. 1, 2, 3

C. 1, 3, 4

D. 2, 3, 5

See Answer in Part B → Q9

@Neet_pg_bot

Q10: The cells lining the isthmus of gastric pits are: (Q856472)

A. Chief cells

B. Stem cells

C. Parietal cells

D. Mucous cells

See Answer in Part B → Q10

@Neet_pg_bot

Q11: The absence of the structure will be present in all except: (Q856471)

A. Pernicious anemia

B. Autoimmune Metaplastic Atrophic Gastritis

C. Vitamin B12 Deficiency

D. Zollinger-Ellison syndrome

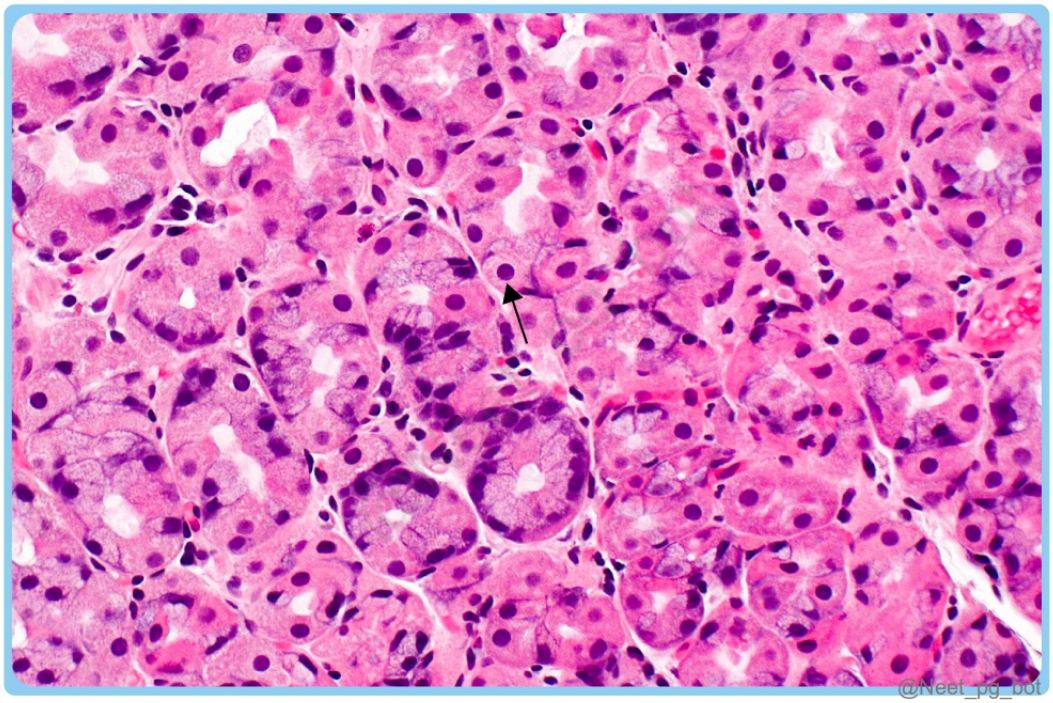

See Answer in Part B → Q11

@Neet_pg_bot

Q12: Which of the following is true about celiac disease? (Q856469)

A. Most common cause of malnutrition in developing countries

B. Can be diagnosed with CECT

C. Improves with food rich in carbohydrates

D. Increased risk of GI lymphoma

See Answer in Part B → Q12

@Neet_pg_bot

Q13: A 17-year-old boy presented with intussusception and was taken up for surgery. He was found to have multiple polyps. The resected section was sent for histopathology, and the whole mount image of the specimen is given below. Identify the lesion. (Q855425)

A. Tubulovillous adenoma

B. Hamartomatous polyp

C. Adenocarcinoma

D. Hyperplastic polyp

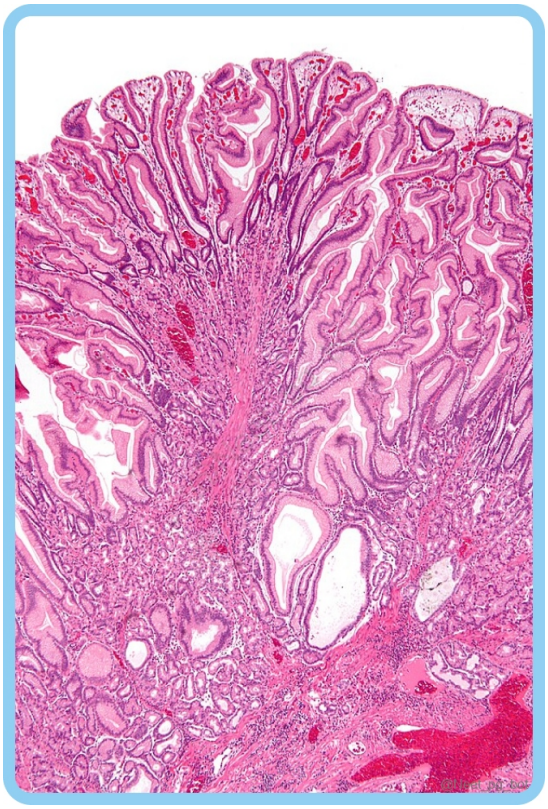

See Answer in Part B → Q13

@Neet_pg_bot

Q14: Which of the following set of statements is true about familial adenomatous polyposis (FAP)? It is autosomal recessive. If not treated, 100% of the cases progress to adenocarcinoma of the colon. Polyps do not arise after puberty. It is associated with congenital hypertrophy of the retinal pigment epithelium. (Q855122)

A. 2 and 4

B. 1 and 4

C. 2 and 3

D. 3 and 4

See Answer in Part B → Q14

@Neet_pg_bot

Q15: In Barrett's oesophagus, which of the following epithelial transformations occurs? (Q866674)

A. Columnar to squamous epithelium

B. Squamous to intestinal columnar epithelium

C. Transitional to squamous epithelium

D. Cuboidal to columnar epithelium

See Answer in Part B → Q15

@Neet_pg_bot

Q16: Which of the following diet is not advised in celiac sprue disease? (Q820577)

A. Rice

B. Wheat

C. Dhal

D. Ragi

See Answer in Part B → Q16

@Neet_pg_bot

Q17: Which of the following intestinal pathologies is associated with dermatitis herpetiformis? (Q860249)

A. Ulcerative colitis

B. Whipple’s disease

C. Celiac disease

D. Crohn’s disease

See Answer in Part B → Q17

@Neet_pg_bot

Q18: In contrast with Ulcerative colitis, which of the following is Crohn's disease is likely to show? (Q840077)

A. Seldom presents with daily hematochezia

B. Increased frequency of perianal fistula

C. Continuous lesion

D. Increased risk of colon cancer

See Answer in Part B → Q18

@Neet_pg_bot

Q19: Which of the following is not associated with GIST? (Q840010)

A. PDGFR Beta

B. SDH

C. c- KIT

D. NRG-1

See Answer in Part B → Q19

@Neet_pg_bot

Q20: An adult man presents with a protruding abdomen, diarrhea, visual disturbances and neurological manifestations. Based on the given peripheral smear,

what is the most likely diagnosis? (Q844190)

A. Abetalipoproteinemia

B. Whipple’s disease

C. Menetrier's Disease

D. Uremia

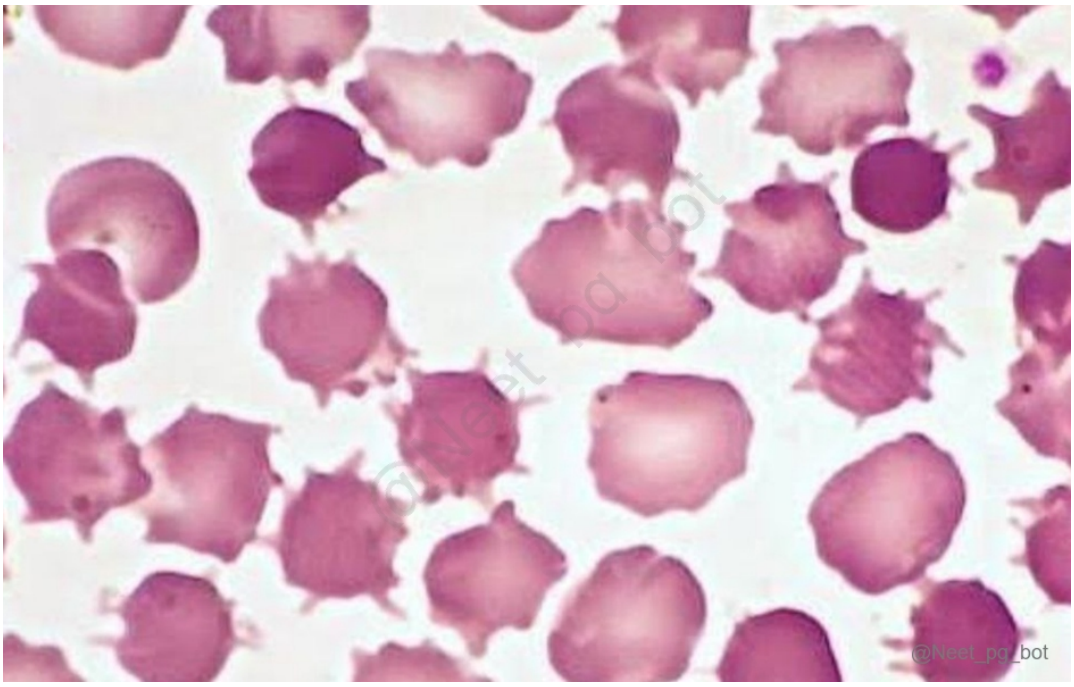

See Answer in Part B → Q20

@Neet_pg_bot

Q21: A child presents with itchy lesions and diarrhea and has been advised to follow a gluten-free diet. What is the most likely diagnosis? (Q844098)

A. Celiac disease

B. Whipple's disease

C. Crohn's disease

D. Ulcerative colitis

See Answer in Part B → Q21

@Neet_pg_bot

Q22: Which vitamin is to be supplemented in a patient following gastrectomy? (Q844083)

A. Vitamin A

B. Vitamin B1

C. Vitamin C

D. Vitamin B12

See Answer in Part B → Q22

@Neet_pg_bot

Q23: A child presents with failure to pass stools and is diagnosed with Hirschsprung disease. Which among the following layers of the colon will show congenital absence of neurons? (Q844079)

A. 1 & 2

B. 2 & 3

C. 3 & 4

D. 1 & 4

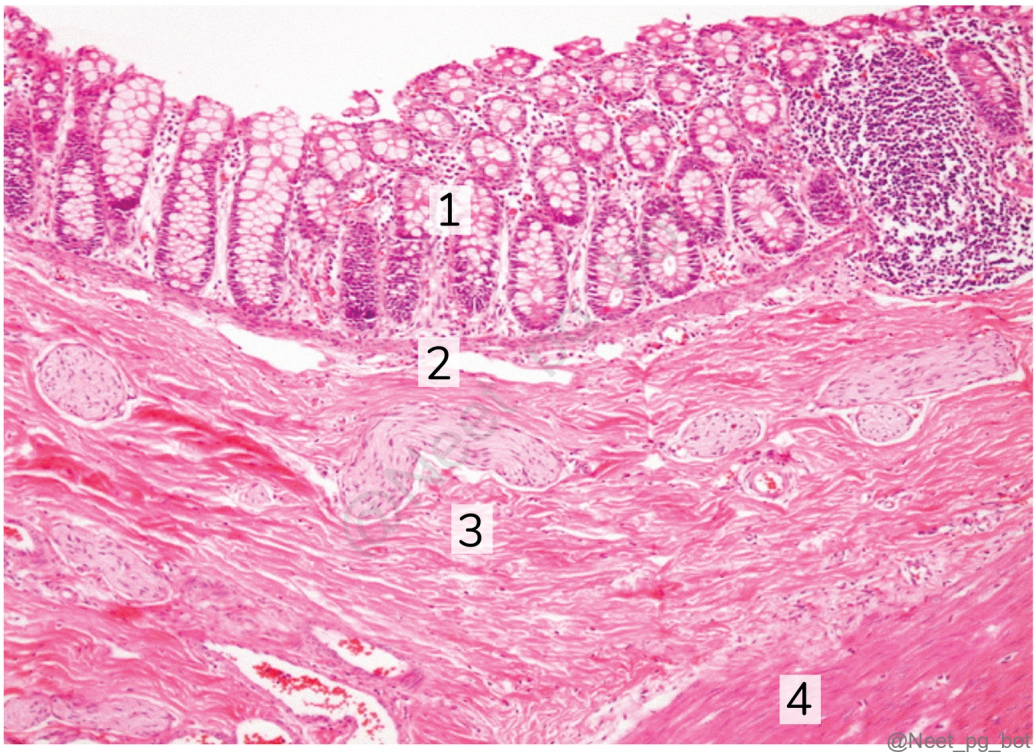

See Answer in Part B → Q23

@Neet_pg_bot

Q24: Which of the following antibodies is associated with celiac disease? (Q843987)

A. Anti-TTG

B. ANCA

C. ASCA

D. AMA

See Answer in Part B → Q24

@Neet_pg_bot

Q25: Match the following diseases with their respective gene mutation: 1. Familial adenomatous polyposis i. SMAD4 2. Juvenile polyposis ii. STK11 3. Tuberous sclerosis iii. APC gene 4. Peutz-Jeghers syndrome iv. TSC1 (Q853371)

A. A-i, B-ii, C-iii, D-iv

B. A-ii, B-iii, C-i, D-iv

C. A-iii, B-i, C-iv, D-ii

D. A-iv, B-ii, C-iii, D-i

See Answer in Part B → Q25

@Neet_pg_bot

Q26: What is the eye manifestation seen in HLA B27-positive patients with ulcerative colitis? (Q866755)

A. Uveitis

B. Conjunctivitis

C. Scleritis

D. Iridocyclitis

See Answer in Part B → Q26

@Neet_pg_bot

Q27: Hereditary non-polyposis colorectal cancer (HNPCC), also known as Lynch syndrome, is caused by mutations in which type of genes? (Q866735)

A. APC

B. MMR

C. MYC

D. TERT1

See Answer in Part B → Q27

@Neet_pg_bot

• [10_Liver_ Biliary System and Pancreas] 044 Hepatobiliary Pathology-I

« Back to Folder Directory

[10_Liver_ Biliary System and Pancreas] 044 Hepatobiliary Pathology-I — Quick Jump

Q1 (p. 465)	*Q2 (p. 465)*	*Q3 (p. 466)*	*Q4 (p. 466)*	*Q5 (p. 466)*	*Q6 (p. 467)*
Q7 (p. 468)	*Q8 (p. 468)*	*Q9 (p. 468)*	*Q10 (p. 469)*	*Q11 (p. 469)*	*Q12 (p. 469)*
Q13 (p. 470)	*Q14 (p. 470)*	*Q15 (p. 471)*	*Q16 (p. 471)*	*Q17 (p. 472)*	*Q18 (p. 472)*
Q19 (p. 473)	*Q20 (p. 473)*	*Q21 (p. 475)*	*Q22 (p. 475)*	*Q23 (p. 475)*	*Q24 (p. 476)*
Q25 (p. 476)					

Q1: Which of the following conditions is not typically associated with Mallory-Denk bodies? (Q845632)

A. Wilson’s Disease

B. Hemochromatosis

C. Indian childhood cirrhosis

D. Alpha-1 antitrypsin deficiency

See Answer in Part B → Q1

@Neet_pg_bot

Q2: Which of the following combinations represents the organs involved in hereditary hemochromatosis? Liver Pancreas Myocardium Basal ganglia (Q890275)

A. 1, 2, and 3 only

B. 1 and 4 only

C. 2 and 4 only

D. 1, 2, 3, and 4

See Answer in Part B → Q2

@Neet_pg_bot

Q3: Which of the following statements regarding secondary hemochromatosis is not true? (Q890274)

A. Bantu siderosis is caused by decreased iron excretion

B. Neonatal hemochromatosis is not a hereditary disorder

C. It can occur after repeated blood transfusions

D. Disease manifests after approximately 20 g of iron accumulation

See Answer in Part B → Q3

@Neet_pg_bot

Q4: Which of the following is the major life-threatening complication of hereditary hemochromatosis? (Q890273)

A. Hepatocellular carcinoma

B. Acute liver failure

C. Splenic rupture

D. Autoimmune hepatitis

See Answer in Part B → Q4

@Neet_pg_bot

Q5: A 42-year-old man presents with fatigue, skin hyperpigmentation, and newly diagnosed diabetes mellitus. Laboratory studies show elevated serum ferritin and transferrin saturation. The gene responsible for this condition is located on which chromosome? (Q890272)

A. Chromosome 6

B. Chromosome 7

C. Chromosome 18

D. Chromosome 21

See Answer in Part B → Q5

@Neet_pg_bot

Q6: ■ A 45-year-old man presents with fatigue, diabetes mellitus, and skin hyperpigmentation. Liver biopsy shows findings as shown. Micronodular cirrhosis is present with minimal inflammation. What is the most likely diagnosis? (Q890271)

A. Wilson disease

B. Primary biliary cholangitis

C. Hereditary hemochromatosis

D. α1-antitrypsin deficiency

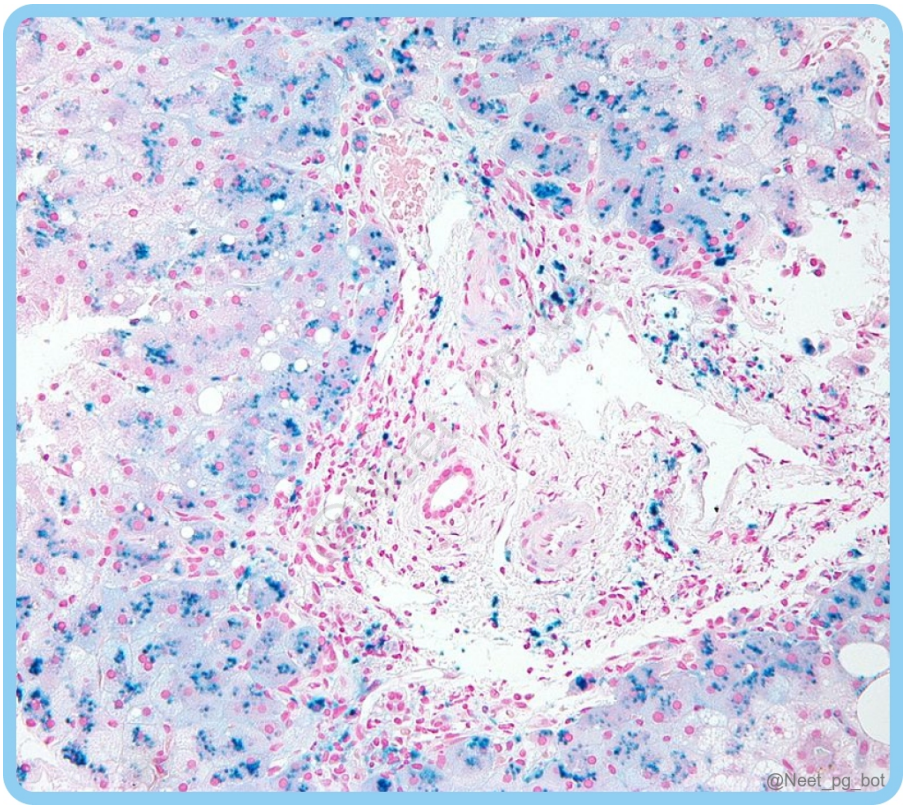

See Answer in Part B → Q6

@Neet_pg_bot

Q7: Which of the following findings is wrong regarding the diagnosis of Wilson's disease? (Q890270)

A. KF rings on slit lamp examination

B. Increased hepatic copper content on liver biopsy

C. Increased urinary copper excretion

D. Elevated serum ceruloplasmin levels

See Answer in Part B → Q7

@Neet_pg_bot

Q8: A 14-year-old boy is diagnosed with Wilson's disease. Genetic testing in the patient identifies a pathogenic mutation in the ATP7B gene. His asymptomatic sibling is evaluated for family screening. Which of the following is the most appropriate test to screen this first-degree relative? (Q890269)

A. Serum ceruloplasmin measurement

B. 24-hour urinary copper excretion

C. Targeted genetic testing for the familial ATP7B mutation

D. Slit-lamp examination for Kayser-Fleischer rings

See Answer in Part B → Q8

@Neet_pg_bot

Q9: Which of the following is not typically associated with developing fatty liver disease? (Q845639)

A. Hepatitis B

B. Hepatitis C

C. Type 2 diabetes

D. Alcoholism

See Answer in Part B → Q9

@Neet_pg_bot

Q10: Which of the following is typically observed in liver biopsy findings of acute hepatitis A infection? (Q845638)

A. Interface hepatitis

B. Councilman bodies

C. Ground glass hepatocytes

D. Bridging fibrosis

See Answer in Part B → Q10

@Neet_pg_bot

Q11: What is the most likely autoantibody detected in Type I autoimmune hepatitis (AIH)? (Q845636)

A. Anti-LKM 1

B. Anti-smooth muscle antibodies (ASMA)

C. Anti-Liver Cytosol 1 (ACL-1)

D. Anti-cyclic citrullinated peptide (anti-CCP)

See Answer in Part B → Q11

@Neet_pg_bot

Q12: A 45-year-old male with diabetes mellitus presents with fatigue and abdominal discomfort. He denies any history of alcohol consumption. Laboratory tests show elevated serum AST and ALT levels. Imaging reveals hepatic steatosis. Which of the following is consistent with the patient's presentation? (Q845635)

A. AST/ALT > 2 with obesity

B. AST/ALT > 2 without alcohol intake

C. AST/ALT < 1 with diabetes mellitus

D. AST/ALT < 1 without dyslipidemia

See Answer in Part B → Q12

@Neet_pg_bot

Q13: Which of the following changes is reversible with alcohol abstinence? (Q845633)

A. Perivenular fibrosis

B. Periportal fibrosis

C. Bridging fibrosis

D. Micronodular cirrhosis

See Answer in Part B → Q13

@Neet_pg_bot

Q14: Which cells are primarily involved in the fibrosis in liver cirrhosis? (Q845617)

A. Kupffer cells

B. Pit cells

C. Stellate cells

D. Hepatocytes

See Answer in Part B → Q14

Q15: A 51-year-old male with a history of chronic alcohol use presents with fatigue, abdominal discomfort, and unintentional weight loss. A biopsy of the liver was done. Which of the following histopathological features is characteristic of the condition depicted in the biopsy image? (Q845631)

A. Mallory-Denk bodies

B. Ground-glass hepatocytes

C. Councilman bodies

D. Glycogenated hepatocytes

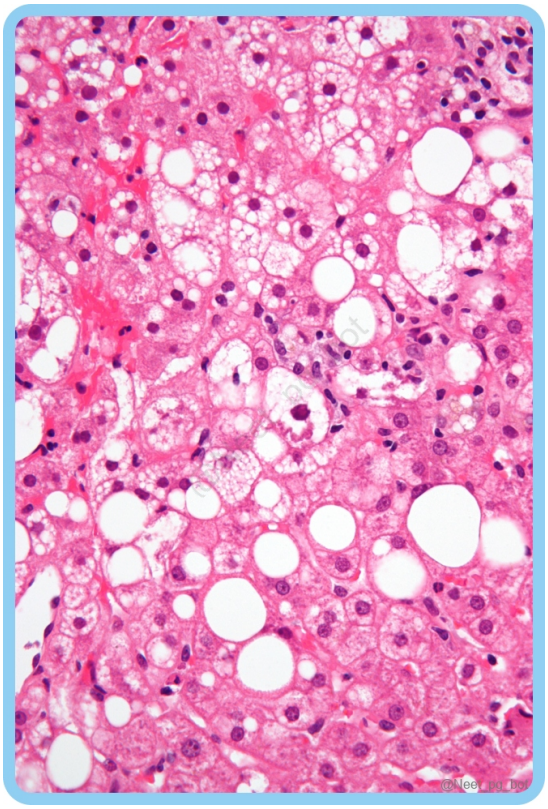

See Answer in Part B → Q15

Q16: A 60-year-old male presents with abdominal distension and jaundice. Examination reveals hepatosplenomegaly. Lab tests show elevated liver enzymes and decreased albumin levels. Imaging shows nodules <3mm throughout the liver. Which of the following conditions can present with these findings? (Q845629)

A. Viral hepatitis

B. Drug-induced hepatitis

C. Hemochromatosis

D. Wilson disease

See Answer in Part B → Q16

@Neet_pg_bot

Q17: Which of the following is the manifestation of increased estrogen levels in Cirrhosis? (Q845628)

A. Increased PT and aPTT

B. Flapping tremors

C. Palmar erythema

D. Jaundice

See Answer in Part B → Q17

@Neet_pg_bot

Q18: Which of the following stains would be most useful for highlighting collagen deposition in the fibrotic areas of the liver? (Q845626)

A. Periodic acid-Schiff (PAS) stain

B. Masson's trichrome stain

C. Masson's fontana stain

D. Congo red stain

See Answer in Part B → Q18

@Neet_pg_bot

Q19: Which type of collagen is predominantly involved in the fibrotic process of cirrhosis? (Q845625)

A. Collagen Type I and III

B. Collagen Type I and IV

C. Collagen Type II and III

D. Collagen Type II and IV

See Answer in Part B → Q19

@Neet_pg_bot

Q20: A 45-year-old male presents with fatigue, pruritus, and jaundice. He has a history of ulcerative colitis. Laboratory tests reveal elevated liver enzymes and conjugated hyperbilirubinemia. MRCP and Histopathological findings from liver biopsy are given below. Which condition is most likely responsible for these findings? (Q845624)

A. Clonorchis/Opisthorchis infection

B. Primary Biliary Cholangitis

C. Primary Sclerosing Cholangitis

D. Biliary stone obstruction

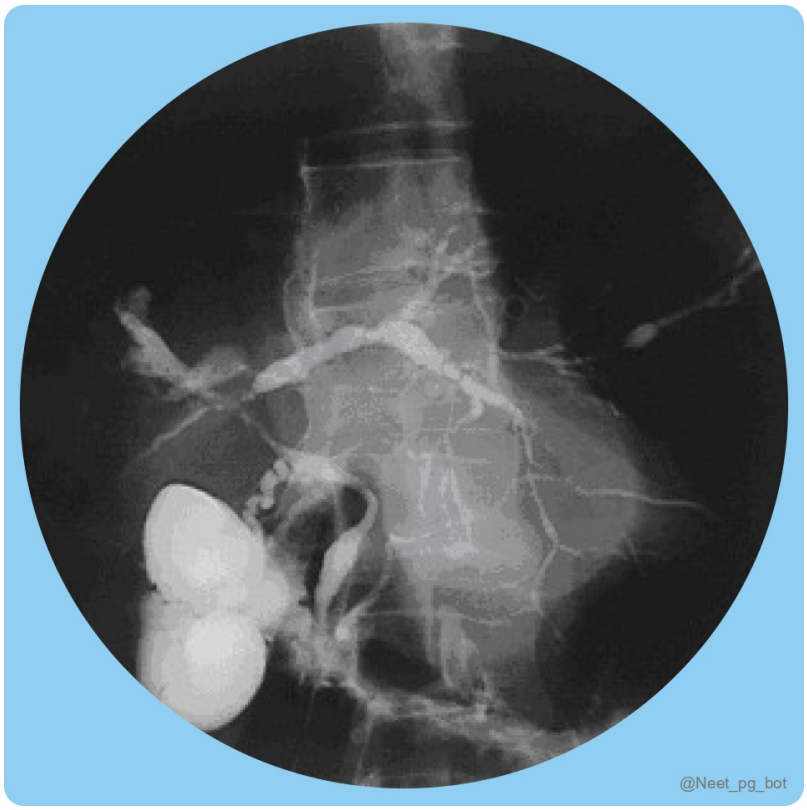

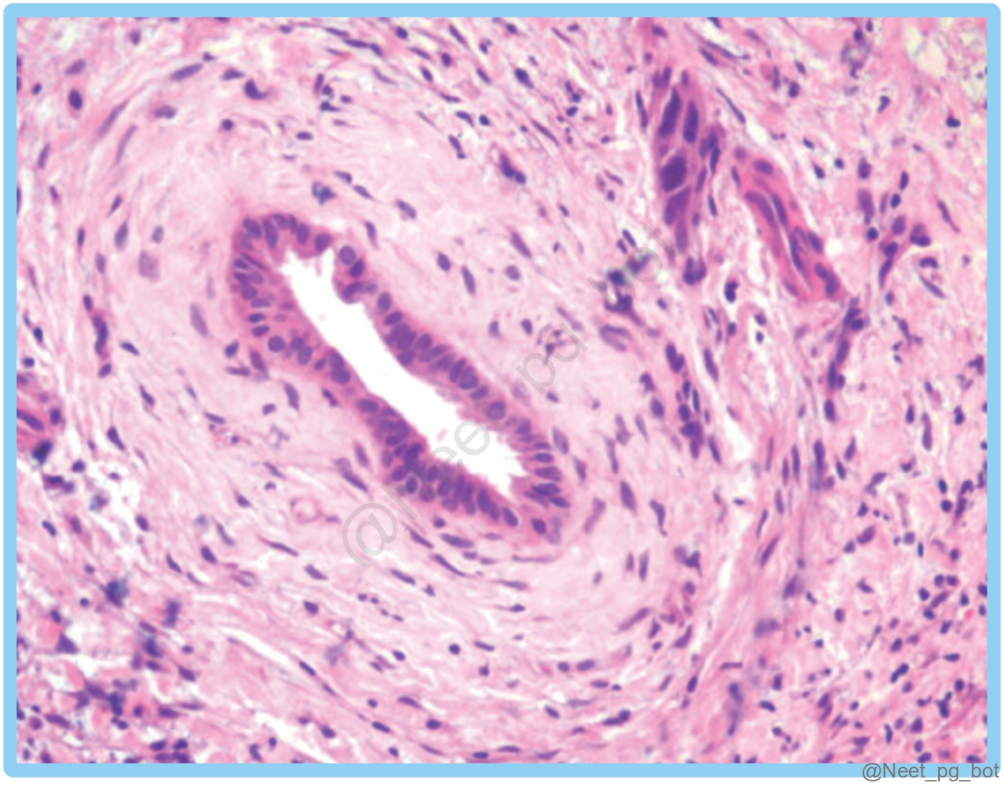

See Answer in Part B → Q20

@Neet_pg_bot

Q21: A 35-year-old male presents with chronic jaundice and mild abdominal discomfort. Examination revealed hepatomegaly. Lab tests indicate elevated levels of direct bilirubin. Upon liver biopsy, a pigmented liver is observed. What is the most likely underlying mechanism for these clinical and pathological findings? (Q845623)

A. Deficiency of UDP glucuronosyl transferase (UGT)

B. OATP transporter defect

C. MRP2 (Multidrug resistance-associated protein 2) defect

D. Deficiency of biliverdin reductase

See Answer in Part B → Q21

@Neet_pg_bot

Q22: A 2-week-old infant presents with persistent jaundice since birth and markedly elevated unconjugated bilirubin levels (>20 mg/dL) despite exposure to sunlight. Genetic testing confirms homozygosity for a specific mutation. What is the likely diagnosis? (Q845622)

A. Criggler-Najjar syndrome type 1

B. Criggler-Najjar syndrome type 2

C. Gilbert syndrome

D. Rotor syndrome

See Answer in Part B → Q22

@Neet_pg_bot

Q23: Which change can be seen in a structure that connects hepatocytes with cholangiocytes? (Q845620)

A. Liver regeneration

B. Amyloid deposition

C. Bile synthesis

D. Fibrosis

See Answer in Part B → Q23

@Neet_pg_bot

Q24: Which zone of the liver lobule is primarily affected by toxins and drug metabolism? (Q845619)

A. Zone 1 (periportal zone)

B. Zone 2 (midzonal zone)

C. Zone 3 (centrilobular zone)

D. Entire lobule uniformly

See Answer in Part B → Q24

@Neet_pg_bot

Q25: Which of the following cytokines is not typically involved in promoting fibrogenesis and hepatic stellate cell activation in chronic liver diseases? (Q845618)

A. Interleukin-6 (IL-6)

B. Platelet-Derived Growth Factor (PDGF)

C. Interleukin-10 (IL-10)

D. Transforming Growth Factor Beta (TGF-β)

See Answer in Part B → Q25

@Neet_pg_bot

• [10_Liver_ Biliary System and Pancreas] 045 Hepatobiliary Pathology-Ii

« Back to Folder Directory

[10_Liver_ Biliary System and Pancreas] 045 Hepatobiliary Pathology-Ii — Quick Jump

Q1 (p. 477) *Q2 (p. 477)* *Q3 (p. 478)* *Q4 (p. 479)* *Q5 (p. 480)* *Q6 (p. 480)*
Q7 (p. 481) *Q8 (p. 482)* *Q9 (p. 483)* *Q10 (p. 484)* *Q11 (p. 484)* *Q12 (p. 485)*
Q13 (p. 486)

Q1: Which of the following mutations is responsible for hereditary haemochromatosis? (Q845720)

A. ATP7B mutation

B. HFE mutation

C. SERPINA 1 mutation

D. UGT1A1 mutation

See Answer in Part B → Q1

@Neet_pg_bot

Q2: A 48-year-old man comes to the OPD with complaints of excessive thirst, excessive micturition, and increased hunger. He also states that his skin colour has changed in the past six months. He is icteric on examination, and his skin examination reveals findings similar to those in the image below. What is the most likely cause of the change in his skin colour? (Q845722)

A. Excessive melanin production due to adrenal insufficiency

B. Excessive deposition of melanin and iron in the skin

C. Insulin resistance

D. Excessive deposition of bilirubin in the skin



See Answer in Part B → Q2

@Neet_pg_bot

Q3: A 38-year-old female presents with fatigue, joint pain, and bronze skin pigmentation. Labs show a heterozygous mutation in the HFE gene. The histopathology image is shown below. Which of the following is the best screening test for this condition? (Q845725)

A. Serum ferritin level

B. Transferrin saturation

C. Liver function tests

D. Genetic testing for the HFE gene

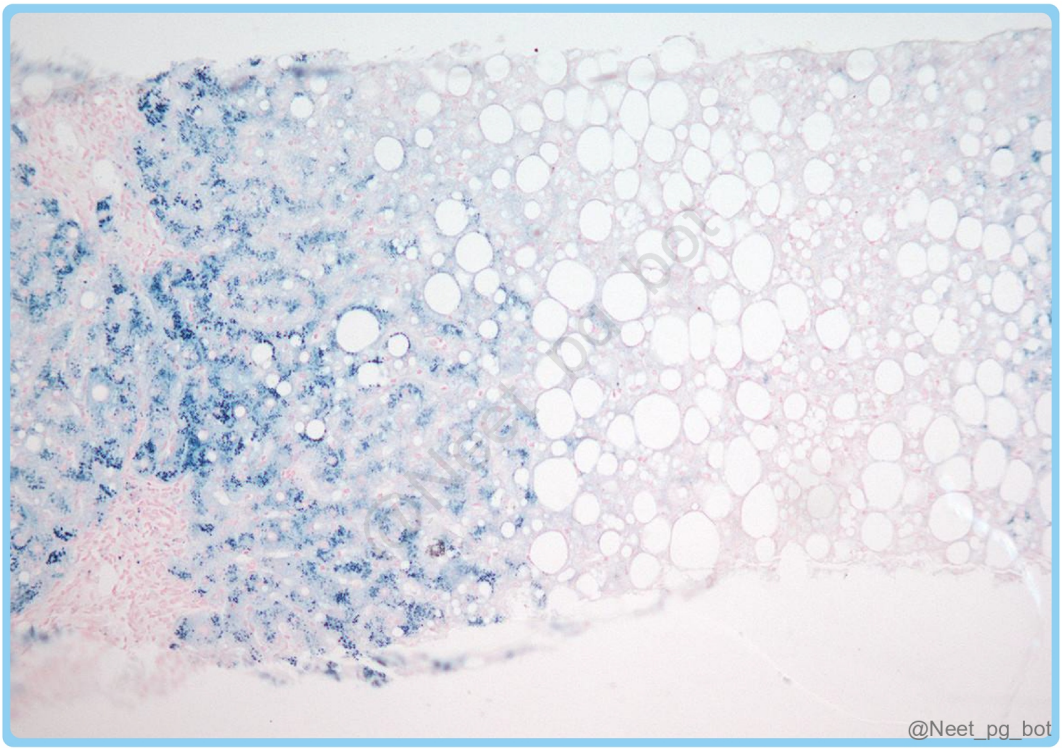

See Answer in Part B → Q3

@Neet_pg_bot

Q4: A 25-year-old patient presents with a history of tremors, dysarthria, and personality changes. Serum ceruloplasmin levels were found to be low. Based on the image below, what ocular finding is associated with the underlying condition? (Q845727)

A. Arcus senilis

B. Kayser-Fleischer rings

C. Roth spots

D. Horner's syndrome

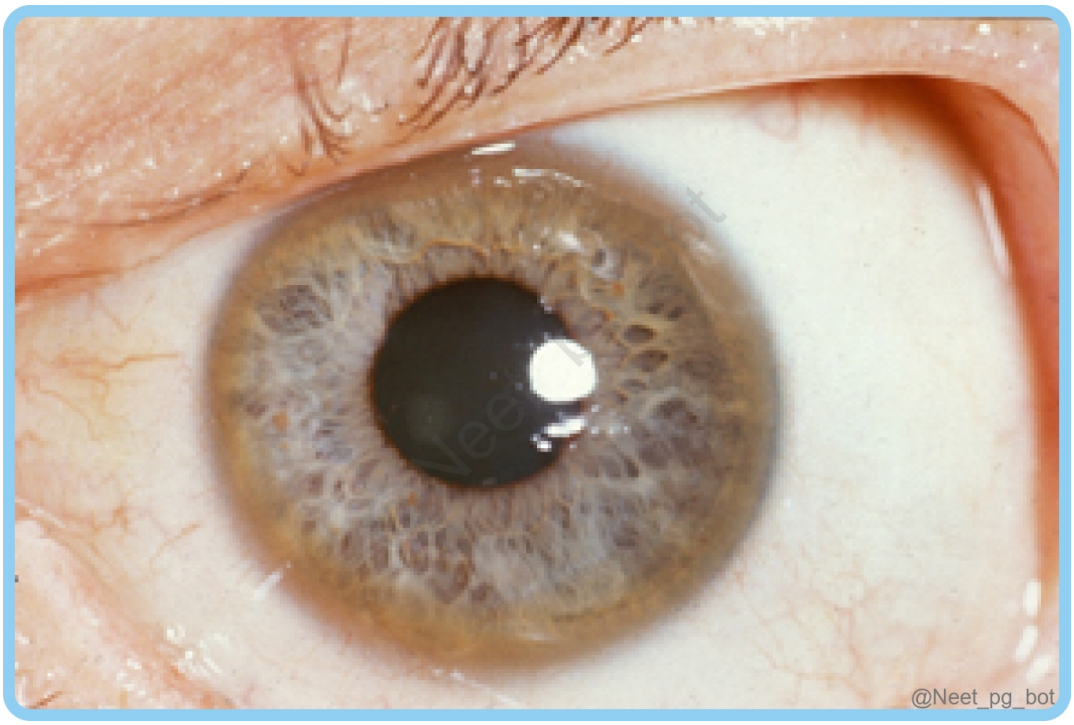

See Answer in Part B → Q4

@Neet_pg_bot

Q5: Which of the following tests is the most specific for confirming the diagnosis of Wilson’s Disease? (Q845730)

A. Serum Ceruloplasmin

B. Urinary excretion of copper

C. LFT

D. Liver Biopsy

See Answer in Part B → Q5

@Neet_pg_bot

Q6: Which special stain is commonly used to aid in the diagnosis of Wilson's disease? (Q845731)

A. Oil Red O stain

B. Periodic acid-Schiff (PAS) stain

C. Rubeanic acid stain

D. Prussian blue stain

See Answer in Part B → Q6

@Neet_pg_bot

Q7: A 50-year-old male presents with a history of chronic alcohol abuse and complains of right upper quadrant abdominal pain. On examination, hepatomegaly is noted. Laboratory investigations show elevated liver enzymes. Gross feature of the liver has a characteristic mottled appearance. Based on these findings and the image below, what is the most likely diagnosis? (Q845733)

A. Cirrhosis

B. Hepatitis

C. Nutmeg Liver

D. Liver Abscess



See Answer in Part B → Q7

@Neet_pg_bot

Q8: A 25-year-old female presents with fatigue, jaundice, and abdominal pain. On examination, hepatomegaly is noted. Hepatocytes show globular inclusions which are strongly periodic acid–Schiff (PAS)-positive. Her sibling died of the same liver condition a few years back. What is the primary function of the enzyme implicated in this condition ? (Q845735)

A. Inhibits neutrophil elastase

B. Stimulates neutrophil elastase

C. Stimulates matrix metalloproteinase activity

D. Regulates aminotransferase activity

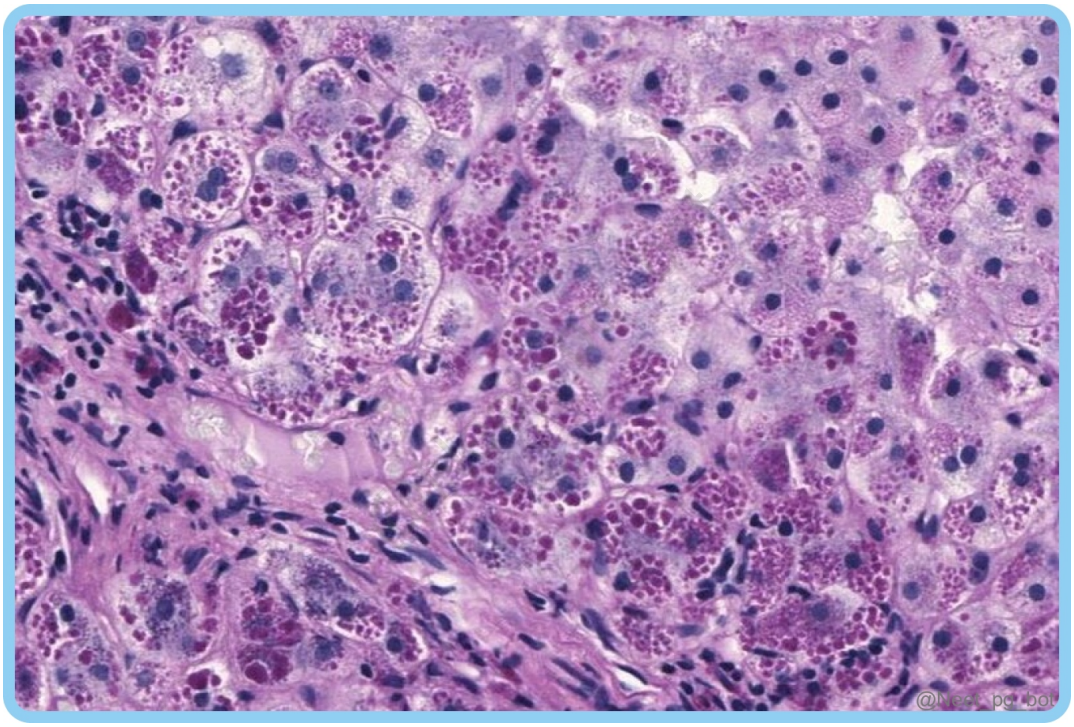

See Answer in Part B → Q8

@Neet_pg_bot

Q9: A 50-year-old patient with a history of recurrent biliary colic and cholangitis undergoes cholecystectomy. Multiple stones are retrieved intraoperatively, and an image of the stones is provided for reference. Which of the following is true about the type of pigmented stones likely seen in this patient? (Q845738)

A. Predominantly found in western populations

B. Associated with metabolic syndrome

C. Found in sterile bile

D. Seen in obesity



See Answer in Part B → Q9

@Neet_pg_bot

Q10: All the following infections are associated with an increased risk of pigmented gallstones, except? (Q845740)

A. Escherichia coli

B. Ascaris lumbricoides

C. Clonorchis sinensis

D. Aspergillus flavus

See Answer in Part B → Q10

@Neet_pg_bot

Q11: Which of the following conditions is not a complication associated with gallstones? (Q845741)

A. Acute pancreatitis

B. Gall bladder carcinoma

C. Bouveret syndrome

D. Budd-Chiari syndrome

See Answer in Part B → Q11

@Neet_pg_bot

Q12: A 45-year-old patient presents to the OPD with severe right upper quadrant pain radiating to the right shoulder, accompanied by nausea and vomiting. Clinical examination revealed a positive result for a clinical test shown in the image down below. An ultrasound of the abdomen shows an enlarged and tense gallbladder. Which of the following findings is most likely associated with this patient's condition? (Q845742)

A. Xanthogranulomatous cholecystitis

B. Rokitansky-Aschoff sinuses

C. Subserosal fibrosis

D. Subserosal haemorrhages



See Answer in Part B → Q12

@Neet_pg_bot

Q13: Which condition is characterised by extensive dystrophic calcification of the gallbladder wall? (Q845743)

A. Porcelain gallbladder

B. Gangrenous cholecystitis

C. Acute cholecystitis

D. Hyalinizing cholecystitis

See Answer in Part B → Q13

@Neet_pg_bot

• [10_Liver_ Biliary System and Pancreas] 046 Hepatic Tumors And Pancreas

« Back to Folder Directory

[10_Liver_ Biliary System and Pancreas] 046 Hepatic Tumors And Pancreas — Quick Jump

Q1 (p. 487) *Q2 (p. 487)* *Q3 (p. 488)* *Q4 (p. 488)* *Q5 (p. 488)* *Q6 (p. 489)*
Q7 (p. 489) *Q8 (p. 490)* *Q9 (p. 490)* *Q10 (p. 491)* *Q11 (p. 491)* *Q12 (p. 492)*
Q13 (p. 493)

Q1: Which of the following is the most common benign tumor of the liver? (Q845809)

A. Cavernous hemangioma

B. Hepatoblastoma

C. Klatskin tumor

D. Hepatic adenoma

See Answer in Part B → Q1

@Neet_pg_bot

Q2: A 30-year-old woman presents to the emergency department with severe abdominal pain and signs of hypovolemic shock. She has a history of long-term contraceptive pill use. Imaging studies reveal a large hepatic mass with evidence of haemorrhage. Laboratory tests show elevated liver enzymes. What is the likely diagnosis based on her clinical presentation and medical history? (Q845810)

A. Angiosarcoma

B. Hepatic adenoma

C. Hepatoblastoma

D. Cholangiocarcinoma

See Answer in Part B → Q2

@Neet_pg_bot

Q3: A 25-year-old sexually active woman who has been on OCP for the past 4 years comes to the ER with severe abdominal pain and features of hypovolemic shock. Ultrasound reveals a large hemorrhagic hepatic mass and fluid in the peritoneum. What is the most probable diagnosis? (Q845811)

A. Hepatocyte nuclear factor 1-alpha (HNF1α)-inactivated hepatocellular adenoma

B. β-Catenin–activated hepatocellular adenoma

C. Nodular regenerative hyperplasia (NRH).

D. Focal Nodular Hyperplasia

See Answer in Part B → Q3

@Neet_pg_bot

Q4: Which of the following conditions presents with a central stellate scar? (Q845812)

A. Metastatic liver lesion

B. Focal Nodular Hyperplasia

C. Liver abscess

D. Liver Cirrhosis

See Answer in Part B → Q4

@Neet_pg_bot

Q5: All of the following increases the risk of Hepatocellular carcinoma, except? (Q845813)

A. Alcohol

B. NASH (Non-Alcoholic Steatohepatitis)

C. Hemochromatosis

D. Gilbert's syndrome

See Answer in Part B → Q5

@Neet_pg_bot

Q6: Which of the following is true regarding the fibrolamellar variant of hepatocellular carcinoma ? (Q845814)

A. Not associated with Hepatitis B, C

B. Increased AFP levels

C. Hematogenous spread

D. Poor prognosis

See Answer in Part B → Q6

@Neet_pg_bot

Q7: A patient with a longstanding history of alcoholism is admitted with jaundice, abdominal distension & weight loss. A liver biopsy done during his previous admission showed the following changes, and suspicion of malignant transformation is raised now. Elevation of which of the following markers will support the differential? HepPar-1 Alpha-fetoprotein (AFP) Glypican-3 (GPC3) CA 15-3 Tissue polypeptide antigen (Q845816)

A. 1, 2 and 4

B. 1, 2 and 3

C. 2, 4 and 5

D. 2, 3 and 4

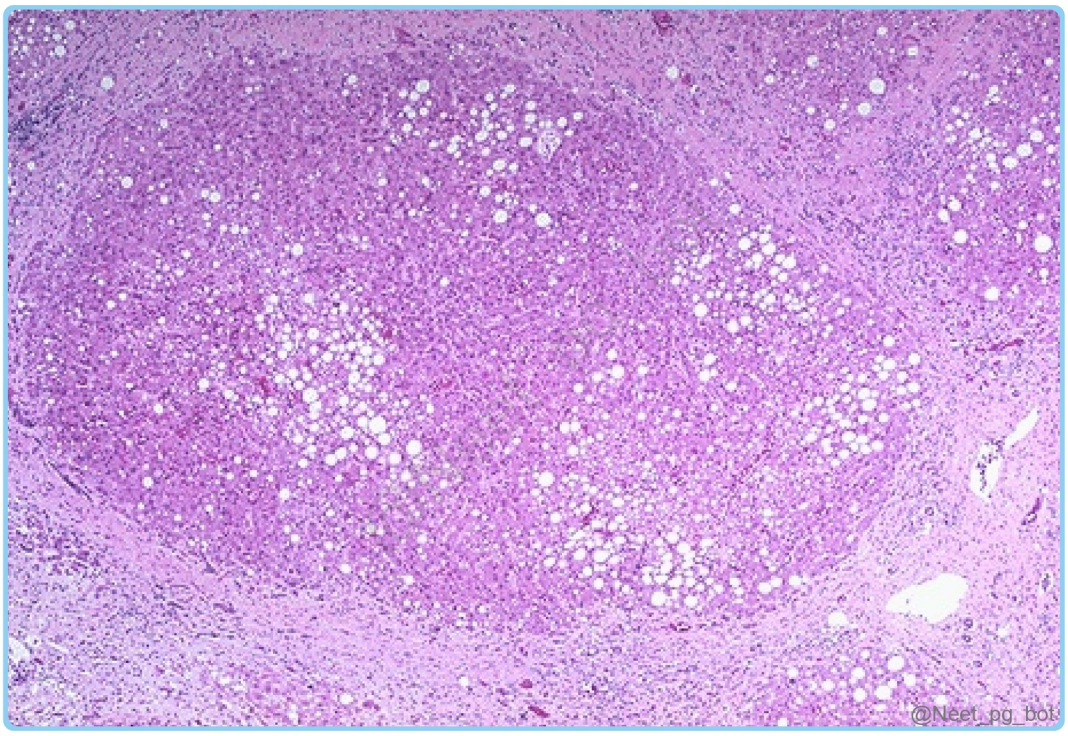

See Answer in Part B → Q7

@Neet_pg_bot

Q8: A 2-year-old child presented with progressive jaundice for the past 2 months. Initial investigations were done, and subsequent histopathological examination of liver biopsy showed changes consistent with hepatoblastoma. Which of the following additional biomarkers will be elevated in this child? (Q845817)

A. CA 19-9

B. AFP

C. Neurotensin

D. CEA

See Answer in Part B → Q8

@Neet_pg_bot

Q9: Which of the following is not a genetic mutation associated with hereditary pancreatitis? (Q845818)

A. PRSS1

B. SPINK1

C. CFTR

D. BRCA1

See Answer in Part B → Q9

@Neet_pg_bot

Q10: Which of the following factors is most strongly associated with the development of acute pancreatitis in adult males? (Q845819)

A. Gallstone disease

B. Alcohol

C. Trauma

D. HIV infection

See Answer in Part B → Q10

@Neet_pg_bot

Q11: A 45-year-old female presented with a history of type-2 diabetes and hypertension presented to hospital with a 3 day history of generalized weakness, diffuse abdominal pain and altered mental status. Upon examination, her GCS was 10 with diffuse abdominal tenderness. Investigations showed elevated glucose, creatinine, lipase, and calcium levels. Histopathological examination suggests which of the following associated findings in this patient? (Q845820)

A. Pancreatic hyperplasia

B. Destruction of pancreatic beta cells

C. Intracellular activation of enzymes

D. Fibrosis of pancreatic ducts

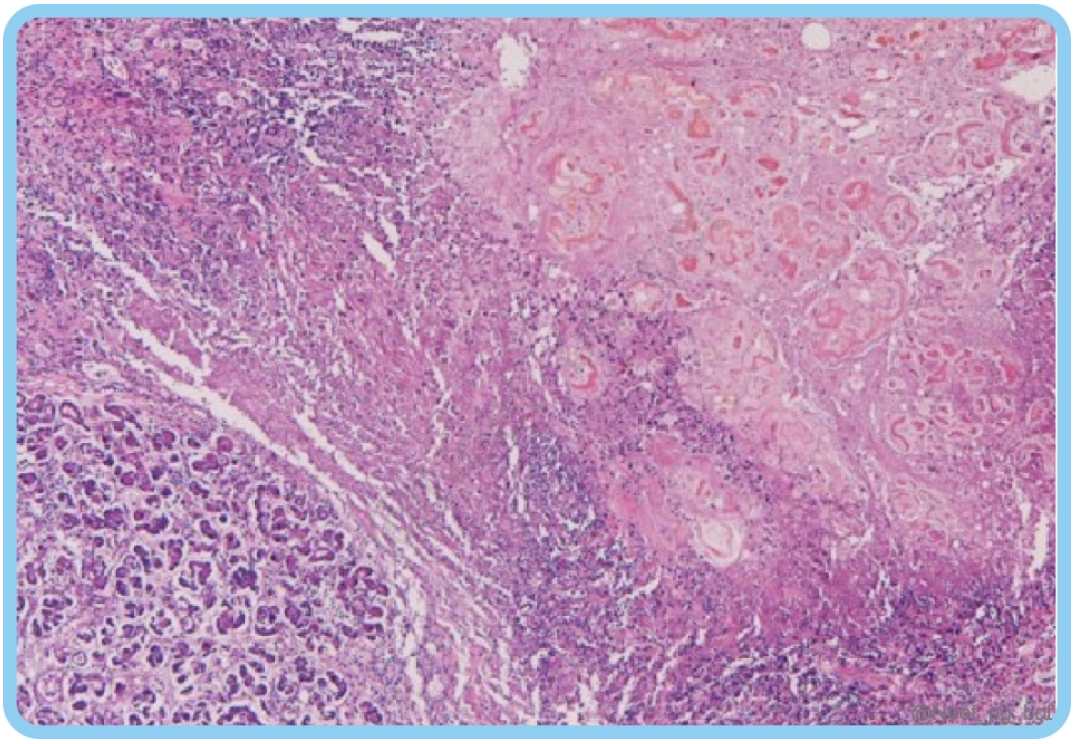

See Answer in Part B → Q11

@Neet_pg_bot

Q12: A female patient presents with progressive jaundice and weight loss for the past six months. She also complains of low grade upper abdominal pain. Lab investigation revealed a random blood sugar of 320mg/dL and a raised serum Ig-G4 levels and a USG scan showed a mass like lesion over the head of pancreas. Based on these findings which of the following is the most likely finding in the histopathological examination ? (Q846627)

A. Pleomorphic cuboidal to columnar epithelial cells

B. Necrotic changes in the acini and ducts

C. Honeycombing appearance with cuboidal epithelium

D. Swirling fibrosis with inflammation of veins

See Answer in Part B → Q12

@Neet_pg_bot

Q13: Which of the following statements about pancreatic cystic neoplasms is true? (Q846628)

A. Serous cystadenomas are commonly malignant.

B. Mucinous cystic neoplasms (MCNs) occur predominantly in males.

C. Intraductal papillary mucinous neoplasms (IPMNs) have a risk of malignant transformation.

D. Mucinous cystic neoplasms typically have a central scar on imaging.

See Answer in Part B → Q13

@Neet_pg_bot

• [10_Liver_ Biliary System and Pancreas] 047 Previous Year Questions

« Back to Folder Directory

[10_Liver_ Biliary System and Pancreas] 047 Previous Year Questions — Quick Jump

Q1 (p. 494)	*Q2 (p. 494)*	*Q3 (p. 495)*	*Q4 (p. 495)*	*Q5 (p. 496)*	*Q6 (p. 496)*
Q7 (p. 497)	*Q8 (p. 497)*	*Q9 (p. 497)*	*Q10 (p. 498)*	*Q11 (p. 499)*	*Q12 (p. 499)*
Q13 (p. 500)	*Q14 (p. 500)*	*Q15 (p. 501)*	*Q16 (p. 502)*		

Q1: A 58-year-old male with history of multiple sexual partners presented with anorexia and jaundice. The biopsy shows ground-glass opacity in the cells. What is the most probable diagnosis? (Q866753)

A. Hepatitis A

B. Hepatitis B

C. Hepatitis C

D. Hepatitis D

See Answer in Part B → Q1

@Neet_pg_bot

Q2: A cut section of liver is shown below. What is the likely diagnosis? (Q866392)

A. Hepatic adenoma

B. Hepatocellular carcinoma

C. Focal nodular hyperplasia

D. Hemangioma

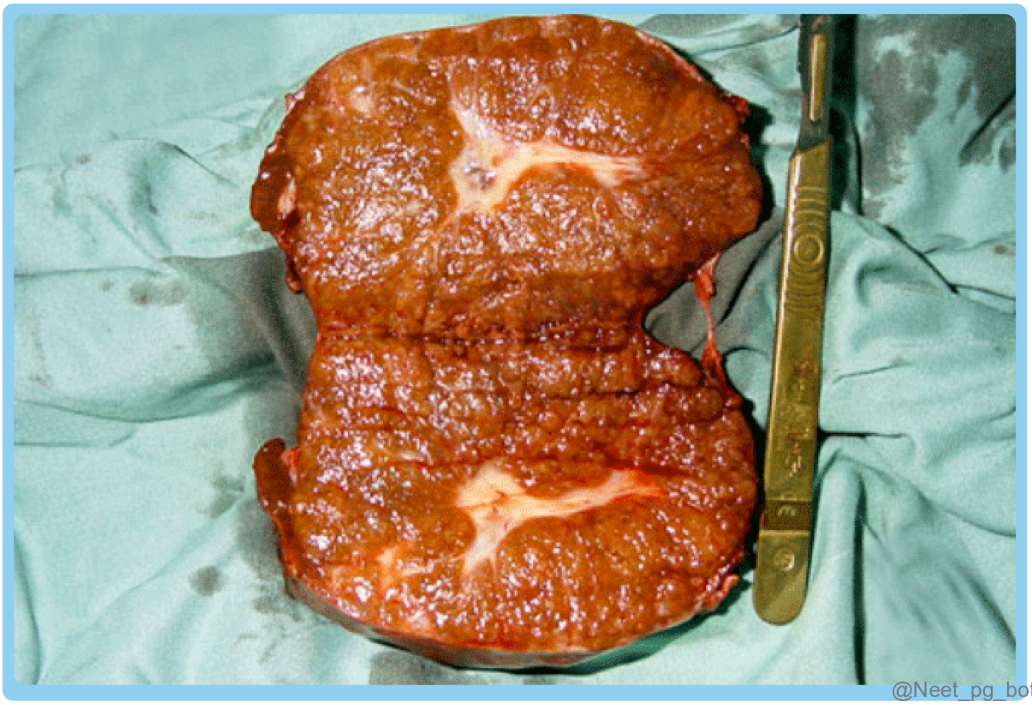

See Answer in Part B → Q2

@Neet_pg_bot

Q3: An alcoholic patient presents with lower back pain and fever. During history-taking, he mentions experiencing similar episodes in the past with elevated amylase levels. Which type of necrosis is likely to be present in the peri-pancreatic fat? (Q860168)

A. Fibrinoid necrosis

B. Fat necrosis

C. Coagulative necrosis

D. Liquefactive necrosis

See Answer in Part B → Q3

@Neet_pg_bot

Q4: Which of the following is associated with conjugated hyperbilirubinemia? (Q860186)

A. Crigler Najar -1 syndrome

B. Crigler Najar -2 syndrome

C. Gilbert syndrome

D. Dubin-Johnson syndrome

See Answer in Part B → Q4

@Neet_pg_bot

Q5: A 45-year-old patient with a history of chronic liver disease presents with symptoms of nausea, vomiting, edema, and ascites. On examination, his liver function tests are severely deranged. Further investigation reveals a diagnosis of hepatocellular carcinoma. The pathogenesis of this condition is most likely related to: (Q820599)

A. Benzol

B. Arsenic

C. Aflatoxin

D. Vinyl chloride

See Answer in Part B → Q5

@Neet_pg_bot

Q6: What is the most likely diagnosis for a 25-year-old male who presented with fever and has the following viral marker results: HBsAg: Positive and IgM anti-HBc antibody: Positive (Q830720)

A. Acute hepatitis

B. Chronic hepatitis

C. Window period

D. Persistent infection

See Answer in Part B → Q6

@Neet_pg_bot

Q7: Which of the following is the best serum marker for alcoholic liver disease? (Q854711)

A. SGPT

B. SGOT

C. Carbohydrate-deficient transferrin (CDT)

D. Serum Bilirubin

See Answer in Part B → Q7

@Neet_pg_bot

Q8: Which of the following cells plays a key role in phagocytosis and chronic inflammation in the liver? (Q858141)

A. Hepatocytes

B. Ito cells

C. Sinusoidal endothelial cells

D. Kupffer cells

See Answer in Part B → Q8

@Neet_pg_bot

Q9: A patient suffering from cholelithiasis underwent cholecystectomy. The image of the specimen is shown below. Which of the following is the correct diagnosis? (Q855934)

A. Chronic cholecystitis

B. Gallbladder cholesterol polyp

C. Carcinoma gallbladder

D. Strawberry gallbladder

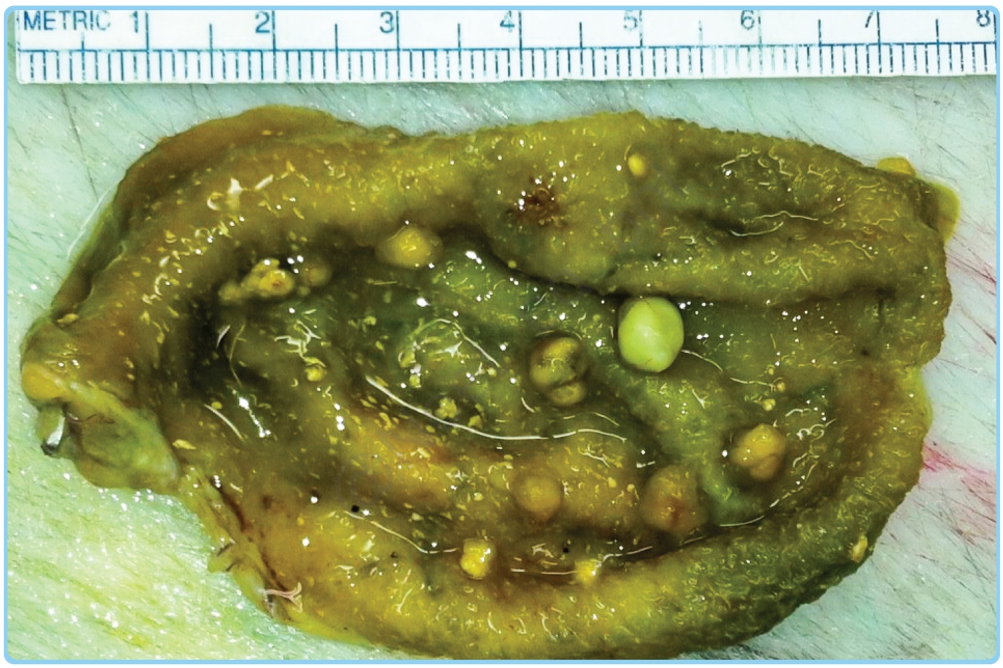

@Neet_pg_bot

See Answer in Part B → Q9

@Neet_pg_bot

Q10: What is the gene mutation seen in hemochromatosis? (Q857113)

A. HFE

B. PTEN

C. ATP7B gene

D. MRP2 protein

See Answer in Part B → Q10

@Neet_pg_bot

Q11: A 30-year-old female presenting with an unsteady gait, forgetfulness, labile moods, and Kayser-Fleischer rings was diagnosed with Wilson's disease. Which of the following options correctly indicates the gene mutated in this condition and its location? (Q857558)

A. ATP7B gene on chromosome 13

B. ATP7A gene on chromosome X (Xq21.1)

C. ATP7B gene on chromosome 17

D. ATP7A gene on chromosome 17

See Answer in Part B → Q11

@Neet_pg_bot

Q12: A patient with cirrhosis and ascites presented to you. The gross appearance of his liver is shown below. Which of the following is true about it? (Q855403)

A. Dark areas represent necrosis, white areas represent viable liver

B. Dark areas represent viable liver tissue, white areas represent necrosis

C. White areas represent central hepatocytes

D. Dark areas represent peri-portal hepatocytes

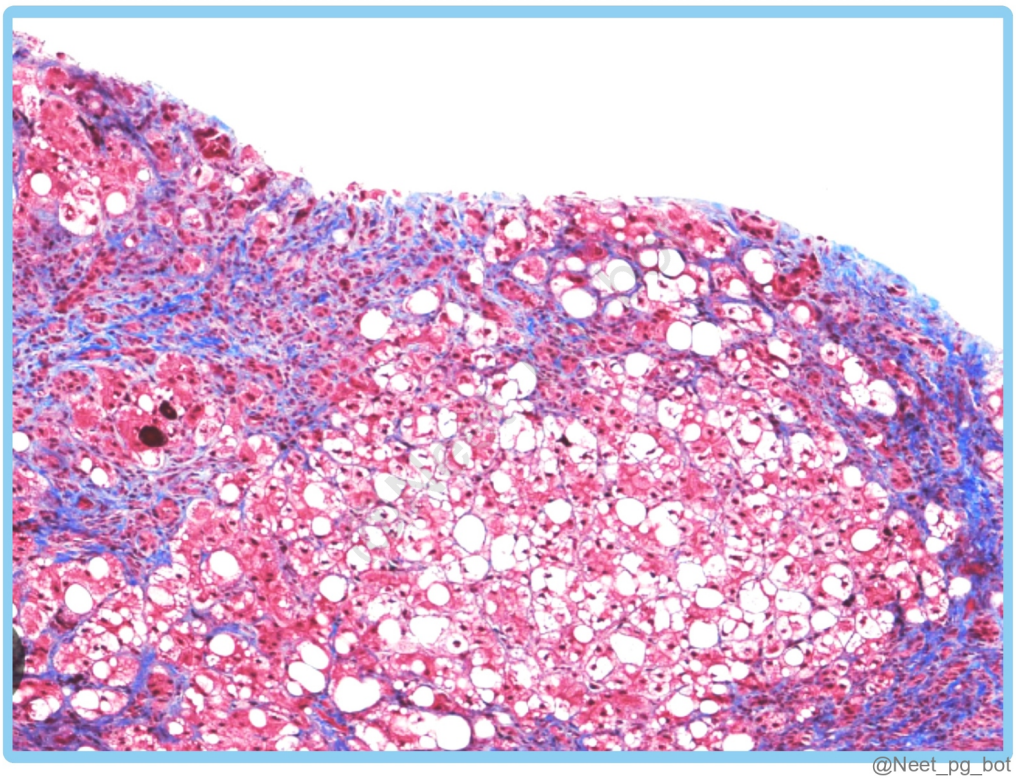

See Answer in Part B → Q12

@Neet_pg_bot

Q13: Which of the following is associated with hepatic angiosarcoma? (Q859271)

A. Iron

B. Copper

C. Zinc

D. Arsenic

See Answer in Part B → Q13

@Neet_pg_bot

Q14: Macrophages play an important role in phagocytosis and chronic inflammation. Which of the following cells perform the same function in the liver? (Q859301)

A. Hepatocytes

B. Merkel cells

C. Sinusoid all cells

D. Kupffer cells

See Answer in Part B → Q14

@Neet_pg_bot

Q15: A 55-year-old man is found to have hepatomegaly on physical examination. He also complains of having dark tan skin despite avoiding sun exposure . His liver microscopy is given on the slide below. What is this patient most likely suffering from? (Q793776)

A. Wilson’s disease

B. Autoimmune hepatitis

C. α-1 antitrypsin deficiency

D. Hemochromatosis

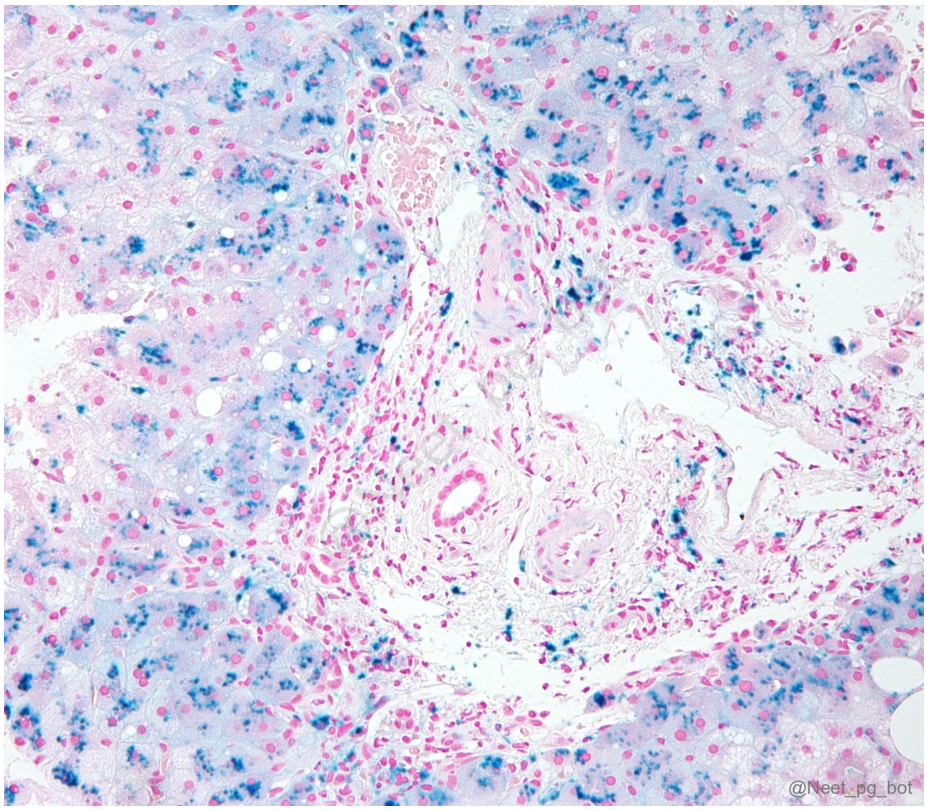

See Answer in Part B → Q15

@Neet_pg_bot

Q16: A health care worker has been found to be seropositive for HBsAg, HBeAg, and anti-HBc IgM, indicating an acute HBV infection with high infectivity. A liver biopsy in such cases is likely to show all the following except: (Q793793)

A. Ballooning change of hepatocytes

B. Ground glass hepatocytes

C. Focal or spotty necrosis

D. Confluent necrosis of hepatocytes

See Answer in Part B → Q16

@Neet_pg_bot

• [11_Renal System] 048 Basics Of Renal Pathology

« Back to Folder Directory

[11_Renal System] 048 Basics Of Renal Pathology — Quick Jump

Q1 (p. 503) *Q2 (p. 503)* *Q3 (p. 503)* *Q4 (p. 504)* *Q5 (p. 505)* *Q6 (p. 505)*
Q7 (p. 506) *Q8 (p. 507)* *Q9 (p. 507)* *Q10 (p. 508)* *Q11 (p. 508)* *Q12 (p. 509)*
Q13 (p. 509) *Q14 (p. 509)* *Q15 (p. 510)* *Q16 (p. 510)*

Q1: Which of the following statements regarding the glomerular basement membrane (GBM) is true? (Q845679)

A. The GBM is primarily composed of collagen type I and elastin.

B. The GBM is a selective barrier between the glomerular capillaries and Bowman's capsule.

C. Thickening of the GBM is a characteristic feature of minimal change disease.

D. The GBM is impermeable to large molecules such as albumin.

See Answer in Part B → Q1

@Neet_pg_bot

Q2: Which of the following kidney findings will be seen in malignant hypertension? (Q845680)

A. Putty kidney

B. Leather grain kidney

C. Flea-bitten kidney

D. Waxy kidney

See Answer in Part B → Q2

@Neet_pg_bot

Q3: A 60-year-old female presents with a history of recurrent urinary tract infections and lower abdominal pain. Upon physical examination, palpable masses are noted in the pelvis. Urinalysis reveals persistent pyuria. A biopsy was done on the bladder lesions, which is shown below. Which of the following conditions is most likely responsible for the patient's presentation? (Q845681)

A. Bladder carcinoma

B. Malakoplakia

C. Schistosomiasis

D. Tuberculous cystitis

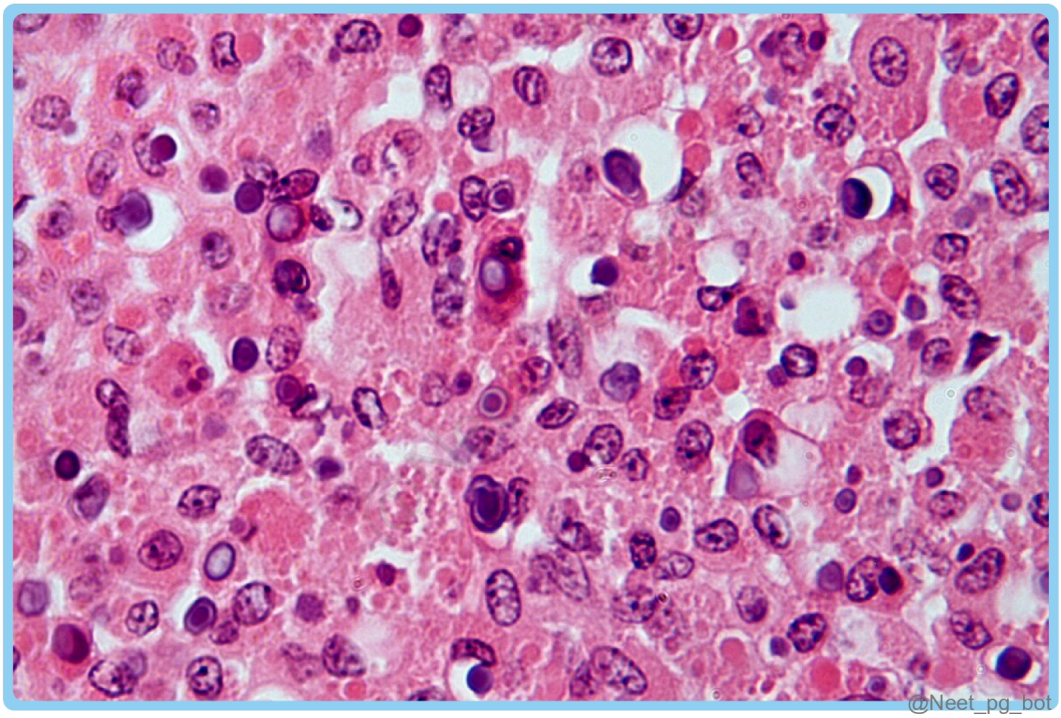

See Answer in Part B → Q3

@Neet_pg_bot

Q4: Which of the following statements are true regarding autosomal dominant polycystic kidney disease? 1) The gene associated with this condition is seen on chromosome 6. 2) The affected protein is fibrocystin. 3) It is associated with cyst formation in other organs. 4) The most common cause of death in these patients is

hypertensive heart disease. (Q845682)

A. 1,2,3,4

B. 3,4

C. 2,3

D. 2,3,4

See Answer in Part B → Q4

@Neet_pg_bot

Q5: Match the following types of renal crystals with their characteristics Types of Renal Crystals Characteristics 1. Calcium Oxalate Monohydrate A. Coffin lid-shaped crystals, commonly found in alkaline urine 2.. Uric Acid B. Rhomboid-shaped crystals, typically seen in acidic urine. 3. Cystine C. Dumbbell or ovoid-shaped crystals are often colourless in acidic urine. 4. . Struvite (Magnesium Ammonium Phosphate) D. Hexagonal plates, often associated with acidic urine (Q845683)

A. 1-D, 2-B, 3-C, 4-A

B. 1-A, 2-B, 3-D, 4-C

C. 1-C, 2-B, 3-D, 4-A

D. 1-C, 2-D, 3-B, 4-A

See Answer in Part B → Q5

@Neet_pg_bot

Q6: A 45-year-old woman presents with complaints of severe lower abdominal pain, dysuria, and hematuria. She has a history of recurrent urinary tract infections (UTIs). Urinalysis reveals a high pH of 8.5 and the presence of white blood cells. Microscopic examination of the urine sediment shows the following finding. Which of the following is the most likely underlying cause of the patient's current presentation? (Q845684)

A. Hypercalcemia

B. Hyperuricemia

C. Infection with urease-producing bacteria

D. Cystinuria



See Answer in Part B → Q6

@Neet_pg_bot

Q7: Match the following renal casts with the conditions they are associated with: Renal Cast Type Condition Associated 1. Hyaline casts A. Nephrotic syndrome 2. Muddy Granular casts B. Chronic Renal Failure 3. Waxy casts C. Acute tubular necrosis 4. Fatty casts D. Fever (Q845685)

A. 1-C, 2-A, 3-B, 4-D

B. 1-B, 2-D, 3-C, 4-A

C. 1-D, 2-C, 3-B, 4-A

D. 1-D, 2-A,3-C, 4-B

See Answer in Part B → Q7

@Neet_pg_bot

Q8: A 45-year-old male presents with confusion, nausea, and abdominal pain after consuming antifreeze due to stress. Urinalysis reveals elevated BUN and creatinine. Microscopic examination is shown below. Identify the type of cast. (Q845687)

A. Hyaline casts

B. Granular casts

C. Waxy casts

D. Muddy brown casts



See Answer in Part B → Q8

@Neet_pg_bot

Q9: All of the following are true about medullary sponge kidney except: (Q845692)

A. It is more common in adults.

B. It is characterised by dilated collecting ducts in the renal medulla.

C. It is caused by an autoimmune destruction of renal tubules.

D. Cysts are lined by cuboidal epithelium.

See Answer in Part B → Q9

@Neet_pg_bot

Q10: A 45-year-old man presents with generalised oedema and frothy urine. Laboratory evaluation shows hypoalbuminemia and hyperlipidemia. Urinalysis reveals heavy proteinuria. What is the minimum daily urinary protein loss required to define nephrotic syndrome in adults? (Q889840)

A. 2.5 g/day

B. 3 g/day

C. 3.5 g/day

D. 4 g/day

See Answer in Part B → Q10

@Neet_pg_bot

Q11: Which of the following mutations are associated with nephrotic syndrome? Nephrin Podocin ACTN4 INF2 TRPC6 (Q889842)

A. 1 and 2 only

B. 1, 2 and 5 only

C. 1, 2, 3 and 4 only

D. 1, 2, 3, 4 and 5

See Answer in Part B → Q11

@Neet_pg_bot

Q12: A 42-year-old man with nephrotic syndrome presents with generalised oedema and frothy urine. Laboratory tests reveal hypoalbuminemia and marked hyperlipidemia. He is noted to have an increased risk of thrombosis. Which of the following plasma proteins is increased in nephrotic syndrome? (Q889844)

A. Antithrombin III

B. Albumin

C. Fibrinogen

D. Immunoglobulin G

See Answer in Part B → Q12

@Neet_pg_bot

Q13: A 40-year-old man presents with nephrotic-range proteinuria. Renal biopsy shows focal and segmental glomerulosclerosis. You are reviewing conditions associated with secondary FSGS. Which of the following is not associated with FSGS? (Q889847)

A. Reflux nephropathy

B. Sickle cell disease

C. ACTN4 mutation

D. Minimal change disease

See Answer in Part B → Q13

@Neet_pg_bot

Q14: Which of the following FSGS variants is associated with the best prognosis, and which is associated with the worst prognosis? (Q889849)

A. Hilar variant - Best; Cellular variant - Worst

B. Tip lesion variant - Best; Collapsing variant - Worst

C. Collapsing variant - Best; Tip lesion variant - Worst

D. Cellular variant - Best; Hilar variant - Worst

See Answer in Part B → Q14

@Neet_pg_bot

Q15: Which of the following conditions is characterised by the absence of mesangial immune complex deposits? (Q889850)

A. IgA nephropathy

B. Lupus nephritis (Class II)

C. Henoch-Schönlein Purpura

D. Anti-GBM disease

See Answer in Part B → Q15

@Neet_pg_bot

Q16: A child with nephrotic syndrome undergoes serum protein electrophoresis. Which protein is increased? (Q889852)

A. Albumin

B. α1-antitrypsin

C. α2-macroglobulin

D. IgG

See Answer in Part B → Q16

@Neet_pg_bot

• [11_Renal System] 049 Nephritic And Nephrotic Syndromes

« Back to Folder Directory

[11_Renal System] 049 Nephritic And Nephrotic Syndromes — Quick Jump

Q1 (p. 511)	*Q2 (p. 512)*	*Q3 (p. 513)*	*Q4 (p. 513)*	*Q5 (p. 514)*	*Q6 (p. 515)*
Q7 (p. 516)	*Q8 (p. 517)*	*Q9 (p. 517)*	*Q10 (p. 518)*	*Q11 (p. 519)*	*Q12 (p. 519)*
Q13 (p. 520)	*Q14 (p. 520)*	*Q15 (p. 521)*	*Q16 (p. 522)*	*Q17 (p. 523)*	*Q18 (p. 524)*

Q1: A 9-year-old boy is brought to the clinic with swelling around the eyes, dark "tea-colored" urine, and decreased urine output. His mother reports that he had a skin infection (impetigo) about 3 weeks ago. On examination, he has mild periorbital edema and elevated blood pressure. Urinalysis shows RBC casts and mild proteinuria. Serum studies reveal low C3 complement levels. A renal biopsy is performed, and electron microscopy reveals following changes. Which of the following is the most likely diagnosis? (Q845704)

A. IgA nephropathy

B. Post-streptococcal glomerulonephritis

C. Membranous nephropathy

D. Minimal change disease

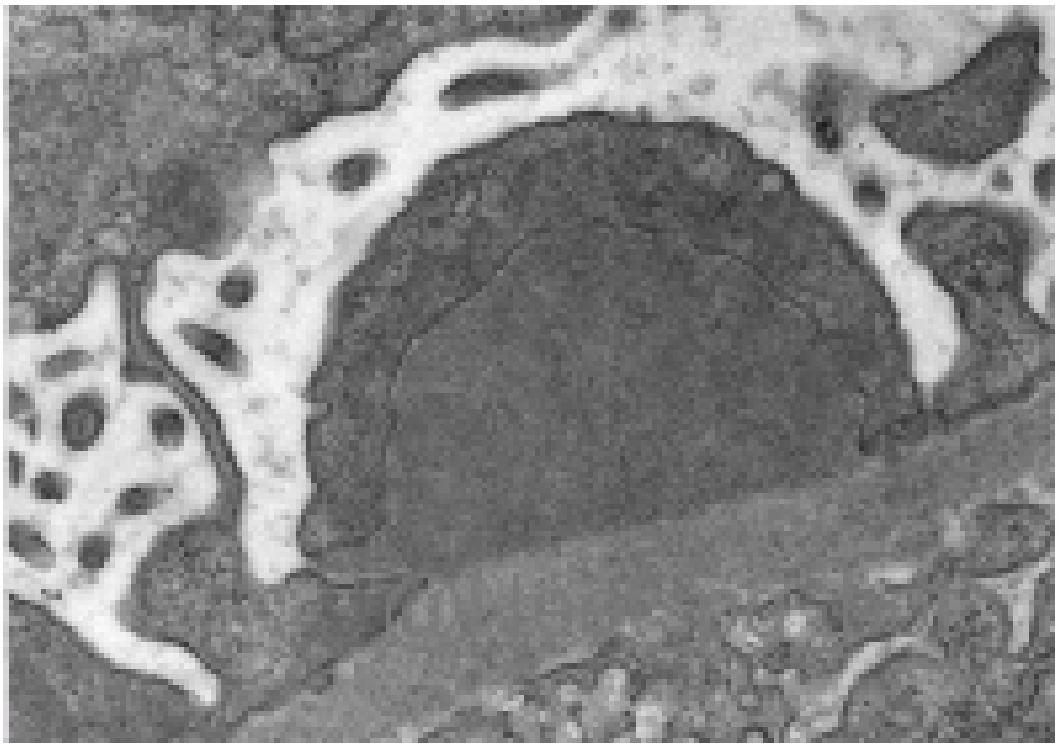

See Answer in Part B → Q1

@Neet_pg_bot

Q2: A 12-year-old male child presents to the clinic with a history of progressive hearing loss, blurred vision, and recurrent episodes of hematuria over the past few months.Electron microscopy reveals the 'basketweave' appearance of GBM. Which of the following morphological findings is responsible for this appearance? (Q846662)

A. Effacement of podocyte foot processes

B. Thickening of the glomerular basement membrane with subepithelial electron-dense deposits

C. Irregular thickening, thinning, and splitting of the glomerular basement membrane

D. Mesangial expansion with GBM thickening and eosinophilic nodular glomerulosclerosis

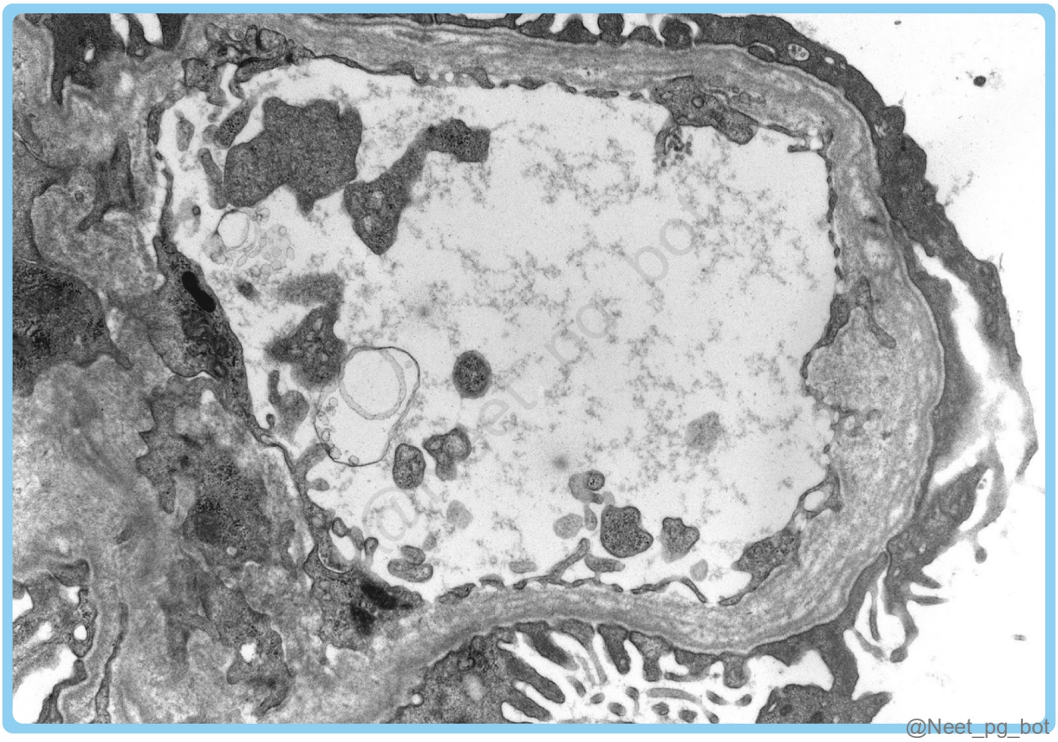

See Answer in Part B → Q2

@Neet_pg_bot

Q3: A 55-year-old patient with a history of poorly controlled diabetes presents with worsening kidney function. Upon examination, renal biopsy reveals glomerular changes consistent with diabetic nephropathy. Which histological findings would be least likely to be observed in the glomeruli of this patient's kidney biopsy? (Q846670)

A. Kimmelstiel-Wilson nodule

B. Diffuse glomerulosclerosis

C. Arteriolar hyalinosis

D. Armani-Ebstein lesion

See Answer in Part B → Q3

@Neet_pg_bot

Q4: A 32-year-old female presents with a history of joint pain, skin rash, and recent onset of shortness of breath. Lab investigations reveal elevated anti-double-stranded DNA antibodies and low complement levels. A kidney biopsy shows >50% involvement of glomeruli with wire loop lesions on light microscopy. Which type of lupus nephritis is most likely observed in the biopsy findings? (Q846669)

A. Class III

B. Class IV

C. Class V

D. Class VI

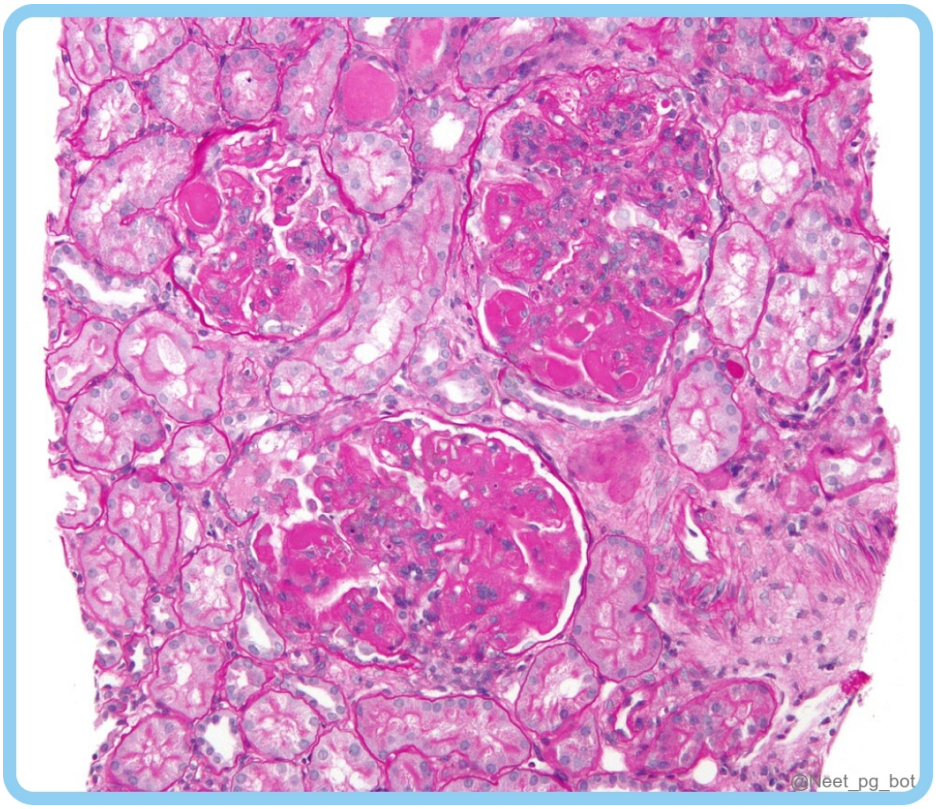

See Answer in Part B → Q4

@Neet_pg_bot

Q5: A 45-year-old male presents with generalised oedema and frothy urine. Laboratory investigations reveal significant proteinuria and hypoalbuminemia. A kidney biopsy reveals diffuse thickening of GBM, a spike and dome pattern on the

silver stain and subepithelial deposits on electron microscopy. Which of the following genetic mutations is most likely associated with this condition? (Q846668)

A. Mutation in PLA2R

B. Mutation in LAMB2 gene

C. Mutations in APOL1 gene

D. Mutations in CFH gene

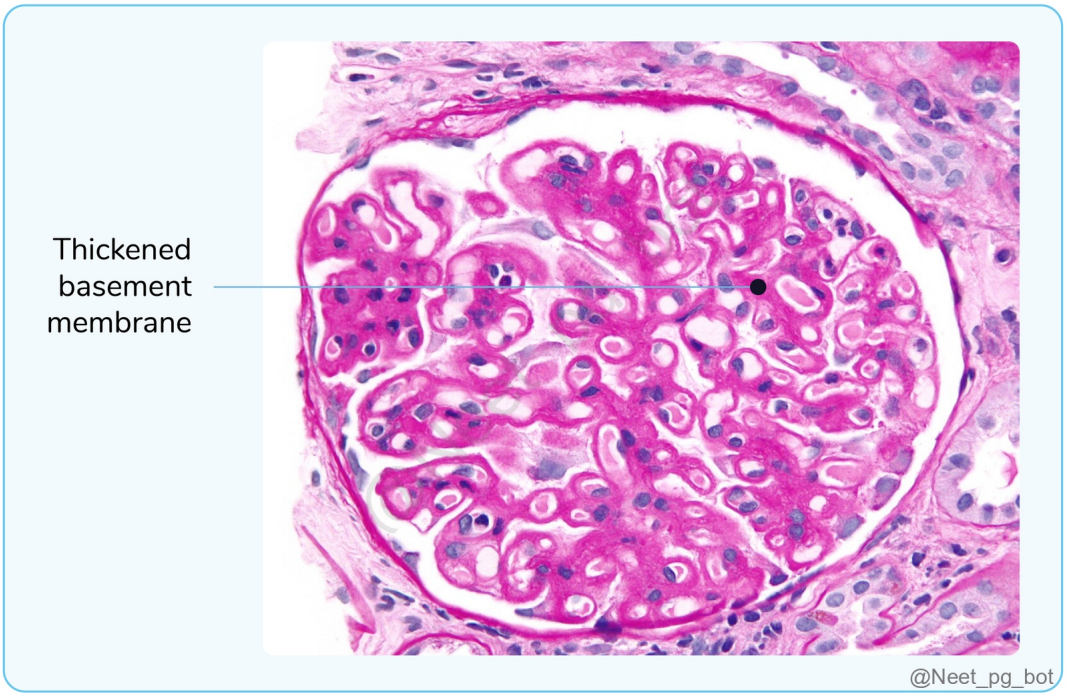

See Answer in Part B → Q5

@Neet_pg_bot

Q6: A 25-year-old female presents with edema, hypertension, significant proteinuria, and hematuria. Kidney biopsy reveals mesangial and endocapillary hypercellularity with mesangial and subendothelial electron-dense deposits, tram track appearance on silver stains and granular staining for IgG and C3 on Immunofluorescence. What is the most likely diagnosis? (Q846667)

A. Type I Membranoproliferative Glomerulonephritis

B. Type II Membranoproliferative Glomerulonephritis

C. Membranous Nephropathy

D. Focal Segmental Glomerulosclerosis

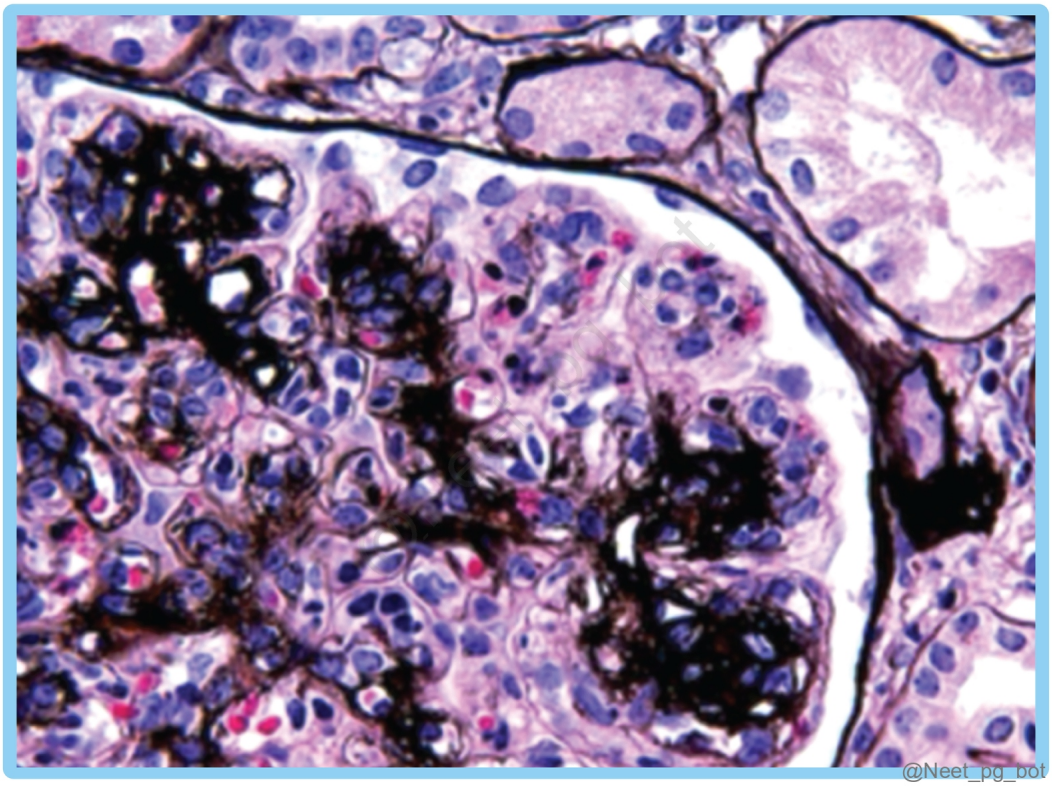

See Answer in Part B → Q6

@Neet_pg_bot

Q7: Which genetic mutation is responsible for a syndrome of steroid-resistant nephrotic syndrome of childhood onset? (Q846666)

A. NPHS1

B. NPHS2

C. α-actinin 4

D. TRPC6

See Answer in Part B → Q7

@Neet_pg_bot

Q8: A 35-year-old man presents with swelling around his eyes, ankles, and abdomen, along with frothy urine. Urinalysis shows proteinuria, elevated serum creatinine, and BUN levels. Image of renal biopsy is given below. Which of the following is not an established cause of this condition? (Q846665)

A. Diabetes mellitus

B. HIV infection

C. Hypertension

D. Sickle cell anaemia

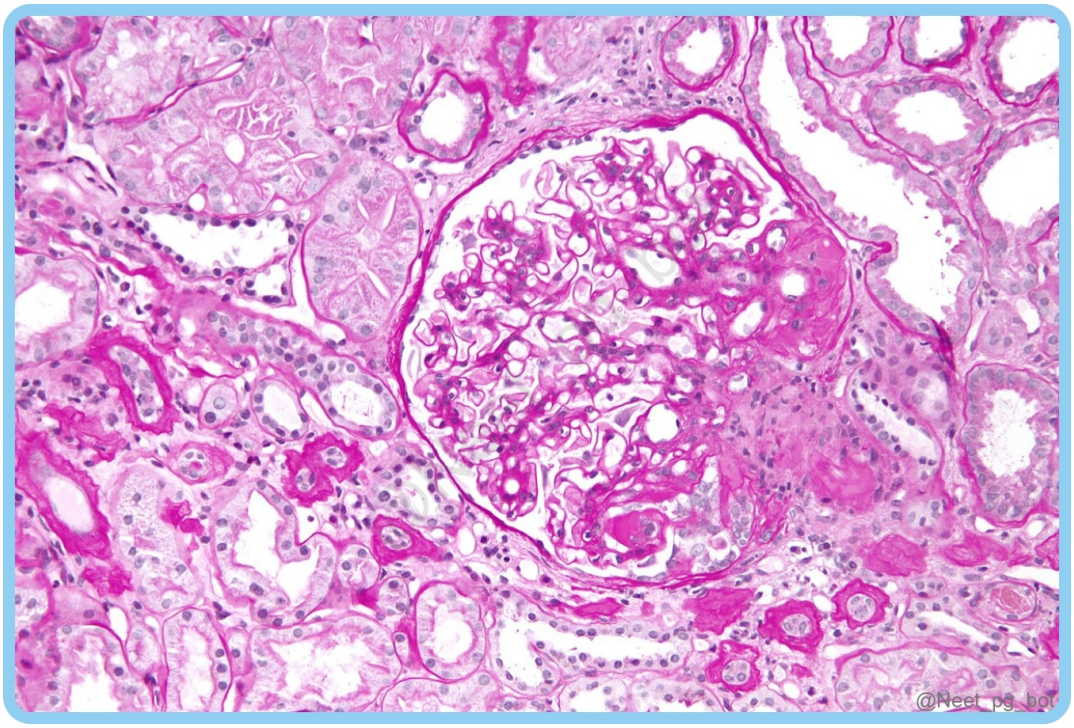

See Answer in Part B → Q8

@Neet_pg_bot

Q9: A 6-year-old boy presents with sudden generalised oedema and frothy urine. Urinalysis reveals heavy proteinuria without hematuria. Renal biopsy widespread effacement of podocyte foot processes on electron microscopy. Which of the following is true regarding this condition? (Q846664)

A. Lipid deposition within glomerular capillaries (tubular cells)

B. Immunofluorescence microscopy reveals granular deposition of IgG and C3 in the glomeruli.

C. Good response to corticosteroid therapy

D. Non-selective proteinuria

See Answer in Part B → Q9

@Neet_pg_bot

Q10: A 7-year-old girl with a recent upper respiratory tract infection presents with generalised swelling and reduced urine output. Urinalysis reveals proteinuria without blood cells or casts. Electron microscopy findings show flattening, retraction, and swelling of podocytes. Which light microscopy findings is characteristic of this condition? (Q846663)

A. Glomerulosclerosis

B. Normal glomeruli

C. Fibrinoid necrosis in glomeruli

D. Wire looping of capillaries

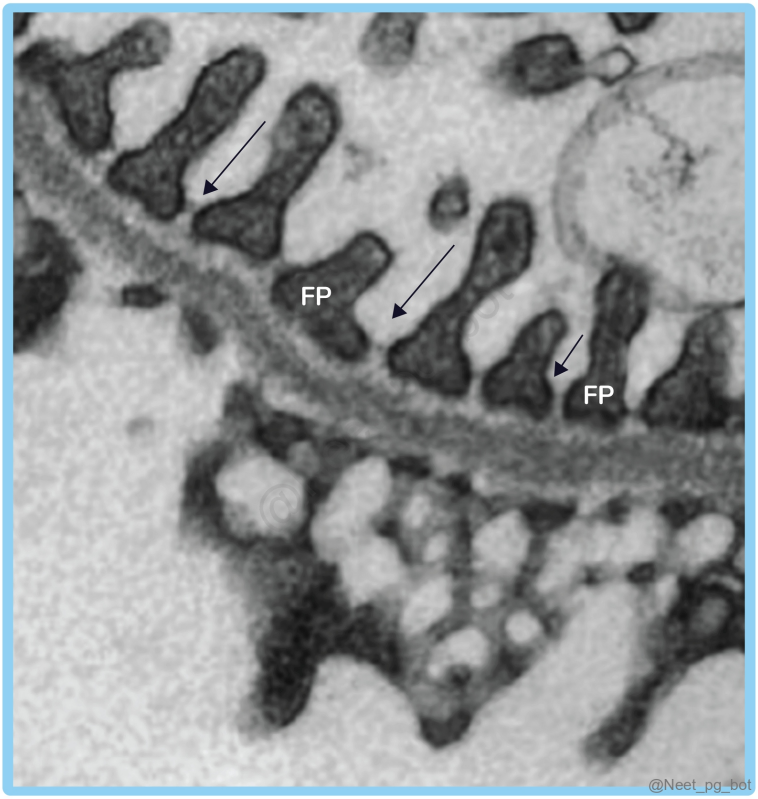

See Answer in Part B → Q10

@Neet_pg_bot

Q11: A 15-year-old boy presents with complaints of blurred vision, hearing loss, and recurrent episodes of hematuria. Genetic testing reveals a mutation in Type 4 collagen. Which of the following genetic mutations is observed in the patient? (Q846661)

A. COL4A3 gene

B. COL4A4 gene

C. COL4A5 gene

D. All of the above

See Answer in Part B → Q11

@Neet_pg_bot

Q12: A 32-year-old male presents with painless hematuria post-upper respiratory infections, normal vital signs, and no oedema. Urinalysis reveals red blood cell casts and further investigation shows elevated serum creatinine and mild proteinuria. Renal biopsy confirms glomerulonephritis. What is the most common type of glomerulonephritis in this case? (Q846660)

A. IgA nephropathy

B. Post-Streptococcal glomerulonephritis

C. Minimal change disease

D. Membranous nephropathy

See Answer in Part B → Q12

@Neet_pg_bot

Q13: A 45-year-old male presents with recurrent hematuria following upper respiratory infections and intermittent proteinuria. Renal biopsy shows mesangial IgA deposits on immunofluorescence and electron-dense deposits in the mesangium on electron microscopy. What is the most likely diagnosis? (Q846659)

A. Berger’s Disease

B. Alport syndrome

C. Membranous nephropathy

D. Buerger's Disease

See Answer in Part B → Q13

@Neet_pg_bot

Q14: A 30-year-old male presents with increasing shortness of breath and hemoptysis. Lab tests show elevated serum creatinine and hematuria. Renal biopsy reveals linear immunofluorescence along the glomerular basement membrane and subepithelial and intramembranous electron-dense deposits on electron microscopy. Which of the following statements regarding the diagnosis is not true? (Q846658)

A. It is a Type III hypersensitivity reaction

B. Defective α3 chain of collagen IV

C. Linear immunofluorescence is due to IgG deposition

D. The most common cause of death is uremia.

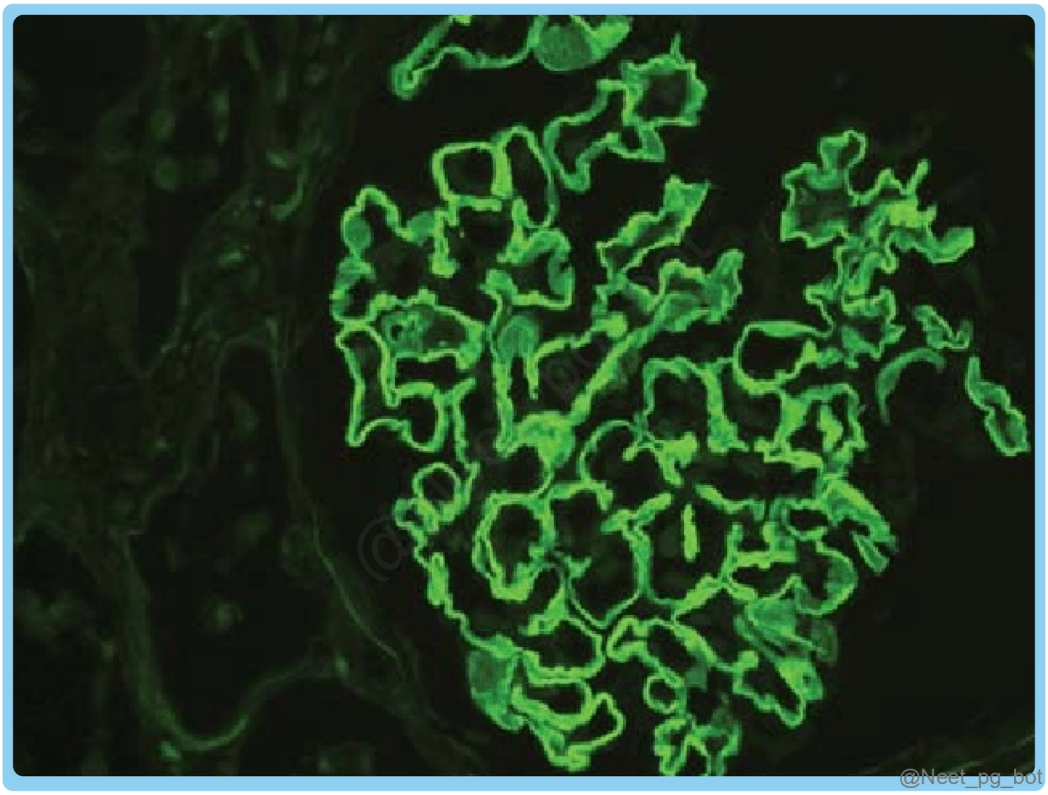

See Answer in Part B → Q14

@Neet_pg_bot

Q15: A 9-year-old boy presents with a recent sore throat, dark urine, fatigue, eye puffiness, and mild limb swelling. Urinalysis reveals hematuria, proteinuria, and red blood cell casts. Serum creatinine levels are slightly elevated. A renal biopsy shows the immunofluorescence image provided below. Which condition is not typically associated with this pattern of rapidly progressive glomerulonephritis? (Q846657)

A. Wegeners granulomatosis

B. Henoch-Schonlein purpura

C. Systemic lupus erythematosus

D. Ig A Nephropathy

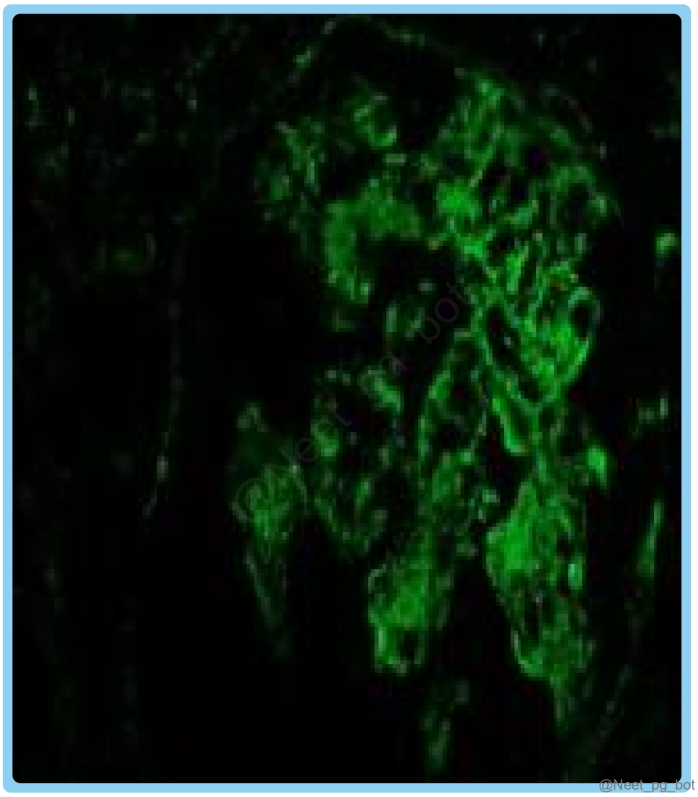

See Answer in Part B → Q15

@Neet_pg_bot

Q16: A 32-year-old woman with a history of SLE presents with fatigue, decreased urine output, and facial swelling. Lab tests show elevated serum creatinine, proteinuria, and hematuria. A renal biopsy is performed, and the histopathological examination image is attached. Which statement is true regarding this condition? (Q846656)

A. >50% of glomeruli showing crescents is diagnostic.

B. More the number of crescents, better the prognosis.

C. Crescents are composed solely of endothelial cells.

D. Primarily caused by bacterial infections.

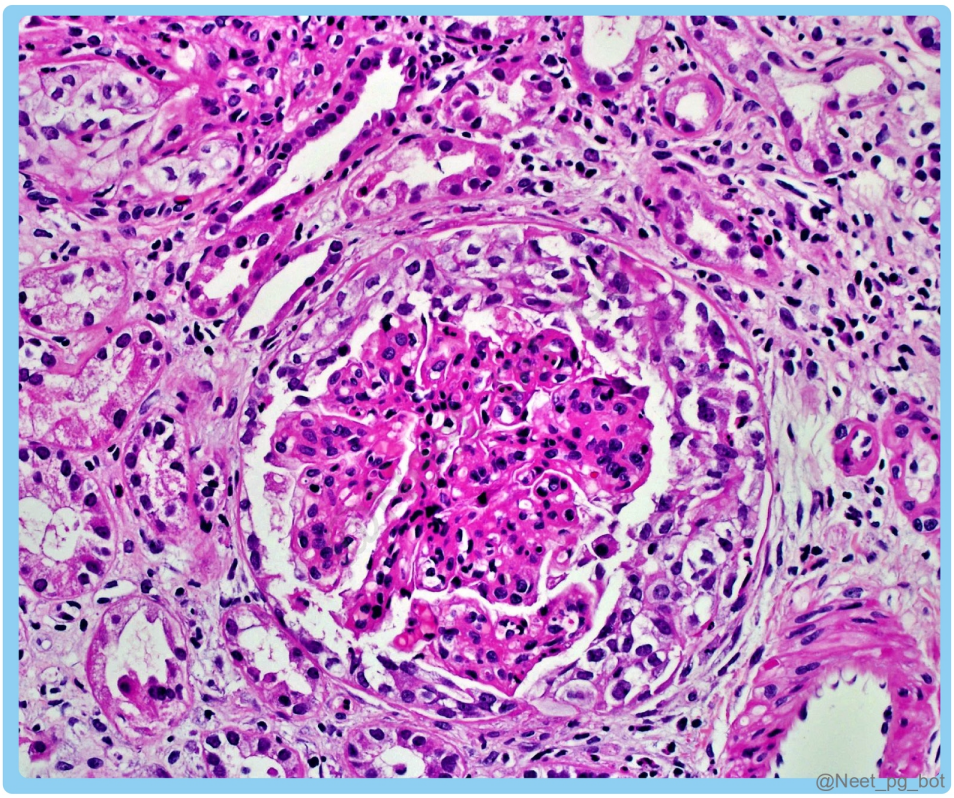

See Answer in Part B → Q16

@Neet_pg_bot

Q17: A 10-year-old boy presents with dark-coloured urine and puffiness around his eyes following a recent sore throat and skin infection. Laboratory tests show elevated serum creatinine, hematuria, and proteinuria. Renal biopsy image is given below. Which condition is most likely associated with these findings? (Q846655)

A. IgA nephropathy

B. Membranoproliferative glomerulonephritis

C. Post-streptococcal glomerulonephritis

D. Alport syndrome

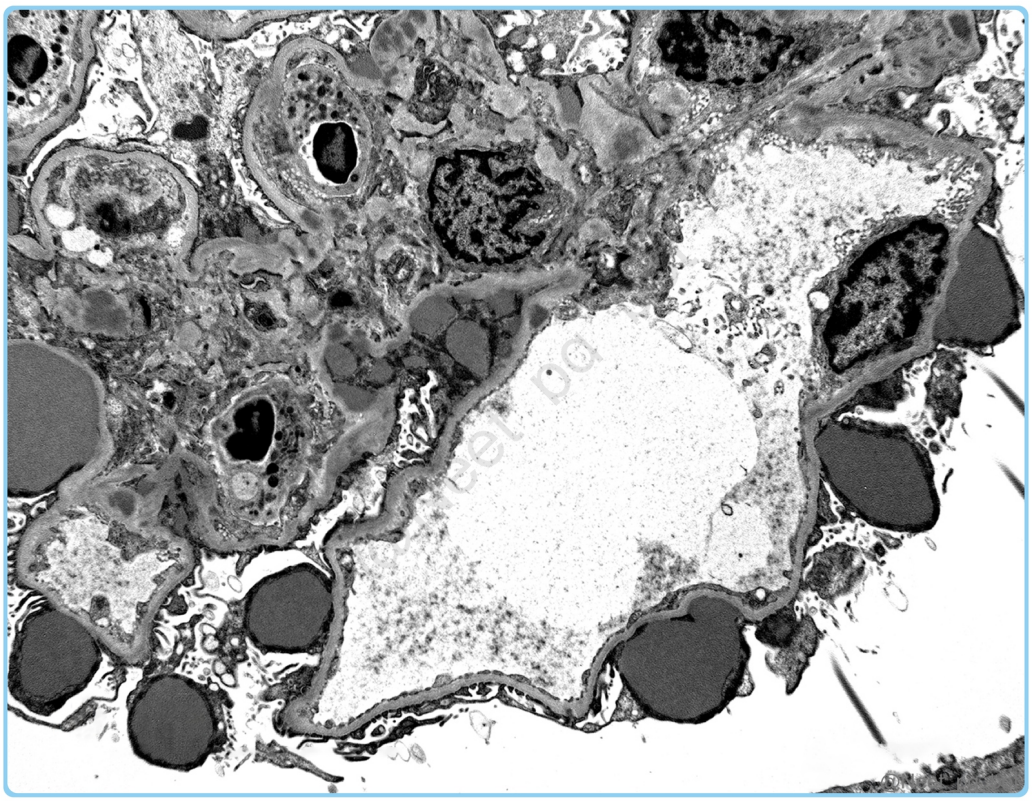

See Answer in Part B → Q17

@Neet_pg_bot

Q18: A 45-year-old patient presents with complaints of frothy urine, as shown below, and severe generalised oedema. On physical examination, there is marked swelling in the legs and abdomen. Laboratory tests reveal significant proteinuria (3+ on dipstick) and hypoalbuminemia. Which of the following findings can be typically observed in this patient? {{caption_text}} (Q846653)

A. Azotemia

B. Hyperlipidemia

C. Red cell casts in the urine

D. Hypertension



See Answer in Part B → Q18

@Neet_pg_bot

• [11_Renal System] 050 Renal Urinary Tract Tumors

« Back to Folder Directory

[11_Renal System] 050 Renal Urinary Tract Tumors — Quick Jump

Q1 (p. 526) *Q2 (p. 527)* *Q3 (p. 527)* *Q4 (p. 528)* *Q5 (p. 528)* *Q6 (p. 529)*
Q7 (p. 529) *Q8 (p. 530)* *Q9 (p. 531)* *Q10 (p. 531)* *Q11 (p. 531)* *Q12 (p. 532)*
Q13 (p. 532) *Q14 (p. 533)* *Q15 (p. 533)* *Q16 (p. 533)*

Q1: A 65-year-old diabetic male presented to the hospital complaining of chronic abdominal discomfort and unexplained weight loss over the past few months. A palpable firm mass was detected on the left upper quadrant upon physical examination. Ultrasound revealed a large mass in the left upper pole of the kidney. Due to suspicion of renal malignancy, the patient underwent a left nephrectomy. Based on the specimen obtained, what is the most likely diagnosis? {{caption_text}} (Q845695)

A. Renal oncocytoma

B. Epithelioid angiomyolipoma

C. Clear cell carcinoma

D. Urothelial carcinoma

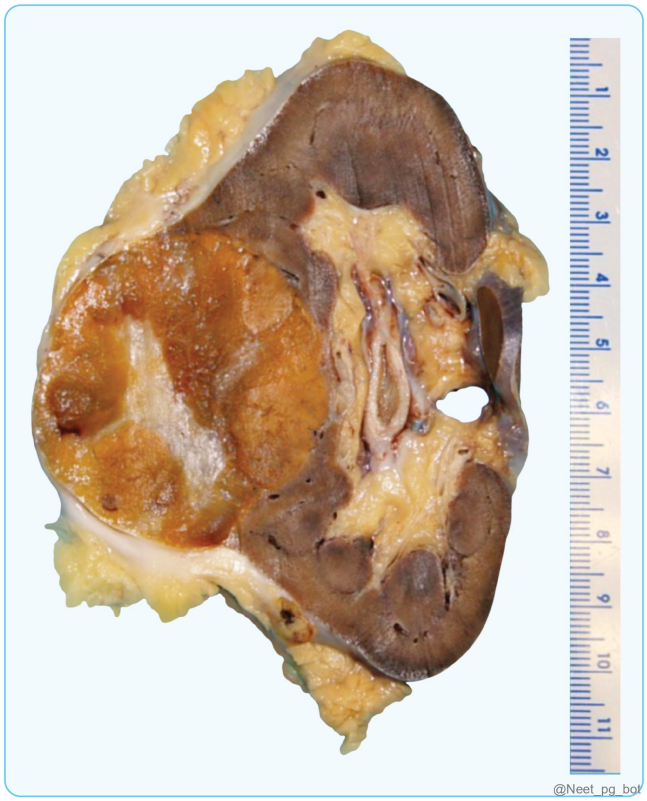

See Answer in Part B → Q1

@Neet_pg_bot

Q2: A child presents with hematuria and fever for the past 4 months. On examination, a mass-like structure was felt at the right flank. Which of the following features is not associated with this condition? (Q845709)

A. Gonadal dysgenesis and renal failure

B. Cryptorchidism and absent iris

C. Bilateral malar and mandibular hypoplasia

D. Adrenal cytomegaly and macroglossia

See Answer in Part B → Q2

@Neet_pg_bot

Q3: A renal biopsy specimen has to be examined under microscopy for the presence of nephroblastoma. Presence of which of the following findings is less likely suggestive of the same? (Q845713)

A. Neuropils

B. Small blue cells

C. Adipose tissue

D. Myxoid stroma

See Answer in Part B → Q3

@Neet_pg_bot

Q4: A histopathological report of renal biopsy done on a child states, “tumour cells suggestive of nephroblastoma along with adjacent sclerotic rests”. What is the risk associated with the presence of such sclerotic rests? (Q845744)

A. Presence of anaplasia

B. Pulmonary metastasis

C. Contralateral tumour

D. Associated lymphoma

See Answer in Part B → Q4

@Neet_pg_bot

Q5: Which of the following statements regarding renal cell carcinoma is false? (Q845745)

A. Clear cell RCC is the most common type overall.

B. Papillary RCC is most commonly associated with dialysis patients.

C. Medullary RCC is commonly seen in sickle cell trait patients.

D. Papillary RCC has the best prognosis.

See Answer in Part B → Q5

@Neet_pg_bot

Q6: A 45-year-old female died within a few months after being diagnosed with renal cell carcinoma. The autopsy revealed a yellowish, spherical neoplasm in one pole of the kidney. The tumour cells invaded the renal vein and inferior vena cava. Histopathology is shown below. What is the most likely diagnosis? {{caption_text}} (Q845896)

A. Collecting duct RCC

B. Papillary RCC

C. Clear cell RCC

D. Chromophobe RCC

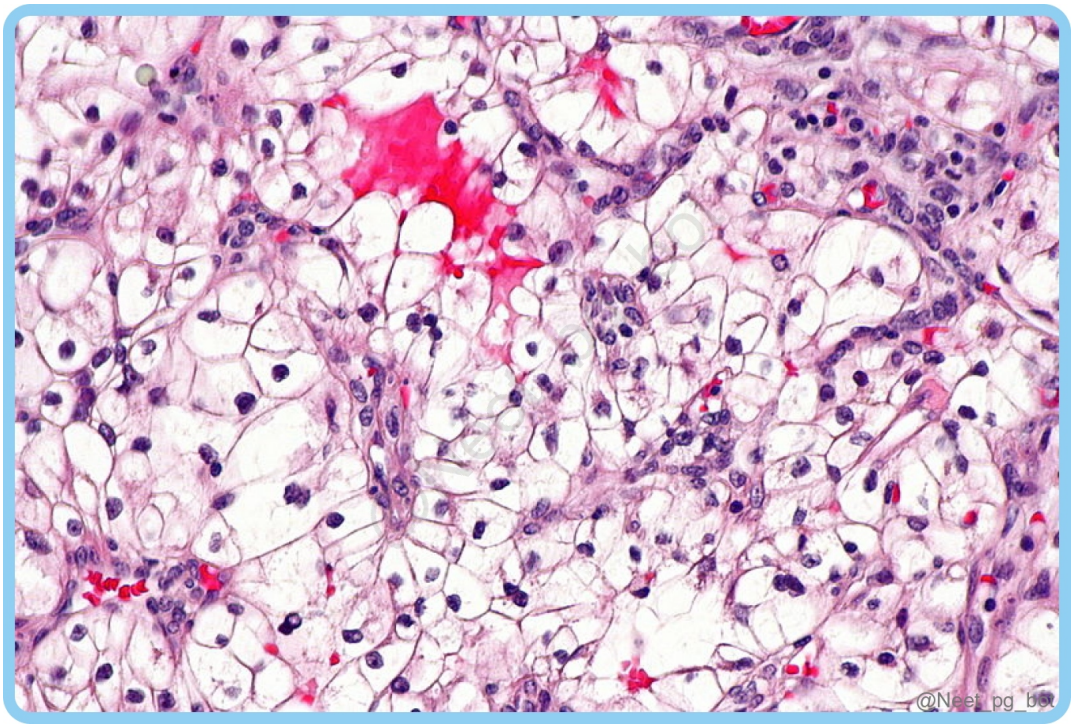

See Answer in Part B → Q6

@Neet_pg_bot

Q7: A 36-year-old woman presents with intermittent flank pain and occasional gross hematuria. Laboratory tests show normal renal function. A renal biopsy of a mass lesion reveals a mixture of mature adipose tissue, thick-walled blood vessels, and bundles of smooth muscle cells. All are true regarding this condition except: {{caption_text}} (Q846649)

A. Commonly associated with tuberous sclerosis

B. More prevalent in males than females

C. Mostly a benign tumor

D. High susceptibility to spontaneous hemorrhage

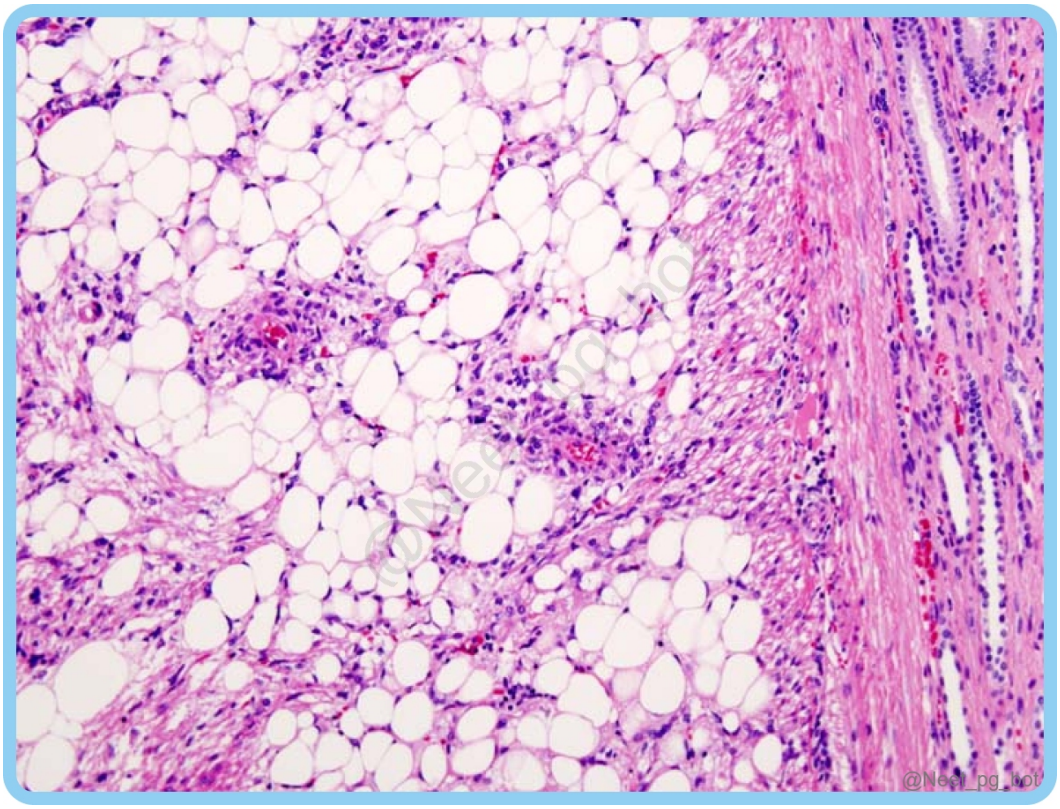

See Answer in Part B → Q7

@Neet_pg_bot

Q8: Hobnail nuclei are seen in which type of renal cell carcinoma? (Q846650)

A. Clear cell renal cell carcinoma.

B. Papillary renal cell carcinoma.

C. Chromophobe renal cell carcinoma.

D. Collecting duct carcinoma.

See Answer in Part B → Q8

@Neet_pg_bot

Q9: On histological examination, which of the following types of renal cell carcinoma shows large cells with a plant-cell-like appearance with a perinuclear halo? (Q846651)

A. Papillary RCC

B. Clear cell RCC

C. Chromophobe RCC

D. Medullary RCC

See Answer in Part B → Q9

@Neet_pg_bot

Q10: Multiple losses of entire chromosomes are seen in which type of Renal Cell Carcinoma? (Q846652)

A. Papillary RCC

B. Clear cell RCC

C. Chromophobe RCC

D. Collecting duct RCC

See Answer in Part B → Q10

@Neet_pg_bot

Q11: Which of the following statements regarding Wilms' tumour is incorrect? (Q889878)

A. It is associated with WAGR syndrome

B. Associated with triphasic morphology

C. The most common renal tumour in children

D. WT1 mutations are present in >80% of sporadic cases

See Answer in Part B → Q11

@Neet_pg_bot

Q12: A 4-year-old child undergoes nephrectomy for a Wilms tumour. Histology shows large hyperchromatic pleomorphic nuclei with abnormal mitotic figures. The tumour shows a poor response to preoperative chemotherapy. Which of the following best explains the chemotherapy resistance in this tumour? (Q889881)

A. Gain-of-function mutation in β-catenin

B. Loss of the WT1 tumour suppressor gene

C. Mutation of TP53 leading to defective apoptosis

D. IGF2 overexpression due to an imprinting abnormality

See Answer in Part B → Q12

@Neet_pg_bot

Q13: A 4-year-old child is diagnosed with Wilms tumour. Histology and genetic studies are reviewed to assess prognosis. Which of the following is not associated with poor prognosis in Wilms tumour? (Q889883)

A. Anaplastic histology

B. Loss of heterozygosity at chromosomes 1p and 16q

C. Gain of chromosome 1q

D. Triphasic histology

See Answer in Part B → Q13

@Neet_pg_bot

Q14: Which of the following most reliably differentiates renal papillary adenoma from papillary renal cell carcinoma? (Q889885)

A. Presence of papillary architecture

B. Low-grade nuclear features

C. Tumour size cut-off

D. Presence of psammoma bodies

See Answer in Part B → Q14

@Neet_pg_bot

Q15: A 50-year-old man with recurrent pneumothorax and multiple facial fibrofolliculomas is found to have bilateral renal masses. Genetic testing reveals an FLCN mutation. Which renal cell carcinoma (RCC) is most commonly associated with the most probable condition? (Q889889)

A. Clear cell RCC

B. Papillary RCC

C. Chromophobe RCC

D. Collecting duct carcinoma

See Answer in Part B → Q15

@Neet_pg_bot

Q16: A 13-year-old girl presents with painless hematuria. Imaging shows a renal mass. Biopsy reveals nested and tubulopapillary architecture. Immunostaining is

positive for TFE3. What is the most likely diagnosis? (Q889892)

A. Clear cell renal cell carcinoma

B. Papillary renal cell carcinoma

C. Chromophobe renal cell carcinoma

D. Xp11 translocation renal cell carcinoma

See Answer in Part B → Q16

@Neet_pg_bot

• [11_Renal System] 051 Previous Year Questions

« Back to Folder Directory

[11_Renal System] 051 Previous Year Questions — Quick Jump

Q1 (p. 535)	*Q2 (p. 535)*	*Q3 (p. 536)*	*Q4 (p. 536)*	*Q5 (p. 537)*	*Q6 (p. 537)*
Q7 (p. 538)	*Q8 (p. 539)*	*Q9 (p. 539)*	*Q10 (p. 540)*	*Q11 (p. 540)*	*Q12 (p. 541)*
Q13 (p. 541)	*Q14 (p. 541)*	*Q15 (p. 542)*	*Q16 (p. 543)*	*Q17 (p. 543)*	

Q1: A 48-year-old man presents with facial puffiness, frothy urine, hypertension, a history of hepatitis B infection, and microscopic hematuria. A kidney biopsy reveals a spike and dome pattern. What is the most likely diagnosis? (Q855413)

A. Minimal change disease

B. Membranous nephropathy

C. Focal segmental glomerulosclerosis

D. PSGN-associated disease

See Answer in Part B → Q1

@Neet_pg_bot

Q2: A 40-year-old man has been diagnosed with solid cancer of the bowel. He also experienced massive proteinuria a few months after the initial diagnosis of cancer. What do you think is the likely cause of the development of urinary findings? (Q859258)

A. Membranous nephropathy

B. Focal segmental glomerulosclerosis

C. Membranoproliferative glomerulonephritis

D. Dense deposit disease

See Answer in Part B → Q2

@Neet_pg_bot

Q3: Effacement of podocyte foot processes is seen in which of the following diseases? (Q858521)

A. Steroid-resistant glomerulonephritis

B. Minimal change disease

C. Rapidly progressive glomerulonephritis

D. Chronic glomerulonephritis

See Answer in Part B → Q3

@Neet_pg_bot

Q4: A 51-year-old male patient presents with complaints of hematuria. On examination, he is normotensive and has pedal edema. Investigations reveal that the patient has no glycosuria and a creatinine level of 9. His renal biopsy finding is given below. Which of the following investigations should be done to identify the disease? (Q854838)

A. ANA

B. Anti-GBM antibodies

C. HIV RNA

D. Urine immunoelectrophoresis

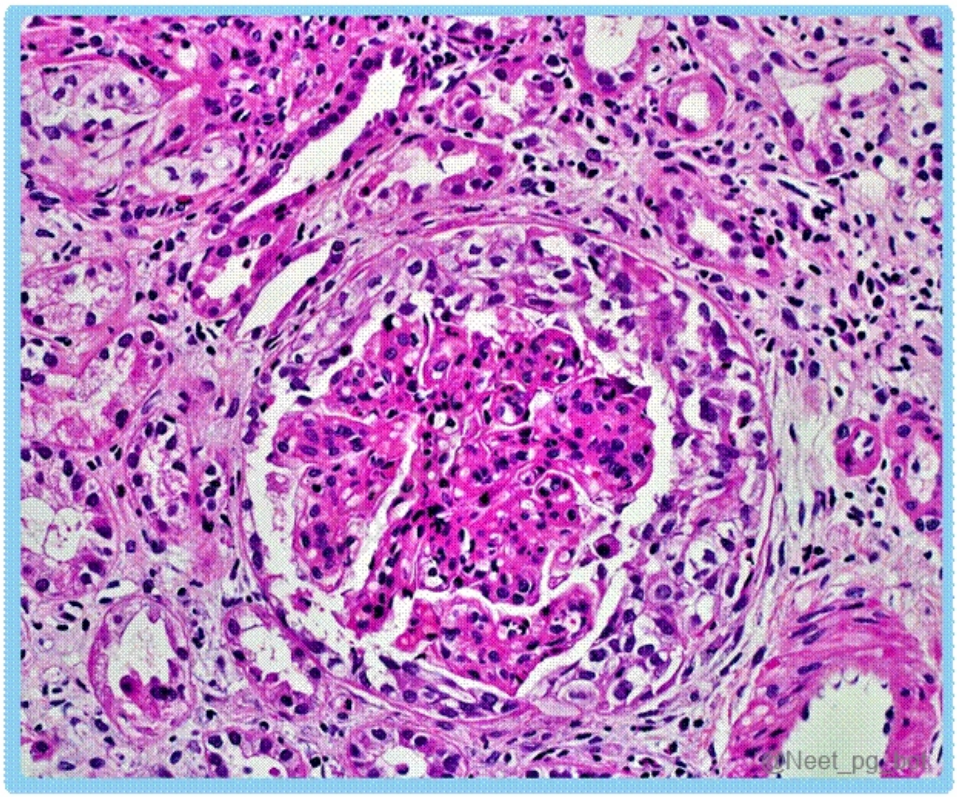

See Answer in Part B → Q4

@Neet_pg_bot

Q5: Membranoproliferative glomerulonephritis is seen in which of the following conditions? HIV SLE CLL Hepatitis B (Q856912)

A. 1, 2, 3

B. 1, 2, 3, 4

C. 2, 3, 4

D. 1, 2

See Answer in Part B → Q5

@Neet_pg_bot

Q6: What type of urinary casts would you expect in a patient diagnosed with Fabry's disease? (Q856895)

A. Waxy cast

B. RBC cast

C. WBC cast

D. Maltese cross cast

See Answer in Part B → Q6

@Neet_pg_bot

Q7: What is the most characteristic feature of diabetic nephropathy, as shown below? {{caption_text}} (Q857168)

A. Kimmelstiel Wilson nodules

B. Armanni Ebstein change

C. Aschoff nodule

D. Anitschkow cell

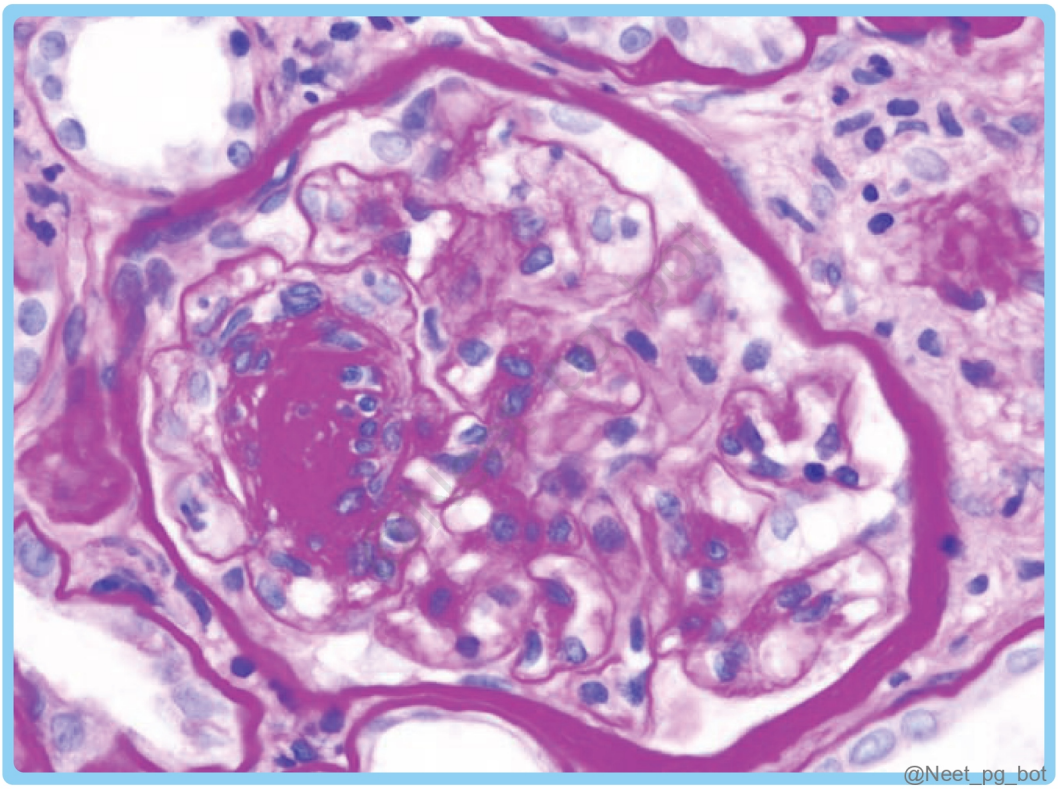

See Answer in Part B → Q7

@Neet_pg_bot

Q8: Which of the following statements is/are true regarding clear cell carcinoma of the kidney? Most common primary renal malignancy Associated with the loss of the short arm of chromosome 3 Not associated with paraneoplastic syndrome The classic triad of flank pain, palpable mass, and hematuria is seen. (Q855070)

A. 1, 2, 4

B. 2, 3

C. 1, 3

D. 1, 4

See Answer in Part B → Q8

@Neet_pg_bot

Q9: Tamm-Horsfall protein is a major component of which of the following? (Q858118)

A. Mural thrombi

B. Curschmann spirals

C. Renal casts

D. Bence-Jones proteins

See Answer in Part B → Q9

@Neet_pg_bot

Q10: A patient with renal disease undergoes a biopsy. On Congo red staining, the deposits show apple-green birefringence under polarised light. What is the most likely diagnosis? (Q866678)

A. Amyloidosis

B. Minimal change disease

C. Diabetic nephropathy

D. Membranous nephropathy

See Answer in Part B → Q10

@Neet_pg_bot

Q11: Which of the following will increase in size on electrophoresis in Nephrotic syndrome? (Q854702)

A. Gamma globulin

B. Alpha 2 globulin

C. Beta globulin

D. Albumin

See Answer in Part B → Q11

@Neet_pg_bot

Q12: A 47-year-old male with 400 ml urine output per 24 hrs. On histology, he had RPGN with Pauci immune glomerulonephritis with crescents. What is the main etiology? (Q854698)

A. Anti GBM

B. ANCA

C. Anti PLA2R

D. ANA

See Answer in Part B → Q12

@Neet_pg_bot

Q13: What is the most likely diagnosis for a 9-year-old boy who presents with hematuria, hypertension, facial puffiness for 3 days, and a recent history of throat infection two weeks ago, with urine examination showing albumin positivity? (Q830713)

A. Group B beta-hemolytic streptococci

B. Staphylococcus aureus

C. Group A beta-hemolytic streptococci

D. Staphylococcus epidermidis

See Answer in Part B → Q13

@Neet_pg_bot

Q14: A patient presents with hematuria and flank pain. A renal mass is shown in the image provided. What is the likely diagnosis? (Q844158)

A. Clear cell carcinoma

B. Papillary renal cell carcinoma

C. Chromophobe renal cell carcinoma

D. Bellini duct carcinoma

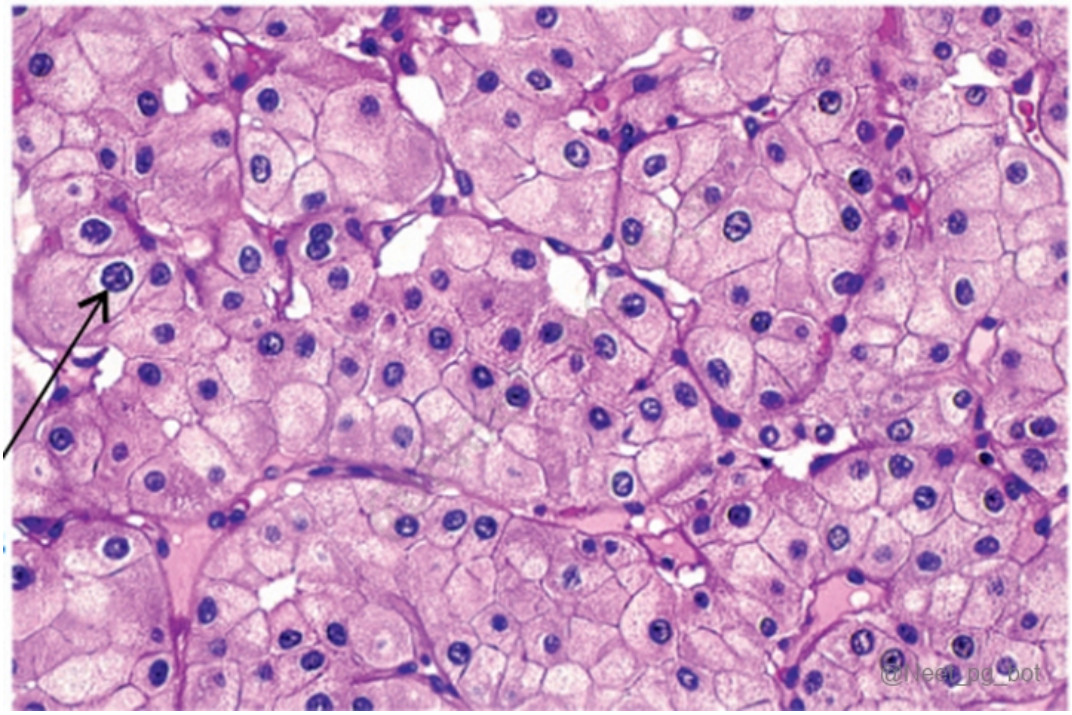

See Answer in Part B → Q14

@Neet_pg_bot

Q15: A patient presents with a cerebellar mass and a renal tumor, along with a similar family history. Which of the following is responsible for his findings? (Q844087)

A. VHL disease

B. NF

C. TSC

D. Li Fraumeni syndrome

See Answer in Part B → Q15

@Neet_pg_bot

Q16: A female presents to the OPD with complaints of dysuria. Based on the microscopic examination, what is the most likely diagnosis? (Q844068)

A. HSV

B. CMV

C. HPV

D. Trichomonas

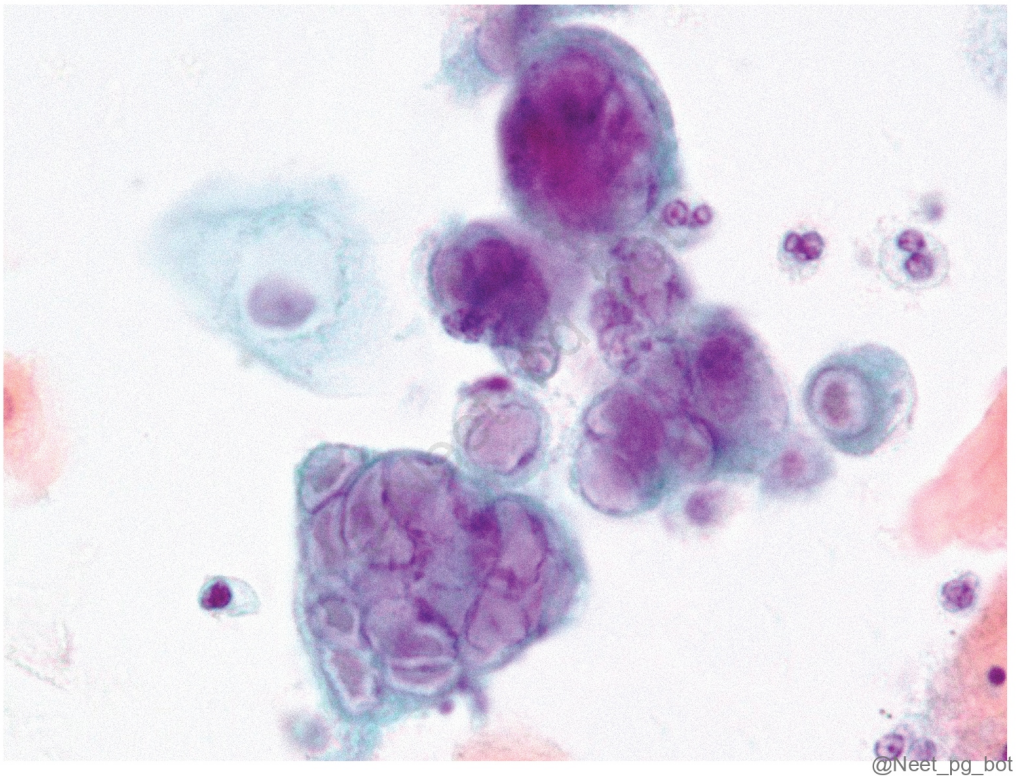

See Answer in Part B → Q16

@Neet_pg_bot

Q17: A pediatric patient presents with cola-coloured urine, high blood pressure, and periorbital oedema. Laboratory tests reveal a creatinine level of 2.5 mg/dL, which rises to 4.5 mg/dL after 3 weeks despite treatment. What electron microscopic finding is most likely in this patient? (Q855409)

A. Subendothelial deposits

B. Subepithelial deposits

C. Crescent formation

D. Mesangial deposits

See Answer in Part B → Q17

@Neet_pg_bot

• [12_Genital System] 052 Pathology Of Male Genital Tract

« Back to Folder Directory

[12_Genital System] 052 Pathology Of Male Genital Tract — Quick Jump

Q1 (p. 545)	*Q2 (p. 545)*	*Q3 (p. 546)*	*Q4 (p. 546)*	*Q5 (p. 547)*	*Q6 (p. 547)*
Q7 (p. 547)	*Q8 (p. 548)*	*Q9 (p. 549)*	*Q10 (p. 549)*	*Q11 (p. 550)*	*Q12 (p. 551)*
Q13 (p. 552)	*Q14 (p. 553)*	*Q15 (p. 554)*	*Q16 (p. 555)*	*Q17 (p. 555)*	

Q1: A 42-year-old male presents with testicular pain and swelling. Physical examination reveals a palpable mass. Subsequent biopsy of the mass provides important diagnostic insights. Which of the following statements regarding sex cord-stromal tumours in males are true? A) They are classified into three main subtypes: Leydig cell and Sertoli cell tumours and yolk sac tumours. B) Sertoli cell tumours are commonly associated with hormonal abnormalities. C) Histologically, Leydig cell tumors demonstrate golden pigment with reinke crystals with eosinophilic cytoplasmic inclusions. D) Sertoli cell tumours are often associated with Carney's complex and are typically malignant. (Q845855)

A. A, B, C

B. A, C, D

C. C

D. A, B, C, D

See Answer in Part B → Q1

@Neet_pg_bot

Q2: A 32-year-old male presents with multiple, small, flesh-coloured growths on the shaft of his penis. A biopsy is performed, and histopathology reveals hyperkeratosis, acanthosis, and koilocytosis. Which of the following is the most likely causative agent of his condition? (Q845863)

A. HPV 6 and 11

B. Treponema pallidum

C. HSV 2

D. Chlamydia trachomatis

See Answer in Part B → Q2

@Neet_pg_bot

Q3: A 65-year-old male presents with difficulty in urination and frequent nocturia. Digital rectal examination reveals a firm, irregular prostate. A subsequent prostate-specific antigen (PSA) test shows elevated levels. A transrectal ultrasound-guided prostate biopsy is performed, and the pathology report provides a Gleason score. Which of the following statements regarding the Gleason score in prostate cancer diagnosis is correct for this patient? (Q845862)

A. The Gleason score indicates the stage of prostate cancer.

B. A Gleason score of 6 suggests a poorly differentiated tumor with a high risk of metastasis.

C. The Gleason score is determined by adding the two least common Gleason grades found in the tumor.

D. The Gleason score is irrelevant in determining the treatment approach for prostate cancer.

See Answer in Part B → Q3

@Neet_pg_bot

Q4: A 60-year-old male presents with increased frequency, nocturia, and weak urine stream. DRE reveals a firm nodule. A prostate biopsy is performed, and the histology image shows complex, branching papillary structures lined by pseudostratified columnar epithelium.What is the most likely diagnosis? (Q845861)

A. Benign Prostatic Hyperplasia (BPH)

B. Prostate Adenocarcinoma-Ductal Type

C. Prostatic Intraepithelial Neoplasia (PIN)

D. Chronic Prostatitis

See Answer in Part B → Q4

@Neet_pg_bot

Q5: Which of the following is a new biomarker used in Prostatic Cancer? (Q845860)

A. NMP22

B. Thymidine kinase

C. NKX 3.1

D. PLAP

See Answer in Part B → Q5

@Neet_pg_bot

Q6: Which of the following is a protective factor associated with prostate cancer? (Q845859)

A. Age over 60 years

B. Family history of prostate cancer

C. High intake of red meat

D. Adequate levels of vitamin D

See Answer in Part B → Q6

@Neet_pg_bot

Q7: A 65-year-old man presents with complaints of increased frequency and urgency of urination, particularly at night. He also mentions a feeling of incomplete bladder emptying and a weak urine stream. The patient's PSA level is within normal limits. The histopathology image is given below. Based on the diagnosis, which of the following is true? (Q845858)

A. Infiltration of lymphocytes

B. Presence of atypical cells with high mitotic activity

C. Increased number of stromal and epithelial cells

D. Dysplastic changes in the glandular architecture

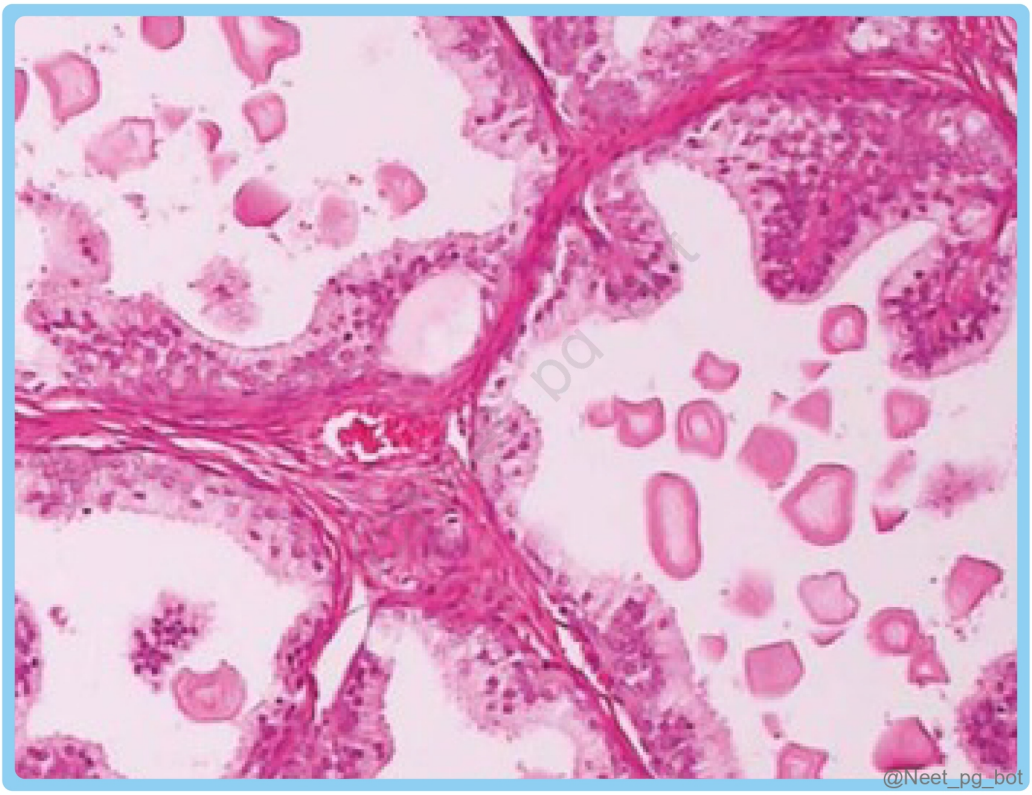

See Answer in Part B → Q7

@Neet_pg_bot

Q8: Which zone of the prostate is primarily affected by benign prostatic hyperplasia (BPH), and which zone is more commonly associated with prostate cancer? (Q845857)

A. Central zone & Peripheral zone

B. Peripheral zone & Transitional zone

C. Transitional zone & Peripheral zone

D. Peripheral zone & Central zone

See Answer in Part B → Q8

@Neet_pg_bot

Q9: Match the following tumour markers (Column A) with the corresponding testicular tumour types (Column B). Column A (Tumor Markers) Column B (Testicular Tumor Types) 1. Alpha-fetoprotein (AFP) A. Seminoma 2. Beta-human chorionic gonadotropin (β-hCG) B. Embryonal Carcinoma 3. CD-30 C. Yolk sac tumour 4. Placental alkaline phosphatase (PLAP) D. Choriocarcinoma 5. Cytokeratin E. Teratoma (Q845856)

A. 1-A, 2-B, 3-C, 4-D, 5-E

B. 1-C, 2-D, 3-A, 4-B, 5-E

C. 1-C, 2-D, 3-B, 4-A, 5-E

D. 1-B, 2-A, 3-D, 4-C, 5-B

See Answer in Part B → Q9

@Neet_pg_bot

Q10: The histological examination of a normal testis is given in the image below. Which of the following callouts is responsible for maintaining the blood testis barrier? (Q845847)

A. 1

B. 2

C. 3

D. 4

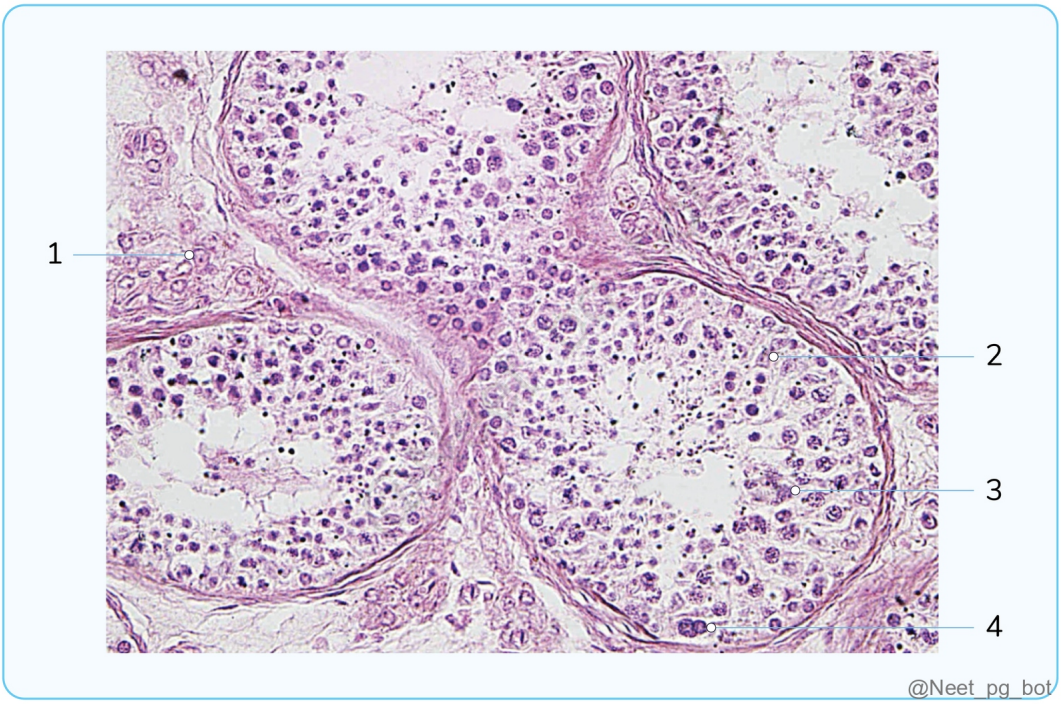

See Answer in Part B → Q10

@Neet_pg_bot

Q11: A 10-month-old boy was referred to the hospital with non-palpable right testes. The physical examination revealed no jaundice, palpable left testes, or right-sided abdominal mass. Subsequent surgical excision of the mass revealed a cystic mass with keratinous debris, and a biopsy image of the specimen was obtained. All of the following statements regarding this condition are true except? (Q845854)

A. Typically present as well-defined, encapsulated masses with cystic and solid components.

B. Often associated with areas of haemorrhage and necrosis.

C. Histologically, it contains differentiated cells or organoid structures embedded in a fibrous or myxoid stroma.

D. Demonstrate homogeneous appearance and are mostly found malignant in young children.

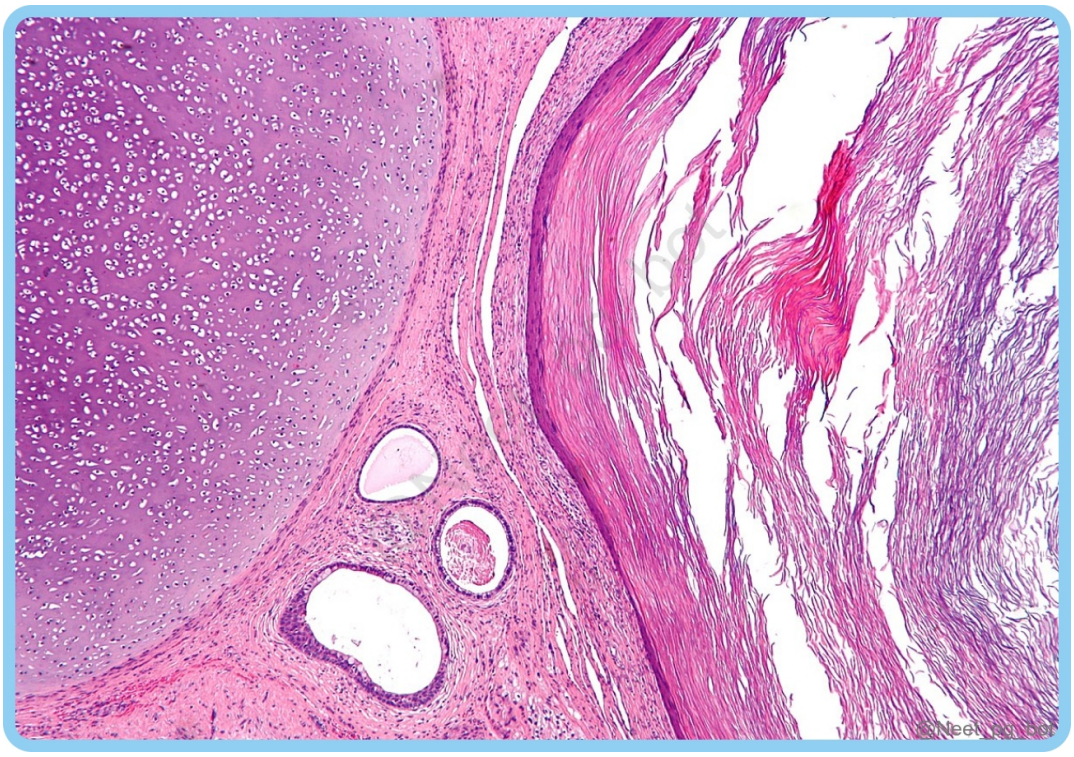

See Answer in Part B → Q11

@Neet_pg_bot

Q12: A 30-year-old male presents with a rapidly enlarging testicular mass associated with testicular pain and gynecomastia. He reports associated mild hemoptysis for the last 4 days. A biopsy of the mass is performed, and both gross and microscopic images are obtained. What is the most likely diagnosis based on the clinical presentation? (Q845853)

A. Choriocarcinoma

B. Embryonal Carcinoma

C. Seminoma

D. Yolk Sac Tumor

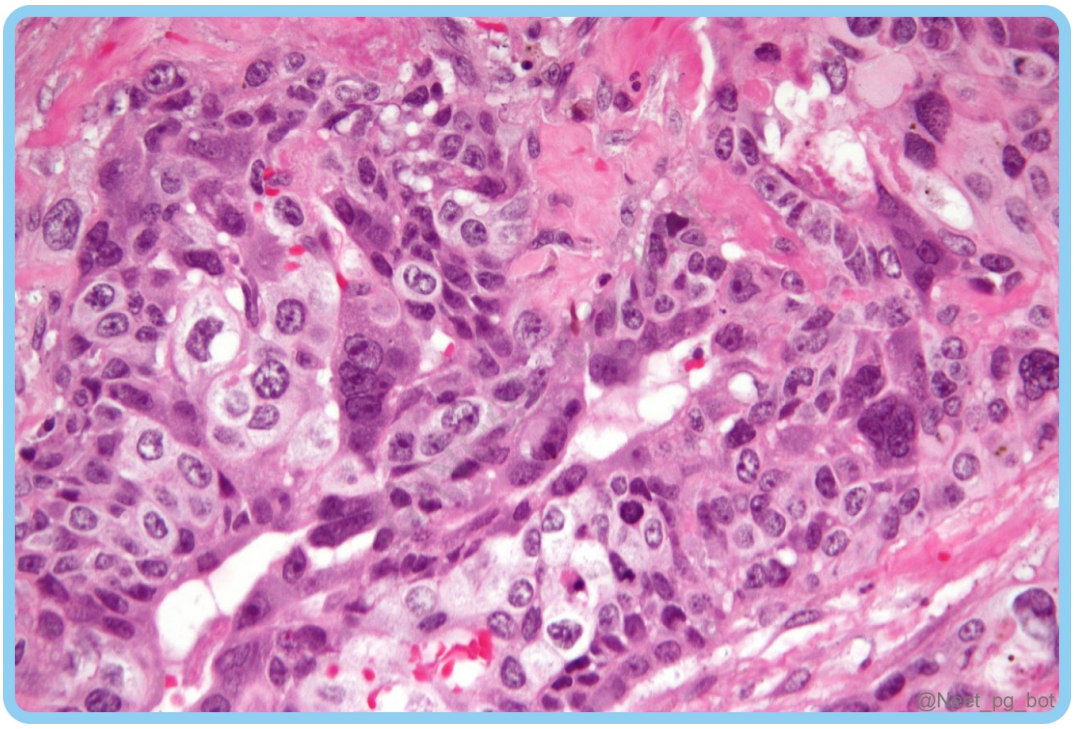



See Answer in Part B → Q12

@Neet_pg_bot

Q13: A 10-year-old male with a painless testicular mass for the past few months. On examination, the right testis was enlarged and the transillumination test was negative. A biopsy of the mass was performed and is shown below. What is the most likely diagnosis? (Q845852)

A. Hydrocoele

B. Yolk Sac tumour

C. Choriocarcinoma

D. Germ Cell tumour

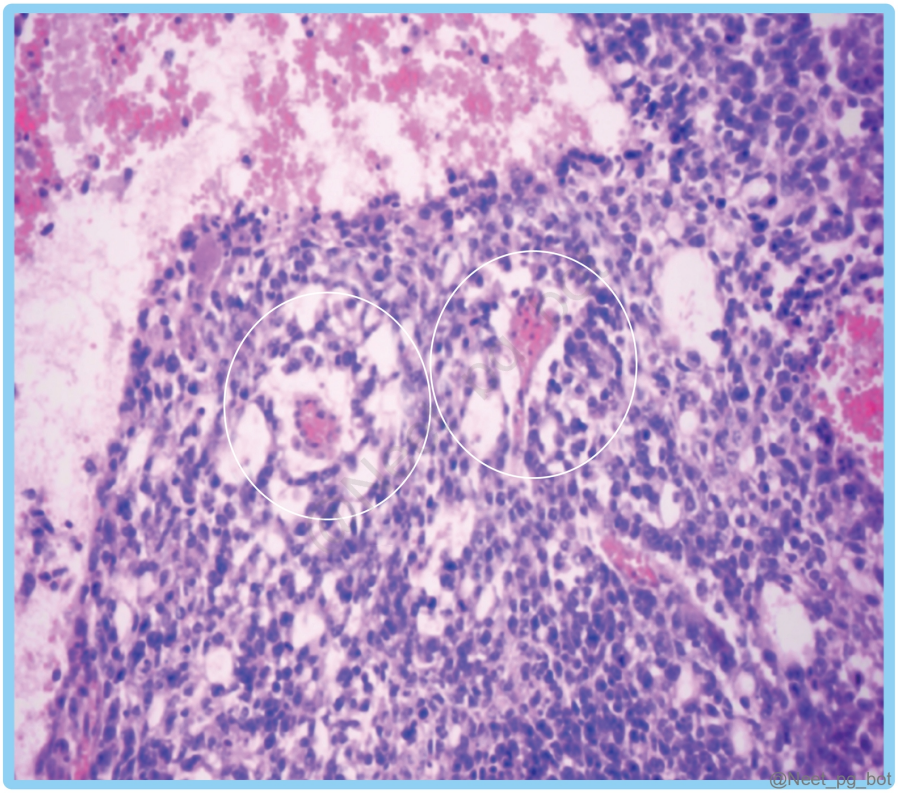

See Answer in Part B → Q13

@Neet_pg_bot

Q14: A 65-year-old male presents to the hospital with a painless scrotal mass. Ultrasound scan reveals a solid testicular mass suspicious for a spermatocytic tumour. Upon further examination, the following histological findings are identified except? (Q845851)

A. Associated with gain of function mutation

B. Presence of inflammatory infiltrates and syncytiotrophoblasts

C. Presence of three intermixed cell distinct cell populations on microscopy

D. Low risk of metastasis following surgical resection

See Answer in Part B → Q14

@Neet_pg_bot

Q15: A patient underwent unilateral orchiectomy for a swelling in the right testis. The specimen is sent for histopathological examination, and its microscopic appearance is depicted in the image below. Which of the following statements is true regarding the diagnosis? (Q845850)

A. 3 different sizes of tumour cells are seen

B. Schiller-Duval bodies are present

C. Tumor cells are arranged in sheets

D. Tumor cells have a watery-clear cytoplasm

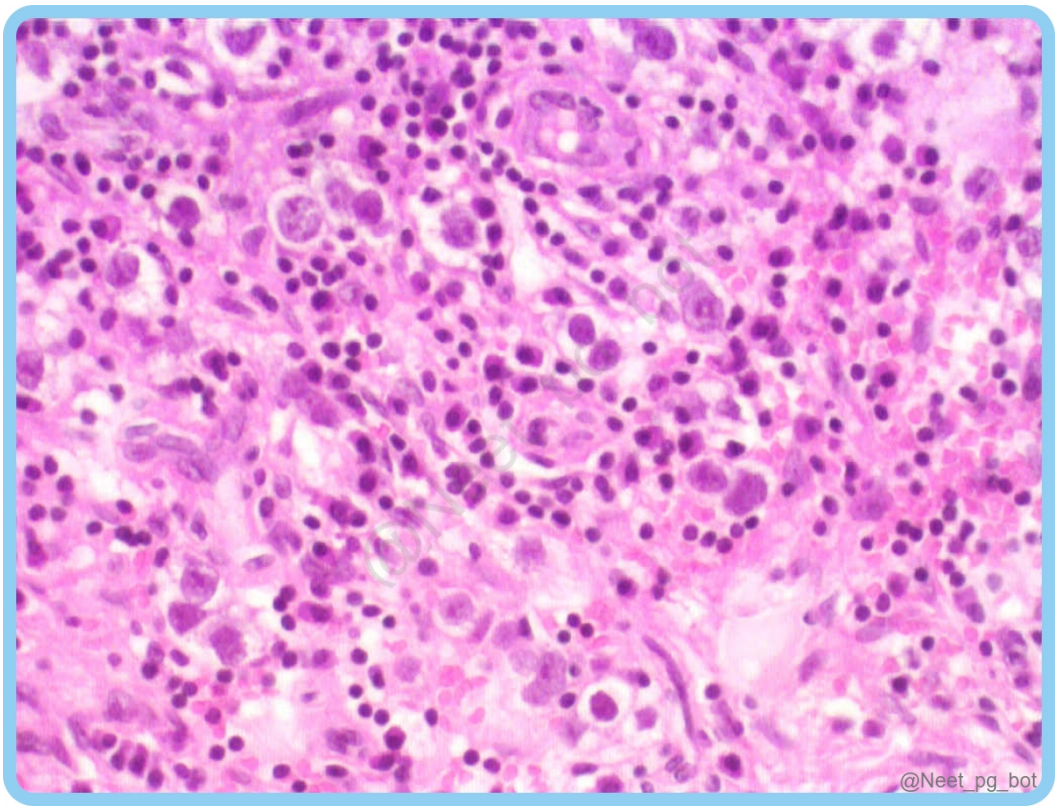

See Answer in Part B → Q15

@Neet_pg_bot

Q16: Which of the following is not a germ cell tumour? (Q845849)

A. Teratoma

B. Embryonal carcinoma

C. Spermatocytic seminoma

D. Sertoli cell tumour

See Answer in Part B → Q16

@Neet_pg_bot

Q17: A 1-year-old boy is brought to the pediatric clinic by his parents, who are concerned about the absence of his left testicle in the scrotum. On physical

examination, the right testicle is palpable in the scrotum, but the left is not. All are true regarding this condition except? (Q845848)

A. It can occur in association with hypospadias.

B. The most common site of arrest of descent is the inguinal canal.

C. It is very commonly associated with a well-defined hormonal disorder.

D. The Leydig cells appear prominent.

See Answer in Part B → Q17

@Neet_pg_bot

• [12_Genital System] 053 Pathology Of Female Genital Tract-I

« Back to Folder Directory

[12_Genital System] 053 Pathology Of Female Genital Tract-I — Quick Jump

Q1 (p. 557) *Q2 (p. 557)* *Q3 (p. 558)* *Q4 (p. 560)* *Q5 (p. 561)* *Q6 (p. 561)*
Q7 (p. 562) *Q8 (p. 563)* *Q9 (p. 563)* *Q10 (p. 564)* *Q11 (p. 565)* *Q12 (p. 566)*

Q1: Which of the following is not a part of the vaginal epithelium? (Q845578)

A. Superficial squamous cells

B. Intermediate squamous cells

C. Columnar cells

D. Parabasal cells

See Answer in Part B → Q1

@Neet_pg_bot

Q2: Which strain of the HPV virus is responsible for causing Condyloma acuminatum? (Q845605)

A. HPV 6 & 11

B. HPV 16 & 18

C. HPV 6 & 16

D. HPV 11 & 18

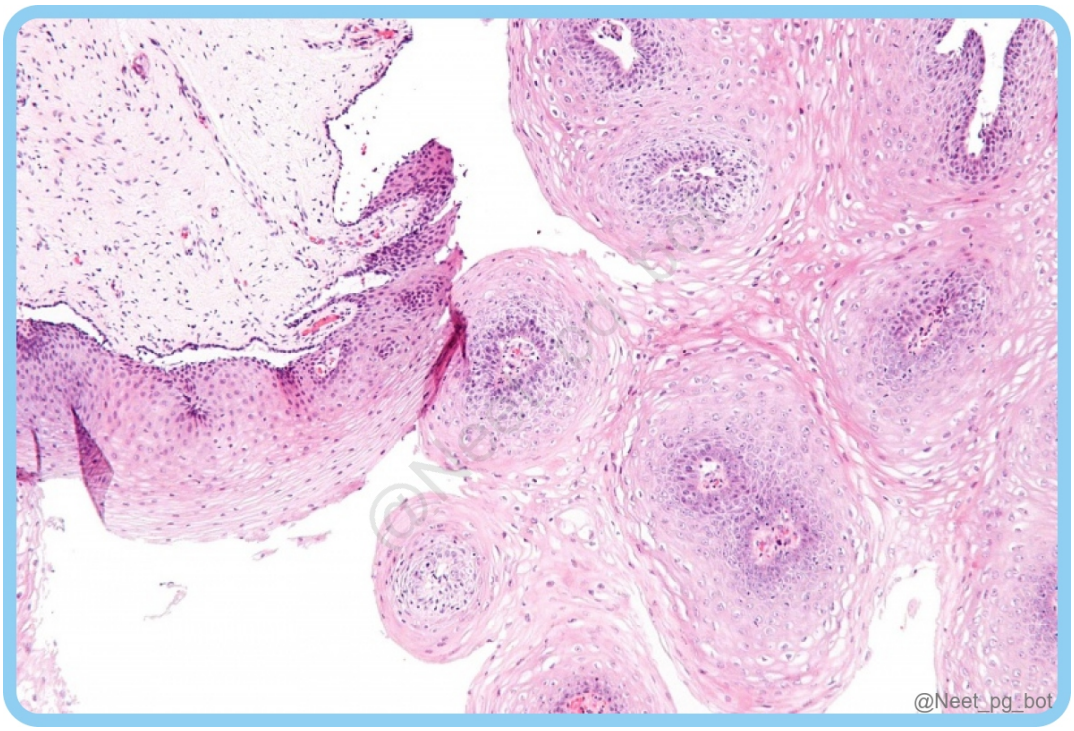

See Answer in Part B → Q2

@Neet_pg_bot

Q3: A 25-year-old sexually active female presents with foul-smelling vaginal discharge and dysuria. Upon examination of the cervix, the following appearance is noted. Wet mount microscopy reveals the findings shown in the image below. Which of the following is most likely responsible for this presentation? (Q845606)

A. Trichomonas vaginalis

B. Candida

C. Herpes simplex virus

D. Human Papilloma virus



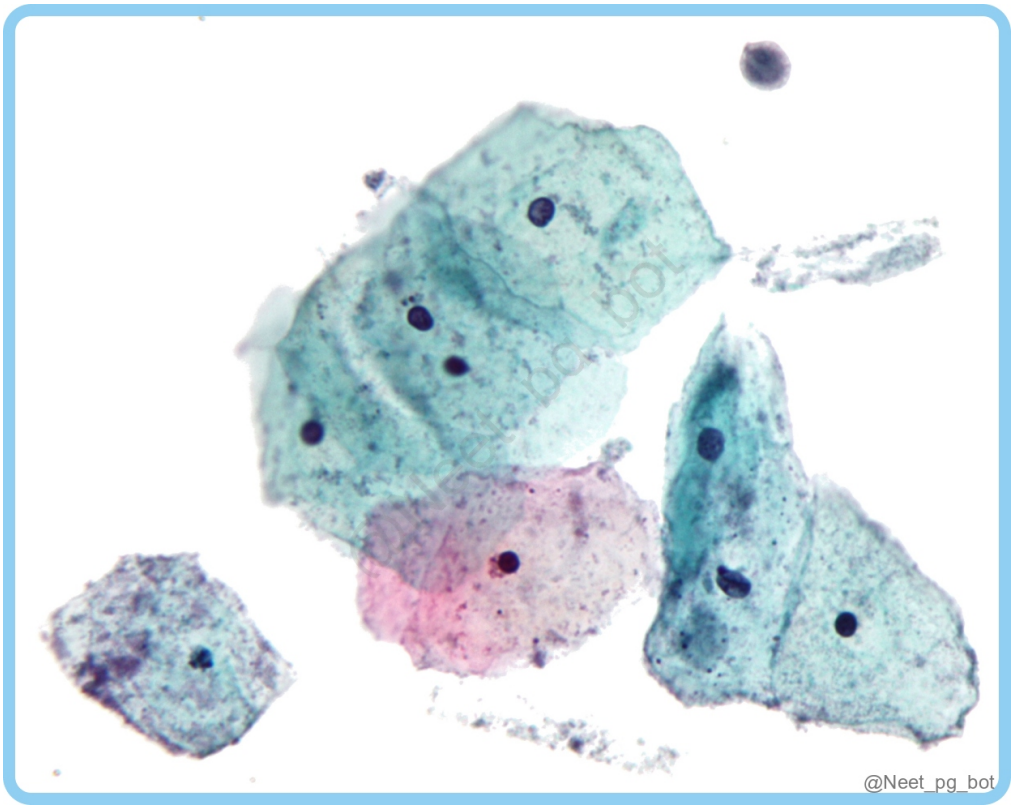

See Answer in Part B → Q3

@Neet_pg_bot

Q4: A 58-year-old woman complains of persistent itching and redness in her vulvar area. On examination, well-defined, erythematous plaques with an eczematous appearance are noted. A biopsy reveals large cells with pale cytoplasm and positive staining for mucopolysaccharides. Immunohistochemical analysis shows positive staining for cytokeratin 7. Based on these findings, what is the most likely diagnosis? (Q845607)

A. Bowen's disease of the vulva

B. Extramammary Paget's disease

C. Papillary Hidradenoma

D. Squamous cell carcinoma



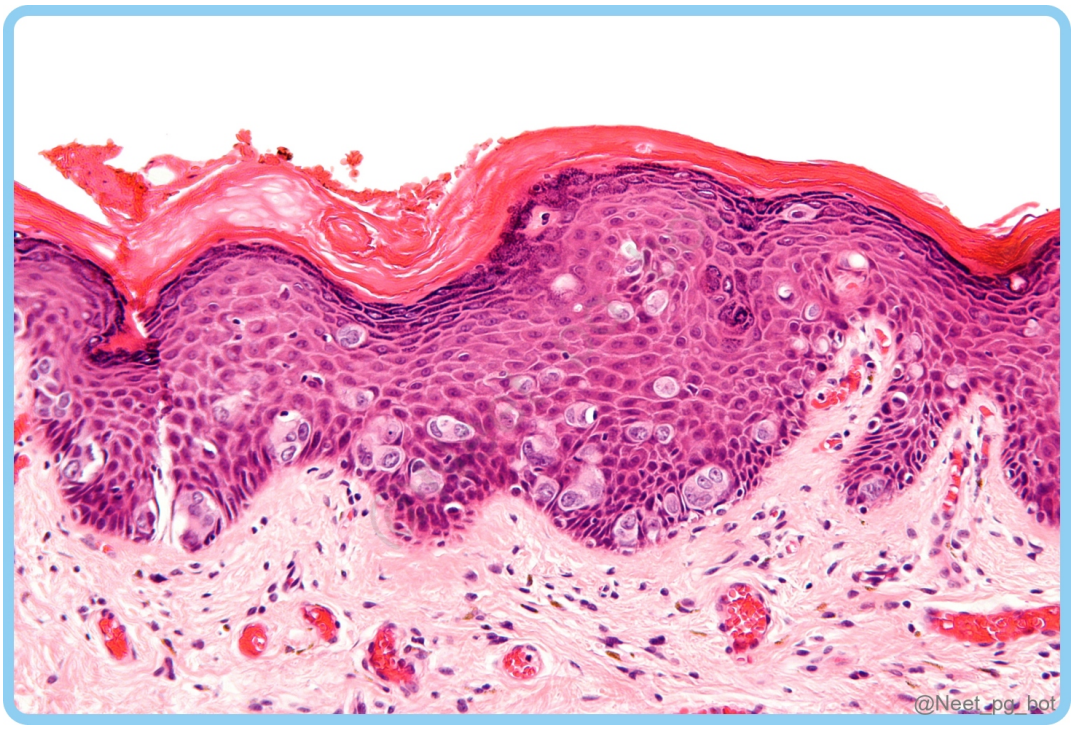

See Answer in Part B → Q4

@Neet_pg_bot

Q5: Which of the following has a strong association with clear cell adenocarcinoma of the vagina? (Q845608)

A. Male partner who has multiple sexual partners

B. In utero exposure to diethylstilbestrol

C. HPV infection

D. Sexual activity at a young age

See Answer in Part B → Q5

@Neet_pg_bot

Q6: A 4-year-old girl presents to the pediatric clinic with complaints of vaginal bleeding and a visible mass protruding from her vagina. On examination, a polypoid mass with a "grape-like" appearance is observed. A biopsy is taken, and

immunohistochemical staining is positive for desmin. Which of the following will show as a biopsy finding? (Q845609)

A. Cells with small protrusions of cytoplasm from one end

B. Marked atypia of cells with numerous keratin pearls

C. Columnar mucinous epithelium

D. Fibrous stroma covered by mucus-secreting endocervical glands



See Answer in Part B → Q6

@Neet_pg_bot

Q7: Which of the following is an advantage of liquid-based cytology (LBC) over the conventional Pap smear? (Q845610)

A. Cost-effective

B. More widely available in resource-limited settings

C. Adequacy of 8,000-12,000 epithelial cells

D. Allows simultaneous HPV testing

See Answer in Part B → Q7

@Neet_pg_bot

Q8: A 45-year-old woman comes to the OPD for regular Pap smear screening. The smear suggests a low-grade squamous intraepithelial lesion. Which of the following abnormal cell types was most likely seen on the smear? {{caption_text}} (Q845611)

A. Doderlein cells

B. Hobnail cells

C. Arias-Stella reaction cells

D. Koilocytes

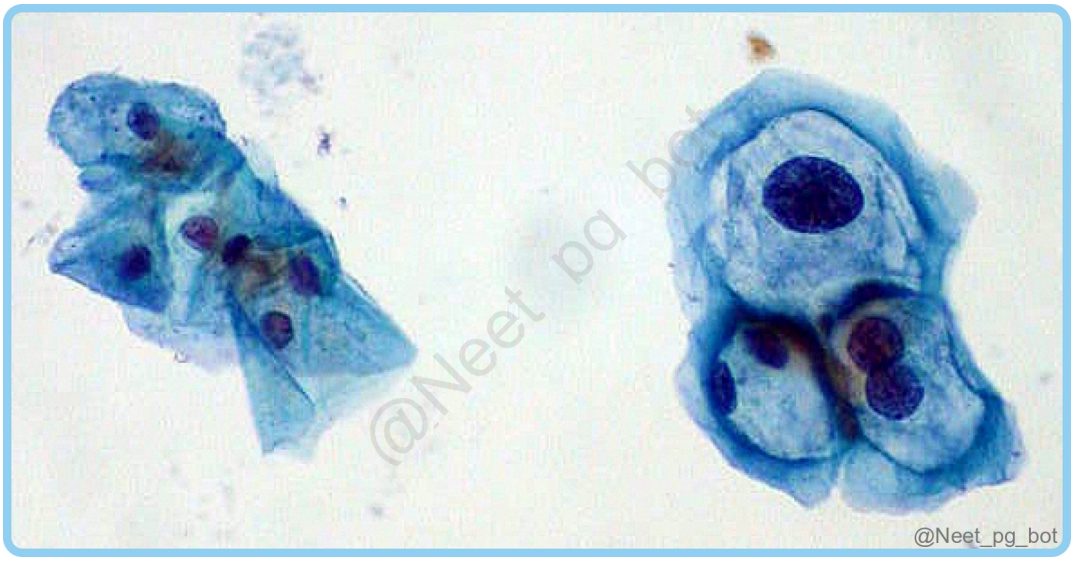

See Answer in Part B → Q8

@Neet_pg_bot

Q9: Which of the following risk factors is not typically associated with cervical cancer? (Q845612)

A. Smoking

B. Multiple sexual partners

C. Oral contraceptive pill use

D. Nulliparity

See Answer in Part B → Q9

@Neet_pg_bot

Q10: A 32-year-old woman undergoes a routine gynecological examination. Abnormalities are detected on her pap smear, and colposcopy-guided biopsy reveals dysplastic changes involving two-thirds of the cervical epithelium. What is the most likely diagnosis? {{caption_text}} (Q845613)

A. Cervical intraepithelial neoplasia 1

B. Cervical intraepithelial neoplasia 2

C. Cervical intraepithelial neoplasia 3

D. Invasive cervical carcinoma

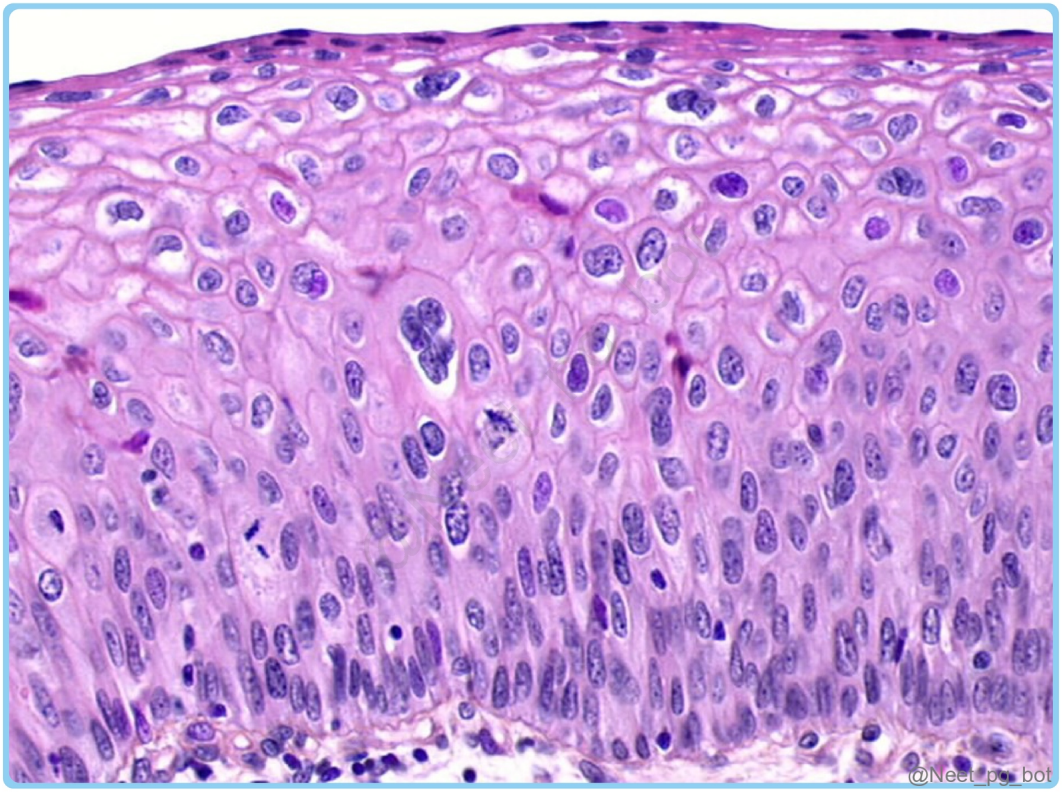

See Answer in Part B → Q10

@Neet_pg_bot

Q11: Which of the following statements is true regarding the squamous cell carcinoma of the cervix? HPV types 16 and 18 are the most common HPV types identified in invasive cervical cancer. The most common site of metastasis is the lungs. E6 protein interferes with the activity of the tumor suppressor proteins p53. Squamous cell carcinoma is the most common histologic subtype. (Q845614)

A. 1,2,3,4

B. 1,2,3

C. 1,3,4

D. Only 1

See Answer in Part B → Q11

@Neet_pg_bot

Q12: Which of the following is most likely associated with basaloid vulvar carcinomas? (Q846624)

A. Not associated with HPV

B. Arise from differentiated vulvar intraepithelial neoplasia

C. Keratinising morphology

D. High-risk HPV

See Answer in Part B → Q12

@Neet_pg_bot

• [12_Genital System] 054 Pathology Of Female Genital Tract-Ii

« Back to Folder Directory

[12_Genital System] 054 Pathology Of Female Genital Tract-Ii — Quick Jump

Q1 (p. 567) *Q2 (p. 568)* *Q3 (p. 568)* *Q4 (p. 569)* *Q5 (p. 569)* *Q6 (p. 570)*
Q7 (p. 571) *Q8 (p. 572)* *Q9 (p. 572)* *Q10 (p. 572)* *Q11 (p. 573)* *Q12 (p. 574)*
Q13 (p. 574) *Q14 (p. 575)* *Q15 (p. 575)* *Q16 (p. 576)* *Q17 (p. 576)* *Q18 (p. 577)*
Q19 (p. 577) *Q20 (p. 577)*

Q1: A 52-year-old woman presents with abdominal bloating, discomfort, and increased abdominal girth. Ascites and a palpable pelvic mass are noted on examination. Histopathological examination shows papillary structures with atypical epithelial cells containing psammoma bodies and elevated CA-125 levels. What is the likely diagnosis? {{caption_text}} (Q845717)

A. Mucinous cystadenocarcinoma

B. Endometrioid carcinoma

C. Serous cystadenocarcinoma

D. Clear cell carcinoma

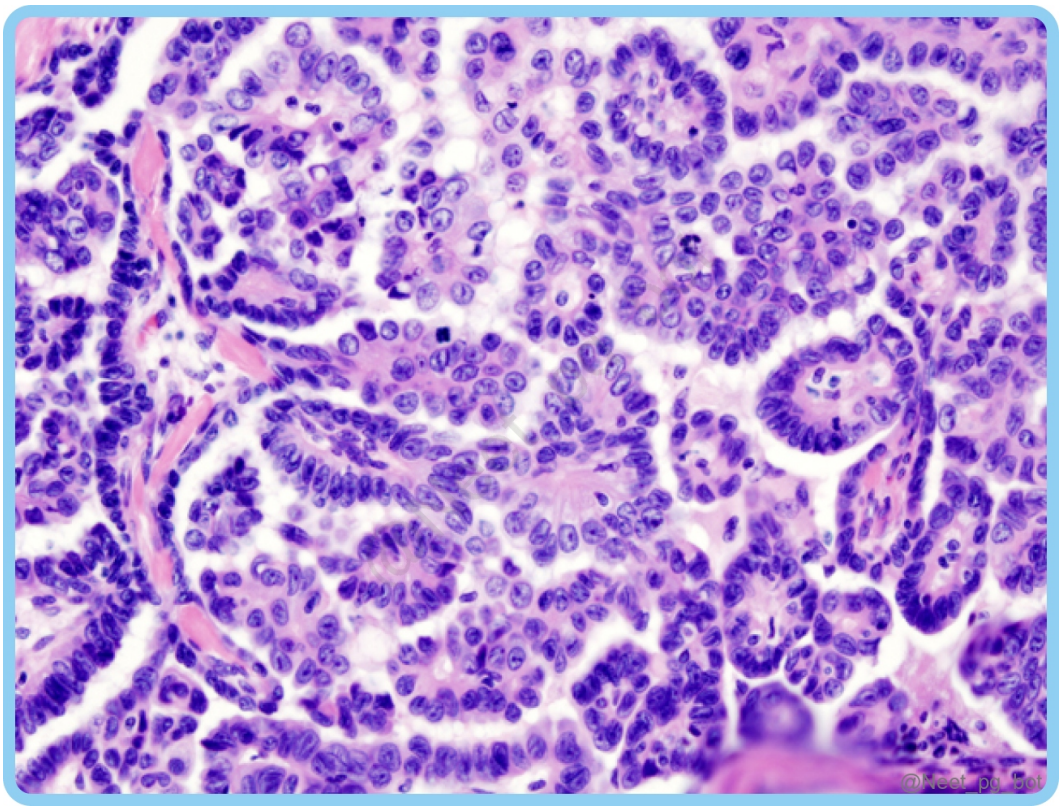

See Answer in Part B → Q1

@Neet_pg_bot

Q2: What is the extent of nonsquamous growth present in Grade 2 endometrial carcinoma? (Q846626)

A. 5% or less nonsquamous solid growth pattern

B. 6 - 50% nonsquamous solid growth pattern

C. > 50% nonsquamous solid growth pattern

D. >75% nonsquamous solid growth pattern

See Answer in Part B → Q2

@Neet_pg_bot

Q3: A 32-year-old woman presents with irregular vaginal bleeding and passage of grape-like clusters at ten weeks of gestation. Ultrasound reveals a heterogeneous pattern with fetal parts. On histopathology, some villi appear enlarged, and there is a presence of fetal tissue admixed with abnormal placental tissue. Which of the following is true regarding this condition? (Q846625)

A. High risk of invasive mole

B. Resulting from androgenetic fertilisation

C. Immunostaining for p57 is negative

D. High risk of malignancy

See Answer in Part B → Q3

@Neet_pg_bot

Q4: A 29-year-old woman at 11 weeks of gestation presents with vaginal bleeding and passage of grape-like clusters. Ultrasound shows a "snowstorm" appearance without fetal parts. On histopathology, most villi are enlarged with central cistern formation and the absence of fetal tissue. Which of the following is characteristic of this condition? (Q845739)

A. Presence of fetal tissue and partially developed placenta

B. Diploid karyotype, typically 46, XX or 46, XY, with no fetal tissue

C. Triploid karyotype, typically 69, XXX or 69, XXY, with some fetal tissue

D. Normal-sized chorionic villi with no trophoblastic proliferation

See Answer in Part B → Q4

@Neet_pg_bot

Q5: A 58-year-old postmenopausal woman presents with progressive abdominal distension, shortness of breath, and pelvic pain. Physical examination reveals ascites and a right-sided pleural effusion. Imaging reveals a solid ovarian mass. A biopsy of the mass shows benign ovarian fibroma. Which of the following is the most likely

diagnosis? (Q845737)

A. Meigs syndrome

B. Pseudo Meigs syndrome

C. Fitz-Hugh-Curtis syndrome

D. Mayer-Rokitansky-Küster-Hauser syndrome

See Answer in Part B → Q5

@Neet_pg_bot

Q6: Which of the following tumours is typically NOT associated with coffee bean nuclei? {{caption_text}} (Q845736)

A. Chondroblastoma

B. Granulosa cell tumour

C. Brenner tumour

D. Yolk sac tumour

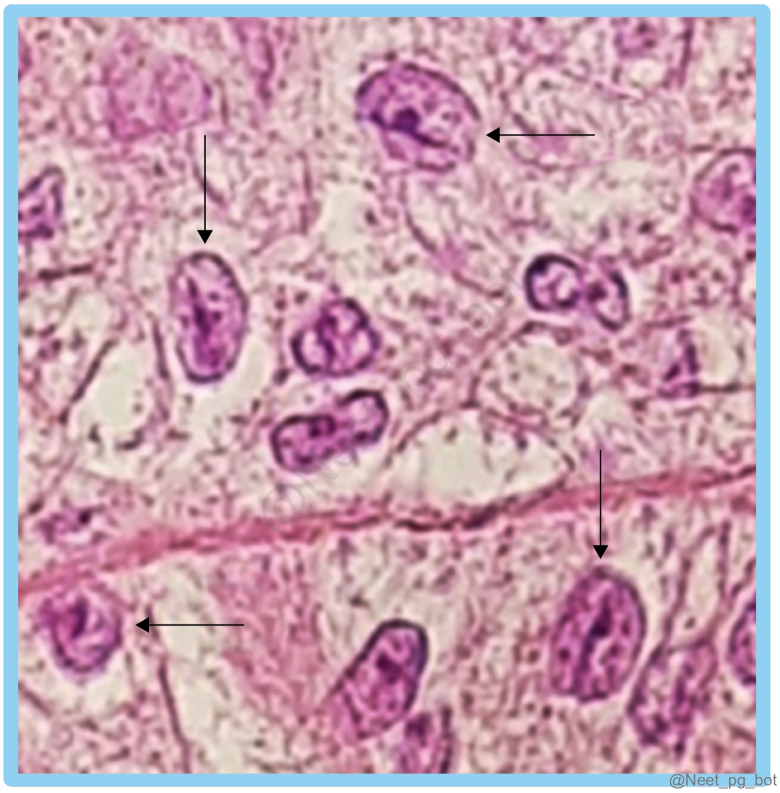

See Answer in Part B → Q6

@Neet_pg_bot

Q7: A 55-year-old postmenopausal woman presents with abnormal uterine bleeding and a pelvic mass. An ultrasound reveals a solid ovarian mass. The mass is surgically removed, and the HPE shows small, follicle-like structures filled with eosinophilic material. Which histological feature is most likely associated with this ovarian tumour? (Q845732)

A. Spindle cells with lipid droplets

B. Call-Exner bodies

C. Reinke crystalloids

D. Signet ring cells

See Answer in Part B → Q7

@Neet_pg_bot

Q8: A 19-year-old woman presents with lower abdominal pain and a rapidly enlarging pelvic mass. Imaging reveals a solid and cystic ovarian tumour. A biopsy of the mass shows immature neural elements and other embryonic-like tissues, indicating a high risk of malignancy. What is the most likely diagnosis? (Q845729)

A. Mature teratoma

B. Immature teratoma

C. Carcinoid tumour

D. Monodermal teratoma

See Answer in Part B → Q8

@Neet_pg_bot

Q9: A 28-year-old woman presents with severe vaginal bleeding and lower abdominal pain six months postpartum. USG reveals a heterogeneous uterine mass with haemorrhage and necrosis, raising suspicion of choriocarcinoma. What tumour marker is most likely elevated in her condition? (Q845724)

A. CA-125

B. LDH

C. AFP

D. HCG

See Answer in Part B → Q9

@Neet_pg_bot

Q10: A 16-year-old female presents with abdominal pain, distension, and a large pelvic mass accompanied by ascites. Elevated serum alpha-fetoprotein levels are detected. Surgical resection of the mass reveals histopathological findings depicted in the image. What is the probable diagnosis? {{caption_text}} (Q845718)

A. Endodermal sinus tumor

B. Dysgerminoma

C. Choriocarcinoma

D. Teratoma

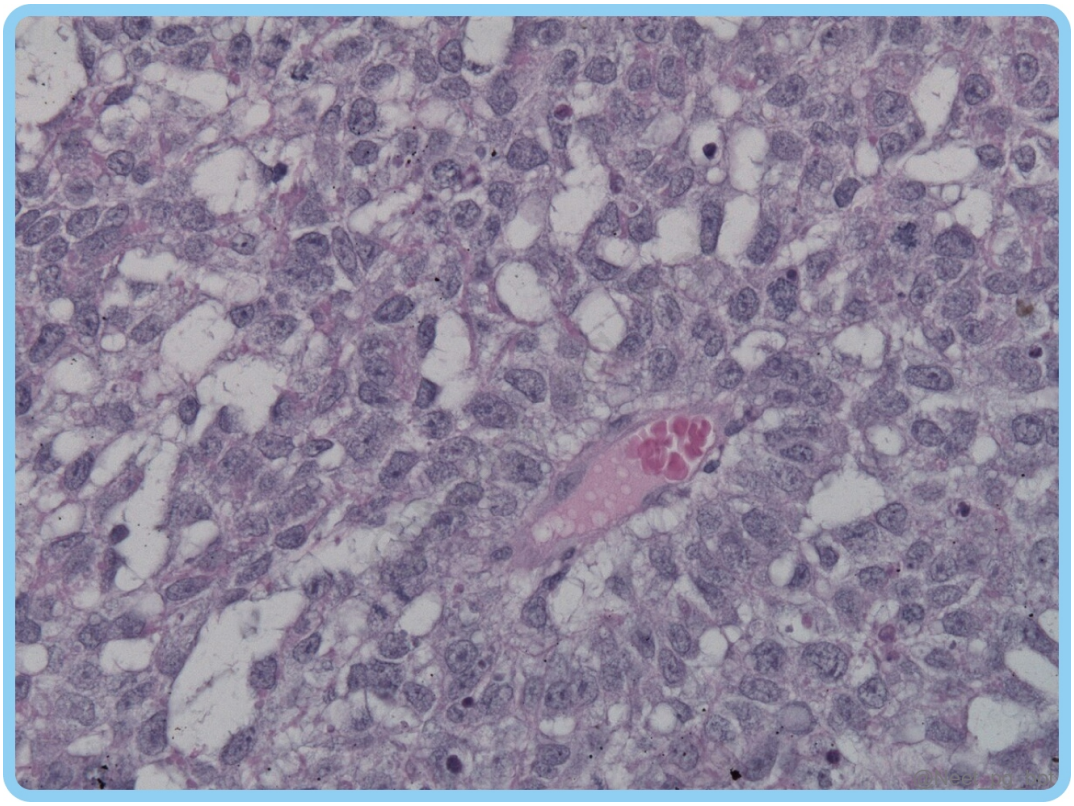

See Answer in Part B → Q10

@Neet_pg_bot

Q11: A 34-year-old woman with irregular menstrual cycles and difficulty conceiving undergoes an endometrial biopsy. HPE reveals glands with tall columnar epithelial cells with subnuclear vacuoles. Which phase of the endometrial cycle is most likely being discussed here? (Q845664)

A. Proliferative phase

B. Early secretory phase

C. Late secretory phase

D. Menstrual phase

See Answer in Part B → Q11

@Neet_pg_bot

Q12: Match the following. Tumors Genetic Mutation a) Serous tumors 1) PIK3CA b) Mucinous tumors 2) KRAS proto-oncogene c) Endometrioid carcinomas 3) PTEN d) Clear cell carcinomas 4) BRCA1 and BRCA2 (Q845715)

A. a-4,b-1,c-2,d-3

B. a-4,b-2,c-3,d-1

C. a-3,b-4,c-1,d-2

D. a-2,b-1,c-3,d-4

See Answer in Part B → Q12

@Neet_pg_bot

Q13: A 25-year-old woman presents with persistent dull lower abdominal pain and increased urinary frequency. A uterine ultrasound reveals a heterogeneous vascular mass with areas of necrosis. Biopsy results show spindle cells with significant atypia, high mitotic activity, and necrosis. What is the most likely diagnosis? {{caption_text}} (Q845699)

A. Endometriosis

B. Endometrial carcinoma

C. Leiomyoma

D. Leiomyosarcoma

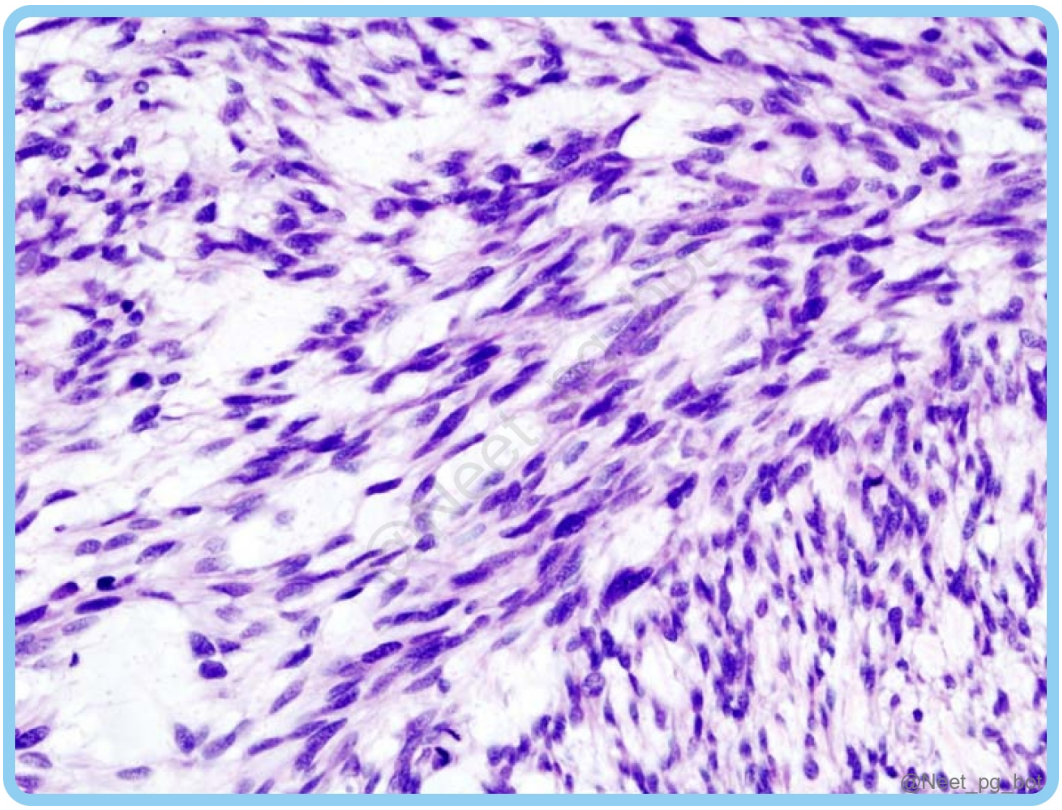

See Answer in Part B → Q13

@Neet_pg_bot

Q14: A 30-year-old pregnant woman at 20 weeks gestation presents with acute onset of severe abdominal pain. On examination, she has a tender, firm uterine mass. Ultrasound shows a fibroid with heterogeneous echotexture and increased vascularity. What type of degeneration is most likely occurring in the fibroid? (Q845698)

A. Hyaline degeneration

B. Calcific degeneration

C. Red degeneration

D. Myxoid degeneration

See Answer in Part B → Q14

@Neet_pg_bot

Q15: A 40-year-old woman presents with heavy menstrual bleeding, pelvic discomfort, and increased urinary frequency. Examination reveals an enlarged, irregular uterus, and imaging shows well-defined, solid myometrial masses.Which of the following genetic rearrangements is seen in leiomyomas? (Q845694)

A. MED12

B. KIT

C. p53

D. BRAF

See Answer in Part B → Q15

@Neet_pg_bot

Q16: A 55-year-old postmenopausal woman presents with abnormal uterine bleeding and pelvic discomfort. On examination, her uterus is mildly enlarged, and an endometrial biopsy reveals hyperplasia with atypia. Further investigation suggests endometrial carcinoma.Which of the following genes is not responsible for the pathogenesis of Endometrial carcinoma? (Q845691)

A. PTEN

B. KRAS

C. CTNNB-1

D. ETV1

See Answer in Part B → Q16

@Neet_pg_bot

Q17: A 49-year-old nulliparous woman with a history of irregular menses and breast cancer treated with tamoxifen presents with vaginal bleeding. Transvaginal ultrasound indicates irregular endometrial thickening, while biopsy confirms complex endometrial hyperplasia with atypia progressing to endometrioid carcinoma. Which of the following is not a risk factor for the above condition? (Q845690)

A. Thin physique

B. Diabetes mellitus

C. Tamoxifen

D. Unopposed estrogenic stimulation of the uterus

See Answer in Part B → Q17

@Neet_pg_bot

Q18: Which of the following genetic mutations is associated with Endometrial hyperplasia? (Q845689)

A. BRCA 1 gene

B. PTEN gene

C. TP53 gene

D. BRCA 2 gene

See Answer in Part B → Q18

@Neet_pg_bot

Q19: Which of the following statements is NOT true about Adenomyosis? (Q845688)

A. It presents with abnormal uterine bleeding.

B. Ectopic endometrial tissue is found at least 2.5 cm from the endometrial junction.

C. It is seen in pre-menopausal women.

D. Biopsy shows irregular nests of endometrial stroma arranged within the myometrium.

See Answer in Part B → Q19

@Neet_pg_bot

Q20: A 28-year-old woman with chronic pelvic pain worsened during menstrual periods and accompanied by heavy bleeding, was found to have a 'chocolate' brown cyst on her ovaries during a laparoscopy. What is the most commonly accepted theory for the pathogenesis of this condition? (Q845686)

A. Benign metastasis theory

B. Metaplastic theory

C. Extrauterine stem/progenitor cell theory

D. Regurgitation theory

See Answer in Part B → Q20

@Neet_pg_bot

• [12_Genital System] 055 Previous Year Questions

« Back to Folder Directory

[12_Genital System] 055 Previous Year Questions — Quick Jump

Q1 (p. 579) *Q2 (p. 579)* *Q3 (p. 580)* *Q4 (p. 581)* *Q5 (p. 582)* *Q6 (p. 582)*
Q7 (p. 583) *Q8 (p. 584)* *Q9 (p. 584)* *Q10 (p. 584)* *Q11 (p. 585)* *Q12 (p. 586)*
Q13 (p. 586)

Q1: A patient presents with ascites and omental caking. Imaging reveals solid components in an adnexal mass, and there is a long-standing history of symptoms. CA-125 is positive. What is the most probable diagnosis? (Q865380)

A. Serous ovarian tumor

B. Mucinous ovarian tumor

C. Endometroid tumor

D. Granulosa cell tumor

See Answer in Part B → Q1

@Neet_pg_bot

Q2: A histopathological image of an ovarian mass in a lady is shown below. Which of the following statements are true regarding this condition? Sex cord stromal tumor Call-Exner bodies are seen CA125 is high Inhibin is a marker (Q865416)

A. 1, 2, 3

B. 1, 2, 4

C. 2, 4

D. 1, 4

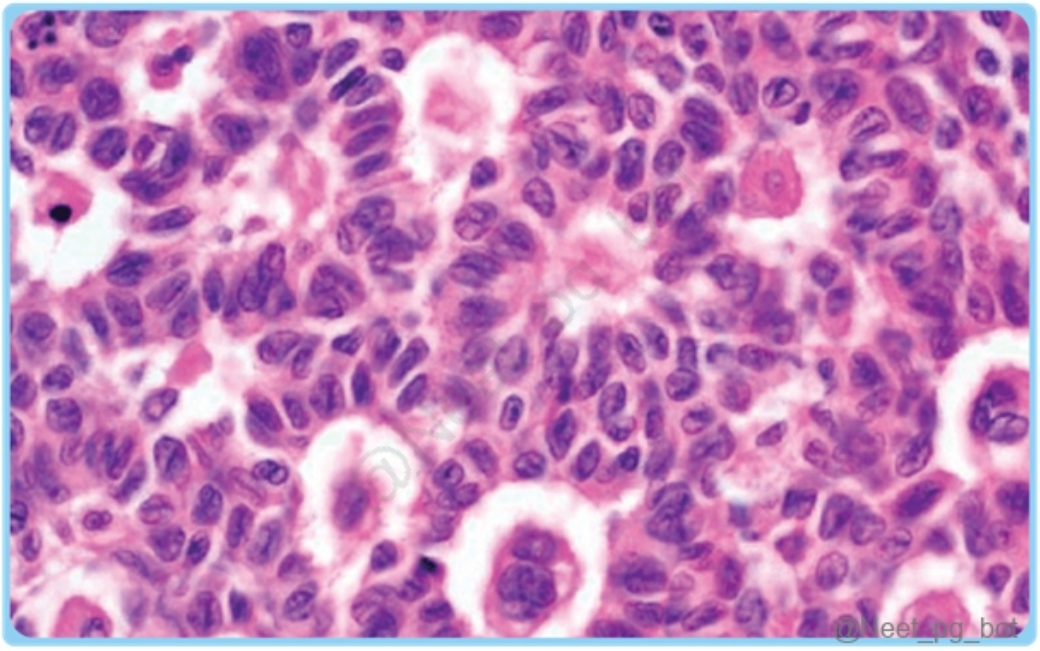

See Answer in Part B → Q2

@Neet_pg_bot

Q3: A 30-year-old man presents with a painless testicular mass. An ultrasound shows a well-circumscribed, homogeneous, non-hemorrhagic testicular tumour. Which of the following is the most likely diagnosis? (Q866364)

A. Yolk sac tumour

B. Choriocarcinoma

C. Teratoma

D. Seminoma

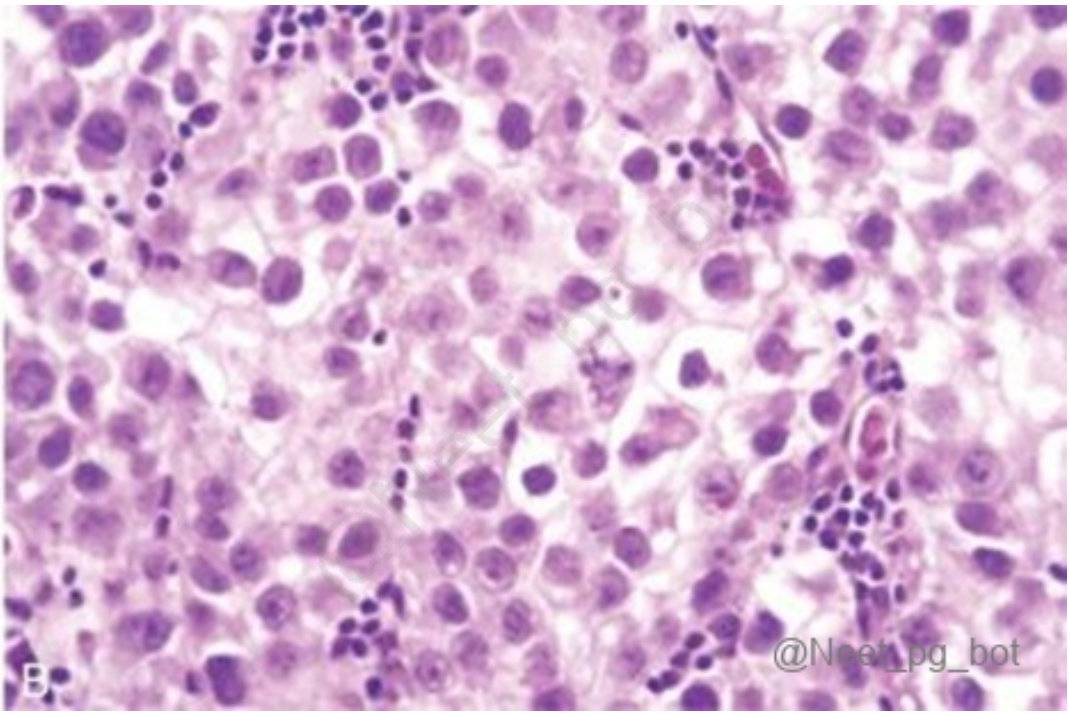

See Answer in Part B → Q3

@Neet_pg_bot

Q4: A patient presents with an ovarian mass that is multiloculated and has a serum CA-125 level >1000 U/mL. What is the most likely diagnosis? (Q866385)

A. Serous cystadenoma

B. Mature teratoma

C. Granulosa cell tumor

D. Serous cystadenocarcinoma



See Answer in Part B → Q4

@Neet_pg_bot

Q5: What is the role of inhibin? (Q860564)

A. Stimulates the release of FSH

B. Inhibits the secretion of FSH

C. Inhibition of PRL

D. Stimulation of PRL

See Answer in Part B → Q5

@Neet_pg_bot

Q6: In the cervical smear below, which of the following stains are used (Q857417)

A. Papanicolaou stain

B. H & E stain

C. Giemsa stain

D. Toluidine blue

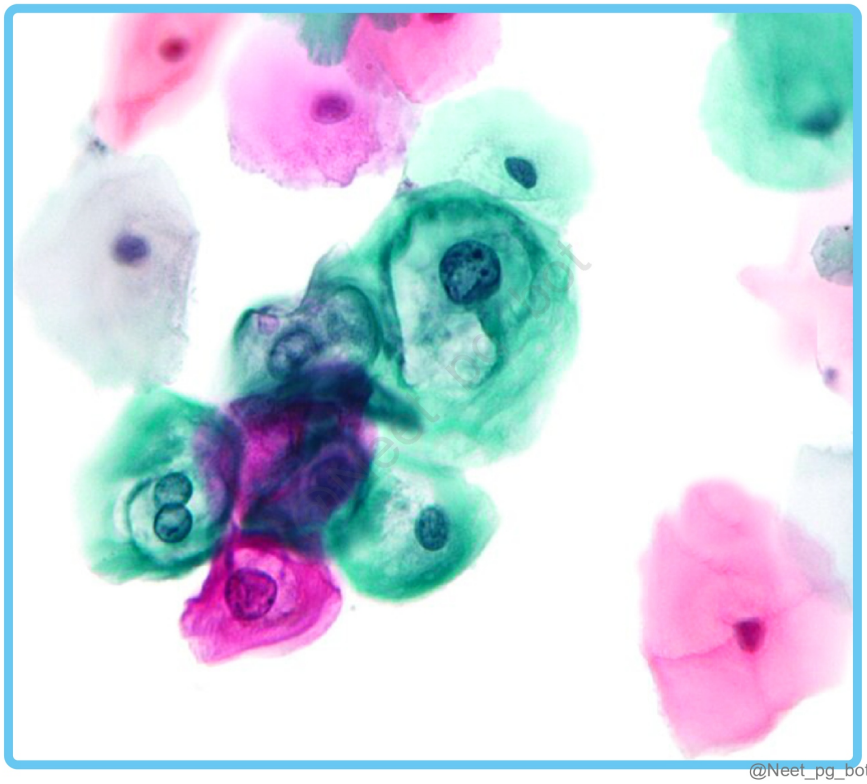

See Answer in Part B → Q6

@Neet_pg_bot

Q7: Which of the following tumour markers are positive for seminoma? PLAP OCT3/4 NANOG HCG (Q854709)

A. 1 only

B. 1 and 2

C. 1, 2 and 3

D. 1, 2, 3 and 4

See Answer in Part B → Q7

@Neet_pg_bot

Q8: Which of the following conditions is NOT caused by high-risk strains of human papillomavirus (HPV)? (Q855950)

A. Cervical cancer

B. Anal cancer

C. Oropharyngeal cancer

D. Laryngeal papillomatosis

See Answer in Part B → Q8

@Neet_pg_bot

Q9: What is the most probable tumour that a 22-year-old woman with a sizable growth in her right ovary, which has been determined to originate from all three germ layers based on histopathology, is experiencing? (Q857106)

A. Dysgerminoma

B. Teratoma

C. Thecoma

D. Theca lutein cyst

See Answer in Part B → Q9

@Neet_pg_bot

Q10: What is the most likely diagnosis for a 48-year-old patient who came with scrotal swelling, had elevated LDH levels but normal AFP levels on tests for testicular tumours, and exhibited a specific histological picture after orchidectomy? (Q857111)

A. Yolk sac tumor

B. Teratoma

C. Seminoma

D. Embryonal carcinoma

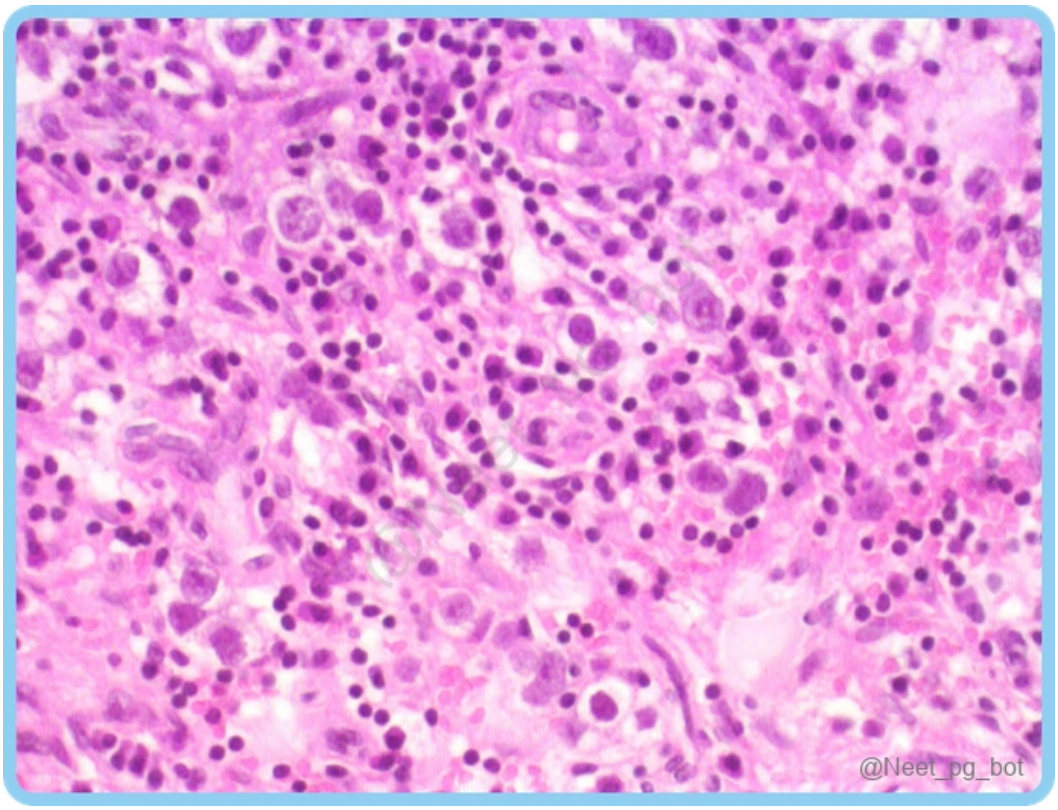

See Answer in Part B → Q10

@Neet_pg_bot

Q11: Which of the following is not a component of Meigs syndrome? (Q857125)

A. Ascites

B. Right-sided hydrothorax

C. Fibromas of ovary

D. Dysgerminoma of ovary

See Answer in Part B → Q11

@Neet_pg_bot

Q12: Which of the following statements is accurate concerning liquid-based cytology? (Q856890)

A. Urine specimen is used

B. Sanger sequencing is used

C. Study of fluid in the tumor microenvironment

D. DNA is collected in microvessels

See Answer in Part B → Q12

@Neet_pg_bot

Q13: Which of the following is not a constituent of the Papanicolaou stain? (Q856892)

A. Light green SF

B. Orange G

C. Eosin B

D. Hematoxylin

See Answer in Part B → Q13

@Neet_pg_bot

• [13_Endocrinology] 056 Thyroid Gland

« Back to Folder Directory

[13_Endocrinology] 056 Thyroid Gland — Quick Jump

Q1 (p. 587)	*Q2 (p. 589)*	*Q3 (p. 589)*	*Q4 (p. 590)*	*Q5 (p. 590)*	*Q6 (p. 591)*
Q7 (p. 591)	*Q8 (p. 592)*	*Q9 (p. 592)*	*Q10 (p. 592)*	*Q11 (p. 593)*	*Q12 (p. 593)*
Q13 (p. 593)	*Q14 (p. 594)*	*Q15 (p. 595)*	*Q16 (p. 595)*	*Q17 (p. 596)*	*Q18 (p. 596)*
Q19 (p. 597)	*Q20 (p. 597)*	*Q21 (p. 598)*	*Q22 (p. 599)*		

Q1: A 40-year-old patient presents with a nodule in the anterior neck and lymphadenopathy. The tumour is found to have spread to the lymphatics. Histopathological examination shows characteristic findings. What is the most likely diagnosis? (Q845553)

A. Follicular thyroid carcinoma

B. Medullary thyroid carcinoma

C. Papillary thyroid carcinoma

D. Anaplastic thyroid carcinoma

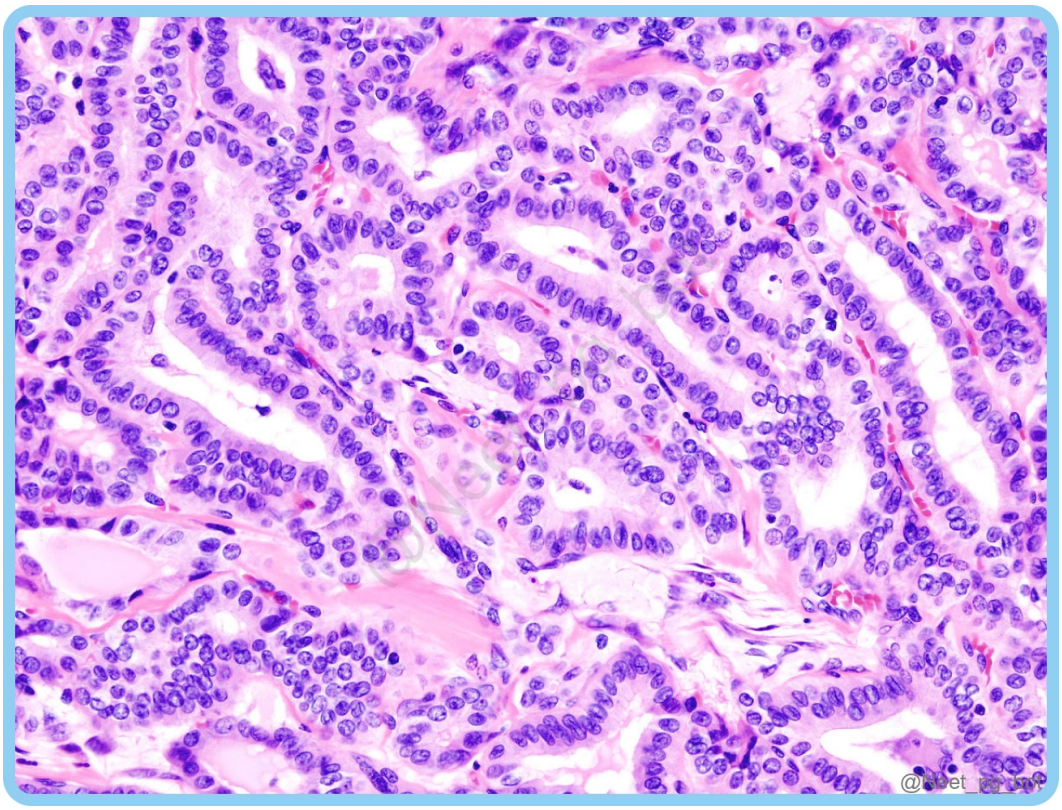

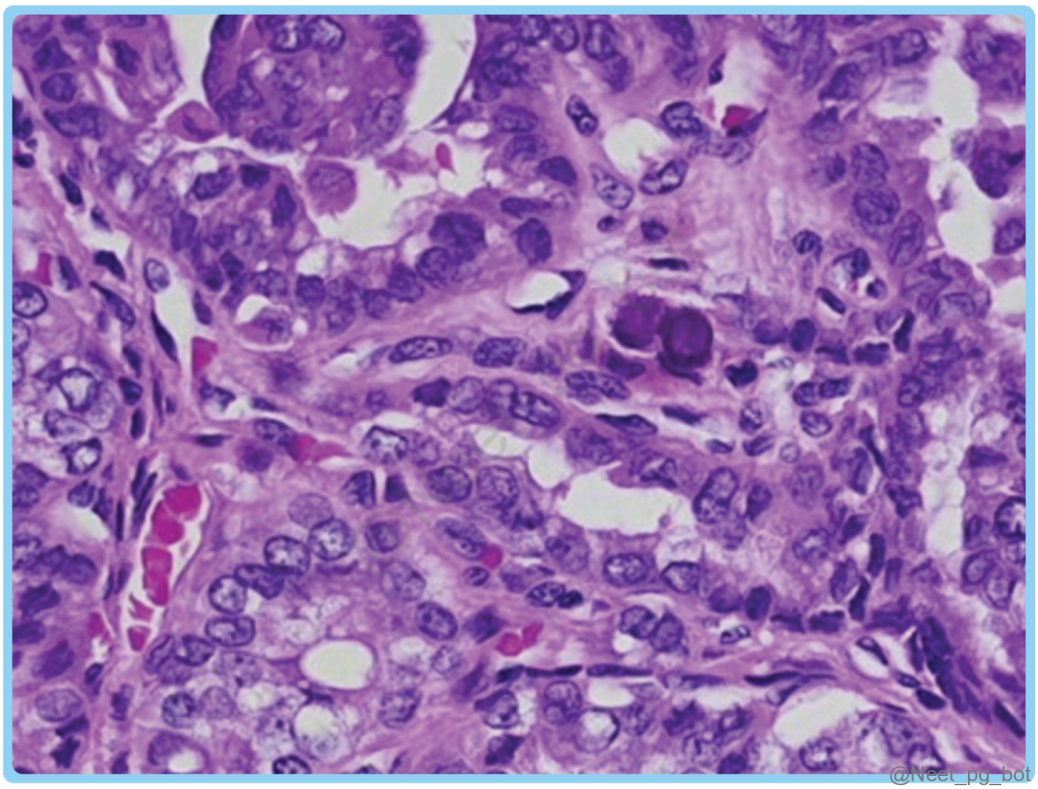

See Answer in Part B → Q1

@Neet_pg_bot

Q2: A 35-year-old patient is diagnosed with papillary thyroid carcinoma. Which of the following statements about papillary thyroid carcinoma is true? (Q890473)

A. Not associated with radiation exposure

B. Hot nodule on scintigraphy

C. Accounts for 85% of thyroid cancers

D. Has a poor prognosis

See Answer in Part B → Q2

@Neet_pg_bot

Q3: A 32-year-old woman presents with a midline neck swelling that moves with deglutition and tongue protrusion. The swelling has been present since childhood but has recently increased in size. Surgical excision is performed. Histopathological examination reveals the following findings. What is the most likely diagnosis? (Q890469)

A. Follicular carcinoma

B. Papillary carcinoma

C. Medullary carcinoma

D. Anaplastic carcinoma

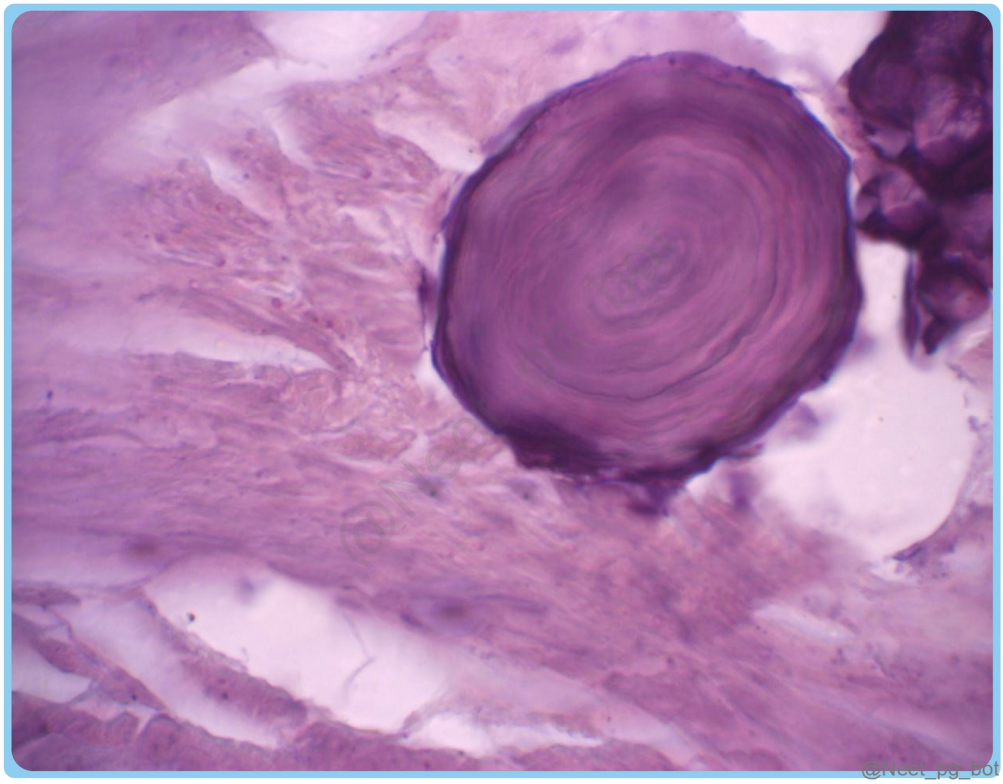

See Answer in Part B → Q3

@Neet_pg_bot

Q4: Which of the following correctly represents the most common and least common thyroid carcinomas, respectively? (Q890467)

A. Papillary carcinoma - Anaplastic carcinoma

B. Follicular carcinoma - Medullary carcinoma

C. Medullary carcinoma - Papillary carcinoma

D. Anaplastic carcinoma - Papillary carcinoma

See Answer in Part B → Q4

@Neet_pg_bot

Q5: Which of the following is the correct statement regarding a solitary thyroid nodule? (Q890465)

A. Most often malignant

B. Incidence decreases with age

C. Rare in the general population

D. Higher risk of malignancy than multiple nodules

See Answer in Part B → Q5

@Neet_pg_bot

Q6: A 45-year-old woman presents with painful enlargement of the thyroid following an upper respiratory infection. Laboratory tests show ↑ T3/T4, ↓ TSH, and low radioactive iodine uptake. What is the most likely diagnosis? (Q890464)

A. Hashimoto thyroiditis

B. Graves disease

C. Subacute granulomatous thyroiditis

D. Riedel thyroiditis

See Answer in Part B → Q6

@Neet_pg_bot

Q7: Which of the following is the most common cause of hypothyroidism in iodine-sufficient areas? (Q890463)

A. Hashimoto thyroiditis

B. Wolff-Chaikoff effect

C. Pituitary failure

D. Thyroid agenesis

See Answer in Part B → Q7

@Neet_pg_bot

Q8: Which of the following histopathological features is not typically seen in Hashimoto thyroiditis? (Q890447)

A. Lymphoid follicles with germinal centres

B. Hürthle (oncocytic) cell change

C. Fibrosis extending beyond the thyroid capsule

D. Dense mononuclear inflammatory infiltrate

See Answer in Part B → Q8

@Neet_pg_bot

Q9: Which of the following statements regarding hyperthyroidism is correct? (Q890446)

A. Graves' disease is the most common cause of hyperthyroidism.

B. Serum TSH levels are increased in primary hyperthyroidism.

C. Osteoporosis is not a complication

D. Constipation is a typical feature of hyperthyroidism.

See Answer in Part B → Q9

@Neet_pg_bot

Q10: A 45-year-old patient presents with a painless lump on the front of the neck, bone pain, fatigue, and episodes of flushed skin. Genetic studies reveal a mutation in the RET gene. Which type of amyloid is typically deposited in this condition? (Q845555)

A. A-β

B. A-CAL

C. A-L

D. A-TTR

See Answer in Part B → Q10

@Neet_pg_bot

Q11: Which of the following is not a common feature of follicular carcinoma of thyroid? (Q845554)

A. Second most common thyroid malignancy

B. Has a Hurthle cell variant

C. Commonly spreads by lymphatic route

D. FNAC is not helpful in diagnosis

See Answer in Part B → Q11

@Neet_pg_bot

Q12: Which system is widely used for reporting thyroid cytopathology? (Q845542)

A. TIRADS

B. Gleason System

C. Bethesda System

D. Duke Classification

See Answer in Part B → Q12

@Neet_pg_bot

Q13: Match each type of thyroid tumour with its most commonly associated risk factor: Thyroid Carcinoma Risk Factors: 1. Papillary thyroid carcinoma A. Iodine

deficiency 2. Follicular thyroid carcinoma B. RET proto-oncogene mutations 3. Medullary thyroid carcinoma C. Radiation exposure 4. Anaplastic thyroid carcinoma D. History of a well-differentiated follicular neoplasm (Q845552)

A. 1-C, 2-A, 3-B, 4-D

B. 1-B, 2-C, 3-D, 4-A

C. 1-A, 2-D, 3-C, 4-B

D. 1-D, 2-B, 3-A, 4-C

See Answer in Part B → Q13

@Neet_pg_bot

Q14: A 55-year-old patient presents with a solitary thyroid nodule. The patient also reports difficulty swallowing, with no complaints of weight loss, fatigue, or heat intolerance. An excisional biopsy reveals >75% of the following characteristic cells. Which genetic mutation is most commonly associated with this type of thyroid tumour? {{caption_text}} (Q845551)

A. BRAF

B. GNAS

C. RAS

D. PTEN

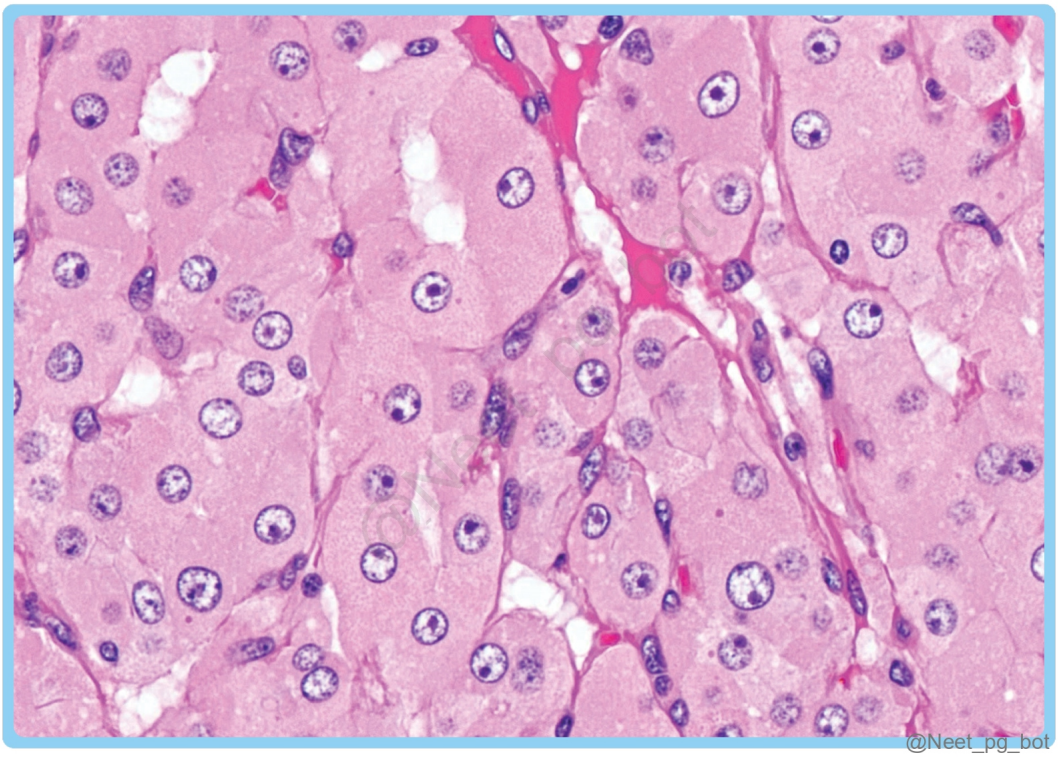

See Answer in Part B → Q14

@Neet_pg_bot

Q15: What is the finding in the histopathological examination of a biopsy specimen from a patient with De Quervain Thyroiditis? (Q845550)

A. Extensive stromal fibrosis extending beyond the thyroid capsule

B. Follicular hyperplasia with scalloping colloid

C. Mononuclear infiltration with well-developed germinal centres

D. Mixed cellular infiltration with occasional multinucleated giant cells

See Answer in Part B → Q15

@Neet_pg_bot

Q16: Which of the following is not a feature of subacute lymphocytic thyroiditis? (Q845549)

A. Also called postpartum thyroiditis

B. Usually presents as a painful enlargement of the thyroid

C. Self-limiting condition

D. Lymphocytic inflammation in the thyroid

See Answer in Part B → Q16

@Neet_pg_bot

Q17: Which of the following best describes the gross morphology of Riedel's thyroiditis? (Q845548)

A. Localised nodule within the gland

B. Diffusely enlarged thyroid gland

C. Mobile and well-circumcised mass

D. Stony and hard consistency

See Answer in Part B → Q17

@Neet_pg_bot

Q18: A 28-year-old woman comes to the office due to progressively worsening eye irritation and double vision over the last two months. She also reports unintentional weight loss, mood swings, diarrhoea, and palpitations. Physical examination shows tachycardia and bilateral proptosis. What is the pathophysiology causing proptosis? (Q845547)

A. Increased activity of orbital fibroblasts

B. Increased breakdown of hyaluronic acid

C. Increased synthesis of thyroid hormones

D. Increase in sympathetic activity

See Answer in Part B → Q18

Q19: A 29-year-old lady has been experiencing loss of appetite, profuse sweating, and palpitations for the past three months. Laboratory tests conclude increased T3 and T4 levels with decreased TSH levels. A representative HPE of this condition is shown below. The most common antibodies in this condition target which of the following? {{caption_text}} (Q845546)

A. TSH receptor

B. Thyroid peroxidase

C. Thyroglobulin

D. Dermal fibroblasts

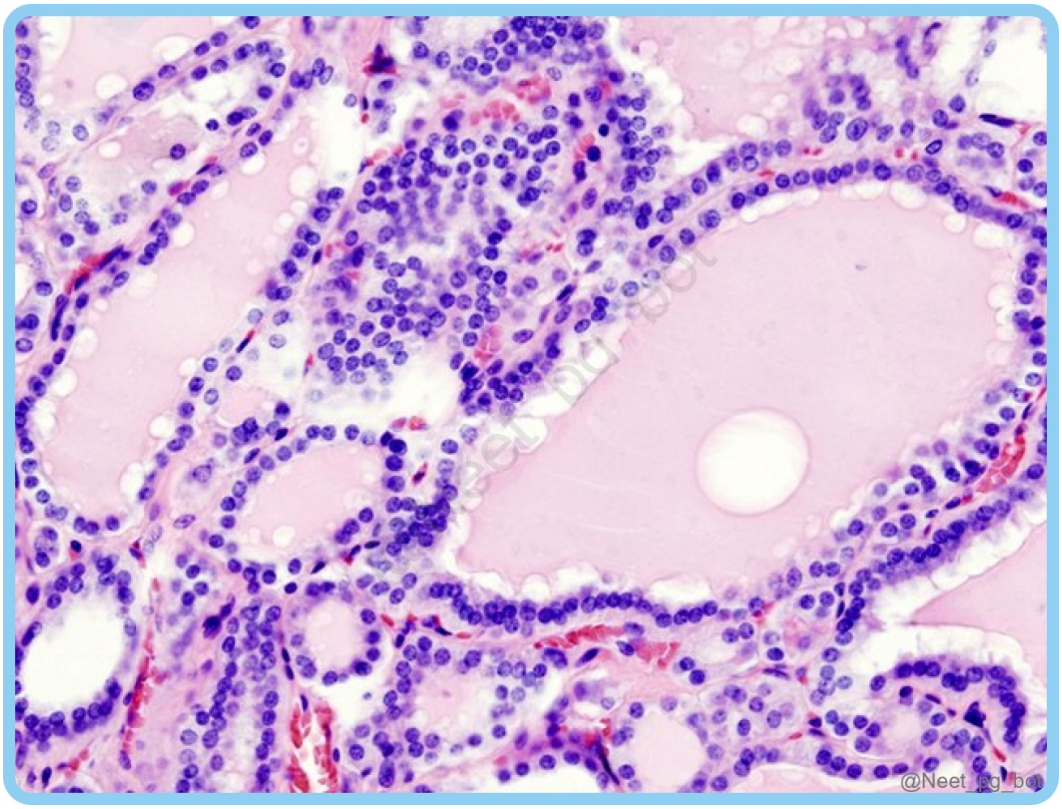

See Answer in Part B → Q19

Q20: Which of the following antibodies are elevated in a patient of Hashimoto's thyroiditis? (Q845545)

A. Thyroid-stimulating immunoglobulins (TSI)

B. Anti-thyroid peroxidase antibodies (Anti-TPO)

C. Anti-thyroid stimulating hormone receptor antibodies (Anti-TSHR)

D. Anti-thyroid hormone antibodies (Anti-T3/T4)

See Answer in Part B → Q20

@Neet_pg_bot

Q21: A 35-year-old female presents with fatigue, weight gain, and cold intolerance. On physical examination, she has diffuse goitre and dry skin. Histopathological examination shows lymphoid infiltration, atrophic thyroid follicles lined in many areas by epithelial cells with abundant eosinophilic, granular cytoplasm as shown below. What is the likely diagnosis? {{caption_text}} (Q845544)

A. Grave’s disease

B. Thyroid nodule

C. Papillary carcinoma

D. Hashimoto thyroiditis

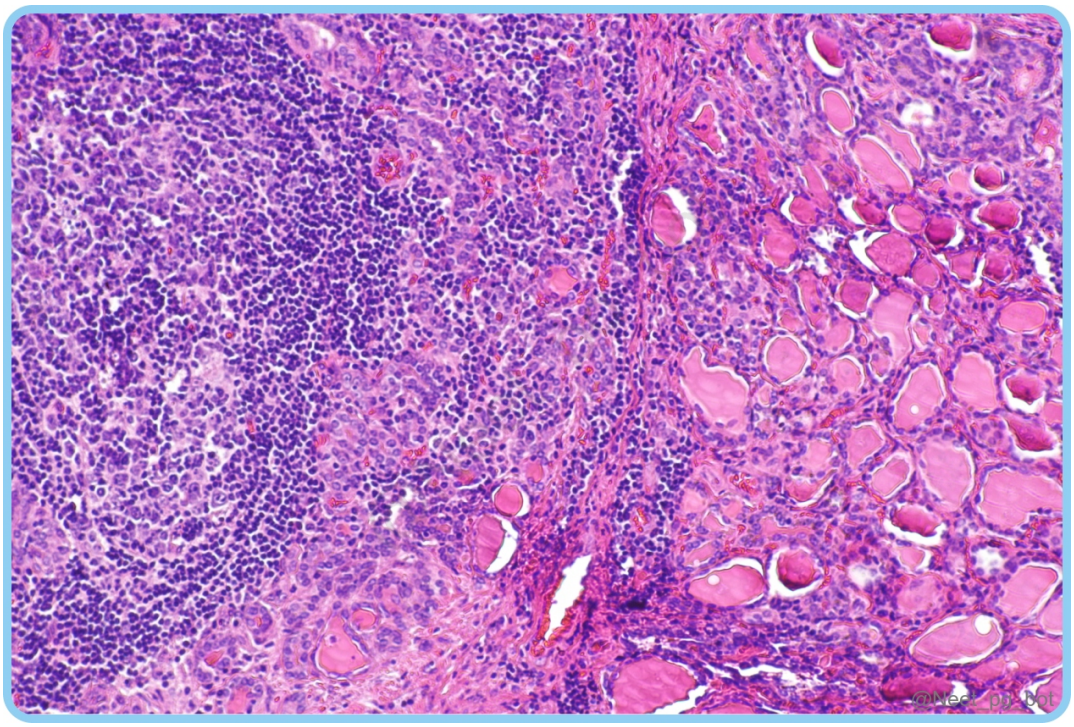

See Answer in Part B → Q21

@Neet_pg_bot

Q22: You are examining a high-resolution microscopic image of thyroid tissue. Which of the following depicts cells responsible for the secretion of calcitonin? {{caption_text}} (Q845543)

A. A

B. B

C. C

D. D

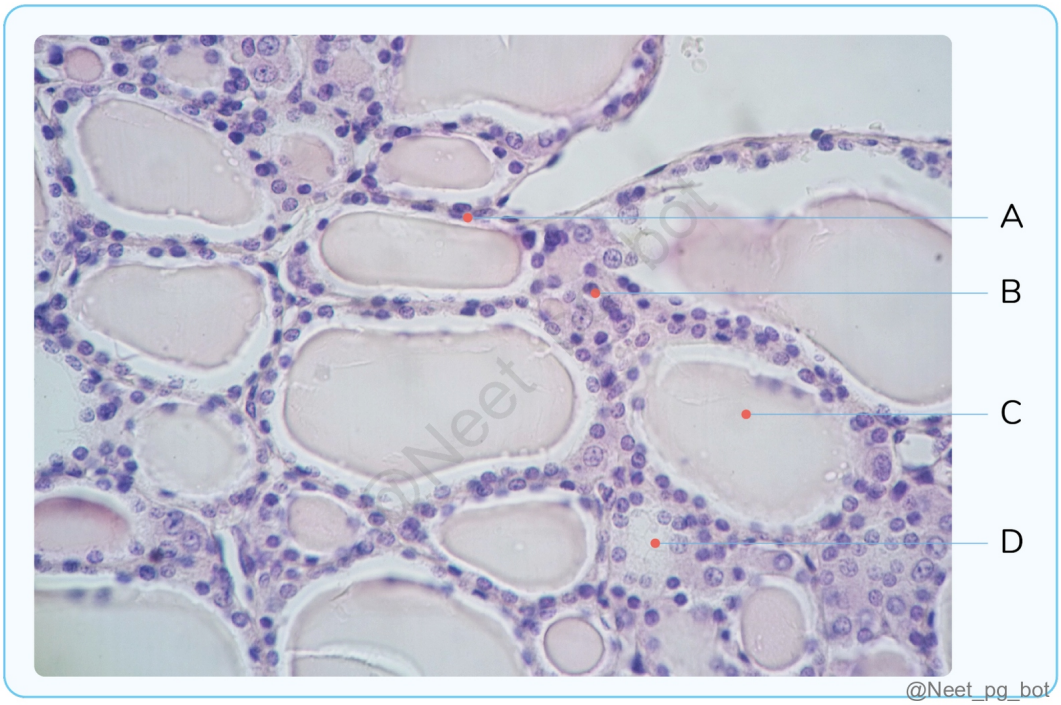

See Answer in Part B → Q22

@Neet_pg_bot

• [13_Endocrinology] 057 Parathyroid Pituitary And Adrenal Glands - I

« Back to Folder Directory

[13_Endocrinology] 057 Parathyroid Pituitary And Adrenal Glands - I — Quick Jump

Q1 (p. 601) *Q2 (p. 602)* *Q3 (p. 602)* *Q4 (p. 603)* *Q5 (p. 604)* *Q6 (p. 605)*
Q7 (p. 605) *Q8 (p. 606)* *Q9 (p. 607)* *Q10 (p. 607)* *Q11 (p. 607)* *Q12 (p. 608)*
Q13 (p. 609) *Q14 (p. 610)*

Q1: Which of the following cell types are typically found in the anterior lobe of the pituitary gland, and which are stained pink and purple, respectively? (Q845580)

A. Sommatotrophs and lactotrophs

B. Lactotrophs and thyrotrophs

C. Corticotrophs and gonadotrophs

D. Gonadotrophs and somatotrophs

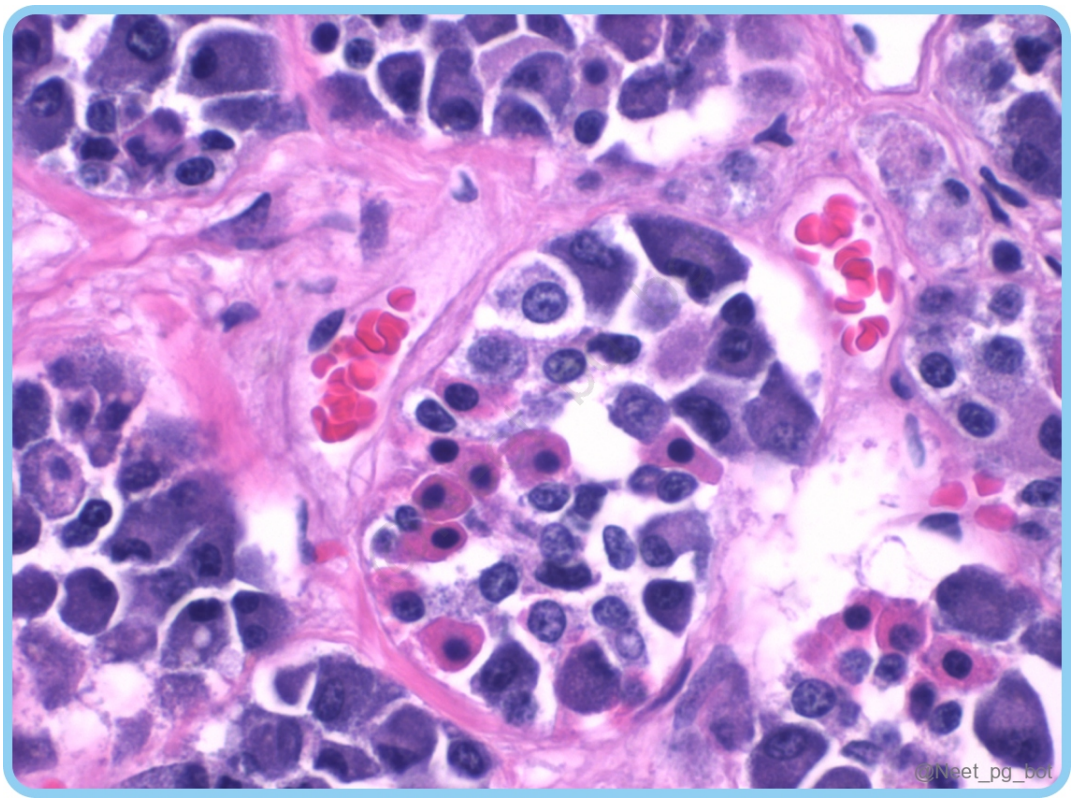

See Answer in Part B → Q1

@Neet_pg_bot

Q2: Pituitary adenomas are often classified based on the hormones they secrete. Which of the following statements correctly matches the type of pituitary adenoma with its primary hormone secretion and associated syndrome? (Q845581)

A. Prolactinoma – Secretes prolactin – Causes Cushing's disease

B. Somatotroph adenoma – Secretes growth hormone – Causes acromegaly

C. Corticotroph adenoma – Secretes thyroid-stimulating hormone – Causes hyperthyroidism

D. Gonadotroph adenoma – Secretes adrenocorticotropic hormone (ACTH) – Causes Addison's disease

See Answer in Part B → Q2

@Neet_pg_bot

Q3: A pathologist examines a surgically resected pituitary tumour under a microscope. The tumour comprises sheets of monomorphic, round to polygonal cells with central nuclei and sparse to absent reticulin network. What is the most likely diagnosis? (Q845582)

A. Pituitary adenoma

B. Pituitary carcinoma

C. Craniopharyngioma

D. Schwannoma

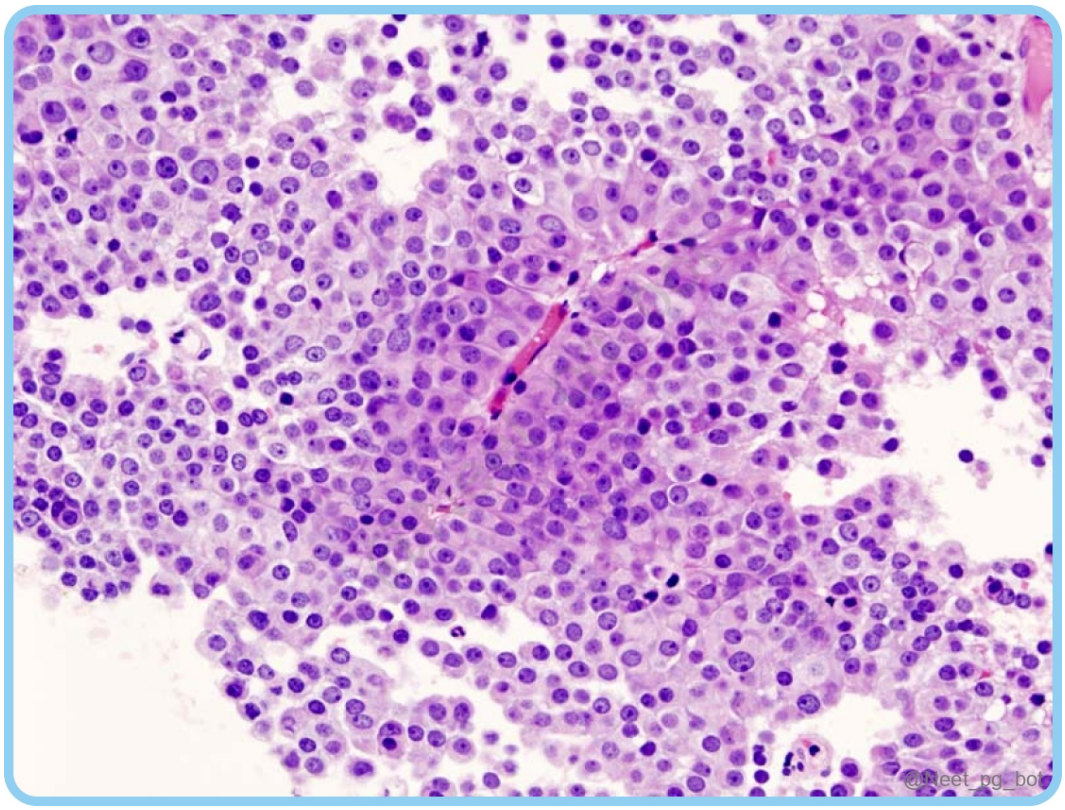

See Answer in Part B → Q3

@Neet_pg_bot

Q4: A 12-year-old child presents with headaches, visual disturbances, and delayed growth. An MRI of the brain reveals a 3 cm cystic mass with calcifications. The growth was found to be encapsulated and multiloculated. What is the most likely diagnosis? (Q845583)

A. Oligodendroglioma

B. Meningioma

C. Craniopharyngioma

D. Pituitary adenoma

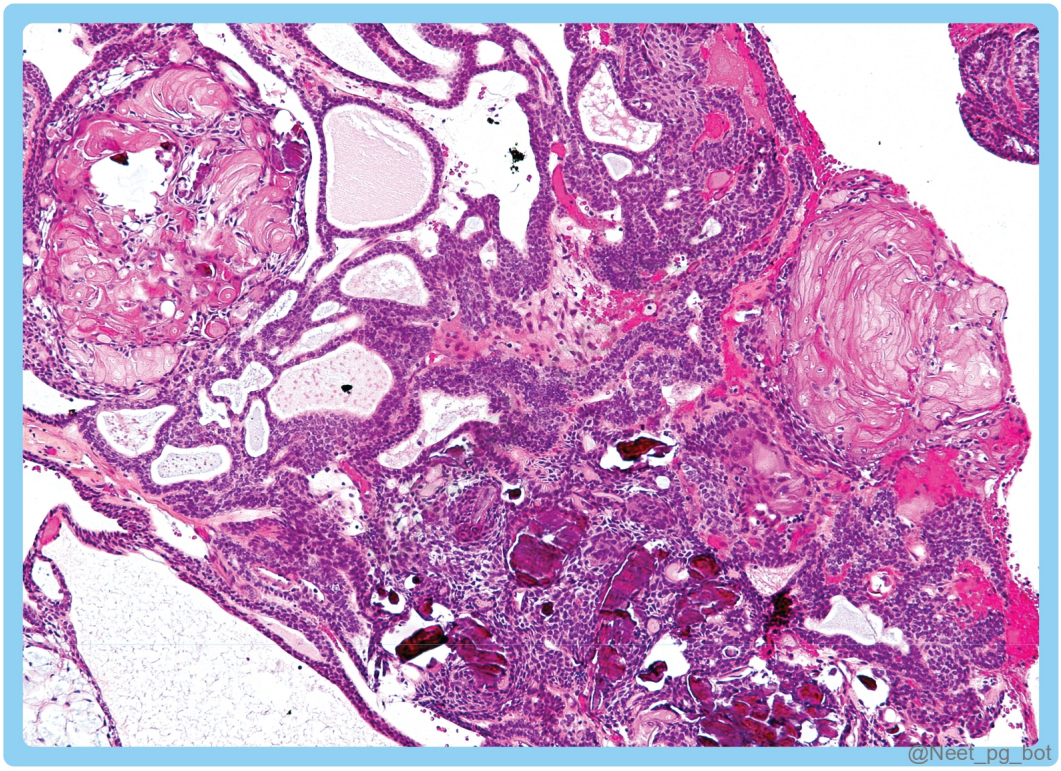

See Answer in Part B → Q4

@Neet_pg_bot

Q5: A 35-year-old male presents with a history of recurrent kidney stones, hypercalcemia, and a recent diagnosis of a pituitary adenoma. Which of the following syndromes is most likely associated with his clinical presentation? (Q845584)

A. MEN 2A syndrome

B. MEN 2B syndrome

C. MEN 4 syndrome

D. MEN 1 syndrome

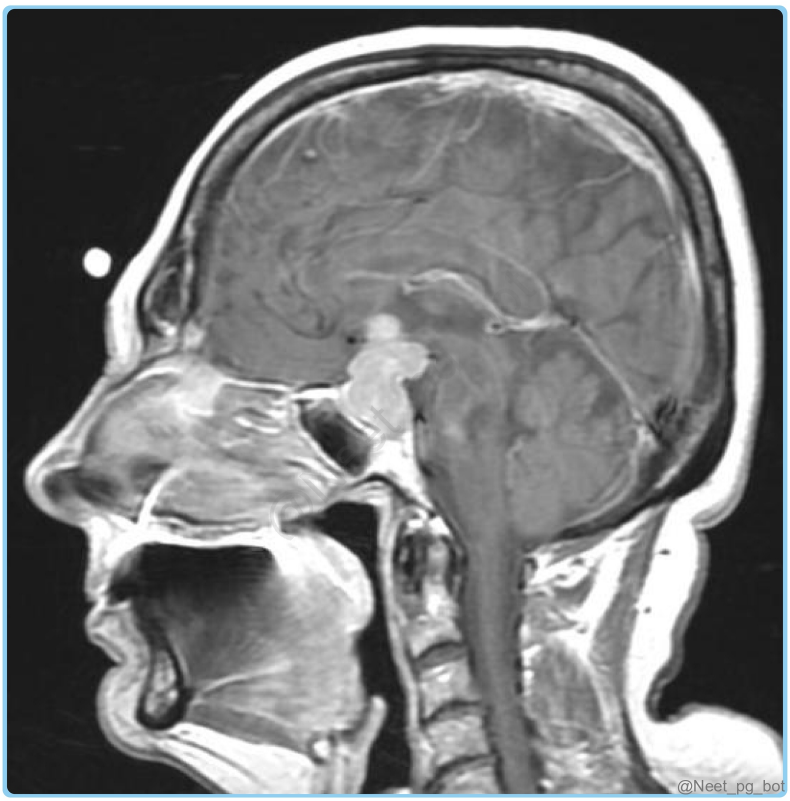

See Answer in Part B → Q5

@Neet_pg_bot

Q6: Which mutation is associated with pituitary carcinoma? (Q845585)

A. AIP

B. CDKN I B

C. HRAS

D. MEN 1

See Answer in Part B → Q6

@Neet_pg_bot

Q7: Identify the marked cells in the histology of the parathyroid below. (Q845586)

A. Oxyphil cells

B. Chief cells

C. Adipocytes

D. Parafollicular cells

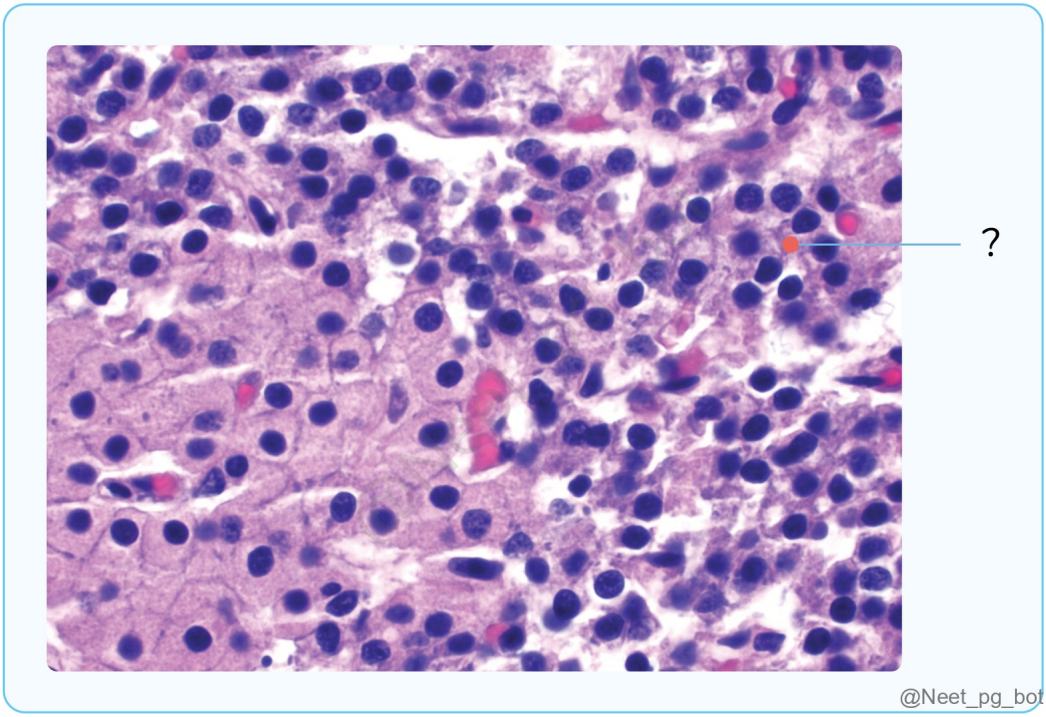

See Answer in Part B → Q7

@Neet_pg_bot

Q8: Which of the following microscopic features is most indicative of a parathyroid adenoma rather than parathyroid hyperplasia? (Q845587)

A. Diffuse hyperplasia of chief cells throughout the parathyroid gland

B. Stromal fat infiltration within the parathyroid tissue

C. Intranuclear cytoplasmic inclusions within chief cells

D. Difficult to distinguish on microscopy

See Answer in Part B → Q8

@Neet_pg_bot

Q9: Which of the following genetic mutations is most commonly associated with pheochromocytoma? (Q845588)

A. Gain of function mutation in n-Myc gene

B. Gain of function mutation in RET gene

C. Loss of function mutation in the RET gene

D. Loss of function mutation in MEN 1 gene

See Answer in Part B → Q9

@Neet_pg_bot

Q10: The 4-year-old kid is brought with complaints of periorbital ecchymosis, miosis, and ptosis. CT scan reveals a tumour on the right kidney with calcifications. A biopsy reveals small, dark blue cells with scanty cytoplasm. Which mutation is most likely connected to this mass? (Q845589)

A. ALK gene mutation

B. RET gene mutation

C. L-MYC gene mutation

D. VHL gene mutation

See Answer in Part B → Q10

@Neet_pg_bot

Q11: A 2-year-old boy is brought with complaints of abdominal lump for 2 months. HPE of the mass is shown below. Which of the following conditions is not associated with a similar finding? (Q845590)

A. Neuroblastoma

B. Medulloblastoma

C. Retinoblastoma

D. Primitive neuroectodermal tumors

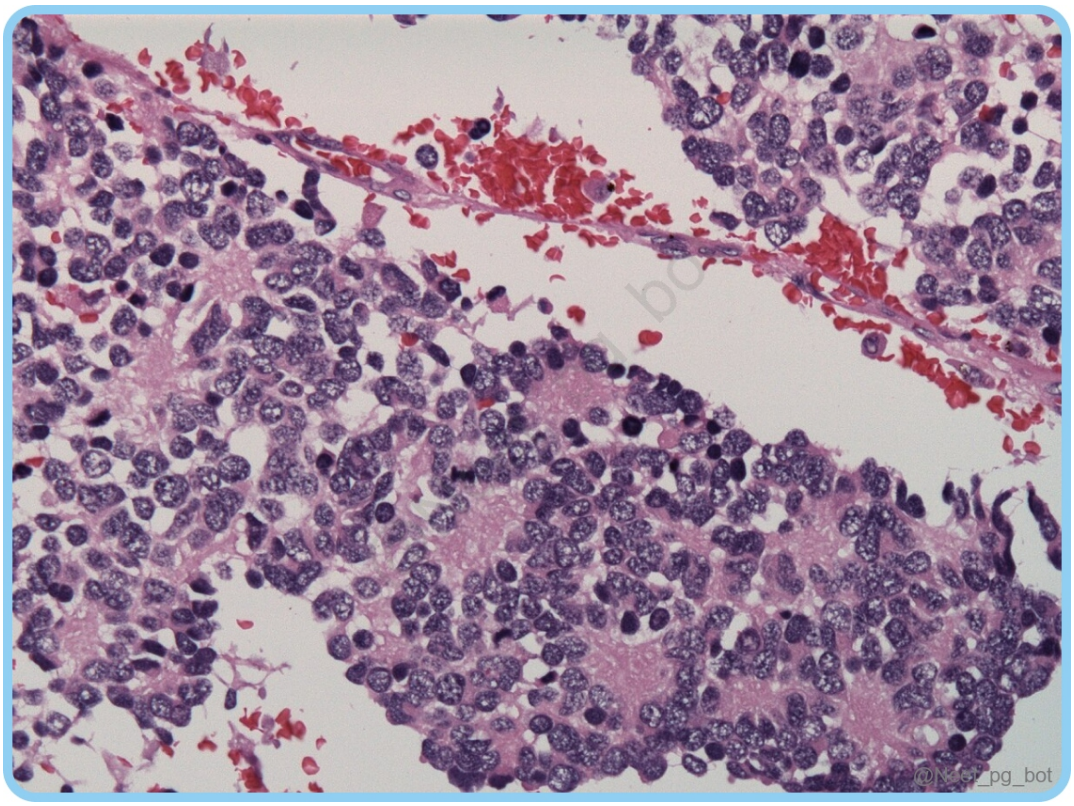

See Answer in Part B → Q11

@Neet_pg_bot

Q12: This histology finding is seen in all these tumors except? (Q845591)

A. Pheochromocytoma

B. Carotid body tumor

C. Neuroblastoma

D. Medullary carcinoma of the thyroid

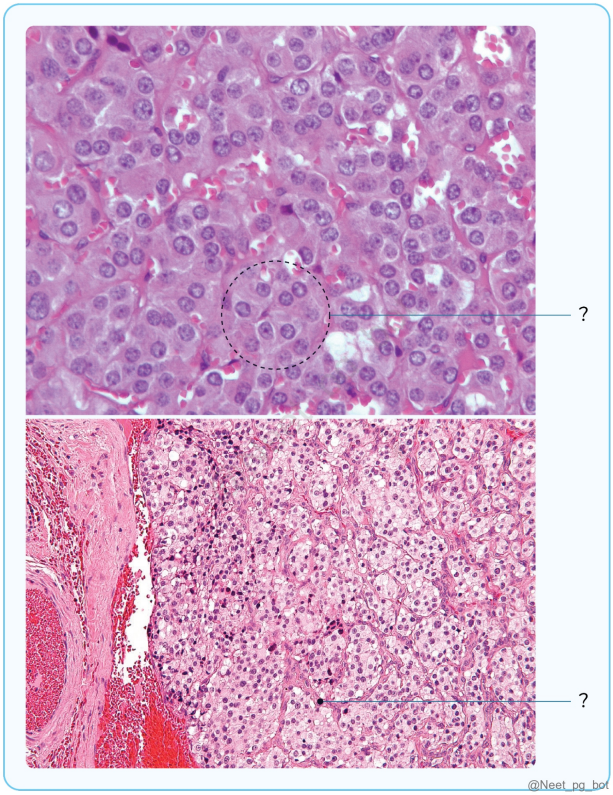

See Answer in Part B → Q12

@Neet_pg_bot

Q13: A 40-year-old woman has been evaluated for intermittent headaches, insomnia, diaphoresis, and unintentional weight loss over the past several months. The patient is found to have a neoplastic mass producing excessive hormones causing symptoms. Histopathology of the same is shown below. These cells marked below stain positive for which of the following immunohistochemical markers? (Q845592)

A. Synaptophysin

B. Chromogranin

C. Neuron-specific enolase

D. S-100

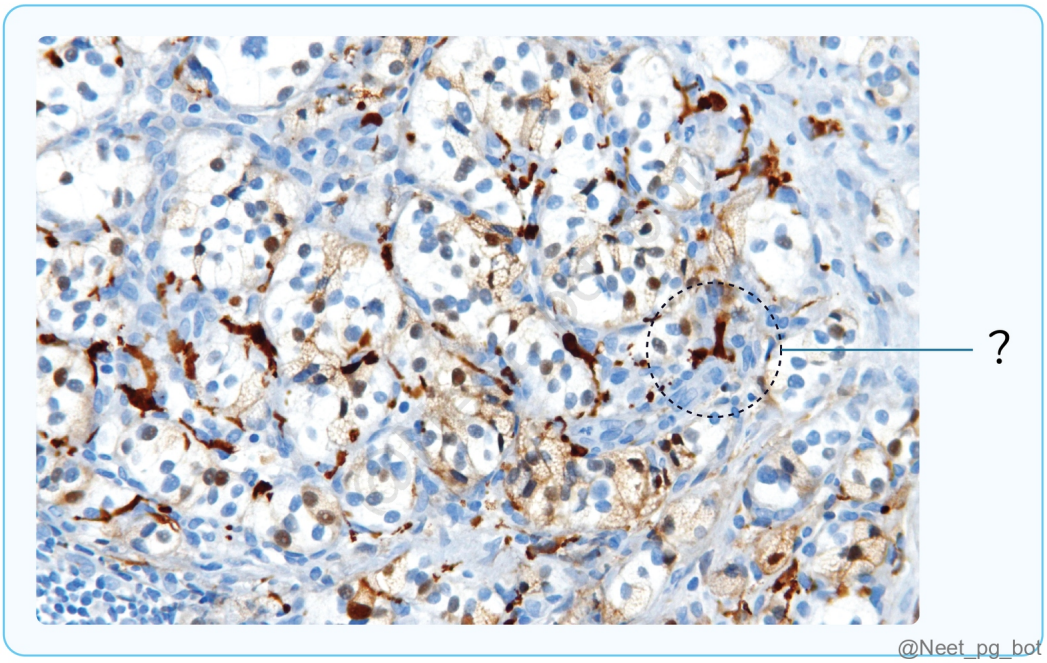

See Answer in Part B → Q13

@Neet_pg_bot

Q14: A 40-year-old woman presents to her primary care physician with a recent diagnosis of medullary thyroid carcinoma (MTC). She reports no significant family history of endocrine disorders. Laboratory investigations show elevated levels of serum calcium and plasma catecholamines and metanephrines. What is the most likely diagnosis in this patient? (Q845593)

A. MEN 1 syndrome

B. MEN 2 A syndrome

C. MEN 2 B syndrome

D. Neurofibromatosis type 1

See Answer in Part B → Q14

@Neet_pg_bot

• [13_Endocrinology] 058 Previous Year Questions

« Back to Folder Directory

[13_Endocrinology] 058 Previous Year Questions — Quick Jump

Q1 (p. 611) *Q2 (p. 611)* *Q3 (p. 612)* *Q4 (p. 612)* *Q5 (p. 613)* *Q6 (p. 614)*
Q7 (p. 614) *Q8 (p. 615)* *Q9 (p. 615)* *Q10 (p. 616)* *Q11 (p. 617)* *Q12 (p. 617)*
Q13 (p. 618) *Q14 (p. 619)* *Q15 (p. 619)*

Q1: Mutation in which of the following genes is most commonly associated with medullary thyroid carcinoma? (Q866734)

A. RAS

B. BRAF

C. RET

D. TP53

See Answer in Part B → Q1

@Neet_pg_bot

Q2: A patient presents with a mass in the front of the neck, along with odynophagia and dyspnea. Histopathology reveals tumour cells positive for TTF-1, synaptophysin, and chromogranin, and there is evidence of amyloid deposition. What is the most likely diagnosis? (Q866374)

A. Papillary thyroid carcinoma

B. Follicular thyroid carcinoma

C. Medullary thyroid carcinoma

D. Anaplastic thyroid carcinoma

See Answer in Part B → Q2

@Neet_pg_bot

Q3: Identify the gene commonly involved in the carcinoma shown in the image below: (Q843990)

A. RAS

B. PAX8–PPARγ

C. BRAF V600

D. P53

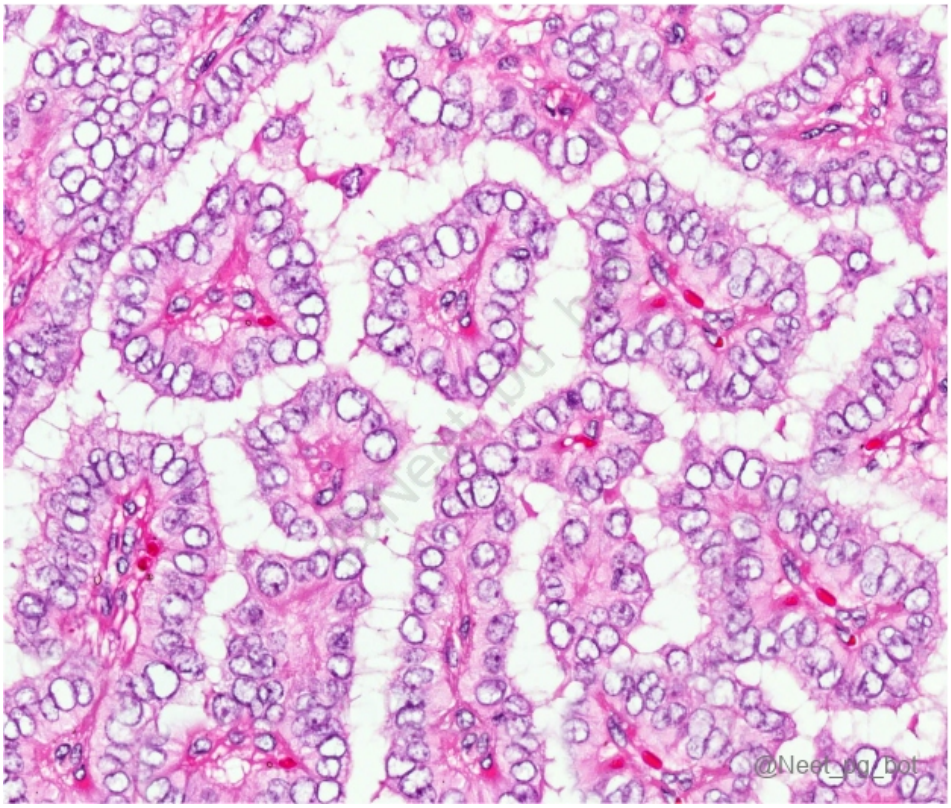

See Answer in Part B → Q3

@Neet_pg_bot

Q4: A patient presents with headaches, palpitations, and hypertension. On laboratory examination, urine VMA is positive. His biopsy findings are given below. Which of the following is a correct statement? (Q844236)

A. Mostly malignant

B. Mostly in children

C. Mostly bilateral

D. Associated with MEN2A

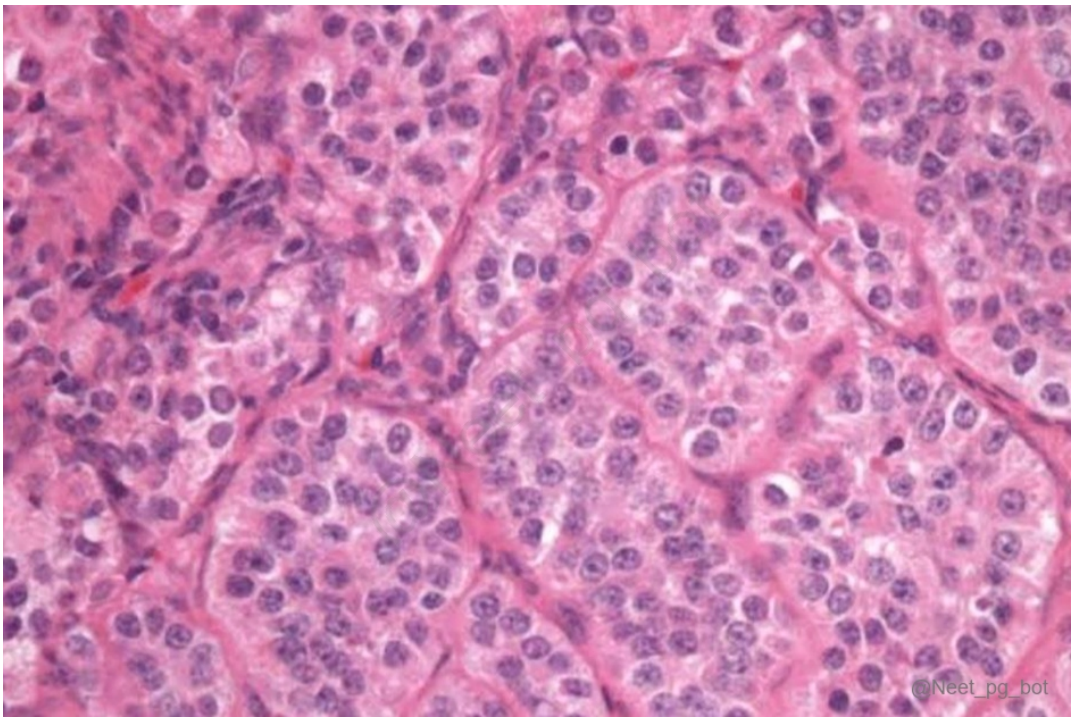

See Answer in Part B → Q4

@Neet_pg_bot

Q5: Which hormone is secreted by the structure marked with an arrow? (Q860565)

A. Glucocorticoid

B. DHEA

C. Androgens

D. Mineralocorticoid

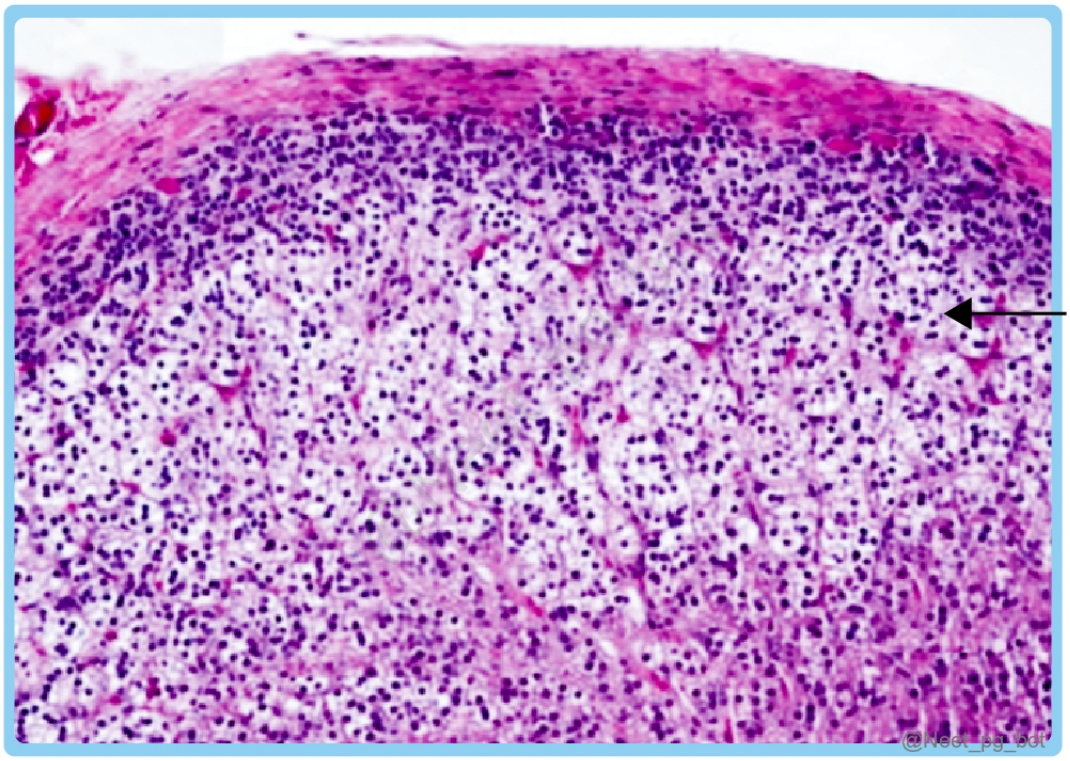

See Answer in Part B → Q5

@Neet_pg_bot

Q6: Which of the following is a new intranuclear immunohistochemistry marker for neuroendocrine tumors? (Q840013)

A. Synaptophysin

B. Chromogranin

C. INSM1

D. NCAM1/ CD56

See Answer in Part B → Q6

@Neet_pg_bot

Q7: A patient presents with neck swelling with compression of the trachea and esophagus. Histopathological assessment shows cell nest and pink extracellular

amyloid stroma. What is the origin of the tumor? (Q840079)

A. Parafollicular C cells

B. Hurthle cell

C. Follicular cells

D. Askanazy cells

See Answer in Part B → Q7

@Neet_pg_bot

Q8: A 26-year-old female patient presents with a palpable thyroid nodule and occasional neck discomfort. She has no history of radiation exposure to the neck. On physical examination, a solitary, firm, non-tender thyroid nodule is noted. Ultrasound reveals a hypoechoic nodule with microcalcifications. Fine-needle aspiration biopsy is performed, and histological analysis reveals characteristic nuclear changes. What is the most common thyroid cancer in this patient? (Q820517)

A. Papillary carcinoma

B. Follicular carcinoma

C. Medullary carcinoma

D. Anaplastic carcinoma

See Answer in Part B → Q8

@Neet_pg_bot

Q9: A 19-year-old female presents with a neck swelling that shifts during swallowing. Ultrasound reveals a 2 cm x 2 cm mass in the left lobe of the thyroid, reaching the strap muscles. Histopathology shows findings as shown in the image. What is the most probable diagnosis? (Q855119)

A. Medullary CA thyroid

B. Follicular CA thyroid

C. Thyroglossal cyst

D. Papillary CA thyroid

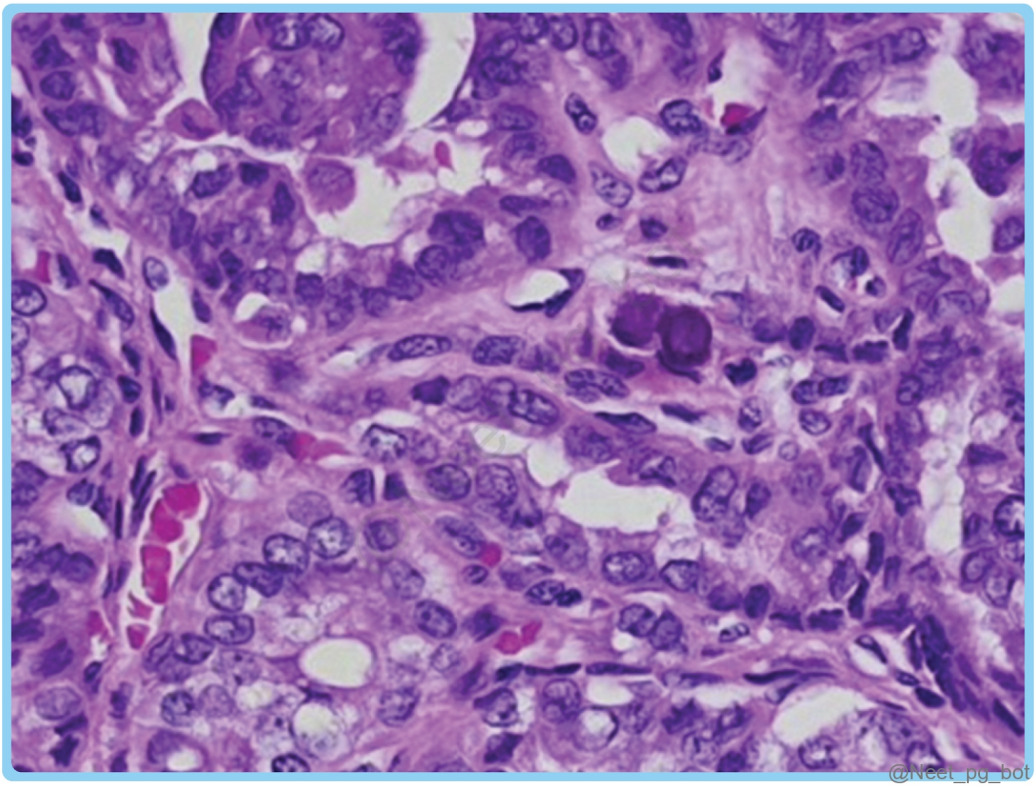

See Answer in Part B → Q9

@Neet_pg_bot

Q10: What is the likely diagnosis for a patient who presents with a swelling in the midline of the neck, based on the biopsy findings, which reveal orphan Annie's eye nuclei as depicted in the image provided? (Q857571)

A. Follicular carcinoma

B. Papillary carcinoma

C. Toxic nodular goiter

D. Medullary carcinoma

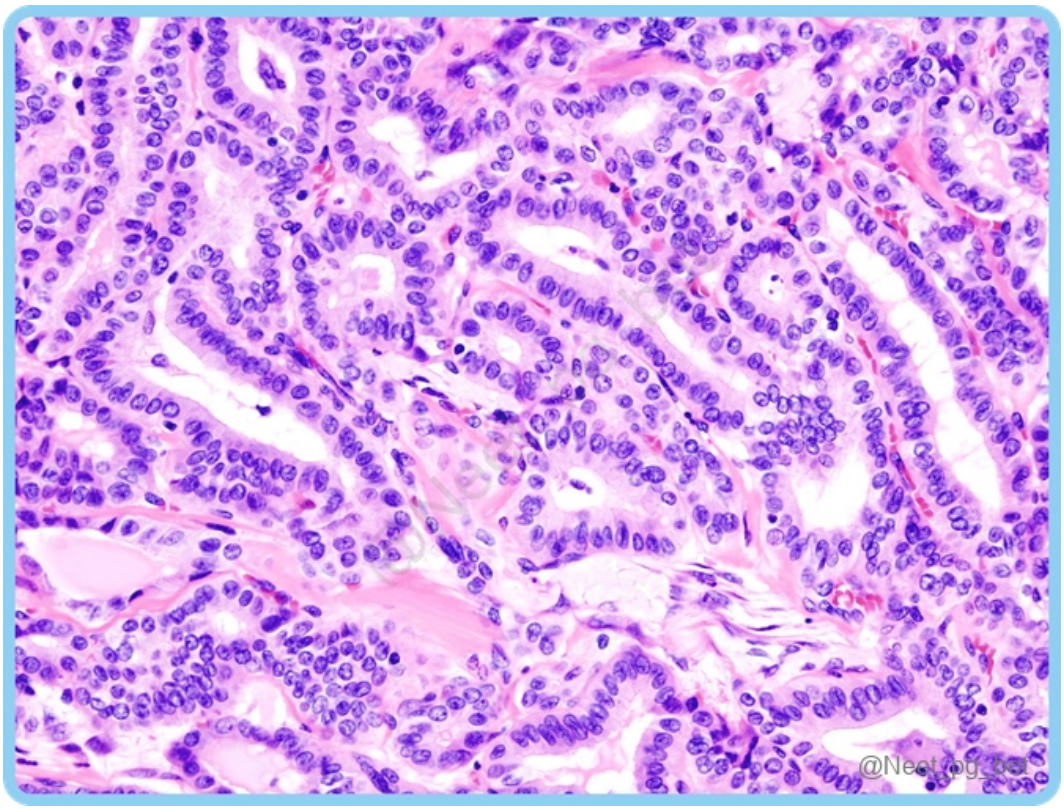

See Answer in Part B → Q10

@Neet_pg_bot

Q11: A patient presented to the OPD with long hands and feet and a protruding lower jaw. Which of the following genes is most likely implicated in this scenario? (Q856900)

A. GATA1

B. PIT1

C. TPIT

D. SF1

See Answer in Part B → Q11

@Neet_pg_bot

Q12: What is the minimum biopsy specimen requirement for an adequate sample in the case of a thyroid biopsy? (Q856910)

A. 15 follicular cell clusters containing 10-12 cells

B. 10 follicular cell clusters containing 6-8 cells

C. 3 follicular cell clusters containing 10-15 cells

D. 6 follicular cell clusters containing 10-15 cells

See Answer in Part B → Q12

@Neet_pg_bot

Q13: A patient presents with a midline swelling in the neck. A biopsy reveals Orphan Annie's eye nuclei, as shown in the image below. What is the diagnosis? (Q854832)

A. Follicular carcinoma

B. Papillary carcinoma

C. Toxic nodular goitre

D. Medullary carcinoma

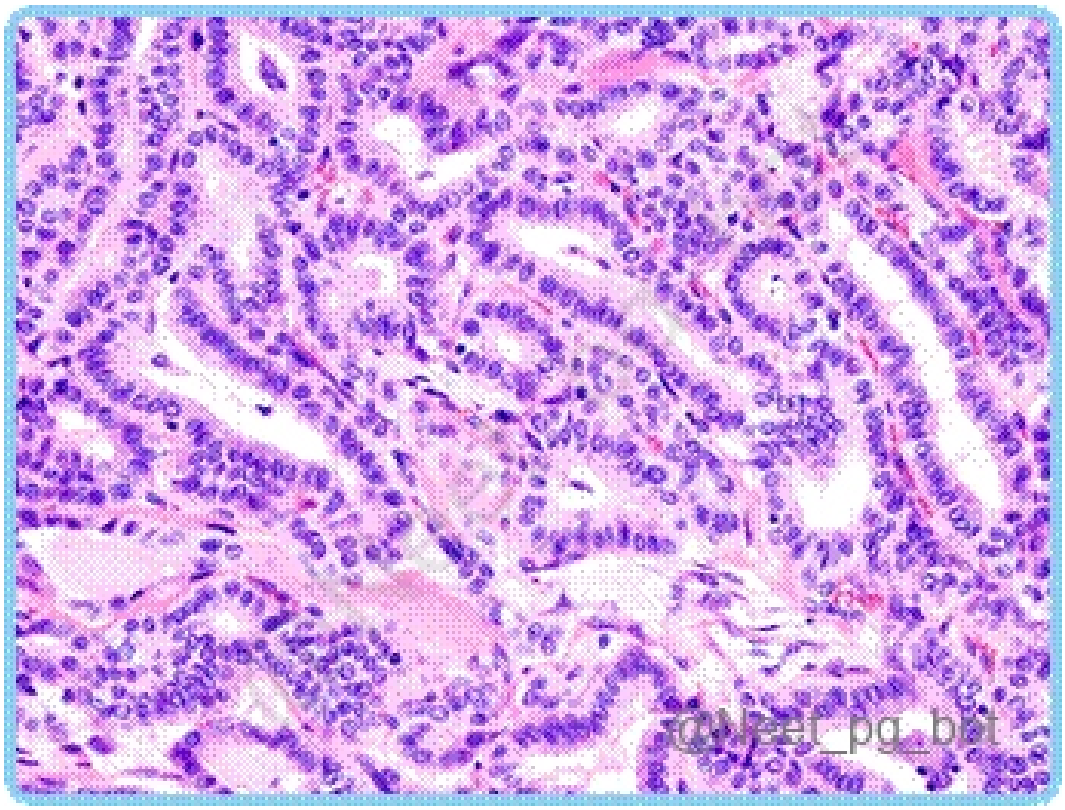

See Answer in Part B → Q13

@Neet_pg_bot

Q14: A middle-aged woman presents with thyroid swelling. Blood tests show elevated TSH levels and the presence of thyroid peroxidase antibodies. Histopathological examination revealed the presence of Hurthle cells. What is the most likely diagnosis? (Q854852)

A. Hashimoto thyroiditis

B. Graves' disease

C. Follicular carcinoma of thyroid

D. Medullary carcinoma of thyroid

See Answer in Part B → Q14

@Neet_pg_bot

Q15: What is the probable diagnosis for a patient who has swelling in the middle of their neck, along with weight loss, and a thyroid biopsy showing the presence of 'Orphan Annie eye nuclei? (Q859243)

A. Follicular thyroid carcinoma

B. Papillary thyroid carcinoma

C. Anaplastic thyroid carcinoma

D. Medullary thyroid carcinoma

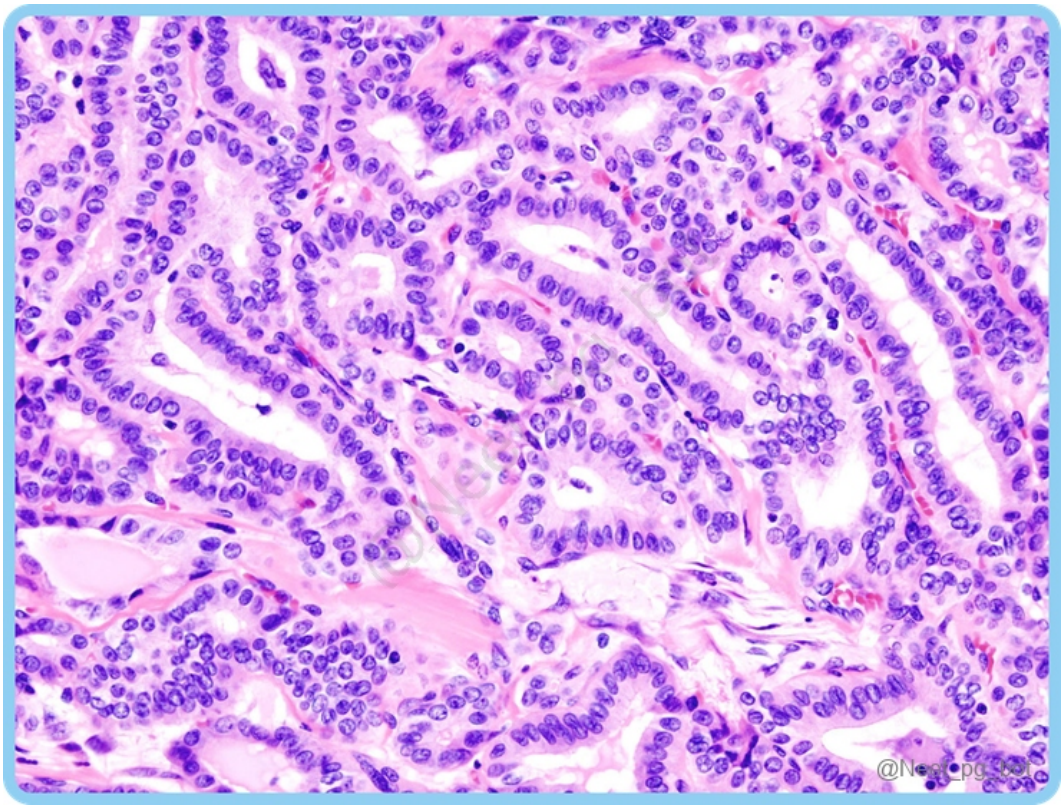

See Answer in Part B → Q15

@Neet_pg_bot

• [14_Breast Pathology] 059 Benign Breast Lesions

« Back to Folder Directory

[14_Breast Pathology] 059 Benign Breast Lesions — Quick Jump

Q1 (p. 621)	*Q2 (p. 624)*	*Q3 (p. 624)*	*Q4 (p. 625)*	*Q5 (p. 625)*	*Q6 (p. 626)*
Q7 (p. 627)	*Q8 (p. 627)*	*Q9 (p. 628)*	*Q10 (p. 628)*	*Q11 (p. 629)*	*Q12 (p. 629)*
Q13 (p. 629)	*Q14 (p. 630)*	*Q15 (p. 630)*	*Q16 (p. 630)*	*Q17 (p. 631)*	*Q18 (p. 632)*
Q19 (p. 632)	*Q20 (p. 633)*	*Q21 (p. 633)*	*Q22 (p. 634)*	*Q23 (p. 635)*	*Q24 (p. 635)*
Q25 (p. 636)	*Q26 (p. 636)*				

Q1: Which of the following breast lesions are correctly paired with their histopathological characteristics? 1. Fibrocystic changes 2. Duct ectasia 3. Phyllodes tumor 4. Invasive Ductal Carcinoma (Q846606)

A. 1, 2, 3

B. 2, 3, 4

C. 1, 3, 4

D. 1, 2, 3, 4

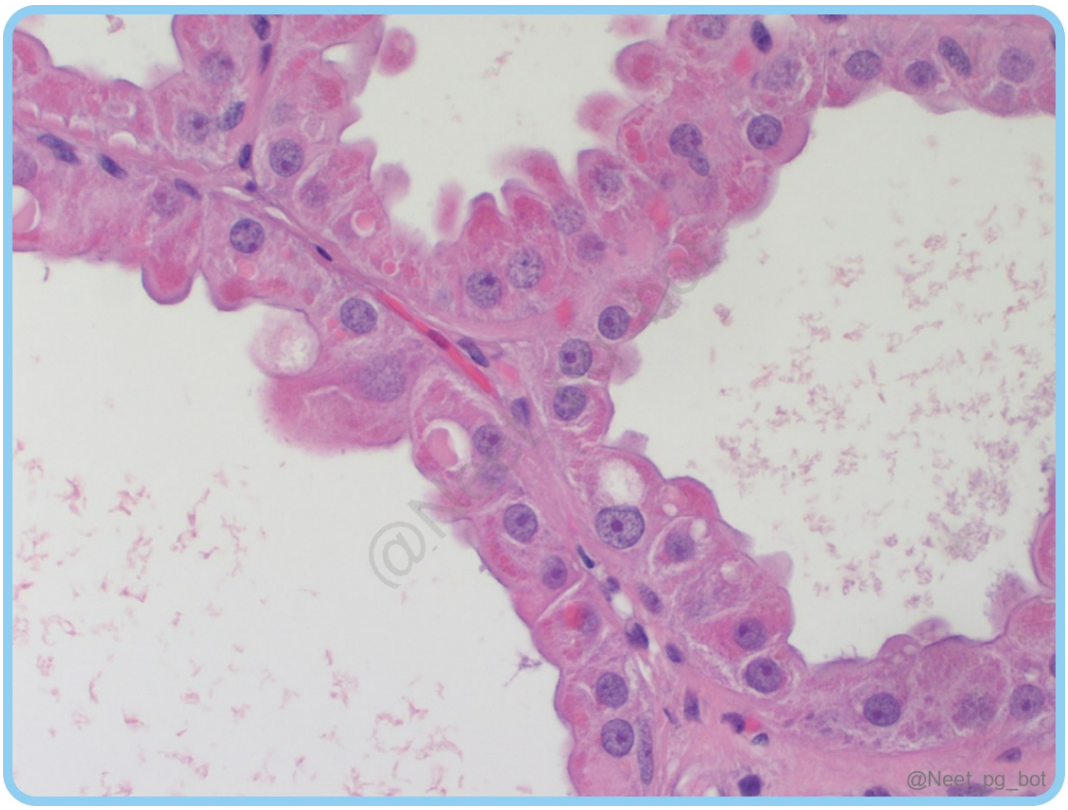
@Neet_pg_bot

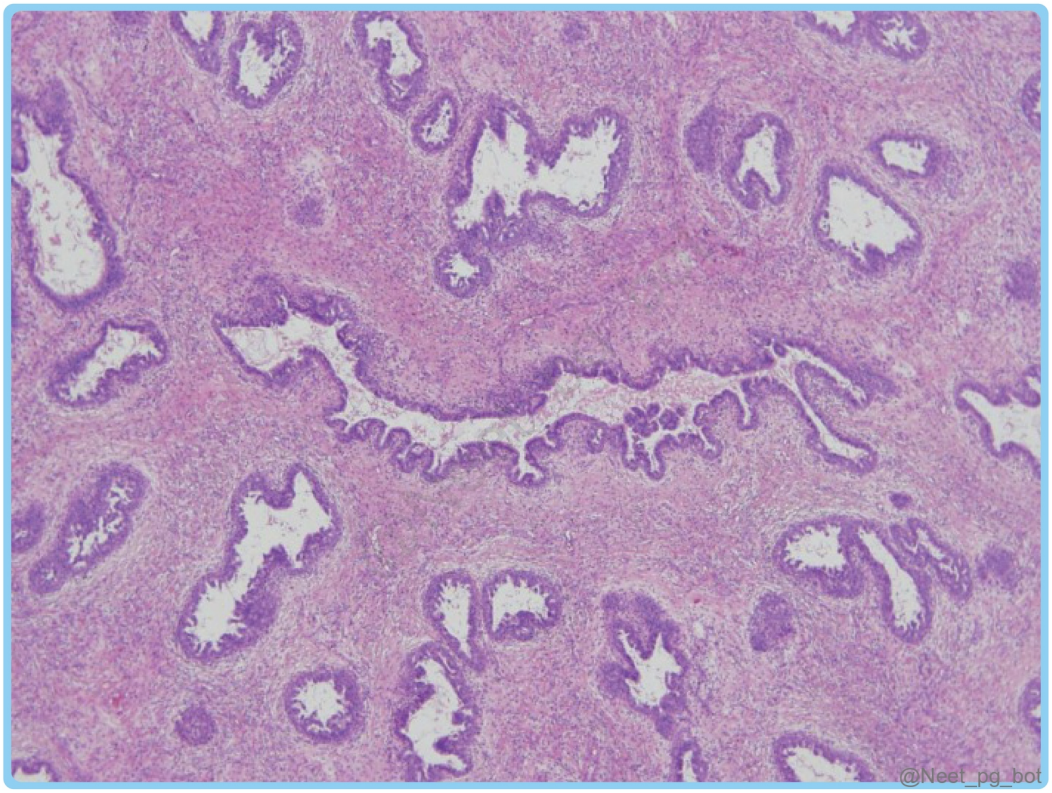
@Neet_pg_bot

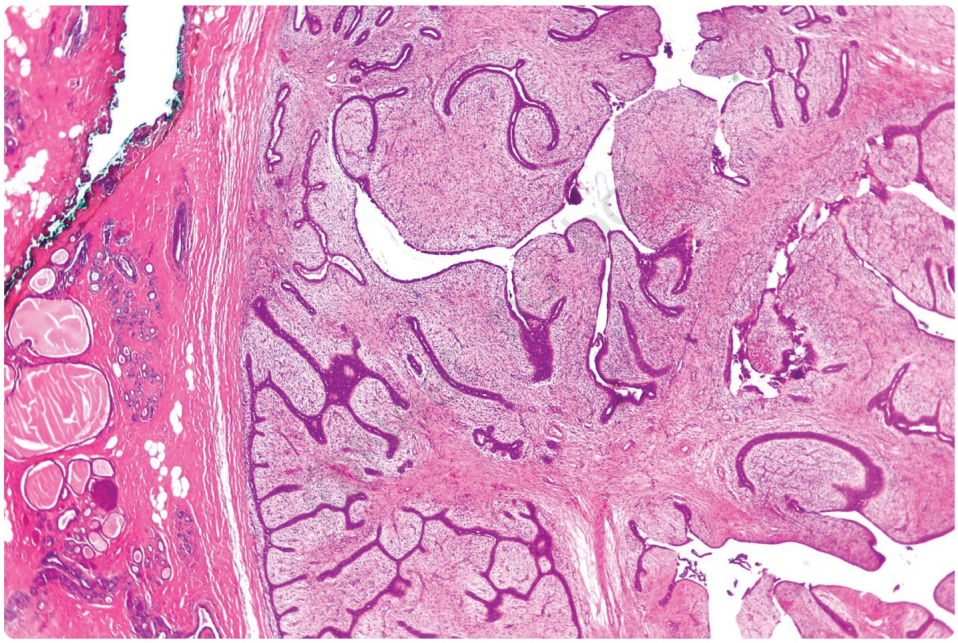

@Neet_pg_bot

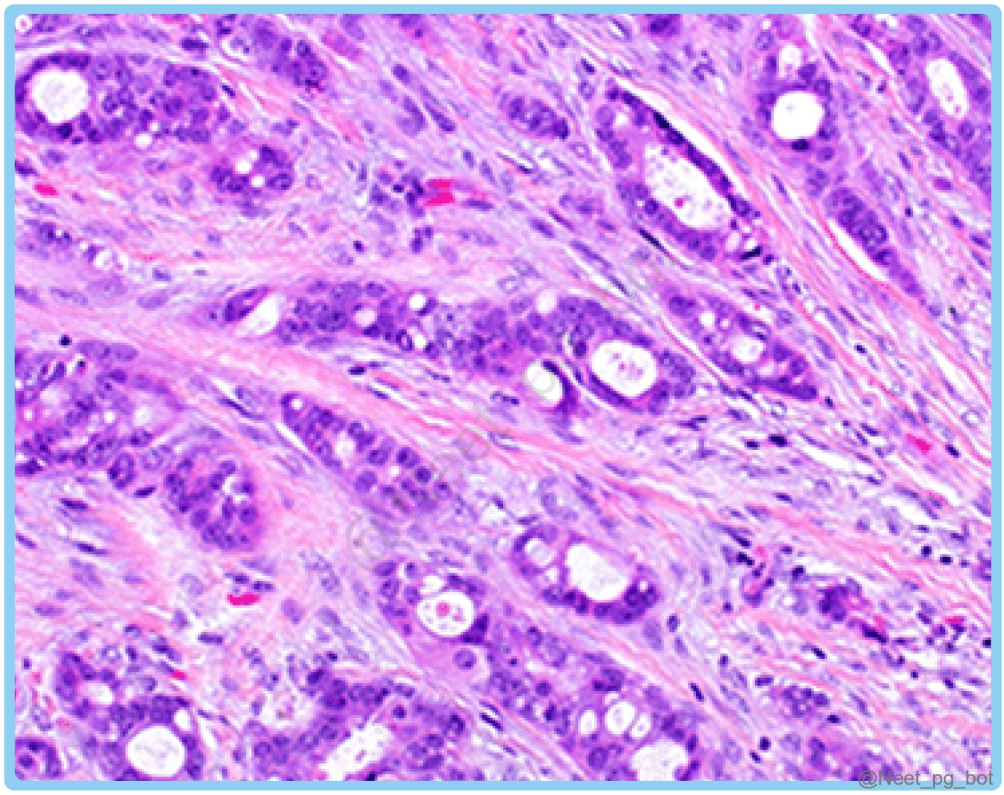

See Answer in Part B → Q1

@Neet_pg_bot

Q2: A 58-year-old woman has a eczematous lesion of the nipple not responding to treatment. Histopathology is shown. What is the most likely diagnosis? (Q890380)

A. Commonly associated with underlying DCIS

B. Malignant cells are present within the nipple epidermis

C. Shows CK7 positivity

D. It commonly presents as a bilateral nipple lesion

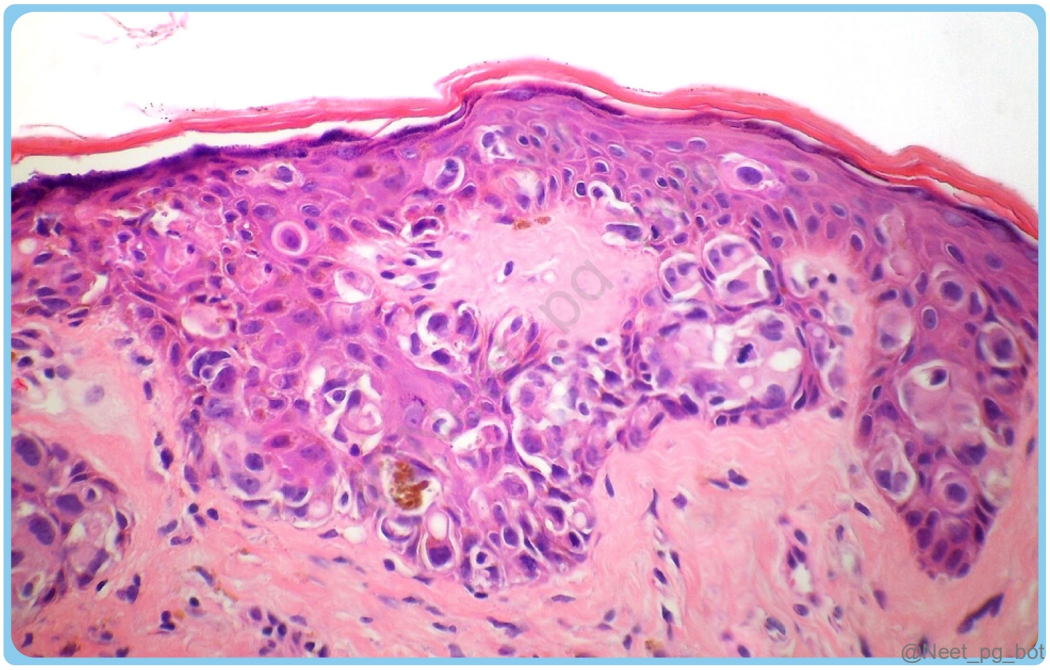

See Answer in Part B → Q2

@Neet_pg_bot

Q3: A 56-year-old woman presents with persistent unilateral erythematous, scaly crusting of the nipple associated with itching for 3 months. Topical treatment for eczema has not improved the lesion. What is the next step in management? (Q890379)

A. Repeat topical corticosteroids

B. Fine-needle aspiration of the breast mass

C. Nipple biopsy

D. Reassurance and follow-up



See Answer in Part B → Q3

@Neet_pg_bot

Q4: Which of the following markers is most useful for distinguishing invasive carcinoma from DCIS? (Q890364)

A. p53

B. p63

C. Cytokeratin 7

D. Estrogen receptor (ER)

See Answer in Part B → Q4

@Neet_pg_bot

Q5: Which of the following findings does not indicate a low risk for breast cancer? (Q890362)

A. Cysts with apocrine metaplasia

B. Fibrosis

C. Adenosis

D. Florid hyperplasia

See Answer in Part B → Q5

@Neet_pg_bot

Q6: A 52-year-old man presents with a painless swelling of the breast as seen in the image. Which of the following conditions are associated with the development of this condition? Liver cirrhosis Marijuana use Klinefelter syndrome Classical Seminoma (Q890352)

A. 1 and 3 only

B. 1, 2 and 3 only

C. 1, 3 and 4 only

D. 1, 2, 3 and 4



See Answer in Part B → Q6

@Neet_pg_bot

Q7: Which of the following conditions is most commonly associated with bloody nipple discharge? (Q890350)

A. Intraductal papilloma

B. Mammary duct ectasia

C. Fibrocystic change

D. Sclerosing adenosis

See Answer in Part B → Q7

@Neet_pg_bot

Q8: Which of the following is a non-proliferative change of the breast? (Q890349)

A. Sclerosing adenosis

B. Radial scar

C. Adenosis

D. Atypical ductal hyperplasia

See Answer in Part B → Q8

@Neet_pg_bot

Q9: Which of the following is not a proliferative breast lesion? (Q890348)

A. Intraductal papilloma

B. Sclerosing adenosis

C. Radial scar

D. Cystic change with apocrine metaplasia

See Answer in Part B → Q9

@Neet_pg_bot

Q10: A 36-year-old woman presents with a painful subareolar mass and recurrent nipple discharge. Examination reveals nipple inversion, and histology shows keratinising squamous metaplasia of lactiferous ducts with keratin plugging. Which of the following is the most important risk factor for this condition? (Q890347)

A. Cigarette smoking

B. Alcohol

C. Nulliparity

D. Family history of breast carcinoma

See Answer in Part B → Q10

@Neet_pg_bot

Q11: Which of the following conditions involves the large ducts of the breast? Mammary duct ectasia Large duct papilloma Paget disease of the nipple Atypical lobular hyperplasia Sclerosing adenosis (Q890346)

A. 1, 2, 3

B. 2, 3, 4

C. 1, 2, 3, 4

D. 2, 4, 5

See Answer in Part B → Q11

@Neet_pg_bot

Q12: Which of the following conditions does not arise from the terminal duct lobular unit? (Q890345)

A. DCIS

B. Sclerosing adenosis

C. Intraductal papilloma

D. Mammary duct ectasia

See Answer in Part B → Q12

@Neet_pg_bot

Q13: A 24-year-old with a 2-month-old infant presents to the OPD with pain in her left breast. The baby is exclusively breastfed. On examination, the nipple is tender and erythematous with a fluctuant mass beneath the areola. Which of the following is the most common cause of this condition? (Q846611)

A. Pseudomonas aeruginosa

B. Staphylococcus aureus

C. Streptococcus sp.

D. Listeria monocytogenes

See Answer in Part B → Q13

@Neet_pg_bot

Q14: The terminal duct lobular unit (TDLU) is the functional unit of the breast. Which of the following is not a part of the TDLU? (Q845782)

A. Intralobular terminal duct

B. Extralobular terminal duct

C. Lactiferous duct

D. Ductules

See Answer in Part B → Q14

@Neet_pg_bot

Q15: Which of the following statements about phyllodes tumors of the breast is incorrect? (Q845804)

A. They originate in the connective tissue of the breast

B. Often present as rapidly growing breast masses

C. They vary in size from a few centimeters to massive lesions

D. These lesions are always benign

See Answer in Part B → Q15

@Neet_pg_bot

Q16: Which of the following is not a feature of complex fibroadenoma? (Q845803)

A. Cysts larger than 0.3cm

B. Sclerosing adenosis

C. Nodules of proliferating stroma forming bulbous protrusions

D. Papillary apocrine change

See Answer in Part B → Q16

@Neet_pg_bot

Q17: A 34-year-old woman comes to the clinic due to a mass in her right breast. A 2-cm nodule is noted on breast examination, and the patient is referred for biopsy. Histologic evaluation of the tissue specimen is shown in the image below. What is the most likely diagnosis? (Q845802)

A. Ductal Carcinoma In Situ

B. Intracanalicular Fibroadenoma

C. Sclerosing adenosis

D. Pericanalicular Fibroadenoma

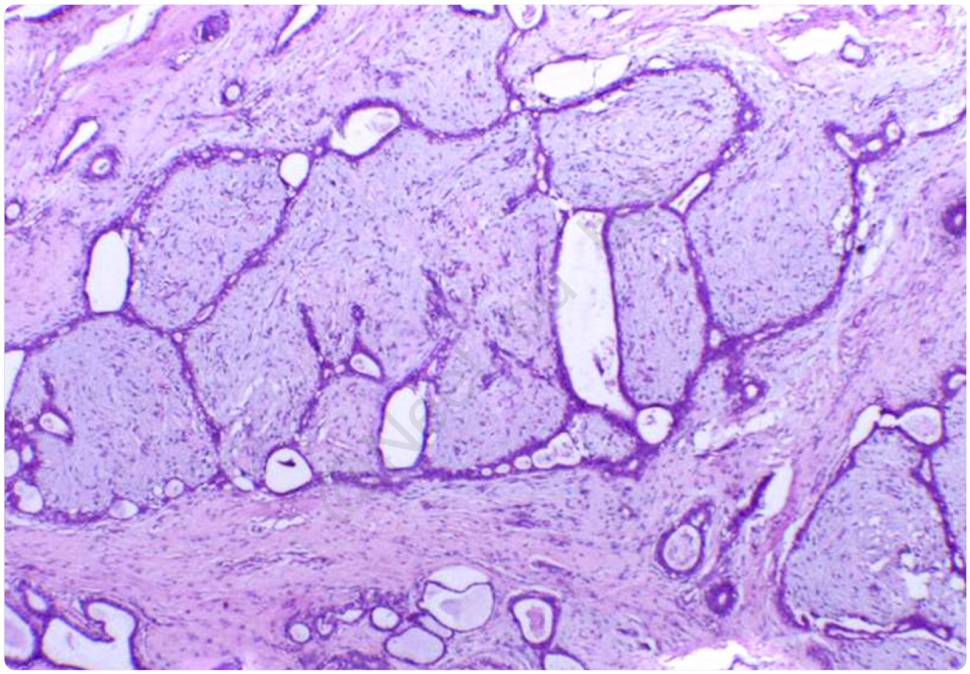

See Answer in Part B → Q17

@Neet_pg_bot

Q18: A 38-year-old woman presents with cyclical breast pain, most severe in the week before her period. She also notices her breasts feeling lumpy and swollen around the time of her period, which subsides later. She denies any fever, nipple discharge, or lumps. What is the most likely finding seen in this pathology? (Q845801)

A. Peau d'orange appearance of the skin

B. Nipple retraction and bloody discharge

C. Blue dome of Bloodgood cyst

D. Eczematous changes of the nipple and areola

See Answer in Part B → Q18

@Neet_pg_bot

Q19: A 38-year-old woman presents with a firm, irregular mass that has been slowly increasing in size over the past few months. Histopathological examination shows the following, what is the most likely diagnosis? (Q845798)

A. Sclerosing adenosis

B. Radial scar

C. Papilloma

D. Paget’s disease

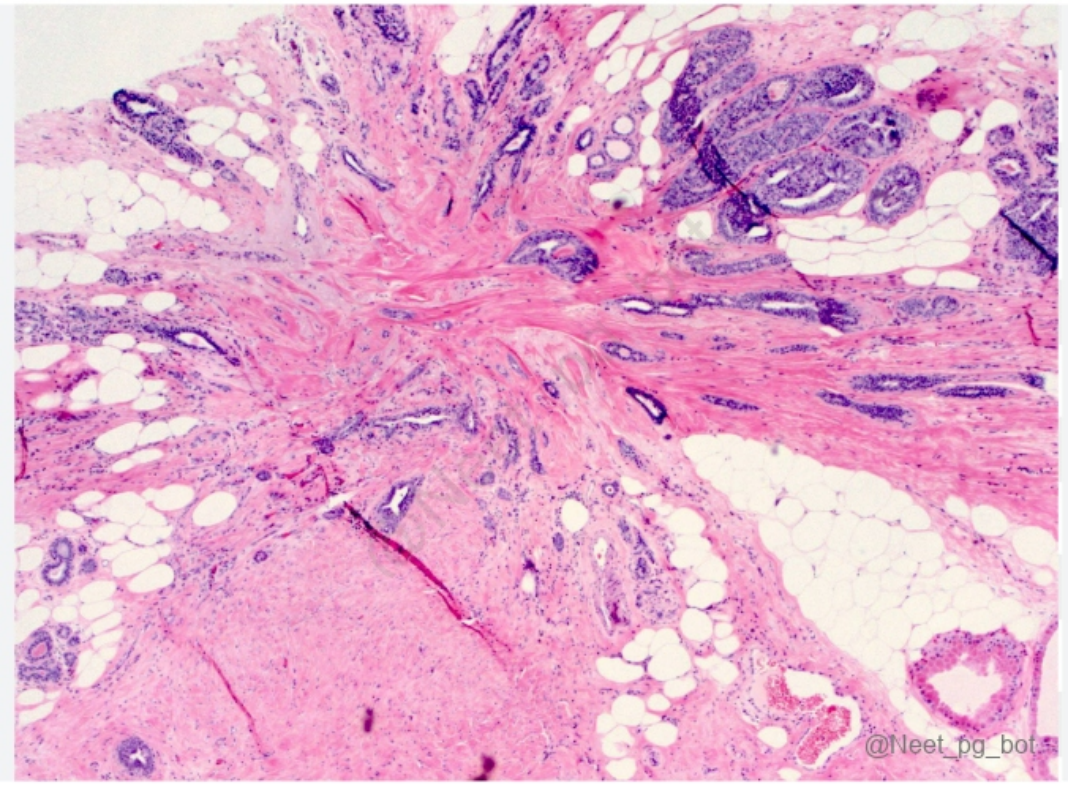

See Answer in Part B → Q19

@Neet_pg_bot

Q20: What is the absolute risk of a fibrocystic lesion of the breast converting to malignancy? (Q845797)

A. <1%

B. 3%

C. 5-7%

D. 13-17%

See Answer in Part B → Q20

@Neet_pg_bot

Q21: Match the following Category Diseases/disorders 1. Non-proliferative breast changes a) Sclerosing adenosis 2. Proliferative diseases without atypia b) Mild

hyperplasia 3. Proliferative breast diseases with atypia c) Precancerous condition 4. Carcinoma in situ d) Atypical ductal hyperplasia (Q845795)

A. 1- b, 2-d, 3-c, 4-a

B. 1- b, 2-a, 3-d, 4-c

C. 1- d, 2-a, 3-b, 4-c

D. 1- d, 2-c, 3-a, 4-b

See Answer in Part B → Q21

@Neet_pg_bot

Q22: A 38-year-old woman presents with a firm, immobile mass in her right breast for the past few days. 2 weeks ago, she bruised her breast while exercising. A mammogram reveals scattered punctate calcifications within the lump. What is the most likely diagnosis? (Q845794)

A. Mastitis

B. Breast abscess

C. Fat Necrosis

D. Inflammatory Breast Cancer

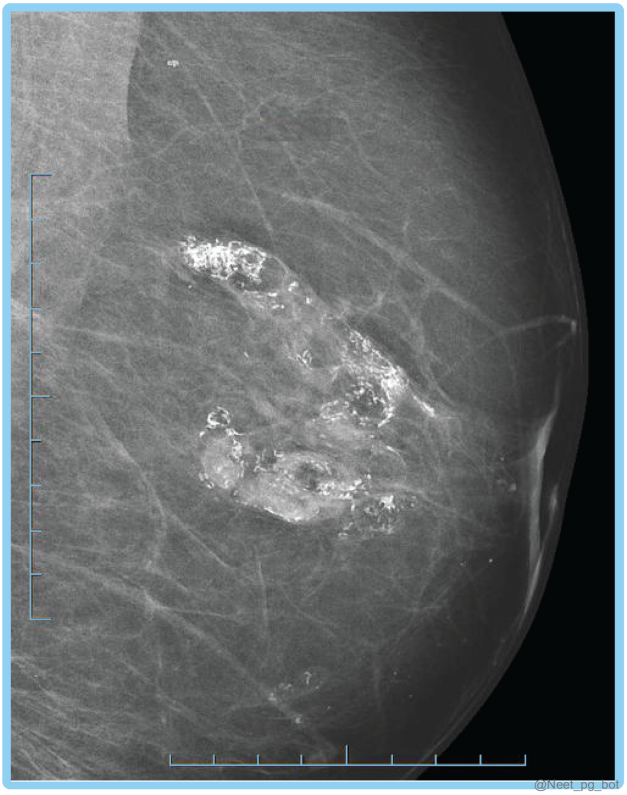

See Answer in Part B → Q22

@Neet_pg_bot

Q23: Which of the following conditions is most likely to cause a sticky, green, or black discharge from the nipple? (Q845793)

A. Duct Papilloma

B. Paget's Disease

C. Duct Ectasia

D. Breast Cancer

See Answer in Part B → Q23

@Neet_pg_bot

Q24: Which of the following statements regarding Zuska's disease is incorrect? (Q845789)

A. There is squamous metaplasia of the lactiferous duct

B. Characterized by the formation of keratin plug

C. Presents as subareolar abscess

D. Alcohol is a major risk factor

See Answer in Part B → Q24

@Neet_pg_bot

Q25: A 48-year-old woman presents with pain in her left breast and associated nipple discharge for the past few weeks. She denies any fever, chills, or recent lactation. On examination, a small ovoid, well-defined subareolar mass is felt. What is the most likely diagnosis? (Q845788)

A. Acute mastitis

B. Duct ectasia

C. Ductal carcinoma in situ

D. Fibroadenoma

See Answer in Part B → Q25

@Neet_pg_bot

Q26: A 24-year-old with a 2-month-old infant presents to the OPD with pain in her left breast. The baby is exclusively breastfed. On examination, the nipple is tender and erythematous with a fluctuant mass beneath the areola. Which of the following is the most common cause of this condition? (Q845786)

A. Pseudomonas aeruginosa

B. Staphylococcus aureus

C. Streptococcus sp.

D. Listeria monocytogenes

See Answer in Part B → Q26

@Neet_pg_bot

• [14_Breast Pathology] 060 Malignant Breast Lesions

« Back to Folder Directory

[14_Breast Pathology] 060 Malignant Breast Lesions — Quick Jump

Q1 (p. 638) *Q2 (p. 638)* *Q3 (p. 639)* *Q4 (p. 639)* *Q5 (p. 640)* *Q6 (p. 640)*
Q7 (p. 641) *Q8 (p. 641)* *Q9 (p. 642)* *Q10 (p. 642)* *Q11 (p. 643)* *Q12 (p. 644)*
Q13 (p. 644) *Q14 (p. 645)* *Q15 (p. 645)* *Q16 (p. 646)* *Q17 (p. 646)* *Q18 (p. 647)*
Q19 (p. 647) *Q20 (p. 648)* *Q21 (p. 649)* *Q22 (p. 649)* *Q23 (p. 651)* *Q24 (p. 652)*
Q25 (p. 652)

Q1: A 52-year-old woman presents with a painless palpable breast mass detected during self-examination. Imaging and biopsy confirm carcinoma of the breast. Which of the following is the most common location for breast carcinoma? (Q890381)

A. Upper outer quadrant

B. Upper inner quadrant

C. Lower outer quadrant

D. Lower inner quadrant

See Answer in Part B → Q1

@Neet_pg_bot

Q2: Which of the following cancers are commonly associated with the BRCA2 mutation? Male breast cancer Ovarian carcinoma Pancreatic carcinoma Prostate carcinoma Colorectal carcinoma (Q890407)

A. 1, 2, 3, 4

B. 1, 2, 5

C. 1, 2, 4, 5

D. 2, 3, 5

See Answer in Part B → Q2

@Neet_pg_bot

Q3: Which of the following is the most common stromal malignancy of the breast? (Q890406)

A. Fibrosarcoma

B. Angiosarcoma

C. Liposarcoma

D. Leiomyosarcoma

See Answer in Part B → Q3

@Neet_pg_bot

Q4: 60-year-old woman presents with a rapidly enlarging breast mass. Histology shows findings as shown. Which of the following statements regarding the most probable condition is incorrect? (Q890404)

A. Most tumours are benign

B. Metastases contain only the stromal component

C. Arises from the intralobular stroma

D. Local recurrence is rare

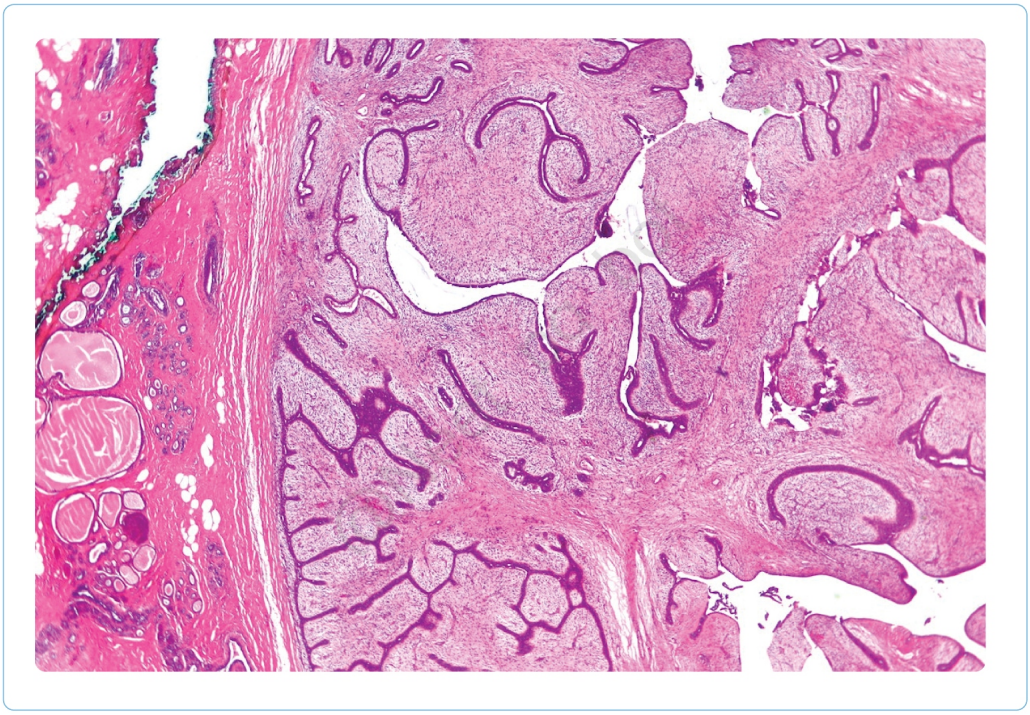

@Neet_pg_bot

See Answer in Part B → Q4

@Neet_pg_bot

Q5: A 55-year-old woman is diagnosed with invasive breast carcinoma. Several tumour characteristics are evaluated to determine prognosis and guide therapy. Which of the following is considered a good prognostic marker in breast cancer? (Q890402)

A. HER2 overexpression

B. ER positivity

C. Presence of BRCA mutation

D. Basal-type breast cancer

See Answer in Part B → Q5

@Neet_pg_bot

Q6: Which of the following IHC requires confirmation with fluorescence in situ hybridisation (FISH) for HER2 gene amplification? (Q890397)

A. D

B. C

C. B

D. A

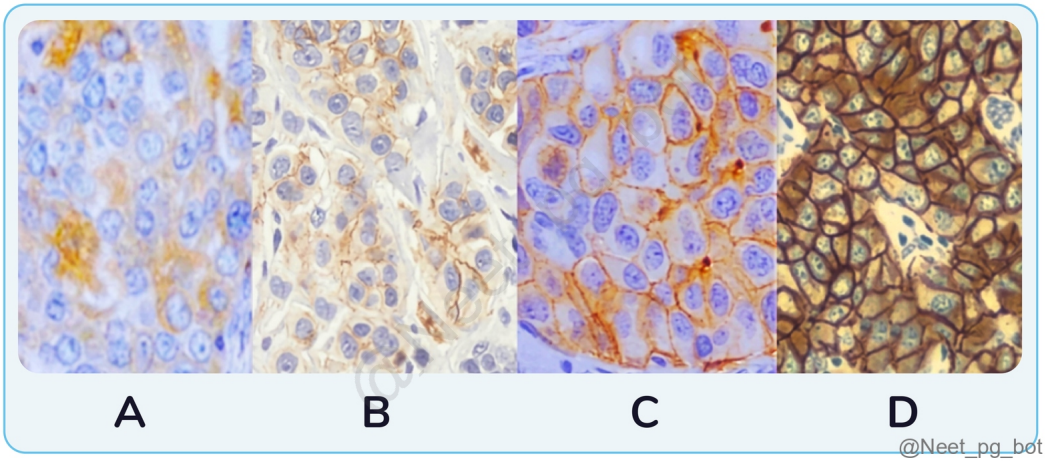

See Answer in Part B → Q6

@Neet_pg_bot

Q7: A breast carcinoma is classified as T4d in the TNM staging system. Which of the following features is not characteristic of this stage? (Q890396)

A. Diffuse breast erythema and oedema

B. Peau d’orange appearance of the skin

C. Tumour emboli within dermal lymphatic vessels

D. Prominent neutrophilic inflammatory infiltrate in the dermis

See Answer in Part B → Q7

@Neet_pg_bot

Q8: Which of the following is the most common clinical presentation of occult breast carcinoma? (Q890395)

A. Palpable breast lump with nipple retraction

B. Axillary lymphadenopathy due to metastatic carcinoma

C. Bloody nipple discharge

D. Diffuse breast skin thickening resembling peau d'orange

See Answer in Part B → Q8

@Neet_pg_bot

Q9: A breast tumour shows strong ER positivity, PR positivity, HER2 negativity, and a low Ki-67 proliferation index. Which of the following histologic types of breast carcinoma is not associated with this subtype? (Q890394)

A. Tubular carcinoma

B. Papillary carcinoma

C. Mucinous carcinoma

D. Secretory carcinoma

See Answer in Part B → Q9

@Neet_pg_bot

Q10: A 50-year-old woman is diagnosed with an aggressive breast carcinoma. Immunohistochemistry shows findings as shown. Which of the following histologic types of breast carcinoma is not associated with this subtype? (Q890386)

A. Medullary carcinoma

B. Metaplastic carcinoma

C. Adenoid cystic carcinoma

D. Mucinous carcinoma

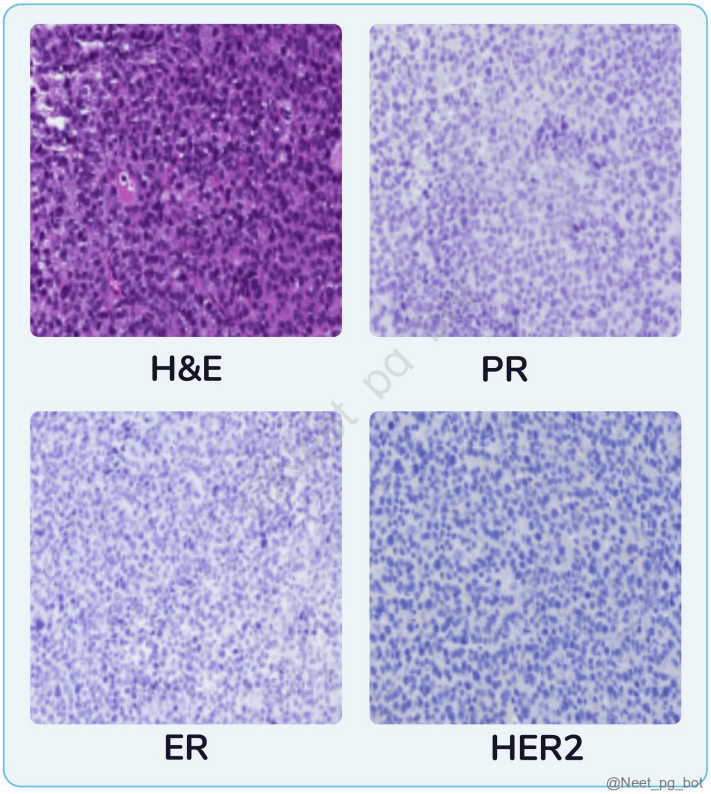

See Answer in Part B → Q10

@Neet_pg_bot

Q11: A 54-year-old woman undergoes a biopsy for a breast mass. Immunohistochemistry shows findings as shown. Which of the following is not a feature of the most probable molecular subtype? (Q890384)

A. Well differentiated

B. Strong luminal gene expression

C. Best prognosis

D. 1q loss

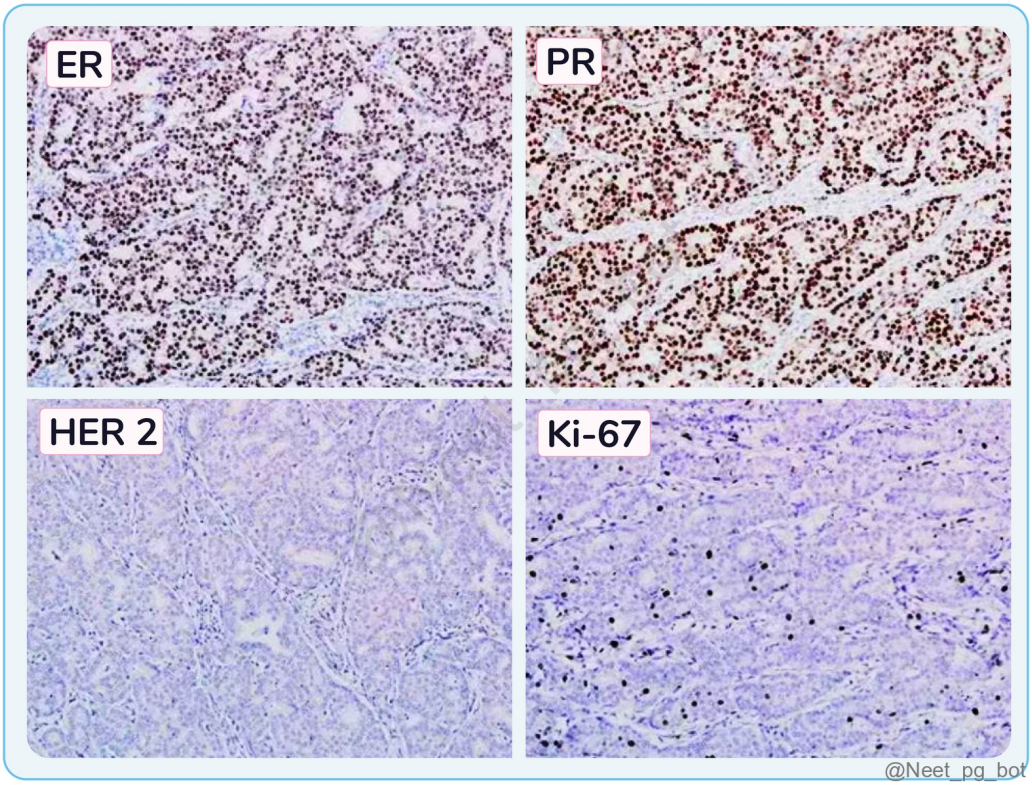

See Answer in Part B → Q11

@Neet_pg_bot

Q12: A 48-year-old woman is diagnosed with an aggressive breast carcinoma. Molecular testing reveals a mutation in the TP53 gene, which is the most common genetic alteration seen in this tumor subtype. Which of the following types of breast carcinoma is most likely present? (Q890383)

A. Luminal A breast carcinoma

B. Luminal B breast carcinoma

C. HER2-enriched carcinoma

D. Triple-negative breast carcinoma

See Answer in Part B → Q12

@Neet_pg_bot

Q13: A 38-year-old woman with a strong family history of early-onset breast and ovarian cancer undergoes genetic testing. Which of the following correctly states the chromosomal locations of BRCA1 and BRCA2? (Q890382)

A. BRCA1 - 17q21; BRCA2 - 13q12.3

B. BRCA1 - 13q12.3; BRCA2 - 17q21

C. BRCA1 - 11p15; BRCA2 - 17p13

D. BRCA1 - 9p21; BRCA2 - 10q23

See Answer in Part B → Q13

@Neet_pg_bot

Q14: A 35-year-old woman comes to the clinic presenting with swelling in the upper quadrant of her left breast. She reports changes in the skin and surrounding nipple areola complex as well. All of the following are risk factors for this condition except? (Q845693)

A. Alcohol

B. Early menarche

C. Age

D. Multiparity

See Answer in Part B → Q14

@Neet_pg_bot

Q15: Which of the following parameters is not assessed in the Bloom-Richardson scoring system? (Q845723)

A. Nuclear size

B. Tubule formation

C. Size of the tumor

D. Mitotic count

See Answer in Part B → Q15

@Neet_pg_bot

Q16: A biopsy taken from a patient's breast lump is subjected to histopathological examination. Upon staining, it is found to be a luminal breast carcinoma with a high proliferative rate. Overexpression of which of the following cellular proteins has led to this interpretation? (Q845721)

A. Alpha catenin

B. Arp-2/3

C. Ki-67

D. Vimentin

See Answer in Part B → Q16

@Neet_pg_bot

Q17: A patient with a lump in her left breast is subjected to a biopsy. Subsequent immunohistochemistry was done and the image is given below. After an MDT discussion, a decision was made to prescribe Trastuzumab as the appropriate management for this patient. What would have been the diagnosis based on the above clinical scenario? (Q845716)

A. Apocrine carcinoma

B. Medullary carcinoma

C. Tubular carcinoma

D. Papillary carcinoma

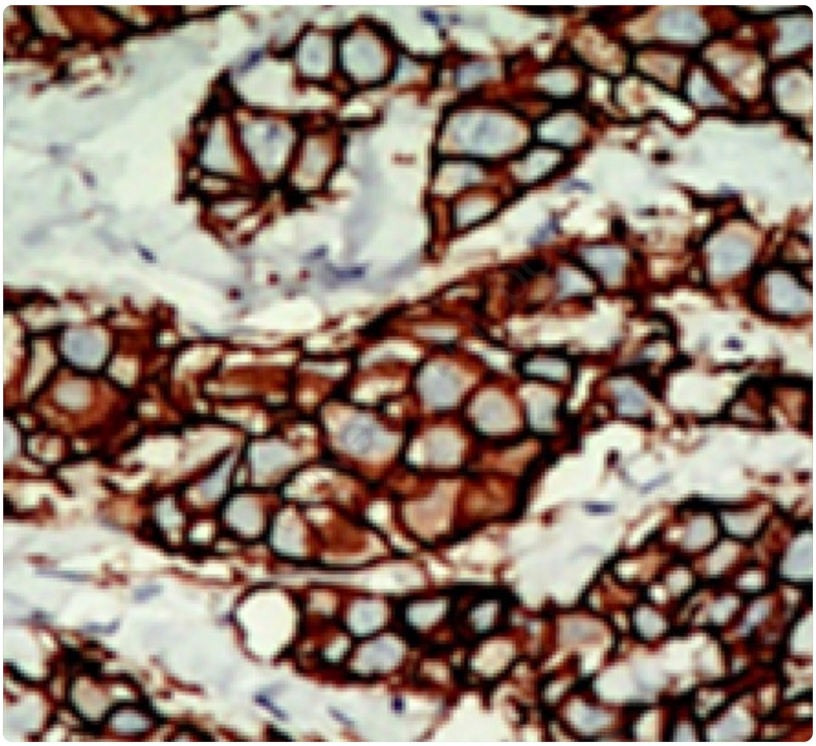

See Answer in Part B → Q17

@Neet_pg_bot

Q18: You are provided with results of receptor status from the biopsy obtained from a patient's breast lump. You realize that her molecular subtype carries a low proliferative rate and a better prognosis. Which of the following will not be the likely histological subtype in this patient? (Q845714)

A. Tubular carcinoma

B. Medullary carcinoma

C. Papillary carcinoma

D. Mucinous carcinoma

See Answer in Part B → Q18

@Neet_pg_bot

Q19: Consider the following statements about Paget's disease of the breast? 1. It is an in-situ cancer. 2. Presence of Paget cells is needed for diagnosis. 3. Underlying carcinoma is usually LCIS. 4. Immunostaining is positive for carcinoembryonic antigen (CEA). Which of the above are true statements? (Q845712)

A. 1,3, and 4

B. 1,2, and 4

C. 1,2, and 3

D. All of the above

See Answer in Part B → Q19

@Neet_pg_bot

Q20: A 60-year-old woman presents with a newly diagnosed left-sided breast mass on routine mammography. Core needle biopsy shows the following findings. Further molecular study revealed the involvement of the CDH1 gene. Which of the following statements are incorrect concerning this type of breast cancer? 1) Increased E-cadherin expression is observed in tumor cells. 2) Minimal desmoplasia and fibrosis were observed on microscopy. 3) A contralateral breast examination is usually required due to bilateral involvement. 4) It is associated with a poor prognosis compared to other types of breast cancer. 5) Metastatic spread affects leptomeninges and retroperitoneum. (Q845710)

A. 1, 2, 3, 4

B. 1, 2, 3

C. 1, 4

D. 1, 2, 4, 5

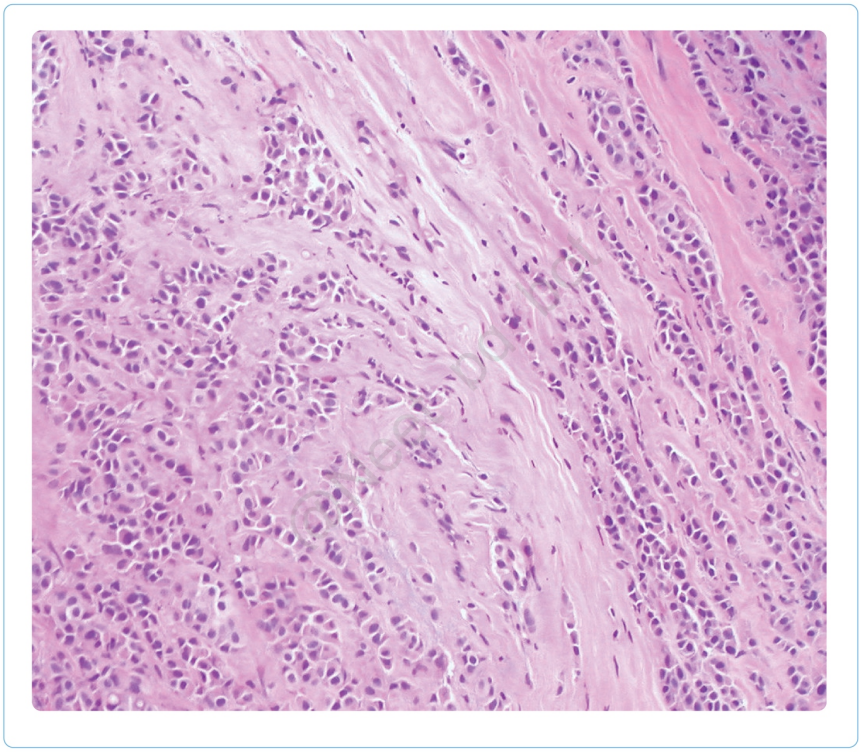

@Neet_pg_bot

See Answer in Part B → Q20

@Neet_pg_bot

Q21: Which of the following is associated with the worst prognosis? (Q845707)

A. Paget’s disease

B. Metaplastic carcinoma

C. Medullary carcinoma

D. Inflammatory carcinoma

See Answer in Part B → Q21

@Neet_pg_bot

Q22: A 50-year-old woman presents with discomfort in her left breast. Mammography reveals a suspicious mass. Ultrasound-guided core needle biopsy is performed. Based

on the histopathological findings, what is the most likely diagnosis? (Q845703)

A. Lobular carcinoma

B. Ductal carcinoma in situ

C. Medullary carcinoma

D. Mucinous carcinoma



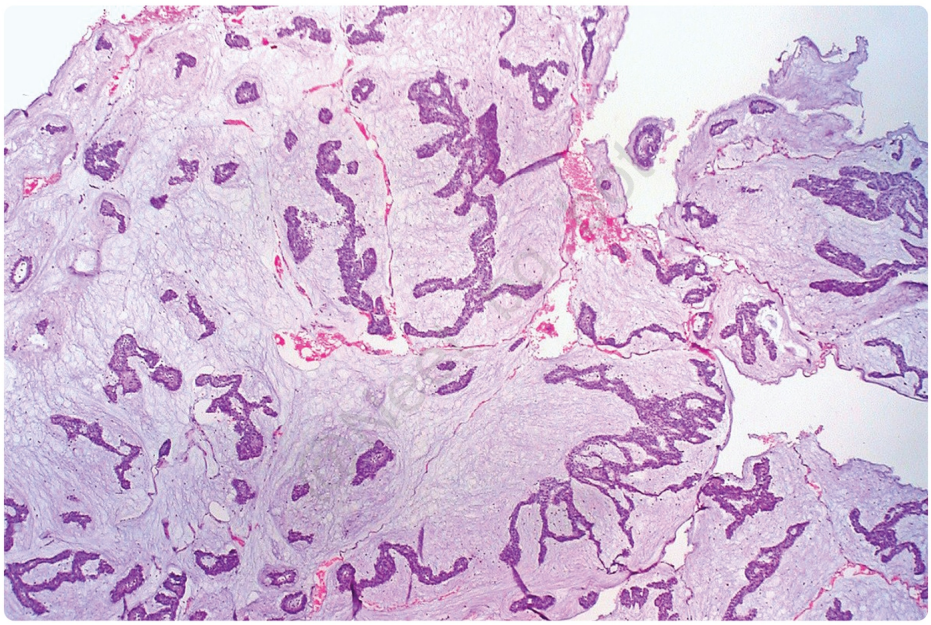

@Neet_pg_bot

See Answer in Part B → Q22

@Neet_pg_bot

Q23: A 45-year-old woman presented with a palpable breast lump detected during a routine self-examination. A biopsy confirmed the diagnosis of infiltrating ductal carcinoma (IDC). Which of the following is not a subtype of IDC? 1. Tubular carcinoma 2. Medullary carcinoma 3. Colloid carcinoma 4. Lobular carcinoma 5. Papillary carcinoma 6. Apocrine carcinoma 7. Secretory carcinoma 8. Myofibroblastoma 9. Angiosarcoma (Q845701)

A. 3, 4, 8, 9

B. 4, 6, 8

C. 2, 4, 7, 9

D. 4, 8, 9

See Answer in Part B → Q23

@Neet_pg_bot

Q24: A 52-year-old woman presents for her routine mammogram, which reveals microcalcifications in the right breast. She has no significant family history of breast cancer and is asymptomatic. A core needle biopsy is performed, and the histopathological image is shown below. Based on histopathology, what is the most likely diagnosis? (Q845697)

A. Invasive Ductal Carcinoma

B. Lobular Carcinoma in Situ

C. Ductal Carcinoma in Situ

D. Fibroadenoma

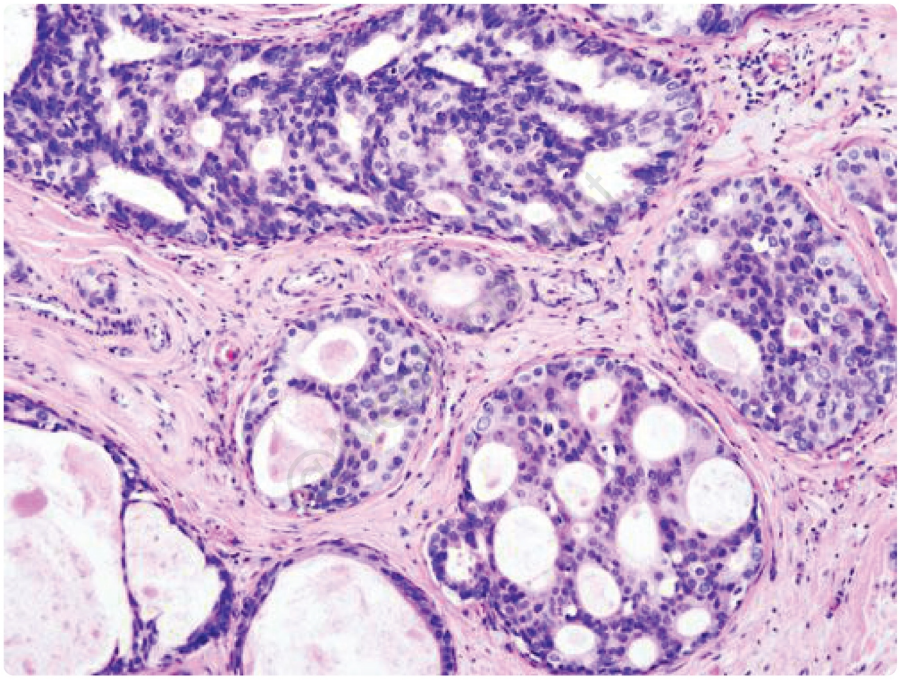

See Answer in Part B → Q24

@Neet_pg_bot

Q25: Mutations in which of the following genes is not associated with breast cancer? (Q845696)

A. BRCA1

B. STK11

C. CDH1

D. CHEK1

See Answer in Part B → Q25

@Neet_pg_bot

• [14_Breast Pathology] 061 Previous Year Questions

« Back to Folder Directory

[14_Breast Pathology] 061 Previous Year Questions — Quick Jump

Q1 (p. 654) *Q2 (p. 655)* *Q3 (p. 655)* *Q4 (p. 656)* *Q5 (p. 656)* *Q6 (p. 657)*

Q1: A 27-year-old woman discovers a well-defined mobile and rubbery breast lump measuring 4x7 cm on self-examination. The lesion is painless and has been stable over several months. What is the most likely diagnosis? (Q860560)

A. Acute mastitis

B. Fibroadenoma

C. Ductal ectasia

D. Sclerosing adenosis

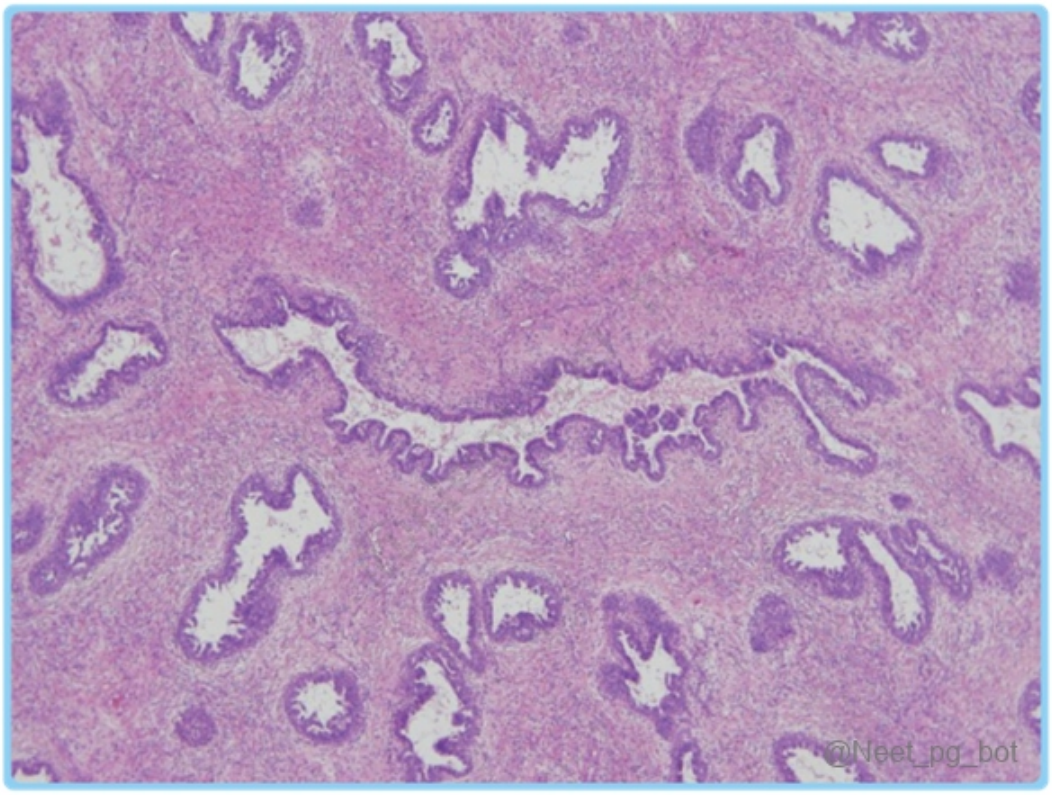

See Answer in Part B → Q1

@Neet_pg_bot

Q2: What does luminal type A tumour refer to? (Q857445)

A. ER+ / HER2 neu- ; mild to moderate proliferation

B. ER+ / HER2 neu+

C. ER- / HER2 neu-

D. ER+ / HER2 neu- ; high proliferation

See Answer in Part B → Q2

@Neet_pg_bot

Q3: A woman presents with a firm and irregular lump in the upper outer quadrant of her breast. The histopathological slide of the mass sample is provided. What is the most likely diagnosis? f (Q830822)

A. Phyllodes tumor

B. Inflammatory breast carcinoma

C. Invasive lobular carcinoma

D. Fibroadenoma

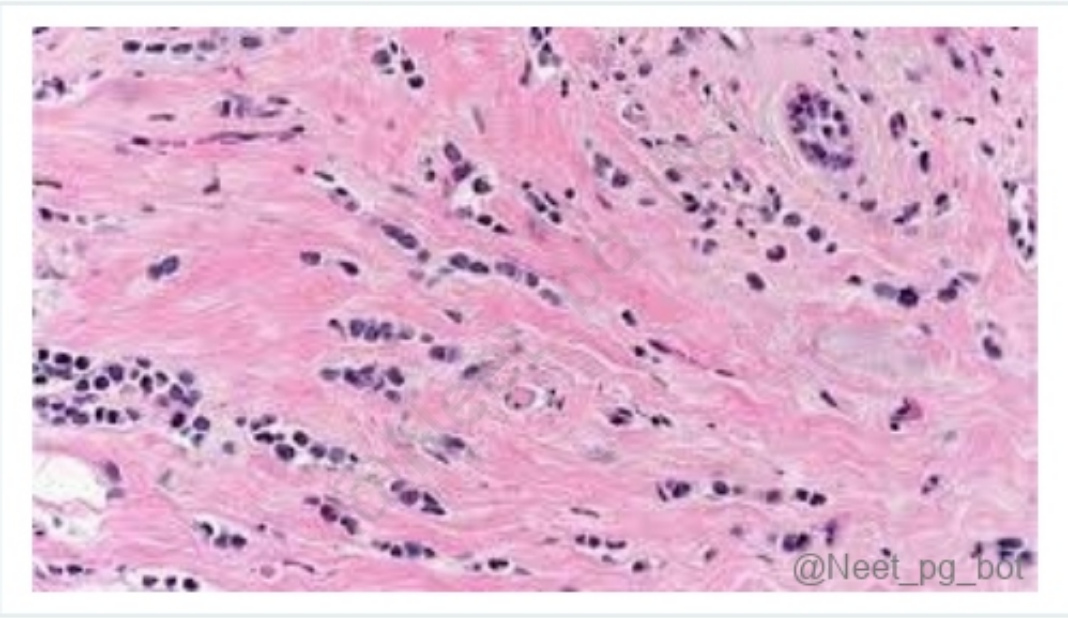

See Answer in Part B → Q3

@Neet_pg_bot

Q4: Which of the following is NOT a favorable prognostic marker for a middle-aged woman diagnosed with breast carcinoma presenting with a lump in her right breast? (Q793798)

A. Luminal subtype

B. Low Ki67 /MIB 1 index

C. Her2 overexpression

D. Mucinous carcinoma

See Answer in Part B → Q4

@Neet_pg_bot

Q5: A 35-year-old woman presents with a lump in the upper outer quadrant of her breast. Histopathological examination of the mass shows cells in mucin pools and faint nuclei. What is the most likely diagnosis? (Q858517)

A. Colloid carcinoma

B. Papillary carcinoma

C. Medullary carcinoma

D. Lobular carcinoma

See Answer in Part B → Q5

@Neet_pg_bot

Q6: A 35-year-old female presents with a lump in the upper outer part of her breast. Histopathological analysis of the mass reveals a signet ring appearance. What is the probable diagnosis? (Q857606)

A. Colloid carcinoma

B. Papillary carcinoma

C. Medullary carcinoma

D. Phyllodes tumour

See Answer in Part B → Q6

@Neet_pg_bot

• [15_Central Nervous System] 062 Cns Pathology

« Back to Folder Directory

[15_Central Nervous System] 062 Cns Pathology — Quick Jump

Q1 (p. 658)	*Q2 (p. 658)*	*Q3 (p. 659)*	*Q4 (p. 659)*	*Q5 (p. 660)*	*Q6 (p. 661)*
Q7 (p. 662)	*Q8 (p. 663)*	*Q9 (p. 664)*	*Q10 (p. 664)*	*Q11 (p. 668)*	*Q12 (p. 669)*
Q13 (p. 669)	*Q14 (p. 669)*	*Q15 (p. 672)*	*Q16 (p. 672)*	*Q17 (p. 672)*	*Q18 (p. 673)*

Q1: Q1. A 40-year-old woman presents with headache and undergoes evaluation for a brain tumor/ cerebellopontine angle. Histopathological examination reveals a tumor composed of Antoni A and Antoni B areas. Which of the following is the most sensitive immunohistochemical marker for this tumor? (Q882188)

A. S-100 protein

B. Glial fibrillary acidic protein (GFAP)

C. Epithelial membrane antigen (EMA)

D. c-KIT

See Answer in Part B → Q1

@Neet_pg_bot

Q2: A 38-year-old woman has a new onset of recurrent seizures. MRI detects a frontal lobe mass. A biopsy of the mass shows cells with a perinuclear halo, as shown in the image. What is the most likely diagnosis? {{caption_text}} (Q845168)

A. Oligodendroglioma

B. Glioblastoma multiforme

C. Meningioma

D. Ependymoma

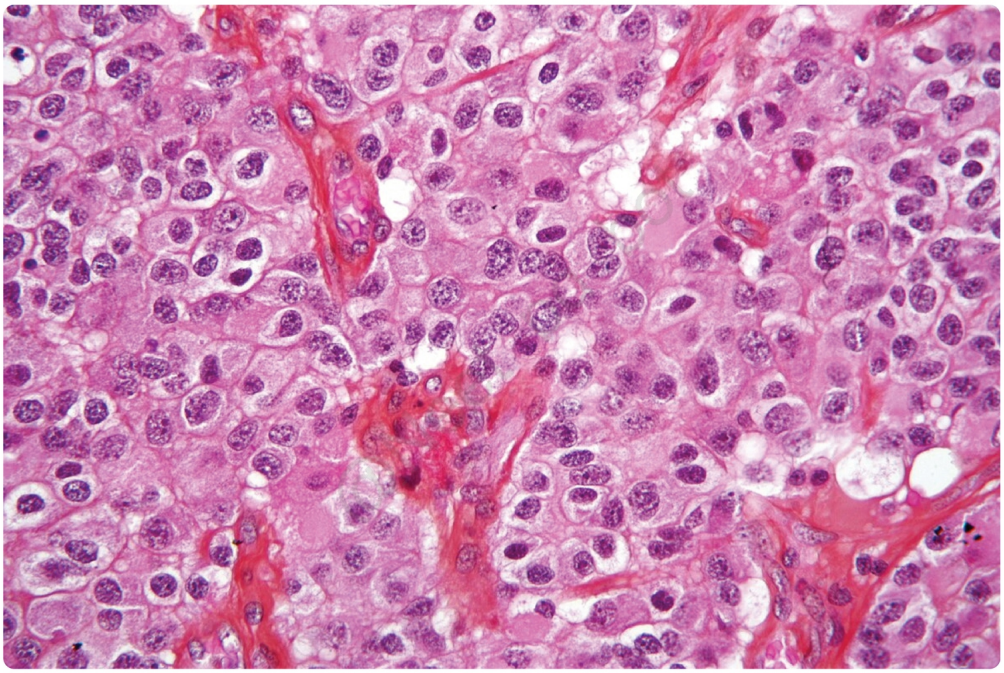

@Neet_pg_bot

See Answer in Part B → Q2

@Neet_pg_bot

Q3: Which genetic mutation is associated with multiple bilateral renal cysts and cerebellar hemangioblastomas and a family history of renal cell carcinoma? (Q845175)

A. VHL gene mutation

B. TSC 1 gene mutation

C. APC gene mutation

D. PTCH gene mutation

See Answer in Part B → Q3

@Neet_pg_bot

Q4: Which of the following is true regarding primary CNS lymphoma? (Q845174)

A. Caused by EB Virus (EBV)

B. Caused by underexpression of PDL1 gene

C. Leptomeningeal spread is common

D. Typically arises from meningeal layers.

See Answer in Part B → Q4

@Neet_pg_bot

Q5: A 45-year-old woman with right-sided hearing loss, tinnitus, and vertigo has an MRI showing a mass at the right cerebellopontine angle from the vestibulocochlear nerve. Biopsy reveals encapsulated tissue with areas of dense cellularity and loose myxoid regions, as depicted in the image below. Which of the following statements is NOT true regarding this condition? (Q845173)

A. Associated with NF-1 gene mutation

B. Typically exhibit verocay bodies

C. Expresses Merlin

D. Immunoreactivity for S-100

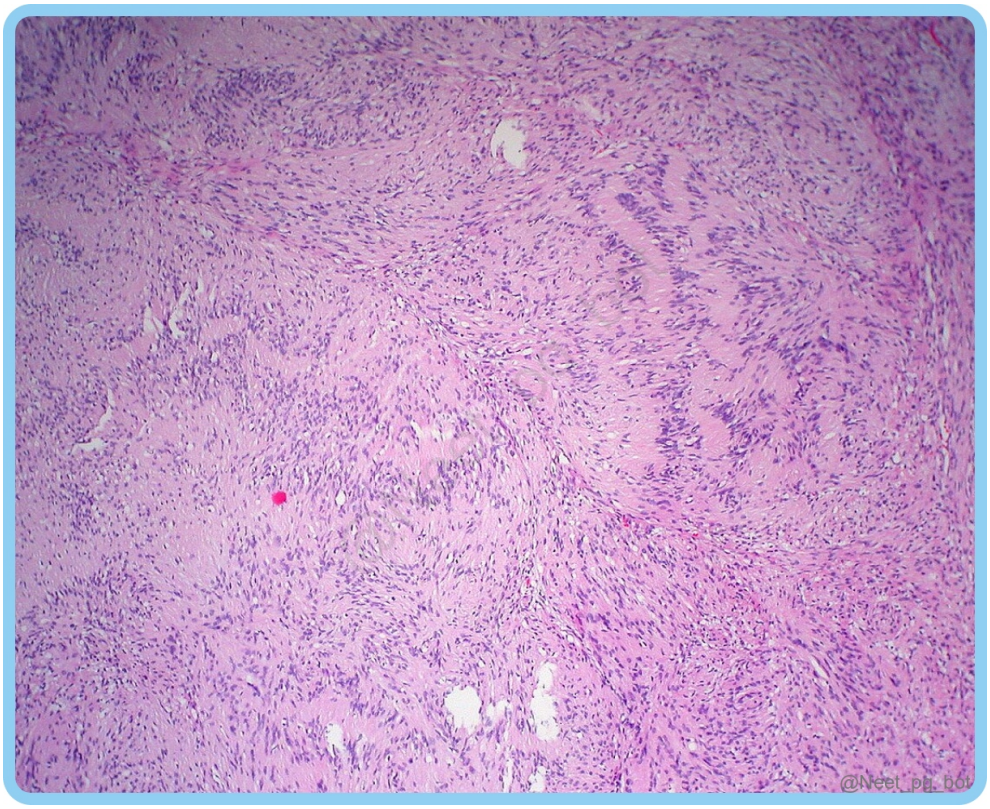

See Answer in Part B → Q5

@Neet_pg_bot

Q6: A 35-year-old female presents with persistent headaches and weakness in her right upper limbs. Imaging reveals a brain tumor that is PR+. Biopsy reveals psammoma bodies with necrosis, cellular atypia, mitosis >4/hpf, and invasion of brain parenchyma. What is the most likely diagnosis? {{caption_text}} (Q845172)

A. Typical meningioma

B. Atypical meningioma

C. Anaplastic meningioma

D. Papillary meningioma

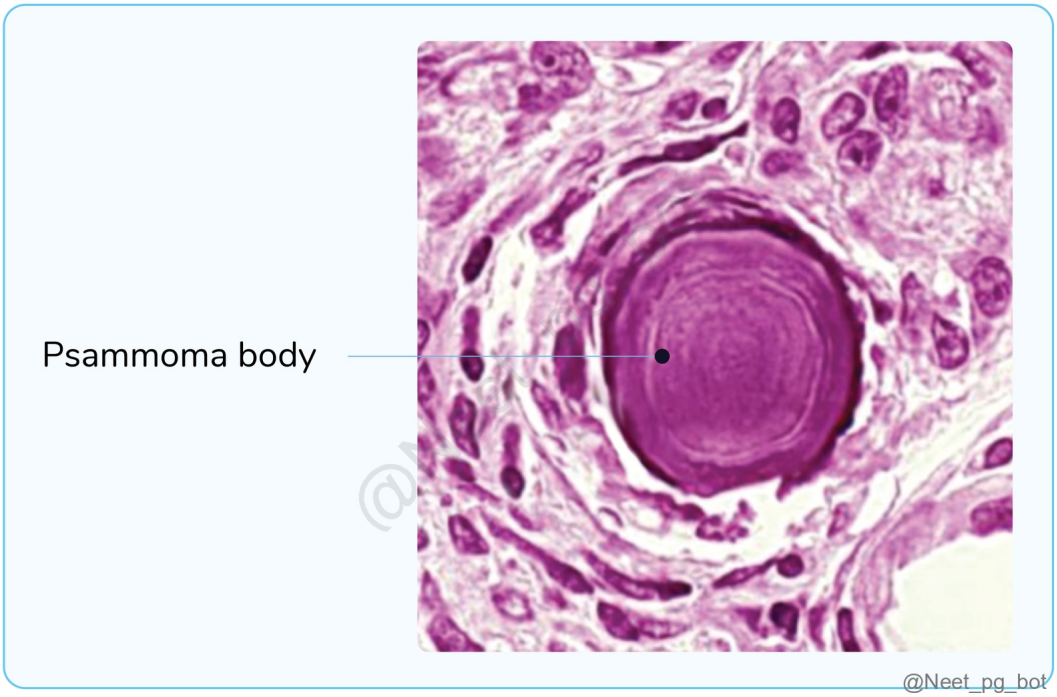

See Answer in Part B → Q6

@Neet_pg_bot

Q7: A 28-year-old gravid woman comes to the ODP due to a severe headache that started during her pregnancy. Investigations reveal the following. Which of the following statements is not true for the above condition? {{caption_text}} (Q845171)

A. Progesterone receptor-positive

B. Risk factors include exposure to radiation

C. Associated with NF2 gene mutation

D. HPE shows perivascular pseudorosettes

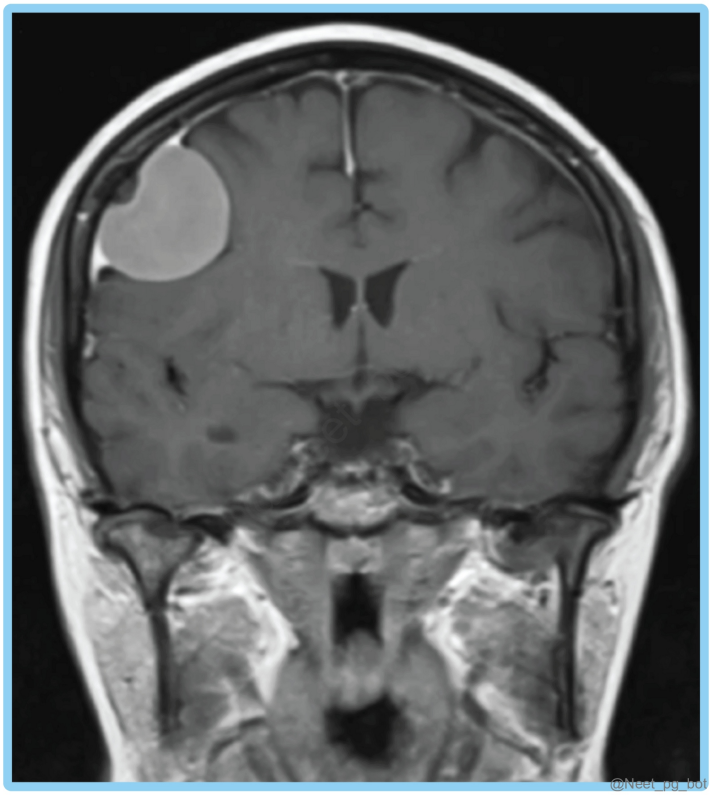

See Answer in Part B → Q7

@Neet_pg_bot

Q8: A 7-year-old boy presents with a history of persistent morning headaches, vomiting, and difficulty with coordination for the past two months. MRI shows a mass in the cerebellum, and HPE shows Homer Wright's rosette. What is the most common route of metastasis? {{caption_text}} (Q845170)

A. Lymphatics

B. Hematogenous

C. Drop metastasis

D. All of the above

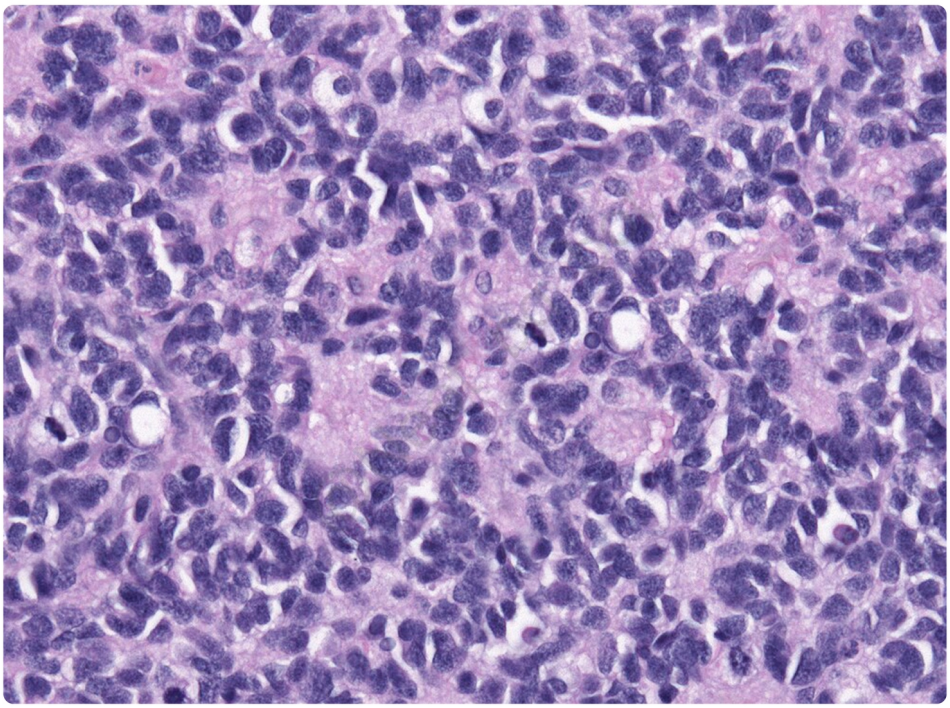

@Neet_pg_bot

See Answer in Part B → Q8

@Neet_pg_bot

Q9: A 28-year-old man comes to the OPD due to a severe headache and blurring of vision. MRI indicates an intraventricular mass in the posterior fossa obstructing the CSF flow. Following surgical resection, which histopathological finding is most probable on examination? (Q845169)

A. Perivascular pseudorosette

B. Perinuclear halo

C. Psammoma bodies

D. Homer Wright rosettes

See Answer in Part B → Q9

@Neet_pg_bot

Q10: Identify the following CNS cells and match them with their specific roles: 1.Fibrous astrocytes A.It is found primarily in white matter and maintains the blood-brain barrier Star-shaped cells Functions: Formation of Blood Brain Barrier (BBB) Involved in repair mechanism IHC stain: Glial Fibrillary Acidic Protein (GFAP) marker 2. Oligodendrocyte B. Line the brain's ventricles and assist in producing cerebrospinal fluid (CSF). Function: Formation of myelin in CNS Perinuclear halo Special stain for Myelin: Luxol fast blue 3. Ependymal cell C. Produce myelin sheath for fast impulse conduction in the CNS. Present in ventricles of the brain Helps in formation of Cerebrospinal fluid (CSF) 4. Protoplasmic astrocytes D. Phagocytize pathogens in CNS and are physiologically and embryologically unrelated to other neural cell types. Location: Found in the grey matter. Help maintain the appropriate concentration of neurotransmitters. 5.Microglia E. They are found in the grey matter and help maintain the appropriate concentration of neurotransmitters. Phagocytize pathogens in the CNS. Origin: Physiologically and embryologically unrelated to other neural cell types (Q845147)

A. 1- A, 2-B, 3-C, 4-D, 5-E

B. 1- A, 2-C, 3-B, 4-E, 5-D

C. 1- B, 2-C, 3-A, 4-E, 5-D

D. 1- E, 2-C, 3-A, 4-B, 5-D

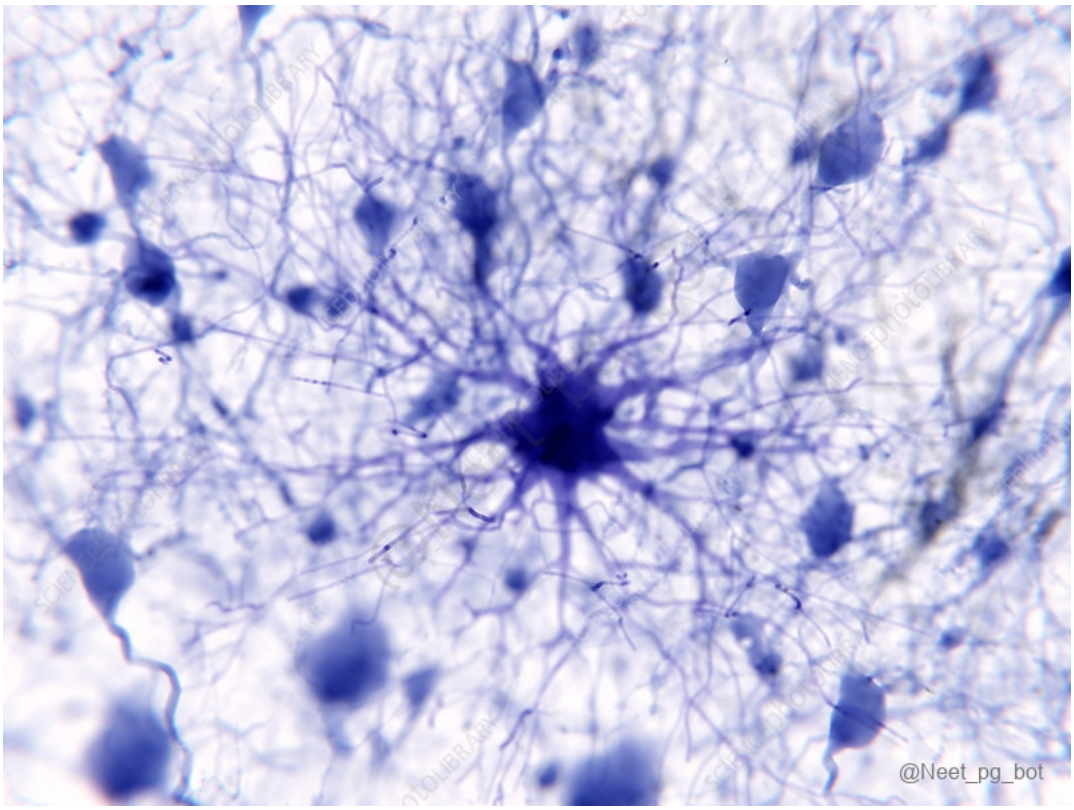
@Neet_pg_bot

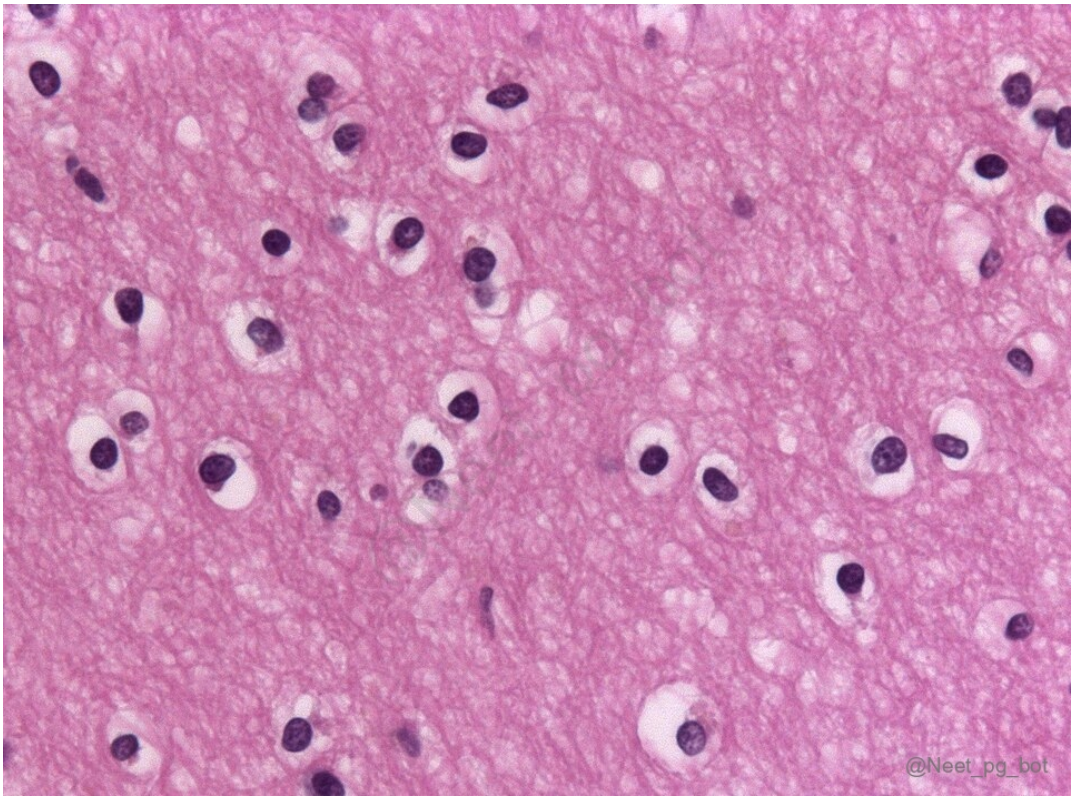
@Neet_pg_bot

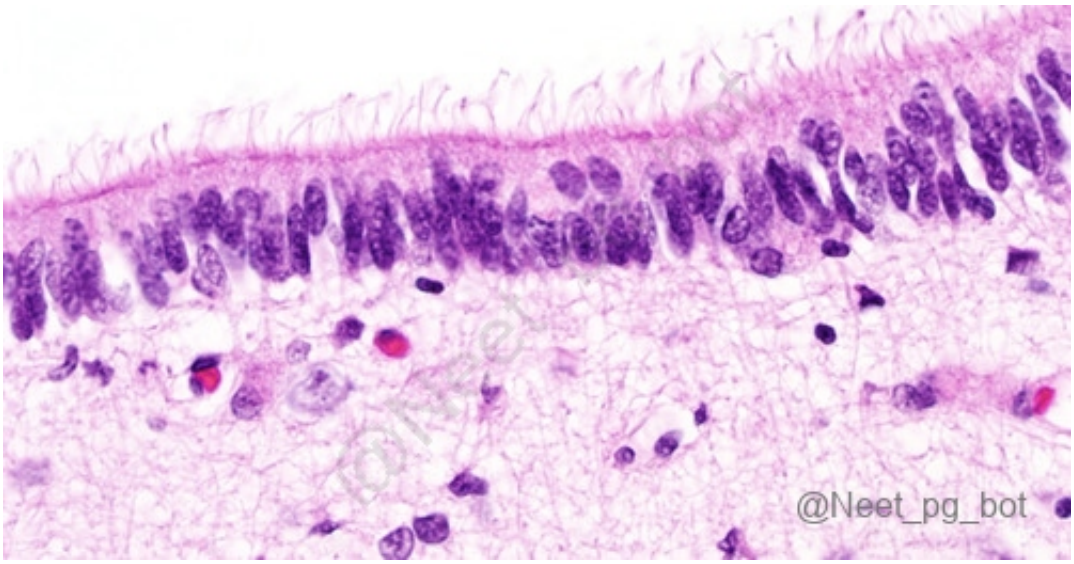
@Neet_pg_bot

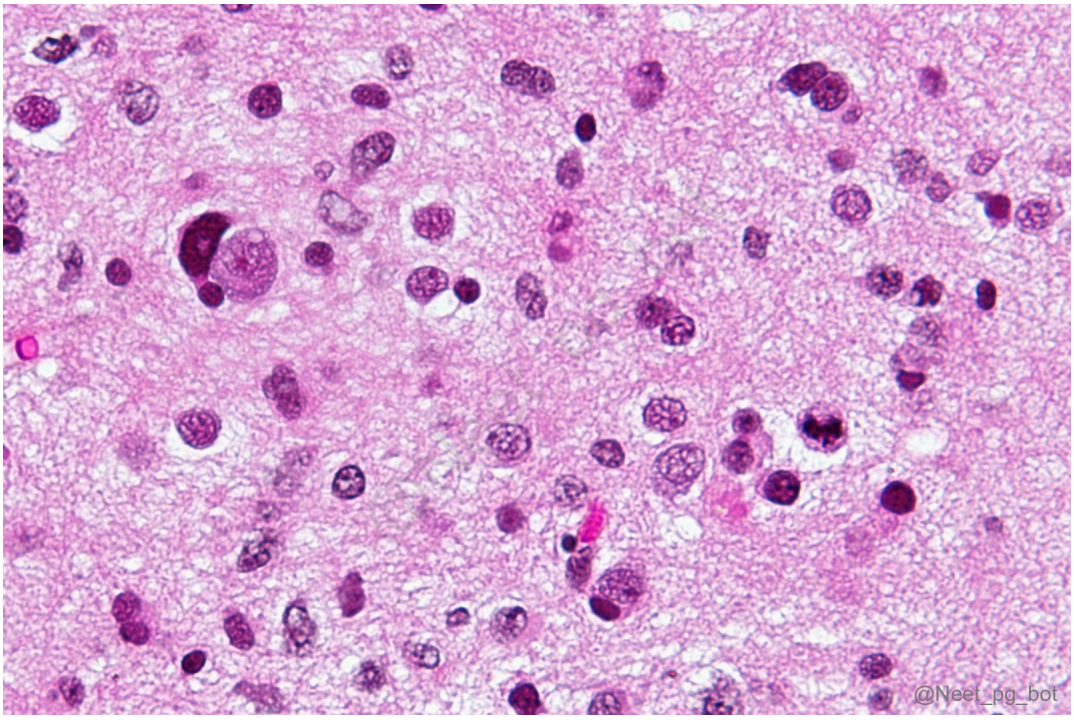
@Neet_pg_bot

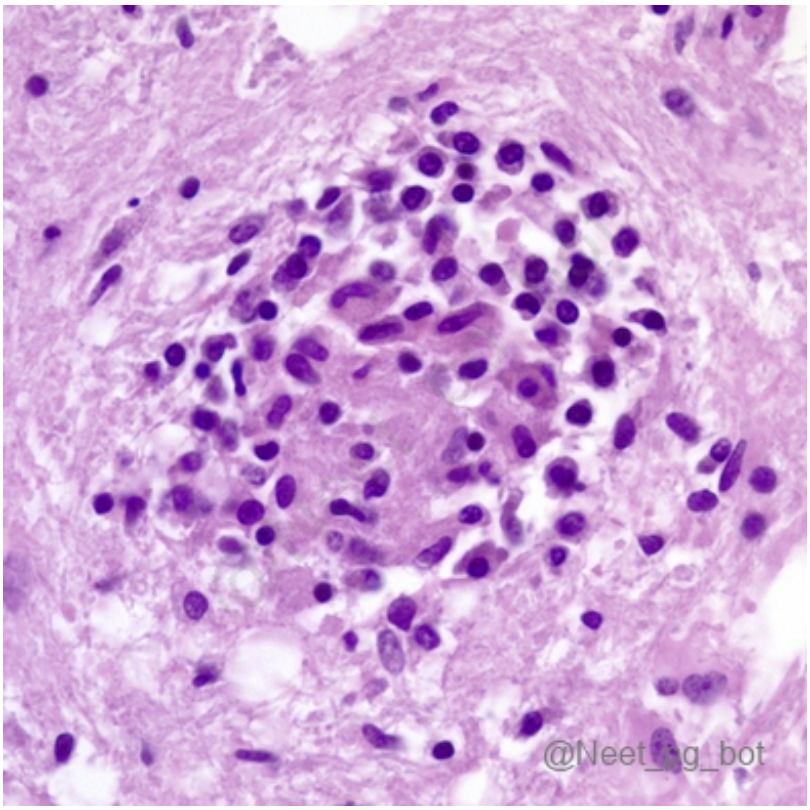

See Answer in Part B → Q10

@Neet_pg_bot

Q11: A 10-year-old child presents with a history of headaches and balance difficulties over the past few months. Histopathological examination of the biopsy shows bipolar cells with long, thin hairlike processes, dense fibrillary meshwork, and characteristic eosinophilic corkscrew-shaped inclusions. Which inclusion bodies are involved in this type of tumor? (Q845167)

A. Rosenthal fibers

B. Glomeruloid bodies

C. Negri bodies

D. Lewy bodies

See Answer in Part B → Q11

@Neet_pg_bot

Q12: According to the Anne Mayo grading system, what grade would be assigned to the tumor showing hypercellularity, nuclear atypia, and mitotic activity but no evidence of microvascular proliferation or necrosis? (Q845166)

A. Grade 1

B. Grade 2

C. Grade 3

D. Grade 4

See Answer in Part B → Q12

@Neet_pg_bot

Q13: A 45-year-old patient presents with new-onset headaches, seizures, and progressive unilateral weakness. Brain MRI reveals a cerebral mass with irregular borders and heterogeneous contrast enhancement. Biopsy shows GFAP-positive glial cells. What is the possible diagnosis? (Q845165)

A. Astrocytoma

B. Neurocytoma

C. Medulloblastoma

D. Meningioma

See Answer in Part B → Q13

@Neet_pg_bot

Q14: Match the following: 1. Neuronophagia a) 2. Rabies b) 3. Microglial nodules c) 4. Globoid bodies d) (Q845164)

A. 1-b,2-c,3-a,4-d

B. 1-a,2-c,3-b,4-d

C. 1-a,2-b,3-d,4-c

D. 1-b,2-d,3-a,4-c

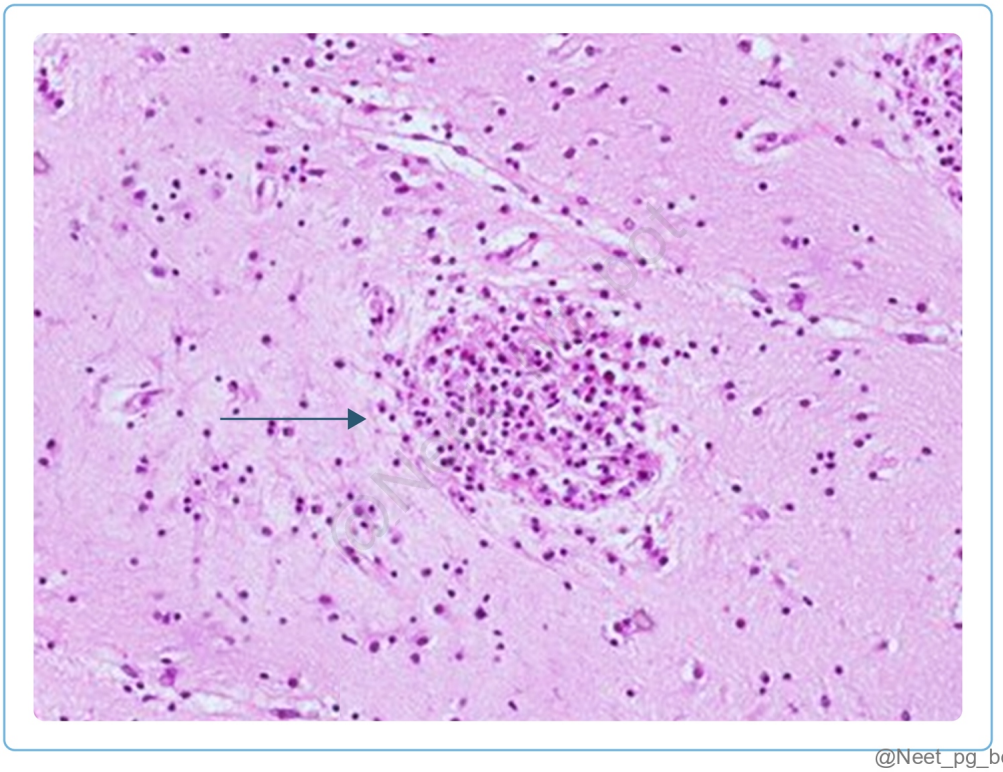

@Neet_pg_bot

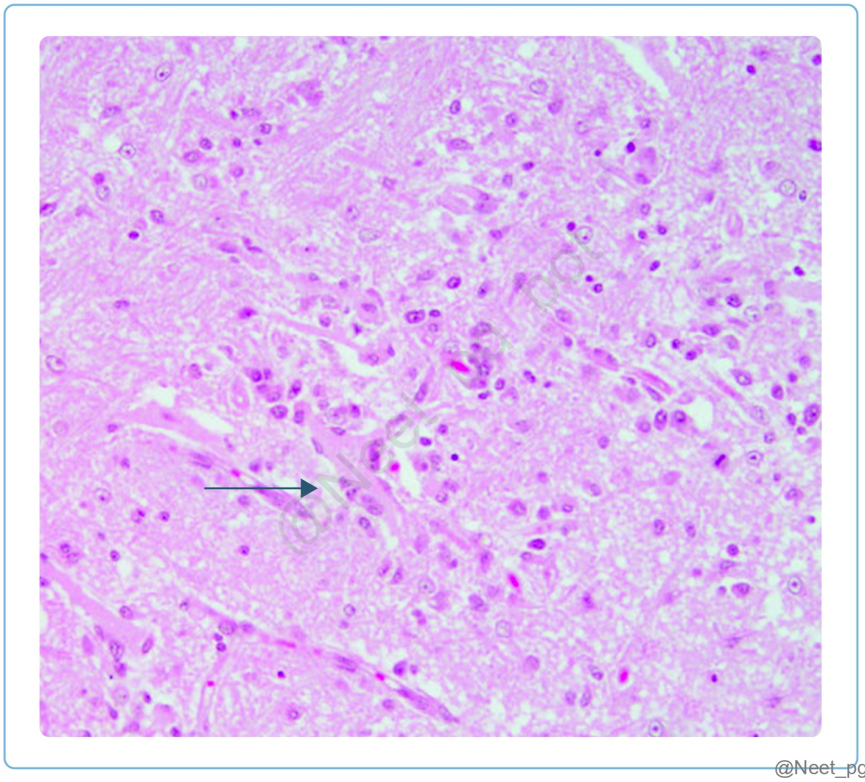

@Neet_pg_bot

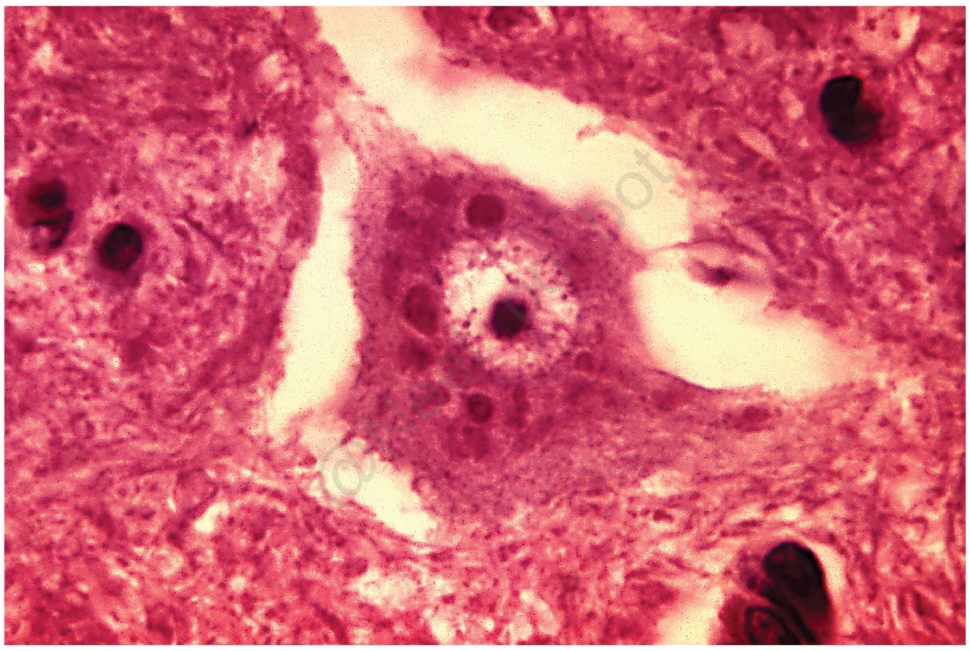

@Neet_pg_bot

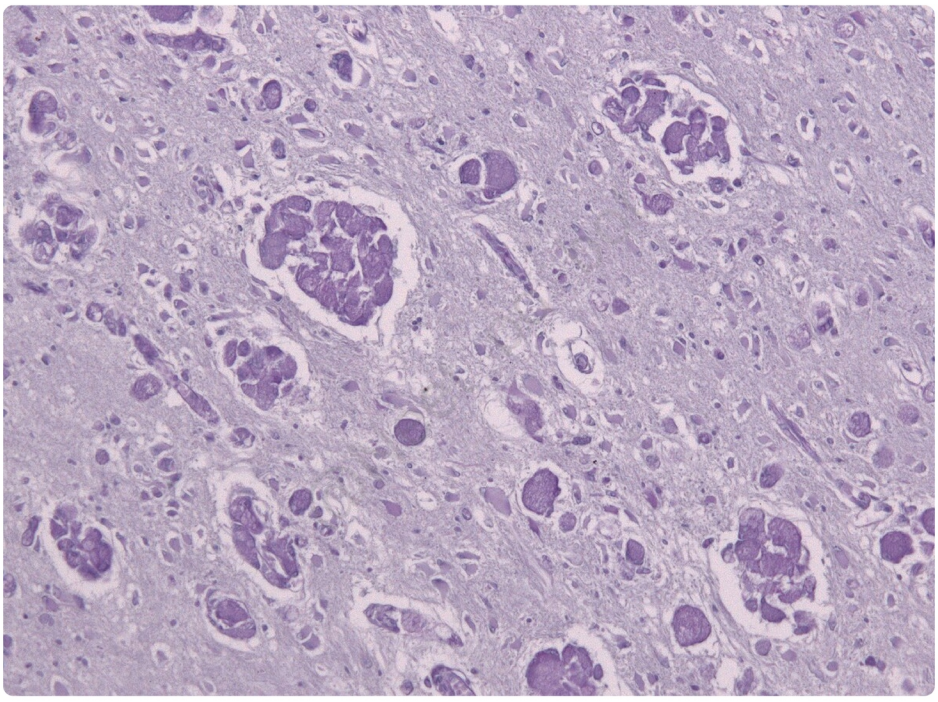

@Neet_pg_bot

See Answer in Part B → Q14

@Neet_pg_bot

Q15: Which of the following features are not seen in Alzheimer's Disease? (Q845163)

A. Bunina bodies

B. Neuritic plaques

C. Neurofibrillary tangles

D. Hirano bodies

See Answer in Part B → Q15

@Neet_pg_bot

Q16: Which of the following statements about Alzheimer's Disease is/are correct? 1) Due to the mutation of the APP gene on Chromosome 21 2) Alpha and Gama secretase pathways are involved 3) APOE2 is a risk factor 4) Affects the frontal, parietal, and temporal lobes. (Q845162)

A. 2,3

B. 2,4

C. 1,3

D. 1,4

See Answer in Part B → Q16

@Neet_pg_bot

Q17: A 65-year-old male presents with a 6-month history of resting tremor in his right hand, which improves with movement. He reports increasing slowness in daily activities and stiffness, particularly in the morning. He has had occasional falls due to unsteadiness while walking. Physical examination reveals a shuffling gait and cogwheel rigidity. All of the following are true statements regarding this condition except? (Q845161)

A. A key pathological feature in the substantia nigra neurons is observed.

B. This condition can occur due to mitochondrial dysfunction.

C. Mutations in LRRK2 are the most common cause of autosomal dominant disease.

D. Homozygous mutation of glucocerebrosidase is an important risk factor for this condition.

See Answer in Part B → Q17

@Neet_pg_bot

Q18: A 55-year-old male presented with behavioral changes and involuntary movements over the past several weeks. Neurological examination revealed ataxia and myoclonus. He passed away after 4 months, and biopsy findings of the brain tissue are shown below. Based on these findings, which of the following statements is false regarding this condition? Proteinaceous particles with single-stranded RNA cause it. It results from the misfolding of PrPsc to PrPc. Spongiform transformation is a characteristic histopathological feature It is associated with a good prognosis if diagnosed early. Familial forms are associated with specific genetic mutations. (Q845160)

A. 1, 2 and 4

B. 1, and 4

C. 2 and 4

D. 3, 4 and 5

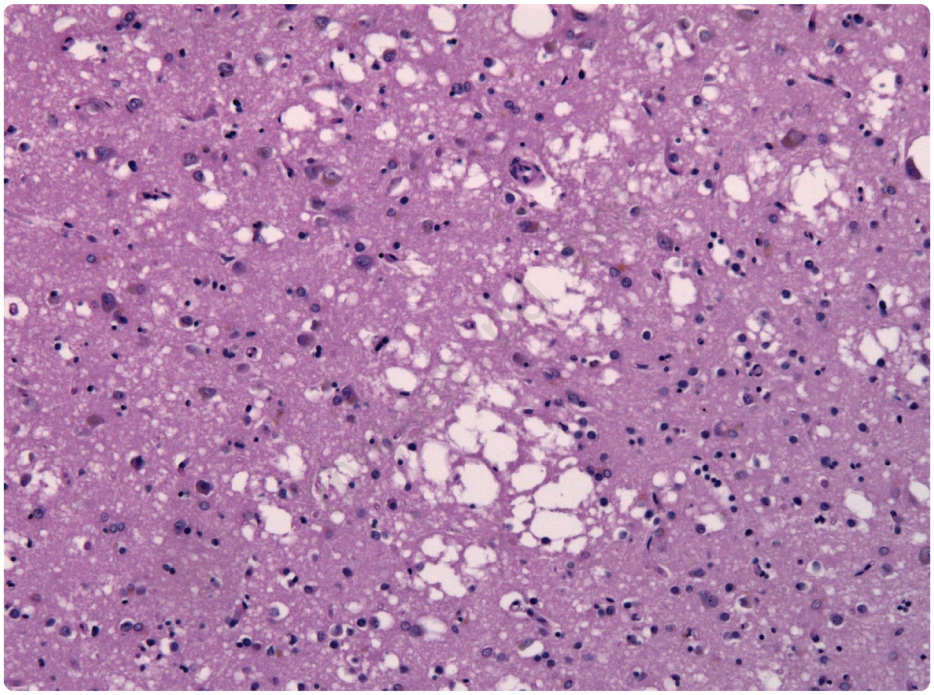

@Neet_pg_bot

See Answer in Part B → Q18

@Neet_pg_bot

• [15_Central Nervous System] 063 Previous Year Questions

« Back to Folder Directory

[15_Central Nervous System] 063 Previous Year Questions — Quick Jump

Q1 (p. 675)	*Q2 (p. 675)*	*Q3 (p. 675)*	*Q4 (p. 676)*	*Q5 (p. 677)*	*Q6 (p. 677)*
Q7 (p. 677)	*Q8 (p. 678)*	*Q9 (p. 678)*	*Q10 (p. 679)*	*Q11 (p. 679)*	*Q12 (p. 679)*
Q13 (p. 680)	*Q14 (p. 680)*	*Q15 (p. 681)*	*Q16 (p. 681)*	*Q17 (p. 682)*	

Q1: A 40-year-old female presents with frequent headaches. The investigation reveals raised intracranial pressure and the presence of a dural-based tumour. Which of the following histological findings correlates with the diagnosis? (Q858139)

A. Fried-egg appearance

B. Flexner-Wintersteiner rosettes

C. Psammoma bodies with whorling of tumor cells

D. Homer-Wright rosettes

See Answer in Part B → Q1

@Neet_pg_bot

Q2: What is the most common cause of berry aneurysm? (Q859895)

A. Endothelial injury of the vessel due to hypertension

B. Muscle intimal elastic lamina layer defect

C. Muscle and adventitial layer defect

D. Adventitia defect

See Answer in Part B → Q2

@Neet_pg_bot

Q3: Tau protein inclusions are involved in: (Q859856)

A. Alzheimer’s disease

B. Huntington's disease

C. Amyotrophic lateral sclerosis

D. CNS lymphoma

See Answer in Part B → Q3

@Neet_pg_bot

Q4: A 40-year-old female presents with the development of seizures, for which a CT-guided biopsy was done. The histopathological image showed the presence of psammoma bodies. What is the most likely diagnosis? (Q859262)

A. Astrocytoma

B. Medulloblastoma

C. Meningioma

D. Ependymoma

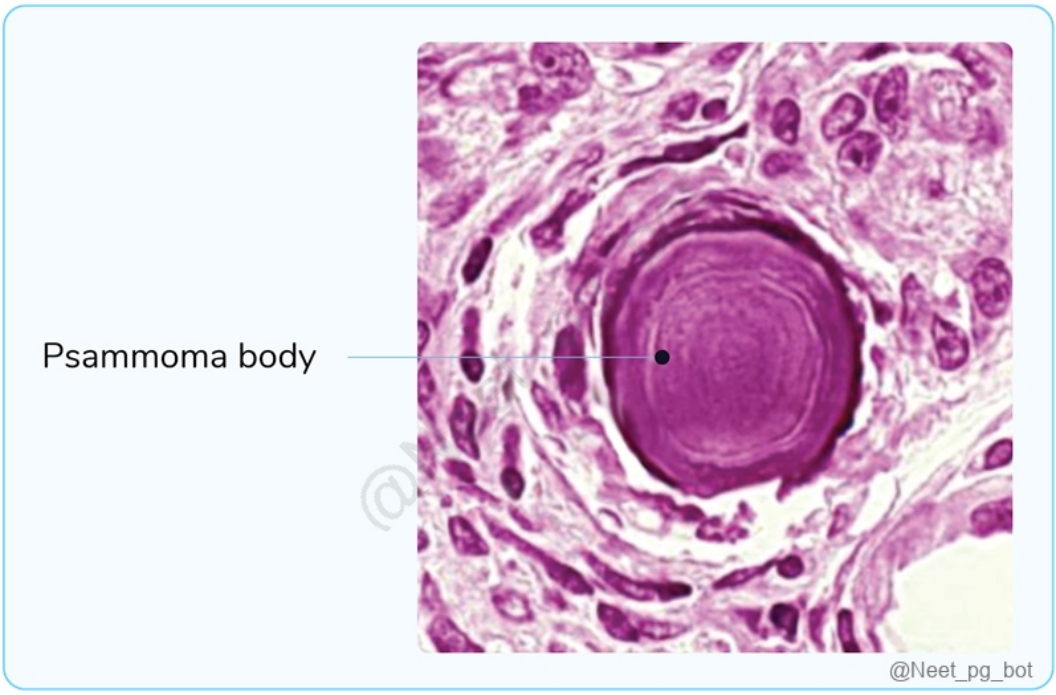

See Answer in Part B → Q4

@Neet_pg_bot

Q5: A 24-year-old patient presented with swelling in the wrist joint. Histopathological examination of the swelling revealed spindle cells with palisading of the nuclei and Verocay bodies. Which of the following is the most likely condition? (Q854862)

A. Schwannoma

B. Neurofibroma

C. Neuroma

D. Glioma

See Answer in Part B → Q5

@Neet_pg_bot

Q6: All of the following conditions are related to the same core pathology, except: (Q856486)

A. Parkinson’s disease

B. Alzheimer’s disease

C. Lewy body dementia

D. Multisystem atrophy

See Answer in Part B → Q6

@Neet_pg_bot

Q7: What is the most common cause of berry aneurysm? (Q857610)

A. Endothelial injury of the vessel due to hypertension

B. Muscle intimal elastic lamina layer defect

C. Muscle and adventitial layer defect

D. Adventitia defect

See Answer in Part B → Q7

@Neet_pg_bot

Q8: A mutation in the SOD1 gene is most commonly associated with which of the following conditions? (Q866751)

A. Huntington's disease

B. Multiple sclerosis

C. Amyotrophic lateral sclerosis (ALS)

D. Parkinson's disease

See Answer in Part B → Q8

@Neet_pg_bot

Q9: A 45-year-old patient presents with severe headaches, seizures, and progressive neurological deficits. Imaging reveals a large mass with areas of necrosis and irregular borders in the brain. The biopsy confirms the diagnosis of a malignant tumor. Which of the following options represents the most common type of brain tumor in adults? (Q820559)

A. Medulloblastoma

B. Meningioma

C. Retinoblastoma

D. Glioblastoma

See Answer in Part B → Q9

@Neet_pg_bot

Q10: A 70-year-old patient presents with progressive memory loss, cognitive decline, and behavioral changes. Imaging reveals characteristic amyloid plaques and neurofibrillary tangles in the brain. On further investigation, the accumulation of a specific protein is found to be a hallmark of this disease. What is the protein responsible for the amyloidosis seen in Alzheimer's disease? (Q820521)

A. Amyloid beta protein

B. ATTR

C. Amyloid beta 2 protein

D. Acal

See Answer in Part B → Q10

@Neet_pg_bot

Q11: Which of the following is the disorder associated with hexanucleotide repeat? (Q860225)

A. Fragile X syndrome

B. Huntington disease

C. Myotonic dystrophy

D. Frontotemporal dementia

See Answer in Part B → Q11

@Neet_pg_bot

Q12: A 5-year-old child presents with a lesion in the right eye. Histopathology reveals the presence of Flexner-Wintersteiner rosettes. What is the likely diagnosis? (Q860515)

A. Retinoblastoma

B. Optic nerve glioma

C. Rhabdomyosarcoma

D. Ocular melanoma

See Answer in Part B → Q12

@Neet_pg_bot

Q13: Which of the following is a marker of Alzheimer's disease? (Q844213)

A. Synuclein

B. Aβ 40 and 42

C. Polyglutamine

D. FUS

See Answer in Part B → Q13

@Neet_pg_bot

Q14: A patient presents with a hand lesion, and the histopathology of the lesion is provided. Which of the following statements is incorrect? (Q853372)

A. It originates from the peripheral nerve

B. Verrocay bodies are seen in light microscopy

C. Associated with neurofibromatosis

D. It is malignant and often metastasizes

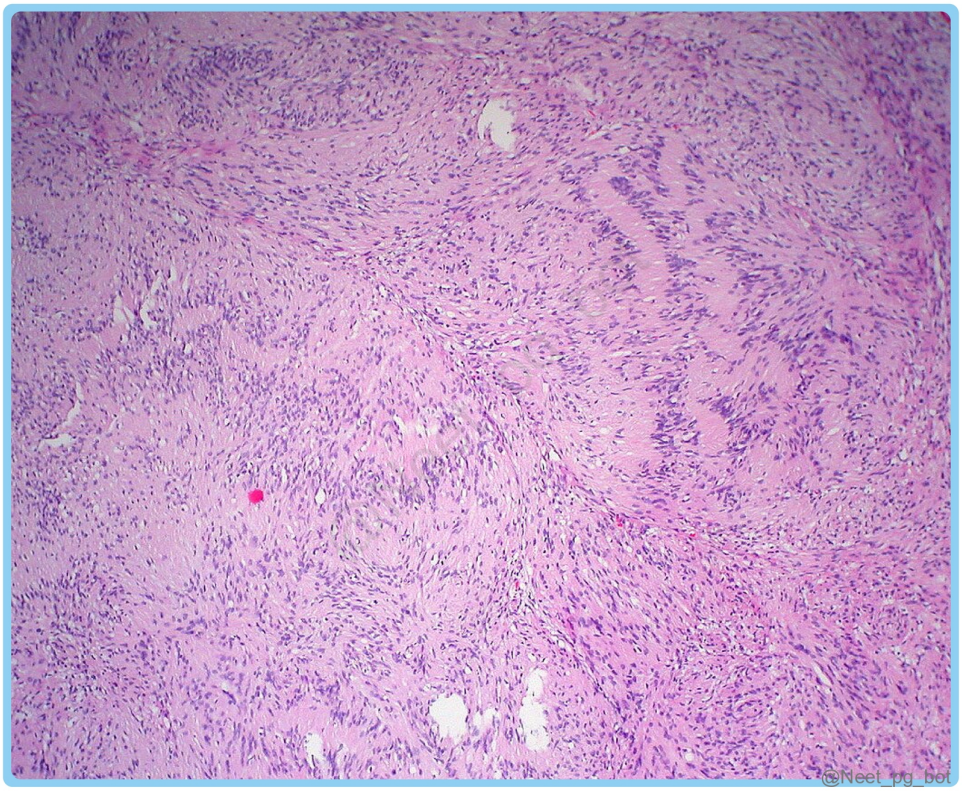

See Answer in Part B → Q14

@Neet_pg_bot

Q15: A child presents with visual disturbances and delayed growth. Imaging reveals a suprasellar mass, and histopathology shows the presence of "wet keratin" (compact, eosinophilic anucleate keratin). What is the most likely diagnosis? (Q866366)

A. Craniopharyngioma

B. Medulloblastoma

C. Glioma

D. Pituitary adenoma

See Answer in Part B → Q15

@Neet_pg_bot

Q16: In the WHO grading of astrocytoma, which grade does glioblastoma fall under? (Q793781)

A. I

B. II

C. III

D. IV

See Answer in Part B → Q16

@Neet_pg_bot

Q17: An electron microscopic picture of a cut section of a nerve fibre is given. Identify the area that will be affected by the most common variant of Guillain-Barre syndrome. (Q855395)

A. 1

B. 2

C. 3

D. 4

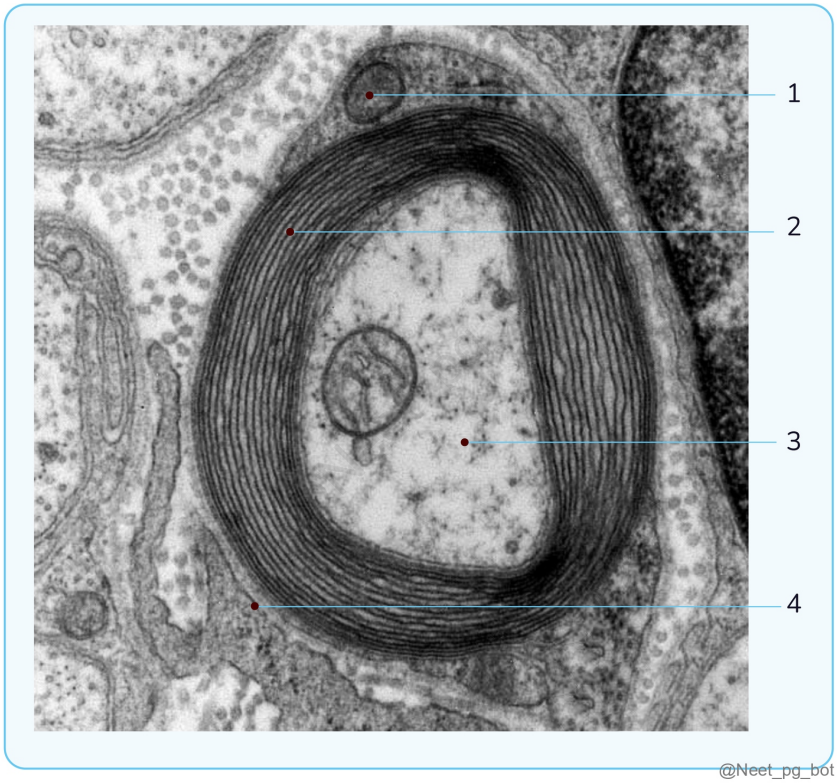

See Answer in Part B → Q17

@Neet_pg_bot

• [16_Skin and Musculoskeletal] 064 Previous Year Questions

« Back to Folder Directory

[16_Skin and Musculoskeletal] 064 Previous Year Questions — Quick Jump

Q1 (p. 684) *Q2 (p. 684)* *Q3 (p. 685)* *Q4 (p. 686)* *Q5 (p. 686)* *Q6 (p. 687)*
Q7 (p. 687) *Q8 (p. 688)*

Q1: A child presents with skin eruptions upon exposure to sunlight and is diagnosed with a DNA repair defect. Which type of repair defect is most likely responsible? (Q844175)

A. Nucleotide excision repair defect

B. Base excision repair defect

C. Mismatch repair defect

D. Recombination repair defect

See Answer in Part B → Q1

@Neet_pg_bot

Q2: Identify the diagnosis based on the image provided: (Q844180)

A. Tuberculosis (TB)

B. Malakoplakia

C. Pyoderma gangrenosum

D. Squamous cell carcinoma (SCC)

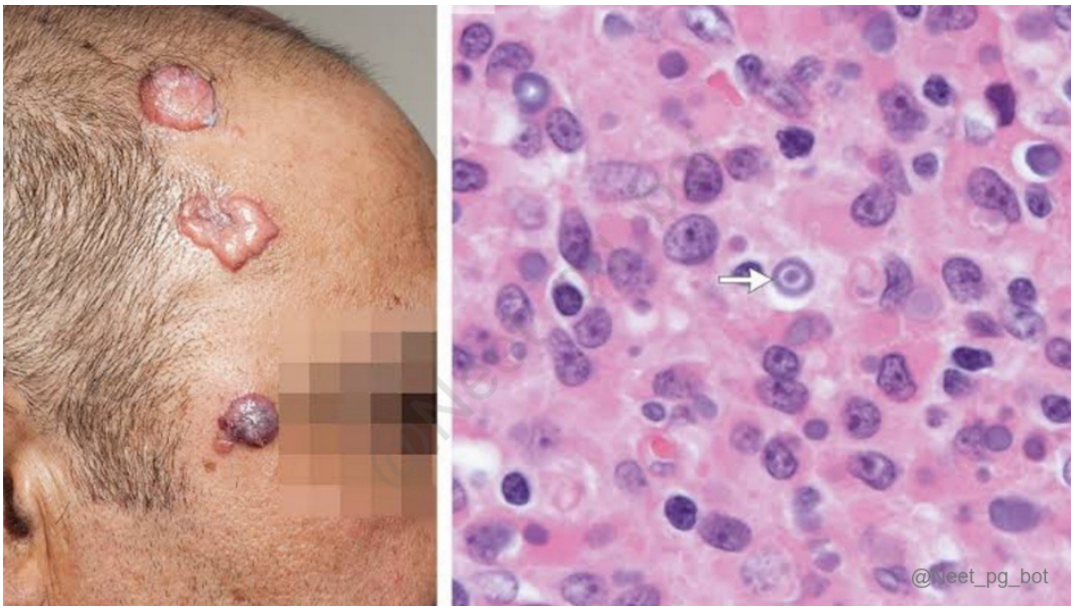

See Answer in Part B → Q2

@Neet_pg_bot

Q3: Identify the given condition. (Q856687)

A. Pemphigus Vulgaris

B. Leprosy

C. Mycosis fungoides

D. Visceral leishmaniasis

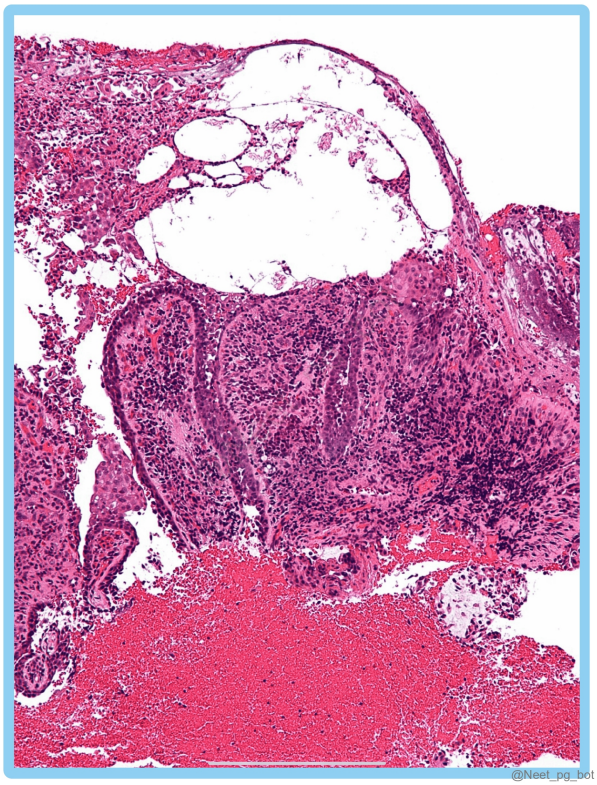

See Answer in Part B → Q3

@Neet_pg_bot

Q4: A 5-year-old child who presented with proptosis of one of the eyes was found to have a desmin-positive tumour. What is the probable diagnosis? (Q856705)

A. Ewing’s sarcoma

B. Embryonal rhabdomyosarcoma

C. Leukaemia

D. Retinoblastoma

See Answer in Part B → Q4

@Neet_pg_bot

Q5: A patient underwent surgery for lipoma 5 weeks ago and now presents with a scar at the incision site, which is limited to the original wound boundaries. What is the most likely diagnosis? (Q857162)

A. Keloid

B. Exuberant granulation

C. Hypertrophic scar

D. Granulation tissue

See Answer in Part B → Q5

@Neet_pg_bot

Q6: An 8-year-old boy presents with progressive muscle weakness and walking difficulties. On examination, pseudohypertrophy of the calf muscles was noted. Which of the following is true regarding this condition? (Q858113)

A. Abnormal collagen

B. Absent dystrophin

C. Expansions of CAG triplet repeats

D. Defective fibrillin

See Answer in Part B → Q6

@Neet_pg_bot

Q7: A farmer has a lesion on the shoulder. What is the most likely diagnosis based on the histopathological image of the lesion given below? (Q860532)

A. SCC

B. BCC

C. Molluscum contagiosum

D. Verrucous carcinoma

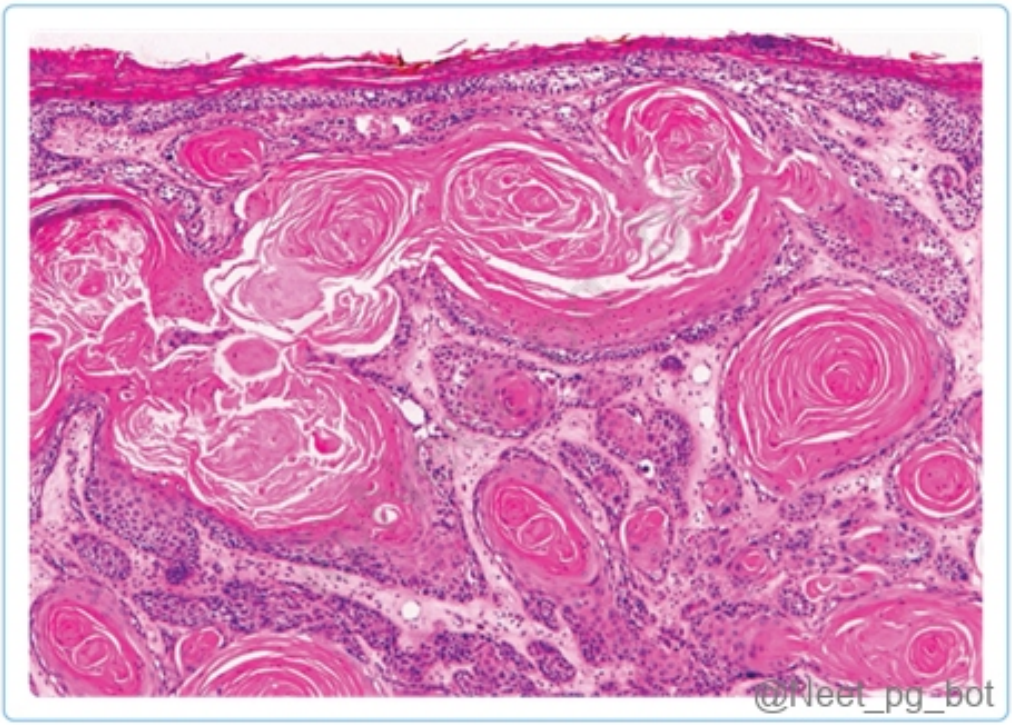

See Answer in Part B → Q7

@Neet_pg_bot

Q8: Identify the histopathological image. (Q860535)

A. Basal cell carcinoma

B. Squamous cell carcinoma

C. Adenocarcinoma

D. Malignant melanoma

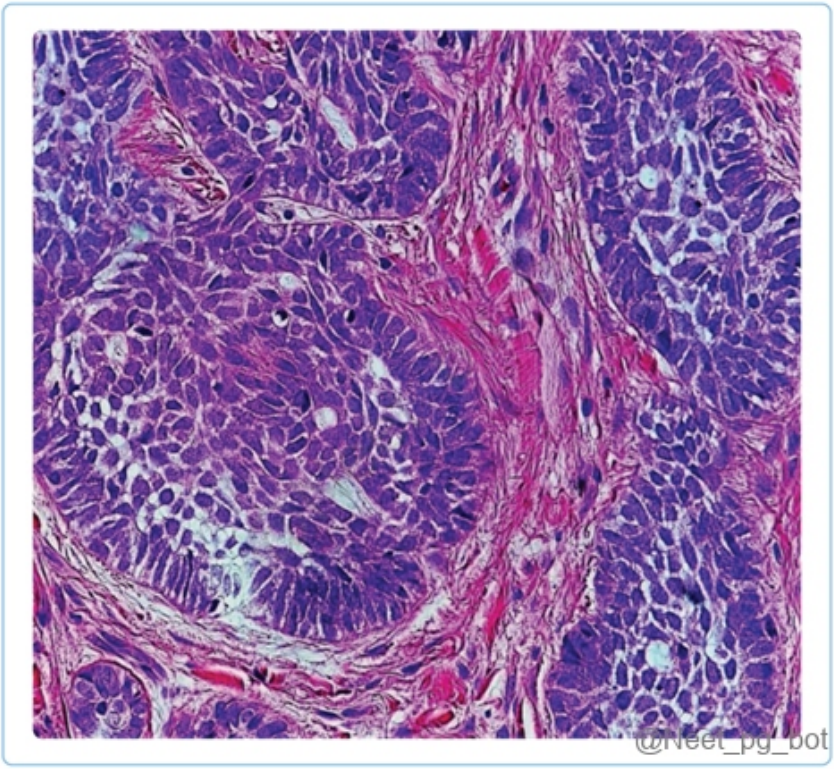

See Answer in Part B → Q8

@Neet_pg_bot

• [17_Hematology_ Red Blood Cells] 065 Introduction To Hematology

« Back to Folder Directory

[17_Hematology_ Red Blood Cells] 065 Introduction To Hematology — Quick Jump

Q1 (p. 690)	*Q2 (p. 690)*	*Q3 (p. 691)*	*Q4 (p. 691)*	*Q5 (p. 691)*	*Q6 (p. 692)*
Q7 (p. 692)	*Q8 (p. 694)*	*Q9 (p. 694)*	*Q10 (p. 694)*	*Q11 (p. 695)*	*Q12 (p. 695)*
Q13 (p. 695)	*Q14 (p. 696)*	*Q15 (p. 696)*	*Q16 (p. 697)*	*Q17 (p. 697)*	*Q18 (p. 697)*
Q19 (p. 698)	*Q20 (p. 698)*				

Q1: What is the most common reason for an elevated reticulocyte count among the conditions? (Q846639)

A. Aplastic anemia

B. Hemolytic anemia

C. Megaloblastic anemia

D. Myelophthisic anemia

See Answer in Part B → Q1

@Neet_pg_bot

Q2: What is the most likely interpretation if Hemoglobin is 9 g/dL, MCV is 104 fL, MCH is 22 pg, and MCHC is 31 g/dL? (Q846648)

A. Microcytic Hypochromic Anaemia

B. Normocytic Normochromic Anaemia

C. Macrocytic Hypochromic Anaemia

D. Microcytic Normochromic Anaemia

See Answer in Part B → Q2

@Neet_pg_bot

Q3: What is the Mean Corpuscular Hemoglobin Concentration (MCHC) using Hemoglobin (Hb) level is 15 g/dL and Hematocrit (Hct) is 45%? (Q846647)

A. 33.3 g/dL

B. 34.0 g/dL

C. 32.0 g/dL

D. 30.0 g/dL

See Answer in Part B → Q3

@Neet_pg_bot

Q4: A 45-year-old male patient presents for a routine check-up. His laboratory results show that his Hemoglobin (Hb) level is 14 g/dL, and his RBC count is 4.7 million cells/μL. Using these values, calculate the Mean Corpuscular Hemoglobin (MCH). (Q846646)

A. 29.8 pg

B. 29.0 pg

C. 30.0 pg

D. 28.5 pg

See Answer in Part B → Q4

@Neet_pg_bot

Q5: Calculate MCV in a patient where RBC count is 4.5 million cells per microliter (cells/μL), Hb 9gm/dl and Hematocrit is 30% (Q846645)

A. 65.7 fL

B. 66.7 fL

C. 67.7 fL

D. 68.7 fL

See Answer in Part B → Q5

@Neet_pg_bot

Q6: RBC indices Definitions 1. MCV a) Indicates the variation in the size of red blood cells. 2. MCH b) Reflects the average volume of a red blood cell. 3. MCHC c) Measures the average amount of haemoglobin in a single red blood cell. 4. RDW d) Represents the amount of haemoglobin per unit volume of red blood cells. (Q846644)

A. 1-b, 2-c, 3-d, 4-a

B. 1-c, 2-a, 3-b, 4-d

C. 1-d, 2-a, 3-c, 4-b

D. 1-b, 2-d, 3-c, 4-a

See Answer in Part B → Q6

@Neet_pg_bot

Q7: A 5-year-old child presented with a fever and his blood sample was taken to measure ESR using the Wintrobe tube. What are the advantages of the instrument (A) over instrument (B)? (Q846643)

A. The test is more sensitive

B. Does not need anticoagulant

C. Useful for estimation of both PCV and ESR

D. More volume of the tube

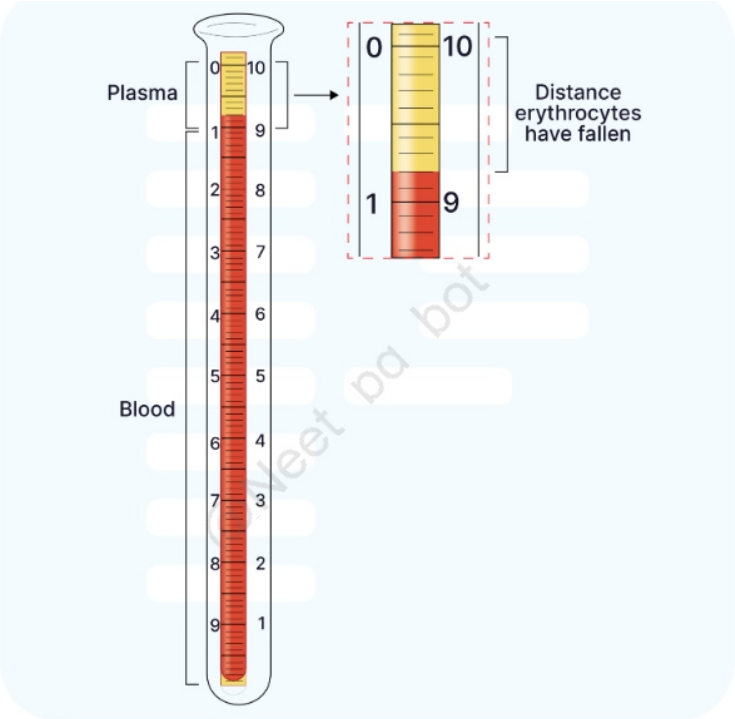

A

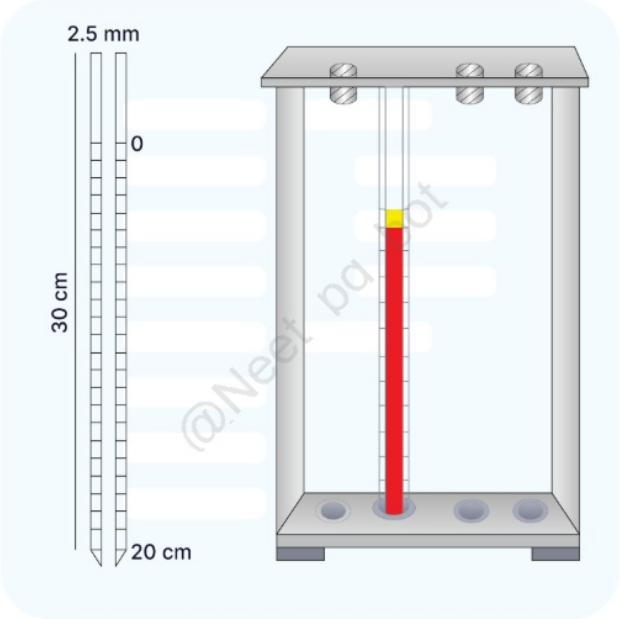

B

See Answer in Part B → Q7

@Neet_pg_bot

Q8: Which statement accurately describes ESR (Erythrocyte Sedimentation Rate)? (Q846642)

A. Non-specific marker of inflammation

B. Proportion of red blood cells in the total blood volume

C. Reflects the oxygen-carrying capacity of the blood

D. Reported in percentage

See Answer in Part B → Q8

@Neet_pg_bot

Q9: A 48-year-old man presents to the clinic with fatigue, palpitations, and shortness of breath. Examination reveals pallor. Using the following values, calculate the reticulocyte production index: Reticulocyte count: 5% Hemoglobin: 9 g/dL Hematocrit: 28% (Q846641)

A. 1.8

B. 1.5

C. 2.5

D. 2.0

See Answer in Part B → Q9

@Neet_pg_bot

Q10: A 30-year-old man presents to the OPD with fatigue, weakness, and breathlessness. He shows pallor and icterus on examination. Given his hemogram results, reticulocyte count of 5%, haemoglobin of 9 g/dL, and hematocrit of 28%, calculate his corrected reticulocyte count. (Q846640)

A. 4.0

B. 5.1

C. 4.5

D. 3.0

See Answer in Part B → Q10

@Neet_pg_bot

Q11: At which site does erythropoiesis primarily occur in an adult human? (Q845922)

A. Bone marrow of long bones

B. Bone marrow of all bones

C. Yolk sac

D. Liver

See Answer in Part B → Q11

@Neet_pg_bot

Q12: What is the approximate maturation time for reticulocytes in the bloodstream to form mature red blood cells? (Q846637)

A. 1-2 days

B. 2-5 days

C. 6-7 days

D. 8-10 days

See Answer in Part B → Q12

@Neet_pg_bot

Q13: What is the normal range for reticulocyte count in adults? (Q846636)

A. 0.5-2%

B. 2-6%

C. 2-3%

D. 0-0.1%

See Answer in Part B → Q13

@Neet_pg_bot

Q14: A 25-year-old woman experiences ongoing fatigue and weakness, appearing pale upon examination. Laboratory investigations reveal low haemoglobin levels, and a peripheral blood smear is ordered. Which stain is most effective for visualising reticulocytes in peripheral blood smears? (Q846635)

A. Prussian Blue

B. New Methylene Blue

C. Periodic acid-Schiff (PAS) stain

D. Wright stain

See Answer in Part B → Q14

@Neet_pg_bot

Q15: Which stage of erythropoiesis is characterised by the expulsion of the nucleus, resulting in a smaller, pyknotic cell with increased haemoglobin content? (Q846634)

A. Reticulocyte

B. Normoblast

C. Basophilic erythroblast

D. Proerythroblast

See Answer in Part B → Q15

@Neet_pg_bot

Q16: Which condition is NOT typically associated with a dry tap during bone marrow aspiration? (Q846633)

A. Aplastic anaemia

B. Hairy cell leukemia

C. Myelofibrosis

D. Chronic Myeloid Leukemia

See Answer in Part B → Q16

@Neet_pg_bot

Q17: If a person is 45 years old, what would be the expected percentage of cellularity in their bone marrow biopsy? (Q845972)

A. 45%

B. 55%

C. 65%

D. 75%

See Answer in Part B → Q17

@Neet_pg_bot

Q18: A 35-year-old man undergoes a bone marrow biopsy, which shows a composition of cells and fat. What is the ratio of hematopoietic cells to fat cells expected in an adult? (Q845971)

A. 1:1

B. 1:3

C. 2:3

D. 3:1

See Answer in Part B → Q18

@Neet_pg_bot

Q19: A 56-year-old male presents with pancytopenia and is scheduled for a bone marrow biopsy to determine the underlying cause. What is the most common site for performing a bone marrow biopsy in this patient? (Q845946)

A. Anterior Superior Iliac spine

B. Posterior Superior Iliac spine

C. Proximal femur

D. Proximal tibia

See Answer in Part B → Q19

@Neet_pg_bot

Q20: Identify the instrument shown in the image below. (Q845945)

A. Salah needle

B. Klima needle

C. Jamshidi needle

D. Quincke needle



See Answer in Part B → Q20

@Neet_pg_bot

• [17_Hematology_ Red Blood Cells] 066 Hemolytic Anemia-I

« Back to Folder Directory

[17_Hematology_ Red Blood Cells] 066 Hemolytic Anemia-I — Quick Jump

Q1 (p. 700)	*Q2 (p. 700)*	*Q3 (p. 701)*	*Q4 (p. 701)*	*Q5 (p. 703)*	*Q6 (p. 704)*
Q7 (p. 704)	*Q8 (p. 705)*	*Q9 (p. 705)*	*Q10 (p. 705)*	*Q11 (p. 706)*	*Q12 (p. 706)*
Q13 (p. 707)	*Q14 (p. 707)*	*Q15 (p. 708)*	*Q16 (p. 710)*	*Q17 (p. 711)*	

Q1: A 30-year-old male presents with severe fatigue, shortness of breath, and dark urine after eating fava beans. He has a history of recurrent hemolytic anemia. On examination, he appears pale and jaundiced. Which statement correctly describes the pathogenesis of his condition? (Q845845)

A. Deficiency in an enzyme leads to oxidative stress-induced hemolysis.

B. Excessive production of glutathione leads to the destruction of red blood cells.

C. Decreased levels of reactive oxygen species (ROS) lead to decreased oxidative damage.

D. The severity is not influenced by environmental factors or dietary triggers like fava beans.

See Answer in Part B → Q1

@Neet_pg_bot

Q2: Which investigation is considered the most definitive for confirming the diagnosis of paroxysmal nocturnal hemoglobinuria (PNH)? (Q890597)

A. Ham’s acid hemolysis test

B. Bone marrow biopsy

C. High-performance liquid chromatography (HPLC)

D. Flow cytometry

See Answer in Part B → Q2

@Neet_pg_bot

Q3: A 12-year-old girl presents for a regular health maintenance visit. There are no active complaints, and she has been feeling well. She has no chronic medical conditions and does not take any medications. She has a positive family history of thalassemia. Which of the following best confirms the diagnosis of thalassemia trait? (Q882123)

A. Elevated HbA2

B. Reticulocytosis

C. NESTROFT

D. Peripheral smear

See Answer in Part B → Q3

@Neet_pg_bot

Q4: Match the following histopathological findings with their correct diagnosis: 1. A. Sickle Cell Anemia 2. B. Hereditary Spherocytosis 3. C. G6PD deficiency 4. D. Thalassemia (Q845892)

A. 1-C, 2-D, 3-A, 4-B

B. 1-D, 2-C, 3-B, 4-A

C. 1-B, 2-A, 3-D, 4-C

D. 1-A, 2-B, 3-C, 4-D

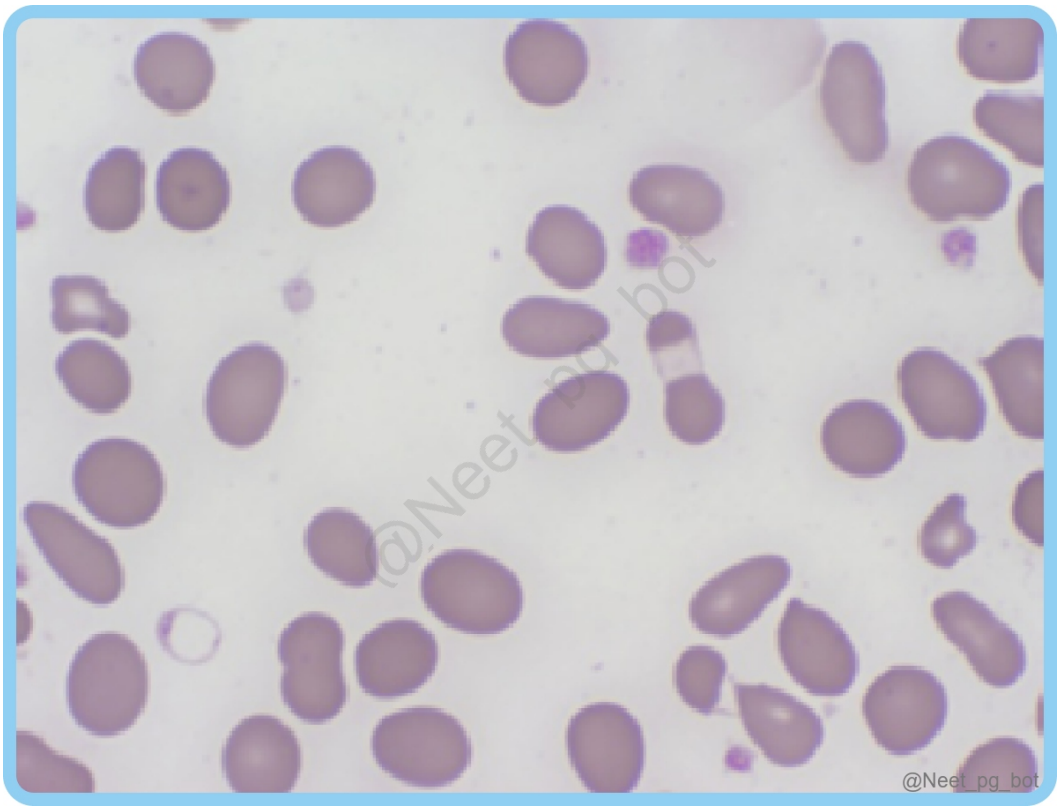
@Neet_pg_bot

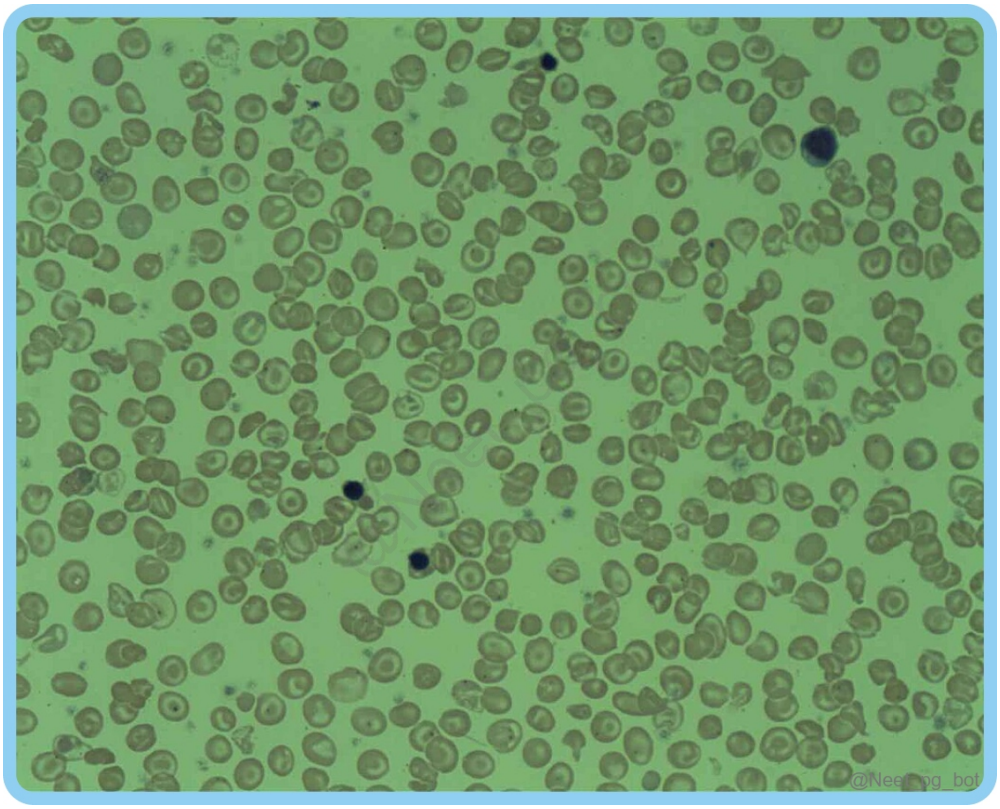
@Neet_pg_bot

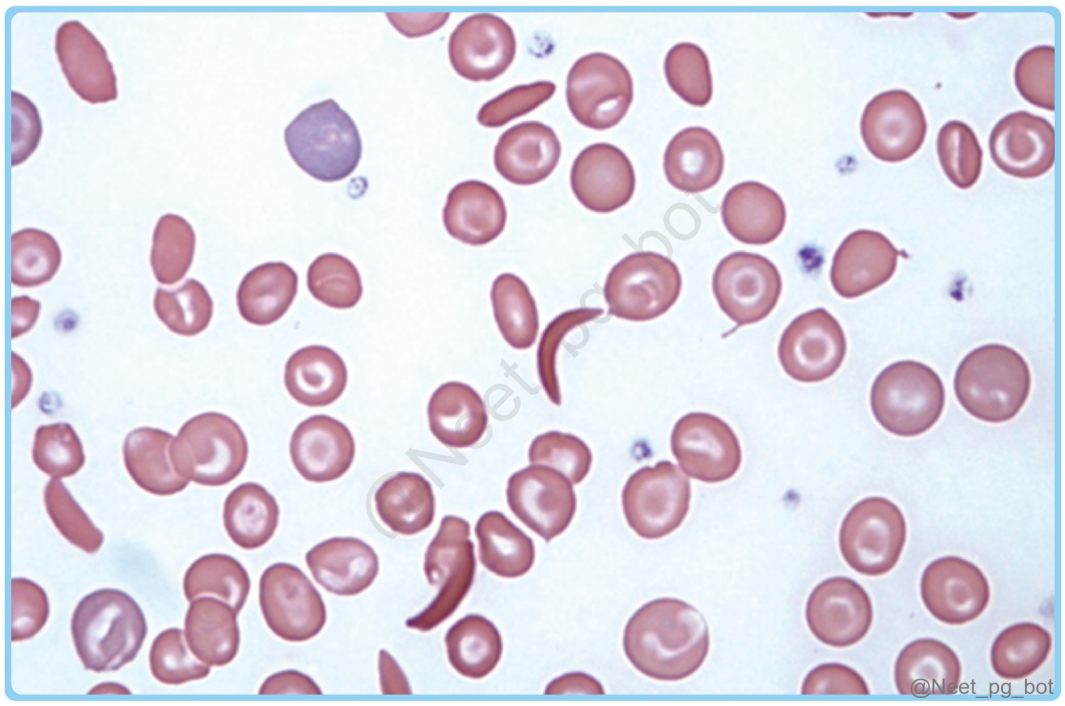

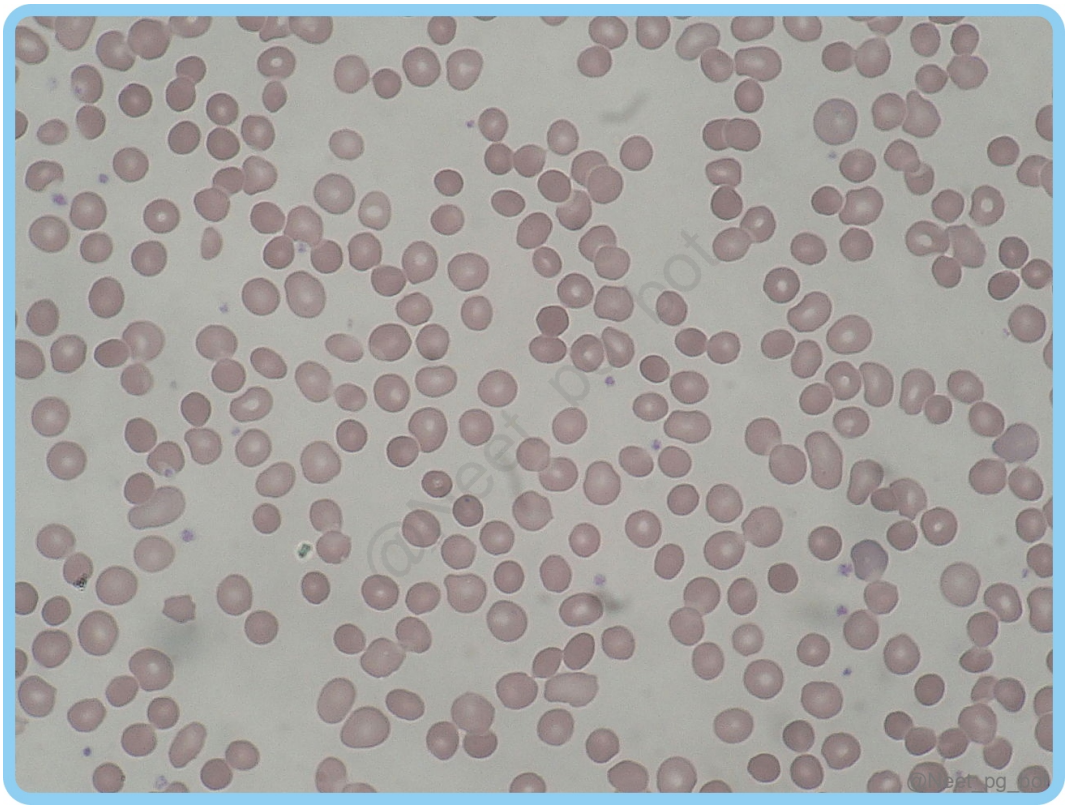

See Answer in Part B → Q4

@Neet_pg_bot

Q5: Which of the following treatments is commonly used for Paroxysmal Nocturnal Hemoglobinuria? (Q845891)

A. Rituximab

B. Bevacizumab

C. Eculizumab

D. Trastuzumab

See Answer in Part B → Q5

@Neet_pg_bot

Q6: Which of the following is the most common cause of death in Paroxysmal Nocturnal Hemoglobinuria? (Q845890)

A. Pancytopenia

B. Acute Myeloid Leukemia

C. Hepatic vein thrombosis

D. Myelodysplastic syndrome

See Answer in Part B → Q6

@Neet_pg_bot

Q7: Which of the following defects is seen in paroxysmal nocturnal hemoglobinuria? (Q845889)

A. Spectrin

B. CD 45 and CD 95

C. G6PD enzyme

D. PIGA gene

See Answer in Part B → Q7

@Neet_pg_bot

Q8: Which of the following statements regarding Paroxysmal Nocturnal Hemoglobinuria (PNH) is true? (Q845888)

A. Causes extravascular hemolysis

B. Splenectomy would be beneficial

C. Causes hemolysis only at night

D. Acquired intracorpuscular defect

See Answer in Part B → Q8

@Neet_pg_bot

Q9: A 45-year-old male presents to the emergency department with symptoms of acute hemolytic anemia. A methemoglobin reduction test is performed, revealing a delayed rate of methemoglobin reduction. What is the underlying principle of the above-mentioned screening test used to diagnose G6PD deficiency? (Q845846)

A. Measures the levels of methemoglobin in red blood cells.

B. Evaluates the ability of red blood cells to reduce methemoglobin back to haemoglobin.

C. Detects G6PD activity by measuring the rate of reduction of a fluorescent dye.

D. Measures the actual activity levels of the G6PD enzyme.

See Answer in Part B → Q9

@Neet_pg_bot

Q10: Which of the following sequences correctly represents the progression of hemoglobin handling in the body during intravascular hemolysis (IVH)? A. Hemoglobin binds to albumin, forming meth albuminemia B. Hemoglobin combines with haptoglobin C. Haptoglobin saturation and hemoglobin binding to hemopexin. D. RBC lysis causes hemoglobin to leak out. (Q845837)

A. D → B → C→ A

B. D → B → A → C

C. D → C → A → B

D. D → C → B → A

See Answer in Part B → Q10

@Neet_pg_bot

Q11: A 6-year-old child presents with a history of recurrent episodes of jaundice, fatigue, and abdominal pain. Physical examination reveals splenomegaly. The child's blood work shows the presence of spherocytes on the peripheral blood smear. An osmotic fragility test is performed. Identify the correct statement about this test. (Q845844)

A. It is a diagnostic test.

B. In thalassemia patients, low osmotic fragility leads to a right shift on the graph.

C. In HS patients, high osmotic fragility leads to a right shift on the graph.

D. Normally, RBC lysis begins at 0.7% NaCl.

See Answer in Part B → Q11

@Neet_pg_bot

Q12: Which of the following is not a typical change in blood indices in patients with hereditary spherocytosis? (Q845843)

A. MCV decreases

B. MCHC increases

C. RDW decreases

D. Hemoglobin decreases

See Answer in Part B → Q12

Q13: A 10-year-old child presents with a history of recurrent episodes of jaundice, fatigue, and abdominal pain. Physical examination reveals splenomegaly, and peripheral blood smear shows the following picture. Coomb's test is negative. What is the most likely diagnosis? (Q845842)

A. Hereditary spherocytosis

B. Autoimmune hemolytic anemia

C. Glucose-6-phosphate dehydrogenase (G6PD) deficiency

D. Thalassemia

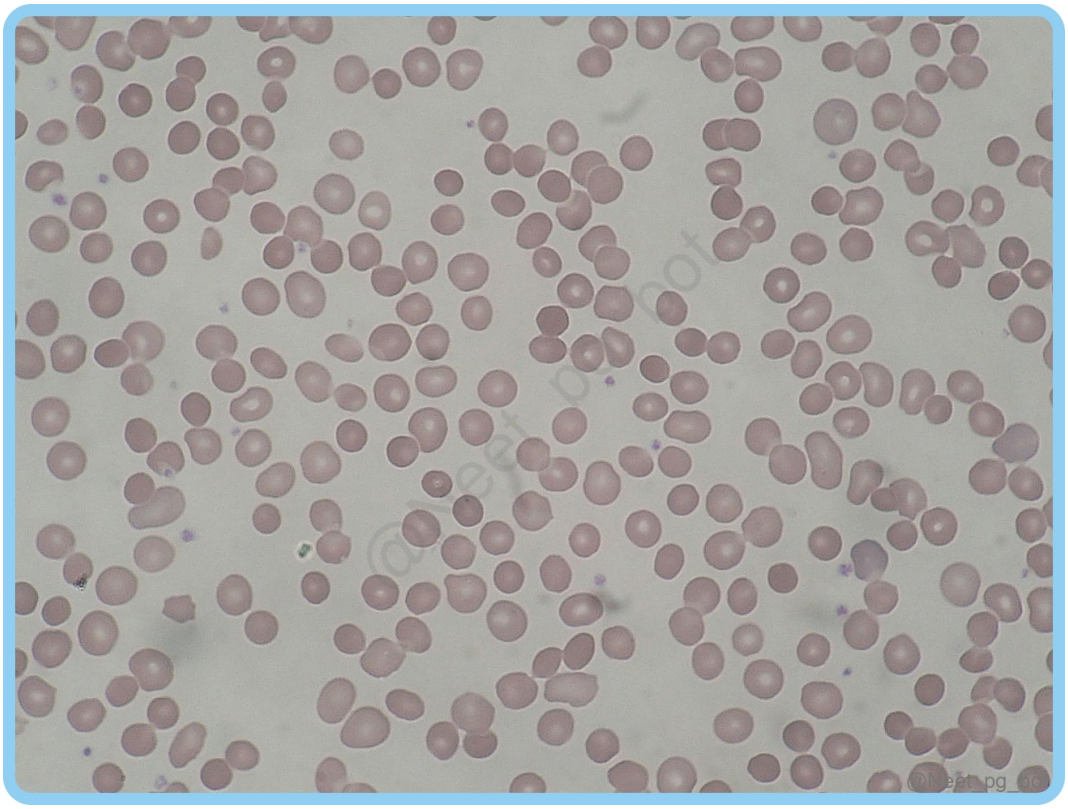

See Answer in Part B → Q13

Q14: A 28-year-old male presents with fatigue, jaundice, splenomegaly, and anemia with elevated MCHC. A peripheral smear is done which is shown below. What is the most common protein defect in this condition? (Q845841)

A. Spectrin

B. Band 3 protein

C. Ankyrin

D. Glycophorin A

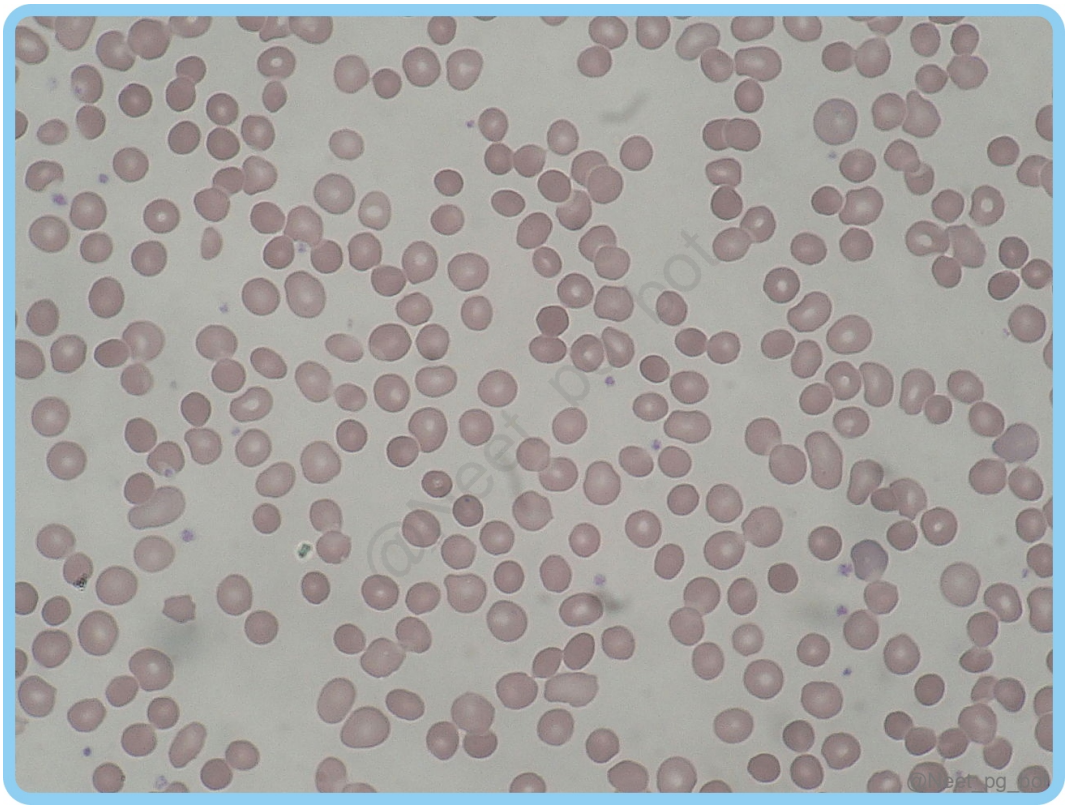

See Answer in Part B → Q14

@Neet_pg_bot

Q15: Examine the provided histopathology image of a blood smear containing two types of abnormal red blood cells. Identify the diseases associated with each cell type. (Q845840)

A. a: Pyruvate kinase deficiency, burns, and uremia; b: Abetalipoproteinemia, liver disease, and vitamin E deficiency.

B. a: Abetalipoproteinemia, liver disease, and vitamin E deficiency; b: Pyruvate kinase deficiency, burns, and uremia.

C. a: Abetalipoproteinemia and burns; b: Pyruvate kinase deficiency and uremia.

D. a: Pyruvate kinase deficiency and liver disease; b: Abetalipoproteinemia and vitamin E deficiency.

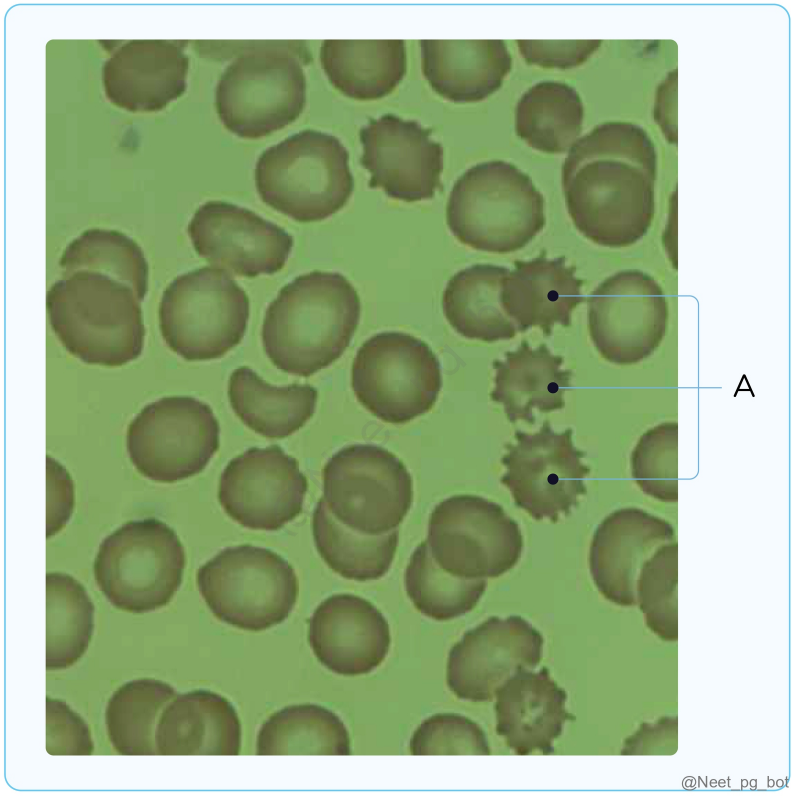

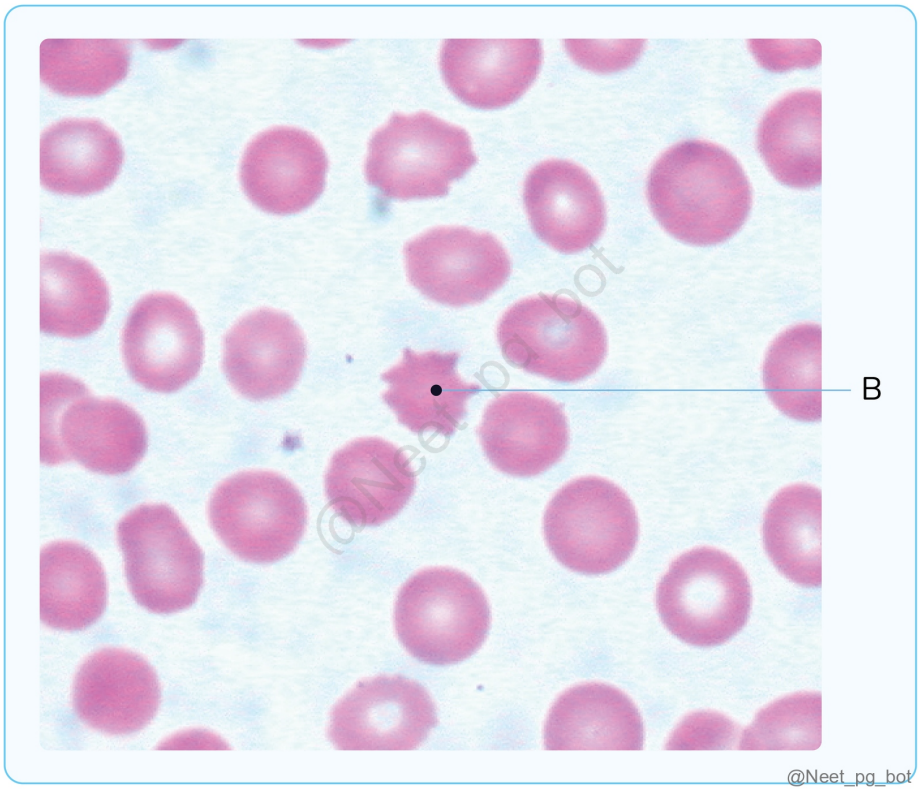

See Answer in Part B → Q15

@Neet_pg_bot

Q16: Match the following causes of hemolysis with their corresponding categories. Categories Causes of hemolysis a. Intracorpuscular defect b. Extracorpuscular defect 1. Hereditary Spherocytosis (HS) 2. G6PD Deficiency 3. Thrombotic Thrombocytopenic Purpura (TTP) 4. Hemoglobin C Disease 5. Hemolytic Uremic Syndrome (HUS) 6. Sickle Cell Anemia (Q845839)

A. 1-a, 2-b, 3-b, 4-a, 5-a, 6-b

B. 1-b, 2-a, 3-b, 4-a, 5-a, 6-a

C. 1-a, 2-a, 3-b, 4-a, 5-b, 6-a

D. 1-a, 2-b, 3-a, 4-b, 5-a, 6-a

See Answer in Part B → Q16

@Neet_pg_bot

Q17: Which of the following conditions can cause intravascular hemolysis (IVH)? Select all that apply. a. Paroxysmal Nocturnal Hemoglobinuria (PNH) b. Glucose-6-Phosphate Dehydrogenase (G6PD) deficiency c. Hereditary spherocytosis d. Paroxysmal Cold Hemoglobinuria (PCH) e. Hemolytic Uremic Syndrome (HUS) f. Thrombotic Thrombocytopenic Purpura (TTP) (Q845838)

A. b, c, d, e and f

B. a, b, d, e, and f

C. a, b, c, e, and f

D. a, b, c, d, and f

See Answer in Part B → Q17

@Neet_pg_bot

• [17_Hematology_ Red Blood Cells] 067 Hemolytic Anemia-Ii

« Back to Folder Directory

[17_Hematology_ Red Blood Cells] 067 Hemolytic Anemia-Ii — Quick Jump

Q1 (p. 712)	*Q2 (p. 712)*	*Q3 (p. 713)*	*Q4 (p. 713)*	*Q5 (p. 713)*	*Q6 (p. 714)*
Q7 (p. 715)	*Q8 (p. 716)*	*Q9 (p. 716)*	*Q10 (p. 716)*	*Q11 (p. 717)*	*Q12 (p. 719)*
Q13 (p. 719)	*Q14 (p. 720)*	*Q15 (p. 721)*	*Q16 (p. 721)*		

Q1: A 1-year-old boy, previously healthy until five months ago, presents with a three-hour history of severe swelling and tenderness of hands and feet. The family history is significant for an older brother who had transfusion-dependent anaemia and died of pneumococcal sepsis at the age of 6. Which haemoglobin molecule composition protected him from developing symptoms until recently? (Q845914)

A. α2γ2

B. α2β2

C. α2δ2

D. α2ε2

See Answer in Part B → Q1

@Neet_pg_bot

Q2: Which of the following points best describes the pathogenesis of sickle cell disease (SCD)? Select all that apply. Nonsense point mutation in 6th position of β-globin chain Mutation promotes the polymerization of oxygenated hemoglobin Glutamic acid is changed to valine at the 6th position of β-globin chain Presence of HbF and HbS is protective against SCD. Patients heterozygous for HbS have more severe diseases than homozygous HbS. Individuals with coexistent α-thalassemia have less severe disease. (Q845915)

A. 1, 5, 4, and 6

B. 3, 4, and 6

C. 2, 5, and 6

D. 1, 2, 5, and 6

See Answer in Part B → Q2

@Neet_pg_bot

Q3: Which of the following conditions does not lead to sickling of RBCs in patients with sickle cell disease? (Q845917)

A. Dehydration

B. Hypoxia

C. Increased pH

D. Decreased HbF

See Answer in Part B → Q3

@Neet_pg_bot

Q4: A 28-year-old man who has received blood transfusions on some occasions and has experienced severe pain in his hands and legs came to follow up. He is currently fine with no complaints and has been receiving treatment that has increased his HbF levels for the past 5 years. Which of the following would be seen in the peripheral smear of this patient? (Q845919)

A. Bite cells

B. Heinz bodies

C. Howell-Jolly bodies

D. Spherocytes

See Answer in Part B → Q4

@Neet_pg_bot

Q5: Match the complications of sickle cell disease (SCD) with their corresponding crises: Complications Crises 1. Acute chest syndrome A. Vaso-occlusive crises 2. Parvovirus B19 infection B. Aplastic crises 3. Splenic enlargement C. Sequestration crisis 4. Splenic fibrosis (Q845921)

A. 1-A, 2-B, 3-C, 4-C

B. 1-A, 2-B, 3-C, 4-A

C. 1-A, 2-A, 3-B, 4-C

D. 1-A, 2-C, 3-B, 4-A

See Answer in Part B → Q5

@Neet_pg_bot

Q6: A 12-year-old girl presents to her primary care physician with complaints of fatigue, pallor, and jaundice. Peripheral smear showed sickling of RBCs. What is the most likely electrophoretic pattern seen in this patient? (Q845923)

A. A

B. B

C. C

D. D

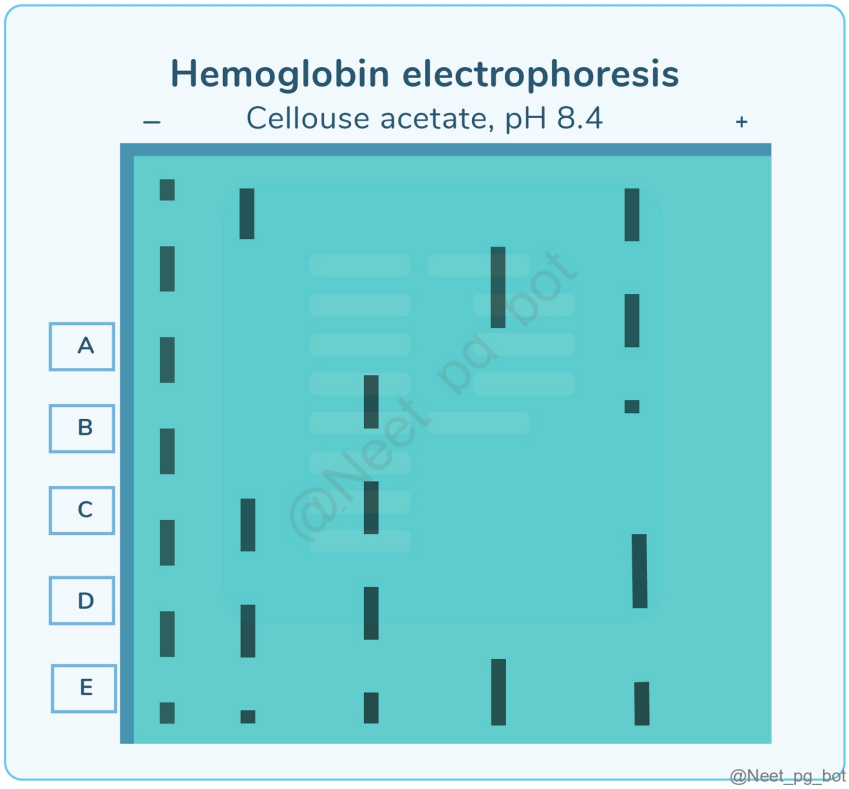

See Answer in Part B → Q6

@Neet_pg_bot

Q7: Which of the following statements regarding the different types of thalassemia is correct? Thalassemia major - mutations in both alleles of the HBB gene - impaired production of beta-globin chains. Beta-thalassemia trait - mutations in one allele of the HBB gene - reduced beta-globin chain synthesis. Alpha-thalassemia trait - deletions in one or more alpha-globin genes - decreased production of alpha-globin chains. Thalassemia intermedia - mutations affecting both alpha and beta-globin genes - severe anemia requiring regular blood transfusions (Q845925)

A. 1, 2, and 4

B. 2, 3, and 4

C. 1, 3 and 4

D. 1, 2, and 3

See Answer in Part B → Q7

@Neet_pg_bot

Q8: A 25-year-old male presents with fatigue, jaundice, and splenomegaly. Laboratory investigations reveal microcytic hypochromic anemia with increased levels of serum iron and ferritin. Further genetic analysis reveals a mutation in the HBB gene. Upon histopathological examination of the bone marrow, there is evidence of erythroid hyperplasia with ineffective erythropoiesis. Which mutation in the HBB gene is most likely responsible for the patient's presentation? (Q845927)

A. Substitution of cytosine for guanine at position 8 in the promoter region of the HBB gene.

B. Substitution of one nucleotide at position +8 in the coding region of the HBB gene.

C. Splicing mutation resulting in the removal of intervening sequence-IVS1-5 G-> C in the HBB gene.

D. Insertion of a nucleotide at position 54 in the coding region of the HBB gene

See Answer in Part B → Q8

@Neet_pg_bot

Q9: A 35-year-old woman with beta-thalassemia major presents to the cardiology clinic with complaints of increasing shortness of breath on exertion and swelling in her ankles. She has been undergoing regular blood transfusions since childhood. She dies after a few days of hospitalization. What is the most common condition leading to her death? (Q845930)

A. Anemia

B. Liver disease

C. Infections

D. Heart failure

See Answer in Part B → Q9

@Neet_pg_bot

Q10: A 25-year-old woman presents to the clinic for routine prenatal care. She has no significant past medical history. Her initial lab work reveals a microcytic, hypochromic anemia. Which of the following statements is most accurate in differentiating between iron deficiency anemia (IDA) and beta-thalassemia minor in this patient? (Q845932)

A. RDW is typically elevated in IDA compared to beta-thalassemia minor

B. RDW is typically lower in IDA compared to beta-thalassemia minor

C. Mentzer index is >13 in beta-thalassemia minor

D. RDW is typically normal in both IDA and beta-thalassemia minor

See Answer in Part B → Q10

@Neet_pg_bot

Q11: A hematologist is reviewing the peripheral blood smears of three patients diagnosed with different types of thalassemia. Patient A has severe anemia, target cells, and nucleated red blood cells (NRBCs). Patient B has mild anemia with microcytosis and hypochromia but no NRBCs. Patient C has mild anemia with microcytosis and hypochromia but also shows a small number of NRBCs and some hemoglobin H inclusions. Based on the peripheral smear findings, which of the following correctly matches the patients with their thalassemia types? (Q845933)

A. Patient A: β-thalassemia major, Patient B: β-thalassemia minor, Patient C: α-thalassemia

B. Patient A: β-thalassemia minor, Patient B: α-thalassemia, Patient C: β-thalassemia major

C. Patient A: α-thalassemia, Patient B: β-thalassemia minor, Patient C: β-thalassemia major

D. Patient A: β-thalassemia major, Patient B: α-thalassemia, Patient C: β-thalassemia minor

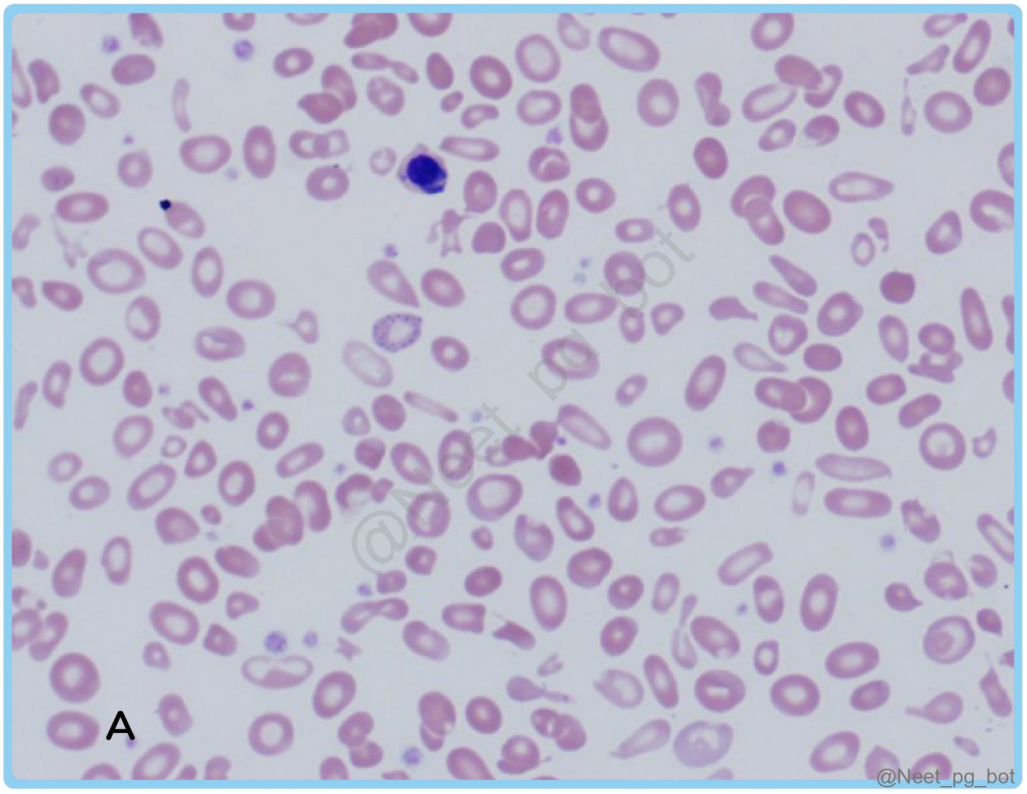
A
@Neet_pg_bot

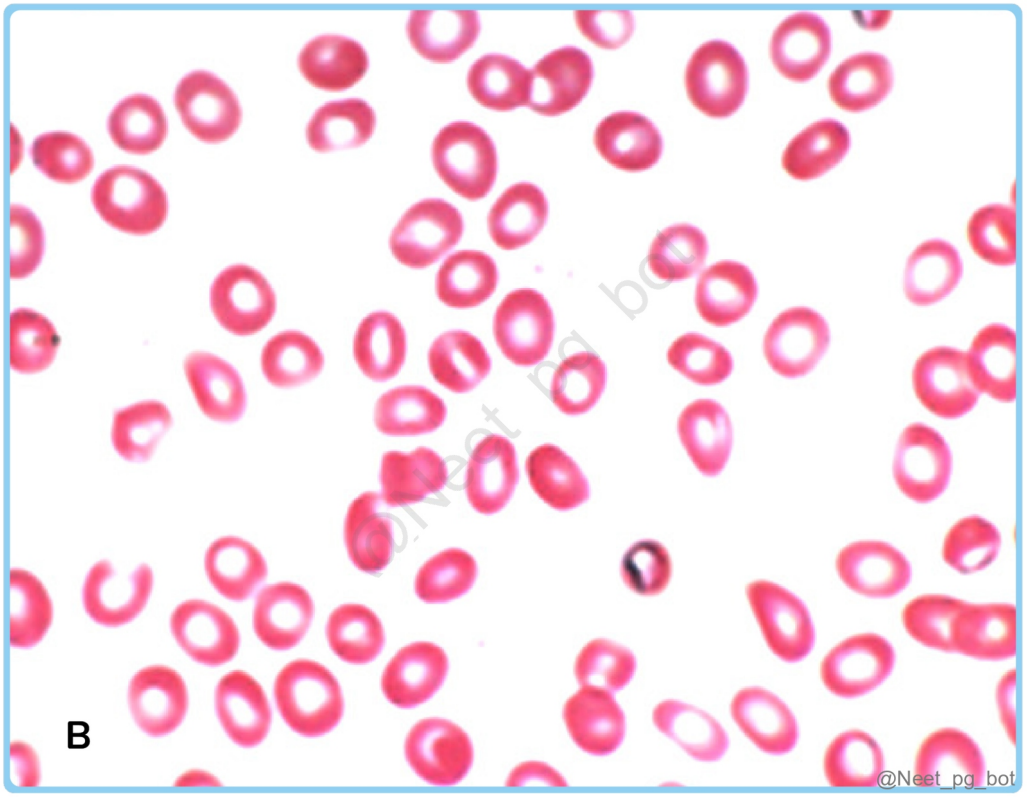
B
@Neet_pg_bot

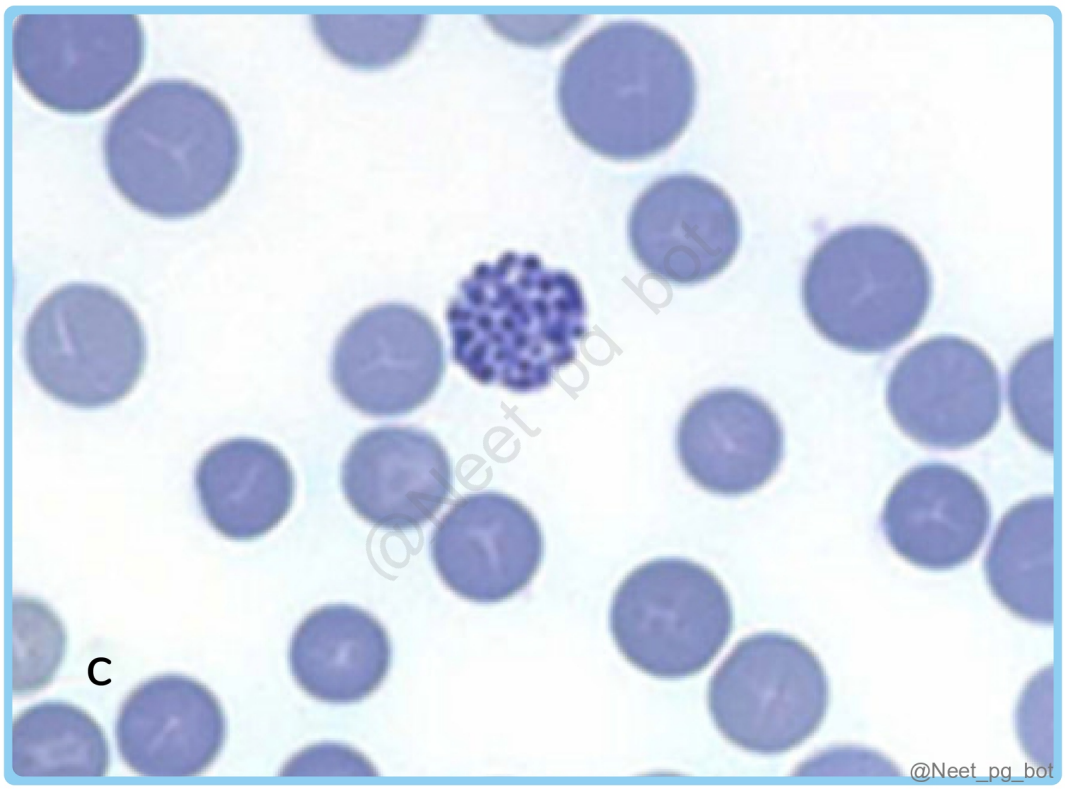

See Answer in Part B → Q11

@Neet_pg_bot

Q12: Which of the following findings is most consistent with β thalassemia major when compared to β thalassemia minor? (Q845934)

A. Decrease in HbA, slight increase in HbA2, and normal HbF; HPLC: HbA2: 6%, HbF: 2%

B. Decrease in HbA, increase in HbA2, and marked increase in HbF; HPLC: HbA2: 6%, HbF: 90%

C. Absent HbA, slight increase in HbA2, and moderate increase in HbF; HPLC: HbA2: 4%, HbF: 20%

D. Decrease in HbA, normal HbA2, and normal HbF; HPLC: HbA2: 2%, HbF: 2%

See Answer in Part B → Q12

@Neet_pg_bot

Q13: A pregnant woman is a silent carrier for α-thalassemia (α-/αα) and is concerned about the risk of her child inheriting α-thalassemia. Her partner has the

α-thalassemia trait (αα/--). What is the probability that their child will have Hemoglobin H (HbH) disease? (Q845937)

A. 0%

B. 25%

C. 50%

D. 75%

See Answer in Part B → Q13

@Neet_pg_bot

Q14: The medical team, aware of the prevalence of genetic disorders in the village decides to implement a screening process using NESTROFT for beta thalassemia. They plan to test the result by observing the solution turning clear by checking the visibility of a black line behind the test and control tubes. Which of the following on Nestrof test would be indicative of a positive result? (Q845940)

A. Black line visible in both tubes

B. Black line visible in only control tubes

C. Black line not visible in only test tubes

D. No black line visible in any of the tubes

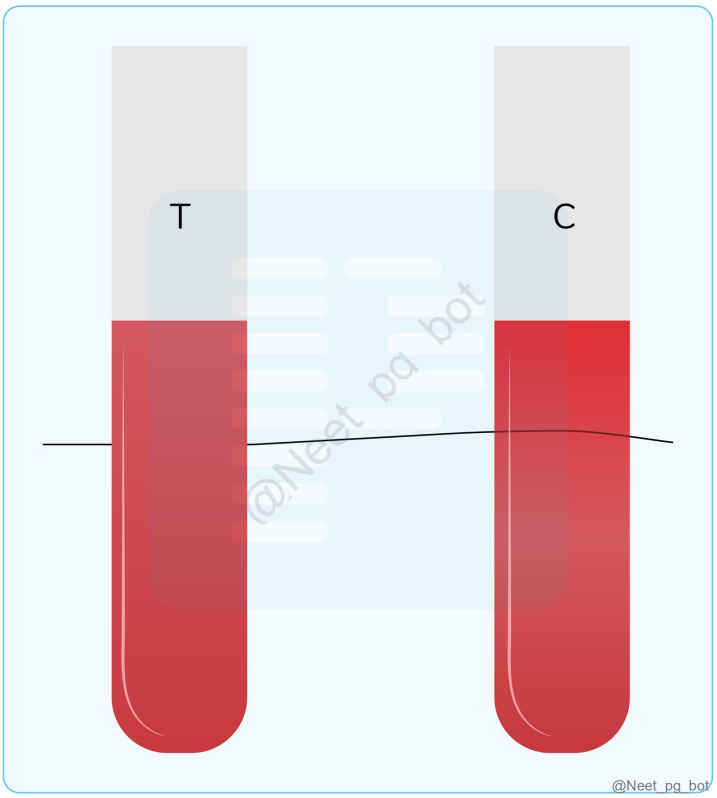

See Answer in Part B → Q14

@Neet_pg_bot

Q15: Match the following diseases with their respective antibodies and target antigens on red blood cells (RBCs): 1. Cold Agglutinin Disease 2. Cold Hemolytic Disease Antibody Target Antigen on RBCs A IgM I antigen B IgG P antigen C IgG I antigen D IgM P antigen Select the correct matching pairs: (Q845943)

A. 1-A, 2-C

B. 1-C, 2-D

C. 1-A, 2-B

D. 1-B, 2-D

See Answer in Part B → Q15

@Neet_pg_bot

Q16: Which of the following statements is false regarding warm antibody-mediated autoimmune hemolytic anemia (AIHA)? (Q845944)

A. It is commonly mediated by IgG antibodies active at 37°C.

B. It can be associated with the intake of drugs like alpha-methyldopa and quinine.

C. It typically involves the destruction of red blood cells primarily in the liver.

D. A positive direct Coombs test is often used to confirm the diagnosis.

See Answer in Part B → Q16

@Neet_pg_bot

• [17_Hematology_ Red Blood Cells] 068 Microcytic Hypochromic Anemia

« Back to Folder Directory

[17_Hematology_ Red Blood Cells] 068 Microcytic Hypochromic Anemia — Quick Jump

Q1 (p. 723)	*Q2 (p. 723)*	*Q3 (p. 724)*	*Q4 (p. 724)*	*Q5 (p. 724)*	*Q6 (p. 725)*
Q7 (p. 725)	*Q8 (p. 725)*	*Q9 (p. 726)*	*Q10 (p. 727)*	*Q11 (p. 727)*	*Q12 (p. 728)*
Q13 (p. 728)	*Q14 (p. 729)*	*Q15 (p. 729)*	*Q16 (p. 730)*	*Q17 (p. 730)*	*Q18 (p. 730)*
Q19 (p. 731)	*Q20 (p. 731)*	*Q21 (p. 732)*	*Q22 (p. 732)*	*Q23 (p. 732)*	*Q24 (p. 733)*
Q25 (p. 733)	*Q26 (p. 734)*	*Q27 (p. 734)*			

Q1: Which of the following conditions is least likely to result in iron deficiency anemia? (Q880000)

A. A young 5-year-old suffering from hookworm infection

B. An elderly 60-year-old male diagnosed with carcinoma of the cecum

C. A middle-aged 54-year-old woman who has undergone Billroth II gastrectomy

D. A 25-year-old female consuming a diet predominantly based on maize

See Answer in Part B → Q1

@Neet_pg_bot

Q2: In the human body, where is the majority of biologically active iron located? (Q879988)

A. Hemoglobin

B. Myoglobin

C. Catalase enzymes

D. Ferritin

See Answer in Part B → Q2

@Neet_pg_bot

Q3: A patient is found to have a mean corpuscular volume (MCV) of 109 fL. Which of the following conditions is least commonly associated with this laboratory finding? (Q879982)

A. Hypothyroidism

B. Vitamin B12 deficiency

C. Orotic aciduria

D. Anemia of chronic disease

See Answer in Part B → Q3

@Neet_pg_bot

Q4: All of the following anemias arise from reduced red cell production, except: (Q879974)

A. Iron deficiency anemia

B. Hereditary spherocytosis

C. Megaloblastic anemia

D. Aplastic anemia

See Answer in Part B → Q4

@Neet_pg_bot

Q5: In individuals living with HIV infection, which hematologic abnormality is observed most commonly? (Q879969)

A. Thrombocytopenia

B. Neutropenia

C. Lymphocytosis

D. Anemia

See Answer in Part B → Q5

@Neet_pg_bot

Q6: What is considered the most significant inflammatory mediator in the pathophysiology of anemia of chronic disease (AOCD)? (Q845881)

A. Interleukin-6

B. Transferrin

C. Interleukin-10

D. Interferon-γ

See Answer in Part B → Q6

@Neet_pg_bot

Q7: A 5-year-old child presents to the clinic with symptoms of irritability, abdominal pain, and vomiting. The physician suspects lead poisoning and orders a complete blood count along with a peripheral blood smear. Which of the following findings would most likely be seen on the peripheral blood smear in lead poisoning? (Q845895)

A. Schistocytes

B. Spherocytes

C. Basophilic stippling

D. Bite cells

See Answer in Part B → Q7

@Neet_pg_bot

Q8: A peripheral blood smear revealed basophilic granules with Prussian blue stain. Which of the following bone marrow cells are associated with this condition? (Q845894)

A. Sideroblast

B. Siderocyte

C. Reticulocyte

D. Bite cells

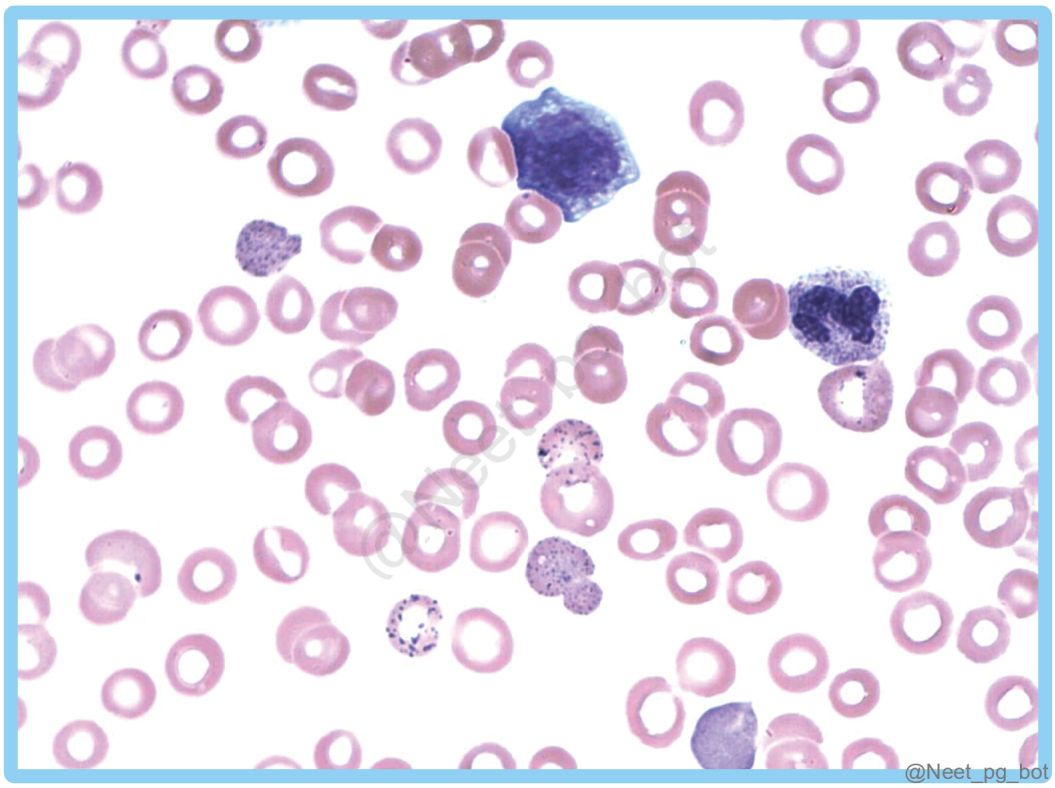

See Answer in Part B → Q8

@Neet_pg_bot

Q9: A 7-year-old girl presents to the clinic with complaints of fatigue, weakness, and pale skin. Her mother mentions that she has developed cravings for ice (pica). Laboratory tests reveal microcytic anaemia, and her serum ferritin levels are significantly low. Which of the following is the most likely infectious cause of her condition? (Q845887)

A. Giardia lamblia

B. Ancylostoma

C. Diphyllobothrium latum

D. Enterobius vermicularis

See Answer in Part B → Q9

@Neet_pg_bot

Q10: Which of the following vitamin deficiencies is most commonly associated with sideroblastic anemia? (Q845886)

A. Vitamin B1 (Thiamine)

B. Vitamin B9 (Folic Acid)

C. Vitamin B6 (Pyridoxine)

D. Vitamin B12 (Cobalamin)

See Answer in Part B → Q10

@Neet_pg_bot

Q11: Which of the laboratory findings are suggestive of sideroblastic anemia? Serum Iron Transferrin saturation Serum Ferritin TIBC A. High High High Low B. Low Low Low High C. Low Low High Low D. High Low High Low (Q845885)

A. A

B. B

C. C

D. D

See Answer in Part B → Q11

@Neet_pg_bot

Q12: A 40-year-old female with a history of treatment for latent tuberculosis presents with fatigue. Physical examination reveals pallor and mild jaundice. Bone marrow smear revealed the following findings.which of the following is the most likely diagnosis? Options: (Q845884)

A. Iron deficiency anemia

B. Megaloblastic anemia

C. Sideroblastic anemia

D. Hemolytic anemia

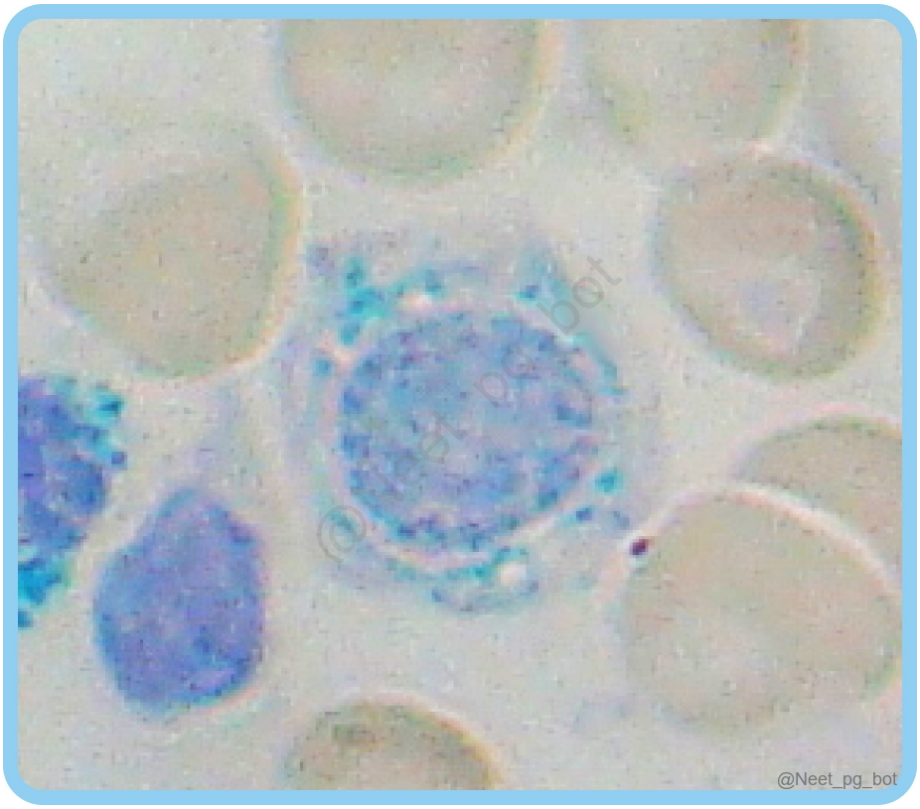

See Answer in Part B → Q12

@Neet_pg_bot

Q13: Which of the following new parameters has high specificity for differentiating anemia of chronic disease (ACD) from iron deficiency anemia (IDA)? (Q845883)

A. Serum transferrin receptor (sTfR)/log - ferritin index >1.5

B. Serum transferrin receptor (sTfR)/log - ferritin index <1.5

C. Reduced reticulocyte index

D. Blood film morphology

See Answer in Part B → Q13

@Neet_pg_bot

Q14: A 52-year-old female complains of fatigue, joint pain, and stiffness, especially in the mornings. Physical examination reveals swollen and tender joints in her wrists with ulnar deviation at metacarpophalangeal joints. Which of the following lab findings is not associated with this condition? (Q845882)

A. Low serum iron

B. Low transferrin saturation

C. High ferritin

D. High total iron-binding capacity (TIBC)

See Answer in Part B → Q14

@Neet_pg_bot

Q15: Which of the following investigations is the least helpful in determining the underlying cause of anemia? (Q845864)

A. MCV

B. MCH

C. Peripheral smear

D. Reticulocyte count

See Answer in Part B → Q15

@Neet_pg_bot

Q16: A 65-year-old female with a history of breast cancer presents with fatigue and pallor. Laboratory results indicate a hemoglobin level of 9.7 g/dL, low serum iron, elevated ferritin, and low total iron-binding capacity (TIBC). All of the following are true regarding this condition except? Anemia is caused by reduced erythroid progenitor proliferation and iron uptake. Causes include chronic infections, autoimmune disorders and lymphoma. Peripheral smear does not show microcytic hypochromic anemia. All the patients benefit from erythropoietin administration. (Q845880)

A. 1, 3, 4

B. 3, 4

C. 4 only

D. 3 only

See Answer in Part B → Q16

@Neet_pg_bot

Q17: Which of the following statements correctly describes the principle of Prussian blue stain? (Q845879)

A. Ferrocyanide to ferricyanide

B. Ferrocyanide to ferric ferrocyanide

C. Ferroferric cyanide to ferrocyanide

D. Ferrocyanide to ferrocyanide

See Answer in Part B → Q17

@Neet_pg_bot

Q18: A 24-year-old female with severe anemia started on parenteral iron. Which of the following would occur first in this patient as a response to therapy? (Q845878)

A. Increase in serum iron level

B. Erythroid hyperplasia in bone marrow

C. Increase in MCV

D. Increase in reticulocyte count

See Answer in Part B → Q18

@Neet_pg_bot

Q19: A 28-year-old female presented with easy fatigability and dyspnea on exertion. She was found to have a hemoglobin of 6 g/dL. What will be most likely finding in the peripheral blood smear of this patient? (Q845877)

A. Macrocytic red cells

B. Cabot ring

C. Hypersegmented neutrophils

D. Microcytic and hypochromic red cells

See Answer in Part B → Q19

@Neet_pg_bot

Q20: A 32-year-old female diagnosed with iron deficiency anemia is prescribed oral iron supplements. Foods containing which of the following can she take to increase iron absorption? (Q845876)

A. Ascorbate

B. Oxalate

C. Carbonate

D. Phosphate

See Answer in Part B → Q20

@Neet_pg_bot

Q21: In a patient diagnosed with iron deficiency anemia, the values of all of the following increase except? (Q845875)

A. Total iron binding capacity

B. RBC protoporphyrin

C. Transferrin saturation

D. Transferrin receptor

See Answer in Part B → Q21

@Neet_pg_bot

Q22: A 10-year-old girl presented with fatigue, weakness and reduced exercise tolerance. Her mother reports that she has pica, frequently eating chalk and ice and the child also complains of brittle nails and occasional glossitis. Her laboratory results show reduced hemoglobin, MCV 75 fl, MCH 22 pg and RDW 28. What is the most likely diagnosis? (Q845874)

A. Iron deficiency anemia

B. Megaloblastic anemia

C. Sideroblastic anemia

D. Thalassemia major

See Answer in Part B → Q22

@Neet_pg_bot

Q23: A 45-year-old male patient was diagnosed with iron deficiency anemia. Which of the following is true about the intracellular regulation of iron in the above condition? IRP- Iron regulatory protein IRE- Iron response elements (Q845873)

A. Ferritin translation is increased by binding IRP to IRE.

B. Ferritin translation is decreased by binding IRP to IRE.

C. Transferrin receptor 1 translation is unaffected by binding IRP to IRE.

D. Transferrin receptor 1 translation is decreased by binding IRP to IRE.

See Answer in Part B → Q23

@Neet_pg_bot

Q24: Which transport molecule facilitates the absorption of Fe2+ into enterocytes in the small intestine? (Q845872)

A. Ferroportin

B. Hephaestin

C. DMT-1

D. Hepcidin

See Answer in Part B → Q24

@Neet_pg_bot

Q25: A 28-year-old woman presents with fatigue and pallor. Lab tests show hemoglobin of 9 g/dL and MCV of 68 fL. Peripheral smear reveals microcytic and hypochromic red blood cells. Her symptoms and laboratory findings are consistent with iron deficiency anemia. Which of the following statements regarding iron deficiency anemia (IDA) is correct? (Q845871)

A. Serum ferritin levels are elevated.

B. Serum ferritin is the gold standard investigation

C. Decreased serum ferritin levels

D. Serum ferritin levels are not affected.

See Answer in Part B → Q25

@Neet_pg_bot

Q26: A 35-year-old woman has been experiencing fatigue, pallor, and shortness of breath for the past six months. Laboratory tests reveal a Hb of 6 gm/dl. Red cell distribution width is increased. Peripheral smear is shown below. Where is the likely site of absorption of the micronutrient deficient in this patient? (Q845870)

A. Jejunum

B. Ileum

C. Duodenum

D. Colon

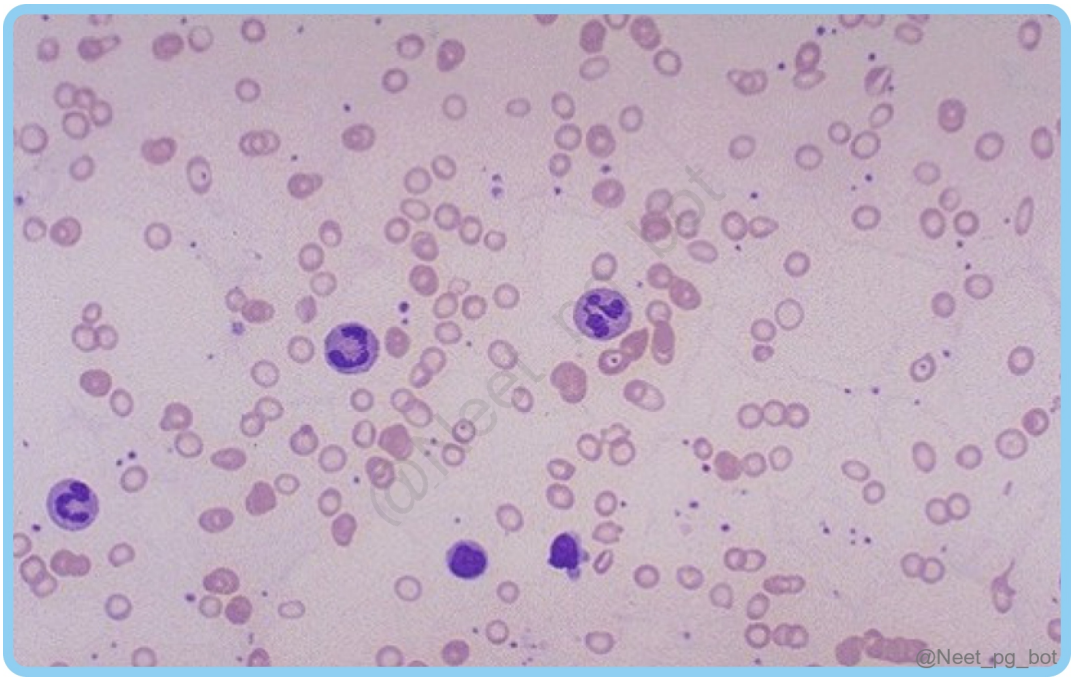

See Answer in Part B → Q26

@Neet_pg_bot

Q27: All of the following are causes of microcytic hypochromic anemia except? (Q845869)

A. Iron deficiency anemia

B. Sideroblastic anemia

C. Thalassemia

D. Hereditary spherocytosis

See Answer in Part B → Q27

@Neet_pg_bot

• [17_Hematology_ Red Blood Cells] 069 Macrocytic Hypochromic Normocytic Anemia

« Back to Folder Directory

[17_Hematology_ Red Blood Cells] 069 Macrocytic Hypochromic Normocytic Anemia — Quick Jump

Q1 (p. 736)	*Q2 (p. 736)*	*Q3 (p. 737)*	*Q4 (p. 737)*	*Q5 (p. 737)*	*Q6 (p. 738)*
Q7 (p. 738)	*Q8 (p. 739)*	*Q9 (p. 739)*	*Q10 (p. 739)*	*Q11 (p. 740)*	*Q12 (p. 740)*
Q13 (p. 741)	*Q14 (p. 741)*	*Q15 (p. 742)*	*Q16 (p. 742)*	*Q17 (p. 743)*	*Q18 (p. 743)*
Q19 (p. 744)					

Q1: A 72-year-old male complains of increasing tiredness and generalised weakness. On examination, a firm 1-cm nodule is palpated in the prostate gland. Laboratory studies show anemia with a normocytic, normochromic blood picture. Peripheral smear demonstrates occasional myelocytes, tear-drop erythrocytes, and about 2 nucleated red cells per 100 leukocytes. Which diagnosis best explains these findings? (Q880071)

A. Myelodysplastic syndrome

B. Myelophthisic anemia

C. Primary myelofibrosis

D. Myeloproliferative neoplasm

See Answer in Part B → Q1

@Neet_pg_bot

Q2: Myelophthisic anemia typically arises when normal bone marrow is replaced by abnormal tissue. Among the following, which is the leading cause? (Q880070)

A. Granulomatous disorders

B. Secondary deposits from malignant tumours

C. Myeloproliferative disorders

D. Prior exposure to radiation

See Answer in Part B → Q2

@Neet_pg_bot

Q3: Which of the following conditions are known to cause pure red cell aplasia? 1. Parvovirus B19 infection 2. Thymoma 3. Chronic neutrophilic leukaemia 4. Diamond–Blackfan anemia 5. Rifampicin use (Q880069)

A. 1, 2

B. 2, 3, 5

C. 1, 4

D. 1, 2, 4

See Answer in Part B → Q3

@Neet_pg_bot

Q4: Aplastic anemia has the potential to evolve into certain hematologic malignancies or disorders over time. Which of the following are known possible transformations? 1. Acute myeloid leukaemia 2. Acute lymphoblastic leukaemia 3. Chronic myeloid leukaemia 4. Chronic lymphocytic leukaemia 5. Myelodysplastic syndrome (Q880036)

A. 2, 3, 4

B. 1, 2

C. 1, 5

D. 1, 3, 5

See Answer in Part B → Q4

@Neet_pg_bot

Q5: Which of the following represents the most common known cause of aplastic anemia? (Q880030)

A. Drugs

B. Autoimmune disorders

C. Infections

D. Radiation exposure

See Answer in Part B → Q5

@Neet_pg_bot

Q6: A 55-year-old female with a history of rheumatoid arthritis on long-term therapy presents with dizziness on standing. Clinical examination reveals pallor and koilonychia. Considering the type of anemia associated with chronic inflammatory states, which of the following statements is correct? (Q880025)

A. Both serum iron and tissue iron are within normal limits

B. The anemia may present as normocytic and normochromic

C. Hepcidin production is suppressed

D. Total iron-binding capacity (TIBC) is increased

See Answer in Part B → Q6

@Neet_pg_bot

Q7: With respect to antibodies associated with pernicious anemia, which of the following descriptions is incorrect? (Q880019)

A. Type I antibody can be detected in both serum and gastric secretions

B. Type I antibody interferes with the attachment of vitamin B12 to intrinsic factor

C. Type II antibody blocks the interaction of the intrinsic factor–B12 complex with ileal receptors

D. Type III antibody targets haptocorrin

See Answer in Part B → Q7

@Neet_pg_bot

Q8: A 28-year-old woman who underwent ileal resection for Crohn's disease presents with features of megaloblastic anemia. Which step in vitamin B12 absorption and transport is most likely impaired in her case? (Q880008)

A. Cubilin receptor–mediated uptake

B. Binding of cobalamin to haptocorrin

C. Transport of cobalamin via transcobalamin II

D. Interaction of vitamin B12 with intrinsic factor

See Answer in Part B → Q8

@Neet_pg_bot

Q9: A patient presents with inflammation of the mouth and tongue. He is a non-vegetarian. As part of the evaluation, a Schilling test was done and found unremarkable. Which of the following investigations could lead to the aetiology behind this presentation? (Q845910)

A. Serum folate levels

B. Peripheral blood smear

C. Anti-IF antibody levels

D. Serum Vitamin B12 levels

See Answer in Part B → Q9

@Neet_pg_bot

Q10: A group of scientists is studying the mechanisms involved in the pathogenesis of megaloblastic Anaemia secondary to vitamin deficiencies. The final study results

demonstrate a "folate trap" as one of the likely pathophysiologic mechanisms of megaloblastic Anaemia. Which of the following is closely associated with the "folate trap"? (Q875986)

A. Normal serum tetrahydrofolate

B. Reduced serum methyltetrahydrofolate

C. Normal serum B12

D. Reduced serum vitamin B12

See Answer in Part B → Q10

@Neet_pg_bot

Q11: Which of the following statements is correct regarding the normal metabolism of vitamin B12? A. Haptocorrin from salivary glands binds to B12 in the stomach. B. It is absorbed in the duodenum with the help of intrinsic factor and transcobalamin II. C. Gastric enzymes play an important role in splitting of haptocorrin-B12 complex. D. It is stored primarily in the liver and has a large reserve capacity. E. It acts as a cofactor for converting homocysteine to methionine and methylmalonyl-CoA to succinyl-CoA. (Q845897)

A. A, B, C, and D

B. A, D, and E

C. A and C

D. C and D

See Answer in Part B → Q11

@Neet_pg_bot

Q12: Which of the following is true when increased urinary formiminoglutamic acid is detected in a patient to whom histidine is given? (Q845907)

A. Presence of antibodies against intrinsic factor

B. Deficiency of folic acid is present

C. Neurological symptoms are common

D. Presence of worm infestation

See Answer in Part B → Q12

@Neet_pg_bot

Q13: Which of the following helps differentiate megaloblastic anaemia caused by vitamin B12 deficiency, not folate? (Q845905)

A. Reduced plasma homocysteine levels

B. Neurological symptoms improve after folate administration

C. Raised urinary methylmalonic acid levels

D. Anaemia doesn’t improve after folate administration

See Answer in Part B → Q13

@Neet_pg_bot

Q14: A patient presents with tiredness and myalgia for the past 3 months. She has hypertension, psoriasis and hyperuricemia, for which she is on multiple medications. A peripheral blood smear is done which is given in the image below. Which of her following medications would have caused these symptoms? (Q845903)

A. Hydrochlorothiazide

B. Adalimumab

C. Methotrexate

D. Colchicine

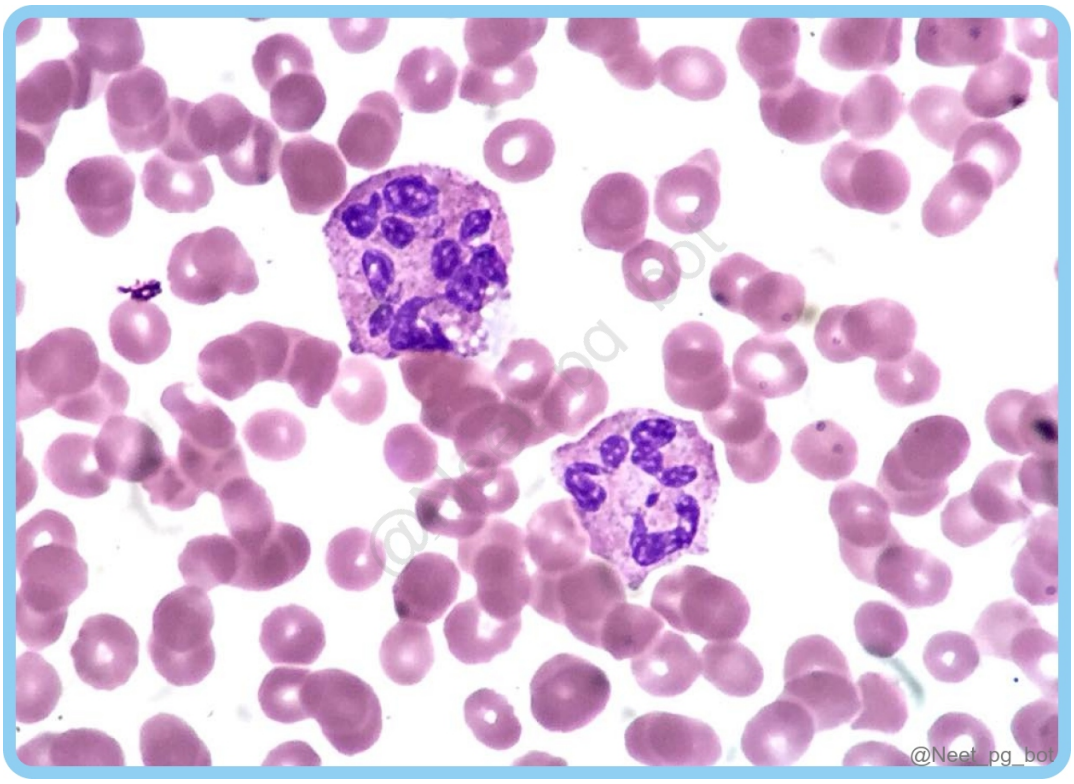

See Answer in Part B → Q14

@Neet_pg_bot

Q15: All the following findings are seen in vitamin B12 deficiency except? (Q845902)

A. Myeloid/erythroid ratio is 3:1

B. Sieve-like chromatin on bone marrow smear

C. Increased LDH levels

D. Increased bilirubin levels

See Answer in Part B → Q15

@Neet_pg_bot

Q16: Which of the following is not a finding on a peripheral blood smear in vitamin B12 deficiency? (Q845901)

See Answer in Part B → Q16

@Neet_pg_bot

Q17: Match the following laboratory findings with the most likely diagnosis. a. Microcytic anaemia, normal homocysteine and methylmalonic acid levels. 1. Vitamin B12 Deficiency b. Macrocytic anaemia, elevated homocysteine and methylmalonic acid levels. 2. Iron Deficiency Anemia (IDA) c. Macrocytic anaemia, elevated homocysteine and normal methylmalonic acid levels. 3. Anaemia of Chronic Disease (ACD) d. Normocytic anaemia, normal homocysteine and methylmalonic acid levels. 4. Folate Deficiency (Q845900)

A. a-2, b-1, c-4, d-3

B. a-1, b-2, c-4, d-3

C. a-2, b-1, c-3, d-4

D. a-3, b-4, c-1, d-2

See Answer in Part B → Q17

@Neet_pg_bot

Q18: A 60-year-old female presents with chronic fatigue, shortness of breath, tingling and numbness in her hands and feet, bloating, and epigastric pain after meals. She has a history of occasional heartburn and nausea. On examination, she is pale, has a smooth, enlarged tongue with the following findings on the hand. Lab investigations show haemoglobin to be 9.6 g% and MCV 112. What is the most likely diagnosis? (Q845899)

A. Iron deficiency anaemia

B. Folate deficiency

C. Pernicious anaemia

D. Thalassemia



See Answer in Part B → Q18

@Neet_pg_bot

Q19: All of the following are the causes of anaemia due to vitamin B12 deficiency, except? (Q845898)

A. Pernicious anemia

B. Chronic alcoholism

C. Diphyllobothrium latum infection

D. Gastric resection

See Answer in Part B → Q19

@Neet_pg_bot

• [17_Hematology_ Red Blood Cells] 070 Previous Year Questions

« Back to Folder Directory

[17_Hematology_ Red Blood Cells] 070 Previous Year Questions — Quick Jump

Q1 (p. 745)	*Q2 (p. 745)*	*Q3 (p. 746)*	*Q4 (p. 746)*	*Q5 (p. 747)*	*Q6 (p. 747)*
Q7 (p. 747)	*Q8 (p. 748)*	*Q9 (p. 748)*	*Q10 (p. 749)*	*Q11 (p. 749)*	*Q12 (p. 750)*
Q13 (p. 750)	*Q14 (p. 751)*	*Q15 (p. 751)*	*Q16 (p. 751)*	*Q17 (p. 752)*	*Q18 (p. 753)*
Q19 (p. 754)	*Q20 (p. 755)*	*Q21 (p. 755)*	*Q22 (p. 755)*	*Q23 (p. 756)*	*Q24 (p. 757)*
Q25 (p. 757)	*Q26 (p. 757)*	*Q27 (p. 758)*	*Q28 (p. 758)*	*Q29 (p. 759)*	*Q30 (p. 759)*
Q31 (p. 760)	*Q32 (p. 761)*	*Q33 (p. 761)*	*Q34 (p. 762)*	*Q35 (p. 762)*	*Q36 (p. 763)*
Q37 (p. 764)	*Q38 (p. 765)*	*Q39 (p. 766)*	*Q40 (p. 766)*	*Q41 (p. 767)*	*Q42 (p. 767)*
Q43 (p. 767)	*Q44 (p. 768)*	*Q45 (p. 769)*	*Q46 (p. 769)*	*Q47 (p. 769)*	*Q48 (p. 770)*
Q49 (p. 770)	*Q50 (p. 771)*	*Q51 (p. 771)*	*Q52 (p. 771)*	*Q53 (p. 772)*	*Q54 (p. 773)*
Q55 (p. 773)	*Q56 (p. 774)*	*Q57 (p. 774)*	*Q58 (p. 775)*	*Q59 (p. 775)*	*Q60 (p. 776)*
Q61 (p. 776)	*Q62 (p. 776)*	*Q63 (p. 777)*	*Q64 (p. 777)*	*Q65 (p. 778)*	*Q66 (p. 778)*
Q67 (p. 778)	*Q68 (p. 779)*	*Q69 (p. 779)*	*Q70 (p. 779)*	*Q71 (p. 780)*	*Q72 (p. 780)*
Q73 (p. 781)	*Q74 (p. 781)*	*Q75 (p. 782)*	*Q76 (p. 783)*	*Q77 (p. 783)*	*Q78 (p. 784)*
Q79 (p. 784)	*Q80 (p. 785)*	*Q81 (p. 785)*	*Q82 (p. 785)*	*Q83 (p. 786)*	*Q84 (p. 787)*
Q85 (p. 787)	*Q86 (p. 787)*	*Q87 (p. 788)*	*Q88 (p. 788)*	*Q89 (p. 789)*	*Q90 (p. 789)*
Q91 (p. 789)	*Q92 (p. 790)*	*Q93 (p. 790)*	*Q94 (p. 790)*	*Q95 (p. 791)*	*Q96 (p. 791)*
Q97 (p. 791)					

Q1: Caspase-1 is primarily involved in which type of programmed cell death? (Q865391)

A. Apoptosis

B. Pyroptosis

C. Necroptosis

D. Necrosis

See Answer in Part B → Q1

@Neet_pg_bot

Q2: A 24-year-old male was brought to the emergency department after suffering severe injuries in a motorcycle accident. His blood pressure was 80/60 mm Hg, and he was tachycardic with cold, clammy skin. An ultrasound examination revealed a ruptured spleen. Arterial blood gas analysis was suggestive of metabolic acidosis. Which of the following conditions most likely caused the patient to suffer? (Q857122)

A. Cardiogenic shock

B. Septic shock

C. Hypovolemic shock

D. Neurogenic shock

See Answer in Part B → Q2

@Neet_pg_bot

Q3: Which of the following is true regarding sirtuins? Increases insulin sensitivity and glucose metabolism Promotes genes that increase longevity They are of 7 types They are one of the types of histone deacetylases (Q855087)

A. 1, 2, 3

B. 1, 2, 3, 4

C. 2, 3

D. 2, 4

See Answer in Part B → Q3

@Neet_pg_bot

Q4: Cell-in-cell appearance is seen in which of the following? (Q855076)

A. Necrosis

B. Apoptosis

C. Necroptosis

D. Entosis

See Answer in Part B → Q4

@Neet_pg_bot

Q5: Senile atrophy occurs due to which of the following? (Q856024)

A. Denervation

B. Decreased nutrition

C. Decreased workload

D. Reduced blood supply

See Answer in Part B → Q5

@Neet_pg_bot

Q6: Which among the following is less related to irreversible cell injury? (Q820573)

A. Blebs formation

B. Karyolysis

C. Amorphous densities

D. Pyknotic nucleus

See Answer in Part B → Q6

@Neet_pg_bot

Q7: Which of the following is an anti-apoptotic gene? (Q857450)

A. BAK

B. MCL1

C. PUMA

D. BAD

See Answer in Part B → Q7

@Neet_pg_bot

Q8: Which of the following diseases is caused by abnormal folding of proteins? (Q857433)

A. Creutzfelt Jakob disease

B. Cirrhosis

C. Nephritic syndrome

D. Sickle cell anemia

See Answer in Part B → Q8

@Neet_pg_bot

Q9: Which nuclear change of cell injury is being shown in the image? (Q857432)

A. Pyknosis

B. Karyorrhexis

C. Karyolysis

D. Normal nucleus



See Answer in Part B → Q9

@Neet_pg_bot

Q10: Identify the correct statements regarding amyloidosis. Amyloidosis is called so because it looks like the deposition of starch. Beta-pleated sheets are seen. AL is a type of secondary amyloidosis. It is an extracellular protein. (Q857424)

A. 1, 2 and 3

B. 1, 4

C. 2, 3 and 4

D. 1, 2 and 4

See Answer in Part B → Q10

@Neet_pg_bot

Q11: Apoptotic bodies comprise of? (Q860513)

A. Include cytoplasm + intranuclear material + organelle

B. Cytoplasm + organelle

C. Organelle + intranuclear material

D. Only organelle

See Answer in Part B → Q11

@Neet_pg_bot

Q12: Which of the following types of cell death involves activation of caspase enzymes? (Q866340)

A. Necrosis and Apoptosis

B. Apoptosis and Pyroptosis

C. Apoptosis and necroptosis

D. Apoptosis only

See Answer in Part B → Q12

@Neet_pg_bot

Q13: Supravital stains are used in the identification of all except? (Q857588)

A. Reticulocytes

B. Copper in tissue

C. Heinz bodies

D. Ribosomal RNA

See Answer in Part B → Q13

@Neet_pg_bot

Q14: A diabetic male presented with seizures. Radiological examination shows a lesion. Histopathological examination shows liquefactive necrosis. What is the most important mechanism responsible for this? (Q866754)

A. Enzymatic degradation

B. Mechanical

C. Ischemic

D. Pressure

See Answer in Part B → Q14

@Neet_pg_bot

Q15: Which of the following is pro-apoptotic? (Q866665)

A. Bcl-2

B. Bcl-xL

C. Mcl-1

D. Bax

See Answer in Part B → Q15

@Neet_pg_bot

Q16: A female patient presented with fatigue and a history of piles. Routine complete blood count analysis showed a hemoglobin of 8.5 g/dL, an MCV of 65 fL, and an RBC count of 3.2 million and RDW is increased. A peripheral smear is given below. Which of the following is the next best investigation for this patient? (Q855974)

A. HbA2 levels

B. Serum ferritin levels

C. Serum folate levels

D. Serum homocysteine levels

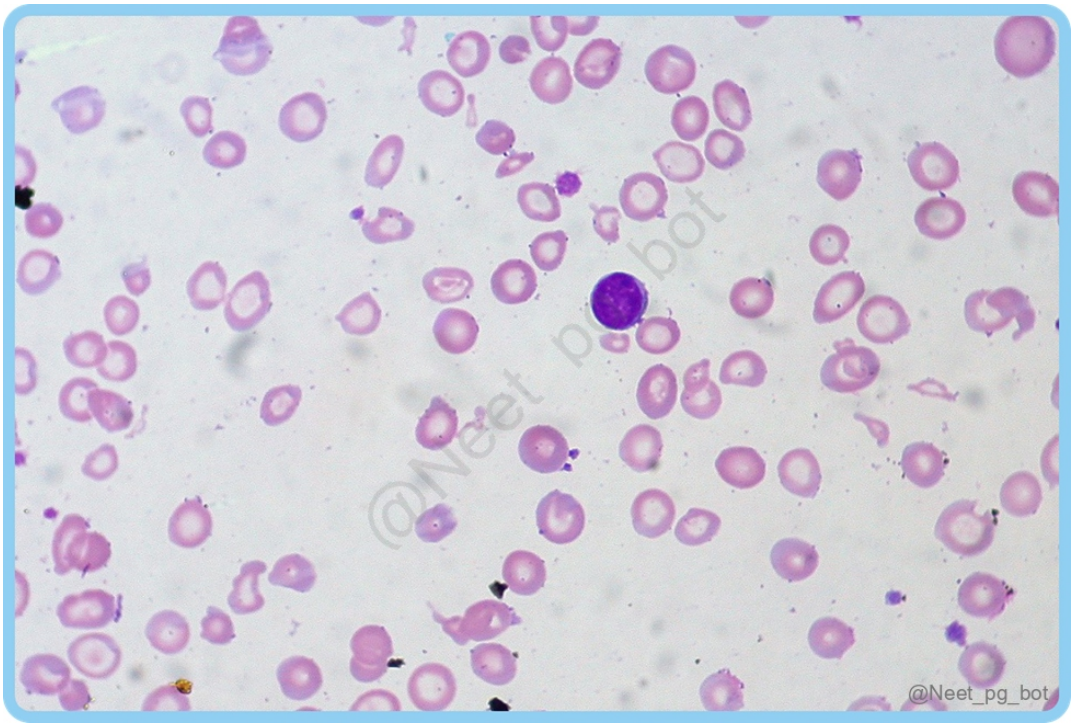

See Answer in Part B → Q16

@Neet_pg_bot

Q17: An elderly patient presents with anemia and hemoglobinuria. Investigations reveal increased bilirubin and lactate dehydrogenase. The peripheral smear image is given below. Which of the following is associated with this? (Q855931)

A. Splenomegaly

B. Mechanical second heart valve

C. Increased HbA2

D. Goitre

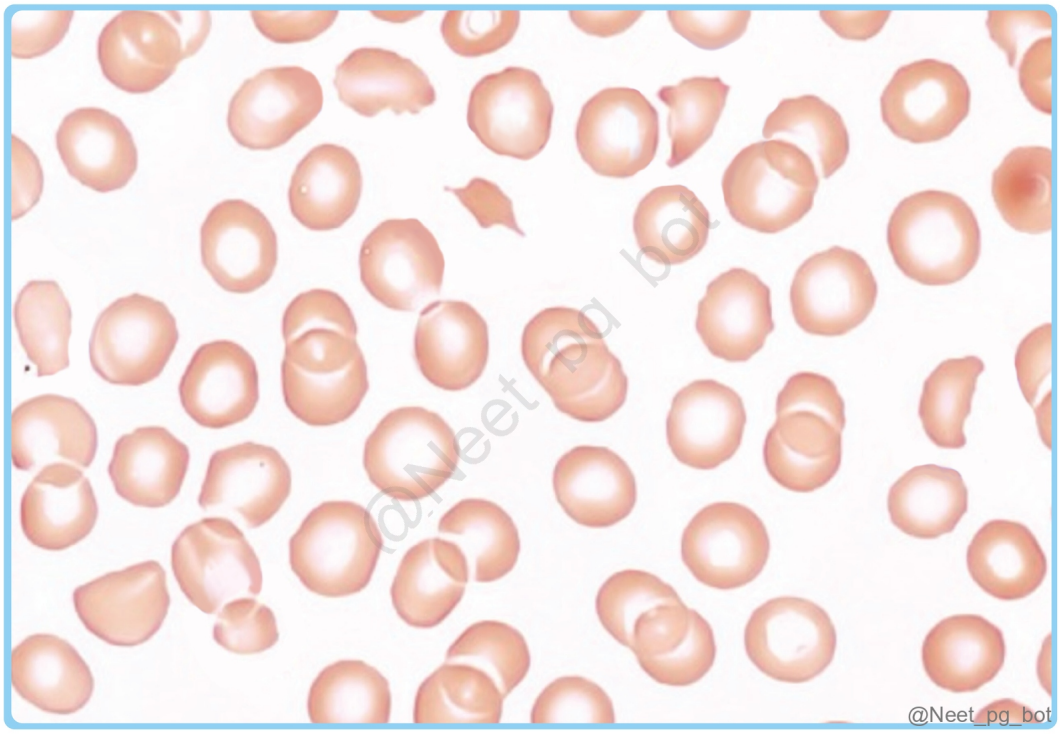

See Answer in Part B → Q17

@Neet_pg_bot

Q18: A child presents with recurrent chest infections and abdominal pain. There is a history of delayed growth and bone problems causing facial changes. On examination, he had icterus and mild splenomegaly. Peripheral smear shows following finding. What is the likely diagnosis? (Q855920)

A. Beta thalassemia

B. HbC disease

C. Sickle cell disease

D. Acute coronary disease



See Answer in Part B → Q18

@Neet_pg_bot

Q19: A 9-month-old boy presents with progressive pallor and abdominal distention. On examination, hepatosplenomegaly and malar eminence are observed. Laboratory investigations reveal a low hemoglobin level, and the Mentzer index is less than 13. Considering these findings, what is the most likely diagnosis for this patient? (Q859851)

A. Megaloblastic anemia

B. Iron deficiency anaemia

C. Thalassemia

D. Pernicious anemia

See Answer in Part B → Q19

@Neet_pg_bot

Q20: A 23-year-old male patient presented with a history of fatigue and tiredness. On investigation, he was found to have Hb = 9 g/dl and MCV = 101 FL. A peripheral smear examination showed macrocytic RBC and hypersegmented neutrophils. Which of the following is the most likely etiology? (Q858518)

A. Lead poisoning

B. Iron deficiency anaemia

C. Hemolytic anemia

D. Chronic alcoholism

See Answer in Part B → Q20

@Neet_pg_bot

Q21: A 52-year-old male patient comes with complaints of abdominal pain, nausea, and vomiting. A peripheral blood smear reveals macrocytes and hypersegmented neutrophils, and an endoscopy reveals atrophic gastritis. Which of the following conditions is likely to be seen in this patient? (Q854855)

A. Vitamin B12 deficiency

B. Folate deficiency

C. Pyridoxine deficiency

D. Niacin deficiency

See Answer in Part B → Q21

@Neet_pg_bot

Q22: What does the vacutainer tube depicted in the provided image contain? (Q856491)

A. Na-EDTA

B. Trisodium citrate

C. NAF-heparin

D. Clot activator



See Answer in Part B → Q22

@Neet_pg_bot

Q23: The JAK2 mutation is most commonly associated with: (Q856485)

A. Polycythemia vera

B. Essential thrombocytosis

C. Chronic myelogenous leukemia (CML)

D. Primary myelofibrosis (PMF)

See Answer in Part B → Q23

@Neet_pg_bot

Q24: A 16-year-old boy presents with jaundice and splenomegaly. His father had a similar illness during adolescence. The MCHC was high. What is the most likely diagnosis? (Q866370)

A. IDA

B. Hereditary spherocytosis

C. Thalassemia major

D. AIHA

See Answer in Part B → Q24

@Neet_pg_bot

Q25: A phlebotomist is asked to collect blood samples for a patient undergoing multiple tests. Which of the following is the correct order of blood collection to avoid contamination of the samples based on the additives in the collection tubes? (Q854685)

A. Light blue → Lavender → Red → Grey

B. Grey → Red → Light blue → Lavender

C. Light blue → Red → Lavender → Grey

D. Red → Lavender → Grey → Light blue

See Answer in Part B → Q25

@Neet_pg_bot

Q26: Which of the following causes microcytic anemia? Iron deficiency Thalassemia Lead poisoning Vitamin B12 deficiency (Q879228)

A. 1, 2, 3

B. 1, 2

C. 1, 3

D. 1, 2, 3, 4

See Answer in Part B → Q26

@Neet_pg_bot

Q27: A patient presents with microcytic hypochromic anemia (MCV: 70–79 fL) and a Mentzer index of 11 with increased RBC count. Peripheral blood smear reveals target cells. Which of the following investigations is the most appropriate for establishing the diagnosis? (Q879222)

A. Bone marrow examination

B. Hb electrophoresis

C. Serum ferritin

D. Serum iron and TIBC

See Answer in Part B → Q27

@Neet_pg_bot

Q28: The vacutainer tube shown in the given image contains the following: (Q855434)

A. EDTA

B. Trisodium citrate

C. NAF - heparin

D. Clot activator



See Answer in Part B → Q28

@Neet_pg_bot

Q29: Which of the following oil red O stain is used? (Q855393)

A. Formalin fixation

B. Frozen section

C. Alcohol fixation

D. Glutaraldehyde fixation

See Answer in Part B → Q29

@Neet_pg_bot

Q30: Which of the following needles is commonly used for bone marrow biopsy? (Q855114)

A. Klima needle

B. Salah needle

C. Jamshidi needle

D. Islam needle

See Answer in Part B → Q30

@Neet_pg_bot

Q31: A child presents with multiple skin lesions over the inner thigh and genital areas. Initially, the lesions started as macules and later developed into nodules. Some of the nodules have a central umbilication. The histology of the lesion is shown below. What would be found on a biopsy? (Q855108)

A. Multinucleate giant cells (Tzanck cells)

B. Donovan bodies

C. Henderson-Patterson bodies

D. Koilocytes

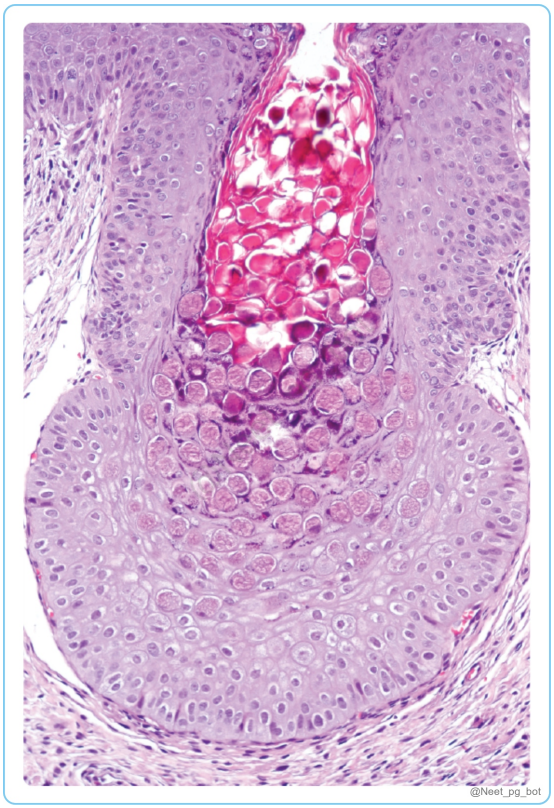

See Answer in Part B → Q31

@Neet_pg_bot

Q32: Pair the stains with their corresponding options Stain Corresponding Option 1. Prussian blue stain a. Iron 2. PAS stain b. Glycogen 3. Congo red stain c. Leprosy 4. Fite-Faraco stain d. Amyloid (Q855085)

A. 1-d, 2-c, 3-b, 4-a

B. 1-c, 2-a, 3-b, 4-d

C. 1-a, 2-b, 3-d, 4-c

D. 1-b, 2-a, 3-c, 4-d

See Answer in Part B → Q32

@Neet_pg_bot

Q33: A woman presents with nodular lesions, 4-6 mm in size, on the inner thighs and peri-anal region. The lesions appear pale, and histopathological examination reveals multiple intracytoplasmic inclusion bodies consistent with Henderson-Patterson bodies. What is the most likely diagnosis? (Q855907)

A. Trichodysplasia spinulosa

B. Condyloma acuminata

C. Molluscum contagiosum

D. Donovanosis

See Answer in Part B → Q33

@Neet_pg_bot

Q34: Which of the following methods is iron in tissues stained? (Q855899)

A. Masson’s trichrome

B. Prussian blue

C. PAS

D. Fite-Faraco

See Answer in Part B → Q34

@Neet_pg_bot

Q35: The following image shows an instrument used to estimate haemoglobin levels. What does it measure? (Q855893)

A. Alkaline hematin

B. Acid hematin

C. Oxyhemoglobin

D. Deoxyhemoglobin



@Neet_pg_bot

See Answer in Part B → Q35

@Neet_pg_bot

Q36: The given inclusion bodies are characteristic of which of the following organisms? (Q858119)

A. Human papillomavirus

B. Cytomegalovirus

C. Epstein-Barr virus

D. Herpes simplex virus

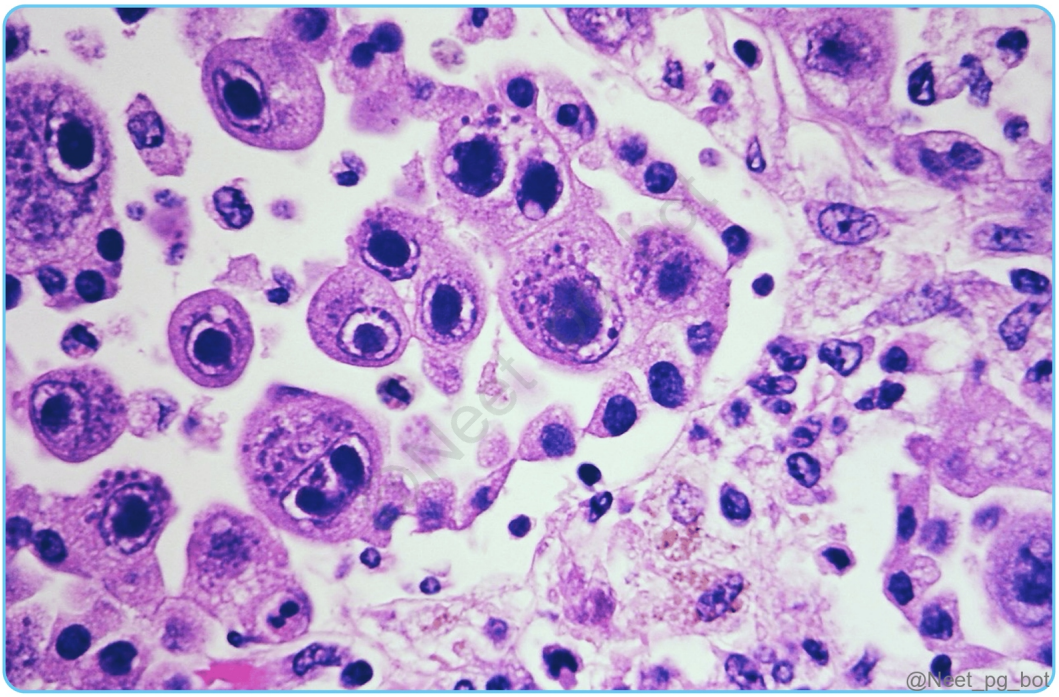

See Answer in Part B → Q36

@Neet_pg_bot

Q37: A 20-year-old female with easy fatiguability and pallor presented to the OPD. The image of her hand is shown below. What is the most likely diagnosis? (Q856480)

A. Aplastic anemia

B. Vitamin B12 deficiency

C. Iron deficiency anaemia

D. Hypoalbuminemia



See Answer in Part B → Q37

@Neet_pg_bot

Q38: The image below represents the presence of HER2 neu cells in a patient with breast carcinoma. What agent is used to produce this characteristic discolouration? (Q854670)

A. FITC

B. Phycoerythrin

C. Cyanate dye

D. Diaminobenzidine

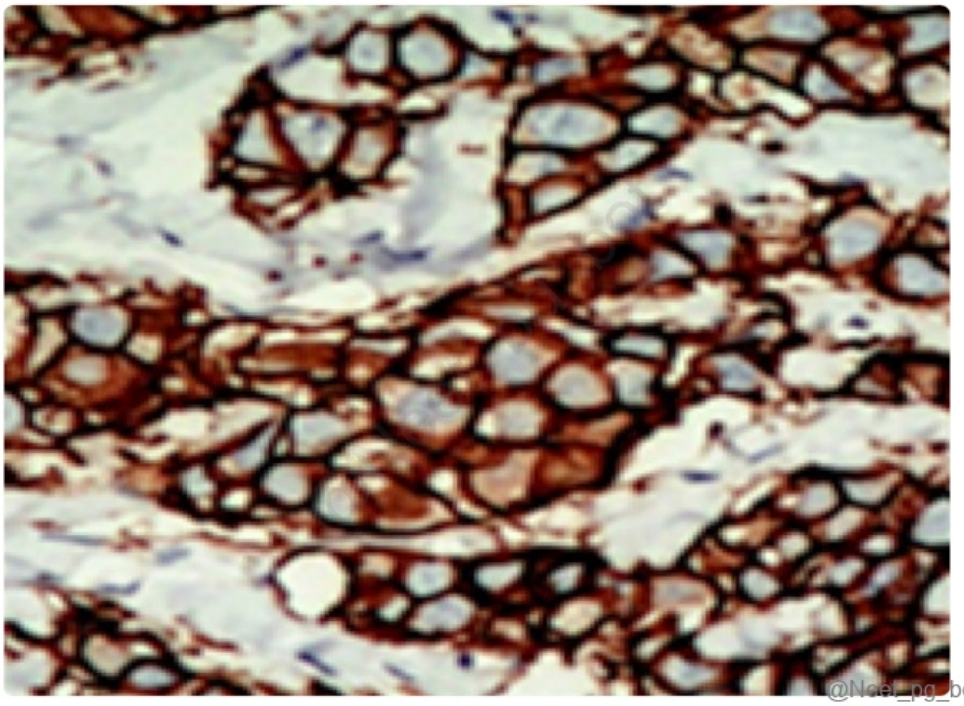

See Answer in Part B → Q38

@Neet_pg_bot

Q39: CD markers can be detected by which of the following tests? (Q866390)

A. Cytogenetics

B. Next-generation sequencing

C. Flow cytometry

D. Karyotype

See Answer in Part B → Q39

@Neet_pg_bot

Q40: In Pap smear cytology, which of the following is the most appropriate fixative used to preserve cellular details immediately after smearing? (Q866744)

A. 50% formaldehyde

B. 95% ethanol

C. 70% ethanol

D. 10% buffered formalin

See Answer in Part B → Q40

@Neet_pg_bot

Q41: Which of the following measures is associated with an increased life span? (Q855961)

A. Regular moderate exercise for 30 min

B. Decrease stress

C. Decreasing calorie intake by 30%

D. Pharmacological intervention with proton pump inhibitors

See Answer in Part B → Q41

@Neet_pg_bot

Q42: Choose the correct statement regarding the telomerase theory of ageing: (Q855914)

A. Telomere stability is associated with ageing

B. Abnormal telomerase activation is associated with ageing

C. Decreased telomere length is associated with ageing

D. Increased telomere length is associated with ageing

See Answer in Part B → Q42

@Neet_pg_bot

Q43: The body of an 82-year-old man has been seen for a post-mortem to determine the cause of death. You are examining a histopathological slide containing a section of his cardiac tissue where you notice some pigmentation. Which is the substance that is seen in the image given below? (Q859859)

A. Melanin

B. Lipofuscin

C. Hemosiderin

D. Iron

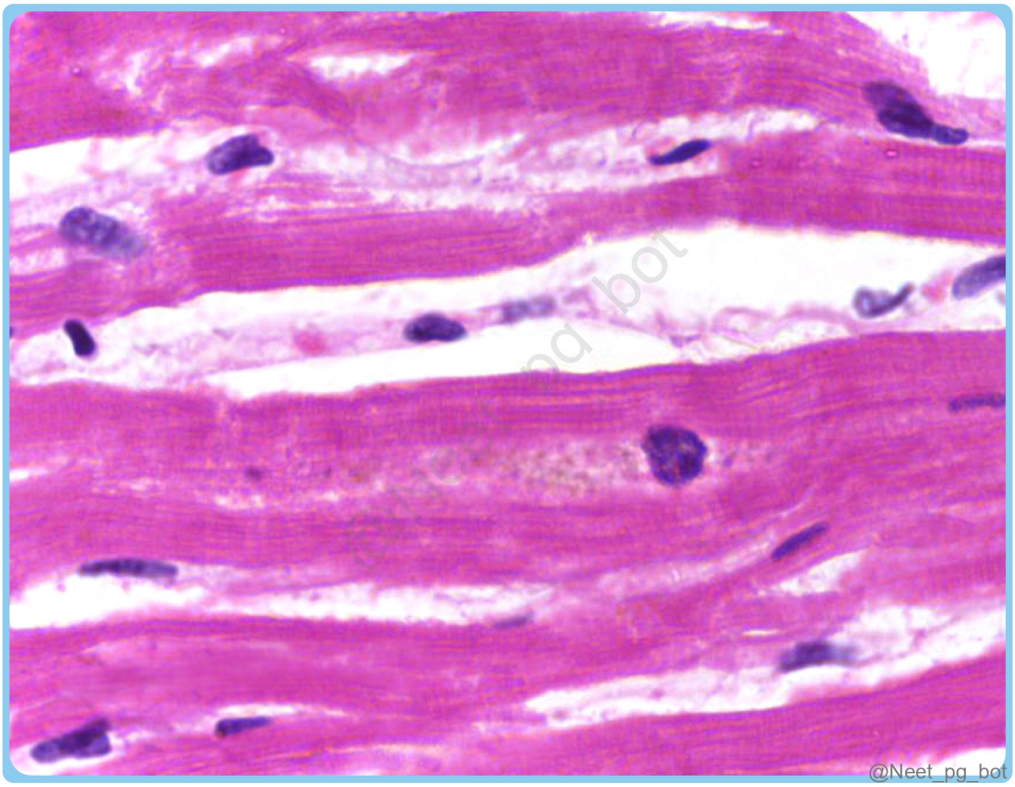

See Answer in Part B → Q43

@Neet_pg_bot

Q44: Among the following, which molecule is required for the presentation of the antigens by the APCs to TH2 cells? (Q859298)

A. NK cells

B. G-protein coupled receptor

C. MHC

D. Lectin receptor

See Answer in Part B → Q44

@Neet_pg_bot

Q45: Which of the following caspases binds to Cyt c and the APAF-1 complex? (Q856488)

A. Caspase 1

B. Caspase 8

C. Caspase 9

D. Caspase 4

See Answer in Part B → Q45

@Neet_pg_bot

Q46: All of the following are crosslinking fixatives except? (Q856893)

A. Glutaraldehyde

B. Formaldehyde

C. Methanol

D. Osmium tetroxide

See Answer in Part B → Q46

@Neet_pg_bot

Q47: A chronic alcoholic patient presented with increasing abdominal girth. On examination, shifting dullness was present, and the liver span was less than 7cm.

Histopathological examination revealed the presence of intracytoplasmic eosinophilic inclusions in hepatocytes. What is the content of these inclusions? (Q856152)

A. Intermediate filaments

B. Actin

C. Microtubules

D. Fibronectin

See Answer in Part B → Q47

@Neet_pg_bot

Q48: A 70-year-old patient presented with cough, fatigue, and weight loss. He was diagnosed with squamous cell carcinoma on bronchoscopy. The resected specimen had a hilar lymph node that was 1 cm in size and showed a black pigment. What is the black pigment likely to be? (Q856097)

A. Anthracotic pigment

B. Melanin

C. Lipochrome

D. Hemosiderin

See Answer in Part B → Q48

@Neet_pg_bot

Q49: A 20-year-old female who is a known case of sickle cell anaemia was rushed to the emergency department with a complaint of extreme pain in the legs and fingers for the past 4 hours. Further examination revealed pain and tenderness in the right upper quadrant, and investigations showed sickle cells on peripheral blood smear and high bilirubin(indirect). What is the diagnosis? (Q860284)

A. IDA

B. Thalassemia

C. Anaemia of chronic disease

D. Sickle cell crisis

See Answer in Part B → Q49

@Neet_pg_bot

Q50: Investigations of a patient being evaluated for leukaemia revealed a WBC count of 450,000/μL, with eosinophilia and basophilia. What is the likely diagnosis in this case? (Q855989)

A. Acute Lymphoblastic Leukemia (ALL)

B. Chronic Myelogenous Leukemia (CML)

C. Chronic Lymphocytic Leukemia (CLL)

D. Acute Myelogenous Leukemia (AML)

See Answer in Part B → Q50

@Neet_pg_bot

Q51: Which of the following is true regarding glucose-6-phosphate dehydrogenase (G6PD) deficiency? (Q856478)

A. Spectrin defect

B. Bite cells are present

C. Cells do not lyse in a hypotonic solution

D. Cells lyse in hypertonic solution

See Answer in Part B → Q51

@Neet_pg_bot

Q52: A 35-year-old woman presents with fatigue. Investigations reveal the following: Hemoglobin (Hb): 5 gm%, low mean corpuscular haemoglobin (MCH), and low mean corpuscular volume (MCV). The peripheral smear shows microcytic hypochromic red blood cells. What is the most likely diagnosis? {{caption_text}} (Q855889)

A. Megaloblastic anaemia

B. Iron deficiency anaemia

C. Thalassemia major

D. Essential thrombocytosis

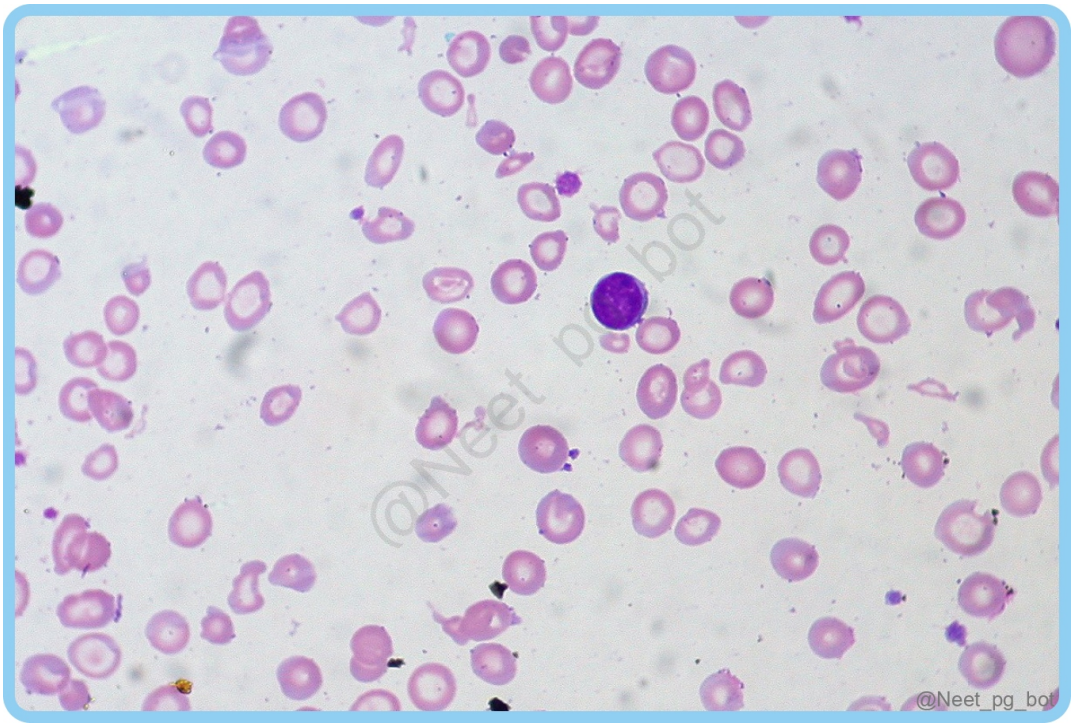

See Answer in Part B → Q52

@Neet_pg_bot

Q53: Match the following cell types with their associated malignancy: Cell Type Associated Malignancy 1. Popcorn cell a. Acute promyelocytic leukemia 2. Faggot cell b. Lymphocyte-predominant Hodgkin's lymphoma 3. Cerebriform nuclei c. Burkitt lymphoma 4. Starry sky appearance d. Sezary syndrome (Q855885)

A. 1-b, 2-a, 3-d, 4-c

B. 1-a, 2-d, 3-c, 4-b

C. 1-b, 2-c, 3-a, 4-c

D. 1-a, 2-b, 3-d, 4-c

See Answer in Part B → Q53

@Neet_pg_bot

Q54: Which of the following is a feature of hemolytic anaemia? (Q858116)

A. Increased haptoglobin

B. Neutropenia

C. Reticulocytopenia

D. Decreased haptoglobin

See Answer in Part B → Q54

@Neet_pg_bot

Q55: A child presents with intermittent jaundice and splenomegaly. There is a history of similar complaints in the elder brother. A peripheral smear shows the following findings. Which of the following is the most appropriate diagnostic test for this condition? (Q855398)

A. Osmotic fragility test - Hereditary spherocytosis

B. Coombs test - Autoimmune hemolytic anaemia

C. Genetic testing - G6PD deficiency

D. Flow cytometry - Paroxysmal nocturnal hemoglobinuria

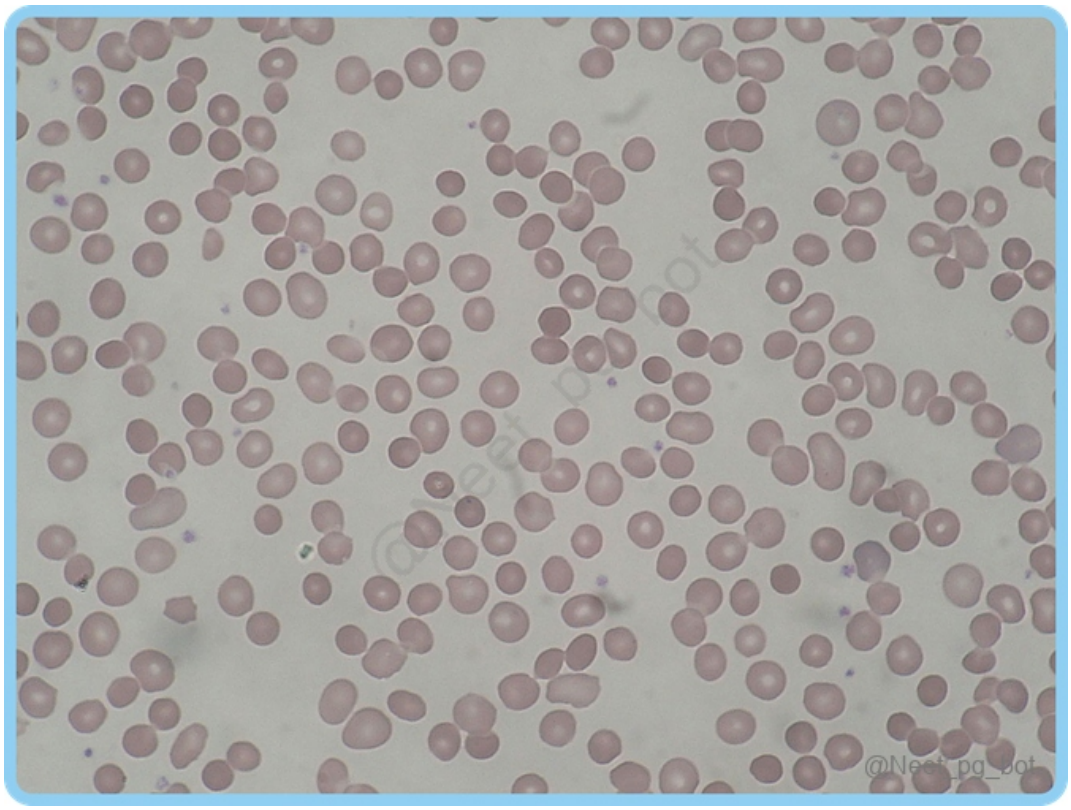

See Answer in Part B → Q55

@Neet_pg_bot

Q56: Serum transferrin saturation level is low. What is the most likely condition? (Q854695)

A. Iron Deficiency Anemia

B. Hemochromatosis

C. Sideroblastic anemia

D. Pernicious anemia

See Answer in Part B → Q56

@Neet_pg_bot

Q57: Which of the following for Sickle cell anaemia is correct? (Q854687)

A. Low mechanical fragility, high osmotic fragility

B. High mechanical fragility, high osmotic fragility

C. Low mechanical fragility, low osmotic fragility

D. High mechanical fragility, low osmotic fragility

See Answer in Part B → Q57

@Neet_pg_bot

Q58: A 45-year-old male patient with a history of chronic inflammatory conditions presents with fatigue, weakness, and pallor. Laboratory investigations reveal microcytic hypochromic anemia. Further evaluation suggests an underlying disorder affecting iron metabolism. Which cytokine is most likely inhibiting the activity of ferroportin in this patient? (Q820595)

A. IL-1

B. IL-6

C. IFN-gamma

D. TNF-Alpha

See Answer in Part B → Q58

@Neet_pg_bot

Q59: A 25-year-old female patient presents to the clinic with complaints of fatigue, weakness, and pale skin. On further investigation, her complete blood count reveals a microcytic anemia. What is the likely diagnosis for this patient? (Q820581)

A. Alcoholism

B. Chronic Kidney disease

C. Hemolytic anemia

D. Iron deficiency anemia

See Answer in Part B → Q59

@Neet_pg_bot

Q60: A patient reports to the outpatient department with complaints of fatigue. Investigation results indicate a Hb of 5.9, increased RDW and TIBC, and low ferritin. What is the most likely diagnosis? (Q860296)

A. Sideroblastic anemia

B. IDA

C. Anaemia of chronic disease

D. Hemolytic anemia

See Answer in Part B → Q60

@Neet_pg_bot

Q61: A 60-year-old woman presents with complaints of fatigue and dyspnea for 2 weeks. On examination, pallor is noted, and haemoglobin is found to be 6 gm/dL. What is the likely finding seen on the peripheral smear? (Q855962)

A. Poikilocytes

B. Microcytic hypochromic cells

C. Macrocytic cells

D. Target cells

See Answer in Part B → Q61

@Neet_pg_bot

Q62: Which of the following cells are located in the centre of the lumen in a venule? (Q860262)

A. Lymphocytes

B. RBCs

C. Neutrophils

D. Platelets

See Answer in Part B → Q62

@Neet_pg_bot

Q63: A 65-year-old patient presents with anaemia. Investigations show low serum iron and ferritin levels, along with increased TIBC. Which of the following is most likely to be present? (Q860216)

A. Iron Deficiency Anemia (IDA)

B. Myelodysplastic Syndrome

C. Aplastic Anemia

D. Anaemia of Chronic Disease

See Answer in Part B → Q63

@Neet_pg_bot

Q64: A 45-year-old patient visits a haematologist with symptoms of weakness and fatigue. Laboratory tests show low haemoglobin, a low reticulocyte count, and normal WBC and platelet counts. The bone marrow analysis reveals a selective reduction in erythroid precursors. What is the likely diagnosis? (Q860156)

A. Aplastic anemia

B. Pure red cell aplasia

C. Iron deficiency anaemia

D. Pernicious anemia

See Answer in Part B → Q64

@Neet_pg_bot

Q65: A patient reports to the outpatient department with complaints of fatigue. Investigation results indicate a Hb of 5.9, increased RDW and TIBC, and low ferritin. What is the most likely diagnosis? (Q860499)

A. Sideroblastic anemia

B. IDA

C. Anaemia of chronic disease

D. Hemolytic anemia

See Answer in Part B → Q65

@Neet_pg_bot

Q66: A 20-year-old female who is a known case of sickle cell anaemia was rushed to the emergency department with a complaint of extreme pain in the legs and fingers for the past 4 hours. Further examination revealed pain and tenderness in the right upper quadrant, and investigations showed sickle cells on peripheral blood smear and high bilirubin(indirect). What is the diagnosis? (Q860485)

A. IDA

B. Thalassemia

C. Anaemia of chronic disease

D. Sickle cell crisis

See Answer in Part B → Q66

@Neet_pg_bot

Q67: Which of the following is not seen after ileal resection? (Q844209)

A. Nuclear cytological asynchrony

B. Neurological manifestations

C. Microcytic hypochromic anemia

D. Reversible dementia

See Answer in Part B → Q67

@Neet_pg_bot

Q68: How is transferrin saturation affected by iron deficiency anemia? (Q844208)

A. Increased

B. Decreased

C. Normal

D. Dynamic

See Answer in Part B → Q68

@Neet_pg_bot

Q69: Which of the following statement is correct regarding Paroxysmal Nocturnal Hemoglobinuria? (Q844193)

A. Sucrose lysis test is used for confirmation

B. Flow cytometry is the best investigation

C. Most common cause of death is heart failure

D. It is an inherited disorder

See Answer in Part B → Q69

@Neet_pg_bot

Q70: In a patient of hereditary spherocytosis, which of the following organisms is likely to attack progenitor cells, resulting in aplastic anemia? (Q844045)

A. CMV

B. EBV

C. Parvovirus B19

D. HSV

See Answer in Part B → Q70

@Neet_pg_bot

Q71: All are hereditary causes of thrombosis except: (Q853369)

A. PNH

B. Protein S deficiency

C. Antithrombin deficiency

D. Homocystinuria

See Answer in Part B → Q71

@Neet_pg_bot

Q72: A patient presents with fever, night sweats, and weight loss for 2 months. On examination, non-tender rubbery nodes are palpable in the supraclavicular and inguinal regions on both sides. A peripheral smear shows the presence of binucleated cells. Which of the following markers will be seen in this condition? CD15 CD30 CD19 CD3 (Q856019)

A. 1, 2, 4

B. 2, 3, 4

C. 2, 3

D. 1, 2

See Answer in Part B → Q72

@Neet_pg_bot

Q73: Which of the following is not true about stem cells? (Q856476)

A. They can differentiate

B. They can replicate

C. They can divide without any regulatory stimulus

D. They can regenerate damaged tissues

See Answer in Part B → Q73

@Neet_pg_bot

Q74: Identify the cells marked in the given image: (Q856905)

A. Lymphocyte-1, Monocyte-4, Eosinophil-2, Basophil-3

B. Lymphocyte-2, Monocyte-4, Eosinophil-1, Basophil-3

C. Lymphocyte-1, Monocyte-2, Eosinophil-3, Basophil-4

D. Lymphocyte-2, Monocyte-1, Eosinophil-3, Basophil-4

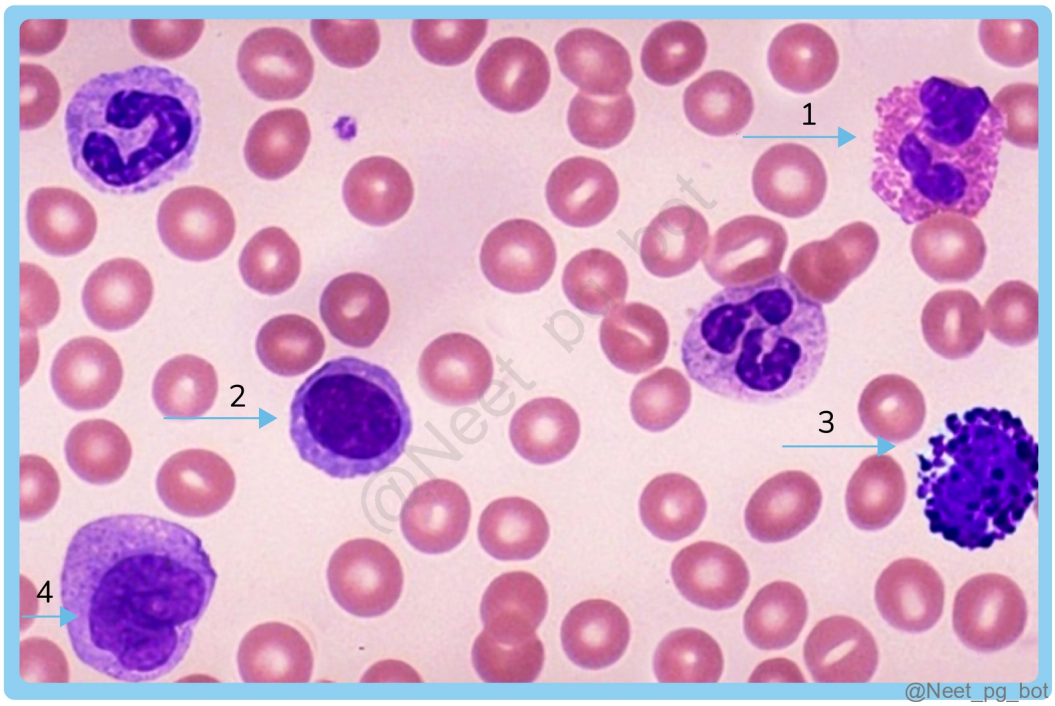

See Answer in Part B → Q74

@Neet_pg_bot

Q75: What is your diagnosis with respect to the findings shown in the peripheral smear: (Q856901)

A. Iron deficiency anaemia

B. Vitamin B12 deficiency

C. Hereditary spherocytosis

D. Acute myeloid leukemia

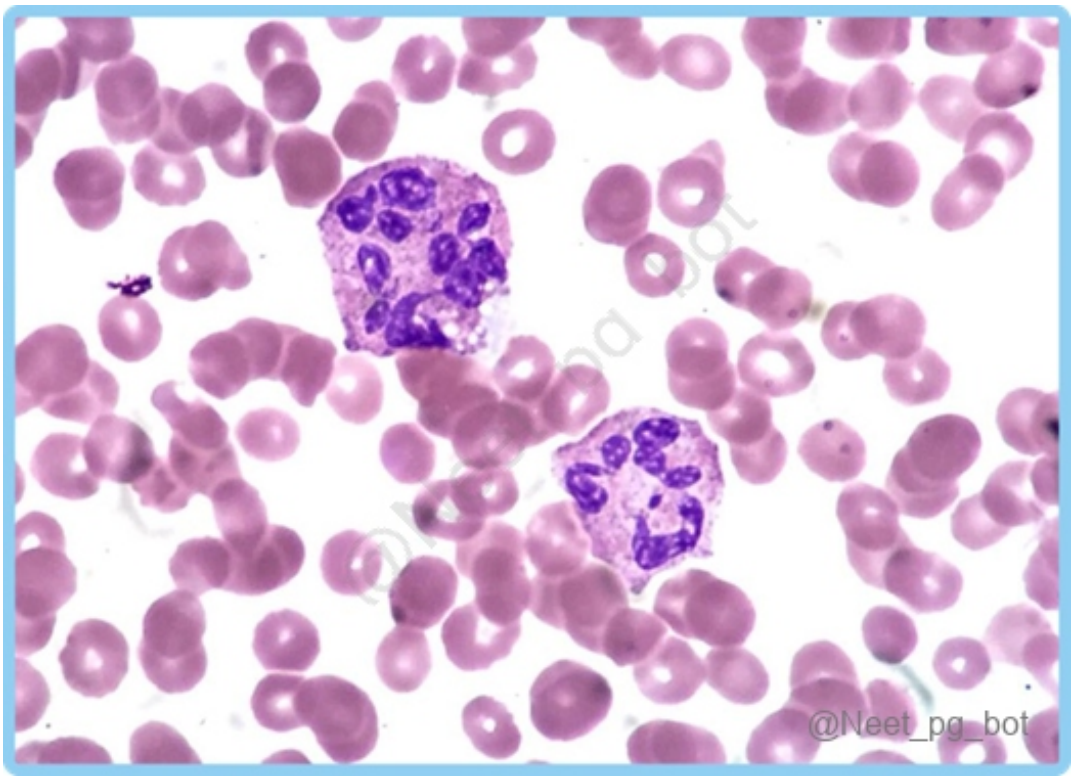

See Answer in Part B → Q75

@Neet_pg_bot

Q76: Rees and Ecker diluting fluid is used in: (Q856896)

A. Wintrobe tube

B. WBC pipette

C. RBC pipette

D. Hemoglobin pipette

See Answer in Part B → Q76

@Neet_pg_bot

Q77: An 18-year-old male presented to the outpatient department with gum bleeding and fever for the past 2 months. The general examination showed pallor, and the systemic examination was unremarkable. Laboratory examination revealed a Hb level

of 3 g/dl, a TLC of 1500/microL, and a platelet count of 15,000/microL. A peripheral smear shows macrocytes, and the reticulocyte count is 0.5%. A bone marrow examination revealed fatty streaks and absent megakaryocytes with no immature cells. What is the likely diagnosis? (Q856143)

A. Idiopathic acquired aplastic anaemia

B. Paroxysmal nocturnal hemoglobinuria

C. Myelodysplastic syndrome

D. Tuberculosis

See Answer in Part B → Q77

@Neet_pg_bot

Q78: Which of the following is used in treating sideroblastic anaemia? (Q855432)

A. Vitamin B12

B. Vitamin B6

C. Vitamin B1

D. Iron

See Answer in Part B → Q78

@Neet_pg_bot

Q79: Which of the following statements regarding the effect of glucose-6-phosphate dehydrogenase deficiency is correct? Decrease in reduced glutathione Decrease NADPH Decreased lipid peroxidation Decreased RBC membrane damage (Q855416)

A. Only 1 is correct

B. 1 & 2 are correct

C. 2 & 3 are correct

D. 1, 2 & 4 are correct

See Answer in Part B → Q79

@Neet_pg_bot

Q80: A child presented with bilateral proptosis. From the peripheral smear, he was suspected to have chloroma. What is the next investigation of choice? (Q855410)

A. Platelet count

B. WBC count

C. Flow cytometry

D. Bone marrow biopsy

See Answer in Part B → Q80

@Neet_pg_bot

Q81: All of the following are associated with massive splenomegaly, except: (Q855400)

A. Chronic myeloid leukemia

B. Aplastic anemia

C. Hairy cell leukemia

D. Lymphoma

See Answer in Part B → Q81

@Neet_pg_bot

Q82: A 45-year-old male patient was diagnosed with iron deficiency anaemia. Which of the following is true about the intracellular regulation of iron in iron deficiency anaemia? (Q855399)

A. Ferritin translation is increased by binding IRP to IRE

B. Ferritin translation is decreased by binding IRP to IRE

C. Transferrin receptor 1 translation is unaffected by binding IRP to IRE

D. Transferrin receptor 1 translation is decreased by binding IRP to IRE

See Answer in Part B → Q82

@Neet_pg_bot

Q83: A 24-year-old male patient presents with anaemia. Both his father and paternal aunt experienced similar illnesses and were effectively treated with splenectomy. The patient's peripheral blood smear resembles the one depicted in the accompanying illustration, showing spherocytes. What other abnormalities can be anticipated? (Q857592)

A. Decreased osmotic fragility

B. Decreased reticulocytes

C. Heinz bodies

D. Howell-Jolly bodies

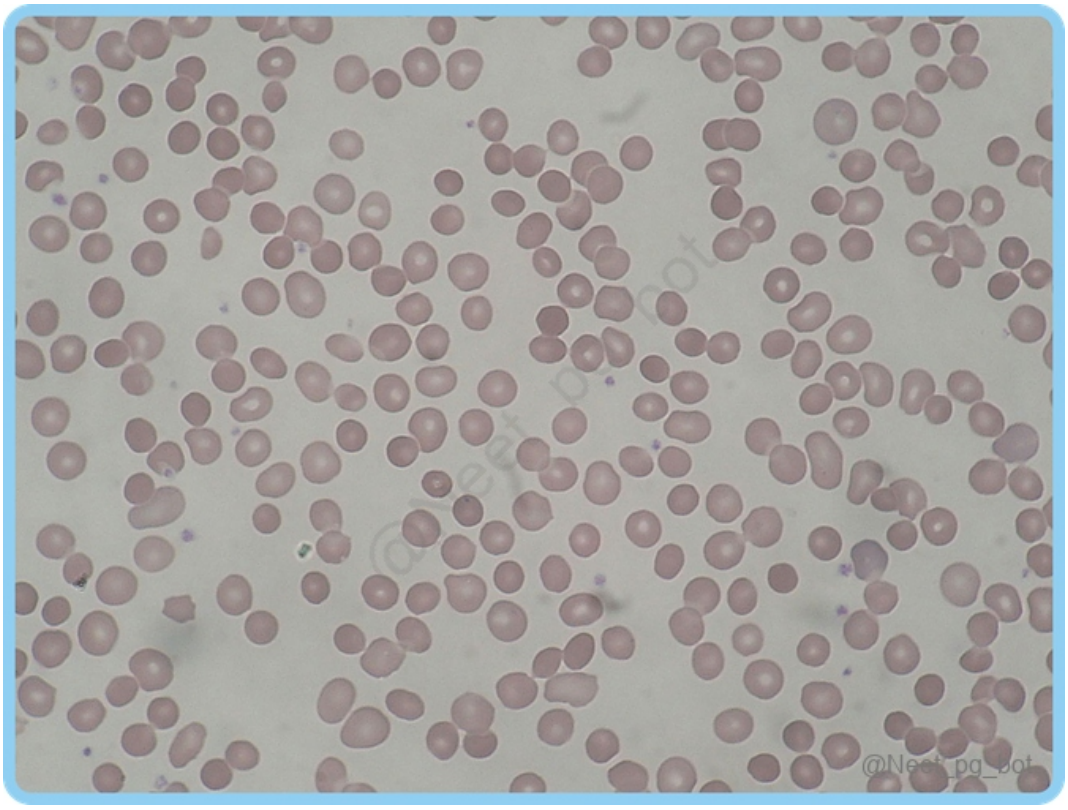

See Answer in Part B → Q83

@Neet_pg_bot

Q84: What is the most likely diagnosis for an 18-year-old male with gum bleeding, fever for two months, pallor, low haemoglobin (3 gm/dL), low TLC (1500/microL), low platelet count (15000/microL), macrocytes on peripheral smear, 0.5% reticulocyte count, and bone marrow examination showing fatty streaks and a lack of megakaryocytes but no immature cells? (Q857108)

A. Idiopathic acquired aplastic anemia

B. Paroxysmal nocturnal hemoglobinuria

C. Myelodysplastic syndrome

D. Tuberculosis

See Answer in Part B → Q84

@Neet_pg_bot

Q85: A 10-year-old boy presents with fatigue. Investigations reveal the following: Hemoglobin: 9 g/dL MCV: 80 fL MCH: 29 pg Serum ferritin: 185 μg/L TLC: Elevated with predominant lymphocytes and neutrophils. What is the likely diagnosis for this patient? (Q855124)

A. Thalassemia

B. Anemia of chronic disorder

C. Iron deficiency anaemia

D. Sickle cell anemia

See Answer in Part B → Q85

@Neet_pg_bot

Q86: All of the following are seen in the anaemia of chronic disease, except: (Q855067)

A. High serum hepcidin

B. Low serum ferritin

C. Chronic infection

D. Normal iron stores

See Answer in Part B → Q86

@Neet_pg_bot

Q87: A patient is diagnosed with B-cell leukaemia. Which of the following are poor prognostic factors? Hyperdiploidy Age <1 year t(9:22) t(4:11) (Q856031)

A. A, C, D

B. C, D

C. A, B, C, D

D. B, C, D

See Answer in Part B → Q87

@Neet_pg_bot

Q88: Which of the following is true about hereditary spherocytosis? (Q856004)

A. Gallstones develop by 4-5 years of age

B. Splenectomy does not protect against developing gallstones

C. Around 75% of cases show an autosomal dominant pattern

D. High MCH is pathognomonic of HS

See Answer in Part B → Q88

@Neet_pg_bot

Q89: Which of the following is not likely to be seen in a patient with paroxysmal nocturnal hemoglobinuria (PNH)? (Q855389)

A. Aplastic anemia

B. Leukaemia

C. Thrombosis

D. Hemolysis

See Answer in Part B → Q89

@Neet_pg_bot

Q90: Which of the following are features describing necrosis? Cell swelling Disrupted cell membrane Induces inflammation Physiological (Q857443)

A. 1 and 2

B. 1, 2 and 4

C. 1, 2 and 3

D. 1 and 3

See Answer in Part B → Q90

@Neet_pg_bot

Q91: In which of the following conditions is macrocytic anemia seen? (Q793648)

A. Thalassemia

B. Anemia of chronic disease

C. Sideroblastic anemia

D. Liver disease

See Answer in Part B → Q91

@Neet_pg_bot

Q92: Which of the following stains is used for the detection of hemosiderin deposits? (Q793650)

A. Mason-Fontana stain

B. Oil Red O

C. Sudan black

D. Perls Prussian blue

See Answer in Part B → Q92

@Neet_pg_bot

Q93: In iron deficiency anaemia, all of the following are increased except: (Q856136)

A. Transferrin saturation

B. RBC protoporphyrin

C. Total iron binding capacity

D. Ferritin soluble receptors

See Answer in Part B → Q93

@Neet_pg_bot

Q94: A child visited the hospital with her mother with complaints of severe fatigue, lethargy, pallor, and irritation. She has a known case of iron deficiency anemia and is on oral iron supplements. On reviewing the child, the physician in charge plans to start IV iron supplementation. What is the next best test to be done in assessing this child? (Q793752)

A. Blood hemoglobin

B. Total iron binding capacity

C. Serum ferritin

D. Hematocrit

See Answer in Part B → Q94

@Neet_pg_bot

Q95: A software engineer presents to the outpatient department with easy fatiguability. He gives a history of sitting in front of the computer for 12-14 hours. He consumes a lot of junk food with very few fruits and vegetables. Hb is 9 g/dl, and MCV is 80 fl. What is the most likely cause of this patient's anemia? (Q856150)

A. Cyanocobalamin deficiency

B. Iron deficiency

C. Folic acid deficiency

D. Hereditary spherocytosis

See Answer in Part B → Q95

@Neet_pg_bot

Q96: Which of the following is not routinely screened before conducting a blood transfusion? (Q793763)

A. Hepatitis A

B. Hepatitis B

C. Hepatitis C

D. HIV 1 / HIV 2

See Answer in Part B → Q96

@Neet_pg_bot

Q97: Metastatic calcification occurs in all except ? (Q793597)

A. Kidney

B. Fundus of the stomach

C. Pulmonary veins

D. Atheroma

See Answer in Part B → Q97

@Neet_pg_bot

• [18_Hematology_ White Blood Cells] 071 Cml And Cll

« Back to Folder Directory

[18_Hematology_ White Blood Cells] 071 Cml And Cll — Quick Jump

Q1 (p. 793) *Q2 (p. 793)* *Q3 (p. 794)* *Q4 (p. 794)* *Q5 (p. 797)* *Q6 (p. 797)*
Q7 (p. 798) *Q8 (p. 799)* *Q9 (p. 799)* *Q10 (p. 800)* *Q11 (p. 800)* *Q12 (p. 800)*
Q13 (p. 801)

Q1: A 45-year-old male complained of fatigue and weakness in daily activities associated with intermittent fever. A blood workup revealed ↑ TLC, ↑ Platelets, and↑ Differential leukocyte count. On further investigations, Chronic Myeloid Leukemia is diagnosed. Which of the following is correct regarding CML? (Q882174)

A. Philadelphia chromosome is present in a minority of cases

B. Tyrosine kinase inhibitors (TKIs) are the drug of choice

C. Most cases present in the blast phase

D. Methotrexate is the drug of choice for AML

See Answer in Part B → Q1

@Neet_pg_bot

Q2: A 65-year-old woman presents with fatigue, night sweats and unintentional weight loss over the past few months. Physical examination reveals palpable lymph nodes and enlarged spleen. Lab tests show significant lymphocytosis (>20,000/μL) with small, mature-appearing lymphocytes. What is true regarding the origin and risk factors of the patient's condition? (Q842739)

A. B cells, no exposure to radiation

B. B-cells, exposure to radiation

C. Myeloid cells; BTK gene mutation

D. Myeloid cells; Philadelphia chromosome

See Answer in Part B → Q2

@Neet_pg_bot

Q3: A 65-year-old male presents with generalised fatigue and night sweats. Lab tests reveals Hemoglobin (Hb) 12 g/dL Platelet count 150,000/µL Absolute lymphocyte count (ALC) 45,000/µL Total leukocyte count (TLC) 70,000/µL Differential leukocyte count (DLC) 70% lymphocytes, 20% neutrophils, 5% monocytes, and 5% eosinophils Based on these lab findings, what is the most likely diagnosis? (Q842740)

A. ALL

B. AML

C. CML

D. CLL

See Answer in Part B → Q3

@Neet_pg_bot

Q4: Match the following peripheral smear images with the respective diagnosis: A. 1. Acute Myeloid Leukemia (AML) B. 2. Chronic Myeloid Leukemia (CML) C. 3. Acute Lymphoblastic Leukemia (ALL) D. 4. Chronic Lymphocytic Leukemia (CLL) (Q842741)

A. 1-B, 2-A, 3-D, 4-C

B. 1-B, 2-C, 3-D, 4-A

C. 1-C, 2-D, 3-B, 4-A

D. 1-D, 2-C, 3-A, 4-B

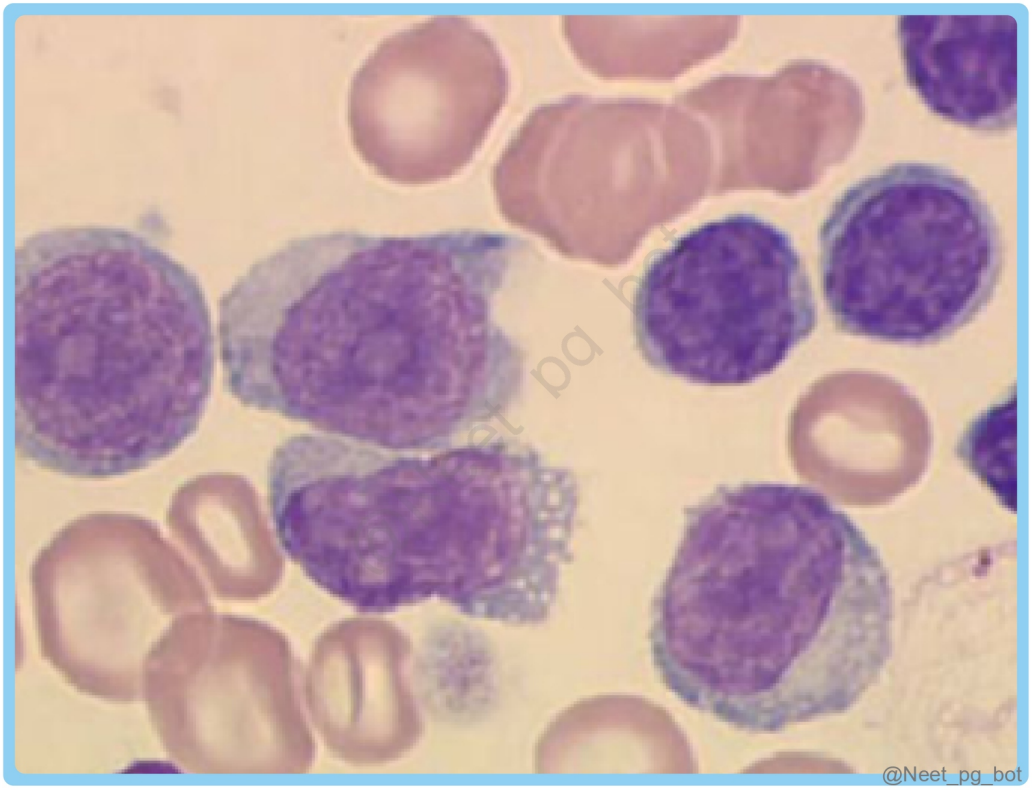
@Neet_pg_bot

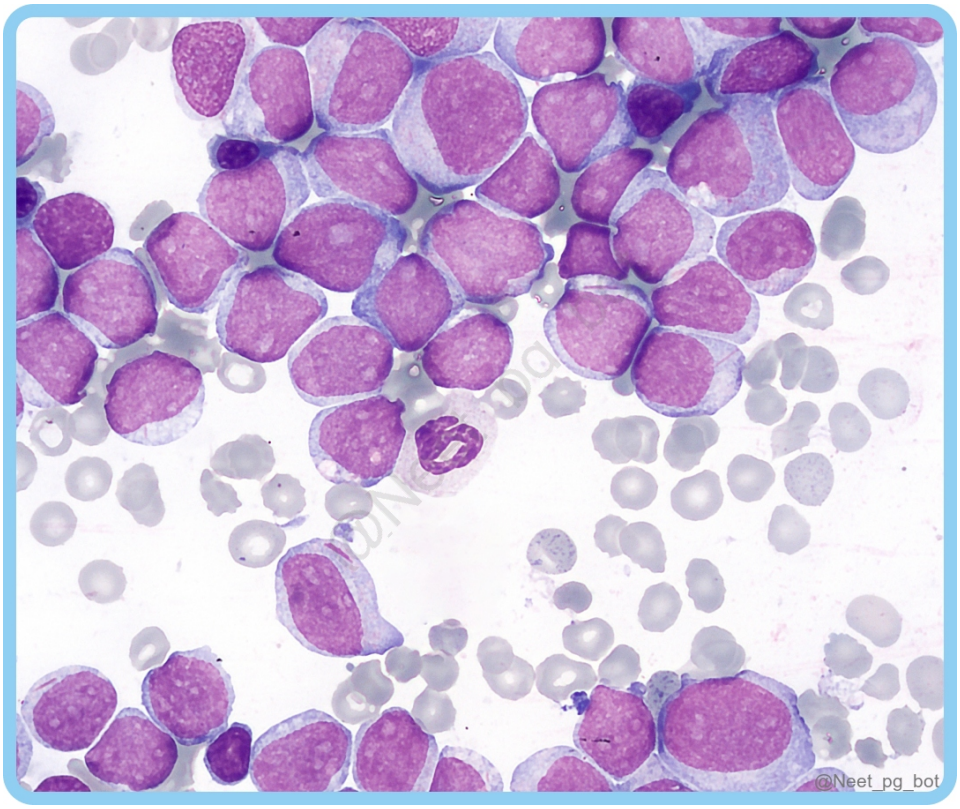
@Neet_pg_bot

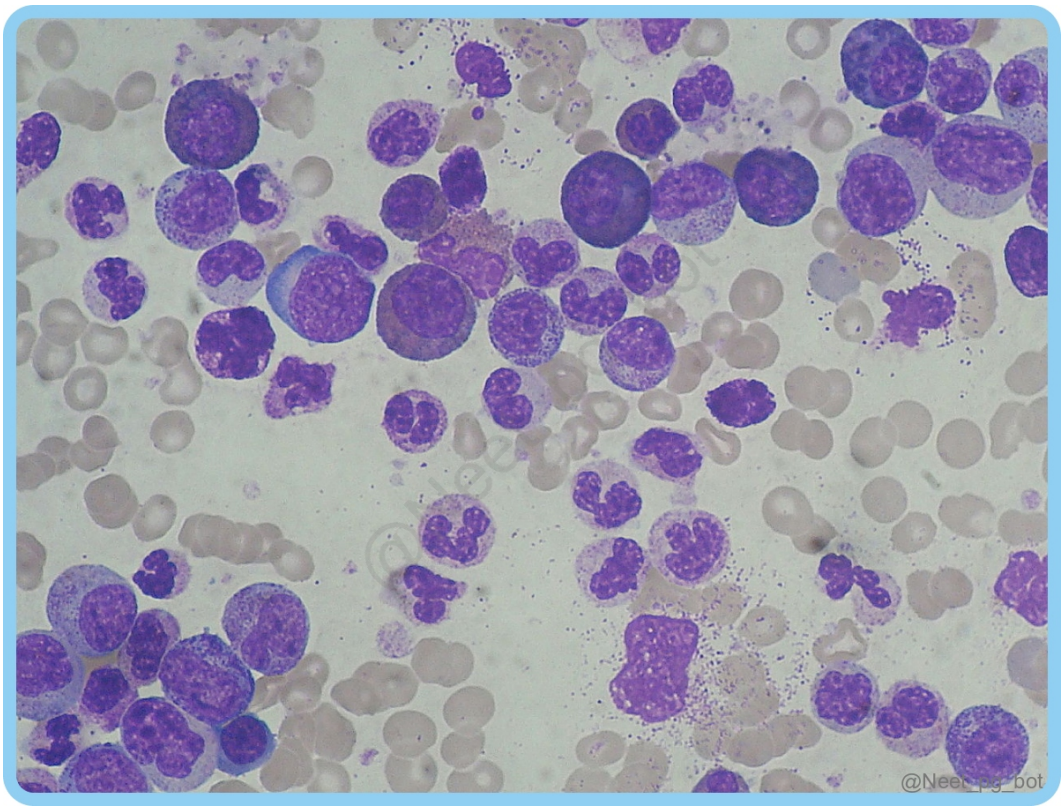

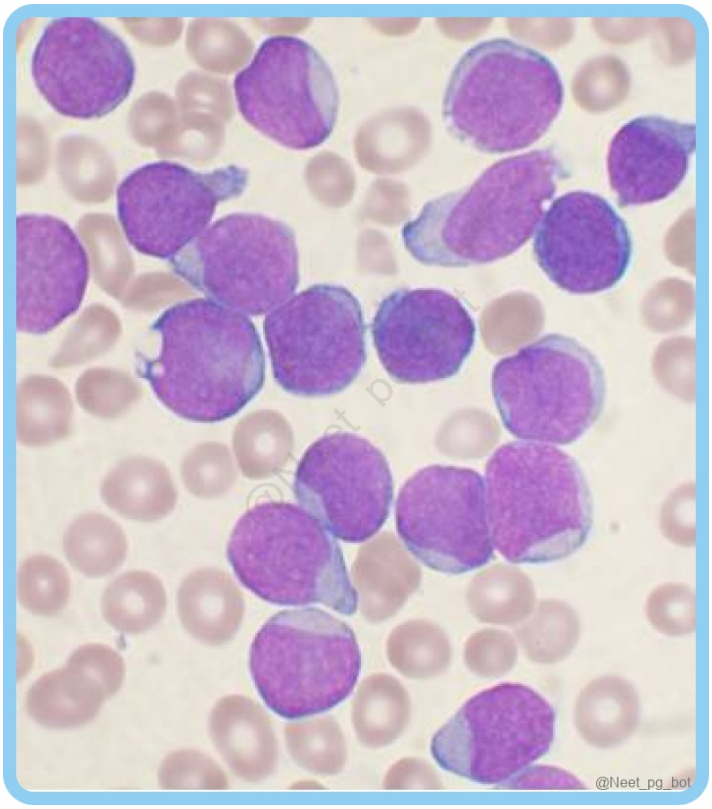

See Answer in Part B → Q4

@Neet_pg_bot

Q5: A 60-year-old man presents with fatigue, night sweats, and unintentional weight loss over the past several months. Examination reveals generalised lymphadenopathy and mild splenomegaly. Peripheral blood smear is shown below. Which of the following is not typically associated with the patient's condition? (Q842742)

A. Autoimmune hemolytic anemia (AIHA)

B. Evan’s syndrome

C. Richter’s syndrome

D. Di Guglielmo Disease

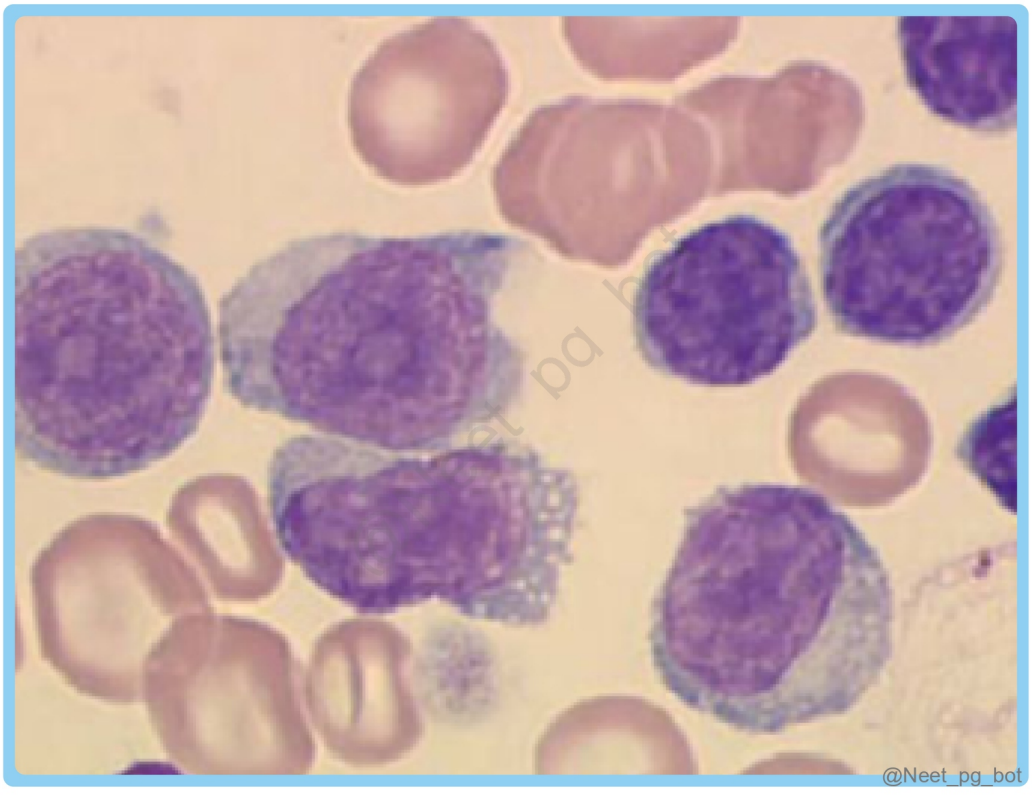

See Answer in Part B → Q5

@Neet_pg_bot

Q6: A 52-year-old male presents with complaints of fatigue, abdominal fullness, and night sweats. His complete blood count shows WBC count of 120,000/μL. A peripheral

blood smear shows an increased number of granulocytes at different stages of maturation. A bone marrow aspirate is shown below. Which of the following features can be seen in this condition? (Q842743)

A. Diffusely effaced lymph node architecture with proliferation centres

B. Presence of Reed-Sternberg cells

C. Normal marrow cellularity with increased blast cells

D. Hypercellular bone marrow with decreased erythroid precursors

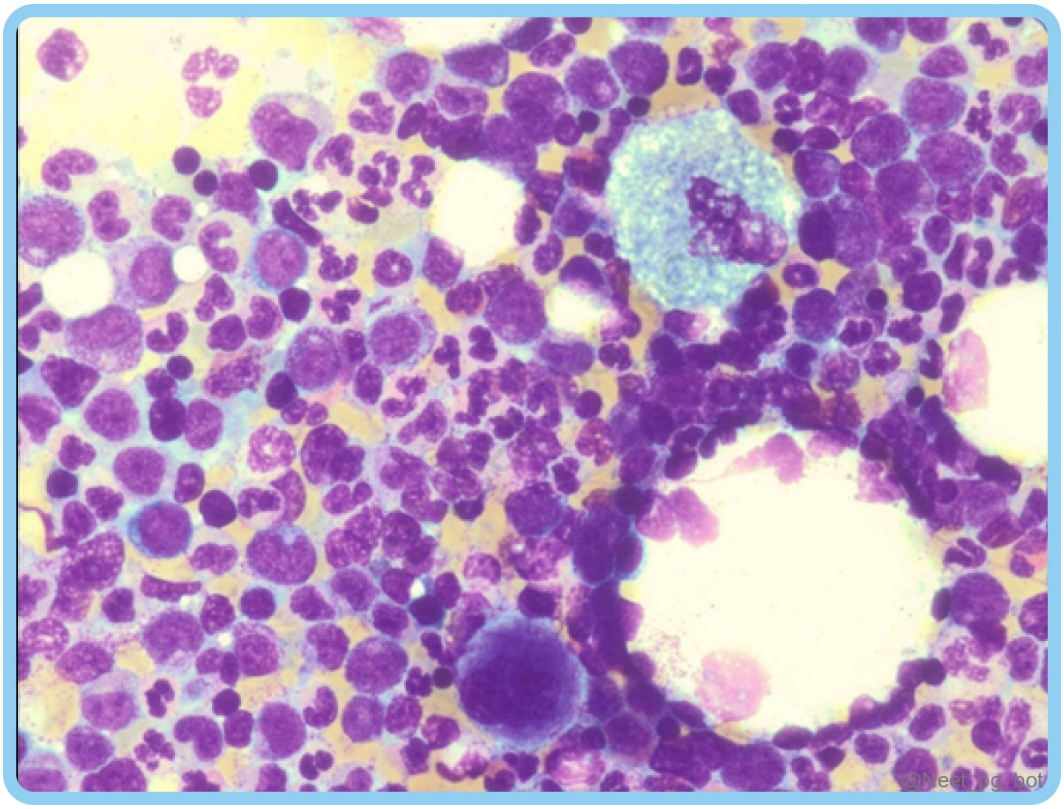

See Answer in Part B → Q6

@Neet_pg_bot

Q7: A 62-year-old woman presents with fatigue, unintentional weight loss, and occasional night sweats over the past few months. On physical examination, cervical lymphadenopathy is noted. A complete blood count reveals leukocytosis with an absolute lymphocyte count of 10,000/mm3. Which of the following flow cytometry marker profiles is most consistent with this form of leukemia? (Q842744)

A. CD5+, CD19+, CD23+, CD10-

B. CD20+, CD79a+, CD5+, CD25-

C. CD3+, CD5+, CD19+, CD20-

D. CD10+, CD19+, CD22+, CD23-

See Answer in Part B → Q7

@Neet_pg_bot

Q8: Which of the following are the good prognostic factors of CLL? (Q842745)

A. NOTCH1 mutations

B. CD38+

C. Expression of Zap 70

D. Expression of MiR-15/16

See Answer in Part B → Q8

@Neet_pg_bot

Q9: A 45-year-old man presents with purulent nasal discharge, headache, sore throat, and nonproductive cough. He has maxillary sinus tenderness, pharyngeal erythema, and tender anterior cervical lymphadenopathy. Laboratory results are as follows: Leukocytes 58,000/mm3 Neutrophils 42% Myelocytes 30% Metamyelocytes 8% Band forms 1% Blast cells 1% Eosinophils 6% Basophils 4% The leukocyte alkaline phosphatase score is low. Which of the following is the most likely diagnosis and its appropriate management/drug for treatment? (Q842746)

A. Leukemoid reaction and Amoxicillin

B. CML and Imatinib mesylate

C. ALL and vincristine

D. AML and stem cell transplant

See Answer in Part B → Q9

@Neet_pg_bot

Q10: A 55-year-old man who is a known case of chronic phase CML presents with increasing fatigue, weight loss, and abdominal discomfort. His physical examination reveals splenomegaly. Lab tests show a persistent decline in platelet counts, increased circulating basophils, and a blast count of 12%. What is the most likely explanation for the patient's clinical presentation and laboratory findings? (Q842747)

A. Progression to accelerated phase CML

B. Development of acute lymphoblastic leukemia

C. Entry into the blast crisis phase of CML

D. Development of secondary myelofibrosis

See Answer in Part B → Q10

@Neet_pg_bot

Q11: A 50-year-old male presents with fatigue, abdominal discomfort, and splenomegaly. Lab tests reveal a markedly elevated WBC count with a left shift and increased myeloid precursor forms on peripheral blood smear. Which of the following statements regarding the leukocyte (neutrophil) alkaline phosphatase (LAP) score in this condition is correct? (Q842748)

A. Normal LAP score

B. Increased due to excessive myeloid cell production

C. Decreased due to cytochemical abnormal WBCs

D. LAP score is relevant only in acute leukemia

See Answer in Part B → Q11

@Neet_pg_bot

Q12: A 55-year-old patient presents with fatigue, weight loss, and abdominal discomfort. Labs reveal a markedly elevated WBC count with a left shift and increased myeloid precursor forms on peripheral blood smear as shown below. Which of the following is the investigation of choice to confirm the diagnosis? (Q842749)

A. Bone Marrow Aspiration and Biopsy

B. Flow Cytometry Analysis of Peripheral Blood

C. Fluorescent in situ hybridisation (FISH)

D. Serum Lactate Dehydrogenase (LDH) Levels

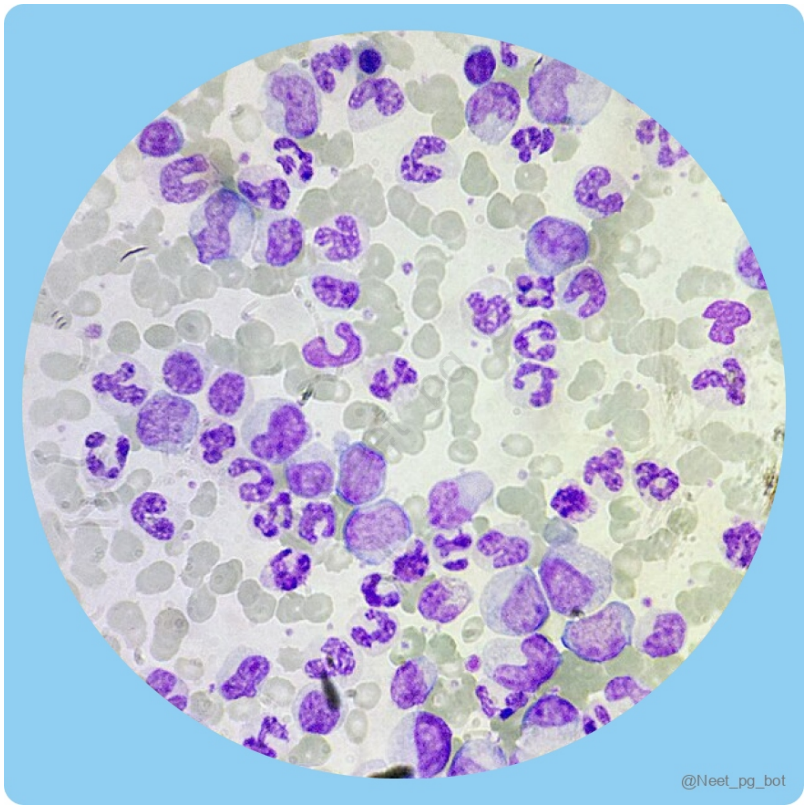

See Answer in Part B → Q12

@Neet_pg_bot

Q13: A 60-year-old male presents with fatigue and abdominal discomfort. Laboratory investigations reveal a markedly elevated WBC count with a left shift and increased myeloid precursor forms on peripheral blood smear. Which of the following features would help differentiate Chronic Myelogenous Leukemia (CML) from a leukemoid

reaction? (Q842750)

A. Massive splenomegaly

B. High LAP score

C. History of recent antibiotic use

D. Resolution of neutrophilia after treating the underlying cause

See Answer in Part B → Q13

@Neet_pg_bot

• [18_Hematology_ White Blood Cells] 072 Plasma Cell Disorders

« Back to Folder Directory

[18_Hematology_ White Blood Cells] 072 Plasma Cell Disorders — Quick Jump

Q1 (p. 803) *Q2 (p. 803)* *Q3 (p. 804)* *Q4 (p. 804)* *Q5 (p. 805)* *Q6 (p. 808)*
Q7 (p. 808) *Q8 (p. 808)* *Q9 (p. 809)* *Q10 (p. 809)* *Q11 (p. 810)* *Q12 (p. 810)*
Q13 (p. 811) *Q14 (p. 811)* *Q15 (p. 811)*

Q1: Which of the following images shows the typical features of a plasma cell in a histopathological examination (HPE) of bone marrow? (Q845746)

See Answer in Part B → Q1

@Neet_pg_bot

Q2: A 55-year-old woman presents with 6 months of persistent fatigue, lower back pain and recurrent infections. Laboratory tests show hypercalcemia, elevated creatinine, and normocytic anemia. Serum protein electrophoresis indicates a monoclonal spike. Bone marrow biopsy shows atypical plasma cells with eccentric nuclei and perinuclear halos, as shown in the image below. Which of the following cytogenetic abnormalities is not typically associated with this condition? (Q845747)

A. Deletion of chromosome 13q

B. Translocation t(11;14)

C. Trisomy 21

D. Deletion of chromosome 17p

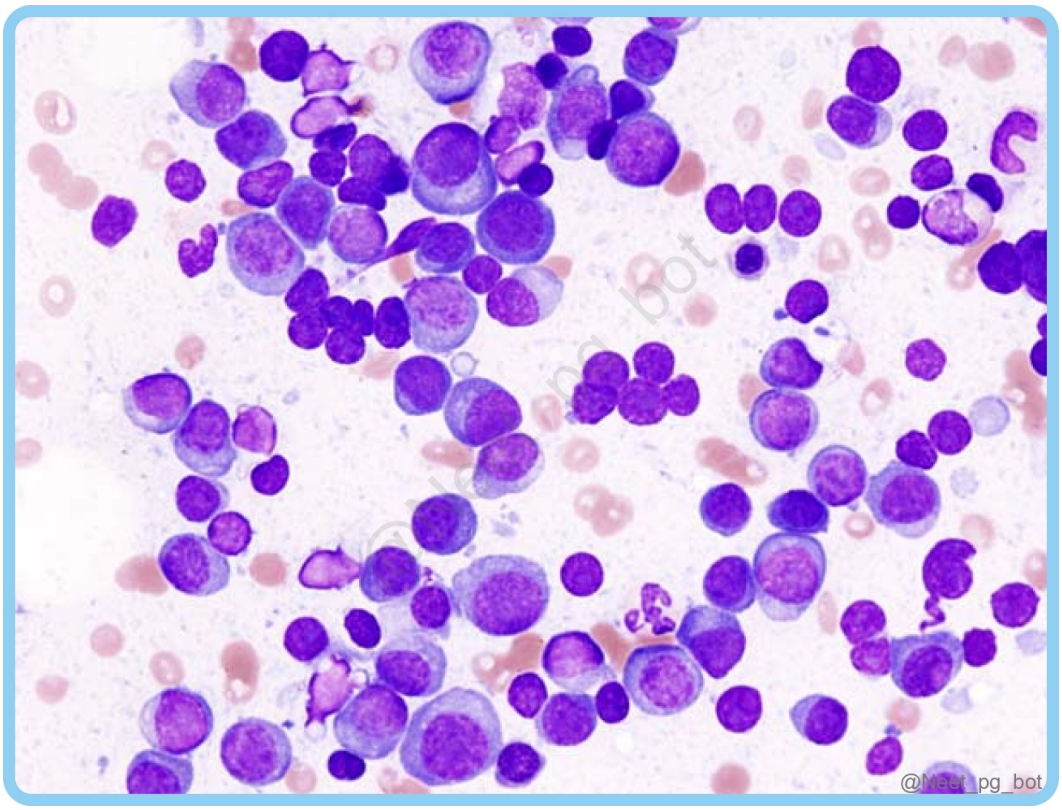

See Answer in Part B → Q2

@Neet_pg_bot

Q3: A 68-year-old man presents with complaints of persistent bone pain, particularly in his lower back and ribs, along with fatigue and recurrent infections over the past few months. Further workup demonstrates Bence Jones proteinuria. What temperature does it precipitate at? (Q845748)

A. 100°C

B. 60°C

C. 0°C

D. 30°C

See Answer in Part B → Q3

@Neet_pg_bot

Q4: A 55-year-old woman presents with bone pain, recurrent infections, elevated serum calcium levels, renal dysfunction, and anaemia. Laboratory tests reveal an M spike on serum protein electrophoresis and the presence of Bence Jones proteins in the urine. Based on this presentation, which of the following is not a criterion for a myeloma-defining event in the diagnostic criteria for this condition? (Q845749)

A. Hypercalcemia

B. Anemia

C. Renal failure

D. Bence jones proteinuria

See Answer in Part B → Q4

@Neet_pg_bot

Q5: A 70-year-old woman is being evaluated for monoclonal gammopathy. Bone marrow examination showed abnormal proliferation of plasma cells with evidence of certain microscopic features. Match the following structures with corresponding histopathological images regarding this condition. 1. Flame Cell a) 2. Mott cell b) 3. Russel bodies c) 4. Dutcher bodies d) (Q845750)

A. 1-d; 2-a; 3-c; 4-b

B. 1-d; 2-c; 3-a; 4-b

C. 1-c; 2-d; 3-a; 4-b

D. 1-c; 2-d; 3-b; 4-a

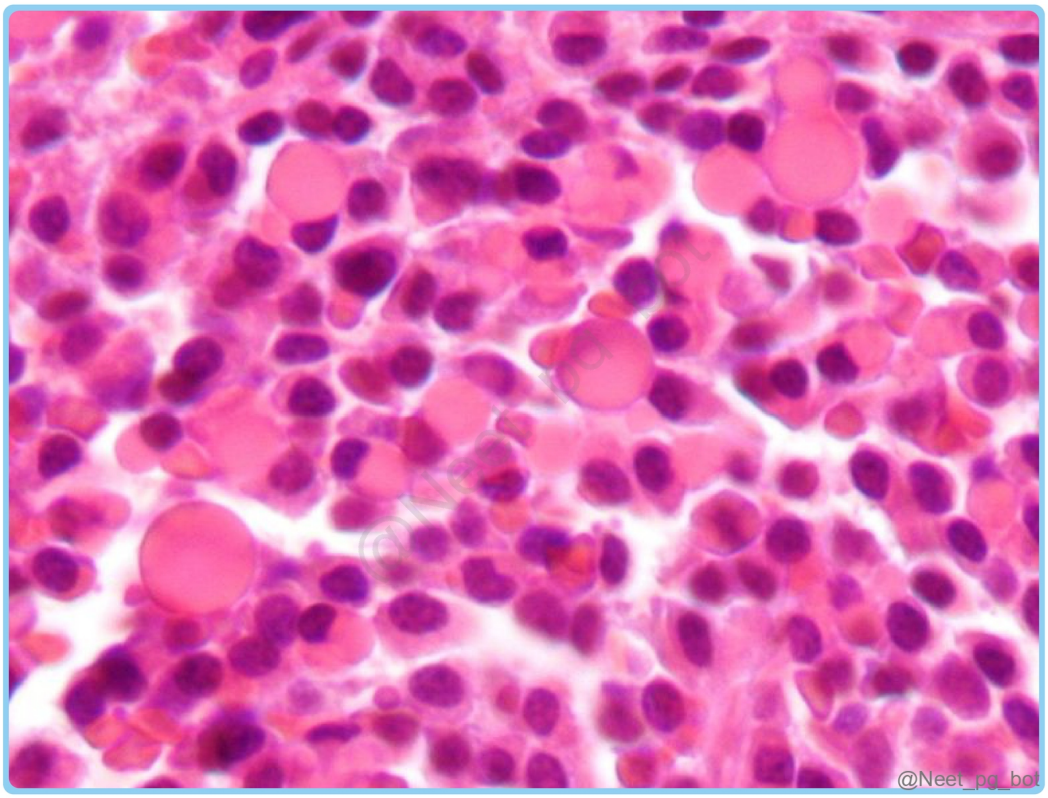
@Neet_pg_bot

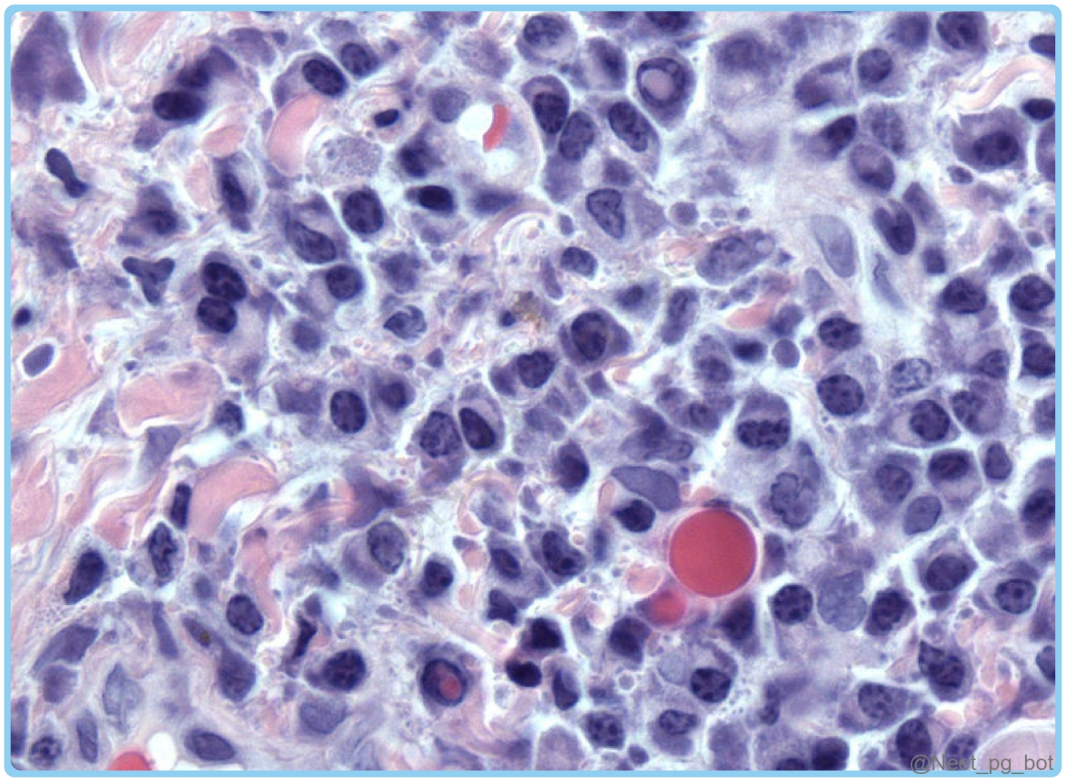
@Neet_pg_bot

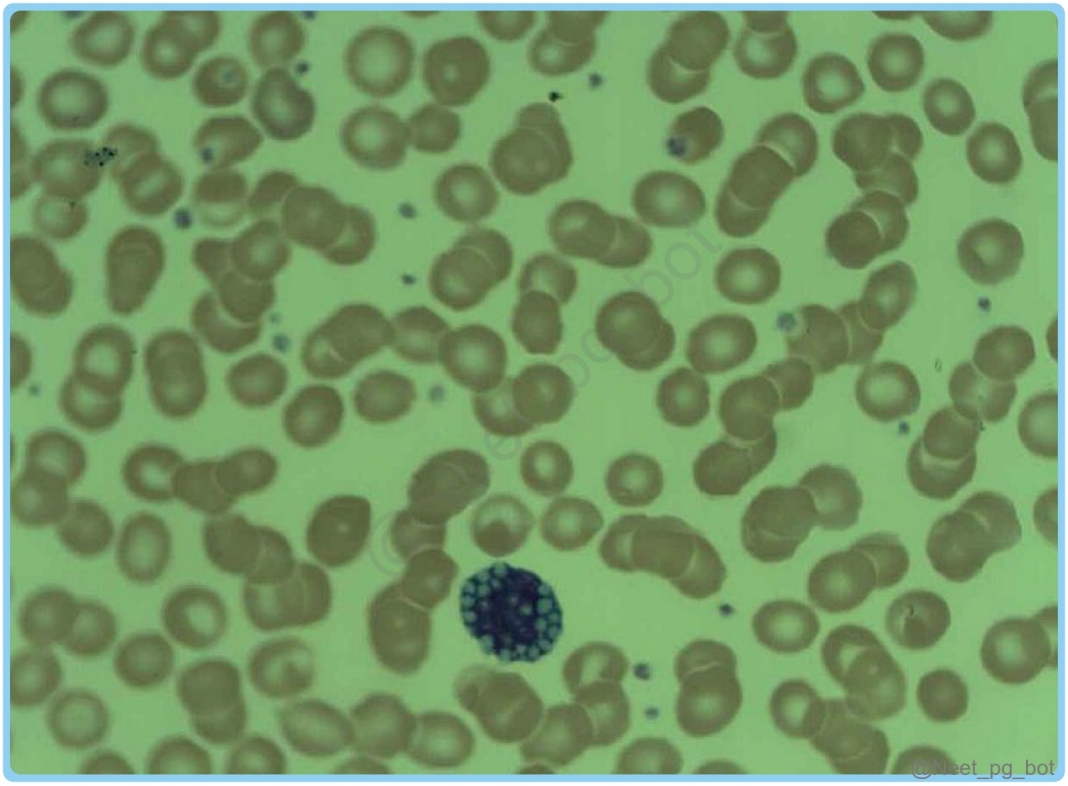

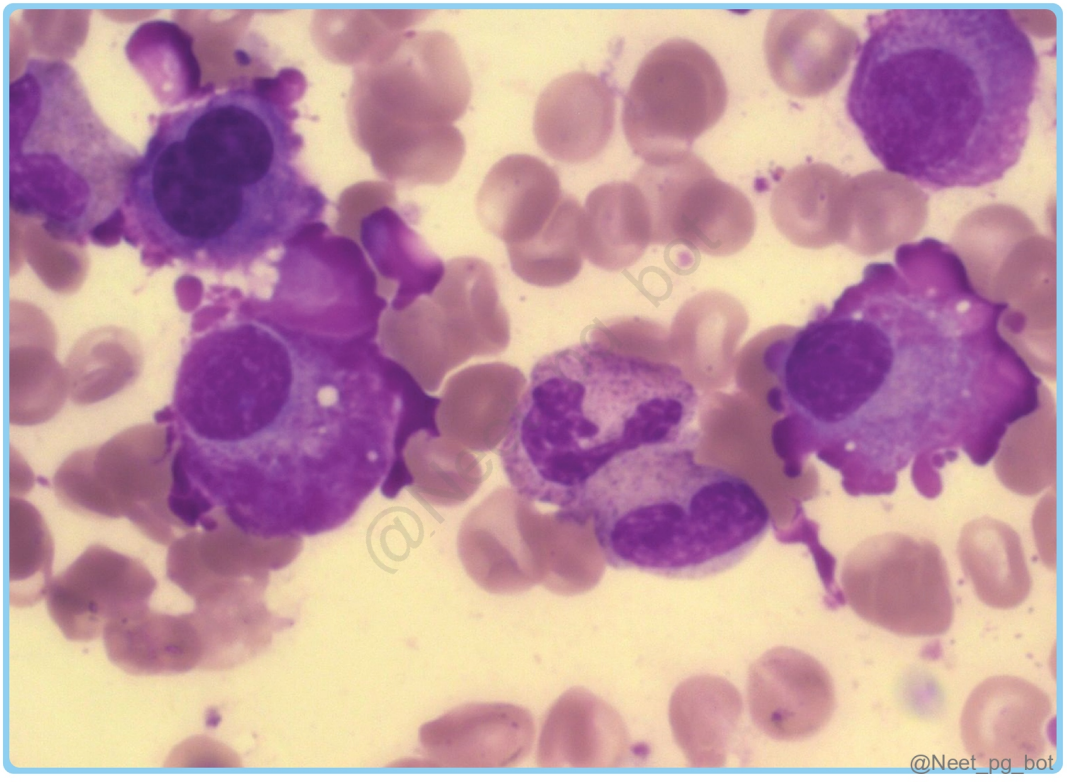

See Answer in Part B → Q5

@Neet_pg_bot

Q6: A 65-year-old male presents with fatigue, bone pain, and recurrent infections. Laboratory tests show elevated IL-6 and beta-2 microglobulin levels, while imaging reveals multiple lytic bone lesions. Bone marrow biopsy showed a high percentage of plasma cells, and cytogenetic analysis revealed a deletion of chromosome 17p. Flow cytometry is performed to distinguish abnormal plasma cells from normal ones in this patient. Which marker commonly shows increased expression on plasma cells in multiple myeloma, aiding in this differentiation? (Q845751)

A. CD19

B. CD38

C. CD56

D. CD117

See Answer in Part B → Q6

@Neet_pg_bot

Q7: A 68-year-old man presents with fatigue, bone pain, and recurrent infections. Laboratory tests reveal hypercalcemia and increased beta-2 microglobulin; imaging shows multiple lytic bone lesions. Which biochemical test is most commonly used to assess renal function and evaluate kidney damage in patients with multiple myeloma? (Q845752)

A. Serum protein electrophoresis (SPEP)

B. Serum creatinine levels

C. Serum calcium levels

D. Urine protein electrophoresis

See Answer in Part B → Q7

@Neet_pg_bot

Q8: A 62-year-old male with a routine health check-up is found to have a serum M protein level of 3.5 g/dL and plasma cells making up 25% of the marrow cellularity. He reports no bone pain, normal kidney function, normal calcium levels, and no lytic bone lesions on imaging. What is the most likely diagnosis? (Q845753)

A. Monoclonal Gammopathy of Undetermined Significance (MGUS)

B. Plasma Cell Leukemia

C. Multiple Myeloma

D. Smouldering Myeloma

See Answer in Part B → Q8

@Neet_pg_bot

Q9: A 70-year-old male presents with blurred vision, dizziness, and epistaxis. Physical examination reveals engorged retinal veins and signs of haemorrhage. Laboratory tests show an elevated serum viscosity. Serum protein electrophoresis reveals a monoclonal IgM spike. What is the most likely cause of the patient's symptoms? (Q845754)

A. Multiple Myeloma

B. Chronic Lymphocytic Leukemia

C. IgA Myeloma

D. Waldenstrom’s Macroglobulinemia

See Answer in Part B → Q9

@Neet_pg_bot

Q10: A 55-year-old male presents with recurrent infections and fatigue. Palatal edema is noted. Laboratory tests show hypogammaglobulinemia and serum protein electrophoresis reveals an absence of normal immunoglobulins but a monoclonal spike in the gamma region. Bone marrow biopsy reveals large lymphoid cells with intracytoplasmic inclusions. Which type of heavy chain disease is most likely causing

the patient's symptoms? (Q845755)

A. Alpha Heavy Chain Disease

B. Gamma Heavy Chain Disease

C. Mu Heavy Chain Disease

D. Delta Heavy Chain Disease

See Answer in Part B → Q10

@Neet_pg_bot

Q11: Which of the following represents the normal serum free κ:λ light chain ratio? (Q889647)

A. 0.01 - 0.10

B. 0.26 - 1.65

C. 1.65 - 3.50

D. 3.50 - 5.00

See Answer in Part B → Q11

@Neet_pg_bot

Q12: A 67-year-old man presents with back pain and anaemia. Skull radiograph shows multiple punched-out lytic lesions. He is diagnosed with multiple myeloma. Which of the following is the most common location of lytic bone lesions in multiple myeloma? (Q889652)

A. Vertebral column

B. Femur

C. Skull

D. Pelvis

See Answer in Part B → Q12

@Neet_pg_bot

Q13: A 66-year-old man with multiple myeloma presents with bone pain and hypercalcemia. Imaging shows multiple punched-out lytic lesions. The increased bone resorption in this condition is primarily mediated by which of the following factors produced by neoplastic plasma cells? (Q889654)

A. Interleukin-2

B. MIP-1α

C. Erythropoietin

D. Transforming growth factor-β

See Answer in Part B → Q13

@Neet_pg_bot

Q14: Excessive production of which of the following proteins is most commonly associated with hyperviscosity in multiple myeloma? (Q889661)

A. IgG3

B. IgG

C. IgM

D. IgG2

See Answer in Part B → Q14

@Neet_pg_bot

Q15: Which type of multiple myeloma is most commonly associated with a higher risk of renal insufficiency? (Q889663)

A. IgG myeloma

B. IgA myeloma

C. IgD myeloma

D. IgE myeloma

See Answer in Part B → Q15

@Neet_pg_bot

• [18_Hematology_ White Blood Cells] 073 Wbc Basics And Instruments

« Back to Folder Directory

[18_Hematology_ White Blood Cells] 073 Wbc Basics And Instruments — Quick Jump

Q1 (p. 813) *Q2 (p. 814)* *Q3 (p. 814)* *Q4 (p. 815)* *Q5 (p. 815)* *Q6 (p. 818)*
Q7 (p. 819) *Q8 (p. 819)* *Q9 (p. 819)*

Q1: A 50-year-old man presents with complaints of fatigue, easy bruising, and recurrent nosebleeds over the past month. Laboratory investigations reveal leukopenia and thrombocytopenia. Peripheral blood smear examination demonstrates the presence of cells with Auer rods. In which stage of myelopoiesis are Auer rods typically found? (Q845756)

A. Myeloblast

B. Myelocyte

C. Metamyelocyte

D. Monoblast

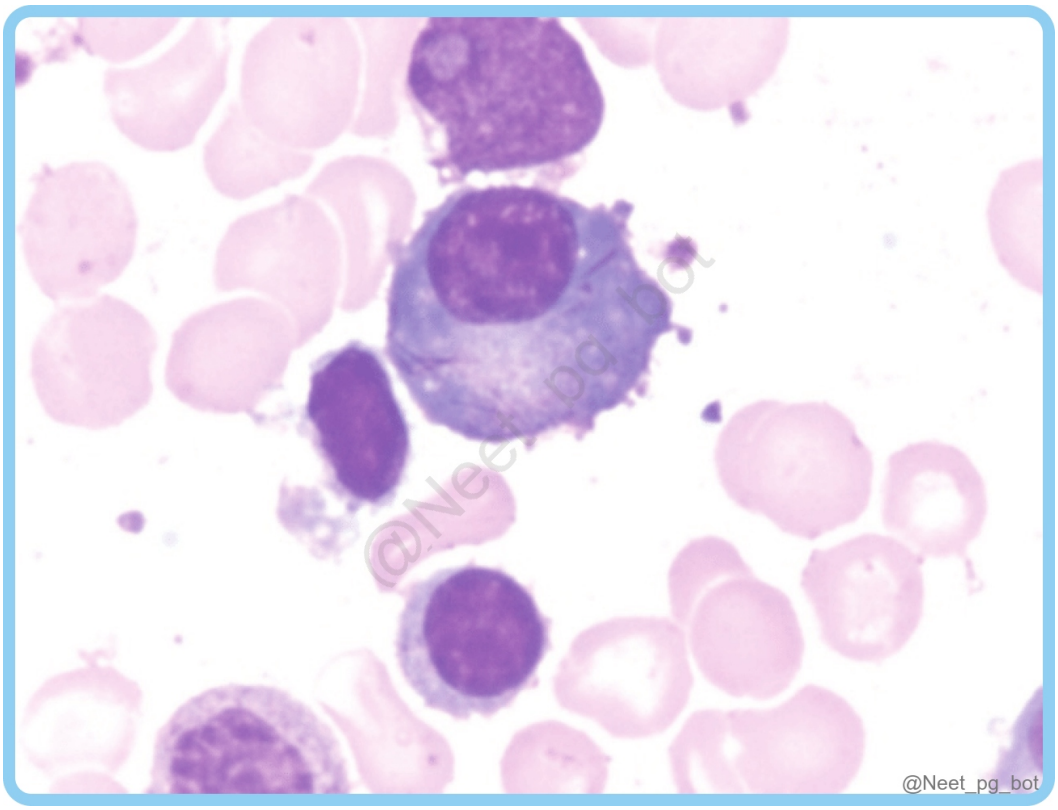

See Answer in Part B → Q1

@Neet_pg_bot

Q2: A 45-year-old man presents with complaints of persistent fever, chills, and generalized weakness for the past week. Lab reports revealed leukocytosis with a left shift, and peripheral blood smear examination shows cells with kidney-shaped nuclei and parasites in ring forms inside RBCs. What is the cell called? (Q845757)

A. Monocyte

B. Neutrophil

C. Basophil

D. Eosinophil

See Answer in Part B → Q2

@Neet_pg_bot

Q3: A 6-year-old child is brought up due to concerns about persistent fever, fatigue, and frequent infections over the past few weeks. There is generalised lymphadenopathy. Laboratory investigations reveal leukocytosis with lymphoblasts on peripheral smear examination. Which of the following stains are used to visualise lymphoblasts? (Q845758)

A. Periodic Acid Schiff (PAS) stain

B. Myeloperoxidase stain

C. Sudan Black stain

D. Wright stain

See Answer in Part B → Q3

@Neet_pg_bot

Q4: A 55-year-old male presents with persistent fatigue, significant weight loss, and night sweats over the past few months. Examination revealed massive splenomegaly. CBC shows elevated white blood cell count. A bone marrow biopsy confirms the diagnosis of CML. Which of the following types of leukocytosis is most commonly associated with this condition? (Q845760)

A. Neutrophilia

B. Eosinophilia

C. Lymphocytosis

D. Basophilia

See Answer in Part B → Q4

@Neet_pg_bot

Q5: Match the following cells with their respective images a) Hypersegmented neutrophil 1) b) Hyposegmented neutrophil 2) c) Dohle bodies 3) d) Alder Reilly anomaly 4) (Q845761)

A. a-3, b-4, c-1, d-2

B. a-2, b-1, c-4, d-3

C. a-4, b-3, c-1, d-2

D. a-2, b-3, c-4, d-1

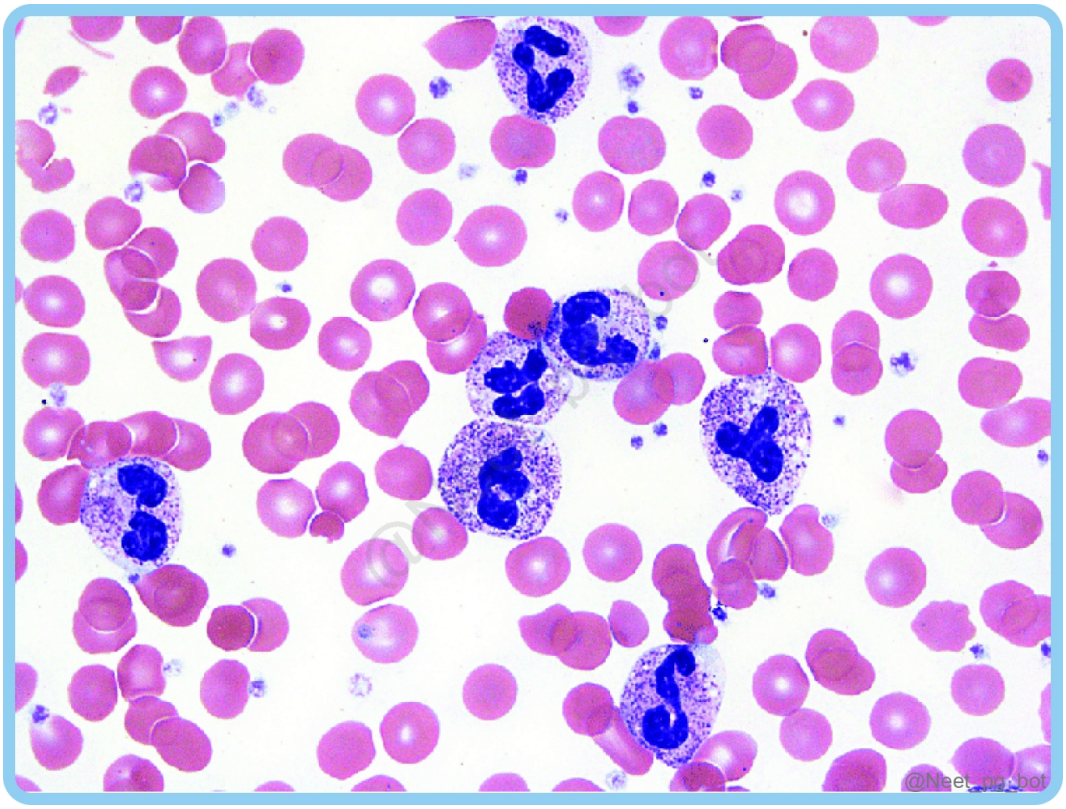

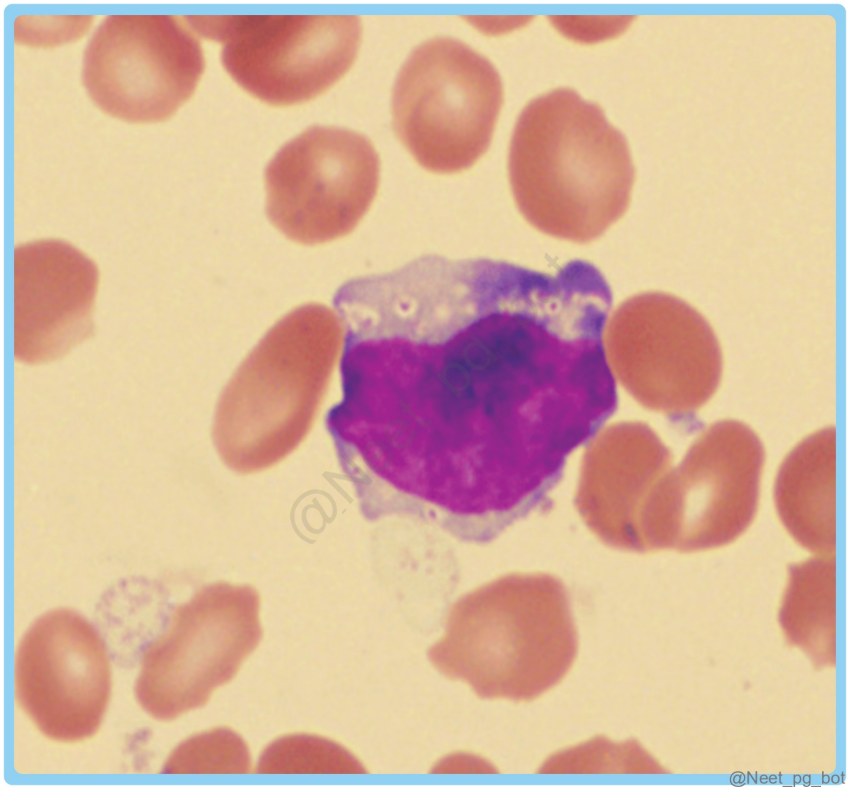
@Neet_pg_bot

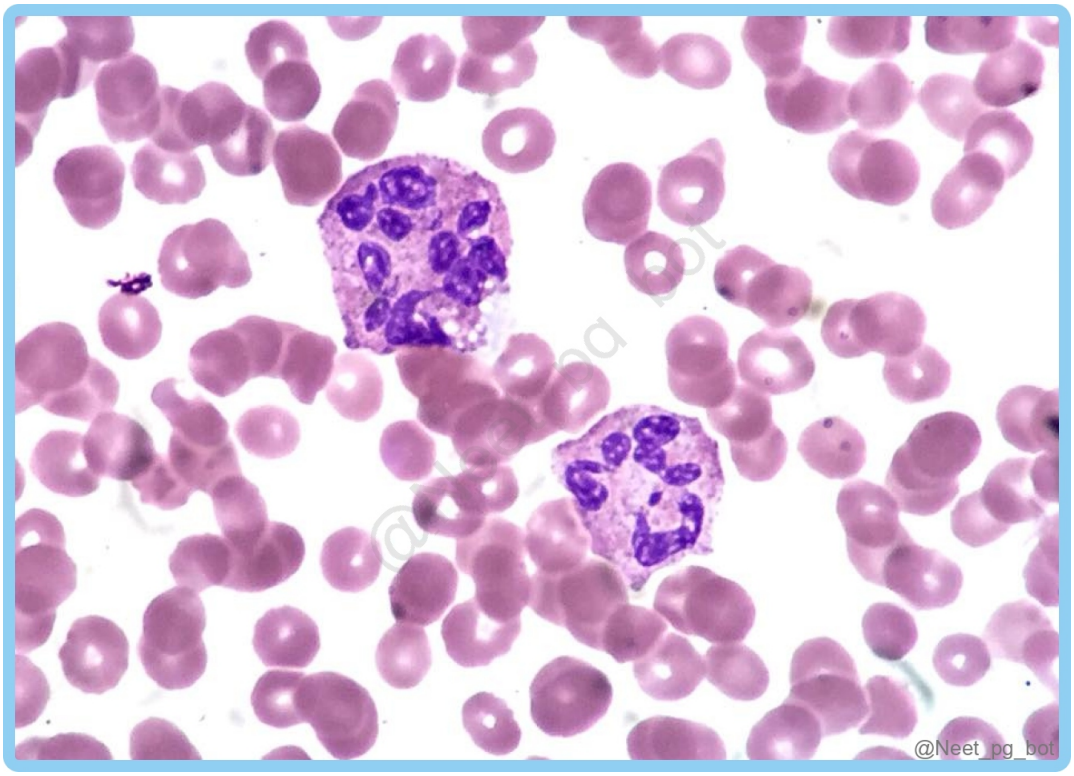
@Neet_pg_bot

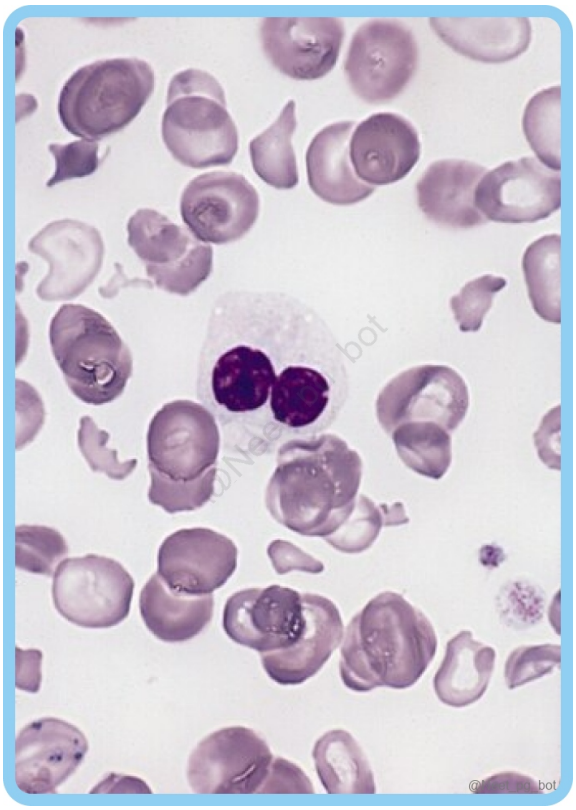

See Answer in Part B → Q5

@Neet_pg_bot

Q6: A 17-year-old boy presented with complaints of a sore throat, fever, and extreme fatigue for the past two weeks. On examination, he has enlarged cervical lymph nodes and an enlarged spleen. A complete blood count reveals lymphocytosis with atypical lymphocytes and is diagnosed as infectious mononucleosis. Which of the following statements is NOT correct? (Q845762)

A. Caused by Epstein-Barr Virus (EBV)

B. The Monospot test is a common diagnostic tool

C. Downey cells are characteristic histopathological features.

D. Also known as Haemophagocytic Lymphohistiocytosis.

See Answer in Part B → Q6

@Neet_pg_bot

Q7: A 58-year-old patient presents with fatigue, night sweats, and significant weight loss. Physical examination reveals generalized lymphadenopathy and splenomegaly. Blood tests show a markedly elevated white blood cell count. Based on the clinical scenario, which diagnosis is most likely if the bone marrow biopsy reveals over 20% blasts? (Q845763)

A. Chronic Lymphocytic Leukemia (CLL)

B. Acute Myeloid Leukemia (AML)

C. Hodgkin’s Lymphoma (HL)

D. Non-Hodgkin’s Lymphoma (NHL)

See Answer in Part B → Q7

@Neet_pg_bot

Q8: A 45-year-old female is undergoing routine blood work. The laboratory technician uses different Vacutainers for various tests. Which Vacutainer colour is used for coagulation studies, such as PT and aPTT? (Q845764)

See Answer in Part B → Q8

@Neet_pg_bot

Q9: Which of the following diluting fluids correctly matches its specific use in haematology? (Q845767)

A. Turk's Solution - Platelets

B. Hayem's Solution - WBCs

C. Gower's Solution - RBCs

D. 1% Ammonium Oxalate - WBCs

See Answer in Part B → Q9

@Neet_pg_bot

• [18_Hematology_ White Blood Cells] 074 All And Aml

« Back to Folder Directory

[18_Hematology_ White Blood Cells] 074 All And Aml — Quick Jump

Q1 (p. 821) *Q2 (p. 821)* *Q3 (p. 821)* *Q4 (p. 822)* *Q5 (p. 823)* *Q6 (p. 823)*
Q7 (p. 824) *Q8 (p. 824)* *Q9 (p. 825)* *Q10 (p. 826)* *Q11 (p. 827)* *Q12 (p. 827)*
Q13 (p. 827) *Q14 (p. 828)*

Q1: As per FAB classification, what percentage of blast cells in bone marrow biopsy is required to diagnose a patient with acute leukaemia? (Q845765)

A. 10

B. 20

C. 25

D. 30

See Answer in Part B → Q1

@Neet_pg_bot

Q2: Which is not included in the FAB classification of acute lymphoblastic leukaemia (ALL) L3 subtype? (Q845766)

A. Presence of lymphoblasts with vacuoles and cytoplasmic blebs

B. Expression of surface immunoglobulins

C. Association with Epstein-Barr virus (EBV)

D. t(9;22) Philadelphia chromosome

See Answer in Part B → Q2

@Neet_pg_bot

Q3: Which of the following is not associated with acute lymphoblastic leukaemia (ALL) regarding chromosomes? (Q845768)

A. t(9;22)

B. t(12;21)

C. t(1;19)

D. t(15;17)

See Answer in Part B → Q3

@Neet_pg_bot

Q4: A 4-year-old male presents with fever, bleeding gums, and fatigue for 5 days. CBC shows Hb of 8g%, TLC 30,000/µL, and platelet count of 40,000/µL. A differential count shows an increased number of immature white blood cells. A bone marrow aspiration is done, as shown below. What is the most likely diagnosis? (Q845769)

A. Chronic myeloid leukaemia.

B. Acute lymphoblastic leukaemia.

C. Acute promyelocytic leukaemia.

D. Aplastic anaemia

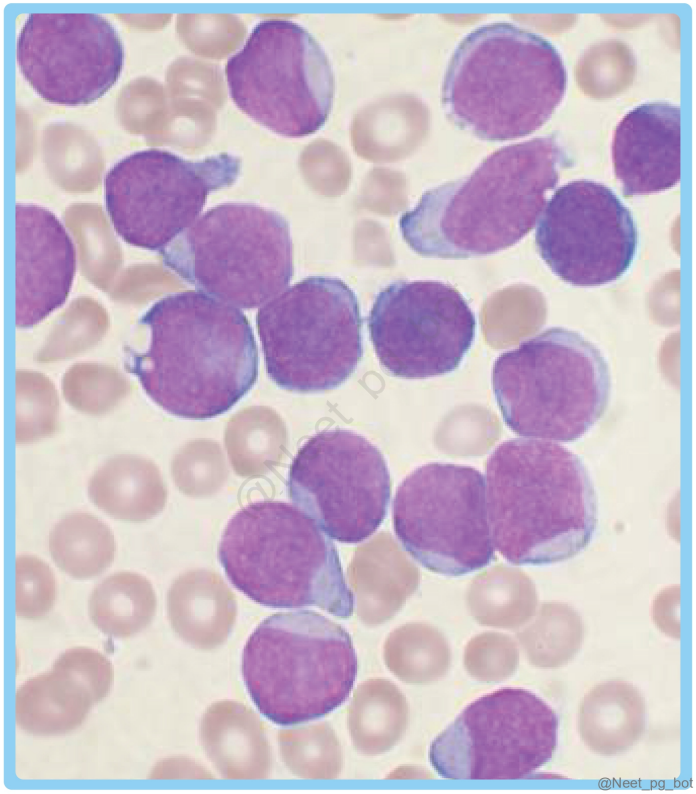

See Answer in Part B → Q4

@Neet_pg_bot

Q5: Which of the following markers will be negative on immunophenotyping of a patient with early pre-B acute leukaemia? (Q845770)

A. TdT

B. DR

C. CD19

D. CD10

See Answer in Part B → Q5

@Neet_pg_bot

Q6: Which of the following statements is incorrect regarding the prognosis of ALL? Adults have a worse prognosis as compared to children aged 2-9 years. White females have a good survival rate as compared to black males. The Philadelphia chromosome (t(9;22)) is associated with a favourable prognosis. Higher white blood cell counts at diagnosis are associated with a better prognosis. Hypodiploidy in B-ALL is associated with a better prognosis. (Q845771)

A. 3, 4 and 5

B. 2, 3 and 4

C. 1, 4 and 5

D. 4 and 5

See Answer in Part B → Q6

@Neet_pg_bot

Q7: A 9-year-old boy presents with fever, fatigue, and worsening shortness of breath. On examination, he has a large anterior mediastinal mass causing respiratory distress . Laboratory findings shows leukocytosis and blasts on peripheral smear. Flow cytometry of blasts reveals the positivity for CD3, CD5, CD7 along with variable expression of CD10. What is the most likely diagnosis? (Q845772)

A. Acute Myeloid Leukemia (AML)

B. T cell Acute Lymphoblastic Leukemia

C. B cell Acute Lymphoblastic Leukemia

D. Chronic Lymphocytic Leukemia (CLL)

See Answer in Part B → Q7

@Neet_pg_bot

Q8: Which of the following statements regarding the M4 subtype of AML based on FAB classification is true? (Q845773)

A. It is associated with t(8:21), called AML with maturation.

B. It is associated with t(15:17), called acute promyelocytic leukaemia

C. It is associated with CBF-MYH fusion, called acute myelomonocytic leukaemia

D. It is associated with MPO positivity, called AML without maturation.

See Answer in Part B → Q8

@Neet_pg_bot

Q9: A 12-year-old boy presents with fatigue, bruising, and intermittent fevers for the past few weeks. Physical examination reveals the following findings. Immunophenotyping of the biopsy specimen shows CD43 and MPO positivity. What is the most likely diagnosis? (Q845774)

A. Acute Lymphoblastic Leukemia (ALL)

B. AML with maturation

C. Acute promyelocytic leukaemia

D. Non-Hodgkin Lymphoma

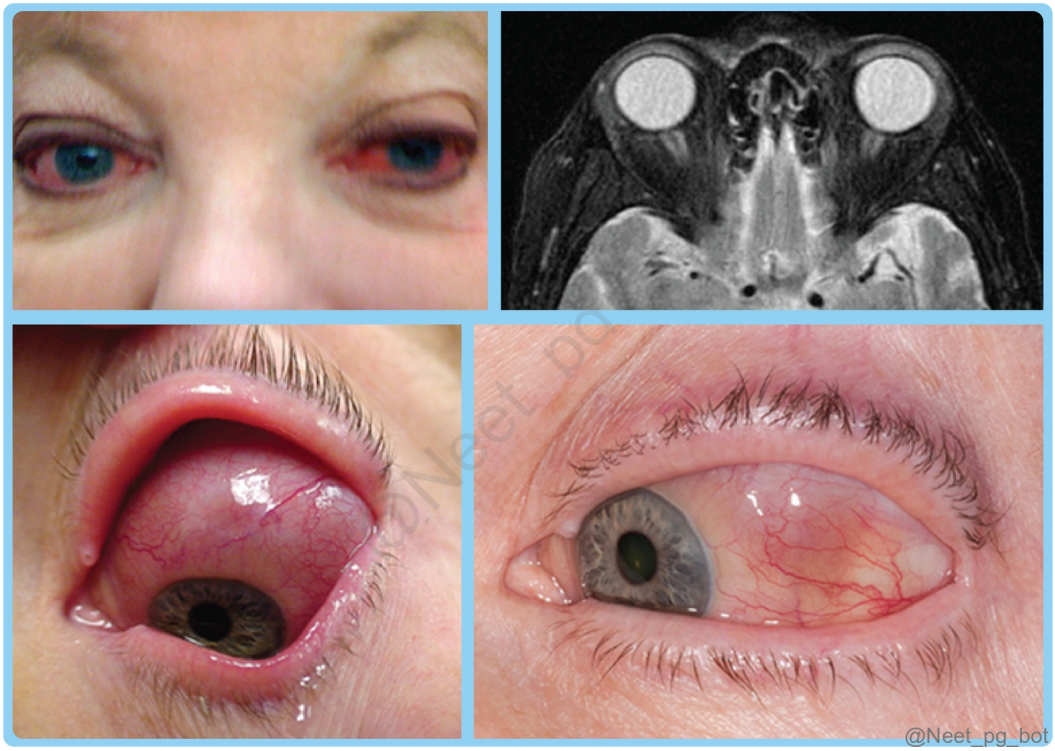

See Answer in Part B → Q9

@Neet_pg_bot

Q10: A 28-year-old female was admitted to the hospital with complaints of frequent nosebleeds, reports of sudden onset chest pain and dyspnea. On examination, she has petechiae and ecchymoses on her skin. Laboratory tests revealed WBC 15,000/µL, haemoglobin 8 g/dL, platelets 20,000/µL and elevated prothrombin time. A peripheral blood smear shows the following findings. Further testing confirms which of the following associated conditions? (Q845775)

A. t(12:21) translocation

B. t(15:17) translocation

C. t(9:22) translocation

D. t(8:21) translocation

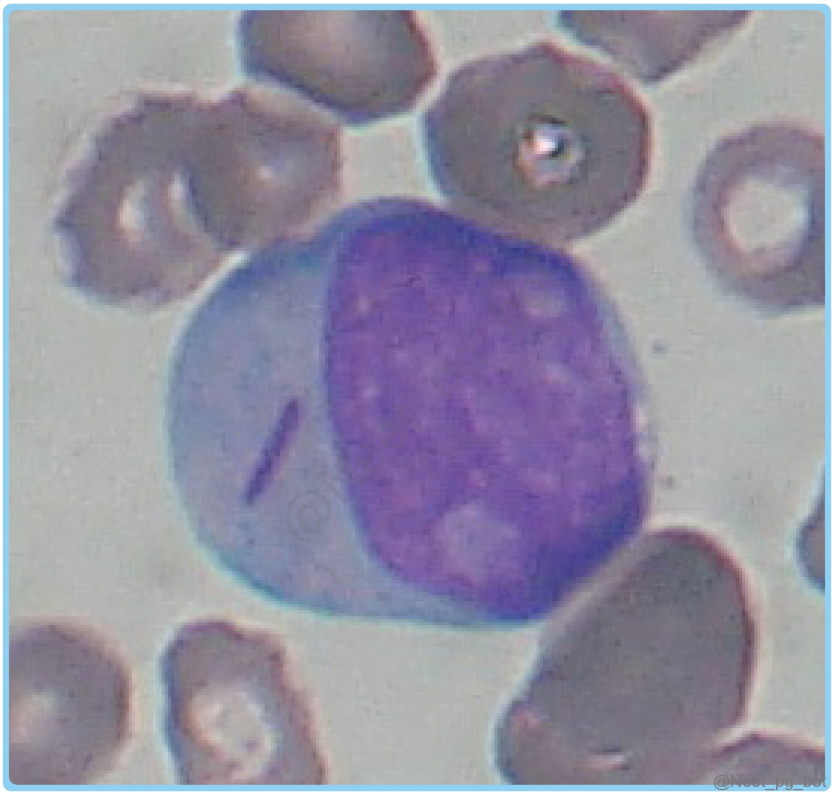

See Answer in Part B → Q10

@Neet_pg_bot

Q11: Which of the following types of AML, according to the FAB classification, is associated with Down's syndrome? (Q845776)

A. Acute erythroid leukaemia

B. Acute myelomonocytic leukaemia

C. Acute megakaryocytic leukaemia

D. Acute monocytic leukaemia

See Answer in Part B → Q11

@Neet_pg_bot

Q12: Which of the following is associated with a good prognosis according to WHO classification of AML? (Q845777)

A. AML: Therapy-related

B. AML with MDS-like features

C. AML with recurrent genetic abnormality

D. AML not otherwise specified

See Answer in Part B → Q12

@Neet_pg_bot

Q13: What is the most likely immunophenotype associated with the condition indicated by the peripheral blood smear shown below? (Q845778)

A. CD13+, CD33+, CD34+, HLA-DR+

B. CD19+, CD20-, CD22+, CD79a-

C. CD3+, CD4+, CD8+, CD5-

D. CD10+, CD19+, CD20+, CD22-

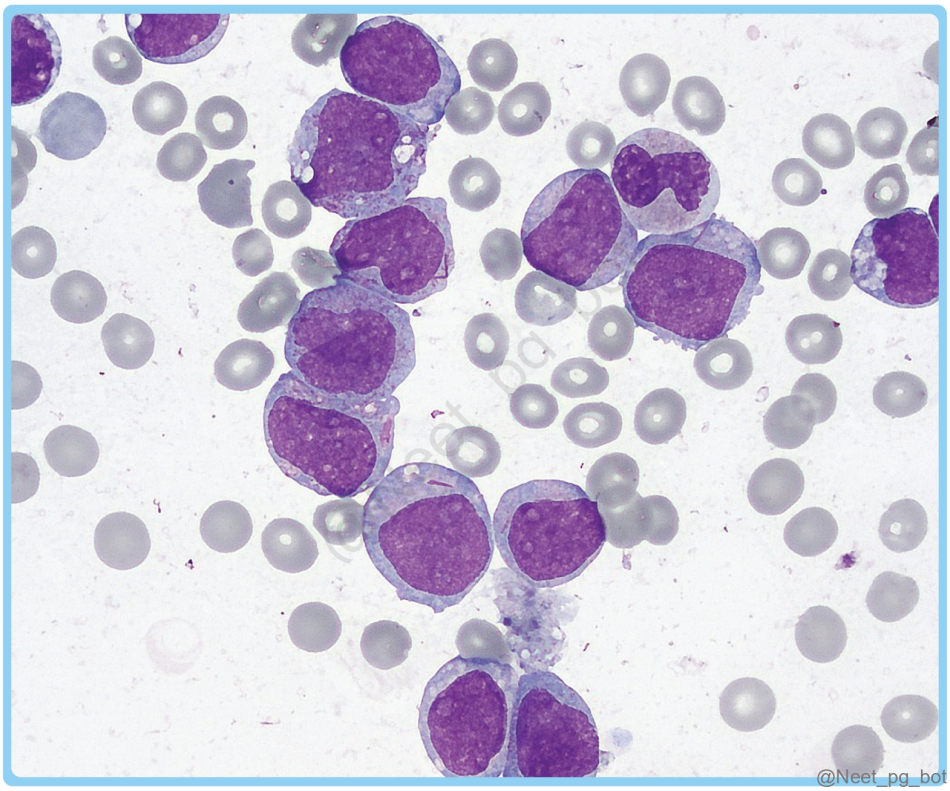

See Answer in Part B → Q13

@Neet_pg_bot

Q14: A 55-year-old female presented with fatigue, easy bruising, and recurrent infections over the past few months. On examination, there is mild splenomegaly, but no lymphadenopathy is noted. Laboratory tests reveal pancytopenia. A peripheral blood smear shows normocytic normochromic red blood cells and bone marrow shows blast count >20%. What is the most likely diagnosis? (Q845779)

A. Aplastic anemia

B. Myelodysplasia

C. Aleukemic leukaemia

D. Myeloproliferative disorder

See Answer in Part B → Q14

@Neet_pg_bot

• [18_Hematology_ White Blood Cells] 075 Myeloid Disorders

« Back to Folder Directory

[18_Hematology_ White Blood Cells] 075 Myeloid Disorders — Quick Jump

Q1 (p. 830) *Q2 (p. 830)* *Q3 (p. 831)* *Q4 (p. 831)* *Q5 (p. 832)* *Q6 (p. 833)*
Q7 (p. 833) *Q8 (p. 834)* *Q9 (p. 834)* *Q10 (p. 835)* *Q11 (p. 835)* *Q12 (p. 835)*
Q13 (p. 836) *Q14 (p. 836)*

Q1: A 45-year-old female presents with complaints of occasional headaches and blurred vision. Laboratory tests reveal isolated thrombocytosis without significant leukocytosis or erythrocytosis. Bone marrow biopsy shows increased megakaryocytes. Which of the following types of myeloproliferative neoplasm (MPN) is most likely to be diagnosed based on these findings? (Q845780)

A. Polycythemia Vera (PV)

B. Essential Thrombocytosis (ET)

C. Chronic Myeloid Leukemia (CML)

D. Primary Myelofibrosis (PMF)

See Answer in Part B → Q1

@Neet_pg_bot

Q2: A 50-year-old male presents with complaints of headaches, dizziness, and pruritus. Physical examination reveals a plethora and splenomegaly. Laboratory tests show elevated hemoglobin and hematocrit levels. Which of the following criteria are consistent with the Polycythemia Vera (PV) diagnosis? (Q845781)

A. Sustained platelet count ≥ 450 x 10^9/L

B. Increased red blood cell mass

C. Presence of JAK2 mutation

D. Presence of CALR or MPL mutation

See Answer in Part B → Q2

@Neet_pg_bot

Q3: A 55-year-old female presents to the clinic with complaints of frequent headaches, dizziness, and occasional burning pain in her hands and feet. Examination reveals splenomegaly. Her complete blood count shows a platelet count of 12,00,000/µL. The peripheral blood smear shows marked thrombocytosis with giant platelets. Which of the following is not true regarding this condition? (Q845783)

A. Characterized by the presence of megakaryocytic hyperplasia.

B. Associated with JAK2, CALR, or MPL mutations.

C. Bone marrow biopsy typically shows increased reticulin fibrosis.

D. Increased risk of thrombotic and hemorrhagic events.

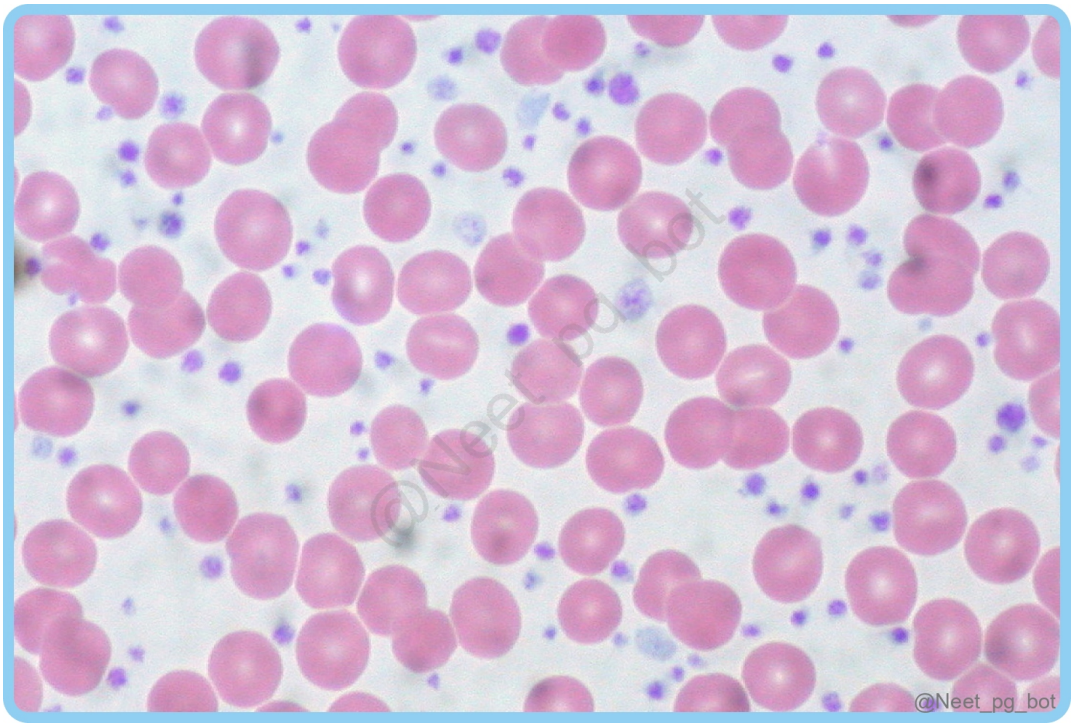

See Answer in Part B → Q3

@Neet_pg_bot

Q4: A 65-year-old man presents with progressive fatigue and significant weight loss for the past six months. Examination reveals a markedly enlarged spleen. Peripheral blood smear shows teardrop-shaped red cells. Bone marrow biopsy confirms the diagnosis of primary myelofibrosis. Which of the following statements regarding the diagnosis is true? 1) It is characterized by extensive marrow fibrosis. 2) Diagnostic criteria include the presence of JAK2, CALR, or MPL mutations. 3) Pathogenesis involves the inappropriate release of fibrogenic factors like PDGF and TGF-β. (Q845784)

A. All statements are true

B. 1,2

C. Only 3

D. 2,3

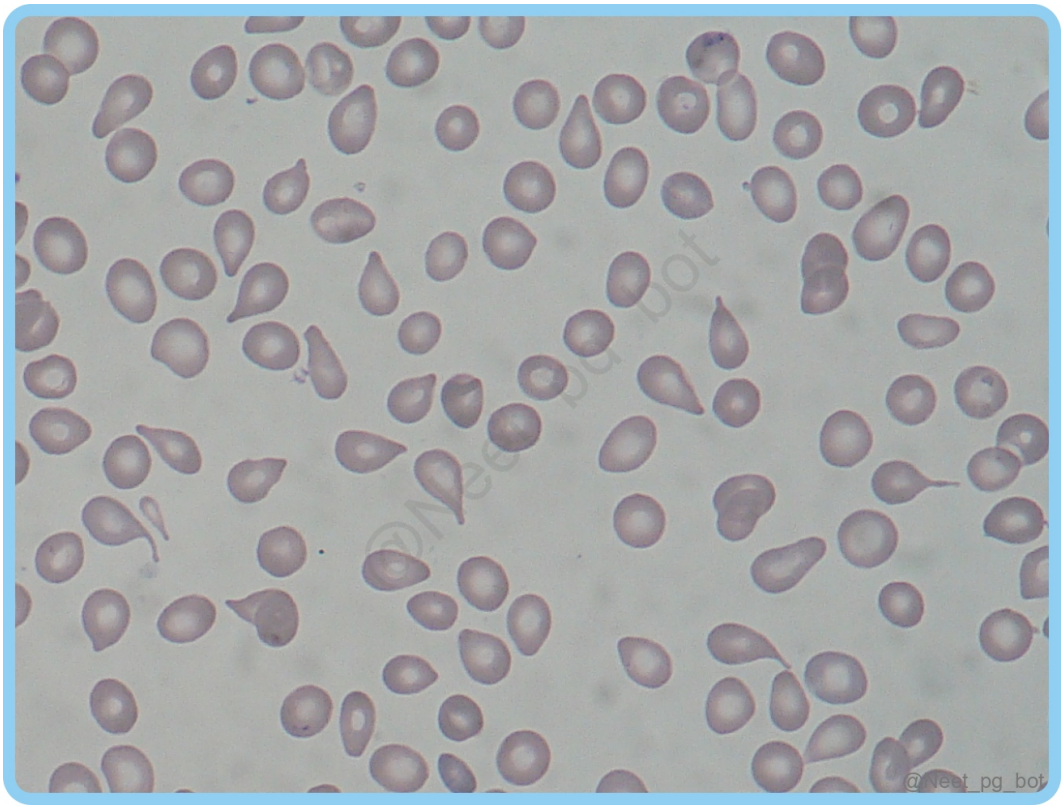

See Answer in Part B → Q4

@Neet_pg_bot

Q5: A 60-year-old man presents with complaints of increasing fatigue, early satiety, and unintentional weight loss over the past few months. On examination, there is palpable splenomegaly. Laboratory reports reveal pancytopenia with dacrocytes on the peripheral smear. Which of the following is not associated with Myelofibrosis? (Q845785)

A. Dry tap

B. Leukoerythroblastic blood picture

C. Dacrocytes

D. Myeloblasts

See Answer in Part B → Q5

@Neet_pg_bot

Q6: A 75-year-old man presents with increasing fatigue, weakness, and easy bruising over the past few months. Labs show pancytopenia. Peripheral blood smear reveals dysplastic differentiation in the erythroid, granulocytic, monocytic, and megakaryocytic lineages. Which condition does this suggest? (Q845787)

A. Hyperlobated megakaryocyte

B. Leukoerythroblastic picture

C. Increased proliferation of RBCs

D. Pawn ball megakaryocyte

See Answer in Part B → Q6

@Neet_pg_bot

Q7: A 5-year-old child presents with a skin rash, recurrent ear infections, bone pain, and polyuria. Imaging revealed lytic bone lesions and a biopsy of one of the lesions showed CD1a and S-100 positive Langerhans cells. Which of the following types of Langerhans cell histiocytosis (LCH) is characterized by multifocal uni system involvement? (Q845790)

A. Eosinophilic granuloma

B. Hand-Schüller-Christian disease

C. Letterer-Siwe disease

D. Both A and C

See Answer in Part B → Q7

@Neet_pg_bot

Q8: Pseudo-Gaucher cells are commonly seen in which of the following conditions? (Q889668)

A. Gaucher disease

B. Chronic myeloid leukaemia

C. Hairy cell leukaemia

D. Multiple myeloma

See Answer in Part B → Q8

@Neet_pg_bot

Q9: Which of the following findings is least likely to be seen in polycythemia vera (PCV)? (Q889669)

A. Low serum erythropoietin

B. Basophilia

C. Budd-chiari syndrome

D. Lymphocytosis

See Answer in Part B → Q9

@Neet_pg_bot

Q10: Which of the following conditions is most likely associated with a leucoerythroblastic blood film? (Q889671)

A. Iron deficiency anaemia

B. Vitamin B12 deficiency

C. Primary myelofibrosis

D. Thalassemia

See Answer in Part B → Q10

@Neet_pg_bot

Q11: Which of the following is not part of the WHO 2022 diagnostic criteria for CMML? (Q889674)

A. Persistent absolute (≥0.5 × 10■/L) and relative (≥10%) peripheral blood monocytosis

B. Blasts constitute <20% in blood and bone marrow

C. Presence of Philadelphia chromosome (BCR::ABL1 fusion)

D. Dysplasia involving ≥1 myeloid lineage

See Answer in Part B → Q11

@Neet_pg_bot

Q12: Which of the following findings is not typically present in juvenile myelomonocytic leukaemia (JMML)? (Q889678)

A. Peripheral blood monocytosis ≥1 × 10■/L

B. Blasts <20% in blood and marrow

C. BCR::ABL1 fusion gene

D. Splenomegaly

See Answer in Part B → Q12

@Neet_pg_bot

Q13: Which of the following numbered conditions are histiocytic and dendritic cell neoplasms? Langerhans Cell Histiocytosis (LCH) Chronic Lymphocytic Leukaemia (CLL) Rosai-Dorfman Disease (RDD) Juvenile Xanthogranuloma (JXG) Erdheim-Chester Disease (ECD) (Q889681)

A. 1, 3, 4, 5

B. 2, 3, 4

C. 1, 2, 5

D. 2, 4, 5

See Answer in Part B → Q13

@Neet_pg_bot

Q14: Which of the following conditions is typically not characterised by pancytopenia? (Q889685)

A. Vitamin B12 deficiency

B. Hairy cell leukaemia

C. Hypocellular myelodysplastic syndrome

D. Immune thrombocytopenic purpura (ITP)

See Answer in Part B → Q14

@Neet_pg_bot

• [18_Hematology_ White Blood Cells] 076 Hodgkin S And Non-Hodgkin S Lymphoma

« Back to Folder Directory

[18_Hematology_ White Blood Cells] 076 Hodgkin S And Non-Hodgkin S Lymphoma — Quick Jump

Q1 (p. 837)	*Q2 (p. 837)*	*Q3 (p. 838)*	*Q4 (p. 838)*	*Q5 (p. 838)*	*Q6 (p. 839)*
Q7 (p. 839)	*Q8 (p. 840)*	*Q9 (p. 840)*	*Q10 (p. 840)*	*Q11 (p. 841)*	*Q12 (p. 843)*
Q13 (p. 843)	*Q14 (p. 843)*	*Q15 (p. 844)*	*Q16 (p. 844)*	*Q17 (p. 845)*	*Q18 (p. 845)*
Q19 (p. 846)	*Q20 (p. 847)*	*Q21 (p. 847)*	*Q22 (p. 848)*	*Q23 (p. 848)*	*Q24 (p. 849)*
Q25 (p. 849)	*Q26 (p. 850)*	*Q27 (p. 850)*	*Q28 (p. 851)*	*Q29 (p. 851)*	*Q30 (p. 852)*
Q31 (p. 852)	*Q32 (p. 853)*	*Q33 (p. 853)*	*Q34 (p. 854)*	*Q35 (p. 855)*	*Q36 (p. 856)*
Q37 (p. 857)	*Q38 (p. 857)*	*Q39 (p. 858)*	*Q40 (p. 860)*	*Q41 (p. 861)*	*Q42 (p. 862)*

Q1: A 64-year-old man presents with persistent lymphocytosis on routine blood work. Flow cytometry shows a clonal B-cell population consistent with CLL/SLL. What absolute lymphocyte count (ALC) is required to diagnose CLL rather than SLL? (Q884880)

A. >1,500/mm³

B. >3,000/mm³

C. >5,000/mm³

D. >10,000/mm³

See Answer in Part B → Q1

@Neet_pg_bot

Q2: Which of the following genetic alterations represents the central pathogenic event in classic Hodgkin lymphoma? (Q884843)

A. Loss-of-function mutation of IKBα (NFKBIA)

B. Activation of NF-κB

C. Loss-of-function mutation of TNFAIP3 (A20)

D. Copy number gain of the REL proto-oncogene

See Answer in Part B → Q2

@Neet_pg_bot

Q3: A patient with classic Hodgkin lymphoma undergoes cytogenetic analysis. The Reed-Sternberg cells show a recurrent copy number gain on chromosome 2p, contributing to increased NF-κB activity. Which gene is most likely amplified? (Q884845)

A. TNFAIP3

B. NFKBIA

C. REL

D. PD-L1

See Answer in Part B → Q3

@Neet_pg_bot

Q4: Reed-Sternberg-like cells (RSLC) are seen in which of the following conditions? Infectious mononucleosis Non-Hodgkin lymphoma Solid tumors Classic Hodgkin lymphoma (Q884847)

A. 1, 2 only

B. 1, 2, 3 only

C. 4 only

D. 1, 2, 3, 4

See Answer in Part B → Q4

@Neet_pg_bot

Q5: A 28-year-old man presents with a 3-month history of painless cervical lymphadenopathy. He reports sharp pain in the neck nodes within minutes of drinking small amounts of alcohol, which resolves spontaneously. He also has intermittent low-grade fever and night sweats. Which of the following is the most likely diagnosis? (Q884849)

A. Non-Hodgkin lymphoma

B. Metastatic squamous cell carcinoma

C. Hodgkin lymphoma

D. Tuberculous lymphadenitis

See Answer in Part B → Q5

@Neet_pg_bot

Q6: Which subtype of Hodgkin lymphoma is associated with biphasic incidence? (Q884854)

A. Nodular sclerosis

B. Mixed cellularity

C. Lymphocyte-rich

D. Nodular lymphocyte predominant

See Answer in Part B → Q6

@Neet_pg_bot

Q7: A 65-year-old man presents with fever, weight loss, and generalized lymphadenopathy (Stage III). Lymph node biopsy shows numerous classic Reed–Sternberg cells in a mixed inflammatory background. Which of the following statements regarding this subtype of hodgkin lymphoma is incorrect? (Q884858)

A. It often presents at advanced stage.

B. EBV positivity is seen in approximately 70% of cases.

C. It accounts for about 20–25% of Hodgkin lymphoma cases.

D. It most commonly presents as a mediastinal mass in young females.

See Answer in Part B → Q7

@Neet_pg_bot

Q8: A lymph node biopsy shows a ring of tightly packed small B lymphocytes surrounding a germinal center and displaced outward by it. Which zone is being described? (Q884865)

A. Germinal center

B. Mantle zone

C. Marginal zone

D. Paracortex

See Answer in Part B → Q8

@Neet_pg_bot

Q9: Which of the following is a T-cell neoplasm? (Q884874)

A. Follicular lymphoma

B. Mantle cell lymphoma

C. Anaplastic large-cell lymphoma

D. Burkitt lymphoma

See Answer in Part B → Q9

@Neet_pg_bot

Q10: Which of the following is the most common site of primary extranodal non-Hodgkin lymphoma? (Q884877)

A. Skin

B. Gastrointestinal tract

C. Central nervous system

D. Bone marrow

See Answer in Part B → Q10

@Neet_pg_bot

Q11: A 65-year-old man presents with lymphadenopathy and lymphocytosis. Lymph node biopsy & peripheral smear findings are as shown. Which feature is pathognomonic for this condition? (Q884878)

A. Smudge cells

B. Diffuse lymph node effacement

C. Proliferation centres

D. Bone marrow involvement

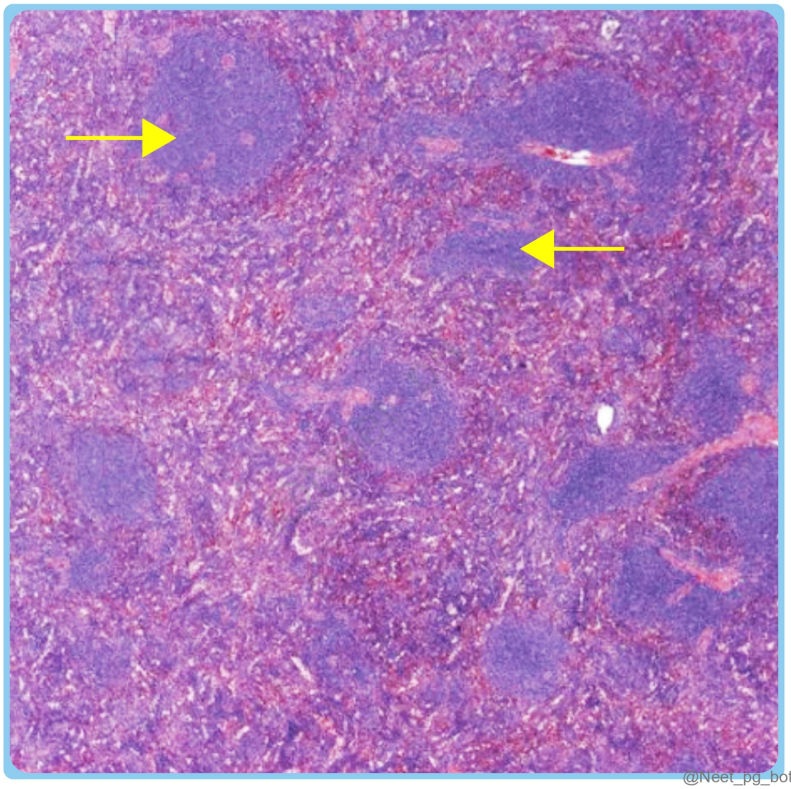

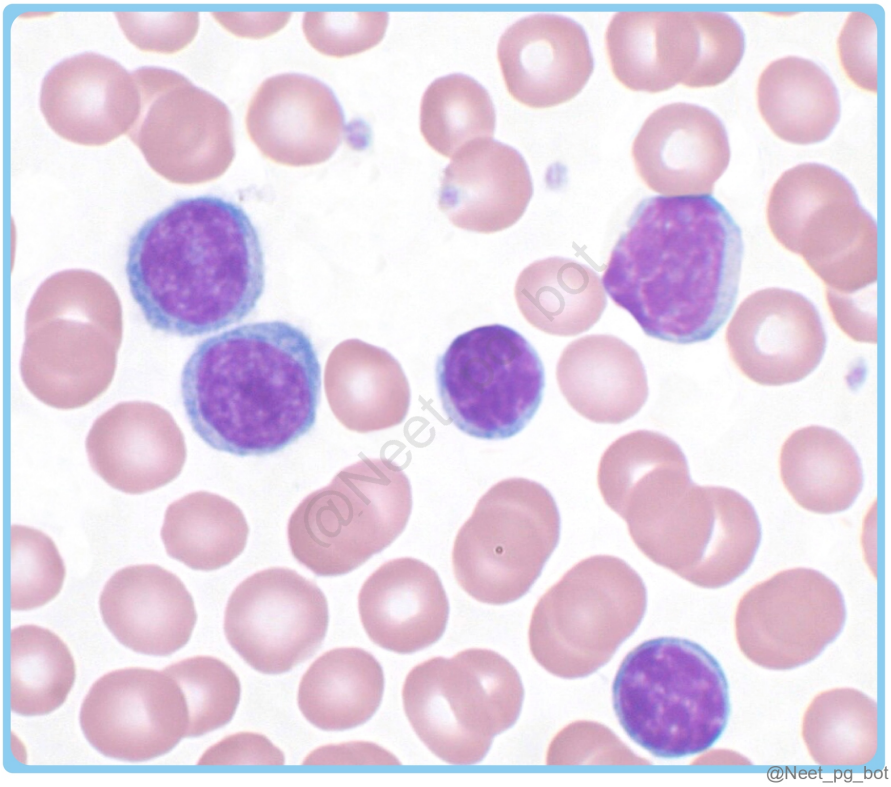

See Answer in Part B → Q11

@Neet_pg_bot

Q12: What is the most common subtype of Hodgkin lymphoma? (Q884841)

A. Lymphocyte-rich

B. Mixed cellularity

C. Nodular sclerosis

D. Lymphocyte-depleted

See Answer in Part B → Q12

@Neet_pg_bot

Q13: Which of the following statements about extranodal marginal zone (MALT) lymphoma is correct? (Q884881)

A. t(11;18) translocation makes it antigen-dependent

B. Spreads systemically early

C. May regress if inciting agent is removed

D. Not associated with chronic inflammation

See Answer in Part B → Q13

@Neet_pg_bot

Q14: Marginal zone lymphoma primarily arises from which type of B cell? (Q884882)

A. Naïve B cells

B. Memory B cells

C. Plasma cells

D. Pre-B cells

See Answer in Part B → Q14

@Neet_pg_bot

Q15: Extranodal marginal zone (MALT) lymphoma is commonly associated with which of the following conditions? Sjögren syndrome Hashimoto thyroiditis Helicobacter pylori gastritis (Q884884)

A. 1 and 2 only

B. 2 and 3 only

C. 1 and 3 only

D. 1, 2, and 3

See Answer in Part B → Q15

@Neet_pg_bot

Q16: A 62-year-old man presents with generalized exfoliative erythroderma and intense pruritus. Examination reveals diffuse lymphadenopathy. Peripheral blood smear shows findings as shown. Skin biopsy demonstrates dermal infiltration by atypical CD4■ T cells. What is the most likely diagnosis? (Q884885)

A. Sézary syndrome

B. Mycosis fungoides

C. Peripheral T-cell lymphoma

D. Adult T-cell leukemia/lymphoma

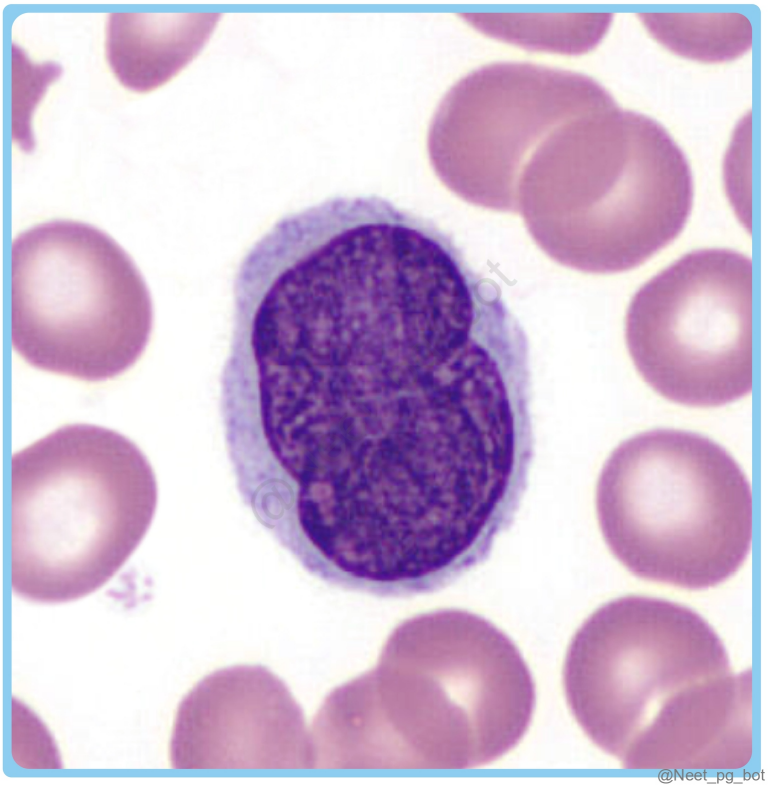

See Answer in Part B → Q16

@Neet_pg_bot

Q17: A 60-year-old woman with rheumatoid arthritis presents with recurrent infections. She has splenomegaly and neutropenia. Peripheral smear shows large lymphocytes with azurophilic granules. Cells are CD3■. What is the most likely diagnosis? (Q884888)

A. Chronic lymphocytic leukemia

B. Hairy cell leukemia

C. Large granular lymphocytic leukemia

D. Sézary syndrome

See Answer in Part B → Q17

@Neet_pg_bot

Q18: A 70-year-old man presents with fever, weight loss, and rapidly enlarging lymph nodes. Biopsy shows diffuse sheets of large CD20+ B cells. EBER in situ hybridisation is positive in tumour cells. What is the most likely diagnosis? (Q884909)

A. Epstein-Barr virus-positive diffuse large B-cell lymphoma

B. Classic Hodgkin lymphoma

C. Burkitt lymphoma

D. Angioimmunoblastic T-cell lymphoma

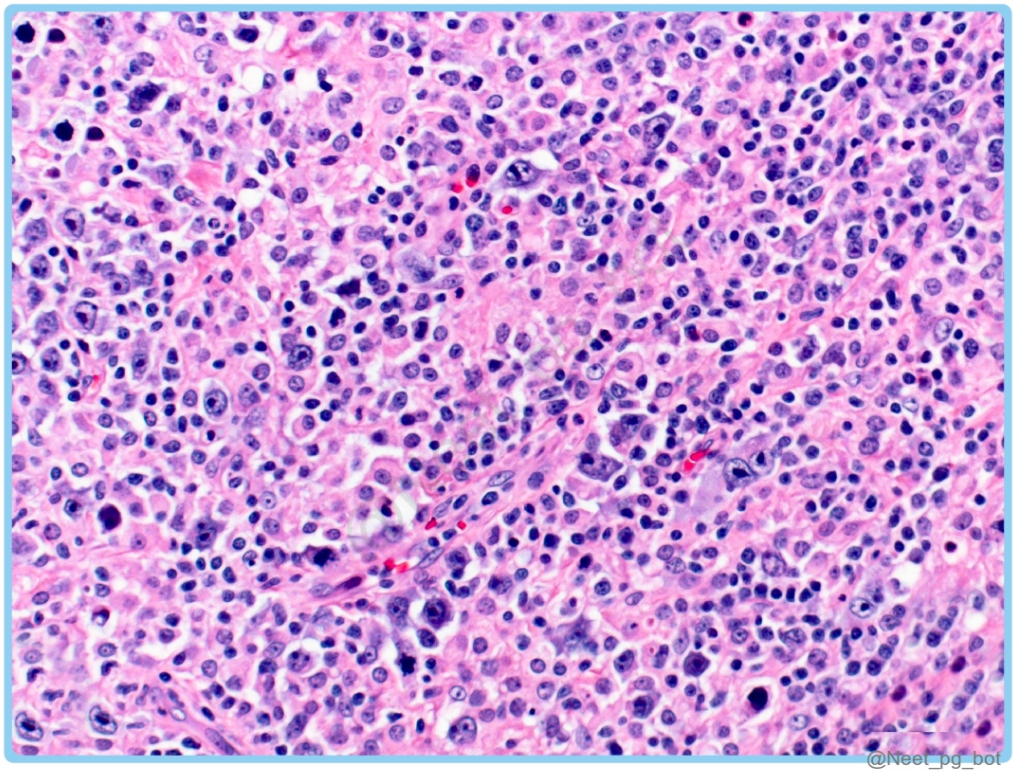

See Answer in Part B → Q18

@Neet_pg_bot

Q19: A 62-year-old man is newly diagnosed with diffuse large B-cell lymphoma. The clinician plans to calculate the International Prognostic Index (IPI) score to assess prognosis. Which of the following are included in the IPI score? Age >60 years Elevated serum lactate dehydrogenase (LDH) Presence of B symptoms ECOG performance status ≥2 More than one extranodal site (Q884910)

A. 1, 2, 3

B. 1, 2, 4, 5

C. 2, 3, 4

D. 1, 3, 5

See Answer in Part B → Q19

@Neet_pg_bot

Q20: A 70-year-old man with a 5-year history of chronic lymphocytic leukaemia develops rapidly enlarging lymph nodes, fever, weight loss, and elevated LDH. Lymph node biopsy shows diffuse large B-cell lymphoma. What is the most likely diagnosis? (Q884911)

A. Progressive CLL

B. Richter syndrome

C. Prolymphocytic transformation

D. Hodgkin lymphoma

See Answer in Part B → Q20

@Neet_pg_bot

Q21: A 15-year-old boy presents with painless lymphadenopathy. Biopsy shows findings as shown. Tumour cells are CD30 positive and ALK positive. What is the most likely diagnosis? (Q884912)

A. Diffuse large B-cell lymphoma

B. Classical Hodgkin lymphoma

C. Anaplastic large-cell lymphoma

D. Adult T-cell leukaemia/lymphoma

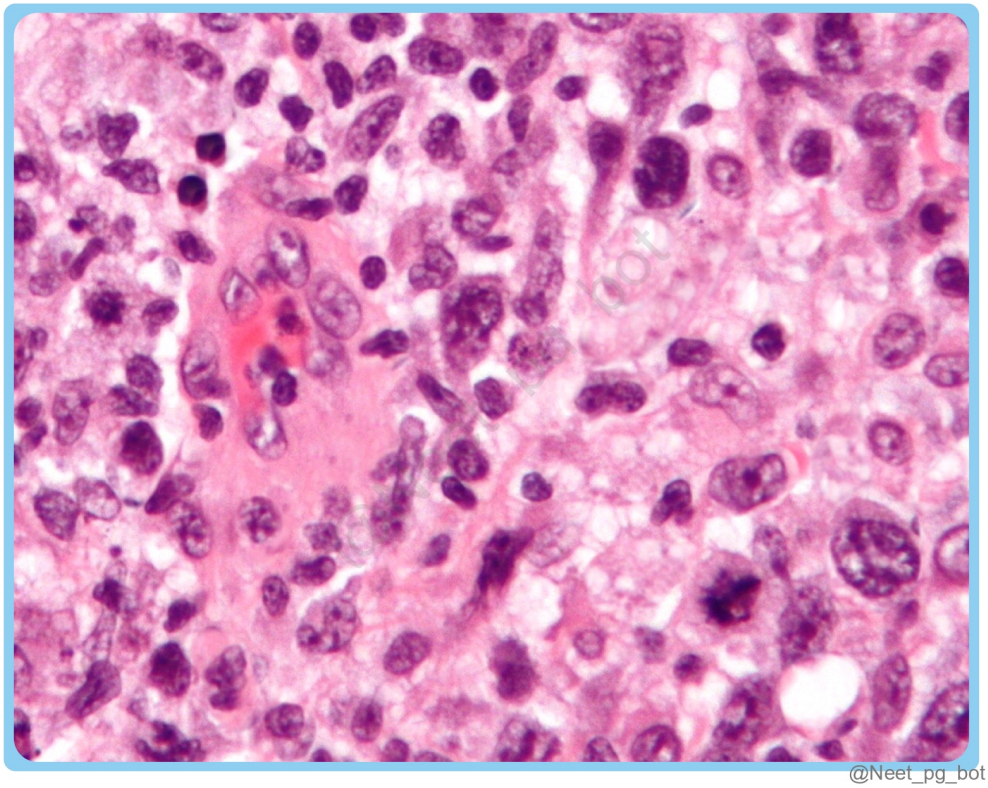

See Answer in Part B → Q21

@Neet_pg_bot

Q22: Match the following lymphomas with their cell of origin. Lymphoma/leukaemia Cell of origin 1. Diffuse large B-cell lymphoma a. Memory B-cell 2. Mantle cell lymphoma b. Germinal/post germinal center B cell 3. Hairy cell lymphoma c. Helper T-cell 4. Mycosis fungoides d. Naive B cell (Q845823)

A. 1-b, 2-a, 3-c, 4-d

B. 1-a, 2-b, 3-d, 4-c

C. 1-d, 2-a, 3-d, 4-c

D. 1-b, 2-d, 3-a, 4-c

See Answer in Part B → Q22

@Neet_pg_bot

Q23: In the WHO classification of Hodgkin lymphoma, which marker is typically expressed in classical Hodgkin lymphoma? (Q845792)

A. CD20

B. CD15

C. CD45

D. BCL-6

See Answer in Part B → Q23

@Neet_pg_bot

Q24: Match the following characteristic cells with their corresponding histopathological variant of Hodgkin lymphoma: Cells A) Popcorn cells B) Lacunar cells C) Mononuclear cells D) Reed-Sternberg cells Histopathology 1. Classical Hodgkin Lymphoma (general type) 2.Mixed Cellularity Classical Hodgkin Lymphoma 3. Nodular Sclerosis Classical Hodgkin Lymphoma 4. Nodular Lymphocyte Predominant Hodgkin Lymphoma (Q845796)

A. A-4, B-3, C-2, D-1

B. A-1, B-4, C-3, D-2

C. A-3, B-2, C-1, D-4

D. A-4, B-1, C-2, D-3

See Answer in Part B → Q24

@Neet_pg_bot

Q25: A 28-year-old female presents with painless swelling in her neck and shortness of breath. Imaging studies reveal a large mediastinal mass. A biopsy of the lymph node shows frequent lacunar cells and Reed-Sternberg cells. The RS cells are positive for CD15 and CD30 and usually negative for EBV. Which subtype of Hodgkin's lymphoma is most likely? (Q845799)

A. Nodular Sclerosis Classical Hodgkin Lymphoma

B. Nodular Lymphocyte-Predominant Hodgkin Lymphoma

C. Lymphocyte-Rich Classical Hodgkin Lymphoma

D. Lymphocyte-depleted classical Hodgkin Lymphoma

See Answer in Part B → Q25

@Neet_pg_bot

Q26: A 35-year-old male presents with painless swelling of multiple lymph nodes, fever, night sweats, and weight loss. A biopsy of the affected lymph node reveals the presence of Reed-Sternberg cells. Which of the following options regarding Mixed cellularity type Hodgkin's Lymphoma is not true? (Q845800)

A. It is characterised by frequent mononuclear and diagnostic Reed-Sternberg (RS) cells.

B. RS cells in this subtype typically express CD15 and CD30.

C. More than 70% of cases are Epstein-Barr virus (EBV) positive.

D. It is usually associated with a better prognosis than other subtypes of Hodgkin's lymphoma.

See Answer in Part B → Q26

@Neet_pg_bot

Q27: A 32-year-old male presents with painless lymphadenopathy in the cervical region. A biopsy reveals the presence of numerous small lymphocytes with scattered large mononuclear Hodgkin and Reed-Sternberg cells, which are CD20 positive and CD15/CD30 negative. Which subtype of Hodgkin's lymphoma is most consistent with these findings? (Q845805)

A. Nodular sclerosis Hodgkin lymphoma

B. Mixed cellularity Hodgkin lymphoma

C. Nodular Lymphocyte-predominant Hodgkin lymphoma

D. Lymphocyte-depleted Hodgkin lymphoma

See Answer in Part B → Q27

@Neet_pg_bot

Q28: A 65-year-old male with a history of HIV presents with fever, night sweats, and weight loss. A lymph node biopsy was done. Immunohistochemical staining shows these cells are CD15 and CD30 positive but CD20 negative. He was diagnosed with Lymphocyte-depleted Hodgkin's lymphoma. Which of the following features is characteristic of lymphocyte-depleted Hodgkin's lymphoma? (Q845806)

A. Presence of fibrous bands

B. Abundance of reactive lymphocytes

C. High number of Reed-Sternberg cells

D. Predominance of nodular growth pattern

See Answer in Part B → Q28

@Neet_pg_bot

Q29: A 35-year-old male presents with painless enlargement of cervical lymph nodes, accompanied by fever, night sweats, and weight loss. Biopsy reveals large, atypical cells with prominent nucleoli and a mixed inflammatory background. Immunohistochemical staining shows these cells are negative for CD15 and CD30. Which marker is most likely to be positive in these cells? (Q845807)

A. CD20

B. CD3

C. CD15

D. CD30

See Answer in Part B → Q29

@Neet_pg_bot

Q30: A 45-year-old male presents with painless swelling of multiple lymph nodes in his neck and groin. He denies experiencing fever, night sweats, or weight loss. Physical examination reveals bilateral cervical and inguinal lymphadenopathy. Based on the Ann Arbor classification, what is this patient's most likely stage of disease? (Q845808)

A. Stage I

B. Stage II

C. Stage III

D. Stage IV

See Answer in Part B → Q30

@Neet_pg_bot

Q31: A 40-year-old male presents with a palpable lump in his right axilla. Physical examination reveals a mobile, non-tender, and rubbery lymph node. FNAC is performed, and the sample is examined under the microscope. Which of the following histological features is characteristic of a normal lymph node? (Q845821)

A. Presence of large pleomorphic cells

B. Disorganized architecture with fibrosis

C. Distorted germinal centres and absence of sinuses

D. Distinct cortex and medulla with germinal centres and sinuses

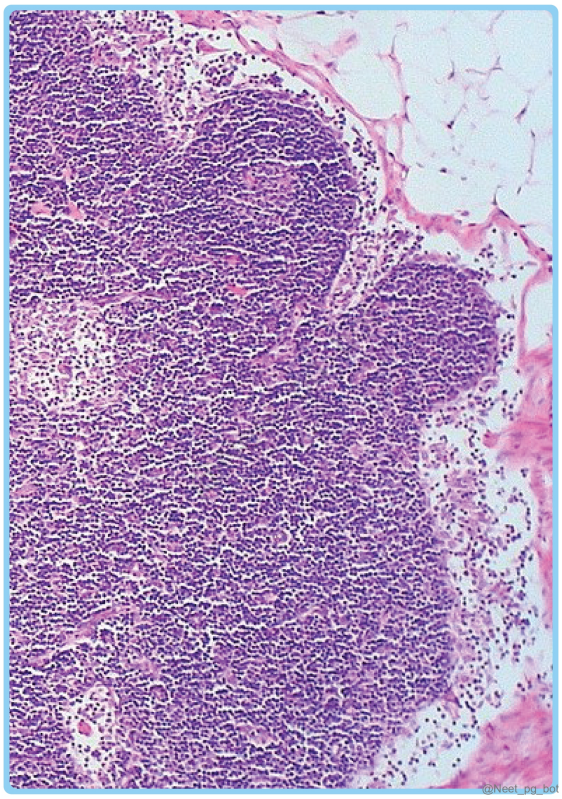

See Answer in Part B → Q31

@Neet_pg_bot

Q32: A 35-year-old woman came with complaints of chronic fatigue and a palpable nodular mass in her axilla. Further investigations reveal a B-cell neoplasm. Which of the following is the least likely diagnosis? (Q845822)

A. Follicular lymphoma

B. Marginal zone lymphoma

C. Hairy cell leukemia

D. Anaplastic large cell lymphoma

See Answer in Part B → Q32

@Neet_pg_bot

Q33: A 30-year-old female presents with painless swelling of the neck, intermittent fever, night sweats and significant weight loss over the past three months. On examination, enlarged cervical and mediastinal lymph nodes are noted. A biopsy reveals the presence of characteristic cells, as shown in the image below. Which of the following about the described condition is NOT true? (Q845791)

A. More often localised to a single axial group of nodes

B. Typically, it spreads in a contiguous manner.

C. Mesenteric nodes and Waldeyer ring involvement are rare.

D. Extranodal presentation is common.

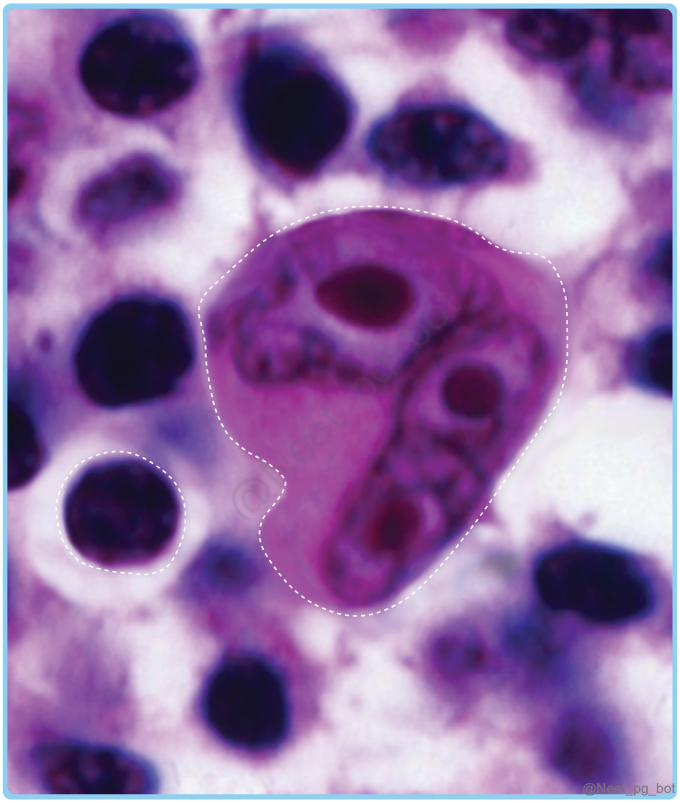

See Answer in Part B → Q33

@Neet_pg_bot

Q34: An 8-year-old boy presents with a large mass over the mandible. On the HPE of the lesion, a 'starry sky pattern' is seen, similar to the image below. This condition is associated with which of the following genetic abnormalities? (Q845824)

A. MYC gene

B. BCL2 gene

C. Cyclin-D1

D. BCL6 gene

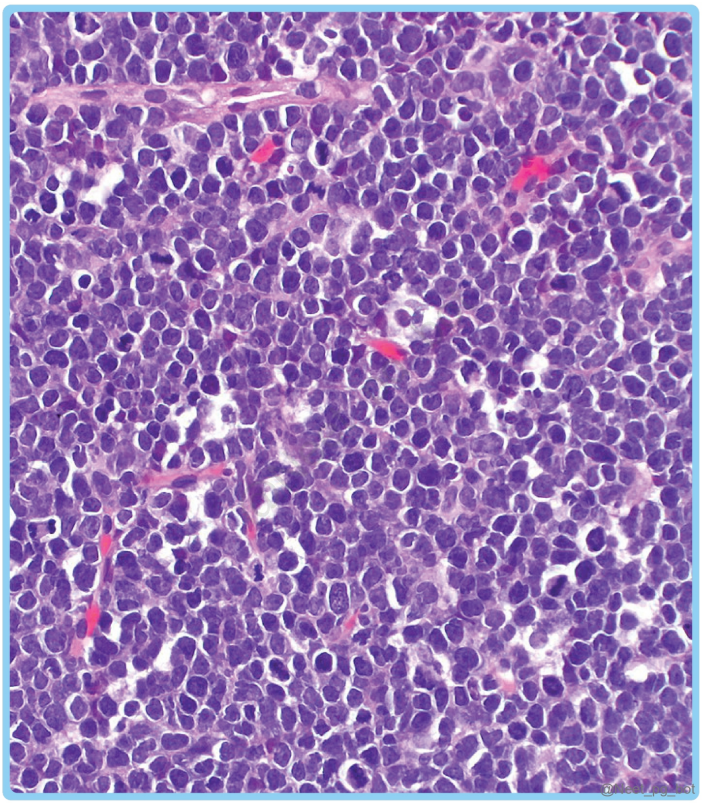

See Answer in Part B → Q34

@Neet_pg_bot

Q35: A 30-year-old man presents to the outpatient department with an axillary mass and complaints of low-grade fever, weight loss, and night sweats for the past 6 months. Histopathological examination (HPE) of a biopsy sample from the mass reveals diffuse follicular growth with centrocytes with cleaved nuclei and centroblasts. Immunohistochemistry shows BCL2 stain positive, CD19, CD20, and CD10 positive, and CD5 negative. What is the most likely diagnosis? (Q845827)

A. Follicular hyperplasia

B. Mantle cell lymphoma

C. Follicular lymphoma

D. Burkitt’s lymphoma

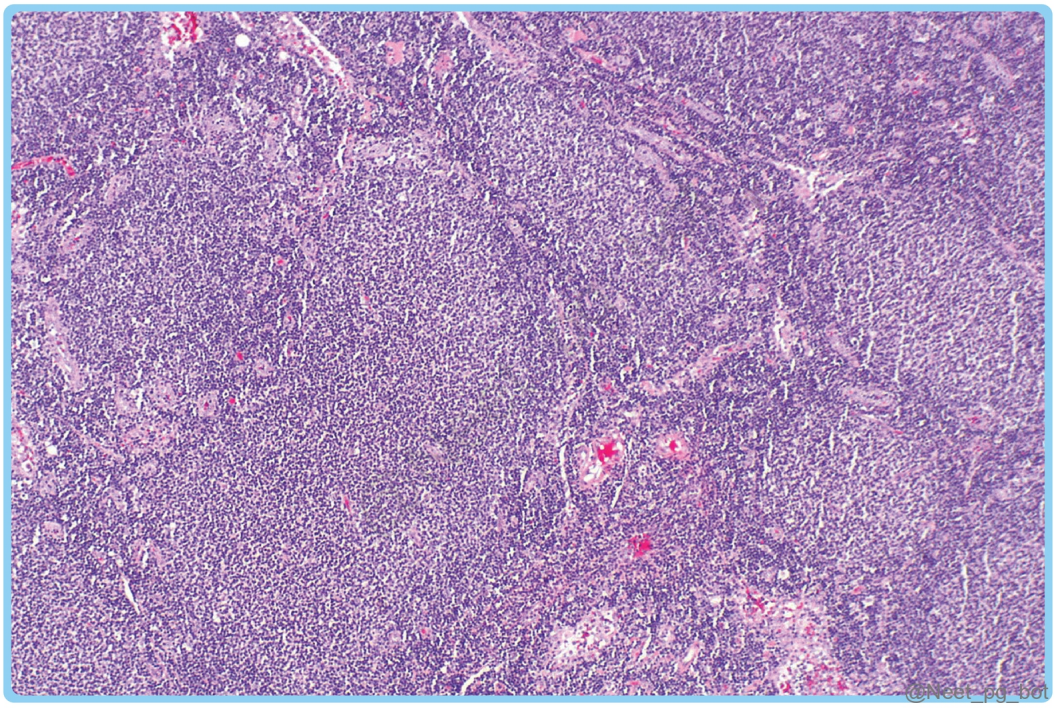

See Answer in Part B → Q35

@Neet_pg_bot

Q36: Match the following neoplasm with its appropriate genetic mutation. Neoplasia Genetic mutation 1. Mantle cell lymphoma A. BCL6 gene 2. Burkitt’s lymphoma B. Cyclin D1 gene 3. Diffuse large B cell lymphoma C. BCL10 / MALT1 4. Marginal zone lymphoma D. MYC gene (Q845828)

A. 1-B, 2-D, 3-A, 4-C

B. 1-B, 2-A ,3-C ,4-D

C. 1-A ,2-C ,3-D,4- B

D. 1-C ,2-D ,3-A ,4- B

See Answer in Part B → Q36

@Neet_pg_bot

Q37: A 14-year-old boy from Bihar presents with a low-grade fever, weight loss, and abdominal pain for the past 2 months. Investigation reveals a mass involving the ileocecal region, with histopathological examination showing a 'starry sky' appearance, immunohistochemistry positive for CD10, CD19, CD20, and BCL6, and FISH indicating a (8:14) translocation involving the MYC gene. This type of presentation is common in which condition? (Q845829)

A. Endemic Burkitt’s lymphoma

B. Sporadic Burkitt’s lymphoma

C. HIV-associated Burkitt’s lymphoma

D. All of the above

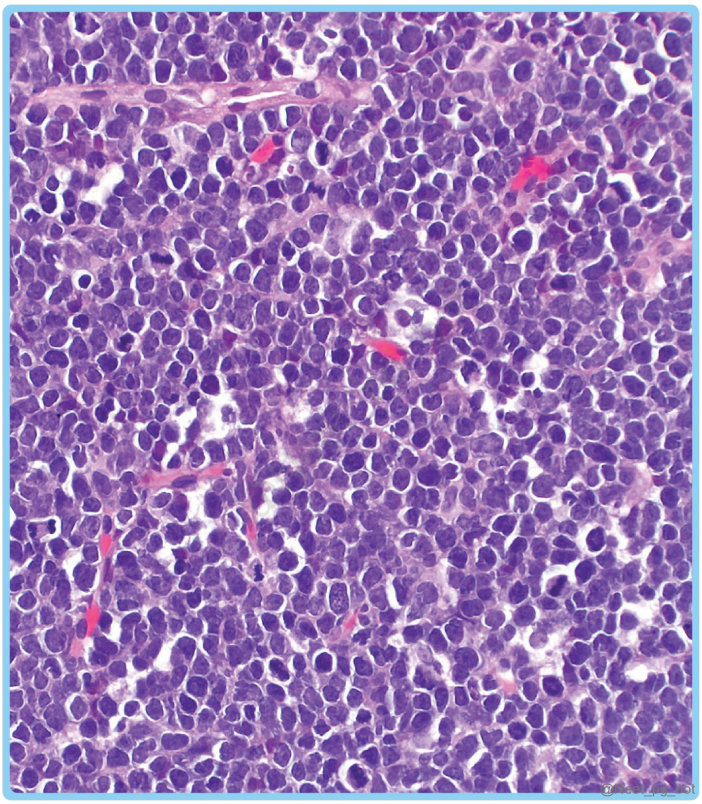

See Answer in Part B → Q37

@Neet_pg_bot

Q38: Which of the following statements correctly differentiates between Primary Effusion Lymphoma (PEL) and Immunodeficiency-associated Large B-cell Lymphoma? (Q845830)

A. PEL presents with lymphomatous masses in solid organs, while Immunodeficiency-associated Large B-cell Lymphoma presents as effusions.

B. PEL is associated with EBV , whereas Immunodeficiency-associated Large B-cell Lymphoma is linked to HHV-8.

C. PEL presents as Effusions and is associated with HHV-8, whereas Immunodeficiency-associated Large B-cell Lymphoma is linked to EBV.

D. Both are predominantly found in immunocompetent individuals without any viral association.

See Answer in Part B → Q38

@Neet_pg_bot

Q39: Match each lymphoma or leukaemia type with its corresponding histopathological finding. Lymphoma/Leukemia Type Histopathological Finding 1.Follicular Lymphoma A) 2. Burkitt's Lymphoma B) 3. Diffuse Large B-Cell Lymphoma (DLBCL) C) 4. Hairy Cell Leukemia D) (Q845833)

A. 1-C, 2-B, 3-A, 4-D

B. 1-B, 2-A, 3-D, 4-C

C. 1-D, 2-C, 3-B, 4-A

D. 1-A, 2-D, 3-C, 4-B

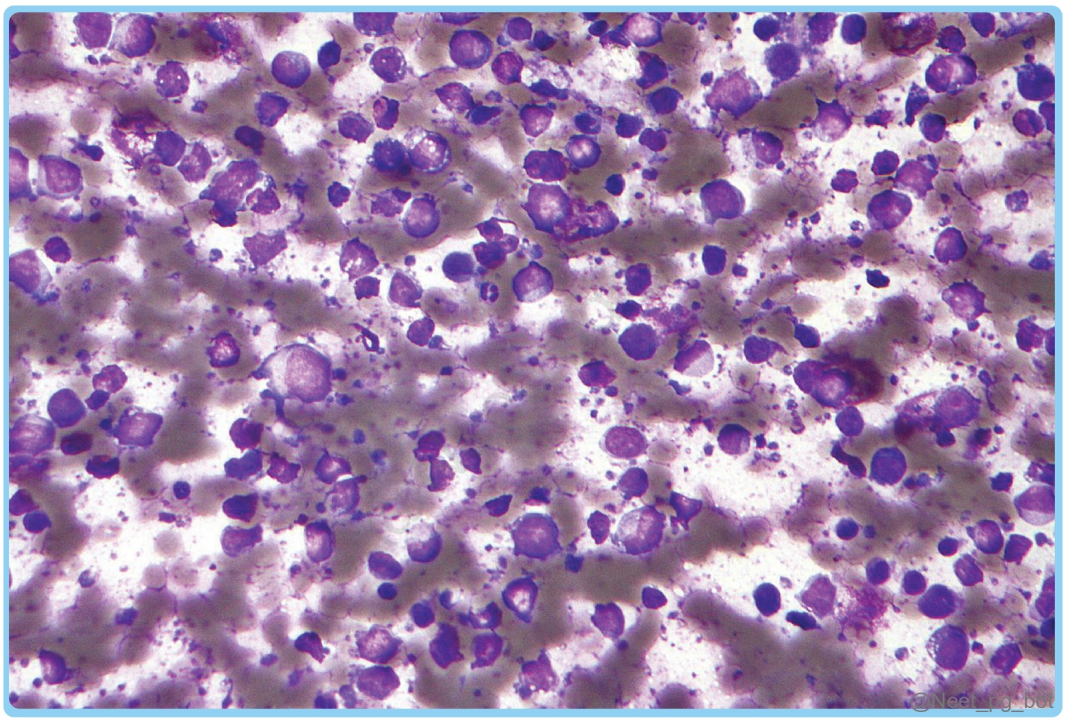

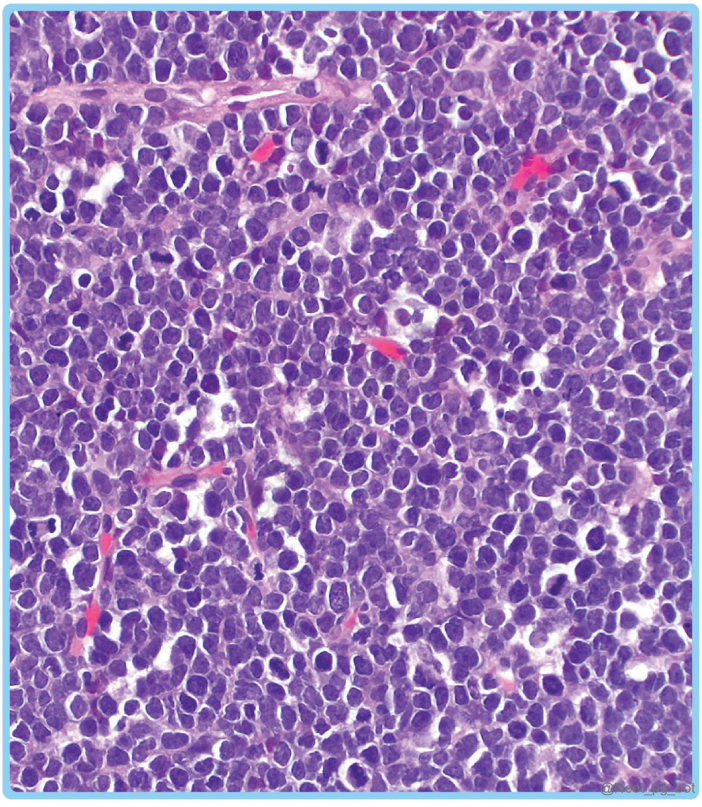

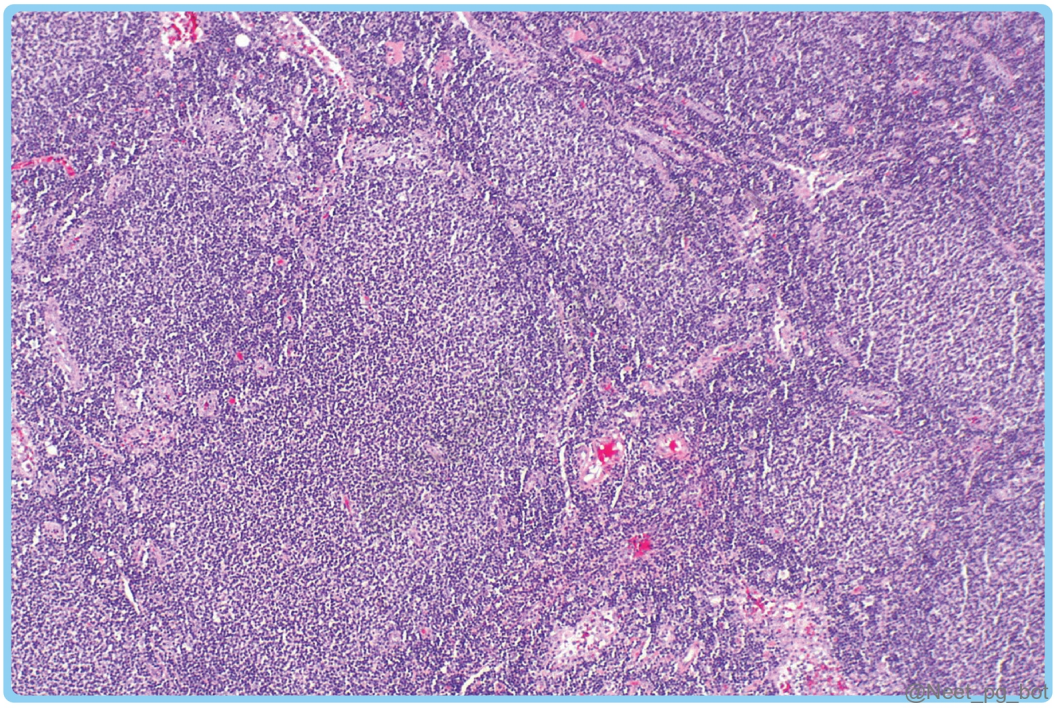

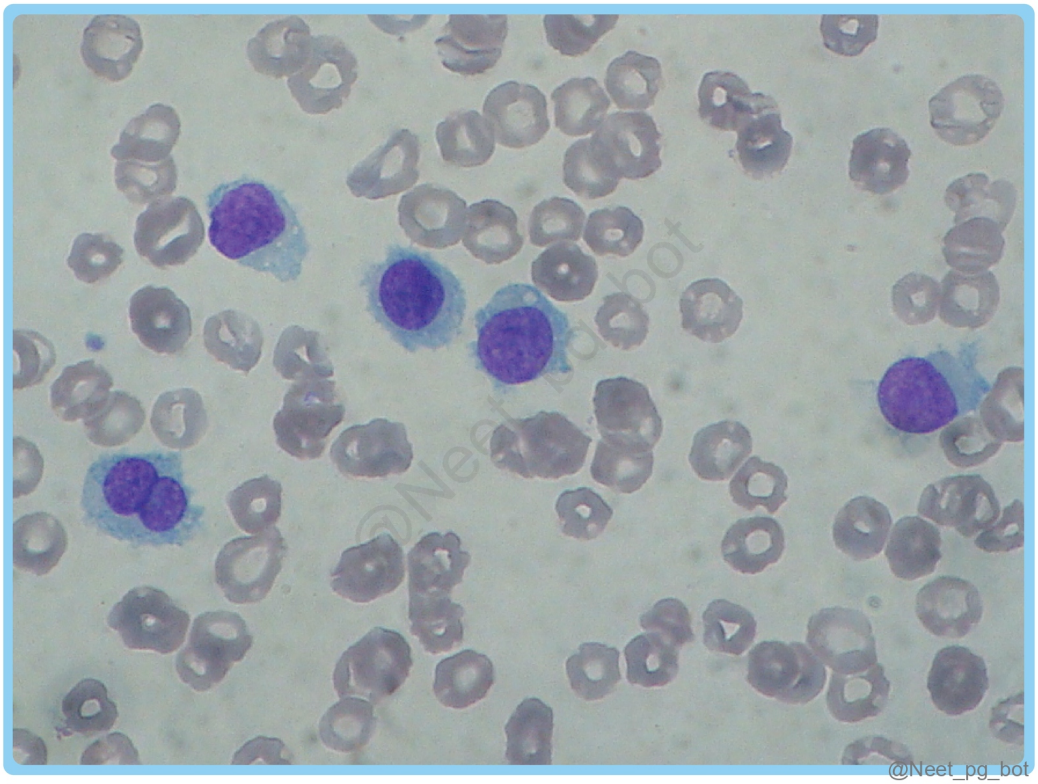

See Answer in Part B → Q39

@Neet_pg_bot

Q40: A 45-year-old male has been complaining of persistent fatigue, recurrent infections, and easy bruising over the past few months. On physical examination, he has a noticeable abdominal mass. A peripheral smear shows the presence of atypical lymphoid cells with cytoplasmic projections, as shown in the image below. Which of the following statements is not true regarding the patient's condition? (Q845834)

A. Associated with the BRAF V600E mutation.

B. Massive splenomegaly is a common clinical feature.

C. The pathogenesis involves the proliferation of immature myeloid cells

D. Typically present with fatigue, infections, and pancytopenia.

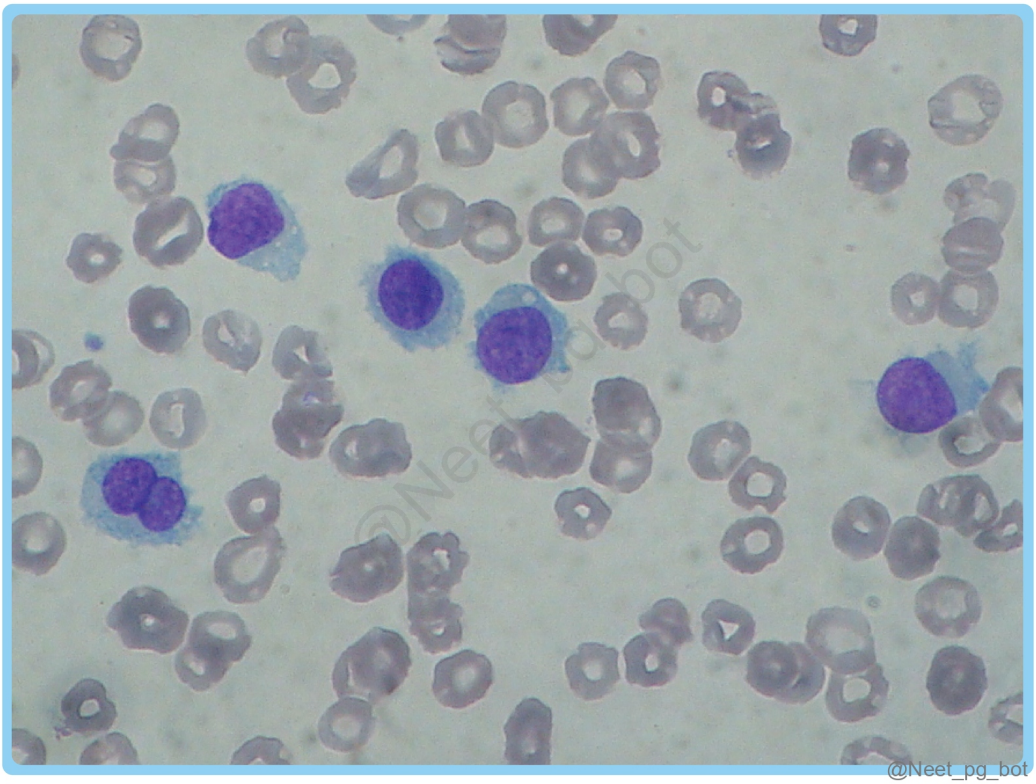

See Answer in Part B → Q40

@Neet_pg_bot

Q41: A 55-year-old male presents with persistent fatigue, splenomegaly, and pancytopenia. Peripheral blood smear shows leukocytosis with mature lymphocytes displaying hairy projections. Flow cytometry confirms the presence of CD11c and

CD25 positive cells. Which of the following is the most specific biomarker commonly useful in the diagnosis of condition? (Q845835)

A. CD 20

B. Annexin V

C. Annexin A1

D. Apolipoprotein A1

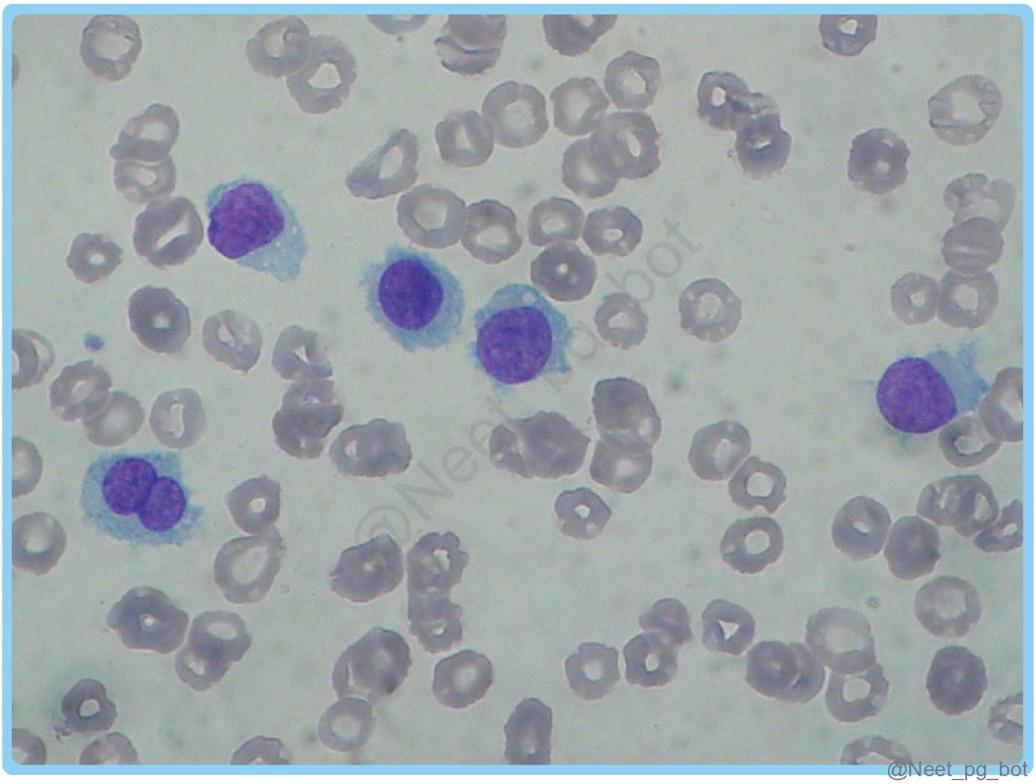

See Answer in Part B → Q41

@Neet_pg_bot

Q42: A 45-year-old male presents with a three-year history of pruritic, erythematous plaques on his trunk and extremities. Physical examination reveals widespread erythematous patches and plaques with a "cerebriform" appearance. Peripheral smear findings reveal the presence of abnormal lymphocytes with convoluted nuclei and abundant cytoplasm. Which of the following is the most likely diagnosis? (Q845836)

A. Mycosis fungoides

B. Adult T-cell leukemia

C. Anaplastic large cell lymphoma

D. Hairy cell leukemia

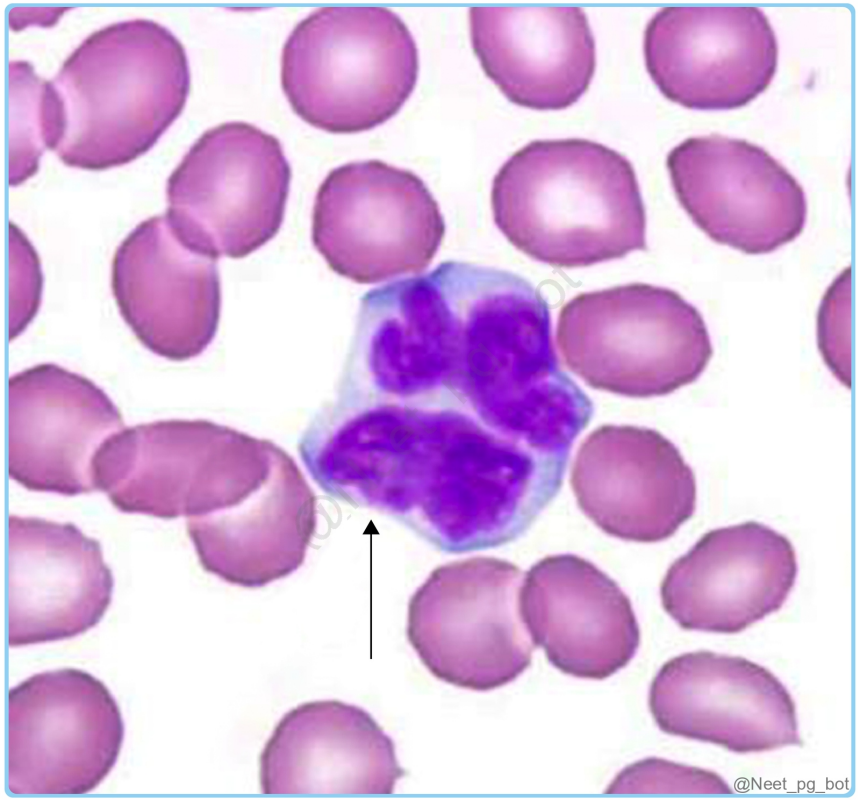

See Answer in Part B → Q42

@Neet_pg_bot

• [18_Hematology_ White Blood Cells] 077 Previous Year Questions

« Back to Folder Directory

[18_Hematology_ White Blood Cells] 077 Previous Year Questions — Quick Jump

Q1 (p. 864)	*Q2 (p. 864)*	*Q3 (p. 865)*	*Q4 (p. 866)*	*Q5 (p. 867)*	*Q6 (p. 867)*
Q7 (p. 868)	*Q8 (p. 868)*	*Q9 (p. 869)*	*Q10 (p. 870)*	*Q11 (p. 870)*	*Q12 (p. 870)*
Q13 (p. 871)	*Q14 (p. 871)*	*Q15 (p. 871)*	*Q16 (p. 872)*	*Q17 (p. 872)*	*Q18 (p. 873)*
Q19 (p. 874)	*Q20 (p. 874)*	*Q21 (p. 875)*	*Q22 (p. 876)*	*Q23 (p. 876)*	*Q24 (p. 877)*
Q25 (p. 877)	*Q26 (p. 878)*	*Q27 (p. 878)*	*Q28 (p. 880)*	*Q29 (p. 880)*	*Q30 (p. 881)*
Q31 (p. 882)	*Q32 (p. 883)*	*Q33 (p. 883)*	*Q34 (p. 883)*	*Q35 (p. 884)*	*Q36 (p. 885)*
Q37 (p. 885)	*Q38 (p. 886)*	*Q39 (p. 887)*	*Q40 (p. 887)*	*Q41 (p. 887)*	*Q42 (p. 888)*
Q43 (p. 889)	*Q44 (p. 890)*	*Q45 (p. 891)*	*Q46 (p. 891)*	*Q47 (p. 892)*	*Q48 (p. 893)*
Q49 (p. 893)					

Q1: Which of the following is not true about nodular lymphocyte-predominant Hodgkin lymphoma (NLPHL)? (Q856479)

A. EBV negative

B. CD 30 negative

C. CD 20 positive

D. Poor prognosis compared to classical HL

See Answer in Part B → Q1

@Neet_pg_bot

Q2: What is the most likely diagnosis for a 5-year-old boy who has weight loss, fever, and a painless swelling in his jaw area, with anaemia and lymphocytosis revealed by a CBC and biopsy findings shown in the accompanying image?\ (Q857579)

A. Hodgkin’s disease

B. Acute lymphocytic leukemia

C. Chloroma

D. Burkitt’s lymphoma

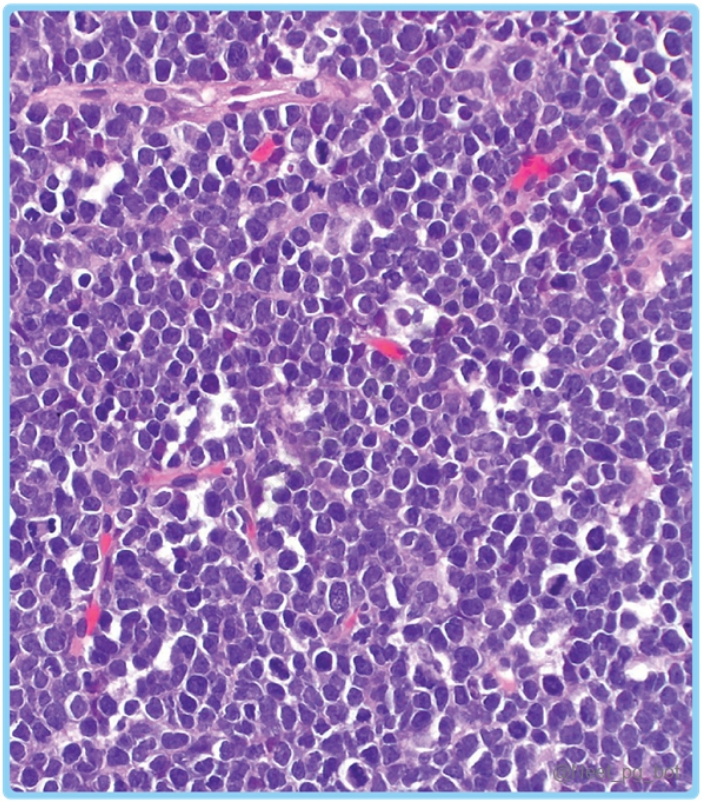

See Answer in Part B → Q2

@Neet_pg_bot

Q3: A 60-year-old male presents with easy fatigability, back pain, and multiple lytic lesions in the skull. The bone marrow biopsy finding is given below. What is the most probable diagnosis? (Q857582)

A. CML (Chronic Myelogenous Leukemia)

B. CLL (Chronic Lymphocytic Leukemia)

C. Multiple Myeloma

D. Hairy Cell Leukemia

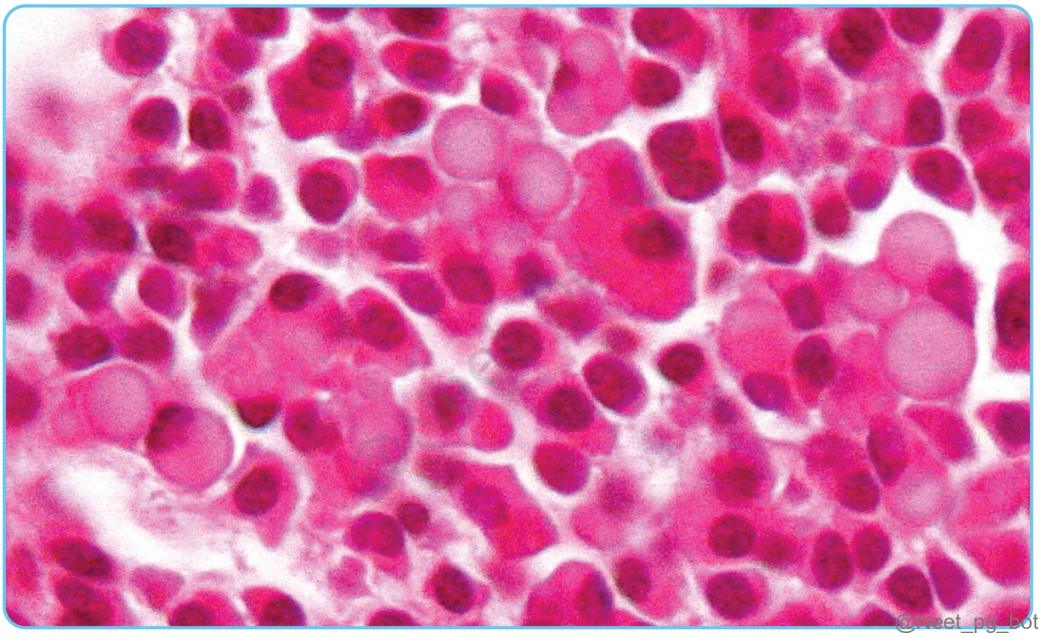

See Answer in Part B → Q3

@Neet_pg_bot

Q4: What is the likely diagnosis for a 10-year-old boy with Down syndrome who presents with a mediastinal mass (SVC-like syndrome), based on the provided bone marrow histology shown below? (Q857605)

A. AML (Acute Myeloid Leukemia)

B. Aplastic anemia

C. ALL (Acute Lymphoblastic Leukemia)

D. Juvenile Myelomonocytic Leukemia (JMML)

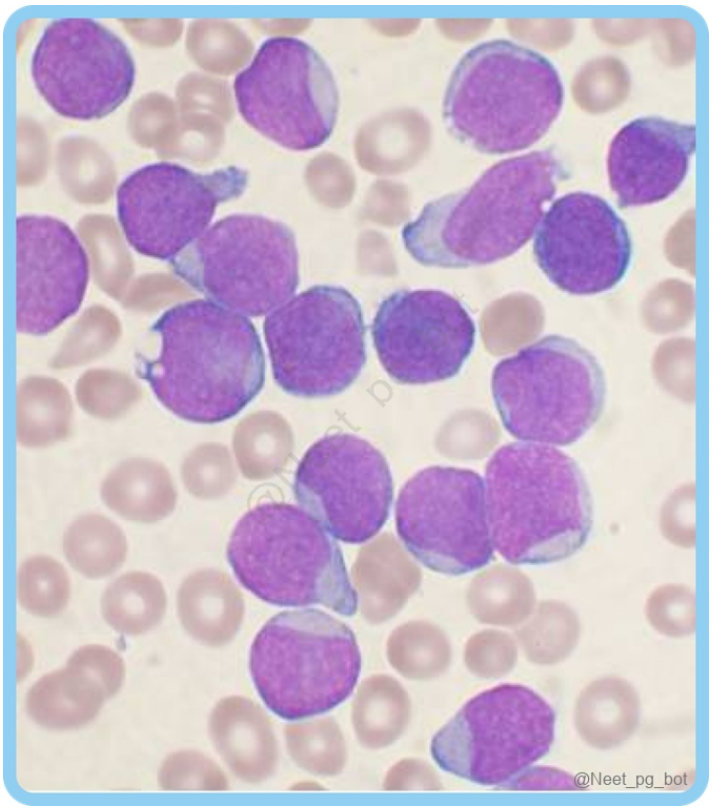

See Answer in Part B → Q4

@Neet_pg_bot

Q5: A 60-year-old patient presented with scrotal swelling and ataxia. Which among the following could likely be a cause? (Q856695)

A. Glioblastoma multiforme

B. Hodgkin lymphoma

C. Non-Hodgkin lymphoma

D. Non seminomatous germ cell tumor

See Answer in Part B → Q5

@Neet_pg_bot

Q6: Which cell is the origin of chronic lymphocytic leukaemia / small lymphocytic lymphoma? (Q856721)

A. Naive B cells

B. Mature T cells

C. Progenitor T cells

D. Granulocytes

See Answer in Part B → Q6

@Neet_pg_bot

Q7: A patient with lytic lesions on the skull is suspected of a diagnosis of Langerhans cell histiocytosis. Which of the following is a characteristic finding of electron microscopy? (Q856725)

A. Histiocytes

B. Birbeck granules

C. Eosinophils

D. Giant cells

See Answer in Part B → Q7

@Neet_pg_bot

Q8: A 6-year-old boy came with bilateral cervical lymphadenopathy. What is the probable diagnosis, cell, and virus associated with the image given below? RS cell: Reed Stemberg cell HIV: Human immunodeficiency virus CMV: Cytomegalovirus EBV: Epstein–Barr virus (Q856726)

A. Non-Hodgkin’s lymphoma, RS cell, EBV

B. Kaposi sarcoma, Giant cell, HIV

C. Hodgkin’s lymphoma, RS cell, EBV

D. Infectious mononucleosis, RS cell, CMV

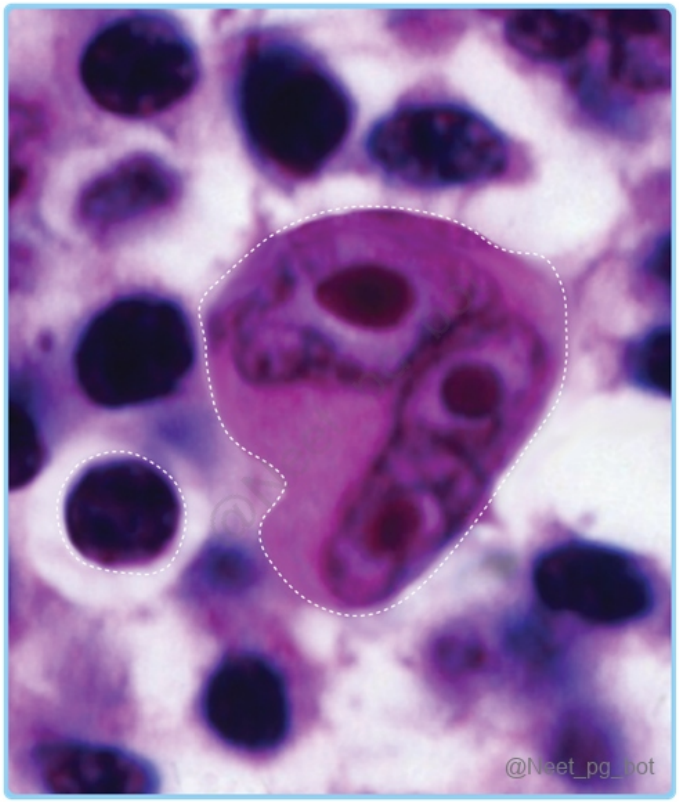

See Answer in Part B → Q8

@Neet_pg_bot

Q9: A 30-year-old male has been complaining of fatigue for the past year. The examination revealed massive splenomegaly. His blood workup shows the presence of anemia, TLC 150,000/microL, and PBS shows 60% neutrophils, 6% basophils, 4% eosinophils, myeloblasts, myelocytes, and metamyelocytes. The myeloid-to-erythroid ratio was 18:1. Which of the following is the most sensitive investigation in this case? (Q856102)

A. Immunophenotyping

B. LAP score

C. FISH and PCR

D. Flow cytometry

See Answer in Part B → Q9

@Neet_pg_bot

Q10: Which of the following is a poor prognostic marker of multiple myeloma? (Q856140)

A. β-2 microglobulin

B. Calcium levels

C. Serum creatinine

D. Protein levels

See Answer in Part B → Q10

@Neet_pg_bot

Q11: A 54-year-old patient presents to the outpatient department with fatigue, tiredness, and cervical lymphadenopathy. The TLC and DLC were normal, with no immature cells. A lymph node biopsy showed diffuse effacement of the lymph node architecture and cells with an indented nucleus and prominent nucleolus that are atypical. CD10 and BCL2 are positive. What is the likely diagnosis? (Q856147)

A. Follicular lymphoma

B. Burkitt lymphoma

C. Mycosis fungoides

D. Chronic myeloid leukaemia

See Answer in Part B → Q11

@Neet_pg_bot

Q12: Which of the following is a possible explanation for the presence of pancytopenia as indicated by the blood examination results? A. Megaloblastic anemia B. Hairy cell leukemia C. MDS with hypocellular BM D. APML (Q856922)

A. B, D

B. A, B, C

C. B, C, D

D. A, B, D

See Answer in Part B → Q12

@Neet_pg_bot

Q13: 2-year-old with fever, lymphadenopathy and H&E has hallmark cells. The diagnosis of anaplastic large cell lymphoma was made. Most likely translocation? (Q866673)

A. t(8;14)

B. t(8;22)

C. t(2;5)

D. t(14;18)

See Answer in Part B → Q13

@Neet_pg_bot

Q14: Identify the correct statement regarding immune surveillance. (Q856493)

A. Anti-CTLA-4 Ab is a new modality in the treatment of advanced cancers

B. Mutation of tumour suppressor genes decreases antigen toxicity

C. PD1/PDL1 activation leading to tumour suppression

D. Binding of CD28 leads to immune tolerance

See Answer in Part B → Q14

@Neet_pg_bot

Q15: All-trans retinoic acid (ATRA) is used in the treatment of tumours associated with which of the following genetic aberrations? (Q854879)

A. PML-RARA

B. BCR-ABL

C. cMYC

D. RUNX1-ETO

See Answer in Part B → Q15

@Neet_pg_bot

Q16: A 70-year-old man has presented with chronic lower back pain, fatigue, and headaches for the last few weeks. On examination, he has pallor and bony tenderness. Lab investigations revealed an increased ESR, and his skull radiograph revealed several punched-out lytic lesions. Which of the following is the best investigation for this patient among the following options? (Q859274)

A. Serum electrophoresis showing IgG

B. Serum levels of CA 15-3

C. Whole-body scan

D. CT head with contrast

See Answer in Part B → Q16

@Neet_pg_bot

Q17: A 65-year-old male underwent a bone marrow examination, which revealed the presence of the following findings, as shown in the image. What is the likely diagnosis of this patient? (Q859279)

A. Multiple myeloma

B. ALL

C. Tuberculosis

D. Sickle cell disease

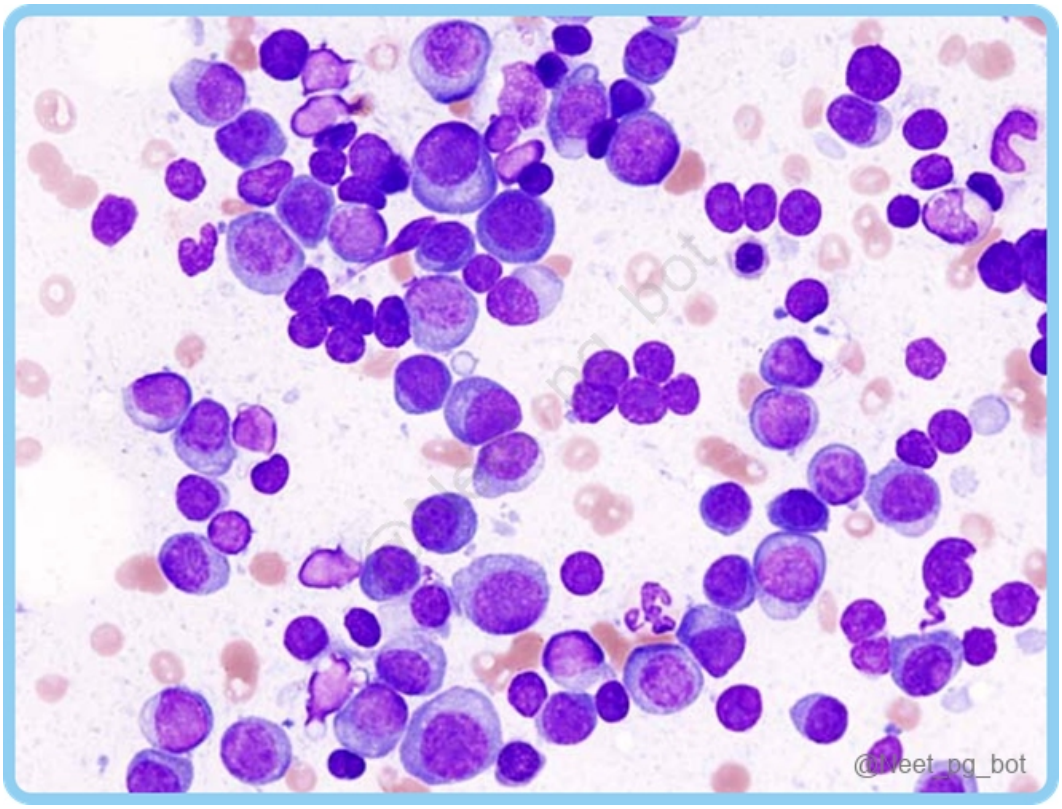

See Answer in Part B → Q17

@Neet_pg_bot

Q18: A 10-year-old boy with Down syndrome presents with mediastinal mass (presenting as SVC-like syndrome), and Peripheral blood and bone marrow have increased lymphoblasts. What is the probable diagnosis? (Q859296)

A. Acute myeloblastic leukemia

B. Chronic lymphoblastic leukemia

C. Acute lymphoblastic leukemia

D. Chronic myeloid leukemia

See Answer in Part B → Q18

@Neet_pg_bot

Q19: What is the diagnosis for a 5-year-old boy who has weight loss, fever, and a painless swelling in his jaw area? CBC results indicate anaemia and lymphocytosis. The image below shows biopsy findings from the swelling. (Q859847)

A. Kikuchi disease

B. Infectious mononucleosis

C. Hodgkins lymphoma

D. Burkitt lymphoma

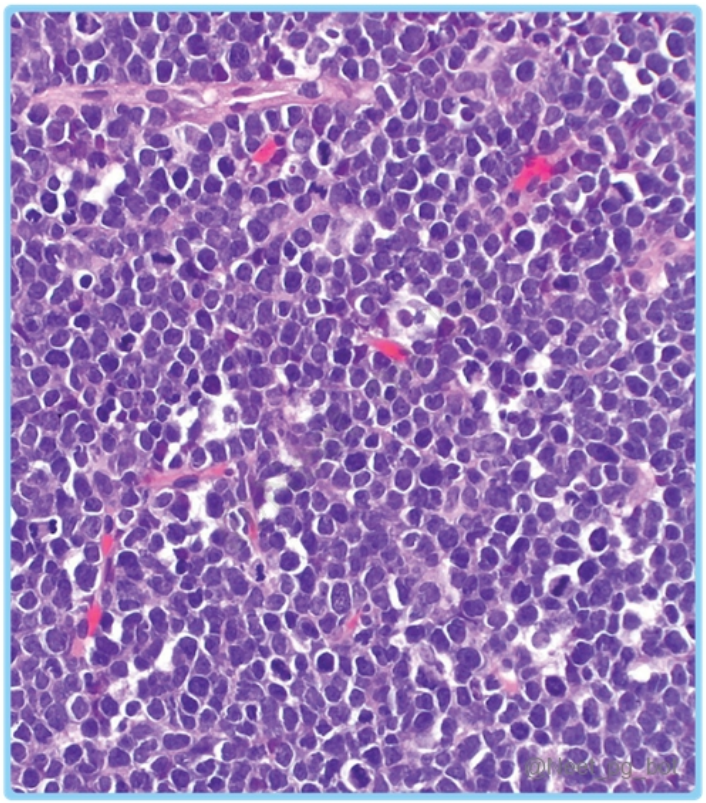

See Answer in Part B → Q19

@Neet_pg_bot

Q20: A 60-year-old male patient presented with anaemia and hepatosplenomegaly. A peripheral smear showed teardrop cells, nucleated RBCs, and giant abnormal platelets. A biopsy showed marrow fibrosis and a few characteristics, as given below.

The most likely diagnosis is: (Q859854)

A. Polycythemia vera

B. Essential thrombocythemia

C. Primary myelofibrosis

D. Chronic myeloid leukemia

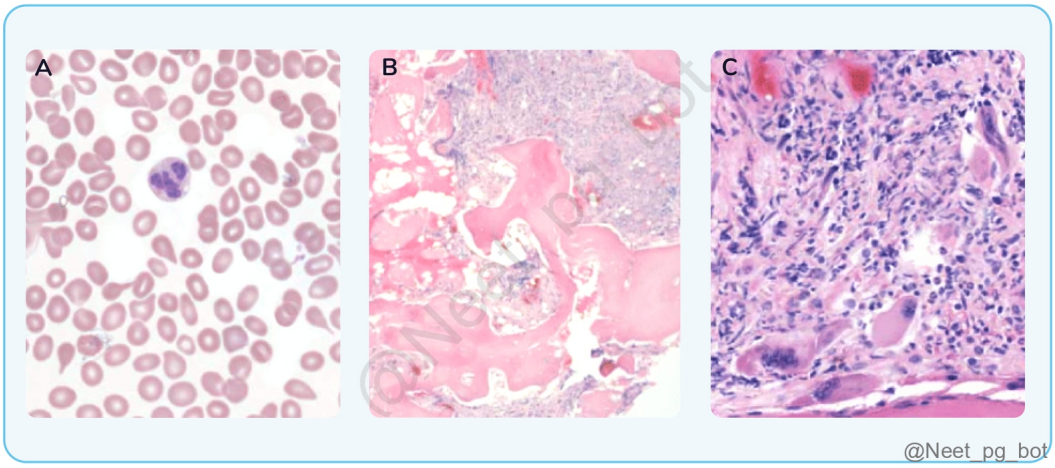

See Answer in Part B → Q20

@Neet_pg_bot

Q21: A 35-year-old man presents with nosebleeds, bleeding gums, and multiple ecchymoses. Lab investigations show: Haemoglobin: 8.5 g/dL Platelet count: 12,000 platelets/mm3 Total leucocyte count: 52,000 cells/mm3 with 83% blasts, as seen below. The blasts are CD33 +ve. The most likely diagnosis is: (Q859860)

A. Acute myeloid leukemia

B. Acute lymphoblastic leukemia

C. Chronic lymphocytic leukemia

D. Myelodysplastic syndrome

See Answer in Part B → Q21

@Neet_pg_bot

Q22: What is the type of cell from which the cell displayed below originates? (Q859892)

A. NK cells

B. CD4 cells

C. B cells

D. CD8 cells

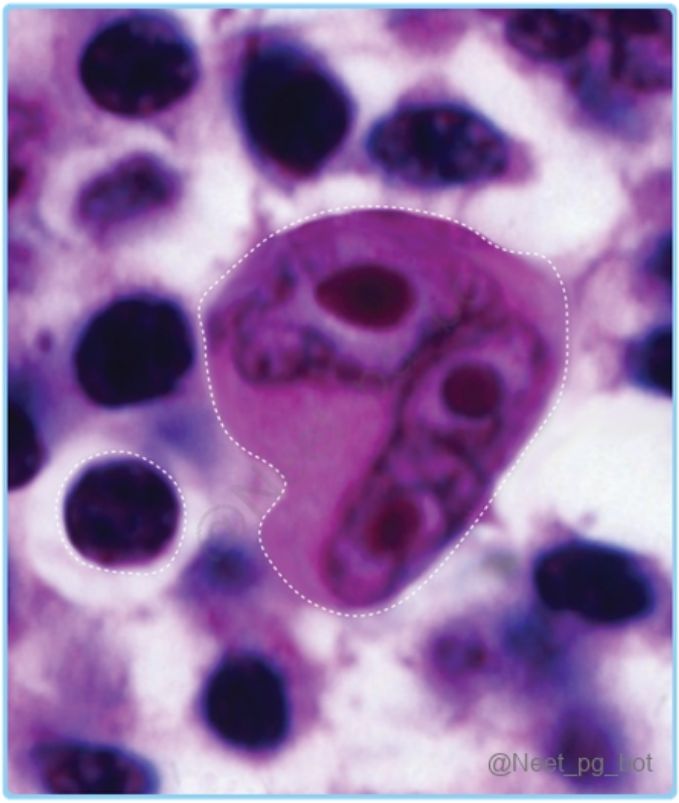

See Answer in Part B → Q22

@Neet_pg_bot

Q23: A 56-year-old man presents with dragging pain in the abdomen. On examination, there is a massive splenomegaly. A peripheral smear shows leukocytosis with increased myelocytes, metamyelocytes, and basophils. Which of the following translocations is seen in this condition? (Q855983)

A. t(9;22)

B. t(8;21)

C. t(15;17)

D. t(8;14)

See Answer in Part B → Q23

@Neet_pg_bot

Q24: A 62-year-old man presents with generalised lymphadenopathy and splenomegaly. Peripheral smear shows small to medium-sized lymphoid cells with irregular nuclear contours. Cytogenetic analysis demonstrates a t(11;14) (q13;q32) translocation. Which of the following markers is most closely associated with the pathogenesis? Cyclin D SOX 11 CD -200 D CD10 (Q879203)

A. 1, 2, 3

B. 1, 2

C. 1, 2, 4

D. 2, 3, 4

See Answer in Part B → Q24

@Neet_pg_bot

Q25: A 30-year-old male presents with fatigue for the past year. Examination reveals massive splenomegaly. His blood workup shows the following findings: Anemia Total leukocyte count (TLC): 150,000/microliter Peripheral smear: 60% neutrophils, 6% basophils, 4% eosinophils, myeloblasts, myelocytes, and metamyelocytes Myeloid to erythroid ratio: 18:1 What is the most likely diagnosis? (Q857164)

A. Acute Lymphoblastic Leukemia (ALL)

B. Acute Myeloid Leukemia (AML)

C. Chronic Myelogenous Leukemia (CML)

D. Chronic Lymphocytic Leukemia (CLL)

See Answer in Part B → Q25

@Neet_pg_bot

Q26: A 68-year-old man presents with bleeding manifestations. The peripheral smear shows the presence of the cells shown below. Which of the following is the most common chromosomal abnormality seen in this condition? (Q866343)

A. t(8:21)

B. t(15:17)

C. t(14:18)

D. Inv(16)



See Answer in Part B → Q26

@Neet_pg_bot

Q27: A young child presents with bleeding gums and bruising for the past two weeks. Bone marrow biopsy and flow cytometry have been performed. What is the diagnosis? (Q853374)

A. Acute myeloid leukemia

B. CLL

C. ALL: B Phenotype

D. ALL: T Phenotype

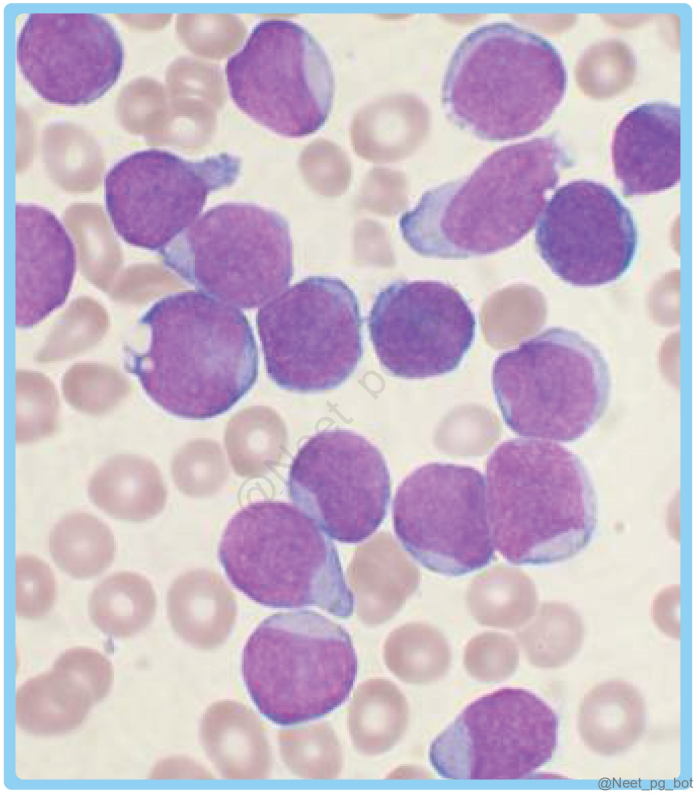

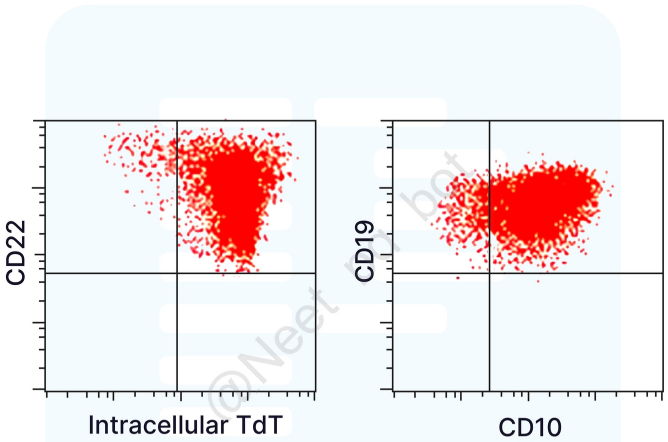

@Neet_pg_bot

See Answer in Part B → Q27

@Neet_pg_bot

Q28: Which gene mutation is most commonly associated with Burkitt's lymphoma? (Q852602)

A. C-myc

B. P-21

C. Rb

D. p53

See Answer in Part B → Q28

@Neet_pg_bot

Q29: A 34-year-old female presents with low hemoglobin, platelet count of 25,000/mm 3 , and raised PT and APTT. The peripheral smear image is shown below. Which of the following fusion genes is likely affected? (Q843988)

A. PML-RARA

B. RUNX1-RUNX1T1

C. INV 16

D. IGH-NSD2

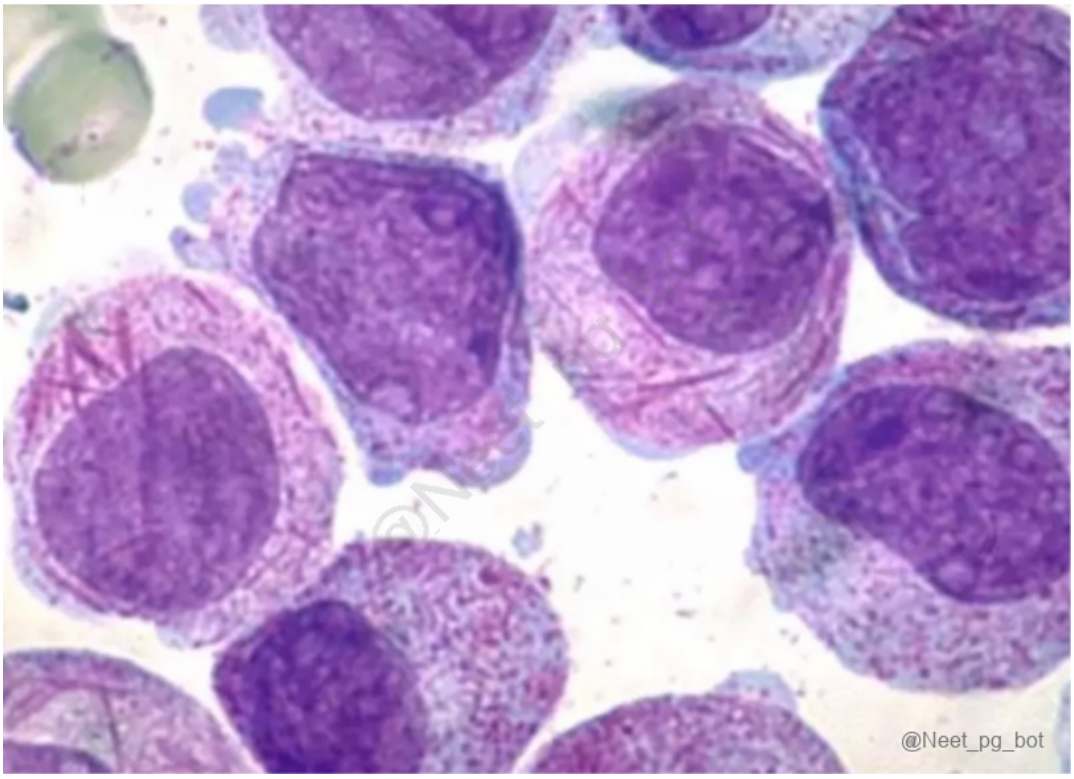

See Answer in Part B → Q29

@Neet_pg_bot

Q30: A patient presents with fever, hepatosplenomegaly, abdominal pain, and WBC count > 50,000/mm 3 . Which of the following genetic abnormalities is involved? (Q844072)

A. t(9;22)

B. del(1q)

C. t(15;17)

D. del 3q

See Answer in Part B → Q30

@Neet_pg_bot

Q31: An elderly patient presents with elevated calcium levels, increased serum creatinine levels, and decreased hemoglobin. Electrophoresis reveals a monoclonal spike. Her immunofixation test findings are given below. Which of the following best describes her condition? (Q844198)

A. Multiple myeloma with increased IgG

B. Multiple myeloma with increased IgM

C. Multiple myeloma with increased IgA

D. Monoclonal gammopathy of unknown significance

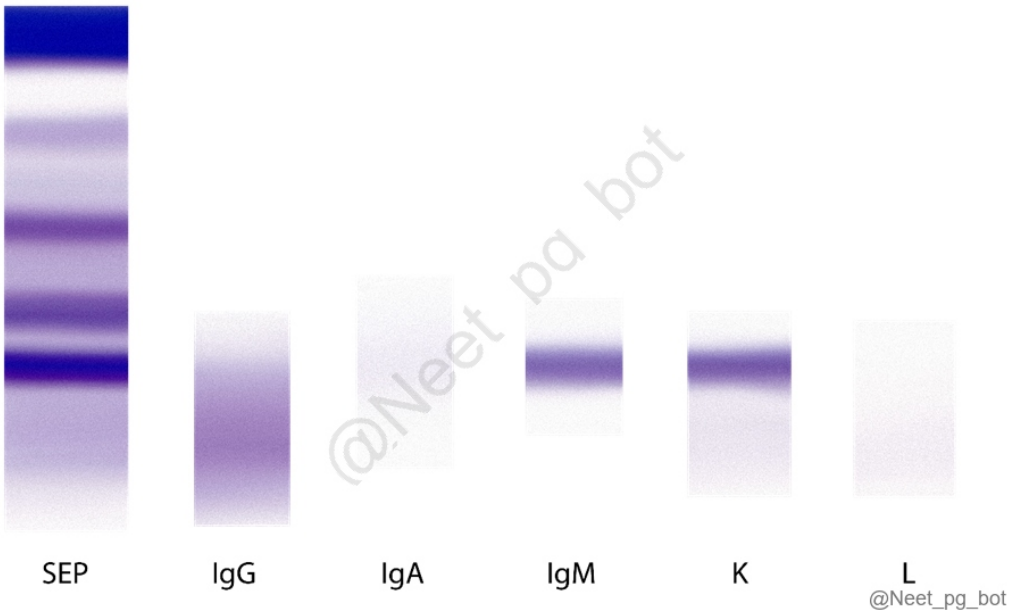

See Answer in Part B → Q31

@Neet_pg_bot

Q32: Which of the following is the investigation of choice for CML? (Q860526)

A. LAP score

B. FISH

C. Karyotyping

D. Reciprocal translocation

See Answer in Part B → Q32

@Neet_pg_bot

Q33: Mark the incorrect statement regarding Hodgkin Lymphoma: (Q840028)

A. Reed Sternberg cells are of B-cell origin

B. Waldeyer's ring is involved

C. Nodular sclerosing is the most common subtype and involves mediastinum

D. CD 15, 30 Positivity in Reed Sternberg cells

See Answer in Part B → Q33

@Neet_pg_bot

Q34: A patient with elevated calcium and normal alkaline phosphatase undergoes a skull X-ray. What is the likely diagnosis? (Q860163)

A. Grave’s disease

B. Paget’s disease

C. Multiple myeloma

D. CML

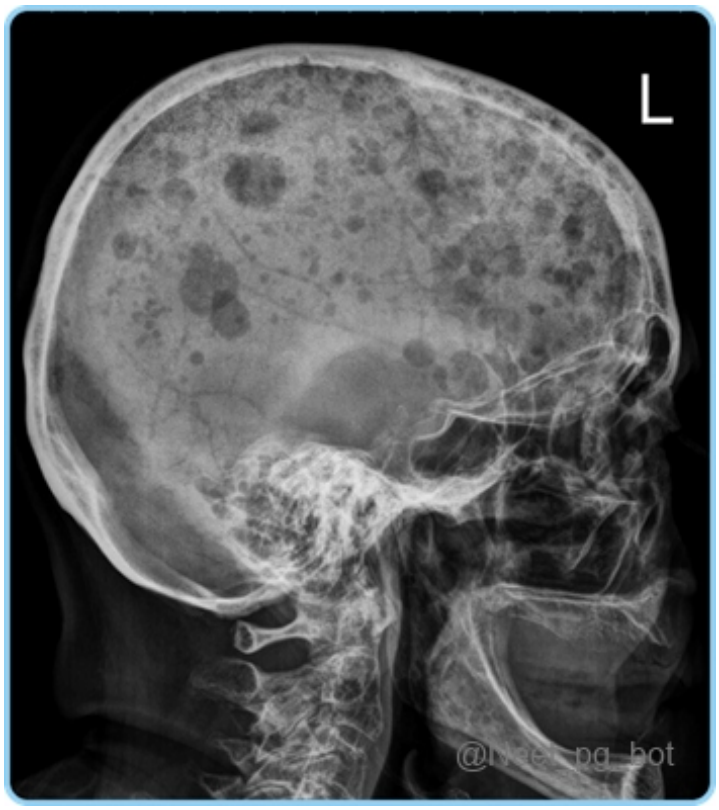

See Answer in Part B → Q34

@Neet_pg_bot

Q35: A 50-year-old male complains of lower back pain with a 1-1.5 mm osteolytic lesion at the T10 vertebra. Histopathological findings are given below. Which of the following options is correct regarding this condition? (Q860232)

A. Presence of Bence-Jones proteinuria

B. Absence of Rouleaux formation

C. Absence of free light chains

D. Decreased Calcium levels in the blood

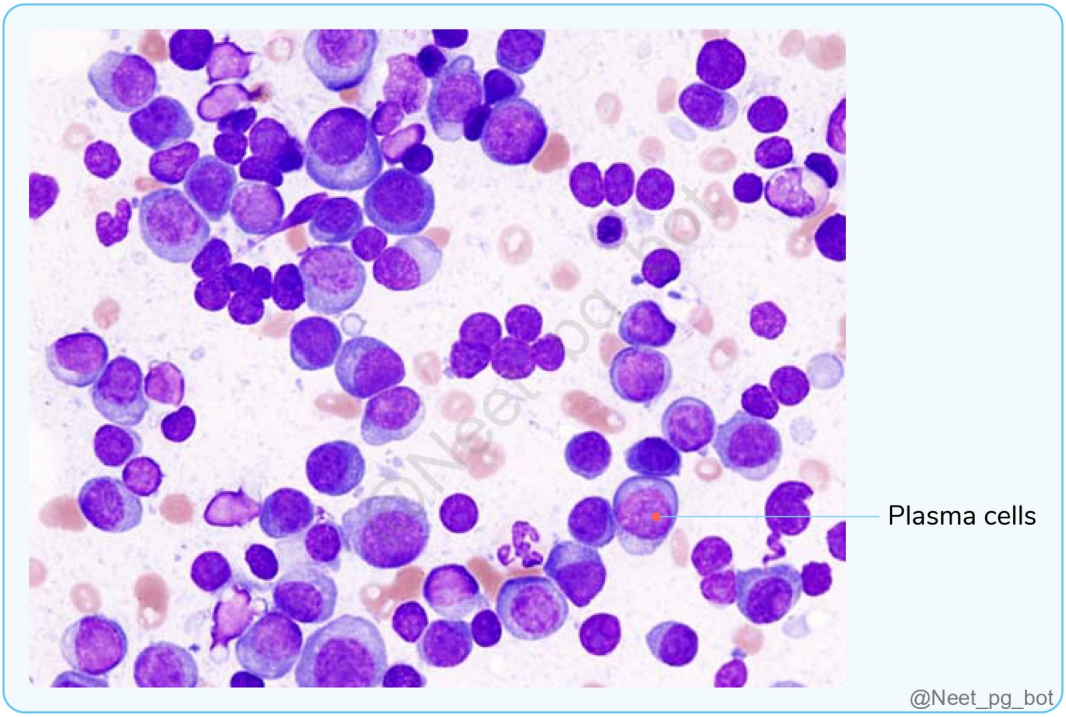

See Answer in Part B → Q35

@Neet_pg_bot

Q36: Which among the following is associated with Cryoglobulinemia? (Q860258)

A. Hepatitis C infection

B. Ovarian cancer

C. Diabetes

D. Leukaemia

See Answer in Part B → Q36

@Neet_pg_bot

Q37: Which of the following cells is shown in the given image? (Q857427)

A. Hairy cell

B. Gaucher cell

C. Sickle cell

D. Target cell

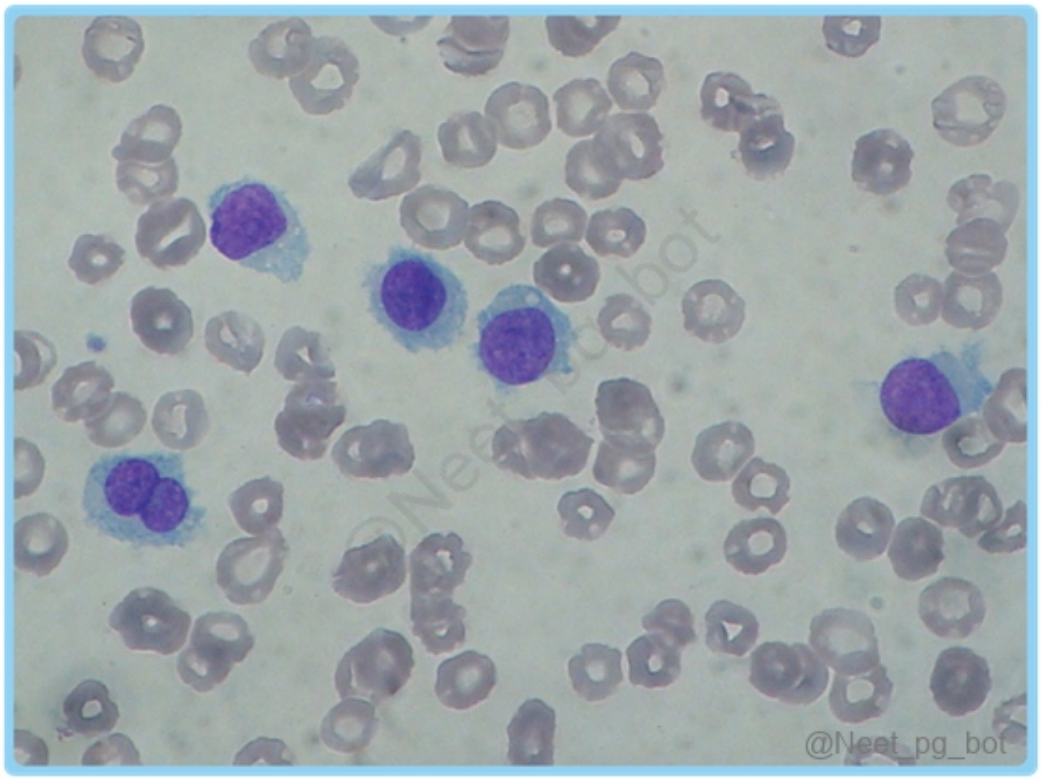

See Answer in Part B → Q37

@Neet_pg_bot

Q38: A 70 year old male presents with low back ache and progressive pallor. On work up: KFT is deranged, LFT is normal with normal level of albumin and gamma globulin increased disproportionately. X-ray spine shows multiple lytic lesions. Which of the following is the most probable diagnosis? (Q820525)

A. Multiple myeloma

B. MGUS

C. Immunoglobulin light chain amyloidosis (AL)

D. Solitary plasmacytoma.

See Answer in Part B → Q38

@Neet_pg_bot

Q39: A 55-year-old male patient presents with fever, night sweats, and pleural effusion. On further investigation, he is diagnosed with Primary Effusion Lymphoma. What is the most likely causative agent responsible for this condition? (Q820628)

A. HHV-8

B. EBV

C. HPV

D. HIV

See Answer in Part B → Q39

@Neet_pg_bot

Q40: What further test should be conducted for a 60-year-old male patient who has presented with widespread lymph node enlargement, elevated white blood cell count, and smudge cells observed on peripheral smear? (Q854682)

A. Cytogenic study

B. Bone marrow biopsy

C. Flow cytometry from peripheral blood

D. X-ray crystallography

See Answer in Part B → Q40

@Neet_pg_bot

Q41: An African child is found to have a mass in the jaw. A biopsy of the mass was done, and it appears as shown in the image below. The child also has a translocation, t(8;14). What is the probable diagnosis? (Q855405)

A. Acute myeloid leukemia

B. Follicular lymphoma

C. Multiple myeloma

D. Burkitt lymphoma

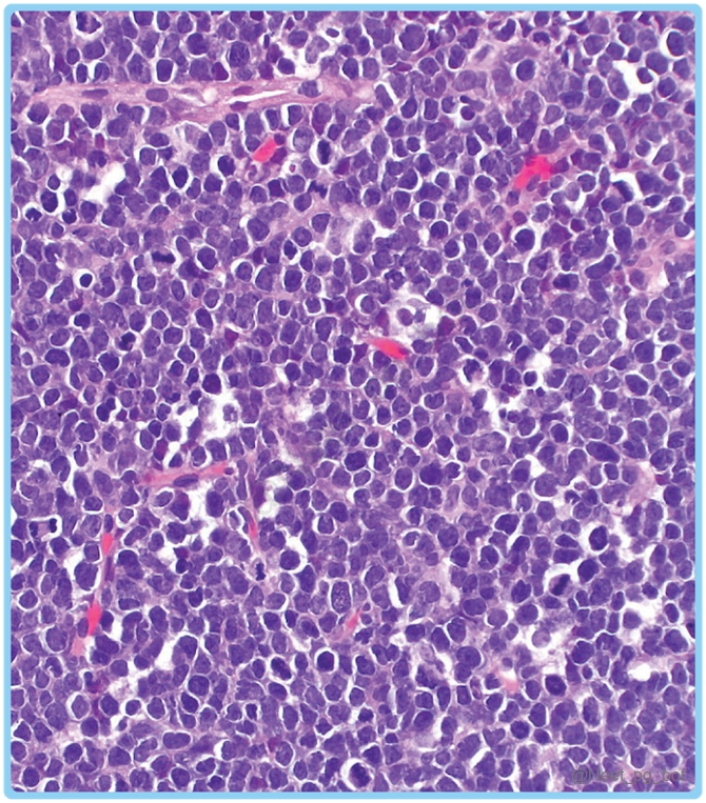

See Answer in Part B → Q41

@Neet_pg_bot

Q42: A 25-year-old male presented with low haemoglobin, a platelet count of 25,000/mL, gum bleeding, and raised PT and aPTT. The image of his peripheral smear is shown below. What is the likely diagnosis? (Q855440)

A. AML with t(8;21)

B. AML with inv(16)

C. AML with t(15;17)

D. AML with t(11;22)

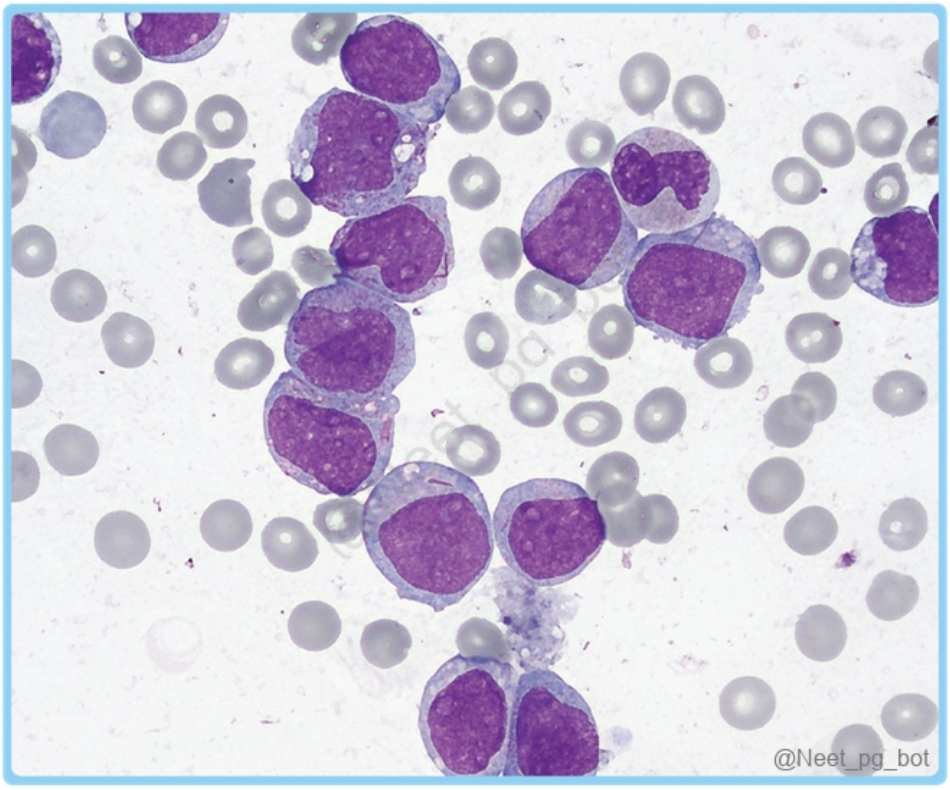

See Answer in Part B → Q42

@Neet_pg_bot

Q43: Which of the following leukaemias is associated with the given peripheral smear? (Q855099)

A. Acute lymphoblastic leukemia

B. Chronic lymphocytic leukemia

C. Acute myeloid leukemia

D. Chronic myelogenous leukemia

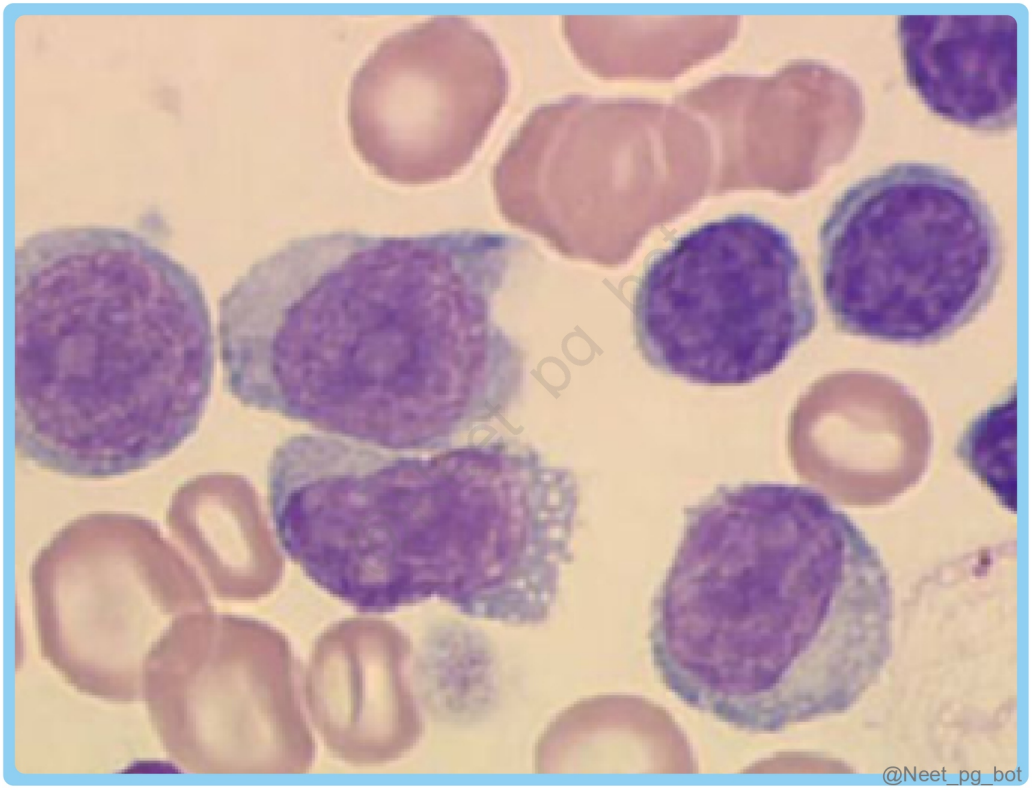

See Answer in Part B → Q43

@Neet_pg_bot

Q44: Identify the cell in the image below: (Q855101)

A. Mast cell

B. Macrophage

C. Plasma cell

D. Fibroblast

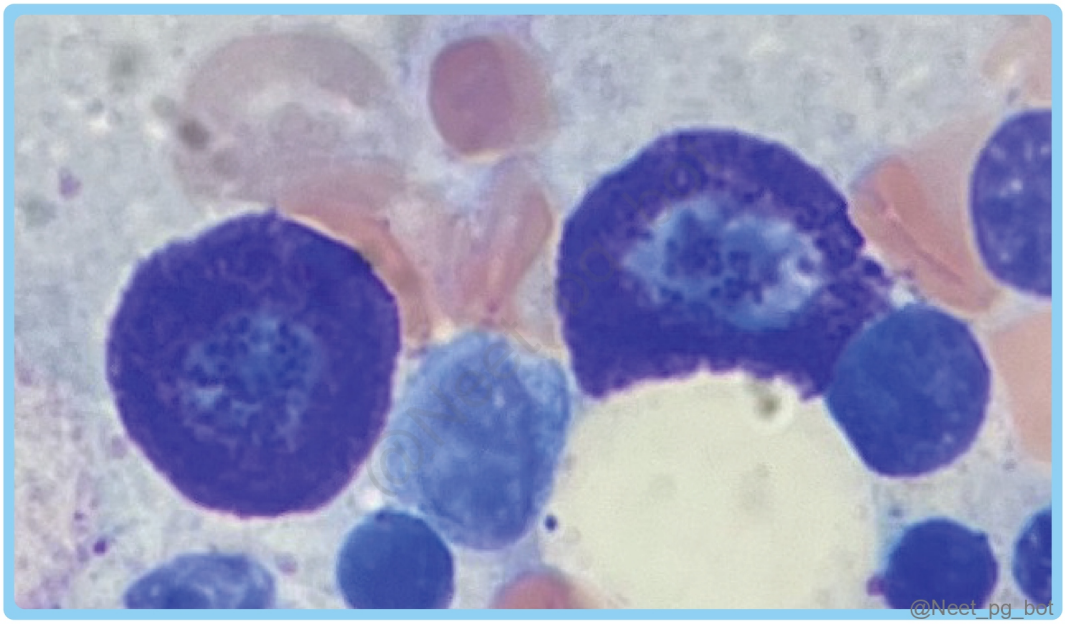

See Answer in Part B → Q44

@Neet_pg_bot

Q45: A patient with cervical lymphadenopathy has a positive t(11;14) translocation. Which of the following markers should be used to confirm the diagnosis? A. CD10 B. CD200 C. SOX11 D. Cyclin D1 (Q856913)

A. A, B

B. B, D

C. A, C

D. C, D

See Answer in Part B → Q45

@Neet_pg_bot

Q46: An elderly male presents for a routine medical examination. Laboratory investigations reveal a very high total leukocyte count (TLC). The peripheral smear shows findings as shown in the image. What is the appropriate next step for this patient? (Q855433)

A. Stem cell transplantation

B. Bone marrow biopsy

C. Flow cytometry

D. Start high-dose chemotherapy

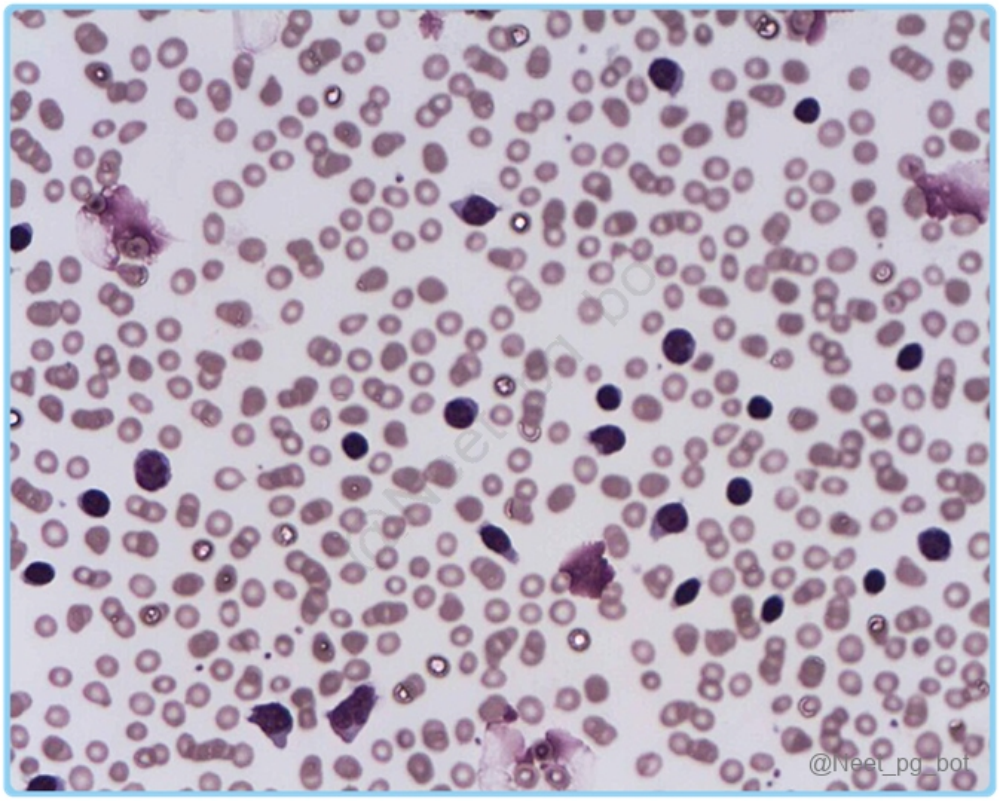

See Answer in Part B → Q46

@Neet_pg_bot

Q47: A 38-year-old man presented with bleeding gums for 20 days. He has gingival hyperplasia and hepatosplenomegaly. On investigation, Hb-11 g/dL, platelet count-95,000 platelets/mm3, and WBC count-45000 cells/mm3. A bone marrow biopsy shows 100% cellularity, with many blast cells that are peroxidase-negative and non-specific esterase-positive . The most likely diagnosis is: (Q793658)

A. Acute myeloid leukemia M2 (AML M2)

B. Acute myeloid leukemia M0 (AML M0)

C. Acute myeloid leukemia M5 (AML M5)

D. Acute myeloid leukemia M7 (AML M7)

See Answer in Part B → Q47

@Neet_pg_bot

Q48: What is the most accurate test for evaluating the effectiveness of treatment in chronic myeloid leukemia (CML)? (Q857166)

A. ■■■

B. RT PCR

C. Cytogenetic test

D. FISH

See Answer in Part B → Q48

@Neet_pg_bot

Q49: Which CD markers are typically positive in Chronic Lymphocytic Leukaemia (CLL)? . (Q866672)

A. CD3, CD5, CD8

B. CD10, CD19, CD22

C. CD19, CD20, CD23, CD5

D. CD13, CD33, CD117

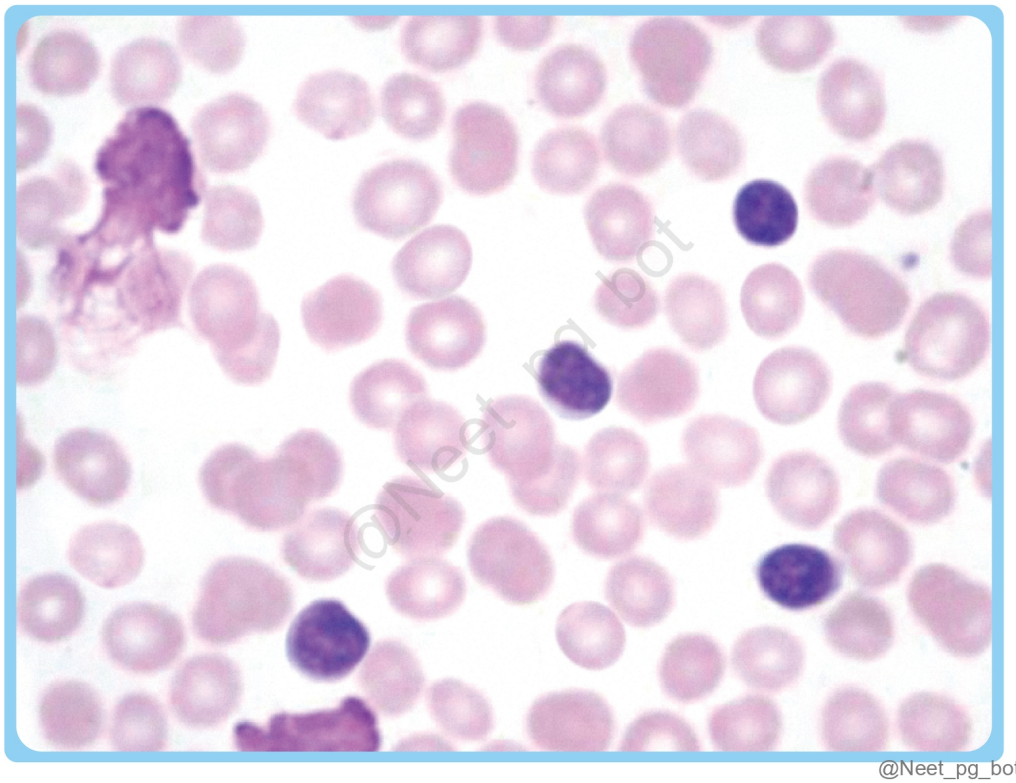

See Answer in Part B → Q49

@Neet_pg_bot

• [19_Platelet and Bleeding Disorders] 078 Platelet And Hemostasis Disorders

« Back to Folder Directory

[19_Platelet and Bleeding Disorders] 078 Platelet And Hemostasis Disorders — Quick Jump

Q1 (p. 895)	*Q2 (p. 895)*	*Q3 (p. 896)*	*Q4 (p. 897)*	*Q5 (p. 897)*	*Q6 (p. 898)*
Q7 (p. 898)	*Q8 (p. 899)*	*Q9 (p. 899)*	*Q10 (p. 900)*	*Q11 (p. 900)*	*Q12 (p. 901)*
Q13 (p. 901)	*Q14 (p. 902)*	*Q15 (p. 902)*	*Q16 (p. 903)*	*Q17 (p. 903)*	*Q18 (p. 904)*
Q19 (p. 904)	*Q20 (p. 905)*	*Q21 (p. 905)*	*Q22 (p. 905)*	*Q23 (p. 906)*	

Q1: An 8-year-old girl has been brought to the pediatric clinic by her parents. She has been suffering from tiny cutaneous haemorrhages spread all over her body. She has been recovering for a week from a flu-like condition. Her Physical examination is unremarkable, and she is vitally stable. Her Laboratory investigations revealed a platelet count of 20,000/mL. The number of megakaryocytes in her bone marrow has increased. Which of the following is the most likely diagnosis for this girl? (Q882287)

A. Antiphospholipid antibody syndrome

B. Disseminated intravascular coagulation

C. Hemolytic-uremic syndrome

D. Idiopathic thrombocytopenic purpura

See Answer in Part B → Q1

@Neet_pg_bot

Q2: A 62-year-old hospitalized woman is evaluated for worsening skin lesions. She was admitted 6 days ago for total hip replacement surgery. The surgery was uncomplicated. She is receiving low-dose subcutaneous heparin for prophylaxis of DVT. O/E, there are several large purple/ black patches seen in the periumbilical region surrounded by erythema. Which of the following is true regarding heparin-induced thrombocytopenia (HIT)? (Q845960)

A. Type 1 is more common than type 2

B. Type 1 is due to antibodies against PF 4

C. HIT can lead to elevated fibrinogen levels

D. Type 2 occurs immediately after the initiation of heparin.



See Answer in Part B → Q2

@Neet_pg_bot

Q3: A 45-year-old woman presents with easy bruising and recurrent nosebleeds. Laboratory investigations reveal a prolonged aPTT. A mixing study is performed, and the aPTT corrects after mixing with normal plasma. What is the most likely diagnosis? (Q845970)

A. Factor deficiency

B. Platelet dysfunction

C. Presence of lupus anticoagulant

D. Vitamin K deficiency

See Answer in Part B → Q3

@Neet_pg_bot

Q4: A 45-year-old male is admitted to the ICU following a road traffic accident. Upon arrival, he is hypotensive and tachycardic. Despite fluid resuscitation and transfusion of packed red blood cells, his condition deteriorates rapidly. Lab investigations show a sudden drop in platelet count and prolonged PT and aPTT. DIC is suspected. The thromboelastogram (TEG) graph is shown below: Which of the following is correct? (Q845969)

A. R time is more in Stage 1

B. K time is more in stage 2

C. Maximum amplitude is more in stage 2

D. Maximum amplitude is less in stage 1



See Answer in Part B → Q4

@Neet_pg_bot

Q5: A 60 y/o man is brought to the hospital following a high-speed head-on collision. O/E, BP is 80/50mmhg and HR is 130bpm. Laboratory studies indicate a significant drop in platelet count, prolonged PT, and aPTT. DIC is suspected, and a thromboelastogram is performed. What term represents the time from the initiation of the test until the initial formation of the clot? (Q845968)

A. R time

B. K Time

C. Maximum Amplitude (MA)

D. LY30

See Answer in Part B → Q5

@Neet_pg_bot

Q6: A 10 y/o boy presents with a history of recurrent nosebleeds and easy bruising since early childhood. O/E, there are multiple petechiae and ecchymoses on his skin. Laboratory investigations reveal normal platelet count but markedly decreased platelet aggregation. Bernard-Soulier Syndrome is suspected. Which of the following features would commonly be observed in platelet aggregometry for this patient? (Q845967)

A. Normal aggregation with ristocetin

B. No aggregation with ristocetin

C. No aggregation with collagen

D. No aggregation with epinephrine

See Answer in Part B → Q6

@Neet_pg_bot

Q7: A 6-year-old girl presents with persistent bleeding from minor cuts and bruises since early childhood. On examination, there are multiple bruises and petechiae on her limbs. Lab investigations reveal normal platelet count but markedly decreased platelet aggregation. Glanzmann thrombasthenia is suspected. Which of the following agonists will be able to demonstrate decreased platelet aggregation? (Q845966)

A. Adenosine diphosphate (ADP)

B. Collagen

C. Epinephrine

D. All of the above

See Answer in Part B → Q7

@Neet_pg_bot

Q8: A 45-year-old man presents with a history of easy bruising and recurrent nosebleeds. Laboratory investigations reveal normal platelet count but prolonged bleeding time. A Platelet aggregometry test is performed, showing a decrease in light transmission. What is the most likely interpretation of the platelet aggregometry results in this patient? (Q845965)

A. Platelet aggregation

B. No platelet aggregation

C. Increase in serum sodium

D. Increase in plasma fibrinogen

See Answer in Part B → Q8

@Neet_pg_bot

Q9: A 12-year-old male presents with a history of frequent nosebleeds and easy bruising. His parents report that he has had these symptoms for several years, but they seem to be worsening recently. On examination, petechiae are noted on his skin, particularly over his legs, and laboratory investigations reveal prolonged bleeding time, elevated aPTT, and PT within normal range. His platelet count is normal. Which of the following is the most likely diagnosis? (Q845964)

A. Hemolytic Uremic Syndrome (HUS)

B. Hemophilia

C. Bernard Soulier syndrome

D. Von Willebrand Disease (vWD)

See Answer in Part B → Q9

@Neet_pg_bot

Q10: A 35-year-old mother underwent a C-section. On post-op day 1, she complains of shortness of breath and bleeding from catheter sites. Her vitals are unstable. Which of the following statements is false concerning her condition? (Q845963)

A. PT, and APTT are normal.

B. AMLM3 is associated with DIC

C. FDP & D-dimer levels are elevated

D. Meningococcemia is associated with DIC

See Answer in Part B → Q10

@Neet_pg_bot

Q11: A 4-year-old child is brought to the emergency department with a history of bloody diarrhea followed by pallor, fatigue, and reduced urine output. Laboratory investigations reveal anemia, thrombocytopenia, and elevated serum creatinine. A peripheral blood smear is done and is given below. What is the most likely cause of this child's diarrhea? (Q845962)

A. O157:H7

B. Defect in ADAM-TS 13

C. Mutation in TGF-beta

D. Prosthetic valves

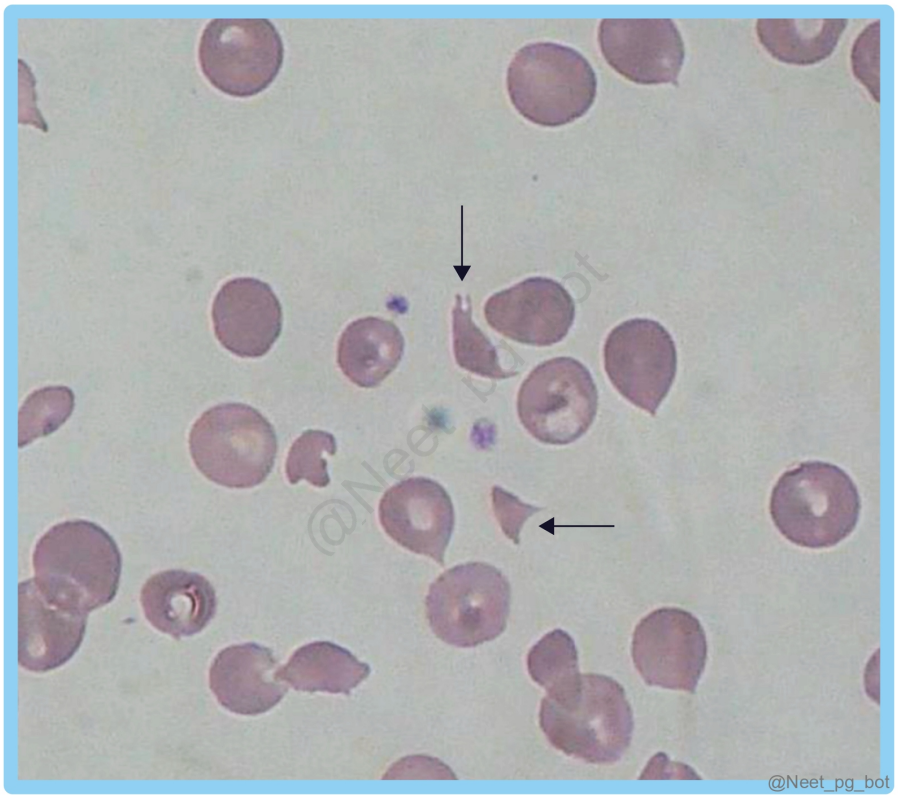

See Answer in Part B → Q11

@Neet_pg_bot

Q12: A 5-year-old boy is brought to the clinic with recurrent episodes of spontaneous bleeding into his joints. Laboratory tests reveal a prolonged activated partial thromboplastin time (aPTT) and reduced factor VIII levels. Based on these findings, what is the most likely diagnosis? (Q845961)

A. Hemophilia A

B. Hemophilia B

C. Hemophilia C

D. Pseudohemophilia

See Answer in Part B → Q12

@Neet_pg_bot

Q13: A 58-year-old woman presents with fatigue, early satiety, and left upper quadrant mass. Lab investigation reveals anemia and thrombocytopenia. Blood smear shows teardrop-shaped RBCs and nucleated RBCs. Bone marrow biopsy confirms myelofibrosis. Which megakaryocyte defect is characteristic in this condition? (Q845949)

A. Dwarf Megakaryocyte

B. Staghorn megakaryocyte

C. Pawn ball megakaryocyte

D. Cloud-like megakaryocyte

See Answer in Part B → Q13

@Neet_pg_bot

Q14: Match the defect with the corresponding syndrome: Defect Syndrome 1. Gp1b/9 a. Hermanski pudlak syndrome 2. Alpha granules b. Bernard Soulier syndrome 3. Delta granules c. Glanzmann thrombasthenia 4. Gp2b/3a d. Gray platelet syndrome (Q845959)

A. 1-c, 2-a, 3-b, 4-b

B. 1-d, 2-c, 3-a, 4-b

C. 1-b, 2-a, 3-d, 4-c

D. 1-b, 2-d, 3-a, 4-c

See Answer in Part B → Q14

@Neet_pg_bot

Q15: A 34-year-old man comes to the physician complaining of occasional dizziness and palpitations in crowded spaces. He is an executive who travels frequently and reports high-stress levels at work. Labs: Hb= 14.0 Platelets = 80,000 Leukocytes = 7,200 RBCs= 5 million Peripheral smear shows a reduced platelet count without clumping or malignant cells. Which of the following is the most appropriate next test

for this patient? (Q845958)

A. EBV virus titers

B. Rapid plasma reagin test

C. Schilling test

D. HIV antibody test

See Answer in Part B → Q15

@Neet_pg_bot

Q16: A 14-year-old adolescent presents with recurrent episodes of unexplained swelling and pain following minor injuries or physical activity. Upon examination, there are signs of localized swelling and tenderness. Lab investigations reveal normal platelet counts and bleeding time, but clotting times are prolonged. Which symptom would strongly suggest a coagulation defect in this patient? (Q845957)

A. Petechiae

B. Purpura

C. Ecchymosis

D. Hemarthrosis

See Answer in Part B → Q16

@Neet_pg_bot

Q17: A 22-year-old woman presents to the clinic with a history of frequent nosebleeds and heavy menstrual periods. She reports prolonged bleeding after minor cuts and has noticed easy bruising. On physical examination, multiple small bruises are on her arms and legs. Which of the following tests is most likely to be abnormal? (Q845956)

A. Bleeding Time (BT)

B. Clotting Time (CT)

C. Prothrombin Time (PT)

D. Activated Partial Thromboplastin Time (aPTT)

See Answer in Part B → Q17

@Neet_pg_bot

Q18: A 2-week-old male infant is brought to the pediatrician by his parents because of prolonged bleeding from the umbilical stump. The parents report that the bleeding started soon after the umbilical cord fell off and has not stopped despite applying pressure. Laboratory tests show normal Prothrombin Time (PT), Activated Partial Thromboplastin Time (aPTT), and platelet count. Which of the following deficiencies is most likely causing the prolonged bleeding? (Q845955)

A. Factor VIII

B. Factor XIII

C. Factor IV

D. Factor IX

See Answer in Part B → Q18

@Neet_pg_bot

Q19: A 30-year-old woman presents with excessive bleeding following a tooth extraction. She reports a history of recurrent nosebleeds and easy bruising since childhood. Lab tests show prolonged activated partial thromboplastin time (aPTT) and normal prothrombin time (PT). Further testing reveals decreased levels of a clotting factor's activity. Which of the following is not an intrinsic factor? (Q845954)

A. Factor XII

B. Factor VII

C. Factor XI

D. Factor IX

See Answer in Part B → Q19

@Neet_pg_bot

Q20: A 55-year-old male patient presents with a history of recurrent episodes of uncontrolled bleeding from minor injuries and easy bruising. Lab investigations reveal prolonged prothrombin time (PT) and activated partial thromboplastin time (aPTT). Considering a potential vitamin K deficiency, which specific clotting factors should be evaluated to confirm the diagnosis in this patient? (Q845953)

A. Tissue thromboplastinLabile factor

B. Labile factor

C. Hageman factor

D. Stable factor

See Answer in Part B → Q20

@Neet_pg_bot

Q21: A 32-year-old woman presents with easy bruising, heavy menstrual bleeding, and prolonged bleeding after cuts and dental extraction. Lab tests show normal platelet counts but impaired platelet function. Which of the following substances, primarily released from alpha granules, might be deficient in this patient's platelets? (Q845952)

A. Serotonin

B. Epinephrine

C. ADP

D. P-selectin

See Answer in Part B → Q21

@Neet_pg_bot

Q22: A 22 y/o woman arrives at the clinic complaining of heavy menstrual flow and recurrent nosebleeds. Upon physical inspection, her arms and legs have several minor bruises. Coagulation studies show high BT, APTT, and normal PT. She is diagnosed with von Willibrand disease. Which type of vWD shows a decrease in binding between VWF and Gp 1b/9? (Q845951)

A. Type 1

B. Type 2a

C. Type 2b

D. Type 3

See Answer in Part B → Q22

@Neet_pg_bot

Q23: A 30-year-old woman is diagnosed with von Willebrand Disease (vWD) after presenting with frequent nosebleeds and prolonged bleeding after minor cuts. Laboratory tests reveal a defect in the von Willebrand factor (vWF). Which of the following is also involved in the pathogenesis of this condition? (Q845950)

A. gp1b-IX

B. gpIIb-IIIa

C. Factor IX

D. Factor XIII

See Answer in Part B → Q23

@Neet_pg_bot

• [19_Platelet and Bleeding Disorders] 079 Previous Year Questions

« Back to Folder Directory

[19_Platelet and Bleeding Disorders] 079 Previous Year Questions — Quick Jump

Q1 (p. 907)	*Q2 (p. 908)*	*Q3 (p. 908)*	*Q4 (p. 909)*	*Q5 (p. 909)*	*Q6 (p. 909)*
Q7 (p. 910)	*Q8 (p. 910)*	*Q9 (p. 910)*	*Q10 (p. 911)*	*Q11 (p. 911)*	*Q12 (p. 912)*
Q13 (p. 912)	*Q14 (p. 912)*	*Q15 (p. 913)*	*Q16 (p. 913)*	*Q17 (p. 913)*	*Q18 (p. 914)*
Q19 (p. 915)	*Q20 (p. 915)*	*Q21 (p. 915)*	*Q22 (p. 916)*	*Q23 (p. 916)*	*Q24 (p. 916)*

Q1: A patient presents with a tingling sensation in both legs, polyuria, and weight loss. Based on the given bone marrow aspirate findings, what is the most likely diagnosis? (Q844224)

A. Multiple myeloma with renal failure

B. SACD with vitamin B12 deficiency

C. SACD with diabetes

D. Waldenstrom's Macroglobulinemia

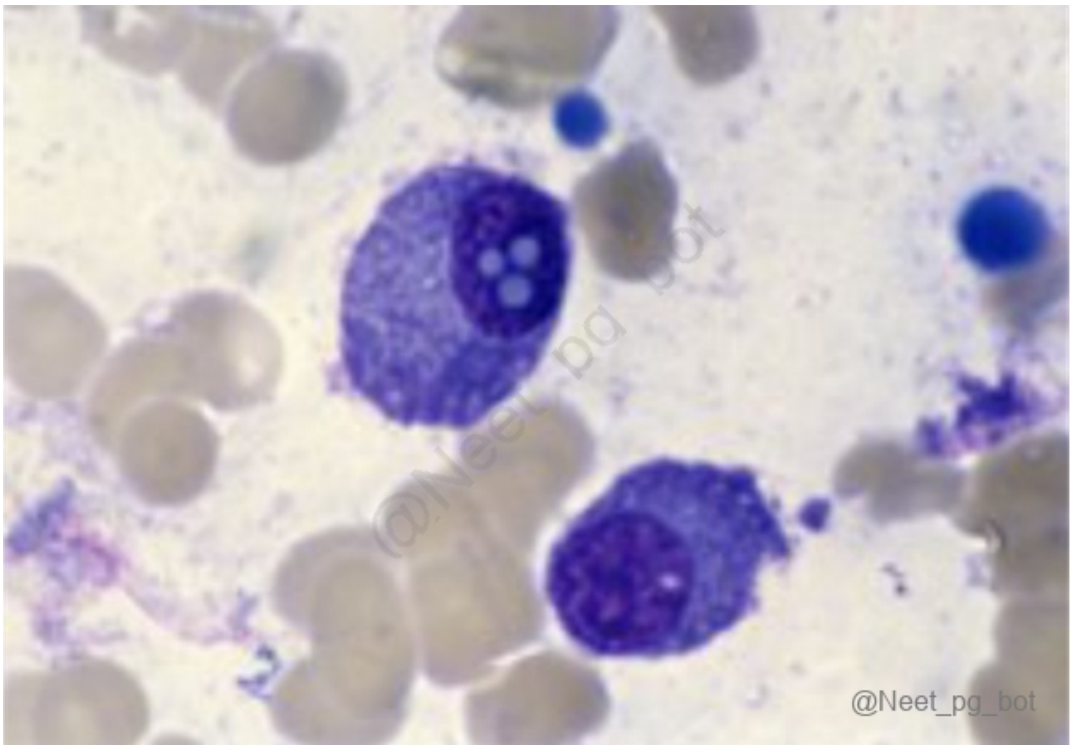

See Answer in Part B → Q1

@Neet_pg_bot

Q2: Most common cause of inherited coagulopathy is: (Q853370)

A. Factor V Leiden mutation

B. Antithrombin III deficiency

C. Protein C deficiency

D. Protein S deficiency

See Answer in Part B → Q2

@Neet_pg_bot

Q3: Which of the following diseases are correctly associated with their respective inclusion bodies? (Q853377)

A. Rabies - Lewy bodies

B. Parkinson’s disease - Dutcher bodies

C. Multiple myeloma - Negri bodies

D. Malakoplakia - Michaelis Gutmann bodies

See Answer in Part B → Q3

@Neet_pg_bot

Q4: Vacutainer used in serum electrolyte estimation: (Q853367)

A. Green

B. Lavender

C. Yellow

D. Grey

See Answer in Part B → Q4

@Neet_pg_bot

Q5: Anticoagulant used in the test tube for estimating HbA1c? (Q853366)

A. Warfarin

B. Sodium Fluoride

C. EDTA

D. Heparin

See Answer in Part B → Q5

@Neet_pg_bot

Q6: A child is brought to the emergency department with a large lesion on his forearm. As a surgery resident, you decide to excise the lesion in the emergency operation theatre. Which of the following investigations will test the entire coagulation

pathway? (Q856915)

A. Activated partial thromboplastin time

B. Prothrombin time

C. Thromboelastography

D. Bleeding time

See Answer in Part B → Q6

@Neet_pg_bot

Q7: What is the commonest cause of a hypercoagulable state? (Q857441)

A. Antithrombin III deficiency

B. Protein C deficiency

C. Factor V Leiden mutation

D. G20210A prothrombin gene mutation

See Answer in Part B → Q7

@Neet_pg_bot

Q8: How does Total plasma exchange help in the management of TTP (Q857426)

A. TPE removes the Von Willebrand factor

B. TPE removes the Antiplatelet antibodies

C. TPE removes Anti ADAMTS13 autoantibodies and thereby increases the ADAMTS protease activity

D. TPE replenishes the coagulation factor

See Answer in Part B → Q8

@Neet_pg_bot

Q9: Which of the following is not seen in a delayed hemolytic transfusion reaction? (Q840056)

A. Raised LDH

B. Raised indirect bilirubin

C. No improvement in Hb despite transfusion

D. Cola-colored urine after 2 hrs

See Answer in Part B → Q9

@Neet_pg_bot

Q10: In a trauma patient with an unknown blood group who is unstable and requires urgent blood transfusion, which type of blood should be transfused? (Q840032)

A. A positive

B. AB positive

C. O positive

D. O negative

See Answer in Part B → Q10

@Neet_pg_bot

Q11: Which of the following is used in the treatment of Hemophilia B? (Q840031)

A. Factor 9

B. Cryoprecipitate

C. Factor 8

D. Tranexamic acid

See Answer in Part B → Q11

@Neet_pg_bot

Q12: Match the following blood products with their shelf lives. a. 1-Granulocytes A- 5 days b. 2- PRBC B- 24 hours c. 3- SDP C- 42 days d. 4- CRYO D- 1 year (Q840026)

A. 1-A, 2-C, 3D, 4-B

B. 1-B, 2-D, 3-A, 4-C

C. 1-C, 2-A, 3-B, 4-D

D. 1-B, 2-C, 3-A, 4-D

See Answer in Part B → Q12

@Neet_pg_bot

Q13: A young boy presents with joint swelling after a fall. Lab investigations show normal PT and raised aPTT. What is the most likely diagnosis? (Q866666)

A. Von Willebrand Disease

B. Hemophilia

C. Iron Deficiency Anaemia (IDA)

D. Platelet function disorder

See Answer in Part B → Q13

@Neet_pg_bot

Q14: Which of the following is the most common inherited bleeding disorder? (Q865368)

A. Von Willebrand Disease

B. Disseminated Intravascular Coagulation

C. Factor V Deficiency

D. Hemophilia

See Answer in Part B → Q14

@Neet_pg_bot

Q15: Which of the following clotting factor deficiencies will not affect clotting in vivo? (Q856490)

A. Factor VII

B. Factor V

C. Factor XII

D. Factor IX

See Answer in Part B → Q15

@Neet_pg_bot

Q16: Leiden mutation is of factor: (Q856167)

A. V

B. VIII

C. I

D. X

See Answer in Part B → Q16

@Neet_pg_bot

Q17: Below is an image of the coagulation cascade activation following closed endothelial injury. Identify the factor ‘L’, which combines with tissue factor to activate factor IX. (Q856684)

A. Factor XII

B. Factor VII

C. Factor VIII

D. vWF

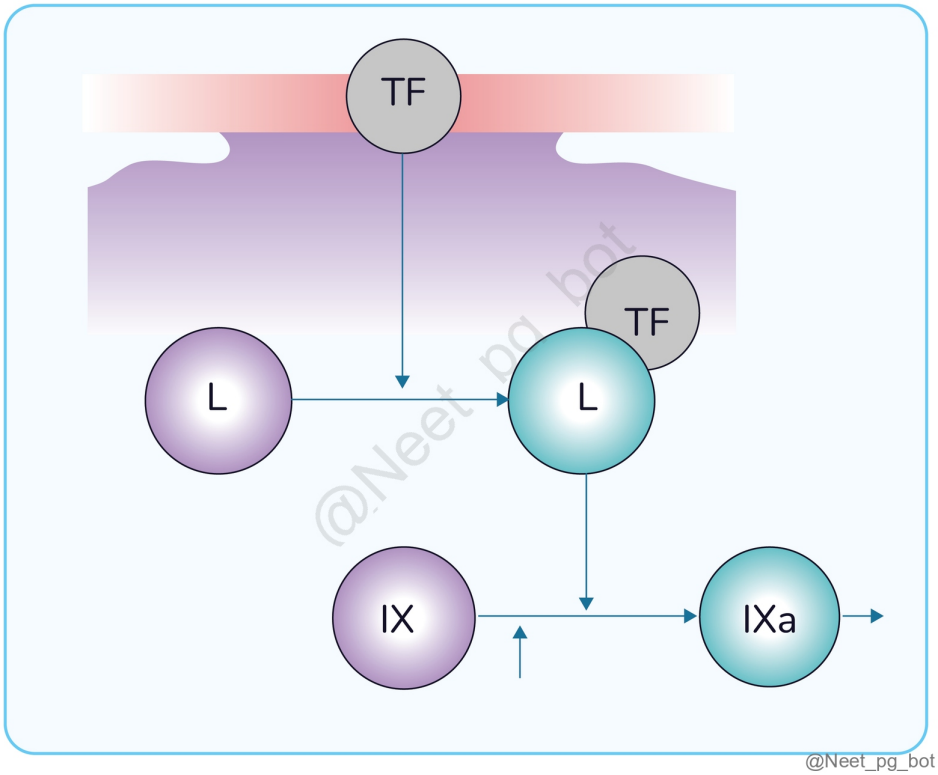

See Answer in Part B → Q17

@Neet_pg_bot

Q18: Stellate granuloma is found in: (Q857169)

A. Cat scratch disease

B. Leprosy

C. Coccidomycosis

D. Histoplasmosis

See Answer in Part B → Q18

@Neet_pg_bot

Q19: Which of the following shows maximum amplitude on thromboelastography? (Q856011)

A. Platelets

B. Intrinsic

C. Extrinsic

D. von Willebrand Disease (vWD)

See Answer in Part B → Q19

@Neet_pg_bot

Q20: A young patient presents with a large retroperitoneal hemorrhage and a history of intermittent knee swelling during strenuous exercise. There is no history of mucosal bleeding. Which of the following deficiencies is responsible for this condition ? (Q855429)

A. Factors VIII and IX

B. GP1b/IX

C. Von Willebrand factor

D. Lupus anticoagulant

See Answer in Part B → Q20

@Neet_pg_bot

Q21: A 26-year-old female with a bleeding disorder following autosomal dominant inheritance. She gave the history of her father and sister having the same bleeding disorders. What is the most likely disorder? (Q854692)

A. Von Willebrand disease

B. Hemophilia A

C. Christmas disease

D. Factor X deficiency

See Answer in Part B → Q21

@Neet_pg_bot

Q22: Which of the following statements about Von Willebrand's disease is incorrect? (Q843976)

A. Type 2 von Willebrand disease is associated with a moderate bleeding tendency.

B. Type 3 von Willebrand disease is associated with a complete absence of von Willebrand factor.

C. Type 1 von Willebrand disease presents with severe bleeding since childhood.

D. Type 2 von Willebrand disease includes subtypes with varying defects in the von Willebrand factor.

See Answer in Part B → Q22

@Neet_pg_bot

Q23: A patient underwent ileal resection and subsequently developed anemia along with peripheral neuropathy and features of SACD. Laboratory findings show hemoglobin (Hb) of 9 g/dL and mean corpuscular volume (MCV) of 110 fL. What is the most likely cause of his anemia? (Q866386)

A. Iron deficiency anemia

B. Vitamin B12 deficiency

C. Folic acid deficiency

D. Sideroblastic anemia

See Answer in Part B → Q23

@Neet_pg_bot

Q24: Bernard-Soulier syndrome is caused by a defect in which of the following platelet glycoproteins? (Q866676)

A. GpIIb/IIIa

B. GpIb/IX complex

C. GpIa/IIa

D. GpIV

See Answer in Part B → Q24

@Neet_pg_bot

• [20_Blood Banking and Transfusion Medicine] 080 Blood Banking And Transfusion Pathology

« Back to Folder Directory

[20_Blood Banking and Transfusion Medicine] 080 Blood Banking And Transfusion Pathology — Quick Jump

Q1 (p. 918) *Q2 (p. 918)* *Q3 (p. 919)* *Q4 (p. 919)* *Q5 (p. 919)* *Q6 (p. 920)*
Q7 (p. 921) *Q8 (p. 921)* *Q9 (p. 921)* *Q10 (p. 922)* *Q11 (p. 922)*

Q1: A pathologist is reviewing the chromosomal locations of blood group antigens. When considering the Rh blood group system, including the Rh antigen, which of the following chromosomes is involved? (Q845924)

A. Chr. 1

B. Chr. 9

C. Chr. 19

D. Chr. 13

See Answer in Part B → Q1

@Neet_pg_bot

Q2: A 32-year-old male requires a blood transfusion after a severe bike accident. He is known to have the Bombay phenotype. Before the transfusion, his blood sample is sent to the laboratory for compatibility testing. Based on his blood group, which of the following statements is incorrect? (Q845926)

A. Lack of H, A and B antigens on RBCs

B. Lack of H, A and B substances in saliva

C. Lack of antigens of several blood group systems

D. H, A and B antibodies will always be present in the serum

See Answer in Part B → Q2

@Neet_pg_bot

Q3: A 23-year-old individual is scheduled to donate blood for a local blood drive. To ensure the safety of the blood supply, the donor's blood will be screened for various infectious diseases. Among the following options, which one is typically not included in the routine screening for donated blood? (Q845928)

A. Malaria

B. Hepatitis B

C. HIV

D. Dengue fever

See Answer in Part B → Q3

@Neet_pg_bot

Q4: Which of the following can be used to store blood for up to 42 days? (Q845929)

A. ACD

B. CPD

C. CPDA

D. SAGM

See Answer in Part B → Q4

@Neet_pg_bot

Q5: Based on the agglutination test shown below, what is the blood group? (Q845931)

A. B Positive

B. B negative

C. A positive

D. AB positive

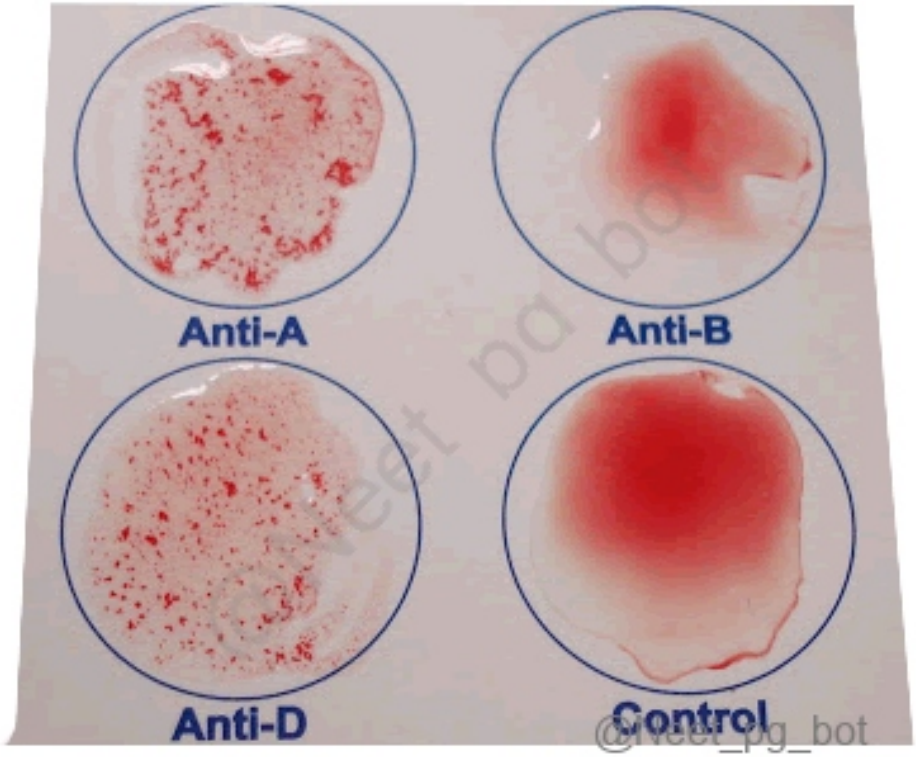

See Answer in Part B → Q5

@Neet_pg_bot

Q6: Match the following: Blood Products Shelf Life A Packed Red Blood Cells (PRBCs) in CPD-A i 1 year B Fresh Frozen Plasma (FFP) ii 35 days C Platelets iii 42 days D PRBC in SAGM iv 5 days (Q845935)

A. A-iii, B-i, C-iv, D-ii

B. A-i, B-iii, C-iv, D-ii

C. A-ii, B-i, C-iv, D-iii

D. A-ii, B-iii, C-i, D-iv

See Answer in Part B → Q6

@Neet_pg_bot

Q7: A unit of packed red blood cells is issued from the blood bank for transfusion to a patient in the emergency department. Due to delays in setting up the IV line, the staff asks how long the unit can safely remain out of refrigeration before the transfusion must be completed.What is the maximum allowable time for transfusing this RBC unit after removal from cold storage? (Q845936)

A. 1 hour

B. 4 hour

C. 8 hour

D. 24 hour

See Answer in Part B → Q7

@Neet_pg_bot

Q8: Which of the following is the most common complication of blood transfusion? (Q845938)

A. TRALI

B. TACO

C. Delayed Hemolytic Reaction

D. Febrile Non-hemolytic reaction

See Answer in Part B → Q8

@Neet_pg_bot

Q9: Which of the following is defined as a massive blood transfusion? (Q845939)

A. Replacement of whole blood volume within 12 hours

B. Replacement of whole blood volume within 48 hours

C. Replacement of whole blood volume within 24 hours

D. Replacement of whole blood volume within 4 hours

See Answer in Part B → Q9

@Neet_pg_bot

Q10: All of the following are complications of massive blood transfusion except? (Q845941)

A. Metabolic Alkalosis

B. Metabolic Acidosis

C. Hyperkalemia

D. Hypocalcemia

See Answer in Part B → Q10

@Neet_pg_bot

Q11: Which of the following is a characteristic feature of Transfusion-Related Acute Lung Injury (TRALI)? (Q845942)

A. Non-cardiogenic pulmonary edema within 6 hours of transfusion

B. Cardiogenic pulmonary edema within 24 hours of transfusion

C. Acute onset of fever and chills without respiratory symptoms

D. Gradual onset of jaundice and anemia several days after transfusion

See Answer in Part B → Q11

@Neet_pg_bot

• [20_Blood Banking and Transfusion Medicine] 081 Previous Year Questions

« Back to Folder Directory

[20_Blood Banking and Transfusion Medicine] 081 Previous Year Questions — Quick Jump

Q1 (p. 923) *Q2 (p. 923)* *Q3 (p. 924)* *Q4 (p. 924)* *Q5 (p. 924)* *Q6 (p. 925)*

Q1: A 28-year-old woman with a known history of beta-thalassemia undergoes a blood transfusion. During the transfusion, she develops symptoms of anxiety, hypotension, and fever. What is the next appropriate step in the management of this patient? (Q860282)

A. Stop the blood transfusion and restart after stabilization

B. Continue the blood transfusion and perform an ECG

C. Investigate for clerical errors in the blood transfusion process

D. Administer corticosteroids and monitor vital signs

See Answer in Part B → Q1

@Neet_pg_bot

Q2: Blood transfusion requires screening of donor blood for all of the following infections except: (Q855917)

A. Hepatitis C virus

B. Dengue virus

C. HIV virus

D. Hepatitis B virus

See Answer in Part B → Q2

@Neet_pg_bot

Q3: A patient has been brought with severe bleeding to your ER. His blood group is unknown. Fresh frozen plasma from which of the following blood groups can be given? (Q855120)

A. O

B. AB

C. B

D. A

See Answer in Part B → Q3

@Neet_pg_bot

Q4: Which of the following can be prevented by transfusing irradiated RBCs? (Q856715)

A. Graft versus host disease

B. HLA alloimmunization

C. Immunomodulation

D. Nonhemolytic Febrile Transfusion Reactions

See Answer in Part B → Q4

@Neet_pg_bot

Q5: A 24-year-old man, after being involved in a road traffic accident (RTA), was brought to the casualty 6 hours later. His B.P. was 90/60 mm Hg, heart rate was 110/min, and SpO2 was 92%. A blood transfusion was administered. A few hours later, the patient becomes febrile and tachypneic and starts bleeding from the IV and NG tube sites. His SpO2 levels begin to drop. What is the likely cause? (Q856483)

A. Transfusion reaction

B. Acute adrenal crisis

C. Fat embolism

D. Hemorrhagic shock

See Answer in Part B → Q5

@Neet_pg_bot

Q6: Which of the following statement regarding blood donation is incorrect? (Q858506)

A. Voluntary blood donation day - 1st october

B. People aged 18-65yrs with comorbidities can not donate blood

C. For people with body weight >55 kg, 49 ml of anticoagulant is required

D. All are correct

See Answer in Part B → Q6

@Neet_pg_bot

• [21_Bone Disorders] 082 Bone And Soft Tissue Pathology - I

« Back to Folder Directory

[21_Bone Disorders] 082 Bone And Soft Tissue Pathology - I — Quick Jump

Q1 (p. 926)	*Q2 (p. 926)*	*Q3 (p. 927)*	*Q4 (p. 927)*	*Q5 (p. 927)*	*Q6 (p. 928)*
Q7 (p. 929)	*Q8 (p. 930)*	*Q9 (p. 931)*	*Q10 (p. 932)*	*Q11 (p. 932)*	*Q12 (p. 933)*
Q13 (p. 933)	*Q14 (p. 934)*	*Q15 (p. 935)*	*Q16 (p. 936)*	*Q17 (p. 936)*	*Q18 (p. 937)*
Q19 (p. 937)	*Q20 (p. 938)*				

Q1: A patient who presents with a painful, progressively enlarging growth from her left upper tibia is suspected to have chondrosarcoma and subjected to a biopsy and examination. The report states, “presence of osteoclast-type giant cells with intralesional bone formation”. Which of the following types of chondrosarcoma does this patient have? (Q845700)

A. Conventional

B. Mesenchymal

C. Clear cell

D. Dedifferentiated

See Answer in Part B → Q1

@Neet_pg_bot

Q2: Match the tumours in column A to their genetic alterations in Column B Tumor Translocation A) Ewing's Sarcoma 1) t(x;18) B) Rhabdomyosarcoma 2) t(12;16) C) Liposarcoma 3) t(1;13) D) Synovial Sarcoma 4) t(11;22) (Q845734)

A. A-4, B-2, C-3, D-1

B. A-4, B-3,C-1, D-2

C. A-4, B-3, C-2, D-1

D. A-3, B-4, C-1, D-2

See Answer in Part B → Q2

@Neet_pg_bot

Q3: A 55-year-old male, presents with a sudden onset of severe pain, redness, and swelling in his right big toe. The right big toe is red, swollen, and extremely tender to touch. There is no fever or other systemic symptoms. He enjoys red meat and seafood, and he drinks alcholol regularly. All of the following are true about his diagnosis except? (Q845728)

A. Deposition of monosodium urate crystals in joints.

B. Thiazide diuretics can precipitate attacks.

C. Rhomboid-shaped, weakly positively birefringent under polarised light confirms the diagnosis.

D. Elevated uric acid levels.

See Answer in Part B → Q3

@Neet_pg_bot

Q4: All of the following are true about rhabdomyosarcoma except? (Q845726)

A. It is the most common soft tissue sarcoma in children.

B. Positive IHC staining for desmin and myogenin.

C. It commonly presents in the extremities of children and adolescents.

D. It has a benign clinical course and rarely metastasizes.

See Answer in Part B → Q4

@Neet_pg_bot

Q5: A 38-year-old female presents with a 6-month history of heavy menstrual bleeding and a sensation of pelvic pressure. She reports that her periods have become increasingly heavy. There is no significant past medical history, and she is not

currently on any medication.Ultrasound reveals a heterogeneous, hypoechoic mass within the uterus. A histology image is given below. What is the most likely diagnosis? (Q845719)

A. Adenomyosis

B. Leiomyosarcoma

C. Endometrial carcinoma

D. Leiomyoma

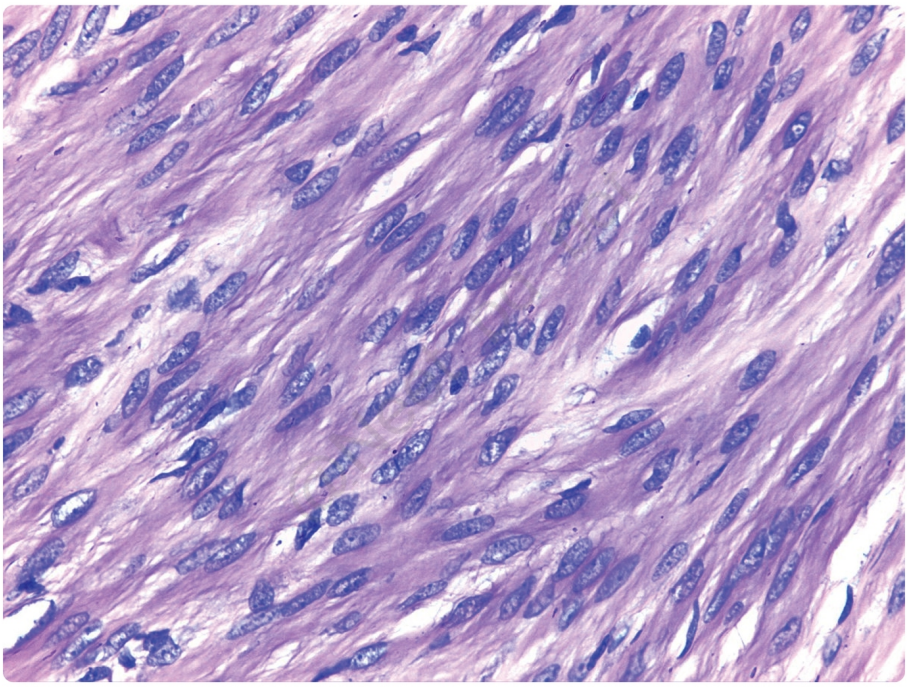

@Neet_pg_bot

See Answer in Part B → Q5

@Neet_pg_bot

Q6: A 65-year-old male presented with an enlarging mass in his left thigh for the last three months. Physical examination revealed a non-tender, palpable mass with indistinct borders. He has a prior history of mass excision in the same location. A biopsy of the lesion is obtained. Based on the presentation, which of the following is the most likely diagnosis? (Q845711)

A. Lipoma

B. Liposarcoma

C. Leiomyosarcoma

D. Rhabdomyosarcoma

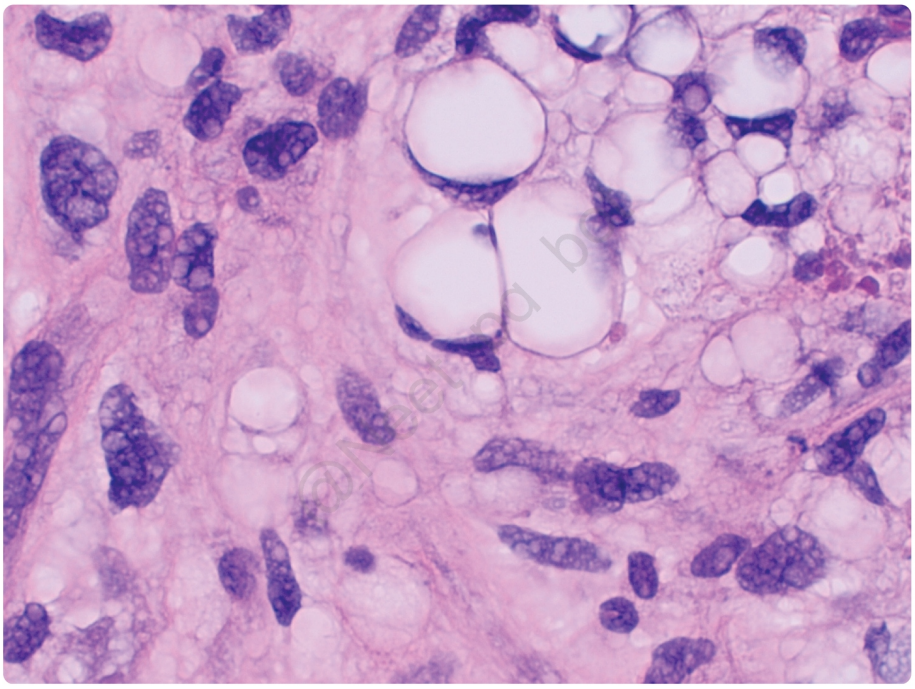

@Neet_pg_bot

See Answer in Part B → Q6

@Neet_pg_bot

Q7: A 17-year-old female presents with worsening pain in her right tibia over the past few months. On examination, there is tenderness and swelling over the proximal right tibia. Biopsy results show blood-filled cystic spaces lined by fibrous septa containing giant cells. All the following statements are true regarding this condition except? (Q845708)

A. Characterised by uniloculated blood-filled spaces with eggshell appearance on x-ray.

B. Often aggressively growing and are frequently discovered in vertebral bodies.

C. Majority cases are found associated with USP6 gene involvement in chromosome 17

D. Nearly one third patients have a distinctive basophilic metaplastic matrix known as blue bone

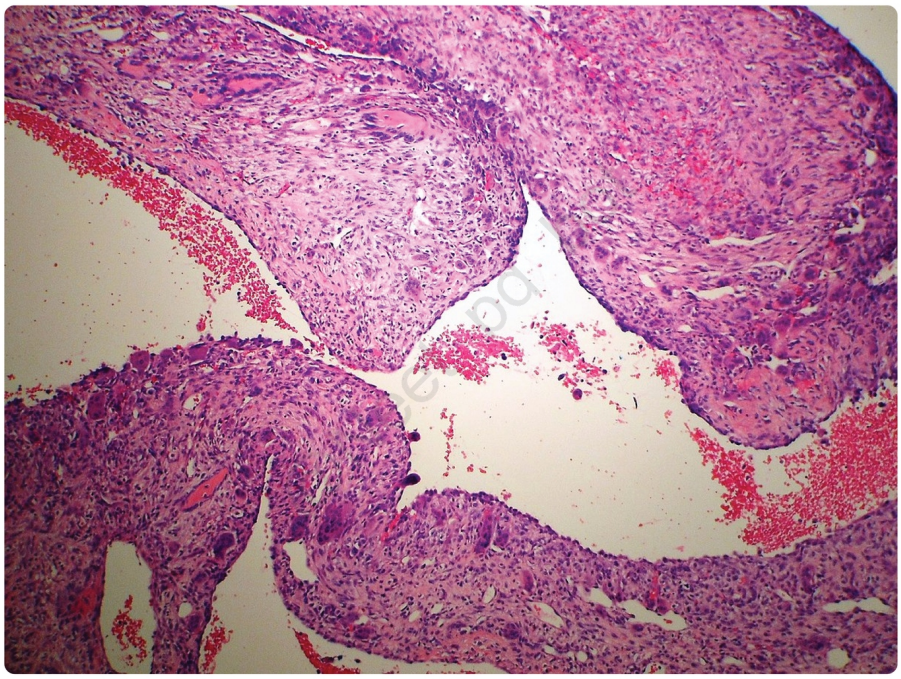

@Neet_pg_bot

See Answer in Part B → Q7

@Neet_pg_bot

Q8: A 14-year-old male presents with left knee pain for several months. Physical examination reveals tenderness and X-ray demonstrates metaphyseal lesion of the distal femur. A biopsy image of the lesion is shown. What is the most likely diagnosis? (Q845706)

A. Chondrosarcoma

B. Ewing sarcoma

C. Non-ossifying fibroma

D. Giant cell tumor of bone

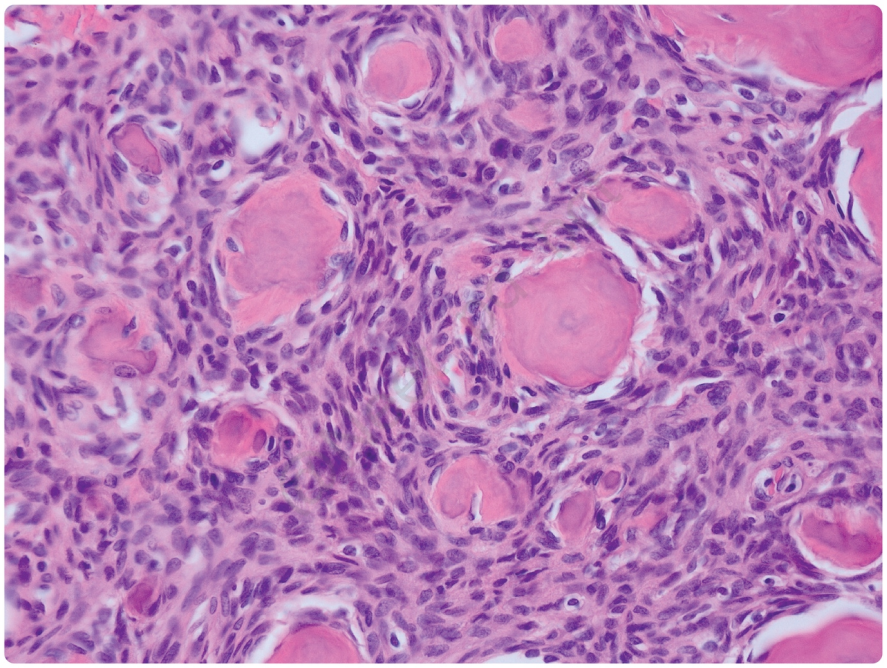

@Neet_pg_bot

See Answer in Part B → Q8

@Neet_pg_bot

Q9: Which of the following statements are true regarding fibrous dysplasia? It is a malignant tumour with components of normal bone unable to differentiate into mature structures Associated with CSF 1 R gene mutation and soft tissue myxoma. Typically occurs in older individuals causing bones to become weak and easily fractured. Histopathological examination shows woven bone trabeculae with disorganised growth plates. Females commonly presents with precocious puberty and irregular dark skin lesions. (Q845705)

A. 1, 3 and 4

B. 2, 3 and 5

C. 3, 4 and 5

D. 4 and 5

See Answer in Part B → Q9

Q10: A 58-year-old male presents with worsening lower back pain and difficulty walking for the last few months. Molecular analysis revealed brachyury gene expression. A biopsy image of the lesion is shown. What is the most likely diagnosis? (Q845702)

A. Chordoma

B. Enchondroma

C. Ewing sarcoma

D. Chondrosarcoma

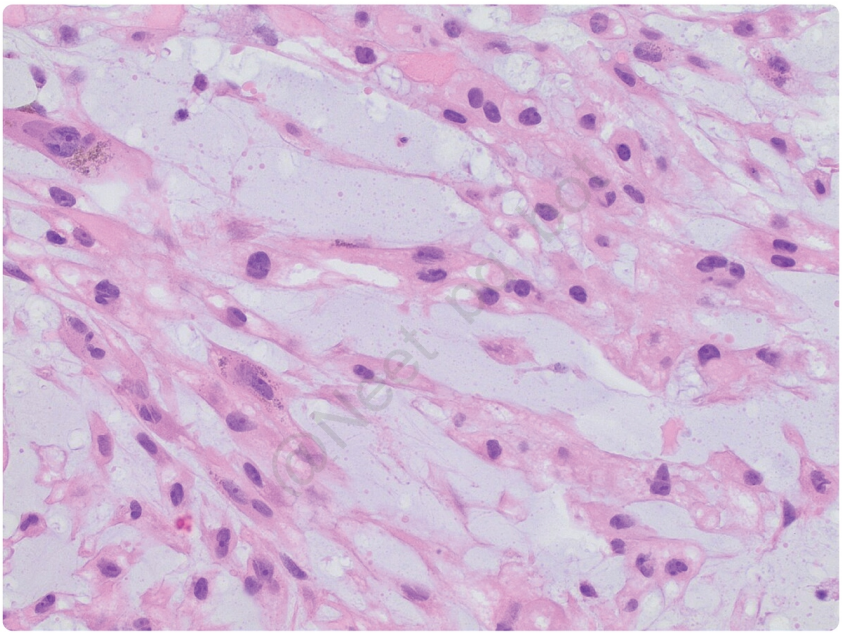

@Neet_pg_bot

See Answer in Part B → Q10

Q11: Which of the following statements regarding normal bone and bone marrow are true? 1. Bone marrow contains a rich network of blood vessels, nerves, and lymphatics, supporting its role as a hematopoietic organ. 2. Osteoblasts are responsible for bone formation, while osteoclasts are involved in bone resorption. 3. Hematopoietic stem cells in the bone marrow give rise to some blood cell lineages. 4. Bone marrow lacks hematopoietic elements and serves primarily as a site for fat storage. 5. Bone remodelling is solely regulated by hormonal factors. (Q845574)

A. Statements 1 and 2 are correct

B. Statements 3 and 4 are correct

C. Statements 4 and 5 are correct

D. Statements 1 and 5 are correct

See Answer in Part B → Q11

@Neet_pg_bot

Q12: Which of the following is incorrect about enchondromas? (Q845647)

A. Maffucci syndrome can also co-exist with brain glioma.

B. Mutations in isocitrate dehydrogenase enzyme genes are common.

C. Histology shows hyaline cartilage encased by reactive bone.

D. Ollier's disease presents as solitary juxta-cortical enchondromas.

See Answer in Part B → Q12

@Neet_pg_bot

Q13: A 14-year-old boy presents with a swelling on his left tibia. An X-ray of the leg shows a destructive process with indistinct borders and an onion-skin pattern of the periosteal bone. A biopsy was performed, as shown in the image below. Identify the true statements regarding this condition. It is a malignant tumour characterised by primitive round cells with obvious differentiation. It affects boys more than girls. More than 90% of the cases are caused due to t(11;22)(q24;q12) mutation. The

presence of rounded cell clusters with a central fibrillary core indicates neuroectodermal differentiation. Chemotherapy-induced necrosis is a negative prognostic indicator. (Q845646)

A. 1, 2, 3

B. 2, 3, 4

C. 1, 3

D. 3, 4, 5

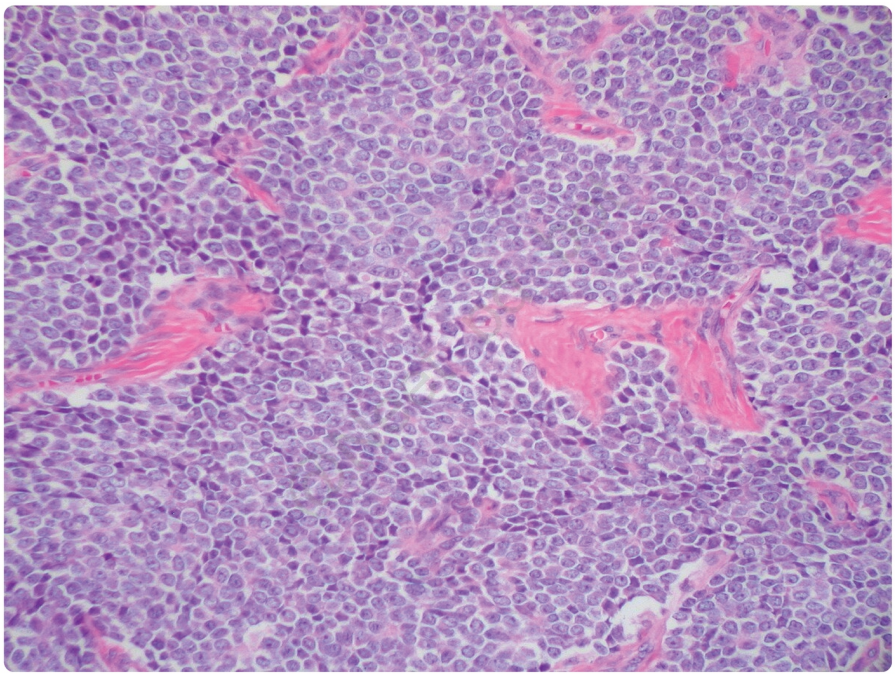

@Neet_pg_bot

See Answer in Part B → Q13

@Neet_pg_bot

Q14: Histopathological examination of a lesion arising from the right distal femur is given as the image below with such characteristic cells. Which of the following is the most probable diagnosis? (Q845645)

A. Osteoclastoma

B. Chondrosarcoma

C. Osteochondroma

D. Ewing’s sarcoma

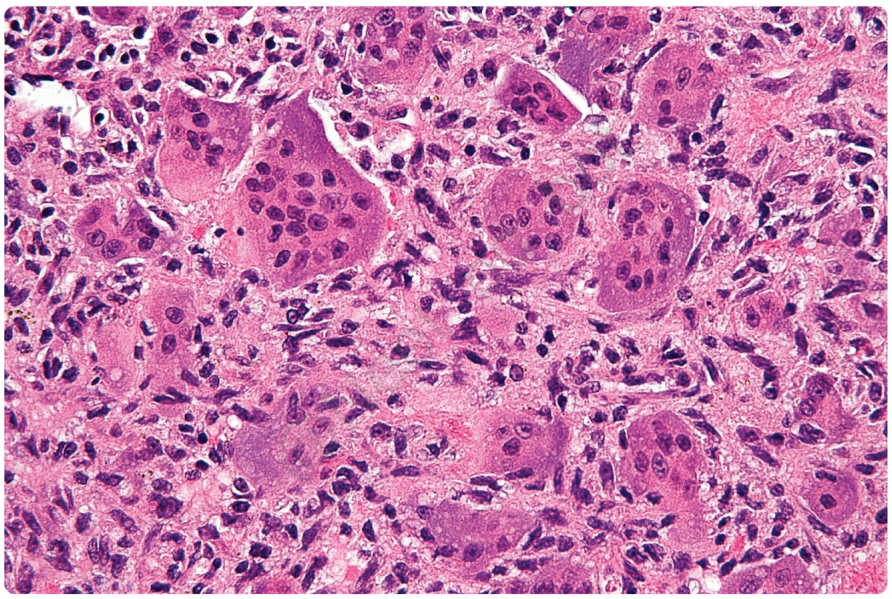

@Neet_pg_bot

See Answer in Part B → Q14

@Neet_pg_bot

Q15: A patient presented with a hard mass over the right tibia, and subsequent imaging revealed the presence of sessile growth in the bone. Biopsy is done later, which shows the presence of “cartilage cap” over the lesion. What is the most likely diagnosis? (Q845604)

A. Osteochondroma

B. Chondroblastoma

C. Enchondroma

D. Chondrosarcoma

See Answer in Part B → Q15

@Neet_pg_bot

Q16: A 15-year-old male presents with persistent knee pain and swelling of two months duration. The pain is persistent, severe at night and not relieved by NSAIDs. On examination there is a firm, tender mass around distal femur. X-ray shows destructive lesion with sunburst pattern and lifting of the perisoteum. A biopsy was performed, and it showed pleomorphism, large hyperchromatic nuclei, and bizarre giant cells producing unmineralised osteoid. What is the most likely diagnosis? (Q845601)

A. Osteoid osteoma

B. Osteoblastoma

C. Osteosarcoma

D. Osteoclastoma

See Answer in Part B → Q16

@Neet_pg_bot

Q17: A 25-year-old male presents with persistent pain in his right leg that worsens at night and is partially relieved by nonsteroidal anti-inflammatory drugs (NSAIDs). Imaging is given below. Based on the clinical presentation and imaging findings, which of the following is incorrect regarding this condition? (Q845596)

A. It has a predilection for the appendicular skeleton.

B. It is less than 2 cm in diameter.

C. It commonly affects the axial skeleton

D. Pain is relieved on taking aspirin



See Answer in Part B → Q17

@Neet_pg_bot

Q18: All of the following are associated with Gardner’s syndrome except? (Q845577)

A. Multiple osteoma

B. Colon polyps with risk of malignancy

C. Enchondroma

D. Supernumerary teeth

See Answer in Part B → Q18

@Neet_pg_bot

Q19: Which of the following is not a metaphyseal tumour? (Q845576)

A. Osteosarcoma

B. Fibrous dysplasia

C. Giant cell tumour of the bone

D. Aneurysmal bone cyst

See Answer in Part B → Q19

@Neet_pg_bot

Q20: A 6-year-old boy presents with a history of frequent fractures, bone pain, and difficulty walking. On examination, he has short stature and cranial nerve palsies. The radiograph is revealed below. Which of the following is the most likely diagnosis? (Q845575)

A. Osteogenesis imperfecta

B. Osteopetrosis

C. Rickets

D. Paget disease of the bone



See Answer in Part B → Q20

@Neet_pg_bot

• [21_Bone Disorders] 083 Previous Year Questions

« Back to Folder Directory

[21_Bone Disorders] 083 Previous Year Questions — Quick Jump

Q1 (p. 940) *Q2 (p. 940)* *Q3 (p. 941)* *Q4 (p. 942)* *Q5 (p. 943)*

Q1: Which HLA is associated with Reiter syndrome? (Q860540)

A. HLA-DR3

B. HLA-B27

C. HLA-DQ8

D. HLA- DR4

See Answer in Part B → Q1

@Neet_pg_bot

Q2: A 15-year-old boy presents with swelling in the upper diaphyseal part of the tibia. X-ray of the swelling showed a periosteal reaction. A histopathological image of the biopsy is given below. Immunohistochemistry was positive for synaptophysin and MIC2. What is the likely diagnosis? (Q855073)

A. Osteosarcoma

B. Ewing sarcoma

C. Metastatic neuroblastoma

D. Osteoclastoma

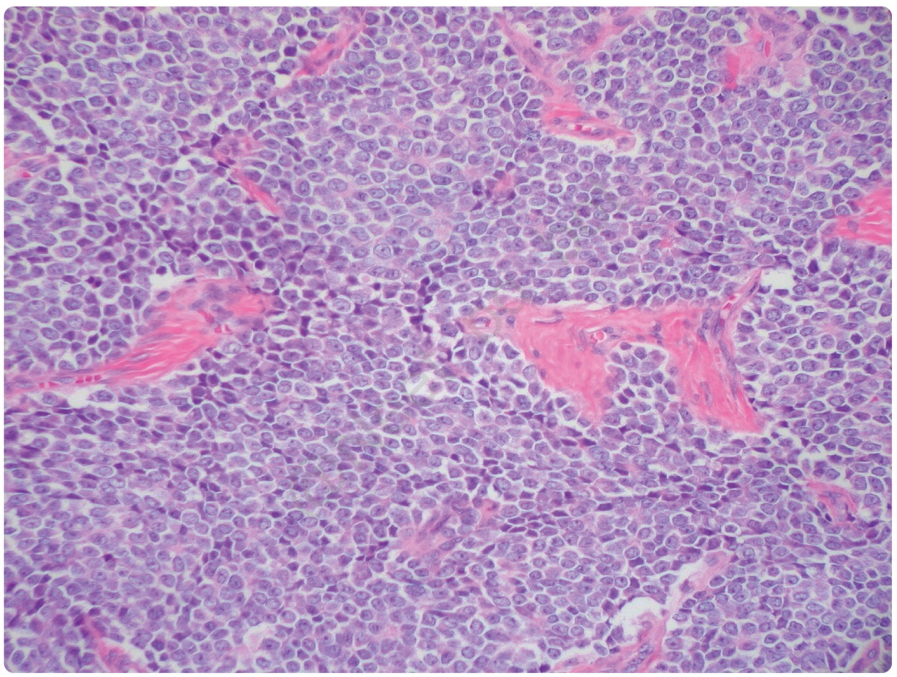

@Neet_pg_bot

See Answer in Part B → Q2

@Neet_pg_bot

Q3: A 30-year-old woman has been experiencing left knee pain for one month. The knee is tender to touch, and an X-ray reveals a 5cm mass in the distal femoral epiphysis with a "soap bubble" appearance. Microscopy findings are provided below. What is the likely diagnosis? (Q857575)

A. Chondroblastoma

B. Osteoclastoma

C. Osteosarcoma

D. Osteochondroma

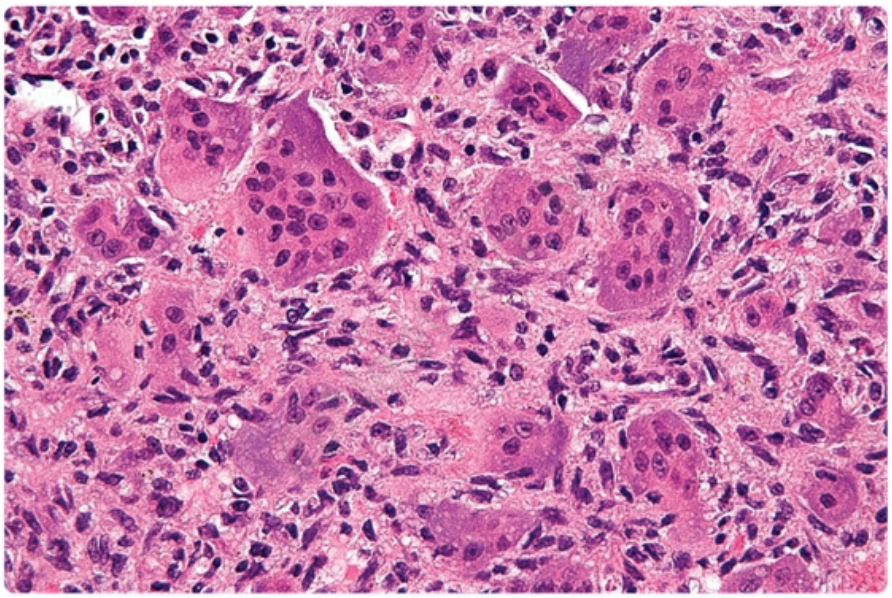

See Answer in Part B → Q3

@Neet_pg_bot

Q4: A woman who had undergone total knee replacement surgery comes back with complaints of knee pain and loosening of implants. The following histopathological slide was obtained, showing foreign body giant cells and the appearance highlighted in the image below. What is your diagnosis? (Q856891)

A. Ochronosis

B. Metallosis

C. Malignant melanoma

D. Rosai-Dorfman disease

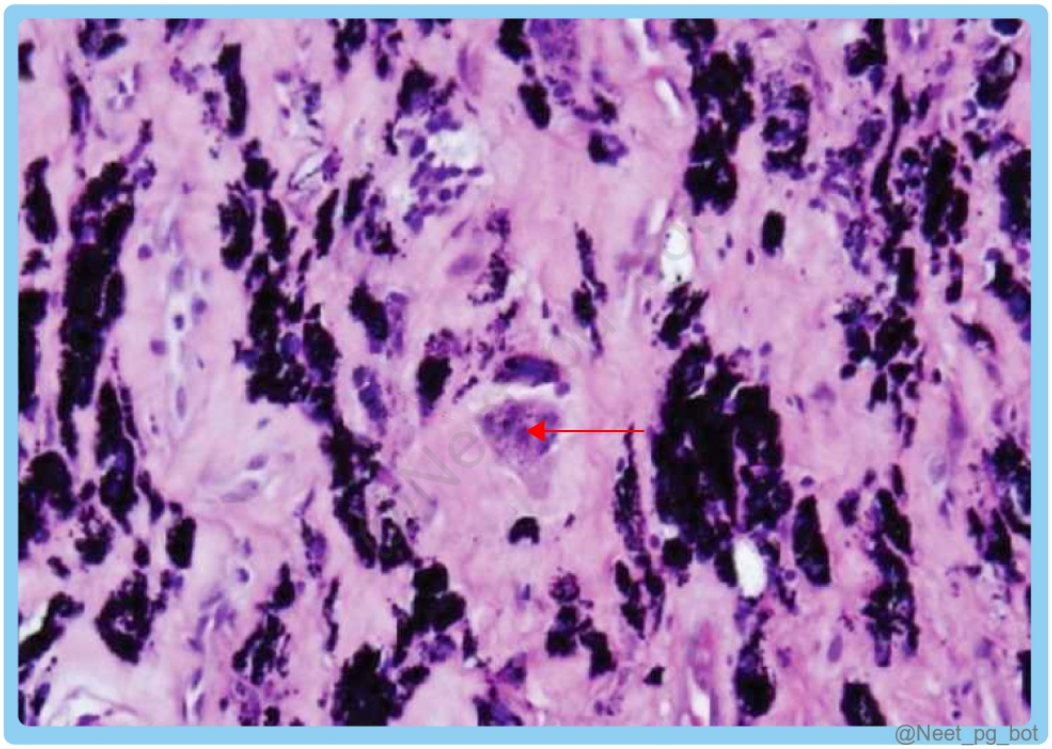

See Answer in Part B → Q4

@Neet_pg_bot

Q5: Which of the following conditions will have the least chance of a dry bone marrow aspiration? (Q856898)

A. Hairy cell leukemia

B. Acute myeloid leukemia (AML)

C. Myelodysplastic syndrome

D. Follicular lymphoma

See Answer in Part B → Q5

@Neet_pg_bot

• [22_Techniques in Pathology] 084 Previous Year Questions

« Back to Folder Directory

[22_Techniques in Pathology] 084 Previous Year Questions — Quick Jump

Q1 (p. 944) *Q2 (p. 945)* *Q3 (p. 945)* *Q4 (p. 945)* *Q5 (p. 946)* *Q6 (p. 947)*
Q7 (p. 947) *Q8 (p. 948)* *Q9 (p. 949)* *Q10 (p. 949)* *Q11 (p. 950)* *Q12 (p. 951)*
Q13 (p. 951)

Q1: The image below represents the presence of HER2 neu cells in a patient with breast carcinoma. What agent is used to produce this characteristic discolouration? (Q854670)

A. FITC

B. Phycoerythrin

C. Cyanate dye

D. Diaminobenzidine

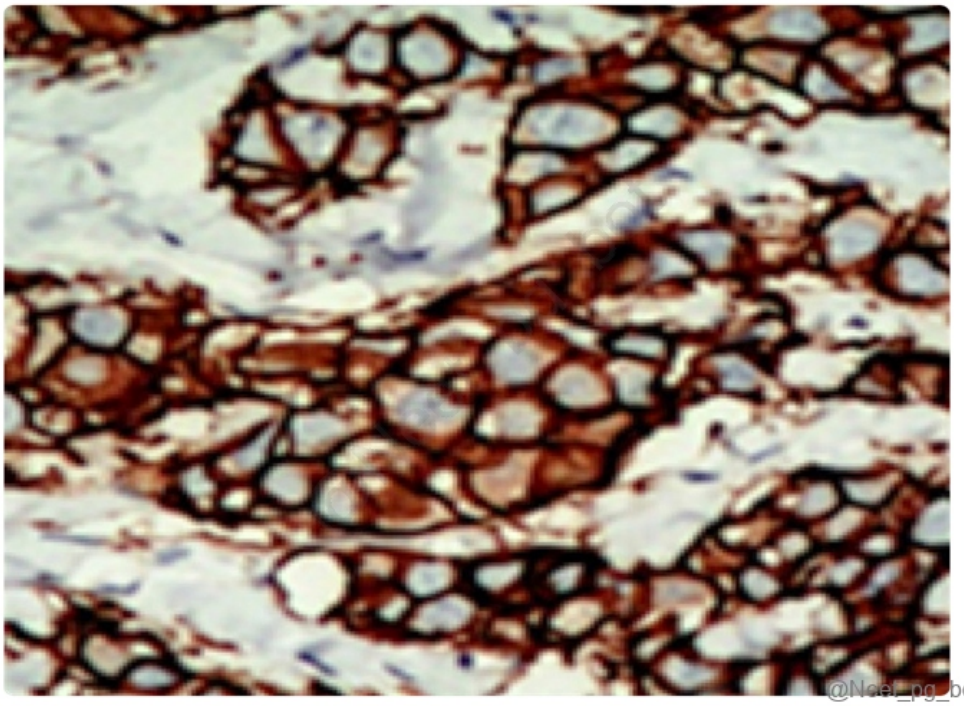

See Answer in Part B → Q1

@Neet_pg_bot

Q2: A phlebotomist is asked to collect blood samples for a patient undergoing multiple tests. Which of the following is the correct order of blood collection to avoid contamination of the samples based on the additives in the collection tubes? (Q854685)

A. Light blue → Lavender → Red → Grey

B. Grey → Red → Light blue → Lavender

C. Light blue → Red → Lavender → Grey

D. Red → Lavender → Grey → Light blue

See Answer in Part B → Q2

@Neet_pg_bot

Q3: Pair the stains with their corresponding options Stain Corresponding Option 1. Prussian blue stain a. Iron 2. PAS stain b. Glycogen 3. Congo red stain c. Leprosy 4. Fite-Faraco stain d. Amyloid (Q855085)

A. 1-d, 2-c, 3-b, 4-a

B. 1-c, 2-a, 3-b, 4-d

C. 1-a, 2-b, 3-d, 4-c

D. 1-b, 2-a, 3-c, 4-d

See Answer in Part B → Q3

@Neet_pg_bot

Q4: A child presents with multiple skin lesions over the inner thigh and genital areas. Initially, the lesions started as macules and later developed into nodules. Some of the nodules have a central umbilication. The histology of the lesion is shown below. What would be found on a biopsy? (Q855108)

A. Multinucleate giant cells (Tzanck cells)

B. Donovan bodies

C. Henderson-Patterson bodies

D. Koilocytes

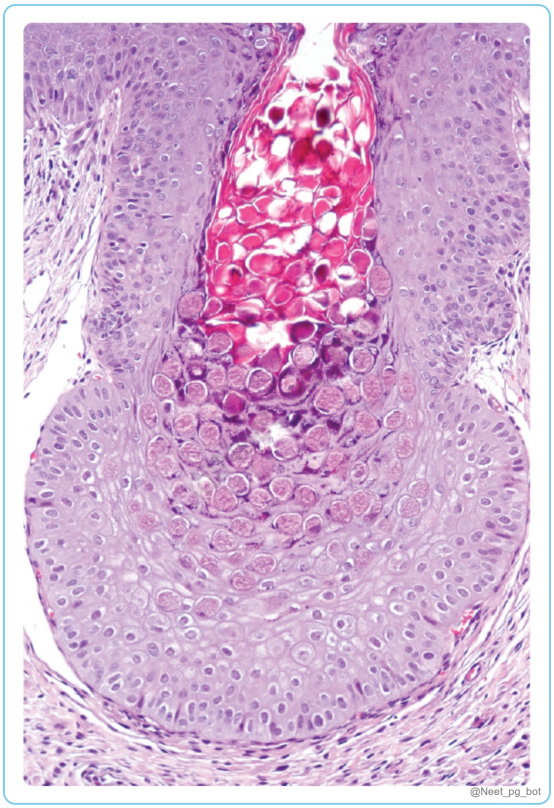

See Answer in Part B → Q4

@Neet_pg_bot

Q5: Which of the following needles is commonly used for bone marrow biopsy? (Q855114)

A. Klima needle

B. Salah needle

C. Jamshidi needle

D. Islam needle

See Answer in Part B → Q5

@Neet_pg_bot

Q6: Which of the following oil red O stain is used? (Q855393)

A. Formalin fixation

B. Frozen section

C. Alcohol fixation

D. Glutaraldehyde fixation

See Answer in Part B → Q6

@Neet_pg_bot

Q7: The vacutainer tube shown in the given image contains the following: (Q855434)

A. EDTA

B. Trisodium citrate

C. NAF - heparin

D. Clot activator



See Answer in Part B → Q7

@Neet_pg_bot

Q8: The following image shows an instrument used to estimate haemoglobin levels. What does it measure? (Q855893)

A. Alkaline hematin

B. Acid hematin

C. Oxyhemoglobin

D. Deoxyhemoglobin



@Neet_pg_bot

See Answer in Part B → Q8

@Neet_pg_bot

Q9: Which of the following methods is iron in tissues stained? (Q855899)

A. Masson’s trichrome

B. Prussian blue

C. PAS

D. Fite-Faraco

See Answer in Part B → Q9

@Neet_pg_bot

Q10: A woman presents with nodular lesions, 4-6 mm in size, on the inner thighs and peri-anal region. The lesions appear pale, and histopathological examination reveals

multiple intracytoplasmic inclusion bodies consistent with Henderson-Patterson bodies. What is the most likely diagnosis? (Q855907)

A. Trichodysplasia spinulosa

B. Condyloma acuminata

C. Molluscum contagiosum

D. Donovanosis

See Answer in Part B → Q10

@Neet_pg_bot

Q11: The given inclusion bodies are characteristic of which of the following organisms? (Q858119)

A. Human papillomavirus

B. Cytomegalovirus

C. Epstein-Barr virus

D. Herpes simplex virus

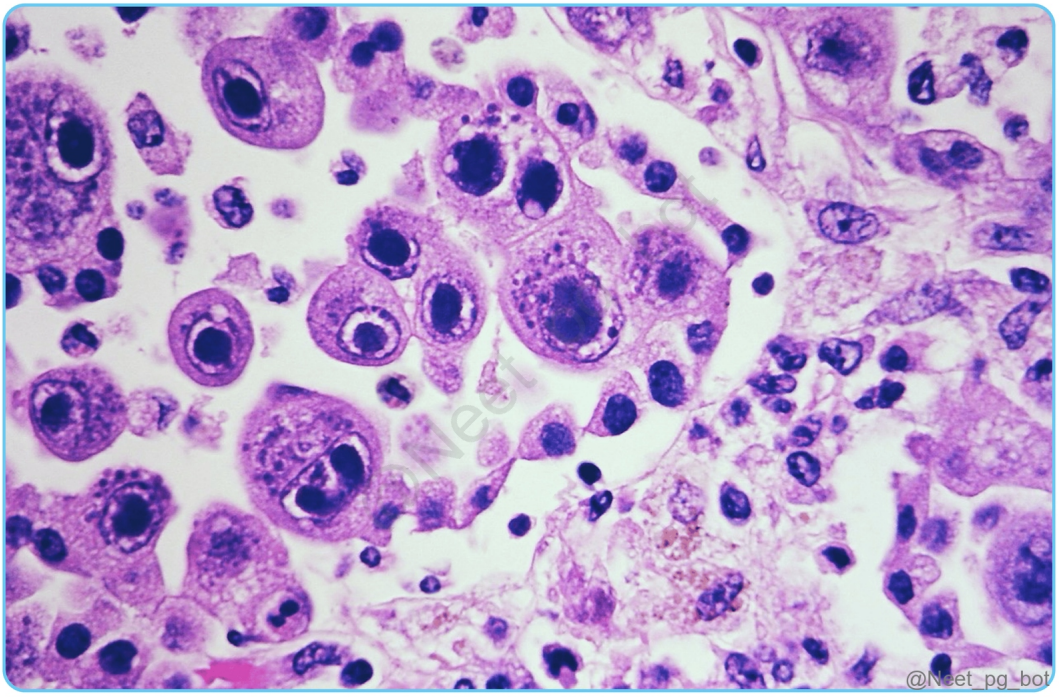

See Answer in Part B → Q11

@Neet_pg_bot

Q12: CD markers can be detected by which of the following tests? (Q866390)

A. Cytogenetics

B. Next-generation sequencing

C. Flow cytometry

D. Karyotype

See Answer in Part B → Q12

@Neet_pg_bot

Q13: In Pap smear cytology, which of the following is the most appropriate fixative used to preserve cellular details immediately after smearing? (Q866744)

A. 50% formaldehyde

B. 95% ethanol

C. 70% ethanol

D. 10% buffered formalin

See Answer in Part B → Q13

@Neet_pg_bot

• [23_Skin Pathology] 085 Skin Pathology

« Back to Folder Directory

[23_Skin Pathology] 085 Skin Pathology — Quick Jump

Q1 (p. 952) *Q2 (p. 952)* *Q3 (p. 953)* *Q4 (p. 953)* *Q5 (p. 954)* *Q6 (p. 955)*
Q7 (p. 955) *Q8 (p. 956)* *Q9 (p. 957)* *Q10 (p. 958)* *Q11 (p. 959)* *Q12 (p. 960)*
Q13 (p. 960) *Q14 (p. 961)*

Q1: In which following layer of the epidermis would you most likely find the melanin-producing cells of the skin? (Q845865)

A. Stratum corneum

B. Stratum spinosum

C. Stratum granulosum

D. Stratum basale

See Answer in Part B → Q1

@Neet_pg_bot

Q2: A 35-year-old male presents with a rash on his hands and feet characterised by clusters of small, fluid-filled blisters. Histopathological examination of a skin biopsy reveals intracellular oedema of keratinocytes. Which term best describes this histological finding? (Q845866)

A. Acanthosis

B. Ballooning

C. Spongiosis

D. Parakeratosis

See Answer in Part B → Q2

@Neet_pg_bot

Q3: A 10-year-old child exhibits rough, scaly skin on the elbows, knees, and trunk, accompanied by hyperkeratotic plaques. Which skin condition is typically associated with this manifestation of excessive keratin buildup? (Q845867)

A. Freckles

B. Lentigo

C. Nevus

D. Ichthyosis

See Answer in Part B → Q3

@Neet_pg_bot

Q4: A 45-year-old woman presents with a dark, irregularly shaped mole on her back that has rapidly increased in size over the past few months. On examination, the lesion has uneven borders and varying shades of colour. Which of the following is true regarding its pathogenesis? (Q845868)

A. Associated with TERT mutations

B. Spreads radially with metastatic potential

C. Spreads vertically with no metastatic potential

D. Associated with mutations that decrease telomerase activity

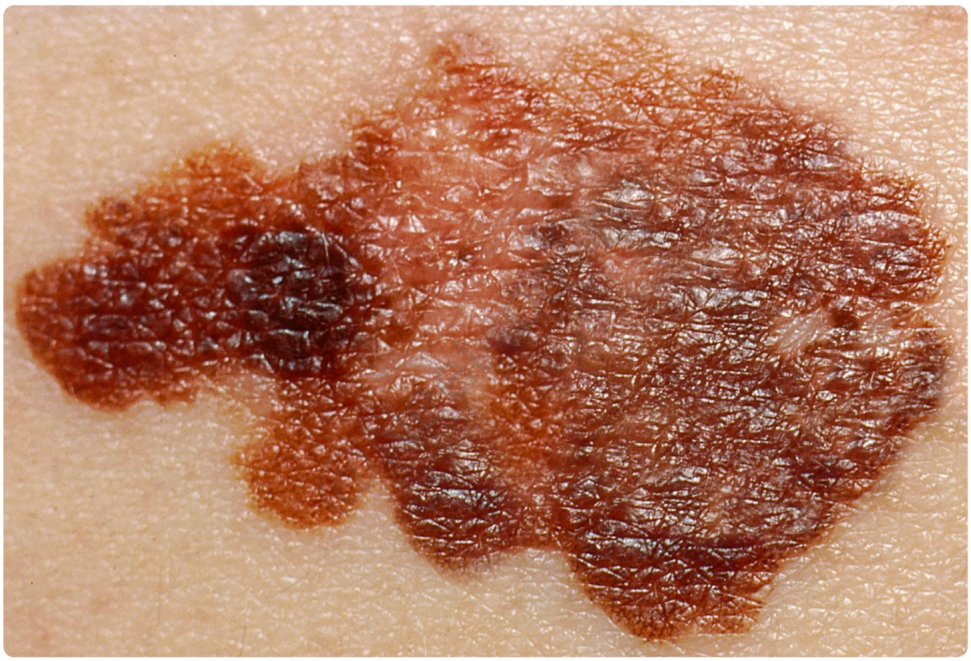

See Answer in Part B → Q4

@Neet_pg_bot

Q5: A 70-year-old woman presents with a finding as shown in the image. A biopsy confirms basal cell carcinoma. Which molecular pathway is primarily involved? (Q845904)

A. Hippo pathway signaling

B. Hedgehog signaling pathway

C. WNT signaling

D. RAS/MAPK signaling



@Neet_pg_bot

See Answer in Part B → Q5

@Neet_pg_bot

Q6: A 25-year-old woman presents with multiple basal cell carcinomas (BCCs) on her face, neck, and back. She also has a history of medulloblastoma, diagnosed during childhood. On examination, she has palmar pits and macrocephaly. Which of the following is not true regarding this syndrome? (Q845906)

A. Associated with odontogenic keratocysts.

B. Associated with mutations in the PTCH gene

C. An Autosomal dominant disorder

D. Associated with loss of nucleotide excision repair mechanism

See Answer in Part B → Q6

@Neet_pg_bot

Q7: A 72-year-old man with a history of extensive sun exposure and recent organ transplant presents with a rapidly growing, painless, reddish nodule on his left cheek over two months. Biopsy shows small, round blue cells with salt and pepper chromatin and positivity for neuroendocrine markers. What marker is typically associated with this condition? (Q845908)

A. S-100

B. CK20

C. Melan-A

D. p40

See Answer in Part B → Q7

@Neet_pg_bot

Q8: An 18-year-old female has multiple itchy silvery scales on her knees and elbows. A biopsy of the lesion revealed the presence of nuclei and neutrophilic infiltration in the stratum corneum. Match the following with their appropriate answers. a. Auspitz sign 1. Nucelated stratum corneum b. Munro's microabscess 2. Pinpoint bleed after scraping off old lesion c. Spongiform pustules of kogoj 3. Neutrophilic infiltrate in stratum corneum d. Parakeratosis 4. Neutrophilic infiltrate in stratum spinosum (Q845909)

A. a-2, b-4, c-3, d-1

B. a-2, b-3, c-4, d-1

C. a-1, b-3, c-4, d-2

D. a-2, b-4, c-3, d-1

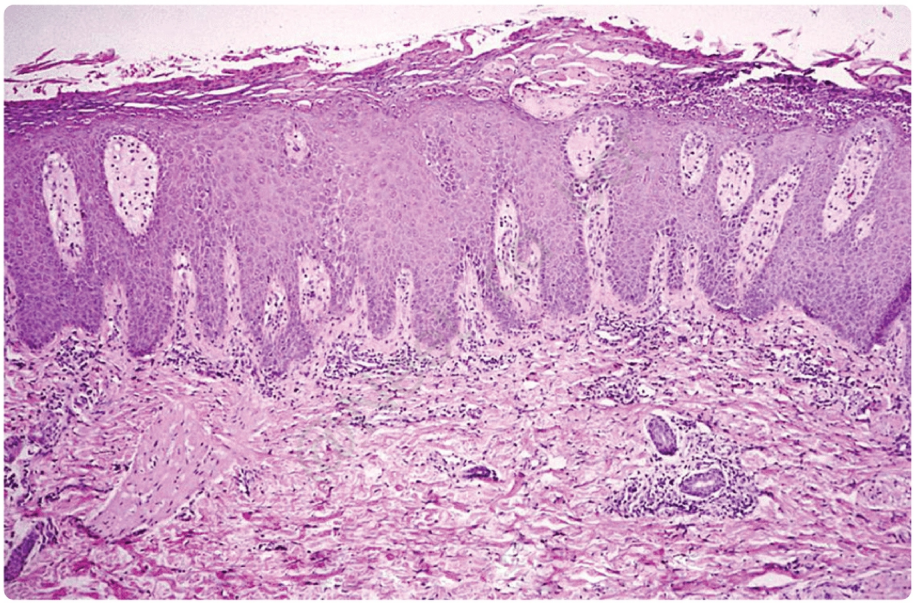

@Neet_pg_bot



@Neet_pg_bot

See Answer in Part B → Q8

@Neet_pg_bot

Q9: A 45-year-old female presents to the dermatology clinic with an itchy rash on her wrists and ankles. On examination, small, flat-topped, polygonal, purple papules with fine white lines on their surface are noted. Which of the following is a characteristic histological finding in this condition? (Q845911)

A. Munro microabscesses

B. Spongiform pustules

C. Sawtoothing of the dermo-epidermal junction

D. Follicular lipping



See Answer in Part B → Q9

@Neet_pg_bot

Q10: A 55-year-old man presents with widespread blistering of the skin and oral mucosa. Skin biopsy reveals acantholysis and intraepidermal blister formation above the basal layer. Which of the following describes the location of the split in this bullous disorder? (Q845912)

A. Subcorneal split

B. Suprabasal split

C. Subepidermal split

D. Intraepidermal split

See Answer in Part B → Q10

@Neet_pg_bot

Q11: A 45-year-old woman presents with a slow-growing, painless nodule on her scalp that has recently enlarged. Examination reveals a firm, well-circumscribed nodule. Histopathology shows ductal differentiation with multiple cysts and papillary projections. Which of the following is the most likely diagnosis? (Q845913)

A. Cylindroma

B. Pilomatrixoma

C. Syringoma

D. Trichilemmoma

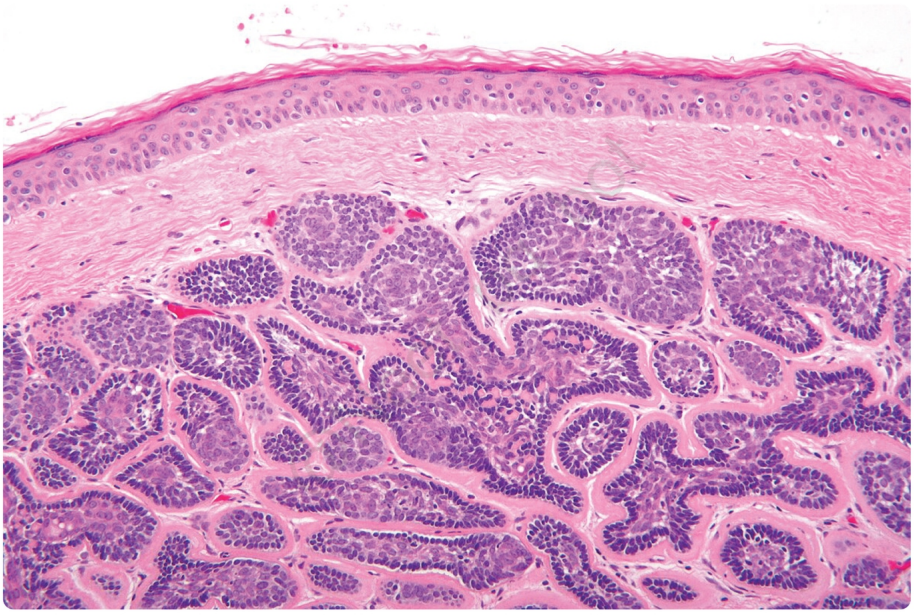

@Neet_pg_bot

See Answer in Part B → Q11

@Neet_pg_bot

Q12: A 38-year-old man complains of severe itching and recurrent skin lesions on his elbows, knees, and upper back. His medical history includes occasional gastrointestinal discomfort. Examination reveals bilateral, symmetric lesions with grouped vesicles. Skin biopsy reveals small microabscesses at the tips of dermal papillae. Which of the following is associated with a disease condition? (Q845916)

A. Associated with Crohn's disease

B. IgA deposits at dermal papilla tips

C. Subendothelial blisters

D. Linear deposits in immunofluorescence

See Answer in Part B → Q12

@Neet_pg_bot

Q13: A 3-year-old child has a chronic, non-healing scalp rash, showing red-brown papules and plaques with crusting on examination. Electron microscopy reveals tennis racket-like structures in histiocytes cytoplasm, and immunohistochemical staining confirms CD1a and S100 protein presence. Which mutation is likely associated with this condition? (Q845918)

A. TP53 mutation

B. RAS mutation

C. BRAF mutation

D. MET mutation



@Neet_pg_bot

See Answer in Part B → Q13

@Neet_pg_bot

Q14: A 65-year-old male presents with tense blisters on his abdomen and extremities, filled with clear fluid. The skin appears normal between the blisters, which are painful but not itchy. A skin biopsy reveals a subepidermal blister with linear IgG and complement deposition along the basement membrane on direct immunofluorescence as shown in the image. What is the most likely diagnosis? (Q845920)

A. Epidermolysis Bullosa Acquisita

B. Bullous Pemphigoid

C. Pemphigus Vulgaris

D. Dermatitis Herpetiformis

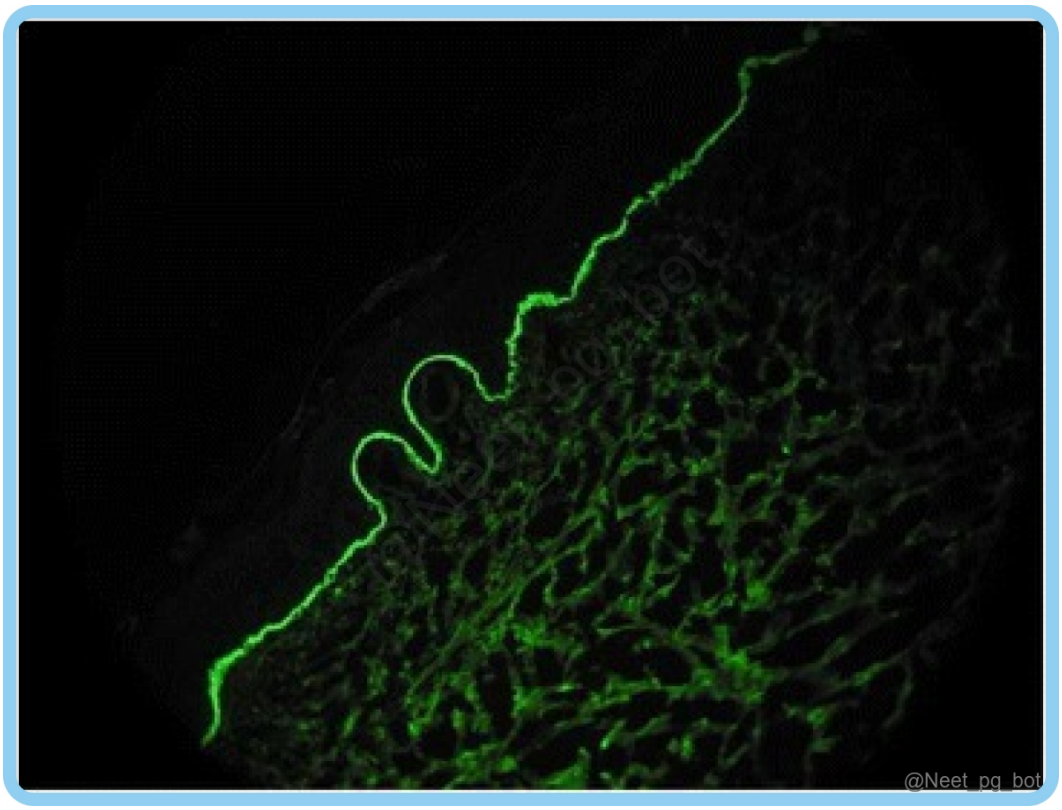

See Answer in Part B → Q14

@Neet_pg_bot

• [23_Skin Pathology] 086 Previous Year Questions

« Back to Folder Directory

[23_Skin Pathology] 086 Previous Year Questions — Quick Jump

Q1 (p. 963) *Q2 (p. 963)* *Q3 (p. 964)* *Q4 (p. 965)* *Q5 (p. 966)* *Q6 (p. 966)*
Q7 (p. 967) *Q8 (p. 968)* *Q9 (p. 968)*

Q1: A child presents with skin eruptions upon exposure to sunlight and is diagnosed with a DNA repair defect. Which type of repair defect is most likely responsible? (Q844175)

A. Nucleotide excision repair defect

B. Base excision repair defect

C. Mismatch repair defect

D. Recombination repair defect

See Answer in Part B → Q1

@Neet_pg_bot

Q2: Identify the diagnosis based on the image provided: (Q844180)

A. Tuberculosis (TB)

B. Malakoplakia

C. Pyoderma gangrenosum

D. Squamous cell carcinoma (SCC)

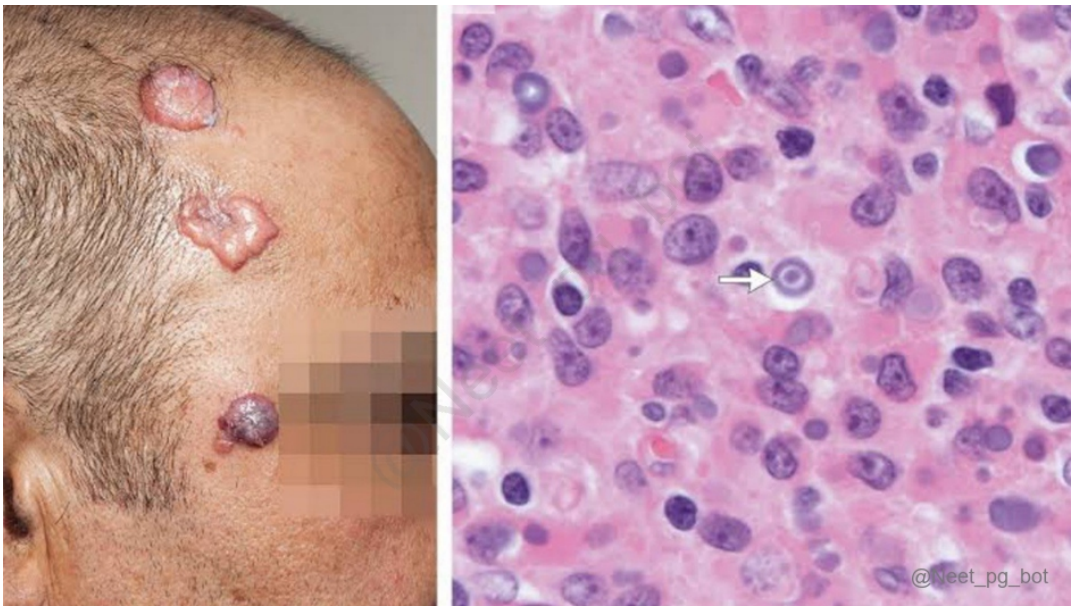

See Answer in Part B → Q2

@Neet_pg_bot

Q3: A farmer has a lesion on the shoulder. What is the most likely diagnosis based on the histopathological image of the lesion given below? (Q860532)

A. SCC

B. BCC

C. Molluscum contagiosum

D. Verrucous carcinoma

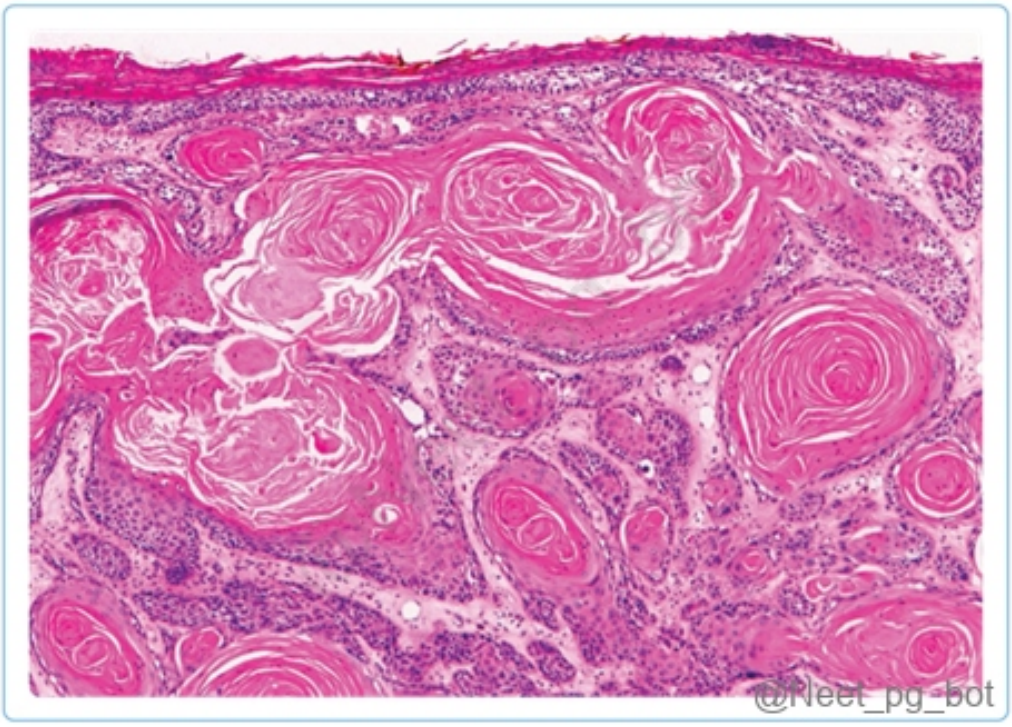

See Answer in Part B → Q3

@Neet_pg_bot

Q4: Identify the histopathological image. (Q860535)

A. Basal cell carcinoma

B. Squamous cell carcinoma

C. Adenocarcinoma

D. Malignant melanoma

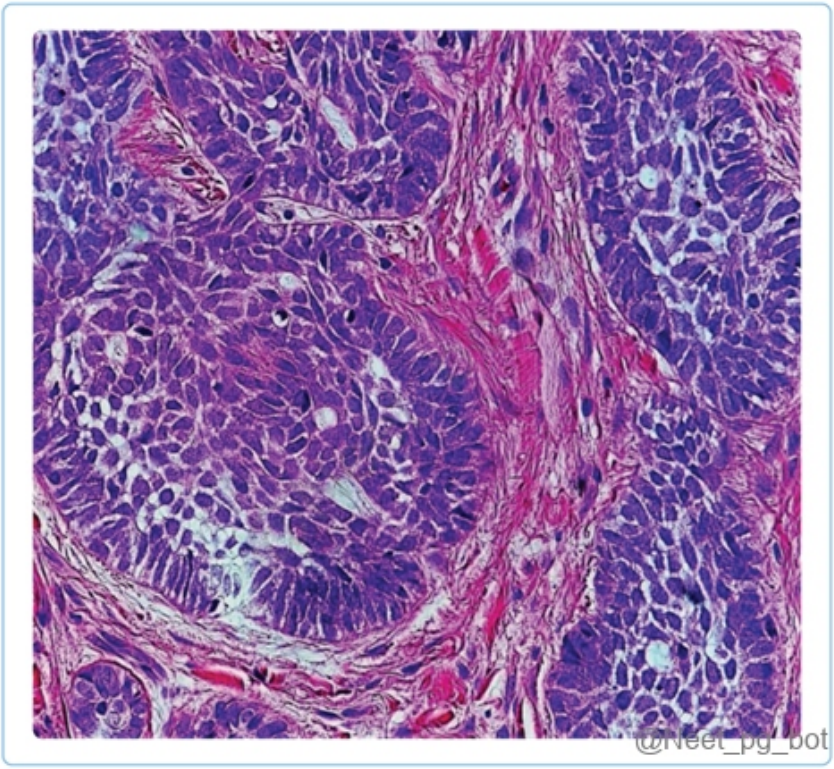

See Answer in Part B → Q4

@Neet_pg_bot

Q5: An 8-year-old boy presents with progressive muscle weakness and walking difficulties. On examination, pseudohypertrophy of the calf muscles was noted. Which of the following is true regarding this condition? (Q858113)

A. Abnormal collagen

B. Absent dystrophin

C. Expansions of CAG triplet repeats

D. Defective fibrillin

See Answer in Part B → Q5

@Neet_pg_bot

Q6: A patient underwent surgery for lipoma 5 weeks ago and now presents with a scar at the incision site, which is limited to the original wound boundaries. What is the most likely diagnosis? (Q857162)

A. Keloid

B. Exuberant granulation

C. Hypertrophic scar

D. Granulation tissue

See Answer in Part B → Q6

@Neet_pg_bot

Q7: Identify the given condition. (Q856687)

A. Pemphigus Vulgaris

B. Leprosy

C. Mycosis fungoides

D. Visceral leishmaniasis

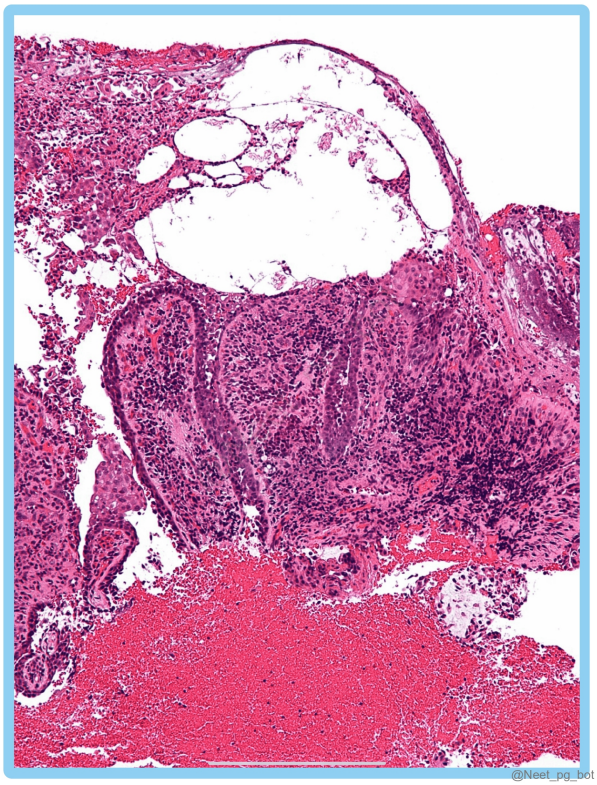

See Answer in Part B → Q7

@Neet_pg_bot

Q8: A 5-year-old child who presented with proptosis of one of the eyes was found to have a desmin-positive tumour. What is the probable diagnosis? (Q856705)

A. Ewing’s sarcoma

B. Embryonal rhabdomyosarcoma

C. Leukaemia

D. Retinoblastoma

See Answer in Part B → Q8

@Neet_pg_bot

Q9: Which connective tissue disorder is not associated with aneurysm formation? (Q840020)

A. Marfan syndrome

B. Scurvy

C. Atherosclerosis

D. Ehler-Danlos syndrome

See Answer in Part B → Q9

@Neet_pg_bot

• [24_Miscellaneous] 087 Previous Year Questions

« Back to Folder Directory

[24_Miscellaneous] 087 Previous Year Questions — Quick Jump

Q1 (p. 970) *Q2 (p. 970)* *Q3 (p. 970)* *Q4 (p. 971)* *Q5 (p. 972)* *Q6 (p. 972)*
Q7 (p. 972) *Q8 (p. 973)* *Q9 (p. 973)* *Q10 (p. 974)* *Q11 (p. 974)*

Q1: For testing blood clotting/ coagulation parameters, blood is collected in which color-coded vacutainer tube? (Q866663)

A. Red

B. Green

C. Blue

D. Gray

See Answer in Part B → Q1

@Neet_pg_bot

Q2: Basophilic stippling of red blood cells is most characteristically seen in which of the following conditions? (Q866743)

A. Iron deficiency anaemia X

B. Lead poisoning

C. Megaloblastic anemia

D. Hereditary spherocytosis

See Answer in Part B → Q2

@Neet_pg_bot

Q3: A chronic smoker presents with a whitish exophytic lesion over the vocal cords, as shown in the image below. During direct laryngoscopy, the ENT surgeon applies a dye to help identify areas of dysplasia and select the most appropriate biopsy site. Which stain is being used? (Q844052)

A. Supravital stain

B. Congo red

C. Hematoxylin and eosin (H&E)

D. Oil red O



See Answer in Part B → Q3

@Neet_pg_bot

Q4: Which among the following is the least radiosensitive cell? (Q860529)

A. Monocytes

B. Platelets

C. Lymphocytes

D. Neutrophils

See Answer in Part B → Q4

@Neet_pg_bot

Q5: Which of the following instruments is not used in the colorimetric method for the estimation of hemoglobin? (Q840012)

See Answer in Part B → Q5

@Neet_pg_bot

Q6: Which of the following is not a part of the criteria for diagnosis of Kawasaki disease? (Q840066)

A. Strawberry tongue

B. Polymorphic rash

C. Purulent conjunctivitis

D. Cervical lymphadenopathy

See Answer in Part B → Q6

@Neet_pg_bot

Q7: Which of the following disorders presents with repeated catalase-positive infections? (Q840071)

A. X linked hypogammaglobinemia

B. SCID

C. Chronic granulomatous disease

D. Chediak Higashi Syndrome

See Answer in Part B → Q7

@Neet_pg_bot

Q8: A Diabetic patient's blood sample is kept in the given container. What will be added to the blood sample? (Q860268)

A. Na fluoride

B. EDTA

C. Na citrate

D. Heparin



See Answer in Part B → Q8

@Neet_pg_bot

Q9: Which amino acid is necessary for the production of nitric oxide in the blood vessels? (Q859910)

A. Citrulline

B. Arginine

C. Histidine

D. Tryptophan

See Answer in Part B → Q9

@Neet_pg_bot

Q10: Which of the following is right regarding these stains? (Q879218)

A. Perl's Prussian blue – stains iron, color red

B. Alizarin Red S – stains calcium, color black

C. Van Gieson – stains elastin, color blue

D. Giemsa – stains mast cells, color purple

See Answer in Part B → Q10

@Neet_pg_bot

Q11: Lipid is best visualised on which technique in pathology? (Q879231)

A. Frozen section / Cryostat

B. Paraffin-embedded section

C. Immunohistochemistry

D. Electron microscopy

See Answer in Part B → Q11

@Neet_pg_bot

• [25_Platelets and Blood Transfusion] 088 Previous Year Questions

« Back to Folder Directory

[25_Platelets and Blood Transfusion] 088 Previous Year Questions — Quick Jump

Q1 (p. 975) *Q2 (p. 975)* *Q3 (p. 975)* *Q4 (p. 976)* *Q5 (p. 976)* *Q6 (p. 977)*
Q7 (p. 977) *Q8 (p. 978)* *Q9 (p. 978)*

Q1: Match the following blood products with their shelf lives. a. 1-Granulocytes A- 5 days b. 2- PRBC B- 24 hours c. 3- SDP C- 42 days d. 4- CRYO D- 1 year (Q840026)

A. 1-A, 2-C, 3D, 4-B

B. 1-B, 2-D, 3-A, 4-C

C. 1-C, 2-A, 3-B, 4-D

D. 1-B, 2-C, 3-A, 4-D

See Answer in Part B → Q1

@Neet_pg_bot

Q2: Which of the following is used in the treatment of Hemophilia B? (Q840031)

A. Factor 9

B. Cryoprecipitate

C. Factor 8

D. Tranexamic acid

See Answer in Part B → Q2

@Neet_pg_bot

Q3: In a trauma patient with an unknown blood group who is unstable and requires urgent blood transfusion, which type of blood should be transfused? (Q840032)

A. A positive

B. AB positive

C. O positive

D. O negative

See Answer in Part B → Q3

@Neet_pg_bot

Q4: Which of the following is not seen in a delayed hemolytic transfusion reaction? (Q840056)

A. Raised LDH

B. Raised indirect bilirubin

C. No improvement in Hb despite transfusion

D. Cola-colored urine after 2 hrs

See Answer in Part B → Q4

@Neet_pg_bot

Q5: A patient presents with a tingling sensation in both legs, polyuria, and weight loss. Based on the given bone marrow aspirate findings, what is the most likely diagnosis? (Q844224)

A. Multiple myeloma with renal failure

B. SACD with vitamin B12 deficiency

C. SACD with diabetes

D. Waldenstrom's Macroglobulinemia

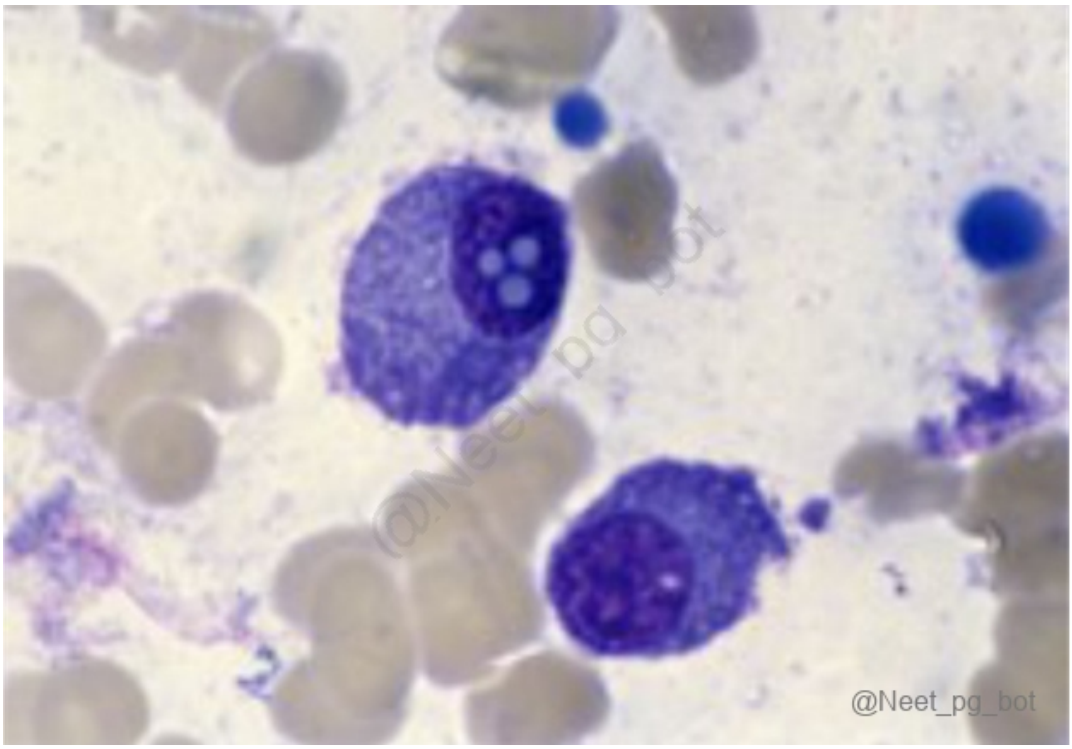

See Answer in Part B → Q5

@Neet_pg_bot

Q6: A child is brought to the emergency department with a large lesion on his forearm. As a surgery resident, you decide to excise the lesion in the emergency operation theatre. Which of the following investigations will test the entire coagulation pathway? (Q856915)

A. Activated partial thromboplastin time

B. Prothrombin time

C. Thromboelastography

D. Bleeding time

See Answer in Part B → Q6

@Neet_pg_bot

Q7: How does Total plasma exchange help in the management of TTP (Q857426)

A. TPE removes the Von Willebrand factor

B. TPE removes the Antiplatelet antibodies

C. TPE removes Anti ADAMTS13 autoantibodies and thereby increases the ADAMTS protease activity

D. TPE replenishes the coagulation factor

See Answer in Part B → Q7

@Neet_pg_bot

Q8: What is the commonest cause of a hypercoagulable state? (Q857441)

A. Antithrombin III deficiency

B. Protein C deficiency

C. Factor V Leiden mutation

D. G20210A prothrombin gene mutation

See Answer in Part B → Q8

@Neet_pg_bot

Q9: Which of the following is the most common inherited bleeding disorder? (Q865368)

A. Von Willebrand Disease

B. Disseminated Intravascular Coagulation

C. Factor V Deficiency

D. Hemophilia

See Answer in Part B → Q9

@Neet_pg_bot

Part B — All Answers & Explanations

• [01_Cell Injury] 001 Cell Injury Free Radical Injury And Er Stress Related

« Back to Folder Directory

[01_Cell Injury] 001 Cell Injury Free Radical Injury And Er Stress Related — Quick Jump

Q1 (p. 979)	*Q2 (p. 980)*	*Q3 (p. 981)*	*Q4 (p. 981)*	*Q5 (p. 982)*	*Q6 (p. 983)*
Q7 (p. 984)	*Q8 (p. 985)*	*Q9 (p. 986)*	*Q10 (p. 987)*	*Q11 (p. 988)*	*Q12 (p. 988)*
Q13 (p. 989)	*Q14 (p. 990)*	*Q15 (p. 991)*	*Q16 (p. 992)*		

Q1: Which of the following are pathological factors that contribute to the development of thrombosis? (Q879510)

A. Endothelial injury, abnormal blood flow, hypercoagulability

B. Increased vascular compliance, reduced platelet activity, and fibrinolysis

C. Decreased vascular tone, enhanced anticoagulant proteins, and vasodilation

D. Smooth muscle hypertrophy, hypocoagulability, and increased tissue perfusion

Correct Answer: A. Endothelial injury, abnormal blood flow, hypercoagulability

Explanation: The primary abnormalities that lead to intravascular thrombosis are the so-called “Virchow triad”. Components of Virchow triad: Endothelial injury- Leads to platelet activation, which almost inevitably underlies thrombus formation in the heart and the arterial circulation. Abnormal blood flow- Turbulence (chaotic blood flow) contributes to arterial and cardiac thrombosis by causing endothelial injury or dysfunction. Hypercoagulability- Refers to an abnormally high tendency of the blood to clot and is usually caused by alterations in coagulation factors.

References:

Robbins & Kumar Pathologic Basis of Disease, 11th Edition, Page no. 66

↑ *Back to this question in Part A*

@Neet_pg_bot

Q2: What is the most common cause of cell injury? (Q845267)

A. Hypoxia

B. Immunologic reactions

C. Drug-induced

D. Nutritional imbalance

Correct Answer: A. Hypoxia

■ *Listen (English)*

■ *Listen (Hindi)*

Explanation: Hypoxia is the most common cause of cell injury. The mechanism of hypoxic cell injury is a decrease in oxygen concentration at the tissue level. The most common cause of hypoxia is ischemia. Ischemia is the hampered blood supply.

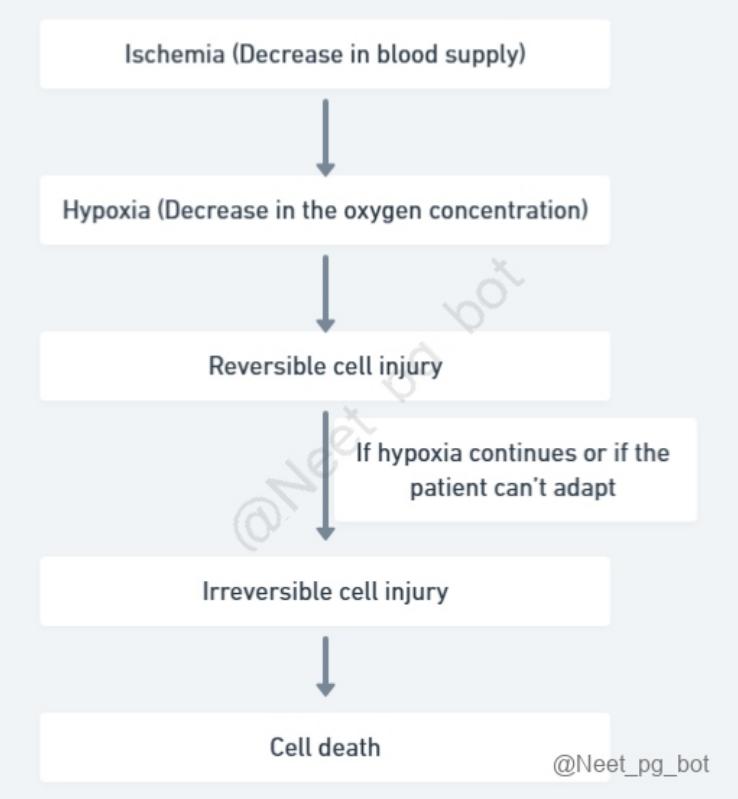

References:

Robbins, Cotran & Kumar Pathologic Basis of Disease, 11th edition, Page 31.

↑ *Back to this question in Part A*

@Neet_pg_bot

Q3: Identify the correct combination of most and least sensitive cells to hypoxia. (Q845270)

A. Most sensitive - hepatocytes and least sensitive - Lymphocytes

B. Most sensitive - bone marrow cells and least sensitive - nerve cells

C. Most sensitive - retina and least sensitive - adipose tissue

D. Most sensitive - neurons and least sensitive - fibroblasts

Correct Answer: D. Most sensitive - neurons and least sensitive - fibroblasts

■ *Listen (English)*

■ *Listen (Hindi)*

Explanation: The cells most sensitive to hypoxia are neurons and the least sensitive are fibroblasts. Neurons or Brain cells : Features of cell injury can be seen after 3 to 5 minutes of hypoxia. Fibroblasts: Hypoxia can be tolerated for more than 60 minutes. Incorrect options: Most sensitive - hepatocytes and least sensitive - Lymphocytes (option A) Hepatocytes are moderately sensitive to hypoxia. Neurons are far more sensitive than hepatocytes (injury within 3–5 minutes). Lymphocytes tolerate hypoxia fairly well, but fibroblasts are the most resistant. Most sensitive - bone marrow cells and least sensitive - nerve cells (option B) Bone marrow cells are sensitive to radiation and toxins, but not the most sensitive to hypoxia . Most sensitive - retina and least sensitive - adipose tissue (option C) The retina is metabolically active but not more sensitive than neurons to hypoxia. Adipose tissue tolerates low oxygen but fibroblasts are even more hypoxia-resistant.

References:

Robbins and Cotran Pathologic Basis of Disease, 10th Edition, Page 37

↑ *Back to this question in Part A*

@Neet_pg_bot

Q4: Which among the following is not a feature of reversible cell injury? (Q845271)

A. Large amorphous densities in the mitochondria

B. Decrease in ATP generation

C. Swelling of the endoplasmic reticulum

D. Detachment of ribosomes from granular ER

Correct Answer: A. Large amorphous densities in the mitochondria

■ *Listen (English)*

■ *Listen (Hindi)*

Explanation: Large amorphous densities are seen in the mitochondria in irreversible cell injury . Amorphous densities in the mitochondria mean calcium deposition in mitochondria, which occurs when the cell membrane has been ruptured. The following changes occur in reversible cell injury: Cellular swelling: Earliest change Na and water accumulate within the cell, causing cellular swelling (swelling of the endoplasmic reticulum) (Option C ruled out) ATP depletion leads to sodium-potassium pump failure (Option B ruled out) Due to ATP dysfunction, ribosomes detach from the endoplasmic reticulum, which stops protein synthesis (Option D ruled out)

References:

Robbins and Cotran Pathologic Basis of Disease, 10th edition, Page 37

↑ *Back to this question in Part A*

@Neet_pg_bot

Q5: Which of the following are features of irreversible cell injury? Increased eosinophilia Pyknosis Decrease in ATP production Small amorphous densities in mitochondria (Q845275)

A. 1, 2

B. 1, 2, 3, 4

C. 1, 2, 4

D. 2, 3

Correct Answer: A. 1, 2

Explanation: The correct statements regarding features of irreversible cell injury are statements 1 and 2. Irreversible cell injury: Defining features: Severe membrane damage. Severe mitochondrial damage leads to the formation of large, flocculant, amorphous densities due to increased calcium influx. (Not small as mentioned in statement 4) Two defining moments of irreversible cell injury are Severe Membrane Damage: The inflow of calcium occurs. It causes the activation of three enzymes: a. Phospholipase b. Protease c. Nuclease Severe Mitochondrial Damage: The calcium sits on the mitochondria causing Amorphous Flocculent Densities Nuclear Changes in Cell Injury: Three stages of nuclear changes in cell injury are: Pyknosis: The nucleus becomes small and dark due to the nuclear chromatin condensing. Karyorrhexis: There will be Nuclear Fragmentation Karyolysis : The nucleus gets dissolved. Increased eosinophilia is seen in H&E stains due to the loss of cytoplasmic RNA and accumulation of denatured cytoplasmic proteins (which bind the red dye eosin). Statements 3 and 4 : A decrease in ATP production and small amorphous densities in the mitochondria are features of reversible cell injury.

Reversible cell injury Irreversible cell injury Decreased ATP production - Failure of Na+ K+ ATPase pump - Cellular, ER, and mitochondrial swelling. Anaerobic glycolysis - Acidic pH- Clumping of nuclear chromatin Detachment of ribosomes from rough ER- Decreased protein synthesis and fatty change. Severe Membrane Damage: The inflow of calcium occurs. It causes the activation of three enzymes: a. Phospholipase b. Protease c. Nuclease Severe Mitochondrial Damage: The calcium sits on the mitochondria causing Amorphous Flocculent Densities Myelin figures/ concentric lamellations: seen in both reversible and irreversible cell injury.

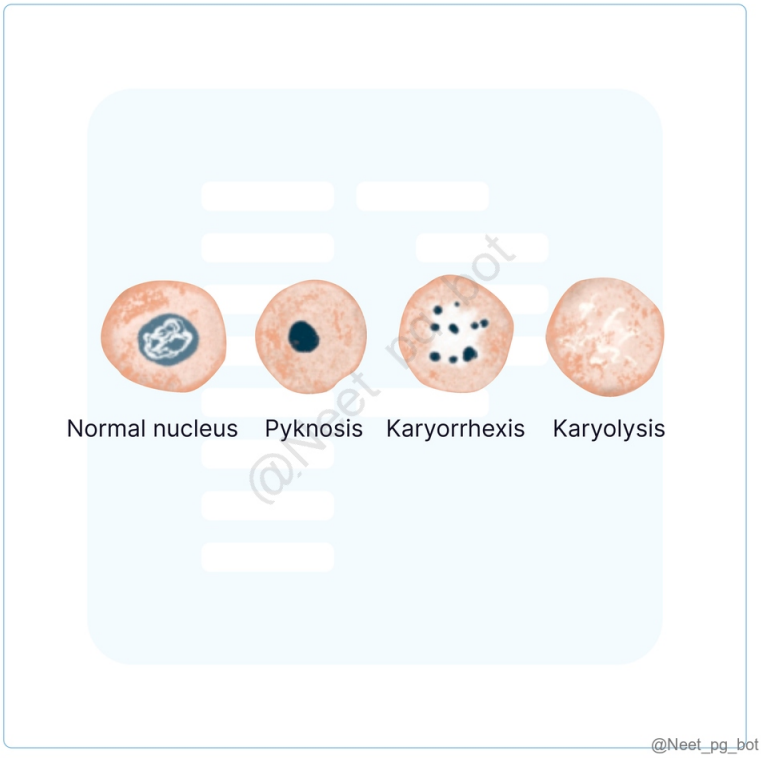

References:

Robbins and Cotran, Pathologic Basis of Disease, 10th edition, Pages 38-40

↑ *Back to this question in Part A*

@Neet_pg_bot

Q6: Match the following descriptions of the nuclear changes in irreversible cell injury. I. Pyknosis a. Nuclear fragmentation II. Karyorrhexis b. Dissolution of nucleus III. Karyolysis c. Shrinking of the nucleus and clumping of nuclear chromatin (Q845280)

A. I-a, II-b, III-c

B. I-b, II-c, III-a

C. I-c, II-a, III-b

D. I-c, II-b, III-a

Correct Answer: C. I-c, II-a, III-b

■ *Listen (English)*

■ *Listen (Hindi)*

Explanation:

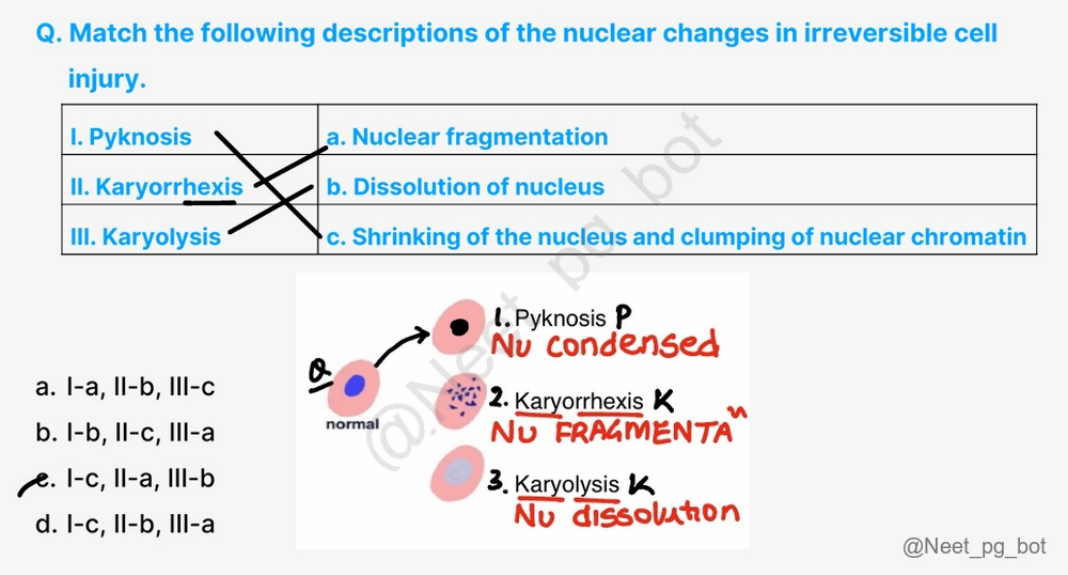

References:

Robbins and Cotran, Pathologic Basis of Disease, Page 40

↑ *Back to this question in Part A*

@Neet_pg_bot

Q7: Which of the following is the most important electron microscopic finding in irreversible cell injury? (Q845288)

A. Small amorphous densities in the mitochondria

B. Swelling of the endoplasmic reticulum

C. Large amorphous densities in the mitochondria

D. Detachment of ribosomes from the granular endoplasmic reticulum

Correct Answer: C. Large amorphous densities in the mitochondria

■ *Listen (English)*

■ *Listen (Hindi)*

Explanation: Large amorphous densities in the mitochondria are the most important electron microscopic finding in irreversible cell injury. It occurs due to an increased calcium influx in the mitochondria. Irreversible cell injury: Severe membrane damage leading to influx of calcium. Severe mitochondrial damage leads to the formation of large, flocculant, amorphous densities due to increased calcium influx. Reversible cell injury: Small amorphous densities in the mitochondria Swelling of the endoplasmic reticulum Detachment of ribosomes from the granular endoplasmic reticulum Feature Reversible Injury Irreversible Injury (Cell Death) Main Definition Pathological changes that can be reversed if the stimulus is removed. Permanent damage leading to cell death regardless of stimulus removal. Mitochondria Swelling (vacuolization) due to influx of water. Severe swelling and appearance of large, amorphous densities in the matrix. Plasma Membrane Blebbing, blunting, or loss of microvilli; structure remains intact. Loss of membrane integrity ; massive leakage of intracellular enzymes. Nucleus Clumping of chromatin. Nuclear shrinkage (pyknosis), fragmentation (karyorrhexis), or dissolution (karyolysis). Lysosomes Generally remain intact. Rupture and release of acid hydrolases into the cytoplasm (autolysis). Endoplasmic Reticulum Swelling and detachment of ribosomes (reduced protein synthesis). Lysis of the ER and total loss of ribosomes. Cytoplasm Increased eosinophilia (pinkness) and "cloudy swelling." Intense eosinophilia; presence of "myelin figures" (whorled phospholipid masses). Energy (ATP) ATP depletion occurs, but can be restored. Profound ATP depletion ; failure of all metabolic pathways.

References:

Robbins and Cotran, Pathologic Basis of Disease, 10th Edition, Pages 38-40

↑ *Back to this question in Part A*

@Neet_pg_bot

Q8: Which of the following statements regarding free radical injury is true? (Q845289)

A. Free radicals are highly stable molecules with unpaired electrons that contribute positively to cellular functions.

B. Free radical injury can lead to cell damage through lipid peroxidation, protein oxidation, and DNA strand breaks.

C. Antioxidants play a minor role in protecting cells from free radical damage.

D. Free radicals primarily cause cell death through apoptosis and do not contribute to necrosis.

Correct Answer: B. Free radical injury can lead to cell damage through lipid peroxidation, protein oxidation, and DNA strand breaks.

■ *Listen (English)*

■ *Listen (Hindi)*

Explanation: Free radical injury can indeed lead to cell damage through processes such as lipid peroxidation (which damages cell membranes), protein oxidation (which affects enzyme function and structural integrity), and DNA strand breaks (which can lead to mutations). Free radicals are highly unstable with unpaired electrons that contribute negatively to cellular functions. (Option A ruled out) Antioxidants play a major role in protecting cells from free radical damage; therefore, the diet should be rich in antioxidants, such as vitamins A, C, and E. (Option C ruled out) Free radicals cause cell death through apoptosis and also contribute to necrosis. (Option D ruled out) Free radical injury: Free Radical: Aka ROS (Reactive Oxygen Species) 3 types: Superoxide; Hydrogen peroxide; Hydroxyl (most potent) Protects every cell Reactive oxygen species → lipid peroxidation → produce Lipofuscin pigment (tell-tale sign) Formation: Protection: Antioxidants like vitamins A, C, and E Transport proteins Transferrin - Fe Ceruloplasmin - Cu Protective Enzymes: SOD, Catalase, Glutathione peroxidase Superoxide dismutase (Due to lamin mutation): 2 types: Cytoplasmic SOD (Cu-Zn SOD) Mitochondrial SOD (Mn SOD) SOD: Protects the brain SOD 1 gene mutation → ALS (Amyotrophic Lateral Sclerosis) M/E: Bunina bodies Affects both UMN and LMN disorders Enzymatic Antioxidants: Superoxide dismutase (SOD): Converts superoxide (O■■) to H■O■ + O■ (mitochondria/cytosol).■ Catalase: Breaks down H■O■ to H■O + ½O■ (peroxisomes).■ Glutathione peroxidase: Reduces H■O■/lipid peroxides using glutathione (cytosol/mitochondria). Non-Enzymatic Antioxidants: Glutathione (GSH): Major intracellular reductant; oxidized to GSSG.■ Vitamin E (α-tocopherol): Membrane-bound, chain-breaking antioxidant against lipid peroxidation.■ Vitamin C (ascorbic acid): Water-soluble, regenerates Vitamin E.■ β-carotene/Vitamin A: Membrane-associated, quenches singlet oxygen.

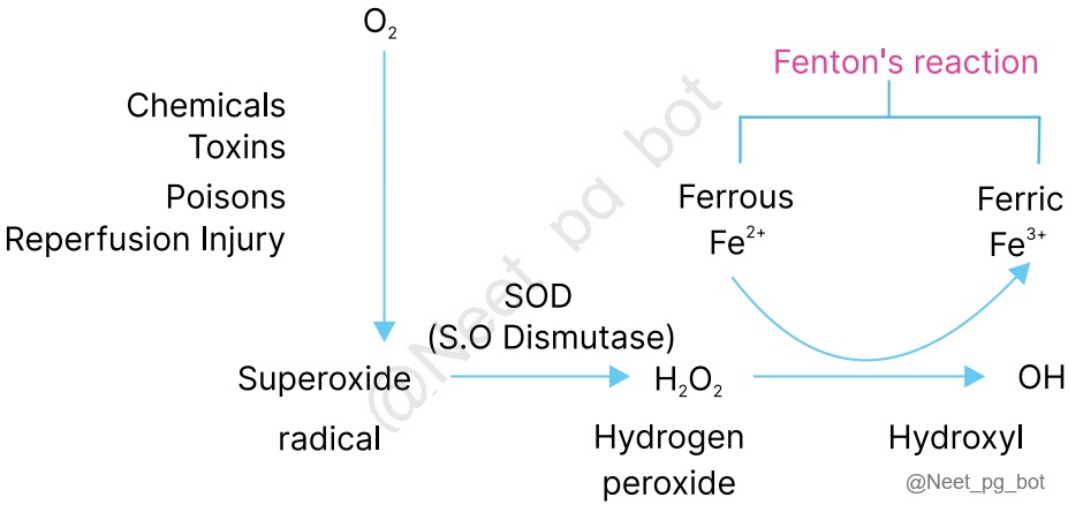

References:

Robbins and Cotran Pathologic Basis of Disease, 10th edition, Pages 67, 68

↑ *Back to this question in Part A*

@Neet_pg_bot

Q9: Which of the following ultrastructural findings given below can be seen in irreversible cell injury? (Q845292)

A. Swelling of endoplasmic reticulum

B. Formation of myelin figures

C. Disaggregation of granular and fibrillar elements

D. Nuclear fragmentation

Correct Answer: B. Formation of myelin figures

Explanation: The given clinical presentation of a male with acute-on-chronic liver failure with severely elevated liver enzymes and hepatic encephalopathy can cause irreversible cell damage in the liver. In the context of irreversible cell injury, the formation of myelin figures is a characteristic ultrastructural finding. Myelin figures: They represent whorled arrangements of membranous material within the cytoplasm, indicating severe disruption and rearrangement of cellular membranes. It is commonly observed under electron microscopy. They are either phagocytosed by other cells or further degraded into fatty acids; calcification of such fatty acid residues results in the deposition of calcium-rich precipitates. Myelin figures can be seen in both reversible and irreversible cell injuries, but they are more common in irreversible injuries. OTHER OPTIONS: Options A and C: Swelling of endoplasmic reticulum and disaggregation of granular and fibrillar elements are electron microscopic features of reversible cellular injury. Option D: Nuclear fragmentation, also known as karyorrhexis , is a light microscopic finding seen in irreversible cellular injury.

References:

Robbins and Cotran, Pathologic Basis of Disease, Page no. 38-40

↑ *Back to this question in Part A*

@Neet_pg_bot

Q10: A sample of tissue preparation is subjected to oxidative stress under experimental conditions. Different types of free radicals are generated in the process. However, the researcher wants to work on the most potent and reactive free radicals among the ones generated. Which of the following will he be working on? (Q845294)

A. Hydroxyl radical (OH•)

B. Nitric oxide radical (NO•)

C. Superoxide anion radical (O2•-)

D. Peroxyl radical (ROO•)

Correct Answer: A. Hydroxyl radical (OH•)

■ *Listen (English)*

■ *Listen (Hindi)*

Explanation: When a tissue sample is exposed to oxidative stress experimentally, various free radicals are produced, with the hydroxyl radical being the most potent and reactive among them. We have a total of 3 free radicals: Superoxide Hydrogen peroxide (H2O2) Hydroxyl (OH) The hydroxyl radical (OH•) is considered the most potent and reactive free radical due to its high reactivity and ability to quickly react with cellular components, leading to oxidative damage. Hydroxyl radicals are primarily formed through the Fenton reaction T he interaction of hydrogen peroxide (H2O2) with transition metal ions such as iron (Fe) or copper (Cu).

References:

Robbins and Cotran Pathologic Basis of Disease, 10th Edition, Pages 67,68

↑ *Back to this question in Part A*

@Neet_pg_bot

Q11: Which of the following is a telltale sign of free radical injury in cells? (Q845295)

A. Increased antioxidant levels in the cell

B. Decreased lipid peroxidation products

C. Generation of Lipofuscin and stress markers such as malondialdehyde (MDA)

D. Enhanced cellular energy production.

Correct Answer: C. Generation of Lipofuscin and stress markers such as malondialdehyde (MDA)

■ *Listen (English)*

■ *Listen (Hindi)*

Explanation: The presence of lipofuscin and stress markers like malondialdehyde (MDA) is a telltale sign of free radical-induced cellular injury. Free radical injury results in oxidative stress (Lipid peroxidation), leading to the accumulation of oxidative stress markers such as malondialdehyde (MDA) and the generation of Lipofuscin. Lipofuscin is positive for Oil Red-O stain. These are the tell-tale signs of free radical injury.

References:

Robbins and Cotran Pathologic Basis of Disease, 10th edition, Pages 67,68

↑ *Back to this question in Part A*

@Neet_pg_bot

Q12: What is the primary function of superoxide dismutase (SOD) in cells? (Q845298)

A. Activation of inflammatory responses.

B. Generation of reactive oxygen species (ROS)

C. Neutralization of superoxide anion radicals (O2•-) into hydrogen peroxide (H2O2)

D. Promotion of lipid peroxidation.

Correct Answer: C. Neutralization of superoxide anion radicals (O2•-) into hydrogen peroxide (H2O2)

■ *Listen (English)*

■ *Listen (Hindi)*

Explanation: Neutralization of superoxide anion radicals (O2•-) into hydrogen peroxide (H2O2) is the primary function of Superoxide Dismutase (SOD) in cells. Dual functions of Superoxide dismutase (SOD): Generation of free radicals by converting superoxide into H2O2 Neutralization (Primary function) (Option C) Its primary function is to catalyze the conversion of superoxide radicals (O2•-) into oxygen (O2) and hydrogen peroxide (H2O2). The only antioxidant that can break free radicals in the brain is Superoxide dismutase. SOD1 gene mutation in humans is associated with Amyotrophic Lateral Sclerosis (ALS). Catalase: Catalase is located in peroxisomes It decomposes H■O■ (from SOD or fatty acid oxidation) into water and oxygen: 2H■O■ → 2H■O + O■. It prevents H■O■ accumulation, which could otherwise damage DNA, proteins, and lipids. It shows high activity in liver/kidney peroxisomes. Glutathione Peroxidase (GPx): GPx uses reduced glutathione (GSH) to reduce H■O■ and lipid hydroperoxides to water/alcohols: H■O■ + 2GSH → GSSG + 2H■O. It is selenium-dependent (at active site). It protects membranes from peroxidation. GSH is regenerated by glutathione reductase (NADPH-dependent).

References:

Robbins and Cotran Pathologic Basis of Disease, 10th Edition, Pages 67, 68

https://www.sigmaaldrich.com/IN/en/technical-documents/technical-article/research-and-disease-areas/cell-signaling/superoxide-dismutase

↑ *Back to this question in Part A*

@Neet_pg_bot

Q13: A 50-year-old male presents with progressive weakness and muscle atrophy, primarily affecting his arms and legs. He reports difficulty with tasks such as buttoning shirts and lifting objects. On examination, you note fasciculations in his upper extremities and decreased muscle strength. His reflexes are brisk, and there is no sensory deficit. Nerve conduction studies show signs of denervation. Genetic testing reveals a mutation in the SOD1 gene. Based on this clinical scenario, what is the most likely diagnosis for this patient? (Q845300)

A. Multiple sclerosis

B. Myasthenia gravis

C. Amyotrophic lateral sclerosis

D. Guillain-Barré syndrome

Correct Answer: C. Amyotrophic lateral sclerosis

■ *Listen (English)*

■ *Listen (Hindi)*

Explanation: This clinical scenario, marked by progressive limb weakness, muscle atrophy with fasciculations, brisk reflexes, denervation on nerve studies, and an SOD1 gene mutation, is diagnostic of Amyotrophic Lateral Sclerosis (ALS) . It is a disease of both upper and lower motor neurons. The SOD1 gene encodes for the enzyme superoxide dismutase 1 (SOD1), which plays a crucial role in protecting cells (Brain) from oxidative stress. Mutations in the SOD1 gene are associated with familial cases of amyotrophic lateral sclerosis (ALS). ALS is a progressive neurodegenerative disease that affects motor neurons in the brain and spinal cord, leading to muscle weakness, atrophy, and eventually paralysis. Bunina bodies are seen on brain biopsy of ALS patients. Clinical features: LMN: Flaccid weakness, atrophy, fasciculations, hyporeflexia early. UMN: Spasticity, hyperreflexia, Babinski. Bulbar: Dysarthria, dysphagia (25% onset). No sensory/cognitive/autonomic involvement (early); respiratory failure → death (3-5 years median). Diagnosis: El Escorial criteria (clinical + EMG denervation/reinnervation) Genetic testing Exclude mimics (anti-GM1, cervical spondylosis). Multiple sclerosis (Option A): Demyelinating CNS disease with sensory deficits, optic neuritis, and relapsing-remitting course; no SOD1 link or denervation on NCS. Myasthenia gravis (Option B): Neuromuscular junction disorder with fatigable weakness, ptosis, diplopia, and normal reflexes; fatigability absent here.■ ■■■■■■■Guillain-Barré syndrome (Option D): Acute inflammatory demyelinating polyneuropathy with ascending weakness, areflexia, sensory symptoms, and albuminocytologic dissociation in CSF; not progressive/chronic.

References:

Robbins and Cotran Pathologic Basis of Disease, 10th Edition, Pages 67, 68

↑ *Back to this question in Part A*

@Neet_pg_bot

Q14: Which of the following best describes the primary function of chaperones within the cellular environment? (Q845304)

A. Facilitating the degradation of misfolded proteins

B. Promoting protein folding and preventing misfolding

C. Catalyzing enzymatic reactions by providing a scaffold

D. Transporting proteins across cellular membranes

Correct Answer: B. Promoting protein folding and preventing misfolding

■ *Listen (English)*

■ *Listen (Hindi)*

Explanation: The primary role of Chaperones (molecular chaperones like Hsp70, Hsp90, GroEL) in the cellular environment is to facilitate proper protein folding and prevent misfolding. Chaperones in the ER are responsible for properly folding newly synthesized proteins, and misfolded polypeptides are shuttled into the cytoplasm where they are ubiquitinated and targeted for proteolysis in proteasomes. Chaperons works by the Ubiquitin Proteasome Pathway (UPP): Corrects the misfolding. Bit if the misfolded protein cannot be corrected then it is sent proteolysis or breakdown. Disease Misfolded protein Creutzfeldt-Jacob disease Prions Cystic fibrosis Cystic fibrosis transmembrane conductance regulator (CFTR) (ΔF508 mutation most common; class II trafficking defect) Alzheimer's Disease Aβ (amyloid-β 40/42 from APP), Tau (hyperphosphorylated → NFTs) Parkinson's Disease α-Synuclein (Lewy bodies) Huntington's Disease Huntingtin (polyglutamine expansion >36 repeats) Amyotrophic Lateral Sclerosis (ALS) SOD1 (mutations), TDP-43, FUS Frontotemporal Dementia (FTD) Tau (some), TDP-43 Fatal Familial Insomnia Prion protein (PRNP mutation) Type 2 Diabetes Islet amyloid polypeptide (IAPP/amylin) Systemic AL Amyloidosis Immunoglobulin light chains (λ > κ) AA (Secondary) Amyloidosis Serum amyloid A (SAA, acute phase reactant) Transthyretin Amyloidosis (ATTR) Transthyretin (TTR, wild/mutant) Dialysis-Related Amyloidosis β■-Microglobulin

References:

Robbins and Cotran Pathologic Basis of Disease, 10th Edition, Page 54

↑ *Back to this question in Part A*

@Neet_pg_bot

Q15: A 60-year-old man has been complaining of fatigue, unintentional weight loss, and swelling in his ankles and legs over the past few months. On physical examination, you notice hepatomegaly and proteinuria. Laboratory tests reveal elevated serum creatinine levels and microscopic hematuria. Which of the following types of amyloid is most likely responsible for this patient's presentation? (Q845308)

A. AA amyloidosis

B. AB amyloidosis

C. AL amyloidosis

D. ATTR amyloidosis

Correct Answer: C. AL amyloidosis

Explanation: AL amyloidosis, also known as primary systemic amyloidosis , is characterized by the deposition of amyloid fibrils derived from monoclonal immunoglobulin light chains (lambda or kappa) produced by clonal plasma cells. In this type of amyloidosis, the deposited amyloid fibrils can infiltrate various organs and tissues, including the kidneys, leading to organ dysfunction. Clinical manifestations commonly include Renal involvement causing proteinuria and renal impairment Hepatomegaly Peripheral oedema due to cardiac involvement. AA amyloidosis (Option A): AA amyloidosis, also known as secondary systemic amyloidosis, occurs secondary to chronic inflammatory conditions such as rheumatoid arthritis, inflammatory bowel disease, or chronic infections. In AA amyloidosis, the amyloid fibrils are derived from serum amyloid A protein, an acute-phase reactant synthesized predominantly by hepatocytes in response to inflammation. AB amyloidosis (Option B): AB amyloidosis is not a recognized subtype of amyloidosis. Amyloid fibrils derived from A Beta peptide are associated with Alzheimer's disease, but they are not a primary cause of systemic amyloidosis involving multiple organs. ATTR amyloidosis (Option D): ATTR amyloidosis, also known as transthyretin amyloidosis, occurs due to the deposition of amyloid fibrils derived from transthyretin protein, a transporter of thyroxine and retinol-binding protein. It can be hereditary (caused by mutations in the transthyretin gene) or acquired (due to wild-type transthyretin protein). It typically affects the heart and peripheral nerves, leading to cardiomyopathy and peripheral neuropathy, respectively.

References:

Robbins and Cotran Pathologic Basis of Disease 10th ed PG: 260-264

↑ *Back to this question in Part A*

@Neet_pg_bot

Q16: Which cellular pathway is primarily involved in the pathogenesis of Amyotrophic Lateral Sclerosis (ALS)?Which of the following pathways are responsible for the pathogenesis of ALS? (Q845311)

A. Autophagy-lysosome pathway

B. Ubiquitin-proteasome pathway

C. Endocytic pathway

D. Apoptotic pathway

Correct Answer: B. Ubiquitin-proteasome pathway

■ *Listen (English)*

■ *Listen (Hindi)*

Explanation: The ubiquitin-proteasome pathway plays a key role in the pathogenesis of ALS (Amyotrophic Lateral Sclerosis) . ALS is due to a mutation in the SOD-1 gene. Mutant proteins start accumulating in brain. The ubiquitin-proteasome pathway is primarily responsible for the degradation of misfolded proteins within the cell. In this pathway, misfolded or damaged proteins are tagged with ubiquitin molecules, which target them for

degradation by the proteasome, a large multi-subunit protein complex. Dysfunction of the ubiquitin-proteasome pathway can lead to the accumulation of misfolded proteins and contribute to the pathogenesis of neurodegenerative diseases such as amyotrophic lateral sclerosis (ALS) and Parkinson's disease. In the SOD-1 gene defect, UPP is not working because of cellular defect. Autophagy–lysosome pathway (Option A): Although involved in protein clearance, it is secondary and not the principal pathway in ALS pathology. Endocytic pathway (Option C): Endocytic defects may contribute to neuronal dysfunction but are not the primary mechanism in ALS. Apoptotic pathway (Option D): Apoptosis represents the final common pathway of neuron death, not the initiating pathogenic mechanism.

References:

https://pubmed.ncbi.nlm.nih.gov/22033150/

↑ *Back to this question in Part A*

@Neet_pg_bot

• [01_Cell Injury] 002 Cell Death

« Back to Folder Directory

[01_Cell Injury] 002 Cell Death — Quick Jump

Q1 (p. 994)	*Q2 (p. 994)*	*Q3 (p. 995)*	*Q4 (p. 996)*	*Q5 (p. 997)*	*Q6 (p. 998)*
Q7 (p. 998)	*Q8 (p. 999)*	*Q9 (p. 1000)*	*Q10 (p. 1001)*	*Q11 (p. 1001)*	*Q12 (p. 1002)*
Q13 (p. 1003)	*Q14 (p. 1004)*	*Q15 (p. 1006)*	*Q16 (p. 1007)*	*Q17 (p. 1008)*	*Q18 (p. 1010)*
Q19 (p. 1011)	*Q20 (p. 1012)*	*Q21 (p. 1013)*	*Q22 (p. 1015)*	*Q23 (p. 1016)*	*Q24 (p. 1017)*

Q1: A construction worker involved in bridge building reports widespread bone pain. Imaging reveals ischemic necrosis affecting both femoral heads, the left tibia, and the right humerus. Which of the following factors is most likely responsible for this condition? (Q879491)

A. Alterations in ambient pressure

B. Changes in blood viscosity

C. Impaired blood flow

D. Increased coagulability

Correct Answer: A. Alterations in ambient pressure

Explanation: Exposure to rapid changes in ambient pressure, as encountered in compressed air work or tunnel construction, predisposes to dysbaric osteonecrosis. Nitrogen gas bubbles form within the marrow vasculature during decompression, causing vascular obstruction, ischemia, and aseptic bone necrosis, particularly affecting weight-bearing bones. Incorrect Options: Changes in blood viscosity (Option B): Although changes in blood viscosity can affect circulation, they are not the primary cause of ischemic bone necrosis in this scenario. Impaired blood flow (Option C): Impaired blood flow is a direct cause of ischemia, but here is secondary to ambient pressure-induced gas embolism. Increased coagulability (Option D): Increased coagulability is not the main factor involved in the pathogenesis of this type of osteonecrosis.

References:

Robbins and Cotran, Pathologic Basis of Disease, 11th Edition, Page no. 115

↑ *Back to this question in Part A*

@Neet_pg_bot

Q2: Which of the following diseases is primarily attributed to protein misfolding, resulting in cellular dysfunction or apoptosis? (Q879402)

A. Cystic fibrosis

B. Familial hypercholesterolemia

C. Tay-Sachs disease

D. All of the above

Correct Answer: D. All of the above

Explanation: Protein misfolding disorders can affect multiple systems and often trigger ER stress and apoptosis if quality control mechanisms fail. Other examples include α1-antitrypsin deficiency, Alzheimer's disease, and Creutzfeldt-Jakob disease . Protein Misfolding and ER Stress: ER chaperones assist in the proper folding of newly synthesized proteins Misfolded proteins are sent to the cytoplasm → Ubiquitinated and degraded by proteasomes. Accumulation triggers the Unfolded Protein Response (UPR) : ↑ Chaperones ↑ Proteasomal degradation ↓ Protein translation (to reduce ER stress) Misfolded proteins are implicated in neurodegenerative diseases and other disorders. Disease Protein Misfolded Effect Cystic fibrosis CFTR Defective chloride transpor Familial hypercholesterolemia LDL receptor Impaired cholesterol clearance Tay-Sachs disease Hexosaminidase β subunit Lysosomal GM2 ganglioside accumulation α1-Antitrypsin deficiency α1-Antitrypsin Hepatocyte apoptosis and lung emphysema Creutzfeldt-Jacob disease Prions (PrP^Sc) Neuronal cell death Alzheimer's disease Aβ peptide Neuronal aggregation and apoptosis

References:

Robbins & Cotran Pathologic Basis of Disease, 10th Edition, Page 54,55

↑ *Back to this question in Part A*

@Neet_pg_bot

Q3: A 65-year-old patient with a neurodegenerative disorder is found to have neuronal death associated with iron accumulation and lipid peroxidation. Which form of cell death is most likely involved? (Q879401)

A. Apoptosis

B. Necrosis

C. Ferroptosis

D. Pyroptosis

Correct Answer: C. Ferroptosis

Explanation: Ferroptosis is a regulated, iron-dependent form of cell death triggered by excessive reactive oxygen species (ROS) and lipid peroxidation, leading to loss of plasma membrane integrity. A regulated, iron-dependent form of cell death triggered by excess intracellular iron or reactive oxygen species (ROS) overwhelming glutathione-dependent antioxidant defenses. Mechanism: Unchecked lipid peroxidation → Disrupting membrane fluidity, lipid-protein interactions, ion/nutrient transport, and signaling → Ultimately leading to loss of plasma membrane integrity . Morphology: Resembles necrosis but is signal-regulated . Ultrastructurally → Loss of mitochondrial cristae and ruptured outer mitochondrial membrane . Prevention: Inhibited by reducing iron levels or limiting lipid peroxidation. Clinical relevance: Implicated in cancer, neurodegenerative diseases, and stroke (role in normal physiology is still uncertain).

References:

Robbins & Cotran Pathologic Basis of Disease, 10th Edition, Page 47,48

↑ *Back to this question in Part A*

@Neet_pg_bot

Q4: A 30-year-old individual has cells that resist Fas-mediated apoptosis despite Fas ligand binding. Which of the following proteins is most likely responsible for blocking caspase-8 activation in this scenario? (Q879400)

A. Bcl-2

B. FLIP

C. BID

D. FADD

Correct Answer: B. FLIP

Explanation: FLIP protein inhibits the extrinsic apoptosis pathway by binding to pro-caspase-8 , preventing its recruitment to FADD and blocking activation. It does not activate caspase-8. The extrinsic pathway of apoptosis occurs in the following order: Presence of Fas on the outer part of the cell membrane The binding of the Fas ligand of T cells to Fas Trimerization of Fas Formation of FADD Activation of caspase 8, 10. This, along with the activation of the intrinsic pathway, leads to the execution phase and apoptosis. FLIP protein → Inhibits the conversion of Procaspases to caspases.

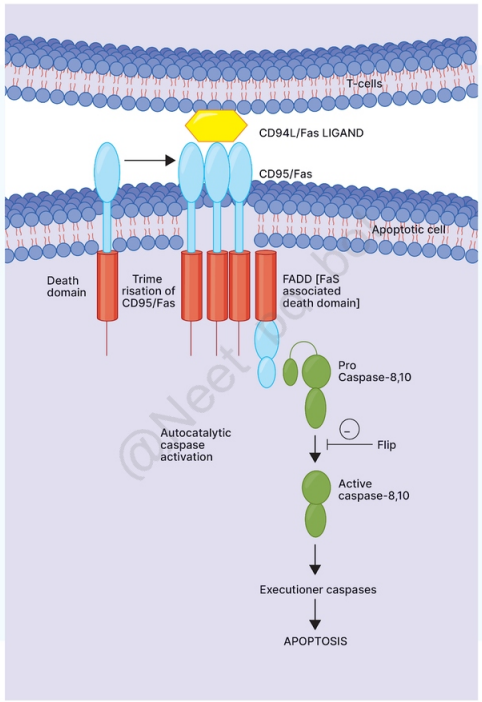

@Neet_pg_bot

References:

Robbins & Cotran Pathologic Basis of Disease, 10th Edition, Page 46

↑ *Back to this question in Part A*

@Neet_pg_bot

Q5: Which of the following statements about caspases is true? (Q879392)

A. Caspases function independently of apoptotic signaling pathways

B. Caspases cleave at cysteine residues

C. Caspases act on asparagine residues

D. Caspases are cysteine proteases

Correct Answer: D. Caspases are cysteine proteases

Explanation: Caspases are cysteine proteases that cleave target proteins after aspartic residues . They exist as inactive zymogens (pro-caspases) and are activated via proteolytic cleavage. This activation triggers the initiation and execution phases of apoptosis .

References:

Robbins & Cotran Pathologic Basis of Disease, 10th Edition, Page 44

↑ *Back to this question in Part A*

@Neet_pg_bot

Q6: Which of the following represents pathological apoptosis rather than physiological apoptosis? (Q879391)

A. Regression of the lactating breast after weaning

B. Elimination of autoreactive T-lymphocytes in the thymus

C. Death of hepatocytes during viral hepatitis

D. Removal of neutrophils after resolution of acute appendicitis

Correct Answer: C. Death of hepatocytes during viral hepatitis

Explanation: Hepatocyte apoptosis in viral hepatitis is a pathological process triggered by viral infection and immune-mediated injury. This is not part of normal tissue homeostasis. Apoptosis in physiological conditions Apoptosis in pathological conditions The removal of supernumerary cells (in excess of the required number) during development. DNA damage. Involution of hormone-dependent tissues on hormone withdrawal, such as endometrial cell breakdown during the menstrual cycle. Accumulation of misfolded proteins Elimination of potentially harmful self-reactive lymphocytes to prevent immune reactions against one’s own tissues Apoptosis can be induced during certain infections, as adenovirus and HIV infections, and viral hepatitis. Death of host cells that have served their useful purpose, such as neutrophils in an acute inflammatory response and lymphocytes at the end of an immune response. It may also contribute to pathologic atrophy in parenchymal organs after duct obstruction, such as occurs in the pancreas, parotid gland, and kidney

References:

Robbins & Cotran Pathologic Basis of Disease, 10th Edition, Page 42,43

↑ *Back to this question in Part A*

@Neet_pg_bot

Q7: A pathology slide shows necrotic cells with intense eosinophilic cytoplasm on H&E staining. Which of the following best explains this increased eosinophilia? (Q879390)

A. Loss of glycogen and lipid droplets

B. Accumulation of denatured cytoplasmic proteins that bind eosin

C. Swelling of mitochondria with amorphous densities

D. Presence of intracytoplasmic myelin figures

Correct Answer: B. Accumulation of denatured cytoplasmic proteins that bind eosin

Explanation: In necrotic cells, increased eosinophilia is mainly due to loss of cytoplasmic RNA (less basophilia) and denatured cytoplasmic proteins binding more eosin dye . This makes the cytoplasm appear bright pink/red. Morphologic Features of Necrotic Cells Increased eosinophilia Due to loss of cytoplasmic RNA (reduced basophilia) and accumulation of denatured cytoplasmic proteins that strongly bind eosin. Glassy homogeneous appearance Primarily caused by the loss of glycogen particles . Vacuolated (“moth-eaten”) cytoplasm Occurs when enzymes digest cell organelles. Myelin figures Large whorled phospholipid precipitates. It may be phagocytosed by other cells or degraded into fatty acids (undergo calcification → calcium-rich deposits). Ultrastructural changes (electron microscopy) Discontinuities in plasma and organelle membranes. Marked mitochondrial dilation with amorphous densities. Intracytoplasmic myelin figures. Amorphous debris and aggregates of fluffy material (denatured proteins).

References:

Robbins & Cotran Pathologic Basis of Disease, 10th Edition, Page 40

↑ *Back to this question in Part A*

@Neet_pg_bot

Q8: Which of the following is true about apoptosis? (Q879389)

A. It is an irreversible type of cell injury

B. It is associated with inflammation

C. It results in nuclear changes such as pyknosis, karyorrhexis, and karyolysis

D. It is an active process

Correct Answer: D. It is an active process

Explanation: Apoptosis is an active process, requiring ATP Apoptosis Necrosis Definition Programmed cell death, an orderly, regulated process Both Physiologic and pathologic Unregulated cell death due to injury or stress Always pathological Triggering Controlled signals (e.g., intrinsic or extrinsic pathways) Acute cell injury (e.g., trauma, infection, ischemia) Cellular Morphology Cell shrinkage, chromatin condensation, and membrane blebbing. Cell swelling, membrane rupture, organelle damage, Nucleus (Pyknosis, Karyorrhexis, Karyolysis). Inflammation No inflammation; phagocytes quickly remove apoptotic bodies Induces inflammation due to the

release of cell contents Energy Dependency Requires ATP and energy; active process Does not require energy; passive process Marker DNA electrophoresis: Step ladder pattern Annexin V, CD95/Fas Tunel stain positive DNA electrophoresis: Smear pattern Tunel stain negative

References:

Robbins & Cotran Pathologic Basis of Disease, 10th Edition, Page 42

↑ *Back to this question in Part A*

@Neet_pg_bot

Q9: A pathology student is reviewing the sequence of nuclear and cellular changes that occur during necrosis. Which of the following correctly represents the order of events? 1. Cell swelling 2. Karyolysis 3. Karyorrhexis 4. Pyknosis (Q879387)

A. 1 → 2 → 3 → 4

B. 1 → 4 → 3 → 2

C. 2 → 3 → 4 → 1

D. 4 → 3 → 2 → 1

Correct Answer: B. 1 → 4 → 3 → 2

Explanation: The earliest change in necrosis is cell swelling due to ATP depletion and loss of ionic homeostasis. Nuclear changes then follow in a characteristic sequence: pyknosis (chromatin condensation), karyorrhexis (fragmentation of the pyknotic nucleus), and finally karyolysis (enzymatic degradation of DNA leading to nuclear fading). The order of nuclear changes in necrosis is: Pyknosis → Karyorrhexis → Karyolysis. Pyknosis Shrinking of the nucleus and clumping of nuclear chromatin Karyorrhexis Nuclear fragmentation Karyolysis Dissolution of the nucleus

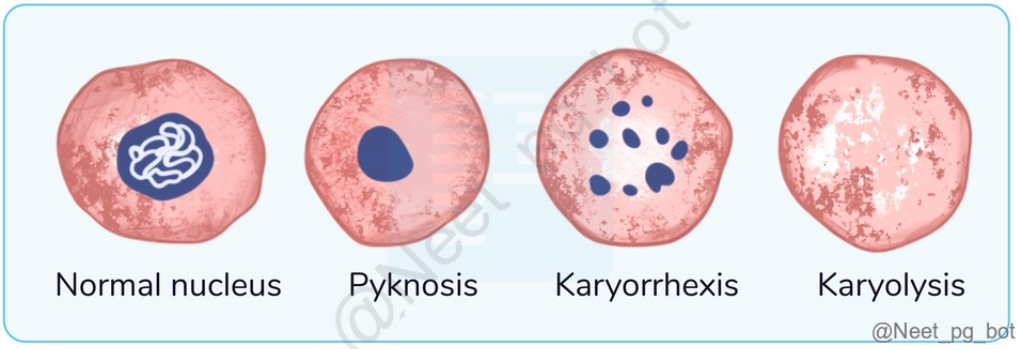

References:

Robbins & Cotran Pathologic Basis of Disease, 11th Edition, Page 81

↑ *Back to this question in Part A*

@Neet_pg_bot

Q10: Which of the following are involved in the pathogenesis of pyroptosis? (Q845353)

A. Caspase 8 and FADD

B. RIPK3 and MLKL

C. Caspase 1 and inflammasome

D. Iron and glutathione antioxidants

Correct Answer: C. Caspase 1 and inflammasome

■ *Listen (English)*

■ *Listen (Hindi)*

Explanation: Caspase 1 and the inflammasome are the entities responsible for a form of cell death known as Pyroptosis . A form of apoptosis in which there is release of the fever-inducing cytokine IL-1. Seen in response to bacterial infections like Salmonella and Shigella. Microbial products entering infected cells are recognized by cytoplasmic receptors, activating the multiprotein complex inflammasome . Inflammasomes are involved in recognition & clearance of necrotic cells. Inflammasome activates caspases 1, 4, 5, and 11. They will together result in the killing of the cell (apoptosis). Caspase 1, which converts the inactive IL-1 to active IL-1, causing fever, inflammation and leucocyte recruitment Caspase 8 and FADD (Option A) are involved in the extrinsic pathway of apoptosis. RIPK3 and MLKL (Option B) are involved in necroptosis. Iron and glutathione antioxidants (Option D) are involved in ferroptosis.

References:

Robbins and Cotran Pathologic Basis of Disease, 10th Edition, Page 46-48

↑ *Back to this question in Part A*

@Neet_pg_bot

Q11: Which type of cell death prevents metastasis? (Q845357)

A. Necroptosis

B. Pyroptosis

C. Anoikis

D. Necrosis

Correct Answer: C. Anoikis

■ *Listen (English)*

■ *Listen (Hindi)*

Explanation: Anoikis is a type of cell death which prevents metastasis. A type of apoptosis in which the cell undergoes programmed cell death when cells detach from the surrounding extracellular matrix (ECM) or neighbouring cells. When cancer cells detach from the primary tumor, they are susceptible to anoikis. Acts as a barrier against the survival and dissemination of these detached cancer cells Anoikis is a type of cell death which, if occurs, prevents spread of cancer or metastasis. Incorrect options: Necroptosis (option A) Programmed necrosis triggered by TNF or other signals. Inflammatory, but does not specifically prevent metastasis. Pyroptosis (option B) Caspase-1-dependent inflammatory cell death. Mainly involved in pathogen defense, not anti-metastatic. Necrosis (option D) ■■■■■■■■■■■■■■■■ Uncontrolled cell death from injury. Can promote inflammation and tumor progression, not prevent metastasis.

References:

https://pubmed.ncbi.nlm.nih.gov/23830918/

↑ *Back to this question in Part A*

@Neet_pg_bot

Q12: Which of the following is true about programmed necroptosis? (Q845354)

A. Caspase-independent programmed cell death.

B. It is non-inflammatory.

C. It is only pathological.

D. It helps kill the Herpes simplex virus.

Correct Answer: A. Caspase-independent programmed cell death.

■ *Listen (English)*

■ *Listen (Hindi)*

Explanation: Necroptosis is a caspase-independent programmed cell death. Programmed necrosis is also known as Necroptosis. It is a type of caspase-independent programmed cell death that presents with Inflammation. (Option B ruled out) It has features of both necrosis and apoptosis. It is both physiological and pathological (Option C ruled out) It helps in killing Cytomegalovirus (CMV) and not HSV. (Option D ruled out)

References:

Robbins and Cotran Pathologic Basis of Disease, 10th Edition, Page 47

↑ *Back to this question in Part A*

@Neet_pg_bot

Q13: Which of the following is true about coagulative necrosis? (Q845314)

A. It is the least common type of necrosis

B. Brain is most likely to undergo coagulative necrosis

C. It causes a wedge-shaped necrosis in the affected organs

D. The tissue architecture is lost

Correct Answer: C. It causes a wedge-shaped necrosis in the affected organs

■ *Listen (English)*

■ *Listen (Hindi)*

Explanation: Coagulative Necrosis causes a wedge-shaped necrosis in the affected organs. Most common type of necrosis. (Option A ruled out) Seen in solid organs like the kidney, liver, and heart (Option B ruled out) . Brain and Pancreas show liquefactive necrosis Most common cause - Thromboembolism Grossly, wedge-shaped necrosis is seen. Usually seen following an infarct (when blood supply is hampered) Tissue architecture is preserved. (Option D ruled out) Microscopically, ghost cells are seen. These show preserved outlines but details are lost. {{caption_text}} {{caption_text}}

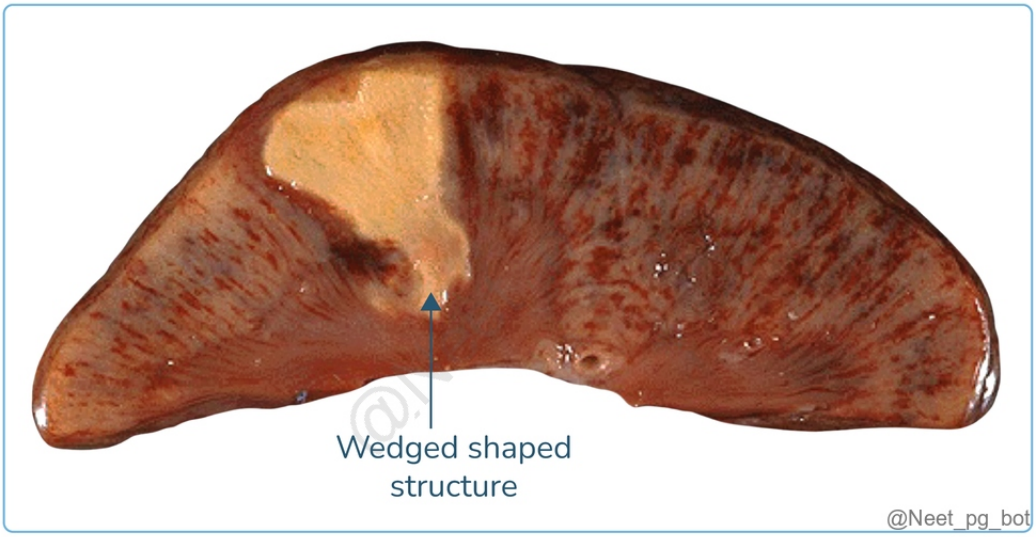

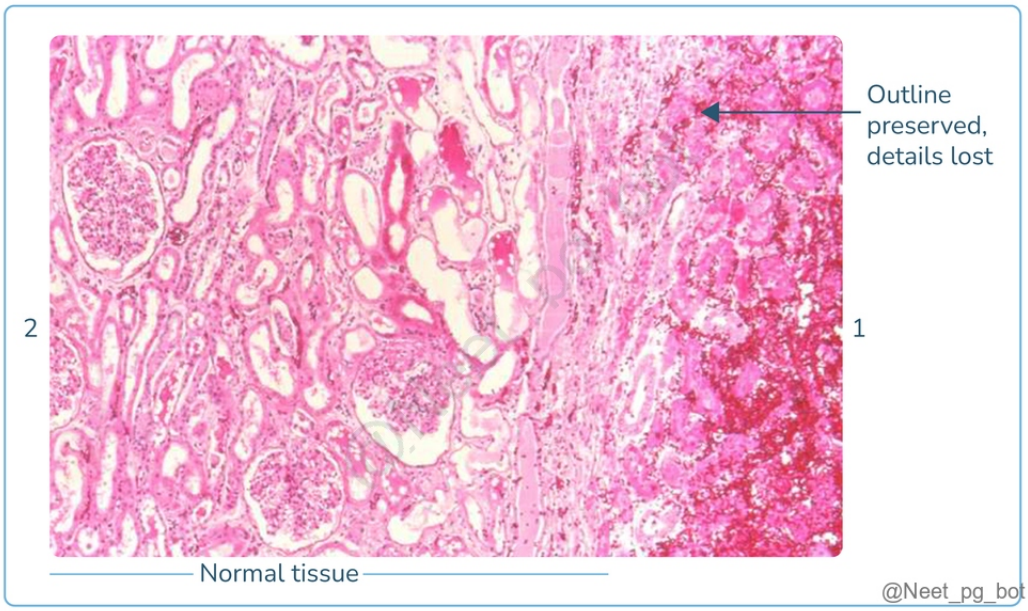

References:

Robbins and Cotran Pathologic Basis of Disease, 10th Edition, Page 39

↑ *Back to this question in Part A*

@Neet_pg_bot

Q14: Which of the following cell deaths is most likely to show pattern B? (Q845352)

A. Apoptosis

B. Necrosis

C. Both

D. None of the above



Correct Answer: A. Apoptosis

- *Listen (English)*
- *Listen (Hindi)*

Explanation: Pattern B shows regular DNA bands (~180–200 bp), forming a “ DNA ladder ,” which is a hallmark of apoptosis. Apoptosis vs Necrosis on Agarose Gel: Feature Apoptosis Necrosis DNA Cleavage Internucleosomal, specific Random and nonspecific Enzyme Involved Activated endonucleases Non-specific degradation by cellular enzymes Electrophoresis Result Ladder pattern (discrete bands) Smear pattern (continuous degradation) Fragment Size Multiples of ~180–200 base pairs Heterogeneous, unorganized fragments Interpretation Indicates controlled cell death Indicates uncontrolled cell death

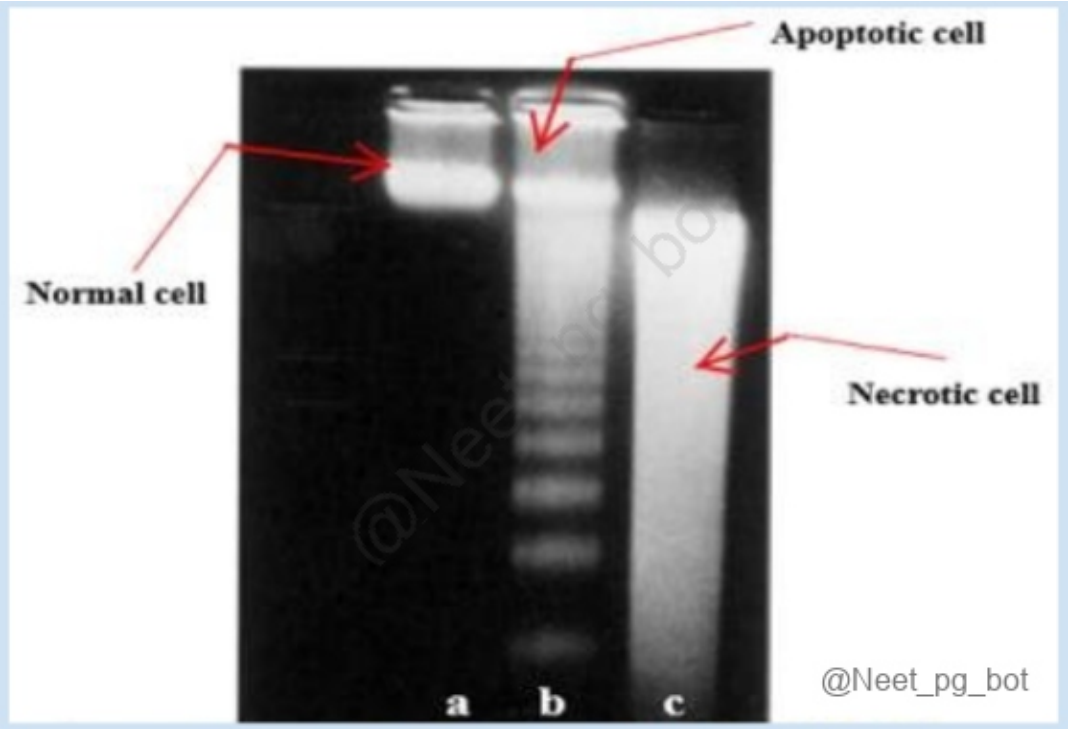

References:

https://pmc.ncbi.nlm.nih.gov/articles/PMC6312709/

https://pubmed.ncbi.nlm.nih.gov/15105553/

https://pmc.ncbi.nlm.nih.gov/articles/PMC4401164/

↑ *Back to this question in Part A*

@Neet_pg_bot

Q15: Which of the following substances is not a component of ‘eat-me signals’ of efferocytosis? (Q845351)

A. C1q

B. Thrombospondin

C. Phosphatidyl serine

D. Fas Ligand

Correct Answer: D. Fas Ligand

■ *Listen (English)*

■ *Listen (Hindi)*

Explanation: Fas ligand is a death receptor ligand that induces apoptosis and not a component of efferocytosis. Its involved in apoptosis initiation. Efferocytosis: The apoptotic bodies give the eat-me signals , which are expressed as C1q, Thrombospondin, and PS (Phosphatidyl Serine) . In the normal cell, the Phosphatidyl Serine is present in the inner leaflet, but in the apoptotic cell, it comes out. This is known as Phosphatidyl Serine Flipping (Defective in Scott syndrome). Based on this flipping, the Macrophage engulfs the apoptotic bodies, which is called Efferocytosis. Apoptotic bodies contain portions of the cytoplasm and nucleus. Eat-me signals list: Phosphatidylserine (PtdSer) Oxidized phospholipids Sugar residues (such as galactose) Deoxyribonucleic acid (DNA) Calreticulin (CALR) Annexin A1 Histones Pentraxin-3 (PTX3) Modified ICAM-3 Cardiolipin

References:

Robbins and Cotran Pathologic Basis of Disease, 10th Edition, Page 46

↑ *Back to this question in Part A*

@Neet_pg_bot

Q16: Which of the following forms the apoptosome complex? (Q845350)

A. SMAC, DIABLO

B. Cyt C and Apaf

C. Procaspase 9 and Caspase 9

D. Caspase 3, 6, 7

Correct Answer: B. Cyt C and Apaf

■ *Listen (English)*

■ *Listen (Hindi)*

Explanation: The A poptosome is a multi-protein complex that plays a critical role in the intrinsic (mitochondrial) pathway of apoptosis, formed when cytochrome C (Cyt C) is released from mitochondria into the cytosol in response to cellular stress or damage. Once in the cytosol: Cytochrome c binds to Apaf-1 (apoptotic protease-activating factor-1) in the presence of dATP/ATP This triggers the formation of the apoptosome complex SMAC/DIABLO (co-released with Cyt C) bind IAPs (XIAP/cIAPs), inhibiting their inhibition of Caspase-9 to amplify apoptosis. (Option A) The apoptosome then recruits and activates procaspase-9, which leads to activation of downstream executioner caspases (3, 6, 7) (Options C & D) Structurally, apoptosomes are composed of a wheel-like hexamer configuration. {{caption_text}} Apoptosis involves both intrinsic and extrinsic pathways of programmed cell death.

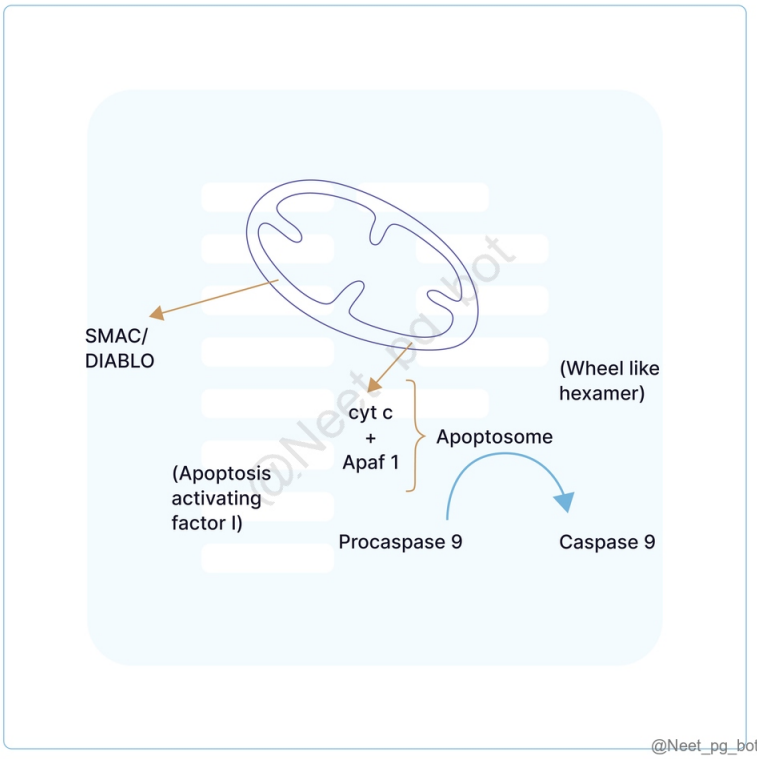

References:

Robbins and Cotran Pathologic Basis of Disease, 10th Edition, Page 44,45.

↑ *Back to this question in Part A*

@Neet_pg_bot

Q17: Arrange the steps of the extrinsic pathway of apoptosis in the correct order. i. Binding of Fas ligand of T cells to Fas ii. Trimerization of Fas iii. Activation of caspase 8, 10. iv. Formation of FADD (Q845349)

A. i>ii>iii>iv

B. iii>i>ii>iv

C. i>ii>iv>iii

D. iv>i>ii>iii

Correct Answer: C. i>ii>iv>iii

■ *Listen (English)*

■ *Listen (Hindi)*

Explanation: Apoptosis occurs in two steps: Initiation and execution. The initiation phase contains extrinsic and intrinsic pathways. Extrinsic pathway: The extrinsic pathway of apoptosis starts outside the cells in the following order: Presence of Fas/CD95 on the outer part of the cell membrane Binding of Fas/CD95 ligand of T cells to Fas Trimerization of Fas Formation of FADD (Fas-associated death domain) Activation of caspase 8, 10 (by conversion of procaspase 8 and 10 to caspase 8 and 10) Intrinsic pathway: Sequence: This pathway responds to internal stresses like DNA damage or hypoxia, involving mitochondria. Activation of Pro-apoptotic Proteins: Internal stress signals activate proteins like Bax and Bak . Mitochondrial Permeabilization (MOMP): Bax and Bak form pores in the outer mitochondrial membrane, often called the "point of no return" . Release of Cytochrome c: Pores allow cytochrome c to leak from the mitochondria into the cytoplasm. Apoptosome Formation: In the cytoplasm, cytochrome c binds with Apaf-1 and procaspase-9 to form a complex known as the apoptosome . Caspase Activation: The apoptosome activates the initiator caspase-9 , which then triggers executioner caspases like caspase-3 . Cell Dismantling: Executioner caspases break down cellular components, leading to DNA fragmentation, cell shrinkage, and the final formation of apoptotic bodies . Step Extrinsic Pathway ■■ Intrinsic Pathway Trigger External ligand (FasL/TNF) binds death receptor Internal stress (DNA damage, hypoxia) via p53/Bcl-2 family Key Complex DISC (FADD + caspase-8) Apoptosome (cytochrome c + Apaf-1 + caspase-9) Initiator Caspase Caspase-8 (-10) Caspase-9 Mitochondrial Link Optional (caspase-8 cleaves Bid → tBid → MOMP) Required (Bax/Bak → MOMP → cyt c release) Convergence Executioner caspases-3/6/7 activated Executioner caspases-3/6/7 activated

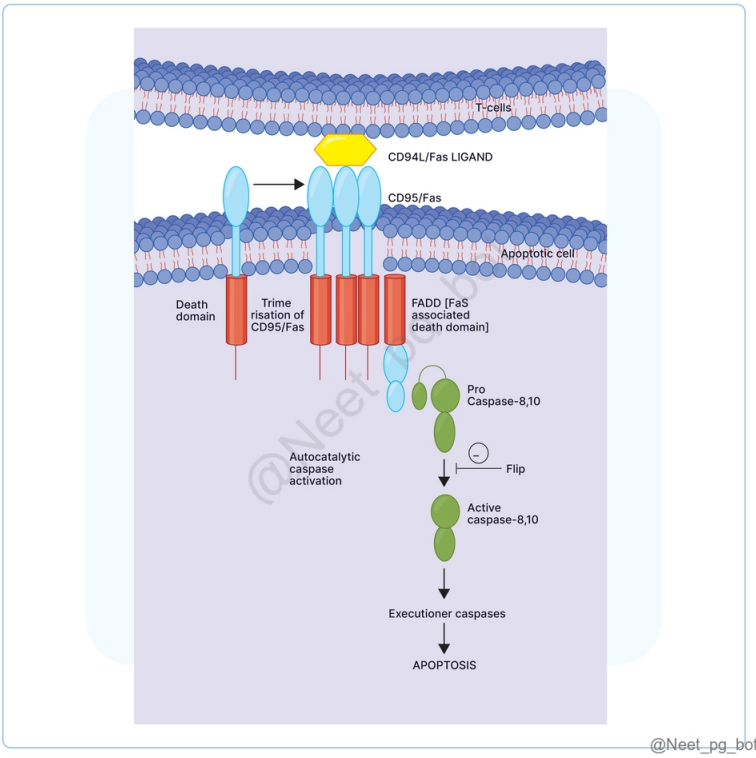

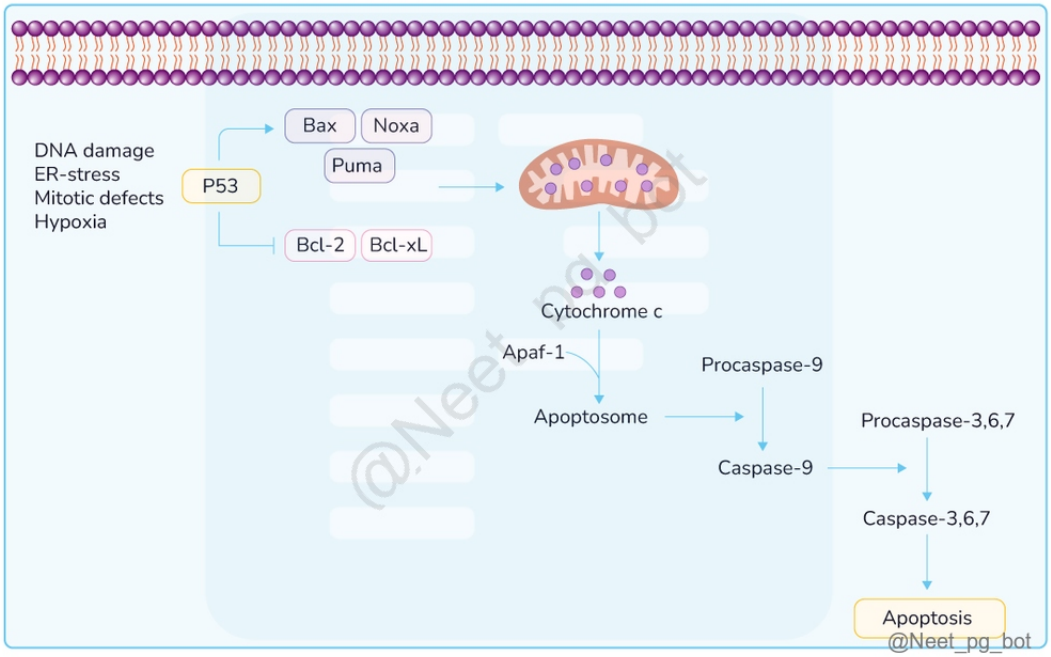

References:

Robbins and Cotran Pathologic Basis of Disease, 10th Edition, Pages 45, 46

↑ *Back to this question in Part A*

@Neet_pg_bot

Q18: Match the following apoptotic genes with their functions: 1. BCL2 , MCL1 a. Allows cytochrome c leakage 2. BAX, BAK b. Initiates apoptosis when upregulated 3. BAD, BID, NOXA c. Prevents leakage of cytochrome C from the cytosol (Q845346)

A. 1-b , 2-c , 3-a

B. 1-c , 2-a , 3-b

C. 1-a , 2-b , 3-c

D. 1-b , 2-a , 3-c

Correct Answer: B. 1-c , 2-a , 3-b

■ *Listen (English)*

■ *Listen (Hindi)*

Explanation: Anti Apoptotic genes :- BCL-2 , BCL-XL , MCL-1 Pro Apoptotic genes:- BAX and BAK Apoptosis initiators (Stress sensors):- BAD, BIM, BID, Noxa and Pum

References:

Robbins and Cotran Pathologic Basis of Disease, 10th Edition, Pages 45, 46

↑ *Back to this question in Part A*

@Neet_pg_bot

Q19: Which of the following statements about apoptosis is false? (Q845342)

A. Characterized by the activation of caspases leading to DNA fragmentation by endonuclease

B. Inflammatory response and release of damage-associated molecular patterns (DAMPs).

C. Chromatin condensation and formation of cytoplasmic blebs.

D. Eliminates cells that are injured beyond repair without eliciting a host reaction.

Correct Answer: B. Inflammatory response and release of damage-associated molecular patterns (DAMPs).

■ *Listen (English)*

■ *Listen (Hindi)*

Explanation: Apoptosis is a non-inflammatory , programmed cell death process. It does not release DAMPs in a way that triggers a strong inflammatory response, unlike necrosis , which does cause inflammation and DAMP release. Apoptosis (Caspase dependent programmed cell death): It is an active process. It eliminates cells that are injured beyond repair without eliciting a host reaction, thus limiting collateral tissue damage. (Option D ruled out) Apoptosis results from the activation of enzymes called caspases leading to DNA fragmentation by endonuclease. (Option A ruled out) Hallmark of apoptosis: Nuclear chromatin condensation and formation of cytoplasmic blebs. (Option C ruled out) Apoptotic bodies

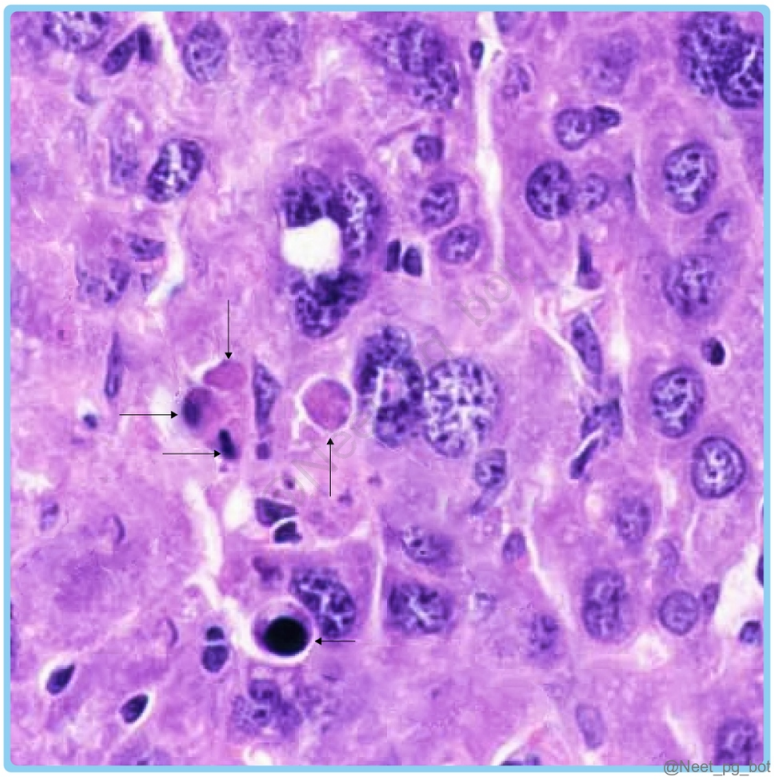

References:

Robbins and Cotran Pathologic Basis of Disease, 10th Edition, Pages 42,43

↑ *Back to this question in Part A*

@Neet_pg_bot

Q20: Identify the correctly matched pair among the following (Q845340)

A. Coagulative necrosis- Leucocytic enzymes- Brain

B. Liquefactive necrosis- Lysosomal enzymes - Heart

C. Fat necrosis- Pancreatic lipase- Omentum

D. Fibrinoid necrosis- Bacterial enzymes- Leg

Correct Answer: C. Fat necrosis- Pancreatic lipase- Omentum

■ *Listen (English)*

■ *Listen (Hindi)*

Explanation: Among the given options, the correctly represented pathology is fat necrosis caused by pancreatic lipases in the breast. In cases of acute pancreatitis, lipase is released from the pancreas which goes to omentum and breaks fat there causing fat necrosis. Type of necrosis Pathology Conditions Coagulative Lysosomal enzymes derived from infiltrating leukocytes Ischemia in all organs except the brain Liquefactive Microbes stimulating leukocyte enzymes Bacterial and fungal infections Ischemia in brain Caseous Formation of granuloma by lymphocytes and activated macrophages (giant cells, epithelioid cells). Tuberculosis,Fungal infections(Histoplasmosis, Coccidioidomycosis) ,Syphilis Gangrenous Ischemia and necrosis Lower and upper limb Fat necrosis Pancreatic enzymes leak out of damaged acinar cells Pancreatitis, traumatic fat necrosis of the breast. Fibrinoid Immune reactions involving blood vessels Polyarteritis nodosa, SLE, Arthus reaction, rheumatic heart disease, malignant hypertension, etc.

References:

Robbins and Cotran Pathologic Basis of Disease, 10th Edition, Pages 40-41

Cell Liquefactive Necrosis - StatPearls - NCBI Bookshelf (nih.gov)

↑ *Back to this question in Part A*

@Neet_pg_bot

Q21: Based on the provided image, which features are indicative of the type of gangrene depicted? {{caption_text}} (Q845334)

A. Presence of gas bubbles in the affected tissue

B. Formation of bullae filled with fluid

C. Dry, shrunken, and mummified appearance with a clear demarcation

D. Presence of foul-smelling discharge and crepitus on palpation



Correct Answer: C. Dry, shrunken, and mummified appearance with a clear demarcation

■ *Listen (English)*

■ *Listen (Hindi)*

Explanation: The image shows dry gangrene, characterized by a dry, shrunken, mummified appearance with a well-defined line of demarcation. Difference between dry gangrene and wet gangrene: Dry gangrene Wet gangrene Site Commonly limbs More common in the bowel Mechanism Arterial occlusion More commonly, venous obstruction Pathology Coagulative necrosis Liquefactive necrosis Macroscopy Organ dry, shrunken, and black Part is moist, soft, swollen, rotten, and dark Line of demarcation Present - at the junction between healthy and gangrenous part No clear-cut line of demarcation Infection No infection, therefore no pus or any fluid Infection present, with pus formation Prognosis Generally better due to little septicemia. Generally poor due to profound toxaemia. Presence of gas bubbles in the affected tissue (Option A) and Presence of foul-smelling discharge and crepitus on palpation (Option D) describe features more characteristic of gas gangrene because of development of gas or bacterial formation leading to formation of gas bubbles. Formation of bullae filled with fluid (Option B) is a feature of Wet gangrene : Wet, swollen, blistered skin that leaks pus/watery fluid with bad smell (infection makes tissue soggy). This image is dry, no blisters/swelling .

References:

Robbins and Cotran Pathologic Basis of Disease, 10th Edition, Page 41

https://www.ncbi.nlm.nih.gov/books/NBK560552/

↑ *Back to this question in Part A*

@Neet_pg_bot

Q22: Which of the following conditions does not involve fibrinoid necrosis? (Q845330)

A. Systemic Lupus Erythematosus.

B. Malignant hypertension

C. Atherosclerosis

D. Polyarteritis Nodosa (PAN)

Correct Answer: C. Atherosclerosis

■ *Listen (English)*

■ *Listen (Hindi)*

Explanation: Atherosclerosis (cholesterol or fat deposition in blood vessels) is not involved in Fibrinoid Necrosis. Fibrinoid necrosis: It is associated with antibody-antigen complex → immune complex deposition in vessel walls → a fibrin-like appearance in vessel walls. It's seen in type I or III hypersensitivity reactions. Observed in conditions like, Polyarteritis nodosa (PAN) (Option D) Rheumatic heart disease (with Aschoff bodies), Systemic lupus erythematosus (SLE) (Option A) Malignant hypertension (Option B) {{caption_text}} Note: Fibrinoid necrosis = plasma proteins (fibrinogen) leak through damaged endothelium → polymerize in vessel wall (eosinophilic, Congo-red negative). Atherosclerosis involves chronic lipid-driven inflammation without this acute vascular wall fibrin deposition.

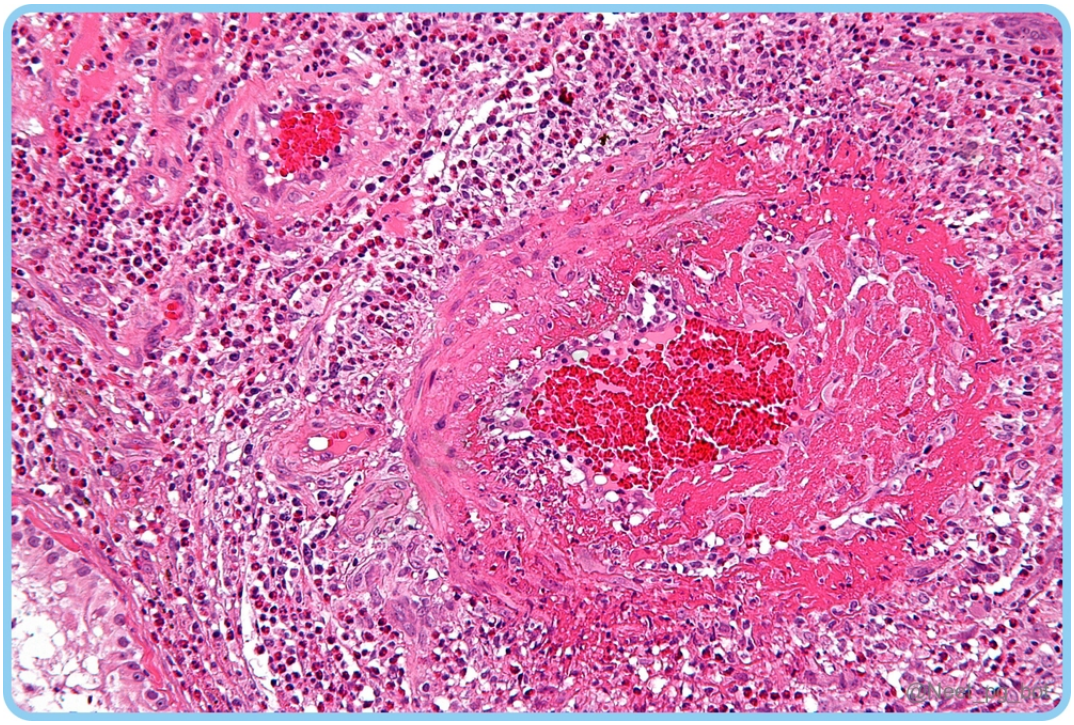

References:

Robbins and Cotran Pathologic Basis of Disease, 10th Edition, Page 41

↑ *Back to this question in Part A*

@Neet_pg_bot

Q23: A 45-year-old man presents to the clinic with a persistent cough, weight loss, and night sweats. A chest X-ray shows cavitary lesions in the upper lobes of the lungs. Sputum analysis is positive for acid-fast bacilli. A biopsy is taken, and a cut section of the lung is shown below.What type of necrosis is most likely present in this patient's lung tissue? (Q845324)

A. Coagulative necrosis

B. Caseous necrosis

C. Fatty necrosis

D. Liquefactive necrosis

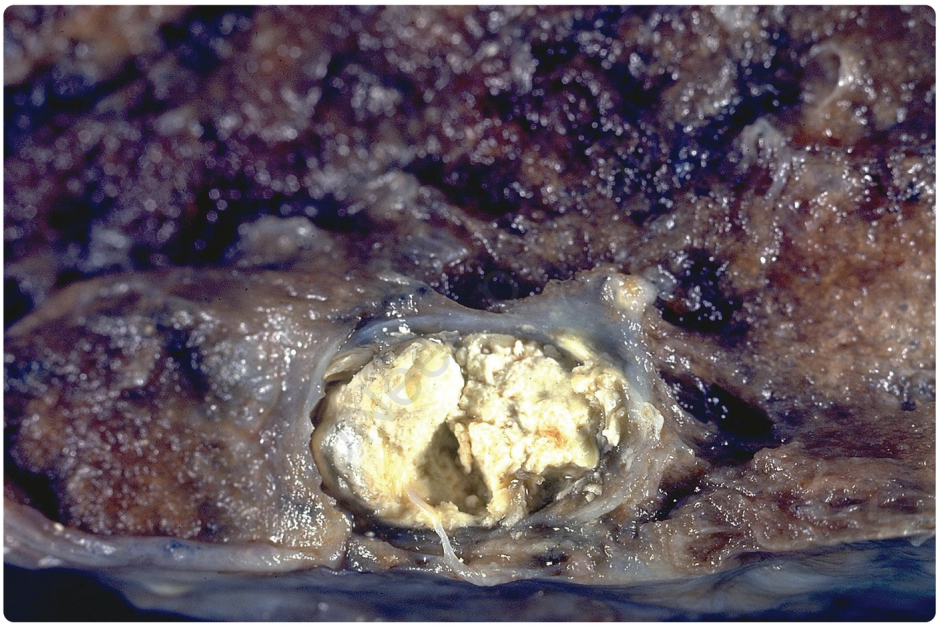

@Neet_pg_bot

Correct Answer: B. Caseous necrosis

■ *Listen (English)*

■ *Listen (Hindi)*

Explanation: This is a case of Pulmonary tuberculosis which presents with Caseous Necrosis in the lungs. Caseous necrosis is characterized by a cheese-like appearance of affected tissues (Option B) Results from the combination of coagulative necrosis (most common form of necrosis) and liquefactive necrosis. It is associated with high lipid content in the cell walls Commonly seen in conditions (high lipid content) such as Tuberculosis (caseating granuloma with mycolic acid deposition), Fungal infections (histoplasmosis, coccidioidomycosis), Syphilis. {{caption_text}}

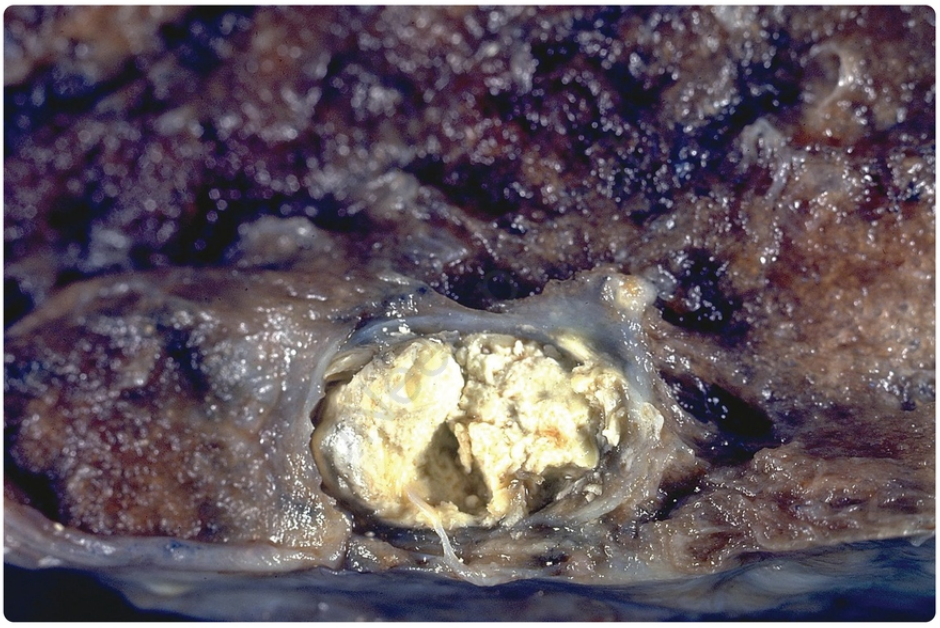

References:

Robbins and Cotran Pathologic Basis of Disease, 10th Edition, Page 40

↑ *Back to this question in Part A*

@Neet_pg_bot

Q24: A 65 year male presents with weakness on the right half of his body. He is a known case of atrial fibrillation, not on any treatment. CT angiography shows a complete occlusion of a small branch of the middle cerebral artery. What is the most likely change seen in this pathology? (Q845318)

A. Coagulative necrosis

B. Liquefactive necrosis

C. Apoptosis

D. Fibrinoid necrosis

Correct Answer: B. Liquefactive necrosis

■ *Listen (English)*

■ *Listen (Hindi)*

Explanation: The given clinical scenario is suggestive of ischemic stroke due to thromboembolism - affected area of the brain shows liquefaction necrosis/colliquative necrosis. Coagulative Necrosis (Option A) is seen in solid organs like the kidney, liver, and heart (Most common) Fibrinoid Necrosis (Option D) is seen in cases where antigen-antibody complexes are formed (E.g., PAN, RHD, Malignant HTN and SLE) Apoptosis (Option C) is a programmed cell death. Physiological: Organogenesis or Embryogenesis. Pathological: 2 bodies: Councilman bodies seen with Hepatitis-C Virus Colloid bodies or Civatte bodies seen in Lichen planus. {{caption_text}}

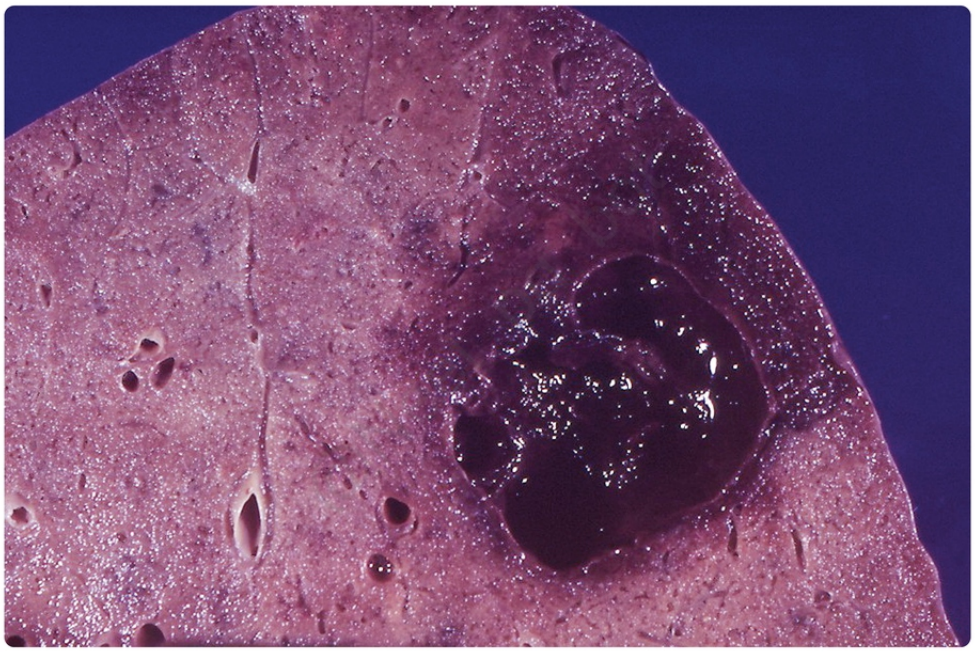

References:

Robbins and Cotran Pathologic Basis of Disease, 10th Edition, Pages 40-41

www.ncbi.nlm.nih.gov/books/NBK430935/

↑ *Back to this question in Part A*

@Neet_pg_bot

• [01_Cell Injury] 003 Cell Ageing Autophagy And Cellular Adaptations

« Back to Folder Directory

[01_Cell Injury] 003 Cell Ageing Autophagy And Cellular Adaptations — Quick Jump

Q1 (p. 1019)	*Q2 (p. 1019)*	*Q3 (p. 1020)*	*Q4 (p. 1021)*	*Q5 (p. 1022)*	*Q6 (p. 1023)*
Q7 (p. 1024)	*Q8 (p. 1024)*	*Q9 (p. 1025)*	*Q10 (p. 1025)*	*Q11 (p. 1026)*	*Q12 (p. 1027)*
Q13 (p. 1027)	*Q14 (p. 1028)*	*Q15 (p. 1030)*	*Q16 (p. 1031)*	*Q17 (p. 1032)*	*Q18 (p. 1033)*
Q19 (p. 1034)	*Q20 (p. 1035)*	*Q21 (p. 1036)*	*Q22 (p. 1036)*	*Q23 (p. 1037)*	*Q24 (p. 1038)*
Q25 (p. 1039)	*Q26 (p. 1040)*				

Q1: Which option best characterizes the cellular phenomenon known as anaplasia? (Q879557)

A. Abnormal increase in cell size

B. Loss of cellular differentiation

C. Replacement of one mature cell type with another

D. Physiological increase in cell number

Correct Answer: B. Loss of cellular differentiation

Explanation: The term anaplasia literally means “backward formation”, implying dedifferentiation, or loss of the structural and functional differentiation of normal cells. Tumors composed of undifferentiated cells are said to be anaplastic, a feature that is a reliable indicator of malignancy.

References:

Robbins & Kumar Pathologic Basis of Disease, 11th Edition, Page no. 188

↑ *Back to this question in Part A*

@Neet_pg_bot

Q2: Bronchial biopsy in a middle-aged chronic smoker shows replacement of columnar epithelium by squamous epithelium. Deficiency of which vitamin can contribute to this metaplastic change? (Q879553)

A. Vitamin K

B. Vitamin E

C. Vitamin D

D. Vitamin A

Correct Answer: D. Vitamin A

Explanation: Vitamin A (retinoic acid) deficiency can also induce squamous metaplasia in the respiratory epithelium and in the cornea, the latter with highly deleterious effects on vision.

References:

Robbins & Kumar Pathologic Basis of Disease, 11th Edition, Page no. 18

↑ *Back to this question in Part A*

@Neet_pg_bot

Q3: Which of the following conditions is associated with metaplastic transformation into connective tissue? (Q879547)

A. Myositis ossificans

B. Squamous metaplasia of bronchi

C. Barrett's esophagus

D. Chronic gastric reflux

Correct Answer: A. Myositis ossificans

Explanation: Connective tissue metaplasia is the formation of cartilage, bone, or adipose cells (mesenchymal tissues) in tissues that normally do not contain these elements. Myositis ossificans- Bone formation in muscle occasionally occurs after intramuscular hemorrhage. This type of metaplasia is less clearly seen as an adaptive response and may be a result of cell or tissue injury. Unlike epithelial metaplasia, this type of metaplasia is not associated with increased cancer risk.

References:

Robbins & Cotran Pathologic Basis of Disease, 10th Edition, Page no. 61

↑ *Back to this question in Part A*

@Neet_pg_bot

Q4: The image below is the lining epithelium of a middle-aged man who is a chronic smoker. Which of the following is the correct marking? (Q879540)

A. 1. Normal columnar epithelium 2. Squamous metaplasia

B. 1. Columnar metaplasia 2. Normal squamous epithelium

C. 1. Normal squamous epithelium 2. Columnar metaplasia

D. 1. Normal columnar epithelium 2. Normal squamous epithelium

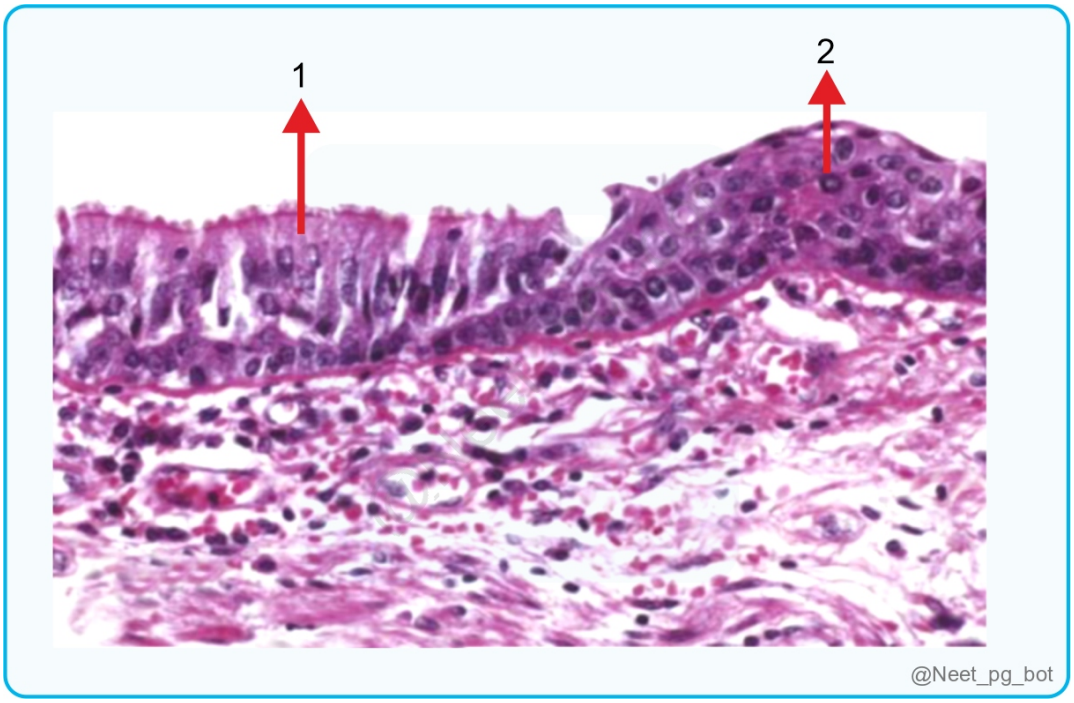

Correct Answer: A. 1. Normal columnar epithelium 2. Squamous metaplasia

Explanation: Epithelial metaplasia is exemplified by the change in the respiratory epithelium that occurs with prolonged cigarette smoking. In this process, the normal, relatively delicate ciliated columnar epithelial cells of the trachea and bronchi are replaced by tough stratified squamous epithelial cells, which are better suited to withstand the noxious chemicals in cigarette smoke.

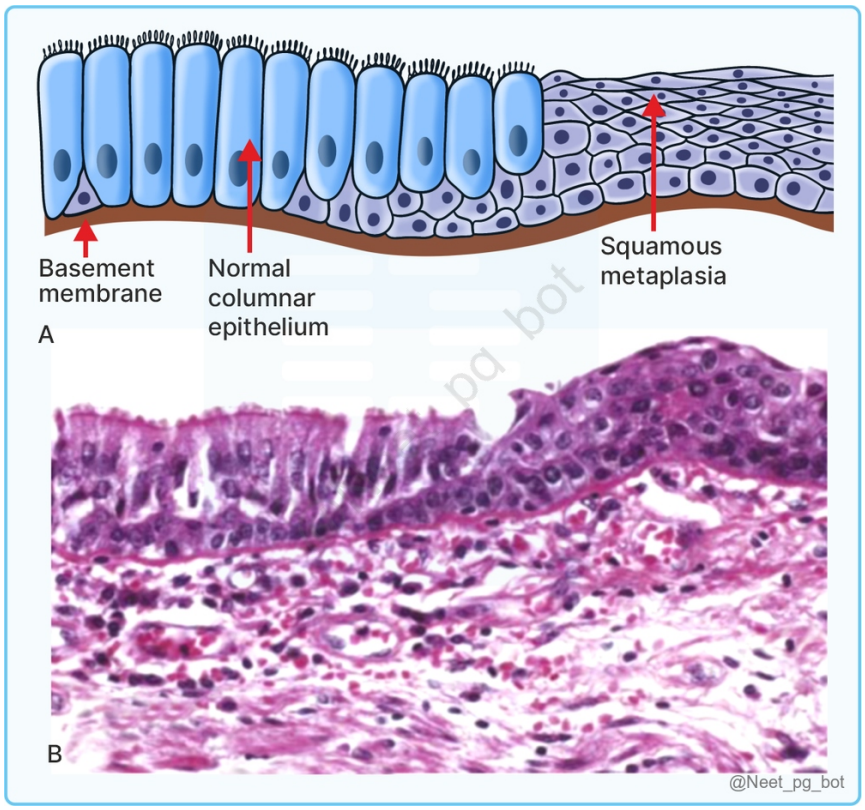

References:

Robbins & Kumar Pathologic Basis of Disease, 11th Edition, Page no. 18

↑ *Back to this question in Part A*

@Neet_pg_bot

Q5: Which epithelial transformation is encountered most frequently as an example of metaplasia? (Q879538)

A. Replacement of squamous epithelium by columnar epithelium

B. Replacement of squamous epithelium by transitional epithelium

C. Replacement of columnar epithelium by transitional epithelium

D. Replacement of columnar epithelium by squamous epithelium

Correct Answer: D. Replacement of columnar epithelium by squamous epithelium

Explanation: The most common epithelial metaplasia is columnar to squamous, as occurs in the respiratory tract in response to chronic irritation. In the habitual cigarette smoker, the normal ciliated columnar epithelial cells of the

trachea and bronchi are often replaced by stratified squamous epithelial cells.

References:

Robbins & Cotran Pathologic Basis of Disease, 10th Edition, Page no. 61

↑ *Back to this question in Part A*

@Neet_pg_bot

Q6: Below is the image of a 79-year-old male with a history of long-standing atherosclerosis who presented with progressive cognitive decline and neurological deficits. What type of atrophy is noticed in the image? (Q879536)

A. Nutritional atrophy

B. Neurogenic atrophy

C. Pressure atrophy

D. Ischemic atrophy



Correct Answer: D. Ischemic atrophy

Explanation: Based on the clinical scenario, the patient had atherosclerotic cerebrovascular disease, and the gross image shows ischemic atrophy. Findings noted: Atrophy of the brain is due to aging and reduced blood supply. Note that loss of brain substance narrows the gyri and widens the sulci. The meninges have been stripped from the bottom half of each specimen to reveal the surface of the brain.

References:

Robbins & Kumar Pathologic Basis of Disease, 11th Edition, Page no. 18

↑ *Back to this question in Part A*

@Neet_pg_bot

Q7: In which of the following scenarios do both physiological hypertrophy and hyperplasia occur? (Q879535)

A. Enlargement of skeletal muscle with exercise

B. Left ventricular thickening in hypertension

C. Uterine growth during pregnancy

D. Enlargement of breast tissue at puberty

Correct Answer: C. Uterine growth during pregnancy

Explanation: Physiologic enlargement of the uterus during pregnancy occurs as a consequence of estrogen-stimulated smooth muscle hypertrophy and hyperplasia. Enlargement of skeletal muscle with exercise (Option A): Skeletal muscles undergo only hypertrophy, as these cell types have a limited capacity to divide. Left ventricular thickening in hypertension (Option B): Left ventricular hypertrophy is a pathological type of hypertrophy occurring due to hypertension. Enlargement of breast tissue at puberty (Option D): Enlargement of breast tissue at puberty due to proliferation of the glandular epithelium is a physiological type of hyperplasia

References:

Robbins & Kumar Pathologic Basis of Disease, 11th Edition, Pages 16 & 17

↑ *Back to this question in Part A*

@Neet_pg_bot

Q8: Which of the following organs undergoes only hypertrophy? (Q879516)

A. Breast

B. Heart

C. Liver

D. Uterus

Correct Answer: B. Heart

Explanation: In response to increased workload, the striated muscle cells in both the skeletal muscle and the heart undergo only hypertrophy, as these cell types have a limited capacity to divide.

References:

Robbins & Kumar Pathologic Basis of Disease, 11th Edition, Page no. 16

↑ *Back to this question in Part A*

@Neet_pg_bot

Q9: By which of the following mechanisms does muscle hypertrophy occur? (Q879514)

A. ■-myosin heavy chain is replaced by the ■ form of the myosin heavy chain

B. ■-myosin heavy chain is replaced by the ■ form of the myosin light chain

C. ■-myosin light chain is replaced by the ■ form of the myosin heavy chain

D. ■ form of the myosin light chain is replaced by the ■-myosin heavy chain

Correct Answer: A. ■-myosin heavy chain is replaced by the ■ form of the myosin heavy chain

Explanation: Activation of signal transduction pathways induces the expression of genes that encode several cellular proteins, resulting in: Synthesis of more myofilaments per cell, which increases the force generated with each contraction, enabling the cell to meet increased work demands. Also, there may be a switch of contractile proteins from adult to fetal or neonatal forms. For example, during hypertrophy, the ■ -myosin heavy chain is replaced by the ■ form of the myosin heavy chain, which produces slower, more energetically efficient contractions.

References:

Robbins & Kumar Pathologic Basis of Disease, 11th Edition, Page no. 16

↑ *Back to this question in Part A*

@Neet_pg_bot

Q10: Which of the following statements accurately describes cellular adaptations in response to environmental changes? (Q879512)

A. Hypertrophy refers to an increase in cell number without a change in cell size

B. Hyperplasia is an increase in cell size without an increase in cell number

C. Metaplasia is a reversible change of one differentiated cell type to another

D. Atrophy results from a combination of increased protein synthesis and decreased protein degradation

Correct Answer: C. Metaplasia is a reversible change of one differentiated cell type to another

Explanation: Metaplasia is a reversible change in which one adult cell type is replaced by another adult cell type. Metaplasia is thought to usually arise by reprogramming of stem cells to differentiate along a new pathway rather than a phenotypic change of differentiated cells (transdifferentiation). Incorrect Options: Hypertrophy refers to an increase in cell number without a change in cell size (Option A): Hypertrophy refers to an enlargement of cells that results in increase in the size of the organ. Hyperplasia is an increase in cell size without an increase in cell number (Option B): Hyperplasia is an increase in the number of cells in an organ that stems from increased proliferation, either of differentiated cells or, in some instances, progenitor cells. Atrophy results from a combination of increased protein synthesis and decreased protein degradation (Option D): Atrophy results from a combination of decreased protein syn- thesis and increased protein degradation.

References:

Robbins, Cotran & Kumar Pathologic Basis of Disease, 11th Edition, Page 55.

↑ *Back to this question in Part A*

@Neet_pg_bot

Q11: A pathology resident is reviewing special stains for detecting tissue deposits. Which of the following stains is not used for demonstrating calcium in histological sections? (Q879411)

A. Congo red

B. Von Kossa stain

C. Alizarin Red S

D. Azan stain

Correct Answer: A. Congo red

Explanation: Congo red is used for amyloid detection, not calcium. Von Kossa stain identifies (Option B) calcium salts as black deposits via silver reduction. Alizarin Red S (Option C) binds calcium directly, producing orange-red coloration. Azan stain (Option D) is mainly for connective tissue, but can highlight calcium secondarily.

References:

Robbins and Cotran, Pathologic Basis of Disease, 11th Edition, Page no. 230,

↑ *Back to this question in Part A*

@Neet_pg_bot

Q12: A 55-year-old man with long-standing hyperlipidemia presents with multiple yellowish nodules over his Achilles tendon and extensor tendons of the hands. Biopsy of one lesion shows foam cells packed with cholesterol and cholesterol esters. Which of the following conditions does this represent? (Q879407)

A. Fabry's disease

B. Xanthoma

C. Niemann-Pick disease type C

D. Strawberry gallbladder

Correct Answer: B. Xanthoma

Explanation: Xanthomas are nodular lesions composed of lipid-laden macrophages filled with cholesterol and cholesterol esters , often seen in hyperlipidemic states. Incorrect Options: Fabry disease (Option A) involves the buildup of sphingolipids (ceramide trihexoside), not cholesterol. Niemann-Pick disease type C (Option C) is a disorder of cholesterol transport, leading to systemic lysosomal storage of cholesterol, not just localized deposits. Strawberry gallbladder(Option D) shows cholesterolosis, where macrophages in the gallbladder wall accumulate cholesterol esters, giving the mucosa a speckled “strawberry” appearance.

References:

Robbins and Cotran, Pathologic Basis of Disease, 11th Edition, Page no. 57,136.

↑ *Back to this question in Part A*

@Neet_pg_bot

Q13: Which of the following statements regarding metaplasia is true? (Q845260)

A. Metaplasia refers to the abnormal growth of cells, often leading to cancer.

B. It is a reversible change in which one adult cell type is replaced by another adult cell type.

C. Metaplasia is always a pathological process and never occurs in response to normal physiological stimuli.

D. Metaplasia is characterized by the replacement of differentiated cells with undifferentiated stem cells.

Correct Answer: B. It is a reversible change in which one adult cell type is replaced by another adult cell type.

■ *Listen (English)*

■ *Listen (Hindi)*

Explanation: Metaplasia is a reversible process in which one adult cell type is replaced by another, typically in response to chronic irritation or inflammation. Either 1 epithelium can change into another or 1 mesenchymal cell can change into another mesenchymal cell In metaplasia, normal cells are involved. If cells are abnormal, then it is Dysplasia (Option A ruled out) Metaplasia can sometimes occur in response to normal physiological stimuli (Option C ruled out) In metaplasis, the programming of stem cells is changing, because of which previous epithelium is replaced by new epithelium (Option D ruled out) Key features of metaplasia: Nature: Reversible if the stimulus (stressor) is removed. Mechanism: Reprogramming of stem cells (not existing cells changing their "shape"). Survival Advantage: The new cells are tougher and can survive the stress better. Functional Loss: The new cells lack the original function (e.g., loss of mucus secretion or cilia in the lungs). Malignant Potential: If the stress persists, metaplasia can progress to Dysplasia and eventually Cancer . Examples of Metaplasia: Epithelial Metaplasia (The most common type): Squamous metaplasia in the respiratory tract: Replacement of ciliated columnar epithelium by stratified squamous epithelium in the lungs of chronic smokers. Barrett’s Esophagus (Gastric/Intestinal metaplasia): Replacement of squamous epithelium of the esophagus by columnar (goblet) cells due to chronic acid reflux (GERD). Squamous metaplasia of the uterine cervix: Replacement of simple columnar epithelium by stratified squamous epithelium due to chronic inflammation or changes in vaginal pH. Squamous metaplasia in the bladder: Replacement of transitional epithelium (urothelium) by squamous epithelium due to irritation from bladder stones or Schistosoma haematobium infection. Squamous metaplasia of the gallbladder: Replacement of columnar epithelium by squamous epithelium due to chronic irritation from gallstones (cholelithiasis). Ductal squamous metaplasia: Replacement of the columnar lining of ducts (salivary glands, pancreas, or bile ducts) by squamous epithelium, usually due to stones (calculi). Connective Tissue (Mesenchymal) Metaplasia: Myositis ossificans: The formation of bone (osseous tissue) within skeletal muscle following a severe intramuscular hematoma or repetitive trauma. Cartilaginous metaplasia: The formation of cartilage in soft tissues where it does not normally belong, often following chronic injury.

References:

Robbins and Cotran Pathologic basis of disease, 10th Edition, Page 61

↑ *Back to this question in Part A*

@Neet_pg_bot

Q14: Which of the following statements best describes the role of telomerase in cellular ageing? (Q845194)

A. Telomerase accelerates ageing by reducing the length of telomeres with each cell division

B. Telomerase maintains the constant telomere length in somatic cells throughout their lifespan.

C. Telomerase prevents the shortening of telomeres by adding DNA sequences to the ends of chromosomes, thus potentially extending cell's lifespan.

D. Telomerase is a Ribozyme delaying cell aging.

Correct Answer: C. Telomerase prevents the shortening of telomeres by adding DNA sequences to the ends of chromosomes, thus potentially extending cell's lifespan.

Listen (English)

Listen (Hindi)

Explanation: Telomerase prevents the shortening of telomeres by adding DNA sequences to the ends of chromosomes, thus potentially extending cells' lifespan. Telomere: It is the sequence present on the terminal of chromosomes. Ageing is due to the shortening of telomeres as the person grows. Telomerase , also known as the immortality gene, is an RNA-dependent DNA polymerase enzyme that adds DNA sequences to the ends of chromosomes, preventing telomere shortening during cell division.

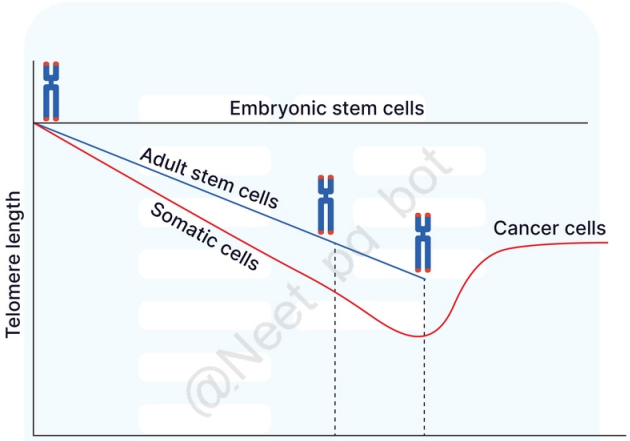

@Neet_pg_bot

References:

Robbins and Cotran Pathologic basis of disease, 10th Edition, Pages 67-68.

↑ *Back to this question in Part A*

@Neet_pg_bot

Q15: Which type of metaplasia characterizes the histological changes observed in Barrett's oesophagus? (Q845257)

A. Transformation of columnar epithelium to squamous epithelium

B. Replacement of squamous epithelium with columnar epithelium containing goblet cells

C. Conversion of glandular epithelium to squamous epithelium

D. Substitution of mesenchymal cells with epithelial cells

Correct Answer: B. Replacement of squamous epithelium with columnar epithelium containing goblet cells

■ *Listen (English)*

■ *Listen (Hindi)*

Explanation: Barrett's oesophagus is characterized by the replacement of the normal squamous epithelium of the lower oesophagus with columnar epithelium containing goblet cells. (Goblet cells contain acidic mucin staining positive with alcian blue, which helps to differentiate from intestinal epithelium) This metaplastic change is considered an adaptive response to chronic exposure to gastric acid and bile reflux in the setting of gastroesophageal reflux disease (GERD). {{caption_text}} Metaplasia: Metaplasia is a reversible change in which one differentiated cell type (epithelial or mesenchymal) is replaced by another adult cell type. Key features of metaplasia: Nature: Reversible if the stimulus (stressor) is removed. Mechanism: Reprogramming of stem cells (not existing cells changing their "shape"). Survival Advantage: The new cells are tougher and can survive the stress better. Functional Loss: The new cells lack the original function (e.g., loss of mucus secretion or cilia in the lungs). Malignant Potential: If the stress persists, metaplasia can progress to Dysplasia and eventually Cancer . Some important metaplasias: Epithelial Metaplasia: Squamous metaplasia (columnar → squamous) : Bronchi in smokers: Ciliated columnar → stratified squamous for durability.■ Salivary ducts/pancreas/bile ducts: Due to stones.■ Endocervix: In prolapse/old age.■ Renal pelvis: Chronic stones.■ Intestinal metaplasia (squamous/columnar → intestinal columnar with goblet cells) : Stomach (H. pylori/chronic gastritis).■ Barrett's esophagus (already discussed).■ Other : Breast: Acinar → apocrine cells (fibrocystic changes).■ Mesenchymal Metaplasia: Osseous metaplasia (soft tissue → bone): Arterial wall (Mönckeberg's sclerosis: aging/diabetes).■ Myositis ossificans (muscle → bone post-trauma).■■ Larynx/bronchi cartilage (elderly).■ Tumor stroma/scars.

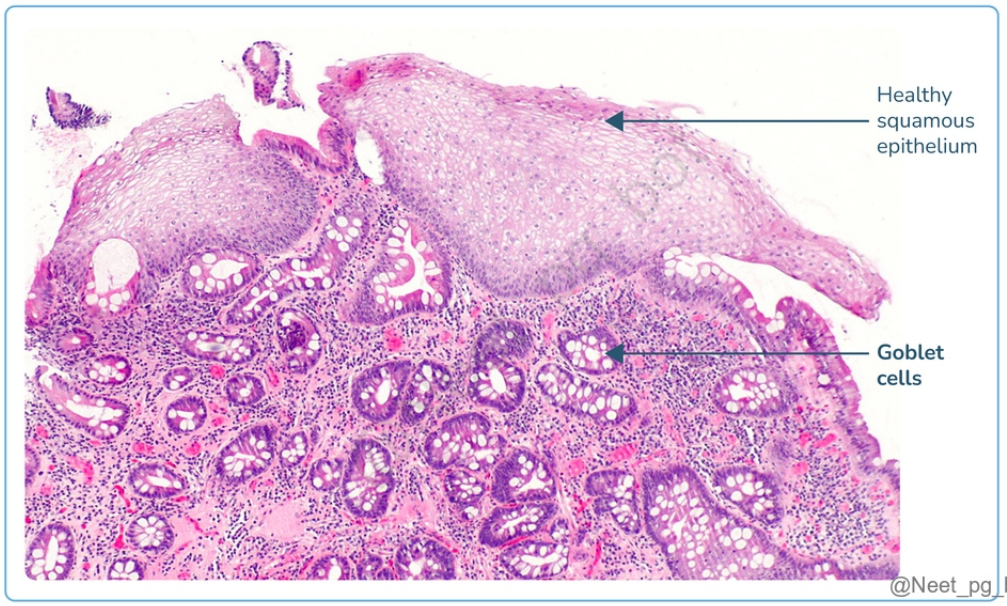

References:

Robbins and Cotran Pathologic basis of disease, 10th Edition, Page 61

↑ *Back to this question in Part A*

@Neet_pg_bot

Q16: Which type of atrophy is observed in a patient with smaller and weaker muscles who is bedridden for several weeks? (Q845255)

A. Disuse atrophy

B. Neurogenic atrophy

C. Endocrine atrophy

D. Senile atrophy

Correct Answer: A. Disuse atrophy

■ *Listen (English)*

■ *Listen (Hindi)*

Explanation: Disuse atrophy is seen in a patient with smaller, weaker muscles after being bedridden for several weeks. During prolonged periods of immobility, such as extended bed rest, the muscles experience decreased mechanical loading and activity. This lack of stimulation decreases muscle protein synthesis and increases protein breakdown, resulting in muscle wasting and weakness. Neurogenic atrophy (Option B): Atrophy due to hampered nerve supply. E.g.- In polio patients, the muscle will become immobile, leading to neurogenic atrophy. Endocrine

atrophy (Option C): Atrophy due to a decrease in hormones. E.g. - A decrease in the level of estrogens leading to endometrial atrophy, which is seen in postmenopausal women. Senile atrophy (Option D): Seen in old age and in patients with Alzheimer's disease.

References:

Robbins and Cotran Pathologic basis of disease, 10th Edition, Page 60

↑ *Back to this question in Part A*

@Neet_pg_bot

Q17: Which of the following is an example of physiological atrophy? (Q845254)

A. Testicular atrophy due to hypogonadism

B. Intestinal villi atrophy in malabsorption syndromes

C. Reduction in thymus gland size during ageing

D. Brain atrophy in neurodegenerative diseases

Correct Answer: C. Reduction in thymus gland size during ageing

■ *Listen (English)*

■ *Listen (Hindi)*

Explanation: Reduction in thymus gland size during ageing is an example of physiological atrophy. Physiological atrophy refers to the normal, programmed decrease in the size or mass of tissues, organs, or structures in the body. The thymus gland, which is involved in the development of the immune system, tends to decrease in size and activity with age, which is an example of physiological atrophy. Some other examples of Physiological atrophy: Reduction in the notochord size during the formation of the vertebral column. Disappearance of the thyroglossal duct during fetal development. Atrophy of the ductus arteriosus after birth to become the ligamentum arteriosum. Atrophy of the umbilical arteries and vein after birth. Atrophy of the branchial clefts during embryonic facial development. Regression of the Wolffian ducts in females and Müllerian ducts in males during fetal sex differentiation. Reduction in size of tonsils and adenoids during late adolescence and adulthood. Reduction in uterine size following childbirth (post-partum involution). Atrophy of mammary glands after the cessation of lactation. Reduction in endometrial thickness following menopause. Atrophy of the ovaries after menopause. Pathological atrophy , on the other hand, refers to the abnormal decrease in the size or mass of tissues, organs, or structures due to disease, injury, or other abnormal conditions. Testicular atrophy, intestinal atrophy and brain atrophy are examples of pathological atrophy. (Options A, B, D ruled out) Some other examples: Disuse Atrophy (Lack of Activity): Reduction in skeletal muscle mass in a limb immobilized by a plaster cast. Atrophy of muscles in patients restricted to prolonged bed rest. Denervation Atrophy (Loss of Nerve Supply): Wasting of skeletal muscles following a spinal cord injury. Reduction in muscle bulk due to damage from poliomyelitis. Atrophy of facial muscles following permanent damage to the facial nerve (Bell's Palsy). Ischemic Atrophy (Reduced Blood Supply): Reduction in brain size (thinning of gyri) due to chronic atherosclerosis of the carotid arteries. Atrophy of the kidneys due to narrowing of the renal arteries (Renal Artery Stenosis). Endocrine Atrophy (Pathological Loss

of Stimulation): Atrophy of the adrenal cortex due to the long-term use of exogenous corticosteroids. Reduction in the size of the thyroid gland due to a lack of TSH from a diseased pituitary gland. Atrophy of the testes following the use of exogenous anabolic steroids or due to hypogonadism

References:

Robbins and Cotran Pathologic basis of disease, 10th Edition, Page 60

↑ *Back to this question in Part A*

@Neet_pg_bot

Q18: Which of the following statements about the mechanism of hypertrophy is inaccurate? (Q845250)

A. Activation of G-protein-coupled receptor-initiated pathways

B. Stimulation of growth factor production such as TGF-β and IGF1

C. Inhibition of transcription factors like GATA4, MEF2, NFAT

D. Activation of downstream pathways including the PI3K/AKT pathway

Correct Answer: C. Inhibition of transcription factors like GATA4, MEF2, NFAT

■ *Listen (English)*

■ *Listen (Hindi)*

Explanation: Hypertrophy actually involves the activation (not inhibition) of transcription factors such as GATA4, NFAT, and MEF2. They enhance the expression of genes encoding muscle proteins, promoting cellular growth and hypertrophy. When transcription factors will increase: More DNA will be converted to RNA, which will create more proteins, leading to an increase in cell size (hypertrophy). Activation of G-protein-coupled receptor-initiated pathways (Option A): Many hypertrophic stimuli (e.g., catecholamines, angiotensin II, endothelin) act via G■protein–coupled receptors (GPCRs) on the cell membrane. These receptors signal through G proteins (especially Gq, Gi) to activate phospholipase C, PKC and MAPK pathways, which promote gene transcription and protein synthesis leading to hypertrophy. Stimulation of growth factor production such as TGF-β and IGF1 (Option B): Growth factors such as TGF■β and IGF■1 are upregulated in response to increased workload or injury and act as potent pro■hypertrophic mediators. IGF■1 in particular drives physiological cardiac and skeletal muscle hypertrophy via its receptor tyrosine kinase, triggering downstream PI3K/AKT signaling and increased protein synthesis. Activation of downstream pathways including the PI3K/AKT pathway (Option D): The PI3K/AKT pathway is a central pro■growth signaling cascade in physiological hypertrophy, especially downstream of IGF■1. Activation of AKT promotes protein synthesis and cell survival and suppresses atrophy pathways (e.g., via inhibition of FOXO), leading to increased cell size consistent with hypertrophy.

References:

Robbins and Cotran Pathologic basis of disease, 10th Edition, Page 57, 58

↑ *Back to this question in Part A*

@Neet_pg_bot

Q19: A 45-year-old female presents with irregular and heavy menstrual bleeding for the past six months. She reports experiencing prolonged periods lasting more than ten days with excessive bleeding, abdominal discomfort, and pelvic pain during her menstrual cycle. On further evaluation, transvaginal ultrasound reveals thickening of the endometrial lining. Endometrial biopsy confirms the presence of abnormal glandular proliferation without cytologic atypia. Which of the following best describes the cellular adaptation observed in this clinical scenario? (Q845248)

A. Physiological hypertrophy

B. Pathological hypertrophy

C. Physiological hyperplasia

D. Pathological hyperplasia

Correct Answer: D. Pathological hyperplasia

■ *Listen (English)*

■ *Listen (Hindi)*

Explanation: This is a case of endometrial hyperplasia, a pathological hyperplasia. Definition Examples Physiological hypertrophy (Option A) Increase in the size of cells or organs. Uterine hypertrophy during pregnancy due to estrogenic hormone signalling. Pathological hypertrophy (Option B) Cell enlargement occurs in response to increased workload or stress Heart enlargement from hypertension or valvular disease. Physiological hyperplasia (Option C) An increase in the number of cells in response to hormonal or growth factor stimulation. Breast glandular epithelium proliferation during puberty or pregnancy. Pathological hyperplasia (Option D) Occurs when there is an abnormal increase in the number of cells in an organ or tissue due to excessive or inappropriate hormonal or growth factor stimulation Endometrial hyperplasia due to disturbance in estrogen-progesterone balance.

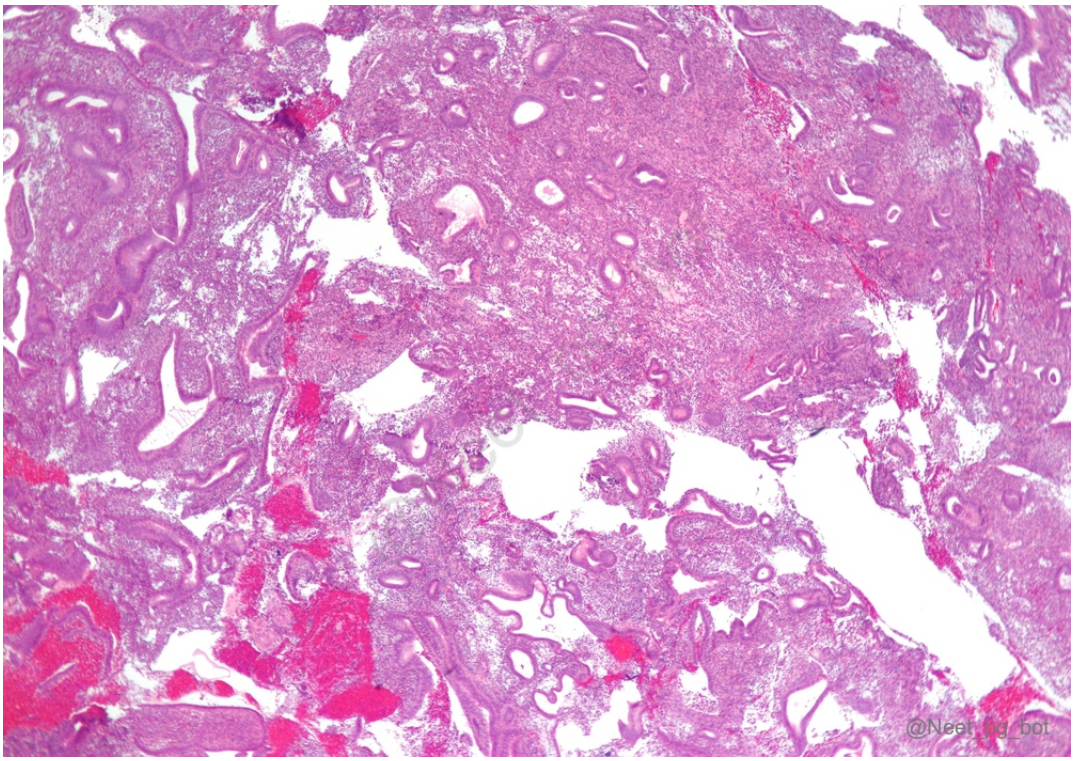

References:

Robbins and Cotran Pathologic basis of disease, 10th Edition, Pages 57-59

↑ *Back to this question in Part A*

@Neet_pg_bot

Q20: Which statement accurately distinguishes between hypertrophy and hyperplasia? (Q845245)

A. Hypertrophy involves an increase in cell number, while hyperplasia involves an increase in cell size.

B. Hypertrophy increases tissue mass, while hyperplasia maintains tissue mass.

C. Hypertrophy is irreversible, while hyperplasia is reversible.

D. Hypertrophy results from increased cellular protein production, while hyperplasia involves growth factor-driven proliferation of mature cells.

Correct Answer: D. Hypertrophy results from increased cellular protein production, while hyperplasia involves growth factor-driven proliferation of mature cells.

■ *Listen (English)*

■ *Listen (Hindi)*

Explanation: Hypertrophy results from increased cellular protein production, while hyperplasia involves growth factor-driven proliferation of mature cells. Hypertrophy Hyperplasia Hypertrophy is characterized by increased cellular protein (GATA4, NFAT, MEF2) production, which leads to the enlargement of cells and tissues due to an increase in cell size. An increase in cellular proteins occurs either through enhanced central dogma processes (transcription and translation) or through an increase of transcription factors. Hyperplasia is described as the result of growth factor-driven proliferation of mature cells. In hyperplasia, the number of cells within an organ or tissue increases. Hypertrophy involves an increase in cell size, while hyperplasia involves an increase in cell number. (Option A ruled out) Both hypertrophy and hyperplasia increase tissue mass. (Option B ruled out) Hypertrophy can be reversible. (Option C ruled out)

References:

Robbins and Cotran Pathologic basis of disease, 10th Edition, Page 57-59

↑ *Back to this question in Part A*

@Neet_pg_bot

Q21: Which of the following biomarkers is associated with autophagy? (Q845243)

A. Annexin A1

B. Annexin V

C. Beclin 1

D. LC3

Correct Answer: D. LC3

■ *Listen (English)*

■ *Listen (Hindi)*

Explanation: LC3, or Microtubule-associated protein 1 light chain 3, is a reliable marker of autophagy. Most important gene for autophagy: ATG1 gene Annexin A1 (Option A): Annexin A1 is a marker of hairy cell leukaemia. Annexin 5 (Option B): Marker of apoptosis Beclin 1 (Option C): Beclin-1 is not a direct marker of autophagy but plays a crucial role in initiating autophagy

References:

Robbins and Cotran Pathologic basis of disease, 10th Edition, Page48

↑ *Back to this question in Part A*

@Neet_pg_bot

Q22: What is the mechanism by which chaperone-mediated autophagy (CMA) targets misfolded proteins for degradation? (Q845240)

A. Direct uptake by lysosomes via endocytosis

B. Activation of mTOR leading to inhibition of ULK1 complex

C. Selective degradation of damaged or dysfunctional mitochondria

D. Binding of chaperones to misfolded proteins, followed by lysosomal entry via LAMP2A for autophagy

Correct Answer: D. Binding of chaperones to misfolded proteins, followed by lysosomal entry via LAMP2A for autophagy

■ *Listen (English)*

■ *Listen (Hindi)*

Explanation: In chaperone-mediated autophagy, chaperone proteins (Eg, Heat shock proteins) recognize and bind to specific protein substrates that are misfolded or damaged. The chaperone-substrate complex then interacts with the lysosomal-associated membrane protein LAMP2A, facilitating the substrate protein's translocation into the lysosome for degradation. Direct uptake by lysosomes via endocytosis (Option A) is mechanism is observed in Microautophagy. Inhibition of mTOR leading to activation of ULK1 complex (Option B) is seen in Macroautophagy. Selective degradation of damaged or dysfunctional mitochondria (Option C) is seen in Mitophagy.

References:

Robbins and Cotran Pathologic basis of disease, 10th Edition, Page 60.

↑ *Back to this question in Part A*

@Neet_pg_bot

Q23: Which cellular process is primarily responsible for the degradation and recycling of unnecessary or dysfunctional cellular components? (Q845237)

A. Autophagy

B. Necrosis

C. Apoptosis

D. Pyroptosis

Correct Answer: A. Autophagy

■ *Listen (English)*

■ *Listen (Hindi)*

Explanation: Autophagy (aka cell cannibalism) is a cellular process by which a cell eats its own contents and plays a critical role in maintaining cellular homeostasis, responding to stressors such as nutrient deprivation, and eliminating potentially harmful cellular materials. Autophagy has 4 types: Macro-autophagy: Eats substrate by forming a membrane around it (Autophagosome) Micro-autophagy: Eats substrate by endocytosis Chaperone-mediated autophagy Mitophagy: Mitochondria are eaten Marker of autophagy: LC3 Most important gene for autophagy: ATG1 gene

References:

Robbins and Cotran Pathologic basis of disease, 10th Edition, Page 60.

↑ *Back to this question in Part A*

@Neet_pg_bot

Q24: A 36-year-old male presents to the clinic with complaints of bilateral cataracts, short stature, premature greying and loss of hair, and skin changes. He also reports joint stiffness and pain, as well as type 2 diabetes mellitus. On examination, the patient appears older than his stated age, with characteristic "bird-like" facies and a high-pitched voice. Which of the following conditions is most likely to be associated with his presentation? (Q845202)

A. Hutchinson-Gilford Syndrome

B. Werner syndrome

C. Wermer syndrome

D. Cockayne Syndrome

Correct Answer: B. Werner syndrome

■ *Listen (English)*

■ *Listen (Hindi)*

Explanation: The clinical presentation points towards Werner syndrome, also known as Adult Progeria Syndrome , an autosomal recessive disorder characterized by premature ageing features that typically manifest in adulthood . It is associated with a DNA helicase defect. Patients with Werner Syndrome are typically present in their third decade of life with symptoms of accelerated ageing. Clinically present with premature ageing features, including bilateral cataracts, short stature, premature greying and loss of hair, skin changes, joint stiffness and pain, and metabolic abnormalities such as type 2 diabetes mellitus. The characteristic "bird-like" facies and high-pitched voice are distinctive features of Werner Syndrome. Genetic mutation: WRN gene . [WRN = Werner syndrome gene (on chromosome 8)]. {{caption_text}} Hutchinson-Gilford Syndrome (Option A): It is a rare genetic

progeroid syndrome characterized by severe premature ageing features that begin in childhood . It is a Laminopathy due to a Lamin-A (LMNA) gene mutation. Wermer Syndrome (Option C): Wermer Syndrome is for as multiple endocrine neoplasia type 1 (MEN 1). Cockayne Syndrome (Option D): It is also a rare autosomal recessive progeroid syndrome. However, it typically presents in childhood. ERCC gene defect.

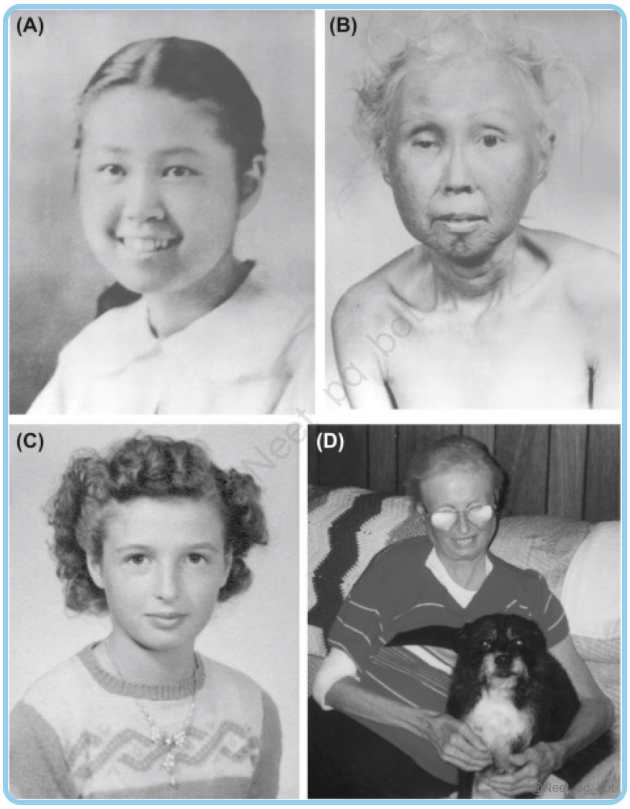

References:

Robbins and Cotran Pathologic basis of disease, 10th Edition, Page 79.

↑ *Back to this question in Part A*

@Neet_pg_bot

Q25: How do “Sirtuins” contribute to cellular ageing? (Q845198)

A. By accelerating telomere shortening.

B. By enhancing cell repair mechanisms and exerting anti-ageing effects.

C. By functioning as histone acetyltransferases, promoting chromatin condensation.

D. By decreasing insulin sensitivity

Correct Answer: B. By enhancing cell repair mechanisms and exerting anti-ageing effects.

■ *Listen (English)*

■ *Listen (Hindi)*

Explanation: Sirtuins are a family of NAD-dependent protein deacetylases produced by SIRT genes (SIRT1-7) that play a key role in DNA repair mechanisms and are involved in maintaining genomic stability Functions/benefits of sirtuins: Anti-ageing Prevents telomeres from shortening (Option A ruled out) Cell repair Increases the insulin sensitivity of tissues: Beneficial for DM patients and slows down ageing. (Option D ruled out) Sirtuins are histone deacetylases (Option C ruled out) Sirtuins increase insulin sensitivity

References:

Robbins and Cotran Pathologic basis of disease, 10th Edition, Page 80.

↑ *Back to this question in Part A*

@Neet_pg_bot

Q26: Which of the following statements is correct about the concept of the Hayflick Limit? (Q845196)

A. The ageing of cells is not determined by telomere length.

B. It refers to the age at which cells cease all metabolic activities and undergo apoptosis.

C. A cell typically undergoes 20-40 cell divisions before reaching senescence.

D. It represents the average number of times a cell can divide before experiencing replicative senescence.

Correct Answer: D. It represents the average number of times a cell can divide before experiencing replicative senescence.

■ *Listen (English)*

■ *Listen (Hindi)*

Explanation: The Hayflick limit or Hayflick’s phenomenon represents the number of cell divisions a cell undergoes before reaching its replicative senescence or ageing. Somatic cells typically undergo around 60 -100 divisions before entering a state of replicative senescence. Cells start to show signs of ageing after a finite number of divisions due to factors like telomere shortening and changes in gene expression. The limit acts as a safeguard against cancer by preventing cells from dividing uncontrollably. Mechanism: The primary driver of the Hayflick Limit is the telomere . Telomeres are protective "caps" of repetitive DNA sequences at the ends of chromosomes. The End Replication Problem: Each time a cell divides, DNA polymerase cannot fully replicate the very tips of the chromosomes. Gradual Erosion: With every division, the telomeres get slightly shorter. Critical Length: Eventually, the telomeres become so short that they can no longer protect the DNA. This sends a signal to the cell to stop dividing to prevent genomic instability. Exceptions to the Rule: Not all cells are bound by the Hayflick Limit. Some have found ways to bypass the "biological countdown": Stem Cells: These cells express an enzyme called telomerase , which rebuilds the telomeres, allowing them to divide much longer (or indefinitely). Germ

Cells: (Sperm and eggs) also maintain telomerase to ensure the next generation starts with full-length telomeres.
Cancer Cells: Most cancer cells "hijack" the telomerase enzyme. This allows them to become immortal , dividing far past the Hayflick Limit and forming tumors.

References:

Robbins and Cotran Pathologic basis of disease, 10th Edition, Page 67.

↑ *Back to this question in Part A*

@Neet_pg_bot

• [01_Cell Injury] 004 Intracellular Accumulations

« Back to Folder Directory

[01_Cell Injury] 004 Intracellular Accumulations — Quick Jump

Q1 (p. 1042) *Q2 (p. 1042)* *Q3 (p. 1044)* *Q4 (p. 1046)* *Q5 (p. 1047)* *Q6 (p. 1048)*
Q7 (p. 1049) *Q8 (p. 1051)* *Q9 (p. 1053)* *Q10 (p. 1055)* *Q11 (p. 1055)* *Q12 (p. 1056)*

Q1: Which of the following pathological conditions involves the accumulation of pigments through exogenous sources? (Q845361)

A. Chronic venous insufficiency

B. Vitiligo

C. Obstructive jaundice

D. Coal worker’s pneumoconiosis

Correct Answer: D. Coal worker’s pneumoconiosis

■ *Listen (English)*

■ *Listen (Hindi)*

Explanation: Among the given options, coal workers' pneumoconiosis involves the accumulation of pigments through exogenous sources. Pigments in pathology Endogenous pigments → produced inside the body (melanin, hemosiderin, bilirubin, lipofuscin). Exogenous pigments → come from outside (carbon, dust, tattoo ink). Pneumoconiosis Lung disease due to inhalation & deposition of exogenous dust particles . Most common form → Coal workers’ pneumoconiosis (Anthracosis) . Anthracosis (Black Lung Disease) Caused by the accumulation of carbon particles in alveolar macrophages (“dust cells”). Called Black Lung because the lungs appear black from heavy carbon deposition. The term Anthracosis comes from “Anthrakos” (Greek = coal/charcoal). Caplan Syndrome: Caplan syndrome (rheumatoid pneumoconiosis) is coal dust exposure + rheumatoid arthritis causing multiple peripheral lung nodules (0.5-5 cm) with necrotic centers, resembling rheumatoid nodules but dust-laden. Often asymptomatic; cough/dyspnea if advanced. Seen in miners; nodules appear rapidly, may cavitate/resolve. Differs from simple coal workers' pneumoconiosis by RA association .

References:

Robbins and Cotran pathologic basis of disease, 10th edition, Page 76

↑ *Back to this question in Part A*

@Neet_pg_bot

Q2: A 83-year-old man presents to his gastroenterologist with complaints of fatigue and discomfort in the upper abdomen. He has a history of hypertension and type 2 diabetes mellitus, for which he takes medications regularly. On physical examination, the liver edge is palpable below the right costal margin, indicating hepatomegaly. Laboratory investigations reveal mildly elevated liver enzymes. Which of the following pigments is most likely responsible for the brown discolouration of the liver observed in this patient? (Q845363)

A. Melanin

B. Glycogen

C. Lipofuscin

D. Bilirubin

Correct Answer: C. Lipofuscin

■ *Listen (English)*

■ *Listen (Hindi)*

Explanation: An 83-year-old man presents with fatigue and upper abdominal discomfort, and physical examination reveals hepatomegaly; mildly elevated liver enzymes are noted on lab tests, and the brown discoloration of the liver is most likely due to the pigment Lipofuscin . Lipofuscin, also known as lipochrome or wear-and-tear pigment, is an insoluble pigment derived from the peroxidation of polyunsaturated lipids in intracellular membranes. It is a telltale sign of free radical injury and lipid peroxidation. It is responsible for the brown atrophy of the liver and heart, where lipofuscin accumulates in the hepatocytes and cardiac myocytes, respectively, due to oxidative damage and impaired cellular turnover, particularly with increasing age. It is also seen in senile atrophy (pigment of the old age). In histopathological examination, it appears as a yellow-brown, finely granular cytoplasmic pigment, often deposited in the perinuclear region. The special stain used for lipofuscin is Oil red O and Acid-fast / Ziehl–Neelsen stain. {{caption_text}} Hemosiderin: Golden-brown iron pigment (Prussian blue+); seen in hemochromatosis (diabetes link), distinguished by iron stain (lipofuscin negative).

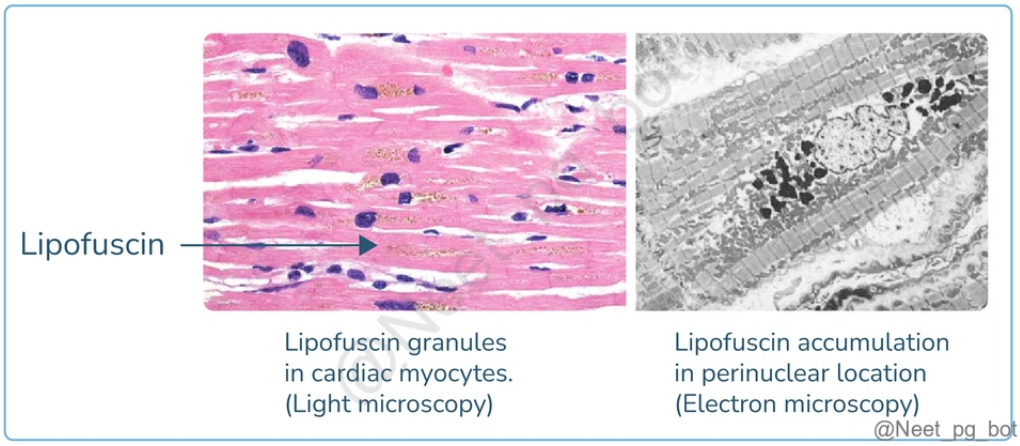

References:

Robbins and Cotran pathologic basis of disease, 10th edition, Page 76, 77

↑ *Back to this question in Part A*

@Neet_pg_bot

Q3: A 45-year-old woman presents with a painless, slow-growing, pigmented lesion on her back with irregular borders and varying shades of brown and black. Excisional biopsy of the lesion is performed, and histopathological examination reveals nests of melanocytes within the dermis, with prominent melanin pigment deposition. Which of the following staining techniques would be most suitable for visualization of the melanin pigment within the melanocytes in this patient's biopsy specimen? (Q845365)

A. Massaon Fontana stain

B. Masson Trichome stain

C. Periodic-Acid-Schiff (PAS) stain

D. Immunohistochemical staining for Melan- A

Correct Answer: A. Massaon Fontana stain

■ *Listen (English)*

■ *Listen (Hindi)*

Explanation: A 45-year-old woman presents with a painless, slow-growing pigmented lesion on her back characterized by irregular borders and varying shades of brown and black; histopathological examination of an excisional biopsy reveals nests of melanocytes in the dermis with prominent melanin deposition, best visualized using the Masson-Fontana stain . Best for seeing the amount & distribution of melanin pigment (inside/outside melanocytes)-Masson–Fontana stain Other methods: Schmorl’s stain → also for melanin pigment. Enzymatic method (DOPA oxidase test) → best test for melanin production capacity. Immunohistochemistry (for melanocytes / pigment-producing cells): HMB-45 Melan-A It is a marker for melanocytes and melanoma cells and is particularly useful in distinguishing melanocytic lesions from other types of skin tumours or metastatic cancers. On the other side, Masson Fontana staining helps to assess the extent of melanin production within tumors. (Option D ruled out) Key distinction: Pigment visualization → Masson–Fontana Cell identification (melanocytes) → HMB-45, Melan-A {{caption_text}} {{caption_text}} Masson Trichome stain (Option B): Masson Trichrome stain primarily differentiates between collagen and smooth muscle fibres. Periodic-Acid-Schiff (PAS) stain (Option C): Periodic Acid-Schiff (PAS) stain detects carbohydrates such as glycogen and mucin.

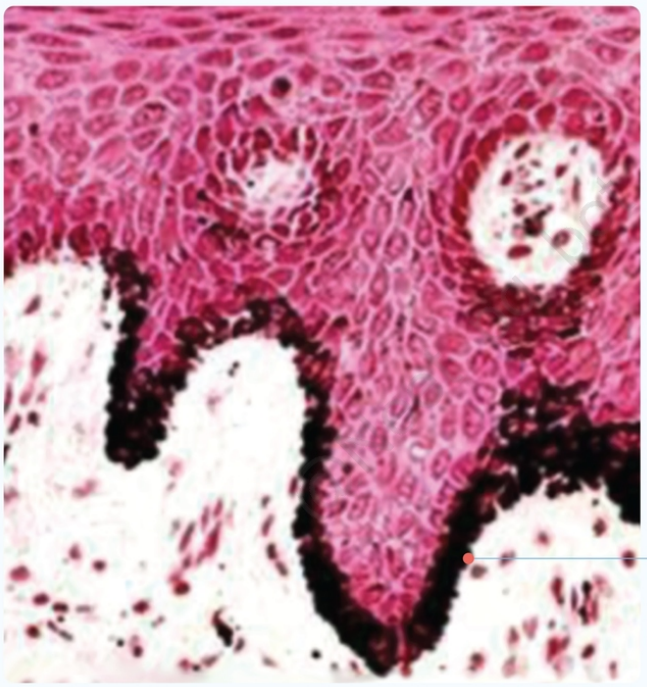

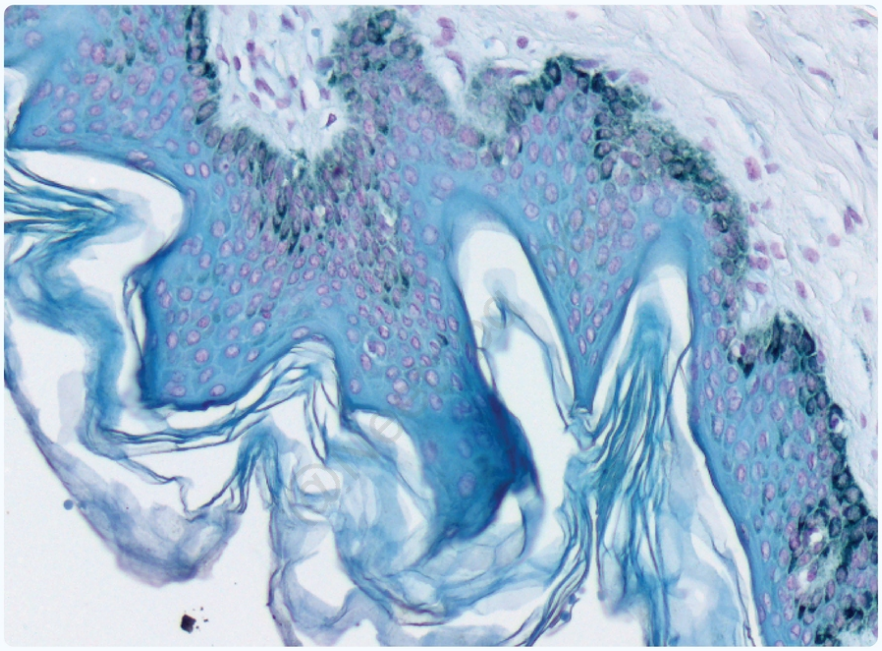

References:

Robbins and Cotran pathologic basis of disease, 10th edition, Page 77

↑ *Back to this question in Part A*

@Neet_pg_bot

Q4: A 45-year-old man presents with complaints of fatigue, joint pain, and abdominal discomfort. On examination, he exhibits bronze-coloured skin pigmentation mainly on the face and hands. Laboratory tests reveal elevated serum ferritin levels and transferrin saturation. Which of the following staining techniques would be most appropriate to visualize hemosiderin deposition in tissues in this patient? (Q845368)

A. Perl’s stain

B. Lillie's stain

C. Rhodanine stain

D. Supravital stains

Correct Answer: A. Perl’s stain

■ *Listen (English)*

■ *Listen (Hindi)*

Explanation: A 45-year-old man presents with fatigue, joint pain, and abdominal discomfort, along with bronze-colored skin pigmentation on the face and hands; laboratory tests show elevated serum ferritin and transferrin saturation, and the most appropriate staining technique to visualize tissue hemosiderin deposition in this patient is Perls' stain . Perl's stain, also known as Prussian Blue stain is the stain used to detect hemosiderin. Gold standard for Fe^{3}■ iron (gives blue color). The given clinical scenario suggests the patient is suffering from Hemochromatosis, an iron overload disorder in which excessive iron is deposited in various tissues as hemosiderin, a golden yellow to brown, granular, or crystalline pigment. Lillie's stain (Option B): Lillie's stain also known as Lillie-Mayer's hematoxylin-eosin stain might help in detecting Ferrous ions (Fe2+) but is not useful for hemosiderin, which is ferric iron (Fe3+) Rhodanine stain (Option C): Rhodanine is utilized as a selective stain for the detection and localization of copper ions that accumulate in tissues such as the liver and brain in copper metabolism disorders, such as Wilson's disease (not to be confused with Rhodamine in microbiology for Mycobacterium TB). Supravital stains (Option D) : Supravital stains are a group of dyes used to stain living cells or tissues without causing cell death. New methylene blue and Brilliant cresyl blue target ribonucleic acid residues in reticulocytes and provide the characteristic blue reticular staining pattern.

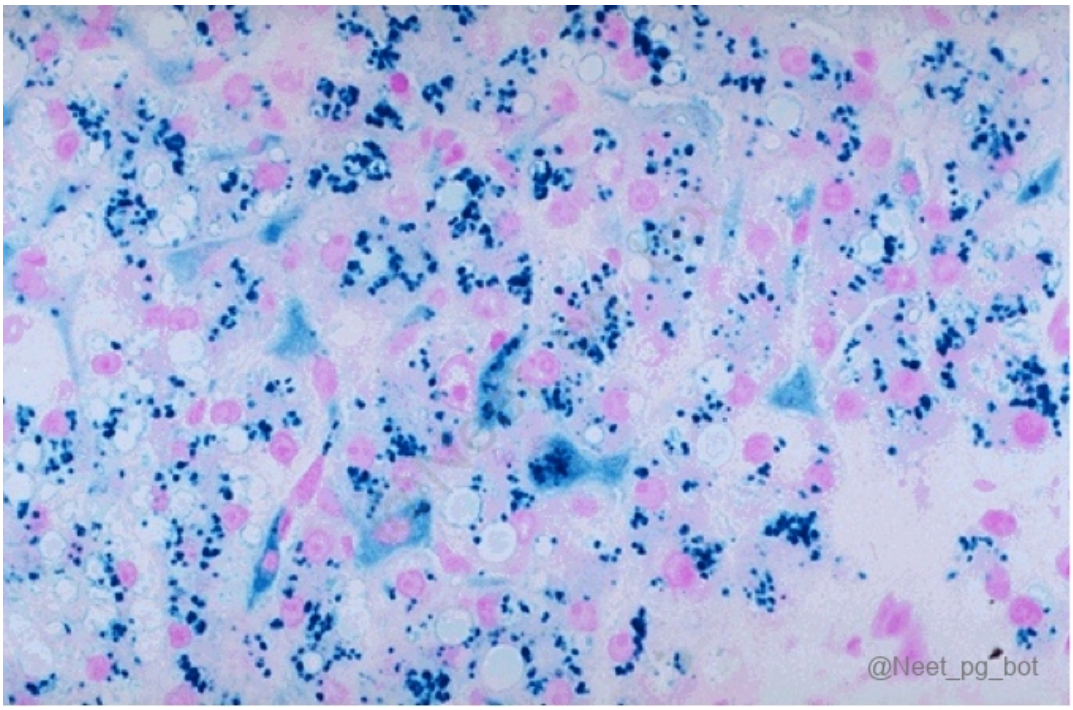

References:

Robbins and Cotran pathologic basis of disease, 10th edition, Page 77

↑ *Back to this question in Part A*

@Neet_pg_bot

Q5: Which of the following pathological conditions is associated with the 'Tabby cat' effect? (Q845369)

A. Diphtheria myocarditis

B. Xanthomas

C. Cholesterolosis

D. Fatty liver

Correct Answer: A. Diphtheria myocarditis

■ *Listen (English)*

■ *Listen (Hindi)*

Explanation: Diphtheria myocarditis is associated with the 'Tabby Cat' Effect. Fat accumulation in the heart gives a characteristic Tigroid or Tabby cat appearance, which appears as yellowish streaks (fatty change) alternating with

reddish streaks (unaffected myocardium). This appearance is seen in conditions such as Diphtheria myocarditis Arrhythmogenic Right Ventricular Cardiomyopathy (ARVCM) Cell injury. Xanthomas (Option B): Xanthomas are found in skin and in tendons. Cholesterolosis (Option C): Cholesterolosis refers to the cholesterol-laden macrophages in the lamina propria of the gallbladder aka strawberry gallbladder. Fatty liver (Option D): Fatty liver, also known as hepatic steatosis, is characterized by the abnormal accumulation of triglycerides within hepatocytes (liver cells).

References:

Robbins and Cotran pathologic basis of disease, 10th edition, Page 62, 63

↑ *Back to this question in Part A*

@Neet_pg_bot

Q6: Which of the following stains is not typically employed for the detection of lipid accumulation in histological samples? (Q845371)

A. Sudan Black

B. Sudan IV

C. Oil red O

D. Toluidine blue

Correct Answer: D. Toluidine blue

■ *Listen (English)*

■ *Listen (Hindi)*

Explanation: Toluidine Blue is not typically employed for the detection of lipid accumulation in histological samples. A special stain for Mast cells and Basophils. It is a metachromatic stain Solution - Blue coloured Colour stained to mast cells and basophils - Purple Stains for fat To preserve fat, tissue is cut as a frozen section (no organic solvents → fat remains in place). Then stains given below can be used to demonstrate lipids. Oil Red O (Option C) Sudan Black B (Option A) Sudan IV (Option B) Osmium Tetroxide {{caption_text}} Note: Toluidine Blue is a special stain for Mast cells and Basophils.



References:

Robbins and Cotran pathologic basis of disease, 10th edition, Page 62, 63

↑ *Back to this question in Part A*

@Neet_pg_bot

Q7: A 60-year-old woman presents with bone pain and tenderness over her lower back. Imaging reveals multiple lytic lesions in the vertebral column. Laboratory tests indicate anaemia, elevated serum calcium levels, and monoclonal gammopathy. A bone marrow biopsy confirms plasma cell proliferation. Microscopic examination of the biopsy reveals intracellular inclusions, as shown in the image. What is the composition of the intracellular inclusions marked in the image? {{caption_text}} (Q845373)

A. Aggregates of misfolded proteins

B. Clusters of ribosomes

C. Accumulations of immunoglobulins

D. Vacuoles containing lipids

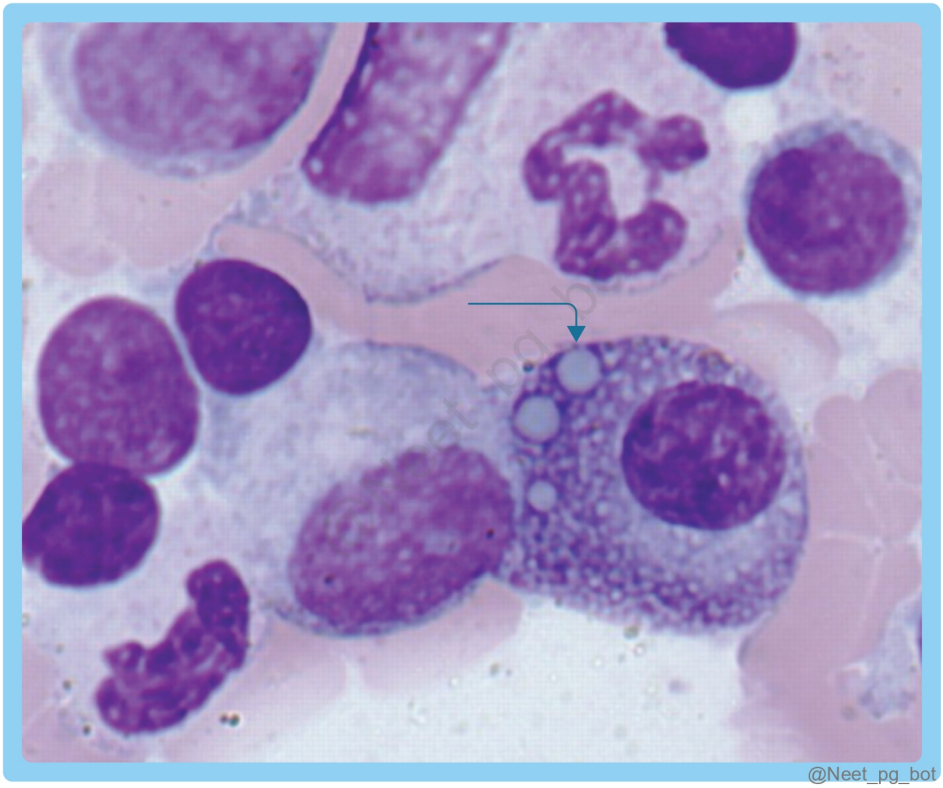

Correct Answer: C. Accumulations of immunoglobulins

- *Listen (English)*
- *Listen (Hindi)*

Explanation: The clinical presentation is highly suggestive of multiple myeloma, a plasma cell dyscrasia characterized by bone pain, lytic lesions, anaemia, hypercalcemia, and monoclonal gammopathy. Microscopic examination of the bone marrow biopsy may reveal the presence of intracellular inclusions, such as Russell bodies (Immunoglobulins in the cytoplasm) and Dutcher bodies (containing Ig in the nucleus), within some plasma cells. {{caption_text}}

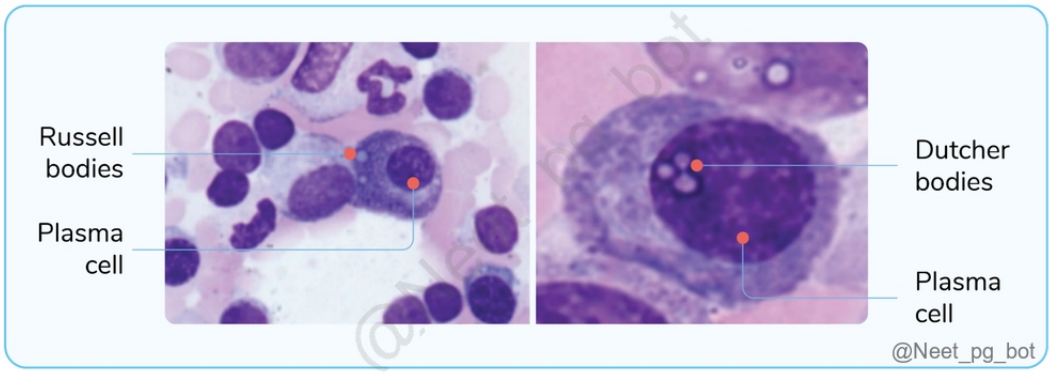

References:

Robbins and Cotran pathologic basis of disease, 10th edition, Page 610

↑ *Back to this question in Part A*

@Neet_pg_bot

Q8: Following the resection of the pituitary adenoma in a patient with Cushing's disease, which intracellular change is most likely in residual adenoma cells? (Q845374)

A. Mallory-Denk bodies

B. Lewy bodies

C. Crooke hyaline change

D. Civatte bodies

Correct Answer: C. Crooke hyaline change

■ *Listen (English)*

■ *Listen (Hindi)*

Explanation: Following resection of a pituitary adenoma in a patient with Cushing's disease, the most likely intracellular change observed in the residual adenoma cells is Crooke's Hyaline Change . It is a histopathological finding seen in the pituitary gland, particularly in corticotroph adenomas associated with Cushing's disease. In crooke hyaline change, the normal granular, basophilic cytoplasm of ACTH-producing cells becomes homogenous and paler due to the accumulation of intermediate cytokeratin (CK) filaments. These changes occur as a response to chronic hypercortisolism. {{caption_text}} Mallory-Denk bodies (Option A): Mallory-Denk bodies or Mallory hyaline bodies are eosinophilic, intracytoplasmic inclusions composed of intermediate filaments, particularly cytokeratin 8 and 18, commonly seen in hepatocytes in conditions such as alcoholic liver disease. {{caption_text}} Lewy bodies (Option B): Lewy bodies are eosinophilic intracytoplasmic inclusions composed of aggregated alpha-synuclein protein and are characteristic of neurodegenerative disorders such as Parkinson's disease and Lewy body dementia. {{caption_text}} Civatte bodies (Option D): They are also known as Colloid Bodies/ Cytoid Bodies and are seen in Lichen Planus.

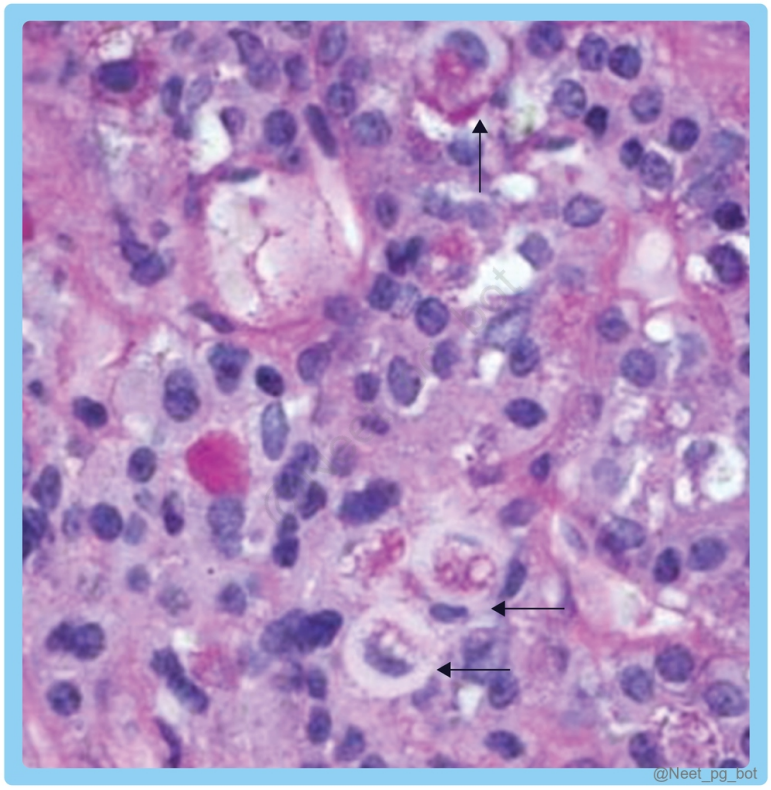
@Neet_pg_bot

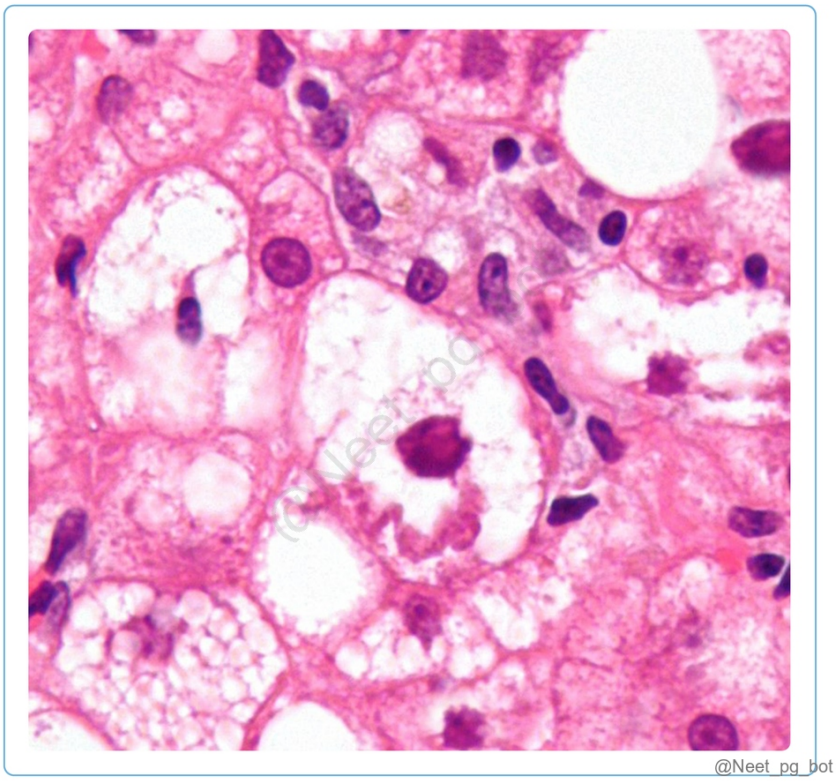
@Neet_pg_bot

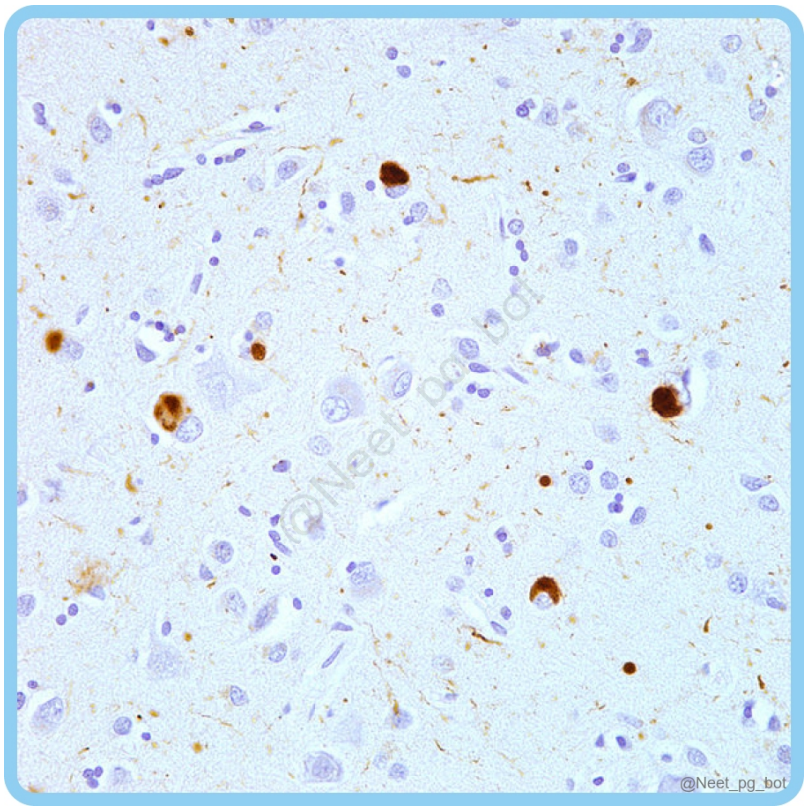

References:

Robbins and Cotran pathologic basis of disease, 10th edition, Page 843, 1116

↑ *Back to this question in Part A*

@Neet_pg_bot

Q9: Which of the following stains would be most appropriate for visualizing glycogen deposits? (Q845375)

A. Hematoxylin and eosin (H&E) stain

B. Periodic acid-Schiff (PAS) stain

C. Masson's trichrome stain

D. Oil Red O stain

Correct Answer: B. Periodic acid-Schiff (PAS) stain

■ *Listen (English)*

■ *Listen (Hindi)*

Explanation: Periodic acid-Schiff (PAS) stain would be most appropriate for visualizing glycogen deposits, among the given options. Glycogen is PAS +ve ; Diastase sensitive Hematoxylin and eosin (H&E) stain (Option A) is a basic stain that stains nuclei blue-purple (hematoxylin) and cytoplasm and extracellular matrix pink (eosin). While it can highlight muscle fibre morphology, it does not specifically stain glycogen. Masson's trichrome stain (Option C) : is used to distinguish collagen fibers, which stain blue, from other tissue components; it stains muscle fibers red, collagen blue, and nuclei blue-black, but it is not specific for detecting glycogen Oil Red O stain (Option D) is used to detect lipids and fat droplets.

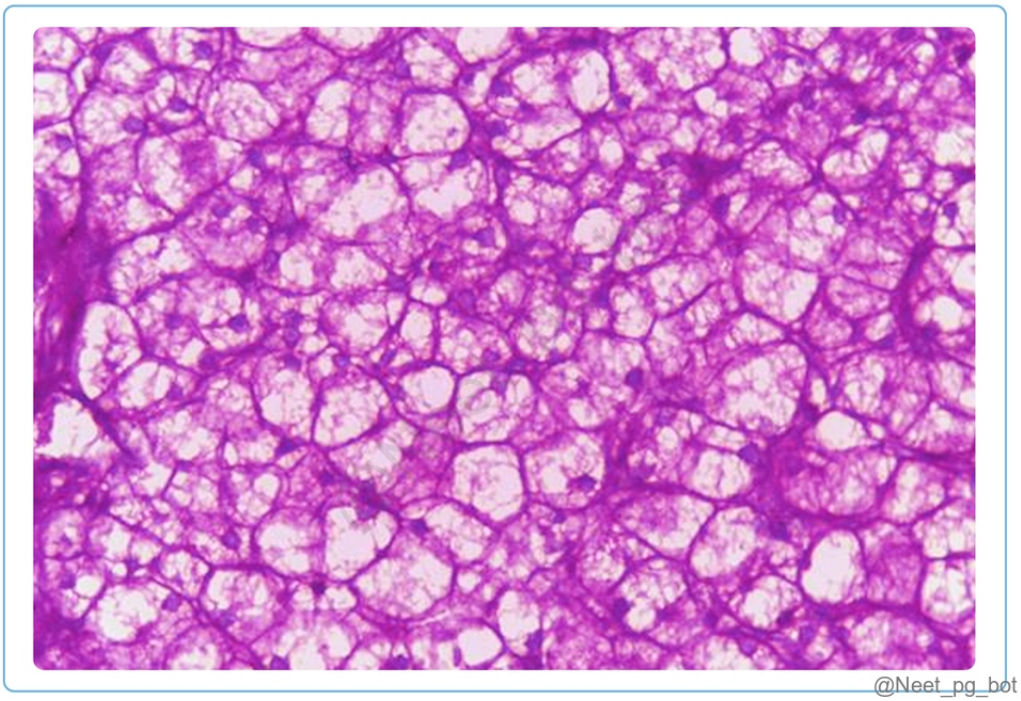



References:

Robbins and Cotran pathologic basis of disease, 10th edition, Page 64

↑ *Back to this question in Part A*

@Neet_pg_bot

Q10: Which of the following statements is incorrect about dystrophic calcification? (Q845376)

A. It occurs in damaged or necrotic tissues.

B. It is characterized by the deposition of calcium salts in normal tissues.

C. It is often seen in areas of chronic inflammation.

D. Serum calcium levels are normal

Correct Answer: B. It is characterized by the deposition of calcium salts in normal tissues.

■ *Listen (English)*

■ *Listen (Hindi)*

Explanation: Calcium deposition is in dead or degenerating tissues. Dystrophic Calcification Metastatic Calcification Dead or degenerating tissues are seen. (Option A ruled out) There will be a normal blood calcium count. (Option D ruled out) Some examples: Dead Parasite TB (chronic inflammation) (Option C ruled out) Atheroma Monckeberg Sclerosis It is also called calcific medial degeneration. It happens in the tunica media. Calcium occurs blue in color It occurs only as an old age phenomenon without any clinical significance. Psammoma Bodies: It is present as a concentric lamellation. It shows an onion-peel appearance Seen in: Papillary carcinoma of thyroid. Papillary renal cell cancer. meningioma. Prolactinoma Serous Cystadenocarcinoma of ovary. Normal tissues are seen. The blood calcium level is elevated The most common organ affected due to Metastatic calcification - The Lungs Some Examples: Hyperparathyroidism Cancer: RCC and Breast cancer show an increase of calcium. Vitamin D intoxication Milk alkali syndrome Multiple myeloma Sarcoidosis

References:

Robbins and Cotran pathologic basis of disease, 10th edition, Page 77

↑ *Back to this question in Part A*

@Neet_pg_bot

Q11: Which of the following case scenarios is not indicative of metastatic calcification? (Q845378)

A. A 60-year-old male with a history of chronic renal failure presented with shortness of breath and bilateral lung opacities on chest X-ray.

B. A 45-year-old female with spinal tuberculosis complained of back pain.

C. A 30-year-old male with a long-standing history of heavy milk and calcium carbonate intake now experiencing recurrent kidney stones.

D. A 55-year-old female with sarcoidosis demonstrated elevated levels of serum vitamin D and calcium.

Correct Answer: B. A 45-year-old female with spinal tuberculosis complained of back pain.

■ *Listen (English)*

■ *Listen (Hindi)*

Explanation: In tuberculosis, tissue death and degeneration lead to dystrophic calcification, which occurs despite normal serum calcium levels. Tuberculosis can lead to dystrophic calcification in bone tissue, resulting in symptoms such as bone pain and fractures. Metastatic calcification → elevated serum calcium Dystrophic calcification → normal serum calcium, dead/degenerating tissue There are four principal causes of hypercalcemia: Increased secretion of parathyroid hormone (PTH) with subsequent bone resorption, as in hyperparathyroidism due to parathyroid tumours, and ectopic secretion of PTH-related protein by malignant tumours Resorption of bone tissue, secondary to primary tumours of bone marrow (e.g., multiple myeloma, leukaemia) or diffuse skeletal metastasis (e.g., breast cancer), accelerated bone turnover (e.g., Paget disease), or immobilization. Vitamin D–related disorders, including vitamin D intoxication, sarcoidosis (in which macrophages activate a vitamin D precursor), and idiopathic hypercalcemia of infancy (Williams syndrome), characterized by abnormal sensitivity to vitamin D (Option D ruled out) Renal failure, which causes phosphate retention, leads to secondary hyperparathyroidism. (Option A ruled out) A 30-year-old male with a long-standing history of heavy milk and calcium carbonate intake now experiencing recurrent kidney stones (Option C): This will lead to increased serum calcium levels whereas dystrophic calcification occurs despite normal calcium levels.

References:

Robbins and Cotran pathologic basis of disease, 10th edition, Page 77

↑ *Back to this question in Part A*

@Neet_pg_bot

Q12: Which staining technique is commonly used to visualize calcium deposits in tissues and is particularly useful for detecting minute amounts of calcium? (Q845380)

A. Masson's trichrome stain

B. Prussian blue stain

C. Alizarin Red S stain

D. Wright-Giemsa stain

Correct Answer: C. Alizarin Red S stain

■ *Listen (English)*

■ *Listen (Hindi)*

Explanation: Alizarin Red S Stain is commonly used to visualize calcium deposits in tissues and is particularly useful for detecting minute amounts of calcium, giving red color to calcium deposits. Stains of Calcium: Von Kossa Stain Imparts black color to calcium. {{caption_text}} Alizarin Red S Imparts red color to calcium. Used for staining minor amounts of calcium. Calcein Fluorescent stain for calcium {{caption_text}} Azan Stain To differentiate mineralized bone from osteoid. {{caption_text}} Masson’s trichrome (Option A): To differentiate collagen (blue) and muscle fibers (red). Prussian blue (Option B): Used for staining Iron. Wright-Giemsa stain (Option D): Used for hematology slides. Important stains: Stain Demonstrates Key Pathology/Example Pigments/Minerals: Perl's Prussian Blue Hemosiderin (iron) Hemochromatosis, hemosiderosis Rhodanine/Rubeanic acid Copper Wilson's disease Von Kossa/Alizarin Red Calcium Dystrophic calcification Carbohydrates/Mucin PAS (Periodic Acid-Schiff) Glycogen, neutral mucin, fungi, basement membrane Glycogen storage disease, Whipple's, alpha-1 AT deficiency (globules), fungi Alcian Blue Acid mucin Intestinal metaplasia, adenocarcinoma Amyloid/Proteins: Congo Red Amyloid (apple-green birefringence) AA/AL amyloidosis Sulfated Alcian Blue Amyloid (pre-Congo Red screen) - Connective Tissue/Fibrosis: Masson's Trichrome Collagen (blue), muscle (red) Cirrhosis, fibrosis Reticulin (Silver) Reticulin fibers Cirrhosis, hepatocellular CA Van Gieson Collagen (red), muscle (yellow) Fibrosis Microorganisms: Ziehl-Neelsen (ZN) Acid-fast bacilli TB, leprosy Wade-Fite Mycobacteria (weaker AF) Leprosy GMS (Gomori Methenamine Silver) Fungi, Pneumocystis Aspergillosis, PCP Giemsa H. pylori, parasites, trypanosomes Gastritis, malaria Gram Bacteria (Gram +/-) General infections Levaditi/Warthin-Starry Spirochetes Syphilis, H. pylori Lipids: Oil Red O/Sudan Black Lipids (frozen sections) Xanthomas, fatty liver Others: Mucin (Mayer's) Mucin Adenocarcinoma Fontana-Masson Melanin Melanoma Immunohistochemistry Specific antigens (e.g., CK7/20, S100) Tumor typing

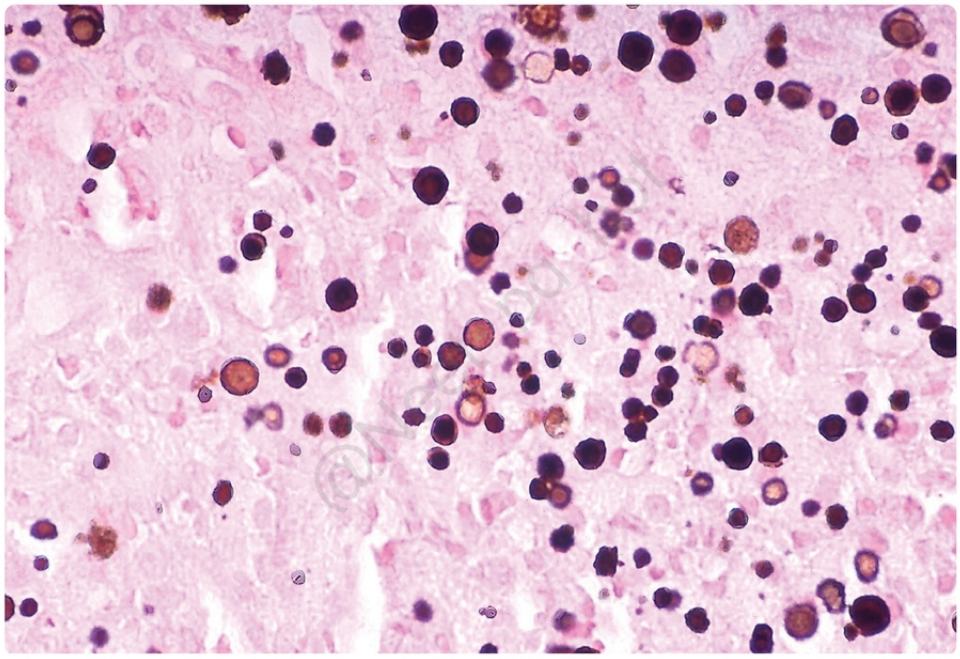

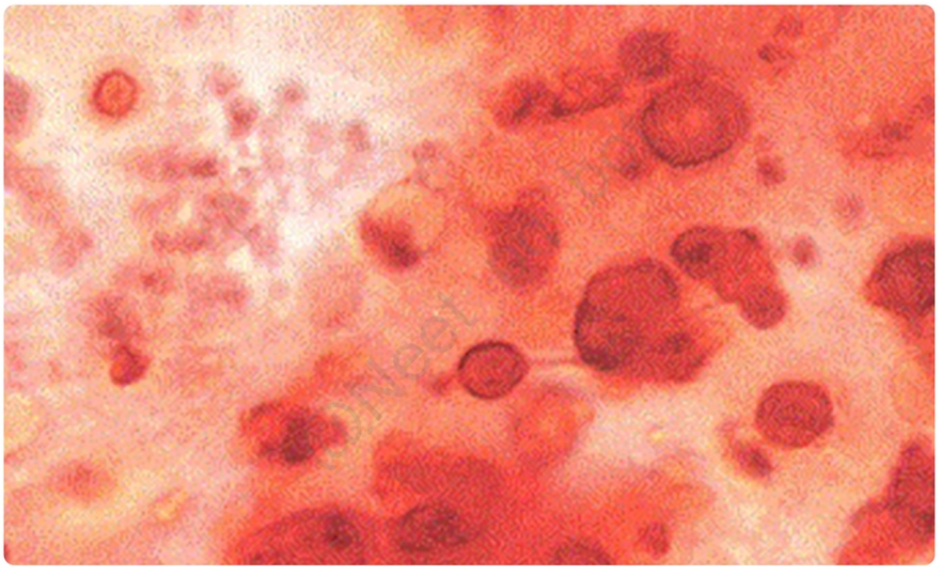
@Neet_pg_bot

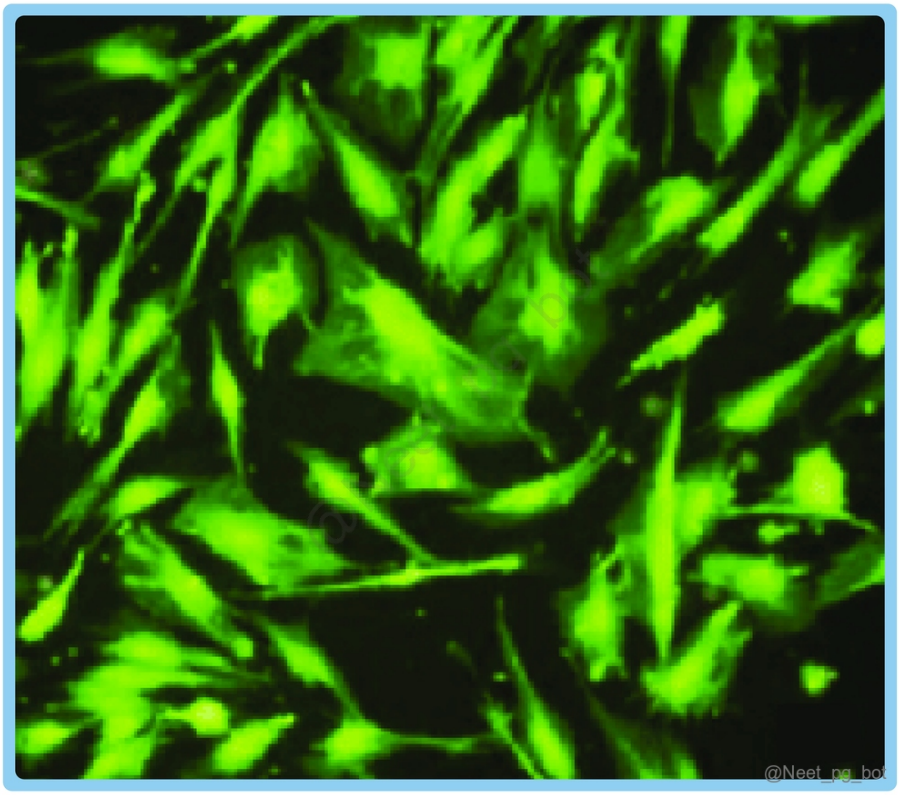
@Neet_pg_bot

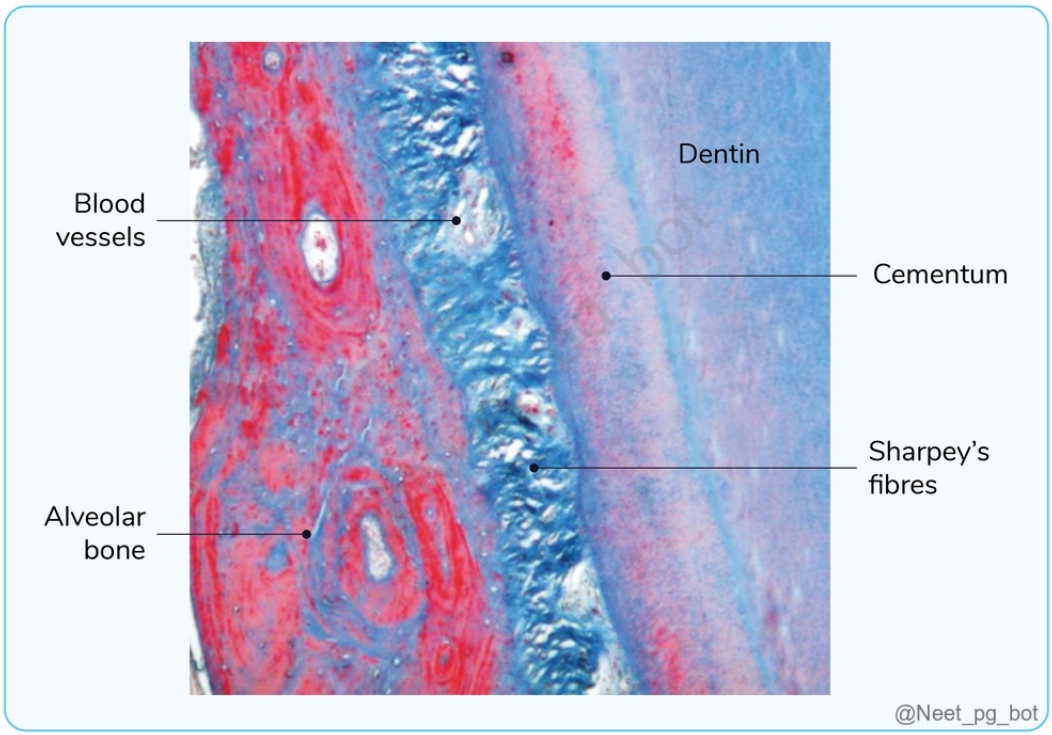

References:

Robbins and Cotran pathologic basis of disease, 10th edition, Page 77

↑ *Back to this question in Part A*

@Neet_pg_bot

• [01_Cell Injury] 005 Previous Year Questions

« Back to Folder Directory

[01_Cell Injury] 005 Previous Year Questions — Quick Jump

Q1 (p. 1060)	*Q2 (p. 1061)*	*Q3 (p. 1062)*	*Q4 (p. 1063)*	*Q5 (p. 1064)*	*Q6 (p. 1065)*
Q7 (p. 1066)	*Q8 (p. 1068)*	*Q9 (p. 1069)*	*Q10 (p. 1070)*	*Q11 (p. 1071)*	*Q12 (p. 1071)*
Q13 (p. 1073)	*Q14 (p. 1074)*	*Q15 (p. 1075)*	*Q16 (p. 1076)*	*Q17 (p. 1077)*	*Q18 (p. 1081)*
Q19 (p. 1082)	*Q20 (p. 1083)*	*Q21 (p. 1084)*	*Q22 (p. 1084)*	*Q23 (p. 1085)*	*Q24 (p. 1086)*
Q25 (p. 1087)					

Q1: Identify the correct statements regarding amyloidosis. Amyloidosis is called so because it looks like the deposition of starch. Beta-pleated sheets are seen. AL is a type of secondary amyloidosis. It is an extracellular protein. (Q857424)

A. 1, 2 and 3

B. 1, 4

C. 2, 3 and 4

D. 1, 2 and 4

Correct Answer: D. 1, 2 and 4

Explanation: Amyloidosis is a group of disorders characterized by the extracellular deposition of amyloid fibrils that are produced by the aggregation of misfolded proteins. (Statement 4) The presence of abundant charged sugar groups in these adsorbed proteins gives the deposits staining characteristics that were thought to resemble starch (amylose). Therefore, the deposits were called amyloid (Statement 1). 95% of amyloid consists of fibril proteins, with the remaining 5% being glycosaminoglycans (dermatan sulfate and heparan sulfate) and plasma proteins, notably serum amyloid P . AL amyloidosis is a primary form of amyloidosis, whereas secondary form can be caused by various etiologies and is associated with characteristic amyloid deposition (Statement 3). Physical nature of amyloid: Light microscopy with H & E stains: Amyloid is an amorphous , eosinophilic , hyaline , and extracellular substance. Electron microscopy: All types of amyloid, regardless of clinical setting or chemical composition, consist of continuous, nonbranching fibrils with a diameter of approximately 7.5 to 10 nm. X-ray crystallography and infrared spectroscopy: Characteristic cross-β-pleated sheet conformation, which is responsible for the distinctive Congo-red staining and apple-green birefringence of the amyloid. (Statement 2)

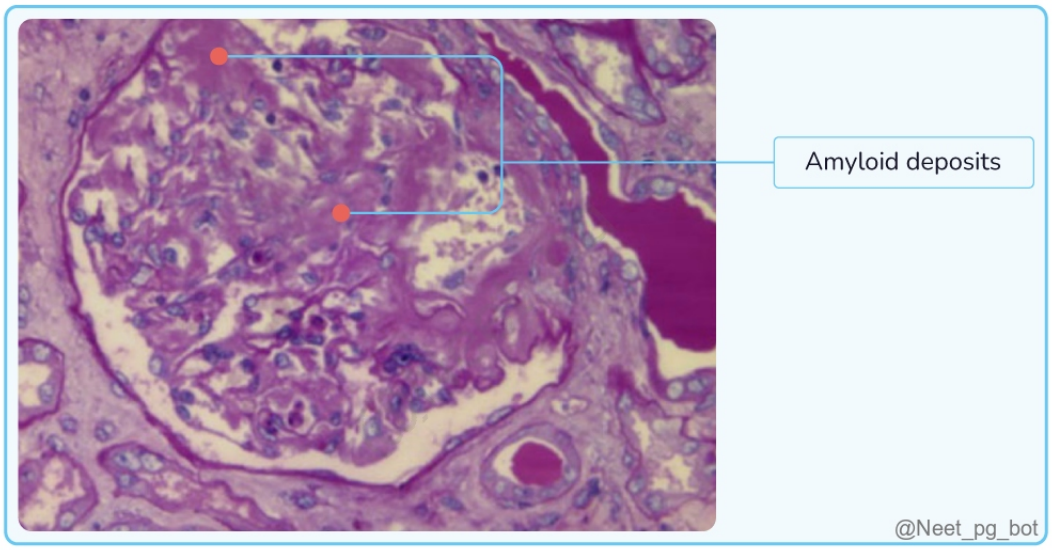

References:

Robbins and Cotran Pathologic Basis of Disease, 10th Edition.

↑ *Back to this question in Part A*

@Neet_pg_bot

Q2: A diabetic male presented with seizures. Radiological examination shows a lesion. Histopathological examination shows liquefactive necrosis. What is the most important mechanism responsible for this? (Q866754)

A. Enzymatic degradation

B. Mechanical

C. Ischemic

D. Pressure

Correct Answer: A. Enzymatic degradation

Explanation: Diabetic patient with seizures → raises suspicion for a brain lesion (possibly abscess, infarct, or infection-related pathology). Histopathology: liquefactive necrosis → classic type of necrosis seen in brain tissue. Liquefactive necrosis in brain is mainly due to hydrolytic enzyme action breaking down tissue. In the CNS, ischemia or infection activates microglia and infiltrating neutrophils. These cells release lysosomal hydrolytic enzymes. Brain tissue is rich in lipids and has little structural stroma, so enzymatic digestion quickly converts tissue into a liquid mass. Mechanism: enzymatic degradation > structural breakdown → liquefactive necrosis. Mechanical (Option B): Trauma can cause hemorrhage or contusion, but necrosis type is not primarily from

mechanical injury alone, here histology points to enzymatic breakdown. Ischemic (Option C): Ischemia in most organs causes coagulative necrosis, except in the brain, where it still leads to liquefactive necrosis, but the mechanism is enzymatic digestion, not ischemia per se. Pressure (Option D): Increased intracranial pressure can cause herniation or atrophy, not liquefactive necrosis by itself.

↑ *Back to this question in Part A*

@Neet_pg_bot

Q3: Which of the following is pro-apoptotic? (Q866665)

A. Bcl-2

B. Bcl-xL

C. Mcl-1

D. Bax

Correct Answer: D. Bax

Explanation: The correct answer is Bax , because it is a pro-apoptotic member of the Bcl-2 protein family. The Bcl-2 family regulates the intrinsic (mitochondrial) apoptosis pathway. Members are divided into: Anti-apoptotic : Bcl-2, Bcl-xL, Mcl-1 → preserve mitochondrial membrane integrity, prevent cytochrome c release. Pro-apoptotic : Bax, Bak, Bok → promote mitochondrial outer membrane permeabilisation (MOMP), allowing cytochrome c release and caspase activation. Mnemonic: "Bax and Bak Break" (break the mitochondrial membrane) → pro-apoptotic. "Bcl and Bcl-xL Build" (preserve the membrane) → anti-apoptotic.

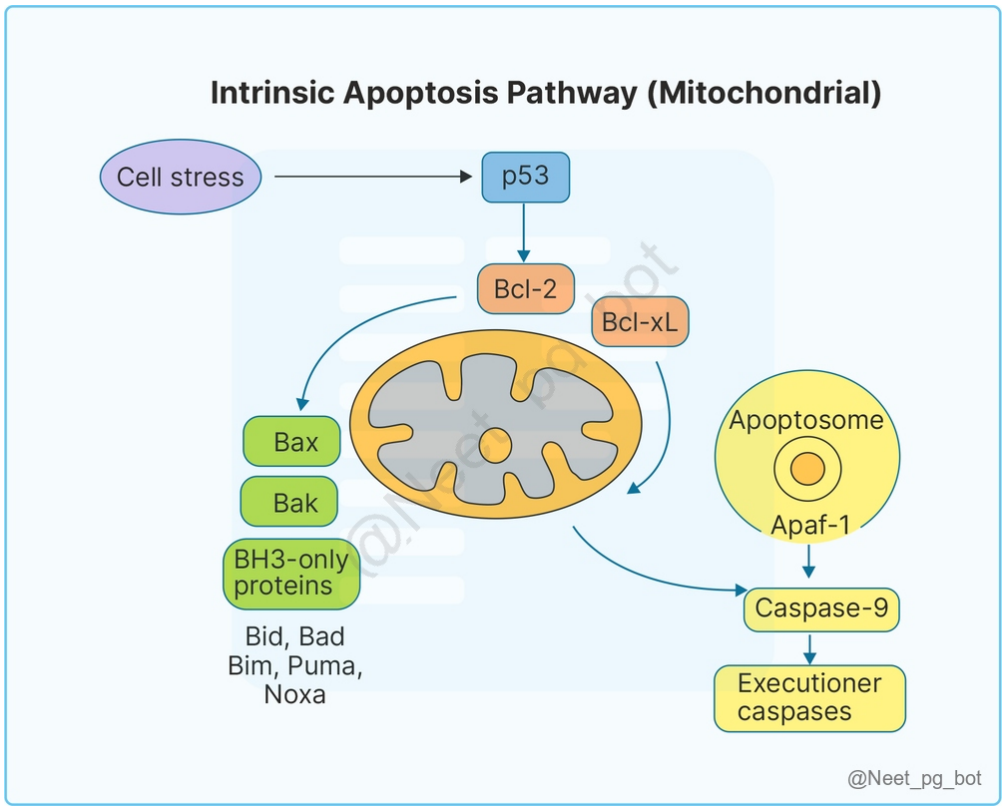

References:

.

↑ *Back to this question in Part A*

@Neet_pg_bot

Q4: Which of the following types of cell death involves activation of caspase enzymes? (Q866340)

A. Necrosis and Apoptosis

B. Apoptosis and Pyroptosis

C. Apoptosis and necroptosis

D. Apoptosis only

Correct Answer: B. Apoptosis and Pyroptosis

Explanation: Apoptosis and Pyroptosis involves activation of caspase enzymes. Apoptosis A tightly regulated suicide program where cells activate enzymes to degrade their DNA and proteins. It’s an active process

eliminating irreparably damaged cells without causing inflammation or tissue damage. Driven by activation of caspases that cause DNA fragmentation Phases: (Option B) Initiation phase: Activation of caspases 8, 9, 10 triggers a cascade. Execution phase: Terminal caspases 3, 6, 7 lead to cellular breakdown. Morphological features: Cell shrinkage Chromatin condensation Cytoplasmic blebs and formation of apoptotic bodies Phagocytosis of apoptotic bodies by macrophages Histopathology: Apoptotic cells appear as round/oval with intensely eosinophilic cytoplasm and dense nuclear chromatin fragments. Pyroptosis It is a form of programmed cell death involving release of IL-1, a fever-inducing cytokine. Microbial products in cells activate the inflammasome complex. Inflammasome activates caspase-1, which converts inactive IL-1 to active IL-1. (Option B) Active IL-1 causes fever, inflammation, and leukocyte recruitment. Pyroptosis helps eliminate infected cells and triggers local inflammation. Necrosis (Option A) is a form of accidental cell death that does not involve caspases. Necroptosis (Option C) is a programmed form of necrosis that occurs independently of caspases.

↑ *Back to this question in Part A*

@Neet_pg_bot

Q5: Caspase-1 is primarily involved in which type of programmed cell death? (Q865391)

A. Apoptosis

B. Pyroptosis

C. Necroptosis

D. Necrosis

Correct Answer: B. Pyroptosis

Explanation: Caspase-1 plays a central role in Pyroptosis , a form of programmed cell death associated with inflammation. It is a form of apoptosis in which there is release of the fever-inducing cytokine IL-1. Microbial products entering infected cells are recognized by cytoplasmic receptors, activating the multiprotein complex inflammasome. This complex activates caspase 1 which converts the inactive IL-1 to active IL-1, causing fever, inflammation and leucocyte recruitment. (Option B) Pyroptosis is the mechanism by which some microbes cause the death of infected cells and trigger local inflammation. Apoptosis (Option A) is a controlled, non-inflammatory cell death involving caspases-8, -9, -3, and -7, but not caspase-1, and serves to remove damaged cells without triggering an immune response. Necroptosis (Option C) is a programmed inflammatory cell death triggered when apoptosis is blocked, involving RIPK1, RIPK3, and MLKL—but not caspase-1, distinguishing it from pyroptosis. Necrosis (Option D) is an uncontrolled, non-programmed cell death due to injury (e.g., trauma or ischemia), causing inflammation without involving caspases, including caspase-1.

References:

Textbook of Robbin and Cotran’s Pathological Basis of Diseases, 10th Edition, Page 46-48.

↑ *Back to this question in Part A*

Q6: Apoptotic bodies comprise of? (Q860513)

A. Include cytoplasm + intranuclear material + organelle

B. Cytoplasm + organelle

C. Organelle + intranuclear material

D. Only organelle

Correct Answer: A. Include cytoplasm + intranuclear material + organelle

Explanation: Apoptotic bodies are comprised of cytoplasm, intranuclear material and cellular organelles. Apoptosis (caspase-dependent programmed cell death): It is a type of cell death that is induced by a tightly regulated suicide program in which cells destined to die activate intrinsic enzymes that degrade the cells' genomic DNA and nuclear and cytoplasmic proteins. It is an active process. It eliminates cells that are injured beyond repair without eliciting a host reaction, thus limiting collateral tissue damage. Apoptosis results from the activation of enzymes called caspases, which leads to DNA fragmentation. The process of apoptosis may be divided into: Initiation phase: Caspases 8,9,10 become catalytically active and unleash a cascade of other caspase Execution phase: During which the terminal caspases 3,6,7 trigger cellular fragmentation. Morphological features:- Cell shrinkage Chromatin condensation Formation of cytoplasmic blebs and apoptotic bodies (cytoplasm and tightly packed organelles, with or without nuclear fragments) (Option A) Phagocytosis of apoptotic bodies, usually by macrophages. Histopathology: The apoptotic cell appears as a round or oval mass of intensely eosinophilic cytoplasm with fragments of dense nuclear chromatin. {{caption_text}} The cell is reduced in size and contains brightly eosinophilic cytoplasm and a condensed nucleus. Types: Apoptosis occurs in two broad contexts: Physiological apoptosis. Pathological apoptosis. Physiological Apoptosis Pathological Apoptosis The removal of supernumerary cells (in excess of the required number) during development. Involution of hormone-dependent tissues on hormone withdrawal, such as endometrial cell breakdown during the menstrual cycle. Elimination of potentially harmful self-reactive lymphocytes to prevent immune reactions against one's own tissues. Death of host cells that have served their useful purpose, such as neutrophils in an acute inflammatory response and lymphocytes at the end of an immune response. DNA damage. Accumulation of misfolded proteins Apoptosis can be induced during certain infections- as in adenovirus and HIV infections and viral hepatitis. It may also contribute to pathologic atrophy in parenchymal organs after duct obstruction, such as occurs in the pancreas, parotid gland, and kidney.

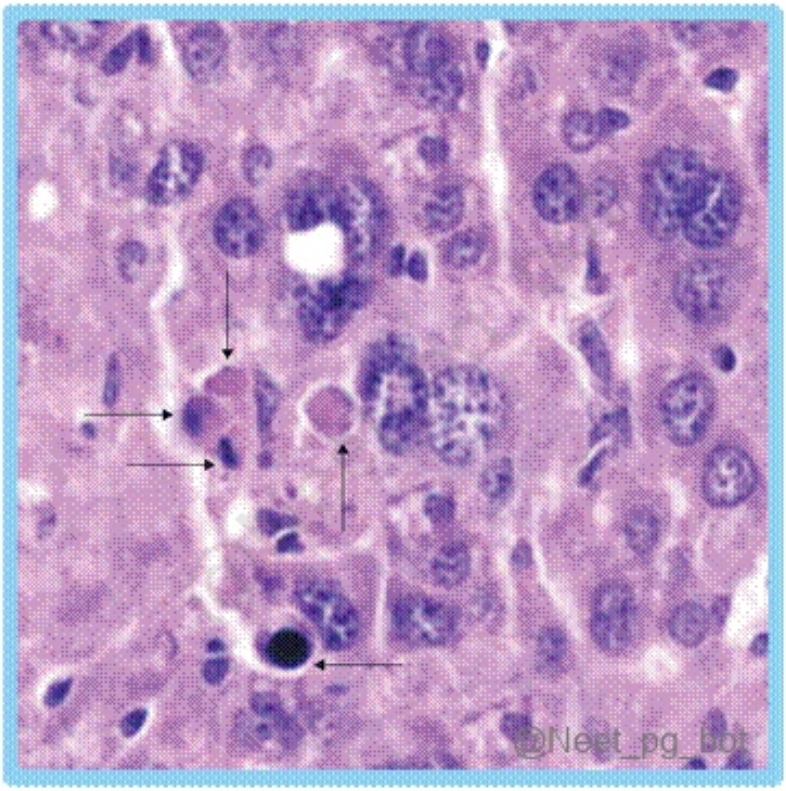

References:

Robbins & Cotran Pathologic Basis of Disease, 10th Edition, Page, 42-43.

↑ *Back to this question in Part A*

@Neet_pg_bot

Q7: The body of an 82-year-old man has been seen for a post-mortem to determine the cause of death. You are examining a histopathological slide containing a section of his cardiac tissue where you notice some pigmentation. Which is the substance that is seen in the image given below? (Q859859)

A. Melanin

B. Lipofuscin

C. Hemosiderin

D. Iron

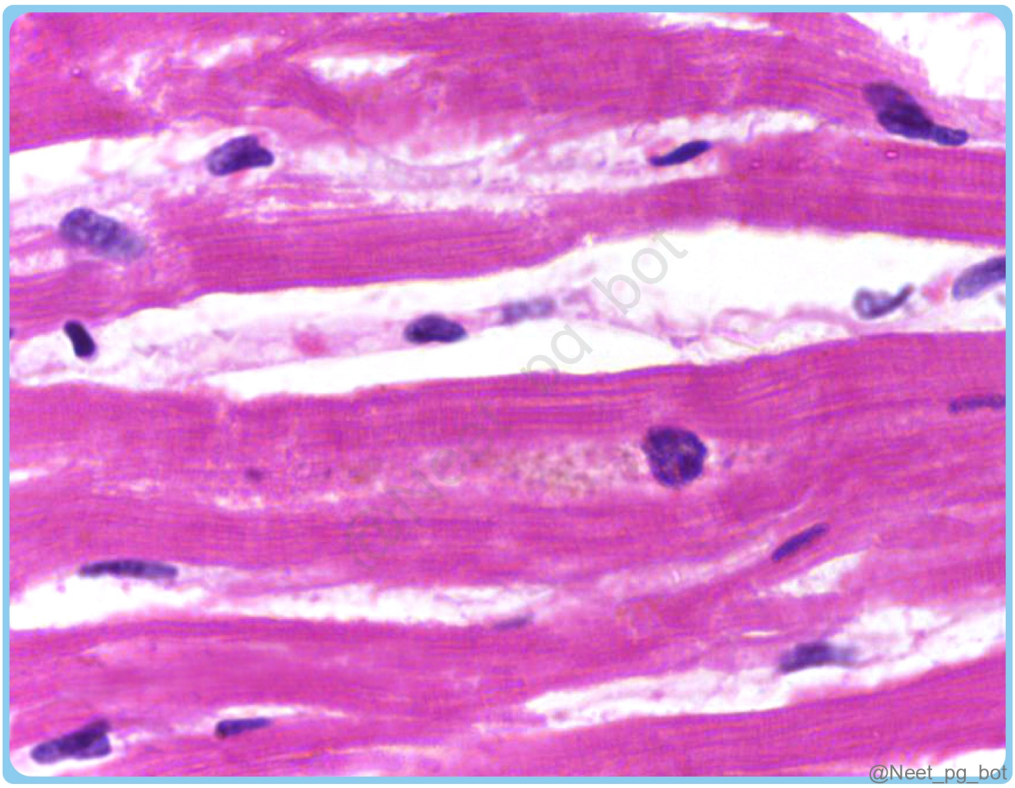

Correct Answer: B. Lipofuscin

Explanation: The histopathological image shows lipofuscin in the section of cardiac tissue. Lipofuscin is a yellow to red-brown pigment found in cardiac muscle cells, particularly around the nucleus in the hearts of elderly, debilitated people. {{caption_text}} Melanin (Option A) is a black or brown pigment found in skin, hair, and certain brain areas, not typically seen in cardiac tissue. Hemosiderin (Option C) is an iron-storage complex resulting from the breakdown of haemoglobin, typically associated with conditions like haemorrhage or hemochromatosis. Iron (Option D) : Elemental iron deposition in tissues is pathological and associated with diseases like hemochromatosis or chronic blood transfusions. Staining with Prussian blue would help confirm iron presence.

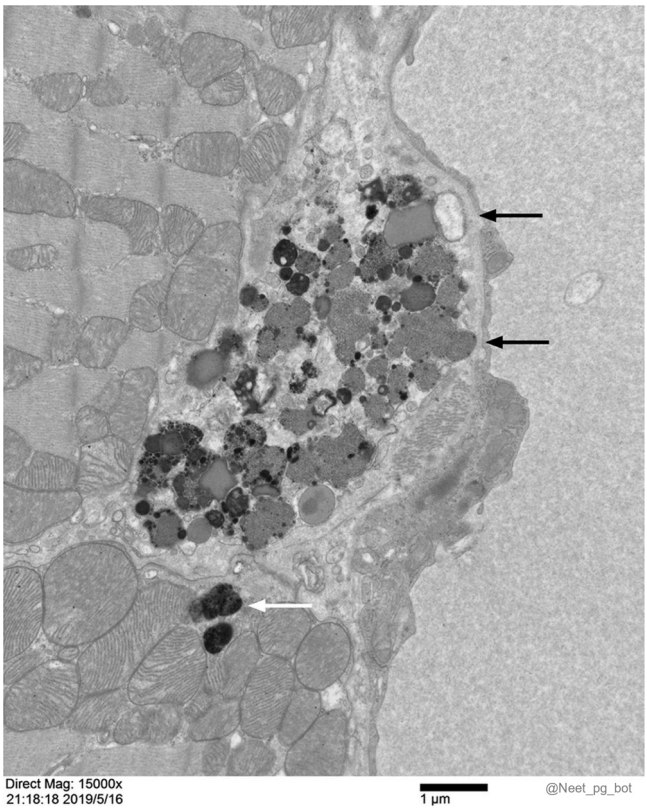

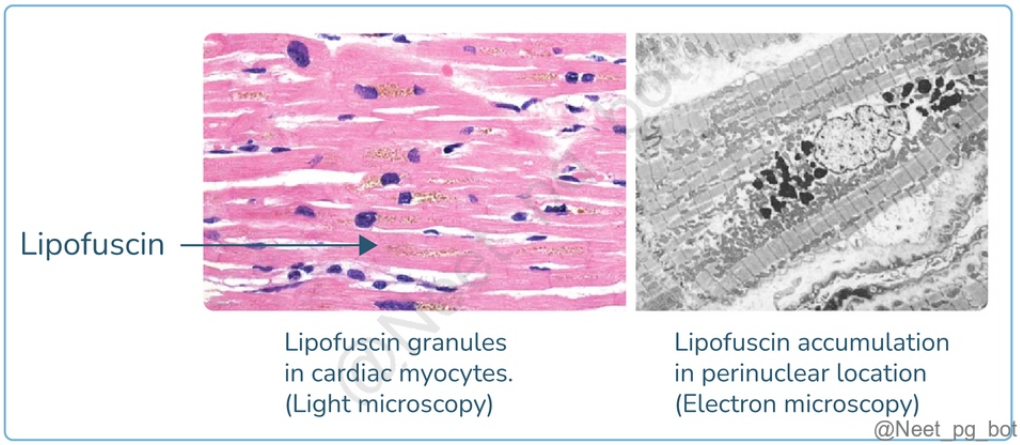

References:

Robbins & Cotran Pathologic Basis of Disease, 10th Edition, Pages 64, 65

↑ *Back to this question in Part A*

@Neet_pg_bot

Q8: Among the following, which molecule is required for the presentation of the antigens by the APCs to TH2 cells? (Q859298)

A. NK cells

B. G-protein coupled receptor

C. MHC

D. Lectin receptor

Correct Answer: C. MHC

Explanation: Antigen-presenting cells (APCs) such as dendritic cells, macrophages, and B cells play a crucial role in the adaptive immune response by presenting antigens to T-helper (TH2) cells . This process requires Major Histocompatibility Complex (MHC) Class II molecules , which are essential for the activation of CD4+ T cells, including TH2 cells. MHC Molecule Role : APCs process antigens and present them on their surface bound to MHC Class II molecules. MHC Class II molecules interact with the T-cell receptor (TCR) on CD4+ T cells. This interaction is critical for the differentiation and activation of TH2 cells, which secrete cytokines to mediate humoral immunity. Incorrect Options: NK cells (Option A) are part of the innate immune system and do not present antigens or directly interact with TH2 cells. G-protein coupled receptors (Option B) are involved in cell signalling but are not involved in antigen presentation to T cells. Lectin receptors (Option D) are involved in innate immune recognition, particularly of carbohydrate molecules, but they do not mediate antigen presentation to TH2 cells.

References:

Robbins and Cotran Pathologic Basis of Disease, 10th Edition, Page 192-200.

↑ *Back to this question in Part A*

@Neet_pg_bot

Q9: Supravital stains are used in the identification of all except? (Q857588)

A. Reticulocytes

B. Copper in tissue

C. Heinz bodies

D. Ribosomal RNA

Correct Answer: B. Copper in tissue

Explanation: Supravital stains are typically used to identify cellular components such as reticulocytes (immature red blood cells), Heinz bodies (denatured haemoglobin), and ribosomal RNA (which is seen in reticulocytes as a network). However, copper in tissue is not identified using supravital stains; it requires special staining techniques like rhodanine stains. {{caption_text}}

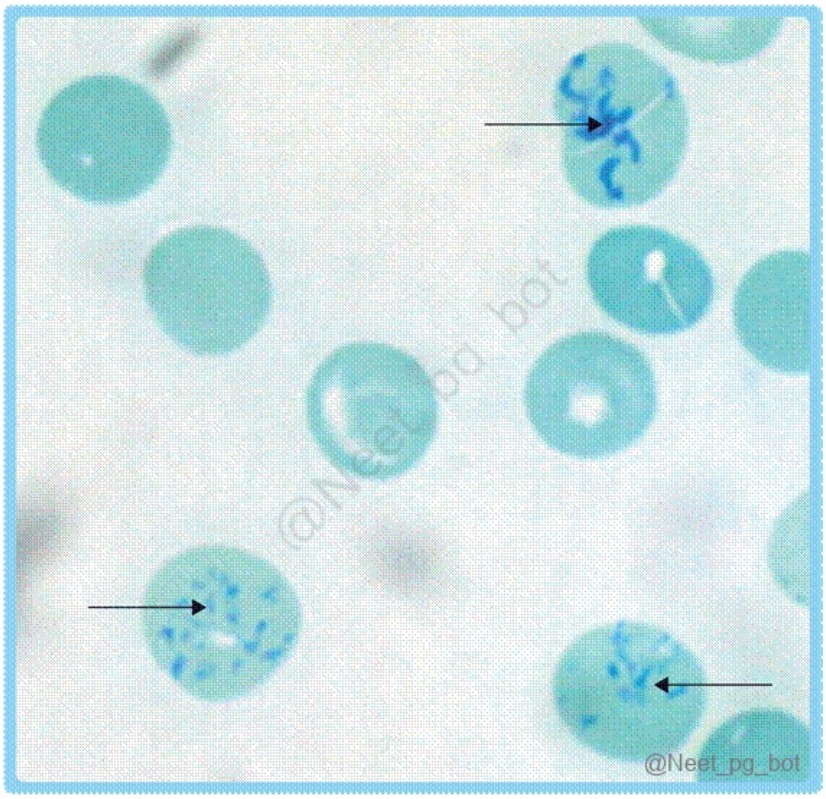

References:

Robbins & Cotran Pathologic Basis of Disease, 10th Edition, Page 641

↑ *Back to this question in Part A*

@Neet_pg_bot

Q10: Which of the following is an anti-apoptotic gene? (Q857450)

A. BAK

B. MCL1

C. PUMA

D. BAD

Correct Answer: B. MCL1

Explanation: MCL1 is an anti-apoptotic gene and part of the BCL-2 family. Apoptosis is a key process for maintaining cell balance and eliminating damaged cells, regulated by the interplay between pro-apoptotic and anti-apoptotic genes. MCL1 inhibits apoptosis by preventing the activation of pro-apoptotic proteins, thereby promoting cell survival. Apoptotic genes: Anti Apoptotic genes :- BCL-2 , BCL-XL , MCL-1 Pro Apoptotic

genes:- BAX and BAK (Option A ruled out) Apoptosis initiators:- BAD, BIM, BID, Noxa and Puma (Option C & D ruled out)

References:

Robbins and Cotran Pathologic Basis of Disease, 10th edition, pages 44, 45

↑ *Back to this question in Part A*

@Neet_pg_bot

Q11: Which of the following diseases is caused by abnormal folding of proteins? (Q857433)

A. Creutzfelt Jakob disease

B. Cirrhosis

C. Nephritic syndrome

D. Sickle cell anemia

Correct Answer: A. Creutzfelt Jakob disease

Explanation: Creutzfeldt-Jakob disease (CJD) is a type of prion disease caused by the abnormal folding of proteins, specifically prion proteins (PrP), which leads to neurodegeneration. It is irreversible and fatal . The disease progresses quickly, and death usually occurs within a year. It is characterised by Rapidly progressive dementia Myoclonus Ataxia Visual disturbances Diagnosis: It is confirmed via MRI (increased signal in basal ganglia) and EEG findings Cirrhosis (Option B) is liver scarring typically caused by chronic liver diseases (e.g., hepatitis, alcoholism), not protein misfolding. Nephritic syndrome (Option C) is a kidney disorder involving inflammation, typically due to immune complex deposition, not protein misfolding. Sickle cell anaemia (Option D) is caused by a genetic mutation in the haemoglobin gene (HbS) that leads to abnormal haemoglobin, but not a misfolding of proteins in the same sense as prion diseases.

References:

Harper’s Illustrated Biochemistry, 32nd Edition, Page 42

Kaplan and Sadock’s Synopsis of Psychiatry, 12th Edition, Pages 763, 764, 765

↑ *Back to this question in Part A*

@Neet_pg_bot

Q12: Which nuclear change of cell injury is being shown in the image? (Q857432)

A. Pyknosis

B. Karyorrhexis

C. Karyolysis

D. Normal nucleus

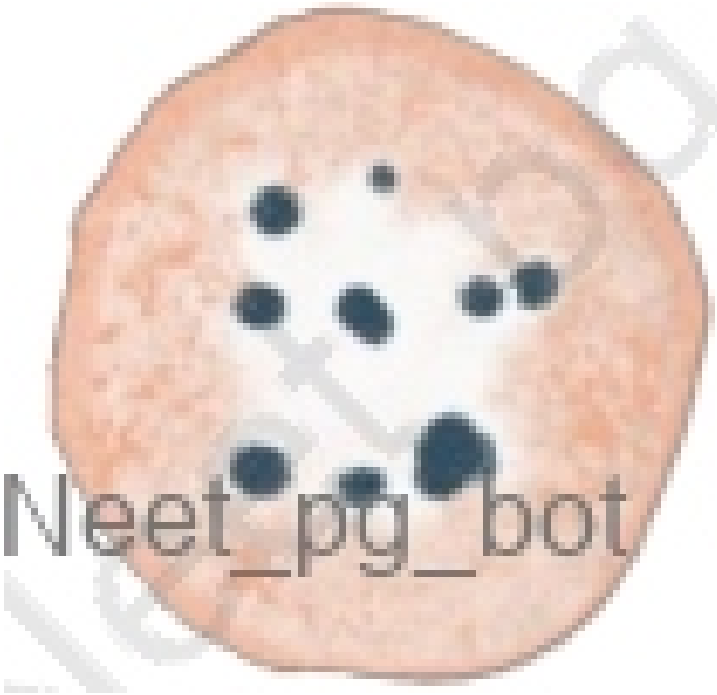

Correct Answer: B. Karyorrhexis

Explanation:

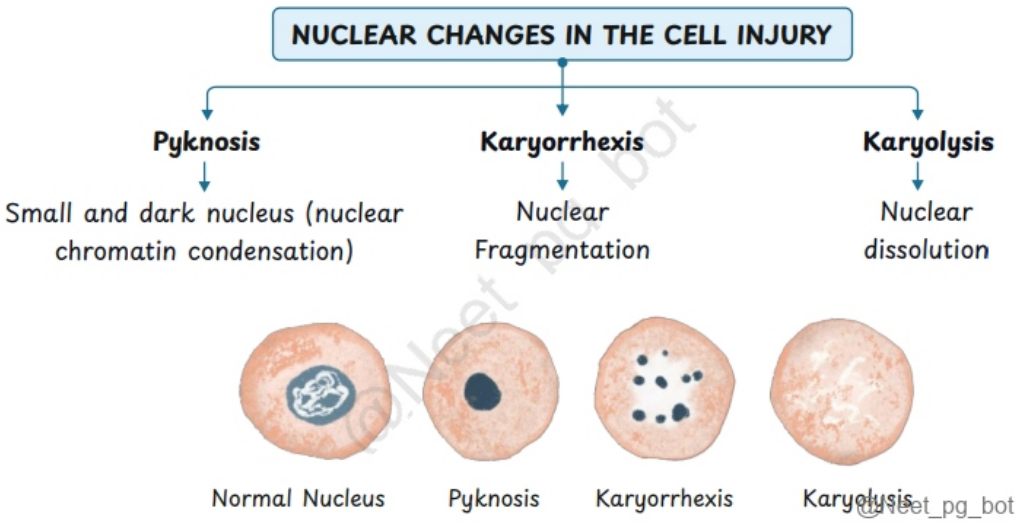

References:

Prepladder notes

↑ *Back to this question in Part A*

@Neet_pg_bot

Q13: A 24-year-old male was brought to the emergency department after suffering severe injuries in a motorcycle accident. His blood pressure was 80/60 mm Hg, and he was tachycardic with cold, clammy skin. An ultrasound examination revealed a ruptured spleen. Arterial blood gas analysis was suggestive of metabolic acidosis. Which of the following conditions most likely caused the patient to suffer? (Q857122)

A. Cardiogenic shock

B. Septic shock

C. Hypovolemic shock

D. Neurogenic shock

Correct Answer: C. Hypovolemic shock

Explanation: Hypovolemic shock occurs due to significant blood or fluid loss, leading to reduced blood volume and inadequate tissue perfusion. This patient's low blood pressure, tachycardia, cold, clammy skin, and metabolic acidosis suggest shock caused by blood loss from the ruptured spleen. Shock is a state of circulatory failure that impairs tissue perfusion and leads to cellular hypoxia. Initially, cellular injury is reversible, but prolonged shock can cause irreversible tissue damage and may be fatal. It can result from various conditions, such as severe

haemorrhage, extensive trauma, burns, myocardial infarction, pulmonary embolism, and microbial sepsis. The causes of shock can be categorised into three main types: Cardiogenic shock: (Option A) Caused by low cardiac output due to myocardial pump failure. This may result from intrinsic myocardial damage (e.g., infarction), ventricular arrhythmias, extrinsic compression (e.g., cardiac tamponade), or outflow obstruction (e.g., pulmonary embolism). Hypovolemic shock: Occurs due to low blood volume, often from massive haemorrhage or fluid loss (e.g., severe burns). This leads to reduced cardiac output and impaired tissue perfusion. Septic shock: (Option B) Sepsis : Life-threatening organ dysfunction due to a dysregulated host response to infection. Septic Shock : A subset of sepsis with profound circulatory, cellular, and metabolic abnormalities that increase mortality risk. Systemic Inflammatory Response Syndrome (SIRS) : A sepsis-like condition triggered by non-microbial insults, such as burns, trauma, or pancreatitis. Both SIRS and septic shock are marked by a massive release of inflammatory mediators, causing arterial vasodilation, vascular leakage, and venous blood pooling, leading to tissue hypoperfusion, cellular hypoxia, and organ dysfunction. Neurogenic Shock (Option D) : Occurs following spinal cord injury, leading to acute vasodilation and hypotension. Anaphylactic Shock : Caused by an IgE-mediated hypersensitivity reaction, resulting in acute vasodilation, hypotension, and tissue hypoperfusion.

References:

Robbins & Cotran Pathologic Basis of Disease, 10th Edition, Page 134,135

↑ *Back to this question in Part A*

@Neet_pg_bot

Q14: All of the following are crosslinking fixatives except? (Q856893)

A. Glutaraldehyde

B. Formaldehyde

C. Methanol

D. Osmium tetroxide

Correct Answer: C. Methanol

Explanation: Methanol is not a crosslinking fixative. It is a dehydrant coagulant fixative. Fixatives are chemicals that preserve biological tissues by stabilizing cellular structures and preventing decay or degradation. The goal is to maintain the tissue in a life-like state as much as possible for microscopic examination. Fixation helps maintain the tissue's integrity by preventing autolysis (self-digestion) and putrefaction (bacterial decay). Crosslinking Fixatives: These fixatives work by forming covalent bonds between the proteins and other cellular structures, effectively "locking" them in place. This preserves the tissue’s structural integrity. Formaldehyde (Option B) : Most commonly used in the form of 10% neutral-buffered formalin. Glutaraldehyde (Option A) : Often used for electron microscopy due to its ability to preserve fine cellular structures. Osmium tetroxide (Option D) : Used primarily for electron microscopy, particularly for preserving lipids and membranes. Precipitating Fixatives: These work by precipitating proteins and other cellular components, which makes them less soluble and helps preserve their structure. Methanol Ethanol Additive Fixatives: They chemically bind to tissue components, such as proteins

or nucleic acids, and stabilize them. They are typically more gentle and produce better preservation of ultrastructure. Formaldehyde Glutaraldehyde Non-Additive Fixatives: Alcohol Acetone

References:

Bancroft's Theory and Practice of Histological Techniques, 8th Edition, Page 40-44.

↑ *Back to this question in Part A*

@Neet_pg_bot

Q15: Which of the following caspases binds to Cyt c and the APAF-1 complex? (Q856488)

A. Caspase 1

B. Caspase 8

C. Caspase 9

D. Caspase 4

Correct Answer: C. Caspase 9

Explanation: In the intrinsic apoptotic pathway , the release of cytochrome c (Cyt c) from the mitochondria triggers the formation of the apoptosome, a complex consisting of Cyt c, apoptotic protease-activating factor 1 (APAF-1), and procaspase 9. This complex is essential for initiating the caspase cascade that leads to cell death. Apoptosis (Caspase-dependent programmed cell death): Apoptosis is a type of cell death that is induced by a tightly regulated suicide program in which cells destined to die activate intrinsic enzymes that degrade the cells' genomic DNA and nuclear and cytoplasmic proteins. It is an active process. It eliminates cells that are injured beyond repair without eliciting a host reaction, thus limiting collateral tissue damage. Apoptosis results from activating enzymes called caspases, leading to DNA fragmentation. The process of apoptosis may be divided into an initiation phase , during which caspases 8,9,10 become catalytically active and unleash a cascade of other caspases, and an execution phase , during which the terminal caspases 3,6,7 trigger cellular fragmentation. Morphological features:- Cell shrinkage Chromatin condensation Formation of cytoplasmic blebs and apoptotic bodies Phagocytosis of apoptotic bodies, usually by macrophages. Histopathology: In H&E-stained tissue, the apoptotic cell appears as a round or oval mass of intensely eosinophilic cytoplasm with fragments of dense nuclear chromatin. {{caption_text}} The above image shows apoptosis of an epidermal cell in an immune reaction. The cell is reduced in size and contains brightly eosinophilic cytoplasm and a condensed nucleus Types: Apoptosis occurs in two broad contexts: Physiological apoptosis. Pathological apoptosis. Apoptosis in physiological conditions Apoptosis in pathological conditions 1. The removal of supernumerary cells (in excess of the required number) during development. 2. Involution of hormone-dependent tissues on hormone withdrawal, such as endometrial cell breakdown during the menstrual cycle. 3. Elimination of potentially harmful self-reactive lymphocytes to prevent immune reactions against one's own tissues. 4. Death of host cells that have served their useful purpose, such as neutrophils in an acute inflammatory response and lymphocytes at the end of an immune response. 1. DNA damage. 2. Accumulation of misfolded proteins 3. Apoptosis can be induced during infections

such as adenovirus , HIV , and viral hepatitis . 4. It may also contribute to pathologic atrophy in parenchymal organs after duct obstruction, such as occurs in the pancreas, parotid gland, and kidney

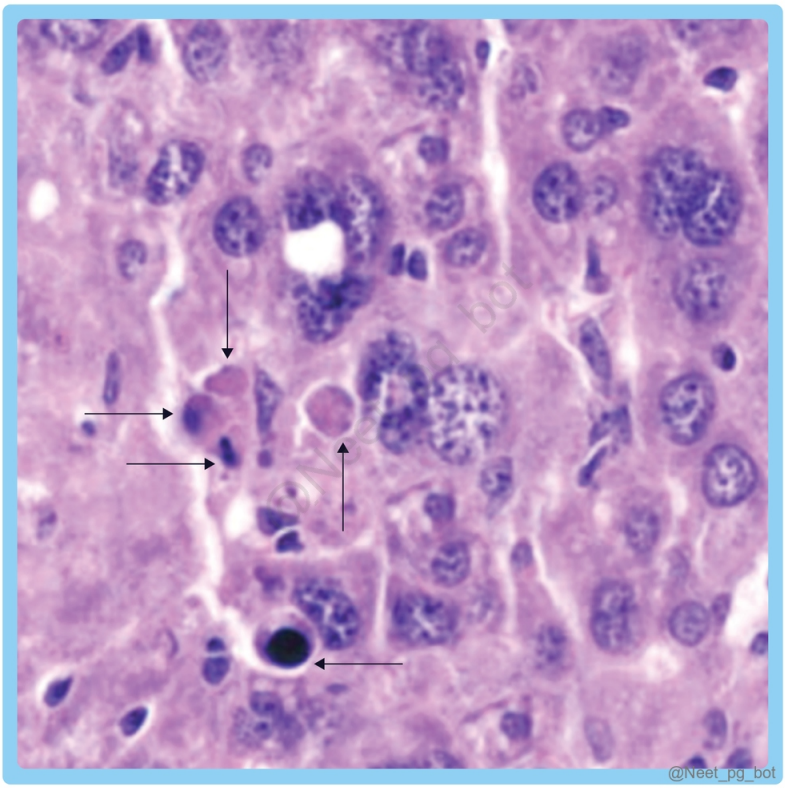

References:

Robbins & Cotran Pathologic Basis of Disease, 10th Edition, Page 42,43

↑ *Back to this question in Part A*

@Neet_pg_bot

Q16: A chronic alcoholic patient presented with increasing abdominal girth. On examination, shifting dullness was present, and the liver span was less than 7cm. Histopathological examination revealed the presence of intracytoplasmic eosinophilic inclusions in hepatocytes. What is the content of these inclusions? (Q856152)

A. Intermediate filaments

B. Actin

C. Microtubules

D. Fibronectin

Correct Answer: A. Intermediate filaments

Explanation: The presence of intracytoplasmic eosinophilic inclusions in hepatocytes is a key finding in alcoholic liver disease. Mallory-Denk bodies or Mallory hyaline bodies are eosinophilic , intracytoplasmic inclusions composed of intermediate filaments, particularly cytokeratin 8 and 18, commonly seen in hepatocytes in conditions such as alcoholic liver disease. Conditions where Mallory Hyaline bodies are seen are (Mnemonic: N ew Indian WATCH) N on-alcoholic fatty liver disease (NAFLD) Indian childhood cirrhosis W ilson's disease A lpha-1 antitrypsin deficiency ; A lcoholic Liver Disease T umor of the liver (Hepatocellular carcinoma) Chronic C holestatic conditions H epatic or Primary Biliary cirrhosis (not seen in Secondary biliary cirrhosis) {{caption_text}} Actin (Option B) is a structural protein found in microfilaments but does not typically form eosinophilic inclusions in alcoholic liver disease. Microtubules (Option C) are involved in intracellular transport and cell division but do not form eosinophilic inclusions in hepatocytes. Fibronectin (Option D) is an extracellular matrix protein , and although it plays a role in tissue repair and scarring , it is not associated with the formation of intracytoplasmic inclusions in liver cells, especially in alcoholic liver disease.

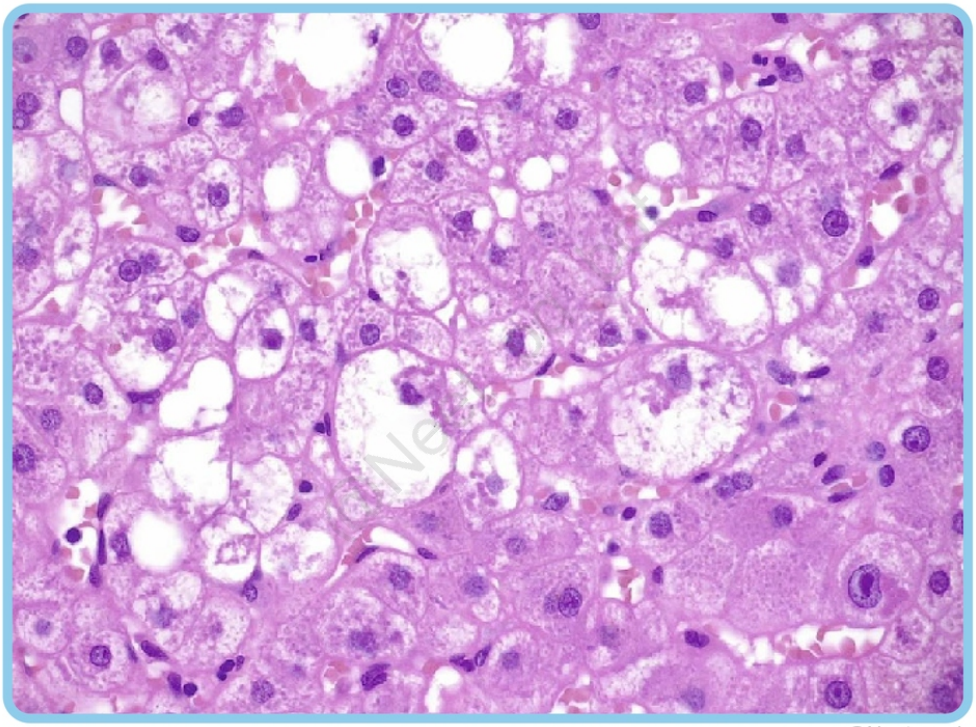

References:

Robbins and Cotran Pathologic Basis of Disease, 10th Edition, Page 843, 1116

↑ *Back to this question in Part A*

@Neet_pg_bot

Q17: A 70-year-old patient presented with cough, fatigue, and weight loss. He was diagnosed with squamous cell carcinoma on bronchoscopy. The resected specimen had a hilar lymph node that was 1 cm in size and showed a black pigment. What is the black pigment likely to be? (Q856097)

A. Anthracotic pigment

B. Melanin

C. Lipochrome

D. Hemosiderin

Correct Answer: A. Anthracotic pigment

Explanation: Anthracotic pigment is a black, carbon-based pigment commonly seen in lymph nodes and lungs, as well as in individuals with chronic smoking or environmental pollution exposure. These particles are engulfed by macrophages in the lungs and then transported to nearby lymph nodes, often leading to anthracosis . HPE shows carbon-laden macrophages. In patients with lung cancer , particularly squamous cell carcinoma , the presence of hilar lymphadenopathy and black pigment is a common finding due to the direct proximity of the lungs and lymphatic drainage of carbon particles. {{caption_text}} Melanin (Option B) is responsible for skin and hair pigmentation and protects against UV radiation. While it can sometimes be found in melanomas (a type of skin cancer), it is not typically found in the lungs or lymph nodes. {{caption_text}} Lipochrome (Option C) is a group of yellow to brown pigments that arise from the breakdown of lipids (fats). On microscopy, it appears as a yellow-brown, finely granular cytoplasmic pigment, often deposited in the perinuclear location. These pigments can be found in various tissues but are not typically associated with lung diseases or lymph node involvement . {{caption_text}} Hemosiderin (Option D) is an iron-containing pigment derived from the breakdown of hemoglobin . While hemosiderin can appear brown, it does not appear as a black pigment in the context of smoking-related lung disease or cancer . {{caption_text}}

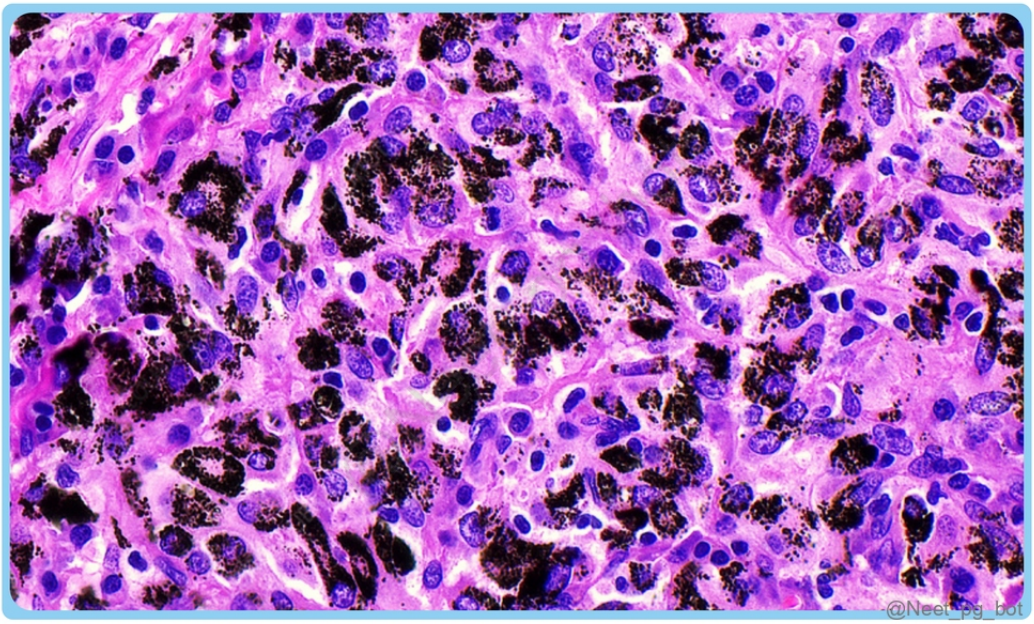
@Neet_pg_bot


Melanin representing
blackish color with
Masson fontasa stain
@Neet_pg_bot

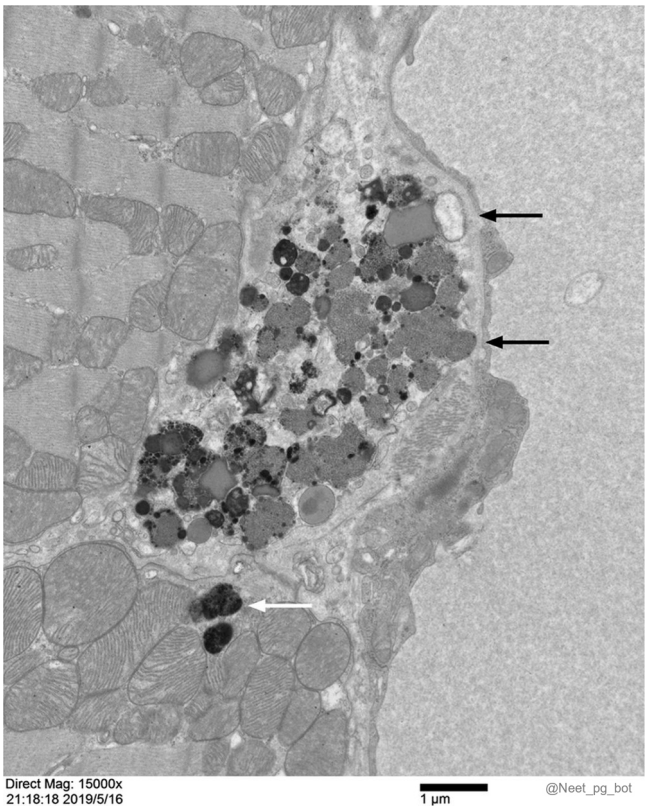
Direct Mag: 15000x
21:18:18 2019/5/16
1 µm
@Neet_pg_bot

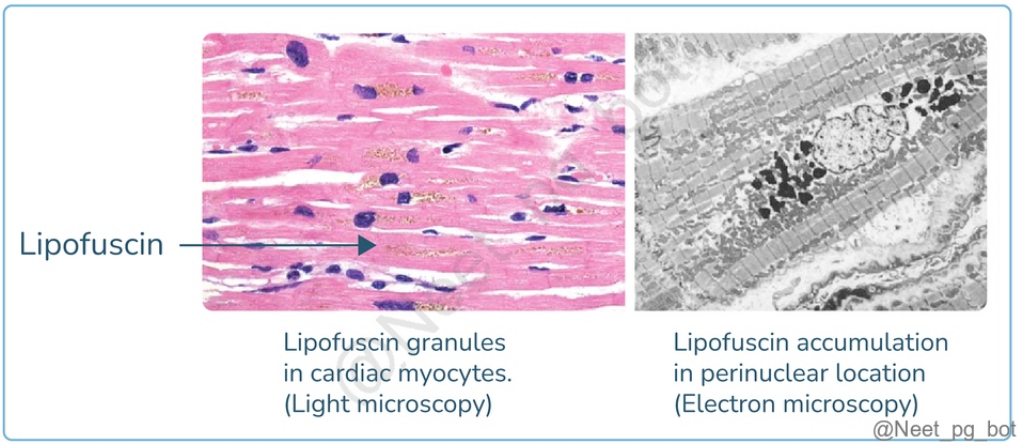
Lipofuscin
Lipofuscin granules
in cardiac myocytes.
(Light microscopy)
Lipofuscin accumulation
in perinuclear location
(Electron microscopy)
@Neet_pg_bot

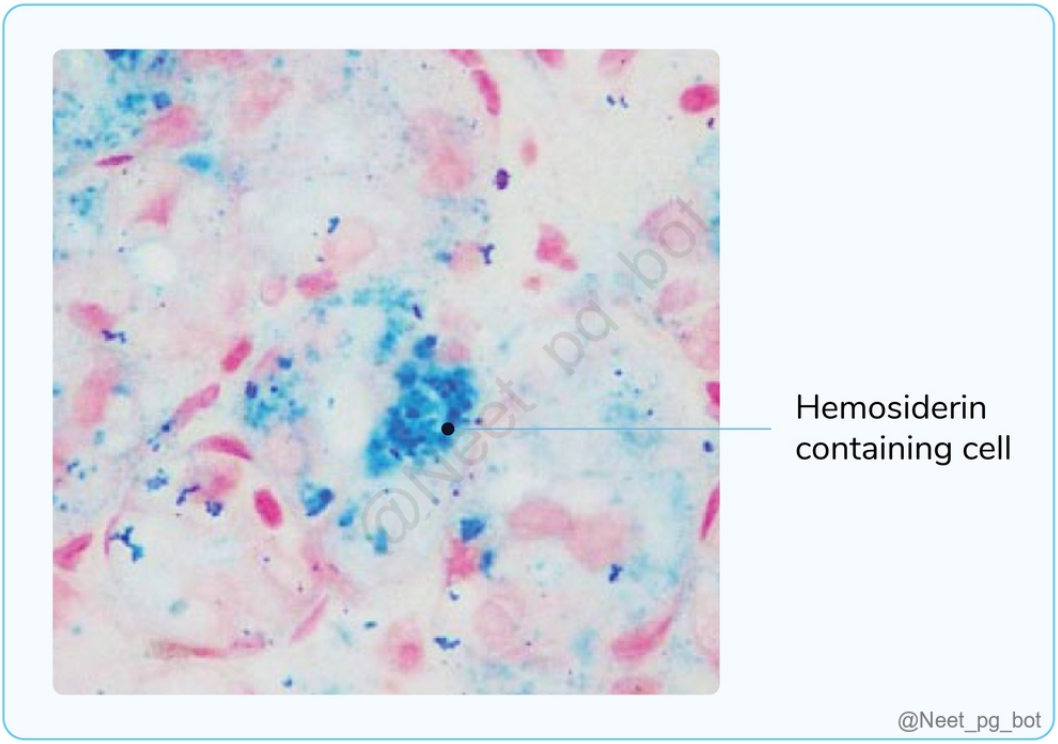

References:

Robbins and Cotran Pathologic Basis of Disease, 10th Edition, Pages 76, 77

Park's Textbook of Preventive and Social Medicine, 27th Edition, Pages 933, 934

↑ *Back to this question in Part A*

@Neet_pg_bot

Q18: Senile atrophy occurs due to which of the following? (Q856024)

A. Denervation

B. Decreased nutrition

C. Decreased workload

D. Reduced blood supply

Correct Answer: D. Reduced blood supply

Explanation: Chronic ischemia from progressive arterial occlusion leads to tissue atrophy. In older adults, reduced cerebral blood flow due to atherosclerosis causes senile atrophy of the brain. Loss of innervation (denervation atrophy) (Option A) : Skeletal muscle metabolism and function rely on nerve supply. Damage to the nerves results

in atrophy of the muscle fibres they innervate. Inadequate nutrition (Option B) : Severe protein-calorie malnutrition, such as marasmus , causes the breakdown of skeletal muscle proteins for energy after fat stores are depleted, leading to muscle wasting (cachexia) . This is common in chronic inflammatory diseases and cancer. In cachectic states, excessive TNF production contributes to appetite suppression and lipid depletion, further exacerbating muscle atrophy. Decreased workload (disuse atrophy) (Option C) : Immobilization of bones, such as through a plaster cast or prolonged bed rest, leads to rapid muscle atrophy. Initially, the decrease in cell size is reversible upon resumption of activity. However, with prolonged disuse, muscle fibres shrink in size and number (due to apoptosis), and muscle atrophy may be accompanied by increased bone resorption, resulting in disuse osteoporosis.

References:

Robbins & Cotran Pathologic Basis of Disease, 10th Edition, Page 60

↑ *Back to this question in Part A*

@Neet_pg_bot

Q19: Which of the following measures is associated with an increased life span? (Q855961)

A. Regular moderate exercise for 30 min

B. Decrease stress

C. Decreasing calorie intake by 30%

D. Pharmacological intervention with proton pump inhibitors

Correct Answer: C. Decreasing calorie intake by 30%

Explanation: aloric restriction has increased lifespan across various species, including nonhuman primates and humans. This is linked to two key neurohormonal circuits regulating metabolism: Insulin and IGF-1 Signaling IGF-1, produced in response to growth hormone, mimics insulin signalling, promoting an anabolic state, cell growth, and replication. Sirtuins These are NAD-dependent deacetylases that help adapt to stressors like food deprivation and DNA damage. They promote longevity by regulating genes that reduce metabolic activity, apoptosis, and oxidative damage. Sirtuins also improve insulin sensitivity and glucose metabolism. Caloric restriction reduces IGF-1 signalling, which may reduce cellular damage while simultaneously increasing sirtuins, particularly sirtuin-6 , to promote DNA repair and metabolic adaptation. Hence, caloric restriction, particularly a reduction in calories by about 20-30%, can reduce IGF-1 signalling and increase sirtuin activity, which together is thought to extend lifespan. Regular moderate exercise for 30 min (Option A) is associated with numerous health benefits, like improved cardiovascular health, better metabolic function, and reduced risk of chronic diseases. While it may increase health span , it is not as directly proven to increase lifespan compared to caloric restriction. Decrease stress (Option B): Chronic stress is associated with a range of negative health effects, all of which can reduce lifespan. Stress management techniques can help improve health and increase longevity, but this relationship is more indirect and variable. Pharmacological intervention with proton pump inhibitors (Option D) :

PPIs are used to reduce stomach acid and treat conditions like GERD and peptic ulcers. While they are effective for symptom relief, they are not associated with increased lifespan.

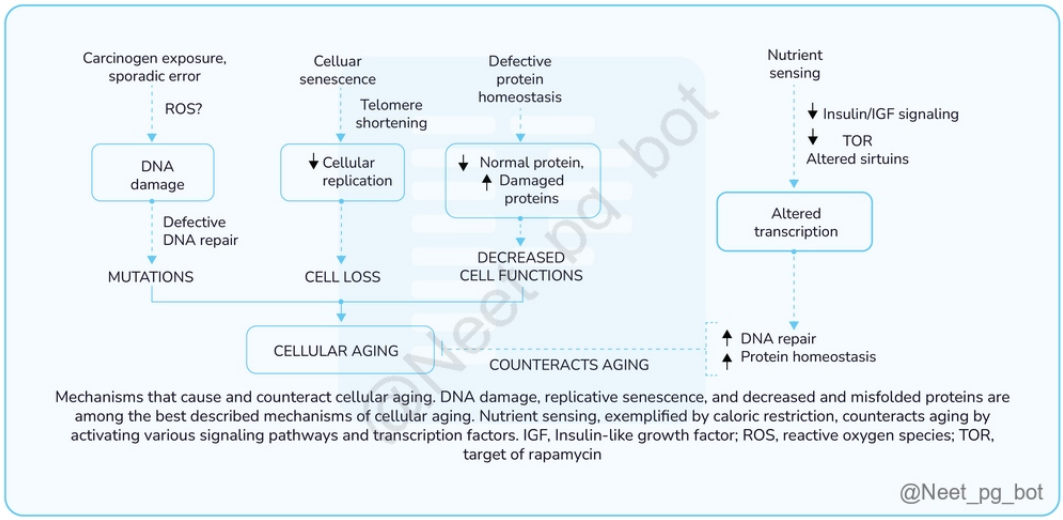

References:

Robbins and Cotran Pathologic Basis of Disease, 10th Edition, Page 80

↑ *Back to this question in Part A*

@Neet_pg_bot

Q20: Choose the correct statement regarding the telomerase theory of ageing: (Q855914)

A. Telomere stability is associated with ageing

B. Abnormal telomerase activation is associated with ageing

C. Decreased telomere length is associated with ageing

D. Increased telomere length is associated with ageing

Correct Answer: C. Decreased telomere length is associated with ageing

Explanation: : Telomere stability refers to maintaining the length of telomeres, which are protective caps at the ends of chromosomes. As we age, telomeres shorten rather than remain stable, which is a key factor in cellular ageing, not stability. Abnormal telomerase activation is associated with ageing (Option B): Abnormal telomerase activation is more commonly associated with cancer (where cells avoid normal ageing and continue to divide) rather than the ageing process itself. In ageing, telomerase activity tends to decline, not increase.

References:

Robbins and Cotran, Pathologic Basis of Disease, 10th Edition, Pages 67, 68

↑ *Back to this question in Part A*

@Neet_pg_bot

Q21: Which of the following is true regarding sirtuins? Increases insulin sensitivity and glucose metabolism Promotes genes that increase longevity They are of 7 types They are one of the types of histone deacetylases (Q855087)

A. 1, 2, 3

B. 1, 2, 3, 4

C. 2, 3

D. 2, 4

Correct Answer: B. 1, 2, 3, 4

Explanation: Sirtuins are NAD-dependent protein deacetylases. (Statement 4) Seven types (Statement 3) of sirtuins exist in mammals, each with unique functions. They help the body adapt to environmental stresses like food deprivation and DNA damage . Longevity : Sirtuins promote genes that increase longevity (Statement 2) , reduce metabolism, inhibit apoptosis, and protect against oxidative damage. Sirtuins enhance insulin sensitivity and glucose metabolism (Statement 1) Caloric restriction : Increases sirtuin activity, reducing IGF-1 signalling, leading to slower cell growth, reduced metabolism, and cellular damage. Sirtuin-6 : Plays a key role in metabolic adaptations and DNA repair by activating repair enzymes. Anti-ageing : Sirtuins are linked to anti-ageing effects. Red wine : A compound in red wine is believed to activate sirtuins, potentially contributing to increased lifespan.

References:

Robbins & Cotran Pathologic Basis of Disease, 10th Edition, Page 68

↑ *Back to this question in Part A*

@Neet_pg_bot

Q22: Cell-in-cell appearance is seen in which of the following? (Q855076)

A. Necrosis

B. Apoptosis

C. Necroptosis

D. Entosis

Correct Answer: D. Entosis

Explanation: Entosis refers to the process where one cell is engulfed by another, leading to a "cell-in-cell" appearance. Entosis : It refers to a homotypic process where one epithelial cell invades the cytoplasm of another epithelial cell. The host cell forms a vacuole around the internalized cell, which deforms its organelles, including the nucleus. The inner cell may survive within the host cell for up to 12 hours or longer, eventually being digested by the outer cell through an autophagosomal mechanism, or it may escape. {{caption_text}} Necrosis (Option A) is an uncontrolled form of cell death characterized by cell swelling, rupture, and inflammation. Apoptosis (Option B) is a controlled, programmed cell death where cells shrink and fragment into apoptotic bodies. Necroptosis (Option C) is a form of regulated cell death that mimics necrosis but is genetically controlled. Unlike apoptosis, it is associated with inflammation and occurs via receptor-interacting protein kinases (RIPK1 and RIPK3), leading to membrane rupture and the release of intracellular contents.

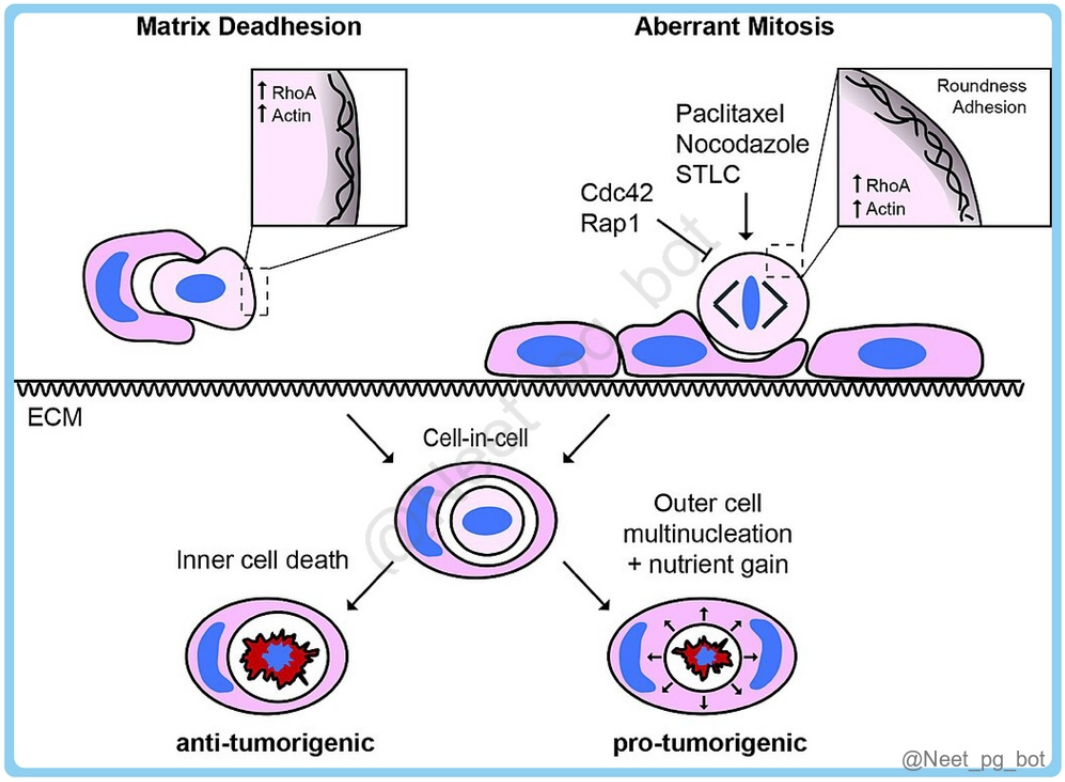

References:

https://pmc.ncbi.nlm.nih.gov/articles/PMC9102690/

↑ *Back to this question in Part A*

@Neet_pg_bot

Q23: Which among the following is less related to irreversible cell injury? (Q820573)

A. Blebs formation

B. Karyolysis

C. Amorphous densities

D. Pyknotic nucleus

Correct Answer: A. Blebs formation

Explanation: Correct Option A - Blebs formation: Blebs formation is actually a characteristic feature of reversible cell injury, not irreversible injury. Blebs formation is less related to irreversibility when compared to other features given in the options. Blebs are small, bubble-like protrusions on the cell membrane that result from cytoskeletal and membrane alterations. They can be observed in conditions like ischemia and toxic injury. Reversibility implies that the cell can recover its normal structure and function when the damaging stimulus is removed. Incorrect Options: Option B - Karyolysis: Karyolysis refers to the dissolution of the cell nucleus due to DNA degradation. This is indeed a feature of irreversible cell injury. In irreversible injury, the cell's nuclear structure and DNA integrity are compromised beyond repair, leading to processes like karyolysis. Option C - Amorphous Densities: The presence of amorphous densities is often associated with irreversible cell injury. These densities can be observed under electron microscopy and represent aggregates of denatured or altered proteins, lipids, and other cellular components. They are a sign of severe damage and cell death. Option D - Pyknotic Nucleus: Pyknosis is the irreversible condensation of chromatin within the nucleus, resulting in a small, darkly stained and shrunken nucleus. This is indeed a feature of irreversible cell injury. Pyknotic nuclei indicate severe cellular damage that cannot be reversed, leading to cell death.

References:

.

↑ *Back to this question in Part A*

@Neet_pg_bot

Q24: Metastatic calcification occurs in all except ? (Q793597)

A. Kidney

B. Fundus of the stomach

C. Pulmonary veins

D. Atheroma

Correct Answer: D. Atheroma

Explanation: Correct Option D - Atheroma: The type of calcification seen in atheroma is dystrophic calcification. Metastatic calcification: Metastatic calcification is caused by increased calcium phosphate in the blood and may result from hypercalcemia, hyperphosphatemia, or both. It is commonly associated with hyperparathyroidism, sarcoidosis, metastatic disease, and myeloma. Dystrophic calcification: The deposition of calcium salt in degenerated tissues in the absence of a systemic imbalance is called dystrophic calcification. It is mostly associated with trauma, inflammation, or infection. ■■■■■■■ Incorrect Options: Metastatic calcification occurs in options A, B, and C .

References:

.

↑ *Back to this question in Part A*

@Neet_pg_bot

Q25: Which of the following are features describing necrosis? Cell swelling Disrupted cell membrane Induces inflammation Physiological (Q857443)

A. 1 and 2

B. 1, 2 and 4

C. 1, 2 and 3

D. 1 and 3

Correct Answer: C. 1, 2 and 3

Explanation: Necrosis is a form of pathological cell death (Statement 4 ruled out) , often occurring due to various injuries, such as physical trauma, ischemia, infection, or exposure to toxic substances. It is characterized by cell swelling, membrane rupture, organelle damage, and nuclear changes (Pyknosis, Karyorrhexis, Karyolysis). Cell swelling occurs because of the loss of cellular integrity and failure of ion pumps (such as the Na+/K+ ATPase pump), leading to an influx of water into the cell. In necrosis, the plasma membrane of the cell is disrupted , allowing the release of intracellular contents. The released substances trigger an immune response, leading to an inflammatory reaction, which is a characteristic of necrosis.

References:

Robbins and Cotran Pathologic Basis of Disease, 10th Edition, Page 42

↑ *Back to this question in Part A*

@Neet_pg_bot

• [02_Inflammation] 006 Acute Inflammation

« Back to Folder Directory

[02_Inflammation] 006 Acute Inflammation — Quick Jump

Q1 (p. 1088)	*Q2 (p. 1089)*	*Q3 (p. 1090)*	*Q4 (p. 1091)*	*Q5 (p. 1091)*	*Q6 (p. 1092)*
Q7 (p. 1092)	*Q8 (p. 1093)*	*Q9 (p. 1094)*	*Q10 (p. 1094)*	*Q11 (p. 1095)*	*Q12 (p. 1096)*
Q13 (p. 1097)	*Q14 (p. 1098)*	*Q15 (p. 1099)*	*Q16 (p. 1100)*	*Q17 (p. 1101)*	*Q18 (p. 1103)*
Q19 (p. 1104)	*Q20 (p. 1106)*	*Q21 (p. 1108)*	*Q22 (p. 1109)*	*Q23 (p. 1110)*	*Q24 (p. 1111)*
Q25 (p. 1113)	*Q26 (p. 1113)*				

Q1: A 42-year-old man comes with swelling of both ankles. On examination, pitting oedema is noted. Which of the following alterations in Starling forces could contribute to the development of this condition? Increased capillary hydrostatic pressure Decreased capillary hydrostatic pressure Increased plasma oncotic pressure Decreased plasma oncotic pressure (Q879471)

A. 1 and 3

B. 2 and 3

C. 1 and 4

D. 2 and 4

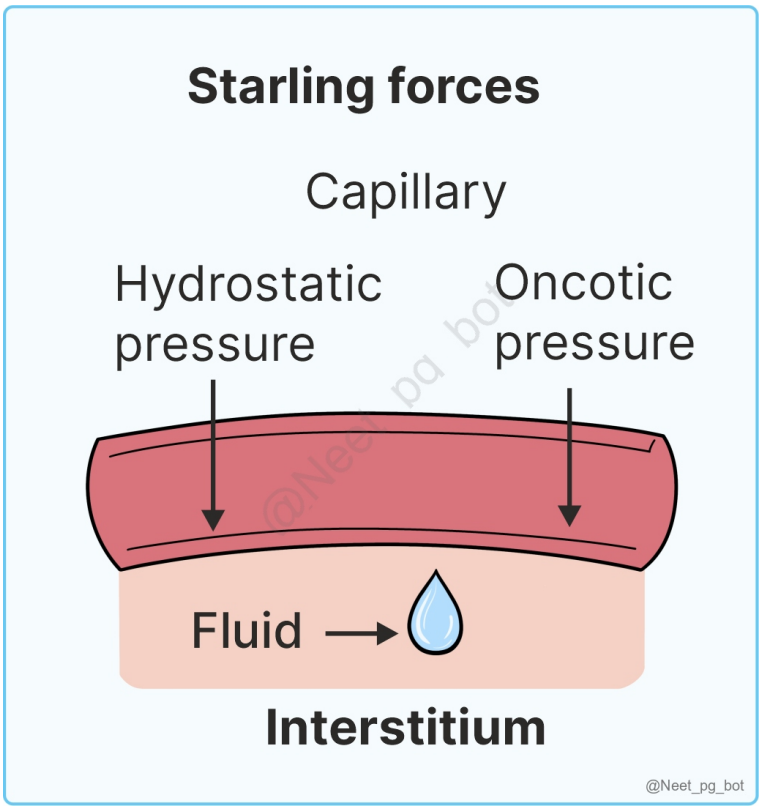

Correct Answer: C. 1 and 4

Explanation: Edema results when the normal balance of Starling forces is disturbed. Increased capillary hydrostatic pressure (e.g., congestive heart failure, venous obstruction) promotes fluid movement out of the vasculature. Decreased plasma oncotic pressure (e.g., hypoalbuminemia from nephrotic syndrome or liver disease) reduces the inward pull of fluid back into capillaries. Both mechanisms lead to the accumulation of interstitial fluid and manifest as pitting oedema. Incorrect Options: 1 and 3 (Option A): Increased capillary hydrostatic pressure increases filtration, but raised plasma oncotic pressure does not favour oedema formation. 2 and 3 (Option B): Decreased capillary hydrostatic pressure and increased plasma oncotic pressure both work to oppose fluid leakage and oedema. 2 and 4 (Option D): Decreased capillary hydrostatic pressure opposes, rather than promotes, oedema.

References:

Robbins and Cotran, Pathologic Basis of Disease, 11th Edition, Page no. 101

↑ *Back to this question in Part A*

@Neet_pg_bot

Q2: Which of the following inflammatory cells contains granules rich in major basic protein, toxic to helminths? (Q879443)

A. Neutrophils

B. Eosinophils

C. Basophils

D. Macrophages

Correct Answer: B. Eosinophils

Explanation: Eosinophils contain major basic protein (MBP) in their granules, which is toxic to helminths and contributes to tissue damage in allergies/asthma. Incorrect Options: Neutrophils (Option A) contain myeloperoxidase and elastase, not MBP. Basophils (Option C) contain histamine and heparin . Macrophages (Option D) contain lysosomal enzymes but no MBP.

References:

Robbins and Cotran, Pathologic Basis of Disease, 11th edition, Page no 89.

↑ *Back to this question in Part A*

@Neet_pg_bot

Q3: A child presents with recurrent pyogenic infections, partial oculocutaneous albinism, and peripheral neuropathy. Which immunodeficiency is most likely due to defective phagolysosome fusion? (Q879442)

A. Chronic granulomatous disease

B. Chediak-Higashi syndrome

C. Mannose-binding lectin deficiency

D. Glanzmann-Rinicker syndrome

Correct Answer: B. Chediak-Higashi syndrome

Explanation: Correct Option B - Chediak-Higashi syndrome Chediak-Higashi syndrome is caused by a defect in the LYST gene, leading to impaired phagolysosome fusion. Clinically presents with recurrent pyogenic infections, partial albinism, and neuropathy. The defect leads to giant, dysfunctional lysosomal granules in various cells, especially neutrophils, melanocytes and nerve cells. Incorrect Options: Chronic granulomatous disease (Option A) Due to an NADPH oxidase defect, resulting in defective respiratory burst rather than defective fusion. Mannose-binding lectin deficiency (Option C) Involves a defect in the complement pathway and is not related to phagolysosome function. Glanzmann thrombasthenia (Option D) A platelet aggregation disorder, not an immune cell fusion defect.

References:

Robbins and Cotran, Pathologic Basis of Disease, 11th edition, Page no 214,104

↑ *Back to this question in Part A*

@Neet_pg_bot

Q4: Which of the following enzymes/proteins is not involved in neutralizing reactive oxygen species? (Q879440)

A. Myeloperoxidase

B. Ceruloplasmin

C. Catalase

D. Glutathione peroxidase

Correct Answer: A. Myeloperoxidase

Explanation: Myeloperoxidase generates hypochlorous acid from H■O■ in neutrophils (microbicidal, not antioxidant). Incorrect Options: Ceruloplasmin (Option B) acts as a ferroxidase, limiting iron-catalyzed free radical formation. Catalase (Option C) decomposes hydrogen peroxide to water and oxygen. Glutathione peroxidase (Option D) reduces hydrogen peroxide and lipid peroxides using glutathione.

References:

Robbins and Cotran, Pathologic Basis of Disease, 11th edition, Page no 74

↑ *Back to this question in Part A*

@Neet_pg_bot

Q5: Which infection is characteristically associated with prolonged neutrophilic infiltration at the site of inflammation, even after 2–3 days? (Q879436)

A. Pseudomonas

B. Staphylococcus

C. Fungal infection

D. Viral infection

Correct Answer: A. Pseudomonas

Explanation: In most infections, neutrophils dominate only in the first 24–48 hours, after which macrophages take over. Pseudomonas is the exception, where neutrophils remain the predominant cell type due to continuous recruitment, even beyond the typical 2–3 day window. Helps differentiate Pseudomonas from other bacterial infections histologically.

References:

Robbins and Cotran, Pathologic Basis of Disease, 11th edition, Page no.71

↑ *Back to this question in Part A*

@Neet_pg_bot

Q6: A 40-year-old woman develops acute pyelonephritis. Within the first 2 days of infection, she experiences high fever, flank pain, and dysuria. Urine microscopy reveals abundant pus cells. Which cell type is the main mediator of tissue damage in this stage of inflammation? (Q879435)

A. Neutrophils

B. Eosinophils

C. Macrophages

D. Plasma cells

Correct Answer: A. Neutrophils

Explanation: Acute inflammation is dominated by neutrophils, which arrive within the first 24–48 hours. They release reactive oxygen species, proteases, and lysosomal enzymes that kill pathogens but also cause collateral tissue injury. Incorrect Options: Eosinophils (Option B) mediate parasitic and allergic responses. Macrophages (Option C) dominate after 48–72 hours and are more important in chronic inflammation. Plasma cells (Option D) are seen in prolonged/chronic inflammation, producing antibodies.

References:

Robbins and Cotran, Pathologic Basis of Disease, 11th edition, Page no. 65,66.

↑ *Back to this question in Part A*

@Neet_pg_bot

Q7: Which of the following adhesion molecules does not serve as a ligand for integrins during leukocyte adhesion? (Q879419)

A. CD54 (ICAM-1)

B. CD102 (ICAM-2)

C. CD106 (VCAM-1)

D. CD34

Correct Answer: D. CD34

Explanation: Integrins on leukocytes bind to members of the immunoglobulin superfamily such as ICAM-1 (CD54), ICAM-2 (CD102), and VCAM-1 (CD106) expressed on endothelial cells. CD34, on the other hand, is a ligand for L-selectin, not integrins.

References:

Robbins and Cotran, Pathologic Basis of Disease, 11th edition, Page no. 71.

↑ *Back to this question in Part A*

@Neet_pg_bot

Q8: Which of the following statements regarding selectins are correct? They mediate the initial rolling of leukocytes on the endothelium There are three main types: L-selectin, E-selectin, and P-selectin P-selectin is expressed on endothelial cells and platelets Selectins mediate firm, high-affinity adhesion of leukocytes (Q879417)

A. 1 and 2 only

B. 1, 2 and 3

C. 2, 3 and 4

D. 1 and 4 only

Correct Answer: B. 1, 2 and 3

Explanation: Selectins are adhesion molecules that mediate low-affinity rolling of leukocytes along the vascular endothelium. The three types are L-selectin (on leukocytes), E-selectin (on endothelial cells), and P-selectin (on platelets and endothelial cells). Firm, high-affinity adhesion is mediated by integrins, not selectins. (Statement 4)

References:

Robbins and Cotran, Pathologic Basis of Disease, 11th edition, Page no. 69.

↑ *Back to this question in Part A*

@Neet_pg_bot

Q9: During normal laminar blood flow in venules, the phenomenon of axial streaming determines the distribution of blood cells. Which cells predominantly occupy the central axial column? (Q879414)

A. Red blood cells

B. Neutrophils

C. Platelets

D. Lymphocytes

Correct Answer: A. Red blood cells

Explanation: In laminar flow, RBCs concentrate in the central axial stream of blood. Leukocytes and platelets are displaced toward the periphery (close to the endothelium), allowing them to migrate out during inflammation or vascular injury. This arrangement facilitates efficient oxygen transport and also enables rapid recruitment of WBCs during acute inflammation.

References:

Robbins and Cotran, Pathologic Basis of Disease, 11th edition, Page no. 67.

↑ *Back to this question in Part A*

@Neet_pg_bot

Q10: A 30-year-old female presents to the clinic with complaints of abdominal discomfort and bloating. Upon further evaluation, an abdominal ultrasound reveals a heterogeneous mass within the right ovary. Subsequent histopathological examination of the ovarian mass demonstrates the presence of entotic cells. Which of the following best describes the process observed in the histopathological findings? (Q845364)

A. Phagocytosis of apoptotic cells by neighboring cells

B. Engulfment of live cells by neighboring cells

C. Fusion of lysosomes within a cell leading to autophagy

D. Exocytosis of cellular debris from a damaged cell

Correct Answer: B. Engulfment of live cells by neighboring cells

■ *Listen (English)*

■ *Listen (Hindi)*

Explanation: A 30-year-old female presents with abdominal discomfort and bloating, and abdominal ultrasound reveals a heterogeneous mass in the right ovary; histopathological examination shows entotic cells, indicating the engulfment of live cells by neighboring cells. Entosis is a phenomenon where live cells are engulfed and internalized by neighbouring cells, forming cell-in-cell structures. It typically occurs in non-phagocytic cells and can be observed in various physiological and pathological contexts, including tumour microenvironments. In the scenario described, the presence of entotic cells within the ovarian mass indicates that live cells are being engulfed by neighbouring cells within the ovary. Phagocytosis of apoptotic cells by neighbouring cells (Option A): Phagocytosis involves the clearance of dead or apoptotic cells by neighbouring phagocytic cells such as macrophages. However, entosis involves the engulfment of live cells, not apoptotic cells. Fusion of lysosomes within a cell leading to autophagy (Option C): Autophagy is a cellular process involved in the degradation and recycling of cellular components but no engulfment of neighboring cells. Exocytosis of cellular debris from a damaged cell (Option D): Exocytosis is the process by which cells release molecules or cellular components into the extracellular space, and it does not involve the engulfment of neighboring cells. Emperipolesis v/s Efferocytosis v/s Entosis: Feature Emperipolesis Efferocytosis Entosis Cell State Viable/intact Apoptotic/dying Viable Phagocyte Histiocytes/tumor Professional (macrophages) Neighboring epithelial Fate No degradation, exits Lysosomal digestion Degraded/persists Purpose Dynamic transit Homeostasis Cell competition Pathology Rosai-Dorfman SLE, atherosclerosis Cancer

References:

https://www.ncbi.nlm.nih.gov/pmc/articles/PMC9102690/

↑ *Back to this question in Part A*

@Neet_pg_bot

Q11: A 6-month-old male infant presents with recurrent bacterial infections, including otitis media and pneumonia. Laboratory investigations reveal markedly reduced levels of all immunoglobulin classes (IgG, IgA, and IgM). Flow cytometry analysis shows a complete absence of mature B cells in peripheral blood. Which of the following gene mutations is most likely responsible for this condition? (Q845372)

A. BTK gene

B. LYST gene

C. WASP gene

D. ADA gene

Correct Answer: A. BTK gene

■ *Listen (English)*

■ *Listen (Hindi)*

Explanation: The given clinical presentation suggests X-linked agammaglobulinemia (XLA) also known as Bruton's Hypogammaglobulinemia, an X-linked recessive disorder characterized by a complete absence or markedly reduced number of mature B cells in peripheral blood due to mutations in the Bruton tyrosine kinase (BTK) gene located on the X chromosome. B cells are absent or markedly decreased in circulation, but the pre-B cell level is normal in the bone marrow. XLA is characterized by markedly reduced levels of all immunoglobulin classes (IgG, IgA, and IgM), leading to hypogammaglobulinemia and defective Opsonization (due to ↓IgG). It typically presents in infancy with recurrent bacterial infections, particularly affecting the respiratory tract, ears, and sinuses. Replacement therapy with immunoglobulins (IVIG) is the mainstay of treatment. Gene mutation Diseases Findings BTK gene X-linked agammaglobulinemia or Bruton's Hypogammaglobulinemia Hypogammaglobulinemia (low IgG, IgA, IgM); absent B cells on flow cytometry. LYST gene (Option B) Chediak-Higashi syndrome Giant granules in neutrophils are visible in peripheral blood smears. WASP gene (Option C) Wiskott-Aldrich Syndrome Triad: Thrombocytopenia, eczema, and recurrent infections. ADA/IL2RG gene (Option D) Severe Combined Immunodeficiency Profound lymphopenia (primarily T-cells); absent/reduced T & B cells; reduced ADA enzyme activity CD40L gene Hyper IgM Syndrome ↑IgM, ↓IgG/IgA; normal B cells; opportunistic infections (PCP) CYBB/gp91phox gene X-linked Chronic Granulomatous Disease (X-CGD) Recurrent catalase+ infections (Aspergillus, Staph. aureus); NBT/DHR test negative■ ITGB2/CD18 gene Leukocyte Adhesion Deficiency (LAD) Delayed separation of the umbilical cord; absent pus formation ; high neutrophils in blood (but they can't reach the site of infection). AIRE/STAT1 gene Chronic Mucocutaneous Candidiasis Non-invasive Candida infections of skin/nails; normal T/B numbers; anti-IL17 autoantibodies; often associated with autoimmune polyendocrine syndrome

References:

Robbins and Cotrans pathologic basis of disease, 10th Edition, Pages 252-255

↑ *Back to this question in Part A*

@Neet_pg_bot

Q12: Which of the following defects is most likely associated with Leukocyte Adhesion Deficiency Type 1 (LAD)-1? (Q845370)

A. Defective synthesis of β2 integrin

B. Defective synthesis of Sialyl Lewis X modified glycoprotein

C. Defective FERMT3 gene

D. Myeloperoxidase deficiency

Correct Answer: A. Defective synthesis of β2 integrin

■ *Listen (English)*

■ *Listen (Hindi)*

Explanation: The given clinical scenario suggests Leukocyte Adhesion Deficiency Type 1 (LAD-1) , which is characterized by defective synthesis of the β2 chain of CD11/CD18 integrins (β2 integrin), resulting in defective leukocyte adhesion to endothelium. Leukocyte Adhesion deficiencies (LAD) are rare autosomal recessive disorders LAD-1 LAD-2 LAD-3 Defective synthesis of β2 chain of CD11/CD18 integrins (β2 integrin). (Option A) Defective synthesis of sialyl-Lewis X modified glycoprotein, a ligand for E- and P-selectins. (Option B) Mutations in the FERMT3 genes. (Option C) Clinical manifestations include delayed separation of the umbilical cord stump in newborns, and recurrent bacterial infections. Clinically, LAD 2 patients may exhibit a Bombay Blood group phenotype. Clinical presentation is similar to LAD-1, along with bleeding disorders due to platelet dysfunction. {{caption_text}} Myeloperoxidase deficiency (Option D) is a rare inherited autosomal recessive disorder in which neutrophils lack functional MPO enzymes, impairing their ability to produce reactive oxygen species (ROS) essential for microbial killing. Due to reduced microbicidal activity, these patients are susceptible to recurrent bacterial and fungal infections, especially in mucosal tissues (invasive candida infection).

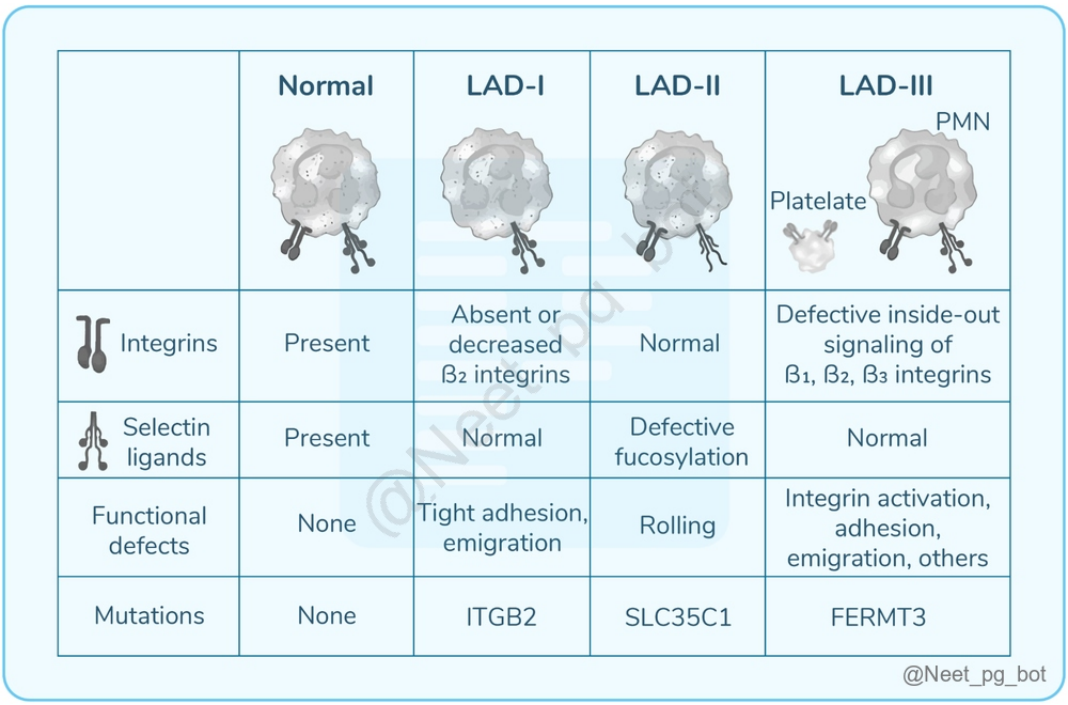

References:

Robbins and Cotrans pathologic basis of disease, 10th Edition, Page 241 https://www.uptodate.com/contents/leukocyte-adhesion-deficiency?search=leukocyte%20adhesion%20deficiency&source=search_result&selectedTitle=1%7E24&usage_type=default&display_rank=1#H29

↑ *Back to this question in Part A*

@Neet_pg_bot

Q13: Which condition is characterized by recurrent catalase positive bacterial, and fungal infections, defective nitroblue tetrazolium (NBT) test results, and deficient

reactive oxygen species production by phagocytes? (Q845366)

A. Leukocyte Adhesion Deficiency

B. Hyper-IgM Syndrome

C. X-linked Agammaglobulinemia

D. Chronic Granulomatous Disease

Correct Answer: D. Chronic Granulomatous Disease

■ *Listen (English)*

■ *Listen (Hindi)*

Explanation: The given clinical presentation, with recurrent catalase-positive bacterial and fungal infections, negative nitroblue tetrazolium (NBT) test results, and deficient reactive oxygen species production by phagocytes, is due to defective NADPH Oxidase, suggesting Chronic Granulomatous Disease (CGD) . It can be X-linked recessive (75% cases) or autosomal recessive (25% cases). diagnosis: Nitroblue tetrazolium test (NBT) is a screening test commonly used to assess the respiratory burst activity of phagocytes. In CGD, phagocytes fail to reduce NBT to its insoluble form, resulting in a negative NBT test. Dihydrorhodamine test (DHR) is the confirmatory test for CGD done by flow cytometry. Leukocyte Adhesion Deficiency (Option A): Leukocyte Adhesion Deficiency (LAD) is a group of disorders characterized by defects in leukocyte adhesion or migration, leading to impaired immune responses. It is of 3 types: LAD I: Defect in β2 integrin LAD II: Deficiency of sialyl-Lewis X LAD III: Mutation in the FERMT3 gene Hyper-IgM Syndrome (Option B) is a group of primary immunodeficiency disorders marked by elevated IgM levels and decreased levels of other immunoglobulin isotypes, resulting from defects in either the CD40 ligand and the CD40 receptor. X-linked Agammaglobulinemia (Option C) , also known as Bruton’s agammaglobulinemia or Bruton's disease, is caused by mutations in the BTK gene and primarily affecting boys, is characterized by a lack of mature B cells and impaired immunoglobulin production, resulting in recurrent bacterial infections■■■■■.

References:

Robbins and Cotrans pathologic basis of disease, 10th Edition, Page 241.

↑ *Back to this question in Part A*

@Neet_pg_bot

Q14: Which among the following is a cardinal sign of inflammation? (Q845313)

A. Prolonged fever

B. Tissue scarring

C. Abrasions

D. Redness

Correct Answer: D. Redness

■ *Listen (English)*

■ *Listen (Hindi)*

Explanation: Among the given options, redness is one of the cardinal signs of inflammation. Cardinal signs of inflammation: Redness (Rubor) is caused by increased blood flow to the affected area due to vasodilation of blood vessels. Heat (Calor): The increased temperature at the site of inflammation due to vasodilation and increased blood flow. Swelling (Tumor): Accumulation of fluid and inflammatory cells, leading to tissue swelling. Pain (Dolor): Sensory nerve stimulation due to tissue damage, increased pressure from swelling, and release of inflammatory mediators. Loss of Function (Functio Laesa): Impairment or loss of normal tissue function. While the 1st four signs were given by Celsus, Functio Laesa was given by Sir Rudolf Virchow. Prolonged fever, Tissue scarring and Abrasions (Option A,B and C) are not cardinal sign of inflammation

References:

https://pubmed.ncbi.nlm.nih.gov/35258243/

↑ *Back to this question in Part A*

@Neet_pg_bot

Q15: Which of the following statements is incorrect regarding Emperipolesis and Phagocytosis? (Q845362)

A. Emperipolesis involves engulfment by any cell depending on disease; Phagocytosis involves engulfment by macrophages, neutrophils, and dendritic cells.

B. Emperipolesis doesn’t involve the killing of the cell; phagocytosis results in the degradation of engulfed cells.

C. Emperipolesis maintains internalized cell membrane integrity; Phagocytosis involves the fusion of engulfed material with lysosomes.

D. Emperipolesis is physiological; phagocytosis is pathological.

Correct Answer: D. Emperipolesis is physiological; phagocytosis is pathological.

■ *Listen (English)*

■ *Listen (Hindi)*

Explanation: Emperipolesis is seen in pathological conditions whereas phagocytosis can be physiological/pathological response. Feature Emperipolesis Phagocytosis Entosis Definition Emperipolesis is a cellular phenomenon characterized by the internalization of one cell within another without causing cell death. Phagocytosis is a cellular process by which certain specialized cells engulf and digest foreign particles, pathogens, dead cells, and cellular debris. Entosis is the internalisation of a live cell by a neighbouring cell, forming a

cell-in-cell structure. Cell Type The large cell dependent on organ/ disease (Option A ruled out) Engulfing cells can be macrophages, neutrophils, and dendritic cells. (Option A ruled out) Typically occurs in non-phagocytic cells (e.g., epithelial or tumor cells). Fate of Internalized Cell No killing of the internalized cell. The engulfed cell often remains viable within the host cell. (Option B ruled out) Typically digest and degrade the engulfed material such as bacteria or cellular debris. (Option B ruled out) The engulfed cell is initially alive , but it is often eventually degraded (cell cannibalism). Mechanism / Integrity The engulfed cell maintains its own membrane integrity. (Option C ruled out) The engulfed material typically fuses with lysosomes for digestion. (Option C ruled out) Driven by actomyosin-mediated contraction; the "loser" cell is internalized by the "winner." Clinical Context It is seen in pathological conditions such as autoimmune diseases, lymphoproliferative disorders, or histiocytic disorders. (Option D) Can be physiological (tissue turnover, apoptotic cells), can be pathological (infection, inflammation). (Option D) Often observed in tumor microenvironments and various physiological/pathological contexts.

References:

Robbins and Cotrans pathologic basis of disease, 10th Edition, Page 80

↑ *Back to this question in Part A*

@Neet_pg_bot

Q16: A 45-year-old male complains of painless bilateral cervical lymphadenopathy for the past six months. Biopsy of a lymph node reveals sheets of large histiocytes with emperipolesis, surrounded by lymphocytes and plasma cells. What is the most likely diagnosis? (Q845360)

A. Hodgkin lymphoma

B. Sarcoidosis

C. Infectious mononucleosis

D. Rosai-Dorfman disease

Correct Answer: D. Rosai-Dorfman disease

■ *Listen (English)*

■ *Listen (Hindi)*

Explanation: The given clinical scenario and histopathological findings suggest Rosai-Dorfman disease which typically presents with painless bilateral cervical lymphadenopathy and is characterized by the presence of large histiocytes with emperipolesis, where intact lymphocytes are seen within the cytoplasm of histiocytes . Emperipolesis is the phenomenon of one cell residing within another cell, usually a macrophage, without causing death to the cell. The internalized cell is enclosed within the cytoplasmic vacuole of the host cell without fusion of their membranes. This phenomenon is seen in conditions like (Mnemonic - MARC) : Myelodysplastic Syndrome/Myeloproliferative Neoplasm (MDS/MPN) Autoimmune Hepatitis (Lymphocytes and plasma cells

may be seen within the cytoplasm of hepatocytes). Rosai-Dorfman disease Chronic Lymphocytic Leukemia (CLL) {{caption_text}} Hodgkin's lymphoma (Option A) is identified by Reed-Sternberg cells (Owl eye appearance), which are large, multinucleated cells with prominent nucleoli but not associated with emperipolesis. Sarcoidosis (Option B) is characterized by non-caseating granulomas. Infectious mononucleosis (Option C) , caused by the Epstein-Barr virus (EBV), can present with cervical lymphadenopathy, but it typically involves lymphoid hyperplasia with reactive lymphocytes but doesn't show large histiocytes with emperipolesis.

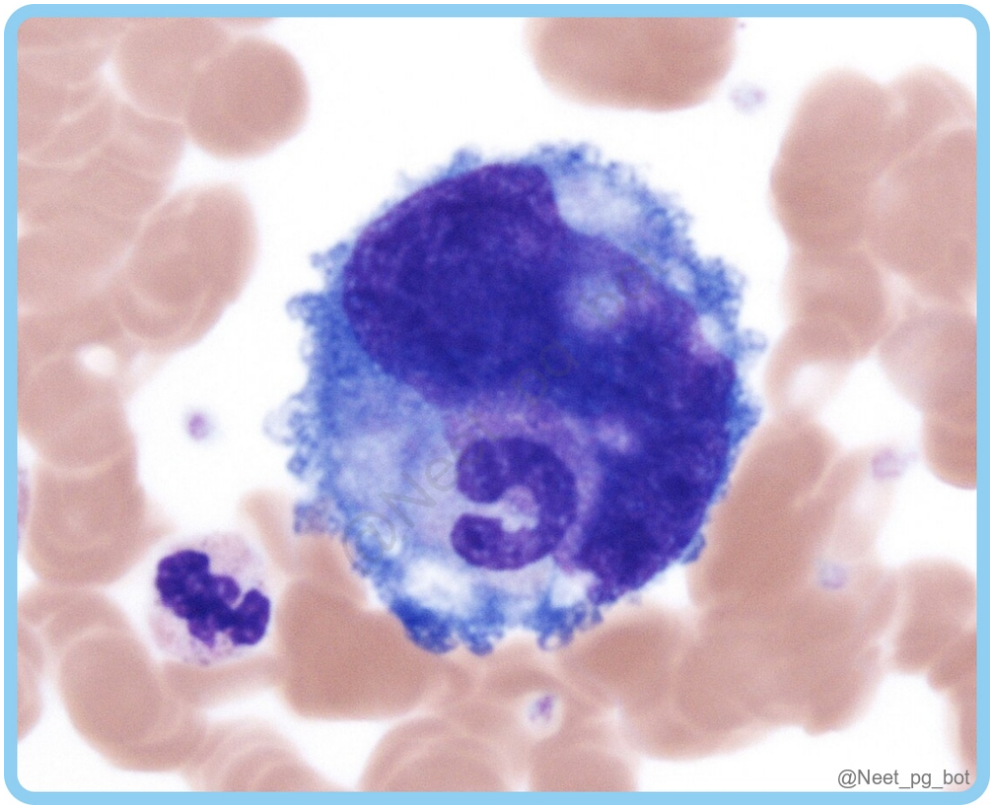

References:

Robbins and Cotrans pathologic basis of disease, 10th Edition, Pages 80, 843

↑ *Back to this question in Part A*

@Neet_pg_bot

Q17: Which of the following statements regarding neutrophil extracellular traps (NETs) is incorrect? (Q845359)

A. NETs are formed in response to infectious pathogens and inflammatory mediators.

B. NETs consist of nuclear chromatin and granule proteins like antimicrobial peptides and enzymes.

C. NET formation is initiated by the release of histones from activated neutrophils.

D. NETs directly phagocytose the invading pathogens.

Correct Answer: D. NETs directly phagocytose the invading pathogens.

■ *Listen (English)*

■ *Listen (Hindi)*

Explanation: Neutrophil extracellular traps (NETs) are extracellular fibrillar structures that localize antimicrobial substances at infection sites and trap microbes, helping to prevent their spread by directly targeting invading pathogens. NETs do not directly phagocytose or engulf the invading pathogens. Instead, they trap pathogens within their structure, immobilizing them and allowing other immune cells, such as macrophages, to recognize and eliminate them. (Option D) They are produced by neutrophils in response to infectious pathogens (mainly bacteria and fungi) and inflammatory mediators (e.g., chemokines, cytokines, complement proteins, and ROS). (Option A ruled out) NET formation starts with ROS-dependent activation of an arginine deaminase that converts arginine to citrulline, leading to chromatin decondensation. NETs are composed of nuclear chromatin and various granule proteins, including antimicrobial peptides and enzymes that help to neutralize and kill pathogens trapped within the NETs. (Option B ruled out) Activated neutrophils release histones into the extracellular space, which helps to unwind and release the DNA, allowing it to combine with granule proteins and form the characteristic web-like structure of NETs. (Option C ruled out) They have been detected in conditions like sepsis, emphasizing their importance in immune protection. The nuclear chromatin in the NETs, which includes histones and associated DNA, has been postulated to be a source of nuclear antigens in systemic autoimmune diseases, particularly lupus, in which individuals react against their own DNA and nucleoproteins. {{caption_text}} {{caption_text}} A neutrophil granulocyte (yellow) has ejected a NET (green) to capture bacteria (purple). A red blood cell (orange) is also trapped in the NET.

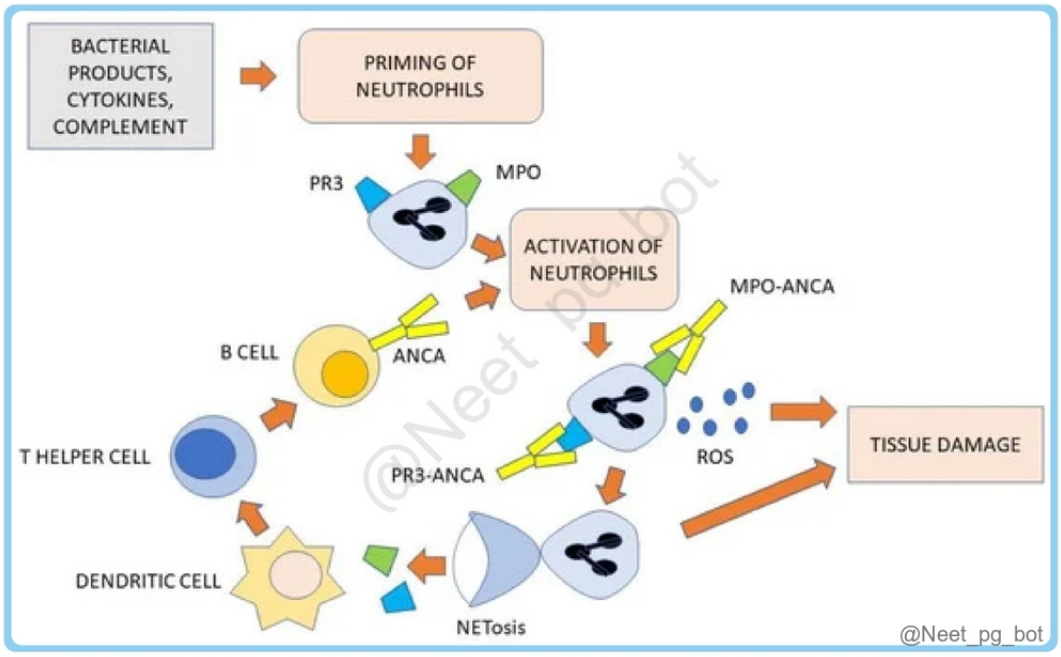

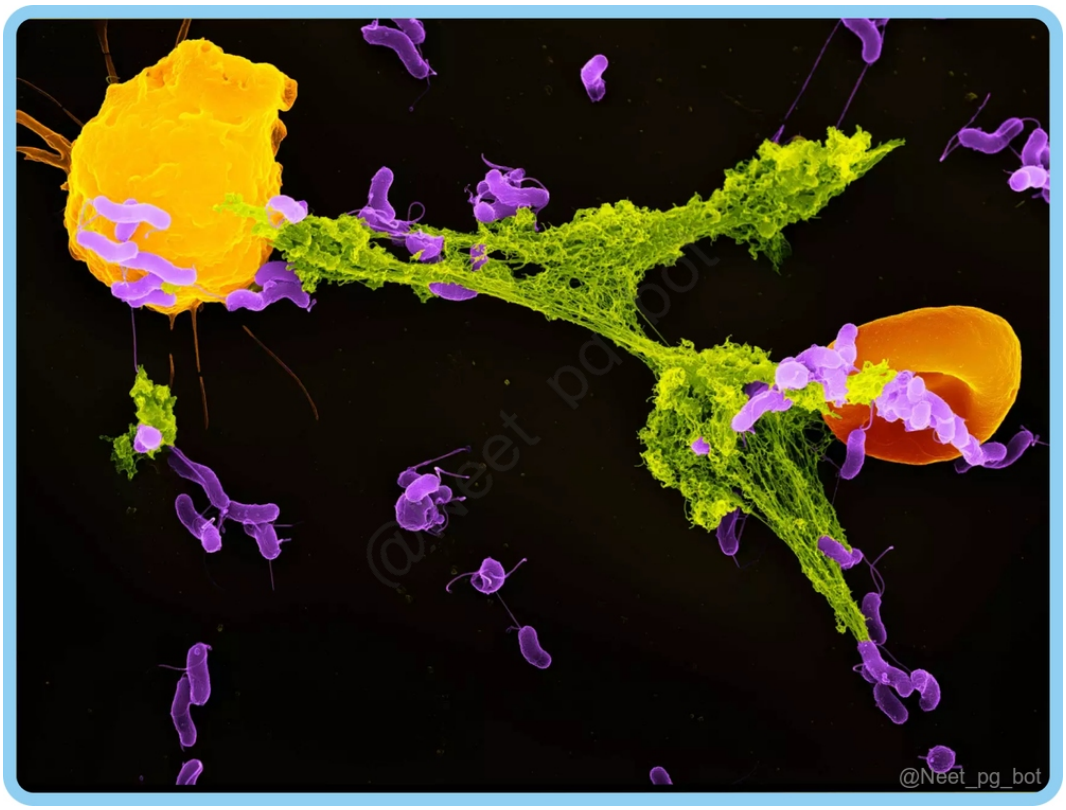

References:

Robbins and Cotrans pathologic basis of disease, 10th Edition, Page 83

↑ *Back to this question in Part A*

@Neet_pg_bot

Q18: A 40-year-old male presents with recurrent bacterial infections. Laboratory tests reveal reduced opsonization activity in his serum. Which of the following processes is primarily affected in this patient? (Q845356)

A. Complement activation

B. Diapedesis

C. Microbial engulfment

D. Leucocyte rolling.

Correct Answer: C. Microbial engulfment

■ *Listen (English)*

■ *Listen (Hindi)*

Explanation: A 40-year-old male presents with recurrent bacterial infections, and laboratory tests show decreased opsonization activity in his serum, indicating that the primary process affected is microbial engulfment. Microbial engulfment refers to the process by which phagocytes engulf and internalize pathogens for destruction. Opsonization plays a critical role in this process by coating pathogens with opsonins that enhance phagocytosis. Reduced opsonization activity in serum directly impacts microbial engulfment, as pathogens are less efficiently recognized and phagocytosed by immune cells. Opsonins are substances that coat pathogens or foreign particles, making them more recognizable and easier for phagocytic cells to engulf. They act as "handles" that bind to both the pathogen and the receptor on the phagocyte. {{caption_text}} Opsonin is divided into 3 Categories: IgG (Most important opsonin) Complement proteins (C 3b , C 4b , C 5b): The most important complement opsonin C 3b Plasma Protein (E.g., Fibrinogen) Effect of reduced opsonization: Phagocytes (macrophages/neutrophils) cannot efficiently engulf microbes Leads to recurrent infections Complement activation (Option A), Diapedesis (Option B), and Leukocyte rolling (Option D) are not affected by reduced opsonization.

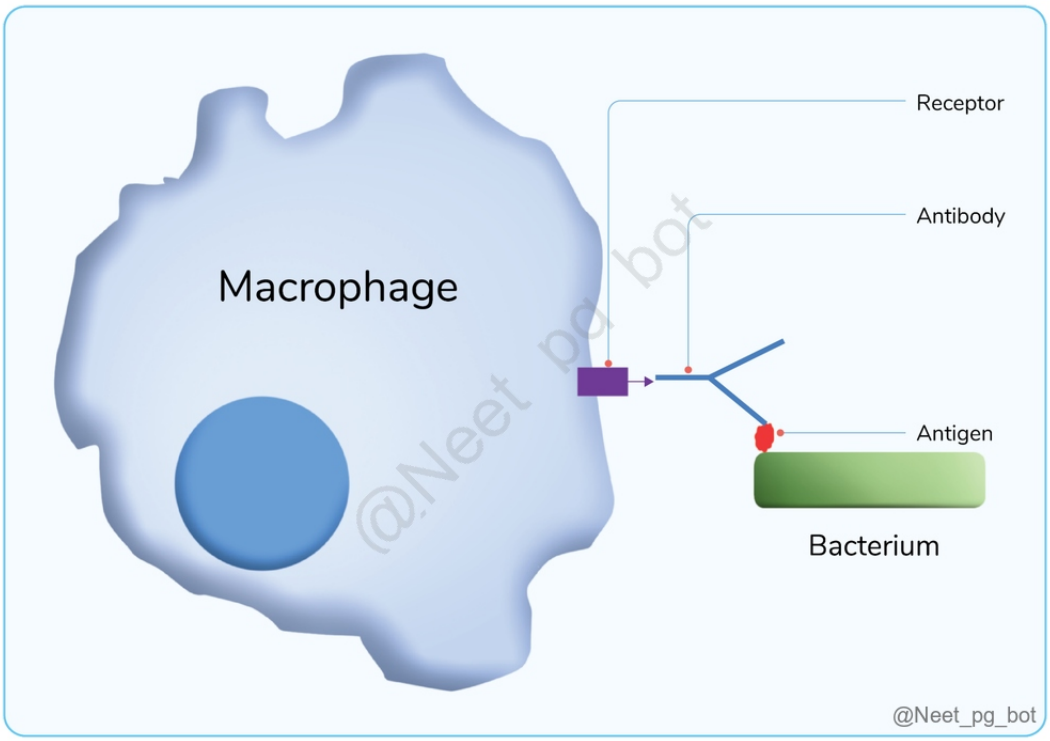

References:

Robbins and Cotrans pathologic basis of disease, 10th Edition, Pages 47-48

↑ *Back to this question in Part A*

@Neet_pg_bot

Q19: A 45-year-old man with a history of poorly controlled diabetes presents to the hospital with complaints of fever, productive cough, and chest pain. Chest imaging

reveals the presence of multiple cavitary lesions in the lung parenchyma. Microscopic examination of lung tissue obtained via biopsy demonstrates numerous neutrophils and macrophages surrounding fungal hyphae. Which of the following phenomena is most likely associated with the formation of these cavitary lesions? (Q845347)

A. Activation of complement proteins

B. Release of lysozymes from neutrophils

C. Impaired phagocytosis

D. Formation of neutrophil extracellular traps (NETs)

Correct Answer: C. Impaired phagocytosis

■ *Listen (English)*

■ *Listen (Hindi)*

Explanation: A 45-year-old man with poorly controlled diabetes presents with fever, productive cough, and chest pain, and chest imaging shows multiple cavitary lesions in the lungs; biopsy reveals fungal hyphae surrounded by neutrophils and macrophages, with the formation of these cavities most likely linked to impaired phagocytosis. In cases of severe infection or in the presence of large pathogen loads, the process of phagocytosis may become ineffective, resulting in incomplete or impaired phagocytosis which is known as ‘ Frustrated Phagocytosis .’ Frustrated phagocytosis: Macrophages cannot engulf large fungal hyphae Leads to the release of lysosomal enzymes Causes tissue necrosis and cavity formation Seen in poorly controlled diabetics with fungal infections Microscopy: Fungal hyphae surrounded by neutrophils and macrophages {{caption_text}} Activation of complement proteins (Option A): Complement opsonizes fungi for phagocytosis but doesn't cause tissue destruction/cavitation; effective in early defense, not lesion formation. Release of lysozymes from neutrophils (Option B) : Lysozymes degrade bacterial peptidoglycan (weak vs. fungal cell walls); ineffective against thick mucormycosis hyphae, so doesn't contribute to necrosis.■ Formation of neutrophil extracellular traps (NETs) (Option D) : NETs trap fungi but are dysregulated in diabetes (excessive/prolonged) and ineffective vs. Mucorales (fungi express enzymes to degrade NETs + high ambient iron blocks NET formation); contribute to inflammation but not primary cavitation mechanism.

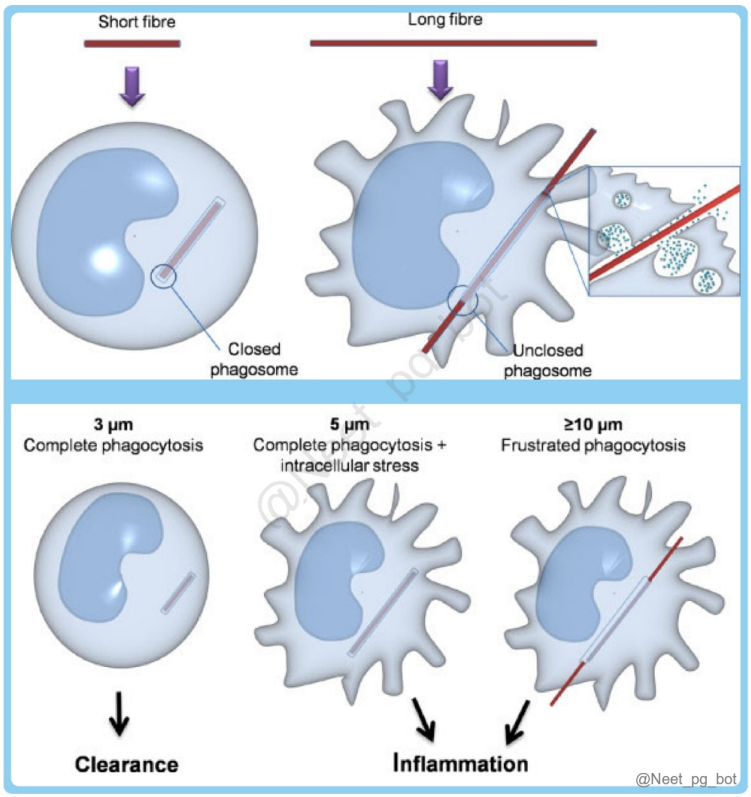

References:

Robbins and Cotrans pathologic basis of disease, 10th Edition, Pages 49-51

↑ *Back to this question in Part A*

@Neet_pg_bot

Q20: Which of the following plays a crucial role in mediating firm adhesion of leukocytes during acute inflammation? (Q845345)

A. CD11a/CD18

B. PECAM 1

C. CD31

D. CD44

Correct Answer: A. CD11a/CD18

■ *Listen (English)*

■ *Listen (Hindi)*

Explanation: CD11a/CD18 plays a crucial role in mediating firm adhesion of leukocytes during acute inflammation. Adhesion types in inflammation: Rolling & weak adhesion → mediated by selectins Firm adhesion → mediated by integrins β■ integrin (VLA) β■ integrin (LFA-1/MAC-1 = CD11/CD18) → mediates firm adhesion (Option A) PECAM 1 (platelet endothelial cell adhesion molecule 1), also known as CD31 , plays a role in leukocyte transmigration across endothelial junctions. (Options B & C ruled out). CD44 (Option D) is a cell surface glycoprotein that serves as a receptor for hyaluronic acid, a component of the extracellular matrix. It does not involve firm adhesion of transmigration of leukocytes. {{caption_text}} Sequence of Acute Inflamation: Stage Process Key Events 1. Vascular Response Vasodilation & Increased Permeability Transient vasoconstriction followed by rapid vasodilation; increased blood flow causes redness (rubor) and heat (calor). 2. Exudation Fluid Leakage Fluid and proteins move into the interstitial tissue (edema), leading to swelling (tumor). 3. Margination Leukocyte Positioning Blood flow slows (stasis), allowing leukocytes to move from the center of the vessel to the periphery (endothelial surface). 4. Rolling & Adhesion Attachment Leukocytes "roll" along the endothelium via selectins and bind firmly via integrins (e.g., CD18). 5. Transmigration Diapedesis Leukocytes squeeze through endothelial gaps, often at post-capillary venules. 6. Chemotaxis Migration Leukocytes follow a chemical gradient (e.g., C5a, LTB4) to the specific site of injury. 7. Phagocytosis Clearance Specialized cells (macrophages, neutrophils) engulf and digest pathogens or debris. Major mediators of inflammation: Mediator Class Specific Examples Principal Action Vasoactive Amines Histamine, Serotonin Cause immediate vasodilation and increased vascular permeability. Arachidonic Acid Metabolites LTB4 (Leukotriene B4), Prostaglandins LTB4 acts as a potent chemoattractant; Prostaglandins mediate pain and fever. Complement System C5a , C3a C5a is a powerful chemotactic factor; C3b acts as an opsonin for phagocytosis. Cytokines TNF, IL-1, IL-2RG (signaling) Mediate systemic acute-phase responses (fever) and leukocyte activation. Chemokines IL-8 Recruit specific subsets of leukocytes to the inflammatory site. Reactive Oxygen Species NADPH oxidase products Used in the "respiratory burst" to kill engulfed pathogens.

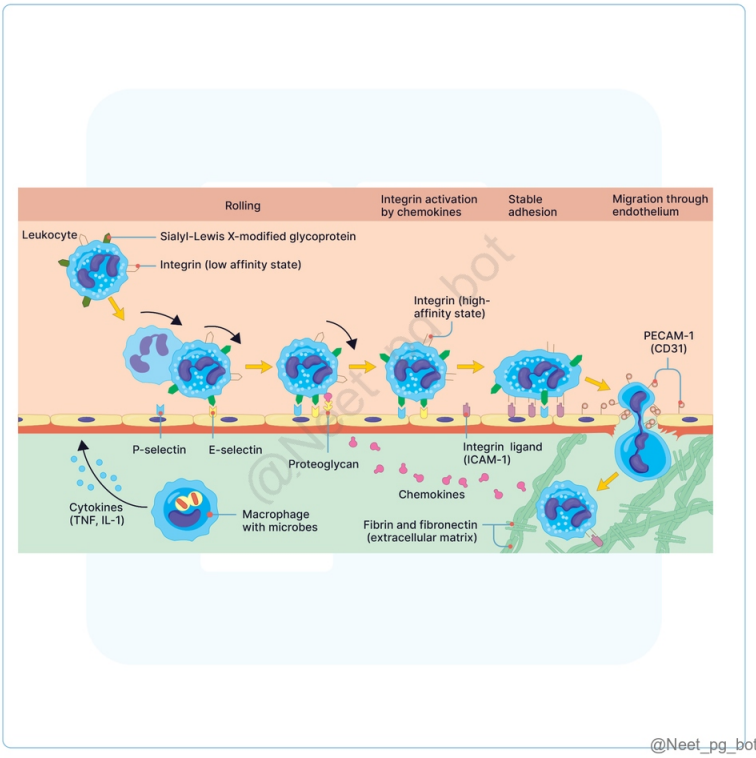

References:

Robbins and Cotrans pathologic basis of disease, 10th Edition, Page 73-74

↑ *Back to this question in Part A*

@Neet_pg_bot

Q21: A patient presents with fluid accumulation in the pleural cavity. Which of the following characteristics would be consistent with a diagnosis of exudate rather than a transudate? (Q845336)

A. High LDH

B. Low protein concentration

C. Presence of mainly albumin

D. Low specific gravity

Correct Answer: A. High LDH

■ *Listen (English)*

■ *Listen (Hindi)*

Explanation: Of the options provided, elevated LDH is a distinguishing feature of an exudate. Features Transudate Exudate Mechanism Ultrafiltrate of plasma due to increased hydrostatic pressure with normal vascular permeability (non-inflammatory process). Inflammatory process with increased vascular permeability Appearance Clear, serous fluid Cloudy/purulent/hemorrhagic Specific gravity (Option D ruled out) Low (<1.018) High (>1.018) Protein (Option B, C ruled out) Low (<2g/dl), mainly albumin High (>2g/dl) Clot Absent Present (Due to high fibrinogen level) Cell count Low High Types of cells Few lymphocytes and mesothelial cells Neutrophils in acute and lymphocytes in chronic inflammation Bacteria Absent Present LDH (Option A) Low High Seen in Congestive cardiac failure Cirrhosis Nephrotic Syndrome Pyogenic infections Malignancy Pancreatitis {{caption_text}} Light's Criteria: To definitively distinguish between the two, clinicians use Light's Criteria . Fluid is classified as an exudate if it meets at least one of the following: Pleural Fluid Protein / Serum Protein ratio > 0.5 Pleural Fluid LDH / Serum LDH ratio > 0.6 Pleural Fluid LDH > 2/3 the upper limit of normal for serum LDH.

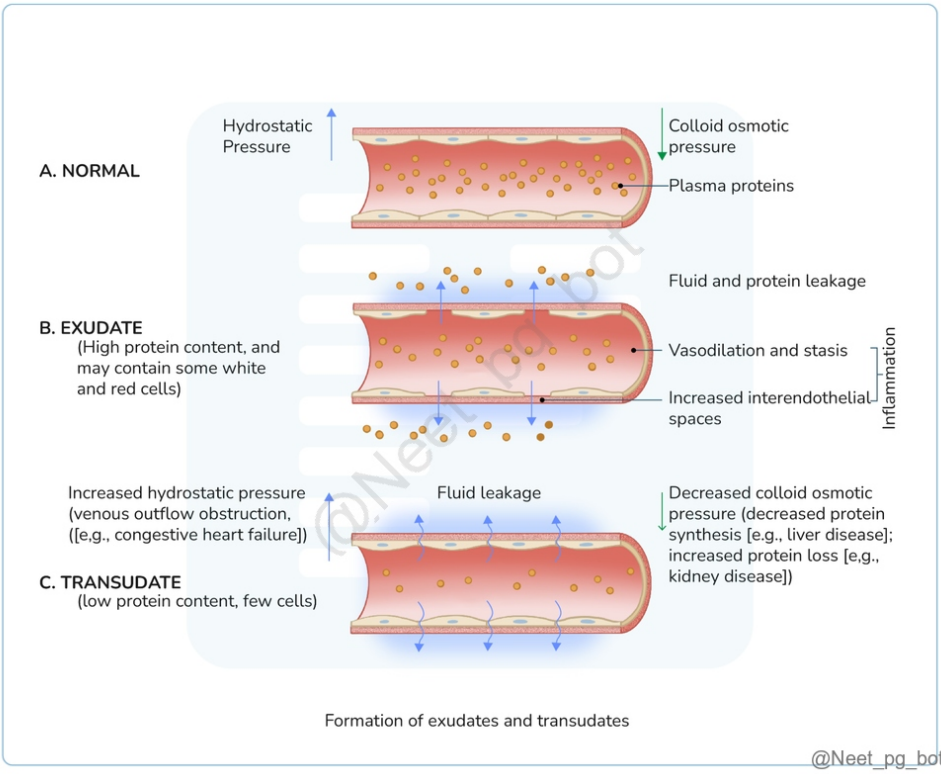

References:

Robbins and Cotrans pathologic basis of disease, 10th Edition, Page 75

↑ *Back to this question in Part A*

@Neet_pg_bot

Q22: Which of the following is considered the hallmark event of acute inflammation? (Q845332)

A. Vasodilation

B. Increased vascular permeability

C. Stasis

D. Leukocyte extravasation

Correct Answer: B. Increased vascular permeability

■ *Listen (English)*

■ *Listen (Hindi)*

Explanation: Increased vascular permeability, particularly in postcapillary venules, is considered the primary hallmark event of acute inflammation. This process enables the passage of plasma proteins, fluids, and white blood cells from the bloodstream into the tissue. Endothelial contraction is the primary cause of increased Vascular Permeability, particularly in the rapid, transient phase of acute inflammation. Vascular events -> Cellular events Transient vasoconstriction. Vasodilation. Increased vascular permeability. Stasis. Margination. Rolling. Adhesion. Transmigration. Chemotaxis. Opsonization. Phagocytosis.

References:

Robbins and Cotrans pathologic basis of disease, 10th Edition, Page 76

↑ *Back to this question in Part A*

@Neet_pg_bot

Q23: Which of the following mechanisms primarily contributed to the increased vascular permeability in this patient's with a right knee injury after fall from stairs? (Q845326)

A. Contraction of endothelial cells resulting in the opening of interendothelial gaps

B. Direct damage to endothelial cells

C. Neutrophil-mediated injury to the endothelium

D. Proliferation of lymphatic vessels

Correct Answer: A. Contraction of endothelial cells resulting in the opening of interendothelial gaps

■ *Listen (English)*

■ *Listen (Hindi)*

Explanation: Increased vascular permeability in this patient with a right knee injury from a fall is mainly caused by endothelial cell contraction, which creates interendothelial gaps. The primary mechanism is the contraction of endothelial cells, leading to the opening of interendothelial gaps. This is mediated by various inflammatory mediators released in response to tissue injury, including histamine, bradykinin, and leukotrienes. Immediate transient response (occurs within minutes and lasts for a short duration) {{caption_text}} Direct damage to endothelial cells (Option B), Neutrophil-mediated injury to the endothelium (Option C), and Proliferation of lymphatic vessels (Option D) do not mediate mechanical injury as given in the scenario.

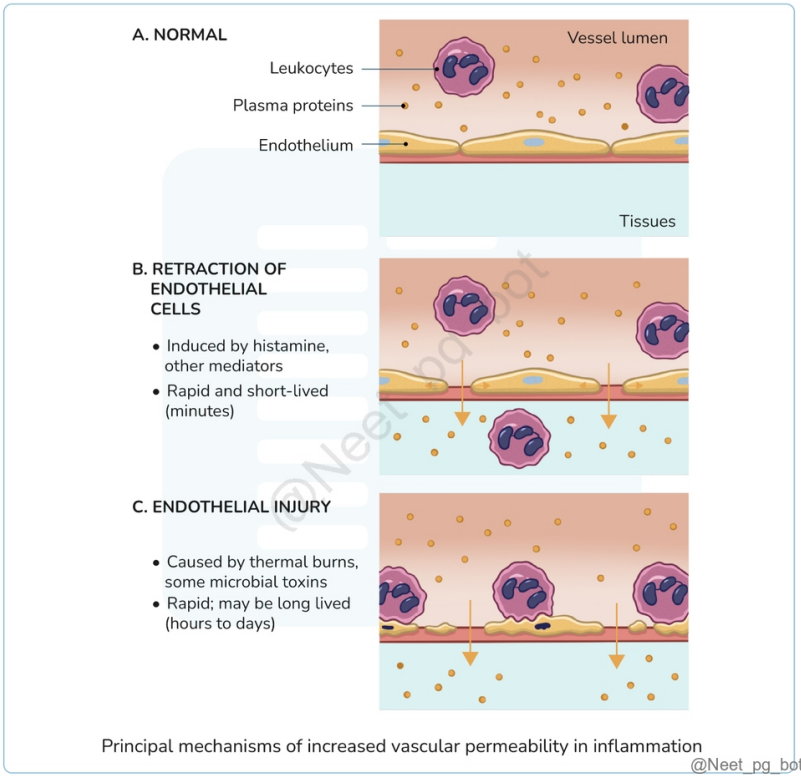

Principal mechanisms of increased vascular permeability in inflammation

@Neet_pg_bot

References:

Robbins and Cotrans pathologic basis of disease, 10th Edition, Page 76

↑ *Back to this question in Part A*

@Neet_pg_bot

Q24: A 30-year-old male presents to the emergency department with sudden onset right lower abdominal pain, accompanied by nausea and fever. On examination, there is tenderness over McBurney's point, and rebound tenderness is noted. Laboratory investigations reveal leukocytosis. Which type of inflammation is most likely to be associated with the following clinical scenario? (Q845322)

A. Serous inflammation

B. Fibrinous inflammation

C. Purulent inflammation

D. Ulcerative inflammation

Correct Answer: C. Purulent inflammation

■ *Listen (English)*

■ *Listen (Hindi)*

Explanation: The given clinical findings point towards the diagnosis of acute appendicitis, and purulent inflammation is likely to be associated with this condition. Purulent inflammation is characterized by the production of pus, an exudate consisting of neutrophils, the liquefied debris of necrotic cells, and oedema fluid. Abscesses are localized collections of pus caused by suppuration buried in tissue, organ, or confined space. Examples: Acute appendicitis ; abscesses; bacterial meningitis; lobar pneumonia; empyema. {{caption_text}} Serous inflammation (Option A): Accumulation of fluid in body cavities is called an effusion, which can occur due to increased vascular permeability or local irritation. Examples : Blister from burn; pleural effusion in viral pleuritis; early-stage transudates. Fibrinous inflammation (Option B): Fibrinous inflammation involves the deposition of fibrin in the extracellular space due to increased vascular permeability. Histologically, fibrin appears as an eosinophilic meshwork of threads or an amorphous coagulum. Examples : Fibrinous pericarditis (bread & butter appearance); fibrinous pneumonia); uremic pericarditis. Ulcerative inflammation (Option D): Ulcerative inflammation involves local defects or excavations of an organ or tissue's surface caused by the shedding of inflamed necrotic tissue, which is common in mucosal surfaces, the skin, and subcutaneous tissues. Examples : Peptic ulcers (stomach/duodenum); aphthous ulcers (canker sores); tuberculous ulcer; amebic colitis.

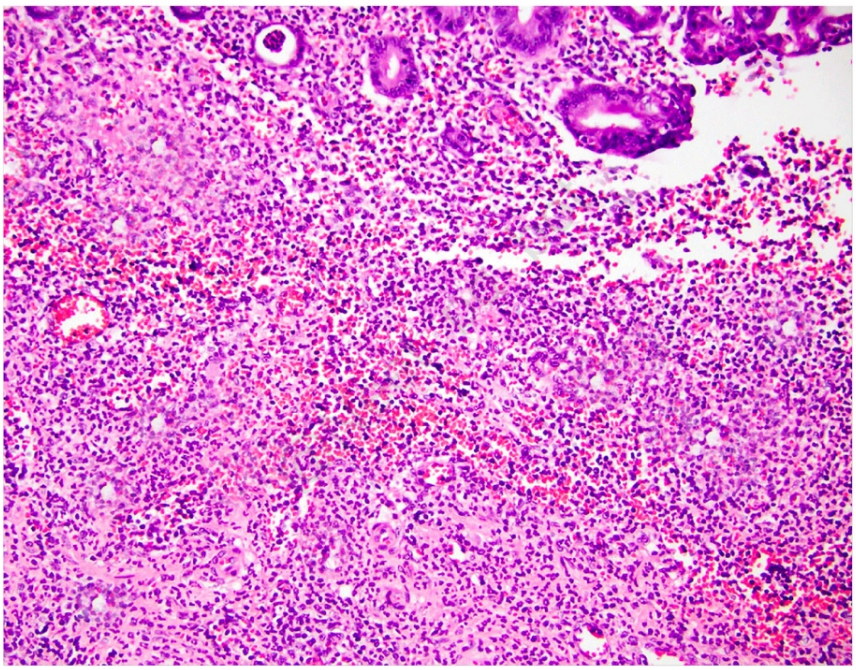

References:

Robbins and Cotrans pathologic basis of disease, 10th Edition, Page 93

↑ *Back to this question in Part A*

@Neet_pg_bot

Q25: Which of the following features is a characteristic of acute inflammation? (Q845319)

A. Presence of granulomas

B. Proliferation of fibroblasts and angiogenesis

C. The predominance of lymphocytes in the inflammatory infiltrate

D. Accumulation of neutrophils at the site of injury

Correct Answer: D. Accumulation of neutrophils at the site of injury

■ *Listen (English)*

■ *Listen (Hindi)*

Explanation: Among the given options, the accumulation of neutrophils at the site of injury is a characteristic of Acute inflammation. Acute inflammation → Predominated by neutrophils Exception: Typhoid → lymphocyte predominance Presence of granulomas (Option A) , Proliferation of fibroblasts and angiogenesis (Option B) , and The predominance of lymphocytes in the inflammatory infiltrate (Option C) are associated with chronic inflammation. Acute v/s Chronic Inflammation: Feature Acute Inflammation Chronic Inflammation Onset Rapid (minutes-hours) Insidious (weeks-months) Duration Short (<2 weeks) Prolonged (>4-6 weeks) Major Cells Neutrophils (PMNs) Lymphocytes, macrophages, plasma cells Mediators Histamine, prostaglandins, LTs, C3a/C5a Cytokines (IL-1, TNF-α), growth factors Vascular Changes Marked vasodilation, ↑permeability Minimal vascular changes Exudate Serous, purulent, fibrinous Minimal exudate; tissue destruction Histology Neutrophils, edema, hyperemia Lymphocytes, fibrosis, angiogenesis Examples Appendicitis, pneumonia, abscess TB, rheumatoid arthritis, atherosclerosis Cause Bacteria, trauma, chemicals Persistent infection, autoimmunity Outcome Resolution, abscess, progression Fibrosis, scarring, organ dysfunction Systemic Signs Fever, leukocytosis (PMN↑) Mild fever, anemia of chronic disease

References:

Robbins and Cotrans pathologic basis of disease, 10th Edition, Page 75

↑ *Back to this question in Part A*

@Neet_pg_bot

Q26: A 30-year-old female presents with a history of recent major surgery, deep vein thrombosis (DVT) in the lower extremities, and a family history of thrombotic events. Which of the following components constitute Virchow's triad, predisposing individuals to thrombosis? (Q845316)

A. Endothelial injury, hypercoagulability, and venous stasis

B. Endothelial dysfunction, leukocytosis, and platelet activation

C. Arterial dilation, decreased platelet count, and fibrinolysis

D. Hypothermia, acidosis, and coagulopathy

Correct Answer: A. Endothelial injury, hypercoagulability, and venous stasis

■ *Listen (English)*

■ *Listen (Hindi)*

Explanation: Virchow's triad consists of three primary factors that contribute to thrombosis: Endothelial injury - Triggers platelet adhesion and clot formation. Stasis or turbulent blood flow - Disrupts normal anticoagulant processes, promoting thrombosis. Hypercoagulability of the blood - An increased tendency of blood to clot, often due to genetic or acquired conditions.

References:

Robbins and Cotrans pathologic basis of disease, 10th Edition, Page 125, 126

↑ *Back to this question in Part A*

@Neet_pg_bot

• [02_Inflammation] 007 Chronic Inflammation

« Back to Folder Directory

[02_Inflammation] 007 Chronic Inflammation — Quick Jump

Q1 (p. 1115) *Q2 (p. 1115)* *Q3 (p. 1116)* *Q4 (p. 1117)* *Q5 (p. 1117)* *Q6 (p. 1118)*
Q7 (p. 1122) *Q8 (p. 1122)* *Q9 (p. 1123)* *Q10 (p. 1124)* *Q11 (p. 1124)* *Q12 (p. 1126)*
Q13 (p. 1130) *Q14 (p. 1131)* *Q15 (p. 1134)* *Q16 (p. 1136)* *Q17 (p. 1136)*

Q1: A 50-year-old man developed a small purulent abscess on his shoulder. After appropriate drainage and infection control measures, the wound healed well, leaving a healthy scar. During the early stages of tissue repair, which type of collagen predominates in the provisional matrix? (Q879470)

A. Type I

B. Type II

C. Type III

D. Type IV

Correct Answer: C. Type III

Explanation: Type III collagen is the main collagen deposited in the early provisional matrix. It forms a delicate, flexible scaffold that supports fibroblast migration and granulation tissue formation before being replaced by Type I collagen in later remodelling phases. Incorrect Options: Type I (Option A): Type I collagen is the most abundant collagen in mature scar tissue, appearing later in wound remodelling. Type II (Option B): Type II collagen is primarily found in cartilage and is not involved in skin wound healing. Type IV (Option D): Type IV collagen is a principal component of basement membranes, not the provisional matrix.

References:

Robbins and Cotran, Pathologic Basis of Disease, 11th Edition, Page no. 94.

↑ *Back to this question in Part A*

@Neet_pg_bot

Q2: A 45-year-old woman undergoes excision of a sebaceous cyst with primary closure of the wound. During the healing process, angiogenesis is initiated early but reaches its

maximum on which postoperative day? (Q879468)

A. Day 4

B. Day 3

C. Day 5

D. Day 7

Correct Answer: C. Day 5

Explanation: Peak neovascularisation usually occurs around day 5, characterised by maximum formation of new blood vessels to support granulation tissue and fibroblast proliferation essential for wound repair. Incorrect Options: Day 4 (Option A): Day 4 is early in the proliferative phase, but neovascularisation is still developing. Day 3 (Option B): Day 3 mainly involves transition from inflammation to proliferation, with early fibroblast activity, but neovascularisation is not yet at its peak. Day 7 (Option D): By day 7, neovascularisation starts stabilising and the wound begins to mature and remodel.

References:

Robbins and Cotran, Pathologic Basis of Disease, 11th Edition, Page no. 97.

↑ *Back to this question in Part A*

@Neet_pg_bot

Q3: During healing by primary intention, the initial acute inflammatory response is dominated by neutrophils. On which postoperative day do macrophages typically replace neutrophils as the predominant inflammatory cells at the wound site? (Q879467)

A. Day 1

B. Day 2

C. Day 3

D. Day 7

Correct Answer: C. Day 3

Explanation: By day 3, macrophages become the predominant cells in the wound. They clear apoptotic neutrophils through efferocytosis, release growth factors and cytokines to promote tissue repair, and orchestrate the transition from the inflammatory to proliferative phase of healing. Their actions are critical for the progression of effective wound repair. Incorrect Options: Day 1 (Option A): Neutrophils are the main inflammatory cells on day 1,

responsible for initial pathogen clearance and tissue debris removal. Day 2 (Option B): Neutrophils still predominate on day 2; macrophages begin to infiltrate but are not yet dominant. Day 7 (Option D): By day 7, macrophages dominate, and the wound is usually transitioning into the remodelling phase.

References:

Robbins and Cotran, Pathologic Basis of Disease, 11th Edition, Page no. 97.

↑ *Back to this question in Part A*

@Neet_pg_bot

Q4: Which of the following is NOT true regarding the actions of Transforming Growth Factor Beta (TGF-β)? (Q879464)

A. TGF-β promotes collagen synthesis by fibroblasts

B. TGF-β enhances the breakdown of extracellular matrix proteins

C. TGF-β contributes to tissue fibrosis in organs

D. TGF-β has anti-inflammatory properties

Correct Answer: B. TGF-β enhances the breakdown of extracellular matrix proteins

Explanation: TGF-β stimulates the production of collagen, fibronectin, and proteoglycans and inhibits collagen degradation by decreasing matrix metalloproteinase (MMP) activity and increasing the activity of tissue inhibitors of metalloproteinases (TIMPs). This inhibition stabilises and accumulates matrix proteins, contributing to fibrosis. Incorrect Options: TGF-β promotes collagen synthesis by fibroblasts (Option A): TGF-β stimulates the synthesis of collagen, especially by inducing fibroblast differentiation to myofibroblasts, which are key in fibrosis development in organs. TGF-β contributes to tissue fibrosis in organs (Option C): TGF-β is a pro-fibrotic cytokine involved in the development of fibrosis in the lung, liver, and kidneys in response to chronic inflammation. TGF-β has anti-inflammatory properties (Option D): It acts as an anti-inflammatory cytokine by inhibiting lymphocyte proliferation and the activity of other leukocytes.

References:

Robbins and Cotran, Pathologic Basis of Disease, 11th Edition, Page no. 95-96.

↑ *Back to this question in Part A*

@Neet_pg_bot

Q5: Which of the following diseases are typically associated with non-caseating granulomas? (Q879462)

A. Leprosy, Sarcoidosis, and Crohn’s disease

B. Tuberculosis and Syphilis

C. Cat-scratch disease only

D. All of the above

Correct Answer: A. Leprosy, Sarcoidosis, and Crohn’s disease

Explanation: Leprosy (Mycobacterium leprae): Non-caseating granulomas with acid-fast bacilli in macrophages. Sarcoidosis: Classic cause of non-caseating granulomas, with abundant activated macrophages. Crohn’s disease: Shows occasional non-caseating granulomas in the intestinal wall. Incorrect Options: Tuberculosis & Syphilis (Option B): Produce caseating granulomas (not non-caseating). Cat-scratch disease (Option C): Produces stellate granulomas with neutrophils, not typical non-caseating.

References:

Robbins, Cotran & Kumar Pathologic Basis of Disease, 11th Edition, Page no. 91

↑ *Back to this question in Part A*

@Neet_pg_bot

Q6: A 30-year-old man presents to the clinic with a raised scar on his chest. He reports that the scar has been gradually increasing in size since he had a minor injury in that area about a year ago. On examination, the scar extends beyond the original wound margins and appears firm and raised. Which of the following is the most likely diagnosis for the scar on the patient's chest? {{caption_text}} (Q845432)

A. Hypertrophic scar

B. Keloid

C. Exuberant granulation tissue

D. Contracture

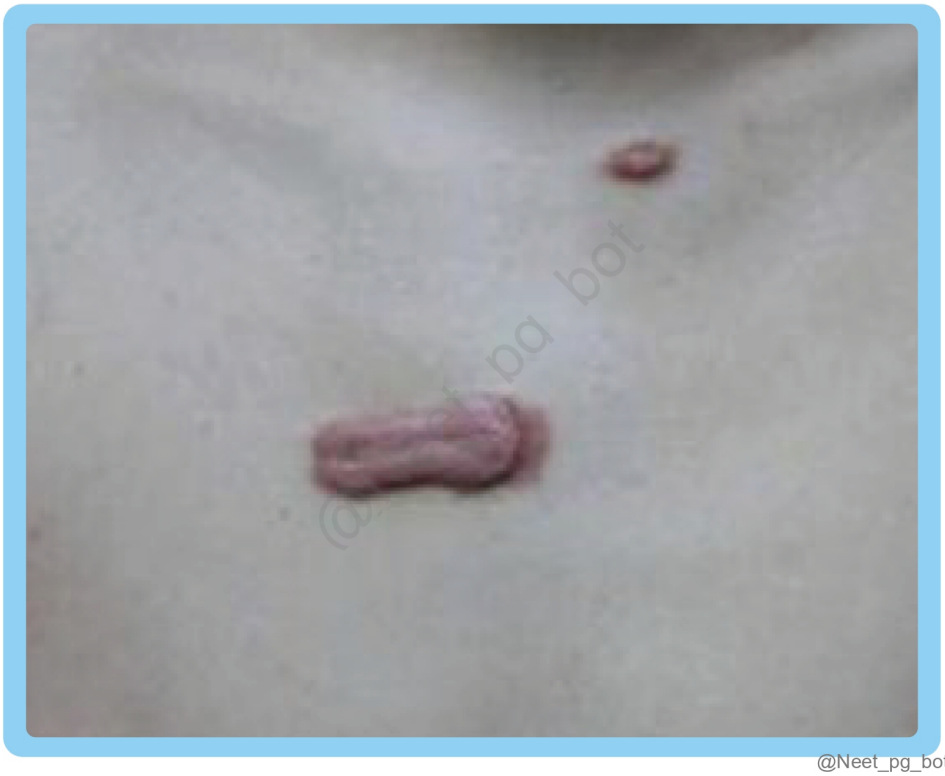

Correct Answer: B. Keloid

- *Listen (English)*
- *Listen (Hindi)*

Explanation: The most likely diagnosis for a raised scar on the patient’s chest is Keloid, characterized by abnormal and excessive growth of scar tissue that grows beyond the boundaries of the original wound and does not regress. Scar grows beyond the original wound → unlike hypertrophic scars Firm, raised, pink or reddish Common sites: Sternum, shoulders, upper back, earlobes Cause: Minor or major injury, surgery, burns Functional impact: Can impair mobility if near joints Treatment: Intralesional injection of steroid (triamcenolone) Hypertrophic scar (Option A): While hypertrophic scars are also raised, they typically remain within the boundaries of the original injury. They may regress over time and are less likely to recur after treatment compared to keloids. {{caption_text}} Keloid v/s Hypertrophic Scar: Feature Hypertrophic Scar Keloid Boundaries Confined to the borders of the original wound. Extends beyond the boundaries of the original wound (claw-like projections). Time of Onset Develops soon after injury (usually within 4 weeks). Can develop months or even years after the initial insult. Symptoms Pruritus, pain, growth Pruritus, stiffness (contracture) Evolution Often regresses or flattens over time. Rarely regresses; often continues to grow or recurs after excision. Collagen Type Primarily Type III collagen; organized parallel to skin surface. Primarily Type I and III collagen; organized in thick, disorganized, "glassy" (hyalinized) bundles. Predisposition Associated with wound tension or deep thermal injury. Genetic predisposition; significantly more common in individuals with darker skin tones. Common Sites Areas of high tension (e.g., joints, neck, knees). Earlobes, shoulders, upper back, and precordium (chest). Recurrence after excision High (>50-80%) Low (<10%) Histology Thick, haphazard collagen nodules; no regular pattern Parallel collagen bundles organized along skin tension lines Treatment Response Steroids + 5FU/silicone; poor response Steroids/silicone; good response Genetics Strong familial tendency (Fitzpatrick IV-VI skin) Less genetic predisposition Exuberant granulation tissue (Option C): Exuberant granulation tissue, also known as proud flesh,

refers to excessive amounts of granulation tissue, which protrudes above the level of the surrounding skin and blocks reepithelialization. {{caption_text}} Contracture(Option D): Contractures occur when scar tissue forms and tightens, leading to restricted movement of nearby joints or tissues. They typically occur in case of burns or deep wounds. Contractures may result in deformity and functional impairment. {{caption_text}}





@Neet_pg_bot



References:

Robbins and Cotrans pathologic basis of diseases 10th ed. page 110

↑ *Back to this question in Part A*

@Neet_pg_bot

Q7: Which of the following statements regarding wound healing is true? (Q847861)

A. The wound regains 20% of its normal strength by 1 week.

B. The wound regains 70-80% of its normal strength by 12 weeks.

C. The wound regains its original strength eventually.

D. The initial collagen formed in the process of wound healing is Type-1 collagen.

Correct Answer: B. The wound regains 70-80% of its normal strength by 12 weeks.

■ *Listen (English)*

■ *Listen (Hindi)*

Explanation: The wound regains 70-80% of its normal strength by 12 weeks. Wound Healing At the end of one week, the wound regains 10% of its original strength. (Option A ruled out) The wound regains 70-80% of its normal strength by 12 weeks. (Option B) The wound never reaches 100% of its original strength . (Option C ruled out) The initial collagen formed in the process of wound healing is Type-III collagen. (Option D ruled out) It is replaced by type-1 collagen (strong and has the highest tensile strength). In the end, the ratio of type-1 to type-III collagen is 4:1.

References:

Robbins and Cotrans Pathologic basis of diseases 10th ed. page 108.

↑ *Back to this question in Part A*

@Neet_pg_bot

Q8: A 55-year-old man undergoes a minor surgical procedure to remove a small skin lesion from his forearm, and the wound is meticulously closed with sutures. Three days after the surgery, he comes to the OPD for review. Which event of the wound healing process is typically observed in this patient? (Q845437)

A. Platelet and fibrin clot formation

B. Neutrophils start to accumulate

C. Replacement of neutrophils by macrophages

D. Collagen bridging initiation

Correct Answer: C. Replacement of neutrophils by macrophages

■ *Listen (English)*

■ *Listen (Hindi)*

Explanation: A 55-year-old man returns three days after a minor surgical removal of a skin lesion closed with sutures, and at this stage of wound healing, the typical event observed is the replacement of neutrophils by macrophages. Events in wound healing: DAY EVENTS DAY 0 Platelets and Fibrin form blood clots. (Option A ruled out) DAY 1 Blood clot remains and recruitment of neutrophils (acute inflammation). (Option B ruled out) DAY 2 Blood clots remain; neutrophils accumulate, followed by thin epithelial layer formation. DAY 3 Chronic inflammation sets in, and macrophages replace neutrophils. (Option C) Granulation tissue begins (blood vessel formation starts) DAY 5 Maximum granulation tissue (Maximum neovascularization) Collagen bridging starts (Option D ruled out) DAY 21(3RD WEEK) Maximum collagen deposition (Type I collagen.)

References:

Robbins and Cotrans Pathologic basis of diseases 10th ed. page 108

↑ *Back to this question in Part A*

@Neet_pg_bot

Q9: Which of the following cell types is classified as stable cells in terms of their proliferative capacity and turnover rate? (Q845435)

A. Neurons in the brain

B. Hematopoietic cells in bone marrow

C. Stratified squamous epithelia of the skin

D. Endothelial cells in blood vessels

Correct Answer: D. Endothelial cells in blood vessels

■ *Listen (English)*

■ *Listen (Hindi)*

Explanation: Endothelial cells in blood vessels are classified as stable cells in terms of their proliferative capacity and turnover rate. Classification of cells based on the proliferative capacity and turnover rate: Labile cells Stable cells Permanent cells These cells are continuously being lost and replaced by maturation from tissue stem cells and by the proliferation of mature cells. Labile cells include hematopoietic cells in the bone marrow and the majority of surface epithelia (Option B, C ruled out) They are quiescent and have minimal proliferative activity from progenitor cells. They divide only when required but limited regeneration compared to labile cells. Stable cells constitute the parenchyma of most solid tissues (liver), endothelial cells (Option D) , fibroblasts, and smooth

muscle cells. These cells are considered to be terminally differentiated and nonproliferative in postnatal life. Permanent cells include Neurons (Option A ruled out) and cardiac and skeletal muscle cells.

References:

Robbins and Cotrans Pathologic Basis of Diseases 10th ed. Page 103

↑ *Back to this question in Part A*

@Neet_pg_bot

Q10: Match the following tissue macrophages with respective organs: 1. Kupffer cells a) liver 2. Dust cells b) spleen 3. Hofbauer cells c) lung 4. Littoral cells d) placenta 5. Mesangial cells e) kidney (Q845403)

A. 1-b, 2-a, 3-d, 4-e, 5-c

B. 1-a, 2-c, 3-d, 4-b, 5-e

C. 1-a, 2-d, 3-e, 4-b, 5-c

D. 1-c, 2-e, 3-b, 4-d, 5-a

Correct Answer: B. 1-a, 2-c, 3-d, 4-b, 5-e

■ *Listen (English)*

■ *Listen (Hindi)*

Explanation: Name of the macrophage Tissue/ Organ Microglia Brain Dust cells or Alveolar Macrophages Lungs Kuppffer cells Liver Littoral cells Spleen Mesangial cells Kidney

References:

Robins and Cotrans Pathologic Basis of Disease, 10th Edition, pg. 97

https://www.ncbi.nlm.nih.gov/pmc/articles/PMC4553254/#:~:text=Thus%2C%20macrophages%20take%20different%20names

↑ *Back to this question in Part A*

@Neet_pg_bot

Q11: A 45-year-old woman undergoes a routine elective surgery for the removal of a benign skin lesion on her forearm. The procedure involves making a small incision, excising the lesion, and closing the wound with sutures. Which of the following

statements accurately describes wound healing by primary intention in this scenario? (Q845430)

A. Myofibroblasts play a significant role in wound contraction.

B. The wound is associated with large tissue deficits.

C. Granulation tissue formation is extensive.

D. The wound is expected to heal with minimal inflammatory response.

Correct Answer: D. The wound is expected to heal with minimal inflammatory response.

■ *Listen (English)*

■ *Listen (Hindi)*

Explanation: In this scenario, the wound is expected to heal with minimal inflammation, which is characteristic of healing by primary intention. Primary Intention Healing: Occurs in clean, small surgical wounds Minimal inflammatory response (Option D) Edges approximated → minimal granulation tissue Fast epithelialization, minimal scarring Secondary Intention Healing: Large, open, dirty wounds (Option B ruled out) Requires myocutaneous flaps or contraction (Option A ruled out) Extensive granulation tissue formation (Option C ruled out) Slower healing, more scarring {{caption_text}}

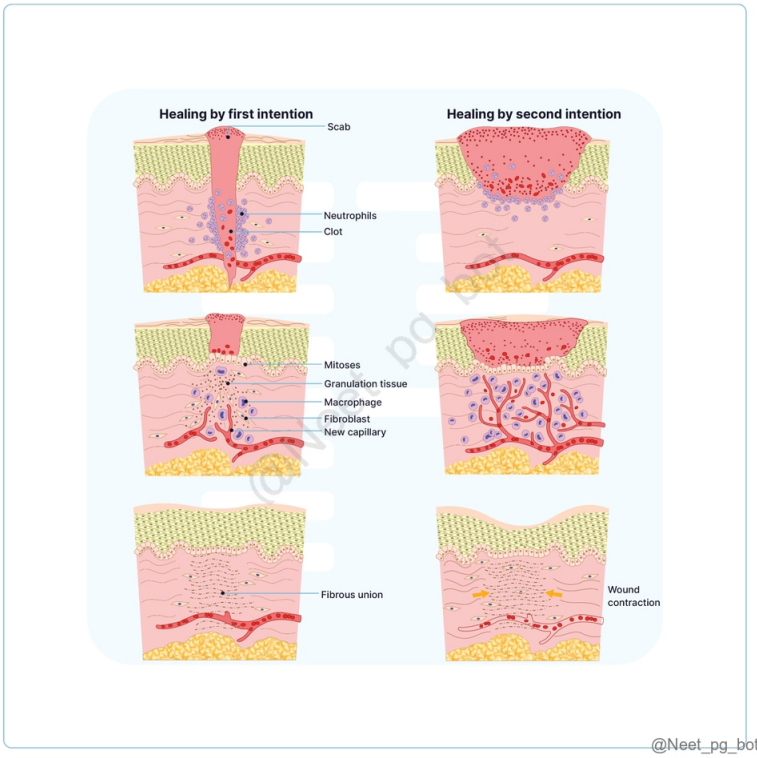

References:

Robbins and Cotrans pathologic basis of diseases 10th edition. page 108

↑ *Back to this question in Part A*

@Neet_pg_bot

Q12: A 45-year-old male presents with a persistent subcutaneous nodule on his forearm. Biopsy reveals the presence of multinucleated giant cells within the lesion, as shown in the accompanying HPE image. Further analysis indicates a central zone of lipid-laden macrophages surrounded by a wreath-like arrangement of nuclei. Which type of giant cell is most likely to be observed in this scenario? {{caption_text}} (Q845424)

A. Touton giant cells

B. Reed-Sternberg Cells

C. Warthin-Finkeldey giant cells

D. Foreign body giant cells

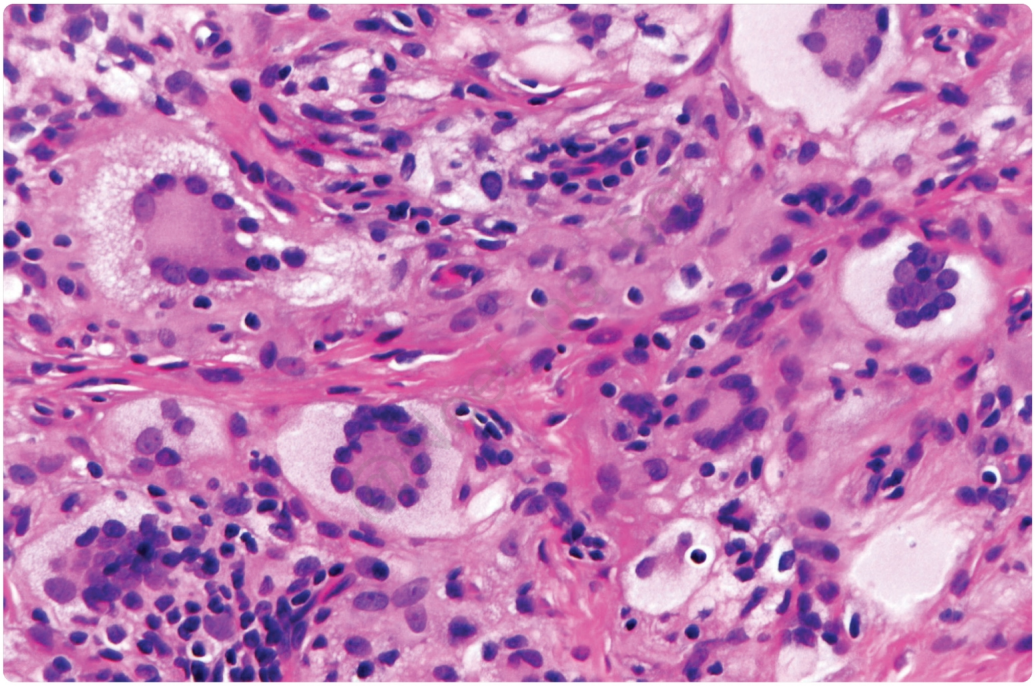

@Neet_pg_bot

Correct Answer: A. Touton giant cells

■ *Listen (English)*

■ *Listen (Hindi)*

Explanation: The multinucleated giant cells described in the scenario, with a central zone of lipid-laden macrophages surrounded by a wreath-like arrangement of nuclei, are characteristic of Touton giant cells. Giant Cell Type Description Seen in Touton Giant Cells (Option A) {{caption_text}} Multinucleated giant cells with a central zone of lipid-laden Macrophages are surrounded by a wreath-like arrangement of nuclei. Xanthogranuloma, xanthoma, fat necrosis Reed-Sternberg Cells (Option B) {{caption_text}} Large, binucleated or multinucleated cells with prominent nucleoli, often with an "owl's eye" appearance (pink nucleoli) (RS cells- also seen in DLBCL, owl’s eye appearance- also seen in CMV infection) Hodgkin lymphoma Warthin-Finkeldey Giant Cells (Option C) {{caption_text}} Large, multinucleated cells with irregularly distributed nuclei and a foamy cytoplasm. May contain intranuclear and intracytoplasmic eosinophilic inclusions. Measles (Rubeola) infection Langhans Giant Cells {{caption_text}} Multinucleated giant cells with nuclei arranged peripherally in a horseshoe-like or semicircular pattern. Tuberculosis, Sarcoidosis Foreign Body Giant Cells (Option D) {{caption_text}} Large, multinucleated cells with multiple nuclei arranged haphazardly. Foreign bodies in tissues like talc, sutures, or crystals

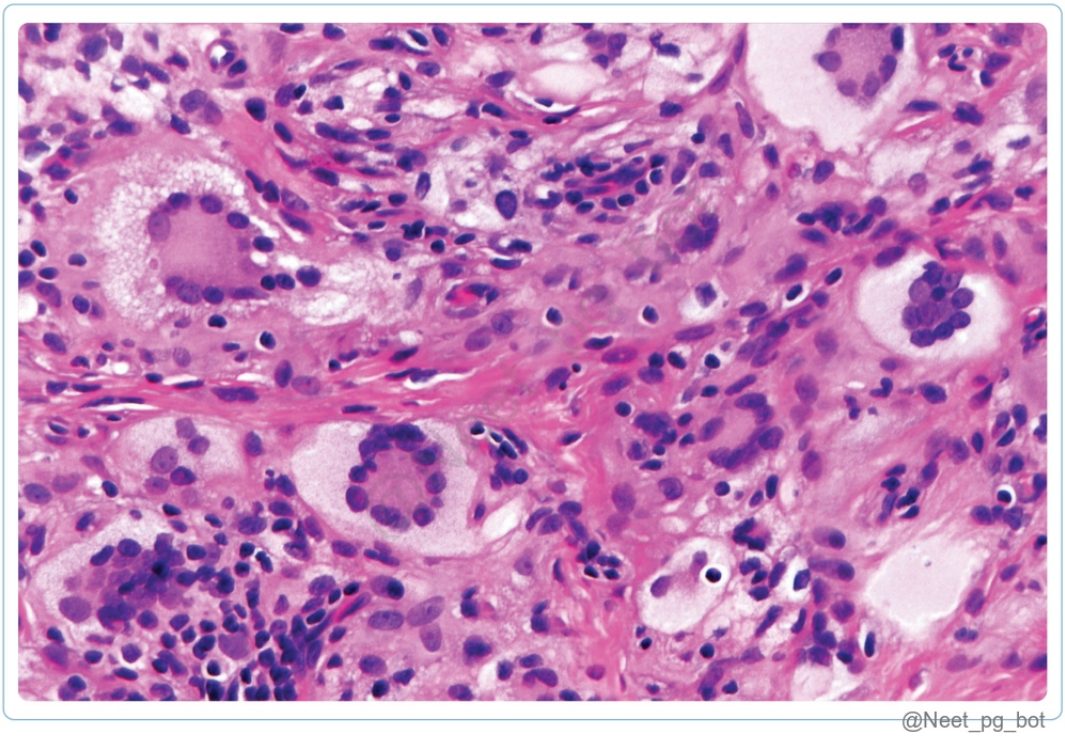

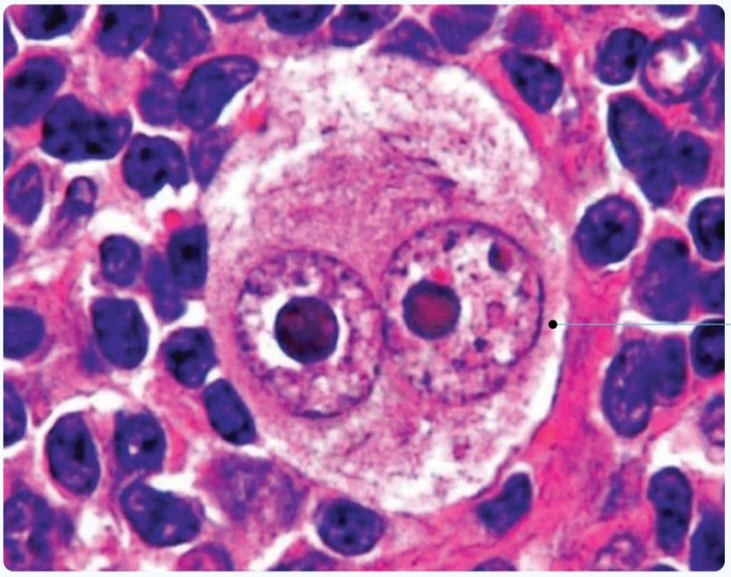

@Neet_pg_bot

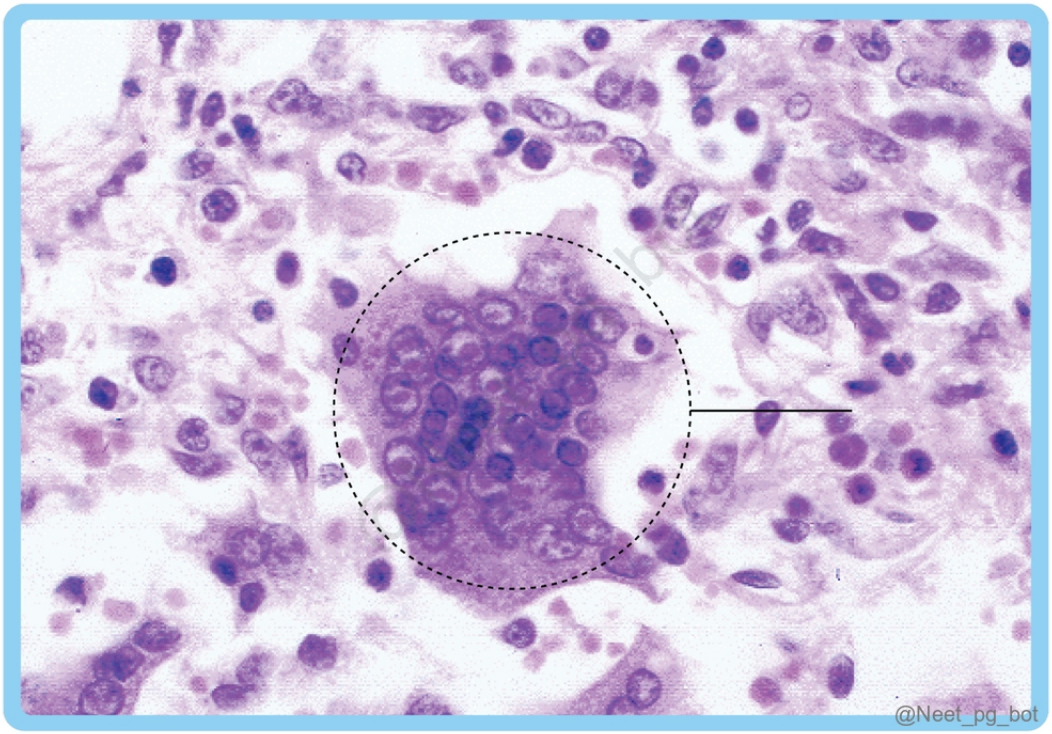

@Neet_pg_bot

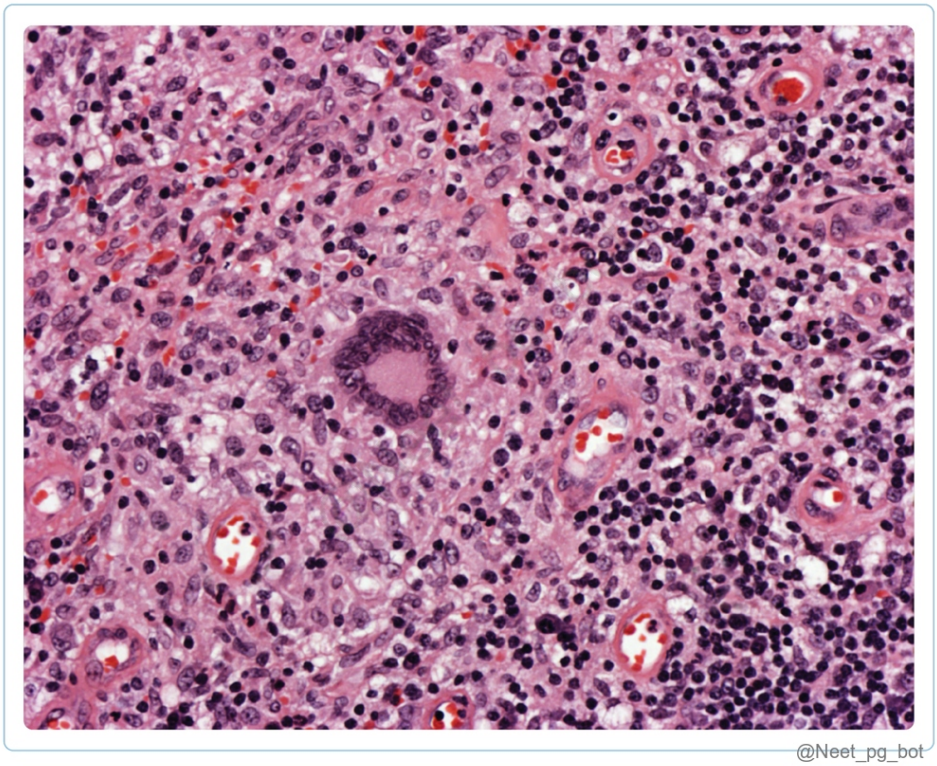

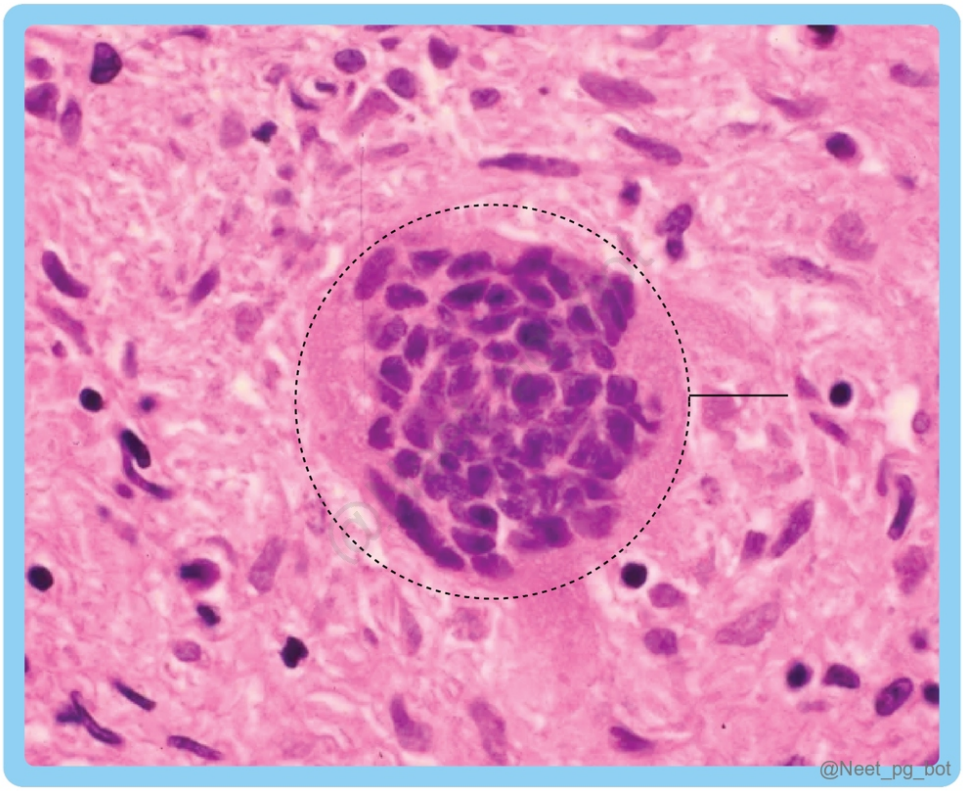

References:

Robins and Cotran Pathologic Basis of Disease, 10th Edition, Pages 100, 350, 612, 613

↑ *Back to this question in Part A*

@Neet_pg_bot

Q13: Which of the following is not a physiological giant cell? (Q845413)

A. Osteoclast

B. Syncytiotrophoblast

C. Megakaryocytes

D. Langhans cells

Correct Answer: D. Langhans cells

■ *Listen (English)*

■ *Listen (Hindi)*

Explanation: Langhans' giant cells are multinucleated giant cells (pathological) formed by the fusion of macrophages. They are often seen in the granulomas formed in response to certain infections or foreign substances. They are typically found associated with tuberculosis. They are characterized by a horseshoe-shaped arrangement of nuclei within the cytoplasm {{caption_text}} Osteoclast (Options A) , Syncytiotrophoblast Options B) , and Megakaryocytes (Options C) are physiological giant cells.

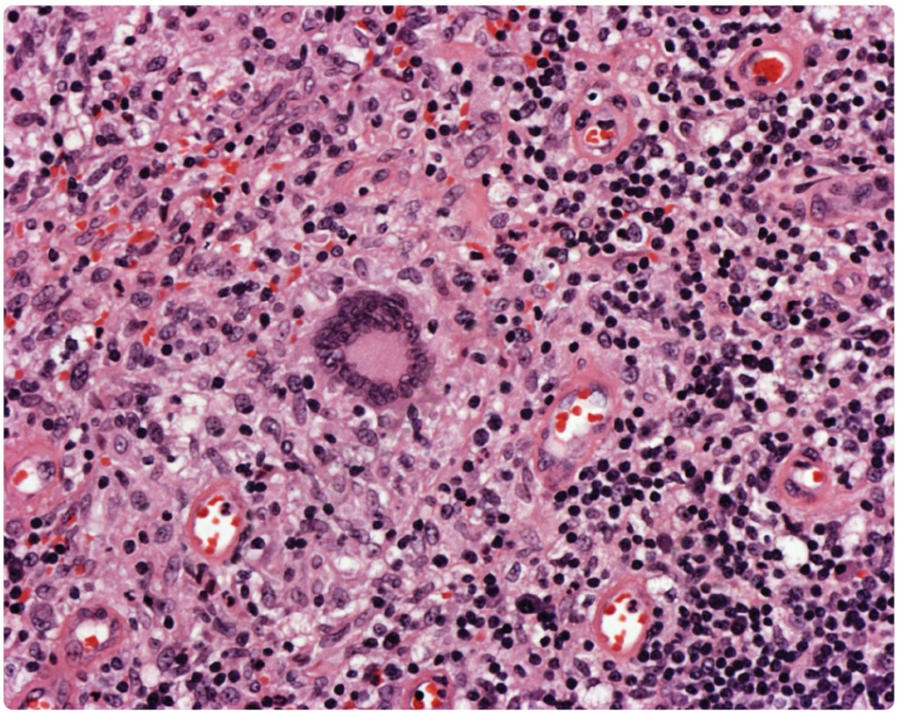

@Neet_pg_bot

References:

https://www.researchgate.net/publication/345064687_Giant_Cells_A_Review

↑ *Back to this question in Part A*

@Neet_pg_bot

Q14: A 40-year-old woman presents with a persistent dry cough, shortness of breath, and bilateral enlargement of the lymph nodes in her chest, incidentally detected on a routine chest X-ray given below. Physical examination reveals fine crackles in her lung bases. Pulmonary function tests show reduced lung volumes and a decreased diffusion capacity for carbon monoxide. Which type of granuloma is commonly associated with the histopathological findings in this patient? {{caption_text}} (Q845412)

A. Naked granuloma

B. Stellate granuloma

C. Eosinophilic granuloma

D. Durck granuloma

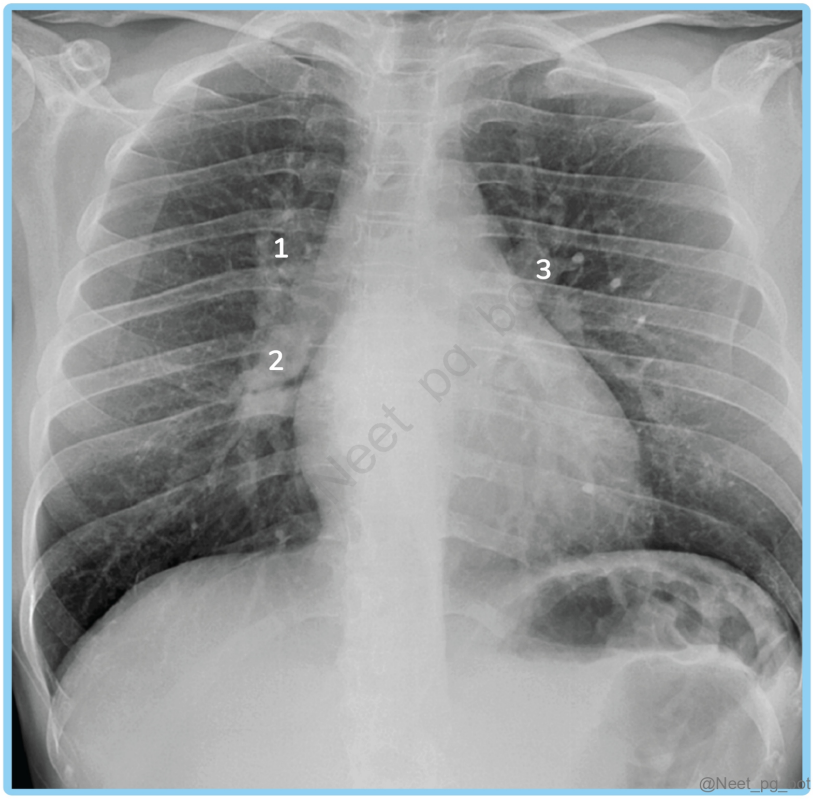

Correct Answer: A. Naked granuloma

- *Listen (English)*
- *Listen (Hindi)*

Explanation: The given clinical presentation suggests Sarcoidosis, a systemic granulomatous disorder characterized by non-caseating granulomas (naked granuloma) composed of epithelioid histiocytes and multinucleated giant cells without associated fibrosis or necrosis. The characteristic histopathological feature of sarcoidosis is "Naked granuloma," which refers to the "absence of lymphocytic collar." Giant cell inclusions like asteroid bodies and Schaumann bodies can be seen. Sarcoidosis is a classic example of a non-infectious cause of granuloma formation. {{caption_text}} Stellate granuloma (Option B) Seen in Cat-scratch disease and lymphogranuloma venereum. {{caption_text}} Eosinophilic granuloma (Option C): Seen in Langerhans cell histiocytosis (LCH) and Churg-Strauss syndrome. Durck granuloma (Option D): Seen in cerebral malaria. {{caption_text}}

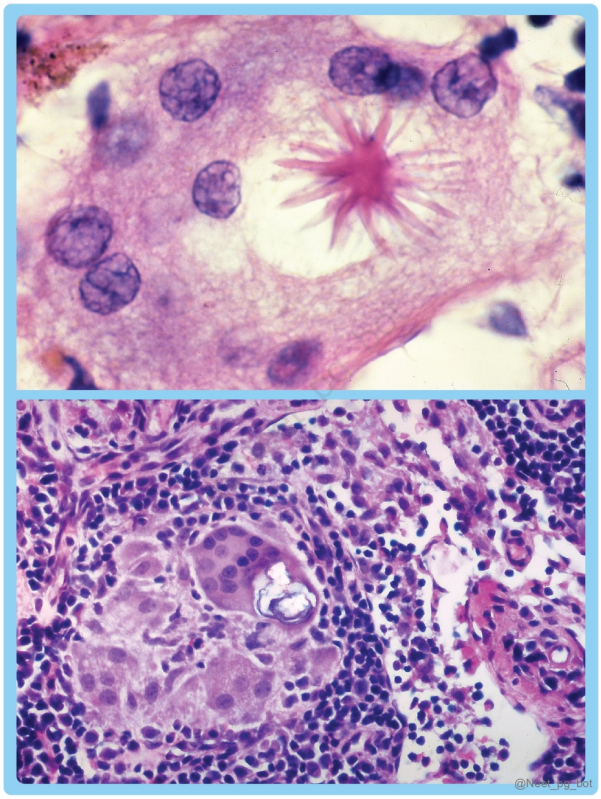

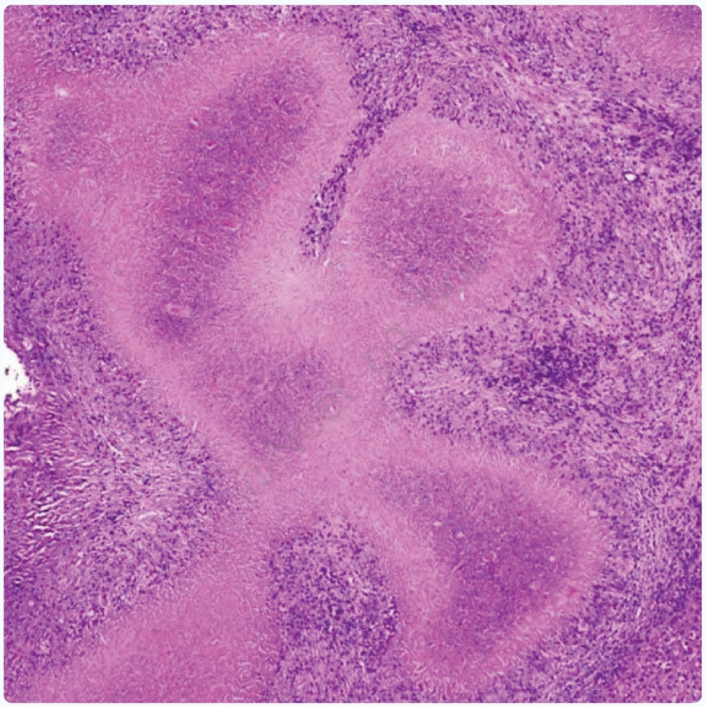

Stellate granuloma

@Neet_pg_bot

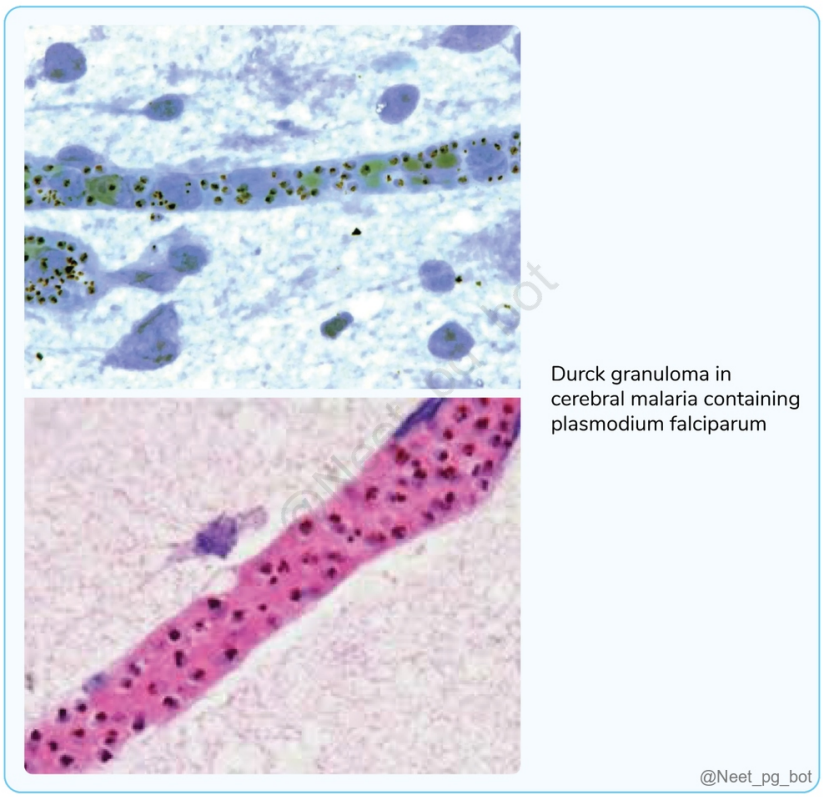

References:

Robins and Cotran Pathologic Basis of Disease, 10th Edition, pg. 101

↑ *Back to this question in Part A*

@Neet_pg_bot

Q15: Which sequence accurately identifies lymphocytes, epithelioid cells, Langhans giant cells, and caseous necrosis in the image given below? (Q845410)

A. b, d, a, c

B. d, b, a, c

C. d, b, c, a

D. b, d, c, a

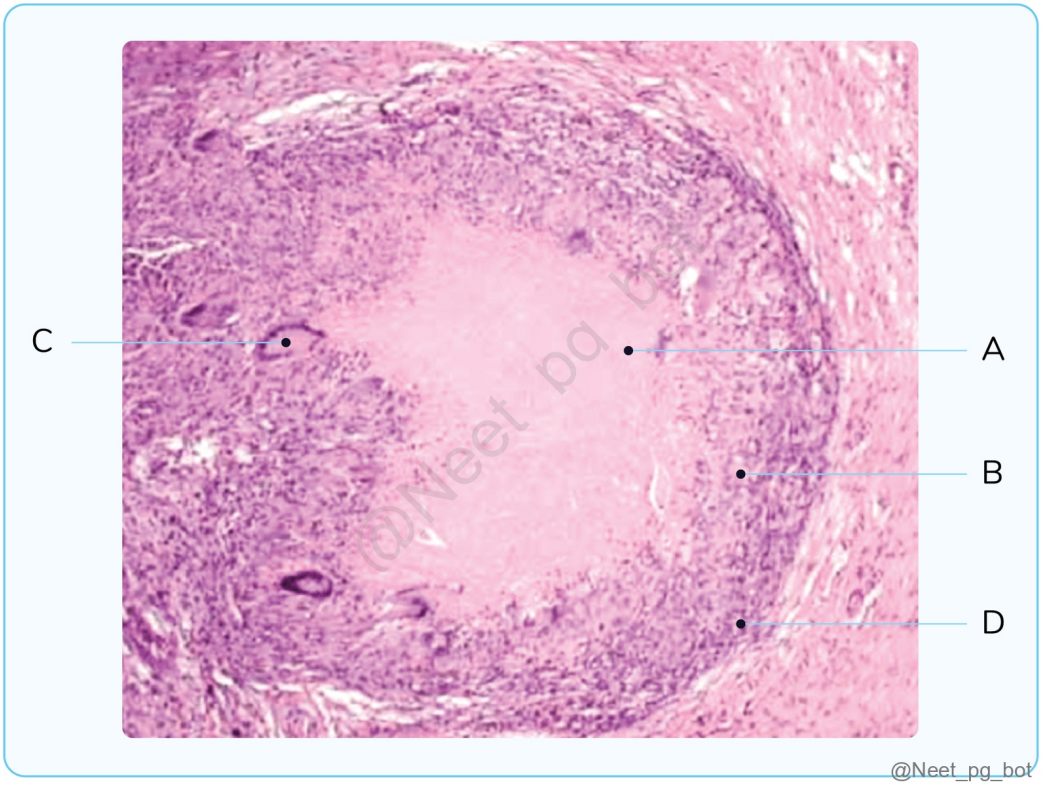

Correct Answer: C. d, b, c, a

- *Listen (English)*
- *Listen (Hindi)*

Explanation:

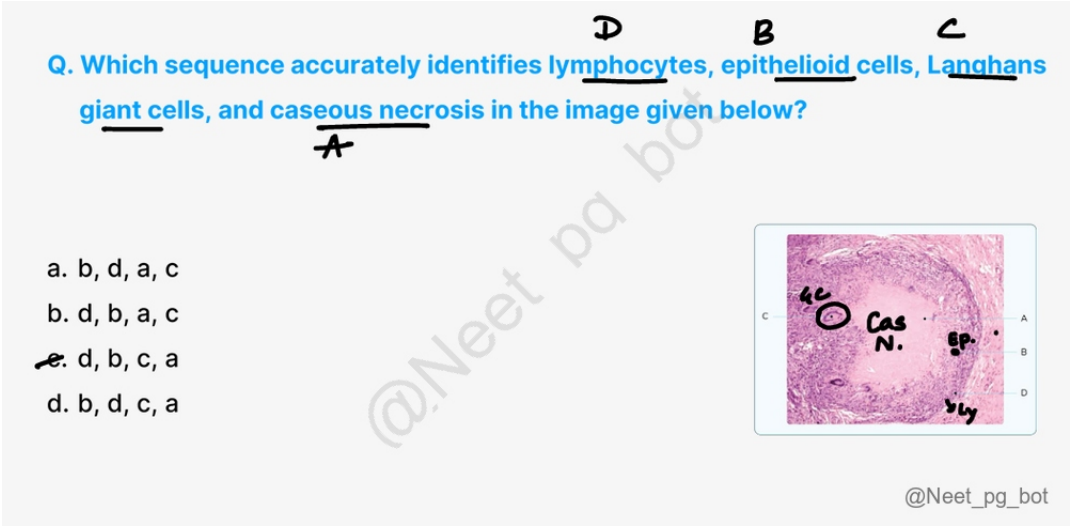

References:

Robins and Cotran Pathologic Basis of Disease, 10th Edition, - Pages 100, 101

↑ *Back to this question in Part A*

@Neet_pg_bot

Q16: Which of the following statements about granulomas is incorrect? (Q845408)

A. Granuloma formation is a Type IV hypersensitivity reaction

B. IFN-gamma is an important cytokine involved in this process

C. CD8+ is the type of T lymphocytes involved in this process

D. Epitheloid cells in granuloma are modified macrophages

Correct Answer: C. CD8+ is the type of T lymphocytes involved in this process

■ *Listen (English)*

■ *Listen (Hindi)*

Explanation: CD4 T cells are involved in the process (Granuloma formation), not CD8+ cells. CD8+ T cells are more commonly associated with cytotoxic responses against infected or abnormal cells rather than granuloma formation. Granulomas Granulomas (Type IV hypersensitivity reaction) typically involve CD4+ T lymphocytes, also known as helper T cells, rather than CD8+ T cells. (Option A ruled out) CD4 T-helper 1 (Th1) cells help activate macrophages and other immune cells, release interferon-gamma (IFN-γ), and maintain granulomas. (Option B ruled out Epithelioid cells in a granuloma are modified macrophages. (Option D ruled out)

References:

Robins and Cotran Pathologic Basis of Disease, 10th Edition, - Pages 100, 101

↑ *Back to this question in Part A*

@Neet_pg_bot

Q17: Which type of macrophages predominantly contributes to tissue repair and resolution of inflammation in patients with chronic obstructive pulmonary disease complicated by pneumonia? (Q845406)

A. M1 macrophages

B. M2 macrophages

C. Both M1 and M2 macrophages

D. Resting macrophages

Correct Answer: B. M2 macrophages

■ *Listen (English)*

■ *Listen (Hindi)*

Explanation: The predominant type of macrophages contributing to tissue repair and resolution of inflammation in this patient's lungs is M2 type of Macrophages, also known as Alternatively activated macrophages. Macrophages are of two types based on their activation: M1 activation M2 activation Also known as “Classical macrophage activation.” “Alternative macrophage activation.” Stimulus for activation Microbial products (e.g., endotoxin); TLRs (Toll-like receptor) T cell-derived signals (e.g., IFN-γ), Foreign substances (e.g., crystals). IL-4 IL-13. Releases Reactive oxygen species (ROS), lysosomal enzymes, nitric oxide (NO) and Pro-inflammatory cytokines TNF-α IL-1; IL-12; IL-23 Anti-inflammatory cytokines IL-10 TGF-β Function Microbicidal destroys pathogens and amplifies inflammation. Terminates the inflammation and promotes tissue repair (fibrosis).

References:

Robins and Cotran Pathologic Basis of Disease, 10th Edition,, pg. 98

↑ *Back to this question in Part A*

@Neet_pg_bot

• [02_Inflammation] 008 Mediators Of Inflammation

« Back to Folder Directory

[02_Inflammation] 008 Mediators Of Inflammation — Quick Jump

Q1 (p. 1138)	*Q2 (p. 1138)*	*Q3 (p. 1139)*	*Q4 (p. 1140)*	*Q5 (p. 1140)*	*Q6 (p. 1141)*
Q7 (p. 1142)	*Q8 (p. 1142)*	*Q9 (p. 1143)*	*Q10 (p. 1143)*	*Q11 (p. 1144)*	*Q12 (p. 1145)*
Q13 (p. 1146)	*Q14 (p. 1146)*	*Q15 (p. 1147)*	*Q16 (p. 1148)*	*Q17 (p. 1149)*	*Q18 (p. 1150)*
Q19 (p. 1151)	*Q20 (p. 1153)*	*Q21 (p. 1153)*	*Q22 (p. 1154)*	*Q23 (p. 1155)*	*Q24 (p. 1155)*
Q25 (p. 1156)	*Q26 (p. 1157)*				

Q1: In some chronic inflammatory reactions, organized lymphoid follicles resembling lymph nodes may form. These are called tertiary lymphoid structures. Which of the following conditions may show these structures? (Q879461)

A. Synovium in long-standing rheumatoid arthritis

B. Thyroid in Hashimoto thyroiditis

C. Infiltrates around some tumors

D. All of the above

Correct Answer: D. All of the above

Explanation: Tertiary lymphoid structures (TLOs) are clusters of lymphocytes, antigen-presenting cells, and plasma cells forming organized follicles at chronic inflammation sites. Found in the synovium of rheumatoid arthritis, thyroid in Hashimoto thyroiditis, and around some tumors. They may sustain and perpetuate the immune reaction locally The exact pathological significance of TLOs is still not fully established.

References:

Robbins, Cotran & Kumar Pathologic Basis of Disease, 11th Edition, Page no. 89

↑ *Back to this question in Part A*

@Neet_pg_bot

Q2: Which of the following mediators is not primarily involved in producing fever during inflammation? (Q879460)

A. IL-1

B. Prostaglandins

C. TNF

D. Histamine

Correct Answer: D. Histamine

Explanation: IL-1 and TNF induce fever by stimulating prostaglandin (PGE2) production in the hypothalamus. Prostaglandins act directly on the thermoregulatory center to raise body temperature. Histamine, however, mainly causes vasodilation and increased vascular permeability, not fever.

References:

Robbins and Cotran, Pathologic Basis of Disease, 11th Edition, Page no. 77

↑ *Back to this question in Part A*

@Neet_pg_bot

Q3: Which of the following inflammatory mediators are correctly matched with their primary actions? 1. Histamine – arteriolar dilation and ↑ vascular permeability causing hypotension in anaphylaxis 2. Bradykinin – major mediator of pain in inflammation 3. Platelet-activating factor (PAF) – bronchoconstriction via activation of platelets and leukocytes with mediator release 4. Neutrophil lysosomal enzymes – cleavage of C3 and C5 to generate active complement fragments 5. Interleukin-1 (IL-1) mediates vasodilation and bronchoconstriction in asthma (Q879459)

A. 1, 2, 3

B. 1, 3, 5

C. 1, 2, 3, 4

D. 2, 4, 5

Correct Answer: C. 1, 2, 3, 4

Explanation: Histamine causes blood vessels to dilate and become leaky, which can lead to a drop in blood pressure during anaphylaxis. Bradykinin is the primary chemical responsible for producing pain in inflammation; it also dilates vessels and increases their permeability. Platelet-activating factor (PAF) makes the airways narrow (bronchoconstriction) by activating platelets and white blood cells, which then release other inflammatory mediators. Neutrophil lysosomal enzymes break down complement proteins C3 and C5 into active fragments (C3a, C5a) that promote inflammation. Interleukin-1 (IL-1) mainly causes fever; it does not dilate blood vessels or

cause bronchoconstriction, so that match is incorrect.

References:

Robbins and Cotran, Pathologic Basis of Disease, 11th Edition, Page no. 77,75,79

↑ *Back to this question in Part A*

@Neet_pg_bot

Q4: A 39-year-old woman with long-standing rheumatoid arthritis presents with fatigue and pallor. Lab tests reveal anemia of chronic disease. Elevated levels of which of the following acute-phase reactants are primarily responsible for this anemia? (Q879458)

A. Fibrinogen

B. C-reactive protein (CRP)

C. Serum amyloid A (SAA)

D. Hepcidin

Correct Answer: D. Hepcidin

Explanation: Hepcidin increases in chronic inflammation and inhibits ferroportin, leading to decreased iron release from macrophages and reduced intestinal absorption, which results in anemia of chronic disease. Fibrinogen, CRP, and SAA (Options A, B, and C) are also positive acute-phase reactants but they do not directly cause anemia.

References:

Robbins and Cotran, Pathologic Basis of Disease, 11th Edition, Page no. 92

↑ *Back to this question in Part A*

@Neet_pg_bot

Q5: During the acute-phase response in inflammation, which of the following acts as a negative acute-phase reactant by decreasing in serum concentration? (Q879456)

A. Albumin

B. Serum amyloid A (SAA)

C. C-reactive protein (CRP)

D. Fibrinogen

Correct Answer: A. Albumin

Explanation: Albumin is a negative acute-phase reactant - its synthesis falls during inflammation (to conserve amino acids for positive acute-phase proteins). SAA, CRP, and fibrinogen are positive acute-phase reactants -their levels rise in inflammation.

References:

Robbins and Cotran, Pathologic Basis of Disease, 11th Edition, Page no. 92

↑ *Back to this question in Part A*

@Neet_pg_bot

Q6: Fractalkine, a unique chemokine with both membrane-bound and soluble forms, belongs to which chemokine family? (Q879453)

A. C

B. CX3C

C. CXC

D. CC

Correct Answer: B. CX3C

Explanation: CX3 C chemokines contain three amino acids between the first two cysteines. The only known member of this class is called fractalkine (CX3CL1). This chemokine exists in two forms: Cell surface–bound protein induced on endothelial cells by inflammatory cytokines that promotes strong adhesion of monocytes and T cells, and Soluble form derived by proteolysis of the membrane-bound protein that has potent chemoattractant activity for the same cells. Incorrect Options: C (Option A) lacks one of the two cysteines (e.g., lymphotactin). CXC (Option C) neutrophil chemotaxis (e.g., IL-8). CC (Option D) monocyte/eosinophil chemotaxis (e.g., MCP-1, RANTES).

References:

Robbins and Cotran, Pathologic Basis of Disease, 11th Edition, Page no. 81.

↑ *Back to this question in Part A*

@Neet_pg_bot

Q7: Which of the following cytokines primarily exhibits anti-inflammatory activity? (Q879452)

A. IL-1

B. IL-4

C. TNF

D. IFN-γ

Correct Answer: B. IL-4

Explanation: IL-4 is anti-inflammatory as it downregulates macrophage activity and promotes Th2 response. IL-1 and TNF are pro-inflammatory, while IFN-γ activates macrophages and enhances inflammation.

References:

Robbins and Cotran, Pathologic Basis of Disease, 11th Edition, Page no. 88

↑ *Back to this question in Part A*

@Neet_pg_bot

Q8: Which of the following statements regarding prostaglandins and related eicosanoids is INCORRECT? (Q879451)

A. Thromboxane A2 (TxA2) is the predominant product of platelets

B. Prostacyclin (PGI2) acts as a vasodilator and inhibits platelet aggregation

C. PGD2 is one of the major prostaglandins released from mast cells

D. Vascular endothelium lacks prostacyclin synthase

Correct Answer: D. Vascular endothelium lacks prostacyclin synthase

Explanation: Vascular Endothelium possesses prostacyclin synthase and produces PGI2, which causes vasodilation and inhibits platelet aggregation. Thus, the statement that endothelium lacks prostacyclin synthase is false. ■■■■■■■ Incorrect Options: TxA2 (Option A) promotes vasoconstriction and platelet aggregation; it is the main prostanoid formed in platelets. PGI2 (prostacyclin , endothelium) (Option B) produced by vascular endothelium; causes vasodilation and inhibits platelet aggregation. PGD2 (Option C): Major prostaglandin produced by mast cells, contributes to bronchoconstriction and vasodilation.

References:

Robbins and Cotran, Pathologic Basis of Disease, 11th Edition, Page no. 78.

↑ *Back to this question in Part A*

@Neet_pg_bot

Q9: Release of arachidonic acid, the precursor of prostaglandins and leukotrienes, is mainly mediated by which of the following enzymes? (Q879449)

A. Phospholipase A1 and C

B. Phospholipase A2 and C

C. Phospholipase B and C

D. Phospholipase A1 and B

Correct Answer: B. Phospholipase A2 and C

Explanation: Phospholipase A2 hydrolyzes membrane phospholipids to release arachidonic acid, the key substrate for eicosanoid synthesis (prostaglandins, thromboxanes, leukotrienes). Phospholipase C generates diacylglycerol (DAG), which can be further converted to arachidonic acid. Phospholipase A1, B play minor roles in lipid metabolism, not the major pathway for arachidonic acid release.

References:

Robbins and Cotran, Pathologic Basis of Disease, 11th Edition, Page no. 77

↑ *Back to this question in Part A*

@Neet_pg_bot

Q10: Which of the following mediators is released immediately during the earliest phase of acute inflammation? (Q879446)

A. Serotonin

B. Interleukins

C. Prostaglandins

D. Bradykinin

Correct Answer: A. Serotonin

Explanation: Serotonin (along with histamine) is stored in pre-formed granules of platelets and mast cells. It is released immediately after injury, making it one of the earliest mediators of inflammation. Incorrect Options: Interleukins (Option B) are cytokines that require new synthesis and act later to sustain inflammation. Prostaglandins (Option C) are synthesized from arachidonic acid after cell activation, so they appear later, not immediately. Bradykinin (Option D) is generated through the kinin cascade and also appears later, mediating pain and vasodilation.

References:

Robbins and Cotran, Pathologic Basis of Disease, 11th Edition, Page no. 77

↑ *Back to this question in Part A*

@Neet_pg_bot

Q11: A 25-year-old female presents to the emergency department with sudden-onset swelling of her face, lips, and tongue. She reports a history of similar episodes occurring intermittently since childhood, often triggered by stress or trauma. On examination, she appears anxious and has marked swelling of her lips and tongue, with difficulty speaking and swallowing. There are no signs of urticaria or pruritus. Her vital signs are stable. Which of the following deficiencies is seen in this condition? (Q845600)

A. Deficiency of properdin

B. Deficiency of C1, C2, C3, C4

C. Deficiency of C1 esterase inhibitor

D. Deficiency of C5-C9

Correct Answer: C. Deficiency of C1 esterase inhibitor

■ *Listen (English)*

■ *Listen (Hindi)*

Explanation: A 25-year-old female presents with sudden facial, lip, and tongue swelling without urticaria or pruritus, and a history of similar episodes since childhood; this condition is associated with a deficiency of C1 esterase inhibitor. The entire complement pathway, especially the classical pathway, is controlled by C1 inhibitor, which prevents the initiation of the complement pathway. If C1 esterase inhibitor is missing from the body, it will lead to Hereditary angioneurotic edema , which is a rare autosomal dominant disorder characterised by recurrent episodes of non-pitting, non-pruritic swelling of the skin and mucous membranes. Deficiency of C1 esterase inhibitor leads to elevated plasma levels of bradykinin, leading to angioedema, and excessive activation of C1 results in a decline in plasma C4 and C2 levels. Swelling in HAE commonly affects areas such as the face, lips, tongue, throat, and extremities, and can lead to airway compromise if it involves the upper respiratory tract

(laryngeal edema).

References:

Harrison’s Principles of Internal Medicine, 21st edition, Page no. 2723

Essentials of Medical Microbiology, Apurba S Sastry, 3rd edition, Page no. 168

Robbins and Cotran, Pathologic Basis of Disease, 10th edition, Page no. 90-92

↑ *Back to this question in Part A*

@Neet_pg_bot

Q12: Pain during inflammation is mediated by? (Q845603)

A. Serotonin

B. Leukotrienes

C. Interleukin-1

D. Bradykinin

Correct Answer: D. Bradykinin

■ *Listen (English)*

■ *Listen (Hindi)*

Explanation: Bradykinin mediates pain during an inflammatory response Two main mediators of pain are Prostaglandin E2 and Bradykinin. Functions of bradykinin : Increases vascular permeability Causes smooth muscle contraction Dilates blood vessels Produces pain when injected into the skin Implicated in allergic reactions, including anaphylaxis These effects are similar to those of histamine. The action of bradykinin is short lived because it is quickly inactivated by an enzyme called kininase (Serotonin) (Option A ruled out) It is responsible for vasodilation , increased vascular permeability, and smooth muscle contraction . In the pathogenesis of asthma, it is responsible for bronchoconstriction. It works similarly to histamine. (Leukotrienes) (Option B ruled out) Leukotrienes are lipid mediators synthesized from arachidonic acid metabolism, primarily by the 5-lipoxygenase pathway. Leukotriene B4 is a chemoattractant. Leukotriene C4, D4 and E4 are slow-reacting substances of anaphylaxis playing role in asthma. (Interleukin-1) (Option C ruled out) Interleukin-1 (IL-1) is responsible for fever.

References:

Robbins and Cotran, Pathologic Basis of Disease, 11th edition, Page no. 83.

↑ *Back to this question in Part A*

@Neet_pg_bot

Q13: Which of the following deficiencies is seen in paroxysmal nocturnal hemoglobinuria? (Q845602)

A. C5-C9

B. CD59

C. C1

D. Factor H

Correct Answer: B. CD59

■ *Listen (English)*

■ *Listen (Hindi)*

Explanation: This case is suggestive of paroxysmal nocturnal hemoglobinuria (PNH), which is due to the deficiency of CD55 and CD59. PNH is a rare acquired hematologic disorder characterized by a mutation of the PIG-A gene . This mutation results in a deficiency of glycosylphosphatidylinositol (GPI)- anchored proteins on the surface of blood cells. This deficiency leads to the absence of important complement regulatory proteins, such as CD55 aka DAF (decay-accelerating factor) and CD59 aka RIML (reactive inhibitor of membrane lysis) , which normally protect red blood cells from complement-mediated destruction. Red coloured uring is passed during night Triad: ■■■■■■■ Hemolytic Anemia: Often resulting in dark urine (hemoglobinuria), fatigue, jaundice, and shortness of breath. Thrombosis: Commonly in veins (deep vein thrombosis, Budd-Chiari syndrome), but also in unusual locations. Pancytopenia/Bone Marrow Failure: Leading to infections, anemia, and bleeding. Diagnosis: Flow Cytometry (Gold Standard): Shows a deficiency or absence of GPI-anchored proteins (CD55/CD59) on RBCs or granulocytes. Coombs Test: Characteristically negative (since the hemolysis is not antibody-mediated). Lab Markers: Elevated LDH, low haptoglobin, and reticulocytosis. C5-C9 (Option A) is a composition of Membrane Attack Complex (MAC), and its deficiency makes the patient prone to Neisseria meningitidis infections. C1 (Option C) is associated with autoimmune disorders like SLE. Factor H (Option D) deficiency causes atypical hemolytic uremic syndrome (Atypical HUS) .

References:

Harrison’s Principles of Internal Medicine, 21st edition, Page 788,789

Robbins and Cotran, Pathologic Basis of Disease, 10th edition, Page no. 92

↑ *Back to this question in Part A*

@Neet_pg_bot

Q14: A 25-year-old female presents to the emergency department with severe allergic reaction symptoms, including urticaria and hypotension, after ingesting a shrimp. How does the vasoactive mediator involved primarily cause hypotension? (Q845563)

A. Vasodilation and increased vascular permeability

B. Enhancing nitric oxide production and vasodilation

C. Inducing the release of other pro-inflammatory cytokines

D. Inhibiting platelet aggregation and causing clotting

Correct Answer: A. Vasodilation and increased vascular permeability

■ *Listen (English)*

■ *Listen (Hindi)*

Explanation: The scenario indicates an allergic reaction, where histamine acts as the key vasoactive mediator responsible for hypotension by dilating arterioles and increasing vascular permeability, as seen in severe allergic responses like anaphylaxis. {{caption_text}}

Basis	Histamine	Serotonin (5HT)
Source	Mast cells (richest source) Basophils Platelets	Enterochromaffin cells (EC cells) (richest sourc) Platelets
Precursor	Histidine	Tryptophan
Function	The functions of Histamine And Serotonin are the same. They are • Helps in vasodilation • Increased vascular permeability • Bronchoconstriction	

@Neet_pg_bot

References:

Robbins and Cotran, Pathologic Basis of Disease, 10th edition, page 86

↑ *Back to this question in Part A*

@Neet_pg_bot

Q15: Which of the following is false regarding the alternate complement pathway? (Q845599)

A. Teichoic acid is an initiator of the alternate complement pathway.

B. The first complement protein to be activated is C1.

C. The C3 convertase of the alternate pathway is C3bBb.

D. Properdin is the stabilizer of the alternate pathway.

Correct Answer: B. The first complement protein to be activated is C1.

■ *Listen (English)*

■ *Listen (Hindi)*

Explanation: The first complement protein to be activated is C1 in the classical complement pathway and not in the alternative complement pathway. The complements involved in the alternate pathway are: Free C3 in the serum (alternate complement pathway starts from C3). Factor B. Factor D. Properdin. Activators (Initiators) of the alternate pathway: Pathogens from microbes Non-microbial initiators Gram (-ve) bacteria: Endotoxins or lipopolysaccharides. Gram (+ve) bacteria: Teichoic acid Fungal cells: Yeast cells. Parasites: Trypanosoma. Virus-infected cells. Human antibodies in complexes: IgA, IgD . Tumor cells. Cobra venom factor. Heterologous RBCs from mice, rabbits, and chickens. Anion polymer like dextran sulfate. Pure carbohydrates like agar and inulin. The image below shows the three complement pathways. {{caption_text}}

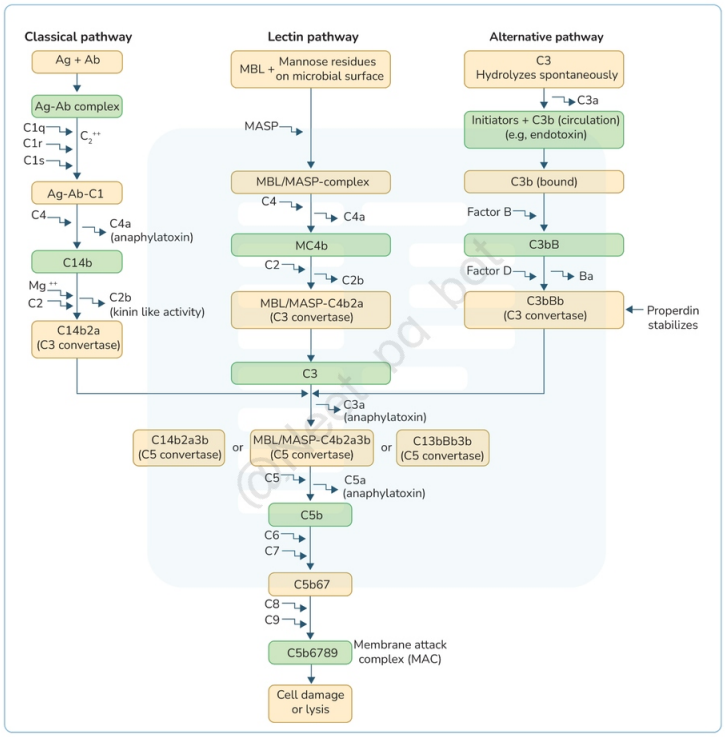

@Neet_pg_bot

References:

Essentials of Medical Microbiology, Apurba S Sastry, 3rd edition, Page no. 165-168

↑ *Back to this question in Part A*

@Neet_pg_bot

Q16: Match the following with their correct answers. 1 C3a i Decay accelerating factor 2 C3b ii EBV receptor 3 CR2 iii Anaphylatoxin 4 CD55 iv Opsonin (Q845597)

A. 1-iii, 2-iv, 3-ii, 4-i

B. 1-iii, 2-iv, 3-i, 4-ii

C. 1-iv, 2-iii, 3-i, 4-ii

D. 1-iv, 2-iii, 3-ii, 4-i

Correct Answer: A. 1-iii, 2-iv, 3-ii, 4-i

■ *Listen (English)*

■ *Listen (Hindi)*

Explanation: Anaphylatoxins: C3a, C4a, and C5a. Opsonins: C3b, C4b, and C5b. Opsonins when coats the bacteria, makes it more tasty for phagocytosis. Overall most important opsonin: IgG Most important complement opsonin: C3b CR2/CD21/C3d: Complement receptor 2 for EBV When EBV enters the body, it attacks the B-cells. To enter into B-cells, it uses CD21/CR2. CD55: Decay-accelerating factor (DAF). CD59: Membrane inhibitor of reactive lysis (MIRL) Missing CD55 and CD59 leads to Paroxysmal nocturnal hemoglobinuria (PNH).

References:

Robbins and Cotran, Pathologic Basis of Disease, 10th edition, Page no. 91

Essentials of Medical Microbiology, Apurba S Sastry, 3rd edition, Page no. 167

↑ *Back to this question in Part A*

@Neet_pg_bot

Q17: A 45-year-old male presents to the clinic with a high fever, chills, and malaise. He reports feeling unwell for the past few days and has noticed redness and swelling around a cut on his forearm. On examination, the healthcare provider observes a localized area of erythema and induration at the site of the wound. Which of the following events is a crucial step in the activation of the complement system in response to the patient's initial condition? (Q845594)

A. Binding of C1q to antigen-antibody complexes

B. Formation of membrane attack complex

C. Cleavage of C3 into C3a and C3b

D. Cleavage of C5 by C5 convertase

Correct Answer: C. Cleavage of C3 into C3a and C3b

■ *Listen (English)*

■ *Listen (Hindi)*

Explanation: A 5-year-old male presents with fever, chills, and a swollen, red wound on his forearm; in response to this localized infection, a key step in complement system activation is the cleavage of C3 into C3a and C3b. Complement system It is a plasma-derived mediator of inflammation. The complement system can be activated by three pathways: Classical pathway Alternate pathway Lectin pathway The cleavage of C3 into its active fragments, C3a and C3b , is the critical event in the complement system and serves as a central step in all three complement activation pathways. The image below shows an overview of the complement pathways. {{caption_text}}

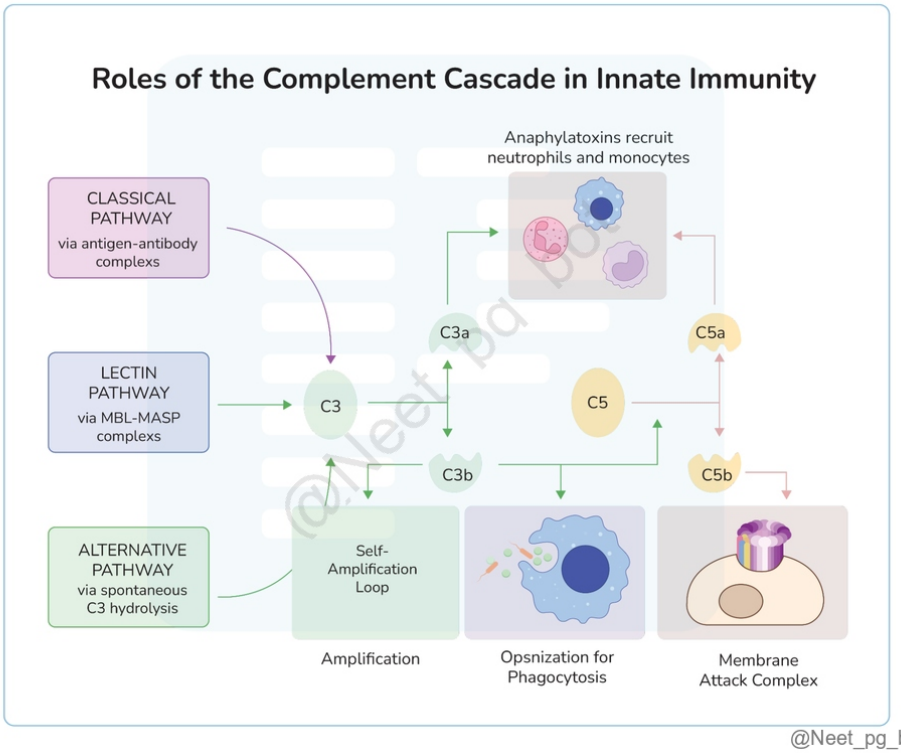

References:

Robbins and Cotran, Pathologic Basis of Disease, 10th edition, Page no. 90, 91

Essentials of Medical Microbiology, Apurba S Sastry, 3rd edition, Page no. 164-166

↑ *Back to this question in Part A*

@Neet_pg_bot

Q18: Select the correct statements about the complement system. 1) The complement system primarily functions by adaptive immunity. 2) Complement proteins are solely produced in the liver. 3) All complement proteins are synthesized in inactive forms and are activated by proteolysis. 4) Complement activation occurs through three pathways. 5) Complements have two equal fragments. (Q845573)

A. 1,2,3

B. 2,4

C. 2,3,5

D. 3,4

Correct Answer: D. 3,4

■ *Listen (English)*

■ *Listen (Hindi)*

Explanation: The correct statements regarding the complement system are statements 3 and 4. Complement System: The complement proteins function in both innate and adaptive immunity for defense against microbial pathogens. (Statement 1 ruled out) Site of synthesis: (Statement 2 ruled out) Liver (major site). Monocytes. Tissue macrophages. Epithelial cells of GIT and genitourinary tract. Activation of complement proteins occurs by three pathways: (Statement 4) Classical pathway. Alternative pathway. Lectin pathway. Activation of complement pathway: All complement proteins are synthesized in inactive forms and are activated by proteolysis. (Statement 3) E.g.: Inactive C3 splitting into active C3a and C3b Complements have two unequal fragments (small and large fragments). (Statement 5 ruled out) The larger fragments are designated as ‘b’ (e.g., C3b), and the smaller fragments are designated as ‘a' (e.g., C3a) (exception: C2a —larger fragment).

References:

Robbins and Cotran, Pathologic Basis of Disease, 10th edition, Page no. 90

Essentials of Medical Microbiology, Apruba S Sastry, 3rd edition, Page no. 163

↑ *Back to this question in Part A*

@Neet_pg_bot

Q19: A 20-year-old male is prescribed naproxen for a musculoskeletal injury. What is naproxen’s mechanism of action? (Q845572)

A. Lipoxygenase inhibition

B. COX-2 inhibition

C. Cycloxygenase (COX) 1 and COX-2 inhibition

D. Prostaglandin (PG) F2 inhibition

Correct Answer: C. Cycloxygenase (COX) 1 and COX-2 inhibition

■ *Listen (English)*

■ *Listen (Hindi)*

Explanation: Naproxen is a non-steroidal anti-inflammatory drug (NSAID). The predominant action of NSAIDs is via COX-1 and COX-2 inhibition, resulting in analgesia and anti-inflammatory effects which is required in this case of musculoskeletal injury. One major adverse effect of NSAIDs is gastric irritation, including ulcers and bleeding. This occurs due to the loss of gastroprotective PGs i.e., PGE2, formed by COX-1. Thus, in patients with previous history of gastric ulcers, selective COX-2 inhibitors may be used - celecoxib, etoricoxib, etc. The Arachidonic Acid Pathway: When cell membranes are injured, phospholipids are converted into arachidonic acid. This acid is then processed via two main enzymatic pathways: the Cyclooxygenase (COX) pathway and the Lipoxygenase (LOX) pathway. Pathway Enzyme Products Inhibitors Effects COX Pathway COX-1 (constitutive) COX-2 (induced) Prostaglandins (PGs), Thromboxane A■ (TXA■), Prostacyclin (PGI■) Naproxen (non-selective NSAID) Celecoxib (COX-2 selective) ↓Inflammation, pain and fever Gastric protection (COX-1) LOX Pathway 5-LOX, 12-LOX, 15-LOX Leukotrienes (LTB■, LTC■) Zileuton (5-LOX) Zafirlukast (LT receptor) Bronchoconstriction, anaphylaxis

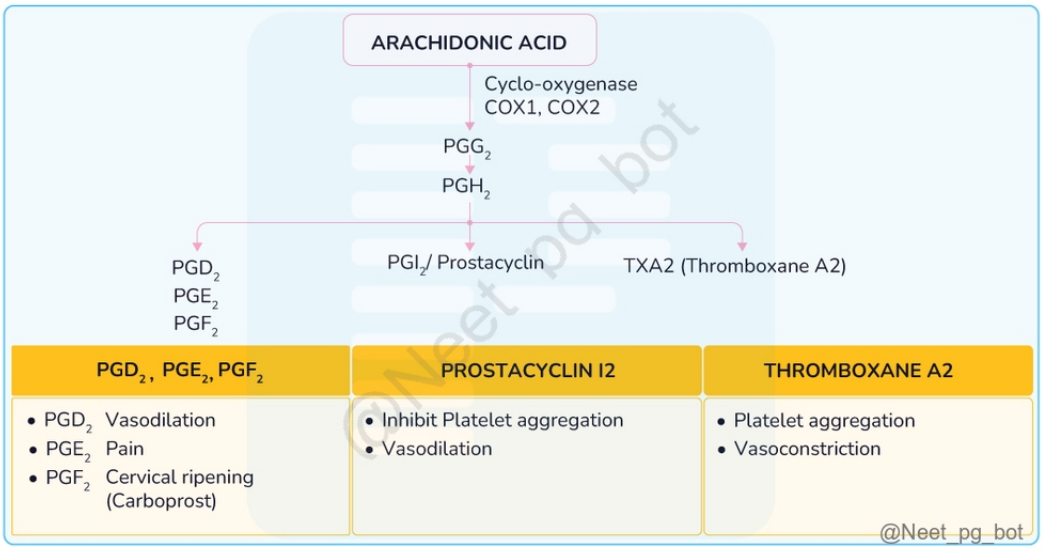

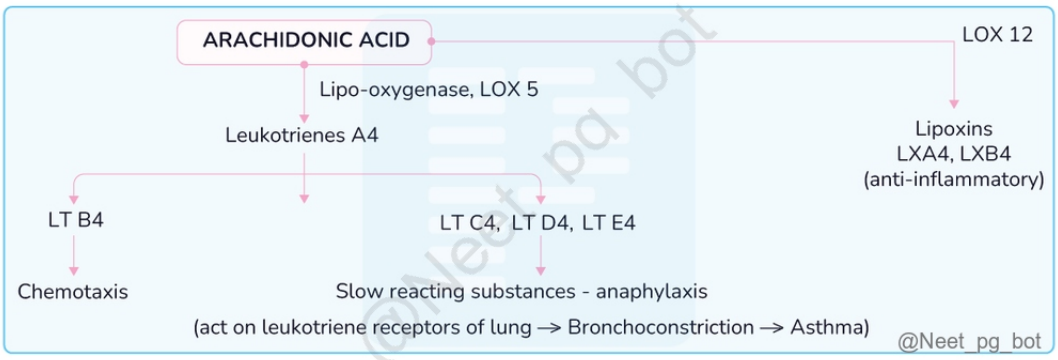

References:

Robbins and Cotran, Pathologic Basis of Disease, 10th edition, Page 98

↑ *Back to this question in Part A*

@Neet_pg_bot

Q20: Which of the following mediators is responsible for cancer cachexia? (Q845571)

A. TNF-alpha

B. IFN-gamma

C. IL-8

D. TGF-beta

Correct Answer: A. TNF-alpha

■ *Listen (English)*

■ *Listen (Hindi)*

Explanation: TNF-alpha is responsible for cancer cachexia. Cancer cachexia means weight loss in cancer patients due to the elevation of TNF-alpha mediators. TNF-alpha also learned as no food appetite, because whenever TNF-alpha is raised in the body (can be due to fever or cancer), appetite of patient decreases and they stop feeling hungry. IFN-gamma (Option B) is responsible for granuloma formation . IL-8 (Option C) is for neutrophil recruitment. TGF-beta (Option D) is the most fibrogenic cytokine.

References:

Robbins and Cotran, Pathologic Basis of Disease, 10th edition, Page 90.

↑ *Back to this question in Part A*

@Neet_pg_bot

Q21: A 35-year-old male presents with a history of chronic obstructive pulmonary disease (COPD) exacerbation. Which of the following chemokines is primarily responsible for recruiting neutrophils to the airways in COPD exacerbations? (Q845570)

A. IL-8

B. MCP-1

C. SDF-1

D. RANTES

Correct Answer: A. IL-8

Listen (English)

Listen (Hindi)

Explanation: Interleukin-8 (IL-8) is a potent chemokine involved in the recruitment of neutrophils to sites of inflammation, particularly in response to bacterial and other microbial infections. IL-8 belongs to the CXC chemokine family. MCP-1(Option B): Belongs to the CC chemokine family. Primarily recruits monocytes and macrophages to sites of inflammation. RANTES(Option D): Belongs to the CC chemokine family. Primarily recruits T-cells to sites of inflammation. SDF-1(Option C): It is a stromal-derived factor. It primarily recruits lymphocytes, monocytes, and hematopoietic stem cells to sites of inflammation.

References:

Robbins and Cotran, Pathologic Basis of Disease, 10th edition, Page no - 90 , 680

↑ *Back to this question in Part A*

@Neet_pg_bot

Q22: A 30-year-old male presents with symptoms of flu-like illness, including fever, sore throat, and fatigue. Further investigation reveals a positive HIV serology. Which of the following chemokine receptors primarily facilitates the entry of HIV into CD4+ T cells? (Q845569)

A. CX3CL1

B. CCR5 , CXCR4

C. CCL11 , MCP-1

D. CXCL8

Correct Answer: B. CCR5 , CXCR4

Listen (English)

Listen (Hindi)

Explanation: Among the given options, CCR5 and CXCR4 are the coreceptors that primarily facilitate HIV entry into CD4+ T cells. Whenever HIV enters the body, it targets CD4 T-cells and macrophages in the body. HIV binds to CD4 T cells and macrophages using glycoproteins: GP120 and GP41. Then, coreceptor binding occurs using

chemokine receptors like CCR5 and CXCR4. CXCR4 coreceptors are predominantly present on CD4 T-cells CCR5 coreceptors are predominantly present on macrophages.

References:

Robbins and Cotran, Pathologic Basis of Disease, 10th edition, Page no - 90

↑ *Back to this question in Part A*

@Neet_pg_bot

Q23: All are chemoattractants among the following except : (Q845568)

A. IL-8

B. C5a

C. LTB4

D. C3b

Correct Answer: D. C3b

■ *Listen (English)*

■ *Listen (Hindi)*

Explanation: Among the given options, C3b is not a chemoattractant. LTB4, IL-8, and C5a are endogenous chemoattractants. These are primarily involved in neutrophil chemotaxis. Can be learned by a mnemonic: LIC C3b (OPTION D): C3b, C4b, and C5b are opsonins that promote phagocytosis by neutrophils and macrophages. It is not a chemoattractant. Overall best opsonin in Immunoglobulin G (IgG) The best complement opsonin is C3b.

References:

Robbins and Cotran, Pathologic Basis of Disease, 10th edition, Page 79.

↑ *Back to this question in Part A*

@Neet_pg_bot

Q24: Which of the following best describes the mechanism of action of PAF in inducing bronchoconstriction? (Q845567)

A. By binding to seven transmembrane G protein–coupled receptors.

B. Causing smooth muscle constriction by directly stimulating muscarinic receptors

C. Induction of smooth muscle relaxation and bronchodilation

D. Activation of platelets and leukocytes leading to release of inflammatory mediators

Correct Answer: D. Activation of platelets and leukocytes leading to release of inflammatory mediators

Explanation: Activation of platelets and leukocytes leading to release of inflammatory mediators: This statement accurately describes one of the primary actions of PAF. Upon binding to its receptor on platelets and leukocytes, PAF activates these cells, leading to the release of inflammatory mediators such as leukotrienes, prostaglandins, and cytokines. These mediators contribute to bronchoconstriction, increased vascular permeability, and airway inflammation. Platelet-activating factor (PAF) is a phospholipid-derived mediator that was discovered as a factor that caused platelet aggregation, but it is now known to have multiple inflammatory effects. A variety of cell types, including platelets, basophils, mast cells, neutrophils, macrophages, and endothelial cells, can elaborate PAF in both secreted and cell-bound forms. In addition to platelet aggregation, PAF causes vasoconstriction and bronchoconstriction, and at low concentrations it induces vasodilation and increased venular permeability By binding to seven transmembrane G protein–coupled receptors (OPTION A) This is not the mechanism of action of PAF. Chemokines mediate their activities by binding to seven transmembrane G protein–coupled receptors. Chemokines are a family of small proteins that act primarily as chemoattractants for specific types of leukocytes. Causing smooth muscle constriction by directly stimulating muscarinic receptors (OPTION B) This is not the mechanism for PAF Acetylcholine, released from intrapulmonary parasympathetic nerves, causes airway smooth muscle constriction by directly stimulating muscarinic receptors. Induction of smooth muscle relaxation and bronchodilation (OPTION C) : This option suggests a contradictory effect to the actual mechanism of PAF. PAF induces smooth muscle contraction and bronchoconstriction rather than relaxation and bronchodilation.

References:

Robbins and Cotran, Pathologic Basis of Disease, 10th edition, Page - 88, 90, 92

↑ *Back to this question in Part A*

@Neet_pg_bot

Q25: Which of the following is the role of neutrophil lysosomal enzymes in acute inflammation? (Q845566)

A. Cleavage of C3 and C5

B. Inhibition of complement proteins

C. Activation of macrophages

D. Degradation of prostaglandins

Correct Answer: A. Cleavage of C3 and C5

Explanation: Neutrophil lysosomal enzymes, especially elastase, cleave C3 and C5 complement proteins into their active C3a/C3b and C5a/C5b forms. These peptides mediate acute inflammation by inducing vasodilation, increased vascular permeability, and leukocyte chemotaxis. Lysosomal enzymes are synthesized in the ER, modified in the Golgi apparatus, and packaged into lysosomes. Enzymes are stored in granules and are released upon cell activation. Azurophil (primary) granules Specific (secondary) granules Myeloperoxidase (MPO) Defensins Acid hydrolases Neutral proteases Elastase Cathepsin G Nonspecific collagenases Proteinase 3 Lysozyme Lysozyme Collagenase Gelatinase Lactoferrin Plasminogen activator Histaminase Enzyme Function Enzyme Function Myeloperoxidase Generates reactive oxygen species for microbial killing Proteinase 3 Degrades proteins in phagolysosomes Defensins Disrupts microbial cell membranes Lysozyme Degrades bacterial cell walls Acid hydrolases Degrades bacteria and debris in phagolysosomes Collagenase Degrades collagen in extracellular matrix Neutral proteases Degrades extracellular matrix components, cleaves complement proteins Gelatinase Degrades gelatin in extracellular matrix Elastase Degrades elastin combats bacterial infections Lactoferrin Binds and sequesters iron due to defects in the alternate pathway. Cathepsin G Degrades proteins in phagolysosomes Plasminogen activator Converts plasminogen to plasmin, fibrinolysis Nonspecific collagenases Degrades collagen in extracellular matrix Histaminase Metabolizes histamine and limits inflammatory response. Inhibition of complement proteins (Option B) Neutrophil lysosomal enzymes do not inhibit complement proteins but rather cleave them to generate bioactive fragments. Activation of macrophages(Option C) Neutrophil lysosomal enzymes primarily act within neutrophils themselves or in the extracellular space, and do not directly activate macrophages. Degradation of prostaglandins(Option D) Neutrophil lysosomal enzymes do not degrade prostaglandins. Prostaglandins are lipid mediators synthesized from arachidonic acid by the action of cyclooxygenases and play a role in inflammation.

References:

Robbins and Cotran, Pathologic Basis of Disease, 10th edition, pg no 83

↑ *Back to this question in Part A*

@Neet_pg_bot

Q26: Which type of nitric oxide synthase (NOS) is involved in microbial killing and is induced in macrophages by cytokines or microbial products? (Q845565)

A. Endothelial NOS (eNOS)

B. Neuronal NOS (nNOS)

C. Inducible NOS (iNOS)

D. None of the above

Correct Answer: C. Inducible NOS (iNOS)

■ *Listen (English)*

■ *Listen (Hindi)*

Explanation: Inducible nitric oxide synthase (iNOS) is involved in microbial killing. iNOS generates nitric oxide (NO) from Arginine which reacts with superoxide (O2•) to produce peroxynitrite (ONOO–). iNOS works on L-Arginine converting it into Nitric oxide and L-citrulline. Peroxynitrite helps combat infections. Type Constitutive Expression Calcium dependency Function Location Endothelial (eNOS) (Option A ruled out) Constitutive (Low levels) Ca²■-dependent (via calmodulin) Maintains vascular tone (Vasodilation) Endothelial cells (Blood vessels) Neuronal (nNOS) (Option B ruled out) Constitutive (Low levels) Ca²■-dependent (via calmodulin) Functions as a neurotransmitter Neurons/Nerves Inducible (iNOS) (Option C) Inducible (Induced in macrophages by cytokines/microbial products) Ca²■-independent (Tight calmodulin binding) Involved in microbial killing, induced by cytokines or microbial products Macrophages and Inflammatory cells . Essential Co-factors of NOS: NADPH: The primary electron donor that initiates the process. FAD & FMN: The electron bridge that transfers electrons from NADPH to the heme group. Heme (Iron): The catalytic site that activates oxygen (O2) to oxidize L-arginine. Tetrahydrobiopterin (BH4): The stabilizer that ensures "coupling," preventing the production of toxic superoxide. Calmodulin (CaM): The molecular switch that triggers electron flow. Note: Binding is Ca²■-dependent for eNOS/nNOS but Ca²■-independent for iNOS. Zinc (Zn²■): The structural anchor that maintains the enzyme's active dimeric shape.

References:

Robbins and Cotran, Pathologic Basis of Disease, 10th edition, page no 83

↑ *Back to this question in Part A*

@Neet_pg_bot

• [02_Inflammation] 009 Previous Year Questions

« Back to Folder Directory

[02_Inflammation] 009 Previous Year Questions — Quick Jump

Q1 (p. 1159)	*Q2 (p. 1160)*	*Q3 (p. 1161)*	*Q4 (p. 1163)*	*Q5 (p. 1164)*	*Q6 (p. 1165)*
Q7 (p. 1166)	*Q8 (p. 1168)*	*Q9 (p. 1169)*	*Q10 (p. 1170)*	*Q11 (p. 1171)*	*Q12 (p. 1172)*
Q13 (p. 1173)	*Q14 (p. 1175)*	*Q15 (p. 1175)*	*Q16 (p. 1177)*	*Q17 (p. 1178)*	*Q18 (p. 1180)*
Q19 (p. 1180)	*Q20 (p. 1181)*	*Q21 (p. 1182)*			

Q1: Which of the following cytokines does not cause the Jarisch-Herxheimer reaction? (Q855911)

A. TNF alpha

B. IL-6

C. IL-8

D. INF-γ

Correct Answer: D. INF-γ

Explanation: IFN-gamma, produced by activated T cells and NK cells, regulates Th1 immune responses but is not typically involved in the Jarisch-Herxheimer reaction. Instead, TNF-alpha, IL-6, and IL-8 play a key role in this reaction. Jarisch-Herxheimer Reaction: It is a dramatic but self-limited inflammatory response that can occur after the initiation of treatment for syphilis. It is characterized by: Fever Chills Myalgia (muscle pain) Headache Tachycardia (increased heart rate) Increased respiratory rate Elevated circulating neutrophil count Vasodilation with mild hypotension This reaction is believed to be triggered by the release of lipoproteins from dying Treponema pallidum organisms. The reaction occurs in approximately 50% of patients with primary syphilis, 90% of those with secondary syphilis, and in a smaller proportion of individuals with later-stage disease. Symptoms typically subside within 12–24 hours. In patients with secondary syphilis, erythema (redness) and oedema (swelling) of cutaneous lesions may worsen temporarily. TNF alpha (Option A) is a pro-inflammatory cytokine produced by macrophages and T cells , playing a central role in inflammation. It is implicated in the Jarisch-Herxheimer reaction , where cytokine release following antibiotic treatment temporarily worsens symptoms. IL-6 (Option B) is a pro-inflammatory cytokine produced by immune cells, fibroblasts, and endothelial cells , regulating immune responses and inflammation. It contributes to the Jarisch-Herxheimer reaction by amplifying the systemic inflammatory response. IL-8 (Option C) is a chemokine that recruits and activates neutrophils , playing a role in infection and inflammation . It contributes to the Jarisch-Herxheimer reaction by enhancing neutrophil recruitment and activation.

References:

Harrison’s Principles of Internal Medicine, 21st Edition, Page 1413

↑ *Back to this question in Part A*

@Neet_pg_bot

Q2: A patient underwent a cystoscopy, which showed multiple yellow-white plaques in the trigone of the bladder. The histopathology image is given below. What is the diagnosis? (Q855952)

A. Interstitial cystitis

B. Malakoplakia

C. Polypoid cystitis

D. Acute cystitis

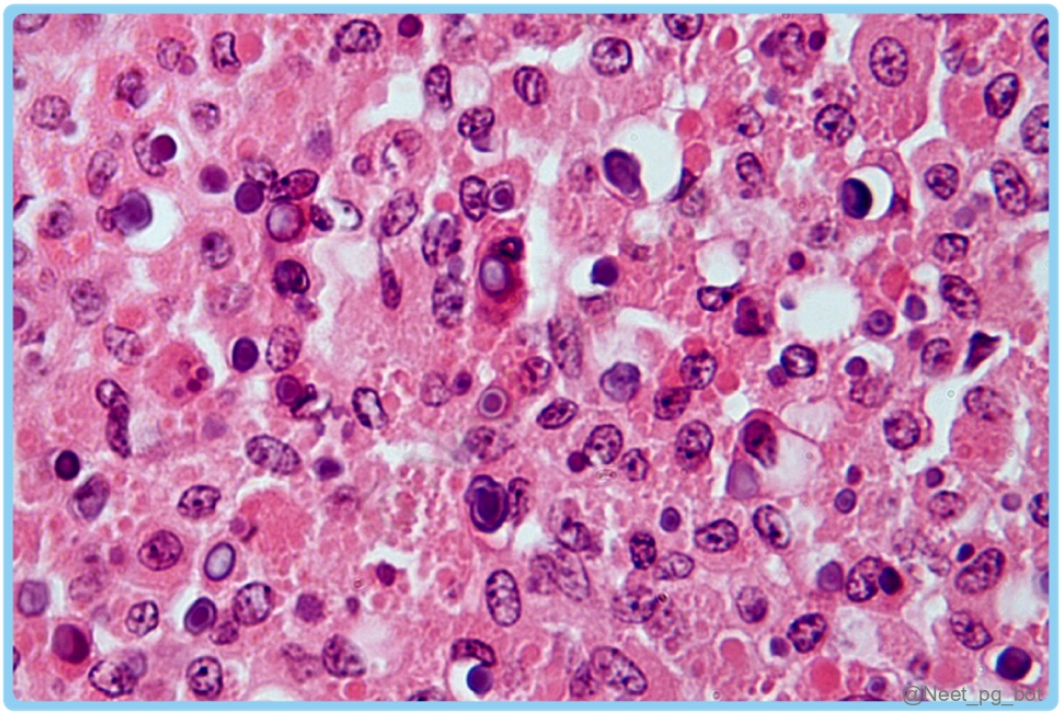

Correct Answer: B. Malakoplakia

Explanation: is a common urinary tract infection that presents with dysuria, frequency, and urgency. It does not cause the formation of yellow-white plaques or Michaelis-Gutmann bodies.

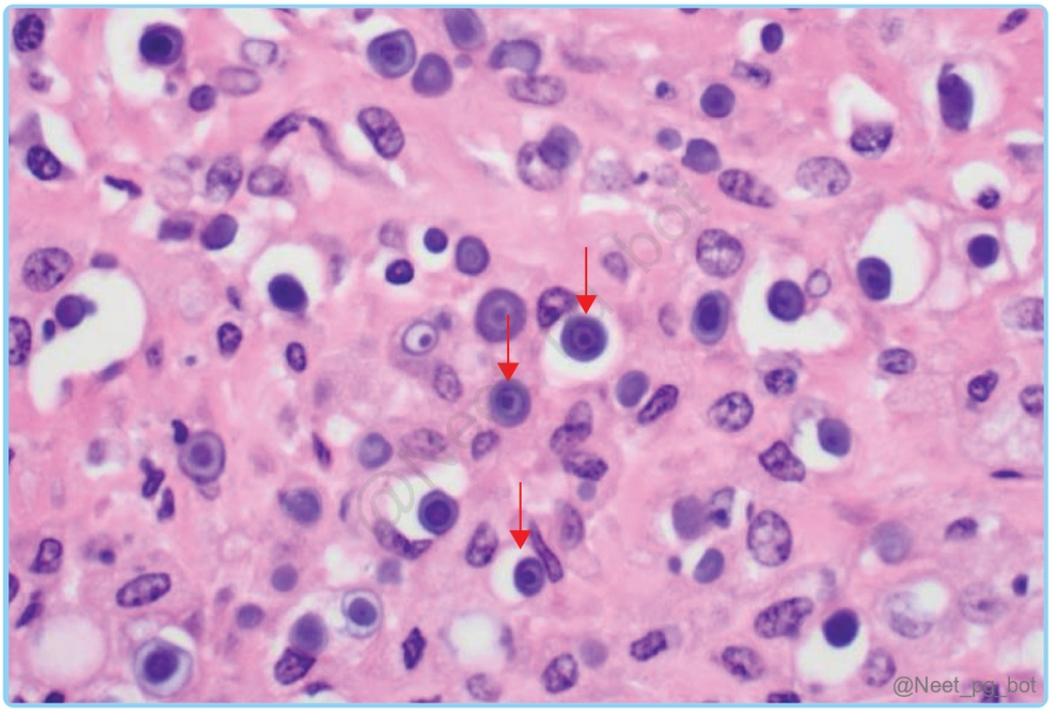

References:

Robbins and Cotran, Pathologic Basis of Disease, 10th Edition, Page 956,

NIHLink,

Pathology outlineLink.

↑ *Back to this question in Part A*

@Neet_pg_bot

Q3: All of the following statements regarding neutrophil extracellular trapping (NET) are true, except? (Q855938)

A. It is detected in blood during sepsis

B. It is produced in response to bacterial infection

C. Mitochondrial DNA is seen

D. It is chromatin with antibacterial enzymes

Correct Answer: C. Mitochondrial DNA is seen

Explanation: Neutrophil extracellular traps: They are produced by neutrophils in response to infectious pathogens (mainly bacteria and fungi) and inflammatory mediators (e.g., chemokines, cytokines, complement proteins, and ROS), their presence can be used as a biomarker for sepsis. (Option B ruled out) NET formation starts with ROS-dependent activation of an arginine deaminase that converts arginine to citrulline, leading to chromatin decondensation. NETs are composed of nuclear chromatin and various granule proteins, including antimicrobial peptides and enzymes that help to neutralise and kill pathogens trapped within the NETs. (Option D ruled out) Activated neutrophils release histones into the extracellular space which helps to unwind and release the DNA, allowing it to combine with granule proteins and form the characteristic web-like structure of NETs. NETs do not directly phagocytose or engulf the invading pathogens . Instead, they trap pathogens within their structure, immobilizing them and allowing other immune cells, such as macrophages, to recognize and eliminate them. The nuclear chromatin in the NETs, including histones and associated DNA, has been postulated to be a source of nuclear antigens in systemic autoimmune diseases, particularly lupus, in which individuals react against their DNA and nucleoproteins. {{caption_text}} A neutrophil granulocyte (yellow) has ejected a NET (green) to capture bacteria (purple). A red blood cell (orange) is also trapped in the NET.

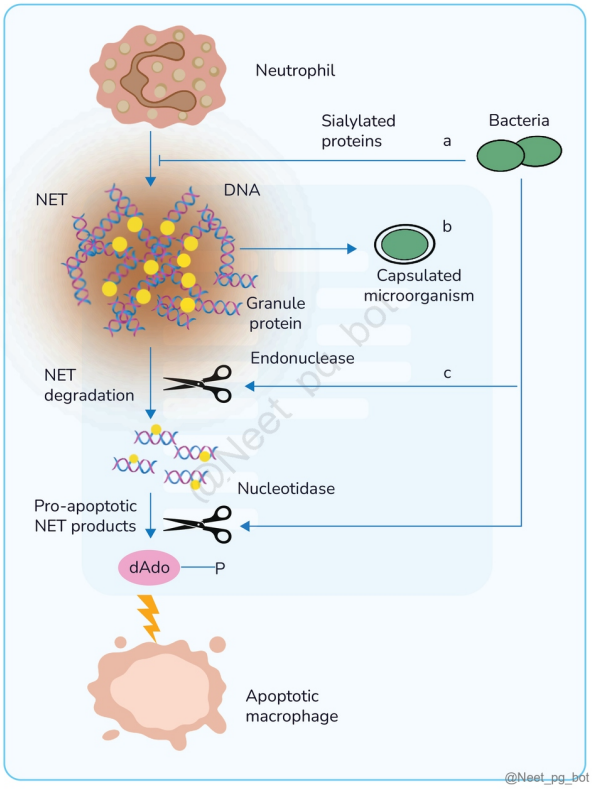

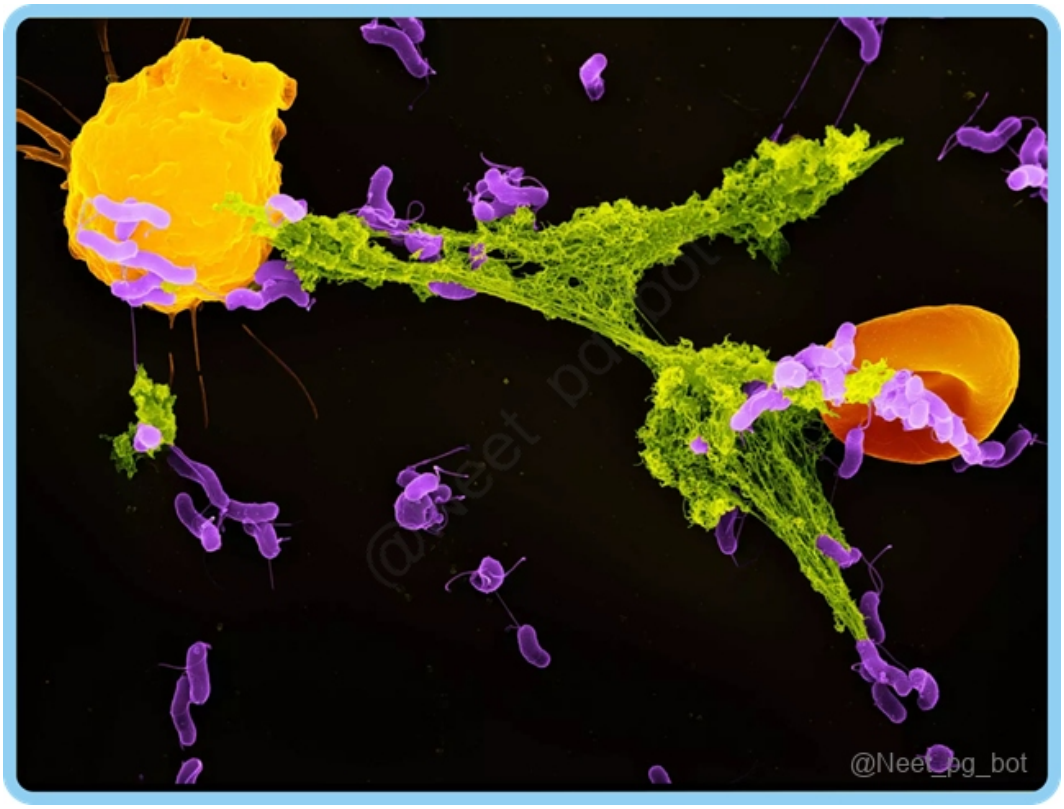

References:

Robbins and Cotran Pathologic Basis of Disease, 10th Edition, Page 83

↑ *Back to this question in Part A*

@Neet_pg_bot

Q4: A 12-year-old child presented with 15 days of cough. On examination, cervical lymphadenopathy was noted, and the lymph node biopsy showed caseating granulomas. What is the most probable diagnosis? (Q854881)

A. Tuberculosis

B. Leprosy

C. Sarcoidosis

D. Syphilis

Correct Answer: A. Tuberculosis

Explanation: In patients presenting with cervical lymphadenopathy (scrofula) and a prolonged cough, histopathology typically reveals granulomatous inflammation. Caseating granulomas (necrotizing granulomas) are hallmark histopathological findings in tuberculosis. Granulomas are composed of epithelioid cells, Langhans giant cells, and a central area of caseous necrosis. Cervical lymphadenopathy (scrofula) is a common manifestation of extrapulmonary TB in children. Clinical history of prolonged cough supports a tubercular infection. Diagnosis is confirmed by AFB staining, culture, or PCR for Mycobacterium tuberculosis. Note: While predominantly caseating, TB can show both caseating and non-caseating granulomas, with caseating > non-caseating . Similar to TB, sarcoidosis can occasionally show small areas of necrosis, but is typically non-caseating > caseating . Leprosy (Option B): Causes non-caseating granulomas; typically involves skin and peripheral nerves, not cervical lymph nodes with caseation. Sarcoidosis (Option C): Characterized by non-caseating granulomas; more common in adults and usually systemic. Syphilis (Option D): Can cause gummatous lesions but not classic caseating granulomas; cervical lymphadenopathy is usually painless.

References:

Robbins & Cotran Pathologic Basis of Disease, 10th Edition, Page 101

↑ *Back to this question in Part A*

@Neet_pg_bot

Q5: During acute inflammation, leukocytes exit the bloodstream and migrate toward the site of tissue injury through several coordinated steps. Arrange the following events in the correct chronological order: Chemotaxis Adhesion Opsonization Rolling Phagocytosis Margination Cytokine-mediated integrin activation Transmigration (Q856703)

A. 1, 2, 3, 4, 5, 6, 7, 8

B. 6, 4, 7, 2, 8, 1, 3, 5

C. 4, 6, 2, 1, 3, 7, 8, 5

D. 2, 1, 4, 3, 5, 6, 7, 8

Correct Answer: B. 6, 4, 7, 2, 8, 1, 3, 5

Explanation: The correct sequence of cellular events of inflammation is as follows: Margination: Due to vasodilation and slowing of blood flow, leukocytes move toward the vessel wall (periphery of the stream). Rolling: Leukocytes transiently attach and detach along the endothelium, mediated by selectins (E-, P-, L-selectin) . Integrin Activation: Chemokines (IL-8, C5a, LTB■) activate leukocyte integrins, converting them from a low- to high-affinity state. Adhesion: Firm binding of leukocytes to the endothelium occurs via integrins (LFA-1, Mac-1) binding to ICAM-1 and VCAM-1 . Transmigration (Diapedesis): Leukocytes squeeze between endothelial cells and cross the basement membrane into the interstitium, mediated by PECAM-1 (CD31) . Chemotaxis: Leukocytes migrate directionally toward the site of injury, guided by gradients of IL-8, C5a, LTB■, and bacterial peptides .

Opsonization: Microbes are coated with opsonins (IgG, C3b) to enhance recognition by phagocytes. Phagocytosis: Leukocytes engulf and destroy pathogens using reactive oxygen species and lysosomal enzymes .

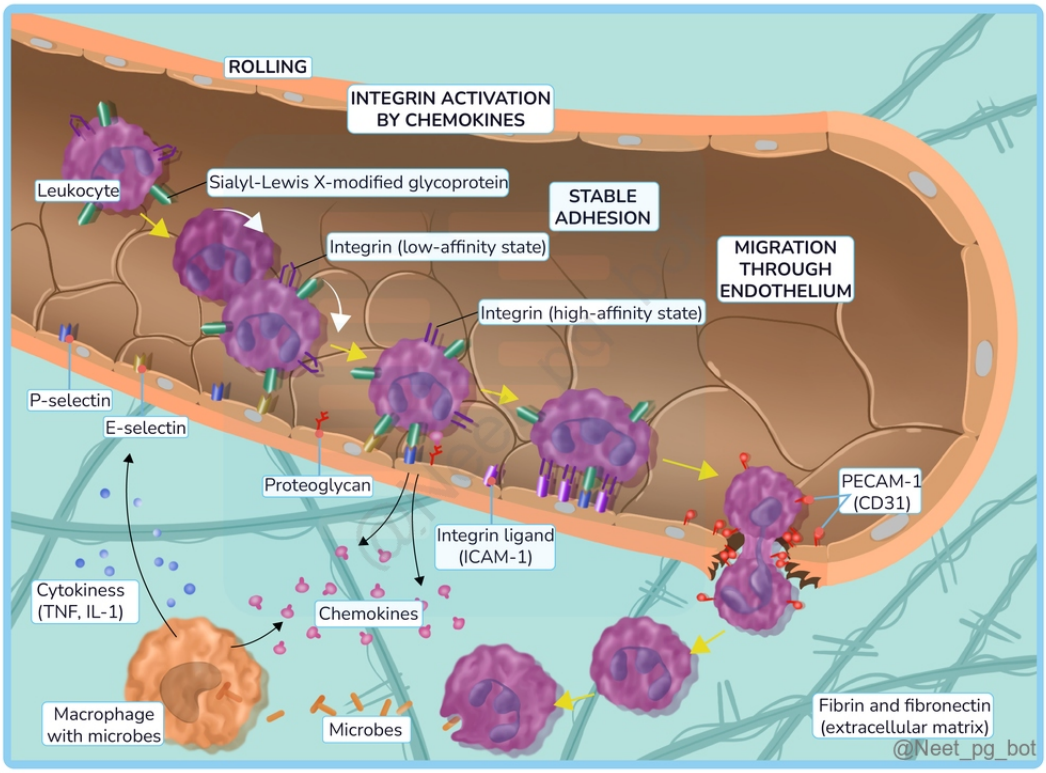

References:

Robbins and Cotran Pathologic Basis of Disease, 10th Edition, Page 77-80.

↑ *Back to this question in Part A*

@Neet_pg_bot

Q6: During wound healing, the cells that appear first, due to chemotaxis, at the site of the wound are: (Q857608)

A. Neutrophils

B. Monocytes

C. Macrophages

D. Lymphocytes

Correct Answer: A. Neutrophils

Explanation: Neutrophils are the first cells to migrate to the site of injury due to chemotaxis during the inflammatory response. They are crucial in the initial stages of wound healing, where they help to clear debris, bacteria, and other pathogens. Events in wound healing Day 0 Platelets and Fibrin form blood clots. Day 1 Blood clot remains and recruitment of neutrophils (acute inflammation). Day 2 Blood clots remain; neutrophils accumulate, followed by the formation of a thin epithelial layer. Day 3 Chronic inflammation sets in, and macrophages replace neutrophils. Granulation tissue begins (blood vessel formation starts) Day 5 Maximum granulation tissue (Maximum neovascularisation) Collagen bridging starts Day 21(3rd Week) Maximum collagen deposition (Type I collagen.) {{caption_text}}

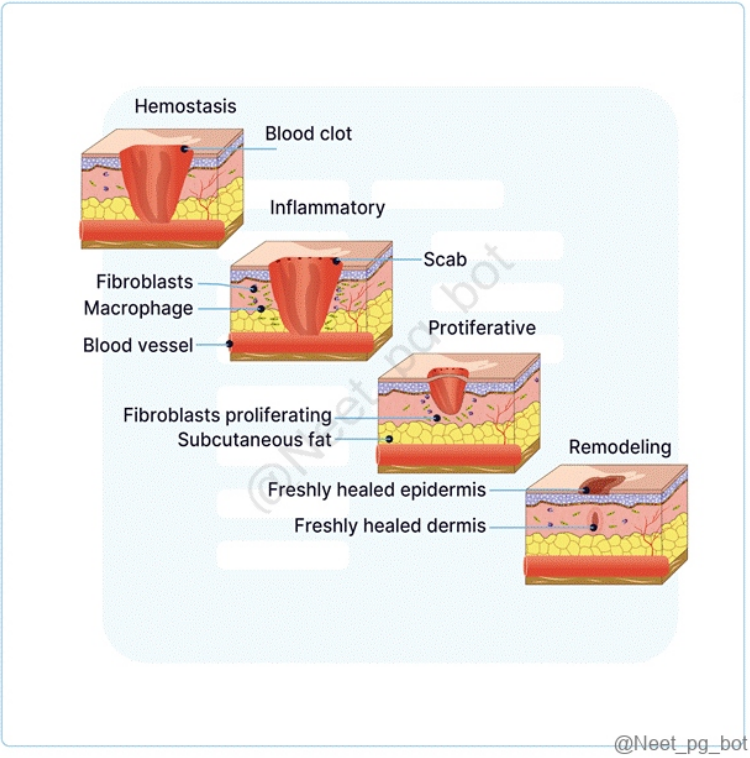

References:

Robbins & Cotran Pathologic Basis of Disease, 10th Edition, Page 108

↑ *Back to this question in Part A*

@Neet_pg_bot

Q7: Which of the following molecules helps in the firm adhesion of the leukocyte to the endothelium during inflammation? (Q857101)

A. P-selectin

B. Platelet-activating factor

C. VCAM-1

D. Complements

Correct Answer: C. VCAM-1

Explanation: VCAM-1 (Vascular Cell Adhesion Molecule-1) is involved in the firm adhesion of leukocytes to the endothelium during inflammation. It binds to integrins on the surface of leukocytes, facilitating their migration through the endothelium to the site of injury or infection. Leukocyte Adhesion to Endothelium: In normal blood flow, leukocytes are pushed to the edges of the vessel. In inflammation, stasis causes leukocytes to slow down and interact with endothelial cells. This interaction involves selectins and integrins , which mediate the rolling and firm adhesion of leukocytes. Selectins : These are responsible for the initial rolling interactions . There are three types: L-selectin on leukocytes E-selectin on endothelial cells P-selectin (Option A) on both platelets and endothelial cells The ligands for selectins are sialylated oligosaccharides on mucin-like glycoproteins. Cytokines like TNF and IL-1 upregulate the expression of selectins, promoting leukocyte rolling along the vessel wall. Integrins : After rolling, leukocytes bind more firmly to the endothelium via integrins, such as VLA-4 and LFA-1 (CD11a & CD18) , which interact with endothelial ligands like VCAM-1 and ICAM-1 . This firm adhesion halts the rolling process and allows leukocytes to flatten and spread on the endothelial surface. Migration: Once firmly adhered, leukocytes migrate through the endothelial layer (transmigration), facilitated by adhesion molecules like PECAM-1 (CD31). After exiting the vessel, they follow the chemotactic gradient toward the site of inflammation. Incorrect Options: Platelet-activating factor (PAF) (Option B) is a potent mediator of inflammation, influencing various processes like platelet aggregation, vasodilation, and immune cell activation, but it does not directly contribute to leukocyte adhesion to the endothelium. Complement (Option D) proteins are part of the immune system and are involved in opsonisation, lysis of pathogens, and inflammation. However, they do not directly mediate the adhesion of leukocytes to the endothelium.

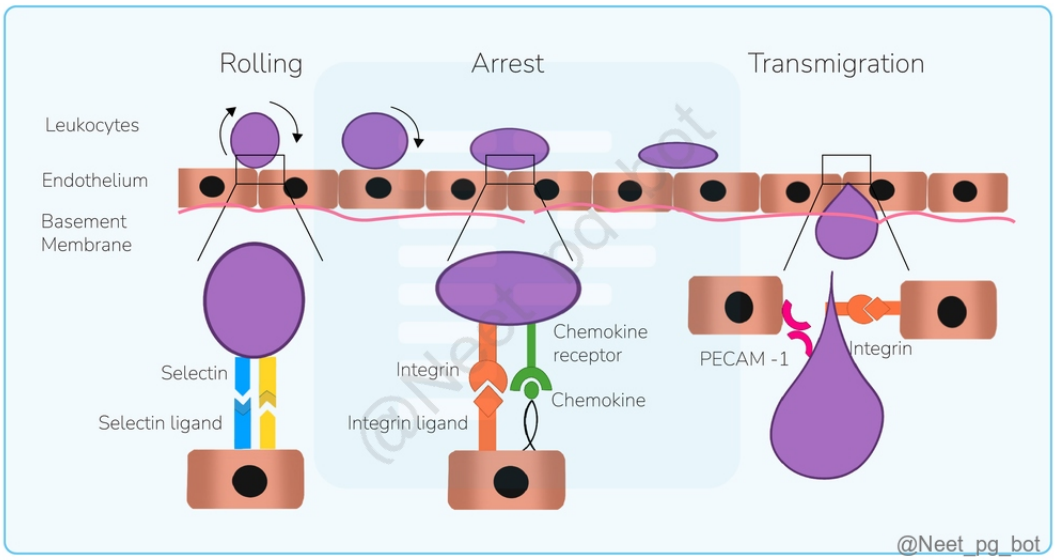

References:

Robbins & Cotran Pathologic Basis of Disease, 10th Edition, Page 77, 78, 79

↑ *Back to this question in Part A*

@Neet_pg_bot

Q8: Cyclooxygenase plays a role in which of the following pathways? (Q855125)

A. Kreb’s cycle

B. Prostaglandin

C. Leukotriene

D. Vitamin K

Correct Answer: B. Prostaglandin

Explanation: Cyclooxygenase (COX) is an enzyme that plays a key role in the prostaglandin synthesis pathway. It converts arachidonic acid into prostaglandins, which are involved in inflammation, pain, and fever. Arachidonic Acid Metabolites: Arachidonic acid (AA) is a 20-carbon polyunsaturated fatty acid (5,8,11,14-eicosatetraenoic acid). It is stored in membrane phospholipids and released through the action of phospholipase A2 . AA is then converted into lipid mediators, known as eicosanoids, through the action of cyclooxygenases and lipoxygenases. {{caption_text}} Prostaglandins (PGs): Produced by Mast cells, macrophages, endothelial cells, and other cell types. Involved in Vascular and systemic reactions of inflammation. Enzymes : Prostaglandins are synthesized via cyclooxygenase enzymes (COX-1 and COX-2). COX-1 is constitutively expressed and performs homeostatic functions, while COX-2 is induced in response to inflammation. Key Prostaglandins : PGI2 (prostacyclin) is produced by the vascular endothelium and acts as a vasodilator and inhibitor of platelet aggregation. TXA2 is produced by platelets and causes platelet aggregation and vasoconstriction. PGD2 and PGE2 cause vasodilation and increase the permeability of postcapillary venules, promoting oedema formation. PGE2 also contributes to pain and fever during inflammation. Leukotrienes: Produced by : Leukocytes and mast cells through the action of lipoxygenase enzymes, particularly 5-lipoxygenase . Involved in vascular reactions, smooth muscle contraction, and leukocyte recruitment. Key Leukotrienes : LTB4 is a potent chemotactic agent that activates neutrophils and promotes adhesion, generates reactive oxygen species (ROS), and releases lysosomal enzymes. Cysteinyl leukotrienes (LTC4, LTD4, LTE4) cause vasoconstriction, bronchospasm (important in asthma), and increase vascular permeability. Lipoxins: Produced by : Lipoxins are synthesized via the lipoxygenase pathway, involving both neutrophils and platelets for transcellular biosynthesis. Function : Lipoxins suppress inflammation by inhibiting neutrophil chemotaxis and adhesion to the endothelium, thus limiting the inflammatory response. Kreb’s cycle (Option A) is part of cellular respiration and involves the metabolism of carbohydrates, fats, and proteins to generate energy. Cyclooxygenase is not involved in this cycle. Leukotriene (Option C) is another class of eicosanoids derived from arachidonic acid, but it is produced via the 5-lipoxygenase pathway, not the cyclooxygenase pathway. Vitamin K (Option D) is involved in the coagulation cascade and is not related to the action of cyclooxygenase.

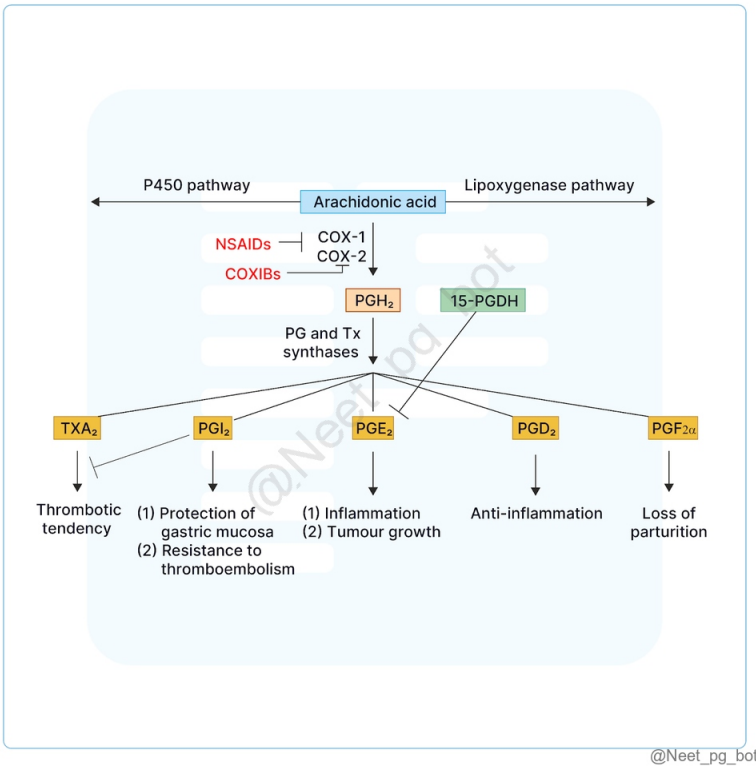

References:

Robbins & Cotran Pathologic Basis of Disease, 10th Edition, Page 86

↑ *Back to this question in Part A*

@Neet_pg_bot

Q9: Match the following cells with their locations: Cells Locations 1. Kupffer cells a. Stomach 2. Parietal cells b. Liver 3. Dust cells c. Alveoli 4. Clara cells d. Bronchioles (Q855088)

A. 1-a, 2-b, 3-c, 4-d

B. 1-c, 2-d, 3-a, 4-b

C. 1-d, 2-a, 3-d, 4-c

D. 1-b, 2-a, 3-c, 4-d

Correct Answer: D. 1-b, 2-a, 3-c, 4-d

Explanation: Cells Locations Kupffer cells Liver Parietal cells Stomach Dust cells Alveoli Clara cells Bronchioles Kupffer cells are specialized macrophages located in the liver. They are part of the liver's immune system and help filter blood and remove pathogens and debris. Parietal cells are found in the stomach lining and secrete hydrochloric acid and intrinsic factors, which are essential for digestion and absorption of vitamin B12. Dust cells : These are alveolar macrophages located in the lungs, specifically in the alveoli. They play a role in clearing out inhaled particles, bacteria, and debris from the lungs. Clara cells are located in the bronchioles (small air passages in the lungs), protect the lungs from oxidative stress and have a role in detoxification by secreting various substances, including surfactant components. Macrophage Eponyms and Locations: Cell Name Location Primary Role Kupffer cells Liver Specialized macrophages that filter blood and remove pathogens. Dust cells Alveoli (Lungs) Alveolar macrophages that clear inhaled debris and bacteria. Microglia Central Nervous System Act as the primary immune defense in the brain and spinal cord. Langerhans cells Skin (Epidermis) Dendritic cells that act as macrophages to process antigens. Osteoclasts Bone Specialized cells responsible for bone resorption and remodeling. Mesangial cells Kidney (Glomerulus) Regulate filtration and clear immune complexes. Histiocytes Connective Tissue General tissue-resident macrophages. Splenic Macrophages Spleen (Red Pulp) Remove aged or damaged red blood cells (erythrophagocytosis). Hofbauer cells Placenta Protect the fetus from pathogens across the placental barrier. Stem Cells: Stem Cell Type Location Differentiation Potential Hematopoietic Stem Cells Bone Marrow Give rise to all blood cells (RBCs, WBCs, Platelets). Basal cells Skin (Stratum Basale) Continuously produce new keratinocytes to renew the epidermis. Crypt cells (Stem cells) Small Intestine Located in the Crypts of Lieberkühn; renew the intestinal lining every few days. Satellite cells Skeletal Muscle Act as precursors to myoblasts to repair damaged muscle fibers. Oval cells Liver (Canals of Hering) Activated when hepatocytes are unable to regenerate effectively. Neural Stem Cells Subventricular Zone Produce new neurons and glial cells in specific brain regions. Limbal Stem Cells Eye (Corneo-scleral junction) Maintain the transparency and integrity of the corneal epithelium.

References:

Robbins & Cotran Pathologic Basis of Disease, 10th Edition, Page 97,104,118,652

Ganong Review of Medical Physiology, 26th Edition, Page 449,610

↑ *Back to this question in Part A*

@Neet_pg_bot

Q10: Match the cytokines with the effector cells 1. IL-4 a. Eosinophils 2. IL-5 b. Mast cells 3. IL-9 c. B cells 4. IL-13 d. Dendritic cells (Q856029)

A. 1-c, 2-a, 3-b, 4-d

B. 1-a, 2-c, 3-d, 4-b

C. 1-b, 2-d, 3-c, 4-a

D. 1-d, 2-b, 3-a, 4-c

Correct Answer: A. 1-c, 2-a, 3-b, 4-d

Explanation: Cytokine Effector Cell IL-4 B cells IL-5 Eosinophils IL-9 Mast cells IL-13 Dendritic cells Interleukins & functions: Interleukin (IL) Function IL-1 Promotes fever and inflammation and activates T cells and macrophages. IL-2 Stimulates growth and activation of T cells, critical for adaptive immunity. IL-3 Supports growth and differentiation of hematopoietic cells (blood cell precursors). IL-4 Stimulates B cell differentiation and promotes IgE production and Th2 response. IL-5 Stimulates eosinophil differentiation and activation. IL-6 Induces fever and acute-phase reactant production and supports B cell differentiation. IL-7 Essential for T and B cell development and survival. IL-8 (CXCL8) Attracts neutrophils to sites of infection (chemotaxis). IL-9 Promotes mast cell growth and regulates Th2 responses. IL-10 Anti-inflammatory; inhibits Th1 responses and macrophage activity. IL-12 Stimulates Th1 cell differentiation and enhances cytotoxic activity of T and NK cells. IL-13 Modulates immune responses and activates macrophages. IL-17 Promotes inflammation and recruitment of neutrophils, which are involved in autoimmunity. IL-21 Stimulates B cell differentiation, plasma cell generation, and Th17 response. IL-22 Induces antimicrobial peptide production and supports tissue repair. IL-23 Promotes Th17 differentiation and inflammatory responses.

References:

Robbins & Cotran Pathologic Basis of Disease, 10th Edition, Page 98, 202

↑ *Back to this question in Part A*

@Neet_pg_bot

Q11: Which of the following molecules helps leukocytes roll over endothelial cells in vessels? (Q856001)

A. Cadherins

B. PECAM-1

C. E-selectin

D. CD11a

Correct Answer: C. E-selectin

Explanation: E-selectin is a molecule expressed on endothelial cells that facilitates the initial rolling of leukocytes along the vessel wall during the inflammatory response. Leukocyte Adhesion to Endothelium: In normal blood flow, leukocytes are pushed to the edges of the vessel. In inflammation, stasis causes leukocytes to slow down and interact with endothelial cells. This interaction involves selectins and integrins , which mediate the rolling and firm adhesion of leukocytes. Selectins : These are responsible for the initial rolling interactions . There are three types: L-selectin on leukocytes E-selectin on endothelial cells P-selectin on both platelets and endothelial cells The ligands for selectins are sialylated oligosaccharides on mucin-like glycoproteins. Cytokines like TNF and IL-1 upregulate the expression of selectins, promoting leukocyte rolling along the vessel wall. Integrins : After rolling, leukocytes bind more firmly to the endothelium via integrins, such as VLA-4 and LFA-1 (CD11a (Option D) & CD18) , which interact with endothelial ligands like VCAM-1 and ICAM-1 . This firm adhesion halts the rolling process and allows leukocytes to flatten and spread on the endothelial surface. Migration: Once firmly adhered,

leukocytes migrate through the endothelial layer in a process called transmigration. It is facilitated by adhesion molecules like PECAM-1 (CD31) (Option B). After exiting the vessel, leukocytes follow the chemotactic gradient toward the site. Cadherins (Option A) are adhesion molecules involved in maintaining cell-cell interactions in tissues, especially in epithelial cells, but they are not directly involved in the rolling of leukocytes on endothelial cells during inflammation.

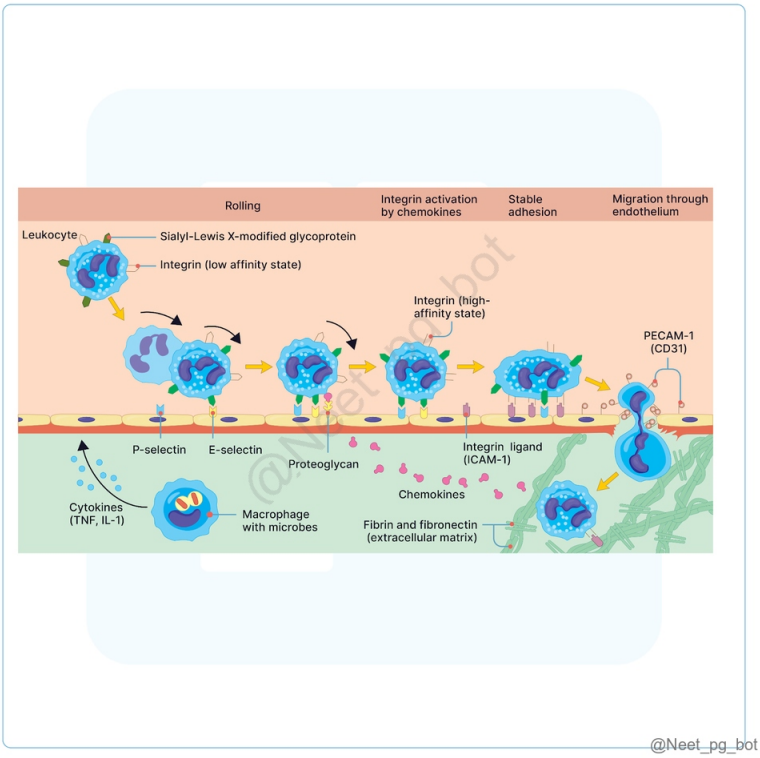

References:

Robbins & Cotran Pathologic Basis of Disease, 10th Edition, Page 77,78,79

↑ *Back to this question in Part A*

@Neet_pg_bot

Q12: Match the following: 1. IL-5 A. Regulates acute phase reactants 2. IL-6 B. T cell maturation 3. IL-7 C. Neutrophil recruitment 4. IL-8 D. Eosinophils activation (Q860495)

A. 1-B, 2-C, 3-D, 4-A

B. 1-D, 2-A, 3-B, 4-C

C. 1-C, 2-D, 3-B, 4-A

D. 1-D, 2-C, 3-B, 4-A

Correct Answer: B. 1-D, 2-A, 3-B, 4-C

Explanation: IL-5 (Interleukin-5) Eosinophils activation IL-6 (Interleukin-6) Regulates acute phase reactants IL-7 (Interleukin-7) T cell maturation IL-8 (Interleukin-8) Neutrophil recruitment Interleukins and Cytokines: Source Main Function Key Role/Disease IL-1 Macrophages Fever, acute phase ↑ Septic shock IL-2 Th1, CD8 T cell growth Immunotherapy (cancer) IL-3 Th2, mast Hematopoietic stem cells Allergy IL-4 Th2, mast B cell class switch (IgE/G4), Th2 diff Asthma/allergy IL-5 Th2, mast Eosinophil activation, IgA switch Parasites/asthma IL-6 Macrophages, Th17 Acute phase, B cell diff, Th17 RA, CRP ↑ IL-7 Stromal T/B/NK development SCID IL-8 Macrophages Neutrophil chemotaxis Bacterial infections IL-9 Th2 Mast cell growth Allergy IL-10 Treg, Th2 Anti-inflammatory ↓MHC-I/II ↓Immune response IL-12 Macrophages/DCs Th1 diff, NK activation TB/viral IL-13 Th2 Mucus hypersecretion, IgE Asthma IL-15 Stromal NK/memory T survival Viral immunity IL-17 Th17 Neutrophil recruitment Psoriasis, fungal IL-18 Macrophages IFN-γ production (w/IL-12) Macrophage activation IL-21 Th17/Tfh B cell proliferation SLE IL-22 Th17 Epithelial defense Gut immunity IL-23 DCs Th17 maintenance Psoriasis IFN-α Plasmacytoid DCs Antiviral, NK activation Hepatitis IFN-β Fibroblasts Antiviral MS IFN-γ Th1, NK/CD8 Macrophage activation TB granuloma TNF-α Macrophages Fever, cachexia, granuloma Septic shock TGF-β Treg, platelets Fibrosis, Treg diff Wound healing

References:

Robbins & Cotran Pathological Basis of Diseases, 10th Edition, Page 79, 88, 202, 242.

↑ *Back to this question in Part A*

@Neet_pg_bot

Q13: A patient presents with complaints of cough, night sweats, and fever. A lung biopsy demonstrates the following histological findings. What is the most likely cytokine involved? (Q854700)

A. Interferon-γ

B. Complement C5a

C. Histamine

D. Bradykinin

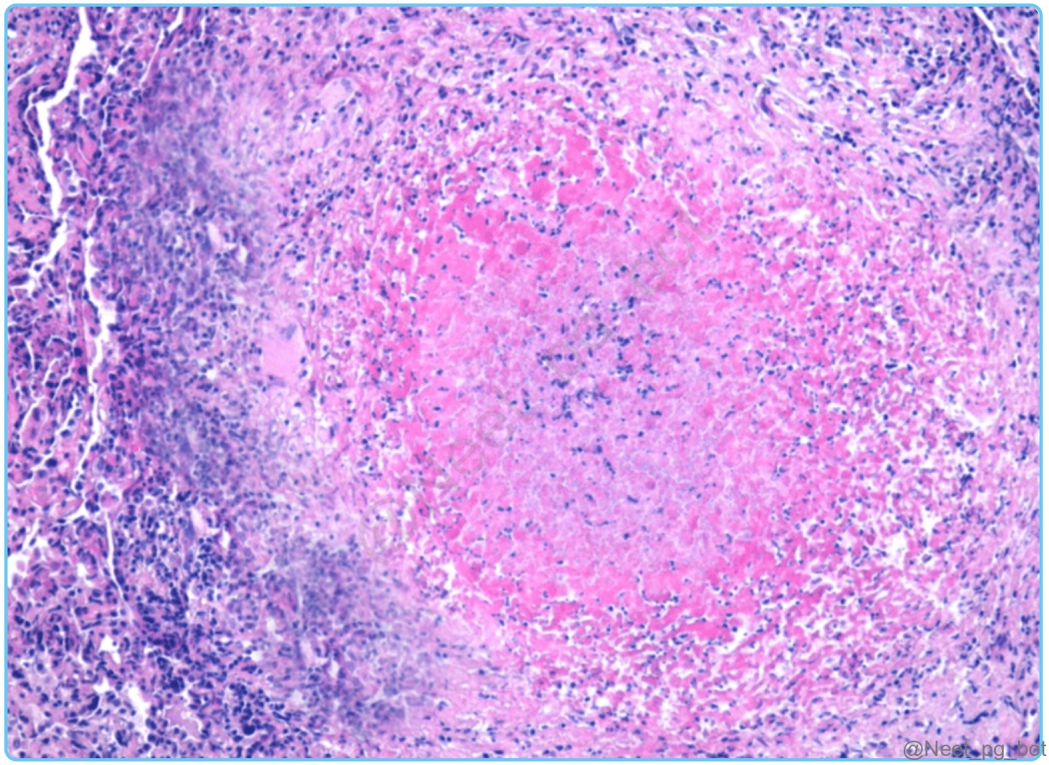

Correct Answer: A. Interferon-γ

Explanation: The patient's presentation with cough, night sweats, and fever, along with the histological finding of granulomas and multinucleated giant cells, is highly indicative of a granulomatous condition like Tuberculosis (TB) , which is typically driven by the immune response, specifically by the cytokine interferon-γ (IFN-γ) T-lymphocytes release IFN-γ when exposed to M. tuberculosis antigens, which activate macrophages, enhancing their ability to kill intracellular bacteria. Despite IFN-γ activation of macrophages, the bacteria are often not completely eliminated, and they can survive inside the macrophages, evading complete eradication. This results in a chronic infection , leading to continued replication of M. tuberculosis and the formation of granulomas . The granuloma acts as a protective structure around the bacteria, but in some cases, it can break down, leading to active disease and further spread of the infection. Components of Granuloma: Epithelioid Cells: Activated macrophages with abundant cytoplasm that resemble epithelial cells. Multinucleated Giant Cells (Langhans-type): Formed by the fusion of multiple activated macrophages; in TB, nuclei are characteristically arranged in a horseshoe pattern at the periphery. Necrosis: In Tuberculosis, the center of the granuloma often undergoes caseous (cheese-like) necrosis , a hallmark of the disease. Note: TB can show both caseating and non-caseating granulomas, but caseating > non-caseating . Lymphocytic Rim: T-cells surrounding the activated macrophages, providing continuous cytokine signaling (like IFN-γ). Complement C5a (Option B) is a chemotactic factor in the complement system . It helps attract neutrophils and other immune cells to the site of infection. However, it does not directly contribute to granuloma formation or the activation of macrophages needed for multinucleated giant cell formation. Histamine (Option C) is involved in the acute inflammatory response , causing vasodilation and increasing vascular permeability . It does not play a direct role in the formation of granulomas or the differentiation of macrophages into giant cells. Bradykinin (Option D) is part of the acute inflammatory response, not the chronic inflammatory response seen in granulomatous diseases. It does not play a role in granuloma formation.

References:

pmc.ncbi.nlm.nih.gov/articles/PMC3215852/

pmc.ncbi.nlm.nih.gov/articles/PMC4226026/#:~:text=TB%20cavity%20formation%20occurs%20usually,event%20in%20the%20lung%20bases

↑ *Back to this question in Part A*

@Neet_pg_bot

Q14: Which substance plays a role as a mediator in chronic inflammation? (Q830804)

A. IL-1

B. TNF-α

C. TGF-β

D. None

Correct Answer: C. TGF-β

■ *Listen (English)*

■ *Listen (Hindi)*

Explanation: TGF-β plays a crucial role in regulating immune responses, cell proliferation, differentiation, and tissue repair. In the context of chronic inflammation, TGF-β is involved in tissue repair and fibrosis. It promotes the production of extracellular matrix components and inhibits the activity of immune cells, contributing to the resolution of inflammation but also leading to tissue remodelling and fibrosis over time. It is important to emphasise that cytokines like IL-1 and TNF-α also take part in chronic inflammation; however, they are primarily associated with the acute phase response . TGF-β is classic for chronic inflammation because of its specific functions in the resolution and repair phases. IL-1 (Option A): IL-1 is a pro-inflammatory cytokine involved in the initial phase of inflammation. IL-1 helps recruit immune cells to sites of infection or damage and promotes the production of other inflammatory mediators. It is associated with acute inflammation. TNF-α (Option B): TNF-α is involved in systemic inflammation and is part of the acute phase response. TNF-α helps mediate the recruitment of immune cells to inflammation sites and stimulates the production of other cytokines and adhesion molecules. TNF-α is associated with acute inflammation.

References:

Robbins, Cotran & Kumar Pathologic Basis of Disease, 11th Edition, Pages 20, 87, 88

↑ *Back to this question in Part A*

@Neet_pg_bot

Q15: All of the following are correct about 'Neutrophil extracellular traps' except? (Q860299)

A. May result in SLE

B. Phagocytosis

C. Sepsis

D. Arginine needed

Correct Answer: B. Phagocytosis

Explanation: NETs (Neutrophil Extracellular Traps) do not directly engulf pathogens through phagocytosis but instead trap and immobilise them, allowing other immune cells to clear the infection. They are extracellular fibrillar networks that concentrate antimicrobial substances at sites of infection and trap microbes, helping to prevent their spread. They don't directly phagocytose pathogens but trap and immobilise them, allowing immune cells like macrophages to eliminate them. (Option B) They are produced by neutrophils in response to pathogens and inflammatory mediators. NET formation begins with ROS-induced activation of arginine deaminase, leading to chromatin decondensation. (Option D ruled out) They are composed of nuclear chromatin and granule proteins, including antimicrobial peptides and enzymes. They are implicated in conditions like sepsis (Option C ruled out) and autoimmune diseases like lupus (Option A ruled out) , where they may contribute to autoimmunity. {{caption_text}} {{caption_text}} A neutrophil granulocyte (yellow) has ejected a Neutrophil extracellular trap (green) to capture bacteria (purple). A red blood cell (orange) is also trapped in the Neutrophil extracellular trap.

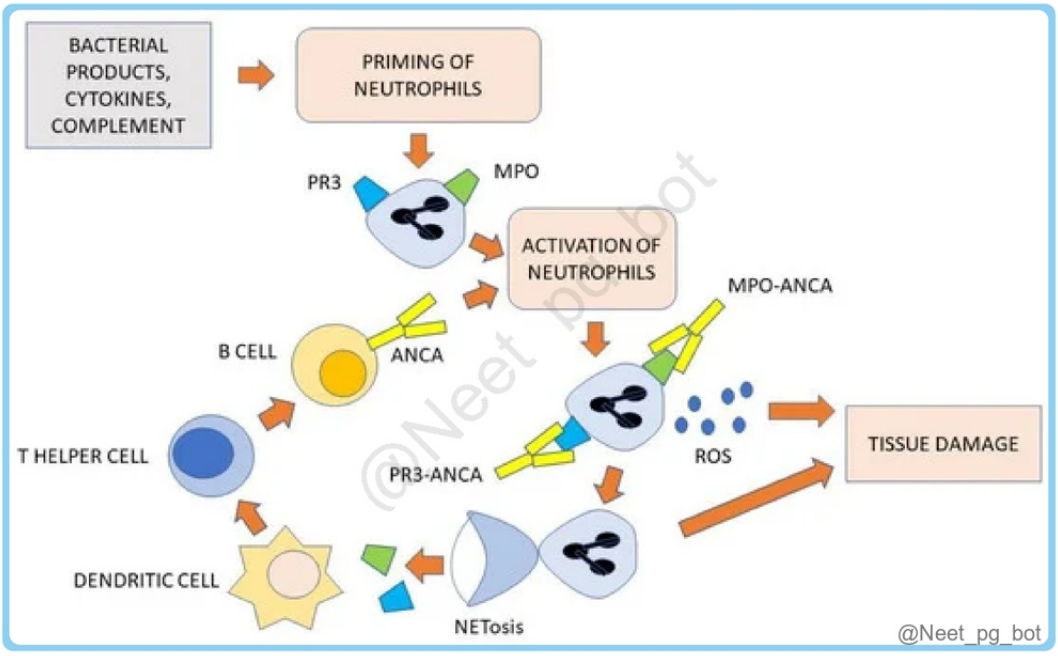

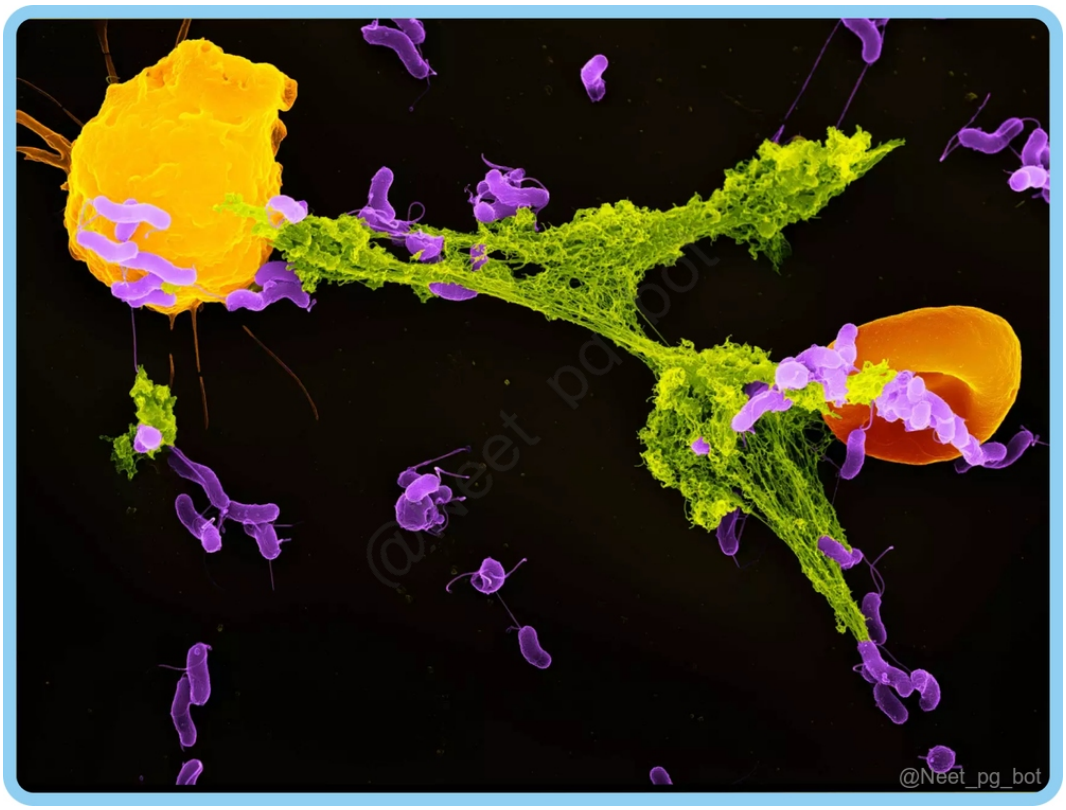

References:

Robbins & Cotran Pathologic Basis of Disease, 10th Edition, Page 83.

↑ *Back to this question in Part A*

@Neet_pg_bot

Q16: Match the following: 1. IL-5 A. Regulates acute phase reactants 2. IL-6 B. T cell maturation 3. IL-7 C. Neutrophil recruitment 4. IL-8 D. Eosinophils activation (Q860293)

A. 1-B, 2-C, 3-D, 4-A

B. 1-D, 2-A, 3-B, 4-C

C. 1-C, 2-D, 3-B, 4-A

D. 1-D, 2-C, 3-B, 4-A

Correct Answer: B. 1-D, 2-A, 3-B, 4-C

Explanation: IL-5 (Interleukin-5) Eosinophils activation IL-6 (Interleukin-6) Regulates acute phase reactants IL-7 (Interleukin-7) T cell maturation IL-8 (Interleukin-8) Neutrophil recruitment ■■■ Interleukins and Cytokines: Source Main Function Key Role/Disease IL-1 Macrophages Fever, acute phase ↑ Septic shock IL-2 Th1, CD8 T cell growth Immunotherapy (cancer) IL-3 Th2, mast Hematopoietic stem cells Allergy IL-4 Th2, mast B cell class switch (IgE/G4), Th2 diff Asthma/allergy IL-5 Th2, mast Eosinophil activation, IgA switch Parasites/asthma IL-6 Macrophages, Th17 Acute phase, B cell diff, Th17 RA, CRP ↑ IL-7 Stromal T/B/NK development SCID IL-8 Macrophages Neutrophil chemotaxis Bacterial infections IL-9 Th2 Mast cell growth Allergy IL-10 Treg, Th2 Anti-inflammatory ↓MHC-I/II ↓Immune response IL-12 Macrophages/DCs Th1 diff, NK activation TB/viral IL-13 Th2 Mucus hypersecretion, IgE Asthma IL-15 Stromal NK/memory T survival Viral immunity IL-17 Th17 Neutrophil recruitment Psoriasis, fungal IL-18 Macrophages IFN-γ production (w/IL-12) Macrophage activation IL-21 Th17/Tfh B cell proliferation SLE IL-22 Th17 Epithelial defense Gut immunity IL-23 DCs Th17 maintenance Psoriasis IFN-α Plasmacytoid DCs Antiviral, NK activation Hepatitis IFN-β Fibroblasts Antiviral MS IFN-γ Th1, NK/CD8 Macrophage activation TB granuloma TNF-α Macrophages Fever, cachexia, granuloma Septic shock TGF-β Treg, platelets Fibrosis, Treg diff Wound healing

References:

Robbins & Cotran Pathological Basis of Diseases, 10th Edition, Page 79, 88, 202, 242.

↑ *Back to this question in Part A*

@Neet_pg_bot

Q17: A 50-year-old female presents with cervical lymphadenopathy. A biopsy has revealed granulomatous necrotising inflammation. Which of the following options is correct? (Q860203)

A. Metastatic calcification with normal serum calcium level

B. Dystrophic calcification with normal serum calcium level

C. Metastatic calcification with increased serum calcium level

D. Dystrophic calcification with increased serum calcium level

Correct Answer: B. Dystrophic calcification with normal serum calcium level

Explanation: The scenario suggests tuberculosis, marked by cervical lymphadenopathy and granulomatous necrotising inflammation, in which Dystrophic Calcification with normal serum calcium levels can be seen. Dystrophic Calcification: It involves the deposition of calcium salts in damaged or abnormal tissues rather than normal tissues . Serum calcium is normal . (Option D ruled out) It is present in the atheromas of advanced atherosclerosis and develops in ageing or damaged heart valves . Macroscopically, the calcium salts appear fine, and white granules or clumps often feel like gritty deposits. Microscopically, calcium salts have a basophilic , amorphous granular, and sometimes clumped appearance. {{caption_text}} Psammoma bodies are small, round, laminated, calcific structures that resemble onion peels . They can be seen in Papillary carcinoma of the thyroid and kidney, Prolactinoma, Serous ovarian carcinoma , Meningioma, and Mesothelioma. Other examples are:

Tuberculosis (Option B) (Option C ruled out) Atheroma Dead parasite Monckeberg Sclerosis Metastatic calcification may occur in normal tissues whenever there is hypercalcemia. (Option A ruled out) There are four principal causes of hypercalcemia: Increased secretion of parathyroid hormone (PTH) : Hyperparathyroidism (parathyroid tumours) and ectopic secretion of PTH-related protein (malignant tumours). Resorption of bone tissue, secondary to primary tumours of bone marrow (e.g., multiple myeloma, leukaemia) or diffuse skeletal metastasis (e.g., breast cancer), accelerated bone turnover (e.g., Paget disease), or immobilisation. Vitamin D–related disorders , including vitamin D intoxication, sarcoidosis, and idiopathic hypercalcemia of infancy (Williams syndrome). Renal failure , which causes retention of phosphate (Secondary hyperparathyroidism). Less common causes include aluminium intoxication, which occurs in patients on chronic renal dialysis, and milk-alkali syndrome, which is due to excessive ingestion of calcium and absorbable antacids such as milk or calcium carbonate. Feature Dystrophic Calcification Metastatic Calcification Definition Calcium deposition in damaged/necrotic tissue Calcium deposition in normal tissues due to hypercalcemia Calcium levels Normal serum Ca^{2}■, PO■^{3}■ Elevated serum Ca^{2}■, PO■^{3}■ Common causes - TB (caseous necrosis) - Fat necrosis - Atherosclerotic plaques - Old hematoma - Degenerating tumors - Hyperparathyroidism - Vitamin D excess - Chronic renal failure - Osteolytic tumors (multiple myeloma) - Milk-alkali syndrome Location - Damaged tissues only - Lungs (TB) - Breast (fat necrosis) - Aorta (atheroma) - Normal tissues - Lung (alveolar septa) - Kidney (basement membranes) - Stomach (mucosa) - Blood vessels Histology/Stain Basophilic deposits; Von Kossa (+) Finely granular; Von Kossa (+) Examples - Calcified TB granuloma - Psammoma bodies - Dystrophic calcification in necrotic tumor - Renal failure → pulmonary calcification - HyperPTH → gastric calcification Clinical Usually asymptomatic Organ dysfunction (renal failure, pulmonary) Clinical Significance Often a sign of previous cell injury ; can cause organ dysfunction (e.g., heart valve stenosis). Sign of an underlying metabolic disorder ; can lead to widespread tissue damage.

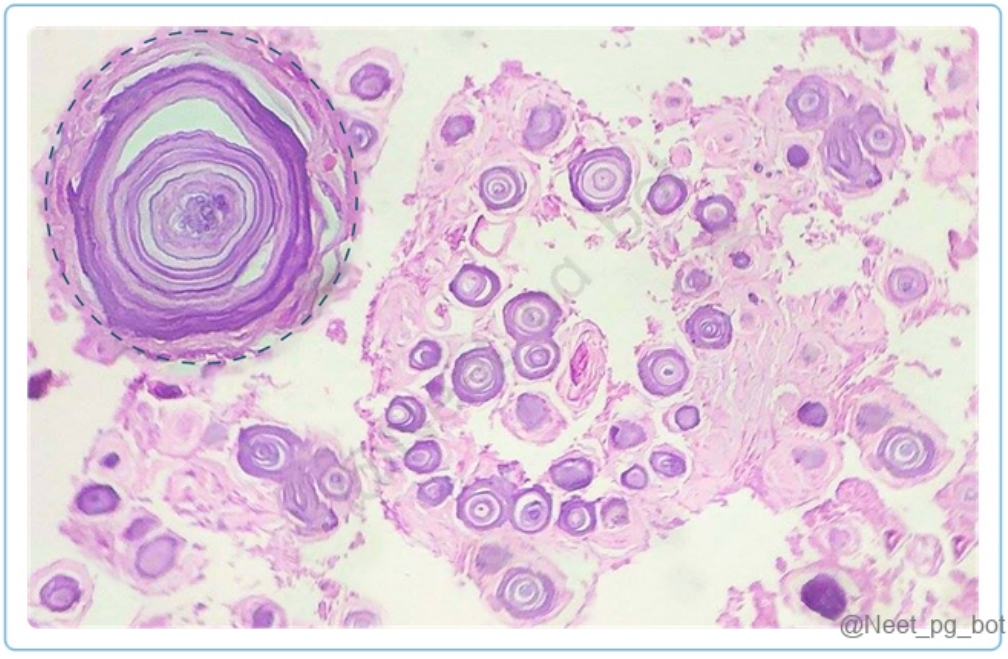

References:

Robbin’s and Cotran Pathologic Basis of Disease, 10th Edition, Page 65-66.

↑ *Back to this question in Part A*

@Neet_pg_bot

Q18: Which of the following is the most effective enzyme in Acute inflammation? (Q860193)

A. NADPH oxidase

B. Defensin

C. Catalase

D. MPO

Correct Answer: A. NADPH oxidase

Explanation: NADPH oxidase is the most effective enzyme in acute inflammation. The Phox gene produces it and is the key enzyme involved in phagocytosis. Reactive oxygen species (ROS) are produced through the rapid assembly and activation of NADPH oxidase (phagocyte oxidase) . This enzyme oxidises NADPH , transferring electrons to molecular oxygen and generating superoxide anion (O■•) . Chronic Granulomatous Disease (CGD): Defect: Mutation in NADPH oxidase (often X-linked gp91phox), which prevents the "respiratory burst". Pathophysiology: Neutrophils cannot produce superoxide (O2-) , leading to a failure in generating reactive oxygen species (ROS) for killing microbes. Infections: High susceptibility to catalase-positive organisms (e.g., S. aureus , Serratia , Aspergillus) that neutralize their own H2O2, leaving the host with no oxidative defence. Clinical Sign: Persistent, ineffective inflammation results in widespread granuloma formation. Diagnosis: Determined via Dihydrorhodamine (DHR) flow cytometry (modern) or the Nitroblue Tetrazolium (NBT) dye test (classic). Defensins (Option B) are small antimicrobial peptides that help eliminate pathogens, but they are not the main enzyme involved in acute inflammation. Catalase (Option C) is an enzyme that decomposes hydrogen peroxide (H■O■) to protect cells from oxidative damage, but it is not the primary enzyme involved in the inflammatory response. MPO (Myeloperoxidase) (Option D) is an enzyme present in neutrophils that utilises hydrogen peroxide (produced by NADPH oxidase) to generate hypochlorous acid (HOCl), a potent antimicrobial agent. However, the most critical enzyme in acute inflammation is NADPH oxidase.

References:

Robbins & Cotran Pathologic Basis of Disease, 10th Edition, Page 82.

↑ *Back to this question in Part A*

@Neet_pg_bot

Q19: Which of the following parameters decreases in acute inflammation? (Q860161)

A. CRP

B. Hepcidin

C. Fibrinogen

D. Albumin

Correct Answer: D. Albumin

Explanation: During acute inflammation, the liver increases the production of positive acute-phase reactants like C-reactive protein (CRP) (Option A) , hepcidin (Option B) , and fibrinogen (Option C) , which help in immune response and coagulation. However, albumin is a negative acute-phase reactant , meaning its levels decrease during inflammation as the liver prioritises synthesising proteins involved in the inflammatory response. They are plasma proteins, mostly synthesised in the liver, whose plasma concentrations may increase several hundred–fold as part of the response to inflammatory stimuli. Few of these examples are: C-reactive protein (CRP) (Option A ruled out) Fibrinogen (Option C ruled out) Serum amyloid A (SAA) protein. Hepcidin (Option B ruled out) Thrombopoietin These are increased during the process of inflammation. Acute Phase Reactants: Feature Positive Acute Phase Reactants Negative Acute Phase Reactants Serum Level Increase during inflammation. Decrease during inflammation. Physiological Goal To assist in host defense, limit tissue damage, and promote repair. To conserve amino acids for the production of positive reactants. Key Examples C-Reactive Protein (CRP) : Opsonin and complement activator. Fibrinogen : Essential for clotting; increases ESR. Ferritin/Hepcidin : Sequestration of iron to starve microbes. Serum Amyloid A : Immune cell recruiter. Complement (C3, C4) : Opsonization and MAC formation. Albumin : Maintains osmotic pressure; levels drop to save resources. Transferrin : Decreases to prevent iron availability to bacteria. Transthyretin (Prealbumin) : Rapidly falls during acute stress. Antithrombin : Decreases, contributing to a pro-coagulant state. Retinol-Binding Protein : Transport protein that decreases significantly.

References:

Robbins and Cotran Pathologic Basis of Disease, 10th Edition, Page 102.

↑ *Back to this question in Part A*

@Neet_pg_bot

Q20: All of the following are growth-promoting proto-oncogenes, except? (Q840061)

A. FGF

B. PDGF

C. TGF-α

D. TGF-β

Correct Answer: D. TGF-β

■ *Listen (English)*

■ *Listen (Hindi)*

Explanation: Correct Option D - TGF-β: Transforming growth factor-beta (TGF-β) is an anti-inflammatory growth factor and is a marker for repair. It is not a growth-promoting oncogene. Incorrect Options: Options A, B, and C: Fibroblast growth factor (FGF), Platelet-derived growth factor (PDGF), and Transforming growth factor-alpha(TGF-α) are growth-promoting oncogenes.

References:

.

↑ *Back to this question in Part A*

@Neet_pg_bot

Q21: All of the following are correct about NETs except? (Q860511)

A. May result in SLE

B. Phagocytosis

C. Sepsis

D. Arginine needed

Correct Answer: B. Phagocytosis

Explanation: NETs (Neutrophil Extracellular Traps) do not directly engulf pathogens through phagocytosis but instead trap and immobilise them, allowing other immune cells to clear the infection. They are extracellular fibrillar networks that concentrate antimicrobial substances at sites of infection and trap microbes, helping to prevent their spread. They don’t directly phagocytose pathogens but trap and immobilise them, allowing immune cells like macrophages to eliminate them. (Option B) They are produced by neutrophils in response to pathogens and inflammatory mediators. NET formation begins with ROS-induced activation of arginine deaminase, leading to chromatin decondensation. (Option D ruled out) They are composed of nuclear chromatin and granule proteins, including antimicrobial peptides and enzymes. They are implicated in conditions like sepsis (Option C ruled out) and autoimmune diseases like lupus (Option A ruled out) , where they may contribute to autoimmunity. {{caption_text}} {{caption_text}} A neutrophil granulocyte (yellow) has ejected a NET (green) to capture bacteria (purple). A red blood cell (orange) is also trapped in the NET.

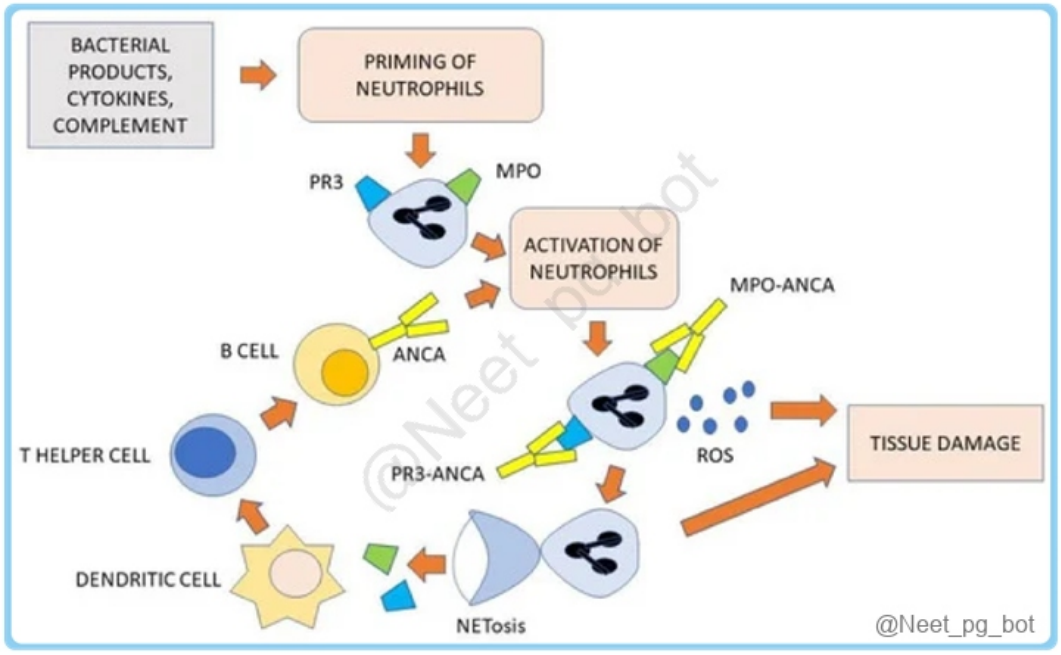

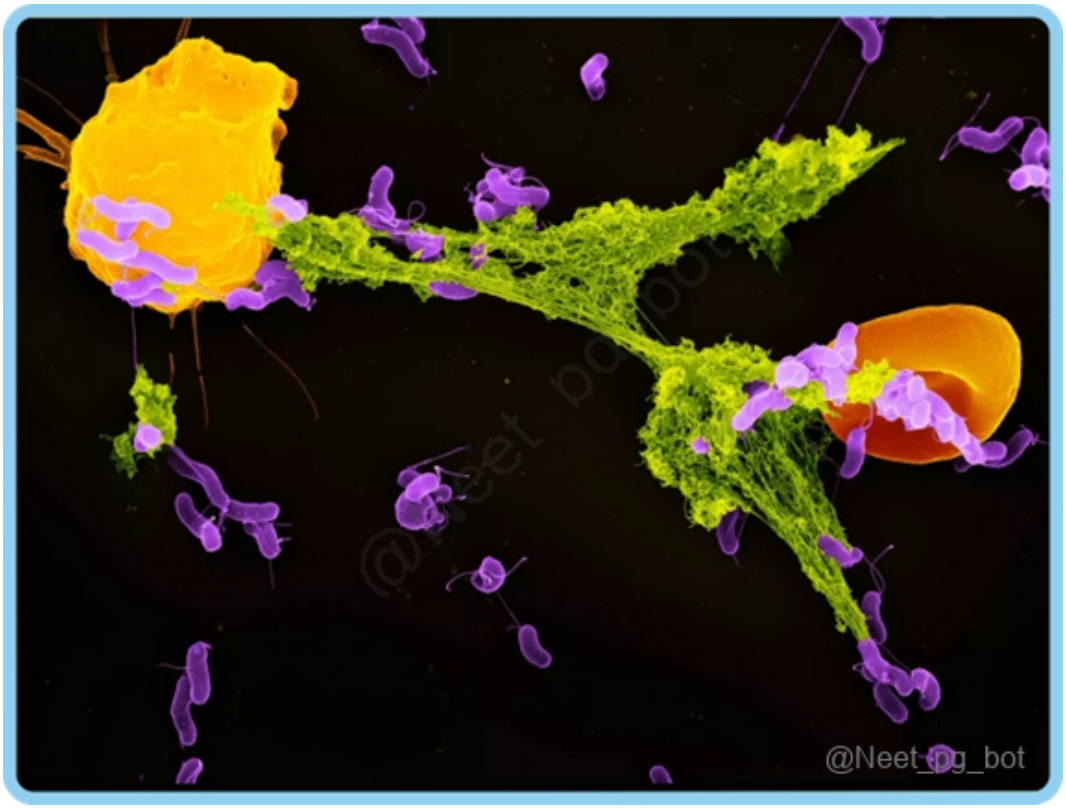

References:

Robbins & Cotran Pathologic Basis of Disease, 10th Edition, Page 83.

↑ *Back to this question in Part A*

@Neet_pg_bot

• [03_Genetics] 010 Genetics- Introduction Mendelian Disorders

« Back to Folder Directory

[03_Genetics] 010 Genetics- Introduction Mendelian Disorders — Quick Jump

Q1 (p. 1185) *Q2 (p. 1185)* *Q3 (p. 1186)* *Q4 (p. 1187)* *Q5 (p. 1189)* *Q6 (p. 1190)*
Q7 (p. 1192) *Q8 (p. 1193)* *Q9 (p. 1194)* *Q10 (p. 1194)* *Q11 (p. 1195)* *Q12 (p. 1196)*
Q13 (p. 1196)

Q1: Match the following with their correct terms. 1 Exon i Non-coding region 2 Intron ii One of the alternate forms of a single gene occupying a given position in a chromosome 3 Locus iii Coding region 4 Allele iv Location of a gene on the chromosome (Q845099)

A. 1-iii, 2-i, 3-iv, 4-ii

B. 1-iii, 2-i, 3-ii, 4-iv

C. 1-i, 2-iii, 3-iv, 4-ii

D. 1-i, 2-iii, 3-ii, 4-iv

Correct Answer: A. 1-iii, 2-i, 3-iv, 4-ii

■ *Listen (English)*

■ *Listen (Hindi)*

Explanation: Exon : An exon is a coding region of a gene that contains the genetic information necessary for producing a functional protein. Intron : An intron is a non-coding region of a gene that intervenes between exons. During gene expression, introns are removed from the pre-mRNA molecule through splicing, which allows exons to be joined together to form the final mRNA transcript before translation into a protein. Locus : A locus refers to the specific location of a gene or DNA sequence on a chromosome. Allele : An allele is one of the alternate forms of a single gene occupying a given position in a chromosome , which can lead to different traits or characteristics. Alleles can be dominant or recessive.

References:

Robbins and Cotrans Pathological Basis of Diseases, 10th Edition, Page 459

↑ *Back to this question in Part A*

@Neet_pg_bot

Q2: A 25-year-old male from a tribal area of Madhya Pradesh presents to the clinic with complaints of fatigue and shortness of breath. On examination, he appears pale, and jaundice is noted. Laboratory investigations reveal low hemoglobin levels and increased reticulocyte count. The peripheral blood smear shows numerous sickle-shaped erythrocytes. What is the most likely molecular mechanism underlying the pathogenesis of this patient's condition? (Q845100)

A. Chromosomal translocation

B. Missense mutation

C. Frameshift mutation

D. Nonsense mutation

Correct Answer: B. Missense mutation

■ *Listen (English)*

■ *Listen (Hindi)*

Explanation: The clinical presentation of a tribal male with the above-mentioned clinical features and sickle-shaped RBCs in the peripheral smear suggests sickle cell disease. A missense mutation (type of point mutation) is the underlying mechanism in the pathogenesis of this disease. Point mutation: A point mutation is a change in which a single base is substituted with a different base. Sickle cell anaemia. This point mutation involves substituting adenine for thymine at the seventh codon of the β-globin gene (GAG to GTG) , replacing glutamic acid with valine in the β-globin chain of haemoglobin. This single nucleotide change results in the formation of abnormal haemoglobin molecules (HbS) .

References:

Robbins and Cotran Pathological Basis of Diseases, 10th Edition, Pages 142,143

↑ *Back to this question in Part A*

@Neet_pg_bot

Q3: A couple visits a genetics counselor due to concerns about their baby's blood type. The father has blood type A (genotype I A I A), and the mother has blood type B (genotype I B I B). The counselor explains that blood type is determined by codominant alleles, where both alleles contribute equally to the phenotype in the heterozygous condition. Which of the following best describes codominance? (Q845101)

A. One allele completely masks the expression of the other allele

B. The phenotype of the heterozygote is intermediate between the phenotypes of the homozygotes

C. Only one allele is expressed, while the other remains silent

D. Both alleles contribute to the phenotype equally in the heterozygous condition

Correct Answer: D. Both alleles contribute to the phenotype equally in the heterozygous condition

■ *Listen (English)*

■ *Listen (Hindi)*

Explanation: Codominance can be defined as a condition in which both the alleles of a gene pair in a heterozygote are equally expressed . Examples: ABO blood group system In the ABO blood group system, the I A and I B alleles are codominant in producing the AB blood group phenotype, in which both A and B-type antigens are produced. The genes responsible for the ABO blood group are located in chromosome 9. The presence of both I A and I B causes the expression of both , forming the AB blood group. HLA gene also shows co dominance One allele completely masks the expression of the other allele (Option A): Complete dominance Example: Mendelian Pea Plants: Purple flowers (P) are dominant over white flowers (p). A Pp plant appears fully purple. The phenotype of the heterozygote is intermediate between the phenotypes of the homozygotes (Option B): Incomplete dominance Example: Snapdragons: Crossing a Red flower (RR) with a White flower (WW) produces a Pink flower (RW). Only one allele is expressed, while the other remains silent (Option C): Epistasis or genomic imprinting Example: Prader-Willi Syndrome: Occurs when specific genes on the paternal chromosome 15 are expressed while the maternal ones are silenced.

References:

Inderbir Singh’s Textbook of Anatomy, Volume 3, 6th edition, Pages 481-484

↑ *Back to this question in Part A*

@Neet_pg_bot

Q4: A 30-year-old man presents to the clinic with a history of tall stature, long limbs, and joint hypermobility. Upon further examination, he also exhibits features such as a high-arched palate, arachnodactyly (long, slender fingers), and aortic root dilation. His father has a similar appearance. Which of the following statements is true regarding the inheritance pattern seen in this condition? (Q845103)

A. Males are more commonly affected than females.

B. Most mutations lead to reduced production of a gene product or give rise to a dysfunctional or inactive protein.

C. Complete penetrance can be seen

D. The least common mode of inheritance

Correct Answer: B. Most mutations lead to reduced production of a gene product or give rise to a dysfunctional or inactive protein.

■ *Listen (English)*

■ *Listen (Hindi)*

Explanation: The given clinical scenario of a male with tall stature , long limbs , joint hypermobility , arachnodactyly , aortic root dilatation , and similar features in his father suggests Marfan's syndrome , an autosomal dominant condition and gene FBN1 (fibrillin-1) on chromosome 15 . The true statement regarding autosomal dominant inheritance is that most proteins lead to reduced production of a gene product or give rise to a dysfunctional or inactive protein. Autosomal dominant inheritance: Autosomal dominant disorders are manifested in the heterozygous state, so at least one parent of an index case is usually affected. It is the most common mode of inheritance. (Option D) Both males and females are affected, and both can transmit the condition. (Option A) They are characterized by: With every autosomal dominant disorder, some proportion of patients do not have affected parents. Clinical features can be modified by variations in penetrance and expressivity: Some individuals inherit the mutant gene but are phenotypically normal. This is referred to as incomplete penetrance . (Option C) If a trait is seen in all individuals carrying the mutant gene but is expressed differently among individuals, the phenomenon is called variable expressivity. In many conditions the age at onset is delayed; symptoms and signs may not appear until adulthood. Pedigree chart: Some examples of autosomal dominant disorders: {{caption_text}}

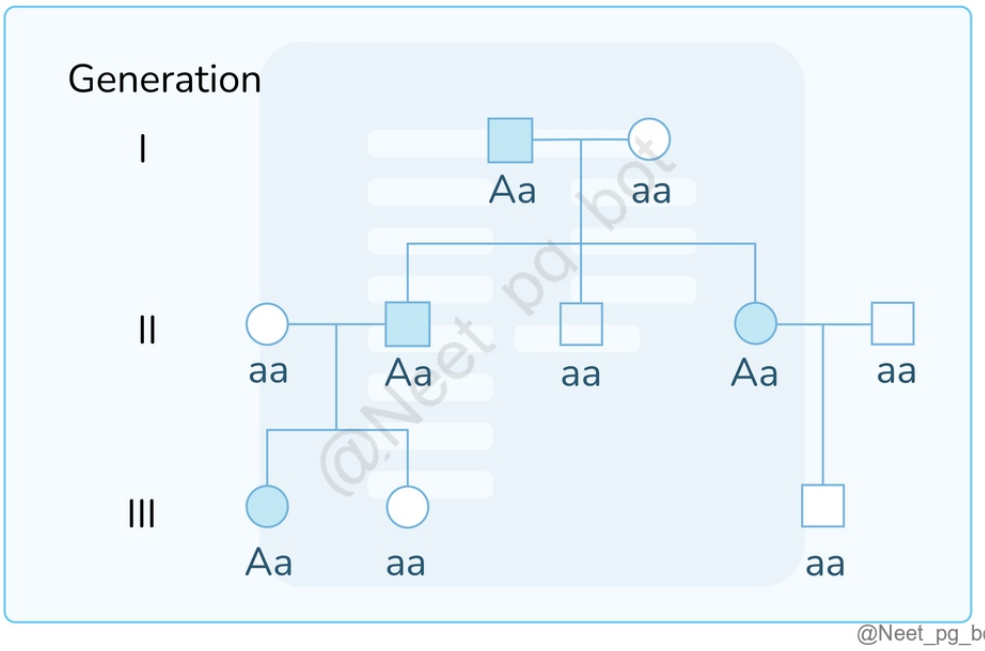

He - Hereditary Spherocytosis (RBC problem), Hereditary Hemorrhagic Telangiectasia (blood vessel problem), Hereditary Non-Polyposis Colon Cancer (HNPCC / Lynch Syndrome)
Has - Huntington's Disease, Hypertrophic Cardiomyopathy
A - Autosomal Dominant Polycystic Kidney Disease (AD PKD)
Very - Von Willebrand Disease (VWD), Von Hippel Lindau Syndrome (VHL Syndrome- chromosome 3p deleted)
DOMINANT - Muscle Dystonia, Osteogenesis imperfecta, Marfan's Syndrome, Intermittent Porphyria, NF 1 & NF 2, Achondroplasia, Noonam Syndrome, Tuberous Sclerosis.
Powerful - Pseudohypoparathyroidism
FATHER - Familial Adenomatous Polyposis (FAP), Li Fraumeni Syndrome (mutation in p53), Familial hypercholesterolemia.

@Neet_pg_bot

References:

Robbins and Cotrans Pathological Basis of Diseases, 10th Edition, Pages 144, 145, 149.

↑ *Back to this question in Part A*

@Neet_pg_bot

Q5: A 6-month-old male infant presents to the pediatric clinic with failure to thrive, recurrent respiratory infections, and hepatosplenomegaly. Upon further examination, the infant also displays signs of skeletal abnormalities including bowed legs and frontal bossing. Lab investigations reveal pancytopenia with markedly decreased platelet count. Genetic testing confirms a diagnosis of Gaucher disease. What is the pattern of inheritance and underlying genetic defect leading to this disorder? (Q845104)

A. Autosomal Dominant Inheritance, Mutation in the CFTR Gene

B. X-linked Recessive Inheritance, Mutation in the GBA Gene

C. Autosomal Dominant Inheritance, Mutation in the HEXA Gene

D. Autosomal Recessive Inheritance, Mutation in the GBA Gene

Correct Answer: D. Autosomal Recessive Inheritance, Mutation in the GBA Gene

■ *Listen (English)*

■ *Listen (Hindi)*

Explanation: Gaucher disease is an autosomal recessive inborn error of metabolism caused by mutations in the glucocerebrosidase - GBA1 gene. All lysosomal storage diseases are autosomal recessive Exceptions (X-linked recessive): Fabry disease & Hunter syndrome Autosomal Dominant Inheritance, Mutation in the CFTR Gene (Option A): Cystic fibrosis (CF) is inherited as an autosomal recessive disorder caused by mutations in the CFTR gene. (chromosome 7) X-linked Recessive Inheritance, Mutation in the GBA Gene (Option B): Gaucher disease is not associated with X-linked inheritance; instead, it follows autosomal recessive inheritance. Autosomal Dominant Inheritance, Mutation in the HEXA Gene (Option C) : Tay-Sachs disease is an autosomal recessive disorder caused by mutations in the HEXA gene, resulting in deficient activity of the enzyme β-hexosaminidase A.

References:

Robbins and Cotrans Pathological Basis of Diseases, 10th Edition, Pages 146, 156, 158, 159.

↑ *Back to this question in Part A*

@Neet_pg_bot

Q6: A 6-month-old infant presents with hepatosplenomegaly, failure to thrive, and hypotonia. The infant has a cherry-red spot on the macula and exhibits poor startle reflexes on physical examination. Further evaluation reveals foam cells in the bone marrow. What is the diagnosis and associated enzyme deficiency? (Q845105)

A. Diagnosis: Niemann-Pick disease type A, Enzyme Deficiency: Acid sphingomyelinase

B. Diagnosis: Tay-Sachs disease, Enzyme Deficiency: Hexosaminidase A

C. Diagnosis: Gaucher disease, Enzyme Deficiency: Glucocerebrosidase

D. Diagnosis: Metachromatic leukodystrophy, Enzyme Deficiency: Arylsulfatase A

Correct Answer: A. Diagnosis: Niemann-Pick disease type A, Enzyme Deficiency: Acid sphingomyelinase

■ *Listen (English)*

■ *Listen (Hindi)*

Explanation: Niemann-Pick disease type A is caused by acid sphingomyelinase deficiency , leading to sphingomyelin accumulation in macrophages, producing foam cells . Classic features include: Hepatosplenomegaly Failure to thrive Hypotonia Cherry-red spot on macula Neurodegeneration Type A is the severe infantile form with early death. Image : Niemann-Pick disease in the liver. The hepatocytes and Kupffer cells have a foamy, vacuolated appearance due to the deposition of lipids. Electron microscopy confirms that the vacuoles are engorged secondary lysosomes called zebra bodies. Image : Zebra bodies Tay-Sachs — Hexosaminidase A deficiency (Option B): Cherry-red spot present No hepatosplenomegaly (key differentiator) Accumulation of GM■ ganglioside; “onion-skin lysosomes,” not foam cells Gaucher — Glucocerebrosidase deficiency (Option C): No cherry-red spot Hepatosplenomegaly present Bone crises and Erlenmeyer flask deformity Gaucher cells : “crumpled tissue paper” macrophages, not foam cells Metachromatic leukodystrophy —

Arylsulfatase A deficiency(Option D): Demyelination with ataxia No cherry-red spot No hepatosplenomegaly Accumulation of sulfatides with metachromatic granules

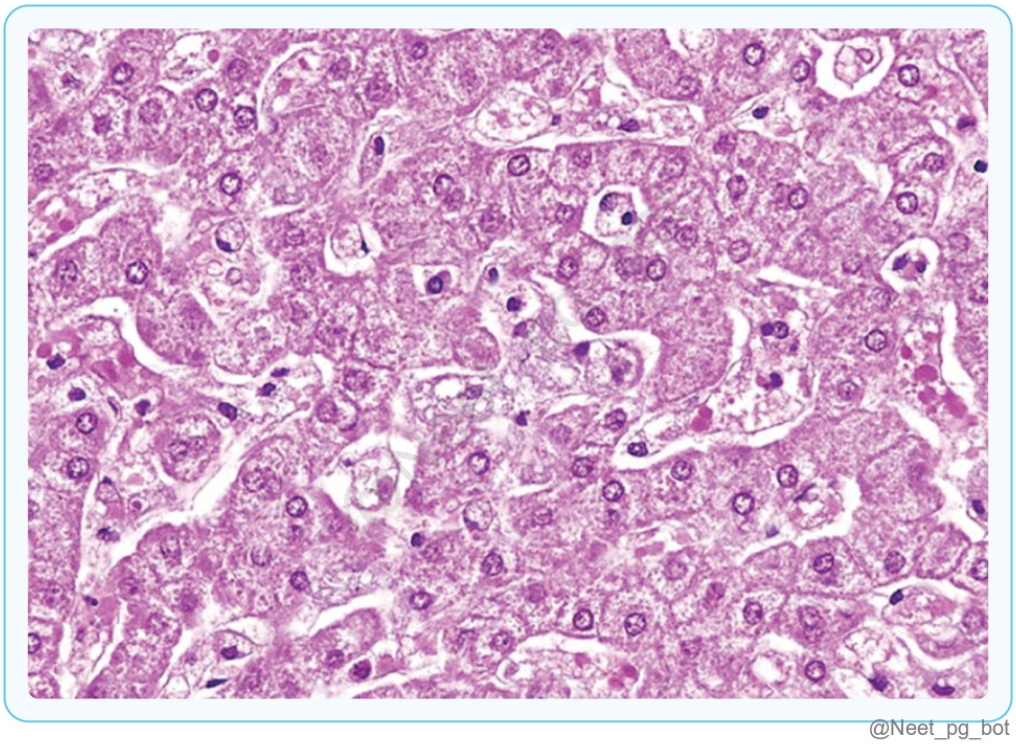
@Neet_pg_bot

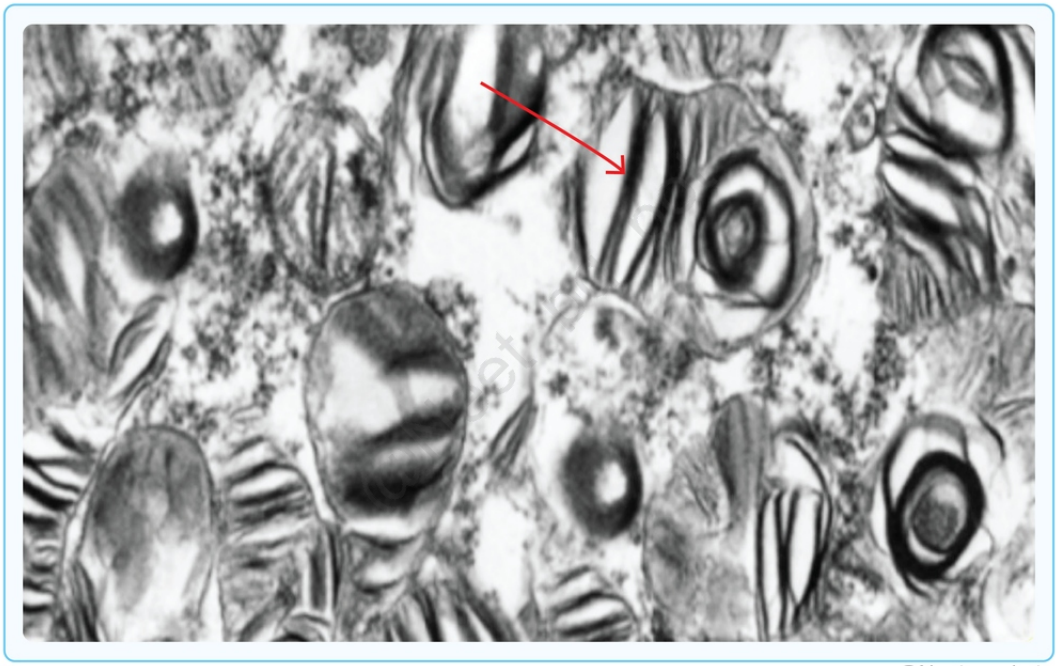
@Neet_pg_bot

References:

Robbins and Cotrans Pathological Basis of Diseases, 10th Edition, Page 157, 158.

↑ *Back to this question in Part A*

@Neet_pg_bot

Q7: Sarah is a 3-year-old girl who is brought to her pediatrician by her parents due to concerns about her development. Her parents report that Sarah has been experiencing a loss of previously acquired skills, such as hand skills and language, stereotypic hand movements and seizure episodes . What is the mode of inheritance? (Q845106)

A. X-linked dominant

B. X-linked recessive

C. Autosomal recessive

D. Autosomal dominant

Correct Answer: A. X-linked dominant

■ *Listen (English)*

■ *Listen (Hindi)*

Explanation: The clinical manifestations in the patients point to Rett Syndrome. It has X-linked dominant inheritance. X-linked dominant disorders affect both males and females. All fathers that are affected by an X-linked dominant disorder will have affected daughters but not affected sons. However, if the mother is also affected then sons will have a chance of being affected, depending on whether a dominant or recessive X chromosome is passed on. When the son is affected, the mother will always be affected. Examples of X-linked dominant disorders (Mnemonic : RAVI-C): R ett Syndrome A lport Syndrome (X-linked) V itamin D-dependent rickets I ncontinentia Pigmenti C harcot-Marie-Tooth disease

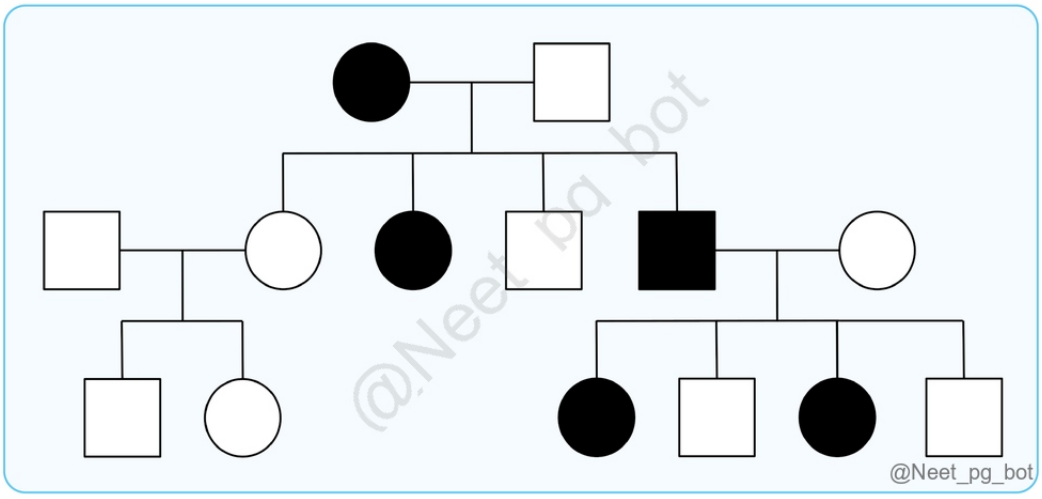

References:

Nelson Textbook of Pediatrics, 21st edition, Page 3193.

↑ *Back to this question in Part A*

@Neet_pg_bot

Q8: A 25-year-old male presents with severe hypotonia at birth, joint hypermobility, scoliosis, fragile skin, and ocular fragility. Genetic testing reveals mutations in the gene encoding Lysyl Hydroxylase. Which subtype of Ehlers-Danlos Syndrome (EDS) is most likely present in this patient and its mode of inheritance? (Q845107)

A. Classical EDS - Autosomal Dominant

B. Hypermobility EDS - Autosomal Dominant

C. Kyphoscoliotic EDS - Autosomal Dominant

D. Kyphoscoliotic EDS - Autosomal Recessive

Correct Answer: D. Kyphoscoliotic EDS - Autosomal Recessive

■ *Listen (English)*

■ *Listen (Hindi)*

Explanation: A young male with severe hypotonia at birth, joint hypermobility, scoliosis, fragile skin, ocular fragility and mutations in the gene encoding Lysyl Hydroxylase points towards Kyphoscoliotic EDS (Type VI), which is Autosomal Recessive.

Type	AKA	Inheritance	Defect
I	Classical EDS	AD (Autosomal Dominant)	Collagen 5
II	Classical EDS	AD	Collagen 5
III	Hypermobile EDS	AD	Free Joints
IV	Vascular type EDS (Flood Blood)	AD	Collagen 3
V	Same as II with a different inheritance	X linked	Collagen 5
VI	Kyphoscoliosis Type	AR (Autosomal Recessive)	LYSYL Hydroxylase
VII A, B	Arthrochalasia Type	AD	Collagen I
VII C	Dermatosparaxis Type	AR	Procollagen Peptidase

@Neet_pg_bot

References:

Robbins and Cotrans Pathological Basis of Diseases, 10th Edition, Page 150.

↑ *Back to this question in Part A*

@Neet_pg_bot

Q9: What type of inheritance pattern is associated with hypertrichosis pinnae? (Q845108)

A. Autosomal Dominant

B. Autosomal Recessive

C. X-Linked Dominant

D. Holandric

Correct Answer: D. Holandric

■ *Listen (English)*

■ *Listen (Hindi)*

Explanation: Hypertrichosis, characterized by excessive hair growth on ears, is a rare genetic condition that can be associated with genes located on the Y chromosome. Since the Y chromosome is only present in males and is passed from fathers to sons, holandric traits are exclusively observed in males and are inherited from fathers.

References:

Robbins and Cotrans Pathological Basis of Diseases, 10th Edition, Page 150.

↑ *Back to this question in Part A*

@Neet_pg_bot

Q10: A 5-year-old boy is brought to the emergency department due to excessive bleeding after a minor injury. His mother reports that his grandfather also had similar bleeding episodes. Laboratory tests reveal a deficiency in factor IX. What is the mode of inheritance for this condition? (Q845109)

A. Autosomal dominant

B. Autosomal recessive

C. X-linked recessive

D. X-linked dominant

Correct Answer: C. X-linked recessive

■ *Listen (English)*

■ *Listen (Hindi)*

Explanation: Factor IX deficiency, associated with Hemophilia B, is an X-linked recessive disorder that predominantly affects males, as evidenced by the family history. X-Linked Recessive : The gene for Hemophilia B is located on the X chromosome. Males (XY) express the disorder if they inherit the affected X chromosome since they lack a second X for compensation. Females (XX) can be carriers if they inherit one affected X chromosome, often showing no symptoms due to the normal allele on the other X. Affected males cannot pass the disorder to sons but can pass the affected X to daughters, making them carriers. Hemophilia A and B is X linked recessive Hemophilia C is autosomal recessive X-linked Recessive (WISE ABCDEFGH) Wise- Wiskott Aldrich Syndrome AB- Hemophilia A, B B- Bruton's Hypogammaglobulinemia . C- Chronic Granulomatous Disease, Red Green Color Blindness D- DMD, BMD E- Lesch Nyhan Syndrome F- Fabry Disease, Fragile X Syndrome G- G6PD Deficiency H- Hunter Disease

References:

Robbins and Cotrans Pathological Basis of Diseases, 10th Edition, Page 146.

↑ *Back to this question in Part A*

@Neet_pg_bot

Q11: If the mother and father have the β-thalassemia trait, what percentage of their children are expected to have β-thalassemia major? (Q845110)

A. 25%

B. 50%

C. 75%

D. 100%

Correct Answer: A. 25%

■ *Listen (English)*

■ *Listen (Hindi)*

Explanation: There is a 25% chance that their child will inherit the genotype β■/β■, corresponding to β-thalassemia major . Mother's Genotype: β/β■ (carrier for β-thalassemia) Father's Genotype: β/β■ (carrier for β-thalassemia) Punnett Square Analysis: β β■ β β/β β/β■ β■ β/β■ β■/β■ Possible Outcomes: β/β (Normal):

25% β/β■ (Carrier): 50% β■/β■ (β-thalassemia major): 25%

References:

Robbins and Cotrans Pathological Basis of Diseases, 10th Edition, Page 145

↑ *Back to this question in Part A*

@Neet_pg_bot

Q12: If a mother has sickle cell trait and the father has sickle cell disease , what percentage of their children are expected to have sickle cell disease? (Q845111)

A. 25%

B. 50%

C. 75%

D. 100%

Correct Answer: B. 50%

■ *Listen (English)*

■ *Listen (Hindi)*

Explanation: There is a 50% chance that their child will inherit the genotype SS, which corresponds to sickle cell disease. Mother's Genotype: AS (carrier) Father's Genotype: SS (sickle cell disease) Punnett Square Analysis: S S A AS AS S SS SS Possible Outcomes: AS (Sickle cell trait): 50% SS (Sickle cell disease): 50%

References:

Robbins and Cotrans Pathological Basis of Diseases, 10th Edition, Page 145

↑ *Back to this question in Part A*

@Neet_pg_bot

Q13: A 10-year-old boy presents to the clinic with a complaint of bone pain. He does not sustain any trauma. He denies a history of fever. On examination, hepatosplenomegaly and bone tenderness are noted. Biopsy specimen from the spleen shows a crumpled tissue paper appearance. Keeping in view the most likely diagnosis, which of the following substance would most likely accumulate in this disorder? (Q882175)

A. Glucocerebroside

B. SphingomyelinSulfatide

C. Sulfatide

D. Ganglioside

Correct Answer: A. Glucocerebroside

Explanation: Option A: Glucocerebroside The boy is most likely suffering from Gaucher disease, in which glucocerebrosides accumulate. Gaucher disease: Aetiology : Autosomal recessive inherited disease Epidemiology Most common lysosomal lipid storage disease Increased incidence of type I in the Ashkenazi Jewish population Pathophysiology : Deficiency of β-glucocerebrosidase → accumulation of glucocerebroside (sphingolipid found in cell membranes that can accumulate in the lysosome of macrophages) in the brain, liver, spleen, and bone marrow Clinical features Vary according to the exact subtype of Gaucher disease Type I: non-neuronopathic Gaucher disease Type II: acute neuronopathic Gaucher disease Type III: chronic neuronopathic Gaucher disease All types Hepatosplenomegaly Bone : bone crises, osteoporosis, avascular necrosis of the femur Blood abnormalities: anaemia, thrombocytopenia, pancytopenia Pulmonary manifestations Growth delays Diagnostics Reduced glucocerebrosidase activity in leukocytes or fibroblasts Accumulation of glucocerebroside in leukocytes or fibroblasts Gaucher cell: lipid-rich macrophages with an enlarged cytoplasm with inclusions that resemble crumpled tissue paper on microscopy Treatment: Enzyme replacement therapy with recombinant glucocerebrosidase or substrate reduction therapy with eliglustat Option B: Sphingomyelin Sphingomyelin accumulation is seen in Niemann-Pick disease. Light microscopy: lipid-laden macrophages (foam cells) in the bone marrow, spleen, and liver Electron microscopy: Zebra bodies (abnormal configuration of myeloid membranes into parallel palisading lamellae in the lysosomal cytoplasm Option C: Sulfatide Arylsulfatase A is deficient in metachromatic leukodystrophy The cerebroside sulfate accumulates The presentation includes demyelination in CNS and PNS, resulting in ataxia and dementia The inheritance is autosomal recessive. Option D: Ganglioside Ganglioside accumulation is seen in Tay Sach disease Hexosaminidase A deficiency → intracellular accumulation of GM2 ganglioside → progressive neurodegeneration

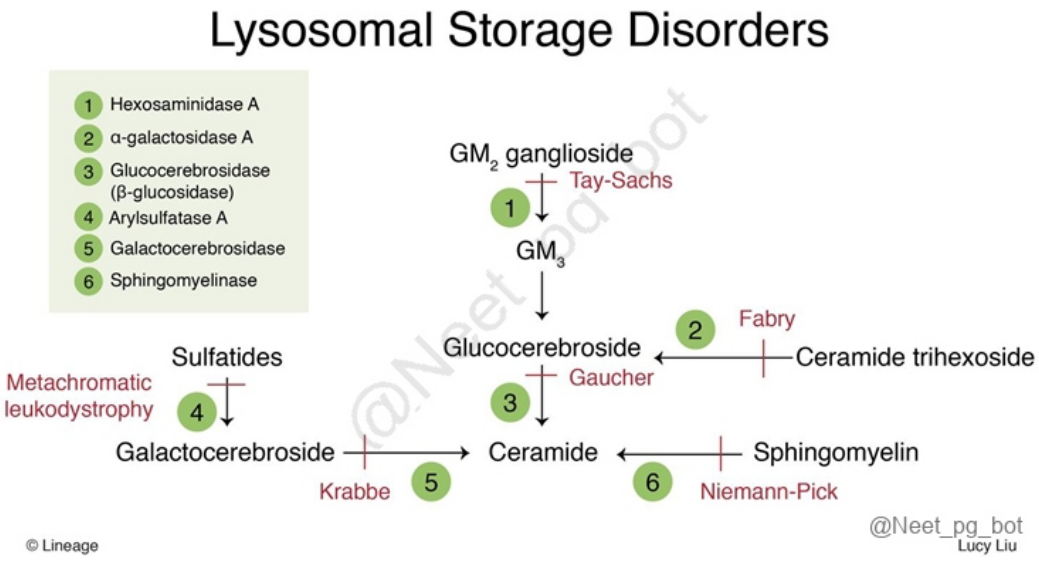

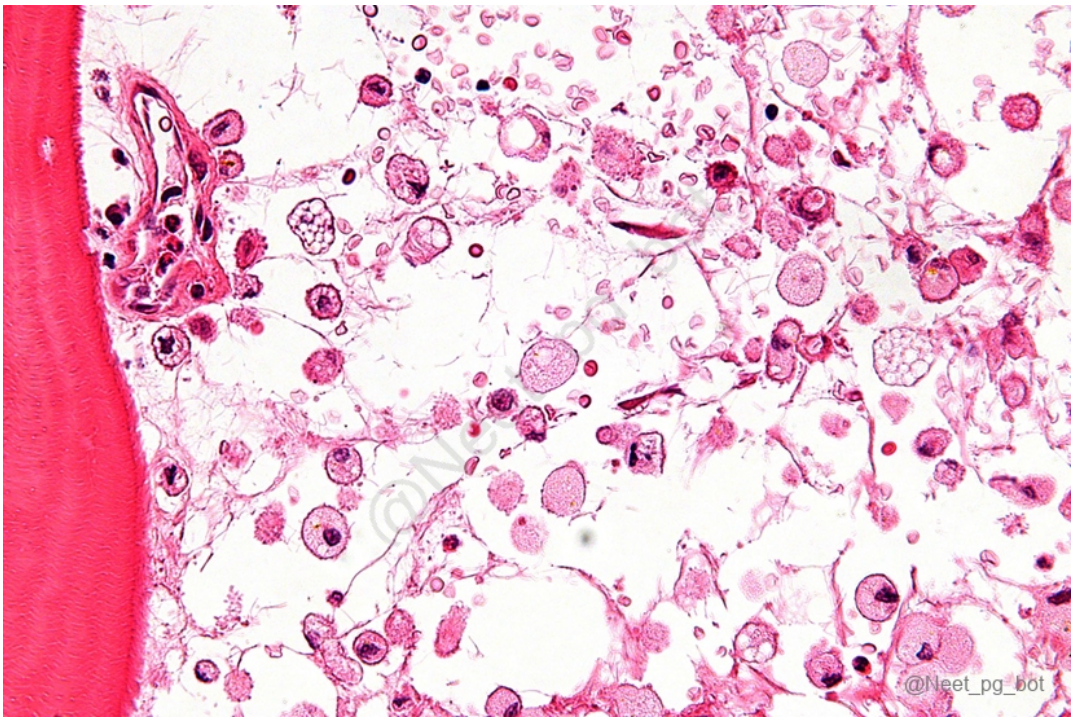

References:

Robbins 10th/262

↑ *Back to this question in Part A*

@Neet_pg_bot

• [03_Genetics] 011 Non-Mendelian Disorders

« Back to Folder Directory

[03_Genetics] 011 Non-Mendelian Disorders — Quick Jump

Q1 (p. 1199)	*Q2 (p. 1200)*	*Q3 (p. 1201)*	*Q4 (p. 1204)*	*Q5 (p. 1205)*	*Q6 (p. 1208)*
Q7 (p. 1210)	*Q8 (p. 1211)*	*Q9 (p. 1212)*	*Q10 (p. 1213)*	*Q11 (p. 1215)*	*Q12 (p. 1216)*
Q13 (p. 1217)	*Q14 (p. 1218)*	*Q15 (p. 1220)*	*Q16 (p. 1220)*	*Q17 (p. 1221)*	*Q18 (p. 1222)*

Q1: Fabry disease is an X-linked lysosomal storage disorder caused by a deficiency of which enzyme? (Q879663)

A. Alpha-galactosidase A

B. Beta-glucocerebrosidase

C. Acid alpha-glucosidase

D. Sphingomyelinase

Correct Answer: A. Alpha-galactosidase A

Explanation: Fabry disease: Inheritance: X-linked recessive Enzyme deficiency: Alpha-galactosidase A → accumulation of globotriaosylceramide (Gb3) in lysosomes Clinical features: Angiokeratomas, acroparesthesias, hypohidrosis, renal and cardiac involvement. Maltese cross crystals in the urine because lipids are coming out into the urine. Incorrect Options: Beta-glucocerebrosidase (Option B) : Deficient in Gaucher disease , leading to accumulation of glucocerebroside. Acid alpha-glucosidase (Option C) : Deficient in Pompe disease , causing glycogen accumulation in lysosomes. Sphingomyelinase (Option D) : Deficient in Niemann-Pick disease , leading to sphingomyelin buildup.

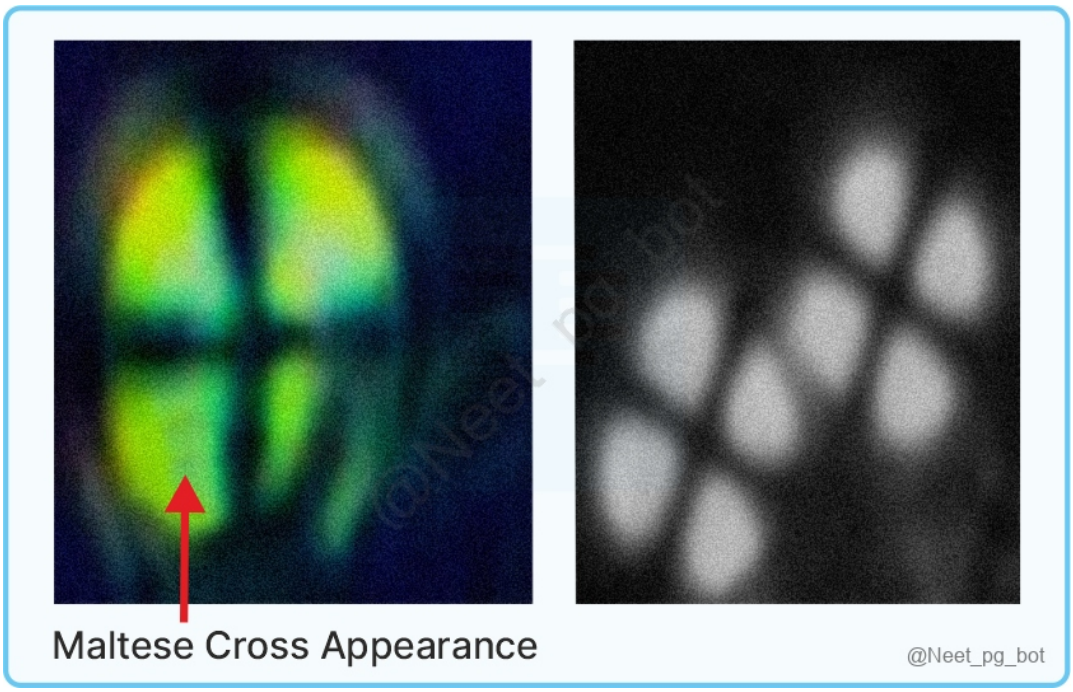

References:

https://www.ncbi.nlm.nih.gov/books/NBK435996/

↑ *Back to this question in Part A*

@Neet_pg_bot

Q2: Which of the following correctly describes the genetic basis of Myotonic Dystrophy type 1? (Q879658)

A. Autosomal recessive disorder caused by CAG expansion in the HTT gene on chromosome 4

B. Autosomal dominant disorder caused by CTG trinucleotide expansion in the DMPK gene on chromosome 19q13.3

C. X-linked disorder caused by CGG repeat expansion in the FMR1 gene

D. Autosomal dominant disorder caused by GAA trinucleotide expansion in the FXN gene

Correct Answer: B. Autosomal dominant disorder caused by CTG trinucleotide expansion in the DMPK gene on chromosome 19q13.3

Explanation: Myotonic Dystrophy type 1: Inheritance: Autosomal dominant Gene: DMPK (Myotonic Dystrophy Protein Kinase) Chromosome: 19q13.3 Mutation: CTG trinucleotide repeat expansion in the 3′ UTR of the gene Pathogenesis: Toxic gain-of-function RNA sequesters muscle splicing regulators → mis-splicing of genes like CLCN1 → myotonia Other manifestations: Insulin resistance due to splicing changes in insulin receptor isoforms

Incorrect Options: CAG expansion in the HTT gene on chromosome 4 (Option A) : Seen in Huntington disease , not Myotonic Dystrophy. CGG repeat expansion in the FMR1 gene (Option C) : Characteristic of Fragile X syndrome , an X-linked disorder . GAA trinucleotide expansion in the FXN gene (Option D) : Found in Friedreich ataxia , an autosomal recessive condition.

References:

Robbins, Cotran & Kumar Pathologic Basis of Disease, 11th Edition, Page. 1123

↑ *Back to this question in Part A*

@Neet_pg_bot

Q3: A one-month-old infant presents with developmental delays and physical features such as a prominent occiput, low-set ears, clenched hands with overlapping fingers, and a small mouth with a protruding tongue. Heart murmurs and rocker-bottom foot deformity are also noted. Which syndrome is the most likely cause of these features? (Q845124)

A. Noonan syndrome

B. Down syndrome

C. Patau syndrome

D. Edward syndrome

Correct Answer: D. Edward syndrome

■ *Listen (English)*

■ *Listen (Hindi)*

Explanation: Edward syndrome is caused by the presence of an extra copy of chromosome 18- Trisomy 18. On USG: Strawberry skull is seen: Prominent occiput and small chin. Features: Low birth weight Clenched fists with overlapping fingers Rocker-bottom feet (seen in trisomy 18 and trisomy 13) Microcephaly Micrognathia Macroglosia (Big protruding tongue) Cardiac and renal malformations Mental retardation Noonan syndrome (Option A): Genetic Cause: Autosomal dominant; mutation in the PTPN11 gene (RAS-MAPK pathway); Normal karyotype (Not trisomy). Phenotype: Often called "Male Turner Syndrome" because of similar features (short stature, webbed neck, pectus excavatum). Differentiator: Unlike Turner Syndrome, it affects both males and females and usually presents with Pulmonic Stenosis (rather than Coarctation of the Aorta). Down syndrome (Option B): Genetic Cause: Trisomy 21; most common live-born trisomy. Physical Traits: Flat facies, epicanthal folds , Simian crease (single transverse palmar crease), and gap between 1st and 2nd toes (Sandals-gap deformity) . Comorbidities: Early-onset Alzheimer's, increased risk of ALL/AML, and duodenal atresia ("double bubble" sign). Heart: Atrioventricular septal defects (Endocardial cushion defects) are highly specific. Patau syndrome (Option C): Genetic Cause: Trisomy 13 Mnemonic "The 3 P's": P olydactyly (extra fingers), P alaps (Cleft lip/Palate), and P unced-out scalp lesions (Aplasia cutis congenita). Midline Defects: Often presents with

Holoprosencephaly (failure of brain to divide) and Microphthalmia (small eyes). Heart: Associated with ASD/VSD and PDA.

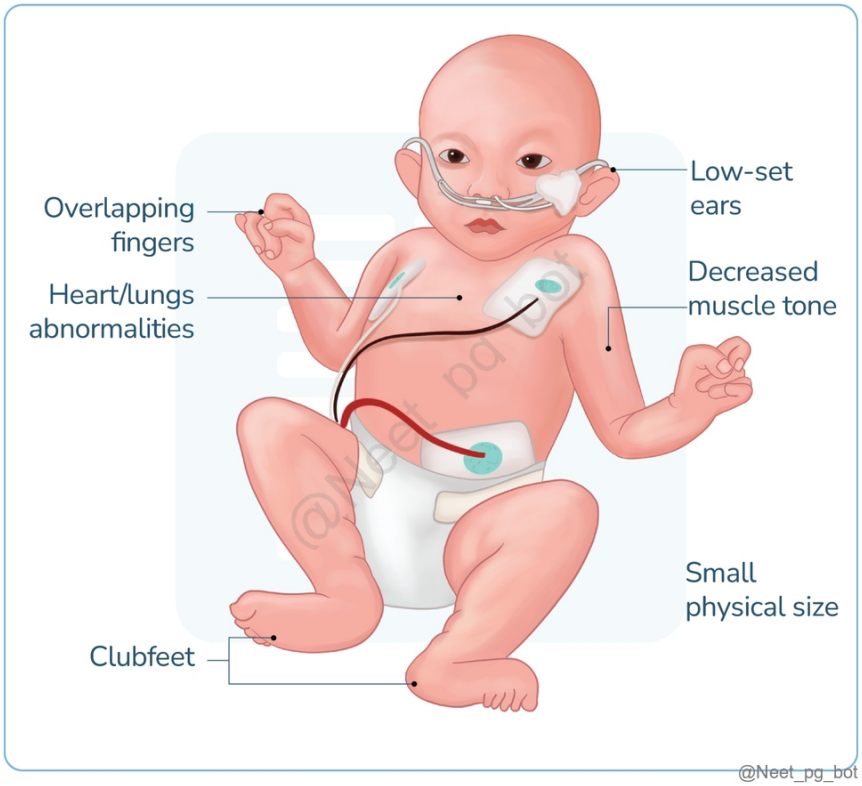

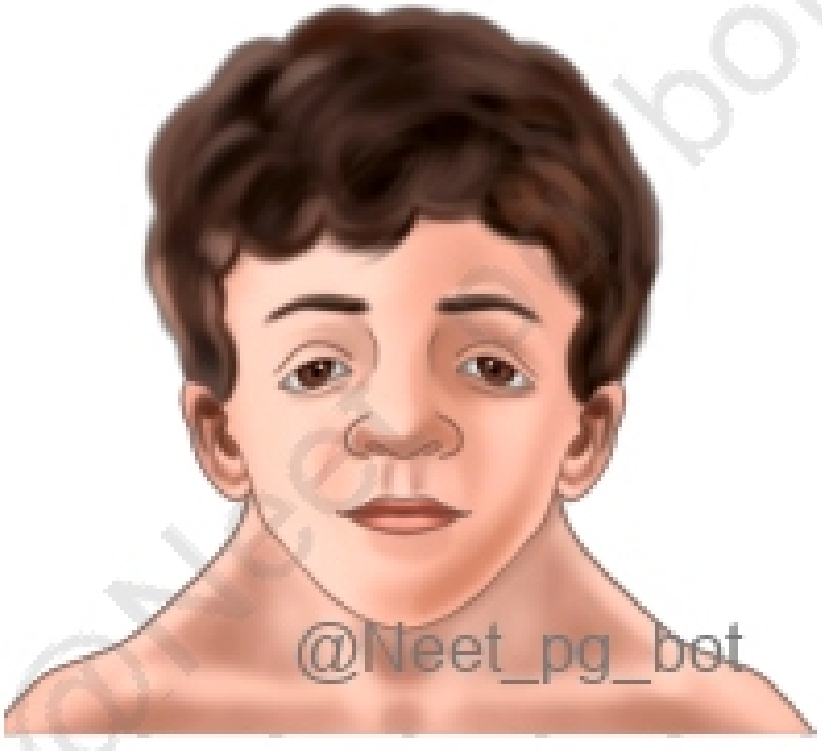

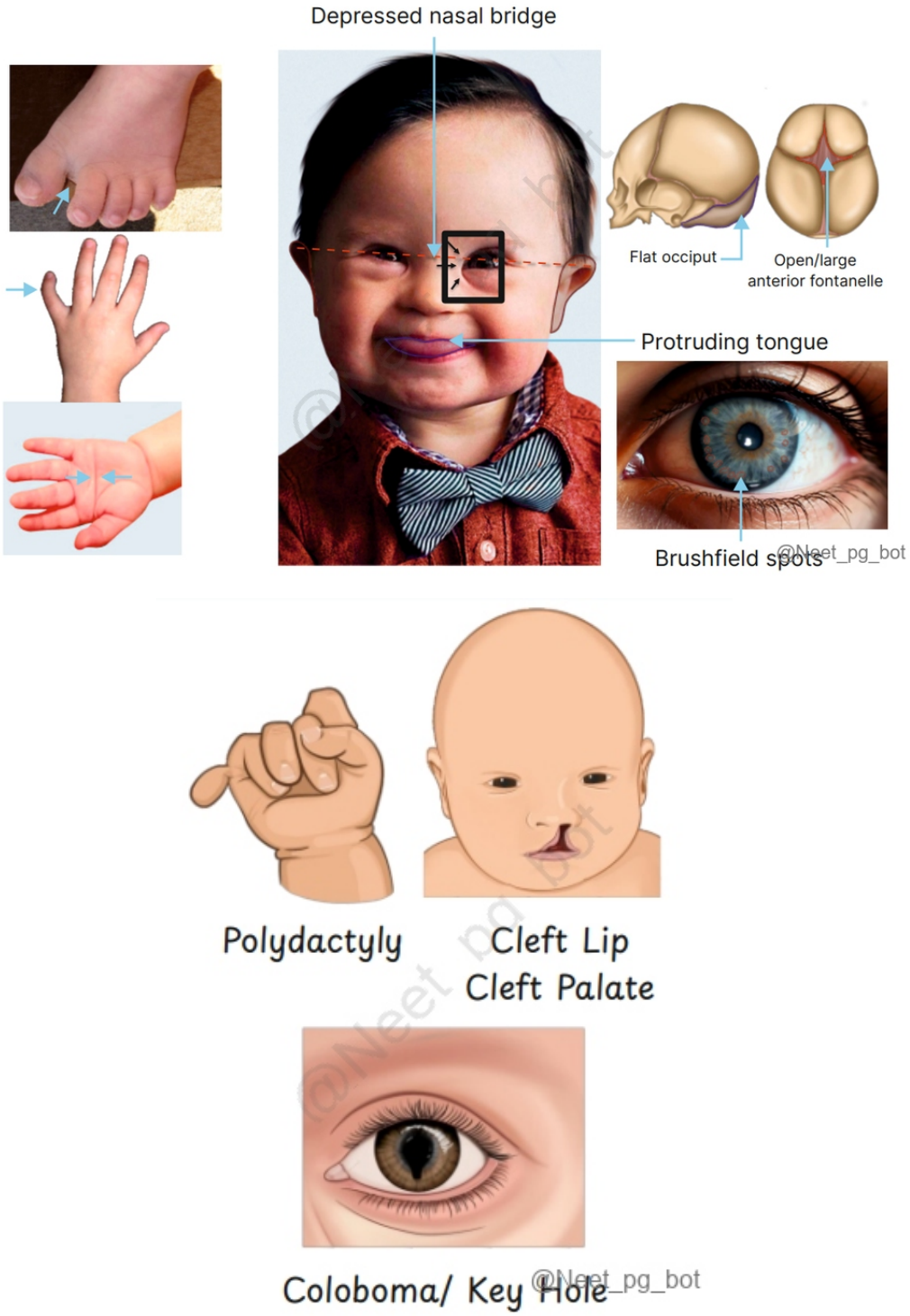

References:

Robbins and Cotran Pathologic basis of disease, 10th edition, Pages 166-169.

↑ *Back to this question in Part A*

@Neet_pg_bot

Q4: A 15-year-old boy presents to the clinic with tall stature and long limbs, along with a history of frequent joint dislocations. Upon physical examination, he exhibits long fingers ,sunken chest, and an echocardiogram shows a dilated aortic root. Considering these clinical features, which of the following genes are commonly mutated in this condition? (Q845130)

A. FBN 1

B. FBN 2

C. FBN 3

D. FBN 4

Correct Answer: A. FBN 1

■ *Listen (English)*

■ *Listen (Hindi)*

Explanation: A 15-year-old boy presents with tall stature, long limbs, joint dislocations, long fingers, a sunken chest, and a dilated aortic root on echocardiogram; these features are consistent with Marfan syndrome , which is commonly caused by mutations in the FBN1 gene An autosomal dominant disorder due to a mutation in the Fibrillin (FBN) 1 Gene on chromosome 15. Clinical Features: Marfan D isease The most common Clinical Manifestation is Skeletal Abnormalities. M itral Valve Prolapse (Most common Cardiac abnormality) A ortic Dissection (Most common cause of death) R etinal Detachment (eye problem) F reely movable Joint (most common Thumb joint) A rachnodactyly (long fingers, spider fingers), High A rched Palate N ine Feet Tall, Pigeon chest (defect in sternum) D islocation of the lens (Ectopia Lentis- Direction of dislocation is Supero Temporal) Steinberg Sign - Positive if the thumb tip extends beyond the palm when folded into a closed fist Walker Sign- Positive if the thumb and fifth finger overlap when you grip your wrist with the opposite hand Homocystinuria: Homocystinuria due to cystathionine beta-synthase (CBS) deficiency is an autosomal recessive disorder causing elevated homocysteine/methionine levels, leading to multisystem involvement. Classic Tetrad (MARFAN-like + Thrombosis) M arfanoid habitus: tall, thin, arachnodactyly, pectus, scoliosis E ctopia lentis (downward dislocation) A therosclerosis/thromboembolism (strokes even in children) R etardation (mild-moderate intellectual disability) Feature Homocystinuria Marfan Syndrome Inheritance Autosomal recessive (CBS gene) Autosomal dominant (FBN1) Lens dislocation Downward Upward Vascular risk Thromboembolism ↑↑ Aortic dilation/rupture Odor Methionine (boiled cabbage) None Mental status Intellectual disability Normal Treatment test Pyridoxine (B6) responsive (~50%) None



References:

Robbins and Cotrans Pathological Basis of diseases, 10th Edition, Page 148, 149

↑ *Back to this question in Part A*

@Neet_pg_bot

Q5: A 3-year-old boy presents with developmental delay, short stature, a heart murmur, and characteristic facial features, as shown in the image below. What is the most likely diagnosis for this patient? (Q845129)

A. Noonan syndrome

B. Down syndrome

C. Williams syndrome

D. Turner syndrome





Correct Answer: A. Noonan syndrome

Explanation: The most likely diagnosis for this patient is Noonan syndrome, which is typically caused by mutations in genes such as PTPN11, SOS1, and RAF1. Noonan syndrome is characterized by distinctive facial features, including wide-set eyes, a large head, a drooping face, short stature, developmental delay, and heart defects. The presence of a heart murmur, along with characteristic facial features and developmental delay, is highly suggestive of Noonan syndrome. Additional clinical factors may include easy bruising or bleeding, dry skin, sensorineural deafness, and lymphedema, which can aid in the diagnosis. Genetic testing can confirm the presence of mutations associated with Noonan syndrome. Down syndrome (Option B) is not the diagnosis due to absence of facial features such as flat face, small nose with a flat bridge, small ears, a short neck, and upward slanting eyes Williams syndrome (Option C) is unlikely due to the absence of characteristic facial features and the uncommon presentation of a heart murmur. Turner syndrome (Option D) is unlikely in a male patient and is characterized by specific physical features not present in this case.



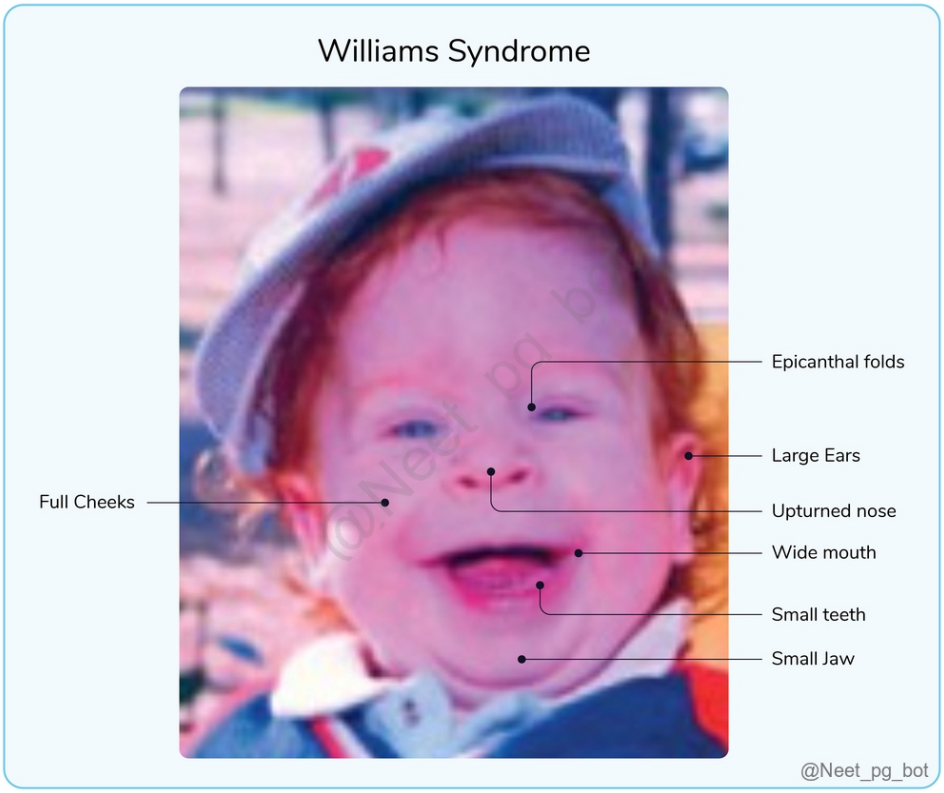

References:

UPTODATE NOONAN SYNDROME

↑ *Back to this question in Part A*

@Neet_pg_bot

Q6: An 18-year-old girl presents to the clinic due to the concern that she hasn't started menstruating yet. The girl has a short stature and a webbed neck. Physical examination reveals a broad chest with widely spaced nipples. What is the most likely diagnosis for this patient? (Q845128)

A. Turner syndrome

B. Mullerian agenesis

C. Congenital adrenal hyperplasia

D. 47, XXX syndrome

Correct Answer: A. Turner syndrome

■ *Listen (English)*

■ *Listen (Hindi)*

Explanation: The scenario is diagnosed as Turner syndrome. Genotype: 45 XO Phenotype: Female Improper breast development leading to widely spaced nipples Improper ovarian development: Female presents with streak ovaries and primary amenorrhea (patient will not attain menarche). Physical symptoms: Short stature and webbed neck Cardiac anomalies: Bicuspid aortic valve and Coarctation of aorta. Usually, IQ is normal. The image below shows karyotyping in Turner syndrome. Turner Syndrome vs Noonan Syndrome: Feature Turner Syndrome Noonan Syndrome Genetics 45, X (Monosomy X) Autosomal Dominant (e.g., PTPN11 gene) Gender Females only Males and Females Heart Defect Coarctation of the aorta , Bicuspid aortic valve Pulmonic Stenosis , Hypertrophic cardiomyopathy Chest Shield chest, widely spaced nipples Pectus excavatum/carinatum Gonads Streak ovaries , primary amenorrhea, infertility Males: cryptorchidism; females usually fertile Puberty Delayed/absent, need estrogen Often delayed but usually spontaneous Karyotype Abnormal (missing X) Normal (46, XX or 46, XY) IQ Typically normal Mild intellectual disability possible

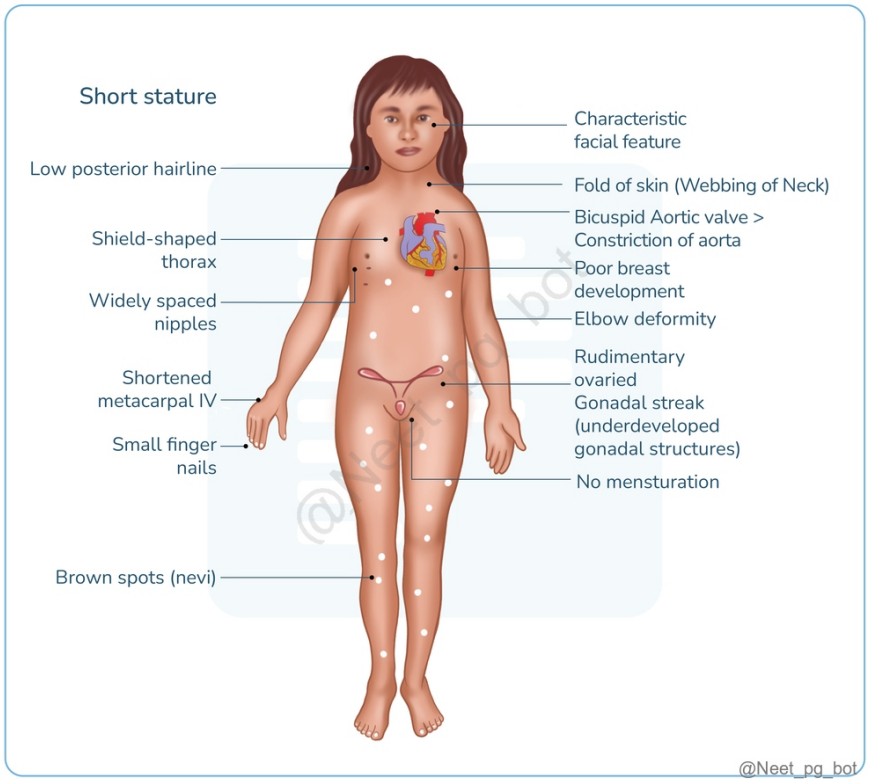



References:

Robbins and Cotrans Pathological Basis of diseases, 10th Edition, Page 172

↑ *Back to this question in Part A*

@Neet_pg_bot

Q7: A 30-year-old tall male patient presents to the clinic for fertility treatment. He undergoes testing and is found to have low sperm counts. He has a history of diabetes, and a physical examination reveals gynecomastia, small testes, and minimal facial and body hair. What chromosomal abnormality is most likely causing this condition in the patient? (Q845127)

A. 45,X

B. 47,XXY

C. 47,XXX

D. 47,XYY

Correct Answer: B. 47,XXY

■ *Listen (English)*

■ *Listen (Hindi)*

Explanation: Klinefelter syndrome is the most common sex chromosome aneuploidy in males, caused by at least one extra X chromosome, leading to hypogonadism and infertility. The classic karyotype is 47, XXY (~90% cases), from meiotic nondisjunction. Mosaics (46, XY/47, XXY) are milder (~10-20%). Clinical features: Initially, the gonads are testes, but because of an extraX chromosome, the testes stay underdeveloped and small (hypogonadism). Physical Appearance: Tall stature with disproportionately long arms and legs. Hypogonadism: Small, firm testes (testicular dysgenesis) and a small penis. Secondary Sex Characteristics: Weak facial and body hair growth; female-type fat distribution (wider hips). Gynecomastia: Development of breast tissue (increases risk of male breast cancer). Fertility: Infertility due to azoospermia (absence of sperm) and atrophy of seminiferous tubules. Cognition: Mild intellectual disability or specific learning disabilities (notably delayed speech). Hormonal profile: Low serum testosterone levels leading to high LH and FSH levels. Marker Level Reason Testosterone Low Leydig cell dysfunction. LH High Loss of negative feedback from low Testosterone. FSH High Loss of negative feedback from low Inhibin B . Estrogen High Increased peripheral conversion of androgens. Most common cancer risk: Male breast cancer (due to high estrogen). Extragonadal Germ Cell Tumors (especially mediastinal). Osteoporosis (due to low testosterone).

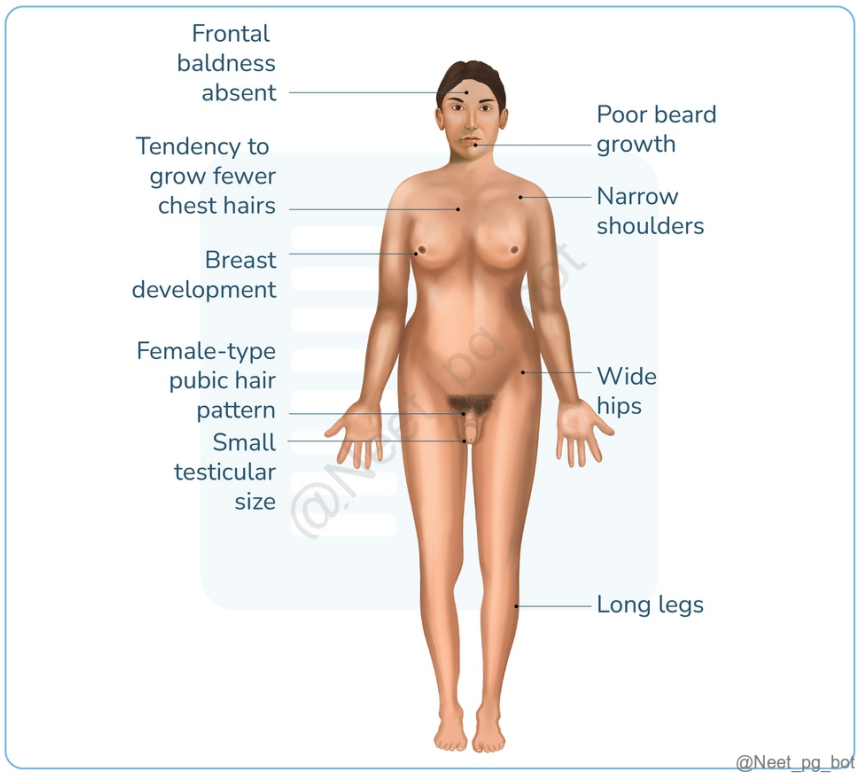

References:

Robbins and Cotrans Pathological Basis of diseases, 10th Edition, Page 170

↑ *Back to this question in Part A*

@Neet_pg_bot

Q8: A 6-month-old child has recently passed away after a long ICU stay. Examination reveals microphthalmia and microcephaly. Other known diagnoses included ventricular septal defect, polycystic kidney disease, and omphalocele at birth. What is the chromosome involved? (Q845126)

A. Chromosome 21

B. Chromosome 18

C. Chromosome 13

D. Chromosome Y

Correct Answer: C. Chromosome 13

■ *Listen (English)*

■ *Listen (Hindi)*

Explanation: The given scenario describes Patau syndrome or Trisomy 13. Clinical features and associations include Rocker-bottom feet (Seen in both trisomy 13 and trisomy 18) Severe intellectual disability Keyhole/ Coloboma (eyes) Microphthalmia, microcephaly, holoprosencephaly Cleft lip/palate Polydactyly Congenital heart disease: PDA (Patent Ductus Arteriosus) or VSD (Ventricular Septal Defect) Renal defects-Polycystic kidney disease Umbilical hernia,Omphalocele Trisomy 18 is Edward syndrome: Clinical features include a prominent occiput (Strawberry skull) and rocker-bottom feet (Option B ruled out) Feature Edward (Trisomy 18) Patau (Trisomy 13) Hands Clenched fists with overlapping fingers■ Polydactyly (extra fingers/toes)■ Feet Rocker-bottom ■ Normal or broad Eyes Microphthalmia, short palpebral fissures Microphthalmia + coloboma ■ Face Low-set ears , micrognathia Cleft lip/palate (90%)■ Brain Small cerebellum (Severe intellectual disability) Holoprosencephaly ■ Head Prominent Occiput Scalp defects (Aplasia cutis)

References:

https://www.uptodate.com/contents/congenital-cytogenetic-abnormalities

↑ *Back to this question in Part A*

@Neet_pg_bot

Q9: A 2-year-old boy is brought to the pediatrician by his parents for delayed milestones. Upon examination, the pediatrician notices several physical features, including upward-slanting eyes, a flat facial profile, a protruding tongue, and a single palmar crease. Which type of inheritance is definitely not present in this child? (Q845125)

A. Meiotic nondisjunction of chromosome 21.

B. Robertsonian translocation

C. Mitotic non-disjunction

D. Autosomal recessive inheritance

Correct Answer: D. Autosomal recessive inheritance

■ *Listen (English)*

■ *Listen (Hindi)*

Explanation: The clinical features are indicative of Down syndrome (Trisomy 21) , which is a chromosomal disorder, so autosomal recessive inheritance is definitely not present . Features: Mongoloid facies: Upward slanting of eyes (because of oblique palpebral fissure) and flat facial profile (because of nasal hypoplasia) Macroglossia (Protruding tongue) Simian crease (single palmar crease) Modes of inheritance of Down syndrome are as follows: Meiotic Nondisjunction of chromosome 21 (~95%) (Option A): ■■■■■■■■■■■■■■■ Cause:

Failure of chromosome 21 to separate during meiosis (usually maternal Meiosis I). Fact: Risk increases significantly with advanced maternal age . Karyotype: 47, XX, +21 or 47, XY, +21. Robertsonian Translocation (4%) (Option B): t(22,14) in mother. Cause: The long arm of chromosome 21 attaches to another chromosome (usually 14 or 21). Inheritance: Can be inherited from a balanced carrier parent. Karyotype: 46, XX, t(14;21) or similar. Note: The t(21;21) Rule: If a parent is a carrier of a 21;21 translocation (where both copies of chromosome 21 are fused), the risk of Down Syndrome in offspring is 100% . This is because the parent can only produce gametes with either "two copies" of 21 (resulting in Trisomy) or "zero copies" (resulting in non-viable Monosomy). Mitotic Nondisjunction (Mosaicism) (~1-2%) (Option C): Cause: Error occurs after fertilization during early cleavage. Presentation: The individual has two cell lines (some 46, some 47): Mosaicism Clinical: Often presents with milder physical and intellectual features. This leads to mosaicism.

References:

Robbins and Cotran Pathological Basis of Diseases, 10th Edition, Pages 166,167.

↑ *Back to this question in Part A*

@Neet_pg_bot

Q10: A young male patient presented with recurrent episodes of acute neurologic dysfunction, cognitive changes, muscle weakness, and lactic acidosis. There is a family history of similar conditions depicted in the pedigree chart below. What is the most likely diagnosis? (Q845115)

A. MELAS

B. MERRF

C. Metachromatic leukodystrophy

D. Adrenoleukodystrophy

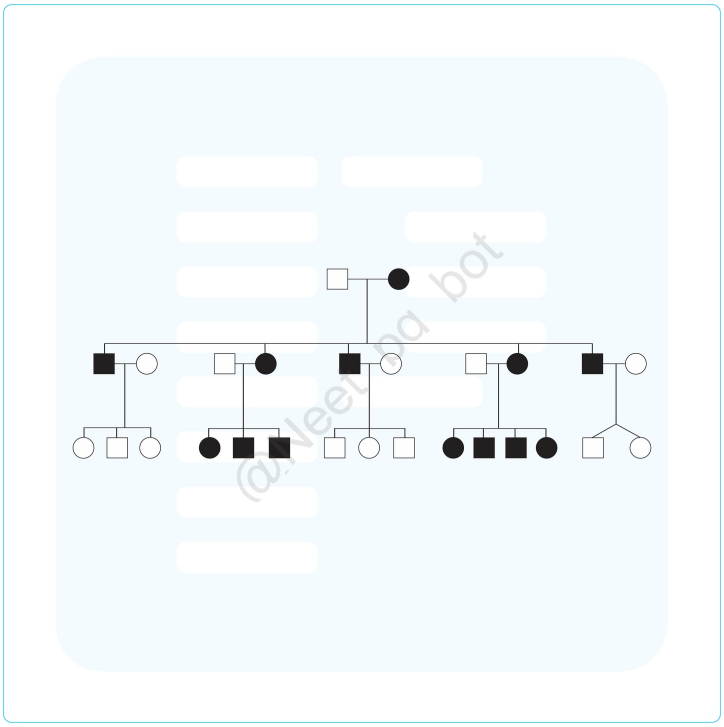

@Neet_pg_bot

Correct Answer: A. MELAS

■ *Listen (English)*

■ *Listen (Hindi)*

Explanation: MELAS -Mitochondrial encephalomyopathy, lactic acidosis, and stroke-like episodes: MELAS follows a unique non-Mendelian pattern of inheritance called maternal inheritance, as mitochondrial DNA is derived entirely from the ovum. Affected mothers and daughters transmit the disease to both male and female children, whereas the affected sons don't transmit the affected DNA. (Mother to all, Father to none.) The most common mitochondrial disease is MELAS. MERRF (Option B): Myoclonic Epilepsy with Ragged Red Fibers presents mainly with myoclonus, generalized seizures, ataxia, ragged■red fibers , not stroke■like episodes with lactic acidosis.■ Metachromatic leukodystrophy (Option C): Autosomal recessive, due to arylsulfatase A deficiency , causes progressive motor and cognitive decline, not maternal inheritance with lactic acidosis and stroke■like events. Adrenoleukodystrophy (Option D): X■linked, affects males only through maternal carrier , with adrenal failure and demyelination; the pedigree would show typical X■linked pattern, not all offspring of an affected mother at risk. Mitochondrial Inheritance (Maternal): Disease Key Features MELAS (Option A) Stroke-like episodes, lactic acidosis, seizures, muscle weakness MERRF (Option B) Myoclonic epilepsy, ragged red fibers, ataxia LHON Leber hereditary optic neuropathy (acute vision loss) NARP Neuropathy, ataxia, retinitis pigmentosa Kearns-Sayre Progressive external ophthalmoplegia, heart block, retinitis Leigh syndrome Encephalopathy, basal ganglia lesions, lactic acidosis X-linked Recessive (Affects males; females carriers): Disease Key Features Adrenoleukodystrophy (ALD) (Option D) Cerebral demyelination, adrenal insufficiency, VLCFA↑ Duchenne MD Proximal weakness, Gower's sign, CK↑↑, dystrophin absent Hunter syndrome MPS II (coarse facies, corneal clouding, cardiac) Hemophilia A/B Factor VIII/IX deficiency, hemarthrosis Fabry disease Angiokeratomas, renal/heart failure, globotriaosylceramide X-linked agammaglobulinemia Absent B cells, recurrent bacterial infections Wiskott-Aldrich Thrombocytopenia, eczema, infections Autosomal Recessive

(Leukodystrophies): Disease Key Features Metachromatic leukodystrophy (MLD) (Option C) Arylsulfatase A def, demyelination, metachromatic granules Krabbe disease Galactocerebrosidase def, globoid cells, spasticity Alexander disease GFAP mutation, Rosenthal fibers, macrocephaly Canavan disease ASPA def, spongy degeneration, megalencephaly Pelizaeus-Merzbacher PLP1 duplication, hypomyelination (XLR but AR forms rare)

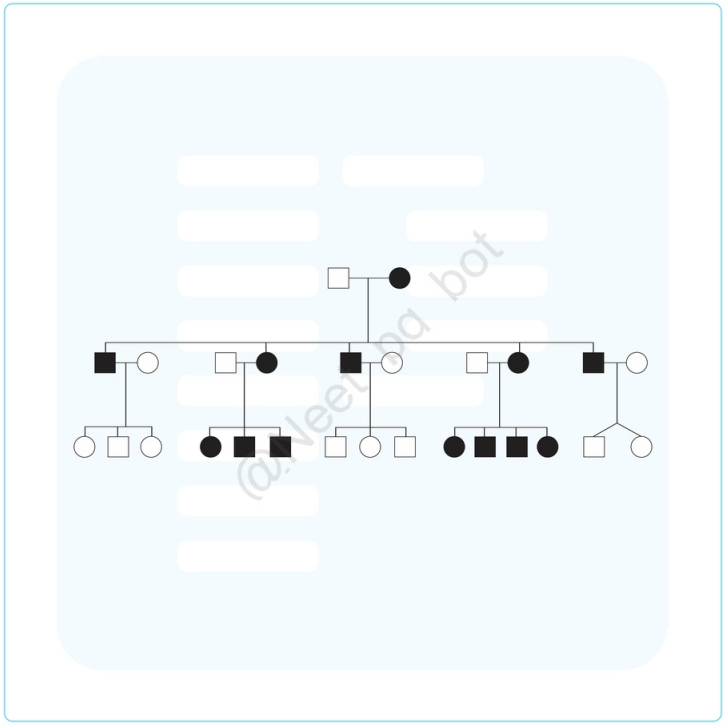

@Neet_pg_bot

References:

Robbins and Cotrans Pathological Basis of diseases, 10th Edition, Pages 1290,1291

www.ncbi.nlm.nih.gov/books/NBK560744/

↑ *Back to this question in Part A*

@Neet_pg_bot

Q11: A 50-year-old man presents with intentional tremors, cerebellar ataxia, and intellectual disability. His father had similar symptoms at 60 and died due to aortic dissection. The patient's son started showing tremors and has an intellectual disability and aggressive behavior. Additionally males of the family have large ears and mandibles. What condition is most likely affecting him? (Q845123)

A. Fragile X syndrome

B. Huntington's disease

C. Parkinson's disease

D. Alzheimer's disease

Correct Answer: A. Fragile X syndrome

■ *Listen (English)*

■ *Listen (Hindi)*

Explanation: Fragile X Syndrome (FXS) results from CGG trinucleotide repeat disorder. CGG repeats <55: Normal individual Premutation (55–200 CGG repeats): Mechanism: The gene is still active, but produces "toxic" mRNA. Causes Fragile X–associated tremor/ataxia syndrome (FXTAS) Seen in older males Symptoms : Intentional tremor, cerebellar ataxia, cognitive decline Full Mutation (>200 CGG repeats): Fragile X syndrome Mechanism: The massive expansion causes DNA methylation , which "silences" the gene completely. Leads to Fragile X syndrome Due to hypermethylation and silencing of FMR1 gene Symptoms: Severe intellectual disability (IQ 20-60), aggressive behavior, and characteristic physical traits: long face, large ears, large mandible, and macroorchidism. Fragile X syndrome: A very common cause of intellectual disability which is seen in all members of the family. IQ = 20-60 Males are affected more than females; females are carriers, but sometimes females can be mildly affected. Physical phenotype: Includes a long face with a large mandible, large ears, and macroorchidism (enlarged testicles). Investigation of choice: Polymerase chain reaction (PCR) If PCR fails then we go for Southern blotting. Huntington’s disease (Option B): Characterized by chorea, behavioural changes, and adult-onset dementia Parkinson’s disease (Option C): Classic resting tremor, rigidity, bradykinesia. Alzheimer’s disease (Option D): Causes progressive memory loss and cognitive decline, not tremor or ataxia.

References:

Robbins and Cotrans Pathological Basis of diseases, 10th Edition, Pages 174, 176

↑ *Back to this question in Part A*

@Neet_pg_bot

Q12: A group of researchers studying genetic material noticed the presence of both wild-type and mutated mitochondrial genomes in different mitochondria of the same cells. What does this finding indicate? (Q845122)

A. Copy number variation

B. Heteroplasmy

C. Trinucleotide expansion

D. Imprinting

Correct Answer: B. Heteroplasmy

■ *Listen (English)*

■ *Listen (Hindi)*

Explanation: The presence of both wild-type and mutated mitochondrial genomes in different mitochondria of the same cell is called heteroplasmy. A minimum number of mutant mtDNAs must be present in a cell to give rise to a disease. This is called the “threshold effect.” Homoplasmy: Every single mitochondrion within a cell contains the exact same genetic sequence. Mitochondrial DNA (mtDNA): Maternal Inheritance: mtDNA is inherited exclusively from the mother. Circular Structure: MtDNA is a double-stranded, circular molecule. Encodes 37 Genes: Codes for 13 proteins (OxPhos), 22 tRNAs, and 2 rRNAs. Lack of Introns: It contains almost no non-coding sequences (introns). High Mutation Rate: This is due to a lack of protective histones and constant exposure to Reactive Oxygen Species (ROS) generated during ATP production. Inefficient Repair: Mitochondria have very limited DNA repair mechanisms. Replicative Segregation: During cell division, mitochondria are distributed randomly into daughter cells. This leads to varying proportions of mutant vs. wild-type DNA (Heteroplasmy). Polyplasmy: Each cell contains hundreds of mitochondria, and each mitochondrion contains multiple copies of mtDNA. Threshold Effect: Disease symptoms only appear when the percentage of mutated mtDNA exceeds a certain level (Heteroplasmy). Unique Genetic Code: For example, UGA codes for Tryptophan instead of acting as a "Stop" codon. Copy number variation (Option A): This refers to the number of copies of a particular gene or DNA segment in the nuclear genome (e.g., deletions or duplications). It doesn't describe the mix of mutant and wild-type genomes. Trinucleotide expansion (Option C): This is a mutation where a specific sequence of three nucleotides repeats excessively (e.g., Huntington’s disease or Fragile X syndrome). Imprinting (Option D): This involves the epigenetic silencing of one parental allele in the nuclear genome, not the mixture of mitochondrial DNA.

References:

Robbins and Cotrans Pathological Basis of diseases, 10th Edition, Pages 1291, 178, 143

www.ncbi.nlm.nih.gov/pmc/articles/PMC8640565/

↑ *Back to this question in Part A*

@Neet_pg_bot

Q13: Which of the following explains a single mutant gene leading to different end effects in sickle cell anemia? (Q845121)

A. Variable expressivity

B. Variable penetrance

C. Pleiotropy

D. Genetic heterogeneity

Correct Answer: C. Pleiotropy

■ *Listen (English)*

■ *Listen (Hindi)*

Explanation: A single mutant gene leading to many end effects is called pleiotropism , whereas mutations at several genetic loci producing a similar phenotypic effect are called genetic heterogeneity. Sickle cell anemia is an example of pleiotropy with a single gene mutation causing multiple physical effects: Mutation at beta-7 position: Glutamic acid is replaced by valine. The mutation produces hemoglobin S (HbS) , which makes red blood cells prone to hemolysis. Additionally, it can lead to complications like splenic fibrosis, organ infarcts, and bone pains. Variable expressivity (Option A) : It refers to the phenomenon where individuals with the same genetic mutation display different levels and types of symptoms or traits. Variable penetrance (Option B) : It refers to a condition where individuals inherit the mutant gene but are phenotypically normal. It is a binary phenomenon where the genotype either causes the disease or it doesn't. Genetic heterogeneity (Option D): Mutations at several genetic loci producing a similar phenotypic effect.

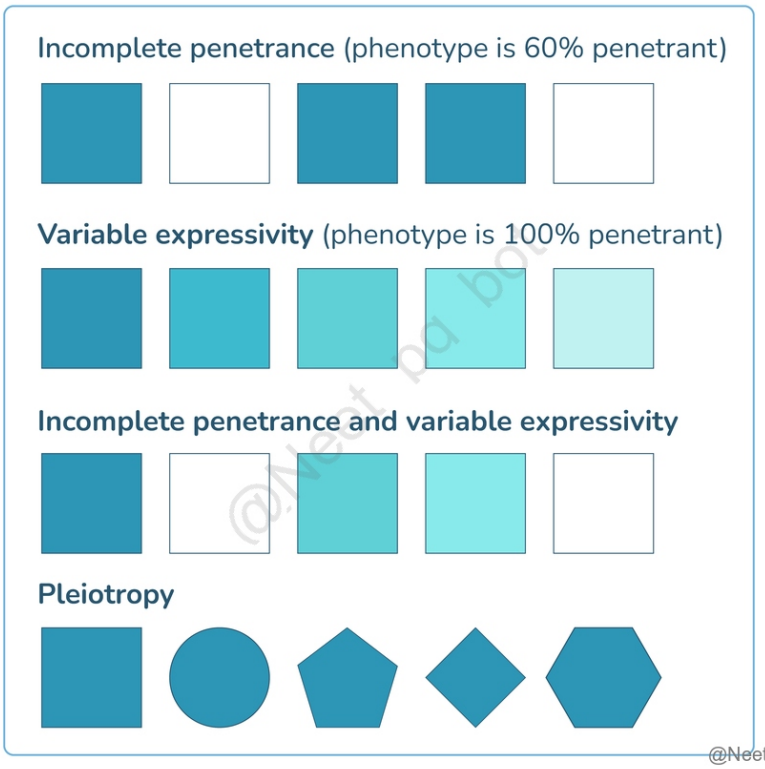

References:

1. Robbins and Cotran Pathological Basis of Diseases, 10th Edition, Page 144. 2. www.ncbi.nlm.nih.gov/pmc/articles/PMC9380816/

↑ *Back to this question in Part A*

@Neet_pg_bot

Q14: A 4-year-old girl is brought to the pediatrician's office for evaluation of developmental delay and seizures. She is very jovial, has microcephaly and is diagnosed with happy puppet syndrome. What is the genetic basis for this child's diagnosis? (Q845120)

A. Imprinting

B. Robertsonian translocation

C. Trinucleotide repeats

D. Monosomy

Correct Answer: A. Imprinting

■ *Listen (English)*

■ *Listen (Hindi)*

Explanation: The given clinical scenario likely describes Angelman syndrome. Classical symptom of Angelman syndrome: Happy puppet syndrome (inappropriate laughter). 2 main disorders of genomic imprinting: Angelman syndrome (AS): Paternal 15q11-q13 region is imprinted, while the maternal region is deleted Prader-Willi syndrome (PWS): Paternal deletion and maternal imprinting on chromosome 15. Feature Angelman Syndrome Prader-Willi Syndrome Genetic Cause Loss of maternal UBE3A expression (deletion 70%, UPD 3-7%, mutation 10%, imprinting defect 3%) Loss of paternal genes (e.g., SNORD116) (deletion 65-75%, maternal UPD 20-30%, imprinting defect 1-3%) Intellectual Disability Severe/profound; absent speech Mild-moderate; speech delay Behavior Happy demeanor, frequent laughter, hand-flapping, hyperactivity Hyperphagia, temper tantrums, obsessive-compulsive, skin picking Motor Issues Ataxia, jerky gait, tremulous movements Neonatal hypotonia; later normal gait Feeding Poor suck in infancy Poor suck in infancy → hyperphagia/obesity after age 2 Seizures Common (>80%, onset <3 years) Rare■ Physical Features Microcephaly, wide mouth, protruding tongue Short stature, small hands/feet, almond eyes Other Sleep disturbance, hypopigmentation Hypogonadism, scoliosis Other important genomic imprinting syndromes: Disorder Chromosome Imprinting Error Primary Features Beckwith-Wiedemann Syndrome (BWS) 11p15.5 Over-expression of paternal genes (IGF2) Overgrowth : Macrosomia (large birth size), macroglossia (large tongue), and increased risk of childhood tumors (Wilms tumor). Silver-Russell Syndrome (SRS) 11p15.5 or Chr 7 Under-expression of paternal genes (opposite of BWS) Growth restriction : Small stature, triangular face, prominent forehead, and body asymmetry. Temple Syndrome 14q32 Excess maternal contribution Low birth weight, hypotonia, early puberty, and short stature. Kagami-Ogata Syndrome 14q32 Excess paternal contribution Skeletal abnormalities (bell-shaped thorax), polyhydramnios (excess amniotic fluid), and developmental delays. Transient Neonatal Diabetes Mellitus (TNDM) 6q24 Over-expression of paternal genes Severe hyperglycemia in the first weeks of life that typically resolves within months, though it may return later. Pseudohypoparathyroidism (Type 1a) 20q13 Loss of maternal expression (GNAS gene) Resistance to parathyroid hormone, short stature, and round face (Albright hereditary osteodystrophy).

References:

Robbins and Cotrans Pathological Basis of Diseases, 10th Edition, Page 178.

↑ *Back to this question in Part A*

@Neet_pg_bot

Q15: A 25-year-old male presents with brief, abrupt, involuntary movements of his arms and face for the last 2 months. A history of Huntington's disease in his father, who was diagnosed at 40 years of age and passed away at the age of 50, is found. What is the mechanism behind this patient's earlier presentation? (Q845119)

A. Anticipation

B. Mosaicism

C. Imprinting

D. Non-penetrance

Correct Answer: A. Anticipation

■ *Listen (English)*

■ *Listen (Hindi)*

Explanation: HD is a CAG trinucleotide repeat disorder, seen in the axon region of a gene present on chromosome 4. HD is characterised by the Anticipation/Sherman Paradox. The number of repeats increases with every generation, leading to early and more severe presentation in the next generation. HD features psychiatric disturbances and choreoathetosis early on, with cognitive disturbance and death later. Examples of diseases showing anticipation include: Autosomal Dominant Autosomal Recessive Multiple spinocerebellar ataxias Huntington's disease – CAG repeats Myotonic dystrophy – CTG Congenital dyskeratosis – TTAGGG (telomere repeating sequence) Friedreich's ataxia – GAA X-linked Fragile X Syndrome – CGG Others Crohn's disease Behcet's disease Mosaicism (Option B) refers to the presence of multiple genetically different cell lines in the same individual. Imprinting (Option C) refers to a gene silencing. Non-penetrance (Option D): It means that the Gene is received from parents but no symptoms are seen in patient.

References:

https://www.uptodate.com/contents/huntington-disease-clinical-features-and-diagnosis

↑ *Back to this question in Part A*

@Neet_pg_bot

Q16: Match the following Disease Trinucleotide repeats a. Fragile X syndrome 1. CAG b. Friedreich ataxia 2. CTG c. Myotonic dystrophy 3. GAA d. Huntington disease 4. CGG (Q845118)

A. a-2, b-1, c-4, d-3

B. a-4, b-3, c-2, d-1

C. a-3, b-2, c-1, d-4

D. a-4, b-1, c-3, d-2

Correct Answer: B. a-4, b-3, c-2, d-1

■ *Listen (English)*

■ *Listen (Hindi)*

Explanation: The below-mentioned disorders are trinucleotide repeat disorders where there is excessive repetition of trinucleotides. In Introns/ Non coding region: Fragile X syndrome - CGG Friedreich ataxia - GAA Myotonic dystrophy -CTG In Exons/ Coding region: Huntington's disease - CAG (Mnemonic- Hunter in a Cage) Fragile X Syndrome (CGG): Inheritance: X-linked dominant; it is the most common cause of inherited intellectual disability. Clinical Scenario: Look for a male child with a long face, large everted ears , and macroorchidism (enlarged testes) post-puberty. Pathophysiology: Caused by hypermethylation of the FMR1 gene, which silences its expression. Friedreich Ataxia (GAA): Inheritance: Autosomal recessive. Clinical Scenario: An adolescent presenting with progressive ataxia, loss of vibratory sense/proprioception , and muscle weakness . Systemic Involvement: Frequently associated with Hypertrophic Cardiomyopathy (the most common cause of death) and Diabetes Mellitus . Pathophysiology: Repeat expansion in the FXN gene leads to decreased frataxin , causing mitochondrial dysfunction. Myotonic Dystrophy Type 1 (CTG): Inheritance: Autosomal dominant; exhibits anticipation (symptoms become more severe/earlier in successive generations). Clinical Scenario: An adult with myotonia (difficulty releasing grip after a handshake), frontal balding , cataracts , and gonadal atrophy . Pathophysiology: Expansion in the DMPK gene leads to abnormal RNA processing. Huntington Disease (CAG): Inheritance: Autosomal dominant with 100% penetrance; also shows anticipation (primarily via paternal transmission). Clinical Scenario: A middle-aged patient (30–50 years) presenting with chorea (involuntary jerky movements), aggression, depression, and progressive dementia. Neuroimaging: Classically shows atrophy of the caudate nucleus and putamen, leading to "boxcar ventricles."

References:

Robbins and Cotrans Pathological Basis of diseases, 10th Edition, Page 174

↑ *Back to this question in Part A*

@Neet_pg_bot

Q17: Which of the following does not show the same pattern of inheritance as Leber hereditary optic neuropathy? (Q845117)

A. MERRF

B. MELAS

C. Fragile-X syndrome

D. NARP

Correct Answer: C. Fragile-X syndrome

■ *Listen (English)*

■ *Listen (Hindi)*

Explanation: Fragile-X syndrome shows X-linked Recessive > X-linked dominant inheritance. Leber hereditary optic neuropathy (LHON) is characterized by permanent loss of vision in young men due to progressive, bilateral optic neuropathy. LHON demonstrates mitochondrial inheritance. Some other examples of mitochondrial inheritance disorders are: Chronic progressive external ophthalmoplegia (CPEO)/ Kearns-Sayre syndrome (KSS) Leigh syndrome Mitochondrial encephalomyopathy with lactic acidosis and stroke-like episodes (MELAS) (Option B ruled out) Myoclonic epilepsy with ragged red fibers (MERRF) (Option A ruled out) Neuropathy, ataxia, and retinitis pigmentosa (NARP) (Option D ruled out) Primary coenzyme Q10 (CoQ10) deficiency

References:

https://www.uptodate.com/contents/mitochondrial-myopathies-clinical-features-and-diagnosis

↑ *Back to this question in Part A*

@Neet_pg_bot

Q18: What is the most likely diagnosis of a 5-year-old child with hyperphagia, delayed milestones, and growth retardation? (Q845116)

A. Angelman syndrome

B. Prader-Willi syndrome

C. Fragile X syndrome

D. Patau syndrome

Correct Answer: B. Prader-Willi syndrome

■ *Listen (English)*

■ *Listen (Hindi)*

Explanation:

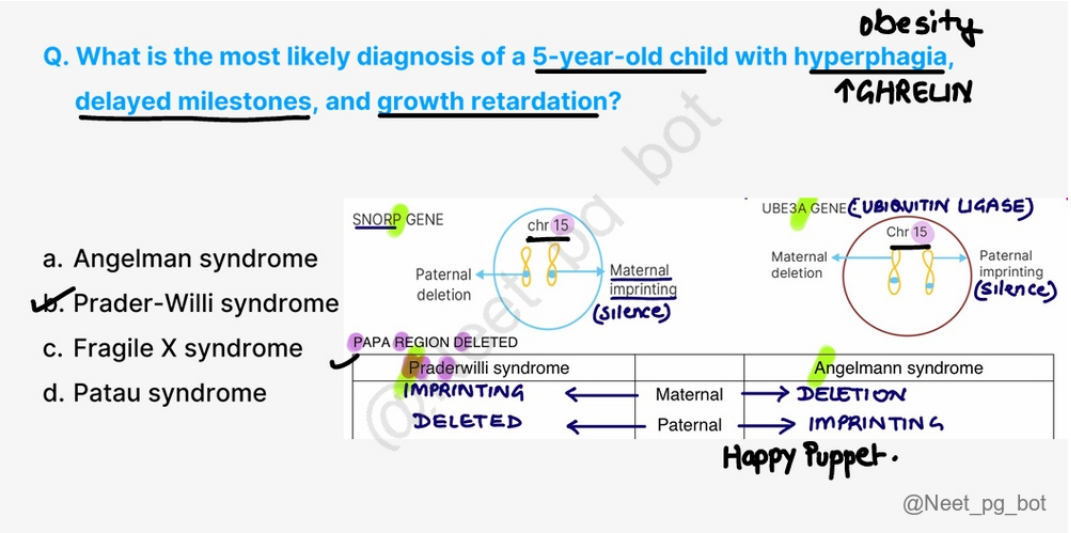

References:

https://www.uptodate.com/contents/prader-willi-syndrome-clinical-features-and-diagnosis

↑ *Back to this question in Part A*

@Neet_pg_bot

• [03_Genetics] 012 Diagnosis Of Genetic Disorders And Miscellaneous

« Back to Folder Directory

[03_Genetics] 012 Diagnosis Of Genetic Disorders And Miscellaneous — Quick Jump

Q1 (p. 1224) *Q2 (p. 1225)* *Q3 (p. 1225)* *Q4 (p. 1226)* *Q5 (p. 1229)* *Q6 (p. 1231)*
Q7 (p. 1232) *Q8 (p. 1233)* *Q9 (p. 1234)* *Q10 (p. 1235)* *Q11 (p. 1236)* *Q12 (p. 1239)*
Q13 (p. 1240) *Q14 (p. 1241)* *Q15 (p. 1242)* *Q16 (p. 1242)* *Q17 (p. 1244)* *Q18 (p. 1246)*
Q19 (p. 1247)

Q1: Which of the following chromosomal aberrations results in a change in the amount of genetic material? (Q879652)

A. Balanced reciprocal translocation

B. Inversion

C. Deletion

D. Paracentric inversion

Correct Answer: C. Deletion

Explanation: Aberrations involving changes in genetic material: Deletion – Loss of a chromosome segment. Can be: Interstitial: Between two breaks → loss of material. Terminal: Single break → fragment lost. Effect: Usually abnormal phenotype due to missing genes. Ring chromosome – Breaks at both ends and fusion; loss of genetic material may occur → abnormal phenotype. Isochromosome – Loss of one arm and duplication of the other → monosomy for lost arm genes and trisomy for duplicated arm genes. Trisomy / Monosomy – Numerical change in chromosomes → gain or loss of genetic material. Incorrect Options: Balanced reciprocal translocation (Option A) : No loss or gain of genetic material - just exchange of segments between nonhomologous chromosomes. Inversion (Option B) : A chromosome segment is reversed end to end, but no genetic material is gained or lost. Paracentric inversion (Option D) : Involves inversion of a segment not including the centromere - no change in total genetic content.

References:

Robbins, Cotran & Kumar Pathologic Basis of Disease, 11th Edition, Page. 145-146

↑ *Back to this question in Part A*

@Neet_pg_bot

Q2: Which of the following chromosomal aberrations and mechanisms is correctly matched? (Q879646)

A. Trisomy – caused by deletion of a chromosome segment.

B. Balanced reciprocal translocation – inversion of a chromosome segment without change in gene copy number.

C. Isochromosome formation – fusion of chromosome ends after breaks.

D. Ring chromosome – breaks at both ends of a chromosome with fusion of the damaged ends.

Correct Answer: D. Ring chromosome – breaks at both ends of a chromosome with fusion of the damaged ends.

Explanation: A ring chromosome occurs when breaks happen at both ends of a chromosome and the broken ends fuse, often resulting in phenotypic abnormalities. Incorrect Options: Trisomy (Option A): Caused by nondisjunction, not deletion Balanced reciprocal translocation (Option B): Exchange of segments without loss, not inversion. Isochromosome formation (Option C): Loss of one arm and duplication of the other, not fusion of ends.

References:

Robbins, Cotran & Kumar Pathologic Basis of Disease, 11th Edition, Page. 145-146

↑ *Back to this question in Part A*

@Neet_pg_bot

Q3: In cytogenetic notation, what does Xp21.2 represent? (Q879644)

A. Long arm of the X chromosome, region 21, band 1, sub-band 2

B. Short arm of the X chromosome, region 2, band 1, sub-band 2

C. Short arm of the X chromosome, region 21, band 2, sub-band 1

D. Long arm of the X chromosome, region 1, band 2, sub-band 1

Correct Answer: B. Short arm of the X chromosome, region 2, band 1, sub-band 2

Explanation: Chromosome arms: p = short arm (petit), q = long arm. Numbering system: Regions are numbered outward from the centromere (1, 2, 3…). Bands and sub-bands: Each region is divided into bands → further subdivided into sub-bands. Example: Xp21.2 = X chromosome, short arm, region 2, band 1, sub-band 2.

References:

Robbins, Cotran & Kumar Pathologic Basis of Disease, 11th Edition, Page. 144-145

↑ *Back to this question in Part A*

@Neet_pg_bot

Q4: A 35-year-old pregnant woman presents for prenatal screening due to advanced maternal age. She undergoes amniocentesis, and chromosome analysis is performed on the fetal cells to assess for chromosomal abnormalities . The results indicate Down syndrome. From the below chromosomal analysis, which of the following results is most likely associated with this case? (Q845185)

Correct Answer: Unknown

■ *Listen (English)*

■ *Listen (Hindi)*

Explanation: B demonstrates the result as trisomy of chromosome 21, as along with two normal chromosomes, one extra chromosome is present, indicating trisomy 21 or Down’s syndrome as a diagnosis. TRISOMY 21: DOWN SYNDROME Karyotypes: Trisomy 21 type: 47,XX, +21 Translocation type: 46,XX,der(14;21)(q10;q10),+21 Mosaic type: 46,XX/47,XX, +21 The given image represents a normal karyotype. (Option A): The given image represents trisomy 18 – Edward syndrome (Option C) The given image represents two X chromosomes and one Y chromosome – Klinefelter’s syndrome (Option D)

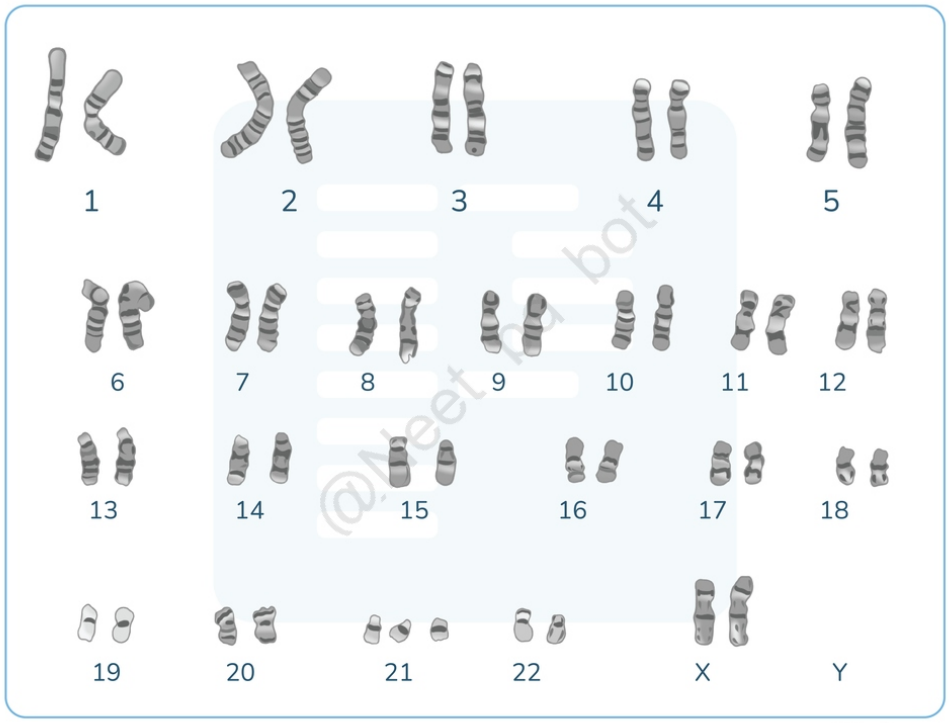

@Neet_pg_bot

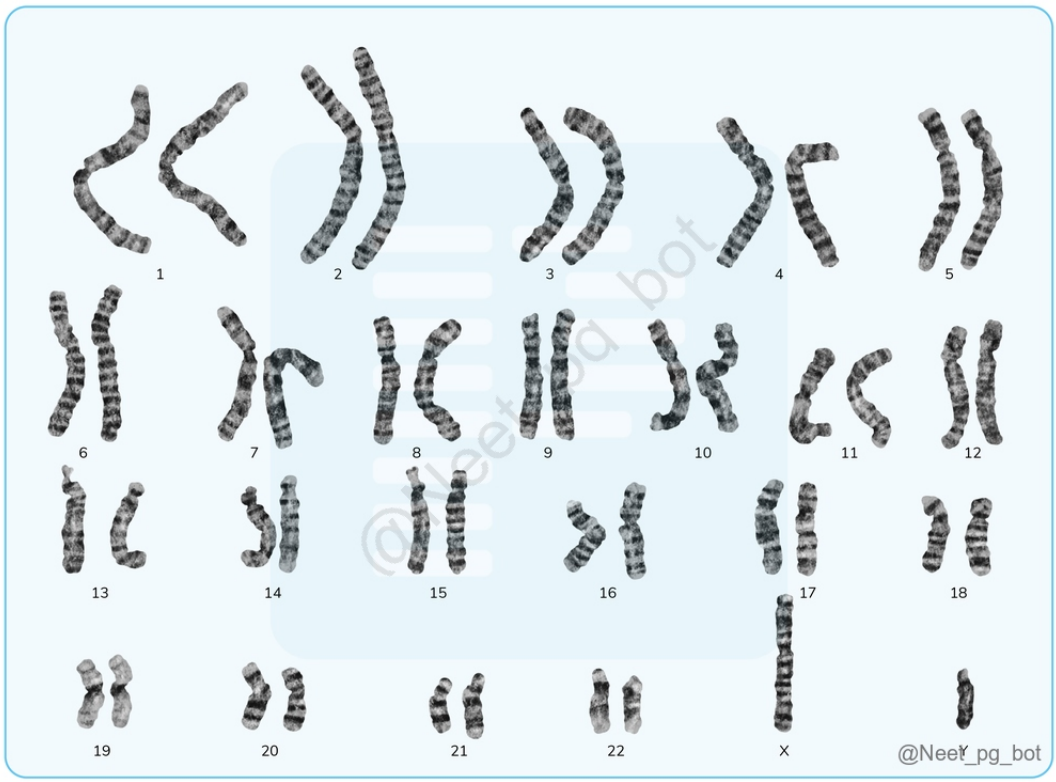

@Neet_pg_bot



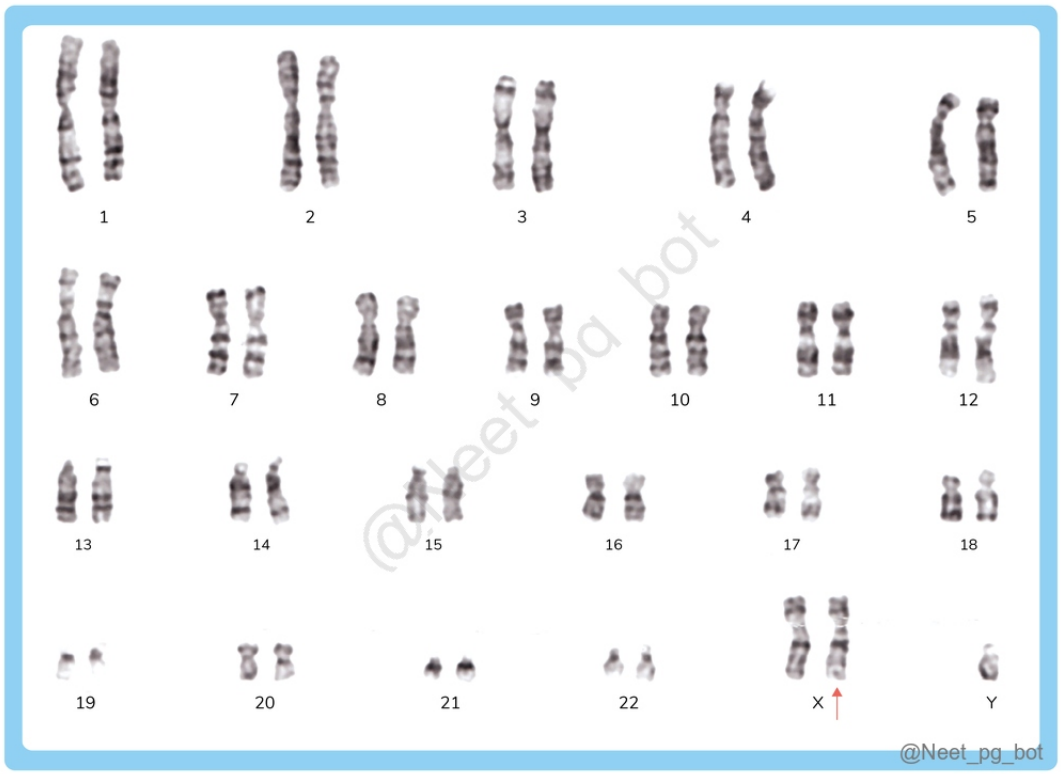

References:

Robbins and Cotran, Pathologic Basis of Disease, 10th edition, Page no.164,168

↑ *Back to this question in Part A*

@Neet_pg_bot

Q5: Arrange the following steps of karyotyping in the correct sequence: Staining/Banding Sample collection Fixative Arrangement of chromosomes Arrest Interpretation (Q847860)

A. 2, 5, 3, 1, 4, 6

B. 2, 3, 5, 1, 4, 6

C. 1, 2, 3, 5, 4, 6

D. 3, 5, 2, 4, 1, 6

Correct Answer: A. 2, 5, 3, 1, 4, 6

- *Listen (English)*
- *Listen (Hindi)*

Explanation: Karyotyping is the study of chromosomes. Sample collection: Patient type Sample type Pregnant woman Amniocentesis Chorionic villous sampling 10 year old boy Lymphocyte blood sample (preferred) Fibroblast skin sample 2.Arrest: It is carried out in metaphase using colchicine. 3.Fixative: Using Carnoy fixative (Methanol: Glacial acetic acid in 3:1 ratio) 4.Staining/ Banding: Chromosome has dark (AT nucleotides rich) and light (CG nucleotides rich) bands. 5.Arrangement of Chromosomes: According to length in descending order. Shortest chromosome is chromosome 21. 6. Interpretations: Trisomy 21 (Down’s syndrome) Trisomy 18 (Edwards syndrome) 47 XXY (Klinefelter syndrome)

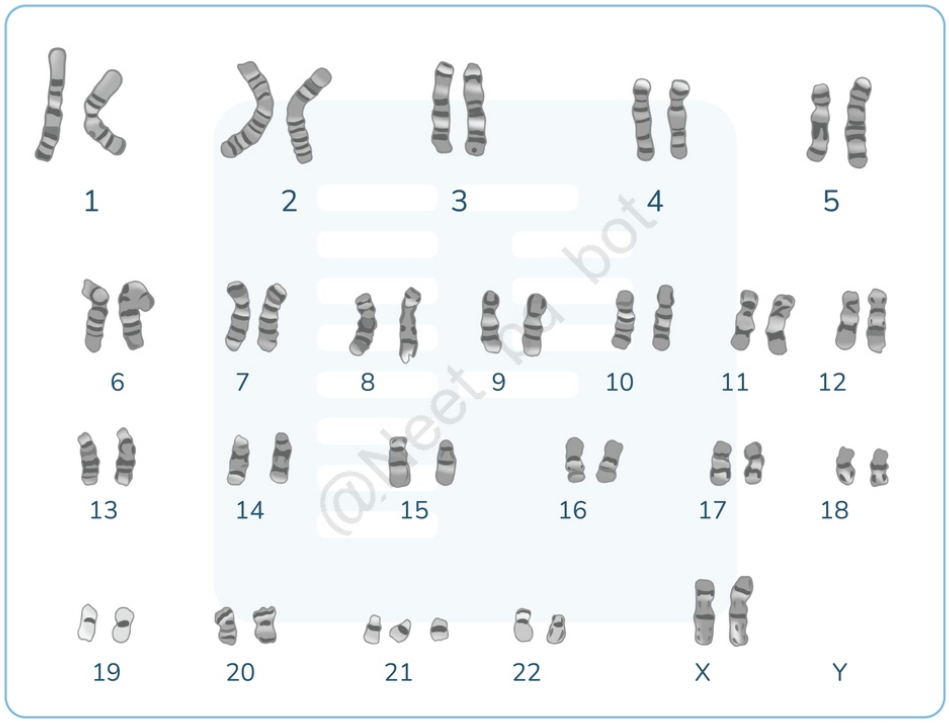

@Neet_pg_bot



@Neet_pg_bot

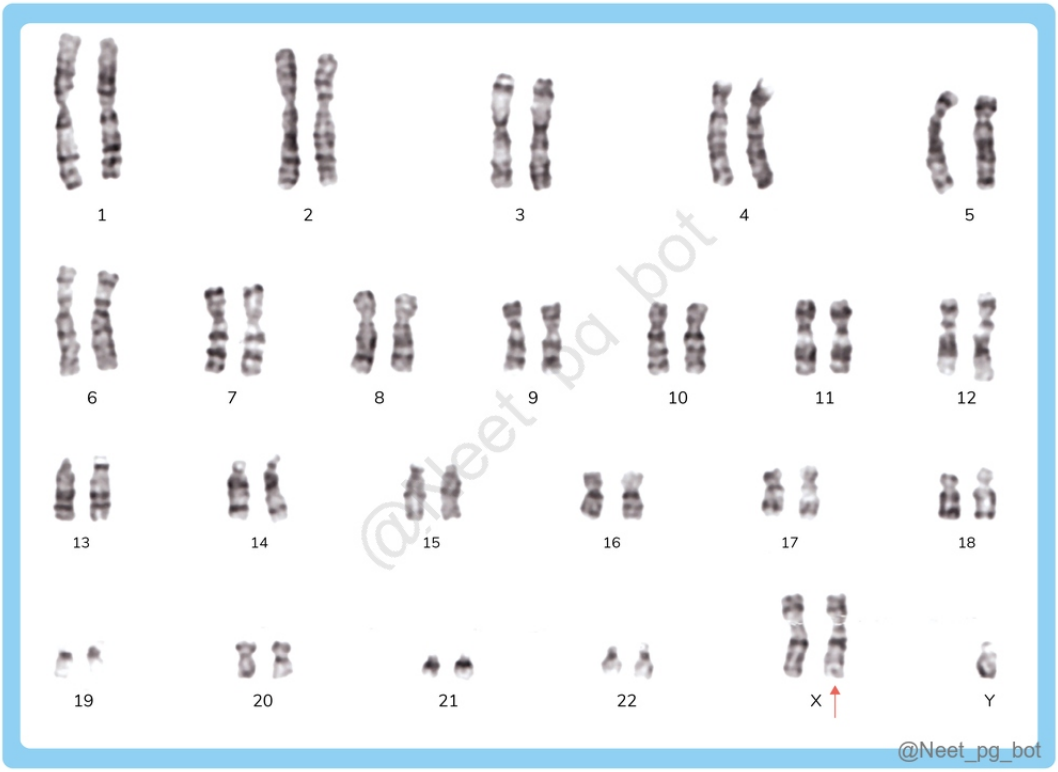

References:

Robbins and Cotran, Pathologic Basis of Disease, 10th Edition, Pages 163,164, 165.

↑ *Back to this question in Part A*

@Neet_pg_bot

Q6: A researcher wants to analyze gene expression levels in a sample using a PCR technique that quantifies the amount of DNA produced after each amplification cycle. Which type of PCR is most suitable for this purpose? (Q845190)

A. Real-time PCR

B. Nested PCR

C. Reverse Transcription PCR (RT-PCR)

D. Multiplex PCR

Correct Answer: A. Real-time PCR

■ *Listen (English)*

■ *Listen (Hindi)*

Explanation: DNA amplification is measured after each cycle using fluorescent dyes or probes Can quantify initial template levels, making it ideal for gene expression analysis. When combined with RT-qPCR, it quantifies mRNA expression accurately Types of PCR: Type of PCR Characteristics Real-time PCR (qPCR) (Option A) Quantitative measurement of DNA amplification in real-time. Allows for gene expression analysis, viral load determination, and quantitative DNA/RNA analysis. Nested PCR (Option B) Two rounds of PCR amplification using two sets of primers. Improves specificity and sensitivity compared to conventional PCR. PCR (RT-PCR) (Option C) Enables gene expression analysis by amplifying RNA targets. Multiplex PCR (Option D) Simultaneous amplification of multiple DNA targets in a single reaction. Reduces time and cost by amplifying multiple targets together. Highly accurate for determining gene expression levels, viral load, and copy number variations. Digital PCR Divides the sample into thousands of individual reactions, allowing for absolute quantification of DNA targets. Provides high precision and sensitivity for rare target detection. Used in rare allele detection, copy number variation analysis, and precise quantification of nucleic acids. Hot Start PCR Minimizes non-specific amplification and primer-dimer formation by activating the DNA polymerase after an initial denaturation step. Prevents background noise and false-positive results. Polymerase Chain Reaction (PCR) involves three main steps: Denaturation , where the DNA double-strand separates into two single strands at 94 degrees Celsius. Annealing , where primers bind to the target DNA sequence at 54 degrees Celsius. Amplification , where DNA polymerase extends the primers to replicate the target sequence at 72 degrees Celsius. Ligation, which is the process of joining DNA fragments together, is not a step in PCR. Multiplex Ligation-dependent Probe Amplification in which ligation is done Key Components of PCR: DNA Template: The sample containing the target sequence. Primers: Two short, synthetic DNA fragments that flank the region to be amplified. Enzyme (DNA Polymerase): Most commonly Taq Polymerase , derived from the bacterium Thermus aquaticus . It is used because it is thermostable and does not denature at high temperatures. dNTPs: Deoxynucleotide triphosphates (A, T, C, G), the building blocks for the new DNA. Buffer & Mg^{2}■: Magnesium ions act as a necessary cofactor for DNA polymerase activity. Low Mg → Poor yield (no cofactor) High Mg → Nonspecific (stabilizes mismatches) Optimal = 1.5-2.5 mM

References:

Robbins and Cotran, Pathologic Basis of Disease, 10th edition, Page no. 181

↑ *Back to this question in Part A*

@Neet_pg_bot

Q7: A 35-year-old female undergoes genetic testing due to a family history of Cystic Fibrosis. The test reveals a suspected deletion in the CFTR gene. Which technique is most suitable for confirming large deletions or duplications in the CFTR gene? (Q845189)

A. Polymerase Chain Reaction (PCR)

B. Comparative Genomic Hybridization (CGH)

C. Multiplex Ligation Dependent Probe Amplification (MLPA)

D. Sanger sequencing

Correct Answer: C. Multiplex Ligation Dependent Probe Amplification (MLPA)

■ *Listen (English)*

■ *Listen (Hindi)*

Explanation: While PCR and Sanger sequencing are excellent for detecting small point mutations, they often fail to detect large heterozygous deletions or duplications (copy number variations). MLPA is the gold standard for this purpose. Multiplex Ligation Dependent Probe Amplification (MLPA) (Option C): Best for: Detecting copy number variations (CNVs) such as large deletions or duplications in a single gene (like CFTR , DMD , or BRCA1). Mechanism: Two probes hybridize to adjacent target DNA sequences. They are then ligated together and amplified. The amount of amplified product is proportional to the number of target DNA copies present. Key Advantage: Can analyze up to 50 different genomic DNA sequences in a single reaction. Polymerase Chain Reaction (PCR) (Option A): Best for: Detecting small deletions, insertions, or counting trinucleotide repeats (e.g., Fragile X). Limitation: Standard PCR may miss a large deletion on one chromosome because the primer will still amplify the "normal" allele on the other chromosome, masking the loss. Enzyme: Uses Taq Polymerase , a thermostable enzyme. Comparative Genomic Hybridization (CGH) (Option B): Best for: Detecting large chromosomal imbalances (deletions/duplications) across the entire genome . Limitation: It is generally used for whole-genome screening rather than specific, high-resolution analysis of a single gene like CFTR unless an array-CGH is specifically designed for it. Sanger Sequencing (Option D): Best for: Identifying point mutations (single nucleotide changes) and very small indels. Limitation: Like PCR, it cannot accurately quantify the number of gene copies, making it unreliable for detecting large heterozygous deletions. Technique Primary Use Case Sanger Sequencing "Gold standard" for point mutations . PCR Amplifying DNA; detecting repeat expansions . MLPA Detecting large deletions/duplications in specific genes. Southern Blot Detecting large expansions or structural changes if PCR fails. Microarray (CGH) Screening the whole genome for gains/losses.

References:

Robbins and Cotran, Pathologic Basis of Disease, 10th edition, Page no. Page 181

↑ *Back to this question in Part A*

@Neet_pg_bot

Q8: Which technique is specifically designed to detect copy number variations (CNVs) in the genome by comparing patient DNA with a reference DNA sample? (Q845188)

A. PCR

B. Comparative Genomic Hybridization (CGH)

C. DNA sequencing

D. Southern blotting

Correct Answer: B. Comparative Genomic Hybridization (CGH)

Explanation: Comparative Genomic Hybridization (CGH) is a molecular cytogenetic technique used to detect copy number variations (CNVs) in the genome, including microdeletions and microduplications. It involves comparing the patient's DNA with a reference DNA sample, often labelled with different fluorescent dyes, to identify gains or losses of genetic material. Schematic for Comparative Genomic Hybridization : Uses of Comparative Genomic Hybridization: Detection of Copy Number Variations (CNVs) : Identifies gains and losses of DNA segments. Diagnosis of Genetic Disorders : Detects chromosomal abnormalities (e.g., microdeletions, microduplications) linked to developmental and congenital disorders (e.g., Williams, DiGeorge syndrome). Cancer Genomics : Identifies chromosomal imbalances in cancer cells, including gene amplifications or deletions (e.g., in breast cancer, and gliomas). Prenatal Screening : Detects chromosomal abnormalities in fetuses, such as Down syndrome and other congenital defects. Assessment of Structural Variations : Identifies larger structural changes (e.g., duplications, deletions, inversions, translocations). Neurodevelopmental Disorders : Identifies CNVs linked to conditions like autism spectrum disorders. Genomic Research : Provides insights into the genetic basis of diseases by identifying recurrent CNVs in patient populations. Personalized Medicine : Identifies genetic alterations that guide targeted therapies, particularly in cancer. PCR: Polymerase Chain Reaction (PCR) is used for amplifying specific DNA sequences and is not specifically designed to detect CNVs. (Option A) DNA sequencing: DNA sequencing is used to determine the precise order of nucleotides in a DNA molecule and is not primarily focused on detecting CNVs. (Option C) Southern blotting: Southern blotting is a technique used to detect specific DNA sequences, often related to gene expression or mutations, but it is not tailored for CNV detection. (Option D)

References:

Robbins and Cotran, Pathologic Basis of Disease, 10th edition, Page no. 181

↑ *Back to this question in Part A*

@Neet_pg_bot

Q9: Which steps are NOT involved in the Polymerase Chain Reaction (PCR) process? (Q845187)

A. Denaturation

B. Annealing

C. Amplification

D. Ligation

Correct Answer: D. Ligation

■ *Listen (English)*

■ *Listen (Hindi)*

Explanation: Polymerase Chain Reaction (PCR) involves three main steps: Denaturation , where the DNA double-strand separates into two single strands at 94 degrees Celsius. Annealing , where primers bind to the target DNA sequence at 54 degrees Celsius. Amplification , where DNA polymerase extends the primers to replicate the target sequence at 72 degrees Celsius. Ligation, which is the process of joining DNA fragments together, is not a

step in PCR. Multiplex Ligation-dependent Probe Amplification in which ligation is done Key Components of PCR: DNA Template: The sample containing the target sequence. Primers: Two short, synthetic DNA fragments that flank the region to be amplified. Enzyme (DNA Polymerase): Most commonly Taq Polymerase , derived from the bacterium Thermus aquaticus . It is used because it is thermostable and does not denature at high temperatures. dNTPs: Deoxynucleotide triphosphates (A, T, C, G), the building blocks for the new DNA. Buffer & Mg^{2}■: Magnesium ions act as a necessary cofactor for DNA polymerase activity. Low Mg → Poor yield (no cofactor) High Mg → Nonspecific (stabilizes mismatches) Optimal = 1.5-2.5 mM PCR Types: Type Purpose Clinical Application Reverse Transcriptase (RT-PCR) Uses RNA as a template to create cDNA before amplification. Detecting RNA viruses (e.g., HIV, SARS-CoV-2). Real-Time PCR (qPCR) Measures DNA amplification in real-time using fluorescent dyes. Quantifying "viral load" or gene expression levels. Nested PCR Uses two sets of primers in two successive runs. Increases sensitivity and specificity for low-abundance DNA. Multiplex PCR Uses multiple primer sets in a single reaction tube. Screening for multiple pathogens or mutations at once. Digital PCR (dPCR) Partitions the sample into thousands of droplets for absolute quantification. Detecting rare mutations or "liquid biopsies" in cancer.

References:

Robbins and Cotran, Pathologic Basis of Disease, 10th edition, Page no.181

↑ *Back to this question in Part A*

@Neet_pg_bot

Q10: In a cytogenetics laboratory, a technician is tasked with preparing chromosomes obtained from a patient's blood sample for analysis under a light microscope. The patient has been experiencing unexplained developmental delays, and the physician suspects a potential chromosomal abnormality. To aid in the identification and analysis of individual chromosomes, which technique will the technician employ to produce distinct banding patterns? (Q845186)

A. G-banding

B. C-banding

C. Q-banding

D. R-banding

Correct Answer: A. G-banding

■ *Listen to Audio 1*

Explanation: G-banding involves staining chromosomes with Giemsa dye, which results in characteristic dark and light bands along the length of each chromosome. G-banding is the most widely used cytogenetic technique to visualize distinct banding patterns on chromosomes. It helps in: Identifying individual chromosomes Detecting structural abnormalities (e.g., deletions, duplications, translocations) Diagnosing chromosomal disorders linked to

developmental delays It allows karyotyping with high accuracy. Each chromosome has a unique banding pattern , making it easier to detect abnormalities like trisomy, deletions, or rearrangements Karyotyping: Step-by-Step Process: Cell Collection: Usually performed using peripheral blood (T-lymphocytes) , but can also use skin fibroblasts, amniotic fluid, or bone marrow. Stimulation: Cells are stimulated to divide using a mitogen , most commonly Phytohemagglutinin (PHA) . Arrest: Cells are arrested in Metaphase using Colchicine or Colcemid. Mechanism: Colchicine inhibits microtubule polymerization (spindle fiber formation), preventing the cell from moving past metaphase where chromosomes are most condensed. Hypotonic Treatment: Cells are placed in a hypotonic solution (typically $0.075 M$ KCl). Purpose: This causes the cells to swell, which spreads the chromosomes apart so they don't overlap on the slide. Fixation: The "fixative" used is Carnoy's Fixative , which is a 3:1 mixture of Methanol and Glacial Acetic Acid . Staining: The slides are prepared and stained, most commonly with G-banding (Giemsa) . C-banding (Option B) selectively stains the centromeric regions Q-banding (Option C) also known as quinacrine staining, involves staining chromosomes with quinacrine mustard, which fluoresces under ultraviolet light R-banding (Option D) or reverse banding, is the reverse of G-banding . it produces light bands where G-banding shows dark, and vice versa.

References:

Robbins and Cotran, Pathologic Basis of Disease, 10th edition, Page no.164,165

↑ *Back to this question in Part A*

@Neet_pg_bot

Q11: In a community where consanguineous marriages are prevalent, a distant relative couple decide to get married. They later have a child who presents with symptoms of anaemia and requires regular blood transfusions. Further investigation reveals that the child has beta-thalassemia, a genetic disorder prevalent in the region. Which of the following symbols can be anticipated in this couple, which is a risk factor for this disease? (Q845176)

A. A

B. B

C. C

D. D

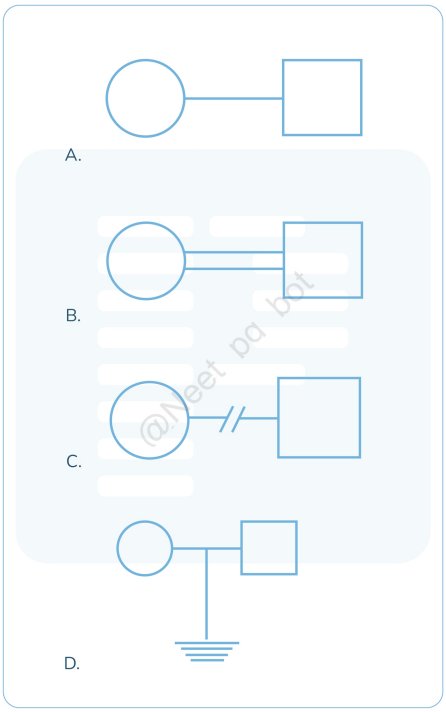

@Neet_pg_bot

Correct Answer: B. B

- *Listen (English)*
- *Listen (Hindi)*

Explanation: Consanguineous marriages (marriages between relatives) increase the risk of their children developing genetic (autosomal recessive) disorders. This symbol represents this risk in the pedigree chart. The symbols used in the pedigree chart:

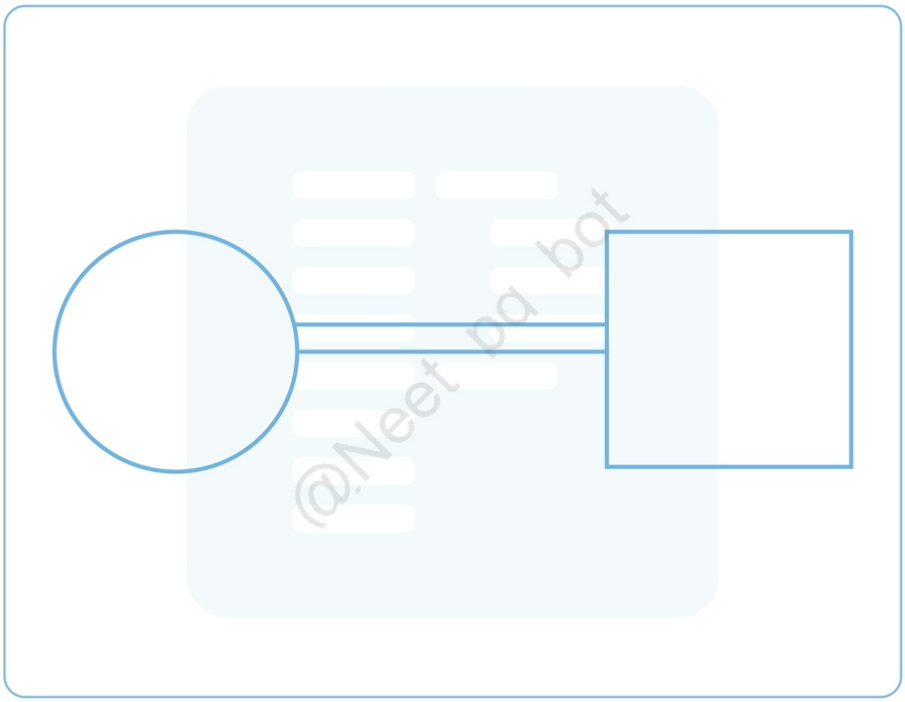

@Neet_pg_bot

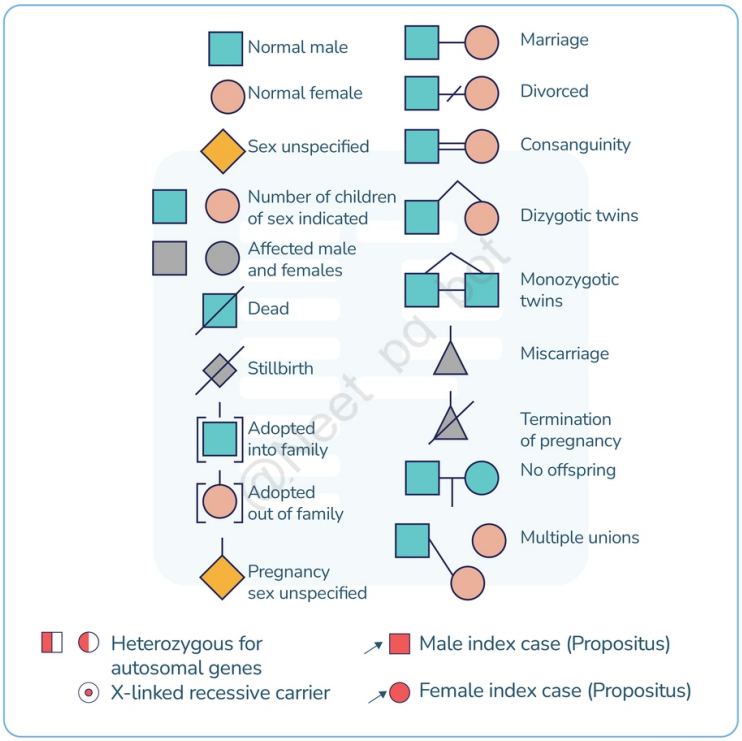

@Neet_pg_bot

References:

Vishram Singh Textbook of Clinical Embryology, 2nd edition, Page no. 328

Inderbir Singh’s Human Embryology, 11th edition, Page no. 16

Robbins and Cotran, Pathologic Basis of Disease, 10th edition, Page no. 145

↑ *Back to this question in Part A*

@Neet_pg_bot

Q12: A 45-year-old woman has been newly diagnosed with breast cancer. Histopathological analysis of the tumour reveals invasive ductal carcinoma. Given the aggressive nature of her tumour, the oncologist wants to determine if the patient's cancer is HER2-positive. Which diagnostic method is most appropriate for detecting HER2/neu amplification in this patient? (Q845184)

A. Immunohistochemistry (IHC)

B. Fluorescence In Situ Hybridization (FISH)

C. Polymerase Chain Reaction (PCR)

D. Western Blotting

Correct Answer: B. Fluorescence In Situ Hybridization (FISH)

■ *Listen (English)*

■ *Listen (Hindi)*

Explanation: FISH uses DNA probes that recognize sequences specific to particular chromosomal regions. In the case of HER2 testing, FISH directly visualizes HER2 gene amplification by labelling the HER2 gene with a fluorescent probe. HER2 protein overexpression is virtually always caused by amplification of the region of chromosome 17q that contains the HER2 gene. The increase in HER2 gene copy number is detected by fluorescence in situ hybridization using a HER2-specific probe (red signal), which is typically co-hybridized to tumour cell nuclei with a second probe specific for the centromeric region of chromosome 17 (green signal), allowing the chromosome 17 copy number to be determined. Scoring / Interpretation: Positive (+1 / +2 / +3 or equivocal): HER2/CEP17 ratio >2.0 → HER2 amplified → positive HER2/CEP17 ratio 1.8–2.0 → equivocal → repeat testing or IHC correlation HER2/CEP17 ratio <2.0 → negative FISH can be used for testing: Chromosomal translocations Deletions Amplifications FISH cannot detect point mutations. Immunohistochemistry (IHC): (Option A) IHC involves staining tissue samples with antibodies specific to HER2/neu protein. While widely used for HER2 testing, it does not directly measure gene amplification Polymerase Chain Reaction (PCR) (Option C) PCR amplifies DNA sequences, including the HER2 gene, from tumour samples. It can detect gene amplification but It is not commonly used for HER2 testing in breast cancer patients. Western Blotting (Option D) Western blotting detects specific proteins in a sample but does not directly measure gene amplification. It is not commonly used for HER2 testing in breast cancer patients.

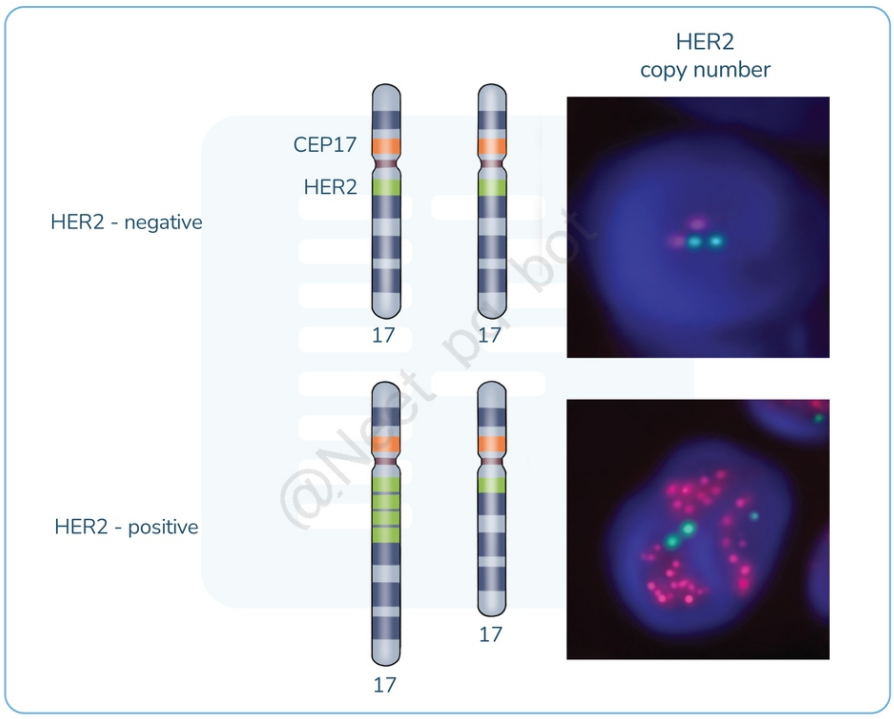

@Neet_pg_bot

References:

Robbins and Cotran, Pathologic Basis of Disease, 10th edition, Page no.183, 1052

↑ *Back to this question in Part A*

@Neet_pg_bot

Q13: Which of the following statements regarding gonadal mosaicism is true? (Q845183)

A. It is associated with autosomal recessive disorders.

B. It occurs due to a pre-zygotic mutation during early embryonic development.

C. It can be associated with osteogenesis imperfecta.

D. It follows the laws of Mendelian inheritance.

Correct Answer: C. It can be associated with osteogenesis imperfecta.

■ *Listen (English)*

■ *Listen (Hindi)*

Explanation: The true statement regarding gonadal mosaicism is that it can be associated with osteogenesis imperfecta. GONADAL MOSAICISM/GERMLINE MOSAICISM The parent's sperm and ova are genotypically normal. On the fusion of normal sperm and normal ova, a normal zygote isformed. Post Zygotic mutation results in the disease. Gonadal mosaicism can be seen in: Osteogenesis imperfecta. Tuberous sclerosis. Achondroplasia

References:

Robbins and Cotran, Pathologic Basis of Disease, 10th edition, Page no. 180

↑ *Back to this question in Part A*

@Neet_pg_bot

Q14: A 25-year-old male has been complaining of painless, progressive central vision loss in both eyes over the past few months. He reports a family history of similar visual problems, with his maternal grandfather and maternal uncle experiencing sudden vision loss in their 20s. On examination, the ophthalmologist notes bilateral optic disc pallor and central scotomas on visual field testing. The patient denies any systemic symptoms or significant medical history. What is the inheritance pattern seen in this condition? (Q845182)

Correct Answer: Unknown

■ *Listen (English)*

■ *Listen (Hindi)*

Explanation: The clinical presentation, along with the family history of sudden vision loss in multiple maternal relatives, is highly suggestive of Leber hereditary optic neuropathy (LHON) , a maternally inherited mitochondrial disorder affecting the optic nerves. Mitochondrial inheritance: A unique feature of mitochondrial DNA (mtDNA) is maternal inheritance. This peculiarity exists because ova contain numerous mitochondria within their abundant cytoplasm, whereas spermatozoa contain few, if any. Hence the mtDNA complement of the zygote is derived entirely from the ovum. Thus, mothers transmit mtDNA to all their offspring , male and female. Father does not transmit mitochondrial DNA → none of his children affected Daughters transmit the DNA to their further progeny. Most common mitochondrial disease: MELAS, Leber hereditary optic neuropathy (LHON) All generations of the family are affected in a vertical pattern with equal male and female involvement. Hence it shows autosomal dominant inheritance.(OPTION A) The mother has transmitted the defective gene to both her son and daughter. But, in the second generation, the father has transmitted the disease only to females. Hence it shows an X-linked dominant inheritance pattern.(OPTION B) The females are carriers in all generations, and only the males are affected by the disease. Hence, it shows an X-linked recessive inheritance pattern.(OPTION C)

References:

Robbins and Cotran, Pathologic Basis of Disease, 10th edition, Page no. 177,178

↑ *Back to this question in Part A*

@Neet_pg_bot

Q15: Hairy pinna is associated with which type of Mendelian inheritance? (Q845181)

A. Autosomal dominant

B. X-linked recessive

C. Mitochondrial inheritance

D. Y-linked inheritance

Correct Answer: D. Y-linked inheritance

■ *Listen (English)*

■ *Listen (Hindi)*

Explanation: Hairy pinna (hypertrichosis of pinna) is associated with Y-linked inheritance/ Holandric inheritance. Other examples: Webbed toes Porcupine man The image below shows a pedigree chart of Y-linked inheritance. Only males are affected, and transmission occurs only to the sons.

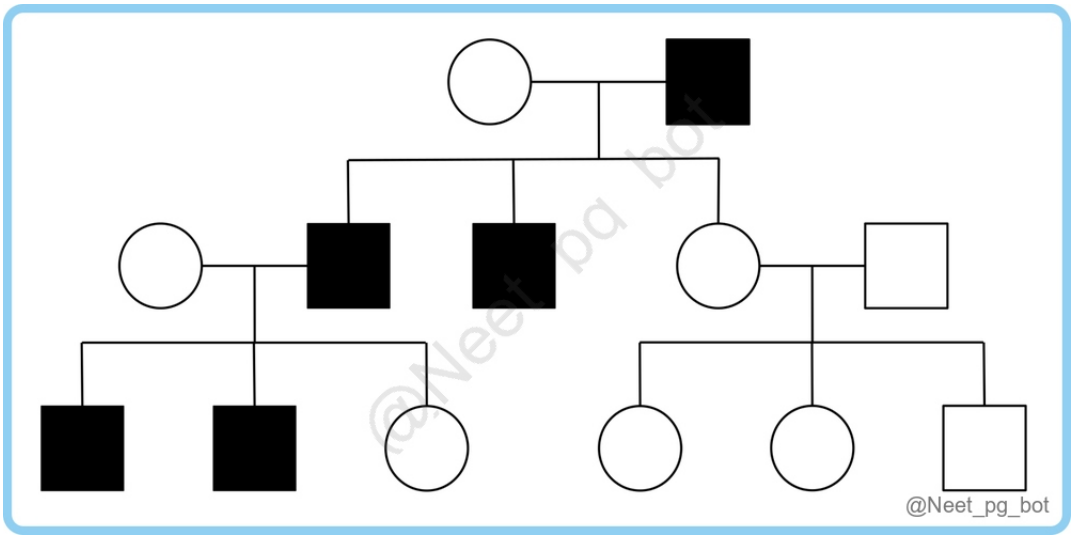

References:

Inderbir Singh's Human Embryology, 11th edition, Page no. 17,18

↑ *Back to this question in Part A*

@Neet_pg_bot

Q16: In which of the following conditions can you see this pedigree chart? (Q845180)

A. Fabry disease

B. Albinism

C. Reye syndrome

D. Alport syndrome

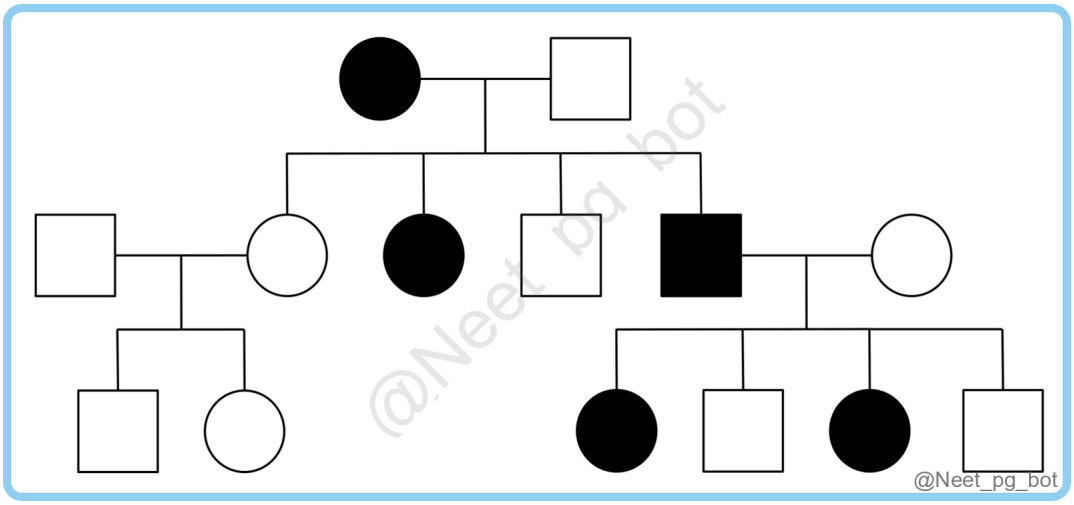

Correct Answer: D. Alport syndrome

■ *Listen (English)*

■ *Listen (Hindi)*

Explanation: An affected male will transmit the disease to all his daughters but not sons. An affected female can transmit the disease to both daughters and sons. Conditions with X-linked dominant inheritance: Rett syndrome. Alport syndrome (M/C inheritance pattern is X-linked dominant). Vitamin D-resistant rickets. Incontinentia pigmenti. Alport syndrome ■■■■■■is X-linked Dominant in inheritance. The "Can't see, can't pee, can't hear a high-C" triad: Eye: Anterior lenticonus (conical lens) and retinopathy. Renal: Progressive hereditary nephritis (hematuria, proteinuria, and renal failure). Ear: Sensorineural deafness. Pathology: Defect in Type IV Collagen (basement membrane). EM Finding: "Basket-weave" appearance of the glomerular basement membrane. Fabry's disease (Option A) is X-linked recessive in inheritance. Deficiency: α-galactosidase A. Accumulation: Ceramide trihexoside. Triad: Episodic peripheral neuropathy, angiokeratomas (reddish-purple skin spots), and hypohidrosis (decreased sweating). Late Complications: Progressive renal failure and cardiovascular disease. Albinism (Option B) is autosomal recessive in inheritance (ocular albinism: X-linked recessive) Mechanism: Deficiency of Tyrosinase or defective tyrosine transporters. Presentation: Absence of pigment in skin, hair, and eyes. Risk: Highly increased risk of skin cancers (Squamous Cell Carcinoma). Reye syndrome (Option C): Acquired/Environmental It is a rare but serious condition primarily affecting children and teenagers Mechanism: Hepatic encephalopathy and fatty liver following aspirin use during a viral infection (e.g., VZV, Influenza). Pathology: Mitochondrial damage leading to decreased β-oxidation. Key Lab: Elevated ammonia and ALT/AST with a microvesicular fatty liver.

References:

Inderbir Singh's Textbook of Anatomy, Volume 3, 6th edition, Page 500

Robbins and Cotran, Pathologic Basis of Disease, 10th disease, Page 146

↑ *Back to this question in Part A*

@Neet_pg_bot

Q17: A 6-year-old boy presents to the clinic with complaints of muscle weakness and difficulty walking. His parents report a family history of similar symptoms. A detailed history was obtained, and a pedigree analysis was done, which is shown below. What is the most likely diagnosis and the inheritance pattern seen in this condition? (Q845179)

A. Dystonia myotonica, autosomal dominant

B. Dystonia myotonica, X-linked recessive

C. Duchenne muscular dystrophy, autosomal recessive

D. Duchenne muscular dystrophy, X-linked recessive

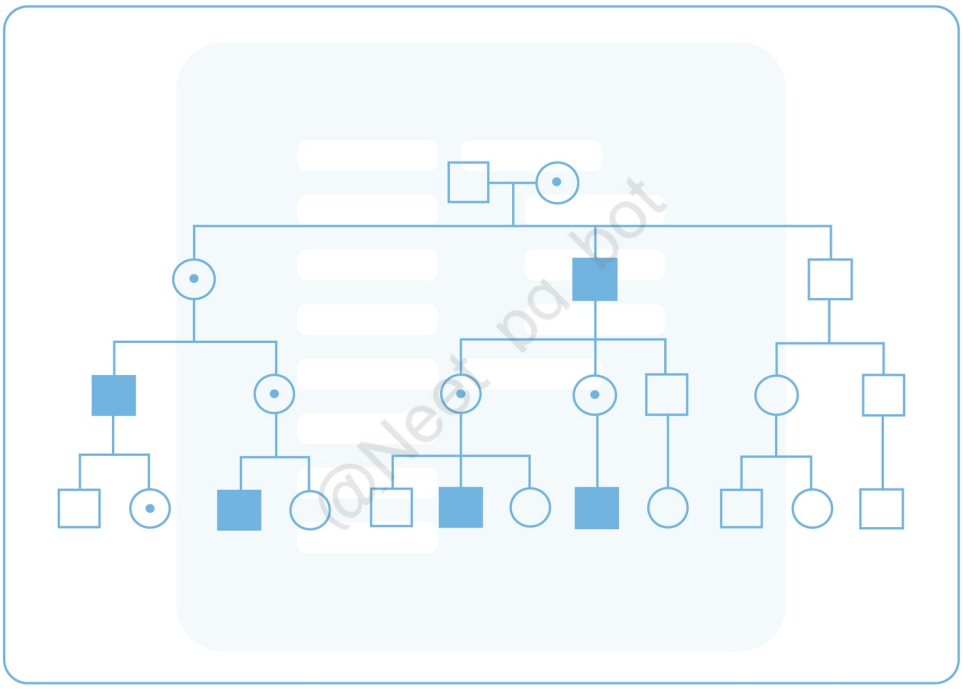

@Neet_pg_bot

Correct Answer: D. Duchenne muscular dystrophy, X-linked recessive

■ *Listen (English)*

■ *Listen (Hindi)*

Explanation: Duchenne muscular dystrophy is an X-linked recessive disease. X-linked recessive disorders: Females (XX) are carriers. Males are affected by the disease. Duchenne Muscular Dystrophy (DMD): X-linked recessive (DMD gene mutation → absent dystrophin <5%) Boys, onset 2-3years : Gowers sign , calf pseudohypertrophy , toe-walking, waddling gait Diagnosis : Genetic testing > biopsy Treatment : Steroids (prolong ambulation), exon-skipping (eteplirsen) Myotonic Dystrophy (DM1) Autosomal dominant (DMPK CTG repeat expansion) – anticipation (worse in kids) Myotonia (can't release grip), hatchet face , frontal baldness, ptosis Congenital : Hypotonia, tented mouth, respiratory failure, MR Multi-system : Cataracts, arrhythmias, diabetes, hypogonadism Diagnosis : EMG (myotonia), genetic (CTG >50) Feature DMD Myotonic Dystrophy Inheritance X-linked Recessive Autosomal Dominant Age of Onset Early Childhood (~3–5 yrs) Adulthood (~20–30 yrs) Mutation Type Frameshift (Deletion) CTG Trinucleotide Repeat Primary Sign Proximal weakness (Gower's) Myotonia (Handshake stiffness) Heart Issues Dilated Cardiomyopathy Conduction defects (Arrhythmia) Associated Signs Calf pseudohypertrophy Balding, Cataracts, Gonadal atrophy Examples of X-linked recessive disorders: Mnemonic Diseases Wise Wiskott-Aldrich syndrome AB Hemophilia A, B Ocular albinism B Bruton’s agammaglobulinemia Becker muscular dystrophy C Chronic granulomatous disease Color blindness (Red-green) D Duchenne Muscular dystrophy E Lesch Nyhan syndrome F Fabry disease Fragile-X syndrome (X-linked recessive > X-linked recessive) G G-6-PD deficiency H Hunter’s disease

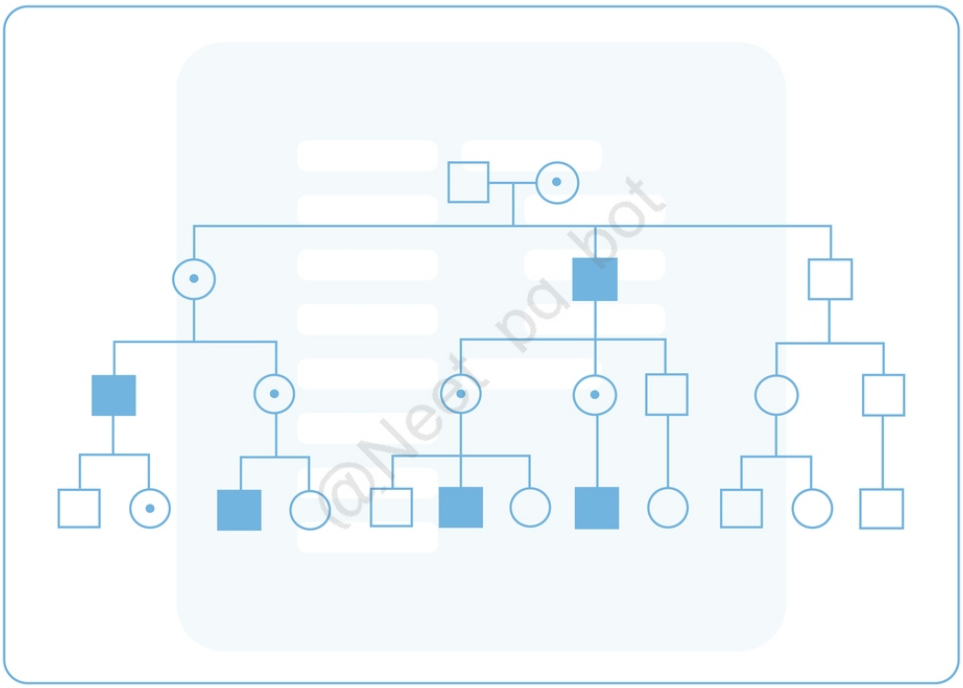

@Neet_pg_bot

References:

Inderbir Singh’s Embryology, 11th edition, Page no. 17

Robbins and Cotran, Pathologic Basis of Disease, 10th edition, Page no. 146

↑ *Back to this question in Part A*

@Neet_pg_bot

Q18: A 10-year-old boy presents to the clinic with complaints of unsteady gait and frequent falls. Upon further inquiry, it is revealed that he has experienced progressive difficulty with coordination and balance over the past few years. His parents report a similar history in his older sister, who is now 15 years old. Interestingly, the parents are both asymptomatic, but the boy's maternal uncle was diagnosed with a similar condition in his late 20s. What is the most likely inheritance pattern seen in this condition? (Q845178)

A. Autosomal Dominant

B. X linked dominant

C. X linked recessive

D. Autosomal Recessive

Correct Answer: D. Autosomal Recessive

■ *Listen (English)*

■ *Listen (Hindi)*

Explanation: The progressive difficulty with coordination and balance in both siblings, along with the maternal uncle's being affected, suggests Friedreich's ataxia, a pattern consistent with autosomal recessive inheritance. In this scenario, both parents are likely carriers of a defective gene responsible for Friedreich's ataxia, and each sibling has inherited two copies of the defective gene , resulting in the development of this disorder. Friedrich Ataxia (FRDA): It is an autosomal recessive trinucleotide repeat disorder that causes progressive damage to the nervous system and heart. Genetics: GAA repeat expansion in the FXN gene (Chromosome 9). Pathophysiology: Deficiency in Frataxin (a mitochondrial protein) leads to iron overload and oxidative stress. Neurological: Ataxia: Progressive gait instability (spinocerebellar tract). Sensory: Loss of vibration/proprioception (dorsal columns). Motor: Muscle weakness (corticospinal tract) with absent reflexes . Skeletal: Pes cavus (high-arched feet) and kyphoscoliosis . Cardiac/Metabolic: Hypertrophic cardiomyopathy (most common cause of death) and Diabetes Mellitus . Mnemonic (GAA): G ait ataxia, A rched feet, A rrhythmia. Examples of autosomal recessive disorders: Mnemonic Disease Pasta P henylketonuria A lkaptonuria S ickle cell anemia T halassemi a Fried F riedrich’s ataxia: Chawal C ystic fibrosis, C ongenital adrenal hyperplasia H emophilia C, H omocystinuria, H emochromatosis A lpha-1-antitrypsin deficiency W ilson’s disease A lbinism L ysosomal storage disorders, g l ycogen storage disorders DNA repair defects Big B loom syndrome Fax F anconi’s anemia A taxia telangiectasia X eroderma pigmentosum X-linked recessive (Option C) is less likely because the sister is affected (females are usually carriers). X-linked dominant (Option B) and autosomal dominant (Option A) are unlikely since parents are asymptomatic , and dominant conditions usually show up in at least one parent.

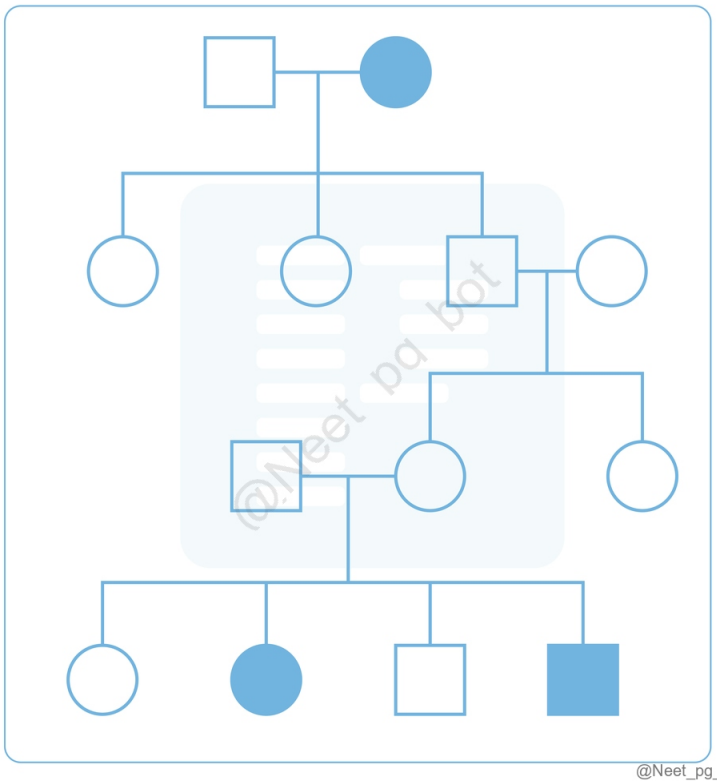

References:

Inberbir Singh’s Embryology, 11th edition, Page no. 17

Robbins and Cotran, Pathologic Basis of Disease, 10th edition, Page no. 145,146

↑ *Back to this question in Part A*

@Neet_pg_bot

Q19: A couple seeks medical advice after their daughter presents with frequent nosebleeds and easy bruising. Lab investigations reveal prolonged bleeding time, prolonged aPTT, and a normal PT. A detailed history and a pedigree analysis were obtained, suspecting a genetic disorder. Based on the pedigree chart, what is this condition's most likely inheritance pattern? (Q845177)

A. Autosomal recessive

B. Autosomal dominant

C. X linked recessive

D. X linked dominant

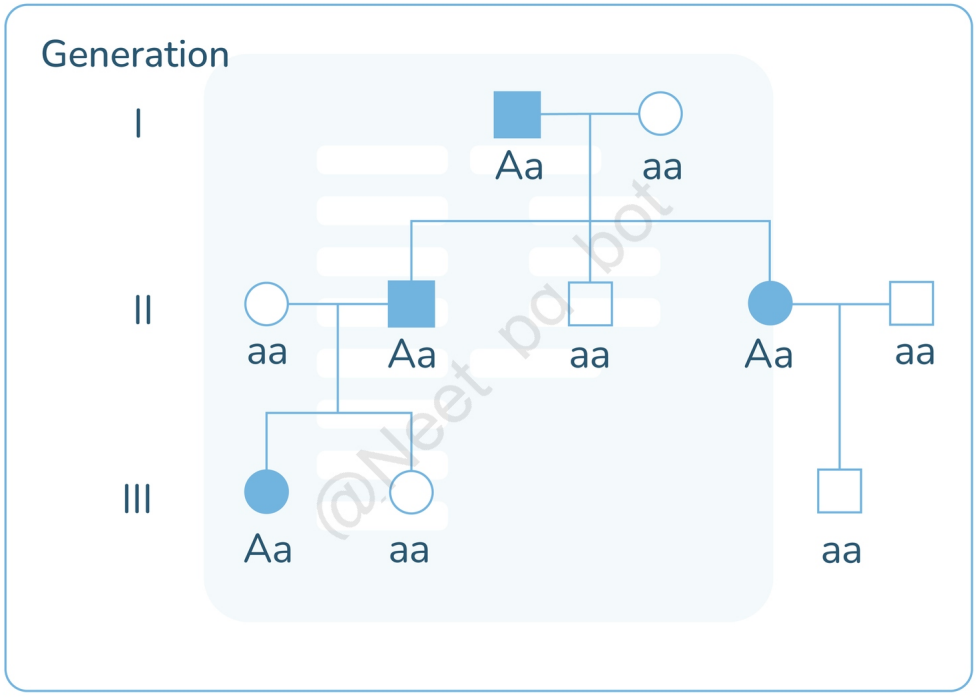

@Neet_pg_bot

Correct Answer: B. Autosomal dominant

- *Listen (English)*
- *Listen (Hindi)*

Explanation: The clinical presentation of a female with frequent nosebleeds, easy bruising, prolonged bleeding time & aPTT, and normal PT is suggestive of Von Willebrand disease. Platelet Function & Factor VIII – 1-Molybdenum Deficiency: Platelet Adhesion: Factor VIII is part of the intrinsic coagulation pathway 1-Molybdenum deficiency → defective platelet adhesion → bleeding time ↑ Coagulation Defect: Factor VIII cannot function normally → factor VIII activity ↓ Leads to prolonged APTT (activated partial thromboplastin time) The pedigree chart shows a vertical transmission pattern with no skipping of generations and is suggestive of autosomal dominant inheritance. Autosomal dominant inheritance pattern: The mode of transmission is vertical . An affected person has an affected parent. There is a 50% chance of the dominant trait being transmitted to offspring. Both males and females are equally affected.

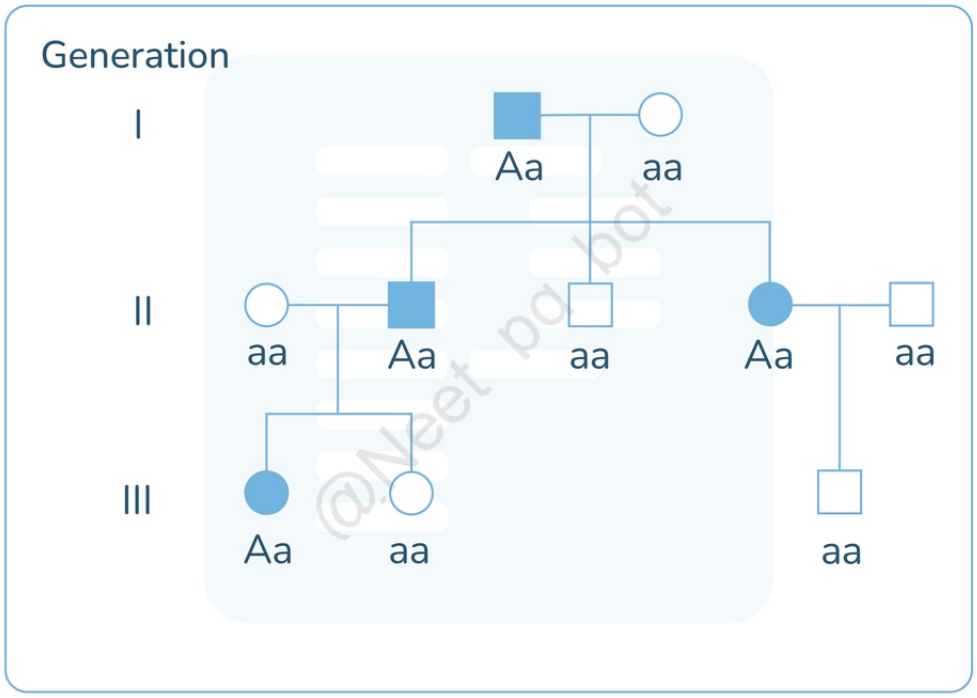

References:

Inderbir Singh’s Human Embryology, 11th edition, Page no. 16,17

Robbins and Cotran, Pathologic Basis of Disease, 10th edition, Page no. 145

↑ *Back to this question in Part A*

@Neet_pg_bot

• [03_Genetics] 013 Previous Year Questions

« Back to Folder Directory

[03_Genetics] 013 Previous Year Questions — Quick Jump

Q1 (p. 1250)	*Q2 (p. 1252)*	*Q3 (p. 1254)*	*Q4 (p. 1256)*	*Q5 (p. 1256)*	*Q6 (p. 1257)*
Q7 (p. 1258)	*Q8 (p. 1258)*	*Q9 (p. 1259)*	*Q10 (p. 1260)*	*Q11 (p. 1262)*	*Q12 (p. 1262)*
Q13 (p. 1264)	*Q14 (p. 1265)*	*Q15 (p. 1266)*	*Q16 (p. 1266)*	*Q17 (p. 1267)*	*Q18 (p. 1268)*
Q19 (p. 1270)	*Q20 (p. 1271)*	*Q21 (p. 1271)*	*Q22 (p. 1272)*	*Q23 (p. 1273)*	*Q24 (p. 1273)*
Q25 (p. 1274)	*Q26 (p. 1277)*	*Q27 (p. 1278)*	*Q28 (p. 1279)*	*Q29 (p. 1280)*	*Q30 (p. 1282)*
Q31 (p. 1283)	*Q32 (p. 1284)*	*Q33 (p. 1285)*	*Q34 (p. 1286)*	*Q35 (p. 1288)*	*Q36 (p. 1288)*
Q37 (p. 1290)	*Q38 (p. 1291)*	*Q39 (p. 1293)*	*Q40 (p. 1294)*	*Q41 (p. 1296)*	*Q42 (p. 1297)*
Q43 (p. 1300)	*Q44 (p. 1303)*				

Q1: A karyotyping image is given below. What are the clinical features most likely to be expected in such patients? (Q856714)

A. Gynecomastia and long limbs

B. Flat occiput

C. Webbing of neck and lymphedema

D. Cleft lip and polydactyly

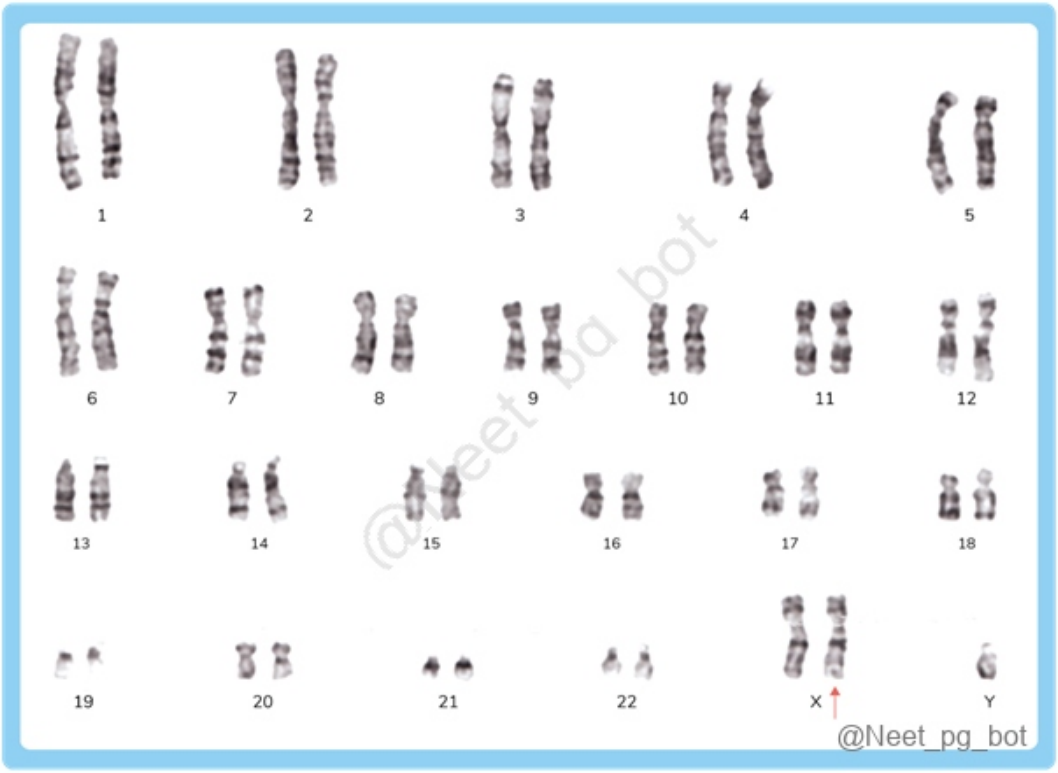

Correct Answer: A. Gynecomastia and long limbs

Explanation: The karyotype image reveals an additional X chromosome, confirming the presence of Klinefelter Syndrome (47, XXY), a condition often associated with features like gynecomastia and longer limbs. It is male hypogonadism resulting from two or more X chromosomes and one or more Y chromosomes. It is an important genetic cause of reduced spermatogenesis and male infertility. Karyotype: The most common is 47, XXY, from meiotic nondisjunction; some have mosaic patterns (e.g., 46, XY/47, XXY). X chromosome genes: Some genes escape inactivation, leading to uneven dosage compensation and overexpression. Clinical features of Klinefelter syndrome: Gynecomastia (breast development) Long limbs Infertility (most common cause of male hypogonadism and infertility). Flat occiput (Option B) is a feature of Down syndrome (Trisomy 21), a genetic condition caused by an extra chromosome 21, leading to intellectual disability, developmental delays, and physical traits like a flat face and almond-shaped eyes. It's linked to heart defects, hearing loss, and other health issues. Webbing of the neck and lymphedema (Option C) are features of Turner's syndrome, a genetic condition that occurs when a female is born with only one full X chromosome (45, X instead of the usual 46, XX). It leads to short stature, infertility, and sometimes heart defects, kidney problems, and hearing loss. Individuals may also have learning difficulties, particularly with spatial reasoning. Cleft lip and polydactyly (Option D) are features of Patau syndrome (Trisomy 13), a genetic disorder caused by an extra copy of chromosome 13. It leads to severe intellectual disability, cleft lip and palate, polydactyly (extra fingers or toes), heart defects, and brain abnormalities. Most affected infants have a short life expectancy, often not surviving beyond the first year.

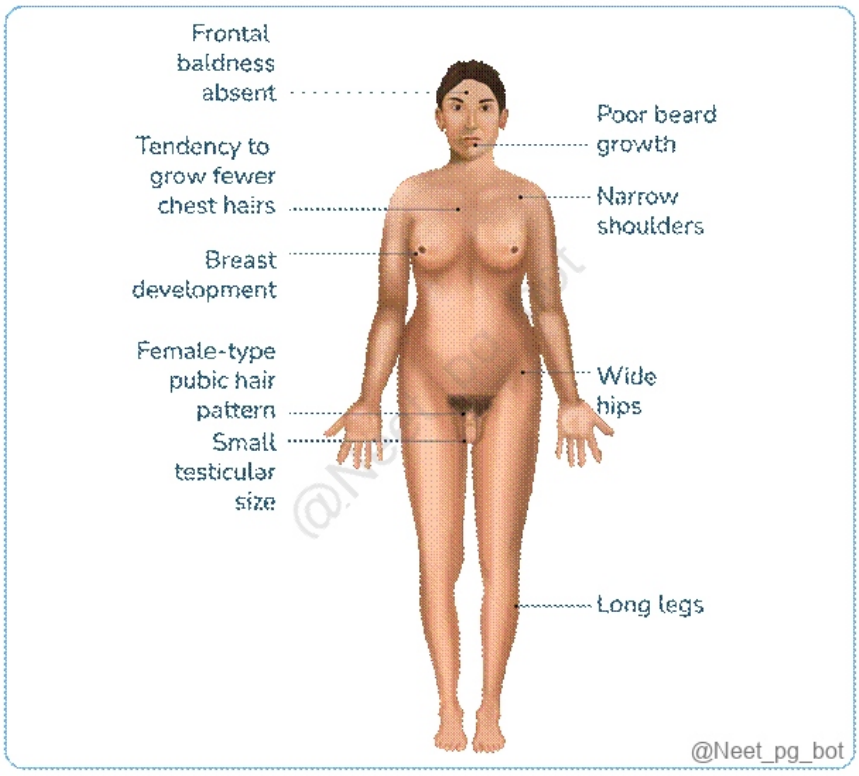

References:

Robbins & Cotran Pathologic Basis of Disease,10th Edition, Page 170-171.

↑ *Back to this question in Part A*

@Neet_pg_bot

Q2: Identify the type of inheritance? (Q820500)

A. Autosomal Dominant

B. Autosomal Recessive

C. X-linked dominant

D. X-linked recessive

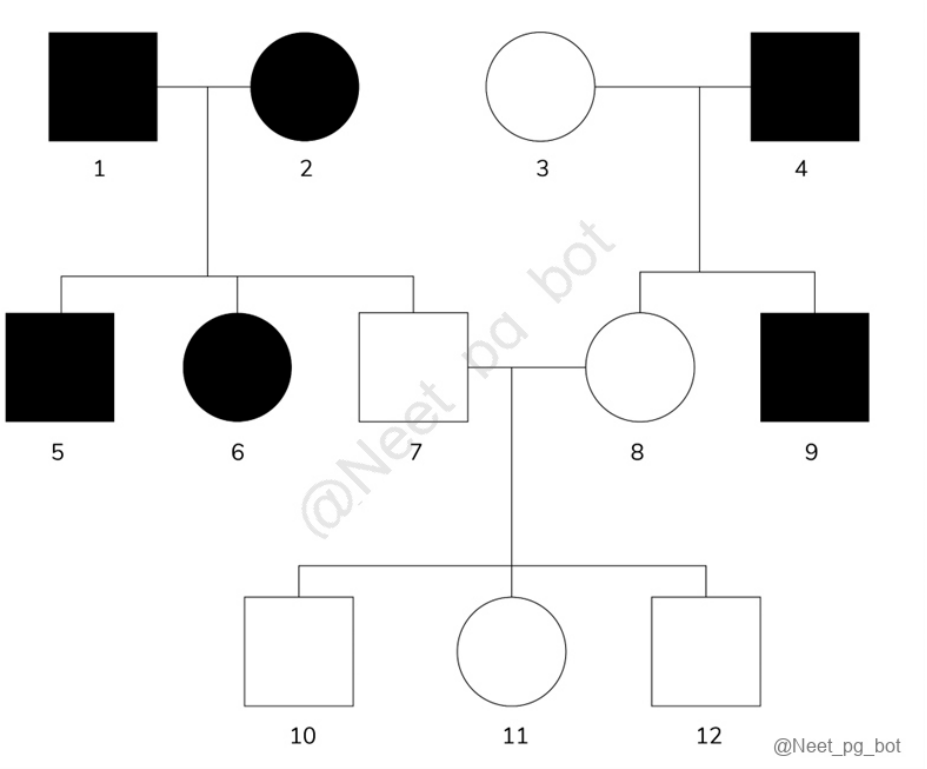

Correct Answer: A. Autosomal Dominant

- *Listen (English)*
- *Listen (Hindi)*

Explanation: Correct Option A - Autosomal Dominant Inheritance: In autosomal dominant inheritance, a single copy of the mutated gene from one parent is enough to cause the trait or disorder. The trait or disorder will be present in every generation, as affected individuals pass the mutated gene to their offspring. Individuals with one affected parent have a 50% chance of inheriting the trait. For example, if a parent has a dominant genetic disorder like Huntington's disease, there's a 50% chance their child will inherit the disorder. Incorrect Options: Option B - Autosomal Recessive Inheritance: In autosomal recessive inheritance, two copies of the mutated gene (one from each parent) are required to manifest the trait or disorder. Carriers of a single mutated gene are usually healthy but can pass on the mutation to their offspring. The trait or disorder might skip generations if carriers do not have affected children. When two carriers have a child, there's a 25% chance the child will have the disorder, a 50% chance of being a carrier, and a 25% chance of having neither the disorder nor being a carrier. An example is cystic fibrosis. Option C - X-Linked Dominant Inheritance: X-linked dominant inheritance involves a mutated gene on the X chromosome. A single copy of the mutated gene on one of the X chromosomes is sufficient to cause the trait or disorder in females (since they have two X chromosomes) and in males (who have one X chromosome). Affected fathers pass the disorder to all their daughters, but not to their sons. Affected mothers have a 50% chance of passing the disorder to both sons and daughters. An example is Rett syndrome. Option D - X-Linked Recessive Inheritance: X-linked recessive inheritance also involves a mutated gene on the X chromosome. Males are more commonly affected because they have only one X chromosome. Carrier mothers (with one normal and one mutated X chromosome) can pass the mutation to their sons (who get their X chromosome from the mother) and to half of their daughters (who inherit the mutated X chromosome). Carrier fathers pass the mutated gene only to their daughters, who become carriers. An example is color blindness.

↑ *Back to this question in Part A*

@Neet_pg_bot

Q3: What is the status of the marked individual? (Q866668)

A. Adopted from another family

B. Has a disease of chronic origin

C. Curable disease

D. Twin

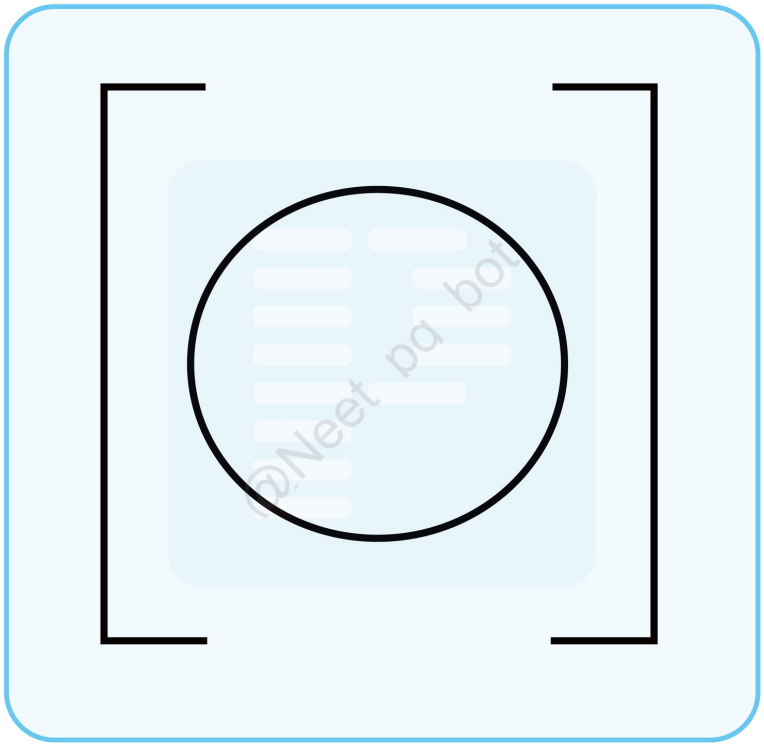

Correct Answer: A. Adopted from another family

Explanation: In standard pedigree notation: An individual marked with brackets around the symbol indicates adoption. If the brackets are dashed, it usually means adopted in (from another family). If the brackets are solid, it usually means adopted out (given to another family). Has a disease of chronic origin / Curable disease (Option B, C): would be indicated by shading or other symbols, not brackets. Twin (Option D) : represented by two siblings connected by a triangle or horizontal bar, not brackets.

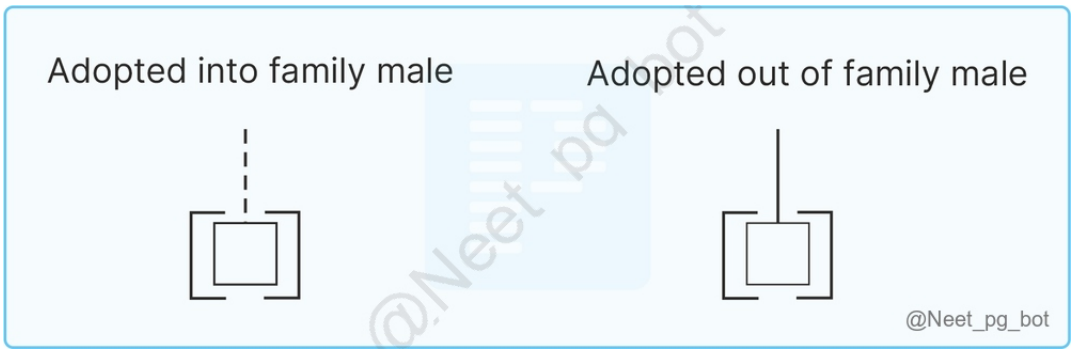
Adopted into family male
Adopted out of family male
@Neet_pg_bot

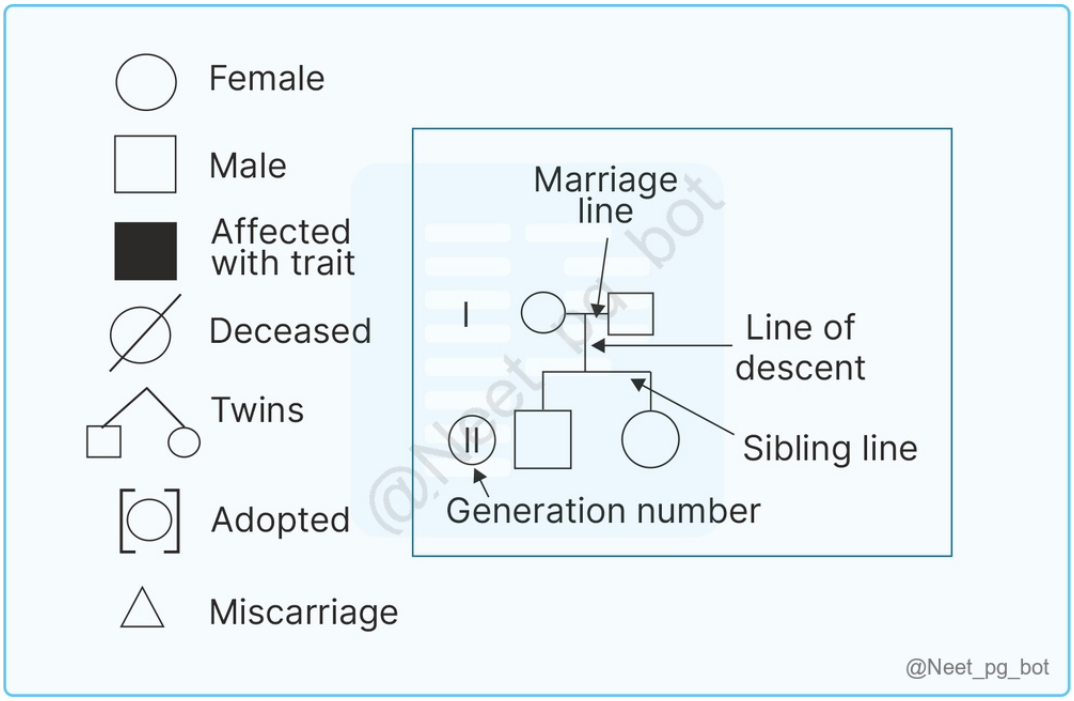
Female
Male
Affected with trait
Deceased
Twins
Adopted
Miscarriage
Marriage line
I
II
Line of descent
Sibling line
Generation number
@Neet_pg_bot

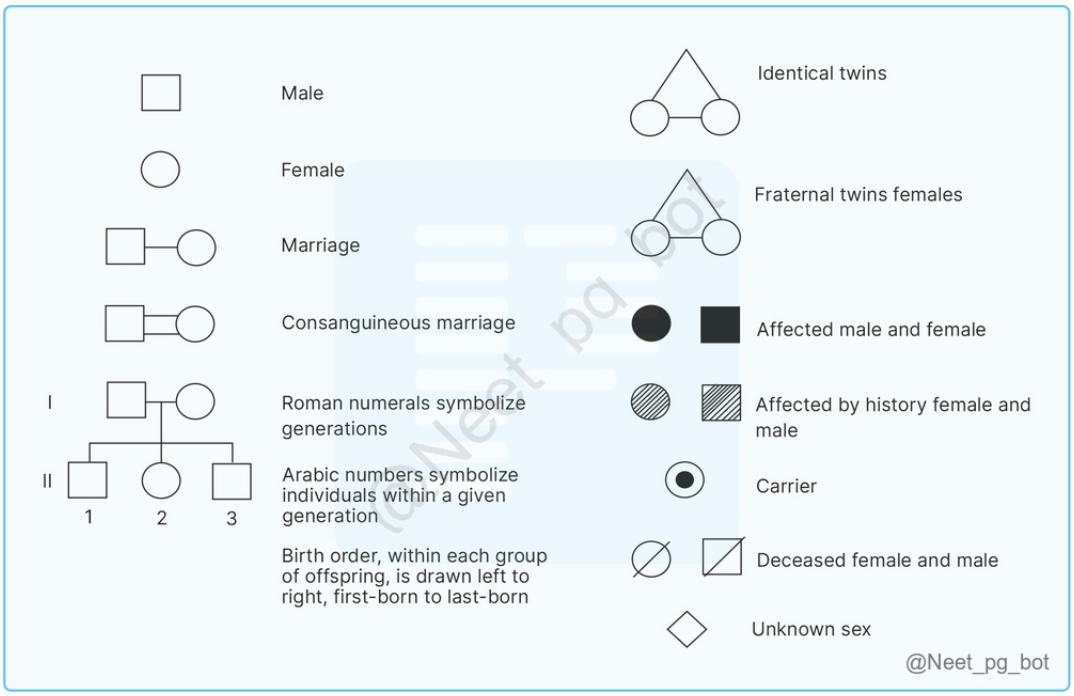
Male
Female
Marriage
Consanguineous marriage
I
II
1
2
3
Roman numerals symbolize generations
Arabic numbers symbolize individuals within a given generation
Birth order, within each group of offspring, is drawn left to right, first-born to last-born
Identical twins
Fraternal twins females
Affected male and female
Affected by history female and male
Carrier
Deceased female and male
Unknown sex
@Neet_pg_bot

References:

.

↑ *Back to this question in Part A*

@Neet_pg_bot

Q4: Which of the following statements regarding Mendelian (single-gene) disorders is correct? (Q855359)

A. X-linked dominant disorders are the most common type of Mendelian disorders.

B. Autosomal recessive disorders always appear in every generation of a family.

C. Y-linked disorders are extremely rare because few genes are present on the Y-chromosome.

D. In autosomal dominant disorders, two defective alleles are required for the disease to manifest.

Correct Answer: C. Y-linked disorders are extremely rare because few genes are present on the Y-chromosome.

Explanation: Y-linked disorders are extremely rare because the Y-chromosome contains very few functional genes. Most Y-linked traits involve male sexual development, so pathogenic mutations are uncommon. Since the Y-chromosome is passed strictly from father to son, any Y-linked disorder shows strict male-to-male inheritance. Because so few Mendelian diseases follow this pattern, Y-linked disorders are among the least common modes of inheritance. Incorrect Options: Option A) X-linked dominant disorders are the most common type : False - they are rare ; autosomal disorders (dominant or recessive) are far more common. Option B) Autosomal recessive disorders appear in every generation : False - they typically skip generations because carriers are asymptomatic. Option D) Autosomal dominant disorders require two defective alleles : False - only one mutant allele is needed for disease expression.

References:

Harrison’s Principles of Internal Medicine, 21st Edition, Page 3652

Robbins and Cotran Pathologic Basis of Disease, 10th Edition, Page 144-146

↑ *Back to this question in Part A*

@Neet_pg_bot

Q5: A 30-year-old pregnant woman who has the thalassemia trait visits the clinic for genetic counselling. Her husband is also confirmed to have the thalassemia trait.

Considering their genetic background, what is the likelihood of their next offspring having thalassemia? (Q858074)

A. 100%

B. 50%

C. 75%

D. 25%

Correct Answer: D. 25%

Explanation: There is a 25% chance that their child will inherit the genotype β■/β■, corresponding to β-thalassemia major . Mother's Genotype: β/β■ (carrier for β-thalassemia) Father's Genotype: β/β■ (carrier for β-thalassemia) Punnett Square Analysis β β■ β β/β β/β■ β■ β/β■ β■/β■ Possible Outcomes: β/β (Normal): 25% β/β■ (Carrier): 50% β■/β■ (β-thalassemia major): 25%

References:

Robbins and Cotran Pathologic Basis of Disease, 10th Edition, Page 145

↑ *Back to this question in Part A*

@Neet_pg_bot

Q6: Which of the following correctly represents the effect of the mutation causing sickle cell anaemia? (Q858078)

A. Glutamate by valine at the 6th position

B. Valine by glutamate at the 6th position

C. Glutamate by valine at the 5th position

D. Valine by glutamate at the 5th position

Correct Answer: A. Glutamate by valine at the 6th position

Explanation: Sickle cell anaemia is caused by a point mutation that involves substituting adenine for thymine at the sixth codon of the β-globin gene (GAG to GTG) , replacing glutamic acid (glutamate) with valine in the β-globin chain of haemoglobin. This single nucleotide change results in the formation of abnormal haemoglobin molecules (HbS) . After deoxygenation, HbS molecules polymerize to form bundles. These polymer bundles cause erythrocytes to adopt a sickle shape and also promote hemolysis of erythrocytes, releasing cell-free Hb into circulation.

References:

Robbins and Cotrans Pathologic Basis of Diseases, 10th Edition, Pages 142,143

↑ *Back to this question in Part A*

@Neet_pg_bot

Q7: B cells express IgM and IgD antibodies at the same time. Which phenomenon is it due to? (Q856008)

A. Somatic hypermutation

B. Alternative RNA splicing

C. Affinity maturation

D. Allelic exclusion

Correct Answer: B. Alternative RNA splicing

Explanation: B cells express IgM and IgD antibodies simultaneously due to alternative RNA splicing . This process allows the same gene for the heavy chain to be spliced in different ways to produce both IgM and IgD isotypes. The IgM and IgD are both produced from the same heavy chain gene but are differentiated through this splicing mechanism. During this process, the RNA transcript for the heavy chain is spliced in two different ways, one to produce IgM and the other to produce IgD . Both these antibodies have the same antigen-binding specificity but differ in their constant regions, which define their isotypes. Somatic hypermutation (Option A) occurs after antigen exposure and increases antibody affinity, but it does not affect the simultaneous expression of IgM and IgD. Affinity maturation (Option C) is a process that occurs during the immune response to improve the affinity of antibodies, not to generate multiple antibody classes at the same time. Allelic exclusion (Option D) ensures that only one allele of the immunoglobulin gene is expressed in a B cell at any given time, which helps in maintaining clonal specificity, but it does not explain the co-expression of IgM and IgD.

References:

https://pmc.ncbi.nlm.nih.gov/articles/PMC4730250/

Robbins & Cotran Pathologic Basis of Disease, 10th Edition, Page 203, 591

↑ *Back to this question in Part A*

@Neet_pg_bot

Q8: Differential expression of a gene depending upon the parent of origin is a feature of: (Q855071)

A. Gonadal mosaicism

B. Genomic imprinting

C. Anticipation

D. Incomplete penetrance

Correct Answer: B. Genomic imprinting

Explanation: Genomic imprinting refers to the phenomenon where the expression of a gene depends on which parent the gene was inherited from. In imprinted genes, one allele is silenced depending on the parent of origin, leading to differential expression. Genomic imprinting: Inheritance : We inherit two copies of each autosomal gene, one from each parent, but functional differences can exist between the maternal and paternal alleles. Mechanism: Imprinting is an epigenetic process that selectively inactivates either the maternal or paternal allele. Maternal imprinting silences the maternal allele, while paternal imprinting silences the paternal allele. Imprinting occurs in the ovum or sperm before fertilization. The imprinting pattern is stably transmitted to somatic cells through mitosis. Imprinting is linked to disorders like Prader-Willi syndrome and Angelman syndrome. Prader-Willi syndrome Chromosome 15q SNORP gene Paternal deletion Maternal imprinting Angelman syndrome Chromosome 15q UBE3A gene Maternal deletion Paternal imprinting Gonadal mosaicism (Option A) refers to a condition where some of an individual's gametes (eggs or sperm) carry a mutation that is not present in the somatic cells. It does not involve differential expression based on the parent of origin, which is specific to genomic imprinting. Anticipation (Option C) refers to the phenomenon where a genetic disorder becomes more severe or appears at an earlier age with each successive generation. It is seen in trinucleotide repeat disorders. Incomplete penetrance (Option D) refers to situations where an individual with a disease-causing genotype does not show the expected phenotype. Example: BRCA1 gene mutations , which increase the risk of breast and ovarian cancer. Some individuals with the mutation never develop cancer despite carrying the gene.

References:

Robbins & Cotran Pathologic Basis of Disease, 10th Edition, Page 178

↑ *Back to this question in Part A*

@Neet_pg_bot

Q9: Which of the following disorders is inherited in an X-linked dominant pattern? (Q855075)

A. Rett syndrome

B. Duchenne muscular dystrophy

C. Huntington’s disease

D. Tuberous sclerosis

Correct Answer: A. Rett syndrome

Explanation: Rett syndrome is inherited in an X-linked dominant pattern, primarily affecting females. X-linked dominant inheritance: The gene responsible for the concerned trait or disorder is present on the X chromosome and can express itself both in homozygous and heterozygous conditions. It is more commonly seen in females than males since females have two X chromosomes. An affected male will transmit the disease to all his daughters but not sons. An affected female can transmit the disease to both daughters and sons. Conditions with X-linked dominant inheritance: Rett syndrome . Alport syndrome Vitamin D-resistant rickets. Incontinentia pigmenti. The pedigree chart below shows an X-linked dominant pattern: The affected mother of the first generation transmitted the disease to both son and daughter. The affected father of the second generation transmitted the disease only to the daughters. {{caption_text}} Duchenne muscular dystrophy (Option B) follows an X-linked recessive inheritance pattern. Huntington's disease (Option C) follows an autosomal dominant inheritance pattern. Tuberous sclerosis (Option D) is inherited in an autosomal dominant pattern. Learning Objective: X-linked dominance is more common in females. Affected males transmit the disease only to their daughters. Affected females transmit the disease to both daughters and sons.

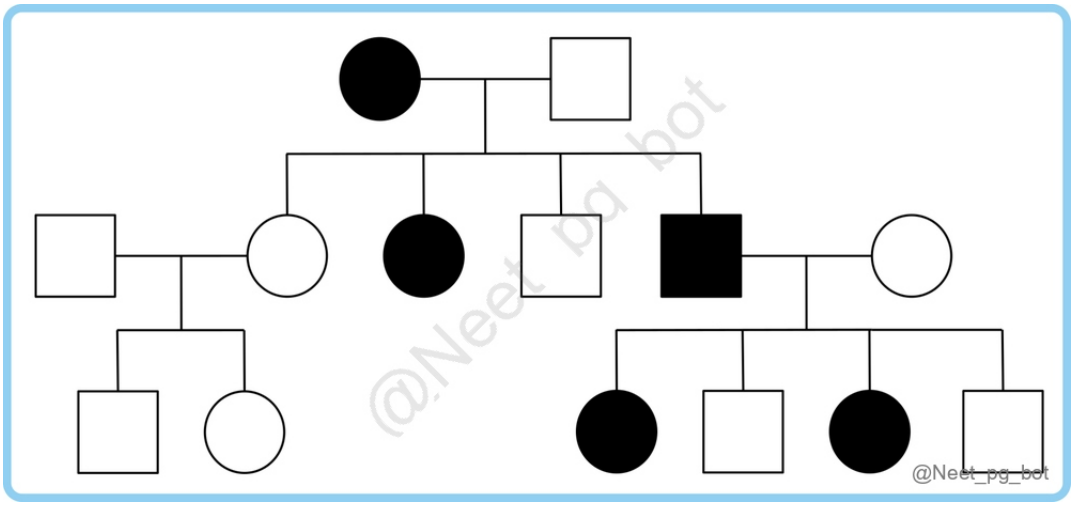

References:

Robbins & Cotran Pathologic Basis of Disease, 10th Edition, Page 146

↑ *Back to this question in Part A*

@Neet_pg_bot

Q10: In cystic fibrosis, which of the following structures is affected in the pancreas? (Q855391)

A. A

B. B

C. C

D. D

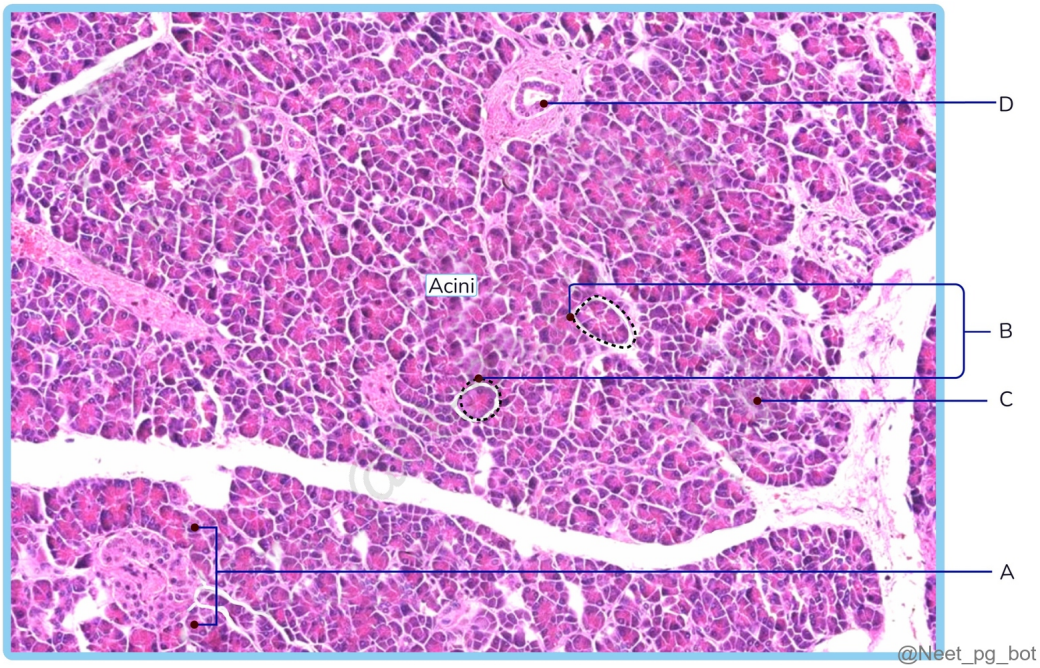

Correct Answer: B. B

Explanation: "B" represents the acini, the functional units of the exocrine pancreas that produce and secrete digestive enzymes into the pancreatic ducts, and these are affected in Cystic Fibrosis, an autosomal recessive genetic disorder. Pathogenesis: It is caused by mutations in the cystic fibrosis transmembrane conductance regulator (CFTR) gene, resulting in a defect in the production or function of the CFTR protein. This leads to thick, sticky mucus forming in various organs, including the pancreas. In the pancreas, the defective CFTR protein affects the secretion of chloride ions and water, dehydrating pancreatic secretions. This thickened mucus obstructs the pancreatic ducts, preventing the proper flow of digestive enzymes from the acini into the duodenum. (Option B) Consequently, there is a reduction in the production and release of pancreatic enzymes, leading to impaired digestion and malabsorption of nutrients. Clinical features: Respiratory system Gastrointestinal and hepatic Others Progressive airway obstruction Infective exacerbations of bronchiectasis Respiratory failure Spontaneous pneumothorax Haemoptysis Lobar collapse due to secretions Pulmonary hypertension Nasal polyps Malabsorption and steatorrhoea Distal intestinal obstruction syndrome Biliary cirrhosis Portal hypertension, varices, and splenomegaly Gallstones Diabetes Delayed puberty, Male infertility Stress incontinence due to repeated forced cough Psychosocial problems Osteoporosis Arthropathy Cutaneous vasculitis A (Option A) is the islets of Langerhans, responsible for the production and secretion of hormones such as insulin and glucagon. It is not the target of cystic fibrosis. C (Option C) is the intralobular duct, which is part of the pancreatic duct system and plays a role in transporting pancreatic enzymes. It is not the target of cystic fibrosis. D (Option D) is the interlobular duct that transports pancreatic secretions and is not the target of cystic fibrosis.

References:

Robbins & Cotran Pathologic Basis of Diseases, 10th Edition, Page 466-471.

↑ *Back to this question in Part A*

@Neet_pg_bot

Q11: A 30-year-old pregnant woman who has the thalassemia trait visits the clinic for genetic counseling. Her husband is also confirmed to have the thalassemia trait. Considering their genetic background, what is the likelihood of their next offspring having thalassemia? (Q820511)

A. 100%

B. 50%

C. 75%

D. 25%

Correct Answer: D. 25%

■ *Listen (English)*

■ *Listen (Hindi)*

Explanation:

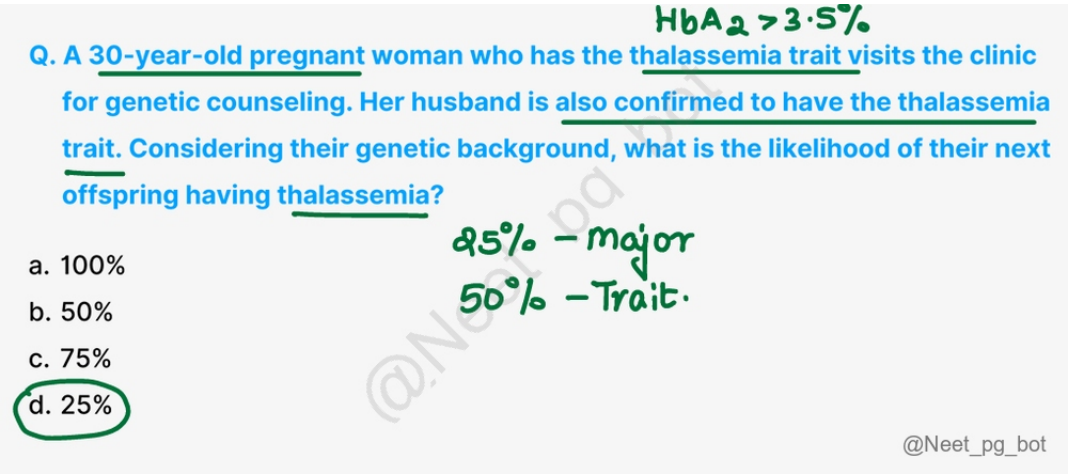

↑ *Back to this question in Part A*

@Neet_pg_bot

Q12: A girl presents with short stature, a webbed neck, thick calves, a shield-shaped chest, swelling of the ankle, and an increased carrying angle. What is the likely diagnosis? (Q856105)

A. Turner syndrome

B. Down syndrome

C. Patau syndrome

D. Edward syndrome

Correct Answer: A. Turner syndrome

Explanation: The clinical features described are characteristic of Turner syndrome , which is a genetic condition caused by the partial or complete absence of one of the X chromosomes (45 XO karyotype). It leads to hypogonadism in phenotypic females. Features of Turner Syndrome: Down syndrome (Option B) results from Trisomy 21. It is associated with features such as intellectual disability , epicanthal folds , flat facial profile , and congenital heart defects but does not include the specific skeletal and physical features seen in Turner syndrome. Patau syndrome (Option C) occurs due to trisomy 13 , and its clinical features include microphthalmia, microcephaly, rocker bottom feet, polycystic kidney disease, and congenital heart disease , none of which are consistent with the features described in the question. Edward syndrome (Option D) is caused by the presence of an extra copy of chromosome 18 (Trisomy 18) and is characterized by severe developmental delay, clenched fists , rocker-bottom feet , and heart defects , which differ significantly from the features seen in Turner syndrome.

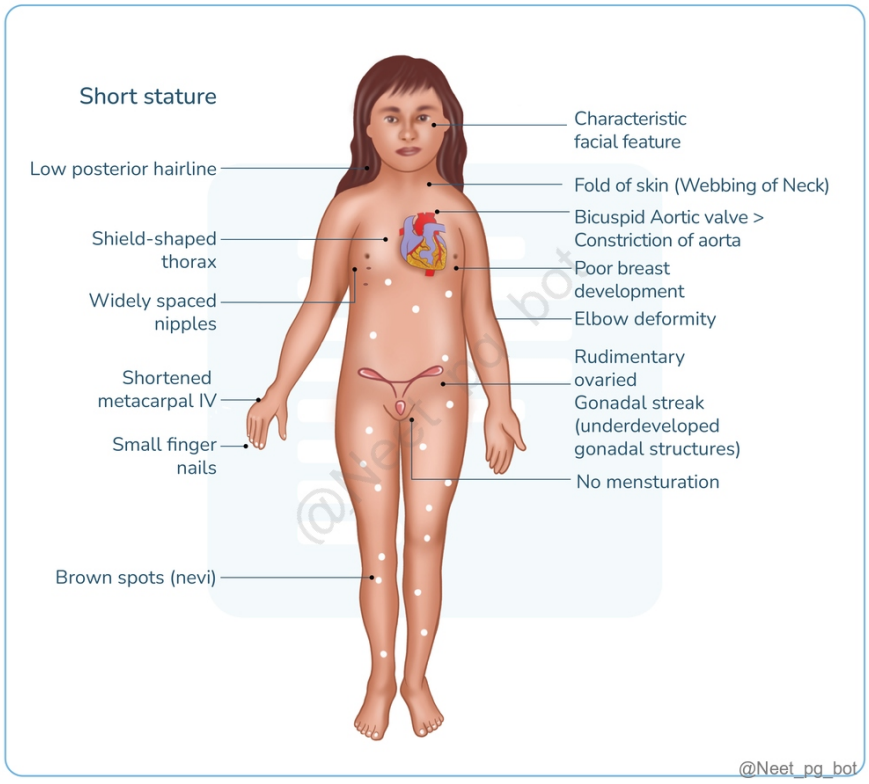

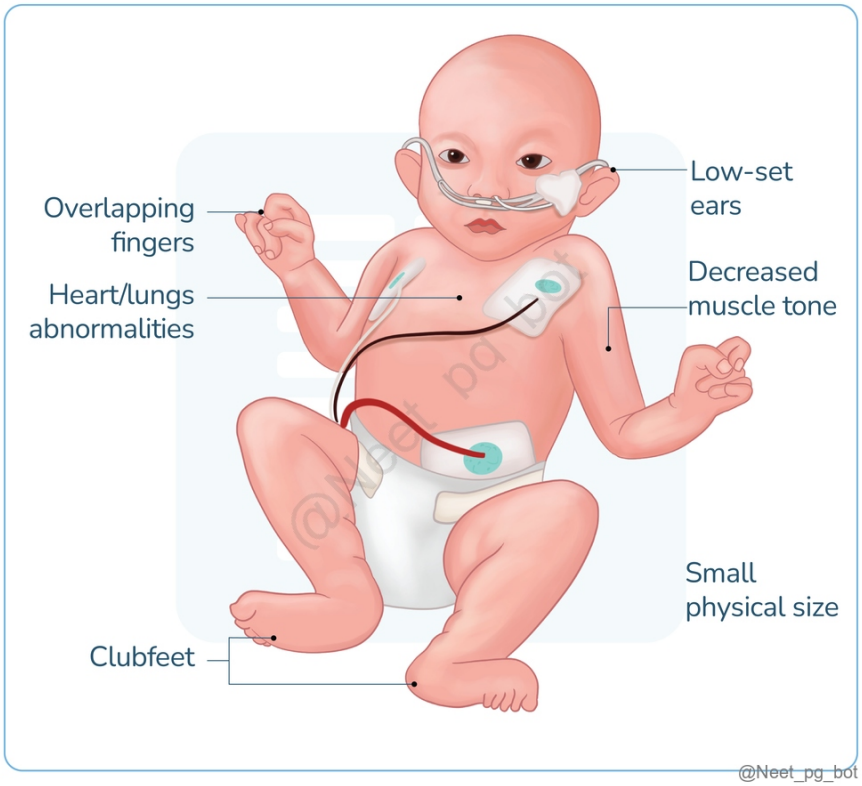

References:

Robbins and Cotran Pathologic Basis of Disease, 10th Edition, Pages 166 - 169, 172.

↑ *Back to this question in Part A*

@Neet_pg_bot

Q13: Which of the following statements is correct about Huntington's chorea? (Q854894)

A. It is a trinucleotide repeat disorder

B. There is a loss of function type of mutation

C. There are abnormal length repeats of CUG

D. Abnormality is seen due to a defect in chromosome 6

Correct Answer: A. It is a trinucleotide repeat disorder

Explanation: Huntington's chorea is a trinucleotide repeat disorder caused by the expansion of the CAG repeat in the HTT gene on chromosome 4. Huntington's disease: HD is an autosomal dominant disorder caused by the

degeneration of striatal neurons, leading to a progressive movement disorder and dementia. Symptoms include chorea , bradykinesia, and rigidity. It is relentlessly progressive and fatal, typically over 15 years. Pathogenesis: HD is a trinucleotide repeat expansion disease caused by a CAG repeat (Option C) in the HTT gene on chromosome 4p16.3 (Option D) , encoding huntingtin protein . Normal HTT genes have 6 to 35 CAG repeats , while pathogenic mutations have expanded repeats, leading to earlier disease onset with paternal transmission causing anticipation & the toxic gain-of-function (Option B) of mutant huntingtin is believed to be the primary pathogenic mechanism. Morphology: The brain exhibits atrophy of the caudate nucleus and putamen , along with ventricular dilation . There is a loss of striatal neurons , particularly affecting GABAergic neurons in the caudate and putamen. Gliosis is more extensive than usual due to neuronal loss. Clinical features: The loss of striatal neurons results in increased motor activity, causing choreoathetosis . Cognitive decline follows, with symptoms such as forgetfulness and dementia . The disease usually manifests in the fourth or fifth decade , and motor symptoms typically precede cognitive symptoms . The leading cause of death is often pneumonia , especially in advanced stages. Suicide rates are higher in HD patients.

References:

Robbins & Cotran Pathologic Basis of Disease, 10th Edition, Page 174, 1285

↑ *Back to this question in Part A*

@Neet_pg_bot

Q14: Premature ageing in Werner syndrome is due to: (Q858514)

A. Increased telomerase activity

B. Defects in DNA helicase

C. Increase in length of telomere due to decrease in telomerase activity

D. Decreased telomerase activity

Correct Answer: B. Defects in DNA helicase

Explanation: Werner syndrome , a rare autosomal recessive disorder, is characterised by premature ageing and accelerated development of age-related diseases. It results from mutations in the WRN gene, which encodes a DNA helicase involved in DNA repair and maintenance of genomic stability. Chromosomal damage accumulates rapidly due to the defective enzyme. This damage mimics normal ageing at a faster rate, leading to premature ageing. Similar conditions like Bloom syndrome and ataxia-telangiectasia also involve mutations in genes responsible for DNA repair . These disorders result in genetic instability and accelerated ageing due to impaired DNA repair mechanisms. Incorrect Options: Increased telomerase activity (Option A) is typically seen in some cancers, where it allows cells to maintain telomere length and avoid senescence. Increase in length of telomere due to decrease in telomerase activity (Option C) and Decreased telomerase activity (Option D) : In Werner syndrome, telomere shortening occurs due to DNA repair defects rather than telomere maintenance problems. Telomerase activity is not significantly altered.

References:

Robbins & Cotran Pathologic Basis of Disease, 10th Edition, Page 67

↑ *Back to this question in Part A*

@Neet_pg_bot

Q15: What is the mode of inheritance in a patient suffering from colour blindness? (Q859300)

A. AD

B. AR

C. XLR

D. XLD

Correct Answer: C. XLR

Explanation: The mode of inheritance in a patient suffering from colour blindness is X-linked recessive (XLR). X-Linked Recessive : The gene for Color blindness is located on the X chromosome. Males (XY) express the disorder if they inherit the affected X chromosome since they lack a second X for compensation. Females (XX) can be carriers if they inherit one affected X chromosome, often showing no symptoms due to the normal allele on the other X. Affected males cannot pass the disorder to sons but can pass the affected X to daughters, making them carriers. X-linked Recessive (WISE ABCDEFGH) Wise- Wiskott Aldrich Syndrome AB- Hemophilia A, B B- Bruton's Hypogammaglobulinemia . C- Chronic Granulomatous Disease, Red Green Color Blindness D- DMD, BMD E- Lesch Nyhan Syndrome F- Fabry Disease, Fragile X Syndrome G- G6PD Deficiency H- Hunter Disease Incorrect Options: Autosomal Dominant (AD) (Option A) disorders affect both sexes equally , and only one mutated allele is required for the disease to manifest. Examples: Marfan syndrome, Achondroplasia, Familial hypercholesterolemia . Autosomal Recessive (AR) (Option B) disorders require both alleles to be mutated for disease manifestation. Examples: Cystic fibrosis, Sickle cell disease, Phenylketonuria (PKU) . Colour blindness is inherited in an X-linked pattern, not AR. X-linked Dominant (XLD) (Option D) affects both males and females , but females more commonly due to having two X chromosomes. Examples: Rett syndrome, Fragile X syndrome, and Hypophosphatemic rickets . Colour blindness is X-linked recessive, not dominant.

References:

Robbins and Cotrans Pathologic Basis of Diseases, 10th Edition, Page 146

↑ *Back to this question in Part A*

@Neet_pg_bot

Q16: A female is heterozygous for an autosomal recessive mitochondrial disorder. What does this involve? (Q879194)

A. Skeletal muscle and immune system

B. Skeletal muscle and cardiac muscle

C. Skeletal muscle and neural tissue

D. Gastric and respiratory tissue

Correct Answer: C. Skeletal muscle and neural tissue

Explanation: Mitochondrial disorders most severely affect tissues with the highest energy (ATP) demand, such as skeletal muscle and neural tissue. Skeletal muscle: High energy requirement Rich in mitochondria ("red fibres") Classic site for mitochondrial myopathies Shows ragged red fibres on biopsy Neural tissue (CNS and peripheral nerves): The brain consumes ~20% of the body's ATP Neurons rely heavily on oxidative phosphorylation Mitochondrial defects cause seizures, hearing loss, neuropathy, and encephalopathy. This is why most mitochondrial syndromes (MELAS, MERRF, LHON, Leigh disease) involve muscle weakness, exercise intolerance, seizures, ataxia and developmental delay. Skeletal muscle and immune system (Option A): The immune system is not the classical target in mitochondrial diseases, and energy demand is lower compared to the CNS or muscle. Skeletal muscle and cardiac muscle (Option B): Cardiac muscle can be involved, but not as characteristically as the CNS in autosomal recessive mitochondrial disorders. Gastric and respiratory tissue (Option D): GI dysmotility can occur in some mtDNA diseases (e.g., MNGIE), but the respiratory epithelium has lower mitochondrial dependence than neural/muscle tissue.

References:

Mitochondrial Disorders

↑ *Back to this question in Part A*

@Neet_pg_bot

Q17: A 3-year-old child presents with unilateral proptosis and leukocoria. Histopathology demonstrates Flexner–Wintersteiner rosettes. Regarding this condition, which of the following statements is false? It is always unilateral Called the guardian of the genome The RB protein is hypophosphorylated in the inactive state Oncogenesis is due to a loss-of-function mutation (Q879199)

A. 1,2,3

B. 1,2,3,4

C. 3,4

D. 2,3

Correct Answer: A. 1,2,3

Explanation: A 3-year-old child presents with unilateral proptosis and leukocoria, and histopathology reveals Flexner–Wintersteiner rosettes , which are diagnostic of Retinoblastoma , a malignant intraocular tumor of the retina in young children. It can be unilateral or bilateral . (Statement 1 ruled out) Sporadic form: usually unilateral. Hereditary form: often bilateral and multifocal. RB is known as the “governor of the cell cycle” . (Guardian is p53) (Statement 2 ruled out) The RB protein is active when hypophosphorylated , binding to E2F transcription factors and suppressing cell cycle progression from the G1 to S phase . When phosphorylated (hyperphosphorylated), RB becomes inactive , releasing E2F and allowing cell cycle progression. (Statement 3 ruled out) Tumor development arises from loss-of-function mutations in the RB1 tumor suppressor gene, which disables its cell cycle regulatory function and leads to uncontrolled cell proliferation. (Statement 4)

References:

Robbins & Cotran, Pathologic Basis of Diseases, 10th Edition, Page 293-294.

↑ *Back to this question in Part A*

@Neet_pg_bot

Q18: Which of the following statements regarding Gaucher disease are correct? Enzyme defect: Sphingomyelinase Enzyme defect: β-glucocerebrosidase Presence of foamy macrophages Macrophages exhibit a “crumpled tissue paper” appearance (Q879204)

A. 1, 2, 3

B. 2, 3, 4

C. 1, 2, 4

D. 1, 3, 4

Correct Answer: B. 2, 3, 4

Explanation: Gaucher’s Disease is an autosomal recessive inborn error of metabolism caused by mutations in the β-glucocerebrosidase - GBA1 gene. (Option 2) Glucocerebrosides accumulate massively within phagocytic cells throughout the body, forming distended foamy macrophages known as Gaucher cells. (Option 3) These cells, found in various organs including the spleen, liver, bone marrow, and lungs, exhibit a fibrillar cytoplasm resembling crumpled tissue paper. (Option 4) They stain intensely positive with periodic acid–Schiff staining. Wright stain - Crumpled tissue paper Enzyme defect sphingomyelinase (Option 1) is a feature of Niemann–Pick disease.

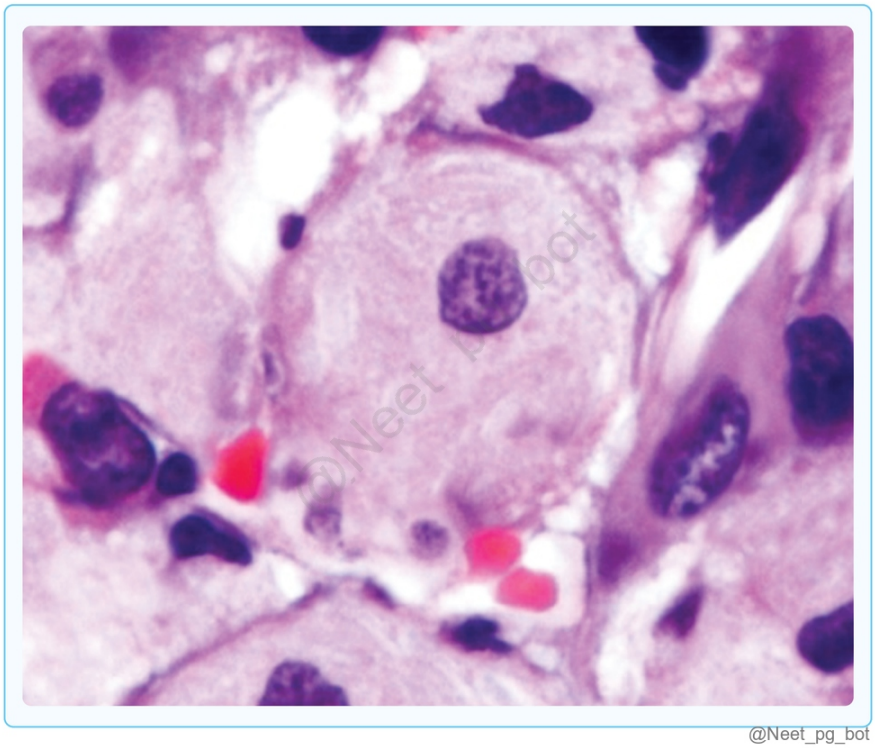

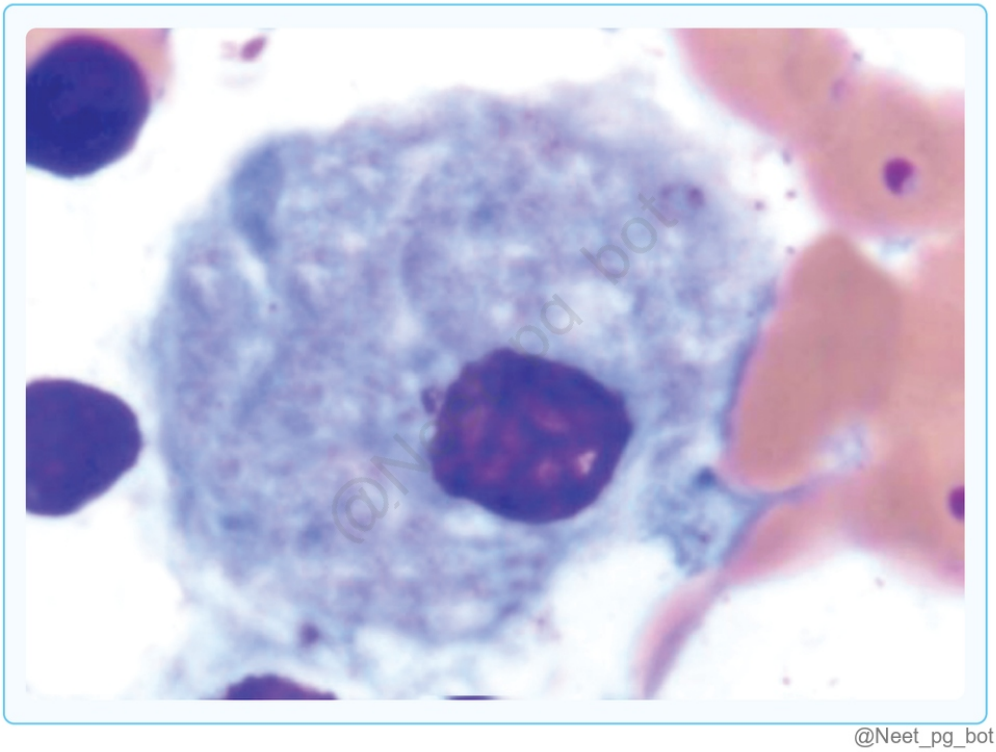

References:

Robbins & Cotran, Pathologic Basis of Diseases, 10th Edition, Pages 156,158,159

↑ *Back to this question in Part A*

@Neet_pg_bot

Q19: What are the steps involved in the polymerase chain reaction (PCR)? (Q879217)

A. Denaturation - Annealing - Extension

B. Denaturation - Annealing - Extension - Hybridization

C. Annealing - Extension - Denaturation

D. Extension - Denaturation - Annealing

Correct Answer: A. Denaturation - Annealing - Extension

Explanation: The correct order of the sequence is Denaturation - Annealing - Extension. Polymerase Chain Reaction (PCR) Step 1 Denaturation Double-stranded DNA is heated to around 95°C to separate into 2 single strands. Step 2 Annealing Addition of two primers, which anneal the flanking sequence of the desired fragments. An optimal temperature (5 degrees less than the average melting temperature of the primers) should be maintained to avoid non-specific amplification. Step 3 Elongation Enzyme used is thermostable Taq (Thermus Aquaticus) DNA polymerase. DNA polymerase elongates new strands in 5'3' direction, and the optimal temperature required for elongation is 72°C. If PCR goes through 'n' number of cycles, then '2n' number of products are formed.

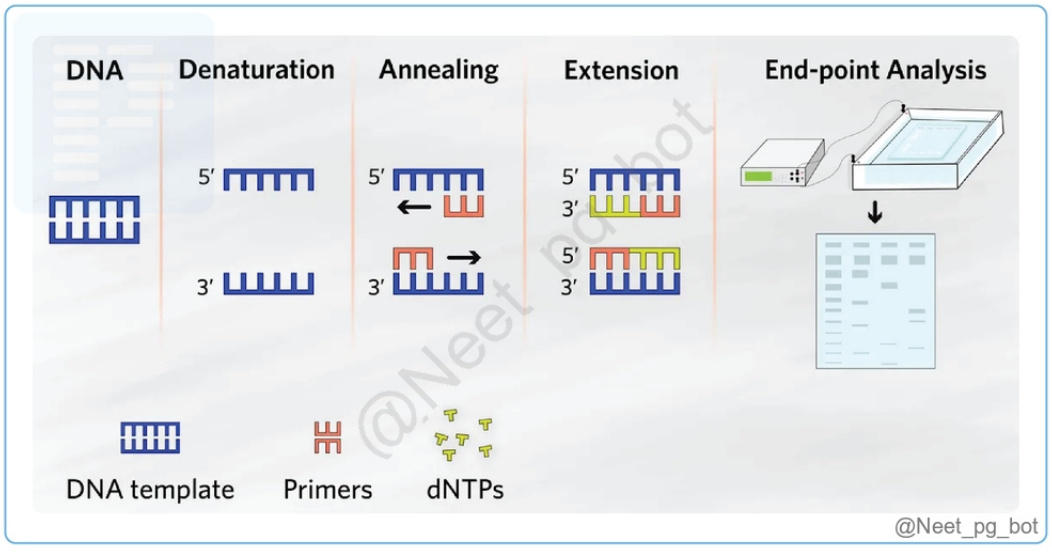

References:

Harper's Biochemistry, 32nd Edition, Page 452, 453.

↑ *Back to this question in Part A*

@Neet_pg_bot

Q20: A boy with karyotype 46,XY del(15)(q11–13) presents with obesity and elevated ghrelin levels. What is the most likely diagnosis? (Q879225)

A. Prader-Willi syndrome

B. Angelman syndrome

C. Cri du chat syndrome

D. Fragile X syndrome

Correct Answer: A. Prader-Willi syndrome

Explanation: Prader-Willi syndrome Explanaation: The boy with karyotype 46,XY del(15)(q11–13), obesity, and elevated ghrelin levels most likely has Prader-Willi syndrome (PWS). It results from paternal deletion of chromosome 15q11–13 . Maternal allele in this region is normally imprinted (silenced), so loss of the paternal copy → loss of gene expression. Features: Hypotonia and poor feeding in infancy → obesity in childhood Hyperphagia and elevated ghrelin levels Short stature, hypogonadism Mild to moderate intellectual disability Incorrect Options: Angelman syndrome (Option B): Due to maternal deletion of 15q11–13 . It features “happy puppet” phenotype with laughter, seizures, and ataxia. Cri du chat syndrome (Option C): Deletion of short arm of chromosome 5 (5p). It features cat-like cry, microcephaly. Fragile X syndrome (Option D): Due to CGG repeat expansion in the FMR1 gene (X chromosome). It features macroorchidism, large ears, intellectual disability.

References:

Robbins & Cotran, Pathologic Basis of Diseases, 10th Edition, Page 178,179

↑ *Back to this question in Part A*

@Neet_pg_bot

Q21: An adult tall male presents with subluxation of the lens, long arm span, pectus excavatum, and cardiac abnormalities. What is the most likely protein found to be defective? (Q844234)

A. Elastin

B. Collagen

C. Fibrillin

D. Laminin

Correct Answer: C. Fibrillin

■ *Listen (English)*

■ *Listen (Hindi)*

Explanation: Correct Option C – Fibrillin: The clinical presentation of the patient is highly suggestive of Marfan syndrome. It is caused by mutations in the FBN1 gene, leading to defective fibrillin, a protein essential for connective tissue integrity. Incorrect Options: Options A, B, and D are not affected by Marfan syndrome.

↑ *Back to this question in Part A*

@Neet_pg_bot

Q22: A 25-year-old man presents with headaches, visual disturbances, and hypertension. MRI brain shows a cerebellar hemangioblastoma, and abdominal imaging reveals multiple cysts in the kidneys along with a solid renal mass suggestive of renal cell carcinoma. His father had similar findings and died from a brain tumor in his 40s.Which of the following chromosomal abnormalities is most likely associated with his condition? (Q866733)

A. Deletion on chromosome 13q

B. Deletion on chromosome 17p

C. Deletion on chromosome 3p

D. Trisomy of chromosome 12

Correct Answer: C. Deletion on chromosome 3p

Explanation: The most likely diagnosis is Von Hippel-Lindau (VHL) disease , a hereditary condition characterised by the development of multiple cysts in the kidneys, pancreas, and other organs. Genetics and pathogenesis: Inheritance : Autosomal dominant Gene : VHL tumour suppressor Chromosomal location: 3p25–26 Pathogenesis: The VHL gene product is part of a complex that degrades hypoxia-inducible factor (HIF) under normal oxygen levels. Mutation or deletion → HIF is not degraded → ↑ VEGF, PDGF → abnormal angiogenesis and tumour formation. Classic tumours/cysts: CNS : Hemangioblastomas (esp. cerebellum, retina, spinal cord) Kidneys : Simple cysts, clear cell RCC Adrenal glands: Pheochromocytoma - headaches, palpitations, and sweating Pancreas: Cysts, neuroendocrine tumours Inner ear: Endolymphatic sac tumours 13q deletion (Option A): RB1 gene loss → retinoblastoma, osteosarcoma. 17p deletion (Option B): TP53 loss → Li-Fraumeni syndrome (sarcomas, breast cancer, brain tumors, adrenal carcinoma). Trisomy 12 (Option D) : common cytogenetic change in CLL.

↑ *Back to this question in Part A*

@Neet_pg_bot

Q23: FBN1 gene mutation is seen in which of the following genetic disorders? (Q866750)

A. Ehlers-Danlos syndrome

B. Marfan syndrome

C. Homocystinuria

D. von Hippel-Lindau syndrome

Correct Answer: B. Marfan syndrome

Explanation: Marfan syndrome is commonly associated with mutations in the FBN1 gene, which encodes the connective protein fibrillin on chromosome 15q21 . Pathophysiology: Abnormal fibrillin-1 → defective microfibrils → weakened elastic fibres. This leads to increased TGF-β activity , which contributes to the characteristic features of the syndrome. Mode of inheritance: Autosomal dominant. Multisystem disorder with involvement of the connective tissues. Clinical features: Skeletal abnormalities: Tall, thin build with long limbs (dolichostenomelia) Arachnodactyly Chest wall abnormalities like pectus excavatum/Pectus carinatum Thumb sign(On folding the thumb, it will protrude beyond the ulnar border of palm) or wrist sign is positive Increased joint laxity Scoliosis CVS abnormalities: Aortic root dilation → aortic regurgitation Risk of aortic aneurysm and dissection Mitral valve prolapse Arrhythmias Eye abnormalities: Ectopia lentis or subluxation of the lens of the eye Blindness, Myopia Pulmonary involvement: Increased risk of pneumothorax Diagnosis: Marfan syndrome is clinically diagnosed using the Ghent criteria Ehlers-Danlos syndrome (Option A): Usually due to collagen synthesis defects (type III or type V collagen), not FBN1. Homocystinuria (Option C): Due to cystathionine β-synthase deficiency → high homocysteine levels; may have marfanoid habitus but with downward lens dislocation and thrombosis risk. Von Hippel–Lindau syndrome (Option D): Due to VHL gene mutation on chromosome 3p, not FBN1; characterized by hemangioblastomas, renal cell carcinoma, and pheochromocytomas.

↑ *Back to this question in Part A*

@Neet_pg_bot

Q24: Which of the following is not an aneuploidy? (Q865426)

A. Bloom syndrome

B. Trisomy 13

C. Trisomy 21

D. Klinefelter syndrome

Correct Answer: A. Bloom syndrome

Explanation: Aneuploidy refers to a numerical abnormality in chromosomes — gain or loss of whole chromosomes. Normal human chromosome number: 46 (2n) Trisomy = 2n + 1 (47 chromosomes) Monosomy = 2n – 1 (45 chromosomes) Bloom Syndrome: Genetic defect : Mutation in BLM gene on chromosome 15. Autosomal recessive disorder caused by loss-of-function mutations in a DNA helicase that is required for homologous recombination repair in DNA repair. Result: Defective DNA repair → Chromosomal instability → Predisposition to cancer. Chromosome number is normal (46) - it's a chromosomal instability disorder , not a numerical abnormality. Condition Description Chromosome Count Aneuploidy Type Trisomy 13 (Option B) Patau syndrome 47 2n + 1 Trisomy 21 (Option C) Down syndrome 47 2n + 1 Klinefelter syndrome (Option D) 47,XXY (extra X chromosome in males) 47 2n + 1 (sex chromosome)

References:

Robbins and Cotran's Pathologic Basis of Disease, 10th Edition, Page 314.

↑ *Back to this question in Part A*

@Neet_pg_bot

Q25: A lymphoma characterised by the presence of centrocytes and centroblasts, along with BCL2 positivity and CD10 expression, is most commonly associated with which chromosomal translocation? (Q866357)

A. t(2;5)

B. t(8;14)

C. t(14;18)

D. t(11;14)

Correct Answer: C. t(14;18)

Explanation: The given HPE findings of the presence of centrocytes and centroblasts are consistent with Follicular lymphoma, which is associated with BCL2- gene translocation and CD10+; the chromosomal translocation associated with it is t(14:18). Follicular lymphoma (FL) is a malignant neoplasm originating from germinal centre B-cells, characterised by the t(14;18) translocation leading to overexpression of BCL2. Clinically, it presents with painless lymphadenopathy and may include systemic symptoms. Histopathologically, FL exhibits a nodular growth pattern with centrocytes(Small cells with cleaved nuclei and scanty cytosol) and centroblasts(Larger cells with open nuclear chromatin, several nucleoli) Immunohistochemistry shows positivity for CD10/19/20, BCL2, and BCL6, and negativity for CD5. Management focuses on palliative approaches due to its indolent but incurable nature. Incorrect Options: t(2;5) (Option A): This translocation is associated with Anaplastic large cell lymphoma. It is seen in children or young adults. It is associated with an ALK gene mutation on chromosome 2. Histopathology reveals large anaplastic cells with horseshoe-shaped nuclei and voluminous cytoplasm (Hallmark cells/Doughnut cells). It usually presents with soft tissue involvement (mimicking metastatic carcinoma). t(8;14) (Option B): This translocation is associated with Burkitt's lymphoma. Histopathological examination reveals numerous mitotic and apoptotic cells, nuclear remnants phagocytosed by benign macrophages with abundant clear

cytoplasm, creating a characteristic "starry sky" pattern. Immunohistochemistry shows positivity for IgM, CD19, CD20, CD10, and BCL6, but negativity for BCL2. t(11;14) (Option D): This translocation is associated with Mantle cell lymphoma. Immunohistochemistry shows positivity for Cyclin D1, CD19, CD20, surface immunoglobulins (usually IgM and IgD), and CD5, but CD23 is negative and HPE shows small lymphoid cells with irregular nuclear outlines, condensed chromatin, and scanty cytoplasm

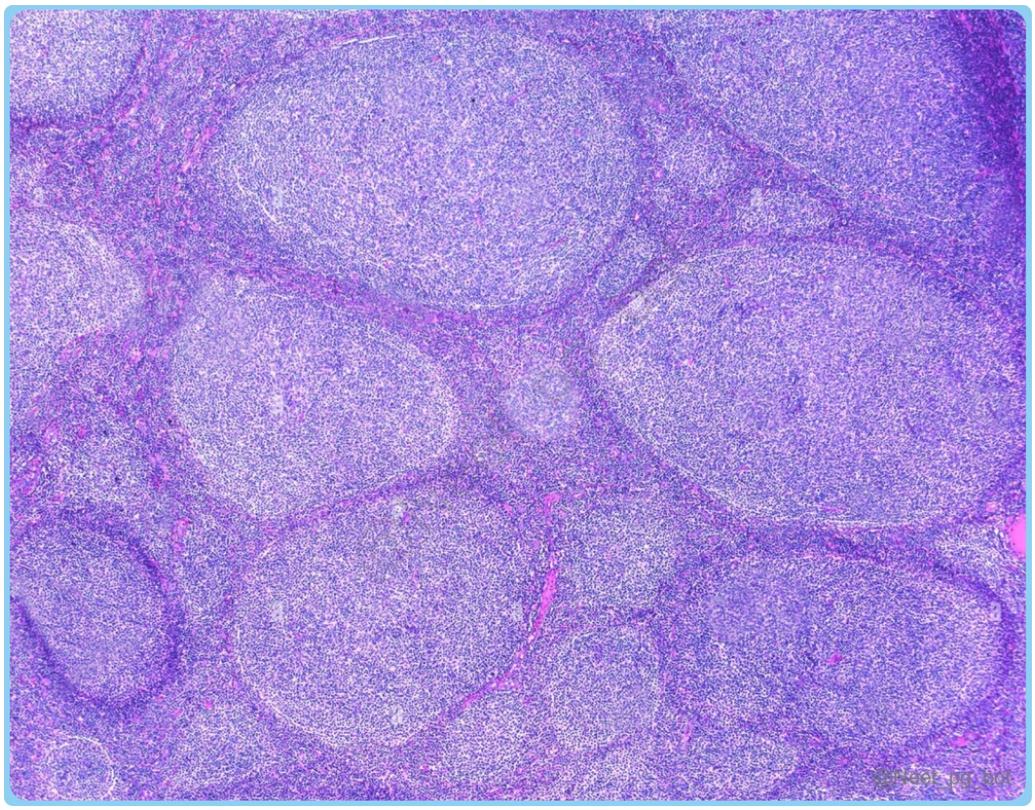

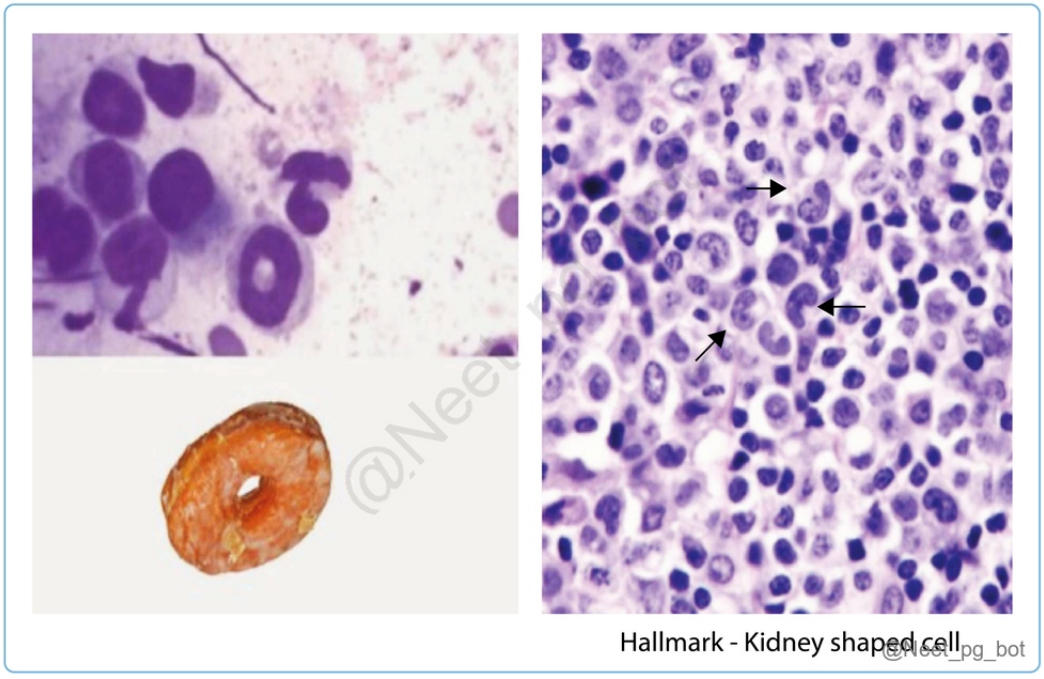

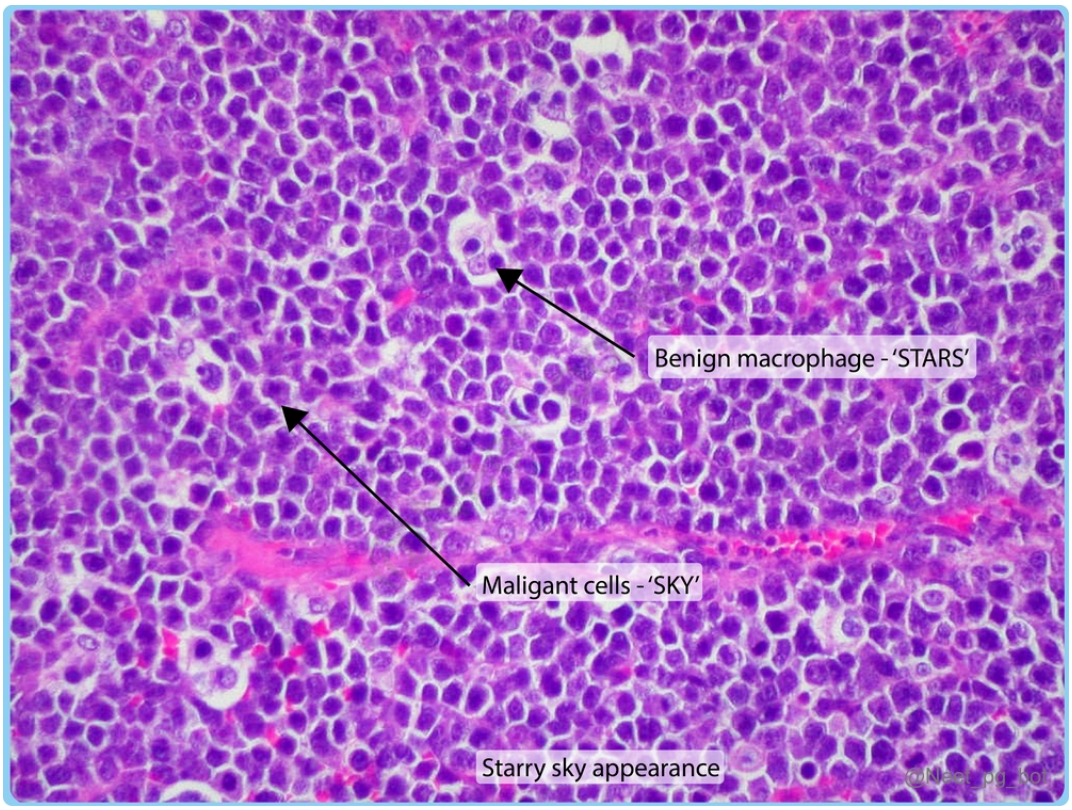

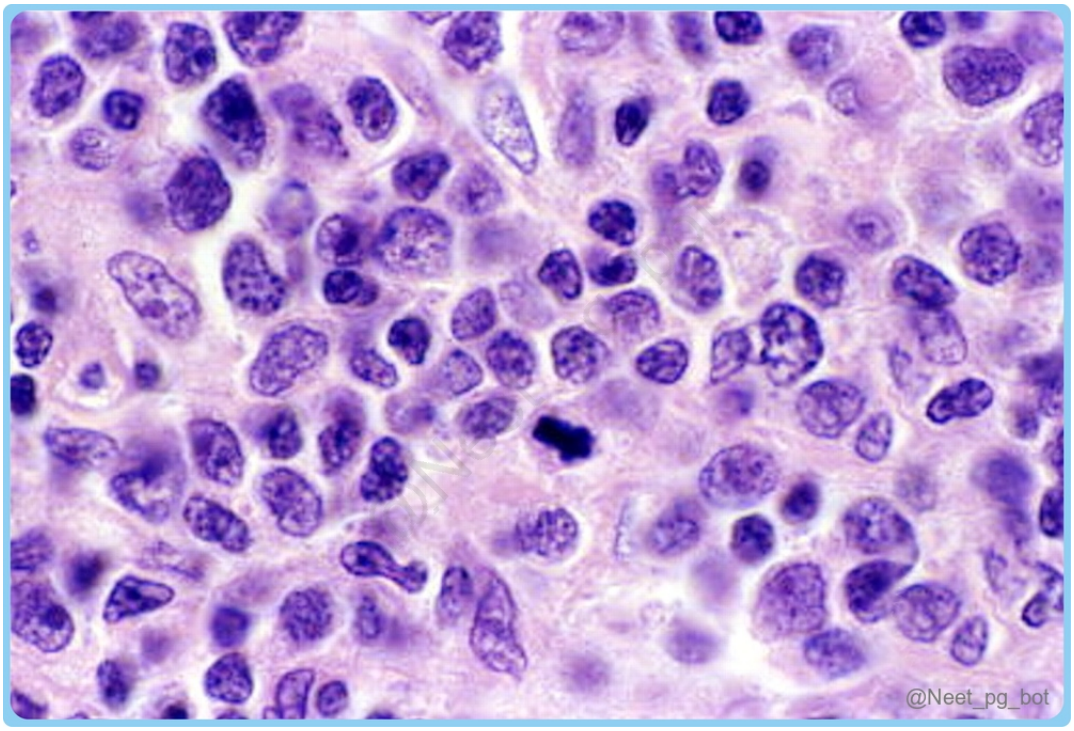

References:

.

↑ *Back to this question in Part A*

Q26: Which of the following diseases exhibits the inheritance pattern shown? (Q866378)

A. Kearns-Sayre syndrome

B. Williams syndrome

C. Achondroplasia

D. Cystic fibrosis

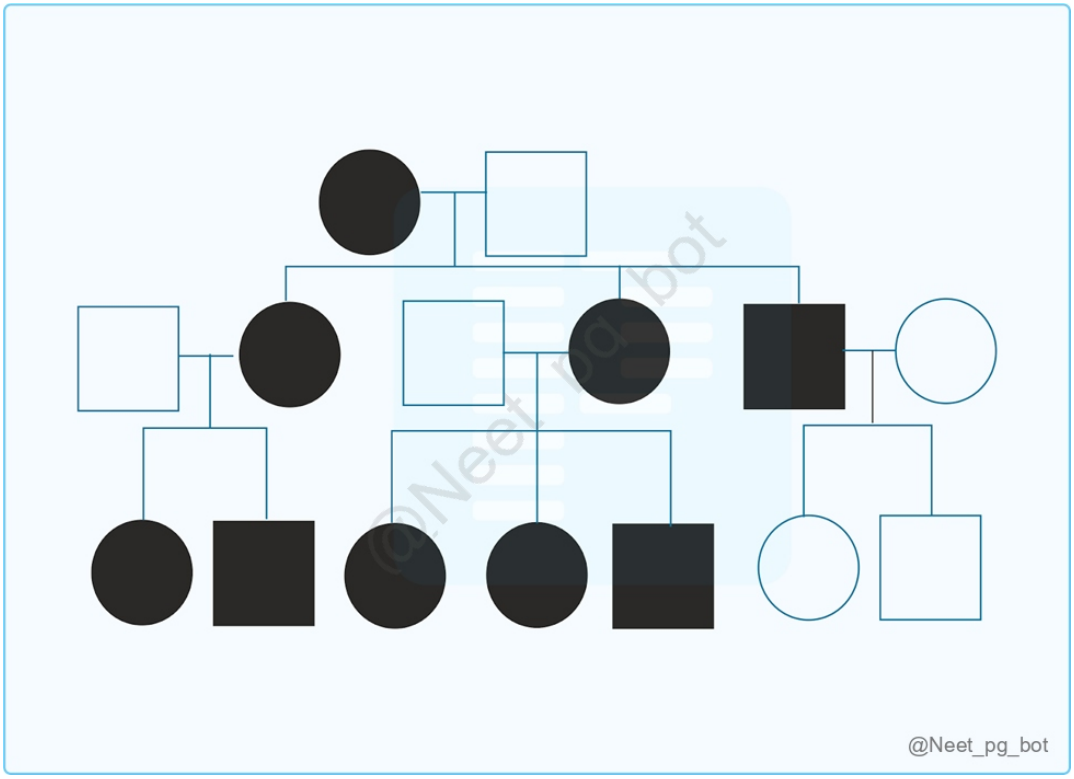

Correct Answer: A. Kearns-Sayre syndrome

Explanation: Kearns-Sayre syndrome follows mitochondrial inheritance, which matches the pedigree pattern shown. Key features of mitochondrial inheritance: Inherit exclusively through the maternal line Affected mothers pass the trait to ALL of their children (both male and female) Affected fathers pass the trait to NONE of their children The trait appears in every generation through maternal lines Both sexes can be affected, but only females transmit the condition Incorrect Options Option C) Achondroplasia - Incorrect ; Inheritance pattern: Autosomal dominant. While autosomal dominant traits do appear in every generation, they show transmission from BOTH affected mothers and affected fathers to their children. In this pedigree, the pattern specifically shows maternal-only transmission, which rules out autosomal dominant inheritance. Option B) Williams Syndrome -

Incorrect; Inheritance pattern: Typically sporadic (de novo deletions on chromosome 7). Williams syndrome is rarely inherited in a familial pattern. It usually occurs as a new mutation in an individual, not passed through multiple generations as shown in this pedigree. The consistent multi-generational pattern here is inconsistent with sporadic occurrence. Option D) Cystic Fibrosis - Incorrect; Inheritance pattern: Autosomal recessive. Autosomal recessive conditions skip generations and typically show two unaffected parents producing affected children. This pedigree shows affected individuals in consecutive generations with clear vertical transmission, which is incompatible with recessive inheritance.

References:

.

↑ *Back to this question in Part A*

@Neet_pg_bot

Q27: Match the following with the appropriate disorder. A. Autosomal recessive Kennedy disease B. Mitochondrial 2. Duchenne’s muscular dystrophy C. X-linked recessive 3. Leber’s disease D. Trinucleotide repeats 4. Cystic fibrosis (Q853376)

A. A-4, B-3, C-1, D-2

B. A-4, B-3, C-2, D-1

C. A-2, B-1, C-3, D-4

D. A-1, B-2, C-4, D-3

Correct Answer: B. A-4, B-3, C-2, D-1

Explanation: Autosomal recessive Cystic fibrosis Mitochondrial Leber’s disease X-linked recessive Duchenne’s muscular dystrophy Trinucleotide repeats Kennedy disease Other genetic disorders: Autosomal Recessive Disorders (Mnemonic: Pasta Fried Chawal/ Big Fax) P - Phenylketonuria A - Alkaptonuria S - Sickle cell anaemia Ta - Thalassemia Fried - Friedreich's ataxia C - Cystic Fibrosis H - Hemophilia C, Homocystinuria, Hemochromatosis A - Alpha 1 Antitrypsin Deficiency W - Wilson Disease A - Albinism, Congenital Adrenal Hyperplasia L - Lysosomal Storage Disease, Glycogen Storage Disease Big -Bloom syndrome Fa - Fanconi anemia, Ataxia telangiectasia X - Xeroderma pigmentosum X-linked Recessive (Mnemonic: WISE ABCDEFGH) Wise- Wiskott Aldrich Syndrome AB- Hemophilia A, B B- Bruton's Hypogammaglobulinemia . C- Chronic Granulomatous Disease, Red Green Color Blindness D- DMD (Duchenne’s muscular dystrophy) , BMD (Becker Muscular Dystrophy) E- Lesch Nyhan Syndrome F- Fabry Disease, Fragile X Syndrome G- G6PD Deficiency H- Hunter Disease Trinucleate-Repeat Disorders Fragile X Syndrome Friedreich ataxia Myotonic dystrophy Spinobulbar muscular atrophy (Kennedy disease) Dentatorubral-pallidoluysian atrophy (Haw River syndrome) Spinocerebellar ataxia Huntington disease

References:

Robbins and Cotran Pathological Basis of Diseases, 10th Edition, Page 145, 146, 174.

↑ *Back to this question in Part A*

@Neet_pg_bot

Q28: Identify the syndrome associated with the following chromosomal pattern on chromosome number 15 : (Q843980)

A. Angelman syndrome

B. Prader-Willi syndrome

C. Rett syndrome

D. Cri-du-chat syndrome

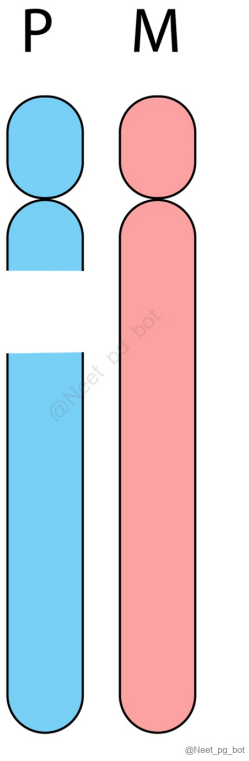

Correct Answer: B. Prader-Willi syndrome

■ *Listen (English)*

■ *Listen (Hindi)*

Explanation: The given image shows a part of paternal chromosome 15 deleted, which is seen in Prader-Willi syndrome. Prader Willi Syndrome In Prader-Willi syndrome, maternal imprinting is done, and paternal deletion

happens. Clinical features: Mental Retardation Short Stature Obesity/hyperphagia (because of an increase in the hormone called Ghrelin) Incorrect Options: Angelman syndrome (Option A): In Angelman syndrome, the maternal region of chromosome 15 is deleted. Rett Syndrome (Option C): Caused by mutation in the MECP2 gene Chromosomal Location: X chromosome (Xq28) Type of Abnormality: Single-gene mutation (not a chromosomal structural abnormality) Cri du Chat Syndrome (Option D): Cause: Deletion of the short arm of chromosome 5 Chromosomal Abnormality: 46,XX or 46,XY, del(5p)

References:

.

↑ *Back to this question in Part A*

@Neet_pg_bot

Q29: A 23-year-old female with a height of 4 feet has a karyotype, as shown in the image below. Which of the following conditions is the most likely etiology? (Q844074)

A. Turner syndrome

B. Klinefelter syndrome

C. Mayer-Rokitansky-Küster-Hauser syndrome (MRKHS)

D. Edwards syndrome

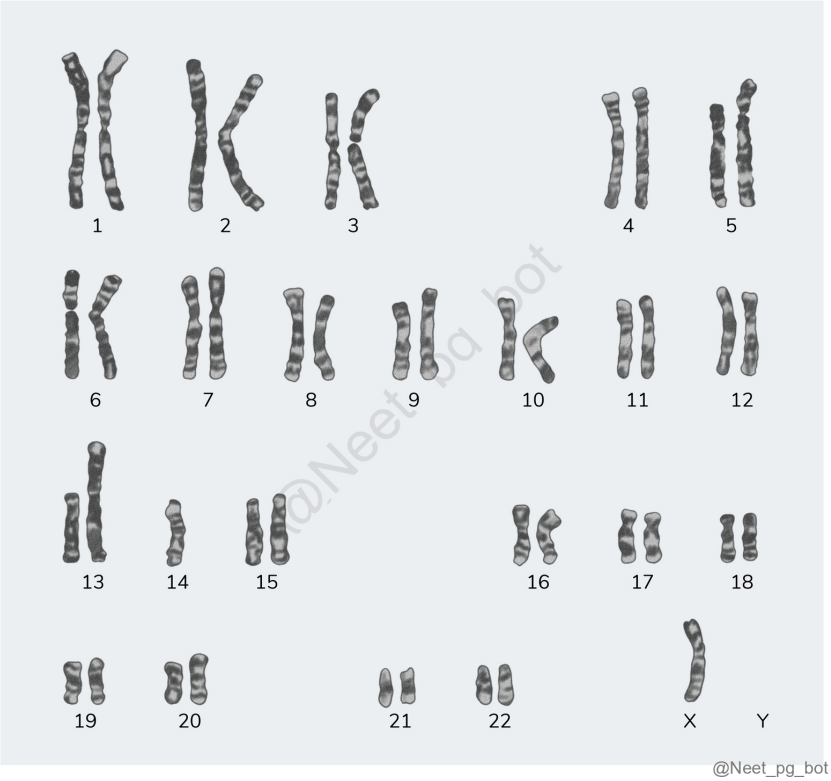

Correct Answer: A. Turner syndrome

- *Listen (English)*
- *Listen (Hindi)*

Explanation: The given karyotype shows an absence of the Y chromosome and monosomy of the X chromosome, which is seen in Turner syndrome. Turner's Syndrome Pathogenesis: Either 45 X0 (deleted) or 46 Xr(X) (Ring Chromosome) In Turner's Syndrome, the IQ is normal. Patients with higher webbing of the neck have higher chances of cardiac symptoms. Clinical features: Incorrect Options: Klinefelter syndrome (Option B): In Klinefelter syndrome, an extra X chromosome is present. Mayer-Rokitansky-Küster-Hauser syndrome (MRKHS) (Option C): Mayer-Rokitansky-Küster-Hauser syndrome is characterized by the failure of the uterus and the vagina to develop properly in women who have normal ovarian function and normal external genitalia. Edwards syndrome (Option D): In Edwards syndrome, there is trisomy of chromosome 18.

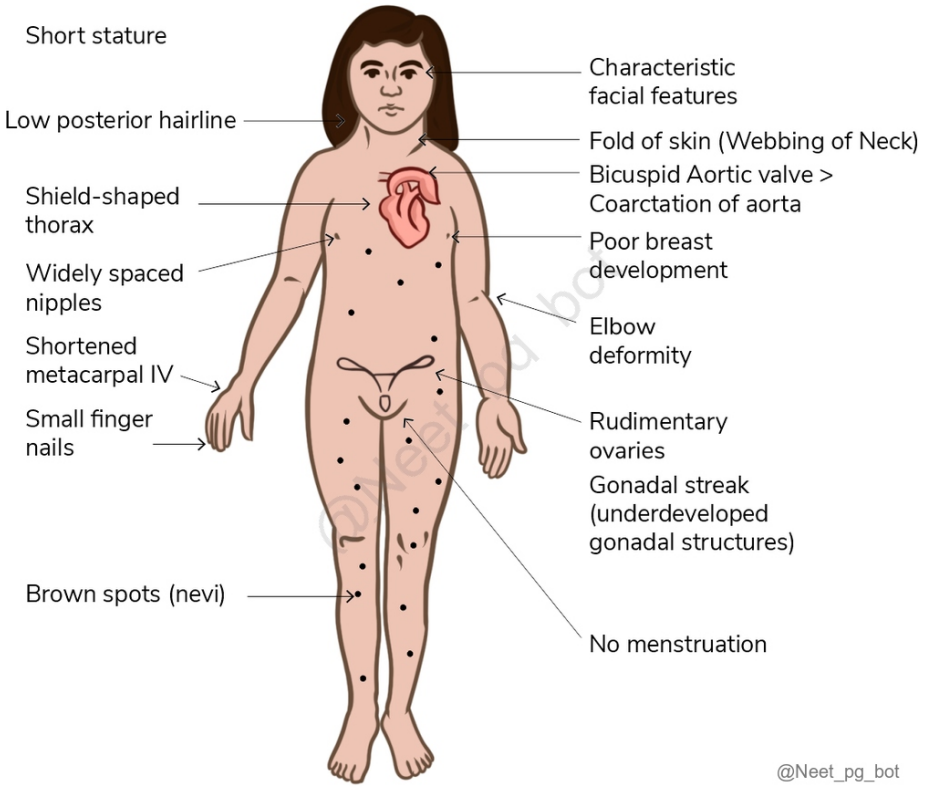

References:

https://www.ncbi.nlm.nih.gov/books/NBK554621/.

↑ *Back to this question in Part A*

@Neet_pg_bot

Q30: Identify the disease associated with the image provided: (Q844143)

A. Gaucher's disease

B. Tay-Sachs disease

C. Sandhoff's disease

D. Fabry's disease

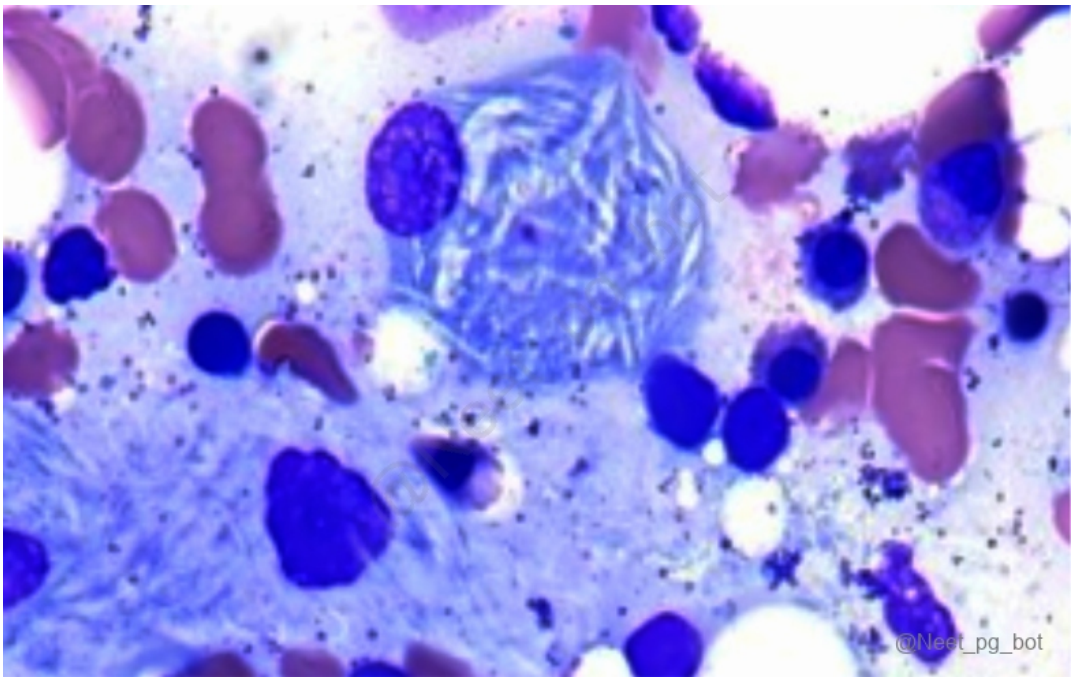

Correct Answer: A. Gaucher's disease

■ *Listen (English)*

■ *Listen (Hindi)*

Explanation: The image shows a Gaucher cell, which is a lipid-laden macrophage. Cytoplasm has a crumpled tissue paper appearance, characteristic of Gaucher's disease. It is caused by deficiency of β-glucocerebrosidase. This leads to accumulation of glucocerebroside in macrophages. Common sites:Bone marrow, spleen, liver. Clinical features include hepatosplenomegaly, anemia,bone pain. Incorrect Options: Option B) Tay-Sachs disease: Shows cherry-red spot on macula, no hepatosplenomegaly. Neurons are affected, not macrophages. Option C) Sandhoff's disease: Similar to Tay-Sachs but with hepatosplenomegaly. Still no Gaucher cells or tissue-paper macrophages. Option D) Fabry's disease: X-linked disorder with angiokeratomas and renal failure. No characteristic macrophages in bone marrow.

References:

.

↑ *Back to this question in Part A*

@Neet_pg_bot

Q31: Which of the following diseases follows the mode of inheritance shown in the image provided? (Q844173)

A. Wiskott-Aldrich syndrome

B. Wilson's disease

C. Prader-Willi syndrome

D. Achondroplasia

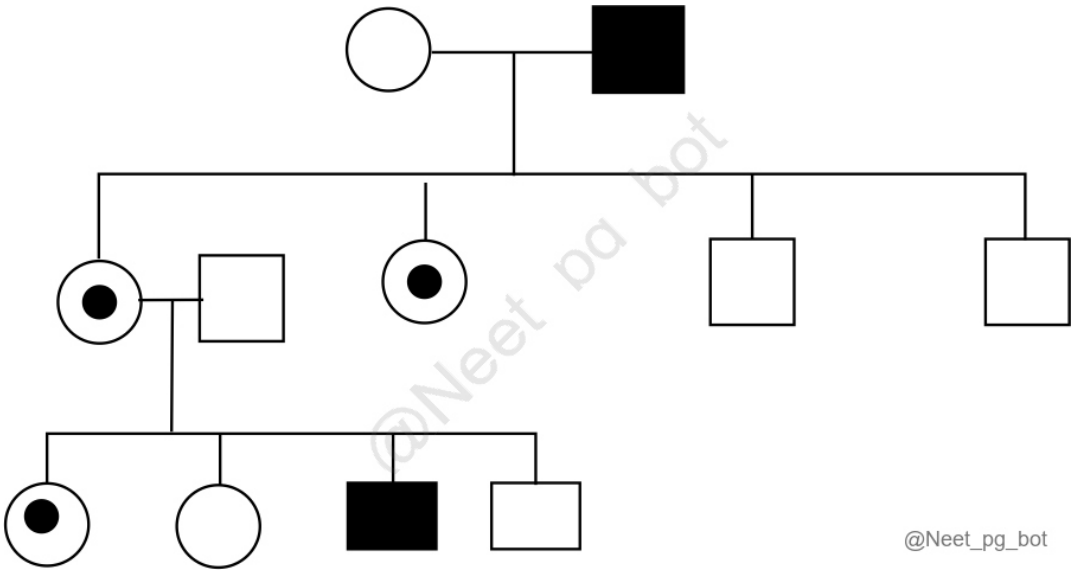

Correct Answer: A. Wiskott-Aldrich syndrome

■ *Listen (English)*

■ *Listen (Hindi)*

Explanation: Correct Option: A) Wiskott-Aldrich syndrome The given pedigree shows X-linked recessive inheritance, which is seen in Wiskott-Aldrich syndrome. Incorrect Options: Wilson's disease (Option B): Autosomal recessive inheritance Prader-Willi syndrome (Option C): Genomic imprinting disorder (not a classic Mendelian pattern) Achondroplasia (Option D): Autosomal dominant

References:

.

↑ *Back to this question in Part A*

@Neet_pg_bot

Q32: The SRY gene is present on: (Q857449)

A. Y-chromosome short arm

B. Y-chromosome long arm

C. X-chromosome short arm

D. X-chromosome long arm

Correct Answer: A. Y-chromosome short arm

Explanation: The SRY (Sex-determining Region Y) gene is crucial for male sex determination. It is located on the distal short arm of the Y chromosome. Yp11.3 is the precise genetic locus where "Yp" refers to the short arm ("p") of the Y chromosome. Mutations in this gene can lead to disorders of sex development (DSDs), such as Swyer syndrome (46, XY gonadal dysgenesis) . Y-chromosome long arm (Option B) is rich in genes related to male reproductive functions, but the SRY gene is located on the short arm (Yp). X-chromosome short arm (Option C) & X-chromosome long arm (Option D): The X chromosome plays no role in initiating male sex determination . Instead, it carries genes like DAX1 (Xp21), which antagonizes SRY function , and XIST (Xq13), which regulates X-inactivation .

References:

Robbins and Cotran Pathologic Basis of Disease, 10th Edition, Page 179

↑ *Back to this question in Part A*

@Neet_pg_bot

Q33: Which mutation is linked to the Philadelphia chromosome? (Q860544)

A. Inversion

B. Deletion

C. Reciprocal translocation

D. Insertion

Correct Answer: C. Reciprocal translocation

Explanation: The Philadelphia Chromosome is a reciprocal translocation involving chromosomes 9 and 22 that is commonly identified in CML (chronic myeloid leukaemia). The two chromosome breaks lie within: ABL gene on chromosome 9 BCR (breakpoint cluster region) gene on chromosome 22. Nonhomologous end-joining causes a reciprocal translocation , resulting in the formation of an oncogenic BCR-ABL fusion gene on the derivative chromosome 22, known as the Philadelphia chromosome. BCR-ABL fusion genes encode chimeric BCR-ABL proteins with constitutive tyrosine kinase activity. Inversion (Option A): In an inversion, a segment of a chromosome is flipped within the same chromosome but remains in its original location. Example of inversion-related disorder: Hemophilia A (due to intrachromosomal inversion in the F8 gene). Deletion (Option B) involves the loss of a chromosome segment, leading to missing genetic material. Example of deletion-related disorder: Cri-du-chat syndrome (chromosome 5p deletion) Insertion (Option D) occurs when a segment of one chromosome is inserted into another chromosome without reciprocal exchange. Example of insertion-related disorder: Some cases of hereditary cancer syndromes due to gene insertions.

References:

Robbins and Cotran Pathologic Basis of Disease, 10th Edition, Page 317.

↑ *Back to this question in Part A*

@Neet_pg_bot

Q34: A teenager was brought to the OPD with complaints of delayed fertility and primary amenorrhea. Physical examination reveals a webbed neck and widely spaced nipples. Which karyotype is associated with a given condition? (Q860555)

A. 45, X

B. 47, XXY

C. 47, XXX

D. 47, XYY

Correct Answer: A. 45, X

Explanation: The teenager presenting with delayed fertility, primary amenorrhea, a webbed neck, and widely spaced nipples is diagnosed with Turner Syndrome , which is characterised by the karyotype 45, X (monosomy X) . It is characterised by complete or partial monosomy of the X chromosome, leading to hypogonadism in phenotypic females. Clinical features: Short stature, webbed neck, lymphedema, and primary amenorrhea. The image below shows karyotyping in Turner syndrome. {{caption_text}} 47, XXY (Option B) is Klinefelter syndrome , which occurs in males with an extra X chromosome, leading to hypogonadism, small testes, gynecomastia, reduced body/facial hair, and infertility. While it is associated with tall stature and sometimes mild intellectual disabilities, it does not present with features like a webbed neck, widely spaced nipples, or primary amenorrhea, which are characteristic of Turner syndrome. 47, XXX (Option C) is Triple X Syndrome , which occurs in females with an extra X chromosome. It is usually asymptomatic or causes mild developmental delays but does not present with primary amenorrhea or webbed neck, which are typical of Turner syndrome. 47, XYY (Option D) is Jacob's Syndrome , which occurs in males with an extra Y chromosome, leading to tall stature and mild intellectual disabilities, but it does not cause primary amenorrhea, webbed neck, or widely spaced nipples, which are characteristic of Turner syndrome.

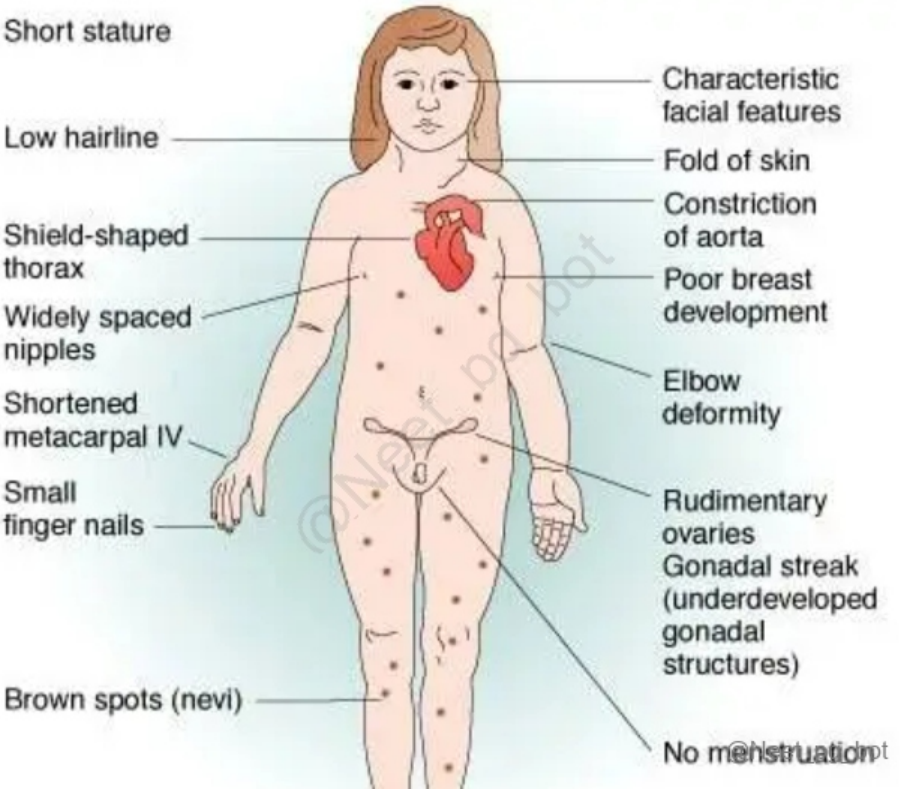

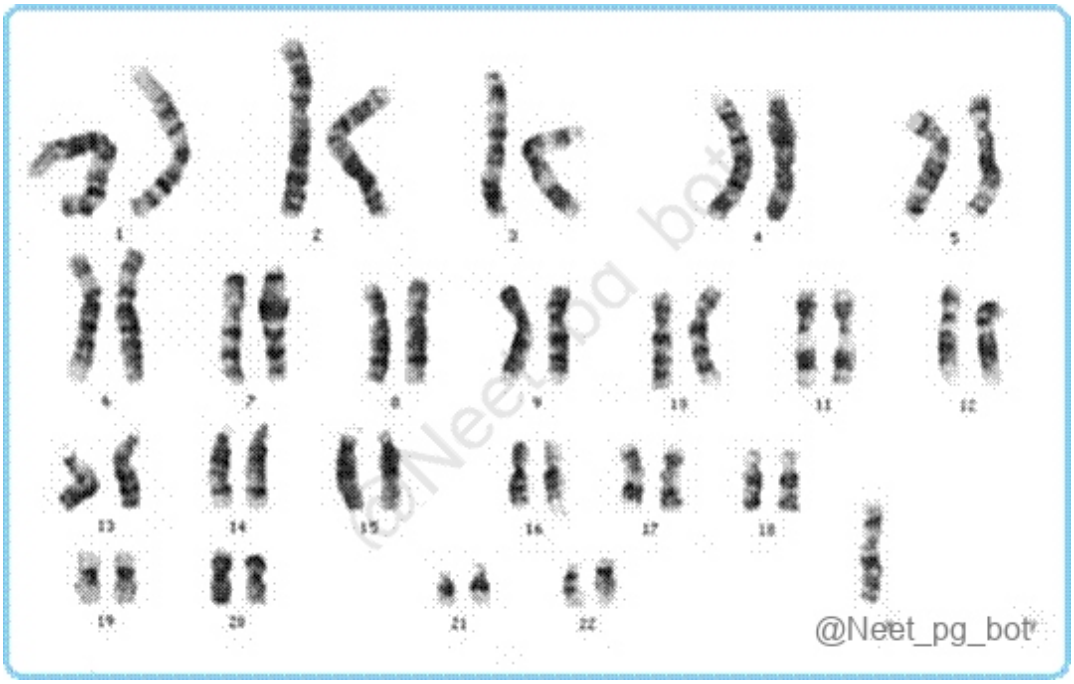

References:

Robbins and Cotran Pathologic Basis of Disease, 10th Edition, Page 172.

↑ *Back to this question in Part A*

@Neet_pg_bot

Q35: Which of the following is not a feature of G6PD deficiency? (Q840016)

A. Males and females are equally affected

B. Oxidative stress

C. Absence of NADPH

D. Presence of Heinz's bodies

Correct Answer: A. Males and females are equally affected

■ *Listen (English)*

■ *Listen (Hindi)*

Explanation: Correct Option A - Males and females are equally affected: G6PD deficiency, being a recessive X-linked trait, puts males at a significantly higher risk of symptomatic disease compared to females. T Incorrect Options: Option B, C, and D: In G6PD deficiency, NADPH does not form, and the glutathione pathway does not occur. This leads to an increase in the concentration of free radicals (oxidative stress). Oxidative stress causes the denaturation of hemoglobin and leads to the formation of Heinz bodies.

References:

.

↑ *Back to this question in Part A*

@Neet_pg_bot

Q36: A child with a strawberry skull, mental retardation, and the given karyotype suggests which diagnosis? (Q860199)

A. Patau syndrome

B. Edward syndrome

C. Prader-Willi syndrome

D. Angelman syndrome

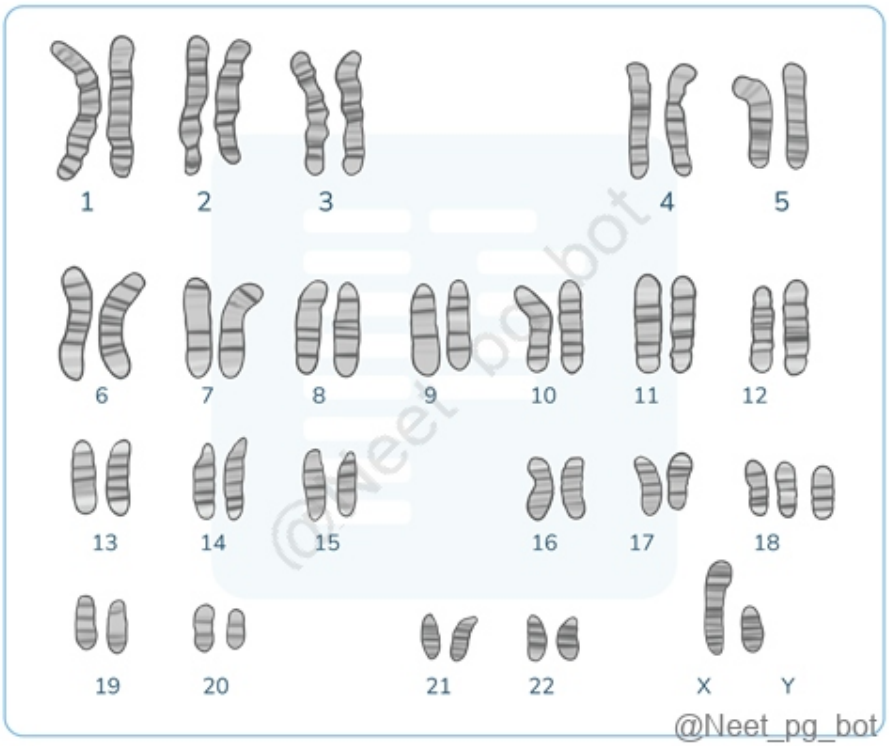

Correct Answer: B. Edward syndrome

Explanation: A child with a "strawberry skull," intellectual disability, and the given karyotype likely has trisomy 18 , indicating a diagnosis of Edwards Syndrome . It is caused by the presence of an extra copy of chromosome 18. Clinical features: Low birth weight Strawberry skull (small chin & prominent occiput/back side of the head). Closed fists with overlapping fingers Rocker-bottom feet Microcephaly Micrognathia Cardiac and renal malformations Mental retardation 95% of cases die in the 1st year of life Patau syndrome (Option A) , caused by trisomy 13 , is characterised by features such as polydactyly (extra fingers), cleft lip and palate, keyhole-shaped pupils/coloboma, intellectual disability, and patent ductus arteriosus (PDA), among others. Prader-Willi syndrome (Option C) occurs when there is maternal disomy of chromosome 15, leading to the absence of the paternal allele. Key features include intellectual disability (MR), short stature, and obesity/hyperphagia due to elevated levels of the hormone ghrelin. Angelman syndrome (Option D), often referred to as "Happy Puppet" syndrome , arises when there is a paternal disomy of chromosome 15, leading to the absence of the maternal allele. Key features include seizures, ataxia, intellectual disability (MR), and inappropriate laughter.

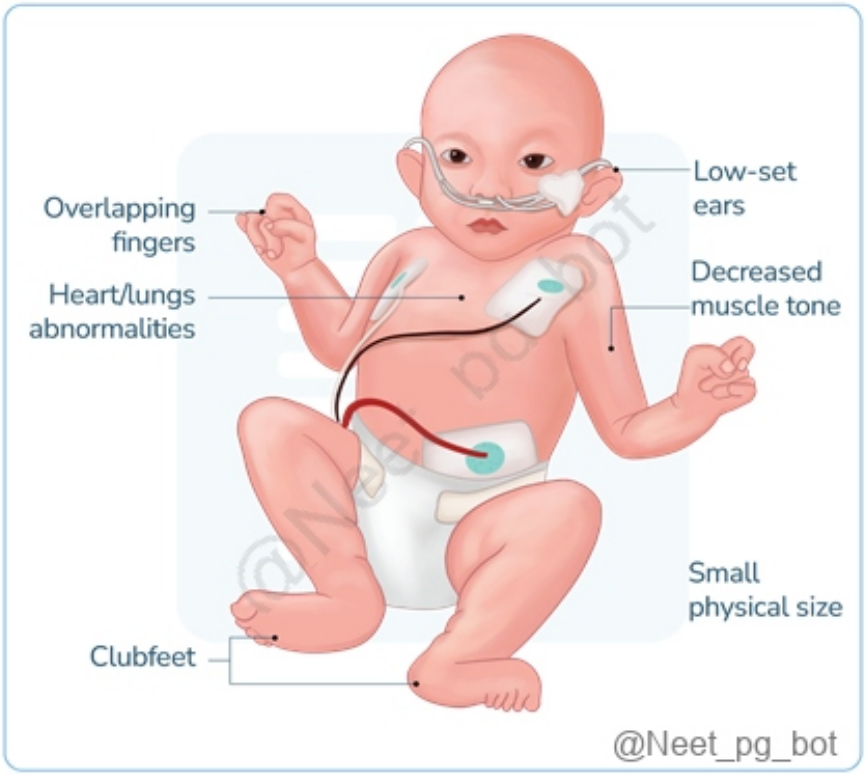

References:

Robbins & Cotran Pathologic Basis of Disease, 10th Edition, Page 166-169.

↑ *Back to this question in Part A*

@Neet_pg_bot

Q37: All of the following are used to detect abnormal gene sequences, except? (Q857421)

A. FISH

B. RFLP analysis

C. Pyrosequencing

D. Flow cytometry

Correct Answer: D. Flow cytometry

Explanation: Flow cytometry is not used to detect abnormal gene sequences . Flow cytometry is a technique primarily used to measure the physical and chemical properties of cells, such as cell size, granularity, and protein

expression. It has numerous uses in genomic studies, with a high focus on monitoring cell cycle phases and cell viability, and is more often employed for immunophenotyping and cell sorting. Fluorescence in situ Hybridization (FISH) (Option A) detects DNA sequence alterations like translocations, deletions, and amplifications using fluorescent probes to bind specific DNA regions, identifying chromosomal abnormalities. RFLP analysis (Option B) (Restriction Fragment Length Polymorphism) detects DNA sequence variations by analyzing the lengths of restriction enzyme-digested DNA fragments. Pyrosequencing (Option C) is a type of DNA sequencing technology that can directly read DNA sequences by measuring the release of pyrophosphate during nucleotide incorporation. It allows for the detection of mutations, SNPs, and other genetic alterations.

References:

Robbins and Cotran Pathologic Basis of Disease, 10th Edition, Page 182 NIH Link

↑ *Back to this question in Part A*

@Neet_pg_bot

Q38: What is the interpretation of the given pedigree chart? (Q857425)

A. Incomplete penetrance

B. Autosomal dominant

C. Autosomal recessive

D. Pseudo-dominance

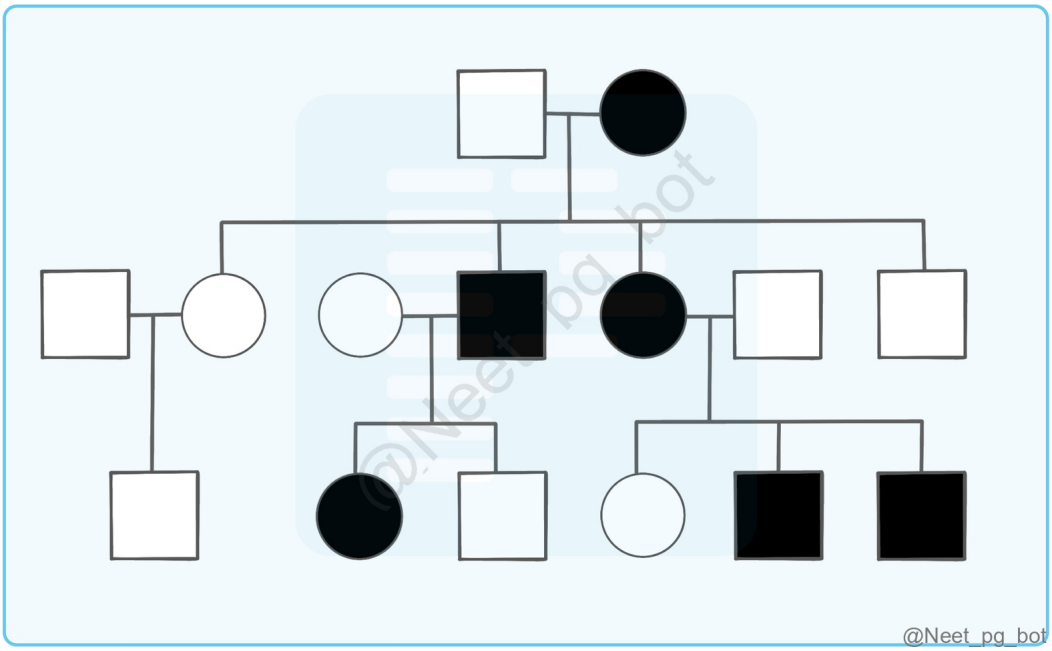

Correct Answer: B. Autosomal dominant

Explanation: The interpretation of the pedigree chart given reveals Autosomal dominant inheritance , which means that an individual only needs one copy of the mutated gene to express the condition. The affected individuals appear in every generation, as one parent passes on the mutated gene to their offspring. Both males and females can be affected equally because the gene is located on one of the autosomes . If an affected person has children, there is a 50% chance that each child will inherit the mutated gene and be affected. Incomplete penetrance (Option A) refers to a situation where some individuals inherit the mutant gene but are phenotypically normal. Autosomal Recessive (Option C) inheritance requires two copies of the mutation for the trait to be expressed. It typically shows horizontal transmission and can skip generations. Pseudo dominance (Option D) occurs when a recessive allele appears to be expressed in the heterozygous condition due to the limited number of crossovers between linked genes.

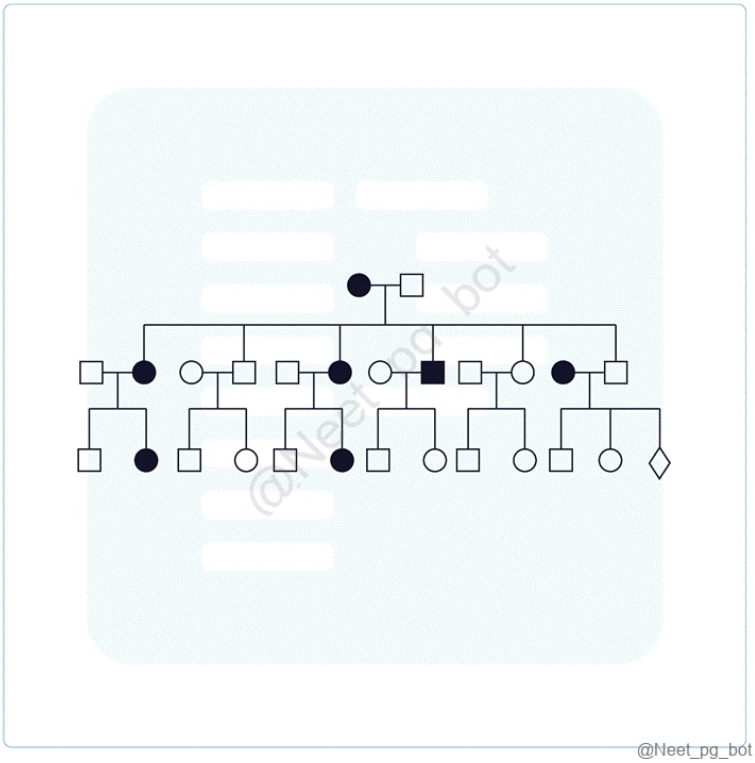

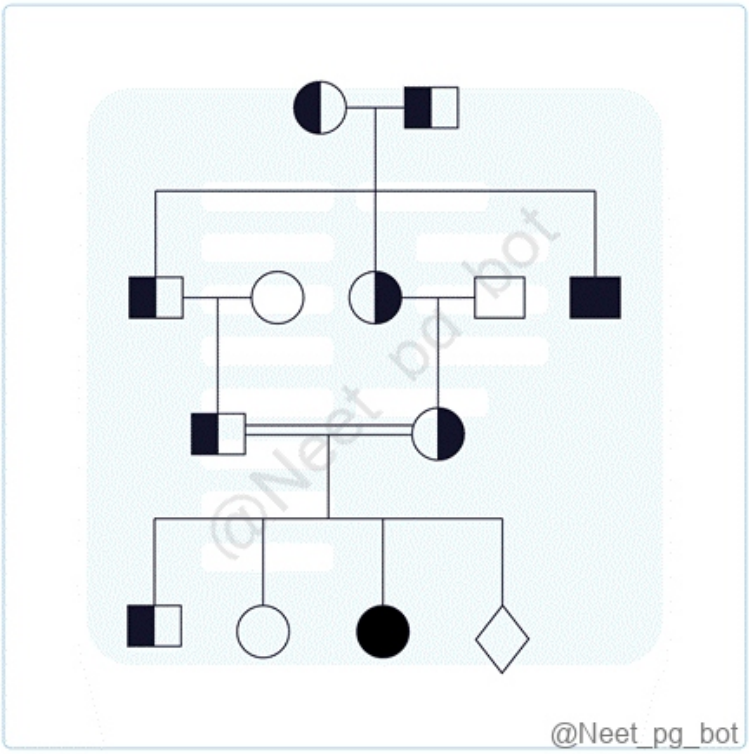

References:

Ghai Textbook of Paediatrics, 10th Edition, Pages 671, 672

↑ *Back to this question in Part A*

@Neet_pg_bot

Q39: Match the following genetic abnormalities with their disorders. A. Trinucleotide repeat Patau syndrome B. Trisomy 18 2. Huntington C. Trisomy 13 3. Sickle cell anemia D. Hb beta chain Glu 4. Edward syndrome (Q857437)

A. A-1, B-3, D-4, D-2

B. A-1, B-2, C-3, D-4

C. A-2, B-4, C-1, D-3

D. A-2, B-1, C-4, D-3

Correct Answer: C. A-2, B-4, C-1, D-3

Explanation: Trinucleotide repeat Huntington Trisomy 18 Edward syndrome Trisomy 13 Patau syndrome Hb beta chain Glu Sickle cell anemia Trinucleotide repeat disorders : These are caused by the expansion of specific three-nucleotide sequences in genes. They are characterized by the instability of repeat numbers, which can increase across generations or even within an individual’s lifetime, a key feature of these conditions. Examples of Trinucleotide repeat and the disease-associated are: Huntington's disease: CAG Fragile X syndrome: CGG Myotonic dystrophy type 1: CTG Trisomy 18 (Edward syndrome): Features include Low birth weight Closed fists with overlapping fingers Rocker-bottom feet Microcephaly Micrognathia Cardiac and renal malformations Mental retardation 95% of cases die in the 1st year of life Trisomy 13 (Patau Syndrome): Features include Rocker-bottom feet Severe intellectual disability Keyhole/ Coloboma (eyes) Microphthalmia, microcephaly, holoprosencephaly Cleft lip/palate Polydactyly Congenital heart disease Renal defects-Polycystic kidney disease Umbilical hernia, Omphalocele Hb beta chain Glu This mutation is seen in sickle cell anaemia and produces haemoglobin S (HbS), making red blood cells prone to hemolysis. This leads to complications such as splenic fibrosis, organ infarcts, and bone pain due to HbS polymerization and vaso-occlusion.

References:

Robbins and Cotrans Pathologic Basis of diseases, 10th Edition, Page 144, 166-169, Pubmed Link Uptodate Link

↑ *Back to this question in Part A*

@Neet_pg_bot

Q40: The family pedigree chart is given below. Identify the mode of inheritance of this condition. (Q854889)

A. Autosomal dominant

B. Autosomal recessive

C. X-linked dominant

D. X-linked recessive

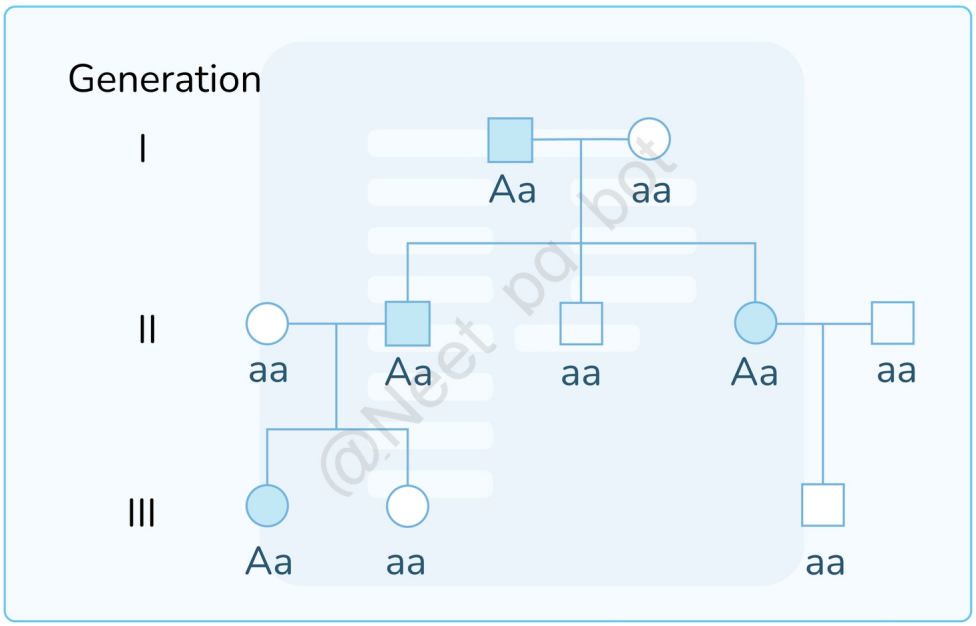

Correct Answer: A. Autosomal dominant

Explanation: The disorder appears in every generation, showing vertical transmission, which strongly suggests an autosomal dominant pattern. Both males and females are affected, excluding sex-linked patterns. An affected father passing the condition to his son rules out X-linked inheritance (X-linked disorders cannot show father-to-son transmission). The pedigree shows affected individuals as Aa, a classic representation for heterozygous dominant. {{caption_text}} Incorrect Options: Option B) Autosomal recessive - Usually skips generations (affected parents often unaffected carriers), which the pedigree does not show; here affected individuals appear in every generation. Option C) X-linked dominant - Would show mother-to-child transmission from affected mothers to sons and daughters, but an affected father passing to a son (seen here) rules this out. Option D) X-linked recessive - Typically more males affected and affected males usually inherit from carrier mothers; here both sexes are similarly affected and the pattern is vertical, not the expected X-linked recessive pattern.

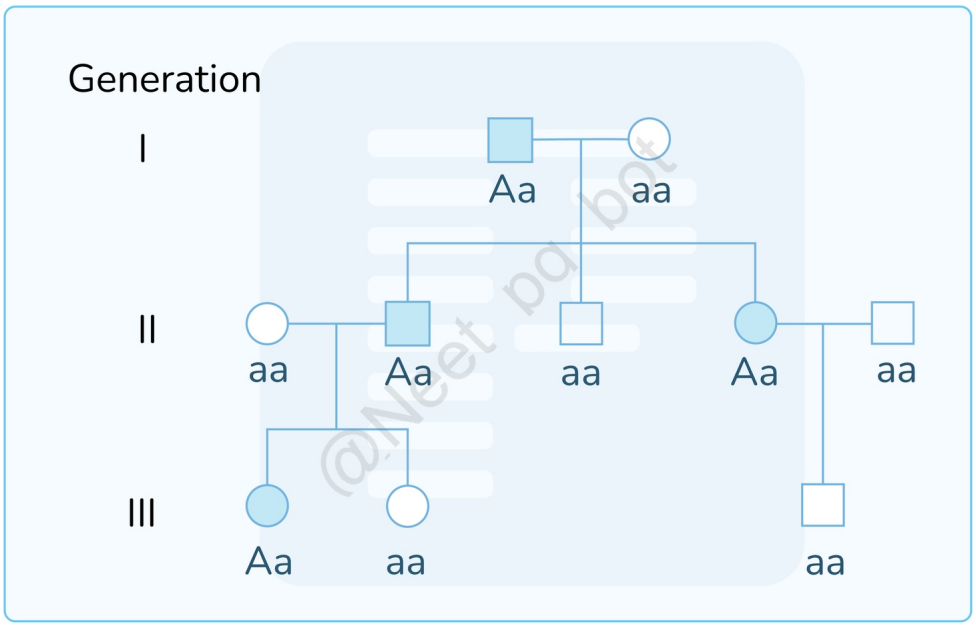

@Neet_pg_bot

References:

Robbins & Cotran Pathologic Basis of Disease, 10th Edition, Page 145

Inderbir Singh's Human Embryology, 11th Edition, Pages 16,17

↑ *Back to this question in Part A*

@Neet_pg_bot

Q41: A boy was diagnosed with a medical condition that is believed to have been passed down from his grandmother to his father, and now to him. What is the pattern of inheritance in this case ? (Q793641)

A. X-linked dominant

B. X-linked recessive

C. Autosomal dominant

D. Autosomal recessive

Correct Answer: C. Autosomal dominant

■ *Listen (English)*

■ *Listen (Hindi)*

Explanation: of the correct answer.

References:

Prepladder Notes

↑ *Back to this question in Part A*

@Neet_pg_bot

Q42: What does the given pedigree chart indicate? (Q860176)

A. Autosomal Dominant (AD)

B. Autosomal Recessive (AR)

C. Mitochondrial Disorder

D. X-linked Recessive (XLR)

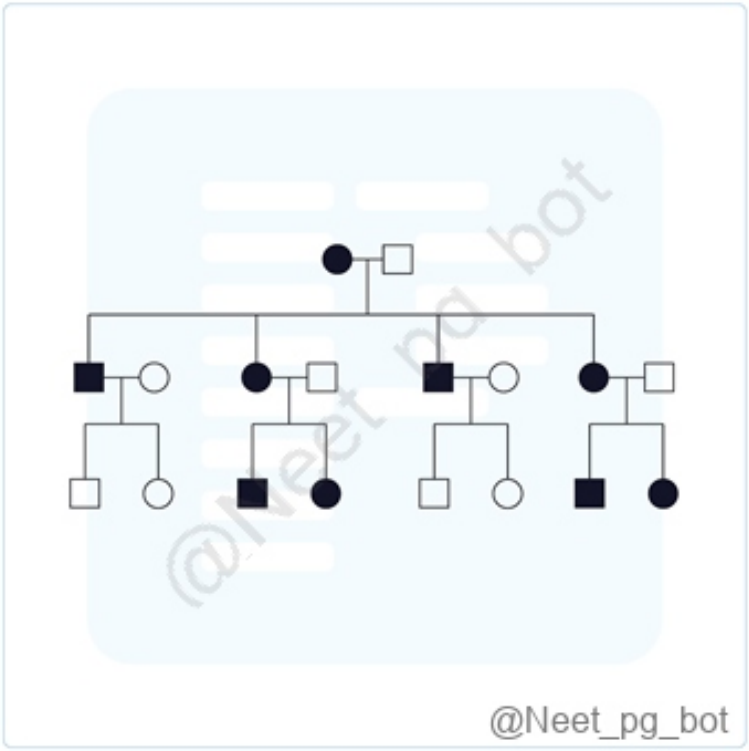

Correct Answer: C. Mitochondrial Disorder

Explanation: The given pedigree suggests a Mitochondrial Disorder , where a defect in maternal mtDNA is inherited by all offspring, while a defect in paternal mtDNA is not passed on to any offspring. They involve

defects in the mitochondria, which are responsible for producing energy in the form of ATP through oxidative phosphorylation. Mitochondrial DNA (mtDNA) is inherited exclusively from the mother (females with pathogenic mtDNA can pass the disease to their offspring). They affect organs with prominent aerobic metabolism (commonly skeletal muscle (myopathy) and nervous system). Some examples are: Leber hereditary optic neuropathy (LHON) Chronic progressive external ophthalmoplegia (CPEO)/ Kearns-Sayre syndrome (KSS) Leigh syndrome Mitochondrial encephalomyopathy with lactic acidosis and stroke-like episodes (MELAS) Myoclonic epilepsy with ragged red fibres (MERRF) Neuropathy, ataxia, and retinitis pigmentosa (NARP) Primary coenzyme Q10 (CoQ10) deficiency The most common mitochondrial disease is MELAS. The most common mitochondrial Myopathy is CPEO (Chronic Progressive External Ophthalmoplegia). Autosomal Dominant (AD) (Option A) inheritance follows a vertical transmission pattern , where an affected individual has an affected parent, and there is a 50% chance of passing the dominant trait to offspring, with both males and females equally affected. Autosomal Recessive (AR) (Option B) inheritance shows horizontal transmission , with the trait appearing in siblings while parents are unaffected, often in consanguineous marriages. Carriers have a 25% chance of an affected child, and males and females are equally affected. It includes most inborn errors of metabolism. X-linked Recessive (XLR) (Option D) inheritance means females (XX) are carriers, while males are affected by the disease.

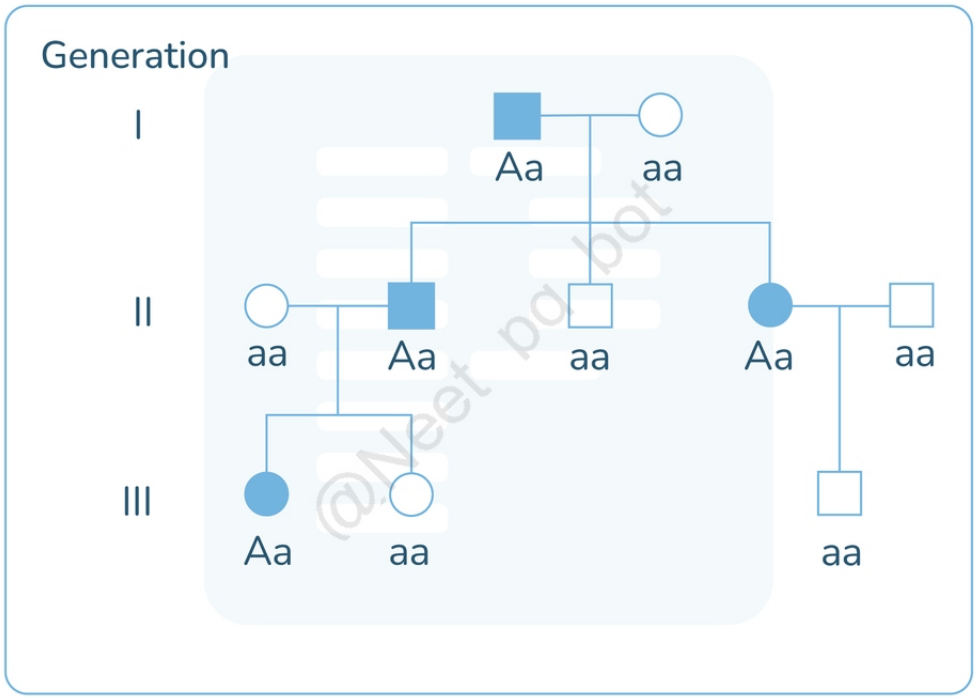

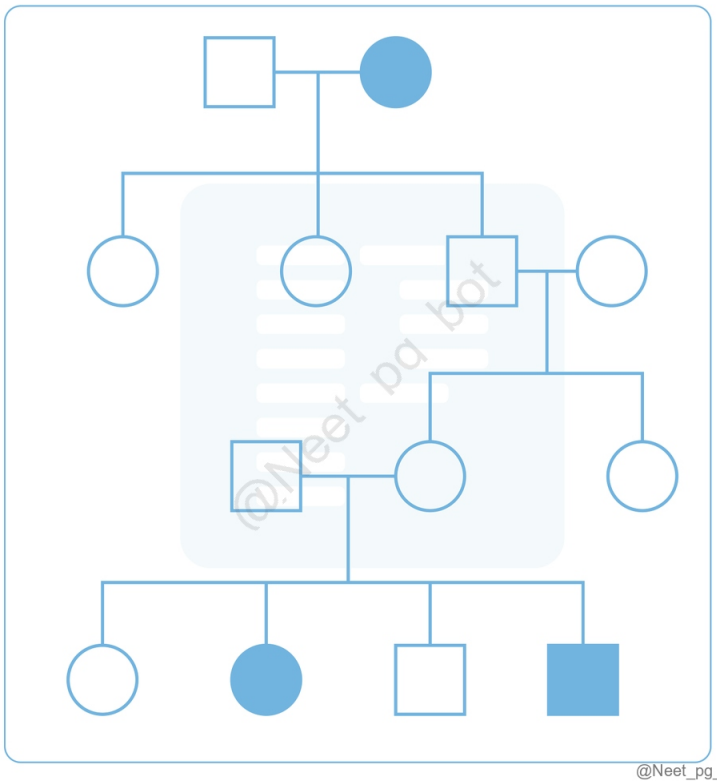

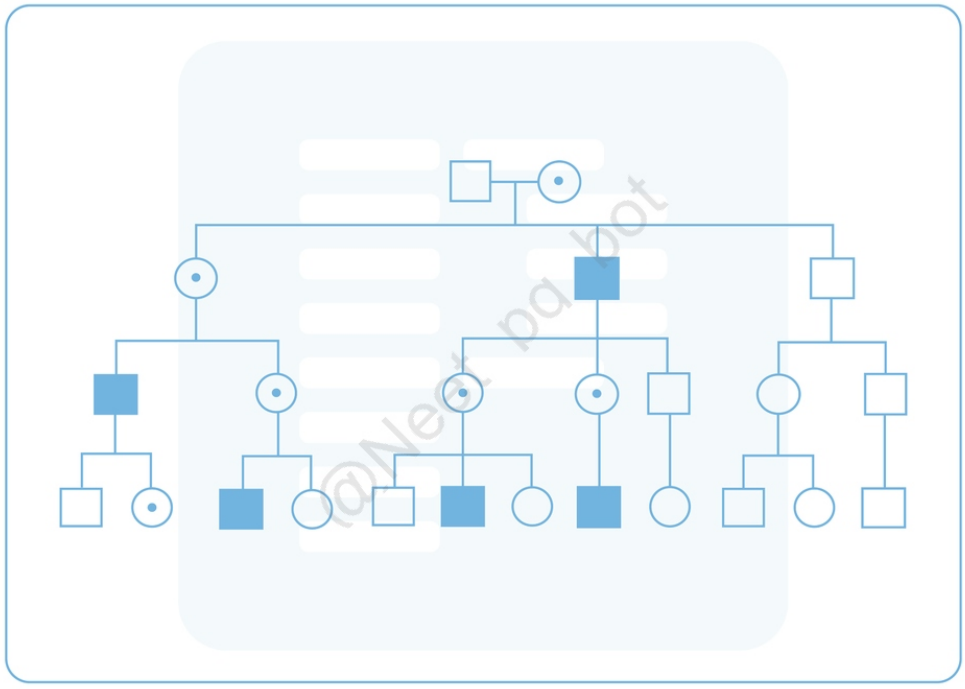

References:

Robbins & Cotran Pathologic Basis of Disease, 10th Edition, Page 1235, 1290-1291.

↑ *Back to this question in Part A*

@Neet_pg_bot

Q43: What is the interpretation of the given pedigree chart? (Q858065)

A. Autosomal dominant

B. Autosomal recessive

C. X-linked recessive

D. X-linked dominant

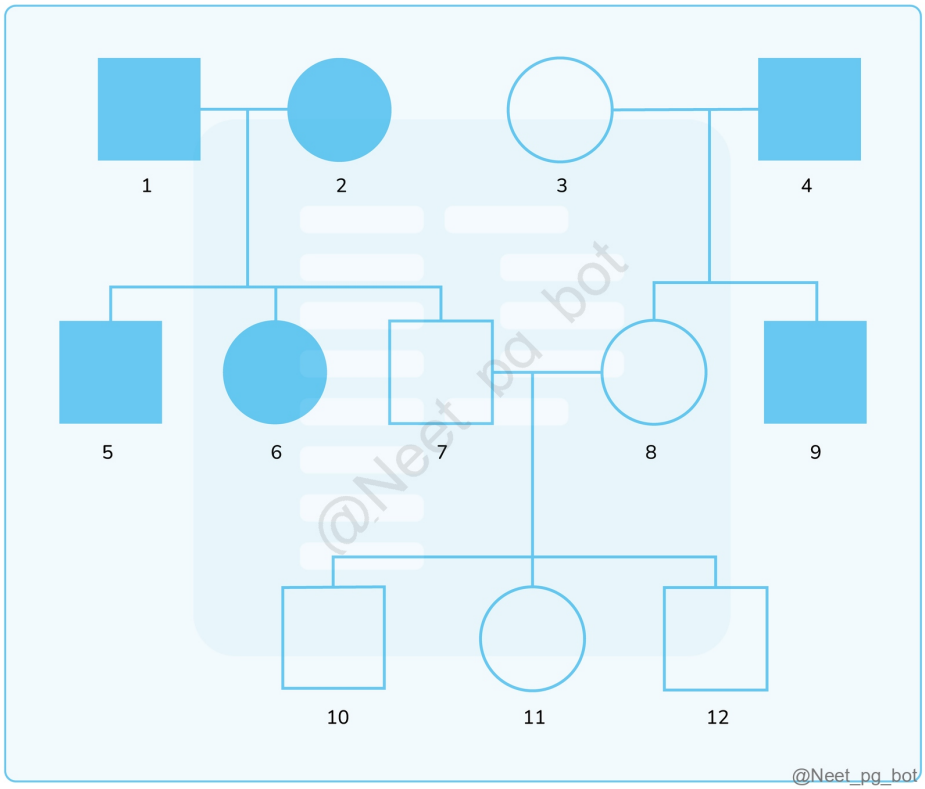

Correct Answer: A. Autosomal dominant

Explanation: The interpretation of the pedigree chart given reveals Autosomal dominant inheritance , which means that an individual only needs one copy of the mutated gene to express the condition. Affected individuals appear in every generation, as one parent passes on the mutated gene to their offspring. Both males and females can be affected equally because the gene is located on one of the autosomes . If an affected person has children, there is a 50% chance that each child will inherit the mutated gene and be affected. Autosomal Recessive (Option B) inheritance is where the Individuals usually do not express the trait unless they inherit two copies of the mutation . This inheritance pattern typically has horizontal transmission and skip generations in between. X-linked recessive (Option C) disorders affect males more than females because males have only one X chromosome. Females need

two copies of the mutation to be affected. Additionally, X-linked recessive disorders often show a pattern where affected males pass the mutated gene to all their daughters but none of their sons. X-linked dominan t (Option D) inheritance means an affected female can pass the condition to both sons and daughters, while an affected male passes it to all daughters but none of his sons. The question contradicts this pattern, so X-linked dominant is not the correct answer.

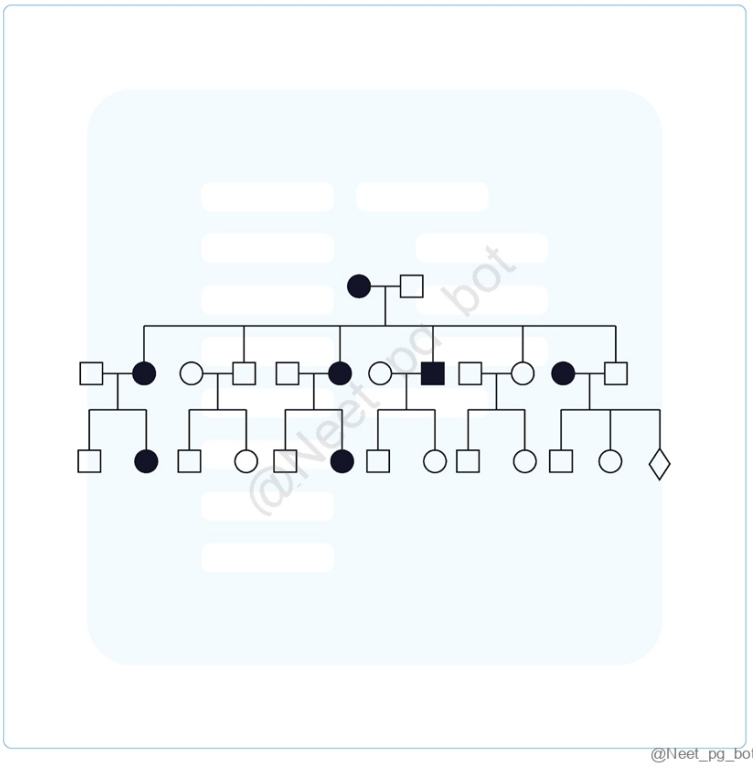

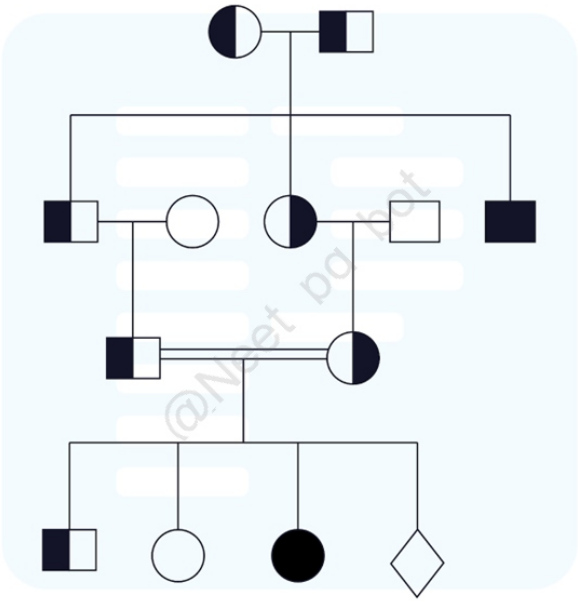

@Neet_pg_bot

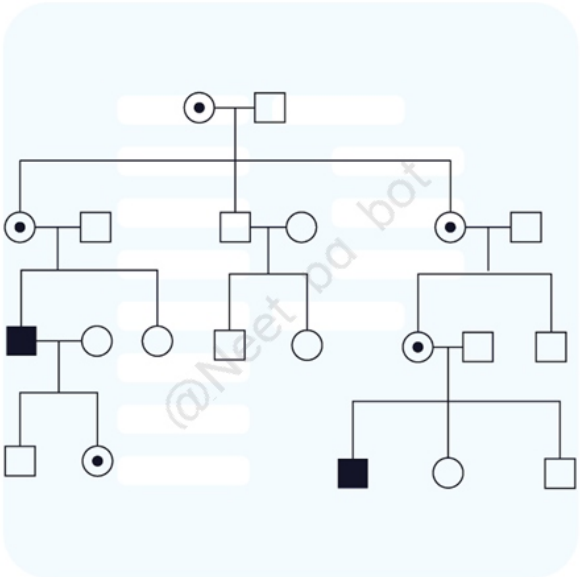

@Neet_pg_bot

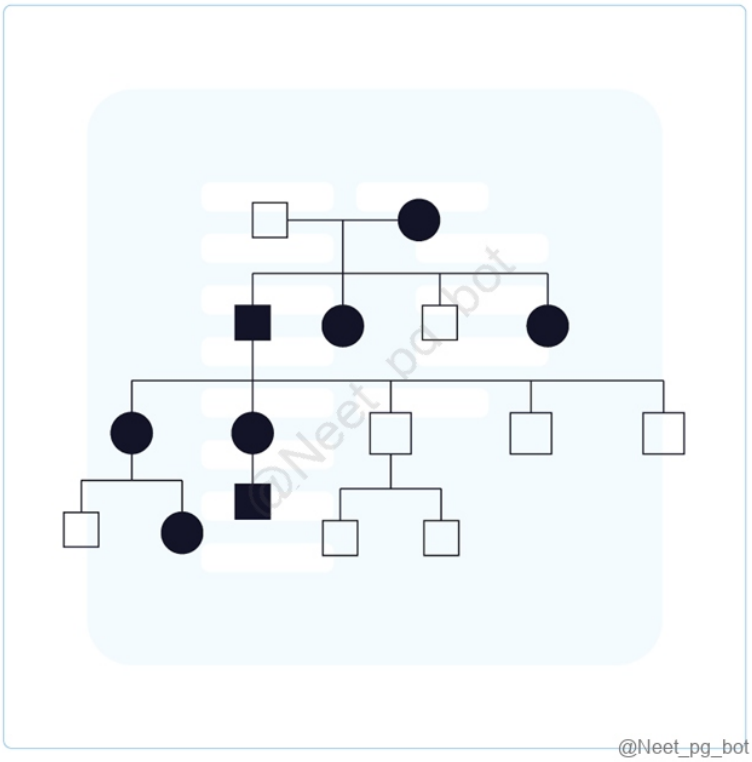

References:

Ghai Textbook of Paediatrics, 10th Edition, Pages 671, 672

↑ *Back to this question in Part A*

@Neet_pg_bot

Q44: Match the columns A. Autosomal dominant 1. Duchenne muscular dystrophy B. X-linked recessive 2. Leber hereditary optic neuropathy C. Autosomal recessive 3. Cystic fibrosis D. Mitochondrial 4. Myotonic dystrophy (Q854706)

A. A-1, B-4, C-2, D-3

B. A-2, B-3, C-4, D-1

C. A-1, B-3, C-2, D-4

D. A-4, B-1, C-3, D-2

Correct Answer: D. A-4, B-1, C-3, D-2

Explanation: Autosomal dominant Myotonic dystrophy X-linked recessive Duchenne muscular dystrophy Autosomal recessive Cystic fibrosis Mitochondrial Leber hereditary optic neuropathy Modes of inheritance Mode of Inheritance Pedigree

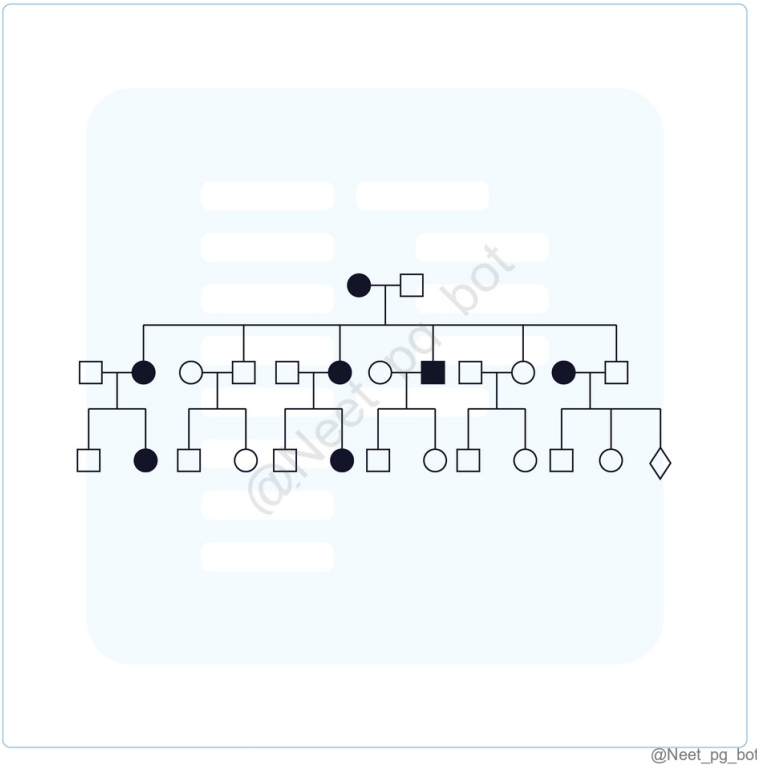
@Neet_pg_bot

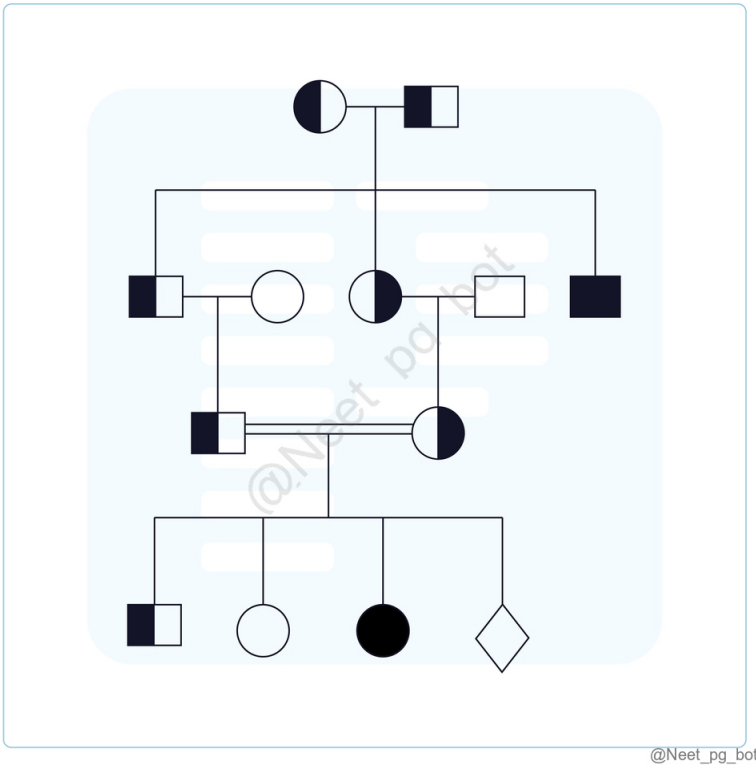
@Neet_pg_bot

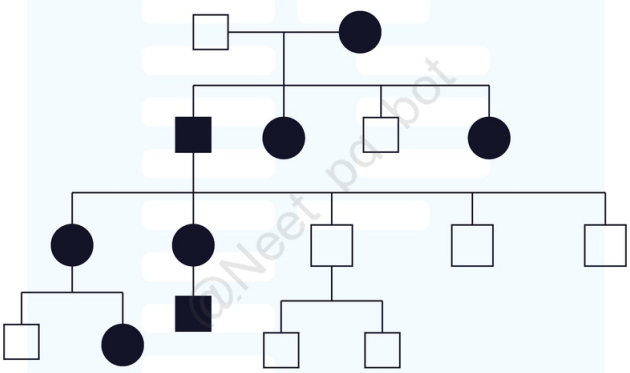

@Neet_pg_bot

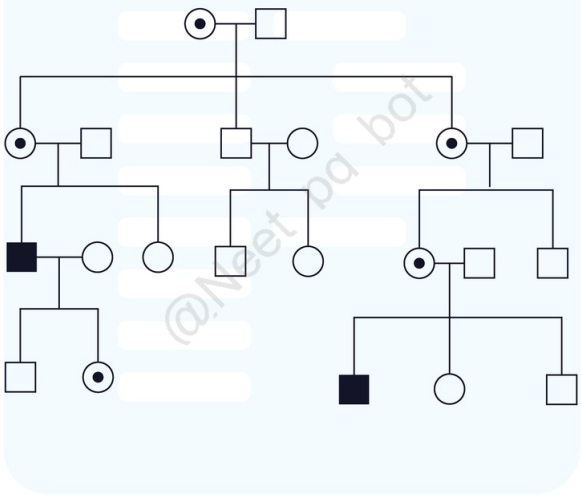

@Neet_pg_bot

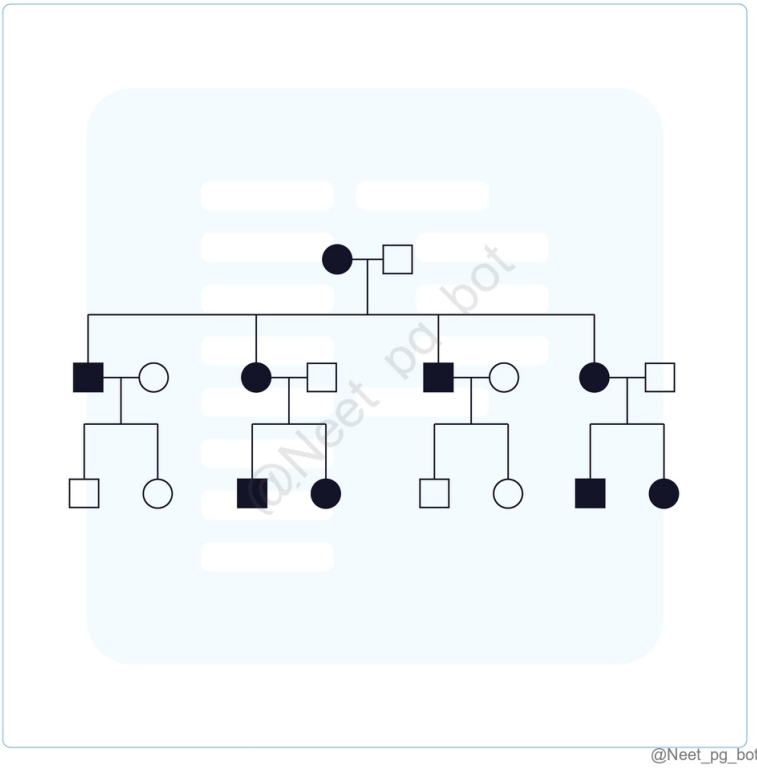

@Neet_pg_bot

References:

Robbins and Cotrans Pathologic Basis of Diseases, 10th Edition, Page 166,167

↑ *Back to this question in Part A*

@Neet_pg_bot

• [04_Neoplasia] 014 Classification And Features Of Neoplasia

« Back to Folder Directory

[04_Neoplasia] 014 Classification And Features Of Neoplasia — Quick Jump

Q1 (p. 1307)	*Q2 (p. 1307)*	*Q3 (p. 1308)*	*Q4 (p. 1309)*	*Q5 (p. 1310)*	*Q6 (p. 1310)*
Q7 (p. 1311)	*Q8 (p. 1312)*	*Q9 (p. 1313)*	*Q10 (p. 1314)*	*Q11 (p. 1315)*	*Q12 (p. 1315)*
Q13 (p. 1316)	*Q14 (p. 1318)*	*Q15 (p. 1320)*	*Q16 (p. 1324)*	*Q17 (p. 1326)*	

Q1: A biopsy from a rapidly enlarging thigh mass in a 35-year-old man reveals a malignant tumor composed of spindle-shaped cells arising from mesenchymal tissue. Which of the following is the most appropriate designation for this neoplasm? (Q879697)

A. Adenocarcinoma

B. Lymphoma

C. Sarcoma

D. Papilloma

Correct Answer: C. Sarcoma

Explanation: Since the origin is mesenchymal, the neoplasm is a sarcoma Sarcomas are malignant tumors that arise from solid mesenchymal tissues (e.g., bone, cartilage, fibrous tissue, muscle, fat, blood vessels). Naming pattern: The cell/tissue of origin is prefixed (e.g., fibrosarcoma from fibrous tissue, chondrosarcoma from cartilage). Spread: Sarcomas typically spread hematogenously (via blood) Incorrect Options: Adenocarcinoma (Option A) and Papilloma (Option D) have epithelial origin. Lymphoma (Option B) has a lymphoid cell origin

References:

https://www.ncbi.nlm.nih.gov/books/NBK519533/

↑ *Back to this question in Part A*

@Neet_pg_bot

Q2: Which of the following statements best characterizes a hamartoma? (Q879693)

A. Malignant neoplasm composed of immature, non-native cells

B. Disorganized but benign proliferation of mature, native cells within an organ

C. Developmental cyst always present from birth and never clonal

D. Metastatic lesion that reproduces the normal architecture of the tissue

Correct Answer: B. Disorganized but benign proliferation of mature, native cells within an organ

Explanation: Hamartomas are disorganized masses of mature cells and tissues native to the organ of origin, but lacking the normal architecture. Once thought to be developmental malformations, many are now recognized as benign neoplasms with clonal chromosomal aberrations. Examples: hemangiomas, lymphangiomas, rhabdomyomas, adenomas of the liver, and some developmental cysts. Despite being benign, they can cause clinical problems depending on their size and location.

References:

Robbins, Cotran & Kumar Pathologic Basis of Disease, 11th Edition, Page. 238, 432

↑ *Back to this question in Part A*

@Neet_pg_bot

Q3: A 4-year-old child presents with an abdominal mass. Biopsy shows a poorly differentiated neoplasm composed of uniform, undifferentiated cells with scant cytoplasm and hyperchromatic nuclei, giving a “small round blue cell” appearance. Which of the following tumors is not typically classified under the group of small round blue cell tumors of childhood?’ (Q879691)

A. Neuroblastoma

B. Wilms tumor

C. Medulloblastoma

D. Hepatoblastoma

Correct Answer: D. Hepatoblastoma

Explanation: Hepatoblastoma is not a small round blue cell tumor; it shows epithelial and/or mixed epithelial-mesenchymal differentiation rather than primitive undifferentiated cells. The classic group of small round blue cell tumors of childhood includes neuroblastoma, Wilms tumor , lymphoma, rhabdomyosarcoma, Ewing sarcoma, medulloblastoma, and retinoblastoma. They are called so because of their primitive histologic appearance. HPE of Wilms Tumor

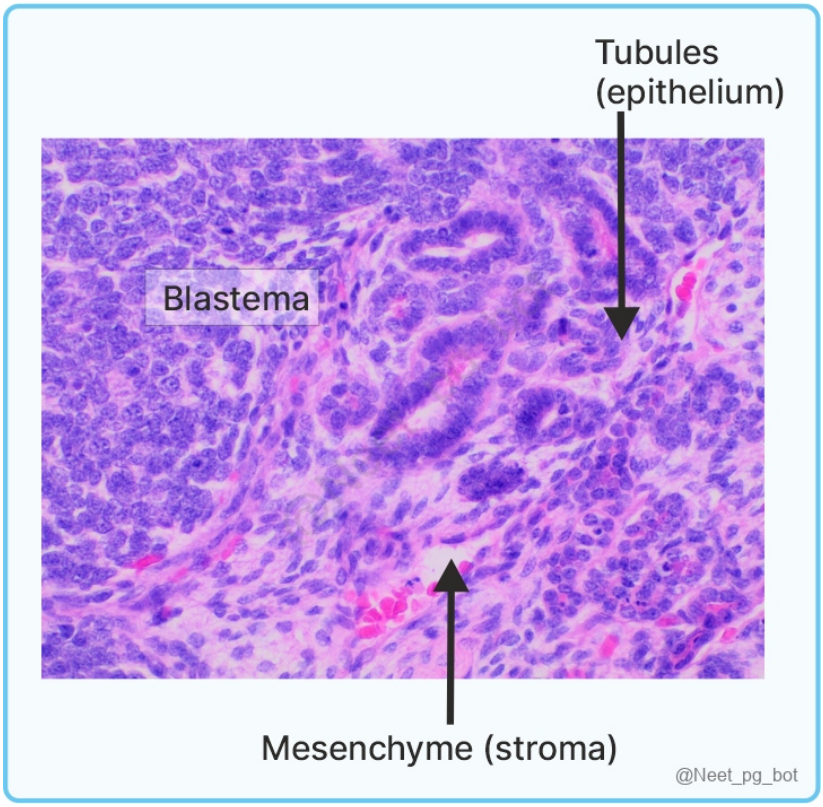

References:

Robbins, Cotran & Kumar Pathologic Basis of Disease, 11th Edition, Page. 434

↑ *Back to this question in Part A*

@Neet_pg_bot

Q4: Which of the following statements about adenomas is correct? (Q879679)

A. Adenoma refers only to benign epithelial tumors that form true glandular structures.

B. Adenoma can refer to benign epithelial tumors of glandular origin, even if they do not form glands

C. Adenoma is a term used for malignant tumors of glandular epithelium

D. Adenoma refers exclusively to tumors of the adrenal cortex

Correct Answer: B. Adenoma can refer to benign epithelial tumors of glandular origin, even if they do not form glands

Explanation: Adenoma is a benign epithelial neoplasm derived from glandular tissue. Tumor cells do not need to form true glandular structures to be called adenomas. Examples: Renal tubular adenoma: Forms tightly clustered

glands. Adrenal cortical adenoma: Grows as a solid sheet without forming glands. The classification depends on the origin from glandular epithelium, not the microscopic appearance. Adenomas are non-invasive and do not metastasize, distinguishing them from adenocarcinomas (malignant glandular tumors).

References:

Robbins, Cotran & Kumar Pathologic Basis of Disease, 11th Edition, Page. 237

↑ *Back to this question in Part A*

@Neet_pg_bot

Q5: A 55-year-old patient is diagnosed with a tumor. Histopathology shows uncontrolled proliferation, invasion into adjacent structures, and the presence of cells with variable differentiation. Which of the following features is the most definitive indicator of malignancy in this tumor? (Q879673)

A. Presence of mitotic figures

B. Tissue of origin identifiable as epithelial

C. Ability to invade surrounding tissues

D. Formation of glandular patterns in some areas

Correct Answer: C. Ability to invade surrounding tissues

Explanation: While mitotic figures, tissue type, and differentiation patterns provide supportive information, the defining feature of malignancy is the ability of the tumor to invade adjacent structures.. Malignancy features: Invasion of adjacent structures - Malignant tumors can infiltrate and destroy nearby tissues. Metastasis - Ability to spread to distant sites. Uncontrolled growth - Rapid and disorganized proliferation of cells. Variable differentiation - Cells may resemble the tissue of origin (well-differentiated) or may lose normal features (poorly differentiated/undifferentiated).

References:

Robbins, Cotran & Kumar Pathologic Basis of Disease, 11th Edition, Page. 238

↑ *Back to this question in Part A*

@Neet_pg_bot

Q6: Which of the following types of cancer is least likely to exhibit distant metastasis? (Q845142)

A. Renal cell carcinoma

B. Melanoma

C. Basal cell carcinoma

D. Prostatic carcinoma

Correct Answer: C. Basal cell carcinoma

■ *Listen (English)*

■ *Listen (Hindi)*

Explanation:

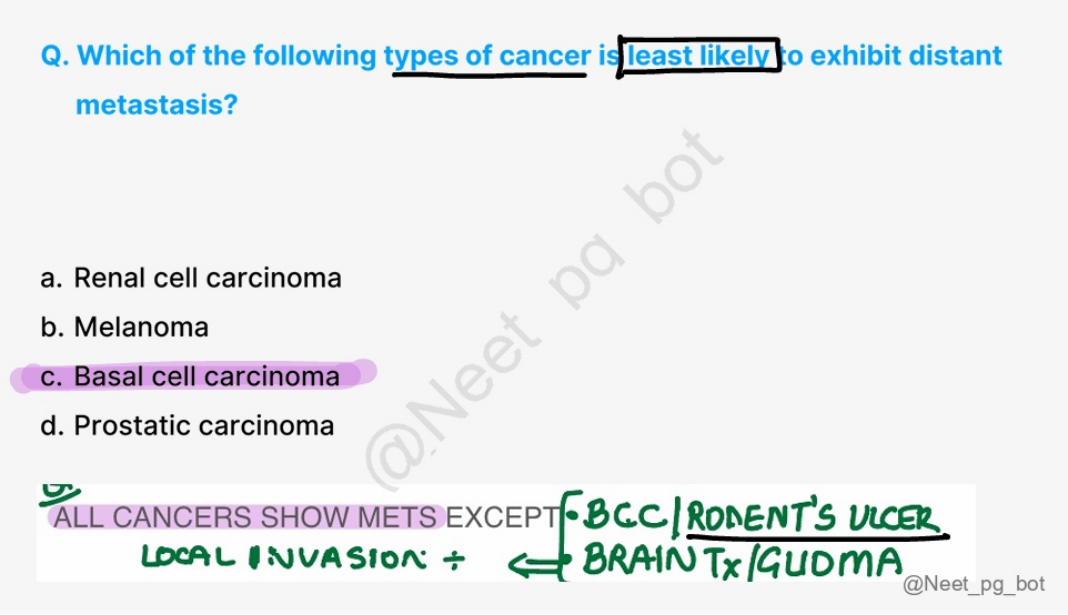

References:

Robbins and Cotrans Pathologic basis of disease 10th edition, page 273, 274

↑ *Back to this question in Part A*

@Neet_pg_bot

Q7: Which of the following is true regarding the Sentinel lymph node? (Q845146)

A. The first lymph node to receive metastasis from a secondary tumour.

B. Also helpful in identifying metastasis in Melanoma.

C. Commonly involved in skip metastasis

D. The presence of cancer cells indicates a good prognosis

Correct Answer: B. Also helpful in identifying metastasis in Melanoma.

■ *Listen (English)*

■ *Listen (Hindi)*

Explanation: Sentinel lymph node (SLN): The first lymph node to receive drainage from a primary tumor site. Example: In breast cancer, usually axillary lymph node is the first lymph node where the lymphatics are drained. Hence, it is the sentinel lymph node. Sometimes, cancer may bypass the sentinel lymph node and spread directly to other lymph nodes. This can occur in patients who have received radiotherapy, as radiation can cause fibrosis and blockage of the lymphatic channels. If the pathway to the sentinel node is obstructed, tumour cells are diverted to alternative routes, resulting in what is known as skip metastasis . Tumors where SLN biopsy is validated are Breast cancer, Melanoma, Vulvar cancer, and Colon cancer. Sentinel Lymph Node (SLN) identification techniques: Gold Standard: Dual Technique (Radioisotope + Blue Dye) – 95-98% detection rate 1. Radioactive Tracer (Lymphoscintigraphy): Agent: A radioactive isotope, most commonly Technetium-99m labeled sulfur colloid. Procedure: The tracer is injected peritumorally or intradermally near the biopsy site. Detection: A handheld gamma probe is used during surgery to locate the "hot" node emitting the highest radioactivity. Pre-operative Imaging: Static images (lymphoscintigrams) are often taken before surgery to map the lymphatic flow and the approximate location of the nodes. 2. Blue Dye Visualization: Agent: Isosulfan blue or Methylene blue . Procedure: The dye is injected near the tumor site shortly before or during the start of the operation. Detection: The surgeon visually inspects the lymphatic channels during dissection; the sentinel node will be stained blue . 3. Combined Technique (The "Gold Standard") : The use of both the radioactive tracer and the blue dye is the preferred method, as it provides both an auditory/numerical guide (the gamma probe) and a visual guide (the blue color). A node is considered "sentinel" if it is: Blue-stained. "Hot" (radioactivity >10% of the most radioactive node). Palpably suspicious (firm or enlarged, even if not hot or blue). Step-by-Step Intraoperative Dual Technique (Breast/Melanoma): Preoperative lymphoscintigraphy (99mTc) Intraop: Inject blue dye peritumorally Incise over "hot spot" (gamma probe) Dissect along blue channel → first blue + hot node Confirm: Probe counts drop >90% after excision The first lymph node to receive metastasis from a secondary tumour (Option A): Sentinal lymph node is the first lymph node to receive drainage from a primary tumor site. Commonly involved in skip metastasis (Option C): Skip metastasis is not a very common phenomenon; it's rather rare. The presence of cancer cells indicates a good prognosis (Option D): Cancer spreading to the sentinel or any other lymph node is always a bad prognosis.

References:

Robbins and Cotrans Pathologic basis of disease 10th edition, page 275

↑ *Back to this question in Part A*

@Neet_pg_bot

Q8: Which of the following tumors do not follow lymphatic route of spread? (Q845145)

A. Rhabdomyosarcoma

B. Krukenberg tumor

C. Follicular thyroid carcinoma

D. Synovial sarcoma

Correct Answer: C. Follicular thyroid carcinoma

■ *Listen (English)*

■ *Listen (Hindi)*

Explanation: Hematogenous spread Lymphatic spread Transcoelomic spread Veins are more prone to invasion than arteries due to their thinner walls. Tumours use existing lymphatic vessels at their margins. Follows natural routes of lymphatic drainage. Invades the serosal wall of the coelomic cavity, releasing tumour fragments into coelomic fluid, which is implanted elsewhere in the body cavity. Seen in most of the sarcomas. Seen in most carcinomas. Krukenberg tumour is a metastatic tumour to the ovary that can show lymphatic or transcoelomic spread. (Option B) Exceptions: Synovial sarcoma (Option D) Rhabdomyosarcoma (Option A) These tumours are spread by the lymphatic route. Exceptions: HCC RCC Follicular carcinoma of the thyroid (Option C) These tumours are spread by a hematogenous route.

References:

Robbins and Cotrans Pathologic basis of disease 10th edition, page 274, 275

↑ *Back to this question in Part A*

@Neet_pg_bot

Q9: Which of the following tumours do not typically exhibit direct seeding of body cavities? (Q845144)

A. Pseudomyxoma peritonei

B. Gastric carcinoma

C. Hepatocellular carcinoma

D. Medulloblastoma

Correct Answer: C. Hepatocellular carcinoma

■ *Listen (English)*

■ *Listen (Hindi)*

Explanation: Hepatocellular carcinoma typically exhibits metastasis by hematogenous spread rather than direct seeding of body cavities. Direct Seeding of Body Cavities or Surfaces: Pseudomyxoma peritonei (Option A) is

characterized by the presence of a gelatinous neoplastic mass filling the peritoneal cavity arising from the rupture of mucin-secreting adenocarcinoma of the appendix (most common cause) or mucin-secreting adenocarcinoma of ovarian. Gastric carcinoma (Option B) can spread to the distal end of the peritoneal cavity (Pouch of Douglas) and is known as the 'Blummer shelf.' Medulloblastoma (Option D) from the cerebellum spreads to the spinal cord by 'Drop metastasis.'

References:

Robbins and Cotrans Pathologic basis of disease, 10th edition, Pages 273, 274

↑ *Back to this question in Part A*

@Neet_pg_bot

Q10: A 45-year-old female presents with a palpable lump in her left breast which is freely mobile and painless. A biopsy of the lump was performed, and a histopathological examination was done. Which feature from the biopsy report is most likely to differentiate between benign and malignant breast lesions? (Q845134)

A. Presence of well-defined glandular structures

B. Evidence of invasion into surrounding tissues

C. Low mitotic rate

D. Presence of fibrous stroma

Correct Answer: B. Evidence of invasion into surrounding tissues

■ *Listen (English)*

■ *Listen (Hindi)*

Explanation: We differentiate benign and malignant tumours based on whether the basement membrane is intact or broken: In benign tumours: The basement membrane is completely intact and normal. In malignant tumours: The basement membrane is broken, so the cancer cells can invade surrounding tissues. Feature Benign Lesions Malignant Lesions Growth Localised Invasive (Option B) Microscopic Appearance Resemble normal tissue and maintain differentiated features. (Option A) Cellular atypia , mitotic figures, loss of tissue organisation. Macroscopic Appearance Well-defined borders Irregular borders, necrosis, hemorrhage. Histological Features Cells are typically uniform in size and shape, with minimal nuclear atypia and low mitotic rate. (Option C) Cells may display pleomorphism, increased nuclear-to-cytoplasmic ratio, high mitotic rate, and evidence of invasion or metastasis.

References:

Robbins and Cotran's Pathologic basis of disease 10th edition, page 268

↑ *Back to this question in Part A*

@Neet_pg_bot

Q11: Which of the following characteristics distinguishes hemangiomas from other benign tumors? (Q845141)

A. Rapid growth rate

B. Presence of extracellular matrix (ECM) deposited by stromal cells

C. Easily resected by excision

D. Unencapsulated

Correct Answer: D. Unencapsulated

■ *Listen (English)*

■ *Listen (Hindi)*

Explanation: A hemangioma is a benign vascular tumour caused by an abnormal overgrowth of blood vessels that is distinguished from other benign tumours by: Lack of well-defined capsule (Hemangiomas are uncapsulated). Tendency to permeate the site of origin making it difficult for surgical excision. Rapid growth rate (Option A): The rapid growth rate is a feature of malignant tumors, not benign tumors which grow slowly and localized to the site of origin. Presence of extracellular matrix (ECM) deposited by stromal cells (Option B): Benign tumours usually has a capsule, which consists of an extracellular matrix (ECM) deposited by stromal cells such as fibroblasts. Since hemangioma is unencapsulated, it is not associated with the deposition of extracellular matrix by stromal cells. Easily resected by excision (Option C): Encapsulation makes benign tumours easily resectable but since hemangiomas are unencapsulated ,they permeate site of origin making it difficult to resect. Some important exceptions: Feature General Rule Exceptions (The Outliers) Capsule Benign tumors are encapsulated. Hemangiomas , Lipomas (occasionally), and Leiomyomas (of the uterus) are often unencapsulated or poorly circumscribed. Metastasis Malignant tumors metastasize. Basal Cell Carcinoma (skin) and Gliomas (brain) are highly invasive but rarely metastasize. Growth Rate Benign is slow; Malignant is fast. Leiomyomas (benign) can grow rapidly during pregnancy due to estrogen; some low-grade cancers grow very slowly. Well-Defined Malignant tumors are poorly defined/invasive. Follicular Thyroid Carcinoma can appear well-encapsulated, making it hard to distinguish from an adenoma without seeing capsular invasion.

References:

Robbins and Cotrans Pathologic basis of disease 10th edition, page 273

↑ *Back to this question in Part A*

@Neet_pg_bot

Q12: Which of the following statements is/are True? The basement membrane remains intact in dysplasia. Dysplasia is always irreversible. Pleomorphism is observed in metaplasia. Myositis ossificans is an example of dysplasia. (Q845140)

A. 1, 3 and 4

B. 1 only

C. 2 and 4

D. 1, 2 and 3

Correct Answer: B. 1 only

■ *Listen (English)*

■ *Listen (Hindi)*

Explanation: Feature Metaplasia Dysplasia Anaplasia Definition Differentiated cell type (epithelial or mesenchymal) is replaced by another cell type Disordered growth and loss of architectural orientation of cells Lack of cellular differentiation and organisation Nature (Statement 2) Adaptive response to stress or injury Preneoplastic Associated with malignant transformation Reversibility Reversible Reversible in early stages (irreversible if whole the epithelium is involved) Irreversible Pleomorphism (Statement 3) Absent Present in low-grade Present in high-grade Nuclear-to-cytoplasmic ratio Normal (1:4 to 1:6) Increased (↑) Increased (↑↑↑) Mitotic figures Absent/minimal at normal places Typical mitotic figures present at abnormal places Atypical, bizarre mitotic figures present at abnormal places Basement membrane integrity Intact Intact Breached Example (Statement 4) Barret's oesophagus, myositis ossificans Cervical dysplasia of squamous cells Carcinoma of the cervix, carcinoma oesophagus

References:

Robbins and Cotrans Pathologic basis of disease 10th edition, Page 270-272

↑ *Back to this question in Part A*

@Neet_pg_bot

Q13: Which of the following features is not a characteristic of anaplasia? (Q845139)

A. Pleomorphism

B. Loss of polarity

C. Increased nuclear-to-cytoplasmic ratio

D. Intact basement membrane

Correct Answer: D. Intact basement membrane

■ *Listen (English)*

■ *Listen (Hindi)*

Explanation: Differentiation between precancer and cancer is based on the basement membrane. If the basement membrane is intact: Precancer/Dysplasia If the basement membrane is broken or breached: Cancer cells can invade into surrounding tissue and spread anywhere: Cancer/Anaplaisa Image showing Mitosis: Mercedes Benz sign Image showing Mitosis: Starburst mitosis Anaplasia and Dysplasia common points: Pleomorphism: Both conditions exhibit cells that vary in size and shape. Nuclear Abnormalities: Both show hyperchromatic (darkly staining) nuclei that are larger than normal. Increased Mitosis: Both demonstrate a higher-than-normal rate of cell division. Atypical Morphology: Both involve a loss of the normal, organized appearance of the tissue of origin. Anaplasia and Dysplasia differentiating points: Feature Dysplasia Anaplasia Definition Disordered growth and maturation of an epithelium. Total lack of differentiation; a "formative backward" state. Clinical Status Pre-malignant (may or may not progress). Malignant (diagnostic hallmark of cancer). Reversibility Potentially reversible if the inciting stress is removed. Irreversible . Basement Membrane The basement membrane remains intact . Often associated with invasion through the basement membrane. N:C Ratio Increased, but usually less severe than anaplasia. Extreme increase; can approach a 1:1 ratio . Mitotic Figures Frequent, but usually follow normal spindle patterns. Atypical/Bizarre mitoses (e.g., tripolar or multipolar spindles). Examples CIN, Barrett's dysplasia Anaplastic carcinoma, sarcoma

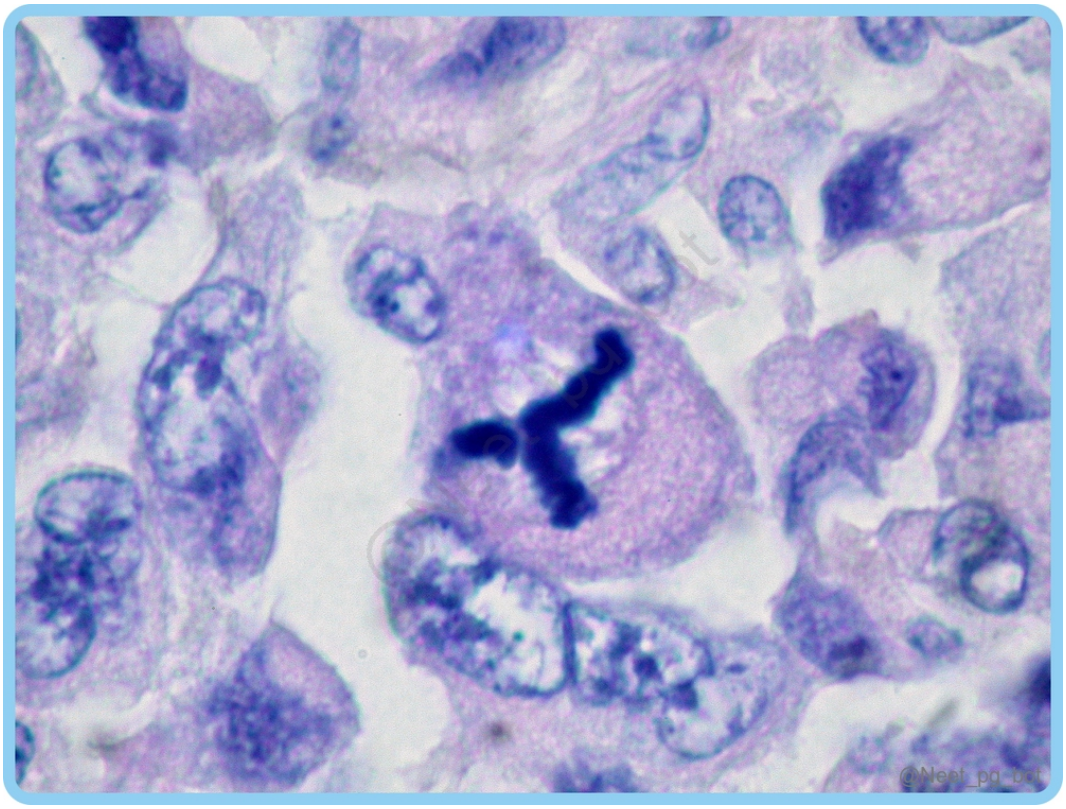

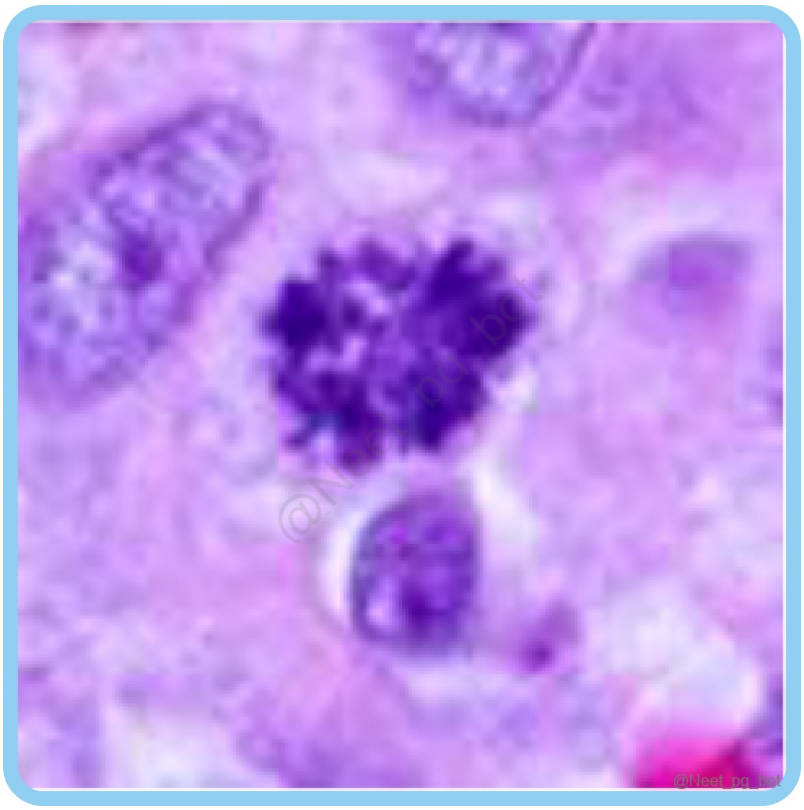

References:

Robbins and Cotrans Pathologic basis of disease 10th edition, Page 270-272

↑ *Back to this question in Part A*

@Neet_pg_bot

Q14: A 55-year-old man presents with chronic heartburn and difficulty swallowing. Upon examination, the physician suspects gastroesophageal reflux disease (GERD) and orders an upper GI endoscopic biopsy, which reveals the presence of columnar epithelium in the lower oesophagus, replacing the normal squamous epithelium. Which of the following terms describes the observed cellular change? (Q845138)

A. Metaplasia

B. Dysplasia

C. Anaplasia

D. Desmoplasia

Correct Answer: A. Metaplasia

- *Listen (English)*
- *Listen (Hindi)*

Explanation: This specific clinical scenario describes Barrett’s Esophagus , where chronic acid reflux causes the esophageal lining to transform to withstand the acidic environment. Metaplasia: Metaplasia is a reversible change in which one adult cell type (epithelial or mesenchymal) is replaced by another adult cell type. Mechanism: It is not a direct "transformation" of existing cells, but rather a reprogramming of stem cells to differentiate along a new pathway. Barrett's Esophagus: Chronic acid reflux causes the squamous lining to become columnar (intestinal metaplasia). Barrett's esophagus is a precancerous condition, and if not treated, it may turn into Adenocarcinoma of esophagus. Squamous Metaplasia: Occurs in the respiratory tract of chronic smokers, where ciliated columnar epithelium is replaced by stratified squamous epithelium. While tougher, this new tissue loses the ability to clear mucus. Connective Tissue Metaplasia: Formation of bone within soft tissue (e.g., myositis ossificans) following injury. Dysplasia (Option B): Dysplasia refers to disordered growth and is typically encountered in epithelial linings. Characteristics: It involves a loss of architectural uniformity and cellular orientation. Cells show pleomorphism (variation in size and shape) and have large, hyperchromatic nuclei. Mitotic Activity: Mitoses are more frequent than normal and may appear in unusual locations within the epithelium (e.g., in the upper layers of the skin). Pre-cancerous Nature: While dysplasia does not necessarily progress to cancer, it is often a precursor. If it involves the entire thickness of the epithelium but does not penetrate the basement membrane, it is termed Carcinoma in situ . Anaplasia (Option C): Anaplasia is defined as a lack of differentiation and is a hallmark of malignancy . Morphological Hallmarks: Pleomorphism: Extreme variation in cell size and shape. Abnormal Nuclear Morphology: Nuclei are disproportionately large, with a nuclear-to-cytoplasmic (N:C) ratio approaching 1:1 (normal is 1:4 or 1:6). Atypical Mitoses: Bizarre, tripolar, or multipolar mitotic spindles. Clinical Significance: The degree of anaplasia determines the grade of the tumor; highly anaplastic tumors are "high-grade" and typically very aggressive. Desmoplasia (Option D): Desmoplasia refers to the stromal (connective tissue) response rather than the epithelial cells themselves. Definition: It is the proliferation of non-neoplastic connective tissue (fibrosis) triggered by certain malignant tumors. Clinical Presentation: This reaction results in a "stony" or "scirrhous" consistency of a tumor. Classic Example: Invasive ductal carcinoma of the breast often shows a strong desmoplastic response, making the lump feel very hard and fixed on palpation.

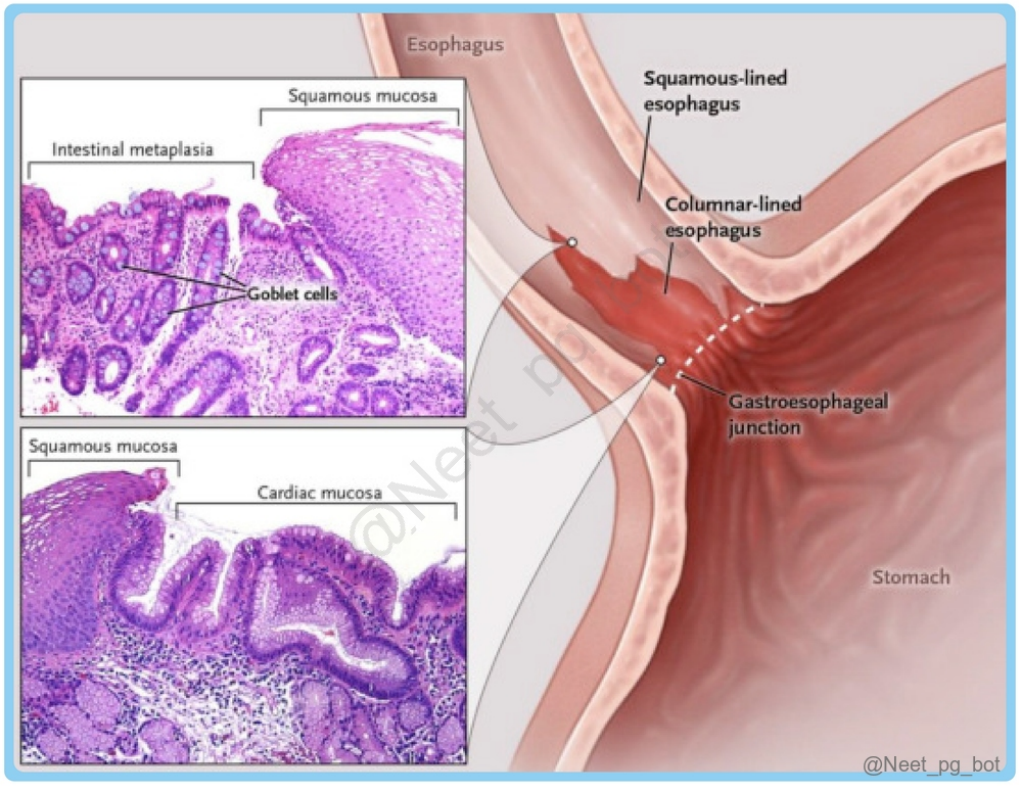

References:

Robbins and Cotrans Pathologic basis of disease, 10th edition, Pages 270-272

↑ *Back to this question in Part A*

@Neet_pg_bot

Q15: A 30-year-old female presents with pelvic pain and irregular menstrual cycles. She undergoes surgical resection of the mass, and histopathological examination reveals a tumour composed of mature tissues derived from multiple germ layers, including hair, teeth, and sebaceous material. Based on the histopathological findings described, which of the following tumours is the most likely diagnosis? (Q845137)

A. Teratoma

B. Serous cystadenoma

C. Mucinous cystadenoma

D. Granulosa cell tumour

Correct Answer: A. Teratoma

- *Listen (English)*
- *Listen (Hindi)*

Explanation: Teratomas arise from 2 or more germ layers Teratomas are commonly seen in the ovaries, but can also be seen in other organs of the body. Teratomas are of 2 types: Mature teratoma: Benign and has all the mature tissues Immature teratoma: Has neuroepithelial cells and has the potential to cause cancer. Mature Cystic Teratoma (Dermoid Cyst): Origin: Derived from all three germ layers: Ectoderm (skin, hair, teeth), Mesoderm (muscle, bone), and Endoderm (gut tissue). Epidemiology: Most common germ cell tumor; typically occurs in young women (ages 20–30). Gross Appearance: Often contains a "Rokitansky protuberance" (a solid nodule from which hair or teeth originate). Complications: * Torsion: The most common complication due to the weight of the mass. Struma Ovarii: A specialized teratoma composed entirely of thyroid tissue, which can lead to hyperthyroidism. Malignant Transformation: Rare (<1%), usually into Squamous Cell Carcinoma. Serous Cystadenoma (Option B): Origin: These arise from the surface epithelium of the ovary rather than germ cells. Histology: They are typically unilocular cysts lined with ciliated columnar epithelium , resembling the lining of the fallopian tube. Key Distinction: They do not contain teeth, hair, or sebum; they are filled with clear, watery (serous) fluid. Note: If these become malignant (Serous Cystadenocarcinoma), they often display Psammoma bodies (concentric lamellated calcifications). Mucinous Cystadenoma (Option C): Origin: Another surface epithelial tumor. Histology: These are often very large, multiloculated masses lined by mucus-secreting cells (resembling endocervical or intestinal mucosa). Key Distinction: Instead of solid tissue like hair or bone, these are filled with thick, gelatinous mucoid material. Clinical Complication: If a mucinous tumor ruptures, it can lead to Pseudomyxoma peritonei , where the abdominal cavity fills with "jelly-like" mucinous ascites. Granulosa Cell Tumor (Option D): Origin: This is a Sex Cord-Stromal tumor , not a germ cell tumor. Function: These tumors are "functional," meaning they secrete Estrogen . Clinical Presentation: * In children: Causes precocious puberty . In adults/postmenopausal women: Causes postmenopausal bleeding and increases the risk of endometrial hyperplasia or cancer. Histology: Characterized by Call-Exner bodies (small, gland-like follicles filled with eosinophilic material) and "coffee-bean" nuclei. Key Distinction: It lacks the multiple germ layers (hair/teeth) found in teratomas.

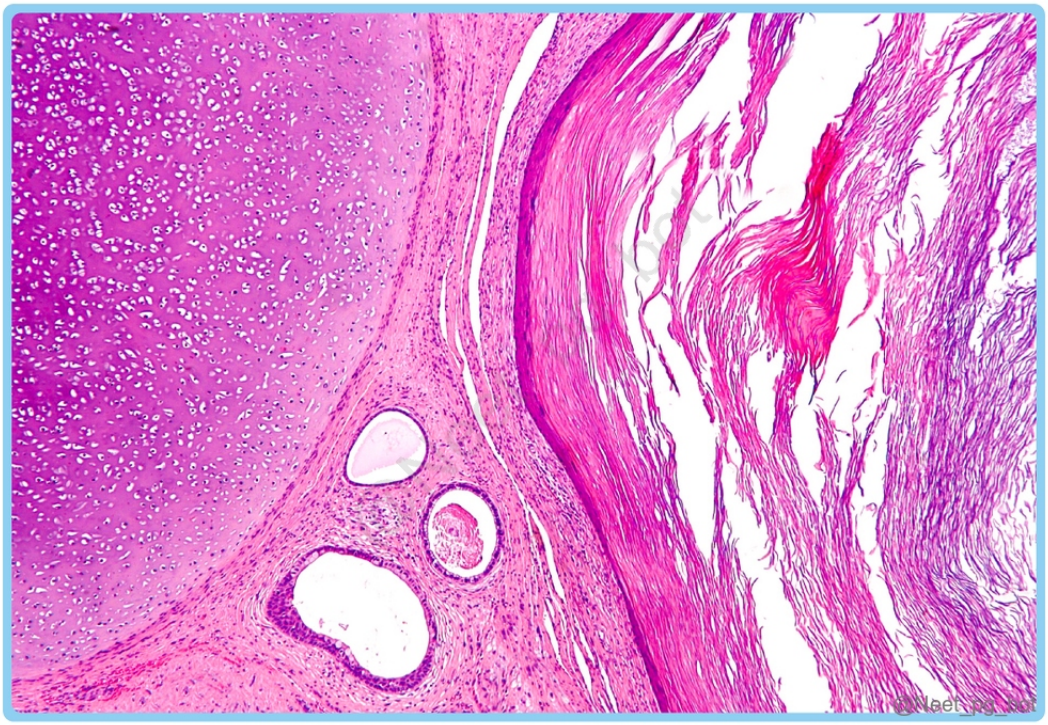
@Neet_pg_bot


@Neet_pg_bot

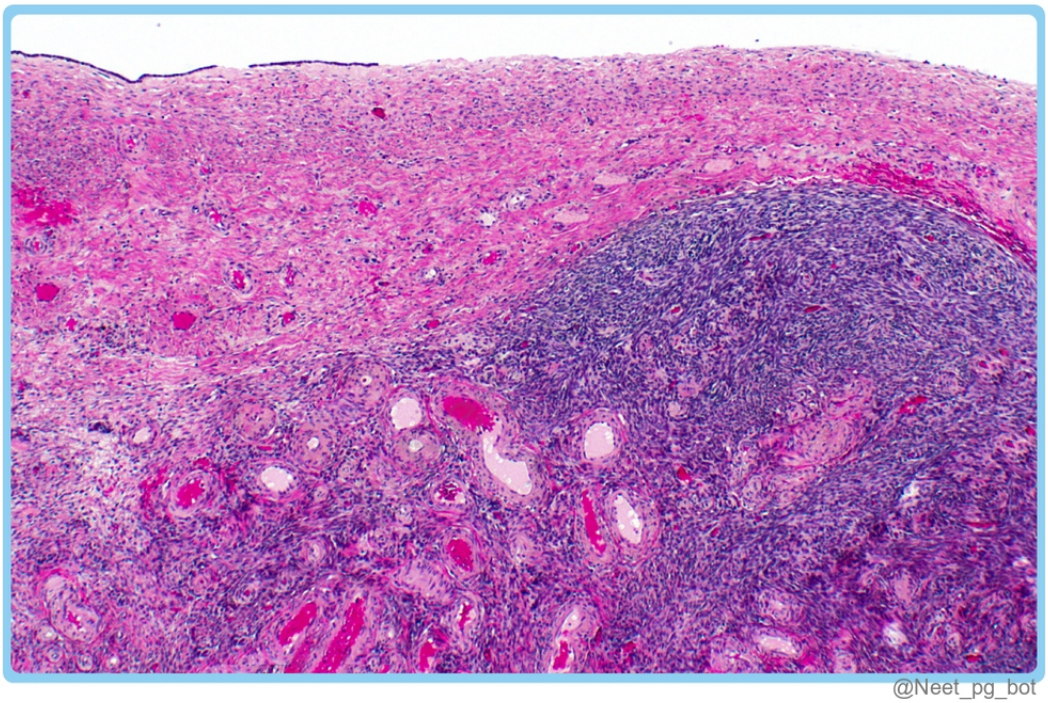
@Neet_pg_bot

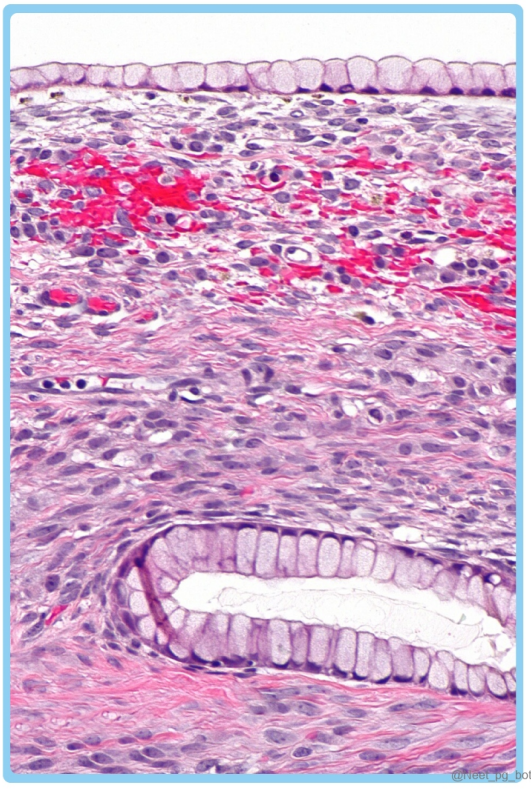
@Neet_pg_bot

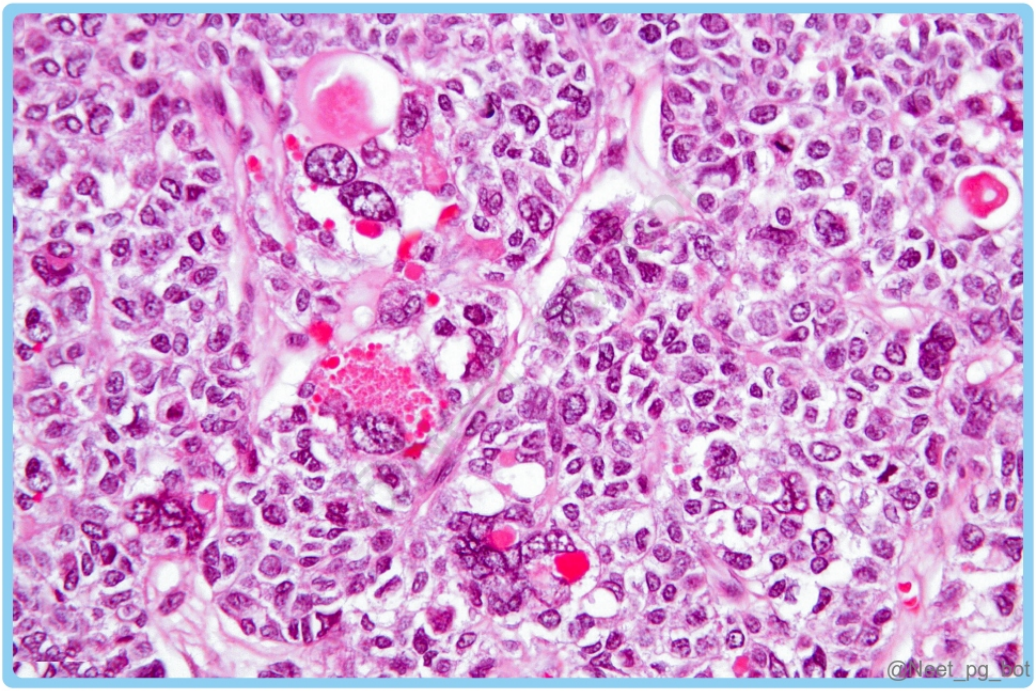

References:

Robbins and Cotrans Pathologic basis of disease, 10th edition, Page 269

↑ *Back to this question in Part A*

@Neet_pg_bot

Q16: What is the most likely diagnosis of a patient with a painless, slowly enlarging mass in the right parotid gland region that is well-defined and heterogeneous, with both epithelial and mesenchymal components present in the biopsy? (Q845136)

A. Pleomorphic adenoma

B. Mucoepidermoid carcinoma

C. Acinic cell carcinoma

D. Warthin tumour

Correct Answer: A. Pleomorphic adenoma

■ *Listen (English)*

■ *Listen (Hindi)*

Explanation: Benign Salivary Gland Tumors: 1. Pleomorphic Adenoma (Mixed Tumor): Pleomorphic adenoma is the most common benign tumour of the salivary glands, often found in the parotid gland. Composition: Pleomorphic adenoma, also known as a mixed tumour, typically contains epithelial components (such as glandular cells) and mesenchymal components (such as myxoid stroma, islands of cartilage, or bone). Pleomorphic adenoma is more commonly found in females. Clinical: Painless, slow-growing, mobile, and firm mass. It has a high recurrence rate if not widely excised because it often has microscopic "finger-like" projections (pseudopods) that extend through the capsule. Treatment: Superficial parotidectomy (facial nerve preservation); recurrence if enucleation only Complication: Can undergo malignant transformation into Carcinoma ex Pleomorphic Adenoma , which usually presents as sudden rapid growth of a long-standing stable mass. 2. Warthin Tumor (Papillary Cystadenoma Lymphomatosum) (Option D): The second most common benign parotid tumor. Demographics: Almost exclusively found in the parotid gland ; highly associated with smoking and older males. Histology: Double layer of oncocytic (eosinophilic) epithelial cells surrounding a dense lymphoid stroma with germinal centers. Key Feature: Often found in the tail of the parotid and is bilateral in about 10% of cases. Malignant Salivary Gland Tumors: 1. Mucoepidermoid Carcinoma (Option B): The most common malignant salivary gland tumor in both adults and children. Composition: A mixture of squamous (epidermoid) cells, mucus-secreting cells, and intermediate cells. Clinical: Can range from low-grade (slow-growing) to high-grade (aggressive). 2. Adenoid Cystic Carcinoma: Histology: Classic "Swiss cheese" appearance (cribriform pattern). Clinical: Very high tendency for perineural invasion . This is a major clue in board exams; if a patient has a parotid mass and facial nerve palsy (pain or weakness) , think of this first. Prognosis: Slow-growing but relentless; it can metastasize many years after initial treatment. 3. Acinic Cell Carcinoma (Option C): Features: Consists of cells resembling normal serous acini (granular cytoplasm). Clinical: Generally low-grade with a relatively good prognosis compared to other malignancies. Tumor Category High-Yield Buzzword Clinical Clue Pleomorphic Adenoma Benign Mixed Tumor / Mesenchymal stroma Most common; mobile mass Warthin Tumor Benign Smoking / Oncocytic / Lymphoid Bilateral; older males Mucoepidermoid Ca Malignant Mucus-secreting cells Most common malignancy Adenoid Cystic Ca Malignant Swiss Cheese / Perineural invasion Painful / Facial nerve palsy

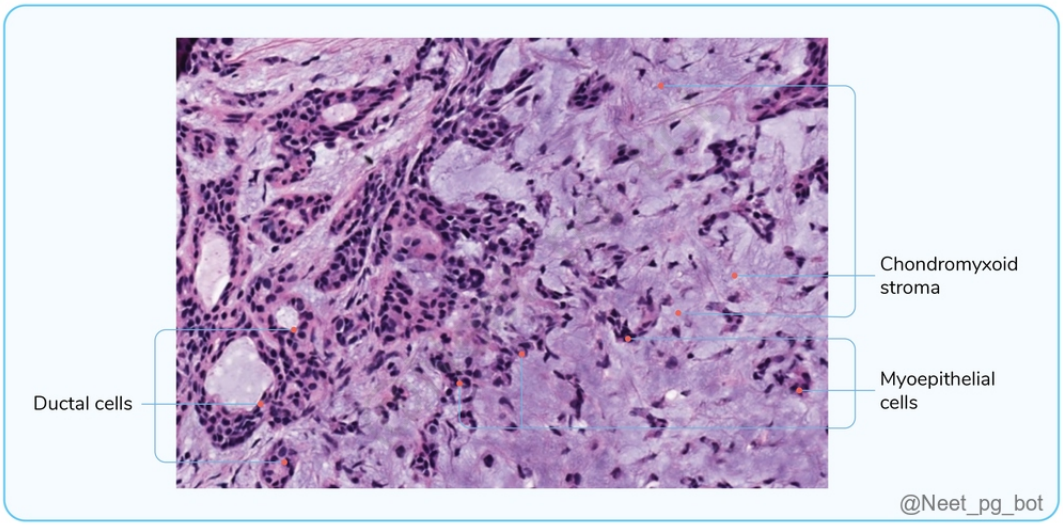

References:

Robbins and Cotrans Pathologic Basis of Disease 10th edition, page 269

↑ *Back to this question in Part A*

@Neet_pg_bot

Q17: Which of the following tumour is of mesenchymal origin? (Q845135)

A. Adenoma

B. Papilloma

C. Seminoma

D. Leiomyoma

Correct Answer: D. Leiomyoma

■ *Listen (English)*

■ *Listen (Hindi)*

Explanation: Leiomyoma is a benign tumour of mesenchymal origin, originating from the smooth muscles of the uterus. Adenoma (Option A): Arises from gland: Epithelial Tumour Papilloma (Option B): Usually arises from surfaces like skin: Epithelial Tumour Seminoma (Option C): Germ cell tumour in testes: Epithelial Tumour Mesenchymal Tumours Epithelial Tumours Origin Connective tissues and derivatives Blood and lymph vessels Hematopoietic stem cells and lymphoid tissue Meninges Mesothelium Smooth muscles and Skeletal muscles Stratified squamous epithelium Melanocytes and basal cells of the skin Glandular epithelium and epithelium of ducts Respiratory, Hepatic, Renal, Transitional, Testicular, Placental epithelium Examples Leiomyosarcoma Lipoma Osteosarcoma Rhabdomyosarcoma Fibrosarcoma Meningioma Synovial sarcoma Adenocarcinoma Squamous cell carcinoma Adenoma Papilloma Seminoma Hepatocellular carcinoma Transitional cell carcinoma Markers Vimentin Desmin S100 Protein Fibronectin Myogenin Cytokeratin Epithelial Membrane Antigen (EMA) E-Cadherin P63, P40 Carcinoembryonic Antigen (CEA)

References:

Robbins and Cotrans Pathologic basis of disease 10th edition, page 270

↑ *Back to this question in Part A*

@Neet_pg_bot

• [04_Neoplasia] 015 Etiology Of Neoplasia

« Back to Folder Directory

[04_Neoplasia] 015 Etiology Of Neoplasia — Quick Jump

Q1 (p. 1327)	*Q2 (p. 1328)*	*Q3 (p. 1329)*	*Q4 (p. 1329)*	*Q5 (p. 1330)*	*Q6 (p. 1331)*
Q7 (p. 1331)	*Q8 (p. 1332)*	*Q9 (p. 1332)*	*Q10 (p. 1333)*	*Q11 (p. 1334)*	*Q12 (p. 1335)*
Q13 (p. 1335)	*Q14 (p. 1336)*	*Q15 (p. 1336)*	*Q16 (p. 1337)*	*Q17 (p. 1338)*	*Q18 (p. 1338)*
Q19 (p. 1340)	*Q20 (p. 1340)*	*Q21 (p. 1342)*	*Q22 (p. 1343)*	*Q23 (p. 1345)*	*Q24 (p. 1346)*
Q25 (p. 1347)	*Q26 (p. 1348)*	*Q27 (p. 1349)*	*Q28 (p. 1349)*	*Q29 (p. 1350)*	*Q30 (p. 1351)*
Q31 (p. 1352)	*Q32 (p. 1352)*	*Q33 (p. 1353)*	*Q34 (p. 1354)*	*Q35 (p. 1355)*	

Q1: Which of the following conditions is most likely associated with vinyl chloride exposure? (Q845149)

A. Hepatocellular carcinoma

B. Hepatic angiosarcoma

C. Cholangiocarcinoma

D. Focal nodular hyperplasia

Correct Answer: B. Hepatic angiosarcoma

■ *Listen (English)*

■ *Listen (Hindi)*

Explanation: Vinyl chloride exposure is associated with hepatic angiosarcoma (cancer that arises from the blood vessels). 3 chemicals cause hepatic angiosarcoma: Vinyl chloride Arsenic Thorotrast Hepatocellular carcinoma (Option A) : Typically associated with cirrhosis, chronic hepatitis B or C infections due to HBV or HCV, alcohol abuse, or non-alcoholic fatty liver disease. Cholangiocarcinoma (Option C): Cholangiocarcinoma (carcinoma of the biliary duct in the liver) includes Primary sclerosing cholangitis (PSC), liver fluke infections such as Clonorchis and Opisthorchis, or certain biliary tract disorders. Focal nodular hyperplasia (Option D) : FNH is more prevalent in women and is associated with hormonal imbalances.

References:

Robbins and Cotrans Pathologic basis of disease 10th edition, page 522

↑ *Back to this question in Part A*

@Neet_pg_bot

Q2: A 35-year-old man presents with painless enlarged lymph nodes in the neck and intermittent low-grade fever. Laboratory studies show normal peripheral blood counts. A biopsy of the lymph node reveals enlarged follicles with prominent vascular proliferation and increased plasma cells. Which of the following is the most likely diagnosis? (Q879869)

A. Angiolymphoma

B. Hodgkin's lymphoma

C. IgG4-related disease

D. Castleman disease

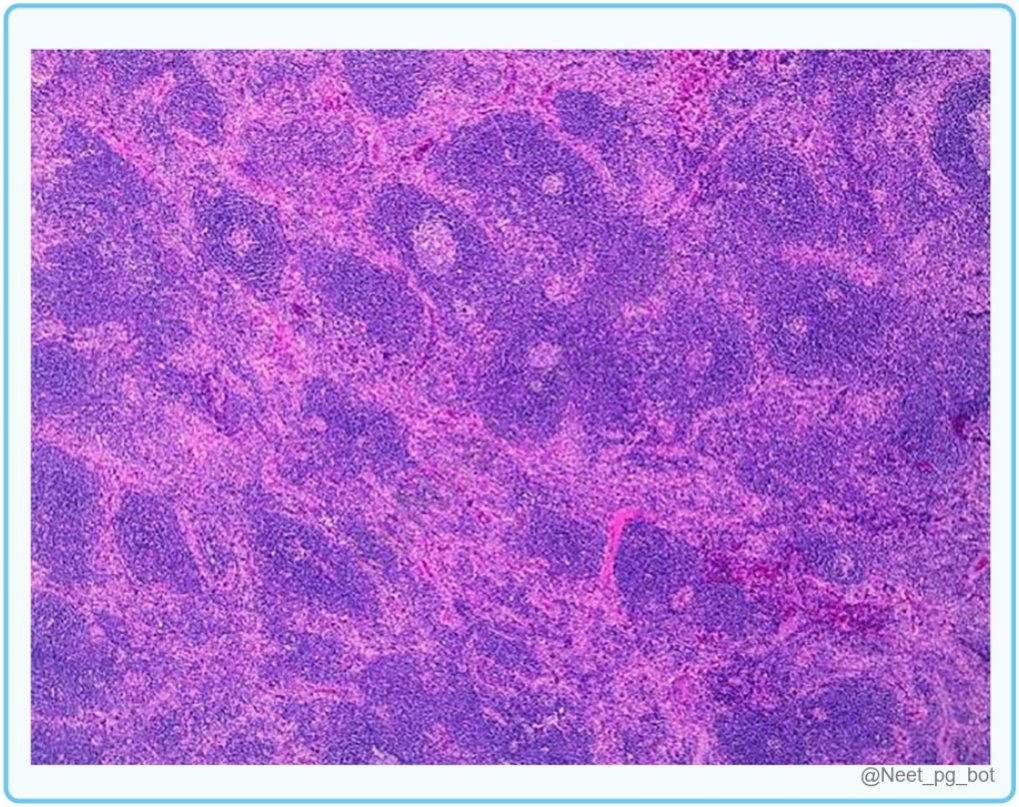

Correct Answer: D. Castleman disease

Explanation: Castleman disease is characterized by enlarged lymph nodes with prominent vascular proliferation and increased plasma cells, often presenting with painless lymphadenopathy and systemic symptoms like low-grade fever. Histopathology: Hyaline-vascular type: small, hyalinized follicles with prominent vascular proliferation ("lollipop" appearance) Plasma-cell type: sheets of plasma cells in interfollicular areas Incorrect Options: Angiolymphoma (Option A) is a benign vascular tumor, usually in the form of subcutaneous nodules in the extremities Hodgkin's lymphoma (Option B): Presence of Reed-Sternberg cells , different morphology IgG4-related disease (Option C) is a systemic fibroinflammatory condition; lymph nodes show dense IgG4 plasma

cells but not classic CD morphology

References:

Robbins and Cotran, Pathologic Basis of Disease, 11th Edition, Page no.228.

↑ *Back to this question in Part A*

@Neet_pg_bot

Q3: A teenager is diagnosed with infectious mononucleosis, confirmed by a positive Monospot (heterophile antibody) test. The virus responsible for this condition is also linked to several malignancies. Which of the following cancers is least likely to be associated with this viral infection? (Q879867)

A. Burkitt lymphoma

B. Hodgkin's lymphoma

C. Nasopharyngeal carcinoma

D. Follicular lymphoma

Correct Answer: D. Follicular lymphoma

Explanation: The teenager has infectious mononucleosis, caused by Epstein–Barr virus (EBV). EBV is associated with: Burkitt lymphoma Hodgkin's lymphoma Nasopharyngeal carcinoma Follicular lymphoma (Option D) arises due to the t(14;18) translocation, leading to overexpression of the BCL2 gene. It is a B-cell non-Hodgkin lymphoma that is not linked to Epstein-Barr virus (EBV) infection.

References:

Robbins and Cotran, Pathologic Basis of Disease, 11th Edition, Page no. 544,228

↑ *Back to this question in Part A*

@Neet_pg_bot

Q4: Infection with Human T-lymphotropic virus type 1 (HTLV-1) is most strongly associated with which of the following hematologic malignancies? (Q879844)

A. Adult T-cell leukemia/lymphoma

B. Enteropathy-associated T-cell lymphoma

C. Diffuse large B-cell lymphoma

D. B-cell lymphomas

Correct Answer: A. Adult T-cell leukemia/lymphoma

Explanation: HTLV-1 is a retrovirus that infects CD4+ T cells, causing adult T-cell leukemia/lymphoma (ATLL) . Clinical features of ATLL: lymphadenopathy, skin lesions, hepatosplenomegaly, and hypercalcemia. Incorrect Options: Enteropathy-associated T-cell lymphoma (Option B) is linked to celiac disease , not HTLV-1 Diffuse large B-cell lymphoma (Option C) is associated with EBV or genetic factors , not HTLV-1 B-cell lymphomas (Option D) is unrelated to HTLV-1

References:

Robbins and Cotran, Pathologic Basis of Disease, 11th Edition, Page no.289

↑ *Back to this question in Part A*

@Neet_pg_bot

Q5: Which of the following cancers is least likely to be linked to an infectious etiology? (Q879840)

A. Burkitt lymphoma

B. Castleman’s disease

C. Adenocarcinoma of the lung

D. Primary effusion lymphoma

Correct Answer: C. Adenocarcinoma of the lung

Explanation: Adenocarcinoma of the lung → primarily caused by tobacco smoke, environmental exposures, and genetic mutations, not by microbial infection. Incorrect Options: Burkitt lymphoma (Option A) is associated with Epstein–Barr virus (EBV) infection. Castleman’s disease (Option B), especially the multicentric type, can be associated with HHV-8 infection. Primary effusion lymphoma (Option D) is strongly associated with HHV-8, often in immunocompromised patients.

References:

Robbins and Cotran, Pathologic Basis of Disease, 11th Edition, Page no. 228,246,290,291

↑ *Back to this question in Part A*

@Neet_pg_bot

Q6: A 52-year-old construction worker with a history of chronic sun exposure presents for a routine skin examination. Which of the following skin conditions are considered UV-induced premalignant or malignant lesions? 1. Squamous cell carcinoma 2. Basal cell carcinoma 3. Seborrheic keratosis 4. Actinic keratosis (Q879835)

A. 1, 2, 3

B. 2, 3, 4

C. 1, 3, 4

D. 1, 2, 4

Correct Answer: D. 1, 2, 4

Explanation: Chronic sun exposure is a major risk factor for: Squamous cell carcinoma (SCC) – UV-induced DNA damage, especially in fair-skinned individuals. (Option 1) Basal cell carcinoma (BCC) is the most common skin cancer, associated with UV exposure. (Option 2) Actinic keratosis (AK) – pre-malignant lesion caused by cumulative UV exposure; can progress to SCC. (Option 4) Seborrheic keratosis (Option 3) : Benign epidermal tumor not related to sun exposure ; arises spontaneously with age.

References:

Robbins and Cotran, Pathologic Basis of Disease, 11th Edition, Page no.1036,1040,1041.

↑ *Back to this question in Part A*

@Neet_pg_bot

Q7: Which of the following compounds acts as a direct-acting carcinogen, meaning it does not require metabolic conversion to become carcinogenic? (Q879831)

A. Cyclophosphamide

B. Benzidine

C. 3-Methylcholanthrene

D. Dimethylaminoazobenzene

Correct Answer: A. Cyclophosphamide

Explanation: Cyclophosphamide is a direct-acting alkylating agent that can interact directly with DNA without requiring metabolic conversion. Incorrect Options: Benzidine (Option B), 3-methylcholanthrene (Option C), and Dimethylaminoazobenzene (Option D) are procarcinogens that require hepatic metabolic activation to become DNA-reactive and carcinogenic.

References:

Robbins and Cotran, Pathologic Basis of Disease, 11th Edition, Page no.287

↑ *Back to this question in Part A*

@Neet_pg_bot

Q8: Which of the following neoplasms is considered the prototype for studying the multi-step process of carcinogenesis? (Q879825)

A. Colon carcinoma

B. Melanoma

C. Thyroid carcinoma

D. Breast carcinoma

Correct Answer: A. Colon carcinoma

Explanation: Colon carcinoma is the classic model of multi-step carcinogenesis, explained by the adenoma–carcinoma sequence . This sequence demonstrates how the accumulation of multiple genetic alterations (both oncogenes and tumor suppressor genes) drives tumor progression. Key genetic events: APC mutation – the earliest change, leading to dysplasia in colonic epithelium. KRAS mutation – promotes the growth of adenomas. Loss of DCC/SMAD genes – progression to advanced adenoma. TP53 mutation – final step to invasive carcinoma. Other tumors (melanoma, thyroid carcinoma, breast carcinoma) also require multiple mutations, but colon carcinoma is the best documented and most extensively studied model .

References:

Robbins and Cotran, Pathologic Basis of Disease, 11th Edition, Page no.286.

↑ *Back to this question in Part A*

@Neet_pg_bot

Q9: Which of the following immune checkpoint interactions is correctly matched with its inhibitory effect on T-cell activation? (Q879809)

A. CTLA-4 binding to B7 molecules on APCs – prevents costimulatory signaling via CD28

B. PD-1 binding to PD-L1/PD-L2 on tumor cells – enhances T-cell cytotoxic activity

C. CD28 binding to B7 molecules on APCs – induces long-lived unresponsiveness of T cells

D. PD-1 blockade – reduces T-cell function in the tumor microenvironment

Correct Answer: A. CTLA-4 binding to B7 molecules on APCs – prevents costimulatory signaling via CD28

Explanation: CTLA-4 competes with CD28 for B7 binding → neutralizes costimulation and may induce T-cell unresponsiveness. PD-1 engagement by PD-L1/PD-L2 activates inhibitory signaling (via phosphatases) → suppresses T-cell activation. Checkpoint blockade therapy (anti-CTLA-4, anti-PD-1, anti-PD-L1) removes these "brakes" to restore antitumor T-cell responses. Incorrect Options: PD-1 binding to PD-L1/PD-L2 on tumor cells – enhances T-cell cytotoxic activity (Option B): PD-1–PD-L1 interaction inhibits, not enhances, T-cell cytotoxicity. CD28 binding to B7 molecules on APCs – induces long-lived unresponsiveness of T cells (Option C): CD28–B7 normally provides positive costimulatory signals, not unresponsiveness. PD-1 blockade – reduces T-cell function in the tumor microenvironment (Option D): Blocking PD-1 restores (not reduces) T-cell function.

References:

Robbins, Cotran & Kumar, Pathologic Basis of Disease, 11th Edition, Page. 278-279

↑ *Back to this question in Part A*

@Neet_pg_bot

Q10: Deletion of which microRNAs is most commonly associated with increased BCL2 expression in chronic lymphocytic leukemia? (Q879806)

A. miR-15 and miR-16

B. miR-155 and miR-21

C. miR-34a and miR-200

D. miR-17 and miR-92

Correct Answer: A. miR-15 and miR-16

Explanation: MicroRNAs (miRs) are small noncoding RNAs (~22 nucleotides) that regulate gene expression by sequence-specific inhibition of mRNAs. Tumor-suppressive miRs normally restrain the translation of oncogenic proteins. Loss of these miRs can increase oncogene expression. In chronic lymphocytic leukemia (CLL), deletion of miR-15 and miR-16 leads to upregulation of BCL2, an anti-apoptotic protein, enhancing tumor cell survival. Onco-miRs are microRNAs whose overexpression promotes tumorigenesis, e.g., miR-155, which indirectly upregulates proliferation-promoting genes like MYC. Altered miR expression in cancer can result from

amplifications or deletions of miR loci and contributes to dysregulated cell growth, survival, and differentiation. Incorrect Options: miR-155 and miR-21 (Option B): These are oncogenic microRNAs commonly upregulated in cancers but not involved in BCL2 suppression in CLL. miR-34a and miR-200 (Option C): These tumor-suppressive microRNAs regulate p53 and EMT pathways, not BCL2 in CLL. miR-17 and miR-92 (Option D): Part of an oncogenic cluster linked to cell proliferation, but not directly associated with BCL2 regulation in CLL.

References:

Robbins, Cotran & Kumar's Pathologic Basis of Disease, 11th Edition, Page. 286

↑ *Back to this question in Part A*

@Neet_pg_bot

Q11: Which of the following genes is most frequently mutated in malignant rhabdoid tumors? (Q879801)

A. SNF5

B. ARID1A

C. PBRM1

D. DNMT3A

Correct Answer: A. SNF5

Explanation: Malignant Rhabdoid Tumors are aggressive pediatric cancers characterized by mutations in genes involved in nucleosome positioning and chromatin remodeling. SNF5 is a core component of the SWI/SNF chromatin remodeling complex, mutated in 100% of malignant rhabdoid tumors. Gene(s) Function Tumor (Approximate Frequency of Mutation) DNMT3A (Option D ruled out) DNA methylation Acute myeloid leukemia (20%) KMT2A Histone methylation Acute leukemia in infants (90%) KMT2D Follicular lymphoma (90%) CREBBP / EP300 Histone acetylation Diffuse large B-cell lymphoma (40%) ARID1A (Option B ruled out) Nucleosome positioning/chromatin remodeling Ovarian clear cell carcinoma (60%), Endometrial carcinoma (30–40%) SNF5 Malignant rhabdoid tumor (100%) PBRM1 (Option C ruled out) Renal carcinoma (30%) H3F3A, HIST1H3B Histone H3 variants (nucleosome components) Pediatric gliomas (30–80%, depending on anatomic location)

References:

Robbins, Cotran & Kumar's Pathologic Basis of Disease, 11th Edition, Page. 285

↑ *Back to this question in Part A*

@Neet_pg_bot

Q12: Which type of circulating blood cell shows the greatest resistance to radiation damage? (Q879733)

A. Lymphocytes

B. Granulocytes

C. Platelets

D. Erythrocytes

Correct Answer: D. Erythrocytes

Explanation: Mature erythrocytes (RBCs) are non-dividing, enucleated cells, hence the least radiosensitive Lymphocytes are the most radiosensitive blood cells; even small doses of radiation can destroy them. Granulocytes and platelets are moderately radiosensitive.

References:

https://pmc.ncbi.nlm.nih.gov/articles/PMC7843614/

↑ *Back to this question in Part A*

@Neet_pg_bot

Q13: Which of the following cancers is most strongly associated with excessive alcohol use? (Q879729)

A. Carcinoma of lip

B. Carcinoma of larynx

C. Carcinoma of pancreas

D. Carcinoma of stomach

Correct Answer: B. Carcinoma of larynx

Explanation: Alcohol increases the risk of oropharyngeal carcinoma (excluding the lip), laryngeal carcinoma , oesophagal carcinoma, and via cirrhosis → hepatocellular carcinoma. The risk of upper airway and digestive tract cancers is markedly higher when combined with tobacco smoking. Incorrect Options: Carcinoma of lip (Option A) : More commonly linked to sun exposure and tobacco , not strongly associated with alcohol. Carcinoma of pancreas (Option C) : Primarily associated with smoking and chronic pancreatitis , not directly with alcohol alone. Carcinoma of stomach (Option D) : Linked to H. pylori infection , dietary factors , and smoking - alcohol plays a

minor role.

References:

Robbins, Cotran & Kumar Pathologic Basis of Disease, 11th Edition, Page. 246

↑ *Back to this question in Part A*

@Neet_pg_bot

Q14: The Notch signaling pathway in angiogenesis is mainly involved in? (Q879725)

A. ECM degradation

B. Vasodilation

C. Regulating sprouting and branching of new vessels

D. Endothelial cell proliferation

Correct Answer: C. Regulating sprouting and branching of new vessels

Explanation: Notch ensures orderly spacing and prevents excessive or chaotic angiogenesis. Angiogenesis promoters / regulators: VEGF (especially VEGF-A) - stimulates endothelial migration, proliferation, capillary sprouting, vasodilation (Option B ruled out) , lumen formation. FGF-2 (Fibroblast Growth Factor-2) - endothelial cell proliferation (Option D ruled out) , macrophage/fibroblast migration, epithelial migration (wound healing). Angiopoietin-1 & Angiopoietin-2 - vessel formation and structural maturation. PDGF (Platelet-Derived Growth Factor) - recruits smooth muscle cells to stabilize vessels. TGF-β (Transforming Growth Factor-beta) - stabilizes vessels Notch signaling pathway - regulates vessel sprouting, branching, and spacing (Option C) . ECM proteins - provide scaffold for vessel growth. MMPs (Matrix Metalloproteinases) - degrade ECM (Option A ruled out) , allow remodeling and extension of vessels.

References:

Robbins, Cotran & Kumar Pathologic Basis of Disease, 11th Edition, Page. 96

↑ *Back to this question in Part A*

@Neet_pg_bot

Q15: A 60-year-old man who has worked in the zinc mines presents to his urologist with urinary symptoms, including increased frequency, hesitancy, and nocturia. During a digital rectal examination, he is found to have an enlarged prostate with a palpable nodule. Which environmental exposure is most likely associated with his

prostate cancer risk? (Q845148)

A. Zinc

B. Benzopyrene

C. Arsenic

D. Cadmium

Correct Answer: D. Cadmium

■ *Listen (English)*

■ *Listen (Hindi)*

Explanation: Occupational exposure to cadmium, commonly found in industries such as zinc mining, smelting of zinc ores, and battery manufacturing, has been associated with an increased risk of prostate cancer. Zinc (Option A): Excessive zinc exposure does not have a direct association with prostate cancer. Benzopyrene (Option B): It is associated with increased risks of lung cancer, bladder cancer, skin cancer, and other malignancies. Arsenic (Option C): It is associated with an increased risk of angiosarcoma of the liver.

References:

Robbins and Cotrans Pathologic basis of disease 10th edition, page 321, 414

↑ *Back to this question in Part A*

@Neet_pg_bot

Q16: A 16-year-old girl presents with a clear-cell vaginal tumour. Upon further inquiry, it was revealed that her mother has a history of taking medication during pregnancy to prevent premature labour. Which medication is most likely associated with the development of this tumour in the daughter? (Q845150)

A. DES (Diethylstilbestrol)

B. Thalidomide

C. Tamoxifen

D. Medroxyprogesterone acetate

Correct Answer: A. DES (Diethylstilbestrol)

■ *Listen (English)*

■ *Listen (Hindi)*

Explanation: DES (Diethylstilbestrol) , a synthetic estrogen previously administered to pregnant women to prevent miscarriages and pregnancy complications, has been associated with a significantly increased risk of clear cell adenocarcinoma of the cervix or vagina in daughters exposed to it in utero. Thalidomide (Option B): Causes severe birth defects like limb deformities (phocomelia), blindness, deafness, heart issues, and brain damage in babies. It is a teratogen, not a carcinogen. Tamoxifen (Option C): Tamoxifen is a selective estrogen receptor modulator used in the treatment of ER-positive breast cancer. Medroxyprogesterone acetate (Option D): Long-term use or high doses of MPA, particularly in combination with estrogen, may increase the risk of breast cancer.

References:

Robbins and Cotrans Pathologic basis of disease 10th edition, page 321, 994

↑ *Back to this question in Part A*

@Neet_pg_bot

Q17: Which of the following is not an indirect-acting carcinogen? (Q845151)

A. Griseofulvin

B. Azo dyes

C. Nitrosoureas

D. Betel nuts

Correct Answer: C. Nitrosoureas

■ *Listen (English)*

■ *Listen (Hindi)*

Explanation: Nitrosoureas are a direct-acting carcinogenic agent. Characteristic Direct-Acting Carcinogens Indirect-Acting Carcinogens Mode of action Directly damage DNA, leading to mutations Require metabolic conversion to become active (ultimate carcinogens) Carcinogenic potency Typically weak More potent Endogenous enzymes involved None Cytochrome P-450 Examples Alkylating agents (Anti-cancer drugs) like nitrosoureas, cyclophosphamide Acylating agents Aromatic hydrocarbons like benzo[a]pyrene Aromatic Amines, Amides, Azo Dyes (Option B ruled out) Natural Plant and Microbial Products like Aflatoxin B1, Griseofulvin, and Betel nuts (Options A, D ruled out) Insecticides, fungicides

References:

Robbins and Cotrans Pathologic basis of disease 10th edition, Page 321, 322

↑ *Back to this question in Part A*

@Neet_pg_bot

Q18: Which of the following radiations is the most common cause of skin cancer? (Q845152)

A. UV-A radiation

B. UV-B radiation

C. UV-C radiation

D. UV-D radiation

Correct Answer: B. UV-B radiation

■ *Listen (English)*

■ *Listen (Hindi)*

Explanation: UV-B radiation is the major cause of sunburn and skin cancer. Wavelengths: 280-320 nm It is responsible for inducing the formation of pyrimidine dimers within DNA, leading to mutations that can result in various types of skin cancer: Squamous cell carcinoma Basal cell carcinoma Malignant melanoma. Basal Cell Carcinoma (BCC): This is the most common skin cancer worldwide. It arises from the basal layer of the epidermis. Clinical Appearance: Typically presents as a "pearly" or waxy papule with prominent, dilated subepidermal blood vessels (telangiectasias). Key Feature: Often exhibits a central ulceration with "rolled" or "peaded" borders (sometimes called a Rodent Ulcer). Histology: Shows nests of "basaloid" cells with peripheral palisading (nuclei at the edge of the nest align in a row). Metastasis: It is highly locally invasive but rarely metastasizes . Treatment: MOHS surgery, imiquimod, vismodegib (Hedgehog pathway) Squamous Cell Carcinoma (SCC): The second most common skin cancer; it arises from the malpighian (prickly) layer of the epidermis. Clinical Appearance: Usually appears as a firm, red, scaling plaque or a nodule with an ulcerated center . Precursor Lesion: Often preceded by Actinic Keratosis (a rough, scaly patch caused by sun damage). Histology: Characterized by Keratin pearls and intercellular bridges (desmosomes). Unique Risk Factors: Associated with chronic non-healing wounds (Marjolin ulcer), arsenic exposure, and immunosuppression Treatment: Excision, Radiotherapy (If elderly/inoperable) Malignant Melanoma: The most aggressive and deadly form of skin cancer; it arises from melanocytes . Identification (ABCDE Criteria): A symmetry B orders (irregular or notched) C olor (variegated/multiple shades) D iameter (usually >6 mm) E volving (changing in size, shape, or color) Prognostic Factor: The Breslow depth (measured in millimeters from the granular layer of the epidermis to the deepest tumor cell) is the most important predictor of metastasis and survival. Markers: Tumor cells are typically positive for S-100 , HMB-45 , and Melan-A . Treatment: Wide excision + SLNB, immunotherapy (anti-PD1), targeted (BRAF) UV-A radiation (Option A): Wavelengths: 320-400 nm. They primarily cause skin ageing. UV-A radiation, particularly in combination with UV-B, can increase the risk of skin cancer. UV-C radiation (Option C): These shorter wavelengths (200-280 nm) are extremely potent in terms of DNA damage, but they are largely filtered out by the Earth's ozone layer and do not reach the surface in significant amounts. UV-D radiation (Option D): The UV spectrum typically consists of UV-A, UV-B, and UV-C and no UV-D radiation.

References:

Robbins and Cotrans Pathologic basis of disease 10th edition,Page 323

↑ *Back to this question in Part A*

@Neet_pg_bot

Q19: A 55-year-old female radiology technician with 25 years of occupational exposure to diagnostic X-rays and fluoroscopy presents with a three-month history of increasing fatigue, unintentional weight loss, and frequent infections. Which cancer type is most likely associated with her occupational history? (Q845153)

A. Acute Myeloid Leukemia

B. Pancreatic cancer

C. Medullary thyroid cancer

D. Chronic Lymphocytic Leukemia

Correct Answer: A. Acute Myeloid Leukemia

■ *Listen (English)*

■ *Listen (Hindi)*

Explanation: Acute Myeloid Leukemia (AML) is a type of blood cancer commonly associated with prolonged exposure to ionizing radiation, such as X-rays and γ-rays, placing affected individuals at increased risk of developing the disease The most common thyroid cancer associated with ionising radiations: Papillary carcinoma thyroid Cancer which is never associated with ionising radiations: CLL

References:

Robbins and Cotrans Pathologic basis of disease 10th edition, Page 323

↑ *Back to this question in Part A*

@Neet_pg_bot

Q20: A 35-year-old woman presents for a routine gynaecological examination. Her Pap smear and biopsy reveals abnormal cells suggestive of cervical dysplasia. Further, HPV testing indicates the presence of specific HPV types associated with cervical cancer. Which HPV types are most commonly linked to an increased risk of cervical cancer in this patient? (Q845154)

A. Low-risk 6, 11

B. High-risk 6, 11

C. Low-risk 16, 18

D. High-risk 16, 18

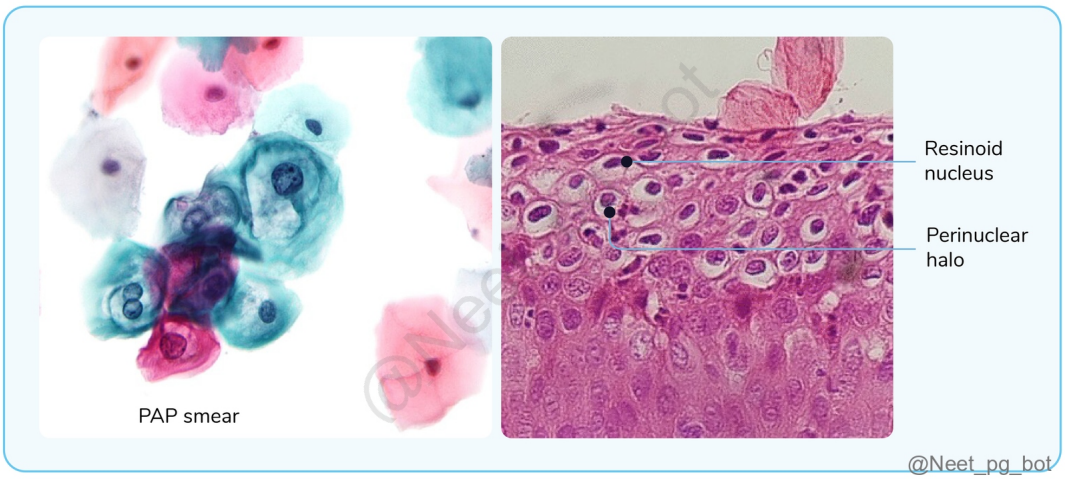

Correct Answer: D. High-risk 16, 18

■ *Listen (English)*

■ *Listen (Hindi)*

Explanation: The abnormal cells in the pap smear and biopsy are known as Koilocytes, characterised by a raisinoid nucleus and a perinuclear halo, which indicates HPV infection. High-Risk HPV (Types 16 and 18): Clinical Condition: Cervical Intraepithelial Neoplasia (CIN) and invasive Cervical Cancer . Mechanism: These types produce two critical oncoproteins: E6: Inhibits p53 (prevents apoptosis). E7: Inhibits Rb (promotes uncontrolled cell cycle progression). Other Cancers: Also strongly linked to vulvar, vaginal, penile, anal, and oropharyngeal cancers. Low-Risk HPV (Types 6 and 11): Clinical Condition: Condyloma Acuminatum (Anogenital warts) and Laryngeal Papillomas . Oncogenic Potential: Very low. They rarely lead to invasive cancer but cause significant physical morbidity. Other Notable Types: HPV 1, 2, 4: Cause Verruca Vulgaris (common skin warts). HPV 3, 10: Cause Verruca Plana (flat warts). HPV 31, 33, 45, 52, 58: Other high-risk types included in the 9-valent vaccine (Gardasil 9) . Risk Group HPV Types Conditions Caused LOW RISK 6, 11, 40, 42, 43, 44, 54, 61, 72 Genital warts (90%), recurrent respiratory papillomatosis HIGH RISK (14 types) 16, 18, 31, 33, 35, 39, 45, 51, 52, 56, 58, 59, 66, 68 Cervical dysplasia/Ca (99%) , anal/oropharyngeal/vulvar/penile/vaginal Ca Oncogenic Microbes & Associated Cancers: Microbe Cancer Mechanism HPV 16/18 Cervical (99%), oropharyngeal E6/E7 → p53/Rb inactivation HBV/HCV Hepatocellular carcinoma Chronic inflammation → cirrhosis EBV Burkitt Lymphoma, Nasopharyngeal Carcinoma, Hodgkin Lymphoma B-cell proliferation H. pylori Gastric adenocarcinoma , MALToma Chronic gastritis → atrophy HHV-8 Kaposi sarcoma Angiogenesis (AIDS) HTLV-1 Adult T-cell leukemia/lymphoma T-cell transformation Schistosoma Bladder Ca (squamous) Chronic inflammation Opisthorchis Cholangiocarcinoma Biliary inflammation

References:

Robbins and Cotrans Pathologic basis of disease 10th edition, page 324

↑ *Back to this question in Part A*

@Neet_pg_bot

Q21: A 35-year-old woman with regular menstrual cycles undergoes routine Pap smear screening, which reveals a high-grade squamous intraepithelial lesion (HSIL) of the cervix. Further testing confirms infection with high-risk HPV type 16. Which of the following mechanisms regarding the oncogenic activity of E6 and E7 of HPV is correct? (Q845155)

A. E6 protein inhibits the degradation of p53.

B. E6 stimulates the expression of TERT.

C. E7 activates CDK inhibitors.

D. E7 can inactivate cyclins A and E

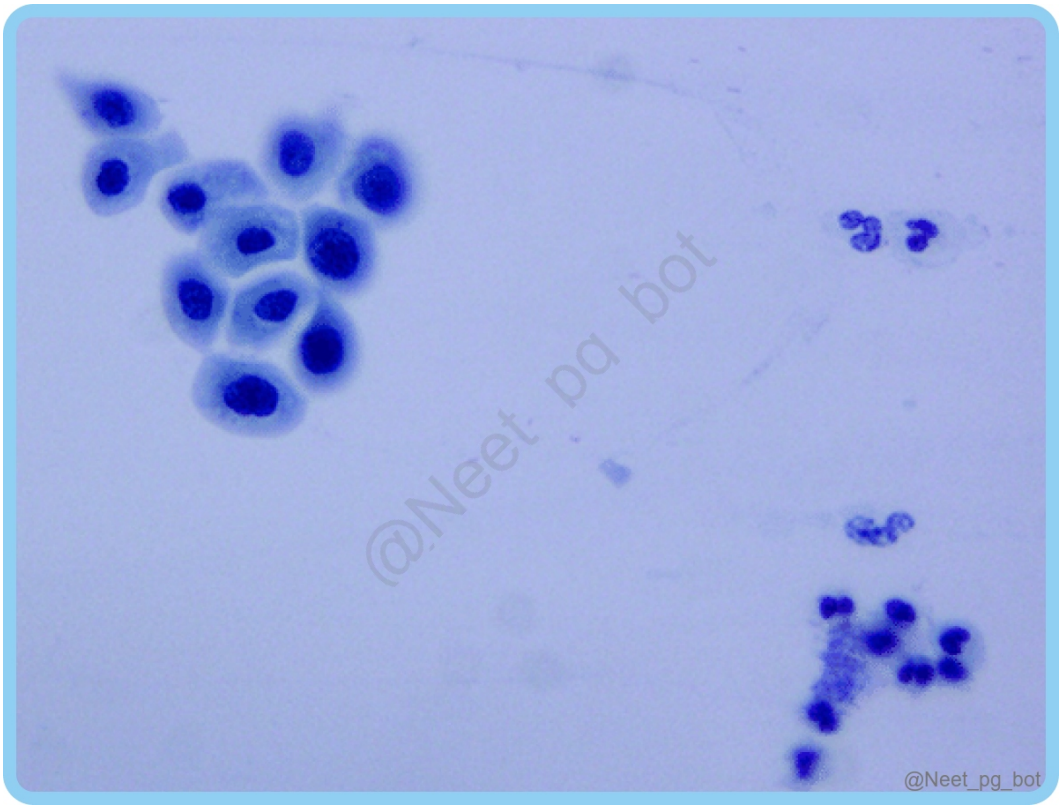

Correct Answer: B. E6 stimulates the expression of TERT.

■ *Listen (English)*

■ *Listen (Hindi)*

Explanation: E6 and E7 proteins from high-risk HPV types exhibit increased affinity for key cellular regulatory proteins (e.g., p53, RB) compared to low-risk HPV types. Oncogenic Activities of E6 Protein Oncogenic Activities of E7 Protein Binds to and promotes degradation of p53 (policeman of the cell) → Impairs cell growth and apoptosis regulation (Option A ruled out). Stimulates expression of TERT (telomerase reverse transcriptase)

→ Facilitates cellular immortalisation by maintaining telomere length. Disrupts interaction between RB gene (governor of genome) and E2F transcription factors Inactivates CDK inhibitors (e.g., p21 and p27) (Option C ruled out). Activates cyclins A and E (Option D ruled out) All these mechanisms enhance cell cycle progression and cellular proliferation in HPV infections.

References:

Robbins and Cotrans Pathologic basis of disease 10th edition, page 324-325

↑ *Back to this question in Part A*

@Neet_pg_bot

Q22: A 10-year-old girl presents with rapidly growing jaw swelling and pain. Further examination reveals bilateral enlargement of the mandible and maxilla. Biopsy suggests the presence of a starry-sky appearance as shown in the image. Which of the following infectious agents is most commonly associated with the pathogenesis of this malignancy? (Q845156)

A. EBV

B. HTLV-1

C. HHV-8

D. Aspergillus flavus

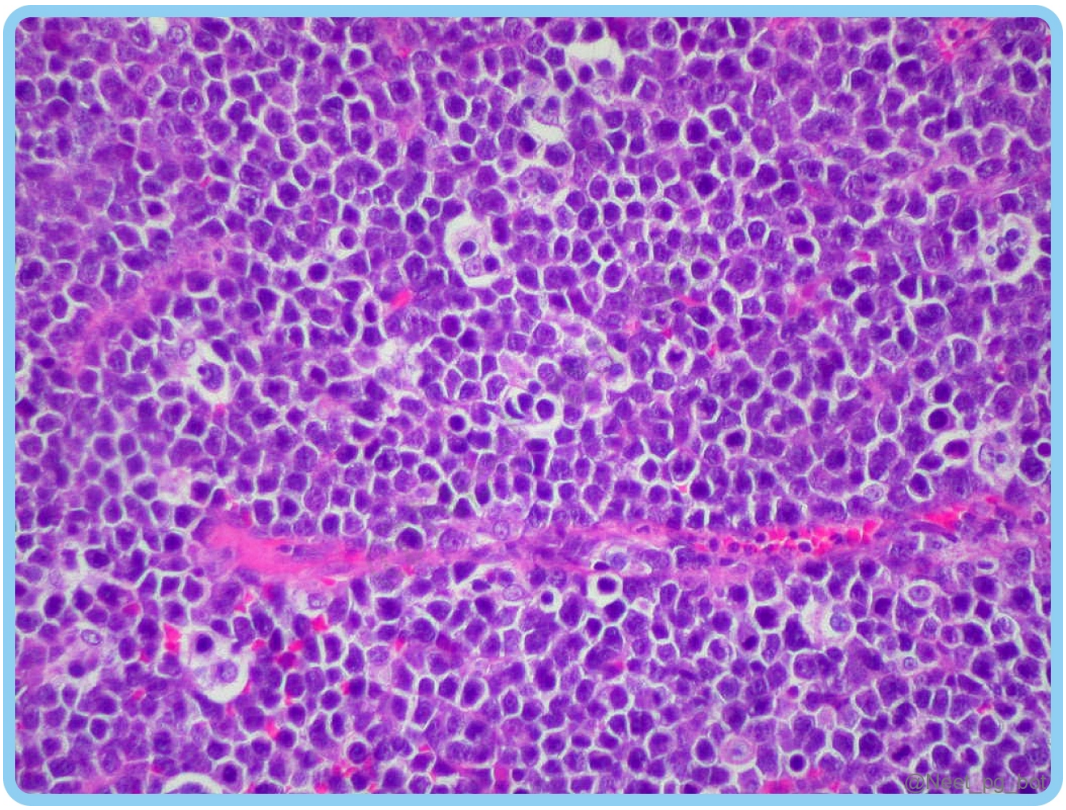

Correct Answer: A. EBV

- *Listen (English)*
- *Listen (Hindi)*

Explanation: The image displays a characteristic "starry sky" appearance , which is typically seen in Burkitt's lymphoma , a type of aggressive B-cell non-Hodgkin lymphoma commonly associated with Epstein-Barr virus (EBV) infection. The ‘starry sky pattern’ of histopathology represents scattered macrophages with phagocytosed cell debris among proliferating lymphoma cells is characteristic of Burkitt lymphoma . Stars (Lighter cells): Macrophages Sky (dark blue cells in background): Tumorous cells of Burkitt lymphoma Burkitt Lymphoma: It is a highly aggressive B-cell non-Hodgkin lymphoma characterized by the fastest doubling time of any human tumor. Pathogenesis: Driven by the translocation of the c-myc proto-oncogene from chromosome 8 to the Ig heavy chain locus on chromosome 14 [t(8;14)]. This leads to the constitutive expression of myc, a potent transcriptional activator that promotes cell cycle progression. Clinical Variants: Endemic (African): Strongly associated with EBV (nearly 100% of cases). Typically presents as jaw or facial bone swelling in children. Sporadic: Occurs worldwide. EBV association is lower (approx. 15–20%). Usually presents as an abdominal mass (ileocecal region). Immunodeficiency-related: Seen in HIV/AIDS patients; often the first manifestation of AIDS. Epstein-Barr Virus (EBV): EBV (Human Herpesvirus 4) is a ubiquitous virus that infects B-cells via the CD21 receptor (CR2). Clinical Conditions Caused by EBV : EBV is associated with both benign proliferative disorders and various malignancies: Infectious Mononucleosis (Glandular Fever): Presentation: Fever, sore throat, lymphadenopathy, and splenomegaly. Diagnosis: Positive Monospot test (heterophile antibodies) and presence of atypical T-lymphocytes (Downey cells) on peripheral blood smear. Nasopharyngeal Carcinoma: A malignant tumor of the head and neck, common in Southern China and East Africa. Hodgkin Lymphoma: Specifically the "Mixed Cellularity" and "Lymphocyte Depleted" subtypes. Oral Hairy Leukoplakia: Non-malignant white, corrugated patches on the lateral borders of the tongue, primarily seen in immunocompromised (HIV) patients. 5.

Primary CNS Lymphoma: An AIDS-defining illness. HTLV-1 (Human T-cell Lymphotropic Virus-1) (Option B): Target Cells: Specifically infects CD4+ T-lymphocytes . Associated Malignancy: Adult T-cell Leukemia/Lymphoma (ATLL) . Differentiating Features: Unlike the B-cell origin of Burkitt lymphoma, ATLL presents with "flower cells" (lymphocytes with highly leaf-like, multilobulated nuclei) in the peripheral blood. Often presents with skin lesions, lymphadenopathy, and lytic bone lesions with hypercalcemia. HHV-8 (Human Herpesvirus 8) (Option C): Also Known As: Kaposi Sarcoma-associated Herpesvirus (KSHV). Target Cells: Endothelial cells. Associated Malignancy: Kaposi Sarcoma , Primary Effusion Lymphoma, and Multicentric Castleman Disease. Differentiating Features: It typically presents as purplish-red skin nodules or plaques, especially in patients with HIV/AIDS . Histology: Shows a proliferation of spindle cells forming slit-like vascular spaces containing red blood cells. Aspergillus flavus (Option D): Nature: This is a fungus , not a virus. Mechanism: It produces Aflatoxins (specifically B1), which contaminate stored grains and nuts. Associated Malignancy: Hepatocellular Carcinoma (HCC) . Differentiating Features: Aflatoxin acts as a dietary carcinogen that causes a specific mutation in the p53 tumor suppressor gene (at codon 249). It does not cause jaw swelling or "starry sky" patterns.

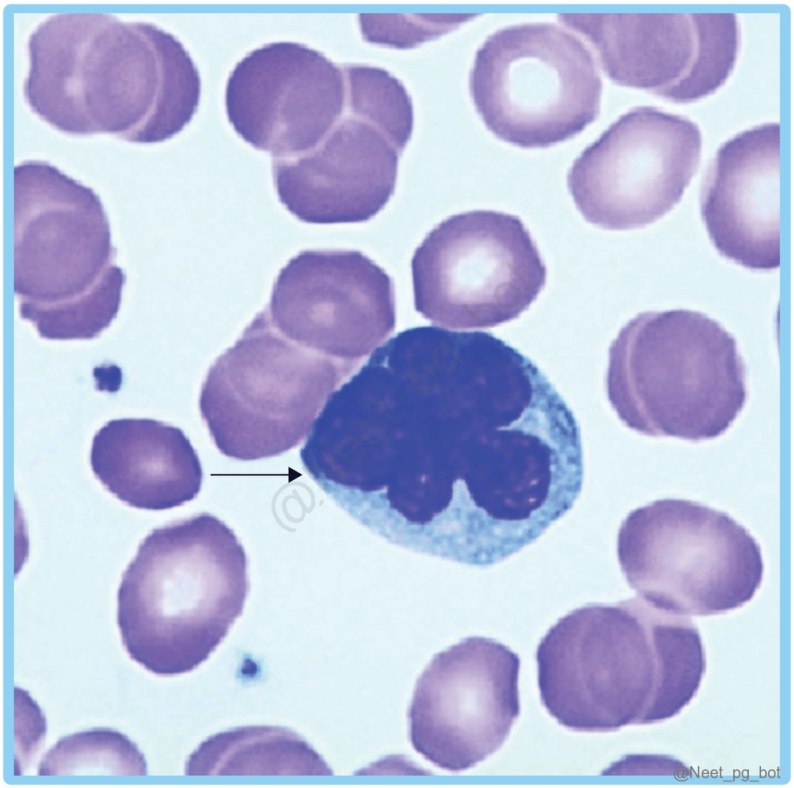

References:

Robbins and Cotrans Pathologic basis of disease, 10th edition, Pages 321-327

↑ *Back to this question in Part A*

@Neet_pg_bot

Q23: Infection with Helicobacter pylori is linked to the development of several gastrointestinal diseases. Which of the following conditions is least likely to be associated with H. pylori infection? (Q845158)

A. Peptic ulcer disease

B. Barrett's esophagus

C. Gastric adenocarcinoma

D. Mucosa-associated lymphoid tissue (MALT) lymphoma

Correct Answer: B. Barrett's esophagus

■ *Listen (English)*

■ *Listen (Hindi)*

Explanation: H. pylori infection causes chronic gastritis leading to decreased acid production in the stomach. Reduced gastric acid secretion lowers the incidence of gastroesophageal reflux disease (GERD). Since GERD is the primary cause of Barrett's esophagus, H. pylori indirectly protects against this condition. Barrett's esophagus results from chronic acid injury to the lower esophagus, not from H. pylori infection. Therefore, it is not associated with H. pylori. Studies show an inverse relationship between H. pylori and Barrett's esophagus. Hence, Barrett's esophagus is the least likely condition linked to H. pylori. Peptic ulcer disease (Option A): Strongly associated with H. pylori, especially in duodenal and gastric ulcers due to mucosal inflammation and increased acid exposure. Gastric adenocarcinoma (Option C) : Chronic H. pylori infection causes atrophic gastritis → intestinal metaplasia → dysplasia → gastric cancer. MALT lymphoma (Option D) : H. pylori stimulates lymphoid proliferation in the stomach, directly leading to MALT lymphoma , which often regresses with eradication therapy.

References:

Robbins and Cotrans Pathologic basis of disease 10th edition, Page 327

↑ *Back to this question in Part A*

@Neet_pg_bot

Q24: Match the following carcinogens with the respective cancer risk 1. Azodyes a) Urothelial carcinoma of the bladder 2. Schistosoma haematobium b) AML & ALL 3. Radon c) Squamous cell carcinoma of the bladder 4. Benzene d) Squamous cell carcinoma of the lung (Q845159)

A. 1-a, 2-c, 3- d, 4-b

B. 1-a, 2-c, 3- b, 4-d

C. 1-c, 2-a, 3- d, 4-b

D. 1-c, 2-a, 3- b, 4-d

Correct Answer: A. 1-a, 2-c, 3- d, 4-b

■ *Listen (English)*

■ *Listen (Hindi)*

Explanation: Risk factor Cancer risk Azodyes/ Beta naphthyl amine/Benzidine Urothelial carcinoma/ Transitional cell carcinoma of the bladder S chistosoma haematobium S quamous cell carcinoma of the urinary bladder Radon Squamous cell carcinoma of the lung Benzene AML & ALL (Blood cancers) Major Carcinogens and Associated Cancers: Category Carcinogen Associated Cancer(s) Occupational / Chemical Asbestos Mesothelioma, Lung cancer (Bronchogenic carcinoma) Benzene Acute Myeloid Leukemia (AML) Arsenic Skin cancer (Squamous cell), Lung cancer, Liver (Angiosarcoma) Vinyl Chloride Liver Angiosarcoma Naphthylamine (Azo dyes) Bladder cancer (Transitional cell) Nickel / Chromium Lung cancer, Nasal cavity cancer Radon Lung cancer (2nd leading cause after smoking) Lifestyle / Dietary Aflatoxin B1 (from Aspergillus) Hepatocellular carcinoma (HCC) Tobacco Smoke Lung, Bladder, Kidney, Pancreas, Esophagus Alcohol Liver, Esophagus (Squamous cell), Breast, Pancreas Nitrosamines (Smoked foods) Stomach cancer (Gastric adenocarcinoma) Infectious Agents Helicobacter pylori Gastric adenocarcinoma, MALT lymphoma Schistosoma haematobium Bladder cancer (Squamous cell carcinoma) Hepatitis B & C (HBV, HCV) Hepatocellular carcinoma Human Papillomavirus (HPV) Cervical, Anogenital, and Oropharyngeal cancers Epstein-Barr Virus (EBV) Burkitt lymphoma, Nasopharyngeal carcinoma HHV-8 Kaposi Sarcoma Radiation / Other UV Radiation (Sunlight) Melanoma, Basal cell, Squamous cell carcinoma Ionizing Radiation Thyroid cancer, Leukemia, Papillary thyroid CA

References:

Robbins and Cotrans Pathologic basis of disease 10th edition, Pages 321-327

https://www.uptodate.com/contents/cigarette-smoking-and-other-possible-risk-factors-for-lung-cancer?

https://pubmed.ncbi.nlm.nih.gov/6741759/

↑ *Back to this question in Part A*

@Neet_pg_bot

Q25: A 60-year-old man who has worked in the zinc mines presents to his urologist with urinary symptoms, including increased frequency, hesitancy, and nocturia. During a digital rectal examination, he is found to have an enlarged prostate with a palpable nodule. Which environmental exposure is most likely associated with his prostate cancer risk? (Q845484)

A. Benzene

B. Benzopyrene

C. Arsenic

D. Cadmium

Correct Answer: D. Cadmium

Explanation: Occupational exposure to cadmium, commonly found in industries such as zinc mining, smelting of zinc ores, and battery manufacturing, has been associated with an increased risk of prostate cancer. The body accumulates cadmium through inhalation of dust and fumes containing cadmium particles. Benzene (Option A) Benzene is a carcinogen that disrupts normal blood cell production and is associated with higher risks of developing acute myeloid leukaemia (AML), myelodysplastic syndromes (MDS), and non-Hodgkin lymphoma (NHL). Benzopyrene (Option B) Benzopyrene, a polycyclic aromatic hydrocarbon (PAH) present in tobacco smoke and combustion products, is associated with increased risks of lung cancer, bladder cancer, skin cancer, and other malignancies. Arsenic (Option C) Prolonged exposure to arsenic can occur through contaminated water, soil, and food, commonly by the use of arsenic-based pesticides and herbicides. It is associated with an increased risk of developing skin, lung, bladder, and liver cancers.

References:

Robbins and Cotrans Pathologic basis of disease 10th edition, pg 321, 414

↑ *Back to this question in Part A*

@Neet_pg_bot

Q26: Which of the following is not an indirect-acting carcinogen? (Q845487)

A. Griseofulvin

B. Azo dyes

C. Nitrosoureas

D. Betel nuts

Correct Answer: C. Nitrosoureas

Explanation: Nitrosoureas is a direct-acting carcinogenic agent. Characteristic Direct-Acting Carcinogens Indirect-Acting Carcinogens Mode of action Directly damage DNA, leading to mutations Require metabolic conversion to become active (ultimate carcinogens) Carcinogenic potency Typically weak More potent Endogenous enzymes involved None Cytochrome P-450 enzymes play a key role Examples Alkylating agents (Anti-cancer drugs) like nitrosoureas, cyclophosphamide Acylating agents Aromatic hydrocarbons like benzo[a]pyrene Aromatic Amines, Amides, Azo Dyes (Option 2) Natural Plant and Microbial Products like Aflatoxin B1, Griseofulvin, and Betel nuts (Options 1, 4) Insecticides, fungicides

References:

Robbins and Cotrans Pathologic basis of disease 10th edition, Pg 321, 322

↑ *Back to this question in Part A*

@Neet_pg_bot

Q27: Which of the following conditions is most likely associated with vinyl chloride exposure? (Q845485)

A. Hepatocellular carcinoma

B. Hepatic angiosarcoma

C. Cholangiocarcinoma

D. Focal nodular hyperplasia

Correct Answer: B. Hepatic angiosarcoma

Explanation: Hepatic angiosarcoma is a high-grade vascular malignancy and is the most common sarcoma arising in the liver, especially in those with significant exposure to Vinyl chloride. It is more common in men and occurs in the elderly. Some other risk factors include arsenic, anabolic steroids, radiation, and thorium dioxide (Thorotrast). Hepatocellular carcinoma (Option A) Hepatocellular carcinoma is the most common primary liver cancer and is typically associated with cirrhosis, chronic hepatitis B or C infections due to HBV or HCV, alcohol abuse, or non-alcoholic fatty liver disease and not associated with exposure to vinyl chloride. Cholangiocarcinoma (Option C) Cholangiocarcinoma (carcinoma of the biliary duct in the liver) includes conditions that lead to chronic inflammation of the bile ducts, such as Primary sclerosing cholangitis (PSC), liver fluke infections such as Clonorchis and Opisthorcis, or certain jbiliary tract disorders. It is not associated with vinyl chloride exposure . Focal nodular hyperplasia (Option D) Focal nodular hyperplasia (FNH) is the second most common benign liver lesion after hepatic hemangioma. It consists of hyperplastic hepatocytes surrounding a central scar, which can result from altered blood flow. FNH is more prevalent in women and is associated with hormonal imbalances but not with vinyl chloride exposure.

References:

Robbins and Cotrans Pathologic basis of disease 10th edition, pg 522

↑ *Back to this question in Part A*

@Neet_pg_bot

Q28: A 16-year-old girl presents with a clear-cell vaginal tumour. Upon further inquiry, it was revealed that her mother has a history of taking medication during pregnancy to prevent premature labour. Which medication is most likely associated with the development of this tumour in the daughter? (Q845486)

A. DES (Diethylstilbestrol)

B. Thalidomide

C. Tamoxifen

D. Medroxyprogesterone acetate

Correct Answer: A. DES (Diethylstilbestrol)

Explanation: In the given scenario, the clear cell vaginal tumour in the daughter is most likely linked to DES (Diethylstilbestrol). DES, a synthetic estrogen previously administered to pregnant women to prevent miscarriages and pregnancy complications, has been associated with a significantly increased risk of clear cell adenocarcinoma of the cervix or vagina in daughters exposed to it in utero. Thalidomide (Option 2): Thalidomide, once used to treat morning sickness in pregnant women, caused severe birth defects like limb deformities (phocomelia), blindness, deafness, heart issues, and brain damage in their babies. It is a teratogen, not a carcinogen. Tamoxifen (Option 3): Tamoxifen is a selective estrogen receptor modulator used in the treatment of ER-positive breast cancer. While it is associated with an increased risk of endometrial cancer in women who take it for breast cancer treatment, it's not linked to clear cell vaginal tumours in their daughters. Medroxyprogesterone acetate (Option 4): It is a synthetic progestin commonly used in hormonal therapies and contraceptives. Long-term use or high doses of MPA, particularly in combination with estrogen, may increase the risk of breast cancer. However, maternal use of it is not typically associated with vaginal tumours in daughters.

References:

Robbins and Cotrans Pathologic basis of disease 10th edition, Page 321, 994

↑ *Back to this question in Part A*

@Neet_pg_bot

Q29: Match the following carcinogens with the respective cancer risk: 1. Azodyes a) Urothelial carcinoma of the bladder 2. Schistosoma haematobium b) Adenocarcinoma of the lung 3. Radon c) Squamous cell carcinoma of the bladder 4. Asbestos d) Squamous cell carcinoma of the lung (Q845494)

A. 1-a, 2-c, 3- d, 4-b

B. 1-a, 2-c, 3- b, 4-d

C. 1-c, 2-a, 3- d, 4-b

D. 1-c, 2-a, 3- b, 4-d

Correct Answer: A. 1-a, 2-c, 3- d, 4-b

Explanation: Risk factor Cancer risk Azodyes/ Beta naphthyl amine Urothelial carcinoma/ Transitional cell carcinoma of the bladder Schistosoma haematobium Squamous cell carcinoma of the bladder Radon Squamous cell carcinoma of the lung Asbestos Adenocarcinoma of the lung (Most common malignancy) Malignant mesothelioma (Most specific malignancy)

References:

Robbins and Cotrans Pathologic basis of disease 10th edition, pg 321-327 https://www.uptodate.com/contents/cigarette-smoking-and-other-possible-risk-factors-for-lung-cancer?search=lung%20cancer%20epidemiology&source=search_result&selectedTitle=1%7E150&usage_type=default&display_rank=1#H21310588 https://pubmed.ncbi.nlm.nih.gov/6741759/

↑ *Back to this question in Part A*

@Neet_pg_bot

Q30: Which of the following statements regarding H. pylori infection and its association with malignancies is correct ? (Q845493)

A. Gastric lymphomas associated with H. pylori infection are primarily of B-cell origin.

B. H. pylori strains associated with gastric adenocarcinomas contain the cytotoxin-associated B gene.

C. VacA, a toxin from H. pylori, causes gastric cell apoptosis, reducing cancer risk.

D. MALT lymphomas associated with t(11;18) translocation respond to anti-H.Pylori therapy.

Correct Answer: A. Gastric lymphomas associated with H. pylori infection are primarily of B-cell origin.

Explanation: H. pylori, the first bacterium classified as a carcinogen, is associated with gastric adenocarcinomas and lymphomas, including MALT lymphomas of B-cell origin. (Option A is correct) Gastric adenocarcinomas arise due to increased epithelial cell proliferation in chronic inflammation caused by H. pylori infection. Pathogenicity genes like CagA (cytotoxin-associated A) trigger uncontrolled growth factor pathways. (Option 2) H. pylori produces a bacterial toxin VacA, inducing apoptosis in gastric epithelial cells and influencing cancer development. (Option 3) Chronic H. pylori infection leads to polyclonal B-cell proliferation triggered by H. pylori-reactive T cells, which contribute to the development of MALT lymphomas. Antibiotic therapy can eradicate H. pylori and "cure" MALT lymphomas by removing the antigenic stimulus for T cells . But, MALT lymphomas associated with t(11;18) translocation are resistant to anti-H.Pylori therapy. (Option 4)

References:

Robbins and Cotrans Pathologic basis of disease 10th edition, Pg 327

↑ *Back to this question in Part A*

@Neet_pg_bot

Q31: A 10-year-old girl presents with rapidly growing jaw swelling and pain. Further examination reveals bilateral enlargement of the mandible and maxilla. Biopsy suggests the presence of a starry-sky appearance. What is the characteristic chromosomal translocation associated with this tumor? (Q845492)

A. t(8;14)

B. t(15;17)

C. t(9;22)

D. t(11;14)

Correct Answer: A. t(8;14)

Explanation: The ‘starry sky pattern’ of histopathology represents scattered macrophages with phagocytosed cell debris among proliferating lymphoma cells, characteristic of Burkitt lymphoma. An aggressive B-cell non-Hodgkin lymphoma. Characterized by the translocation t(8;14)(q24;q32) , involving the MYC gene on chromosome 8q24 and the immunoglobulin heavy chain (IGH) locus on chromosome 14q32. It is most commonly associated with Epstein-Barr virus (EBV) infection, which is endemic in central Africa and New Guinea, where it is the most common childhood tumour. t(15;17) (Option B): Acute promyelocytic leukemia (PML::RARA fusion). t(9;22) (Option C): Chronic myeloid leukemia and some cases of ALL (BCR::ABL fusion, Philadelphia chromosome). t(11;14) (Option D): Mantle cell lymphoma (Cyclin D1 overexpression).

References:

1. Robbins and Cotrans Pathologic Bais of Diseases, 10th Edition, Page 321-327 2. Robbins, Cotran & Kumar, Pathologic Basis of Disease, 11th Edition, Page no. 283

↑ *Back to this question in Part A*

@Neet_pg_bot

Q32: A 35-year-old woman with regular menstrual cycles undergoes routine Pap smear screening, which reveals a high-grade squamous intraepithelial lesion (HSIL) of the cervix. Further testing confirms infection with high-risk HPV type 16. Which of the following mechanisms regarding the oncogenic activity of E6 and E7 of HPV is correct? (Q845491)

A. E6 protein inhibits the degradation of p53.

B. E6 stimulates the expression of TERT.

C. E7 activates CDK inhibitors.

D. E7 can inactivate cyclins A and E.

Correct Answer: B. E6 stimulates the expression of TERT.

Explanation: E6 and E7 proteins from high-risk HPV types exhibit increased affinity for key cellular regulatory proteins (e.g., p53, RB) compared to low-risk HPV types. This enhanced affinity allows high-risk HPV-infected cells to evade tumour suppressor mechanisms, dysregulate cell cycle control, and promote oncogenic transformation. Oncogenic Activities of E6 Protein Oncogenic Activities of E7 Protein Binds to and promotes degradation of p53 → Impairs cell growth and apoptosis regulation (Option 1). Stimulates expression of TERT (telomerase reverse transcriptase) → Facilitates cellular immortalisation by maintaining telomere length. Disrupts interaction between RB protein and E2F transcription factors Inactivates CDK inhibitors (e.g., p21 and p27) (Option 3). Activates cyclins A and E (Option 4) All these mechanisms enhance cell cycle progression and cellular proliferation in HPV infections.

References:

Robbins and Cotrans Pathologic basis of disease 10th edition, pg 324-325

↑ *Back to this question in Part A*

@Neet_pg_bot

Q33: A 35-year-old woman presents for a routine gynaecological examination. Her Pap smear and biopsy reveals abnormal cells suggestive of cervical dysplasia. Further, HPV testing indicates the presence of specific HPV types associated with cervical cancer. Which HPV types are most commonly linked to an increased risk of cervical cancer in this patient? (Q845490)

A. Low-risk 6, 11

B. High-risk 6, 11

C. Low-risk 16, 18

D. High-risk 16, 18

Correct Answer: D. High-risk 16, 18

Explanation: The abnormal cells in the pap smear and biopsy are known as Koilocytes characterised by a raisinoid nucleus and a perinuclear halo, which indicates HPV infection. High-risk HPV types like HPV 16 and HPV 18 are strongly linked to a higher risk of cervical cancer, including high-grade cervical dysplasia and invasive cancer. Low-risk HPV types such as HPV 6 and HPV 11 are often associated with genital warts such as condyloma

acuminatum and low-grade changes in cervical cells (Option 1). Integration of viral DNA within the E1/E2 open reading frame disrupts the E2 viral repressor gene, leading to increased expression of the HPV E6 and E7 oncogenes. Integration of high-risk HPV DNA is a critical step in the oncogenic process, distinguishing it from low-risk HPV infections.

References:

Robbins and Cotrans Pathologic basis of disease 10th edition, pg 324

↑ *Back to this question in Part A*

@Neet_pg_bot

Q34: A 55-year-old female radiology technician with 25 years of occupational exposure to diagnostic X-rays and fluoroscopy presents with a three-month history of increasing fatigue, unintentional weight loss, and frequent infections. Which cancer type is most likely associated with her occupational history? (Q845489)

A. Acute Myeloid Leukemia

B. Pancreatic cancer

C. Medullary thyroid cancer

D. Chronic Lymphocytic Leukemia

Correct Answer: A. Acute Myeloid Leukemia

Explanation: Due to prolonged exposure to ionising radiation the patient is at an increased risk of developing Acute Myeloid Leukemia (M/C cancer in individuals with exposure to ionising radiation). Ionising radiation, which includes electromagnetic (x-rays, γ rays) and particulate (α particles, β particles, protons, neutrons) radiations, is carcinogenic. It can cause cancer by directly damaging cellular DNA, leading to mutations that disrupt normal gene function and structure. Leukaemia often has a relatively short latent period, typically around 7 years or less after exposure to certain factors like radiation or chemicals. Solid tumours like breast, colon, thyroid, and lung cancers generally have longer latent periods compared to leukaemia. Pancreatic cancer (Option 2) Risk of Pancreatic cancer is more associated with cigarette smoking, heavy alcohol drinking, obesity, and diet (high intake of saturated fat and/or meat, particularly smoked or processed meats). Medullary thyroid cancer (Option 3) Medullary thyroid cancer is primarily associated with genetic factors, specifically mutations in the RET proto-oncogene, rather than radiation exposure. However, the risk of Papillary carcinoma of the thyroid and Follicular carcinoma of the thyroid have a high association with radiation exposure. Chronic Lymphocytic Leukemia (Option 4) Chronic Lymphocytic Leukemia (CLL) is the only leukaemia not associated with radiation exposure.

References:

Robbins and Cotrans Pathologic basis of disease 10th edition, Pg 323

↑ *Back to this question in Part A*

@Neet_pg_bot

Q35: Which of the following radiations is the most common cause of skin cancer? (Q845488)

A. UV-A radiation

B. UV-B radiation

C. UV-C radiation

D. UV-D radiation

Correct Answer: B. UV-B radiation

Explanation: UV-B radiation is the major cause of sunburn and skin cancer. These medium wavelengths (280-320 nm) primarily affect the outer layers of the skin and are highly mutagenic. It is responsible for inducing the formation of pyrimidine dimers within DNA, leading to mutations that can result in various types of skin cancer, including squamous cell carcinoma, basal cell carcinoma, and melanoma. Fair-skinned individuals are at higher risk. UV-A radiation (Option 1): UV-A rays are longer wavelengths (320-400 nm) and penetrate deeper into the skin. They primarily cause skin ageing. UV-A radiation, particularly in combination with UV-B, can increase the risk of skin cancer. UV-C radiation (Option 3) These shorter wavelengths (200-280 nm) are extremely potent in terms of DNA damage, but they are largely filtered out by the Earth's ozone layer and do not reach the surface in significant amounts. UV-D radiation (Option 4): The UV spectrum typically consists of UV-A, UV-B, and UV-C and no UV-D radiation.

References:

Robbins and Cotrans Pathologic basis of disease 10th edition, Page 323

↑ *Back to this question in Part A*

@Neet_pg_bot

• [04_Neoplasia] 016 Diagnosis Of Tumors And Paraneoplastic Syndromes

« Back to Folder Directory

[04_Neoplasia] 016 Diagnosis Of Tumors And Paraneoplastic Syndromes — Quick Jump

Q1 (p. 1356)	*Q2 (p. 1356)*	*Q3 (p. 1357)*	*Q4 (p. 1358)*	*Q5 (p. 1358)*	*Q6 (p. 1359)*
Q7 (p. 1359)	*Q8 (p. 1360)*	*Q9 (p. 1361)*	*Q10 (p. 1362)*	*Q11 (p. 1363)*	*Q12 (p. 1363)*
Q13 (p. 1364)	*Q14 (p. 1367)*	*Q15 (p. 1367)*	*Q16 (p. 1368)*	*Q17 (p. 1369)*	*Q18 (p. 1370)*
Q19 (p. 1371)	*Q20 (p. 1372)*	*Q21 (p. 1373)*			

Q1: Which of the following best describes the change in the nuclear-to-cytoplasmic ratio seen in malignant cells compared to normal cells? (Q879702)

A. Decreased ratio due to abundant cytoplasm

B. Increased ratio due to larger nuclei and scant cytoplasm

C. No change; ratio remains constant across benign and malignant cells

D. Decreased ratio due to nuclear shrinkage (pyknosis)

Correct Answer: B. Increased ratio due to larger nuclei and scant cytoplasm

Explanation: Normal cells:N: C ratio ≈ 1:4 to 1:6 (small nucleus, abundant cytoplasm). Malignant/anaplastic cells:N: C ratio increases to 1:1 or higher, because nuclei become large, hyperchromatic, and cytoplasm is relatively scant. Diagnostic importance: High N: C ratio is a hallmark of anaplasia and malignancy; used in cytology (e.g., Pap smear, FNAC) to identify malignant cells.

References:

https://pubmed.ncbi.nlm.nih.gov/35977407/

↑ *Back to this question in Part A*

@Neet_pg_bot

Q2: Which of the following markers is not used to identify gastrointestinal stromal tumors (GISTs)? (Q879908)

A. KIT

B. SDH

C. PDGFRA

D. NRG-1

Correct Answer: D. NRG-1

Explanation: NRG-1 is not used to identify Gastrointestinal stromal tumors (GISTs) → mesenchymal tumors of the GI tract. Markers used for diagnosis: KIT (CD117): Expressed in ~95% of GISTs; key diagnostic marker. PDGFRA mutations: Found in a subset of KIT-negative GISTs; also drives tumor growth. SDH (succinate dehydrogenase): Loss of SDH subunits is seen in SDH-deficient GISTs , a distinct subgroup.

References:

Robbins and Cotran, Pathologic Basis of Disease, 11th Edition, Page no.253,709

↑ *Back to this question in Part A*

@Neet_pg_bot

Q3: Which of the following is not classified as an oncofetal tumor marker? (Q879907)

A. Alpha-fetoprotein

B. Carcinoembryonic antigen

C. Prostate-specific antigen

D. Both A and B

Correct Answer: C. Prostate-specific antigen

Explanation: Alpha-fetoprotein and carcinoembryonic antigen are classic Oncofetal Tumor Markers expressed during fetal development and certain cancers, while prostate-specific antigen is a tissue-specific marker unrelated to fetal proteins. Oncofetal antigens are proteins expressed during fetal life and re-expressed in certain malignancies. Examples: Alpha-fetoprotein (AFP): (Option A ruled out) Normally produced by the fetal liver and yolk sac. Reappears in hepatocellular carcinoma, yolk sac tumors, some GI carcinomas . Carcinoembryonic antigen (CEA): (Option B ruled out) Produced in fetal gut, pancreas, liver. Seen in colorectal carcinoma, pancreatic carcinoma, gastric carcinoma, breast carcinoma .

References:

Robbins and Cotran, Pathologic Basis of Disease, 11th Edition, Page no.300

↑ *Back to this question in Part A*

@Neet_pg_bot

Q4: Which of the following tumor markers is most useful for diagnosing pheochromocytoma? (Q879906)

A. Calcitonin

B. Catecholamine

C. Alpha-fetoprotein

D. Carcinoembryonic antigen

Correct Answer: B. Catecholamine

Explanation: Pheochromocytomas are tumors of chromaffin cells of the adrenal medulla (or extra-adrenal paraganglia). They characteristically produce catecholamines (epinephrine, norepinephrine, dopamine) . Diagnosis is confirmed by measuring catecholamines and their metabolites (metanephrines, VMA) in plasma or urine. Incorrect Options: Calcitonin (Option A): Marker for medullary thyroid carcinoma, not pheochromocytoma. Alpha-fetoprotein (AFP) (Option C): Elevated in hepatocellular carcinoma, yolk sac tumors, and non-seminomatous germ cell tumors. Carcinoembryonic antigen (Option D): Marker for colorectal carcinoma and pancreatic carcinoma , not pheochromocytoma.

References:

Robbins and Cotran, Pathologic Basis of Disease, 11th Edition, Page no.300.

↑ *Back to this question in Part A*

@Neet_pg_bot

Q5: A 48-year-old man develops recurrent, painful, red, tender nodules that appear and disappear on his arms and legs over several weeks. This clinical picture suggests migratory thrombophlebitis. Which of the following cancers is not commonly associated with this condition? (Q879904)

A. Uterine carcinoma

B. Pancreatic carcinoma

C. Bronchogenic carcinoma

D. Bladder carcinoma

Correct Answer: D. Bladder carcinoma

Explanation: The condition described is Migratory Superficial Thrombophlebitis , which results from tumor-induced hypercoagulability; however, bladder carcinoma is not associated with this manifestation. Most common tumor associations: Pancreatic adenocarcinoma (classic) (Option B ruled out) Bronchogenic carcinoma (Option C ruled out) Uterine carcinoma (Option A ruled out)

References:

Robbins and Cotran, Pathologic Basis of Disease, 11th Edition, Page no.294

↑ *Back to this question in Part A*

@Neet_pg_bot

Q6: A 55-year-old man presents with headache, dizziness, and blurred vision. He has a ruddy complexion and mild hypertension. Labs show hemoglobin 19.2 g/dL and hematocrit 60%. Secondary polycythemia from ectopic erythropoietin is suspected. Which tumor is least likely to be responsible? (Q879901)

A. Melanoma

B. Renal cell carcinoma

C. Cerebellar hemangioma

D. Hepatocellular carcinoma

Correct Answer: A. Melanoma

Explanation: Melanoma is not associated with polycythemia. Paraneoplastic polycythemia occurs due to ectopic production of erythropoietin (EPO) by certain tumors. Tumors commonly associated with increased EPO and secondary polycythemia include: Renal cell carcinoma (Option B ruled out) Cerebellar hemangioblastoma (Option C ruled out) Hepatocellular carcinoma (Option D ruled out)

References:

Robbins and Cotran, Pathologic Basis of Disease, 11th Edition, Page no.294

↑ *Back to this question in Part A*

@Neet_pg_bot

Q7: Based on the image and clinical presentation of this 58-year-old obese female, which of the following tumors is not commonly associated with this dermatologic condition? (Q879896)

A. Gastric carcinoma

B. Bladder carcinoma

C. Uterine carcinoma

D. Thymoma



Correct Answer: B. Bladder carcinoma

Explanation: The image is consistent with Acanthosis Nigricans - Bladder carcinoma is not a recognized cause. It may be: Benign - associated with obesity and insulin resistance. Malignant (paraneoplastic) - most often associated with gastric carcinoma , and less frequently with uterine carcinoma and thymic tumors . (Option A, B, C ruled out)

References:

Robbins and Cotran, Pathologic Basis of Disease, 11th Edition, Page no.294

↑ *Back to this question in Part A*

@Neet_pg_bot

Q8: A 55-year-old patient presents with generalized fatigue, muscle weakness, and bone pain. Laboratory tests reveal a serum calcium level of 14.2 mg/dL. Which type of lung cancer is most commonly associated with this hypercalcemia? (Q879874)

A. Squamous cell carcinoma

B. Small cell carcinoma

C. Adenocarcinoma

D. Large cell carcinoma

Correct Answer: A. Squamous cell carcinoma

Explanation:

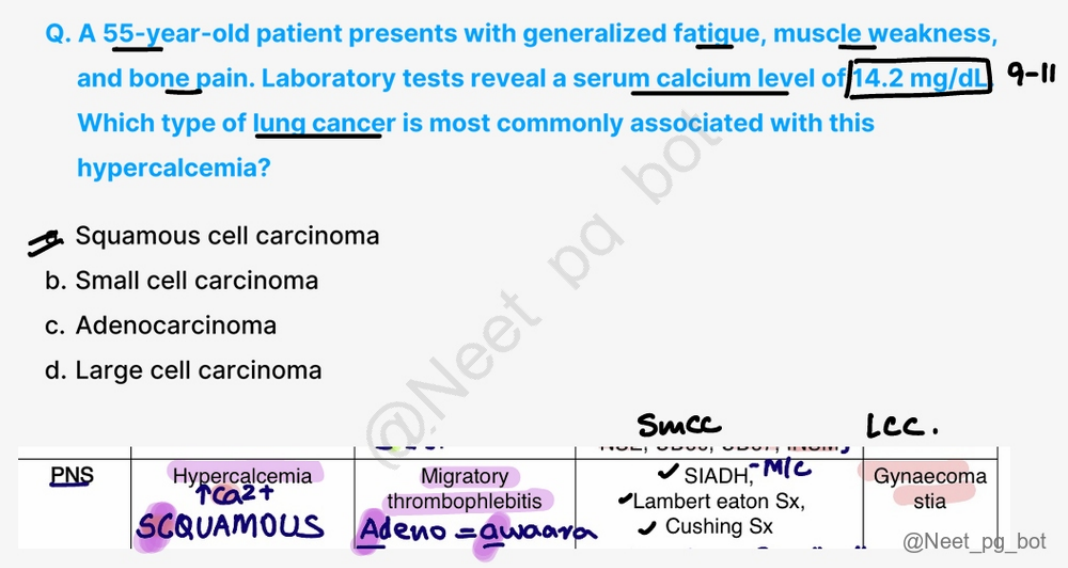

References:

Robbins and Cotran, Pathologic Basis of Disease, 11th Edition, Page no. 294

↑ *Back to this question in Part A*

@Neet_pg_bot

Q9: Which subtype of acute myeloid leukemia is characteristically linked to disseminated intravascular coagulation (DIC) as a paraneoplastic syndrome? (Q879871)

A. AML minimally differentiated

B. Acute promyelocytic leukemia

C. Acute myelomonocytic leukemia

D. Acute megakaryoblastic leukemia

Correct Answer: B. Acute promyelocytic leukemia

Explanation: Acute promyelocytic leukemia (APL, AML-M3) is characterized by the t(15;17)(q22;q12) translocation, leading to the PML-RARA fusion gene. DIC as a paraneoplastic manifestation: APL blasts contain primary granules rich in tissue factor and procoagulants . Upon lysis (spontaneous or chemotherapy-induced), these trigger massive activation of the coagulation cascade , resulting in DIC. Incorrect Options: AML minimally differentiated (Option A): Rare, lacks specific features of DIC Acute myelomonocytic leukemia (M4) (Option C) can present with leukostasis or organ infiltration, but DIC is uncommon Acute megakaryoblastic leukemia (M7) (Option D): More often associated with myelofibrosis and thrombocytopenia , not classic DIC

References:

Robbins and Cotran, Pathologic Basis of Disease, 11th Edition, Page no. 294

↑ *Back to this question in Part A*

@Neet_pg_bot

Q10: Choose the correct option regarding tumor invasion and metastasis: Assertion (A): All tumors that show invasive properties eventually metastasize. Reason (R): The ability to invade allows tumor cells to penetrate blood vessels or lymphatics, facilitating spread to distant organs. (Q879708)

A. Both A and R are true, and R correctly explains A

B. Both A and R are true, but R does not explain A

C. A is false, but R is true

D. A is true, but R is false

Correct Answer: C. A is false, but R is true

Explanation: Invasion is a hallmark of malignancy, but not all invasive tumors metastasize (e.g., basal cell carcinoma of the skin invades locally but rarely metastasizes). The reason is true: invasive ability allows tumors to enter lymphatics or blood vessels, which is a prerequisite for metastasis.

References:

Robbins, Cotran & Kumar Pathologic Basis of Disease, 11th Edition, Page. 242

↑ *Back to this question in Part A*

@Neet_pg_bot

Q11: A biopsy from a liver mass in a 60-year-old man reveals clusters of malignant epithelial cells forming irregular glands. The surrounding liver architecture is compressed but not invaded by native hepatocytes. Which histological feature most strongly suggests that this mass represents a metastatic carcinoma rather than a primary liver tumor? (Q879705)

A. Presence of malignant epithelial cells with atypia

B. Lack of normal organ-specific architecture within the tumor

C. Presence of mitotic figures in tumor cells

D. Hyperchromatic nuclei with increased nuclear-to-cytoplasmic ratio

Correct Answer: B. Lack of normal organ-specific architecture within the tumor

Explanation: Key Histological Features of Metastatic Cancer: Tumor cells often do not reproduce the normal architecture of the host organ. Histology resembles the primary site (e.g., breast adenocarcinoma metastasis showing ductal/glandular patterns in bone/liver). Disruption or replacement of native tissue. Atypia, pleomorphism, abnormal mitoses, high N:C ratio (features of malignancy, but not specific for metastasis). Sometimes multiple nodules at the metastatic site. Incorrect Options: Presence of malignant epithelial cells with atypia (Option A) : This indicates malignancy but does not differentiate primary from metastatic tumors. Presence of mitotic figures in tumor cells (Option C) : Shows proliferation but is not specific to metastasis. Hyperchromatic nuclei with increased nuclear-to-cytoplasmic ratio (Option D) : Feature of malignancy, not specific for metastatic vs primary.

References:

https://pmc.ncbi.nlm.nih.gov/articles/PMC10165727/

↑ *Back to this question in Part A*

@Neet_pg_bot

Q12: Which of the following is used in immunohistochemical (IHC) staining as a chromogen to diagnose tumours of unknown origin? (Q845495)

A. Diaminobenzidine

B. Congo Red

C. Masson's Trichrome

D. Mucicarmine

Correct Answer: A. Diaminobenzidine

■ *Listen (English)*

■ *Listen (Hindi)*

Explanation: 3,3′ Diaminobenzidine (DAB) is a chromogen used in histochemical and IHC staining. In IHC, DAB is a substrate for a peroxidase enzyme coupled to a primary or secondary antibody. It is oxidised and converted to an insoluble polymer, precipitating as a dark brown pigment, which allows visualisation of the target molecule. Congo red can stain (Option B) amyloid fibres in red and orange. When viewed under polarised light in a microscope, Congo-red-stained tissues high in amyloid will show bright apple-green birefringence . Masson's Trichrome stain (Option C) is a three-color stain that highlights collagen in blue, muscle in red, and nuclei in blue-black. It helps identify fibrosis in the heart, lungs, and kidney . Mucicarmine stains (Option D) mucin, a secretion produced in epithelial and connective tissue and capsule of Cryptococcus . IHC Markers for Tumors: Marker Type Marker Name Associated Tumor / Tissue Epithelial Cytokeratins (CK) Carcinomas (e.g., Lung, Breast, Colon) Mesenchymal Vimentin Sarcomas Melanocytic S100, HMB-45, Melan-A Melanoma Leukocyte CD45 (LCA) Lymphomas Muscle Desmin, Myogenin Rhabdomyosarcoma, Leiomyosarcoma Neural NSE, Synaptophysin, Chromogranin Neuroendocrine tumors (Small cell CA, Carcinoid) Vascular CD31, ERG Angiosarcoma Prostate PSA Prostate Adenocarcinoma Germ Cell AFP, β-hCG Yolk sac tumor, Choriocarcinoma

References:

www.ncbi.nlm.nih.gov/pmc/articles/PMC5775208/

www.ncbi.nlm.nih.gov/books/NBK557663/

↑ *Back to this question in Part A*

@Neet_pg_bot

Q13: An appendix specimen, whose HPE is shown below, had a 2 cm submucosal nodule identified. Electron microscopy showed numerous neurosecretory granules in the cytoplasm. Twenty-four-hour urine analysis showed an elevation of 5-hydroxy indoleacetic acid (5-HIAA). Which of the following would not be seen in this condition? (Q845506)

A. Flushing

B. Diarrhea

C. Valvular heart disease

D. Bronchodilation

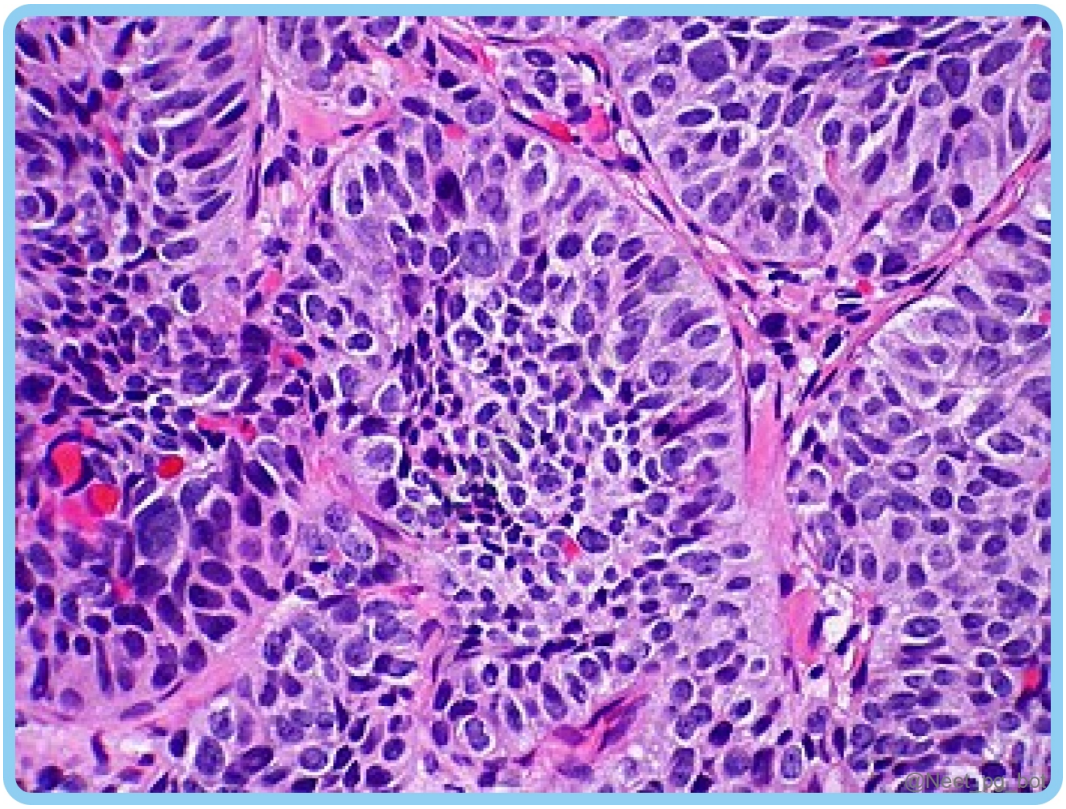

Correct Answer: D. Bronchodilation

■ *Listen (English)*

■ *Listen (Hindi)*

Explanation: A submucosal nodule with neurosecretory granules on electron microscopy and elevated 5-HIAA confirms a neuroendocrine (carcinoid) tumor of the appendix, typically at the tip, and it is not associated with bronchodilation Common Microscopic features of Neuroendocrine tumors: The "Salt-and-Pepper" Nuclei: The most diagnostic feature is the chromatin . It appears as a mix of fine and coarse clumps, creating a "speckled" or grainy look (similar to spilled salt and pepper) within a round, uniform nucleus. Organoid Growth Patterns: The cells don't grow in random clumps; they arrange themselves in organized, gland-like structures: Nests: Solid clusters of cells. Trabeculae: Long, thin ribbons or cords. Rosettes: Cells arranged in a circle around a central point. Granular Cytoplasm: The cells typically have an eosinophilic (pink) , granular cytoplasm. These granules represent the storage of hormones or neurotransmitters. Key Markers (IHC): To confirm the diagnosis, pathologists stain for specific proteins: Synaptophysin (Most sensitive) Chromogranin A (Most specific) {{caption_text}} Image showing cells arranged in the form of a rosette (cells in nests) {{caption_text}} Image showing salt and pepper chromatin Carcinoid tumors: Cell of Origin: Derived from Argentaffin cells (also known as Kulchitsky cells). Vasoactive Mediators: While serotonin (5-HT) is primary, these tumors also secrete kallikrein, bradykinin, histamine, and prostaglandins . Primary Locations: Most common in the midgut (ileum, appendix). They are also found in the bronchi and ovaries. Clinical features: S - S ystemic fibrosis H - H epatomegaly, H eart disorders (valvular heart disorders - tricuspid regurgitation) (Option C ruled out) I - I ntestinal motility increases (diarrhoea, abdominal cramping) (Option B ruled out) V - V asodilation (flushing, pruritus)

(Option A ruled out) A - A sthma-like features - wheezing, dyspnea (bronchoconstriction) (Option D) The "Liver Rule": GI carcinoid tumors only cause systemic syndrome after they metastasize to the liver , as the liver normally metabolizes serotonin before it reaches systemic circulation. Biochemical Marker: The gold standard for screening is the 24-hour urine collection for 5-HIAA (5-hydroxyindoleacetic acid), a metabolite of serotonin. Dietary Interference: Students should know that eating walnuts, pecans, or bananas can falsely elevate 5-HIAA levels. Vitamin Deficiency: Chronic carcinoid syndrome can lead to Pellagra (Niacin/B3 deficiency) because the tumor uses up all the body's Tryptophan to make serotonin.

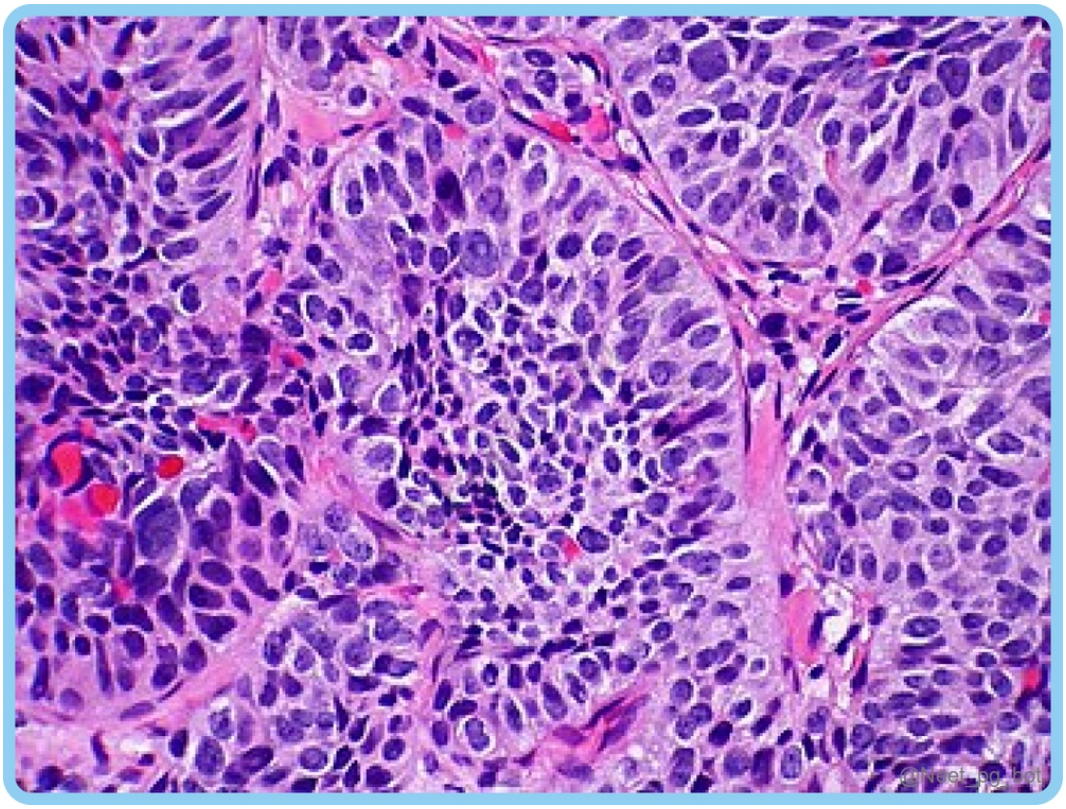

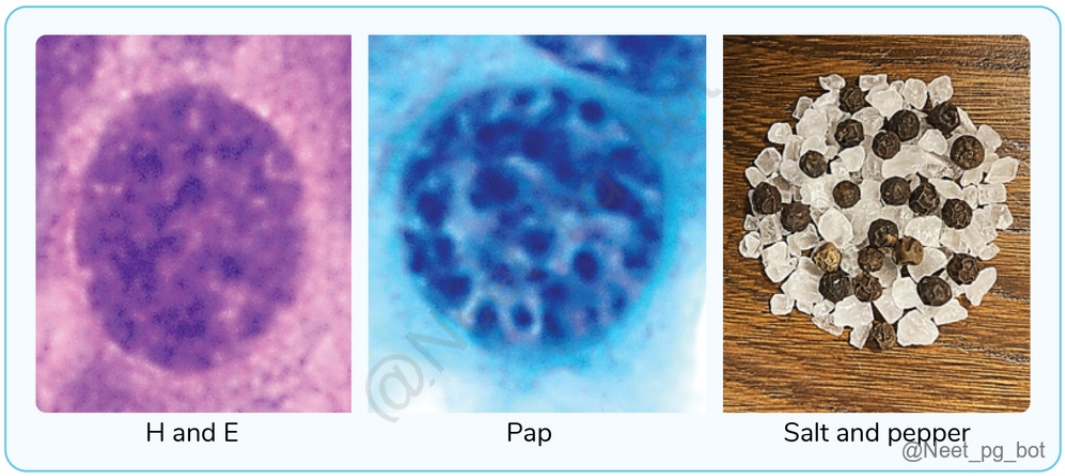

References:

Robbins Pathology 10th edition: Page no: 723, 565

www.ncbi.nlm.nih.gov/books/NBK448096/

↑ *Back to this question in Part A*

@Neet_pg_bot

Q14: Which of the following paraneoplastic syndrome is not associated with lung cancer? (Q845504)

A. Dermatomyositis

B. Acanthosis nigricans

C. Myasthenia

D. Red cell aplasia

Correct Answer: D. Red cell aplasia

■ *Listen (English)*

■ *Listen (Hindi)*

Explanation: Red cell aplasia is associated with thymic neoplasms and not lung cancer. Paraneoplastic syndromes associated with lung cancer are as follows: Cushing syndrome (Ectopic ACTH) Small cell carcinoma of the lung , Pancreatic tumours SIADH (Inappropriate ADH) Small cell carcinoma of the lung , CNS tumors Hypercalcemia (PTHrP) Squamous cell carcinoma of the lung Myasthenia (Lambert-Eaton) (Option C) Bronchogenic carcinoma Acanthosis nigricans (Option B) Adenocarcinoma lung, Gastric adenocarcinoma Dermatomyositis (Option A) Bronchogenic carcinoma Hypertrophic osteoarthropathy and clubbing of the fingers Adenocarcinoma lung Venous thrombosis (Trousseau phenomenon Pancreatic carcinoma, Bronchogenic carcinoma Polycythemia (Ectopic EPO) Renal cell carcinoma , Hepatocellular carcinoma, Hemangioblastoma Nonbacterial Thrombotic Endocarditis Advanced Adenocarcinomas (esp. Pancreatic) Opsoclonus-myoclonus syndrome Neuroblastoma (children), Small cell lung cancer (adults) Pure Red Cell Aplasia Thymoma Hypoglycemia Hepatocellular carcinoma , Mesothelioma, Insulinomas

References:

Robbins Pathology 10th edition: Page no: 329

www.ncbi.nlm.nih.gov/pmc/articles/PMC4127595/

↑ *Back to this question in Part A*

@Neet_pg_bot

Q15: A 60-year-old male was diagnosed with a lung malignancy two months ago. He now came with complaints of malaise, abdominal pain, bone pain, lethargy, and confusion. The intern suspects a condition related to lung cancer and decides to send a blood test. Which of the following would be the appropriate test? (Q845503)

A. Erythropoietin

B. Adrenocorticotrophic hormone

C. Parathyroid hormone-related protein

D. Antidiuretic hormone

Correct Answer: C. Parathyroid hormone-related protein

■ *Listen (English)*

■ *Listen (Hindi)*

Explanation: The clinical scenario indicates paraneoplastic hypercalcemia likely linked to lung cancer, and the appropriate diagnostic test is parathyroid hormone-related protein (PTHrP). Paraneoplastic syndrome: Refers to signs and symptoms that cannot be explained by the tumour's anatomic distribution or hormones indigenous to the tumour tissue. These occur in about 10% of patients with cancer It may be the earliest manifestation of an occult neoplasm. It may mimic metastatic disease and confound treatment. PTHRP leads to hypercalcemia, which can present as Nausea, vomiting, Abdominal pain (groans) , Bone pain (bones) , Renal stones (stones) , Fatigue malaise (moans) , Polyuria, polydipsia, Constipation (thrones) , Lethargy, confusion, depression, Memory loss (psychic overtones). PTHRP is also associated with Squamous cell carcinoma of the lung Breast carcinoma Renal carcinoma Adult T-cell leukaemia/lymphoma Erythropoietin (Option A) levels can be checked in polycythemia, which associated with renal carcinoma, cerebellar hemangioma, and hepatocellular carcinoma . Adrenocorticotropic hormone(ACTH) (Option B) levels can be checked in Cushing’s syndrome which is associated with small cell carcinoma of the lung, pancreatic carcinoma, and neural tumours . Antidiuretic hormone (Option D) levels can be checked in Syndrome of inappropriate antidiuretic hormone secretion(SIADH) which is associated with small cell carcinoma of the lung and intracranial neoplasms .

References:

Robbins Pathology 10th edition: Page no 328-329

www.ncbi.nlm.nih.gov/books/NBK430714/

↑ *Back to this question in Part A*

@Neet_pg_bot

Q16: Match the given neoplasias with their respective immunohistochemistry markers. 1. Carcinoma A. S100 2. Sarcoma B. Leucocyte common antigen 3.

Lymphoma C. Cytokeratin 4. Melanoma D. Vimentin (Q845502)

A. 1-C, 2-A, 3-B, 4-D

B. 1-A, 2-C, 3-B, 4-D

C. 1-C, 2-D, 3-B, 4-A

D. 1-A, 2-D, 3-B, 4-C

Correct Answer: C. 1-C, 2-D, 3-B, 4-A

■ *Listen (English)*

■ *Listen (Hindi)*

Explanation: The correctly matched pair of neoplasias and their respective immunohistochemistry(IHC) markers are: Carcinoma (epithelial origin/squamous cell carcinoma) Cytokeratin Cytokeratin 1, cytokeratin 10 Sarcoma Vimentin, desmin(skeletal muscle) Lymphoma Leucocyte common antigen, CD 45 Melanoma S100, HMB45 , Melan A

References:

Robbins Pathology 10th edition: Page no 332

www.ncbi.nlm.nih.gov/pmc/articles/PMC3439132/

↑ *Back to this question in Part A*

@Neet_pg_bot

Q17: A 45-year-old female presents with a breast lump. On biopsy, the tissue shows anaplastic cells without any differentiation. Immunohistochemistry (IHC) staining is performed to characterise the tumour further. Which marker would be most appropriate to confirm the epithelial origin of the tumour cells in breast cancer? (Q845500)

A. CD20

B. p63

C. TTF-1

D. CK7

Correct Answer: D. CK7

■ *Listen (English)*

■ *Listen (Hindi)*

Explanation: In a female with a breast lump and presence of anaplastic cells, CK7 (cytokeratin 7) is the most appropriate marker to confirm the epithelial origin of the tumor, as cytokeratins are commonly expressed in all carcinomas. In I mmunohistochemistry (IHC) , a CK7 and CK20 profile is commonly used to help determine the tumor origin. Most female-origin cancers (breast, endometrial, thyroid, cervical) typically show a CK7-positive and CK20-negative pattern. (Option D) ER (estrogen receptor), PR (progesterone receptor), and HER2 (human epidermal growth factor receptor 2) are other markers that can be positive in breast cancer, which help in deciding management. CD20 (Option A) is a B-cell marker that is typically positive in B-cell lymphomas, including non-Hodgkin lymphoma (NHL). Pp3 (Option B) is a marker positive in squamous cell carcinoma in the lung. TTF-1(thyroid transcription factor-1) (Option D) is a marker positive in the adenocarcinoma of the lung.

References:

Robbins Pathology 10th edition - Pg- 993, 719, 593, 1056,718 Panels of immunohistochemical markers help determine primary sites of metastatic adenocarcinoma - PubMed (nih.gov)

↑ *Back to this question in Part A*

@Neet_pg_bot

Q18: Which of the following conditions is FNAC helpful in establishing diagnosis ? (Q845499)

A. Follicular adenoma of the thyroid

B. Testicular cancer

C. Hydatid cyst

D. Medullary thyroid carcinoma

Correct Answer: D. Medullary thyroid carcinoma

■ *Listen (English)*

■ *Listen (Hindi)*

Explanation: FNAC serves as an initial diagnostic tool for medullary thyroid carcinoma (MTC), often revealing pinkish amyloid material alongside malignant cells—findings that are highly suggestive of MTC. Limitations of FNAC: Cystic changes cannot be identified. Inadequate cell sampling may require repeated procedure Indications Contraindications /limitations Thyroid disorders Follicular disorders of the thyroid (Limitation) (Option A ruled out) Breast lesions Infections, septicemia Lymph node evaluation Bleeding disorders Pancreatic malignancy Hydatid cyst- Risk of anaphylaxis (Option C ruled out) Most solid organ masses accessible via FNAC Testicular cancer- Increased risk of spread of cancer (Option B ruled out) Follicular adenoma of the thyroid (Option A): FNAC cannot definitively diagnose follicular neoplasms, as the key distinction between benign and malignant forms lies in detecting capsular and vascular invasion. This assessment isn't possible with FNAC, as the thin

needle doesn't allow evaluation of tissue architecture.

References:

Robbins pathology, 10th edition, Pg 331. Fine Needle Aspiration - StatPearls - NCBI Bookshelf (nih.gov)
Problems and limitations with fine needle aspiration cytology of solitary thyroid nodules - PubMed (nih.gov)

↑ *Back to this question in Part A*

@Neet_pg_bot

Q19: What needle size is typically employed for Fine Needle Aspiration Cytology (FNAC) procedures? (Q845498)

A. 18-gauge needle

B. 22-gauge needle

C. 25-gauge needle

D. 30-gauge needle

Correct Answer: C. 25-gauge needle

■ *Listen (English)*

■ *Listen (Hindi)*

Explanation: The appropriate needle size commonly used for FNAC procedures is the 25-27-gauge needle. Fine Needle Aspiration Cytology (FNAC): FNAC is a rapid, minimally invasive diagnostic technique used to investigate lumps or masses. A slender needle is used to extract cells for cytological examination. Needle Size: The typically employed size is a 25–27 gauge needle . This provides effective sample collection while minimizing patient discomfort and tissue damage. Thinner needles (higher gauge) are often preferred for vascular organs like the thyroid gland to reduce the risk of hematoma or complications. Procedure: The lesion is identified via palpation or imaging (ultrasound, CT, or MRI). The needle is inserted into the lesion, and gentle suction is applied to draw cells into the syringe. Multiple passes are often made to ensure a sufficient sample volume. Material is smeared onto glass slides or preserved in a fixative solution for analysis. Contraindications (C/I) for FNAC: While generally safe, FNAC should be avoided or performed with extreme caution in the following scenarios: Bleeding Diathesis: Patients with severe coagulopathy or those on high-dose anticoagulants (risk of uncontrollable hematoma). Suspected Pheochromocytoma: Needle entry can trigger a massive release of catecholamines, leading to a hypertensive crisis. Suspected Echinococcal (Hydatid) Cyst: Aspiration can lead to fluid leakage, potentially causing life-threatening anaphylactic shock or peritoneal seeding. Lack of Safe Access: If the lesion is located behind major blood vessels or vital structures that cannot be avoided. Critical Diagnostic Limitations: ■■■■■■■ Follicular Adenoma vs. Carcinoma: FNAC cannot differentiate between a follicular adenoma and a follicular carcinoma of the thyroid. Distinction between the two requires observing capsular or vascular invasion , which can only be seen on formal histology (biopsy), not on a cell smear. Non-Diagnostic Samples: Highly cystic lesions or very hard, fibrotic tumors may yield "inadequate" or "pauci-cellular" samples.



References:

Robbins pathology, 10th edition, Pg 331.

pubmed.ncbi.nlm.nih.gov/30464152/

↑ *Back to this question in Part A*

@Neet_pg_bot

Q20: Which of the following is used to determine treatment response in patients with colorectal cancer? (Q845497)

A. Alpha-fetoprotein

B. Carcinoembryonic antigen

C. Human Chorionic Gonadotropin

D. Calcitonin

Correct Answer: B. Carcinoembryonic antigen

■ *Listen (English)*

■ *Listen (Hindi)*

Explanation: Carcinoembryonic antigen (CEA) can be used to assess responsiveness to treatment in colorectal cancers. Persistent elevation of CEA after successful tumor resection suggests residual or recurrent disease and warrants further investigation. It is associated with the following cancers: (Mnemonic: C K a P i L SH arma) C - CEA K - Colon cancer P - Pancreatic cancer L - Lung cancer S - Stomach cancer H - Heart tumors
Alpha-fetoprotein (Option A) is associated with yolk sac tumours and hepatic tumors (hepatocellular carcinoma, hepatoblastoma). Human Chorionic Gonadotropin (Option C) is elevated in choriocarcinoma and non-seminomatous germ cell tumors. Calcitonin (Option D) is a tumor marker for Medullary thyroid carcinoma.

References:

Robbins pathology, 10th edition, 335,336.

↑ *Back to this question in Part A*

@Neet_pg_bot

Q21: Which of the following is a marker for breast cancer? (Q845496)

A. CA-19-9

B. CA-125

C. CA-15-3

D. β - HCG

Correct Answer: C. CA-15-3

■ *Listen (English)*

■ *Listen (Hindi)*

Explanation: CA-15-3 is the tumour marker seen in breast cancer. Tumor marker Associated conditions Alpha-fetoprotein (AFP) Hepatocellular carcinoma (HCC) Hepatoblastoma Yolk sac tumour (endodermal sinus tumour) Nonseminomatous germ cell tumour of testis ↑ AFP: abdominal wall defects, neural tube defects ↓ AFP: associated with trisomy 21, 18, and 13 β-HCG (Option D ruled out) Nonseminomatous testicular germ cell tumours (choriocarcinoma, embryonal cell carcinoma, mixed germ cell tumour, seminoma) Ovarian cancer: choriocarcinoma (gestational trophoblastic disease) Carcinoembryonic antigen (CEA) Colorectal cancer Pancreatic cancer Breast cancer Lung cancer (especially in non-small cell cancers) Gastric cancer Prostate-specific antigen (PSA) Prostate cancer Benign prostatic hyperplasia Prostatitis Calcitonin Medullary thyroid cancer (both sporadic and associated with MEN 1 and MEN 2) Alkaline phosphatase Metastases to bone or liver Paget disease of the bone Placental alkaline phosphatase Seminoma Lactate dehydrogenase Ovarian cancer (dysgerminoma) Testicular germ cell tumours (both seminoma and nonseminoma) Lymphomas Ewing's sarcoma Neuron specific enolase (NSE) Neuroendocrine tumors Small cell lung cancer Carcinoid tumour Neuroblastoma CA 19–9 (Option A ruled out) Pancreatic adenocarcinoma Colon cancer Cholangiocarcinoma CA 15–3 and CA 27–29 (Option C) Breast cancer CA 125 (Option B ruled out) Ovarian carcinoma Other gynecologic malignancies S-100 protein (S100A) and (S100B) Malignant melanoma SMRP Mesothelioma

References:

Robbins pathology, 10th edition, Pg 336.

↑ *Back to this question in Part A*

@Neet_pg_bot

• [04_Neoplasia] 017 Fundamentals Of Neoplasia

« Back to Folder Directory

[04_Neoplasia] 017 Fundamentals Of Neoplasia — Quick Jump

Q1 (p. 1374)	*Q2 (p. 1374)*	*Q3 (p. 1375)*	*Q4 (p. 1376)*	*Q5 (p. 1377)*	*Q6 (p. 1377)*
Q7 (p. 1378)	*Q8 (p. 1378)*	*Q9 (p. 1379)*	*Q10 (p. 1380)*	*Q11 (p. 1381)*	*Q12 (p. 1381)*
Q13 (p. 1382)	*Q14 (p. 1383)*	*Q15 (p. 1383)*	*Q16 (p. 1384)*	*Q17 (p. 1385)*	*Q18 (p. 1385)*
Q19 (p. 1386)	*Q20 (p. 1387)*	*Q21 (p. 1387)*	*Q22 (p. 1388)*	*Q23 (p. 1389)*	*Q24 (p. 1390)*
Q25 (p. 1391)	*Q26 (p. 1392)*	*Q27 (p. 1393)*	*Q28 (p. 1394)*		

Q1: What is the consequence of the RB protein being in its hypophosphorylated (active) state? (Q879748)

A. Cell cycle is halted at the G2 phase

B. Cell cycle is arrested at the G1 phase

C. RB protein’s phosphorylation status does not impact the cell cycle

D. Cell cycle continues normally, leading to cell division

Correct Answer: B. Cell cycle is arrested at the G1 phase

Explanation: Hypophosphorylated RB binds E2F transcription factors, blocking progression into S phase. RB (Retinoblastoma) is a tumor suppressor protein encoded by the RB1 gene . RB is a key negative regulator of the G1/S transition, acting as a “governor” of cell proliferation Hypophosphorylated RB: Active, binds and inhibits E2F transcription factors → prevents G1/S progression. (Option B) Hyperphosphorylated RB: Inactive, releases E2F → allows S-phase entry and cell cycle progression. RB mutations are linked to retinoblastoma, osteosarcoma, and somatic mutations in glioblastoma, lung, breast, and bladder cancers. Incorrect Options: Cell cycle is halted at the G2 phase (Option A): RB controls the G1 to S transition, not G2. RB protein’s phosphorylation status does not impact the cell cycle (Option C): RB phosphorylation is essential for G1/S progression. Cell cycle continues normally, leading to cell division (Option D): Hypophosphorylated RB inhibits E2F, preventing S-phase entry.

References:

Robbins, Cotran & Kumar Pathologic Basis of Disease, 11th Edition, Page no. 260-262

↑ *Back to this question in Part A*

@Neet_pg_bot

Q2: Which of the following disorders is unrelated to defects in homologous recombination-mediated DNA repair pathways? (Q879792)

A. Bloom syndrome

B. Ataxia-telangiectasia

C. Fanconi anemia

D. Li-Fraumeni syndrome

Correct Answer: D. Li-Fraumeni syndrome

Explanation: Li-Fraumeni syndrome is caused by germline TP53 mutations; it is associated with defective p53-mediated cell cycle control and apoptosis, not directly with homologous recombination repair. Homologous Recombination (HR) repair is a critical pathway for repairing DNA double-strand breaks and cross-links. Disorders caused by defects in HR factors include: Bloom syndrome: Caused by loss-of-function mutations in a helicase required for HR, associated with developmental anomalies and increased cancer risk. (Option A ruled out) Ataxia-telangiectasia: Caused by ATM defects; patients show impaired DNA double-strand break repair via HR, immunodeficiency, and cancer predisposition. (Option B ruled out) Fanconi anemia: Mutations in Fanconi pathway genes disrupt HR-mediated repair of DNA cross-links, leading to bone marrow failure and leukemia. (Option C ruled out)

References:

Robbins, Cotran & Kumar's Pathologic Basis of Disease, 11th Edition, Page. 282

↑ *Back to this question in Part A*

@Neet_pg_bot

Q3: Which of the following oncogenes, when mutated, can give rise to neoantigens recognized by the immune system? (Q879786)

A. KRAS

B. TP53

C. CDKN2A

D. PTEN

Correct Answer: A. KRAS

Explanation: KRAS is an oncogene; point mutations produce altered proteins that can serve as tumor neoantigens. Neoantigens are protein antigens produced from genes bearing driver or passenger mutations. Mutated oncogenes

such as KRAS encode variant proteins that have never been seen by the immune system and can therefore be recognized as non-self by CD8+ cytotoxic T cells. These neoantigens contribute to protective antitumor immunity and are often associated with tumors having high mutational loads. Incorrect Options: TP53 (Option B): Tumor suppressor gene; mutations generally do not produce oncogenic proteins recognized as neoantigens. CDKN2A (Option C): Tumor suppressor involved in cell cycle regulation; loss-of-function mutations do not generate neoantigens. PTEN (Option D): Tumor suppressor regulating PI3K signaling; mutations are typically inactivating and do not produce immunogenic neoantigens.

References:

Robbins, Cotran & Kumar's Pathologic Basis of Disease, 11th Edition, Page. 277

↑ *Back to this question in Part A*

@Neet_pg_bot

Q4: Which of the following changes does not convert a proto-oncogene into an oncogene? (Q879784)

A. Gene amplification

B. Point mutation

C. Chromosomal translocation

D. Gene deletion

Correct Answer: D. Gene deletion

Explanation: Gene deletion typically results in loss of function and therefore does not convert a proto-oncogene into an oncogene. Proto-oncogenes→ Normal cellular genes that, when altered, promote excessive cell growth. They can be activated into oncogenes by multiple mechanisms: Gene amplification (Option A ruled out) ERBB2 (HER2) - Breast carcinoma FGF3 - Stomach, bladder, breast cancers NMYC - Neuroblastoma CCND1 - Breast and esophageal cancers. Point mutations (Option B ruled out) KRAS - Colon, lung, and pancreatic tumors HRAS - Bladder and kidney tumors NRAS - Melanomas BRAF - Melanomas, leukemias, and colon carcinoma JAK2 - Myeloproliferative neoplasms. Chromosomal translocations (Option C ruled out) MYC - Burkitt lymphoma CCND1 - Mantle cell lymphoma and multiple myeloma ABL (BCR-ABL) - Chronic myeloid leukemia and ALL ALK - Lung adenocarcinoma and some lymphomas NOTCH1 - Leukemias and lymphomas.

References:

Robbins, Cotran & Kumar's Pathologic Basis of Disease, 11th Edition, Page. 253

↑ *Back to this question in Part A*

@Neet_pg_bot

Q5: Which of the following is a receptor tyrosine kinase, rather than a nonreceptor tyrosine kinase? (Q879766)

A. ABL

B. BCR-ABL

C. JAK2

D. EGFR

Correct Answer: D. EGFR

Explanation: EGFR is a receptor tyrosine kinase located at the plasma membrane. Nonreceptor tyrosine kinases are cytoplasmic or nuclear enzymes that become oncogenic through translocations, rearrangements, or point mutations. ABL (Option A ruled out) and JAK2 (Option C ruled out) fall into this group. BCR-ABL (Option B) represents a fusion protein with constitutive activity.

References:

Robbins, Cotran & Kumar, Pathologic Basis of Disease, 11th Edition, Page no. 255- 256

↑ *Back to this question in Part A*

@Neet_pg_bot

Q6: Which gene plays a key role in promoting epithelial-mesenchymal transition (EMT) in carcinomas? (Q879764)

A. E-cadherin

B. SNAIL

C. Vimentin

D. Smooth muscle actin

Correct Answer: B. SNAIL

Explanation: SNAIL is a transcription factor that promotes Epithelial-mesenchymal transition (EMT) by downregulating epithelial markers and upregulating mesenchymal markers, thereby facilitating tumor invasion and metastasis. Epithelial cells lose their polarity and adhesion properties and acquire mesenchymal traits (enhancing motility and invasiveness). Dissociation of cancer cells is often due to loss of intercellular adhesion. E-cadherin mediates epithelial cell-cell adhesion; its loss facilitates EMT. EMT is controlled by transcription factors SNAIL

and TWIST. Involves downregulation of epithelial markers (E-cadherin) and upregulation of mesenchymal markers (vimentin, smooth muscle actin). EMT contributes to a promigratory phenotype, aiding metastasis in carcinomas like breast and prostate cancers. Incorrect Options: E-cadherin (Option A): A cell adhesion molecule; its loss occurs during EMT but it does not drive the transition. Vimentin (Option C): A mesenchymal marker upregulated during EMT, not a transcriptional regulator. Smooth muscle actin (Option D): Another mesenchymal marker; indicates EMT but does not initiate it.

References:

Robbins, Cotran & Kumar's Pathologic Basis of Disease, 11th Edition, Page. 274

↑ *Back to this question in Part A*

@Neet_pg_bot

Q7: Which of the following mechanisms is commonly used by cancer cells to evade apoptosis? (Q879763)

A. Overexpression of pro-apoptotic BAX and BAK proteins

B. Loss of TP53 function and overexpression of anti-apoptotic BCL2 family proteins

C. Increased activation of caspase-9

D. Enhanced release of cytochrome c from mitochondria

Correct Answer: B. Loss of TP53 function and overexpression of anti-apoptotic BCL2 family proteins

Explanation: Loss of TP53 and overexpression of BCL2 block apoptosis and allow tumor survival. The intrinsic (mitochondrial) pathway is the main regulator of apoptosis in cancer. BH3-only proteins (BIM, BAD, BID, PUMA) promote apoptosis by neutralizing anti-apoptotic BCL2 members. Loss of p53 or BCL2 overexpression allows resistance to chemotherapy and radiation. Incorrect Options: Overexpression of BAX and BAK (Option A): Promotes apoptosis rather than preventing it. Increased caspase-9 activation (Option C): Caspase-9 activation triggers apoptosis, so this does not help cancer cells evade death. Enhanced cytochrome c release (Option D): Promotes apoptosis; cancer cells inhibit this process to survive.

References:

Robbins, Cotran & Kumar's Pathologic Basis of Disease, 11th Edition, Page. 270-271

↑ *Back to this question in Part A*

@Neet_pg_bot

Q8: Which of the following statements about BRCA mutations is correct? (Q879762)

A. BRCA1 and BRCA2 are involved in DNA repair via homologous recombination

B. BRCA proteins primarily use nonhomologous end-joining (NHEJ) for DNA repair

C. BRCA1 mutations are not associated with ovarian cancer

D. BRCA2 mutations cause only breast cancer

Correct Answer: A. BRCA1 and BRCA2 are involved in DNA repair via homologous recombination

Explanation: BRCA1 and BRCA2 are essential for DNA repair by homologous recombination, maintaining genomic stability (Option A) (Option B ruled out) Defects in this pathway shift cells to error-prone NHEJ, leading to chromosomal aberrations. BRCA1 mutations: increase risk of breast, ovarian (Option C ruled out) , and prostate cancers. BRCA2 mutations: associated with breast (male & female), ovary, prostate, pancreas, stomach, bile ducts, melanoma, and B-cell malignancies (Option D ruled out)

References:

Robbins, Cotran & Kumar's Pathologic Basis of Disease, 11th Edition, Page. 282

↑ *Back to this question in Part A*

@Neet_pg_bot

Q9: A 45-year-old man presents with progressive abdominal discomfort and weight loss. Endoscopy reveals a gastric mass, and biopsy confirms diffuse gastric carcinoma. Which protein responsible for maintaining cell-to-cell adhesion and inhibiting cell motility is most likely mutated in this condition? (Q879760)

A. p63

B. p53

C. E-cadherin

D. Integrin

Correct Answer: C. E-cadherin

Explanation: Loss-of-function mutations in E-cadherin (CDH1 gene) are strongly associated with diffuse gastric carcinoma and lobular breast carcinoma. Role: Maintains cell–cell adhesion; binds β-catenin; mediates contact inhibition of growth. Pathogenesis: Loss of adhesion → increased motility and invasiveness; β-catenin release → nuclear translocation → activation of Wnt target genes → increased proliferation Syndromes (Germline Mutations): Familial gastric carcinoma (autosomal dominant) Associated Sporadic Tumors: Gastric carcinoma

(diffuse type), lobular breast carcinoma, esophageal carcinoma, colon carcinoma, ovarian carcinoma, prostate carcinoma. Incorrect Options: p63 (Option A) is important for epithelial differentiation, not cell adhesion in gastric cancer. p53 (Option B) regulates apoptosis and DNA repair, not adhesion. Integrin (Option D) mediates cell-extracellular matrix interactions, not the main defect here.

References:

Robbins, Cotran & Kumar Pathologic Basis of Disease, 11th Edition, Page no. 259, 265, 267

↑ *Back to this question in Part A*

@Neet_pg_bot

Q10: A 19-year-old woman presents with recurrent episodes of abdominal pain and melena. On physical examination, she has dark-blue to brown macules on her lips and buccal mucosa. Genetic testing reveals germline loss-of-function mutations in the STK11 gene. What is the most likely diagnosis? (Q879758)

A. HNPCC

B. Gorlin syndrome

C. von Hippel-Lindau syndrome

D. Peutz-Jeghers syndrome

Correct Answer: D. Peutz-Jeghers syndrome

Explanation: In Peutz-Jeghers Syndrome , STK11 germline loss-of-function mutations cause hamartomatous GI polyps, mucocutaneous pigmentation, and increased cancer risk. Gene: STK11 (also called LKB1 – Liver kinase B1) Protein function: Activator of the AMPK family of kinases; suppresses cell growth under low nutrient and energy conditions. Pathogenesis: Germline loss-of-function mutations → failure to suppress growth under nutrient/energy stress → tumorigenesis. Features: Hamartomatous GI polyps, GI cancers, mucocutaneous pigmentation, increased risk of pancreatic carcinoma, and other carcinomas. Incorrect Options: HNPCC (Option A) is associated with mismatch repair gene mutations and colorectal cancer, without mucocutaneous pigmentation. Gorlin syndrome (Option B) is caused by PTCH1 mutations, characterized by basal cell carcinomas and jaw cysts. von Hippel-Lindau syndrome (Option C) is caused by VHL gene mutations, associated with hemangioblastomas and renal cell carcinoma.

References:

Robbins, Cotran & Kumar Pathologic Basis of Disease, 11th Edition, Page no. 259

↑ *Back to this question in Part A*

@Neet_pg_bot

Q11: Which of the following is the etiology of Gorlin syndrome? (Q879757)

A. Germline loss-of-function mutation in STK11

B. Germline missense mutation in SDHB

C. Germline loss-of-function mutation in WT1

D. Germline loss-of-function mutation in PTCH1

Correct Answer: D. Germline loss-of-function mutation in PTCH1

Explanation: PTCH1 mutations cause Gorlin Syndrome (nevoid basal cell carcinoma syndrome) , resulting in multiple basal cell carcinomas, jaw keratocysts, and skeletal anomalies. Gene: PTCH (Patched) Pathogenesis: Germline loss-of-function mutations → constitutive Hedgehog pathway activation → tumor formation Protein function: Tumor suppressor Regulates cell proliferation by controlling Hedgehog signaling Features: Basal cell carcinoma, medulloblastoma, various benign tumors Incorrect Options: Germline loss-of-function mutation in STK11 (Option A): Causes Peutz-Jeghers syndrome. Germline missense mutation in SDHB (Option B) is associated with hereditary paraganglioma-pheochromocytoma syndrome. Germline loss-of-function mutation in WT1 (Option C) is linked to Wilms tumor.

References:

Robbins, Cotran & Kumar Pathologic Basis of Disease, 11th Edition, Page no. 259

↑ *Back to this question in Part A*

@Neet_pg_bot

Q12: A 25-year-old woman experiences progressive balance issues and bilateral sensorineural hearing loss. Imaging reveals tumors affecting both vestibular nerves. This clinical picture is characteristic of a hereditary condition involving a mutation in which protein that plays a role in linking the cytoskeleton to the cell membrane? (Q879756)

A. Neurofibromin

B. Merlin

C. PATCHED

D. RB protein

Correct Answer: B. Merlin

Explanation: Merlin is the NF2 gene product, involved in cytoskeletal stability and tumor suppression; mutation causes bilateral vestibular schwannomas (neurofibromatosis type 2) . Gene: NF2; Chromosome 22q12 Inheritance: Autosomal dominant Protein function: Tumor suppressor Cytoskeletal stability Activator of the Hippo signaling pathway Integrates cytoskeletal signals Features: Bilateral acoustic schwannomas, meningiomas, and other schwannomas Associated Disorders: Neurofibromatosis type 2 Incorrect Options: Neurofibromin (Option A): NF1 gene product, regulates RAS, associated with neurofibromatosis type 1. PATCHED (Option C): Receptor in Hedgehog signaling, associated with basal cell nevus syndrome. RB protein (Option D): Regulator of G1/S cell cycle, associated with retinoblastoma.

References:

Robbins, Cotran & Kumar Pathologic Basis of Disease, 11th Edition, Page no. 259, 1042

↑ *Back to this question in Part A*

@Neet_pg_bot

Q13: A 35-year-old woman presents with multiple trichilemmomas on her face, a history of breast cancer, and the recent discovery of endometrial hyperplasia. She also reports that her father had colon polyps. Germline loss-of-function mutations of which gene are most likely responsible for her condition? (Q879753)

A. CDKN2A

B. SMAD2

C. APC

D. PTEN

Correct Answer: D. PTEN

Explanation: The scenario is Cowden Syndrome caused by a Germline loss-of-function mutation of the PTEN gene. Gene: PTEN (Phosphatase and Tensin Homologue) - Chromosome 10q23 Inheritance: Autosomal dominant Pathogenesis: Germline loss-of-function mutations → dysregulated PI3K/AKT pathway → uncontrolled cell growth Clinical features: Benign follicular appendage tumors (trichilemmomas), lipomas Hamartomatous/inflammatory intestinal polyps, ganglioneuromas; generally no increased risk of GI cancers Benign growths in the CNS Increased risk of breast, endometrial, and thyroid carcinoma; diverse cancers, particularly carcinomas and lymphoid tumors Incorrect Options: CDKN2A (Option A) is associated with familial melanoma and pancreatic cancer. SMAD2 (Option B) is involved in TGF-β signaling, not this syndrome. APC (Option C) is associated with familial adenomatous polyposis (FAP), but not with skin lesions or breast/endometrial cancers.

References:

Robbins, Cotran & Kumar Pathologic Basis of Disease, 11th Edition, Page no. 1042, 259, 266, 267, 737

↑ *Back to this question in Part A*

@Neet_pg_bot

Q14: Which of the following statements about p53 is true? (Q879752)

A. p53 is rarely altered in cancers

B. p53 is induced by DNA damage

C. p53 promotes cell cycle progression by downregulating p21

D. p53 inhibits apoptosis by suppressing BAX

Correct Answer: B. p53 is induced by DNA damage

Explanation: p53 is a tumor suppressor protein that is altered in the majority of human cancers (Option A ruled out) It is activated in response to DNA damage (Option B) and plays a crucial role in maintaining genomic stability. It causes cell cycle arrest by upregulating the cyclin-dependent kinase inhibitor p21, allowing time for DNA repair (Option C ruled out) It can induce apoptosis by upregulating BAX and other pro-apoptotic genes when the damage is irreparable (Option D ruled out)

References:

Robbins, Cotran & Kumar Pathologic Basis of Disease, 11th Edition, Page no. 257

↑ *Back to this question in Part A*

@Neet_pg_bot

Q15: Which of the following statements about Knudson’s two-hit hypothesis for retinoblastoma is true? (Q879746)

A. Both familial and sporadic cases require two somatic mutations in the same retinoblast

B. In familial cases, one defective RB allele is inherited in the germline, and the second hit occurs somatically

C. Sporadic cases are caused by inheritance of one defective RB allele and a spontaneous second hit

D. Only one mutation is sufficient to cause retinoblastoma in any case

Correct Answer: B. In familial cases, one defective RB allele is inherited in the germline, and the second hit occurs somatically

Explanation: Knudson’s hypothesis states that: Two loss-of-function mutations (“hits”) of both RB alleles are required to cause retinoblastoma. In familial cases, one defective RB allele is inherited (first hit), and the second hit occurs somatically in a retinoblast. In sporadic cases, both RB alleles undergo independent somatic mutations in the same cell. This explains why retinoblastoma is more common in familial cases and rare in sporadic cases. Incorrect Options: Both familial and sporadic cases require two somatic mutations in the same retinoblast (Option A): Familial cases inherit the first hit germline. Sporadic cases are caused by inheritance of one defective RB allele and a spontaneous second hit (Option C): Sporadic cases involve two independent somatic mutations, not inheritance. Only one mutation is sufficient to cause retinoblastoma in any case (Option D): Both alleles must be inactivated.

References:

Robbins, Cotran & Kumar Pathologic Basis of Disease, 11th Edition, Page no. 258

↑ *Back to this question in Part A*

@Neet_pg_bot

Q16: Which of the following cancers is typically associated with a translocation involving cyclin D1? (Q879744)

A. Chronic myeloid leukemia

B. Non-Hodgkin's lymphoma

C. Acute lymphoblastic leukemia

D. Mantle cell lymphoma

Correct Answer: D. Mantle cell lymphoma

Explanation: Mantle Cell Lymphoma characteristically shows t(11;14)(q13;q32) translocation, leading to overexpression of cyclin D1, promoting cell cycle progression. Cyclin D1 is a cell cycle regulator proto-oncogene It is involved in translocation in mantle cell lymphoma and multiple myeloma It can undergo amplification in breast and esophageal cancers. Incorrect Options: Chronic myeloid leukemia (Option A): Associated with BCR-ABL translocation, not cyclin D1. Non-Hodgkin's lymphoma (Option B): A broad group; cyclin D1 translocation specifically occurs in the mantle cell subtype. Acute lymphoblastic leukemia (Option C): Associated with various chromosomal abnormalities, not cyclin D1 translocation.

References:

Robbins, Cotran & Kumar Pathologic Basis of Disease, 11th Edition, Page no. 253

↑ *Back to this question in Part A*

@Neet_pg_bot

Q17: Which type of proteins are produced as a result of MYC gene expression? (Q879741)

A. Proteins that control the cell division cycle

B. Proteins that regulate gene activity within the nucleus

C. Proteins involved in transmitting signals inside the cell

D. Proteins that act as receptors for growth-promoting signals

Correct Answer: B. Proteins that regulate gene activity within the nucleus

Explanation: MYC codes for nuclear regulatory proteins that act as transcription factors and master regulators of cell growth. Specifically, MYC influences the expression of genes involved in: Cell cycle progression - e.g., D cyclins. Ribosome biogenesis and protein synthesis - upregulates rRNA genes and rRNA processing. Metabolism - upregulates glycolytic enzymes and glutamine metabolism factors (metabolic reprogramming / Warburg effect). Telomerase expression - contributing to replicative immortality. Stemness/pluripotency - reprogramming somatic cells into pluripotent stem cells. Incorrect Options: Proteins that control the cell division cycle (Option A): MYC activates them but does not encode them. Proteins involved in transmitting signals inside the cell (Option C): MYC regulates signaling indirectly, does not encode them. Proteins that act as receptors for growth-promoting signals (Option D): MYC acts downstream of these, does not encode them.

References:

Robbins, Cotran & Kumar Pathologic Basis of Disease, 11th Edition, Page no. 256

↑ *Back to this question in Part A*

@Neet_pg_bot

Q18: Which gene mutation is associated with the development of astrocytoma? (Q845511)

A. PDGFB

B. HST1

C. FGF3

D. HGF

Correct Answer: A. PDGFB

■ *Listen (English)*

■ *Listen (Hindi)*

Explanation: Astrocytomas commonly show overexpression or mutation of the PDGF-B gene , which encodes a potent mitogenic growth factor . Growth factor Proto-oncogene Tumour-associated Fibroblast growth factor HST Osteosarcoma FGF3 Urinary bladder and Gastric cancers Hepatocyte growth factor HGF Hepatocellular carcinomas

References:

Robbins and Cotran, Pathologic Basis of Disease,10th edition- Page no. 285

↑ *Back to this question in Part A*

@Neet_pg_bot

Q19: Which of the following genetic events best describes the carcinogenesis mechanism in a patient with retinoblastoma? (Q876253)

A. Balanced translocation

B. Expansion of trinucleotide repeat

C. Gene amplification

D. Loss of heterozygosity

Correct Answer: D. Loss of heterozygosity

Explanation: Correct Option D- Loss of heterozygosity: Retinoblastomas are malignant ocular tumors of young children. In hereditary retinoblastoma, an affected child inherits one defective Rb allele and one normal gene; this heterozygous state is sufficient to prevent the development of retinoblastoma. If the remaining normal Rb allele is inactivated by deletion or mutation, the loss of its suppressor function results in the appearance of a neoplasm. Loss of heterozygosity is the term for this genetic process. Incorrect Options: Option A- Balanced translocation: Sometimes a section from one chromosome of a particular pair changes places with a section from a chromosome of another pair. When the two breaks do not pass through a gene, and there is no gain or loss of material when the chromosomes are looked at under a microscope, it is called a balanced translocation. When one couple member carries a balanced chromosome translocation, the risk of miscarriage is approximately doubled. One partner has a balanced translocation in 3-5% of couples with recurrent miscarriages. Option B- Expansion of trinucleotide repeat: The mutation, referred to as “trinucleotide repeat (TNR) expansion," occurs when the number of triplets in a mutated gene exceeds the number found in a normal gene. Additionally, the number of triplets in the disease gene continues to increase as the disease gene is inherited. Slippage in DNA replication can cause trinucleotide repeats to grow. Therefore, with each cell division, the number of repeats can rise. Expanded repeats can lengthen and are also inherited. Option C- Gene amplification : Gene amplification refers to various organic and synthetic mechanisms that increase a gene's copy number "without a commensurate rise in other genes." A rise in the gene's copy number. Additionally, there can be an increase in the RNA and protein produced by that gene. An increase in the number of copies of a gene in a genome is called gene amplification. In response to signals from other cells or the environment, cancer cells, for instance, occasionally make extra copies of a gene or genes.

References:

Robbins 10th ed, Pg 291

↑ *Back to this question in Part A*

@Neet_pg_bot

Q20: Which of the following mechanisms is not employed by tumour cells to evade the host immune system? (Q845522)

A. Selective outgrowth of the antigen-negative variants

B. Reduced expression of MHC molecules

C. Secretion of immunosuppressive factors

D. Enhanced antigen presentation to promote T cell activation

Correct Answer: D. Enhanced antigen presentation to promote T cell activation

■ *Listen (English)*

■ *Listen (Hindi)*

Explanation: Enhanced antigen presentation is not a mechanism tumour cells employ to evade the host immune system. Antigen presentation is a crucial step in activating T cells and initiating an immune response against tumour cells. Antigen-presenting cells (dendritic cells) present tumour antigens to T cells via major histocompatibility complex (MHC) molecules, leading to T cell activation and anti-tumour immune responses. While tumour cells may downregulate or alter the expression of MHC molecules to evade immune recognition, enhancing antigen presentation to promote T-cell activation is not a typical strategy employed by tumour cells for immune evasion. Mechanisms by which tumour cells evade the host immune system: Selective outgrowth of the antigen-negative variants (Option A ruled out). Reduced expression of MHC molecules (Option Bruled out). Secretion of immunosuppressive factors (Option C ruled out). Engagement of pathways that inhibit T-cell activation. Immune checkpoint inhibitors have been developed that inhibit CTLA-4, PD-1, and PD-L1. These can be used in the treatment of malignancies such as melanoma, non-small cell lung cancer, head and neck cancers, and lymphomas Immune checkpoint inhibitors CTLA-4 inhibitors PD-1 inhibitors PD-L1 (PD-1 ligand) inhibitors Ipilimumab Pembrolizumab Nivolumab Atezolizumab Avelumab Durvalumab

References:

Robbins and Cotran, Pathologic Basis of Disease, Page no. 311,312,313

↑ *Back to this question in Part A*

@Neet_pg_bot

Q21: Which of the following is true regarding the Warburg effect? (Q845521)

A. Cancer cells primarily rely on oxidative phosphorylation for ATP production.

B. It involves a shift from glycolysis to oxidative phosphorylation in cancer cells.

C. Cancer cells exhibit increased glucose uptake and preferentially metabolise glucose via glycolysis, even in the presence of oxygen.

D. It is characterised by decreased glucose uptake and utilisation by cancer cells.

Correct Answer: C. Cancer cells exhibit increased glucose uptake and preferentially metabolise glucose via glycolysis, even in the presence of oxygen.

■ *Listen (English)*

■ *Listen (Hindi)*

Explanation: The Warburg Effect , a distinctive metabolic feature of cancer cells, involves increased glucose uptake and a preference for glycolysis over oxidative phosphorylation, even in the presence of oxygen. Otto Warburg was awarded the Nobel Prize in 1931 for this theory. Even in the presence of ample oxygen, cancer cells demonstrate a distinctive form of cellular metabolism characterised by high glucose uptake levels and increased glucose conversion to lactose (fermentation) via glycolysis (Option D ruled out) Even though ATP production is low with lactate formation compared to mitochondrial oxidative phosphorylation, it provides metabolic intermediates needed for synthesising cellular components. Application: Positive emission tomography (PET). Patients are injected with 18F-fluorodeoxyglucose (FDG) , a non-metabolizable glucose derivative preferentially taken up into tumour cells (due to glucose hunger), which can be detected by PET scan. Cancer cells primarily rely on oxidative phosphorylation for ATP production (Option A), which is not true, as cancer cells prefer glycolysis, even in the presence of oxygen. It involves a shift from glycolysis to oxidative phosphorylation in cancer cells (Option B), which is incorrect because the Warburg effect involves the opposite: a shift toward glycolysis.

References:

Robbins and Cotran, Pathologic Basis of Disease, 10th edition, Page no. 299,300

↑ *Back to this question in Part A*

@Neet_pg_bot

Q22: Which of the following statements are true regarding Lynch syndrome? (Q845519)

A. It is autosomal recessive in inheritance.

B. It is also known as hereditary breast and ovarian cancer syndrome.

C. It is caused by mutations in genes involved in nonhomologous end-joining repair.

D. Amsterdam II criteria are used for diagnosis.

Correct Answer: D. Amsterdam II criteria are used for diagnosis.

■ *Listen (English)*

■ *Listen (Hindi)*

Explanation: Among the given options, the Amsterdam II criteria are used to diagnose Lynch syndrome (also called Hereditary Non-Polyposis Colorectal Cancer or HNPCC). An autosomal dominant disorder (Option A ruled out) Caused by mutations in DNA mismatch repair (MMR) genes, such as MLH1, MSH2, MSH6, PMS2, and EPCAM. (Option c ruled out) Amsterdam II criteria and Revised Bethesda guidelines are clinical tools used for screening and diagnosing Lynch syndrome. (Option D) Feature Description Inheritance Autosomal dominant Also known as Hereditary Non-Polyposis Colorectal Cancer (HNPCC) Caused by Mutations in MMR genes (not NHEJ genes) Diagnostic criteria Amsterdam II criteria , Bethesda criteria Associated cancers Colorectal, endometrial, ovarian, gastric, small bowel, urinary tract It is also known as hereditary breast and ovarian cancer syndrome (Option B): Incorrect – that refers to BRCA1/2 mutations, not Lynch syndrome.

References:

Robbins and Cotran, Pathologic Basis of Disease, 10th edition, Page no. 314 SRB Manual of Surgery, 6th edition, Page no. 892

↑ *Back to this question in Part A*

@Neet_pg_bot

Q23: Which of the following diseases is associated with a defect in homologous DNA repair? (Q845517)

A. Trichothiodystrophy

B. Fanconi anemia

C. Endometrial carcinoma

D. Wermer syndrome

Correct Answer: B. Fanconi anemia

■ *Listen (English)*

■ *Listen (Hindi)*

Explanation: Fanconi Anaemia is associated with a defect in homologous DNA repair. An autosomal recessive disorder due to failure to repair ds DNA breaks (caused by UV lights) due to defective homologous repair (due to mutation in multiple genes). Characterised by: Developmental abnormalities (short stature, skeletal abnormalities). Hypersensitivity to chemotherapeutic agents that cross-link DNA. Increased risk of bone marrow failure (aplasia) and leukaemia. Other diseases associated with a defect in homologous DNA repair: Bloom syndrome. Ataxia

telangiectasia. Familial breast cancer (mutations in BRCA 1 and BRCA 2). Werner syndrome. Rothmund-Thomson syndrome. Trichothiodystrophy (TTD) (Option A) is a rare autosomal recessive multisystem disorder characterised by defect in the TC-NER pathway (Transcription coupled-nucleotide excision repair pathway). Endometrial carcinoma (Option C): Certain subsets of endometrial cancer (most often) and colon cancer harbour mutations in DNA polymerase that result in a loss of proofreading function and the accumulation of numerous point substitutions. Wermer syndrome (Option D) : Wermer syndrome, also known as multiple endocrine neoplasia 1 (MEN 1) is characterised by tumors of the Parathyroid (adenoma), Pancreas (M/C- gastrinoma), and Pituitary adenoma (M/C- prolactinoma).

References:

Robbins and Cotran, Pathologic Basis of Disease, 10th Edition, Pages 314, 315.

Fitzpatrick's Dermatology, 9th Edition, Page 2345.

↑ *Back to this question in Part A*

@Neet_pg_bot

Q24: A 9-year-old child presents with multiple freckle-like dark spots on sun-exposed areas such as the face and arms. The child complains of discomfort and pain upon exposure to sunlight, and there is evidence of sunburn even after brief periods outdoors. Upon further questioning, they reveal a family history of skin cancer in relatives who also experienced similar skin issues from a young age. What is the most likely diagnosis and the genetic defect in this condition? (Q845516)

A. Xeroderma pigmentosum, defective homologous repair

B. Cockyane syndrome, nucleotide excision repair

C. Xeroderma pigmentosum, nucleotide excision repair

D. Bloom syndrome, defective homologous repair

Correct Answer: C. Xeroderma pigmentosum, nucleotide excision repair

■ *Listen (English)*

■ *Listen (Hindi)*

Explanation: This presentation is suggestive of Xeroderma pigmentosum (XP) , a condition caused by defective nucleotide excision repair of DNA, leading to extreme sun sensitivity, freckling, and a family history of early-onset skin cancer■■■■■■. An autosomal recessive disorder characterized by sun sensitivity, with approximately 50% of patients having acute burning on minimal sun exposure. UV radiation causes the cross-linking of pyrimidine residues , preventing normal DNA replication. Nucleotide excision repair (NER) prevents this DNA damage. Inherited loss-of-function mutations in any of these genes give rise to xeroderma pigmentosum. The onset of freckling (lentigines) on sun-exposed skin before age two years in most patients. At an

early age, there is a significantly increased risk of sunlight-induced cutaneous neoplasms (basal cell carcinoma, squamous cell carcinoma, melanoma) . Xeroderma pigmentosum, defective homologous repair (Option A): It is not caused by defective homologous repair. Cockayne syndrome, nucleotide excision repair (Option B): It is an autosomal recessive disorder caused by defective nucleotide excision repair, but unlike XP, it doesn't increase cancer risk. It is classified as a progeroid (premature aging) syndrome. Bloom syndrome, defective homologous repair (Option D): It is an autosomal recessive disorder caused by loss-of-function mutations in a helicase required for homologous recombination repair.

References:

Robbins and Cotran, Pathologic Basis of Disease, 10th edition, Page no. 314

Fitzpatrick's Dermatology, 9th edition, Page no. 2343, 2347

↑ *Back to this question in Part A*

@Neet_pg_bot

Q25: Which of the following cyclin-CDK combinations is incorrectly matched? (Q845515)

A. Cyclin A- CDK 2

B. Cyclin B- CDK 6

C. Cyclin D- CDK 4

D. Cyclin E- CDK 2

Correct Answer: B. Cyclin B- CDK 6

■ *Listen (English)*

■ *Listen (Hindi)*

Explanation: The incorrectly matched Cyclin-CDK Combination is Cyclin B - CDK 6 The cyclins, cyclin-dependent kinases, and their functions are Cyclin CDK Function Cyclin A (Option A ruled out) CDK1, CDK2 Activates DNA replication in the S phase The transition from S phase to the G2 phase Cyclin B (Option B) CDK1 Promotes assembly of mitotic spindle (G2-to-M) Cyclin D (Option C ruled out) CDK4, CDK6 Promotes G1-to-S transition by phosphorylating Rb Cyclin E (Option D ruled out) CDK2 Promotes G1-to-S transition by phosphorylating Rb Initiates DNA synthesis Cell cycle progression: Cyclins CDK (Cyclin-dependent Kinases) Mnemonic: Dhoni Ek Acha Batsman Cyclins CDK D 4, 6 E 2 A 2 B 1 Cell cycle mutations: Cyclin D1 → Mantle Cell Lymphoma Mnemonic: Mantle Mental Dumb CDK4 →Glioblastoma (Grade 4 tumor)

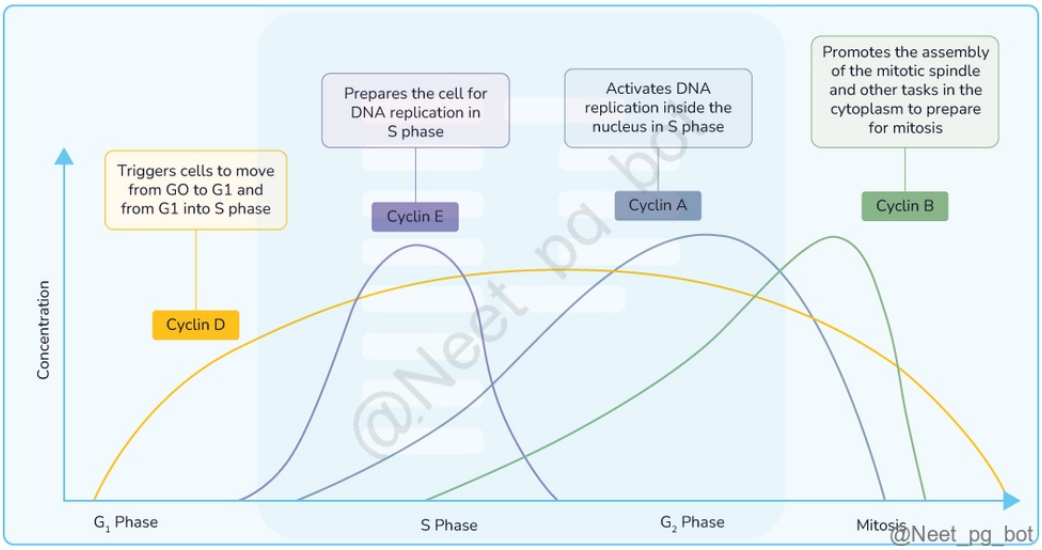

References:

Robbins and Cotran, Pathologic Basis of Disease,10th edition- Page no: 27, 290

www.ncbi.nlm.nih.gov/pmc/articles/PMC7139603/

↑ *Back to this question in Part A*

@Neet_pg_bot

Q26: Match the following protooncogenes with their malignancies. Proto-oncogene Malignancy 1. JAK-2 a. Hairy cell leukemia 2. BRAF b. Neuroblastoma 3. N Myc c. Burkitt's lymphoma 4. C Myc d. Polycythemia vera (Q845514)

A. 1-b, 2-a, 3-d, 4-c

B. 1-d, 2-a, 3-b, 4-c

C. 1-c, 2-a, 3-b, 4-d

D. 1-d, 2-b, 3-c, 4-a

Correct Answer: B. 1-d, 2-a, 3-b, 4-c

■ *Listen (English)*

■ *Listen (Hindi)*

Explanation: The correctly matched pair of proto-oncogenes and their malignancies is: Proto-oncogene Malignancy JAK-2 Polycythemia vera Essential thrombocythemia Acute lymphoblastic leukaemia BRAF HCL(Hairy cell leukemia) LCH (Langerhans cell histiocytosis) Papillary carcinoma thyroid Pilocytic astrocytoma

(Brain) Melanoma Colon cancer N Myc Neuroblastoma C Myc Burkitt's lymphoma L Myc Small Cell lung cancer

References:

Robbins and Cotran, Pathologic Basis of Disease,10th edition- Page no: 285, 622, 1087, 334, 627, 1296

www.ncbi.nlm.nih.gov/pmc/articles/PMC5406863/

pubmed.ncbi.nlm.nih.gov/2997622/

↑ *Back to this question in Part A*

@Neet_pg_bot

Q27: Identify the correctly matched pair of RAS mutation and its associated malignancy. (Q845513)

A. KRAS- Bladder cancer

B. HRAS- Lung cancer

C. KRAS- Kidney cancer

D. NRAS- Melanoma

Correct Answer: D. NRAS- Melanoma

■ *Listen (English)*

■ *Listen (Hindi)*

Explanation: The correctly matched pair of RAS mutation and its associated malignancy is NRAS-melanoma. RAS proteins are associated with small G proteins. They flip back and forth between an excited signal-transmitting state(bound to GTP) and a silent state (bound to GDP). Stimulation of receptor tyrosine kinases by growth factors leads to an exchange of GDP for GTP. This activates RAS, which is transient because of an intrinsic GTPase activity that is accelerated by GTPase-activating proteins (GAPs) Many subtypes of RAS are associated with malignancies. Signal Transduction Protein (GTP-binding proteins) Malignancies KRAS (Option A, C ruled out) Colon, Lung, Pancreatic tumours HRAS (Option B ruled out) Bladder and kidney tumors NRAS (Option D) Melanomas, AML

References:

Robbins and Cotran, Pathologic Basis of Disease,10th edition- Page no: 285

www.ncbi.nlm.nih.gov/pmc/articles/PMC7376066/

↑ *Back to this question in Part A*

@Neet_pg_bot

Q28: A 70-year-old male presented with a persistent cough, weight loss, and shortness of breath. A CT scan of the chest revealed a lesion consistent with adenocarcinoma of the lung. Which of the following growth factor receptor mutations can lead to adenocarcinoma of the lungs? (Q845512)

A. FLT3 and RET

B. ALK and ERBB1

C. RET and KIT

D. KIT and FLT3

Correct Answer: B. ALK and ERBB1

■ *Listen (English)*

■ *Listen (Hindi)*

Explanation: Mutations in ALK (Anaplastic Lymphoma Kinase receptor) and ERBB1 (which encodes the Epidermal Growth Factor Receptor) are associated with the development of lung adenocarcinoma. The following table summarises the mutations in proto-oncogenes encoding for growth factor receptors Proto-oncogene for growth factor receptor Associated tumour ERBB (EGFR) (Option B) ERBB2 (HER2) Adenocarcinoma of lung Amplification Breast carcinoma FLT3 (Option A, D ruled out) Leukaemia RET (Option A, C ruled out) Mnemonic: RET 10 Mad MEN M - Familial m edullary thyroid carcinomas MEN - M ultiple e ndocrine n eoplasia 2A and B, ALK (Option B) Adenocarcinoma of lung Neuroblastoma Certain lymphomas KIT (Option C, D ruled out) Mnemonic - GAMMS G - Gastrointestinal stromal tumors A - AML M - Mastocytosis M - Melanoma S - Seminomas PDGFR-B Brain tumours

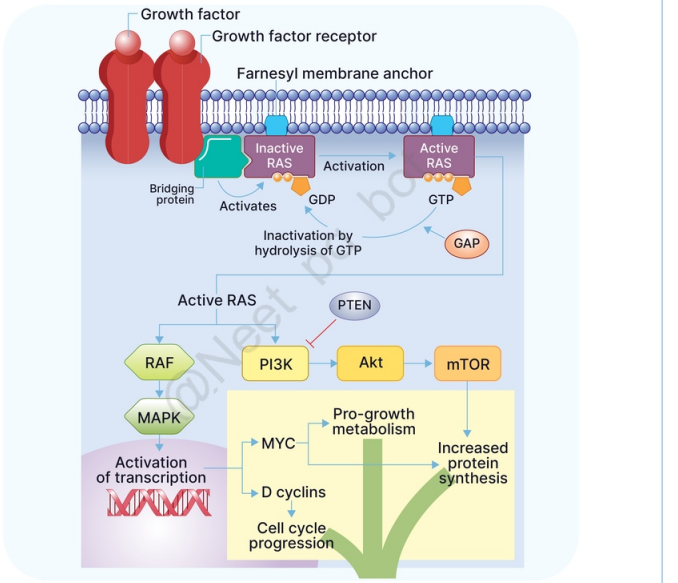

@Neet_pg_bot

References:

Robbins and Cotran, Pathologic Basis of Disease,10th edition- Page no: 285-287, 622, 1140

↑ *Back to this question in Part A*

@Neet_pg_bot

• [04_Neoplasia] 018 Previous Year Questions

« Back to Folder Directory

[04_Neoplasia] 018 Previous Year Questions — Quick Jump

Q1 (p. 1396)	*Q2 (p. 1396)*	*Q3 (p. 1397)*	*Q4 (p. 1400)*	*Q5 (p. 1401)*	*Q6 (p. 1404)*
Q7 (p. 1405)	*Q8 (p. 1407)*	*Q9 (p. 1408)*	*Q10 (p. 1409)*	*Q11 (p. 1410)*	*Q12 (p. 1412)*
Q13 (p. 1413)	*Q14 (p. 1414)*	*Q15 (p. 1414)*	*Q16 (p. 1415)*	*Q17 (p. 1416)*	*Q18 (p. 1420)*
Q19 (p. 1420)	*Q20 (p. 1423)*	*Q21 (p. 1425)*	*Q22 (p. 1430)*	*Q23 (p. 1433)*	*Q24 (p. 1436)*
Q25 (p. 1436)	*Q26 (p. 1437)*	*Q27 (p. 1442)*	*Q28 (p. 1443)*	*Q29 (p. 1443)*	*Q30 (p. 1444)*
Q31 (p. 1445)					

Q1: Match the malignancies in Column A with the genes in Column B: Column A Column B 1. Pleomorphic adenoma a. Rb 2. Burkitt lymphoma b. N-MYC 3. Neuroblastoma c.C-MYC 4. Retinoblastoma d. PLAG1 (Q855077)

A. 1-c, 2-b, 3-d, 4-a

B. 1-b, 2-c, 3-d, 4-a

C. 1-d, 2-c, 3-b, 4-a

D. 1-b, 2-d, 3-c, 4-a

Correct Answer: C. 1-d, 2-c, 3-b, 4-a

■ *Listen (English)*

■ *Listen (Hindi)*

Explanation: Column A Gene Pleomorphic adenoma PLAG1 Burkitt lymphoma cMyc Neuroblastoma nMyc Retinoblastoma Rb

References:

Robbins & Cotran Pathologic Basis of Disease, 10th Edition, Page 285, 601, 602, 748, 1324

↑ *Back to this question in Part A*

@Neet_pg_bot

Q2: Which of the following best describes the mechanism by which mutations in the Ras/MAP kinase gene cause oncogenicity? (Q879232)

A. Constitutive activation of a GTP-binding protein leading to continuous MAP kinase signalling

B. Enhanced DNA repair leading to genomic instability

C. Inactivation of a tumour suppressor gene resulting in loss of cell cycle checkpoint control

D. Increased activity of tyrosine kinase receptors through gene amplification

Correct Answer: A. Constitutive activation of a GTP-binding protein leading to continuous MAP kinase signalling

Explanation: RAS is a proto-oncogene that encodes a GTP-binding protein (G-protein) involved in transmitting growth signals from the cell membrane to the nucleus. When mutated, RAS becomes constitutively active (locked in the GTP-bound form), leading to continuous downstream signalling through the MAP kinase pathway , causing uncontrolled cell proliferation - a key event in oncogenesis. Incorrect Options: Enhanced DNA repair leading to genomic instability (Option B) : RAS mutations do not enhance DNA repair; rather, they promote proliferation, not repair. Genomic instability arises from defects in DNA repair genes (e.g., BRCA1, MSH2). Inactivation of a tumour suppressor gene resulting in loss of cell cycle checkpoint control (Option C) : This describes tumour suppressor genes like RB or TP53, not RAS, which is an oncogene (gain-of-function mutation). Increased activity of tyrosine kinase receptors through gene amplification (Option D) : Seen in HER2/neu or EGFR oncogenes, not RAS. RAS acts downstream of these receptors.

References:

Robbins & Cotran, Pathologic Basis of Diseases, 10th Edition, Pages 287.

↑ *Back to this question in Part A*

@Neet_pg_bot

Q3: All of the following are correct about neuroendocrine tumours except? It has a salt and pepper appearance of chromatin Tumours arising from different organs have different microscopic features Light microscopy reveals secretory granules On microscopic examination, small, round, blue cells forming a rosette pattern are visible (Q879192)

A. 1, 2, and 3

B. Only 3

C. 2, 3, and 4

D. 1, 3, and 4

Correct Answer: B. Only 3

Explanation: The only false statement given is 'Light microscopy reveals secretory granules'. Electron microscopy reveals secretory granules. Neuroendocrine tumours (NETs) are neoplasms that arise from cells of the endocrine (hormonal) and nervous systems . They most commonly, but not only, occur in the intestine, where they are often called carcinoid tumours. Microscopic Features: Uniform, small-to-medium round cells (Statement 4) Moderate eosinophilic cytoplasm Characteristic “salt and pepper” (stippling) chromatin (Statement 1) Electron Microscopy features: Presence of electron-dense neurosecretory granules (Statement 3) Immunohistochemistry: NETs are characteristically positive for: Chromogranin A (CgA) Synaptophysin Neuron-specific enolase (NSE) CD56 High-grade NET (small-cell carcinoma) typically have a high mitotic rate and a very high Ki-67 index (>20%) Although there are many kinds of NETs, they are treated as a group of tissues because the cells of these neoplasms share common features, including a similar histological appearance, having special secretory granules , and often producing biogenic amines and polypeptide hormones (Statement 2) .

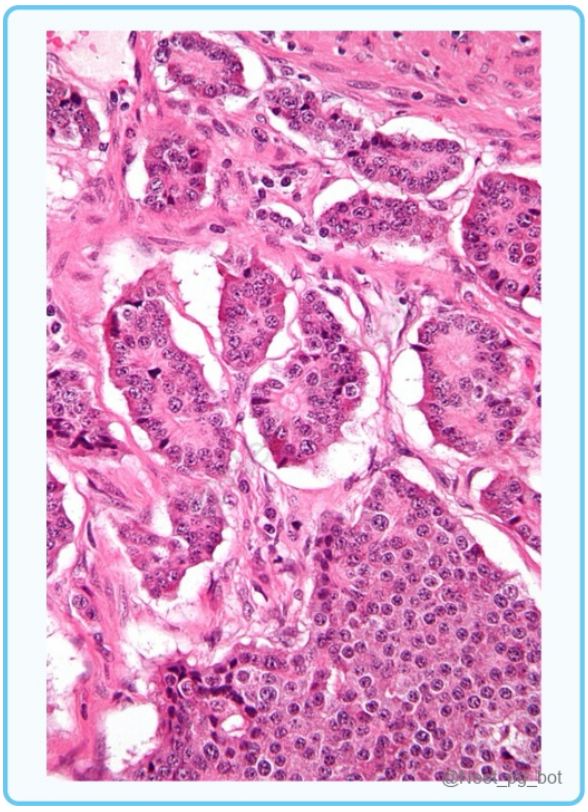

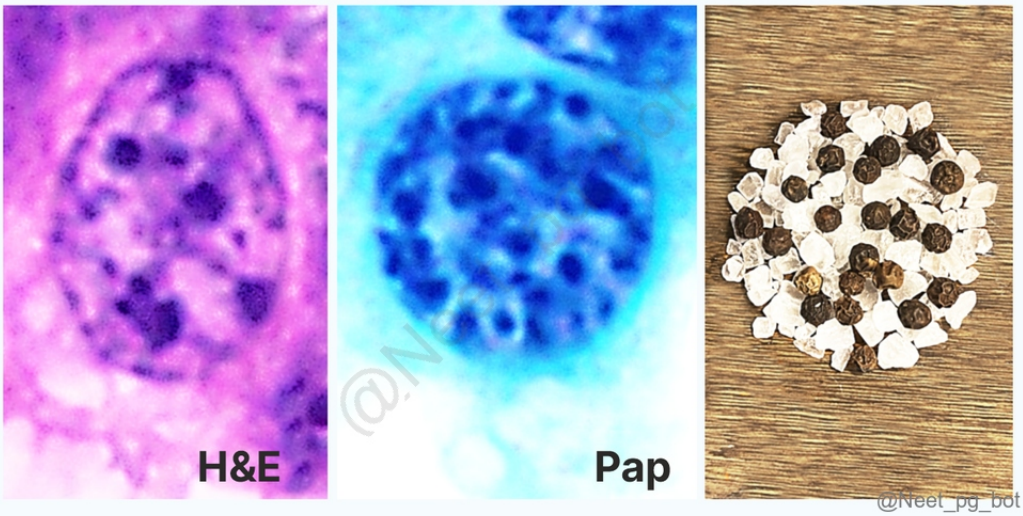
H&E
Pap
@Neet_pg_bot

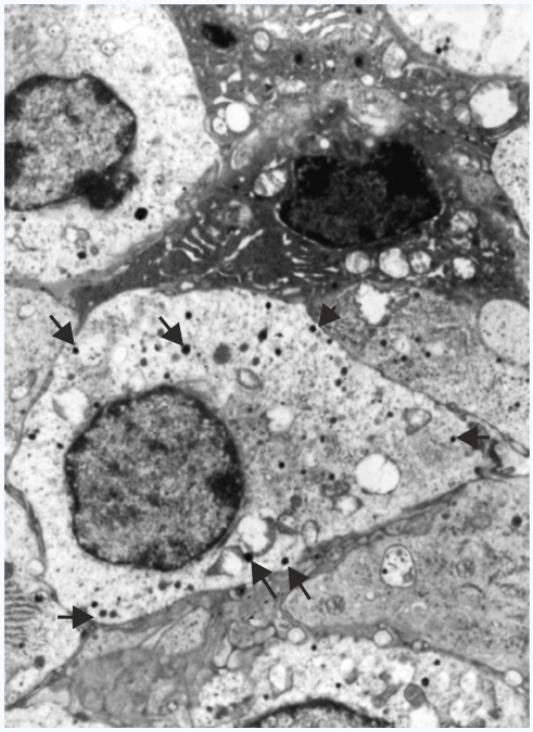
@Neet_pg_bot

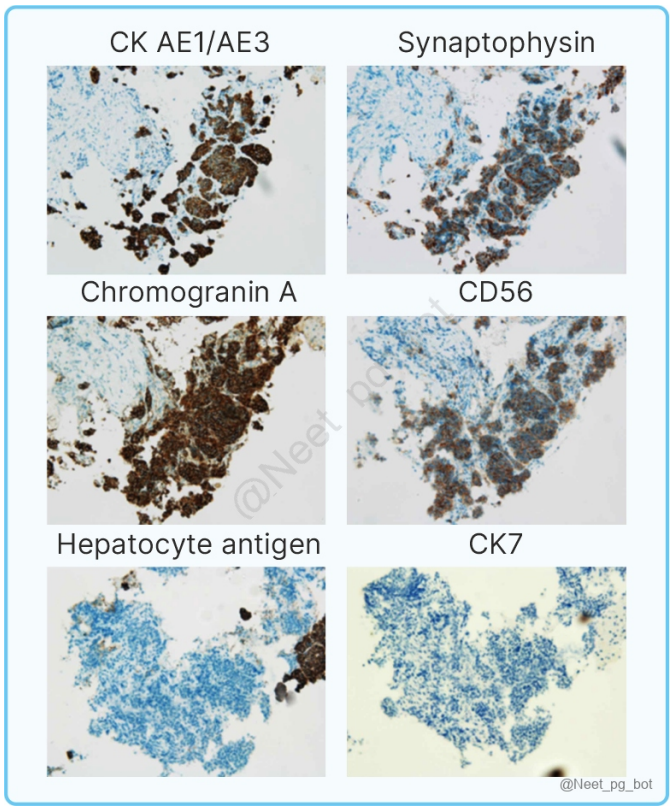

References:

Robbins & Cotran Pathologic Basis of Diseases, 10th Edition, Page 719, 777.

↑ *Back to this question in Part A*

@Neet_pg_bot

Q4: Why do neoplastic cells utilise Warburg metabolism? (Q855927)

A. It decreases glucose utilization by neoplastic cells

B. It forms metabolic intermediates which are needed for cell growth and multiplication

C. It provides more energy in the form of increased ATP production

D. It prevents apoptosis and makes the cancer immortal

Correct Answer: B. It forms metabolic intermediates which are needed for cell growth and multiplication

Explanation: It forms metabolic intermediates which are needed for cell growth and multiplication The Warburg effect is a distinct metabolic feature of cancer cells, where, even in the presence of sufficient oxygen, cancer cells demonstrate a distinctive form of cellular metabolism characterised by high glucose uptake levels (Option A ruled

out) and increased glucose conversion to lactose (fermentation) via glycolysis. This shift does not increase ATP production but provides key metabolic intermediates needed for rapid cell growth and division. (Option C ruled out) Otto Warburg was awarded the Nobel Prize in 1931 for this theory. The Warburg effect is the basis of positive emission tomography (PET). Patients are injected with 18F-fluorodeoxyglucose (FDG) , a non-metabolizable glucose derivative preferentially taken up into tumour cells (due to glucose hunger), which can be detected by PET scan. It prevents apoptosis and makes the cancer immortal (Option D): While Warburg metabolism can be linked to cellular survival and resistance to certain forms of stress, its primary function is not directly about preventing apoptosis or making the cell immortal. Instead, it helps meet the increased metabolic demands of rapidly proliferating cancer cells.

References:

Robbins and Cotran Pathologic Basis of Disease, 10th Edition, Pages 299,300

↑ *Back to this question in Part A*

@Neet_pg_bot

Q5: A 3-year-old boy was brought by his parents with concerns about being increasingly clumsy for the past 6 months. On examination, there is leukocoria with an absence of the red reflex in the left eye. As further workup reveals a tumour, the eye is enucleated, and the microscopic appearance is as shown in the image. Molecular analysis of the tumour indicates a loss of cell cycle control in the tumour cells. What is the most likely diagnosis? (Q859874)

A. Wilms tumor

B. Retinoblastoma

C. Ependymoma

D. Neuroblastoma

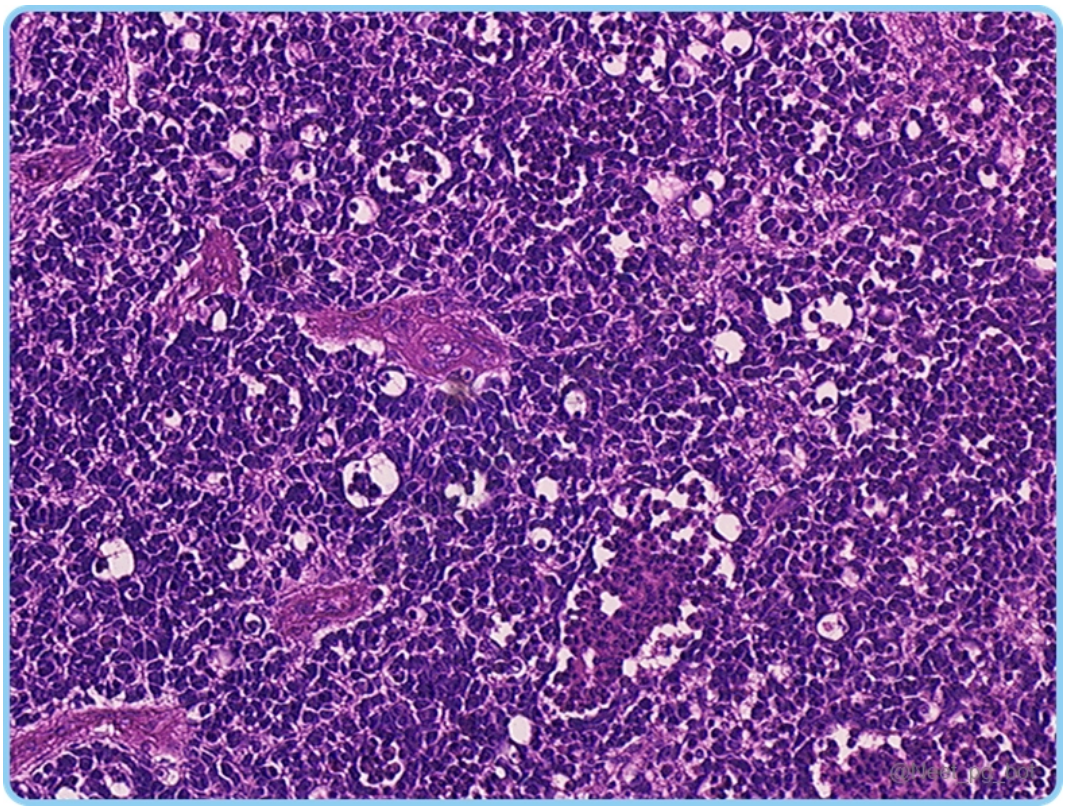

Correct Answer: B. Retinoblastoma

- *Listen (English)*
- *Listen (Hindi)*

Explanation: The child presents with leukocoria (white pupillary reflex) and progressive clumsiness, raising suspicion for an intraocular malignancy. The absence of a red reflex suggests an opaque mass within the eye, which is highly indicative of retinoblastoma , the most common primary intraocular malignancy in children. Age of Presentation: Usually before 3 years, with non-familial cases diagnosed by 1 year. Clinical Features: Leukocoria (most common presenting sign) Strabismus (misaligned eyes) due to loss of vision Proptosis in advanced cases Orbital invasion and metastasis in late stages. Histopathology: Small round blue cells are characteristic of primitive neuroectodermal tumours. Anastomosing areas of necrosis Flexner-Wintersteiner rosettes (well-differentiated tumours) Molecular Pathogenesis: RB1 gene mutation on chromosome 13q14 , leading to loss of cell cycle control. Loss of both alleles of RB1 leads to uncontrolled retinal cell proliferation. Wilms tumour (Option A), a nephroblastoma, typically presents with an abdominal mass, hematuria, and hypertension and histologically shows a triphasic pattern with blastemal, stromal, and epithelial components. {{caption_text}} Ependymoma (Option C) arises in the fourth ventricle or spinal cord, leading to obstructive hydrocephalus, and shows perivascular pseudorosettes and true rosettes on histology. {{caption_text}} PA Neuroblastoma (Option D), a neural crest tumour usually originating in the adrenal gland or sympathetic chain, presents with an abdominal mass, periorbital ecchymoses ("raccoon eyes"), and opsoclonus-myoclonus syndrome, with histology showing Homer-Wright rosettes and immunohistochemical positivity for chromogranin, synaptophysin, and neuron-specific enolase (NSE). {{caption_text}}

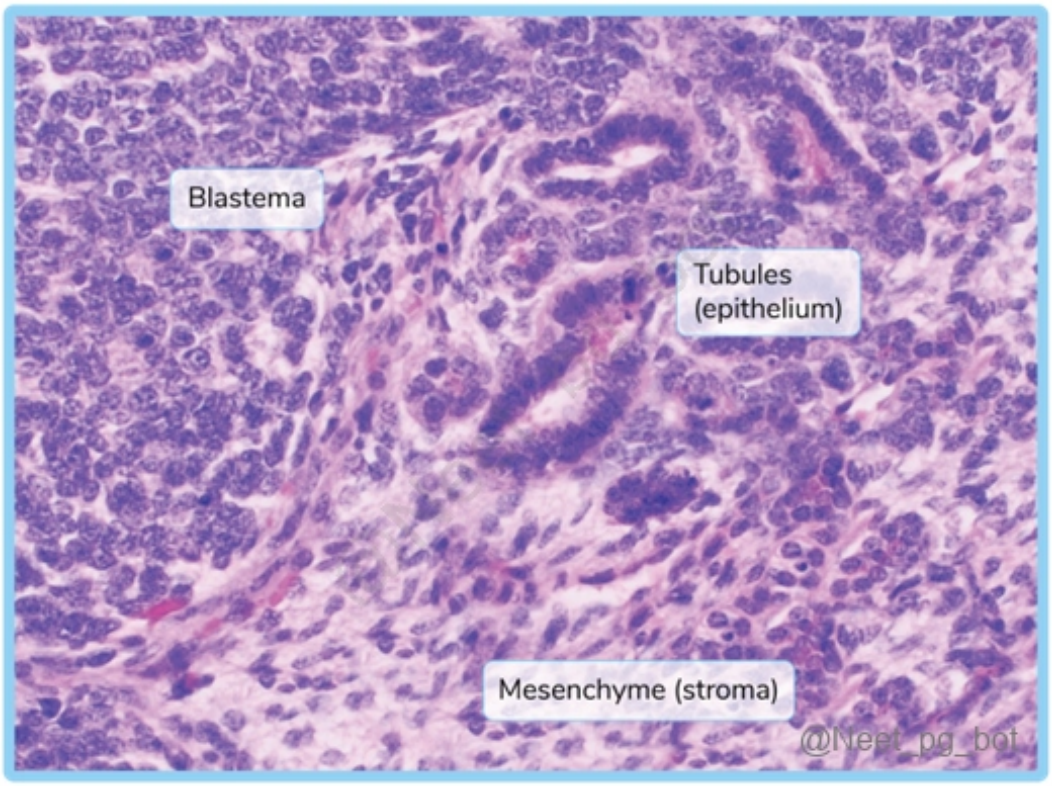

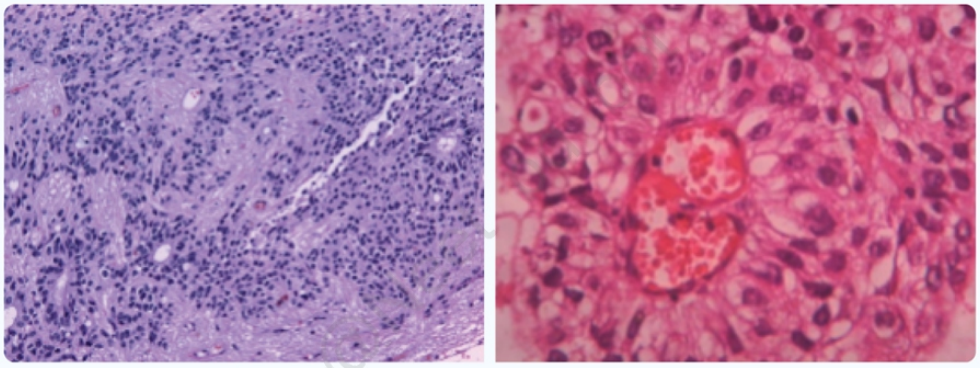

HPE of Ependymoma : Perivascular pseudorosette

@Neet_pg_bot

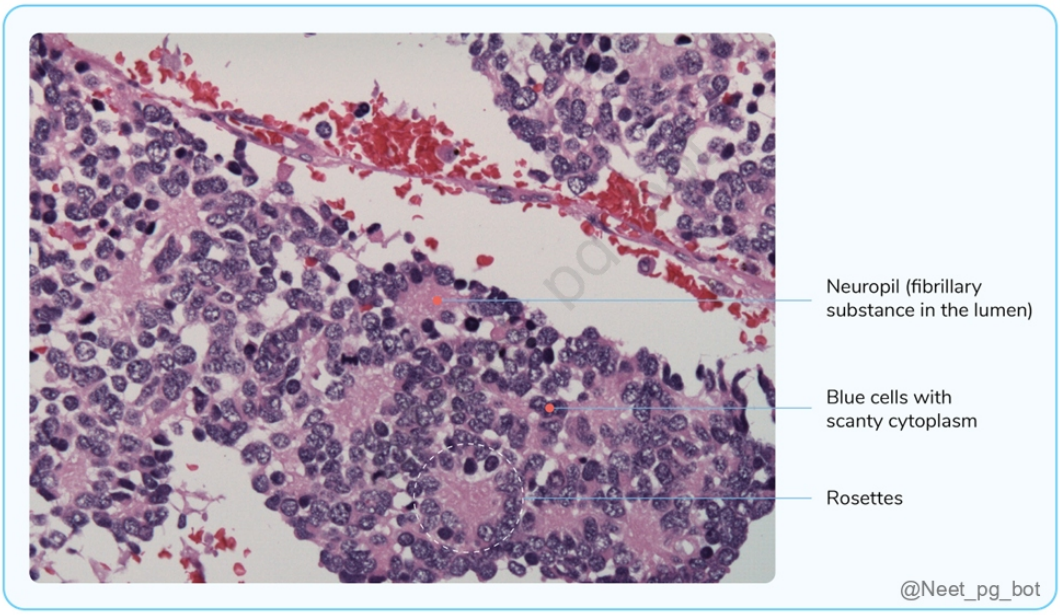

References:

Robbins and Cotran Pathologic Basis of Disease, 10th Edition, Page 1324,1325

↑ *Back to this question in Part A*

@Neet_pg_bot

Q6: Which of the following enzymes is responsible for the immortality of cancer cells? (Q859238)

A. Telomerase

B. Topoisomerase

C. Helicase

D. RNA polymerase

Correct Answer: A. Telomerase

■ *Listen (English)*

■ *Listen (Hindi)*

Explanation: Telomerase maintains telomere length , preventing chromosome degradation. Telomere shortening occurs with each cell division, contributing to cellular ageing and death . However, telomerase extends telomeres , enabling indefinite division . In cancer cells , its overexpression promotes uncontrolled proliferation and immortality . Incorrect Options: Topoisomerase (Option B) is responsible for manipulating the structure of DNA

by inducing and resolving DNA strand breaks. Helicase (Option C) unwinds the DNA double helix, allowing other enzymes to access and replicate the DNA. RNA polymerase (Option D) synthesises RNA from a DNA template during transcription, essential for gene expression and protein synthesis. While its dysregulation can occur in cancer, it is not directly linked to cancer cell immortality.

References:

Robbins & Cotran Pathologic Basis of Disease, 10th Edition, Pages 303 - 305

↑ *Back to this question in Part A*

@Neet_pg_bot

Q7: The lining epithelium of the respiratory tract of a middle-aged man who is a chronic smoker shows a change from columnar to stratified squamous epithelium, as depicted in the image below. The change is called what? {{caption_text}} (Q858510)

A. Dysplasia

B. Hypertrophy

C. Atrophy

D. Metaplasia

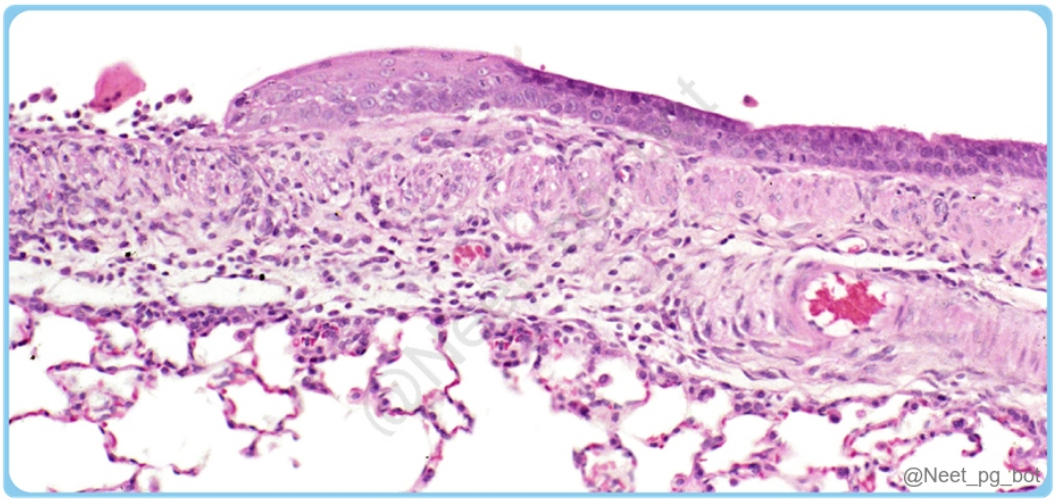

Correct Answer: D. Metaplasia

■ *Listen (English)*

■ *Listen (Hindi)*

Explanation: Metaplasia refers to the reversible change in which one type of adult cell is replaced by another type. In this case, the columnar epithelium of the respiratory tract is replaced by stratified squamous epithelium, often as

a result of chronic irritation, such as smoking. Metaplasia: Metaplasia is a reversible change in which another cell type replaces one differentiated cell type (epithelial or mesenchymal). Metaplasia is a change in the phenotype of differentiated cells, often in response to chronic irritation that makes cells better able to withstand stress; usually induced by altered differentiation pathway of tissue stem cells, may result in reduced functions or increased propensity for malignant transformation. Barrett's oesophagus is characterised by the replacement of the normal squamous epithelium of the lower oesophagus with columnar epithelium containing goblet cells & is considered an adaptive response to chronic exposure to gastric acid and bile reflux in the setting of GERD. The presence of Barrett's oesophagus increases the risk of developing oesophagal adenocarcinoma. {{caption_text}} Transformation of columnar epithelium to squamous epithelium: In the respiratory tract , in response to chronic irritation, such as smoking, the columnar epithelium undergoes metaplasia to squamous epithelium, leading to a condition known as squamous metaplasia. Conversion of glandular epithelium to squamous epithelium: This type of metaplasia can be seen in the cervix , where the normal glandular epithelium undergoes metaplasia to the squamous epithelium in response to chronic inflammation or irritation, leading to a condition known as cervical squamous metaplasia. Substitution of mesenchymal cells with epithelial cells: An example of this can be seen in osseous metaplasia , where mesenchymal cells differentiate into bone-forming osteoblasts, leading to the formation of ectopic bone within soft tissues. Incorrect Options: Dysplasia (Option A) refers to the abnormal development or growth of cells or tissues. It is characterised by disordered cell structures and is considered a precursor to cancer. Hypertrophy (Option B) is the increase in the size of cells, leading to the enlargement of an organ or tissue. It typically occurs in response to increased functional demand or external stimulation. Atrophy (Option C) is the reduction in the size or number of cells, leading to the shrinkage of an organ or tissue. It can result from factors such as disuse, loss of nerve supply, or inadequate blood flow.

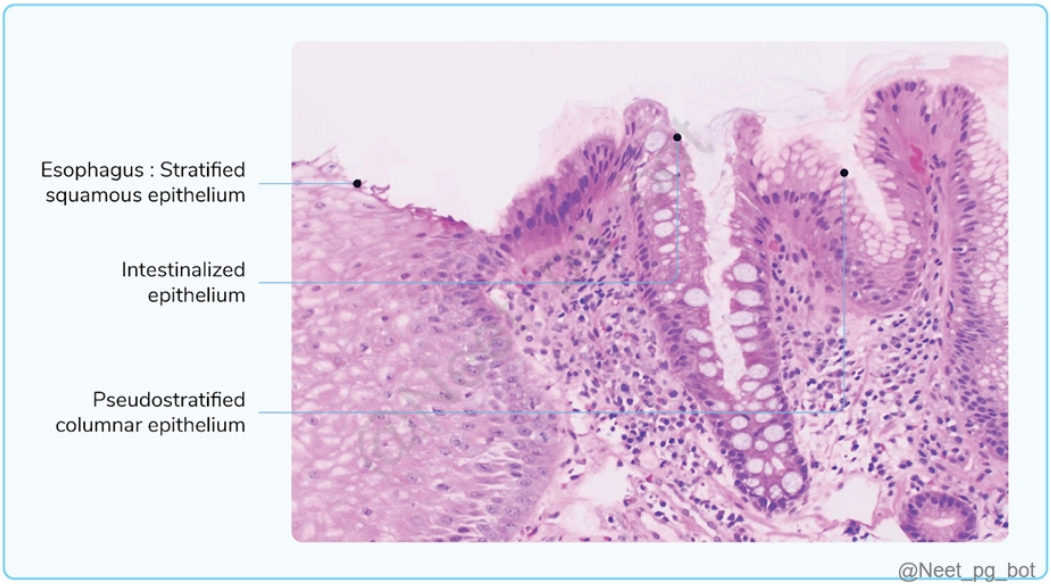

References:

Robbins & Cotran Pathologic Basis of Disease, 10th Edition, Page 61

↑ *Back to this question in Part A*

@Neet_pg_bot

Q8: What is the fixation technique employed to examine fat in histopathology? (Q856484)

A. IHC

B. Frozen section

C. Liquid paraffin

D. Formalin-fixed

Correct Answer: B. Frozen section

- *Listen (English)*
- *Listen (Hindi)*

Explanation: The frozen section is done for the fixation of fats. It is a technique used to examine tissue samples quickly by freezing them and then cutting them into thin slices for immediate microscopic examination. This method is often preferred for fat tissue examination because it prevents the loss of lipid content, which can be affected by formalin fixation. {{caption_text}} Advantages: It provides rapid results & ideal for intraoperative consultations (e.g., determining malignancy during surgery). It is essential for preserving certain tissue components like fat, enzymes, and lipids that might be damaged by formalin fixation. Fixatives & uses: Technique / Tissue Fixative Electron microscopy Glutaraldehyde Bone marrow (Trephine biopsy) Zenker's fluid GI biopsy Bouin's fluid Brain Formalin ammonium chloride Adrenal biopsy Orth's fluid Pap smear Ethanol IHC (Immunohistochemistry) (Option A) is used to detect specific proteins or antigens in tissue sections using targeted antibodies. Although IHC can identify markers associated with fat cells, it is not a fixation method for examining fat. Liquid paraffin (Option C) is not a fixation agent but a mounting medium applied to tissue sections on slides. It provides optical clarity and preserves the specimen but does not fix or preserve fat specifically. Formalin fixation (Option D) is a commonly used method to preserve tissue samples in histopathology. While it preserves the general structure of tissues, it is not ideal for preserving fat. Formalin can cause partial extraction of fat, leading to the loss of fat droplets and artefacts during tissue processing.



References:

Robbins & Cotran Pathologic Basis of Disease, 10th Edition, Page 132

https://www.patholjournal.com/articles/433/4-3-37-909.pdf

↑ *Back to this question in Part A*

@Neet_pg_bot

Q9: A woman was diagnosed with metastatic liver adenocarcinoma with CK7-, CK20+, and CDX1+ immunohistochemistry (IHC) markers. Which of the following is the most likely primary site of origin for this metastasis? (Q856914)

A. Colon carcinoma

B. Breast carcinoma

C. Pancreatic carcinoma

D. Ovarian carcinoma

Correct Answer: A. Colon carcinoma

■ *Listen (English)*

■ *Listen (Hindi)*

Explanation: Colon carcinoma typically shows a CK7- and CK20+ pattern , and CDX1 is a transcription factor often expressed in the intestinal epithelium, further supporting a colon origin for the metastasis. CK7: Positive in carcinomas from the lung, breast, ovary, and pancreas. Negative in most gastrointestinal tract carcinomas, including those originating from the colon. CK20: Positive in colorectal and urothelial carcinomas. Negative in carcinomas of the lung, breast, and ovary. CDX1: Positive in adenocarcinomas of the gastrointestinal tract, particularly colorectal carcinomas. Negative in most non-gastrointestinal carcinomas, such as those from the breast, lung, ovary, and pancreas. Tumor Type CK7 CK20 CDX1 Colon carcinoma - + + Breast carcinoma + - - Pancreatic carcinoma + + - Ovarian carcinoma + - -

References:

https://pubmed.ncbi.nlm.nih.gov/35390310/

↑ *Back to this question in Part A*

@Neet_pg_bot

Q10: A pap smear taken from a patient revealed hyperchromatic nuclei, irregular nuclear borders, and a low maturation index involving the whole thickness but did not breach the basement membrane. What is the diagnosis? (Q856160)

A. Dysplasia

B. Carcinoma

C. Metaplasia

D. Hyperplasia

Correct Answer: A. Dysplasia

■ *Listen (English)*

■ *Listen (Hindi)*

Explanation: The findings described in the pap smear hyperchromatic nuclei, irregular nuclear borders, and low maturation index are characteristic of dysplasia , a pre-cancerous condition. Dysplasia is abnormal cell growth and differentiation, often seen in the epithelial layer , without penetration through the basement membrane . This is reversible in the early stages (may become irreversible if the entire epithelium is involved). Carcinoma (Option B) refers to invasive cancer where the abnormal cells have breached the basement membrane and spread beyond the epithelial layer. The description clearly states that the basement membrane is intact, ruling out carcinoma. Metaplasia (Option C) is the replacement of one type of cell with another, often occurring in response to tissue damage, repair, chronic irritation, or regeneration. It does not explain the nuclear changes (hyperchromasia and irregularity) seen in the pap smear. Hyperplasia (Option D) is an increase in the number of cells in a tissue, typically in response to a stimulus. It does not usually involve abnormal nuclear features like hyperchromasia and irregular borders, which are more indicative of dysplasia .

References:

Robbins and Cotran Pathologic Basis of Disease, 10th Edition, Page 270, 271, 272

↑ *Back to this question in Part A*

@Neet_pg_bot

Q11: A 65-year-old female patient is diagnosed with pure red cell aplasia and a mediastinal mass. Which of the following is a likely cause? (Q856155)

A. Thymoma

B. Non-Hodgkin lymphoma

C. Bronchogenic carcinoma

D. Germ cell tumour

Correct Answer: A. Thymoma

■ *Listen (English)*

■ *Listen (Hindi)*

Explanation: The diagnosis of pure red cell aplasia (PRCA) in this patient, coupled with a mediastinal mass , strongly suggests a thymoma, a tumor of the thymus gland , which is located in the anterior mediastinum . It is often asymptomatic initially but can cause a range of paraneoplastic syndromes and is also associated with autoimmune diseases like myasthenia gravis. One of the paraneoplastic syndromes associated with thymoma is PRCA . In PRCA, red blood cell production in the bone marrow is selectively failed, while white blood cells and platelets are usually unaffected. This leads to severe anemia in the absence of any abnormalities in other cell lines. Thymoma Clinical features Mostly asymptomatic (small tumor), incidentally detected. It may compress the trachea (dyspnea), esophagus (dysphagia), recurrent laryngeal nerve (dysphonia or hoarseness of voice), and superior vena cava (superior vena cava syndrome). Investigations CT scan Investigation of choice It is used to determine the extent of the disease. {{caption_text}} Histology (definitive diagnosis) Noninvasive thymomas: Medullary-type epithelial cells (elongated or spindle-shaped) or a mixture of medullary- and cortical-type epithelial cells (admixture of polygonal cortical-type epithelial cells and a denser infiltrate of thymocytes). {{caption_text}} Invasive thymoma: Cytologically benign but locally invasive. The epithelial cells have abundant cytoplasm and rounded vesicular nuclei mixed with numerous thymocytes. {{caption_text}} Cytokeratin (marker to distinguish thymoma from lymphoma; thymomas are positive for cytokeratin) Non-Hodgkin lymphoma (Option B) can cause lymphadenopathy and mediastinal masses , but it is not associated with pure red cell aplasia. Bronchogenic carcinoma (Option C) may cause mediastinal masses due to lymph node involvement or direct tumour extension, but it is not commonly associated with pure red cell aplasia . Germ cell tumours (Option D) in the mediastinum can cause a mediastinal mass and are not typically linked with pure red cell aplasia .

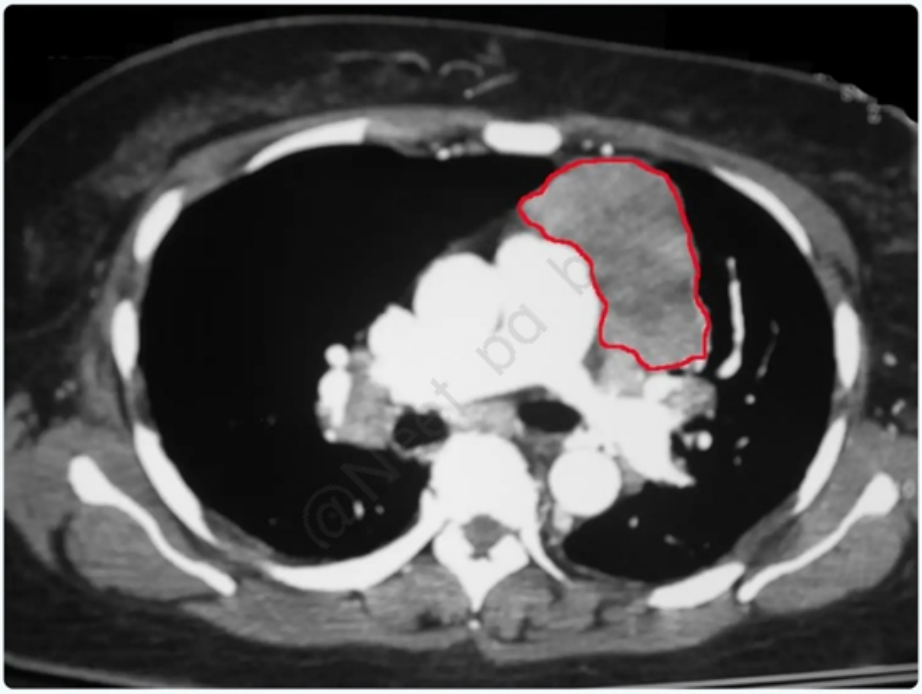

CT scan of thymoma

@Neet_pg_bot

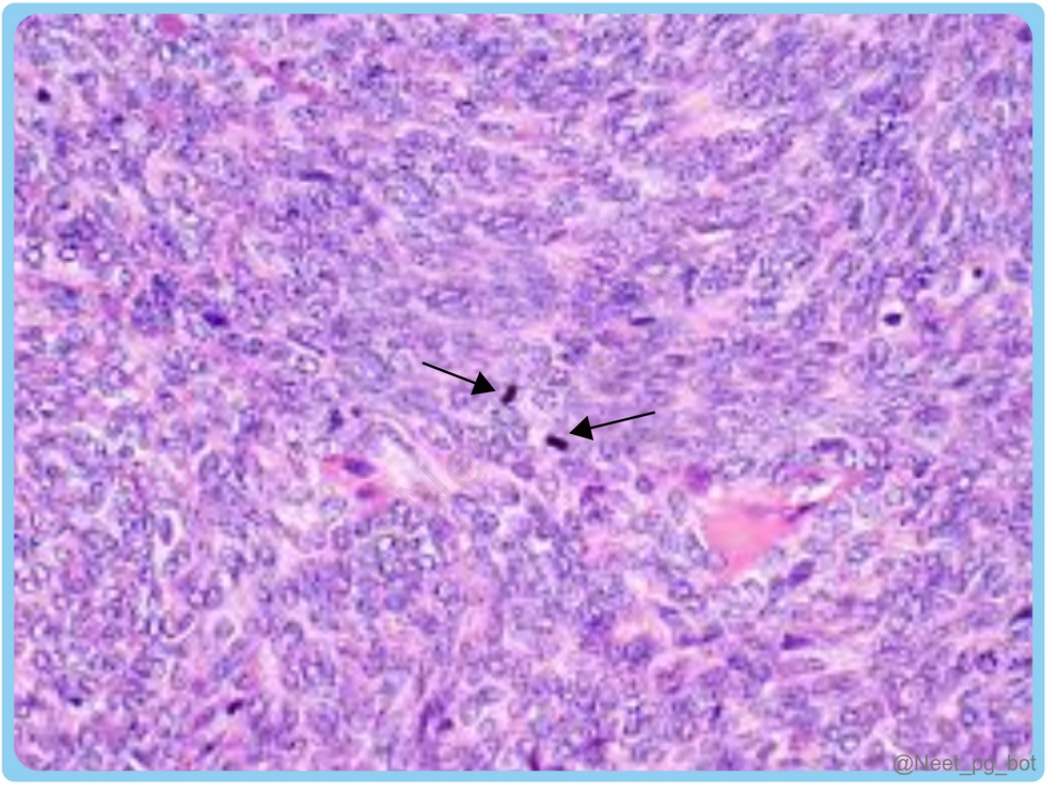

@Neet_pg_bot

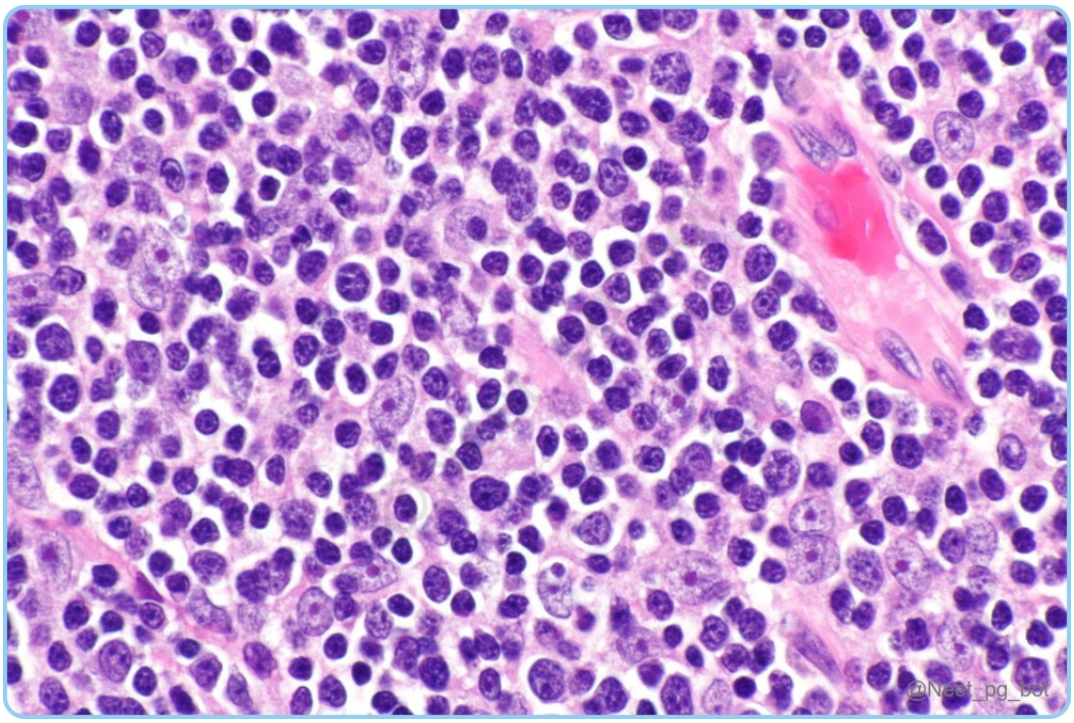

References:

Bailey & Love's Short Practice of Surgery, 28th Edition, Page 992

↑ *Back to this question in Part A*

@Neet_pg_bot

Q12: A patient with occupational exposure to benzene presents with repeated infections, easy fatigability, weight loss, and an evening rise in temperature. This occupational exposure will predispose him to which of the following cancers? (Q856108)

A. Leukemia

B. Lung cancer

C. Bladder cancer

D. Skin cancer

Correct Answer: A. Leukemia

■ *Listen (English)*

■ *Listen (Hindi)*

Explanation: Occupational exposure to benzene is a well-established risk factor for the development of leukemia , particularly AML and ALL. It is a known carcinogen that can cause damage to the bone marrow, leading to disruption of normal blood cell production , which can result in leukemia . The clinical features in this case, such as repeated infections , fatigability , weight loss , and fever , also suggest a hematological malignancy like leukemia. Risk of specific carcinomas related to specific exposure Risk of carcinoma Occupation exposure Lungs (Option B ruled out) Arsenic, beryllium, cadmium, chromium, Asbestosis, Silica, radon, Nickel, and aromatic hydrocarbon. Bladder (Option C ruled out) Benzidine, Auramine, Beta-naphthylamine, Para amino-diphenyl, Magenta. Liver Vinyl chloride , Arsenic. Leukaemia Benzene , ethylene oxide. Skin (Option D ruled out) Arsenic, ionising radiation, Polycyclic aromatic hydrocarbons. Scrotum Polycyclic aromatic hydrocarbons.

References:

Park’s Textbook of Preventive and Social Medicine, 27th Edition, Pages 935 - 936

↑ *Back to this question in Part A*

@Neet_pg_bot

Q13: Which of the following is true? BRCA1 is an oncogene HER2neu is amplified only in a fraction of breast cancer EGFR+ is seen in non-small cell lung cancer N-MYC is a tumor suppressor gene (Q856708)

A. 1, 2

B. 1, 3

C. 2, 3

D. All of these

Correct Answer: C. 2, 3

■ *Listen (English)*

■ *Listen (Hindi)*

Explanation: HER2/neu is amplified only in a fraction of breast cancer: In breast cancer, amplification of the HER2 gene and overexpression of the HER2 protein can occur. HER2 amplification is not observed in all breast cancers but only in a fraction of cases. (Statement 2) Breast cancers that show HER2 amplification are referred to as HER2-positive breast cancers and can be targeted with specific therapies like trastuzumab. EGFR is seen in non-small cell lung cancer (NSCLC): In non-small cell lung cancer, mutations or overexpression of the EGFR gene can occur. (Statement 3) EGFR-targeted therapies, such as tyrosine kinase inhibitors, are used in the treatment of EGFR-positive NSCLC. BRCA1 (Breast Cancer 1) It is classified as a tumour suppressor gene. (Statement 1 ruled out) Mutations increase the risk of cancers such as breast, ovarian, prostate, and pancreatic cancers and are inherited in an autosomal dominant pattern. N-MYC It is an oncogene. (Statement 4 ruled out) It is associated with neuroblastoma (most common), small-cell lung cancer, and medulloblastoma.

References:

Robbins and Cotran Pathologic Basis of Disease, 10th Edition, Page 281, 287, 336.

↑ *Back to this question in Part A*

@Neet_pg_bot

Q14: The human papillomavirus inactivates the Rb gene by which of the following proteins? (Q855392)

A. E6

B. E7

C. L1

D. L2

Correct Answer: B. E7

■ *Listen (English)*

■ *Listen (Hindi)*

Explanation: The human papillomavirus (HPV) inactivates the retinoblastoma (RB) gene primarily through the action of the E7 protein. The E7 protein of high-risk HPV types, such as HPV-16 and HPV-18, promotes cell cycle progression by inactivating the retinoblastoma protein (p105Rb). E7 binds to p105Rb, disrupting its interaction with the E2F transcription factor, which releases E2F to activate genes essential for cell cycle progression and DNA replication. Consequently, the cell cycle becomes dysregulated, and uncontrolled cell proliferation can occur, a hallmark of HPV-associated cancers. High-risk HPV types (HPV 16, 18): High-grade cervical dysplasia and invasive cancer. Low-risk HPV types (HPV 6, 11): Genital warts (condyloma acuminatum and low-grade changes in cervical cells). Oncogenic Activities of E6 Protein (Option A ruled out) Oncogenic Activities of E7 Protein (Option B) Binds to and promotes degradation of p53 → Impairs cell growth and apoptosis regulation. Stimulates expression of TERT (telomerase reverse transcriptase) → Facilitates cellular immortalisation by maintaining telomere length. Disrupts interaction between RB protein and E2F transcription factors Inactivates CDK inhibitors (e.g., p21 and p27). Activates cyclins A and E L1 (Option C) protein is the major capsid protein of HPV and plays a role in the virus particle assembly. L2 (Option D) protein is a capsid protein of HPV, which assists in entering the viral DNA into the host cell during infection.

↑ *Back to this question in Part A*

@Neet_pg_bot

Q15: Which of the following is true about anaplasia? (Q857175)

A. Loss of cohesion between cells

B. Loss of differentiation

C. Change of epithelium type

D. Benign and fully reversible

Correct Answer: B. Loss of differentiation

Explanation: Anaplasia refers to the loss of differentiation of cells. It is a characteristic feature of malignant tumours and is associated with the loss of normal tissue organisation and cellular features. Anaplastic cells often exhibit pleomorphism, hyperchromatic nuclei, an increased nuclear-to-cytoplasmic ratio, and increased mitotic activity. Loss of cohesion between cells (Option A) is a characteristic feature of malignancy. Change of epithelium type (Option C) : Metaplasia refers to the reversible change of one mature cell type to another mature cell type in response to certain stimuli or chronic irritation. Benign and fully reversible (Option D) : Anaplasia is typically seen in malignant tumours and is not fully reversible.

References:

Robbins and Cotrans Pathologic Basis of Disease, 10th Edition, Pages 270-272

↑ *Back to this question in Part A*

@Neet_pg_bot

Q16: Which of the following statements is true about proto-oncogenes? KIT has decreased expression via the tyrosine kinase signalling pathway in GIST. KRAS mutation is more commonly associated with small-cell lung cancer. ERBB2 is overexpressed in association with breast carcinomas. PDGFR-β has suppressed expression in colorectal cancer. (Q855121)

A. 2 only

B. 3 only

C. 1 and 4

D. 2 and 3

Correct Answer: B. 3 only

■ *Listen (English)*

■ *Listen (Hindi)*

Explanation: ERBB2 (HER2/neu) is a proto-oncogene encoding a receptor tyrosine kinase. In many breast cancers, ERBB2 undergoes gene amplification, increasing HER2 protein levels. (Statement 3) This leads to excessive receptor activation and uncontrolled signaling. It stimulates key cancer pathways like RAS–MAPK and

PI3K–AKT. About 15–20% of breast carcinomas show HER2 overexpression. These tumors are biologically aggressive if left untreated. HER2 status is determined using IHC and FISH in clinical practice. Trastuzumab and other HER2-targeted drugs significantly improve outcomes, confirming its oncogenic role. KIT has decreased expression in GIST (Statement 1) - Incorrect.GIST most often shows activating mutations and increased activity of the KIT tyrosine kinase receptor (CD117+), not decreased expression. KRAS mutation is more common in small-cell lung cancer (Statement 2) - Incorrect. KRAS mutations are common in non–small cell lung cancer (especially adenocarcinoma), not in small-cell lung cancer. PDGFR-β has suppressed expression in colorectal cancer (Statement 4) - Incorrect. There is no characteristic suppression of PDGFR-β in colorectal cancer; proto-oncogene involvement typically means activation, not decreased expression.

References:

Robbins & Cotran Pathologic Basis of Disease, 10th Edition, Page 285-287,622,1140

↑ *Back to this question in Part A*

@Neet_pg_bot

Q17: A 25-year-old woman presents with lower abdominal discomfort. The surgical image is given below. What is the most likely diagnosis? (Q866741)

A. Serous cystadenoma

B. Immature teratoma

C. Mature cystic teratoma

D. Endometrioma



Correct Answer: C. Mature cystic teratoma

Explanation: Teratomas are tumours that originate from all three germ layers (ectoderm, mesoderm, and endoderm) and are commonly found in the ovaries. They are often seen in young women and can contain a variety of tissue types, such as hair, teeth, and muscle, which reflects their origin from all three germ layers. Mature teratoma Mature teratomas, or dermoid cysts , are common benign ovarian tumours found in young women. They are bilateral in 10-15% of cases. They contain tissues from all three germ layers, including skin, hair, and teeth, and can rarely undergo malignant transformation to squamous cell carcinoma. Grossly, they are unilocular cysts with a thin wall and hair; microscopically, they have stratified squamous epithelium and sebaceous glands. Immature teratoma: (Option B) Bulky, solid ovarian tumours that contain immature neuroepithelium, cartilage, bone, and muscle, with areas of necrosis and haemorrhage. They grow rapidly, often spreading beyond the ovary. They are seen in young females and have a high risk of malignancy. They have small, round blue cells (Immature neural components). Monodermal teratoma: Monodermal teratomas consist predominantly of a single type of tissue, such as thyroid tissue in struma ovarii or neuroendocrine cells in carcinoid tumours. They lack immature or embryonic-like tissues and typically do not have a high risk of malignancy. Serous cystadenoma (Option A): It is the most common ovarian epithelial tumor, usually seen in older women. It is unilocular, bilateral in >50% and is mostly malignant. The characteristic histologic feature is the presence of psamomma bodies (seen in 40-45%) which is composed of concentric rings of lamellar calcifications. Endometrioma (Option D): “chocolate cyst” of endometriosis, filled with old blood, not sebaceous material or calcified teeth.


@Neet_pg_bot

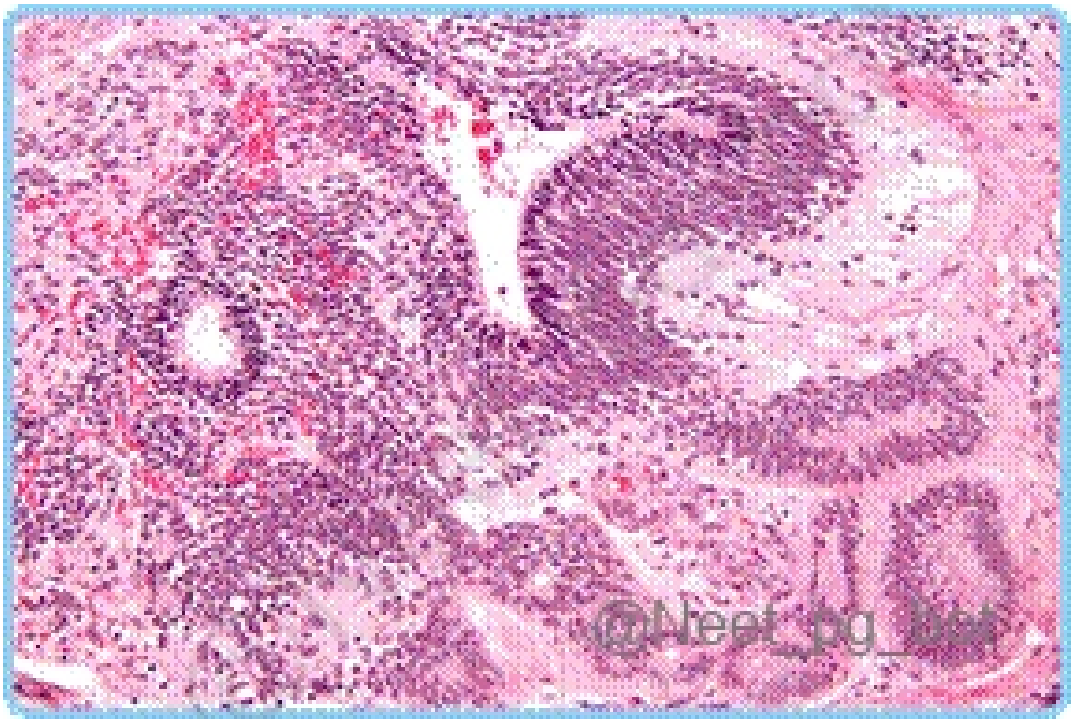
@Neet_pg_bot

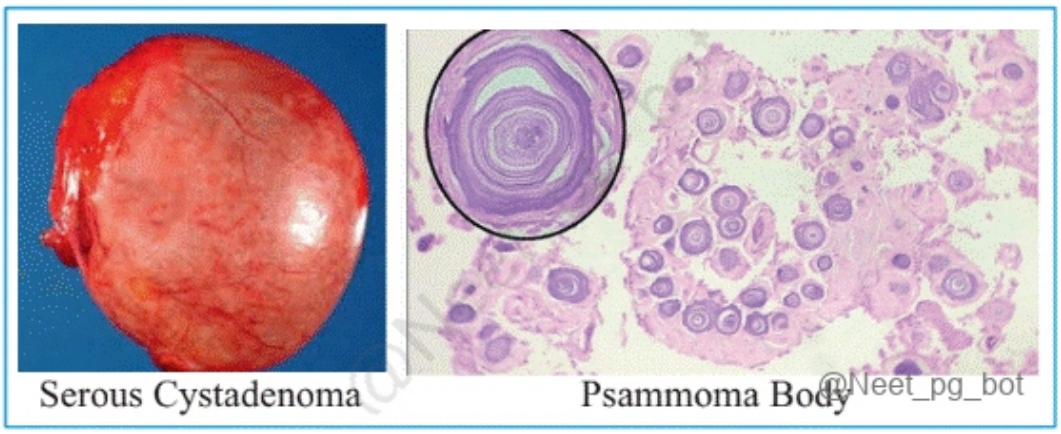

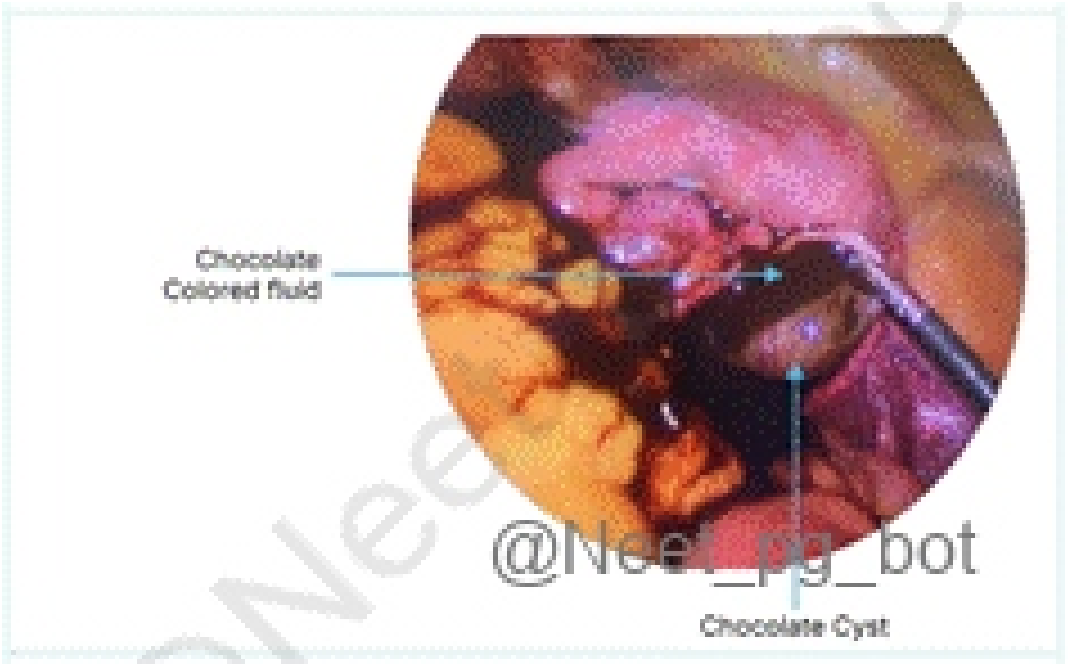

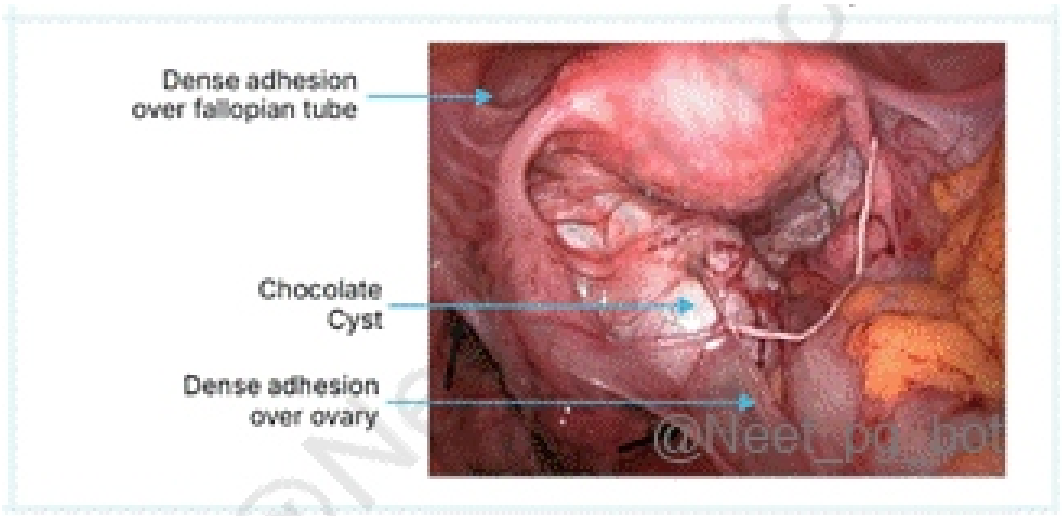

↑ *Back to this question in Part A*

@Neet_pg_bot

Q18: Neurosecretory bodies are seen in all of the following, except: (Q855069)

A. Medullary thyroid carcinoma

B. Pituitary adenoma

C. Paraganglioma

D. Adrenal cortical tumour

Correct Answer: D. Adrenal cortical tumour

Explanation: Neurosecretory bodies are collections of secretory granules, typically seen in tumours that arise from neuroendocrine cells, such as medullary thyroid carcinoma, pituitary adenoma, and paraganglioma. However, adrenal cortical tumours originate from the adrenal cortex and do not typically contain neurosecretory bodies. Adrenocortical Neoplasms: It causes various forms of hyperadrenalism, including both adenomas and carcinomas. These tumours are common in adults, with carcinomas being more prevalent in children. Li-Fraumeni syndrome (due to TP53 mutations) and Beckwith-Wiedemann syndrome (linked to IGF-2 overexpression) increase the risk for adrenocortical carcinoma. Types of Adrenocortical Neoplasms: Functional adenomas : It often causes hyperaldosteronism or Cushing syndrome, with virilizing neoplasms usually being carcinomas. Some neoplasms do not secrete hormones; their functionality is assessed via clinical evaluation and hormone testing. Nonfunctional Adenomas : Usually asymptomatic, often detected incidentally. Small, well-circumscribed lesions (up to 2.5 cm) have a normal surrounding adrenal cortex and are yellow-brown due to lipid content. Microscopically, they resemble normal adrenal cortex cells with minimal mitotic activity and a Ki-67 index < 5%. Adrenocortical Carcinomas : Rare and typically more functional than adenomas, often associated with virilism and other hyperadrenalism symptoms. These large, invasive tumours (>20 cm) can invade the adrenal vein, vena cava, and lymphatics, with frequent metastases to regional nodes and distant organs. Survival rates are low, with a median of 2 years. Neuroendocrine tumors: Carcinoid tumor Pituitary adenoma (Option B) Pancreatic Neuroendocrine Tumor (PanNET) Medullary Thyroid Carcinoma (MTC) (Option A) Pheochromocytoma Paraganglioma (Option C) Small Cell Lung Cancer (SCLC) Large Cell Neuroendocrine Carcinoma (LCNEC) Neuroblastoma

References:

Robbins & Cotran Pathologic Basis of Disease, 10th Edition, Page 717, 746, 1070, 1091,1 125, 1126

↑ *Back to this question in Part A*

@Neet_pg_bot

Q19: Match the following microscopic appearance and the respective tumour in which they are seen Microscopic appearance Tumor 1. Schiller Duval bodies a. Krukenberg tumor 2. Presence of teeth, hair, etc B. Granulosa cell tumor 3. Signet ring cells C.

Yolk sac tumour 4. Call-Exner bodies d. Teratoma (Q855924)

A. 1-c, 2-a, 3-d, 4-b

B. 1-b, 2-c, 3-a, 4-d

C. 1-d, 2-b, 3-c, 4-a

D. 1-c, 2-d, 3-a, 4-b

Correct Answer: D. 1-c, 2-d, 3-a, 4-b

■ *Listen (English)*

■ *Listen (Hindi)*

Explanation: Microscopic Appearance Tumor Schiller Duval bodies Yolk sac tumour Presence of teeth, hair, etc. Teratoma Signet ring cells Kruckenberg tumor Call-Exner bodies Granulosa cell tumor Yolk Sac tumour or endodermal sinus tumour: Common in infants and children up to 3 years old. Morphology: Gross : Solid grey-white with a gelatinous or mucoid appearance. Microscopy: 50% of the tumours show a lace-like network of medium-sized cuboidal, flattened, or spindled cells with endodermal sinuses (Schiller-Duval or glomerular bodies). {{caption_text}} Eosinophilic, hyaline-like globules containing α-fetoprotein (AFP) and α1-antitrypsin are present. Granulosa cell tumour: Originates from granulosa cells of the ovarian follicle. Occurs in postmenopausal women (adult type) or at any age (juvenile type) Juvenile cases may present with precocious sexual development, while adults may experience abnormal uterine bleeding and endometrial hyperplasia (which can lead to carcinoma) Microscopically, Call-Exner bodies and coffee bean nuclei are observed Elevated inhibin levels, CD99 positivity, and FOXL2 mutations are seen. {{caption_text}} Signet ring cells: They are typically associated with Krukenberg tumours, which are metastases of diffuse gastric carcinoma to the ovaries. Grossly, Krukenberg tumours often present with bilateral, symmetric ovarian enlargement with an intact capsule. Signet ring cells contain mucin that pushes the nucleus to the periphery, creating a "signet ring" appearance. {{caption_text}} Teratoma: Teratomas in adult males are typically large , ranging from 5 to 10 cm in diameter , with a heterogeneous appearance consisting of various organoid structures , such as neural tissue, muscle, epidermis, cartilage, thyroid gland, or intestinal wall. These elements may be mature or immature , sharing histologic features with fetal or embryonic tissue. Microscopically, these structures are embedded in a fibrous or myxoid stroma. {{caption_text}}

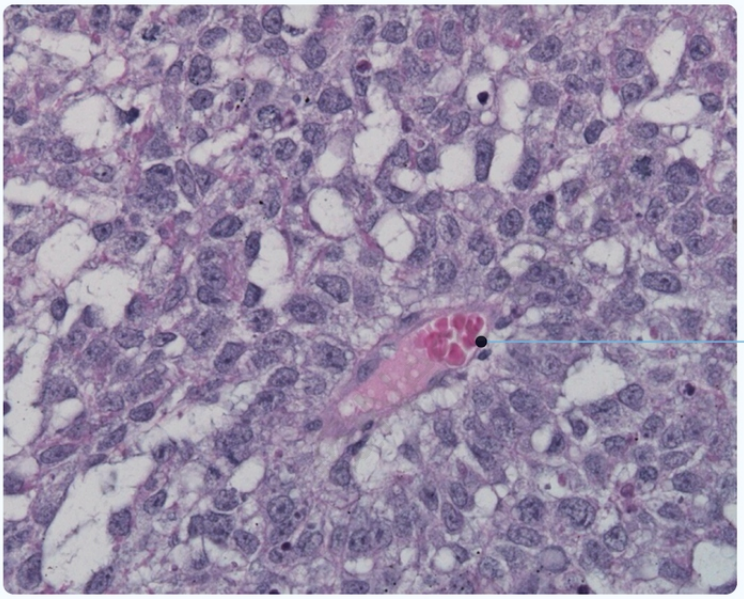

@Neet_pg_bot

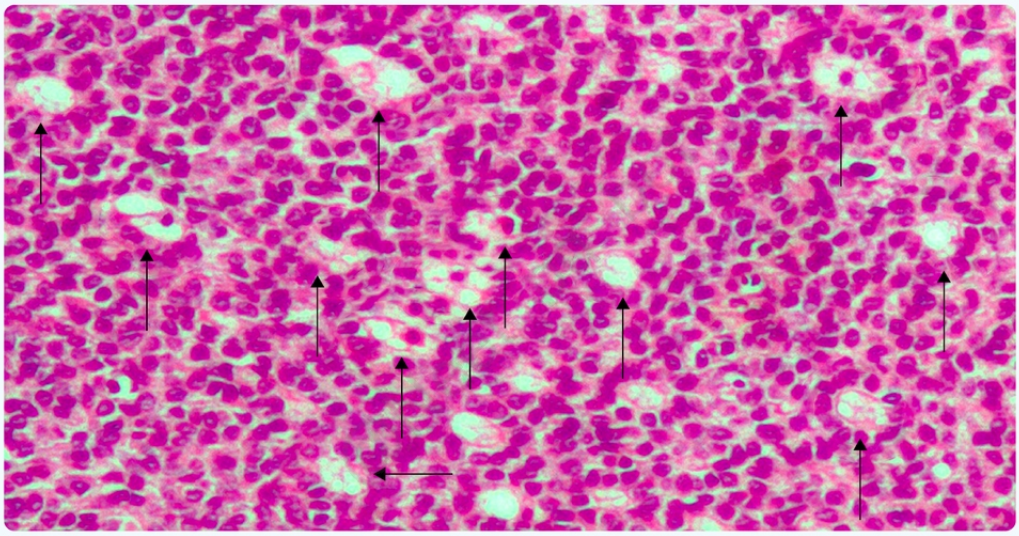

Call-Exner bodies

@Neet_pg_bot

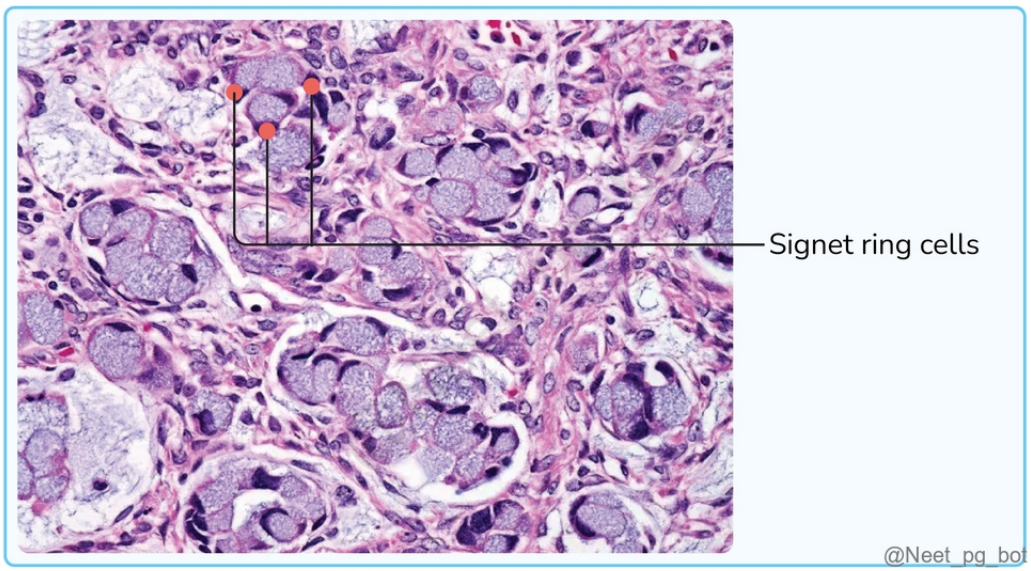

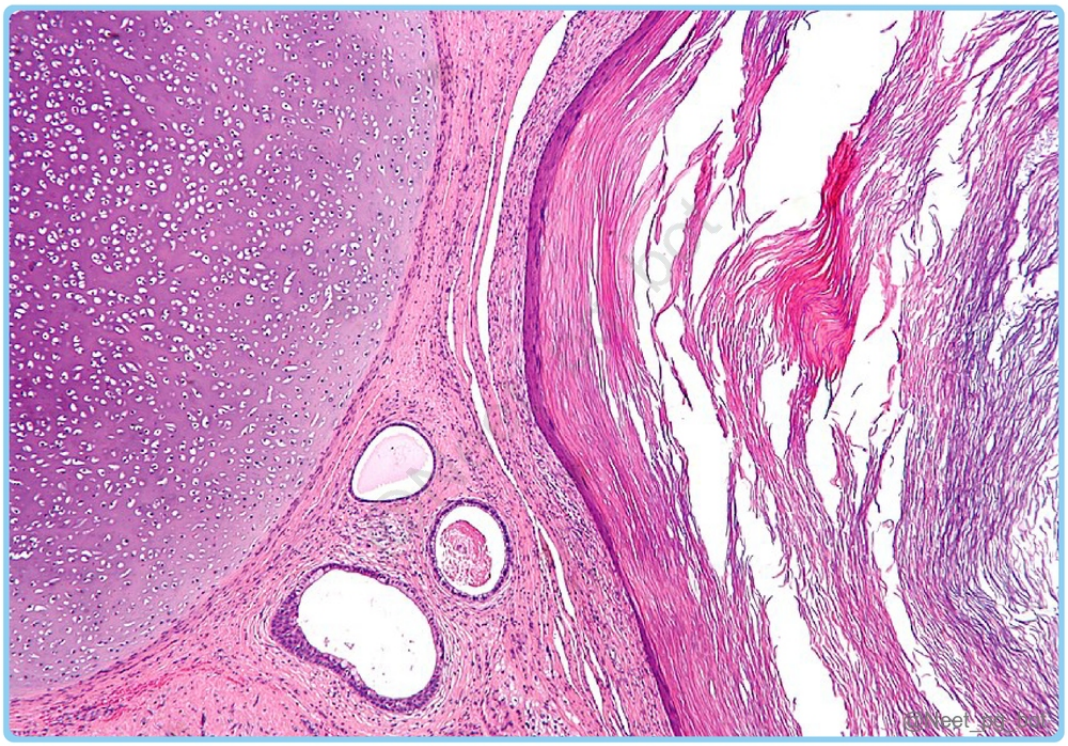

References:

Robbins & Cotran Pathologic Basis of Disease, 10th Edition, Page 971, 972, 1026-1028

↑ *Back to this question in Part A*

@Neet_pg_bot

Q20: The type of cancer that rarely spreads through the lymphatic system is: (Q855915)

A. Squamous cell carcinoma

B. Merkel cell carcinoma

C. Basal cell carcinoma

D. Malignant melanoma

Correct Answer: C. Basal cell carcinoma

Explanation: BCC (basal cell carcinoma) is typically localized, grows slowly, and has a low metastasis potential. It rarely spreads to lymph nodes or distant organs, making it less likely to disseminate than SCC (Squamous Cell Carcinoma), MCC (Merkel Cell Carcinoma), or malignant melanoma. Metastasis (distant spread) All cancers are going to show metastasis except: BCC (Basal cell carcinoma / Rodent's ulcer) Brain Tumor/Glioma Types of metastatic spread: Hematogenous spread Lymphatic spread Transcoelomic spread Direct seeding of body cavities or surfaces Hematogenous spread Lymphatic spread Transcoelomic spread Veins are more prone to invasion than arteries due to their thinner walls. Tumours use existing lymphatic vessels at their margins. Follows natural routes of lymphatic drainage. Tumour invades the serosal wall of the coelomic cavity, releasing tumour fragments into coelomic fluid, which is implanted elsewhere in the body cavity. Seen in most of the sarcomas. Seen in most carcinomas. Seen in Krukenberg tumour in the ovary due to metastasis from gastric carcinoma to the ovary. Exceptions: Synovial sarcoma Rhabdomyosarcoma *These tumours are spread by the lymphatic route. Exceptions: HCC RCC Follicular carcinoma of the thyroid Choriocarcinoma *These tumours are spread by a hematogenous route. Direct Seeding of Body Cavities or Surfaces: It occurs when malignant neoplasms spread to anatomical spaces that lack physical barriers, such as the peritoneal cavity (more commonly), but they can also affect other body cavities, such as the pleural, pericardial, subarachnoid, and joint spaces. Examples include: Pseudomyxoma peritonei is characterized by the presence of a gelatinous neoplastic mass filling the peritoneal cavity arising from the rupture of mucus-secreting appendiceal (most common cause) or ovarian carcinomas. Gastric carcinoma can spread to the distal end of the peritoneal cavity (Pouch of Douglas) and is known as the ‘Blummer shelf.’ Medulloblastoma from the cerebellum spreads to the spinal cord by ‘Drop metastasis.’ Squamous cell carcinoma (SCC) (Option A) arises from squamous cells in the outermost skin layer and can occur in the skin, lips, mouth, throat, esophagus, lungs, and other organs. It has a higher metastatic potential than basal cell carcinoma, often spreading via the lymphatic route. Merkel cell carcinoma (MCC) (Option B) is a rare, aggressive skin cancer arising from touch-sensitive Merkel cells. It typically occurs on sun-exposed areas like the head, neck, and arms and has a high tendency to spread via the lymphatic system. Malignant melanoma (Option D) is an aggressive skin cancer arising from melanocytes, with a high potential for lymphatic and hematogenous metastasis to organs like the liver, lungs, brain, and bones. Early detection and treatment are crucial for better outcomes.

References:

Robbins and Cotran Pathologic Basis of Disease, 10th Edition, Page 274-275.

↑ *Back to this question in Part A*

@Neet_pg_bot

Q21: The following picture shows a lymph node biopsy of a 30-year-old male with cervical lymphadenopathy. The diagnosis is: (Q858133)

A. Acute myeloid leukemia (AML)

B. Hodgkin disease

C. Human papillomavirus (HPV)

D. Chronic lymphocytic leukemia (CLL)

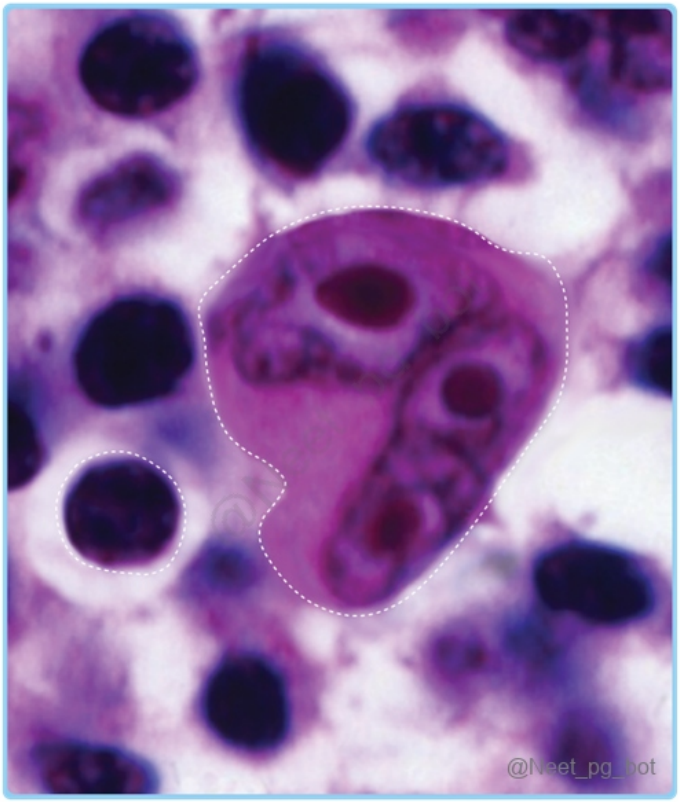

Correct Answer: B. Hodgkin disease

■ *Listen (English)*

■ *Listen (Hindi)*

Explanation: The given clinical scenario and histopathological findings suggest a diagnosis of Hodgkin lymphom a, and the HPE reveals the presence of characteristic Reed-Sternberg cells. Hodgkin lymphoma typically spreads in an orderly, contiguous manner from one lymph node group to the next adjacent group without skipping areas. Histopathological variants of Hodgkin's Lymphoma 1. Mononuclear cells {{caption_text}} Single nucleus with a large, inclusion-like nucleolus with abundant cytoplasm. Seen in Mixed Cellularity Hodgkin Lymphoma 2. Popcorn cells {{caption_text}} Cells with multiple infolded nuclear membranes, small nucleoli, fine chromatin, and abundant pale cytoplasm. Seen in Nodular lymphocyte - Predominant Hodgkin lymphoma. 3. Reed-sternberg

cell {{caption_text}} It is characterised by two nuclear lobes, large inclusion-like nucleoli , and abundant cytoplasm and is typically surrounded by lymphocytes, macrophages, and an eosinophil. 4. Lacunar cells {{caption_text}} Typically found in the nodular sclerosis subtype. Nuclei are more delicate, folded, or multilobate. Abundant pale cytoplasm often gets disrupted during sectioning, creating an appearance where the nucleus sits in an empty space (lacuna). Incorrect Options: Acute myeloid leukaemia (AML) (Option A) is a type of cancer characterized by the rapid proliferation of abnormal myeloid blasts in the bone marrow and peripheral blood and is characterised by the presence of blasts ≥ 20% and myeloblasts with Auer rods. {{caption_text}} Human papillomavirus (HPV) (Option C) is a sexually transmitted virus, including low-risk strains 6 & 11, causing benign genital warts, and high-risk strains 16 & 18 , linked to cervical carcinoma, vulvar intraepithelial neoplasia (VIN), and vulvar carcinoma. It is characterised by the presence of enlarged, hyperchromatic nuclei with perinuclear halos (koilocytes) in the superficial layers of the epithelium. {{caption_text}} Chronic lymphocytic leukaemia (CLL) (Option D) is a malignancy of mature B-cells not associated with lytic bone lesions or elevated calcium. It shows Smudge cells (or parachute/basket cells) due to the fragility of lymphocytes during slide preparation and convent girl appearance (a lot of homogenous, small, mature-like, round lymphocytes with scant cytoplasm). {{caption_text}}

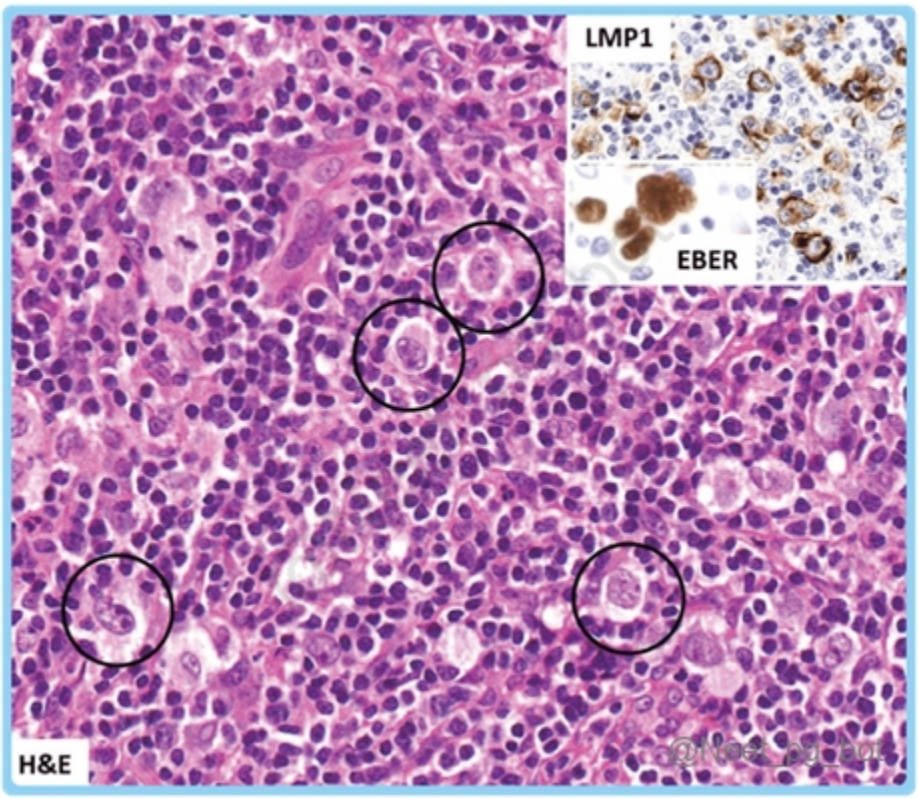

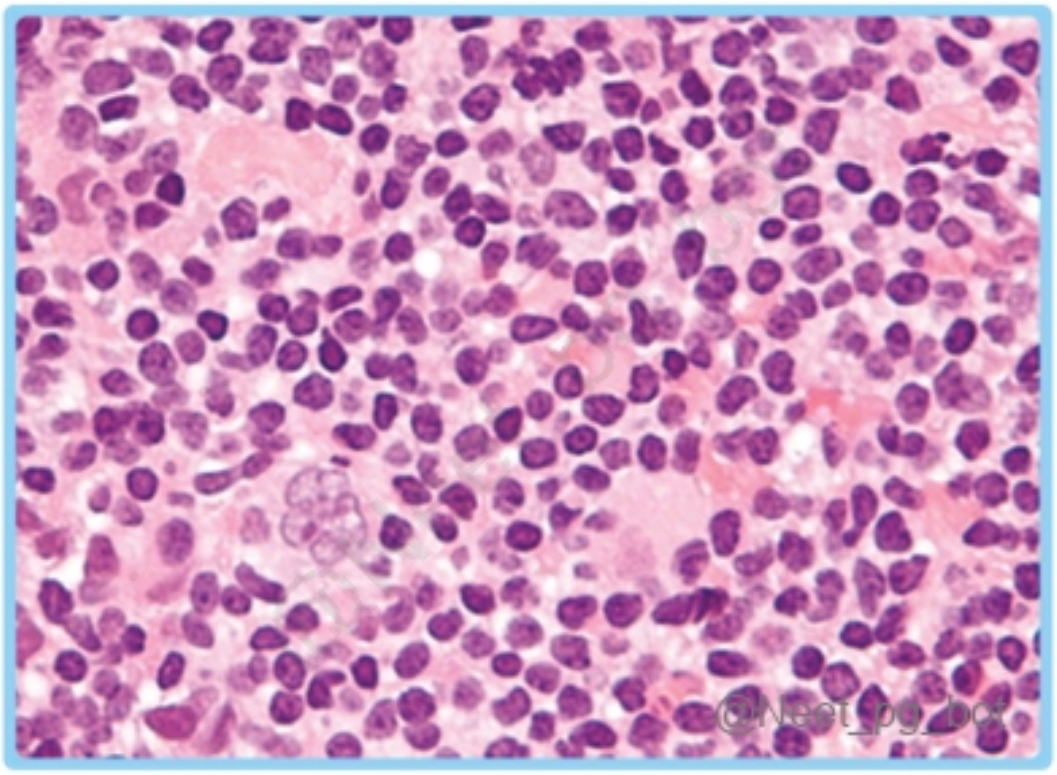
@Neet_pg_bot

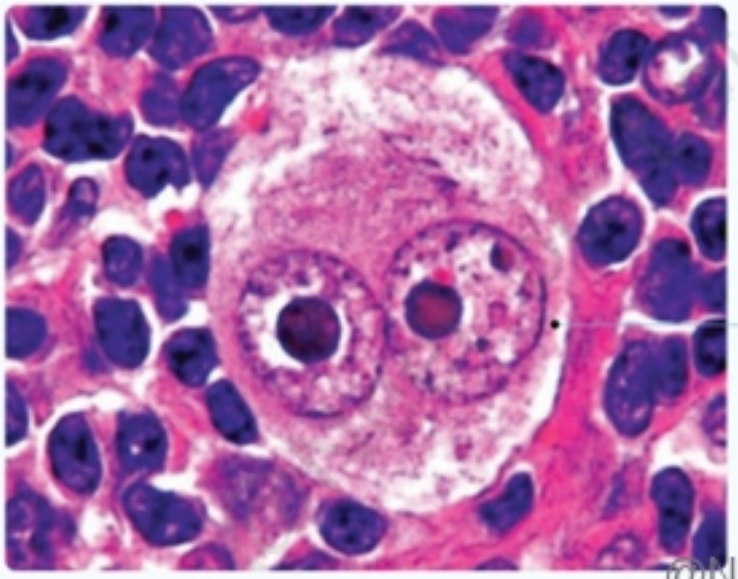

@Neet_pg_bot

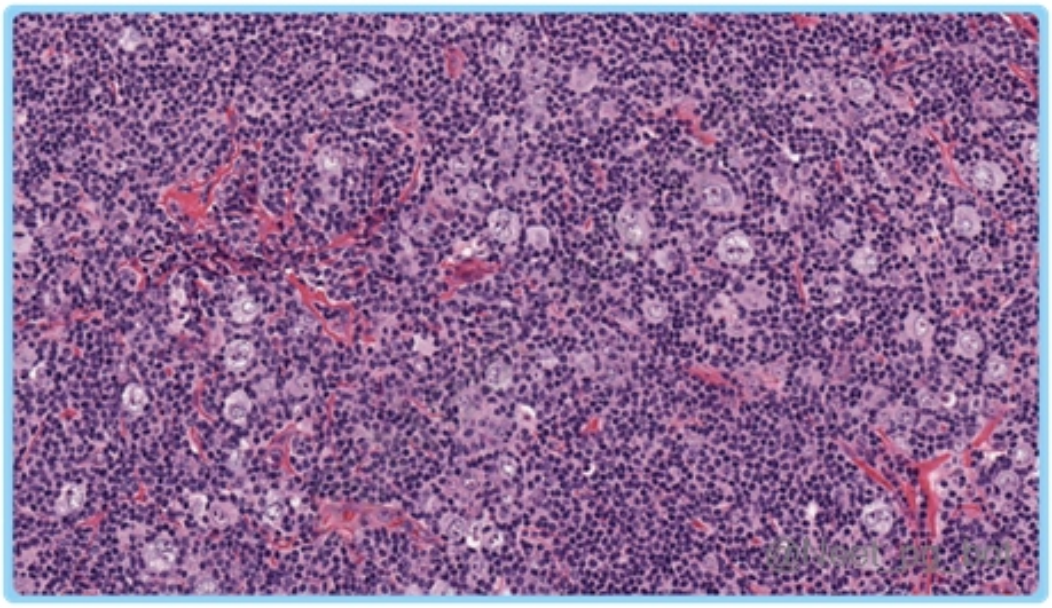

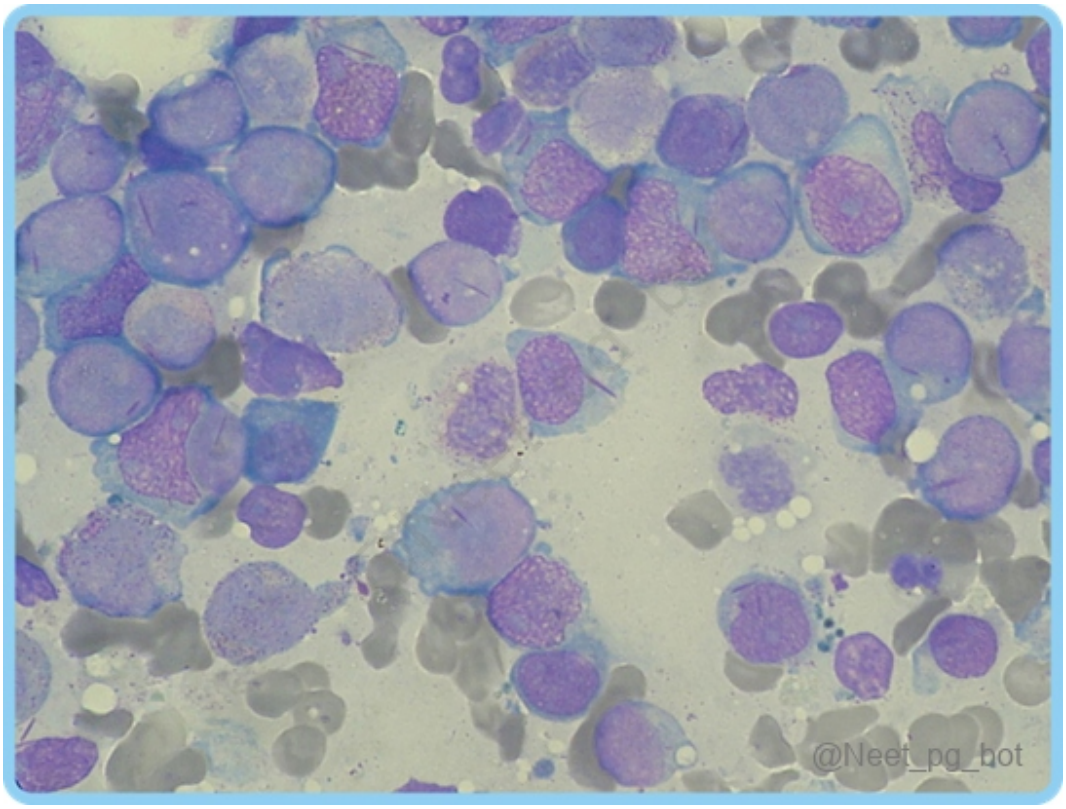
@Neet_pg_bot



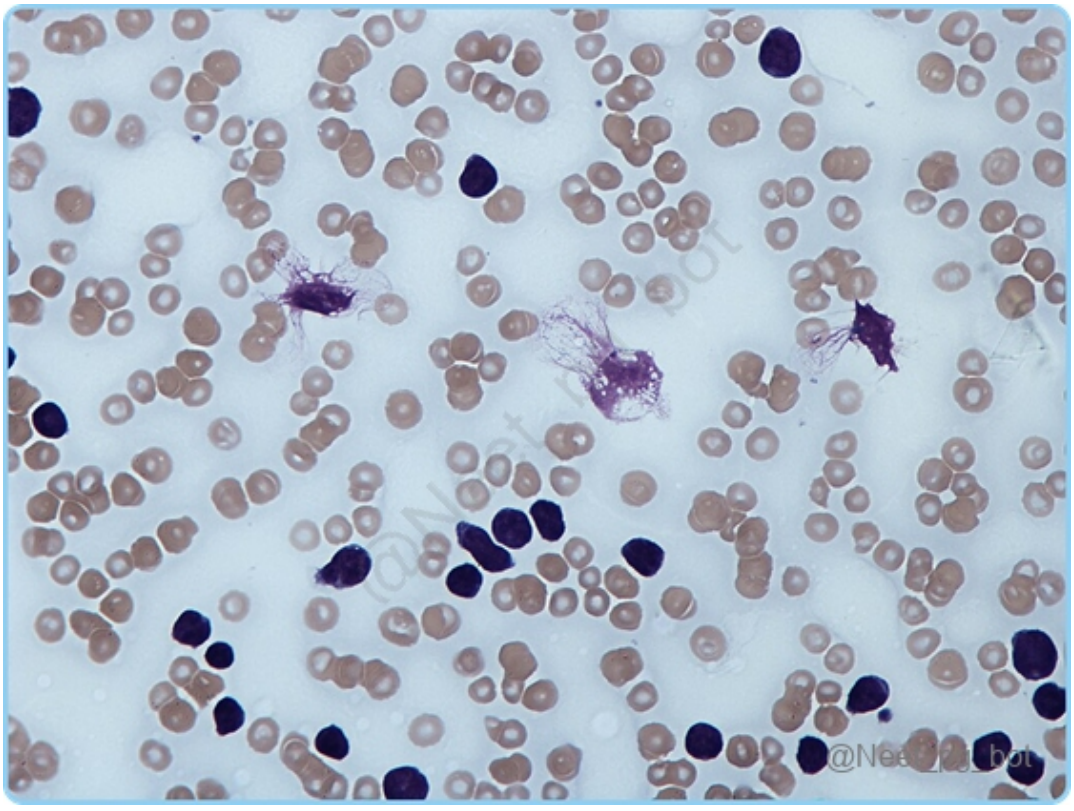

References:

Robbins & Cotran, Pathologic Basis of Disease, 10th Edition, Page 612

↑ *Back to this question in Part A*

Q22: A 70-year-old male comes with complaints of hip pain. An X-ray of the hip shows lytic lesions and elevated serum calcium levels. Bone marrow plasma cells are 42%, and the cells seen are given in the image below. What is the most likely diagnosis? (Q858126)

A. Multiple myeloma

B. CLL

C. ALL

D. CML

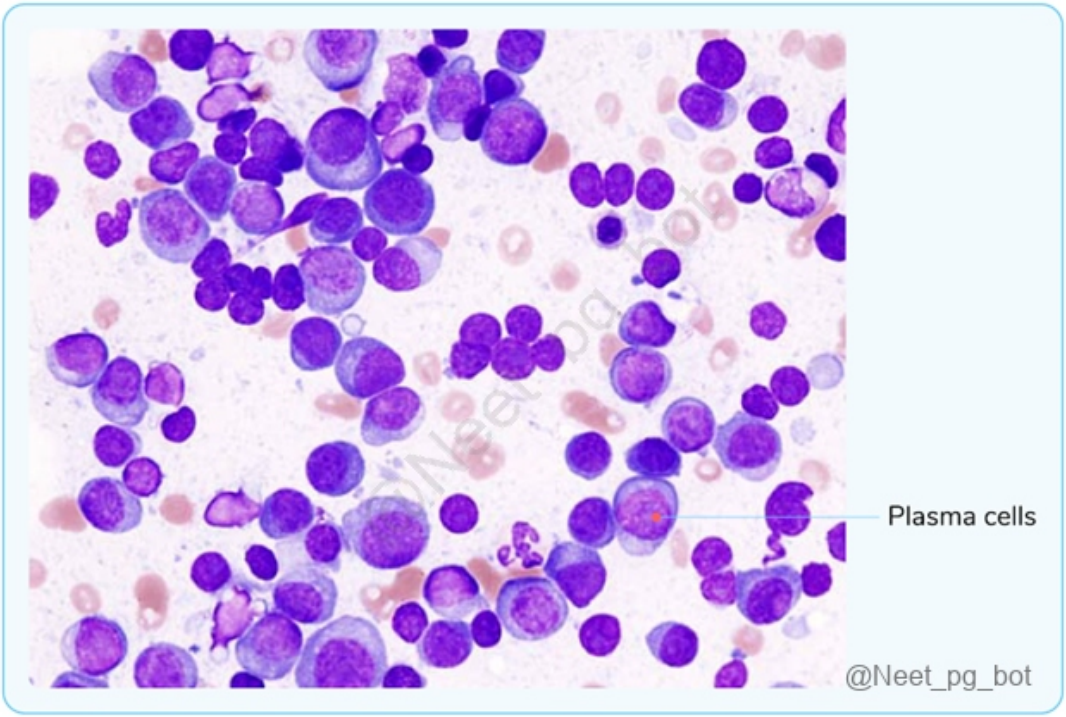

Correct Answer: A. Multiple myeloma

Listen (English)

Listen (Hindi)

Explanation: Multiple myeloma is characterised by malignant plasma cell proliferation in the bone marrow, leading to lytic bone lesions and elevated serum calcium levels (due to bone resorption). The presence of plasma cells further supports the diagnosis. Bone Marrow Biopsy Findings of Multiple Myeloma: Increased number of plasma cells in the marrow, often >30% of cellularity. Plasma cells may infiltrate the interstitium subtly or completely replace normal elements. HPE: Eccentric nucleus with perinuclear clearing (prominent Golgi) and

abundant basophilic cytoplasm. {{caption_text}} Normal-appearing plasma cells, plasmablasts with vesicular nuclear chromatin and prominent single nucleolus, or bizarre, multinucleated cells may predominate. Other Cytologic Variants (due to dysregulated Ig synthesis and secretion): Flame cells: Fiery red cytoplasm. Mott cells: Contain multiple grapelike cytoplasmic droplets. {{caption_text}} Inclusions: Russell bodies: Globular cytoplasmic inclusions. Dutcher bodies: Globular nuclear inclusions. Incorrect Options: CLL (Option B) is a malignancy of mature B-cells, not associated with lytic bone lesions or elevated calcium. It shows Smudge cells (or parachute/basket cells) due to the fragility of lymphocytes during slide preparation and convent girl appearance (a lot of homogenous, small, mature-like, round lymphocytes with scant cytoplasm). {{caption_text}} ALL (Option C) affects immature lymphocytes and typically presents with other hematologic symptoms, not lytic bone lesions and elevated calcium. It shows Lymphoblasts in bone marrow >=20%, Cytoplasmic vacuolations, fat (Oil Red O Positive) and hand mirror-shaped cells. {{caption_text}} CML (Option D) is a myeloproliferative disorder that primarily affects granulocytes and is not associated with plasma cells or lytic bone lesions. It presents with Leukocytosis with cell types including Neutrophils (multilobed nucleus), metamyelocytes (indented nucleus), myelocytes (D-shaped nucleus), and eosinophils (orange cells) College girl/garden party appearance: Due to the variety of cell appearances Shift to the Left: Presence of immature cell types, mainly immature neutrophils, in the blood.

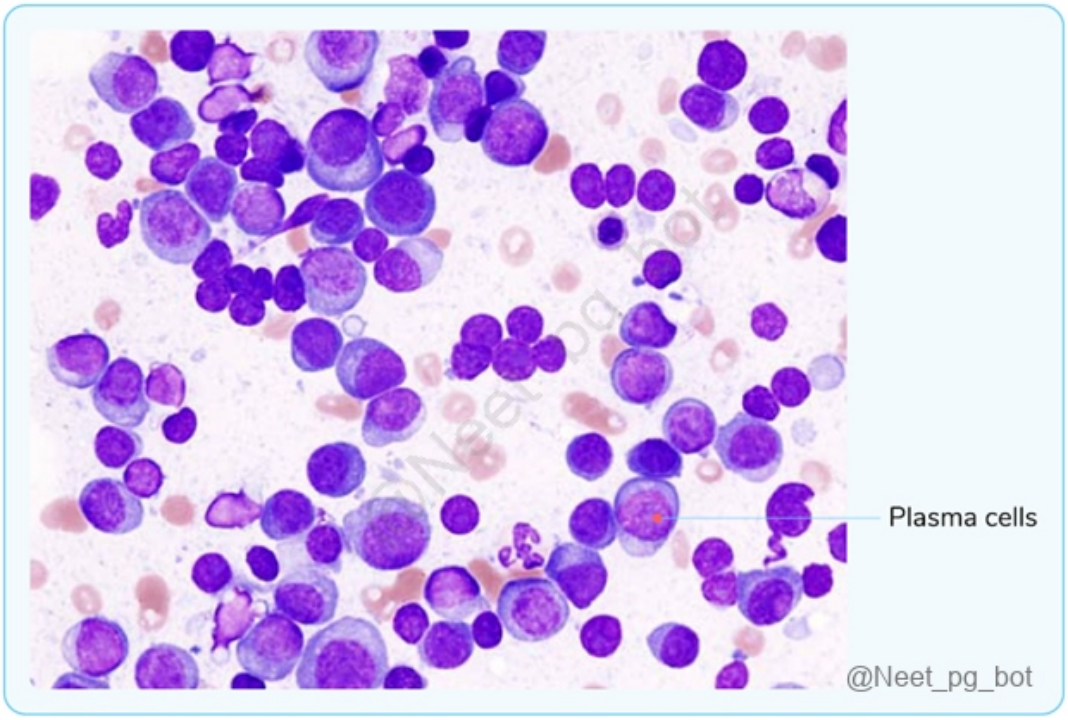

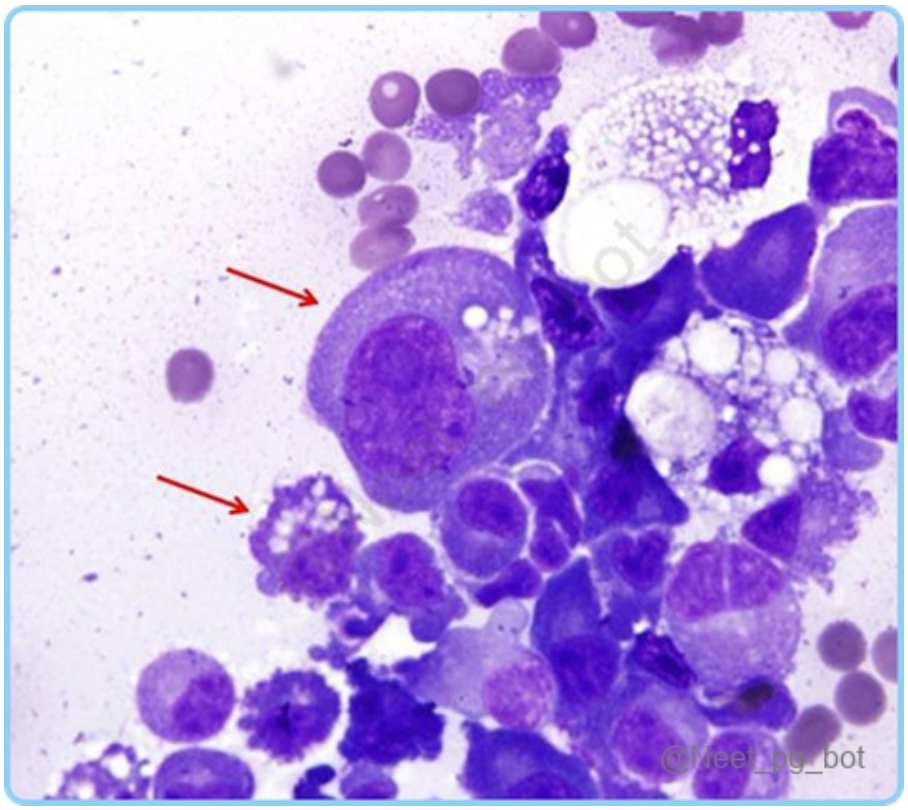
@Neet_pg_bot

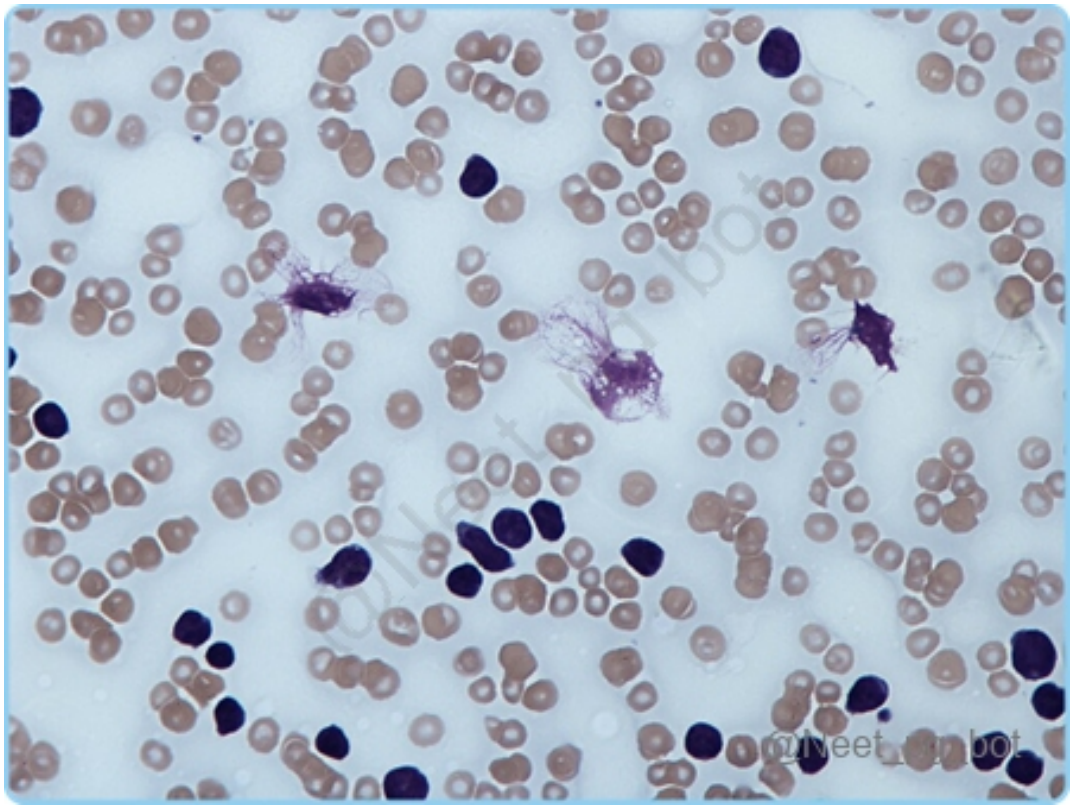
@Neet_pg_bot

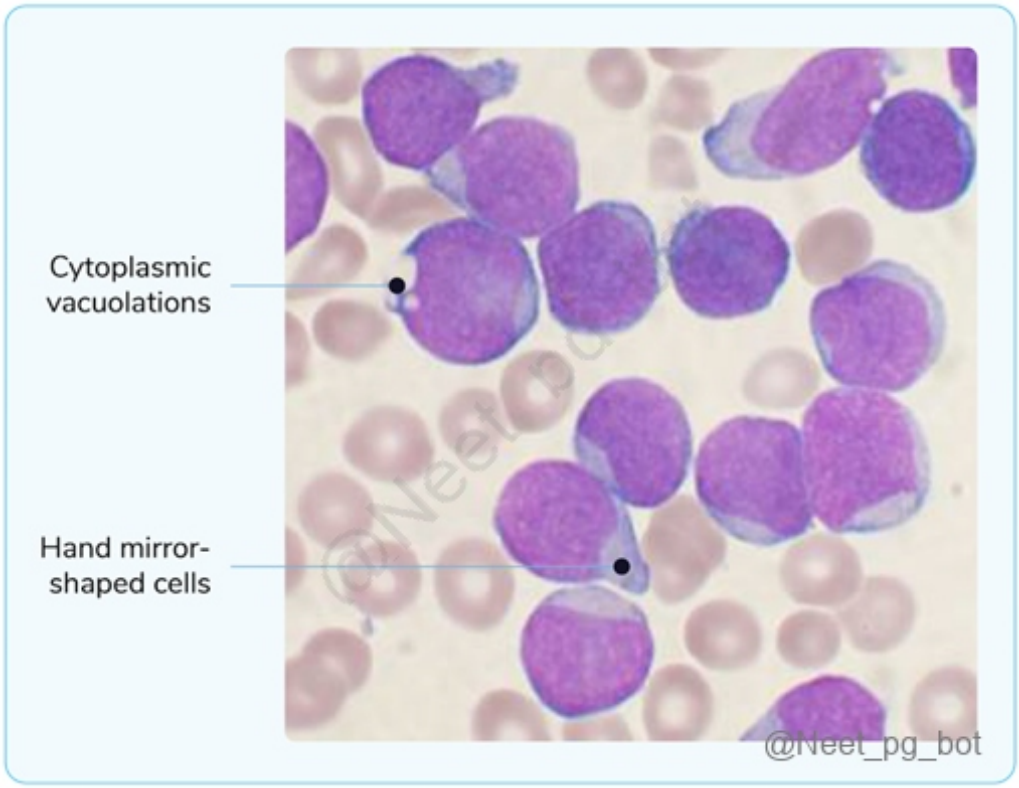

References:

Robbins & Cotran Pathologic Basis of Disease, 10th Edition, Page 608

↑ *Back to this question in Part A*

@Neet_pg_bot

Q23: Asbestos exposure may be associated with which of the following malignancies? (Q858108)

A. Mesothelioma

B. Acute myeloid leukemia

C. Hepatic angiosarcoma

D. Skin carcinoma

Correct Answer: A. Mesothelioma

■ *Listen (English)*

■ *Listen (Hindi)*

Explanation: Asbestos exposure is most strongly associated with mesothelioma Mesothelioma A rare cancer arising from mesothelial cells that most commonly affects the pleura. It can also affect the peritoneum, pericardium and tunica vaginalis. Aetiology Asbestos: Mesothelioma is the most specific asbestos-associated cancer It is not associated with smoking Pathology Advanced pleural mesothelioma can cause extensive pleural fibrosis and thickening, making the affected side rigid and immobile. Later stages fix the mediastinum in place due to pleural thickening and fibrosis. The mediastinal shift is not a characteristic feature of mesothelioma. M/C cytogenetic abnormality in mesothelioma: Homozygous deletion of chromosome 9p , leading to loss of tumour suppressor gene - CDKN2A. Clinical features Progressive dyspnea, chest pain, weight loss, chronic cough, hemoptysis. Decreased breath sounds and dullness to percussion (due to pleural effusion or thickening). Diagnosis CT scan: Pleural thickening, effusion, or frozen hemithorax (not causing a mediastinal shift in the presence of effusion) Confirmed by biopsy: Epithelioid mesothelioma shows tubules, nests, or papillary structures with uniform round to oval nuclei and eosinophilic cytoplasm. Sarcomatoid mesothelioma consists of spindle-shaped cells resembling fibrosarcoma. Biphasic mesothelioma displays a mixture of both patterns. Specific markers for mesothelioma: Calretinin Epithelial membrane antigen Cytokeratin Mesothelin Prognosis Poor (median survival of 9-21 months). {{caption_text}} Mesothelioma- Gross {{caption_text}} Mesothelioma- H & E stain {{caption_text}} Mesothelioma- Calretinin stain Incorrect Options: Acute myeloid leukaemia (Option B) : While there are some associations between certain environmental toxins and leukaemia, asbestos is not a significant cause of AML. Other agents like benzene are more strongly linked with leukaemia. Hepatic angiosarcoma (Option C) is primarily associated with exposure to vinyl chloride and arsenic , not asbestos. Skin carcinoma (Option D) , particularly basal cell carcinoma and squamous cell carcinoma, is largely linked to UV radiation . Asbestos exposure is not a major risk factor for skin carcinoma.



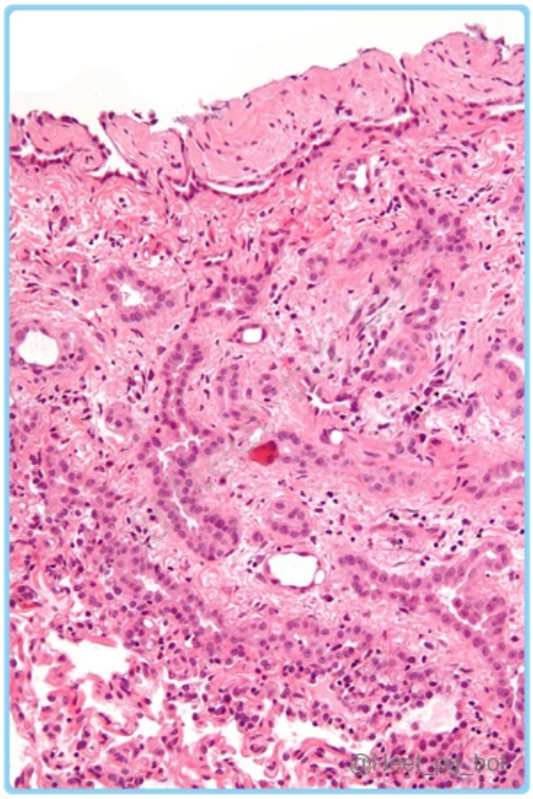

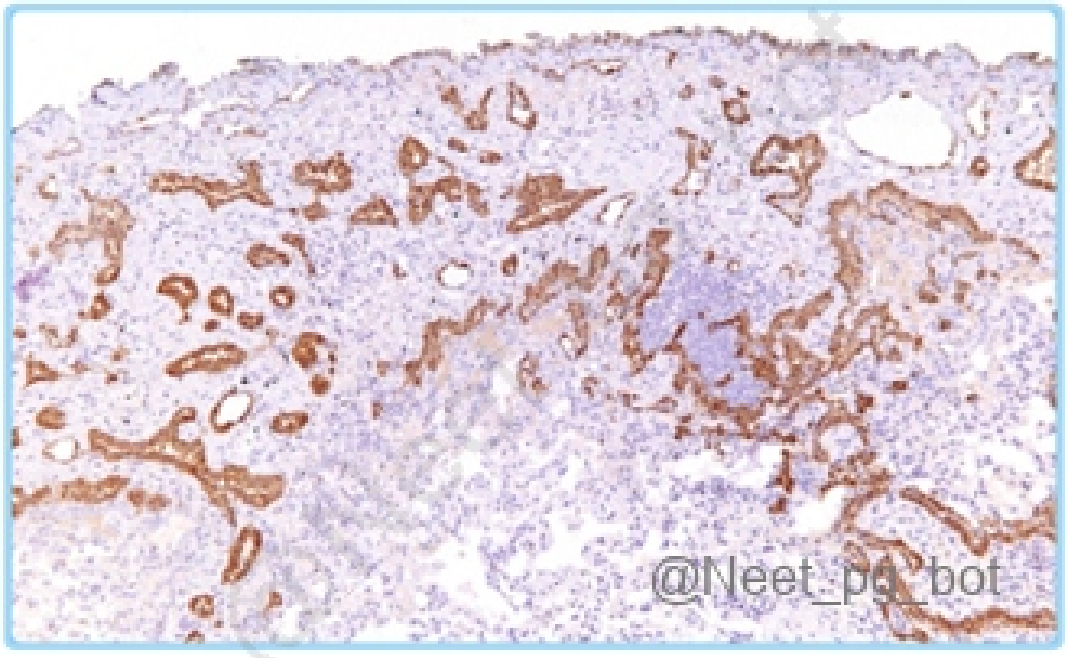

References:

Robbins and Cotran, Pathologic Basis of Disease, 10th Edition, Pages 726, 727.

Harrison’s Principles of Internal Medicine, 21st Edition, Pages 2168, 2198

↑ *Back to this question in Part A*

@Neet_pg_bot

Q24: Match the given mutations with the respective cancers: A. K-RAS Myeloproliferative neoplasm B. KIT 2. Adenocarcinoma C. JAK 2 3. Pancreatic cancer D. ALK 4. GIST (Q854690)

A. A-3, B-4, C-1, D-2

B. A-2, B-3, C-4, D-1

C. A-1, B-3, C-2, D-4

D. A-2, B-4, C-3, D-1

Correct Answer: A. A-3, B-4, C-1, D-2

■ *Listen (English)*

■ *Listen (Hindi)*

Explanation: A. K-RAS Pancreatic cancer B. KIT GIST C. JAK 2 Myeloproliferative neoplasm D. ALK Adenocarcinoma

References:

Robbins and Cotran Pathologic Basis of Disease, 10th Edition, Pages 285-287, 622, 1087, 334, 627, 1296

↑ *Back to this question in Part A*

@Neet_pg_bot

Q25: Which of the following features does not distinguish between necrosis and apoptosis? (Q840014)

A. Enzymatic degradation

B. Association with underlying pathology

C. Lipid change

D. Intact membrane

Correct Answer: B. Association with underlying pathology

Explanation: Correct Option B - Association with underlying pathology : Underlying pathological condition is not an important feature of differentiation between necrosis and apoptosis as necrosis and apoptosis both can be triggered by an underlying disease/ pathological condition. Incorrect Options: Option A - Enzymatic degradation: In necrosis, cellular contents leak out and undergo enzymatic digestion, while in apoptosis, they're enclosed until released as apoptotic bodies, with the membrane intact until engulfed by phagocytic cells. Option C - Lipid change: In apoptosis, inflammation is rare, while in necrosis, it's common due to released cellular contents triggering inflammation. Option D - Intact membrane: In apoptosis, the cell membrane remains intact, whereas in necrosis, it is disrupted.

References:

.

↑ *Back to this question in Part A*

@Neet_pg_bot

Q26: A 35-year-old male presents with a testicular mass, and a gross image of the mass is provided. What is the most likely diagnosis? (Q860552)

A. Teratoma

B. Seminoma

C. Yolk sac tumour

D. Choriocarcinoma

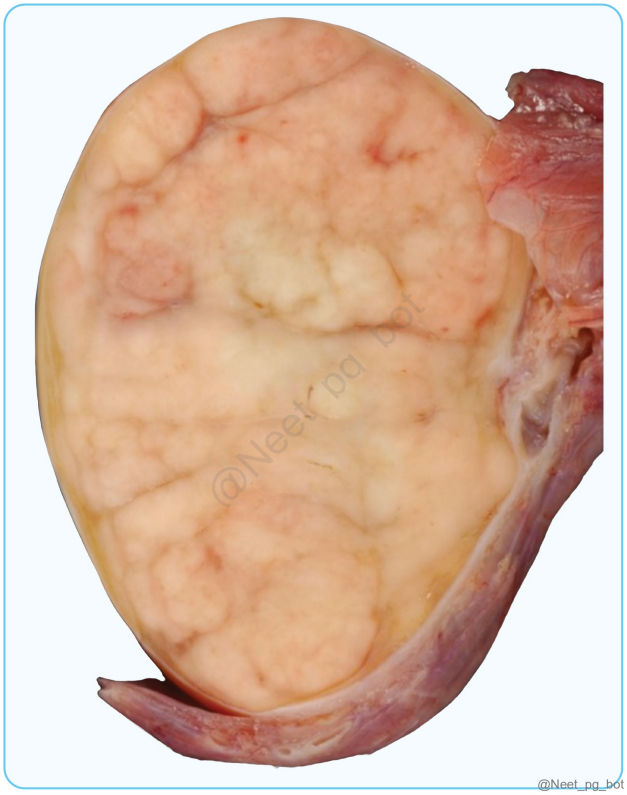

Correct Answer: B. Seminoma

■ *Listen (English)*

■ *Listen (Hindi)*

Explanation: The testicular mass described, with a homogeneous, grey-white, lobulated cut surface and no signs of haemorrhage or necrosis, is most consistent with a diagnosis of Seminoma . It is the most common germ cell tumour of the testis. A similar presentation in the ovary is called dysgerminoma , and germinoma is present in the pineal gland . Incidence: Peak incidence in the fourth decade. Genetics: Seminomas contain isochromosome 12p and express OCT3/4 & NANOG. Gross: Seminoma has a homogeneous, grey-white, lobulated cut surface, usually devoid of haemorrhage or necrosis. Generally, the tunica albuginea is not penetrated, but extension to the epididymis, spermatic cord, or scrotal sac occasionally occurs. {{caption_text}} Histology of seminoma : It consists of sheets of monomorphic cells arranged in poorly defined lobules, separated by fibrous septa with lymphocytic (T cell) infiltration. Classic seminoma cells are large, round to polyhedral, with distinct membranes, central nuclei, and prominent nucleoli. The cytoplasm is clear or watery containing glycogen. {{caption_text}} Teratoma (Option A) are germ cell tumours containing tissues from all three germ layers (ectoderm, mesoderm, and endoderm). They can be benign (mature) or malignant (immature) and are commonly found in the testes, ovaries, or midline. Histologically, they present as heterogeneous masses with various tissue types (e.g., neural, muscle, epidermis, cartilage, thyroid, or intestinal tissue), often showing necrosis, calcification, or hair/teeth/bone. {{caption_text}} Yolk sac tumor (Option C) is a malignant germ cell tumour, commonly found in the testes or ovaries, especially in children and young adults. It produces alpha-fetoprotein (AFP) and appears as a solid mass with haemorrhage and necrosis, presenting in younger patients, particularly in the first two years of life. Microscopically, show a lace-like network of cuboidal or spindled cells with Schiller-Duval bodies and eosinophilic globules containing α-fetoprotein (AFP). {{caption_text}} Choriocarcinoma (Option D) is a rare, highly malignant germ cell tumour, typically in the testes, ovaries, or placenta, that secretes hCG. It presents with

pain, swelling, and elevated hCG levels, often with haemorrhage, necrosis, and mixed trophoblastic cells. Microscopically, it contains syncytiotrophoblasts (multinucleated, hCG-containing) and cytotrophoblasts (polygonal, clear cytoplasm). {{caption_text}} {{caption_text}}

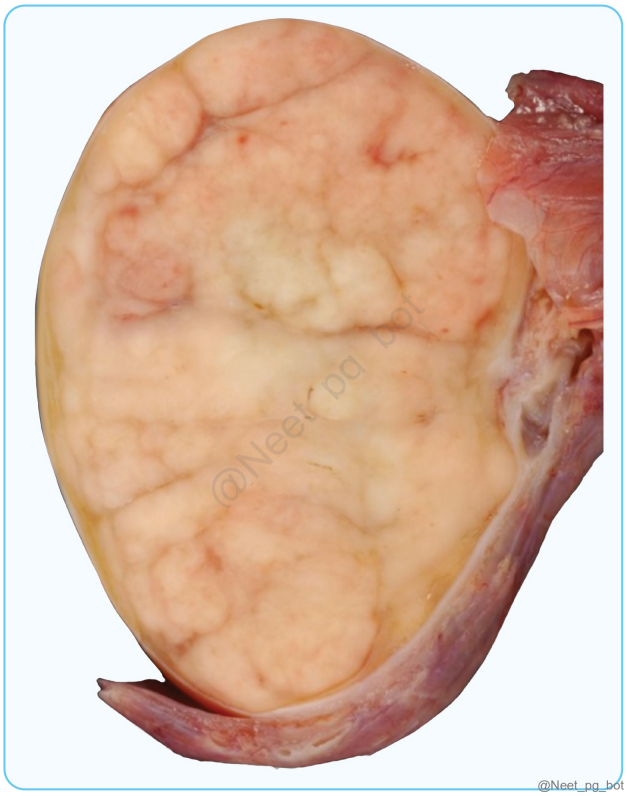

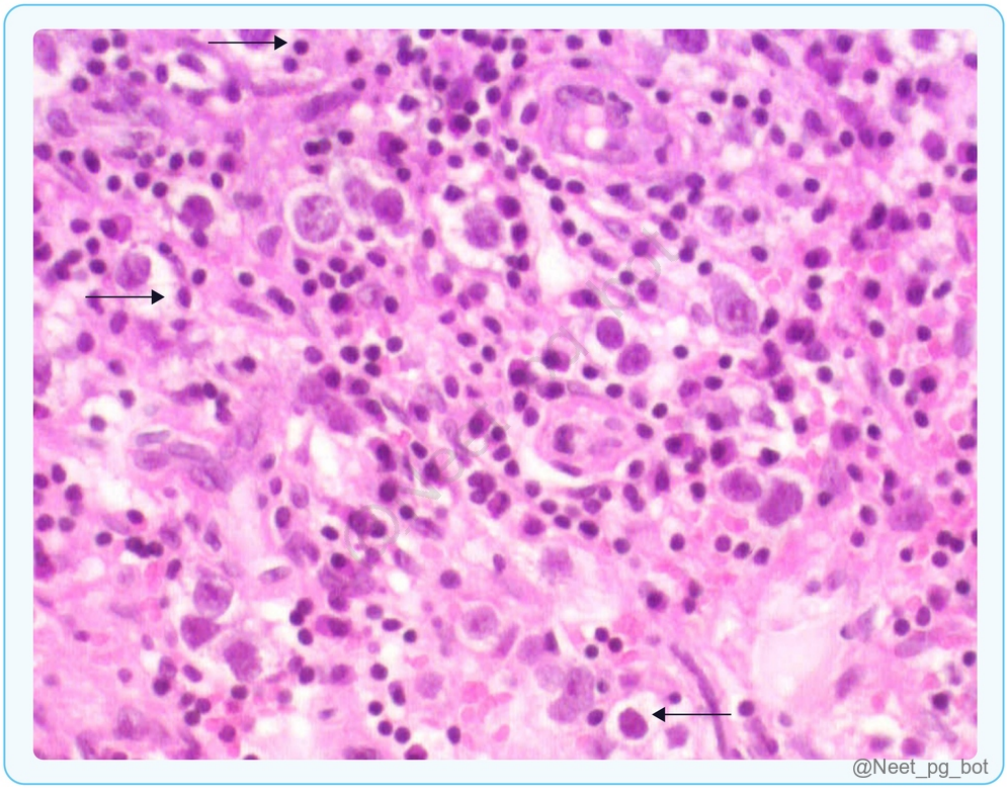


@Neet_pg_bot

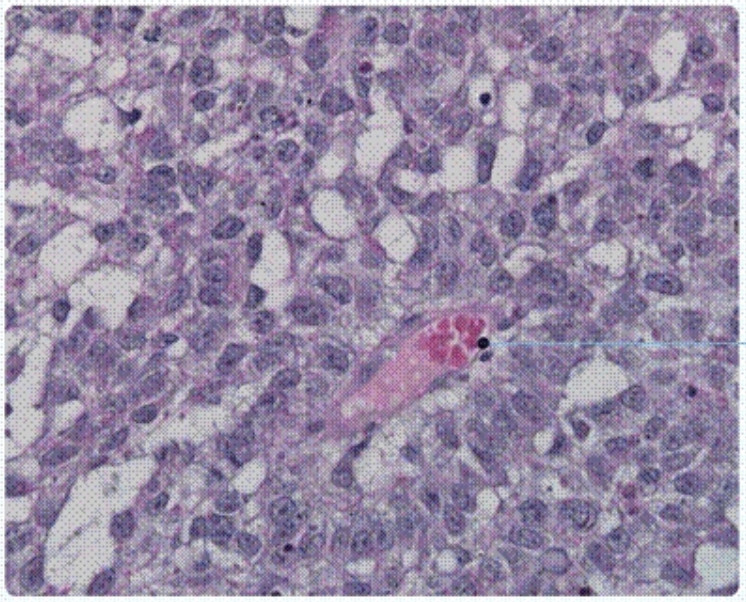

@Neet_pg_bot

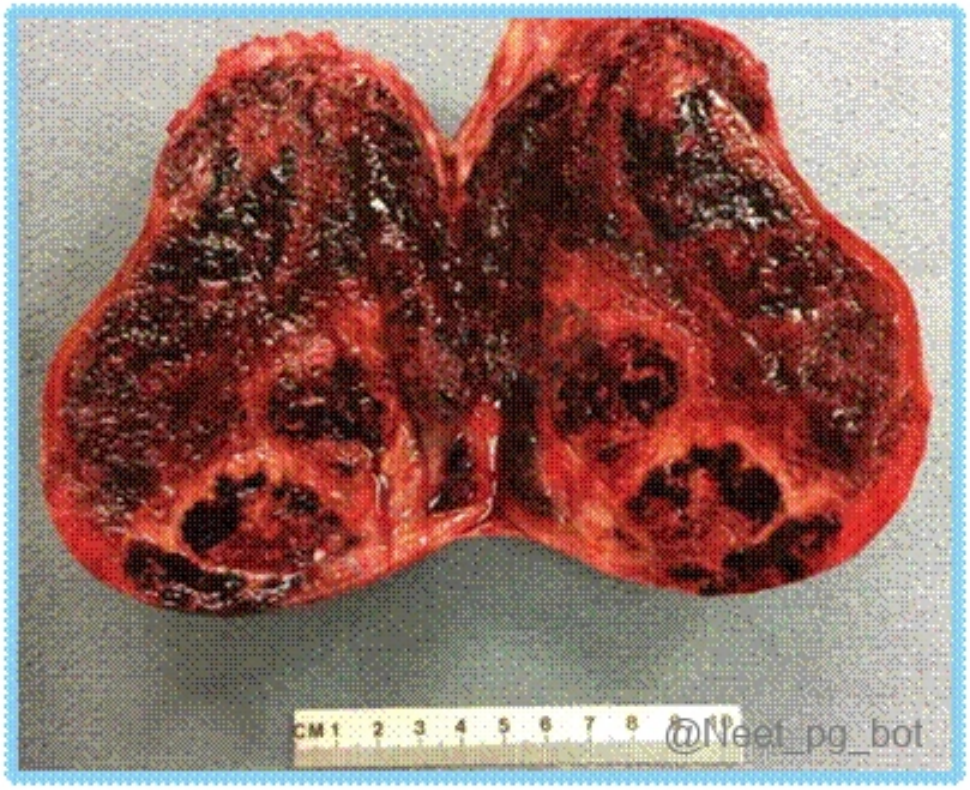

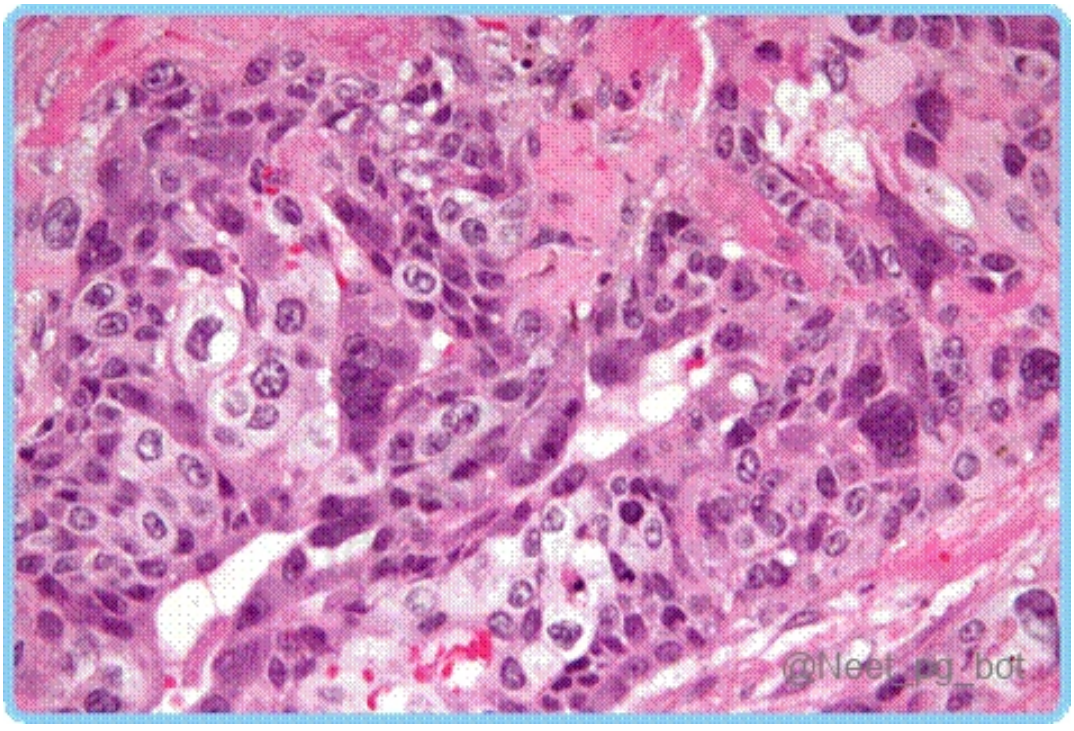

References:

Robbins and Cotran Pathologic Basis of Disease, 10th Edition, Page 970-971.

↑ *Back to this question in Part A*

Q27: What is the tumour marker for a carcinoid tumour? (Q860551)

A. Beta-HCG

B. Calcitonin

C. 5-HIAA

D. Alpha-fetoprotein

Correct Answer: C. 5-HIAA

■ *Listen (English)*

■ *Listen (Hindi)*

Explanation: The tumour marker for a Carcinoid Tumor is 5-HIAA (5-hydroxy indole acetic acid). Carcinoids are derived from Argentaffin cells that secrete serotonin. It is commonly caused by neuroendocrine tumours of the midgut that metastasise to the liver. It is also seen with ovarian tumours or bronchial carcinoids. They secrete mediators like serotonin (5-hydroxytryptamine), kallikrein, bradykinin, histamine, and prostaglandins. Clinical features: Diarrhea and abdominal cramping Flushing and pruritus due to histamine Wheezing and dyspnea due to bronchospasm Pellagra (diarrhoea, dermatitis, dementia) Carcinoid heart disease: Tricuspid regurgitation leading to right heart failure Diagnosis: Elevated twenty-four-hour urine for 5-HIAA. Elevated serum serotonin. Elevated serum chromogranin A. Octreoscan for localising the source. Tumor marker Associated conditions Alpha-fetoprotein (AFP) (Option D ruled out) Hepatocellular carcinoma (HCC) Hepatoblastoma Yolk sac tumour (endodermal sinus tumour) Nonseminomatous germ cell tumour of testis ↑ AFP: abdominal wall defects, neural tube defects ↓ AFP: associated with trisomy 21, 18, and 13 β-HCG (Option A ruled out) Nonseminomatous testicular germ cell tumours (choriocarcinoma, embryonal cell carcinoma, mixed germ cell tumour, seminoma) Ovarian cancer: choriocarcinoma (gestational trophoblastic disease) Carcinoembryonic antigen (CEA) Colorectal cancer Pancreatic cancer Breast cancer Lung cancer (especially in non-small cell cancers) Gastric cancer Prostate-specific antigen (PSA) Prostate cancer Benign prostatic hyperplasia Prostatitis Calcitonin (Option B ruled out) Medullary thyroid cancer (both sporadic and associated with MEN 1 and MEN 2) Alkaline phosphatase Metastases to bone or liver Paget disease of the bone Placental alkaline phosphatase Seminoma Lactate dehydrogenase Ovarian cancer (dysgerminoma) Testicular germ cell tumours (both seminoma and nonseminoma) Lymphomas Ewing's sarcoma Neuron specific enolase (NSE) Neuroendocrine tumors Small cell lung cancer Carcinoid tumour Neuroblastoma CA 19–9 Pancreatic adenocarcinoma Colon cancer Cholangiocarcinoma CA 15–3 and CA 27–29 Breast cancer CA 125 Ovarian carcinoma Other gynecologic malignancies S-100 protein (S100A) and (S100B) Malignant melanoma SMRP Mesothelioma

References:

Robbins and Cotran Pathologic Basis of Disease, 10th Edition, Page 565.

↑ *Back to this question in Part A*

Q28: Epithelial-mesenchymal transition induced by which pair of transcription factors? (Q853375)

A. TF IIA & TF IIB

B. Cathepsin & MMP 8

C. SNAIL & TWIST

D. STAT-5 & HIF-1 alpha

Correct Answer: C. SNAIL & TWIST

■ *Listen (English)*

■ *Listen (Hindi)*

Explanation: Epithelial-mesenchymal transition (EMT) is induced by the transcription factors SNAIL and TWIST. It is a process where epithelial cells lose their polarity and cell-cell adhesion, gaining migratory and invasive properties to transform into mesenchymal stem cells, multipotent stromal cells. t is hypothesized that E-cadherin (transmembrane glycoproteins that mediate the homotypic adhesion of epithelial cells) expression is transiently silenced through this process. It is controlled by the transcription factors SNAIL and TWIST. There is downregulation of epithelial markers (e.g., E-cadherin) and also upregulation of mesenchymal markers (e.g., vimentin and smooth muscle actin). TF IIA & TF IIB (Option A) are essential general transcription factors that are key to the initiation of transcription by RNA polymerase II. TFIIA contributes to transcriptional regulation by modulating the initiation process and ensuring correct gene expression. TFIIB is responsible for forming the transcription initiation complex and facilitating the transition from initiation to elongation. Cathepsin & MMP 8 (Matrix Metalloproteinase-8) (Option B) are enzymes that degrade proteins in the extracellular matrix, playing key roles in tissue remodelling and inflammation. Cathepsins aid in wound healing and immune responses but can contribute to cancer metastasis and inflammation. Elevated MMP-8 is linked to diseases like periodontal disease, arthritis, and cancer, where it contributes to tissue damage and remodelling. STAT-5 & HIF-1 alpha (Option D) are transcription factors. STAT-5, activated by cytokine receptors, regulates cell survival, differentiation, and immune responses and is key in hematopoiesis and cancers like leukaemia. HIF-1 alpha responds to low oxygen levels, activating genes for angiogenesis, metabolism, and erythropoiesis, and plays a critical role in tumour growth in hypoxic environments.

References:

Robbins and Cotran Pathologic Basis of Diseases, 10th Edition, Page 307.

↑ *Back to this question in Part A*

@Neet_pg_bot

Q29: Match the following: A. Medullary thyroid cancer i. Catecholamine B. Hepatoblastoma ii. AFP C. Choriocarcinoma iii. Calcitonin D. Pheochromocytoma iv. Beta HCG (Q853373)

A. A-i, B-ii, C-iii, D-iv

B. A-iii, B-ii, C-iv, D-i

C. A-iv, B-iii, C-ii, D-i

D. A-ii, B-i, C-iii, D-iv

Correct Answer: B. A-iii, B-ii, C-iv, D-i

■ *Listen (English)*

■ *Listen (Hindi)*

Explanation: Tumor marker Associated conditions Alpha-fetoprotein (AFP) Hepatocellular carcinoma (HCC) Hepatoblastoma Yolk sac tumour (endodermal sinus tumour) Nonseminomatous germ cell tumour of testis ↑ AFP: abdominal wall defects, neural tube defects ↓ AFP: associated with trisomy 21, 18, and 13 β-HCG Nonseminomatous testicular germ cell tumours (choriocarcinoma , embryonal cell carcinoma, mixed germ cell tumour, seminoma) Ovarian cancer: choriocarcinoma (gestational trophoblastic disease) Carcinoembryonic antigen (CEA) Colorectal cancer Pancreatic cancer Breast cancer Lung cancer (especially in non-small cell cancers) Gastric cancer Prostate-specific antigen (PSA) Prostate cancer Benign prostatic hyperplasia Prostatitis Calcitonin Medullary thyroid cancer (both sporadic and associated with MEN 1 and MEN 2) Alkaline phosphatase Metastases to bone or liver Paget disease of the bone Catecholamine and metabolites Pheochromocytoma and related tumors Placental alkaline phosphatase Seminoma Lactate dehydrogenase Ovarian cancer (dysgerminoma) Testicular germ cell tumours (both seminoma and nonseminoma) Lymphomas Ewing's sarcoma Neuron specific enolase (NSE) Neuroendocrine tumors Small cell lung cancer Carcinoid tumour Neuroblastoma CA 19–9 Pancreatic adenocarcinoma Colon cancer Cholangiocarcinoma CA 15–3 and CA 27–29 Breast cancer CA 125 Ovarian carcinoma Other gynecologic malignancies S-100 protein (S100A) and (S100B) Malignant melanoma SMRP Mesothelioma

References:

Robbins & Cotran Pathologic Basis of Disease, 10th Edition, Page 335-336.

↑ *Back to this question in Part A*

@Neet_pg_bot

Q30: Which of the following is not correct? (Q853368)

A. C- MYC - Burkitts lymphoma

B. Least radiosensitive phase is S phase of cell cycle

C. Least radiosensitive cell is platelet

D. Cyclin E triggers cells to move from G0 to G1 and G1 to S phase

Correct Answer: D. Cyclin E triggers cells to move from G0 to G1 and G1 to S phase

Explanation: Cyclin D triggers cells to move from G0 to G1 and G1 to S phase Cyclin E prepares the cell for DNA replication in S phase Cyclin A activates DNA replication inside nucleus in S phase Cyclin B promotes the assembly of mitotic spindle and other tasks in the cytoplasm to prepare for mitosis Option A, B, C are correct.

References:

Prepladder notes

↑ *Back to this question in Part A*

@Neet_pg_bot

Q31: Which of the following is an incorrect gene-disease association? (Q865377)

A. STK11 - Breast Cancer

B. PTEN - Thyroid Carcinoma

C. TP53 - Mucosal Neuroma

D. BRCA2 - Prostate Carcinoma

Correct Answer: C. TP53 - Mucosal Neuroma

Explanation: TP53 is not associated with mucosal neuroma. Gene Associated tumours BRCA1 Breast, ovarian, fallopian tube, pancreas, and prostate. BRCA2 (Option D ruled out) Breast, ovarian, pancreas, and prostate. Associated with male breast cancer. TP53 Breast, sarcoma, leukaemia, and brain tumours. PTEN (Option B ruled out) Breast, thyroid, and endometrium. STK11 (Option A ruled out) Breast, ovarian, colon, and pancreas. CDH1 Breast, gastric signet ring cell carcinoma, and colon. PALPB2 Breast, pancreas, and prostate. CHEK2 Prostate, thyroid, colon, and kidney.

References:

Textbook of Robbin and Cotran’s Pathological Basis of Diseases, 10th Edition, Page 1049.

↑ *Back to this question in Part A*

@Neet_pg_bot

• [05_Immunity] 019 Types Of Immunity

« Back to Folder Directory

[05_Immunity] 019 Types Of Immunity — Quick Jump

Q1 (p. 1446) *Q2 (p. 1447)* *Q3 (p. 1449)* *Q4 (p. 1450)* *Q5 (p. 1451)* *Q6 (p. 1452)*
Q7 (p. 1453) *Q8 (p. 1456)* *Q9 (p. 1457)* *Q10 (p. 1459)* *Q11 (p. 1460)* *Q12 (p. 1461)*

Q1: Which of the following is not a feature of innate immunity? (Q845264)

A. Present since birth

B. Made of epithelial barriers, phagocytes, innate lymphoid cells (ILCs) and NK cells

C. Quick, non-specific response

D. Has a lag phase between exposure and response

Correct Answer: D. Has a lag phase between exposure and response

■ *Listen (English)*

■ *Listen (Hindi)*

Explanation: The lag phase between exposure and response is not a feature of innate immunity as it acts rapidly against pathogens. The lag phase is a feature of adaptive immunity. It specifically targets the pathogen causing infection, so it first needs to recognize the pathogen. This means that it’s slower to respond than the innate immune system, but it’s more accurate when it does respond. Because of immunological memory, the next time it faces the same pathogen, there is a quick and robust response. Innate immunity is the body's first line of defense against pathogens, present since birth. It responds similarly to all germs and foreign substances, hence the term non-specific immune system. Adaptive Immunity : Requires time to recognize specific pathogens, resulting in a slower initial response, but it develops immunological memory for a quicker, more robust response upon re-exposure. Difference between innate and acquired immunity: Innate/native immunity Acquired/adaptive immunity Present since birth (Option A) Occurs after exposure to the pathogen Quick, non-specific response (Option C) Slower, specific response to a pathogen No immunological memory Has immunological memory Examples include : Epithelial barriers like skin, GIT. (Option B) Plasma proteins like C-reactive protein. Phagocytes: Neutrophils, macrophages, dendritic cells. Natural Killer (NK) cells : Specialized lymphocytes that destroy virally infected or tumor cells. Complement System : Specifically the Alternative and Lectin pathways. Cells are of 2 types : B lymphocytes: Provides humoral immunity and produces antibodies T lymphocytes: Involved in cell-mediated immunity and help with immunity against intracellular microbes Complement System : Specifically the Classical pathway (activated by antibody-antigen complexes).

References:

Robbins & Cotran Pathologic Basis of Disease, 10th Edition, Page 203.

www.ncbi.nlm.nih.gov/books/NBK279396/

↑ *Back to this question in Part A*

@Neet_pg_bot

Q2: A 45-year-old male presents with a fever, sore throat, and swollen lymph nodes. He is diagnosed with a viral infection. Which of the following cells is most likely involved in the early defense against the offending agent in this patient? (Q845266)

A. NK cells

B. T cells

C. Macrophages

D. Histocytes

Correct Answer: A. NK cells

■ *Listen (English)*

■ *Listen (Hindi)*

Explanation: In this scenario, the patient has a viral infection, and the body's initial defense mechanism against the virus is Natural Killer (NK) cells. Natural Killer cell (NK) : First line of defence against Tumor cells and Virus NK cell: < 10 % Produced by a large granular lymphocyte. Constitutes 5 to 10% of circulating blood lymphocytes. Function: It can be part of both innate and adaptive immunity. Innate immunity: Directly kill the virus-infected cells or tumour cells. Adaptive immunity: Antibody-dependent cell-mediated cytotoxicity. Structure of NK cell: Has 2 arms Activating receptor → NKG2D Inhibitory receptor → CD94 CD Markers: CD16 → Receptor for Fc IgG CD56 CD 94 NK cells towards self cells & foreign cells: NK cells and Self cells NK cells and Foreign cells Do not kill their own cells All self-cells express MHC-I When MHC-I is detected, NK cells use their inhibitory arm to prevent killing self-cells Viruses & cancer cells suppress MHC-I expression When MHC-I is downregulated, the activating arm of NK cells becomes dominant and kills the cell T cells (Option B) are important in the adaptive immune response against viruses, they are not typically involved in the body's immediate defense mechanism during the early stages of infection. Macrophages and Histiocytes (Option C & D) are part of the innate immune system and play a role in the immune response to viral infections. However, NK cells are more directly involved in the early defence against viruses due to their ability to recognize and kill virus-infected cells without prior sensitization.

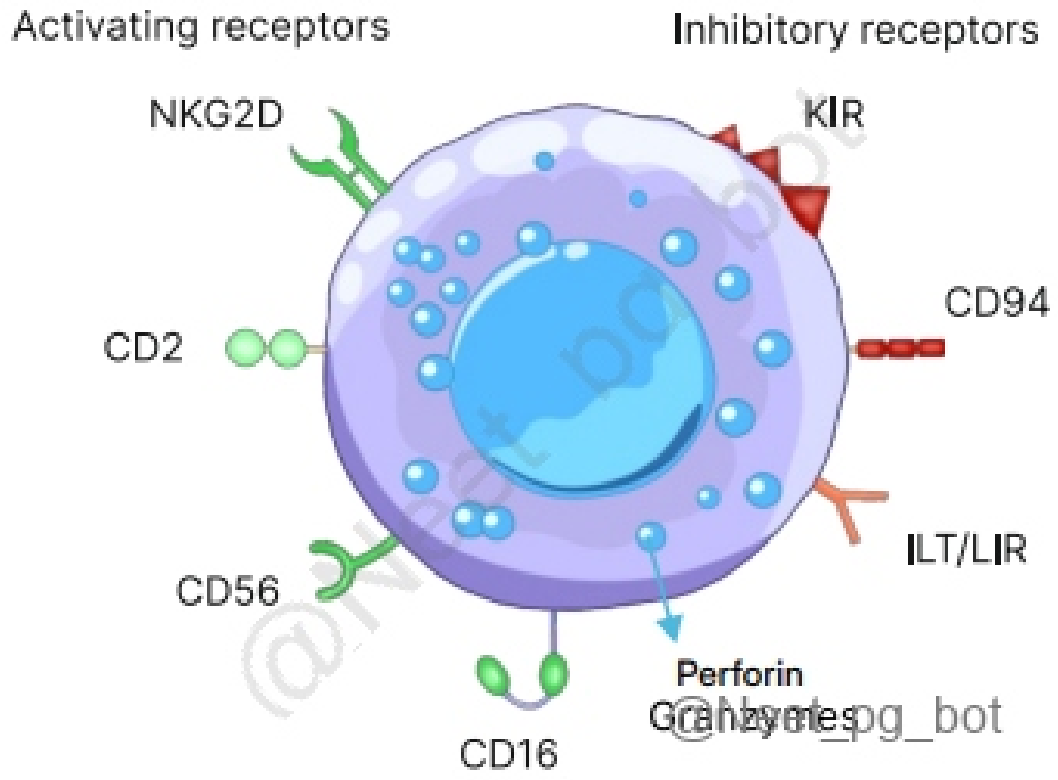

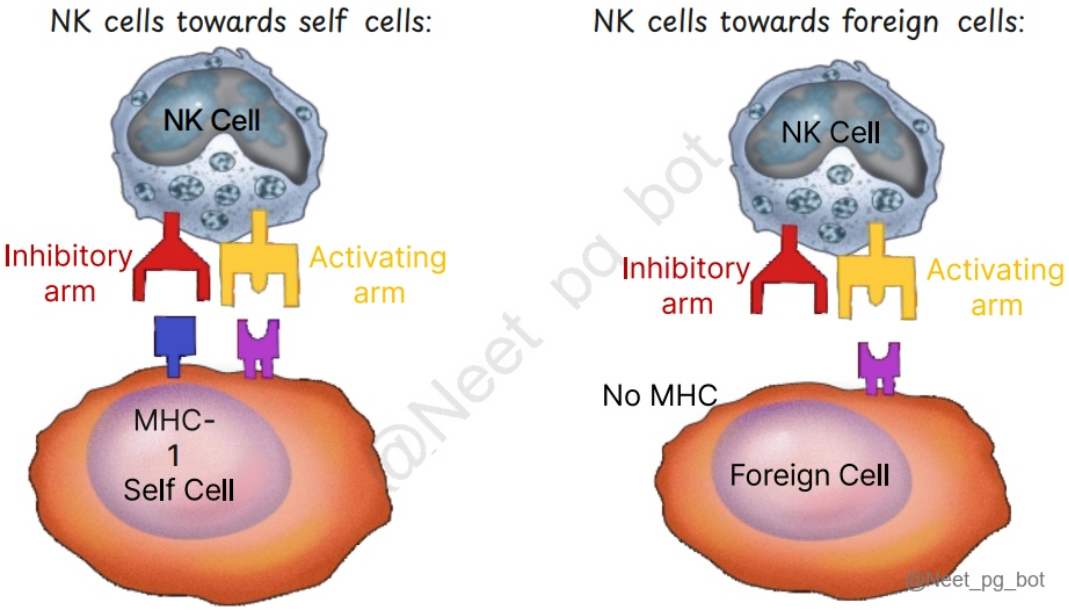

References:

Robbins & Cotran Pathologic Basis of Disease, 10th Edition, Page 192,193.

www.ncbi.nlm.nih.gov/books/NBK565844/

↑ *Back to this question in Part A*

@Neet_pg_bot

Q3: A 20-year-old medical student went for a screening health test and was injected with PPD intradermally. Identify the immune cell in the skin that picks up the PPD to present it to T cells. (Q845274)

A. Langhans cells

B. Follicular dendritic cells

C. Langerhans cells

D. Natural killer cells

Correct Answer: C. Langerhans cells

■ *Listen (English)*

■ *Listen (Hindi)*

Explanation: The given clinical scenario describes the Mantoux test. Langerhans cells are specialized dendritic cells found in the skin and mucosa. They are responsible for antigen presentation in the immune system. They are part of the body's first line of defense and belong to the innate immune system. Dendritic cells(DC) are the most potent antigen-presenting cells(APC) for initiating T-cell responses against protein antigens. Dendritic cell properties: They have many cytoplasmic processes resembling dendrites and receptors that sense microbes and cell damage that stimulate the secretion of cytokines. This has a critical role in inflammation and antiviral defense. They express receptors for capturing antigens, including TLRs and lectins. They are located under the epithelia and interstitia of all tissues, which are common sites for capturing antigens. They have a higher concentration of MHCs and are present in greater numbers in the epidermis than other APCs. Immature DCs within the epidermis are called Langerhans cells. Antigen Presenting Cells: This antigen will be presented on the MHC, and then given to T cells. Langhans cells/Langhans giant cells (Option A) are multinucleated giant cells found in granulomas. They consist of huge cytoplasm and multiple nuclei that are derived from the fusion of multiple activated macrophages. Follicular dendritic cells (Option B) are specialized cells found in lymphoid follicles within lymph nodes and the spleen. They play a crucial role in presenting antigens to B cells and are involved in the formation and maintenance of the germinal center reaction. NK cells (Option D) are not APCs. They destroy abnormal cells, such as virus-infected or malignant cells.

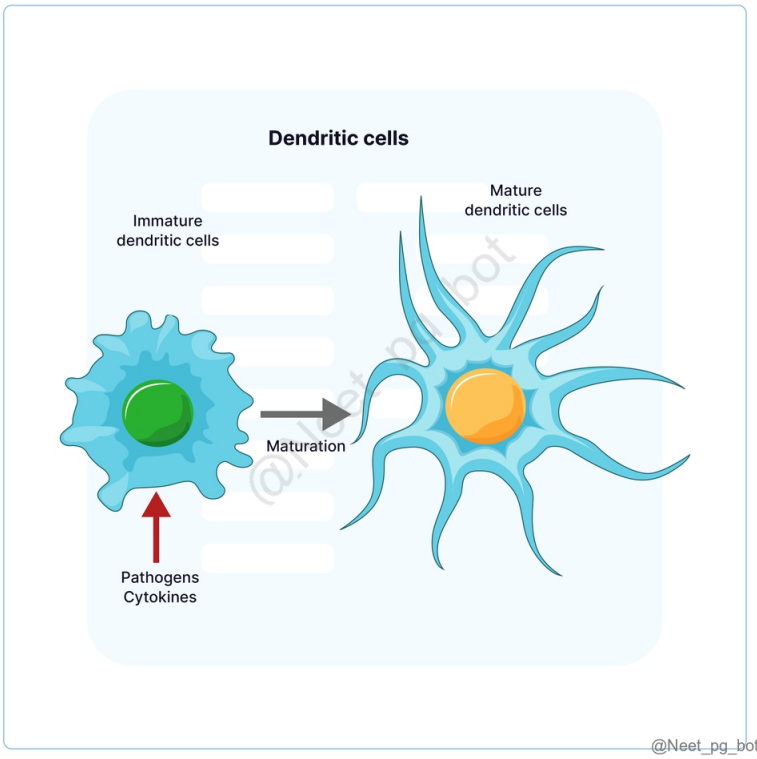

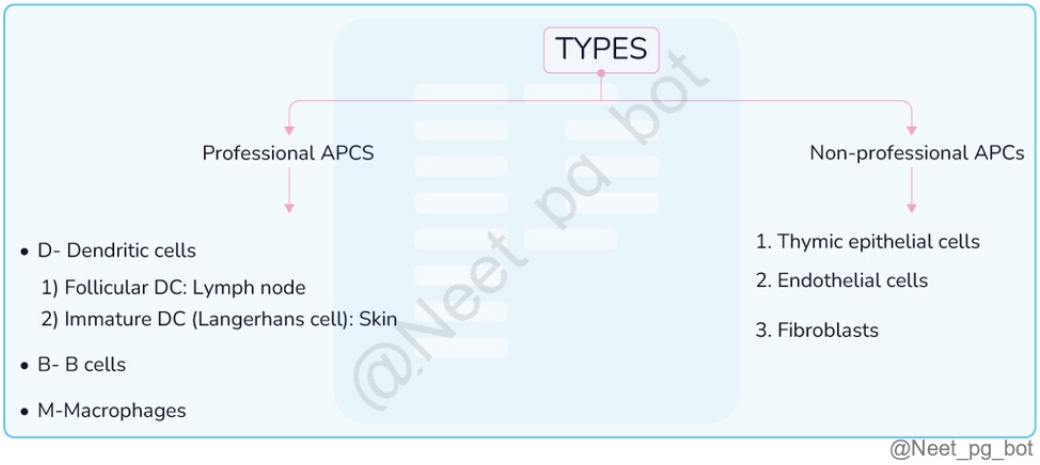

References:

Robbins & Cotran Pathologic Basis of Disease, 10th Edition, Pages 100,190,196.

↑ *Back to this question in Part A*

@Neet_pg_bot

Q4: Match the following immune cells with their markers. Cells Markers 1. Natural killer cell a. CD 19 2. T lymphocyte b. CD 16 3. B lymphocyte c. CD 11 4. Monocyte d. CD 3 (Q845278)

A. 1-a; 2-d; 3-b; 4-c

B. 1-b; 2-a; 3-c; 4-d

C. 1-b; 2-d; 3-a; 4-c

D. 1-a; 2-c; 3-d; 4-b

Correct Answer: C. 1-b; 2-d; 3-a; 4-c

■ *Listen (English)*

■ *Listen (Hindi)*

Explanation: Cells Markers Natural killer cell CD 16, 56, 94 T lymphocyte CD 1, 2, 3, 4, 5, 6, 7, 8, 28, 40L. B lymphocyte CD 10, 19, 20, 21, 22, 23, 40, 79 Monocyte CD 11, 14, 64

References:

Robbins & Cotran Pathologic Basis of Disease, 10th Edition, Page 593.

↑ *Back to this question in Part A*

@Neet_pg_bot

Q5: Toll-like receptors are predominantly expressed in which of the following cell types? (Q845386)

A. Macrophages

B. Endothelial cells

C. Natural killer cells

D. All of the above

Correct Answer: D. All of the above

■ *Listen (English)*

■ *Listen (Hindi)*

Explanation: Toll-like receptors (TLRs) are a family of pattern-recognition receptors expressed on immune cells like macrophages, dendritic cells, and natural killer cells, as well as on non-immune cells like endothelial cells.

Pattern recognition receptors Receptor Type Cellular Compartment Function Toll-like Receptors (TLRs) Plasma membrane, endosomal vesicles Detect microbial components (e.g., bacterial lipopolysaccharides, viral RNA) The final effect of antigen binding to TLR is the activation of transcription factors: 1. NF-κB : Stimulates the synthesis and secretion of cytokines and expression of adhesion molecules. 2. Interferon regulatory factors (IRFs): stimulate the production of antiviral cytokines and interferons.

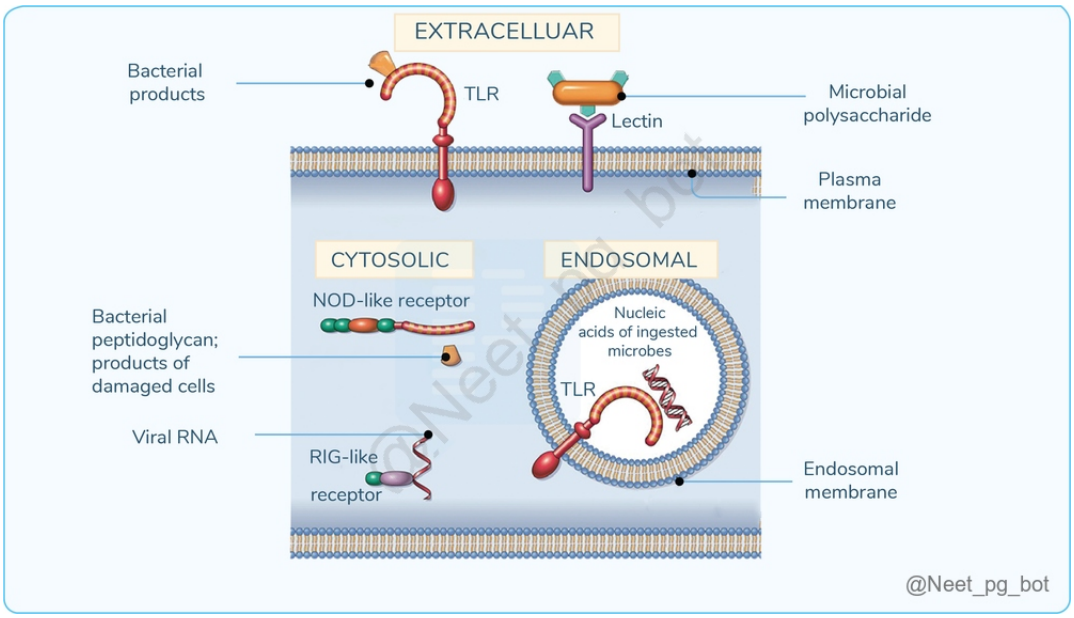

References:

Robbins & Cotran Pathologic Basis of Disease, 10th Edition, Page 101.

↑ *Back to this question in Part A*

@Neet_pg_bot

Q6: An 8-year-old child is brought with complaints of fever and burning micturition. She was diagnosed to have UTI with toxin-producing strains of E.coli. Where are blood-borne antigens trapped in the immune response to these toxins? (Q845387)

A. Lymph nodes

B. Thymus

C. Bone marrow

D. Spleen

Correct Answer: D. Spleen

Explanation: In the immune response to toxin-producing strains of E. coli causing UTI, blood-borne antigens are primarily trapped and processed in the spleen. The spleen is an important secondary lymphoid organ where circulating antigens, including those derived from bacteria and their toxins, are captured by specialized cells such as macrophages. These antigens are then presented to immune cells, initiating an immune response to neutralize the toxins and clear the infection. Secondary Lymphoid Organs: This group includes the spleen, lymph nodes, and mucosal/cutaneous lymphoid tissues (MALT/SALT), all of which are sites where adaptive immune responses are initiated. Lymph Nodes (Option A): While also secondary lymphoid organs, lymph nodes are responsible for trapping and filtering tissue-borne antigens that arrive via the lymphatic vessels, rather than those circulating in the blood. Primary Lymphoid Organs (Options B & C): The thymus and bone marrow are where immune cells (T and B lymphocytes) develop and mature; they are not the primary sites for trapping foreign antigens during an active infection.

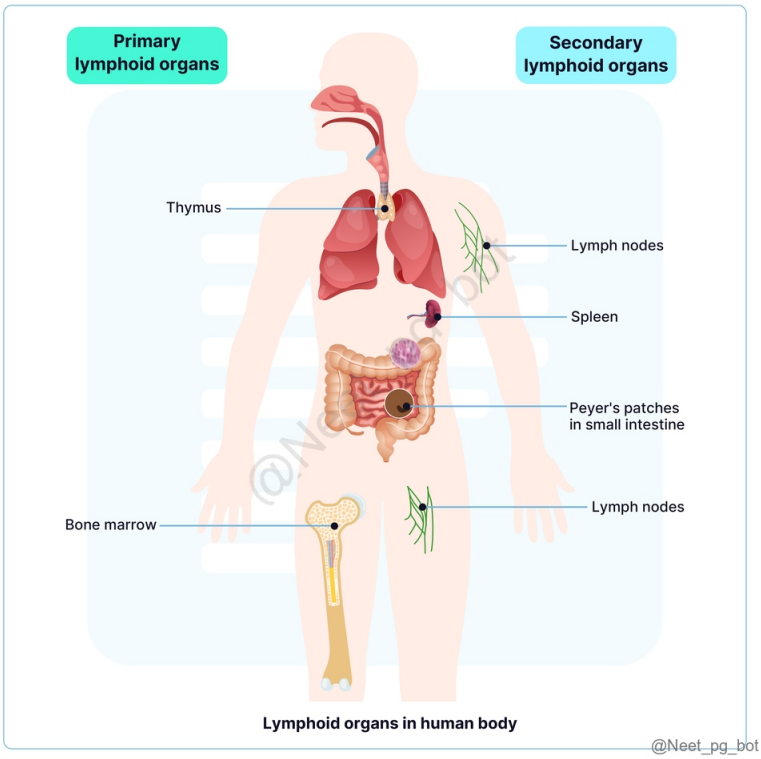

References:

Robbins & Cotran Pathologic Basis of Disease, 10th Edition, Page 197.

↑ *Back to this question in Part A*

@Neet_pg_bot

Q7: Which of the following HLA gene regions encodes Class II MHC molecules? (Q845389)

A. HLA-A

B. HLA-B

C. HLA-C

D. HLA-D

Correct Answer: D. HLA-D

■ *Listen (English)*

■ *Listen (Hindi)*

Explanation: Class II MHC molecules are encoded in a region called HLA-D. Major Histocompatibility Complex (MHC): Made by HLA gene Located on the short arm of chromosome 6p The structure of HLA gene: HLA consists of three regions, which have been designated as class I, class II, and class III based on the structure and function of gene products. Gene region Encoded products Class I HLA-A, HLA-B, HLA-C, HLA-E, and HLA-G MHC-I Class II HLA-DP, HLA-DQ, and HLA-DR. MHC-II Class III C2, C4, Properdin, Tumor necrosis factor (TNF), complement and heat shock proteins HLA E → Help in the processing of Natural Killer cells HLA G (Gestationalis): Feto-maternal tolerance Fetal cells are coated with HLA G and hence mother does not treat those as foreign cells Difference between MHC-I and MHC-II: Characteristics MHC-I MHC-II Structure It has α1 chain, α2 chain, α3 chain, and β-2 microglobulin It has α1 chain, α2 chain, β1 Chain, β2 Chain Antigen Binding Cleft At the junction of α1 and α2 At the junction of α1 and β1 Present on cells All nucleated cells in the body Platelets Present in all the antigenpresenting cells Not present RBC (Adsorb MHC-1 from surrounding cells), Sperms - Present to cells MHC I → CD8 cells MHC II → CD4 cells Testing Alloantisera testing Mixed lymphocyte reaction testing

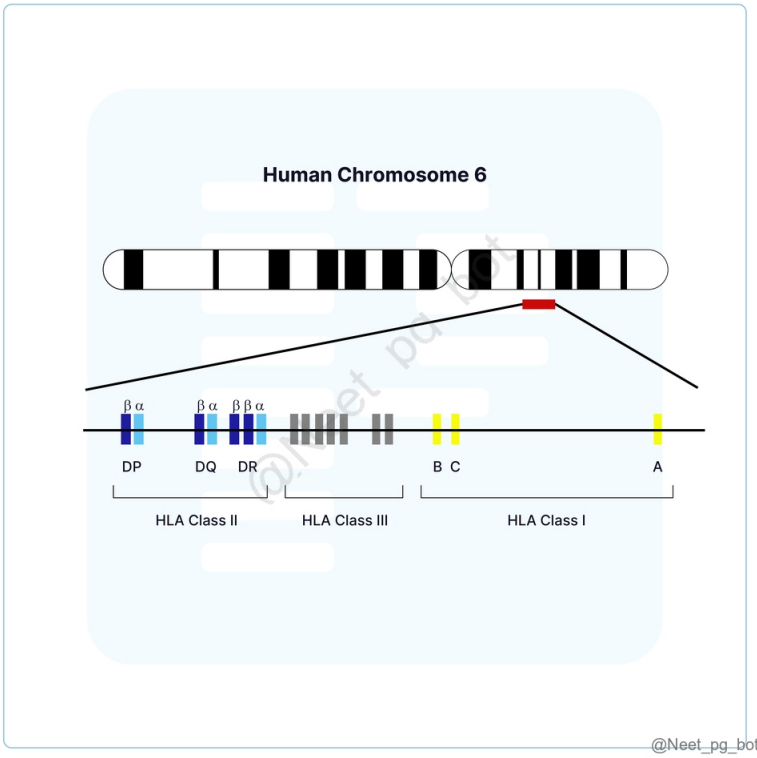

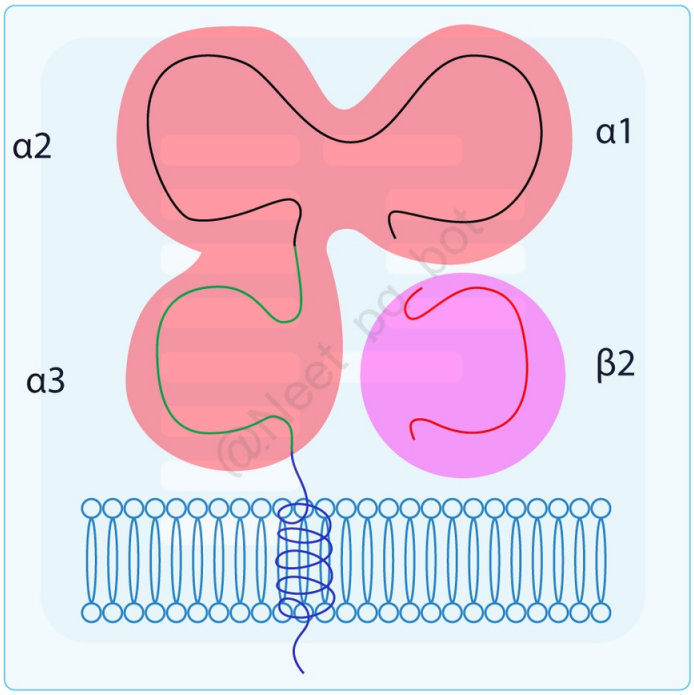

@Neet_pg_bot

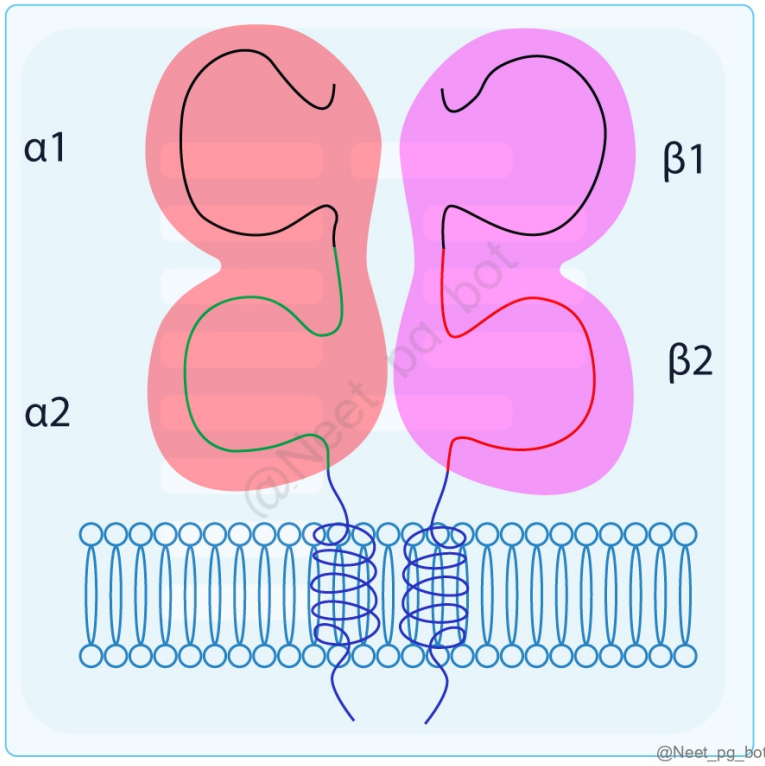

@Neet_pg_bot

References:

Robbins & Cotran Pathologic Basis of Disease, 10th Edition, Pages 198, 199.

www.ncbi.nlm.nih.gov/books/NBK459467/

www.sciencedirect.com/topics/neuroscience/hla-e

↑ *Back to this question in Part A*

@Neet_pg_bot

Q8: A patient presented with a fever and loose stool for one week. He was diagnosed with typhoid infection. Which of the following MHC class is responsible for antigen presentation in this patient? (Q845390)

A. Class I

B. Class II

C. Class III

D. Non-MHC-dependent antigen presentation

Correct Answer: B. Class II

Explanation: In a patient with typhoid infection (caused by Salmonella typhi), antigen presentation primarily involves MHC class II molecules, which present antigens derived from extracellular pathogens to activate an immune response. Class I MHC class I molecules present endogenous antigens derived from intracellular pathogens, such as viruses and some bacteria. Class II MHC class II molecules present exogenous antigens derived from extracellular pathogens, such as Salmonella typhi, the bacterium responsible for typhoid fever. Class III MHC class III molecules are not involved in antigen presentation. They encode components of the complement system and other immune-related molecules. Non-MHC-dependent antigen presentation While non-MHC-dependent antigen presentation can occur through mechanisms like CD1 molecules presenting lipid antigens. Class II MHC molecules are expressed on the surface of antigen-presenting cells (APCs), such as dendritic cells, macrophages, and B cells. These cells process exogenous antigens derived from extracellular microbes and proteins after internalization into endosomes or lysosomes. The internalized proteins are broken down into peptides and associated with class II MHC in the vesicles and transported to the cell surface as stable peptide-MHC complexes. The class II-peptide complex is recognized by CD4+/helper T cells. Class II MHC molecules present antigens derived from extracellular pathogens to CD4+ helper T cells, initiating an immune response.

References:

Robbins & Cotran Pathologic Basis of Disease, 10th Edition, Page 198,199.

↑ *Back to this question in Part A*

@Neet_pg_bot

Q9: Which component functions as the antigen binding site in MHC complexes 1 and 2, respectively? (Q845404)

A. MHC 1 - beta microglobulin; MCH 2 - alpha 3 domain

B. MHC 1 - alpha 1 and 2; MHC 2 - alpha 1 and beta 1

C. MHC 1 - alpha 1 and beta 1; MHC 2 - alpha 1 and 2

D. MHC 1 - invariant chain; MHC 2 - beta microglobulin

Correct Answer: B. MHC 1 - alpha 1 and 2; MHC 2 - alpha 1 and beta 1

■ *Listen (English)*

■ *Listen (Hindi)*

Explanation: In MHC class I molecules, the alpha 1 and beta 1 domains together form the antigen-binding site, which binds to peptides derived from intracellular proteins. MHC-1 molecules are expressed on all nucleated cells, antigen-presenting cells, and platelets Mature RBCs that lack a nucleus don't express MHC-1 They are heterodimers with a polymorphic α or heavy chain linked non-covalently to a smaller β2-microglobulin. The antigen is bound within a groove between the α1 and α2 domains of the alpha chain. This, along with the β2-microglobulin, forms a stable complex to be displayed on the cell surface. B cells, dendritic cells, and mononuclear phagocytes expresses MHC class II molecules, as they are professional antigen-presenting cells involved in initiating immune responses. In MHC class II molecules, similar to MHC class I, the antigen-binding site is also formed by the alpha 1 and beta 1 domains, binding peptides derived from extracellular proteins presented by antigen-presenting cells. They consist of 2 alpha and 2 beta chains of equal length. The invariant chain is a protein structure associated with MHC-2. It is associated with MHC-2 within endosomes to prevent the binding of endogenous antigens. The invariant chain is later broken down, while MHC-2 is moved to the cell surface.

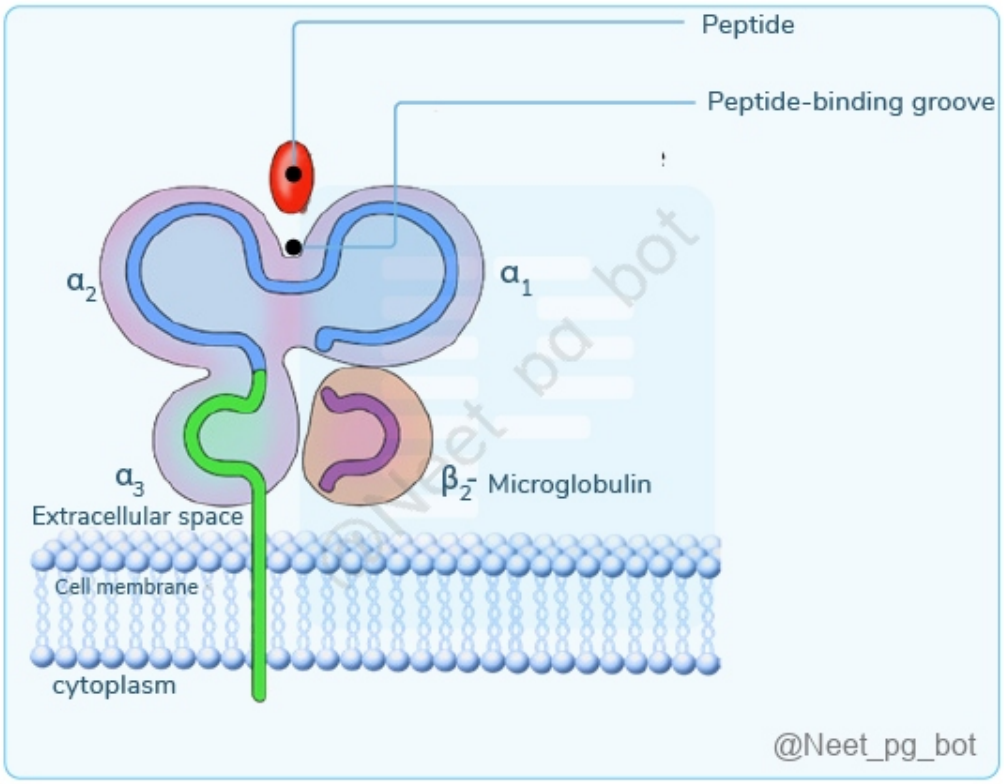

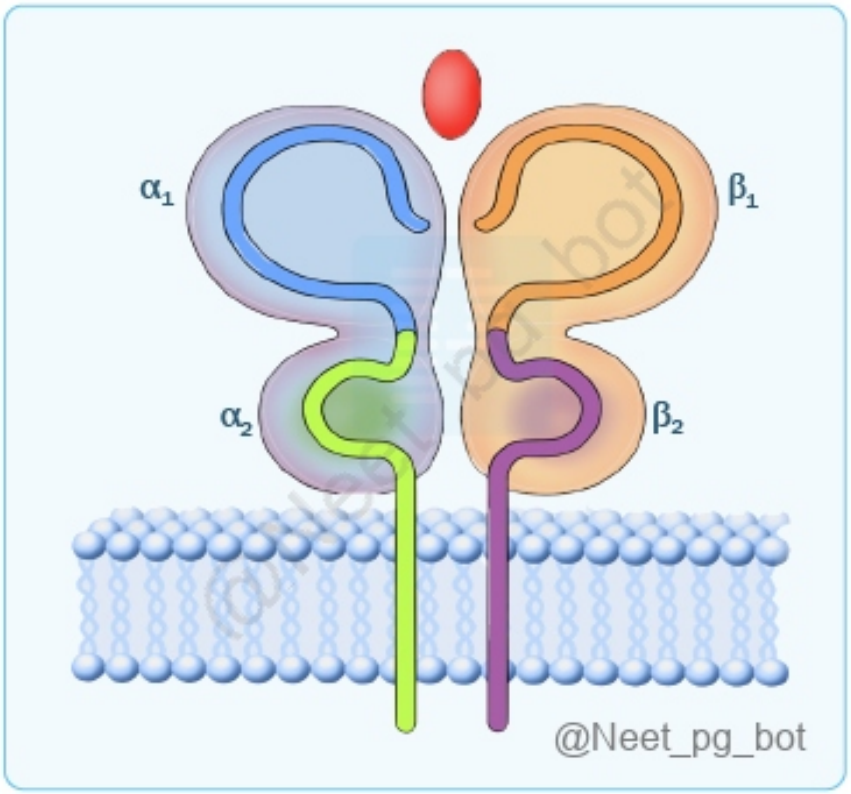

References:

Robbins & Cotran Pathologic Basis of Disease, 10th Edition, Page 198,199.

https://www.ncbi.nlm.nih.gov/pmc/articles/PMC3711407/

↑ *Back to this question in Part A*

@Neet_pg_bot

Q10: A newborn delivered by a mother who received no prenatal care is being evaluated. On examination, the baby has severe oedema, icterus, and organomegaly and is in respiratory distress. What immunoglobulin class was responsible for this child's presentation? (Q845407)

A. IgG

B. IgM

C. IgA

D. IgE

Correct Answer: A. IgG

■ *Listen (English)*

■ *Listen (Hindi)*

Explanation: The given clinical scenario describes Hemolytic disease of the newborn (HDN) , also known as erythroblastosis fetalis. This occurs when maternal antibodies cross the placenta and attack fetal red blood cells (RBCs). Pathophysiology: This condition is often caused by Rh (Rhesus) blood group incompatibility, where the mother is Rh-negative and the fetus is Rh-positive. During pregnancy, maternal antibodies of the IgG class against the Rh antigen can cross the placenta and attack the fetal red blood cells (RBCs), leading to hemolysis (destruction of RBCs) in the fetus. This results in various degrees of anaemia and potentially severe complications for the newborn. Mechanism: This crossing is facilitated by active transplacental transfer mechanisms, primarily mediated by syncytiotrophoblast cells expressing neonatal Fc receptors (FcRn) . These receptors interact with the Fc domain of IgG, permitting their transfer. Result: This leads to hemolysis, severe anemia, edema (hydrops fetalis), and icterus (jaundice). This phenomenon is also responsible for newborns' passive immunity, with IgG being the most abundant antibody in their circulation. IgM (Option A) are multinucleated giant cells found in granulomas. They consist of huge cytoplasm and multiple nuclei that are derived from the fusion of multiple activated macrophages. It cannot cross the placenta due to its large size (pentameric structure). IgD and IgE (Option C and D) are also incapable of crossing the placenta. Key Features of Immunoglobulins (The "GAMED" Table): Class Key Characteristics & Functions IgG Most abundant in serum. The only antibody that crosses the placenta (provides passive immunity to the newborn). Fixes complement and opsonizes bacteria. IgA Found in secretions (tears, saliva, mucus, colostrum). Prevents attachment of bacteria and viruses to mucous membranes. Exists as a dimer with a J-chain. IgM First antibody produced in an initial immune response. Large pentameric structure (highest avidity). Excellent at fixing complement. Cannot cross placenta. IgE Mediates Type I Hypersensitivity (allergic) reactions. Binds to mast cells and basophils. Provides defense against parasitic infections (helminths). IgD Found primarily on the surface of B cells as an antigen receptor. Its precise physiological function in serum is unclear.

Name	Properties	Structure
IgA	Found in mucous, saliva,tears, and breast milk. Protects against pathogens.	
IgD	Part of the B cell receptor. Activates basophils and mast cells.	
IgE	Protects against parasitic worms. Responsible for allergic reactions.	
IgG	Secreted by plasma cells in the blood. Able to cross the placenta into the fetus.	
IgM	May be attached to the surface of a B cell or secreted into the blood. Responsible for early stages of immunity.	

@Neet_pg_bot

References:

https://www.uptodate.com/contents/rhd-alloimmunization-in-pregnancy-overview

↑ *Back to this question in Part A*

@Neet_pg_bot

Q11: A 65-year-old male presents to the emergency department with a fever, productive cough, and shortness of breath. He is diagnosed with pneumonia. Which of the following cytokines is most likely to be elevated in this patient due to the activation of classical macrophages in response to the infection? (Q845411)

A. Interleukin- 1

B. Interleukin- 2

C. Interleukin- 4

D. Interleukin- 10

Correct Answer: A. Interleukin- 1

■ *Listen (English)*

■ *Listen (Hindi)*

Explanation: Interleukin-1 will be elevated in this patient due to the activation of classical macrophages in response to the infection. Macrophages act as antigen-presenting cells and play vital roles in innate, humoral and cell-mediated immune responses. The two main pathways of macrophage function are classical (M1) and

alternative (M2) pathways, each driven by different stimuli and resulting in different macrophage functions. Stimuli Functions and Secretions Role Classical (M1) Activation Microbial products (e.g., LPS), IFN-γ Pro-inflammatory and microbicidal functions: NO, lysosomal enzymes, TNF-α, IL-1, IL-12, IL-23 Host defense Microbial destruction Inflammation Alternative (M2) Activation IL-4, IL-13 (Option C) Tissue repair, resolution of inflammation, secretion of TGF-β, growth factors, IL-10 Tissue remodeling Angiogenesis, Immunoregulation Wound healing Tissue repair and homeostasis Interleukin-2 (IL-2) (Option B) aka T-cell growth factor is a cytokine with pleiotropic effects on the immune system and is not associated with classical macrophage activation. Interleukin-10 (IL-10) (Option D) is an anti-inflammatory cytokine released from alternatively activated macrophages.

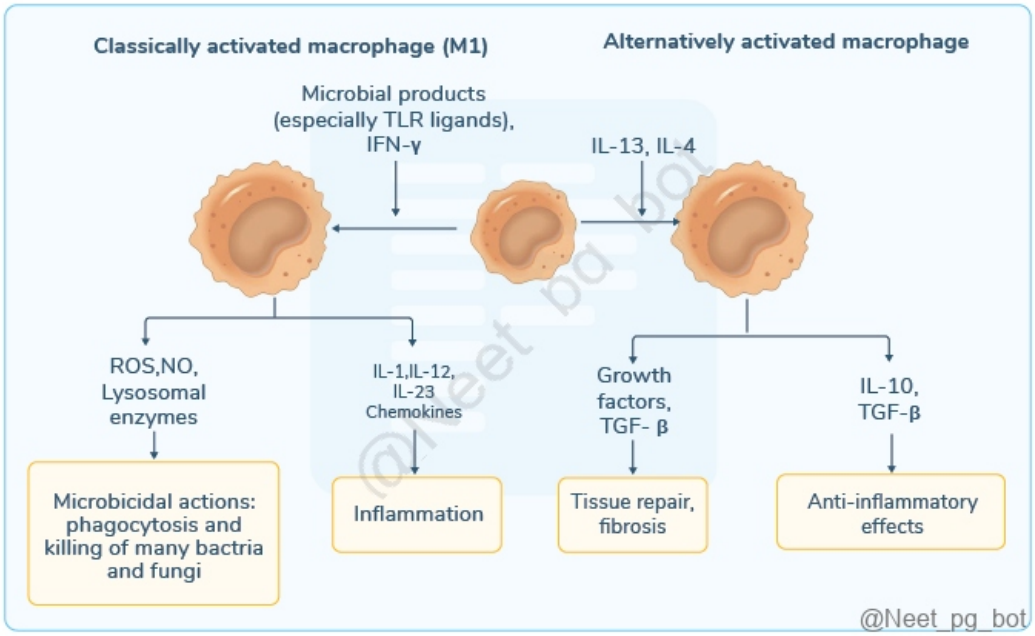

References:

Robbins & Cotran Pathologic Basis of Disease, 10th Edition, Page 98.

↑ *Back to this question in Part A*

@Neet_pg_bot

Q12: A 10-year-old boy is brought with a history of eating sand. His stool examination showed Ascaris eggs. What type of T-cell is responsible for dealing with this infection? (Q845415)

A. TH1 cells

B. TH2 cells

C. TH17 cells

D. Treg cells

Correct Answer: B. TH2 cells

- *Listen (English)*
- *Listen (Hindi)*

Explanation: TH2 cells (CD4+) are responsible for dealing with helminthic (parasitic) infections. IL-4 is the main cytokine that induces naive CD4+ T cells to differentiate into T-helper type 2 (Th2) cells. Five major CD4 T helper cell (TH) subsets have been identified: TH1, TH2, TH17, Treg (T regulatory), and Tfh (follicular T helper) cells. Subtype Function and Characteristics Key Cytokines TH1 (Option A) Involved in chronic inflammatory diseases. Activated by IL-12 from APCs. Secrete IFN-gamma, activating macrophages. Stimulates macrophages to form epithelioid cells and giant cells. IFN-gamma TH2 Responsible for the alternative pathway of macrophage activation. Release cytokines IL-4, IL-5, and IL-13. To expel parasites from the body, stimulate eosinophil activation, antibody production (especially IgE), and mucus production. IL-4, IL-5, IL-13 TH17 (Option C) Defend against extracellular bacteria and fungi. Secrete IL-17 and IL-22, attracting neutrophils and monocytes. IL-17, IL-22 Treg (T regulatory) (Option D) Suppresses immune response, maintains homeostasis and self-tolerance. Inhibit T cell proliferation and cytokine production, preventing autoimmune reaction. IL-10, TGF-beta Tfh (Follicular T helper) Assist B cells in rapid proliferation and antibody production. Help produce antibodies with greater affinity. IL-21

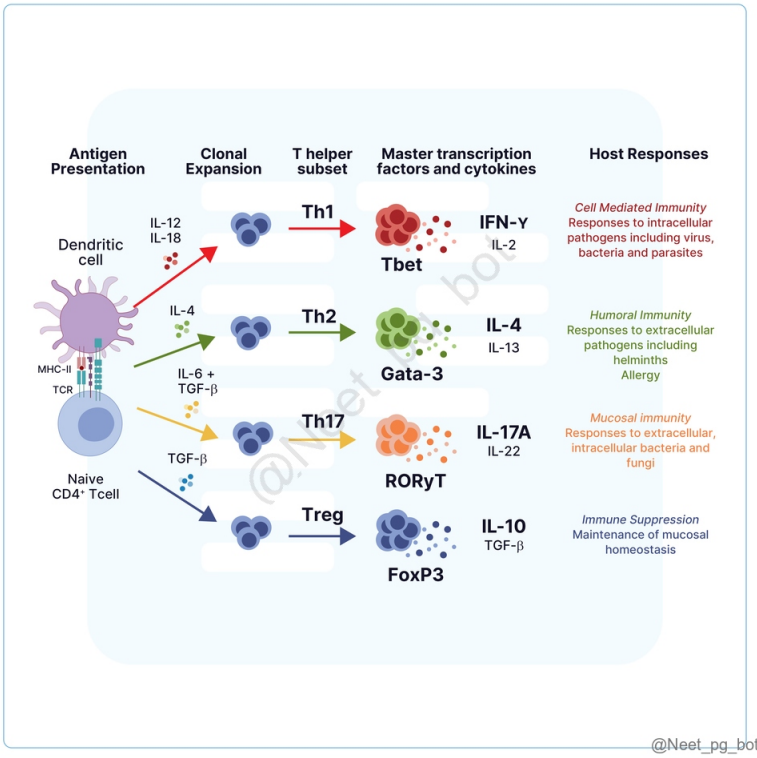

References:

Robbins & Cotran Pathologic Basis of Disease, 10th Edition, Page 202

CD4 T Helper Cell Subsets and Related Human Immunological Disorders - PubMed (nih.gov)

↑ *Back to this question in Part A*

@Neet_pg_bot

• [05_Immunity] 020 Types Of Hypersensitivity Reactions

« Back to Folder Directory

[05_Immunity] 020 Types Of Hypersensitivity Reactions — Quick Jump

Q1 (p. 1464) *Q2 (p. 1465)* *Q3 (p. 1467)* *Q4 (p. 1469)* *Q5 (p. 1469)* *Q6 (p. 1470)*
Q7 (p. 1471) *Q8 (p. 1472)* *Q9 (p. 1473)* *Q10 (p. 1474)* *Q11 (p. 1475)* *Q12 (p. 1476)*

Q1: A 35-year-old woman presents to the clinic with sudden hives, facial swelling, and difficulty breathing shortly after eating shrimp at a restaurant. She reports similar reactions in the past. She appears anxious, with pronounced facial swelling and wheezing. Which sequence correctly describes the immunological events in this type of reaction? (Q845417)

A. Allergen exposure → Mast cell activation → IgE production → Th2 cell activation → Release of inflammatory mediators

B. Th2 cell activation → Allergen exposure → IgE production → Mast cell activation → Release of inflammatory mediators

C. Allergen exposure → Th2 cell activation → IgE production → Mast cell activation → Release of inflammatory mediators

D. Allergen exposure → Th2 cell activation → Mast cell activation → IgE production → Release of inflammatory mediators

Correct Answer: C. Allergen exposure → Th2 cell activation → IgE production → Mast cell activation → Release of inflammatory mediators

■ *Listen (English)*

■ *Listen (Hindi)*

Explanation: The given scenario is an example of anaphylaxis following shrimp intake, which is an example of a type 1 hypersensitivity reaction. Rapid anaphylactic reactions triggered by allergens like food or insect stings are IgE-mediated Type I hypersensitivity responses. Step 1: First Exposure (Sensitization phase) Allergen enters the body. Naive CD4+ T-cells → differentiate into TH2 cells . TH2 cells release cytokines : IL-4 → stimulates B-cells to class switch and produce IgE . IL-5 → activates eosinophils . IL-13 → enhances IgE production and mucus secretion. IgE antibodies bind to FCERI receptors on mast cells (mast cells now become sensitized). Step 2: Second Exposure (Effector phase) Allergen re-enters the body. It binds to IgE already attached on mast cells . This causes cross-linking (polymerization) of IgE molecules. Cross-linking triggers mast cell degranulation . Mast cells release mediators : Histamine → vasodilation, increased vascular permeability, itching, bronchospasm. Leukotrienes & Prostaglandins → prolonged inflammation. Cytokines → recruit more immune cells Note: Anaphylactoid reactions: Anaphylactoid reactions involve direct degranulation of mast cells and basophils, causing symptoms similar to anaphylaxis but without IgE mediation (non-immunologically mediated. These

reactions can occur even on first exposure since prior sensitization is not required. They are commonly triggered by drugs such as NSAIDs.

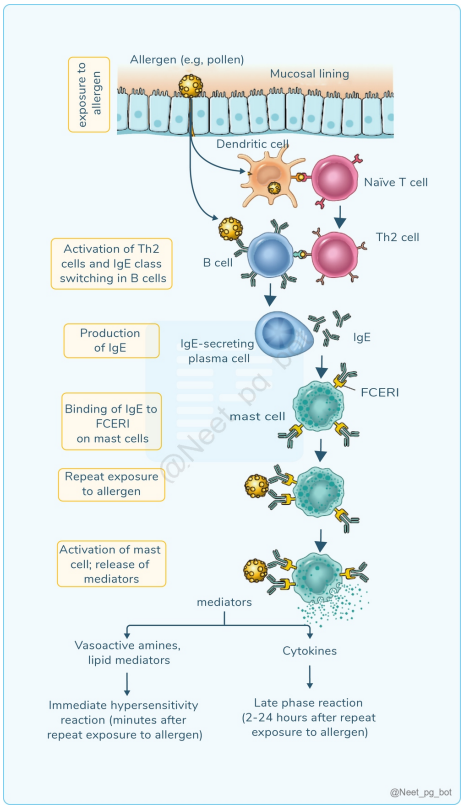

References:

Robbins & Cotran Pathologic Basis of Disease, 10th Edition, Pages 205-208

↑ *Back to this question in Part A*

@Neet_pg_bot

Q2: Which of the following cytokines acts on B cells to stimulate class switching to IgE and promotes the development of additional Th2 cells in type I hypersensitivity reactions? (Q845419)

A. IL-4

B. IL-5

C. IL-13

D. IL-10

Correct Answer: A. IL-4

■ *Listen (English)*

■ *Listen (Hindi)*

Explanation: Interleukins Role IL-4 Key cytokine in driving the allergic response Enhances Ig E-mediated reaction Stimulates B cells to undergo class switching to IgE and promotes the expansion of Th2 cells IL-5 (Option B) Development and activation of eosinophils→ Recruited to the site of allergen exposure→ Release inflammatory mediators and enzymes→ Tissue damage and inflammation IL-13 (Option C) Amplifies IgE production Acts on epithelial cells to stimulate mucus secretion IL-10 (Option D) Anti-inflammatory cytokine Inhibits cytokine production by Th1 cells and macrophages. Th-Cell Differentiation Pathway: When a naive $CD 4+ T cell encounters an antigen, the local cytokine environment determines its specialization: Th Cell Type Inducing Cytokines Key Cytokines Produced Primary Immune Function Th1 IL-12, IFN- γ IFN-γ , IL-2 Cell-mediated immunity ; activates macrophages to kill intracellular pathogens (e.g., TB). Th2 IL-4 IL-4, IL-5, IL-13 Humoral immunity ; defense against helminths and mediates Type I Hypersensitivity . Th17 TGF-β, IL-6 IL-17, IL-22 Recruitment of neutrophils ; defense against extracellular bacteria and fungi. Treg TGF-β, IL-2 TGF-β, IL-10 Immune tolerance ; suppresses autoimmunity and limits the inflammatory response.

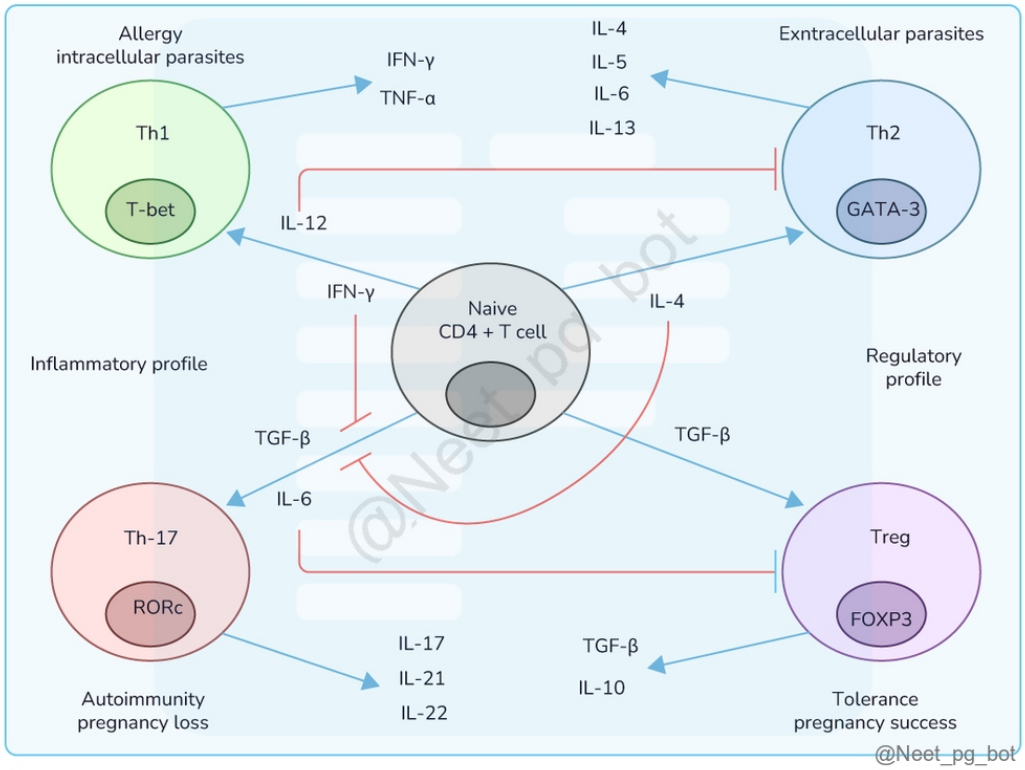

References:

Robbins & Cotran Pathologic Basis of Disease, 10th Edition, Page 207

↑ *Back to this question in Part A*

@Neet_pg_bot

Q3: A 45-year-old patient with a history of allergic asthma presents with worsening respiratory symptoms. The sputum sample shows the presence of Charcot-Leyden crystals. Which of the following is NOT typically associated with this phase of hypersensitivity reaction? (Q845420)

A. Recruitment of eosinophils to the site of inflammation by chemokines like eotaxin

B. Production of IL-5 by Th2 cells to activate eosinophils

C. Release of histamine and tryptase by eosinophils

D. Liberation of major basic protein and eosinophil cationic protein by activated eosinophils

Correct Answer: C. Release of histamine and tryptase by eosinophils

■ *Listen (English)*

■ *Listen (Hindi)*

Explanation: The given scenario suggests that the patient's presentation involves eosinophils, particularly the identification of Charcot-Leyden crystals (composed of galectin-10 protein) in the extracellular space, which is derived from eosinophils. (suggestive of delayed phase of type 1 HSR). Histamine and tryptase are preformed mediators released by mast cells during the early phase of Type I hypersensitivity (Option B) , not by eosinophils in the late phase. Early phase reaction Late phase reaction Onset Immediate (within minutes of allergen exposure). Delayed (several hours after exposure) and can last for days. Cells involved Mast cells, basophils. Eosinophils, T lymphocytes. Cellular events Activation of mast cells and basophils. Recruitment and activation of leukocytes, especially eosinophils. Mediators Histamine, leukotrienes (LTB4, LTC4, LTD4), prostaglandins (PGD2) and Platelet-activating factor (PAF). Cytokines (e.g., IL-4, IL-5, TNF), chemokines (e.g., eotaxin) Initiating event Exposure to allergen triggers cross-linking of IgE on mast cells/basophils. Recurrent inflammation, sustained by recruited leukocytes. Effect on tissues Vasodilation, increased vascular permeability, smooth muscle contraction. Sustained inflammation and tissue damage due to leukocyte infiltration. Clinical manifestations Allergic rhinitis (hay fever), urticaria (hives), Angioedema bronchoconstriction. Allergic asthma exacerbation, persistent inflammation, and tissue damage. Therapeutic Approach Antihistamines for symptomatic relief. Adrenaline in anaphylactic shock Broad-spectrum anti-inflammatory drugs (e.g., steroids) to suppress inflammation and prevent tissue damage.

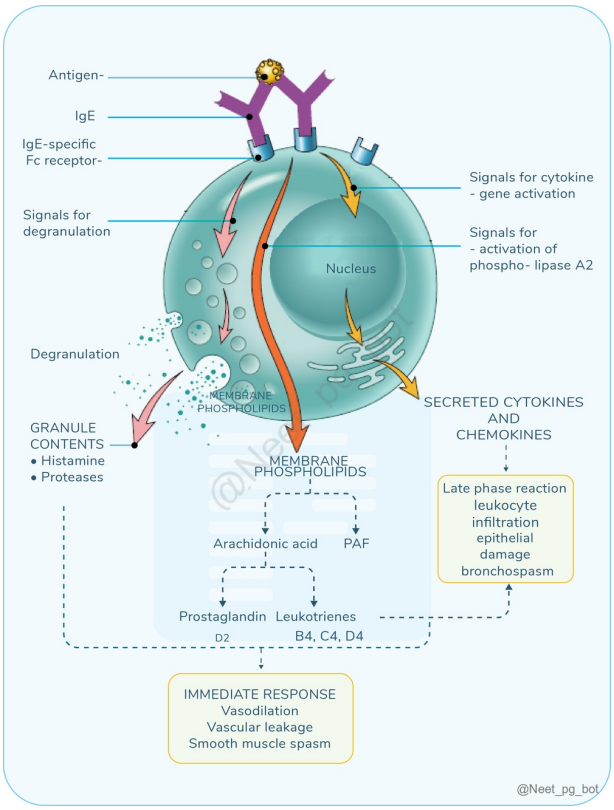

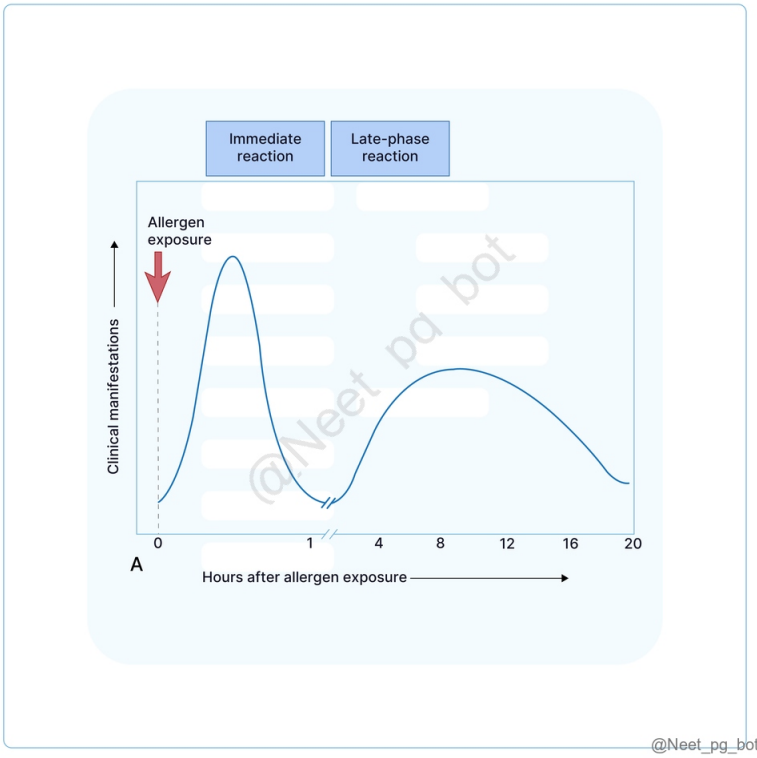

References:

Robbins & Cotran Pathologic Basis of Disease, 10th Edition, Pages 205-208

↑ *Back to this question in Part A*

@Neet_pg_bot

Q4: Which of the following is not an example of a Type I hypersensitivity reaction? (Q845421)

A. Graft rejection

B. Vernal Keratoconjunctivitis

C. Casoni test

D. P-K reactions

Correct Answer: A. Graft rejection

■ *Listen (English)*

■ *Listen (Hindi)*

Explanation: Graft rejection is not an example of a type I hypersensitivity reaction. Acute graft rejection involves Type II and Type IV hypersensitivity reactions. Hyperacute graft rejection involves Type II hypersensitivity reactions. Chronic graft rejection involves Type IV hypersensitivity reactions. Examples of Type I hypersensitivity reactions: Allergic conditions include Allergic rhinitis, Allergic dermatitis, Allergic conjunctivitis, or Vernal Keratoconjunctivitis (Option B). Bronchial asthma Casoni test: Done for detection of Echinococcus granulosus (Hydatid cyst) (Option C) . Drug reactions P-K reactions (Option D) The PK reaction is a laboratory technique used to demonstrate type I hypersensitivity, which involves IgE antibodies and mast cell degranulation, often leading to immediate allergic reactions. Theobald Smith phenomenon.(Theobald Smith phenomenon is the term for the development of hypersensitivity to bacteria in animals after repeated injections)

References:

Robbins & Cotran Pathologic Basis of Disease, 10th Edition, Page 208

↑ *Back to this question in Part A*

@Neet_pg_bot

Q5: Which of the following diseases is not an example of a Type II hypersensitivity reaction? (Q845426)

A. Rheumatic fever

B. Multiple sclerosis

C. Immune thrombocytopenic purpura

D. Pernicious anaemia

Correct Answer: B. Multiple sclerosis

■ *Listen (English)*

■ *Listen (Hindi)*

Explanation: Multiple sclerosis is an example of a type IV hypersensitivity reaction, not type II. Examples of Type II hypersensitivity reactions are: Mnemonic: My Blood Group Is Rh Positive My Myasthenia Gravis Blood Blood transfusion reaction Group Good pasture syndrome, Graves disease Is Immune hemolytic anaemia, Immune thrombocytopenic purpura R Rh incompatibility, Rheumatic fever H Hyperacute transplant rejection Positive Pemphigus (Bullous), Pernicious Anemia

Type B hypersensitivity (Antibody-mediated)	
Opsonization and complement → Phagocytosis	Transfusion reaction, erythroblastosis fetalis, AIHA, ITP.
Complement, F_c receptor-mediated → Inflammation	Goodpasture syndrome, Acute Rheumatic fever, vascular rejections, vasculitis.
Antibody-mediated cellular dysfunctions	Myasthenia gravis, Pemphigus Vulgaris, Graves disease, Pernicious Anemia, Insulin-resistant diabetes, Hemolytic disease of the newborn.

@Neet_pg_bot

References:

Robbins & Cotran Pathologic Basis of Disease, 10th Edition, Pages 204-215

↑ *Back to this question in Part A*

@Neet_pg_bot

Q6: Which of the following statements regarding pernicious anaemia is incorrect? (Q845428)

A. Natural Killer (NK) cells participate in Antibody-dependent cellular cytotoxicity.

B. Opsonisation involves IgG antibodies coating cells, enhancing phagocytosis via Fc receptors.

C. When antibodies deposit in intracellular tissues, the injury is due to inflammation and not phagocytosis or cell lysis.

D. Myasthenia gravis is an example of antibody-mediated cell surface receptor dysfunction.

Correct Answer: C. When antibodies deposit in intracellular tissues, the injury is due to inflammation and not phagocytosis or cell lysis.

■ *Listen (English)*

■ *Listen (Hindi)*

Explanation: In pernicious anemia, the type of hypersensitivity involved is Type II hypersensitivity, also known as antibody-mediated hypersensitivity. Antibodies cannot reach intracellular antigens in living cells, they target cell surface/extracellular matrix antigens. Immune complex mediated injury occurs in extracellular tissue spaces, not inside cells. Mechanisms of Hypersensitivity Reactions: Type Name Primary Mediator Detailed Mechanism Clinical Examples I Immediate IgE Antigens cross-link IgE on mast cells/basophils, triggering release of histamine and vasoactive mediators. Anaphylaxis, Asthma, Hay fever. II Antibody-Mediated IgG & IgM Antibodies bind to antigens on cell surfaces or extracellular matrix. Damage occurs via opsonization , phagocytosis , complement-mediated lysis , or ADCC (via NK cells). Pernicious Anemia , Myasthenia Gravis , Autoimmune Hemolytic Anemia. III Immune Complex Antigen-Antibody Complexes Complexes form in circulation and deposit in blood vessel walls or tissues, triggering complement activation and neutrophil-mediated inflammation. SLE (Lupus), Serum sickness, Glomerulonephritis. IV Cell-Mediated T-Lymphocytes Delayed response (lag phase) driven by CD4+ T cells (cytokine-mediated inflammation) or CD8+ T cells (direct cell killing). No antibodies involved. Tuberculin (Mantoux) test, Contact dermatitis, Type 1 Diabetes.

References:

Robbins & Cotran Pathologic Basis of Disease, 10th Edition, Pages 209, 210

↑ *Back to this question in Part A*

@Neet_pg_bot

Q7: An 11-year-old boy presents to the emergency department with swelling in his face and legs, decreased urine output, and dark-colored urine. His parents reported that he had a sore throat about three weeks ago, which resolved without treatment. Urinalysis shows proteinuria and hematuria. Which type of hypersensitivity reaction is associated with this condition? (Q845438)

A. Type I hypersensitivity

B. Type II hypersensitivity

C. Type III hypersensitivity

D. Type IV hypersensitivity

Correct Answer: C. Type III hypersensitivity

■ *Listen (English)*

■ *Listen (Hindi)*

Explanation: The given clinical scenario suggests Post-streptococcal glomerulonephritis (PSGN), a classic example of a Type III hypersensitivity reaction . PSGN is an immune complex-mediated disease caused by the deposition of circulating immune complexes (composed of streptococcal antigens and antibodies) in the kidney glomeruli, leading to inflammation and damage. Examples of type III hypersensitivity: (mnemonic- SHARP) Serum sickness, Schick test, SLE (Hematological lesion) Henoch Schonlein purpura Arthus reaction Reactive arthritis Post-streptococcal Glomerulonephritis (PSGN), Polyarteritis Nodosa (PAN) PSGN vs HSP: Feature Post-Streptococcal Glomerulonephritis (PSGN) Henoch-Schönlein Purpura (HSP) / IgA Vasculitis Hypersensitivity Type III (Immune complex-mediated) Type III (Systemic small-vessel vasculitis) Primary Trigger Preceding Group A Strep infection (Pharyngitis or Skin/Impetigo) Often follows an Upper Respiratory Infection (URI) Major Antibody IgG and IgM complexes IgA -dominant immune complexes Kidney Biopsy (IF) "Starry Sky" or Lumpy-bumpy appearance (C3 and IgG deposits) Mesangial IgA deposits (identical to IgA Nephropathy) Complement Levels Low C3 levels (classic finding) Normal complement levels Systemic Features Limited primarily to the kidney (Nephritic syndrome) Tetrad: Palpable purpura (legs/buttocks), Arthralgia, Abdominal pain, Renal disease Latent Period 1–3 weeks after Strep infection Days after URI (much shorter or concurrent)

References:

Robbins & Cotran Pathologic Basis of Disease, 10th Edition, Pages 210-212

↑ *Back to this question in Part A*

@Neet_pg_bot

Q8: Which of the following is typically associated with localized immune-complex mediated hypersensitivity? (Q845440)

A. Serum sickness

B. Arthus reaction

C. Membranous glomerulonephritis

D. Reactive arthritis

Correct Answer: B. Arthus reaction

■ *Listen (English)*

■ *Listen (Hindi)*

Explanation: The “Arthus reaction” is localized immune-complex mediated or Type III hypersensitivity reaction, characterized by localized tissue necrosis caused by acute immune complex vasculitis, often occurring in the skin. Systemic type III hypersensitivity Localised type III hypersensitivity Involves the widespread formation of immune complexes in circulation and can deposit in various tissues and organs throughout the body, including the kidneys (leading to glomerulonephritis), joints, skin, blood vessels, and other sites. (e.g., in chronic infections or autoimmune diseases). Immune complexes are deposited at specific sites of antigen exposure, such as the skin (as in the Arthus reaction) or joint spaces, leading to local inflammation (localized swelling, redness, pain) and tissue

damage. Clinical Examples : Systemic Lupus Erythematosus (SLE) : Complex deposition in multiple organs. Serum Sickness : Reaction to foreign serum proteins (e.g., antivenom or certain medications). Post-Streptococcal Glomerulonephritis (PSGN) : Occurs after certain streptococcal infections. Reactive Arthritis : Joint inflammation triggered by an infection elsewhere in the body. Clinical Examples : Arthus Reaction : Localized skin necrosis following subcutaneous injection of an antigen in a sensitized individual. Hypersensitivity Pneumonitis : Localized lung inflammation (e.g., Farmer's lung) due to inhaled environmental antigens. Local Swelling/Pain : Redness and pain at the site of antigen exposure.

References:

Robbins & Cotran Pathologic Basis of Disease, 10th Edition, Pages 210- 212

↑ *Back to this question in Part A*

@Neet_pg_bot

Q9: A 40-year-old man presents with jaundice and fatigue, recently diagnosed with hepatitis B infection. Further investigation reveals abnormal liver function tests, indicating hepatic injury. Which of the following statements regarding the mechanisms of hypersensitivity involved in this case is true? (Q845442)

A. CD8+ T cells differentiate into Th1 and Th17 cells upon antigen exposure

B. CD4+ T cells differentiate into Th2 cells upon exposure to antigen

C. Cytotoxic T-lymphocytes (CTLs) directly kill virus-infected cells via the Fas-Fas ligand pathway

D. Perforin-granzyme-dependent killing is a mechanism employed by CD4+ T cells

Correct Answer: C. Cytotoxic T-lymphocytes (CTLs) directly kill virus-infected cells via the Fas-Fas ligand pathway

■ *Listen (English)*

■ *Listen (Hindi)*

Explanation: The type of hypersensitivity involved in hepatitis B virus (HBV) infection is Type IV. Mechanisms of Type IV hypersensitivity Description Examples Cytokine-mediated inflammation (mediated by CD4+ T cells) CD4+ T cells recognise protein antigens presented by APCs and differentiate into Th1 and Th17 cells (Options A and B ruled out) . Th1 cells secrete cytokines like IFN-γ, activating macrophages to cause tissue damage and fibrosis. Th17 cells produce IL-17 to recruit neutrophils, promoting inflammation. Tuberculin test (a classic example of delayed-type hypersensitivity) Granulomas Contact dermatitis Rheumatoid arthritis Multiple sclerosis IBD Psoriasis T cell-mediated cytotoxicity (mediated by CD8+ T cells) Cytotoxic T lymphocytes (CTLs) directly kill antigen-bearing target cells, including tumour cells, virus-infected cells, and allogeneic tissue, during graft rejection. CTLs use perforin-granzyme-dependent killing (Option D ruled out) and Fas-Fas ligand-dependent killing mechanisms to induce apoptosis in target cells. (Option C) Type 1 DM Hepatic injury in HBV infection

Graft vs host disease

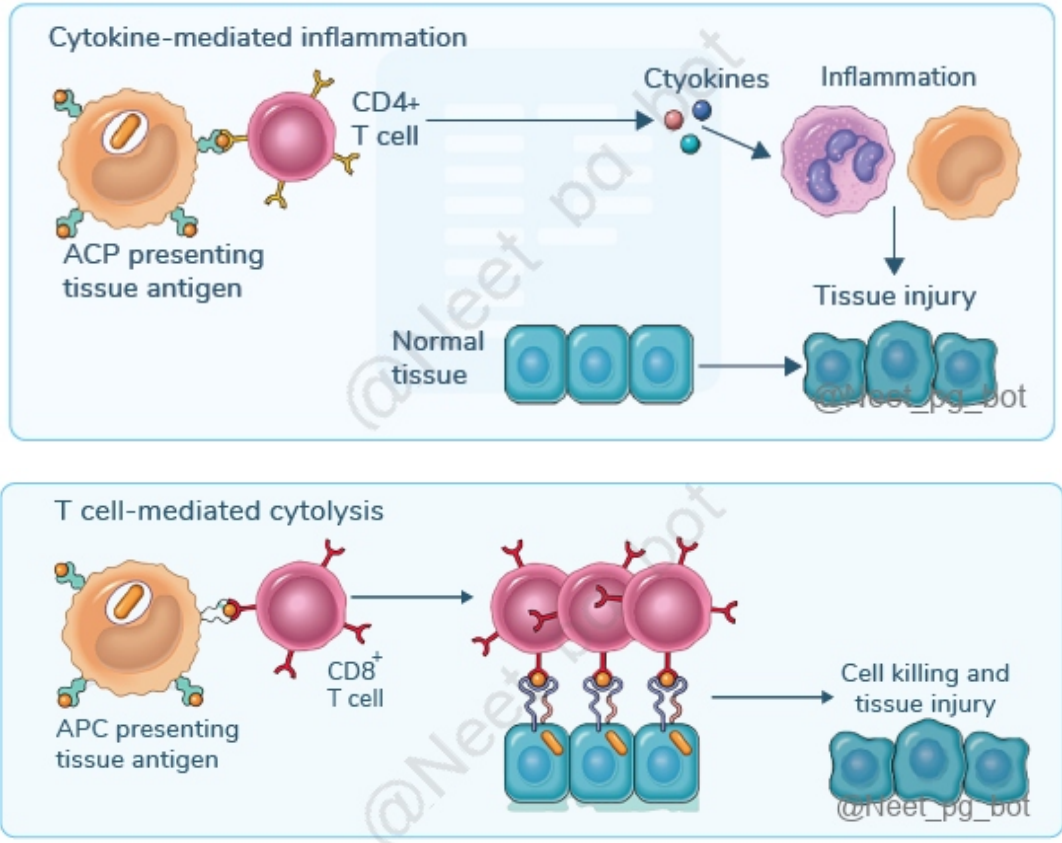

References:

Robbins & Cotran Pathologic Basis of Disease, 10th Edition, Pages 212-215

↑ *Back to this question in Part A*

@Neet_pg_bot

Q10: A 35-year-old woman presents with a history of persistent cough and unintentional weight loss. The physician suspects a TB infection and performs a tuberculin skin test. Which of the following is not an example of the type of hypersensitivity reaction associated with this test? (Q845444)

A. Contact dermatitis from poison ivy exposure.

B. Rheumatoid arthritis.

C. Crohn's disease.

D. Reactive arthritis.

Correct Answer: D. Reactive arthritis.

■ *Listen (English)*

■ *Listen (Hindi)*

Explanation: Reactive arthritis shows Type III hypersensitivity. The tuberculin skin test (TST) mentioned in the scenario represents a cell-mediated hypersensitivity reaction (Type IV or delayed-type hypersensitivity reaction). The tuberculin skin test (TST), or Mantoux test, detects latent tuberculosis infection (LTBI) by injecting a small amount of purified protein derivative (PPD) intradermally over the forearm. Examples of Type IV hypersensitivity reactions: Contact dermatitis from exposure to Urushiol from poison ivy or poison oak Detergent Artificial jewellery (Ni and Cd) Granuloma Mantoux test Lepromin test Inflammatory Bowel Disease (Crohn's disease) Rheumatoid arthritis (Type IV > Type III hypersensitivity) Multiple sclerosis Sarcoidosis Psoriasis



References:

Robbins & Cotran Pathologic Basis of Disease, 10th Edition, Pages 213

↑ *Back to this question in Part A*

@Neet_pg_bot

Q11: Which of the following statements accurately describes Type V hypersensitivity? (Q845446)

A. Antibodies bind to cell surface receptors, leading to altered cellular function

B. Immune complexes form and deposit in tissues, triggering localized inflammation and damage.

C. Antibodies target cell surface antigens, resulting in complement activation and cell destruction.

D. IgE antibodies mediate the release of histamine from mast cells, causing immediate allergic reactions.

Correct Answer: A. Antibodies bind to cell surface receptors, leading to altered cellular function

■ *Listen (English)*

■ *Listen (Hindi)*

Explanation: Type V hypersensitivity: Involves IgG antibodies binding to cell surface receptors, altering the normal function of those cells. The antibodies may mimic hormones or block receptor function Leads to altered cellular activity without direct destruction of the cells. It can cause overstimulation or inhibition of normal cellular functions. Graves' disease: Antibodies stimulate the thyroid hormone receptor, causing hyperthyroidism. Myasthenia gravis : Antibodies block acetylcholine receptors at the neuromuscular junction, leading to muscle weakness. IgE antibodies mediate the release of histamine from mast cells, causing immediate allergic reactions (Option B) is a hallmark of Type I hypersensitivity, involving immediate reactions and allergic responses mediated by IgE. Immune complexes form and deposit in tissues, triggering localized inflammation and damage (Option C) describes Type III hypersensitivity, which involves immune complex deposition leading to inflammation. Antibodies target cell surface antigens, resulting in complement activation and cell destruction (Option D) is characteristic of Type II hypersensitivity, where antibody binding leads to direct cell damage through complement activation.

References:

https://www.medicalnewstoday.com/articles/hypersensitivity-reactions#type-3

https://dermnetnz.org/topics/allergies-explained

↑ *Back to this question in Part A*

@Neet_pg_bot

Q12: Which of the following sequences correctly describes the phases of pathogenesis in Type III hypersensitivity? (Q845447)

A. Formation of immune complexes → Inflammation and tissue injury → Deposition in blood vessels.

B. Deposition of immune complexes → Formation of antibodies → Tissue injury and inflammation.

C. Formation of immune complexes → Deposition in tissues → Inflammation and tissue injury.

D. Antibody production → Immune complex formation → Activation of cytotoxic T cells.

Correct Answer: C. Formation of immune complexes → Deposition in tissues → Inflammation and tissue injury.

■ *Listen (English)*

■ *Listen (Hindi)*

Explanation: Phases of Type 3 hypersensitivity: 1. Formation of Immune Complexes : After introducing a protein antigen, antibodies are formed (typically within one week) and react with the antigen in circulation, creating antigen-antibody complexes. 2. Deposition of Immune Complexes : These complexes circulate and are deposited in blood vessels, particularly in organs like the kidneys and joints. Medium-sized complexes formed in slight antigen excess are most pathogenic. 3. Inflammation and Tissue Injury: Deposited immune complexes trigger acute inflammation about 10 days post-antigen exposure, leading to symptoms like fever, joint pain, and proteinuria. Complement activation contributes to tissue injury, with serum C3 levels potentially serving as a marker for disease activity.

References:

Robbins & Cotran Pathologic Basis of Disease, 10th Edition, Pages 211, 212

↑ *Back to this question in Part A*

@Neet_pg_bot

• [05_Immunity] 021 Immune Tolerance And Autoimmune Disease

« Back to Folder Directory

[05_Immunity] 021 Immune Tolerance And Autoimmune Disease — Quick Jump

Q1 (p. 1478)	*Q2 (p. 1478)*	*Q3 (p. 1479)*	*Q4 (p. 1480)*	*Q5 (p. 1481)*	*Q6 (p. 1482)*
Q7 (p. 1483)	*Q8 (p. 1484)*	*Q9 (p. 1484)*	*Q10 (p. 1485)*	*Q11 (p. 1486)*	*Q12 (p. 1486)*
Q13 (p. 1487)	*Q14 (p. 1488)*	*Q15 (p. 1488)*	*Q16 (p. 1489)*	*Q17 (p. 1490)*	*Q18 (p. 1491)*
Q19 (p. 1492)	*Q20 (p. 1493)*	*Q21 (p. 1497)*	*Q22 (p. 1500)*	*Q23 (p. 1502)*	*Q24 (p. 1503)*
Q25 (p. 1505)	*Q26 (p. 1507)*	*Q27 (p. 1509)*	*Q28 (p. 1510)*	*Q29 (p. 1513)*	*Q30 (p. 1514)*
Q31 (p. 1516)	*Q32 (p. 1517)*				

Q1: In healthy individuals, what is the typical ratio of CD4+ to CD8+ T lymphocytes? (Q890517)

A. 1:2

B. 2:1

C. 1:4

D. 4:1

Correct Answer: B. 2:1

Explanation: In the peripheral blood of healthy adults, T lymphocytes constitute about 60–70% of circulating lymphocytes , of which approximately 60% are CD4+ (helper T cells) and about 30% are CD8+ (cytotoxic T cells) , resulting in a CD4+:CD8+ ratio of approximately 2:1 . CD4+ T cells primarily function as helper cells that activate macrophages and B cells, whereas CD8+ T cells function as cytotoxic T lymphocytes that destroy infected cells. A decreased CD4+:CD8+ ratio is classically seen in HIV infection due to progressive depletion of CD4+ T cells.

References:

Robbins, Cotran & Kumar Pathologic Basis of Disease, 11th Edition, Page 173

↑ *Back to this question in Part A*

@Neet_pg_bot

Q2: Which of the following conditions belongs to the spectrum of IgG4-related disorders? Mikulicz syndrome Riedel thyroiditis Idiopathic retroperitoneal fibrosis Autoimmune pancreatitis Sclerosing cholangitis (Q890556)

A. 1,2

B. 1,2,4

C. 1,4,5

D. All of the above

Correct Answer: D. All of the above

Explanation: IgG4-related disease (IgG4-RD) is a systemic fibroinflammatory disorder characterized by dense lymphoplasmacytic infiltrates rich in IgG4-positive plasma cells, storiform fibrosis, and obliterative phlebitis , often with increased serum IgG4 levels . It can involve multiple organ systems, and several conditions previously thought to be isolated diseases are now recognized as part of this spectrum, including: Mikulicz syndrome (salivary and lacrimal gland involvement) Riedel thyroiditis Idiopathic retroperitoneal fibrosis Autoimmune pancreatitis (prototype lesion) Sclerosing cholangitis These conditions represent different manifestations of a single multisystem disease process .

References:

Robbins, Cotran & Kumar Pathologic Basis of Disease, 11th Edition, Page 207

↑ *Back to this question in Part A*

@Neet_pg_bot

Q3: Which of the following best describes the cell type that forms the characteristic lupus erythematosus (LE) cell? (Q890555)

A. Monocyte

B. Neutrophil

C. Basophil

D. Lymphocyte

Correct Answer: B. Neutrophil

Explanation: The classic lupus erythematosus (LE) cell is a phagocytic leukocyte, most commonly a neutrophil that has engulfed the denatured nuclear material of another injured cell. This nuclear material is coated with antinuclear antibodies (ANA) , forming a homogeneous, round inclusion called an LE body , which

characteristically displaces the neutrophil nucleus to the periphery . This phenomenon reflects immune complex formation against nuclear antigens in systemic lupus erythematosus (SLE) and was historically used as a diagnostic test. Monocyte (Option A): Occasionally, monocytes can form LE cells by engulfing denatured nuclear material, but this is less common. Basophil (Option C): Basophils do not form LE cells; their role is mainly in allergic reactions. Lymphocyte (Option D): Lymphocytes are the source of autoantibodies but do not form LE cells.

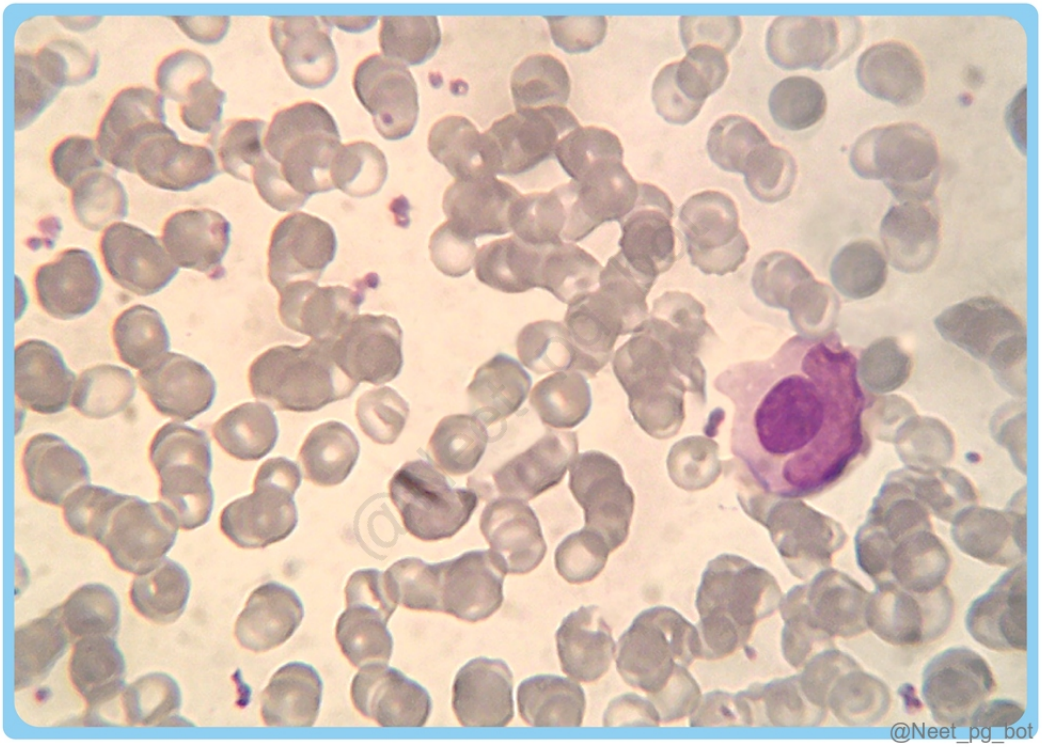

References:

Robbins, Cotran & Kumar Pathologic Basis of Disease, 11th Edition, Page 200

↑ *Back to this question in Part A*

@Neet_pg_bot

Q4: Which of the following autoantibodies is least likely to cause a homogeneous nuclear staining pattern on immunofluorescence? (Q890554)

A. Anti-histone antibodies

B. Anti-chromatin antibodies

C. Anti-double-stranded DNA antibodies

D. Anti-RNA antibodies

Correct Answer: D. Anti-RNA antibodies

Explanation: Anti-RNA-associated antibodies (such as anti-Sm and anti-U1 RNP) target ribonucleoproteins and characteristically produce a speckled nuclear staining pattern on immunofluorescence rather than a homogeneous pattern. In contrast, a homogeneous (diffuse) nuclear staining pattern is typically produced by antibodies directed against double-stranded DNA, chromatin (nucleosomes), and histones , which are components of tightly packed nuclear material. Anti-histone antibodies (Option A) are associated with homogeneous staining , commonly seen in drug-induced lupus. Anti-chromatin antibodies (Option B) target nucleosomes and produce a homogeneous pattern . Anti-double stranded DNA antibodies (Option C) are classically associated with a homogeneous nuclear staining pattern and are strongly linked to systemic lupus erythematosus.

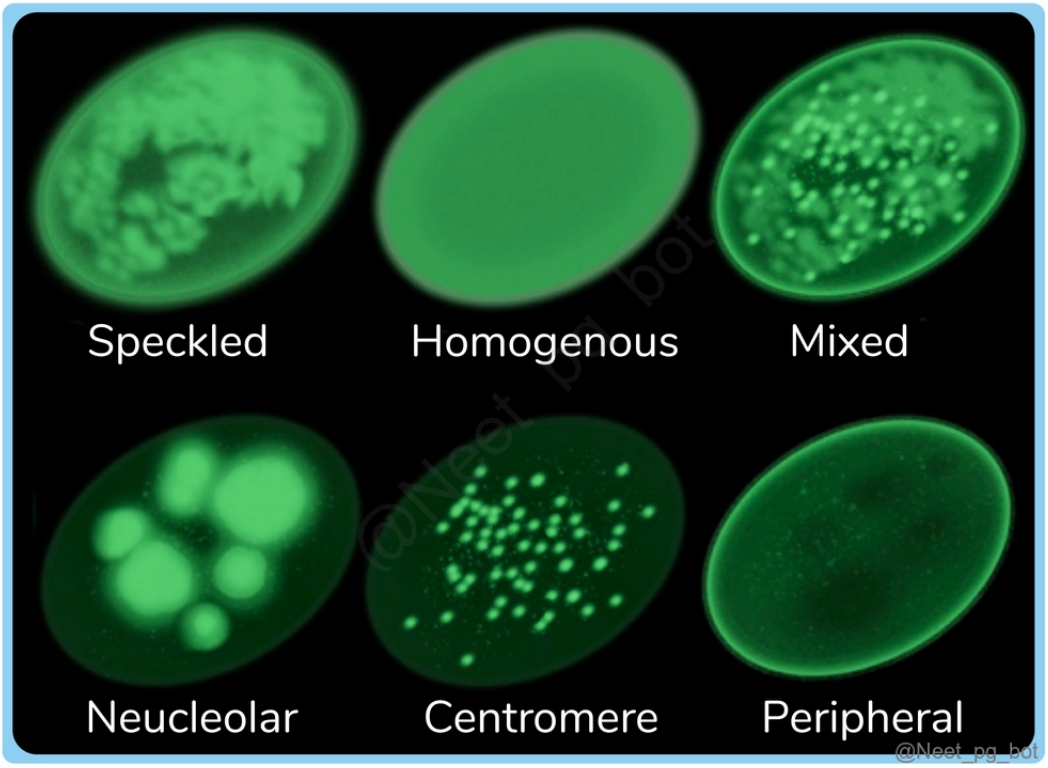

References:

Robbins, Cotran & Kumar Pathologic Basis of Disease, 11th Edition, Page 198

↑ *Back to this question in Part A*

@Neet_pg_bot

Q5: Which mechanism primarily contributes to the development of autoimmunity in Epstein-Barr virus infection? (Q890553)

A. Molecular mimicry

B. Polyclonal B-cell activation

C. Upregulation of co-stimulatory molecules

D. Cross-reactive antigen recognition

Correct Answer: B. Polyclonal B-cell activation

Explanation: Epstein-Barr virus (EBV) infects B lymphocytes via the CD21 receptor and induces their proliferation and survival by activating signaling pathways such as NF-κB and JAK/STAT . EBV acts as a polyclonal B-cell mitogen , leading to expansion of multiple B-cell clones. This nonspecific activation of B cells can result in the production of a wide range of antibodies, including potentially autoreactive antibodies , thereby contributing to breakdown of self-tolerance and development of autoimmunity. Molecular mimicry (Option A) is a general mechanism of autoimmunity but is not the primary mechanism associated with EBV in this context. Upregulation of co-stimulatory molecules (Option C) represents a general mechanism of immune activation and is not specific to EBV-induced autoimmunity. Cross-reactive antigen recognition (Option D) overlaps with molecular mimicry and is not the dominant mechanism in EBV infection.

References:

Robbins, Cotran & Kumar Pathologic Basis of Disease, 11th Edition, Page 291

↑ *Back to this question in Part A*

@Neet_pg_bot

Q6: Which of the following genes is a frequently implicated non-HLA susceptibility gene associated with multiple autoimmune diseases? (Q890552)

A. FOXP3

B. PTPN22

C. NOD2

D. AIRE

Correct Answer: B. PTPN22

Explanation: Polymorphisms in the PTPN22 gene are frequently associated with multiple autoimmune diseases , including type 1 diabetes, rheumatoid arthritis, systemic lupus erythematosus, Graves' disease, and Hashimoto thyroiditis. PTPN22 encodes a protein tyrosine phosphatase that negatively regulates T-cell receptor signaling , and disease-associated variants may impair this regulatory function, leading to excessive activation of self-reactive lymphocytes and loss of immune tolerance. FOXP3 (Option A) mutations cause immune dysregulation syndromes such as IPEX due to defective regulatory T cells, but these are rare monogenic disorders and not broadly

associated with common autoimmune diseases. NOD2 (Option C) is primarily associated with Crohn's disease , involving innate immune dysfunction and abnormal responses to gut microbes rather than generalized autoimmunity. AIRE (Option D) mutations cause autoimmune polyendocrine syndrome type 1 (APS-1) , a rare monogenic disorder due to defective central tolerance.

References:

Robbins, Cotran & Kumar Pathologic Basis of Disease, 11th Edition, Page 194

↑ *Back to this question in Part A*

@Neet_pg_bot

Q7: Which of the following autoimmune diseases is predominantly driven by T cell-mediated inflammation, although autoantibodies and immune complexes also contribute to its pathogenesis? (Q890551)

A. Pemphigus vulgaris

B. Pernicious anemia

C. Rheumatoid arthritis

D. Goodpasture syndrome

Correct Answer: C. Rheumatoid arthritis

Explanation: Rheumatoid arthritis is a chronic systemic autoimmune disease predominantly driven by CD4■ T cells (Th1 and Th17) , which initiate and sustain synovial inflammation through cytokines such as TNF-α, IL-17, IL-6, and IFN-γ . These cytokines activate macrophages and synovial fibroblasts, leading to chronic inflammation, angiogenesis, and formation of pannus , an invasive granulation tissue that progressively destroys articular cartilage and subchondral bone . In addition, autoantibodies , notably rheumatoid factor (RF) and anti-cyclic citrullinated peptide (anti-CCP) form immune complexes that further amplify inflammation via complement activation. Thus, rheumatoid arthritis is a T-cell-dominant autoimmune disease with significant contribution from humoral immunity , representing a mixed (Type IV + Type III) mechanism of tissue injury . Pemphigus vulgaris (Option A) is an antibody-mediated (Type II hypersensitivity) disorder caused by IgG antibodies against desmogleins, leading to loss of cell adhesion (acantholysis) and blister formation. Pernicious anemia (Option B) is primarily antibody-mediated , involving antibodies against intrinsic factor and parietal cells, causing vitamin B12 deficiency; associated T-cell-mediated gastric mucosal damage may also contribute. Goodpasture syndrome (Option D) is a classic Type II hypersensitivity disease in which antibodies against basement membrane (type IV collagen) trigger complement activation and inflammation, leading to glomerulonephritis and pulmonary hemorrhage.

References:

Robbins, Cotran & Kumar Pathologic Basis of Disease, 11th Edition, Pages 187, 190

↑ *Back to this question in Part A*

@Neet_pg_bot

Q8: Which of the following proteins are encoded by genes in the MHC class III region? Complement component C4 Tumour necrosis factor (TNF) Heat shock proteins β2-microglobulin (Q890532)

A. 2,3

B. 1,3,4

C. 1,2,3

D. 4 only

Correct Answer: C. 1,2,3

Explanation: The MHC class III region (located on chromosome 6p21.3) encodes a variety of proteins involved in inflammation and innate immunity , rather than antigen presentation. These include: Complement components such as C2, C4, and factor B Cytokines , including TNF-α and lymphotoxins (LTA, LTB) Heat shock proteins Unlike MHC class I and II molecules, MHC class III does not encode antigen-presenting molecules , but instead produces proteins that participate in immune and inflammatory responses. β2-microglobulin (4): It is a component of MHC class I molecules but is encoded outside the MHC locus (chromosome 15).

References:

Robbins, Cotran & Kumar Pathologic Basis of Disease, 11th Edition, Page 175

https://en.wikipedia.org/wiki/MHC_class_III

↑ *Back to this question in Part A*

@Neet_pg_bot

Q9: Which of the following cytokines is a potent activator of basophils? (Q890529)

A. IL-3

B. IL-2

C. IFN-γ

D. TNF-α

Correct Answer: A. IL-3

Explanation: IL-3 is a key cytokine that promotes basophil growth, survival, and activation , and enhances their effector functions such as histamine release and leukotriene production . It also increases basophil responsiveness to various stimuli , making it a potent activator in allergic and inflammatory responses. IL-2 (Option B): Primarily stimulates T-cell proliferation and activation , with no major role in basophil activation. IFN-γ (Option C): Activates macrophages and promotes Th1 immune responses , not basophil activation. TNF-α (Option D): A pro-inflammatory cytokine involved in systemic inflammation, but not a primary activator of basophils.

References:

https://pmc.ncbi.nlm.nih.gov/articles/PMC2119199/

↑ *Back to this question in Part A*

@Neet_pg_bot

Q10: Which of the following statements about γδ T-cells are correct? They kill extracellular bacteria using granulysin and perforin. They require antigen processing and presentation for recognition. They can directly kill infected macrophages. They protect against mycobacterial infections. (Q890528)

A. 2 only

B. 1,2

C. 2,3,4

D. 1,3,4

Correct Answer: D. 1,3,4

Explanation: γδ T cells are a subset of T lymphocytes that recognise peptides, lipids, and small molecules without requiring MHC-mediated antigen presentation , and are commonly found at epithelial surfaces , where they contribute to early immune defence. They possess cytotoxic functions and can release molecules such as perforin and granulysin , contributing to antimicrobial activity. (Statement 1) γδ T cells have cytotoxic potential and can target infected macrophages. (Statement 3) They also contribute to host defence against intracellular pathogens , including mycobacteria, through cytotoxic activity and cytokine production. (Statement 4) γδ T cells do not require classical MHC-restricted antigen presentation. (Statement 2)

References:

Robbins, Cotran & Kumar Pathologic Basis of Disease, 11th Edition, Pages 172-173

↑ *Back to this question in Part A*

@Neet_pg_bot

Q11: Which of the following cell types shows recirculation? (Q890526)

A. Plasma cells

B. T lymphocytes

C. Plasma cells and T lymphocytes

D. B lymphocytes and plasma cells

Correct Answer: B. T lymphocytes

Explanation: Lymphocytes continuously recirculate between the blood and secondary lymphoid organs. This process is most important for T lymphocytes , which migrate through lymphoid tissues to encounter antigen and to sites of infection to perform effector functions. Although B lymphocytes also recirculate , plasma cells are terminally differentiated cells that reside in the bone marrow and lymphoid tissues and do not recirculate, as they secrete antibodies that act at distant sites. Plasma cells (Option A): Do not recirculate; they are tissue-resident antibody-secreting cells.

References:

Robbins, Cotran & Kumar Pathologic Basis of Disease, 11th Edition, Page 174

↑ *Back to this question in Part A*

@Neet_pg_bot

Q12: Papain digestion of an immunoglobulin molecule produces which of the following end products? (Q890525)

A. 2 Fc and 1 Fab fragments

B. 1 variable chain and 1 constant chain

C. 1 Fc and 2 Fab fragments

D. 2 Fc and 2 Fab fragments

Correct Answer: C. 1 Fc and 2 Fab fragments

Explanation: Papain cleaves the immunoglobulin molecule at the hinge region above the interchain disulfide bonds , separating the antigen-binding arms from the constant region. This produces two Fab fragments , each with a single antigen-binding site (monovalent), and one intact Fc fragment , which mediates effector functions such as

complement activation and Fc receptor binding. In contrast, pepsin cleaves below the hinge region , resulting in a single F(ab')■ fragment , in which the two Fab portions remain linked (bivalent), while the Fc region is degraded into smaller fragments. Thus, papain generates separate Fab fragments and an intact Fc , whereas pepsin preserves the linkage between Fab regions but destroys the Fc portion.

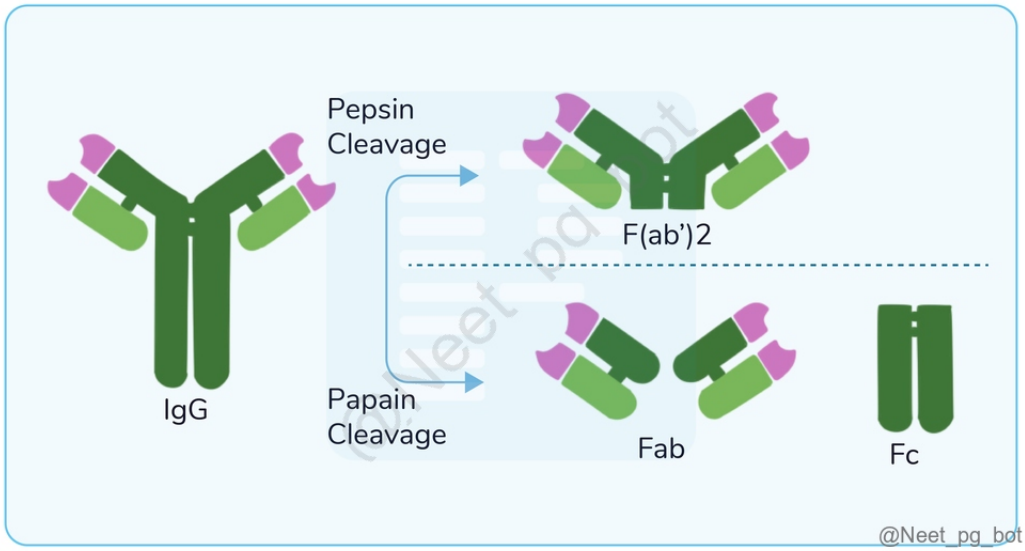

References:

https://pmc.ncbi.nlm.nih.gov/articles/PMC9137653/

↑ *Back to this question in Part A*

@Neet_pg_bot

Q13: Which class of antibodies is primarily produced in response to polysaccharide and lipid antigens? (Q890524)

A. IgG

B. IgM

C. IgD

D. IgA

Correct Answer: B. IgM

Explanation: Polysaccharide and lipid antigens are T-cell-independent antigens that activate B cells without T-cell help. Because these responses lack CD40L and cytokine-mediated signals from helper T cells , there is minimal or no class switching , and the predominant antibody produced is IgM . In contrast, protein antigens induce T cell-dependent responses , which involve helper T cells and lead to isotype switching with production of IgG, IgA,

or IgE , as well as affinity maturation. IgG (Option A): Produced after class switching in T cell-dependent responses. IgD (Option C): Primarily expressed on the surface of naive B cells and not secreted in significant amounts. IgA (Option D): Produced after class switching, especially in mucosal immune responses.

References:

Robbins, Cotran & Kumar Pathologic Basis of Disease, 11th Edition, Page 179

↑ *Back to this question in Part A*

@Neet_pg_bot

Q14: Which cytokine primarily stimulates B cells to induce and produce IgE antibodies? (Q890523)

A. IL-1

B. IL-2

C. IL-4

D. IL-6

Correct Answer: C. IL-4

Explanation: IL-4 is the principal cytokine that induces class switch recombination to IgE in B cells. It is produced by Th2 helper T cells and plays a central role in type 2 immune responses and allergic diseases . IL-4–mediated IgE production leads to sensitisation of mast cells and is a key mechanism in type I hypersensitivity reactions . IL-13 may also promote IgE production , but IL-4 is the primary cytokine responsible for class switching. IL-1 (Option A): A pro-inflammatory cytokine involved in innate immune responses; it does not induce IgE class switching. IL-2 (Option B): Primarily promotes T-cell proliferation and survival, without a direct role in IgE production. IL-6 (Option D): Promotes B-cell differentiation into plasma cells , but is not specifically involved in IgE class switching.

References:

Robbins, Cotran & Kumar Pathologic Basis of Disease, 11th Edition, Page 624

↑ *Back to this question in Part A*

@Neet_pg_bot

Q15: On antigen-presenting cells, which of the following molecules provide the necessary costimulatory signals to activate T cells? (Q890521)

A. CD28 and CD86

B. CD80 only

C. CD28 and CD80

D. CD80 and CD86

Correct Answer: D. CD80 and CD86

Explanation: The principal costimulators for T-cell activation are the B7 proteins—CD80 (B7-1) and CD86 (B7-2) , which are expressed on antigen-presenting cells (APCs) and bind to CD28 on naive T cells . Activation of T cells requires two signals: Signal 1: Recognition of antigen presented by MHC molecules via the T-cell receptor (TCR) Signal 2 (costimulation): Interaction of CD80/CD86 on APCs with CD28 on T cells Costimulatory molecules are induced on APCs during innate immune responses to microbes , ensuring that adaptive immune responses are generated appropriately. In the absence of costimulation, T cells become anergic (functionally unresponsive) . CD28 and CD86 (Option A): CD28 is expressed on T cells, not on APCs. CD80 only (Option B): Both CD80 and CD86 function as costimulators; CD80 alone is not sufficient as the best answer. CD28 and CD80 (Option C): CD28 is present on T cells, whereas CD80 is on APCs; both are not expressed on APCs.

References:

Robbins, Cotran & Kumar Pathologic Basis of Disease, 11th Edition, Page 177

↑ *Back to this question in Part A*

@Neet_pg_bot

Q16: Which feature is shared by both natural killer (NK) cells and cytotoxic T lymphocytes (CTLs)? (Q890519)

A. They are restricted by MHC class I molecules

B. They need antibodies to mediate their effect

C. They can target virus-infected cells

D. Their activity is antigen-specific

Correct Answer: C. They can target virus-infected cells

Explanation: Both natural killer (NK) cells (innate immunity) and cytotoxic T lymphocytes (CTLs) (adaptive immunity) are capable of killing virus-infected cells . NK cells recognise target cells with reduced MHC class I expression and do not require antigen-specific recognition. CTLs (CD8+ T cells) recognise viral peptides presented on MHC class I molecules and require antigen-specific activation. Thus, while their mechanisms differ, both cell types share the ability to eliminate virus-infected cells. They are restricted by MHC class I molecules (Option A): Only CTLs are MHC class I–restricted; NK cells are not restricted and instead detect decreased MHC

class I expression. They need antibodies to mediate their effect (Option B): NK cells can mediate antibody-dependent cellular cytotoxicity (ADCC), but CTLs do not use antibodies and kill target cells directly. Their activity is antigen-specific (Option D): CTLs are antigen-specific, whereas NK cells are not and act through innate immune recognition.

References:

https://arxiv.org/abs/2002.09325

Robbins, Cotran & Kumar Pathologic Basis of Disease, 11th Edition, Page 647

↑ *Back to this question in Part A*

@Neet_pg_bot

Q17: A 5-year-old boy presents with severe, chronic diarrhoea, failure to thrive, and a rash. His medical history includes a diagnosis of type 1 diabetes mellitus and thyroiditis. Laboratory tests show elevated levels of anti-enterocyte antibodies. Based on these findings, which mechanism is most likely impaired in this patient's condition? (Q845501)

A. Central tolerance

B. Peripheral tolerance

C. Anergy

D. Hidden antigen

Correct Answer: B. Peripheral tolerance

■ *Listen (English)*

■ *Listen (Hindi)*

Explanation: The clinical scenario likely describes IPEX (immune dysregulation, polyendocrinopathy, enteropathy, X-linked) due to defective peripheral tolerance. IPEX is an X-linked immune dysregulation disorder that presents in childhood. It occurs due to defects in the FOXP3 gene, which plays a crucial role in peripheral tolerance mediated by CD4+ T regulatory cells. Defects in FOXP3 lead to dysfunctional CD4+ T regulatory cells, impairing their ability to maintain immune tolerance and resulting in autoimmune reactions against various tissues, particularly within the gastrointestinal tract. Tolerance: Two types of tolerance: Central tolerance Peripheral tolerance Central tolerance: Peripheral tolerance: If central tolerance fails, peripheral tolerance works T Regulatory cells: They are type of CD4 T cells, that started expressing CD25+/IL2 Receptor on them T regulatory cell is made by FOXP3 gene They have an immunosuppressive action Immunosuppression is achieved by ↑-CTLA4 gene and ↑PD1 gene Mutation in FOXP3 gene → IPEX Immune Dysregulation Polyendocrinopathy X linked disorder Mutation of IL2 Receptor is seen in: Inflammatory Bowel disease Multiple sclerosis Killing of Self-reactive cells: Killing occurs by Apoptosis Apoptosis is mediated by CD95/Fas CD95/Fas mutation →

Autoimmune lymphoproliferative syndrome (ALPS) Anergy: T cells: When an antigen enters a cell, the APC presents it via MHC to T cell receptor (made up of α and β chains) Signal 1: Antigen has been presented between the MHC and the T cell receptor Signal 2: Binding of CD28 with CD80 and Cd86 T cell activation requires two signals T cells contain CD28 molecule When CD28 binds to B7.1 (CD80) and B7.2 (CD86), present on APC → signal 2 gets generated When both signals are generated → T cell Activation For Foreign Ag: Signal 1 and 2 will be generated and T cell gets activated In case of Self Ag: Signal 2 will not be generated If only one signal is present, the T cell go into anergy B cells: Signal 1 B cells have IgM and IgD B cell present the antigen to the T cell Signal 2: CD40 receptor on the B cell, binds to CD40 ligand on the T® cell, creating a co-stimulatory signal For Foreign Ag: Signal 1 and 2 will be generated → B cell Activation For Self Ag: Only Signal 1 gets generated → B cell go into anergy Cryptic/Hidden Antigen: Sites where antigens are not exposed to B and T cells B - Brain antigens All brain antigens are hidden by Blood brain barrier, except area Prostema E – Eyes All Eye antigens are hidden by Blood Ocular Barrier, except optic nerve T – Testes All antigens of testes are hidden by Blood Testicular Barrier, except epididymis Example Trauma of eye → Damage to Blood Ocular Barrier → All Ag of the Eye are exposed to B and T cells → Ag considered foreign → Killing (B/L Traumatic Uveitis)

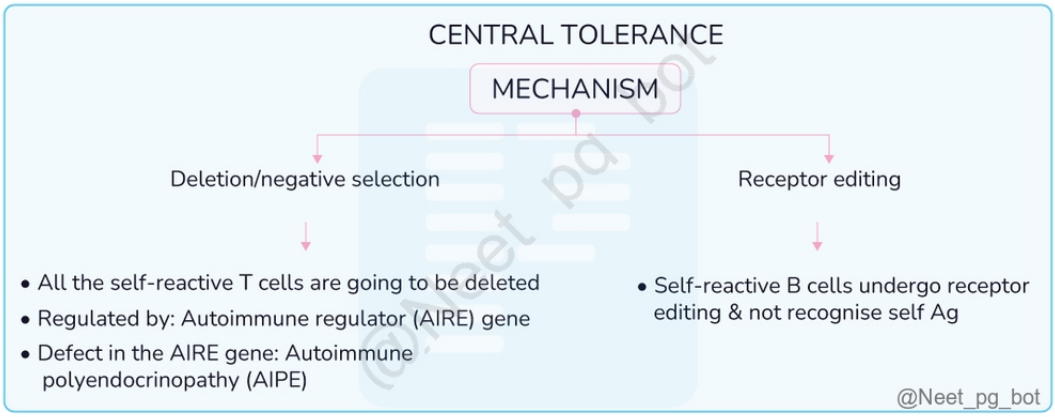

References:

Robbins and Cotran Pathologic Basis of Disease, 10th Edition, Page 217, 1123

https://www.uptodate.com/contents/ipex-immune-dysregulation-polyendocrinopathy-enteropathy-x-linked

↑ *Back to this question in Part A*

@Neet_pg_bot

Q18: Activation of NOD-like receptors by gain-of-function mutations is most likely to result in which of the following conditions? (Q890516)

A. Malignancy

B. Granulomatous disease

C. Autoinflammatory syndrome

D. Autoimmune disorders

Correct Answer: C. Autoinflammatory syndrome

Explanation: Gain-of-function mutations in NOD-like receptors (NLRs) lead to inappropriate activation of the inflammasome , resulting in increased production of interleukin-1 (IL-1) and inflammation. These mutations cause autoinflammatory syndromes , which are characterised by innate immune dysregulation and occur without involvement of adaptive immunity . Although certain mutations (e.g., NOD2) may be associated with granulomatous inflammation , the primary classification of these conditions is autoinflammatory rather than granulomatous or autoimmune. Malignancy (Option A): NOD-like receptor (NLR) gain-of-function mutations are not primarily associated with neoplastic transformation; they mainly cause dysregulated innate immune activation and inflammation. Granulomatous disease (Option B): Granulomatous inflammation can occur (e.g., NOD2 in Blau syndrome), but these conditions are primarily classified as autoinflammatory syndromes rather than granulomatous diseases. Autoimmune disorders (Option D): Autoimmune diseases involve adaptive immunity (T and B cells), whereas autoinflammatory syndromes result from innate immune dysregulation, particularly involving inflammasome activation and IL-1 production.

References:

Robbins, Cotran & Kumar Pathologic Basis of Disease, 11th Edition, Page 67

↑ *Back to this question in Part A*

@Neet_pg_bot

Q19: Which of the following immune cells are capable of mediating antibody-dependent cellular cytotoxicity (ADCC)? (Q890515)

A. Only macrophages

B. Only natural killer (NK) cells

C. Neutrophils and eosinophils

D. NK cells, neutrophils, and eosinophils

Correct Answer: D. NK cells, neutrophils, and eosinophils

Explanation: Antibody-dependent cellular cytotoxicity (ADCC) is a mechanism in which target cells coated with IgG antibodies are recognised by immune effector cells via Fc receptors (FcγR) and are lysed without phagocytosis. Natural killer (NK) cells are the primary and most important mediators of ADCC. Macrophages also play a significant role. In addition, neutrophils and eosinophils can participate in ADCC through Fc receptor–mediated mechanisms. Thus, ADCC is mediated by multiple immune cells, with NK cells being the principal effectors.

References:

Robbins, Cotran & Kumar Pathologic Basis of Disease, 11th Edition, Page 186

https://en.wikipedia.org/wiki/Antibody-dependent_cellular_cytotoxicity

↑ *Back to this question in Part A*

@Neet_pg_bot

Q20: Which of the following is not a feature of dermatomyositis? (Q845621)

Correct Answer: Unknown

- *Listen (English)*
- *Listen (Hindi)*

Explanation: Image B represents panniculitis (raised reddish lesions on skin) which is commonly seen in diseases like erythema nodosum. Dermatomyositis: An inflammatory myopathy that affects skin as well as skeletal muscles. Proximal muscles will be involved. Characteristic rashes include: Gottron papules (Option A) - Raised erythematous rash over metacarphalangeal and interphalangeal joints. Heliotrope rash (Option C) - Erythematous discoloration of eyelids with periorbital edema. Mechanic's hands (Option D) - Presence of fissures/cracks on hands and palms. V-sign (Necklace sign) - Rash on the sun-exposed anterior neck and chest. Shawl sign over the back of the neck and shoulders. Nail bed changes with dilated capillaries. The histological hallmark of dermatomyositis: Perifascicular atrophy (Atrophy of the muscle fibers which are located at the periphery).




@Neet_pg_bot


@Neet_pg_bot


@Neet_pg_bot


@Neet_pg_bot


@Neet_pg_bot


@Neet_pg_bot

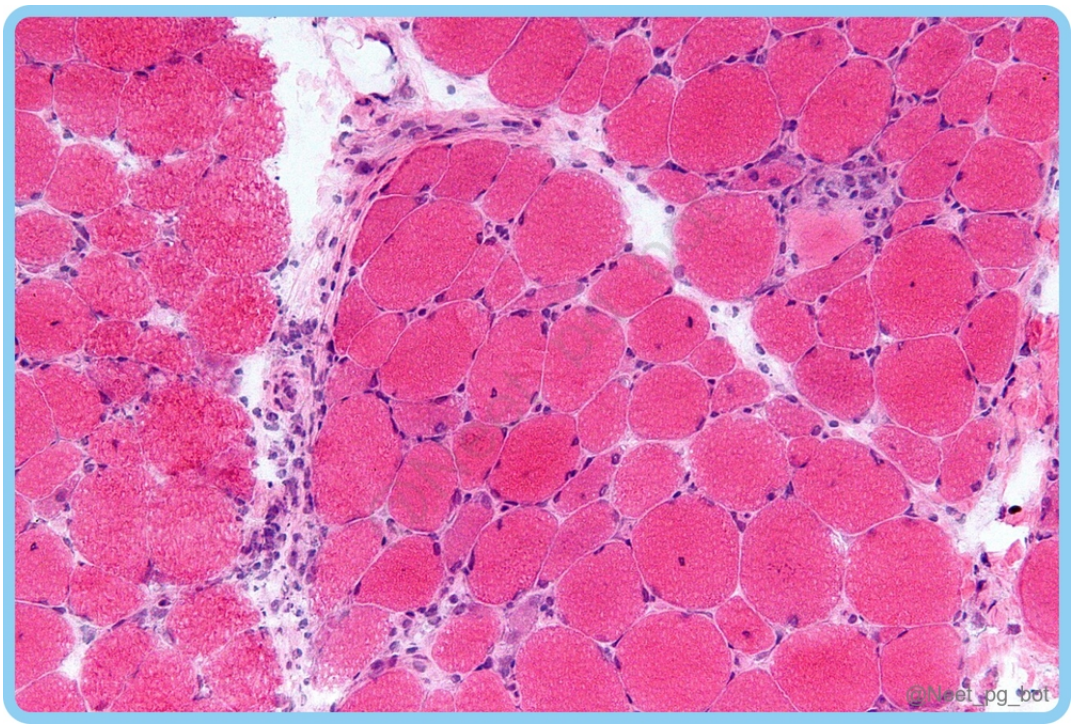

References:

Robbins & Cotran Pathologic Basis of Disease, 10th Edition, Page 1228 - 1230

https://www.ncbi.nlm.nih.gov/books/NBK558917/#article-20389.s8

↑ *Back to this question in Part A*

@Neet_pg_bot

Q21: A 28-year-old female presents with fatigue, joint pain, and a rash. A blood test reveals positive anti-nuclear antibodies. Which of the following fluorescence patterns is most commonly associated with systemic lupus erythematosus (SLE)? (Q845616)

Correct Answer: Unknown

Explanation: The homogeneous fluorescence pattern of ANA is often associated with SLE, reflecting uniform nucleus staining. The most common test for ANAs is indirect immunofluorescence, which detects antibodies to nuclear antigens, with fluorescence patterns indicating the specific antibody type. Four basic patterns are recognized Homogeneous or diffuse staining of nuclei (Option A) Antibodies reactive with dsDNA, nucleosomes, and histones, and is common in systemic lupus erythematosus Speckled pattern (Option B) Antibodies against various nuclear antigens, including Sm and RNPs Nucleolar pattern (Option C) Antibodies against nucleolar proteins Anti-centromere antibodies (Option D) Systemic sclerosis, Sjögren syndrome, and other diseases

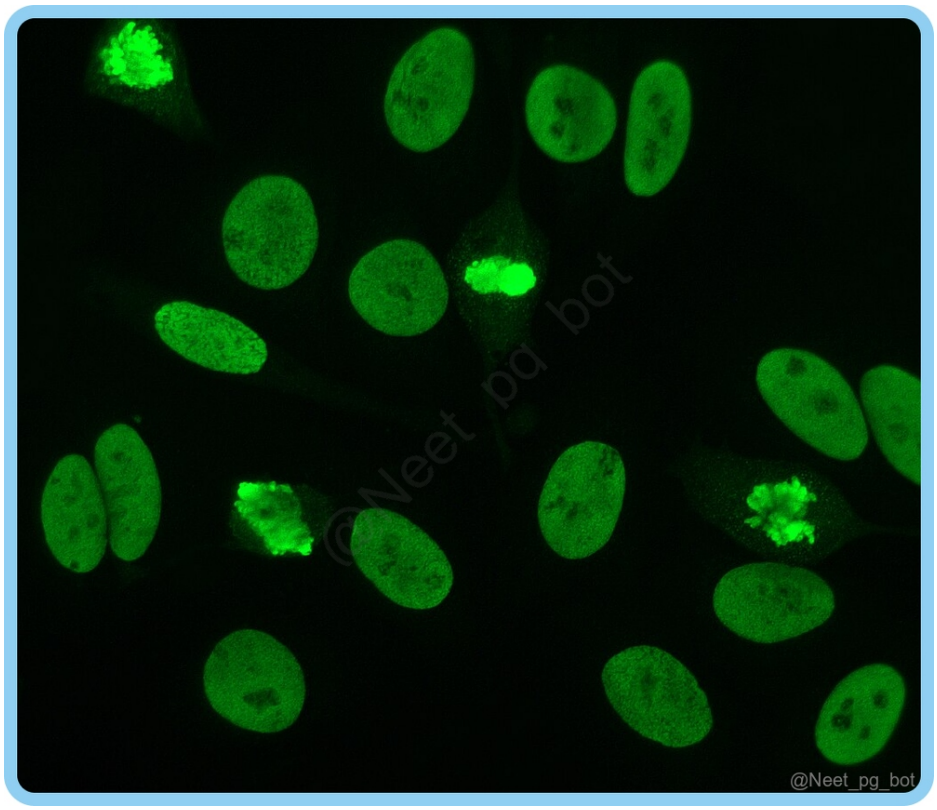
@Neet_pg_bot

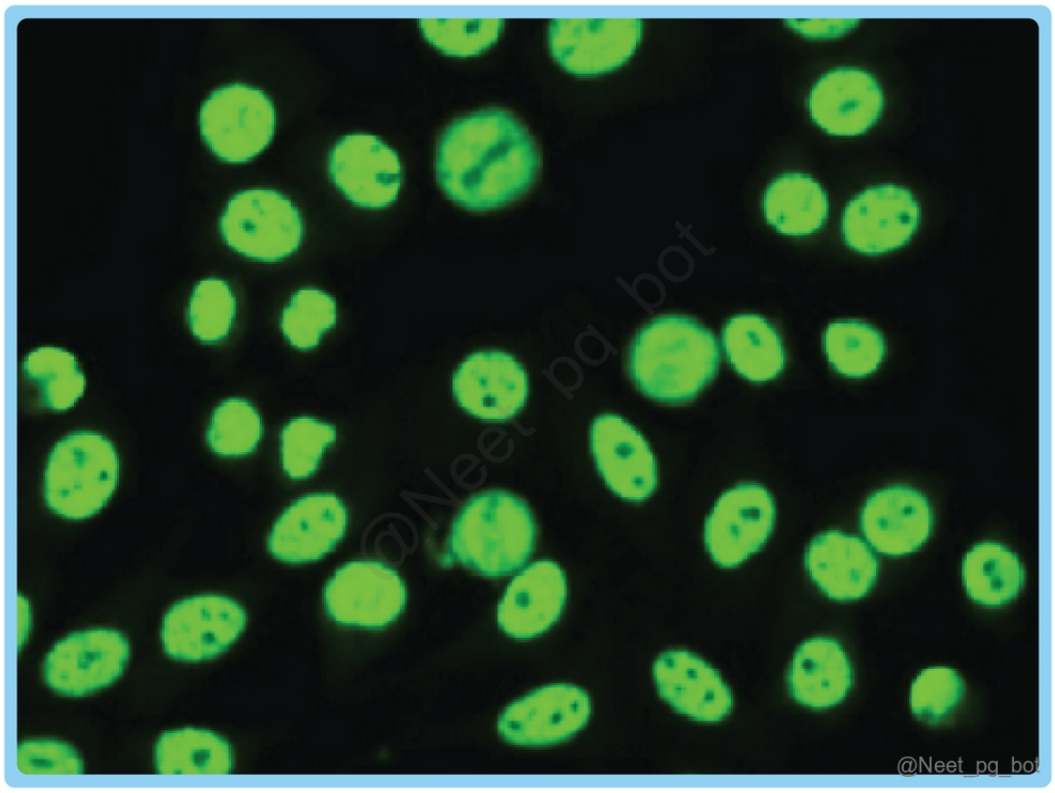
@Neet_pg_bot

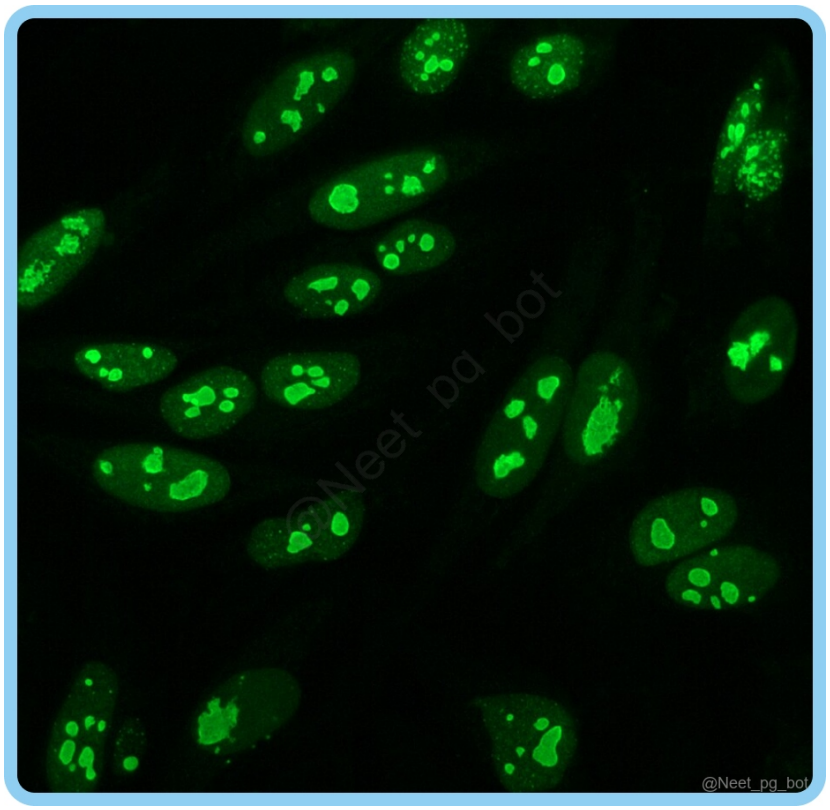

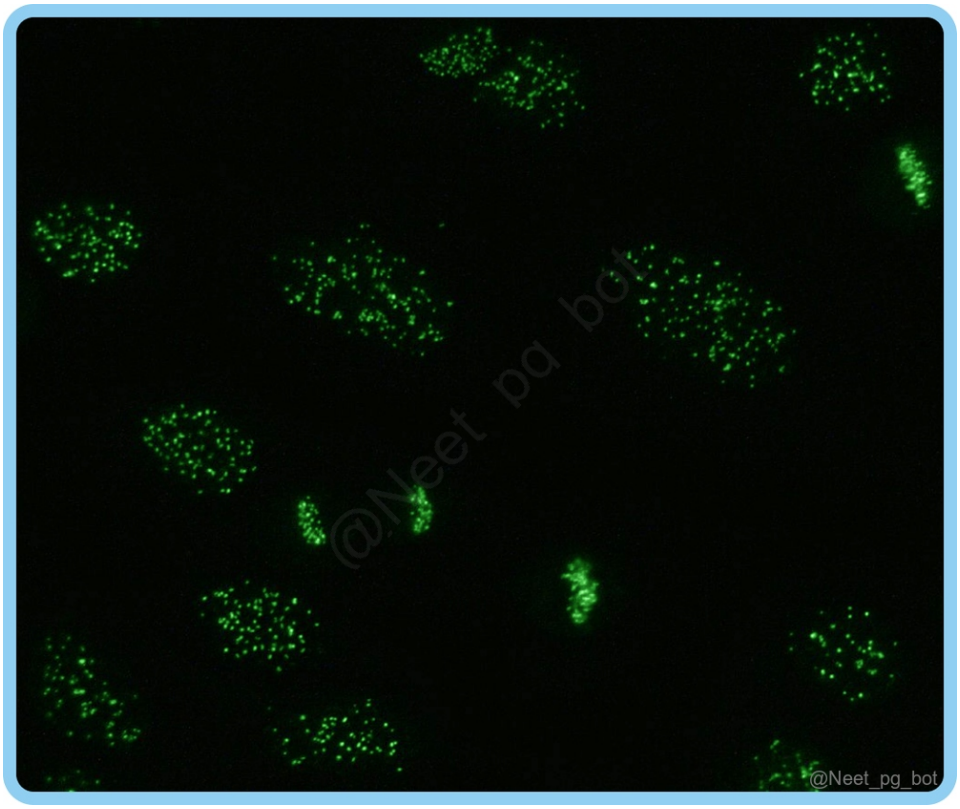

References:

Robbins & Cotran Pathologic Basis of Disease, 10th Edition, Page 223

↑ *Back to this question in Part A*

@Neet_pg_bot

Q22: A 30-year-old woman is being evaluated for proximal muscle weakness. Which of the following is consistent with a diagnosis of polymyositis? (Q845529)

A. CD4+ T cell infiltration in affected tissue

B. Endomysial inflammation

C. Associated with underlying malignancies

D. Vascular injury involved in pathogenesis

Correct Answer: B. Endomysial inflammation

■ *Listen (English)*

■ *Listen (Hindi)*

Explanation: Endomysial inflammation is a consistent feature of polymyositis. Polymyositis is an inflammatory myopathy that typically presents with proximal muscle weakness. It is mediated by CD8+ T lymphocytes . Histologically, it is characterized by an endomysial inflammatory infiltrate with patchy necrosis. Dermatomyositis Histologic findings include ■■■■■■peripheral or peri fascicular infiltrates and atrophy in a segmental pattern. Perifascicular infiltrates: Perifascicular atrophy:

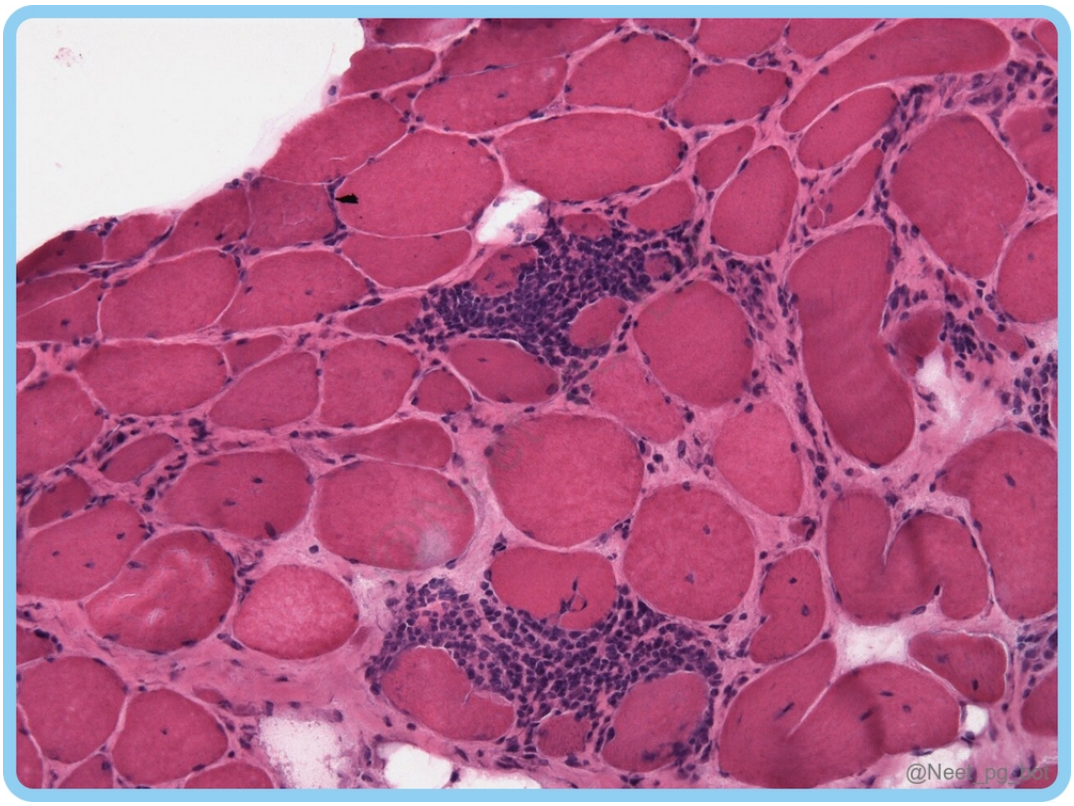

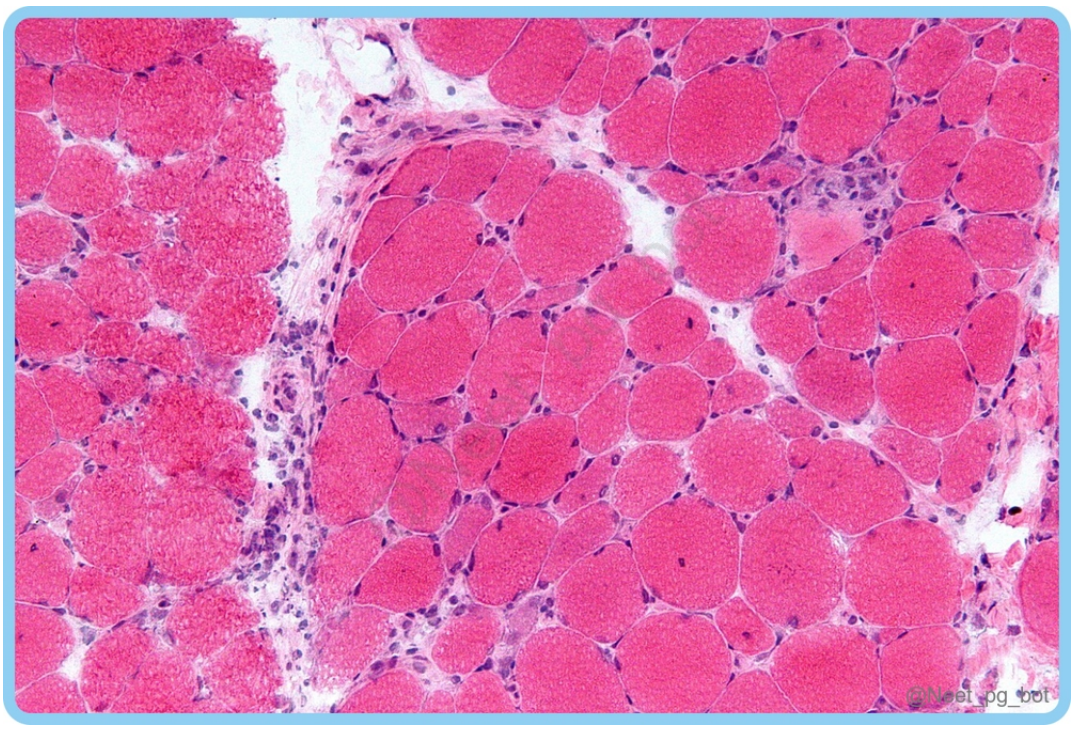

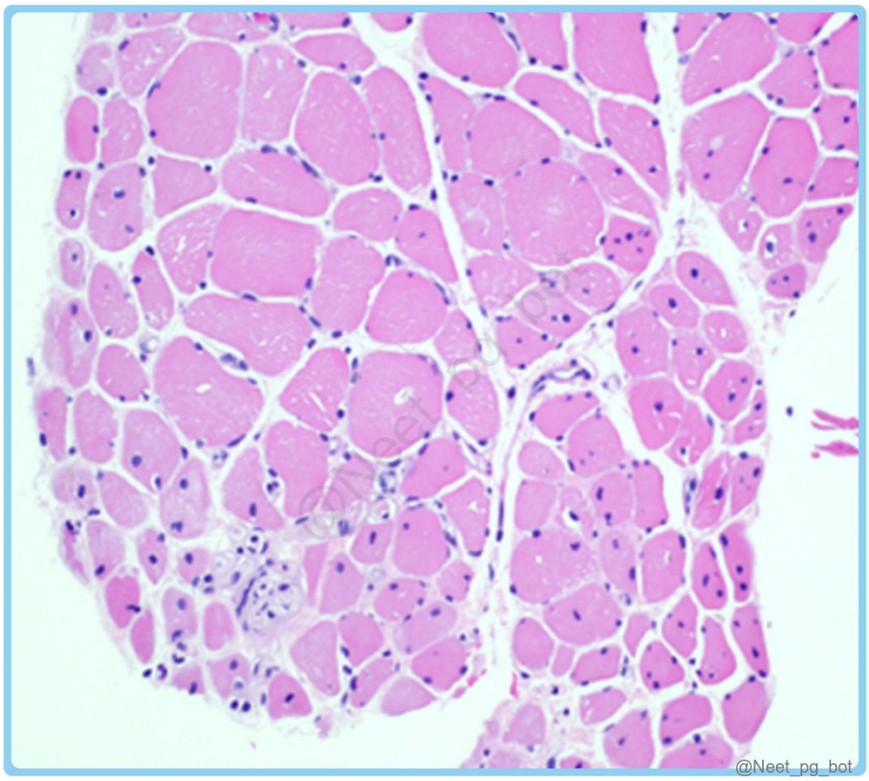

References:

Robbins & Cotran Pathologic Basis of Disease, 10th Edition, Page 1128-1130

www.uptodate.com/contents/clinical-manifestations-of-dermatomyositis-and-polymyositis-in-adults

↑ *Back to this question in Part A*

@Neet_pg_bot

Q23: A 32-year-old woman presents with fatigue, muscle weakness, and joint pain. On examination, she has a rash over her cheeks, along with Raynaud's phenomenon and swollen fingers. Laboratory tests reveal positive anti-U1 RNP antibodies. Which of the following conditions is this patient most likely suffering from? (Q845527)

A. Systemic lupus erythematosus

B. Scleroderma

C. Mixed connective tissue disease

D. Sjögren's syndrome

Correct Answer: C. Mixed connective tissue disease

■ *Listen (English)*

■ *Listen (Hindi)*

Explanation: Mixed connective tissue disease (MCTD) is characterised by a combination of features, including muscle weakness, joint pain, a rash over the cheeks (often referred to as a butterfly or malar rash), Raynaud's phenomenon, and anti-U1 RNP antibodies. MCTD features overlap between systemic lupus erythematosus, scleroderma (systemic sclerosis), and polymyositis . It is characterised by synovitis in the fingers, Raynaud's phenomenon, myositis, and mild renal involvement. Over time, MCTD may progress to classic systemic lupus erythematosus (SLE) or systemic sclerosis. Antibody: Anti-U1 RNP (ribonucleoprotein) antibody . Treatment: Corticosteroids .

References:

Robbins & Cotran Pathologic Basis of Disease, 10th Edition, Page 234

↑ *Back to this question in Part A*

@Neet_pg_bot

Q24: A 45-year-old woman presents with progressive proximal muscle weakness over the past 6 months. On examination, the hip and shoulder girdle muscles have symmetrical weakness. Laboratory investigations show elevated serum creatine kinase (CK) levels. A muscle biopsy reveals endomysial inflammation with CD8+ T lymphocytes and muscle fiber necrosis. Which of the following is the most likely diagnosis? (Q845525)

A. Dermatomyositis

B. Myasthenia gravis

C. Inclusion body myositis

D. Polymyositis

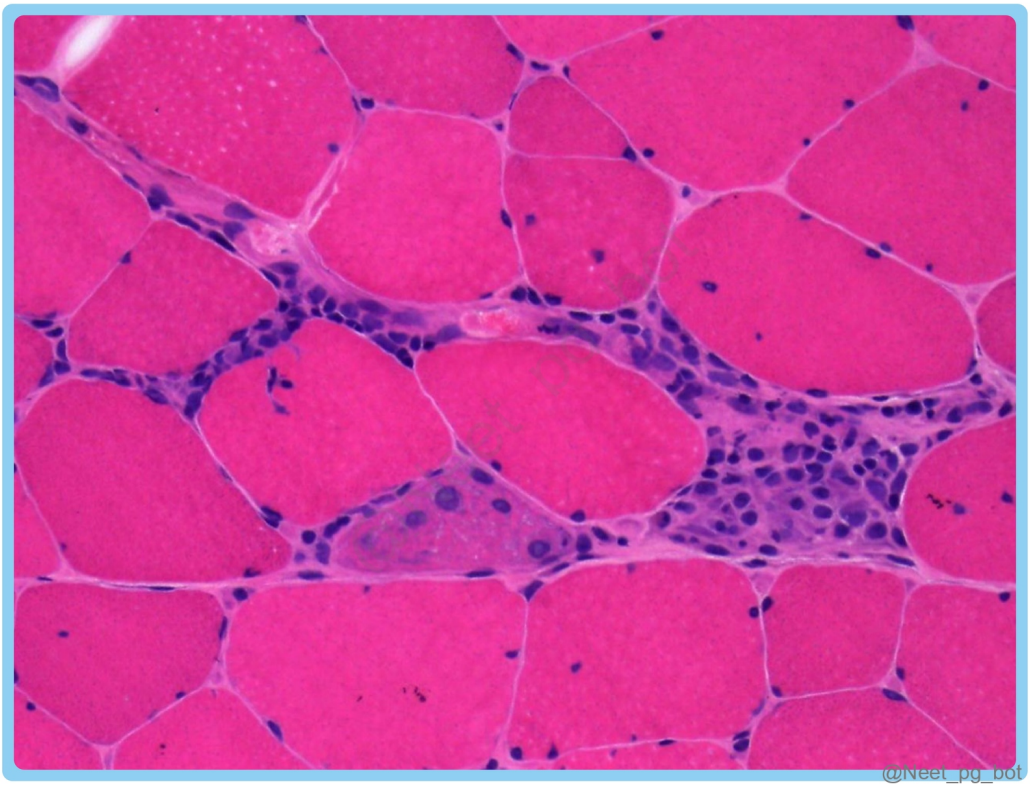

Correct Answer: D. Polymyositis

- *Listen (English)*
- *Listen (Hindi)*

Explanation: The features of progressive proximal muscle weakness along with the findings of endomysial inflammation on biopsy and no dermatological findings, suggest the diagnosis of polymyositis. In Polymyositis, endomysial inflammation is seen with no skin findings and no atrophy.It presents with proximal muscle weakness. Dermatomyositis (Option A) also presents with proximal muscle weakness and elevated CK levels, but it typically includes skin manifestations (e.g., heliotrope rash, Gottron's papules on hands, mechanic's hands), which are not mentioned here. Muscle biopsy in dermatomyositis typically shows perifascicular atrophy and inflammation. Inclusion Body Myositis (IBM) (Option C): Involves the distal muscles. Muscle biopsy shows inclusion bodies (amyloid-like material which forms inclusions in muscle fibres), which are positive for Congo-red staining.

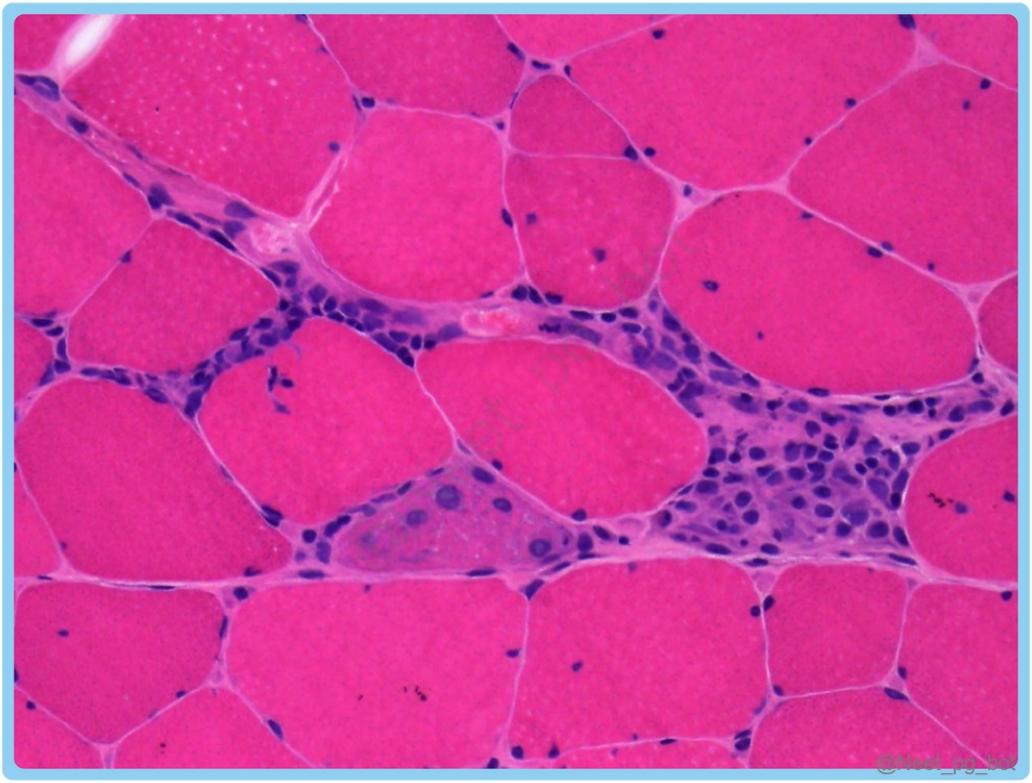

References:

Robbins & Cotran Pathologic Basis of Disease, 10th Edition, Page 1225-1230

↑ *Back to this question in Part A*

@Neet_pg_bot

Q25: A 60-year-old woman complains of bilateral hand pain and stiffness, especially in the morning. On examination, you notice diffuse thickening and tightening of the skin all over her body. Echo showed pulmonary hypertension. Laboratory tests show positive Anti-SCL-70 antibodies What is the most likely diagnosis? (Q845523)

A. Rheumatoid arthritis

B. Osteoarthritis

C. CREST syndrome

D. Systemic sclerosis

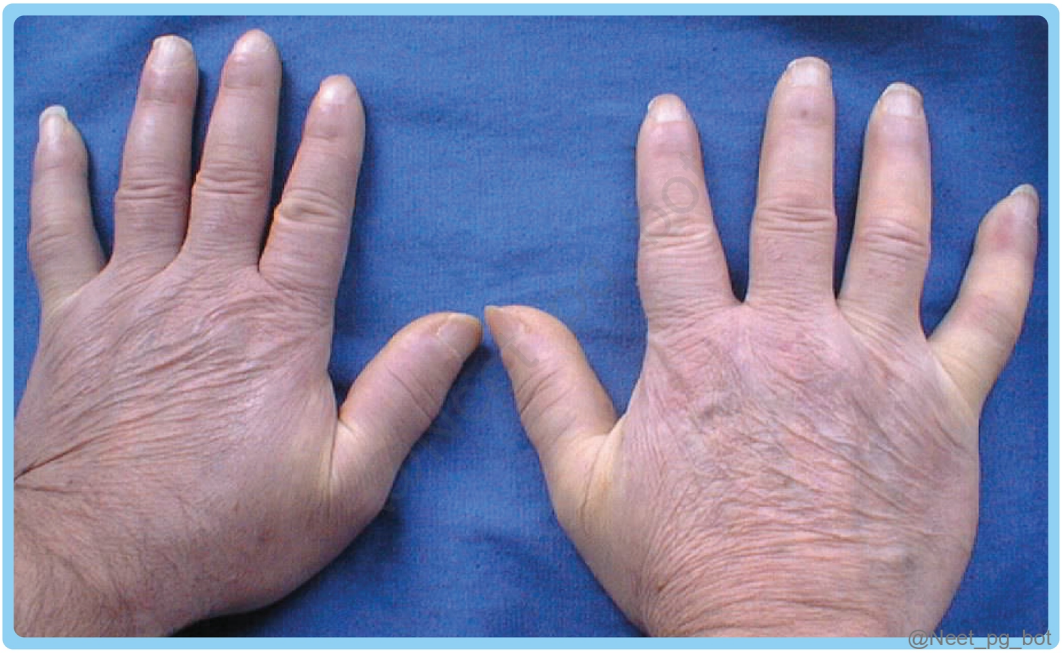

Correct Answer: D. Systemic sclerosis

- *Listen (English)*
- *Listen (Hindi)*

Explanation: The patient's presentation of diffuse sclerosis and echo showing pulmonary hypertension is highly suggestive of systemic sclerosis, also known as scleroderma. Scleroderma, also known as systemic sclerosis, is a rare autoimmune disease characterized by excessive collagen production, which leads to thickening and hardening of the skin and other organs. Subtypes In systemic sclerosis: Limited systemic sclerosis (CREST syndrome) features calcinosis, Raynaud phenomenon, oesophagal dysmotility, sclerodactyly, and telangiectasia. It is characterized by a positive anti-centromere antibody (option C) Diffuse systemic sclerosis (scleroderma) features widespread skin thickening starting from fingers, positive Anti-SCL-70/Anti-topoisomerase antibody , and extensive organ involvement: GIT dysfunction, musculoskeletal inflammation, scleroderma renal crisis, interstitial lung fibrosis, pulmonary hypertension, and cardiac manifestations.\ Feature Limited Sclerosis (CREST) Diffuse Systemic Sclerosis Skin Involvement Restricted to distal extremities (fingers/hands/feet) and the face. Widespread ; involves trunk, proximal limbs, and face. Onset Gradual/Indolent. Rapidly progressive. Classic Mnemonic CREST Syndrome (Calcinosis, Raynaud’s, Esophageal dysmotility, Sclerodactyly, Telangiectasia). N/A (More aggressive systemic disease). Antibody Marker Anti-Centromere (Highly specific). Anti-Scl-70 (Anti-DNA topoisomerase I) and Anti-RNA polymerase III . Vascular Disease Late-onset Pulmonary Arterial Hypertension (PAH) . Early-onset Raynaud’s phenomenon (precedes skin changes). Organ Involvement Late or limited organ involvement (except PAH). Early and severe Interstitial Lung Disease , Renal Crisis, and Cardiac involvement. Prognosis Generally better long-term survival. Higher mortality due to early organ failure. Rheumatoid arthritis (Option A) : This condition is characterized by symmetrical joint pain and swelling and is distinguished by the presence of rheumatoid factor and anti-cyclic citrullinated peptide. Osteoarthritis (Option B) is a degenerative joint disease affecting weight-bearing joints without skin involvement or autoimmune features.

References:

Robbins and Cotran's Pathologic Basis of Disease, 10th Edition, Page 231

www.ncbi.nlm.nih.gov/books/NBK430875/

↑ *Back to this question in Part A*

@Neet_pg_bot

Q26: A 20-year-old female complains of recurrent episodes of her fingers turning symmetrically white, which are associated with pain and a tingling sensation. This is worse when exposed to cold water and is relieved when she dips her fingers in warm water. The autoimmune panel is negative. What is the likely diagnosis? (Q845520)

A. Primary Raynaud phenomenon

B. Dermatomyositis

C. Secondary Raynaud phenomenon

D. Calcinosis cutis

Correct Answer: A. Primary Raynaud phenomenon

■ *Listen (English)*

■ *Listen (Hindi)*

Explanation: The given clinical scenario describes the Raynaud phenomenon (an exaggerated vasoconstriction of arteries and arterioles in response to cold or emotional stress. The fingers classically show these colour changes in this order: Red: Proximal vasodilation White: Central vasoconstriction Blue: Distal cyanosis. Primary Raynaud's phenomenon is characterized by symmetric episodes of finger whitening induced by cold, resulting from hyper reactive smooth muscle cells in the blood vessel walls. It occurs without an underlying disorder and typically does not lead to ulcers. Tests for autoimmune conditions yield negative results in such cases. Secondary Raynaud's phenomenon results from underlying arterial disease seen in autoimmune disorders like mixed connective tissue disease, CREST syndrome, and SLE. It shows asymmetric finger involvement and progressive worsening of symptoms over time. (Option C) Dermatomyositis (Option B) may involve the hands, with classical lesions being Gottron papules (multiple hyperkeratotic, flat, red papules over the dorsum of the metacarpophalangeal joints) and mechanic hands (fissuring with hyperkeratotic papules, scaling, and fissures along the sides of the fingers and palms). Autoimmune panel is positive. Calcinosis cutis (Option D) is a characteristic lesion of CREST syndrome, referring to the deposition of calcific nodules in the skin of the hands. It is an autoimmune disorder because of anti-centromeric antibody.





References:

Robbins and Cotran's Pathologic Basis of Disease, 10th Edition, Page 516, 1129 Primary vs Secondary Raynauds
https://www.uptodate.com/contents/clinical-manifestations-and-diagnosis-of-raynaud-phenomenon

↑ *Back to this question in Part A*

@Neet_pg_bot

Q27: A 55-year-old woman has had persistent dry eyes and mouth for the past several months. She also reports difficulty in swallowing solid foods and occasional blurred vision. On examination, she has bilateral parotid gland enlargement. She has a history of rheumatoid arthritis. Which antibodies are specific for this disease? (Q845518)

A. Anti-Sm

B. Anti La

C. Anti-Scl 70

D. Anti-U1 RNP



Correct Answer: B. Anti La

■ *Listen (English)*

■ *Listen (Hindi)*

Explanation: Based on the above clinical scenario, the patient can be diagnosed with Sjogren's syndrome. Clinical presentation: Xerophthalmia (Dry Eyes): Leads to a "gritty" sensation and can cause keratoconjunctivitis sicca. Xerostomia (Dry Mouth): Causes difficulty swallowing dry food, dental caries, and parotid gland enlargement. Extraglandular Manifestations: Can include Raynaud phenomenon, cutaneous vasculitis, interstitial lung disease, and peripheral neuropathy. Patient presents with: Dry eyes due to antibodies attacking the lacrimal gland. Dry mouth due to antibodies attacking the salivary gland. Pathogenesis: Salivary gland involvement → Dry mouth (Xerostomia) → Halitosis (Bad breath) Lacrimal gland involvement → Dry eyes (Keratoconjunctivitis sicca) → Gritty sensation in eyes Antibodies are of 2 types: Anti-SS-A (Anti-Ro) antibodies: Most sensitive Anti-SS-B (Anti-La) antibodies: Most specific Diagnosis: Rheumatoid Factor (RF): Often positive even in the absence of Rheumatoid Arthritis. ANA: Typically positive in a speckled pattern. Lip Biopsy: The "gold standard" for diagnosis, showing focal lymphocytic sialadenitis (clusters of lymphocytes around minor salivary glands). Schirmer Test: Used to quantify decreased tear production. Histology: Intense lymphocytic infiltrate (primarily CD4 + T cells) with germinal center formation. Ductal Changes: Hyperplasia of lining cells leading to the formation of epimyoepithelial islands . Management: Sicca Symptoms: Artificial tears, frequent water intake, and pilocarpine or cevimeline (muscarinic agonists to stimulate secretions). Systemic Disease: Hydroxychloroquine or immunosuppressants (methotrexate) for joint or skin involvement. Regular Screening: Critical monitoring for the development of lymphoma, especially if there is persistent parotid swelling or lymphadenopathy. Autoantibody Associated Autoimmune Condition Anti-Sm (Smith) (Option A) Systemic lupus erythematosus (SLE) Anti-Scl-70 (anti-topoisomerase I) (Option C) Diffuse systemic sclerosis (scleroderma) Anti-U1 RNP (Ribonucleoprotein) (Option D) Mixed connective tissue disease (MCTD)

References:

Robbins and Cotran's Pathologic Basis of Disease, 10th Edition, Page 230

↑ *Back to this question in Part A*

@Neet_pg_bot

Q28: A 45-year-old woman with SLE complains of red, frothy urine for the past two months despite being on treatment. Urine analysis shows RBCs and proteins. An image of renal biopsy is given below. Which of the following accurately describes the histopathological findings? (Q845510)

A. Diffuse capillary wall thickening.

B. Wire loop lesions

C. Glomerular crescents

D. Kimmelstiel-Wilson lesion

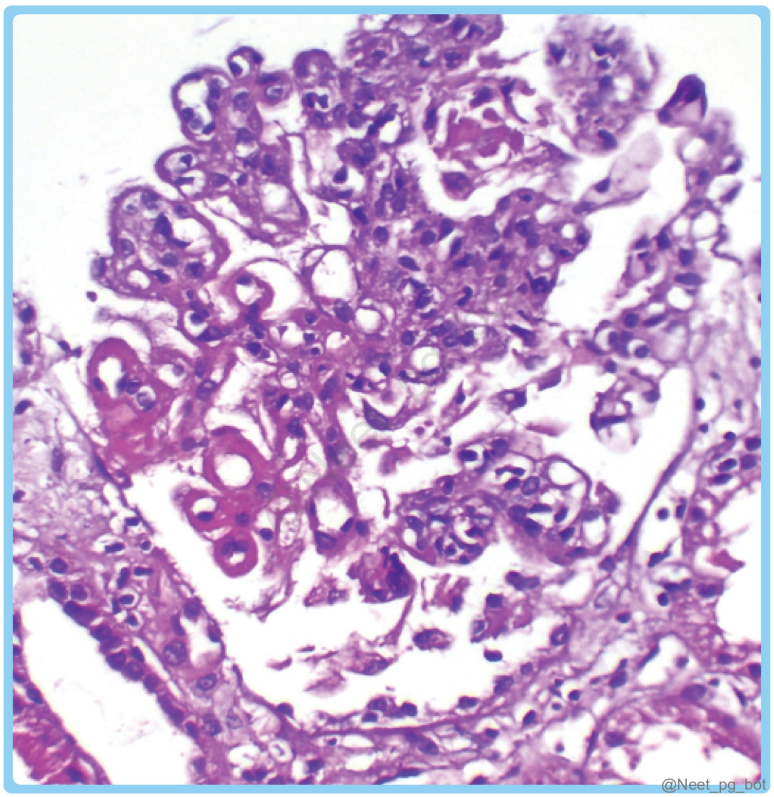

Correct Answer: B. Wire loop lesions

- *Listen (English)*
- *Listen (Hindi)*

Explanation: Wire loop lesions are a characteristic histopathological finding in lupus nephritis. Wire loop means that capillary loop has become thicker due to subendothelial deposits. Seen more commonly in classes 3,4, and 5 of lupus nephritis (There are a total of 6 classes). Lupus Nephritis (LN): Lupus Nephritis (LN) is a frequent and serious complication of Systemic Lupus Erythematosus (SLE), representing a Type III Hypersensitivity reaction where immune complexes deposit within the glomeruli. 6 Classes of Lupus Nephritis: Class Type Key Pathological Features Class I Minimal Mesangial LN Normal appearance on light microscopy; immune complexes seen only on immunofluorescence or electron microscopy. Class II Mesangial Proliferative LN Purely mesangial hypercellularity or mesangial matrix expansion. Usually presents with mild hematuria/proteinuria. Class III Focal LN Active or inactive focal, segmental, or global endo- or extracapillary glomerulonephritis involving < 50% of all glomeruli. Class IV Diffuse LN Same as Class III but involving ≥ 50% of all glomeruli. This is the most common and severe form . Class V Membranous LN Global or segmental subepithelial immune deposits. Often presents with high-grade nephrotic syndrome . Class VI Advanced Sclerotic LN ≥90% of glomeruli are globally sclerosed without residual activity. Represents end-stage renal disease. Management of Lupus Nephritis: Generally divided into two phases: Induction (to achieve remission) and Maintenance (to prevent flares). General Measures (For all patients): Hydroxychloroquine: Recommended for all SLE patients to reduce flares and protect the kidneys. ACE Inhibitors/ARBs: Used to control blood pressure and reduce proteinuria. Statins: To manage hyperlipidemia associated with nephrotic syndrome. Classes I & II: Usually require no specific immunosuppressive therapy for the kidneys; treatment is directed at extra-renal SLE symptoms. Classes III & IV (Proliferative): Aggressive therapy is required. Induction: High-dose Corticosteroids plus either Mycophenolate Mofetil (MMF) or Cyclophosphamide . Maintenance: Low-dose steroids with MMF or Azathioprine . Class V

(Membranous): If nephrotic-range proteinuria is present, treat similarly to proliferative LN (MMF + Steroids). Class VI (Sclerotic): Immunosuppression is usually not effective; management focuses on preparation for dialysis or renal transplantation. Glomerular crescents (Option C) are seen in crescentic/Rapidly Progressive Glomerulonephritis(RPGN), Kimmelstiel-Wilson lesion (Option D) is a feature of diabetic nephropathy.

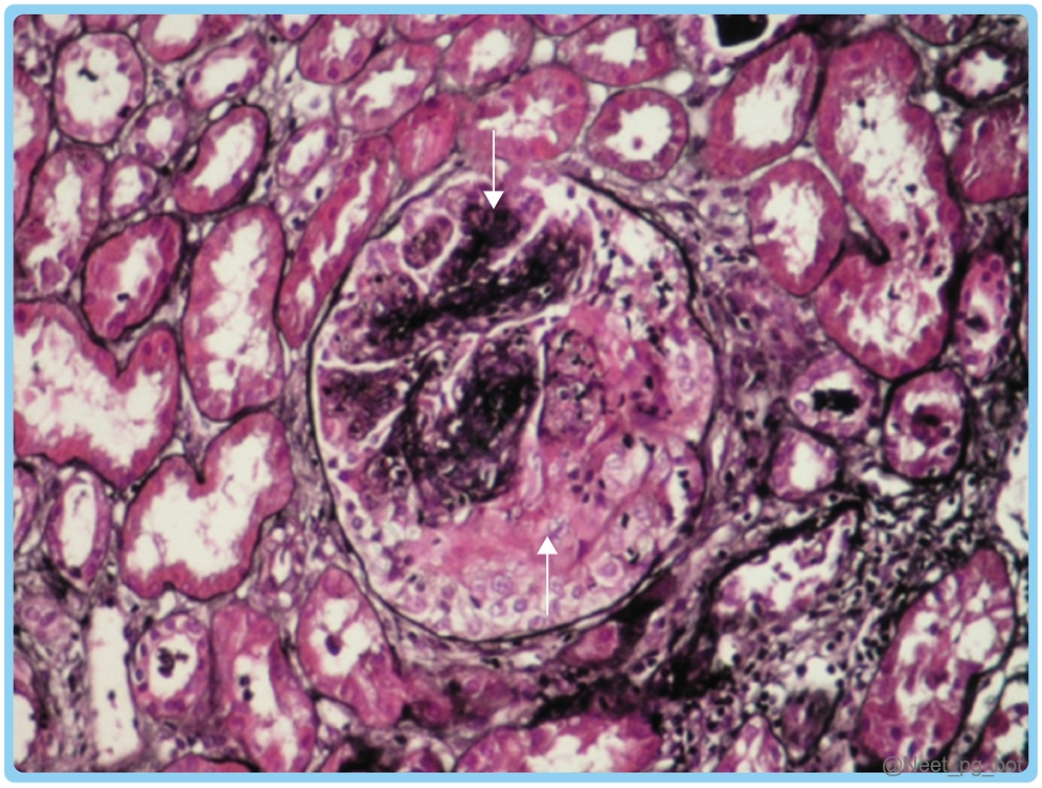

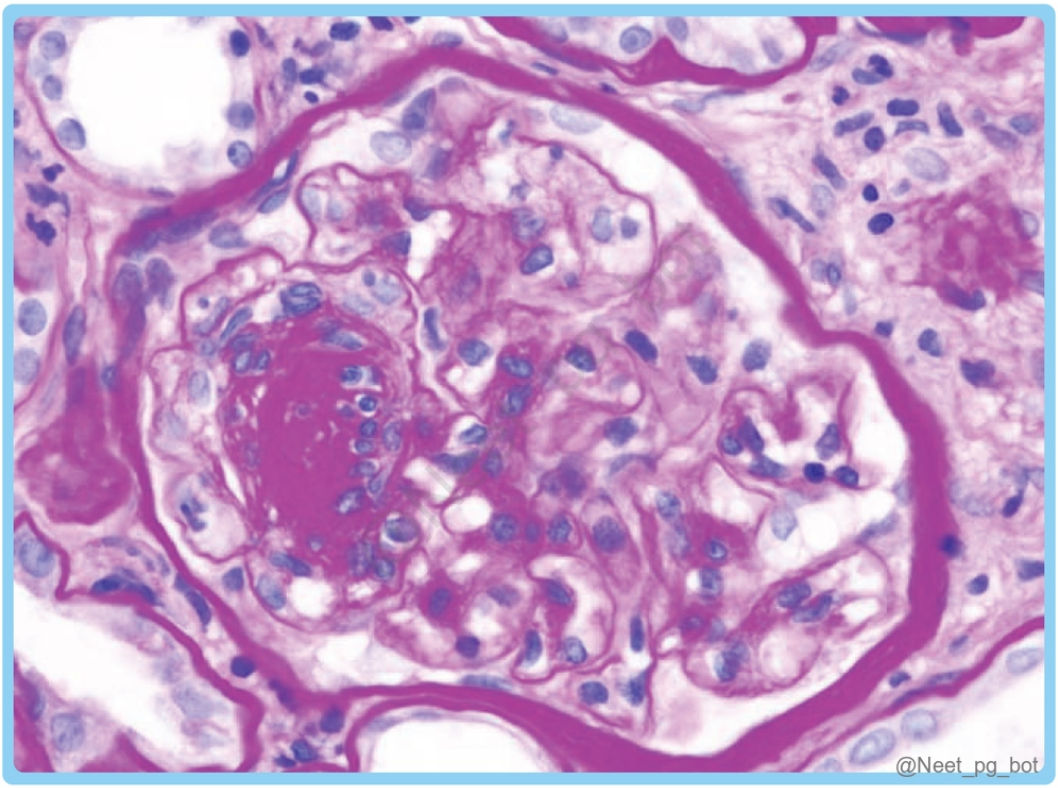

References:

Robbins and Cotran's Pathologic Basis of Disease, 10th Edition, Page no 226, 909, 1111

↑ *Back to this question in Part A*

@Neet_pg_bot

Q29: A 19-year-old woman presents with malaise, joint pain, and fever for the past 3 months. Physical examination shows a malar rash and mouth ulcers. She has significant proteinuria and decreased GFR. Which of the following antibodies are most specific and most sensitive, respectively? (Q845509)

A. ANA, Anti ds DNA

B. Anti-Sm, ANA

C. Anti- Ro, Anti- La

D. Anti-beta-2-glycoprotein, Anticardiolipin

Correct Answer: B. Anti-Sm, ANA

■ *Listen (English)*

■ *Listen (Hindi)*

Explanation: Based on the above clinical scenario mentioning malar rash and multi-organ involvement, the most likely diagnosis is systemic lupus erythematosus (SLE). Anti-Smith antibodies (ASA) are most specific for SLE. Anti-double-stranded DNA (dsDNA) antibodies are most sensitive for SLE. Marker/Antibody Clinical Significance Anti-Smith (anti-Sm) antibodies Highly specific for SLE (<30% of patients) Anti-dsDNA antibodies Highly specific for SLE (60-70% of patients); correlates with the disease Antinuclear antibodies (ANA) Highly sensitive but not specific for SLE Anti-Ro (SSA) and Anti-La (SSB) antibodies Found in SLE and Sjögren syndrome; associated with neonatal lupus Anti-ribosomal-P antibodies Specific for neuropsychiatric manifestations in SLE Anti-histone antibodies Seen in drug-induced lupus; less specific for SLE Complements C3 and C4 Low levels indicate complement consumption and disease activity

References:

Robbins and Cotran's Pathologic Basis of Disease, 10th Edition, Page 222 Systemic Lupus Erythematosus - StatPearls - NCBI Bookshelf (nih.gov) Autoantibodies in SLE: Specificities, Isotypes and Receptors - PMC (nih.gov)

↑ *Back to this question in Part A*

@Neet_pg_bot

Q30: A 30-year-old woman presents with a history of fatigue, fever, and weight loss. She also reports joint pain, swelling and a rash, as shown below. What is the most likely diagnosis? (Q845508)

A. Dermatomyositis

B. Systemic Lupus Erythematosus

C. Psoriatic Arthritis

D. Ankylosing Spondylitis



Correct Answer: B. Systemic Lupus Erythematosus

■ *Listen (English)*

■ *Listen (Hindi)*

Explanation: The patient's clinical presentation suggests systemic lupus erythematosus (SLE). Systemic Lupus Erythematosus (SLE): It is a combination of type 2 and type 3 hypersensitivity reactions (Type3>2) Genetic Associations: HLA DQ Polymorphism Early complement deficiency (C1, C2, C4) Klinefelter syndrome (47XXY) Immunological Association: Associated with NETS (Neutrophil extracellular traps) Environmental Associations: Associated with UV Exposure Gender Bias (More common in females) SLE - Criteria: Total of 11 criteria; 4 are needed for the diagnosis Mnemonic: MD SOAP BRAIN M - Malar Rash: Butterfly-shaped rash on face (sparing nasolabial fold) D - Discoid Rash S – Serositis: ■■■■■■■ Pleuritis Pericarditis O - Oral Ulcer: Aphthous (painless) ulcers A - Arthritis: ■■■■■■■ Non-erosive arthritis ≥2 Peripheral joints P - Photosensitivity B - Blood: ■■■■■■■ Pancytopenia Microscopically → formation of LE cells + R - Renal: Lupus Nephritis Has a total of 6 classes (Class I to Class VI) Most characteristic lesion → Wire loop lesion (Seen in Class III, IV, & V) Maximum wire loop lesions seen in Class IV Sub-endothelial deposits of Ag-Ab complex result in Wire loop lesions A - ANA (Anti-nuclear antibody) I - Immunological (antibody) N - Neurological (Psychosis) LE cell: Neutrophil or a monocyte that has engulfed damaged nuclear material (Hematoxylin body)-Damaged by ANA Antibodies in SLE: Most sensitive: ANA (Anti-nuclear antibody) Most specific: Anti-Smith (Anti-Sm) antibody Antibody that is both sensitive & specific: Anti-dsDNA antibody Anti-Ro antibody: Associated with Neonatal Lupus, Shrinking lung, Photosensitivity, and Congenital Heart Block Anti-Ribosomal P Ab: Associated with Psychosis Anti U1 RNP Ab: Associated with Raynaud's Phenomenon Anti-phospholipid antibody (APLA) syndrome → Recurrent abortions Immunofluorescence patterns of ANA: Mnemonic: HPNSC H - Homogeneous pattern (Entire nucleus is green): Antibodies against: Chromatin, Histone, and Anti-dsDNA P - Peripheral or Rim pattern ■■■■■■■ Enhancement at periphery Antibodies against Anti- dsDNA Bright green dots-r RNA

nucleous N - Nucleolar pattern : Antibody against RNA S - Speckled pattern: Mpst common and least specific pattern Antibodies against Anti-Sm, AntiRo & Anti-La (Sjogren's Syndrome) C - Centromeric pattern: Anti-centromere antibody Associated with CREST syndrome Other organs affected by SLE: Heart: Libman-Sach Endocarditis Lungs: Shrinking Lung Spleen: Onion-skinning around blood vessels

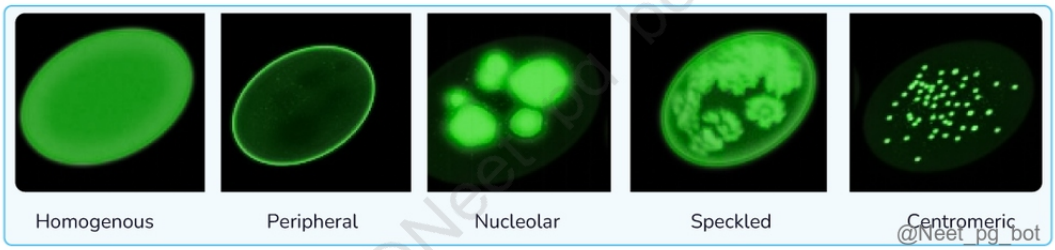

References:

Robbins and Cotran Pathologic basis of disease, 10th Edition, Page 230-236.

↑ *Back to this question in Part A*

@Neet_pg_bot

Q31: Which of the following is an immune-privileged site? (Q845507)

A. Heart

B. Lung

C. Kidney

D. Testis

Correct Answer: D. Testis

■ *Listen (English)*

■ *Listen (Hindi)*

Explanation: Among the given options, the testis is an immune-privileged site. The testis, eye, and brain are called immune-privileged sites because antigens are sequestered/isolated from the immune system without communicating with blood and lymph. Brain Blood-brain barrier Eyes Blood-ocular barrier Testes Blood-testicular barrier These tissues fail to elicit immune responses and are ignored by the immune system. If the antigens of these tissues are released as a consequence of trauma or infection, an immune response will result, leading to prolonged inflammation and injury. This is the postulated mechanism for post-traumatic orchitis and uveitis.

References:

Robbins and Cotrans Pathologic Basis of Disease, 10th Edition, Page 217-218

↑ *Back to this question in Part A*

@Neet_pg_bot

Q32: Match the following processes in immune tolerance with their associated regulators. Process Regulators 1. Negative selection a. CD-28 2. Anergy b. FOXP3 3. Deletion by apoptosis c. AIRE 4. Suppression by regulatory T cells d. CD95 (Q845505)

A. 1-c, 2-a, 3-d, 4-b.

B. 1-a, 2-c, 3-d, 4-b.

C. 1-c, 2-b, 3-d, 4-a.

D. 1-a, 2-d, 3-c, 4-b.

Correct Answer: A. 1-c, 2-a, 3-d, 4-b.

■ *Listen (English)*

■ *Listen (Hindi)*

Explanation: Negative selection or clonal deletion : Process in which T cells expressing receptors for self-antigens encounter these antigens in the thymus and are then killed by apoptosis. AIRE (autoimmune regulator) is a regulator protein critical for deleting these T cells. A defect in AIRE leads to autoimmune polyendocrine syndrome (AIPS). Tolerance: Two types of tolerance: Central tolerance Peripheral tolerance Central tolerance: Peripheral tolerance: If central tolerance fails, peripheral tolerance works T Regulatory cells: They are type of CD4 T cells, that started expressing CD25+/IL2 Receptor on them T regulatory cell is made by FOXP3 gene They have an immunosuppressive action Immunosuppression is achieved by ↑CTLA4 gene and ↑PD1 gene Mutation in FOXP3 gene → IPEX Immune Dysregulation Polyendocrinopathy X linked disorder Mutation of IL2 Receptor is seen in: Inflammatory Bowel disease Multiple sclerosis Killing of Self-reactive cells: Killing occurs by Apoptosis Apoptosis is mediated by CD95/Fas CD95/Fas mutation → Autoimmune lymphoproliferative syndrome (ALPS) Anergy: T cells: When an antigen enters a cell, the APC presents it via MHC to T cell receptor (made up of α and β chains) Signal 1: Antigen has been presented between the MHC and the T cell receptor Signal 2: Binding of CD28 with CD80 and Cd86 T cell activation requires two signals T cells contain CD28 molecule When CD28 binds to B7.1 (CD80) and B7.2 (CD86), present on APC → signal 2 gets generated When both signals are generated → T cell Activation For Foreign Ag: Signal 1 and 2 will be generated and T cell gets activated In case of Self Ag: Signal 2 will not be generated If only one signal is present, the T cell go into anergy B cells: Signal 1 B cells have IgM and IgD B cell present the antigen to the T cell Signal 2: CD40 receptor on the B cell, binds to CD40 ligand on the T® cell, creating a co-stimulatory signal For Foreign Ag: Signal 1 and 2 will be generated → B cell Activation For Self Ag: Only Signal 1 gets generated → B cell go into anergy Cryptic/Hidden Antigen: Sites where antigens are not exposed to B and T cells B - Brain antigens All brain antigens are hidden by Blood brain barrier, except area Prostema E – Eyes All Eye antigens are hidden by Blood Ocular Barrier, except optic nerve T – Testes All antigens of testes are hidden by Blood Testicular Barrier, except epididymis Example Trauma of eye → Damage to Blood Ocular Barrier → All Ag of the Eye are exposed to B and T cells → Ag considered foreign → Killing (B/L Traumatic Uveitis)

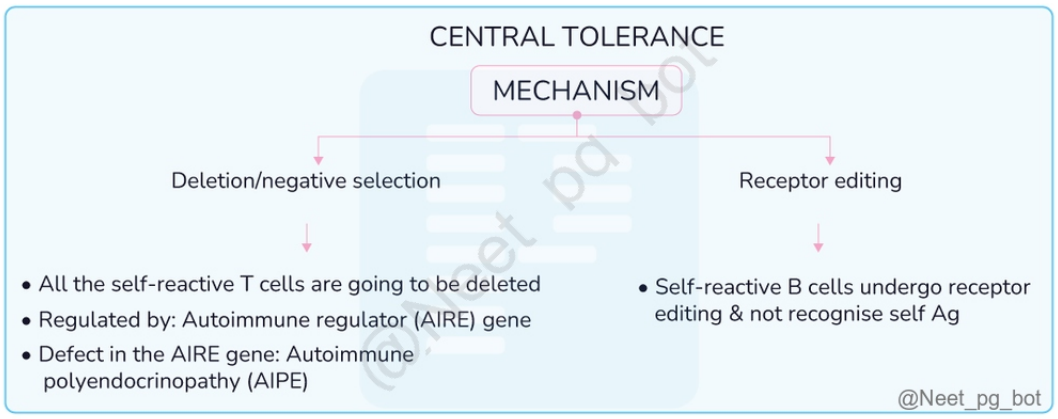

References:

Robbins and Cotran Pathologic Basis of Disease, 10th Edition, Page 216-217, 219

↑ *Back to this question in Part A*

@Neet_pg_bot

• [05_Immunity] 022 Immunodeficiency Disorders

« Back to Folder Directory

[05_Immunity] 022 Immunodeficiency Disorders — Quick Jump

Q1 (p. 1519)	*Q2 (p. 1520)*	*Q3 (p. 1521)*	*Q4 (p. 1522)*	*Q5 (p. 1523)*	*Q6 (p. 1523)*
Q7 (p. 1524)	*Q8 (p. 1525)*	*Q9 (p. 1526)*	*Q10 (p. 1526)*	*Q11 (p. 1527)*	*Q12 (p. 1528)*
Q13 (p. 1529)	*Q14 (p. 1530)*	*Q15 (p. 1531)*	*Q16 (p. 1532)*	*Q17 (p. 1532)*	*Q18 (p. 1533)*
Q19 (p. 1535)	*Q20 (p. 1536)*	*Q21 (p. 1539)*	*Q22 (p. 1540)*	*Q23 (p. 1542)*	*Q24 (p. 1543)*
Q25 (p. 1544)	*Q26 (p. 1545)*	*Q27 (p. 1545)*	*Q28 (p. 1546)*	*Q29 (p. 1548)*	*Q30 (p. 1548)*

Q1: Assertion: Patients with Common Variable Immunodeficiency (CVID) commonly present with recurrent respiratory infections, gastrointestinal issues, and autoimmune disorders. Reason: Defects in the BTK gene lead to impaired B cell signaling, resulting in decreased maturation of B cells from pre-B-cells. (Q845677)

A. Both Assertion and Reason are true, and Reason is the correct explanation for Assertion

B. Both Assertion and Reason are true, but Reason is not the correct explanation for Assertion

C. Assertion is true, but Reason is false

D. Assertion is false, but Reason is true

Correct Answer: B. Both Assertion and Reason are true, but Reason is not the correct explanation for Assertion

■ *Listen (English)*

■ *Listen (Hindi)*

Explanation: for Assertion.

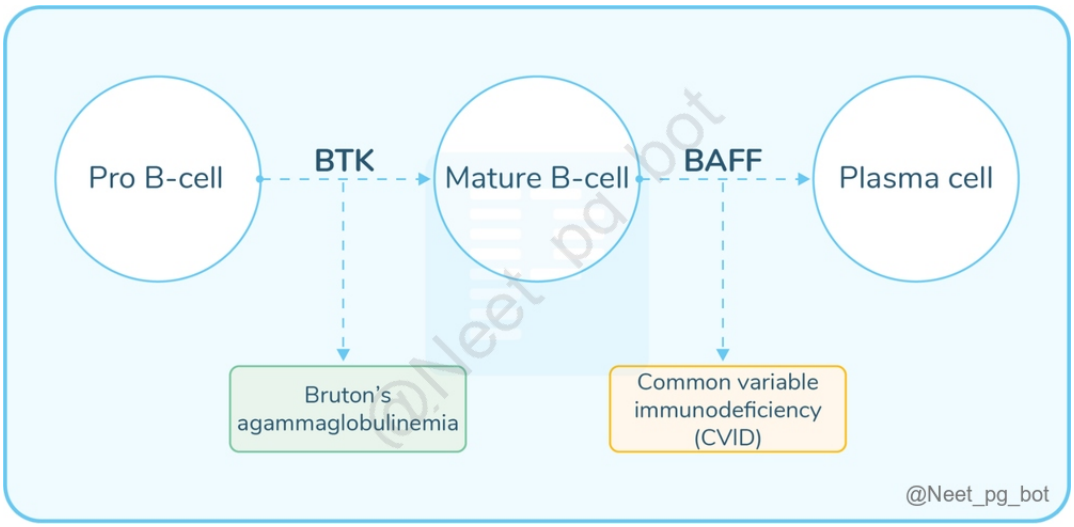

References:

Robbins & Cotran Pathologic Basis of Disease, 10th Edition, Pages 244, 245

↑ *Back to this question in Part A*

@Neet_pg_bot

Q2: A 52-year-old HIV-positive male presents with multiple raised, violaceous plaques and nodules over both legs. The lesions have gradually increased in number over the past few months. Skin biopsy shows a dermal lesion composed of irregular, slit-like vascular spaces lined and surrounded by plump, spindle-shaped cells. The stroma contains extravasated red blood cells, hemosiderin deposits, areas of haemorrhage, and a mixed mononuclear inflammatory infiltrate. Occasional mitotic figures are seen. Which of the following infectious agents is associated with this tumour? (Q890583)

A. Human herpesvirus type 8

B. Epstein-Barr virus

C. Cytomegalovirus

D. Human papillomavirus

Correct Answer: A. Human herpesvirus type 8

Explanation: The described lesion is classic for Kaposi sarcoma (KS) , the most common neoplasm in patients with AIDS . Clinically, it presents as violaceous plaques and nodules , and histologically shows: Proliferation of spindle-shaped cells Irregular, slit-like vascular spaces Extravasated red blood cells and hemosiderin deposition

Chronic inflammatory infiltrate Kaposi sarcoma is strongly associated with human herpesvirus 8 (HHV-8) , which is necessary but not sufficient for tumour development. In AIDS patients, HIV-induced immunosuppression acts as a cofactor , allowing widespread HHV-8 infection and tumour progression. HHV-8 establishes latent infection and produces viral proteins that: Promote cell proliferation (e.g., viral cyclin D homologues) Inhibit tumour suppressors such as p53 Stimulate angiogenesis and inflammation , contributing to lesion formation KS lesions are unique in that many are polyclonal or oligoclonal , especially in early stages, reflecting a proliferation driven by cytokines and angiogenic factors rather than purely malignant transformation. Epstein-Barr virus (Option B) is associated with B-cell lymphomas (e.g., Burkitt lymphoma, primary CNS lymphoma), not Kaposi sarcoma. Cytomegalovirus (Option C) causes opportunistic infections such as retinitis, pneumonitis, and gastrointestinal ulcers , not vascular tumours. Human papillomavirus (Option D) is associated with epithelial neoplasms , including cervical and anogenital cancers, not vascular tumours like Kaposi sarcoma.

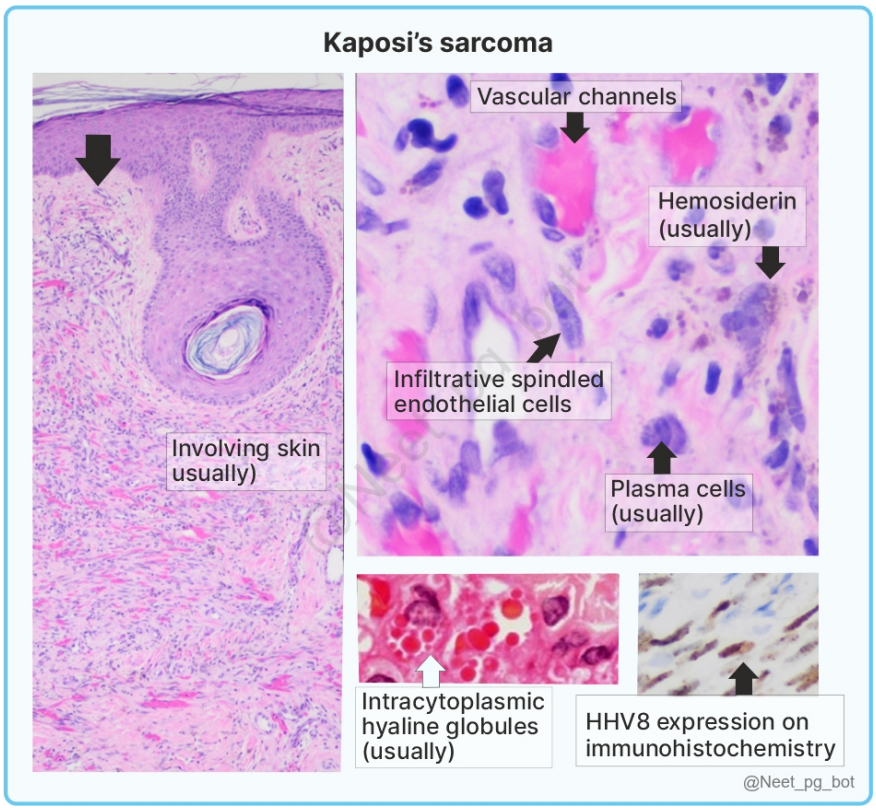

References:

Robbins, Cotran & Kumar Pathologic Basis of Disease, 11th Edition, Pages 227-228

↑ *Back to this question in Part A*

@Neet_pg_bot

Q3: A 30-year-old HIV-positive patient presents with persistent, painless swelling of multiple lymph nodes. A lymph node biopsy is performed. Which of the following histopathological findings is least likely to be observed in this patient? (Q890582)

A. Florid follicular hyperplasia

B. Destruction of germinal centres

C. Hematoxylin bodies

D. Expansion of monocytoid B cells in the sinuses

Correct Answer: C. Hematoxylin bodies

Explanation: Hematoxylin bodies are not seen in HIV lymphadenopathy. They represent denatured nuclear material bound by autoantibodies and are characteristic of systemic lupus erythematosus (SLE) . HIV-associated lymphadenopathy demonstrates dynamic, stage-dependent morphologic changes reflecting progressive immune dysfunction. In early HIV infection , there is marked follicular hyperplasia (Option A) characterised by: Enlarged, irregular (“serpiginous”) germinal centres Attenuation of mantle zones Germinal centres encroaching into interfollicular T-cell areas Underlying mechanism: polyclonal B-cell activation As the disease progresses, this hyperplastic phase evolves into lymphoid involution , with: Destruction and eventual hyalinization of germinal centres (Option B) Disruption of the follicular dendritic cell (FDC) network Marked lymphocyte depletion “Burnt-out” lymph nodes that may contain opportunistic pathogens with minimal inflammatory response Expansion of monocytoid B cells in the sinuses (Option D) may occur as a reactive change in lymph nodes and can be seen in chronic immune stimulation.

References:

Robbins, Cotran & Kumar Pathologic Basis of Disease, 11th Edition, Page 200, 229

↑ *Back to this question in Part A*

@Neet_pg_bot

Q4: In patients with HIV/AIDS, which of the following is the most frequently observed brain tumour? (Q890581)

A. Oligodendroglioma

B. Primary CNS lymphoma

C. Ependymoma

D. Pilocytic astrocytoma

Correct Answer: B. Primary CNS lymphoma

Explanation: In patients with HIV/AIDS and other forms of immunosuppression, the most common primary brain tumour is primary CNS lymphoma , which is typically a diffuse large B-cell lymphoma . These tumours are often multifocal , involve deep periventricular regions , and show a characteristic tendency for perivascular infiltration .

In immunosuppressed individuals, the malignant B cells are commonly latently infected with Epstein-Barr virus (EBV) , which plays a key role in tumour pathogenesis. These lymphomas are aggressive and have a worse prognosis compared to similar tumours in immunocompetent individuals. A critical clinical point is that opportunistic infections (especially toxoplasmosis) are more common than tumours in AIDS patients and may present as ring-enhancing lesions , often mimicking CNS lymphoma. Other listed tumors such as oligodendroglioma, ependymoma, and pilocytic astrocytoma, are not associated with HIV-related immunosuppression .

References:

Robbins, Cotran & Kumar Pathologic Basis of Disease, 11th Edition, Page 1182

↑ *Back to this question in Part A*

@Neet_pg_bot

Q5: Which of the following immune cells is least likely to be directly infected by HIV during the course of the disease? (Q890580)

A. Helper T cells (CD4+ cells)

B. Neutrophils

C. Dendritic cells

D. Macrophages

Correct Answer: B. Neutrophils

Explanation: HIV infects cells by binding to the CD4 receptor and chemokine co-receptors CCR5 or CXCR4 , which determine viral tropism: R5 (CCR5-using) strains → infect monocytes/macrophages and dendritic cells (M-tropic) X4 (CXCR4-using) strains → infect CD4+ T cells (T-tropic) The major target cells include: CD4+ helper T cells (Option A) → primary targets; progressive depletion leads to immunodeficiency Macrophages (Option D) → infected due to low-level CD4 expression; serve as long-lived viral reservoirs Dendritic cells (Option C) → capture HIV at mucosal sites and transfer it to T cells, facilitating infection In contrast, neutrophils (Option B) lack CD4 receptors and the required chemokine co-receptors , and therefore are not directly infected by HIV , making them the least likely target.

References:

Robbins, Cotran & Kumar Pathologic Basis of Disease, 11th Edition, Page 220

↑ *Back to this question in Part A*

@Neet_pg_bot

Q6: A 6-year-old boy presents with recurrent eczema, recurrent pneumonia and otitis media since infancy, and easy bruising. Laboratory investigations show thrombocytopenia with small platelets and abnormal immunoglobulin levels. Which of the following statements regarding his condition is correct? Serum IgE is elevated Serum IgA is elevated Serum IgM is normal Serum IgG is normal (Q890569)

A. 2, 3 and 4

B. 1, 2 and 4

C. 2 and 4 only

D. 1, 2 and 3

Correct Answer: B. 1, 2 and 4

Explanation: Wiskott-Aldrich syndrome (WAS) is an X-linked immunodeficiency caused by mutations in the WAS gene , which encodes a protein involved in linking cell surface receptors to the actin cytoskeleton , thereby affecting lymphocyte activation, migration, and immune synapse formation. It is characterised by the triad of: Eczema Recurrent infections Thrombocytopenia with small platelets (microthrombocytopenia) The characteristic immunoglobulin profile is: IgE ↑ (Statement 1: correct) IgA ↑ (Statement 2: correct) IgM ↓ (Statement 3: incorrect) IgG usually normal (Statement 4: correct) Patients also have defective antibody responses, particularly to polysaccharide antigens , and progressive defects in T-cell function.

References:

Robbins, Cotran & Kumar Pathologic Basis of Disease, 11th Edition, Page 218

↑ *Back to this question in Part A*

@Neet_pg_bot

Q7: In patients diagnosed with common variable immunodeficiency (CVID), which of the following best describes the typical finding in peripheral B-cell numbers? (Q890567)

A. B-cell count is consistently reduced

B. B-cell count is markedly increased

C. B-cells are completely absent

D. B-cell count is usually within the normal range

Correct Answer: D. B-cell count is usually within the normal range

Explanation: Common variable immunodeficiency (CVID) is characterised by hypogammaglobulinemia due to impaired differentiation of B cells into plasma cells , resulting in defective antibody production. Despite this functional defect, most patients have normal or near-normal numbers of circulating B cells in peripheral blood and lymphoid tissues. The primary abnormality lies in the failure of B cells to mature into antibody-secreting plasma cells , rather than a deficiency in B-cell numbers. This leads to recurrent sinopulmonary infections , along with increased susceptibility to certain viral and gastrointestinal infections, and a higher risk of autoimmune diseases and lymphoid malignancies.

References:

Robbins, Cotran & Kumar Pathologic Basis of Disease, 11th Edition, Page 217

↑ *Back to this question in Part A*

@Neet_pg_bot

Q8: Mutation in which of the following is responsible for the development of X-linked lymphoproliferative disorder, characterised by an abnormal immune response to Epstein-Barr virus (EBV)? (Q890564)

A. SLAM-associated protein

B. WAS gene

C. LYST gene

D. FOXP3 gene

Correct Answer: A. SLAM-associated protein

Explanation: X-linked lymphoproliferative disease (XLP) is characterised by an inability to eliminate Epstein-Barr virus (EBV) , leading to severe or fatal infectious mononucleosis and an increased risk of B-cell lymphomas . The disorder is most commonly caused by mutations in the SH2D1A gene , which encodes the SLAM-associated protein (SAP) . SAP is required for effective T-cell and natural killer (NK) cell activation , particularly in response to EBV-infected B cells. Its deficiency results in impaired cytotoxic function and uncontrolled lymphoproliferation. SAP is also essential for the development of T follicular helper (Tfh) cells , and its absence leads to defective germinal centre formation and impaired production of high-affinity antibodies . WAS gene (Option B) mutations cause Wiskott-Aldrich syndrome . LYST gene (Option C) mutations cause Chediak-Higashi syndrome . FOXP3 gene (Option D) mutations cause IPEX syndrome , characterised by regulatory T-cell dysfunction and autoimmunity.

References:

Robbins, Cotran & Kumar Pathologic Basis of Disease, 11th Edition, Page 218

↑ *Back to this question in Part A*

@Neet_pg_bot

Q9: Individuals with selective IgA deficiency most commonly show reduced levels of which IgG subclass? (Q890563)

A. IgG1

B. IgG2

C. IgG3

D. IgG4

Correct Answer: B. IgG2

Explanation: Selective IgA deficiency is the most common primary immunodeficiency and is characterised by markedly reduced or absent serum and secretory IgA , leading to impaired mucosal immunity. It is frequently associated with deficiencies in IgG subclasses, most consistently IgG2 . IgG2 plays a critical role in immune responses against polysaccharide antigens of encapsulated bacteria such as Streptococcus pneumoniae and Haemophilus influenzae . Deficiency of IgG2 results in impaired opsonisation and clearance of these organisms, contributing to recurrent sinopulmonary infections , a hallmark clinical feature in symptomatic patients. Although deficiencies of other IgG subclasses (such as IgG3 or IgG4) may occasionally be seen, these associations are variable and less consistent , making IgG2 deficiency the most reliable and clinically significant finding .

References:

https://primaryimmune.org/understanding-primary-immunodeficiency/types-of-pi/selective-iga-deficiency

https://pmc.ncbi.nlm.nih.gov/articles/PMC3099256/

https://pmc.ncbi.nlm.nih.gov/articles/PMC1905297

↑ *Back to this question in Part A*

@Neet_pg_bot

Q10: Which of the following genes is not typically associated with the development of severe combined immunodeficiency (SCID)? (Q890562)

A. IL-7Rα

B. RAG1 and RAG2

C. JAK3

D. BTK

Correct Answer: D. BTK

Explanation: Severe combined immunodeficiency (SCID) results from genetic defects that impair T-cell development , leading to combined defects in both cell-mediated and humoral immunity . Several genes are commonly involved: IL-7Rα (Option A) mutations impair T-cell development, causing an autosomal recessive form of SCID (T■ B■ NK■). RAG1 and RAG2 (Option B) are required for V(D)J recombination; mutations prevent normal T- and B-cell maturation, resulting in SCID (T■ B■). JAK3 (Option C) is involved in signalling through the common γ-chain cytokine receptor; mutations lead to SCID (T■ B■ NK■). In contrast, BTK (Option D) mutations cause X-linked agammaglobulinemia (XLA) , characterised by defective B-cell maturation with normal T-cell function . Therefore, BTK is not associated with SCID.

References:

Robbins, Cotran & Kumar Pathologic Basis of Disease, 11th Edition, Pages 215-216

↑ *Back to this question in Part A*

@Neet_pg_bot

Q11: A 7-month-old infant presents with persistent oral thrush and extensive diaper rash. History reveals multiple serious infections since birth, requiring repeated hospital admissions. Oral examination shows easily scrapable white patches. Thymic biopsy demonstrates underdeveloped Hassall's corpuscles. Which of the following statements about this condition is correct? The most common form of SCID is X-linked Adenosine deaminase (ADA) enzyme deficiency is the most common cause Hematopoietic stem cell transplantation is the preferred treatment It is due to defects in both humoral and cell-mediated immune responses (Q890561)

A. 1,2

B. 2,3,4

C. 1,3,4

D. All of the above

Correct Answer: C. 1,3,4

Explanation: Severe combined immunodeficiency (SCID) is a group of disorders characterised by profound defects in both cell-mediated (T-cell) and humoral (B-cell) immunity , leading to severe, recurrent infections early in life, including opportunistic infections such as candidiasis. The most common form is X-linked SCID , caused by mutations in the common γ-chain (IL2RG) of cytokine receptors, resulting in defective T-cell development

(Statement 1). Adenosine deaminase (ADA) deficiency is the most common autosomal recessive cause of SCID but is not the most common overall cause (Statement 2). Hematopoietic stem cell transplantation (HSCT) is the mainstay of treatment and can restore immune function (Statement 3). Because T cells are essential for B-cell activation, SCID results in combined defects in both humoral and cell-mediated immunity (Statement 4).

References:

Robbins, Cotran & Kumar Pathologic Basis of Disease, 11th Edition, Pages 215-216

↑ *Back to this question in Part A*

@Neet_pg_bot

Q12: A young adult develops recurrent episodes of facial and lip swelling accompanied by abdominal pain and vomiting following minor stress or trauma. There is no associated urticaria. Which of the following complement deficiencies is most likely responsible? (Q890560)

A. C1 inhibitor

B. C2

C. C3

D. C5,C6, C7, C8, C9

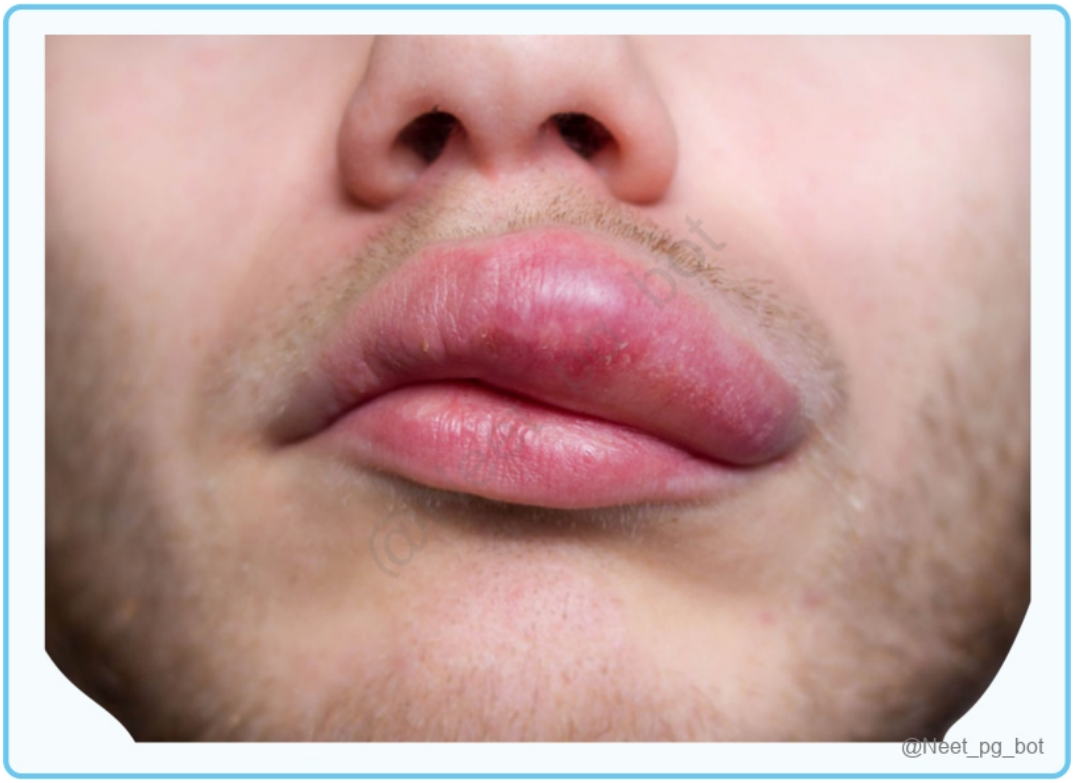

Correct Answer: A. C1 inhibitor

Explanation: Hereditary angioedema is caused by a deficiency of C1 esterase inhibitor (C1-INH) , an autosomal dominant disorder. This leads to unregulated activation of the kallikrein-kinin system and increased production of bradykinin , resulting in increased vascular permeability and recurrent, non-urticarial edema of the skin and mucosal surfaces, including the gastrointestinal tract. Episodes are often triggered by minor trauma or emotional stress . C2 (Option B) deficiency is associated with increased susceptibility to infections and SLE-like autoimmune disease , not angioedema. C3 (Option C) deficiency leads to severe recurrent pyogenic infections due to impaired opsonisation. Deficiencies of terminal complement components C5-C9 (Option D) impair formation of the membrane attack complex and predispose to recurrent Neisseria infections .

References:

Robbins, Cotran & Kumar Pathologic Basis of Disease, 11th Edition, Pages 214-215

↑ *Back to this question in Part A*

@Neet_pg_bot

Q13: Which of the following complement deficiencies is correctly matched with its associated disorder? (Q890559)

A. C1 esterase inhibitor - Hereditary angioedema

B. C3 - Recurrent Neisseria infections

C. Factor H - Glomerulonephritis

D. C6-C9 - Hemolytic uremic syndrome

Correct Answer: A. C1 esterase inhibitor - Hereditary angioedema

Explanation: Deficiency of C1 esterase inhibitor (C1-INH) causes hereditary angioedema , an autosomal dominant disorder characterised by recurrent episodes of oedema involving the skin, mucous membranes, and airways. This results from unregulated activation of the kallikrein system and increased bradykinin production , leading to increased vascular permeability. Complement deficient Disorder C1 esterase inhibitor Hereditary angioedema C3 (Option B) Recurrent pyogenic infections with encapsulated bacteria (like pneumococci) Factor H (Option C) Atypical hemolytic uremic syndrome (aHUS) and thrombotic microangiopathy C6-C9 (Option D) Recurrent Neisseria (gonococcal and meningococcal) infections C2, C4, or C1q SLE

References:

Robbins, Cotran & Kumar Pathologic Basis of Disease, 11th Edition, Page 214

↑ *Back to this question in Part A*

@Neet_pg_bot

Q14: A 6-month-old infant presents with persistent fever and rapid breathing for 1 week. History reveals multiple previous infections. Blood culture grows Serratia marcescens. Nitroblue tetrazolium (NBT) test is negative. Which of the following statements about this condition is true? (Q890558)

A. It is inherited in an autosomal dominant manner

B. Due to lymphocytic inflammatory reaction

C. Primarily affects the adaptive immune system

D. It is due to defects in leukocytic superoxide production

Correct Answer: D. It is due to defects in leukocytic superoxide production

Explanation: Chronic granulomatous disease (CGD) is caused by inherited defects in components of the phagocyte NADPH oxidase complex , leading to impaired generation of superoxide (O■•) and reactive oxygen species . This defect results in impaired intracellular killing of microbes , particularly catalase-positive organisms such as Serratia marcescens . The nitroblue tetrazolium (NBT) test is negative due to failure of the oxidative burst. Most cases are X-linked (gp91phox deficiency) , while others are autosomal recessive (e.g., p47phox, p67phox) ; it is not inherited in an autosomal dominant manner (Option A). The disease is a defect of innate immunity affecting phagocytes , not a lymphocyte-mediated process (Option B) and does not primarily involve the adaptive immune

system (Option C) . The impaired neutrophil response leads to chronic inflammation with macrophage-rich granuloma formation .

References:

Robbins, Cotran & Kumar Pathologic Basis of Disease, 11th Edition, Pages 48, 214

↑ *Back to this question in Part A*

@Neet_pg_bot

Q15: In a pediatric clinic, a six-year-old male presents with a history of frequent respiratory and skin infections, eczema flare-ups, and microthrombocytopenia. Given these symptoms, which genetic evaluation method would be the most effective for confirming the suspected diagnosis? (Q845948)

A. WASP gene mutation analysis

B. ANA titer

C. FISH

D. B cell tyrosine kinase activity detection

Correct Answer: A. WASP gene mutation analysis

■ *Listen (English)*

■ *Listen (Hindi)*

Explanation: WASP gene mutation analysis, specific to Wiskott-Aldrich syndrome. Wiskott-Aldrich syndrome is an X-linked recessive disease characterized by the triad of: Thrombocytopenia Eczema Recurrent infections Wiskott-Aldrich syndrome is caused by mutations in the gene located at Xp11.23, which encodes the Wiskott-Aldrich syndrome protein (WASP). ANA titre (Option B): These are typically associated with SLE (systemic lupus erythematosus) FISH (Option C): FISH (Fluorescence In Situ Hybridization) is a molecular cytogenetic technique used to detect and localize specific DNA sequences within the chromosomes. It is used for identifying microdeletion, amplification or translocation. B cell tyrosine kinase activity detection (Option D): Detection of B-cell tyrosine kinase activity is relevant for X-linked agammaglobulinemia (XLA), characterized by the absence of mature B cells and low levels of immunoglobulins.

References:

Robbins and Cotran Pathologic Basis of Disease, 10th Edition, Page 169

↑ *Back to this question in Part A*

@Neet_pg_bot

Q16: In a pediatric clinic, a six-year-old male presents with a history of frequent respiratory and skin infections, eczema flare-ups, and thrombocytopenia. Given these symptoms, which genetic evaluation method would be the most effective for confirming the suspected diagnosis? (Q845648)

A. WASP gene mutation analysis

B. ANA titer

C. FISH

D. B cell tyrosine kinase activity detection

Correct Answer: A. WASP gene mutation analysis

■ *Listen (English)*

■ *Listen (Hindi)*

Explanation: WASP gene mutation analysis, specific to Wiskott-Aldrich syndrome. Wiskott-Aldrich syndrome is an X-linked recessive disease characterised by the triad of: Thrombocytopenia Eczema Recurrent infections Wiskott-Aldrich syndrome is caused by mutations in the gene located at Xp11.23, which encodes the Wiskott-Aldrich syndrome protein (WASP). Pathophysiology: WASP is a key regulator of the actin cytoskeleton in hematopoietic cells. Its absence leads to defective T-cell interaction and abnormal platelet formation. Confirmation: Genetic analysis to identify mutations in the WAS gene is the definitive method for confirming this diagnosis.\ ANA Titer (Option B): Anti-Nuclear Antibody (ANA) titers are used as a screening tool for systemic autoimmune diseases , such as Systemic Lupus Erythematosus (SLE). While patients with immunodeficiencies can have associated autoimmunity, an ANA titer is not specific for any primary immunodeficiency and would not identify the underlying genetic cause of this child's symptoms. FISH (Fluorescence In Situ Hybridization) (Option C): FISH is used to detect and locate specific DNA sequences on chromosomes. It is the classic test for diagnosing DiGeorge Syndrome (detecting the 22q11.2 deletion). While FISH is a powerful genetic tool, it is not the primary method for detecting the point mutations or small deletions typically found in the WAS gene. B-cell tyrosine kinase activity detection (Option D): This test evaluates the function of Bruton Tyrosine Kinase (BTK) . Reduced BTK activity or expression is diagnostic for X-linked Agammaglobulinemia (Bruton's) . While Bruton's presents with recurrent infections, it does not feature the thrombocytopenia or eczema seen in this patient.

References:

Robbins and Cotran Pathologic Basis of Disease, 10th Edition, Page 169

↑ *Back to this question in Part A*

@Neet_pg_bot

Q17: A 35-year-old male with a known history of selective IgA deficiency receives a blood transfusion during surgery. Shortly after the transfusion, he develops acute allergic reactions, including hives and difficulty breathing. Given his IgA deficiency, which blood products should have been considered to minimize the risk of such complications? (Q845676)

A. Standard red blood cells with no modification

B. Plasma products that are rich in IgA

C. Washed red blood cells

D. Fresh frozen plasma

Correct Answer: C. Washed red blood cells

■ *Listen (English)*

■ *Listen (Hindi)*

Explanation: Patients with selective IgA deficiency risk developing anaphylactic reactions if they receive IgA blood products. To minimize this risk, it is essential to transfuse blood products that have been processed to reduce IgA levels, such as washed red blood cells with normal saline multiple times to remove plasma components such as antibodies. In contrast, standard red blood cells or IgA-rich products could trigger severe allergic reactions, as seen in this patient. Selective IgA deficiency: Selective IgA deficiency is the most common primary immunodeficiency . It is characterized by a significant decrease or total absence of serum and secretory IgA, while other immunoglobulin levels (IgG, IgM) and T-cell counts remain normal. Clinical Presentation: ■■■■■■■ Recurrent Sinopulmonary Infections: Such as sinusitis, otitis media, and pneumonia. Gastrointestinal Infections: Frequent giardiasis due to lack of mucosal protection. Autoimmune Disorders: Strong association with Celiac disease, SLE, and Rheumatoid Arthritis. Atopy: Increased incidence of asthma, eczema, and food allergies. Some patients develop anti-IgA antibodies (IgE class). Diagnosis: Measure serum IgA (quantitative nephelometry); confirm with normal IgG/IgM and vaccine responses (e.g., pneumococcal). Screen for anti-IgA antibodies if transfusion reactions occur. Comparison with other B-cell Deficiencies: Feature Selective IgA Deficiency X-linked Agammaglobulinemia (Bruton) Common Variable Immunodeficiency (CVID) Ig Levels Only IgA low All Ig classes low Multiple classes low (IgG/IgA/IgM) B-cell Count Normal Decreased/Absent Normal Age of Onset Any age; often asymptomatic After 6 months (loss of maternal IgG) 2nd–4th decade (20s–30s) Special Risk Anaphylaxis to blood Enteroviral infections High risk of gastric cancer/Lymphoma

References:

Robbins & Cotran Pathologic Basis of Disease, 10th Edition, Page 245

https://www.ncbi.nlm.nih.gov/books/NBK564340/

↑ *Back to this question in Part A*

@Neet_pg_bot

Q18: A 7-year-old child presents with recurrent skin abscesses and pneumonia. He also has a history of skeletal abnormalities, including scoliosis and delayed shedding of primary teeth. His lab work shows elevated serum IgE levels. What is the most likely diagnosis? (Q845675)

A. Job syndrome

B. Bruton's Agammaglobulinemia

C. Wiskott-Aldrich syndrome

D. Ataxia-Telangiectasia

Correct Answer: A. Job syndrome

■ *Listen (English)*

■ *Listen (Hindi)*

Explanation: The clinical presentation of recurrent infections with delayed shedding of primary teeth, along with the findings of elevated serum IgE levels, indicates the diagnosis of Job syndrome or hyper IgE syndrome . Hyper IgE syndrome (Job syndrome): Deficiency of Th17 cells due to STAT3 mutation → impaired recruitment of neutrophils to sites of infections. The clinical presentation is classically remembered by the mnemonic FATED : F – Facies: Coarse facial features. A – Abscesses: Recurrent "cold" (non-inflamed) staphylococcal abscesses. T – Teeth: Retained (delayed shedding) of primary teeth. E – IgE: Massive elevation of serum IgE . D – Dermatological: Eczema/Dermatitis. Skeletal: Bone abnormalities such as scoliosis and frequent fractures from minor trauma. Bruton's Agammaglobulinemia (X-linked Agammaglobulinemia) (Option B): Defect: Mutation in Bruton Tyrosine Kinase (BTK) , which is essential for B-cell maturation. Key Lab Findings: Absence of B cells (CD19+, CD20+) in peripheral blood and low levels of all immunoglobulin classes (IgG, IgA, IgM, IgE). Clinical Presentation: Recurrent bacterial and enteroviral infections starting after 6 months of age (once maternal IgG wanes). Why it's wrong: This patient has elevated IgE, whereas Bruton patients have near-zero IgE. Wiskott-Aldrich Syndrome (Option C): Defect: Mutation in the WASP gene ; T cells cannot reorganize their actin cytoskeleton. Clinical Triad (WATER): W iskott- A ldrich, T hrombocytopenia (small platelets/purpura), E czema, and R ecurrent pyogenic infections. Key Lab Findings: Low IgM , high IgA, and high IgE. Why it's wrong: While IgE is high, Wiskott-Aldrich is dominated by bleeding/purpura due to microthrombocytopenia, not skeletal or dental issues. Ataxia-Telangiectasia (Option D): Defect: Mutation in the ATM gene , leading to failure of DNA double-strand break repair. Clinical Triad: Ataxia (cerebellar atrophy), Telangiectasias (spider angiomas, often in the eyes), and IgA deficiency . Key Lab Findings: Low IgA, IgG, and IgE ; characteristically elevated Alpha-fetoprotein (AFP) . Why it's wrong: It presents with neurological decline and vascular markings, not skeletal abnormalities or high IgE. Feature Job Syndrome Bruton's (XLA) Wiskott-Aldrich Ataxia-Telangiectasia Main Defect Th17/STAT3 B-cell maturation (BTK) Actin cytoskeleton DNA Repair (ATM) Signature Lab ↑ ■■■■ ■■■↑ IgE ↓ All Ig classes ↑ IgE/IgA, ↓ IgM ↑ AFP , ↓ IgA Unique Sign Retained teeth Absent tonsils Small platelets Ataxia/Spider veins Infections "Cold" Abscesses Encapsulated bacteria Encapsulated bacteria Sinopulmonary

References:

Harrison's Principles of Internal Medicine, 21st Edition, Page 449

↑ *Back to this question in Part A*

@Neet_pg_bot

Q19: A 4-year-old boy presents with recurrent bacterial infections, including pneumonia and otitis media. He also has a history of chronic diarrhoea. Laboratory tests reveal elevated IgM levels with markedly reduced IgG, IgA, and IgE levels. Flow cytometry shows normal numbers of CD19+ B cells and CD3+ T cells. Genetic testing reveals a mutation in the CD40L gene. Which of the following pathogens is the patient most at risk for developing severe infections with? (Q845674)

A. Streptococcus pneumoniae

B. Haemophilus influenzae

C. Staphylococcus aureus

D. Pneumocystis jirovecii

Correct Answer: D. Pneumocystis jirovecii

■ *Listen (English)*

■ *Listen (Hindi)*

Explanation: The clinical presentation of recurrent infections along with the findings of mutation in CD40L gene suggests the diagnosis of Hyper IgM syndrome . Hyper IgM syndrome: It follows X-linked mode of inheritance. Normally, the antigen binds to the antibody on B cells and is then presented to the T cells and the B-cell and T-cell numbers remains normal. CD40L (also known as CD154) on antigen-activated CD4+ helper T cells binds to CD40 on B cells, macrophages, and dendritic cells (DCs). This interaction is crucial for triggering Ig class switching (from IgM to IgG, IgA, and IgE) and affinity maturation in B cells. In hyper IgM syndrome, there is a defect in the CD40 receptor or CD40 ligand (most common). As a result, patients have high IgM levels but low levels of IgG, IgA, and IgE, and are prone to recurrent infections. In addition, these patients are also susceptible to pneumonia caused by Pneumocystis jirovecii . Autoimmune disorders are a common complication of Hyper IgM syndrome, and autoimmune hemolytic anemia is one of the more frequent autoimmune manifestations. Clinical Features of Hyper IgM syndrome: Recurrent sinopulmonary infections (pneumocystis pneumonia, bacterial otitis/sinusitis). Opportunistic: cryptosporidium (causes sclerosing cholangitis), chronic diarrhea Neutropenia (especially X-HIGM), hepatobiliary disease, autoimmunity (anemia, thrombocytopenia), and malignancy risk (liver cancer, lymphoma). Diagnosis of Hyper IgM syndrome : Labs: Hypogammaglobulinemia (low IgG/A/E, high/normal IgM); poor vaccine responses Flow cytometry: absent CD40L on activated T cells; genetic testing Management of Hyper IgM syndrome: IVIG/SCIG replacement, PCP prophylaxis (TMP-SMX), antibiotics for neutropenia (G-CSF if severe) HSCT as curative option (best early for X-HIGM) Gene therapy under investigation

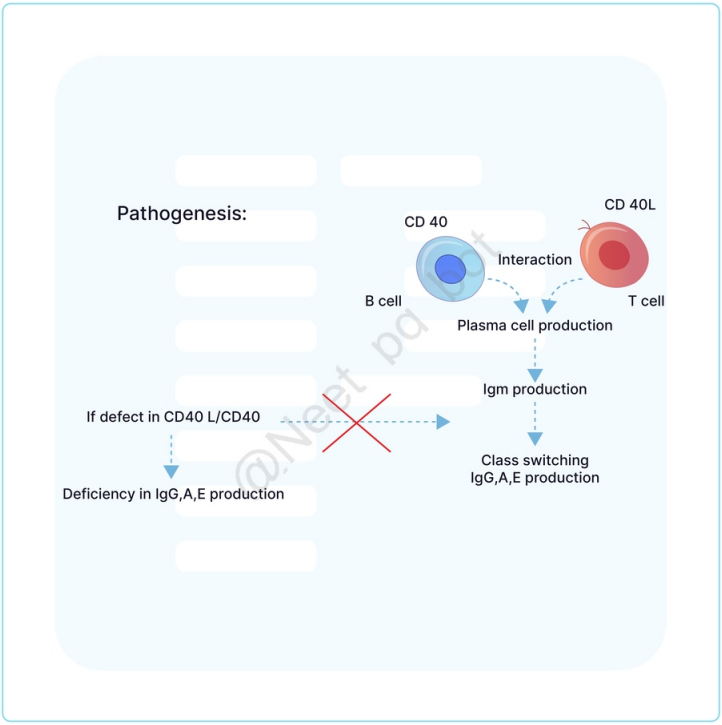

@Neet_pg_bot

References:

Robbins & Cotran Pathologic Basis of Disease, 10th Edition, Page 244, 245

↑ *Back to this question in Part A*

@Neet_pg_bot

Q20: A patient presents with autoimmune hemolytic anemia, thrombocytopenia and neutropenia. Based on the flow cytometry findings, what is the most likely diagnosis? (Q845673)

A. Paroxysmal Nocturnal Hemoglobinuria

B. Hyper IgE syndrome

C. Hyper IgM syndrome

D. Glanzmann Thrombasthenia

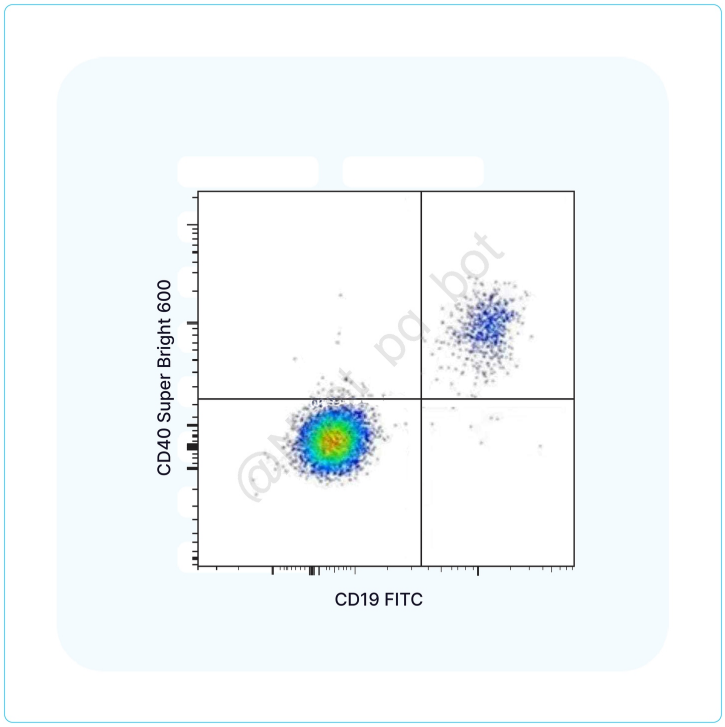

@Neet_pg_bot

Correct Answer: C. Hyper IgM syndrome

Explanation: The clinical presentation of autoimmune hemolytic anaemia, thrombocytopenia and neutropenia with the flow cytometry findings showing CD40 negative and CD19 negative, is most likely suggestive of Hyper IgM syndrome. Hyper IgM syndrome: In hyper IgM syndrome, mature B cells are present, but they are incapable of Ig class switching and affinity maturation because of a defect in the CD40 receptor or CD40 ligand . The patient's serum will have elevated levels of IgM but no IgA or IgE and extremely low levels of IgG. Occasionally, the IgM antibodies react with blood cells, giving rise to autoimmune hemolytic anemia, thrombocytopenia, and neutropenia. Flow cytometry: Flow cytometry results are typically represented as histograms or dot plots: Histograms : Represent the frequency distribution of a single parameter. Dot plots : Display two parameters on the x- and y-axes. The given image is a dot plot and it has 4 quadrants as follows: Quadrant 1 (green) Negative for antigen A, positive for antigen B Quadrant 2 (purple) Negative for both antigens Quadrant 3 (yellow) Positive for both antigens Quadrant 4 (red) Positive for antigen A, negative for antigen B The dot plot in the question has CD19 (pan B-cell marker) on the X-axis and CD40 on the Y-axis . The majority of the cells are in the double negative quadrant, indicating that both CD40 and CD19 are almost negative in this patient, suggesting the diagnosis of hyper IgM syndrome. Hyper IgM syndrome (Option C) is characterized by CD40L deficiency (X-linked) or CD40 deficiency (autosomal recessive), which affects both B and T cells. Paroxysmal Nocturnal Hemoglobinuria (Option A): A flow cytogram of blood from a patient with PNH shows a population of red cells that is deficient in both CD55 and CD59. Glanzmann Thrombasthenia (Option D): It is a platelet disorder characterized by glycoprotein IIb/IIIa defect, also known as CD41 (GpIIb) and CD61 (GpIIIa). Hence CD41 and CD61 are both negative on flow cytometry.

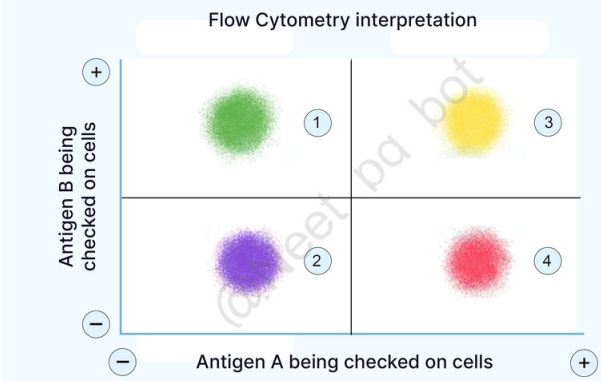

@Neet_pg_bot

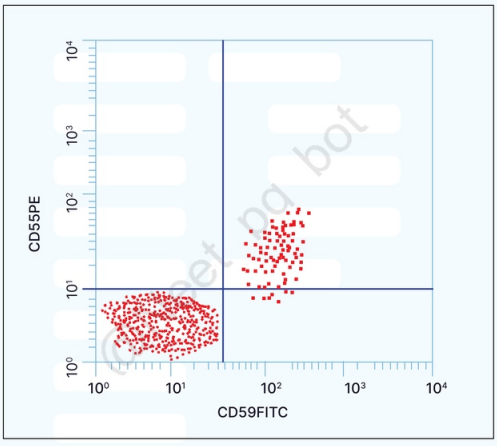

@Neet_pg_bot

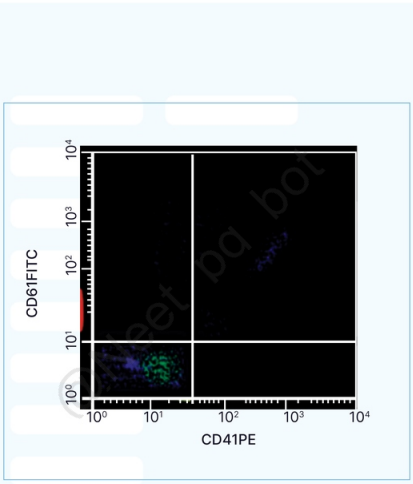

@Neet_pg_bot

References:

Robbins & Cotran Pathologic Basis of Disease, 10th Edition, Page 120, 244, 245, 649

↑ *Back to this question in Part A*

@Neet_pg_bot

Q21: A 7-year-old boy is brought to the pediatric clinic due to recurrent infections, including pneumonia and abscesses. He has a history of photophobia and exhibits partial oculocutaneous albinism. On examination, he has notable nystagmus and ataxia. Genetic testing confirms a defect in the LYST gene. Which of the following laboratory findings would be most characteristic of this patient's condition? (Q845672)

A. Decreased immunoglobulin levels

B. Elevated eosinophil count

C. Presence of giant granules in leukocytes

D. Elevated platelet count

Correct Answer: C. Presence of giant granules in leukocytes

■ *Listen (English)*

■ *Listen (Hindi)*

Explanation: This patient is presenting with the classical signs of Chédiak-Higashi Syndrome (CHS) , a rare autosomal recessive disorder caused by a mutation in the LYST gene (Lysosomal Trafficking gene defect). Chédiak-Higashi Syndrome (CHS): C: C NS/neurological abnormalities HE: He morrhage DI: D ecreased I mmunity → ↑ Inflammation A: A lbinism (silvery gray hair), hypopigmentation K: Coarse cytoplasmic granules Decreased immunoglobulin levels (Option A): While patients are immunodeficient, the primary defect is in phagocytic function and Natural Killer (NK) cell activity, not necessarily a lack of antibodies (though advanced stages can see various shifts). Elevated eosinophil count (Option B): This is characteristic of Hyper-IgE syndrome (Job Syndrome), which also presents with "cold" abscesses and skin issues, but lacks albinism and giant granules. Elevated platelet count (Option D): Patients with CHS actually often have thrombocytopenia (low platelet count) and defective dense granules in platelets, leading to easy bruising and bleeding tendencies.

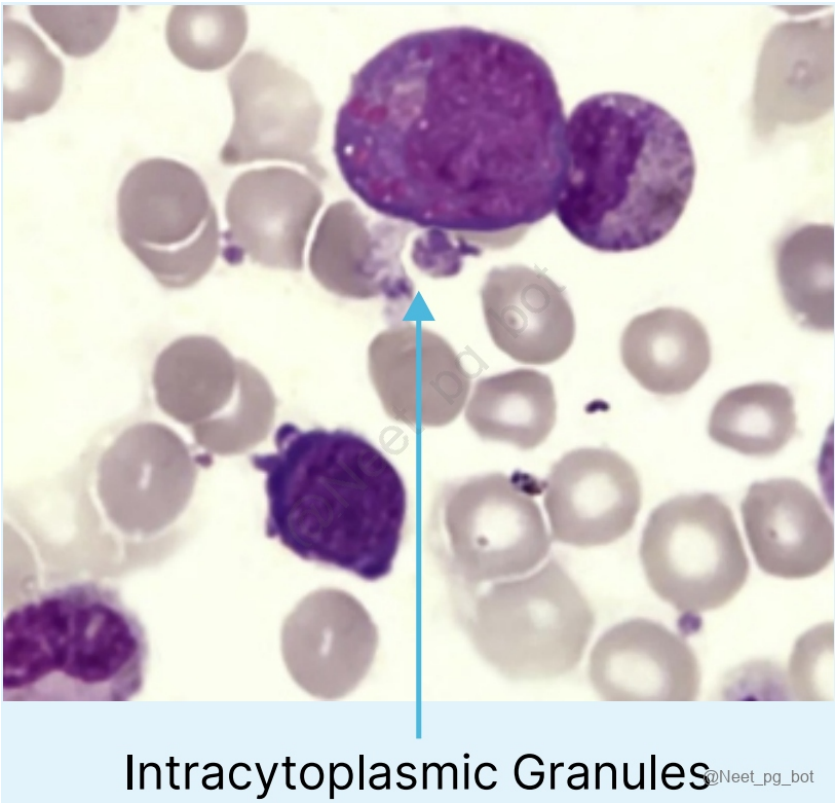

References:

Robbins & Cotran Pathologic Basis of Disease, 10th Edition, Page 241

↑ *Back to this question in Part A*

@Neet_pg_bot

Q22: Match the following. i) X-linked Agammaglobulinemia a) WAS ii) Job syndrome b) LYST iii) Wiskott-Aldrich syndrome c) STAT3 iv) Ataxia Telangiectasia d) BTK v) Chediak-Higashi syndrome e) ATM (Q845671)

A. i-d, ii-c, iii-b, iv-e, v-a

B. i-c, ii-d, iii-a, iv-e, v-b

C. i-d, ii-b, iii-a, iv-e, v-c

D. i-d, ii-c, iii-a, iv-e, v-b

Correct Answer: D. i-d, ii-c, iii-a, iv-e, v-b

■ *Listen (English)*

■ *Listen (Hindi)*

Explanation: X-linked (Bruton) Agammaglobulinemia BTK Job syndrome (Hyper IgE syndrome) STAT3 Wiskott-Aldrich syndrome WAS Ataxia Telangiectasia ATM Chediak-Higashi syndrome LYST 1. Job Syndrome (Hyper-IgE Syndrome): Gene: Autosomal dominant mutation in STAT3 . Mechanism: Defective STAT3 leads to a failure of Th17 cell differentiation. Without Th17 cells, there is a lack of IL-17, which is essential for recruiting neutrophils to sites of fungal and bacterial infections. Clinical Points: Massive elevation of IgE . "Cold" abscesses: Staphylococcal skin infections that lack the typical warmth and redness because neutrophils aren't recruited properly. Skeletal/Dental: Retention of primary teeth (delayed shedding), coarse facial features, and scoliosis. 2. X-linked (Bruton) Agammaglobulinemia: Gene: Mutation in BTK (Bruton Tyrosine Kinase). Mechanism: The BTK gene is located on the X chromosome and is vital for B-cell signaling. A defect prevents pre-B cells from maturing into mature B cells. Clinical Points: Absent B cells: Extremely low levels of CD19+, CD20+, and CD21+ cells in peripheral blood. Hypogammaglobulinemia: Very low levels of all immunoglobulin classes (IgG, IgA, IgM, IgD, IgE). Infections: Recurrent sinopulmonary and GI infections (e.g., Giardia) starting after 6 months of age once maternal IgG disappears. 3. Wiskott-Aldrich Syndrome: Gene: X-linked recessive mutation in the WAS gene. Mechanism: The WASP protein is responsible for organizing the actin cytoskeleton in hematopoietic cells. Without it, T cells cannot properly interact with other cells, and platelets are formed incorrectly. Clinical Points: Thrombocytopenia: Characterized by small platelets and a low platelet count, leading to bleeding and purpura. Immunology: Low to normal IgG and IgM; elevated IgA and IgE . Triad: Recurrent infections, eczema, and thrombocytopenia. 4. Ataxia-Telangiectasia: Gene: Autosomal recessive mutation in the ATM gene. Mechanism: The ATM protein detects DNA double-strand breaks and coordinates repair. A defect leads to accumulated DNA damage, cell cycle instability, and hypersensitivity to ionizing radiation. Clinical Points: Neurological: Progressive cerebellar ataxia (difficulty walking). Vascular: Telangiectasias (spider-like dilated capillaries) usually seen on the conjunctiva or skin. Lab Markers: Low IgA and IgG; characteristically elevated Alpha-fetoprotein (AFP) . 5. Chédiak-Higashi Syndrome: Gene: Autosomal recessive mutation in the LYST (Lysosomal Trafficking Regulator) gene. Mechanism: Defective vesicle fusion and lysosomal trafficking . This results in the formation of giant granules in neutrophils and prevents cytotoxic T cells from secreting their granules. Clinical Points: Microscopy: Pathognomonic giant granules in neutrophils and platelets. Albinism: Partial oculocutaneous albinism (melanocytes cannot distribute pigment granules). Neurological: Peripheral neuropathy and progressive neurodegeneration.

References:

Robbins & Cotran Pathologic Basis of Disease, 10th Edition, Page 241-246

Harrison’s Principles of Internal Medicine, 21st Edition, Page 2715

↑ *Back to this question in Part A*

@Neet_pg_bot

Q23: An 8-month-old male infant presents with a history of severe, recurrent bacterial infections. On physical examination, the tonsils were found to be absent. Peripheral blood examination reveals an absence of B cells, while the T cell count is normal. Additionally, serum analysis reveals undetectable levels of immunoglobulins (IgG, IgA, and IgM). Which of the following most accurately explains the molecular mechanism responsible for this patient's immunodeficiency? (Q845670)

A. BTK gene mutation

B. RAG1/2 gene mutation

C. CD40L deficiency

D. BAFF receptor abnormality

Correct Answer: A. BTK gene mutation

■ *Listen (English)*

■ *Listen (Hindi)*

Explanation: The clinical vignette suggests that the infant is suffering from Bruton's agammaglobulinemia (X-linked agammaglobulinemia) , which is due to a defect in the BTK gene. It is a X-linked recessive disorder, most commonly seen in boys and symptoms usually start after 6 months, when maternal antibodies decline. A BTK gene defect prevents B-cell precursors from maturing into functional B cells, blocking plasma cell formation and causing low immunoglobulin levels. Lymphoid germinal centers remain underdeveloped. RAG1/2 gene mutation (Option B) leads to severe combined immunodeficiency (SCID) , where both B and T cell functions are impaired due to defective V(D)J recombination. CD40 ligand deficiency (Option C) leads to Hyper IgM syndrome , where T-B cell interactions are defective, but B cells are still present. BAFF (B-cell activating factor) receptor abnormality (Option D) can contribute to common variable immunodeficiency (CVID) . However, CVID typically presents later in childhood or adulthood and is characterized by low serum immunoglobulin levels and impaired antibody responses with the presence of B cells.

References:

Robbins & Cotran Pathologic Basis of Disease, 10th Edition, Page 243, 244, 245

Harrison’s Principles of Internal Medicine, 21st Edition, Page 2716, 2717

Davidson’s Principles and Practice of Medicine, 24th Edition, Page 78

Essentials of Medical Microbiology, Apurba S Sastry, 3rd Edition, Page 209

https://www.ncbi.nlm.nih.gov/books/NBK549865/

↑ *Back to this question in Part A*

@Neet_pg_bot

Q24: A 30-year-old female patient presents with a history of recurrent respiratory infections, chronic diarrhoea, and autoimmune manifestations. Laboratory investigations reveal low levels of serum immunoglobulins (IgG, IgA, and IgM). BAFF gene defect noted. Which of the following immunodeficiency disorders is most likely associated with these clinical findings? (Q845669)

A. X-linked agammaglobulinemia (XLA)

B. Common variable immunodeficiency (CVID)

C. Hyper IgM syndrome

D. Severe Combined Immunodeficiency (SCID)

Correct Answer: B. Common variable immunodeficiency (CVID)

■ *Listen (English)*

■ *Listen (Hindi)*

Explanation: The above mentioned case scenario of a middle aged women with recurrent infections and autoimmune manifestations along with low sreum levels of IgG, IgA and IgM with BAFF gene defect points towards the diagnosis of Common variable immunodeficiency (CVID). Incorrect options: X-linked agammaglobulinemia (XLA) (Option A): Usually presents in male infants Caused by BTK gene defect → absence of mature B cells Females are usually carriers, not affected Hyper IgM Syndrome(Option C): It is caused due to impaired class switching and affinity maturation of antibodies, resulting in elevated IgM levels and reduced IgG and IgA. It also presents with recurrent bacterial infections. Severe Combined Immunodeficiency (SCID) (Option D): Severe infections in infancy Defect in T-cell development , often affecting B cells secondarily Not compatible with adult onset

References:

Robbins and Cotran Pathologic Basis of Disease, 10th Edition, Page 245

↑ *Back to this question in Part A*

@Neet_pg_bot

Q25: A 6-year-old child presents with recurrent bacterial infections, delayed wound healing, and poor pus formation. Genetic testing reveals a mutation in the SLC35C1 gene, leading to a deficiency in Sialyl Lewis X (SLex) synthesis. Which of the following is the most likely consequence of this deficiency? (Q845668)

A. Leukocyte adhesion deficiency II

B. Defective opsonisation

C. Reduced chemokine production

D. Increased neutrophil apoptosis

Correct Answer: A. Leukocyte adhesion deficiency II

■ *Listen (English)*

■ *Listen (Hindi)*

Explanation: The clinical presentation of recurrent bacterial infections, delayed wound healing, and poor pus formation suggests a failure of white blood cells to migrate from the blood into the tissues. The specific mutation in the SLC35C1 gene leads to Leukocyte Adhesion Deficiency Type II (LAD II) . Mechanism: This gene encodes a fucose transporter. Its deficiency prevents the synthesis of Sialyl Lewis X (SLex) , which is the ligand on neutrophils that binds to E-selectin and P-selectin on the endothelium. Without this binding, neutrophils cannot "roll" along the vessel wall, which is the essential first step of extravasation. Unlike LAD I, LAD II is also associated with severe growth retardation and the Bombay blood phenotype because fucose is required for the H-antigen in the ABO system. Feature LAD I LAD II LAD III Defect CD18 (common β 2 subunit of Integrins) SLC35C1 (Fucose transporter / Sialyl Lewis X) FERMT3 (Kindlin-3 / Integrin activation) Process Affected Firm Adhesion and Transmigration Rolling (Initial tethering) Integrin activation Unique Clinical Signs Delayed separation of the umbilical cord Growth retardation, Bombay blood group, Intellectual disability Bleeding tendency (Glanzmann-like platelet defect) Pus Formation Poor/Absent Poor/Absent Poor/Absent Defective Opsonization (Option B): Mechanism: Opsonization involves coating a pathogen with antibodies (IgG) or complement proteins (C3b) to make it more "appetizing" to phagocytes. While this would lead to recurrent infections, it does not explain the failure of leukocytes to enter the tissue (lack of pus) or the specific SLex deficiency mentioned in the prompt. Reduced Chemokine Production (Option C): Mechanism: Chemokines (like IL-8) are signaling proteins that create a chemical gradient to guide neutrophils to the site of injury. In LAD, the signals (chemokines) are usually present, but the "machinery" on the leukocyte (integrins or selectin ligands) is broken, so they cannot respond to those signals. Increased Neutrophil Apoptosis (Option D): Mechanism: This would lead to Neutropenia (low absolute neutrophil count). In LAD II, the blood work typically shows Leukocytosis (elevated white cell count) because the neutrophils are "trapped" in the bloodstream and cannot exit into the tissues.

References:

Robbins and Cotran Pathologic Basis of Disease, 10th Edition, Page 241.

↑ *Back to this question in Part A*

@Neet_pg_bot

Q26: A 2-year-old child presents with recurrent bacterial infections, delayed wound healing, and poor pus formation despite having a normal leukocyte count. Upon further investigation, a defect is identified in the integrin-mediated adhesion of leukocytes. Which of the following conditions is most likely responsible for this clinical presentation? (Q845667)

A. Chronic granulomatous disease (CGD)

B. Leukocyte Adhesion Deficiency Type 1 (LAD-1)

C. Hyper IgM syndrome

D. Severe Combined Immunodeficiency (SCID)

Correct Answer: B. Leukocyte Adhesion Deficiency Type 1 (LAD-1)

■ *Listen (English)*

■ *Listen (Hindi)*

Explanation: A young child with repeated infections and delayed wound healing, but with a normal WBC count, suggests that its a qualitative issue as opposed to a quantitative WBC issue. The defect identified in integerin-mediated adhesion of leukocytes also suggests a functional issue, suggesting the diagnosis of LAD 1. Leukocyte adhesion deficiency 1 (I=Integrin) Defective leukocyte adhesion because of mutations in the β2 chain of CD11/CD18 Integrins, with history of delayed umbilical cord shedding. Chronic Granulomatous Disease (CGD) (Option A): Defect in PHOX gene, resulting in deficiency of NADPH oxidase. Hyper IgM Syndrome (Option C): Loss of function of CD40 or CD40 ligand results in impaired class switching and affinity maturation of antibodies. SCID (Option D): SCID is caused by multiple genetic defects with both X-linked and AR inheritance.

References:

Robbins and Cotran Pathologic Basis of Disease, 10th Edition, Page 241.

↑ *Back to this question in Part A*

@Neet_pg_bot

Q27: Which of the following disorders is characterised by absent tonsils and lymph nodes, markedly decreased levels of serum immunoglobulins (particularly IgG, IgA, and IgM), and a lack of mature B cells in peripheral blood? (Q845666)

A. Common Variable Immunodeficiency (CVID)

B. Severe Combined Immunodeficiency (SCID)

C. X-linked Agammaglobulinemia (XLA)

D. Hyper-IgM Syndrome

Correct Answer: C. X-linked Agammaglobulinemia (XLA)

■ *Listen (English)*

■ *Listen (Hindi)*

Explanation: The above-mentioned clinical scenario points towards the diagnosis of X-linked agammaglobulinemia (Bruton Agammaglobulinemia). More commonly seen in B oys. Defect in B -cells - mature B-cells are not formed, due to a defective B TK gene Since mature B-cells are not formed, there is a deficiency in plasma cells, which leads to decreased levels of immunoglobulin, out of which IgG is most severely decreased. Since IgG is required for opsonization, there will be increased susceptibility to infections by capsulated organisms. Common Variable Immunodeficiency (CVID) (Option A): B- and T-cell deficiency. Options B, D: Absent tonsils and lymph nodes are not specific to SCID and Hyper-IgM Syndrome.

References:

Robbins and Cotran Pathologic Basis of Disease, 10th Edition, Page 243,244

↑ *Back to this question in Part A*

@Neet_pg_bot

Q28: A 5-year-old male presents with progressive difficulty in coordinating movements, slurred speech, and frequent infections. Physical examination reveals the findings shown in the image below and dysarthria. Laboratory investigations show decreased levels of serum IgA, IgG, and IgE. Which of the following is the most likely diagnosis? (Q845665)

A. Hereditary spastic paraplegia

B. Friedreich ataxia

C. Ataxia Telangiectasia

D. Spinocerebellar ataxia type 1



Correct Answer: C. Ataxia Telangiectasia

■ *Listen (English)*

■ *Listen (Hindi)*

Explanation: The clinical scenario (dysarthria, slurred speech, recurrent infections, telangiectasia shown in the image above, decreased serum IgA, IgG, and IgE) suggests ataxia telangiectasia. Ataxia Telangiectasia (AT) is an autosomal-recessive disorder, characterized by abnormal gait(ataxia), vascular malformations (telangiectases), neurological deficits, increased tumors, and immunodeficiency. It affects both B and T cells, mainly causing defective production of IgA, IgE and IgG antibodies. Patients frequently experience respiratory tract infections, autoimmune issues, and There is increased risk of malignancy. It is caused by a mutation in the gene on chromosome 11q22 encoding the ATM protein kinase. Hereditary spastic paraplegia (Option A) presents with spasticity in the lower limbs but does not typically present with immunodeficiencies or telangiectasias. Friedreich ataxia (Option B) is a trinucleotide repeat disorder that presents with progressive gait and limb ataxia, with GAA repeats in the genome.It does not typically present with telangiectasias or immunodeficiency. Spinocerebellar ataxia (Option D) type 1 is characterised by progressive cerebellar ataxia but does not typically present with telangiectasias or immunodeficiency.

References:

Robbins and Cotran Pathologic Basis of Disease, 10th Edition, Page 255

↑ *Back to this question in Part A*

@Neet_pg_bot

Q29: An 8-month-old infant is brought to the clinic with a history of persistent, severe respiratory infections since birth. Physical examination reveals failure to thrive and absent tonsils and lymph nodes. The child is diagnosed with adenosine deaminase deficiency; what is the most appropriate diagnosis? (Q845650)

A. DiGeorge Syndrome

B. X-linked Agammaglobulinemia (XLA)

C. Hyper-IgM Syndrome

D. Severe Combined Immunodeficiency (SCID)

Correct Answer: D. Severe Combined Immunodeficiency (SCID)

■ *Listen (English)*

■ *Listen (Hindi)*

Explanation: The above clinical scenario with adenosine deaminase (ADA) deficiency points towards the diagnosis of Severe Combined Immunodeficiency (SCID) . Severe Combined Immunodeficiency (SCID): B cells, T cells, and NK cells are affected Types: XLR (X-linked recessive variety) AR (Autosomal Recessive Variety) X-linked Recessive (XLR) Variety Autosomal Recessive (AR) Variety Most common type . Defect in g amma subunit of cytokine receptor → IL-2, IL-4, IL-7, IL-15 will not form IL-2 and IL-15: Defective NK cells . IL-7: Defective T-cell development . IL-4: No isotype switching → failure to produce IgG, IgA, and IgE . In XLR type of SCID → Primarily T cells and NK cells are defective; B cell maturity alone is affected. Types: ADA (Adenosine deaminase) deficiency: Most common in AR SCID. ADA deficiency → ↑ toxic metabolites → damage to B, T, and NK cells . JAK-3 defect: Affects cytokine development. Defective T and NK cells . RAG-1 and 2 gene (Recombinant Activation Gene) defect: Responsible for development of B and T cell receptors . Options A, B, and C do not typically lead to a virtual absence of peripheral lymphoid organs, as seen in adenosine deaminase deficiency.

References:

Robbins and Cotran Pathologic Basis of Disease, 10th Edition, Page 242, 243

↑ *Back to this question in Part A*

@Neet_pg_bot

Q30: A 4-year-old child presents with recurrent infections, congenital heart defects, and facial dysmorphisms, including a long face with a prominent nasal bridge. Genetic testing reveals a microdeletion on chromosome 22q11. What is the most likely diagnosis? (Q845649)

A. Down syndrome

B. Turner syndrome

C. DiGeorge syndrome

D. Cri-du-chat syndrome

Correct Answer: C. DiGeorge syndrome

■ *Listen (English)*

■ *Listen (Hindi)*

Explanation: DiGeorge syndrome , or 22q11.2 deletion syndrome , is characterised by a microdeletion on chromosome 22q11. Clinical features represented by CATCH22 C : Cardiac defects, especially conotruncal anomalies A : Abnormal facial features, such as low set ears, hypertelorism, and short philtrum T : Thymic hypoplasia C : Cleft palate or cellular immune deficiency H : Hypoparathyroidism with hypocalcemia In DiGeorge syndrome, there is failure or hypoplasia of the 3rd and 4th pharyngeal pouches , which leads to: Thymic hypoplasia or aplasia , causing T-cell immunodeficiency. Parathyroid hypoplasia or aplasia , causing hypocalcemia. Down syndrome (Option A): Down syndrome is characterized by trisomy 21. Turner syndrome (Option B): Turner syndrome results from complete or partial monosomy of the X chromosome. Cri-du-chat syndrome (Option D): Cri-du-chat syndrome is caused by a deletion on the short arm of chromosome 5. It presents with a high-pitched cat-like cry, intellectual disability, microcephaly, and facial dysmorphisms but lacks the cardiac anomalies and thymic aplasia seen in DiGeorge syndrome.

References:

Robbins and Cotran Pathologic Basis of Disease, 10th Edition, Page 244

↑ *Back to this question in Part A*

@Neet_pg_bot

• [05_Immunity] 023 Amyloidosis

« Back to Folder Directory

[05_Immunity] 023 Amyloidosis — Quick Jump

Q1 (p. 1550) *Q2 (p. 1550)* *Q3 (p. 1551)* *Q4 (p. 1552)* *Q5 (p. 1552)* *Q6 (p. 1553)*
Q7 (p. 1553) *Q8 (p. 1554)* *Q9 (p. 1555)* *Q10 (p. 1555)* *Q11 (p. 1556)* *Q12 (p. 1557)*
Q13 (p. 1558)

Q1: Which of the following sites is most commonly affected in secondary (AA) amyloidosis? (Q879914)

A. Heart and brain

B. Kidneys and liver

C. Lungs and spleen

D. Skin and skeletal muscle

Correct Answer: B. Kidneys and liver

Explanation: Secondary (AA) amyloidosis is systemic and typically associated with chronic inflammatory conditions (e.g., rheumatoid arthritis, ankylosing spondylitis, IBD). Caused by the deposition of serum amyloid A (SAA) protein secondary to chronic inflammatory conditions. Kidneys are the most commonly affected organ, often leading to proteinuria and renal dysfunction. Liver and spleen may also be involved, but deposition in the heart and brain is rare in AA amyloidosis.

References:

Robbins, Cotran & Kumar Pathologic Basis of Disease, 11th Edition, Page. 232

↑ *Back to this question in Part A*

@Neet_pg_bot

Q2: A 58-year-old man with end-stage renal disease has been receiving hemodialysis for 6 years. He now presents with joint pain, carpal tunnel syndrome, and shoulder stiffness. Laboratory tests show normal inflammatory markers and no evidence of plasma cell disorder. Which type of amyloid is most likely responsible for his symptoms? (Q879916)

A. AA amyloid

B. AL amyloid

C. Aβ2-m

D. ATTR

Correct Answer: C. Aβ2-m

Explanation: β2-microglobulin amyloidosis occurs in patients on long-term hemodialysis due to the accumulation of β2-microglobulin, which is poorly cleared by older dialysis membranes. Clinical manifestations are usually musculoskeletal, including joint, tendon, ligament, and muscle involvement, with carpal tunnel syndrome being relatively common. The incidence of this complication has decreased with modern dialysis filters that better remove β2-microglobulin. Incorrect Options: AA amyloid (Option A): Derived from serum amyloid A during chronic inflammation; associated with chronic infections or autoimmune diseases, not dialysis. AL amyloid (Option B): Composed of immunoglobulin light chains; seen in plasma cell dyscrasias like multiple myeloma, not in long-term dialysis patients. ATTR (Option D): Transthyretin-derived amyloid; associated with hereditary amyloidosis and senile cardiac amyloidosis, not dialysis-related disease.

References:

Robbins, Cotran & Kumar Pathologic Basis of Disease, 11th Edition, Page. 233

↑ *Back to this question in Part A*

@Neet_pg_bot

Q3: Which type of amyloid is commonly deposited in the pancreas of patients with type 2 diabetes mellitus? (Q879919)

A. AL amyloid

B. AA amyloid

C. Islet amyloid polypeptide (IAPP)

D. β2-microglobulin

Correct Answer: C. Islet amyloid polypeptide (IAPP)

Explanation: In type 2 diabetes, amyloid deposits are localized to the islets of Langerhans. The protein responsible is IAPP (amylin), co-secreted with insulin by β-cells. These deposits contribute to β-cell dysfunction, worsening hyperglycemia. AL amyloid (Option A) is from plasma cell disorders, AA amyloid (Option B) is secondary to chronic inflammation, and β2-microglobulin (Option D) occurs in long-term hemodialysis.

References:

Robbins, Cotran & Kumar Pathologic Basis of Disease, 11th Edition, Page. 233

↑ *Back to this question in Part A*

@Neet_pg_bot

Q4: In medullary thyroid carcinoma, amyloid deposits are primarily derived from which of the following? (Q879920)

A. Thyroglobulin

B. Calcitonin

C. Parathyroid hormone

D. Islet amyloid polypeptide

Correct Answer: B. Calcitonin

Explanation: Medullary thyroid carcinoma (MTC) arises from C-cells of the thyroid. These cells secrete calcitonin, which can form amyloid deposits (sometimes called ACal deposits) within the tumor. These deposits are localized and serve as a helpful diagnostic feature. Thyroglobulin (Option A) is secreted by follicular cells, parathyroid hormone (Option C) by parathyroid glands, and IAPP (Option D) is related to pancreatic islets.

References:

Robbins, Cotran & Kumar Pathologic Basis of Disease, 11th Edition, Page. 233

↑ *Back to this question in Part A*

@Neet_pg_bot

Q5: Which of the following organs is most commonly affected in AL (primary) amyloidosis? (Q879921)

A. Kidneys

B. Liver

C. Heart

D. Pancreas

Correct Answer: A. Kidneys

Explanation: AL amyloidosis is caused by deposition of immunoglobulin light chains produced by clonal plasma cells. The kidneys are most frequently involved, often presenting with proteinuria and nephrotic syndrome. Other commonly affected organs include the heart (restrictive cardiomyopathy), liver , and peripheral nerves, but the kidneys are the primary target. Pancreatic involvement is rare in AL amyloidosis; localized islet amyloid in diabetes involves IAPP, not AL protein.

References:

Robbins, Cotran & Kumar Pathologic Basis of Disease, 11th Edition, Page. 231-232

↑ *Back to this question in Part A*

@Neet_pg_bot

Q6: In primary (AL) amyloidosis, the typical bone marrow finding is? (Q879936)

A. Extensive osteolytic lesions with >30% plasma cells

B. Modest increase in plasma cells producing monoclonal light chains

C. Normal plasma cell count with no monoclonal proteins

D. Hypercellular marrow with granulocytic predominance

Correct Answer: B. Modest increase in plasma cells producing monoclonal light chains

Explanation: In AL amyloidosis, most patients do not have overt multiple myeloma. Bone marrow typically shows a modest increase in plasma cells that secrete monoclonal immunoglobulins or free light chains (kappa or lambda). These light chains deposit in tissues as amyloid, causing systemic manifestations.

References:

Robbins, Cotran & Kumar Pathologic Basis of Disease, 11th Edition, Page. 231-232

↑ *Back to this question in Part A*

@Neet_pg_bot

Q7: Which of the following is the preferred initial investigation for suspected systemic amyloidosis? (Q879937)

A. Kidney biopsy

B. Abdominal fat pad aspiration stained with Congo red

C. Bone marrow aspirate

D. Radiolabeled serum amyloid P scintigraphy

Correct Answer: B. Abdominal fat pad aspiration stained with Congo red

Explanation: Abdominal fat pad aspiration is minimally invasive and can detect systemic amyloid deposits with Congo red staining. Amyloidosis Investigation: Tissue Biopsy (gold standard) Kidney (if renal manifestations present) Rectal or gingival tissue Abdominal fat aspirate stained with Congo red (specific but less sensitive) Serum and Urine Studies (especially in AL amyloidosis) Protein electrophoresis Immunoelectrophoresis to detect monoclonal proteins or free light chains Bone Marrow Aspirate Shows monoclonal plasmacytosis, even if overt multiple myeloma is absent Imaging / Scintigraphy Radiolabeled serum amyloid P component scintigraphy Rapid, specific, shows extent of amyloid deposition and can monitor treatment response

References:

Robbins, Cotran & Kumar Pathologic Basis of Disease, 11th Edition, Page. 234

↑ *Back to this question in Part A*

@Neet_pg_bot

Q8: Which of the following stains is most commonly used to detect amyloid deposits in kidney biopsies? (Q879938)

A. Hematoxylin and eosin

B. Congo red

C. Masson’s trichrome

D. Periodic acid–Schiff

Correct Answer: B. Congo red

Explanation: Congo red is the standard stain for detecting amyloid in kidney tissue, including glomeruli, vessels, and interstitium. When viewed under polarized light, amyloid shows apple-green birefringence, confirming the diagnosis. Other stains may show structural changes but cannot specifically identify amyloid. Incorrect Options: Hematoxylin and eosin (Option A): Shows eosinophilic deposits but is nonspecific for amyloid. Masson’s trichrome (Option C): Highlights collagen and fibrosis, not amyloid. Periodic acid–Schiff (Option D): Stains basement membranes and carbohydrates, not specific for amyloid.

References:

Robbins, Cotran & Kumar Pathologic Basis of Disease, 11th Edition, Page. 234

↑ *Back to this question in Part A*

@Neet_pg_bot

Q9: When stained with Congo red and viewed under polarized light, amyloid deposits in tissue typically show? (Q879939)

A. Bright red fluorescence

B. Apple-green birefringence

C. Blue-black metachromasia

D. Orange-red color under light microscope only

Correct Answer: B. Apple-green birefringence

Explanation: Congo red stain is the standard for detecting amyloid in tissues such as kidney, rectal mucosa, fat pad, or gingiva. Under polarized light, amyloid deposits exhibit apple-green birefringence , which is considered diagnostic. The test is specific but less sensitive, so negative results do not completely exclude amyloidosis.

References:

Robbins, Cotran & Kumar Pathologic Basis of Disease, 11th Edition, Page. 234

↑ *Back to this question in Part A*

@Neet_pg_bot

Q10: Identify the false statements regarding the amyloid. 1) It is a proteoglycan. 2) It is a misfolded protein seen intracellularly. 3) They show cross-β-pleated sheet conformation in light microscopy. 4) 95% of amyloid consists of fibril proteins. 5) It appears as an amorphous, basophilic, hyaline, extracellular substance. (Q845450)

A. 1,2,3

B. 2,5

C. 3,4

D. 2,3,5

Correct Answer: D. 2,3,5

■ *Listen (English)*

■ *Listen (Hindi)*

Explanation: Amyloid is defined as a proteoglycan and a misfolded protein , seen extracellularly . (Statements 1 and 2) The presence of abundant charged sugar groups in these adsorbed proteins gives the deposits staining characteristics that were thought to resemble starch (amylose). Therefore, the deposits were called amyloid 95% of amyloid consists of fibril proteins, with the remaining 5% being glycosaminoglycans (dermatan sulfate and heparan sulfate) and plasma proteins, notably serum amyloid P . (Statement 4) Physical nature of amyloid: Light microscopy with H & E stains: Amyloid is an amorphous , eosinophilic , hyaline , and extracellular substance. (Statement 5) Electron microscopy: All types of amyloid, regardless of clinical setting or chemical composition, consist of continuous, nonbranching fibrils with a diameter of approximately 7.5 to 10 nm. X-ray crystallography and infrared spectroscopy: Characteristic cross-β-pleated sheet conformation is responsible for the distinctive Congo-red staining and apple-green birefringence of the amyloid. (Statement 3)

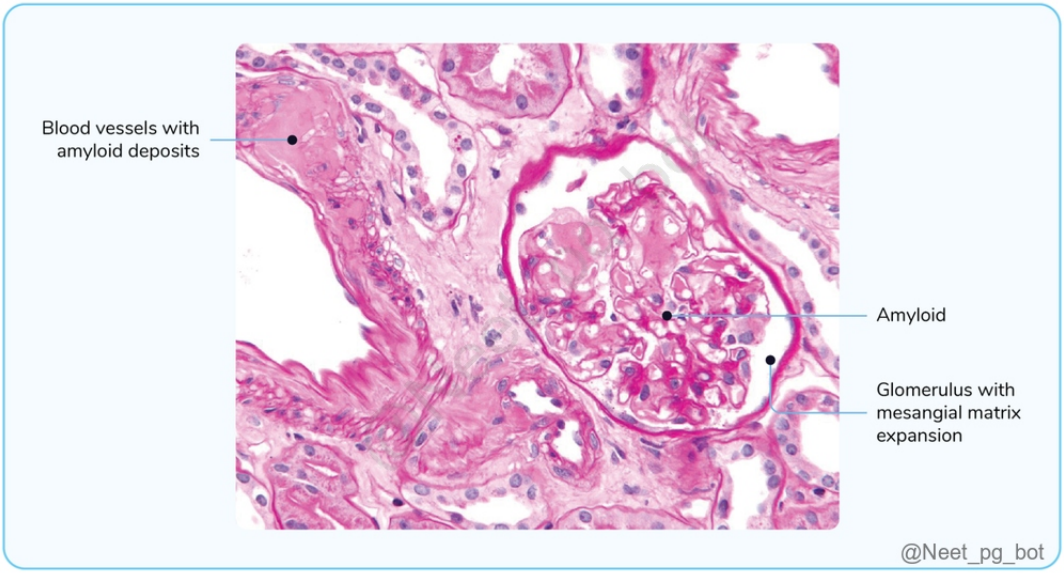

References:

Robbins and Cotran, Pathologic Basis of Disease, 10th edition, Page no. 259, 260

↑ *Back to this question in Part A*

@Neet_pg_bot

Q11: Match the following. Condition Amyloid protein 1 Chronic inflammation i ATTR 2 Alzheimer’s disease ii AA 3 Familial amyloid polyneuropathy iii AIAPP 4 Diabetes mellitus iv Aβ (Q845453)

A. 1-i, 2-ii, 3-iii, 4-iv

B. 1-ii, 2-iv, 3-iii, 4-i

C. 1-ii, 2-iv, 3-i, 4-iii

D. 1-iii, 2-ii, 3-i, 4-iv

Correct Answer: C. 1-ii, 2-iv, 3-i, 4-iii

■ *Listen (English)*

■ *Listen (Hindi)*

Explanation: Amyloidosis is a condition characterised by extracellular deposits of fibrillar proteins. These abnormal fibrils are produced by the aggregation of misfolded proteins. Important amyloid-disease associations: Disease Amyloid Multiple myeloma and other monoclonal plasma cell disorders AL Chronic inflammation AA Alzheimer's disease Aβ Familial amyloid polyneuropathy ATTR (mutated form of transthyretin) Diabetes mellitus AIAPP Hemodialysis associated amyloidosis Aβ 2 m Familial Meditterean Fever AA Senile systemic amyloidosis ATTR (Increased quantity of TTR, no mutation is seen) Medullary carcinoma of the thyroid Acal Isolated atrial amyloidosis AANF Types: Primary amyloidosis. Seen in multiple myeloma and other monoclonal plasma cell proliferations . AL type of amyloidosis is seen. Amyloid light chain (AL) protein is made up of complete immunoglobulin light chains, the amino-terminal fragments of light chains, or both. Most of the AL proteins analyzed are composed of λ light chains or their fragments, but κ chains are present in some cases. The AL type of amyloid fibril protein is produced from free Ig light chains secreted by monoclonal plasma cells. Secondary amyloidosis (Reactive systemic amyloidosis). Occurs secondary to chronic inflammatory conditions such as: Rheumatoid arthritis Chronic infections (e.g. tuberculosis, osteomyelitis) Inflammatory bowel disease In this condition, serum amyloid A (SAA) , an acute-phase reactant protein, is produced in high quantities by the liver in response to inflammation. When SAA is persistently elevated, it misfolds and deposits as AA amyloid fibrils in tissues.

References:

Robbins and Cotran, Pathologic Basis of Disease, 10th edition, Page no. 259-262

↑ *Back to this question in Part A*

@Neet_pg_bot

Q12: A 65-year-old male with a history of multiple myeloma in remission presents with fatigue, weight loss, and abdominal discomfort. He reports early satiety and a palpable firm mass in the left upper quadrant. Which finding is not associated with this condition? (Q845454)

A. Sago's spleen

B. Lardaceous spleen

C. Carpal tunnel syndrome

D. Nephritic syndrome

Correct Answer: D. Nephritic syndrome

■ *Listen (English)*

■ *Listen (Hindi)*

Explanation: The given clinical scenario of a male with fatigue , weight loss , abdominal discomfort , swelling in the left upper quadrant (splenomegaly), and a history of multiple myeloma is suggestive of AL amyloidosis . Nephritic syndrome is not associated with this condition, rather, nephrotic syndrome can be seen. Sago spleen (Option A): It refers to amyloid deposits largely limited to the splenic follicles (white pulp), producing tapioca-like granules on gross inspection. Lardaceous spleen (Option B): This involves amyloid deposition in the walls of the splenic sinuses and connective tissue framework in the red pulp. Carpal tunnel syndrome (Option C): Can be associated with amyloidosis, especially in patients on long-term hemodialysis due to amyloid deposition in the carpal ligament. Nephrotic syndrome: Amyloidosis more commonly causes nephrotic syndrome (not nephritic) due to glomerular amyloid deposition. Nephritic syndrome is characterised by inflammation, while amyloidosis involves protein deposition without significant inflammation. The image below shows a histopathological biopsy of renal amyloidosis.

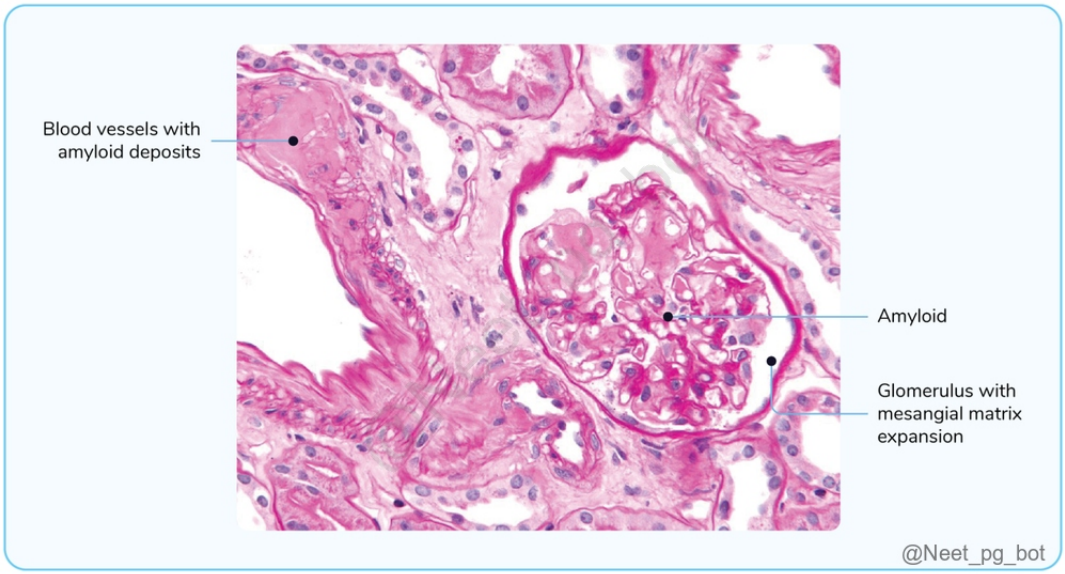

References:

Robbins and Cotran, Pathologic Basis of Disease, 10th edition, Page no. 263,264

↑ *Back to this question in Part A*

@Neet_pg_bot

Q13: A 60-year-old man with poorly controlled hypertension and diabetes presents with fatigue, shortness of breath, ankle swelling, hepatomegaly, and bilateral lower extremity oedema. Labs show proteinuria and elevated serum creatinine. Which staining technique is most appropriate to confirm the diagnosis? (Q845458)

A. Periodic acid Schiff (PAS) stain

B. Masson trichome stain

C. Congo red stain

D. Oil red O

Correct Answer: C. Congo red stain

Explanation: The clinical presentation of a patient with poorly controlled diabetes and hypertension, hepatomegaly, bilateral lower extremity oedema, proteinuria, and elevated serum creatinine highly point towards a diagnosis of AA amyloidosis , where chronic inflammation leads to the production of SAA , resulting in amyloid deposition in various organs. Congo red stain is the most appropriate technique to confirm the diagnosis of amyloidosis. Detection Feature Gross stain Lugol's iodine Mahogany brown colour Microscopic stain 1. Congo red (Best stain) Light microscopy: Salmon pink Polarizing microscopy: Apple Green birefringence 2. Thioflavin T Require UV light to visualize it under microscope 3. Methyl Violet 4. Crystal Violet 5. PAS The given images below show Congo red staining in amyloidosis. Periodic acid Schiff (PAS) stain(Option A): While positive for amyloid, it's not specific and less commonly used for diagnosis. Masson trichrome stain(Option B): Primarily used for connective tissue (collagen appears blue, smooth muscles appear red, the nucleus appears black), not specific for amyloid. Oil red O(Option D): Used for lipids, not applicable for amyloid detection.

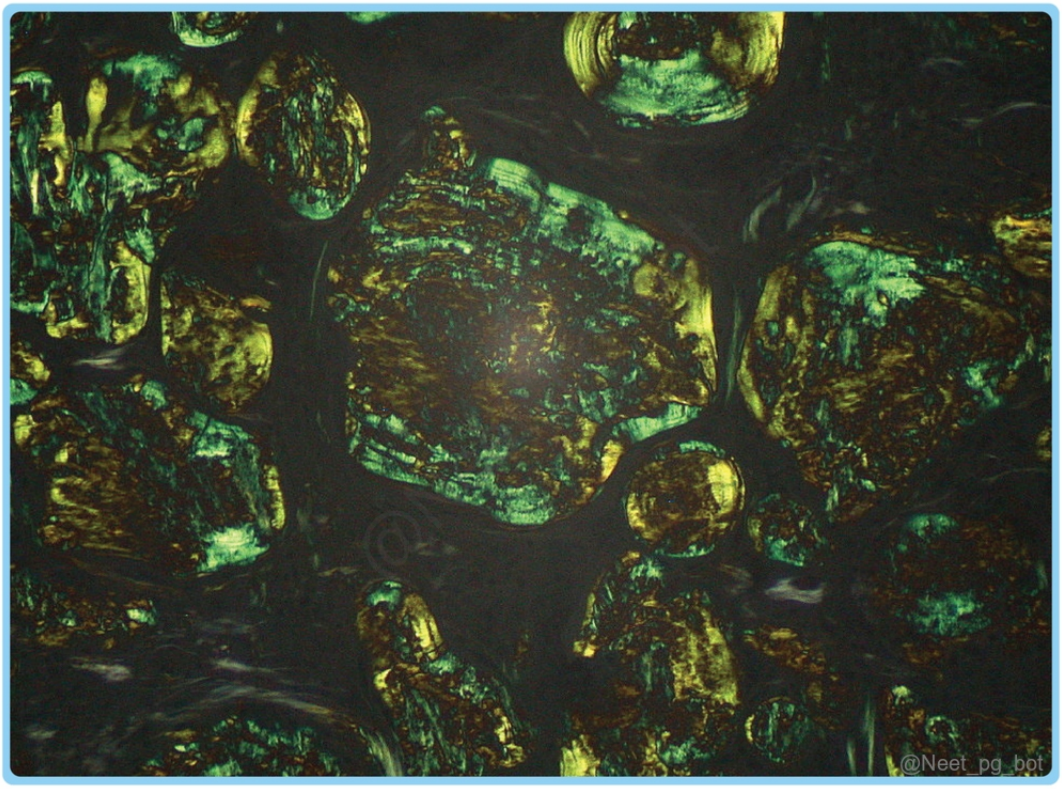

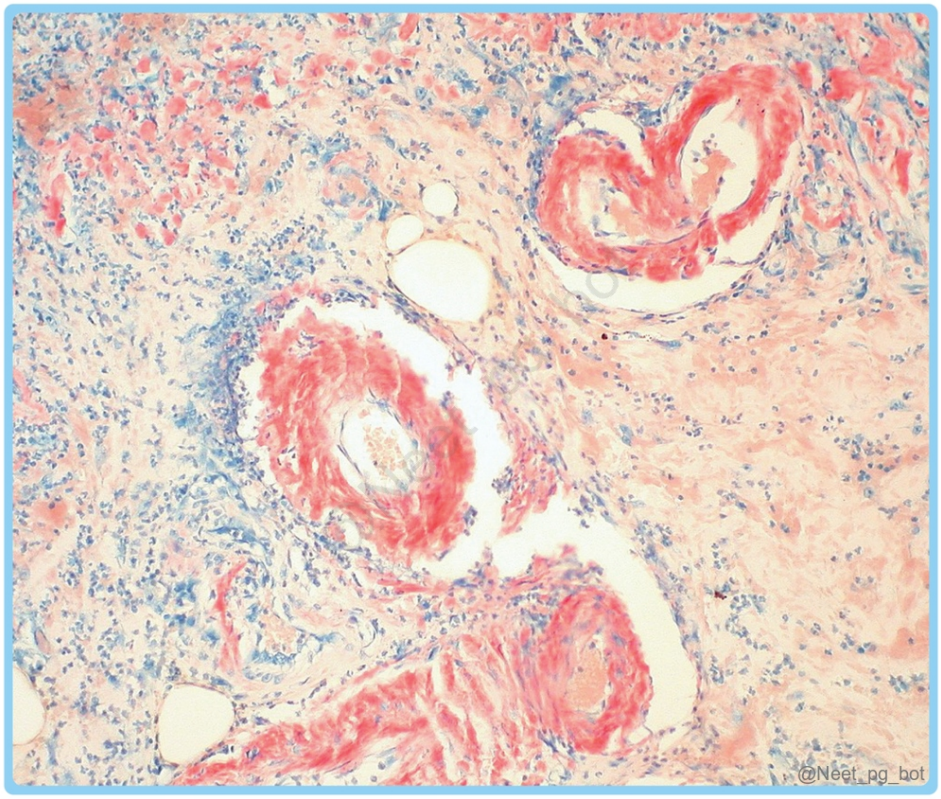

References:

Robbins and Cotran, Pathologic Basis of Disease, 10th edition, Page no. 260-264

↑ *Back to this question in Part A*

@Neet_pg_bot

• [05_Immunity] 024 Transplant Immunity

« Back to Folder Directory

[05_Immunity] 024 Transplant Immunity — Quick Jump

Q1 (p. 1561) *Q2 (p. 1561)* *Q3 (p. 1562)* *Q4 (p. 1563)* *Q5 (p. 1563)* *Q6 (p. 1564)*
Q7 (p. 1565) *Q8 (p. 1566)* *Q9 (p. 1567)* *Q10 (p. 1568)*

Q1: Which immune cells primarily mediate acute cellular rejection of a kidney allograft? (Q879941)

A. B cells producing preformed antibodies

B. CD8■ cytotoxic T lymphocytes and CD4■ helper T cells

C. Natural killer (NK) cells only

D. Macrophages without T cell involvement

Correct Answer: B. CD8■ cytotoxic T lymphocytes and CD4■ helper T cells

Explanation: Acute cellular rejection is mediated mainly by T cells: CD8■ cytotoxic T lymphocytes (CTLs) directly kill graft cells expressing alloantigens. CD4■ helper T cells secrete cytokines that recruit and activate other inflammatory cells, causing tissue damage. Acute antibody-mediated (humoral) rejection involves antibodies binding to graft endothelium, activating complement. Hyperacute rejection is mediated by preformed antibodies (often IgM) causing immediate endothelial injury. Chronic rejection involves T cells and alloantibodies promoting fibrosis and graft arteriosclerosis over months to years. Incorrect Options: B cells producing preformed antibodies (Option A) : These are primarily involved in hyperacute rejection , not acute cellular rejection. Natural killer (NK) cells only (Option C) : NK cells may play a minor role but are not the primary mediators of acute cellular rejection. Macrophages without T cell involvement (Option D) : Macrophages are involved in inflammation, but they require activation by T cells ; they don’t mediate acute rejection independently.

References:

Robbins, Cotran & Kumar Pathologic Basis of Disease, 11th Edition, Page. 209-210

↑ *Back to this question in Part A*

@Neet_pg_bot

Q2: A kidney transplant patient develops sudden anuria immediately after reperfusion. The graft is cyanotic and mottled. Biopsy shows fibrinoid necrosis of

arteries and thrombi in arterioles, with neutrophilic infiltration. What type of rejection is most likely? (Q879955)

A. Hyperacute rejection

B. Acute cellular (T cell–mediated) rejection

C. Acute antibody-mediated rejection

D. Chronic rejection

Correct Answer: A. Hyperacute rejection

Explanation: Hyperacute rejection occurs immediately after transplantation due to preformed antibodies against donor antigens. Pathologic features: Fibrinoid necrosis of arteries and arterioles Thrombosis of small vessels Neutrophilic infiltration Clinically, the graft is nonfunctional and must be removed. Incorrect Options: Acute cellular rejection (Option B) occurs days to weeks later, mediated by CD8■ and CD4■ T cells, with tubulitis and endotheliitis. Acute antibody-mediated rejection (Option C) involves antibody and complement deposition (C4d) in glomeruli and peritubular capillaries. Chronic rejection (Option D) develops over months to years, with interstitial fibrosis, vascular occlusion, and glomerulopathy

References:

Robbins, Cotran & Kumar Pathologic Basis of Disease, 11th Edition, Page. 209-210

↑ *Back to this question in Part A*

@Neet_pg_bot

Q3: Which of the following organs are primarily affected in acute graft-versus-host disease (GVHD)? (Q879962)

A. Skin, liver (bile ducts), and intestines

B. Heart, lungs, and kidneys

C. Brain, pancreas, and spleen

D. Lymph nodes and bone marrow only

Correct Answer: A. Skin, liver (bile ducts), and intestines

Explanation: Acute GVHD occurs days to weeks after allogeneic HSC transplant. Major target organs: Skin : lymphocyte infiltration and keratinocyte apoptosis → rash (neck, ears, palms, soles, then generalized) Liver : destruction of small bile ducts → cholestatic jaundice Gut : mucosal ulceration → bloody diarrhea Chronic GVHD can involve additional systemic features (skin fibrosis, thymic involution, autoimmunity).

References:

Robbins, Cotran & Kumar Pathologic Basis of Disease, 11th Edition, Page. 211-212

↑ *Back to this question in Part A*

@Neet_pg_bot

Q4: A 20-year-old girl was diagnosed with acute lymphoblastic leukaemia (ALL). Her medical team has determined that a bone marrow transplant is necessary to achieve remission and prevent disease recurrence. She has an identical twin sister, who is an eligible donor. What type of grafting was done on this patient? (Q845524)

A. Allograft

B. Autograft

C. Isograft

D. Xenograft

Correct Answer: C. Isograft

■ *Listen (English)*

■ *Listen (Hindi)*

Explanation: A graft from an identical twin donor is called an isograft. An isograft is an organ or tissue taken from a donor and transplanted to a recipient with the same genetic constitution as the donor. Type of Graft Description Autograft (Option B) An organ or tissue is taken from an individual and grafted on him/ herself Isograft Grafts between genetically identical individuals, such as identical twins Allograft (Option A) Graft between two genetically non-identical members of the same species (e.g. organ transplants between two non-identical and compatible individuals. Xenograft (Option D) Graft from one species to another (e.g., pig skin is a temporary substitute for burn treatment). Synthetic Graft Artificial materials or bioengineered constructs replace or support damaged tissue (e.g., artificial skin substitutes, bone graft substitutes).

References:

Ananthanarayan and Paniker's Textbook of Microbiology, 10th Edition, Pages 185-186

↑ *Back to this question in Part A*

@Neet_pg_bot

Q5: What is the minimum HLA matching that should be achieved to proceed with the transplant in the pediatric population? (Q845526)

A. 4/6

B. 6/6

C. 6/8

D. 8/10

Correct Answer: A. 4/6

■ *Listen (English)*

■ *Listen (Hindi)*

Explanation: Three alleles from each parent (hence, 6) are required in a pediatric group for allogeneic transplants, including HLA-A, HLA-B, and HLA-DR . In children, a match of at least 4/6 genes involving HLA-A, B, and DR is required to proceed for grafting.. Identical twins will always have complete 6/6 matching genes.

References:

www.ncbi.nlm.nih.gov/pmc/articles/PMC9821192/

www.uptodate.com/contents/kidney-transplantation-in-adults-hla-matching-and-outcomes

↑ *Back to this question in Part A*

@Neet_pg_bot

Q6: A 35-year-old woman with end-stage renal disease recently received a compatible donor organ from her brother. The kidney transplant surgery proceeds as planned, but within minutes of reperfusion, the kidney becomes mottled, cyanotic and anuric. What is the cause for this presentation? (Q845528)

A. Preformed antibodies in the donor

B. Preformed antibodies in the recipient

C. Cytotoxic T-lymphocyte-mediated injury

D. CD4+ cells mediated inflammation

Correct Answer: B. Preformed antibodies in the recipient

■ *Listen (English)*

■ *Listen (Hindi)*

Explanation: The given clinical scenario suggests hyperacute graft rejection due to preformed antibodies in the recipient. Hyperacute Graft Rejection Hyperacute Graft Rejection is the most rapid and catastrophic form of graft rejection, occurring immediately on the operating table or within the first 48 hours of transplantation. Pathogenesis: Hyperacute rejection is caused by preformed circulating IgG antibodies against donor antigens (mainly HLA or ABO), which may arise from prior pregnancies, multiple blood transfusions, or previous organ transplants. Mechanism: Preformed antibodies bind to donor endothelial antigens, activating complement and causing widespread thrombosis, vascular occlusion, ischemia, and graft necrosis, leading to a kidney that rapidly becomes cyanotic, flaccid, and anuric (sometimes with a few drops of blood). Clinical features: Hyperacute rejection presents with a mottled blue ischemic kidney, loss of graft tone, and absent urine output (anuria) or occasionally hematuria (few drops of blood). Immunologically, hyperacute rejection represents a Type II hypersensitivity reaction mediated by antibodies .

References:

Robbins and Cotran Pathologic Basis of Disease, 10th edition, page no. 235-236

↑ *Back to this question in Part A*

@Neet_pg_bot

Q7: A 45-year-old man, two weeks post-kidney transplant, presents with sudden oliguria, fever, and graft site swelling. Biopsy shows glomerular and peritubular capillary inflammation with complement deposition. What is the most likely diagnosis? (Q845530)

A. Acute humoral rejection

B. Acute calcineurin inhibitor nephrotoxicity

C. Acute cellular rejection

D. BK virus infection

Correct Answer: A. Acute humoral rejection

■ *Listen (English)*

■ *Listen (Hindi)*

Explanation: Acute humoral rejection, also known as acute antibody-mediated rejection (ABMR), is the most likely diagnosis. Acute rejection occurs days to weeks after transplant. It is of 2 types: Acute humoral rejection → mediated by antibodies. Acute cellular rejection (option 3) → cell-mediated by T-lymphocytes. Acute humoral rejection: Newly formed antibodies cause damage to kidneys leading to inflammation. This damage to kidneys activates the complement system and the C4d complement gets deposited around the peritubular capillaries. C4d complement is the marker of acute humoral rejection. Incorrect options: Acute Calcineurin Inhibitor (CNI) Nephrotoxicity (option 2) Presents with sudden rise in creatinine, hypertension, and vasoconstriction Biopsy

shows arteriolar hyalinosis, isometric tubular vacuolization. BK Virus Infection (option 4) Occurs 2–12 months post-transplant Biopsy shows viral inclusions in tubular epithelial cells (“decoy cells”), tubulointerstitial nephritis, not glomerular or peritubular capillary inflammation. No C4d complement deposition.

References:

Robbins and Cotran Pathologic Basis of Disease 10th edition, Page236 Cyclosporine and tacrolimus nephrotoxicity - UpToDate BK Virus Nephropathy in Kidney Transplantation: A State-of-the-Art Review - PMC (nih.gov)

↑ *Back to this question in Part A*

@Neet_pg_bot

Q8: A 45-year-old male patient presents with a widespread rash, severe diarrhoea, and jaundice. He underwent bonemarrow transplantation for acute myeloid leukaemia and received cells from a matched, unrelated donor. Which is the most likely diagnosis? (Q845531)

A. Acute transplant rejection

B. Chronic transplant rejection

C. Graft-versus-host disease

D. Immune reconstitution inflammatory syndrome

Correct Answer: C. Graft-versus-host disease

■ *Listen (English)*

■ *Listen (Hindi)*

Explanation: The given clinical presentation and history of hematopoietic stem cell (HSC) transplant suggests that the patient most likely has graft-versus-host disease (GVHD) Graft-versus-Host Disease (GVHD) : The three key organs involved in GVHD are Skin (rash), Intestine (diarrhoea) and Liver (jaundice). GVHD is like a war between the graft and the host . Mechanism: Graft (donor marrow) → rich in immunocompetent T-cells Host (recipient) → immunocompromised (due to cancer + immunosuppressive drugs) The immunocompetent graft cells will attack the weaker host tissues, most commonly affecting the skin, intestine, and liver. Tupes of GVHD: Acute GVHD : Occurs within the first 100 days of transplant. Chronic GVHD : Occurs ≥100 days post-transplant.

References:

Robbins and Cotran Pathologic Basis of Disease 10th edition, Page 239 Immune Reconstitution Inflammatory Syndrome - StatPearls - NCBI Bookshelf (nih.gov)

↑ *Back to this question in Part A*

@Neet_pg_bot

Q9: A 55-year-old male patient who has undergone kidney transplantation is now presenting with signs of renal dysfunction. Which complement activation product is a known histological marker for the diagnosis of antibody-mediated rejection in transplant biopsies? (Q845532)

A. C3d

B. C5a

C. C3b

D. C4d

Correct Answer: D. C4d

■ *Listen (English)*

■ *Listen (Hindi)*

Explanation: Antibody-mediated rejection means humoral rejection. Types of acute graft rejection: Acute humoral rejection (antibody-mediated). Acute cellular rejection (cell-mediated). Mechanism: In a cute humoral rejection, the recipient forms new antibodies against donor tissue. These antibodies activate the complement system, which produces C4d. C4d deposition around tubules and capillaries serves as a key marker of acute humoral (antibody-mediated) rejection. Image: Immunoperoxidase stain shows C4d deposition in peritubular capillaries and a glomerulus.

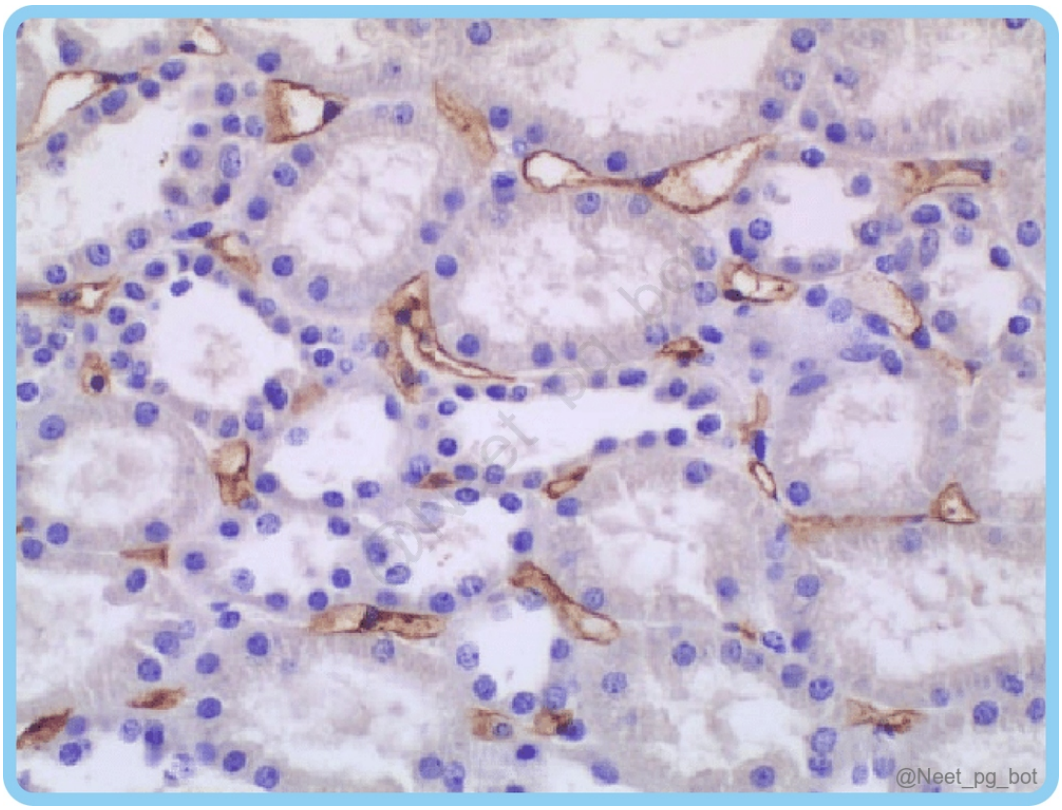

References:

Robbins and Cotran Pathologic Basis of Disease 10th ed page 580, 238.

↑ *Back to this question in Part A*

@Neet_pg_bot

Q10: A patient presented with oliguria for the last three days. She is a known case of diabetic nephropathy and underwent an allogeneic renal transplant four years ago. The physician suspects a possibility of graft rejection. Which of the following is not true regarding the suspected condition in this patient? (Q845533)

A. Predominantly antibody-mediated reaction

B. Manifests as interstitial fibrosis and narrowing of graft blood vessels

C. HPE shows duplication of the basement membrane

D. Its morphologic correlate in the lung is bronchiolitis obliterans

Correct Answer: A. Predominantly antibody-mediated reaction

■ *Listen (English)*

■ *Listen (Hindi)*

Explanation: An allogenic transplant refers to a transplant between members of the same species, and the development of symptoms 4 years post-transplant indicates chronic graft rejection. Morphological hallmark features of chronic renal graft rejection (GOTI): G → Glomerular Basement Membrane Duplication (Option C) . O → Obliteration of blood vessels. T → Tubular atrophy. I → Interstitial fibrosis (Option B) . In lung transplant , chronic graft rejection morphologically correlates with bronchiolitis obliterans (Option D) . Chronic rejection is a Type IV hypersensitivity reaction, driven mainly by T-cell–mediated immune responses rather than antibodies (Option A) . Graft arteriosclerosis is caused by T-cell cytokines and antibody deposition in chronic graft rejection.

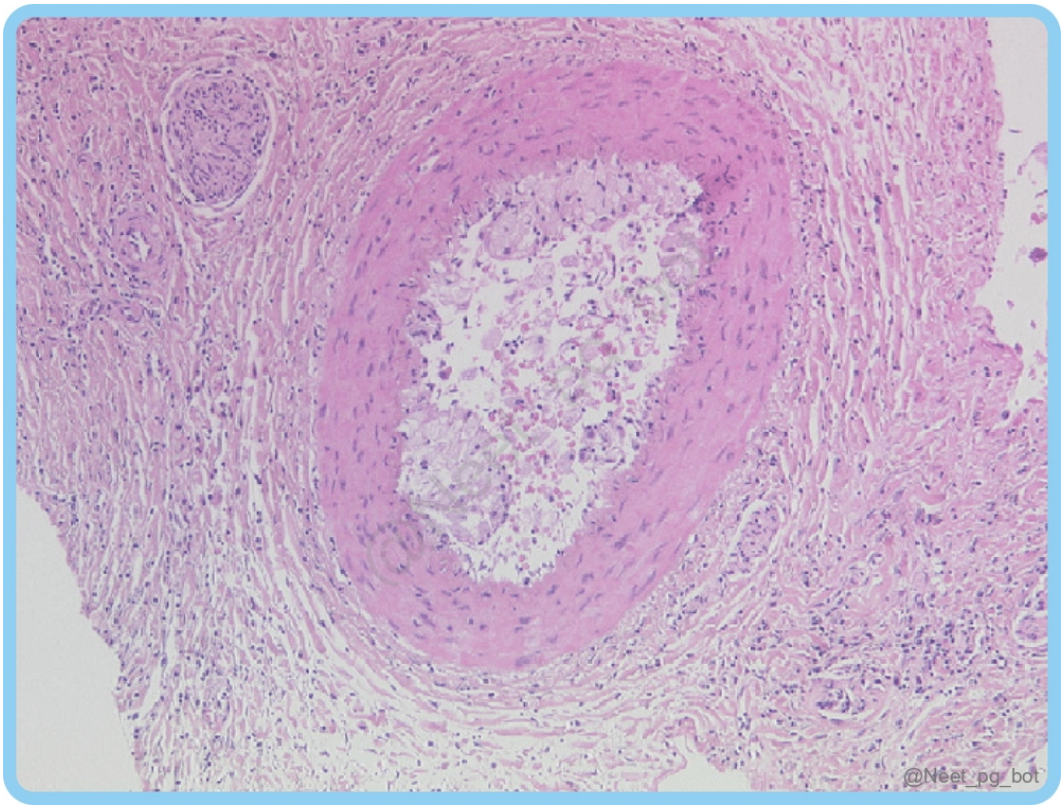

References:

Robbins and Cotran Pathologic Basis of Disease,10th edition, Page 238, 715, 580

↑ *Back to this question in Part A*

@Neet_pg_bot

• [05_Immunity] 025 Previous Year Questions

« Back to Folder Directory

[05_Immunity] 025 Previous Year Questions — Quick Jump

Q1 (p. 1570)	*Q2 (p. 1571)*	*Q3 (p. 1572)*	*Q4 (p. 1573)*	*Q5 (p. 1574)*	*Q6 (p. 1576)*
Q7 (p. 1577)	*Q8 (p. 1578)*	*Q9 (p. 1579)*	*Q10 (p. 1580)*	*Q11 (p. 1581)*	*Q12 (p. 1582)*
Q13 (p. 1583)	*Q14 (p. 1585)*	*Q15 (p. 1586)*	*Q16 (p. 1586)*	*Q17 (p. 1587)*	*Q18 (p. 1588)*
Q19 (p. 1589)	*Q20 (p. 1590)*	*Q21 (p. 1591)*	*Q22 (p. 1592)*	*Q23 (p. 1593)*	*Q24 (p. 1594)*
Q25 (p. 1595)	*Q26 (p. 1597)*	*Q27 (p. 1597)*	*Q28 (p. 1598)*	*Q29 (p. 1599)*	*Q30 (p. 1600)*
Q31 (p. 1600)	*Q32 (p. 1601)*	*Q33 (p. 1602)*	*Q34 (p. 1603)*	*Q35 (p. 1605)*	*Q36 (p. 1609)*
Q37 (p. 1609)					

Q1: A 78-year-old male presents with fatigue, breathlessness, and palpitations. On examination, he has pedal oedema, with a pulse rate of 55 bpm, BP of 100/70 mmHg, and oxygen saturation of 94%. ECG is normal, and echocardiography reveals restrictive cardiomyopathy. A cardiac biopsy stained with Congo red shows apple-green birefringence under polarised light. What is the most likely diagnosis? (Q857590)

A. Heart failure

B. Cardiac amyloidosis

C. Hemosiderosis

D. Dystrophic calcification

Correct Answer: B. Cardiac amyloidosis

Explanation: The hallmark feature is apple-green birefringence under polarised light after Congo red staining, characteristic of amyloid deposits. Cardiac amyloidosis causes restrictive cardiomyopathy, presenting with symptoms like fatigue, breathlessness, and oedema. Congo red stain identifies amyloid fibrils in tissue. {{caption_text}} Amyloidosis is abnormal extracellular deposits of fibrillar proteins that cause tissue damage and functional compromise. These proteins are misfolded and aggregate, forming amyloid deposits. Amyloid deposits appear as eosinophilic, hyaline, and extracellular substances on hematoxylin and eosin stains. They are confirmed by Congo red staining, which shows red under ordinary light and apple-green birefringence under polarised light. Morphology: Amyloid deposition is often widespread, but organ involvement can vary: Kidney: Most commonly and severely affected, with amyloid deposits in the glomeruli, arteries, and arterioles. Spleen: Enlarged, showing two patterns of amyloid deposits: "sago spleen" (follicular) and "lardaceous spleen" (sinusoidal). Liver: Amyloid deposits in the space of Disse; liver function is generally preserved despite enlargement. Heart: Commonly

involved in senile systemic amyloidosis, with deposits starting subendocardially and in the myocardium. Other organs: May include the tongue (macroglossia), lungs (respiratory tract involvement), and brain (Alzheimer's plaques). Types: Type of Amyloidosis Amyloid Protein Associated Conditions Primary Amyloidosis (AL) Amyloid Light Chain (AL) Plasma cell disorders (e.g., multiple myeloma) Secondary Amyloidosis (AA) Amyloid-Associated (AA) Chronic inflammation (e.g., rheumatoid arthritis, IBD) Hereditary Amyloidosis Transthyretin (TTR) Familial amyloid polyneuropathies (e.g., familial Mediterranean fever) Hemodialysis-Associated β2-Microglobulin Long-term hemodialysis Senile Systemic Amyloidosis Transthyretin (TTR) Ageing, mutations in TTR Localised Amyloidosis Varies (often AL type) Specific organs (e.g., tongue, lung, skin, bladder) Endocrine Amyloidosis Medullary thyroid carcinoma (Acal) Endocrine tumours (e.g., medullary thyroid carcinoma, pancreatic islet tumours)

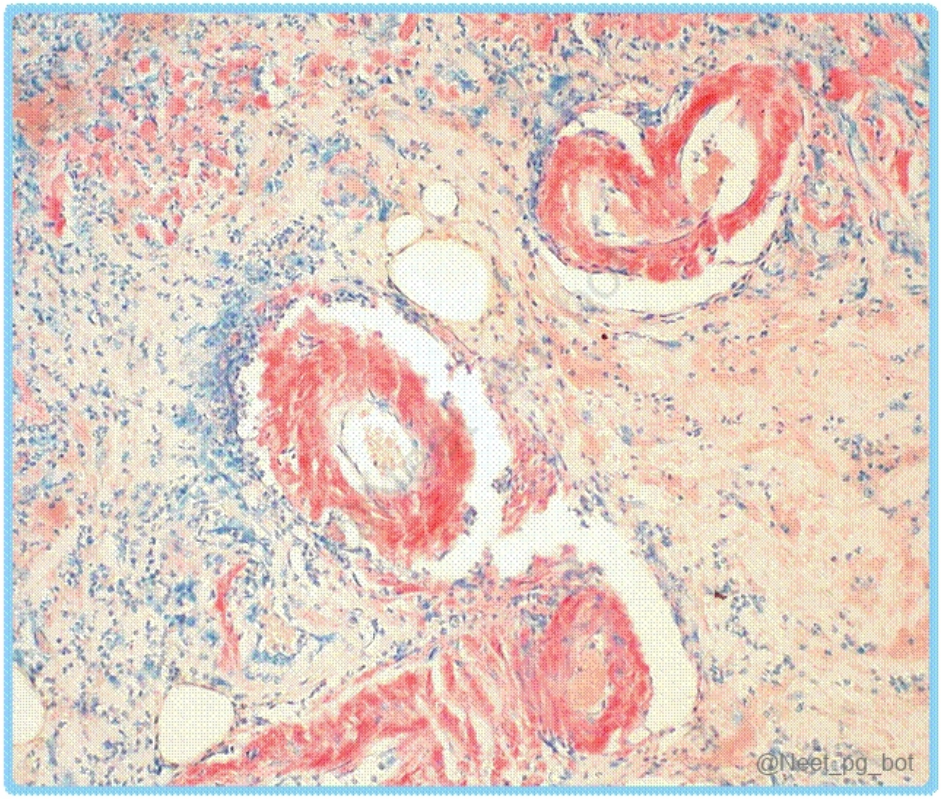

References:

Robbins & Cotran Pathologic Basis of Disease, 10th Edition, Page 260-264

↑ *Back to this question in Part A*

@Neet_pg_bot

Q2: In a patient with Bare Lymphocyte Syndrome, graft-versus-host disease (GVHD) does not occur. Which of the following causes it? (Q855987)

A. Complement deficiency

B. Deficiency of CD4 T lymphocytes

C. MHC Class II deficiency in lymphocytes

D. MHC Class I deficiency in lymphocytes

Correct Answer: C. MHC Class II deficiency in lymphocytes

Explanation: Bare Lymphocyte Syndrome (BLS) caused by MHC Class II deficiency (most common form) prevents the development of CD4+ T cells , which are essential for initiating graft-versus-host disease (GVHD). Bare Lymphocyte Syndrome: Typically caused by mutations in transcription factors essential for the expression of Class II MHC genes . The absence of Class II MHC molecules leads to the underdevelopment of CD4+ T cells , which play a crucial role in cellular immunity and assist B cells. As a result, Class II MHC deficiency results in a combined immunodeficiency. Additionally, other forms of the syndrome can be caused by mutations in antigen receptor chains or signalling molecules critical for the maturation of T or B cells. Complement deficiency (Option A) does not affect T cell function or MHC expression, making it unrelated to GVHD, which requires donor T cell recognition of host MHC. Deficiency of CD4 T lymphocytes (Option B) is a secondary effect, not the cause of bare lymphocyte syndrome or prevention of GVHD. MHC Class I deficiency in lymphocytes (Option D) affects CD8■ T cell function but does not significantly impair CD4■ T cell-mediated GVHD, which relies on MHC Class II recognition.

References:

Robbins & Cotran Pathologic Basis of Disease, 10th Edition, Page 244

↑ *Back to this question in Part A*

@Neet_pg_bot

Q3: Which of the following is not a part of innate immunity? (Q855074)

A. Alpha defensins

B. B lymphocytes

C. Gamma delta T lymphocytes

D. Alternate pathway

Correct Answer: B. B lymphocytes

Explanation: B cells are antigen-specific immune cells. They require antigen recognition and T-cell help for activation. They undergo clonal expansion and antibody production. These features belong to adaptive immunity, not innate immunity. Incorrect Options: Option A) Alpha-defensins : Antimicrobial peptides from neutrophils & Paneth cells. Directly kill microbes without prior exposure. Part of innate immunity. Option C) Gamma-delta T lymphocytes : Act quickly and do not require classical antigen presentation. Recognize stress antigens and provide

early defense. Considered innate-like immunity. Option D) Alternate complement pathway: Triggered directly by microbial surfaces. Does not require antibodies for activation. A major component of innate immunity.

References:

Robbins & Cotran Pathologic Basis of Disease, 10th Edition, Page 203

↑ *Back to this question in Part A*

@Neet_pg_bot

Q4: Which of the following cytokines is not involved in the Th1 response? (Q855089)

A. IFN gamma

B. IL-2

C. IL-12

D. IL-4

Correct Answer: D. IL-4

Explanation: IL-4 is primarily associated with the Th2 response , not the Th1 response. It promotes the differentiation of T cells into Th2 cells and is involved in humoral immunity and allergic responses. Subtype Function and Characteristics Key Cytokines TH1 Involved in chronic inflammatory diseases. Activated by IL-12 (Option C) from APCs. Secrete IFN-gamma, activating macrophages. Stimulates macrophages to form epithelioid cells and giant cells. IFN-gamma (Option A) IL-2 (Option B) TH2 Responsible for the alternative pathway of macrophage activation. Release cytokines IL-4 , IL-5, and IL-13. To expel parasites from the body, stimulate eosinophil activation, antibody production (especially IgE), and mucus production. IL-4 , IL-5, IL-13 TH17 Defend against extracellular bacteria and fungi. Secrete IL-17 and IL-22, attracting neutrophils and monocytes. IL-17, IL-22 Treg (T regulatory) It suppresses immune response and maintains homeostasis and self-tolerance. Inhibit T cell proliferation and cytokine production, preventing autoimmune reaction. IL-10, TGF-beta Tfh (Follicular T helper) Assist B cells in rapid proliferation and antibody production. Help produce antibodies with greater affinity. IL-21 {{caption_text}}

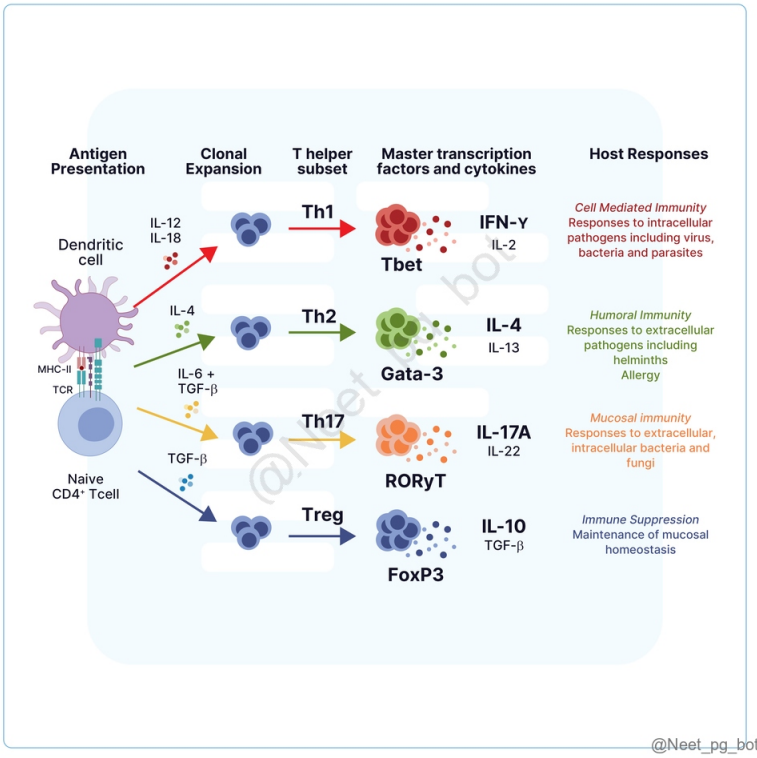

References:

Robbins & Cotran Pathologic Basis of Disease, 10th Edition, Page 202

CD4 T Helper Cell Subsets and Related Human Immunological Disorders.

↑ *Back to this question in Part A*

@Neet_pg_bot

Q5: A person was brought to the emergency department with facial swelling, itching, and hypotension following a bee sting. The mentioned clinical features are due to the increase in which of the following immunoglobulins? (Q857097)

A. IgA

B. IgE

C. IgM

D. IgG

Correct Answer: B. IgE

Explanation: The clinical features of facial swelling, itching, and hypotension suggest anaphylaxis, an allergic reaction mediated by IgE antibodies that trigger the release of histamine and other inflammatory mediators from mast cells and basophils upon exposure to an allergen, such as a bee sting. Type I hypersensitivity reactions involve an immediate (early) and a late-phase reaction. Early phase reaction Late phase reaction Onset Immediate (within minutes of allergen exposure). Delayed (several hours after exposure) and can last for days. Cells involved Mast cells, basophils. Eosinophils, T lymphocytes. Cellular events Activation of mast cells and basophils. Recruitment and activation of leukocytes, especially eosinophils. Mediators Histamine , leukotrienes (LTB4, LTC4, LTD4), prostaglandins (PGD2) and Platelet-activating factor (PAF). Cytokines (e.g., IL-4, IL-5, TNF), chemokines (e.g., eotaxin). Initiating event Exposure to allergen triggers cross-linking of IgE on mast cells/basophils. Recurrent inflammation, sustained by recruited leukocytes. Effect on tissues Vasodilation, increased vascular permeability, smooth muscle contraction. Sustained inflammation and tissue damage due to leukocyte infiltration. Clinical manifestations Allergic rhinitis (hay fever), urticaria (hives), Angioedema bronchoconstriction. Allergic asthma exacerbation, persistent inflammation, and tissue damage. Therapeutic Approach Antihistamines for symptomatic relief. Adrenaline in anaphylactic shock. Broad-spectrum anti-inflammatory drugs (e.g., steroids) to suppress inflammation and prevent tissue damage. IgA (Option A) primarily involves mucosal immunity and protects against pathogens at mucosal surfaces (e.g., in the respiratory and gastrointestinal tracts), not in allergic reactions. IgM (Option C) is the first antibody produced in response to infection but is not involved in allergic reactions like those caused by bee stings. IgG (Option D) plays a crucial role in immunity and neutralising toxins, but it is not the primary immunoglobulin involved in allergic reactions, which are driven by IgE.

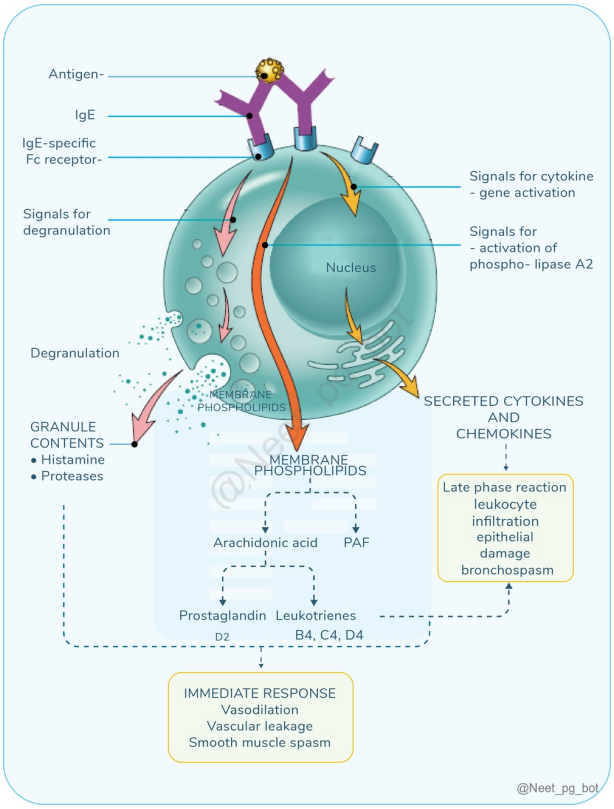

References:

Robbins & Cotran Pathologic Basis of Disease, 10th Edition, Page 205-208

↑ *Back to this question in Part A*

Q6: A Rh-negative mother delivered an Rh-positive baby, and Coomb's test was positive for the baby. What is the mechanism of hypersensitivity seen in this scenario? (Q857100)

A. Antigen-dependent cellular cytotoxicity

B. Antibody-dependent cellular cytotoxicity

C. Antigen-antibody immune complex deposition

D. CD4 T-cell-mediated cytokine release

Correct Answer: B. Antibody-dependent cellular cytotoxicity

Explanation: This scenario involves Type II hypersensitivity, where the Rh-negative mother's immune system produces IgG antibodies against her fetus's Rh-positive red blood cells. These antibodies cross the placenta and bind to the fetal red blood cells, initiating their destruction by activating immune cells through antibody-dependent cellular cytotoxicity (ADCC). This leads to hemolytic disease in the newborn and results in a positive Coomb's test, which detects antibodies bound to the fetal red blood cells. Mechanisms of Type II hypersensitivity Description Examples Opsonisation and Phagocytosis IgG antibodies coat cells, helping phagocytes recognise circulating antigen-opsonin complexes through Fc receptors or complement activation, leading to phagocytosis. Autoimmune hemolytic anemia Immune thrombocytopenic purpura Rh hemolytic disease of the newborn . Complement activation and inflammation Antibody deposition in extracellular tissues triggers inflammation rather than phagocytosis or cell lysis. The deposited antibodies activate the complement system, attracting neutrophils and monocytes via their Fc receptors. Activated leukocytes release enzymes, causing tissue damage. Goodpasture syndrome. Acute rheumatic fever. Antibody-dependent cellular cytotoxicity (ADCC) Natural killer cells bind to antibody-antigen complexes, inducing apoptotic cell death. Pernicious anemia Insulin resistant diabetes Antibody-mediated cellular dysfunction (non-cytotoxic) Antibodies physically impair or dysregulate cellular function by binding to cell surface receptors. This includes both activation (e.g., thyroid hormone receptor in Graves disease) and inhibition (e.g., acetylcholine receptor in Myasthenia gravis). Graves disease Myasthenia gravis Note: Myasthenia gravis and Graves disease are now classified as Type V hypersensitivity (Type V > Type II) Type V hypersensitivity reaction: Antibodies against cellular receptors. Mnemonic: My Blood Group Is Rh Positive My Myasthenia Gravis Blood Blood transfusion reaction Group Good pasture syndrome, Graves disease Is Immune hemolytic anaemia, Immune thrombocytopenic purpura R Rh incompatibility , Rheumatic fever H Hyperacute transplant rejection Positive Pemphigus (Bullous), Pernicious Anemia Type II hypersensitivity (Antibody-mediated) Opsonisation and complement activation→Phagocytosis Transfusion reaction, erythroblastosis fetalis , AIHA, ITP. Complement, F c receptor-mediated →Inflammation. Goodpasture syndrome, Acute Rheumatic fever, vascular rejections, vasculitis. Antibody-mediated cellular dysfunctions. Myasthenia gravis, Pemphigus Vulgaris, Graves disease, Pernicious Anemia, Insulin-resistant diabetes, Hemolytic disease of the newborn.

References:

Robbins & Cotran Pathologic Basis of Disease, 10th Edition, Page 204-215

↑ *Back to this question in Part A*

@Neet_pg_bot

Q7: Which of the following conditions is associated with hypocalcemia, thymic hypoplasia, cardiac abnormalities, and deletion of chromosome 22q11.2? (Q857124)

A. Williams syndrome

B. Pitt syndrome

C. DiGeorge syndrome

D. Cri-du-chat syndrome

Correct Answer: C. DiGeorge syndrome

Explanation: DiGeorge syndrome (22q11.2 deletion syndrome) is caused by a deletion on the long arm of chromosome 22. It is characterised by hypocalcemia, thymic hypoplasia, and cardiac abnormalities and occurs in 1 in 4000 births. The condition is often overlooked due to its variable clinical features. These features include: Congenital heart defects Abnormalities of the palate Facial dysmorphism Developmental delay T-cell immunodeficiency Hypocalcemia Key features: Thymic hypoplasia leading to T-cell immunodeficiency Parathyroid hypoplasia causing hypocalcemia Cardiac malformations affecting the outflow tract Facial anomalies (e.g., mild facial dysmorphology) Diagnosis: The condition is suspected clinically but confirmed by FISH (Fluorescence in situ hybridisation) testing. Around 90% of DiGeorge syndrome and 80% of velocardiofacial syndrome cases show the 22q11.2 deletion. This test can also identify deletions in individuals with conotruncal cardiac defects but no other features of the syndrome. Williams Syndrome (Option A) is a genetic disorder caused by a deletion on chromosome 7 , not 22q11.2. It is characterised by cardiovascular problems, developmental delays, and distinctive facial features, but it does not involve thymic hypoplasia, cardiac abnormalities like those seen in DiGeorge syndrome, or hypocalcemia. Pitt Syndrome (Option B) is a rare genetic condition linked to mutations in the FLNA gene, leading to developmental and cardiac abnormalities. It doesn’t involve the same chromosome 22q11.2 deletion or the associated features of thymic hypoplasia, immunodeficiency, or hypocalcemia seen in DiGeorge syndrome. Cri-du-chat Syndrome (Option D) is caused by a deletion on the short arm of chromosome 5. The main features include a distinctive high-pitched cry, intellectual disability, and certain facial features, but it does not include the hallmark features of DiGeorge syndrome, such as thymic hypoplasia, cardiac defects, and hypocalcemia.

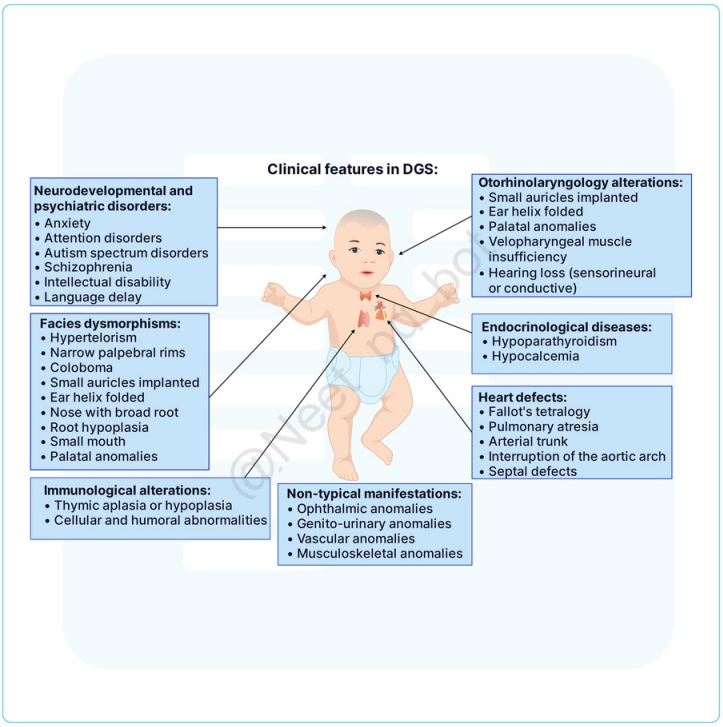

@Neet_pg_bot

References:

Robbins & Cotran Pathologic Basis of Disease, 10th Edition, Page 169

↑ *Back to this question in Part A*

@Neet_pg_bot

Q8: A 24-year-old female patient presented with a malar rash, recurrent oral ulcers, and multiple joint pains. She has a relevant past history and does not take any medication. Upon further investigations, thrombocytopenia was seen, and the anti-Smith (anti-Sm) antibody was positive. What is the most likely diagnosis? (Q857140)

A. Scleroderma

B. Sjögren syndrome

C. Systemic lupus erythematosus (SLE)

D. Rheumatoid arthritis

Correct Answer: C. Systemic lupus erythematosus (SLE)

Explanation: The most likely diagnosis is Systemic Lupus Erythematosus (SLE) , an autoimmune disorder that commonly affects young women and presents with features such as: Malar rash (butterfly-shaped rash over the cheeks and nose), Recurrent oral ulcers , Joint pain (often non-erosive arthritis), Thrombocytopenia , Positive anti-Smith (anti-Sm) antibodies , which are highly specific for SLE. While scleroderma , Sjögren syndrome , and rheumatoid arthritis share overlapping symptoms, the positive anti-Sm antibody is most specific to SLE, confirming the diagnosis. SLE is a chronic autoimmune disease with the production of many antibodies like antinuclear antibodies (ANAs), anti-double-stranded DNA (dsDNA), and anti-Smith (Sm). These autoantibodies form immune complexes that deposit in tissues, causing inflammation and damage. It is more common in women. Clinical Manifestations of SLE: Skin: Malar rash (butterfly rash), photosensitivity, discoid lesions, and mucosal ulcers. Joints: Non-erosive arthritis commonly affects the hands, wrists, and knees. Renal: Lupus nephritis ranging from asymptomatic proteinuria to severe kidney failure. The major cause of morbidity and mortality in SLE. Cardiovascular: Pericarditis, myocarditis, increased risk of atherosclerosis and coronary artery disease. Pulmonary: Pleurisy and pleural effusion, pulmonary hypertension and interstitial lung. Neurologic: Neuropsychiatric symptoms ranging from headaches and cognitive dysfunction to seizures and psychosis. Hematologic: Anemia, leukopenia, and thrombocytopenia. The risk of thrombotic events is increased. Marker/Antibody Clinical Significance Anti-Smith (anti-Sm) antibodies Highly specific for SLE (<30% of patients) Anti-dsDNA antibodies Highly specific for SLE (60-70% of patients); correlates with the disease Antinuclear antibodies (ANA) Highly sensitive but not specific for SLE Anti-Ro (SSA) and Anti-La (SSB) antibodies Found in SLE and Sjögren syndrome; associated with neonatal lupus Anti-ribosomal-P antibodies Specific for neuropsychiatric manifestations in SLE Anti-histone antibodies Seen in drug-induced lupus; less specific for SLE Complements C3 and C4 Low levels indicate complement consumption and disease activity

References:

Robbins & Cotran Pathologic Basis of Disease, 10th Edition, Page 222, 230-236

↑ *Back to this question in Part A*

@Neet_pg_bot

Q9: Xenograft is: (Q857173)

A. Graft across species

B. Grafts from the same species

C. Graft from the same individual

D. Graft between genetically identical individuals

Correct Answer: A. Graft across species

Explanation: Type of Graft Description Autograft An organ or tissue is taken from an individual and grafted on him/ herself (Option C ruled out) Isograft Grafts between genetically identical individuals, such as identical twins (Option D ruled out) Allograft Graft between two genetically non-identical members of the same species (e.g.

organ transplants between two non-identical and compatible individuals. (Option B ruled out) Xenograft Graft from one species to another (e.g., pig skin is a temporary substitute for burn treatment). (Option A) Synthetic Graft Artificial materials or bioengineered constructs replace or support damaged tissue (e.g., artificial skin substitutes, bone graft substitutes).

References:

Ananthanarayan and Paniker's Textbook of Microbiology, 10th Edition, Page no. 185 and 186

↑ *Back to this question in Part A*

@Neet_pg_bot

Q10: A child, upon disturbing a bee hive, had several stings. After a few minutes, the child developed symptoms of shock, respiratory failure, and vascular collapse. Which of the following is the principal mediator of this reaction? (Q857559)

A. Adrenaline

B. Histamine

C. Dopamine

D. Substance P

Correct Answer: B. Histamine

Explanation: The reaction indicates anaphylaxis , a severe allergic response to bee stings. Histamine, released by mast cells and basophils, is the principal mediator, causing vasodilation, increased vascular permeability, bronchoconstriction, and smooth muscle contraction, leading to shock, respiratory failure, and vascular collapse. Type I hypersensitivity reactions involve an immediate (early) and a late-phase reaction. Early phase reaction Late phase reaction Onset Immediate (within minutes of allergen exposure). Delayed (several hours after exposure) and can last for days. Cells involved Mast cells, basophils. Eosinophils, T lymphocytes. Cellular events Activation of mast cells and basophils. Recruitment and activation of leukocytes, especially eosinophils. Mediators Histamine , leukotrienes (LTB4, LTC4, LTD4), prostaglandins (PGD2) and Platelet-activating factor (PAF). Cytokines (e.g., IL-4, IL-5, TNF), chemokines (e.g., eotaxin). Initiating event Exposure to allergen triggers cross-linking of IgE on mast cells/basophils. Recurrent inflammation, sustained by recruited leukocytes. Effect on tissues Vasodilation, increased vascular permeability, smooth muscle contraction. Sustained inflammation and tissue damage due to leukocyte infiltration. Clinical manifestations Allergic rhinitis (hay fever), urticaria (hives), Angioedema bronchoconstriction. Allergic asthma exacerbation, persistent inflammation, and tissue damage. Therapeutic Approach Antihistamines for symptomatic relief. Adrenaline in anaphylactic shock. Broad-spectrum anti-inflammatory drugs (e.g., steroids) to suppress inflammation and prevent tissue damage. {{caption_text}}

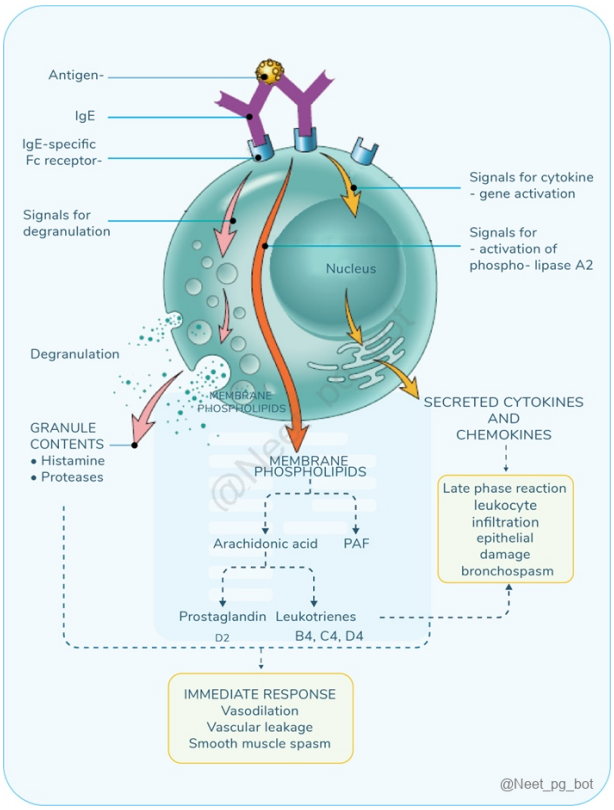

References:

Robbins & Cotran Pathologic Basis of Disease, 10th Edition, Page 205-208

↑ *Back to this question in Part A*

@Neet_pg_bot

Q11: A boy presents with recurrent episodes of melena. On examination, there is eczema of the skin with multiple petechiae. His platelet count is low, with normal RBC and WBC counts. Which of the following is the diagnostic investigation for this patient? (Q855956)

A. WASP gene mutation

B. Anti-platelet antibodies

C. Bone marrow biopsy

D. Electron microscopy

Correct Answer: A. WASP gene mutation

Explanation: The patient's presentation of recurrent melena (indicative of gastrointestinal bleeding), eczema, petechiae (small skin haemorrhages), and low platelet count with normal RBC and WBC counts suggests Wiskott-Aldrich Syndrome (WAS) , an X-linked recessive disease characterized by the triad of: Thrombocytopenia Eczema Recurrent infections It is caused by mutations in the gene located at Xp11.23, which encodes the Wiskott-Aldrich syndrome protein (WASP). WASP belongs to a family of proteins that are believed to link membrane receptors, such as antigen receptors, to cytoskeletal elements. IgM levels in the serum are low , but levels of IgG are usually normal. Paradoxically, the levels of IgA and IgE are often elevated . Patients are also prone to developing B-cell lymphomas. WASP may be involved in cytoskeleton-dependent responses, including cell migration and signal transduction. It may lead to early death. The only treatment is hematopoietic stem cell (HSC) transplantation . Anti-platelet antibodies (Option B) are typically found in conditions like immune thrombocytopenic purpura (ITP), but the patient's history and presentation point more toward WAS. Bone marrow biopsy (Option C) is generally used to assess hematologic disorders like leukaemia or myelodysplastic syndromes, which do not match this case. Electron microscopy (Option D) is helpful for diagnosing certain intracellular abnormalities, but it's not the first diagnostic test for WAS.

References:

Robbins & Cotran Pathologic Basis of Disease, 10th Edition, Page 169

↑ *Back to this question in Part A*

@Neet_pg_bot

Q12: Which of the following mediators is involved in the early phase of type 1 hypersensitivity? Mast cell Histamine Neutrophils Prostaglandins Leukotrienes (Q855445)

A. 1, 5

B. 1, 2, 3, 4

C. 1, 2, 4, 5

D. 2, 3, 4

Correct Answer: C. 1, 2, 4, 5

Explanation: The mediators involved in the early phase of Type 1 Hypersensitivity include mast cells, histamine, prostaglandins, and leukotrienes. Mast cells Histamine Prostaglandins Leukotrienes Primary effector cells. Activated by allergens cross-linking with IgE antibodies. Released by mast cells. Causes vasodilation, increased vascular permeability, smooth muscle contraction, and mucus production. They are lipid mediators released by mast cells. Contribute to vasodilation, vascular permeability, and bronchoconstriction. A group of lipid mediators released by mast cells. Promote bronchoconstriction, increased vascular permeability, and the recruitment of other inflammatory cells. It involves an immediate (early) and a late-phase reaction. Early phase reaction Late phase reaction Onset Immediate (within minutes of allergen exposure). Delayed (several hours after exposure) and can last for days. Cells involved Mast cells, basophils. Eosinophils, T lymphocytes. Cellular events Activation of mast

cells and basophils. Recruitment and activation of leukocytes, especially eosinophils. Mediators Histamine, leukotrienes (LTB4, LTC4, LTD4), prostaglandins (PGD2) and Platelet-activating factor (PAF). Cytokines (e.g., IL-4, IL-5, TNF), chemokines (e.g., eotaxin) Initiating event Exposure to allergen triggers cross-linking of IgE on mast cells/basophils. Recurrent inflammation, sustained by recruited leukocytes. Effect on tissues Vasodilation, increased vascular permeability, smooth muscle contraction. Sustained inflammation and tissue damage due to leukocyte infiltration. Clinical manifestations Allergic rhinitis (hay fever), urticaria (hives), Angioedema bronchoconstriction. Allergic asthma exacerbation, persistent inflammation, and tissue damage. Therapeutic Approach Antihistamines for symptomatic relief. Adrenaline in anaphylactic shock Broad-spectrum anti-inflammatory drugs (e.g., steroids) to suppress inflammation and prevent tissue damage. {{caption_text}}

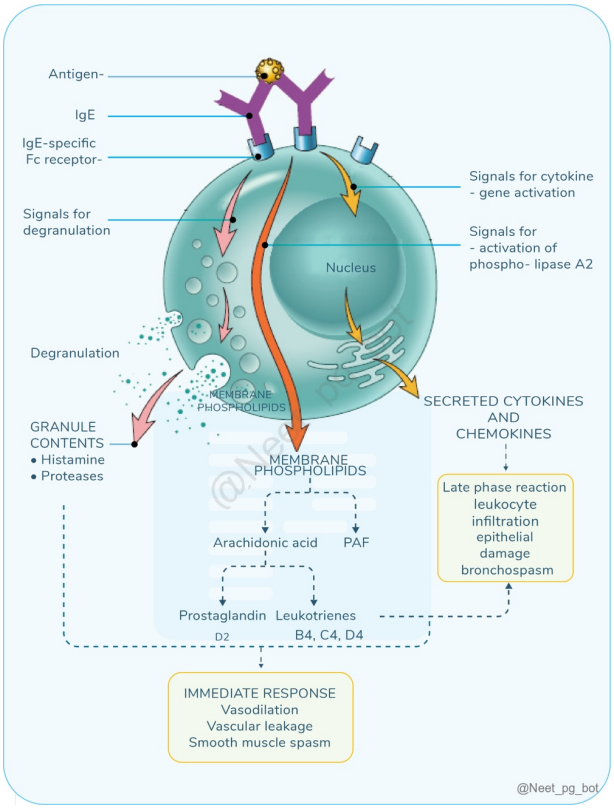

References:

Robbins & Cotran Pathologic Basis of Disease, 10th Edition, Pages 205-208.

↑ *Back to this question in Part A*

@Neet_pg_bot

Q13: A person was brought to the emergency department with facial swelling, itching, and hypotension following a bee sting. The mentioned clinical features are due to an increase in which immunoglobulin? (Q856690)

A. IgA

B. IgE

C. IgM

D. IgG

Correct Answer: B. IgE

Explanation: The clinical features of facial swelling, itching, and hypotension following a bee sting are due to an Allergic Reaction (Type 1 Hypersensitivity Reaction) mediated by the immune system, particularly through IgE (Immunoglobulin E) antibodies. IgE plays a key role in allergic responses by binding to receptors on mast cells and basophils after exposure to an allergen, like bee venom. Upon re-exposure to the allergen, it binds to IgE on mast cells and basophils, triggering the release of histamine, leukotrienes, and prostaglandins, which cause the symptoms. Symptoms: Characteristic symptoms of an allergic reaction are: Facial swelling (angioedema) Itching, and Hypotension. Histamine causes blood vessel dilation and increased permeability, leading to facial swelling and itching. In severe cases, it can induce hypotension and trigger anaphylaxis. IgA (Option A) is primarily involved in mucosal immunity, protecting the mucous membranes of the respiratory, digestive, and genitourinary tracts. It is not typically associated with immediate hypersensitivity reactions like those seen in response to bee stings. IgM (Option C) is the first antibody produced during an immune response. It is involved in the primary immune response and is not specifically associated with allergic reactions or the symptoms described in the scenario. IgG (Option D) is the most abundant antibody in the bloodstream and is involved in long-term immunity. While IgG can play a role in some types of allergic reactions, it is not the primary immunoglobulin responsible for the immediate hypersensitivity reactions seen in response to a bee sting.

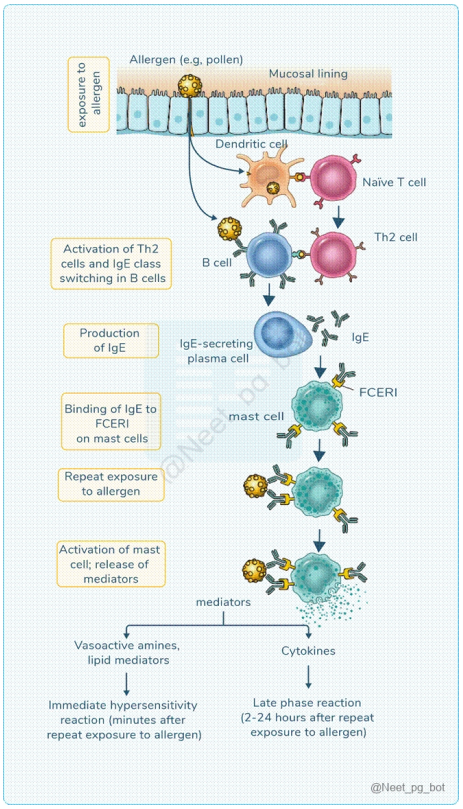

References:

Robbins & Cotran Pathologic Basis of Disease, 10th Edition, Page 205-208.

↑ *Back to this question in Part A*

@Neet_pg_bot

Q14: Isotype switching is seen in: (Q856894)

A. Helper T cells

B. Activated B cells

C. Cytotoxic T cells

D. B cells

Correct Answer: B. Activated B cells

Explanation: Isotype switching , also known as class switching, occurs in activated B cells . This process allows B cells to produce different classes of antibodies (e.g., IgM, IgG, IgA, IgE) in response to specific signals, such as cytokines from helper T cells, during an immune response. Isotype switching , also referred to as class switching or immunoglobulin class switch recombination (CSR), is a process that takes place in activated B cells. During this process, B cells change the class of antibodies they produce, transitioning from IgM to other isotypes such as IgG, IgA, or IgE. Isotype switching enables B cells to generate antibodies with diverse effector functions while preserving the antigen-binding specificity of the original antibody. IL-4 Key cytokine in driving the allergic response Enhances Ig E-mediated reaction Stimulates B cells to undergo class switching to IgE and promotes the expansion of Th2 cells Defect in class switching - Hyper IgM Syndrome, caused by defects in CD40L (X-linked) or CD40/AID/UNG (autosomal recessive), leads to high IgM with low IgG, IgA, and IgE, causing recurrent infections. Diagnosis involves immunoglobulin levels and genetic testing, with treatment including IVIG and prophylactic antibiotics.

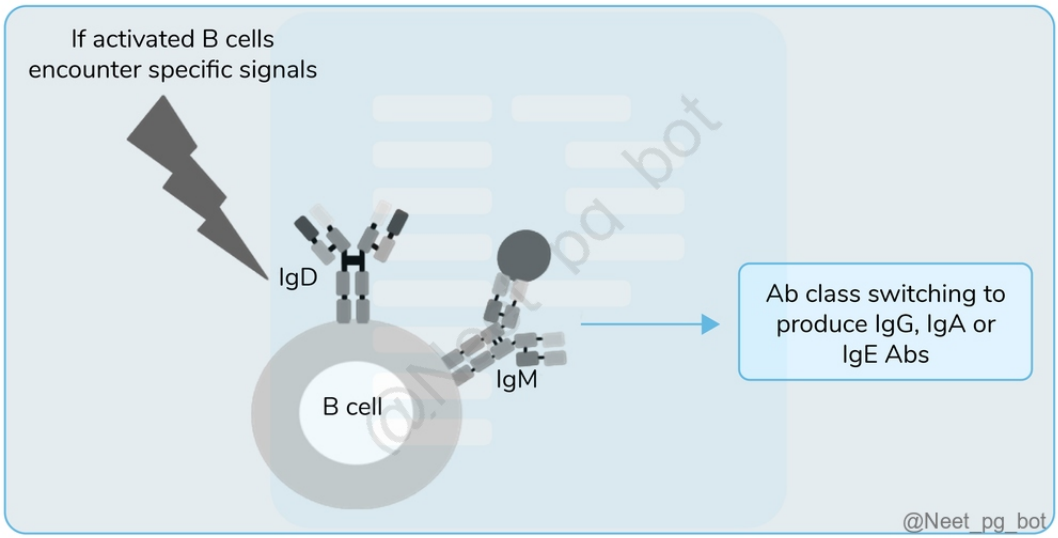

References:

Robbins & Cotran Pathologic Basis of Disease, 10th Edition, Page 202.

↑ *Back to this question in Part A*

@Neet_pg_bot

Q15: B-cells are induced to produce IgE by which of the following? (Q854863)

A. IL-2

B. IL-4

C. IL-1

D. IL-6

Correct Answer: B. IL-4

Explanation: IL-4 plays a crucial role in the activation of B-cells to produce immunoglobulin E (IgE). It is a cytokine primarily produced by Th2 helper cells, mast cells, and basophils. IL-4 stimulates B-cells to undergo class switching to IgE, which is an important mediator in allergic reactions and responses to parasitic infections. Interleukins in Type-1 hypersensitivity reaction: Interleukins Role IL-4 Key cytokine in driving the allergic response Enhances Ig E-mediated reaction Stimulates B cells to undergo class switching to IgE and promotes the expansion of Th2 cells IL-5 Development and activation of eosinophils→ Recruited to the site of allergen exposure→ Release inflammatory mediators and enzymes→ Tissue damage and inflammation IL-13 Amplifies IgE production Acts on epithelial cells to stimulate mucus secretion IL-10 Anti-inflammatory cytokine Inhibits cytokine production by Th1 cells and macrophages. IL-2 (Option A) is primarily involved in the growth and proliferation of T-cells, especially CD4+ and CD8+ T-cells, and does not induce IgE production. IL-1 (Option C) is a pro-inflammatory cytokine that promotes fever and immune responses, but it does not directly induce IgE production. IL-6 (Option D) is involved in the acute-phase response and the differentiation of B-cells into plasma cells, but it is not specifically involved in inducing IgE production.

References:

Robbins & Cotran Pathologic Basis of Disease, 10th Edition, Page 207

↑ *Back to this question in Part A*

@Neet_pg_bot

Q16: A graft from an identical twin is called: (Q854871)

A. Allograft

B. Autograft

C. Isograft

D. Xenograft

Correct Answer: C. Isograft

Explanation: Isograft is a graft transplanted between two genetically identical individuals, such as identical twins. Since there is no genetic difference between the individuals, the recipient's immune system typically does not recognise the graft as foreign, resulting in no rejection. Type of Graft Description Autograft (Option B) An organ or tissue is taken from an individual and grafted on him/ herself. Isograft Grafts between genetically identical individuals, such as identical twins Allograft (Option A) Graft between two genetically non-identical members of the same species (e.g. organ transplants between two non-identical and compatible individuals. Xenograft (Option D) Graft from one species to another (e.g., pig skin is a temporary substitute for burn treatment). Synthetic Graft Artificial materials or bioengineered constructs replace or support damaged tissue (e.g., artificial skin substitutes, bone graft substitutes).

References:

Ananthanarayan and Paniker's Textbook of Microbiology, 10th Edition, Pages 185,186

↑ *Back to this question in Part A*

@Neet_pg_bot

Q17: Graft from an identical twin is called: (Q859849)

A. Allograft

B. Autograft

C. Isograft

D. Xenograft

Correct Answer: C. Isograft

Explanation: Type of Graft Description Autograft An organ or tissue is taken from an individual and grafted on him/ herself (Option B ruled out) Isograft Grafts between genetically identical individuals, such as identical twins (Option C) Allograft Graft between two genetically non-identical members of the same species (e.g. organ transplants between two non-identical and compatible individuals. (Option A ruled out) Xenograft Graft from one species to another (e.g., pig skin is a temporary substitute for burn treatment). (Option D ruled out) Synthetic Graft Artificial materials or bioengineered constructs replace or support damaged tissue (e.g., artificial skin substitutes, bone graft substitutes).

References:

Ananthanarayan and Paniker's Textbook of Microbiology, 10th Edition, Pages 185 and 186

↑ *Back to this question in Part A*

@Neet_pg_bot

Q18: A teenager developed swelling of the face, lips, and tongue and also found it difficult to breathe within a few minutes of consuming prawns. What type of hypersensitivity is seen here? (Q859855)

A. Type 1

B. Type 2

C. Type 3

D. Type 4

Correct Answer: A. Type 1

Explanation: The above clinical case is suggestive of an anaphylactic reaction to prawns, which is a type-1 hypersensitivity reaction. Type I hypersensitivity is also known as an immediate reaction and involves the IgE-mediated release of antibodies against the soluble antigen. This results in mast cell degranulation and the release of histamine and other inflammatory mediators. Type Mechanism Immune Components Features Examples Type I: Immediate (Option A) IgE-mediated degranulation of mast cells and basophils after allergen binding. IgE antibodies Mast cells Histamine Rapid onset (minutes) Localised or systemic reactions Mediated by histamine. Anaphylaxis Allergic rhinitis Asthma Urticaria (hives) Food allergies Type II: Cytotoxic (Option B ruled out) Antibody-mediated destruction or dysfunction of target cells. IgG , IgM antibodies Complement Phagocytes Targets specific cells or tissues. Cell lysis or dysfunction. Involves complement activation. Autoimmune hemolytic anemia Goodpasture syndrome Myasthenia gravis Graves' disease Type III: Immune Complex (Option C ruled out) Deposition of immune complexes in tissues, leading to inflammation and damage. IgG , IgM Antibodies Complement Neutrophils Immune complex deposition in vessels. Tissue inflammation and damage (vasculitis). Systemic lupus erythematosus (SLE) Post-streptococcal glomerulonephritis Serum sickness Type IV: Delayed (Option D ruled out) T-cell-mediated immune response, leading to inflammation and tissue damage. T cells (CD4+, CD8+) Macrophages Delayed onset (48–72 hours). Involves cytokine release and macrophage recruitment. Contact dermatitis Tuberculin skin test (PPD) Granulomatous inflammation (e.g., tuberculosis)

References:

Robbins & Cotran Pathologic Basis of Disease, 10th Edition, Pages 204 - 214

↑ *Back to this question in Part A*

@Neet_pg_bot

Q19: Which type of cells are implicated in the development of contact dermatitis in a 12-year-old boy who presented to the emergency department? (Q859906)

A. Helper T cells

B. Neutrophils

C. NK cells

D. Cytotoxic T cells

Correct Answer: A. Helper T cells

Explanation: Contact dermatitis is an inflammatory skin condition that occurs when the skin comes into contact with an allergen or irritant. The pathogenesis involves a complex interplay between various immune cells, including antigen-presenting cells (such as dendritic cells), T cells (including helper T cells), and other immune mediators. Helper T cells are activated upon recognition of the allergen, and they release cytokines that recruit and activate other immune cells, leading to the characteristic inflammation and skin reactions seen in contact dermatitis. The type of hypersensitivity involved in contact dermatitis is Type IV . Mechanisms of Type IV hypersensitivity Description Examples Cytokine-mediated inflammation (mediated by CD4+ T cells) CD4+ T cells recognise protein antigens presented by APCs and differentiate into Th1 and Th17 cells . Th1 cells secrete cytokines like IFN-γ, activating macrophages to cause tissue damage and fibrosis. Th17 cells produce IL-17 to recruit neutrophils, promoting inflammation. Tuberculin test (a classic example of delayed-type hypersensitivity) Granulomas Contact dermatitis Rheumatoid arthritis Multiple sclerosis IBD Psoriasis T cell-mediated cytotoxicity (mediated by CD8+ T cells) Cytotoxic T lymphocytes (CTLs) directly kill antigen-bearing target cells, including tumour cells, virus-infected cells, and allogeneic tissue, during graft rejection. CTLs use perforin-granzyme-dependent killing and Fas-Fas ligand-dependent killing mechanisms to induce apoptosis in target cells. Type 1 DM Hepatic injury in HBV infection Graft vs host disease Helper T cells play a crucial role in the immune response by coordinating and regulating other immune cells. They release cytokines that activate and recruit other cells to the site of inflammation, including in the case of contact dermatitis. Neutrophils (Option B) are typically involved in acute inflammation and play a major role in fighting bacterial infections. While neutrophils may be recruited to the site of inflammation in some cases of contact dermatitis, they are not the primary cells involved in the pathogenesis of the condition. NK cells (Option C) are a type of cytotoxic lymphocyte that plays a role in the innate immune response. They are primarily involved in recognising and eliminating virally infected and tumour cells. NK cells are not typically the primary cells involved in contact dermatitis. Cytotoxic T cells (Option B) are a type of T lymphocyte that directly kills infected or abnormal cells. They play a critical role in the immune response against viruses and tumour cells. While they may be involved in certain immune responses, they are not the primary cells in contact dermatitis.

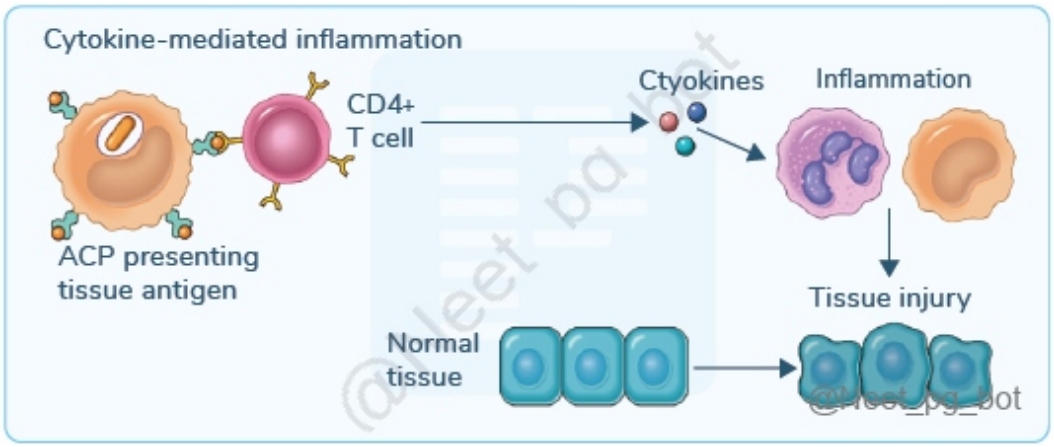

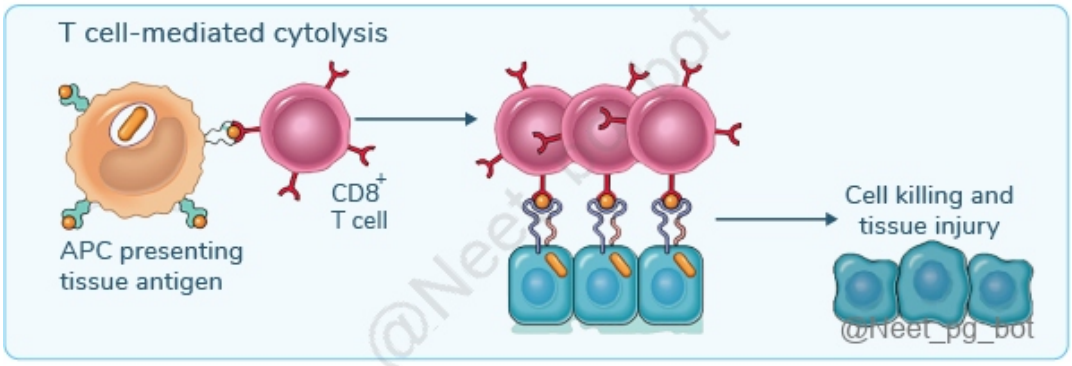

References:

Robbins & Cotran Pathologic Basis of Disease, 10th Edition, Pages 212-215

↑ *Back to this question in Part A*

@Neet_pg_bot

Q20: A patient with a deficiency of CD40 is most likely to exhibit which of the following immunological abnormalities? (Q857448)

A. Absence of B cells

B. Absence of T cells

C. Elevated IgM levels

D. Elevated IgG levels

Correct Answer: C. Elevated IgM levels

Explanation: CD40 deficiency is a primary immunodeficiency disorder that results in a form of Hyper IgM Syndrome . The CD40 molecule on B cells normally interacts with CD40 ligand (CD40L) on activated T helper cells, which is essential for immunoglobulin class switching from IgM to IgG, IgA, and IgE. In CD40 deficiency, this interaction is defective, so B cells cannot switch antibody classes properly. Consequently, the patient has normal or increased IgM levels with decreased levels of IgG, IgA, and IgE. This leads to increased susceptibility to infections, especially sinopulmonary and gastrointestinal infections. Other immune abnormalities like neutropenia and opportunistic infections may also occur. Absence of B cells (Option A): B cells are present but functionally impaired. Absence of T cells (Option B): T cells are present. Elevated IgG levels (Option D): IgG is decreased due to defective class switching.

References:

Apurba S Shastry, Sandhya Bhat, Essentials of Medical Microbiology, 3rd Edition, Page 184 -191

↑ *Back to this question in Part A*

@Neet_pg_bot

Q21: A patient underwent a bone marrow transplant without HLA matching. In which of the following disorders transplant rejection does not occur: (Q865422)

A. Bare lymphocyte syndrome

B. Chediak Higashi syndrome

C. Wishkott Aldrich syndrome

D. Job’s syndrome

Correct Answer: A. Bare lymphocyte syndrome

Explanation: Bone marrow transplant (BMT) rejection is mediated by recipient T lymphocytes recognizing donor HLA antigens as foreign. Therefore, the integrity and function of recipient T cells (especially CD8■ cytotoxic T cells) are crucial for mounting a rejection response. Bare Lymphocyte Syndrome (BLS): It is a type of MHC class II deficiency , and in some forms, MHC class I expression is also defective. Because of absent or defective HLA expression , CD4■ (helper) and sometimes CD8■ (cytotoxic) T cells are profoundly dysfunctional or absent. Result: These patients are immunologically unable to recognize or reject transplanted tissue , even in the absence of HLA matching. Hence, rejection does not occur in BLS due to lack of HLA molecule expression and impaired T cell function . Chediak-Higashi Syndrome (Option B) is an autosomal recessive condition with defect in lysosomal trafficking regulator gene (LYST), leading to defective neutrophil function. T and B cell immunity is relatively intact — rejection is possible. Wiskott-Aldrich Syndrome (Option C) X-linked disorder with combined immunodeficiency, characterized by thrombocytopenia, eczema, and recurrent infection. It is caused by mutations in the gene located at Xp11.23 that encodes Wiskott-Aldrich syndrome protein (WASP). Although T-cell dysfunction is present, it is not severe enough to completely prevent rejection . Job’s Syndrome (Hyper-IgE syndrome) (Option C) Impaired Th17 pathway with eosinophilia and recurrent infections. T cell immunity is abnormal but not absent , so rejection can occur . Syndrome T Cell Function Graft Rejection Expected? Bare

Lymphocyte Syndrome Severely impaired/absent ■ No rejection Chediak-Higashi Syndrome Mostly intact ■ Yes Wiskott-Aldrich Syndrome Impaired, not absent ■ Possible Job's Syndrome Impaired Th17 cells ■ Possible

References:

Robbins and Cotran's Pathologic Basis of Disease, 10th Edition, Page 241, 246.

↑ *Back to this question in Part A*

@Neet_pg_bot

Q22: A patient presented to the OPD with hepatosplenomegaly, and his bone marrow showed 22% of plasma cells. Biopsy reveals pinkish acellular material deposition. What is the most likely diagnosis? (Q844184)

A. Myxoid degeneration of the bone marrow

B. Amyloidosis

C. Plasma cell leukemia

D. Hemolytic anemia

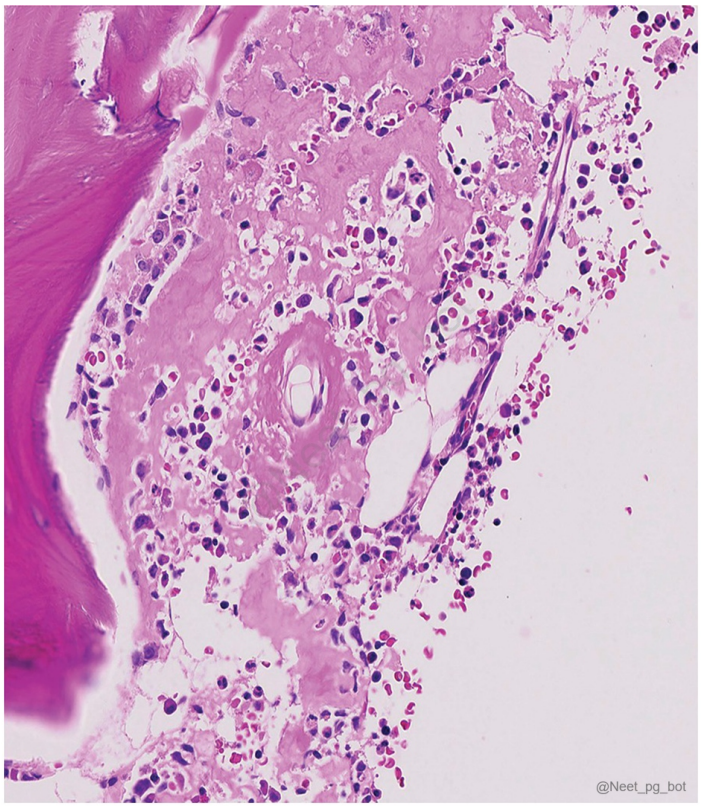

Correct Answer: B. Amyloidosis

Explanation: The given clinical features, along with increased plasma cells and microscopic findings of pinkish acellular material deposition, are suggestive of primary amyloidosis. Primary amyloidosis results from a plasma cell dyscrasia , most commonly multiple myeloma , where abnormal plasma cells produce excess light chains (κ or λ) . These light chains misfold and deposit as amyloid fibrils in tissues. Biopsy shows Amorphous pink material on H&E , Apple-green birefringence with Congo red stain, λ light chain more commonly involved than κ. Increased plasma cells produce IgG antibodies with excess light chains that deposit as AL protein, deposition in the kidney, resulting in myeloma kidney. The excess proteins are excreted in the urine, called Bence Jones proteinuria Light chain cast Light chain cast in the kidney is referred to as a fractured cast because it will have pink areas with gaps (white). Incorrect Options: Option A) Myxoid degeneration of the bone marrow : Myxoid change shows basophilic, gelatinous, mucopolysaccharide-rich material, not pink acellular eosinophilic deposits. Does not correlate with elevated plasma cells. Option C) Plasma cell leukemia : Requires >20% circulating plasma cells in peripheral blood , not just bone marrow involvement. Histology would show sheets of plasma cells, not acellular eosinophilic material. Option D) Hemolytic anemia : Bone marrow in hemolysis shows erythroid hyperplasia , not pink acellular deposits. Does not cause this histological picture.

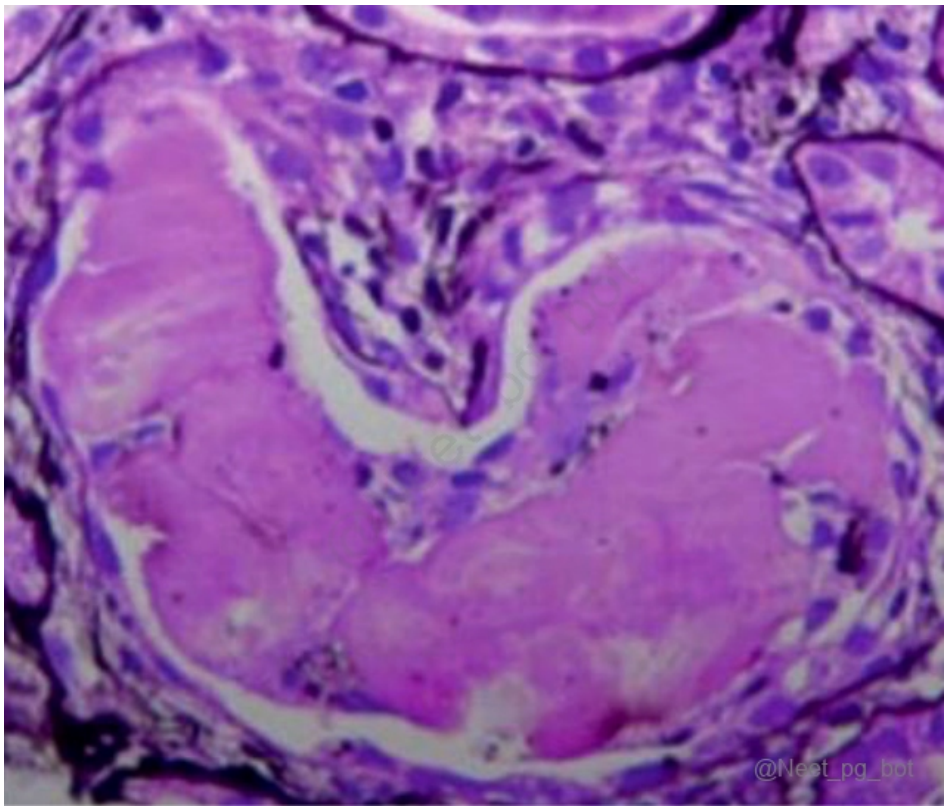

References:

.

↑ *Back to this question in Part A*

@Neet_pg_bot

Q23: A child is brought to the OPD by his parents with complaints of recurrent infections. On mediastinal imaging, the thymus gland was found to be absent. Based on further investigation, ADA levels are low. What is the most likely diagnosis? (Q844212)

A. Bruton's hypogammaglobulinemia

B. Bare lymphocyte syndrome

C. DiGeorge syndrome

D. Severe combined immunodeficiency (autosomal recessive)

Correct Answer: D. Severe combined immunodeficiency (autosomal recessive)

Explanation: Correct Option D - Severe combined immunodeficiency (autosomal recessive): Severe combined immunodeficiency (SCID) is characterized by a lack of both T and B cells, leading to severe immune deficiency. Adenosine deaminase (ADA) deficiency is seen in autosomal recessive SCID. Incorrect Options: Options A, B, and C do not have ADA deficiency.

References:

Prepladder notes

↑ *Back to this question in Part A*

@Neet_pg_bot

Q24: A 7-year-old boy presents with a history of recurrent bacterial and fungal infections, particularly involving the skin and respiratory tract. The patient's parents report that he has had multiple abscesses and lymphadenitis. Dihydrorhodamine test results show an abnormal pattern. What is the primary suspicion based on these findings? (Q860539)

A. CGD

B. SCID

C. Sialyl Lewis X

D. LAD

Correct Answer: A. CGD

Explanation: The history of recurrent bacterial and fungal infections, especially affecting the skin and respiratory tract, along with multiple abscesses, lymphadenitis, and an abnormal Dihydrorhodamine (DHR) test result, strongly suggests Chronic Granulomatous Disease (CGD). It is characterised by increased susceptibility to recurrent infections caused by catalase-positive organisms. Cause : Defect in NADPH oxidase, an enzyme complex in phagocytes. Mechanism : A defect in NADPH oxidase leads to the inability to produce the reactive oxygen species (ROS) required to kill certain bacteria and fungi. Clinical Presentation : Recurrent infections, particularly with catalase-positive organisms (e.g., Staphylococcus aureus, Aspergillus), granuloma formation. This defect is identified by the abnormal DHR test, which measures the production of ROS in neutrophils. SCID (Severe Combined Immunodeficiency) (Option B) is a genetic disorder affecting both humoral and cell-mediated immunity, presenting with thrush, diaper rash, and failure to thrive in infants. It involves defects in T and B cells, leading to severe, broad immune deficiencies, unlike the phagocyte-specific defect seen in CGD. Sialyl Lewis X (Option C) is a carbohydrate on leukocytes that helps with adhesion and migration during immune responses. Its deficiency impairs neutrophil trafficking, leading to immune deficiency and recurrent infections, but does not typically cause abnormalities in the DHR test. LAD (Leukocyte Adhesion Deficiency) (Option D) is a genetic disorder causing defective neutrophil adhesion, impairing migration to infection sites, leading to recurrent infections, poor wound healing, and delayed umbilical cord separation. The DHR test is normal in LAD, as it assesses phagocyte function, not adhesion.

References:

Robbins and Cotran Pathologic Basis of Disease, 10th Edition, Page 241.

↑ *Back to this question in Part A*

@Neet_pg_bot

Q25: Which of the following organs is a primary lymphoid organ? (Q860208)

A. Lymph node

B. Spleen

C. Thymus

D. MALT

Correct Answer: C. Thymus

Explanation: The thymus is a primary lymphoid organ. Lymphoid Organs are structures involved in the production, maturation, and storage of immune cells, essential for the immune system to detect and respond to pathogens. They are classified as: Primary lymphoid organ (Development and maturation of T and B lymphocytes) Secondary lymphoid organ (Site of adaptive immune responses to antigens) Primary Lymphoid Organs Secondary Lymphoid Organs Bone Marrow: Origin of all blood cells from pluripotent hematopoietic stem cells (a process called hematopoiesis). Hematopoiesis shifts to bone marrow from the liver after fetal life, eventually confined to axial bones after puberty. Progenitor T and B cells develop in bone marrow; B cells mature here, while T cell progenitors migrate to the thymus. Lymph Nodes: (Option A ruled out) Filter antigens and activate T and B cells.

Structured into cortex (B cell area), paracortex (T cell area), and medulla (rich in plasma cells). Spleen: (Option B ruled out) Largest secondary lymphoid organ, involved in filtering blood-borne antigens. Contains white pulp (T and B cells) and red pulp (site of RBC destruction). Thymus: (Option C) Site of T cell proliferation and maturation. Developed from the third/fourth pharyngeal pouch in embryonic life. Active during childhood, decreases in size after puberty. Thymic hormones (e.g., thymulin, thymopoietin) help attract and mature T cells. Central tolerance occurs here, removing self-reactive T cells to prevent autoimmunity. Mucosa-associated Lymphoid Tissue (MALT): (Option D ruled out) Located in mucosal sites (intestine, respiratory, urogenital tracts) to protect against pathogens. Includes loose clusters of lymphoid cells and organised structures (e.g., tonsils, Peyer's patches in intestines). {{caption_text}}

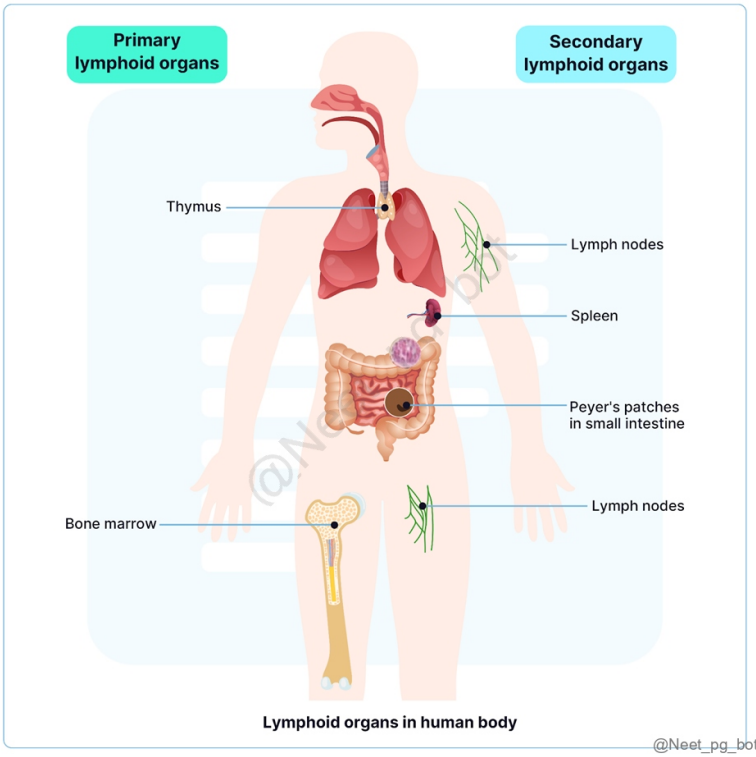

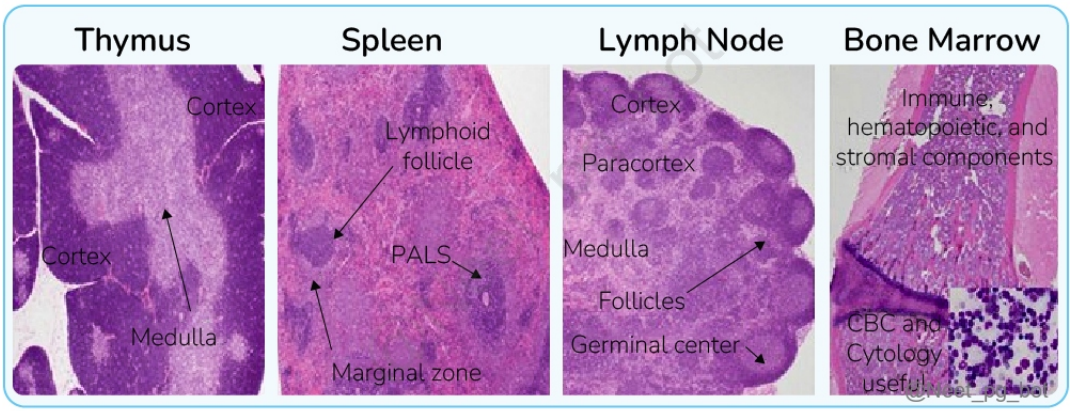

References:

Robbins & Cotran Pathologic Basis of Disease, 10th Edition, Page 197.

Apurba Sastry Essentials of Medical Microbiology, 3rd Edition, Page 169-171.

↑ *Back to this question in Part A*

@Neet_pg_bot

Q26: Which of the following antibodies is specific for scleroderma? (Q857434)

A. Anti-topoisomerase/Anti-scl 70 antibody

B. Anti-La antibody

C. Anti-Jo-1 antibody

D. Anti-U1 RNP antibodies

Correct Answer: A. Anti-topoisomerase/Anti-scl 70 antibody

Explanation: Anti-topoisomerase/Anti-scl 70 antibody are highly specific for scleroderma, especially diffuse scleroderma Anti centromere antibody is involved in limited scleroderma (also known as CREST syndrome). Scleroderma (systemic sclerosis) is an autoimmune disease characterized by fibrosis of the skin and internal organs. Diffuse & Limited Systemic Sclerosis Features Diffuse Limited Skin involvement Proximal & Distal extremities, face, trunk Distal to elbows, face Raynaud's Phenomenon Onset <1 year/at the time of skin changes Precede skin diseases by years Organ Involvement Pulmonary (Interstitial fibrosis), Renal (Renovascular hypertensive crisis), GI & Cardiac GI, Biliary cirrhosis, Pulmonary artery hypertension Nail fold capillaries Dilatation and dropout Dilatation without significant dropout Antinuclear antibodies Anti-topoisomerase 1 Anticentromere Antibodies Conditions Anti-La antibody (Option B) Sjogren's syndrome Anti-Jo-1 antibody (Option C) Dermatomyositis Anti-U1 RNP antibodies (Option D) Mixed connective tissue disease (MCTD)

References:

Robbins and Cotran Pathologic Basis of Disease, 10th Edition, Page 223

Harrison's Principles of Internal Medicine, 21st Edition, Pages 2780 - 2782

↑ *Back to this question in Part A*

@Neet_pg_bot

Q27: Which of the following genes is responsible for the regulation of T lymphocytes by the thymus? (Q857440)

A. AIRE

B. Notch 1

C. E2A

D. Rag1/2

Correct Answer: A. AIRE

Explanation: AIRE (autoimmune regulator) is a gene responsible for regulating T cell selection in the thymus. During negative selection, T cells that recognize self-antigens are eliminated through apoptosis. AIRE plays a crucial role in this process by promoting the deletion of self-reactive T cells. A defect in AIRE results in autoimmune polyendocrine syndrome (APS). Notch 1 (Option B) is involved in the initial development of T cells , including determining whether a progenitor cell will become a T cell, but it does not regulate the elimination of self-reactive T cells , which is the role of AIRE . E2A (Option C) is a transcription factor more relevant to B cell development and not directly related to T cell selection in the thymus. Rag1/2 (Option D) are enzymes responsible for the rearrangement of T cell receptor (TCR) genes during T cell development, but they do not directly regulate negative selection.

References:

Robbins and Cotran Pathologic Basis of Disease, 10th Edition, Pages 216-217, 219

↑ *Back to this question in Part A*

@Neet_pg_bot

Q28: Blood transfusion reactions are mediated by which type of hypersensitivity reaction? (Q866752)

A. Type I

B. Type II

C. Type III

D. Type IV

Correct Answer: B. Type II

Explanation: Blood transfusion reactions (specifically acute hemolytic transfusion reactions) occur when the recipient’s immune system attacks donor red blood cells due to ABO incompatibility. Mechanism: Type of hypersensitivity: Type II (antibody-mediated cytotoxic). Pathophysiology: Pre-existing IgM antibodies in the recipient bind to antigens (A or B) on donor RBCs. This activates the complement cascade, leading to: RBC lysis (intravascular hemolysis) Release of haemoglobin Inflammatory cytokine release Clinical presentation: fever, chills, hypotension, flank pain, hemoglobinuria, possible DIC. Type I (Option A): IgE-mediated (allergies, anaphylaxis). Type III (Option C): Immune complex–mediated (e.g., serum sickness, post-strep GN). Type IV (Option D): T-cell–mediated (delayed, e.g., TB skin test, contact dermatitis).

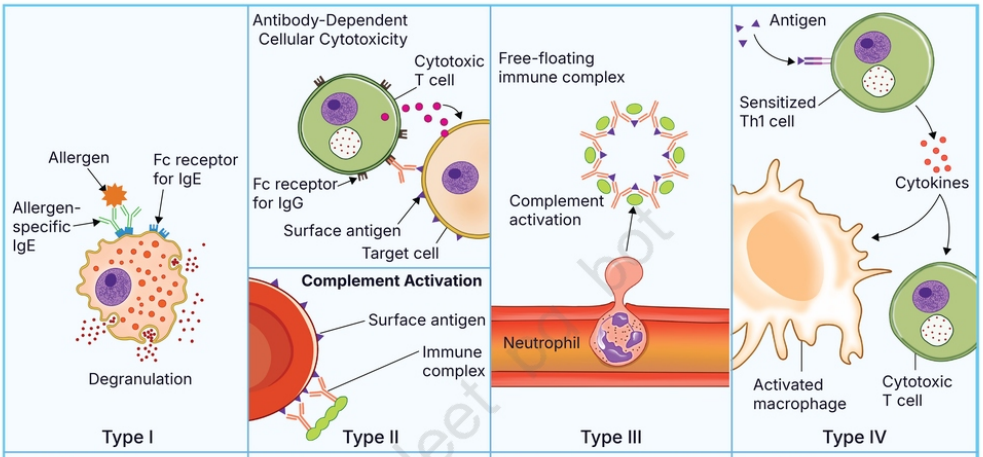

IgE-Mediated Hypersensitivity	IgG-Mediated Cytotoxic Hypersensitivity	Immune Complex-Mediated Hypersensitivity	Cell-Mediated Hypersensitivity
IgE is bound to mast cells via its Fc portion. When an allergen binds to these antibodies, crosslinking of IgE induces degranulation.	Cells are destroyed by bound antibody, either by activation of complement or by a cytotoxic T cell with and Fc receptor for the antibody (ADCC)	Antigen-antibody complexes are deposited in tissues, causing activation of complement, which attracts neutrophils to the site	Th1 cells secrete cytokines, which activate macrophages and cytotoxic T cells and can cause macrophage accumulation at the site
Causes localized and systemic anaphylaxis, seasonal allergies including hay fever, food allergies such as those to shellfish and peanuts, hives and eczema	Red blood cells destroyed by complement and antibody during a transfusion of mismatched blood type or during erythroblastosis fetalis	Most common forms of immune complex disease are seen in glomerulonephritis, rheumatoid arthritis, and systemic lupus erythematosus	Most common forms are contact dermatitis, tuberculin reaction, autoimmune diseases such as diabetes mellitus type I, multiple sclerosis , and rheumatoid arthritis

@Neet_pg_bot

References:

.

↑ *Back to this question in Part A*

@Neet_pg_bot

Q29: Which type of hypersensitivity reaction is a type 2 lepra reaction? (Q820565)

A. Type I hypersensitivity

B. Type II hypersensitivity

C. Type III hypersensitivity

D. Type IV hypersensitivity

Correct Answer: C. Type III hypersensitivity

Explanation: Correct Option C - Type III hypersensitivity: Type 2 lepra reaction, also known as erythema nodosum leprosum, is a type III hypersensitivity reaction. The type 2 lepra reaction occurs in patients with: Lepromatous leprosy Borderline lepromatous leprosy Incorrect Options: Options A, B, and D are incorrect.

↑ *Back to this question in Part A*

@Neet_pg_bot

Q30: After class switching, a particular class of antibody is produced, but IgM and IgD are expressed concomitantly on the surface of a B cell due to which of the following phenomena? (Q854696)

A. Allelic exclusion

B. Alternate RNA splicing

C. Somatic hypermutation

D. Affinity maturation

Correct Answer: B. Alternate RNA splicing

Explanation: B cells express both IgM and IgD antibodies simultaneously due to alternative RNA splicing . This mechanism allows the same heavy chain gene to be spliced in different ways, resulting in the production of both IgM and IgD isotypes. Although IgM and IgD are derived from the same heavy chain gene, the splicing process generates distinct versions of the RNA transcript, one for IgM and one for IgD. Both antibodies share the same antigen-binding specificity but differ in their constant regions , which determine their respective isotypes. Allelic exclusion (Option A) ensures that only one allele of the immunoglobulin gene is expressed in a B cell at a time, maintaining clonal specificity, but it does not account for the co-expression of IgM and IgD. Somatic hypermutation (Option C) takes place after antigen exposure and enhances the affinity of antibodies, but it does not play a role in the simultaneous expression of IgM and IgD. Affinity maturation (Option D) is a process that improves antibody affinity during the immune response, but it does not generate multiple antibody classes concurrently.

References:

Robbins & Cotran Pathologic Basis of Disease, 10th Edition, Pages 203, 591 NIH Link

↑ *Back to this question in Part A*

@Neet_pg_bot

Q31: What method is employed for the detection of autoantibodies? (Q854704)

A. Direct Immunofluorescence

B. ELISA

C. Indirect Immunofluorescence

D. FISH

Correct Answer: C. Indirect Immunofluorescence

Explanation: Indirect immunofluorescence is used to detect autoantibodies, particularly antinuclear antibodies (ANA), a hallmark of autoimmune diseases. The test employs a single anti-human globulin fluorescent conjugate, making it versatile and reducing the need for multiple conjugates. Type Description Limitation Direct Immunofluorescence Detects antigen directly using a fluorescent-labelled antibody. (Option A ruled out) Requires separate fluorescent conjugates for each antigen. Indirect Immunofluorescence It uses antiglobulin fluorescent conjugate to detect human antibodies, enhancing versatility. Allows the use of a single anti-human conjugate. ELISA (Option B) is widely used for quantifying specific autoantibodies , but it is not the first-line method for detecting autoantibodies broadly. FISH (Option D) is a molecular cytogenetic technique used to detect and localize specific DNA sequences within the chromosomes. It is not for detecting autoantibodies.

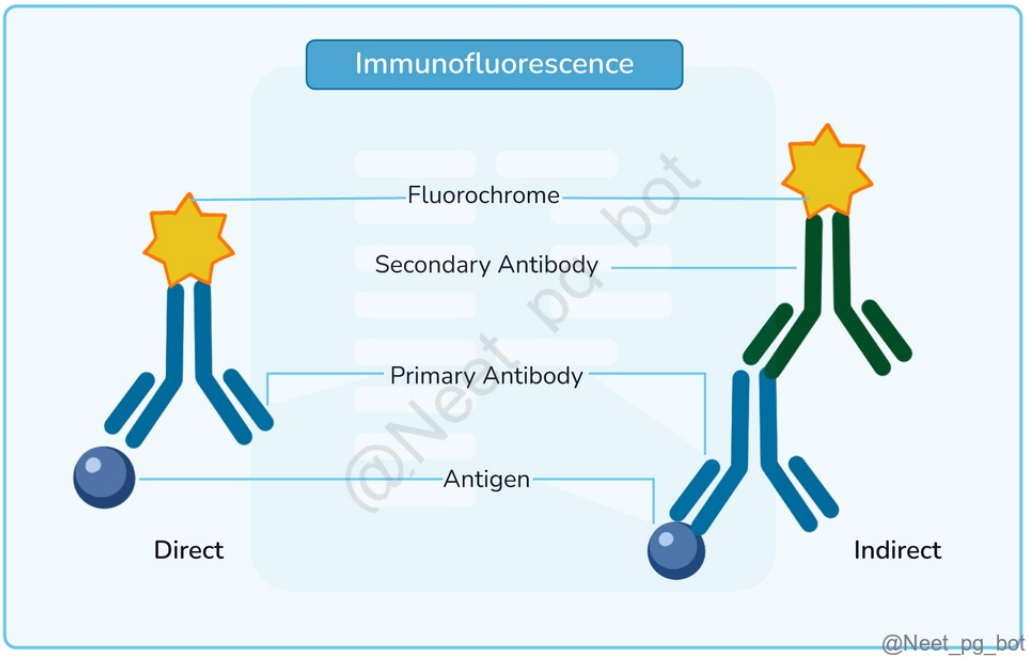

References:

Ananthanarayan & Paniker Textbook of Microbiology, 10th Edition, Page 118, 119

↑ *Back to this question in Part A*

@Neet_pg_bot

Q32: A young person with recurrent seasonal conjunctivitis presents with itchiness and eye-watering. What is the most likely cell involved in the immediate phase of this condition? (Q858100)

A. Eosinophils

B. Mast cells

C. Neutrophils

D. Lymphocytes

Correct Answer: B. Mast cells

Explanation: The condition described is allergic conjunctivitis , where the immediate phase involves an IgE-mediated hypersensitivity reaction , with mast cells playing a central role in the response. Type I Hypersensitivity (early) is an immediate IgE-mediated reaction where mast cells release histamine and other mediators upon allergen exposure, causing itching, eye-watering, redness, and swelling. There are two phases in Type I hypersensitivity: the immediate and late-phase responses. Type I hypersensitivity reaction phases and its features Phase Timing Mechanism Immediate Phase Seconds to minutes Mast cell/basophil degranulation : IgE cross-linking leads to the release of histamine and other mediators. Late Phase 4-12 hours, peaks at 24-48 hours, lasting up to days Inflammatory cell recruitment : Cytokines/chemokines attract eosinophils, neutrophils, and macrophages, causing sustained inflammation. (Options A & C ruled out) Lymphocytes (Option D) , especially T-helper cells , play a role in delayed hypersensitivity (Type IV hypersensitivity), but they are not the primary cells involved in the immediate response.

References:

Robbins and Cotran Pathologic Basis of Disease,10th Edition, Pages 204 - 208

↑ *Back to this question in Part A*

@Neet_pg_bot

Q33: Which of the following is implicated in the pathogenesis of rheumatoid arthritis? (Q858104)

A. IgE-mediated

B. Defective cellular and humoral immunity

C. Autoimmunity

D. Chronic microbial infections

Correct Answer: C. Autoimmunity

Explanation: Rheumatoid arthritis (RA) is a chronic autoimmune disorder where the immune system mistakenly attacks healthy tissues. The pathogenesis of rheumatoid arthritis (RA) begins with antigenic exposure in genetically predisposed individuals, leading to the activation of CD4+ T-cells . These T-cells release inflammatory

cytokines such as TNF-α , IL-1 , IL-6 , and interferon-γ , which activate endothelial cells , B lymphocytes , and macrophages . This cascade of immune activation leads to chronic inflammation , joint damage , and deformities that characterise RA. Rheumatoid arthritis Epidemiology Male to female ratio - 1:3. Peaks between 25 and 55 years. Remains constant between 55 and 75. Genetics Strongly associated with the HLA-DRβ1 gene. Higher concordance in monozygotic twins. Triggers and suppressors Cigarette smoking and infections can trigger RA in genetically predisposed individuals by citrullination of proteins. RA may remit during pregnancy and can first appear postpartum due to immune suppression and hormonal changes. Pathogenesis Incorrect Options: IgE-mediated (Option A) immune response is primarily seen in allergic reactions, not in rheumatoid arthritis. Defective cellular and humoral immunity (Option B) : While immune dysfunction plays a role in RA, the specific issue is not a general defect in immunity but rather an autoimmune response where the immune system attacks its own tissues. Chronic microbial infections (Option D) can trigger or exacerbate autoimmune diseases , but they are not the direct cause of RA. However, certain infections may contribute to disease flares or trigger the initial immune response.

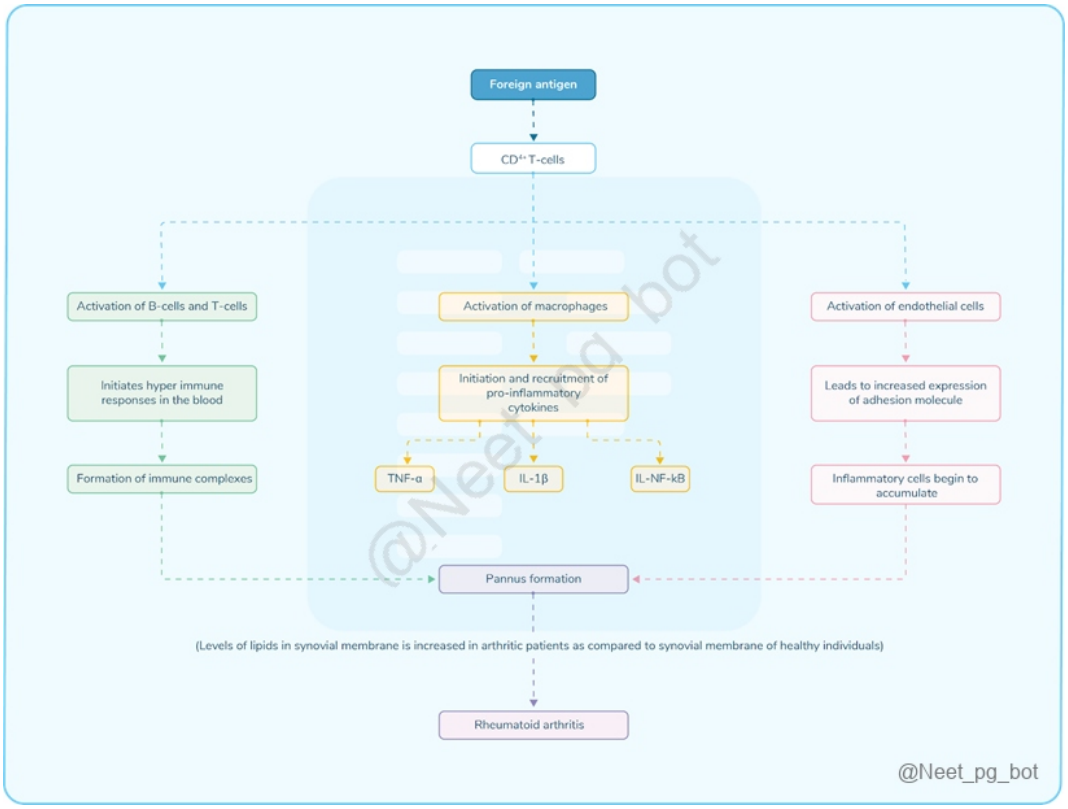

References:

Harrison’s Principles of Internal Medicine, 21st Edition, Pages 2751, 2754

↑ *Back to this question in Part A*

@Neet_pg_bot

Q34: Which of the following is a marker of natural killer cells? (Q855942)

A. CD68

B. CD3

C. CD25

D. CD94

Correct Answer: D. CD94

Explanation: CD94 is a marker associated with natural killer (NK) cells and plays a role in regulating their activity and interactions with other immune cells. Natural Killer cell (NK) : Produced by a large granular lymphocyte. Constitutes 5 to 10% of circulating blood lymphocytes. Function: It can be part of both innate and adaptive immunity. Innate immunity: Directly kill the virus-infected cells or tumour cells. Adaptive immunity: Antibody-dependent cell-mediated cytotoxicity. Markers for NK cells : CD 16, CD 56, CD 94 . CD 56: The role is still not fully understood. CD 16: Detect and bind to Fc fragment of IgG on target cells and kill the cell by perforins and by releasing toxins and granzymes. Nk cells have 2 different kinds of receptors. Activating receptors: NKG2D. Inhibitory receptors: CD94 , CD 96 (these prevent self-cells from being attacked by NK cells). Cytokines produced by Nk cells : IFN-Y: (Cytokine majorly responsible for granuloma formation). This cytokine leads to the activation of macrophages in epithelioid cells. Cytokines responsible for the proliferation of NK cells: IL-2 and IL-15. CD68 (Option A) : A marker of macrophages and other monocytes, not NK cells. CD3 (Option B) : Found on T cells, particularly T cell receptors. CD25 (Option C) : The alpha chain of the IL-2 receptor, primarily expressed on activated T cells.

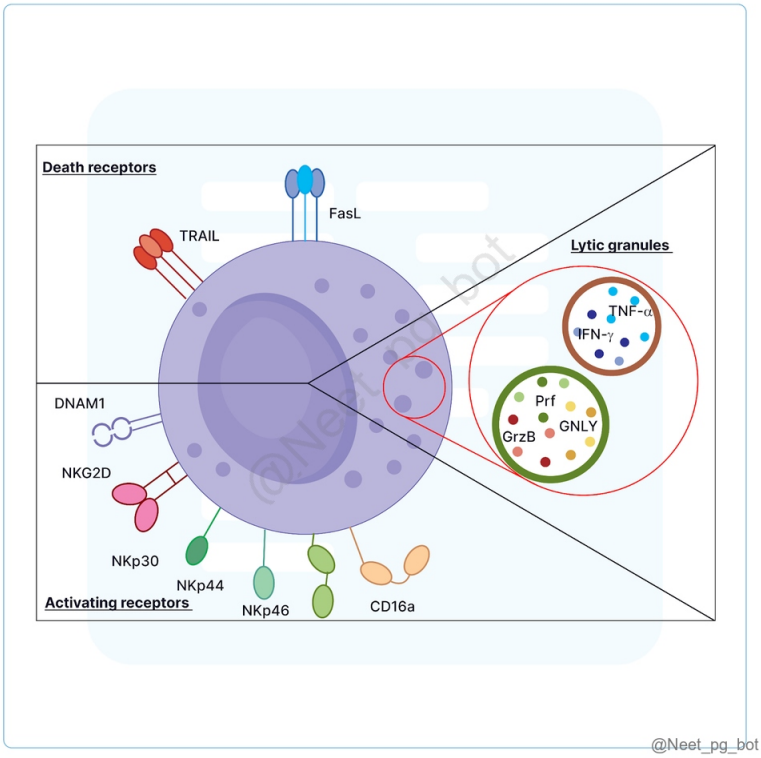

References:

Robbins & Cotran Pathologic Basis of Disease, 10th Edition, Page 192,193
https://www.ncbi.nlm.nih.gov/books/NBK565844/

↑ *Back to this question in Part A*

@Neet_pg_bot

Q35: The below-given ANA pattern on immunofluorescence (IF) is seen; identify the pattern. (Q857429)

A. Nucleolar

B. Speckled

C. Centromeric

D. Diffuse

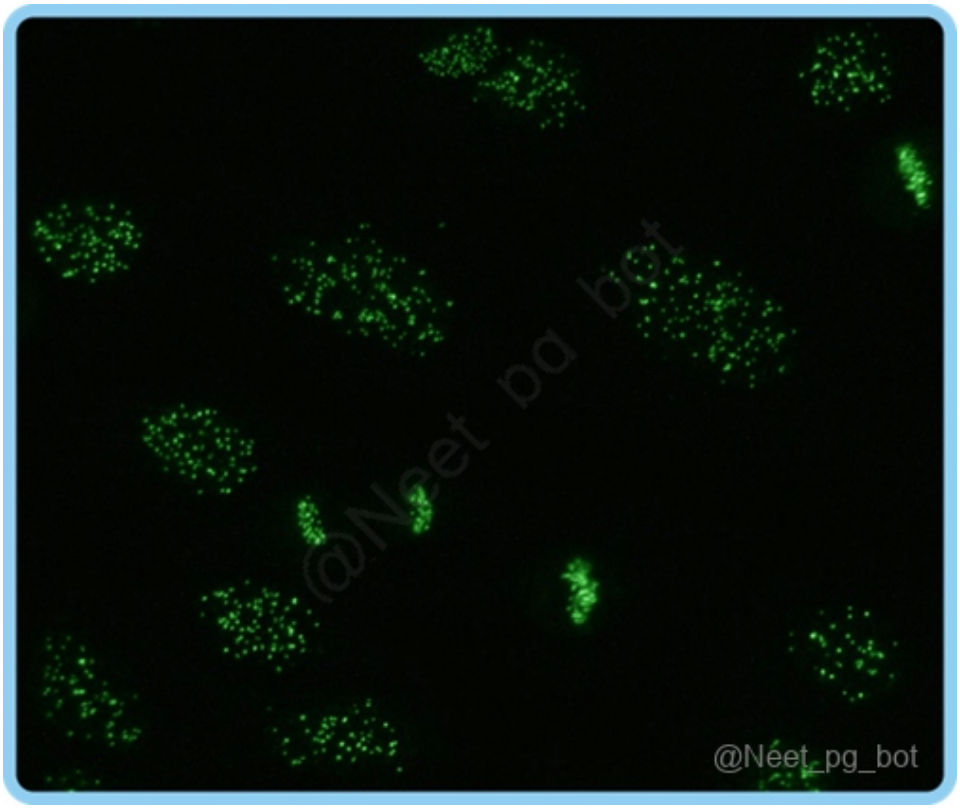

Correct Answer: C. Centromeric

Explanation: The image shows a centromeric ANA pattern, which refers to the staining of the centromere region of chromosomes, producing a pattern of discrete speckles or dots concentrated in the centre of the nucleus. This pattern is seen in conditions such as Limited Scleroderma or CREST syndrome . Homogeneous or diffuse staining of nuclei (Option D ruled out) Antibodies reactive with dsDNA, nucleosomes, and histones, This is seen in SLE,

Drug-induced lupus Mixed connective tissue disorder {{caption_text}} Speckled pattern (Option B ruled out) Antibodies against various nuclear antigens, including Sm and RNPs It is seen in SLE Scleroderma Sjogren's syndrome {{caption_text}} Nucleolar pattern (Option A ruled out) Antibodies against nucleolar proteins. It is seen in Scleroderma and Polymyositis. {{caption_text}} Anti-centromere antibodies (Option C) Systemic sclerosis, Sjögren syndrome, and other diseases {{caption_text}} {{caption_text}}

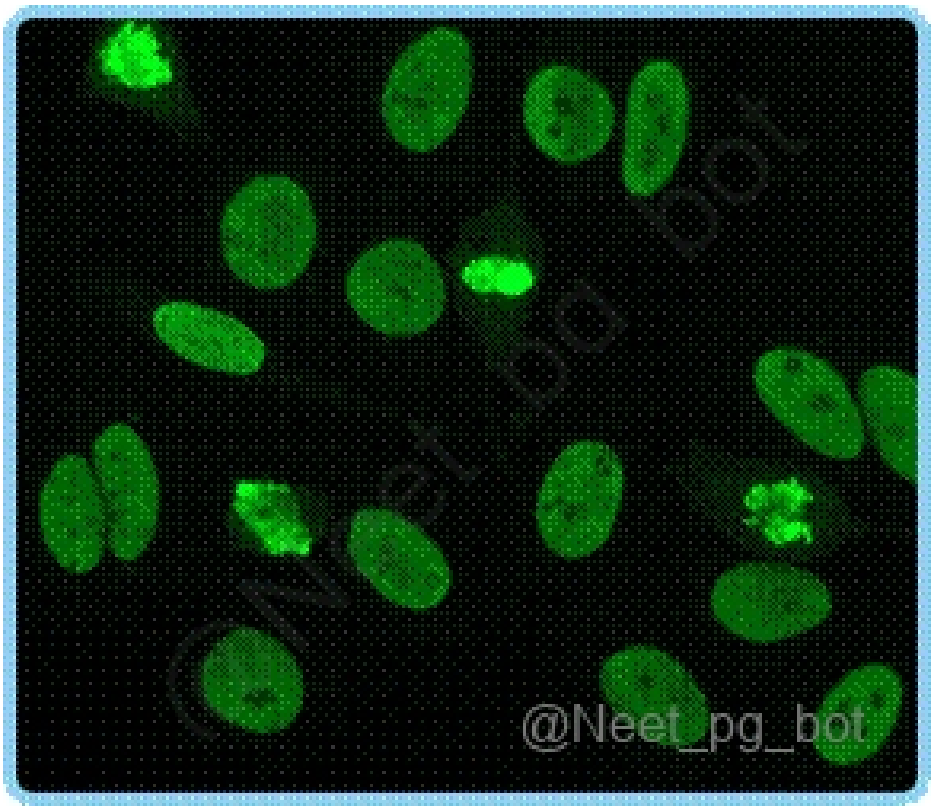

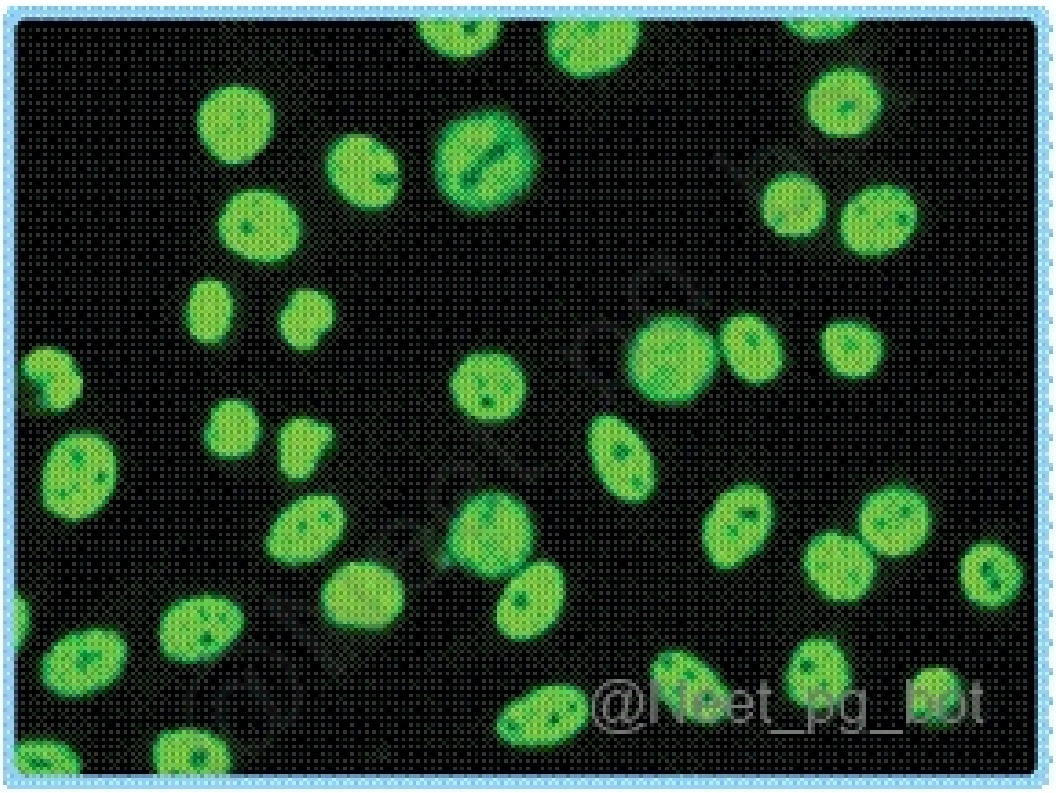
@Neet_pg_bot


@Neet_pg_bot

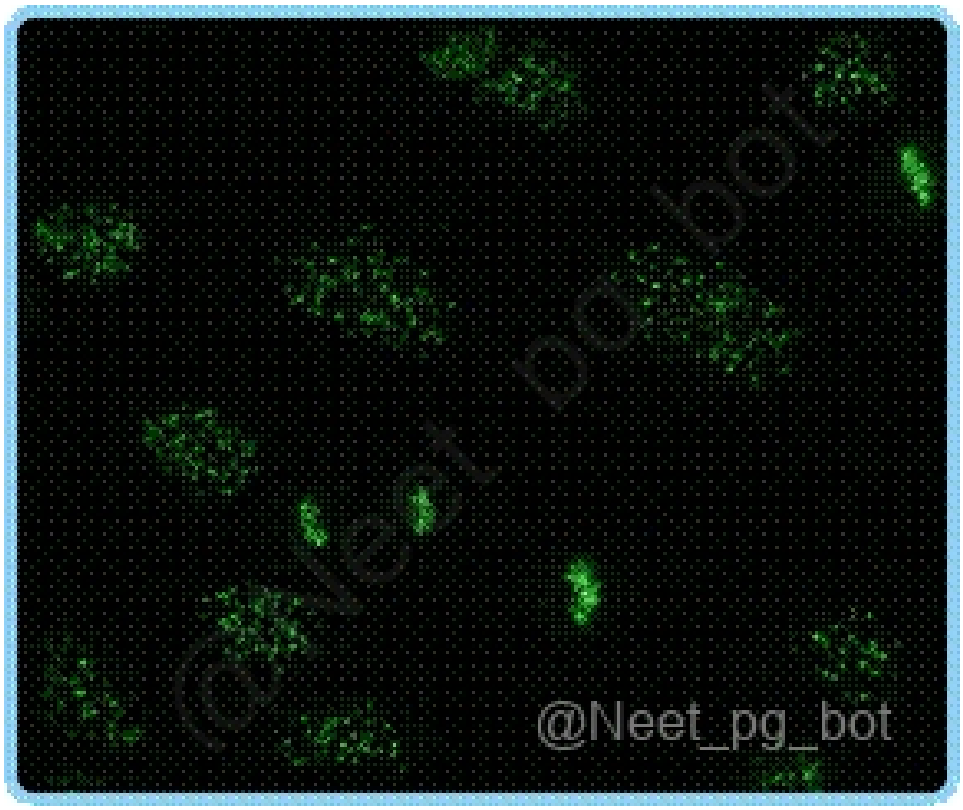

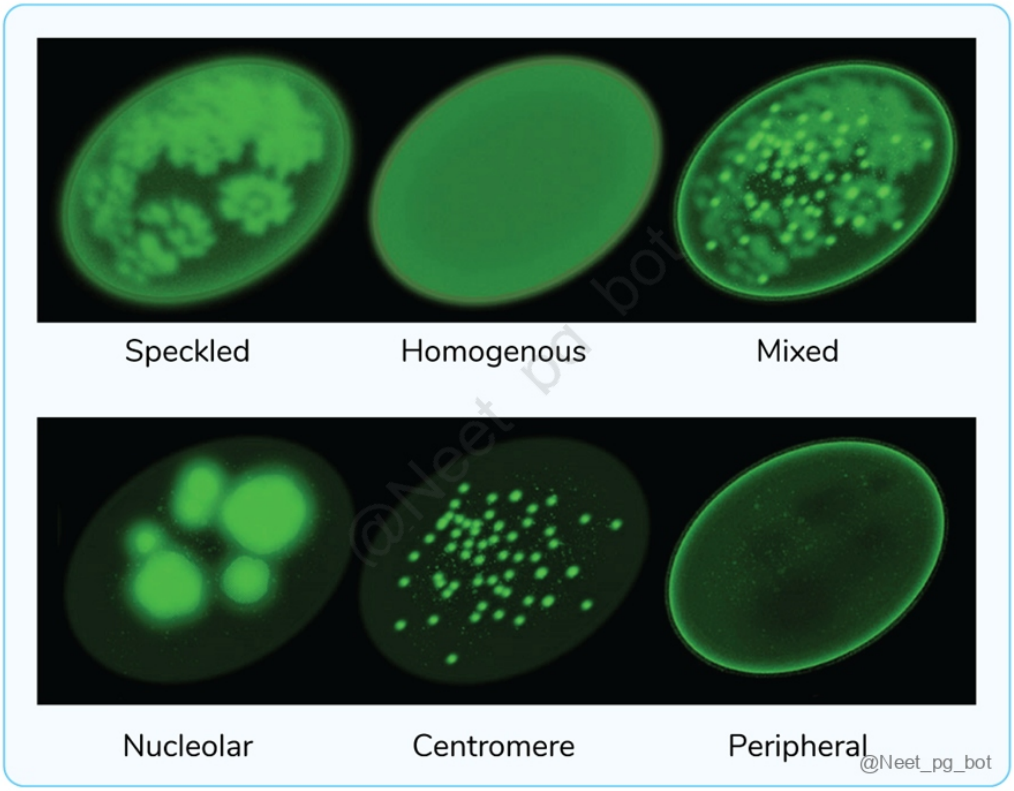

References:

Robbins and Cotran Pathologic Basis of Disease, 10th Edition, Page 223

↑ *Back to this question in Part A*

@Neet_pg_bot

Q36: Which of the following cells is responsible for graft rejection? (Q793603)

A. Macrophages

B. T cells

C. B cells

D. Plasma cells

Correct Answer: B. T cells

Explanation: Correct Option B - T cells: When a graft is transplanted into a recipient, the immune system recognizes the graft as foreign and triggers an immune response. This response is primarily mediated by T cells, which can recognize and respond to specific foreign antigens. The T cells recognize and bind to the foreign antigens expressed by the graft. This triggers the activation of other immune cells, such as macrophages, which can help to engulf and destroy the foreign tissue. Incorrect Options: Options A, C, and D are incorrect.

References:

.

↑ *Back to this question in Part A*

@Neet_pg_bot

Q37: The X-ray of a middle-aged man showed multiple lytic lesions , following which a urine examination was done . The sample revealed Bence Jones proteins. Which is the most common immunoglobulin associated with this condition ? (Q793750)

A. IgA

B. IgD

C. IgG

D. IgM

Correct Answer: C. IgG

Explanation: of the correct answer.

References:

.

↑ *Back to this question in Part A*

@Neet_pg_bot

• [06_CVS_ Blood Vessels and Vasculitis] 026 Sclerosis And Vascular Tumors

« Back to Folder Directory

[06_CVS_ Blood Vessels and Vasculitis] 026 Sclerosis And Vascular Tumors — Quick Jump

Q1 (p. 1611) *Q2 (p. 1612)* *Q3 (p. 1614)* *Q4 (p. 1616)* *Q5 (p. 1616)* *Q6 (p. 1619)*
Q7 (p. 1620) *Q8 (p. 1621)* *Q9 (p. 1622)* *Q10 (p. 1624)* *Q11 (p. 1625)*

Q1: A 60-year-old male with a chronic history of diabetes, hypertension and hypercholesterolemia came to the clinic for follow-up. His BP has not been under control for many years. He has a vascular lesion similar to the image shown below. What does this image indicate? {{caption_text}} (Q845201)

A. Atheromatous plaques

B. Thick arterial wall due to deposition of pink, hyaline material

C. Onion-skin appearance

D. Lipid deposition within the vessel wall

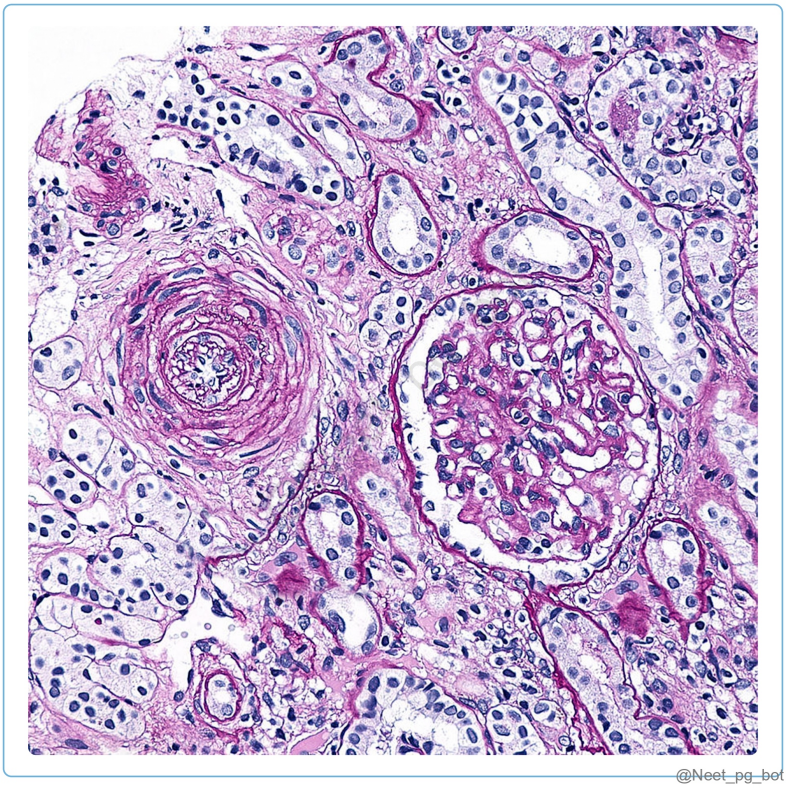

Correct Answer: C. Onion-skin appearance

■ *Listen (English)*

■ *Listen (Hindi)*

Explanation: Onion-skin appearance refers to hyperplastic arteriolosclerosis, where the arteriole shows concentric, laminated (onion-layered) smooth muscle proliferation and basement membrane duplication. It is characteristically seen in malignant hypertension, where severe, long-standing elevation of BP causes narrowing of arterioles. The laminated layers give the vessel wall a “onion-skin” morphology on histology. This is a hallmark change in accelerated or malignant hypertension. Incorrect Options: Option A) Atheromatous plaques : Seen in large arteries, not arterioles. Option B) Thick arterial wall due to deposition of pink, hyaline material : Describes hyaline arteriolosclerosis of benign hypertension/diabetes, not the laminated “onion-skin” pattern. Option D) Lipid deposition within the vessel wall : Refers to fatty streaks/atherosclerosis, not arteriolar hyperplasia.

References:

Robbins and Cotran, Pathologic Basis of Disease, 10th edition, Pages 492, 493.

↑ *Back to this question in Part A*

@Neet_pg_bot

Q2: A 65-year-old male presents with high pulse pressure. Histopathological examination is shown below. The arteries appear thickened, but there is no significant

luminal narrowing. Which of the following conditions is the likely cause? {{caption_text}} (Q845207)

A. Atherosclerosis

B. Monckeberg medial calcific sclerosis

C. Hyperplastic arteriosclerosis

D. Hyaline arteriosclerosis

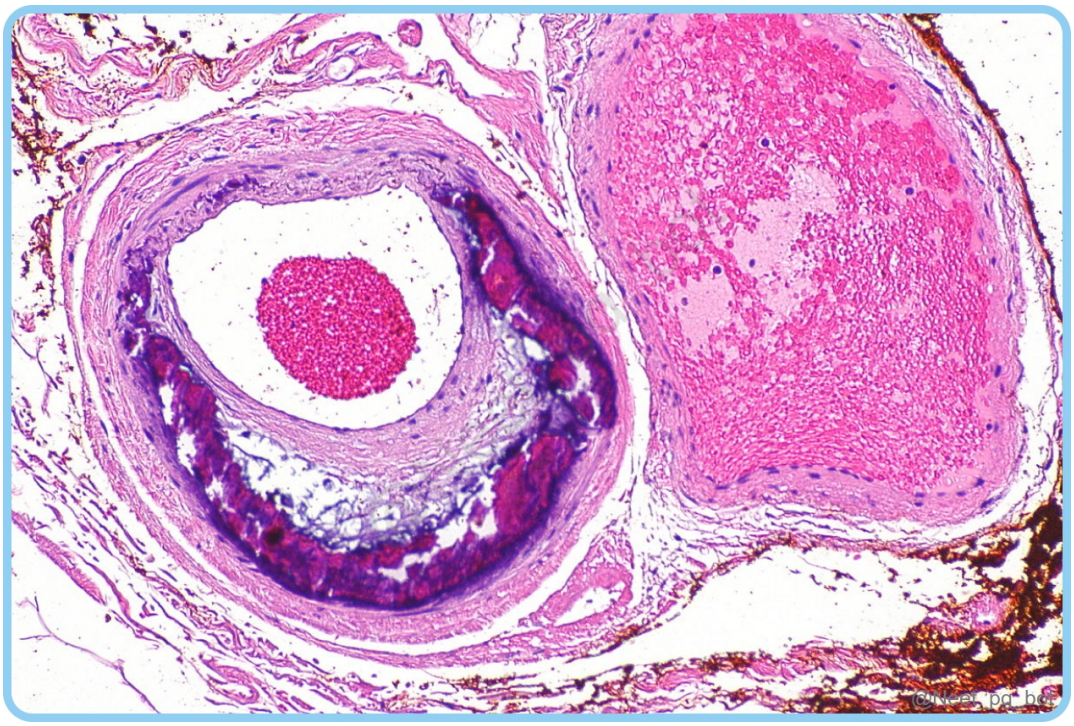

Correct Answer: B. Monckeberg medial calcific sclerosis

- *Listen (English)*
- *Listen (Hindi)*

Explanation: Monckeberg medial calcific sclerosis, also known as calcific medial degeneration: Calcific: Blue coloured dystrophic calcification due to old age. Medial: Calcium is getting deposited into the tunica media of the blood vessel. Degeneration: Degeneration occurring due to old age and not due to any pathology. It is often asymptomatic and discovered incidentally in imaging studies such as X-rays or histopathological examinations. {{caption_text}} {{caption_text}} Atherosclerosis (Option A): Due to hypercholesterolemia, and on HPE foam cells are seen in blood vessels. Hyperplastic arteriosclerosis (Option C): Seen in malignant hypertension. Hyaline arteriosclerosis (Option D): Seen in benign hypertension and diabetes.



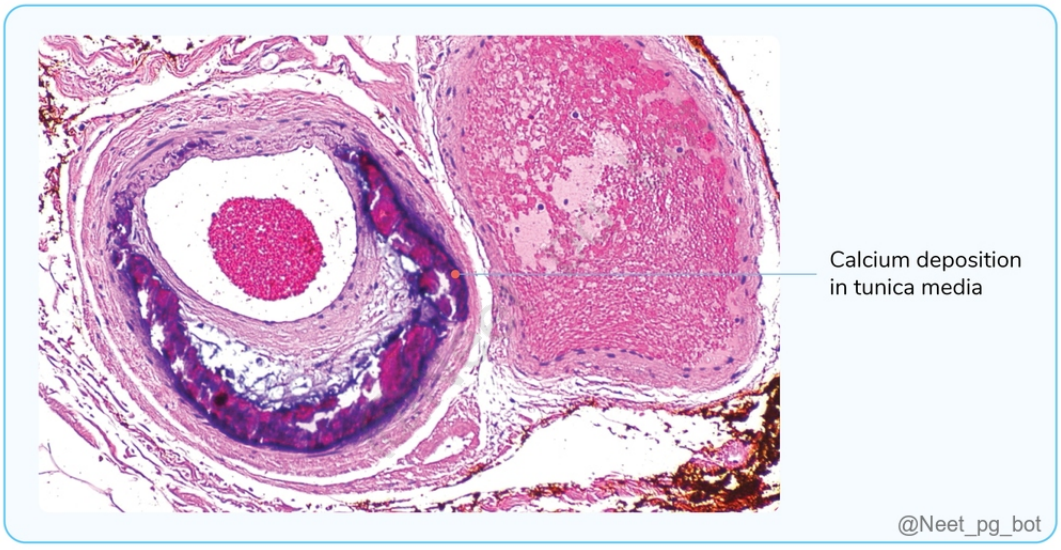

References:

Robbins and Cotran, Pathologic Basis of Disease, 10th edition, Pages 492, 493.

↑ *Back to this question in Part A*

@Neet_pg_bot

Q3: Arrange the following steps of atherosclerosis formation in the correct order. Endothelial injury and dysfunction Accumulation of lipoproteins Platelet adhesion and factor release Smooth muscle and collagen formation (Q845209)

A. 1>2>3>4

B. 1>2>4>3

C. 2>3>4>1

D. 1>3>2>4

Correct Answer: A. 1>2>3>4

Explanation: Atherosclerosis is the thickening and hardening of arteries due to plaque buildup in the inner lining of an artery, representing a chronic inflammatory and healing response of arterial wall's to endothelial injury. The pathogenesis of atherosclerosis is as follows: Endothelial injury and dysfunction cause increased vascular permeability, leukocyte adhesion, and thrombosis. (Statement 1) Accumulation of lipoproteins (LDL) (Statement 2) Monocyte adhesion to the endothelium, migration into intima and transformation into macrophages and foam cells. Platelet adhesion .(Statement 3) Factor release from activated platelets, macrophages inducing SMC(smooth muscle cell) recruitment SMC proliferation, extracellular matrix production(ECM) Lipid accumulation is both extracellular and within macrophages and SMC. Calcification of ECM and necrotic debris.

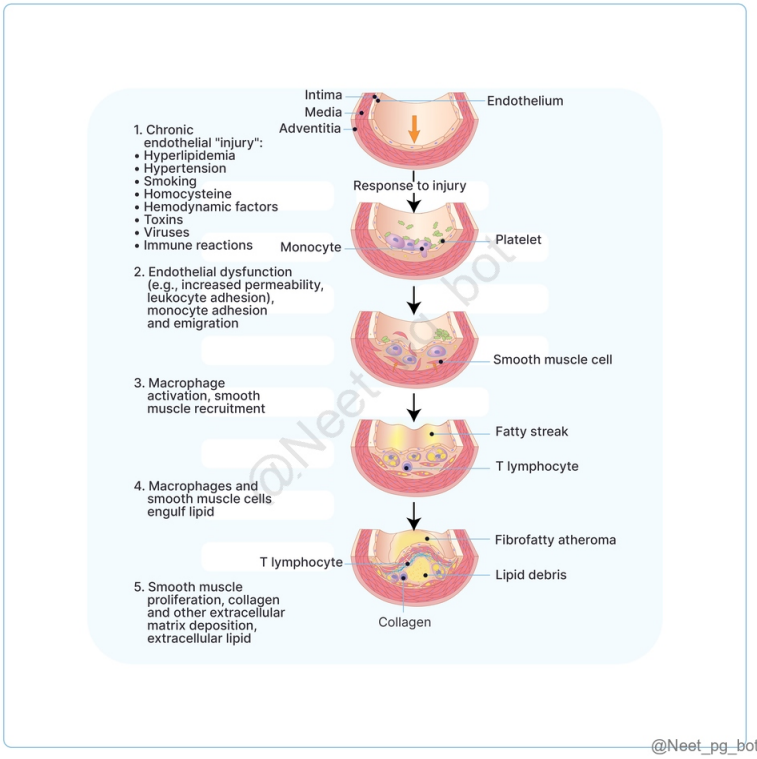

References:

Robbins and Cotran, Pathologic Basis of Disease, 10th edition, Pages 493-498

↑ *Back to this question in Part A*

@Neet_pg_bot

Q4: A 65-year-old male presents with sudden-onset severe abdominal pain radiating to his back. On physical examination, a pulsatile mass is palpated in his abdomen. He has a history of hypertension, hyperlipidemia, and smoking. Based on the clinical presentation and risk factors, which of the following is the most likely diagnosis? (Q845213)

A. Takayasu's arteritis

B. Diverticulitis

C. Abdominal aortic aneurysm

D. Pancreatitis

Correct Answer: C. Abdominal aortic aneurysm

■ *Listen (English)*

■ *Listen (Hindi)*

Explanation: The clinical presentation of sudden-onset severe abdominal pain radiating to the back, along with a pulsatile abdominal mass, is highly suggestive of an abdominal aortic aneurysm (AAA). Aneurysms are mainly due to atherosclerosis, but may also arise from genetic disorders, trauma, or infections. AAA results from medial degeneration weakening the aortic wall. It may be silent or present with sudden abdominal/back pain, pulsatile mass, and shock on rupture. Management : Depending on the aneurysm size, symptoms, and patient’s condition. <5.5 cm & asymptomatic: Monitor >5.5 cm, symptomatic, or rapidly enlarging: Elective repair Medical: Control risk factors to slow progression

References:

Robbins and Cotran, Pathologic Basis of Disease, 10th edition, Pages 504-507.

↑ *Back to this question in Part A*

@Neet_pg_bot

Q5: Match the following types of aortic dissections. a. {{caption_text}} 1. Stanford Type A b. {{caption_text}} 2. Debakey type I c. {{caption_text}} 3. Debakey II 4.

Debakey III (Q845216)

A. A-2, B-4, C-1

B. A-3, B-1, C-4

C. A-2, B-1, C-4

D. A-4, B-3, C-1







Correct Answer: C. A-2, B-1, C-4

■ *Listen (English)*

■ *Listen (Hindi)*

Explanation: Aortic aneurysms are divided into various types with respect to Stanford and DeBakey classification as follows: DeBakey Classification Stanford Classification DeBakey Classification: Type Origin Extent Type I (Option A) Ascending aorta Extends into arch and descending aorta Type II Ascending aorta Confined to ascending aorta Type III (Option C) Descending aorta Starts distal to left subclavian artery IIIa Limited to thoracic aorta IIIb Extends below diaphragm {{caption_text}} Stanford Classification: Type Description Management Implication Type A (Option B) Involves the ascending aorta (± arch, descending aorta) Surgical emergency Type B Involves only the descending aorta , distal to the left subclavian artery Medical management unless complications arise Relation Between Stanford and DeBakey: Stanford Type A = DeBakey Type I and II Stanford Type B = DeBakey Type III

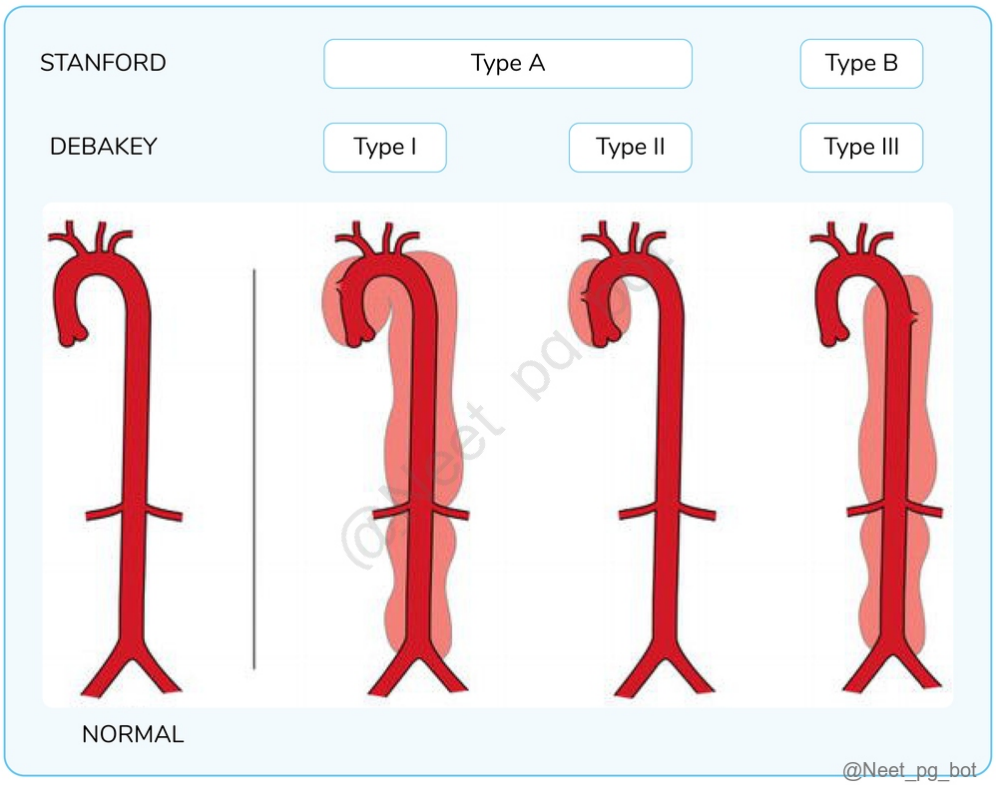

References:

Robbins and Cotran, Pathologic Basis of Disease, 10th edition, Pages 507, 508.

↑ *Back to this question in Part A*

@Neet_pg_bot

Q6: Which of the following is an intermediate-grade vascular tumour? (Q845224)

A. Kaposi sarcoma

B. Angiosarcoma

C. Hemangiopericytoma

D. Pyogenic granuloma

Correct Answer: A. Kaposi sarcoma

■ *Listen (English)*

■ *Listen (Hindi)*

Explanation: Classification of vascular tumours: Benign vascular tumour: Hemangioma, pyogenic granuloma, etc. Intermediate vascular tumour: Kaposi sarcoma Malignant vascular tumour: Angiosarcoma, hemangiopericytoma Kaposi sarcoma is an intermediate-grade vascular tumour. It is caused by Human Herpes Virus 8. (HHV8) It is associated with HIV/Immunodeficiency. M/c location is skin of lower limbs > lymph nodes

References:

Robbins and Cotran, Pathologic Basis of Disease, 10th edition, Page 518.

↑ *Back to this question in Part A*

@Neet_pg_bot

Q7: A 6-month-old infant is brought to the clinic with a rapidly expanding, clearly defined, bright red lesion on the face. Upon examination, the lesion feels soft, yields to pressure, and temporarily loses color when pressure is applied. Which of the following is the most likely diagnosis? (Q845227)

A. Pyogenic granuloma

B. Infantile hemangioma

C. Nevus flammeus

D. Venous malformation

Correct Answer: B. Infantile hemangioma

Explanation: The given clinical scenario suggests infantile/capillary hemangioma. Capillary hemangiomas are common benign vascular tumors in infants. They may be isolated or part of PHACE syndrome (posterior fossa malformations, hemangiomas, arterial anomalies, cardiac defects, eye abnormalities, and sternal clefting). and typically undergo rapid growth followed by spontaneous regression. They typically present as swiftly enlarging, vivid red lesions. A key distinguishing trait is their soft, yielding texture, which momentarily loses colour under pressure due to their abundant blood supply. {{caption_text}}



References:

Robbins and Cotran, Pathologic Basis of Disease, 10th edition, Pages 519, 520.

↑ *Back to this question in Part A*

@Neet_pg_bot

Q8: A 30-year-old patient presents with a history of multiple tumours in various organs, including the brain, retina, and kidneys. On examination, retinal angiomas and cerebellar hemangioblastomas are noted. The patient's family history reveals similar manifestations in relatives. Which of the following lesions is commonly associated with this syndrome? (Q845327)

A. Glioblastoma multiforme

B. Adenomatous polyps

C. Capillary hemangioma

D. Cavernous hemangioma

Correct Answer: D. Cavernous hemangioma

■ *Listen (English)*

■ *Listen (Hindi)*

Explanation: The clinical scenario represents von Hippel-Lindau syndrome , commonly associated with cavernous hemangiomas. VHL Syndrome is associated with the deletion of chromosome 3p. Inheritance: Autosomal dominant It is associated with Cavernous hemangiomas. {{caption_text}}

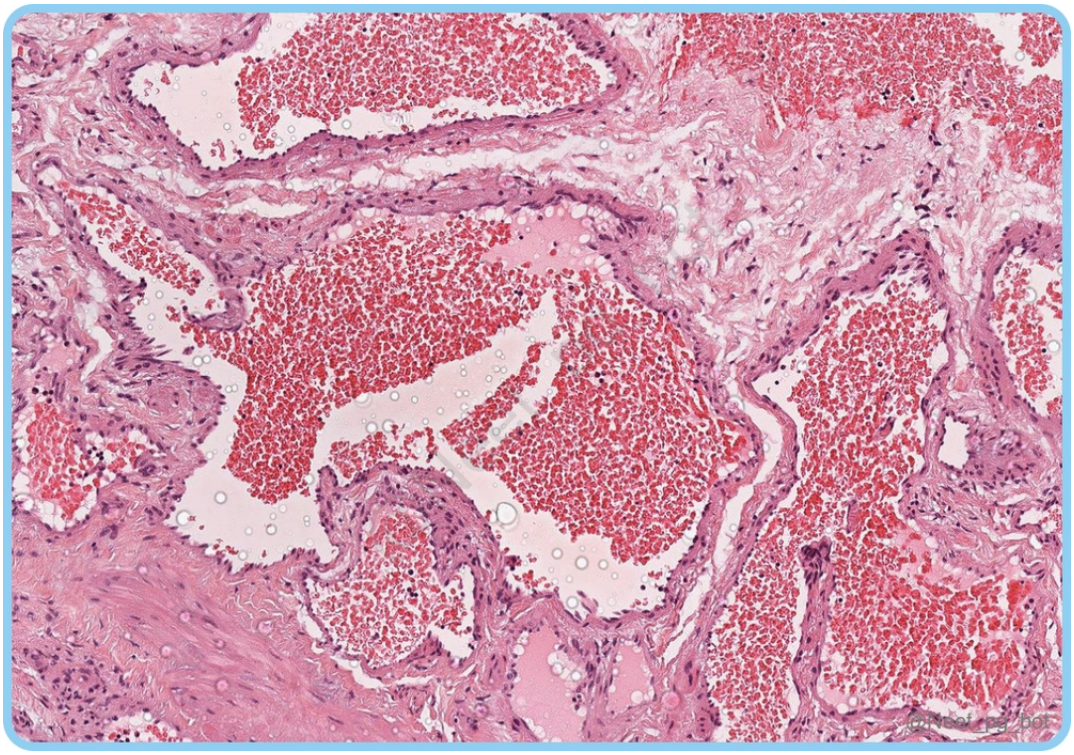

References:

Robbins and Cotran, Pathologic Basis of Disease, 10th edition, Page 520.

↑ *Back to this question in Part A*

@Neet_pg_bot

Q9: A 45-year-old individual complains of a throbbing mass on the tip of their index finger. Upon examination, the lesion is bluish and extremely tender to the touch. Which of the following is the most probable diagnosis? (Q845331)

A. Ganglion cyst

B. Bacillary angiomatosis

C. Glomus tumour

D. Cavernous lymphangioma

Correct Answer: C. Glomus tumour

- *Listen (English)*
- *Listen (Hindi)*

Explanation: Glomus tumours are benign tumours originating from the glomus bodies of blood vessels. -modified smooth muscle cells specialised in temperature regulation. Glomus bodies: These are the arterio-venous (A-V) anastomoses responsible for thermoregulation of the body. Usually present at the tip of fingers, They typically manifest as excruciatingly painful, pulsating masses , often found under the nails of the fingers (subungual swelling). {{caption_text}} Ganglion cyst (Option A): A Ganglion cyst is a benign cystic swelling arising from tendon sheaths or joint capsules, commonly seen on the dorsum of the wrist. It is typically smooth, soft, and fluctuant and may cause mild discomfort, but not severe tenderness. Bacillary angiomatosis (Option B): Bacillary angiomatosis is a vascular proliferative infection caused by Bartonella species (usually Bartonella henselae or Bartonella quintana). It occurs mainly in immunocompromised individuals, especially AIDS patients and produces multiple red or purple vascular skin lesions that may resemble pyogenic granulomas. However, these lesions are not typically localized to the fingertip, and intense localized tenderness with throbbing pain is not characteristic. Cavernous lymphangioma (Option D): A Cavernous lymphangioma is a benign congenital malformation of lymphatic vessels. It usually appears in infancy or childhood, and is commonly found in the neck, axilla, or oral cavity. The lesions are soft, compressible, and painless



References:

Robbins and Cotran, Pathologic Basis of Disease, 10th Rdition, Page 520

↑ *Back to this question in Part A*

@Neet_pg_bot

Q10: A 60-year-old HIV-positive patient presents with multiple reddish-purple nodules on the lower extremities. On examination, the lesions are non-tender, non-pruritic, and do not blanch with pressure. There is also evidence of mucosal involvement in the oral cavity. Which of the following is the most likely diagnosis? (Q845338)

A. Hemangiopericytoma

B. Hemangioendothelioma

C. Kaposi sarcoma

D. Angiosarcoma

Correct Answer: C. Kaposi sarcoma

■ *Listen (English)*

■ *Listen (Hindi)*

Explanation: Kaposi sarcoma is an intermediate-grade vascular tumour. Most commonly associated with immunocompromised individuals, particularly those with HIV/AIDS. It arises from blood vessels and typically presents with multiple reddish-purple nodules on the skin. It is caused by Human Herpes Virus 8 (HHV8) M/c location is skin of lower limbs > lymph nodes The Latency Associated Nuclear Antigen (LANA) is positive, it is an antigen for HHV8. {{caption_text}}



References:

Robbins and Cotran, Pathologic Basis of Disease, 10th edition, Pages 520-523.

↑ *Back to this question in Part A*

@Neet_pg_bot

Q11: A 28-year-old woman, 20 weeks pregnant, presents with a painful, growing, reddish lump on her gums (as shown below) that bleeds when brushing or eating. The lesion is tender, and she denies any history of trauma or irritation. What is the most likely diagnosis? {{caption_text}} (Q846620)

A. Hemangiopericytoma

B. Kasabach-Merritt Syndrome

C. Angiosarcoma

D. Lobular Capillary Hemangioma



Correct Answer: D. Lobular Capillary Hemangioma

■ *Listen (English)*

■ *Listen (Hindi)*

Explanation: The scenario and image are consistent with a diagnosis of Lobular Capillary Hemangioma (also known as Pyogenic Granuloma or Granuloma Gravidarum or Pregnancy Tumor). It regresses after pregnancy, so in most cases, surgical ressection or any treatment is not needed. Microscopically: Lobular capillary hemangioma (LCH) {{caption_text}} {{caption_text}}

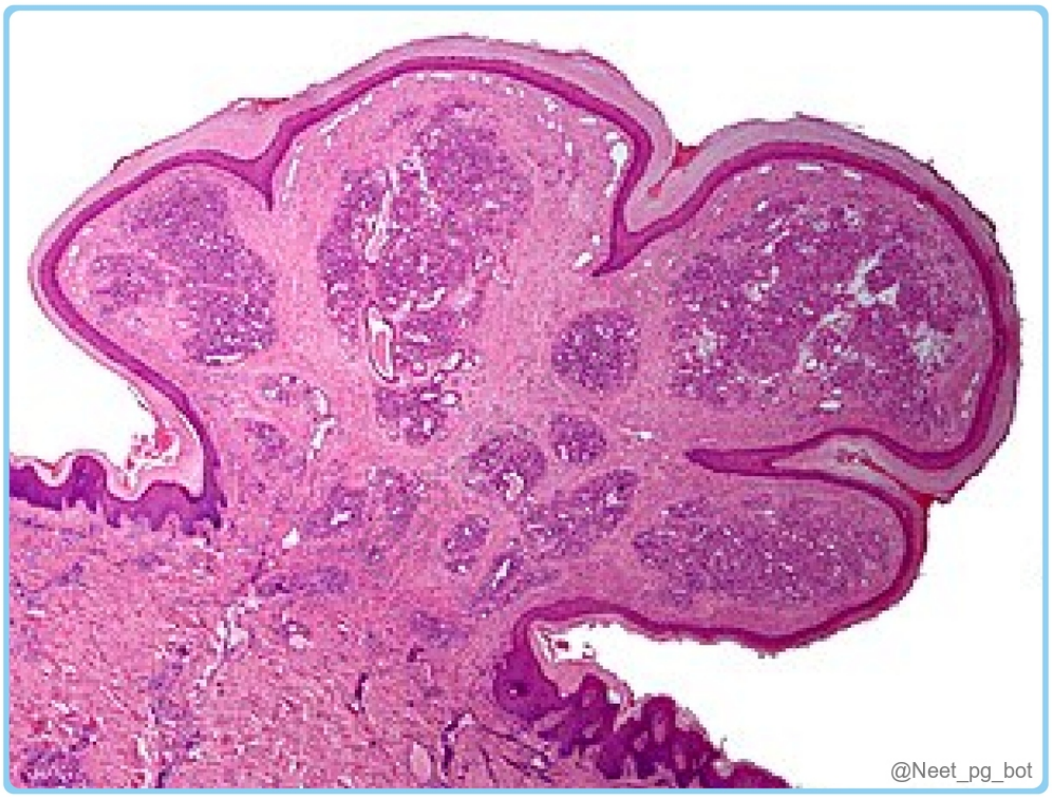



References:

Robbins and Cotran, Pathologic Basis of Disease, 10th edition, Page 732.

↑ *Back to this question in Part A*

@Neet_pg_bot

• [06_CVS_ Blood Vessels and Vasculitis] 027 Ischemic Heart Disease And Myocardial Infarction

« Back to Folder Directory

[06_CVS_ Blood Vessels and Vasculitis] 027 Ischemic Heart Disease And Myocardial Infarction — Quick Jump

Q1 (p. 1629)	*Q2 (p. 1630)*	*Q3 (p. 1631)*	*Q4 (p. 1631)*	*Q5 (p. 1632)*	*Q6 (p. 1633)*
Q7 (p. 1633)	*Q8 (p. 1634)*	*Q9 (p. 1635)*	*Q10 (p. 1636)*	*Q11 (p. 1637)*	*Q12 (p. 1638)*
Q13 (p. 1639)	*Q14 (p. 1640)*	*Q15 (p. 1641)*	*Q16 (p. 1642)*	*Q17 (p. 1645)*	*Q18 (p. 1646)*
Q19 (p. 1647)	*Q20 (p. 1647)*	*Q21 (p. 1649)*			

Q1: Which of the following best describes using Triphenyl tetrazolium chloride (TTC) in myocardial infarction? (Q845321)

A. It is used to measure blood flow in coronary arteries

B. It helps visualize viable myocardial tissue after an infarction.

C. It acts as an anticoagulant to prevent clot formation.

D. It assists in the diagnosis of arrhythmias following a heart attack.

Correct Answer: B. It helps visualize viable myocardial tissue after an infarction.

■ *Listen (English)*

■ *Listen (Hindi)*

Explanation: TPTC, or Triphenyl Tetrazolium Chloride, is a stain or dye applied to heart tissue, which is used as a gross stain rather than a microscopic stain. Procedure: The heart specimen is cut into slices, and drops of TPTC are applied to each slice. Principle: TPTC stains LDH1 (lactate dehydrogenase isoenzyme 1). Normal, viable heart tissue contains LDH1 and stains brick-red, whereas infarcted, dead heart tissue has lost LDH1 and therefore appears pale. A brick-red color indicates viable myocardium, while pale color indicates infarcted myocardium. Thus, TPTC is used to visualize myocardial tissue viability after myocardial infarction. {{caption_text}}

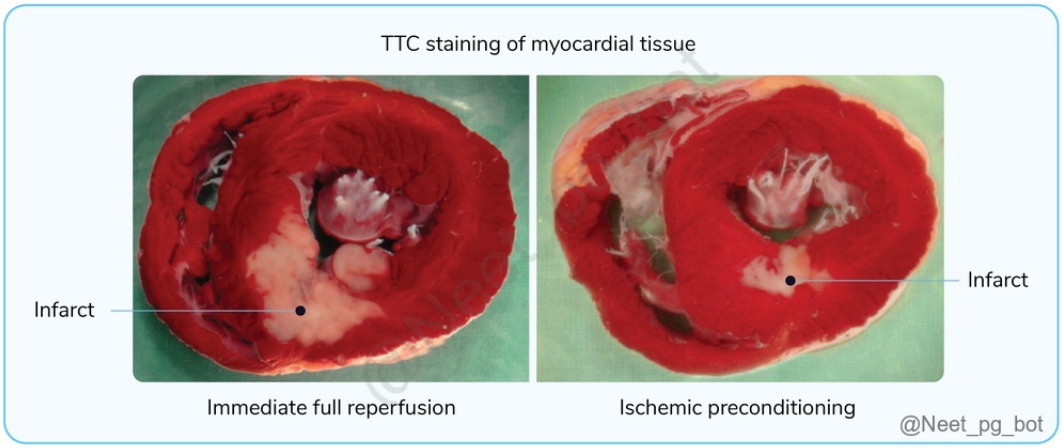

References:

Robbins and Cotran Pathologic Basis of Disease, 10th edition, Page 548

↑ *Back to this question in Part A*

@Neet_pg_bot

Q2: A pathology report of a heart specimen describes "brisk interstitial infiltrate of neutrophils" and "coagulative necrosis with loss of nuclei. What is the most likely age of this infarct? (Q884942)

A. 4-12 hours

B. 1-3 days

C. 7-10 days

D. >2 months

Correct Answer: B. 1-3 days

Explanation: While coagulative necrosis begins as early as 4 hours, the presence of a brisk neutrophilic infiltrate and the total loss of nuclei and striations specifically characterise the 1-to-3-day window. Evolution of Morphologic Changes: Time Frame Gross Features Light Microscope Findings 0-0.5 hr None None; Electron microscope shows mitochondrial swelling and glycogen loss 0.5-4 hr None Variable waviness of fibres at the borders 4-12 hr Occasional dark mottling Early coagulative necrosis , oedema, and haemorrhage 1-3 days Mottling with a yellow-tan centre Loss of nuclei/striations; brisk neutrophilic infiltrate 3-7 days Hyperemic border; central softening Macrophage phagocytosis begins; early granulation tissue 10-14 days Red-grey depressed borders New blood vessels and collagen deposition 2-8 weeks Gray-white scar Increased collagen and decreased cellularity >2 months Scarring complete Dense collagenous scar

References:

Robbins, Cotran & Kumar, Pathologic Basis of Disease, 11th Edition, Page 497

↑ *Back to this question in Part A*

@Neet_pg_bot

Q3: A 68-year-old woman is admitted with an acute anterior wall myocardial infarction. On hospital day 5, she suddenly develops hypotension and pulseless electrical activity. Bedside echocardiography shows a large pericardial effusion with tamponade physiology. At what time after myocardial infarction does this complication most commonly occur? (Q884940)

A. Within the first 2 days

B. 2-3 weeks

C. 3-7 days

D. After 3 weeks

Correct Answer: C. 3-7 days

Explanation: Myocardial free wall rupture most commonly occurs 3-7 days after MI , when necrotic myocardium undergoes maximal enzymatic degradation and is replaced by soft, friable granulation tissue, making the wall prone to tearing. Mechanical Complication of MI: Myocardial Rupture: Occurs in 1-3% of myocardial infarctions - frequently fatal Types of Rupture: Left Ventricular Free Wall Rupture (Most common): Hemopericardium, cardiac tamponade Often rapidly fatal Ventricular Septal Rupture Papillary Muscle Rupture Timing: Most common 3-7 days post-MI Occurs when: Necrotic myocardium undergoes maximal lysis Infarcted area becomes soft, friable granulation tissue Risk Factors (Especially for Free Wall Rupture): Age > 60 years Female sex First MI Anterior or lateral wall infarction Absence of left ventricular hypertrophy

References:

Robbins, Cotran & Kumar, Pathologic Basis of Disease, 11th Edition, Page 502

↑ *Back to this question in Part A*

@Neet_pg_bot

Q4: A 62-year-old man presents with severe substernal chest pain that began 90 minutes ago. ECG shows ST-segment elevation in the inferior leads. Which of the following events is most likely occurring at this time in ischemic cardiac myocytes? (Q884937)

A. ATP reduced to 50% of normal

B. Loss of contractility

C. Irreversible cell injury

D. Microvascular injury

Correct Answer: D. Microvascular injury

Explanation: Microvascular injury typically occurs after more than 1 hour of sustained severe ischemia. Timeline of Ischemic Events in Cardiac Myocytes: The progression from initial oxygen deprivation to permanent tissue death follows a specific chronological order: Immediate Response (Seconds): ATP depletion begins almost instantly after blood flow is interrupted. Early Functional Loss (<2 minutes): The heart muscle loses its ability to contract within 2 minutes. (Option B) Progression of ATP Loss: 10 minutes: ATP levels drop to 50% of normal. (Option A) 40 minutes: ATP levels drop to a critical 10% of normal. The Point of No Return (20–40 minutes): Irreversible cell injury (necrosis) typically sets in during this window. (Option C) Vascular Damage (>1 hour): Damage to the microscopic blood vessels (microvascular injury) occurs after an hour of sustained ischemia.

References:

Robbins, Cotran & Kumar, Pathologic Basis of Disease, 11th Edition, Page 495

↑ *Back to this question in Part A*

@Neet_pg_bot

Q5: Which hormone is associated with an increased risk of myocardial infarction in post-menopausal women? (Q884936)

A. Progesterone

B. Estrogen

C. Prolactin

D. Oxytocin

Correct Answer: B. Estrogen

Explanation: After menopause, a decline in estrogen levels is associated with increased risk of myocardial infarction due to loss of its protective cardiovascular effects (favourable lipid profile, anti-inflammatory and vasodilatory effects). Myocardial Infarction (MI): Death of cardiac muscle due to prolonged ischemia Commonly called a heart attack Major cause: Atherosclerosis (most common underlying cause) Sex differences: Males: Higher risk in middle age Females: Relatively protected during reproductive years (estrogen effect) Postmenopause: Risk increases → IHD becomes the leading cause of death in older women Hormone replacement

therapy: Not protective May increase risk (possible prothrombotic effect)

References:

Robbins, Cotran & Kumar, Pathologic Basis of Disease, 11th Edition, Page 494

↑ *Back to this question in Part A*

@Neet_pg_bot

Q6: A patient with chronic lung disease presents with pedal oedema, raised JVP, and hepatomegaly. He is diagnosed with isolated right heart failure. What is the structural cause of his right-sided heart failure? (Q884935)

A. Left ventricular hypertrophy

B. Right ventricular hypertrophy and dilatation

C. Mitral stenosis

D. Decreased systemic vascular resistance

Correct Answer: B. Right ventricular hypertrophy and dilatation

Explanation: In patients with chronic lung disease (like COPD or interstitial fibrosis), the right ventricle must pump against increased pulmonary vascular resistance. This leads to Cor Pulmonale . Initially, the right ventricle undergoes hypertrophy (thickening of the wall) to compensate for the pressure. Eventually, the ventricle fails and undergoes dilatation , leading to the clinical signs of systemic venous congestion like pedal oedema, raised Jugular Venous Pressure (JVP), and hepatomegaly. Left ventricular hypertrophy (Option A) : This is the response to systemic hypertension or aortic stenosis. In isolated right heart failure, the left ventricle is typically normal in size or may even be compressed by the bulging interventricular septum. Mitral stenosis (Option C) : While this can lead to right-sided heart failure, it is a left-sided valvular disease. The question specifies "isolated" right heart failure caused by chronic lung disease. Decreased systemic vascular resistance (Option D) : Decreased resistance (as seen in septic shock) would actually decrease the afterload on the left heart. It is increased pulmonary vascular resistance that drives right-sided failure in this scenario.

References:

Robbins, Cotran & Kumar, Pathologic Basis of Disease, 11th Edition, Page 484

↑ *Back to this question in Part A*

@Neet_pg_bot

Q7: Which of the following is a cause of isolated right-sided heart failure? (Q884932)

A. Systemic hypertension

B. Mitral valve stenosis

C. Primary pulmonary hypertension

D. Aortic regurgitation

Correct Answer: C. Primary pulmonary hypertension

Explanation: Isolated right-sided heart failure most commonly results from pulmonary disorders causing pulmonary hypertension (cor pulmonale). This condition directly increases the pressure the right ventricle must work against without primarily involving the left side of the heart. Right-Sided Heart Failure (RHF): Causes: Most common: Left-sided heart failure Isolated RHF → Cor pulmonale (due to lung disease) Parenchymal lung disease Primary pulmonary hypertension Recurrent pulmonary thromboembolism Pulmonary vasoconstriction (OSA, high altitude) Key Differences from Left-Sided HF: Minimal pulmonary congestion Marked systemic & portal venous congestion

References:

Robbins, Cotran & Kumar, Pathologic Basis of Disease, 11th Edition, Page 484

↑ *Back to this question in Part A*

@Neet_pg_bot

Q8: A 68-year-old patient presents with exertional dyspnea. Echocardiography shows preserved ejection fraction with impaired left ventricular relaxation. He is diagnosed with left-sided diastolic heart failure (HFpEF). Which of the following is the most common cause of left-sided diastolic heart failure? (Q884931)

A. Hypertension

B. Cardiac amyloidosis

C. Ischemic heart disease

D. Constrictive pericarditis

Correct Answer: A. Hypertension

Explanation: Chronic hypertension leads to left ventricular hypertrophy and stiffness, making it the most common cause of diastolic heart failure. Left-Sided Heart Failure: Common causes: Ischemic heart disease (most common) Hypertension Aortic or mitral valvular disease Primary myocardial disease Types: Systolic Failure (HFrEF) ↓ Ejection fraction Impaired contractility Diastolic Failure (HFpEF): Preserved EF Stiff, noncompliant LV Commonly due to hypertension Also: fibrosis, amyloidosis, ageing Constrictive pericarditis can mimic

References:

Robbins, Cotran & Kumar, Pathologic Basis of Disease, 11th Edition, Page 484

↑ *Back to this question in Part A*

@Neet_pg_bot

Q9: A patient with long-standing left-sided heart failure develops progressive dyspnea. Sputum cytology shows findings as shown in the image. What are these cells most appropriately termed? (Q884929)

A. Dust cells

B. Hemosiderin-laden macrophages

C. Foam cells

D. Langhans giant cells



Correct Answer: B. Hemosiderin-laden macrophages

Explanation: The correct answer is Hemosiderin-laden macrophages . These pigment-containing alveolar macrophages are classically known as heart failure cells , formed due to chronic pulmonary congestion with RBC

extravasation and iron accumulation. In left-sided heart failure, the weakened left ventricle causes blood to back up into the pulmonary vasculature, leading to pulmonary hypertension and congestion . The high pressure causes small amounts of blood (RBCs) to leak into the alveoli. Alveolar macrophages phagocytose these RBCs and break down the haemoglobin into hemosiderin , a golden-brown pigment.

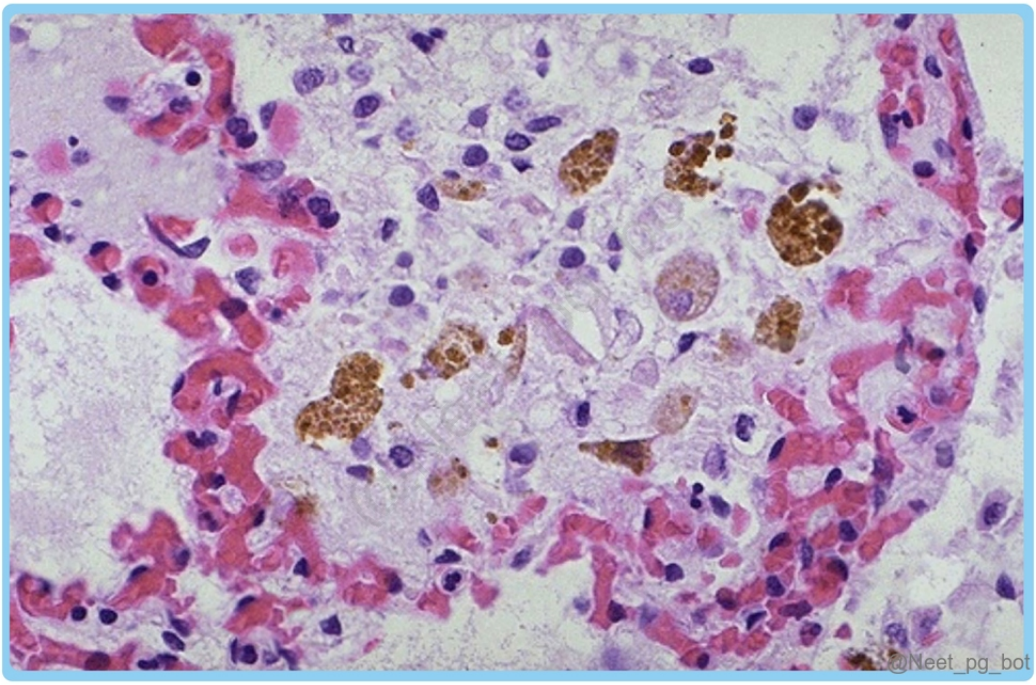

References:

Robbins, Cotran & Kumar, Pathologic Basis of Disease, 11th Edition, Page

↑ *Back to this question in Part A*

@Neet_pg_bot

Q10: A histologic examination of the heart in an elderly individual reveals several age-related changes. Which of the following is not typically seen in the ageing heart? (Q884928)

A. Lipofuscin deposition in myocytes

B. Transthyretin amyloid deposition

C. Decreased left atrial cavity size

D. Decreased left ventricular cavity size

Correct Answer: C. Decreased left atrial cavity size

Explanation: Ageing is associated with increased left atrial size, not decreased. Effects of Ageing on the Heart: ↑ Prevalence of heart disease with age Major contributors: atherosclerosis, valvular degeneration, myocardial stiffening Chambers: ↑ Left atrial size ↓ Left ventricular cavity size (Option D) Sigmoid septum (basal septal bulge) Valves: Aortic & mitral calcification Leaflet thickening Lambl excrescences Myocardium: ↓ Myocytes, ↑ fibrosis Lipofuscin (brown atrophy) (Option A) Transthyretin amyloid → stiffness (Option B) Coronaries: Tortuosity, calcification Atherosclerosis Aorta: Dilated, tortuous Elastic fragmentation Calcification

References:

Robbins, Cotran & Kumar, Pathologic Basis of Disease, 11th Edition, Page 481

↑ *Back to this question in Part A*

@Neet_pg_bot

Q11: A histologic section of a normal cardiac valve is examined under microscopy. Which of the following correctly lists the layers of a normal cardiac valve? (Q884927)

A. Intima, media, adventitia

B. Fibrosa, spongiosa, ventricularis

C. Endocardium, myocardium, epicardium

D. Tunica interna, tunica externa

Correct Answer: B. Fibrosa, spongiosa, ventricularis

Explanation: The correct answer is Fibrosa, spongiosa, ventricularis . While blood vessels have the traditional intima/media/adventitia layers, cardiac valves have a specialised three-layer architecture designed for mechanical durability and flexibility. Normal cardiac valves consist of three layers: Fibrosa - Dense collagen; mechanical strength Spongiosa - Loose connective tissue core Ventricularis/Atrialis - Elastin-rich; recoil Endocardium, myocardium, epicardium (Option C) : These are the layers of the heart wall itself, representing the inner lining, the muscle layer, and the outer covering. Tunica interna, tunica externa (Option D) : These are alternate names for the layers of a blood vessel wall.

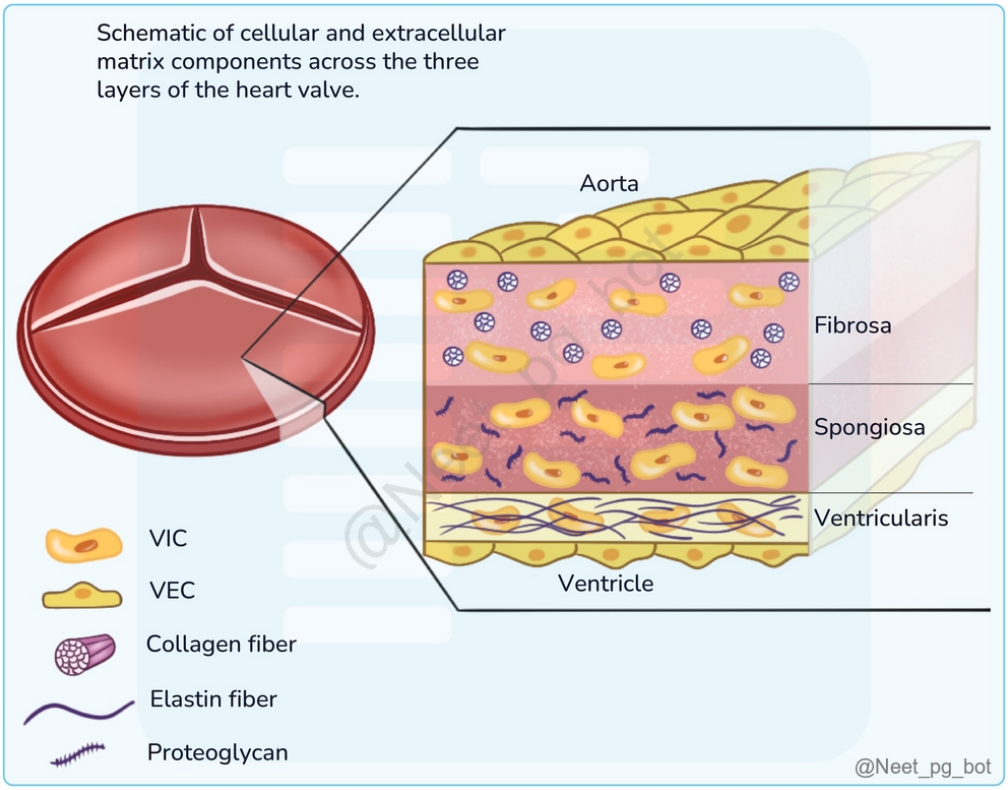

References:

Robbins, Cotran & Kumar, Pathologic Basis of Disease, 11th Edition, Page 480

↑ *Back to this question in Part A*

@Neet_pg_bot

Q12: A 65-year-old male with a history of hypertension and coronary artery disease presents with worsening shortness of breath and orthopnea. Chest X-ray reveals pulmonary congestion. Bronchoalveolar lavage shows hemosiderin-laden macrophages, as shown in the image below. What is the most likely diagnosis? {{caption_text}} (Q845258)

A. Right-sided heart failure

B. Left-sided heart failure

C. Pulmonary embolism

D. Acute myocardial infarction

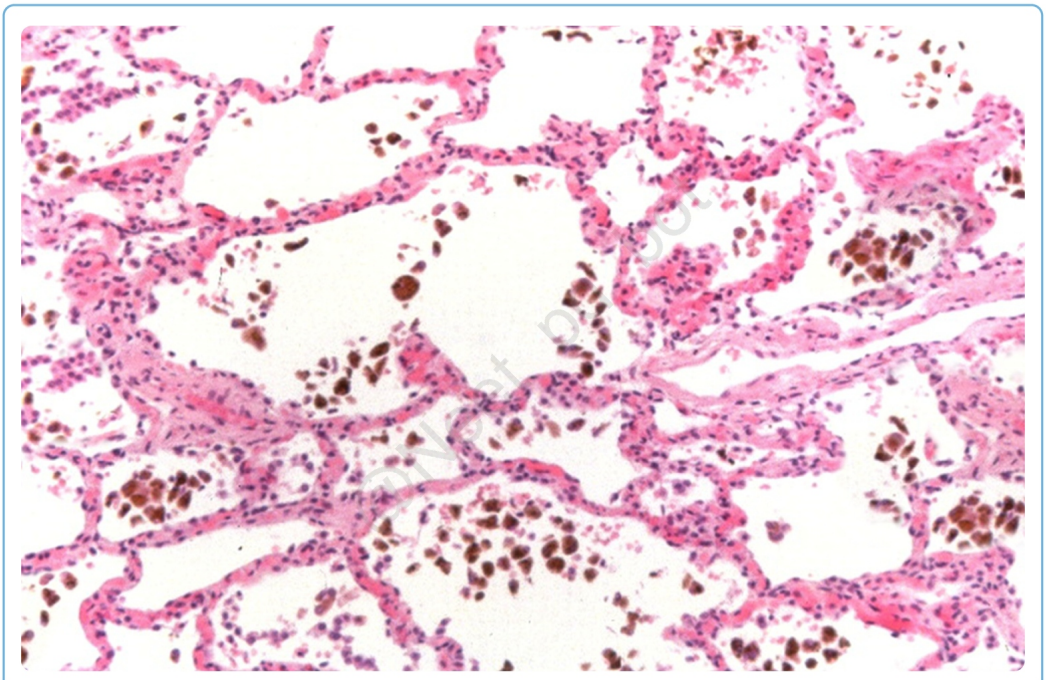

Correct Answer: B. Left-sided heart failure

■ *Listen (English)*

■ *Listen (Hindi)*

Explanation: The patient's symptoms and the histopathological findings of hemosiderin - laden macrophages known as ‘ Heart failure cells ’ are consistent with Left-sided heart failure. This condition is characterized by the heart's inability to pump blood effectively, causing backflow of blood, leading to pulmonary congestion and oedema. In pulmonary edema, the lungs appear wet and boggy, and chest X-ray shows characteristic Kerley B lines. Chronic congestion and microhemorrhages in the lungs result in the accumulation of hemosiderin - laden macrophages (Heart failure cells). These cells can be identified using special stains such as Perl's or Prussian blue , which detect hemosiderin's presence. Right-sided heart failure (Option A): causes systemic congestion, not pulmonary congestion → no hemosiderin-laden macrophages Pulmonary embolism (Option C): causes acute obstruction, not chronic congestion → no heart failure cells Acute myocardial infarction (Option D): can cause left-sided HF, but the finding itself is specific to left-sided HF, not MI directly

References:

Robbins and Cotran Pathologic Basis of Disease, 10th edition, Pages 530-534

↑ *Back to this question in Part A*

@Neet_pg_bot

Q13: A 58-year-old male presents with complaints of chest pain and shortness of breath. He had a history of MI one month ago, for which he received appropriate

medical management. His vitals are stable, and his physical examination reveals a pericardial rub. An ECG shows diffuse ST-segment elevation. Which of the following is the most likely cause of this condition? (Q845320)

A. Ventricular aneurysm

B. Dressler syndrome

C. Arrhythmia

D. Myocardial rupture

Correct Answer: B. Dressler syndrome

■ *Listen (English)*

■ *Listen (Hindi)*

Explanation: Dressler syndrom: From the given clinical presentation, the most likely cause is Dressler syndrome (autoimmune pericarditis or post-myocardial infarction pericarditis), which is a late complication of myocardial infarction and is characterised by pericardial inflammation. It typically presents weeks to months after the acute myocardial infarction event. Pathophysiology: After myocardial infarction, a necrotic (dead) area develops in the myocardium. In response, the body mounts an immune reaction against this dead tissue, leading to the formation of autoantibodies. These autoantibodies initiate an immune attack that targets the pericardium, resulting in pericardial inflammation. Clinically , this condition may manifest as a pericardial rub, chest pain, and characteristic ECG changes.

References:

Robbins and Cotran Pathologic Basis of Disease, 10th edition, Page 551

↑ *Back to this question in Part A*

@Neet_pg_bot

Q14: A 55-year-old male with a history of hypertension and smoking presents with chest pain and shortness of breath. ECG shows ST-segment elevation in inferior leads. He undergoes PCI but, within hours, develops deteriorating cardiac function. What is the most likely primary mechanism of cardiac deterioration in this patient? (Q845317)

A. Oxidative stress

B. Intracellular calcium overload

C. Activation of coagulation cascade

D. Activation of the complement system

Correct Answer: B. Intracellular calcium overload

■ *Listen (English)*

■ *Listen (Hindi)*

Explanation: Paradoxical worsening of myocardial damage after restoring blood flow is called reperfusion injury , where reopening a blocked coronary artery post-PCI unexpectedly causes further myocardial damage instead of improvement. Mechanism: Before reperfusion (during ischemia): At the blocked site, there is accumulation of free radicals and also calcium buildup inside ischemic tissue. After reperfusion (after PCI): Restoration of blood flow flushes these free radicals and calcium into the heart tissue. This sudden surge causes further myocardial injury instead of recovery. So the main cause of deterioration is Calcium overload which triggers mitochondrial dysfunction and cell death; worsening the cardiac injury The presence of ' Contraction bands ' in cardiac muscle tissue serves as histological markers of re-perfusion injury. {{caption_text}}

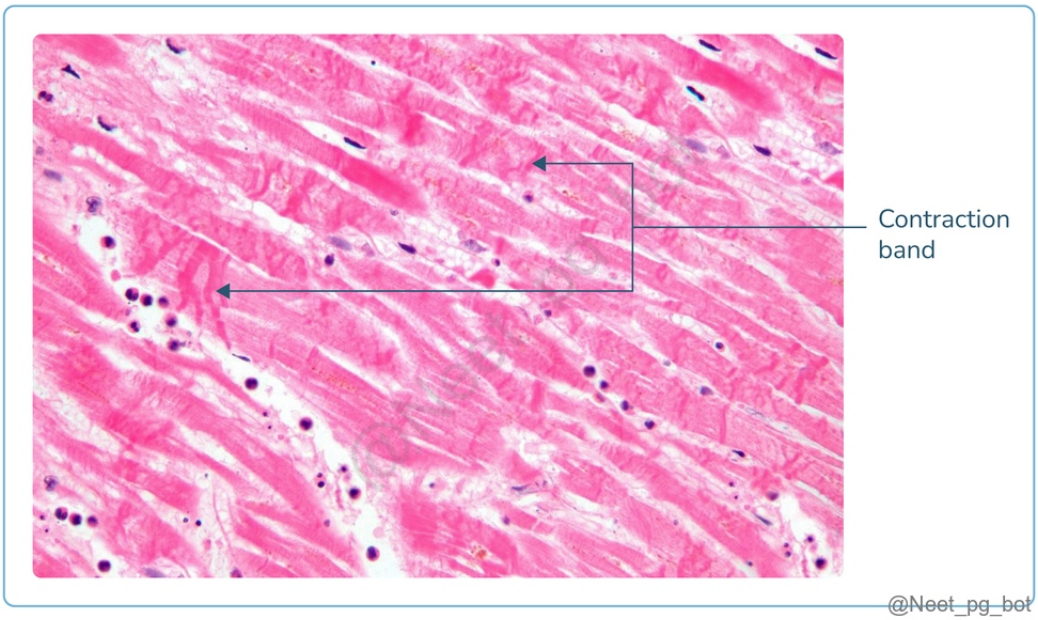

References:

Robbins and Cotran Pathologic Basis of Disease,10th edition, Pages 52, 56

↑ *Back to this question in Part A*

@Neet_pg_bot

Q15: Which histopathological feature would not be expected in the myocardium within the first 24 hours after the infarction onset? (Q845315)

A. Coagulative necrosis

B. Marginal contraction band necrosis

C. Neutrophilic infiltration

D. Neovascularisation

Correct Answer: D. Neovascularisation

■ *Listen (English)*

■ *Listen (Hindi)*

Explanation: After Myocardial infarction , histopathological changes occur in a predictable time sequence . Within the first 24 hours , the myocardium mainly shows early necrosis and acute inflammatory changes , while repair processes such as angiogenesis (neovascularization) occur later during healing around 7–10 days after infarction. Coagulative necrosis (Option A): Coagulative necrosis is an early hallmark of myocardial infarction and begins within the first few hours after ischemia. Myocytes lose nuclei and cross-striations and cytoplasm becomes eosinophilic due to protein denaturation. Marginal contraction band necrosis (Option B): Contraction band necrosis may appear early after myocardial ischemia , especially in reperfusion injury and catecholamine excess. It is characterized by hypercontracted sarcomeres forming dense eosinophilic bands within myocardial fibers. These changes can occur within the first few hours to the first day after infarction, so they may be seen within 24 hours. Neutrophilic infiltration (Option C): Neutrophils begin to infiltrate the infarcted myocardium within 6–12 hours after infarction. Their numbers increase markedly by 24 hours . They release proteolytic enzymes , contributing to further tissue damage and removal of necrotic debris.

References:

Robbins and Cotran Pathologic Basis of Disease, 10th Edition, Page 547

↑ *Back to this question in Part A*

@Neet_pg_bot

Q16: At what phase of myocardial infarction does the myocardium exhibit Mottling with a yellow-tan infarct center? (Q845303)

A. 4-12 hours

B. 1-3 days

C. 7-10 days

D. 4-8 weeks

Correct Answer: B. 1-3 days

■ *Listen (English)*

■ *Listen (Hindi)*

Explanation: Time Gross Features Light Microscope Reversible Injury 0– 1/2 hour None None Irreversible Injury 1/2 –4 hours None No change; border fibre waviness; myocyte vacuolation {{caption_text}} 4–12 hours (Option A) Occasional dark mottling Early coagulative necrosis, oedema, haemorrhage 12–24 hours Dark mottling Coagulative necrosis; nuclear pyknosis; hypereosinophilic myocytes; contraction bands; early neutrophils 1–3 days (Option B) Mottling with yellow-tan infarct centre Coagulative necrosis with nuclear and striation loss; dense neutrophilic infiltrate (acute inflammation) {{caption_text}} 3–7 days Hyperemic border; central yellow-tan softening Myofiber breakdown; neutrophil death; early macrophage phagocytosis 7–10 days (Option C) Soft yellow-tan center with red-tan depressed margins Well-developed phagocytosis of dead cells; granulation tissue at margins (Repair) {{caption_text}} 10–14 days Red-gray depressed infarct borders Well-established granulation tissue with new blood vessels and collagen deposition 2–8 weeks (Option D) Grey-white scar extending from border to core Increased collagen deposition, with decreased cellularity >2 months Scarring complete Dense collagenous scar {{caption_text}}

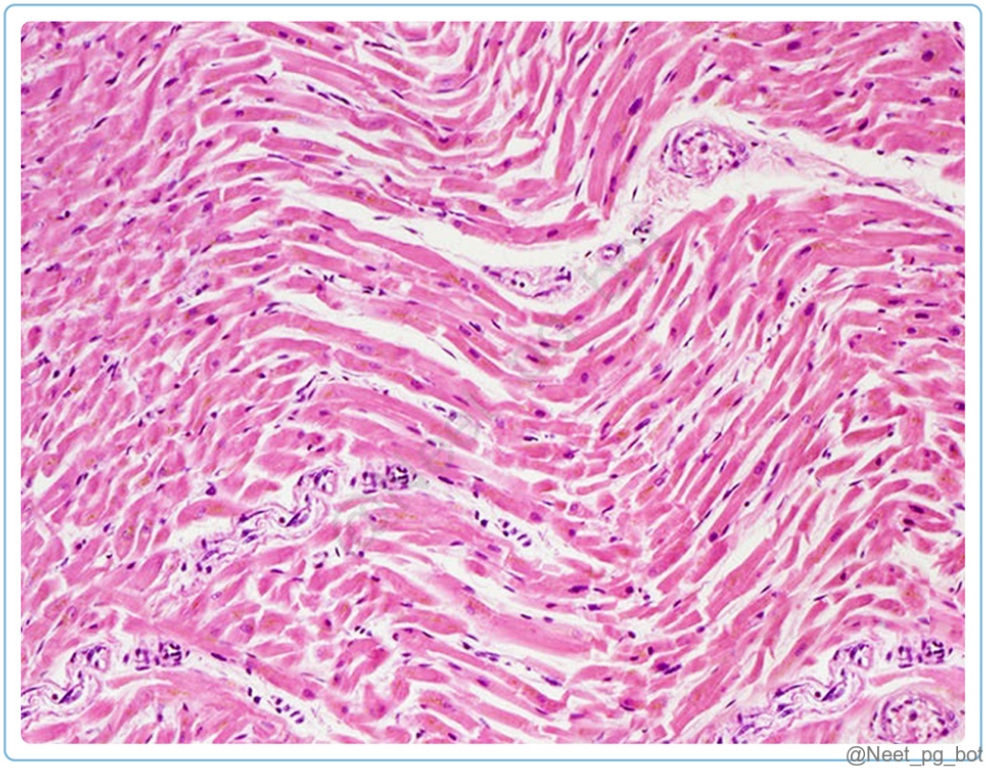

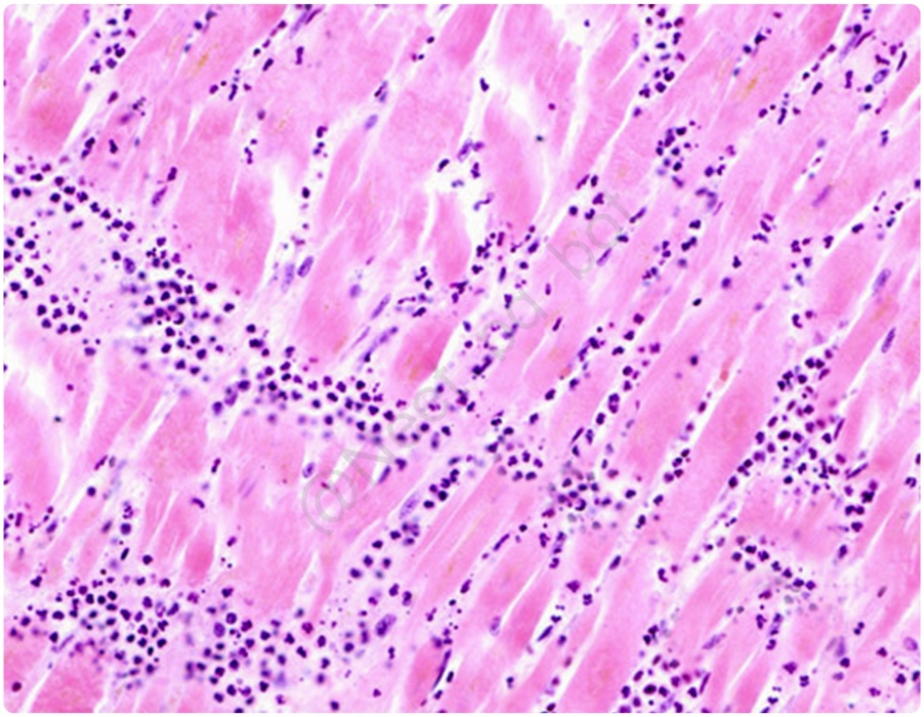

@Neet_pg_bot

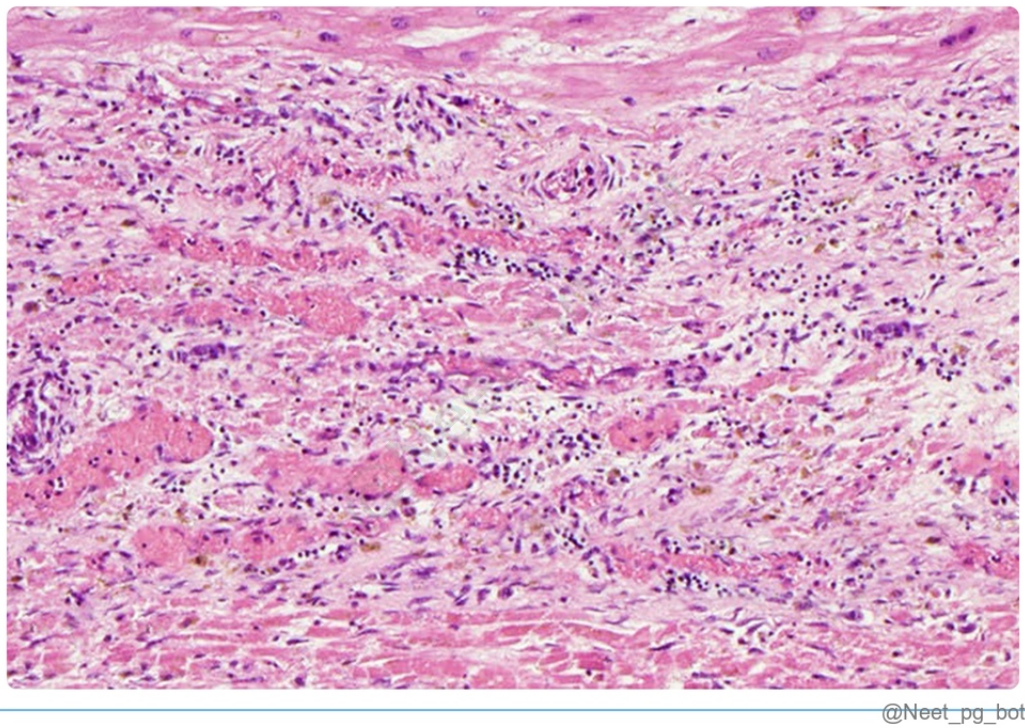

@Neet_pg_bot

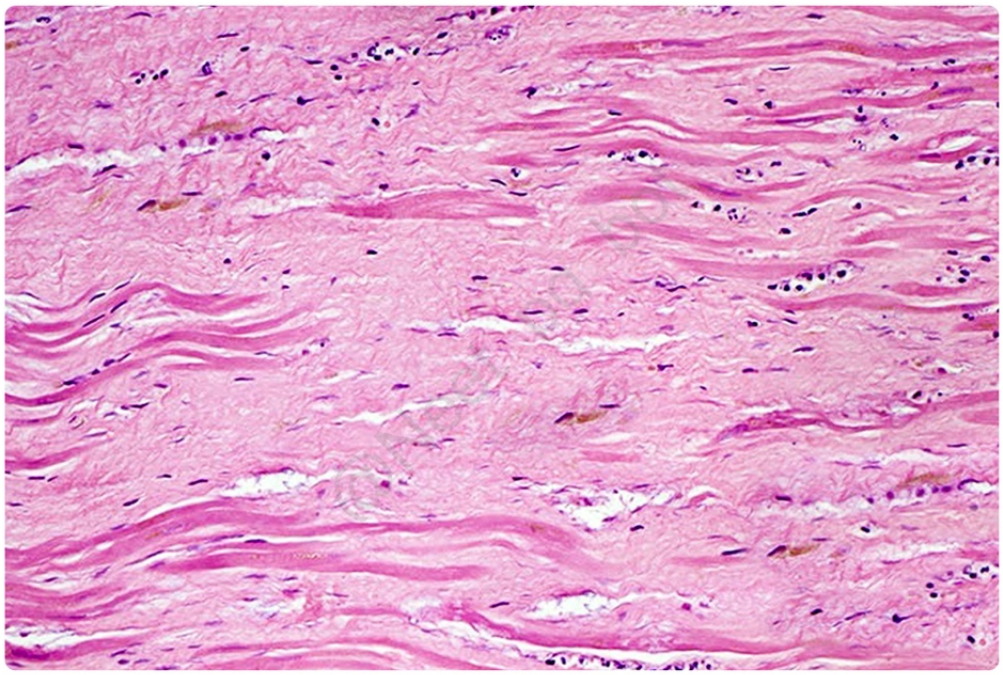

References:

Robbins and Cotran Pathologic Basis of Disease, 10th edition, Page 547

↑ *Back to this question in Part A*

@Neet_pg_bot

Q17: What histopathological changes are typically observed during the reversible phase of myocardial infarction? Mitochondrial swelling Sarcolemmal disruption Relaxation of myofibrils (Q845301)

A. 1, 2, and 3

B. 1 and 3

C. 2 and 3

D. Only 3

Correct Answer: B. 1 and 3

■ *Listen (English)*

■ *Listen (Hindi)*

Explanation: Chest pain, shortness of breath, and ST-segment elevation on ECG indicate myocardial infarction (MI). Mitochondrial swelling and relaxation of myofibrils are the histopathological changes observed during the reversible phase of MI . HPE changes in MI Reversible injury Irreversible injury Earliest change in Electron microscopy Relaxation of myofibrils (Statement 3) , Mitochondrial swelling (Statement 1) Sarcolemmal disruption (Statement 2) , Mitochondrial amorphous densities. Earliest change in Light microscopy None The waviness of cardiac fibres and myocyte vacuolisation.

References:

Robbins and Cotran Pathologic Basis of Disease, 10th edition, Page 547

↑ *Back to this question in Part A*

@Neet_pg_bot

Q18: In a patient with acute myocardial infarction, which of the following is a characteristic change in LDH isoenzyme levels indicative of myocardial damage in this patient? (Q845299)

A. Elevated LDH2 levels

B. Decreased LDH1/LDH2 ratio

C. Increased LDH2/LDH1 ratio

D. Increased LDH1/LDH2 ratio

Correct Answer: D. Increased LDH1/LDH2 ratio

■ *Listen (English)*

■ *Listen (Hindi)*

Explanation: LDH isoenzyme levels in blood: In healthy individuals LDH2>>LDH1 In MI patients LDH1>>LDH2 LDH1, which is predominantly found in heart tissue, is released into the bloodstream when cardiac fibers die during myocardial infarction. Flipping of LDH ratio: Ratio of LDH2/LDH1 >1 in healthy individuals is flipped in MI patients as LDH1/LDH2 >1 Isoenzymes of LDH and CK & their common locations Isoenzymes Location Isoenzymes of LDH LDH - 1 Mainly in heart & RBC LDH - 2 WBC, (small amounts in heart and RBC) LDH - 3 Lungs LDH - 4 Kidneys & Pancreas; Placenta (in pregnancy) LDH - 5 Liver & skeletal muscles

References:

Robbins and Cotran Pathologic Basis of Disease, 10th edition, Page 550

https://pubmed.ncbi.nlm.nih.gov/3780075/

↑ *Back to this question in Part A*

@Neet_pg_bot

Q19: A 58-year-old man presents to the emergency department with sudden-onset chest pain radiating to his left arm and jaw, along with diaphoresis and anxiety. His vital signs show a blood pressure of 160/90 mmHg, heart rate of 110 bpm, and oxygen saturation of 94% on room air. An ECG reveals ST-segment elevation in leads II, III, and aVF, suggestive of acute myocardial infarction (MI). Which of the following biomarkers is most reliable for confirming myocardial injury in this condition? (Q845297)

A. Myoglobin

B. CK-MB (Creatine Kinase-MB)

C. Cardiac-specific troponin I (cTn I)

D. Atrial natriuretic peptide (ANP)

Correct Answer: C. Cardiac-specific troponin I (cTn I)

■ *Listen (English)*

■ *Listen (Hindi)*

Explanation: Cardiac-specific troponins are of different types, like Troponin I (cTNI) and Troponin T (cTnT). cTnI is considered as the most specific cardiac-specific troponin for MI. Troponin levels rise within 2–4 hours after myocardial infarction, peak at 24–48 hours, remain elevated for several days, and gradually fall by the 7th–10th day. Similar rising time is also seen with CK-MB, but it falls within 2-3 days. (Option B ruled out) Myoglobin is the earliest cardiac marker to rise after MI, rising within 2 hours, but it also falls rapidly, returning to normal within 24 hours. Rise of myoglobin is considered non-specific for MI because it can also rise in any cardiac or skeletal muscle injury like a crush injury after RTA. (Option B ruled out)

References:

Robbins and Cotran Pathologic Basis of Disease, 10th edition, Page 550

↑ *Back to this question in Part A*

@Neet_pg_bot

Q20: A 50-year-old woman presents to the emergency department with recurrent episodes of chest pain radiating to her left arm and jaw that occur at rest and are not triggered by physical exertion. ECG during an episode shows transient ST-segment

elevation. Troponin levels are normal. Which type of angina is most likely responsible for her symptoms? (Q845263)

A. Stable Angina

B. Unstable Angina

C. Silent Angina

D. Prinzmetal Angina

Correct Answer: D. Prinzmetal Angina

Explanation: Angina pectoris is characterized by paroxysmal and usually recurrent attacks of substernal or precordial chest discomfort caused by transient myocardial ischemia without the death of myocytes. Type Stable Angina (Option A) Prinzmetal variant angina Unstable or crescendo angina (Option B) Trigger Physical exertion/stress At rest At rest or minimal exertion Cause Chronic coronary stenosis Coronary vasospasm Plaque disruption, ↑ MI risk Treatment response Responds well. Responds well. Need immediate medical intervention. Silent angina (Option C) is asymptomatic myocardial ischemia, detected incidentally on ECG, stress test, or Holter.

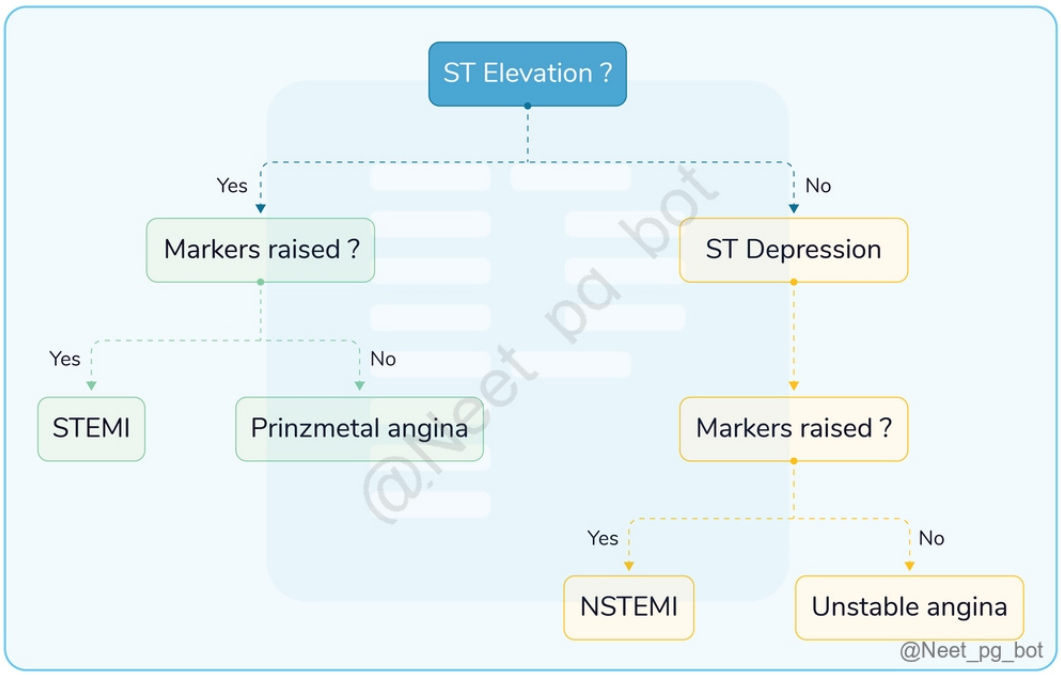

References:

Robbins and Cotran Pathologic Basis of Disease, 10th edition, Page 543

↑ *Back to this question in Part A*

@Neet_pg_bot

Q21: Which of the following statements is incorrect regarding the pathologic changes in right-sided heart failure? (Q845262)

A. Nutmeg liver appearance.

B. Pretibial oedema is the hallmark of right-sided heart failure.

C. Fibrosis in periportal areas of the liver

D. Congestive splenomegaly due to portal hypertension

Correct Answer: C. Fibrosis in periportal areas of the liver

■ *Listen (English)*

■ *Listen (Hindi)*

Explanation: Periportal fibrosis occurs in chronic liver diseases (hepatitis, alcohol, NAFLD, autoimmune), while right-sided heart failure causes centrilobular fibrosis from chronic congestion, termed cardiac cirrhosis . Options A, B, and D are the pathological changes seen in Right-sided heart failure. Nutmeg liver appearance (Option A): Severe right-sided heart failure causes venous congestion, producing a nutmeg liver with pericentral congestion, periportal pallor, hepatomegaly, elevated liver enzymes, and possible centrilobular necrosis. {{caption_text}} Pretibial oedema (Option B): Pretibial edema, from fluid pooling in dependent areas, is a hallmark of right-sided heart failure. Congestive splenomegaly (Option D): Splenomegaly in right-sided heart failure occurs due to portal hypertension, causing increased portal pressure and platelet sequestration.

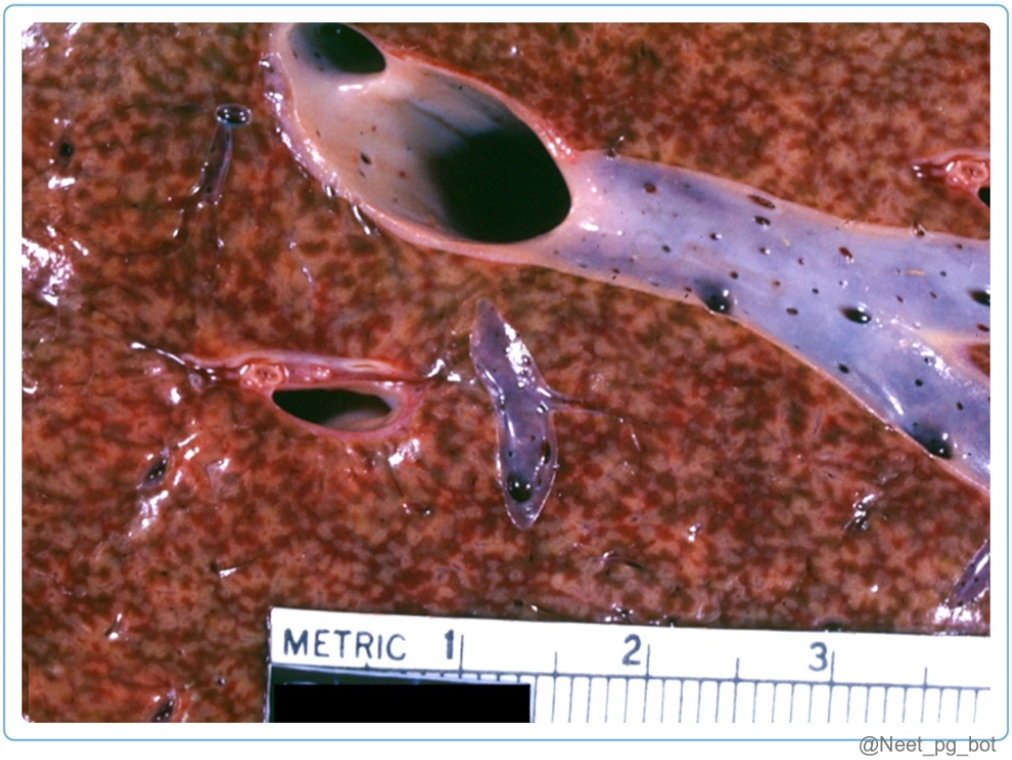

@Neet_pg_bot

References:

Robbins and Cotran Pathologic Basis of Disease, 10th edition, Pages 530-534

↑ *Back to this question in Part A*

@Neet_pg_bot

• [06_CVS_ Blood Vessels and Vasculitis] 028 Rhd And Infective Endocarditis

« Back to Folder Directory

[06_CVS_ Blood Vessels and Vasculitis] 028 Rhd And Infective Endocarditis — Quick Jump

Q1 (p. 1651) *Q2 (p. 1652)* *Q3 (p. 1652)* *Q4 (p. 1653)* *Q5 (p. 1655)* *Q6 (p. 1657)*
Q7 (p. 1657) *Q8 (p. 1658)* *Q9 (p. 1661)* *Q10 (p. 1662)* *Q11 (p. 1663)* *Q12 (p. 1664)*
Q13 (p. 1666)

Q1: Which of the following statements about rheumatic heart disease (RHD) is incorrect? (Q845229)

A. An abnormal immune response to Group A Streptococcus infection causes RHD.

B. RHD commonly affects the pulmonary valve, resulting in valvular stenosis or regurgitation.

C. Chronic inflammation and scarring of heart valves.

D. Prevented with timely treatment of streptococcal infections with antibiotics.

Correct Answer: B. RHD commonly affects the pulmonary valve, resulting in valvular stenosis or regurgitation.

■ *Listen (English)*

■ *Listen (Hindi)*

Explanation: Pulmonary valve is the least common valve affected by rheumatic heart disease (RHD). The mitral valve is most commonly affected. RHD is a condition that develops as a complication of untreated or inadequately treated acute rheumatic fever (ARF), which is caused by an abnormal immune response to an infection with Group A beta-hemolytic Streptococcus bacteria (aka Streptococcus pyogenes) (Option A is ruled out). The bacteria trigger an immune response that leads to chronic inflammation and scarring of heart valves (Option C is ruled out) , commonly causing mitral stenosis . Early treatment of streptococcal infections with antibiotics can help prevent initial rheumatic fever and subsequent rheumatic heart disease (Option D is ruled out) .

References:

Robbins and Cotran Pathologic Basis of Disease, 10th edition, Page 560

↑ *Back to this question in Part A*

@Neet_pg_bot

Q2: A 10-year-old child presents to the clinic with complaints of shortness of breath and fatigue. Upon examination, a diastolic murmur along the left sternal border is detected. An echocardiogram reveals mitral valve stenosis and regurgitation, consistent with Rheumatic heart disease (RHD). What is the most common predisposing condition for this patient to develop RHD? (Q845231)

A. Streptococcal pharyngitis

B. Streptococcal skin infections

C. Streptococcal glomerulonephritis

D. All the above

Correct Answer: A. Streptococcal pharyngitis

■ *Listen (English)*

■ *Listen (Hindi)*

Explanation: Rheumatic heart disease (RHD) is caused by Group A beta-hemolytic streptococcus (GABHS) , also known as Streptococcus pyogenes . Streptococcal pharyngitis is the infection that most commonly predisposes to RHD. RHD can develop 2–3 weeks after an episode of streptococcal pharyngitis. The typical age group affected is 5–15 years, and approximately 3% of children with streptococcal pharyngitis may develop RHD. Streptococcal skin infections (Option B) (e.g., impetigo) are associated with streptococcus but are not linked to RHD. Streptococcal glomerulonephritis (Option C): PSGN is also caused by streptococcus but does not predispose to RHD.

References:

Robbins and Cotran Pathologic Basis of Disease, 10th edition, Page 560

↑ *Back to this question in Part A*

@Neet_pg_bot

Q3: A 7-year-old child presented to the clinic with fever, joint pain, and rash with a history of sore throat about three weeks ago, which resolved without treatment. Examination reveals a rash characterized by pink to red lesions with well-defined borders and tender, swollen joints. What is the primary mechanism underlying the development of acute rheumatic fever (ARF) in this patient following the untreated sore throat? (Q845232)

A. Direct invasion of tissues by streptococcal bacteria

B. Delayed hypersensitivity reaction to streptococcal exotoxins

C. Cross-reactivity between streptococcal antigens and host proteins

D. Activation of complement by streptococcal toxins

Correct Answer: C. Cross-reactivity between streptococcal antigens and host proteins

■ *Listen (English)*

■ *Listen (Hindi)*

Explanation: Acute rheumatic fever (ARF): Symptoms / Clinical Features: Fever, Arthralgia / joint pain, Rash, Sore throat (3 weeks ago, indicative of prior streptococcal infection). Causative agent of ARF is Group A beta-hemolytic Streptococcus (GABHS), also called Streptococcus pyogenes. Underlying Mechanism: Molecular Mimicry / Cross-Reactivity: ■■■■■■■ Streptococcus M-protein is the major bacterial antigen. Human glycoproteins are present in the heart, joints, and skin. Similarity between M-protein and human glycoproteins ("twin brothers") leads to mimicry.

References:

Robbins and Cotran Pathologic Basis of Disease, 10th edition, Page 562

↑ *Back to this question in Part A*

@Neet_pg_bot

Q4: A 35-year-old male presented with severe dyspnea and a history of recurrent sore throat in childhood. An echocardiogram reveals thickened, immobile, prolapsed mitral valve leaflets. An endomyocardial biopsy reveals characteristic histopathological findings, as shown in the image. Which of the following is not a characteristic histopathological finding in this patient? {{caption_text}} (Q845235)

A. Presence of Anitschkow cells

B. Infiltration of lymphocytes, plasma cells, and macrophages

C. Presence of fibrinoid necrosis

D. Presence of granulation tissue

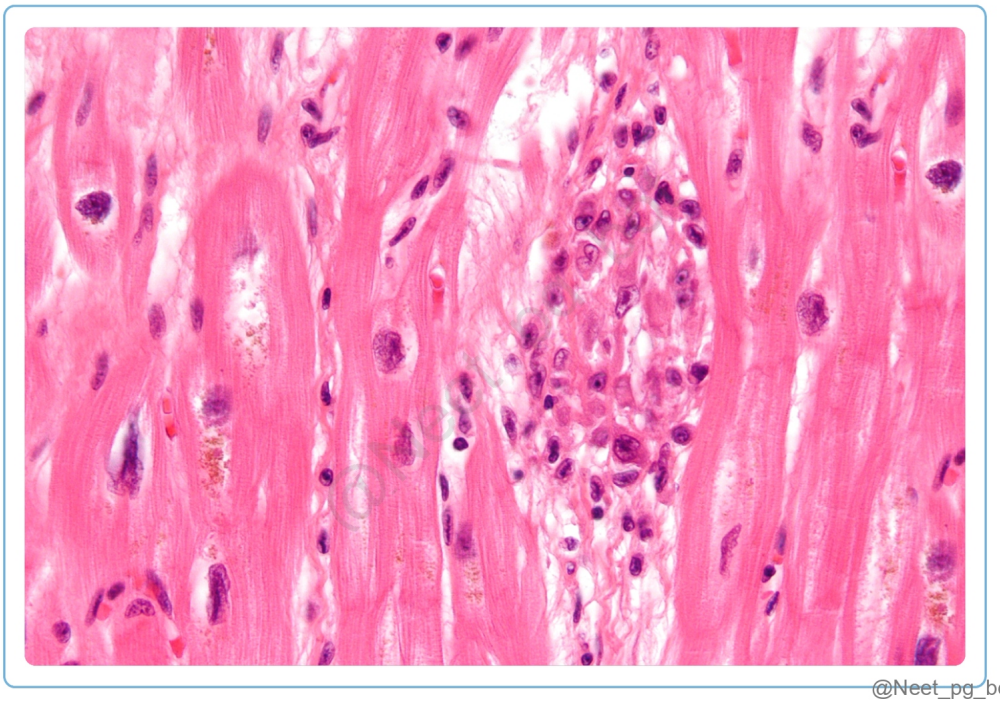

Correct Answer: D. Presence of granulation tissue

- *Listen (English)*
- *Listen (Hindi)*

Explanation: The patient's presentation with a history of recurrent sore throat (suggests Streptococcus pyogenes infection) in childhood and evidence of mitral valve prolapse suggests the possibility of rheumatic heart disease (RHD). Histopathological features of RHD: Aschoff Body is the pathognomonic lesion in Rheumatic Heart Disease which is composed of: Fibrinoid necrosis (necrotic centre) (Option C ruled out) Chronic inflammatory infiltrate : lymphocytes, plasma cells, macrophages are seen (Option B ruled out) Anitschkow cells (Option A ruled out) Anitschkow Cells are modified histiocytes within Aschoff bodies, which show two nuclear appearances: Caterpillar cells → zigzag nucleus Owl-eye appearance → round nucleus Both appearances represent the same cell {{caption_text}} {{caption_text}}

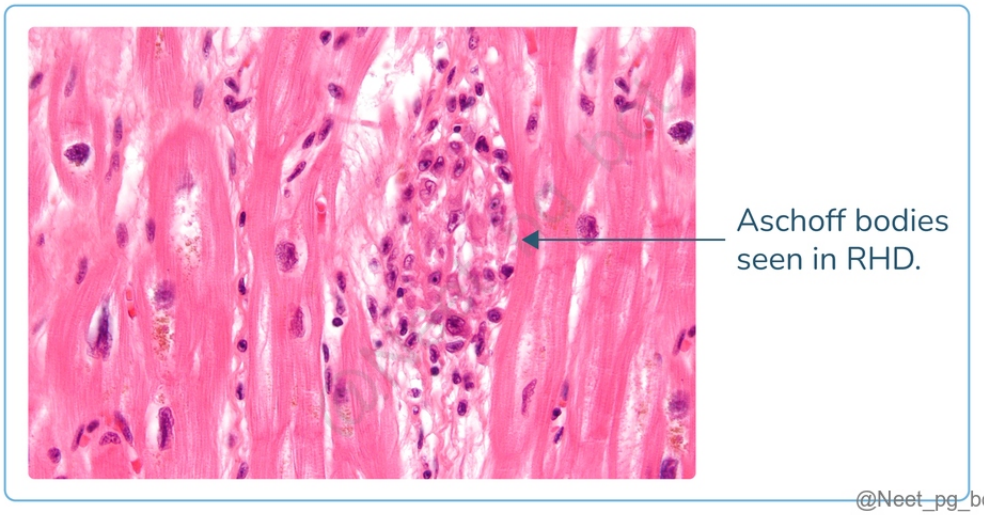

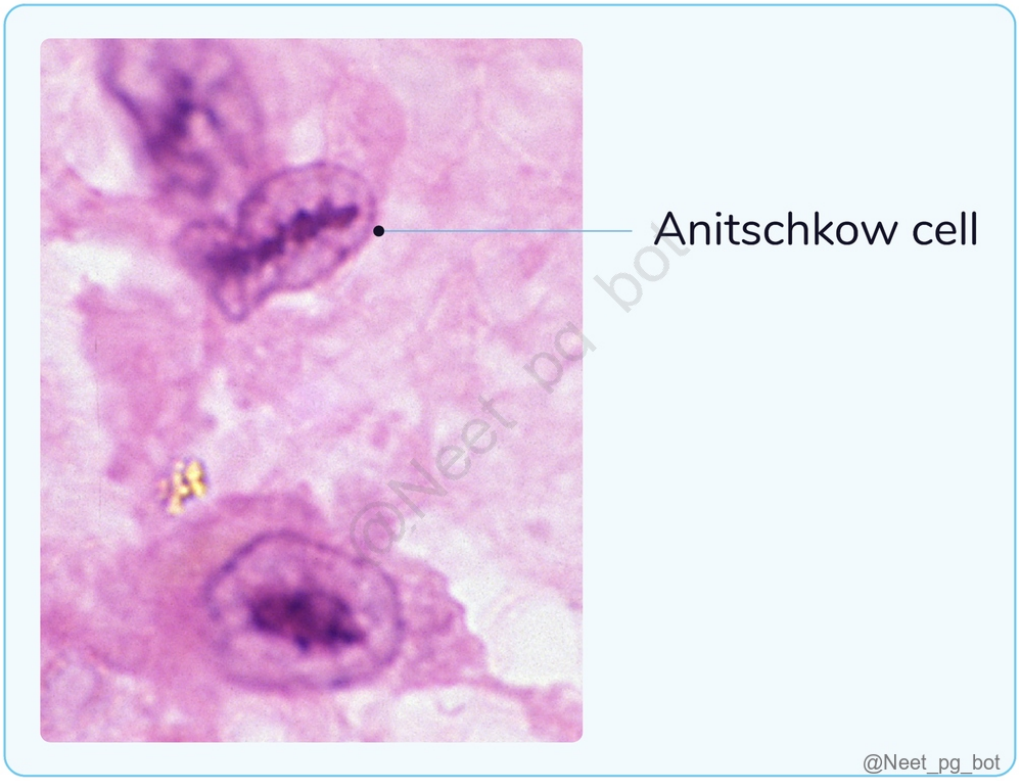

References:

Robbins and Cotran Pathologic Basis of Disease, 10th edition, Page 561

↑ *Back to this question in Part A*

@Neet_pg_bot

Q5: Which of the following is a major criterion in the Jones criteria for diagnosing acute rheumatic fever (ARF)? (Q845241)

A. Polyarthralgia involving two or more joints

B. Fever (≥38.5°C)

C. Elevated acute phase reactants

D. Subcutaneous nodules over bony prominences

Correct Answer: D. Subcutaneous nodules over bony prominences

■ *Listen (English)*

■ *Listen (Hindi)*

Explanation: Jones criteria for diagnosing acute rheumatic fever (ARF): Used for diagnosis of Rheumatic Fever (RF): The presence of two major criteria, or one major criterion + two minor criteria (along with evidence of preceding streptococcal infection), supports the diagnosis of acute rheumatic fever (ARF) according to the Jones criteria. Major criteria Minor criteria Clinical or subclinical evidence of Carditis/Pancarditis (e.g., new murmur) Migratory polyarthritis (Two or more joints involved) Sydenham chorea (involuntary movements, late manifestation) Erythema marginatum (characteristic skin rash) Subcutaneous nodules over bony prominences (Option D) Clinical: Previous rheumatic fever or rheumatic heart disease Fever (≥38.5°C) (Option B) Poly or mono arthralgia (Option A) Laboratory: Elevated acute phase reactants (e.g., CRP, ESR) (Option C) Prolonged PR interval on ECG Supporting evidence of prior streptococcal infection: Proof within past 45 days of: Throat swab culture for Streptococcus Antigen testing for Streptococcus Antibody titers (e.g., ASO titer) {{caption_text}}



References:

Robbins and Cotran Pathologic Basis of Disease, 10th edition, Page 562

↑ *Back to this question in Part A*

@Neet_pg_bot

Q6: A 54-year-old man with a history of mitral valve prolapse presents to the clinic with fever and malaise following a recent dental procedure. On examination, a new regurgitant murmur is auscultated. Blood cultures are obtained, and subsequent testing reveals the presence of gram-positive cocci in chains. Which of the following organisms is most likely responsible for the new onset murmur in this patient? (Q845246)

A. Staphylococcus aureus

B. Streptococcus viridans

C. Staphylococcus epidermidis

D. Enterococci

Correct Answer: B. Streptococcus viridans

■ *Listen (English)*

■ *Listen (Hindi)*

Explanation: The presence of gram-positive cocci in chains in blood cultures suggests an infection with a streptococcal species. Streptococcus viridans is a commensal organism found in the oral cavity, upper respiratory tract, and gastrointestinal tract . While normally harmless, it can enter the bloodstream after dental procedures or mucosal injury , leading to subacute infective endocarditis in individuals with underlying valve abnormalities like mitral valve prolapse . Staphylococcus aureus (Option A): Bunch of grapes appearance. Staphylococcus epidermidis (Option C): It is a cocci, but without any specific shape. Enterococci (Option D): Spectacles shaped

References:

Robbins and Cotran Pathologic Basis of Disease, 10th edition, Page 563

https://www.uptodate.com/contents/prosthetic-valve-endocarditis-epidemiology-clinical-manifestations-and-diagnosis?search=Infective%20endocarditis&topicRef=2151&source=see_link#H7

↑ *Back to this question in Part A*

@Neet_pg_bot

Q7: Which of the following statements best describes the nature of vegetation in infective endocarditis (IE)? (Q845247)

A. Smooth and non-destructive lesions

B. Typically contain only fibrin and inflammatory cells

C. Prone to embolisation

D. Most commonly found on the tricuspid valve

Correct Answer: C. Prone to embolisation

■ *Listen (English)*

■ *Listen (Hindi)*

Explanation: Vegetation in infective endocarditis is large and bulky , typically composed of fibrin, platelets, microorganisms, and inflammatory cells (Option B) Embolization: Due to bulkiness , parts of the vegetation can break off, and these detached fragments are called emboli, which can travel through the bloodstream, causing systemic embolization. Embolization is common but not guaranteed. {{caption_text}} Smooth and non-destructive lesions (Option A): Seen in non-bacterial thrombotic endocarditis (NBTE), not in infective endocarditis. Contain only fibrin and inflammatory cells (Option B): IE vegetations also include microorganisms and platelets. Most commonly found on the tricuspid valve (Option D): True mainly in IV drug users ; overall, the mitral valve is the most commonly affected.

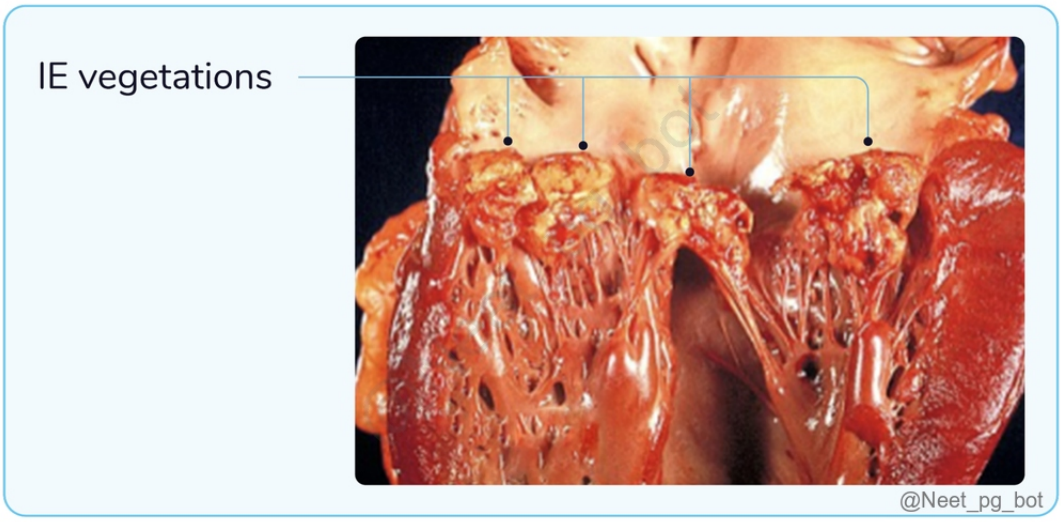

References:

Robbins and Cotran Pathologic Basis of Disease, 10th edition, Pages 563-564

↑ *Back to this question in Part A*

@Neet_pg_bot

Q8: A 30-year-old man with a history of intravenous drug use presents with fever, chills, and fatigue for the past week. On examination, the patient has multiple lesions on the palms and soles as shown below. The patient also has a new heart murmur.

Blood cultures are positive for Staphylococcus aureus. What are these lesions shown below? {{caption_text}} (Q845249)

A. Splinter hemorrhages

B. Osler nodes

C. Janeway lesions

D. Roth spots



Correct Answer: C. Janeway lesions

■ *Listen (English)*

■ *Listen (Hindi)*

Explanation: The given clinical scenario suggests Infectious endocarditis (IE) occurred as a complication of Rheumatic Heart Disease (RHD). The clinical finding shown in the image is ‘Janeway lesions’ seen in Infective endocarditis, which are painless, erythematous or hemorrhagic lesions on the palms or soles resulting from septic microemboli affecting the small blood vessels in the skin. Splinter hemorrhages (Option A): Painless linear hemorrhages under fingernails Osler nodes (Option B): Painful nodules, commonly on fingers and toes Roth spots (Option D): Retinal hemorrhages: Not specific for IE, as also seen in diabetic/hypertensive retinopathy. Janeway lesions: {{caption_text}} Splinter hemorrhages {{caption_text}} Osler nodes: {{caption_text}} Roth spots: {{caption_text}}


@Neet_pg_bot


@Neet_pg_bot



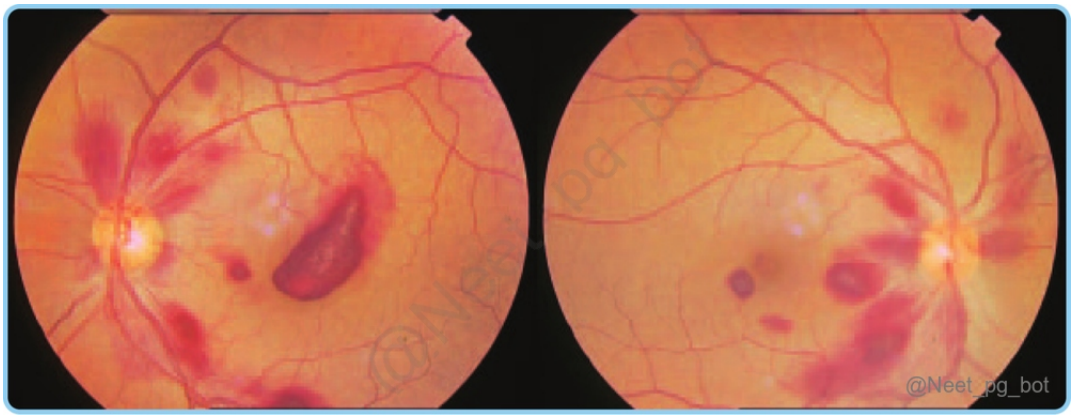

References:

Robbins and Cotran Pathologic Basis of Disease, 10th edition, Page 564

↑ *Back to this question in Part A*

@Neet_pg_bot

Q9: Which of the following is not a predisposing factor for Nonbacterial Thrombotic Endocarditis (NBTE)? (Q845251)

A. Advanced malignancy

B. Antiphospholipid antibody syndrome

C. Systemic lupus erythematosus

D. Traumatic injury to the heart valves

Correct Answer: D. Traumatic injury to the heart valves

■ *Listen (English)*

■ *Listen (Hindi)*

Explanation: NBTE = Non-Bacterial Thrombotic Endocarditis Non-bacterial → not caused by any bacterial infection Thrombotic → formation of sterile thrombi (blood clots) Endocarditis → affects the heart valves Thrombi in NBTE form on damaged or hypercoagulable valves, so only conditions that promote thrombus formation can lead to its development. Predisposing Factors: Advanced malignancies, such as pancreatic or lung cancer, where tumors produce mucin that is thrombogenic and promotes valve thrombus formation. ■■■■■■■ Autoimmune Disorders like SLE (Systemic Lupus Erythematosus) or APLA (Antiphospholipid Antibody Syndrome), which cause valve damage or a hypercoagulable state leading to thrombi. Non-Predisposing Factor: Traumatic injury does not predispose to NBTE, as trauma does not produce sterile thrombi on valves.

References:

Robbins and Cotran Pathologic Basis of Disease, 10th edition, Page 564

↑ *Back to this question in Part A*

@Neet_pg_bot

Q10: Match the following pathologies with the correct pattern of vegetative endocarditis caused by them: 1. Rheumatic Heart Disease a) Small, warty, sterile vegetations along the line of closure of valve leaflets 2. Infective Endocarditis b) Small, bland, sterile vegetation along the line of closure 3.Non-bacterial thrombotic endocarditis (NBTE) c) Small or medium-sized sterile vegetations on both sides of valvular leaflets. 4. Libman-Sacks endocarditis d) Large, bulky, infected, friable, irregular mass along the line of closure or on valvular cusps. (Q845253)

A. 1-a, 2-d, 3-c, 4-b

B. 1-a, 2-d, 3-b, 4-c

C. 1-b, 2-d, 3-c, 4-a

D. 1-d, 2-c, 3-b, 4-a

Correct Answer: B. 1-a, 2-d, 3-b, 4-c

■ *Listen (English)*

■ *Listen (Hindi)*

Explanation: Condition Vegetations and site Rheumatic heart disease Small, warty, sterile vegetations along the line of closure of valve leaflets. Infective Endocarditis Large, bulky, infected, friable, irregular mass along the line of closure or on valvular cusps, more on the atrial side. They cause damage to cordae tendinae and papillary muscles. Non-bacterial Thrombotic Endocarditis Small, bland, sterile vegetation along the line of closure. Libman-Sacks Endocarditis (Endocarditis of SLE) Small or medium-sized sterile vegetations on either or both sides of valvular leaflets, most commonly on the lower side. {{caption_text}}

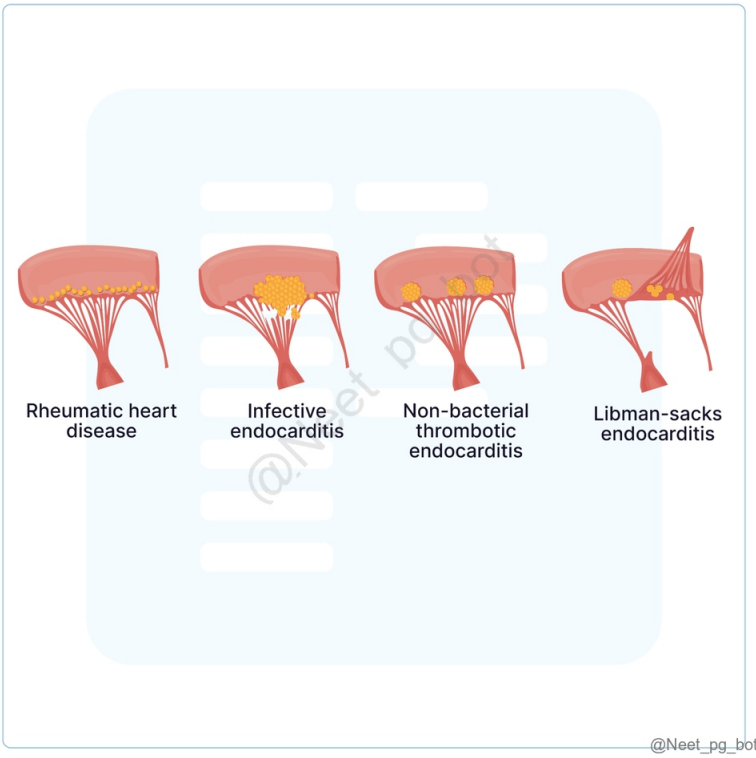

References:

Robbins and Cotran Pathologic Basis of Disease,10th edition, Page 562

↑ *Back to this question in Part A*

@Neet_pg_bot

Q11: Which of the following correctly lists the valves in order from most commonly to least commonly affected in chronic rheumatic heart disease? (Q889827)

A. Mitral > Aortic > Tricuspid > Pulmonary

B. Aortic > Mitral > Tricuspid > Pulmonary

C. Mitral > Tricuspid > Aortic > Pulmonary

D. Pulmonary > Tricuspid > Mitral > Aortic

Correct Answer: A. Mitral > Aortic > Tricuspid > Pulmonary

Explanation: Mitral > Aortic > Tricuspid > Pulmonary is correct because the mitral valve is affected in nearly all cases of chronic rheumatic heart disease, followed by the aortic valve. Tricuspid involvement is uncommon, and pulmonary valve involvement is rare. Chronic Rheumatic Heart Disease (RHD): Mitral Valve (Most Commonly Affected): Leaflet thickening Commissural fusion Thickened, shortened, fused chordae tendineae Leads to mitral stenosis ("fish-mouth" valve) Valve involvement pattern: Mitral alone → ~65% Mitral + aortic → ~25% Tricuspid → uncommon Pulmonary → rare

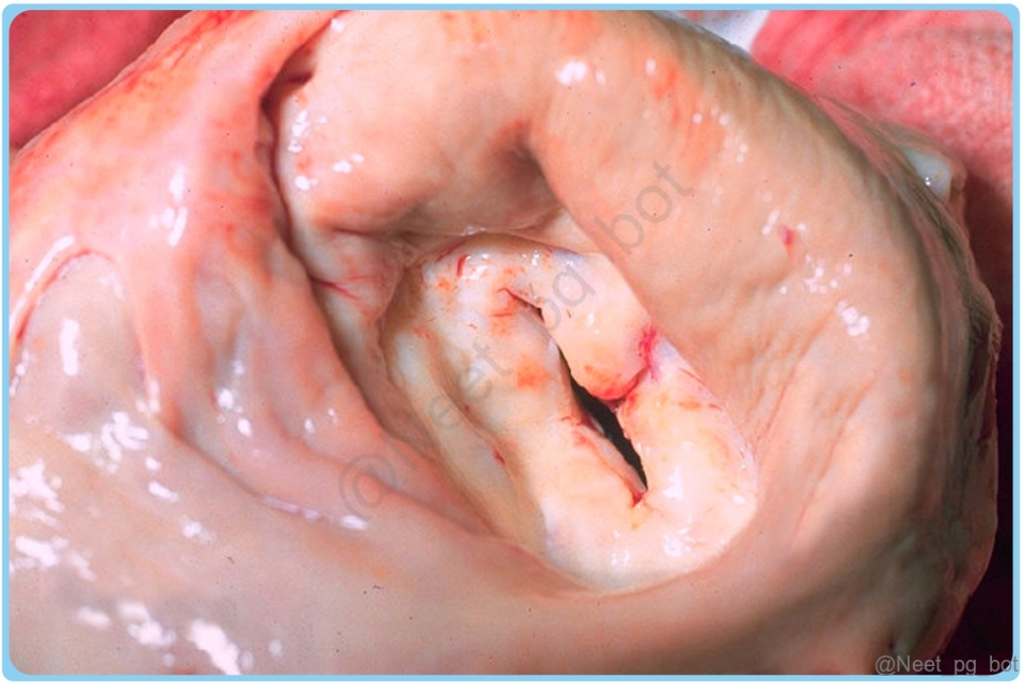

References:

Robbins, Cotran & Kumar, Pathologic Basis of Disease, 11th Edition, Page 510

↑ *Back to this question in Part A*

@Neet_pg_bot

Q12: A 40-year-old woman with a history of Acute rheumatic fever in childhood had long-standing exertional dyspnea and palpitations. At autopsy, the mitral valve shows

findings as shown. Which pathological process is primarily responsible for this deformity? (Q889828)

A. Vegetation formation

B. Myxomatous degeneration

C. Calcification and fibrosis

D. Fibrofatty replacement

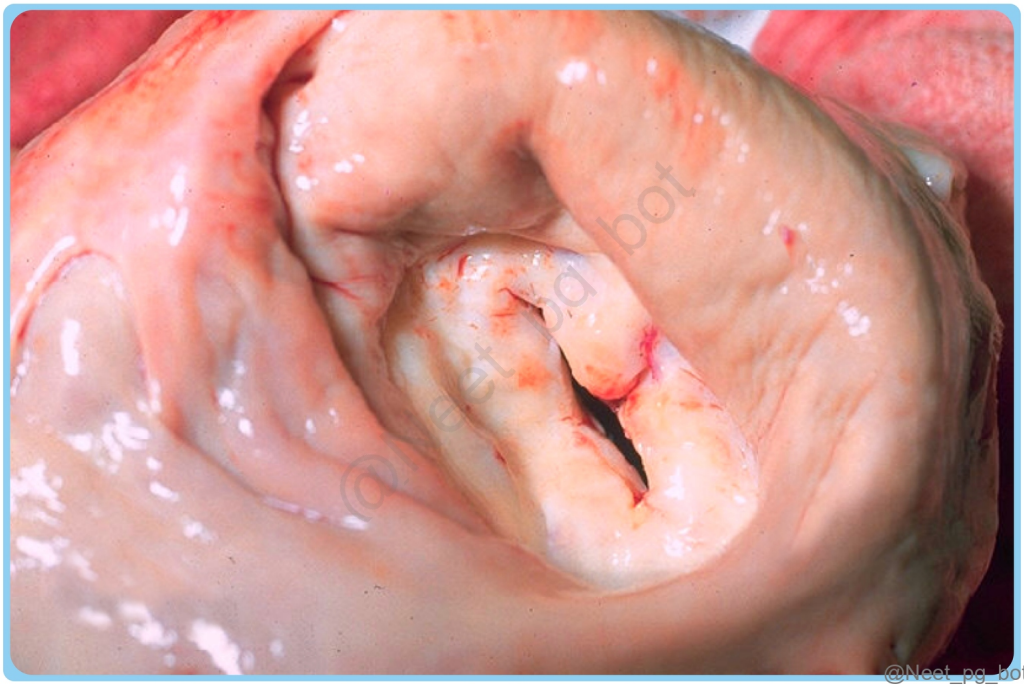

Correct Answer: C. Calcification and fibrosis

Explanation: Chronic rheumatic heart disease is characterised by organised inflammation that leads to fibrous thickening of the valve leaflets and commissural fusion . This fusion, often accompanied by calcification, creates the rigid, stenotic, "fish-mouth" deformity typical of the mitral valve in these patients. Gross Features: Commissural fusion + fibrous bridging Leaflet thickening and calcification Classic “fish-mouth” stenosis Vegetation formation (Option A): Seen in acute rheumatic carditis or infective endocarditis; does not produce chronic stenosis. Myxomatous degeneration (Option B): Associated with mitral valve prolapse and regurgitation, not stenosis. Fibrofatty replacement (Option D): Characteristic of arrhythmogenic right ventricular cardiomyopathy, not valvular disease.

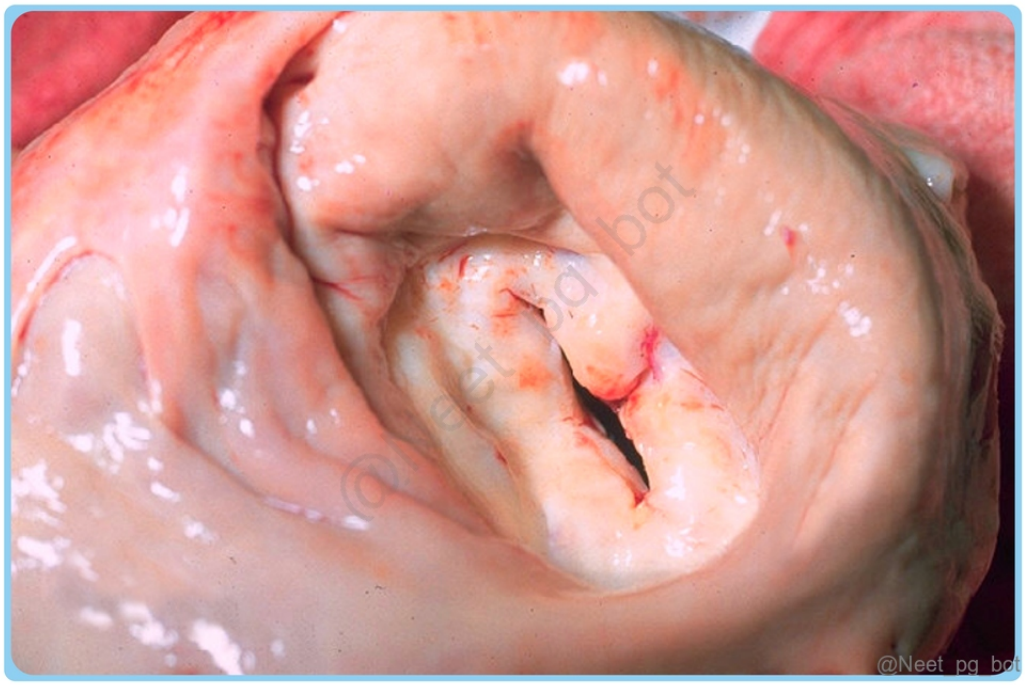

References:

Robbins, Cotran & Kumar, Pathologic Basis of Disease, 11th Edition, Page 511

↑ *Back to this question in Part A*

@Neet_pg_bot

Q13: Which organism is most commonly responsible for infective endocarditis in a previously normal valve? (Q889832)

A. Viridans streptococci

B. Staphylococcus aureus

C. Enterococcus faecalis

D. HACEK organisms

Correct Answer: B. Staphylococcus aureus

Explanation: The most likely organism is Staphylococcus aureus, as it is highly virulent and can infect previously normal valves, causing acute, rapidly destructive infective endocarditis. Infective Endocarditis - Pathogenesis: Predisposing Cardiac Lesions: Rheumatic heart disease (historically most common) Mitral valve prolapse Degenerative calcific stenosis Bicuspid aortic valve Prosthetic valves Congenital heart disease Common Causative Organisms: Native, damaged valves (50–60%): Viridans streptococci (Option A) (oral flora) Most common

overall: Staphylococcus aureus Infects normal or abnormal valves Most common in IV drug users Others: Enterococci HACEK group (oral commensals) (Option D) Gram-negative bacilli Fungi (rare) Prosthetic valve endocarditis: Early (<2 months): S. aureus, S. epidermidis (skin flora) Late (>1 year): Streptococci, S. aureus

References:

Robbins, Cotran & Kumar, Pathologic Basis of Disease, 11th Edition, Page 512

↑ *Back to this question in Part A*

@Neet_pg_bot

• [06_CVS_ Blood Vessels and Vasculitis] 029 Carditis And Cardiac Tumors

« Back to Folder Directory

[06_CVS_ Blood Vessels and Vasculitis] 029 Carditis And Cardiac Tumors — Quick Jump

Q1 (p. 1668)	*Q2 (p. 1669)*	*Q3 (p. 1669)*	*Q4 (p. 1670)*	*Q5 (p. 1671)*	*Q6 (p. 1672)*
Q7 (p. 1673)	*Q8 (p. 1673)*	*Q9 (p. 1675)*	*Q10 (p. 1676)*	*Q11 (p. 1677)*	*Q12 (p. 1678)*
Q13 (p. 1679)	*Q14 (p. 1680)*	*Q15 (p. 1681)*	*Q16 (p. 1682)*	*Q17 (p. 1683)*	*Q18 (p. 1684)*
Q19 (p. 1685)	*Q20 (p. 1686)*	*Q21 (p. 1687)*	*Q22 (p. 1688)*		

Q1: A 30-year-old woman from a rural area presents with progressively worsening dyspnea on exertion and bilateral lower limb swelling for the past few months. She reports a history of recurrent fevers and weight loss over the past year. Physical examination reveals elevated jugular venous pressure, ascites, and hepatomegaly. Chest X-ray shows an enlarged cardiac silhouette. Echocardiography reveals restrictive filling patterns with apical obliteration and thickened endocardium. What is the most likely diagnosis? (Q845431)

A. Hypertrophic cardiomyopathy

B. Dilated cardiomyopathy

C. Endomyocardial fibrosis

D. Constrictive pericarditis

Correct Answer: C. Endomyocardial fibrosis

Explanation: Congestive heart failure (dominant right-sided symptoms) and echo findings are highly suggestive of endomyocardial fibrosis , a form of restrictive cardiomyopathy. Endomyocardial fibrosis: Endomyocardial fibrosis, mainly affecting children and young adults in tropical regions, causes fibrous thickening of the ventricular endocardium from the apex upward, often involving tricuspid and mitral valves. This fibrosis reduces chamber volume and compliance, leading to restrictive heart function, and is linked to nutritional deficiencies and parasitic-related inflammation. Thrombus formation within the ventricles can also occur.

References:

Robbins and Cotran, Pathologic Basis of Disease, 10th edition, Page 574

↑ *Back to this question in Part A*

@Neet_pg_bot

Q2: A 6-month-old infant presents with progressive heart failure. Echocardiography shows diffuse fibroelastic thickening of the left ventricular endocardium with reduced ventricular compliance. There is a history of intrauterine viral exposure. Which infection is most commonly associated with this condition? (Q889821)

A. Rubella

B. Mumps

C. Epstein-Barr virus

D. Cytomegalovirus

Correct Answer: B. Mumps

Explanation: Intrauterine mumps infection is classically associated with endocardial fibroelastosis in infants. Endocardial Fibroelastosis (EFE): Rare pediatric heart disease Fibroelastic thickening of the left ventricular endocardium Most common in children < 2 years ~1/3 cases associated with: Aortic valve obstruction Other congenital heart defects Etiology: Viral infections (e.g., intrauterine mumps) Tafazzin gene mutation (mitochondrial membrane protein defect) Pathology: Diffuse LV endocardial thickening Leads to reduced compliance → diastolic dysfunction Rapid, progressive heart failure May result in early death if diffuse and severe Rubella (Option A): Associated with congenital heart defects such as patent ductus arteriosus and pulmonary artery stenosis, but not classically with endocardial fibroelastosis. Epstein-Barr virus (Option C): Not associated with endocardial fibroelastosis. Primarily causes infectious mononucleosis and certain lymphoproliferative disorders. Cytomegalovirus (Option D): Can cause congenital infection and myocarditis, but is not the classic association described for endocardial fibroelastosis.

References:

Robbins, Cotran & Kumar, Pathologic Basis of Disease, 11th Edition, Page 522

↑ *Back to this question in Part A*

@Neet_pg_bot

Q3: A 32-year-old man presents with progressive dyspnea. Labs show marked eosinophilia. Imaging shows endomyocardial fibrosis with mural thrombus. Which type of cardiomyopathy is most likely? (Q889817)

A. Dilated cardiomyopathy

B. Hypertrophic cardiomyopathy

C. Restrictive cardiomyopathy

D. Arrhythmogenic RV cardiomyopathy

Correct Answer: C. Restrictive cardiomyopathy

Explanation: The most likely diagnosis is Restrictive cardiomyopathy . The clinical triad of endomyocardial fibrosis , mural thrombi , and marked eosinophilia is characteristic of Loeffler endomyocarditis, a major cause of the restrictive phenotype. This condition is characterised by a primary decrease in ventricular compliance, resulting in impaired ventricular filling during diastole. Loeffler endomyocarditis: Endomyocardial fibrosis + large mural thrombi Marked peripheral eosinophilia Eosinophilic infiltration of multiple organs Pathogenesis: Eosinophil major basic protein → necrosis → thrombus → fibrosis May be associated with myeloid neoplasm Responds to tyrosine kinase inhibitors Dilated cardiomyopathy (Option A) : Ventricular dilation with systolic dysfunction, not fibrosis from eosinophilia. Hypertrophic cardiomyopathy (Option B) : Asymmetric septal hypertrophy without eosinophilia or mural thrombus. Arrhythmogenic RV cardiomyopathy (Option D) : Fibrofatty replacement of the right ventricle, not eosinophil-mediated fibrosis.

References:

Robbins, Cotran & Kumar, Pathologic Basis of Disease, 11th Edition, Page 522

↑ *Back to this question in Part A*

@Neet_pg_bot

Q4: A 13-year-old boy presents with recurrent syncope and palpitations. He has tightly curled woolly hair since birth and diffuse palmoplantar keratoderma since early childhood. ECG shows T-wave inversion in V1-V3, and echocardiography reveals right ventricular dilatation. What is the most likely diagnosis? (Q889814)

A. Carvajal syndrome

B. Naxos disease

C. Noonan syndrome

D. Isolated ARVC

Correct Answer: B. Naxos disease

Explanation: Naxos disease presents with the classic triad: woolly hair (from birth), palmoplantar keratoderma, and arrhythmogenic right ventricular cardiomyopathy. Naxos disease: Rare autosomal recessive genodermatosis combining: Woolly hair + Palmoplantar keratoderma + Cardiomyopathy . Caused by mutations affecting desmosomal proteins , especially: Plakoglobin gene - classic Naxos. Desmoplakin gene mutations - seen in a

Carvajal syndrome variant with left-ventricular involvement. Clinical features: Hair: Woolly, sparse, curly hair present from birth. Skin: Diffuse palmoplantar keratoderma emerging in infancy. Heart: Arrhythmogenic right ventricular cardiomyopathy (ARVC) typically develops by adolescence, with high penetrance . Early asymptomatic ventricular changes can occur in childhood Management: Close cardiac follow-up with ECG and imaging. Preventive strategies include: Implantable cardioverter-defibrillator (ICD) in symptomatic or high-risk patients Carvajal syndrome (Option A) also presents with woolly hair and palmoplantar keratoderma, but it predominantly involves left ventricular cardiomyopathy rather than right ventricular disease. Noonan syndrome (Option C) is associated with facial dysmorphism, short stature, and pulmonary valve stenosis or hypertrophic cardiomyopathy, not woolly hair with palmoplantar keratoderma. Arrhythmogenic right ventricular cardiomyopathy (Option D) : Isolated ARVC lacks the characteristic cutaneous findings (woolly hair and palmoplantar keratoderma) seen in Naxos disease.

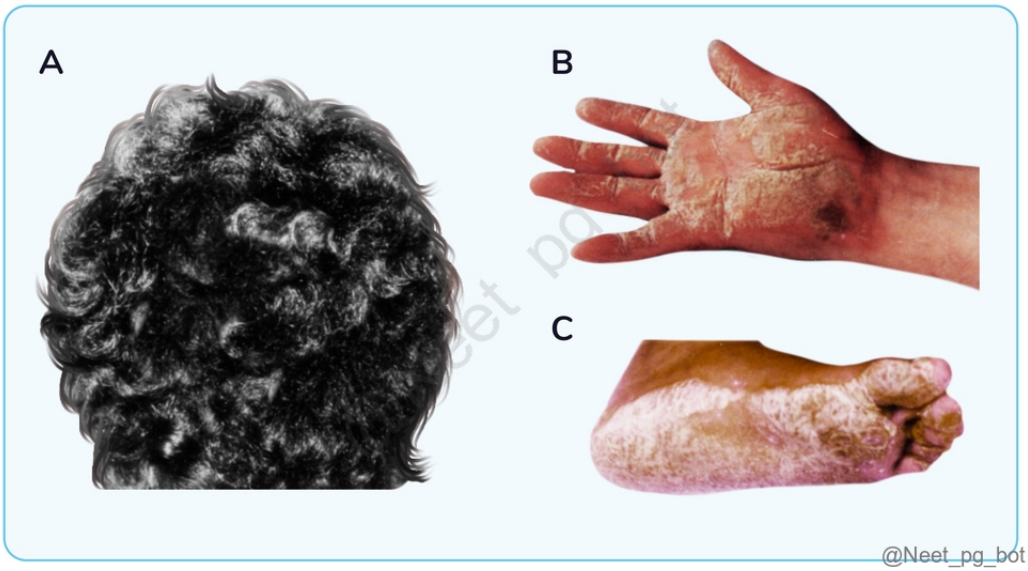

References:

https://ijdvl.com/naxos-disease-a-rare-occurrence-of-cardiomyopathy-with-woolly-hair-and-palmoplantar-keratoderma/

↑ *Back to this question in Part A*

@Neet_pg_bot

Q5: Which of the following deficiencies is associated with the development of dilated cardiomyopathy? Thiamine deficiency Selenium deficiency Vitamin B12 deficiency Carnitine deficiency (Q889812)

A. 1, 2 and 4

B. 1 and 3

C. 2 and 3

D. 3 and 4

Correct Answer: A. 1, 2 and 4

Explanation: Dilated cardiomyopathy can result from metabolic and nutritional deficiencies that impair myocardial energy production. Metabolic Causes of DCM: Nutritional deficiency: Thiamine (Vitamin B1) Deficiency : This leads to "Wet Beriberi," characterised by high-output heart failure and significant ventricular dilatation. Selenium Deficiency : Associated with Keshan disease , a specific form of dilated cardiomyopathy originally identified in regions with selenium-poor soil. Carnitine Deficiency : Carnitine is essential for transporting fatty acids into the mitochondria for energy production; a deficiency impairs myocardial metabolism, frequently resulting in a dilated phenotype. Electrolyte deficiency: calcium, phosphate, magnesium Endocrine disorders: thyroid disease, pheochromocytoma Diabetes, obesity Hemochromatosis

References:

Harrison’s Principles of Internal Medicine, 21st Edition, Page 1959

↑ *Back to this question in Part A*

@Neet_pg_bot

Q6: A 48-year-old man presents with progressive dyspnea and echocardiographic evidence of dilated cardiomyopathy; which of the following is the most likely risk factor? (Q889810)

A. Hypertension

B. Alcohol abuse

C. Hyperlipidemia

D. Rheumatic fever

Correct Answer: B. Alcohol abuse

Explanation: Alcohol abuse is a well-established risk factor for dilated cardiomyopathy. Chronic alcohol consumption causes direct myocardial toxicity (via ethanol and acetaldehyde), leading to progressive ventricular dilation and systolic dysfunction. Dilated Cardiomyopathy (DCM): Four-chamber dilation with systolic dysfunction Most common cardiomyopathy (age 20-50 yrs) Causes: Genetic: Most common: Titin (TTN) mutation Others : Lamin A/C, dystrophin AD > X-linked > mitochondrial Myocarditis: Often viral (e.g., Coxsackie B) Toxins: Alcohol (acetaldehyde toxicity, thiamine deficiency) Chemotherapy (doxorubicin) Heavy metals (cobalt) Peripartum cardiomyopathy: Late pregnancy / ≤5 months postpartum Antiangiogenic factors implicated Iron overload: Hemochromatosis or transfusion-related Catecholamine excess / Stress: Pheochromocytoma, cocaine Takotsubo (“broken heart syndrome”) Hypertension (Option A): Typically causes

left ventricular hypertrophy and diastolic dysfunction rather than primary dilated cardiomyopathy. Hyperlipidemia (Option C): Predisposes to atherosclerosis and ischemic heart disease, not primary DCM. Rheumatic fever (Option D): Leads to valvular heart disease, particularly mitral stenosis, not dilated cardiomyopathy.

References:

Robbins, Cotran & Kumar, Pathologic Basis of Disease, 11th Edition, Page 516

↑ *Back to this question in Part A*

@Neet_pg_bot

Q7: Which of the following is the least common type of cardiomyopathy? (Q889806)

A. Dilated cardiomyopathy

B. Hypertrophic cardiomyopathy

C. Restrictive cardiomyopathy

D. Peripartum cardiomyopathy

Correct Answer: C. Restrictive cardiomyopathy

Explanation: Restrictive cardiomyopathy is the least common of the three major pathologic patterns of cardiomyopathy. Among the primary categories, dilated cardiomyopathy is the most common (~90% of cases), while restrictive cardiomyopathy is the rarest. Cardiomyopathies are intrinsic myocardial diseases causing cardiac dysfunction. Primary → Predominantly confined to the myocardium Secondary → Cardiac manifestation of a systemic disorder Etiology: Inflammatory disorders → Myocarditis Immunologic diseases → Sarcoidosis Metabolic disorders → Hemochromatosis Muscular dystrophies Genetic disorders affecting myocardial fibres Major patterns: Dilated Cardiomyopathy (DCM) (Option A): Most common (~90%) Hypertrophic Cardiomyopathy (HCM) (Option B) Restrictive Cardiomyopathy (RCM) Least common Peripartum cardiomyopathy (Option D): A subtype of dilated cardiomyopathy occurring in late pregnancy or the early postpartum period; more common than restrictive cardiomyopathy.

References:

Robbins, Cotran & Kumar, Pathologic Basis of Disease, 11th Edition, Page 516

↑ *Back to this question in Part A*

@Neet_pg_bot

Q8: A 28-year-old male presents with palpitations and dizziness during a soccer match. He is diagnosed with ARVC (Arrhythmogenic Right Ventricular

Cardiomyopathy). Which of the following statements about this condition is true? Statement 1 - It is an autosomal recessive disorder Statement 2 - Associated with NAXOS syndrome Statement 3 - Marked by fatty infiltration and focal fibrosis within the ventricle Statement 4 - It involves mutation in Plakoglobin (Q846623)

A. 1, 2, 3

B. 1, 3, 4

C. 2, 3, 4

D. 1, 2, 3,4

Correct Answer: C. 2, 3, 4

■ *Listen (English)*

■ *Listen (Hindi)*

Explanation: Arrhythmogenic Right Ventricular Cardiomyopathy (ARVC) is an autosomal dominant disorder. (Statement 1 ruled out) The right ventricular wall is markedly thinned due to myocyte loss, with extensive yellowish fatty infiltration and focal fibrosis (Statement 3) . ARVC occurs due to desmosomes mutation. Mutations in genes encoding desmosomal junctional proteins at the intercalated disk (e.g., plakoglobin) (Statement 4) Associated with NAXOS syndrome (Statement 2) , it includes: Arrhythmogenic Right Ventricular Cardiomyopathy (ARVC) Woolly hair Palmo-plantar keratoderma (Thick palms and soles due to hyperkeratosis) NAXOS syndrome is an autosomal recessive disorder.



References:

Robbins and Cotran, Pathologic Basis of Disease, 10th edition, Page 572.

↑ *Back to this question in Part A*

@Neet_pg_bot

Q9: A 6-month-old infant presents with cyanosis and respiratory distress. Physical examination reveals a murmur and a palpable liver edge. Echocardiography demonstrates multiple intracardiac masses located primarily in the ventricular walls. What is the most likely diagnosis? (Q845436)

A. Rhabdomyoma

B. Cardiac fibroma

C. Myxoma

D. Metastatic neuroblastoma

Correct Answer: A. Rhabdomyoma

■ *Listen (English)*

■ *Listen (Hindi)*

Explanation: RHABDOMYOMA Most common cardiac tumor in adults: Myxoma, occuring more commonly in left atria. Rhabdomyoma is the most common benign tumor in children, which is most commonly found in left ventricle. On histopathology, Myxoma shows Lepidic cells and Rhabdomyoma shows spider cells. Microscopy shows spider cells showing vacuolated cytoplasm comprised of glycogen. These are positive for PAS Stain. Rhabdomyoma is associated with tuberous sclerosis. Tuberous sclerosis is a syndrome which is caused by TSC gene (TSC1 and TSC2 genes). All hamartomas occur under this syndrome, and rhabdomyoma is also considered a hamartoma. The image below shows spider cells. {{caption_text}}

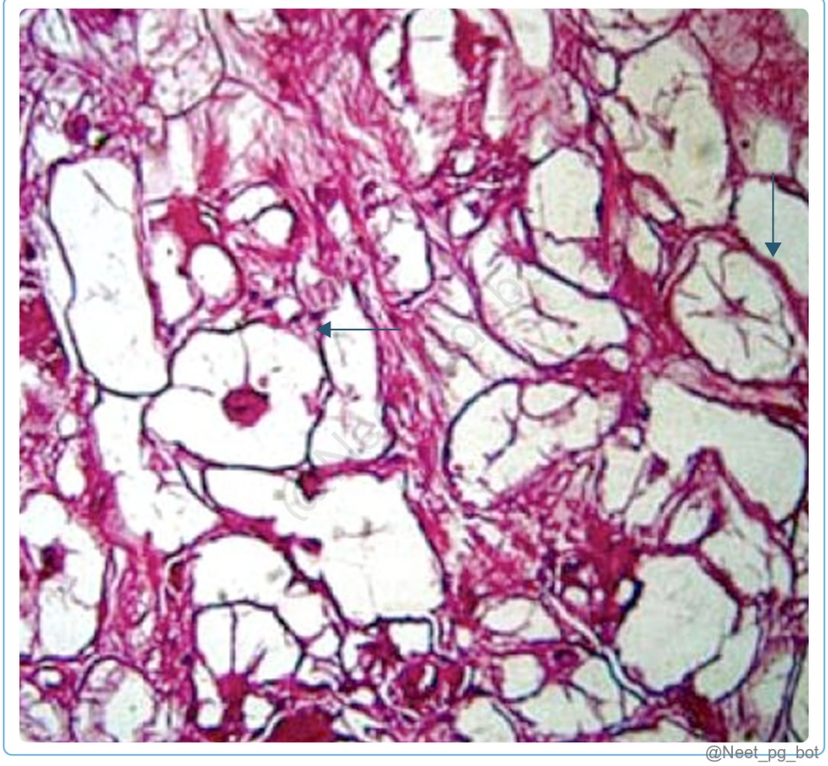

References:

Robbins and Cotran, Pathologic Basis of Disease, 10th edition, Pages 579,580

↑ *Back to this question in Part A*

@Neet_pg_bot

Q10: Identify the true statements regarding atrial myxoma. 1) It is the most common primary tumor of the heart in adults. 2) It is a malignant neoplasm. 3) It is associated with mutations in the GNAS1 gene. 4) 90% of these tumors arise from ventricles. 5) Histologically, it contains lepidic cells (Q845434)

A. 1,2,3

B. 1,2,3,4,5

C. 1,3,4

D. 1,3,5

Correct Answer: D. 1,3,5

■ *Listen (English)*

■ *Listen (Hindi)*

Explanation: Atrial myxoma: The most Common Benign Tumor Of the Heart (Statement 1) It is a benign tumour. Site- Most Commonly arises from Left Atria. Gross Appearance- Gelatinous It is associated with mutations in the GNAS1 gene. (Statement 3) Also associated with McCune-Albright syndrome and Carney Complex. Histologically- Stellate Or Lepidic Cells Seen (Statement 5) {{caption_text}}

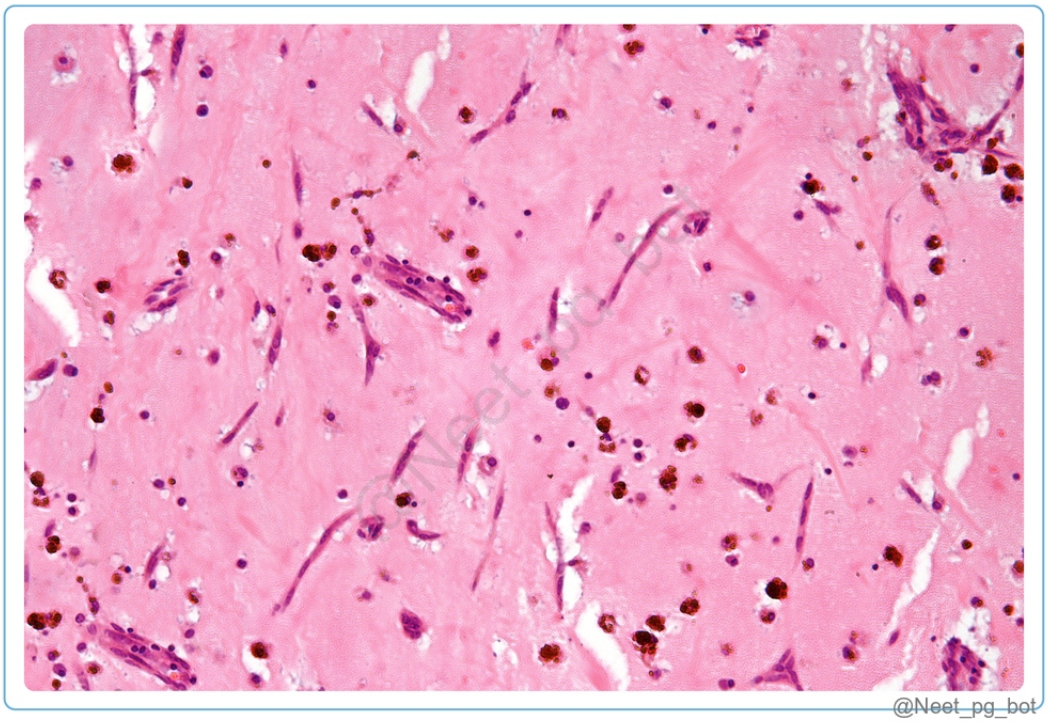

References:

Robbins and Cotran, Pathologic Basis of Disease, 10th edition, Page 579

↑ *Back to this question in Part A*

@Neet_pg_bot

Q11: What is the most likely diagnosis based on the image given below? It is a stained specimen of endomyocardial tissue. {{caption_text}} (Q845433)

A. Hypertrophic cardiomyopathy

B. Dilated cardiomyopathy

C. Cardiac amyloidosis

D. Sarcoidosis



Correct Answer: C. Cardiac amyloidosis

■ *Listen (English)*

■ *Listen (Hindi)*

Explanation: The image shows a specimen of endomyocardial tissue. The image shows characteristic extracellular deposition of amorphous material with apple-green birefringence under polarized light on Congo red staining , confirming the diagnosis of Amyloidosis It is the most common cause of Restrictive Cardiomyopathy. Hypertrophic cardiomyopathy (Option A): Banana-shaped heart and Myofiber disarray are seen Dilated cardiomyopathy (Option B): Ninja-star nucleus is seen Sarcoidosis (Option D): Non-caseating granulomas are seen

References:

Robbins and Cotran, Pathologic Basis of Disease, 10th edition, Pages 574, 575

↑ *Back to this question in Part A*

@Neet_pg_bot

Q12: Which viral organism is most commonly associated with myocarditis? (Q845392)

A. Influenza

B. Human immunodeficiency virus (HIV)

C. Coxsackievirus

D. Epstein-Barr virus (EBV)

Correct Answer: C. Coxsackievirus

■ *Listen (English)*

■ *Listen (Hindi)*

Explanation: Coxsackievirus is a common cause of viral myocarditis, especially in young adults. Other virus includes the Herpes virus and Trichinella Spirali (parasitic). Coxsackievirus is of 2 types: Coxsackie A and Coxsackie B Both are responsible for causing Hand, foot, and mouth disease (HFMD) in children. Coxsackie A is also associated with acute hemorrhagic conjunctivitis .

References:

Robbins and Cotran, Pathological Basis of Disease, 10th Edition, Page 560

↑ *Back to this question in Part A*

@Neet_pg_bot

Q13: Which of the following is not a cause for restrictive cardiomyopathy? (Q845429)

A. Hemochromatosis

B. Amyloidosis

C. Sarcoidosis

D. Alcohol

Correct Answer: D. Alcohol

■ *Listen (English)*

■ *Listen (Hindi)*

Explanation: Alcohol is not a cause of restrictive cardiomyopathy. Rather, it is a cause of dilated cardiomyopathy. Restrictive cardiomyopathy occurs when something gets deposited and causes restrictions in the movement of the heart, mainly diastolic dysfunction/restriction. CAUSES OF RESTRICTIVE CARDIOMYOPATHY Amyloidosis (Pink extracellular amyloids deposition) (Option B) Hemochromatosis (Iron deposition) (Option A) Radiation Scleroderma Tropical endomyocardial fibrosis Hypereosinophilic syndrome (Löffler’s endocarditis) Sarcoidosis (Option C)

References:

Robbins and Cotran, Pathologic Basis of Disease, 10th edition, Page 574

Harrison’s Principles of Internal Medicine, 21st edition, Page 1968

↑ *Back to this question in Part A*

@Neet_pg_bot

Q14: A 19-year-old boy collapsed during a football game and was brought dead to the hospital. Suspecting a heart condition, a biopsy was done, which showed asymmetric septal hypertrophy. Which of the following histological findings will not be seen in this condition? (Q845425)

A. Massive myocyte hypertrophy

B. Myofibre disarray

C. Fibrotic narrowing of small intramural arteries

D. Ninja star nuclei

Correct Answer: D. Ninja star nuclei

■ *Listen (English)*

■ *Listen (Hindi)*

Explanation: The clinical presentation of a young male who collapsed and died (sudden cardiac death) with a biopsy showing asymmetric septal hypertrophy is suggestive of hypertrophic cardiomyopathy. Histology of HCM includes: Myofibre Hypertrophy (Option A) Myofibre Disarray (Halter-salter appearance) (Option B) Fibrotic narrowing of intramural arteries (Option C) . Ninja star nuclei are seen in Dilated Cardiomyopathy. {{caption_text}} The images below show the gross and histological features of HCM. {{caption_text}}

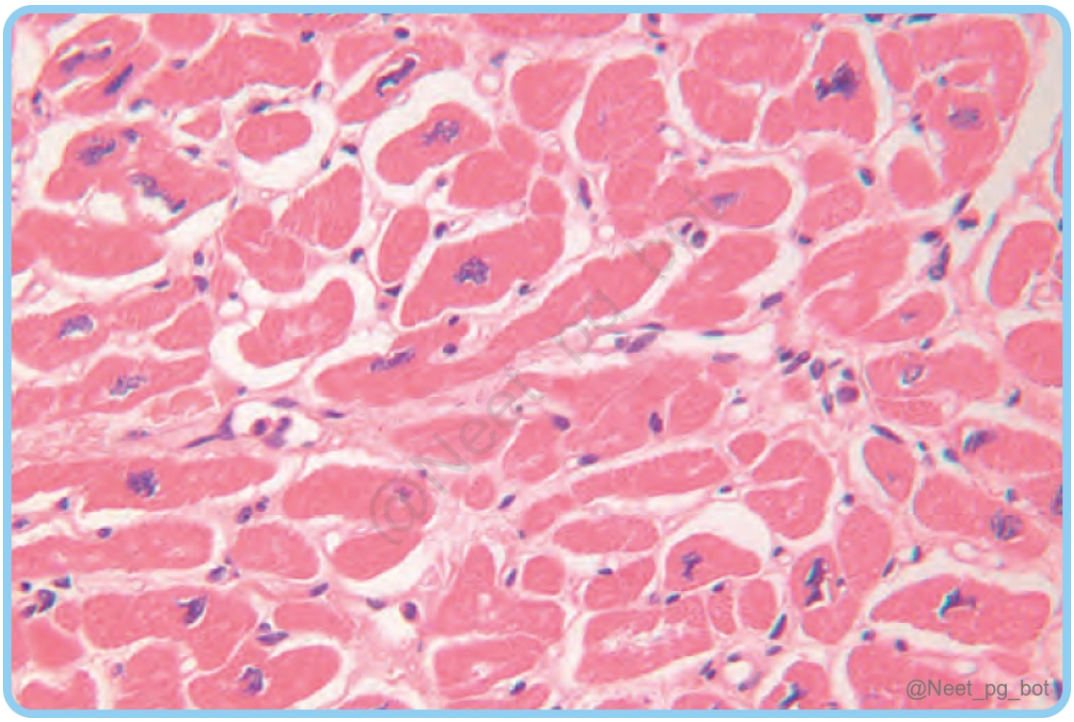

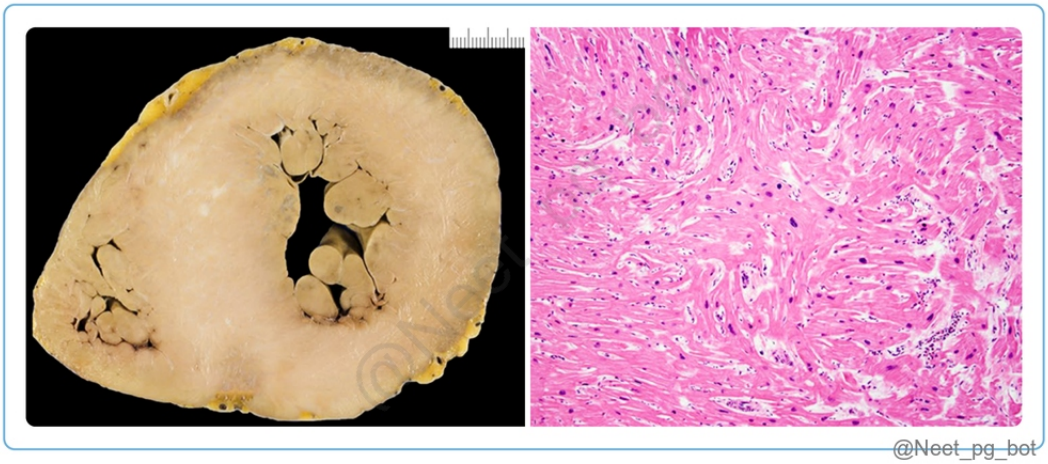

References:

Robbins and Cotran, Pathologic Basis of Disease, 10th edition, Pages 571,573

↑ *Back to this question in Part A*

@Neet_pg_bot

Q15: A 22-year-old man presents to his cardiologist with complaints of exertional chest pain and shortness of breath. His family history is significant for the sudden cardiac death of his brother at the age of 28. Physical examination reveals a harsh

systolic murmur and irregular heart sounds. Which of the following genes is most commonly involved in this condition? (Q845423)

A. Titin

B. Beta-myosin heavy chain

C. Troponin T

D. Alpha-tropomyosin

Correct Answer: B. Beta-myosin heavy chain

■ *Listen (English)*

■ *Listen (Hindi)*

Explanation: Hypertrophic cardiomyopathy (HCM): HCM is an autosomal dominant condition that occurs due to a mutation in the beta-myosin heavy chain . In HCM, hypertrophy can occur in any part of heart but ir occurs maximally in the interventricular septum. Due to hypertrophy of interventricular septum, left ventricle is narrowed and starts looking like a banana-shaped cavity. Left ventricle is responsible for pumping blood to the body which will be affected due to this narrowing. So in conditions like heavy physical activity, where body wants more blood, it can lead to sudden collapse and sometimes death of patient. Under microscopic examination during autopsy, cardiac muscle fibres shows the classical halter-salter appearance (haphazardly arranged cardiac muscle fibres) Titin (Option A) : Titin mutations are seen in dilated cardiomyopathy.

References:

Robbins and Cotran, Pathologic Basis of Disease, 10th edition, Page 572

↑ *Back to this question in Part A*

@Neet_pg_bot

Q16: Which of the following conditions is characterised by transient left ventricular dysfunction, often triggered by emotional or physical stress, presenting with symptoms mimicking acute coronary syndrome but with normal coronary arteries on angiography? (Q845401)

A. Acute Myocardial Infarction (AMI)

B. Takotsubo Cardiomyopathy (TCM)

C. Hypertrophic Cardiomyopathy (HCM)

D. Dilated Cardiomyopathy (DCM)

Correct Answer: B. Takotsubo Cardiomyopathy (TCM)

■ *Listen (English)*

■ *Listen (Hindi)*

Explanation: Takotsubo cardiomyopathy also known as BROKEN HEART SYNDROME, is a dilated cardiomyopathy following extreme psychological or emotional stress. This stress leads to excessive release of catecholamines in body. Catecholamines can act on all the chambers of heart but maximum receptors for catecholamines are present in left ventricle. The left ventricle is dilated with apical ballooning resembling a JAPANESE POT named TAKOTSUBO used for catching Octopus. Because LV is dilated and blood is not reaching rest of the body, the patient presents with symptoms resembling acute coronary syndrome such as chest pain. It mimics heart attack or MI but there is no blockage found on coronary angiography as this is not a coronary artery disease.

References:

Robbins and Cotran, Pathological Basis of Disease, 10th Edition, Page 575

↑ *Back to this question in Part A*

@Neet_pg_bot

Q17: A 55-year-old woman presents to the emergency department with sudden-onset chest pain and shortness of breath following the news of death of her son. An electrocardiogram shows ST-segment elevation in the anterior leads, and cardiac biomarkers are elevated. Coronary angiography reveals no significant coronary artery disease. Which of the following is the most likely underlying mechanism in this patient? (Q845400)

A. Excessive release of catecholamines

B. Viral myocarditis

C. Autoimmune response

D. Genetic predisposition

Correct Answer: A. Excessive release of catecholamines

■ *Listen (English)*

■ *Listen (Hindi)*

Explanation: Excessive release of catecholamines is the most likely underlying mechanism for the development of Takotsubo cardiomyopathy in this patient. Emotional or physical stress, such as the news of a family member's death, can trigger a surge of catecholamines (e.g., adrenaline and noradrenaline). In Takotsubo cardiomyopathy (aka Broken Heart Syndrome), excessive catecholamines act on left ventricle (LV), leading to left ventricle

dilatation. Dilated left ventricle cannot contract properly, leading to a hampered blood supply to the body.

References:

Robbins and Cotran, Pathological Basis of Disease, 10th Edition, Page 570

↑ *Back to this question in Part A*

@Neet_pg_bot

Q18: Which of the following genes is most commonly associated with inherited forms of dilated cardiomyopathy? (Q845398)

A. BRCA1 gene

B. TTN gene

C. CFTR gene

D. SCN5A gene

Correct Answer: B. TTN gene

■ *Listen (English)*

■ *Listen (Hindi)*

Explanation: TTN gene mutation, which is specific to inherited dilated cardiomyopathy is the correct option. TTN gene encodes for titin protein which is the largest protein of human body with over 30000 amino acids. Defect in titin protein can lead to dilated cardiomyopathy. Microscopically it shows a classical Ninja star nucleus appearance .

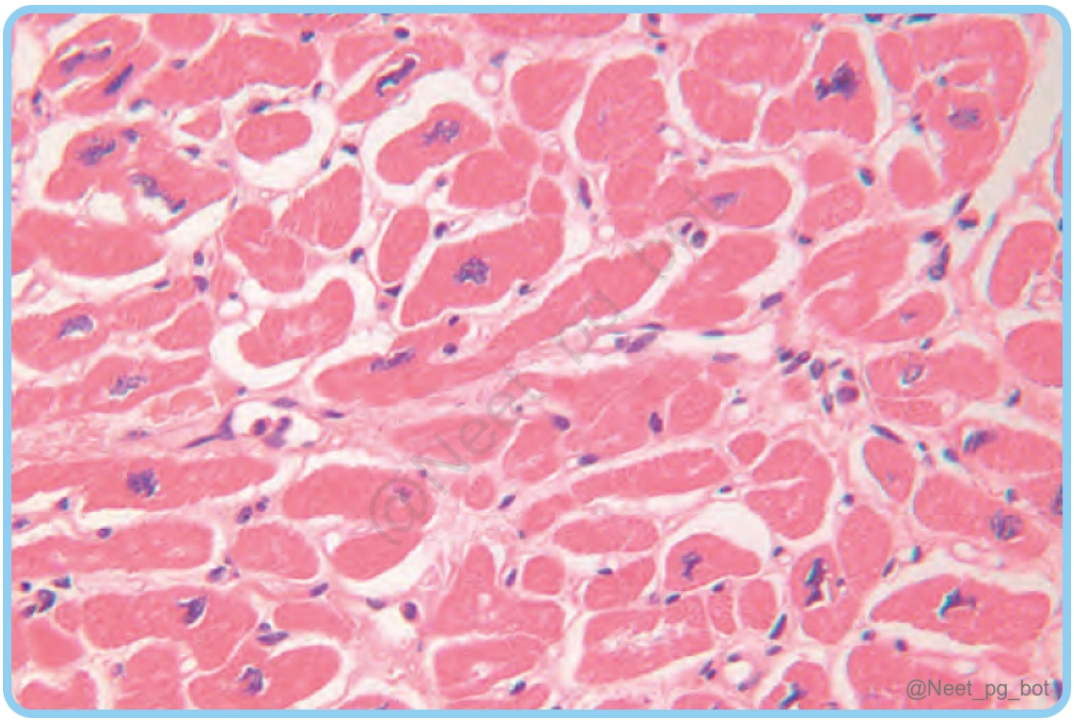

References:

Robbins and Cotran, Pathological Basis of Disease, 10th Edition, Page 569

↑ *Back to this question in Part A*

@Neet_pg_bot

Q19: A 45-year-old male with a history of intravenous drug abuse, presenting with fever, malaise, and a new-onset heart murmur, reports recent injection site infections. On examination, there are multiple healing scars on the upper extremities, and a grade III/VI holosystolic murmur is auscultated at the left sternal border. His temperature is 38.5°C, heart rate is 110 bpm. Which criterion amongst the following is a major criterion for the condition diagnosed? (Q845397)

A. Fever of unknown origin lasting more than 7 days

B. IV drug abuse

C. Predisposing cardiac condition such as a prosthetic heart valve

D. Positive blood cultures for typical microorganisms persistently isolated from blood cultures

Correct Answer: D. Positive blood cultures for typical microorganisms persistently isolated from blood cultures

■ *Listen (English)*

■ *Listen (Hindi)*

Explanation: The diagnosis in a 45-year-old male with a history of intravenous drug abuse, presenting with fever, malaise, and a new-onset heart murmur is Infective Endocarditis. Duke's Criteria: Major Criteria Minor Criteria Positive blood cultures for typical microorganisms persistently isolated from blood cultures (2 cultures > 12 hrs apart, single positive culture for Coxiella) Predisposing cardiac conditions such as a prosthetic heart valve (Option C), IV drug abuse (Option B) Evidence of endocardial involvement on echocardiography (vegetations or abscesses) Fever (≥38.0°C) (Option A) New valvular regurgitation Vascular phenomena (e.g., emboli, Janeway lesions) Immunological phenomena (e.g., glomerulonephritis, Osler's nodes) Microbiological evidence not meeting major criteria (e.g., positive blood culture but not persistently positive) For diagnosis, either of the following should be present: 2 major criteria OR 1 major criteria and 3 minor criteria OR 5 minor criteria

References:

Robbins and Cotran, Pathological Basis of Disease, 10th Edition, Page 563

↑ *Back to this question in Part A*

@Neet_pg_bot

Q20: Which of the following is not a major criterion according to Jones Criteria for Rheumatic Heart Disease? (Q845395)

A. Polyarthritis

B. Carditis

C. Subcutaneous nodules

D. Fever

Correct Answer: D. Fever

■ *Listen (English)*

■ *Listen (Hindi)*

Explanation: Jones Criteria: Major Criteria Minor Criteria Carditis (Pancarditis) (Option B) Polyarthritis (Option A) Sydenham's chorea (involuntary movements) Subcutaneous nodules (usually painless) (Option C) Erythema marginatum (skin rash) Clinical Fever Polyarthralgia Prolonged PR interval Lab Increased ESR Increased CRP The presence of either two major criteria or one major criterion plus two minor criteria, along with evidence of a preceding streptococcal infection, supports the diagnosis of acute rheumatic fever according to the Jones Criteria.

References:

Robbins and Cotran, Pathological Basis of Disease, 10th Edition, Page 561

↑ *Back to this question in Part A*

Q21: Which of the following findings is most likely present in the myocardial biopsy of a Rheumatic Heart disease patient? (Q845394)

A. Fibrous thickening of the endocardium

B. Areas of lymphocytic infiltrates, Anitschkow cells and fibroblasts in all layers of the heart

C. Calcific nodules on the valve leaflets

D. Disruption of the endothelial lining of blood vessels

Correct Answer: B. Areas of lymphocytic infiltrates, Anitschkow cells and fibroblasts in all layers of the heart

■ *Listen (English)*

■ *Listen (Hindi)*

Explanation: Areas of lymphocytic infiltrates, plump macrophages and fibroblasts in all layers of the heart are the characteristic features of Rheumatic Heart Disease. Aschoff bodies , characterized by areas of lymphocytic infiltrates, plump macrophages (Anitschkow cells) , and fibroblasts, are commonly found in all layers of the heart (maximum in myocardium) of patients with Rheumatic Heart Disease. Anitschkow cells: Appearance of nuclei: Caterpillar chromatin pattern: Zig-zag nucleus "Owl eye" appearance: If nucleus is cut from center and is appearing round.

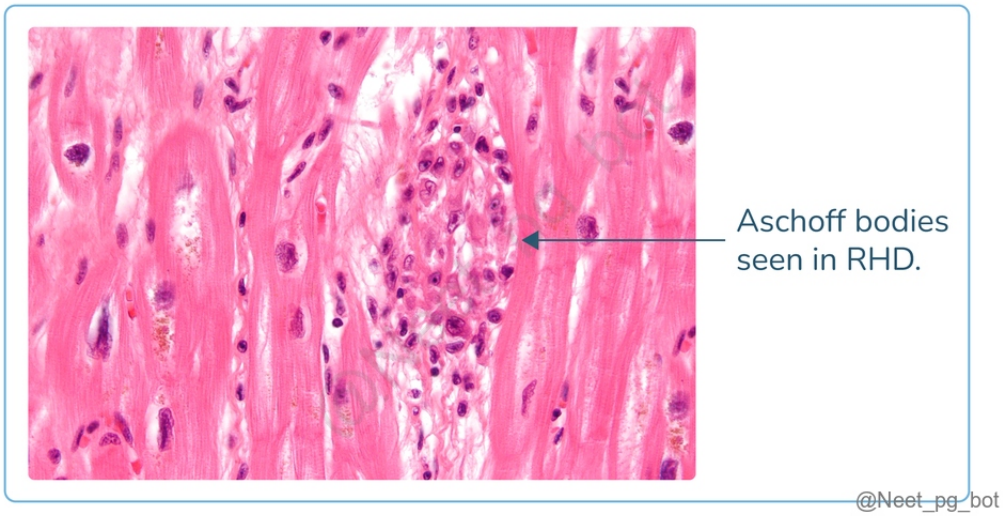

References:

Robbins and Cotran, Pathological Basis of Disease, 10th Edition, Page 564

↑ *Back to this question in Part A*

@Neet_pg_bot

Q22: Which of the following statements best describes the vegetation found in Infective Endocarditis compared to other conditions? (Q845393)

A. Vegetations in Infective Endocarditis are typically small, friable, sterile and composed of fibrin, and platelets.

B. Vegetations in Infective Endocarditis are large, verrucous, and primarily consist of fibrin, inflammatory cells, and microorganisms.

C. Nonbacterial Thrombotic Endocarditis (NBTE) commonly presents with small, non-sterile vegetations composed mainly of fibrin and platelets.

D. Libman-Sacks Endocarditis is characterised by tiny, marantic vegetations consisting of fibrin and micro-organisms.

Correct Answer: B. Vegetations in Infective Endocarditis are large, verrucous, and primarily consist of fibrin, inflammatory cells, and microorganisms.

■ *Listen (English)*

■ *Listen (Hindi)*

Explanation: Vegetations of Infective endocarditis are very large and bulky, which sometimes fall off and form emboli via blood vessels to different parts of body. They comprises of fibrin and inflammatory cells with microorganisms within. Rheumatic heart disease Infective Endocarditis Non-bacterial Thrombotic Endocarditis (Option C) Libman-Sacks Endocarditis (Option D) Small and warty Large and bulky (Option B) (Option A ruled out) Small and friable Medium sized Along lines of closure Upper surface of cusps Along lines of closure Both surface of valves (M/C-lower surface) Sterile Non-sterile (Infected) Sterile Sterile Emboli - Emboli +/- Emboli +++ Emboli -

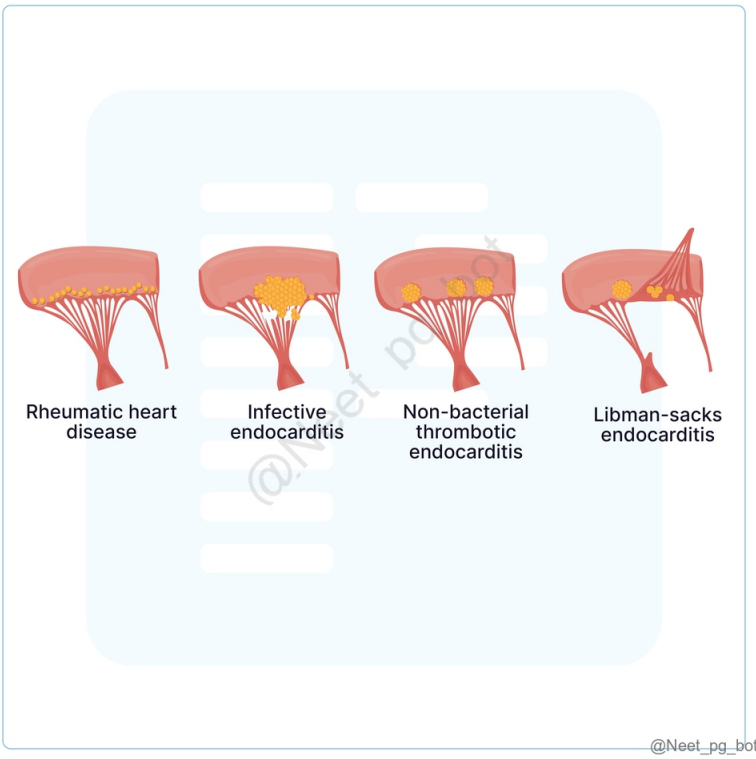

References:

Robbins and Cotran, Pathological Basis of Disease, 10th Edition, Page 560

↑ *Back to this question in Part A*

@Neet_pg_bot

• [06_CVS_ Blood Vessels and Vasculitis] 030 Vasculitis

« Back to Folder Directory

[06_CVS_ Blood Vessels and Vasculitis] 030 Vasculitis — Quick Jump

Q1 (p. 1690)	*Q2 (p. 1691)*	*Q3 (p. 1692)*	*Q4 (p. 1692)*	*Q5 (p. 1693)*	*Q6 (p. 1694)*
Q7 (p. 1695)	*Q8 (p. 1696)*	*Q9 (p. 1696)*	*Q10 (p. 1697)*	*Q11 (p. 1698)*	*Q12 (p. 1699)*
Q13 (p. 1700)	*Q14 (p. 1701)*	*Q15 (p. 1702)*	*Q16 (p. 1704)*	*Q17 (p. 1704)*	*Q18 (p. 1708)*

Q1: A 55-year-old female presents with hematuria, hemoptysis, and sinusitis. Renal biopsy reveals pauci-immune necrotising crescentic glomerulonephritis. What is the most likely diagnosis? (Q845459)

A. Wegener's Granulomatosis

B. Goodpasture Syndrome

C. Systemic Lupus Erythematosus (SLE)

D. Microscopic Polyangiitis (MPA)

Correct Answer: A. Wegener's Granulomatosis

■ *Listen (English)*

■ *Listen (Hindi)*

Explanation: The clinical presentation of a 55-year-old female with hematuria, hemoptysis, sinusitis, and renal biopsy showing pauci-immune necrotising crescentic glomerulonephritis is suggestive of Wegener’s granulomatosis. Rapidly Progressive Glomerulonephritis (RPGN) classification: Type I (Anti-GBM disease) → Anti-GBM antibodies → Goodpasture’s Type II (Immune complex) → SLE, IgA nephropathy, PSGN Type III (Pauci-immune) → ANCA-associated vasculitis (GPA , MPA, EGPA) Wegener's Granulomatosis (Granulomatosis with Polyangiitis-GPA): It is characterised by pauci-immune necrotising granulomatous vasculitis affecting small- to medium-sized vessels. It causes Necrotizing granulomas in 3 key organs : Respiratory tract (upper + lower) → sinusitis, otitis media, nasal septal perforation, hemoptysis Kidneys → crescentic glomerulonephritis (RPGN type III) → hematuria Blood vessels → systemic small vessel vasculitis In GPA, there is a presence of anti-neutrophil cytoplasmic antibodies (ANCA), specifically cytoplasmic ANCA (c-ANCA) targeting proteinase 3 (PR3) and sometimes p-ANCA targeting myeloperoxidase (MPO) . Another classical triad of GPA (ENT triad): E: Ear → otitis media N: Nose → nasal septal perforation (“saddle-nose”) T: Throat/mouth → strawberry gums Goodpasture Syndrome (Option B): It causes RPGN I and shows Anti-glomerular basement membrane antibodies (anti-GBM antibodies). SLE (Option C): It is a multi-system disorder causing RPGN II and has Anti-Nuclear antibodies (ANA). Microscopic polyangiitis (Option D) (MPA): It can also cause RPGN III, but it doesn't show other symptoms like hemoptysis and sinusitis

References:

Robbins and Cotran, Pathologic Basis of Disease, 10th Edition, Page 514.

↑ *Back to this question in Part A*

@Neet_pg_bot

Q2: A 3-year-old child presents with persistent high fever, bilateral conjunctival erythema, strawberry tongue, erythema of palms and soles, desquamating rash, and cervical lymphadenopathy. This presentation is classically referred to as which of the following? (Q889802)

A. Mucocutaneous lymph node syndrome

B. Polyarteritis nodosa

C. Takayasu arteritis

D. Henoch-Schönlein purpura

Correct Answer: A. Mucocutaneous lymph node syndrome

Explanation: Kawasaki disease , also known as mucocutaneous lymph node syndrome , is an acute febrile medium-vessel vasculitis that primarily affects children younger than 5 years. Kawasaki disease: Clinical (Mucocutaneous LN syndrome): Persistent high fever Bilateral non-exudative conjunctivitis Strawberry tongue Polymorphous rash with desquamation Erythema of palms and soles Cervical lymphadenopathy Complications: Coronary arteritis → aneurysm, thrombosis, MI, rupture ~20% untreated patients develop cardiac complications Treatment: IV immunoglobulin (IVIG) + aspirin Markedly reduces coronary complications Polyarteritis nodosa (Option B) : Medium-vessel necrotising vasculitis; does not present with mucocutaneous lymph node syndrome. Takayasu arteritis (Option C) : Large-vessel granulomatous vasculitis in patients <50 years; characterised by weak pulses, not mucocutaneous features. Henoch-Schönlein purpura (Option D) : IgA-mediated small-vessel vasculitis; presents with palpable purpura, abdominal pain, and renal involvement.



References:

Robbins, Cotran & Kumar, Pathologic Basis of Disease, 11th Edition, Page 468

↑ *Back to this question in Part A*

@Neet_pg_bot

Q3: Anti-endothelial cell antibodies are most commonly associated with which of the following conditions? (Q889800)

A. Polyarteritis nodosa

B. Kawasaki disease

C. Takayasu arteritis

D. Granulomatosis with polyangiitis

Correct Answer: B. Kawasaki disease

Explanation: The presence of anti-endothelial cell antibodies (AECA) is a classic association for Kawasaki disease and is thought to contribute to the vascular damage seen in the coronary arteries. Kawasaki disease: Acute febrile medium-vessel vasculitis 80% <5 years old Transmural inflammation Self-limited but clinically significant due to coronary artery involvement Pathogenesis: Likely triggered by a viral infection in genetically susceptible children Delayed-type hypersensitivity → Cytokine release Polyclonal B-cell activation Autoantibodies to endothelial & smooth muscle cells Polyarteritis nodosa (Option A): A medium-vessel necrotizing vasculitis often associated with immune complex deposition and hepatitis B infection, not classically associated with AECA. Takayasu arteritis (Option C): A large-vessel granulomatous vasculitis that is primarily T-cell mediated , not characteristically associated with AECA. Granulomatosis with polyangiitis (Option D): Associated with c-ANCA (PR3-ANCA) , not anti-endothelial cell antibodies.

References:

Robbins, Cotran & Kumar, Pathologic Basis of Disease, 11th Edition, Page 468

↑ *Back to this question in Part A*

@Neet_pg_bot

Q4: A 27-year-old woman presents with fatigue, weak upper limb pulses, and visual disturbances. Imaging reveals narrowing of major branches of the aorta. She is diagnosed with Takayasu arteritis. Which of the following statements is correct? (Q889799)

A. The renal artery is spared

B. It commonly involves the aortic arch

C. B-cell mediated disease

D. It is a medium vessel granulomatous vasculitis

Correct Answer: B. It commonly involves the aortic arch

Explanation: Takayasu arteritis classically affects the aortic arch and its major branches , leading to diminished upper limb pulses (“pulseless disease”). Takayasu arteritis: Granulomatous large-vessel vasculitis (Option D) Affects the aorta (especially the aortic arch) & major branches Occurs mainly in patients <50 years Also called “pulseless disease” T-cell-mediated autoimmune aetiology (Option C) Common vessels: Aortic arch (most common) Great vessels Pulmonary arteries (~50%) Coronary & renal arteries May involve the entire aorta Morphology: Transmural thickening of the vessel wall Intimal hyperplasia → luminal narrowing/obliteration Granulomatous inflammation with giant cells Patchy medial necrosis Late stage: fibrosis of all layers Aortic root dilation → aortic regurgitation (occasionally) Clinical features: Weak/absent upper limb pulses (“pulseless disease”) ↓ BP in arms Visual & neurologic symptoms Renal artery stenosis (Option A) → hypertension

References:

Robbins, Cotran & Kumar, Pathologic Basis of Disease, 11th Edition, Pages 465, 466

↑ *Back to this question in Part A*

@Neet_pg_bot

Q5: A 68-year-old woman presents with new-onset temporal headache, jaw claudication, and transient vision loss. ESR is elevated. Which of the following statements is correct regarding this condition? (Q889798)

A. A negative temporal artery biopsy excludes the diagnosis

B. The disease uniformly affects the entire length of the artery

C. A negative biopsy does not exclude the diagnosis

D. The aorta is spared

Correct Answer: C. A negative biopsy does not exclude the diagnosis

Explanation: The clinical presentation of a temporal headache, jaw claudication, and vision loss in an elderly patient with an elevated ESR is classic of Giant Cell (Temporal) Arteritis . Giant cell arteritis has segmental (skip) lesions, so that biopsy may miss affected areas. If clinical suspicion is high, treatment (corticosteroids) is started immediately to prevent permanent blindness, even if the biopsy is initially negative. Giant cell arteritis: Chronic

granulomatous vasculitis of large- and medium-sized arteries Commonly involves the temporal, vertebral, and ophthalmic arteries Can involve the aorta (giant cell aortitis) (Option D) Risk: sudden irreversible blindness Morphology: Patchy lesions → biopsy ≥1 cm required (Option B) Intimal thickening → luminal narrowing Granulomatous inflammation in the media Fragmentation of the internal elastic lamina Multinucleated giant cells (~75%) Healed lesions → fibrosis & medial scarring Clinical features: Age >50 years Fever, fatigue, weight loss Temporal headache & scalp tenderness Jaw claudication Ocular symptoms → diplopia or vision loss Diagnosis: Temporal artery biopsy (negative biopsy does not exclude due to patchy involvement) (Option A and C) Treatment: Immediate corticosteroids Anti-TNF therapy in resistant cases Tocilizumab (anti-IL-6 receptor) in refractory or steroid-dependent cases

References:

Robbins, Cotran & Kumar, Pathologic Basis of Disease, 11th Edition, Pages 464, 465

↑ *Back to this question in Part A*

@Neet_pg_bot

Q6: A 72-year-old woman presents with temporal headache, scalp tenderness, and transient visual disturbances. ESR is markedly elevated. Temporal artery biopsy confirms Giant cell arteritis. Which of the following statements is incorrect regarding this condition? (Q889797)

A. It commonly affects individuals older than 50 years

B. It is characterised by granulomatous inflammation with giant cells

C. It can also involve veins

D. Risk of vision loss

Correct Answer: C. It can also involve veins

Explanation: Giant cell arteritis is a large- and medium-sized arterial vasculitis and does not involve veins. Giant cell arteritis: Chronic granulomatous vasculitis of large- and medium-sized arteries Commonly involves the temporal, vertebral, and ophthalmic arteries Risk: sudden irreversible blindness (Option D) Pathogenesis: T-cell-mediated immune response to the vessel wall antigen Key cytokines: IFN-γ, IL-17 Associated with MHC class II haplotypes Morphology: Patchy lesions → biopsy ≥1 cm required Intimal thickening → luminal narrowing Granulomatous inflammation in the media (Option B) Fragmentation of the internal elastic lamina Multinucleated giant cells (~75%) Healed lesions → fibrosis & medial scarring Clinical features: Age >50 years (Option A) Fever, fatigue, weight loss Temporal headache & scalp tenderness Jaw claudication Ocular symptoms → diplopia or vision loss Diagnosis: Temporal artery biopsy (negative biopsy does not exclude due to patchy involvement) Treatment: Immediate corticosteroids Anti-TNF therapy in resistant cases Tocilizumab (anti-IL-6 receptor) in refractory or steroid-dependent cases

References:

Robbins, Cotran & Kumar, Pathologic Basis of Disease, 11th Edition, Pages 464, 465

↑ *Back to this question in Part A*

@Neet_pg_bot

Q7: A 25-year-old girl with a history of asthma presents with wheezing and rhinitis. Lab reports show eosinophilia and antibodies against neutrophil myeloperoxidase. What is the most likely diagnosis? (Q845462)

A. Churg-Strauss syndrome

B. PAN

C. Buerger's disease

D. Wegener granulomatosis

Correct Answer: A. Churg-Strauss syndrome

■ *Listen (English)*

■ *Listen (Hindi)*

Explanation: The clinical presentation of a 25-year-old girl, k/c/o asthma with wheezing, rhinitis, and antibodies against neutrophil myeloperoxidase is suggestive of Churg Strauss syndrome. Eosinophilic Granulomatosis with Polyangiitis (EGPA / Churg–Strauss): p-ANCA: p-ANCA (perinuclear ANCA) shows antibody clustering around the nucleus on immunofluorescence, with the target antigen being myeloperoxidase (MPO), which is why it is also called MPO-ANCA. Diseases associated with p-ANCA (MPO-ANCA): Microscopic polyangiitis Eosinophilic granulomatosis with polyangiitis (EGPA/Churg–Strauss) Sometimes, Granulomatosis with polyangiitis (GPA/Wegener's). Clinical features of EGPA: Asthma → hallmark of EGPA (not seen in GPA or MPA) Eosinophilia → classic clue (not present in GPA or MPA) Allergic rhinitis → part of atopic background p-ANCA positive → consistent with EGPA Polyarteritis Nodosa (Option B) is a systemic necrotizing vasculitis that primarily affects medium-sized arteries. It is associated with Hepatitis B, fibrinoid necrosis and is ANCA negative. Buerger's disease (Option C): It is strongly associated with heavy smoking. It primarily affects the extremities and presents with claudication, raynaud's phenomenon, gangrene, and ischemic ulcers. It does not involve asthma, eosinophilia, or MPO antibodies. Wegener Granulomatosis (Option D): May show p-ANCA, but usually c-ANCA (PR3-ANCA) and does not cause eosinophilia or asthma

References:

Robbins and Cotran, Pathologic Basis of Disease, 10th edition, Page 515

↑ *Back to this question in Part A*

@Neet_pg_bot

Q8: A 30-year-old male patient presents with recurrent oral ulcers, genital ulcers, and skin lesions on the lower extremities. He also complains of blurred vision and pain in his right eye. On examination, there are multiple oral and genital ulcers with posterior uveitis evident on ophthalmologic evaluation. Which of the following is false regarding the condition? (Q845461)

A. HLA B27 positivity

B. Painful scarring genital ulcers

C. Erythema nodosum

D. Positive pathergy test

Correct Answer: A. HLA B27 positivity

■ *Listen (English)*

■ *Listen (Hindi)*

Explanation: Based on the clinical presentation along with examination finding this patient is most likely suffering from Behcet's disease which is not associated with HLA B27 Behcet's disease Associations HLA-B51 Clinical features A clinical triad of recurrent oral aphthous ulcers + genital ulcers + uveitis is seen Oral Aphthous Ulcers : Hallmark feature Genital Ulcers : Painful and may leave scars after healing. (Option B) Uveitis : Most serious manifestation due to its potential for causing blindness. Other Symptoms: Joint pain (arthritis), skin lesions (erythema nodosum) (Option C) , vascular manifestations (thrombophlebitis, deep vein thrombosis), and neurological involvement Diagnosis Pathergy test (A skin test for Behcet's disease) (Option D)

References:

Harrison's Principles of Internal Medicine, 21st edition, Pages 2817, 2818

↑ *Back to this question in Part A*

@Neet_pg_bot

Q9: A 45-year-old female presents with rapidly progressive hematuria, hemoptysis, and peripheral neuropathy. Serological testing reveals the presence of perinuclear anti-neutrophil cytoplasmic antibodies (p-ANCA) targeting myeloperoxidase (MPO). What is the most likely diagnosis based on these serological findings? (Q845460)

A. Microscopic Polyangiitis

B. Granulomatosis with Polyangiitis

C. Eosinophilic Granulomatosis with Polyangiitis

D. Goodpasture Syndrome

Correct Answer: A. Microscopic Polyangiitis

■ *Listen (English)*

■ *Listen (Hindi)*

Explanation: The clinical presentation of rapidly progressive hematuria, hemoptysis, peripheral neuropathy, and MPO positivity points towards the diagnosis of microscopic polyangiitis. Microscopic Polyangiitis (MPA): MPA is a small-vessel vasculitis showing multi-organ involvement. p-ANCA (MPO-ANCA) positivity is the hallmark of MPA. Multi-organ involvement : Kidneys → rapidly progressive glomerulonephritis (RPGN III) → hematuria Lungs → alveolar capillaritis → hemoptysis Nerves → mononeuritis multiplex → peripheral neuropathy No granulomas (this differentiates it from GPA/Churg-Strauss) Granulomatosis with Polyangiitis (Option B) is typically c-ANCA (PR3-ANCA) positive, though p-ANCA may also be seen, and can present with hematuria, hemoptysis, and neuropathy. It is characterized by granuloma formation with ENT involvement such as nasal septal perforation and strawberry gums. Eosinophilic Granulomatosis with Polyangiitis (EGPA) (Option C), formerly known as Churg-Strauss Syndrome, is a p-ANCA–positive small vessel vasculitis characterized by peripheral eosinophilia along with asthma or allergic rhinitis as defining features. Goodpasture Syndrome (Option D) is characterized by rapidly progressive glomerulonephritis (RPGN) with hemoptysis, caused by anti-GBM antibodies rather than ANCA, and is limited to the kidney and lung without neuropathy or systemic vasculitis.

References:

Robbins and Cotran, Pathologic Basis of Disease, 10th Edition, Page 513.

↑ *Back to this question in Part A*

@Neet_pg_bot

Q10: Weibel-Palade bodies consist of which of the following components? (Q845439)

A. Collagen

B. von Willebrand factor (vWF)

C. Platelet-derived growth factor (PDGF)

D. Tumor necrosis factor (TNF)

Correct Answer: B. von Willebrand factor (vWF)

■ *Listen (English)*

■ *Listen (Hindi)*

Explanation: Weibel-Palade bodies primarily store and release von Willebrand factor (vWF) and P-selectin . Weibel Palade bodies are primarily located in endothelial cells lining small blood vessels . Contents: Contents Vascular functions Von Willebrand factor Thrombosis Factor VIIIa t-PA Fibrinolysis P-selectin Inflammation IL-8 Eotaxin α-1,3-fucosyltransferase VI CD63 (Lamp 3) Exocytosis Endothelin 1 Vasoconstriction Endothelin converting enzyme Calcitonin gene-related peptide Vasodilation Angiopoietin 2 Angiogenesis

References:

Robbins and Cotran, Pathologic Basis of Disease, 10th edition, Page 78

Endothelial Biomedicine, William C. Aird, 2007, Pages 657-659

↑ *Back to this question in Part A*

@Neet_pg_bot

Q11: A 10-year-old child presents with palpable purpura on the lower extremities, arthralgia, and abdominal pain. Laboratory tests show elevated serum IgA levels and red blood cell casts in urine. What is the most likely diagnosis? (Q845457)

A. Henoch-Schönlein Purpura

B. Systemic Lupus Erythematosus

C. Kawasaki Disease

D. Rheumatic Fever

Correct Answer: A. Henoch-Schönlein Purpura

■ *Listen (English)*

■ *Listen (Hindi)*

Explanation: The clinical presentation of a 10-year-old child with palpable purpura, arthralgia, abdominal pain, elevated serum IgA levels, and RBC casts in urine is suggestive of Henoch-Schonlein purpura (HSP). Clinical features (PAAARpura): P: Palpable purpura (typically lower extremities and buttocks) A: Arthralgia / joint pain A: Abdominal involvement (pain, nausea, GI bleeding possible) A: Associated with elevated IgA (causative immunoglobulin) R: Renal involvement (hematuria, red blood cell casts) Pathophysiology: HSP is a Small-vessel vasculitis mediated by IgA immune complex deposition. IgA deposits weaken vessel walls, leading to purpura and bleeding. Because the platelet count is normal, also called as non-thrombocytopenic purpura .

References:

Robbins and Cotran, Pathologic Basis of Disease, 10th Edition, Page 509.

↑ *Back to this question in Part A*

@Neet_pg_bot

Q12: Which of the following is a characteristic feature of Buerger disease? (Q845456)

A. Segmental fibrinoid necrosis of the media with focal transmural necrotising lesions

B. Segmental thrombosing vasculitis affecting small and medium-sized arteries

C. Granulomatous inflammation of vessel walls

D. Adventitial mononuclear infiltrates with perivascular cuffing of the vasa vasorum

Correct Answer: B. Segmental thrombosing vasculitis affecting small and medium-sized arteries

- *Listen (English)*
- *Listen (Hindi)*

Explanation: Segmental thrombosing vasculitis affecting small and medium-sized arteries is the hallmark feature of Buerger's disease. It involves inflammation and thrombosis of small and medium-sized arteries , particularly in the distal extremities , leading to ischemia and tissue damage. {{caption_text}} In the above image, the lumen is occluded by thrombin-containing abscesses, and the vessel wall is infiltrated with leukocytes. Segmental fibrinoid necrosis of the media with focal transmural necrotising lesions (Option A) is a hallmark feature of polyarteritis nodosa (PAN). Granulomatous inflammation of vessel walls (Option C) is a hallmark of large-vessel vasculitides, such as giant cell arteritis (GCA) and Takayasu arteritis. Adventitial mononuclear infiltrates with perivascular cuffing of the vasa vasorum (Option D) in syphilitic aortitis, part of tertiary syphilis.

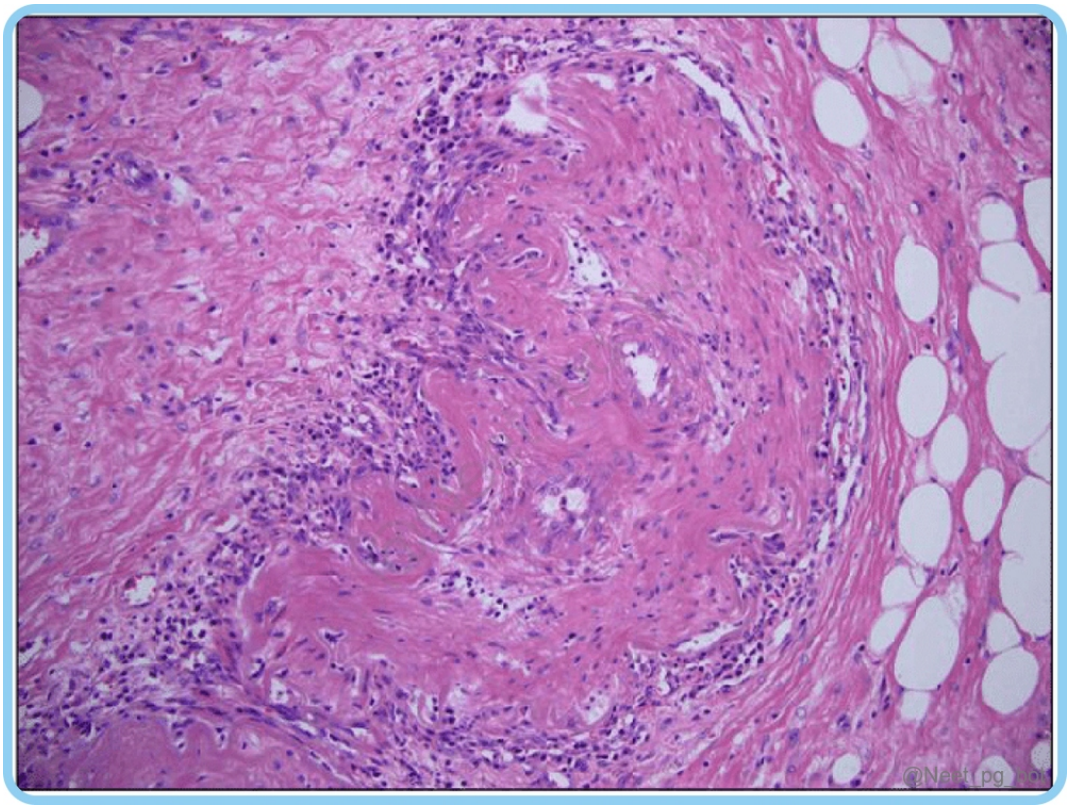

References:

Robbins and Cotran, Pathological Basis of Disease, 10th Edition, Page 521

↑ *Back to this question in Part A*

@Neet_pg_bot

Q13: A 42-year-old male heavy smoker presents with a history of recurrent episodes of pain and discolouration in his fingers and toes, particularly when exposed to cold temperatures. On examination, you notice superficial migratory thrombophlebitis in his lower extremities. Doppler ultrasound reveals segmental occlusions in the arteries of his lower limbs. Considering his clinical presentation, which of the following is the most likely diagnosis? (Q845455)

A. Thromboangiitis Obliterans

B. Raynaud's Phenomenon

C. Atherosclerosis

D. Giant Cell Arteritis

Correct Answer: A. Thromboangiitis Obliterans

■ *Listen (English)*

■ *Listen (Hindi)*

Explanation: Thromboangiitis Obliterans (Buerger's Disease): Clinical Features: Segmental arterial occlusion in medium-sized vessels (medium-vessel vasculitis) Pain and discoloration of the digits that worsen with cold exposure can initially mimic Raynaud's phenomenon , but: Raynaud's phenomenon: Does not cause arterial occlusion and is not strongly associated with smoking (Option B ruled out) Superficial migratory thrombophlebitis is characteristic. Pathophysiology: Thrombo - blood clot Angitis - inflammation of blood vessels Obliterans - occlusion of blood vessels due to clot + inflammation Etiology: This has a strong association with heavy smoking, as tobacco triggers inflammatory and thrombotic processes in the blood vessels. Intermittent claudication due to insufficient blood supply during activity can potentially progress to digital ischemia, ulceration, or gangrene Treatment: The most important treatment is complete cessation of smoking, which provides symptomatic relief and helps prevent disease progression.

References:

Robbins and Cotran, Pathological Basis of Disease, 10th Edition, Page 521

↑ *Back to this question in Part A*

@Neet_pg_bot

Q14: A 3-year-old child presents with a high fever persisting for five days, along with bilateral conjunctival injection, strawberry tongue, and rash on the trunk and extremities. There is also swelling and erythema of the hands and feet. What is the most likely diagnosis? (Q845452)

A. Measles

B. Scarlet fever

C. Henoch-Schönlein purpura

D. Kawasaki disease

Correct Answer: D. Kawasaki disease

■ *Listen (English)*

■ *Listen (Hindi)*

Explanation: Based on the clinical presentation, the child is suffering from Kawasaki disease, which is an acute, febrile, usually self-limited illness of infancy and childhood associated with large- to medium-sized vessel arteritis . Kawasaki disease, the most common vasculitis in children, is mediated by anti-endothelial cell antibodies and can lead to coronary artery involvement, including aneurysms, coronary arteritis, and myocardial infarction. Clinical Features (Mnemonic: CREAM-F.): C onjunctivitis (non-exudative & non-purulent). R ash (Polymorphous, non-vesicular). E dema (or erythema) of hands & feet. A denopathy (Cervical, often unilateral & non-suppurative). M ucosal involvement (strawberry tongue). F ever (Most important constitutional symptom) . A diagnosis of Kawasaki disease is confirmed when a patient presents with ≥4 of 5 criteria + fever . The image below shows the strawberry tongue. {{caption_text}} Measles (Option A): P resents with a prodrome of fever , cough , coryza , and conjunctivitis followed by a maculopapular rash spreading from head to toe. Scarlet fever (Option B): Measles classically presents with the “three Cs”: coryza , cough , and conjunctivitis , along with Koplik spots on the buccal mucosa. Henoch-Schönlein purpura (Option C): HSP) is the most common pediatric vasculitis, an IgA-mediated small-vessel vasculitis, typically presenting with features such as purpura.



References:

Robbins and Cotran, Pathological Basis of Disease, 10th Edition, Page 513

↑ *Back to this question in Part A*

@Neet_pg_bot

Q15: A 52-year-old woman presents with a 3-month history of muscle aches, joint pain, and numbness in her hands and feet and blood in stools. She also reports experiencing episodes of abdominal pain and nausea. Physical examination reveals decreased sensation in the distal extremities and decreased peripheral pulses. Laboratory tests show elevated erythrocyte sedimentation rate (ESR) and C-reactive protein (CRP). Nerve conduction studies indicate peripheral neuropathy. What is the most likely diagnosis? (Q845449)

A. Polyarteritis nodosa (PAN)

B. Wegener's granulomatosis

C. Churg-Strauss syndrome

D. Giant cell arteritis

Correct Answer: A. Polyarteritis nodosa (PAN)

■ *Listen (English)*

■ *Listen (Hindi)*

Explanation: The patient's symptoms, including fever, fatigue, weight loss, blood in stools, abdominal pain, and skin manifestations (livedo reticularis), along with the laboratory findings of elevated inflammatory markers, are all consistent with polyarteritis nodosa , a medium-vessel vasculitis that can affect multiple organ systems. Polyarteritis Nodosa (PAN): PAN is a Medium-vessel vasculitis, which is often seen in Hepatitis B-positive individuals. Clinical Features: Multi-organ involvement : almost every medium vessel can be affected Most commonly: renal vessels Others: GI tract, peripheral nerves, skin, muscles Pulmonary vessels are spared due to which pulmonary symptoms are absent in PAN. Peripheral neuropathy : due to ischemic nerve injury Raised inflammatory markers : ESR, CRP Histopathology: Fibrinoid necrosis of vessel walls (pink amorphous material) Segmental transmural inflammation : Segmental → only parts of vessel affected Transmural → full thickness of the vessel wall involved in affected segments {{caption_text}} Wegener's granulomatosis (Option B): Shows granulomas; often involves kidneys and lungs Churg-Strauss syndrome (Option C): Characterized by eosinophilic infiltration Giant Cell Arteritis (Option D): Large-vessel vasculitis characterized by giant cells, usually affecting individuals over 50 years of age, and commonly involves the temporal artery.

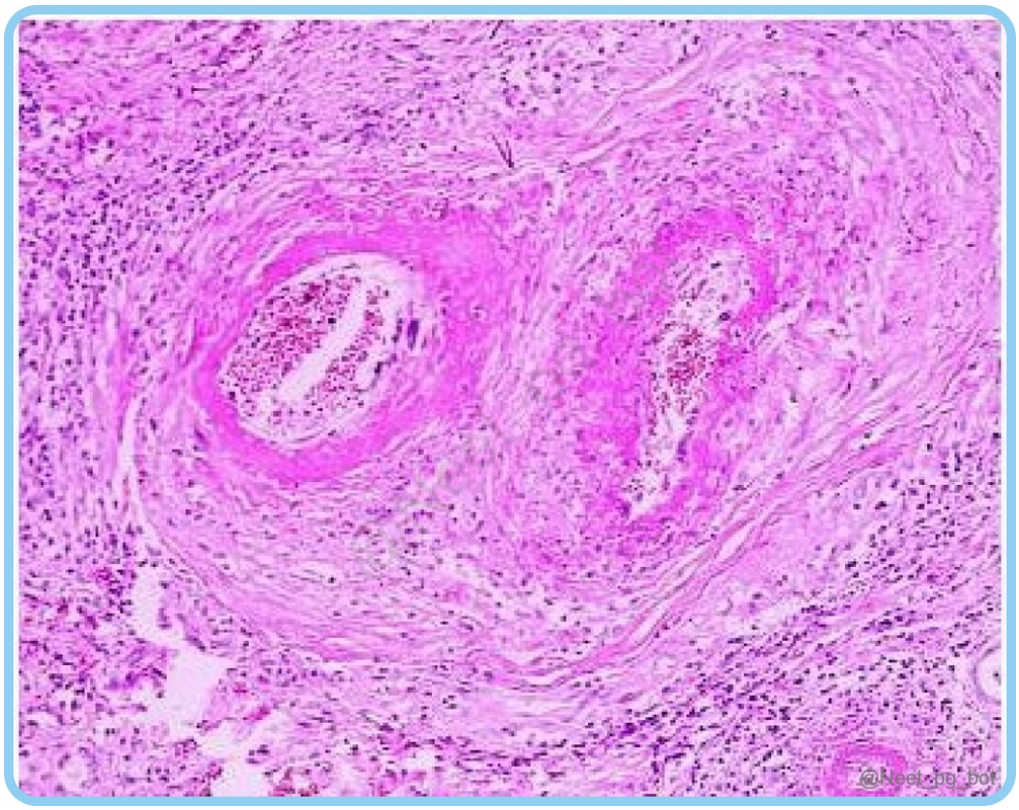

References:

Robbins and Cotran, Pathological Basis of Disease, 10th Edition, Page 513

↑ *Back to this question in Part A*

Q16: A 28-year-old female presents to the outpatient department with complaints of fatigue, weight loss, and intermittent claudication in her upper limbs. On further questioning, she reports occasional headaches and dizziness. Physical examination reveals absent pulses in both brachial arteries and decreased blood pressure in the upper extremities compared to the lower extremities. Laboratory investigations show elevated ESR & CRP, and Doppler ultrasound shows diffuse narrowing and irregularities in the brachial and subclavian arteries. What is the most likely diagnosis? (Q845448)

A. Rheumatoid arthritis

B. Takayasu arteritis

C. Polyarteritis nodosa

D. Microscopic polyangiitis

Correct Answer: B. Takayasu arteritis

■ *Listen (English)*

■ *Listen (Hindi)*

Explanation: The clinical presentation is suggestive of Takayasu arteritis. Takayasu arteritis: Patient age is a key differentiating factor in vasculitis, helping distinguish Takayasu arteritis, which typically affects individuals under 50 years, from Giant Cell Arteritis, which usually occurs in those over 50 years. Symptoms: Predominantly upper limb involvement Pulseless disease → absent brachial pulses Neurological symptoms: headache, dizziness Subclavian artery narrowing: Subclavian artery is the most commonly affected vessel in Takayasu Arteritis. Doppler confirms brachial and subclavian artery stenosis Rheumatoid arthritis (Option A): primarily affects the joints and no upper limb arterial involvement . Polyarteritis nodosa (Option C): Medium-vessel vasculitis; multi-system involvement , often Hepatitis B-associated; not limited to upper limbs Microscopic polyangiitis (Option D): Small vessel vasculitis; associated with ANCA antibodies ,

References:

Robbins and Cotran, Pathologic Basis of Disease, 10th edition, Page 512

↑ *Back to this question in Part A*

Q17: An arterial biopsy of an elderly male was performed and is shown below. What is the most likely diagnosis? {{caption_text}} (Q845445)

A. Giant cell arteritis

B. Takayasu arteritis

C. Polyarteritis nodosa

D. Microscopic polyangiitis

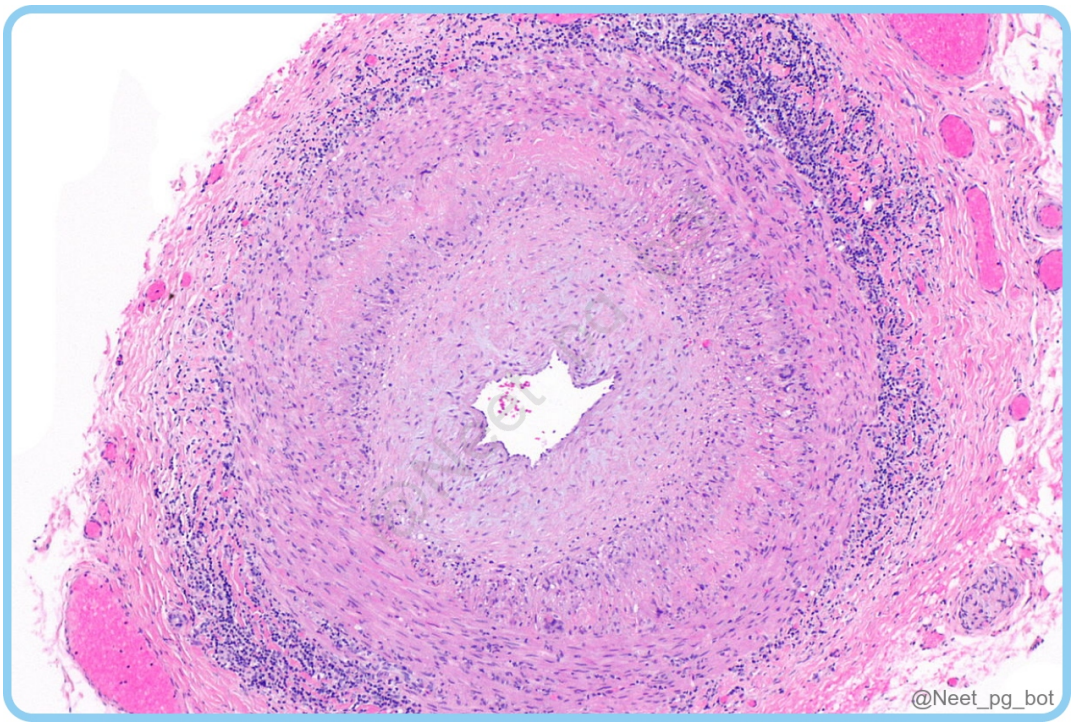

Correct Answer: A. Giant cell arteritis

- *Listen (English)*
- *Listen (Hindi)*

Explanation: An arterial biopsy obtained from an elderly patient showing narrowed lumen , chronic inflammation (blue-coloured lymphocytes), giant cells (present in the arterial wall) and internal elastic lamina fragmentation suggests giant cell arteritis. Giant Cell Arteritis (GCA) , also known as Temporal Arteritis Key Histopathological Features of GCA: Giant cells in the arterial wall Chronic inflammatory infiltrate (lymphocytes) Narrowed lumen due to intimal thickening Commonly affects patients >50 years old {{caption_text}} Takayasu arteritis (Option B) Can show giant cells but typically <50 years old Polyarteritis nodosa (Option C) Shows fibrinoid necrosis (pink necrotic material). {{caption_text}} Microscopic polyangiitis (Option D) AKA leukocytoclastic vasculitis which shows broken white blood cells. {{caption_text}}

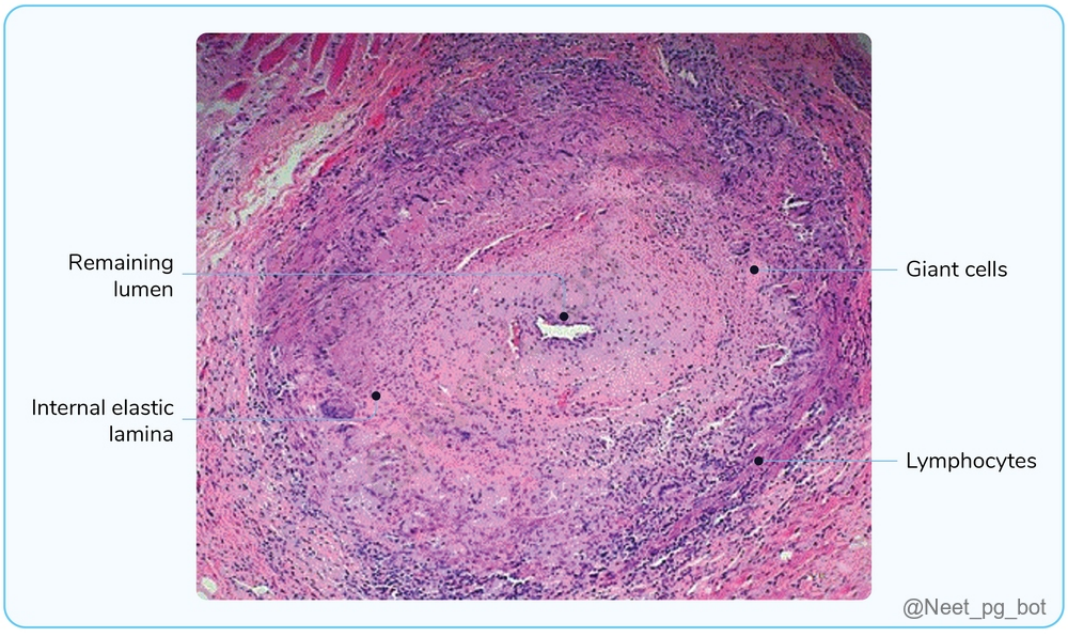
Remaining lumen
Internal elastic lamina
Giant cells
Lymphocytes
@Neet_pg_bot

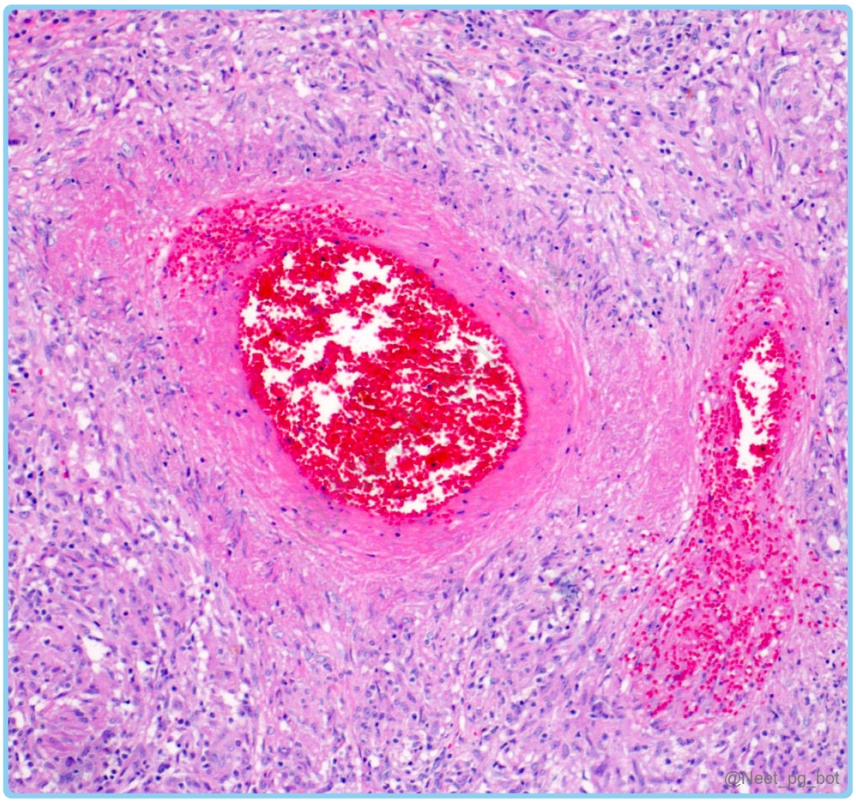
@Neet_pg_bot

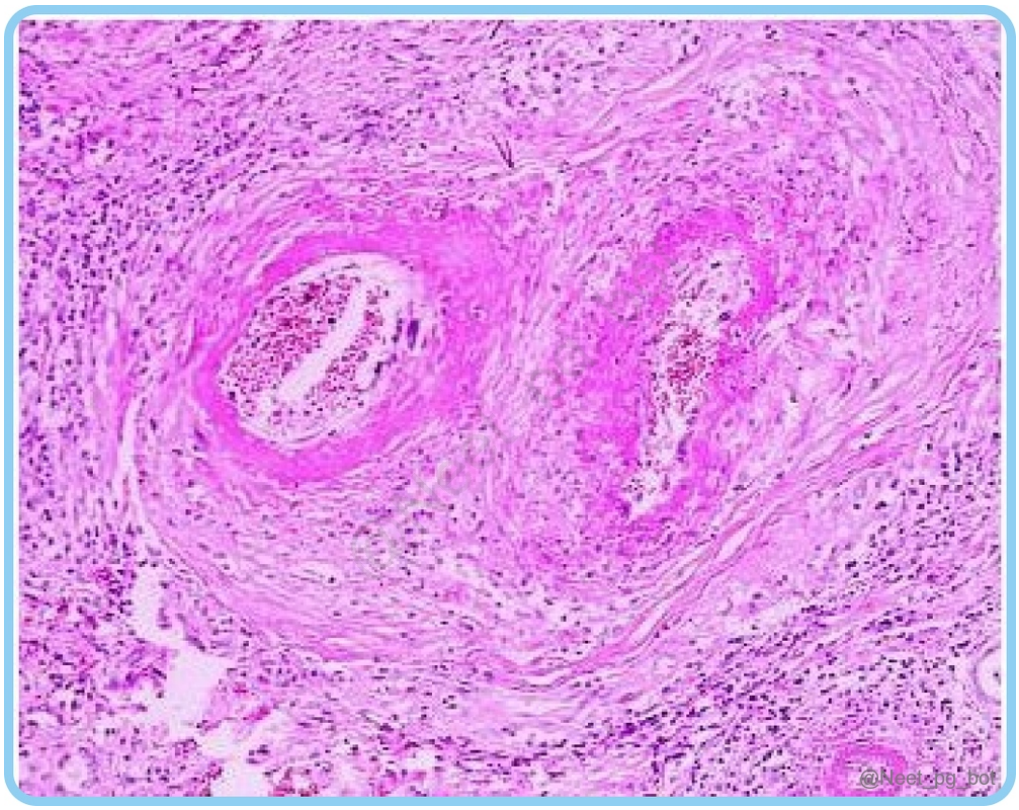

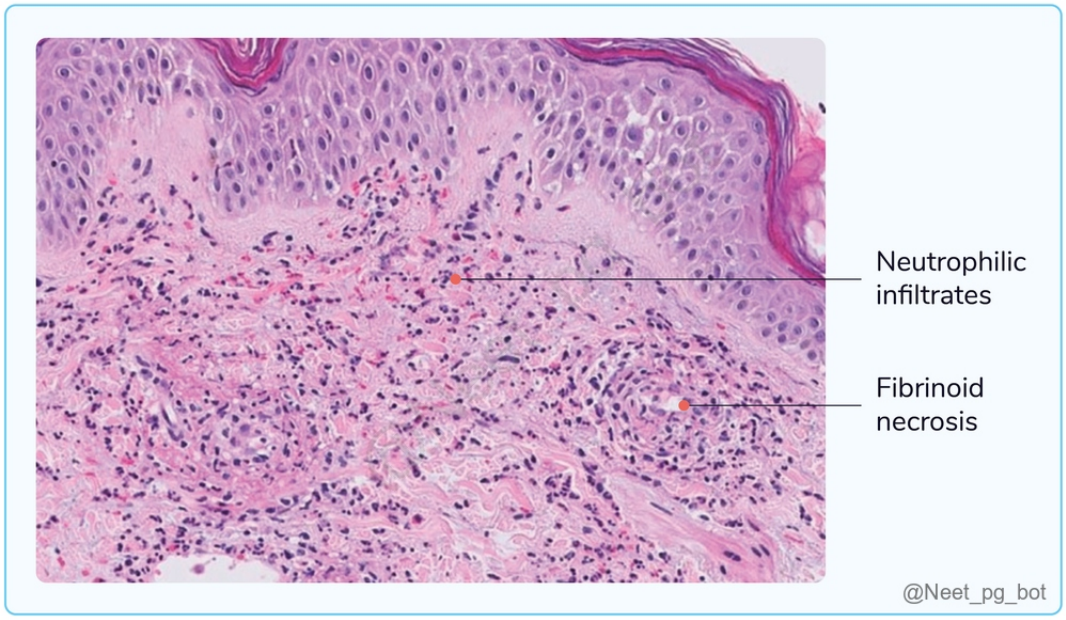

References:

Robbins and Cotran, Pathologic Basis of Disease, 10th edition, Pages 511-514

↑ *Back to this question in Part A*

@Neet_pg_bot

Q18: A 68-year-old woman presents to the emergency department with a three-week history of progressively worsening temporal headaches, jaw pain, and visual disturbances. On examination, her right temporal artery appears swollen and tender to palpation. Which of the following statements regarding this condition are false? (Q845441)

A. Involves large to medium-sized arteries

B. It is the most common cause of vasculitis in adults

C. It occurs as a result of a B cell-mediated immune response

D. It is associated with polymyalgia rheumatica

Correct Answer: C. It occurs as a result of a B cell-mediated immune response

■ *Listen (English)*

■ *Listen (Hindi)*

Explanation: The clinical presentation of a 68-year-old woman with worsening temporal headaches (classical symptom), jaw pain (most specific symptom), visual disturbances (most dangerous complication), and tender and swollen right temporal artery points towards the diagnosis of giant cell arteritis. Temporal arteritis/Giant cell arteritis: Giant cell (temporal) arteritis involves large- to medium-sized arteries. (Option A ruled out) Epidemiology: Most common type of vasculitis in adults (usually >50 years old) (Option B ruled out) It is frequently associated with polymyalgia rheumatica. (Option D ruled out) It is a T-cell-mediated immune response (Option C) Biopsy findings: Giant cells Granulomas Fragmentation of internal elastic lamina Special stain : Verhoeff-Van Gieson stain (to visualize elastic lamina) Fragmentation of internal elastic lamina: Elastic lamina is mostly present everywhere but fragmented in some places.

References:

Robbins and Cotran, Pathologic Basis of Disease, 10th edition, Page 511

↑ *Back to this question in Part A*

@Neet_pg_bot

• [06_CVS_ Blood Vessels and Vasculitis] 031 Previous Year Questions

« Back to Folder Directory

[06_CVS_ Blood Vessels and Vasculitis] 031 Previous Year Questions — Quick Jump

Q1 (p. 1709)	*Q2 (p. 1709)*	*Q3 (p. 1710)*	*Q4 (p. 1711)*	*Q5 (p. 1712)*	*Q6 (p. 1716)*
Q7 (p. 1717)	*Q8 (p. 1718)*	*Q9 (p. 1720)*	*Q10 (p. 1721)*	*Q11 (p. 1722)*	*Q12 (p. 1727)*
Q13 (p. 1730)	*Q14 (p. 1731)*	*Q15 (p. 1733)*	*Q16 (p. 1734)*	*Q17 (p. 1735)*	*Q18 (p. 1736)*
Q19 (p. 1737)	*Q20 (p. 1739)*				

Q1: Which of the following syndromes can lead to pulmonary hemorrhage in a patient and show p-ANCA positivity? (Q844207)

A. Monckeberg's Sclerosis

B. Microscopic polyangiitis

C. Wegener granulomatosis

D. Polyarteritis nodosa

Correct Answer: B. Microscopic polyangiitis

Explanation: Microscopic polyangiitis is a type of small-vessel vasculitis associated with p-ANCA (perinuclear antineutrophil cytoplasmic antibodies) and can lead to pulmonary hemorrhage. Incorrect Options: Monckeberg's Sclerosis (Option A): Monckeberg's sclerosis does not cause pulmonary hemorrhage or p-ANCA positivity. Wegener granulomatosis (Option C): Wegener granulomatosis, now called Granulomatosis with Polyangiitis (GPA), is predominantly associated with c-ANCA. Polyarteritis nodosa (Option D): Polyarteritis nodosa (PAN) is not associated with p-ANCA positivity.

References:

https://www.ncbi.nlm.nih.gov/books/NBK531484/

↑ *Back to this question in Part A*

@Neet_pg_bot

Q2: Which of the following statements regarding rheumatic fever are correct? (Q879221)

A. Characterized by the presence of Aschoff bodies

B. Caused by Group B β-hemolytic Streptococci

C. Manifests only as myocarditis

D. Associated with aortic valve rupture

Correct Answer: A. Characterized by the presence of Aschoff bodies

Explanation: Rheumatic heart disease (RHD) is a chronic sequel of acute rheumatic fever (ARF) , which follows infection with Group A β-hemolytic Streptococcus (Streptococcus pyogenes) . Its hallmark is Aschoff bodies in the myocardium - distinctive granulomatous lesions that confirm rheumatic carditis. It develops as a complication of untreated or inadequately treated acute rheumatic fever (ARF), which is caused by an abnormal immune response to an infection with Group A beta-hemolytic Streptococcus bacteria. (Option B ruled out) The bacteria trigger an immune response that leads to chronic inflammation and scarring of heart valves, commonly affecting the mitral valve. Order of valves affected in RHD : Mitral > aortic > tricuspid > pulmonary. Manifests only as myocarditis (Option C) : RHD involves all three layers of the heart (pancarditis) - endocarditis (valvulitis), myocarditis (Aschoff bodies), and pericarditis ("bread-and-butter" appearance). Associated with aortic valve rupture (Option D) : Chronic RHD causes valvular fibrosis and stenosis, most often mitral stenosis, not rupture. Aortic valve involvement causes regurgitation, not rupture.

References:

Robbins & Cotran, Pathologic Basis of Diseases, 10th Edition, Pages 561

↑ *Back to this question in Part A*

@Neet_pg_bot

Q3: A 65-year-old man was admitted to the emergency ward with severe, sudden-onset chest pain radiating to the left arm and profuse sweating. The ECG showed ST-segment elevation in precordial leads. The person succumbed after 3 hours. During the autopsy, his heart was taken out and immersed in a solution. The normal area of the heart turned brick-red, whereas the infarcted portion turned pale. Which of the following is a likely component of the solution? (Q859250)

A. Formalin

B. Triphenyl tetrazolium chloride

C. Ethanol

D. Glutaraldehyde

Correct Answer: B. Triphenyl tetrazolium chloride

Explanation: Triphenyl tetrazolium chloride (TTC) is a histochemical stain that differentiates viable from non-viable myocardium by reacting with dehydrogenases in active mitochondria. Viable myocardial tissue stains brick-red, while infarcted tissue, lacking dehydrogenase activity, remains pale and unstained. {{caption_text}} Incorrect Options: Formalin (Option A) is a fixative used for tissue preservation. It cannot differentiate between viable and infarcted myocardium. Ethanol (Option C) is a solvent and fixative used in histological procedures. It does not specifically stain or differentiate between viable and infarcted myocardial tissue. Glutaraldehyde (Option D) is a fixative used in electron microscopy. While it preserves cellular structures, it does not differentiate between viable and infarcted tissues.

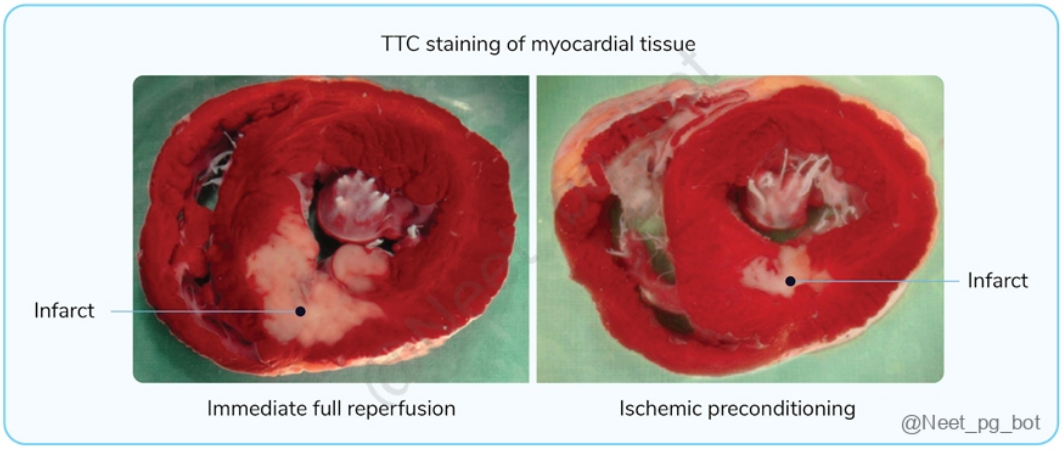

References:

Robbins & Cotran Pathologic Basis of Disease, 10th Edition, Page 505.

↑ *Back to this question in Part A*

@Neet_pg_bot

Q4: How is thrombosis initiated? (Q858519)

A. Platelet activation

B. Endothelial injury

C. Coagulation cascade

D. Vasoconstriction of vessels

Correct Answer: B. Endothelial injury

Explanation: Thrombosis is initiated by endothelial injury, which exposes underlying collagen and pro-coagulant factors, leading to platelet activation and adhesion. This triggers the coagulation cascade, resulting in thrombus

formation. Endothelial injury is considered the primary event that starts the sequence leading to thrombosis. Virchow’s triad is a concept used to explain the three primary factors that contribute to the development of thrombosis Endothelial Injury : Damage to the inner lining of blood vessels (endothelium) can lead to the exposure of underlying tissues, such as collagen and tissue factor, which activate the clotting process. Conditions like atherosclerosis, trauma, or inflammation can cause endothelial injury. Abnormal Blood Flow (Stasis or Turbulence) : Disruptions in normal blood flow, such as slow or stagnant blood flow (stasis) or turbulent flow, can promote clot formation. This is commonly seen in conditions like atrial fibrillation, prolonged immobility, or varicose veins. Hypercoagulability : An increased tendency of the blood to clot, which can be due to genetic factors (such as factor V Leiden mutation), acquired conditions (such as cancer or pregnancy), or certain medications that contribute to thrombosis.

References:

Robbins & Cotran Pathologic Basis of Disease, 10th Edition, Page 125,126

↑ *Back to this question in Part A*

@Neet_pg_bot

Q5: Which of the following features does the histology of the reperfused myocardium show? (Q854873)

A. Wavy fibres

B. Neutrophils in cardiac muscle

C. Swelling of cells

D. Eosinophilic contraction band

Correct Answer: D. Eosinophilic contraction band

Explanation: Eosinophilic contraction bands are a hallmark feature of reperfusion injury in the myocardium. Reperfusion injury: Intracellular calcium overload is the most likely the primary mechanism responsible for the reperfusion injury in this patient. During PCI, reperfusion of the occluded coronary artery can lead to a sudden influx of calcium into cardiomyocytes, known as calcium paradox , which can cause cell injury and dysfunction. This phenomenon is characterised by increased mitochondrial calcium levels, leading to mitochondrial permeability transition pore opening, mitochondrial dysfunction, and cell death. The presence of 'Contraction bands' in cardiac muscle tissue serves as histological markers of reperfusion injury. {{caption_text}} Morphological features of myocardium in MI: Time Gross Features Light Microscope Electron Microscope Reversible Injury 0– 1/2 hour None None Relaxation of myofibrils; glycogen loss; mitochondrial swelling Irreversible Injury 1/2 –4 hours None Usually none; variable waviness of fibres at the border; myocyte vacuolisation {{caption_text}} Sarcolemmal disruption; mitochondrial amorphous densities (Calcium in mitochondria) 4–12 hours Occasional dark mottling Early coagulative necrosis, oedema, haemorrhage 12–24 hours Dark mottling Ongoing coagulative necrosis; pyknosis of nuclei; myocyte hypereosinophilia; marginal contraction band necrosis; early neutrophilic infiltrate 1–3 days Mottling with yellow-tan infarct centre

Coagulative necrosis, with loss of nuclei and striations; brisk interstitial infiltrate of neutrophils (Acute inflammation) {{caption_text}} 3–7 days Hyperemic border; central yellow-tan softening Beginning disintegration of dead myofibers, with dying neutrophils; early phagocytosis of dead cells by macrophages at the infarct border (Chronic inflammation) 7–10 days Maximally yellow-tan and soft, with depressed red-tan margins Well-developed phagocytosis of dead cells; granulation tissue at margins (Repair) {{caption_text}} 10–14 days Red-gray depressed infarct borders Well-established granulation tissue with new blood vessels and collagen deposition 2–8 weeks Grey-white scar, progressive from the border toward the core of the infarct Increased collagen deposition, with decreased cellularity >2 months Scarring complete Dense collagenous scar {{caption_text}}

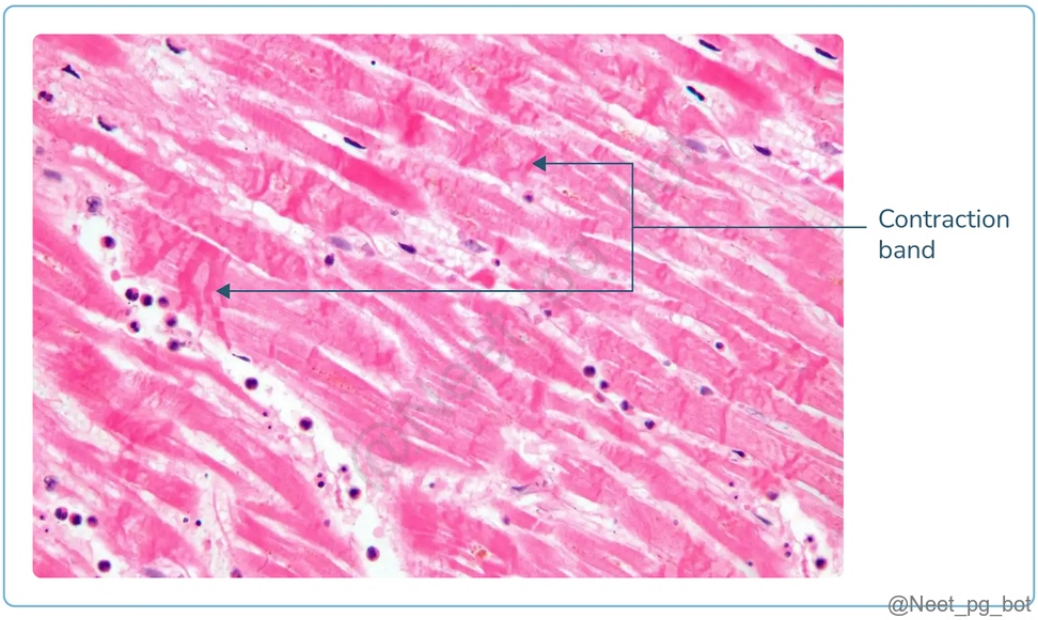

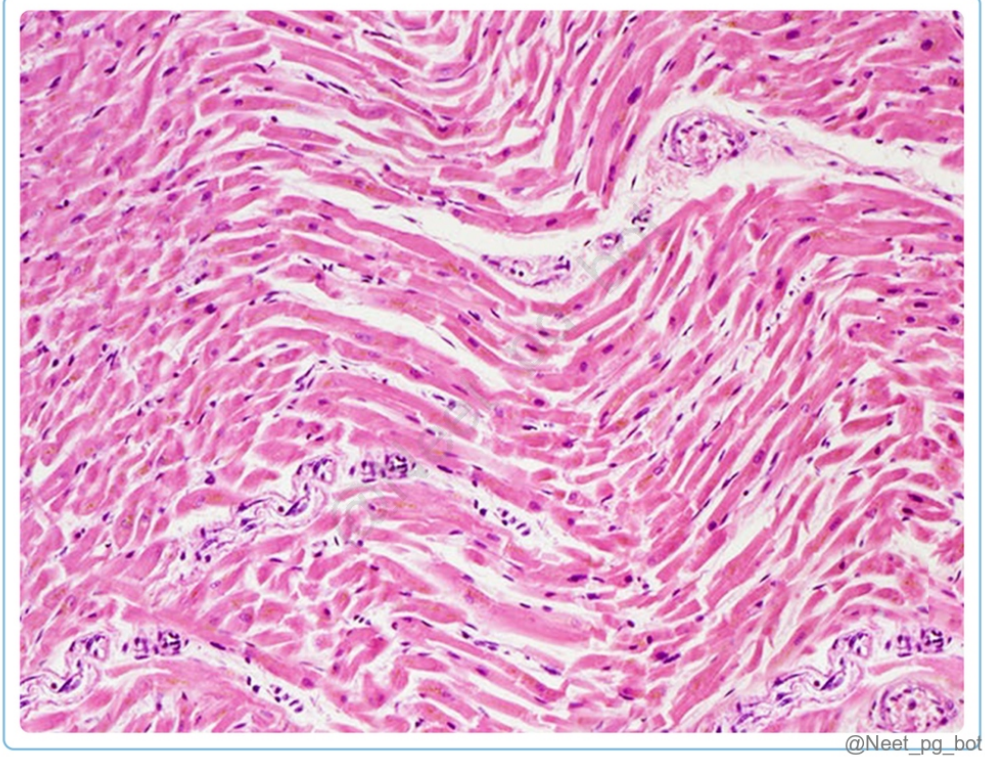

@Neet_pg_bot

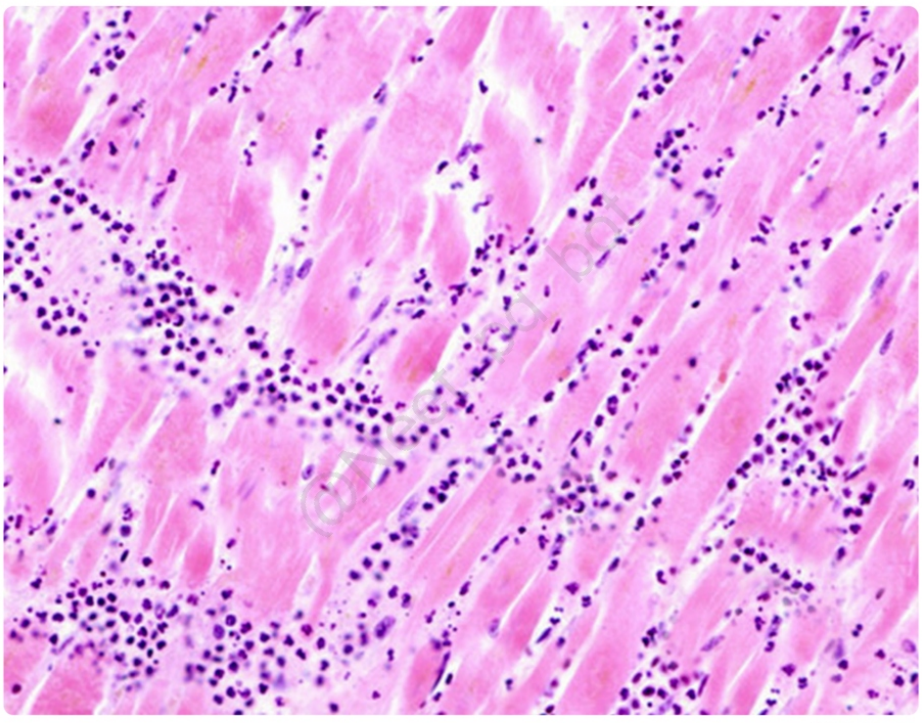

@Neet_pg_bot

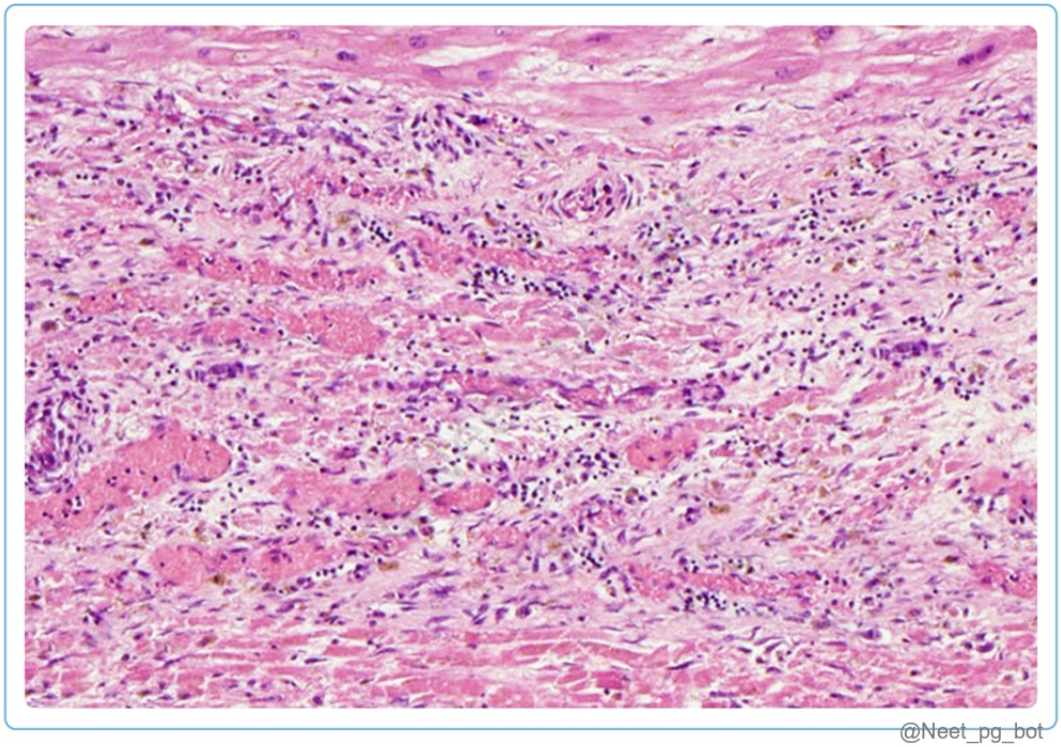

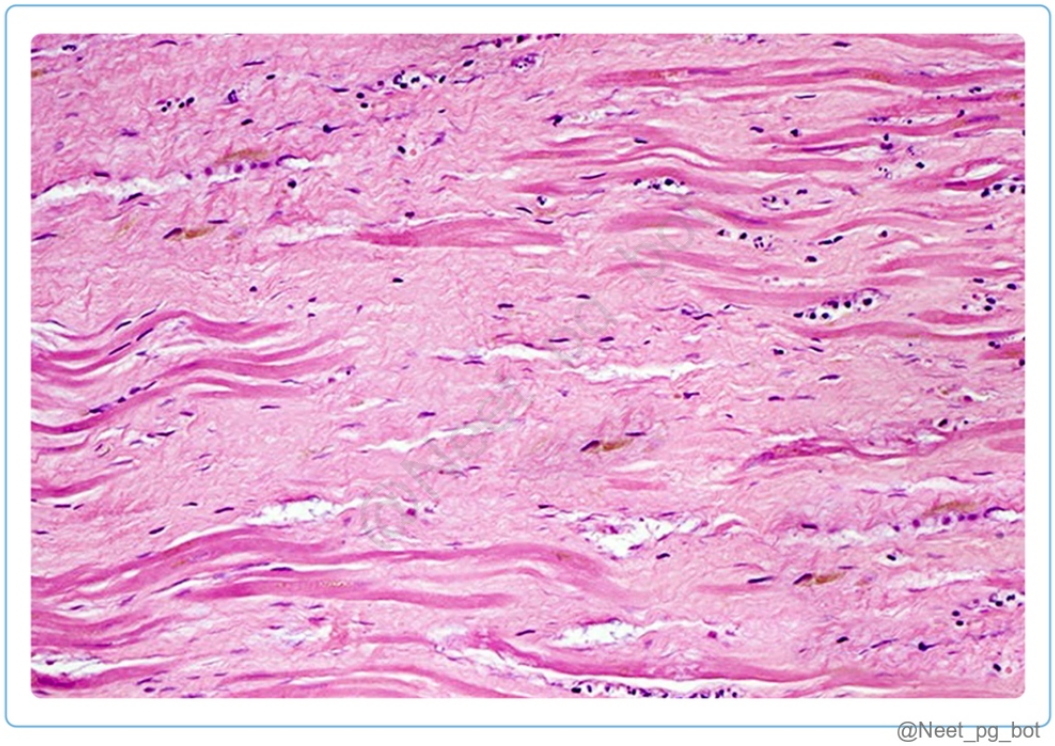

References:

Robbins & Cotran Pathologic Basis of Disease, 10th Edition, Page 52,56,547

↑ *Back to this question in Part A*

@Neet_pg_bot

Q6: A 3-year-old child has been brought to the hospital with complaints of fever, rash, and swelling of her hands and feet for the past 5 days. There is desquamative skin rash, edema of hands and feet, erythema of palms and soles, oral erythema, and cervical lymphadenopathy. What is the likely condition? (Q854849)

A. Kawasaki disease

B. Measles

C. Scarlet fever

D. Henoch-Schonlein purpura

Correct Answer: A. Kawasaki disease

Explanation: The classic features of this disease are the swelling of hands and feet, rash, and the other symptoms described in the case, making Kawasaki disease the most likely diagnosis. It is an acute, febrile, usually self-limited illness of infancy and childhood associated with large- to medium-sized vessel arteritis . 80% of the patients are younger than 4 years of age. It presents with fever, conjunctival injection, desquamative rash, erythema of palms and soles, oral erythema (strawberry tongue), and cervical lymphadenopathy. Coronary arteritis can result in aneurysms that rupture or thrombose, causing myocardial infarction . In genetically susceptible persons, a variety of infectious agents (mostly viral) have been posited to trigger the disease. The vasculitis may result from a delayed-type hypersensitivity response directed against cross-reactive or newly uncovered vascular antigens. Subsequent cytokine production and polyclonal B-cell activation result in autoantibodies to ECs and SMCs that precipitate the vasculitis. Clinical Features Mnemonic: CREAM-F. C onjunctivitis (non-exudative & non-purulent). R ash (Polymorphous, non-vesicular). E dema (or erythema of hands & feet). A denopathy (Cervical, often unilateral & non-suppurative). M ucosal involvement (Erythema or fissures or crusting at times, referred to as strawberry tongue). F ever (Most important constitutional symptom) . The image below shows the strawberry tongue. {{caption_text}} Measles (Option B) is a viral infection characterised by a maculopapular rash, Koplik spots in the mouth, and fever. It does not present with the swelling of hands and feet or the specific oral erythema seen in Kawasaki disease. Scarlet fever (Option C) is caused by a group A Streptococcus infection , typically presenting with a sandpaper-like rash, fever, and sore throat. It does not cause the desquamative rash or the extensive lymphadenopathy seen in Kawasaki disease. Henoch-Schonlein purpura (Option D) is a small vessel vasculitis commonly presenting with purpura, abdominal pain, and arthritis. The signs of erythema of palms and soles and the specific rash described are not characteristic of this condition.



References:

Robbins & Cotran Pathologic Basis of Disease, 10th Edition, Page 513

↑ *Back to this question in Part A*

@Neet_pg_bot

Q7: Large, friable, irregular vegetation on heart valves is seen in which condition? (Q854841)

A. Infective endocarditis

B. Rheumatic heart disease

C. Libman-Sacks endocarditis

D. Non-bacterial thrombotic carditis

Correct Answer: A. Infective endocarditis

Explanation: Infective endocarditis is characterised by the presence of large, friable, and irregular vegetations on heart valves. These vegetations are composed of a mixture of microorganisms, fibrin, and inflammatory cells.

Condition Vegetations and site Rheumatic heart disease (Option B) Small, warty, sterile vegetations along the line of closure of valve leaflets. Infective Endocarditis Large, bulky, infected, friable, irregular mass along the line of closure or on valvular cusps, more on the atrial side. Non-bacterial Thrombotic Endocarditis (Option D) Small, bland, sterile vegetation along the line of closure. Libman-Sacks Endocarditis (Option C) Small or medium-sized sterile vegetations on either or both sides of valvular leaflets, most commonly on the lower side.

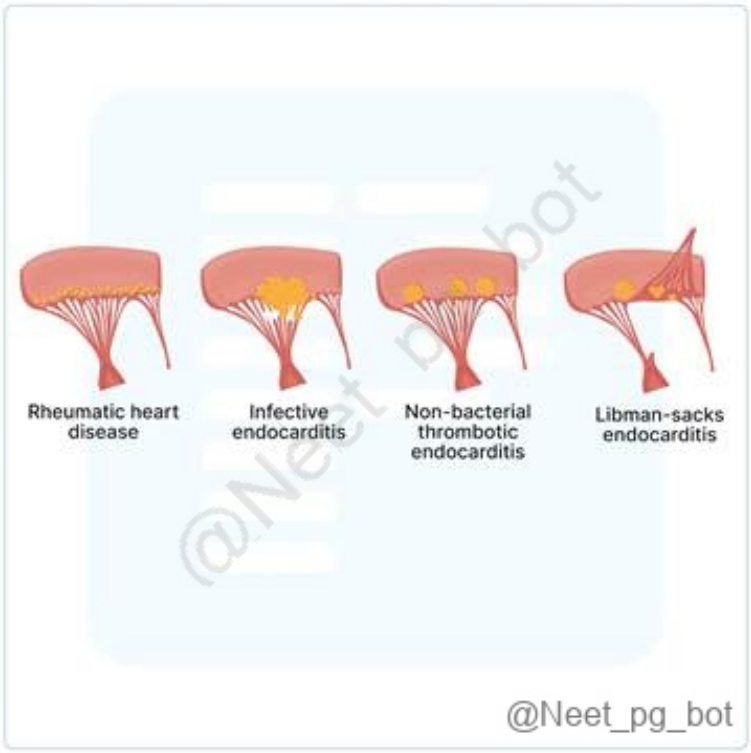

References:

Robbins & Cotran Pathologic Basis of Disease, 10th Edition, Page 562

↑ *Back to this question in Part A*

@Neet_pg_bot

Q8: A 34-year-old female patient presented to the outpatient department with migratory arthritis, and examination revealed a pan-systolic murmur. An echocardiography was performed, which was suggestive of mitral regurgitation. A biopsy specimen was obtained, and the image is provided below. What is the most likely lesion shown in the histopathology slide? {{caption_text}} (Q856158)

A. Aschoff’s bodies

B. Epithelioid granuloma

C. Granulomatous vasculitis

D. Granuloma inguinale

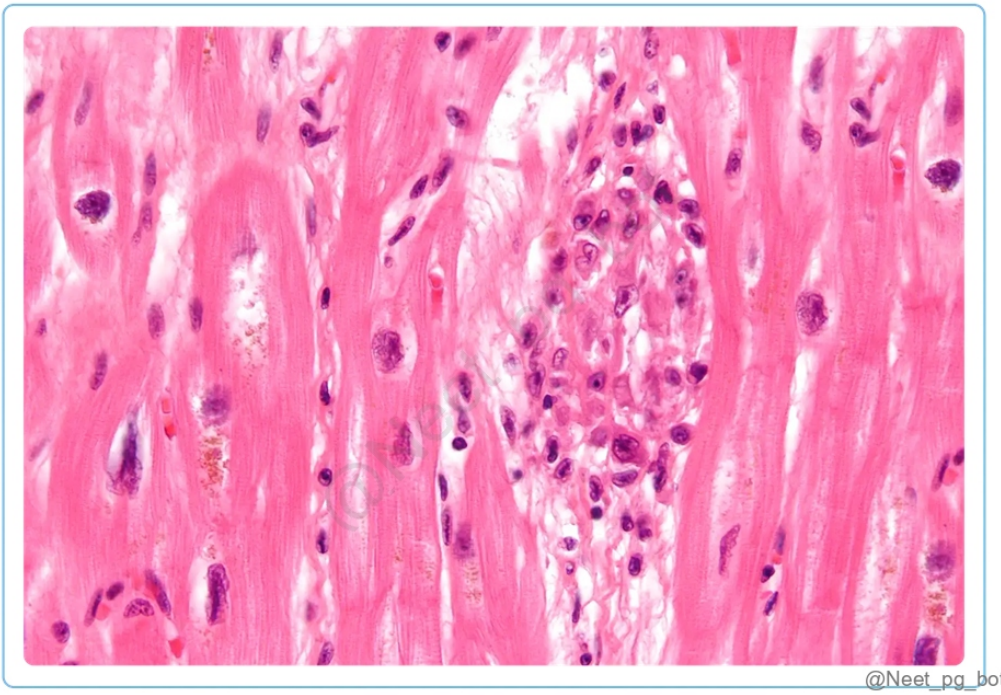

Correct Answer: A. Aschoff’s bodies

Explanation: Aschoff's bodies are the hallmark histopathological findings in rheumatic fever . This patient’s symptoms of migratory arthritis, pan-systolic murmur, and mitral regurgitation, along with the characteristic granulomatous lesions, point to rheumatic heart disease caused by rheumatic fever . Histopathological features of RHD Aschoff bodies They are focal areas of inflammation with infiltration of lymphocytes, plasma cells and activated macrophages or histiocytes. An endomyocardial biopsy showing Aschoff's bodies helps in confirming the diagnosis of RHD. {{caption_text}} Anitschkow cells They are activated macrophages with elongated and wavy nuclei commonly found within Aschoff bodies. They appear as caterpillars in longitudinal sections (hence also called Caterpillar cells) and owls in cross sections. {{caption_text}} Fibrinoid necrosis This is seen in areas of the valves affected by inflammation. Granulation tissue is seen in cases of repair. It comprises proliferating blood vessels, inflammatory cells and fibroblasts. Epithelioid granuloma (Option B) is a characteristic feature of tuberculosis and other granulomatous diseases (like sarcoidosis). These granulomas are not typically seen in rheumatic fever. Granulomatous vasculitis (Option C) refers to a condition where there is inflammation of the blood vessels, and granulomas form in the vessel walls. This is typically seen in diseases like Wegener's granulomatosis or Takayasu arteritis , not rheumatic fever. Granuloma inguinale (Option D) is a sexually transmitted infection caused by Klebsiella granulomatis . It causes ulcerative lesions in the genital area and does not lead to heart murmurs, mitral regurgitation, or migratory arthritis.

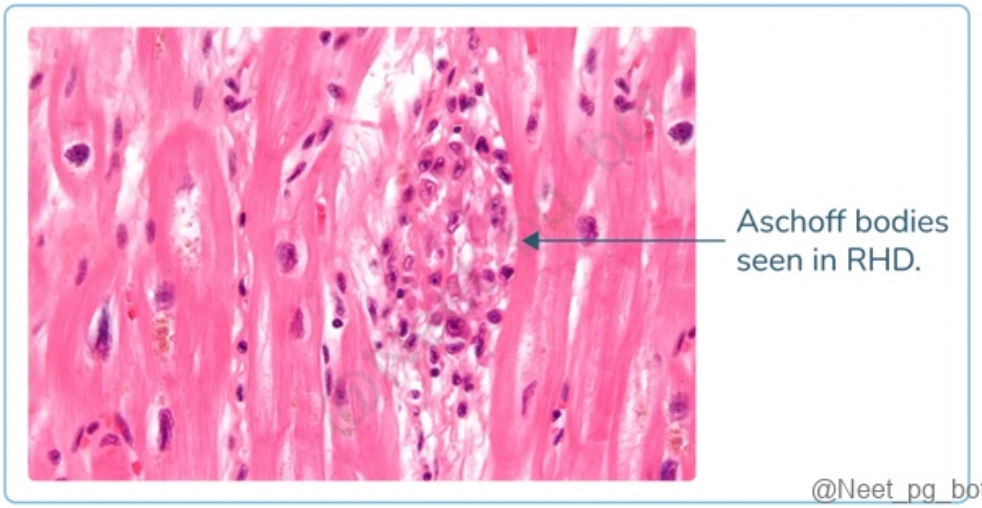



References:

Robbins and Cotran, Pathologic Basis of Disease, 10th Edition, Page 56

↑ *Back to this question in Part A*

@Neet_pg_bot

Q9: A child is presenting with palpable blanching purpura, abdominal pain, and pain in the knee joint resulting from arthritis. Urine examination showed hematuria and proteinuria. What is the most likely diagnosis? (Q856146)

A. Immune thrombocytopenic purpura

B. Dengue

C. Churg-Strauss syndrome

D. Henoch-Schonlein purpura

Correct Answer: D. Henoch-Schonlein purpura

Explanation: The child’s presentation of palpable blanching purpura, abdominal pain, arthritis (joint pain), hematuria and proteinuria is most consistent with Henoch-Schonlein purpura (HSP). Henoch-Schönlein Purpura (IgA vasculitis) Definition It is a systemic vasculitis characterised by inflammation of small blood vessels , primarily affecting children, but can also occur in adults. Etiology Often follows upper respiratory tract infections Pathology Immune complex deposition of IgA in small blood vessels leads to inflammation Clinical features Inflammation of small blood vessels primarily affects children but can also occur in adults. Associated with elevated serum IgA levels Skin : Palpable purpura, most prominently on the lower limbs and buttocks. Musculoskeletal : Arthralgia or arthritis, often transient and non-deforming. Gastrointestinal : Abdominal pain, nausea, vomiting, and sometimes gastrointestinal bleeding, Intussusception is a severe but rare complication. Renal : Hematuria, proteinuria, and red blood cell casts in urine. It can progress to IgA nephropathy in severe cases. Management Supportive care : Hydration, rest, and pain management with NSAIDs for arthralgia. Glucocorticoids : For severe abdominal pain, renal involvement, or systemic symptoms. Intussusception : Surgical intervention if required. Nephritis : Immunosuppressants (e.g., cyclophosphamide) in severe cases. Immune thrombocytopenic purpura (Option A) is characterised by isolated thrombocytopenia without significant involvement of other systems. The purpura is typically non-blanching and is not associated with arthritis, abdominal pain, or renal symptoms. Dengue (Option B) often presents with high fever, rash, severe headache, and retro-orbital pain. While petechiae can occur, Dengue is not commonly associated with purpura or renal involvement. Churg-Strauss syndrome (Option C) is also called Eosinophilic Granulomatosis with Polyangiitis and is a vasculitis that is associated with asthma , eosinophilia , and granulomatous inflammation . It is part of the group of ANCA-associated vasculitis . It normally does not present with palpable purpura or renal involvement, as seen in HSP.

References:

Robbins and Cotran, Pathologic Basis of Disease, 10th Edition, Page 509

↑ *Back to this question in Part A*

@Neet_pg_bot

Q10: What is the gold standard investigation for the diagnosis of myocarditis? (Q856719)

A. Endo-myocardial biopsy

B. Magnetic Resonance Imaging

C. Brain Natriuretic Peptide

D. LDH1 to LDH2 ratio

Correct Answer: A. Endo-myocardial biopsy

Explanation: Endo-myocardial biopsy is considered the gold standard investigation for the diagnosis of myocarditis. It involves obtaining a small tissue sample from the endocardium or the myocardium to examine it under a microscope. This biopsy allows for direct visualization of the cardiac tissue and assessment of cellular inflammation, the presence of viral particles, and other histopathological changes characteristic of myocarditis. Myocarditis It is a diverse group of pathologic entities in which infectious microorganisms and/or a primary inflammatory process cause myocardial injury. Pathogenesis Infections: Viruses (e.g., Coxsackievirus, Echovirus, Influenza, HIV, Cytomegalovirus) Chlamydiae (e.g., Chlamydophila psittaci) Rickettsiae (e.g., Rickettsia typhi, Typhus fever) Bacteria (e.g., Corynebacterium diphtheriae, Neisseria meningococcus, Borrelia) Fungi (e.g., Candida) Protozoa (e.g., Trypanosoma cruzi [Chagas disease], toxoplasmosis) Helminths (e.g., Trichinosis) Immune-Mediated Reactions Postviral Poststreptococcal (Rheumatic fever) Systemic lupus erythematosus Drug hypersensitivity (e.g., methyldopa, sulfonamides) Transplant rejection Immune checkpoint inhibitor therapies Unknown Sarcoidosis Giant cell myocarditis Clinical features It can be asymptomatic (recovery without sequelae) Heart failure Arrhythmias Sudden death Symptoms include fatigue, dyspnea, palpitations, precordial discomfort, and fever. Magnetic Resonance Imaging (Option B) can offer valuable supportive evidence for diagnosing myocarditis, but it is not regarded as the gold standard. Cardiac MRI can reveal myocardial oedema, inflammation, and tissue characterization through specific sequences like T2-weighted imaging and late gadolinium enhancement. Brain Natriuretic Peptide (BNP) (Option C) is a hormone secreted by the heart in response to increased stretching of the cardiac chambers, commonly observed in conditions like heart failure. Although BNP levels can be elevated in myocarditis due to associated cardiac dysfunction, it is not a specific test for diagnosing myocarditis. LDH1 to LDH2 ratio (Option D) is not a specific diagnostic marker for myocarditis. Lactate dehydrogenase (LDH) is an enzyme present in various tissues, including the heart. In myocarditis, LDH levels may be elevated due to myocardial injury.

References:

Robbins & Cotran Pathologic Basis of Disease,10th Edition, Page 575-577.

↑ *Back to this question in Part A*

@Neet_pg_bot

Q11: A patient presented with complaints of dyspnea on exertion for 1 month. Echocardiography showed the presence of mitral stenosis and left ventricular

hypertrophy. Identify the histopathological finding given below and the probable diagnosis. (Q855407)

A. Aschoff body; Rheumatic heart disease

B. Calcification of valve; Mitral stenosis

C. Granuloma; Sarcoidosis

D. Non-caseating granuloma; Tuberculosis

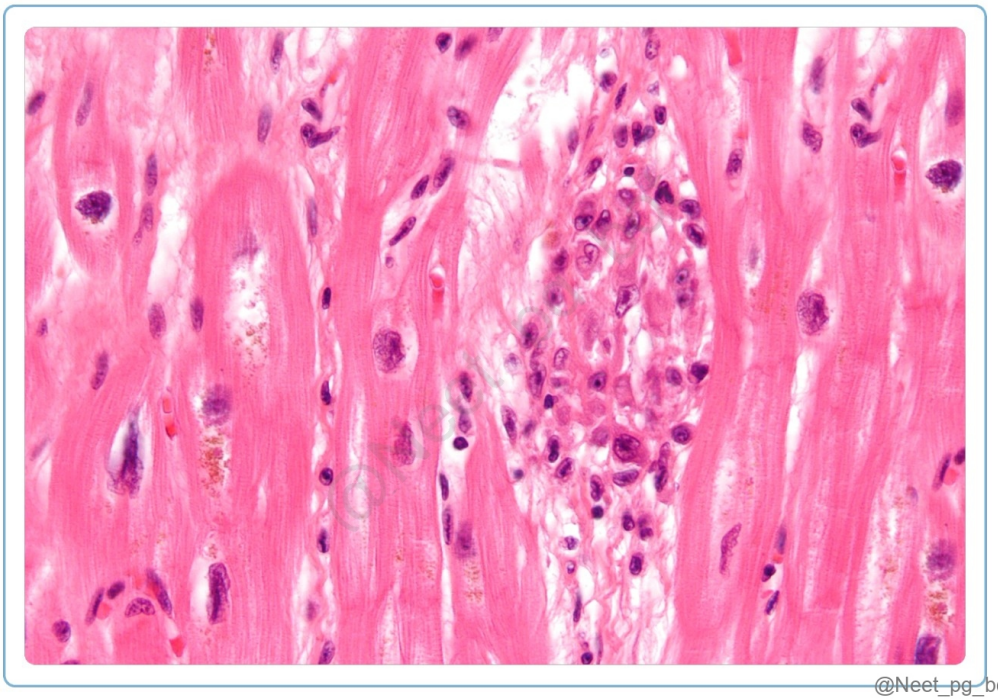

Correct Answer: A. Aschoff body; Rheumatic heart disease

Explanation: The given scenario, featuring dyspnea on exertion for one month, mitral stenosis and left ventricular hypertrophy, along with histopathological evidence of Aschoff bodies, is consistent with a diagnosis of Rheumatic Heart Disease (RHD). It is caused by an autoimmune reaction following a Group A Streptococcus infection. Predisposing factor: Acute Rheumatic fever typically occurs 2-3 weeks after the onset of Streptococcal pharyngitis (Group A beta-hemolytic Streptococci). Pathogenesis: Acute rheumatic fever (ARF) results from an immune response to group A streptococcal antigens, particularly the M proteins, which can cross-react with host proteins, including cardiac self-antigens. This molecular mimicry produces antibodies and activates CD4+ T cells that ultimately cause inflammation and tissue damage, particularly in the heart. Histopathological findings: Involve changes in the heart valves due to chronic inflammation and scarring. They include: Aschoff bodies: Consist of areas of chronic inflammation infiltrated with lymphocytes, plasma cells, and activated macrophages or histiocytes known as Anitshkow cells. Anitshkow cells: These are activated macrophages with a characteristic “caterpillar-like appearance” due to the presence of a central, slender and wavy nucleus. Fibrinoid necrosis results from the deposition of fibrin and inflammatory cells and is seen in areas of the valves affected by inflammation. {{caption_text}} {{caption_text}} Complications of RHD: Valvular stenosis and regurgitation Heart failure

Arrhythmias, particularly atrial fibrillation in the setting of mitral stenosis Pulmonary arterial hypertension (PAH) Recurrence of acute rheumatic fever Cardio-embolic stroke Cardiomyopathy Infective endocarditis Ruptured heart valve. Calcification of valve; Mitral stenosis (Option B): Mitral stenosis is a narrowing of the mitral valve opening, caused by valve calcification, which restricts blood flow from the left atrium to the left ventricle, leading to symptoms such as shortness of breath, fatigue, and heart palpitations. {{caption_text}} Granuloma; Sarcoidosis (Option C): Sarcoidosis is an inflammatory condition marked by the development of granulomas. While the exact cause remains unknown, it is thought to result from an abnormal immune response, potentially triggered by genetic and environmental factors. Histologically, it presents with non-caseating granuloma or naked granuloma (lymphocytic collar absent). Asteroid bodies (stellate, pink-staining inclusions in giant cells) are commonly found but not specific. {{caption_text}} Non-caseating granuloma; Tuberculosis (Option D): Tuberculosis is a bacterial infection caused by Mycobacterium tuberculosis, characterized histologically by a granulomatous inflammatory response with both caseating and non-caseating tubercles. {{caption_text}}

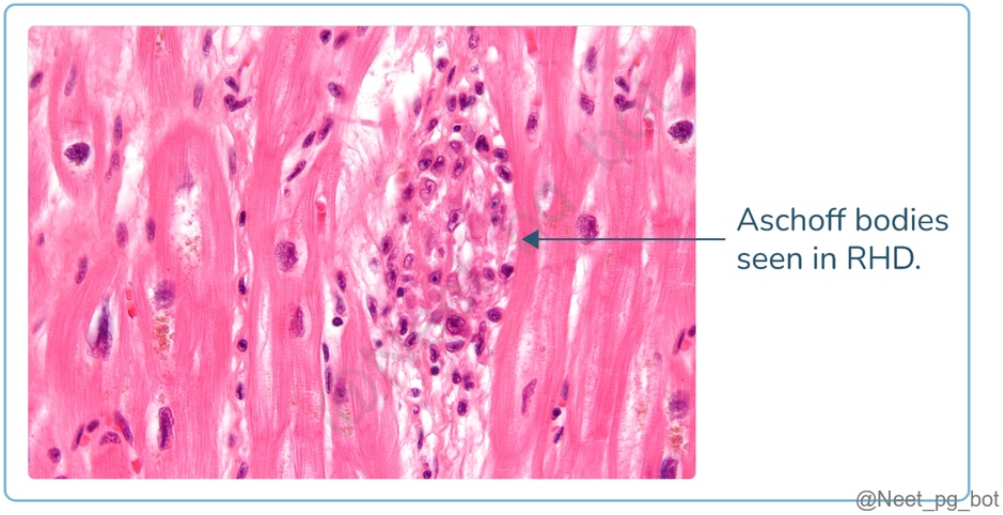



@Neet_pg_bot

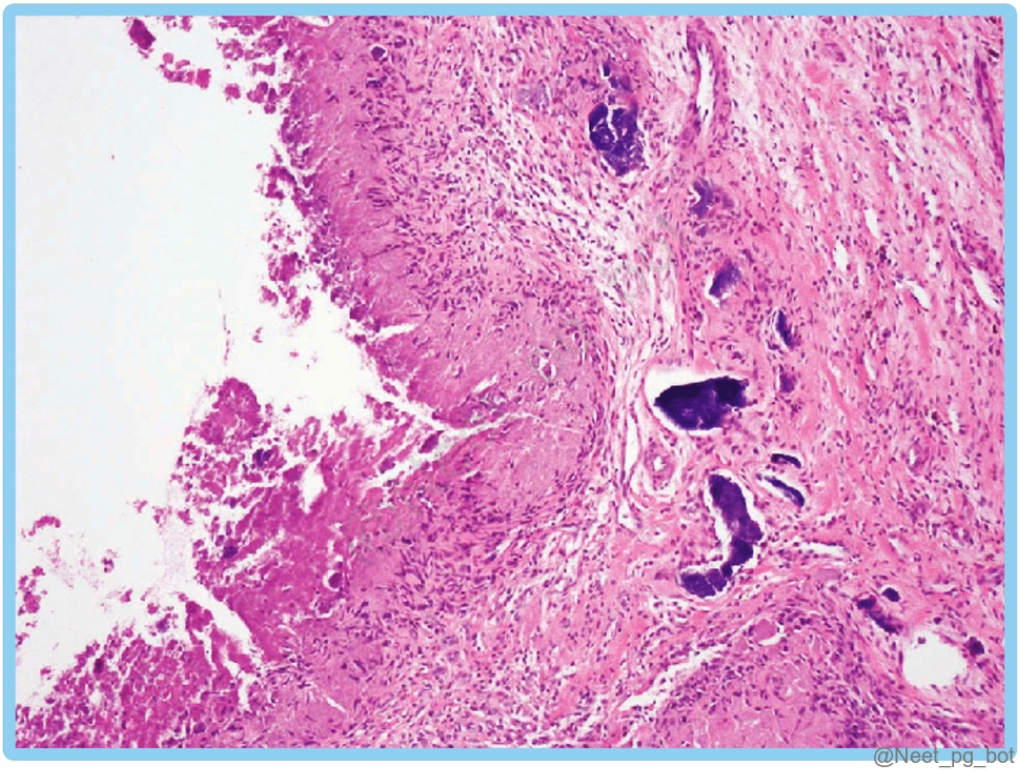

@Neet_pg_bot

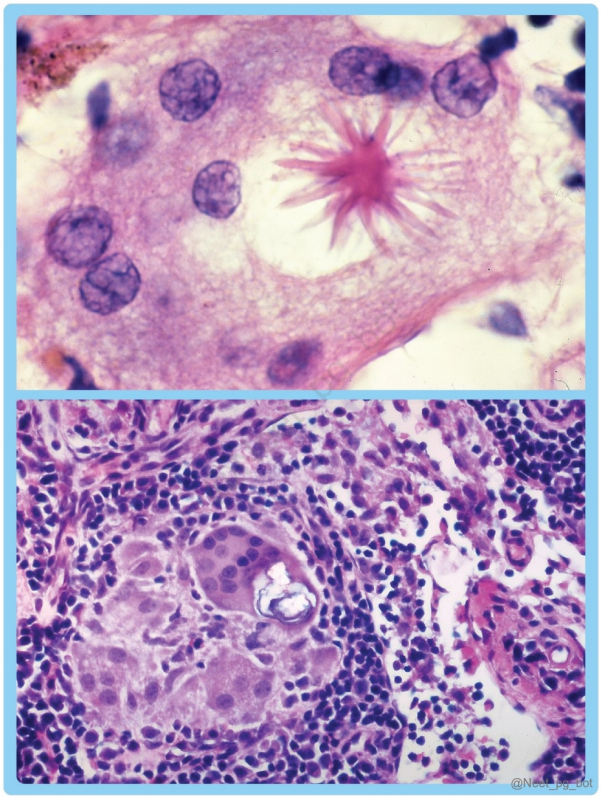

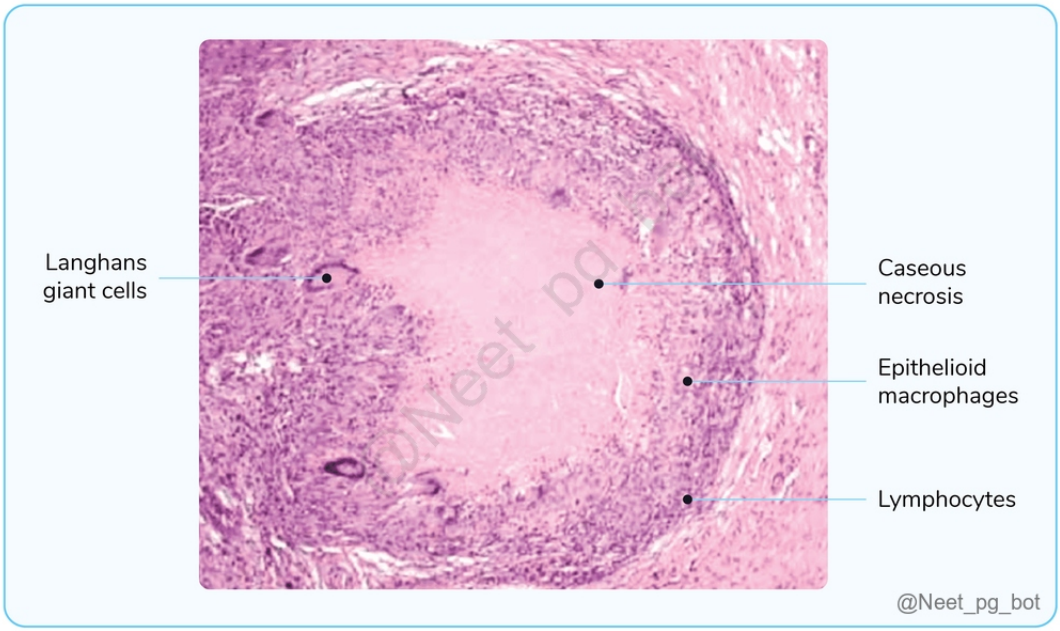

References:

Robbins & Cotran Pathologic Basis of Diseases, 10th Edition, Page 560-563.

↑ *Back to this question in Part A*

@Neet_pg_bot

Q12: Which of the following histopathological findings is not seen 12 hours after an ischemic injury to the heart? (Q857177)

A. Karyorrhexis of myocytes

B. Neocapillary invasion of myocytes

C. Hyper-eosinophilia of myocytes

D. Coagulation necrosis of myocytes

Correct Answer: B. Neocapillary invasion of myocytes

Explanation: Neocapillaries appear as part of granulation tissue , which develops 7–10 days after MI. Too early to see new vessel formation at 12 hours. Time Gross Features Light Microscope Electron Microscope Reversible Injury 0– 1/2 hour None None Relaxation of myofibrils; glycogen loss; mitochondrial swelling Irreversible Injury 1/2 –4 hours None Usually none; variable waviness of fibres at the border; myocyte vacuolisation {{caption_text}} Sarcolemmal disruption; mitochondrial amorphous densities (Calcium in mitochondria) 4–12 hours Occasional dark mottling Early coagulative necrosis, oedema, haemorrhage 12–24 hours Dark mottling Ongoing coagulative necrosis; pyknosis of nuclei; myocyte hypereosinophilia; marginal contraction band necrosis; early neutrophilic infiltrate 1–3 days Mottling with yellow-tan infarct centre Coagulative necrosis, with loss of nuclei and striations; brisk interstitial infiltrate of neutrophils (Acute inflammation) {{caption_text}} 3–7 days Hyperemic border; central yellow-tan softening Beginning disintegration of dead myofibers, with dying neutrophils; early phagocytosis of dead cells by macrophages at the infarct border (Chronic inflammation) 7–10 days Maximally yellow-tan and soft, with depressed red-tan margins Well-developed phagocytosis of dead cells; granulation tissue at margins (Repair) {{caption_text}} 10–14 days Red-gray depressed infarct borders Well-established granulation tissue with new blood vessels and collagen deposition. 2–8 weeks Grey-white scar, progressive from the border toward the core of the infarct Increased collagen deposition, with decreased cellularity. >2 months Scarring complete Dense collagenous scar {{caption_text}}

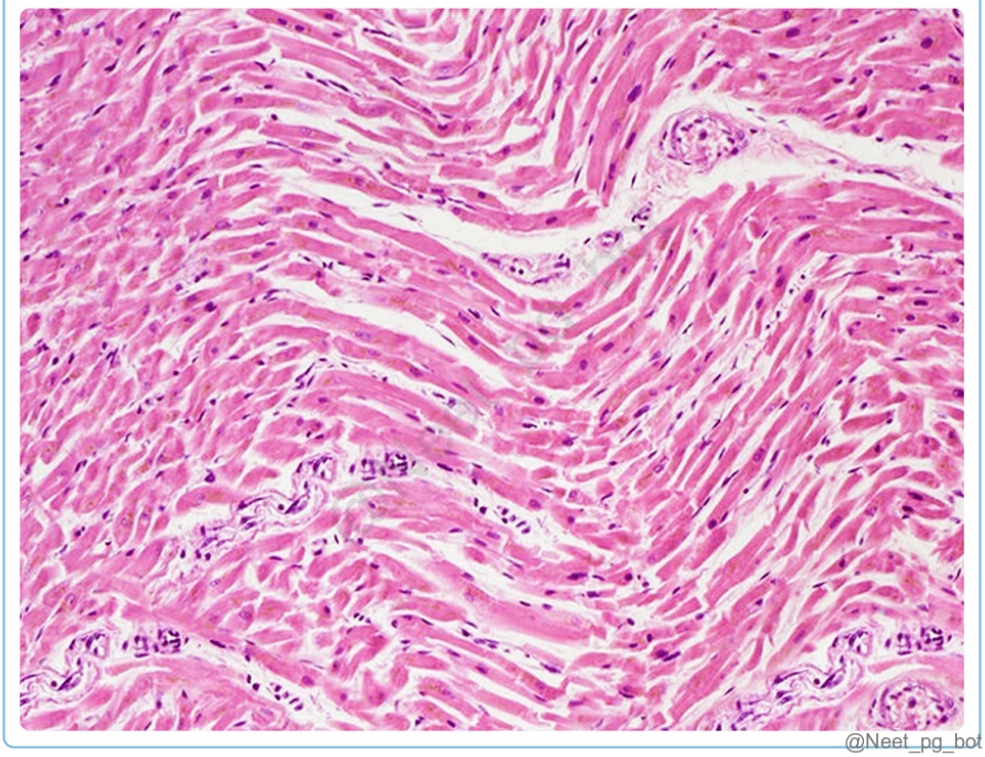

@Neet_pg_bot

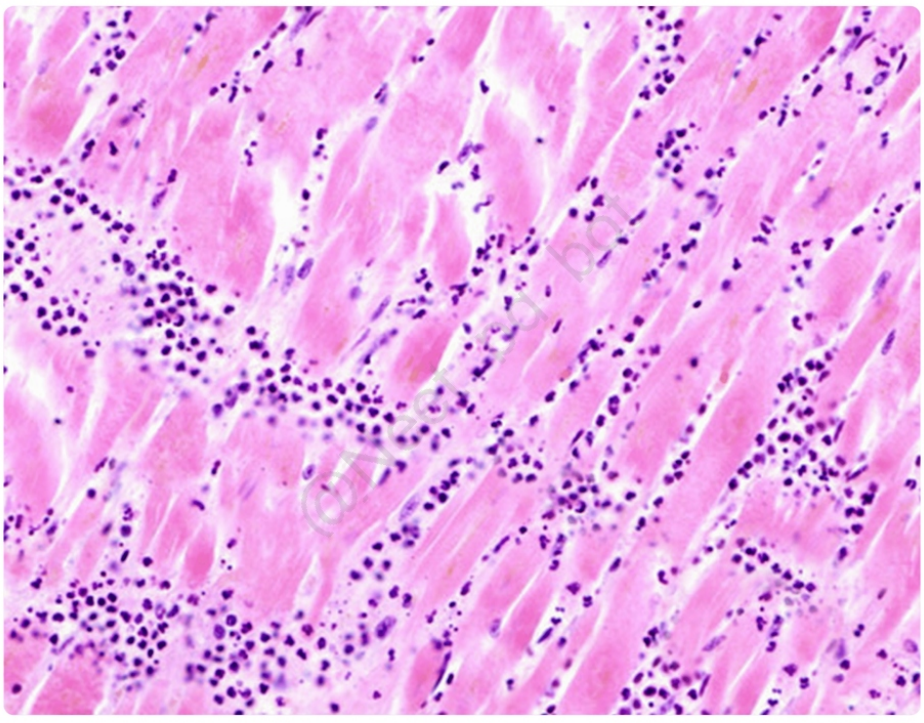

@Neet_pg_bot

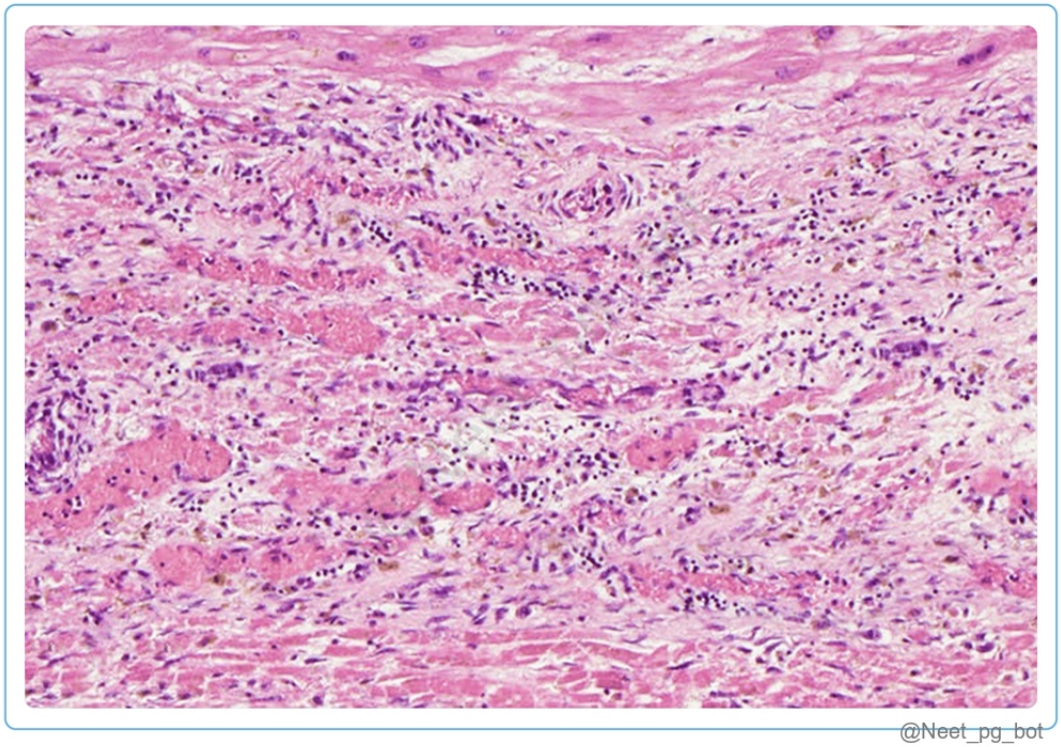

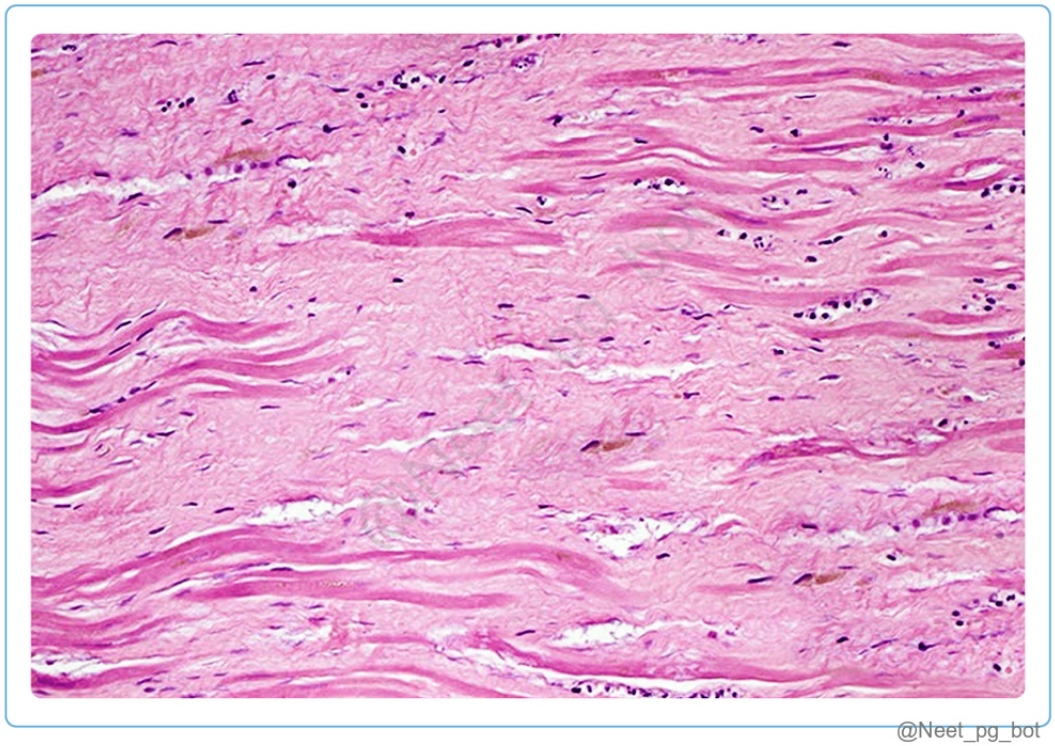

References:

Robbins and Cotran Pathologic Basis of Disease,10th Edition, Page 547

↑ *Back to this question in Part A*

@Neet_pg_bot

Q13: A 65-year-old man dies due to a myocardial infarction. Which stains can be used to see the infarct in the heart while conducting an autopsy? (Q858094)

A. Oil Red O

B. Triphenyl tetrazolium chloride

C. Sudan black B

D. Masson's trichrome

Correct Answer: B. Triphenyl tetrazolium chloride

Explanation: Triphenyl tetrazolium chloride (TTC) is a stain commonly used in autopsies to identify myocardial infarction (MI). In myocardial infarction (MI), within the first 4 hours , gross examination may not show any visible infarcted area. However, immersion of tissue slices in TTC solution can highlight the necrotic area. This histochemical stain imparts a brick-red colour to intact, non-infarcted myocardium with preserved lactate dehydrogenase activity. Conversely, infarcted tissue appears as an unstained pale zone because of leakage of dehydrogenases through the damaged membranes of dead cells. {{caption_text}} {{caption_text}} Incorrect Options: Oil Red O (Option A) stain optimally detects lipids in frozen sections by staining them bright red and is commonly used to detect fat accumulation or atherosclerotic plaques, but it is not used for identifying infarcts in myocardial tissue. Sudan black B (Option C) is a lipid-specific stain primarily used to identify lipid-rich substances by staining them black , but it does not detect myocardial infarction. Masson's trichrome (Option D) stain is used to differentiate collagen fibres (stain blue) from other tissue components. It is not specific for visualising glycogen.

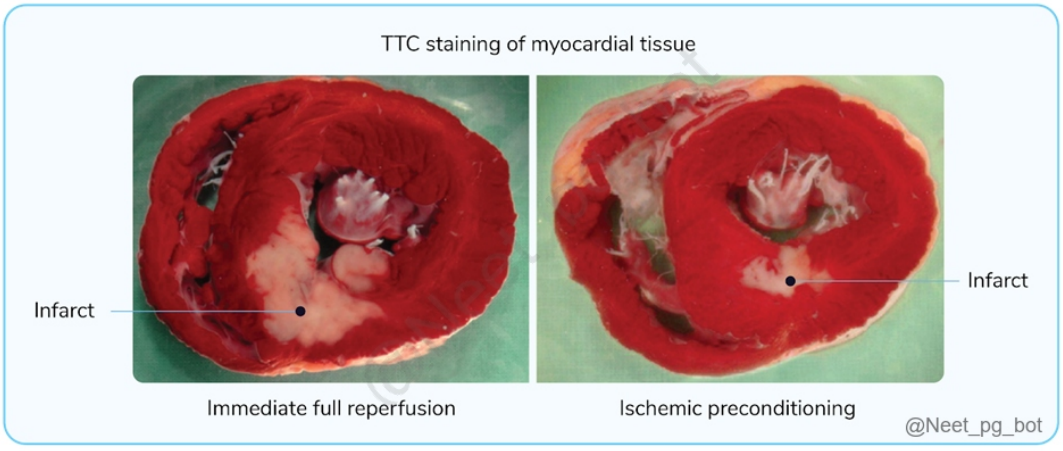



References:

Robbins and Cotran Pathologic Basis of Disease,10th Edition, Pages 548, 62, 63

↑ *Back to this question in Part A*

@Neet_pg_bot

Q14: A 34-year-old female patient presented to the outpatient department with migratory arthritis, and examination revealed a pan-systolic murmur. An echocardiography was performed, which was suggestive of mitral regurgitation. A biopsy specimen was obtained, and the image is provided below. What is the most likely lesion shown in the histopathology slide? (Q858083)

A. Aschoff's bodies

B. Epithelioid granuloma

C. Granulomatous vasculitis

D. Granuloma inguinale

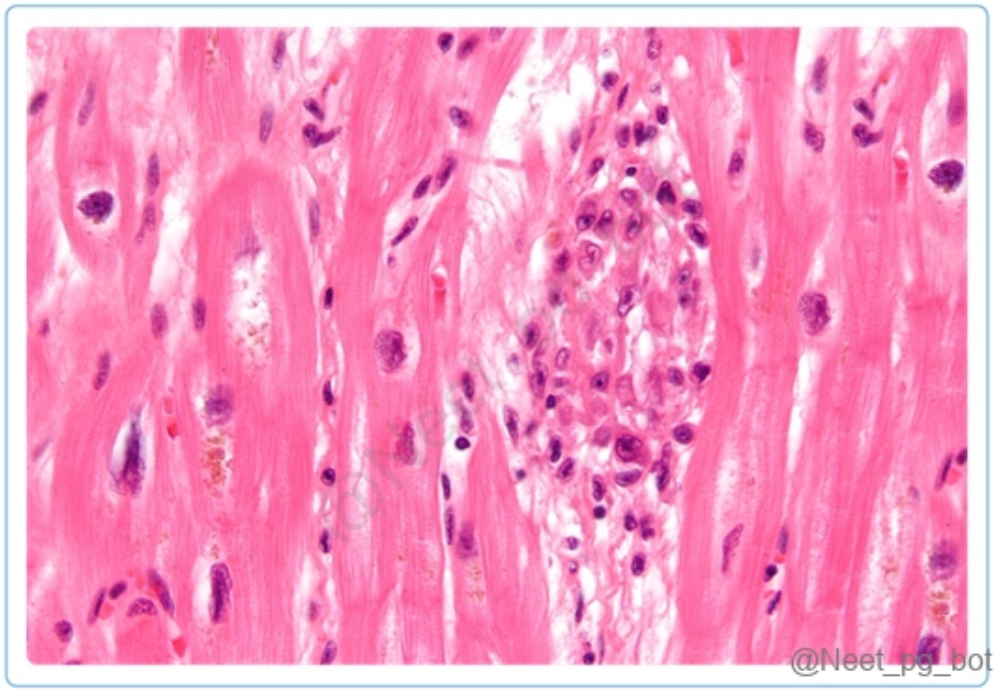

Correct Answer: A. Aschoff’s bodies

Explanation: This patient's symptoms of migratory arthritis, pan-systolic murmur (mitral regurgitation), and Aschoff bodies on biopsy are indicative of rheumatic fever , a complication of Group A Streptococcus throat infection. Histopathological features of RHD: Aschoff bodies are focal areas of inflammation with infiltration of lymphocytes, plasma cells and activated macrophages or histiocytes. An endomyocardial biopsy showing Aschoff's bodies helps in confirming the diagnosis of RHD. Anitschkow cells or Caterpillar cells are activated macrophages with elongated and wavy nuclei commonly found within Aschoff bodies. Fibrinoid necrosis is seen in areas of the valves affected by inflammation. Note: Granulation tissue is seen in cases of repair. It comprises proliferating blood vessels, inflammatory cells and fibroblasts. {{caption_text}} Incorrect Options: Epithelioid granuloma (Option B) is typically seen in granulomatous conditions like tuberculosis or sarcoidosis . The clinical presentation given does not align with these conditions. Granulomatous vasculitis (Option C) refers to inflammation of blood vessels with granuloma formation, often seen in diseases like Wegener’s granulomatosis , but again, the clinical signs do not point to these disorders. Granuloma inguinale (Option D), also called Donovanosis, is a sexually transmitted infection caused by Klebsiella granulomatis and typically presents with genital ulcers.

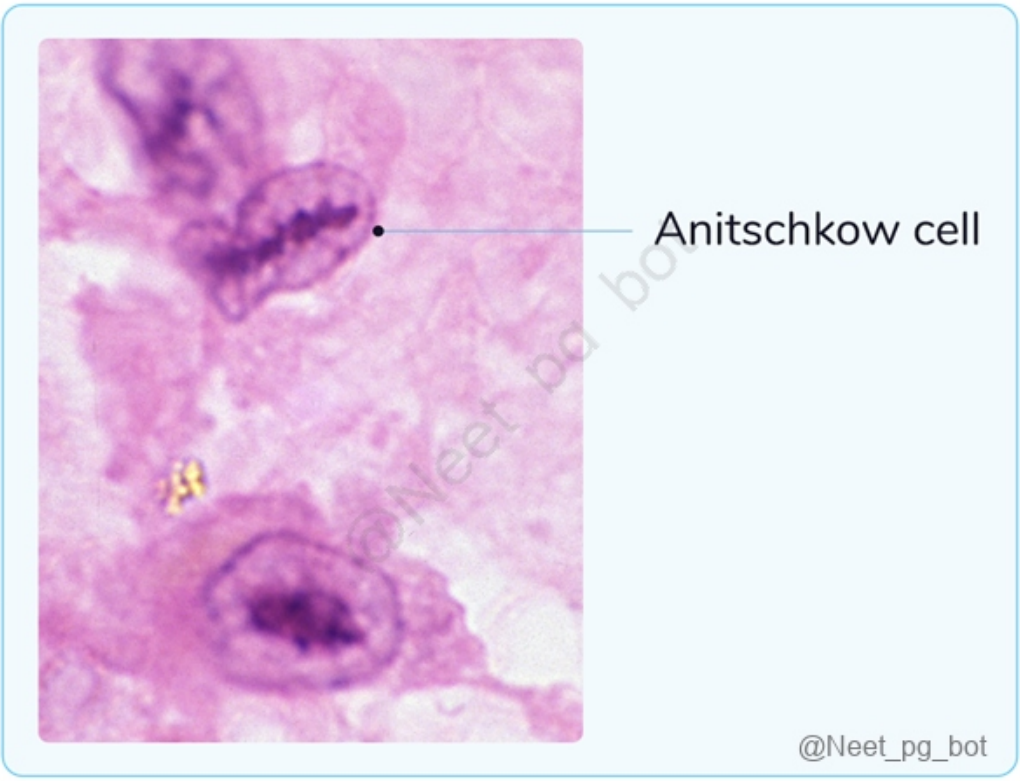

References:

Robbins and Cotran Pathologic Basis of Disease,10th Edition, Page 561

↑ *Back to this question in Part A*

@Neet_pg_bot

Q15: A 5-year-old child presents with fever, fatigue, and left ventricular dysfunction. An endomyocardial biopsy is shown below. What is the most likely diagnosis? (Q855420)

A. Acute rheumatic fever

B. Chagas cardiomyopathy

C. Pyogenic myocarditis

D. Lymphocytic myocarditis

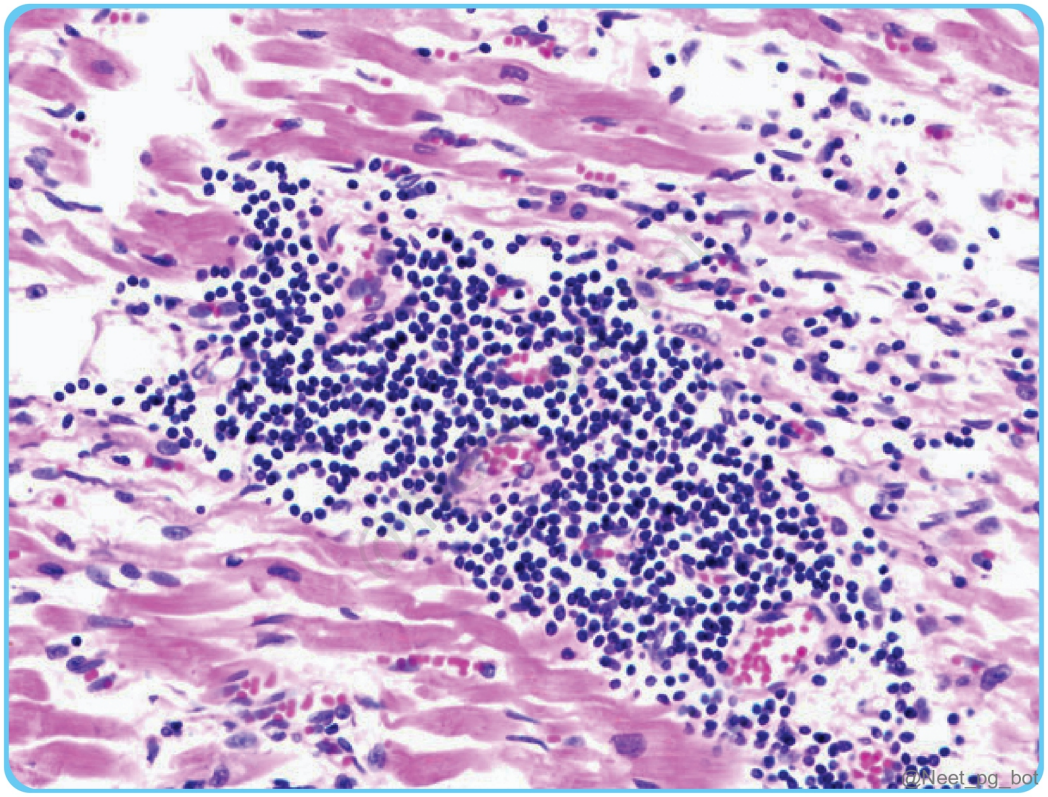

Correct Answer: D. Lymphocytic myocarditis

Explanation: The clinical scenario of a child with complaints of fever, fatigue & LV dysfunction & biopsy showing lymphocytic infiltration is suggestive of Lymphocytic myocarditis , an inflammatory condition of the heart muscle characterised by the infiltration of lymphocytes, which are immune cells involved in viral or autoimmune responses. Etiology: Viral infections (e.g., enteroviruses, adenoviruses) Postviral reactions Autoimmune diseases (e.g., systemic lupus erythematosus, rheumatoid arthritis) Idiopathic cases (unknown cause) Pathological finding: Lymphocytic infiltration : Predominantly, lymphocytes infiltrate the myocardium, especially in the left ventricle. Myocyte necrosis : The inflammation leads to the death of myocardial cells. Fibrosis : Chronic cases may develop fibrosis and scarring in the heart tissue. Dilated cardiomyopathy : Severe cases can lead to heart enlargement and dysfunction. Prognosis: The prognosis depends on the underlying cause, extent of myocardial damage, and response to treatment. Viral myocarditis can resolve with supportive care, but severe cases may lead to heart failure or require a heart transplant. Chronic forms may lead to dilated cardiomyopathy .

References:

Robbins and Cotran Pathologic Basis of Disease, 10th Edition, Page 576

https://pmc.ncbi.nlm.nih.gov/articles/PMC6198272/

↑ *Back to this question in Part A*

@Neet_pg_bot

Q16: Which of the following is the earliest marker to rise in a case of myocardial infarction (MI)? (Q860196)

A. CKMB (Creatine Kinase-MB)

B. Troponin

C. LDH

D. Heart fatty acid binding protein

Correct Answer: D. Heart fatty acid binding protein

Explanation: H-FABP(Heart fatty acid binding protein) is the earliest marker to rise in a case of myocardial infarction (MI). Cardiac Markers Cardiac Troponin (Troponin T and I) (Option B ruled out) Preferred biochemical markers due to their sensitivity and specificity. Troponin levels: Increase within 3-6 hours. Peak at around 36 hours. Remains elevated for 7-10 days after STEMI. Troponin should be measured at presentation and repeated at 1-3 hours (high-sensitivity assays) or 3-6 hours (conventional assays). Cardiac troponin levels remain elevated for several days after an acute myocardial infarction (AMI), making them unreliable for detecting reinfarction. Creatine Phosphokinase (CK) and CK-MB (Option A ruled out) CK rises within 4-8 hours. Peaks by 24 hours. Returns to normal within 48-72 hours. CK-MB elevated: Cardiac surgery Myocarditis Electrical cardioversion CK-MB levels normalise within 48 to 72 hours, so a subsequent rise can confirm reinfarction. Lactate Dehydrogenase (LDH) (Option C ruled out) Increase in the blood 6 to 12 hours after ACS. Peak within 24 to 72 hours. Normalise within 8 to 14 days. LDH is no longer used to diagnose myocardial infarction because it is not specific to cardiac myocytes. Heart-type Fatty Acid-Binding Protein (H-FABP) (Option D) It is the earliest marker to rise in a case of myocardial infarction (MI). It has higher sensitivity than troponin and CK-MB for detecting AMI within 4 hours of symptom onset, but its specificity is lower.

References:

Robbins & Cotran Pathologic Basis of Disease, 10th Edition, Page, 550-551.

Harrison’s Principles of Internal Medicine, 21st Edition, Page 106.

Ischemia-Modified Albumin: Origins and Clinical Implications - PMC

↑ *Back to this question in Part A*

@Neet_pg_bot

Q17: A 35-year-old patient presents with colicky abdominal pain, joint pain, and palpable purpura. Urinalysis shows only red blood cells with no other significant findings. Which of the following is the likely diagnosis? (Q860153)

A. IgA vasculitis

B. Granulomatosis with polyangiitis

C. Microscopic polyangiitis

D. Behçet's disease

Correct Answer: A. IgA vasculitis

Explanation: The scenario of colicky abdominal pain, joint pain, palpable purpura, and hematuria without proteinuria suggests Henoch-Schönlein Purpura (IgA Vasculitis). It is an IgA-mediated small vessel vasculitis characterized by inflammation of small blood vessels. The exact cause of HSP is unclear, but it is thought to involve an abnormal immune response, where IgA immune complexes deposit in blood vessel walls, causing inflammation and damage. It is more common in children but can occur in adults. It is characterized by Henoch Schonlein purpura (palpable purpura) Purpuric rash in lower limbs Abdominal pain Arthralgia Renal (hematuria) It is associated with elevated serum IgA levels. Urinalysis: The presence of red blood cells cast in urine. Granulomatosis with polyangiitis (GPA) (Option B) , also known as Wegener's granulomatosis , is an autoimmune condition that primarily affects the small- to medium-sized blood vessels, leading to granulomatous inflammation and necrosis. It involves respiratory symptoms and renal issues, while Henoch-Schönlein Purpura (HSP) is more likely here due to abdominal pain, joint pain, and palpable purpura, which are hallmark features of HSP with IgA deposition. Microscopic polyangiitis (MPA) (Option C) is a small-vessel vasculitis primarily affecting the kidneys and lungs, often presenting with rapidly progressive glomerulonephritis and pulmonary symptoms like hemoptysis, along with ANCA positivity. Behcet's disease (Option D) is a systemic vasculitis that presents with oral and genital ulcers, ocular involvement, and skin lesions like erythema nodosum.

References:

Robbins and Cotran, Pathological Basis of Diseases, 10th Edition, Page 509.

↑ *Back to this question in Part A*

@Neet_pg_bot

Q18: A 30-year-old football player is brought to the emergency department after he collapsed due to sudden cardiac arrest. Based on the biopsy findings of his cardiac tissue, what is the most likely cause of his death? (Q844091)

A. Hypertrophic obstructive cardiomyopathy

B. Dilated cardiomyopathy

C. Restrictive cardiomyopathy

D. Arrhythmogenic cardiomyopathy

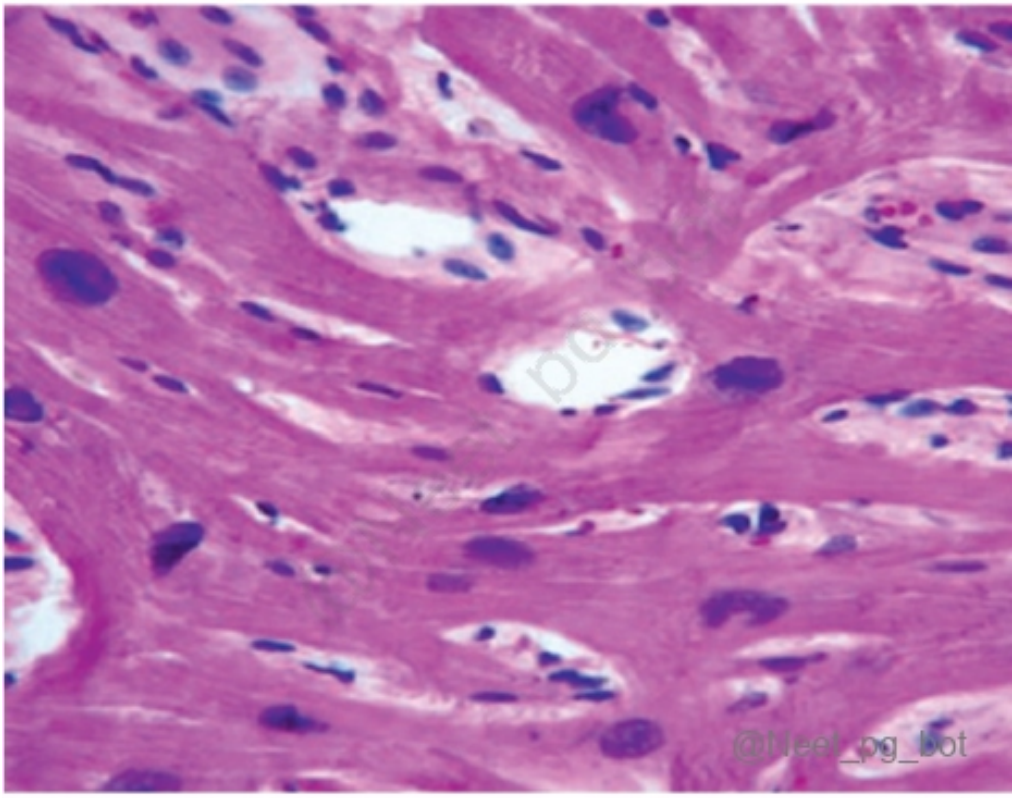

Correct Answer: A. Hypertrophic obstructive cardiomyopathy

Explanation: The biopsy shows myocyte hypertrophy with disarray, which is characteristic of HOCM. HOCM is a genetic disorder (usually autosomal dominant) involving mutations in sarcomeric proteins. It commonly affects young athletes and is the most frequent cause of sudden cardiac death in this population. The histologic hallmark is myocyte disarray with interstitial fibrosis, leading to arrhythmias. Obstruction of the left ventricular outflow tract may or may not be present, but sudden death is usually due to ventricular arrhythmia. Incorrect Options : Option B) Dilated cardiomyopathy – Shows ventricular dilation and thin walls, not myocyte disarray; usually causes heart failure rather than sudden death in athletes. Option C) Restrictive cardiomyopathy – Characterized by fibrosis or amyloid deposition, with normal wall thickness; arrhythmic sudden death is less common. Option D) Arrhythmogenic cardiomyopathy – Shows fibrofatty replacement of right ventricular myocardium, not myocyte disarray in the left ventricle.

References:

.

↑ *Back to this question in Part A*

@Neet_pg_bot

Q19: A 20-year-old athlete suddenly collapsed while playing football and was taken to the hospital, where he was declared dead. His autopsy image is given below. Which of

the following is the most likely cause of death? (Q855424)

A. Valvular heart disease due to RHD

B. Sudden cardiac death due to arrhythmia

C. Sudden cardiac death due to hypertrophic cardiomyopathy

D. Sudden cardiac death due to atherosclerosis

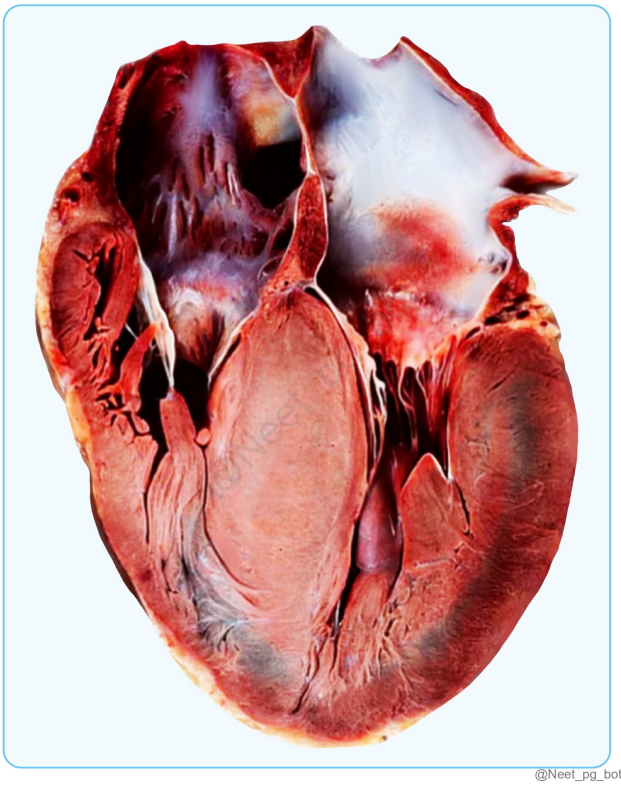

Correct Answer: C. Sudden cardiac death due to hypertrophic cardiomyopathy

Explanation: The autopsy image reveals signs of cardiac hypertrophy, indicating hypertrophic cardiomyopathy (HCM) as a likely cause of death, which is a common contributor to Sudden Cardiac Death (SCD) in young athletes due to abnormal thickening of the heart muscle, particularly in the left ventricle. Sudden Cardiac Death (SCD) Sudden Cardiac Death (SCD) is defined as unexpected death occurring within an hour of symptom onset due to cardiac causes, including unwitnessed deaths in individuals who seemed healthy within the last 24 hours. Risk Factors Structural Heart Disease: The presence of structural heart issues or inherited arrhythmia syndromes significantly increases SCD risk. Major Risk Factors: Coronary Heart Disease (CHD) Heart Failure Diabetes Hypertension Smoking Family History of SCD In Athletes Younger Athletes: The leading causes of SCD are inherited cardiac conditions, particularly Hypertrophic Cardiomyopathy (HCM). (Option C) Older Athletes: Risks are primarily associated with atherosclerotic coronary artery disease (CAD). Precipitating Factors SCD and Sudden Cardiac Arrest (SCA) frequently occur at specific times (e.g., mornings, winter months) and in public places. Vigorous exertion, especially in men, can trigger SCD; however, regular exercise may reduce this risk. Underlying Heart Disease The most common cause of SCD is Ventricular fibrillation Many SCD cases are linked

to coronary artery disease (CAD), but non-ischemic cardiomyopathies and other heart conditions also contribute. Common mechanisms leading to SCD include: Acute Myocardial Infarction Bradyarrhythmias Ventricular scars leading to arrhythmias Commotio Cordis Commotio cordis is a specific cause of SCD, often resulting from an impact to the left chest by a hard object, such as a baseball, during sports. This can induce ventricular fibrillation and cardiac arrest in an otherwise structurally normal heart. Valvular heart disease due to RHD (Option A): The autopsy image shows no significant abnormalities in the heart valves, excluding valvular heart disease as the cause of death. RHD, which results from untreated or inadequately treated streptococcal infections, leads to inflammation and scarring of the heart valves. However, typical signs of RHD, such as thickened or damaged valves, are not observed in this image. Sudden cardiac death due to arrhythmia (Option B): Sudden cardiac death (SCD) is an unexpected and rapid loss of heart function, typically caused by a life-threatening arrhythmia. In athletes, the most frequent cause of SCD is hypertrophic cardiomyopathy (HCM), which is characterized by abnormal thickening of the heart muscle. Sudden cardiac death due to atherosclerosis (Option D): Atherosclerosis involves the accumulation of plaques in the arteries, which narrows and restricts blood flow. Although atherosclerosis can lead to heart attacks and sudden cardiac death, the autopsy image shows no signs of significant plaque buildup or obstruction in the coronary arteries.

References:

Harrison’s Principles of Internal Medicine, 21st Edition, Page 2257,2259.

Athletes

↑ *Back to this question in Part A*

@Neet_pg_bot

Q20: A 34-year-old female patient presented to the outpatient department with migratory arthritis , and examination revealed a pan-systolic murmur . An echocardiography was performed, which was suggestive of mitral regurgitation . A biopsy specimen was obtained, and the image is provided below. What is the most likely lesion shown in the histopathology slide? (Q799426)

A. Aschoff’s bodies

B. Epithelioid granuloma

C. Granulomatous vasculitis

D. Granuloma inguinale

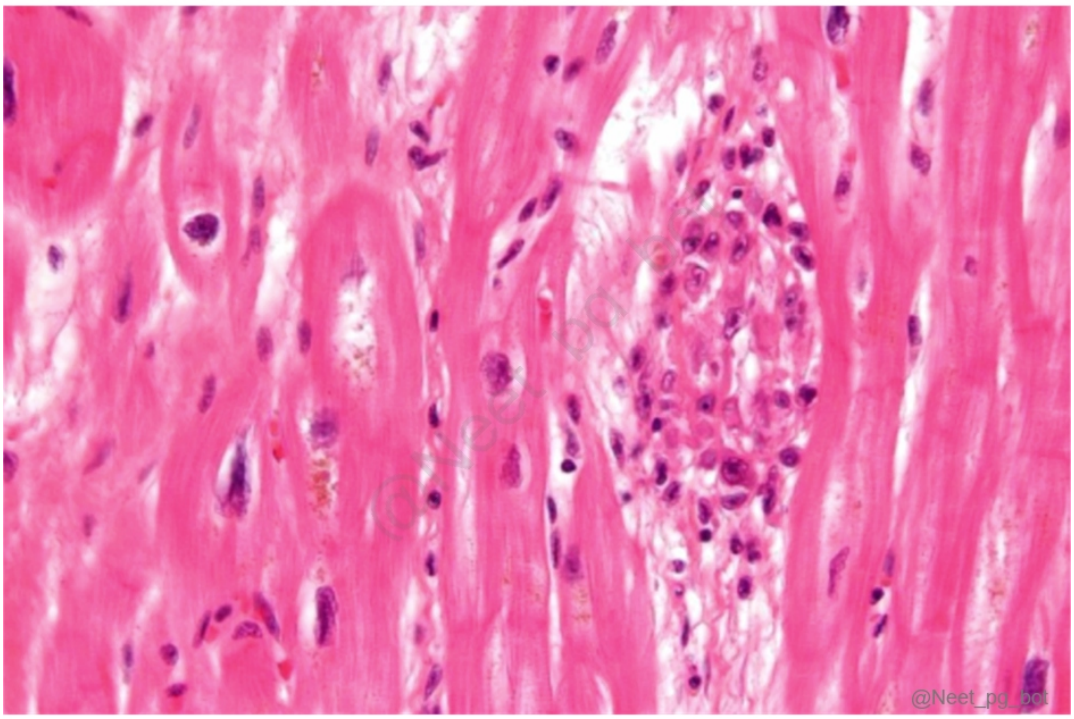

Correct Answer: A. Aschoff’s bodies

Explanation: Correct Option A - Aschoff’s bodies : The patient's presentation with migratory arthritis, a pan-systolic murmur, and mitral regurgitation is suggestive of rheumatic heart disease. Aschoff's bodies are characteristic histopathological features seen in rheumatic heart disease. Aschoff's bodies are focal areas of chronic inflammation within the myocardium. They consist of a central focus of fibrinoid necrosis, surrounded by Anitschkow cells. Incorrect Options: Option B - Epithelioid granuloma: Epithelioid granulomas are associated with granulomatous diseases such as tuberculosis and sarcoidosis. Option C - Granulomatous vasculitis: Granulomatous vasculitis typically involves inflammation and damage to blood vessels. Option D - Granuloma inguinale: Granuloma inguinale, also known as Donovanosis, is a sexually transmitted infection characterized by genital ulcers.

References:

.

↑ *Back to this question in Part A*

@Neet_pg_bot

• [07_Respiratory System] 032 Obstructive Lung Disease

« Back to Folder Directory

[07_Respiratory System] 032 Obstructive Lung Disease — Quick Jump

Q1 (p. 1741) *Q2 (p. 1741)* *Q3 (p. 1744)* *Q4 (p. 1745)* *Q5 (p. 1746)* *Q6 (p. 1747)*
Q7 (p. 1748) *Q8 (p. 1749)* *Q9 (p. 1753)* *Q10 (p. 1753)* *Q11 (p. 1754)* *Q12 (p. 1755)*

Q1: A 20-year-old male presented with cough and breathing difficulty and was diagnosed with emphysema after radiographic examination. Which of the following genetic conditions should be suspected as a possible cause? (Q845463)

A. Cystic fibrosis

B. Asthma

C. Alpha-1 antitrypsin deficiency

D. Bronchiectasis

Correct Answer: C. Alpha-1 antitrypsin deficiency

■ *Listen (English)*

■ *Listen (Hindi)*

Explanation: Alpha-1 antitrypsin deficiency is a genetic condition characterised by low levels or dysfunctional alpha-1 antitrypsin protein. Alpha-1 antitrypsin deficiency: It is an autosomal recessive disorder caused by mutations in the alpha-1 antitrypsin gene located on Chromosome 14 . The condition primarily affects the lungs, leading to panacinar emphysema and the liver, causing cirrhosis due to abnormal protein accumulation. Cystic fibrosis (Option A) is a genetic disorder caused by CFTR gene mutations, leading to thick mucus, chronic lung infections, and bronchiectasis. While it causes obstructive lung disease, emphysema is not typical. Asthma (Option B) is a chronic inflammatory condition causing reversible airway obstruction and episodic wheezing, coughing, and breathlessness. It does not typically result in emphysema or structural lung damage. Bronchiectasis (Option D) is a condition of permanently dilated bronchi due to chronic infections or inflammation. While it causes cough and sputum production, it does not primarily lead to emphysema.

References:

Robbins and Cotran Pathologic Basis of Disease, 10th Edition, Pages 679, 680

↑ *Back to this question in Part A*

@Neet_pg_bot

Q2: Match the following types of emphysema with their characteristic features: Types of Emphysema Characteristic Features 1) Centriacinar emphysema A) Uniformly affects the entire acinus, commonly associated with alpha 1 antitrypsin deficiency 2) Panacinar emphysema B) Predominantly involves the upper lobes, often associated with bullae formation. Alveolar ducts and sacs are spared 3) Paraseptal emphysema C) Associated with scarring and fibrosis, often seen in patients with chronic inflammation or recurrent infections 4) Irregular emphysema D) Involves the distal airways and is often associated with spontaneous pneumothorax (Q845464)

A. 1-a, 2-c, 3-b, 4-d

B. 1-b, 2-a, 3-d, 4-c

C. 1-a, 2-b, 3-c, 4-d

D. 1-d, 2-b, 3-a, 4-c

Correct Answer: B. 1-b, 2-a, 3-d, 4-c

■ *Listen (English)*

■ *Listen (Hindi)*

Explanation: Emphysema is classified according to its anatomic distribution within the lobule. Based on the segments of the respiratory units that are involved, emphysema is subdivided into four major types: Features Centriacinar (M/C) Panacinar Paraseptal Irregular Involves Proximal acinus Proximal & distal acini Distal acinus Irregular involvement Site Upper lobes especially apical segments Lower zones & anterior margins of the lung. More severe at the base of the lung. The upper half of the lungs (more severe). Airspaces can form cyst-like structures. Any part of the lung can be involved. Aetiology Smokers Chronic bronchitis α1-antitrypsin deficiency Spontaneous pneumothorax Depends on involvement, most found in autopsy The image below shows centriacinar emphysema. The image below shows paraseptal emphysema.



@Neet_pg_bot

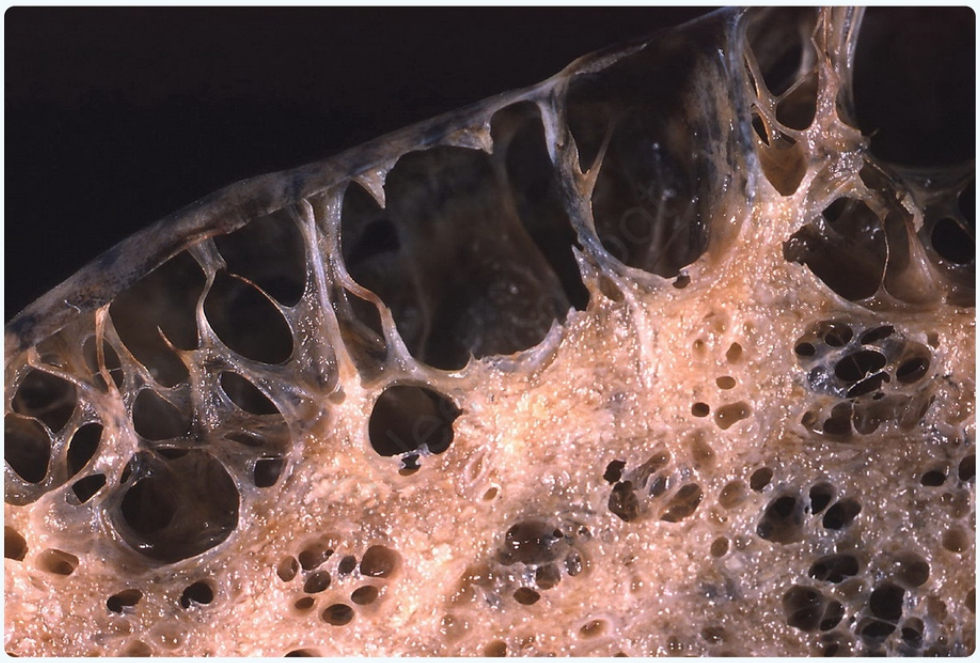

The image shows paraseptal Emphysema

@Neet_pg_bot

The image below shows panacinar emphysema



@Neet_pg_bot

References:

Robbins and Cotran Pathologic Basis of Disease, 10th Edition, Pages 679, 680

↑ *Back to this question in Part A*

@Neet_pg_bot

Q3: Which of the following mechanisms is not involved in the development of emphysema? (Q845465)

A. Toxic injury and inflammation leading to variable degrees of parenchymal destruction.

B. Protease-antiprotease imbalance with a relative deficiency of protective antiproteases.

C. The presence of T and B cells in affected parts of the lung indicates a robust adaptive immune response.

D. Oxidative stress induced by substances in tobacco smoke, alveolar damage, and inflammatory cells.

Correct Answer: C. The presence of T and B cells in affected parts of the lung indicates a robust adaptive immune response.

■ *Listen (English)*

■ *Listen (Hindi)*

Explanation: Chronic inflammation in emphysema does lead to the accumulation of T and B cells in affected parts of the lung, but the role of adaptive immunity is currently uncertain. Therefore, it's not considered a defining feature of the disease. Pathophysiology of emphysema: Inhaled cigarette smoke and other noxious particles cause damage to respiratory epithelium and inflammation, resulting in parenchymal destruction, which is a hallmark of emphysema. In patients with emphysema, there is often a relative deficiency of protective antiproteases, which allows proteases released from inflammatory cells and epithelial cells to break down connective tissue components, contributing to tissue destruction. Substances in tobacco smoke, alveolar damage, and inflammatory cells all produce oxidants, which contribute to tissue damage, endothelial dysfunction, and inflammation, further exacerbating the pathology of emphysema.

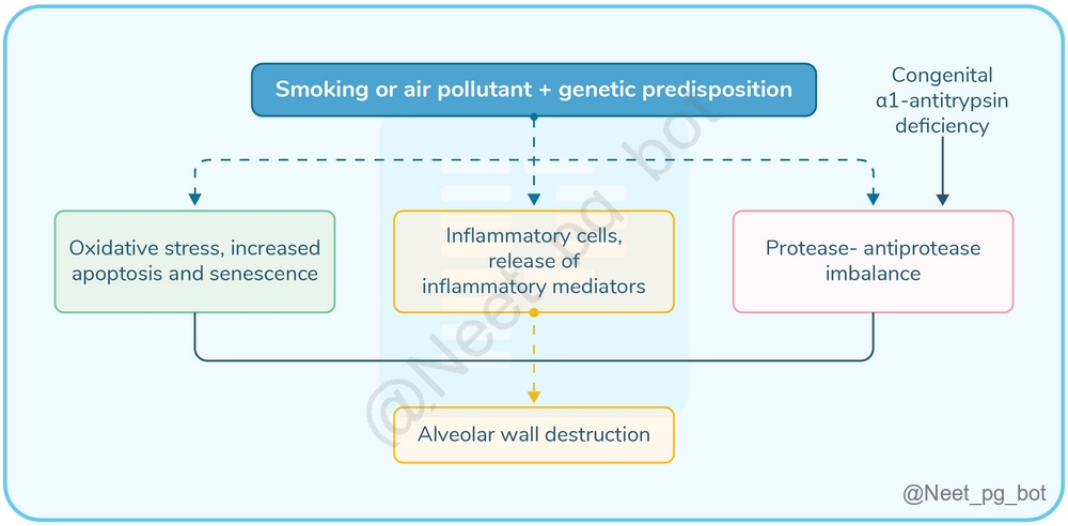

References:

Robbins and Cotran Pathologic Basis of Disease, 10th Edition, Page 680

↑ *Back to this question in Part A*

@Neet_pg_bot

Q4: A 65-year-old man has been a heavy smoker for the past 40 years and presents with complaints of progressive shortness of breath, especially with exertion, and a chronic cough with occasional scanty sputum production. Physical examination reveals a barrel-shaped chest, decreased breathing sounds, and a prolonged expiratory phase. Based on the clinical presentation and history, what is the most likely diagnosis? (Q845466)

A. Chronic bronchitis

B. Emphysema

C. Pulmonary fibrosis

D. Asthma

Correct Answer: B. Emphysema

■ *Listen (English)*

■ *Listen (Hindi)*

Explanation: The patient's history of heavy smoking, chronic cough with occasional scanty sputum production , progressive shortness of breath, especially with exertion and physical examination showing barrel-shaped chest, decreased breath sounds, and a prolonged expiratory phase is highly suggestive of COPD with emphysema. Clinically significant emphysema is largely confined to smokers and patients with α1-antitrypsin deficiency. Chronic bronchitis (Option A) presents insidiously with slowly increasing dyspnea on exertion and chronic cough with sputum production, slight at first but increasing over time. Pulmonary fibrosis (Option C) is characterized by progressive scarring of the lungs, leading to decreased lung compliance and restrictive lung disease. Asthma (Option D) is characterized by reversible airflow obstruction, wheezing, and chest tightness, but the patient's history of heavy smoking and clinical presentation is not typical of asthma.

References:

Robbins and Cotran Pathologic Basis of Disease, 10th Edition, Page 679

↑ *Back to this question in Part A*

@Neet_pg_bot

Q5: A 45-year-old male patient presents with a history of chronic cough, increased sputum production, and shortness of breath. He reports that these symptoms have been present for several years and have gradually worsened over time. The patient is a lifelong smoker, having smoked one pack of cigarettes per day for the past 20 years. What is the likely diagnosis? (Q845469)

A. Emphysema

B. Asthma

C. Chronic bronchitis

D. Lung cancer

Correct Answer: C. Chronic bronchitis

Explanation: The patient's symptoms of chronic cough, increased sputum production, and shortness of breath, combined with his history of long-term smoking, are highly suggestive of chronic bronchitis. Emphysema (Option A): is characterized by the destruction of the alveoli in the lungs, leading to airflow obstruction. While emphysema

can co-occur with chronic bronchitis, the patient's primary symptoms of chronic cough and increased sputum production indicate more chronic bronchitis. Asthma (Option B): c haracterized by intermittent symptoms that worsen with triggers rather than the persistent, progressive symptoms described in the case. Lung cancer (Option D): Lung cancer can also present with cough and shortness of breath, but the gradual, chronic nature of the patient's symptoms makes lung cancer a less likely diagnosis compared to chronic bronchitis.

References:

Robbins and Cotran Pathologic Basis of Disease, 10th Edition, Page 681

↑ *Back to this question in Part A*

@Neet_pg_bot

Q6: Which of the following is not true regarding chronic bronchitis? (Q845472)

A. Reid index >0.4

B. The most common cause is smoking

C. The most common cause of exacerbation is Haemophilus influenzae.

D. Recurrent, episodic attacks of wheezing, prolonged expiration, dyspnea (shortness of breath), and chest tightness.

Correct Answer: D. Recurrent, episodic attacks of wheezing, prolonged expiration, dyspnea (shortness of breath), and chest tightness.

■ *Listen (English)*

■ *Listen (Hindi)*

Explanation: Recurrent, episodic attacks of wheezing, prolonged expiration, dyspnea (shortness of breath), and chest tightness are seen in asthma. Chronic bronchitis is defined clinically as persistent cough with sputum production for at least 3 months in at least 2 consecutive years in the absence of any other identifiable cause. Reid's Index: RI = Thickness of submucosal gland layer / overall thickness of the wall The Reid index (normally 0.4) is increased in chronic bronchitis (>0.4), usually in proportion to the severity and duration of the disease. The primary or initiating factor in the genesis of chronic bronchitis is exposure to noxious or irritating inhaled substances such as tobacco smoke (90% of those affected are smokers, making it the commonest cause) and dust from grain, cotton, and silica. (Option B) The most common cause of exacerbation in COPD is Haemophilus influenzae and the second most common cause is Moraxella. (Option C)

References:

Robbins and Cotran Pathologic Basis of Disease, 10th Edition, Page 681

↑ *Back to this question in Part A*

@Neet_pg_bot

Q7: A 32-year-old female presents with recurrent episodes of wheezing, coughing, and shortness of breath. On further testing, a diagnosis of asthma was made. Which of the following best describes the underlying pathophysiological changes seen in this patient's condition? (Q845474)

A. Reduced goblet cell secretion

B. Thinning of the basement membrane

C. Increase in airway inflammation and remodeling

D. Decreased submucosal gland activity

Correct Answer: C. Increase in airway inflammation and remodeling

■ *Listen (English)*

■ *Listen (Hindi)*

Explanation: The clinical presentation of recurrent wheezing, coughing, and shortness of breath suggests airway inflammation and remodelling , which are characteristic of asthma. These changes contribute to airway hyperresponsiveness and the symptoms experienced by the patient. Pathophysiology of Asthma: Atopic asthma , the most common form of the disease, is caused by a Th2-mediated IgE response to environmental allergens in genetically predisposed individuals. (Type 1 hypersensitivity) Airway inflammation is central to the disease pathophysiology and causes airway dysfunction partly through the release of potent inflammatory mediators and partly through the remodelling of the airway wall. As the disease becomes more severe, there is increased local secretion of growth factors, which induce mucous gland enlargement , smooth muscle proliferation , angiogenesis , and fibrosis . Images A & B Comparison of a normal airway and an airway involved in asthma. The asthmatic airway is marked by the accumulation of mucus in the bronchial lumen secondary to Increase in the number of mucus-secreting goblet cells in the mucosa (Option A) Hypertrophy of submucosal glands (Option D) , intense chronic inflammation due to the recruitment of eosinophils, macrophages, and other inflammatory cells. The basement membrane is thickened (Option B), and there is hypertrophy and hyperplasia of smooth muscle cells.

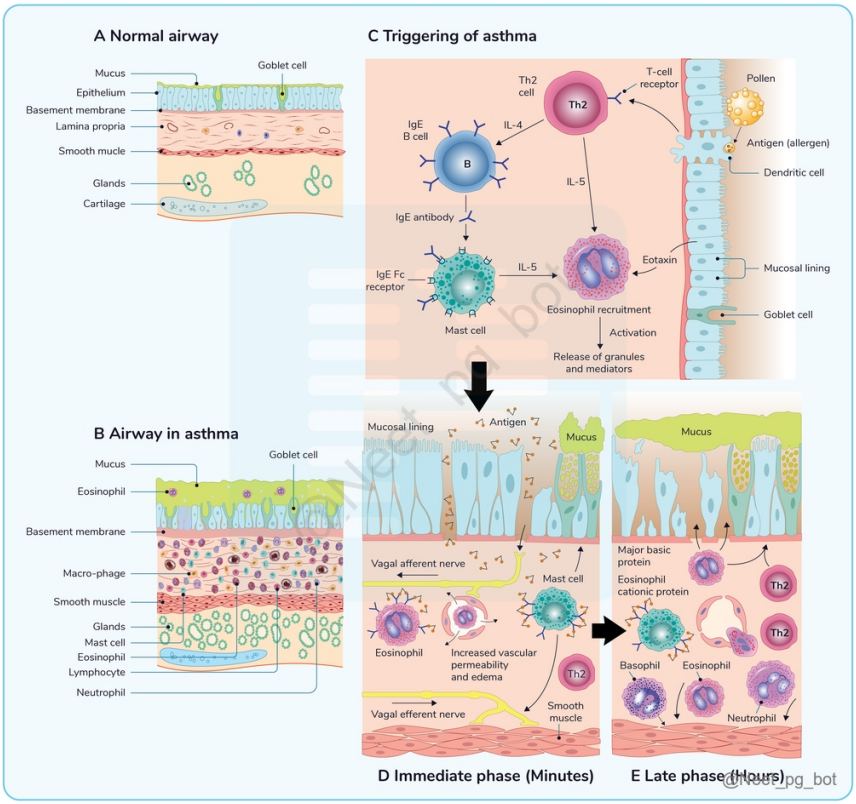

References:

Robbins and Cotran Pathologic Basis of Disease, 10th Edition, Page 683

↑ *Back to this question in Part A*

@Neet_pg_bot

Q8: A 45-year-old male has a history of recurrent wheezing, coughing, and shortness of breath. His sputum microscopy, shown in the image below, reveals the following finding. Which best describes this finding? (Q845476)

A. Extrusion of mucus plugs from the subepithelial mucous gland ducts or bronchioles.

B. Ciliated columnar cells sloughed from the bronchial mucosa.

C. Polypoid plugs of loose organizing connective tissue within the bronchioles.

D. They are composed of Galectin 10.

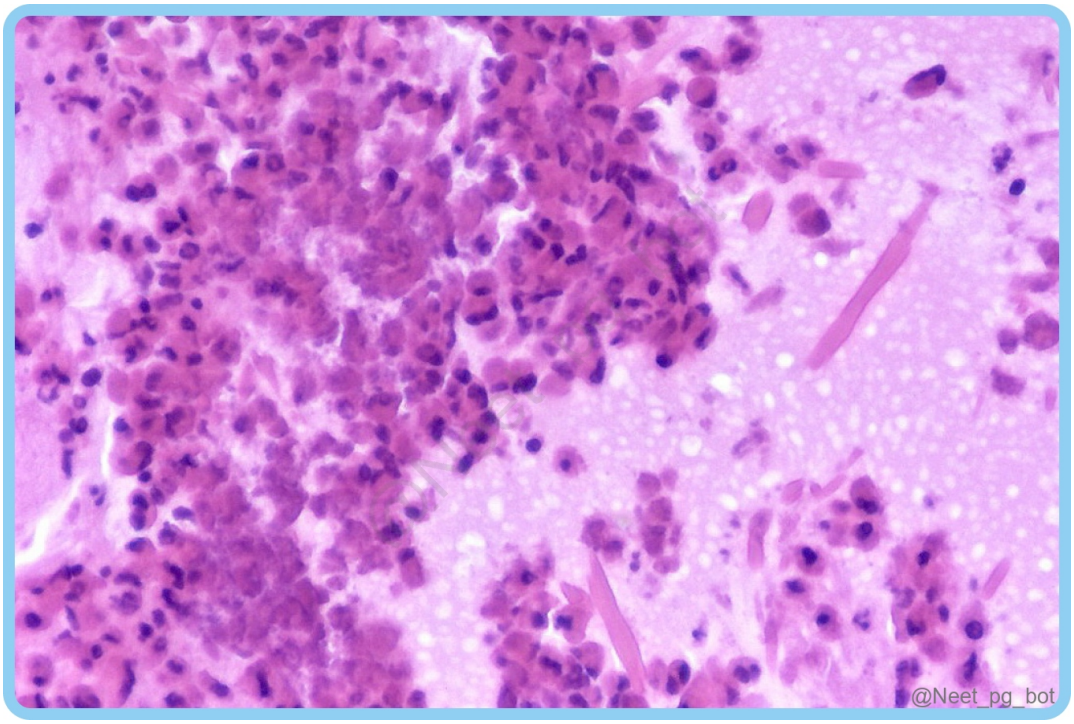

Correct Answer: D. They are composed of Galectin 10.

- *Listen (English)*
- *Listen (Hindi)*

Explanation: The clinical presentation points towards a diagnosis of bronchial asthma, with sputum culture showing Charcot-Leyden crystals Charcot-Leyden crystals: They are microscopic, needle-shaped crystals that are often found in the sputum of asthma patients, particularly during exacerbations . They are primarily composed of galectin-10 (derived from the eosinophils) also known as Charcot-Leyden crystal protein (CLC). Strong inducers of inflammation and mucus production. Extrusion of mucus plugs from the subepithelial mucous gland ducts or bronchioles describes the Curschmann spirals. They are a characteristic finding in asthma. (Option A) Ciliated columnar cells sloughed from the bronchial mucosa describe the Creola bodies seen in bronchial asthma. (Option B) Polypoid plugs of loose organizing connective tissue within the bronchioles, alveolar ducts, and alveoli describe Masson bodies , which are seen in cryptogenic organising pneumonia. (Option C)

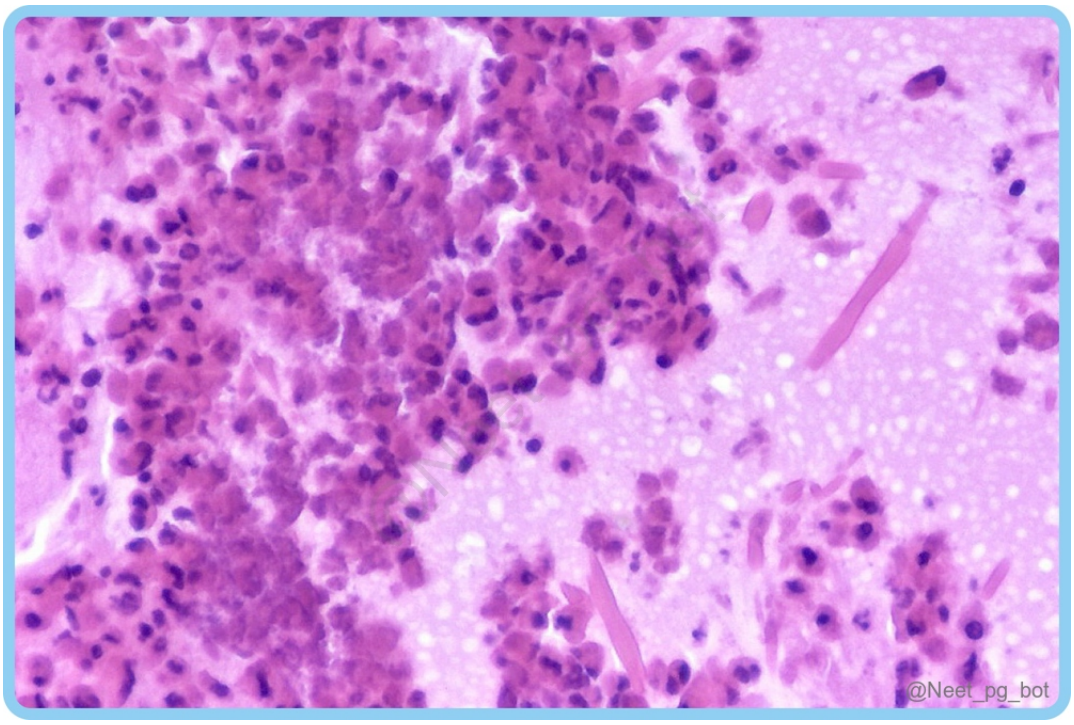
@Neet_pg_bot

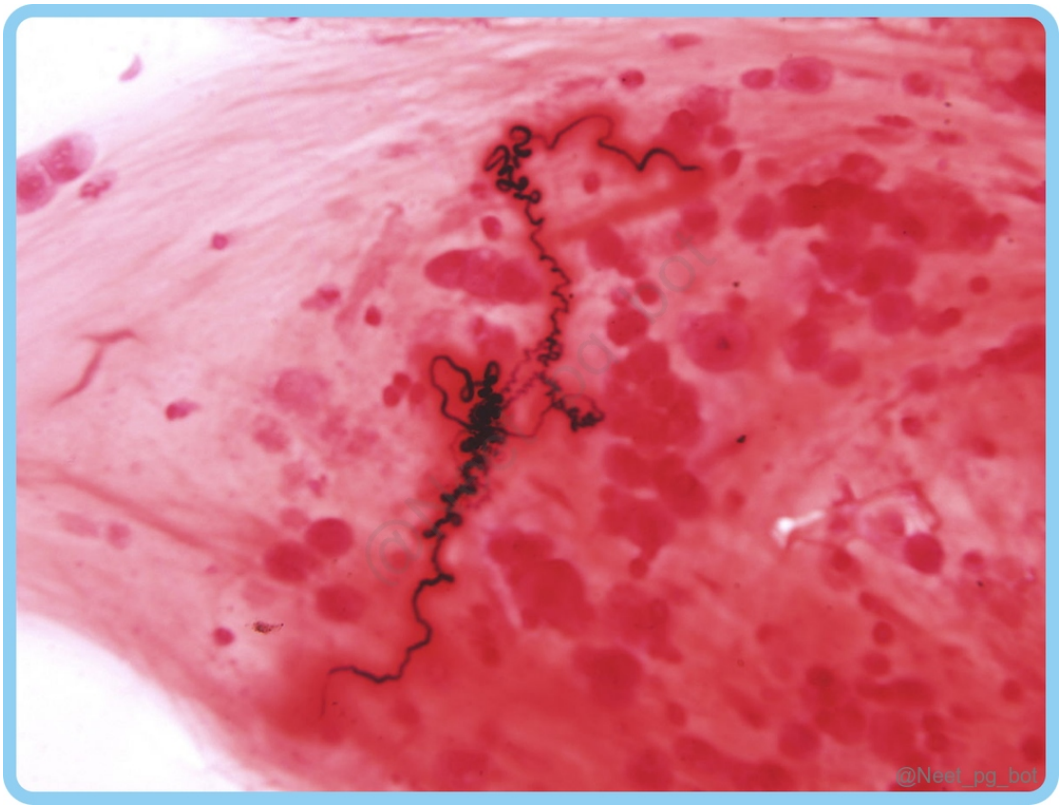
@Neet_pg_bot

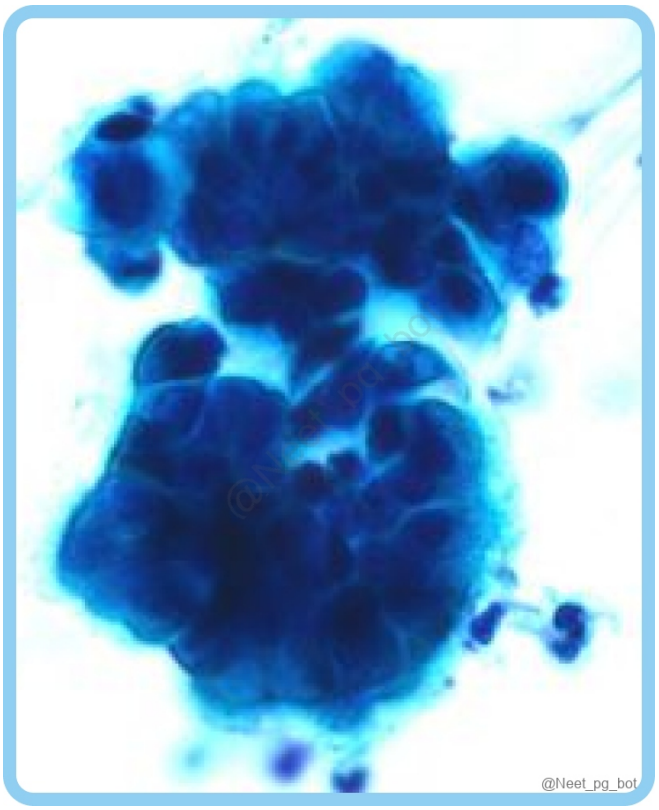



References:

Robbins and Cotran Pathologic Basis of Disease, 10th Edition, Page 683

↑ *Back to this question in Part A*

@Neet_pg_bot

Q9: A 30-year-old patient presents with a history of recurrent wheezing, coughing, and shortness of breath. Upon further investigation, it is found that the patient has a family history of allergies and asthma. Which genetic factor is most likely co-related to the severity of this condition? (Q845477)

A. Variant IL-4 receptor gene

B. IL-13 polymorphism

C. ADAM33 polymorphism

D. YKL40 gene mutation

Correct Answer: D. YKL40 gene mutation

■ *Listen (English)*

■ *Listen (Hindi)*

Explanation: The YKL40 (a chitinase-like glycoprotein) gene mutation has been found to be correlated with the severity of asthma. YKL40 levels are associated with inflammation and tissue remodelling in the airways, contributing to the progression and severity of asthma symptoms. Genetic Factors in Asthma: A susceptibility locus for asthma located on chromosome 5q , near the gene cluster, encoding the cytokines IL-3, IL-4, IL-5, IL-9, and IL-13 and the IL-4 receptor. Polymorphisms in the IL13 gene have the strongest and most consistent associations with asthma or allergic disease. The IL-4 receptor gene variants are associated with atopy , elevated total serum IgE , and asthma. Variants associated with the genes encoding IL-33 ADAM33 polymorphism.

References:

Robbins and Cotran, Pathological Basis of Disease, 10th Edition, Page 684

↑ *Back to this question in Part A*

@Neet_pg_bot

Q10: A 35-year-old male presents to the emergency department with complaints of chronic cough with production of purulent sputum, intermittent hemoptysis, and recurrent respiratory infections over the past several years. He reports a history of childhood respiratory infections and no significant past medical history. Physical examination reveals coarse crackles and rhonchi on auscultation of the chest. Chest X-ray shows bilateral bronchial wall thickening and tram-line shadows. Which of the

following is unlikely to be a cause for this condition? (Q845478)

A. Primary ciliary dyskinesia

B. Bronchial Asthma

C. Cystic fibrosis

D. Kartagener syndrome

Correct Answer: B. Bronchial Asthma

■ *Listen (English)*

■ *Listen (Hindi)*

Explanation: The clinical findings along with radiographic findings are suggestive of bronchiectasis and bronchial asthma is not a cause. Bronchiectasis is the permanent dilation of the bronchi and bronchioles. Aetiology of Bronchiectasis: Congenital or hereditary conditions (Options A, C, and D) Cystic fibrosis Primary ciliary dyskinesia Kartagener syndrome Severe necrotising pneumonia Caused by bacteria, viruses, or fungi This may be a single severe episode or recurrent infection Bronchial obstruction Tumor Foreign body Idiopathic (50% of the cases) Dysfunctional host immunity to infectious agents leads to chronic inflammation

References:

Robbins and Cotran Pathologic Basis of Disease, 10th Edition, Pages 687, 688

↑ *Back to this question in Part A*

@Neet_pg_bot

Q11: Which of the following statements accurately describes the pathophysiology of Kartagener's syndrome? (Q845479)

A. Mutation in the CFTR gene leading to impaired ciliary function.

B. Autosomal dominant inheritance pattern affecting the cilia in the respiratory tract.

C. The primary defect involves dynein arm proteins, leading to impaired ciliary motility.

D. Characterized by an excess of cilia in the respiratory epithelium.

Correct Answer: C. The primary defect involves dynein arm proteins, leading to impaired ciliary motility.

■ *Listen (English)*

■ *Listen (Hindi)*

Explanation: Kartagener’s syndrome is a rare genetic disorder that is part of the broader spectrum of primary ciliary dyskinesia (PCD). The primary defect lies in the dynein arm proteins; there is impaired ciliary motility. This impairment leads to ineffective clearance of mucus, debris, and pathogens from the respiratory tract, sinuses, and other ciliated surfaces in the body. Kartagener’s syndrome is characterised by a triad of: Bronchiectasis. Situs inversus Sinusitis. Infertility can be seen in males due to sperm dysmotility (Asthenospermia). Mutation in the CFTR gene leading to impaired ciliary motility (Option A): Cystic fibrosis is a genetic disorder caused by CFTR gene mutations, leading to thick mucus buildup in the lungs and digestive system. Autosomal dominant inheritance pattern affecting the cilia in the respiratory tract (Option B): Kartagener's syndrome follows an autosomal recessive inheritance pattern, not autosomal dominant. Additionally, it affects the structure and function of cilia throughout the body, not just in the respiratory tract. Characterized by an excess of cilia in the respiratory epithelium (Option D): Kartagener's syndrome is characterized by defects in ciliary structure and function, leading to impaired ciliary motility rather than an excess of cilia.

References:

Robbins and Cotran, Pathological Basis of Disease, 10th Edition, Page 687

↑ *Back to this question in Part A*

@Neet_pg_bot

Q12: A 45-year-old male presents with a chronic cough productive of copious sputum. He reports frequent respiratory infections over the past several years. Physical examination reveals digital clubbing and coarse crackles on auscultation. An HRCT is done and shown below. Which of the following is the most likely diagnosis? (Q845480)

A. Tuberculosis

B. Asthma

C. Chronic obstructive pulmonary disease

D. Bronchiectasis

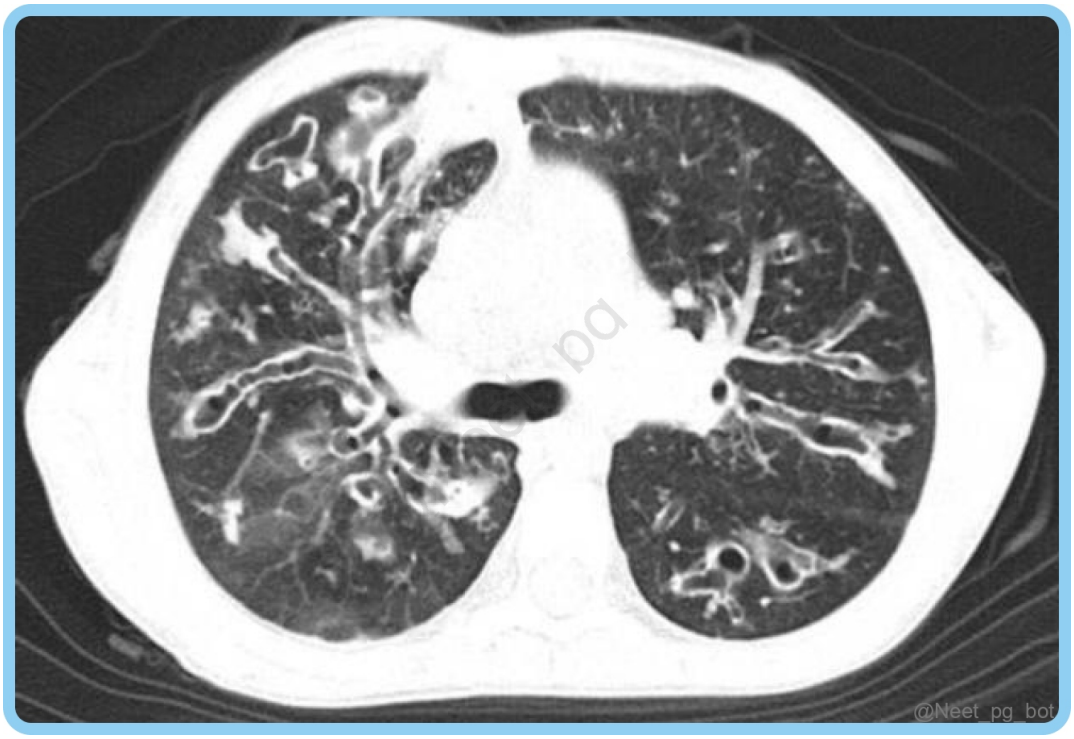

Correct Answer: D. Bronchiectasis

- *Listen (English)*
- *Listen (Hindi)*

Explanation: The clinical presentation of a male with chronic cough, copious sputum, past history of frequent respiratory infections, clubbing, coarse crackles on auscultation, and HRCT showing thickened and dilated bronchi (tram-track appearance) is suggestive of bronchiectasis. Bronchiectasis is characterised by the irreversible dilation and distortion of bronchi , typically due to chronic inflammation and recurrent infections. The image below shows bronchiectasis with markedly dilated bronchi in the upper and lower lobes. {{caption_text}} Tuberculosis (Option A): HRCT shows cavitary lesions, tree-in-bud nodules, or consolidations, not the bronchial dilation seen in bronchiectasis. Asthma (Option B): HRCT is usually normal or may show bronchial wall thickening but not bronchial dilation. COPD (Option C): HRCT shows emphysematous changes (air trapping, bullae) and airway narrowing but lacks the tram-track or signet ring appearance seen in bronchiectasis.



References:

Robbins and Cotran, Pathologic Basis of Disease, 10th Edition, Page 688

Harrison’s Principles of Internal Medicine, 21st Edition, Page 2174

↑ *Back to this question in Part A*

@Neet_pg_bot

• [07_Respiratory System] 033 Pulmonary Hypertension And Lung Tumors

« Back to Folder Directory

[07_Respiratory System] 033 Pulmonary Hypertension And Lung Tumors — Quick Jump

Q1 (p. 1758)	*Q2 (p. 1760)*	*Q3 (p. 1761)*	*Q4 (p. 1762)*	*Q5 (p. 1763)*	*Q6 (p. 1763)*
Q7 (p. 1764)	*Q8 (p. 1765)*	*Q9 (p. 1769)*	*Q10 (p. 1769)*	*Q11 (p. 1771)*	*Q12 (p. 1772)*
Q13 (p. 1773)	*Q14 (p. 1775)*	*Q15 (p. 1776)*	*Q16 (p. 1777)*	*Q17 (p. 1779)*	*Q18 (p. 1780)*
Q19 (p. 1782)	*Q20 (p. 1783)*	*Q21 (p. 1784)*	*Q22 (p. 1786)*		

Q1: A 50-year-old female presents with a chronic cough and recurrent episodes of wheezing. Bronchoscopy reveals a "coat button lesion" within the bronchus, as shown in the image. Biopsy of the lesion shows nesting of cells with uniform round nuclei and moderate eosinophilic cytoplasm. What is the most likely diagnosis based on the described features? (Q845562)

A. Small cell lung carcinoma

B. Squamous cell carcinoma

C. Bronchial carcinoid tumor

D. Adenocarcinoma

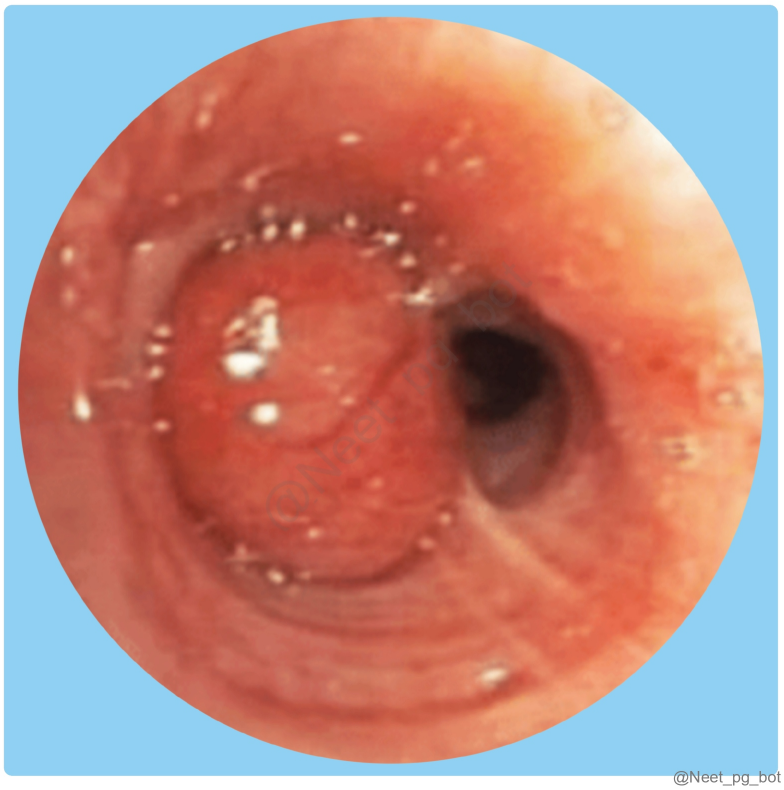

Correct Answer: C. Bronchial carcinoid tumor

- *Listen (English)*
- *Listen (Hindi)*

Explanation: The features described in the scenario suggest bronchial carcinoid tumour, a neuroendocrine tumour of bronchial epithelium characterised by nesting of cells with uniform round nuclei, moderate eosinophilic cytoplasm , and the characteristic "salt and pepper" appearance of chromatin within the nuclei. Typical carcinoids exhibit <2 mitoses per 10 high-power fields and lack necrosis. Atypical carcinoids may show 2-10 mitoses per 10 high-power fields and/or foci of necrosis. Characteristic Small Cell Carcinoma (Option A) Squamous Cell Carcinoma (Option B) Carcinoid Tumor (Option C) Adenocarcinoma (Option D) Origin Neuroendocrine cells of the lung. Squamous cells of the lung. Neuroendocrine cells of bronchial epithelium. Glandular cells of the lung. Cells in histopathology Small, round to oval, blue cells with scant cytoplasm and finely granular chromatin with a “salt and pepper” appearance. Sheets of polygonal cells with keratinisation and intercellular bridges Nesting (organoid) growth pattern with uniform round nuclei, moderate eosinophilic cytoplasm, and a “salt-and-pepper” chromatin pattern. Glandular or epithelial cells forming acinar, papillary, or solid patterns Mitotic rate High Variable Low to moderate Variable Electron microscopy findings Dense core neurosecretory granules. Desmosomes, tonofilaments, keratinisation Dense core neurosecretory granules. Variable organelles, sometimes containing mucin vacuoles IHC markers Positive for neuroendocrine markers (e.g., chromogranin, synaptophysin). P63, p40, CK5/6 Positive for neuroendocrine markers (e.g., chromogranin, synaptophysin) Variable (e.g., TTF-1, Napsin A for primary lung adenocarcinoma)

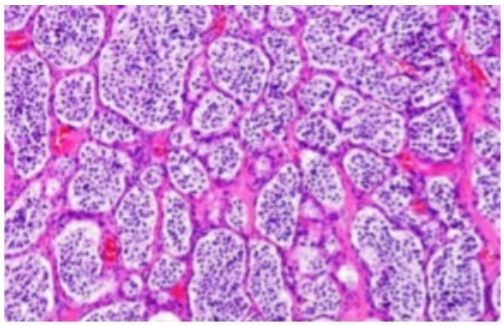

Carcinoid tumor (Nesting pattern)

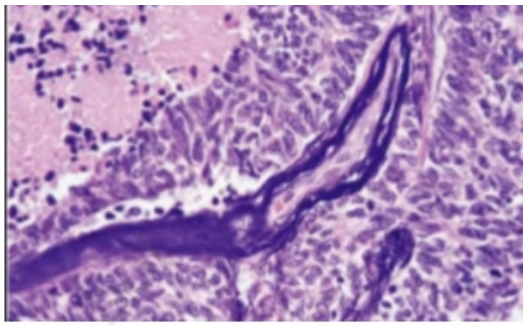

Small cell cancer (showing Azzopardi effect)

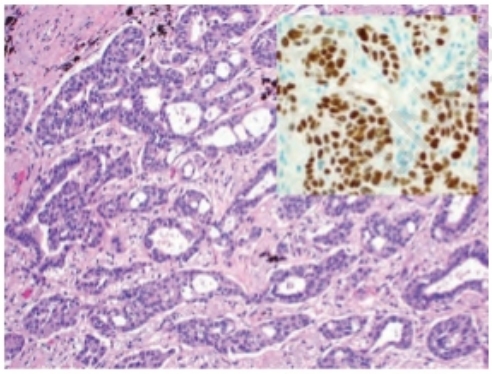

Adenocarcinoma (Inset showing IHC)

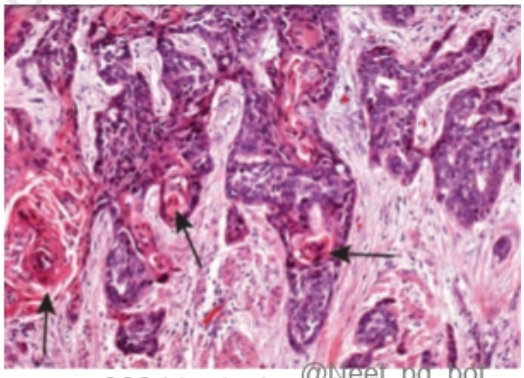

SCC (showing keratinization)

@Neet_pg_bot

References:

Robbins and Cotran, Pathologic Basis of Disease, 10th edition, Pages 716-724

↑ *Back to this question in Part A*

@Neet_pg_bot

Q2: Which of the following lung cancer subtypes has the highest mutational burden and is the most aggressive? (Q890492)

A. Adenocarcinoma

B. Squamous cell carcinoma

C. Small cell carcinoma

D. Large cell carcinoma

Correct Answer: C. Small cell carcinoma

Explanation: Small cell carcinoma has the highest mutational burden among lung cancers and is the most aggressive subtype. Small Cell Carcinoma (Lung): Highly aggressive; strong smoking association No preinvasive

phase; early widespread metastasis Highest mutational burden TP53 inactivation, RB loss, and 3p loss are common MYC amplification frequent Histology:■ Small cells, scant cytoplasm Salt & pepper chromatin Nuclear molding High mitoses, extensive necrosis Azzopardi effect ■ Chromogranin, Synaptophysin, and CD56 positive Most common lung cancer causing ectopic hormone production Adenocarcinoma (Option A): Most common lung cancer overall, usually peripheral and associated with EGFR, ALK, KRAS mutations ; less aggressive than small cell carcinoma. Squamous cell carcinoma (Option B): Smoking-related central lung tumor showing keratinization and intercellular bridges ; aggressive but slower than small cell carcinoma. Large cell carcinoma (Option D): Poorly differentiated non-small cell carcinoma lacking glandular or squamous differentiation; not the most aggressive subtype.

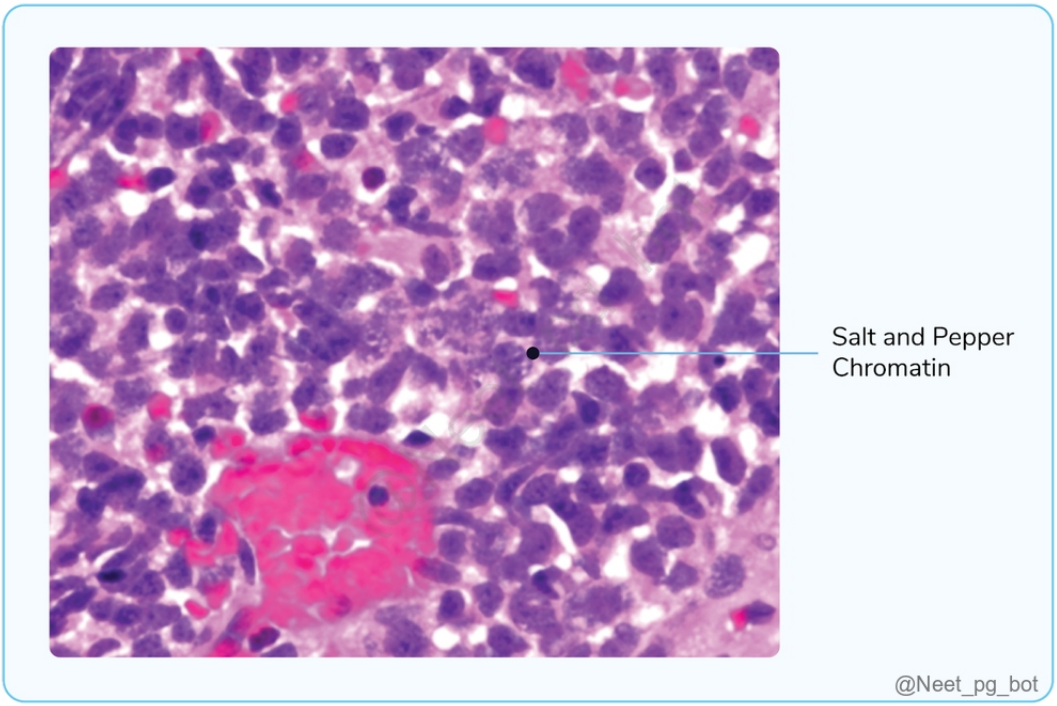

References:

Robbins, Cotran & Kumar, Pathologic Basis of Disease, 11th Edition, Pages 652, 654

↑ *Back to this question in Part A*

@Neet_pg_bot

Q3: Which of the following is the most common presenting symptom of lung carcinoma? (Q890491)

A. Cough

B. Hemoptysis

C. Chest pain

D. Weight loss

Correct Answer: A. Cough

Explanation: Cough is the most common presenting symptom of lung carcinoma, occurring in approximately 75% of patients. It usually results from involvement or irritation of the central airways by the tumour. Common Presenting Complaints (Lung Cancer): Cough - 75% (Most common) Weight loss - 40% (Option D) Chest pain - 40% (Option C) Dyspnea - 20% Local Effects of Lung Tumour Spread: Clinical Feature Pathologic Basis Cough (50-75%) Involvement of the central airways Hemoptysis (25-50%) (Option B) Tumour haemorrhage into the airway Chest pain Extension into the mediastinum, pleura, or chest wall Pneumonia / Abscess / Lobar collapse Airway obstruction by tumor Pleural effusion Tumour spread to the pleura Hoarseness Recurrent laryngeal nerve invasion Dysphagia Esophageal invasion SVC syndrome Superior vena cava compression Horner syndrome Sympathetic ganglia invasion Pericarditis / Cardiac tamponade Pericardial involvement

References:

Robbins, Cotran & Kumar, Pathologic Basis of Disease, 11th Edition, Pages 656, 657

↑ *Back to this question in Part A*

@Neet_pg_bot

Q4: Which of the following represents the most common histologic subtype of lung cancer worldwide? (Q890490)

A. Adenocarcinoma > Squamous cell carcinoma > Small cell carcinoma

B. Small cell carcinoma > Large cell carcinoma > Adenocarcinoma

C. Adenocarcinoma > Small cell carcinoma > Squamous cell carcinoma

D. Squamous cell carcinoma > Adenocarcinoma > small cell carcinoma

Correct Answer: A. Adenocarcinoma > Squamous cell carcinoma > Small cell carcinoma

Explanation: Adenocarcinoma is the most common histologic subtype of lung cancer worldwide (~50%), followed by squamous cell carcinoma (~20%), and then small cell carcinoma (~15%). Adenocarcinoma has surpassed squamous cell carcinoma globally and is also the most common subtype in never-smokers. Lung Carcinoma: Most frequently diagnosed major cancer worldwide Leading cause of cancer mortality Age Distribution: Common between 55-84 years Peak: 65-74 years Only 2% occur <40 years Major Histologic Types: Adenocarcinoma (50%) Squamous cell carcinoma (20%) Small cell carcinoma (15%) Large cell carcinoma (2%) Others (13%)

References:

Robbins, Cotran & Kumar, Pathologic Basis of Disease, 11th Edition, Page 652

↑ *Back to this question in Part A*

@Neet_pg_bot

Q5: What is the diagnosis for a patient who has a history of smoking 24 packs, is currently experiencing breathlessness and chest pain, and is found to have a lung tumor with positive chromogranin staining? (Q882173)

A. Adenocarcinoma

B. Squamous cell carcinoma

C. Mesothelioma

D. Small cell carcinoma

Correct Answer: D. Small cell carcinoma

Explanation: Small cell lung cancer (SCLC) is a highly aggressive type of lung cancer that is strongly associated with smoking. It tends to grow rapidly and is often diagnosed at an advanced stage. SCLC is characterized by positive staining for neuroendocrine markers, including chromogranin, which confirms its neuroendocrine origin. This cancer typically arises centrally in the lung, often in the bronchi, and can cause symptoms such as breathlessness and chest pain. Cancer Type Smoking Location Markers Genes Histopathology Notes Adenocarcinoma (Option A) Weak association Peripheral TTF-1, Napsin A EGFR, ALK, KRAS Lepidic spread Most common overall (India and World) Small cell carcinoma (Option D) Strong association Central Chromogranin, Synaptophysin, NSE, Bombensin L-myc Azzopardi effect, Salt and pepper chromatin Neuroendocrine, aggressive Squamous cell carcinoma (Option B) Strong association Central p40/p63 p53 Keratin Pearls Hypercalcemia (PTHrP) Mesothelioma (Option C) Asbestos Pleura Calretinin, Ck5/6, WT-1 BAP-1 Long and slender microvilli seen on electron microscopy Pleural tumor

References:

Robbins and Cotran Pathologic Basis of Disease, 10th Edition, Page 715-722

↑ *Back to this question in Part A*

@Neet_pg_bot

Q6: Which of the following is not an IHC marker for small-cell lung carcinoma? (Q846630)

A. Napsin A

B. Chromogranin

C. NSE

D. CD56

Correct Answer: A. Napsin A

■ *Listen (English)*

■ *Listen (Hindi)*

Explanation: NAPSIN A, MUC 1, and TTF 1 are the IHC (immunohistochemistry) markers for adenocarcinoma of the lung. IHC markers for small cell lung carcinoma are: Synaptophysin Chromogranin (Option B) Bombesin NSE (Neuron-Specific Enolase) (Option C) INSM CD56 (Option D) CD57

References:

Robbins and Cotran, Pathologic Basis of Disease, 10th edition, Page 719.

↑ *Back to this question in Part A*

@Neet_pg_bot

Q7: A 56-year-old male presents with persistent shoulder pain radiating to the ulnar aspect of the forearm and progressive weakness in his right hand. Examination reveals muscle wasting in the right hand. Imaging of the chest shows a mass at the apex of the right lung involving nearby neurovascular structures. Which syndrome is most likely associated with this presentation? (Q845630)

A. Horner syndrome

B. Superior vena cava (SVC) syndrome

C. Caplan syndrome

D. Carcinoid syndrome

Correct Answer: A. Horner syndrome

■ *Listen (English)*

■ *Listen (Hindi)*

Explanation: The patient's presentation and the presence of a lung apex mass involving nearby neurovascular structures suggests a Pancoast tumour (superior sulcus tumour) located at the apex of the lung, typically involving nearby neurovascular structures. Compression or invasion of nearby nerves, including the sympathetic chain, can result in Horner syndrome, characterised by a combination of ptosis (drooping eyelid), miosis (constricted pupil), and anhidrosis (lack of sweating) on the affected side of the face and sometimes enophthalmos (sunken appearance

of the eyeball). Superior vena cava syndrome (Option B): SVC syndrome is characterised by symptoms related to compression or obstruction of the superior vena cava, typically by a tumour in the mediastinum leading to facial swelling, dilated veins, and other signs of venous congestion but not neurological manifestations. Caplan syndrome (Option C): Caplan syndrome is the combination of rheumatoid arthritis and pneumoconiosis (Coal workers' pneumoconiosis) with characteristic pulmonary nodules . It is not associated with any neurological symptoms. Carcinoid syndrome (Option D): Carcinoid syndrome is associated with symptoms such as flushing, diarrhoea, and wheezing due to the release of vasoactive substances from carcinoid tumours, and it has no association with neurological manifestations.

References:

Robbins and Cotran, Pathologic Basis of Disease, 10th edition, Page 722

↑ *Back to this question in Part A*

@Neet_pg_bot

Q8: A 55-year-old woman has an incidental finding of a lung mass on imaging. CT scan reveals a well-circumscribed lesion with calcifications. Biopsy revealed spindle and epithelioid cells with an eosinophilic cytoplasm, perivascular growth, and positive HMB-45 staining. What is the most likely diagnosis? (Q845627)

A. Pulmonary hamartoma

B. Sugar tumour (PEComa)

C. Solitary fibrous tumour

D. Carcinoid tumour

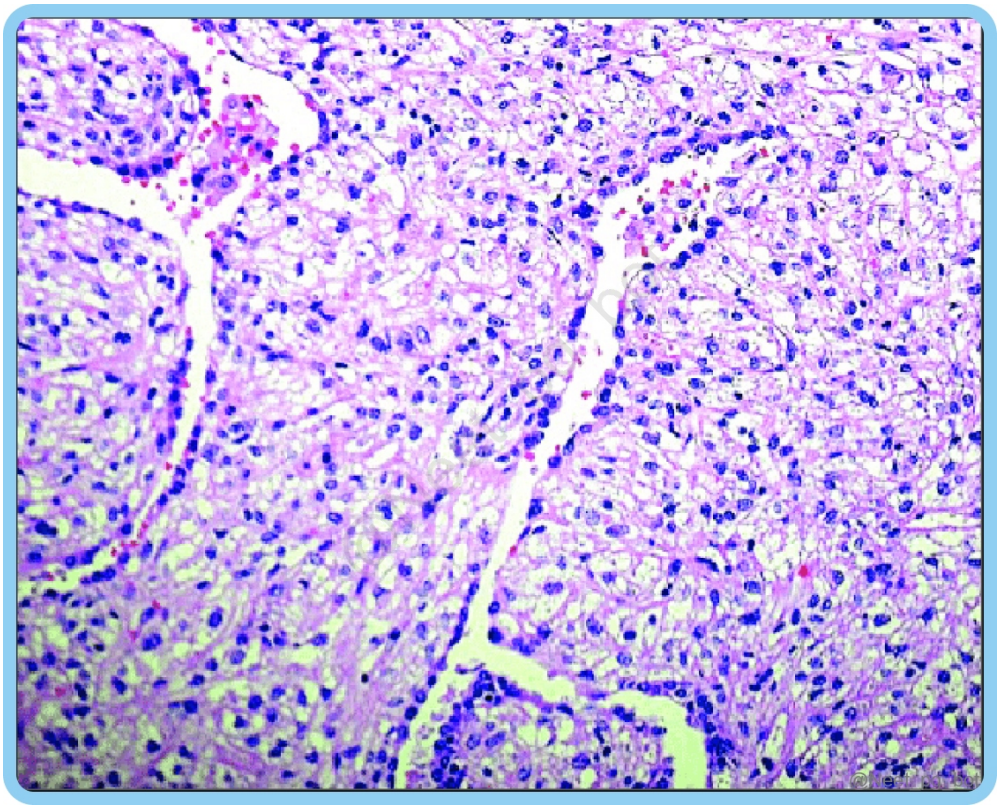

Correct Answer: B. Sugar tumour (PEComa)

- *Listen (English)*
- *Listen (Hindi)*

Explanation: The clinical scenario of a well-circumscribed lung mass with calcifications and histological features of spindle and epithelioid cells with eosinophilic cytoplasm, perivascular growth pattern , and positivity for HMB-45 immunostaining is highly suggestive of a sugar tumour. It is also known as a perivascular epithelioid cell tumour (PEComa). PEComa It is a rare mesenchymal tumour . It can lead to cystic, emphysema-like dilation of terminal airspaces and obstruction of lymphatic vessels . Treatment involves surgical resection, and mTOR inhibitors are considered for un-resectable or metastatic cases. Pulmonary hamartomas (Option A): Pulmonary hamartomas are benign lung tumours of mesenchymal and epithelial components like cartilage, fat, and fibrous tissue . They are often discovered incidentally on imaging scans as small, well-defined, rounded opacities (coin lesions). Microscopically, they show nodules of connective tissue with epithelial clefts, often containing cartilage and lined by ciliated or non-ciliated epithelium. Solitary fibrous tumour (Option C): Solitary fibrous tumours are rare mesenchymal tumours of the lung and are well-circumscribed masses composed of spindle and epithelioid cells . They typically stain positive for CD34 and STAT6 , with a favourable prognosis after surgical resection. Carcinoid tumor (Option D): Carcinoid tumours are neuroendocrine tumours typically manifest as polypoid masses in the bronchi. Their histopathological features include the nesting of cells with uniform round nuclei, moderate eosinophilic cytoplasm, and chromatin's characteristic 'salt and pepper' appearance within the nuclei . These tumours stain positive for neuroendocrine markers like Synaptophysin and Chromogranin.

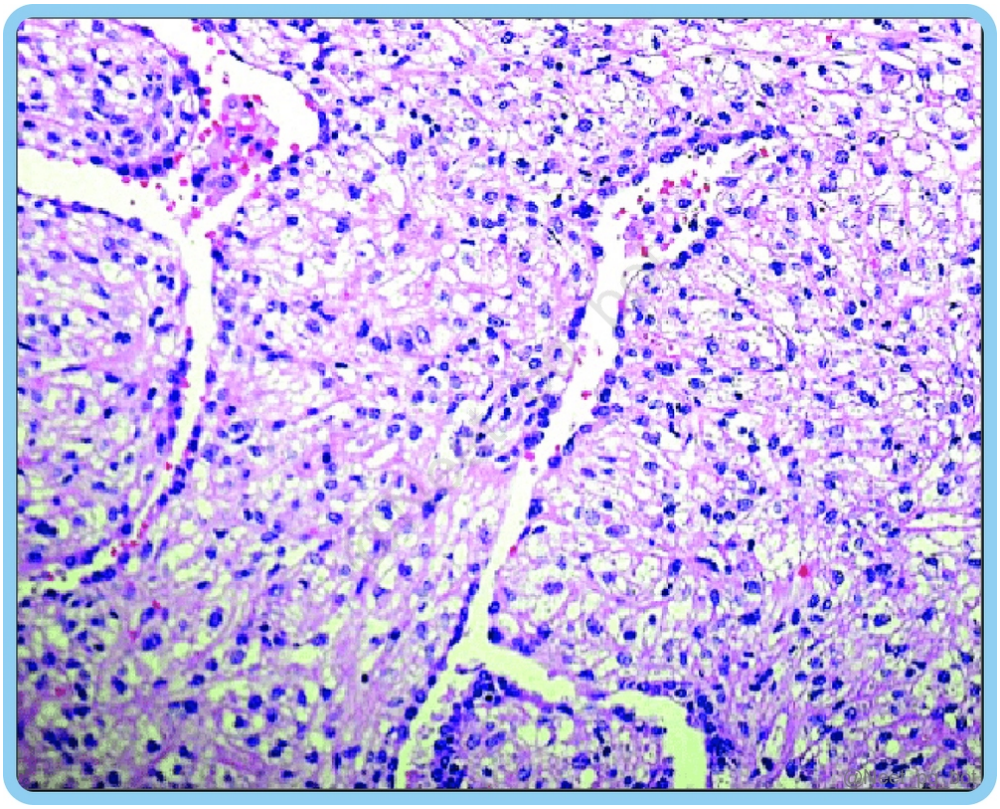

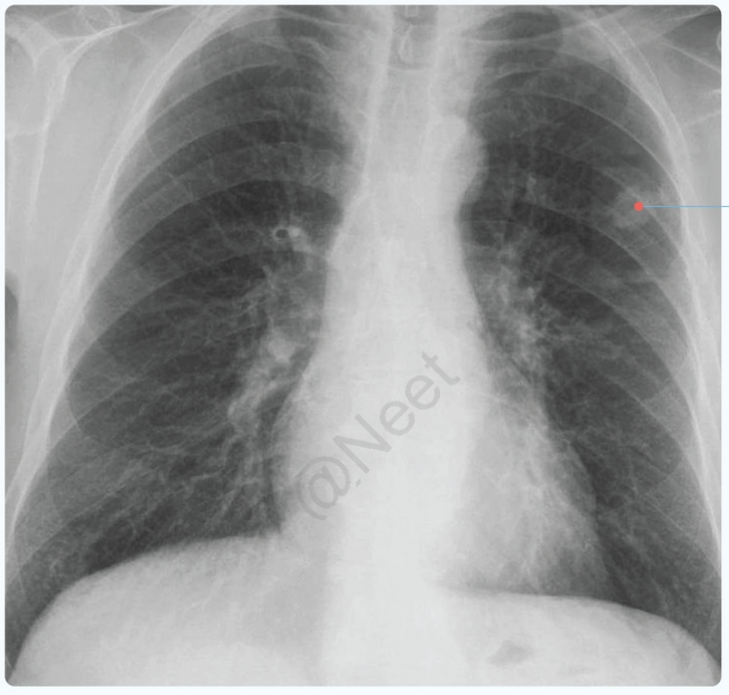

@Neet_pg_bot

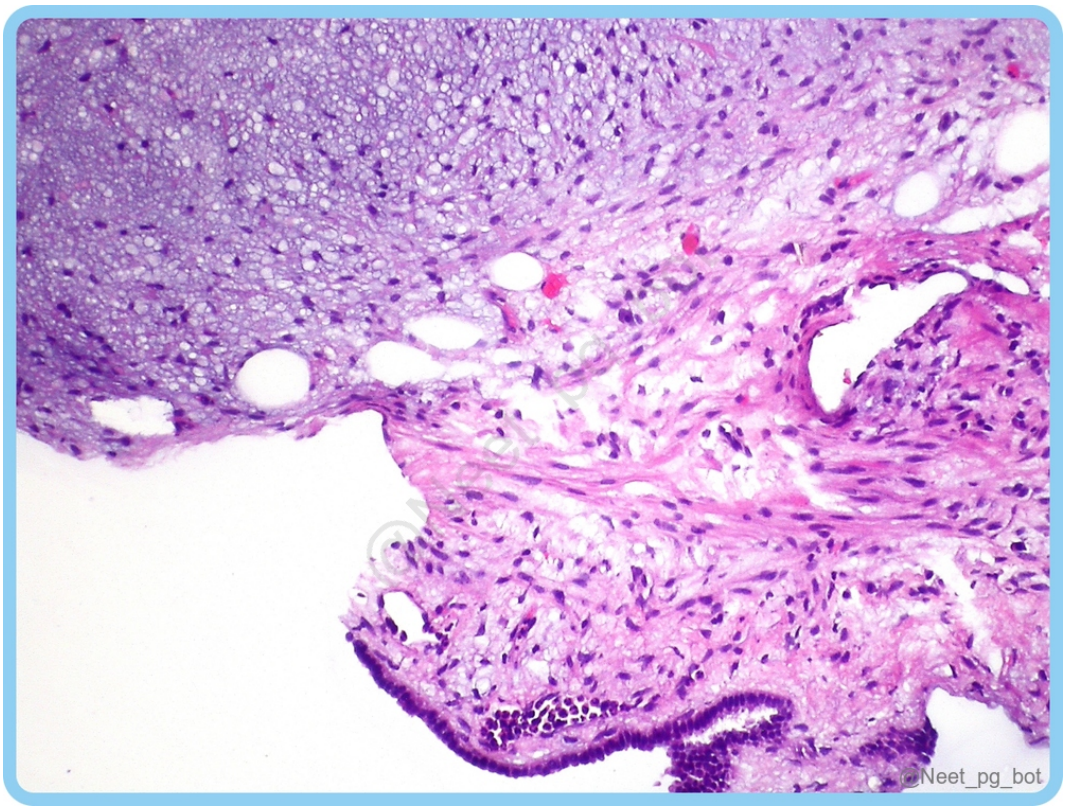

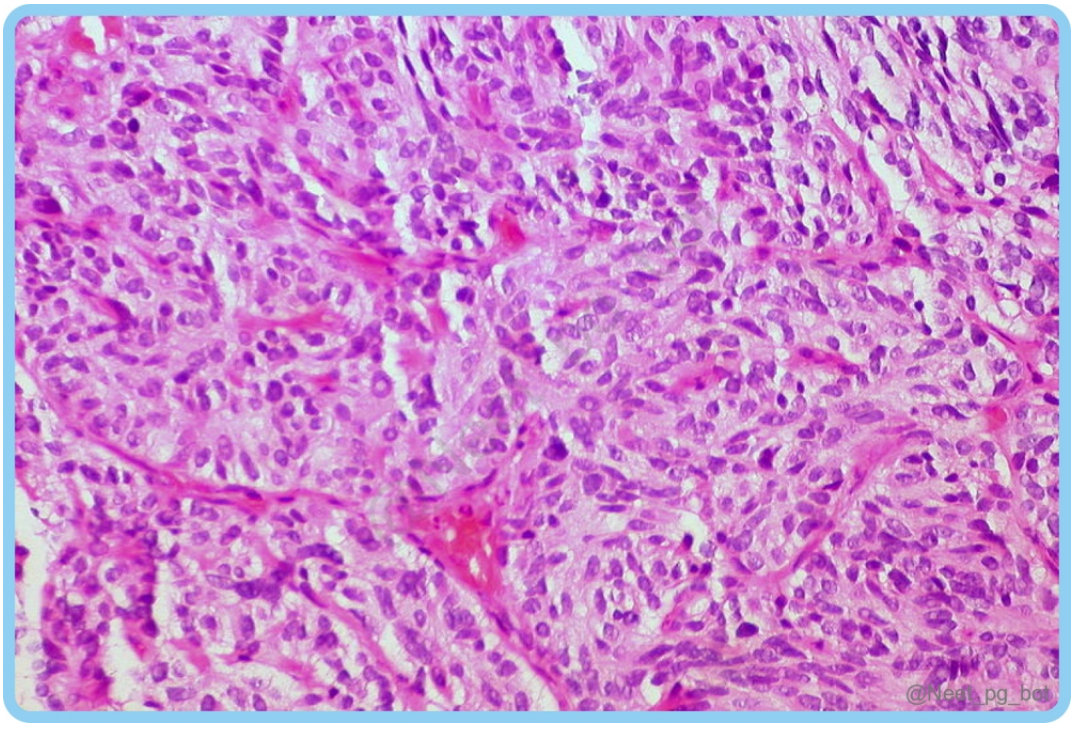

References:

Robbins and Cotran, Pathologic Basis of Disease, 10th Edition, Pages 722-724

↑ *Back to this question in Part A*

@Neet_pg_bot

Q9: A 55-year-old former shipyard worker presents with progressive dyspnea and left-sided chest pain for three months. He has a history of occupational asbestos exposure. Physical examination reveals decreased breath sounds over the left lung base. Imaging shows left-sided pleural thickening and effusion. Biopsy confirms mesothelioma. Which of the following statements is not accurate about mesothelioma and adenocarcinoma following asbestos exposure? (Q845595)

A. Adenocarcinoma often has a shorter latency period compared to mesothelioma following asbestos exposure.

B. Mesothelioma under electron microscopy, reveals non-branching microvilli.

C. Mesothelioma often presents with positive staining for calretinin and WT-1.

D. Adenocarcinoma is commonly associated with EGFR mutation.

Correct Answer: B. Mesothelioma under electron microscopy, reveals non-branching microvilli.

■ *Listen (English)*

■ *Listen (Hindi)*

Explanation: Characteristic Malignant mesothelioma Adenocarcinoma lung Origin Arises from mesothelial cells lining the pleura. Arises from glandular epithelial cells. Association with asbestos exposure Most specific tumours due to asbestos exposure M/C carcinoma in asbestos exposure. Latency period 25-45 years after asbestos exposure 10-30 years after asbestos exposure (Option A) Specific genetic mutations NF2, BAP1, chromosome 9p deletion EGFR, ALK, KRAS (Option D) Pathological features Epithelioid, sarcomatoid, or biphasic patterns Various growth patterns, glandular differentiation Immunohistochemistry Keratin, Calretinin, WT-1 (Option C), cytokeratin 5/6, podoplanin Thyroid transcription factor-1 (TTF-1) Electron microscopy Long, slender, branching microvilli (Option B) Short and non-branching microvilli

References:

Robbins and Cotran, Pathologic Basis of Disease, 10th edition, Pages 716-724

↑ *Back to this question in Part A*

@Neet_pg_bot

Q10: A 55-year-old male presents with pleuritic chest pain and a pleural-based mass observed on imaging studies. Histopathological examination of a biopsy from the mass

reveals spindle-shaped cells within a collagenous stroma. Which immunohistochemical marker would be most useful in differentiating solitary fibrous tumour (SFT) from mesothelioma? (Q845579)

A. CD34

B. Calretinin

C. WT1

D. TTF-1 (Thyroid transcription factor 1)

Correct Answer: A. CD34

■ *Listen (English)*

■ *Listen (Hindi)*

Explanation: CD34 is a marker often expressed in solitary fibrous tumours. It is most useful for identifying solitary fibrous tumours due to its high rate of positivity in SFT and its absence in mesothelioma. Characteristic Solitary Fibrous Tumor (SFT) Malignant Mesothelioma Nature of the tumour Mostly benign, rare malignant Malignant Histopathology Dense fibrous tissue, spindle cells, occasional cysts Diffuse, invasive tumour growth across the pleural surface Immunohistochemistry Positive for CD34 and STAT6. Negative for Keratin. Positive for Calretinin, WT1, cytokeratin 5/6, and podoplanin. Morphology Tumours, often pedunculated and attached to the pleural surface, may have a whorled appearance. Thick, firm, gelatinous tissue ensheathing the lung; often extensive effusion. Microscopic appearance Spindle cells are arranged in whorls among reticulin and collagen fibres. Variable : Epithelioid (tubular/papillary structures), sarcomatoid (fibrosarcoma-like), or biphasic Calretinin (Option B): Calretinin is a calcium-binding protein commonly used as a marker for mesothelioma. It is typically expressed in the epithelial and some biphasic types of mesothelioma but is not usually expressed in solitary fibrous tumours . WT1 (Wilms' tumour 1) (Option C): WT1 is another frequently positive marker in mesothelioma, particularly in epithelial mesothelioma. This marker, however, is not usually expressed in solitary fibrous tumours. TTF-1 (Thyroid transcription factor 1) (Option D): TTF-1 is primarily used to identify carcinoma of lung and thyroid origin and is not useful for distinguishing between solitary fibrous tumours and mesothelioma. TTF-1 is positive in the adenocarcinoma of the lung.

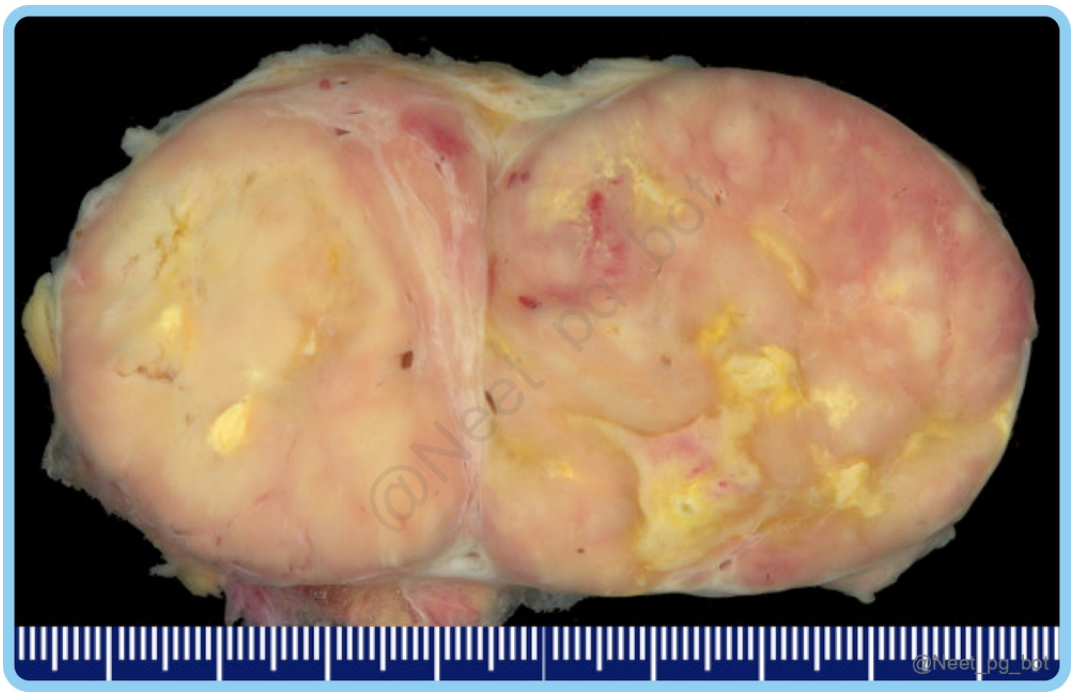

References:

Robbins and Cotran, Pathologic Basis of Disease, 10th edition, Page 725

↑ *Back to this question in Part A*

@Neet_pg_bot

Q11: A 45-year-old nonsmoking woman presents with a persistent cough and hemoptysis. Imaging reveals a solitary pulmonary nodule in the right lung. Biopsy shows cells with neuroendocrine features, including round to oval nuclei, stippled chromatin, and abundant granular cytoplasm arranged in nests and trabeculae. Which cell type is most likely involved in the origin of this patient's lung tumour? (Q845564)

A. Type II pneumocytes

B. Clara cells

C. Kulchitsky cells

D. Alveolar macrophages

Correct Answer: C. Kulchitsky cells

■ *Listen (English)*

■ *Listen (Hindi)*

Explanation: The clinical scenario, along with biopsy features, suggest a Carcinoid tumour , a neuroendocrine tumour arising from Kulchitsky cells (Neuroendocrine cells) within the bronchial epithelium. These cells produce and secrete bioactive substances such as serotonin (5-HT) and other peptides that can influence smooth muscle contraction, immune responses, and other physiological processes. Type II pneumocytes (Option A): Type II pneumocytes are surfactant-producing cells in the alveoli and are associated with adenocarcinoma rather than carcinoid tumours. Clara cells (Option B): Clara cells are non-ciliated cells found in the bronchioles and are not involved in the origin of bronchial carcinoid tumours. These cells secrete proteins and lipids that maintain and protect the airway epithelium. Alveolar macrophages (Option D): Alveolar macrophages are immune cells responsible for phagocytosis within the alveoli and are not related to the development of carcinoid tumours.

References:

Robbins and Cotran, Pathologic Basis of Disease, 10th edition, Page 724

↑ *Back to this question in Part A*

@Neet_pg_bot

Q12: A 45-year-old female presents progressive shortness of breath, especially on exertion, fatigue, and ankle swelling. Physical examination reveals elevated jugular venous pressure. Echocardiography shows right ventricular hypertrophy and elevated pulmonary artery pressure. Which of the following conditions can predispose her to this condition? (Q845467)

A. High altitude

B. Recurrent thromboembolic

C. Scleroderma

D. All the above

Correct Answer: D. All the above

■ *Listen (English)*

■ *Listen (Hindi)*

Explanation: The patient's clinical presentation with symptoms of exertional dyspnea, signs of right heart failure (elevated jugular venous pressure, right ventricular hypertrophy), and echocardiographic evidence of elevated pulmonary artery pressure suggest the presence of pulmonary hypertension. Pulmonary hypertension results from vascular remodelling and vasoconstriction in the pulmonary arterioles, leading to increased pulmonary vascular resistance and elevated pulmonary arterial pressure. Manifestations include exertional dyspnea, fatigue, chest pain, syncope, right heart failure with jugular venous distension, and peripheral oedema. Causes of Pulmonary

hypertension Primary Pulmonary Hypertension (Idiopathic) Secondary Pulmonary Hypertension High altitude (Chronic hypoxia) (Option A) Chronic Obstructive Pulmonary Disease (COPD) Interstitial lung disease (e.g., Pulmonary fibrosis) Left Heart Failure (e.g. Mitral stenosis, Systolic dysfunction) Recurrent thromboembolism events (Pulmonary embolism) (Option B) Autoimmune diseases (e.g. Systemic sclerosis) (Option C) Congenital Heart Disease (e.g. Atrial Septal Defect; Eisenmenger Syndrome) Obstructive Sleep apnea High altitude (Option A): Living at high altitudes with reduced oxygen can lead to pulmonary hypertension as: Recurrent thromboembolic events (Option B): Repeated pulmonary embolisms can obstruct blood vessels in the lungs, increasing pulmonary vascular resistance and causing pulmonary hypertension. Scleroderma (Option C): Scleroderma or Systemic Sclerosis can lead to lung vessel fibrosis and narrowing, raising pulmonary vascular resistance and contributing to pulmonary hypertension.

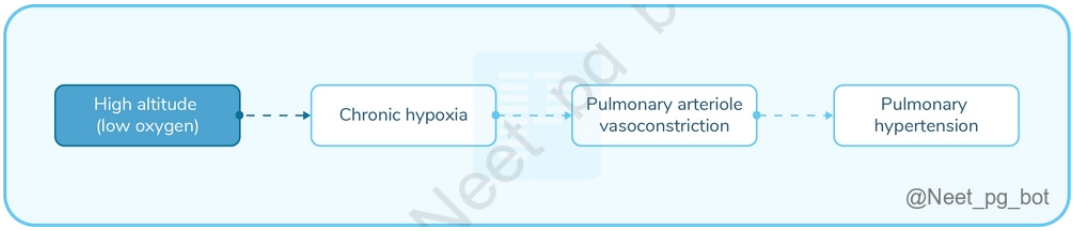

References:

Robbins and Cotran, Pathologic Basis of Disease, 10th edition, Page 702

↑ *Back to this question in Part A*

@Neet_pg_bot

Q13: A 50-year-old heavy smoker presents with a persistent cough and unintentional weight loss. Imaging shows a right lung mass with mediastinal lymphadenopathy. Biopsy reveals small, round cells with scant cytoplasm and nuclei exhibiting a salt-and-pepper chromatin pattern. Immunohistochemistry (IHC) is positive for neuroendocrine markers. Which of the following features is incorrectly associated with this clinical condition? (Q845561)

A. Both glandular and squamous differentiation are seen

B. Encrustation of tumour cells along the blood vessels with DNA material

C. Presence of dense neurosecretory granules on electron microscopy

D. High proliferative index

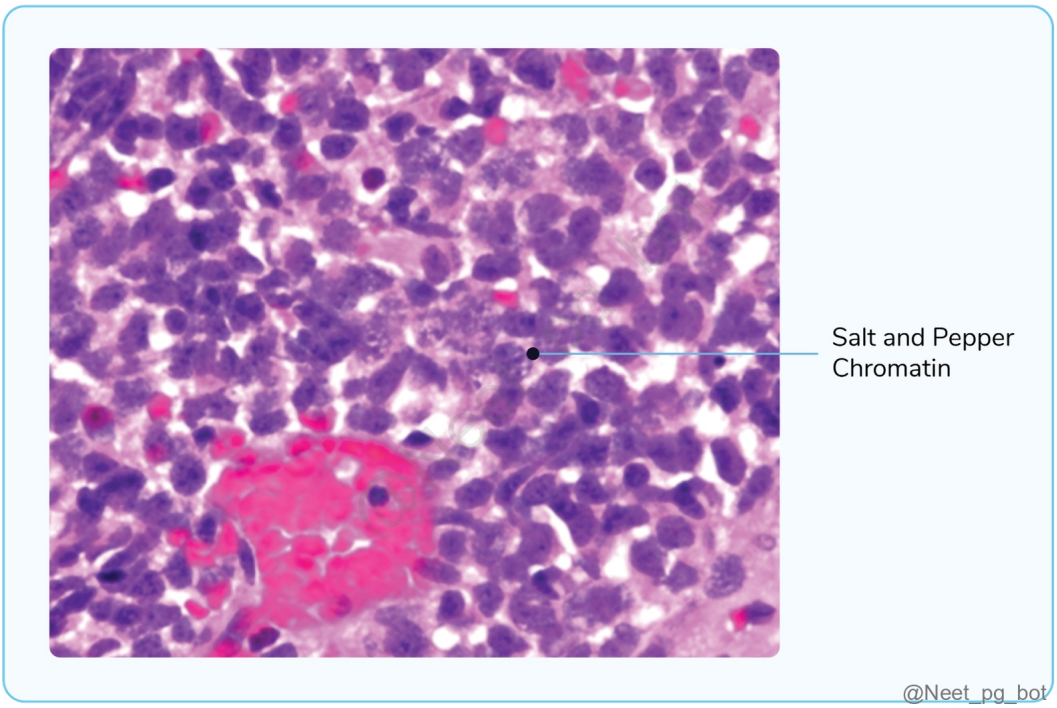

Correct Answer: A. Both glandular and squamous differentiation are seen

■ *Listen (English)*

■ *Listen (Hindi)*

Explanation: The clinical presentation and histological features described suggest small-cell lung carcinoma, a highly malignant neuroendocrine tumour with a strong relationship to cigarette smoking. Small cell lung cancer (SCLC) primarily exhibits neuroendocrine characteristics without the glandular histological features seen in adenocarcinoma or the squamous differentiation seen in squamous cell carcinoma. Encrustation of tumour cells along the blood vessels with DNA material(Option B) The encrustation of necrotic tumour cells along the blood vessels with DNA material causes basophilic staining of vascular walls . It is known as the ‘Azzopardi effect’ , a characteristic feature often observed in Small-cell lung carcinoma. Presence of dense neurosecretory granules on electron microscopy (Option C): Small-cell lung carcinoma shows neuroendocrine differentiation and dense neurosecretory granules on electron microscopy. High proliferative index (Option D): Small-cell lung carcinoma is known for its aggressive behaviour and rapid growth, both clinically and histologically. This is reflected in a high proliferative index, with many cells in active cell cycle phases.

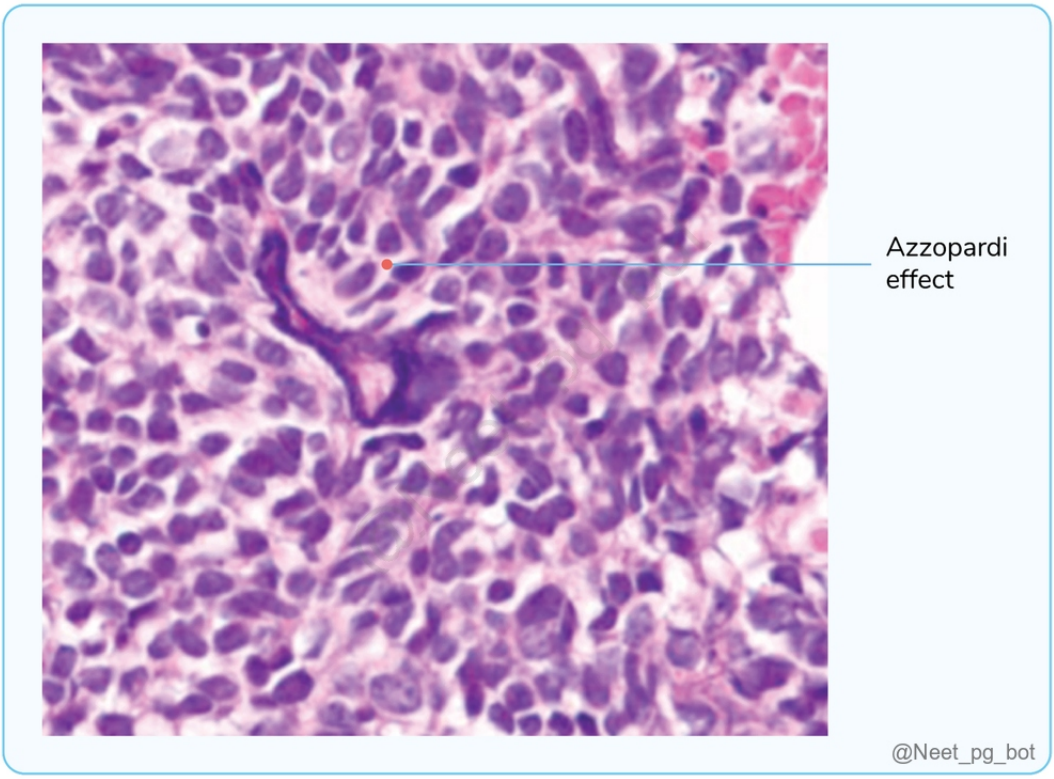

References:

Robbins and Cotran, Pathologic Basis of Disease, 10th edition, Page 718

↑ *Back to this question in Part A*

@Neet_pg_bot

Q14: A 52-year-old male, non-smoker, presents with progressive shortness of breath, persistent dry cough, and chest pain. A CT scan reveals a peripheral mass in the lower lobe of left lung, and a biopsy of the nodule demonstrates a glandular pattern with mucinous differentiation, as shown in the image below. Which of the following markers is least likely to be positive in this patient's lung lesion? (Q845560)

A. TTF-1 (Thyroid Transcription Factor-1)

B. MUC1

C. Napsin A

D. Chromogranin

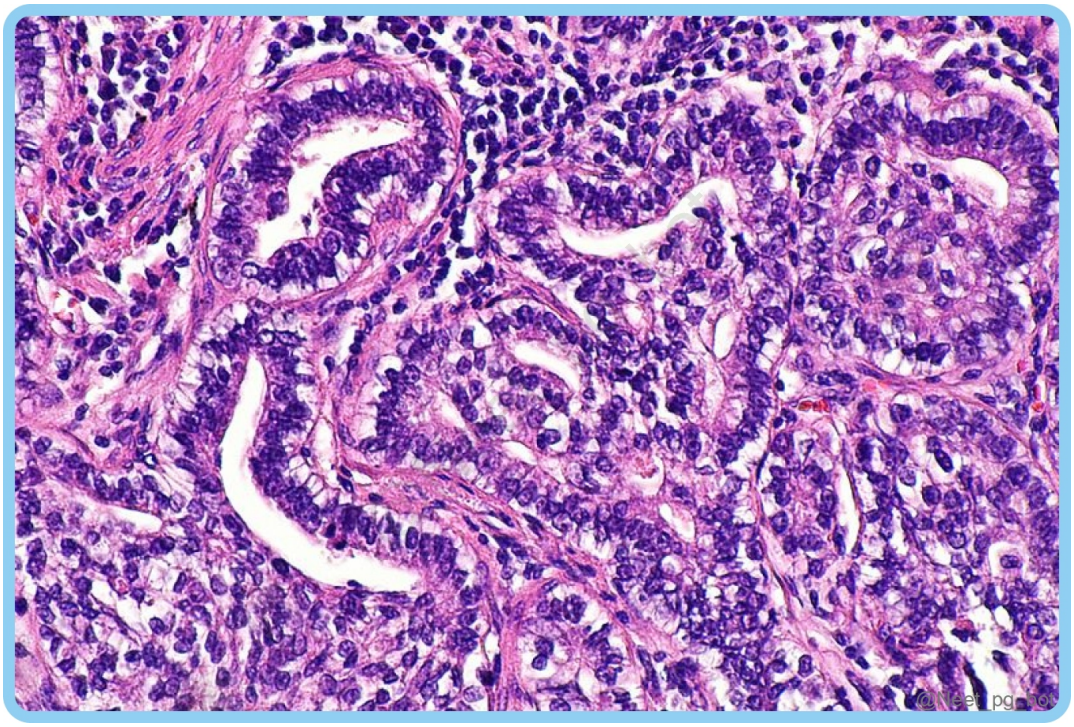

Correct Answer: D. Chromogranin

■ *Listen (English)*

■ *Listen (Hindi)*

Explanation: The morphology is consistent with pulmonary adenocarcinoma, particularly mucinous adenocarcinoma. Adenocarcinomas typically express TTF-1, Napsin A, and MUC1, reflecting glandular differentiation. (Option A,B & C ruled out) Chromogranin is a neuroendocrine marker, expressed in small-cell carcinoma, carcinoid tumors, and other neuroendocrine tumors, not in conventional adenocarcinomas. Therefore, chromogranin is least likely to be positive in this lesion.

References:

Robbins and Cotran, Pathologic Basis of Disease, 10th Edition, Pages 719

↑ *Back to this question in Part A*

@Neet_pg_bot

Q15: A 59-year-old heavy smoker presents with loss of appetite and a persistent cough for the past few months. Imaging reveals a central lung mass involving the right bronchus and mediastinal lymph nodes. Immunohistochemical staining of a lung mass biopsy is positive for chromogranin and synaptophysin. Which set of genes is most likely involved in the underlying pathology of this patient's condition? P53 RB L-myc (Q845559)

A. 1, 2

B. 1, 2, 3

C. Only 2

D. 2, 3

Correct Answer: B. 1, 2, 3

■ *Listen (English)*

■ *Listen (Hindi)*

Explanation: The patient's clinical presentation and positive staining for neuroendocrine markers such as Chromogranin and synaptophysin are highly suggestive of Small-cell lung cancer (SCLC) originating from neuroendocrine cells. It is a highly malignant form of lung cancer associated with smoking and is known for its aggressive behaviour and early metastasis. The genetic landscape of SCLC typically involves the inactivation of TP53 and RB genes. L-MYC amplification is a common feature in some SCLC cases, contributing to the tumour's rapid growth and aggressive nature.

References:

Robbins and Cotran, Pathologic Basis of Disease, 10th edition, Page 717

↑ *Back to this question in Part A*

@Neet_pg_bot

Q16: A 57-year-old male smoker with a persistent cough and weight loss is found to have a lung mass on imaging. The biopsy showed keratin pearls and intercellular bridges. Which of the following paraneoplastic syndromes is highly associated with this diagnosis? (Q845558)

A. Hypercalcemia

B. Syndrome of Inappropriate Antidiuretic Hormone Secretion (SIADH)

C. Migratory thrombophlebitis

D. Cushing's syndrome

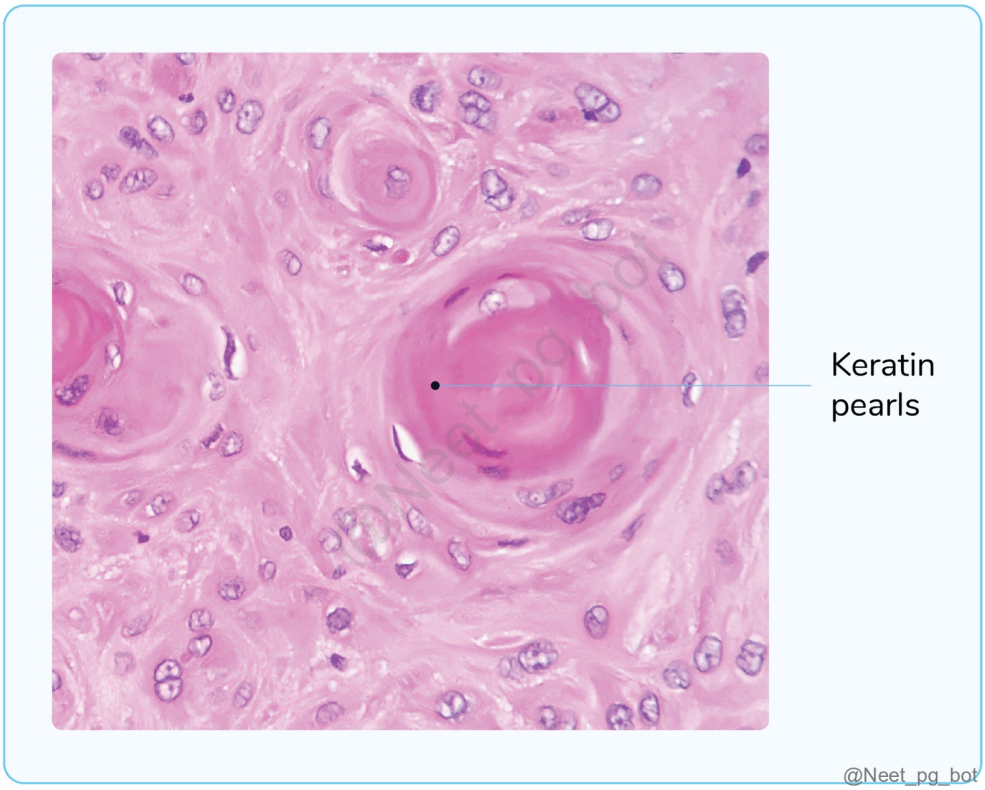

Correct Answer: A. Hypercalcemia

■ *Listen (English)*

■ *Listen (Hindi)*

Explanation: The given clinical presentation and histological findings point towards the diagnosis of squamous cell carcinoma, one of the major subtypes of non-small cell lung cancer, which typically arises from the central bronchi and can cause symptoms like coughing, chest pain, and hemoptysis. Hypercalcemia is the most common paraneoplastic syndrome associated with squamous cell carcinoma of the lung. SCC of the lung can produce parathyroid hormone-related protein (PTHrP) , leading to elevated calcium levels in the blood. This condition is characterised by symptoms such as fatigue, confusion, excessive thirst and urination, and nausea. Syndrome of Inappropriate Antidiuretic Hormone Secretion (SIADH) (Option B): It is more commonly associated with small cell lung cancer rather than SCC. SIADH leads to excessive release of antidiuretic hormone, causing water retention and dilutional hyponatremia, which can result in symptoms like muscle cramps, nausea, headaches, and disorientation. Migratory thrombophlebitis (also known as Trousseau’s syndrome) (Option C): While this can be seen in many types of cancers, it is typically more associated with adenocarcinoma rather than with SCC. This syndrome involves the formation of blood clots that migrate within the venous system. Cushing's syndrome (Option D): It is characterised by the ectopic production of ACTH, most frequently associated with small cell lung cancer, not SCC. Patients may experience symptoms such as weight gain, muscle weakness, and a rounded face (moon face).

References:

Robbins and Cotran, Pathologic Basis of Disease, 10th edition, Page 722

↑ *Back to this question in Part A*

Q17: A 67-year-old male smoker presents with a persistent cough and weight loss. Imaging reveals a lung mass in the upper lobe of the right lung. The biopsy reveals typical features, including keratin pearls, intercellular bridges, and nests of malignant squamous cells with abundant eosinophilic cytoplasm. Based on this scenario, which of the following statements is incorrect? (Q845557)

A. Keratin pearls are not seen in poorly differentiated squamous cell carcinoma.

B. p40 is the best marker for squamous cell carcinoma.

C. Squamous dysplasia is a precursor lesion of squamous cell carcinoma

D. The squamous cell carcinoma described is likely a peripheral lung lesion.

Correct Answer: D. The squamous cell carcinoma described is likely a peripheral lung lesion.

■ *Listen (English)*

■ *Listen (Hindi)*

Explanation: Squamous Cell Carcinoma is typically found in the central regions of the lungs (Not peripheral), often originating in the major bronchi near the hilum. It can cause symptoms by obstructing airways. Histopathologically, it is characterised by keratin pearls, intercellular bridges, and nests of malignant squamous cells with abundant eosinophilic cytoplasm. Location of lung carcinomas: Central: Squamous cell carcinoma, Small cell carcinoma and Bronchial carcinoids. Peripheral: Adenocarcinoma and Large-cell carcinoma. Keratin pearls are not seen in poorly differentiated squamous cell carcinoma (Option A): Keratin pearls are a characteristic feature of well-differentiated squamous cell carcinoma p40 is the best marker for squamous cell carcinoma (Option B): p40 is the most specific and best marker for squamous cell carcinoma Squamous dysplasia is a recognised precursor lesion for squamous cell carcinoma (Option C): Squamous cell carcinomas often arise from pre-existing bronchial epithelial conditions such as squamous metaplasia or dysplasia.

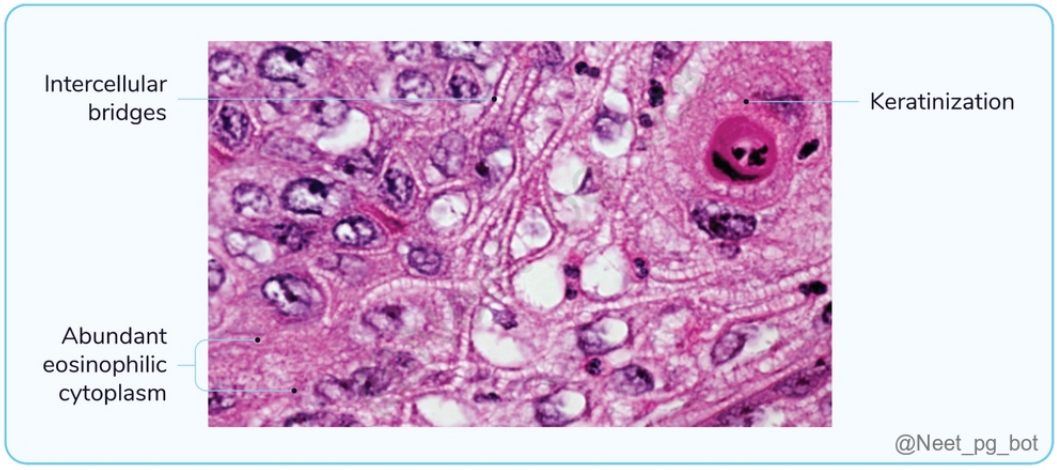

References:

Robbins and Cotran, Pathologic Basis of Disease, 10th edition, Page 717

↑ *Back to this question in Part A*

@Neet_pg_bot

Q18: A 58-year-old male smoker presents with a persistent cough and mild shortness of breath. Chest imaging reveals a solitary pulmonary nodule. A biopsy is performed, and a histopathological examination of the lung tissue is shown in the image below. What is the most likely diagnosis? (Q845556)

A. Carcinoma in situ

B. Adenomatous hyperplasia

C. Adenocarcinoma in situ

D. Diffuse idiopathic pulmonary neuroendocrine cell hyperplasia

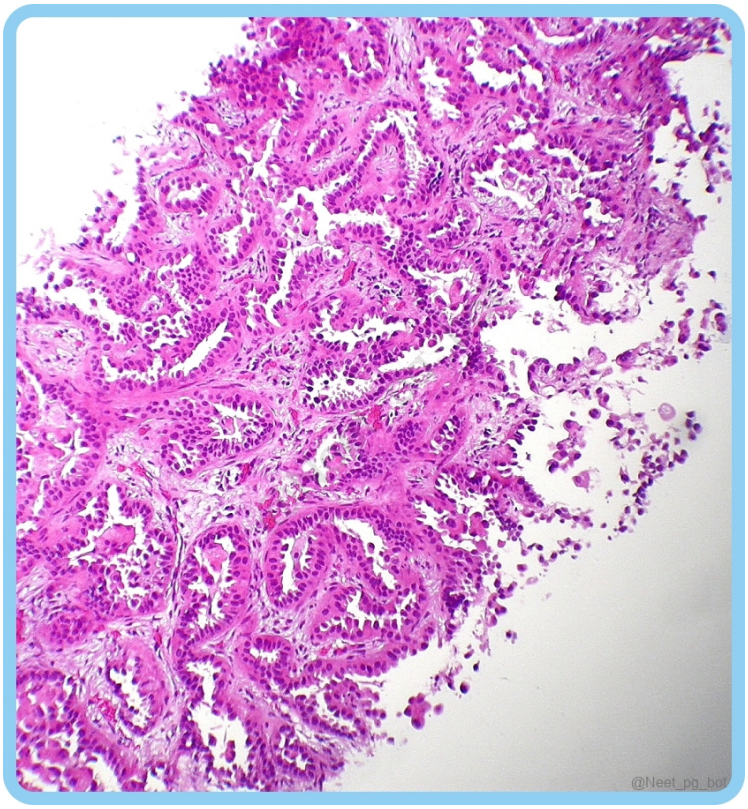

Correct Answer: C. Adenocarcinoma in situ

■ *Listen (English)*

■ *Listen (Hindi)*

Explanation: The histopathological image shows a localised proliferation of dysplastic cells along pre-existing alveolar septa, indicative of adenocarcinoma in situ (AIS) or bronchioloalveolar carcinoma which is a precancerous lesion of adenocarcinoma of the lung with severe cytologic atypia . AIS is an early stage of lung cancer where abnormal glandular cells are confined to the airway lining without invasion and exhibit a “lepidic growth pattern” (or butterfly on fence pattern), spreading along intact alveolar structures without invasion. Lesions are usually small, measuring ≤ 3 cm. Carcinoma in situ (Option A): Carcinoma in situ involves abnormal squamous cells confined to the epithelium without invading the surrounding structures. Adenomatous hyperplasia (Option B): Atypical adenomatous hyperplasia (AAH) is a precursor lesion of lung adenocarcinoma with mild cytologic atypia, characterised by dysplastic pneumocytes lining alveolar walls. These lesions are typically small, ≤5 mm , and can be single or multiple. AAH may be adjacent to invasive tumours or independently within the lung tissue and signifies an initial stage in adenocarcinoma development. Diffuse idiopathic pulmonary neuroendocrine cell hyperplasia (Option D): DIPNECH (Diffuse idiopathic pulmonary neuroendocrine cell hyperplasia) is a preneoplastic condition characterised by the abnormal proliferation of neuroendocrine cells in the lungs, which can progress to develop into neuroendocrine tumours over time like small cell carcinoma and carcinoid tumours.

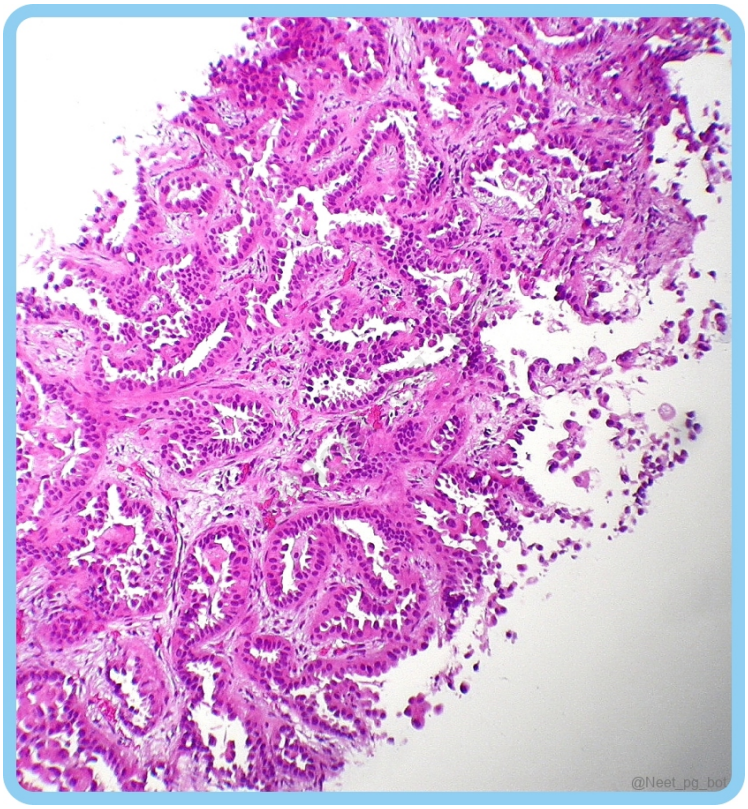

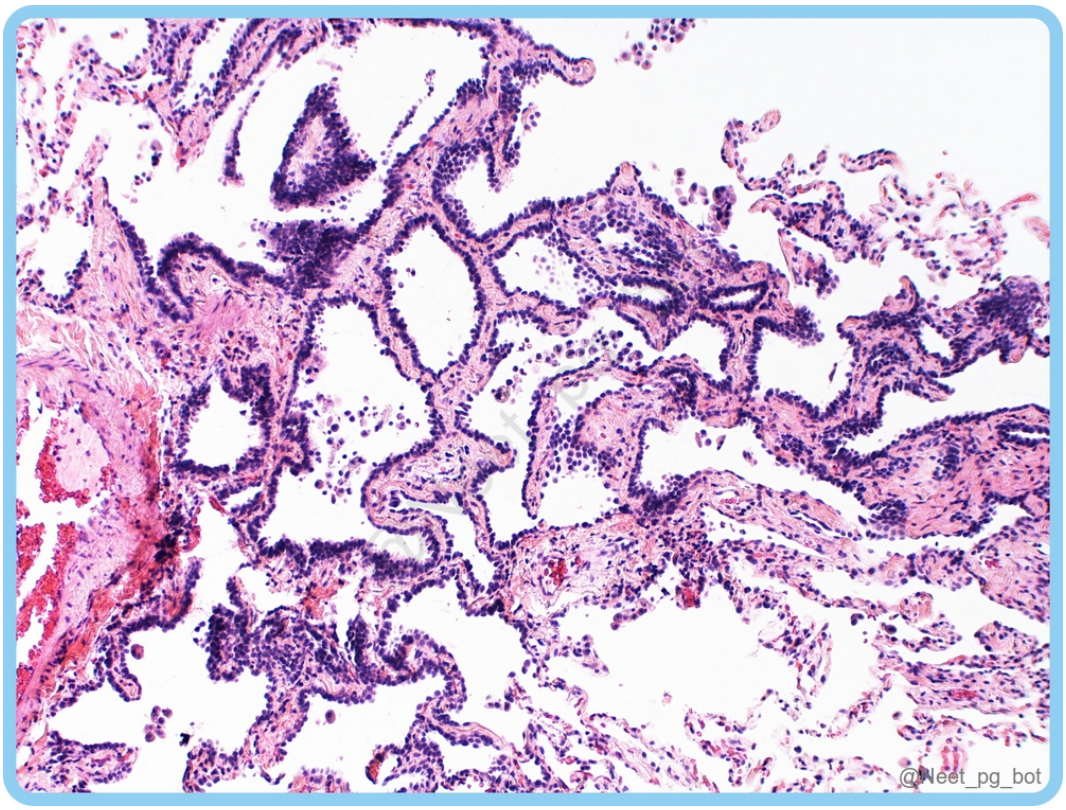

References:

Robbins and Cotran, Pathologic Basis of Disease, 10th edition, Pages 716-724

↑ *Back to this question in Part A*

@Neet_pg_bot

Q19: A 55-year-old male smoker presents to the clinic with chronic cough and hemoptysis. He has been smoking two packs of cigarettes per day for the past 30 years. Upon further evaluation, a biopsy reveals lung carcinoma. Which of the following statements regarding risk factors for lung carcinoma is false? (Q845473)

A. Smoking is a major risk factor for squamous cell carcinoma of the lung.

B. Smoking has no association with adenocarcinoma of the lung.

C. Smoking is a significant risk factor for small-cell lung carcinoma.

D. Asbestosis exposure, along with smoking, multiplies the risk of lung cancer.

Correct Answer: B. Smoking has no association with adenocarcinoma of the lung.

■ *Listen (English)*

■ *Listen (Hindi)*

Explanation: Smoking significantly increases the risk of adenocarcinoma of the lung, although to a lesser extent than other types. Adenocarcinoma, commonly found in non-smokers, can still occur due to tobacco smoking. It often involves mutations in growth factor receptor pathways and is the most prevalent subtype in non-smokers. Smoking is a major risk factor for squamous cell carcinoma of the lung (Option A): Smoking significantly increases the risk of squamous cell carcinoma of the lung as it has a strong association, resulting in chromosomal deletions involving tumour suppressor loci involving 3p,9p and 17p. Smoking is a significant risk factor for small-cell lung carcinoma (Option C): Small-cell carcinoma is almost always linked to smoking, exhibiting the highest mutation rate among lung cancers. SCLC is almost exclusively caused by smoking and usually involves the inactivation of both TP53 and RB genes. Asbestosis exposure, along with smoking, multiplies the risk of lung cancer (Option D): Asbestos exposure, especially when combined with smoking, significantly raises the risk of lung cancer . Non-smokers exposed to asbestos have a five-fold higher risk, while smokers have a 55-fold increased risk compared to non-smokers.

References:

Robbins and Cotran, Pathologic Basis of Disease, 10th edition, Pages 716, 717

↑ *Back to this question in Part A*

@Neet_pg_bot

Q20: A 55-year-old man presents with severe shortness of breath, cough, and fever after recent bacterial pneumonia. Physical examination shows tachypnea, hypoxia, and diffuse crackles on chest auscultation. Chest X-ray reveals bilateral opacities suggestive of pulmonary oedema. Histopathological examination of lung biopsy shows congested, edematous lungs with inflammation. Which histopathological finding is characteristic of the acute exudative stage in this patient's lung injury? (Q845471)

A. Proliferation of type II pneumocytes

B. Formation of fibrotic thickening in the alveolar septa

C. Presence of waxy hyaline membranes lining the alveolar walls

D. Resolution of granulation tissue in the alveolar spaces

Correct Answer: C. Presence of waxy hyaline membranes lining the alveolar walls

■ *Listen (English)*

■ *Listen (Hindi)*

Explanation: In the acute exudative stage of lung injury, such as acute respiratory distress syndrome (ARDS) triggered by bacterial pneumonia, lungs exhibit characteristic waxy hyaline membranes lining the alveolar walls.

These membranes comprise fibrin-rich oedema fluid mixed with remnants of necrotic epithelial cells, representing a hallmark feature of acute lung injury and ARDS. Pathological changes seen in acute respiratory distress syndrome (ARDS) Stage Features 1. Acute Exudative Stage Lungs appear heavy, firm, red, and boggy. Manifestations include congestion, interstitial and intra-alveolar oedema, inflammation, fibrin deposition, and diffuse alveolar damage. Alveolar walls are lined with “waxy hyaline membranes” composed of fibrin-rich oedema fluid mixed with remnants of necrotic epithelial cells. 2. Proliferative or Organizing Stage Proliferation of Type II pneumocytes. Granulation tissue forms in the alveolar walls and spaces. 3. Late Fibrotic Stage Fibrotic thickening of alveolar septa indicates persistent fibrosis and scarring that may develop in some cases of lung injury.

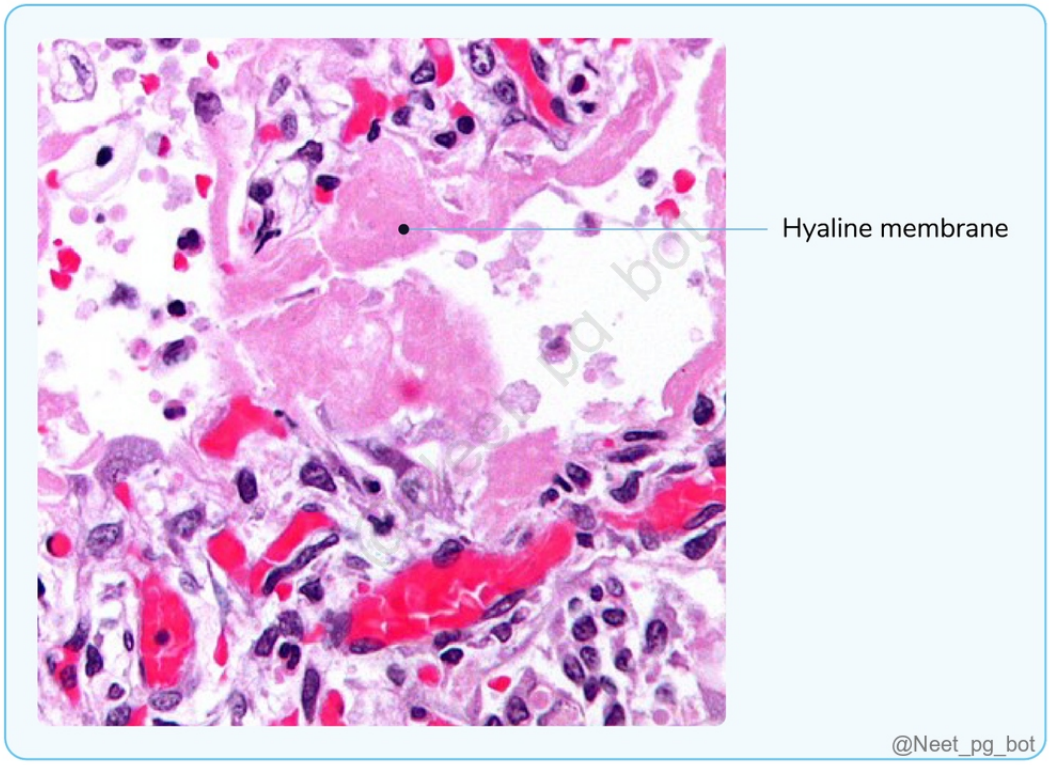

References:

Robbins and Cotran, Pathologic Basis of Disease, 10th edition, Page 677

↑ *Back to this question in Part A*

@Neet_pg_bot

Q21: Which of the following statements regarding the pathogenesis sequence of non-cardiogenic pulmonary oedema (NCPE) and acute respiratory distress syndrome (ARDS) is incorrect? Endothelial activation is the hallmark of pathogenesis. Release of cytokines by alveolar epithelial cells Macrophage activation resulting in the release of IL-8 and TNF Recruitment of lymphocytes by IL-8 (Q845470)

A. 1 and 3

B. 1, 2 and 3

C. 2 and 4

D. 1 and 4

Correct Answer: C. 2 and 4

- *Listen (English)*
- *Listen (Hindi)*

Explanation: In ARDS/NCPE, the primary source of pro-inflammatory cytokines is the alveolar macrophage, not the alveolar epithelial cell. Alveolar epithelial cells (type I and II pneumocytes) are secondarily injured and are mainly targets of inflammation rather than initiators. IL-8 is a potent neutrophil chemotactic factor, not a lymphocyte recruiter. The key inflammatory cells responsible for lung injury in ARDS are neutrophils, not lymphocytes. Pathogenesis of NCPE / ARDS: A precipitating insult (sepsis, trauma, aspiration, pancreatitis) triggers lung injury. Alveolar macrophages are activated and release cytokines such as TNF-α, IL-1, IL-6, and IL-8. (Statement 3) These mediators cause endothelial activation and injury, which is the hallmark of ARDS. (Statement 1) IL-8 recruits neutrophils to the pulmonary microcirculation and alveoli. Neutrophils release proteases, reactive oxygen species, and inflammatory mediators. This results in increased alveolar-capillary permeability, leading to protein-rich non-cardiogenic pulmonary oedema, hyaline membrane formation, and severe hypoxemia.

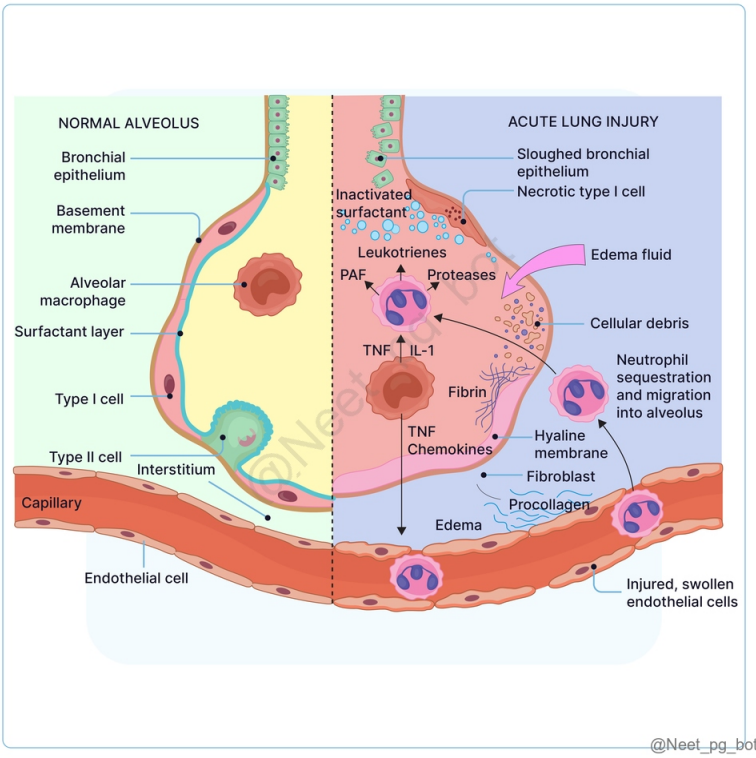

References:

Robbins and Cotran, Pathologic Basis of Disease, 10th edition, Page 676

↑ *Back to this question in Part A*

@Neet_pg_bot

Q22: A 45-year-old woman presents with progressive shortness of breath and fatigue. On examination, she has elevated jugular venous pressure and a loud pulmonary component of the second heart sound. Echocardiography reveals right ventricular hypertrophy and dilation. Which of the following statements is correct regarding the vascular changes of this condition? (Q845468)

A. BMPR2 mutations result in endothelial and vascular smooth muscle cell apoptosis.

B. Classic atherosclerotic changes are commonly observed in pulmonary arteries.

C. Plexiform lesions are early changes of pulmonary hypertension.

D. Pulmonary arterioles show medial hypertrophy and intimal fibrosis, narrowing the lumens.

Correct Answer: D. Pulmonary arterioles show medial hypertrophy and intimal fibrosis, narrowing the lumens.

■ *Listen (English)*

■ *Listen (Hindi)*

Explanation: The patient's clinical presentation with symptoms of right heart failure, elevated jugular venous pressure, and findings of right ventricular hypertrophy and dilation on echocardiography suggest pulmonary hypertension. Histopathologically, pulmonary hypertension is characterised by the remodelling of pulmonary arterioles, which typically exhibit medial hypertrophy (thickening of the smooth muscle layer) and intimal fibrosis. These changes lead to the narrowing of the vessel lumens, increased pulmonary vascular resistance, and subsequent right heart strain. BMPR2 mutations result in endothelial and vascular smooth muscle cell apoptosis. (Option A): BMPR2 mutations are associated with familial pulmonary arterial hypertension, commonly associated with dysregulation of endothelial and vascular cellular processes involved in vascular homeostasis, including aberrant proliferation and resistance to apoptosis. Classic atherosclerotic changes are commonly observed in pulmonary arteries. (Option B): Classic atherosclerotic changes, such as plaque formation and lipid deposition, are not typical findings in pulmonary arteries affected by pulmonary hypertension. Plexiform lesions are early changes of pulmonary hypertension. (Option C): Plexiform lesions are characterised by tufts of capillary formations that are more specific to certain types of pulmonary hypertension, particularly in idiopathic and familial cases. Plexiform lesions of small arteries are characteristic of advanced pulmonary hypertension rather than early changes.

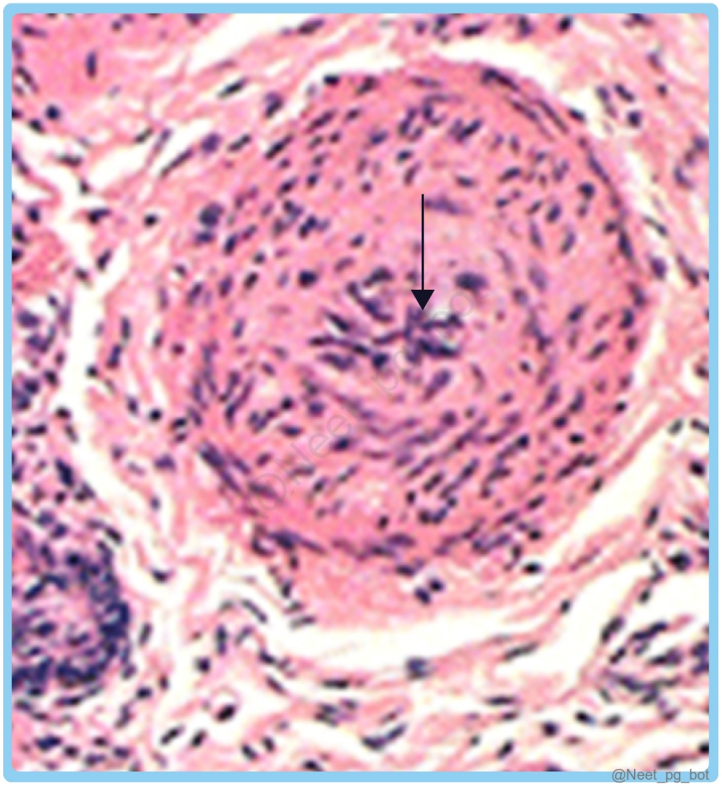

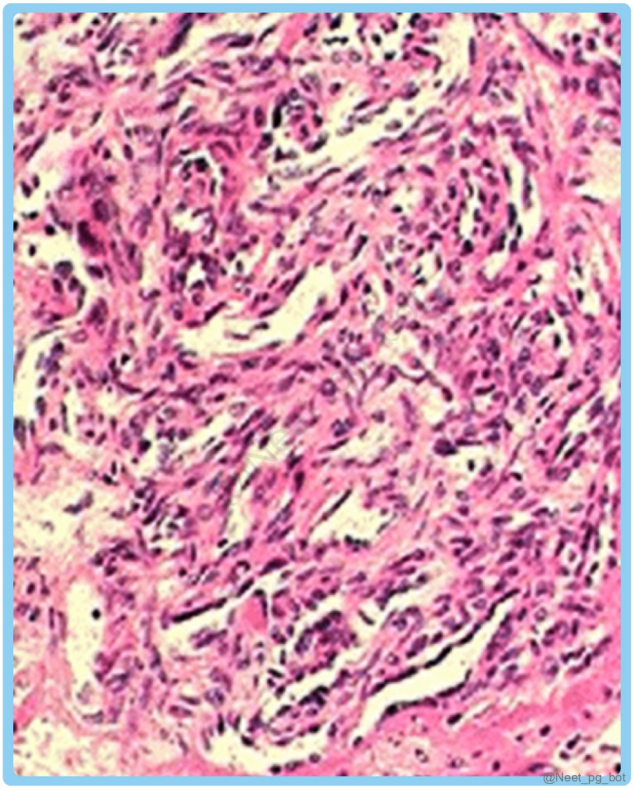

References:

Robbins and Cotran, Pathologic Basis of Disease, 10th edition, Pages 703, 704

↑ *Back to this question in Part A*

@Neet_pg_bot

• [07_Respiratory System] 034 Congenital Anomalies And Lung Infections

« Back to Folder Directory

[07_Respiratory System] 034 Congenital Anomalies And Lung Infections — Quick Jump

Q1 (p. 1789) *Q2 (p. 1790)* *Q3 (p. 1791)* *Q4 (p. 1793)* *Q5 (p. 1795)* *Q6 (p. 1796)*
Q7 (p. 1797) *Q8 (p. 1802)* *Q9 (p. 1803)* *Q10 (p. 1804)*

Q1: Ciliocytophthoria is seen in? (Q845391)

A. Kartagener syndrome

B. Cystic fibrosis

C. Situs inversus

D. Acute respiratory infection

Correct Answer: D. Acute respiratory infection

■ *Listen (English)*

■ *Listen (Hindi)*

Explanation: Ciliocytophthoria is a degenerative process of the ciliated cells , occurring in viral infections such as acute respiratory infections and characterized by typical morphological changes. The images below show the ciliary changes: Kartagener's syndrome (Immotile cilia syndrome) (Option A) : It is a form of primary ciliary dyskinesia, characterized by a triad of: Sinusitis. Situs inversus (Option C) . Bronchiectasis. The ciliary ultrastructure is normal in cystic fibrosis (Option B)



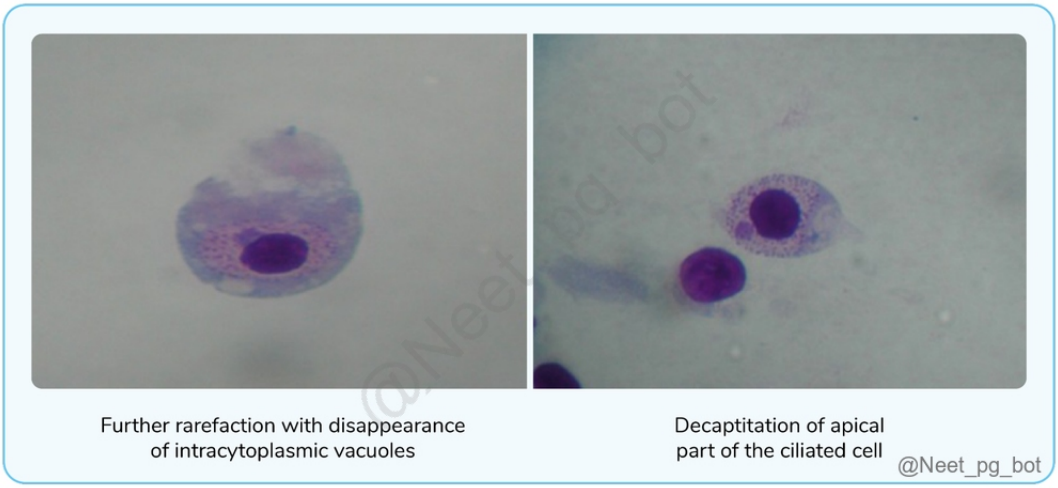

References:

www.ncbi.nlm.nih.gov/pmc/articles/PMC6502078/

↑ *Back to this question in Part A*

@Neet_pg_bot

Q2: Which of the following is false regarding extralobular sequestration? (Q845396)

A. It is external to the lung.

B. It most commonly presents as a mass lesion.

C. It most often occurs in older children.

D. It has a separate pleural covering.

Correct Answer: C. It most often occurs in older children.

■ *Listen (English)*

■ *Listen (Hindi)*

Explanation: The false statement regarding extra lobar sequestration is that it most often occurs in older children, most commonly in infants . Pulmonary sequestration is a discrete area of lung tissue not connected to the airways and has an abnormal blood supply from the aorta or its branches. It is of two types: Extralobar sequestration. Intralobar sequestration. Extralobar sequestration Intralobar sequestration Location External to the lung parenchyma (Option A) Within the lung parenchyma Pleural covering It has a separate pleural covering (Option D) Shares pleura with adjacent lung tissue Embryological origin Congenital anomaly of the primitive foregut Association It causes a mass effect (Option B) Localized infection or bronchiectasis Venous return The right side of the heart through IVC Pulmonary veins

References:

Robbins and Cotran, Pathologic Basis of Disease, 10th Edition, Page 674

↑ *Back to this question in Part A*

@Neet_pg_bot

Q3: A 65-year-old female presents to the clinic with a productive cough, fever, and fatigue for the past two weeks. She has a history of poorly controlled diabetes mellitus and reports recent hospitalisation for a urinary tract infection. On physical examination, coarse crackles are auscultated over the right lower lung fields. The chest X-ray is shown below. Which of the following is the most common risk factor for developing this condition? (Q845399)

A. Antecedent primary lung infection

B. Aspiration of infective material

C. Septic embolism

D. Neoplasia

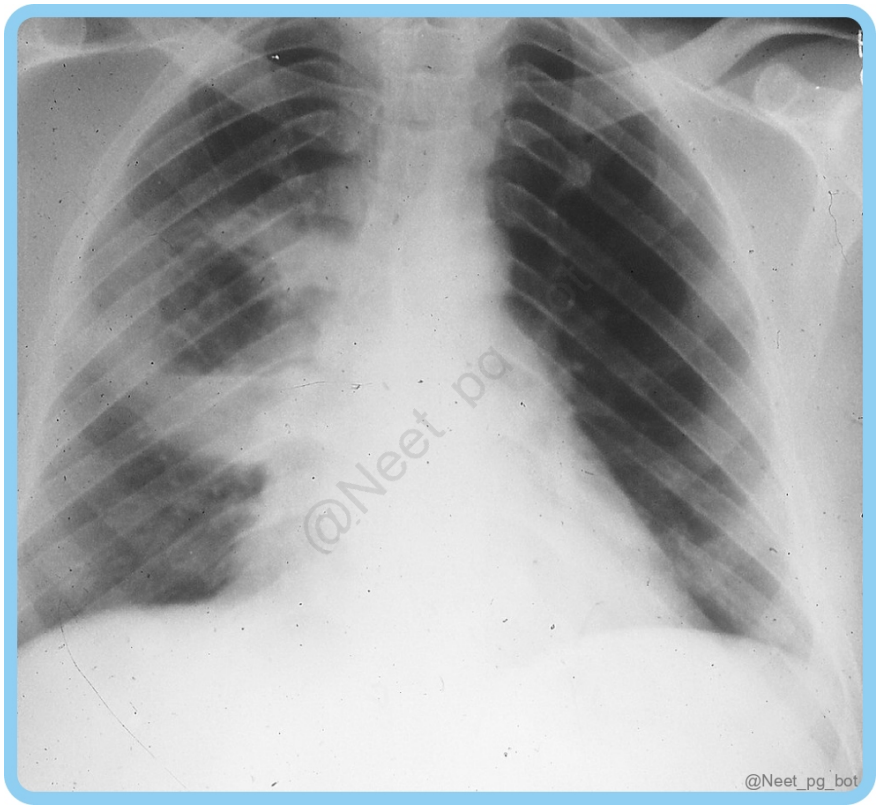

Correct Answer: B. Aspiration of infective material

■ *Listen (English)*

■ *Listen (Hindi)*

Explanation: Given the clinical presentation of productive cough, fever, fatigue, and the presence of a thick-walled cavity with surrounding consolidation on chest X-ray, the most likely diagnosis is a lung abscess. Lung abscess: It describes a local suppurative process that produces necrosis of the lung tissue. Aetiology: Bacteroides , Fusobacterium , and Peptostreptococcus (the three most common bacteria). Aerobic and anaerobic Streptococci, S. aureus, and gram-negative organisms. Risk factors: Aspiration of infective material (the most frequent cause) (Option B) . Septic embolism. (Option C) Morphology: Pulmonary abscesses due to aspiration are more common on the right (because of the more vertical right main bronchus) and are most often single. The cardinal histologic change in all abscesses is the suppurative destruction of the lung parenchyma within the central area of cavitation. The image below shows a lung abscess

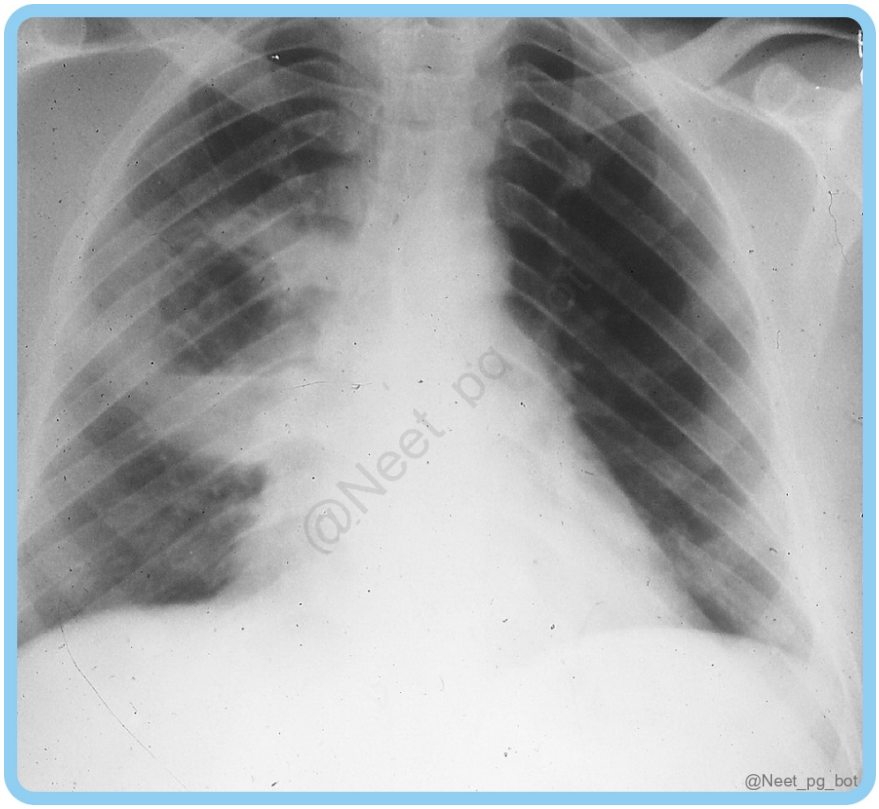



References:

Robbins and Cotran, Pathologic Basis of Disease, 10th Edition, Page 711,712

↑ *Back to this question in Part A*

@Neet_pg_bot

Q4: A 29-year-old previously healthy male presents with a one-week history of progressively worsening dry cough, fever, and shortness of breath. He denies any recent travel but mentions attending a crowded social gathering a week ago. He is febrile, tachypneic, and has crackles on auscultation. Laboratory investigations reveal leukocytosis. A chest X-ray demonstrates patchy infiltrates in the lower lobes bilaterally. Which of the following features is not associated with this condition? (Q845402)

A. Inflammatory changes are confined to the pulmonary interstitium.

B. Neutrophils are involved in this infection.

C. It is associated with viral infections

D. It is also known as walking pneumonia.

Correct Answer: B. Neutrophils are involved in this infection.

■ *Listen (English)*

■ *Listen (Hindi)*

Explanation: The clinical presentation of a patient with a history of attending a crowded social gathering, worsening dry cough, fever, shortness of breath, crackles on auscultation, and chest X-ray showing bilateral patchy infiltrates in the lower lobes is suggestive of Mycoplasma pneumoniae infection (Atypical pneumonia) . Neutrophils are not involved in this condition; rather, lymphocytes are involved. Neutrophils are involved in typical pneumonia. Atypical pneumonia: Definition An acute febrile respiratory disease characterised by patchy inflammatory changes in the lungs, largely confined to the alveolar septa and pulmonary interstitium. (Option A) Aetiology Atypical organisms: Mycoplasma pneumoniae (Most common). It is also known as walking pneumonia , as the patient is not bedridden. (Option D) Chlamydia pneumoniae. Coxiella burnetii (Q-fever). Viruses Morphology Interstitial inflammatory reaction , virtually localised within the walls of the alveoli. Alveolar septa are widened and edematous and usually have a mononuclear inflammatory infiltrate of lymphocytes , macrophages, and occasionally plasma cells. Herpes simplex , varicella , and adenovirus may be associated with bronchial and alveolar epithelium necrosis and acute inflammation. Typical pneumonia: Cause: Bacterial Streptococcus pneumoniae (most common). Haemophilus influenzae. Klebsiella pneumoniae. Neutrophils are involved in this condition. Features: Intra-alveolar exudate and productive cough.





References:

Robbins and Cotran, Pathologic Basis of Disease, 10th Edition, Page no. 707

Harrison's Principles of Internal Medicine, 21st Edition, Page no.1441,1442

↑ *Back to this question in Part A*

@Neet_pg_bot

Q5: Red hepatisation of the lungs is seen on which day? (Q845405)

A. 1-2

B. 2-4

C. 5-7

D. Beyond 7 day

Correct Answer: B. 2-4

■ *Listen (English)*

■ *Listen (Hindi)*

Explanation: Stages of bacterial pneumonia: Stage Days Characteristics Congestion 1-2 (Option A) Gross: The lung is heavy, boggy, and red. Microscopic: Vascular engorgement , intra-alveolar fluid with neutrophils & bacteria. Red hepatization 2-4 (Option B) Gross: Red , firm, and airless , with a liver-like consistency , hence the term hepatization. Microscopic: Confluent exudation with neutrophils, RBCs , and fibrin filling the alveoli. Grey hepatization 5-8 (Option C) Gross: Greyish brown and dry surface. Microscopic: Disintegration of RBCs and persistence of a fibrinosuppurative exudate. Resolution 8-9 (Option D) Exudates within the alveoli are broken down by enzymatic digestion to produce granular debris. Debris may be reabsorbed/ingested by macrophages/expectorated/ organised by fibroblasts.

References:

Robbins & Cotran Pathologic Basis of Disease, 10th Edition, Page 708

↑ *Back to this question in Part A*

@Neet_pg_bot

Q6: A 55-year-old male with a long-standing history of chronic alcohol abuse presents with a one-week history of high-grade fever, productive cough with thick, mucoid, blood-tinged "currant jelly" sputum, and right-sided pleuritic chest pain. He reports frequent binge drinking episodes and he had several recent episodes of aspiration while intoxicated. On examination, he appears ill, with a temperature of 39.5°C, tachypnea, and signs of consolidation over the right upper lung fields. Laboratory investigations reveal leukocytosis with neutrophilia and elevated inflammatory markers. Chest X-ray shows bulging of right upper lobe fissure consistent with a dense lobar consolidation. What is the most likely organism implicated in this condition? (Q845409)

A. Mycoplasma pneumoniae

B. Legionella pneumophila

C. Moraxella catarrhalis

D. Klebsiella pneumoniae

Correct Answer: D. Klebsiella pneumoniae

■ *Listen (English)*

■ *Listen (Hindi)*

Explanation: The clinical presentation of a patient who is a known alcoholic , presenting with high-grade fever, productive cough, blood-tinged " currant jelly" sputum, right-sided pleuritic chest pain, signs of consolidation over the right upper lung fields, and neutrophilia is suggestive of pneumonia caused by Klebsiella pneumoniae.

Klebsiella pneumoniae: It is the most common cause of gram-negative bacterial pneumonia. It causes typical pneumonia with neutrophil-rich exudate that fills the bronchi, bronchioles, and adjacent alveolar spaces. It commonly afflicts debilitated and malnourished people , particularly chronic alcoholics. Thick, mucoid (blood-tinged) sputum is characteristic because the organism produces an abundant viscid capsular polysaccharide , which the patient may have difficulty expectorating. Mycoplasma Pneumonia (Option A) Mycoplasma pneumonia causes atypical pneumonia with dry cough, fever, and fatigue. It often presents with mild symptoms but can lead to complications. It presents with a persistent dry cough, low-grade fever, sore throat, headache, and fatigue. Chest X-ray findings may appear worse than clinical symptoms. It spreads via respiratory droplets and is common in young adults and crowded settings. Treatment includes macrolides or tetracyclines. Legionella pneumophila (Option B): Legionella pneumophila is the agent of legionnaires' disease and Pontiac fever , a self-limited upper respiratory tract infection. It flourishes in artificial aquatic environments, such as water-cooling towers and the tubing systems of domestic (potable) water supplies. It is common in individuals with predisposing conditions such as cardiac, renal, immunologic, or hematologic disease and organ transplant recipients . Moraxella catarrhalis (Option C): Moraxella catarrhalis is recognised as a cause of bacterial pneumonia, especially in the elderly . It is the second most common bacterial cause of acute exacerbation of COPD. Along with S. pneumoniae and H. influenzae, M. catarrhalis is one of the three most common causes of otitis media in children.

References:

Robbins & Cotran Pathologic Basis of Disease, 10 Edition Page 708

↑ *Back to this question in Part A*

@Neet_pg_bot

Q7: Match the following: 1) Pneumocystis pneumonia a) 2) Blastomycosis b) 3) Aspergillus c) 4) Measles d) (Q845414)

A. 1-b, 2-d, 3-c, 4-a

B. 1-a, 2-d, 3-c, 4-b

C. 1-c, 2-d, 3-b, 4-a

D. 1-b, 2-a, 3-c, 4-d

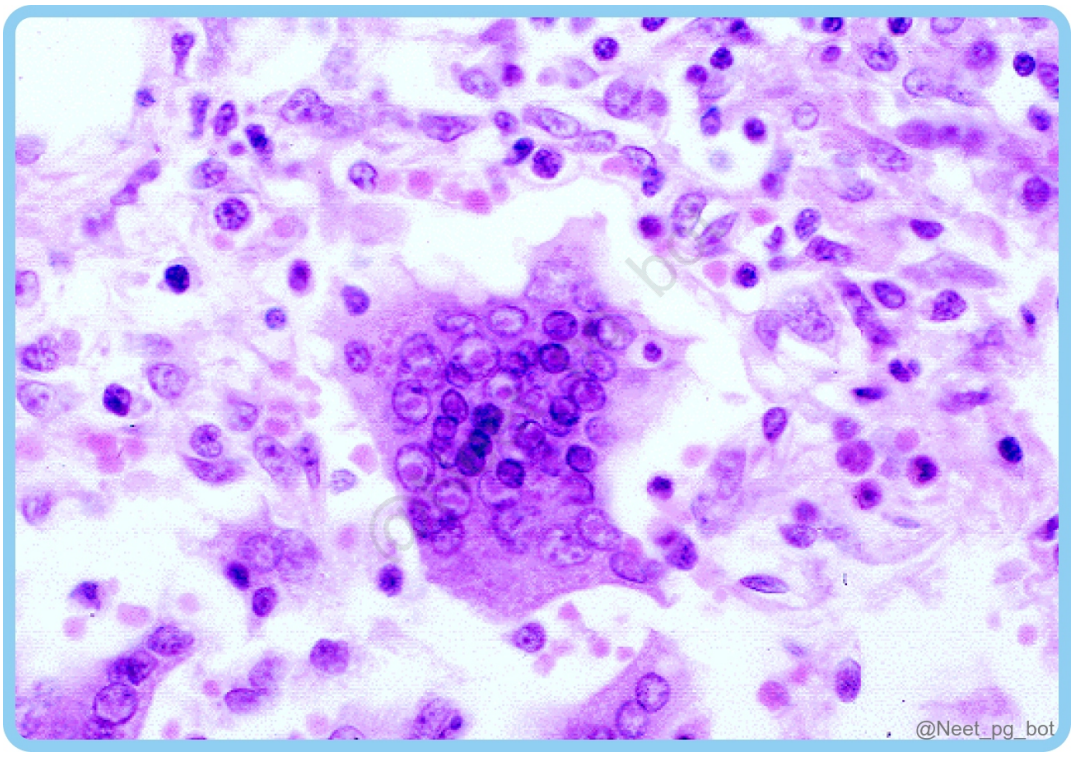
@Neet_pg_bot

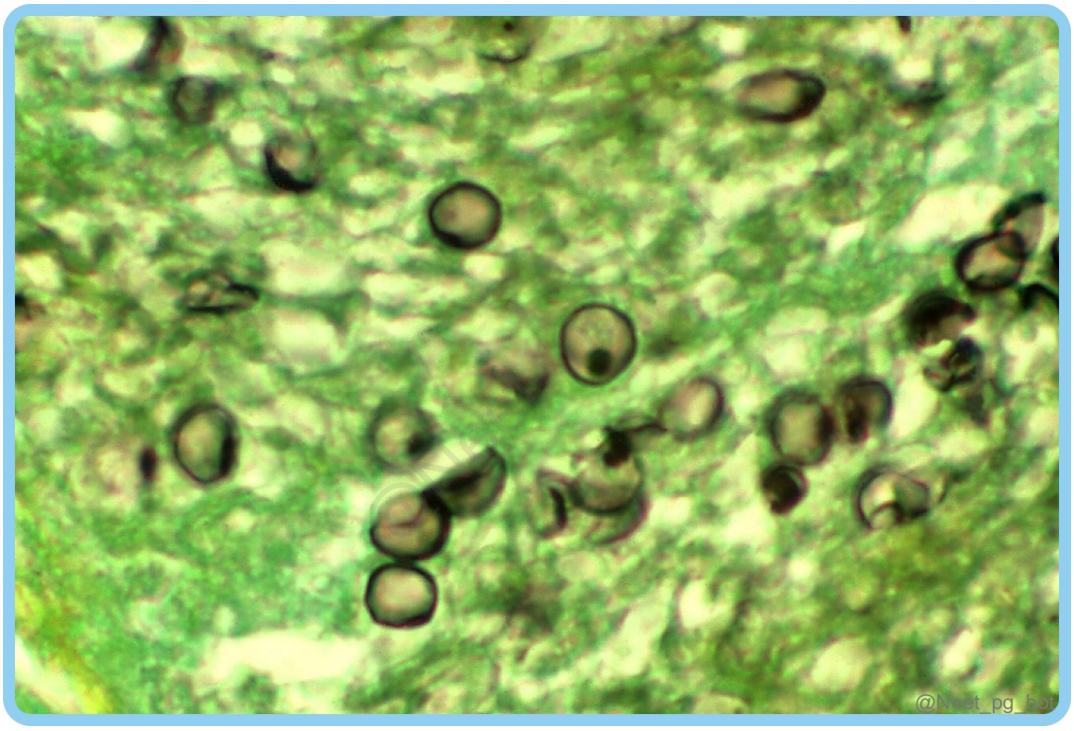
@Neet_pg_bot

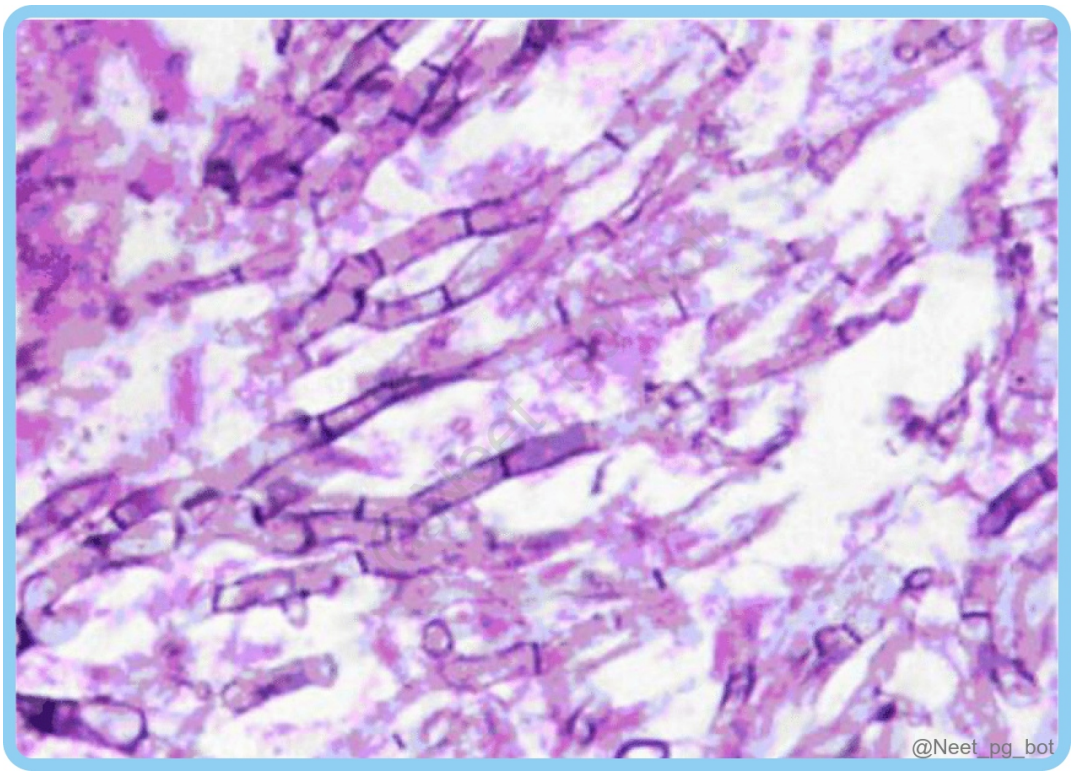

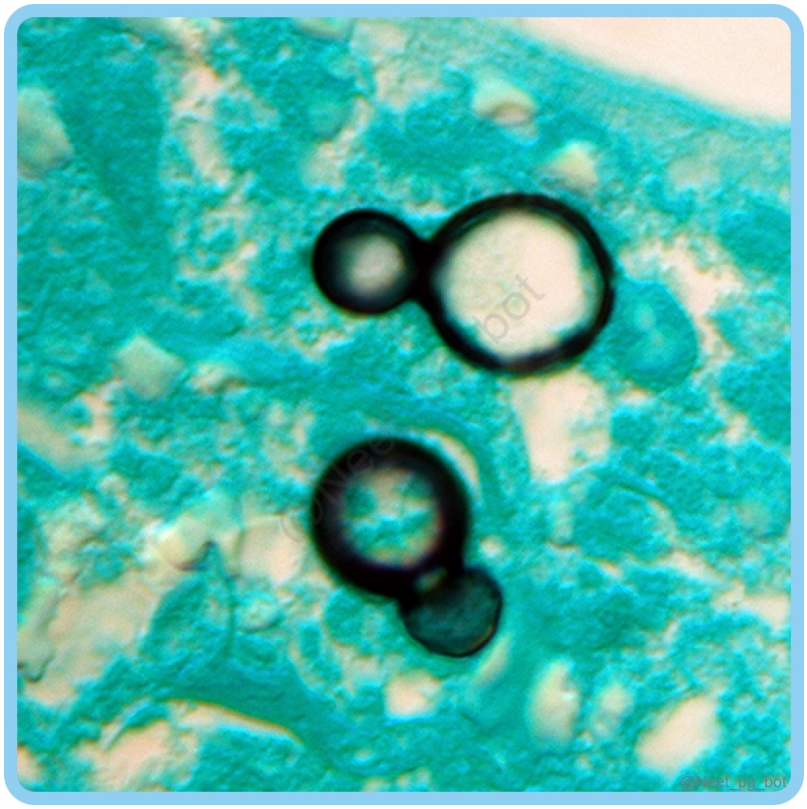

Correct Answer: A. 1-b, 2-d, 3-c, 4-a

■ *Listen (English)*

■ *Listen (Hindi)*

Explanation: Pneumocystis jirovecii: Pneumocystis jirovecii is an opportunistic fungus that causes Pneumocystis pneumonia (PCP). PCP primarily affects immunocompromised individuals . Gomori's methenamine silver (GMS) staining is the method of choice to demonstrate the cysts of P. jirovecii. The cysts resemble black-coloured crushed ping-pong balls against the green background. Blastomycosis: Blastomycosis is a fungal infection caused by Blastomyces dermatitidis found in moist soil. Morphology: In the normal host, the lung lesions of blastomycosis are suppurative granulomas. Macrophages have a limited ability to ingest and kill B. dermatitidis, and the persistence of the yeast cells leads to the recruitment of neutrophils . In tissue, B. dermatitidis is a round, 5- to 15-µm yeast cell divided by broad-based budding. It has a thick, double-contoured cell wall and visible nuclei. Aspergillus: Aspergillosis is an invasive and allergic disease caused by a hyaline mould named Aspergillus. Glucocorticoid use is the most important risk factor for aspergillosis. Pulmonary aspergillosis is the most common form. KOH (10%) mount or histopathological staining of specimens reveals characteristic narrow septate hyaline hyphae with acute angle branching. Measles: The measles virus is a single-stranded RNA virus of the Paramyxoviridae family. It causes measles, an acute, highly contagious childhood disease characterised by fever and respiratory symptoms followed by a typical maculopapular rash. Virus isolation: Cytopathic effect may be observed after 7–10 days of inoculation into cell lines characterised by multinucleated giant cells (Warthin-Finkeldey cells) containing intranuclear and intracytoplasmic inclusion bodies. It can cause giant-cell pneumonitis (Hecht's pneumonia) in immunocompromised children and HIV-infected people.

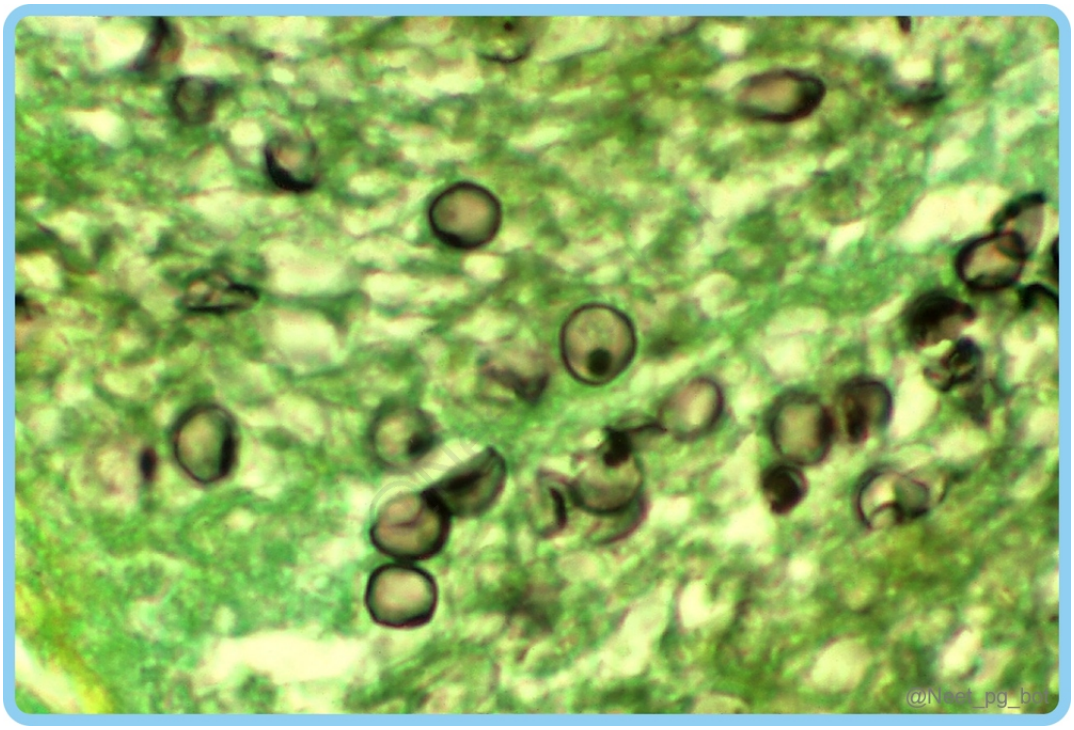

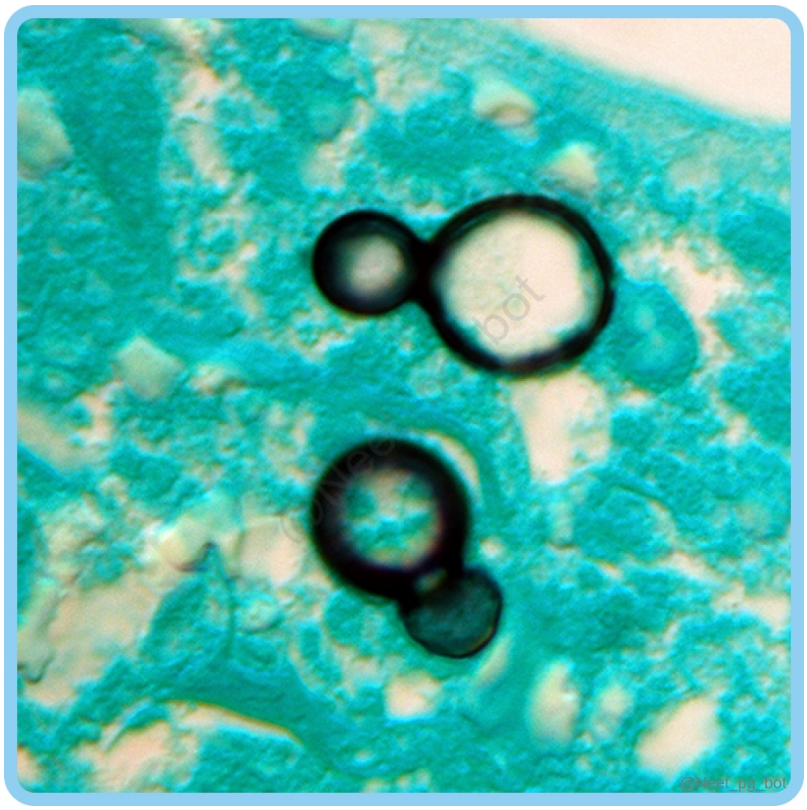
@Neet_pg_bot

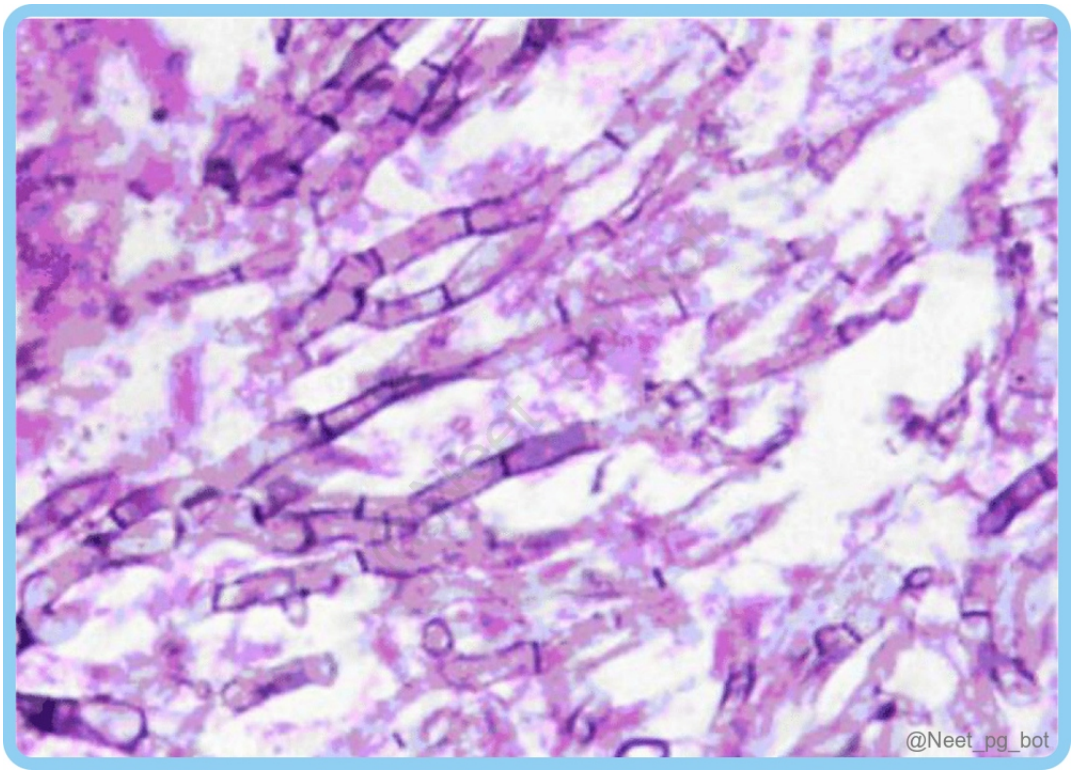
@Neet_pg_bot

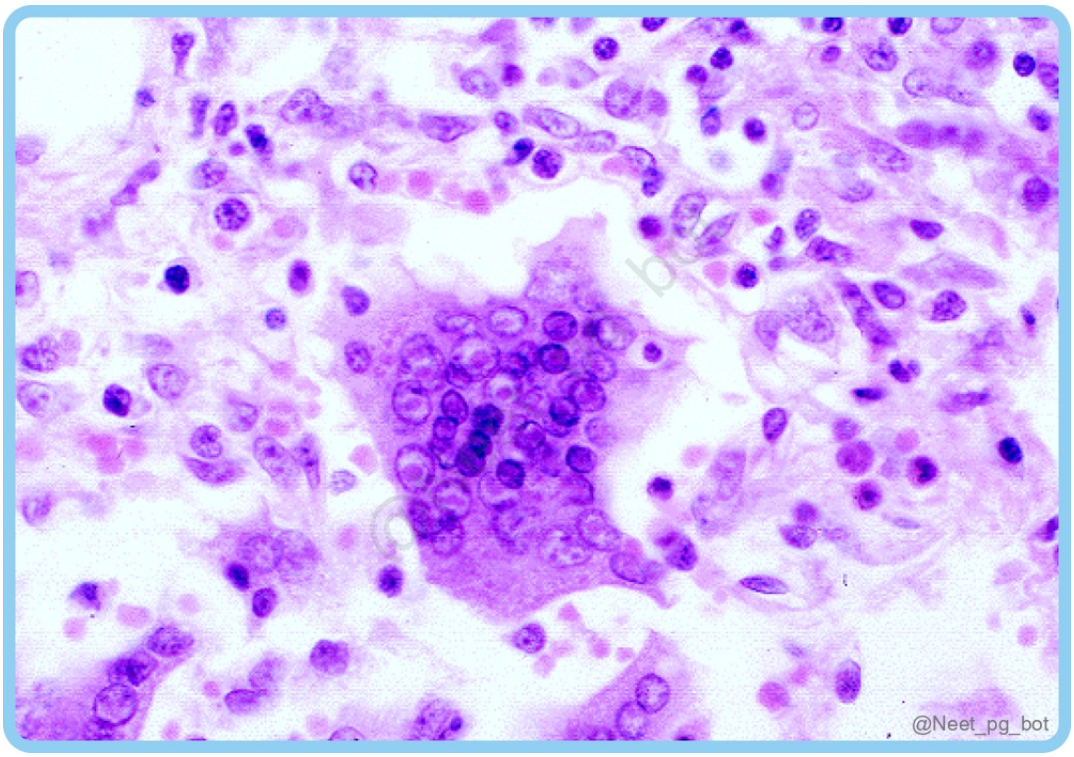

References:

Essentials of Medical Microbiology, Apurba S Sastry, 3rd edition, Page no. 679,681,682 Robbins and Cotran, Pathologic Basis of Disease, 10th edition, Page no. 350

↑ *Back to this question in Part A*

@Neet_pg_bot

Q8: Which of the following conditions is not associated with aspiration? (Q845418)

A. Mendelson syndrome

B. Lipoid pneumonia

C. Meconium aspiration syndrome

D. Nelson syndrome

Correct Answer: D. Nelson syndrome

■ *Listen (English)*

■ *Listen (Hindi)*

Explanation: Nelson syndrome is not associated with aspiration. It is a rare disorder that occurs in some individuals who have undergone surgical removal of both adrenal glands to treat Cushing's disease. It is characterised by the growth of a pituitary tumour, often resulting in elevated levels of ACTH and increased skin pigmentation. Aspiration pneumonia: It occurs in markedly debilitated patients or those who aspirate gastric contents either while unconscious (e.g., after a stroke) or during repeated vomiting. Predisposing factors: Abnormal gag and swallowing reflexes. The resultant pneumonia is partly chemical due to the irritating effects of gastric acid and partly bacterial (from the oral flora). More than one organism is recovered in culture (aerobes > anaerobes). It is often necrotising with a fulminant clinical course, and a frequent cause of death. In patients who survive, lung abscess is a common complication. Conditions associated with aspiration: Mendelson syndrome (Option A): It occurs due to aspiration of gastric contents during general anaesthesia. Risk factors: Pregnancy. Gastric volume >25 ml (0.4 mL/kg). Gastric pH <2.5 Meconium aspiration syndrome (Option C) : It usually occurs in term or post-term babies who are small for gestational age (IUGR). Lipoid pneumonia/Golden pneumonia (Option B): Associated with Oil aspiration- Mineral oil industry. Macrophages engulf the lipids. The image below shows the histology of lipoid pneumonia

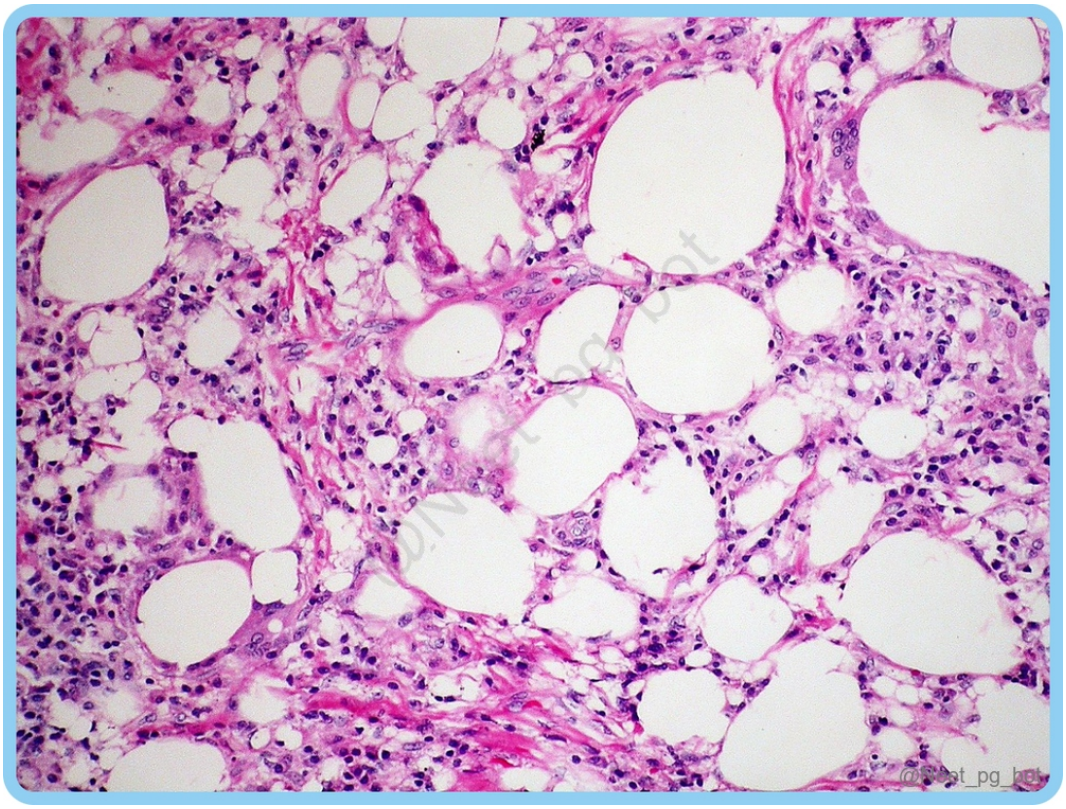

References:

Robbins & Cotran, Pathologic Basis of Disease, 10th Edition, Page no. 711 Harrison’s Principles of Internal Medicine, 21st Edition, Page no. 1352

↑ *Back to this question in Part A*

@Neet_pg_bot

Q9: A 45-year-old man presents with a persistent cough, night sweats, and unintentional weight loss. Chest X-ray reveals an infiltrate in the upper lobe of the right lung. Which of the following pathological processes is not seen in this condition? (Q845422)

A. Th2-mediated macrophage activation and killing of bacteria.

B. The bacterium blocks phagolysosome formation.

C. M. tuberculosis is recognised by innate immunity receptors.

D. It causes granulomatous inflammation and damage.

Correct Answer: A. Th2-mediated macrophage activation and killing of bacteria.

■ *Listen (English)*

■ *Listen (Hindi)*

Explanation: The clinical presentation of a 45-year-old male with a persistent cough, night sweats, unintentional weight loss, and chest X-ray showing an infiltrate in the upper lobe of the right lung is suggestive of pulmonary tuberculosis. Th2-mediated macrophage activation and bacteria killing is not seen in tuberculosis. Rather, a Th-1-mediated response is seen. Pathogenesis of tuberculosis: Infection by M. tuberculosis proceeds in steps, from initial infection of macrophages to a subsequent Th1 response that both contains the bacteria and causes tissue damage. Early in infection, M. tuberculosis replicates essentially unchecked within macrophages, and later in infection, the cell response stimulates macrophages to contain the proliferation of the bacteria. The steps for infection are as follows: Entry into macrophages M. tuberculosis enters macrophages by phagocytosis . Replication in macrophages M. tuberculosis inhibits the maturation of the phagosome. It blocks the formation of the phagolysosome (Option B) , allowing the bacterium to replicate unchecked within the vesicle. Thus, during the earliest stage of primary tuberculosis (<3 weeks) in the nonsensitized individual, bacteria proliferate in the pulmonary alveolar macrophages and air spaces, resulting in bacteremia and seeding of multiple sites. Despite the bacteremia, most people at this stage are asymptomatic or have a mild flu-like illness. Innate immunity (Option C) Mycobacterial lipoarabinomannan binds TLR2 , and unmethylated CpG nucleotides bind TLR9. These interactions initiate and enhance the innate and adaptive immune responses to M. tuberculosis, as described below. Th1 response , Th1 mediated macrophage activation, and killing of the bacteria (mediated by IFN-γ). Granulomatous inflammation and damage (mediated by Th1 response) (Option D) . Caseous necrosis and giant cell formation (epithelioid histiocytes-giant cells, mediated by IFN-γ).

References:

Robbins & Cotran Pathologic Basis of Disease,10th Edition, Page 378

↑ *Back to this question in Part A*

@Neet_pg_bot

Q10: Match the following lesions with their site of occurrence. Lesion Site 1 Puhl's focus i Lung + Lymph node 2 Simon focus ii Blood vessels 3 Ghon complex iii Supraclavicular region of the lung 4 Weighert focus iv The apex of the lung (Q845427)

A. 1-iii, 2-iv, 3-i, 4-ii

B. 1-iii, 2-iv, 3-ii, 4-i

C. 1-iv, 2-iii, 3-i, 4-ii

D. 1-iv, 2-i, 3-ii, 4-iii

Correct Answer: A. 1-iii, 2-iv, 3-i, 4-ii

■ *Listen (English)*

■ *Listen (Hindi)*

Explanation: Puhl's focus Supraclavicular region of the lung Simon focus Apex of the lung Ghon complex Lung + Lymph node Weighert focus Blood vessel Tuberculosis is a bacterial infection caused by M. tuberculosis. It is of the following types. Primary tuberculosis It develops in a previously unexposed and therefore unsensitized person. The primary organ involved is mostly the lungs . Location: Sub-pleural region. Lower part of the upper lobe & upper part of the lower lobe. Ghon's focus: Grey-white area of inflammation with consolidation. Ghon's complex: Ghon's focus + inflamed regional lymph nodes (Statment iii) . Histology: Granulomatous inflammatory reaction with both caseating and non-caseating tubercles. Simon's focus: Occult hematogenous dissemination to the apex of the lung. (Statement ii) Fate: 95% of the cases are controlled by immunity, calcified, healed lesions and hilar lymph nodes (Ranke complex). 5% of the cases are progressive (Progressive primary TB). Resembles acute bacterial pneumonia. Lymphohematogenous dissemination may cause tuberculous meningitis and/or miliary TB. Secondary tuberculosis It arises in a previously sensitised host. It may follow shortly after primary tuberculosis, but more commonly, it appears months to years after the initial infection, usually when the host resistance is weakened. The apical and posterior lobe segments are involved due to high O 2 concentration (Puhl's focus) (Statement i) . The infraclavicular lesion is called Assman's focus. Regional lymph node involvement is late. Cavitation occurs readily with the erosion of the cavities into an airway. Histology: Active lesions show coalescent tubercles with central caseation (Caseous necrosis). Disseminated TB: Spread to other organs. The images below show the caseous necrosis seen in TB. Other foci: Simmond focus: Liver. Weighert focus: Blood vessels (Statement iv) Rich's focus: Brain.



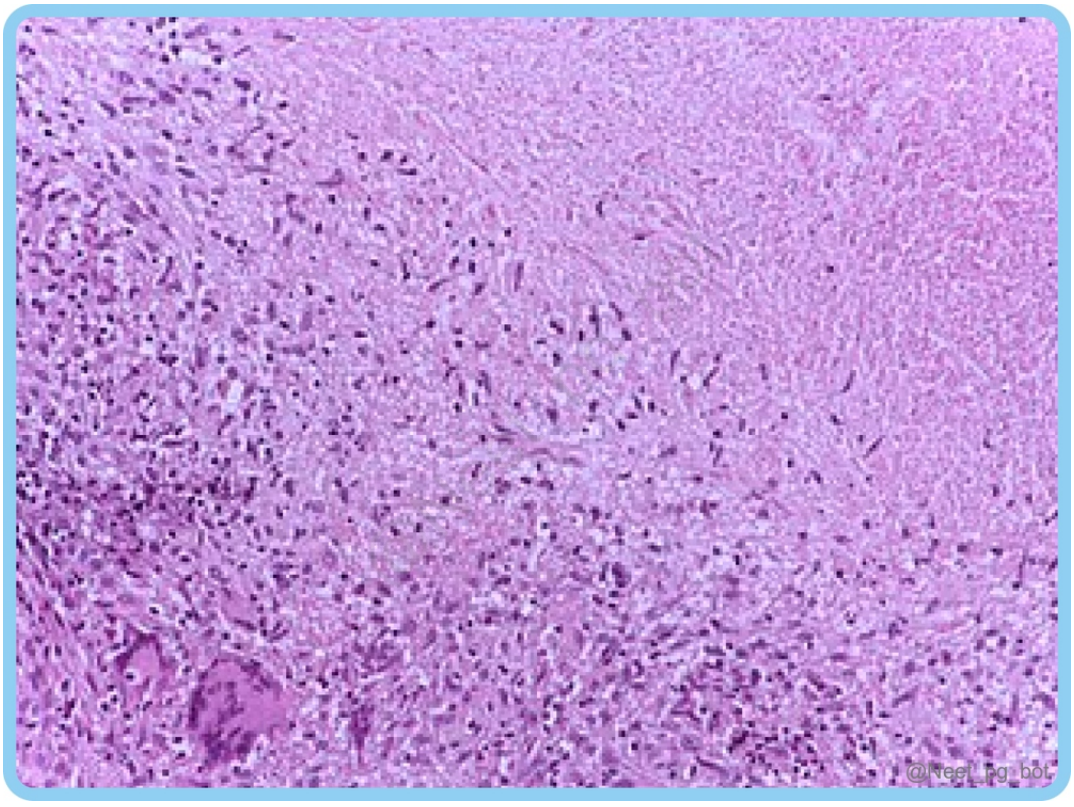

References:

Robbins & Cotran Pathologic Basis of Disease,10th Edition, Page 371-373

↑ *Back to this question in Part A*

• [07_Respiratory System] 035 Sarcoidosis And Occupational Lung Diseases

« Back to Folder Directory

[07_Respiratory System] 035 Sarcoidosis And Occupational Lung Diseases — Quick Jump

Q1 (p. 1808) *Q2 (p. 1808)* *Q3 (p. 1811)* *Q4 (p. 1811)* *Q5 (p. 1812)* *Q6 (p. 1815)*
Q7 (p. 1817) *Q8 (p. 1817)* *Q9 (p. 1820)* *Q10 (p. 1821)* *Q11 (p. 1822)*

Q1: Which immunologic abnormalities are observed in the local milieu of sarcoid granulomas? (Q845654)

A. Accumulation of CD8+ T cells and increased CD8/CD4 T-cell ratio

B. Oligoclonal expansion of B-cell subsets

C. Increased levels of Th1 cytokines such as IL-4 and IL-10

D. Accumulation of CD4+ T cells and increased CD4/CD8 T-cell ratios

Correct Answer: D. Accumulation of CD4+ T cells and increased CD4/CD8 T-cell ratios

■ *Listen (English)*

■ *Listen (Hindi)*

Explanation: Sarcoidosis is a systemic granulomatous disease of unknown cause involving multiple organs. These abnormalities include: Intra-alveolar and interstitial accumulation of CD4+ T cells, resulting in increased CD4/CD8 T-cell ratios ranging from 5:1 to 15:1 (Normally it is 2:1), suggesting pathogenic involvement of CD4+ helper T cells. There is an oligoclonal expansion of T-cell subsets (Option B) Increased T cell-derived Th1 cytokines such as IL-2 and interferon (IFN)-γ may be responsible for T-cell expansion and macrophage activation, respectively. (Option C) Microscopically, sarcoid granulomas are typically non-caseating, and because the surrounding lymphocytic collar is usually absent, they are often referred to as “ naked granulomas .” Two bodies are seen in sarcoid granulomas: Asteroid bodies Schaumann bodies

References:

Robbins and Cotran, Pathologic Basis of Disease, 10th edition, Page 696

↑ *Back to this question in Part A*

@Neet_pg_bot

Q2: A 40-year-old male presents with fever, bilateral hilar lymphadenopathy, erythema nodosum, and acute polyarthritis affecting ankles and knees. He has a history of recurrent uveitis. Laboratory tests show elevated serum angiotensin-converting enzyme (ACE) levels and hypercalcemia. What is the most likely diagnosis? (Q845655)

A. Lupus pernio

B. Lofgren's syndrome

C. Mikulicz syndrome

D. Systemic Lupus Erythematosus

Correct Answer: B. Lofgren's syndrome

- *Listen (English)*
- *Listen (Hindi)*

Explanation: This patient's clinical presentation and lab findings are suggestive of Lofgren’s syndrome, which is associated with sarcoidosis. Multi-organ involvement in Lofgren's syndrome, which is associated with Sarcoidosis: (Mnemonic: Lofgren) L: Lymphadenopathy O: Ouch: Joint pain and arthralgia F: Fever GR: Granulomas (Sarcoidosis shows non-caseating granulomas) EN: Erythema nodosum (Skin finding) Recurrent uveitis is also a feature of Sarcoidosis Microscopic finding in sarcoidosis: It shows non-caseating granulomas and naked granulomas 2 bodies which are seen in sarcoidosis: Asteroid bodies Schaumann bodies Lupus pernio (Option A): Cutaneous manifestation of sarcoidosis characterised by violaceous or erythematous indurated plaques distributed on the central face, particularly the nose and cheeks. Mikulicz syndrome (Option C): Defined as diffuse and bilateral enlargement of the salivary and lacrimal glands. It can occur as an isolated phenomenon or as a part of systemic diseases like sarcoidosis, Sjögren syndrome, etc. Systemic Lupus Erythematosus (Option D): Autoimmune disease affecting multiple organs, including the skin, joints, kidneys, and heart. Common symptoms of SLE include joint pain, skin rash (such as the classic butterfly rash), fatigue, and organ involvement.





References:

Harrison’s Principles of Internal Medicine, 21st Edition, Page 2829

Clinical manifestations and diagnosis of sarcoidosis - UpToDate

File: Lupus pernio 01.jpg - Wikimedia Commons

ENlegs - Erythema nodosum - Wikipedia

↑ *Back to this question in Part A*

@Neet_pg_bot

Q3: In a histopathological examination of a lung biopsy from a patient with suspected sarcoidosis, which of the following microscopic features would be most characteristic and supportive of the diagnosis? (Q845656)

A. Macrophages with abundant cytoplasm containing dusty brown pigment

B. Non-necrotizing granulomas with asteroid bodies and Schaumann bodies

C. Coalescent tubercles with central caseation

D. Curschmann spirals and Charcot-Leyden crystals

Correct Answer: B. Non-necrotizing granulomas with asteroid bodies and Schaumann bodies

■ *Listen (English)*

■ *Listen (Hindi)*

Explanation: Sarcoidosis is characterised by non-necrotizing granulomas containing asteroid bodies (stellate-shaped structures) and Schaumann bodies (calcium and protein inclusions). Composition of Schaumann bodies: Calcium Non-caseating granulomas are common, but caseating granulomas can also be seen rarely. Caseating granulomas are mainly indicative of necrotising TB. (Option C ruled out) Macrophages with abundant cytoplasm containing dusty brown pigment is a normal finding seen after inhalation of dust particles. (Option A ruled out) Curschmann spirals and Charcot-Leyden crystals are associated with Asthma (Option D ruled out)

References:

Robbins and Cotran, Pathologic Basis of Disease, 10th edition, Page 696, 699, 372, 686

↑ *Back to this question in Part A*

@Neet_pg_bot

Q4: A 55-year-old male presents with a chronic cough, dyspnea, and chest tightness. On examination, fine crackles are heard bilaterally. A lung biopsy reveals collections of carbon-laden macrophages within the respiratory bronchioles and alveolar ducts, along with focal fibrosis and occasional small granulomas. Which of the following is not a condition associated with this patient? (Q845657)

A. Anthracosis

B. Simple Coal Worker’s Pneumoconiosis

C. Complicated coal Worker’s pneumoconiosis

D. Psittacosis

Correct Answer: D. Psittacosis

■ *Listen (English)*

■ *Listen (Hindi)*

Explanation: As the histopathology shows carbon-laden macrophages, it is not associated with Psittacosis which is a zoonotic bacterial infection caused by Chlamydia psittaci, contracted from exposure to infected birds, such as parrots. Technical term for carbon pigment is Anthracotic pigment. Stages of Coal worker’s pneumoconiosis (CWP) . Anthracosis (Option A): Inhaled carbon pigment accumulates in lung & lymphatics leading to black lungs which is usully asymptomatic. Simple Coal Workers’ Pneumoconiosis (CWP) (Option B): When carbon is inhaled for some years, it can lead to centrilobular emphysema. Complicated CWP (Option C): Exposure to carbon for many years can lead to large fibrotic masses in lung (>2 cm), which can lead to respiratory insufficiency, pulmonary hypertension, cor pulmonale .

References:

Robbins and Cotran, Pathologic Basis of Disease, 10th edition, Page 692

Psittacosis - StatPearls - NCBI Bookshelf (nih.gov)

↑ *Back to this question in Part A*

@Neet_pg_bot

Q5: A 50-year-old sandblaster presents with chronic cough, dyspnea, and chest pain. Further investigation reveals a history of prolonged exposure to sandblasting. He has also worked for several years in mines, where he was exposed to chronic asbestos and beryllium. A chest X-ray was taken, which is shown below. What is the most likely diagnosis? (Q845658)

A. Byssinosis

B. Silicosis

C. Asbestosis

D. Berylliosis



Correct Answer: B. Silicosis

- *Listen (English)*
- *Listen (Hindi)*

Explanation: The chest X-ray shows calcification of hilar lymph nodes, called eggshell calcification. The clinical picture, along with eggshell calcification, suggests silicosis. Silicosis: It is the most prevalent occupational lung disease in the world. Cause: Inhalation of proinflammatory crystalline silicon dioxide (silica). After many years of exposure, it typically manifests as a slowly progressive, nodular, fibrosing pneumoconiosis, which is later characterized by “egg-shell” calcifications of the hilar lymph nodes. Silicosis increases the risk of tuberculosis and cancers.

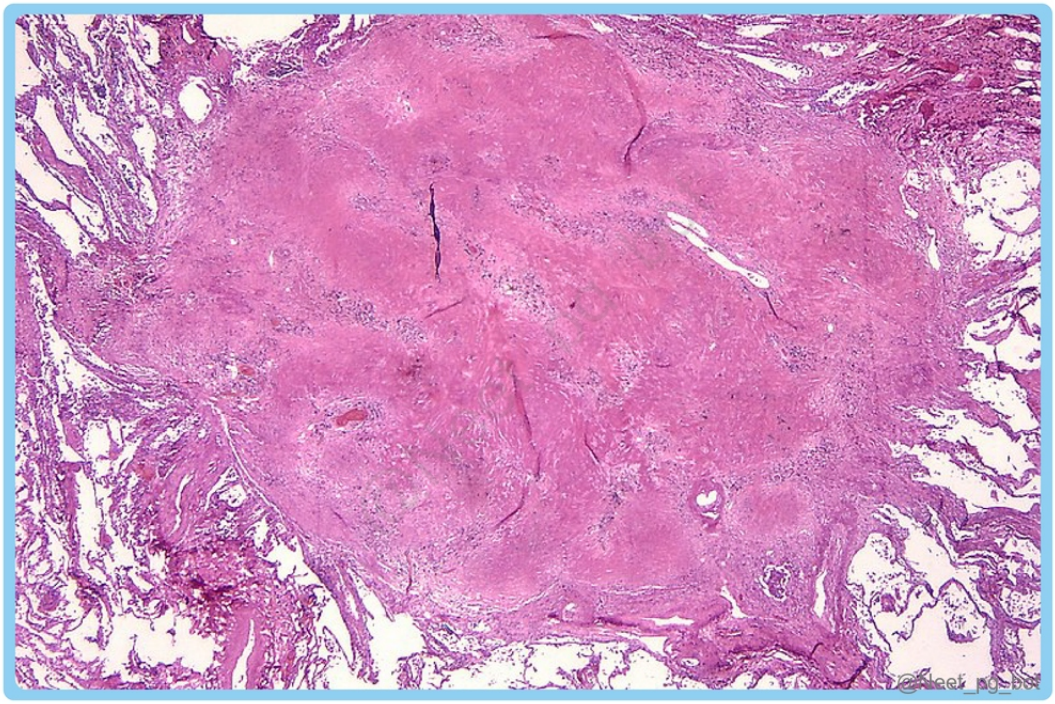

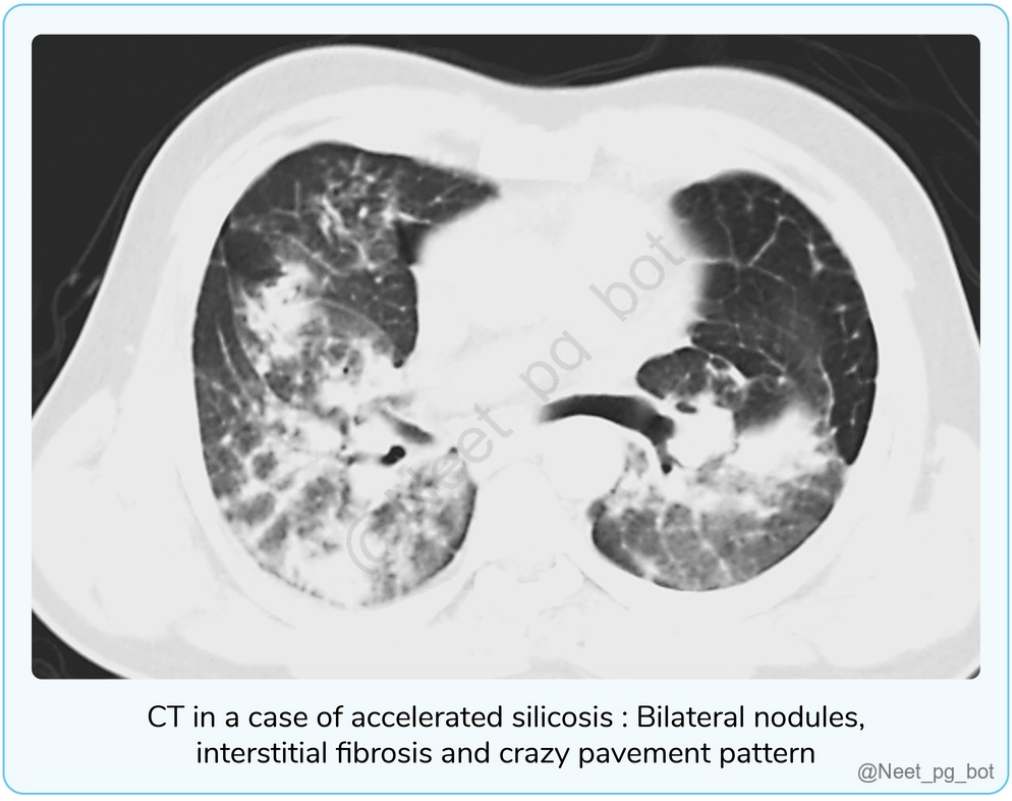

CT in a case of accelerated silicosis : Bilateral nodules, interstitial fibrosis and crazy pavement pattern

@Neet_pg_bot

References:

Robbins and Cotran, Pathologic Basis of Disease, 10th edition, Page 691

Eggshell calcification (lymph nodes) | Radiology Reference Article | Radiopaedia.org

↑ *Back to this question in Part A*

@Neet_pg_bot

Q6: Which of the following is not a cause of eggshell calcification? (Q845659)

A. Silicosis

B. Sarcoidosis

C. Post-radiation therapy

D. Metastatic lymph nodes

Correct Answer: D. Metastatic lymph nodes

■ *Listen (English)*

■ *Listen (Hindi)*

Explanation: Eggshell calcification is not seen in metastatic lymph nodes. Eggshell calcification refers to a ring of calcification at the periphery of a lymph node and not in other parts of the lymph nodes Eggshell calcifications can also be seen in: Silicosis (Option A) Coal workers pneumoconiosis Sarcoidosis (Option B) Post-radiotherapy (Option C) Post-irradiation lymphoma Tuberculosis Amyloidosis Histoplasmosis Blastomycosis

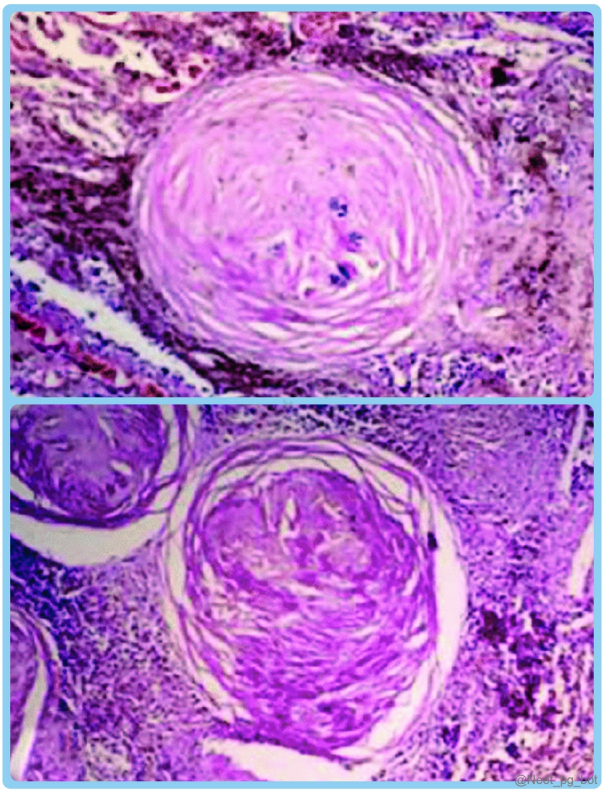

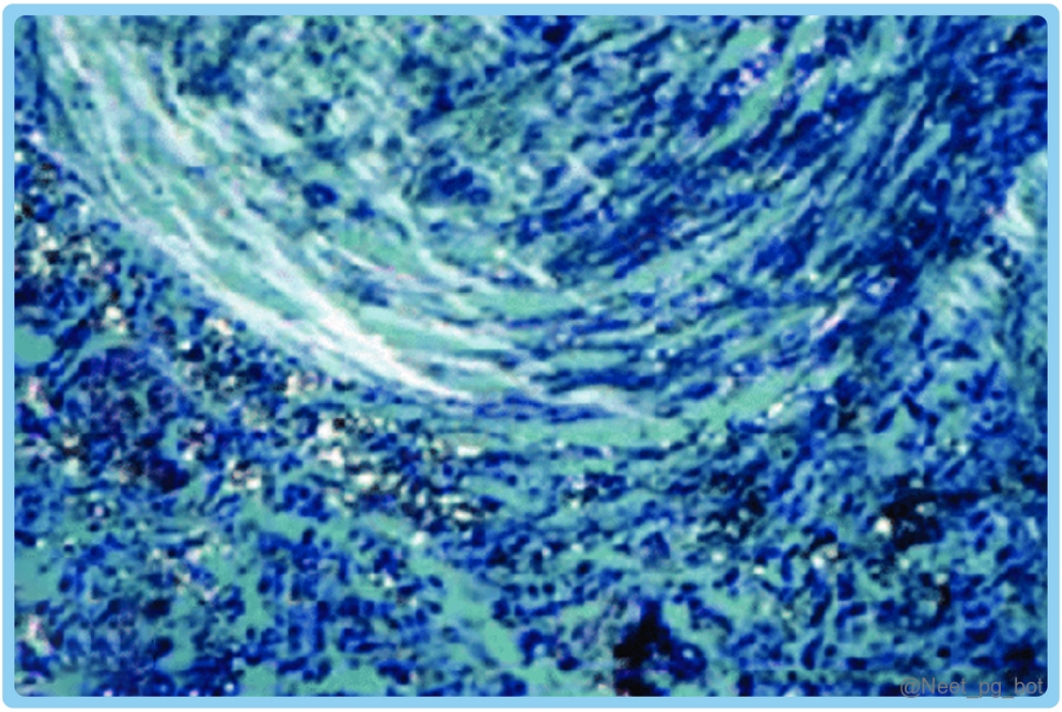



References:

Robbins and Cotran, Pathologic Basis of Disease, 10th Edition, Page 696

Silicosis (with egg shell calcification) | Radiology Case | Radiopaedia.org

↑ *Back to this question in Part A*

@Neet_pg_bot

Q7: Which of the following forms of asbestos is more toxic? (Q845660)

A. Serpentine

B. Amphibole

C. Chrysolite

D. Erionite

Correct Answer: B. Amphibole

■ *Listen (English)*

■ *Listen (Hindi)*

Explanation: Serpentine/ Chrysolite Amphibole/ Crocidolite/ Amosite Wavy (Snake like) Rigid and straight More common (90% of the asbestos) More pathogenic (amphiboles particularly associated with mesothelioma) Mnemonic: I am crying (Chrysotile) After looking at a snake (Serpentine) Snake is wavy Snakes can be seen more commonly (more common) Mnemonic: Saw a Crocodile (Crocidolite) Which is an Amphibian (Amosite) Crocodile is straight (rigid) Erionite is a type of asbestos. Exposure to it is associated with increased risks of lung cancer and mesothelioma. (Option D)

References:

Robbins and Cotran, Pathologic Basis of Disease, 10th edition, Page 694

↑ *Back to this question in Part A*

@Neet_pg_bot

Q8: A patient has been experiencing dyspnea for the past few weeks. A biopsy of his lungs has revealed the finding given below. What is the characteristic finding shown below in this patient? (Q845661)

A. Creola body

B. Schaumann body

C. Ferruginous body

D. Asteroid body

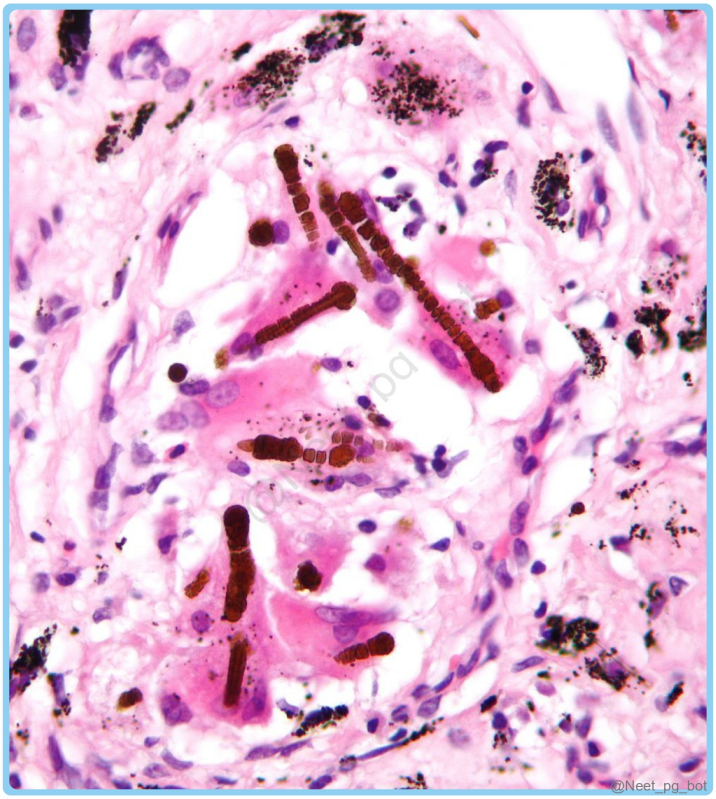

Correct Answer: C. Ferruginous body

- *Listen (English)*
- *Listen (Hindi)*

Explanation: The histopathological slide shows golden brown, fusiform, or beaded rods with a translucent core containing asbestos fibres, when inhaled, our body deposits iron around it and thereafter it is known as ferruginous bodies . Asbestosis: It is due to occupational exposure associated in people working in shipyard or cement industry. It effects the pleura (outer covering of lung), so the first lesion formed is pleural plaque. After many years of exposure, pleural plaques may develop into pleural nodules, which, with prolonged exposure, can progress to cancers. Most common cancer seen in Asbestosis: Adenocarcinoma lung. Most specific cancer seen in Asbestosis: Mesothelioma lung Creola bodies (Option A): Seen in asthma. Schaumann bodies (Option B): These are calcium deposits that are seen in sarcoidosis. Asteroid bodies (Option D): Seen in sarcoidosis; Sporothrix schenckii (Rose gardner's disease), a fungal infection.

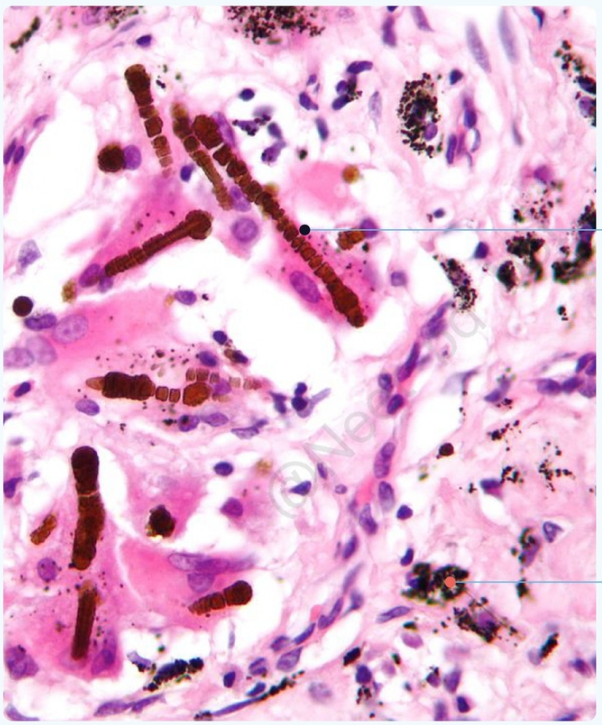

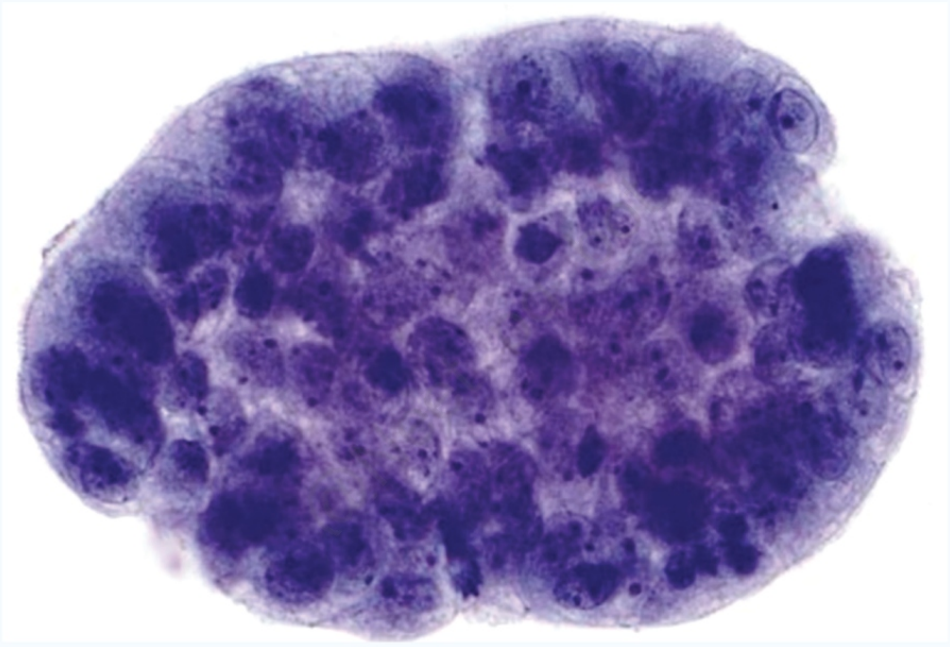

Creola bodies

References:

Robbins and Cotran, Pathologic Basis of Disease, 10th Edition, Page 697

↑ *Back to this question in Part A*

@Neet_pg_bot

Q9: A 55-year-old male presents to the clinic with complaints of persistent chest pain, shortness of breath, and unexplained weight loss. He was chronically exposed to minerals when he worked as a shipbuilder. Imaging studies revealed a growth that was subjected to needle biopsy. What is the most common lung malignancy associated with his occupational exposure? (Q845662)

A. Squamous cell carcinoma

B. Adenocarcinoma

C. Mesothelioma

D. Small cell cancer

Correct Answer: B. Adenocarcinoma

■ *Listen (English)*

■ *Listen (Hindi)*

Explanation: The patient's occupational history where he worked as a Shipbuilder (Shipyard industry) suggests that he was chronically exposed to Asbestos and the most common lung malignancy seen with occupational asbestos exposure is adenocarcinoma . Most specific lung cancer seen with occupational asbestos exposure is mesothelioma .

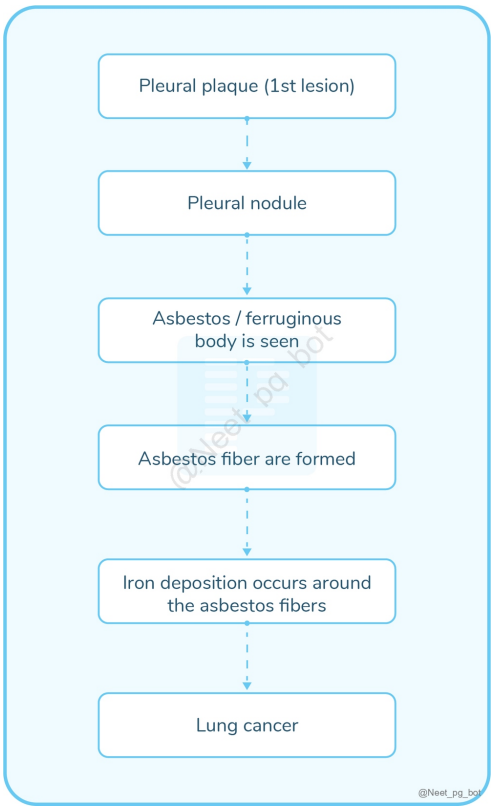

References:

Robbins and Cotran, Pathologic Basis of Disease, 10th edition, Page 694

www.ncbi.nlm.nih.gov/books/NBK555985/

↑ *Back to this question in Part A*

@Neet_pg_bot

Q10: Match the following occupational lung diseases with their characteristics. A) Byssinosis 1. Iron exposure B) Bagassosis 2. Monday disease C) Siderosis 3. Non-caseating granuloma. D) Berylliosis 4. Sugarcane dust exposure (Q845663)

A. A-4, B-2, C-1, D-3

B. A-2, B-4, C-1, D-3

C. A-3, B-1, C-4, D-2

D. A-2, B-1, C-4, D-3

Correct Answer: B. A-2, B-4, C-1, D-3

■ *Listen (English)*

■ *Listen (Hindi)*

Explanation: Byssinosis: Cotton dust/ organic dust exposure. The patient usually complains that the symptoms worsen when they come to work on Monday, hence the name Monday chest syndrome. They get better when off work, and symptoms reduce as the week progresses. This cycle is repeated. This occurs because, after a gap of 1–2 days, re-exposure takes place and the symptoms return. Bagassosis: sugarcane dust exposure. Siderosis: iron exposure. Berylliosis is caused by beryllium exposure. It leads to non-caseating granulomas in the lungs, as in sarcoidosis and can be differentiated based on industry exposure.

References:

Robbins and Cotran, Pathologic Basis of Disease, 10th edition, Page 692 Byssinosis - StatPearls - NCBI Bookshelf (nih.gov) Bagassosis - StatPearls - NCBI Bookshelf (nih.gov)

↑ *Back to this question in Part A*

@Neet_pg_bot

Q11: Which of the following is incorrect about mesothelioma? (Q846631)

A. Most specific cancer associated with asbestos exposure

B. Can lead to frozen hemithorax

C. Leads to a mediastinal shift

D. Not associated with smoking

Correct Answer: C. Leads to a mediastinal shift

■ *Listen (English)*

■ *Listen (Hindi)*

Explanation: Malignant mesothelioma is a pleural malignancy that arises from mesothelial cells of the pleura and is classically associated with asbestos exposure, commonly seen in occupations such as shipyard work, cement, and insulation industries. Malignant mesothelioma causes diffuse pleural thickening that encases the lung, leading to restrictive lung disease and pleural effusion. A characteristic description is the “ frozen hemithorax ,” where the lung appears encased in a rind-like thick pleura. Clinically, it presents with dyspnea, chest pain, and recurrent pleural effusions. (Option B) Asbestos exposure is the strongest and most specific association. (Option A) Unlike bronchogenic carcinoma, smoking has no role in the causation of mesothelioma. In bronchogenic carcinoma, smoking and asbestos act synergistically. (Option C) A common genetic alteration is deletion on chromosome 9p21, resulting in loss of CDKN2A. In mesothelioma, pleural thickening/fibrosis causes lung entrapment, does not cause mediastinal shift unlike large pleural effusions or pneumothorax. (Option B) Mesothelioma- Gross Mesothelioma- H & E stain Mesothelioma- Calretinin stain Lobulated pleural soft tissue mass encasing the right lung. Associated erosion of the right 3rd rib anteriorly. Calcified pleural plaques were noted bilaterally, indicating previous asbestos exposure. Coarse, partially calcified right pleural plaques, accompanied by massive right pleural

effusion, causing total right lung collapse and mass effect.



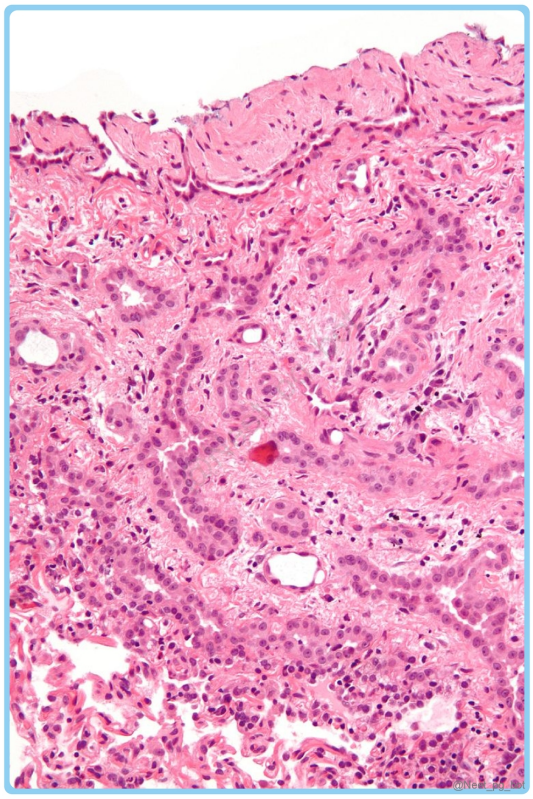

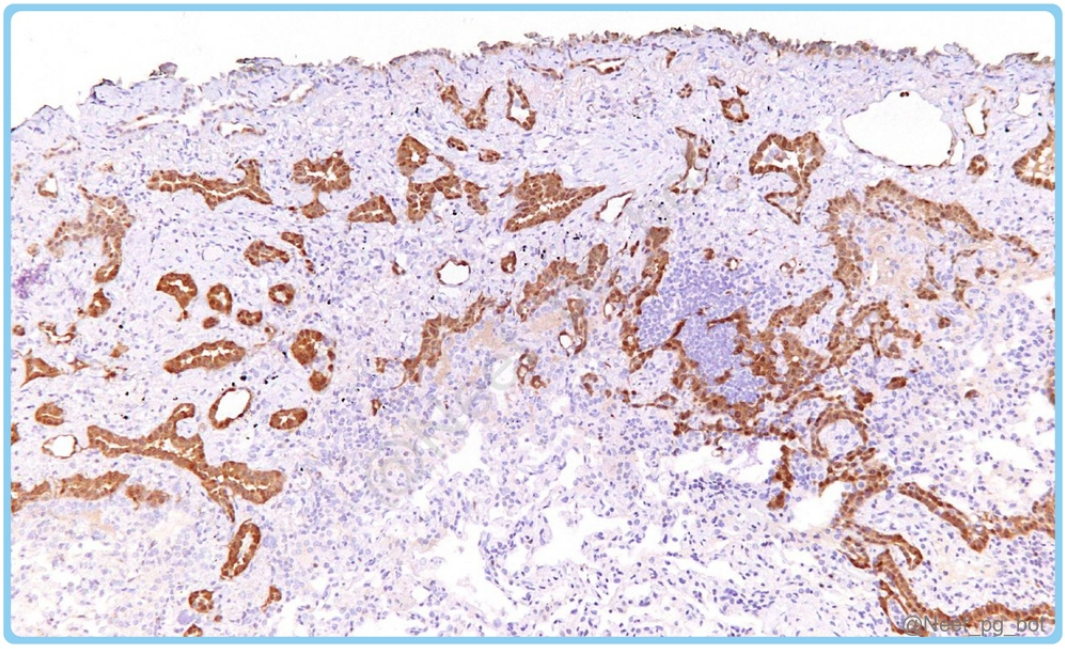
@Neet_pg_bot

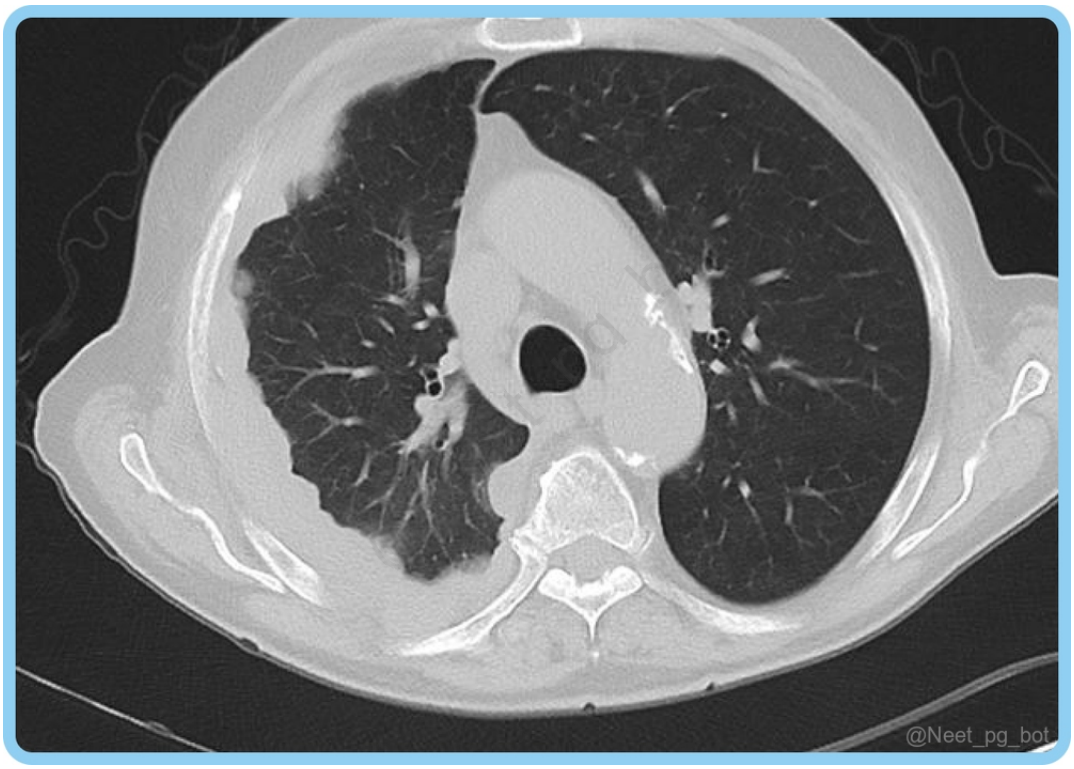
@Neet_pg_bot

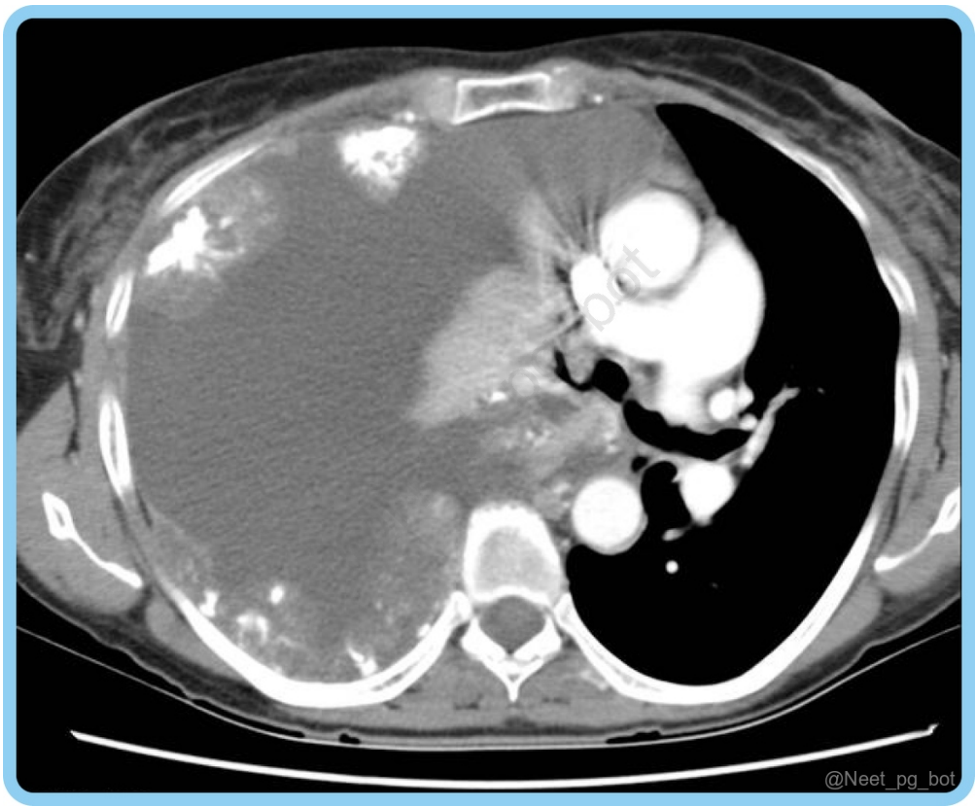

References:

Robbins and Cotran, Pathologic Basis of Disease, 10th Edition, Pages 726 & 727. Harrison’s Principles of Internal Medicine, 21st Edition, Pages 2168 & 2198

↑ *Back to this question in Part A*

@Neet_pg_bot

• [07_Respiratory System] 036 Previous Year Questions

« Back to Folder Directory

[07_Respiratory System] 036 Previous Year Questions — Quick Jump

Q1 (p. 1826)	*Q2 (p. 1828)*	*Q3 (p. 1828)*	*Q4 (p. 1831)*	*Q5 (p. 1834)*	*Q6 (p. 1835)*
Q7 (p. 1838)	*Q8 (p. 1841)*	*Q9 (p. 1842)*	*Q10 (p. 1843)*	*Q11 (p. 1845)*	*Q12 (p. 1848)*
Q13 (p. 1852)	*Q14 (p. 1853)*	*Q15 (p. 1857)*	*Q16 (p. 1858)*	*Q17 (p. 1859)*	*Q18 (p. 1861)*
Q19 (p. 1862)	*Q20 (p. 1865)*	*Q21 (p. 1867)*	*Q22 (p. 1867)*	*Q23 (p. 1868)*	*Q24 (p. 1869)*
Q25 (p. 1870)					

Q1: A chronic smoker who worked in a cement factory for 20 years developed mesothelioma. It is due to? (Q855446)

A. Silicosis

B. Asbestosis

C. Coal worker pneumoconiosis

D. Bagassosis

Correct Answer: B. Asbestosis

Explanation: Mesothelioma is primarily caused by exposure to asbestos fibres, which is a known risk factor for this type of cancer. Long-term exposure to asbestos, especially in industries such as cement factories, is the most common occupational cause of mesothelioma. Asbestos exposure is a well-established risk factor for developing laryngeal, ovarian, colon, lung, and pleural cancers. Lung mesothelioma is a more specific tumour associated with asbestos exposure. It is common but is less prevalent than Adenocarcinoma. Mesothelioma A rare cancer arising from mesothelial cells that most commonly affects the pleura, and it can also affect the peritoneum, pericardium, and tunica vaginalis Etiology Mesothelioma is the most specific asbestos-associated cancer Pathology Advanced pleural mesothelioma can cause extensive pleural fibrosis and thickening, making the affected side rigid and immobile Later stages fix the mediastinum in place due to pleural thickening and fibrosis. A mediastinal shift is not a characteristic feature of mesothelioma. Clinical features Progressive dyspnea, chest pain, weight loss, chronic cough, hemoptysis Decreased breath sounds and dullness to percussion (due to pleural effusion or thickening). Diagnosis CT scan shows Pleural thickening, effusion, or frozen hemithorax (not causing a mediastinal shift in the presence of effusion) {{caption_text}} {{caption_text}} Biopsy (Diagnosis can be confirmed) Epithelioid mesothelioma shows tubules, nests, or papillary structures with uniform round to oval nuclei and eosinophilic cytoplasm. Sarcomatoid mesothelioma consists of spindle-shaped cells resembling fibrosarcoma. Biphasic mesothelioma displays a mixture of both patterns. Specific markers for mesothelioma Calretinin Epithelial membrane antigen Cytokeratin Mesothelin Prognosis Poor - median survival of 9-21 months Incorrect Options: Silicosis (Option A) is caused by the inhalation of silica dust , commonly seen in industries such as mining and construction. While silica exposure can lead to lung fibrosis, it is not a direct cause of

mesothelioma. Coal worker pneumoconiosis (Option C), also known as black lung disease , results from the inhalation of coal dust. This condition affects the lungs but is not linked to mesothelioma. Bagassosis (Option D) is caused by the inhalation of mouldy sugarcane dust and can lead to lung disease, but it is not associated with mesothelioma.

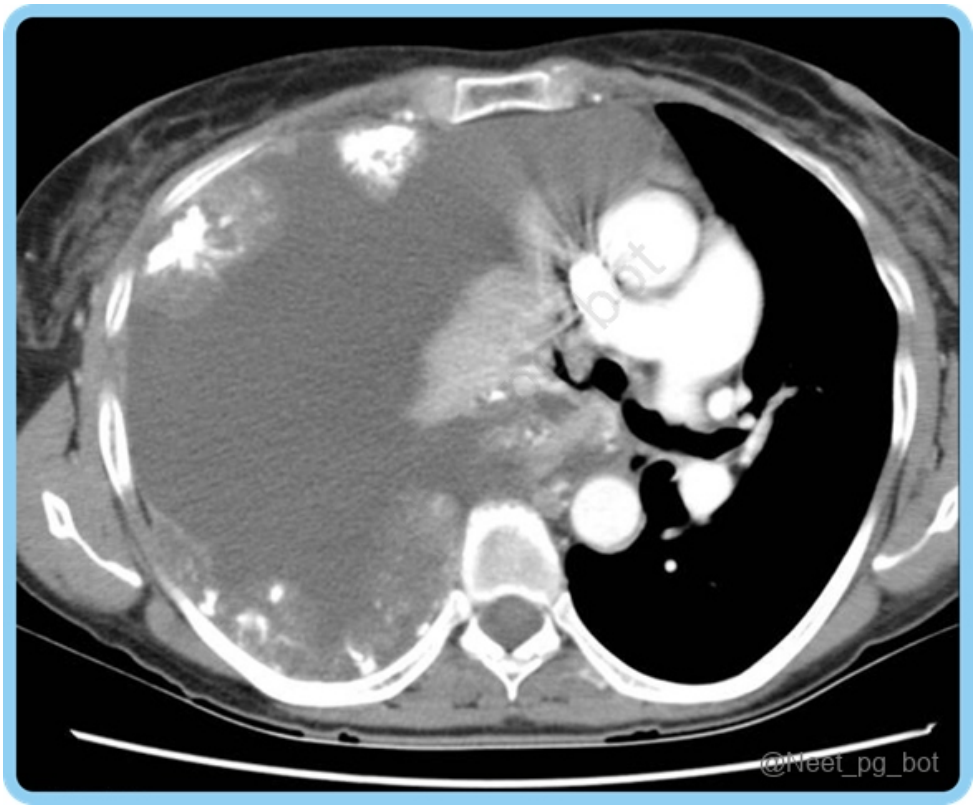

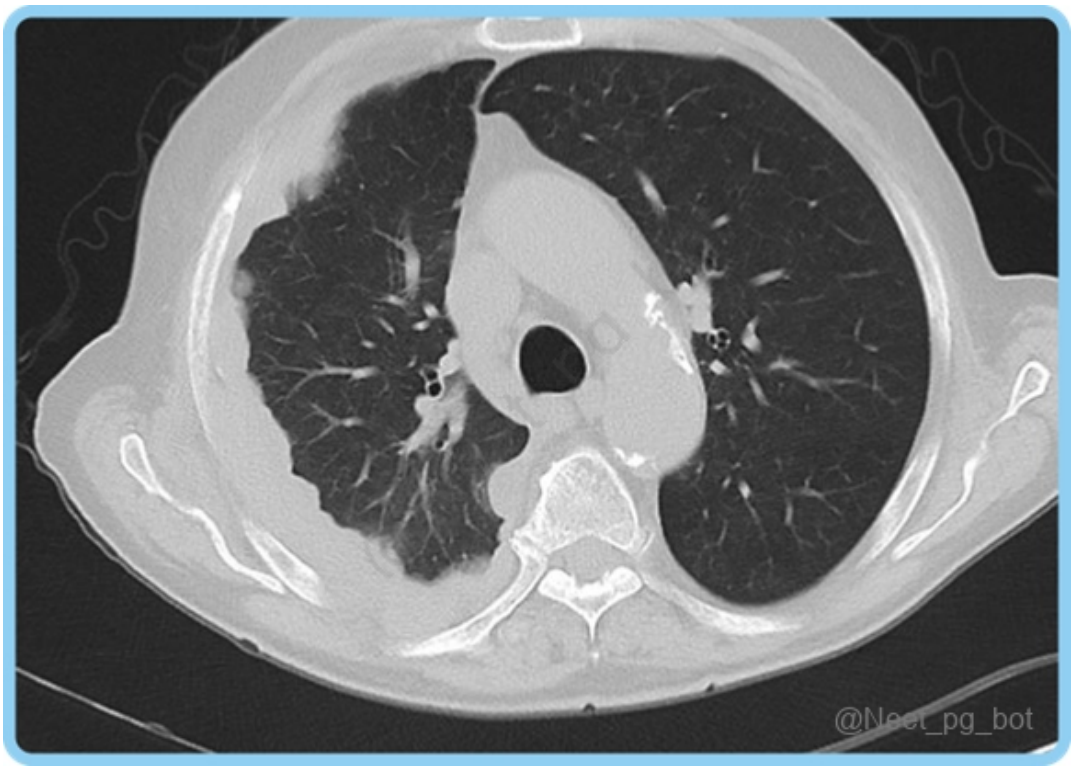

References:

Robbins and Cotran Pathologic Basis of Disease, 10th Edition, Page 694

https://www.ncbi.nlm.nih.gov/books/NBK555985/

↑ *Back to this question in Part A*

@Neet_pg_bot

Q2: Which of the following is a post-mortem finding seen in the lung after the death of a patient from COVID-19 after a week? (Q855970)

A. Fresh and old intra-alveolar hemorrhage

B. Thick layer of fibrin

C. Perivascular cuffing

D. Pulmonary artery hypertrophy with increased resistance

Correct Answer: B. Thick layer of fibrin

Explanation: : These can occur in COVID-19, especially in the acute phase; it is typically seen in earlier stages of the disease, not necessarily after a week. After a week, haemorrhage may be less prominent, and fibrin deposition would be a more characteristic finding. Perivascular cuffing (Option C) refers to the accumulation of lymphocytes around blood vessels, commonly seen in viral infections, usually in the early stages . By the later week , this feature may still be present but is not as defining as fibrin deposition after a week of death in COVID-19. Pulmonary artery hypertrophy with increased resistance (Option D) can develop with long-standing lung disease or after multiple episodes of severe illness. However, this is a chronic finding rather than an acute post-mortem feature . Pulmonary artery hypertrophy is a very rare complication after COVID-19 and would not commonly be a primary finding after one week of death from COVID-19.

References:

NIH Link

↑ *Back to this question in Part A*

@Neet_pg_bot

Q3: A 30-year-old woman with a long history of dyspnea, chronic cough with sputum, and wheezing died of respiratory failure following a bout of lobar pneumonia. She was

not a smoker or an alcoholic. The lung at autopsy is shown in the image below. Which of the following is most likely to cause the pathological changes shown? (Q854883)

A. Alpha-1 antitrypsin deficiency

B. Cystic fibrosis

C. Mutation in dynein arms

D. Antibodies against type-IV collagen



Correct Answer: A. Alpha-1 antitrypsin deficiency

Explanation: The clinical presentation and the gross specimen showing emphysematous damage involving the enlargement of the entire acinus are consistent with panacinar emphysema . This pattern of emphysema is most commonly associated with alpha-1 antitrypsin deficiency . Alpha-1 antitrypsin deficiency: It is an autosomal recessive disorder caused by mutations in the alpha-1 antitrypsin gene located on Chromosome 14 . Normal individuals have the PiMM genotype , while those with the disease have the PiZZ genotype. This results in significantly reduced levels of functional alpha-1 antitrypsin protein. Carriers possess the PiMZ genotype. The condition primarily affects the lungs, leading to panacinar emphysema and the liver, causing cirrhosis due to abnormal protein accumulation. Emphysema is classified according to its anatomic distribution within the lobule. Based on the segments of the respiratory units that are involved, emphysema is subdivided into four major types: Features Centriacinar (M/C) Panacinar Paraseptal Irregular Involves Proximal acinus Proximal & distal acini Distal acinus Irregular involvement Site Upper lobes, especially apical segments Lower zones & anterior margins of the lung. More severe at the base of the lung. The upper half of the lungs (more severe). Airspaces can form

cyst-like structures. Any part of the lung can be involved. Aetiology Smokers Chronic bronchitis α1-antitrypsin deficiency Spontaneous pneumothorax Depends on involvement, most found in autopsy The image below shows centriacinar emphysema. {{caption_text}} {{caption_text}} {{caption_text}}

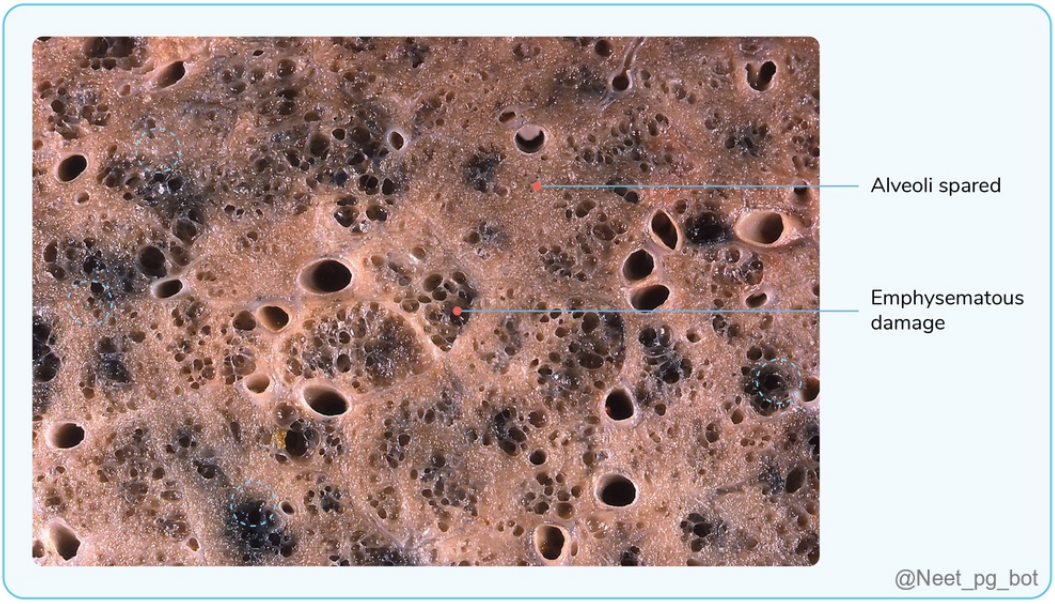

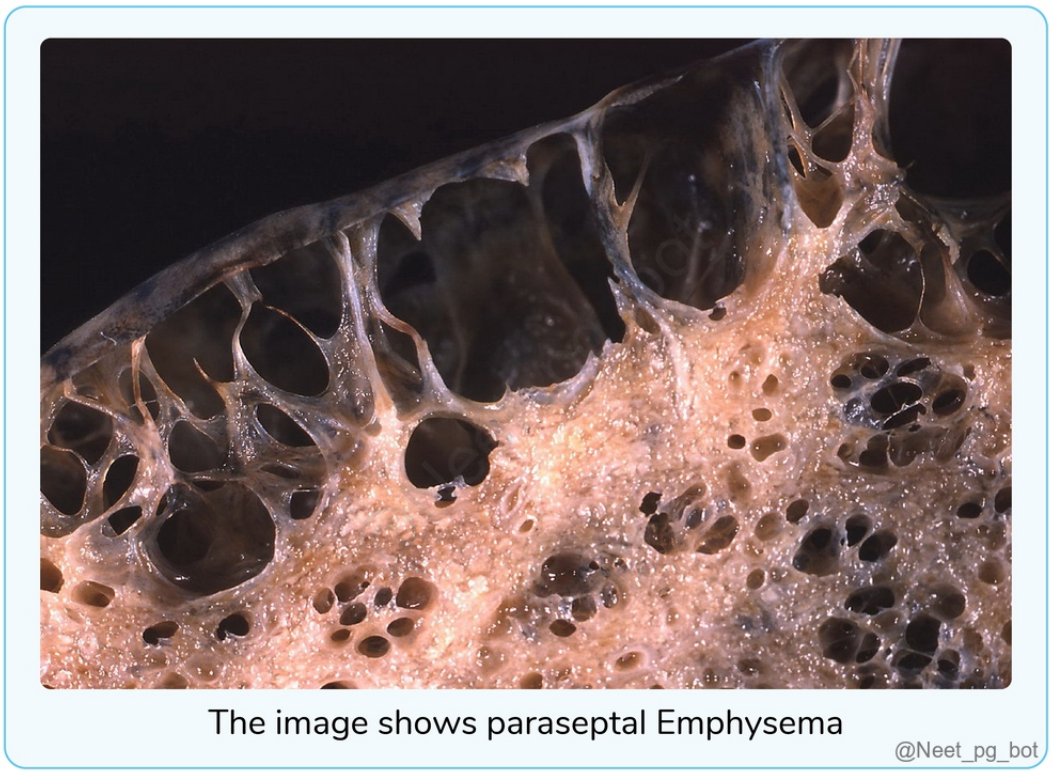

The image below shows panacinar emphysema



@Neet_pg_bot

References:

Robbins & Cotran Pathologic Basis of Disease, 10th Edition, Page 679,680

↑ *Back to this question in Part A*

@Neet_pg_bot

Q4: A 55-year-old male presents with a chronic cough, shortness of breath, and chest pain. He has a history of working in construction for several decades, where he was exposed to asbestos. Physical examination reveals decreased breath sounds over the lower lung fields. A chest X-ray shows bilateral, diffuse interstitial opacities. Pulmonary function tests reveal a restrictive pattern. High-resolution computed tomography (HRCT) of the chest demonstrates "honeycombing" in the lung parenchyma. What is the diagnosis? (Q856495)

A. Tuberculosis

B. Chronic Obstructive Pulmonary Disease (COPD)

C. Asbestosis

D. Pneumonia

Correct Answer: C. Asbestosis

Explanation: The patient’s prolonged asbestos exposure, chronic cough, shortness of breath, and chest pain suggest asbestosis, a form of interstitial lung disease (ILD). Imaging findings, including bilateral interstitial opacities and honeycombing on HRCT, along with a restrictive pattern on pulmonary function tests, support the diagnosis of asbestos-induced pulmonary fibrosis. Asbestos exposure is a well-established risk factor for developing laryngeal, ovarian, colon, lung, and pleural cancers. {{caption_text}} Asbestos-related lung carcinoma is markedly magnified by smoking. Thus, asbestos workers (particularly those who smoke) are at much higher risk of dying of lung carcinoma than mesothelioma. Compared to other occupational lung diseases, which affect the upper lobes of the lungs, it commonly affects the lower lobes. Adenocarcinoma (primary bronchogenic carcinoma) is the most common type of cancer, accounting for about 45%, followed by squamous cell carcinoma. Lung mesothelioma is a more specific tumour associated with asbestos exposure but is less prevalent than Adenocarcinoma.

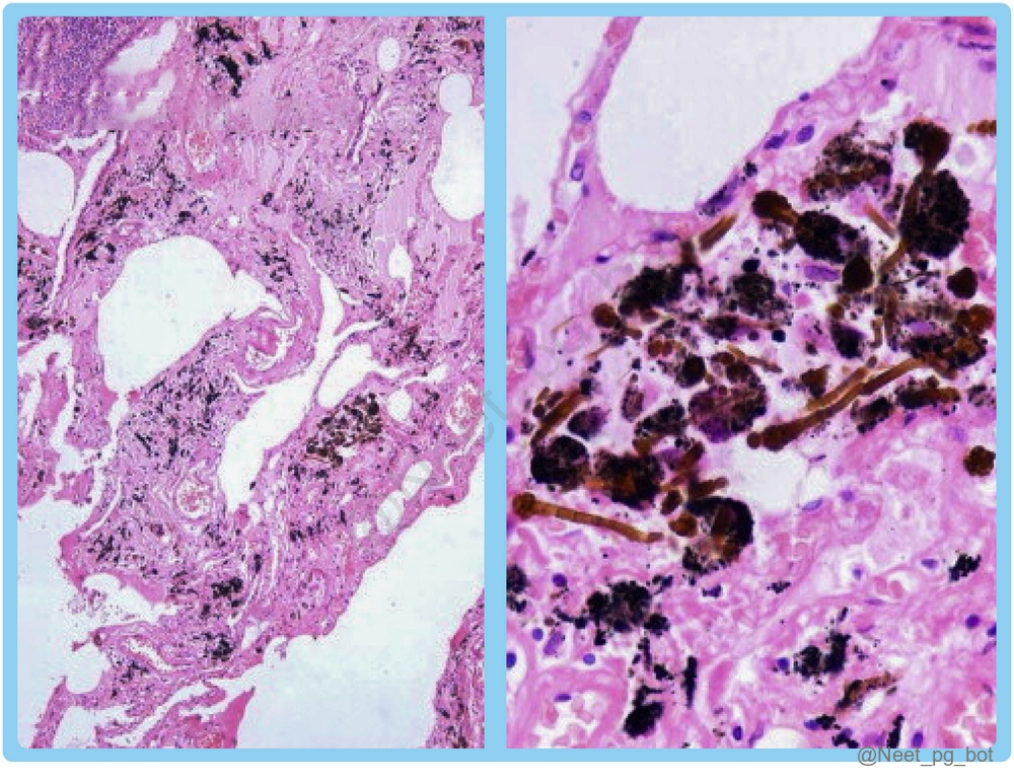

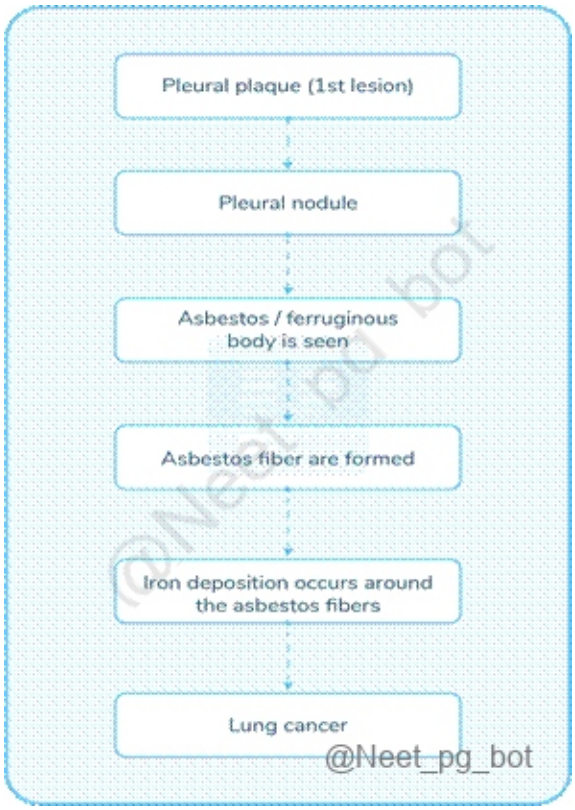

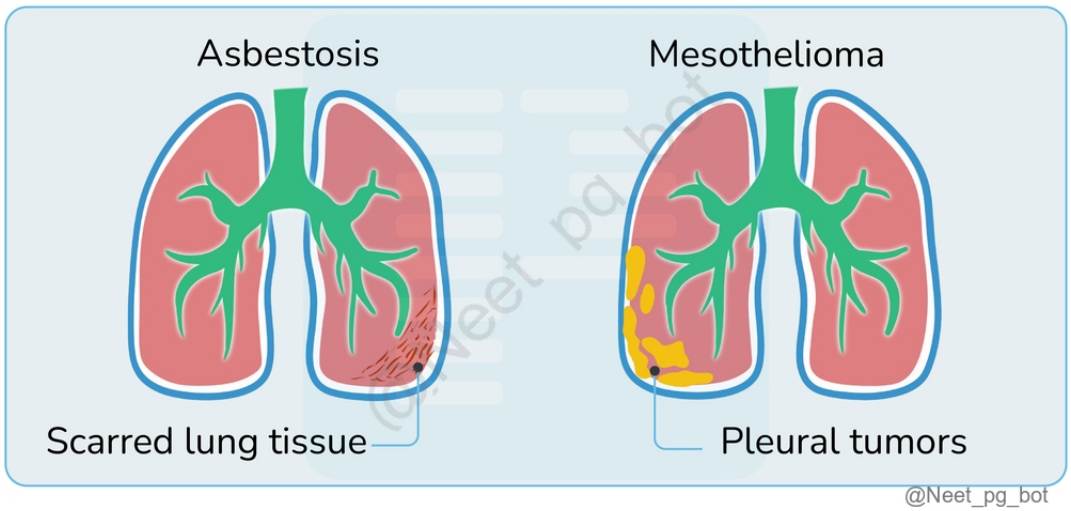

References:

Robbins & Cotran Pathologic Basis of Disease, 10th Edition, Page 694

https://www.ncbi.nlm.nih.gov/books/NBK555985/

↑ *Back to this question in Part A*

@Neet_pg_bot

Q5: The most common lung finding in a COVID-19 infection is: (Q856477)

A. Pulmonary infarction

B. Diffuse alveolar damage

C. Endothelial injury

D. Fibrin clots

Correct Answer: B. Diffuse alveolar damage

Explanation: The most common lung finding in COVID-19 is diffuse alveolar damage (DAD). It represents the histopathological correlate of ARDS, frequently seen in moderate to severe cases. DAD shows hyaline membrane formation, alveolar edema, and type II pneumocyte hyperplasia. It results from widespread injury to alveolar epithelial cells. DAD explains the severe hypoxemia seen clinically. It is the hallmark lesion in the lungs during both early (exudative) and later (organizing) phases of COVID-19. Hence, DAD is the characteristic and most common pathological finding. {{caption_text}} Incorrect Options: Option A) Pulmonary infarction: Not a common feature; seen only when significant thromboembolic events occur, which are less frequent. Option C) Endothelial injury: Present in COVID-19 but not the main lung pathology; it contributes to severity, not the primary finding. Option D) Fibrin clots: Microthrombi can occur, but they are secondary features and not the dominant or most common lung lesion.

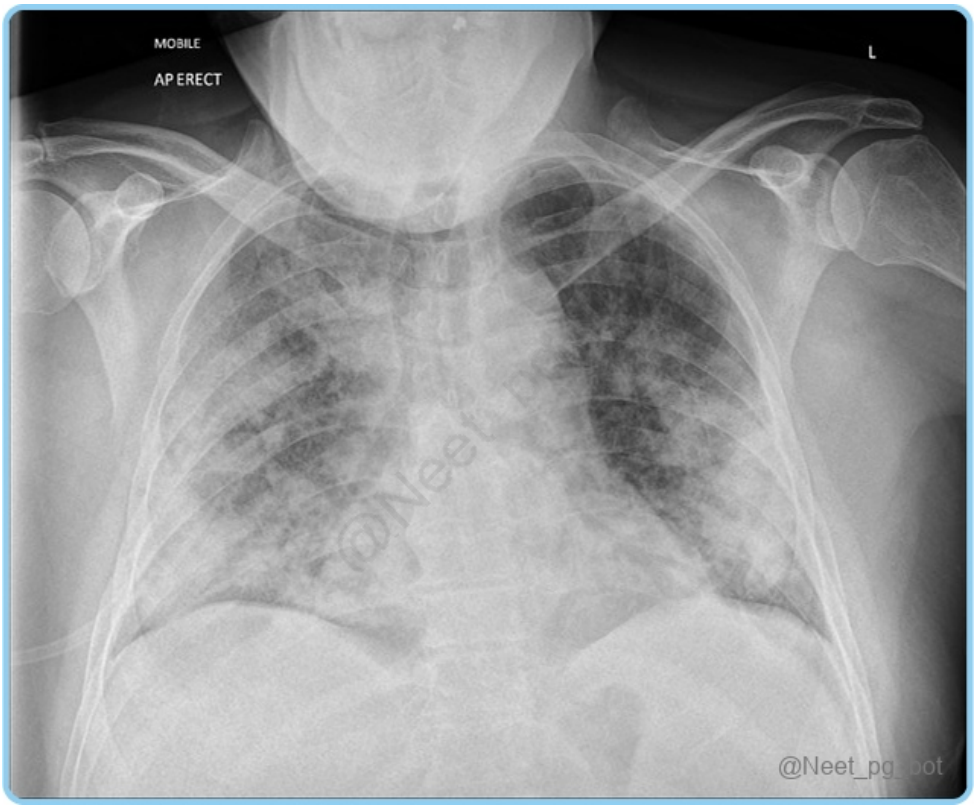

References:

Robbins & Cotran Pathologic Basis of Disease, 10th Edition, Page 353

↑ *Back to this question in Part A*

@Neet_pg_bot

Q6: A 42-year-old female patient presents with a cough, a low-grade fever, and hemoptysis. Investigations reveal a cavitary lesion on her right lung apex, which, on biopsy, reveals caseous necrosis. The underlying pathophysiology is: (Q856728)

A. Enzyme degradation

B. Type-4 hypersensitivity reaction

C. Fibrinoid deposition

D. Sudden cut off of blood supply

Correct Answer: B. Type-4 hypersensitivity reaction

Explanation: The given scenario of cough, fever, hemoptysis, and a cavitary lesion with caseous necrosis at the right lung apex strongly suggests Pulmonary Tuberculosis , which involves a type-4 hypersensitivity reaction. CD4+ T cells activate macrophages, but Mycobacterium tuberculosis survives within them, causing granuloma formation with caseous necrosis, driven by a type 4 hypersensitivity reaction and resulting in tissue damage. It is a bacterial infection caused by Mycobacterium tuberculosis and can be classified into the following types: 1. Primary tuberculosis It develops in a previously unexposed and, therefore, unsensitized person. The primary organ involved is mostly the lungs. Location: Sub-pleural region. Lower part of the upper lobe & upper part of the lower lobe. Ghon’s focus: Grey-white area of inflammation with consolidation. Ghon’s complex: Ghon’s focus + inflamed regional lymph nodes. Histology : Granulomatous inflammatory reaction with both caseating and non-caseating tubercles. {{caption_text}} Simon’s focus: Occult hematogenous dissemination to the apex of the lung. Fate: 95% of the cases are controlled by immunity, calcified, healed lesions and hilar lymph nodes (Ranke complex) . 5% of the cases are progressive (Progressive primary TB) . Resembles acute bacterial pneumonia. Lymphohematogenous dissemination may cause tuberculous meningitis and/or miliary TB. 2. Secondary tuberculosis It arises in a previously sensitised host. It may follow shortly after primary tuberculosis, but more commonly, it appears months to years after the initial infection, usually when the host resistance is weakened. The apical and posterior lobe segments are involved due to high O 2 concentration (Puhl’s focus) . The infraclavicular lesion is called Assman’s focus. Regional lymph node involvement is late. Cavitation occurs readily with the erosion of the cavities into an airway. Histology: Active lesions show coalescent tubercles with central caseation (Caseous necrosis). 3. Disseminated TB : Spread to other organs. The images below show the caseous necrosis seen in TB. {{caption_text}} {{caption_text}} Enzyme degradation (Option A) may be involved in the breakdown of tissue during infection. The primary mechanism of tissue damage in tuberculosis is the type-4 hypersensitivity reaction. Fibrinoid deposition (Option C) refers to the accumulation of fibrin-like material in the walls of blood vessels. It is typically associated with conditions such as vasculitis. Sudden cutoff of blood supply (Option D) occurs when the blood supply to a tissue is abruptly interrupted, leading to ischemia and subsequent tissue death. In the case of tuberculosis, the tissue damage is primarily caused by the immune response and the

formation of granulomas.

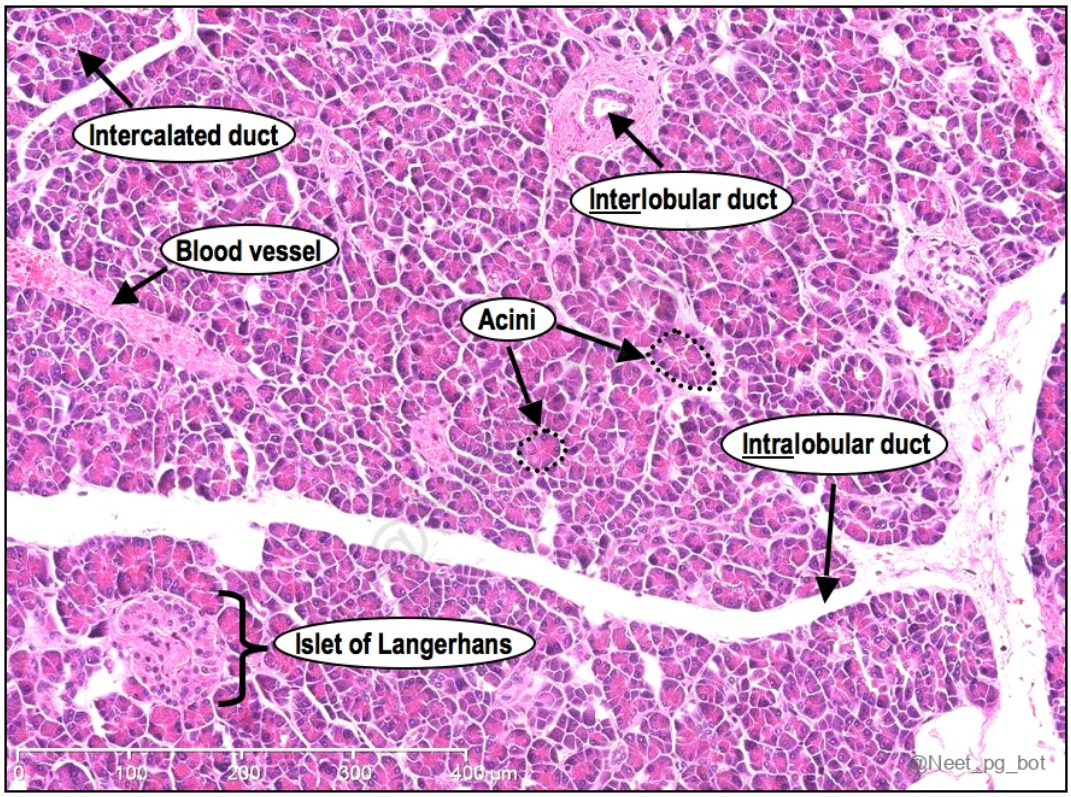

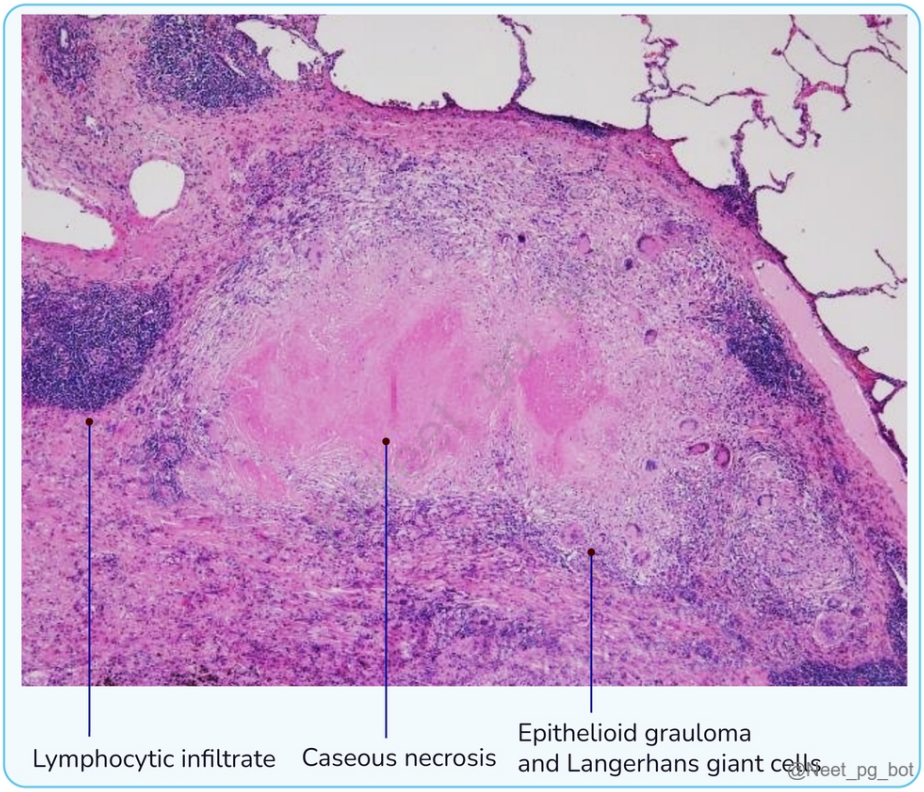



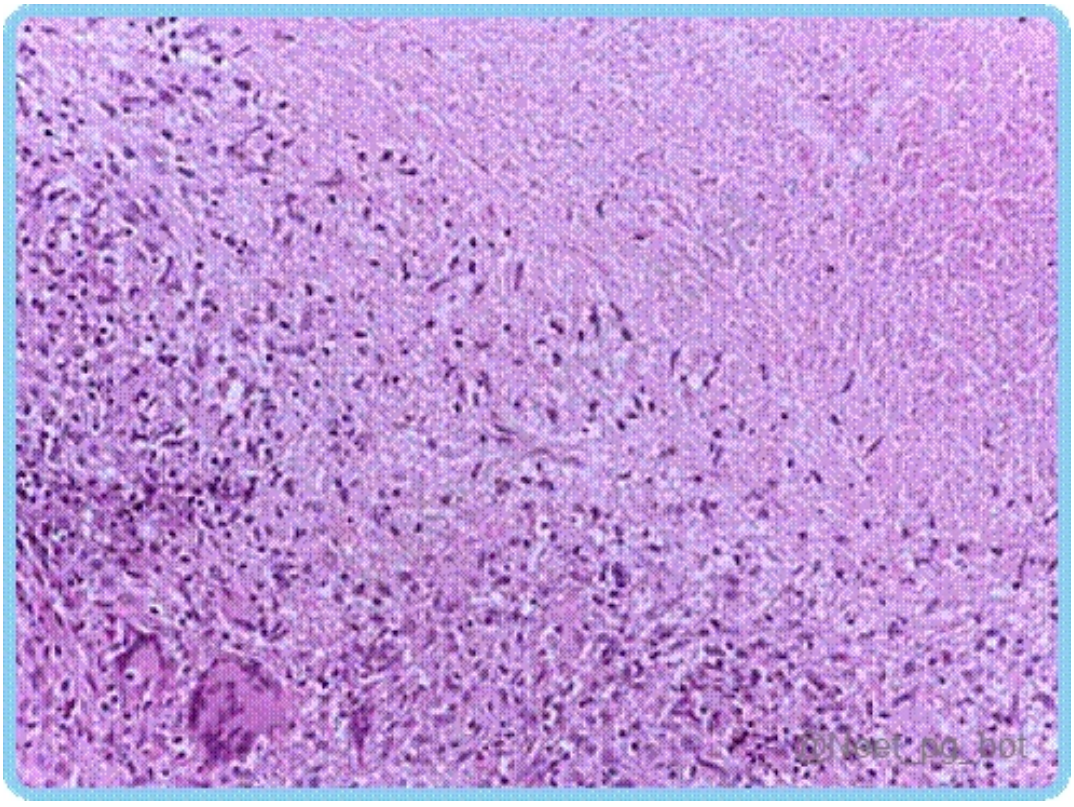

References:

Robbins & Cotran Pathologic Basis of Disease,10th Edition, Page 371-373.

↑ *Back to this question in Part A*

Q7: A person working in an industry for a long time develops progressive breathlessness. The histopathological image of his lung biopsy is given below. What industry was the person most likely working in? (Q856697)

A. Silica

B. Asbestos

C. Coal dust

D. Cotton

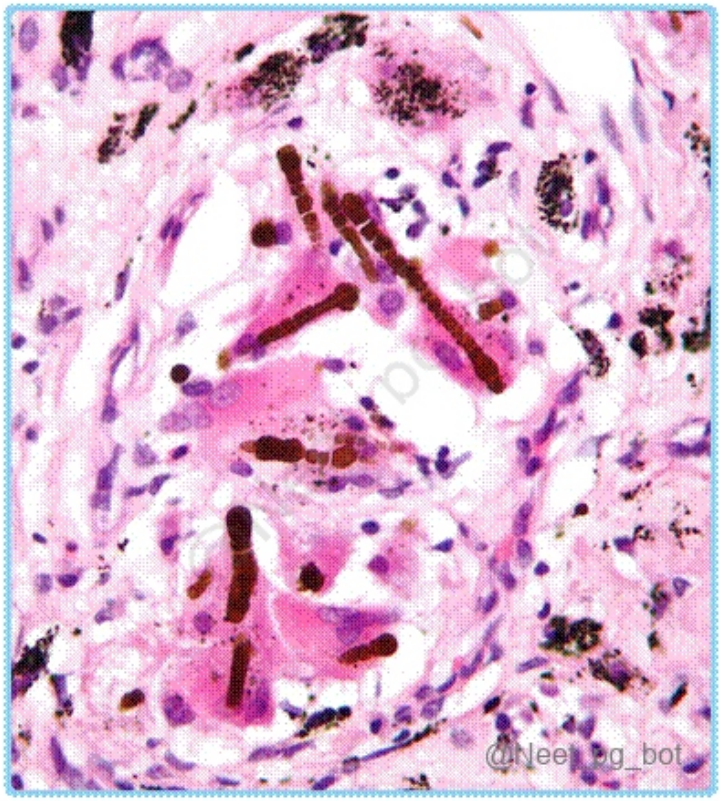

Correct Answer: B. Asbestos

Explanation: The histopathological image shows ferruginous bodies, suggestive of Asbestosis , indicating the person likely worked in the asbestos industry. It is a chronic lung condition caused by the inhalation of asbestos fibres over a prolonged period. These fibres accumulate in the lung tissue, leading to inflammation, fibrosis, and scarring. Symptoms: Includes shortness of breath, coughing, and chest tightness The histopathological features seen in asbestosis include: Interstitial fibrosis: Asbestos fibres cause injury to the lung parenchyma, resulting in the deposition of collagen and fibrous tissue in the interstitium. This fibrosis leads to thickening of the alveolar walls

and restrictive lung function. Ferruginous bodies: Asbestos fibres can be recognized in the lung tissue as long, golden-brown, rod-shaped structures called ferruginous bodies. These bodies are composed of asbestos fibre coated with iron and protein. {{caption_text}} Silica (Option A) exposure is associated with a lung disease called silicosis. Histopathological features of silicosis include nodular lesions with silica particles, collagenous fibrosis, and concentric silicotic nodules featuring central collagen and a peripheral zone of dust-laden macrophages. {{caption_text}} Coal dust (Option C) exposure is associated with coal worker's pneumoconiosis (CWP). Histopathological features of CWP include the presence of coal macules (collections of carbon-laden macrophages) and coal nodules (fibrotic lesions with central cores of coal dust). {{caption_text}} Cotton (Option D) exposure can lead to a lung disease known as byssinosis, also called brown lung disease. Histopathological findings in byssinosis include bronchiolitis and chronic bronchitis with peribronchiolar fibrosis. {{caption_text}}

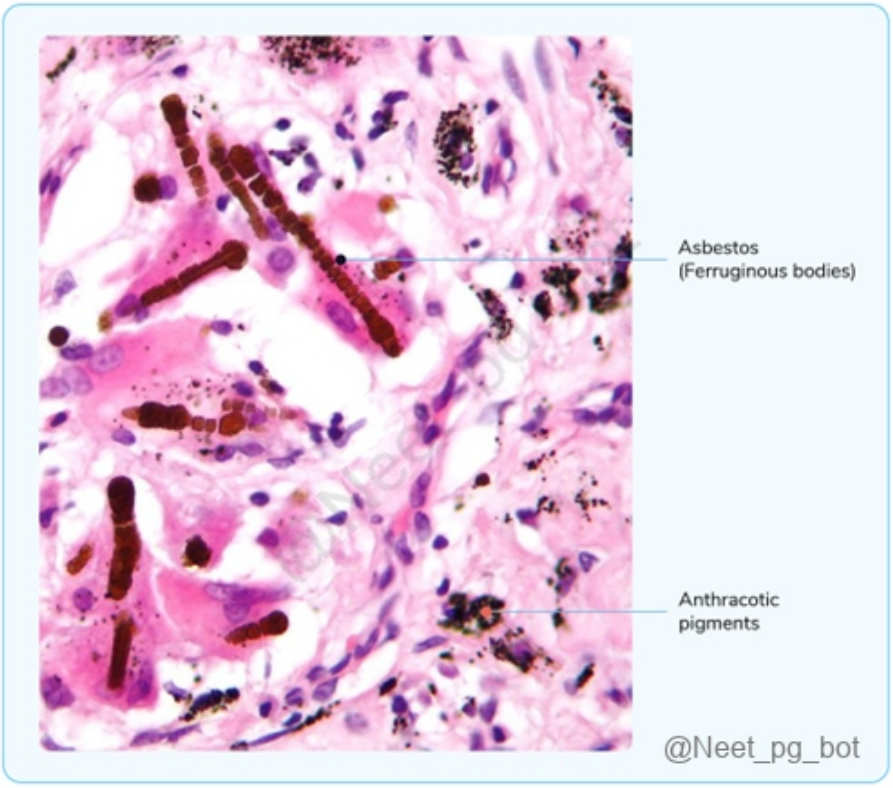

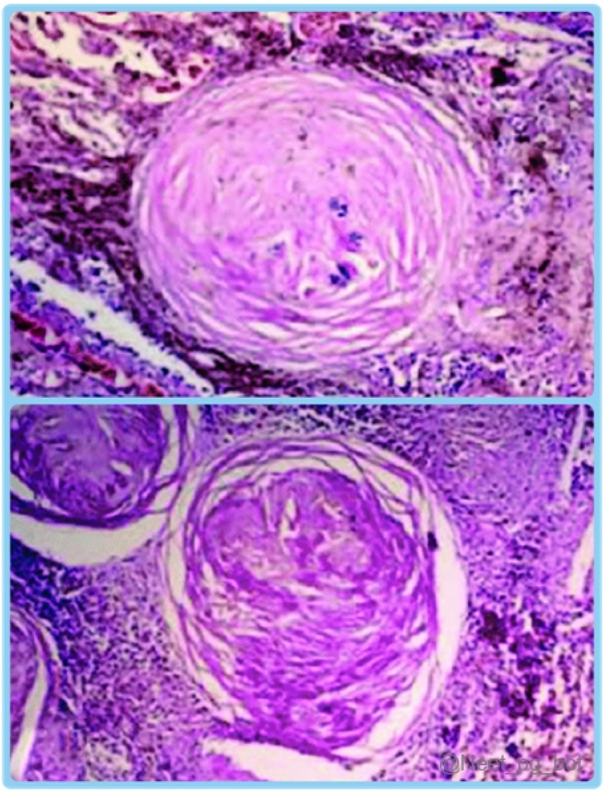
@Neet_pg_boy

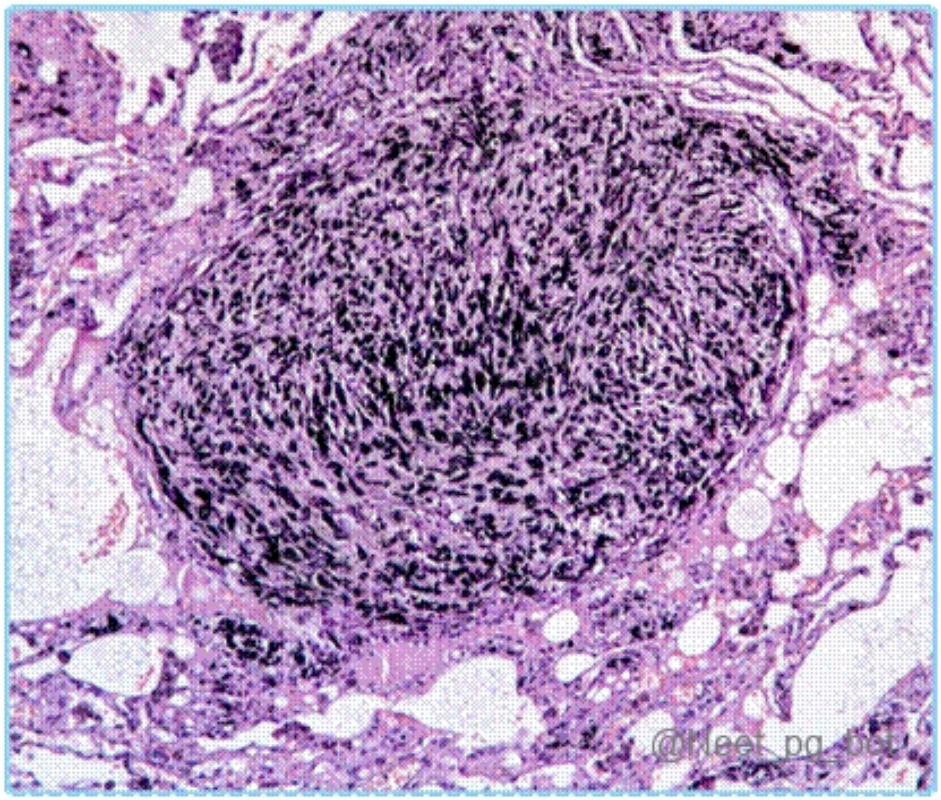
@Neet_pg_boy

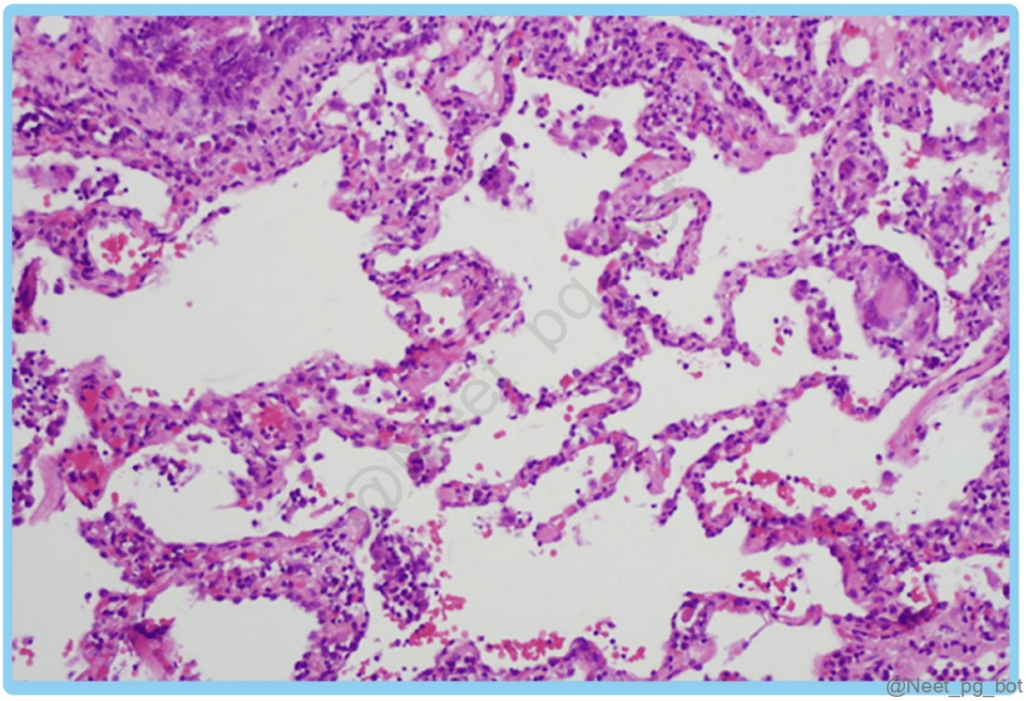

References:

Robbins and Cotran Pathologic Basis of Disease, 10th Edition, Page 694.

↑ *Back to this question in Part A*

@Neet_pg_bot

Q8: Below is an electron microscopic image of lung tissue. A patient infected with SARS-CoV2 presents with ARDS. The infection would affect and expand in which of the following labelled layers? (Q855415)

A. B

B. A

C. D

D. None of the above

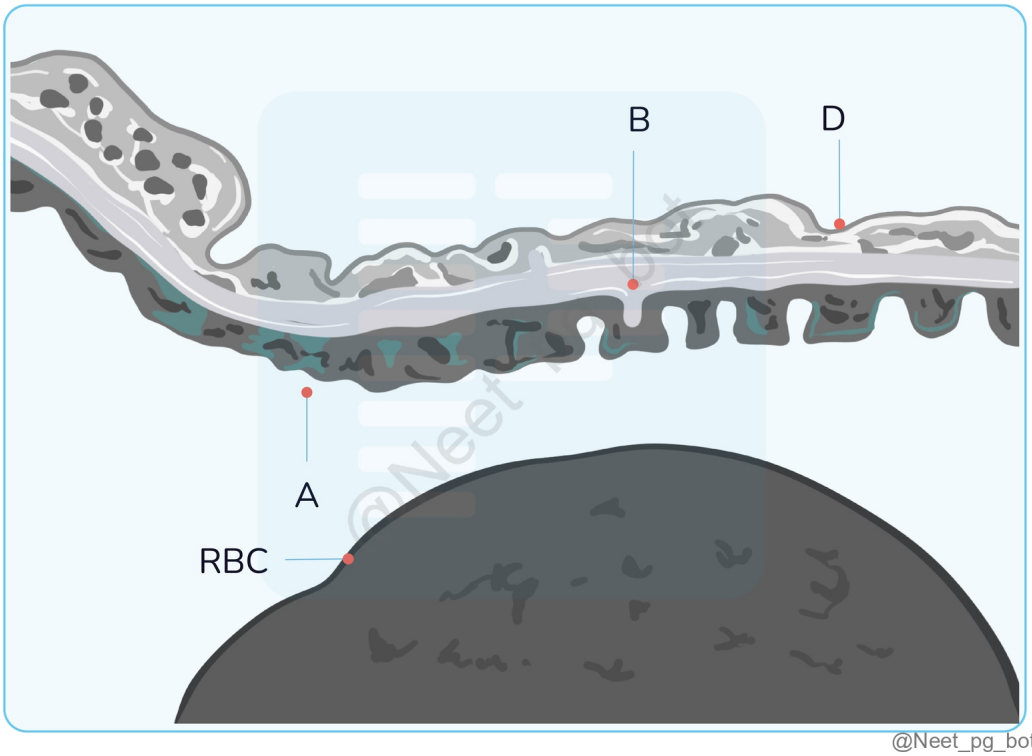

Correct Answer: B. A

Explanation: In the electron microscopic image of the lung tissue, the structure labelled "A" represents the endothelium, where SARS-CoV-2 infection would impact and cause expansion. It is the virus causing COVID-19. It leads to acute respiratory distress syndrome (ARDS). Mechanism: The virus can directly infect the endothelial cells that line the blood vessels in the lungs, disrupting the normal function and integrity of the endothelial cells, resulting in increased vascular permeability, inflammation, and the onset of pulmonary edema. (Option B) Layer B (Option A) represents the basal lamina, which offers structural support to the epithelial cells and separates them from the underlying connective tissue. However, it is not the primary site of infection in SARS-CoV-2-related ARDS. Layer D (Option C) represents epithelium that lines the airways and plays a key role in the respiratory system's defence mechanisms. However, it is not the primary target in SARS-CoV-2-related ARDS, where the main pathological changes occur in the endothelium.

References:

Endothelial dysfunction in COVID-19: an overview of evidence, biomarkers, mechanisms and potential therapies | Acta Pharmacologica Sinica .

↑ *Back to this question in Part A*

@Neet_pg_bot

Q9: A 45-year-old patient who has been working in a factory for the past 20 years presents with breathlessness. HRCT of the chest shows pleural thickening and fibrosis.

What is the person suffering from? (Q857611)

A. Asbestosis

B. Coal worker pneumoconiosis

C. Silicosis

D. Berylliosis

Correct Answer: A. Asbestosis

Explanation: The patient's history of working in a factory for a prolonged period, along with the HRCT chest findings of pleural thickening and fibrosis, points towards the diagnosis of Asbestosis , a lung disease caused by the inhalation of asbestos fibres commonly encountered in occupational settings. Prolonged exposure to asbestos can lead to the deposition of fibres in the lungs, triggering an inflammatory response that results in fibrosis and scarring of lung tissue, including the pleura. Occupational Lung Disease Associated Agents Features Diagnostic Tools Preventive Measures Asbestosis (Option A) Asbestos fibers Characterised by progressive pulmonary fibrosis. Symptoms include dyspnea, non-productive cough, and chest pain. Often associated with pleural plaques and increased risk of mesothelioma and lung cancer. HRCT, pulmonary function tests, occupational history Use of protective gear, proper ventilation, asbestos abatement programs Silicosis (Option C ruled out) Crystalline silica (quartz dust) Presents with nodular pulmonary fibrosis, primarily in the upper lobes. Increased risk of TB and other respiratory infections. Chronic exposure can lead to progressive massive fibrosis. Chest X-ray, HRCT, occupational history Dust control measures, respirators, regular health check-ups Coal Worker's Pneumoconiosis (CWP) (Option B ruled out) Coal dust Also known as "black lung disease." Features similar to silicosis but usually affect the upper lungs with coal dust deposition and fibrosis, without the silicotic nodules. Chest X-ray, HRCT, pulmonary function tests Dust control, respiratory protective equipment, regular monitoring Byssinosis Cotton, flax, hemp dust "Monday fever" describes worsening symptoms at the beginning of the workweek. Symptoms include chest tightness and wheezing, predominantly in textile workers. Clinical evaluation, occupational history Improved ventilation, dust suppression, health education Berylliosis (Option D ruled out) Beryllium and its compounds Acute or chronic lung disease caused by beryllium. Chronic form mimics sarcoidosis with systemic symptoms and granulomatous inflammation. Lung biopsy, beryllium lymphocyte proliferation test (BeLPT), imaging Limiting exposure, personal protective equipment, medical surveillance Farmer's Lung Moldy hay, crops, and compost dust A type of hypersensitivity pneumonitis caused by inhaling organic dust, presenting with malaise, cough, and breathlessness that may become chronic. HRCT, pulmonary function tests, specific IgG testing for antigens Respiratory protective equipment, proper storage of agricultural products

References:

Robbins & Cotran Pathologic Basis of Disease, 10th Edition, Pages 687 to 692.

↑ *Back to this question in Part A*

@Neet_pg_bot

Q10: A 12-year-old child presents with a persistent cough for 15 days. Upon examination, cervical lymphadenopathy is observed. A lymph node biopsy image is given below. What is the most likely diagnosis? (Q857586)

A. Tuberculosis

B. Leprosy

C. Sarcoidosis

D. Syphilis

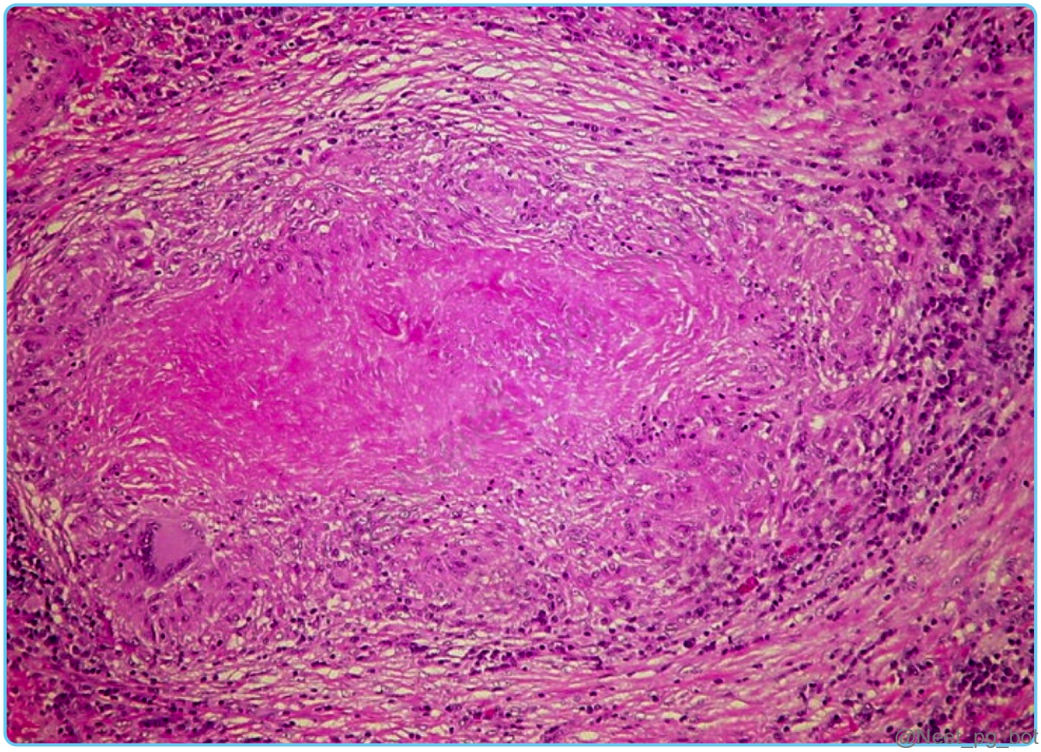

Correct Answer: A. Tuberculosis

Explanation: The clinical presentation and caseating granulomas (central necrosis surrounded by epithelioid macrophages and lymphocytes) in the biopsy strongly suggest Tuberculosis. {{caption_text}} Type of Granuloma Examples Caseating Granuloma Tuberculosis, Histoplasmosis, Coccidioidomycosis, Syphilis Non-caseating Granuloma Sarcoidosis , Crohn’s disease, Leprosy Foreign Body Granuloma Silicosis, Asbestos-related diseases, Foreign body reactions Immune Granuloma Wegener’s granulomatosis, Giant cell arteritis Durck’s Granuloma Cerebral malaria Stellate Granuloma Cat scratch disease Causes of granuloma formation Infectious causes Non-infectious causes TB (Caseating and non-caseating granuloma) Leprosy Syphilis Malaria (Durck granuloma) Cat-scratch disease and Lymphogranuloma venerum (Stellate granuloma) Q fever (Doughnut granuloma/ Fibrin ring granuloma) Sarcoidosis (Naked granuloma) Giant cell arteritis Crohn’s disease Churg-Strauss syndrome (Eosinophilic granuloma) Berylliosis (Foreign body granuloma)

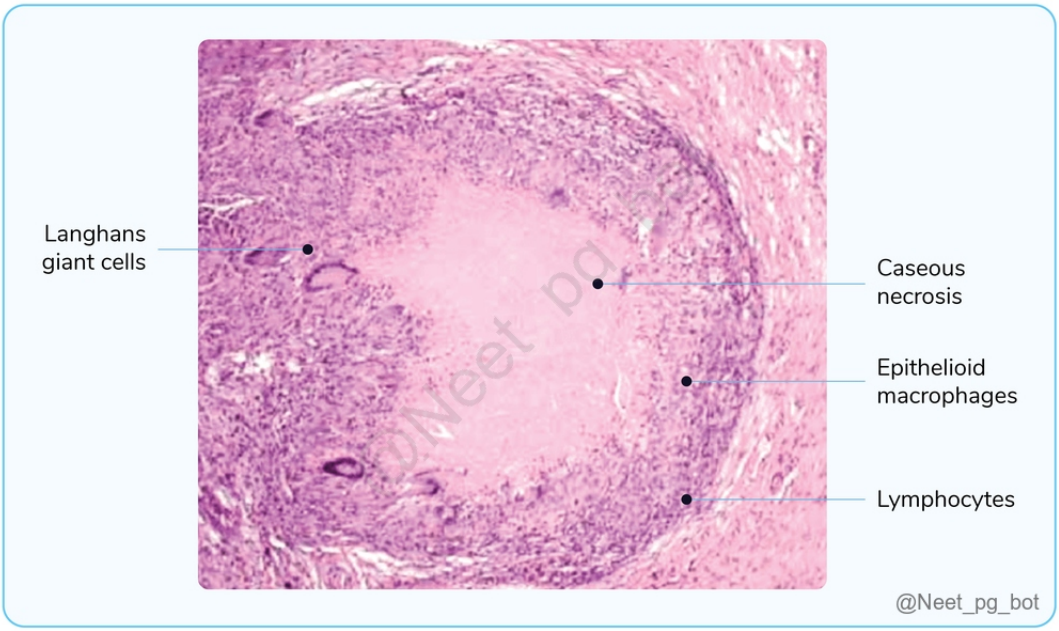

References:

Robbins & Cotran Pathologic Basis of Disease, 10th Edition, Page 101

↑ *Back to this question in Part A*

@Neet_pg_bot

Q11: A middle-aged man working in the sandblasting industry developed hemoptysis and a productive cough. A chest x-ray is suggestive of tuberculosis. Which of the following is associated with the same? (Q857109)

A. Asbestosis

B. Silicosis

C. Anthracosis

D. Siderosis

Correct Answer: B. Silicosis

Explanation: Silicosis is a type of pneumoconiosis caused by inhalation of crystalline silica dust, which is commonly found in industries like sandblasting. It is associated with a higher risk of developing tuberculosis due to the impairment of the immune response in the lung Silicosis: It is the most prevalent occupational lung disease in the world. Cause: Inhalation of proinflammatory crystalline silicon dioxide (silica). After decades of exposure, it usually presents as slowly progressing, nodular, fibrosing pneumoconiosis. Occupations at risk: Foundry work.

Sandblasting. Hard rock mining. Stone cutting. Jewellers using chalk moulds. Pathogenesis: Phagocytosis of inhaled silica crystals by macrophages activates the inflammasome and stimulates the release of inflammatory mediators, particularly IL-1 and IL-18. This, in turn, recruits additional inflammatory cells and activates interstitial fibroblasts, leading to collagen deposition. Forms of silica: Amorphous. Crystalline (quartz, cristobalite, and tridymite)- more fibrogenic. Forms of silicosis: Acute Heavy exposure in closed spaces Associated with Silico-tuberculosis and Secondary pulmonary alveolar proteinosis (SPAP) Can present within 2 years. Chronic (simple): Long-term (10-30 years) less intense exposure. Chronic Complicated: Chronic cough and progressive dyspnea on exertion. Morphology: Discrete nodules in hilar nodes and upper zones of lungs. Hard collagenous scars. Fibrotic lesions in nodes and pleura (pleural thickening). Eggshell calcification (thin sheets of calcification in lymph nodes; calcium surrounding a zone lacking calcification). Progressive massive fibrosis (1-10 cm). Lung cancer (2-fold risk). Increased susceptibility to tuberculosis infection. Histological hallmark: Central collagen with a peripheral zone of dust-laden macrophages. Polarized microscopy: Weakly birefringent silicate particles. CT scan: Crazy pavement pattern and interstitial fibrosis. {{caption_text}} {{caption_text}} Asbestosis (Option A) is caused by inhaling asbestos fibres, primarily leading to lung fibrosis and increasing the risk of lung cancer and mesothelioma. However, it is not directly linked to an increased risk of tuberculosis. {{caption_text}} Anthracosis (Option C) , or "coal miner’s lung," results from inhaling coal dust. It can cause chronic bronchitis or emphysema but does not have a direct association with tuberculosis. {{caption_text}} Siderosis (Option D) is caused by inhaling iron oxide dust, typically seen in occupations like welding. It can lead to pulmonary fibrosis but does not significantly increase the risk of tuberculosis. {{caption_text}}

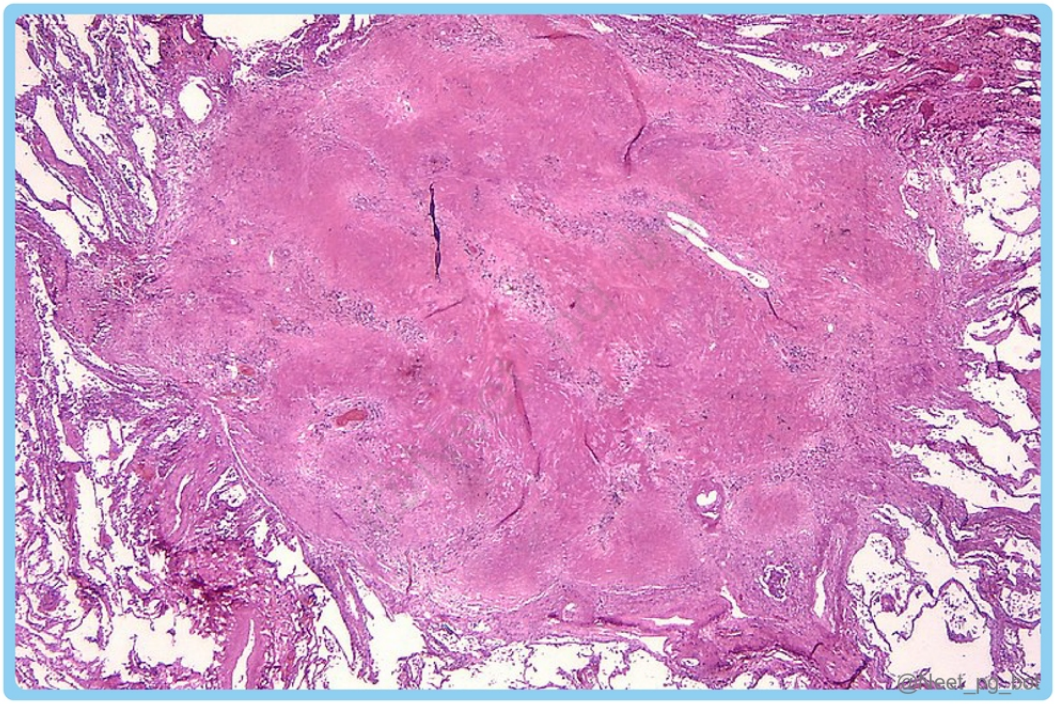

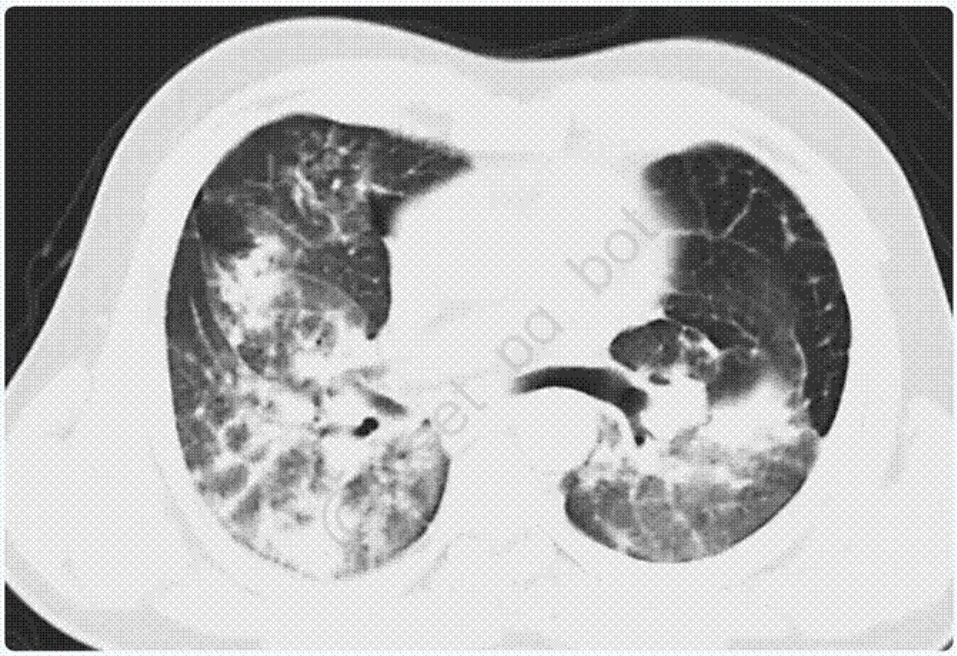

CT in a case of accelerated silicosis : Bilateral nodules, interstitial fibrosis and crazy pavement pattern

@Neet_pg_bot

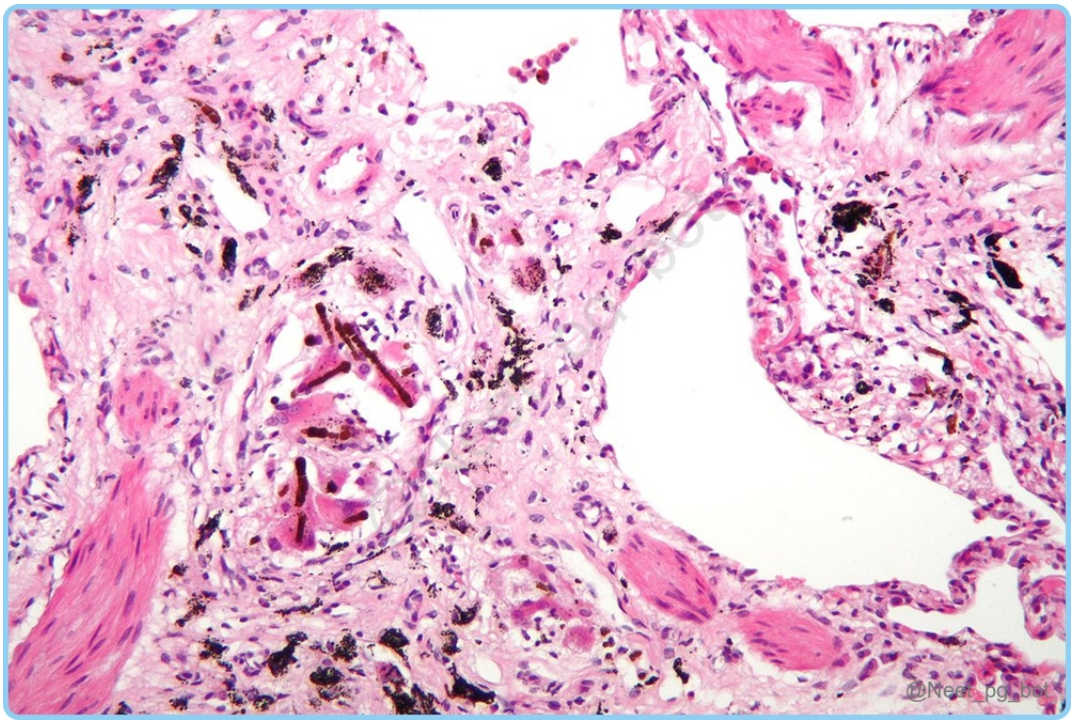

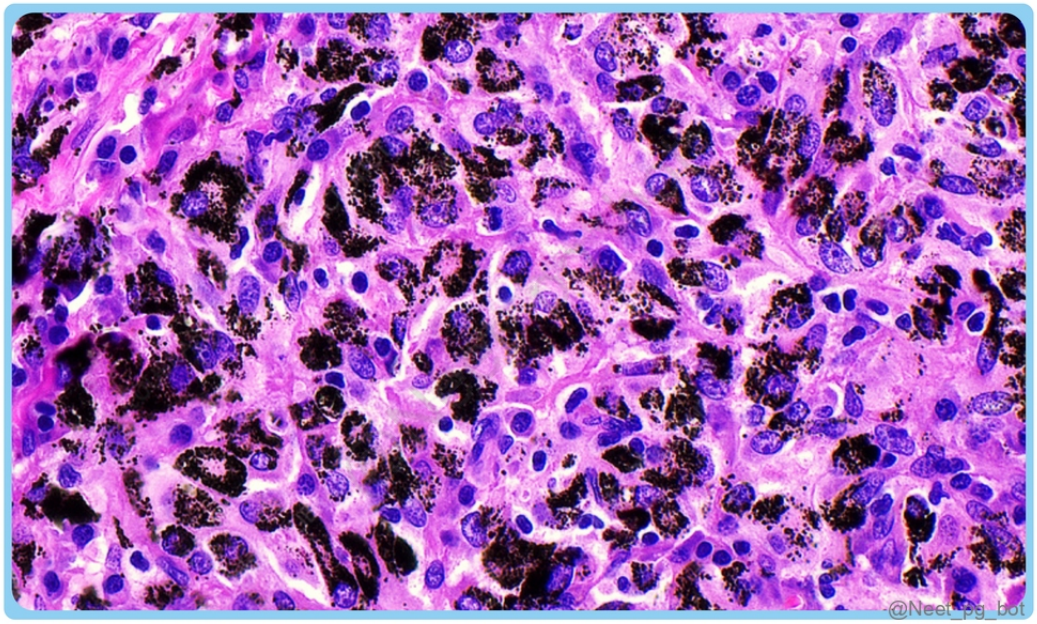

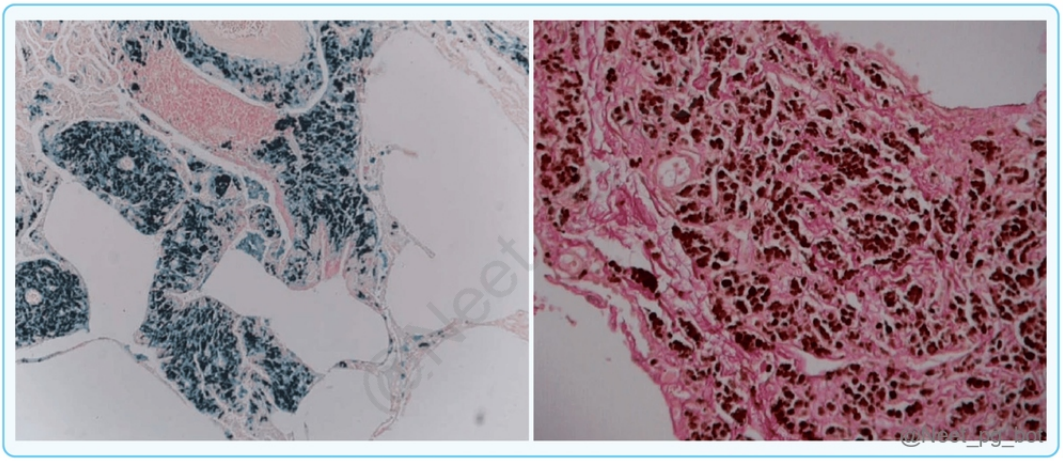

References:

Robbins & Cotran Pathologic Basis of Disease, 10th Edition, Page 691

Eggshell calcification (lymph nodes) | Radiology Reference Article | Radiopaedia.org

↑ *Back to this question in Part A*

@Neet_pg_bot

Q12: What is the diagnosis for a patient with a history of smoking 24 packs, currently experiencing breathlessness and chest pain, and found to have a lung tumour with positive chromogranin staining? (Q855092)

A. Adenocarcinoma

B. Squamous cell carcinoma

C. Mesothelioma

D. Small cell carcinoma

Correct Answer: D. Small cell carcinoma

Explanation: The patient's clinical presentation and positive staining for neuroendocrine markers such as Chromogranin and synaptophysin are highly suggestive of Small-cell lung cancer (SCLC) originating from neuroendocrine cells. It is a highly malignant form of lung cancer associated with smoking and is known for its aggressive behaviour and early metastasis. The genetic landscape of SCLC typically involves the inactivation of TP53 and RB genes. L-MYC amplification is a common feature in some SCLC cases, contributing to the tumour's rapid growth and aggressive nature. Characteristic Small Cell Carcinoma Squamous Cell Carcinoma (Option B) Carcinoid Tumor Adenocarcinoma (Option A) Origin Neuroendocrine cells of the lung. Squamous cells of the lung. Neuroendocrine cells of bronchial epithelium. Glandular cells of the lung. Cells in histopathology Small, round to oval, blue cells with scant cytoplasm and finely granular chromatin with a “salt and pepper” appearance. Sheets of polygonal cells with keratinization and intercellular bridges Nesting (organoid) growth pattern with uniform round nuclei, moderate eosinophilic cytoplasm , and a “ salt-and-pepper” chromatin pattern. Glandular or epithelial cells forming acinar, papillary, or solid patterns Mitotic rate High Variable Low to moderate Variable Electron microscopy findings Dense core neurosecretory granules. Desmosomes, tonofilaments, keratinisation Dense core neurosecretory granules. Variable organelles, sometimes containing mucin vacuoles IHC markers Positive for neuroendocrine markers (e.g., chromogranin, synaptophysin). P63, p40 , CK5/6 Positive for neuroendocrine markers (e.g., chromogranin, synaptophysin) Variable (e.g., TTF-1, Napsin A for primary lung adenocarcinoma) {{caption_text}} {{caption_text}} {{caption_text}} {{caption_text}} Mesothelioma (Option C) is a cancer associated with asbestos exposure, not typically associated with smoking. Additionally, it does not usually show chromogranin positivity. It usually arises from the pleura and presents with different symptoms, such as pleuritic chest pain and shortness of breath.

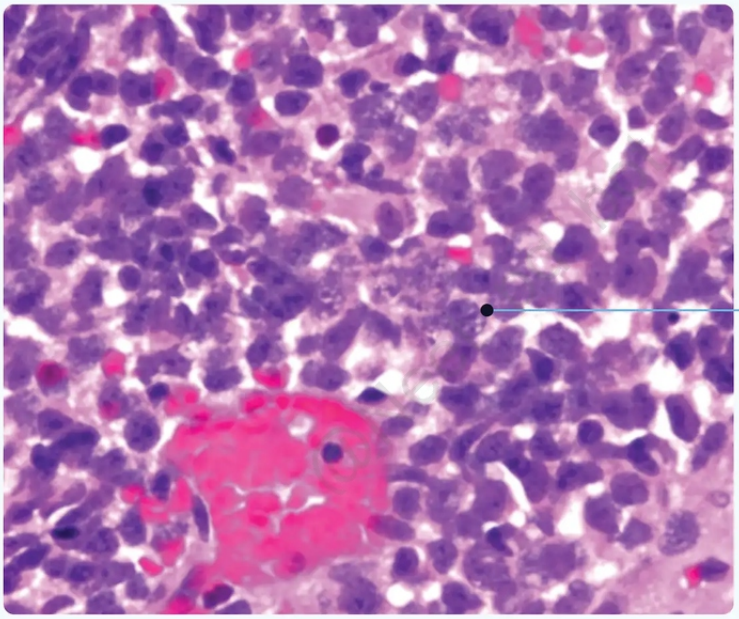

@Neet_pg_bot

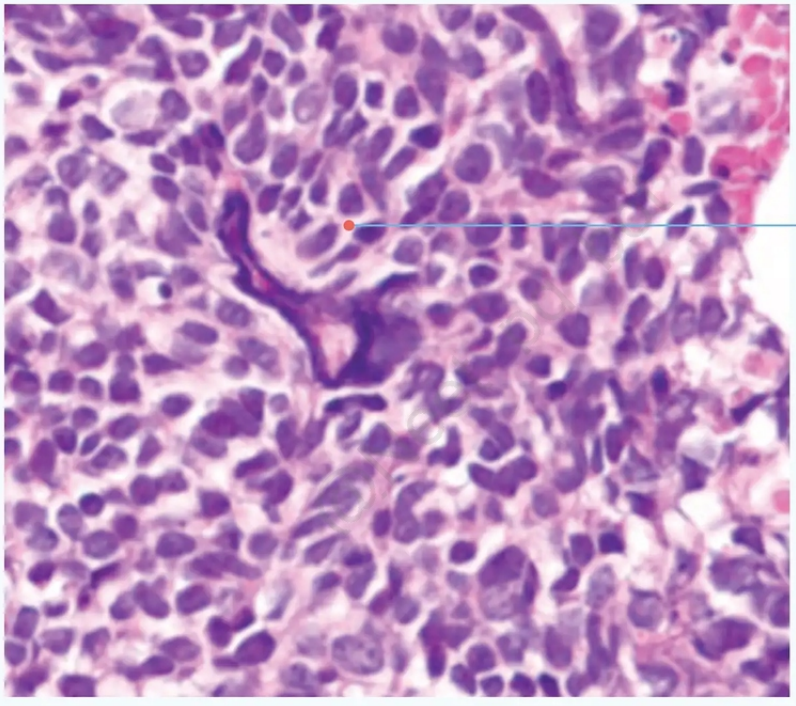

@Neet_pg_bot

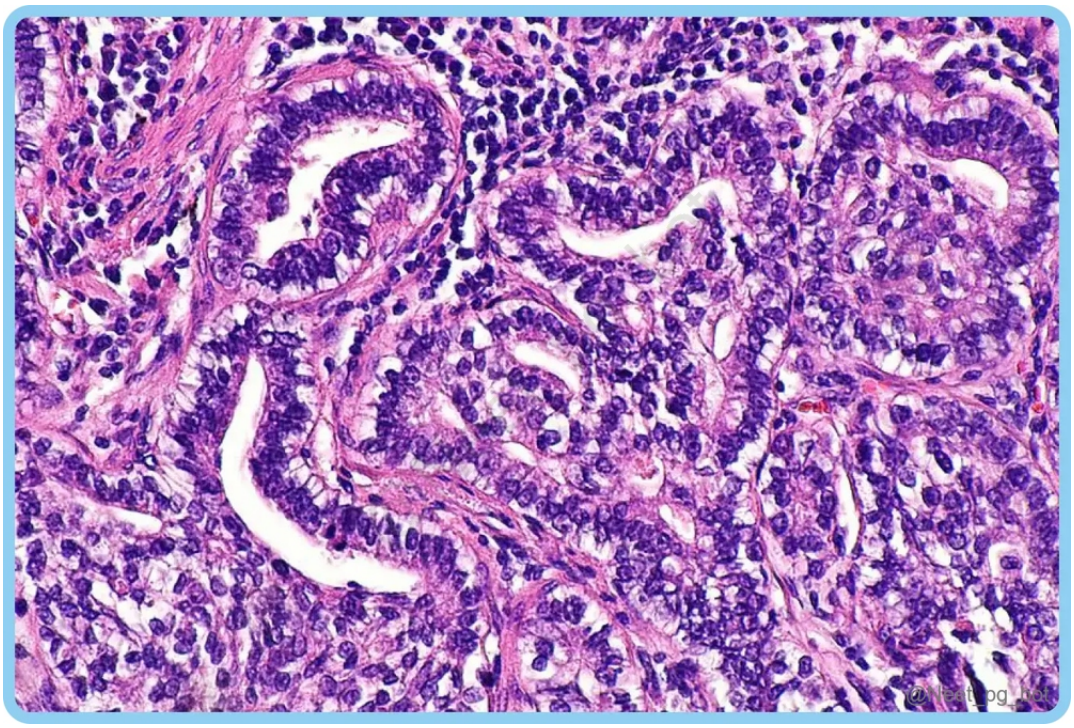

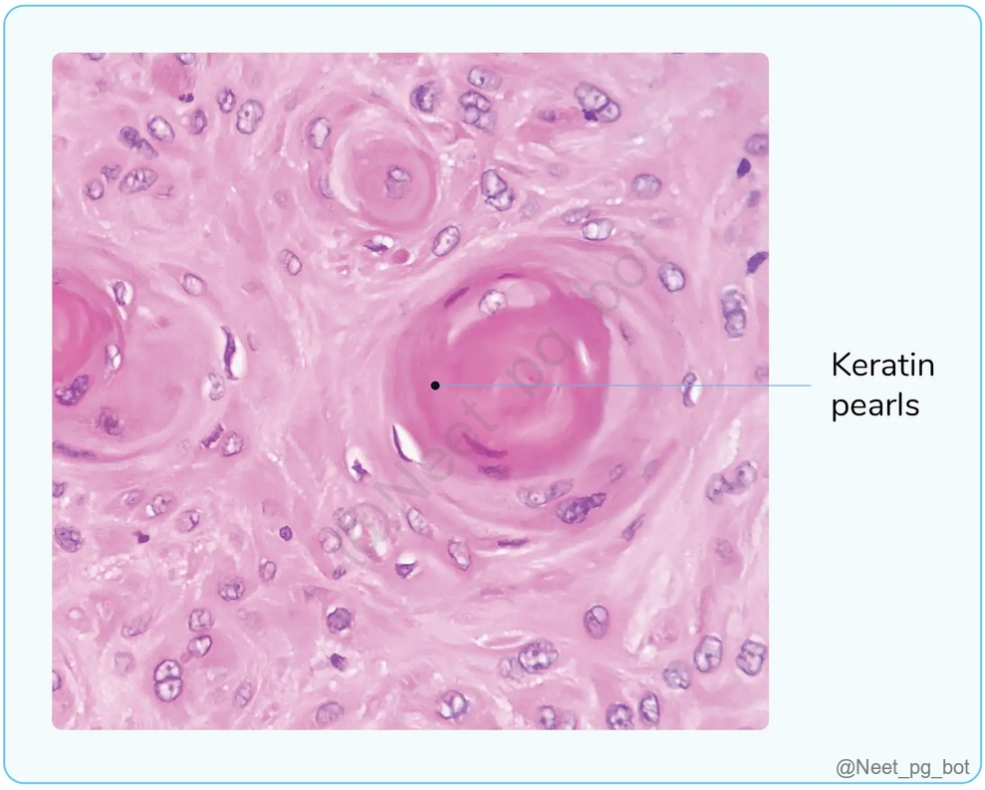

References:

Robbins & Cotran Pathologic Basis of Disease, 10th Edition, Page 717

↑ *Back to this question in Part A*

Q13: A chronic smoker who worked in a cement factory for the past 20 years developed mesothelioma. This association is most likely due to? (Q866738)

A. Bagassosis

B. Silicosis

C. Asbestosis

D. Adenocarcinoma

Correct Answer: C. Asbestosis

Explanation: Mesothelioma is a malignant tumour of the pleura (and sometimes peritoneum or pericardium) that is strongly associated with asbestos exposure. Asbestos fibres are commonly encountered in: Shipbuilding Construction Cement manufacturing Insulation materials Chronic inhalation of asbestos fibres → fibres lodge in pleura → chronic inflammation & fibrosis → mutations → mesothelioma (and also increased risk of bronchogenic carcinoma, especially in smokers). Asbestos exposure is a well-established risk factor for developing laryngeal, ovarian, colon, lung, and pleural cancers. Asbestos-related lung carcinoma is markedly magnified by smoking. Thus, asbestos workers (particularly those who smoke) are at much higher risk of dying of lung carcinoma than mesothelioma. Compared to other occupational lung diseases, which affect the upper lobes of the lungs, it commonly affects the lower lobes. Adenocarcinoma (primary bronchogenic carcinoma) is the most common type of cancer, accounting for about 45%, followed by squamous cell carcinoma. Lung mesothelioma is a more specific tumour associated with asbestos exposure but is less prevalent than Adenocarcinoma.

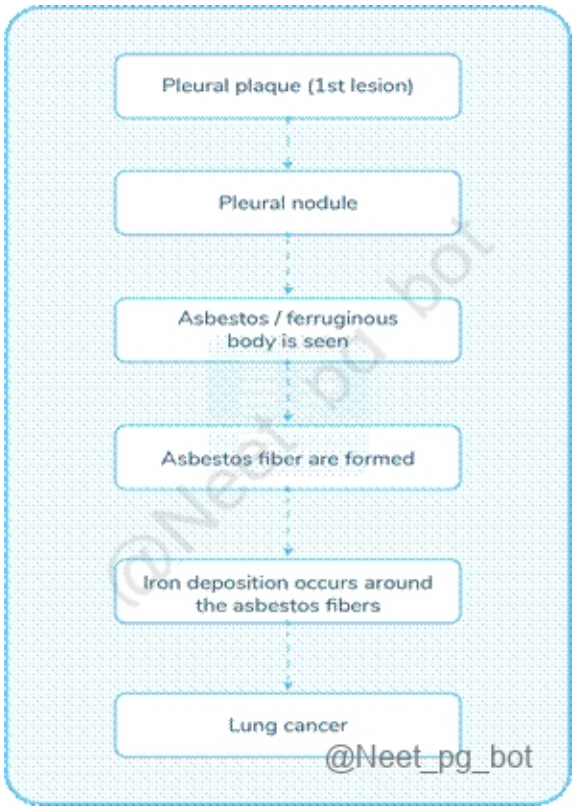

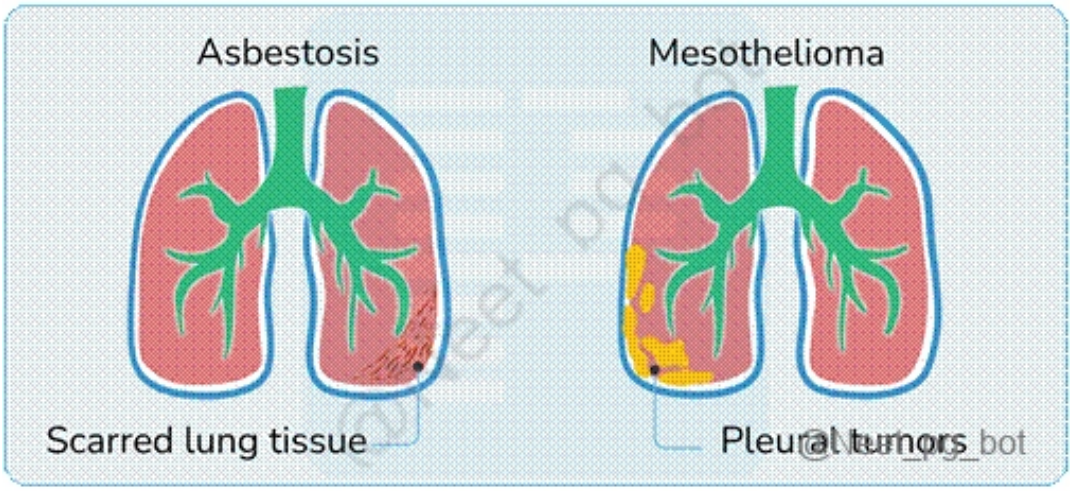

References:

.

↑ *Back to this question in Part A*

@Neet_pg_bot

Q14: An elderly male smoker presents with a chronic cough, significant weight loss, and fatigue. The serum calcium level is raised. A lung biopsy reveals large atypical cells with hyperchromasia. What is the probable diagnosis? (Q855423)

A. Large cell neuroendocrine tumour

B. Small cell carcinoma

C. Adenocarcinoma

D. Squamous cell carcinoma

Correct Answer: D. Squamous cell carcinoma

Explanation: An elderly male smoker with chronic cough, weight loss, fatigue, and elevated serum calcium likely has squamous cell carcinoma of the lung. This cancer is associated with paraneoplastic hypercalcemia due to PTHrP secretion . The biopsy showing large atypical cells with hyperchromasia supports this diagnosis. Smoking significantly increases the risk of squamous cell carcinoma of the lung as it has a strong association, resulting in chromosomal deletions involving tumour suppressor loci involving 3p,9p and 17p. Squamous cell carcinoma: Squamous Cell Carcinoma is typically found in the central regions of the lungs (Not peripheral) , often originating in the major bronchi near the hilum. It can cause symptoms by obstructing airways. Histopathologically, it is characterised by keratin pearls, intercellular bridges , and nests of malignant squamous cells with abundant eosinophilic cytoplasm. {{caption_text}} Location of lung carcinomas: Central: Squamous cell carcinoma, Small cell carcinoma, and Bronchial carcinoids. Peripheral: Adenocarcinoma and Large-cell carcinoma. Type of Lung Carcinoma Paraneoplastic Syndrome Squamous cell carcinoma Hypercalcemia Adenocarcinoma Migratory thrombophlebitis (Trousseau syndrome) Small cell or oat cell Carcinoma SIADH (syndrome of inappropriate anti-diuretic hormone secretion) Cushing's syndrome Lambert Eaton syndrome Large cell carcinoma Gynaecomastia Characteristic Small Cell Carcinoma (Option B) Squamous Cell Carcinoma (Option D) Carcinoid Tumor (Option A) Adenocarcinoma (Option C) Origin Neuroendocrine cells of the lung. Squamous cells of the lung. Neuroendocrine cells of bronchial epithelium. Glandular cells of the lung. Cells in histopathology Small, round to oval, blue cells with scant cytoplasm and finely granular chromatin with a “salt and pepper” appearance. {{caption_text}} Sheets of polygonal cells with keratinisation and intercellular bridges {{caption_text}} Nesting (organoid) growth pattern with uniform round nuclei, moderate eosinophilic cytoplasm , and a “ salt-and-pepper” chromatin pattern. {{caption_text}} Glandular or epithelial cells forming acinar, papillary, or solid patterns {{caption_text}} Mitotic rate High Variable Low to moderate Variable Electron microscopy findings Dense core neurosecretory granules. Desmosomes, tonofilaments, keratinisation Dense core neurosecretory granules. Variable organelles, sometimes containing mucin vacuoles IHC markers Positive for neuroendocrine markers (e.g., chromogranin, synaptophysin). P63, p40 , CK5/6 Positive for neuroendocrine markers (e.g., chromogranin, synaptophysin) Variable (e.g., TTF-1, Napsin A for primary lung adenocarcinoma)

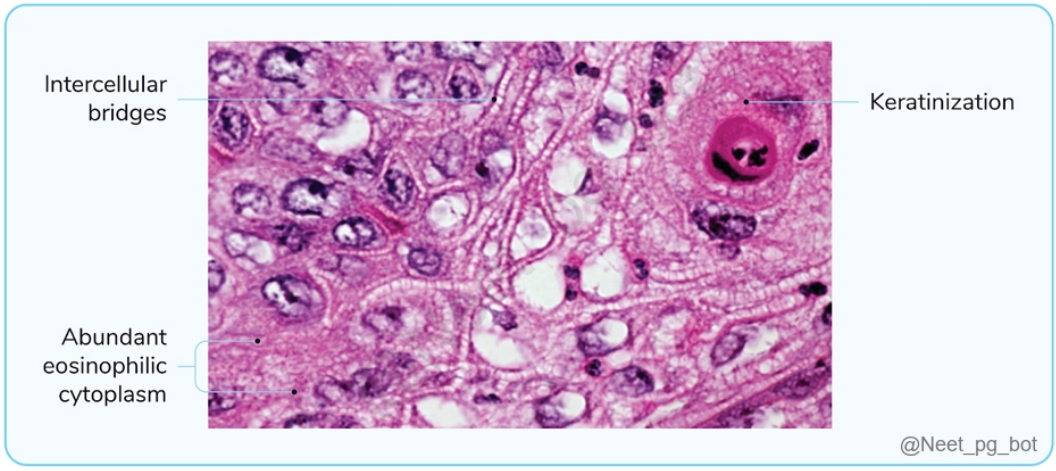
Intercellular bridges
Keratinization
Abundant eosinophilic cytoplasm
@Neet_pg_bot

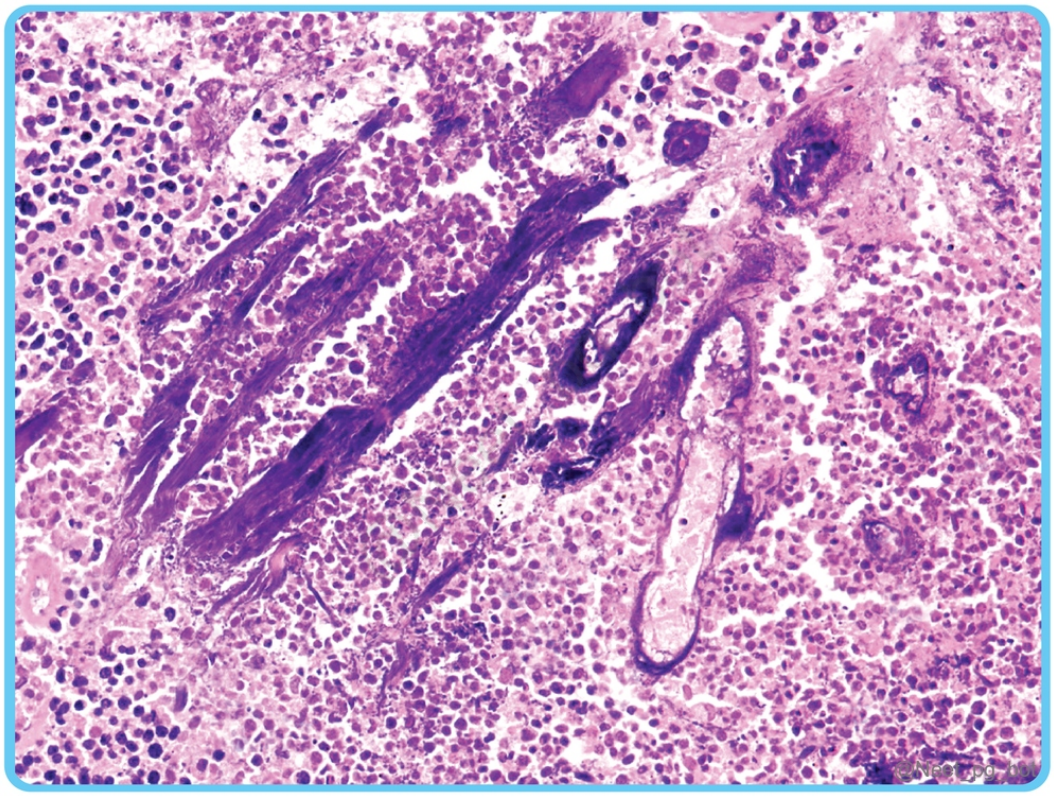

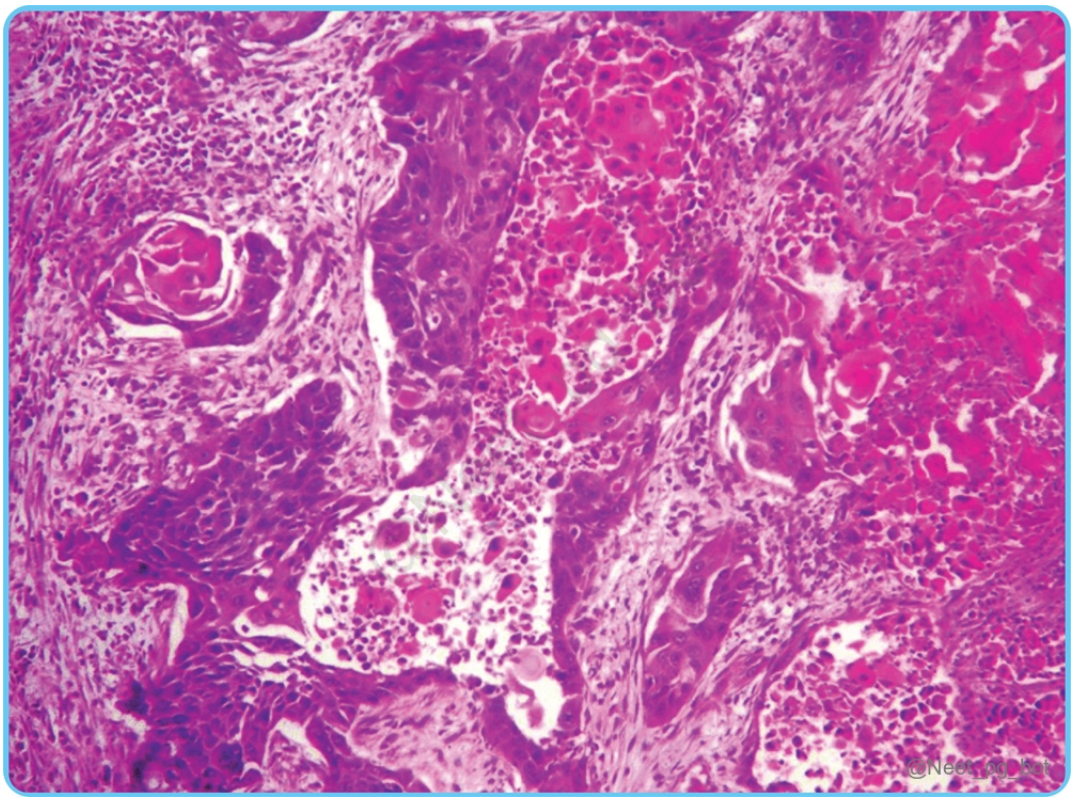

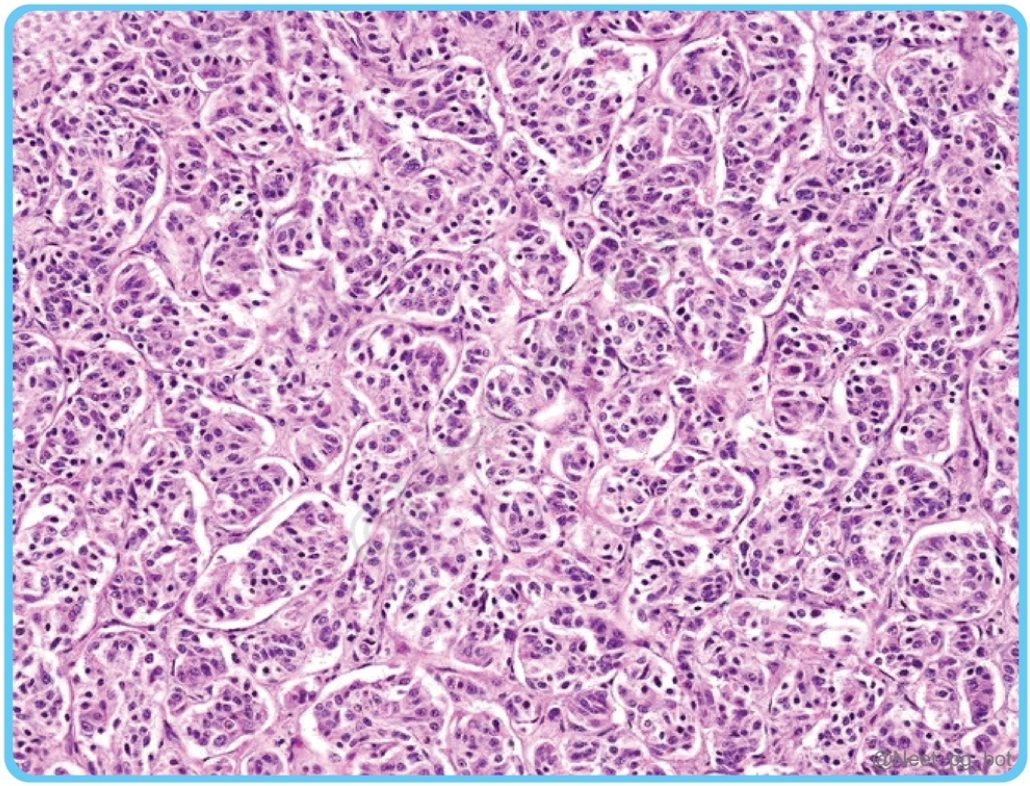

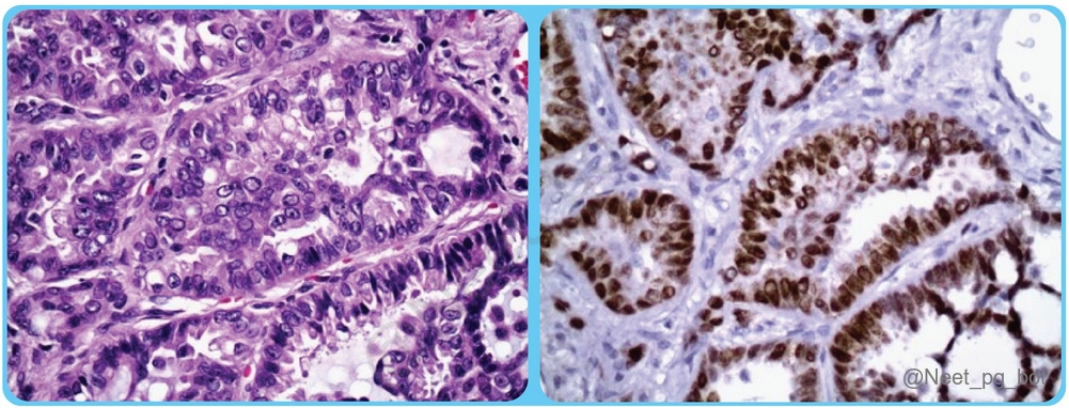

References:

Robbins and Cotran Pathologic Basis of Disease, 10th Edition, Page 717 - 724

↑ *Back to this question in Part A*

@Neet_pg_bot

Q15: A 30-year-old patient arrives at the emergency room with complaints of respiratory discomfort. The patient has been experiencing shortness of breath, coughing, and chest pain for the past few weeks. The patient's medical history is unremarkable, and there is no significant smoking history. Upon further investigation, a lung biopsy is performed, and microscopic examination reveals the presence of asteroid bodies. What is the most likely diagnosis for this patient? (Q820569)

A. Sarcoidosis

B. RA

C. Sjogren syndrome

D. SLE

Correct Answer: A. Sarcoidosis

Explanation: Correct Option A - Sarcoidosis: The patient's presentation with shortness of breath, coughing, and chest pain for the past few weeks with lung biopsy performed and microscopic examination revealing the presence of asteroid bodies is suggestive of sarcoidosis. Asteroid bodies are star-shaped inclusions seen within giant cells in granulomas and are a hallmark of sarcoidosis. Incorrect Options: Options B, C, and D are incorrect.

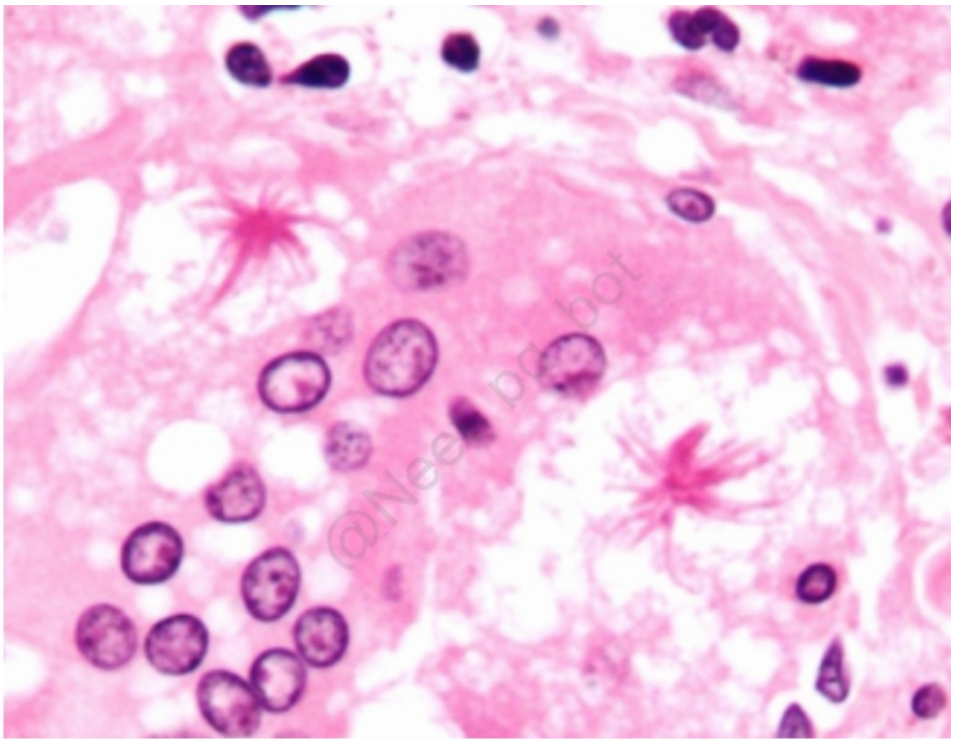

Asteroid bodies in Multinucleated giant cell

References:

.

↑ *Back to this question in Part A*

@Neet_pg_bot

Q16: Match the following: A. Caplan's syndrome 1. Found first in coal worker B. Asbestosis 2. Crazy pavement C. Mesothelioma 3. Involves lower lobe D. Silicosis 4. Pleural effusion (Q857428)

A. A-1, B-3, C-4, D-2

B. A-2, B-4, C-1, D-3

C. A-3, B-2, C-1, D-4

D. A-4, B-1, C-2, D-3

Correct Answer: A. A-1, B-3, C-4, D-2

Explanation: A. Caplan’s syndrome It is characterised by the formation of multiple well-defined pulmonary nodules, typically located in the lung periphery, in individuals with rheumatoid arthritis who have been exposed to inorganic dust. It is primarily associated with coal worker's pneumoconiosis but can also occur in other forms of pneumoconiosis. B. Asbestosis It primarily affects the lower lobes of the lungs and increases the risk of laryngeal, ovarian, colon, lung, and pleural cancers, with lung cancer risk significantly heightened in smokers. Asbestos-related lung carcinoma typically targets the lower lobes, unlike other occupational lung diseases that affect the upper lobes. C. Mesothelioma It is a rare cancer originating from mesothelial cells, most commonly affecting the pleura. CT scan typically shows pleural thickening, effusion, or frozen hemithorax. It can also involve the peritoneum, pericardium, and tunica vaginalis. D. Silicosis It is the most prevalent occupational lung disease and is caused by inhaling proinflammatory crystalline silica. After decades of exposure, it typically presents as slowly progressing, nodular, fibrosing pneumoconiosis. The CT scan shows a "crazy pavement" pattern and interstitial fibrosis.

References:

Robbins and Cotran Pathologic Basis of Disease, 10th Edition, Pages 691, 694,

Harrison’s Principles of Internal Medicine, 21st Edition, Page 2753

↑ *Back to this question in Part A*

@Neet_pg_bot

Q17: What is the most probable diagnosis based on the provided histopathology of the enlarged cervical lymph node? (Q840059)

A. Sarcoidosis

B. Tuberculosis

C. Histoplasmosis

D. Brucellosis

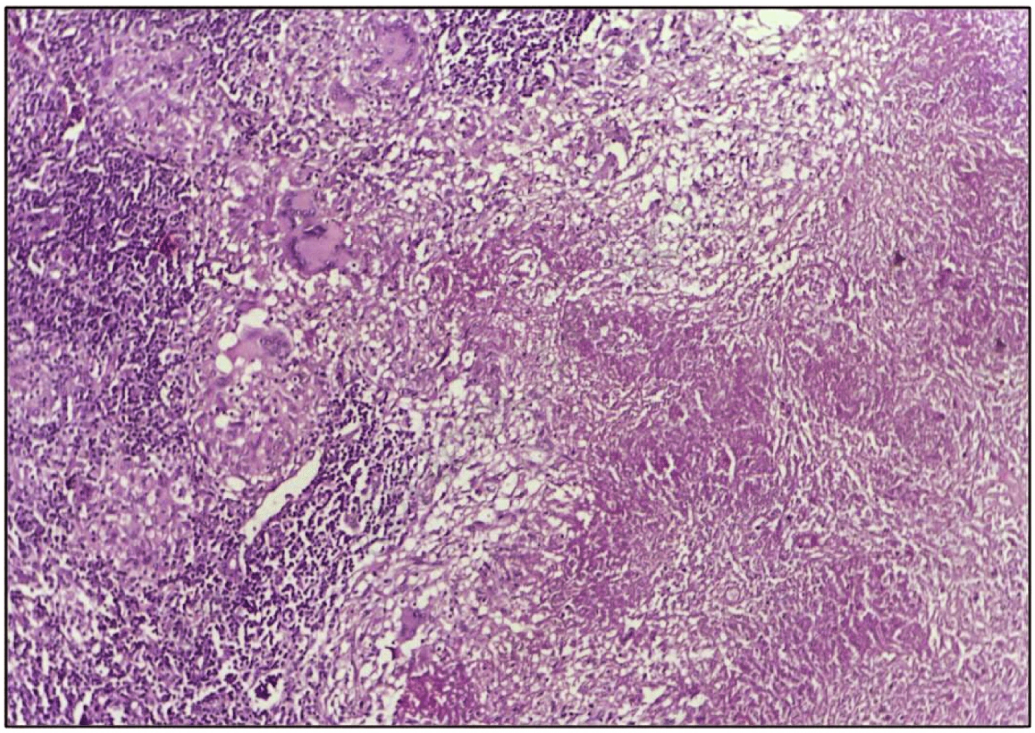

Correct Answer: B. Tuberculosis

Explanation: The given histopathological image shows signs of chronic granulomatous inflammation, along with areas of caseous necrosis (seen as pink-colored areas) and Langerhans giant cells. All these findings are suggestive of Tuberculosis. Incorrect Options: Sarcoidosis (Option A): Sarcoidosis typically presents with non-caseating granuloma or naked granuloma (lymphocytic collar absent). Histoplasmosis (Option C): Histoplasmosis shows the presence of small Histoplasma capsulatum yeasts. Brucellosis (Option D): Brucellosis does not show caseous necrosis and Langerhans giant cells.

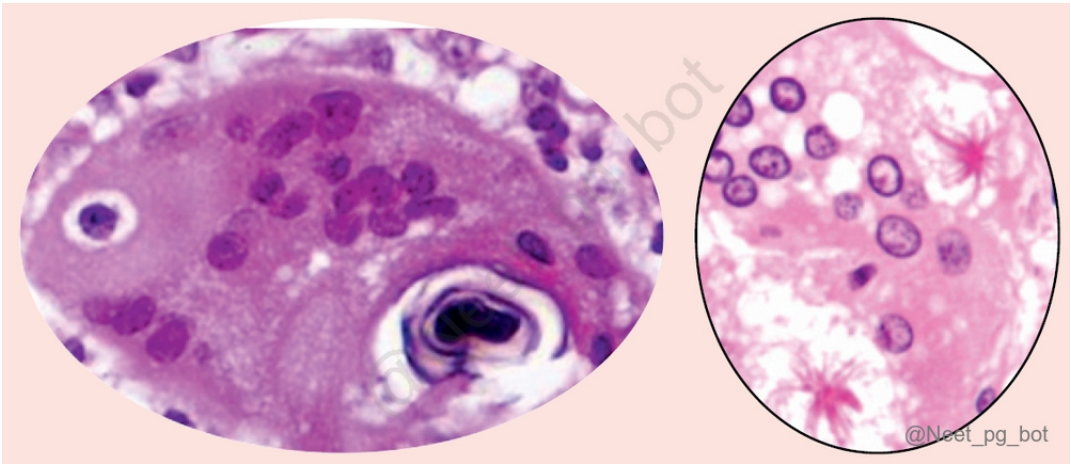

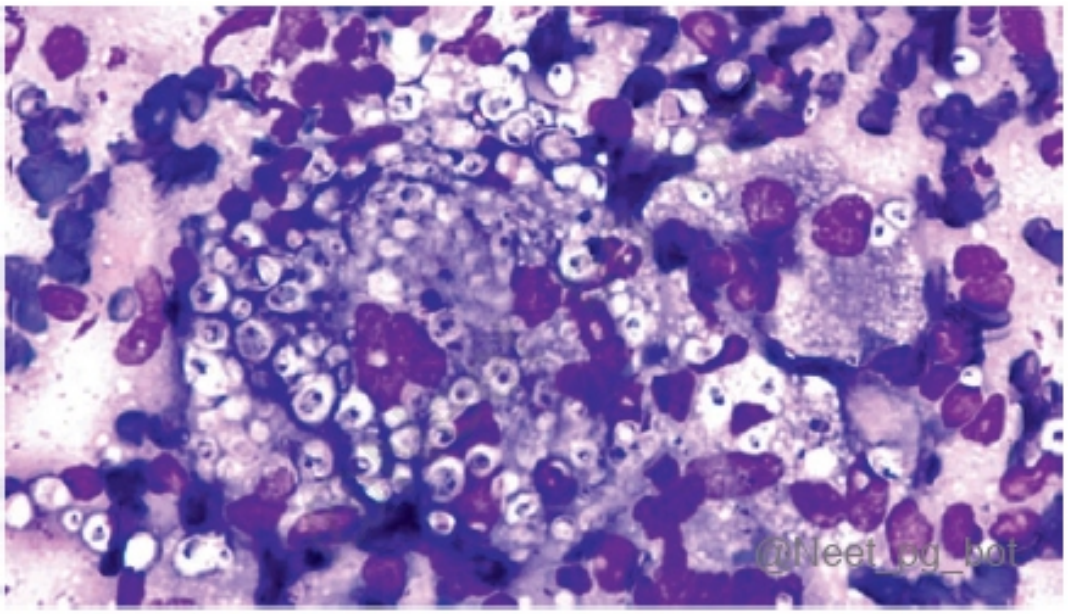

References:

.

↑ *Back to this question in Part A*

@Neet_pg_bot

Q18: Based on the biopsy image given below, what is the most probable diagnosis? (Q840057)

A. Adenocarcinoma

B. Squamous cell carcinoma

C. Small cell carcinoma

D. Large cell carcinoma

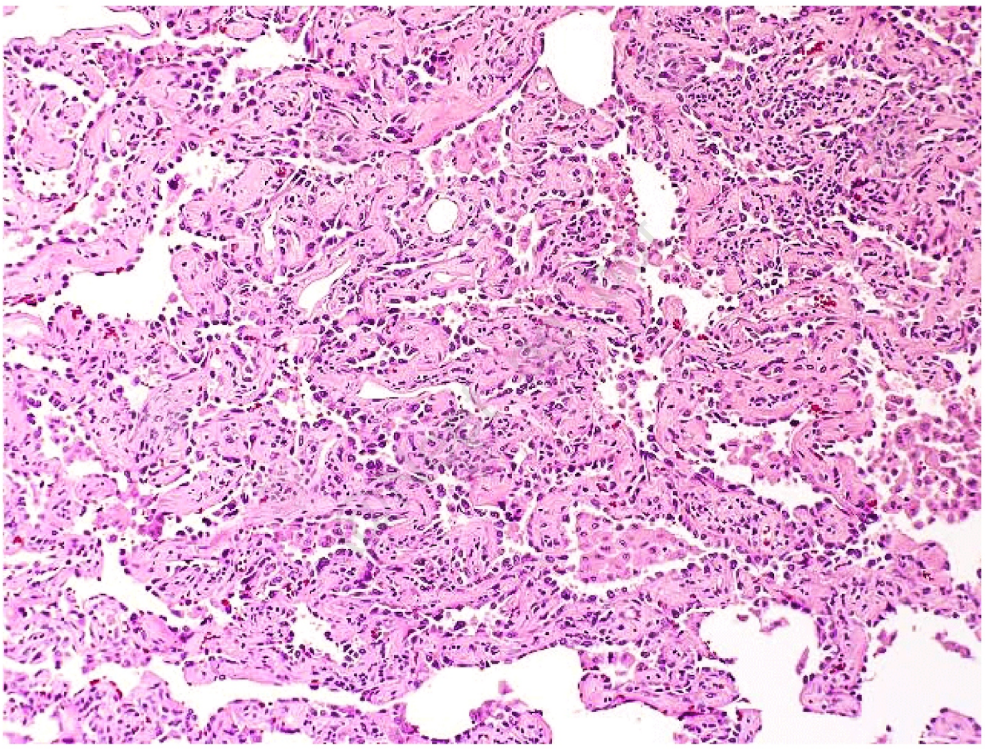

@Neet_pg_bot

Correct Answer: A. Adenocarcinoma

Explanation: Correct Option A – Adenocarcinoma : The presence of glands in the given histopatholgy image indicates adenocarcinoma of the lung. In adenocarcinoma of the lung, neoplastic epithelial cells proliferate in a glandular pattern, forming well-differentiated tumors characterized by distinct glandular structures. Incorrect Options: Option B - Squamous cell carcinoma: The absence of keratin pearls and desmosomes in the image indicates that it does not correspond to squamous cell carcinoma. Option C - Small cell carcinoma: The image does not exhibit the salt and pepper appearance of chromatin or the Azzopardi Effect, features of small cell carcinoma. Option D - Large cell carcinoma: Large cell carcinoma is an undifferentiated tumor characterized by the presence of large nuclei.

References:

.

↑ *Back to this question in Part A*

@Neet_pg_bot

Q19: A 65-year-old patient on immunosuppressive therapy presents with a cough, fever, and pneumonia. A biopsy reveals the given findings. Which organism is responsible for the infection? (Q860561)

A. EBV

B. CMV

C. Pox virus

D. Chickenpox

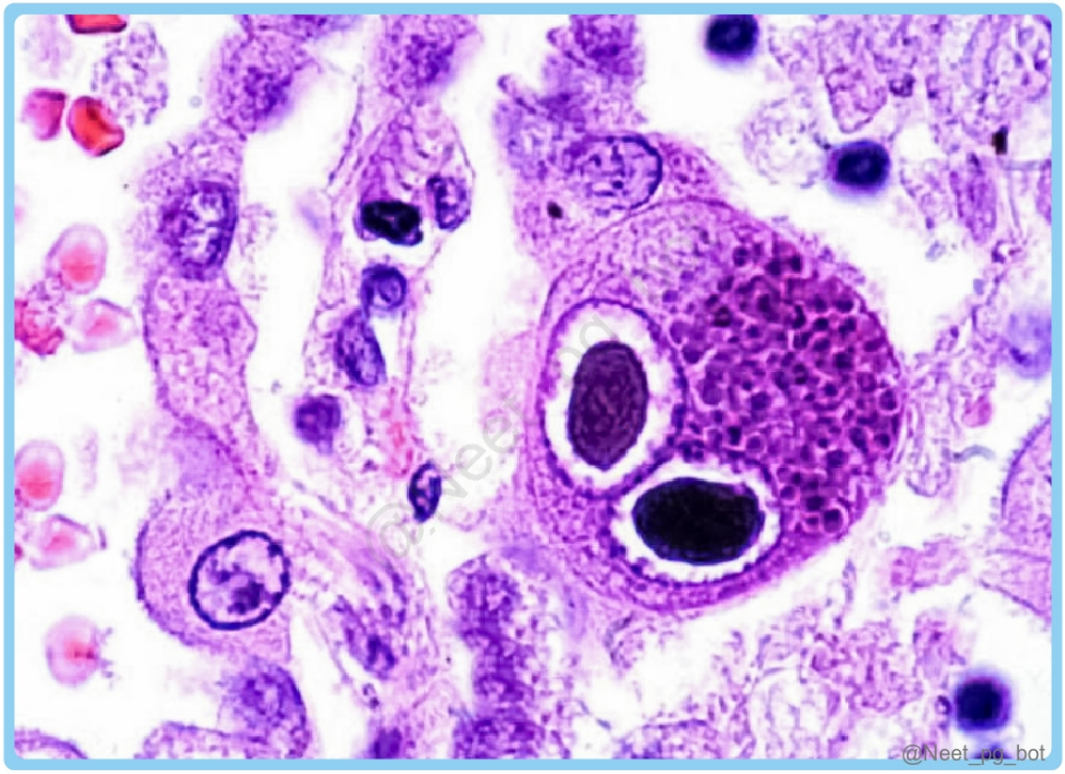

Correct Answer: B. CMV

Explanation: The patient's presentation with fever and breathlessness for 2 weeks and history of HIV with owl eye appearance in the image is suggestive of CMV (cytomegalovirus) pneumonia. CMV (cytomegalovirus) Class Betaherpesvirinae subfamily of the Herpesviridae family. Modes of transmission Oral route, respiratory & body secretions (most common) Vertical transmission Sexual transmission Organ transplantation Blood transfusion Host cells Salivary gland Kidney Clinical features Congenital infection Most common intrauterine infection with congenital defects. Common presentation: Petechiae Hepatosplenomegaly Jaundice Less common presentation: Microcephaly Cerebral calcifications Intrauterine growth retardation Prematurity Other defects: Sensorineural hearing loss. Perinatal infection Commonly asymptomatic. Occasionally, premature infants present with interstitial pneumonitis. Immunocompromised This is seen in AIDS, HIV, organ transplant patients and cancer patients undergoing chemotherapy. Presentations in AIDS and HIV CMV chorioretinitis Progressive dementia, Cranial nerve defects, Presentations in Organ transplant Bilateral interstitial pneumonia Febrile leukopenia Obliterative bronchiolitis Graft atherosclerosis Rejection of renal allografts. Immunocompetent Usually, it occurs following a blood transfusion. It presents similar to infectious mononucleosis, but heterophile antibody tests would be negative. Investigations Peripheral smear: Owl’s eye appearance of inclusion bodies. {{caption_text}} Virus isolation It is done by Human fibroblast cell line culture Shell vial culture Antigen detected: PP65 Antibody detection It is done by ELISA, and the antibodies detected are CMV IgM antibodies CMV IgG antibodies Against

PP150 and PP65, Against the PP52 PCR Used in detecting CMV DNA Quantitative nucleic acid testing (QNAT) by PCR is the most sensitive and specific testing. Treatment Ganciclovir (Drug of choice) Foscarnet (in Ganciclovir resistance) CMV immunoglobulins and Ganciclovir are given to bone marrow transplant patients. EBV (Epstein Barr virus) (Option A) primarily causes infectious mononucleosis, marked by fever, sore throat, swollen lymph nodes, and fatigue, and usually does not lead to pneumonia. Downey cells, or atypical lymphocytes, are large, vacuolated, and often display a ballerina skirt appearance. {{caption_text}} Pox virus (Option C) , like smallpox (eradicated) and molluscum contagiosum , causes skin lesions such as pustules or bumps. While they don't typically cause pneumonia, they can lead to systemic infections, especially in immunocompromised individuals. Chickenpox (Option D) , caused by varicella-zoster virus (VZV), leads to a rash of red spots and blisters. In immunocompromised patients, it can cause severe complications like varicella pneumonia, though less commonly than CMV or bacterial pneumonia, and may require antiviral treatment.

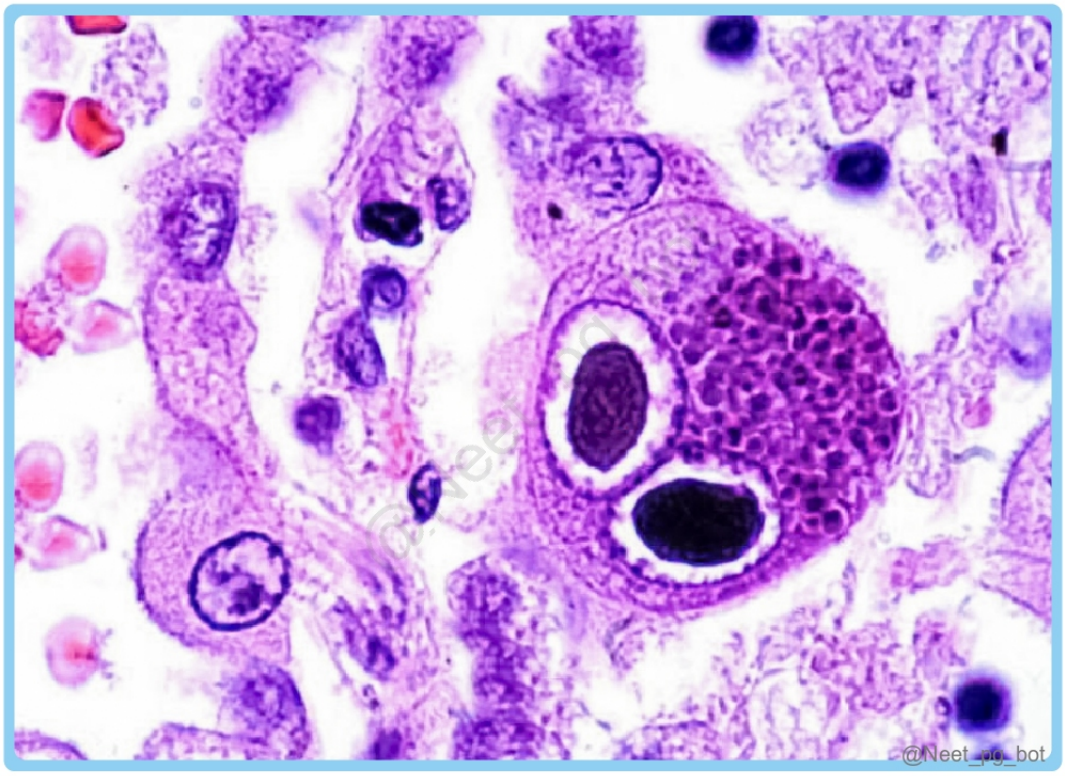

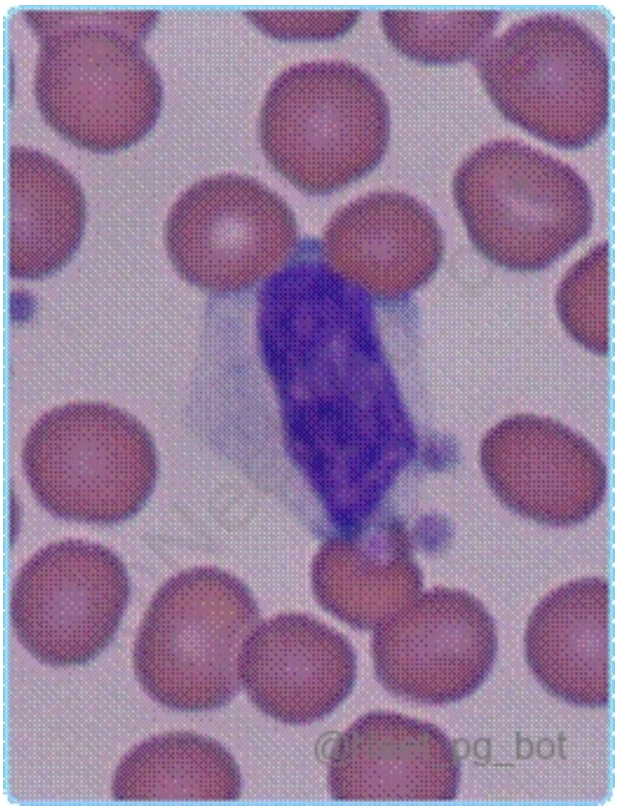

References:

Ananthanarayan and Paniker’s Textbook of Microbiology, 10th edition, Page 479, 480.

Apurba S Sastry’s Essentials of Medical Microbiology, 3rd edition, Page 795, 796, 797.

↑ *Back to this question in Part A*

@Neet_pg_bot

Q20: A patient presented with interstitial lung disease with an occupational history of working in a factory for 20 years and underwent a biopsy. Based on the findings, what is the most likely diagnosis? (Q844241)

A. Stanosis

B. Silicosis

C. Byssinosis

D. Asbestosis

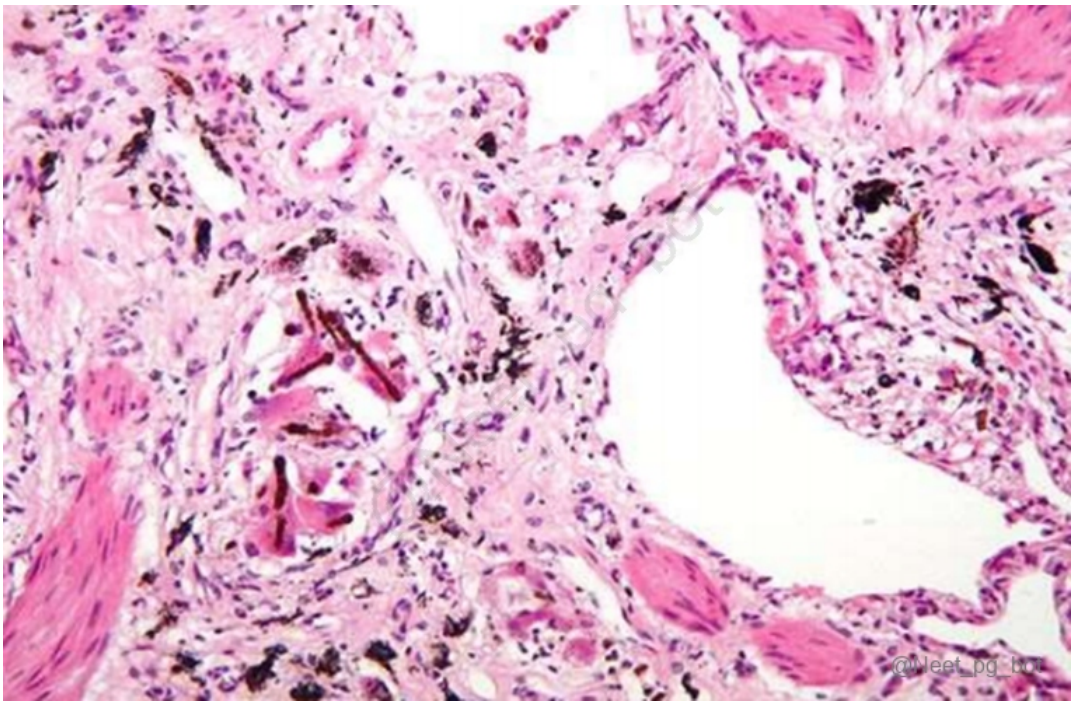

Correct Answer: D. Asbestosis

Explanation: Correct Option D – Asbestosis: The given image shows dumbbell-shaped asbestos bodies, which, along with the history, suggests asbestosis. Incorrect Options: Option A – Stanosis: Stanosis occurs due to tin/lead exposure. Option B – Silicosis: Silicosis will show silicon particles on polarizing microscopy. Option C – Byssinosis: Byssinosis occurs due to cotton dust/organic dust exposure, which is not mentioned in the patient's history.

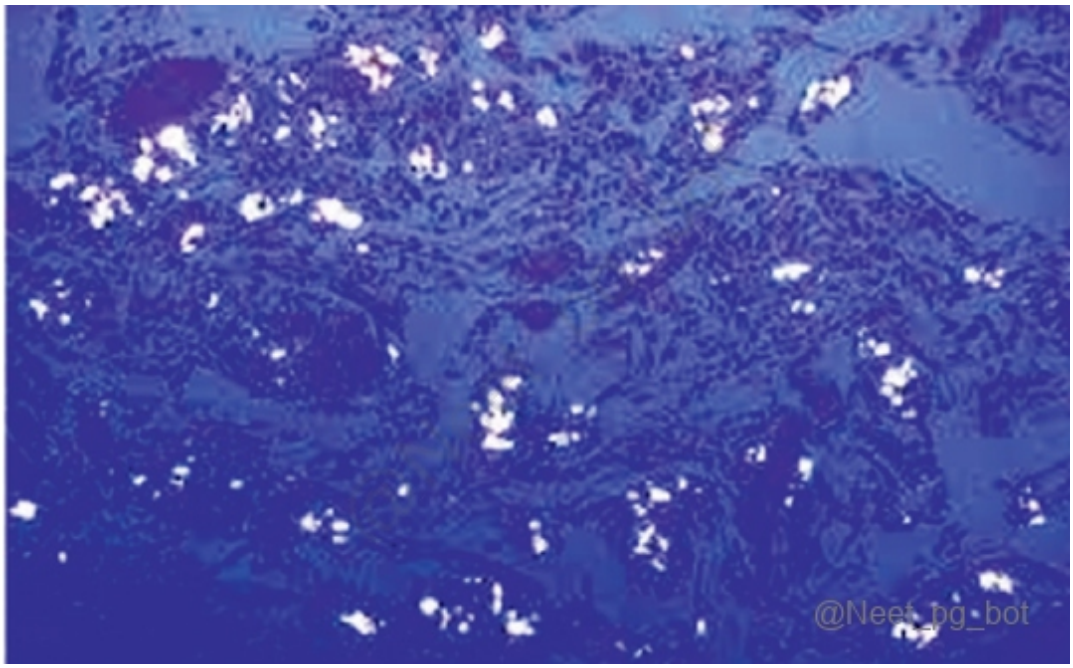

↑ *Back to this question in Part A*

@Neet_pg_bot

Q21: A patient presents with respiratory distress and is diagnosed with pan-acinar emphysema. Which deficiency is responsible for his condition? (Q844156)

A. Type 1 surfactant

B. Type 2 surfactant

C. Alpha-1 antitrypsin deficiency

D. Albumin

Correct Answer: C. Alpha-1 antitrypsin deficiency

Explanation: Alpha-1 antitrypsin (A1AT) is a protease inhibitor that protects alveoli from neutrophil elastase. Deficiency of A1AT leads to unopposed elastase activity, causing destruction of alveolar walls. This manifests as pan-acinar emphysema, classically involving lower lobes of the lungs. It can present in younger patients (40s–50s), often with family history, and may be associated with liver disease. Other types of emphysema (centrilobular) are usually related to smoking, not A1AT deficiency. Incorrect Options: Option A) Type 1 surfactant – Deficiency causes neonatal respiratory distress syndrome, not emphysema. Option B) Type 2 surfactant – Also associated with alveolar collapse in neonates, causes neonatal respiratory distress syndrome, not emphysema. Option D) Albumin – Low albumin causes edema, not emphysematous changes.

References:

.

↑ *Back to this question in Part A*

@Neet_pg_bot

Q22: A male patient is diagnosed with ARDS and is not responding to oxygen therapy. What is the role of IL-8 in ARDS? (Q844145)

A. Endothelial cell activation

B. Neutrophil recruitment

C. Macrophage activation

D. Promotion of surfactant production

Correct Answer: B. Neutrophil recruitment

Explanation: Correct Option B - Neutrophil recruitment: Interleukin-8 (IL-8) is a potent chemokine that plays a significant role in the inflammatory response in Acute Respiratory Distress Syndrome (ARDS). Its primary function is to recruit neutrophils to the site of inflammation in the lungs. Once recruited, neutrophils release enzymes and reactive oxygen species that contribute to lung tissue damage, a hallmark of ARDS. Incorrect Options: Options A, C, and D are not influenced by IL-8.

↑ *Back to this question in Part A*

@Neet_pg_bot

Q23: TTF-1 immunohistochemical marker is associated with which of the following cancers? (Q844039)

A. Squamous cell carcinoma

B. Lung adenocarcinoma

C. Small cell carcinoma

D. Large cell carcinoma

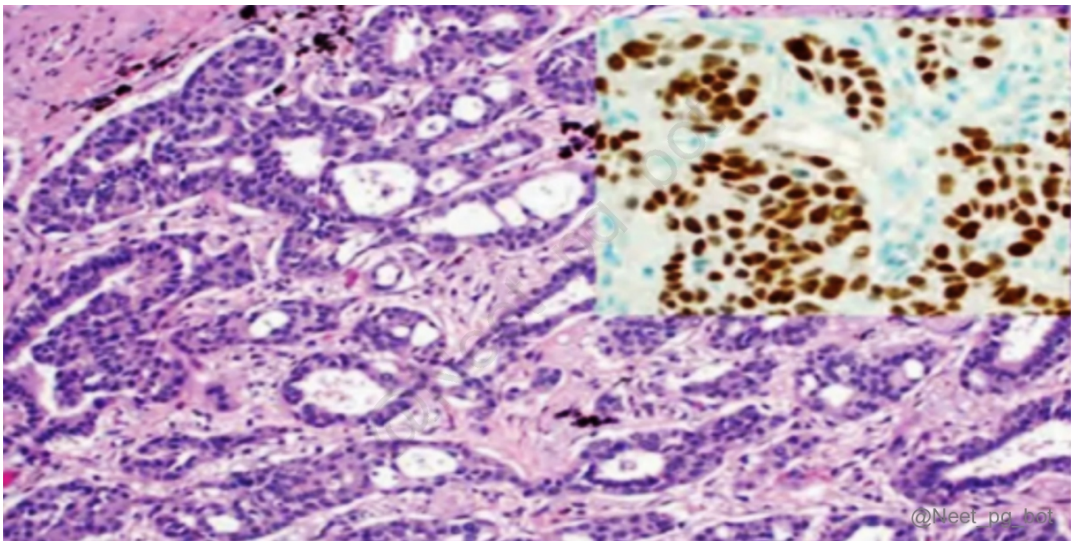

Correct Answer: B. Lung adenocarcinoma

Explanation: Correct Option B - Lung adenocarcinoma: TTF-1 is an immunohistochemical marker for lung adenocarcinoma. Incorrect Options: Options A, C, and D: TTF -1 is not an immunohistochemical marker for these tumors.

References:

.

↑ *Back to this question in Part A*

@Neet_pg_bot

Q24: A 40-year-old female patient presents with skin lesions, respiratory symptoms, and enlarged lymph nodes. Skin lesions appear as raised, erythematous nodules, and a chest X-ray shows bilateral hilar lymphadenopathy. A biopsy of the affected tissues is performed. Microscopic examination reveals the presence of granulomas without central necrosis. What is the most likely histological finding in this scenario? (Q820587)

A. Caseating granuloma

B. Stellate granuloma

C. Non-caseating granuloma

D. Eosinophilic granuloma

Correct Answer: C. Non-caseating granuloma

Explanation: Correct Option C - Non-caseating granuloma: . The patient's presentation with raised erythematous nodules and a chest X-ray shows bilateral hilar lymphadenopathy is suggestive of sarcoidosis. Sarcoidosis is associated with non-caseating granulomas with Schaumann bodies. Incorrect Options: Options A, B, and D are incorrect.

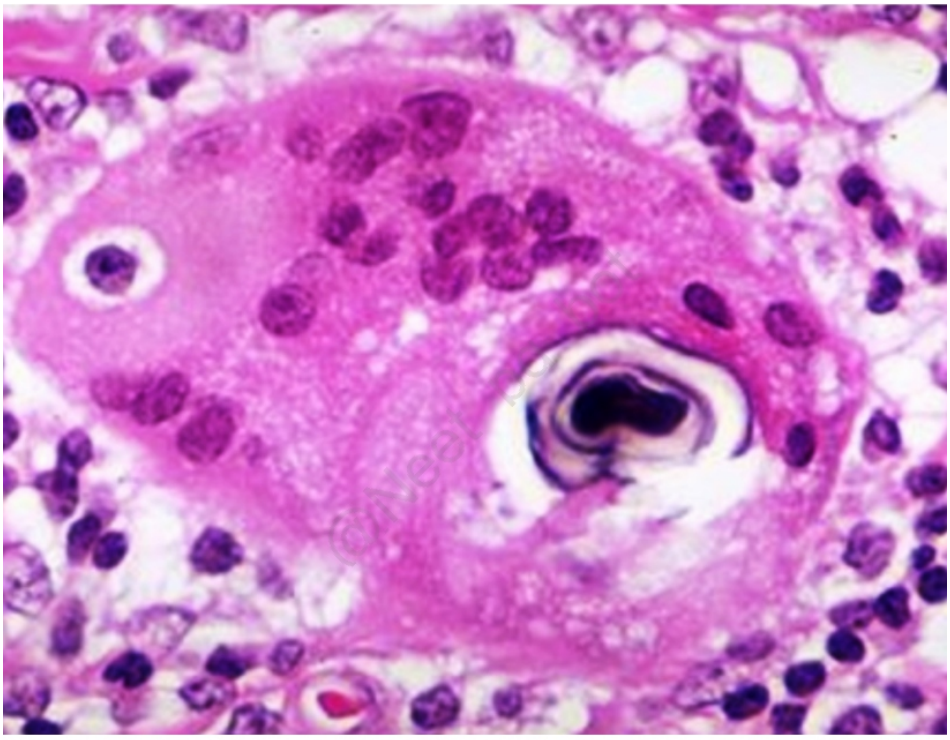

Schaumann bodies in Multinucleated giant cell

@Neet_pg_bot

References:

.

↑ *Back to this question in Part A*

@Neet_pg_bot

Q25: Which malignancy is most commonly associated with asbestosis? (Q857561)

A. Mesothelioma

B. Anthracosis

C. Hepatocellular carcinoma

D. Renal cell carcinoma

Correct Answer: A. Mesothelioma

Explanation: Asbestosis, a pneumoconiosis caused by asbestos inhalation, is strongly associated with mesothelioma, a malignancy of the pleura or peritoneum. Asbestos exposure also increases the risk of lung, laryngeal, ovarian, colon, and pleural cancers. Smoking significantly amplifies the risk of asbestos-related lung carcinoma, making asbestos workers, especially smokers, more likely to die from lung cancer than mesothelioma.

{{caption_text}} {{caption_text}} Compared to other occupational lung diseases, which affect the upper lobes of the lungs, it commonly affects the lower lobes. Adenocarcinoma (primary bronchogenic carcinoma) is the most common type of cancer, accounting for about 45%, followed by squamous cell carcinoma. Lung mesothelioma is a more specific tumour associated with asbestos exposure. It is common but is less prevalent than Adenocarcinoma. {{caption_text}} Anthracosis (Option B) , associated with bronchial arthrofibrosis (BAF), is a condition characterised by the black staining of the bronchial mucosa, which can obstruct the bronchial lumen. It typically manifests in elderly non-smokers, either male or female, with a chronic course of symptoms like dyspnea and/or cough. It occurs due to the accumulation of carbon, silica, and quartz particles in macrophages, mucosa, and submucosa, leading to anthracosis. {{caption_text}} Hepatocellular carcinoma (HCC) (Option C) is the most common form of primary liver cancer. It typically develops in individuals with chronic liver diseases such as cirrhosis, which can be caused by chronic Hepatitis B or C infection. Other causes of cirrhosis include alcohol abuse, autoimmune diseases, chronic liver inflammation, and iron overload (hemochromatosis). HCC arises from long-term liver damage and scarring. Renal cell carcinoma (RCC) (Option D) is the most common type, accounting for approximately 90–95% of adult kidney cancers. It originates in the lining of the proximal convoluted tubules (PCTs). Symptoms of RCC include blood in the urine, flank pain, abdominal mass, weight loss, fever, high blood pressure, night sweats, and malaise. When RCC metastasises, it commonly spreads to the lymph nodes, lungs, liver, adrenal glands, brain, or bones.

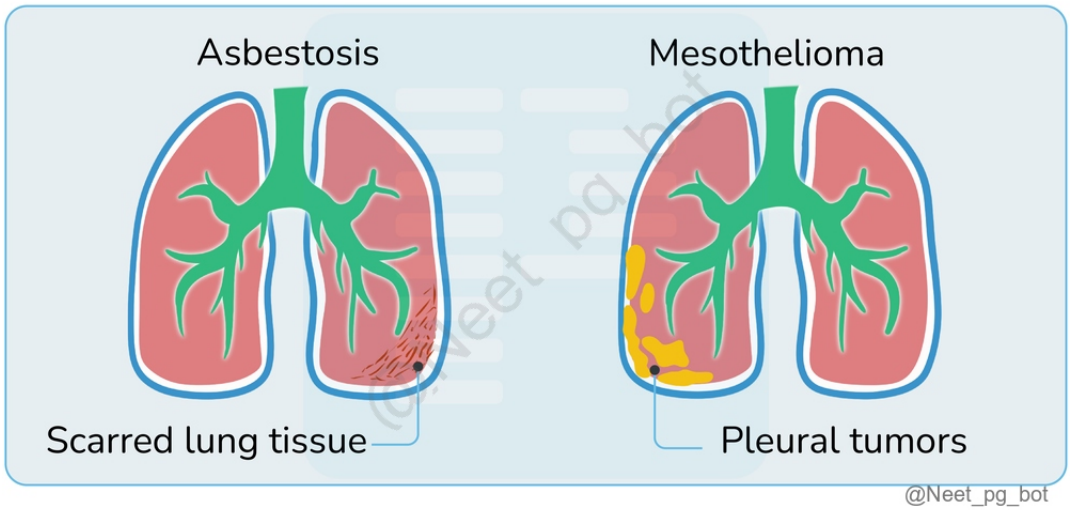

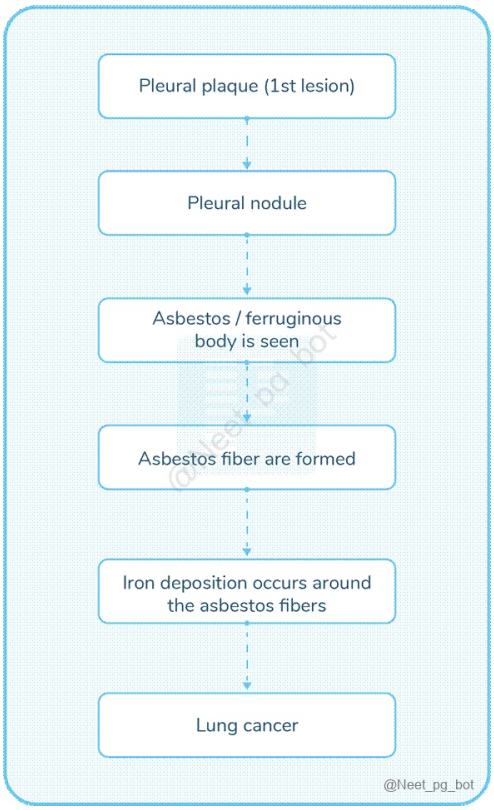
Pleural plaque (1st lesion)
Pleural nodule
Asbestos / ferruginous body is seen
Asbestos fiber are formed
Iron deposition occurs around the asbestos fibers
Lung cancer
@Neet_pg_bot

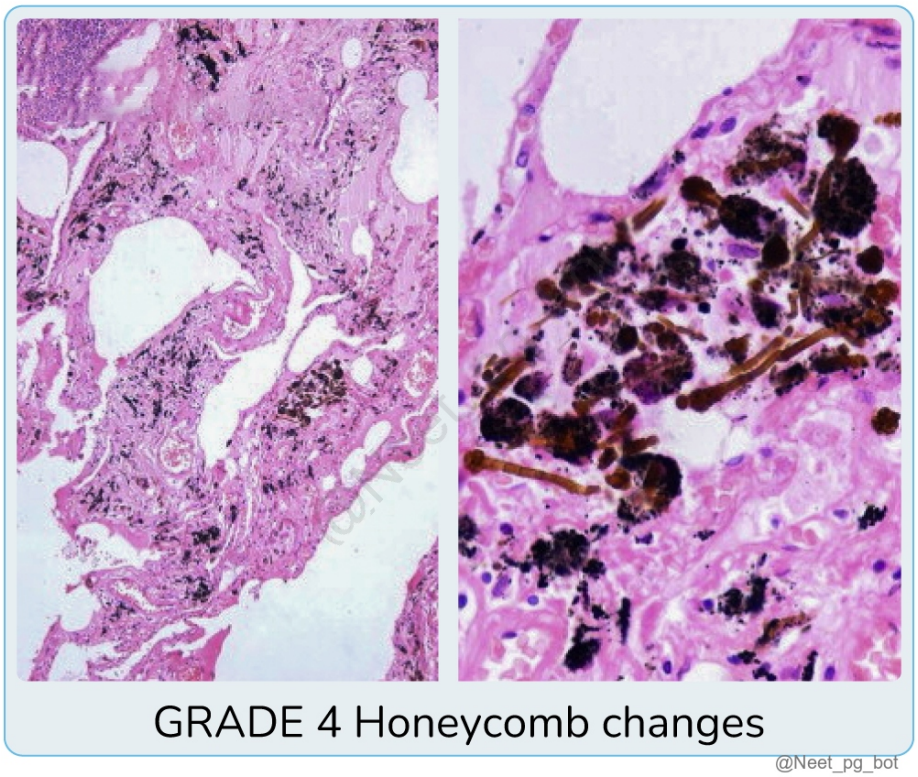
GRADE 4 Honeycomb changes
@Neet_pg_bot



References:

Robbins & Cotran Pathologic Basis of Disease, 10th Edition, Page 694.

↑ *Back to this question in Part A*

@Neet_pg_bot

• [08_Salivary Glands] 037 Salivary Gland Pathology

« Back to Folder Directory

[08_Salivary Glands] 037 Salivary Gland Pathology — Quick Jump

Q1 (p. 1874) *Q2 (p. 1875)* *Q3 (p. 1878)* *Q4 (p. 1879)* *Q5 (p. 1880)* *Q6 (p. 1881)*
Q7 (p. 1882) *Q8 (p. 1884)*

Q1: A 28-year-old female presents with a painless, bluish, fluctuant and translucent swelling on the lower lip that enlarges with eating or pressure, as shown in the image below. She reports a history of accidentally biting her lip frequently. What histopathological feature would be expected on biopsy of the lesion? (Q845534)

A. Mucin-filled cavity surroundedby granulation tissue and chronic inflammatory cells.

B. Proliferation of ductal cells within fibrous connective tissue

C. Epithelial dysplasia and atypical cells.

D. Eosinophilic granuloma with multinucleated giant cells



Correct Answer: A. Mucin-filled cavity surroundedby granulation tissue and chronic inflammatory cells.

■ *Listen (English)*

■ *Listen (Hindi)*

Explanation: The clinical presentation and the image suggest Mucocele, a benign cystic lesion caused by the accumulation of saliva due to trauma or obstruction of the salivary gland duct. Histologically, it is characterized by a mucin-filled cavity without an epithelial lining (in the extravasation type), surrounded by granulation tissue and chronic inflammatory cells , especially macrophages (mucinophages). Mucin-filled cavity incites an inflammatory response, and for the repair of this, the body will start making granulation tissue. A mucocele is an extravasation cyst : Due to excessive lip biting or any trauma, accumulation of lots of saliva and mucus occurs, resulting in a cystic lesion. It does not have any ductal epithelium or ductal lining. A t rue cyst lined by ductal epithelium. Treatment: Cryotherapy Laser Treatment Surgical Excision: Removal of the cyst Ranula: A ranula is a mucous extravasation cyst occurring in the floor of the mouth due to leakage of saliva from the Sublingual gland. It is the most common cystic swelling of the floor of the mouth and is not a true cyst because it lacks an epithelial lining. Usually arises from: Sublingual gland (most common) Rarely from minor salivary glands Clinical Features: ■■■ Soft, fluctuant swelling in the floor of the mouth Located lateral to the midline Bluish and translucent in appearance Usually painless As it enlarges, it may cause: Difficulty in speech Interference with chewing Elevation of the tongue It typically lies above the Mylohyoid muscle , confined to the oral cavity. Diagnosis: Ultrasound or MRI is used if deeper extension is suspected. Aspiration reveals thick, mucinous fluid with high amylase content. Management: Simple drainage has a high recurrence rate. Marsupialization may be attempted but often recurs. Definitive treatment is excision of the sublingual gland , because the gland is the source of mucus leakage. Plunging Ranula: A plunging ranula is a deeper extension of a ranula into the neck. Instead of remaining confined above the mylohyoid muscle, the mucus dissects through a defect or passes around the posterior border of the Mylohyoid muscle and enters the submandibular space. Pathophysiology: The mylohyoid muscle normally forms a diaphragm separating the oral cavity from the neck. If there is: A congenital defect A dehiscence Or posterior free border passage Mucus from the sublingual gland tracks downward into the neck, producing a swelling in the submandibular region. Clinical Presentation: Plunging ranula typically presents as: A painless, soft swelling in the upper neck Located in the submandibular region Usually without skin discoloration MRI may show the “tail sign” , which indicates communication with the sublingual space.

References:

Robbins and Cotran Pathologic basis of disease, 10th Edition, Page 747

https://pmc.ncbi.nlm.nih.gov/articles/PMC4211243/

↑ *Back to this question in Part A*

@Neet_pg_bot

Q2: A 40-year-old female presents with a slowly growing painless mass in her left parotid gland region that has been present for several months. On examination, a firm, mobile, non-tender mass is palpable in the preauricular area. Fine needle aspiration cytology (FNAC) reveals epithelial and myoepithelial cells in a

chondromyxoid background. What is the most likely diagnosis? (Q845535)

A. Pleomorphic adenoma

B. Warthin tumor

C. Mucoepidermoid carcinoma

D. Adenoid cystic carcinoma

Correct Answer: A. Pleomorphic adenoma

■ *Listen (English)*

■ *Listen (Hindi)*

Explanation: Type of tumour Nature of the tumour HPE features Pleomorphic adenoma Benign mixed tumor Commonly seen in the parotid gland. More common in females Mixed tumor with epithelial and mesenchymal components. Epithelial component: Cells Mesenchymal component: Chondromyxoid stroma Warthin tumour (Option B) Benign Oncocytic cells with double-layered lining Mucoepidermoid carcinoma (Option C) Low to intermediate malignant potential Mucinous and squamous epithelial cells, variable cystic spaces Adenoid cystic carcinoma (Option D) Intermediate to high-grade malignant Cribriform pattern, perineural invasion

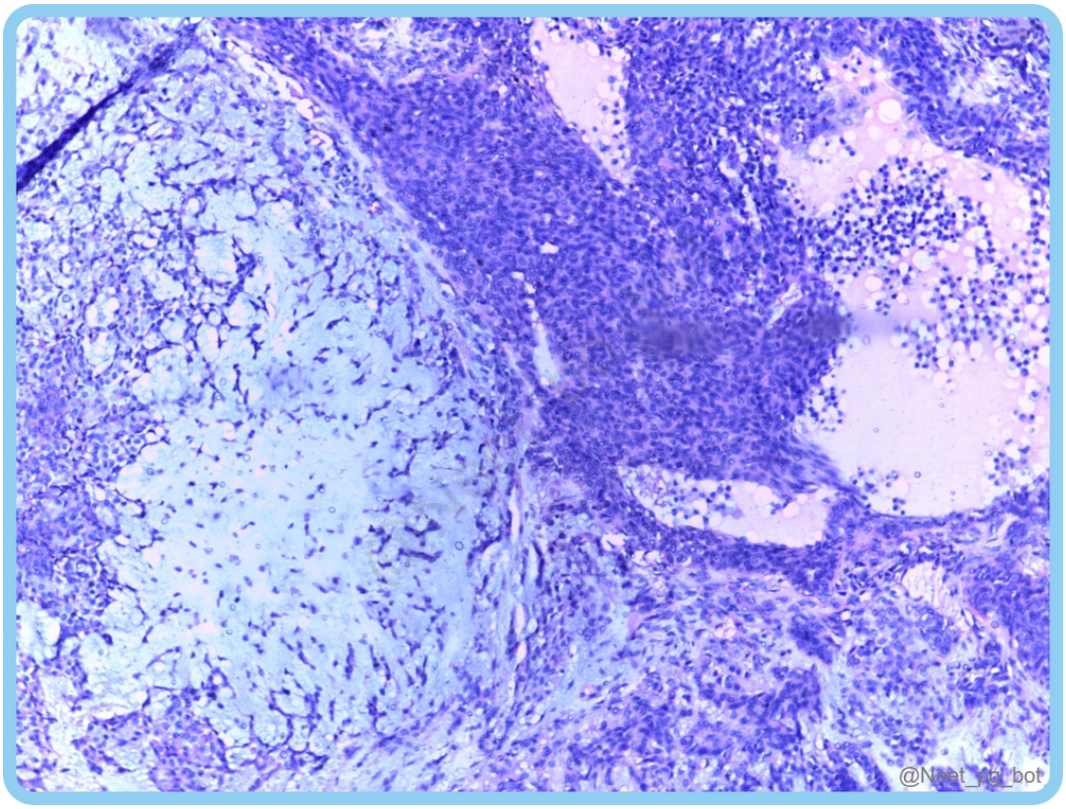

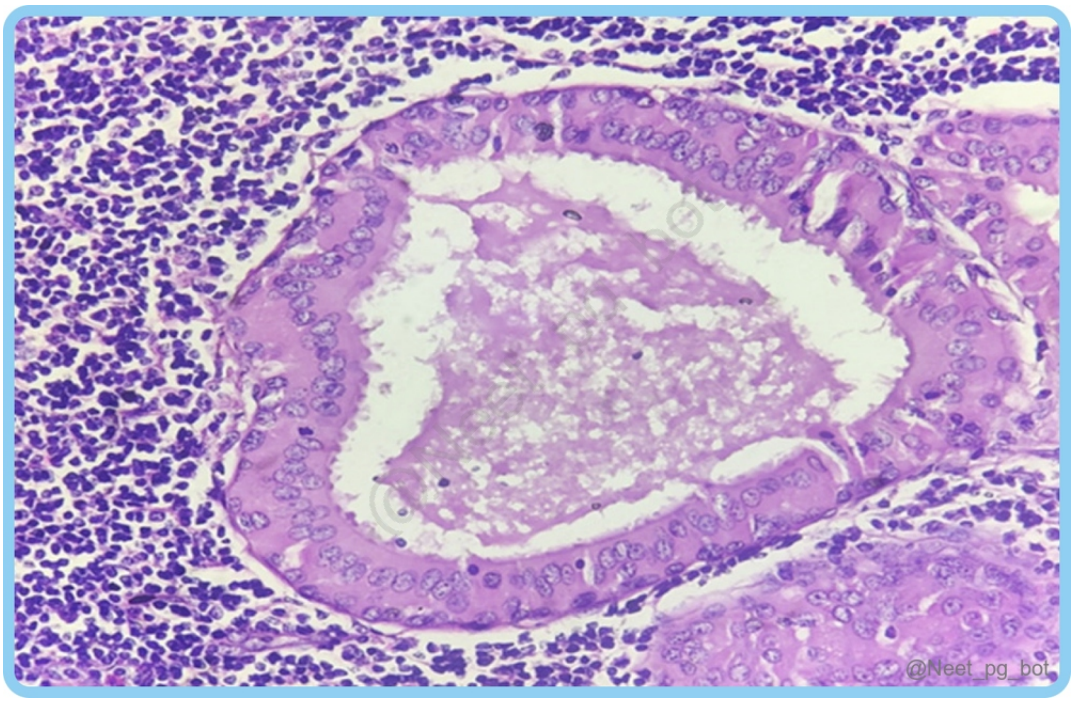
@Neet_pg_bot

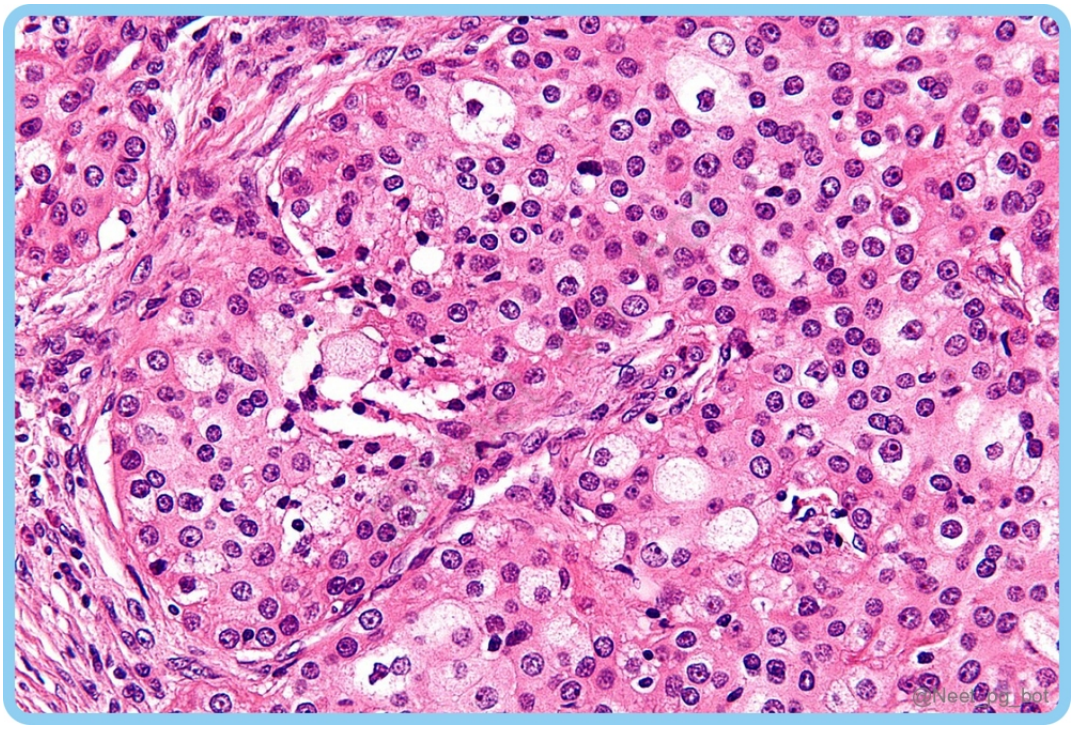
@Neet_pg_bot

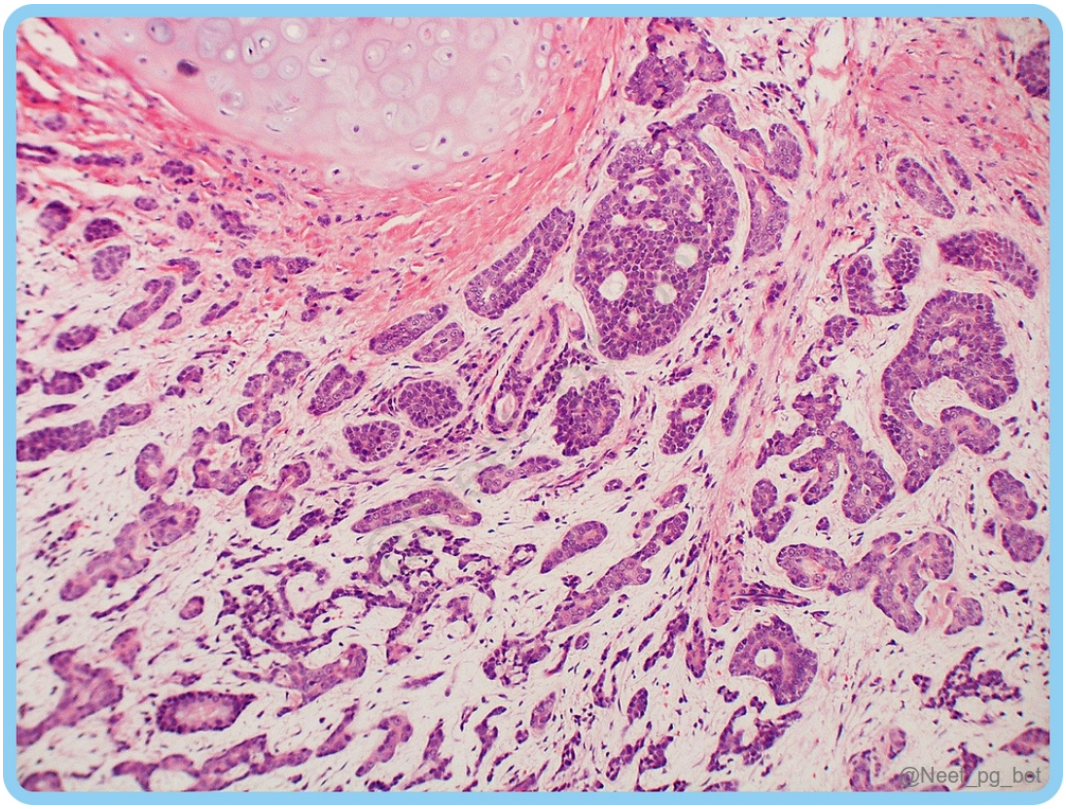

References:

Robbins and Cotran Pathologic basis of disease, 10th edition, Page 748

↑ *Back to this question in Part A*

@Neet_pg_bot

Q3: A 45-year-old female presents with a painless, slowly growing mass in her left parotid gland. Examination reveals a firm, mobile mass. Biopsy confirms pleomorphic adenoma with characteristic islands of cartilage and foci of bone in a myxoid stroma. Which of the following is incorrect regarding this condition? (Q845536)

A. Mostly found in the parotid gland

B. Mixed tumours with ductal, myoepithelial and mesenchymal cells

C. Radiation exposure is a risk factor

D. Down-regulation of PLAG1 results in abnormal cell proliferation

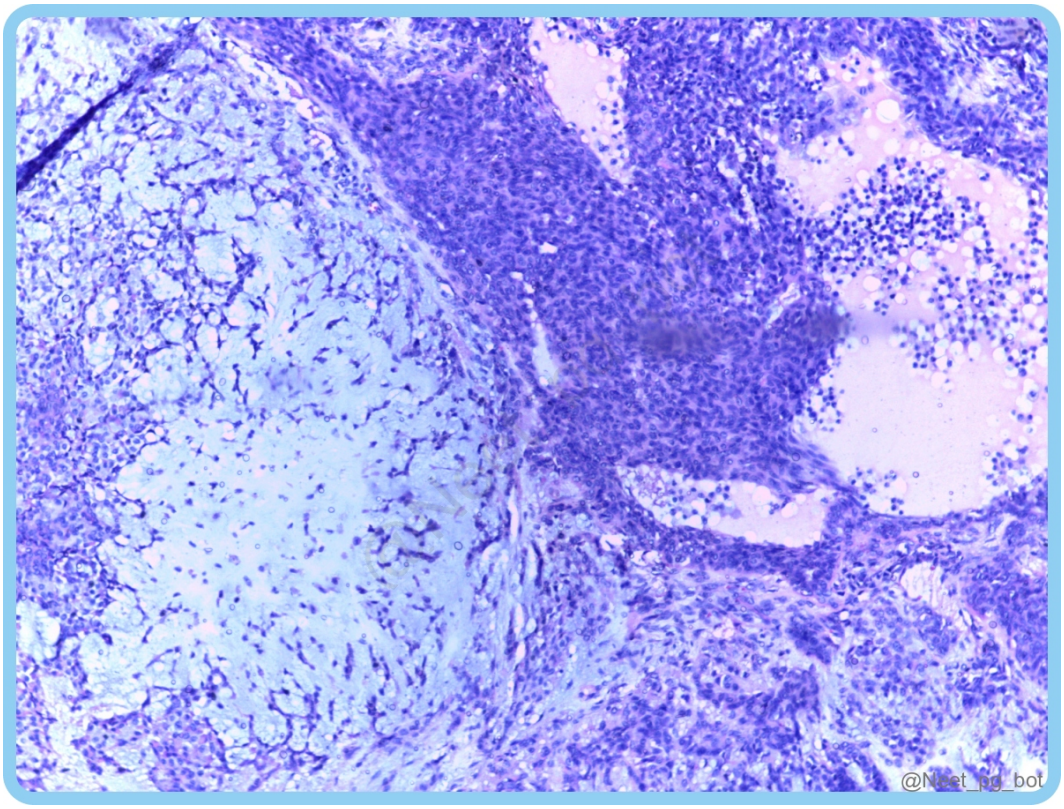

Correct Answer: D. Down-regulation of PLAG1 results in abnormal cell proliferation

■ *Listen (English)*

■ *Listen (Hindi)*

Explanation: Pleomorphic adenoma is a benign mixed tumor predominantly of the parotid gland and is commonly seen in females. It contains both epithelial (ductal and myoepithelial) and mesenchymal components (myxoid, chondroid, and osseous tissue). Radiation exposure is a known risk factor for salivary gland tumors, including pleomorphic adenoma. The PLAG1 (PLAG= Pleomorphic Adenoma Gene) gene is an oncogene, and up-regulation or overexpression (not down-regulation) of PLAG1 leads to abnormal cell proliferation and tumorigenesis in pleomorphic adenoma.

References:

Robbins and Cotran Pathologic Basis of Disease, 10th Edition, Page 748

↑ *Back to this question in Part A*

@Neet_pg_bot

Q4: A 55-year-old male has a painless, slowly enlarging mass in the left parotid gland over several years. Examination reveals a firm, mobile, non-tender mass. Histological findings confirm pleomorphic adenoma. Which factor is associated with an increased risk of malignant transformation in pleomorphic adenomas? (Q845537)

A. Younger age of the patient

B. Larger size of the tumour

C. Increased age of the lesion

D. Presence of hyalinized stroma within the tumour

Correct Answer: C. Increased age of the lesion

■ *Listen (English)*

■ *Listen (Hindi)*

Explanation: Rates of malignant transformation in pleomorphic adenoma correlate with the age of the lesion When the age of pleomorphic adenoma's lesion exceeds 15-20 years, the chances of malignant transformations increase: Carcinoma ex pleomorphic adenoma (Carcinoma has originated inside a pre-existing pleomorphic adenoma). Pleomorphic adenoma It is a benign mixed tumor Most common salivary gland tumor and most commonly occurs in the parotid. Mostly seen in females. On FNAC or biopsy: It shows epithelial and mesenchymal cells (mixed tumor) Epithelial components: Epithelia, myoepithelial and ductal cells Mesenchymal tissue comprise of chondromyxoid stroma

References:

Robbins and Cotran Pathologic Basis of Disease, 10th Edition, Page 748

↑ *Back to this question in Part A*

@Neet_pg_bot

Q5: A 50-year-old male smoker presents with a painless swelling in the parotid region. Fine needle aspiration cytology (FNAC) reveals murky fluid. Which of the following histopathological features is true regarding this condition? (Q845538)

A. Proliferation of squamous epithelial cells with keratinisation

B. Oncocytic cells with double-layered lining

C. Neuroendocrine differentiation

D. Papillary architecture with psammoma bodies

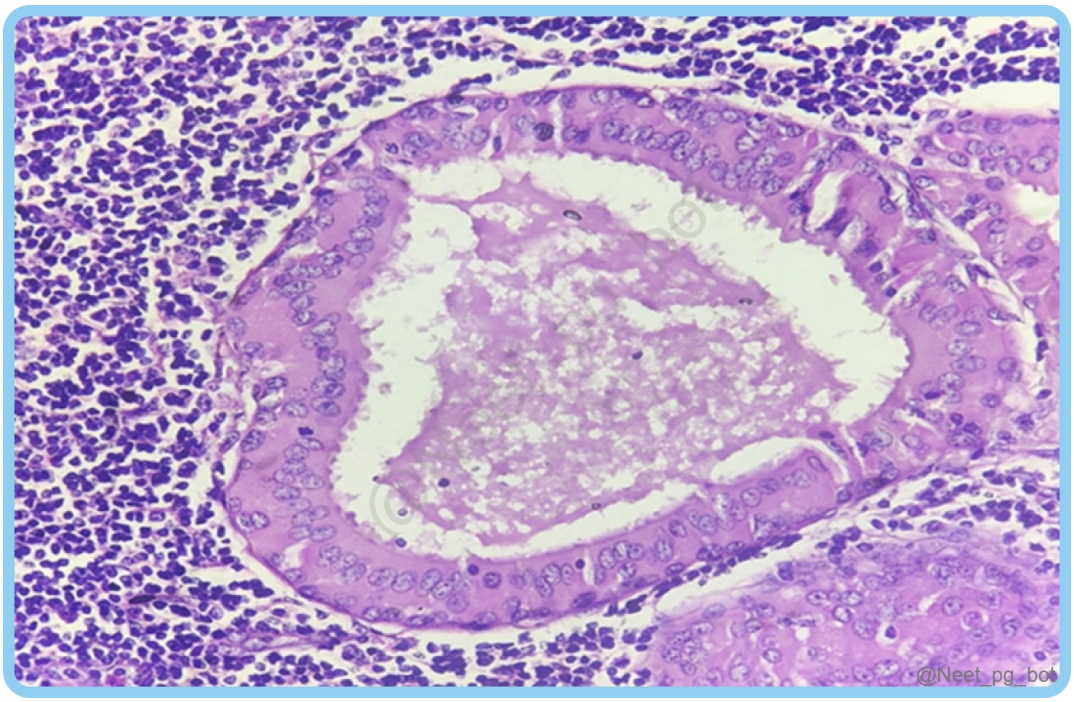

Correct Answer: B. Oncocytic cells with double-layered lining

■ *Listen (English)*

■ *Listen (Hindi)*

Explanation: The clinical presentation (history of chronic smoking) and histopathological image (Murky fluid on FNAC) suggest a Warthin tumour or Papillary cystadenoma lymphomatosum , a benign salivary gland tumour that typically occurs in the parotid gland. On histopathology i t is characterised by : Pink coloured oncocytic cells, which are double-layered. Deep blue coloured lymphocytes. Papillary cystadenoma lymphomatosum: Papillary: Shows papillary projections Cyst: Cyst which is filled with murky fluid which is aspirated on FNAC. Adenoma: Because it is a benign tumor Lymphomatosum: It contains significant lymphoid components. It is seen in chronic smokers and commonly involves bilateral parotid glands. This characteristic appearance is often referred to as "Cystic oncocytic hyperplasia." ■■■■■■■Proliferation of squamous epithelial cells with keratinisation (Option A): Seen in pleomorphic adenoma

References:

Robbins and Cotran Pathologic Basis of Disease, 10th Edition, Pages 749 - 750

↑ *Back to this question in Part A*

@Neet_pg_bot

Q6: Which of the following statements about Warthin's tumour is true? (Q845539)

A. It is the most common malignant tumour of the salivary glands.

B. They are typically located in the parotid gland.

C. It is more common in females.

D. Associated with human papillomavirus (HPV) infection.

Correct Answer: B. They are typically located in the parotid gland.

■ *Listen (English)*

■ *Listen (Hindi)*

Explanation: Warthin tumour or Papillary cystadenoma lymphomatosum is a benign salivary gland tumour primarily affecting the parotid gland. It is more common in males and is strongly associated with a history of smoking. Parotid involvement can be bilateral. On FNAC, Murky fluid is aspirated. Histopathological features: Shows papillary projections It is a benign tumour with cyst formation. Cells: Double-layered pink-coloured oncocytic cells and a lot of lymphocytic infiltrates. It is the most common malignant tumour of the salivary glands (Option A): Warthin tumour is a benign tumour It is more common in females (Option C): It is more common in males, especially with a history of smoking. Associated with human papillomavirus (HPV) infection (Option D): It is associated with heavy chronic smoking.

References:

Robbins and Cotran Pathologic Basis of Disease, 10th Edition, Page 751

↑ *Back to this question in Part A*

@Neet_pg_bot

Q7: A 45-year-old female presents with a slow-growing painless mass in the left submandibular gland region. Imaging studies reveal a solid lesion with cystic components. Fine needle aspiration cytology (FNAC) shows a mixture of mucin-producing, epidermoid, and intermediate cells. A histopathology image is given below. Which of the following features is true regarding this condition? (Q845540)

A. Most commonly found in the sublingual salivary glands.

B. Most are associated with a (11;19) translocation.

C. Encapsulated tumours.

D. Histologically characterized by the presence of spindle cells

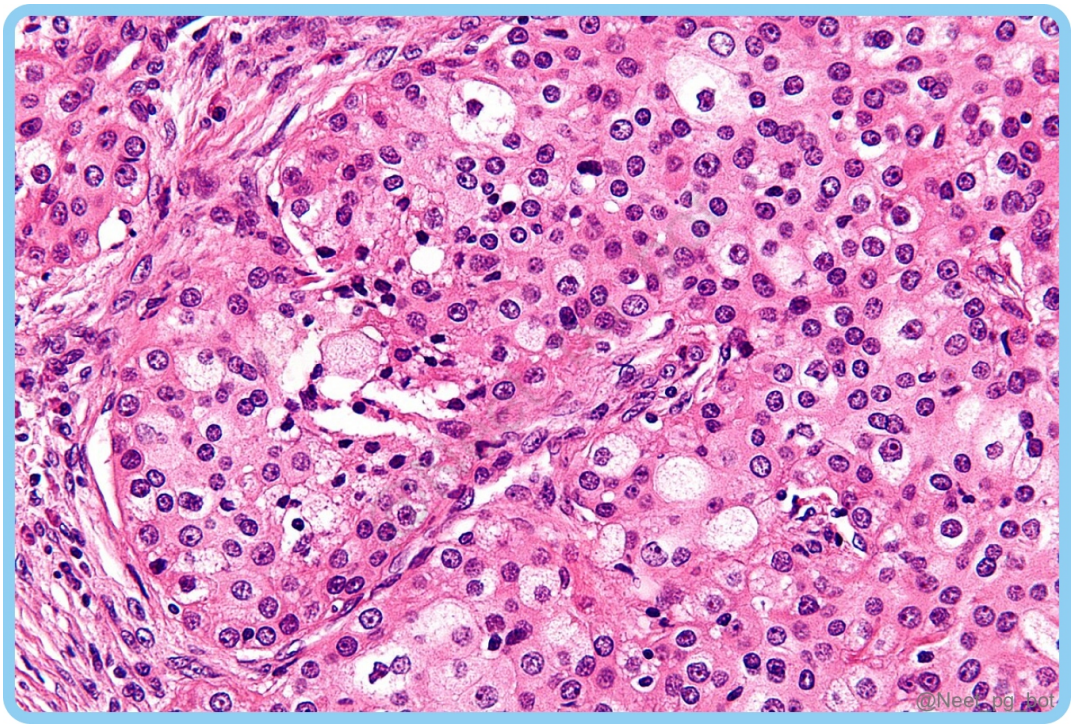

Correct Answer: B. Most are associated with a (11;19) translocation.

- *Listen (English)*
- *Listen (Hindi)*

Explanation: Mucoepidermoid carcinoma (MEC): It is the most common malignant tumour of salivary glands, often found in parotid and submandibular glands. (Option A) It does not have a capsule (Option C) It is associated with the (11;19) chromosomal translocation, creating CRTC1-MAML2 fusion protein. Histologically, it exhibits squamous and mucous cell features. (Option D) There are 3 types of cells in Mucoepidermoid carcinoma: Mucus-producing cells Epidermoid or Squamoid cells Intermediate cells. Grading: Low grade MEC: If mucus component is predominant. High grade MEC: If epidermoid or squamoid component is predominant. Image: Low-power view showing sheets and micro cysts containing cells of varying morphologies in Mucoepidermoid Carcinoma.

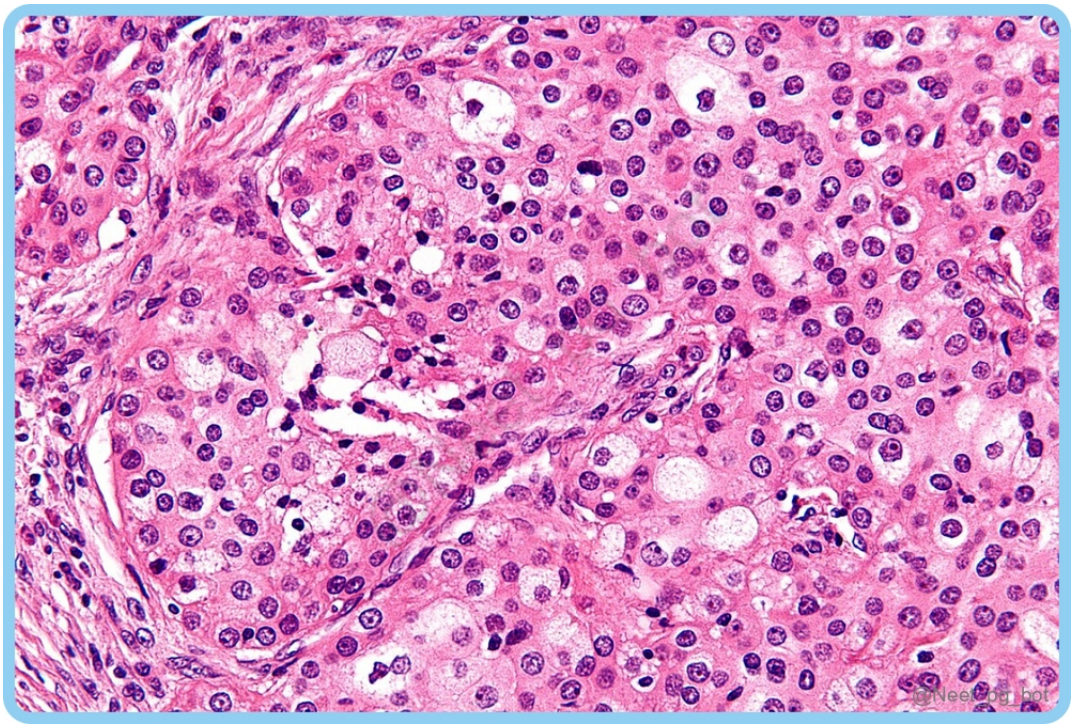

References:

Robbins and Cotran Pathologic Basis of Disease, 10th Edition, Page 751.

↑ *Back to this question in Part A*

@Neet_pg_bot

Q8: A 55-year-old male presents with a slowly enlarging painless mass in the right parotid gland region. Imaging studies reveal a solid tumour with a characteristic "Swiss cheese" appearance on MRI. Fine needle aspiration cytology (FNAC) shows basaloid cells with cribriform and tubular patterns. Which of the following statements is true regarding this condition? (Q845541)

A. Most commonly occur in the parotid and submandibular glands.

B. MYB-NFIB gene rearrangements are present in all cases

C. Encapsulated lesions with a smooth surface.

D. Tend to grow rapidly and have a high mitotic rate.

Correct Answer: A. Most commonly occur in the parotid and submandibular glands.

■ *Listen (English)*

■ *Listen (Hindi)*

Explanation: The clinical presentation and characteristic ‘Swiss cheese’ appearance on MRI with basaloid cells and cribriform pattern on FNAC suggest Adenoid cystic carcinoma, which most commonly affects parotid and submandibular glands. Cribriform pattern in a salivary gland tumor always tells us about Adenoid Cystic Carcinoma. MYB-NFIB gene rearrangements are present in all cases (Option B): MYB-NFIB gene rearrangements are present in a subset of adenoid cystic carcinomas and not in all cases. Encapsulated lesions with a smooth surface (Option C): It is poorly capsulated Tend to grow rapidly and have a high mitotic rate (Option D): Adenoid cystic carcinomas are slow-growing tumours that tend to invade perineural spaces (therefore painful lesions), indicating a low mitotic rate. Image: Three typical growth patterns, including cribriform (left), tubular (center), and solid (right).

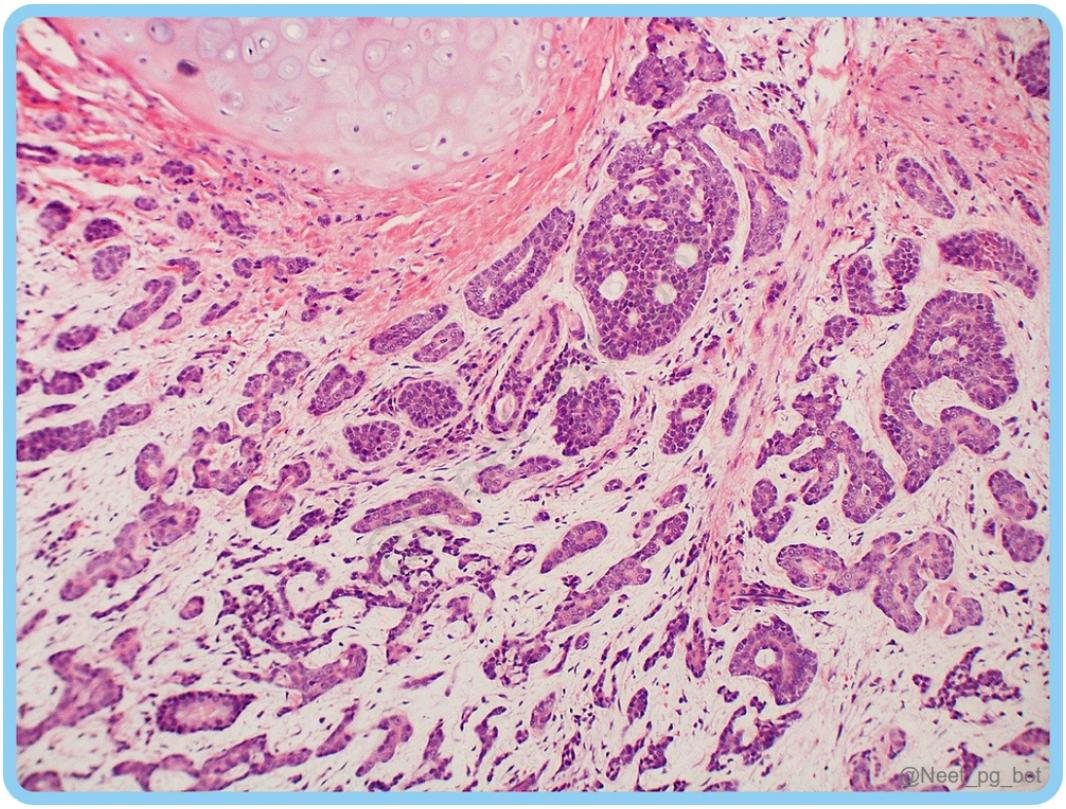

References:

Reference: Robbins and Cotran Pathologic Basis of Disease, 10th Edition, Page 751.

↑ *Back to this question in Part A*

@Neet_pg_bot

• [08_Salivary Glands] 038 Previous Year Questions

« Back to Folder Directory

[08_Salivary Glands] 038 Previous Year Questions — Quick Jump

Q1 (p. 1886) *Q2 (p. 1887)* *Q3 (p. 1887)*

Q1: A middle-aged woman presents with dry eyes and dry mouth. Laboratory tests reveal positive anti-Ro (SSA) and anti-La (SSB) antibodies. What is the most likely underlying pathological mechanism? (Q866381)

A. Destruction of exocrine glands by neutrophils

B. IgE-mediated hypersensitivity reaction

C. Lymphocytic infiltration and destruction of salivary and lacrimal glands

D. Deposition of amyloid in salivary glands

Correct Answer: C. Lymphocytic infiltration and destruction of salivary and lacrimal glands

Explanation: This presentation is classic for Sjögren’s syndrome , an autoimmune disorder characterised by chronic lymphocytic infiltration of the salivary and lacrimal glands, leading to xerostomia (dry mouth) and keratoconjunctivitis sicca (dry eyes). The condition is most common in middle-aged women and is associated with anti-Ro (SSA) and anti-La (SSB) autoantibodies. Pathophysiology Epithelial cells aS active players. Salivary/lacrimal epithelial cells (the target tissue) can act like antigen-presenting cells under stress or after viral/other triggers. They upregulate type I interferons, express costimulatory molecules and release chemokines that recruit lymphocytes. Autoantigen exposure. Apoptosis or other epithelial injury exposes intracellular ribonucleoproteins (Ro/SSA, La/SSB) to the immune system, promoting an autoimmune response. T-cell-driven inflammation. Early lesions are dominated by CD4■ T cells that home to the glands and cause inflammation and cytokine release (TH1/TH17 pathways are implicated). B-cell activation & ectopic germinal centres. Chronic inflammation induces local B-cell activation, formation of ectopic germinal–centre–like structures within glands, and production of autoantibodies (anti-Ro/SSA, anti-La/SSB, rheumatoid factor). Elevated BAFF (B-cell activating factor) supports B-cell survival. Structural loss of secretory tissue. Progressive acinar atrophy, ductal dilation and replacement by lymphoid infiltrates/fibrosis → functional loss of saliva and tears. Incorrect Options: Destruction of exocrine glands by neutrophils (Option A): is more typical of suppurative infections, not autoimmune Sjögren’s. IgE-mediated hypersensitivity reaction (Option B): occurs in allergies and anaphylaxis, not in this chronic autoimmune process. Deposition of amyloid in salivary glands (Option D): can occur in systemic amyloidosis, but is not the main mechanism in Sjögren’s syndrome.

↑ *Back to this question in Part A*

@Neet_pg_bot

Q2: Warthin's tumor is also called? (Q820513)

A. Adenolymphoma

B. Pleomorphic adenoma

C. Mucoepidermoid carcinoma

D. Acinic cell carcinoma

Correct Answer: A. Adenolymphoma

Explanation: Correct Option A - Adenolymphoma: Warthin's tumor is also known as adenolymphoma. It's a benign tumor that most commonly occurs in the parotid gland, which is a salivary gland located in the cheek. It's characterized by its unique histological appearance, with cystic spaces and papillary projections lined by double-layered oncocytic epithelial cells and lymphoid stroma. Incorrect Options: Option B - Pleomorphic Adenoma: Pleomorphic adenoma is another type of salivary gland tumor. It is the most common type of salivary gland tumor, but it is distinct from Warthin's tumor. Pleomorphic adenoma is characterized by a mixture of epithelial and myoepithelial cells in a chondromyxoid stroma. Option C - Mucoepidermoid Carcinoma: Mucoepidermoid carcinoma is a malignant salivary gland tumor. It is not synonymous with Warthin's tumor. Mucoepidermoid carcinoma is characterized by a combination of mucous-secreting, epidermoid (squamous), and intermediate cells. It is one of the most common malignant salivary gland tumors. Option D - Acinic Cell Carcinoma: Acinic cell carcinoma is another type of malignant salivary gland tumor. It is characterized by the presence of acinar cells, which produce serous (watery) secretions. It is not the same as Warthin's tumor.

References:

.

↑ *Back to this question in Part A*

@Neet_pg_bot

Q3: Which of the following features is not observed in pleomorphic adenoma? (Q855079)

A. Myoepithelial cells

B. Keratin pearls

C. Chondroid differentiation

D. Perineural invasion

Correct Answer: D. Perineural invasion

Explanation: Perineural invasion is not observed in pleomorphic adenoma, as it is a benign tumour. Perineural invasion occurs in carcinoma ex pleomorphic adenoma , a malignant transformation of pleomorphic adenoma. Pleomorphic Adenoma: Most common salivary gland neoplasm : Represents ~60% of parotid tumours, less common in submandibular and minor salivary glands. Benign tumour : Composed of ductal (epithelial) , myoepithelial , and mesenchymal cells (also called mixed tumour). Risk factors : Radiation exposure increases risk. Chromosomal rearrangements, including overexpression of PLAG1 and mutations in HMGA2 , are commonly associated. Clinical presentation : Painless, slow-growing, mobile, discrete masses, usually in the parotid, submandibular, or buccal cavity. Recurrence : 4% recurrence rate after parotidectomy; 25% after simple enucleation due to tumour extension beyond the capsule. Malignant transformation : Occurs more often with the age of the lesion. 2% of tumours present <5 years develop malignancy; 10% present >15 years develop malignancy, usually adenocarcinomas or undifferentiated carcinomas. Aggressive cancers : If malignant transformation occurs, cancers are highly infiltrative, with a 30-50% mortality rate at 5 years. Morphology: Size : Typically rounded, well-demarcated masses <6 cm. Histological features : Heterogeneous morphology with ductal, acinar, tubule-like structures, and myoepithelial cells (Option A) . Background of myxoid, hyaline, and chondroid stroma (Option C) (cartilage-like areas). Rare bone foci. No significant epithelial dysplasia or mitotic activity. Tumour behaviour : Similar clinical course regardless of whether epithelial or mesenchymal elements dominate. Keratin pearls (Option B) : While rare, keratin pearls can occasionally be observed in pleomorphic adenoma, especially when there is squamous metaplasia within the tumour.

References:

Robbins & Cotran Pathologic Basis of Disease, 10th Edition, Page 748,749

↑ *Back to this question in Part A*

@Neet_pg_bot

• [09_Gastrointestinal Tract] 039 Basics Of Git And Esophagus

« Back to Folder Directory

[09_Gastrointestinal Tract] 039 Basics Of Git And Esophagus — Quick Jump

Q1 (p. 1889) *Q2 (p. 1891)* *Q3 (p. 1893)* *Q4 (p. 1895)* *Q5 (p. 1896)* *Q6 (p. 1899)*
Q7 (p. 1902) *Q8 (p. 1903)* *Q9 (p. 1904)* *Q10 (p. 1905)* *Q11 (p. 1907)* *Q12 (p. 1908)*
Q13 (p. 1909) *Q14 (p. 1911)*

Q1: Which of the following statements regarding the layers of the digestive tract is incorrect? (Q845634)

A. The mucosa is the first layer of the digestive tract.

B. The submucosa is absent in the gallbladder.

C. The muscularis propria is present throughout the GIT.

D. The esophagus lacks the submucosal layer.

Correct Answer: D. The esophagus lacks the submucosal layer.

■ *Listen (English)*

■ *Listen (Hindi)*

Explanation: The GIT is histologically made up of 4 layers: Mucosa Submucosa: Absent in Gallbladder Muscularis Propria Serosa: Absent in esophagus

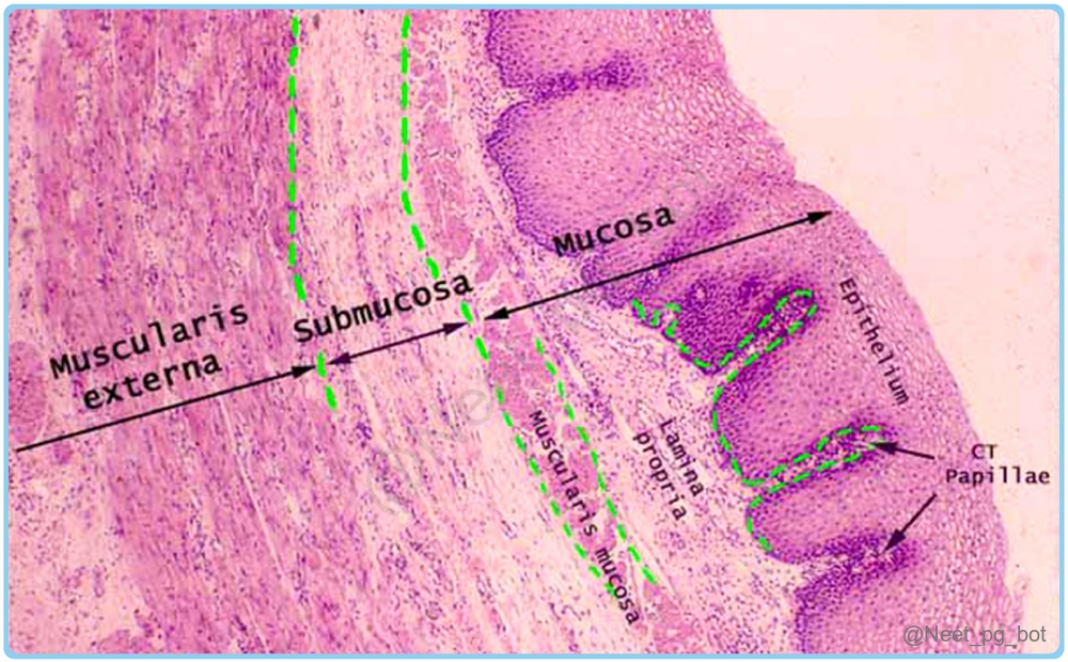

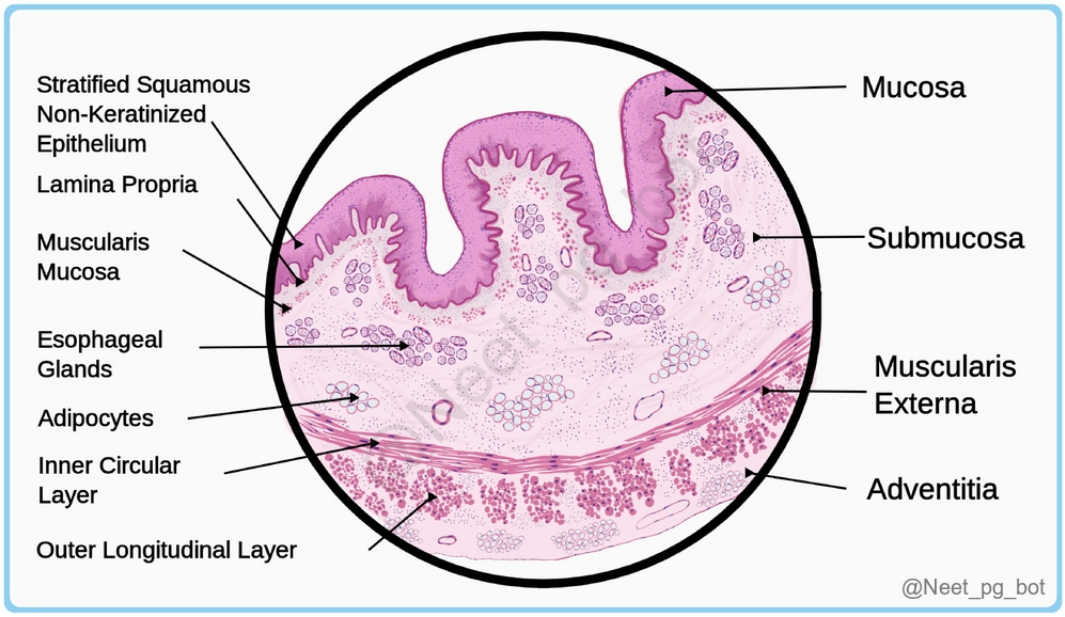

References:

Robbins and Cotran, Pathologic Basis of Disease, 10th Edition, Page 757

www.nature.com/gimo/contents/pt1/full/gimo6.html

training.seer.cancer.gov/anatomy/digestive/structure.html

↑ *Back to this question in Part A*

@Neet_pg_bot

Q2: A 58-year-old male presents with chronic heartburn and regurgitation. Upper endoscopy reveals the presence of Barrett's esophagus. What is the primary cellular change seen in this condition? (Q845637)

A. Metaplasia of squamous epithelium

B. Dysplasia of squamous epithelium

C. Hyperplasia of columnar epithelium

D. Hypertrophy of columnar epithelium

Correct Answer: A. Metaplasia of squamous epithelium

Listen (English)

Listen (Hindi)

Explanation: The primary cellular change seen in Barrett's oesophagus is metaplasia of squamous epithelium into intestinal columnar epithelium because of acid reflux/GERD. Intestinal columnar epithelium has goblet cells , which are filled with acidic mucin. Acidic mucin is stained by the Alcian blue stain . Metaplasia is 100% reversible. So this metaplasia can be reversed if GERD is controlled with the help of drugs. If GERD is not controlled, then it can lead to adenocarcinoma of esophagus.

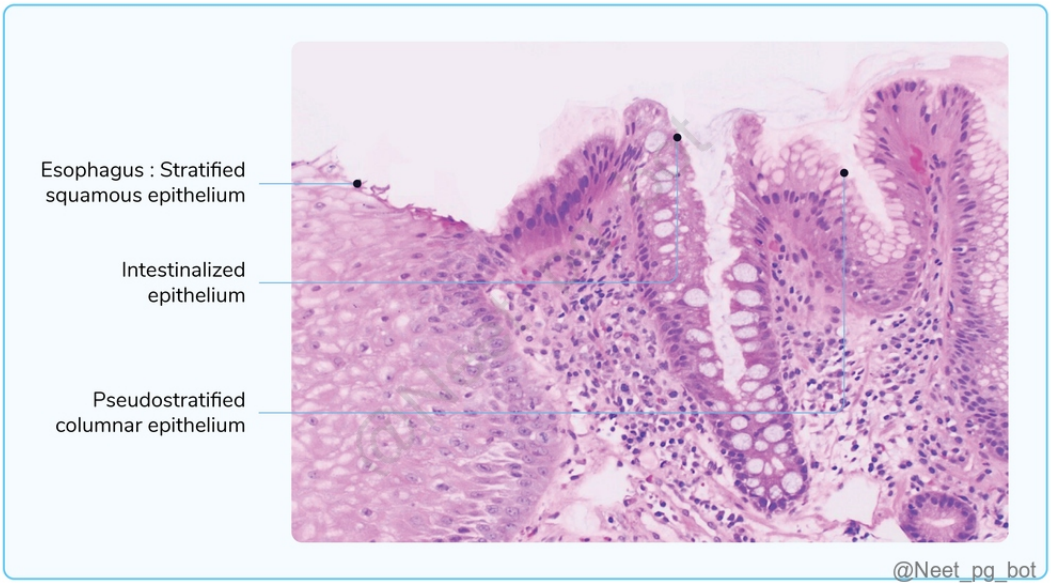

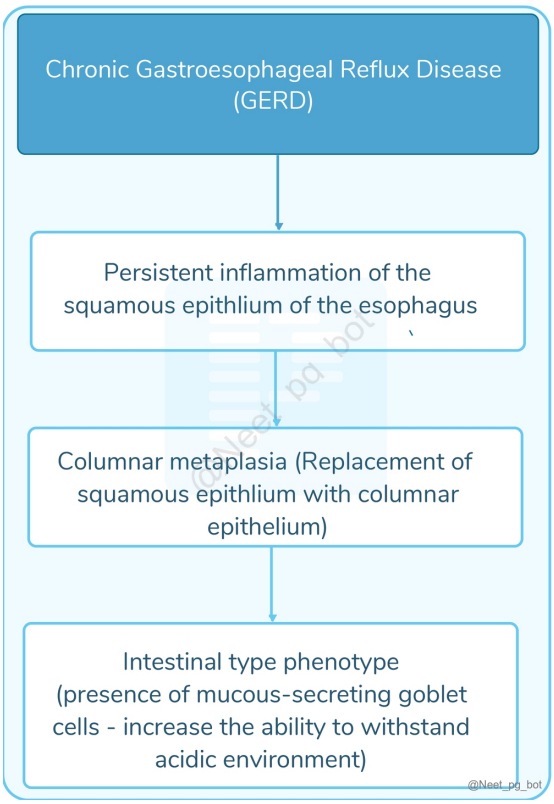

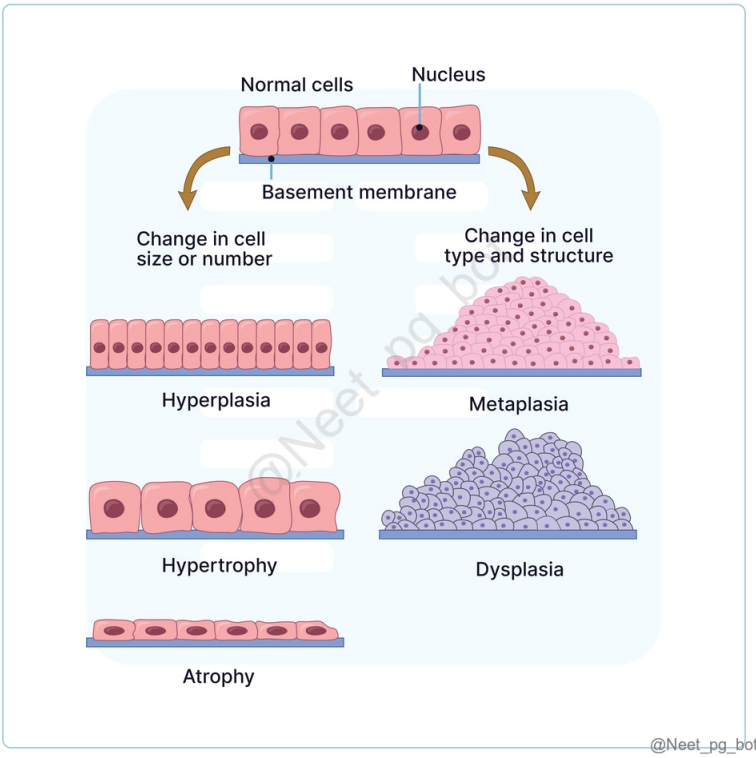

References:

Robbins and Cotran, Pathologic Basis of Disease, 10th Edition, Page no: 762, 272

↑ *Back to this question in Part A*

@Neet_pg_bot

Q3: A 50-year-old male presents with chronic heartburn for two years. An endoscopy is performed, and the biopsy of the esophageal specimen stained with special stain is shown below. Which of the following conditions is the patient at an increased risk of? (Q845640)

A. Squamous cell carcinoma

B. Adenocarcinoma

C. Plummer Vinson syndrome

D. MALToma

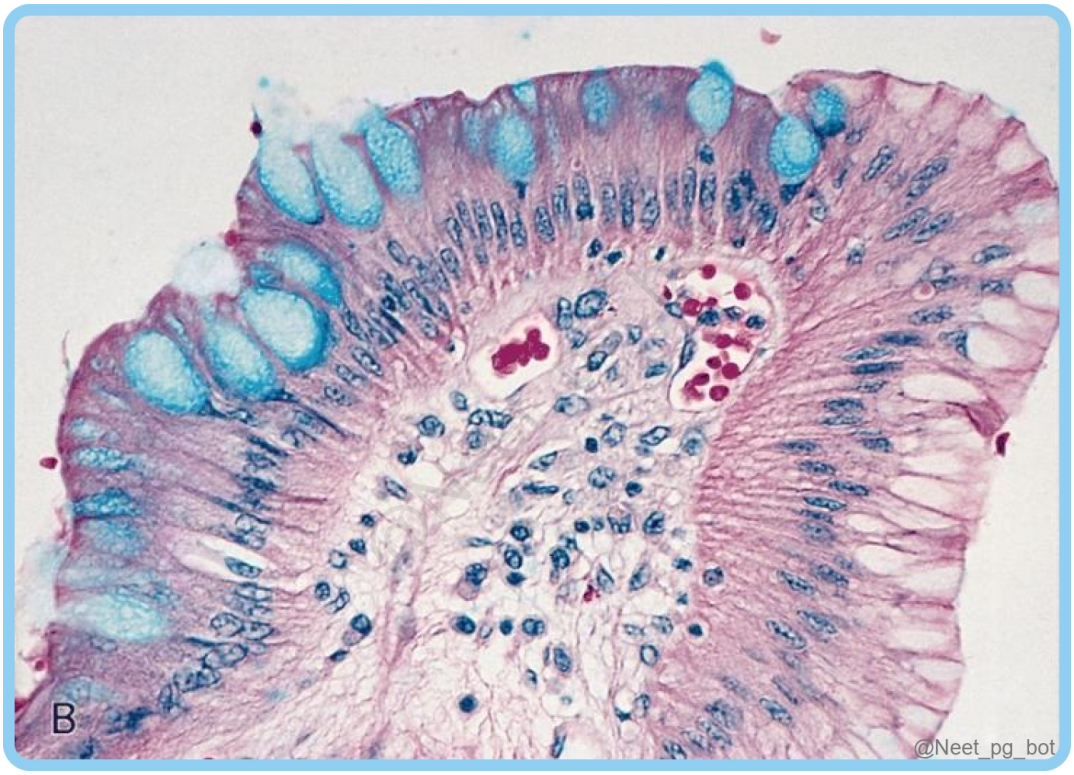

Correct Answer: B. Adenocarcinoma

■ *Listen (English)*

■ *Listen (Hindi)*

Explanation: The above scenario and an image showing goblet cells within the columnar epithelium suggest Barret's esophagus, which puts the patient at an increased risk of adenocarcinoma of the esophagus .

Microscopically, the squamous layer is replaced with intestinal-type metaplasia containing goblet cells. Goblet cells are diagnostic of Barrett esophagus and have distinct mucous vacuoles that stain blue with Alcian blue . Esophageal disease progression: A: Normal esophagus; B: Esophagitis; C: BE with goblet cells; D: Dysplasia; E: EAC. EAC: Esophageal adenocarcinoma; BE: Barrett's esophagus. Squamous Cell Carcinoma and Adenocarcinoma: Feature Squamous Cell Carcinoma (SqCC) Adenocarcinoma (Adeno) Cell of Origin Stratified squamous epithelium Glandular cells (metaplastic columnar) Primary Location Mid to Upper 1/3 of the esophagus Distal (Lower) 1/3 and GE junction Major Risk Factors Alcohol, Tobacco, Hot liquids, Poor nutrition GERD, Obesity, Tobacco, Barrett's Esophagus Global Prevalence Most common worldwide (90% of cases) Rising in Western/Developed countries Demographics Associated with lower SES; more common in Black populations (US) More common in White males; associated with higher SES Precursor Lesion Squamous dysplasia Barrett’s Esophagus Molecular Profile Similar to Head & Neck SCC Similar to Gastric/Chromosomal Instability (CIN) Chemosensitivity Generally more sensitive to radiation Often less responsive to chemoradiation alone Surgical Approach Frequently requires cervical anastomosis Usually Ivor-Lewis (intrathoracic anastomosis)

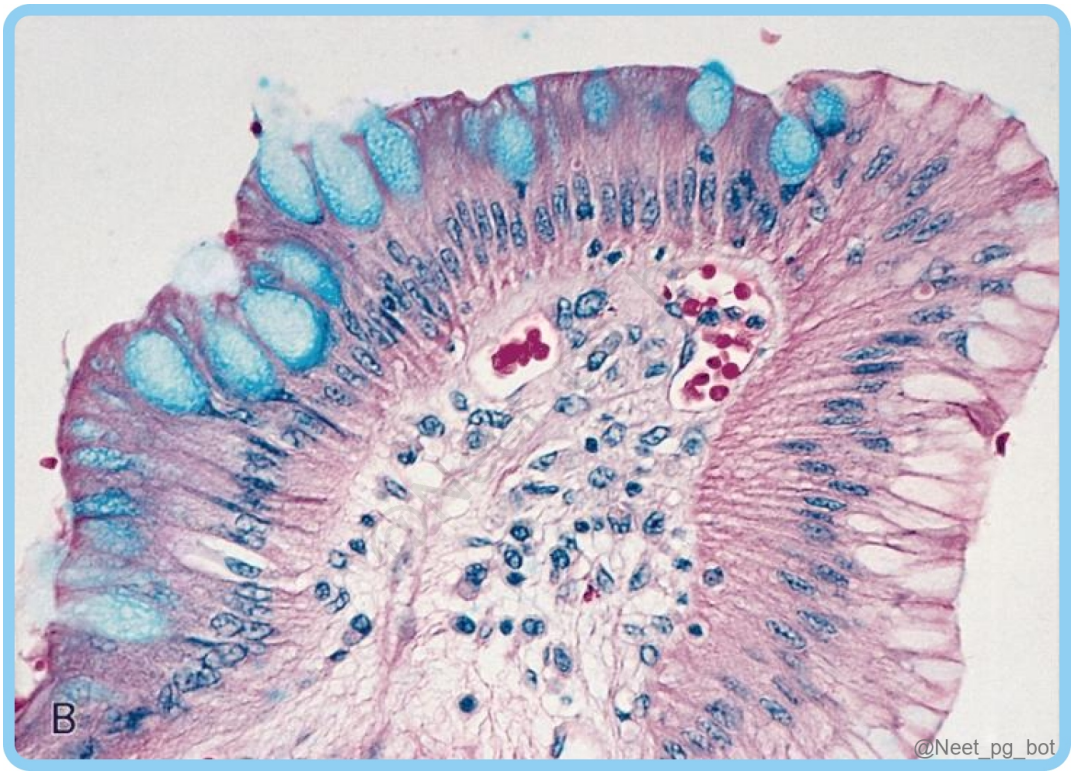

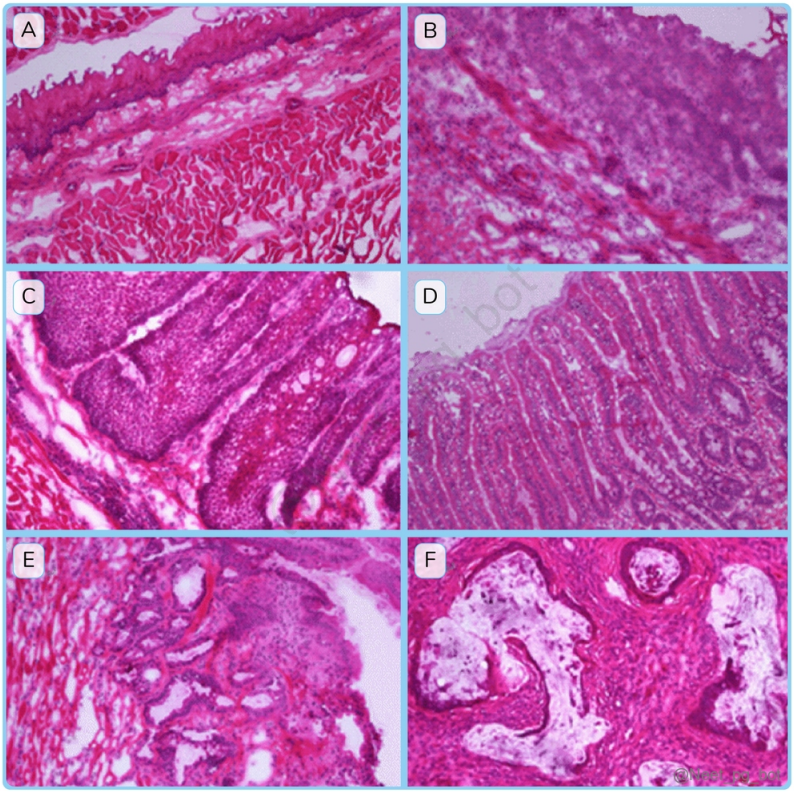

References:

Robbins and Cotran, Pathologic Basis of Disease, 10th Edition, Pages 761-763, 767.

↑ *Back to this question in Part A*

@Neet_pg_bot

Q4: A woman presented with dysphagia to solids for a month. On examination, there are multiple lesions on the lips. An endoscopy reveals obstructive lesions in the upper oesophagus. Which of the following additional findings can be seen in this patient? (Q845641)

A. Development of GI polyps

B. Degeneration of nitric oxide–producing neurons

C. Iron deficiency anemia

D. Apple core appearance on imaging

Correct Answer: C. Iron deficiency anemia

■ *Listen (English)*

■ *Listen (Hindi)*

Explanation: This patient's condition is most likely suggestive of Plummer-Vinson syndrome, which is associated with iron deficiency anemia. Plummer-Vinson Syndrome (Sideropenic Dysphagia) Other names: Paterson-Brown-Kelly syndrome Characterized by a triad of: Iron-deficiency anemia (Sideropenia) Atrophic glossitis Post- Cricoid Dysphagia (Upper esophageal webs) Common in middle-aged women Increased risk of squamous cell carcinoma (pharynx and proximal esophagus) Post cricoid Dysphagia is caused by esophageal webs/rings in the upper esophagus which leads to swallowing difficulties.

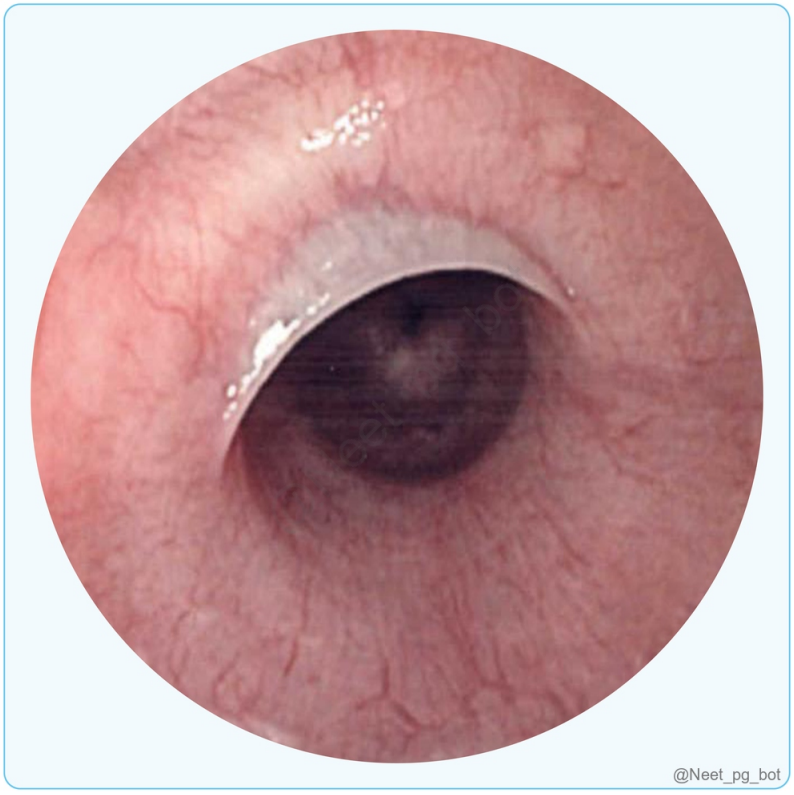

References:

Robbins and Cotran Pathologic Basis of Disease, 10th Edition, Page 757.

www.ncbi.nlm.nih.gov/pmc/articles/PMC1586011/

radiopaedia.org/cases/oesophageal-carcinoma-8

↑ *Back to this question in Part A*

@Neet_pg_bot

Q5: A 45-year-old male presents with complaints of severe odynophagia, retrosternal chest pain, and difficulty in swallowing solids and liquids for the past week. He has a

history of untreated HIV infection with a CD4 count of 80 cells/mm^3. An upper gastrointestinal endoscopy image is shown below. What is the most likely diagnosis? (Q845642)

A. CMV esophagitis

B. HSV esophagitis

C. Eosinophilic esophagitis

D. Candida esophagitis



Correct Answer: D. Candida esophagitis

■ *Listen (English)*

■ *Listen (Hindi)*

Explanation: The clinical scenario and endoscopy showing curd-like plaques suggest Candida esophagitis. Candida esophagitis is an opportunistic infection seen in immunocompromised individuals (e.g., HIV/AIDS, cancer patients, long-term corticosteroid therapy or long-term immunosuppressive therapy) CMV esophagitis (Option A): Shallow, linear, or serpiginous ulcers on endoscopy. HSV esophagitis (Option B): Punched-out ulcers on endoscopy Eosinophilic esophagitis (Option C): Seen in patients with allergy and atopy but not associated with immunodeficiency.

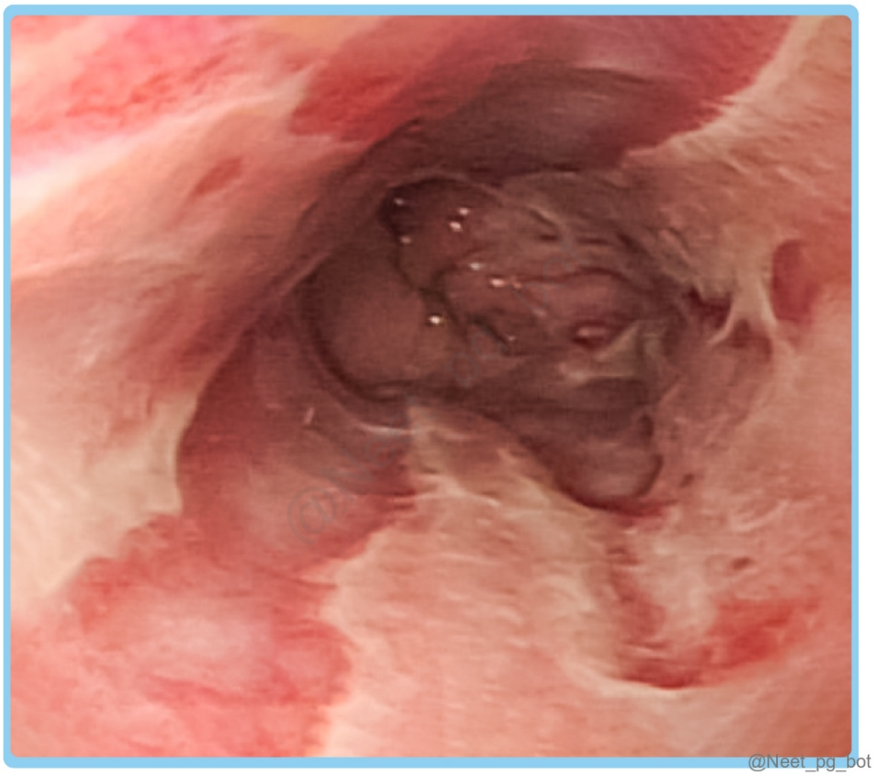
@Neet_pg_bot


@Neet_pg_bot

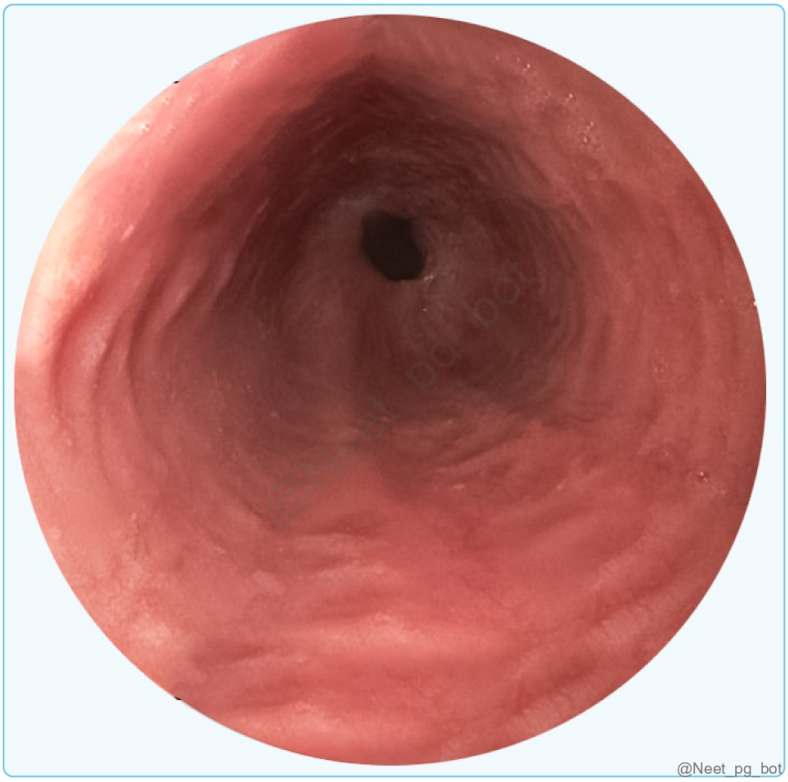

References:

Robbins and Cotran, Pathologic Basis of Disease, 10th Edition, Page 758-759

↑ *Back to this question in Part A*

@Neet_pg_bot

Q6: Which of the following is true regarding the condition shown in the endoscopic image below? (Q845643)

A. Its cause is primarily infectious.

B. Characteristic rat tail appearance.

C. Interleukin 5 has a major role in pathogenesis.

D. Diagnosed by observing at least ten lymphocytes/HPF.

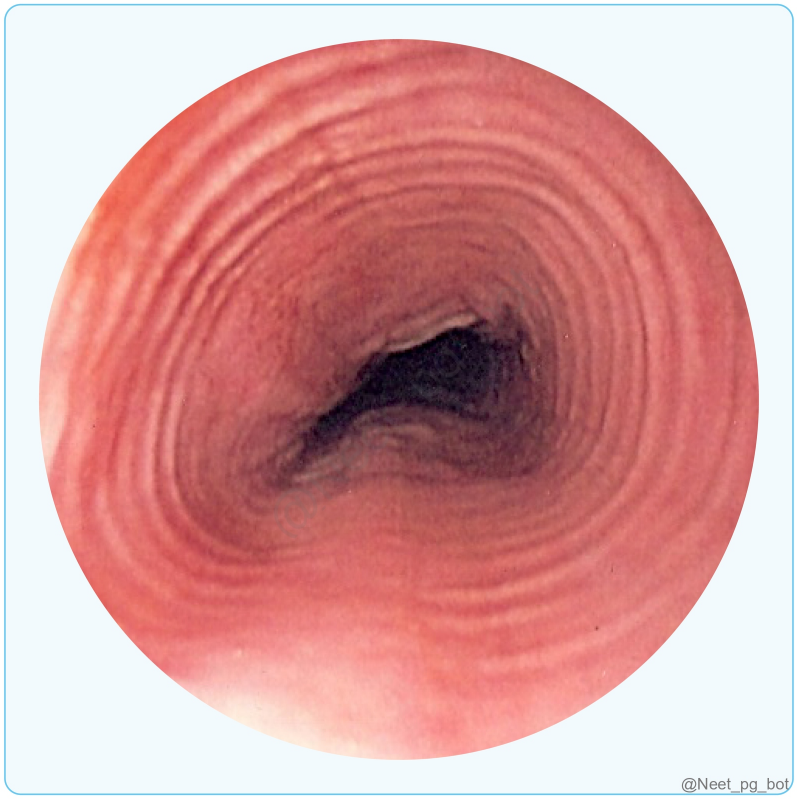

Correct Answer: C. Interleukin 5 has a major role in pathogenesis.

- *Listen (English)*
- *Listen (Hindi)*

Explanation: The given image suggests eosinophilic esophagitis, where Interleukin 5 has a major role in pathogenesis. Eosinophilic Esophagitis: Triggered by allergic reactions to food or environmental allergens (Option A) Associated with atopic dermatitis, allergic rhinitis, asthma, and peripheral eosinophilia Pathophysiology Interleukin 5 (IL-5) key cytokine for eosinophil maturation and activation Clinical Manifestations Dysphagia Epigastric pain Dyspepsia Chest pain Food impaction Diagnostic Criteria Eosinophils ≥ 15 per high power field (HPF) on HPE (Option D) Endoscopic Findings: Stacked circular rings ("feline esophagus") (Option C) Strictures Linear furrows Characteristic rat tail appearance (Option B)- Rat tail appearance is seen in achalasia cardia. The characteristic appearance seen in eosinophilic esophagitis on endoscopy is "feline esophagus" which refers to the presence of stacked circular rings.

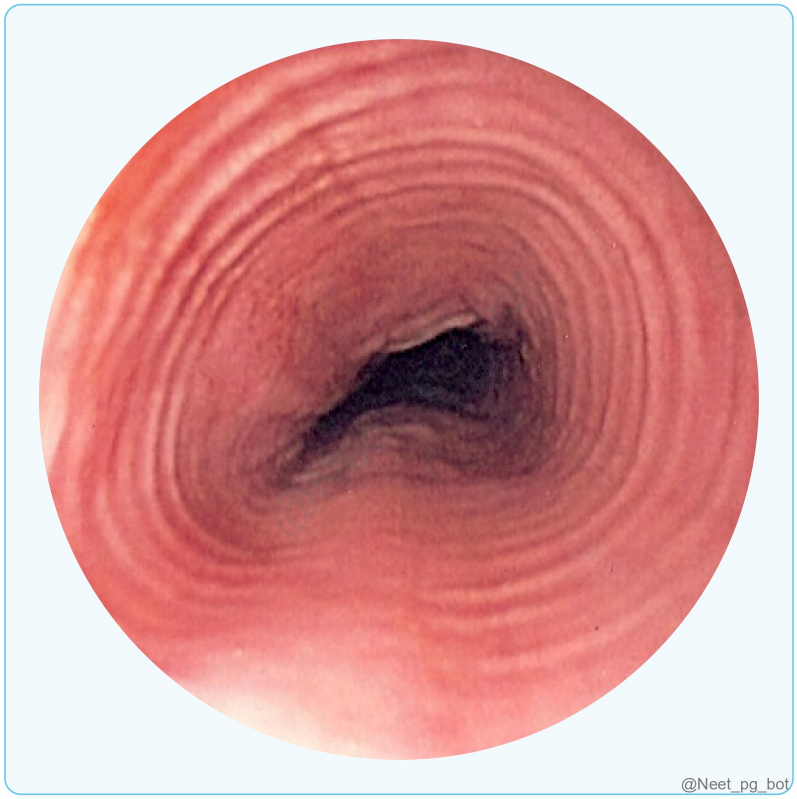

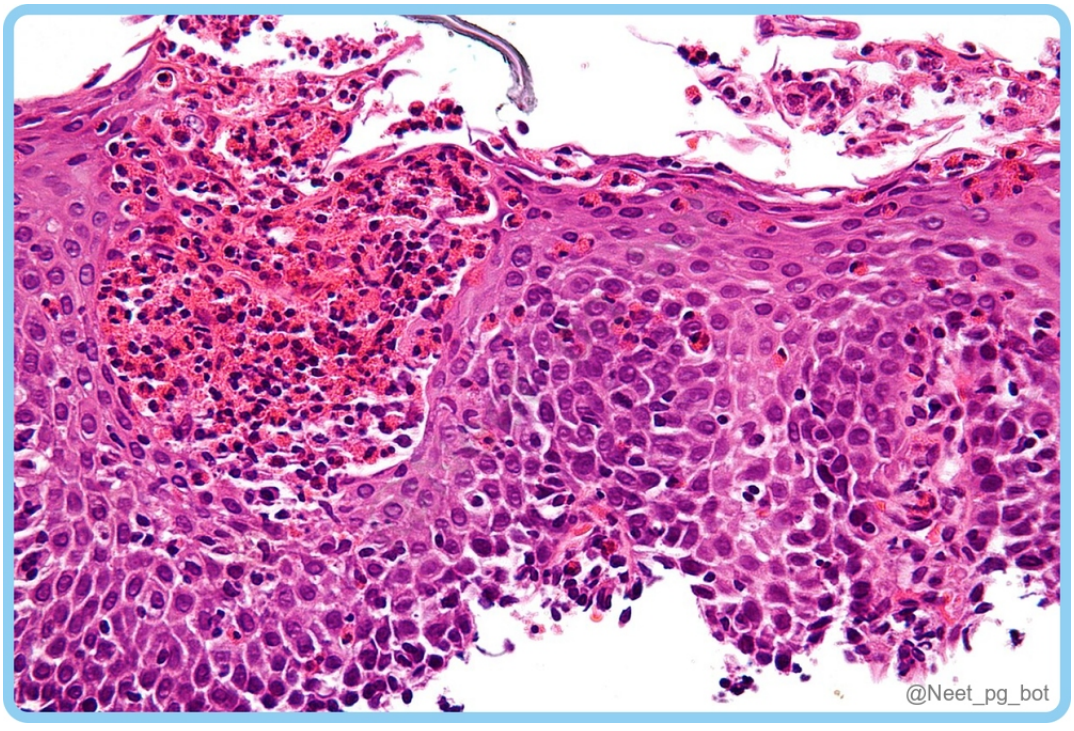

References:

Robbins and Cotran, Pathologic Basis of Disease, 10th Edition, Page no: 760

Drug-Induced Esophagitis - StatPearls - NCBI Bookshelf

↑ *Back to this question in Part A*

@Neet_pg_bot

Q7: Identify the correct statement/s regarding carcinoma of the oesophagus SCC is more common in the lower two-thirds of the oesophagus Smoking increases the risk of both SCC and adenocarcinoma H. pylori is associated with a decreased risk of oesophageal adenocarcinoma Adenocarcinoma is the overall most common type SCC is linked to fermented milk- mursik, which contains acetaldehyde (Q845644)

A. 1, 3, 5

B. 2, 3, 5

C. 1, 2, 4

D. 2, 4, 5

Correct Answer: B. 2, 3, 5

■ *Listen (English)*

■ *Listen (Hindi)*

Explanation: Characteristic Squamous Cell Carcinoma (SCC) Adenocarcinoma of Esophagus Predominant location Upper two-thirds of the oesophagus (Statement 1 ruled out) The lower third of the oesophagus, near GE junction Epidemiology Overall, the more common type (Statement 4 ruled out) Increasing due to an increase in GERD Risk Factors Smoking, Alcohol HPV infection Caustic esophageal injury, Achalasia Tylosis Plummer-Vinson syndrome Diets deficient in fruits or vegetables Frequent consumption of very Hot beverages. Previous radiation to the mediastinum Fermented milk (mursik) containing acetaldehyde Chronic gastroesophageal reflux disease (GERD) Obesity Smoking Low fruit and vegetable diet Scleroderma p16 and RB gene mutations Protective factor Healthy diet H.pylori- reduces acid, hence reducing GERD. Precursor Lesion None Barrett's oesophagus (metaplasia of squamous to columnar) Histology Keratinisation and pearl formation Glandular differentiation Clinical Presentation Dysphagia, weight loss, chest pain Dysphagia, GERD symptoms, weight loss Prognosis Generally less favourable Generally more favourable

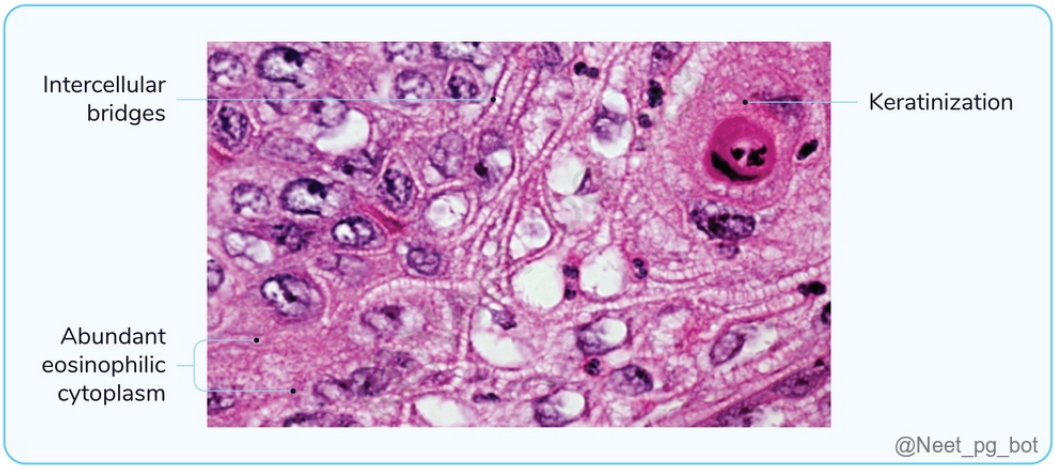

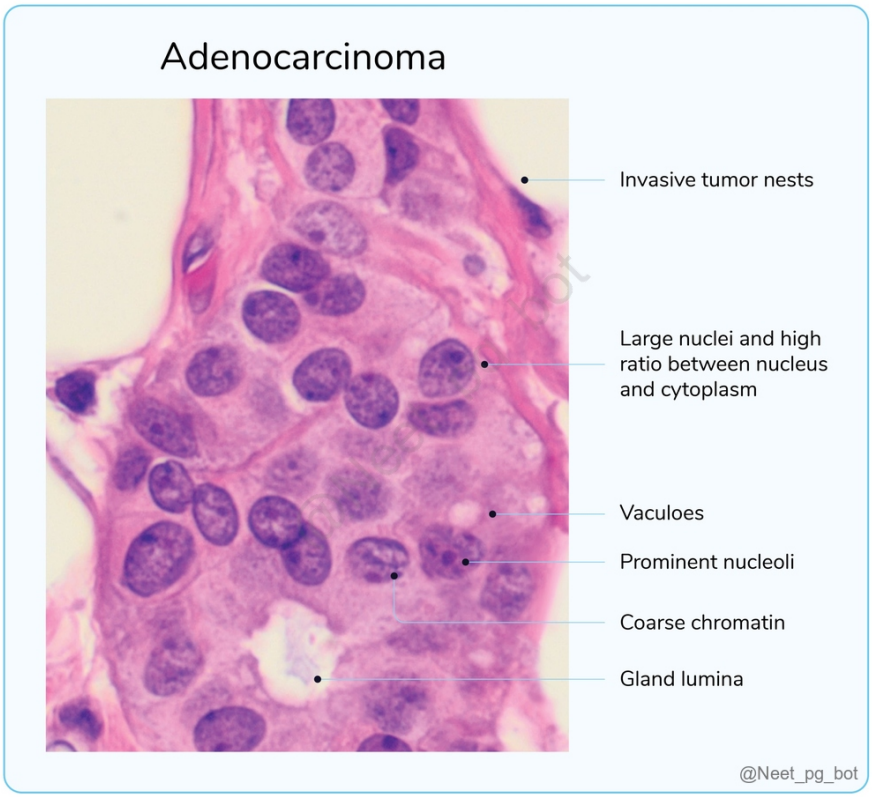

References:

Robbins and Cotran, Pathologic Basis of Disease, 10th Edition, Page no: 762-764 Esophageal Cancer - StatPearls - NCBI Bookshelf (nih.gov)

↑ *Back to this question in Part A*

@Neet_pg_bot

Q8: Which of the following is the most common site of fistulization in congenital GI anomalies? (Q890287)

A. Ileum

B. Colon

C. Esophagus

D. Stomach

Correct Answer: C. Esophagus

Explanation: The most common congenital fistula involving the gastrointestinal tract is a tracheoesophageal fistula (TEF) , which involves an abnormal communication between the esophagus and the trachea. TEF is most often associated with esophageal atresia and represents the most frequent site of fistulization among congenital GI anomalies. The most common pattern is proximal esophageal atresia with a distal tracheoesophageal fistula . Atresia: A complete obstruction of the lumen due to failure of normal recanalisation during development (e.g., esophageal or intestinal atresia). Fistula: An abnormal communication between two epithelial-lined structures , such as the trachea and esophagus in tracheoesophageal fistula. Ileum (Option A): Congenital anomalies of the ileum most commonly include Meckel diverticulum or intestinal atresia , rather than fistula formation. Colon (Option B): Congenital fistulas involving the colon may occur in anorectal malformations , but they are less common than tracheoesophageal fistula. Stomach (Option D): Congenital fistulas involving the stomach are rare and are not the most common form of fistulization in GI developmental anomalies.

References:

Robbins, Cotran & Kumar, Pathologic Basis of Disease, 11th Edition, Page 688

↑ *Back to this question in Part A*

@Neet_pg_bot

Q9: Heterotopic (ectopic) gastric mucosa most commonly occurs in which of the following locations? (Q890289)

A. Cervical oesophagus

B. Rectum

C. Ileum (outside Meckel diverticulum)

D. Colon

Correct Answer: A. Cervical oesophagus

Explanation: Ectopic gastric mucosa most commonly occurs in the proximal (cervical) oesophagus as an “inlet patch”. It is usually a congenital lesion located just below the upper oesophageal sphincter and is often asymptomatic, discovered incidentally during endoscopy. Endoscopic appearance: Well-defined salmon-coloured patch Contrasts with the normal grey-white squamous oesophageal mucosa Most inlet patches are asymptomatic Possible complications: Esophagitis Ulceration Stricture formation Bleeding or fistula formation (rare) Dysplasia and adenocarcinoma (very rare)

References:

https://www.pathologyoutlines.com/topic/esophagusectopicgastric.html

https://pmc.ncbi.nlm.nih.gov/articles/PMC12432125/

↑ *Back to this question in Part A*

@Neet_pg_bot

Q10: A 48-year-old man has intermittent dysphagia to solids with occasional food impaction. Endoscopy shows a thin ring, as shown in the image, at the gastroesophageal junction. What is the diagnosis? (Q890292)

A. Esophageal web

B. Achalasia

C. Schatzki ring

D. Type A ring

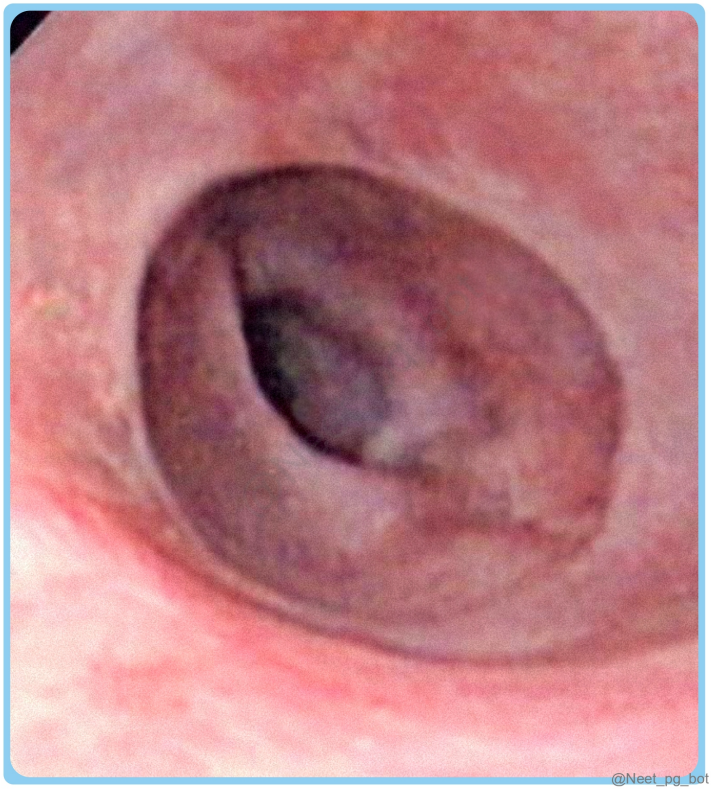

Correct Answer: C. Schatzki ring

Explanation: Schatzki ring presents with intermittent, non-progressive, solid dysphagia and is located at the gastroesophageal junction . Oesophageal Webs and Rings: Oesophageal webs (Option A): Found in the proximal oesophagus Covered by stratified squamous epithelium . Oesophageal rings: Found in the distal oesophagus near the gastroesophageal junction. Ring Type Location Structure Type A ring (Option D) Above the gastroesophageal junction Muscular ring formed by distal esophageal muscle Type B ring (Schatzki ring) At the gastroesophageal junction Thin mucosal ring causing luminal narrowing Type C ring Below the gastroesophageal junction Indentation produced by the diaphragm (not a true ring) Schatzki rings are the most common type of ring and can cause symptoms if luminal narrowing occurs. Achalasia (Option B): Achalasia results from failure of lower esophageal sphincter relaxation due to loss of inhibitory neurons in the myenteric plexus. It causes progressive dysphagia to both solids and liquids , rather than intermittent dysphagia.

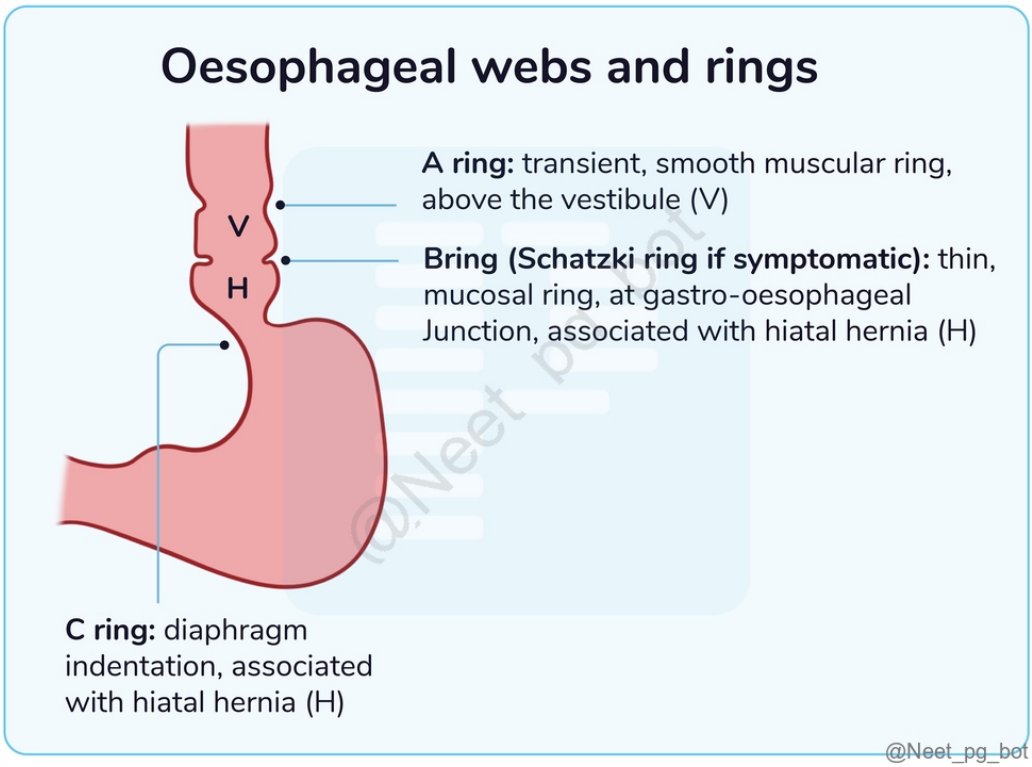

References:

https://www.ncbi.nlm.nih.gov/books/NBK539771/

https://radiopaedia.org/articles/schatzki-ring

↑ *Back to this question in Part A*

@Neet_pg_bot

Q11: A 40-year-old man from rural South America presents with progressive dysphagia to solids and liquids and chronic constipation. Imaging shows findings as shown. What is the mechanism of his oesophageal disease? (Q890295)

A. Degeneration of nitric oxide-producing neurons

B. Autoimmune destruction of inhibitory neurons

C. Destruction of the myenteric plexus

D. Smooth muscle fibrosis

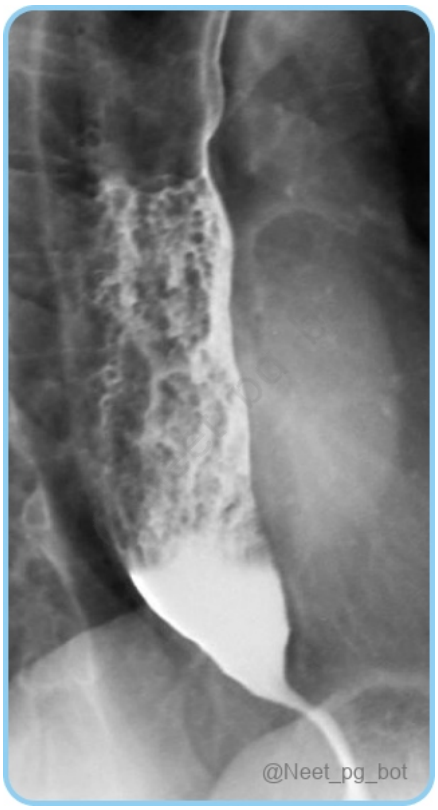

Correct Answer: C. Destruction of the myenteric plexus

Explanation: This clinical presentation is typical of secondary achalasia caused by Chagas disease (American trypanosomiasis) . The disease is caused by Trypanosoma cruzi , which infects and destroys the Auerbach (myenteric) plexus of the gastrointestinal tract. Loss of the myenteric plexus results in: Failure of esophageal peristalsis Impaired relaxation of the lower esophageal sphincter (LES) Progressive dilation of the esophagus (megaesophagus) Chagas disease can also affect other regions containing the myenteric plexus , including the colon (megacolon) and occasionally the duodenum and ureters . Chagas Disease Cause: Trypanosoma cruzi infection Transmission: Triatomine (“kissing”) bug Mechanism: Destruction of Auerbach (myenteric) plexus Major GI manifestations: Megaesophagus Megacolon Degeneration of nitric oxide-producing neurons (Option A) : Seen in primary achalasia. Autoimmune destruction of inhibitory neurons (Option B) : Proposed in idiopathic achalasia. Smooth muscle fibrosis (Option D) : Seen in systemic sclerosis (hypotensive LES).

References:

Robbins, Cotran & Kumar, Pathologic Basis of Disease, 11th Edition, Page 689

↑ *Back to this question in Part A*

@Neet_pg_bot

Q12: Which of the following statements regarding primary achalasia is incorrect? (Q890298)

A. Degeneration of nitric oxide-producing inhibitory neurons

B. May involve degeneration of the dorsal motor nucleus of the vagus

C. Not associated with autoimmune conditions

D. Loss of LES relaxation

Correct Answer: C. Not associated with autoimmune conditions

Explanation: Primary achalasia is thought to have an immune-mediated component, supported by associations with autoimmune disorders and immunoregulatory gene polymorphisms. Primary Achalasia: Motility disorder characterised by failure of the lower esophageal sphincter (LES) relaxation (Option D) and absence of normal esophageal peristalsis. The underlying mechanism is degeneration of inhibitory neurons in the Auerbach (myenteric) plexus , particularly those producing nitric oxide (NO) and vasoactive intestinal peptide (VIP) . (Option A) May involve: Extraesophageal vagus nerve Dorsal motor nucleus of vagus (Option B) Possible immune-mediated mechanism: Association with HSV-1 exposure Immunoregulatory gene polymorphisms Coexistence with autoimmune disorders (e.g., Sjögren syndrome, autoimmune thyroid disease)

References:

Robbins, Cotran & Kumar, Pathologic Basis of Disease, 11th Edition, Page 689

↑ *Back to this question in Part A*

@Neet_pg_bot

Q13: Which of the following statements regarding eosinophilic esophagitis is incorrect? (Q890302)

A. Commonly associated with atopic disorders

B. Characterised by superficial intraepithelial eosinophils

C. Strongly associated with Barrett's oesophagus

D. Endoscopic dilation relieves dysphagia but not inflammation

Correct Answer: C. Strongly associated with Barrett's oesophagus

Explanation: Eosinophilic esophagitis has no association with Barrett's oesophagus . Eosinophilic Esophagitis (EoE): Chronic, immune-mediated oesophageal inflammation associated with atopy . (Option A) Associations: Asthma, allergic rhinitis, atopic dermatitis, and mild peripheral eosinophilia. Not associated with Barrett's oesophagus. Symptoms: Dysphagia, food impaction GERD-like symptoms Vomiting & feeding intolerance (infants) Histology: ■ Numerous superficial intraepithelial eosinophils (Option B) Clusters/sheets + intercellular edema Not specific → exclude GERD, Crohn disease, infections Endoscopy: “Feline oesophagus” (stacked rings) ■ ■■ Linear furrows, strictures Treatment: Empiric elimination of cow’s milk and related dairy products

Pharmacologic treatment: Proton pump inhibitors Topical corticosteroids IL-4/IL-13 receptor antagonist Dilation for strictures (does not reduce inflammation) (Option D)

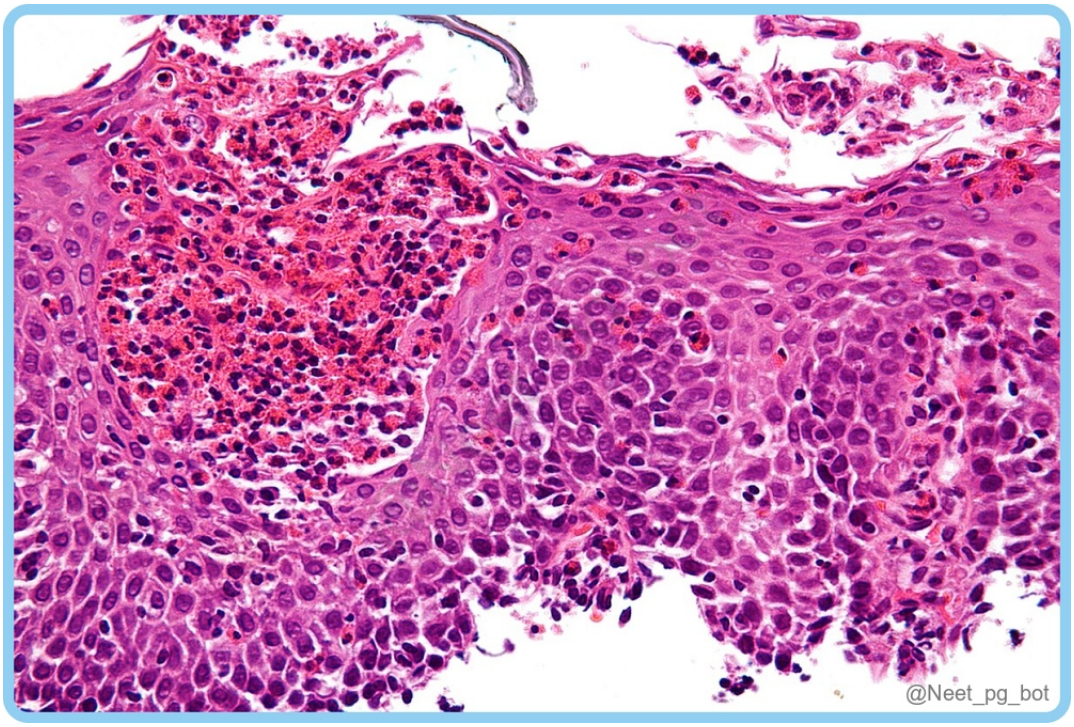

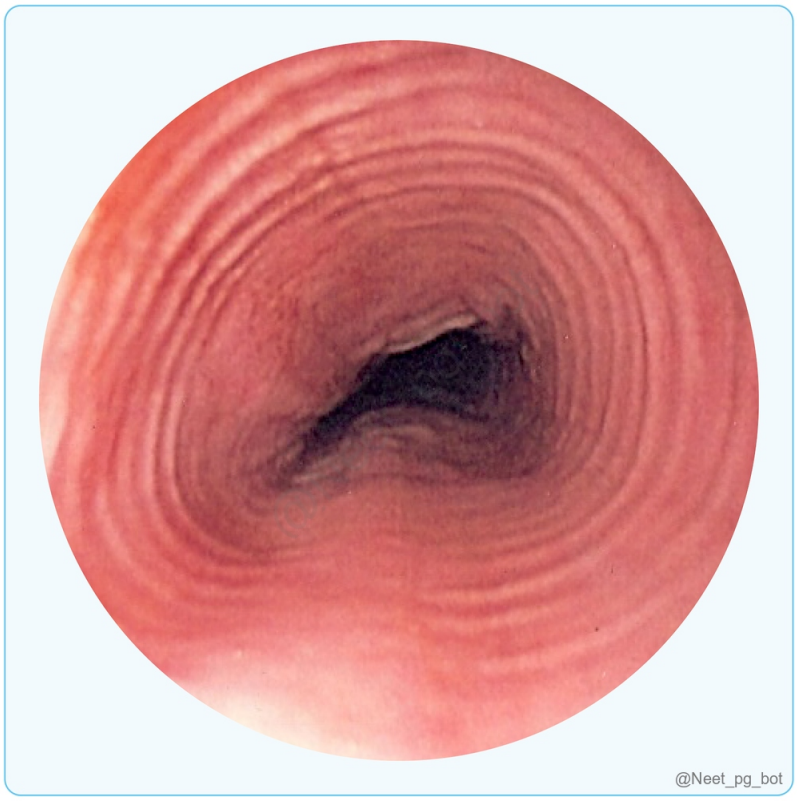



References:

Robbins, Cotran & Kumar, Pathologic Basis of Disease, 11th Edition, Pages 690, 691

↑ *Back to this question in Part A*

@Neet_pg_bot

Q14: Which of the following statements regarding Mallory-Weiss tear is incorrect? (Q890305)

A. Usually longitudinal and located near the GEJ

B. Commonly result from severe retching or vomiting

C. Transmural perforation of the oesophageal wall

D. Most cases resolve without surgical intervention

Correct Answer: C. Transmural perforation of the oesophageal wall

Explanation: Mallory-Weiss tears are mucosal lacerations , not transmural perforations. Transmural rupture characterises Boerhaave syndrome. Mallory-Weiss tear: Longitudinal mucosal laceration at the gastroesophageal

junction (GEJ). (Option A) At or across GEJ May extend into the proximal stomach Feature Boerhaave Syndrome Mallory-Weiss Syndrome Definition Oesophageal perforation Mucosal laceration near the gastroesophageal junction Cause Forceful vomiting Forceful vomiting, retching, coughing, or straining (Option B) Location The lower part of the oesophagus (left side) Gastroesophageal junction Symptoms Vomiting, chest pain, subcutaneous emphysema, pleural effusion, fever, tachycardia, tachypnea, and a crunching sound on heart auscultation Vomiting, hematemesis, upper abdominal pain, hypotension, tachycardia Complications Pleural effusion, increased morbidity and mortality if delayed diagnosis and treatment Rarely massive bleeding, associated with portal hypertension Diagnosis Clinical evaluation, imaging studies Clinical evaluation, endoscopy Treatment Drainage, closure of perforation, and supportive measures Endoscopic methods (multipolar electrocoagulation, epinephrine injection, band ligation), angiographic transarterial embolisation, and rarely surgery Prognosis Poor if not treated promptly Usually conservative (Option D) Rarely requires surgery

References:

Sabiston Textbook of Surgery, 21st edition, Page 1235

Bailey and Love’s Short Practice of Surgery, 28th Edition, Pages 1127-1129

Robbins, Cotran & Kumar, Pathologic Basis of Disease, 11th Edition, Page 689

↑ *Back to this question in Part A*

@Neet_pg_bot

• [09_Gastrointestinal Tract] 040 Peptic Ulcer Disease Gastric Polyps And Tumors - I

« Back to Folder Directory

[09_Gastrointestinal Tract] 040 Peptic Ulcer Disease Gastric Polyps And Tumors - I — Quick Jump

Q1 (p. 1913)	*Q2 (p. 1915)*	*Q3 (p. 1916)*	*Q4 (p. 1916)*	*Q5 (p. 1917)*	*Q6 (p. 1918)*
Q7 (p. 1919)	*Q8 (p. 1921)*	*Q9 (p. 1923)*	*Q10 (p. 1924)*	*Q11 (p. 1924)*	*Q12 (p. 1925)*
Q13 (p. 1926)	*Q14 (p. 1928)*	*Q15 (p. 1930)*	*Q16 (p. 1931)*	*Q17 (p. 1932)*	*Q18 (p. 1934)*
Q19 (p. 1934)	*Q20 (p. 1935)*	*Q21 (p. 1936)*			

Q1: A 45-year-old patient presents with persistent abdominal discomfort, nausea, weight loss, and occasional diarrhoea. He was recently diagnosed with a viral infection. The following gross image of the gastric mucosa is observed upon upper gastrointestinal endoscopy. Which of the following is correct regarding the patient's condition? (Q845222)

A. Associated with excessive secretion of TNF-α.

B. Histopathologically, villous atrophy is observed.

C. Increases the risk of gastric carcinoma.

D. More common in females and can cause protein-losing enteropathy.

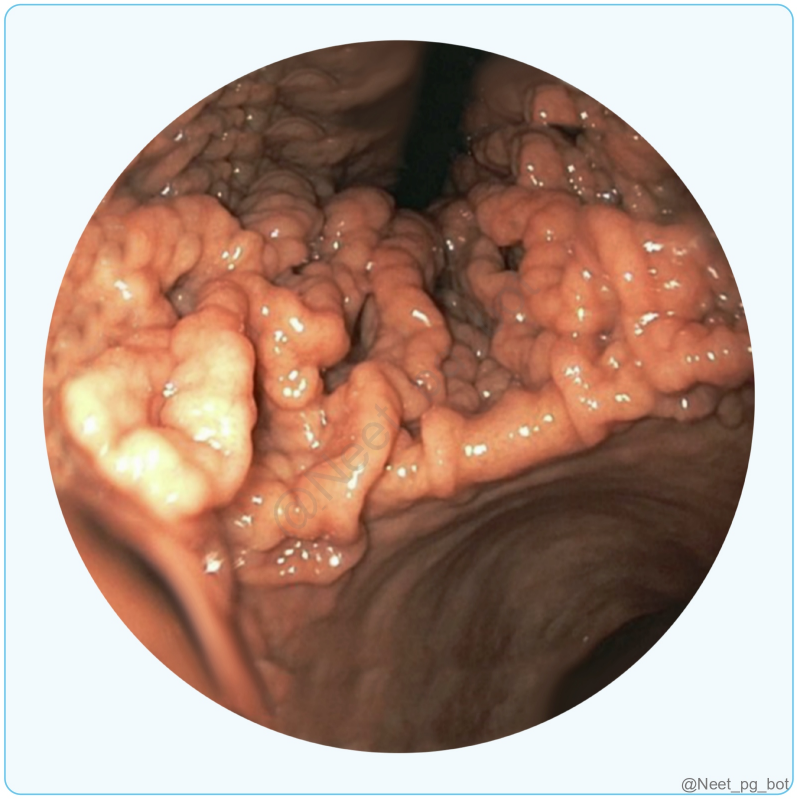

Correct Answer: C. Increases the risk of gastric carcinoma.

■ *Listen (English)*

■ *Listen (Hindi)*

Explanation: The endoscopic picture reveals thickened or giant gastric folds (referred to as Cerebriform rugae) seen in Menetrier's disease. Menetrier's disease is more common in males. (Option D ruled out) It is associated with an increased risk of gastric adenocarcinoma. (Option C). It is caused due to elevated secretions of a mediator called TGF-α. (Option A ruled out) Histopathology reveals elongated, cystic foveolar mucous cell hyperplasia. (Option B ruled out) Menetrier's disease: Menetrier's disease is a rare, acquired premalignant condition characterized by massive overgrowth of the gastric mucous cells (foveolar hyperplasia). Pathophysiology and Associations: TGF-α Overexpression: The disease is caused by the elevated secretion of Transforming Growth Factor-alpha (TGF-α), which activates the epidermal growth factor receptor. CMV Association: In children, the condition is often acute and strongly associated with Cytomegalovirus (CMV) infection; it usually resolves spontaneously after the infection clears. H. pylori Association: In adults, there is a recognized association with Helicobacter pylori infection, though it typically follows a more chronic course than the pediatric form. Anatomical and Endoscopic Findings: Cerebriform Rugae: Endoscopy reveals giant, thickened gastric folds that resemble the gyri of the brain. Antrum Sparing: A classic diagnostic hallmark is that these giant folds typically involve the fundus and body (corpus) of the stomach while sparing the antrum . Protein-Losing Gastropathy: The excessive mucus production leads to significant protein loss, often resulting in hypoalbuminemia and peripheral edema. Pathology and Risk: Histopathology: Shows elongated, "corkscrew" cystic foveolar mucous cell hyperplasia with a concomitant decrease in parietal (acid-producing) cells. Malignancy Risk: It is considered a premalignant state that increases the overall risk of developing gastric adenocarcinoma .

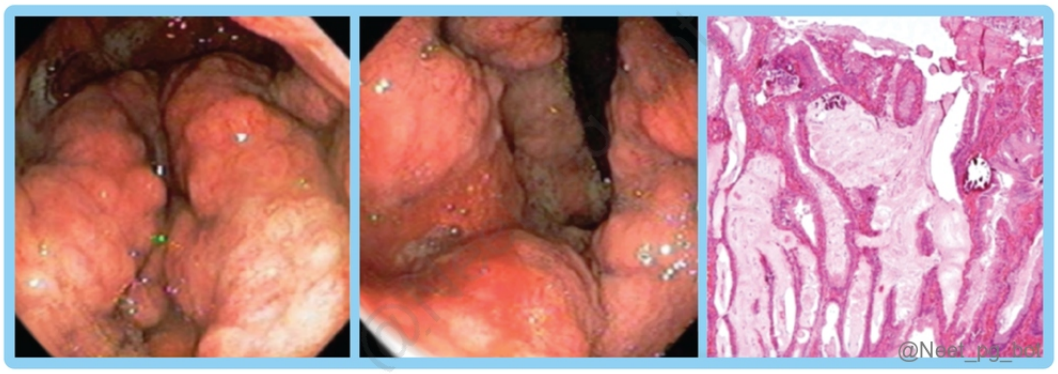

References:

Robbins and Cotran Pathologic Basis of Disease, 10th Edition, Pages 771, 772

↑ *Back to this question in Part A*

@Neet_pg_bot

Q2: A 60-year-old man presents with vague abdominal discomfort and early satiety. Imaging reveals a large mass in the gastric fundus. He undergoes surgical resection of the mass, and histopathology confirms a gastrointestinal stromal tumor (GIST). Which of the following factors is a favorable prognostic indicator of this condition? (Q845244)

A. Tumor size > 10 cm

B. Epithelioid cell type

C. Gastric location

D. Intestinal location

Correct Answer: C. Gastric location

■ *Listen (English)*

■ *Listen (Hindi)*

Explanation: Prognostic factors of GISTs Features Good prognosis Bad prognosis Tumor size < 5cm >10cm (Option A) Mitotic rate < 5 per HPF >10 per HPF Location Gastric Intestinal (Jejunum, Ileum, Rectum) (Option D) Cell type Spindle cell type Epithelioid cell type (Option B) Mutations Wild type GIST (Lack mutations in KIT, PDGFR) Specific PDGFRA mutations, such as the D842V mutation in exon 18 Treatment Responds to Tyrosine kinase inhibitors. Resistant to Tyrosine kinase inhibitors.

References:

Robbins and Cotran Pathologic Basis of Disease, 10th Edition, Page 778

https://www.uptodate.com/contents/clinical-presentation-diagnosis-and-prognosis-of-gastrointestinal-stromal-tumors

↑ *Back to this question in Part A*

@Neet_pg_bot

Q3: Which of the following markers will help confirm the diagnosis of GIST in C-kit negative cases? (Q845242)

A. CD34

B. DOG1

C. S-100

D. CD117

Correct Answer: B. DOG1

■ *Listen (English)*

■ *Listen (Hindi)*

Explanation: 3 markers for GIST: CD117 (C-kit) expression is a hallmark of GISTs and it is the most sensitive marker on immunohistochemistry. (Option D) CD34: Non-specific marker of GIST. (Option A) DOG1: Most specific and specific marker in C-Kit negative cases. (Option B) S-100(Option C): S100 is a marker commonly associated with neural and melanocytic tumors, not typically expressed in GISTs.

References:

Robbins and Cotran Pathologic Basis of Disease, 10th Edition, Page 778

↑ *Back to this question in Part A*

@Neet_pg_bot

Q4: Which of the following is the most common mutation found in GIST (Gastrointestinal Stromal Tumor)? (Q845238)

A. KIT mutation

B. PDGFRA mutation

C. SDH mutation

D. BRAF mutation

Correct Answer: A. KIT mutation

■ *Listen (English)*

■ *Listen (Hindi)*

Explanation: Genetic mutations in GIST: KIT (C-KIT or CD117) mutation is the most common found in GIST. (Option A) PDGFRA mutation (Platelet-Derived Growth Factor Receptor Alpha) (Option B): Seen in a subset of GIST SDH mutation (Succinate Dehydrogenase) (Option C): Usually GIST is seen in pediatric patients when SDH mutation occurs.

References:

Robbins and Cotran Pathologic Basis of Disease, 10th Edition, Page 779

↑ *Back to this question in Part A*

@Neet_pg_bot

Q5: A 55-year-old man with intermittent abdominal pain, nausea, and early satiety has a palpable epigastric mass. Imaging shows a well-defined, heterogeneously enhancing stomach mass, and endoscopic biopsy reveals CD117-positive spindle cells. What is the likely origin of this condition? (Q845236)

A. Cajal cells

B. Goblet cells

C. Paneth cells

D. G cells

Correct Answer: A. Cajal cells

■ *Listen (English)*

■ *Listen (Hindi)*

Explanation: Gastrointestinal Stromal Tumor (GIST): Cells of origin Cajal cells (Pacemaker cells of GIT) Location Stomach > Intestine GIST is the most common mesenchymal tumor of stomach. Mutations Most common- c-KIT/CD117 Others: PDGFR S uccinate dehydrogenase (SDH)- S mall baby(Pediatric GIST) Mechanism c-KIT mutation- Increase in tyrosinase kinase activity Markers Most sensitive marker of GIST: CKIT/CD117 Most specific marker of GIST: DOG1 Treatment Surgery Tyrosine Kinase inhibitors- Imatinib

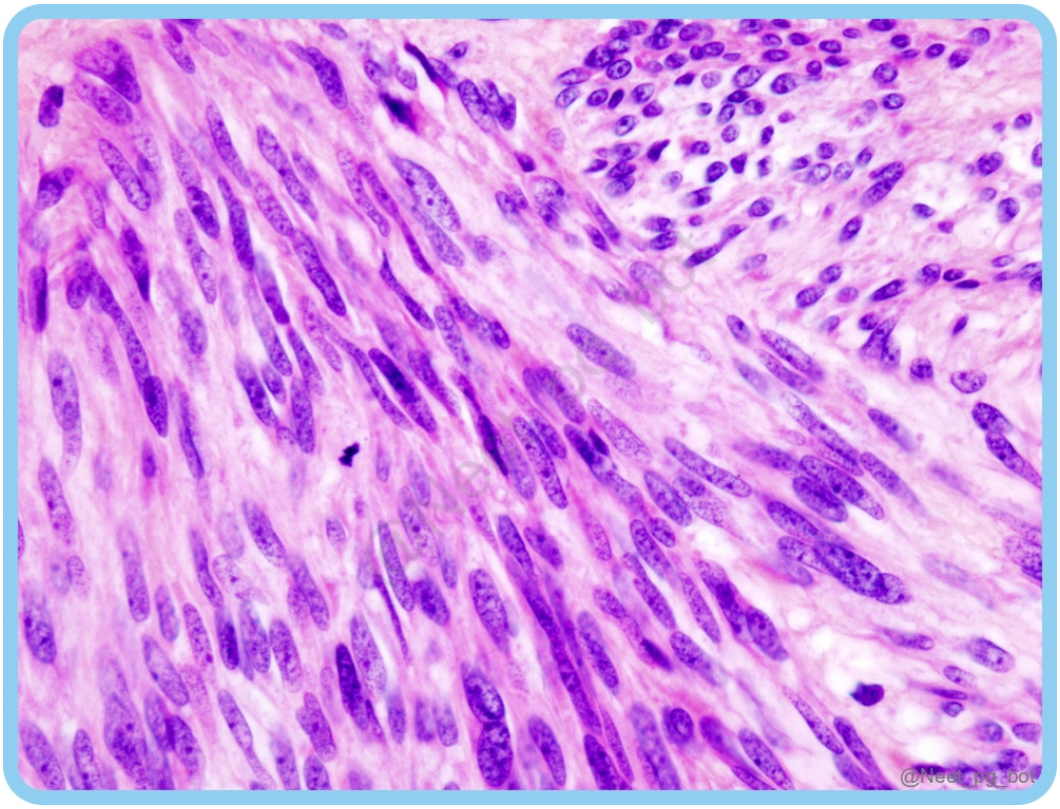

References:

Robbins and Cotran Pathologic Basis of Disease, 10th Edition, Page 778

↑ *Back to this question in Part A*

@Neet_pg_bot

Q6: A 55-year-old male presents with episodes of flushing, sweating, and colicky abdominal pain. Upper gastrointestinal endoscopy reveals a yellow-tan intramural mass in the stomach. Biopsy revealed sheets of uniform cells with scant granular cytoplasm. What is the most likely diagnosis? (Q845234)

A. Carcinoid tumor

B. Gastric outlet obstruction

C. Hypertrophic pyloric stenosis

D. Crohn's disease

Correct Answer: A. Carcinoid tumor

■ *Listen (English)*

■ *Listen (Hindi)*

Explanation: Based on the patient's presentation and histological findings, the most likely diagnosis is a Carcinoid tumor that originates from scattered neuroendocrine cells in the GIT. Carcinoid tumor arises from neuroendocrine cells. They present with symptoms like flushing, bronchospasm, abdominal pain, diarrhea, and occasionally weight loss due to the secretion of vasoactive substances like serotonin , leading to carcinoid syndrome . Gastric outlet obstruction (Option B): Can be caused by hypertrophic pyloric stenosis in children. Metabolic abnormalities like metabolic alkalosis and paradoxical aciduria are seen. Hypertrophic pyloric stenosis is a congenital condition where an olive-shaped lump can be palpated in the child's abdomen. Crohn's disease (Option D): Crohn's disease is a chronic granulomatous inflammation that affects the entire gastrointestinal tract (most commonly intestine), characterized by non-caseating granulomas in intestine and stomach.

References:

Robbins and Cotran Pathologic Basis of Disease, 10th Edition, Pages 777, 778

↑ *Back to this question in Part A*

@Neet_pg_bot

Q7: A 48-year-old female presents with recurrent abdominal pain, bloating, and early satiety for the past few months. Endoscopic biopsy revealed lympho-epithelial lesions with infiltration of small lymphoid cells. Which of the following statements is true regarding this condition? (Q845233)

A. Dense neutrophilic infiltrate

B. Reactive-appearing T-cell follicles seen

C. Plasmacytic differentiation seen

D. Presents as discrete small nodules in the GI tract

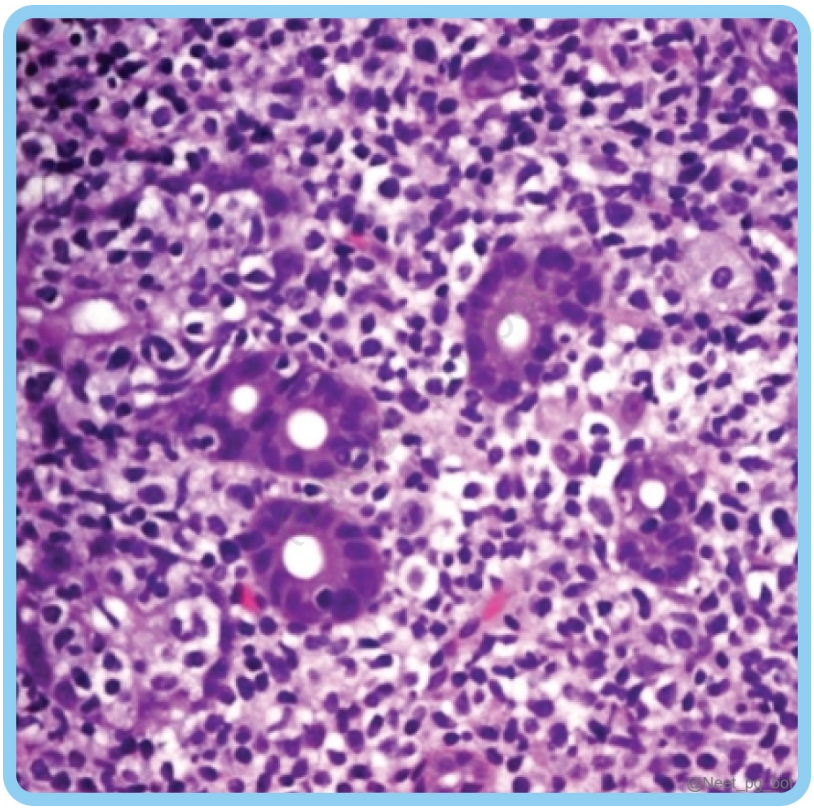

Correct Answer: C. Plasmacytic differentiation seen

■ *Listen (English)*

■ *Listen (Hindi)*

Explanation: Plasmacytic differentiation seen The given presentation and biopsy findings suggest gastric MALT lymphoma , a type of non-Hodgkin lymphoma originating from the stomach's mucosa-associated lymphoid tissue (MALT). Biopsy finding: Lympho-epithelial lesions with infiltration of small lymphoid cells. Lympho → malignant lymphoid (B-cells) infiltrate. Epithelial → invasion and destruction of gastric glands by these malignant lymphocytes. It is characterised by a dense lymphocytic infiltrate in the lamina propria , creating lympho-epithelial lesions indicative of B-cell involvement (Option A ruled out) . Gastric MALToma involves B-cell follicles and not T-cell follicles (Option B ruled out) . Gastric lymphoma usually causes diffuse thickening , not a discrete polyp/nodule. (Option D ruled out) Gastric MALToma belongs to the category of Marginal Zone Lymphomas (MZL). The major causes include: H. pylori infection , where chronic antigenic stimulation leads to lymphoid proliferation and eventually neoplastic transformation. C hromosomal translocation t(11;18)(q21;q21) , which creates the API2–MALT1 fusion gene . This fusion activates NF-κB signaling, resulting in uncontrolled B-cell survival.

References:

Robbins and Cotran Pathologic Basis of Disease, 10th Edition, Page 777

↑ *Back to this question in Part A*

@Neet_pg_bot

Q8: A 45-year-old female has a history of intermittent epigastric discomfort, nausea, and early satiety. Upper endoscopy reveals gastric wall thickening with a leather bottle appearance. Biopsy of the lesion shows signet ring cells infiltrating the gastric mucosa. What is the most likely diagnosis? (Q845228)

A. Intestinal-type gastric adenocarcinoma

B. Diffuse-type gastric adenocarcinoma

C. Peptic ulcer disease

D. Gastric lymphoma

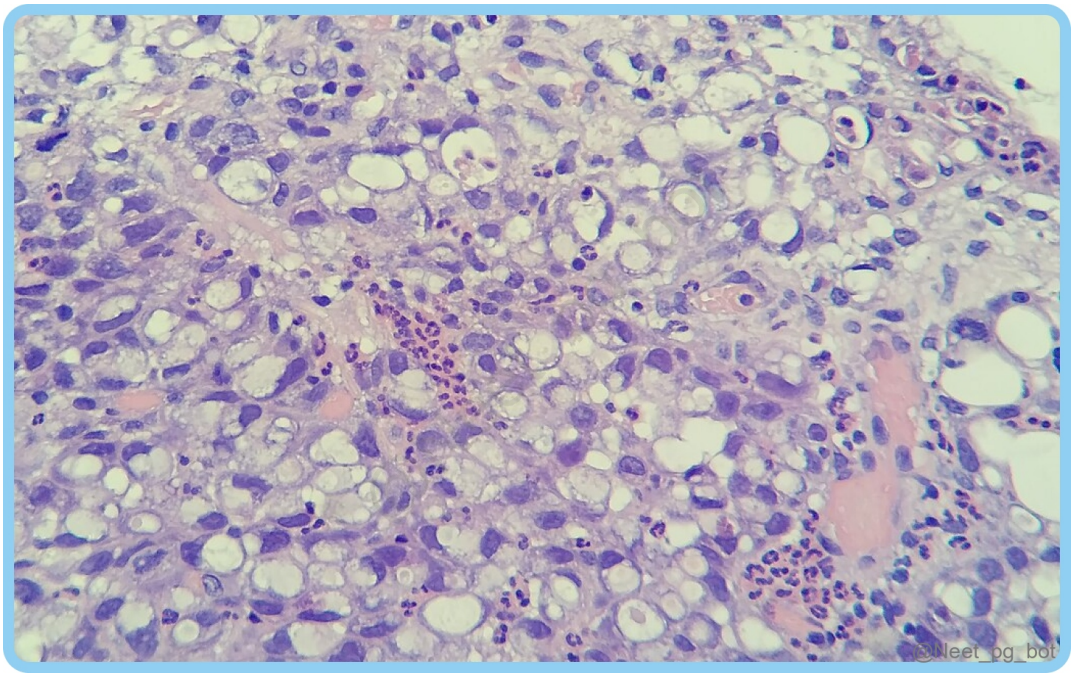

Correct Answer: B. Diffuse-type gastric adenocarcinoma

■ *Listen (English)*

■ *Listen (Hindi)*

Explanation: Diffuse-type gastric adenocarcinoma The given findings suggest diffuse-type gastric adenocarcinoma, characterised by diffuse thickening of the gastric wall and signet ring cells infiltrating the gastric mucosa. Lauren classification: Features Intestinal type Gastric adenocarcinoma (Option A) Diffuse-type gastric adenocarcinoma (Option B) Location Predominantly in the antrum or pyloric region Diffuse involvement of gastric body and fundus Risk factors H. pylori infection, high intake of smoked/pickled foods, smoking, chronic gastritis, old age CDH1 gene mutation, younger age. Genetically diffuse type gastric adenocar shows loss of E-cadherin (CDH1) gene Appearance on endoscopy Ulcerative, polypoid masses (localised growth) Thickening of gastric wall (due to diffuse infiltration). Linitis plastica (leather bottle appearance) Histology Well-differentiated glandular structures with intestinal metaplasia. Signet ring cells and infiltration of poorly cohesive cells into the

gastric mucosa. Seen because cells are filled with mucin. Prognosis Better Poorer Peptic Ulcer Disease (PUD) (Option C) don't show signet ring cells on biopsy.. Gastric Lymphoma (Option D): Usually a maltoma which shows Lympho-Epithelial lesion (LEL).

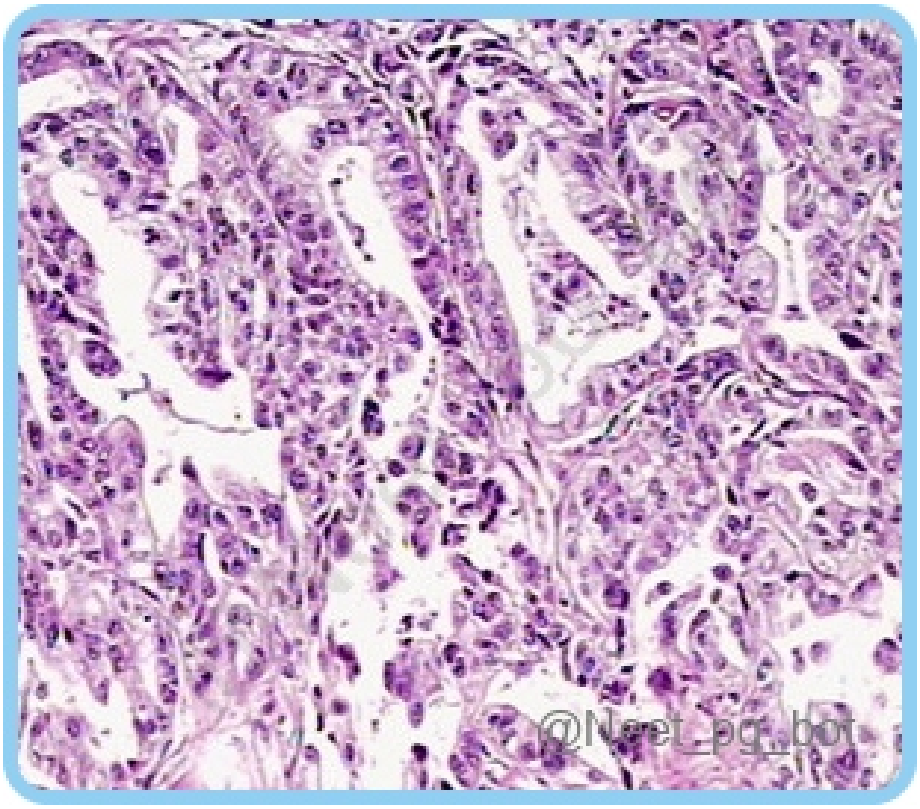

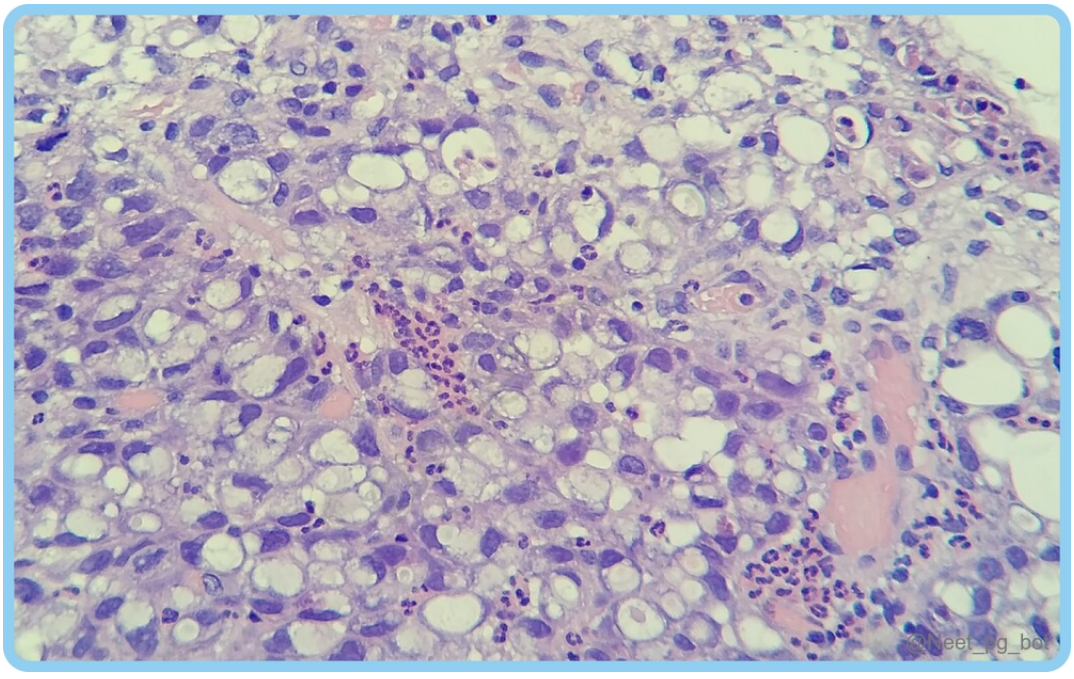

References:

Robbins and Cotran Pathologic Basis of Disease, 10th Edition, Pages 775 - 776

↑ *Back to this question in Part A*

@Neet_pg_bot

Q9: A 60-year-old male presents with a history of epigastric pain, unintentional weight loss, and early satiety over the past few months. An upper GI endoscopy revealed a nodular mass on the gastric wall, and a biopsy revealed well-differentiated glandular structures with intestinal metaplasia. Which of the following is least likely associated with this condition? (Q845226)

A. Helicobacter pylori (H. pylori) infection

B. APC gene mutation

C. CDH-1 gene mutation

D. High intake of smoked or pickled foods

Correct Answer: C. CDH-1 gene mutation

■ *Listen (English)*

■ *Listen (Hindi)*

Explanation: The clinical presentation and biopsy revealing well-differentiated glandular structures with intestinal metaplasia suggest the diagnosis of ‘ Intestinal type of gastric adenocarcinoma ’, which has no significant association with CDH-1 gene mutation. Mutations in the CDH1 gene (E-cadherin), associated with hereditary diffuse gastric cancer (HDGC), can lead to an increased risk of diffuse-type gastric cancer but not related to the intestinal type of gastric cancer. Risk factors for intestinal type of gastric adenocarcinoma: Helicobacter pylori (H. pylori) infection (Option A) High intake of smoked or pickled foods (Option D) APC gene mutation (Option B) : Associated with familial adenomatous polyposis (FAP), which causes adenomas in the entire GI tract. Feature Intestinal-Type Diffuse-Type Microscopic Pattern Cohesive cells form glandular/tubular structures Poorly cohesive cells; often includes Signet Ring Cells Gross Morphology Bulky, exophytic masses or well-demarcated ulcers Infiltrative growth; leads to thickened wall (Linitis Plastica) Primary Location Distal stomach (Antrum/Lesser Curvature) Gastric body/Cardia; can involve the whole stomach Major Risk Factors H. pylori, smoking, diet (nitrates/high salt) Primarily Genetic ; CDH1 mutations Pathogenesis Stepwise progression (Correa Pathway) from metaplasia Arises de novo ; no defined precursor lesions Demographics Older age (mean 55+); more common in males Younger age; equal sex distribution or slight female predilection Spread Pattern Primarily Hematogenous (e.g., to the Liver) Primarily Peritoneal or transmural dissemination Surgical Margin Typically 4-5 cm proximal margin Requires much wider margins (8-10 cm) or total gastrectomy Prognosis Relatively better Poor; highly aggressive

References:

Robbins and Cotran Pathologic Basis of Disease, 10th Edition, Page 775

↑ *Back to this question in Part A*

@Neet_pg_bot

Q10: Which of the following is NOT a recognised risk factor for gastric adenocarcinoma? (Q845225)

A. Alcohol

B. Hot beverages

C. Blood group O

D. H. pylori

Correct Answer: C. Blood group O

■ *Listen (English)*

■ *Listen (Hindi)*

Explanation: Blood group O is not a specific risk factor for gastric adenocarcinoma, but blood group A is a recognised risk factor. Bloog group O patients are at increased risk of Peptic ulcer disease. Blood group A patients are at increased risk of Adenocarcinoma of stomach (gastric adenoma) . The risk factors for gastric adenocarcinoma include : Alcohol (Option A) Smoking Hot beverages (Option B) Smoked and salted food Pernicious anemia Adenomatous polyps Blood group A H. pylori infection (Option D)

References:

Robbins and Cotran Pathologic Basis of Disease, 10th Edition, Page 774

↑ *Back to this question in Part A*

@Neet_pg_bot

Q11: A 45 y/o male presents with recurrent episodes of abdominal pain and persistent heartburn. Upper gastrointestinal endoscopy reveals multiple duodenal ulcers. Lab investigations show elevated serum gastrin levels (> 1000 pg/ml). Which features are most likely associated with the patient's condition? (Q845223)

A. Presence of gastrin-secreting tumors in the stomach

B. Presence of erosive esophagitis and hiatal hernia

C. Hyperplasia of parietal cells within the stomach

D. Association with MEN2 gene mutation

Correct Answer: C. Hyperplasia of parietal cells within the stomach

■ *Listen (English)*

■ *Listen (Hindi)*

Explanation: The characteristic features described in the scenario, including recurrent abdominal pain, heartburn, multiple duodenal ulcers, and elevated serum gastrin levels, strongly suggest a diagnosis of Zollinger-Ellison syndrome. Gastrinomas most commonly arise in the duodenum or pancreas, rather than in the stomach. (Option A ruled out) Mechanism: A gastrinoma secretes excess gastrin, which stimulates the parietal cells, leading to their hyperplasia. The hyperplastic parietal cells then cause marked acid hypersecretion, and the resulting excess acid leads to multiple, refractory peptic ulcers, often located distal to the duodenal bulb. (Option C) Presence of erosive esophagitis and hiatal hernia (Option B): These features are commonly associated with gastroesophageal reflux disease (GERD), not Zollinger-Ellison syndrome. Association with MEN2 gene mutation (Option D): Gastrinomas are sporadic in 75% of cases. Approximately 25% of patients with gastrinomas have MEN1 (not MEN2).

References:

Robbins and Cotran Pathologic Basis of Disease, 10th Edition, Page 773

↑ *Back to this question in Part A*

@Neet_pg_bot

Q12: Which cells are primarily responsible for secreting neutral mucin that forms a protective layer in the stomach? (Q845197)

A. Parietal cells

B. Chief cells

C. Foveolar cells

D. Enterochromaffin cells

Correct Answer: C. Foveolar cells

■ *Listen (English)*

■ *Listen (Hindi)*

Explanation: The neutral mucin that forms the protective mucosal layer in the stomach is mainly secreted by 'Foveolar cells' located in the topmost layer of the stomach mucosa and acts as a barrier. Cells of the stomach and their function Cells Functions Parietal cells (Option A) Secrete hydrochloric acid (HCl) and intrinsic factor. Chief cells (Option B) Secrete pepsinogen (Inactive precursor of the pepsin). Enterochromaffin cells (Option D) Release of serotonin and histamine to regulate gastric functions.

References:

Robbins and Cotran Pathologic Basis of Disease, 10th Edition, Page 764

↑ *Back to this question in Part A*

@Neet_pg_bot

Q13: A 58-year-old female presents with recurrent epigastric discomfort and intermittent nausea. Histopathological examination of gastric biopsy samples reveals irregular, cystically dilated, and elongated foveolar glands. She also has a history of untreated H. pylori infection. What type of lesions is most likely to be associated with these findings? (Q845219)

A. Hyperplastic polyps

B. Gastric adenomas

C. Inflammatory fibroid polyps

D. Juvenile polyps

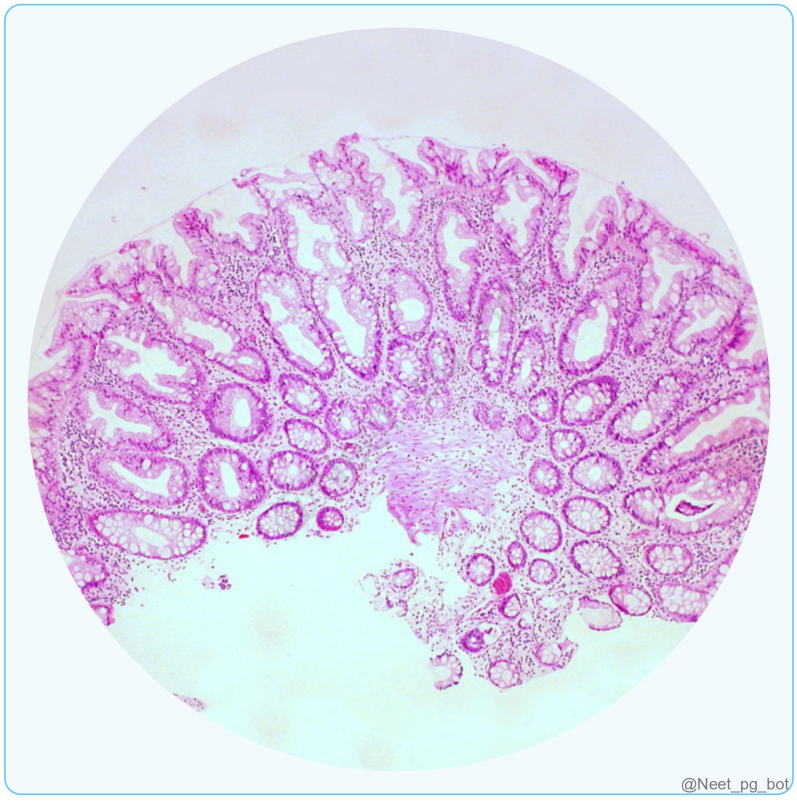

Correct Answer: A. Hyperplastic polyps

■ *Listen (English)*

■ *Listen (Hindi)*

Explanation: Based on the patient's symptoms, endoscopic findings, and history of untreated H. pylori infection, hyperplastic (or inflammatory) polyps are the most likely associated lesion. Hyperplastic Polyps: Frequently associated with H. pylori infection . Hypertrophy leads to the formation of multiple layers and an increase in foveolar cells. The risk of dysplasia increases with size, especially in pedunculated polyps >1 cm in diameter. Gastric adenomas (Option B) These are associated with APC gene mutation which increasestheir association with Familial Adenomatous Polyposis (FAP) syndrome. Lesions >2 cm carry a high risk of adenocarcinoma. Inflammatory fibroid polyps (Option C) Rare benign lesions in the GI tract, mostly sporadic, but some are familial (PDGFRA gene mutations). Peutz-Jeghers polyps (Option D) Oral or mucocutaneous pigmentations and jejunal polyps are seen with Peutz-Jeghers polyps. These are not common in stomach but if occurs then are known as arborising or christmas tree polyps. Associated with STK11 mutations.

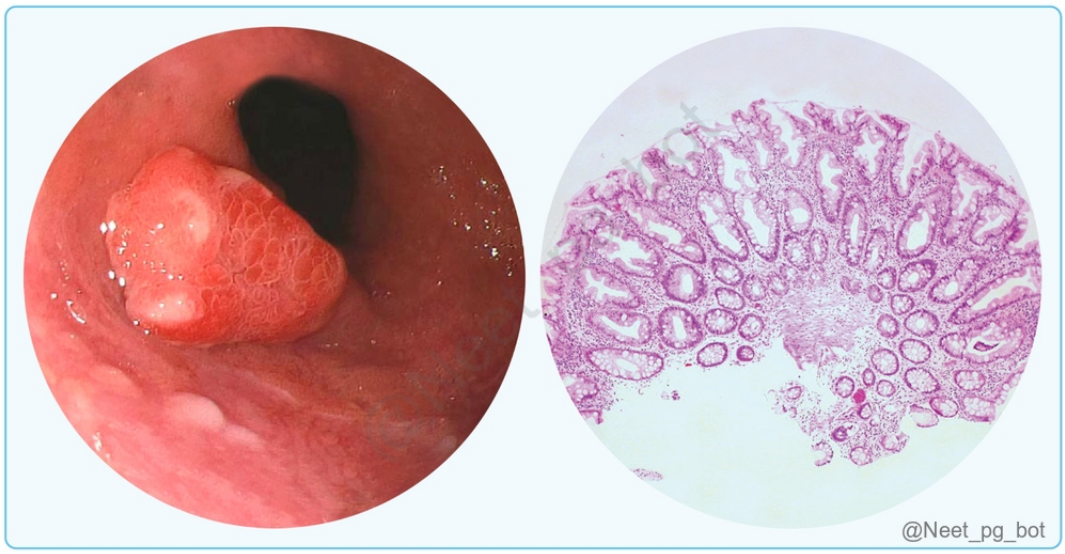

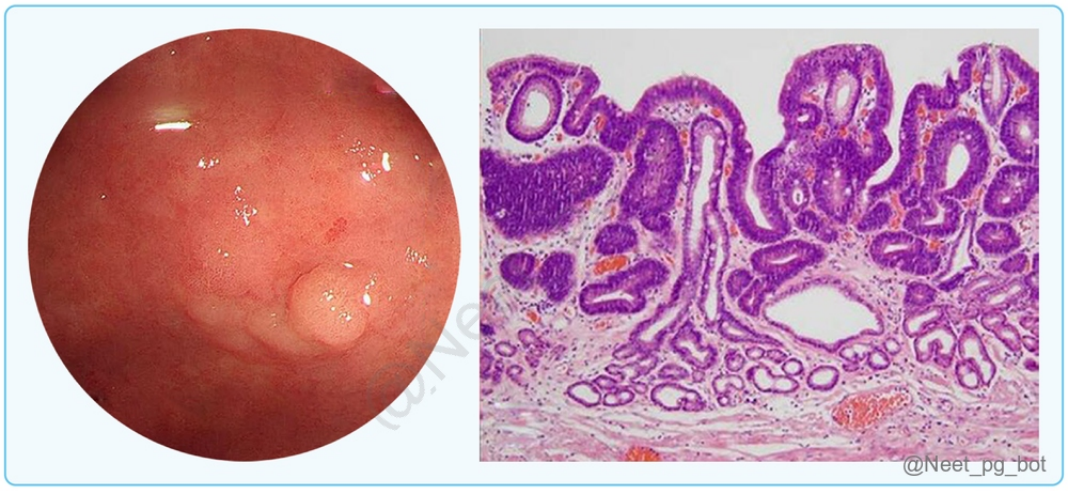

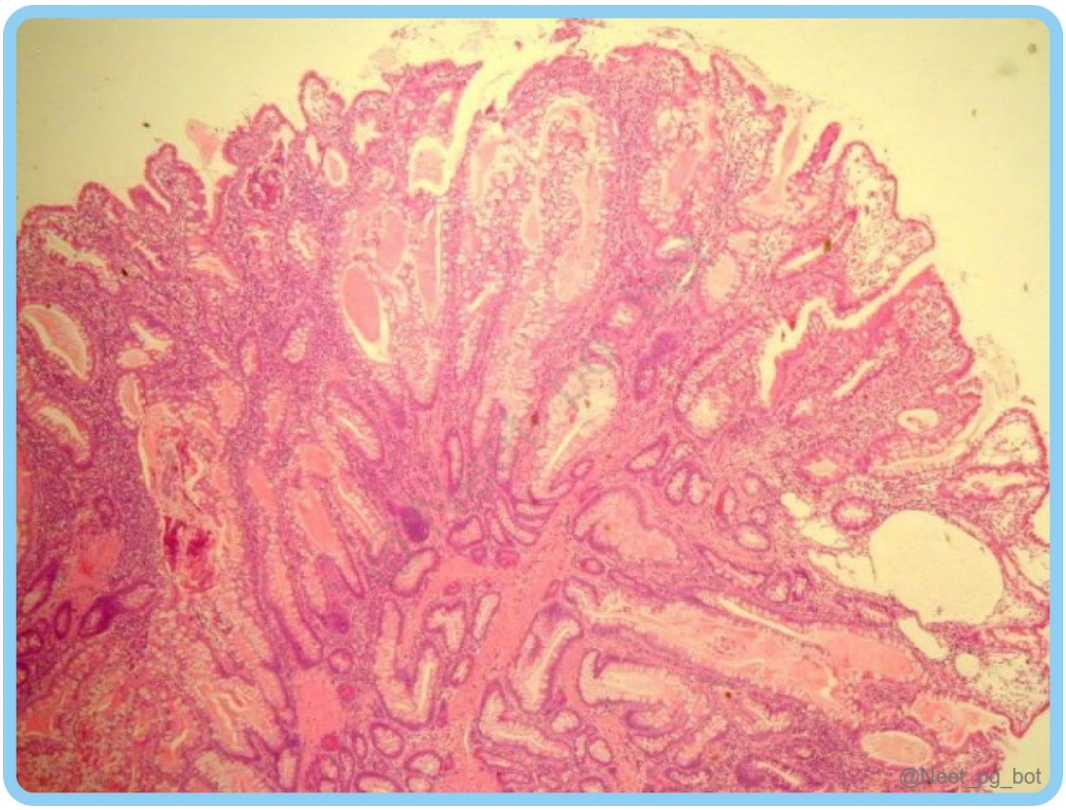

References:

Robbins and Cotran Pathologic Basis of Disease, 10th Edition, Page 773, 774, 809, 810

https://www.uptodate.com/contents/gastric-polyps

↑ *Back to this question in Part A*

@Neet_pg_bot

Q14: A 60-year-old man on long-term proton pump inhibitor therapy for acid reflux undergoes an upper gastrointestinal endoscopy for recurrent epigastric discomfort. The endoscopy reveals smooth-surfaced lesions in the gastric body and fundus. Which statement about these findings is likely correct? (Q845215)

A. PPIs decrease gastrin secretion, reducing the risk of fundic gland polyps

B. Fundic gland polyps are commonly associated with H. pylori infection.

C. Composed of cystically dilated glands lined by parietal, chief, and foveolar cells.

D. Sporadic fundic gland polyps carry a significant risk of neoplasia.

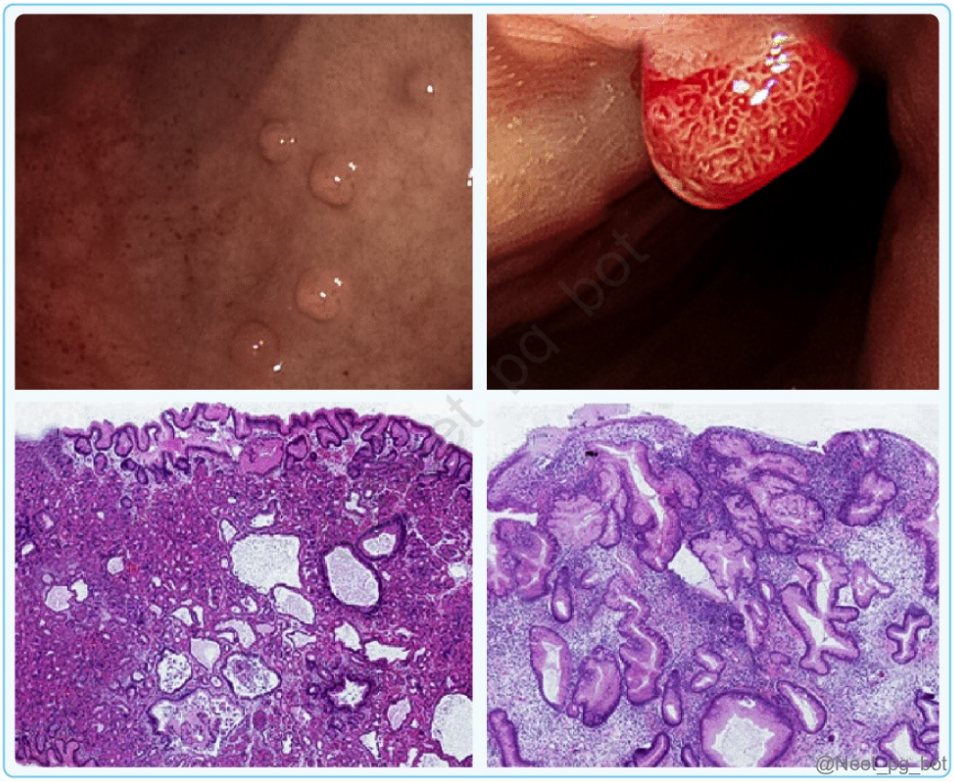

Correct Answer: C. Composed of cystically dilated glands lined by parietal, chief, and foveolar cells.

■ *Listen (English)*

■ *Listen (Hindi)*

Explanation: The patient's presentation of smooth-surfaced lesions in the gastric body and fundus and a history of long-term proton pump inhibitor therapy suggest Fundic gland polyps. Histologically, they are characterised by irregular, cystically dilated glands lined by parietal, chief, and foveolar cells, with minimal inflammation. (Option C) Incorrect options: PPIs decrease gastrin secretion, reducing the risk of fundic gland polyps (Option A): Proton pump inhibitors (PPIs) inhibit acid production, leading to increased gastrin secretion, which can contribute to the growth of fundic gland polyps. Fundic gland polyps are commonly associated with H. pylori infection (Option B): H. pylori infection is more associated with hyperplastic polyps. Sporadic fundic gland polyps carry a significant risk of neoplasia(Option D): Sporadic fundic gland polyps are usually benign with very low malignant potential.

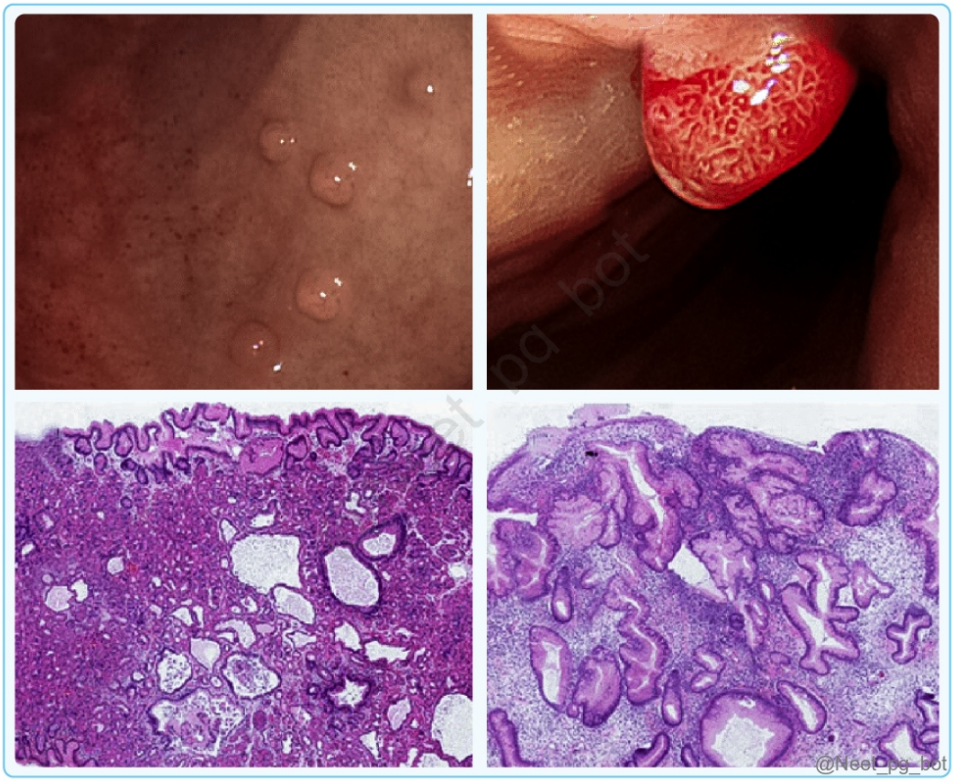

References:

Robbins and Cotran Pathologic Basis of Disease, 10th Edition, Page 773

↑ *Back to this question in Part A*

@Neet_pg_bot

Q15: Which type of gastritis is associated with a distinctive endoscopic appearance characterised by thickened folds, small nodules, and central aphthous ulceration affecting the entire stomach? (Q845214)

A. Eosinophilic gastritis

B. Lymphocytic gastritis

C. Granulomatous gastritis

D. Chemical gastritis

Correct Answer: B. Lymphocytic gastritis

Explanation: The clinical presentation with thickened folds, nodules, and central aphthous ulcers throughout the stomach suggests lymphocytic (varioliform) gastritis, characterized by increased intraepithelial T lymphocytes and often linked to celiac disease. Eosinophilic gastritis (Option A): It shows dense eosinophil infiltration in the gastric mucosa and muscularis, mainly in the antrum or pylorus. It is often linked to allergies in children and lacks the characteristic endoscopic features described. Granulomatous gastritis (Option C): It contains granulomas and is caused by conditions like Crohn's disease, sarcoidosis, and infections. It is not linked to the described endoscopic appearance. Chemical gastritis (Option D): Chemical gastritis, or reactive gastropathy, is mucosal damage caused by irritants such as NSAIDs, alcohol, or bile reflux, leading to inflammation, erosion, and ulcers.

References:

Robbins and Cotran Pathologic Basis of Disease, 10th Edition, Page 769

↑ *Back to this question in Part A*

@Neet_pg_bot

Q16: A 45-year-old female presents with chronic epigastric pain, nausea, and occasional vomiting. Upper gastrointestinal endoscopy reveals diffuse mucosal atrophy. Biopsy confirms chronic gastritis. Which of the following is a characteristic feature of Chronic Gastritis Type A? (Q845212)

A. Predominantly affects the antrum of the stomach

B. Autoimmune destruction of parietal cells

C. Associated with H. pylori infection

D. Increased risk of gastric carcinoma

Correct Answer: B. Autoimmune destruction of parietal cells

■ *Listen (English)*

■ *Listen (Hindi)*

Explanation: Characteristic Chronic Gastritis Type A Chronic Gastritis Type B Location Fundus and body of the stomach Antrum and pyloric region of the stomach (Option A) Aetiology Autoimmune H. pylori infection or NSAID use Pathophysiology Autoimmune destruction of parietal cells (Option B) H. pylori-induced inflammation of gastric mucosa (Option C) Autoantibodies Autoantibodies against parietal cells and Antibodies against intrinsic factors (Vit B12 absorption: Megaloblastic anemia) Not autoimmune; may have H. pylori antibodies. Intrinsic factor Reduced due to parietal cell destruction. It may be normal unless atrophic gastritis is present. Gastric acid production Autoantibodies against parietal cells lead to decreased/absent HCl secretion and ↑gastrin synthesis. Normal to increased acid secretion due to H. pylori. Histological findings Lymphocytic and plasma cell infiltrate. Neutrophilic infiltrate, lymphoid follicles. Complications Pernicious anaemia, gastric carcinoid, adenocarcinoma. Peptic ulcers, gastric adenocarcinoma, MALToma. Risk of gastric carcinoma Low Increased, especially with H. pylori infection (Option D)

References:

Robbins and Cotran Pathologic Basis of Disease, 10th Edition, Page 766, 767

↑ *Back to this question in Part A*

@Neet_pg_bot

Q17: A 55-year-old patient presents with recurrent epigastric pain and signs of gastrointestinal bleeding. An upper endoscopy reveals gastric ulcers, and a biopsy is performed for further evaluation. Which stain is best for identifying the causative organism in this condition? (Q845210)

A. Z-N stain

B. Wright stain

C. Modified Giemsa stain

D. Gram stain

Correct Answer: C. Modified Giemsa stain

■ *Listen (English)*

■ *Listen (Hindi)*

Explanation: The given clinical presentation suggests peptic ulcer disease (PUD), and the organism involved in this condition is Helicobacter pylori . 3 stains for H. pylori: Warthin-Starry silver stain Steiner stain Modified Giemsa stain Modified Giemsa stain Warthin Starry silver stain

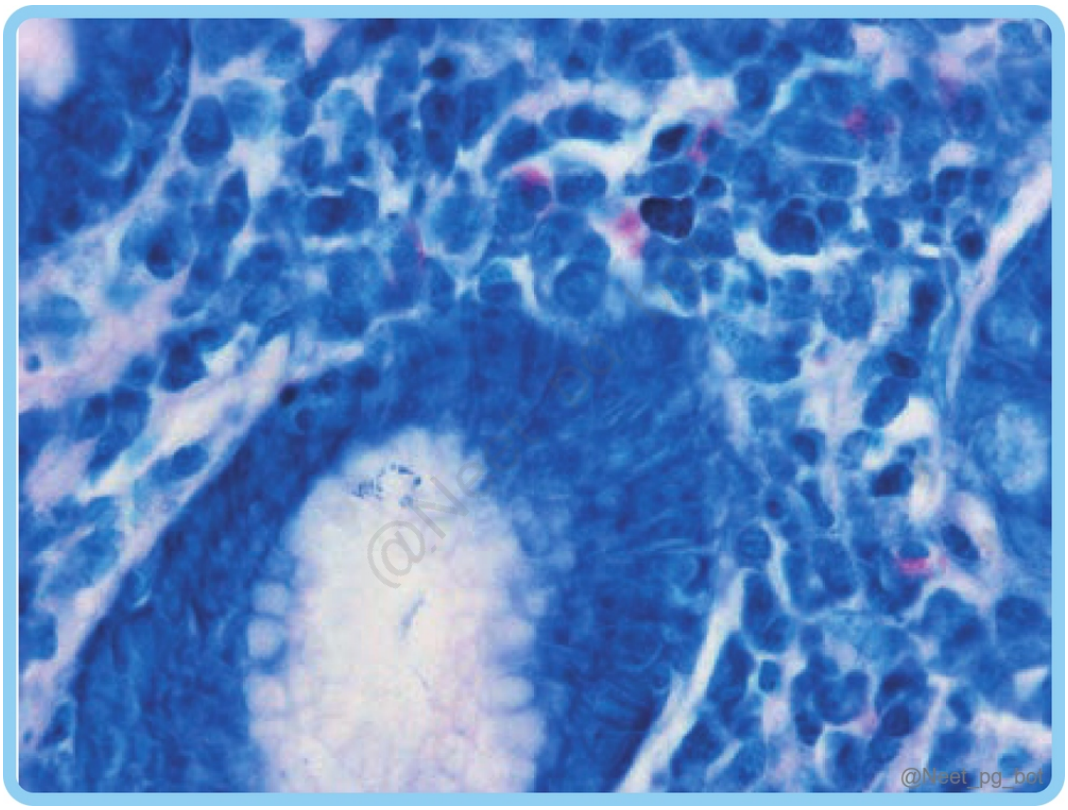

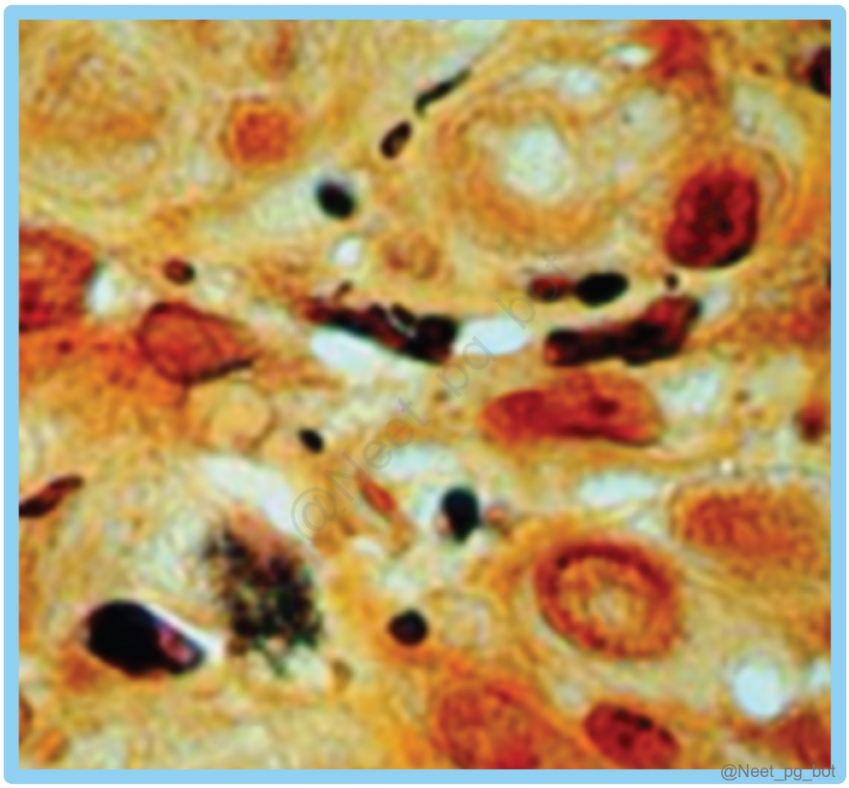

References:

Robbins and Cotran Pathologic Basis of Disease, 10th Edition, Page 768

↑ *Back to this question in Part A*

@Neet_pg_bot

Q18: Which of the following is NOT a protective factor against Peptic Ulcer Disease? (Q845208)

A. Mucus

B. Bicarbonate

C. COX-1

D. Pepsin

Correct Answer: D. Pepsin

■ *Listen (English)*

■ *Listen (Hindi)*

Explanation: Pepsin is not considered a protective factor for peptic ulcer disease (PUD). Excessive pepsin activity, especially in the presence of acid, can lead to tissue damage and ulcer formation. Therefore, pepsin is considered a contributing factor to ulceration rather than a protective factor against PUD. Peptic Ulcer Disease Protective factors Damaging factors Mucus (Option A) Bicarbonate (Option B) COX 1 (Option C) HCl Pepsin H.pylori Mucus and bicarbonate form a protective lining along the stomach wall, protecting it from the acids secreted by the stomach and parietal cells. COX-1 is a gastroprotective enzyme, and its inhibition by NSAIDs such as aspirin can lead to peptic ulcer disease (PUD) as a side effect.

References:

Robbins and Cotran Pathologic Basis of Disease, 10th Edition, Page 770

↑ *Back to this question in Part A*

@Neet_pg_bot

Q19: A 45-year-old man experiences recurrent upper abdominal pain worsened after meals, unresponsive to over-the-counter antacids. Which of the following is NOT typically a risk factor for the patient’s presentation? (Q845206)

A. Helicobacter pylori infection

B. Cocaine use

C. Cigarette smoking

D. Obesity

Correct Answer: D. Obesity

■ *Listen (English)*

■ *Listen (Hindi)*

Explanation: The patient's presentation may raise suspicion for gastrointestinal conditions like peptic ulcer disease (PUD). Risk factors of PUD: .Helicobacter pylori infectiojn (Option A ruled out) Any substabce abuse like alcohol, cigarette smoking (Option C ruled out) , cocaine use (Option B ruled out) , tobacco. Obesity is not typically a common risk factor for PUD. (Option D)

References:

Robbins and Cotran Pathologic Basis of Disease, 10th Edition, Page 770

↑ *Back to this question in Part A*

@Neet_pg_bot

Q20: A 55-year-old female with traumatic brain injury undergoes emergency craniotomy and is now intubated in the neurosurgical ICU. She suddenly develops hematemesis despite stabilisation. What is the most likely cause of the patient's bleeding? (Q845205)

A. Curling ulcer

B. Cushing ulcer

C. Gastric antral vascular ectasia (GAVE)

D. Dieulafoy lesions

Correct Answer: B. Cushing ulcer

■ *Listen (English)*

■ *Listen (Hindi)*

Explanation: In the given scenario, the patient's acute onset hematemesis following a traumatic brain injury and neurosurgical intervention suggests the likely development of a stress-related ulcer, particularly a Cushing ulcer. Feature Cushing's Ulcers (Option B) Curling Ulcers (Option A) Location Usually found in the stomach (cardia), oesophagus, or duodenum Typically occur in the proximal duodenum Associated condition Elevated intracranial pressure (e.g., head trauma, intracranial haemorrhage) Severe burns (involving >30% of body surface area) or trauma Pathogenesis Increased vagal activity stimulates gastric acid secretion, leading to ulcer formation. Result from decreased mucosal blood flow due to systemic hypotension or stress-induced vasoconstriction Ulcer

characteristics Deep ulcers; increased risk of perforation. Superficial ulcers.

References:

Robbins and Cotran Pathologic Basis of Disease, 10th Edition, Page 766

↑ *Back to this question in Part A*

@Neet_pg_bot

Q21: A 55-year-old male presents to the gastroenterology clinic with complaints of persistent abdominal pain, nausea, and unintentional weight loss over the past three months. His medical history is significant for peptic ulcer disease and he is a former smoker. An upper endoscopy reveals multiple gastric lesions, and a biopsy is taken for histological examination. The results indicate the presence of gastric adenocarcinoma, and positive for Helicobacter pylori. Which protein produced by Helicobacter pylori is primarily associated with this condition? (Q845199)

A. Urease

B. CagA

C. SRC

D. SHP2

Correct Answer: B. CagA

Explanation: CagA (Cytotoxin-associated gene A): CagA, secreted by H.pylori alters signaling pathways in the gastric epithelial cells, leading to increased inflammation and cell proliferation, leading to the development of gastric cancer. Urease(Option A): This enzyme helps H. pylori survive in the acidic environment of the stomach by neutralizing gastric acid. Although urease is important for colonization and inflammation, it does not have a direct role in the mechanisms leading to gastric cancer. SRC and SHP2 are involved in the downstream pathways of CagA signaling, but are not produced by H.pylori. (Options C and D).

References:

Robbins and Cotran Pathologic Basis of Disease, 10th Edition, Page 775

↑ *Back to this question in Part A*

@Neet_pg_bot

• [09_Gastrointestinal Tract] 041 Intestinal Polyps And Intestinal Carcinoma - I

« Back to Folder Directory

[09_Gastrointestinal Tract] 041 Intestinal Polyps And Intestinal Carcinoma - I — Quick Jump

Q1 (p. 1937) *Q2 (p. 1938)* *Q3 (p. 1939)* *Q4 (p. 1941)* *Q5 (p. 1942)* *Q6 (p. 1943)*
Q7 (p. 1945) *Q8 (p. 1946)* *Q9 (p. 1947)* *Q10 (p. 1948)* *Q11 (p. 1949)* *Q12 (p. 1950)*
Q13 (p. 1951) *Q14 (p. 1952)*

Q1: During a routine colonoscopy of a 60-year-old male, a small polyp is identified in the colon. Subsequent biopsy results confirm the presence of a hyperplastic polyp. Which characteristic is typically associated with this condition? (Q845256)

A. Commonly found in the right colon

B. Pathogenesis involves increased epithelial cell turnover

C. Lacks malignant potential

D. Histologically composed of immature goblet cells

Correct Answer: C. Lacks malignant potential

■ *Listen (English)*

■ *Listen (Hindi)*

Explanation: The characteristic of hyperplastic polyps is that they lack malignant potential. Hyperplastic polyps: Lacks malignant potential Benign epithelial proliferations occurring commonly in the 6th-7th decade. Formed due to decreased epithelial cell turnover and delayed shedding, resulting in a piling up of goblet and absorptive cells. (Option B) Usually less than 5 mm with a smooth, nodular appearance and commonly found in the left colon. (Option A) Mature goblet cells and absorptive cells with serrated surface architecture are hallmark findings. (Option D)

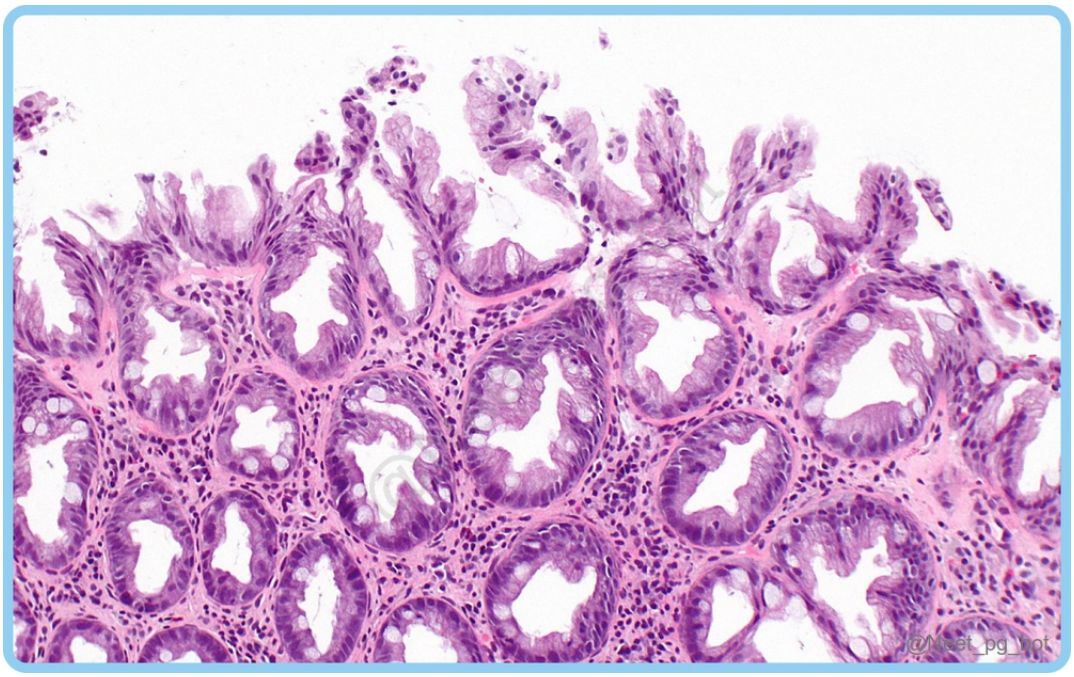

References:

Robbins and Cotran Pathologic Basis of Disease, 10th Edition, Page 807

↑ *Back to this question in Part A*

@Neet_pg_bot

Q2: A 55-year-old man undergoes a routine colonoscopy. During the procedure, a polyp is discovered. Histological examination reveals serrated architecture, as shown in the image. Which of the following is true about this polyp? (Q845259)

A. It has malignant potential

B. Predominantly found in the left colon

C. Serrated architecture is limited to the surface of the lesions

D. Do not require surveillance or follow-up after detection

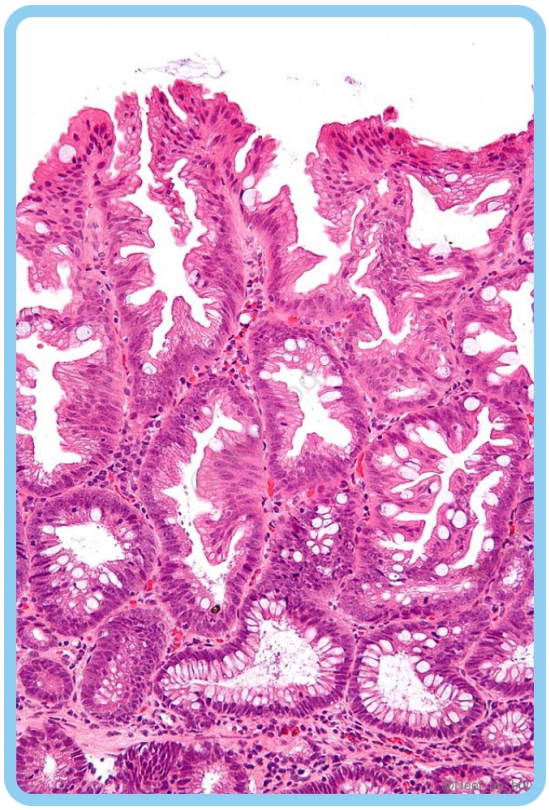

Correct Answer: A. It has malignant potential

■ *Listen (English)*

■ *Listen (Hindi)*

Explanation: The above image shows serrations throughout the full length of the glands including crypt base which is suggestive of sessile serrated adenoma which has malignant potential. Sessile Serrated Adenomas (SSA): Exhibit serrated architecture throughout the full length of the gland while hyperplastic polyps have serrated architecture only in the upper third of the crypt. (Option C) It has malignant potential More commonly located in the right colon. (Option B) Lack typical cytologic features of dysplasia found in other adenomas. Early precursor lesions in the serrated neoplasia pathway. Associated with BRAF-mutated colorectal carcinomas. Require follow-up surveillance for monitoring changes or growth. (Option D)

References:

Robbins and Cotran Pathologic Basis of Disease, 10th Edition, Pages 811, 812, 807

↑ *Back to this question in Part A*

@Neet_pg_bot

Q3: A 4-year-old girl presents to the OPD with complaints of rectal bleeding and abdominal pain for the past six months. Investigations reveal approximately 40 hamartomatous colon polyps. The biopsy shows cystic spaces with dilated glands filled

with mucin and inflammatory debris. What is the most likely diagnosis for this patient? (Q845265)

A. Familial adenomatous polyposis

B. Adenocarcinoma colon

C. Juvenile polyposis syndrome

D. Sessile Serrated Adenoma

Correct Answer: C. Juvenile polyposis syndrome

■ *Listen (English)*

■ *Listen (Hindi)*

Explanation: The given clinical presentation and investigation findings suggests a possible diagnosis of Juvenile Polyposis Syndrome (JPS). Juvenile polyposis Syndrome Primarily affects children under 5 years old. Autosomal dominant inheritance Can be sporadic or syndromic. Sporadic: Single polyps. Syndromic: 3-100 polyps. Linked to mutations in the SMAD4 and BMPR1A genes, part of the TGF-β signaling pathway. Pedunculated polyp which is usually less than 3 cm in diameter. Contains cystic spaces filled with mucin and inflammatory debris. Extra-intestinal manifestations include congenital malformations, digital clubbing.

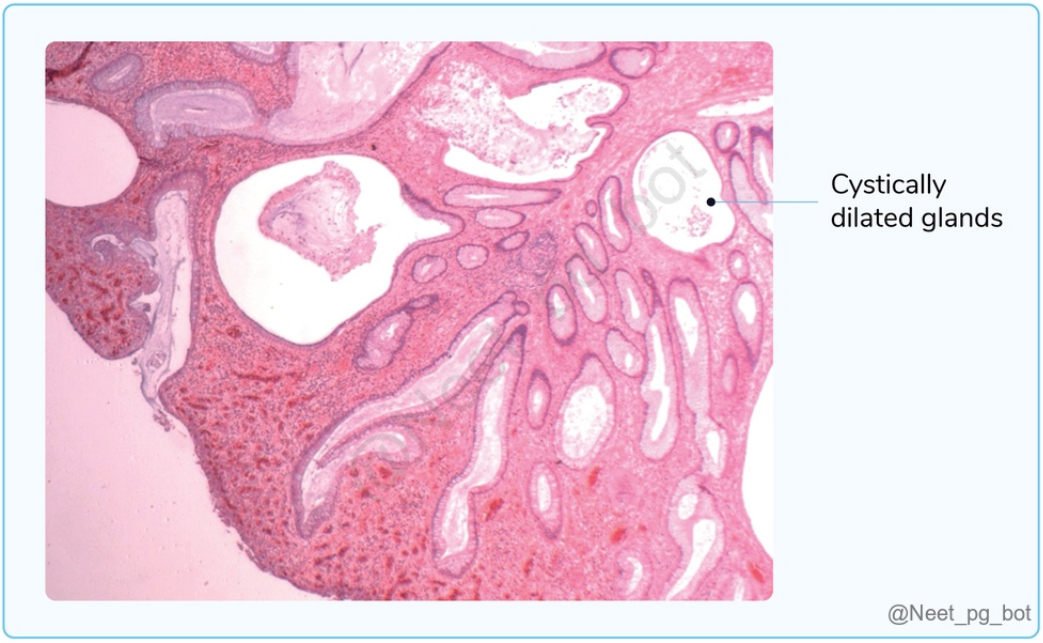

References:

Robbins and Cotran Pathologic Basis of Disease, 10th Edition, Page 808-809

↑ *Back to this question in Part A*

@Neet_pg_bot

Q4: A 13-year-old female presents to the OPD due to abdominal pain and blood in stools. On examination, she had pigmented macules on her lips and oral mucosa. Endoscopy reveals multiple large, pedunculated polyps in the small intestine which shows an arborizing pattern of smooth muscle and glands lined by normal epithelium. Which of the following statements is incorrect about this condition? Autosomal dominant disorder Polyps are more common in the colon Increased risk of developing colon, pancreatic, and breast cancers Gain-of-function mutation in STK11 gene (Q845268)

A. 1 and 2

B. 2 and 4

C. 3 and 4

D. 1 and 3

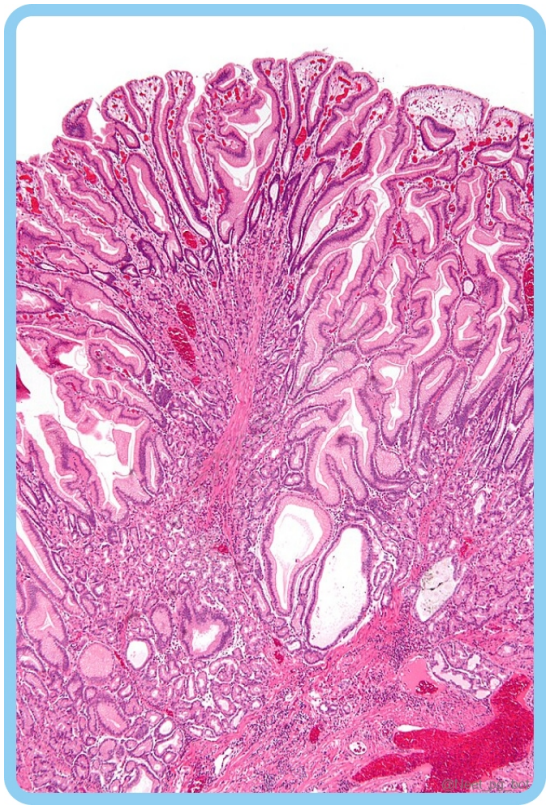

Correct Answer: B. 2 and 4

■ *Listen (English)*

■ *Listen (Hindi)*

Explanation: The given clinical scenario and histological findings point towards the diagnosis of Peutz-Jeghers syndrome. Peutz-Jeghers syndrome : Autosomal dominant disorder. (statement 1) Caused by a loss of function mutation in the STK11 gene (statement 4) Presents around 11 years of age. Characterized by: Gastrointestinal hamartomatous polyps especially in the small intestine (statement 2) Mucocutaneous hyperpigmentation (macules on lips, nostrils, buccal mucosa, and extremities). Polyps are large, pedunculated, and lobulated. Histology - an arborizing pattern of smooth muscle and glands lined by normal epithelium. Significantly increased cancer risk (statement 3) Gastrointestinal tract, pancreas, breasts, gonads, and uterus. Lifetime cancer risk estimated at 40%



References:

Robbins and Cotran Pathologic Basis of Disease, 10th Edition, Page 809

↑ *Back to this question in Part A*

@Neet_pg_bot

Q5: A 58-year-old female presents with weight loss, nail changes, alopecia, and skin hyperpigmentation. Colonoscopy reveals multiple hamartomatous polyps in the intestine. Family history is negative for intestinal cancers. What is the most likely diagnosis? (Q845281)

A. Tuberous sclerosis

B. Bannayan-Ruvalcaba-Riley Syndrome

C. Cowden syndrome

D. Cronkhite-Canada Syndrome

Correct Answer: D. Cronkhite-Canada Syndrome

■ *Listen (English)*

■ *Listen (Hindi)*

Explanation: The clinical presentation and multiple noncancerous polyps in the colon, coupled with a lack of family history of similar symptoms suggests Cronkhite-Canada Syndrome (CCS). Cronkhite-Canada syndrome Rare, non-hereditary condition Mean age of presentation: >50 years Characterized by: Widespread non cancerous/hamartomatous gastrointestinal polyposis Cutaneous changes - alopecia, hyperpigmentation) Nail dystrophy Polyps: Symptoms: Malabsorption, diarrhea, weight loss Tuberous sclerosis (Option A) is a neurocutaneous disorder resulting from mutations in the TSC1 (hamartin) or TSC2 (tuberin) genes. Patients exhibit neurological symptoms like seizures, along with skin abnormalities. The syndrome also includes hamartomatous polyps in the intestine. Bannayan-Ruvalcaba-Riley Syndrome (Option B) is a genetic condition characterized by macrocephaly, intestinal hamartomatous polyps and pigmented maculae of the glans penis. Cowden syndrome (Option C) is caused by mutation of PTEN gene on chromosome 10. It is associated with multiple hamartomatous polyps, benign skin tumors like trichilemmoma and an increased risk of breast, thyroid, and endometrial cancers.

References:

Robbins and Cotran Pathologic Basis of Disease, 10th Edition, Page 809

↑ *Back to this question in Part A*

@Neet_pg_bot

Q6: A 20-year-old man with a family history of colorectal carcinoma presents with chronic abdominal discomfort and occasional rectal bleeding.Upon further evaluation, a mutation in APC gene is identified leading to a diagnosis of Familial Adenomatous Polyposis. Which of the following statement is true regarding FAP? (Q845282)

A. Mutation in 6th chromosome

B. 50 % risk of colon cancer if untreated

C. Presence of a minimum of 100 polyps

D. Congenital atrophy of the retinal pigment epithelium

Correct Answer: C. Presence of a minimum of 100 polyps

■ *Listen (English)*

■ *Listen (Hindi)*

Explanation: Classic FAP is characterized by the presence of a minimum of 100 polyps Familial Adenomatous Polyposis (FAP) Autosomal dominant disorder caused by APC gene mutations on chromosome 5 (Option A) Numerous intestinal polyps develop Classic FAP: Diagnosed with at least 100 polyps (Option C) Almost 100% risk of colorectal cancer if untreated (Option B) Commonly develops by 30 years, almost always by 50 years Attenuated FAP (AFAP): Primarily affects the proximal colon Fewer polyps (average <30 polyps) Associated with congenital hypertrophy of the retinal pigment epithelium (Option D) Standard treatment: Prophylactic colectomy to prevent colorectal cancer Post-colectomy risks: Cancer at extracolonic sites, including the ampulla of Vater and stomach



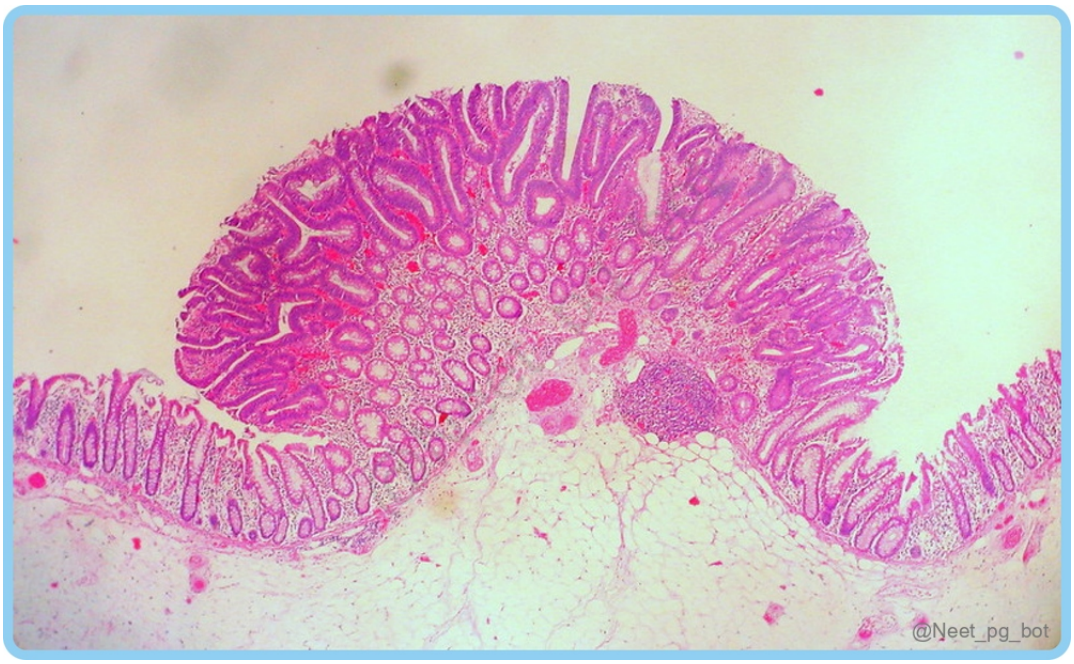

References:

Robbins and Cotran Pathologic Basis of Disease, 10th Edition, Page 812

https://www.uptodate.com/contents/clinical-manifestations-and-diagnosis-of-familial-adenomatous-polyposis?

↑ *Back to this question in Part A*

@Neet_pg_bot

Q7: A 28-year-old woman presents with a history of unexplained weight loss along with multiple sebaceous cysts on her face and scalp. She has a family history of colorectal cancer. Upon further examination, she is found to have a bony lesion on her jaw. What is the most likely diagnosis? (Q845283)

A. Turcot syndrome

B. Gardner syndrome

C. Lynch syndrome

D. MUTYH Associated Polyposis (MAP)

Correct Answer: B. Gardner syndrome

■ *Listen (English)*

■ *Listen (Hindi)*

Explanation: The clinical findings given suggest Gardner syndrome as a possible diagnosis. Gardner syndrome An autosomal dominant condition Characterized by colonic polyposis and extracolonic manifestations Due to mutations in APC gene Predisposition to colo-rectal cancer present Extracolonic manifestations include Osteomas (commonly in skull and mandible) Supernumerary teeth Epidermoid cysts Fibromas Thyroid and desmoid tumors Supernumerary teeth Option A) Turcot syndrome: Turcot syndrome can also arise from mutations in APC genes. But, there is association with brain tumors along with colorectal cancer Option C) Lynch syndrome: AKA HNPCC(hereditary non polyposis colorectal cancer) Autosomal dominant condition due to mutations in MLH 1 and MSH 2 Characterized by increases risk of colorectal cancer, endometrial, ovarian, uterus and Pancreatic cancers Option D) MUTYH Associated Polyposis (MAP) Rare autosomal recessive disorder due to mutations in the MUTYH gene. Occurs later in life compared to other polyposis syndromes Involves fewer than 100 polyps and individuals with MAP have an increased risk of colorectal cancer. Unlike Gardner syndromes, MAP is not associated with osteomas or epidermoid cysts.



References:

Robbins and Cotran Pathologic Basis of Disease, 10th Edition, Page 809, 813

Gardner syndrome - UpToDate

↑ *Back to this question in Part A*

@Neet_pg_bot

Q8: A 6 cm polyp is identified in the descending colon during a routine colonoscopy. Histological examination reveals villous architecture with high-grade dysplasia. Based

on this scenario, which factors most strongly correlate with the risk of malignancy in colorectal adenomas? (Q845284)

A. Presence of villous architecture

B. Size of the adenoma

C. Histologic grade of dysplasia

D. Location within the gastrointestinal tract

Correct Answer: B. Size of the adenoma

Explanation: The size of colorectal adenomas is the most critical factor associated with the risk of malignancy. Larger adenomas are most likely to develop into invasive carcinoma Adenomas larger than 4 cm in diameter have nearly a 40% chance of containing invasive cancer. Villous architecture (Option A) : Villous adenomas are associated with a higher incidence of cancer than tubular adenomas, but this correlation primarily arises from their larger size rather than their architectural characteristics alone. Histologic grade of dysplasia(Option C): High-grade dysplasia within an individual polyp increases its risk of harboring cancer. However, histologic grade of dysplasia is not the primary factor correlating with the overall risk of malignancy across adenomas. Gastrointestinal tract location (Option D): While certain types of polyps may have preferences for specific locations within the gastrointestinal tract (e.g., sessile serrated lesions are more common in the right colon), location alone is not the strongest predictor of malignancy in colorectal adenomas.

References:

Robbins and Cotran Pathologic Basis of Disease, 10th Edition, Pages 810 - 811

↑ *Back to this question in Part A*

@Neet_pg_bot

Q9: A patient underwent genetic testing after being diagnosed with colon cancer. Testing reveals a mutation associated with Hereditary Nonpolyposis Colorectal Cancer (HNPCC). Which of the following genes is defective in this patient? (Q845285)

A. SMAD4, BMPR1

B. STK11

C. APC, MUTYH

D. MLH1, MSH2

Correct Answer: D. MLH1, MSH2

■ *Listen (English)*

■ *Listen (Hindi)*

Explanation: Hereditary Nonpolyposis Colorectal Cancer (HNPCC), also known as Lynch syndrome, is caused by inherited mutations in DNA mismatch repair (MMR) genes: MSH2 and MLH1. Genes mutation Manifestation MLH1, MSH2 (Option D) Results in microsatellite instability Causes cluster of cancer: Colorectal, Endometrial, Ovarian, Pancreatic cancers Colon cancer develops at a young age and it usually occurs in the right side SMAD4 and BMPR1 (Option A) Juvenile polyposis syndrome STK11 (Option B) Peutz-Jeghers syndrome APC gene (Option C) Familial Adenomatous Polyposis(FAP), sporadic colon cancer, Gardner syndrome and Turcot syndrome MUTYH (Option C) MUTYH-associated polyposis.

References:

Robbins and Cotran Pathologic Basis of Disease, 10th Edition, Pages 809, 813

↑ *Back to this question in Part A*

@Neet_pg_bot

Q10: A 55-year-old male presents to the clinic with complaints of recurrent abdominal discomfort and changes in bowel habits over the past few months. Further investigation with colonoscopy confirmed the presence of adenocarcinoma. Which of the following factors is most closely associated with this condition? (Q845286)

A. Use of aspirin

B. Estrogen replacement therapy

C. High intake of unabsorbable vegetable fiber

D. High consumption of red meat

Correct Answer: D. High consumption of red meat

■ *Listen (English)*

■ *Listen (Hindi)*

Explanation: High consumption of red meat is associated with increased risk of adenocarcinoma of the colon Factors increasing the risk Factors decreasing the risk Low fiber, high fat diet High intake of red meat and processed meat Increased calorie intake and obesity Family history of colon cancer Personal history of adenomas Smoking and alcohol Inflammatory bowel disease Lynch syndrome FAP Acromegaly Pelvis irradiation Streptococcus bovis septicemia Ureterosigmoidoscopy High fiber diet Intake of fish (omega-3 fatty acids), fruits and vegetables (Vit A, C, E) NSAID use, particularly Aspirin Folic acid Calcium Hormone replacement therapy

References:

Robbins and Cotran Pathologic Basis of Disease, 10th Edition, Page 814

https://www.uptodate.com/contents/epidemiology-and-risk-factors-for-colorectal-cancer

↑ *Back to this question in Part A*

@Neet_pg_bot

Q11: A 55-year-old female presents with abdominal pain, changes in bowel habits, unintended weight loss. A previous colonoscopy showed a polyp, but a recent one confirmed colorectal adenocarcinoma. Which gene mutations are characteristically associated with development of colorectal adenocarcinoma? (Q845287)

A. APC, TGFBR2, SMAD2, and BAX

B. TP53, BRAF, TGFBR2, and BAX

C. APC, KRAS, SMAD4 and TP53

D. APC, KRAS, TP53, and MYC

Correct Answer: C. APC, KRAS, SMAD4 and TP53

■ *Listen (English)*

■ *Listen (Hindi)*

Explanation: The genes associated with development of colorectal carcinoma are APC, KRAS, SMAD4 and TP53. Adenoma-Carcinoma Sequence: Accounts for up to 80% of sporadic cancers. APC Gene Mutations: Leads to β-catenin accumulation and Wnt pathway activation. "First hit": Sporadic inactivation of APC. "Second hit": Loss of second APC copy KRAS Mutations: Promote growth and prevent apoptosis. SMAD2 and SMAD4 Mutations: Disrupt TGF-β pathway, causing uncontrolled proliferation. TP53 Mutations: Occur in later stages of tumor progression.

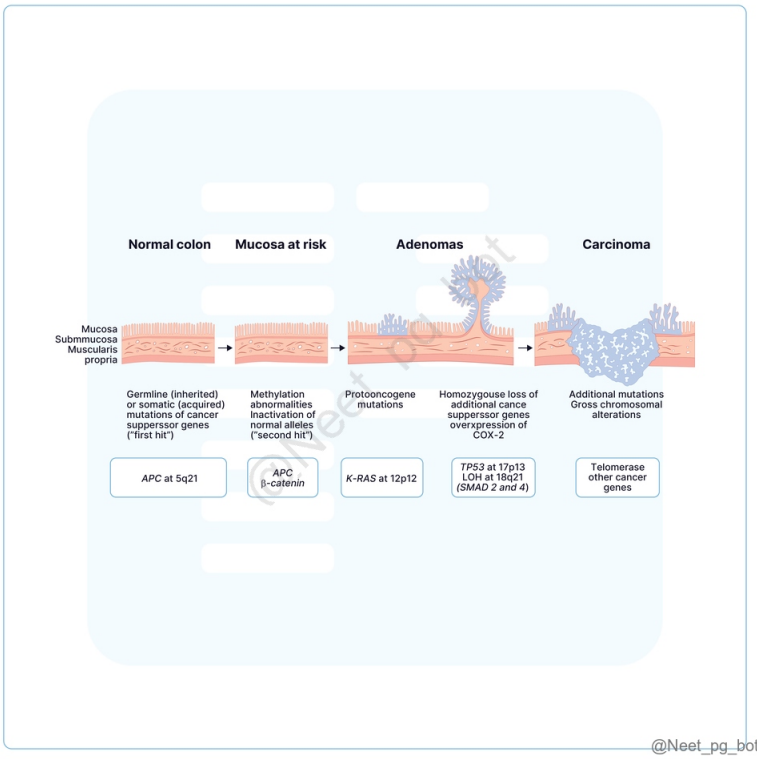

References:

Robbins and Cotran Pathologic Basis of Disease, 10th Edition, Page 815

↑ *Back to this question in Part A*

@Neet_pg_bot

Q12: A 45-year-old female presents with abdominal pain, changes in bowel habits, and weight loss. Her mother and aunt were diagnosed with endometrial and ovarian cancer in their 50s. A colonoscopy and a biopsy confirm well-differentiated adenocarcinoma. Which genetic pathway is most likely associated with adenocarcinoma in this patient? (Q845290)

A. APC/β-catenin pathway

B. TGF-β signaling pathway

C. DNA mismatch repair pathway

D. BAX pathway

Correct Answer: C. DNA mismatch repair pathway

■ *Listen (English)*

■ *Listen (Hindi)*

Explanation: The patient's family history of endometrial and ovarian cancer, combined with her well-differentiated adenocarcinoma, suggests Lynch syndrome (HNPCC) which is associated with DNA mismatch repair pathway Lynch syndrome occurs due to germline mutations in DNA mismatch repair (MMR) genes resulting in microsatellite instability (MSI) Option A: APC/β-catenin pathway: This is commonly associated with the classic adenoma-carcinoma sequence in colorectal adenocarcinoma. Options B & D): TGF-β signaling pathway and pro-apoptotic protein BAX regulate cell growth, differentiation, and apoptosis. While these signalling pathways are alterations in colorectal cancer, they are not commonly associated with MSI or Lynch syndrome.

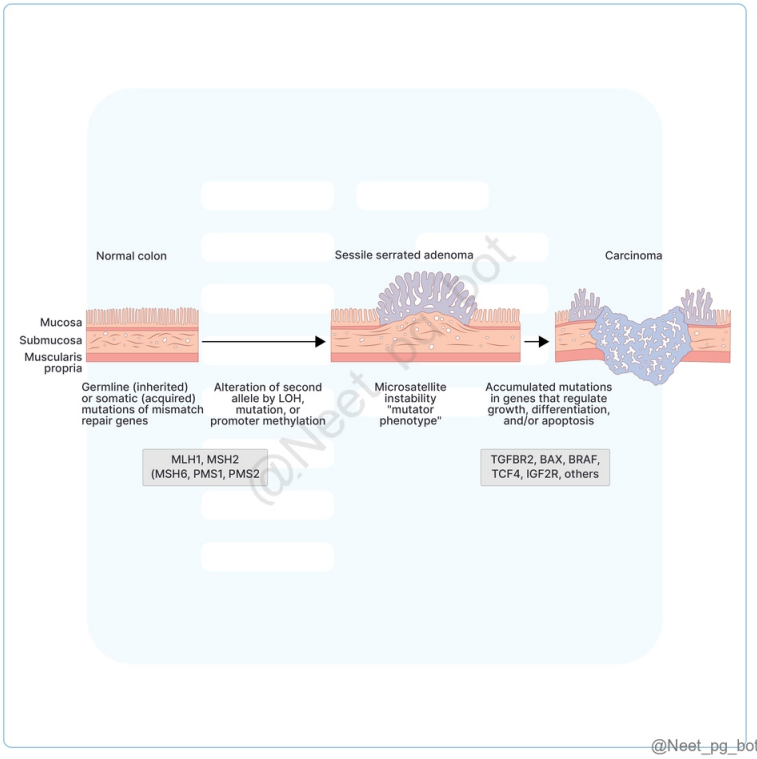

References:

Robbins and Cotran Pathologic Basis of Disease, 10th Edition, Page 815

↑ *Back to this question in Part A*

@Neet_pg_bot

Q13: Which of the following is the most common site of metastasis for colon adenocarcinoma? (Q845291)

A. Brain

B. Lungs

C. Bones

D. Liver

Correct Answer: D. Liver

■ *Listen (English)*

■ *Listen (Hindi)*

Explanation: The liver is the most common site of distant metastasis for colon adenocarcinoma. This is due to the portal venous drainage of the colon, which allows cancer cells to spread easily to the liver. Other sites :Lymph nodes, lungs, and bones can metastasize Prognostic factors Depth of invasion Lymph node metastases. Colon adenocarcinoma: Prevalence It is the most common (M/c) type of intestinal carcinoma. Risk Factors High fat, low fiber, alcohol, smoking, FAP, HNPCC (Lynch Syndrome), and inflammatory bowel diseases (Ulcerative Colitis, Crohn's). Protective Factors Omega-3 fatty acids and NSAIDs are considered protective. Diagnostic Gold Standard Biopsy and Histopathology. Prognostic Factors Lymph node metastasis and the depth of invasion. Pathogenic Mechanisms: Colonic adenocarcinoma develops through multistep carcinogenesis via several distinct pathways: Adenoma-Carcinoma Sequence (Mnemonic: AK53): Involves a progression from APC mutation (2 Hits) → KRAS → p53, SMAD 2 & 4 → Telomere activation. Sessile Serrated Adenoma (SSA) Pathway: Characterized by MMR (Mismatch repair gene) defects (MLH1, MSH2,6, PMS1,2) leading to Microsatellite Instability (MSI) and BRAF mutation. CIMP-BRAF: Features CpG island hypermethylation phenotype (CIMP) leading to MSI and BRAF mutation without an initial MMR mutation. CIMP-KRAS: Involves CIMP leading to KRAS mutation; notably, this pathway does not involve MSI or MMR mutations. Clinical presentation by location: Feature Proximal (Right-Sided) Distal (Left-Sided) Appearance Proliferative mass with a "cauliflower" appearance. "Napkin ring" appearance. Primary Symptoms Occult blood loss leading to Iron Deficiency Anemia (IDA). Occult bleeding and significant changes in bowel habits. Diagnosis and Staging: Barium Enema: May show a characteristic "apple core" deformity . Tumor Marker: CEA (Carcinoembryonic antigen) is the primary marker used. Screening: Occult blood testing in stool is performed using the Guaiac test . Staging System: Duke's staging is utilized to categorize the extent of the cancer.

References:

Robbins and Cotran Pathologic Basis of Disease, 10th Edition, Page 816

www.ncbi.nlm.nih.gov/pmc/articles/PMC6678078/

www.ncbi.nlm.nih.gov/pmc/articles/PMC5444408/

www.ncbi.nlm.nih.gov/pmc/articles/PMC6093020/

↑ *Back to this question in Part A*

@Neet_pg_bot

Q14: A 60-year-old male presents with abdominal pain, altered bowel habits and 5kg weight loss in one month. A barium enema study showed the following finding. Which of the following statements is true about the patient's condition? (Q845293)

A. Presents asweakness due to iron deficiency anemia

B. Leads to a napkin-ring constriction and luminal narrowing

C. Growth tends to be polypoidal (growth is into the wall of the intestine?)

D. HPE commonly shows signet-ring cells

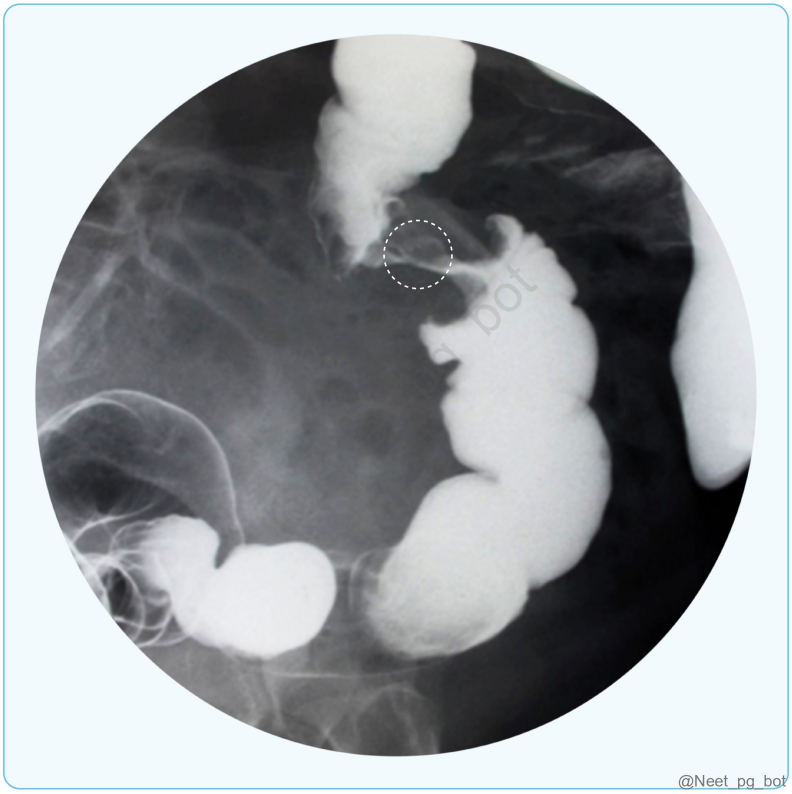

Correct Answer: B. Leads to a napkin-ring constriction and luminal narrowing

■ *Listen (English)*

■ *Listen (Hindi)*

Explanation: Distal colorectal carcinoma leads to formation of a napkin ring constriction and luminal narrowing which can be seen as an apple core appearance on barium enema study Proximal adenocarcinoma (masses on the caecum and ascending colon) Grow as polypoidal and exophytic masses which extend along one wall. (Option C) Present with occult anemia, causing late-stage weakness. (Option A) Distal Adenocarcinoma Equally distributed along the colon. Lesions are annular, causing napkin-ring constrictions and luminal narrowing.(Option B) Barium study - apple core appearance Present early with changes in bowel habits, Hematochezia, cramping, left lower quadrant pain. Cell Composition: Tall columnar cells resembling dysplastic epithelium in adenomas. Mucinous Adenocarcinoma:Contains signet-ring cells producing abundant mucin. They are rare and associated with poor

prognosis. (Option D)

References:

Robbins and Cotran Pathologic Basis of Disease, 10th Edition, Page 816

www.ncbi.nlm.nih.gov/books/NBK470380/

↑ *Back to this question in Part A*

@Neet_pg_bot

• [09_Gastrointestinal Tract] 042 Malabsorption Syndrome Celiac Disease And Ibd

« Back to Folder Directory

[09_Gastrointestinal Tract] 042 Malabsorption Syndrome Celiac Disease And Ibd — Quick Jump

Q1 (p. 1955) *Q2 (p. 1956)* *Q3 (p. 1958)* *Q4 (p. 1959)* *Q5 (p. 1960)* *Q6 (p. 1961)*
Q7 (p. 1962) *Q8 (p. 1966)* *Q9 (p. 1967)* *Q10 (p. 1970)* *Q11 (p. 1971)* *Q12 (p. 1972)*
Q13 (p. 1973) *Q14 (p. 1974)*

Q1: A 47-year-old male presents with chronic diarrhoea, unintentional weight loss, joint pain, pallor, and generalised weakness. Upper GI endoscopy and biopsy revealed characteristic histopathological findings suggestive of Whipple's disease. Which of the following histopathological features would have led to the diagnosis? (Q845296)

A. Foamy macrophages filled with PAS-positive granules

B. Villous atrophy and blunting of the small intestinal mucosa

C. Lymphoplasmacytic infiltrate in the lamina propria

D. Presence of caseating granulomas and acid-fast bacilli

Correct Answer: A. Foamy macrophages filled with PAS-positive granules

■ *Listen (English)*

■ *Listen (Hindi)*

Explanation: Whipple's disease is a malabsorption problem: Nothing will get absorbed from the intestine, especially fats, leading to Steatorrhea. Whipple’s disease: Feature

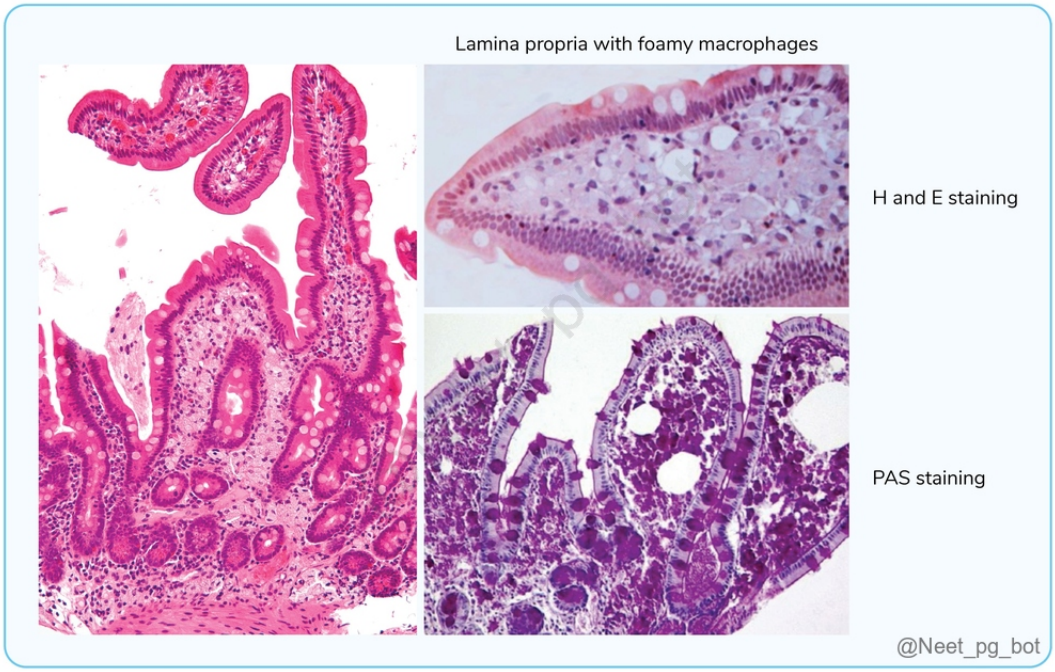

References:

Robbins and Cotran Pathologic Basis of Disease, 10th Edition, Page 794

↑ *Back to this question in Part A*

@Neet_pg_bot

Q2: A 35-year-old female presents with chronic diarrhoea, abdominal bloating, and unintended weight loss. She reports discomfort after consuming gluten-containing foods. Laboratory tests show elevated tissue transglutaminase (tTG) and anti-endomysial antibodies (EMA) levels, prompting a small intestinal biopsy via upper endoscopy. Which of the following combinations of histopathological features will be seen in this condition? Intraepithelial CD8+ T Lymphocytes Crypt hyperplasia Villous atrophy Decreased mitotic activity Inflammatory cell infiltration in lamina propria (Q845302)

A. 1, 2, 3

B. 1, 2, 3, 4

C. 2, 4, 5

D. 1, 2, 3, 5

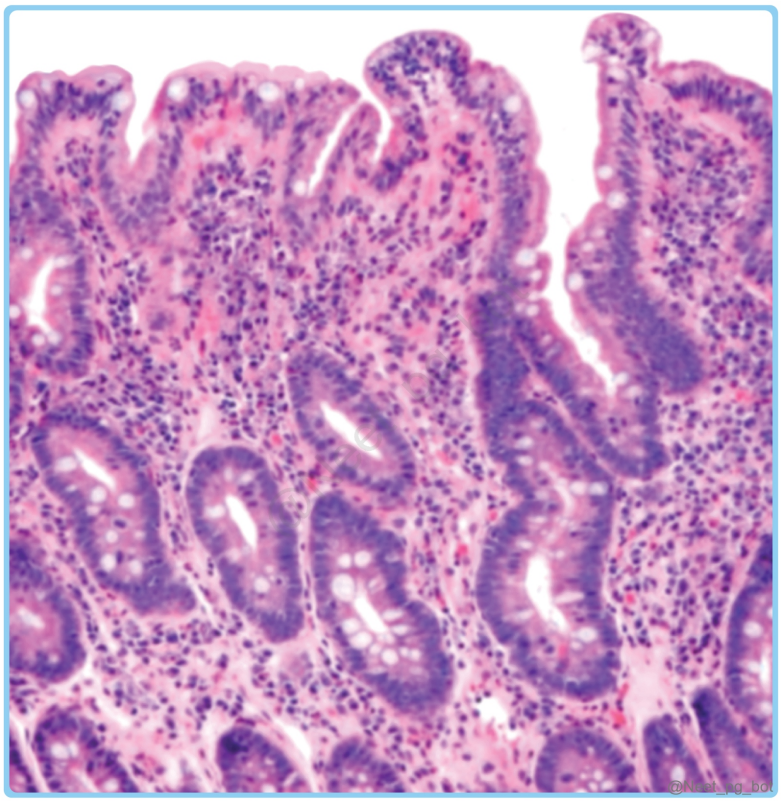

Correct Answer: D. 1, 2, 3, 5

- *Listen (English)*
- *Listen (Hindi)*

Explanation: The clinical scenario is classic for Celiac disease , an autoimmune disorder triggered by gluten ingestion , confirmed by: Positive anti-tTG and anti-EMA antibodies Small bowel biopsy is the gold standard for diagnosis Marsh criteria of celiac disease: Because the antibodies are formed due to consumption of gluten, they first attack the villi of intestine (Villous atrophy) Histopathological features in Celiac disease: Feature Seen in Celiac?

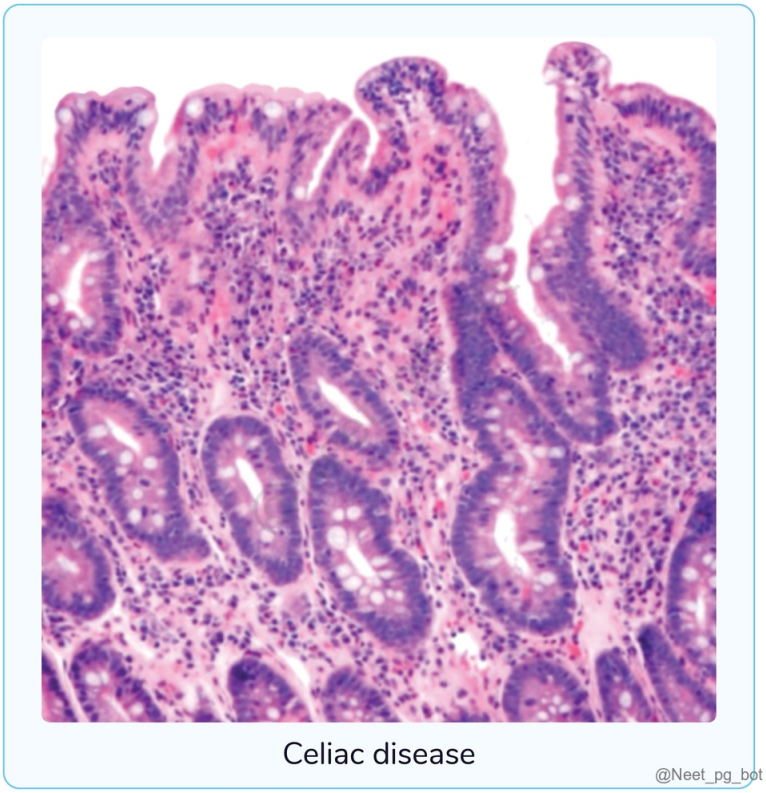

References:

Robbins and Cotran Pathologic Basis of Disease, 10th Edition, Page 785

↑ *Back to this question in Part A*

@Neet_pg_bot

Q3: A 45-year-old woman presents to the clinic with a history of chronic abdominal pain and diarrhoea, worsening notably after consuming wheat-based foods. Physical examination reveals signs suggestive of malabsorption. Considering celiac disease as a possible diagnosis, which of the following statements regarding its pathogenesis is NOT correct? (Q845306)

A. Gliadin peptides in the lamina propria are deamidated by tissue transglutaminase.

B. HLA-DR2 or HLA-DR8 significantly influences celiac disease susceptibility.

C. Gliadin peptides may induce epithelial cells to express IL-15, activating CD8+ lymphocytes.

D. Type 1 diabetes, Sjögren syndrome, and IgA nephropathy are associated with celiac disease.

Correct Answer: B. HLA-DR2 or HLA-DR8 significantly influences celiac disease susceptibility.

■ *Listen (English)*

■ *Listen (Hindi)*

Explanation: Celiac disease (aka celiac sprue or gluten-sensitive enteropathy) is an immune-mediated condition triggered by consuming foods containing gluten, such as barley, rye, oats, and wheat. It is influenced by HLA-DQ2 or HLA-DQ8 , not HLA-DR2 or HLA-DR8 Gliadin is released when these patient consumes gluten. Pathogenesis of Celiac disease: Gliadin peptides ↓ Deamidated by Tissue transglutaminase (TTG) enzyme of intestine ↓ IL-15 expression ↓ CD8+ t-lymphocytes activated ↓ Epithelial damage Genetic variations may link celiac disease to other immune disorders, such as type 1 diabetes, thyroiditis, Sjogren syndrome, and IgA nephropathy. (Option D)

References:

Robbins and Cotran Pathologic Basis of Disease, 10th Edition, Pages 784, 785

↑ *Back to this question in Part A*

@Neet_pg_bot

Q4: A 35-year-old female who recently returned from a tropical region presents with persistent diarrhoea, weight loss, fatigue, anaemia, and vitamin deficiencies, along with a small intestine biopsy findings of villous atrophy and chronic mucosal inflammation. Which part of the gastrointestinal tract is typically NOT affected in this condition? (Q845307)

A. Duodenum

B. Jejunum

C. Ileum

D. Colon

Correct Answer: D. Colon

■ *Listen (English)*

■ *Listen (Hindi)*

Explanation: The clinical scenario, with a history of returning from a tropical region and biopsy findings, points towards diagnosing Tropical enteropathy or Environmental enteropathy that does not affect the colon. This disease often occurs after E. coli infection. Tropical sprue: Predominantly affects the small intestine(duodenum, jejunum, and ileum) and presents with Iron deficiency anemia or megaloblastic anemia. Part of the small intestine Nutrient absorbed Duodenum Iron Jejunum Folic acid Ileum Vitamin B12

References:

Robbins and Cotran Pathologic Basis of Disease, 10th Edition, Page 785

↑ *Back to this question in Part A*

@Neet_pg_bot

Q5: A 6-month-old infant presents with failure to thrive, chronic diarrhoea, and poor weight gain. A peripheral blood smear revealed a characteristic appearance, as shown in the image below. Biochemical investigations reveal very low levels of triglycerides, cholesterol, and fat-soluble vitamins. Which genetic mutation is most likely responsible for these findings? (Q845309)

A. APOB gene mutation

B. MTTP gene mutation

C. MYO5B gene mutation

D. LPL gene mutation

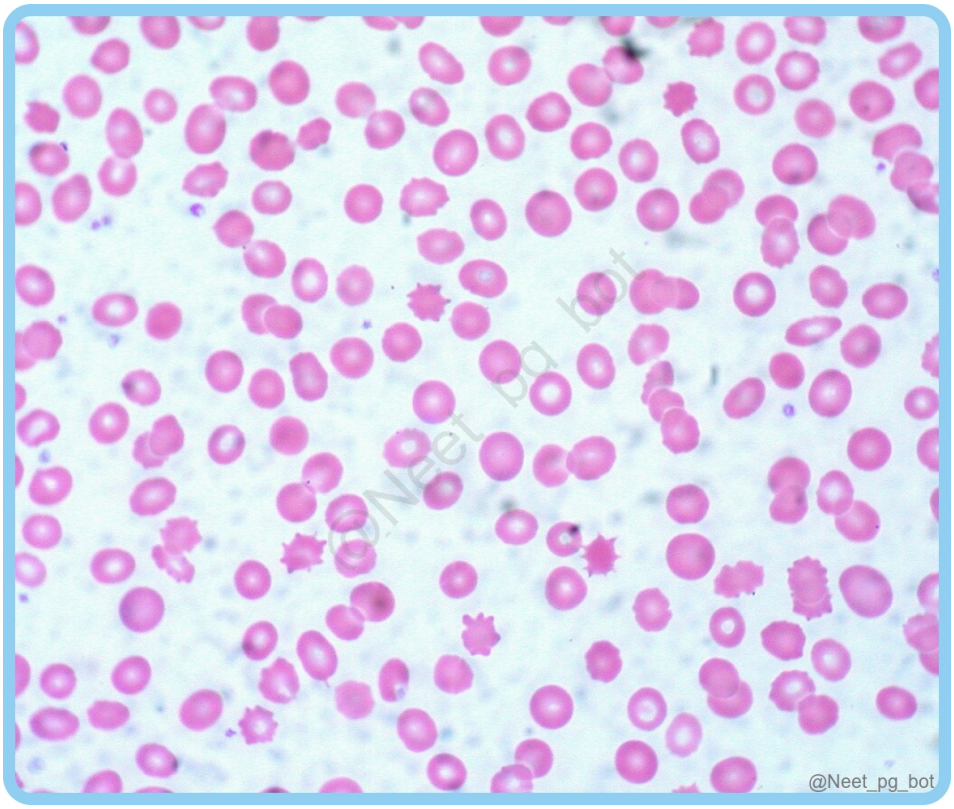

Correct Answer: B. MTTP gene mutation

■ *Listen (English)*

■ *Listen (Hindi)*

Explanation: The given clinical scenario and peripheral smear findings suggest Abetalipoproteinemia, caused by a mutation in Microsomal triglyceride transfer protein (MTTP), which is required for the transfer of lipids to nascent apolipoprotein B polypeptide in the endoplasmic reticulum. Abetalipoproteinemia: Aetiology Mutation in Microsomal triglyceride transfer protein (MTTP) Presentation Extremely low cholesterol and triglycerides Malabsorption of fat-soluble vitamins. Intestine shows lipid vacuoles because of problem in lipid transfer. Biochemical investigation Low triglyceride cholesterol levels Low fat soluble vitamin levels Symptoms Presents in infancy with failure to thrive, diarrhoea, and steatorrhea. Peripheral smear Presence of acanthocytes -RBCs with peripheral spikes

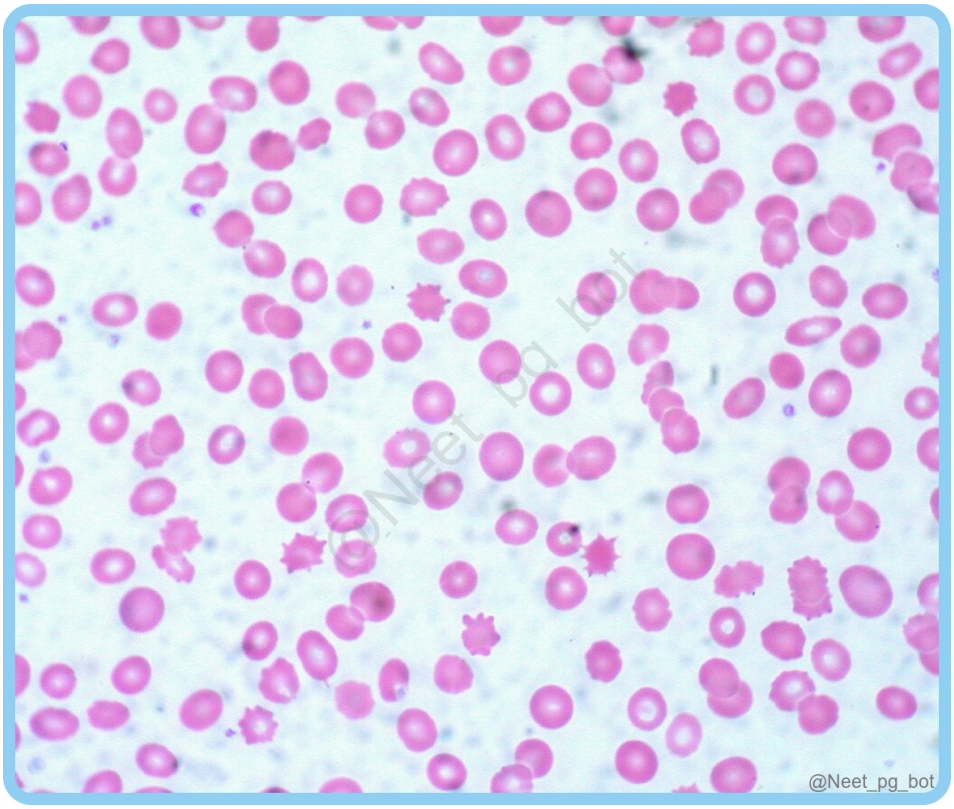

References:

Robbins and Cotran Pathologic Basis of Disease, 10th Edition, Page 787

↑ *Back to this question in Part A*

@Neet_pg_bot

Q6: A 4-week-old infant presents with severe watery diarrhoea and failure to thrive since birth. Stool studies are negative for pathogens. A small bowel biopsy shows villous atrophy, cytoplasmic inclusion bodies within enterocytes, and reduction of microvilli on the enterocyte surface. Which of the following statements is true

regarding this condition? (Q845310)

A. It is characterised by the absence of ganglion cells in the distal part of the colon.

B. It is associated with mutations in the MYO5B or STX3 genes.

C. Histological findings include villous atrophy and crypt hyperplasia.

D. It is commonly caused by rotavirus infection, which leads to persistent diarrhoea.

Correct Answer: B. It is associated with mutations in the MYO5B or STX3 genes.

■ *Listen (English)*

■ *Listen (Hindi)*

Explanation: The clinical presentation suggests Microvillous Inclusion Disease (MVID). It is a rare autosomal recessive disorder characterised by severe, intractable watery diarrhoea from early infancy. It presents with inclusion bodies and reduction in microvilli. Aetiology: Mutations in the MYO5B or STX3 genes. It is characterised by the absence of ganglion cells in the distal part of the colon (Option A): Seen in Hirschsprung disease. Histological findings include villous atrophy and crypt hyperplasia (Option C): Seen in celiac disease or gluten insensitivity. It is commonly caused by rotavirus infection, which leads to persistent diarrhoea (Option D): Stool studies are negative for pathogen in this case.

References:

Robbins and Cotran Pathologic Basis of Disease, 10th Edition, Page 786

↑ *Back to this question in Part A*

@Neet_pg_bot

Q7: A 28-year-old female presents with foul-smelling, greasy diarrhoea, bloating, and abdominal cramps following a hiking trip in a remote area. Stool microscopy reveals cysts containing motile trophozoites. A duodenal biopsy shows luminal organisms, as shown in the image, without tissue invasion. Based on the clinical presentation and biopsy findings, what is the most likely causative organism? (Q845312)

A. Cryptosporidium

B. Tropheryma whipplei

C. Entamoeba histolytica

D. Giardia lamblia

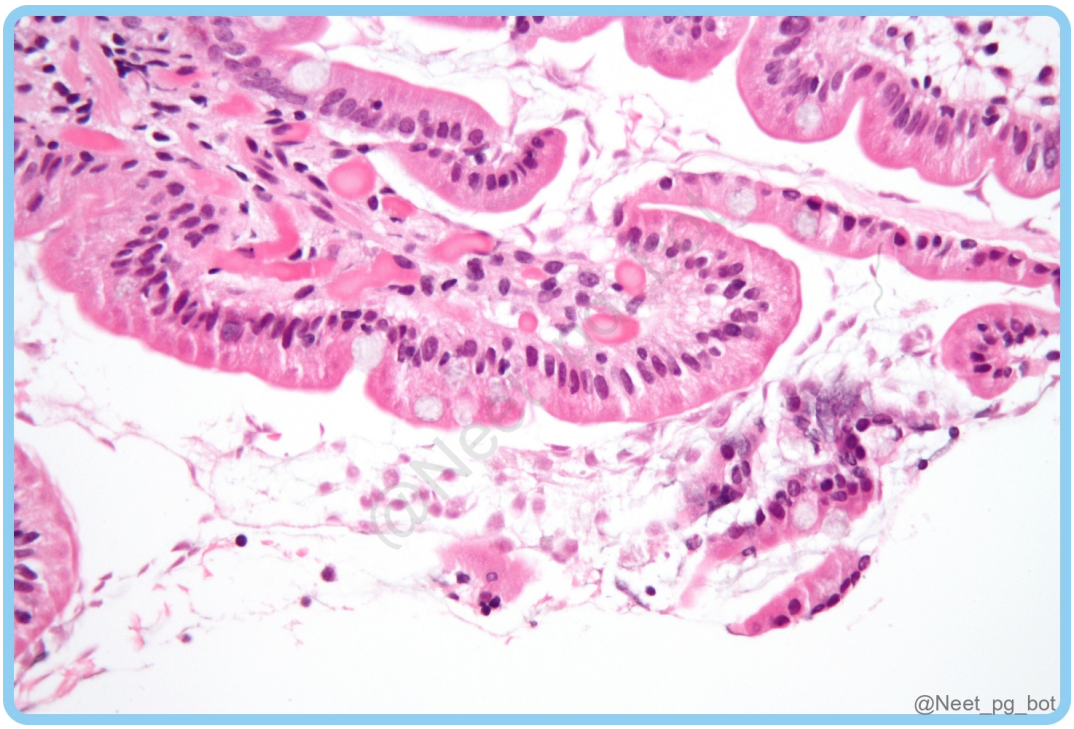

Correct Answer: D. Giardia lamblia

- *Listen (English)*
- *Listen (Hindi)*

Explanation: The scenario is of Giardia lamblia infestation Giardia lamblia: Definition Flagellated protozoan parasite Commonly associated with contaminated water sources. Symptoms Foul-smelling-greasy diarrhoea Bloating Abdominal cramps. Biopsy findings Luminal organisms attached to the intestinal epithelium Blunting of the villi and inflammation without tissue invasion. Giardia trophozoites on biopsy are often described as resembling "falling leaves" {{caption_text}} Cryptosporidium (Option A) Coccidian parasite Usually present along brush border of the intestine. Causes watery diarrhoea, especially in immunocompromised individuals Tropheryma whipplei (Option B) Causes Whipple's disease Histology: PAS-positive foamy macrophages in the intestinal mucosa Entamoeba histolytica (Option C) Protozoan parasite It causes amoebic ulcer in intestine identified by flask shaped ulcers.

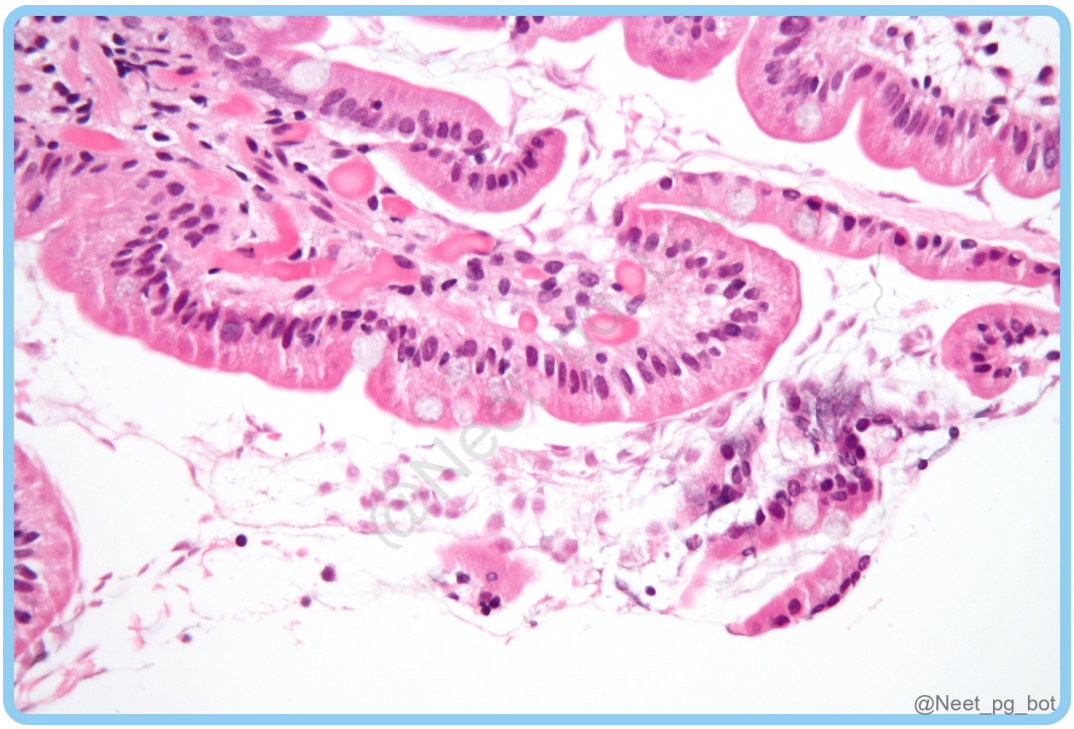
@Neet_pg_bot

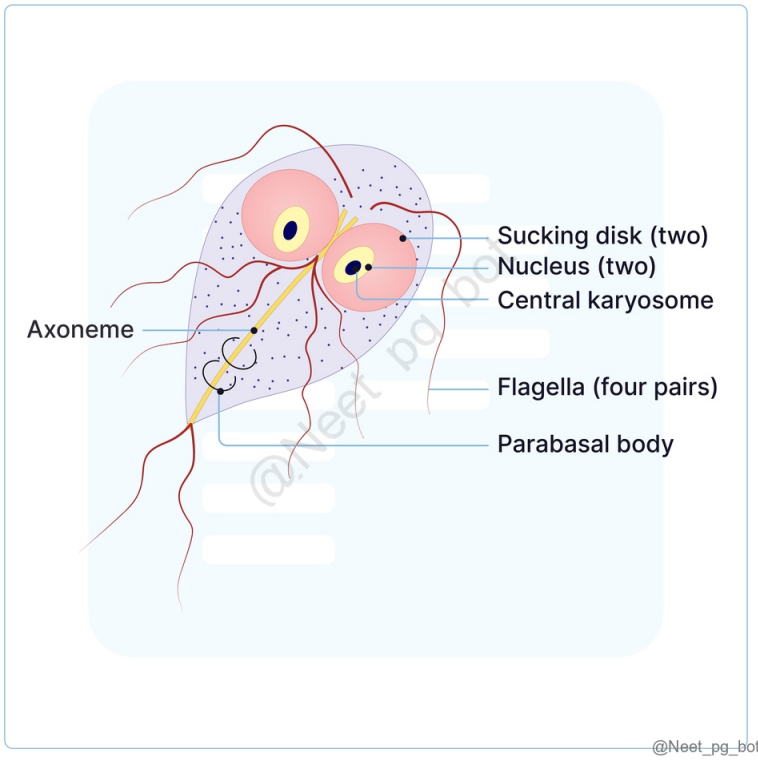
Sucking disk (two)
Nucleus (two)
Central karyosome
Axoneme
Flagella (four pairs)
Parabasal body
@Neet_pg_bot

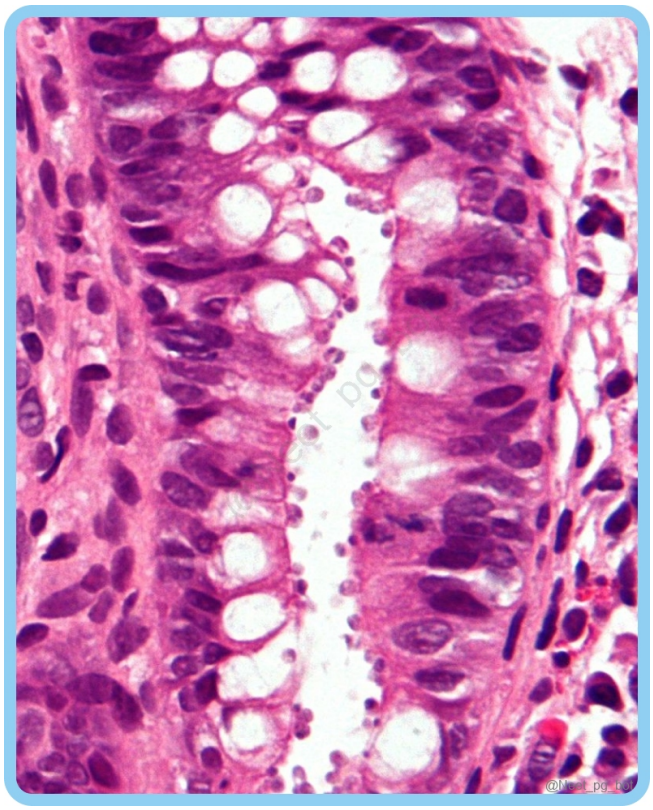

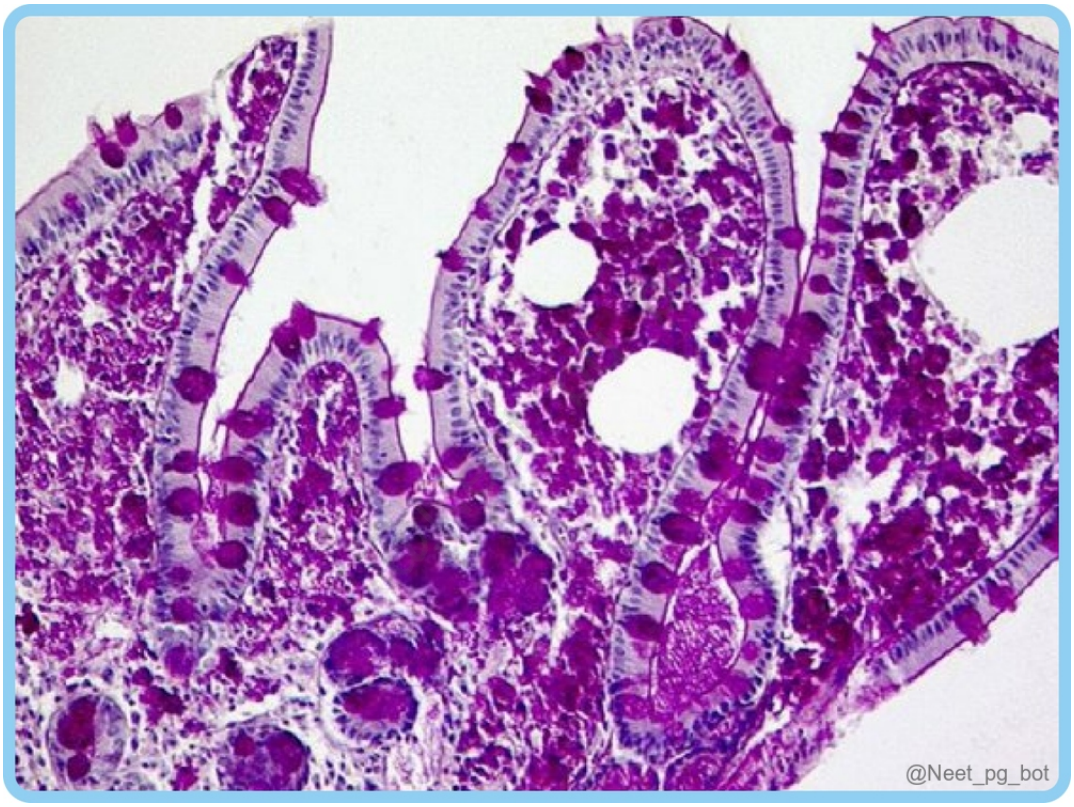
@Neet_pg_bot

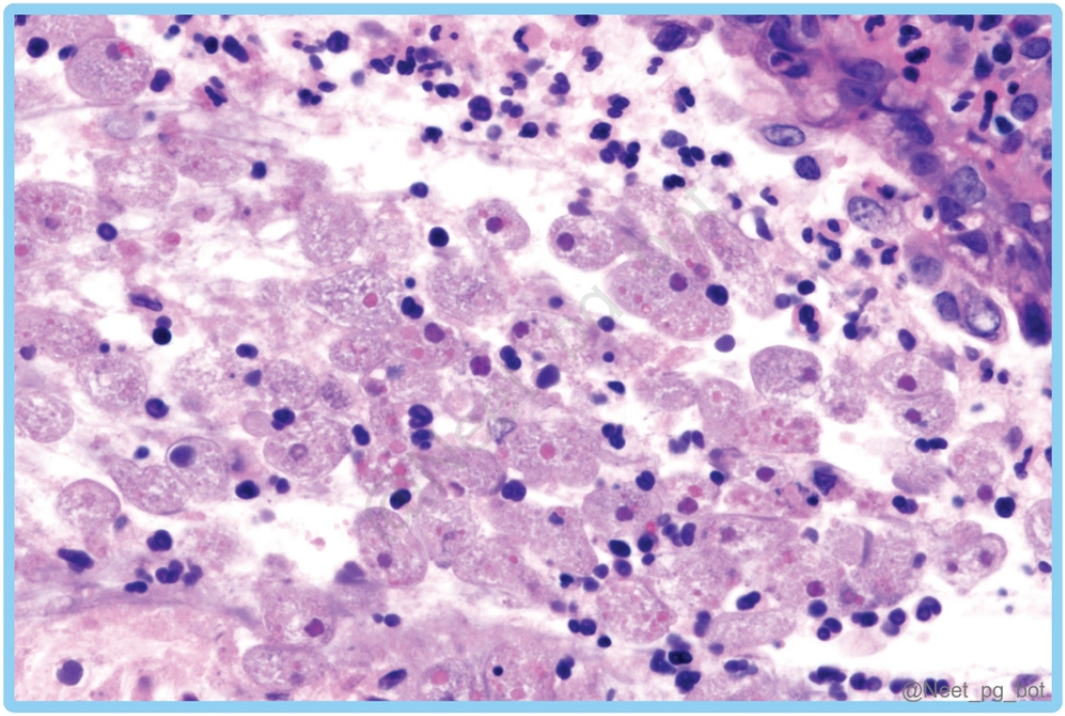

References:

Robbins and Cotran Pathologic Basis of Disease, 10th Edition, Page 787

↑ *Back to this question in Part A*

@Neet_pg_bot

Q8: Which type of ulcer is characterised by flask shaped, multiple punched-out ulcers with undermined edges and necrotic bases on histopathological examination? (Q845325)

A. TB ulcer

B. Typhoid ulcer

C. Amoebic ulcer

D. Peptic ulcer

Correct Answer: C. Amoebic ulcer

■ *Listen (English)*

■ *Listen (Hindi)*

Explanation: On histopathological examination, amoebic ulcers caused by Entamoeba histolytica present as multiple punched-out ulcers with undermined edges and necrotic bases (flask-shaped ulcers). The ulcers often have surrounding inflammation and contain trophozoites of Entamoeba histolytica. When Entamoeba histolytica goes to liver: It breaks the liver tissue into brown coloured pus known as Encovy sauce appearance TB ulcer (Option A): Transverse ulcer in direction. Typhoid ulcer (Option B): Longitudinal ulcer in direction.

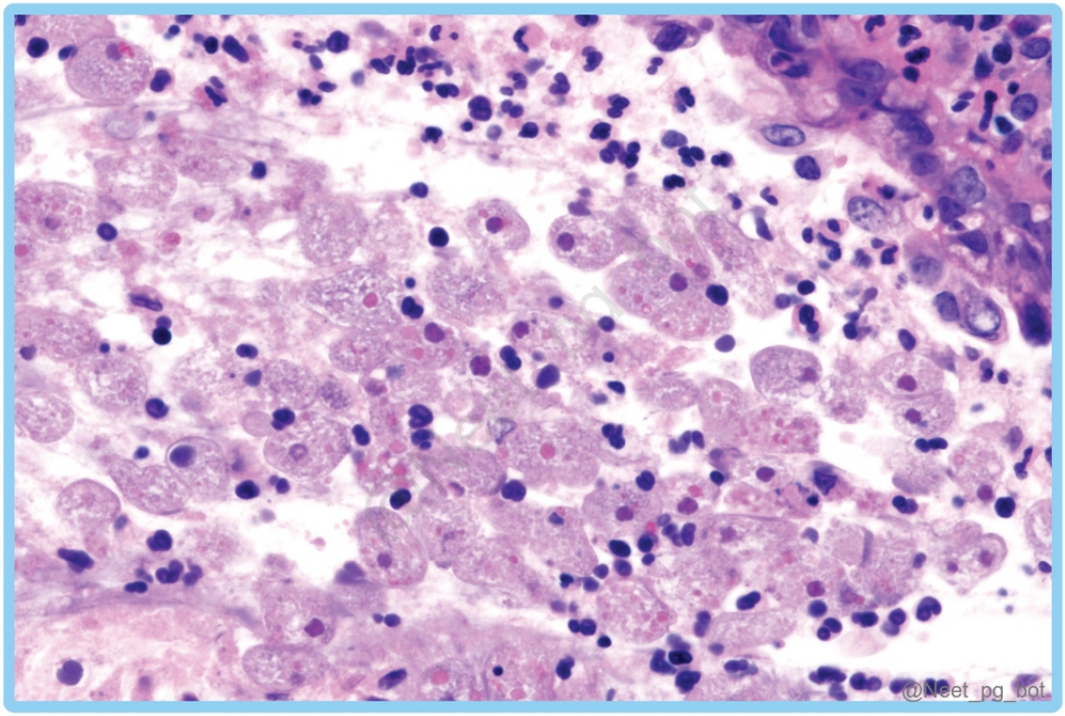

References:

Robbins and Cotran Pathologic Basis of Disease, 10th Edition, Pages 767, 791

↑ *Back to this question in Part A*

@Neet_pg_bot

Q9: A 60-year-old patient presents with severe diarrhoea and abdominal pain after completing a course of broad-spectrum antibiotics for a respiratory infection. Stool studies detect the presence of Clostridioides difficile (C. difficile) toxin. A colonoscopy revealed diffuse yellowish plaques covering the colonic mucosa, as shown in the image. Which inflammatory cell type predominantly infiltrates the lamina propria and surface epithelium in this condition? (Q845329)

A. Lymphocytes

B. Eosinophils

C. Neutrophils

D. Plasma cells



Correct Answer: C. Neutrophils

■ *Listen (English)*

■ *Listen (Hindi)*

Explanation: The given clinical condition suggests Pseudomembranous enterocolitis (PMEC). Pseudomembranous: On colonoscopy, diffuse yellowish plaques covering the colonic mucosa are seen. Enterocolitis: Inflammation of intestine Long term antibiotics alters the gut flora and makes person prone to C. difficile infection, which damages the intestine and forms pseudomembrane. Necrosis and damaged cells are always associated with neutrophilic infiltrations (Option C) Patient presents with watery diarrhoea (rarely can present with bloody diarrhoea), Caused by 2 toxins of C. difficile: Toxin A and Toxin B On biopsy: Classical volcano like erruptions Drug of choice: Vancomycin ± Metronidazole New drug: Fidaxomicin



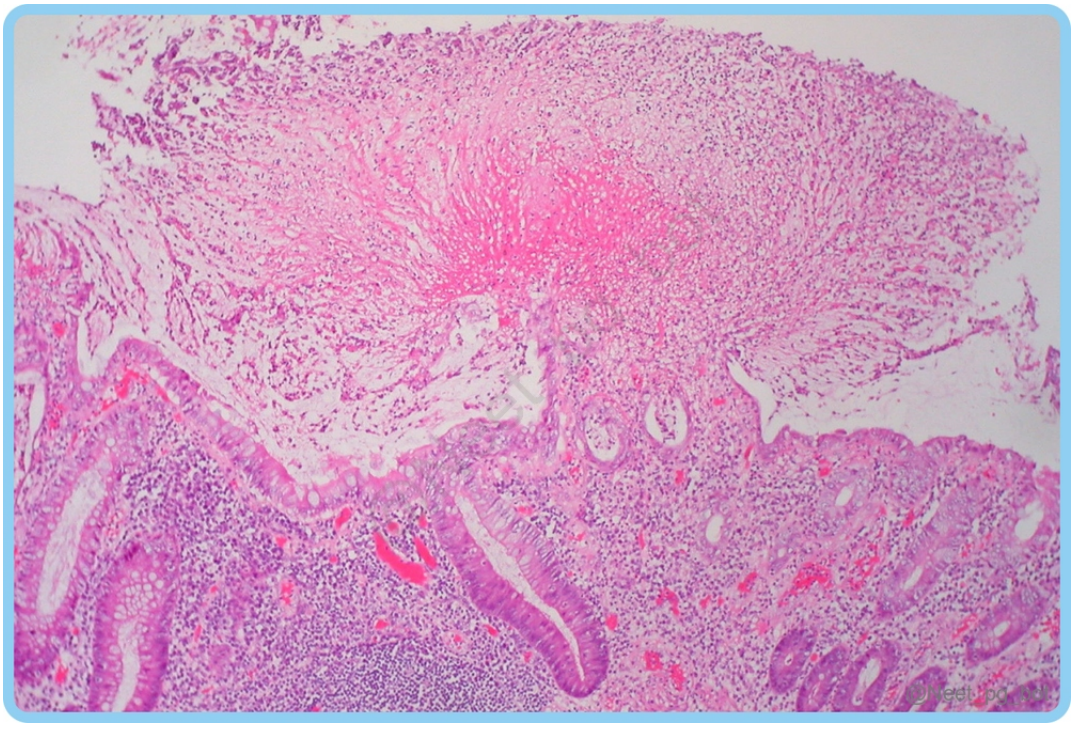

References:

Robbins and Cotran Pathologic Basis of Disease, 10th Edition, Page 793

↑ *Back to this question in Part A*

Q10: A 32-year-old man presents with chronic abdominal pain, diarrhoea, weight loss, and occasional blood in the stool. A colonoscopy reveals skip lesions with areas of normal mucosa alternating with segments, cobblestoning and deep linear fissuring ulcers in the patchy terminal ileum and colon. The histopathological findings from the affected area are shown below. What histopathological features are observed in this patient's condition? (Q845333)

A. Presence of noncaseating granulomas

B. Smooth transition between ulcerated and adjacent normal mucosa

C. Absence of metaplastic changes in the epithelium

D. Uniform distribution of inflammation throughout the affected areas

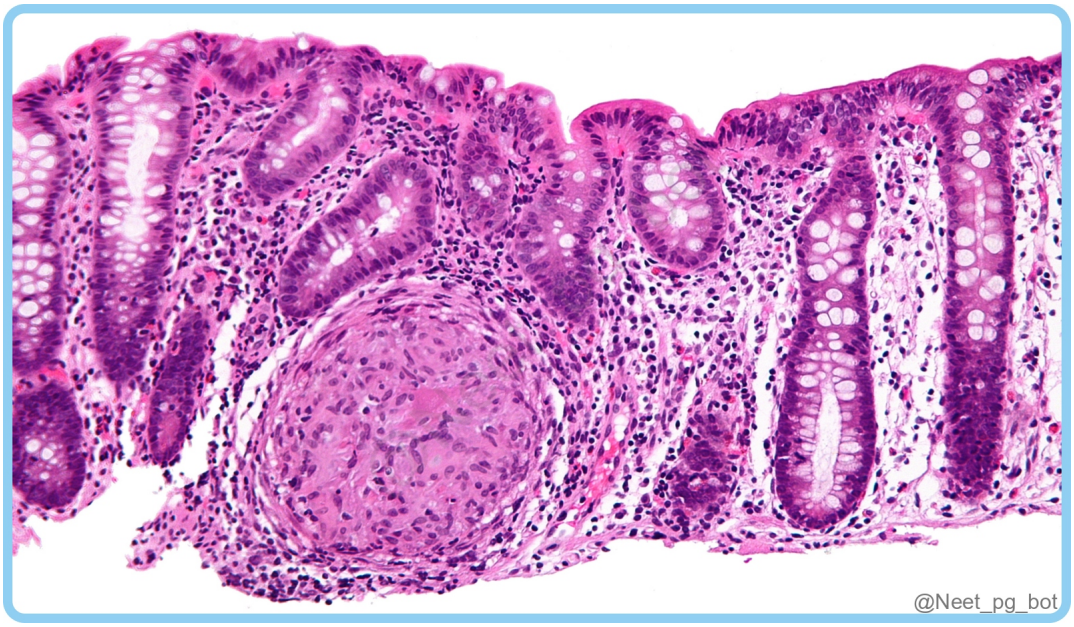

Correct Answer: A. Presence of noncaseating granulomas

■ *Listen (English)*

■ *Listen (Hindi)*

Explanation: The clinical presentation and biopsy findings showing noncaseating granulomas and skip lesions suggest Crohn’s disease. Noncaseating granulomas are round lesions with multinucleated giant cells within them.

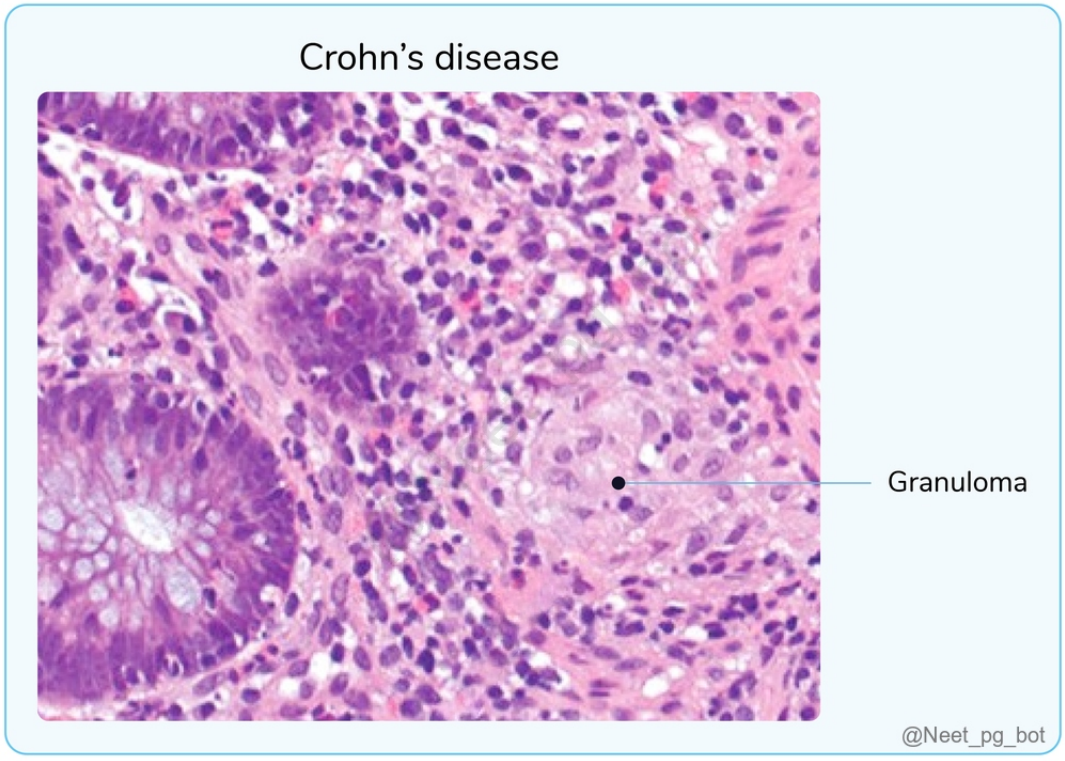

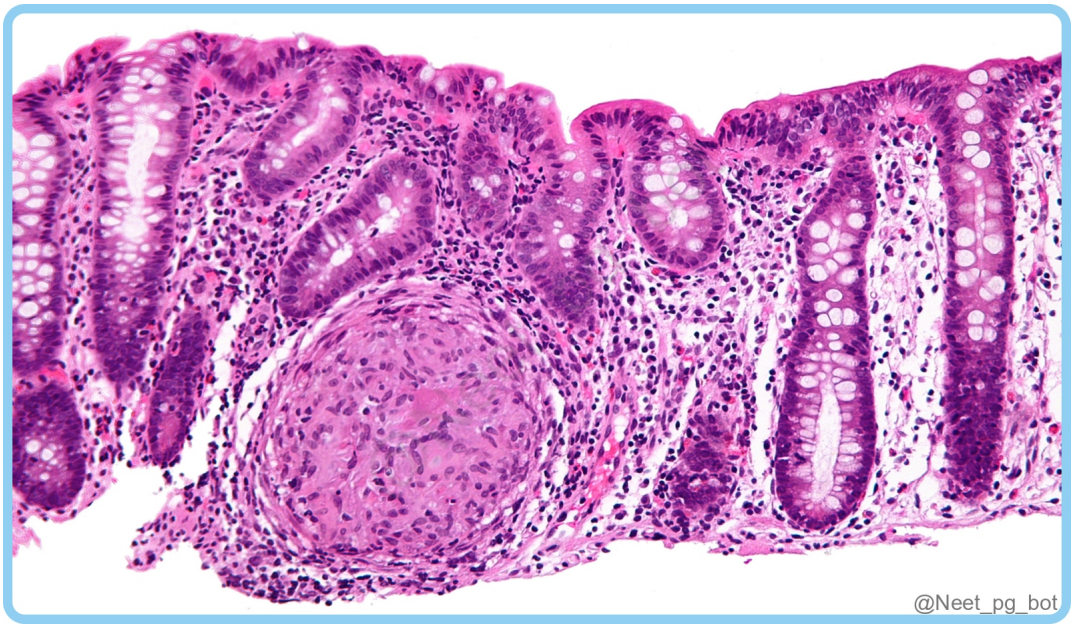

References:

Robbins and Cotran Pathologic Basis of Disease, 10th Edition, Page 801

↑ *Back to this question in Part A*

@Neet_pg_bot

Q11: A 32-year-old male presents with a 6-month history of abdominal pain, diarrhoea, and weight loss. A colonoscopy reveals findings consistent with Crohn's diseaseWhat histological features would you observe in this patient's biopsy? (Q845339)

A. Inflammation is limited superficial layer

B. Fibrosis is not seen

C. Ulcers are limited to mucosa

D. Ulcers can extend beyond the mucosa

Correct Answer: D. Ulcers can extend beyond the mucosa

■ *Listen (English)*

■ *Listen (Hindi)*

Explanation: Crohn’s disease presents with transmural inflammation, which causes deep ulcers. It is characterised by transmural inflammation and can affect the entire intestinal wall thickness, from the mucosa to the serosa, which can lead to fissures and fistulas. (Option A ruled out) Strictures or fibrosis are commonly seen in this condition (Option B ruled out) Ulcers are intially superficial and then goes deep extending to every layer of intestine. (Option C ruled out)

References:

Robbins and Cotran Pathologic Basis of Disease, 10th Edition, Page 799

↑ *Back to this question in Part A*

@Neet_pg_bot

Q12: Which statement is true regarding inflammatory bowel disease (IBD) pathogenesis? (Q845341)

A. NOD2 polymorphisms are closely associated with Crohn's disease in Asian populations.

B. ATG16L1 mutation promotes ATG16L1 degradation and enhances autophagy.

C. Dysbiosis is often established at disease presentation in IBD.

D. All of the above

Correct Answer: C. Dysbiosis is often established at disease presentation in IBD.

■ *Listen (English)*

■ *Listen (Hindi)*

Explanation: "Dysbiosis" is an imbalance in gut microbiota marked by shifts in microbial populations and reduced diversity. It commonly occurs at inflammatory bowel disease (IBD) onset and leads to increased inflammation and impaired gut barrier, contributing to IBD progression. Patients with newly diagnosed, treatment-naïve IBD often show: Reduced diversity of gut microbiota Decreased beneficial bacteria (e.g., Firmicutes, Bacteroidetes) Increased pro-inflammatory species (e.g., Enterobacteriaceae) This suggests that dysbiosis occurs early in the disease process , though it may be both a cause and consequence of inflammation. Dysbiosis Triggers the IL-23/IL-17 Pro-inflammatory Axis: The shift toward pro-inflammatory bacterial species (like Enterobacteriaceae) stimulates innate immune cells (dendritic cells and macrophages) to secrete IL-23 . Role of IL-23: Acts as a critical survival factor for Th17 cells . Role of IL-17: Secreted by Th17 cells, it recruits neutrophils to the gut mucosa and promotes the release of other inflammatory cytokines (like TNF-α). Result: This pathway creates a "feed-forward" loop where immune activation further damages the gut barrier, worsening the dysbiosis. NOD2 polymorphisms are closely associated with Crohn's disease in Asian populations (Option A) : NOD2 polymorphisms are closely associated with Crohn's disease but not with Crohn's disease in Asian populations. ATG16L1 mutation promotes ATG16L1 degradation and enhances autophagy (Option B) : The ATG16L1 mutation limits autophagy rather than enhancing it by promoting ATG16L1 degradation.

References:

Robbins and Cotran Pathologic Basis of Disease, 10th Edition, Pages 799-800

↑ *Back to this question in Part A*

@Neet_pg_bot

Q13: Which of the following statements regarding ulcerative colitis and Crohn's disease is true? (Q845344)

A. Ulcerative colitis is characterised by skip lesions, whereas Crohn’s disease typically presents with continuous inflammation.

B. Cobblestone appearance is a feature seen in ulcerative colitis and Crohn's disease but is more commonly associated with Crohn's disease.

C. Ulcerative colitis typically begins in the rectum and extends proximally, whereas Crohn's disease can involve any part of the GI tract with rectal sparing.

D. Fistulae, strictures, and abscesses are more commonly seen in ulcerative colitis than in Crohn's disease.

Correct Answer: C. Ulcerative colitis typically begins in the rectum and extends proximally, whereas Crohn's disease can involve any part of the GI tract with rectal sparing.

■ *Listen (English)*

■ *Listen (Hindi)*

Explanation: Features Ulcerative colitis Crohn’s disease Location Typically begins in the rectum and extends proximally affecting entire large and small intestines: Backwash ileitis Can involve any part of the GI tract: Primarily it starts most commonly from Ileum and then it can effect any part of GI tract in the forn of skip lesions. Distribution Diffused continuous lesion Patchy, with skip lesions . (Option A) Gross appearance Mucosal erythema and granularity Broad-based ulcers with a continuous pattern Pseudopolyps Mucosal atrophy Smooth, continuous inflammation Transmural inflammation Aphthous ulcers Cobblestone appearance (Option B) Fistulae, strictures, abscesses Creeping fat (mesenteric fat wrapping) Complications Toxic megacolon Colonic dilation Mucosal bridges. Strictures Fistulae Fissures (Option D)

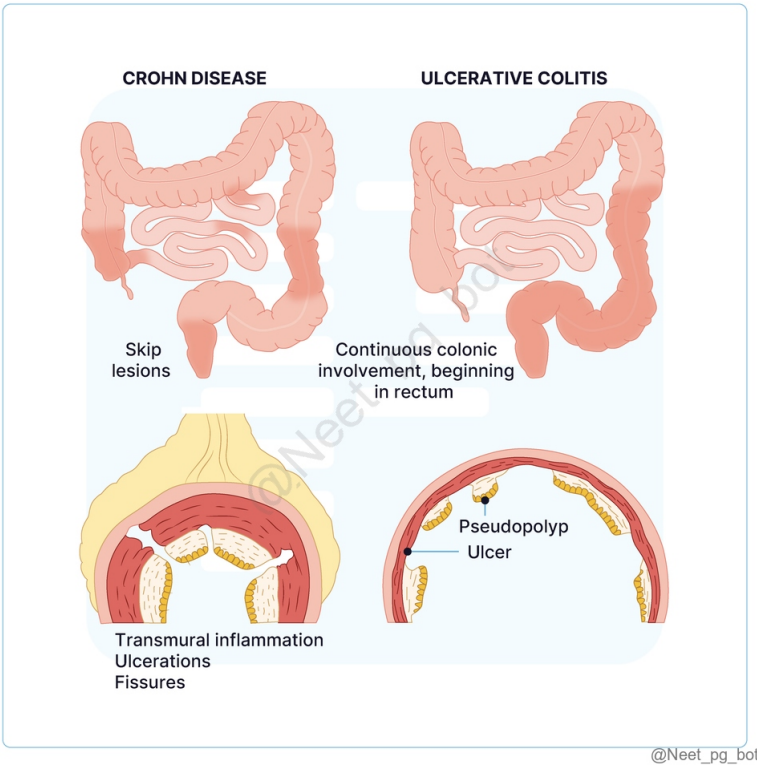

References:

Robbins and Cotran Pathologic Basis of Disease, 10th Edition, Pages 798-805

↑ *Back to this question in Part A*

@Neet_pg_bot

Q14: A 32-year-old male presents to the outpatient clinic with a 5-day history of non-bloody, watery diarrhea. He reports that he recently returned from a hiking trip in a rural area where he drank water from a nearby stream. On examination, he appears dehydrated but is otherwise stable. A stool sample was sent for analysis, which revealed the presence of oocysts. Which of the following is the most likely cause

of this patient's gastrointestinal symptoms? (Q846629)

A. Cryptosporidium

B. Microsporidium

C. Giardia lamblia

D. Entamoeba histolytica

Correct Answer: A. Cryptosporidium

■ *Listen (English)*

■ *Listen (Hindi)*

Explanation: Cryptosporidiosis is a significant cause of diarrhea worldwide. Cryptosporidium is known to cause non-bloody, watery diarrhea and is commonly associated with drinking contaminated water, particularly from untreated sources such as streams or lakes . The presence of oocysts in the stool supports this diagnosis C. hominis and C. parvum usually presents with waterry diarrhea and many times the patient is immunocompromised like HIV+. Oocysts are present in stool and measures 4-6µm. Cold ZN stain or Kinyoun stain is used to see oocytes. On biopsy of intestine, Cryptosporidium is found along the brush border of epithelium. Microsporidium (Option B): Rarely presents with oocysts in stool sample. Giardia lamblia (Option C): Do not have oocysts. Entamoeba histolytica (Option D): Do not have oocysts

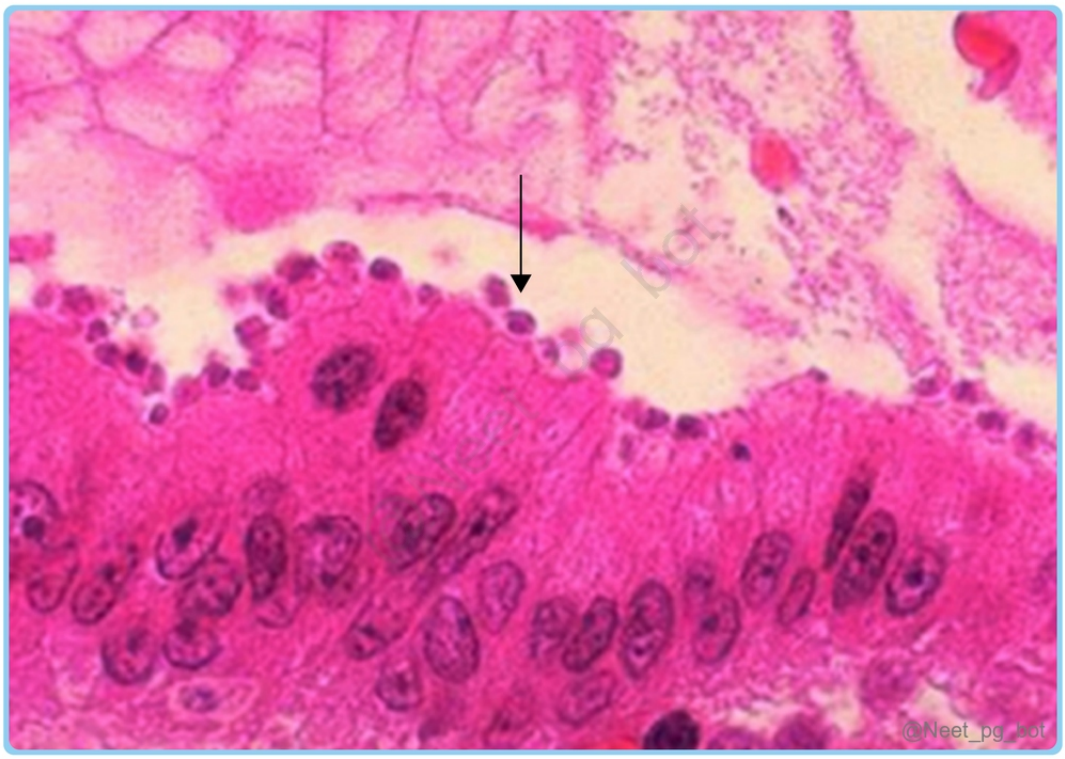

References:

Robbins and Cotran Pathologic Basis of Disease, 10th Edition, Pages 796-798

↑ *Back to this question in Part A*

@Neet_pg_bot

• [09_Gastrointestinal Tract] 043 Previous Year Questions

« Back to Folder Directory

[09_Gastrointestinal Tract] 043 Previous Year Questions — Quick Jump

Q1 (p. 1977)	*Q2 (p. 1978)*	*Q3 (p. 1979)*	*Q4 (p. 1981)*	*Q5 (p. 1982)*	*Q6 (p. 1984)*
Q7 (p. 1985)	*Q8 (p. 1985)*	*Q9 (p. 1987)*	*Q10 (p. 1989)*	*Q11 (p. 1990)*	*Q12 (p. 1993)*
Q13 (p. 1994)	*Q14 (p. 1997)*	*Q15 (p. 2000)*	*Q16 (p. 2002)*	*Q17 (p. 2002)*	*Q18 (p. 2004)*
Q19 (p. 2005)	*Q20 (p. 2006)*	*Q21 (p. 2007)*	*Q22 (p. 2007)*	*Q23 (p. 2008)*	*Q24 (p. 2009)*
Q25 (p. 2009)	*Q26 (p. 2010)*	*Q27 (p. 2010)*			

Q1: Which of the following is a sensitive and specific marker of intestinal inflammation? (Q858080)

A. Procalcitonin

B. Fecal lactoferrin

C. Tissue transglutaminase IgA

D. High-sensitivity C-reactive protein

Correct Answer: B. Fecal lactoferrin

Explanation: Faecal lactoferrin is a sensitive and specific marker for intestinal inflammation , particularly in conditions like inflammatory bowel diseases (IBD). It is a glycoprotein released by the neutrophils. Fecal calprotectin and Fecal lactoferrin are both non-invasive biomarkers used to assess intestinal inflammation . They are particularly useful in the diagnosis and monitoring of IBD and in identifying and separating between inflammatory bowel disease (IBD) and non-inflammatory conditions like irritable bowel syndrome (IBS). Incorrect Options: Procalcitonin (Option A) is a biomarker produced in response to bacterial infections , particularly sepsis. It's used to monitor bacterial infections and guide antibiotic therapy. It is not specific for intestinal inflammation . Tissue transglutaminase IgA (Option C) is an antibody commonly used in the diagnosis of celiac disease , an autoimmune disorder where the ingestion of gluten leads to intestinal damage. It is not a marker for general intestinal inflammation . High-sensitivity C-reactive protein (Option D) is a more sensitive version of CRP, often used to assess the risk of coronary artery disease. It increases in response to generalised inflammation and does not specifically pinpoint conditions like IBD.

References:

Harrison’s Principles of Internal Medicine, 21st Edition, Page 2475

↑ *Back to this question in Part A*

@Neet_pg_bot

Q2: A 12-year-old boy presents with multiple dark-brown macules around the lips and oral mucosa. Upper GI endoscopy shows numerous hamartomatous polyps in the jejunum. Which of the following statements regarding this condition are correct? Autosomal recessive inheritance Presence of congenital retinal pigmentation (CRPE) Loss-of-function mutation in the STK11 gene. Arborising pattern due to the proliferation of smooth muscle in the polyp histology (Q879201)

A. 1, 2

B. 1, 3, 4

C. 3, 4

D. 2, 3, 4

Correct Answer: C. 3, 4

Explanation: The presentation is classic for Peutz–Jeghers Syndrome (PJS) . Inheritance: Autosomal dominant (Statement 1 ruled out) Gene: STK11 - tumour suppressor, loss-of-function mutation (Statement 3) Clinical features: Multiple hamartomatous polyps (mainly jejunum, also stomach/colon) Mucocutaneous pigmentation – dark macules on lips, buccal mucosa, palms, genitalia, perianal area Complications: Intussusception, ↑ risk of GI, pancreatic, breast, ovarian, uterine cancers (~40%) Histology: Arborising pattern of smooth muscle, lamina propria, and glands with normal epithelium (Statement 4). ■ Congenital retinal pigmentation (Statement 2) is not a feature of PJS.

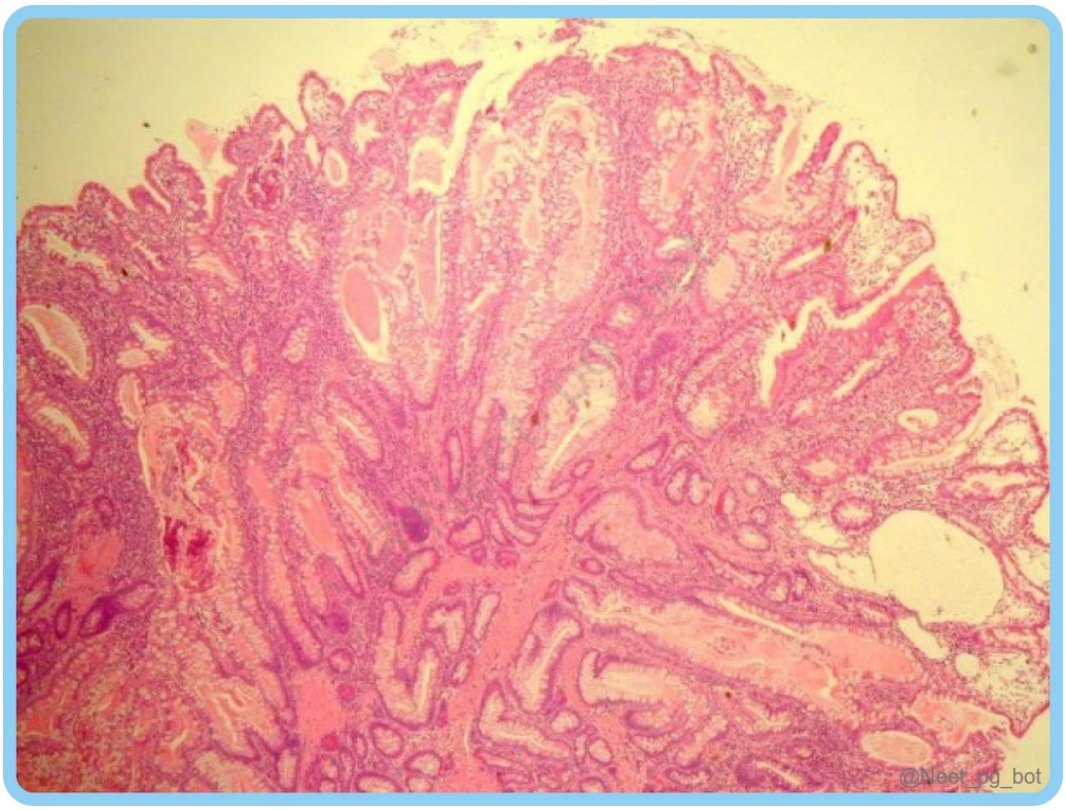

References:

Robbins & Cotran, Pathologic Basis of Diseases, 10th Edition, Page 809,810

↑ *Back to this question in Part A*

@Neet_pg_bot

Q3: Which of the following is a characteristic feature of Barrett's oesophagus? (Q859302)

A. Squamous metaplasia

B. Severe dysplasia

C. Intestinal metaplasia

D. Cuboidal metaplasia

Correct Answer: C. Intestinal metaplasia

Explanation: The primary cellular change seen in Barrett's oesophagus is metaplasia of squamous epithelium into intestinal/columnar epithelium. {{caption_text}} {{caption_text}} Incorrect Options: Squamous Metaplasia

(Option A) is the replacement of normal columnar epithelium with stratified squamous epithelium , typically due to chronic irritation (e.g., bronchial epithelium in smokers or the cervix). In Barrett's oesophagus , the reverse occurs, with squamous epithelium replaced by columnar epithelium . Severe Dysplasia (Option B) is disordered cellular growth and a precancerous condition . In Barrett's oesophagus , dysplasia (low-grade or high-grade) may arise as a progression from intestinal metaplasia toward adenocarcinoma , but it is not a defining feature-rather, a complication. Cuboidal Metaplasia (Option D) is not a recognised feature of Barrett's oesophagus or any other oesophagal condition. Barrett's oesophagus is specifically defined by intestinal metaplasia , with goblet cells present within the columnar epithelium.

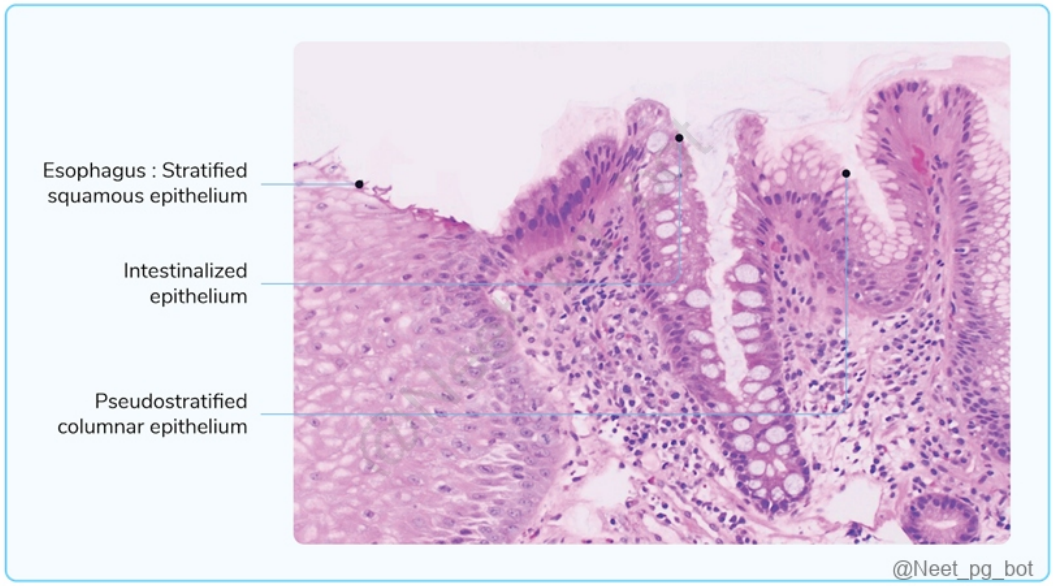

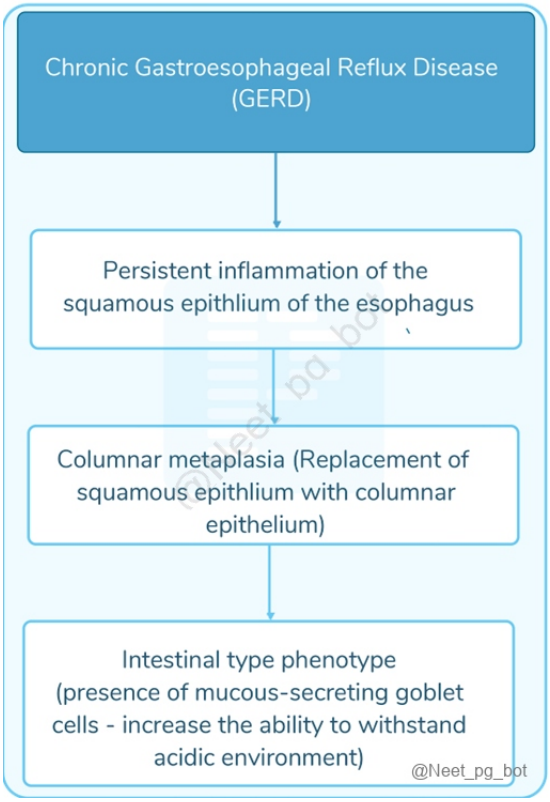

References:

Robbins and Cotran Pathologic Basis of Disease, 10th Edition, Pages 762, 272

↑ *Back to this question in Part A*

@Neet_pg_bot

Q4: A 5-year-old child was admitted to the hospital with a history of prolapsing rectal mass and painless rectal bleeding. The histopathological image of the mass is shown below. What is the most likely diagnosis? (Q858520)

A. Peutz-Jegher syndrome

B. Villous adenoma

C. Juvenile polyp

D. Tubular adenoma

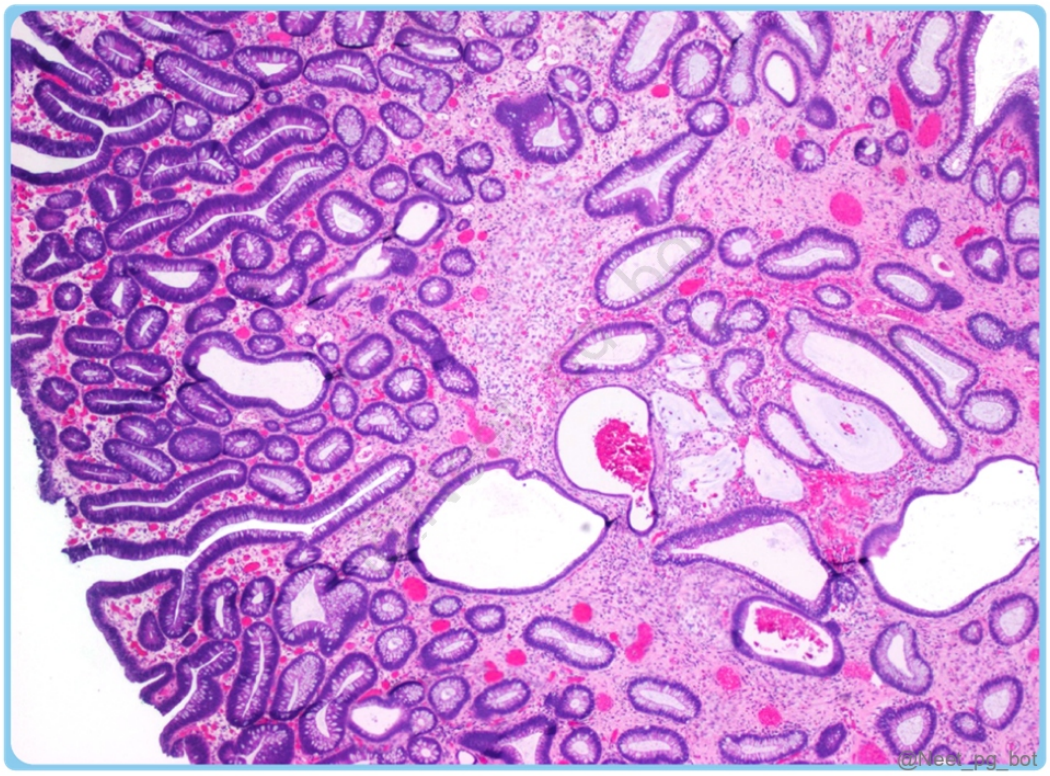

Correct Answer: C. Juvenile polyp

Explanation: The clinical presentation and HPE image showing characteristic cystically dilated crypts & glands are suggestive of Juvenile polyp. Juvenile Polyps: Occurrence : Common in children under 5 years old; can be sporadic or syndromic. Size & Appearance : Typically less than 3 cm, pedunculated, smooth-surfaced, reddish with cystic spaces. Histology : Dilated glands filled with mucin and inflammatory debris, mixed inflammatory infiltrates, and sometimes attenuated muscularis mucosae. {{caption_text}} Pathogenesis : Linked to mucosal hyperplasia ; mutations in SMAD4 and BMPR1A (TGF-β pathway). Dysplasia : Rare in sporadic polyps but present in juvenile polyposis syndrome. Complications : Juvenile polyposis syndrome can lead to colonic adenocarcinoma (30-50% risk by age 45). Peutz-Jeghers Syndrome (Option A) is an autosomal dominant condition characterised by hamartomatous polyps throughout the gastrointestinal tract. While rectal polyps may occur in this syndrome, the histopathological image seen in this case is more indicative of juvenile polyps. Villous Adenoma (Option B) are adenomatous polyps commonly seen in adults, characterised by finger-like projections with abundant mucin production. Tubular Adenoma (Option D) are common adenomatous polyps found in adults, characterized by glandular structures with tubular architecture.

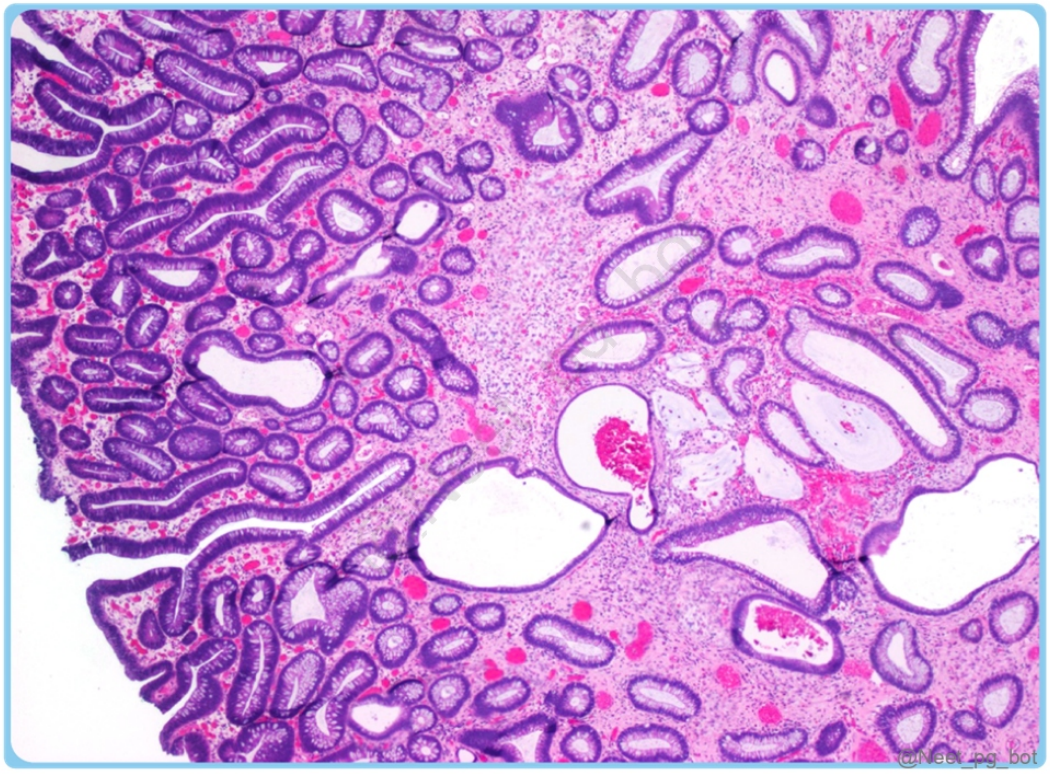

References:

Robbins & Cotran Pathologic Basis of Disease, 10th Edition, Page 808,809

↑ *Back to this question in Part A*

@Neet_pg_bot

Q5: A 50-year-old man presented with a retroperitoneal mass. A biopsy of the lesion is shown in the image below. Molecular analysis revealed t(12;16). What is the most likely condition? (Q858516)

A. Myxoid liposarcoma

B. Lipoma

C. Spindle lipoma

D. Polymorphic lipoma

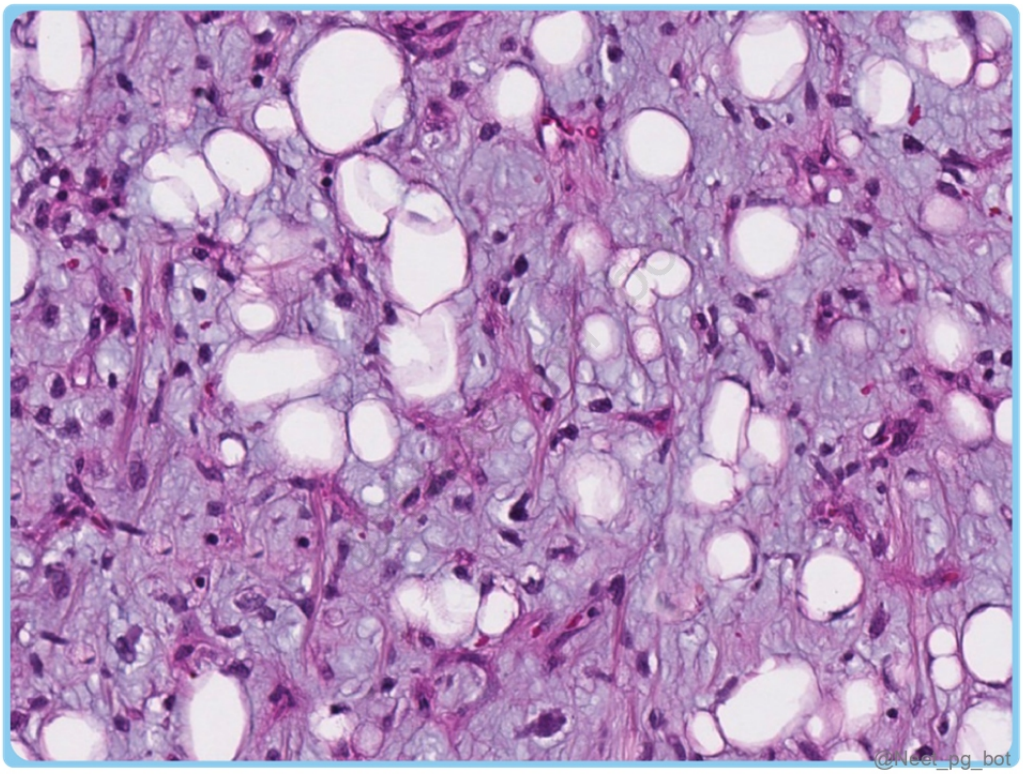

Correct Answer: A. Myxoid liposarcoma

Explanation: - Myxoid liposarcoma The presence of a retroperitoneal mass with the molecular finding of t(12;16) translocation & image showing abundant ground substance, with branching capillaries and few immature adipocytes, is highly suggestive of Myxoid liposarcoma . Liposarcoma, malignant tumours of adipose tissue, is the most common type of sarcoma in adults. These tumours typically arise in the deep soft tissues of the proximal extremities and retroperitoneum, commonly affecting individuals in their sixth and seventh decades of life. Pathogenesis: The three subtypes of liposarcoma—well-differentiated, myxoid, and pleomorphic—have distinct genetic abnormalities: Well-differentiated liposarcomas exhibit amplifications in the chromosome region 12q13–q15, which includes the p53 inhibitor MDM2. Myxoid liposarcomas are characterised by a fusion gene caused by a t(12;16) translocation, which arrests adipocyte differentiation, leading to uncontrolled proliferation of primitive cells. Pleomorphic liposarcomas display complex karyotypes without consistent genetic abnormalities. Histopathological findings: Well-differentiated liposarcomas are composed primarily of mature adipocytes with

scattered atypical spindle cells. Myxoid liposarcomas are characterised by a rich basophilic extracellular matrix, arborizing capillaries, and primitive cells at different stages of adipocyte differentiation, resembling fetal fat. Pleomorphic liposarcomas feature sheets of anaplastic cells with bizarre nuclei intermixed with varying numbers of immature adipocytes, called lipoblasts. Lipomas (Option B) are benign tumours made up of mature adipose tissue. They are typically well-defined and do not show the cellular atypia or genetic abnormalities associated with liposarcomas. Spindle Lipoma (Option C) is a benign variant of lipoma characterised by spindle-shaped cells within the fatty tissue. It lacks the genetic mutations seen in myxoid liposarcoma. Polymorphic Lipoma (Option D) , also referred to as pleomorphic lipoma, is a benign lipomatous tumour made of mature adipose tissue containing various cell types. It does not exhibit the specific t(12;16) translocation found in myxoid liposarcoma.

References:

Robbins & Cotran Pathologic Basis of Disease, 10th Edition, Page 1209

↑ *Back to this question in Part A*

@Neet_pg_bot

Q6: A 30-year-old female presents with chest pain, recurrent heartburn, and dysphagia. A barium swallow shows a bird beak sign. Which of the following statements is true regarding the condition in this patient? (Q854892)

A. Relaxation of LES

B. Increased peristalsis

C. Decreased release of NO and VIP in the distal esophagus

D. Decreased tone of LES

Correct Answer: C. Decreased release of NO and VIP in the distal esophagus

Explanation: The clinical presentation & the bird beak sign on barium swallow suggests achalasia , a condition characterized by the inability of the lower esophageal sphincter (LES) to relax and an absence of peristalsis in the distal esophagus. It is caused by a decreased release of nitric oxide (NO) and vasoactive intestinal peptide (VIP) , which are essential for smooth muscle relaxation. This results in increased tone of the LES and impaired peristalsis. Achalasia: Pathology: Incomplete LES relaxation/Increased LES tone/Aperistalsis of the esophagus Symptoms: Dysphagia (difficulty swallowing), Difficulty in belching, Chest pain Primary Achalasia: It is caused by degeneration of nitric oxide-producing neurons that normally induce LES relaxation. Degeneration of the extraesophageal vagus nerve or dorsal motor nucleus of the vagus may occur. Secondary Achalasia: Chagas disease (Trypanosoma cruzi infection) destroys the myenteric plexus, leading to peristalsis failure and esophageal dilation. Associated with conditions like: Diabetic autonomic neuropathy Infiltrative disorders (e.g., malignancy , amyloidosis , sarcoidosis) Systemic sclerosis Dorsal motor nuclei lesions (post-polio) Down syndrome or Allgrove syndrome (achalasia, alacrima, ACTH-resistant adrenal insufficiency). Some cases linked to HSV1 infection , immunoregulatory gene polymorphisms, Sjögren syndrome , or autoimmune thyroid disease , suggesting immune-mediated destruction of inhibitory esophageal neurons. Treatment: Laparoscopic myotomy

Pneumatic balloon dilation Botulinum neurotoxin (Botox) injections to inhibit cholinergic neuron contraction.

References:

Robbins & Cotran Pathologic Basis of Disease, 10th Edition, Page 757,758

↑ *Back to this question in Part A*

@Neet_pg_bot

Q7: Which of the following is true about the pathogenesis of Hirschsprung disease? (Q854856)

A. Failure of migration of neural crest cells

B. Increase in ganglion cells

C. Visceral myopathy

D. Obstruction by inflammatory strictures

Correct Answer: A. Failure of migration of neural crest cells

Explanation: Hirschsprung disease arises when the migration of neural crest cells is arrested , causing a lack of ganglion cells (Option B ruled out) in the affected segment, leading to a lack of peristalsis in the affected bowel segment, causing functional obstruction and bowel dilation without inflammation or strictures (Option D ruled out) . This leads to aganglionosis, preventing peristalsis and causing bowel dilation. Morphology: Histopathological confirmation involves identifying the absence of ganglion cells, and acetylcholinesterase staining aids in diagnosis. The disease typically involves the rectum, with short-segment or long-segment Hirschsprung disease based on the extent of involvement. Clinical Features: Symptoms include failure to pass meconium, abdominal distension, constipation, and bilious vomiting. Complications such as enterocolitis, perforation, and peritonitis can occur. Surgical resection of the aganglionic segment is the primary treatment. Acquired Megacolon: Acquired Megacolon, seen in conditions like Chagas disease and ulcerative colitis , may share a similar pathophysiology with Hirschsprung disease, particularly in cases involving the loss of ganglion cells. Visceral myopathy (Option C) refers to smooth muscle dysfunction, which can affect gastrointestinal motility but is not the cause of Hirschsprung disease.

References:

Robbins & Cotran Pathologic Basis of Disease, 10th Edition, Page 755,766

↑ *Back to this question in Part A*

@Neet_pg_bot

Q8: A 20-year-old patient presents with a history of malabsorption, diarrhea, and poor appetite. A duodenal biopsy shows crypt hyperplasia, villi atrophy, and CD8+ cells in the lamina propria. What is the most probable diagnosis? (Q854843)

A. Environmental enteropathy

B. Celiac disease

C. Whipple’s disease

D. Chronic pancreatitis

Correct Answer: B. Celiac disease

Explanation: Celiac disease is an autoimmune disorder triggered by the ingestion of gluten in genetically predisposed individuals. The immune response leads to damage in the small intestine, causing malabsorption, diarrhea, and poor appetite. On histopathological examination, crypt hyperplasia, villous atrophy, and increased CD8+ T lymphocytes in the lamina propria are classic features of celiac disease. Celiac disease Definition Autoimmune disorder triggered by ingesting gluten-containing foods in genetically susceptible individuals. Synonym Gluten-sensitive enteropathy Celiac sprue Diagnosis Biopsy of the second part of the duodenum or proximal jejunum Serum markers Anti-tissue transglutaminase (tTG)-most sensitive Anti-endomysial antibodies (EMA)-most specific Histology Increased intraepithelial CD8+ T lymphocytes (intraepithelial lymphocytosis), Crypt hyperplasia (increased mitosis) Villous atrophy (reduced mucosal surface area, causing malabsorption) Inflammatory cells infiltration {{caption_text}} Environmental enteropathy (Option A) is a condition marked by chronic inflammation and structural changes in the small intestine. It is commonly seen in individuals from regions with poor sanitation and hygiene. Whipple's disease (Option C) is a rare bacterial infection caused by Tropheryma whipplei . It primarily affects the small intestine but can also involve other organs. The biopsy findings in Whipple's disease are different and typically show PAS-positive macrophages. Chronic pancreatitis (Option D) is characterised by persistent inflammation and fibrosis of the pancreas, leading to impaired pancreatic function. It can cause malabsorption, but the biopsy would not show the characteristic findings of celiac disease, such as villous atrophy and crypt hyperplasia.

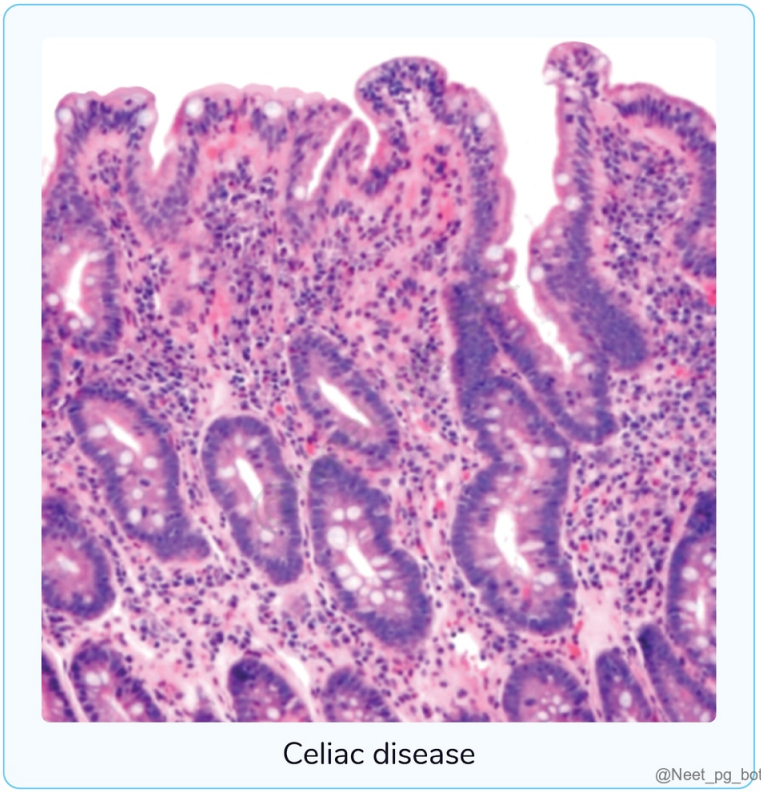

References:

Robbins & Cotran Pathologic Basis of Disease, 10th Edition, Page 785

↑ *Back to this question in Part A*

@Neet_pg_bot

Q9: Which of the following statements regarding Peutz-Jeghers syndrome is correct? An arborizing pattern of smooth muscle Loss of heterozygosity in STK11 gene Multiple GI polyps Autosomal recessive inheritance Congenital hypertrophy of retinal pigmental epithelium is seen (Q856473)

A. 2, 4, 5

B. 1, 2, 3

C. 1, 3, 4

D. 2, 3, 5

Correct Answer: B. 1, 2, 3

Explanation: Peutz-Jeghers Syndrome: Inheritance : Autosomal dominant. Age of Onset : Median age of 11 years. Key Features : Multiple GI hamartomatous polyps. Mucocutaneous hyperpigmentation (dark macules on lips, buccal mucosa, palms, genitalia, and perianal region). {{caption_text}} Polyps are most common in the small intestine but may also occur in the stomach, colon, bladder, and lungs. Complications: Risk of intussusception , potentially fatal. Increased cancer risk (lifetime risk ~40%), including cancers of the GI tract, testes, pancreas, breast, lung, ovarian, and uterus. Pathogenesis: It is caused by germline mutations in the STK11 gene, a tumour suppressor gene regulating cell polarization and growth. Somatic loss of the second STK11 gene copy in cancers. Morphology: Polyps are pedunculated and lobulated. Histology shows an arborizing network of smooth muscle, connective tissue, lamina propria, and glands. {{caption_text}} Congenital hypertrophy of retinal pigmental epithelium is not typically associated with Peutz-Jeghers syndrome . Congenital hypertrophy of the retinal pigment epithelium (CHTPE) is more commonly seen in other conditions, such as familial adenomatous polyposis (FAP) .



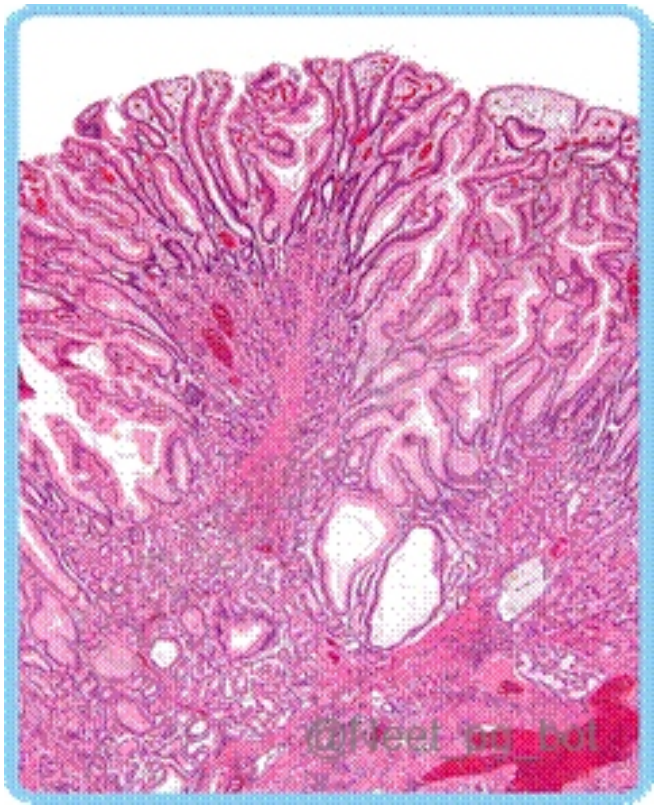

References:

Robbins & Cotran Pathologic Basis of Disease, 10th Edition, Page 809, 810.

↑ *Back to this question in Part A*

@Neet_pg_bot

Q10: The cells lining the isthmus of gastric pits are: (Q856472)

A. Chief cells

B. Stem cells

C. Parietal cells

D. Mucous cells

Correct Answer: B. Stem cells

Explanation: The isthmus of the gastric pits contains stem cells , which are responsible for replenishing the various cell types in the gastric mucosa. These stem cells differentiate into different types of gastric cells, including parietal cells, chief cells, and mucous cells, as they migrate along the pit. Cell Type Location Function Stem cells Isthmus of gastric pits Regenerate the various types of gastric epithelial cells. Parietal cells Fundus and body of the stomach It secretes hydrochloric acid (HCl) and intrinsic factors that are important for digestion and vitamin B12 absorption. Chief cells Fundus and body of the stomach Secrete pepsinogen, which is converted to pepsin in the acidic environment, to aid in protein digestion. Mucous cells Surface epithelium of the stomach lining and neck of gastric pits Secrete mucus to protect the stomach lining from the acidic environment and digestive enzymes. Endocrine cells (G cells) Antrum of the stomach Secrete gastrin, which stimulates acid secretion by parietal cells and gastric motility. Enteroendocrine cells Throughout the gastric mucosa Secrete various hormones such as somatostatin, serotonin, and histamine to regulate gastric functions.

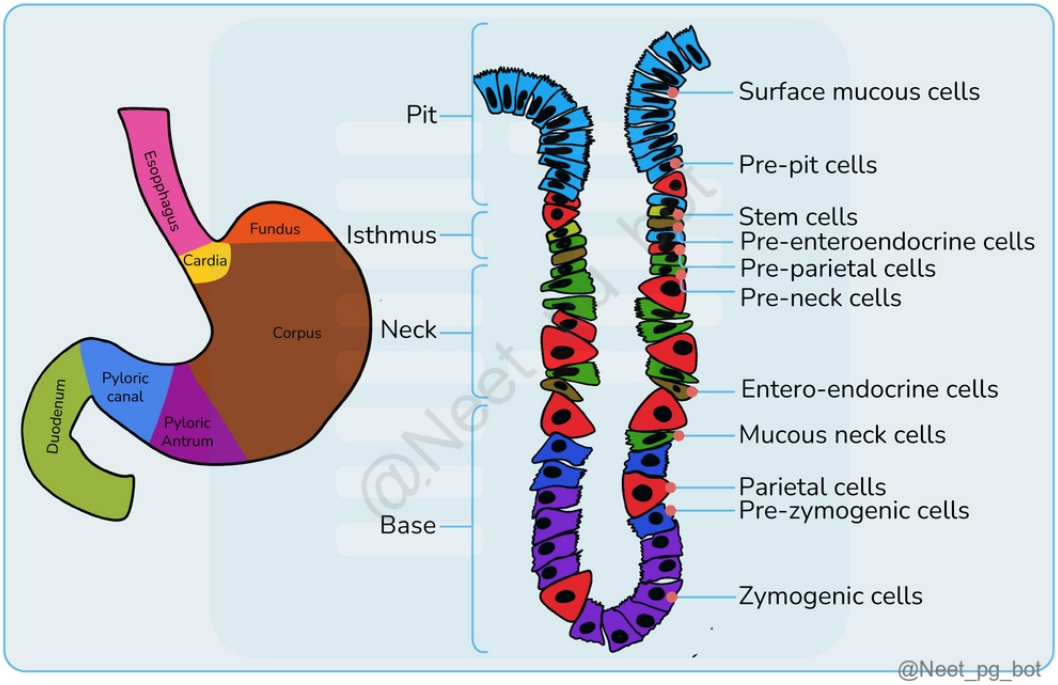

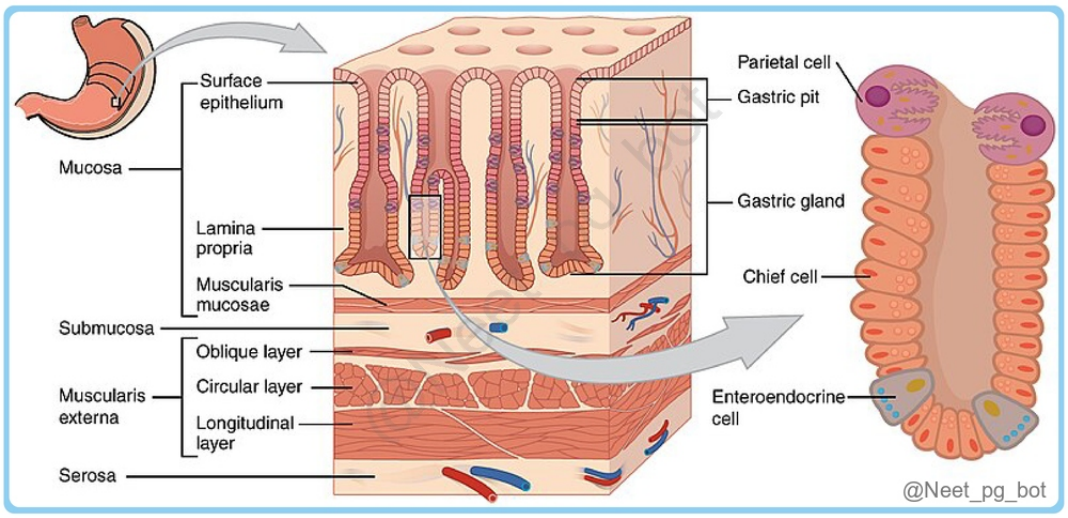

References:

https://pmc.ncbi.nlm.nih.gov/articles/PMC3708552/

↑ *Back to this question in Part A*

@Neet_pg_bot

Q11: The absence of the structure will be present in all except: (Q856471)

A. Pernicious anemia

B. Autoimmune Metaplastic Atrophic Gastritis

C. Vitamin B12 Deficiency

D. Zollinger-Ellison syndrome

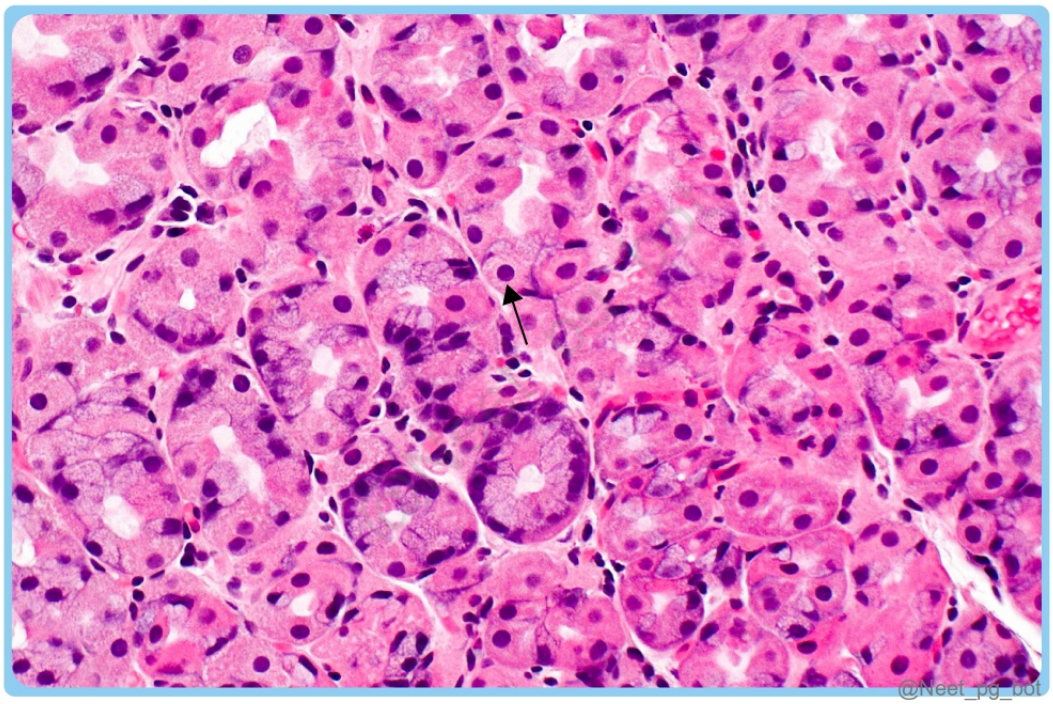

Correct Answer: D. Zollinger-Ellison syndrome

Explanation: The marked structure shows eosinophilic cells indicative of parietal cells. Zollinger-Ellison syndrome , which is characterized by excess gastrin secretion from tumours, is not related to the absence of parietal cells. Zollinger-Ellison syndrome: Cause : Gastrin-secreting neuroendocrine tumours (gastrinomas) located mainly in the small intestine or pancreas . {{caption_text}} Presentation : Duodenal ulcers Chronic diarrhoea Marked increase in oxyntic mucosal thickness due to parietal cell hyperplasia {{caption_text}} Gastrin also induces hyperplasia of the mucous neck and endocrine cells . Sporadic, solitary lesions in 75% of cases. Multiple endocrine neoplasia type 1 (MEN1) in 25% of cases and is associated with younger age, duodenal tumours, and metastasis. Treatment: Proton pump inhibitors (PPIs) block acid hypersecretion, promoting ulcer healing and preventing gastric perforation. Focus on treating the gastrinomas , which influence long-term survival. Pernicious Anemia (Option A) is an autoimmune disorder caused by the destruction of gastric parietal cells , leading to intrinsic factor deficiency. Since intrinsic factor is essential for vitamin B12 absorption in the intestines, its absence results in vitamin B12 deficiency . The loss of parietal cells is a hallmark of pernicious anaemia. Autoimmune Metaplastic Atrophic Gastritis (Option B) is an autoimmune condition that targets the parietal cells, causing hypochlorhydria (low stomach acid) and a decreased production of intrinsic factors. Vitamin B12 Deficiency (Option C) can arise from various causes, including pernicious anaemia or inadequate dietary intake. Pernicious anaemia occurs due to the loss or dysfunction of parietal cells , which produce intrinsic factors essential for vitamin B12 absorption. The resulting intrinsic factor deficiency impairs B12 absorption, leading to deficiency.

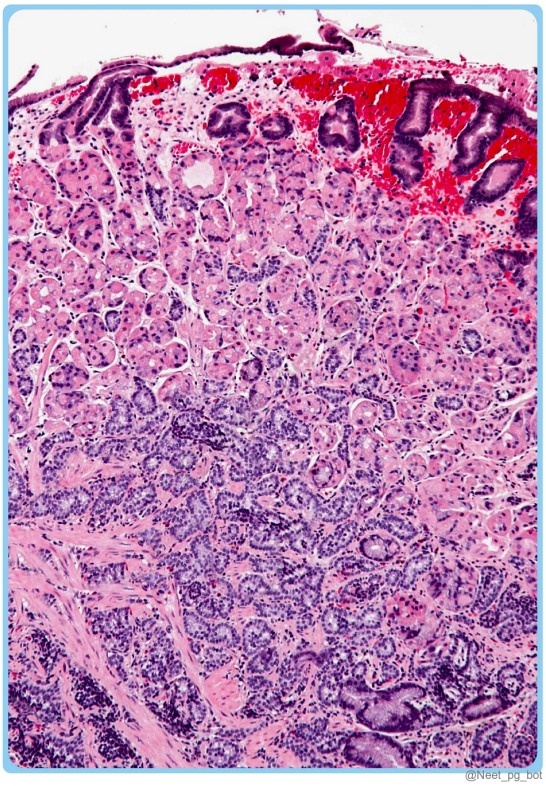

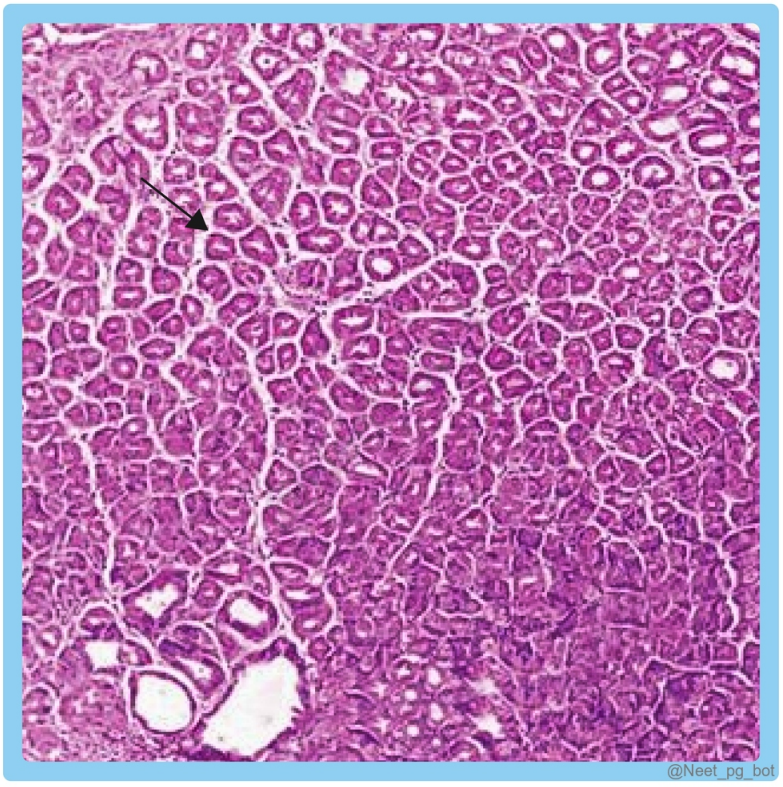

References:

Robbins & Cotran Pathologic Basis of Disease, 10th Edition, Page 773

↑ *Back to this question in Part A*

@Neet_pg_bot

Q12: Which of the following is true about celiac disease? (Q856469)

A. Most common cause of malnutrition in developing countries

B. Can be diagnosed with CECT

C. Improves with food rich in carbohydrates

D. Increased risk of GI lymphoma

Correct Answer: D. Increased risk of GI lymphoma

Explanation: Celiac disease is an autoimmune disorder that affects the small intestine, triggered by the ingestion of gluten. It is associated with an increased risk of gastrointestinal lymphoma, particularly enteropathy-associated T-cell lymphoma (EATL). Celiac disease Definition Autoimmune disorder triggered by ingesting gluten-containing foods in genetically susceptible individuals. Synonym Gluten-sensitive enteropathy Celiac sprue Diagnosis Biopsy of the second part of the duodenum or proximal jejunum Serum markers Anti-tissue transglutaminase (tTG): Most sensitive Anti-endomysial antibodies (EMA): Most specific Histology Increased intraepithelial CD8+ T lymphocytes (intraepithelial lymphocytosis), Crypt hyperplasia (increased mitosis) Villous atrophy (reduced mucosal surface area, causing malabsorption) Inflammatory cells infiltration {{caption_text}} Celiac disease is more commonly diagnosed in developed countries (Option A) , particularly among populations of European descent, rather than being the leading cause of malnutrition in developing countries. CECT (contrast-enhanced computed tomography) is not used to diagnose celiac disease (Option B) . The diagnosis is typically based on clinical evaluation, serological tests (e.g., anti-tissue transglutaminase antibodies), and confirmation through a small bowel biopsy. Celiac disease does not improve with a carbohydrate-rich diet (Option C) . The primary treatment for celiac disease is a strict gluten-free diet, which requires avoiding foods containing gluten.

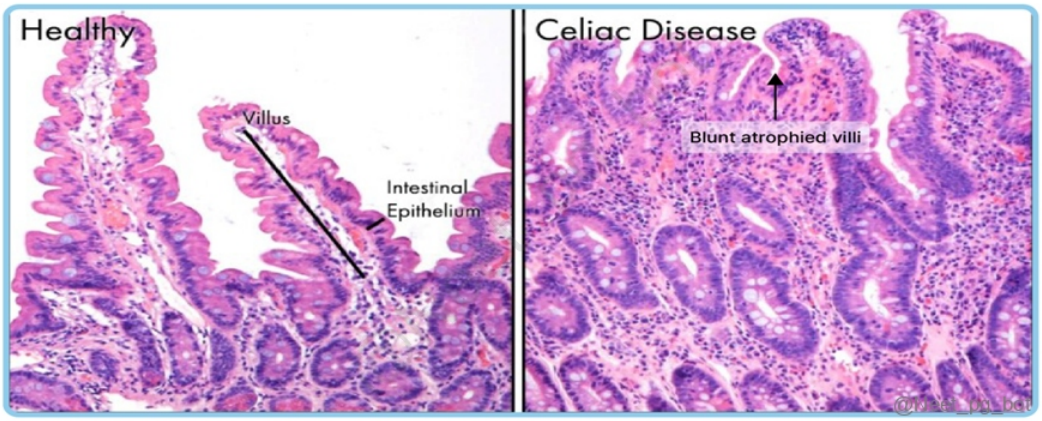

References:

Robbins & Cotran Pathologic Basis of Disease, 10th Edition, Page 785

↑ *Back to this question in Part A*

@Neet_pg_bot

Q13: A 17-year-old boy presented with intussusception and was taken up for surgery. He was found to have multiple polyps. The resected section was sent for histopathology, and the whole mount image of the specimen is given below. Identify the lesion. (Q855425)

A. Tubulovillous adenoma

B. Hamartomatous polyp

C. Adenocarcinoma

D. Hyperplastic polyp

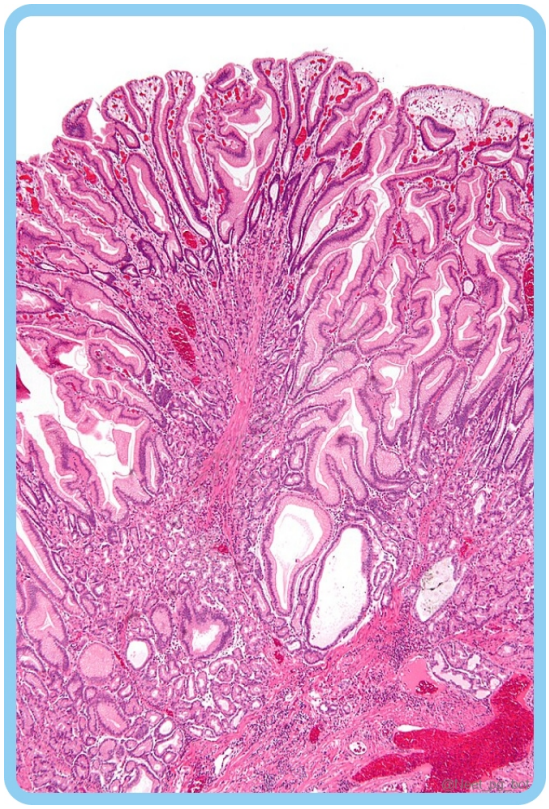

Correct Answer: B. Hamartomatous polyp

Explanation: The histopathological image reveals a Hamartomatous Polyps, characterized by an arborizing pattern of connective tissue, smooth muscle, glands, and lamina propria. They are non-neoplastic growths resulting from

the disorganized overgrowth of normal tissues within an organ. These polyps are often associated with genetic syndromes, including: Features Peutz-Jeghers syndrome (PJS) Juvenile polyposis syndrome (JPS) Inheritance pattern Autosomal dominant disorder Autosomal dominant inheritance Age Presents around 11 years of age Primarily affects children under 5 years old. Features Caused by a loss of function mutation in the STK11 gene Characterized by: Gastrointestinal hamartomatous polyps, especially in the small intestine Mucocutaneous hyperpigmentation (macules on lips, nostrils, buccal mucosa, and extremities). Polyps are large, pedunculated, and lobulated. Can be sporadic or syndromic. Sporadic: Single polyps. Syndromic: 3-100 polyps. Linked to mutations in the SMAD4 and BMPR1A genes, part of the TGF-β signalling pathway. Pedunculated polyp, which is usually less than 3 cm in diameter. Extra-intestinal manifestations include congenital malformations and digital clubbing. Microscopy An arborizing pattern of smooth muscle and glands lined by normal epithelium. {{caption_text}} Contains cystic spaces filled with mucin and inflammatory debris. {{caption_text}} Tubulovillous adenoma (Option A) is a premalignant lesion featuring both tubular and villous components, with the potential to progress to adenocarcinoma. However, the image does not display the typical characteristics of a tubulovillous adenoma, such as dysplasia or dysplastic cells within the epithelial lining. {{caption_text}} Adenocarcinoma (Option C) is a malignant tumour that originates from the glandular cells of an organ and is characterized by invasive growth and the presence of dysplastic cells. However, the image does not reveal features typical of adenocarcinoma, such as tissue infiltration or cytological atypia. {{caption_text}} Hyperplastic polyps (Option D) are non-neoplastic growths marked by an increase in the number of cells in the epithelial layer of an organ. They are typically small, sessile, and have a smooth surface. However, the image does not resemble the usual appearance of hyperplastic polyps, which are generally smaller and more uniform in size. {{caption_text}}

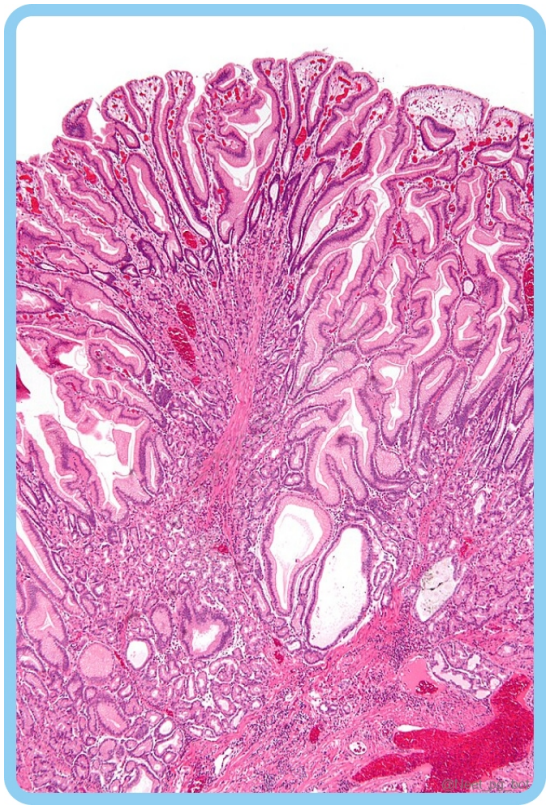

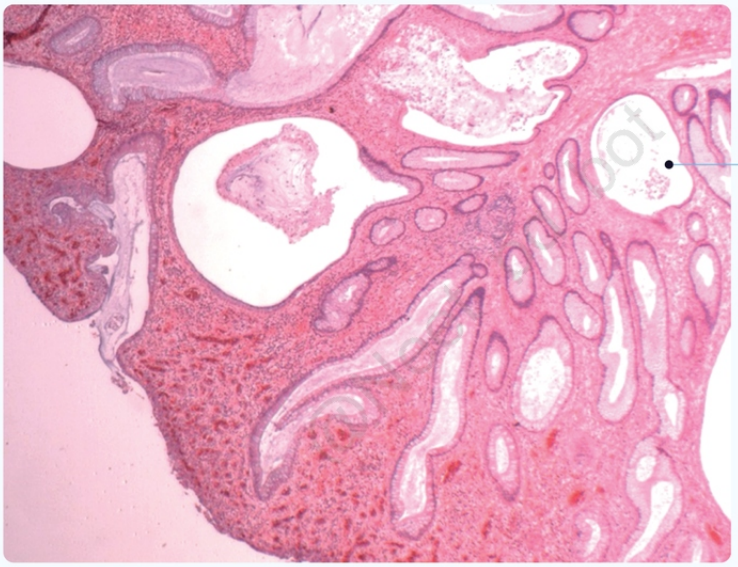

@Neet_pg_bot

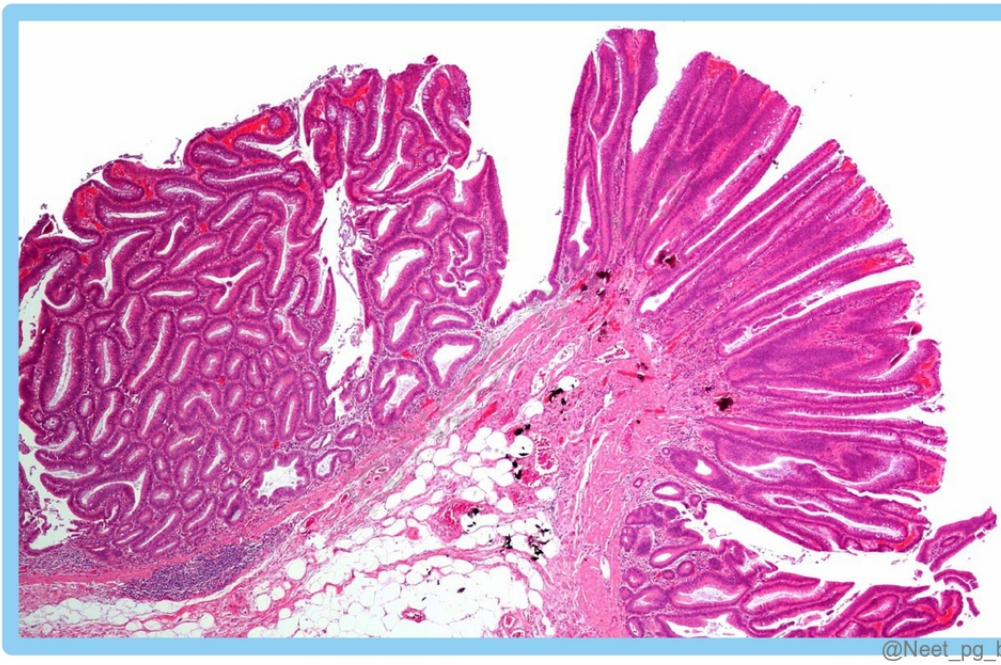

@Neet_pg_bot

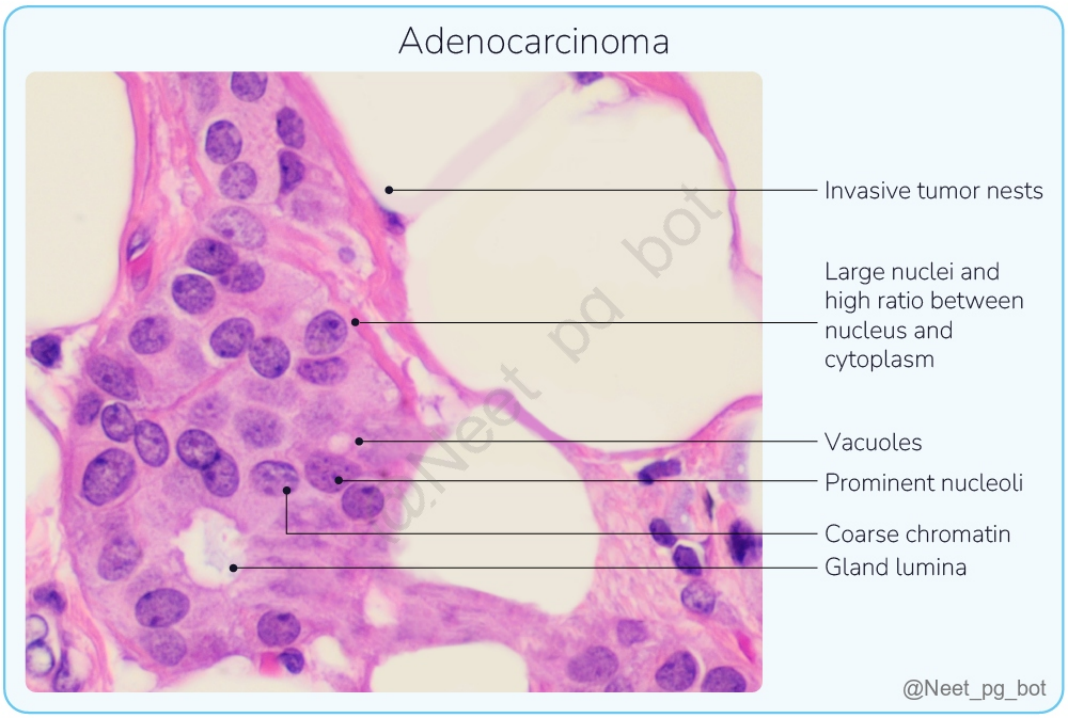

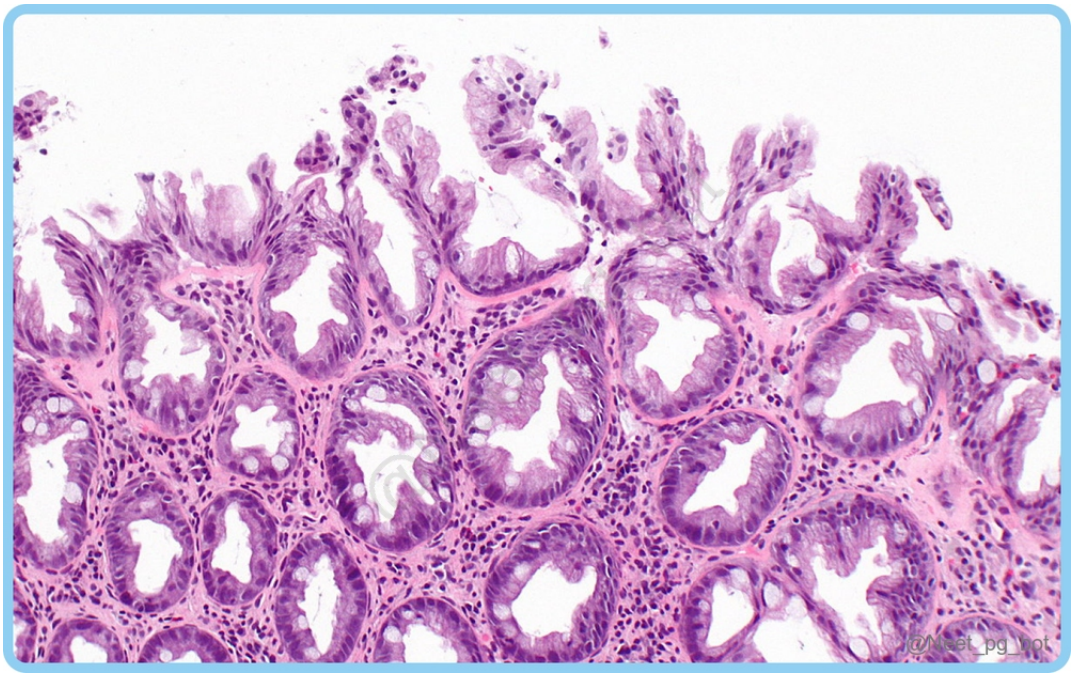

References:

Robbins & Cotran Pathological Basis of Diseases, 10th Edition, Page, 808-810.

↑ *Back to this question in Part A*

@Neet_pg_bot

Q14: Which of the following set of statements is true about familial adenomatous polyposis (FAP)? It is autosomal recessive. If not treated, 100% of the cases progress to adenocarcinoma of the colon. Polyps do not arise after puberty. It is associated with congenital hypertrophy of the retinal pigment epithelium. (Q855122)

A. 2 and 4

B. 1 and 4

C. 2 and 3

D. 3 and 4

Correct Answer: A. 2 and 4

Explanation: Familial Adenomatous Polyposis: (FAP) {{caption_text}} An autosomal dominant disorder caused by APC gene mutations on chromosome 5 (Statement 1) Numerous intestinal polyps develop. Classic FAP: Diagnosed with at least 100 polyps. There is almost 100% risk of colorectal cancer if untreated (Statement 2) Commonly develops in 30 years, almost always by 50 years (Statement 3) {{caption_text}} Attenuated FAP (AFAP): Primarily affects the proximal colon Fewer polyps (average <30 polyps) Associated with congenital hypertrophy of the retinal pigment epithelium (Statement 4) {{caption_text}} Standard treatment: Prophylactic colectomy to prevent colorectal cancer. Post-colectomy risks: Cancer at extracolonic sites, including the ampulla of Vater and stomach



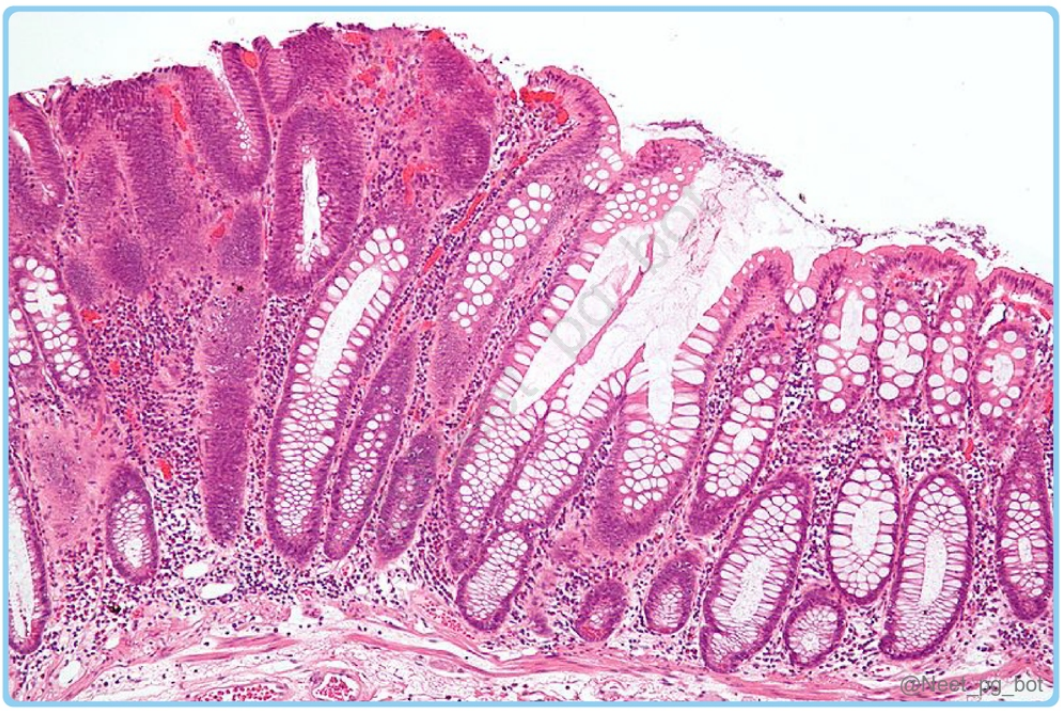

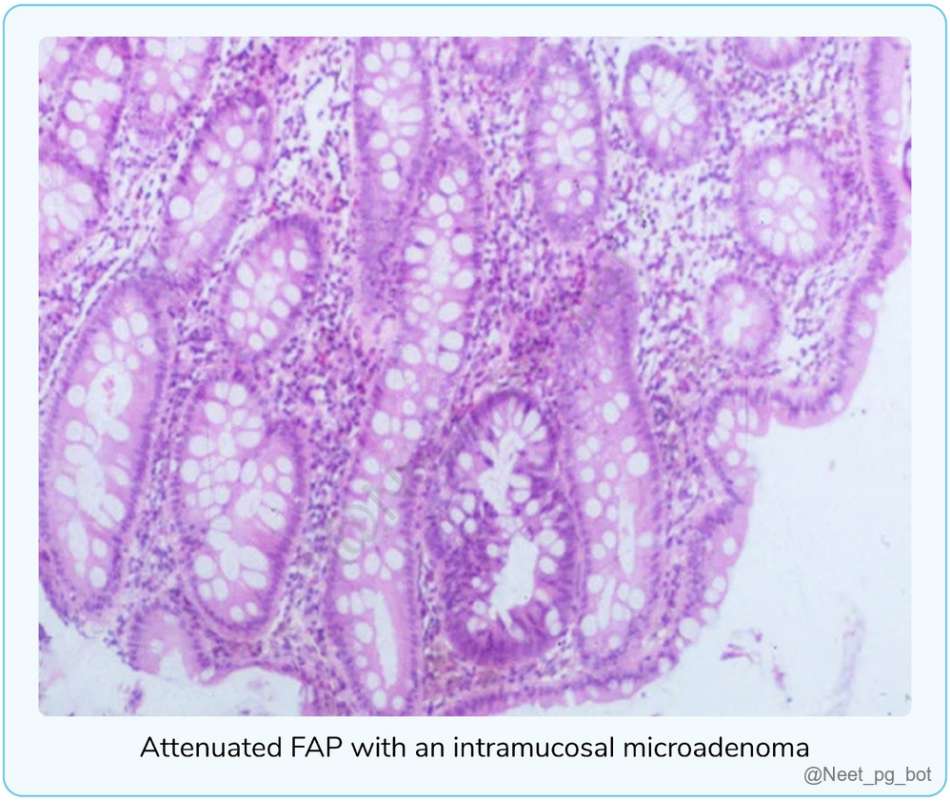

References:

Robbins & Cotran Pathologic Basis of Disease, 10th Edition, Page 812

↑ *Back to this question in Part A*

Q15: In Barrett’s oesophagus, which of the following epithelial transformations occurs? (Q866674)

A. Columnar to squamous epithelium

B. Squamous to intestinal columnar epithelium

C. Transitional to squamous epithelium

D. Cuboidal to columnar epithelium

Correct Answer: B. Squamous to intestinal columnar epithelium

Explanation: Barrett's oesophagus is a complication of chronic GERD, characterised by intestinal metaplasia (Option B) in the oesophageal squamous mucosa. It increases the risk of oesophageal adenocarcinoma. Occurs in 10% of individuals with symptomatic GERD. Affects up to 2% of the general population. Most common in white males, typically between ages 40 and 60. Cancer Risk: Increases the risk of oesophageal adenocarcinoma. The majority of oesophageal adenocarcinomas are associated with Barrett's oesophagus, but not all individuals with it will develop cancer. Recognised as red, velvety mucosa (Barrett's mucosa) extending upward from the gastroesophageal junction & alternating with pale squamous mucosa and light-brown gastric mucosa. Subclassified as long segment (≥3 cm) or short segment (<3 cm). Short-segment disease carries a lower cancer risk compared to long-segment disease. Intestinal-type metaplasia with goblet cells replacing squamous epithelium. Goblet cells are diagnostic of Barrett oesophagus and have distinct mucous vacuoles that stain blue with Alcian blue. This imparts the shape of a wine goblet to the remaining cytoplasm. Goblet cells are diagnostic , with pale blue mucous vacuoles resembling a wine goblet. Non-goblet columnar cells, like gastric-type foveolar cells, may also be present. Incorrect Options: Columnar to squamous (Option A): occurs in squamous metaplasia (e.g., chronic irritation in bronchi of smokers), not Barrett’s. Transitional to squamous (Option C): occurs in the bladder with chronic irritation (e.g., schistosomiasis). Cuboidal to columnar (Option D): not typical in Barrett’s; cuboidal epithelium is seen in small ducts/glands, not in the oesophagus.

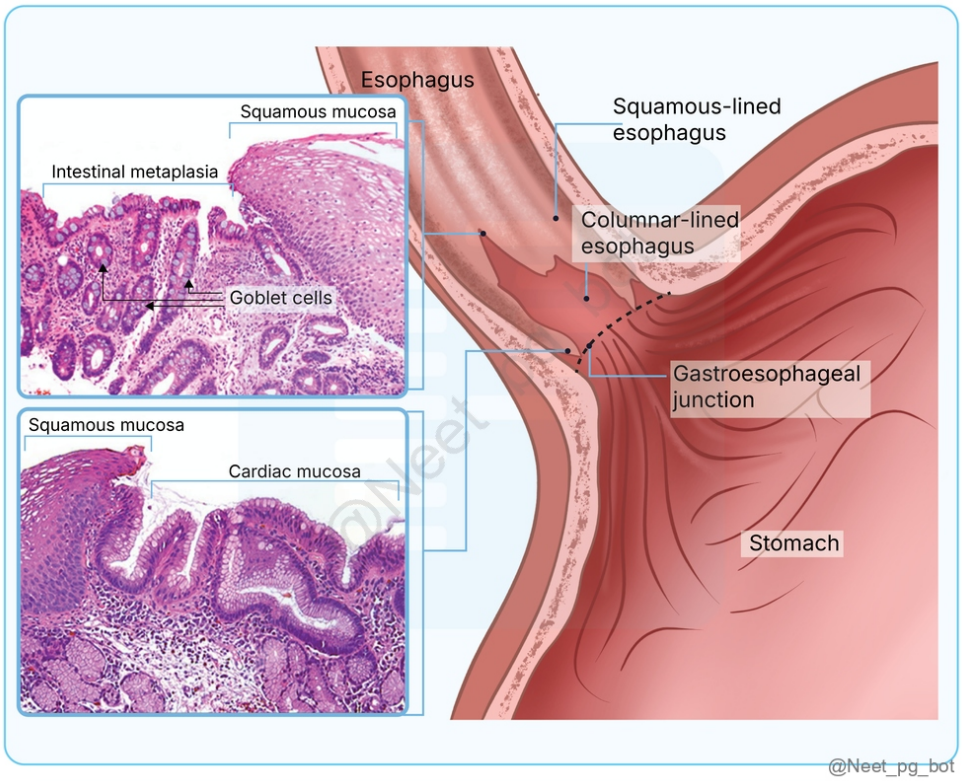
Esophagus
Squamous mucosa
Intestinal metaplasia
Goblet cells
Squamous-lined esophagus
Columnar-lined esophagus
Gastroesophageal junction
Squamous mucosa
Cardiac mucosa
Stomach
@Neet_pg_bot

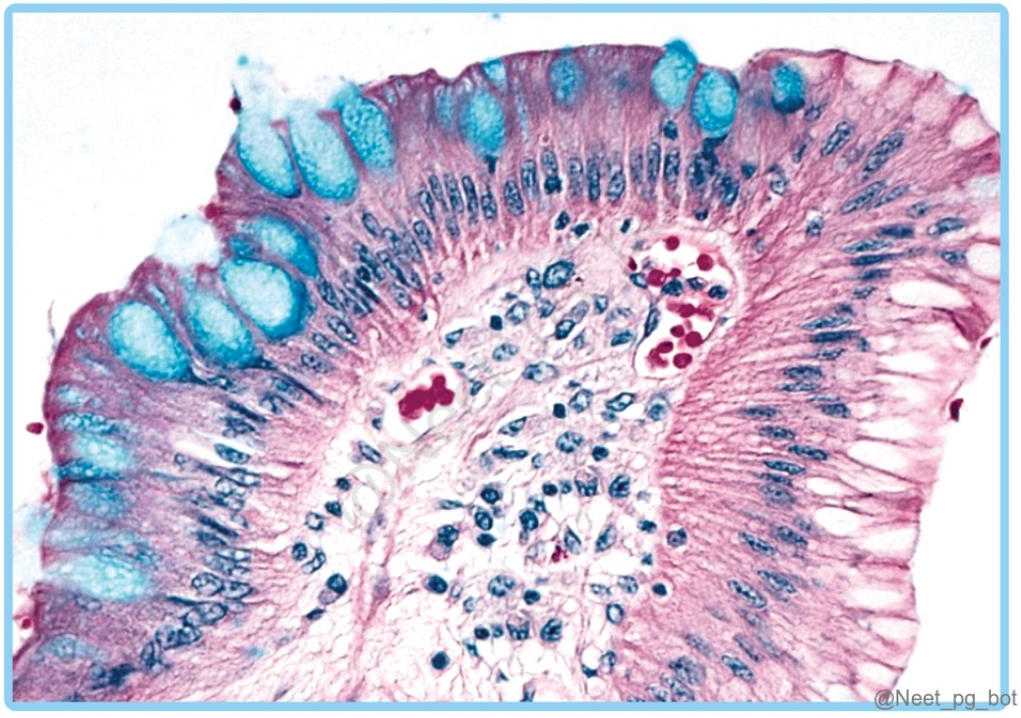
@Neet_pg_bot

References:

.

↑ *Back to this question in Part A*

@Neet_pg_bot

Q16: Which of the following diet is not advised in celiac sprue disease? (Q820577)

A. Rice

B. Wheat

C. Dhal

D. Ragi

Correct Answer: B. Wheat

Explanation: Correct Option B - Wheat: The diet not advised for individuals with celiac sprue disease is option B (Wheat), as it contains gluten, which can lead to harmful immune reactions and damage to the small intestine. Incorrect Options: Option A - Rice: Rice is generally considered safe for individuals with celiac sprue disease. It does not contain gluten, which is the protein responsible for triggering adverse reactions in people with celiac disease. Option C - Dhal (Lentils): Lentils are naturally gluten-free and are usually safe for individuals with celiac disease. However, it's important to ensure that lentils are not contaminated with gluten-containing grains during processing or cooking. Option D - Ragi: Ragi also known as finger millet is gluten free and can be used by individuals with celiac disease

References:

.

↑ *Back to this question in Part A*

@Neet_pg_bot

Q17: Which of the following intestinal pathologies is associated with dermatitis herpetiformis? (Q860249)

A. Ulcerative colitis

B. Whipple’s disease

C. Celiac disease

D. Crohn’s disease

Correct Answer: C. Celiac disease

Explanation: Celiac Disease (also referred to as Gluten-sensitive Enteropathy or Celiac Sprue) is associated with Dermatitis herpetiformis. Celiac Disease Definition Autoimmune disorder triggered by ingesting gluten-containing foods in genetically susceptible individuals. It is influenced by HLA-DQ2 or HLA-DQ8. Pathogenesis Clinical features Adults: Commonly between the ages of 30 and 60. More frequent in females Silent celiac disease (positive serology and villous atrophy without symptoms) Latent celiac disease (positive serology is not accompanied by villous atrophy) It may be associated with chronic diarrhoea, bloating, chronic fatigue, or asymptomatic. Anaemia (iron and vitamin malabsorption). Dermatitis herpetiformis (itchy, blistering skin lesion) might be present. (Option C) Pediatric cases: Both sexes were affected equally. It may present with malabsorption. Begins after the introduction of gluten to the diet (6-24 months of age) Manifestations include irritability, abdominal distention, anorexia, chronic diarrhoea, failure to thrive, weight loss, or muscle wasting. It may also present as abdominal pain, nausea, vomiting, bloating, or constipation. Extraintestinal complaints include arthritis or joint pain, aphthous stomatitis, iron deficiency anaemia, delayed puberty, and short stature. Serum markers IgA antibodies against tissue transglutaminase (tTG): Most sensitive. Anti-endomysial antibodies (EMA): Most specific. IgG antibodies against gliadin (a component of gluten). Histology Biopsy of the second part of the duodenum or proximal jejunum: Increased intraepithelial CD8+ T lymphocytes (intraepithelial lymphocytosis). Crypt hyperplasia (Increased mitosis). Villous atrophy (Reduced mucosal surface area, causing malabsorption). Inflammatory cell infiltration. {{caption_text}} Ulcerative colitis (Option A) is a chronic inflammatory bowel disease (IBD) that affects the colon and rectum. It causes ulceration and inflammation of the inner lining of the colon, leading to symptoms like bloody diarrhoea, abdominal pain, cramping, and weight loss. The condition is characterised by periods of flare-ups and remissions and is believed to have an autoimmune origin. Whipple’s disease (Option B) is a rare bacterial infection caused by Tropheryma whipplei . It primarily affects the small intestine, causing malabsorption, diarrhoea, and weight loss, and can also involve the joints, heart, nervous system, and lungs. It is characterised by PAS-positive macrophages in tissue samples. Crohn’s disease (Option D) is a chronic inflammatory bowel disease that can affect any part of the GI tract, causing symptoms like abdominal pain, diarrhoea, and weight loss. It involves transmural inflammation and skip lesions. The exact cause is unknown, but it’s linked to an autoimmune response.

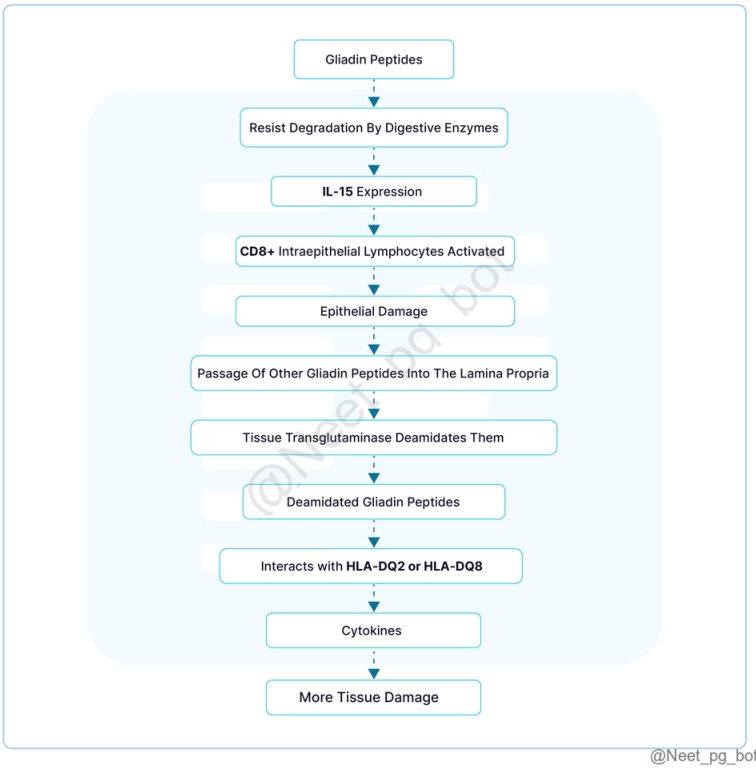

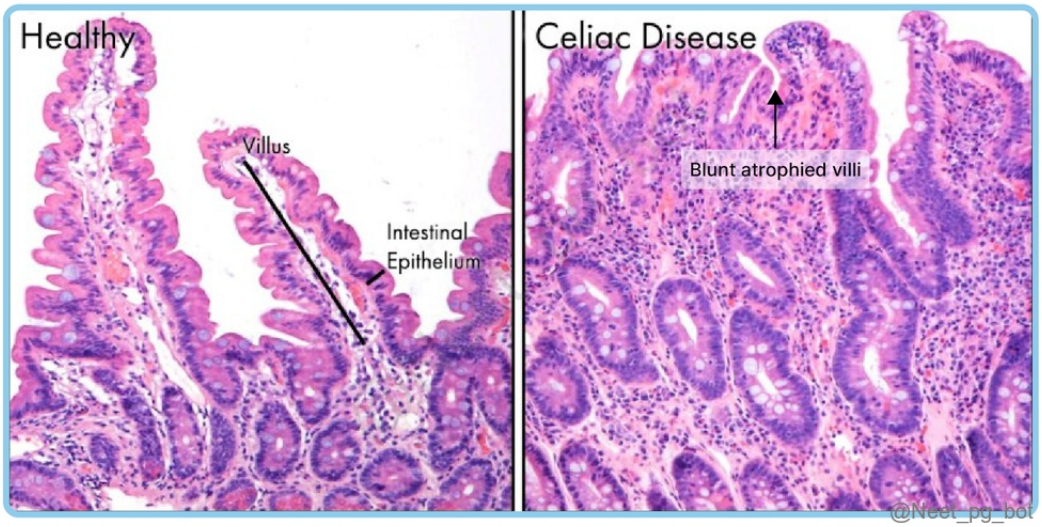

References:

Robbins & Cotran Pathologic Basis of Diseases, 10th Edition, Page 784-785, 1163.

↑ *Back to this question in Part A*

@Neet_pg_bot

Q18: In contrast with Ulcerative colitis, which of the following is Crohn's disease is likely to show? (Q840077)

A. Seldom presents with daily hematochezia

B. Increased frequency of perianal fistula

C. Continuous lesion

D. Increased risk of colon cancer

Correct Answer: B. Increased frequency of perianal fistula

Explanation: Correct Option B - Increased frequency of perianal fistula: Perianal fistulas are seen only in Crohn's disease and not in ulcerative colitis. Fissures frequently develops and may extend deeply to become fistula tracts or sites of perforation. Incorrect Options: Options A, C & D: These are features of ulcerative colitis.

↑ *Back to this question in Part A*

@Neet_pg_bot

Q19: Which of the following is not associated with GIST? (Q840010)

A. PDGFR Beta

B. SDH

C. c- KIT

D. NRG-1

Correct Answer: D. NRG-1

Explanation: Neuregulin/NRG-1 is not a marker for GIST diagnosis. It is seen in non-TRU type lung adenocarcinoma, including mucinous adenocarcinoma(most common subtype - 38.1%), followed by TRU type lung adenocarcinoma (23.8%) and GI and PB adenocarcinoma(23.8%). Gastrointestinal stromal tumors (GIST) Mutations: Most common: c-KIT (Option C) Others: PDGFRβ (Option A) Succinate dehydrogenase (SDH) (Option B) Markers: CD117 - Most sensitive DOG1 - Most specific CD34 - Miscellaneous

References:

.

↑ *Back to this question in Part A*

@Neet_pg_bot

Q20: An adult man presents with a protruding abdomen, diarrhea, visual disturbances and neurological manifestations. Based on the given peripheral smear, what is the most likely diagnosis? (Q844190)

A. Abetalipoproteinemia

B. Whipple’s disease

C. Menetrier's Disease

D. Uremia

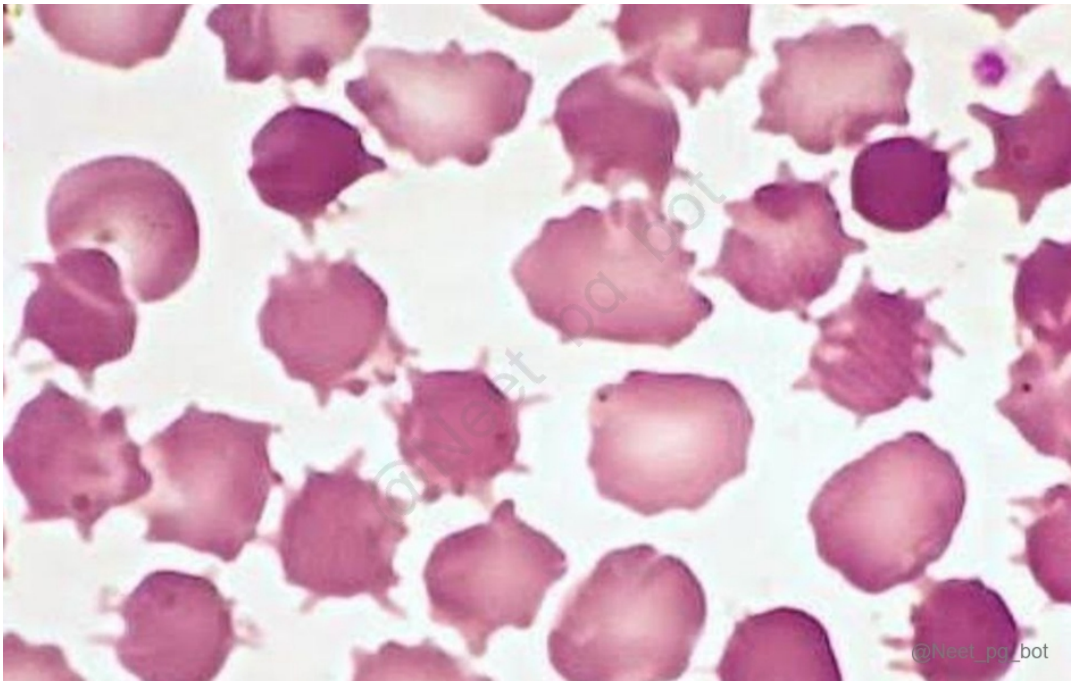

Correct Answer: A. Abetalipoproteinemia

Explanation: Correct Option A – Abetalipoproteinemia: Abetalipoproteinemia is characterized by the presence of acanthocytes (spur cells) on peripheral smear and results from mutations in the MTTP gene. Incorrect Options: Option B - Whipple’s disease: Whipple’s disease shows foamy macrophages in the intestinal biopsy. Option C - Menetrier's Disease: Menetrier's Disease shows foveolar cell hyperplasia. Option D – Uremia: Uremia does not show spur cells.

References:

.

↑ *Back to this question in Part A*

@Neet_pg_bot

Q21: A child presents with itchy lesions and diarrhea and has been advised to follow a gluten-free diet. What is the most likely diagnosis? (Q844098)

A. Celiac disease

B. Whipple's disease

C. Crohn's disease

D. Ulcerative colitis

Correct Answer: A. Celiac disease

Explanation: The presence of an itchy lesion along with gluten sensitivity is suggestive of celiac disease. Itchy lesions → Suggestive of dermatitis herpetiformis , a skin manifestation of celiac disease. Diarrhea → Classic gastrointestinal symptom of malabsorption. Gluten-free diet advised → Strongly points toward gluten sensitivity, which is central to celiac disease. Celiac disease Cause: Autoimmune reaction to gluten (in wheat, barley, rye) Symptoms: Diarrhea, abdominal bloating, failure to thrive (in children), irritability, and skin lesions Dermatologic sign: Dermatitis herpetiformis – intensely itchy, blistering rash (usually elbows, knees, buttocks) Diagnosis: Positive anti-TTG or anti-endomysial antibodies; confirmed by duodenal biopsy Treatment: Strict lifelong gluten-free diet Incorrect Options: Whipple's disease, Crohn's disease and Ulcerative colitis (Options B, C, and D) do not show gluten sensitivity.

References:

https://pubmed.ncbi.nlm.nih.gov/28722929/

↑ *Back to this question in Part A*

@Neet_pg_bot

Q22: Which vitamin is to be supplemented in a patient following gastrectomy? (Q844083)

A. Vitamin A

B. Vitamin B1

C. Vitamin C

D. Vitamin B12

Correct Answer: D. Vitamin B12

Explanation: Correct Option D - Vitamin B12: Vitamin B12 deficiency can occur following gastrectomy due to intrinsic factor deficiency and hence can lead to pernicious anemia. Therefore, to prevent this, vitamin B12 supplementation is done following gastrectomy. Incorrect Options: Options A, B, and C are not usually supplemented in a patient following gastrectomy.

↑ *Back to this question in Part A*

@Neet_pg_bot

Q23: A child presents with failure to pass stools and is diagnosed with Hirschsprung disease. Which among the following layers of the colon will show congenital absence of neurons? (Q844079)

A. 1 & 2

B. 2 & 3

C. 3 & 4

D. 1 & 4

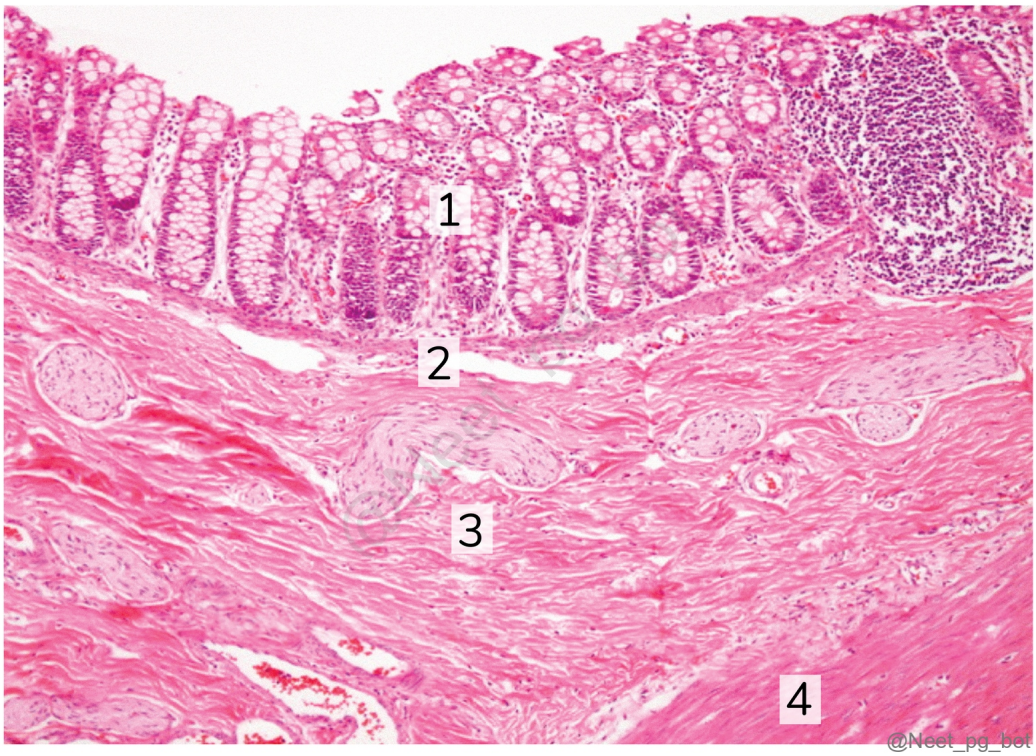

Correct Answer: B. 2 & 3

Explanation: Correct Option B - 2 & 3: In Hirschsprung disease, the congenital absence of neurons is seen in the submucosa (Meissner's plexus, Layer 2) and the muscularis propria (myenteric plexus, Layer 3). This absence leads to the failure of peristalsis and the subsequent inability to pass stools. Incorrect Options: Options A, C, and D: Layers 1 and 4 are not affected by Hirschsprung disease.

References:

.

↑ *Back to this question in Part A*

@Neet_pg_bot

Q24: Which of the following antibodies is associated with celiac disease? (Q843987)

A. Anti-TTG

B. ANCA

C. ASCA

D. AMA

Correct Answer: A. Anti-TTG

Explanation: Correct Option A - Anti-TTG: Anti-tissue transglutaminase is associated with celiac disease. Incorrect Options: Options B, C, and D: Anti-neutrophil cytoplasmic antibodies (ANCA), Anti-Saccharomyces cerevisiae antibodies (ASCA) and Anti-mitochondrial antibody (AMA) are not associated with celiac disease.

↑ *Back to this question in Part A*

@Neet_pg_bot

Q25: Match the following diseases with their respective gene mutation: 1. Familial adenomatous polyposis i. SMAD4 2. Juvenile polyposis ii. STK11 3. Tuberous sclerosis iii. APC gene 4. Peutz-Jeghers syndrome iv. TSC1 (Q853371)

A. A-i, B-ii, C-iii, D-iv

B. A-ii, B-iii, C-i, D-iv

C. A-iii, B-i, C-iv, D-ii

D. A-iv, B-ii, C-iii, D-i

Correct Answer: C. A-iii, B-i, C-iv, D-ii

Explanation: Below are some gene mutations and their associated manifestations: Genes mutation Manifestations MLH1, MSH2 Results in microsatellite instability Causes cluster of cancer: Colorectal, Endometrial, Ovarian, Pancreatic cancers Colon cancer develops at a young age, and it usually occurs on the right side. SMAD4 and BMPR1 Juvenile polyposis syndrome STK11 Peutz-Jeghers syndrome APC gene Familial Adenomatous Polyposis(FAP), sporadic colon cancer, Gardner syndrome and Turcot syndrome MUTYH MUTYH-associated polyposis. TSC1 (hamartin) or TSC2 (tuberin) Tuberous sclerosis

References:

Robbins & Cotran Pathological Basis of Diseases, 10th Edition, Page 809, 813.

↑ *Back to this question in Part A*

@Neet_pg_bot

Q26: What is the eye manifestation seen in HLA B27-positive patients with ulcerative colitis? (Q866755)

A. Uveitis

B. Conjunctivitis

C. Scleritis

D. Iridocyclitis

Correct Answer: A. Uveitis

Explanation: Uveitis Ulcerative colitis is an inflammatory bowel disease (IBD) with possible extraintestinal manifestations. HLA-B27–positive patients have a higher risk of certain autoimmune complications, particularly in the eye. The most classic ocular manifestation is acute anterior uveitis . Features of uveitis in HLA-B27–associated IBD: Usually unilateral , sudden onset. Symptoms: eye pain, redness, photophobia, blurred vision. Exam: ciliary flush, cells & flare in anterior chamber. Can be recurrent. Conjunctivitis (Option B): It is more common in reactive arthritis (Reiter's syndrome), not as strong an association with ulcerative colitis. Conjunctivitis involves superficial eye redness without the deep inflammation of uveitis. Scleritis (Option C): Deep, boring eye pain; associated with systemic autoimmune diseases like rheumatoid arthritis. It is less commonly seen in ulcerative colitis. Iridocyclitis (Option D): refers to inflammation of the iris and ciliary body (a subset of anterior uveitis).

↑ *Back to this question in Part A*

@Neet_pg_bot

Q27: Hereditary non-polyposis colorectal cancer (HNPCC), also known as Lynch syndrome, is caused by mutations in which type of genes? (Q866735)

A. APC

B. MMR

C. MYC

D. TERT1

Correct Answer: B. MMR

Explanation: HNPCC / Lynch syndrome is caused by germline mutations in DNA mismatch repair (MMR) genes. The most commonly affected genes are: MLH1 MSH2 MSH6 PMS2 Loss of these MMR proteins → failure to correct base-pairing errors → microsatellite instability (MSI) → increased risk of colorectal cancer (esp. right-sided) and extra-colonic cancers (endometrial, ovarian, gastric, urinary tract). Lynch syndrome is associated with germline mutations in DNA mismatch repair (MMR) genes, leading to microsatellite instability (MSI). MSI is a hallmark of Lynch syndrome-associated tumours, including colorectal adenocarcinoma. APC (Option A): tumor suppressor gene mutated in Familial Adenomatous Polyposis (FAP) , not Lynch syndrome. MYC (Option C): proto-oncogene involved in Burkitt lymphoma (t(8;14)), not colorectal cancer syndromes. TERT1 (Option D): encodes telomerase reverse transcriptase; mutations linked to certain familial cancers but not HNPCC.

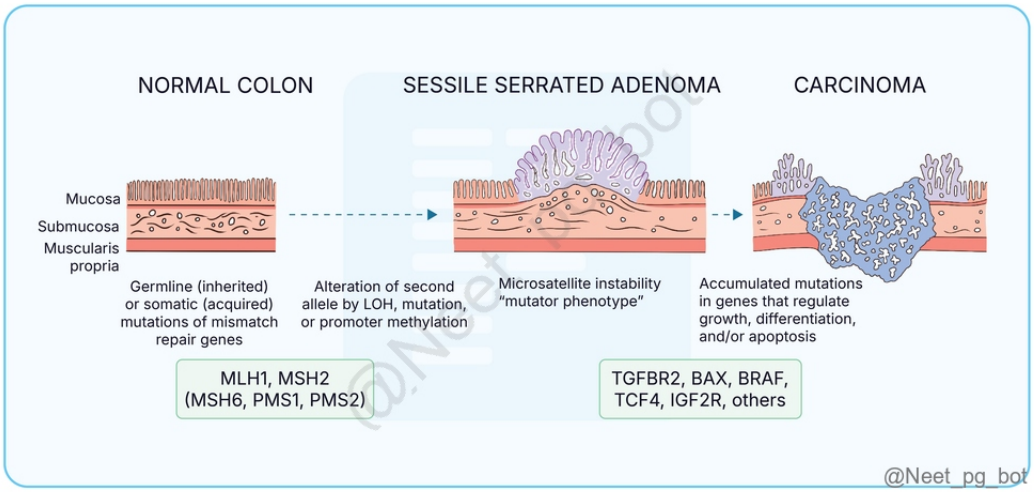

References:

.

↑ *Back to this question in Part A*

@Neet_pg_bot

• [10_Liver_ Biliary System and Pancreas] 044 Hepatobiliary Pathology-I

« Back to Folder Directory

[10_Liver_ Biliary System and Pancreas] 044 Hepatobiliary Pathology-I — Quick Jump

Q1 (p. 2012)	*Q2 (p. 2012)*	*Q3 (p. 2013)*	*Q4 (p. 2014)*	*Q5 (p. 2014)*	*Q6 (p. 2015)*
Q7 (p. 2017)	*Q8 (p. 2018)*	*Q9 (p. 2019)*	*Q10 (p. 2020)*	*Q11 (p. 2021)*	*Q12 (p. 2024)*
Q13 (p. 2024)	*Q14 (p. 2025)*	*Q15 (p. 2026)*	*Q16 (p. 2030)*	*Q17 (p. 2032)*	*Q18 (p. 2032)*
Q19 (p. 2034)	*Q20 (p. 2035)*	*Q21 (p. 2039)*	*Q22 (p. 2039)*	*Q23 (p. 2040)*	*Q24 (p. 2041)*
Q25 (p. 2042)					

Q1: Which of the following conditions is not typically associated with Mallory-Denk bodies? (Q845632)

A. Wilson’s Disease

B. Hemochromatosis

C. Indian childhood cirrhosis

D. Alpha-1 antitrypsin deficiency

Correct Answer: B. Hemochromatosis

■ *Listen (English)*

■ *Listen (Hindi)*

Explanation: Among the given options, Hemochromatosis is not associated with Mallory-Denk bodies. Mallory-Denk bodies are seen in: Alcoholic liver disease (ALD) Non-alcoholic fatty liver disease (NAFLD) Indian childhood cirrhosis (ICC) (Option C) Wilson's disease (Option A) Alpha-1 antitrypsin deficiency (Option D) Hepatocellular carcinoma Cholestasis Hepatic or primary biliary diseases. Mallory-Denk bodies are not seen in: Hemochromatosis (Option B) Secondary biliary diseases.

References:

Robbins and Cotran, Pathological Basis of Disease, 10th Edition, Page 343

↑ *Back to this question in Part A*

@Neet_pg_bot

Q2: Which of the following combinations represents the organs involved in hereditary hemochromatosis? Liver Pancreas Myocardium Basal ganglia (Q890275)

A. 1, 2, and 3 only

B. 1 and 4 only

C. 2 and 4 only

D. 1, 2, 3, and 4

Correct Answer: A. 1, 2, and 3 only

Explanation: Hereditary hemochromatosis mainly causes parenchymal iron deposition in liver, pancreas, heart, and endocrine organs , not the basal ganglia. Organs involved in Hemochromatosis: Organ Effect Pancreas Fibrosis → Diabetes Heart Cardiomyopathy, arrhythmia Skin Slate-gray pigmentation Joints Pseudogout (CPPD deposition) Pituitary/Testes Hypogonadism Liver: Early: Golden-yellow hemosiderin in periportal hepatocytes Prussian blue positive No significant inflammation Progression → micronodular cirrhosis Late: Small, shrunken, dark brown liver

References:

Robbins, Cotran & Kumar, Pathologic Basis of Disease, 11th Edition, Page 773

↑ *Back to this question in Part A*

@Neet_pg_bot

Q3: Which of the following statements regarding secondary hemochromatosis is not true? (Q890274)

A. Bantu siderosis is caused by decreased iron excretion

B. Neonatal hemochromatosis is not a hereditary disorder

C. It can occur after repeated blood transfusions

D. Disease manifests after approximately 20 g of iron accumulation

Correct Answer: A. Bantu siderosis is caused by decreased iron excretion

Explanation: Bantu siderosis results from increased oral iron intake and absorption, not decreased excretion (there is no regulated iron excretion). Secondary Hemochromatosis (Hemosiderosis): Transfusional / Parenteral iron overload: Repeated blood transfusions (Option C) Chronic hemolytic anaemias (e.g., sickle cell disease) Severe thalassemia, aplastic anaemia Increased iron absorption: β-thalassemia Myelodysplastic syndrome Increased oral intake of iron: African iron overload (Bantu siderosis) Chronic liver diseases: Alcoholic liver disease, porphyria

cutanea tarda Neonatal hemochromatosis: Develops in utero Not hereditary (Option B) Iron Burden: Normal Severe Hemochromatosis Total body iron: 2-6 g May exceed 50 g Liver stores: ~0.5 g >1/3 of total iron Disease manifests after ~20 g of iron accumulation. (Option D)

References:

Robbins, Cotran & Kumar, Pathologic Basis of Disease, 11th Edition, Pages 771, 772

↑ *Back to this question in Part A*

@Neet_pg_bot

Q4: Which of the following is the major life-threatening complication of hereditary hemochromatosis? (Q890273)

A. Hepatocellular carcinoma

B. Acute liver failure

C. Splenic rupture

D. Autoimmune hepatitis

Correct Answer: A. Hepatocellular carcinoma

Explanation: Hereditary hemochromatosis markedly increases the risk of HCC, especially in patients with cirrhosis. Iron-induced oxidative DNA damage predisposes to malignant transformation. Clinical Features: Triad: Cirrhosis Diabetes mellitus Skin pigmentation Hepatomegaly, abdominal pain, cardiac dysfunction Atypical arthritis, hypogonadism More common in males (5-7:1). Symptoms usually appear after 40 years (earlier in men; delayed in women due to menstruation). Major Complication: Hepatocellular carcinoma Risk is ~200-fold increased Risk persists even after iron reduction Acute liver failure (Option B): Hereditary hemochromatosis typically causes chronic progressive liver injury leading to fibrosis and cirrhosis , rather than acute liver failure. Liver damage develops gradually due to progressive iron accumulation and oxidative injury . Splenic rupture (Option C): Splenic rupture is not a recognised complication of hereditary hemochromatosis. Although mild splenomegaly may occur secondary to portal hypertension in advanced cirrhosis , spontaneous rupture is not associated with this condition. Autoimmune hepatitis (Option D): Autoimmune hepatitis is an immune-mediated inflammatory liver disease characterised by autoantibodies and interface hepatitis .

References:

Robbins, Cotran & Kumar, Pathologic Basis of Disease, 11th Edition, Page 773

↑ *Back to this question in Part A*

@Neet_pg_bot

Q5: A 42-year-old man presents with fatigue, skin hyperpigmentation, and newly diagnosed diabetes mellitus. Laboratory studies show elevated serum ferritin and transferrin saturation. The gene responsible for this condition is located on which chromosome? (Q890272)

A. Chromosome 6

B. Chromosome 7

C. Chromosome 18

D. Chromosome 21

Correct Answer: A. Chromosome 6

Explanation: The most likely diagnosis is Hereditary Hemochromatosis , and the gene responsible (HFE) is located on Chromosome 6 . Hereditary Hemochromatosis: Caused by mutations affecting hepcidin regulation: HFE gene (the most common cause) TFR2 (transferrin receptor 2) HAMP (hepcidin gene) HJV (hemojuvelin) → juvenile hemochromatosis Mutations in HFE, HJV, HAMP, or TFR2 → Reduced hepcidin synthesis → Increased ferroportin activity → Increased intestinal iron absorption → Systemic iron overload Most Common Genetic Cause: HFE mutation C282Y (cysteine → tyrosine at position 282) Present in ≥70% of cases Homozygosity frequency ≈ 1 in 220 Low penetrance H63D mutation → milder, worldwide distribution

References:

https://pmc.ncbi.nlm.nih.gov/articles/PMC6660136/

↑ *Back to this question in Part A*

@Neet_pg_bot

Q6: ■ A 45-year-old man presents with fatigue, diabetes mellitus, and skin hyperpigmentation. Liver biopsy shows findings as shown. Micronodular cirrhosis is present with minimal inflammation. What is the most likely diagnosis? (Q890271)

A. Wilson disease

B. Primary biliary cholangitis

C. Hereditary hemochromatosis

D. α1-antitrypsin deficiency

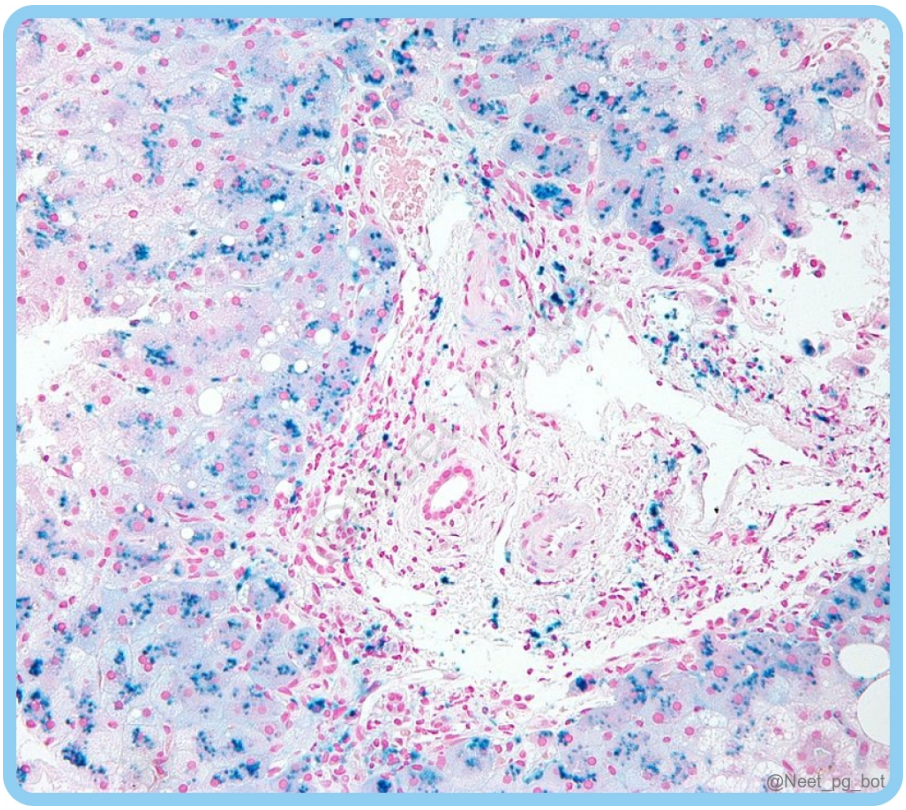

Correct Answer: C. Hereditary hemochromatosis

Explanation: The correct diagnosis is Hereditary hemochromatosis , because iron deposition begins in periportal hepatocytes, appears as Prussian blue-positive hemosiderin, and progresses to micronodular cirrhosis with minimal inflammation. Hemochromatosis - Morphology: Liver: Earliest deposition in periportal hepatocytes Golden-yellow hemosiderin granules Prussian blue positive Inflammation is typically minimal. Progression → micronodular cirrhosis Late stage → small, shrunken, dark brown liver Other organs: Pancreas → fibrosis → diabetes mellitus Heart → cardiomyopathy, arrhythmias Skin → slate-grey pigmentation Joints → pseudogout (calcium pyrophosphate deposition) Pituitary/testes → hypogonadism Wilson's disease (Option A) involves copper accumulation. Copper is stained with Rhodanine or Orcein stains, not Prussian blue. It also typically presents at a younger age. Primary Biliary Cholangitis (PBC) (Option B) is an autoimmune destruction of the bile ducts. It typically presents with itching (pruritus) and elevated alkaline phosphatase, mainly in women. α1-antitrypsin deficiency (Option D) shows PAS-positive, diastase-resistant pink globules in the hepatocytes, not iron-positive granules.

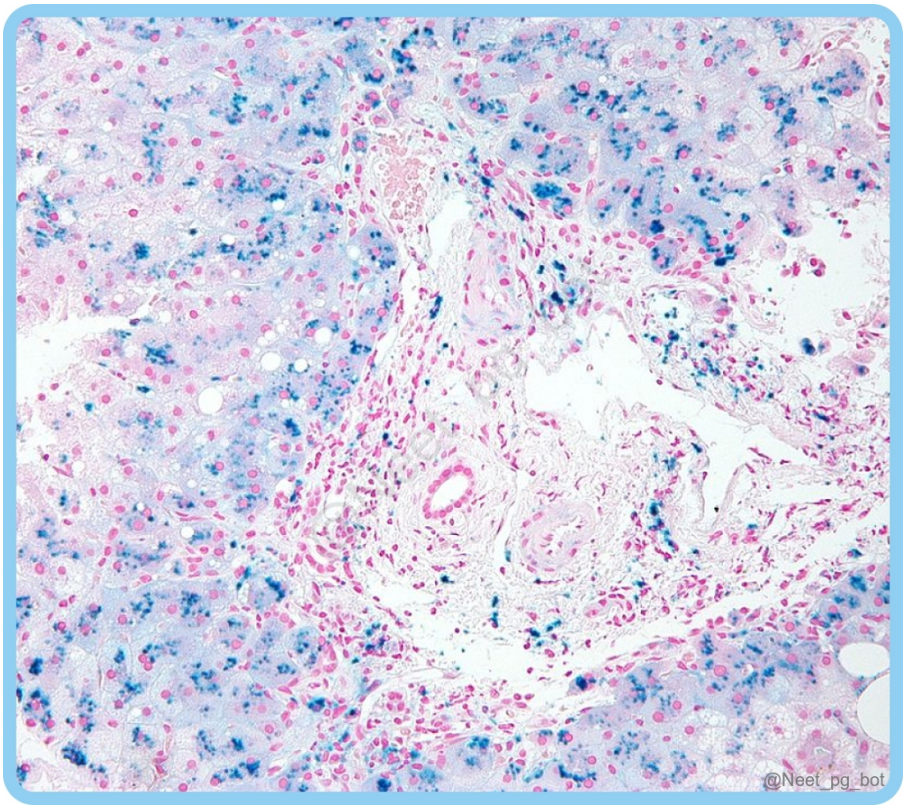

References:

Robbins, Cotran & Kumar, Pathologic Basis of Disease, 11th Edition, Pages 771-773

↑ *Back to this question in Part A*

@Neet_pg_bot

Q7: Which of the following findings is wrong regarding the diagnosis of Wilson's disease? (Q890270)

A. KF rings on slit lamp examination

B. Increased hepatic copper content on liver biopsy

C. Increased urinary copper excretion

D. Elevated serum ceruloplasmin levels

Correct Answer: D. Elevated serum ceruloplasmin levels

Explanation: Wilson's disease is characterised by decreased serum ceruloplasmin due to impaired incorporation of copper into apoceruloplasmin from ATP7B dysfunction. Tests for diagnosis in Wilson’s disease: Test Finding

Utility Serum ceruloplasmin ↓ Screening Hepatic copper content (Option B) ↑ Most sensitive & accurate Urinary copper (Option C) ↑ Most specific Slit lamp exam KF rings (Option A) Supportive ATP7B sequencing Mutation Family screening & if biochemistry equivocal

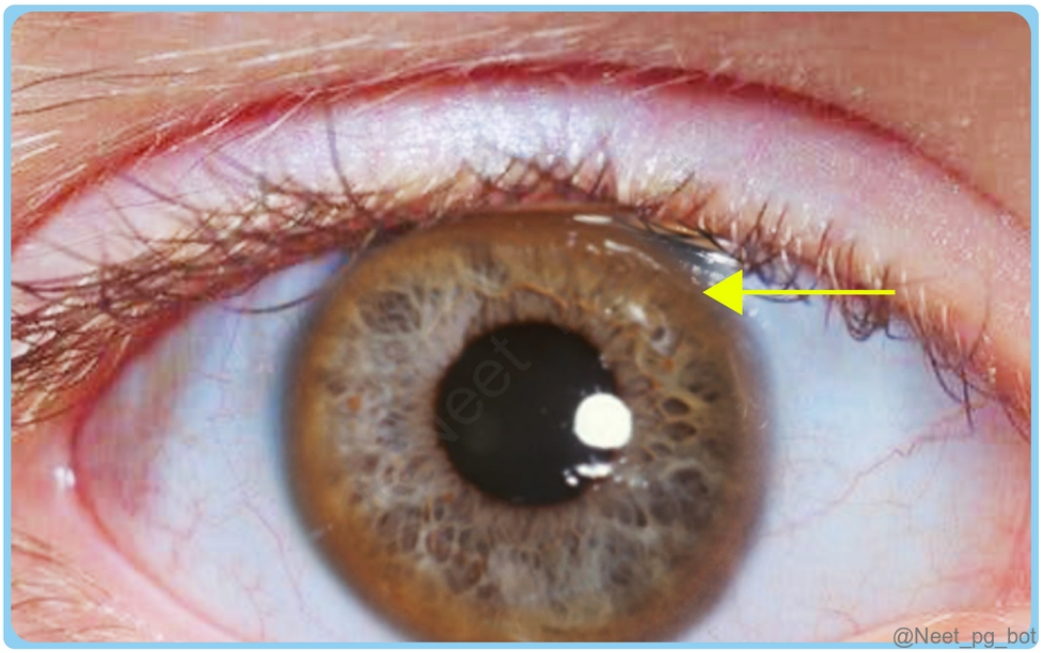

References:

Robbins, Cotran & Kumar, Pathologic Basis of Disease, 11th Edition, Page 774

https://www.niddk.nih.gov/health-information/liver-disease/wilson-disease/diagnosis

↑ *Back to this question in Part A*

@Neet_pg_bot

Q8: A 14-year-old boy is diagnosed with Wilson's disease. Genetic testing in the patient identifies a pathogenic mutation in the ATP7B gene. His asymptomatic sibling is evaluated for family screening. Which of the following is the most appropriate test to screen this first-degree relative? (Q890269)

A. Serum ceruloplasmin measurement

B. 24-hour urinary copper excretion

C. Targeted genetic testing for the familial ATP7B mutation

D. Slit-lamp examination for Kayser-Fleischer rings

Correct Answer: C. Targeted genetic testing for the familial ATP7B mutation

Explanation: Wilson disease is an autosomal recessive disorder caused by mutations in the ATP7B gene , resulting in impaired biliary copper excretion and accumulation of copper in the liver, brain, and other tissues. When a specific pathogenic ATP7B mutation has already been identified in the affected patient (proband) , the most appropriate method for screening asymptomatic first-degree relatives is targeted genetic testing for the known familial mutation . This allows early identification of affected individuals before clinical manifestations develop and enables timely initiation of therapy. The diagnosis of Wilson's disease is usually based on biochemical findings such as: Decreased serum ceruloplasmin levels Increased hepatic copper content (the most sensitive and accurate test) Increased urinary copper excretion (the most specific test) Demonstration of Kayser-Fleischer rings on slit-lamp examination However, ATP7B mutation analysis is useful for confirming the diagnosis and for screening family members , particularly when the familial mutation is already known . Serum ceruloplasmin measurement (Option A): Often decreased in Wilson disease and used in biochemical screening, but levels may be normal in some patients or altered by liver injury. 24-hour urinary copper excretion (Option B): A highly specific diagnostic test, commonly used in the evaluation of suspected Wilson disease, but less definitive for screening when the familial mutation is known. Slit-lamp examination for Kayser-Fleischer rings (Option D): Helpful supportive finding, especially in patients with neurologic disease, but rings may be absent in early or asymptomatic cases.

References:

Robbins, Cotran & Kumar, Pathologic Basis of Disease, 11th Edition, Page 774

https://www.niddk.nih.gov/health-information/liver-disease/wilson-disease/diagnosis

↑ *Back to this question in Part A*

@Neet_pg_bot

Q9: Which of the following is not typically associated with developing fatty liver disease? (Q845639)

A. Hepatitis B

B. Hepatitis C

C. Type 2 diabetes

D. Alcoholism

Correct Answer: A. Hepatitis B

■ *Listen (English)*

■ *Listen (Hindi)*

Explanation: Hepatitis B primarily affects the liver by causing inflammation and can lead to chronic liver disease, cirrhosis, and liver cancer, but it does not directly cause fatty liver disease. Fatty liver disease is often associated

with several factors, such as alcoholism (Option D) , obesity, insulin resistance, metabolic syndrome, and type 2 diabetes (Option C). Chronic Hepatitis C (Option B) can cause liver inflammation and damage, potentially resulting in fat accumulation in the liver cells and leading to fatty liver disease.

References:

Robbins and Cotran, Pathological Basis of Disease, 10th Edition, Page 837, 842

↑ *Back to this question in Part A*

@Neet_pg_bot

Q10: Which of the following is typically observed in liver biopsy findings of acute hepatitis A infection? (Q845638)

A. Interface hepatitis

B. Councilman bodies

C. Ground glass hepatocytes

D. Bridging fibrosis

Correct Answer: B. Councilman bodies

■ *Listen (English)*

■ *Listen (Hindi)*

Explanation: Councilman bodies, also known as acidophilic or apoptotic bodies, are eosinophilic structures representing apoptotic hepatocytes. These are characteristic findings of acute viral hepatitis. Biopsy findings of acute viral hepatitis Ballooning degeneration of hepatocytes Councilman bodies Spotty necrosis Dropout necrosis and Kupffer cell hyperplasia (Empty space lined by Kupffer cells) Absent or mild portal inflammation Interface hepatitis (Option A) is characterised by inflammatory cell infiltrates at the interface between the portal tracts and hepatic lobules and is prominent in Chronic viral hepatitis rather than acute. Ground glass hepatocytes (Option C) (aka Shikata cells) are densely eosinophilic cells with glassy cytoplasm due to HBsAg. They are seen in chronic Hepatitis B infection but not acute hepatitis. Bridging fibrosis (Option D) refers to fibrous septa or thick collagenous bands connecting adjacent portal tracts and central veins. It is typically observed in Chronic hepatitis and is indicative of advanced liver fibrosis.

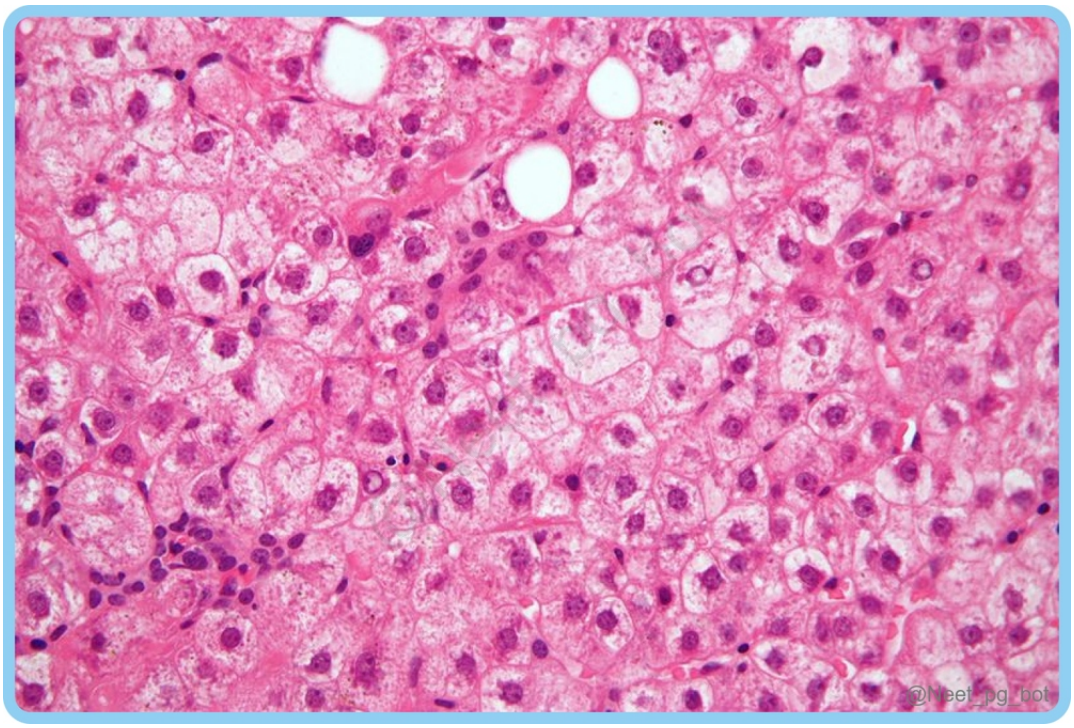

References:

Robbins and Cotran, Pathological Basis of Disease, 10th Edition, Page831

↑ *Back to this question in Part A*

@Neet_pg_bot

Q11: What is the most likely autoantibody detected in Type I autoimmune hepatitis (AIH)? (Q845636)

A. Anti-LKM 1

B. Anti-smooth muscle antibodies (ASMA)

C. Anti-Liver Cytosol 1 (ACL-1)

D. Anti-cyclic citrullinated peptide (anti-CCP)

Correct Answer: B. Anti-smooth muscle antibodies (ASMA)

■ *Listen (English)*

■ *Listen (Hindi)*

Explanation: Autoimmune hepatitis (AIH) is characterised by the presence of autoantibodies targeting various liver antigens. In Type 1 AIH, the most commonly detected autoantibody is anti-smooth muscle antibodies

(ASMA), which target actin filaments in the smooth muscle cells of blood vessels and the liver. Features Type I AIH Type II AIH More common in Young female Children Auto-antibodies Anti SMA (Anti smooth muscle antibody) (Option B) ANA (Anti-nuclear antibody) Anti-soluble liver antigen Anti LKM- 1 (Hepatitis C) (Option A) Anti–liver cytosol-1 (ACL-1) (Option C) Anti LKM- 3 (Hepatitis D) Microscopic Examination of AIH: Interphase Hepatitis: 1 st change, present at interphase (between portal triad and hepatocytes): Max conc of antibodies Piecemeal Necrosis Emperipolesis/Entosis (Hepatocyte Eating Lymphocyte): Cell within cell appearance Hepatic Rosette: Hepatocytes arranged in round alignment

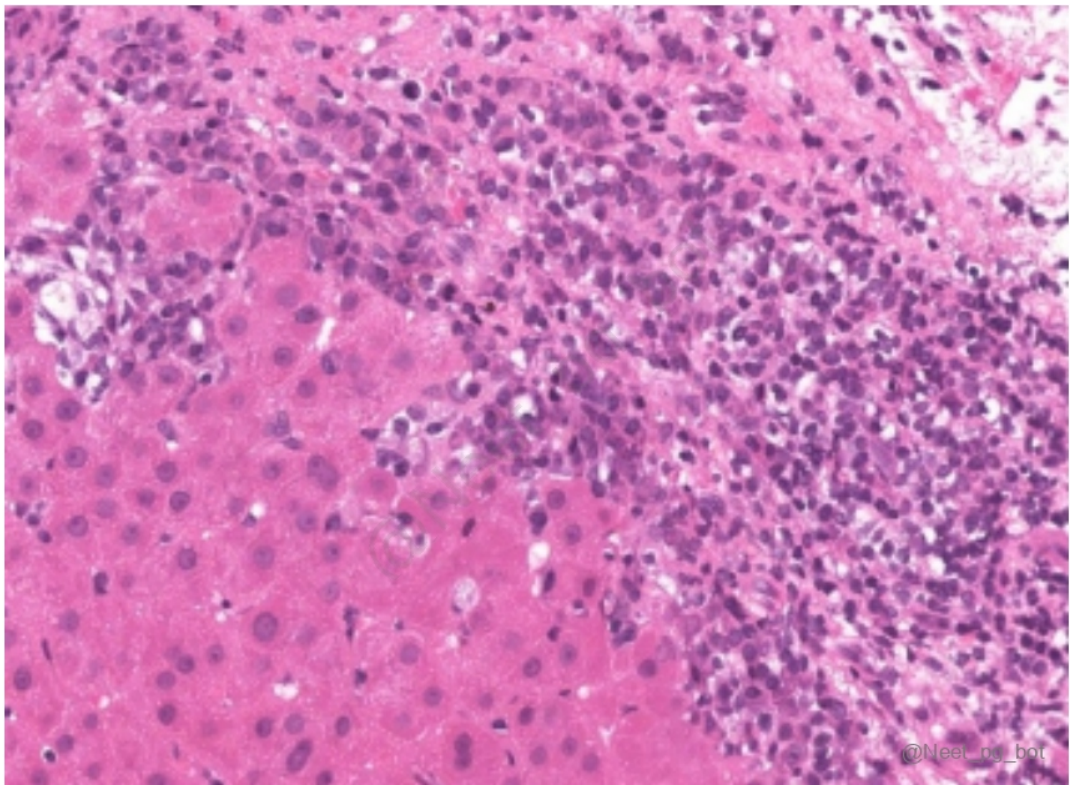

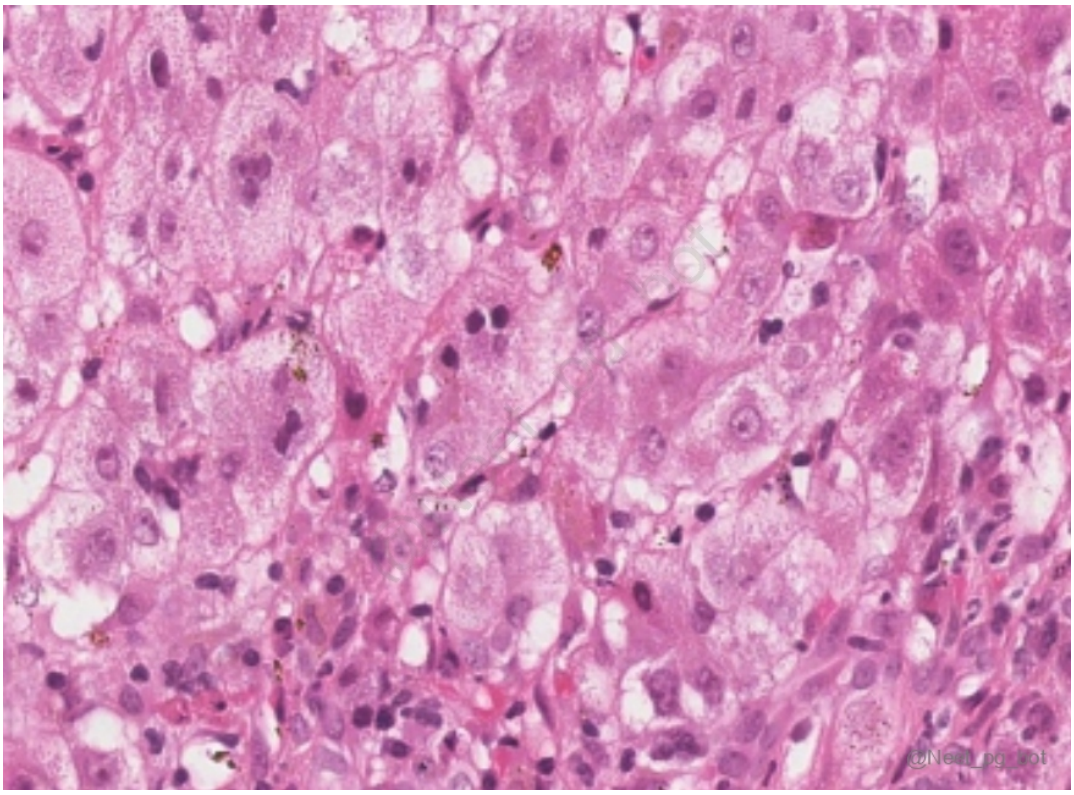

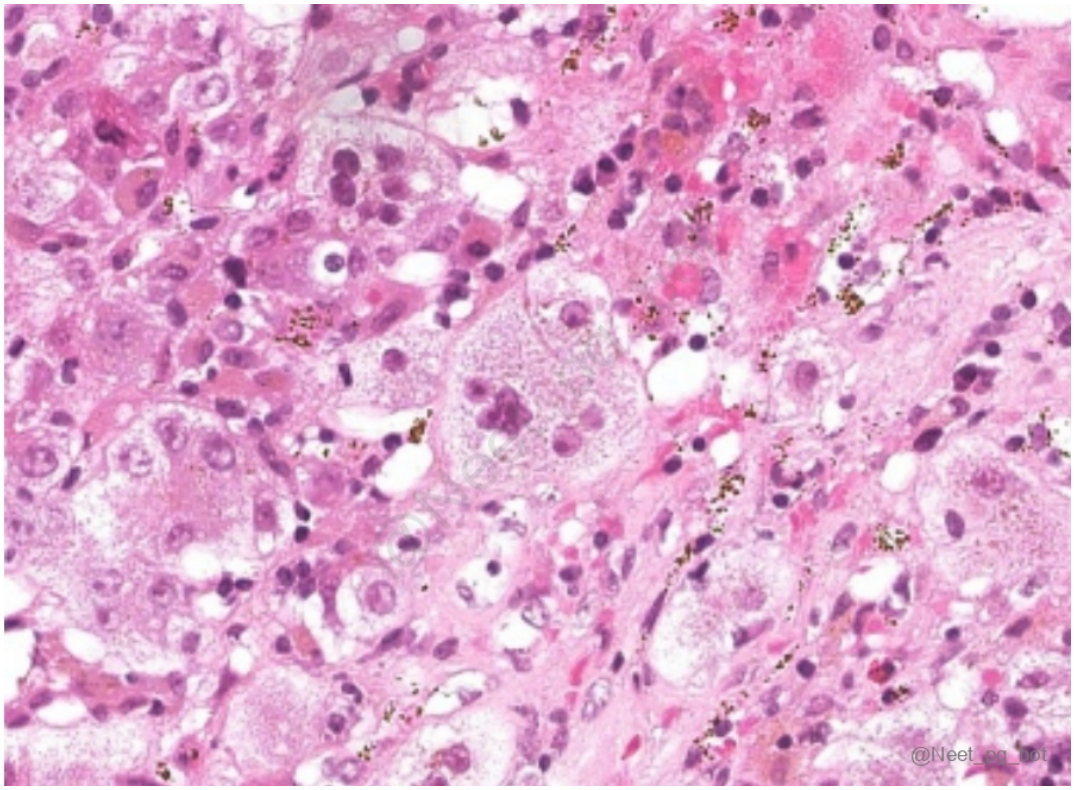

References:

Robbins and Cotran, Pathological Basis of Disease, 10th Edition, Pages 839-840

↑ *Back to this question in Part A*

@Neet_pg_bot

Q12: A 45-year-old male with diabetes mellitus presents with fatigue and abdominal discomfort. He denies any history of alcohol consumption. Laboratory tests show elevated serum AST and ALT levels. Imaging reveals hepatic steatosis. Which of the following is consistent with the patient's presentation? (Q845635)

A. AST/ALT > 2 with obesity

B. AST/ALT > 2 without alcohol intake

C. AST/ALT < 1 with diabetes mellitus

D. AST/ALT < 1 without dyslipidemia

Correct Answer: C. AST/ALT < 1 with diabetes mellitus

■ *Listen (English)*

■ *Listen (Hindi)*

Explanation: The clinical presentation is consistent with Non-alcoholic steatohepatitis, characterised by AST/ALT < 1. Features NASH (Non-alcoholic steatohepatitis) Alcoholic steatohepatitis Risk factors Obesity Diabetes mellitus (Option C) Dyslipidemia (Option D ruled out) Alcohol intake AST/ALT Ratio AST/ALT < 1 (Option A and B ruled out) AST/ALT > 2 GGT levels Normal Increased

References:

Robbins and Cotran, Pathological Basis of Disease, 10th Edition, Page 842- 846

↑ *Back to this question in Part A*

@Neet_pg_bot

Q13: Which of the following changes is reversible with alcohol abstinence? (Q845633)

A. Perivenular fibrosis

B. Periportal fibrosis

C. Bridging fibrosis

D. Micronodular cirrhosis

Correct Answer: A. Perivenular fibrosis

■ *Listen (English)*

■ *Listen (Hindi)*

Explanation: In the early stages of alcoholic liver disease, fibrosis typically begins around the central veins (central venules) in the liver lobules (perivenular or centrilobular zone) with a characteristic "chicken wire" appearance. With cessation of alcohol intake and appropriate treatment, this perivenular or pericellular fibrosis can regress, leading to improvement in liver function and histology.

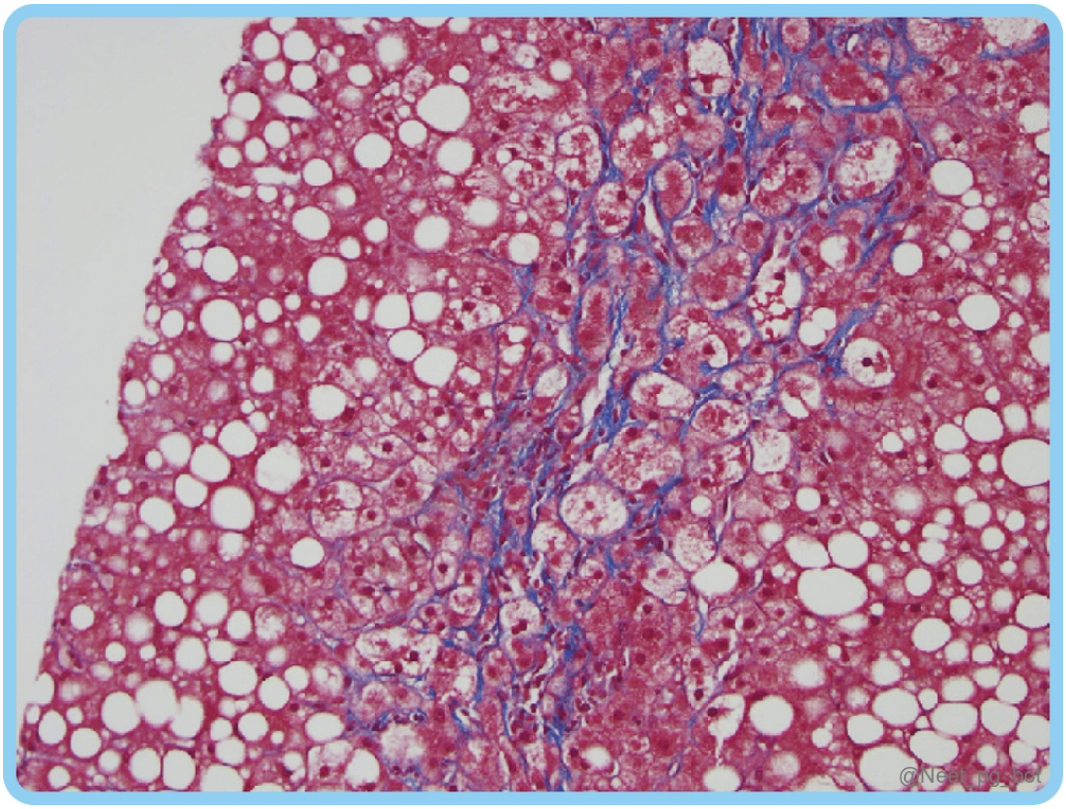

References:

Robbins and Cotran, Pathological Basis of Disease, 10th Edition, Page 844

↑ *Back to this question in Part A*

@Neet_pg_bot

Q14: Which cells are primarily involved in the fibrosis in liver cirrhosis? (Q845617)

A. Kupffer cells

B. Pit cells

C. Stellate cells

D. Hepatocytes

Correct Answer: C. Stellate cells

■ *Listen (English)*

■ *Listen (Hindi)*

Explanation: Hepatic stellate cells (or Ito cells) are pericytes located in the space of Disse, between hepatocytes and sinusoidal endothelial cells in the liver. In the healthy liver, these cells store vitamin A in lipid droplets and regulate sinusoidal blood flow. Upon liver injury, they activate and transform into myofibroblast-like cells, release TGFβ, and lead to fibrosis by producing excessive extracellular matrix, such as collagen. Pathogenesis of Fibrosis: Upon activation by TGF-β (the most potent fibrogenic cytokine) and PDGF (which drives cell proliferation), Stellate cells transform into myofibroblasts. This leads to: Collagen Shift: The normal Type IV collagen in the Space of Disse is replaced by heavy Type I and Type III collagen (fibrillar collagen). Fibrogenic Interleukins: Pro-inflammatory cytokines like IL-13, IL-1, and TNF-α further stimulate the production of extracellular matrix (ECM). Matrix Imbalance: Stellate cells release TIMPs (Tissue Inhibitors of Metalloproteinases). These inhibit the enzymes (MMPs) that normally break down scar tissue, leading to unchecked collagen accumulation. Capillarization: The dense collagen buildup causes sinusoidal endothelial cells to lose their fenestrations (pores), blocking nutrient exchange between blood and hepatocytes. Kupffer cells (Option A) are macrophages found in sinusoids of the liver, involved in phagocytosis. Pit cells (Option B) are liver-associated lymphocytes, primarily NK (Natural Killer) cells. They contribute to liver immune surveillance but are not directly implicated in liver fibrosis. Hepatocytes (Option D) are vital liver cells.

References:

Robbins and Cotran Pathological Basis of Disease, 10th Edition, Page 824

↑ *Back to this question in Part A*

@Neet_pg_bot

Q15: A 51-year-old male with a history of chronic alcohol use presents with fatigue, abdominal discomfort, and unintentional weight loss. A biopsy of the liver was done. Which of the following histopathological features is characteristic of the condition depicted in the biopsy image? (Q845631)

A. Mallory-Denk bodies

B. Ground-glass hepatocytes

C. Councilman bodies

D. Glycogenated hepatocytes

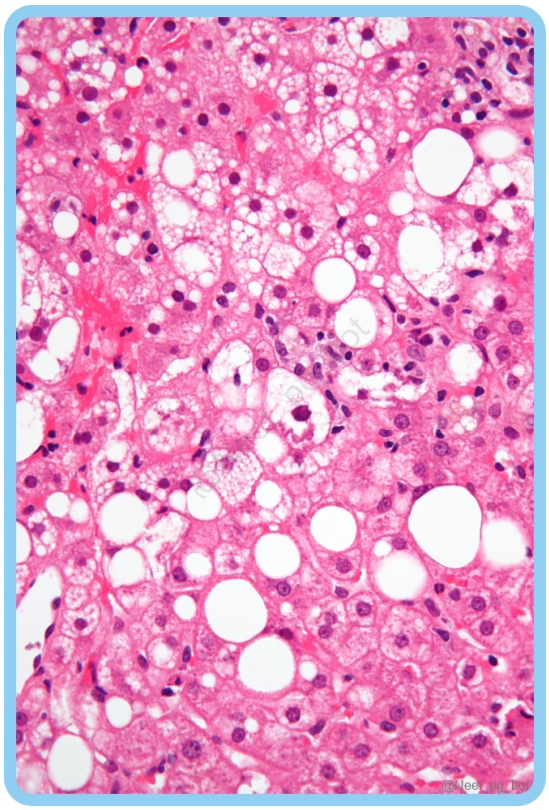

Correct Answer: A. Mallory-Denk bodies

- *Listen (English)*
- *Listen (Hindi)*

Explanation: The histopathological feature characteristic of the condition depicted in the biopsy image is Mallory-Denk bodies , a hallmark of both alcohol-induced and nonalcoholic steatohepatitis. These are eosinophilic cytoplasmic inclusions seen in hepatocytes. They comprise intermediate filaments, primarily cytokeratin 8 and 18, and other proteins like ubiquitin. They indicate cellular injury and are often associated with hepatocyte ballooning and inflammation. Mallory - Denk bodies are also seen in (New Indian WATCH) N on alcoholic fatty liver disease Indian childhood cirrhosis W ilson’s disease A lcoholic liver disease T umors like hepatocellular carcinoma C hronic cholestasis Focal nodular H yperplasia Ground-glass hepatocytes (Option B): This morphological change is seen in chronic hepatitis B infection, where hepatocytes display a granular, homogenous eosinophilic cytoplasm due to the accumulation of HBsAg in the swollen smooth endoplasmic reticulum. Councilman bodies (Option C): Councilman bodies (or acidophilic bodies) are eosinophilic, round structures representing hepatocyte apoptosis. They are typically seen in acute viral hepatitis and indicate severe hepatocellular injury. Glycogenated hepatocytes (Option D): Glycogenated hepatocytes are hepatocytes with increased intracytoplasmic glycogen content. This finding is often seen in conditions associated with metabolic disturbances, such as glycogen storage diseases or acute fatty liver of pregnancy.

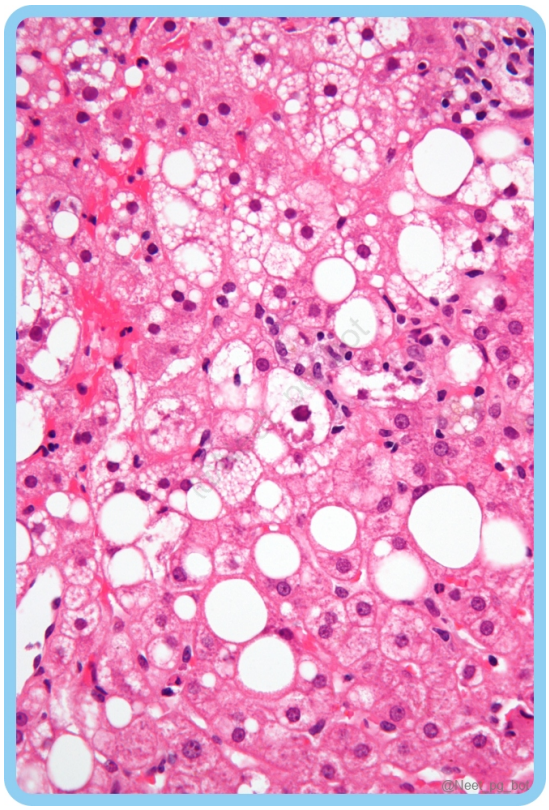

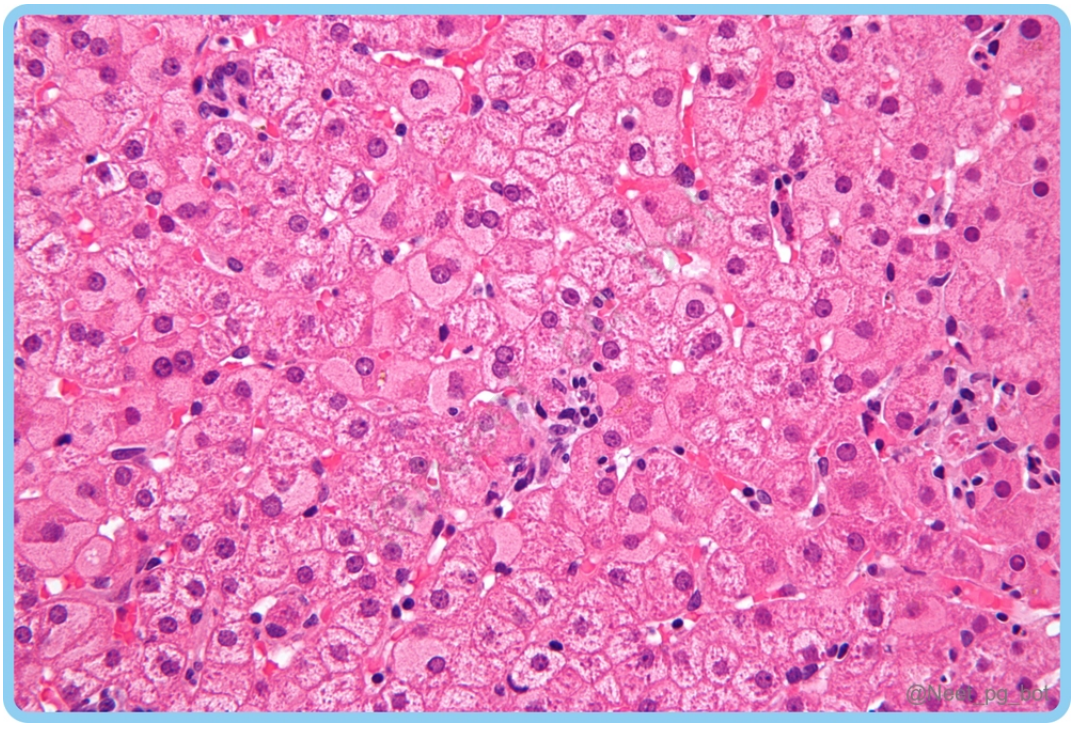

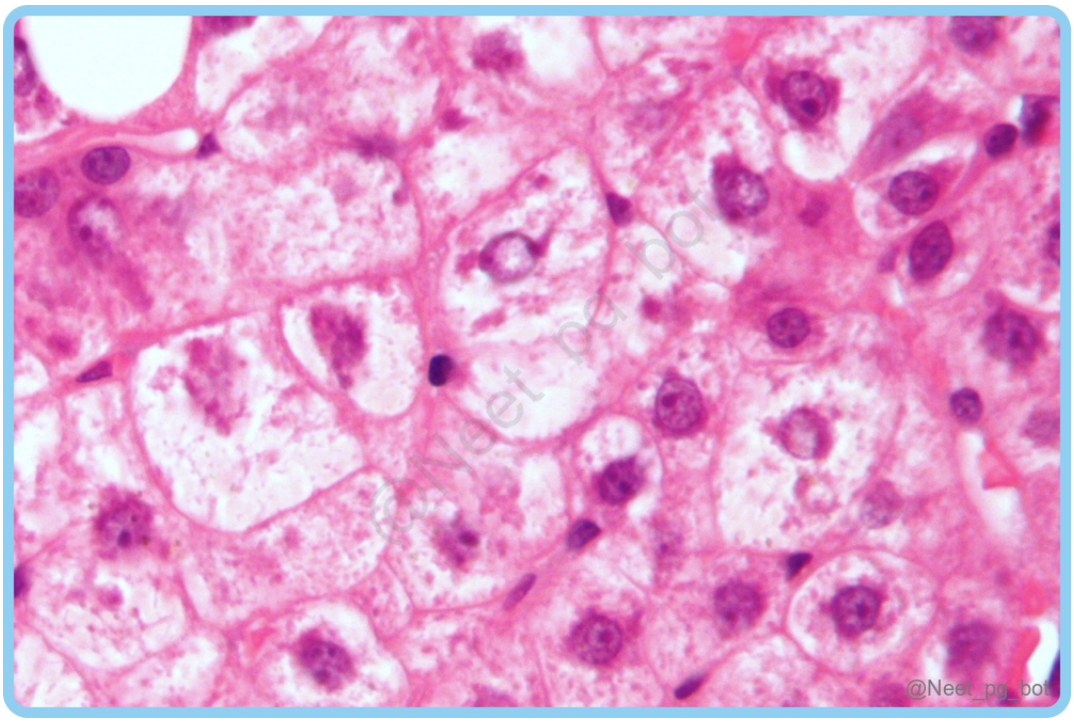

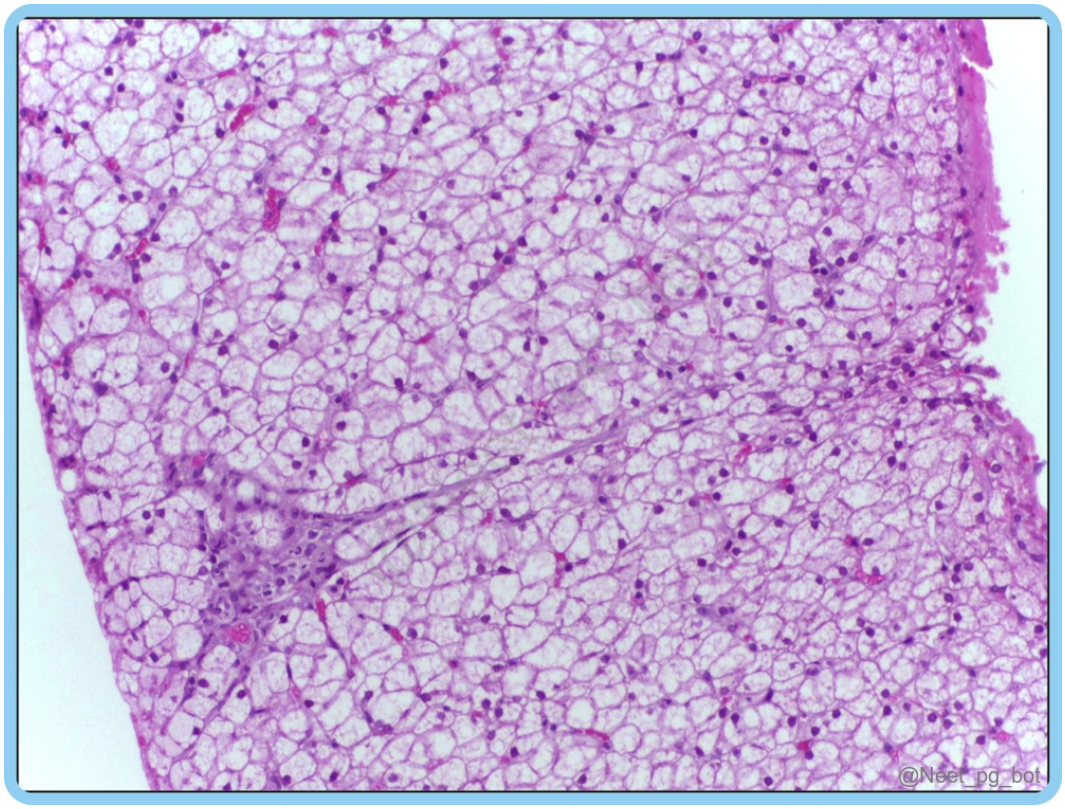

References:

Robbins and Cotran, Pathological Basis of Disease, 10th Edition, Page 343-345

↑ *Back to this question in Part A*

Q16: A 60-year-old male presents with abdominal distension and jaundice. Examination reveals hepatosplenomegaly. Lab tests show elevated liver enzymes and decreased albumin levels. Imaging shows nodules <3mm throughout the liver. Which of the following conditions can present with these findings? (Q845629)

A. Viral hepatitis

B. Drug-induced hepatitis

C. Hemochromatosis

D. Wilson disease

Correct Answer: C. Hemochromatosis

■ *Listen (English)*

■ *Listen (Hindi)*

Explanation: The clinical presentation suggests micronodular liver cirrhosis with nodules <3mm. Hemochromatosis is one of the causes of micronodular cirrhosis. Causes of micronodular cirrhosis (Granule size <3mm) Causes of macronodular cirrhosis (Granule size >3mm) Early stage of Alcoholic Liver Disease (ALD) Indian Childhood Cirrhosis (ICC) Primary Biliary Cirrhosis (PBC) Hemochromatosis (Option C) Hepatic venous outflow obstruction (Budd-Chiari syndrome) Late stage of alcoholic liver disease (ALD) Viral hepatitis (Option A) Wilson disease (Option D) Drug-induced hepatitis (Option B) Alpha-1 antitrypsin deficiency





References:

Robbins and Cotran, Pathological Basis of Disease, 10th Edition, Page 844

↑ *Back to this question in Part A*

@Neet_pg_bot

Q17: Which of the following is the manifestation of increased estrogen levels in Cirrhosis? (Q845628)

A. Increased PT and aPTT

B. Flapping tremors

C. Palmar erythema

D. Jaundice

Correct Answer: C. Palmar erythema

■ *Listen (English)*

■ *Listen (Hindi)*

Explanation: Increased estrogen levels in chronic liver failure lead to vascular changes, resulting in palmar erythema and spider angiomas. This condition can also cause hypogonadism and gynecomastia in males. Increased PT and aPTT (Option A) are primarily due to impaired synthesis of clotting factors by the damaged liver rather than the effects of hyperestrogenemia. Flapping tremors (aka asterixis) (Option B) are commonly associated with hepatic encephalopathy in cirrhosis, primarily due to elevated ammonia levels rather than estrogen. Jaundice (Option D) seen in cirrhosis is a result of impaired bilirubin metabolism due to liver dysfunction rather than being directly influenced by estrogen levels.

References:

Robbins and Cotran, Pathological Basis of Disease, 10th Edition, Page. 828

↑ *Back to this question in Part A*

@Neet_pg_bot

Q18: Which of the following stains would be most useful for highlighting collagen deposition in the fibrotic areas of the liver? (Q845626)

A. Periodic acid-Schiff (PAS) stain

B. Masson's trichrome stain

C. Masson's fontana stain

D. Congo red stain

Correct Answer: B. Masson's trichrome stain

■ *Listen (English)*

■ *Listen (Hindi)*

Explanation: Masson's trichrome stain is commonly used to visualize collagen fibers, making it suitable for highlighting fibrotic areas in liver tissue. Periodic acid-Schiff (PAS) stain (Option A): It stains carbohydrates (glycogen), basement membranes, and fungal walls. In the Liver, it is primarily used to identify Alpha-1 antitrypsin deficiency . In this condition, "globules" of misfolded protein in the hepatocytes stain a deep magenta/purple . Why it's wrong for fibrosis: While it can show basement membranes, it does not provide the color contrast needed to distinguish the thick bundles of Type I and III collagen from the surrounding liver tissue. Masson's Fontana stain (Option C): It stains Melanin and argentaffin granules (substances that reduce silver). In the Liver, it is rarely used but can help identify certain pigments or neuroendocrine cells. Why it's wrong for fibrosis: It has no affinity for collagen. Despite the similar name ("Masson's"), it is a silver-based stain used for completely different diagnostic purposes. Congo Red stain (Option D): This is the definitive diagnostic tool for Amyloidosis , a condition where insoluble, misfolded proteins (amyloid) deposit in the extracellular space. While amyloid can cause liver enlargement and firmness that mimics fibrosis, it is structurally a protein deposit, not a collagen scar. The hallmark of this stain is its unique apple-green birefringence when viewed under polarized light .

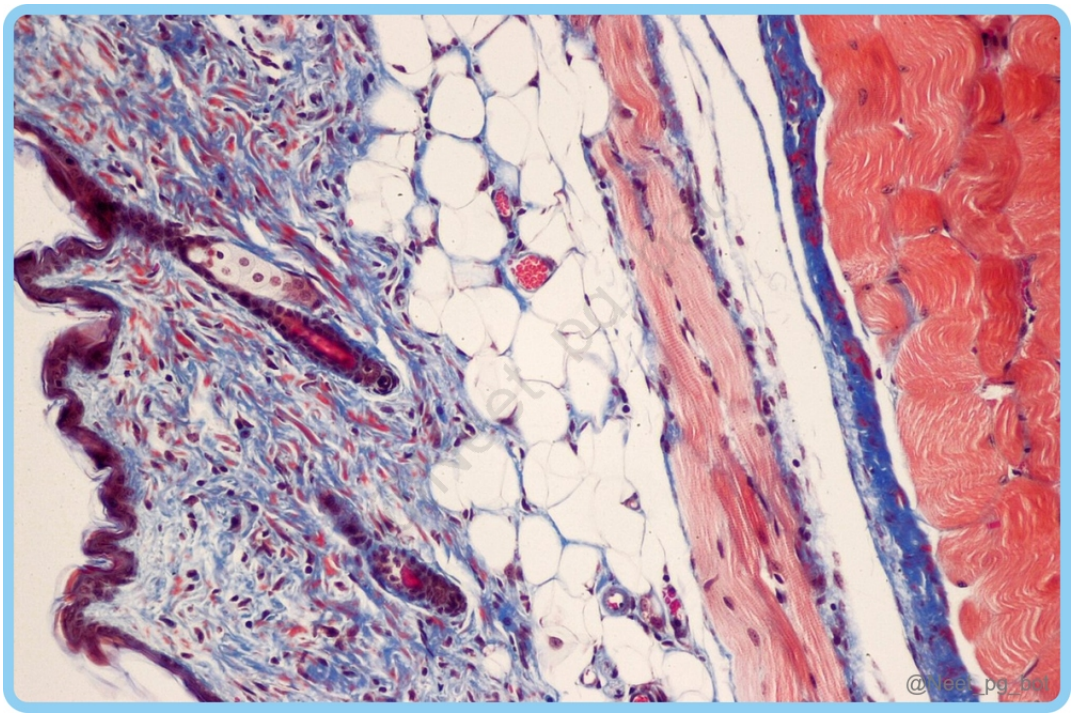

References:

Robbins and Cotran Pathological Basis of Disease, 10th Edition, Page 826

↑ *Back to this question in Part A*

@Neet_pg_bot

Q19: Which type of collagen is predominantly involved in the fibrotic process of cirrhosis? (Q845625)

A. Collagen Type I and III

B. Collagen Type I and IV

C. Collagen Type II and III

D. Collagen Type II and IV

Correct Answer: A. Collagen Type I and III

■ *Listen (English)*

■ *Listen (Hindi)*

Explanation: The fibrotic process in cirrhosis primarily involves activating hepatic stellate cells, leading to collagen deposition by myofibroblasts. These cells predominantly produce Collagen Types I and III. Pathogenesis of Liver Fibrosis: 1. Primary Insult (The Trigger): Chronic Injury (Alcohol, HBV/HCV, NASH/NAFLD) → Hepatocyte death. Release of Reactive Oxygen Species (ROS) and damage-associated molecular patterns (DAMPs). Kupffer cells (macrophages) become activated and release pro-inflammatory cytokines. 2. Activation of Hepatic Stellate Cells (HSCs): Paracrine Signaling: Cytokines from damaged hepatocytes and Kupffer cells reach the Space of Disse. Phenotypic Switch: Quiescent HSCs (Vitamin A-storing) → Myofibroblasts (Contractile and Fibrogenic). Key Growth Factors: PDGF: Stimulates HSC proliferation . TGF-β: The most potent stimulus for collagen synthesis . 3. The "Cytokine Symphony" (Fibrogenic Interleukins): IL-1 and TNF-α: Initial inflammatory "wake-up" call for HSCs. IL-13: Directly promotes TGF-β production and enhances the fibrogenic phenotype. IL-6: Contributes to the acute phase response and sustains the survival of activated myofibroblasts. Chemokines (MCP-1): Recruit more inflammatory cells, creating a self-perpetuating loop. 4. ECM Remodeling & Collagen Deposition The Shift: Normal Type IV collagen (basement membrane-like) is replaced by fibrillar Type I and Type III collagen . Matrix Imbalance: Activated HSCs secrete TIMPs (Tissue Inhibitors of Metalloproteinases). Inhibition: TIMPs bind to and neutralize MMPs (Matrix Metalloproteinases), preventing the degradation of the newly formed scar tissue. 5. Structural Consequences (Cirrhosis) Capillarization of Sinusoids: The dense collagen "seals" the pores (fenestrae) in endothelial cells, blocking nutrient/oxygen exchange. Increased Vascular Resistance: Myofibroblast contraction and structural scarring lead to Portal Hypertension . Regenerative Nodules: Surviving hepatocytes proliferate within the fibrous "cages," forming the classic nodules seen in cirrhosis.

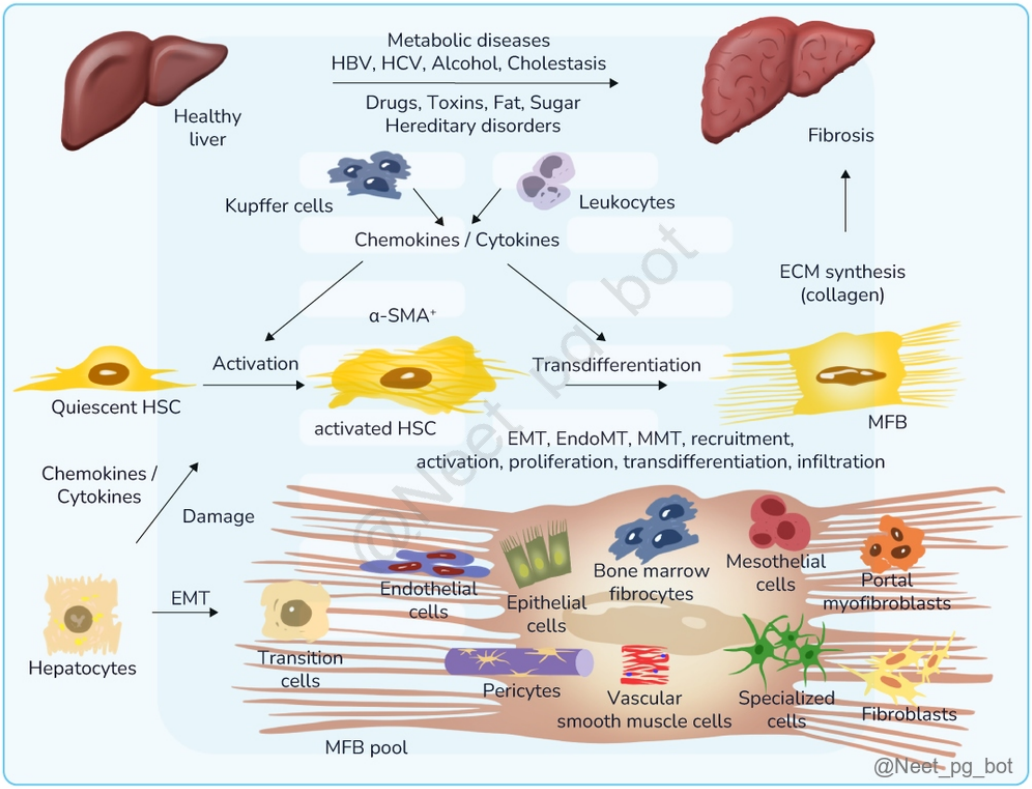

References:

Robbins and Cotran Pathological Basis of Disease, 10th Edition, Pages 825 - 826

↑ *Back to this question in Part A*

@Neet_pg_bot

Q20: A 45-year-old male presents with fatigue, pruritus, and jaundice. He has a history of ulcerative colitis. Laboratory tests reveal elevated liver enzymes and conjugated hyperbilirubinemia. MRCP and Histopathological findings from liver biopsy are given below. Which condition is most likely responsible for these findings? (Q845624)

A. Clonorchis/Opisthorchis infection

B. Primary Biliary Cholangitis

C. Primary Sclerosing Cholangitis

D. Biliary stone obstruction

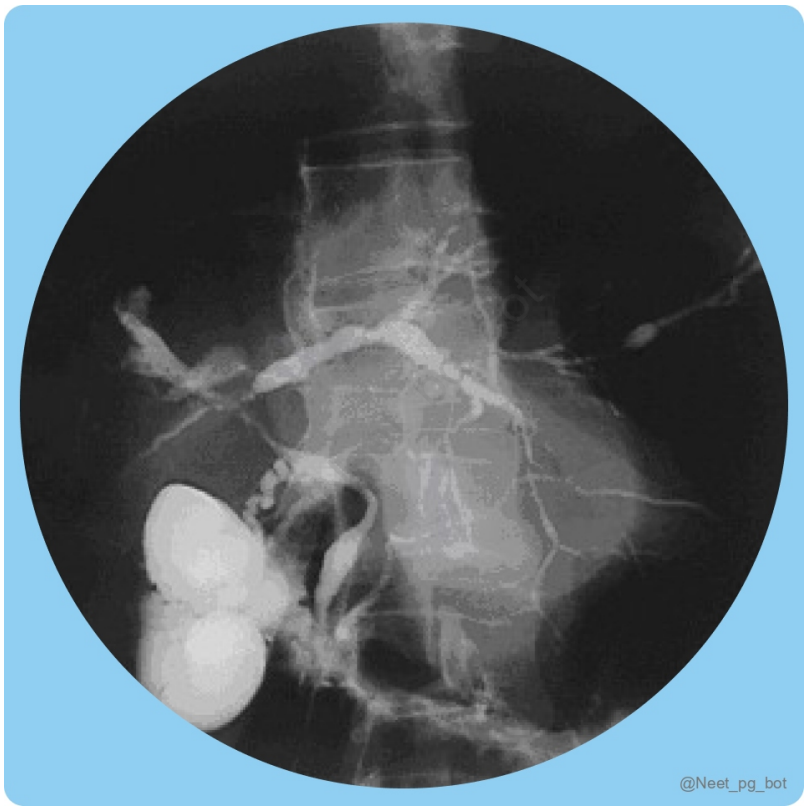

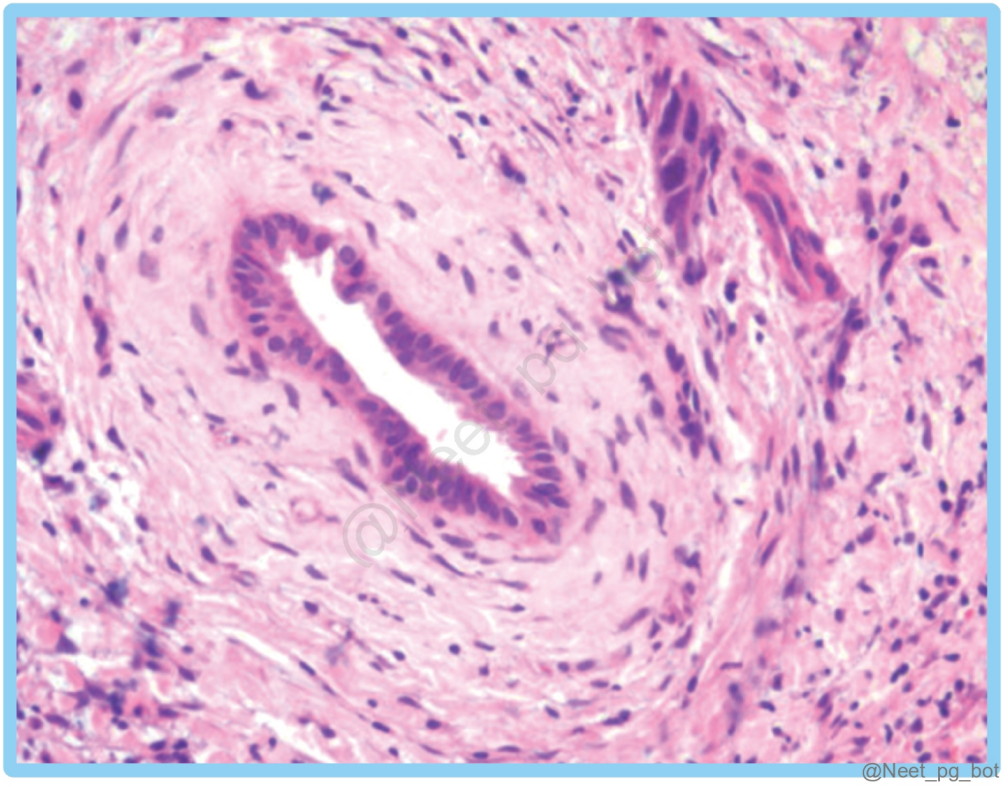

Correct Answer: C. Primary Sclerosing Cholangitis

■ *Listen (English)*

■ *Listen (Hindi)*

Explanation: Primary sclerosing cholangitis (PSC) Primary biliary cholangitis or Primary biliary cirrhosis (PBC) (Option B) Seen in 30 years old; M>F Seen in >50 years old; F>M p-ANCA positive p-ANCA is also seen in Microscopic polyangitis Churg Strauss syndrome Ulcerative colitis Primary sclerosing cholangitis Goodpasture syndrome Pauci-immune glomerulonephritis Rheumatoid arthritis AMA(Anti-mitochondrial antibody) and ANA(anti-nuclear antibody) positive Associated with ulcerative colitis, HLA-B8 Associated with Sjogren syndrome, scleroderma Intrahepatic and extrahepatic bile ducts are affected Intrahepatic bile ducts affected HPE: Concentric periductal fibrosis (Onion skin fibrosis) Radiology: Pruning of small bile ducts; Strictures and beading of large bile ducts. Radiology: Normal

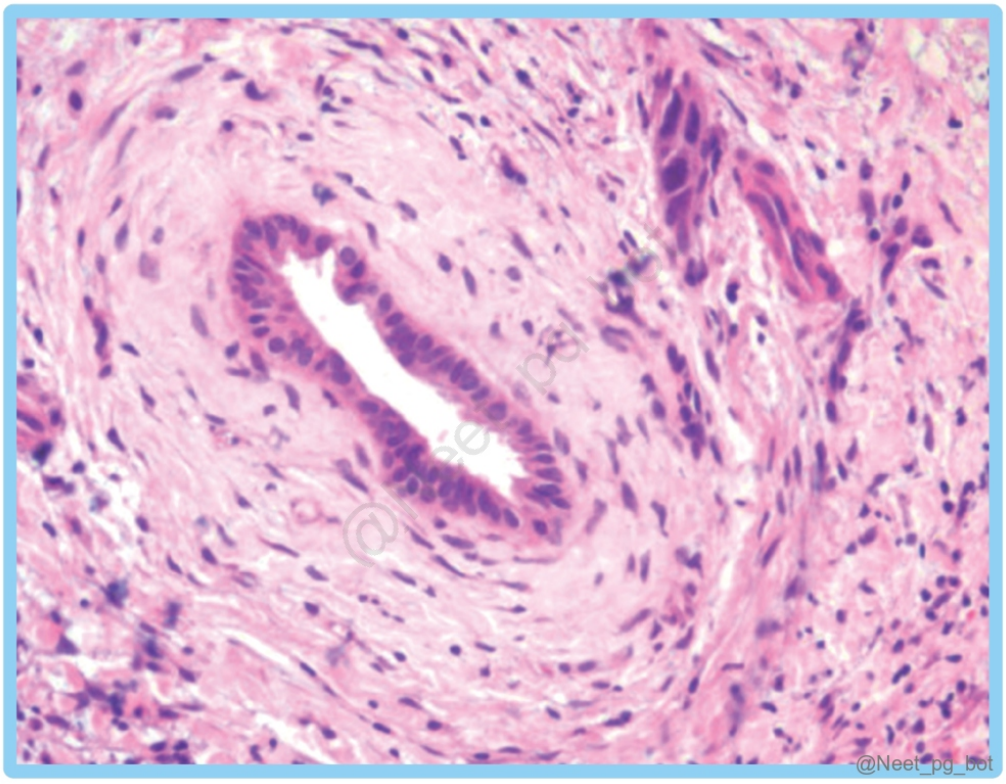

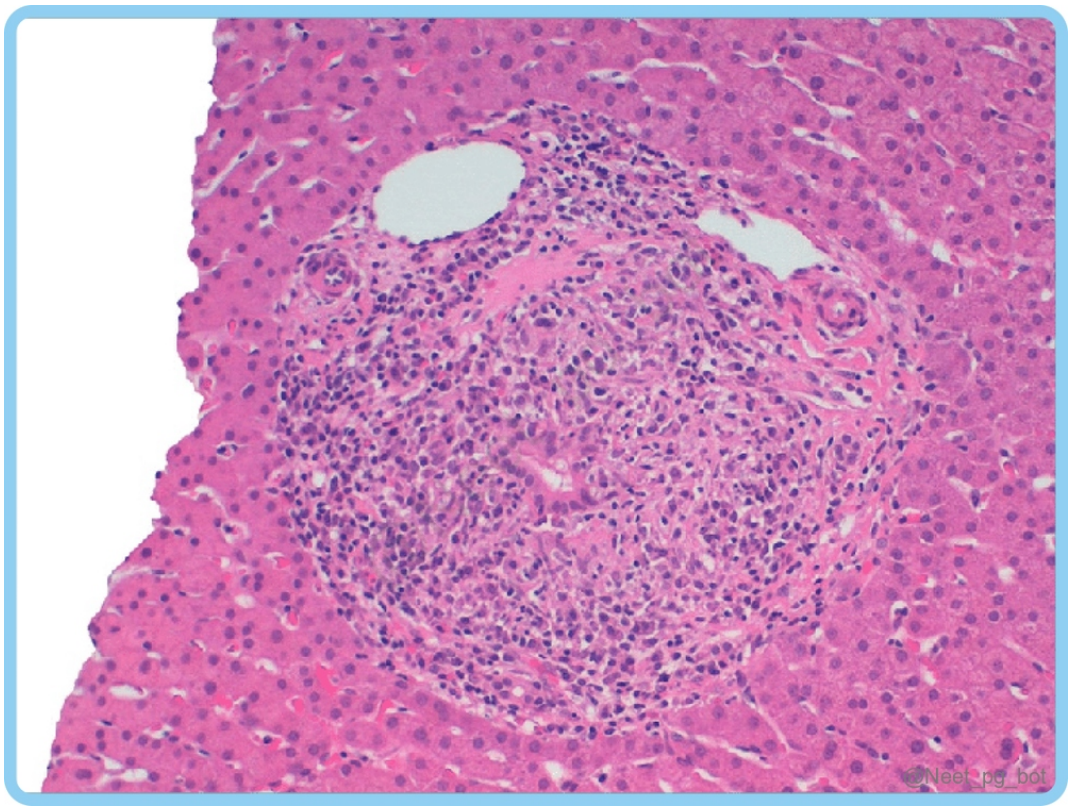

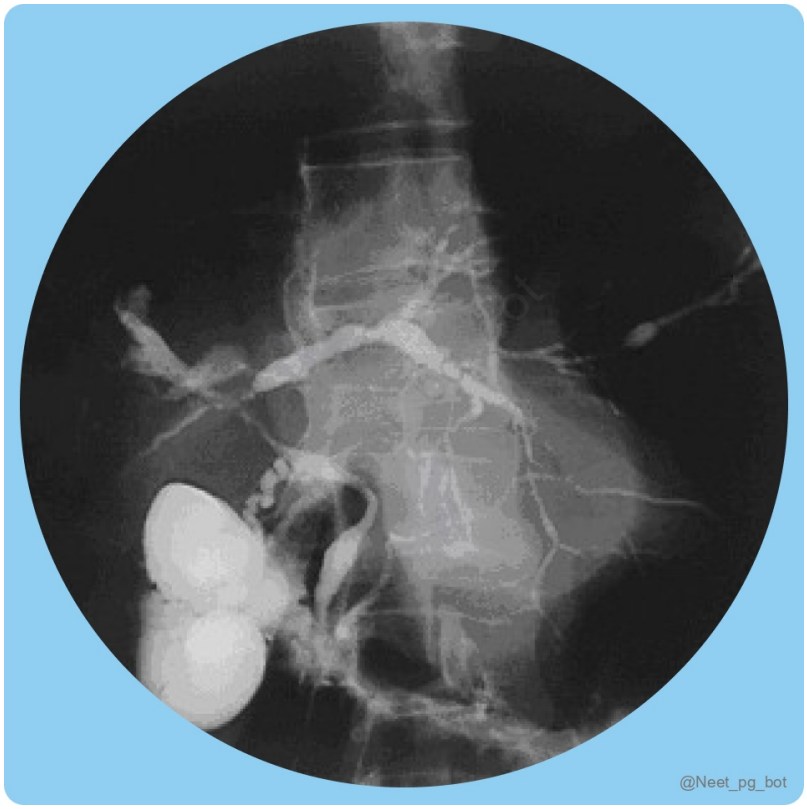

References:

Robbins and Cotran, Pathological Basis of Disease, 10th Edition, Page 857-859

↑ *Back to this question in Part A*

@Neet_pg_bot

Q21: A 35-year-old male presents with chronic jaundice and mild abdominal discomfort. Examination revealed hepatomegaly. Lab tests indicate elevated levels of direct bilirubin. Upon liver biopsy, a pigmented liver is observed. What is the most likely underlying mechanism for these clinical and pathological findings? (Q845623)

A. Deficiency of UDP glucuronosyl transferase (UGT)

B. OATP transporter defect

C. MRP2 (Multidrug resistance-associated protein 2) defect

D. Deficiency of biliverdin reductase

Correct Answer: C. MRP2 (Multidrug resistance-associated protein 2) defect

■ *Listen (English)*

■ *Listen (Hindi)*

Explanation: The clinical and pathological findings are consistent with Dubin-Johnson syndrome, which is characterised by impaired excretion of conjugated bilirubin into bile due to a defect in the MRP2 transporter leading to conjugated hyperbilirubinemia. The characteristic pigmented liver is due to the accumulation of epinephrine metabolite (not bilirubin). Type of hyperbilirubinemia Disorder Defect Unconjugated hyperbilirubinemia Crigler-Najjar syndrome type 1 Complete deficiency of UGT. (Option A) Crigler-Najjar syndrome type 2 Partial deficiency of UGT. Gilbert syndrome Very mild deficiency of UGT. Conjugated hyperbilirubinemia Dubin Johnson syndrome Defect in canalicular MRP2 protein. (Option C) Pigmented liver (due to epinephrine metabolite) Rotor syndrome Defect in ATPs (decreased biliary excretion) Non-pigmented liver

References:

Robbins and Cotran, Pathological Basis of Disease, 10th Edition, Page 852-854

↑ *Back to this question in Part A*

@Neet_pg_bot

Q22: A 2-week-old infant presents with persistent jaundice since birth and markedly elevated unconjugated bilirubin levels (>20 mg/dL) despite exposure to sunlight. Genetic testing confirms homozygosity for a specific mutation. What is the likely

diagnosis? (Q845622)

A. Criggler-Najjar syndrome type 1

B. Criggler-Najjar syndrome type 2

C. Gilbert syndrome

D. Rotor syndrome

Correct Answer: A. Criggler-Najjar syndrome type 1

■ *Listen (English)*

■ *Listen (Hindi)*

Explanation: Based on the provided scenario, the likely diagnosis is Crigler-Najjar syndrome type 1, a rare autosomal recessive disorder characterised by the complete deficiency of the enzyme UDP-glucuronosyltransferase 1A1 (UGT1A1), leading to severe unconjugated hyperbilirubinemia. Without treatment, this condition can progress to kernicterus, a potentially fatal neurologic complication due to bilirubin deposition in the brain. It is 100% fatal if left untreated. Syndromes of Unconjugated hyperbilirubinemia Disorder Defect Severity of Unconjugated hyperbilirubinemia Crigler-Najjar syndrome type 1 (Option A) Complete deficiency of UGT Severe Crigler-Najjar syndrome type 2 (Option B) Partial deficiency of UGT Mild to moderate Gilbert syndrome (Option C) Very mild deficiency of UGT Mild, asymptomatic Syndromes of Conjugated hyperbilirubinemia Disorder Defect Gross Feature of liver Dubin Johnson syndrome Defect in canalicular MRP2 protein. Pigmented liver (due to epinephrine metabolite) Rotor syndrome (Option D) Defect in ATPs (decreased biliary excretion) Non pigmented liver

References:

Robbins and Cotran, Pathological Basis of Disease, 10th Edition, Page 856

↑ *Back to this question in Part A*

@Neet_pg_bot

Q23: Which change can be seen in a structure that connects hepatocytes with cholangiocytes? (Q845620)

A. Liver regeneration

B. Amyloid deposition

C. Bile synthesis

D. Fibrosis

Correct Answer: A. Liver regeneration

■ *Listen (English)*

■ *Listen (Hindi)*

Explanation: The structure connecting hepatocytes with cholangiocytes is the Canals of Hering. It contains oval cells (aka liver stem cells), which play a pivotal role in liver regeneration. Therefore, changes observed in this structure are related to liver regeneration.

References:

Robbins and Cotran, Pathological Basis of Disease, 10th Edition, Page 824

↑ *Back to this question in Part A*

@Neet_pg_bot

Q24: Which zone of the liver lobule is primarily affected by toxins and drug metabolism? (Q845619)

A. Zone 1 (periportal zone)

B. Zone 2 (midzonal zone)

C. Zone 3 (centrilobular zone)

D. Entire lobule uniformly

Correct Answer: C. Zone 3 (centrilobular zone)

■ *Listen (English)*

■ *Listen (Hindi)*

Explanation: Zone 3 (centrilobular) is primarily affected by toxins and drug metabolism because Zone 3 hepatocytes are close to the central vein and have the highest levels of cytochrome P450 activity and lowest oxygen tension. Zone Location Hepatocyte characteristics Sensitivity to Injury Zone 1 (periportal zone) (Option A) Around the portal tracts High oxygenation, reduced metabolic activity, Rich blood supply Least susceptibile to toxin-mediated and ischemic injury Zone 2 (mid zonal zone) (Option B) Between zone 1 and zone 3 Intermediate oxygenation, metabolic activity and blood supply Moderate susceptibility to toxin-mediated and ischemic injury Zone 3 (pericentral zone) (Option C) Around the central vein Low oxygenation, active metabolism, Poor blood supply Susceptible to drugs/toxin-mediated damage and ischemic injury during hypoperfusion of the liver

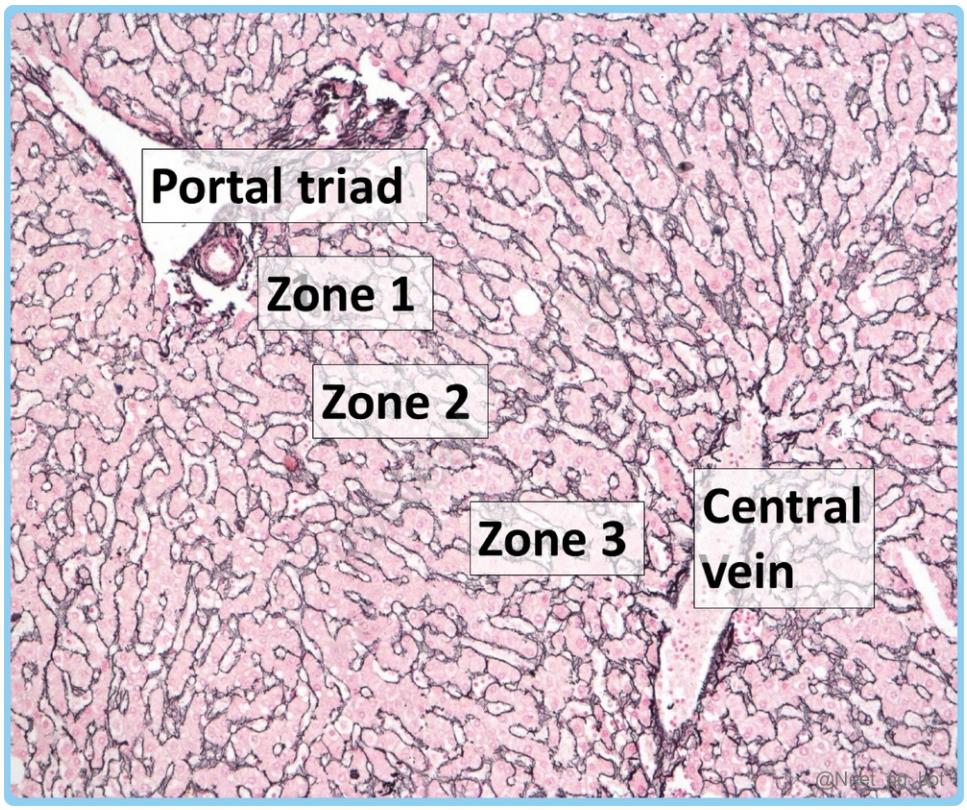

References:

Robbins and Cotran, Pathological Basis of Disease, 10th Edition, Page 823, 824

↑ *Back to this question in Part A*

@Neet_pg_bot

Q25: Which of the following cytokines is not typically involved in promoting fibrogenesis and hepatic stellate cell activation in chronic liver diseases? (Q845618)

A. Interleukin-6 (IL-6)

B. Platelet-Derived Growth Factor (PDGF)

C. Interleukin-10 (IL-10)

D. Transforming Growth Factor Beta (TGF-β)

Correct Answer: C. Interleukin-10 (IL-10)

■ *Listen (English)*

■ *Listen (Hindi)*

Explanation: Factors Role in hepatic pathology Interleukin 10 (Option C) Antiinflammatory Inhibits hepatic stellar cell activation Reduces fibrogenesis by counteracting pro-inflammatory cytokines Interleukin 6 (Option A) Pro-inflammatory Stimulates hepatic stellar cell activation Promotes fibrogenesis and inflammation in chronic liver diseases Associated with hepatic regeneration Platelet derived growth factor (PDGF) (Option B) Stimulates hepatic stellar cell activation Promotes proliferation and migration of HSC to site of injury Contributes to fibrogenesis Transforming growth factor - β (TGF-β) (Option D) Promotes profibrotic cytokines in liver diseases Stimulates HSC activation and transformation into myofibroblast Enhances Extracellular Matrix production and inhibits ECM degradation

References:

Robbins and Cotran, Pathological Basis of Disease, 10th Edition, Page 826

↑ *Back to this question in Part A*

@Neet_pg_bot

• [10_Liver_ Biliary System and Pancreas] 045 Hepatobiliary Pathology-Ii

« Back to Folder Directory

[10_Liver_ Biliary System and Pancreas] 045 Hepatobiliary Pathology-Ii — Quick Jump

Q1 (p. 2044) *Q2 (p. 2046)* *Q3 (p. 2049)* *Q4 (p. 2050)* *Q5 (p. 2053)* *Q6 (p. 2054)*
Q7 (p. 2055) *Q8 (p. 2057)* *Q9 (p. 2059)* *Q10 (p. 2061)* *Q11 (p. 2062)* *Q12 (p. 2063)*
Q13 (p. 2065)

Q1: Which of the following mutations is responsible for hereditary haemochromatosis? (Q845720)

A. ATP7B mutation

B. HFE mutation

C. SERPINA 1 mutation

D. UGT1A1 mutation

Correct Answer: B. HFE mutation

■ *Listen (English)*

■ *Listen (Hindi)*

Explanation: Hereditary hemochromatosis is due to an HFE gene mutation on chromosome 6p that causes excess iron absorption, leading to increased iron deposition. This results in the classic triad of cirrhosis , secondary diabetes mellitus , and bronze skin . Hereditary Hemochromatosis: Key laboratory findings: High ferritin, high serum iron and low TIBC. Liver biopsy: Golden-yellow hemosiderin granules in periportal hepatocytes that appear blue with a Prussian blue stain followed by a micronodular pattern of cirrhosis. Other findings: Dilated cardiomyopathy (m/c cardiac manifestation). Increased risk of hepatocellular carcinoma HJV (Hemojuvelin gene) causes juvenile hemochromatosis. Wilson disease is an autosomal recessive disorder involving the ATP7B gene mutation (Option A) Gilbert syndrome , a harmless autosomal recessive disease, results from UGT1A1 gene mutation (Option B) α1-Antitrypsin deficiency is an autosomal recessive disorder occurring due to mutation in SERPINA1 gene leading to pulmonary emphysema and cirrhosis. Liver biopsy shows positive periodic acid-schiff stain and diastase resistance, highlighting the characteristic magenta cytoplasmic granules (Option C)

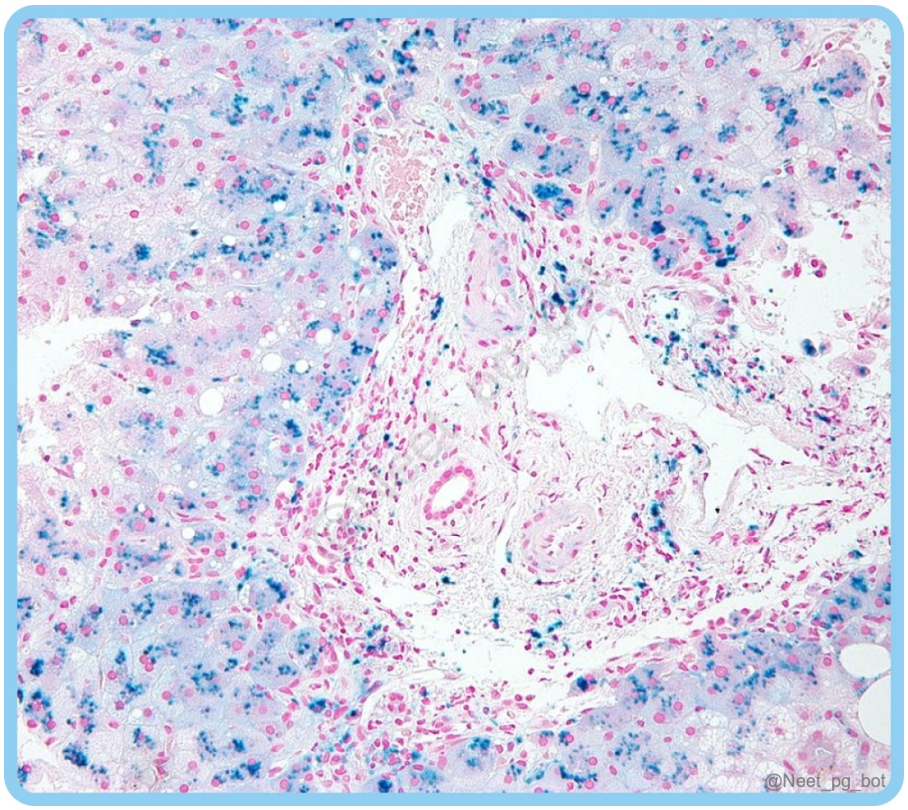
@Neet_pg_bot

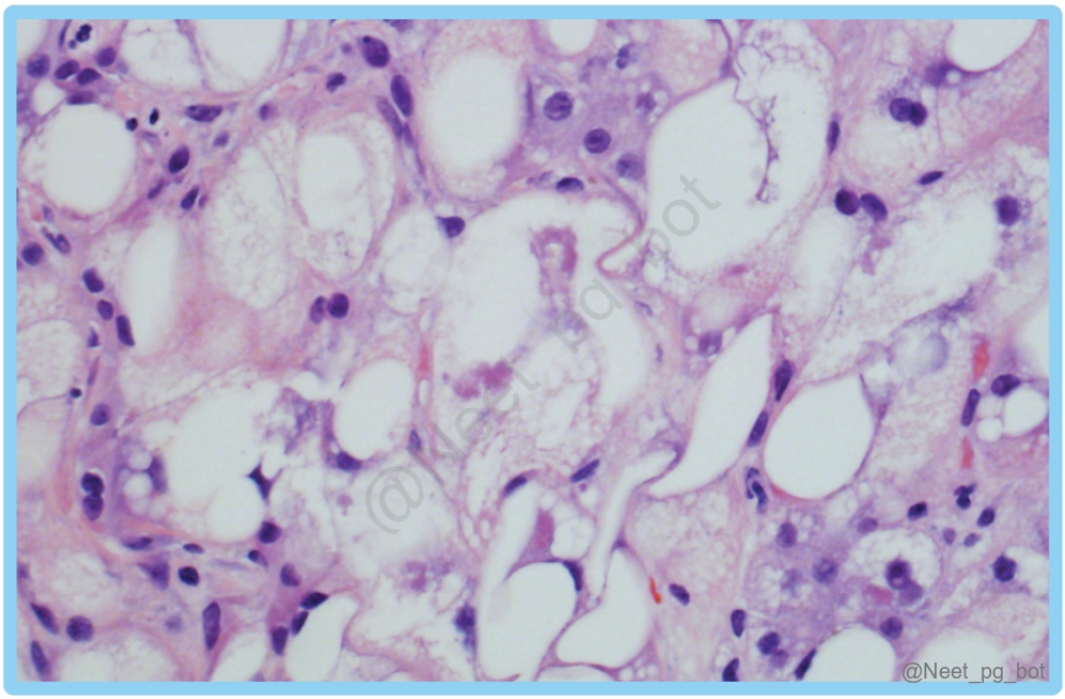
@Neet_pg_bot

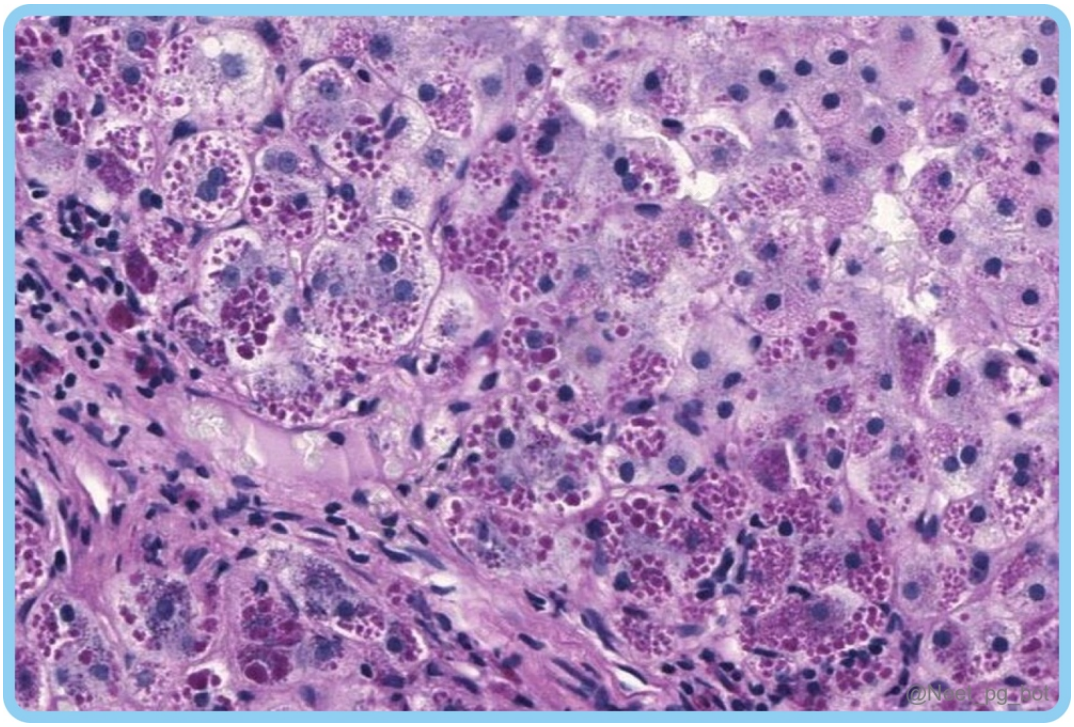

References:

Robbins and Cotran, Pathological Basis of Disease, 10th Edition, Page 848-850

↑ *Back to this question in Part A*

@Neet_pg_bot

Q2: A 48-year-old man comes to the OPD with complaints of excessive thirst, excessive micturition, and increased hunger. He also states that his skin colour has changed in the past six months. He is icteric on examination, and his skin examination reveals findings similar to those in the image below. What is the most likely cause of the change in his skin colour? (Q845722)

A. Excessive melanin production due to adrenal insufficiency

B. Excessive deposition of melanin and iron in the skin

C. Insulin resistance

D. Excessive deposition of bilirubin in the skin



Correct Answer: B. Excessive deposition of melanin and iron in the skin

- *Listen (English)*
- *Listen (Hindi)*

Explanation: The above patient has features of “ Bronze diabetes ” and liver dysfunction, which are typically seen in hemochromatosis. In Hemochromatosis, skin colour changes due to the deposition of excessive melanin >> iron in the skin. It is also known as "bronze diabetes" due to skin discolouration and associated pancreatic disease. The disease typically manifests after 20 g of stored iron has accumulated in the body. Organs affected Clinical features Liver Hepatomegaly, elevated liver enzymes, risk of HCC Pancreas Iron induced damage of beta cells - diabetes mellitus Heart Cardiomyopathy , arrhythmias, congestive heart failure Skin Hyperpigmentation - bronze skin due to melanin and iron deposition Joints Arthropathy and joint pain CNS Rarely - memory issues, depression and fatigue Excessive melanin production due to adrenal insufficiency (Option A) is typically seen in Addison’s disease, where adrenal insufficiency leads to increased ACTH derived from Proopiomelanocortin, which also produces MSH and Endorphins, thus leading to melanogenesis, causing darkening of the skin and mucosal membranes Insulin resistance (Option C) gives rise to Acanthosis Nigricans, which are hyperpigmented, velvety plaques typically found in body folds such as the neck, axillae, and groin. It is also associated with gastric adenocarcinoma Bilirubin (Option D) deposition leads to jaundice, characterized by a yellowish discoloration of the skin, not the bronze pigmentation seen in hemochromatosis. Jaundice is related to liver dysfunction or hemolysis, not iron overload


BEFORE
NOW
@Neet_pg_bot


@Neet_pg_bot

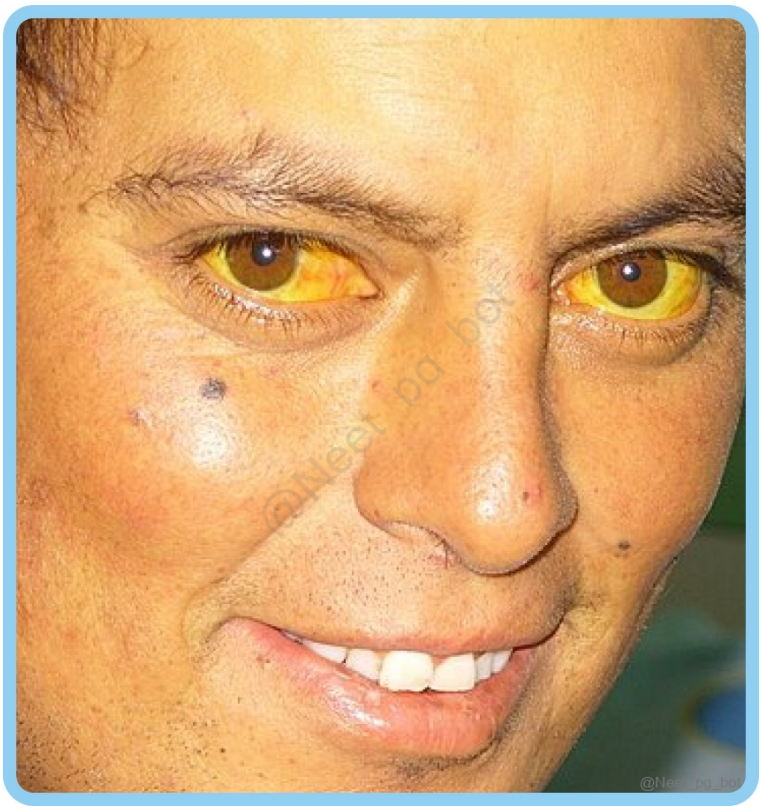

References:

Robbins and Cotran, Pathological Basis of Disease, 10th Edition, Pages 848-850

https://www.ncbi.nlm.nih.gov/books/NBK430862/

https://www.ncbi.nlm.nih.gov/pmc/articles/PMC3636818/

↑ *Back to this question in Part A*

@Neet_pg_bot

Q3: A 38-year-old female presents with fatigue, joint pain, and bronze skin pigmentation. Labs show a heterozygous mutation in the HFE gene. The histopathology image is shown below. Which of the following is the best screening test for this condition? (Q845725)

A. Serum ferritin level

B. Transferrin saturation

C. Liver function tests

D. Genetic testing for the HFE gene

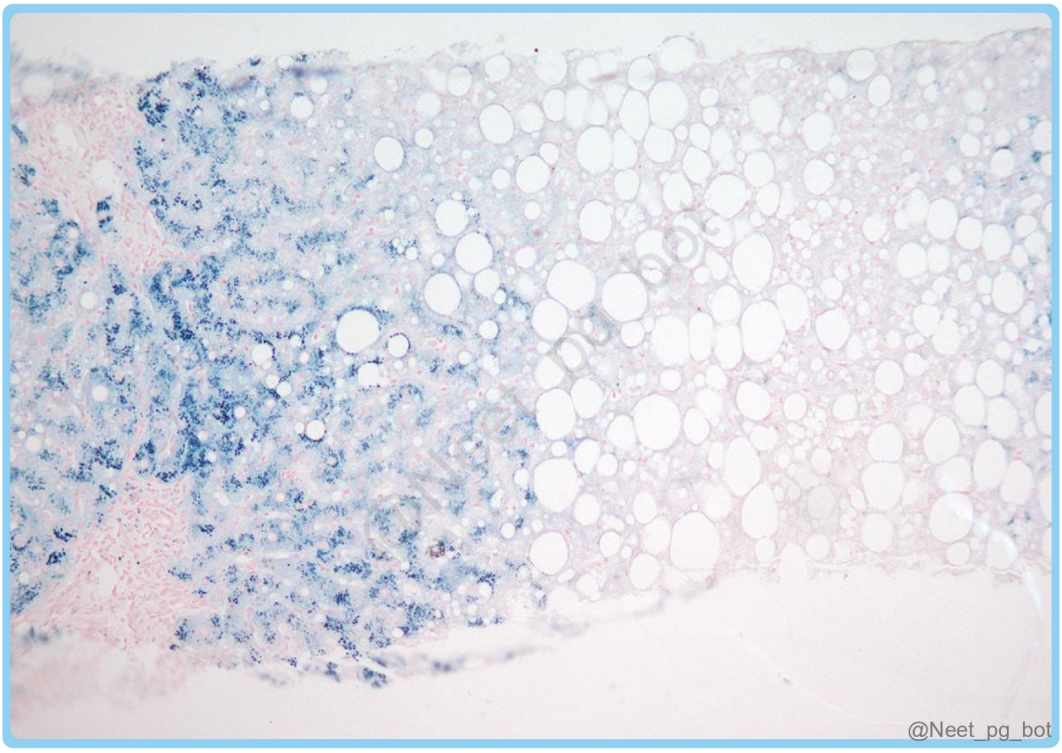

Correct Answer: B. Transferrin saturation

Explanation: The diagnosis in this case is hemochromatosis . Transferrin saturation (TSAT) is the best screening test for hereditary hemochromatosis. Serum ferritin (Option A) is a protein that stores iron in the body. However, while serum ferritin levels can be a useful indicator, they are not as specific as transferrin saturation (TSAT) for diagnosing hemochromatosis. In hereditary hemochromatosis, LFTs (Option C) may show abnormalities in advanced stages of the disease when iron overload has caused liver damage (e.g., elevated alanine transaminase or AST levels). However, LFTs are not specific screening tests for hemochromatosis . Genetic testing (Option D) for mutations in the HFE gene is the definitive diagnostic test for hereditary hemochromatosis .

References:

Robbins and Cotran, Pathological Basis of Disease, 10th Edition, Page 848

↑ *Back to this question in Part A*

@Neet_pg_bot

Q4: A 25-year-old patient presents with a history of tremors, dysarthria, and personality changes. Serum ceruloplasmin levels were found to be low. Based on the image below, what ocular finding is associated with the underlying condition? (Q845727)

A. Arcus senilis

B. Kayser-Fleischer rings

C. Roth spots

D. Horner's syndrome

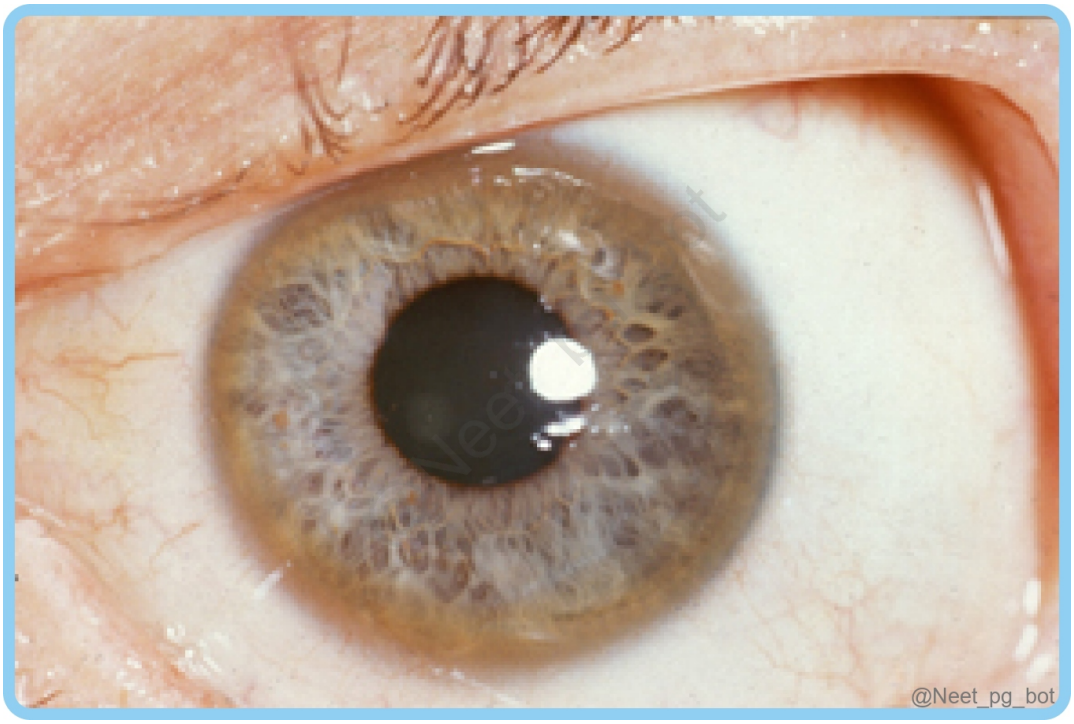

Correct Answer: B. Kayser-Fleischer rings

■ *Listen (English)*

■ *Listen (Hindi)*

Explanation: The image shows characteristic Kayser-Fleischer rings, a brownish-green discolouration in the cornea. These rings are associated with Wilson's disease, a genetic disorder involving copper metabolism. Wilson's disease is a genetic disorder characterised by impaired copper metabolism. It leads to copper accumulation primarily in the liver, brain, and other organs. Molecular genetic testing can identify mutations in the ATP7B gene, which is responsible for Wilson's disease. Clinical Features: Kayser-Fleischer Rings: These are characteristic brownish-green rings seen in the cornea due to copper deposition and are a hallmark feature of Wilson's disease. Serum copper is raised, while ceruloplasmin levels (a copper-binding protein) are decreased in Wilson's disease. Increased urinary copper excretion is a characteristic finding in Wilson's disease. Arcus senilis refers to a white or greyish ring around the cornea that is commonly seen in elderly individuals. It is caused by lipid deposits in the peripheral cornea and is generally considered a normal age-related change. (Option A) Roth spots are retinal haemorrhages with a white or pale centre. Roth spots can be seen in various medical conditions, including bacterial endocarditis, leukemia, and diabetic retinopathy (Option C) Horner's syndrome is a clinical syndrome characterised by a triad of eye and face symptoms. It includes ptosis (drooping of the upper eyelid), miosis (constriction of the pupil), and anhidrosis (decreased sweating) on the affected side of the face (Option D)

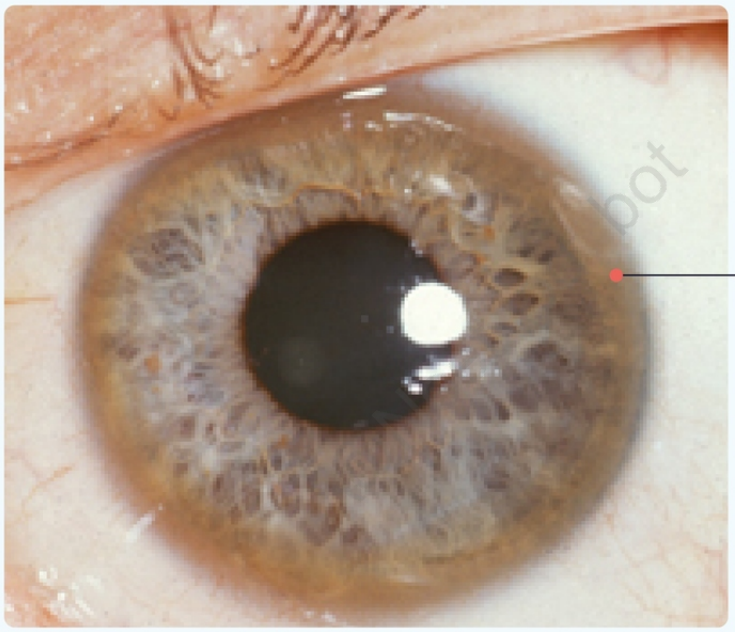

@Neet_pg_bot

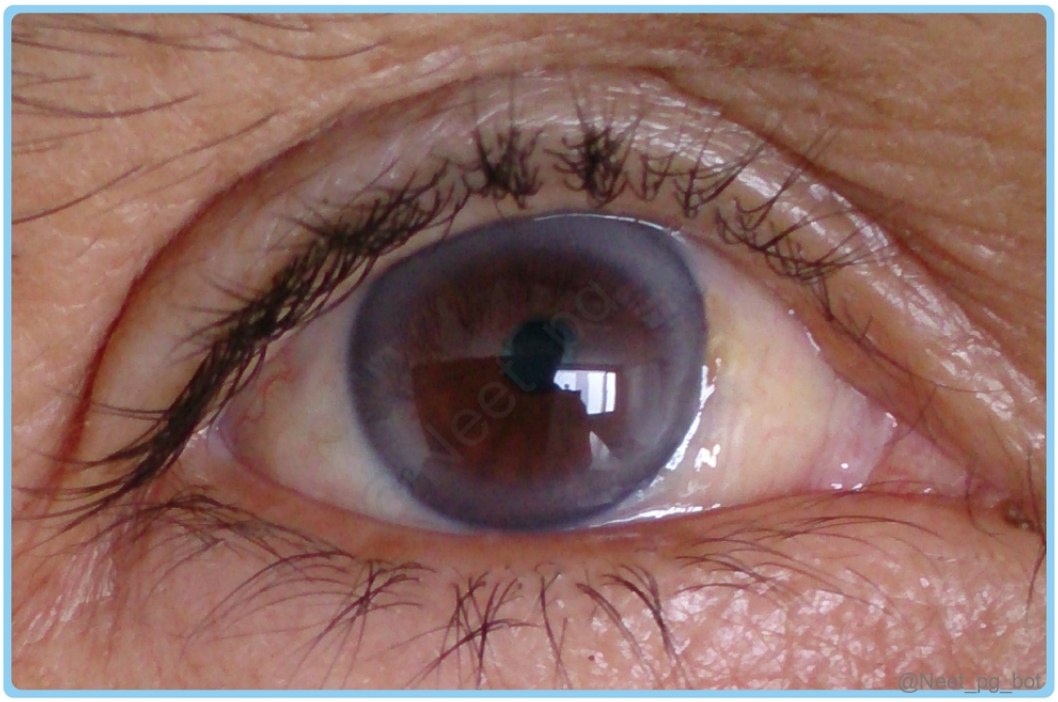

@Neet_pg_bot

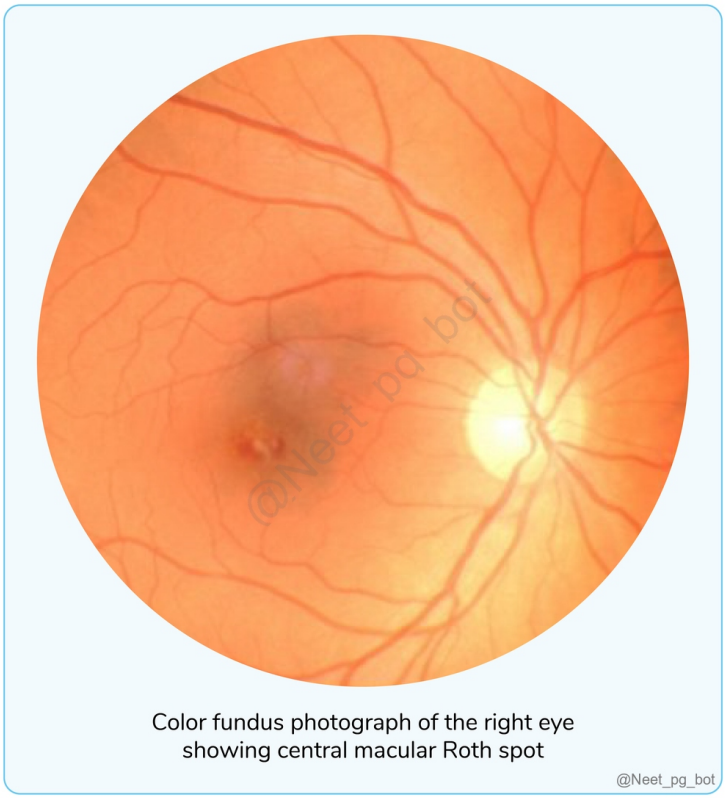

Color fundus photograph of the right eye showing central macular Roth spot



References:

Robbins and Cotran, Pathological Basis of Disease, 10th Edition, Page 850

↑ *Back to this question in Part A*

@Neet_pg_bot

Q5: Which of the following tests is the most specific for confirming the diagnosis of Wilson's Disease? (Q845730)

A. Serum Ceruloplasmin

B. Urinary excretion of copper

C. LFT

D. Liver Biopsy

Correct Answer: D. Liver Biopsy

■ *Listen (English)*

■ *Listen (Hindi)*

Explanation: Testing for Wilson's disease: Serum Ceruloplasmin (Option A) : Low levels are suggestive. 24-Hour Urinary Copper Excretion (Option B) : Increased in Wilson's disease Liver Function Tests (LFTs) (Option C): May show abnormalities. Kayser-Fleischer Rings Examination: Greenish-brown rings in the cornea. Genetic Testing: For ATP7B gene mutations, confirming diagnosis. Liver Biopsy (Option D) : Demonstrates hepatic copper accumulation (Most specific). Brain Imaging: MRI to assess neurological involvement.

References:

Robbins and Cotran Pathological Basis of Disease, 10th Edition, Page 850

↑ *Back to this question in Part A*

@Neet_pg_bot

Q6: Which special stain is commonly used to aid in the diagnosis of Wilson's disease? (Q845731)

A. Oil Red O stain

B. Periodic acid-Schiff (PAS) stain

C. Rubeanic acid stain

D. Prussian blue stain

Correct Answer: C. Rubeanic acid stain

■ *Listen (English)*

■ *Listen (Hindi)*

Explanation: The Rubeanic acid stain, also known as the Rhodanine stain, is commonly used to detect copper accumulation in liver tissue, particularly in the hepatocytes' cytoplasmic granules. This stain forms a distinctive brown-black color when it reacts with copper, aiding in the diagnosis of Wilson's disease. Rubeanic acid stain Stains the copper present within cytosolic granules of hepatocytes Oil red O stain Stains lipids (Option A) PAS

stain Stains cells with high glycogen storage and also stains basement membrane (Option B) Prussian stain Stains hemosiderin / stored iron (Option D)

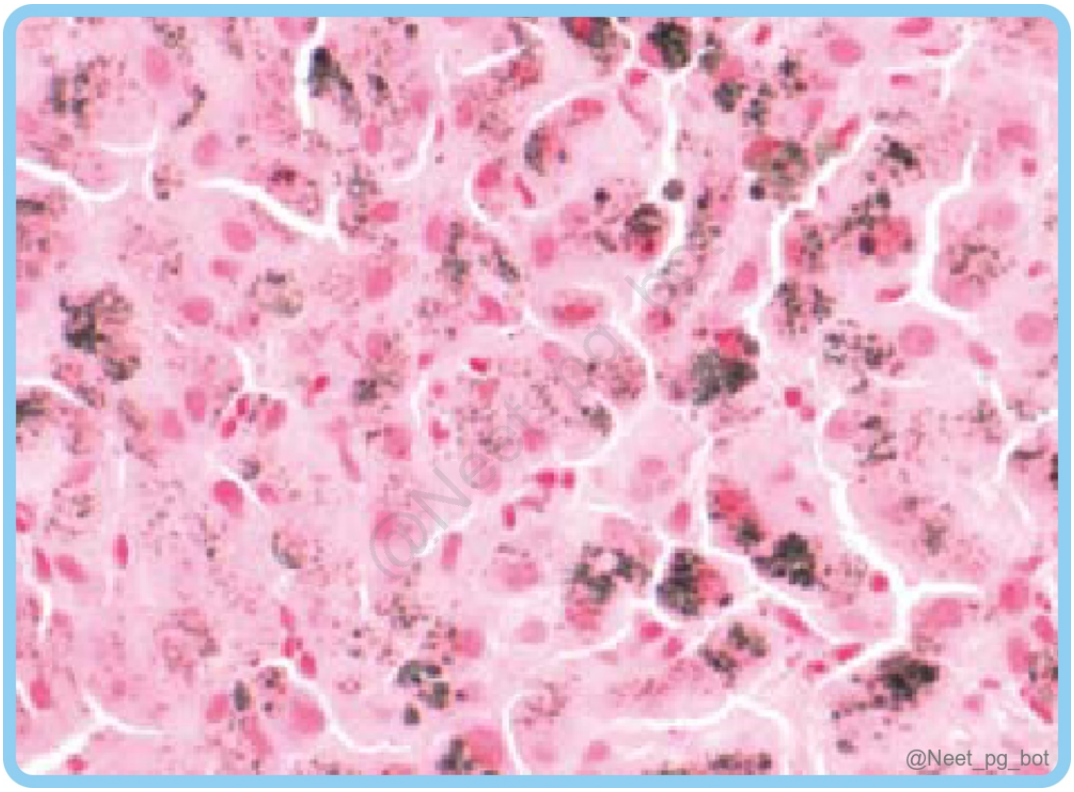

References:

Robbins and Cotran Pathological Basis of Disease, 10th Edition, Page 850

↑ *Back to this question in Part A*

@Neet_pg_bot

Q7: A 50-year-old male presents with a history of chronic alcohol abuse and complains of right upper quadrant abdominal pain. On examination, hepatomegaly is noted. Laboratory investigations show elevated liver enzymes. Gross feature of the liver has a characteristic mottled appearance. Based on these findings and the image below, what is the most likely diagnosis? (Q845733)

A. Cirrhosis

B. Hepatitis

C. Nutmeg Liver

D. Liver Abscess



Correct Answer: C. Nutmeg Liver

- *Listen (English)*
- *Listen (Hindi)*

Explanation: The patient's history of chronic alcohol abuse and the characteristic mottled appearance of the liver on imaging studies point towards Nutmeg Liver as the most likely diagnosis. Nutmeg liver, also known as congestive hepatopathy or passive hepatic congestion, is a condition characterized by a mottled appearance of the liver on imaging studies, resembling the cross-section of a nutmeg seed. This appearance is due to centrilobular congestion and haemorrhage caused by chronic passive congestion of the liver , often secondary to right-sided heart failure , chronic venous congestion , or conditions leading to hepatic venous outflow obstruction. Acute passive congestion (“nutmeg liver”). (A) The cut surface of the liver has a variegated mottled red appearance, representing congestion and haemorrhage in the centrilobular regions of the parenchyma. (B) On microscopic examination, the centrilobular region is suffused with red blood cells, and atrophied hepatocytes are not easily seen. Portal tracts and the periportal parenchyma are intact.

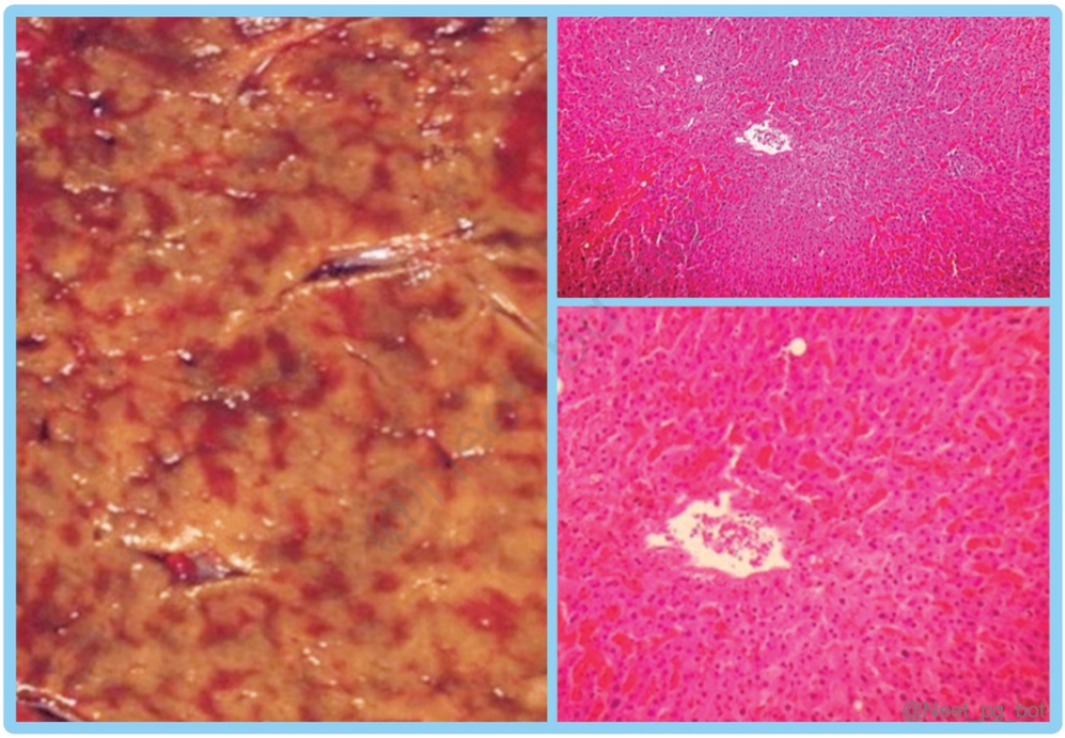

References:

Robbins and Cotran, Pathological Basis of Disease, 10th Edition, Page 864

↑ *Back to this question in Part A*

@Neet_pg_bot

Q8: A 25-year-old female presents with fatigue, jaundice, and abdominal pain. On examination, hepatomegaly is noted. Hepatocytes show globular inclusions which are strongly periodic acid–Schiff (PAS)-positive. Her sibling died of the same liver condition a few years back. What is the primary function of the enzyme implicated in this condition ? (Q845735)

A. Inhibits neutrophil elastase

B. Stimulates neutrophil elastase

C. Stimulates matrix metalloproteinase activity

D. Regulates aminotransferase activity

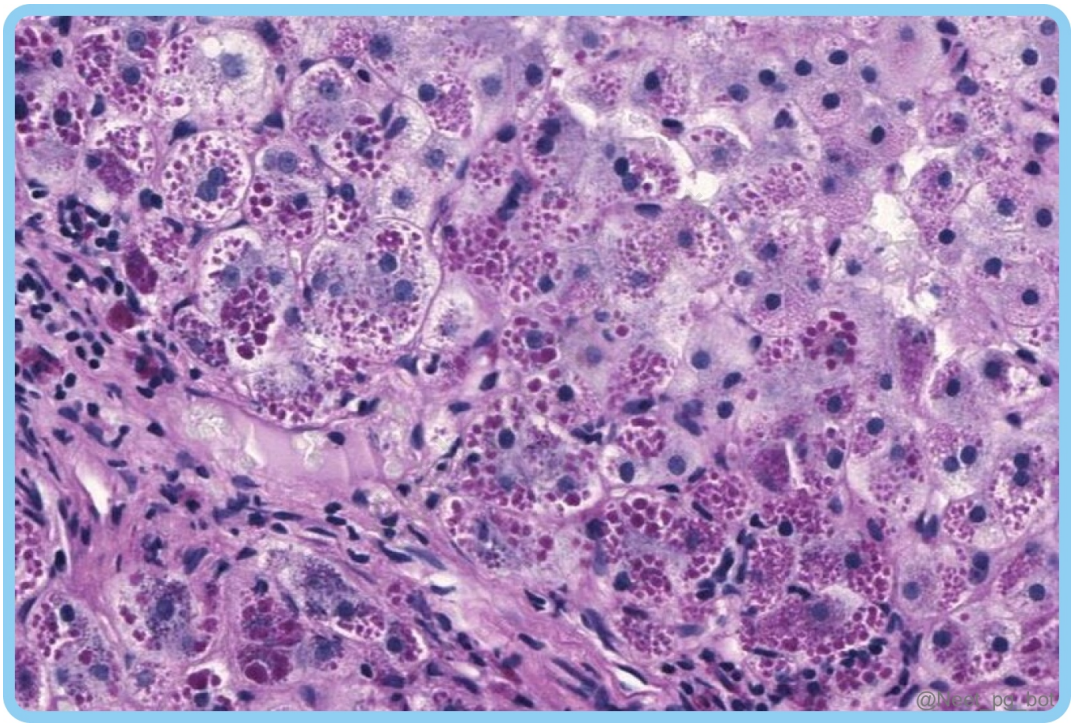

Correct Answer: A. Inhibits neutrophil elastase

- *Listen (English)*
- *Listen (Hindi)*

Explanation: Alpha-1 antitrypsin (α1AT) is a serine protease inhibitor that plays a crucial role in inhibiting proteases, particularly neutrophil elastase. Alpha-1 Antitrypsin (α1AT) deficiency is an autosomal recessive (AR) disorder with defective gene in Chromosome 14 - SERPINA1 gene In Alpha-1 Antitrypsin Deficiency (AATD), there is a deficiency or dysfunction of α1AT, leading to decreased inhibition of neutrophil elastase . This results in uncontrolled protease activity , particularly neutrophil elastase, which can cause tissue damage, especially in the lungs and liver leading to pan-acinar emphysema and liver cirrhosis respectively Genotype PiZZ: This is the most severe form of AATD. It results from a homozygous mutation in the SERPINA1 gene on Chromosome 14 . Individuals with the PiZZ genotype have the lowest serum levels of α1AT, leading to uncontrolled protease activity. This causes pan-acinar emphysema in the lungs and liver cirrhosis .
Histopathology: The deficiency is characterised by the presence of round-to-oval cytoplasmic globular inclusions in hepatocytes, which are strongly periodic acid–Schiff (PAS)-positive and diastase-resistant.

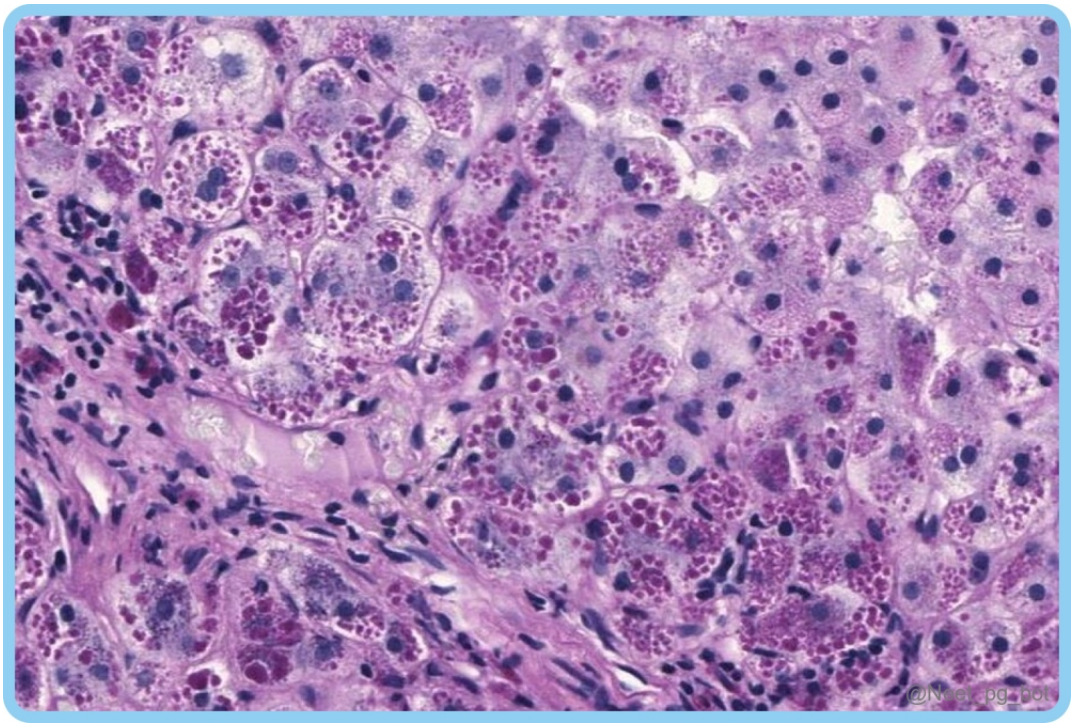

References:

Robbins and Cotran Pathological Basis of Disease, 10th Edition, Page 851

↑ *Back to this question in Part A*

@Neet_pg_bot

Q9: A 50-year-old patient with a history of recurrent biliary colic and cholangitis undergoes cholecystectomy. Multiple stones are retrieved intraoperatively, and an image of the stones is provided for reference. Which of the following is true about the type of pigmented stones likely seen in this patient? (Q845738)

A. Predominantly found in western populations

B. Associated with metabolic syndrome

C. Found in sterile bile

D. Seen in obesity



Correct Answer: C. Found in sterile bile

■ *Listen (English)*

■ *Listen (Hindi)*

Explanation: The provided image and clinical scenario depicting black-pigmented stones retrieved during cholecystectomy. Feature Cholesterol Stones Pigment Stones Predisposing conditions Seen in Western populations (Option A) , related to metabolic syndrome (Option B) , obesity (Option D) and common in females Chronic hemolytic anaemia - Black stones Bacterial infections, parasitic infestations - Brown stones Composition >50% crystalline cholesterol monohydrate Calcium salts of unconjugated bilirubin and inorganic calcium salts Appearance Pale yellow, round to ovoid, granular, hard external surface Brown to black, soft, soap-like, spiculated or moulded contours Location Arise exclusively in the gallbladder Found in sterile gallbladder bile (black stones) or infected large bile ducts (brown stones) (Options C). Radiopacity Radiolucent (may become radiopaque with calcium carbonate) Black stones: 50-75% are radiopaque, Brown stones: Radiolucent

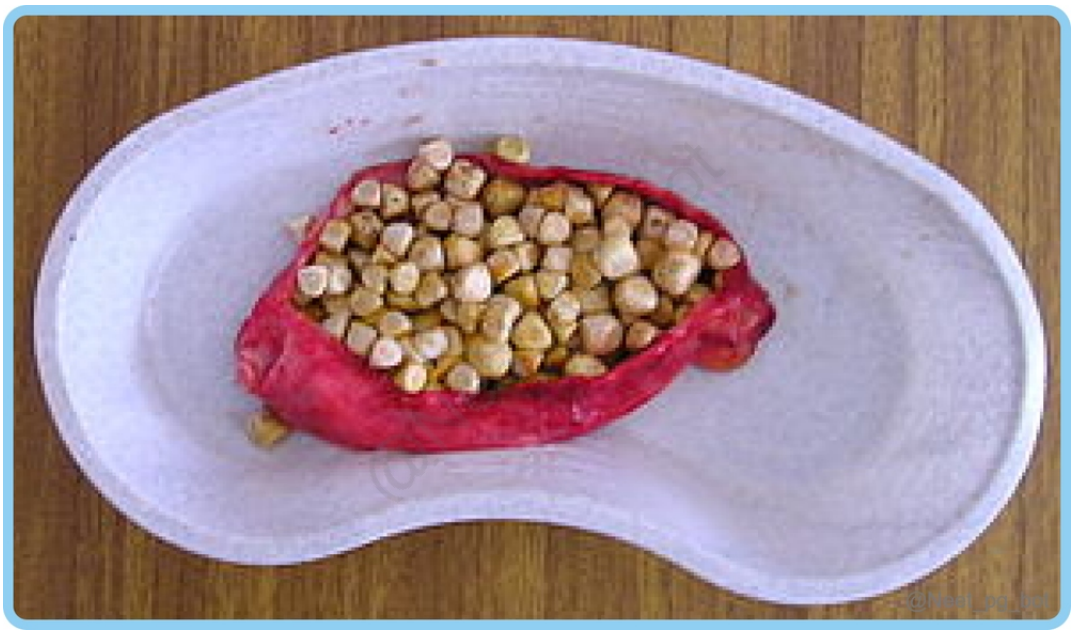



References:

Robbins and Cotran, Pathological Basis of Disease, 10th Edition, Page 874

↑ *Back to this question in Part A*

@Neet_pg_bot

Q10: All the following infections are associated with an increased risk of pigmented gallstones, except? (Q845740)

A. Escherichia coli

B. Ascaris lumbricoides

C. Clonorchis sinensis

D. Aspergillus flavus

Correct Answer: D. Aspergillus flavus

■ *Listen (English)*

■ *Listen (Hindi)*

Explanation: Aspergillus flavus is an acute branching septate fungi, that produces aflatoxins, which are potent carcinogens that can cause liver damage, oxidative stress, and DNA mutations and ultimately increase the risk of hepatocellular carcinoma. They are not associated with an increased risk of gallstones. It causes allergic bronchopulmonary aspergillosis (ABPA), aspergilloma, invasive aspergillosis, and otomycosis. Pigmented gallstones are linked to infections that cause increased unconjugated bilirubin in bile. Brown pigment stones are also associated with the presence of foreign bodies within the bile ducts, such as endoprostheses (stents) or parasites such as Clonorchis sinensis and Ascaris lumbricoides (Option B & C) . Gallstones are solid concretions in the gallbladder or biliary tree formed due to imbalance in bile components (cholesterol, bile salts, bilirubin). Type Composition Mechanism Key Associations Cholesterol stones Cholesterol (>70%) Supersaturation of bile with cholesterol Obesity, female, OCPs, pregnancy Pigment stones Calcium bilirubinate ↑ Unconjugated bilirubin Hemolysis, infection Pigment Stones – Subtypes: Type Color Cause Location Black pigment stones Black Sterile bile, hemolysis Gallbladder Brown pigment stones Brown Infection (bacteria/parasites) Bile ducts E. coli (option A) : Produces β-glucuronidase, leading to deconjugation of bilirubin.

References:

Robbins and Cotran, Pathological Basis of Disease, 10th Edition, Pages 873, 874

↑ *Back to this question in Part A*

@Neet_pg_bot

Q11: Which of the following conditions is not a complication associated with gallstones? (Q845741)

A. Acute pancreatitis

B. Gall bladder carcinoma

C. Bouveret syndrome

D. Budd-Chiari syndrome

Correct Answer: D. Budd-Chiari syndrome

Explanation: Complications of gallstones: Empyema Perforation Fistula formation Inflammation of the biliary tree (cholangitis) Obstructive cholestasis Pancreatitis (Option A) Gallstone ileus (Bouveret syndrome) (Option C) Increased risk of gallbladder carcinoma (Option B)

References:

Robbins and Cotran, Pathological Basis of Disease, 10th Edition, Page 875

↑ *Back to this question in Part A*

@Neet_pg_bot

Q12: A 45-year-old patient presents to the OPD with severe right upper quadrant pain radiating to the right shoulder, accompanied by nausea and vomiting. Clinical examination revealed a positive result for a clinical test shown in the image down below. An ultrasound of the abdomen shows an enlarged and tense gallbladder. Which of the following findings is most likely associated with this patient's condition? (Q845742)

A. Xanthogranulomatous cholecystitis

B. Rokitansky-Aschoff sinuses

C. Subserosal fibrosis

D. Subserosal haemorrhages



Correct Answer: D. Subserosal haemorrhages

Explanation: Based on the provided clinical vignette and positive murphy sign, the patient's presentation aligns with acute cholecystitis. The most likely finding associated with this condition is subserosal hemorrhages. Characteristics Acute cholecystitis Chronic cholecystitis Gall bladder appearance Thickened, tense, edematous, bright red or green-black Thickened, fibrotic, opaque grey-white Serosa Subserosal haemorrhages (Option D) , fibrinopurulent exudate Smooth serosa with Subserosal fibrosis (Option C) (subepithelial fibrosis also seen) Histology Erosion of mucosa, Edema, congestion, sparse neutrophils Scattered lymphocytes, plasma cells, macrophages, fibrosis, Rokitansky-Aschoff sinuses (Option B) Special forms Gallbladder empyema (pure pus), gangrenous cholecystitis, emphysematous cholecystitis Porcelain gallbladder, adenomyomatosis, Xanthogranulomatous cholecystitis (Option A) , IgG4-related sclerosing cholecystitis, hydrops of the gallbladder

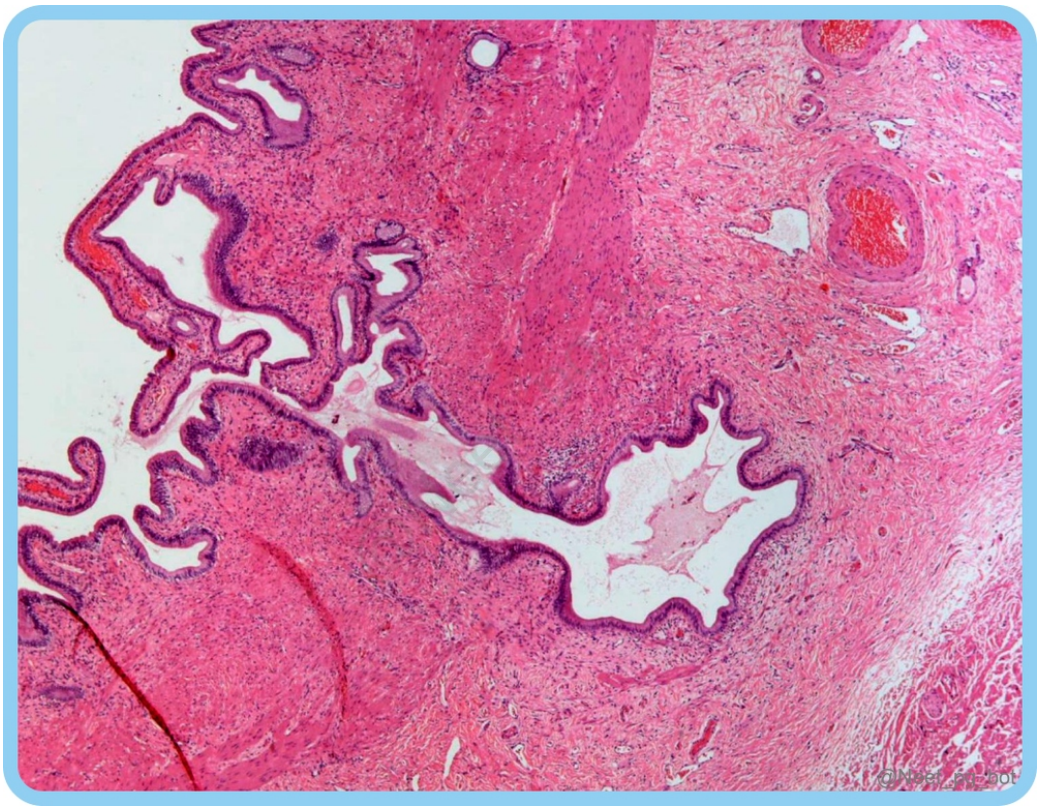

References:

Robbins and Cotran, Pathological Basis of Disease, 10th Edition, Page 875 - 876

↑ *Back to this question in Part A*

@Neet_pg_bot

Q13: Which condition is characterised by extensive dystrophic calcification of the gallbladder wall? (Q845743)

A. Porcelain gallbladder

B. Gangrenous cholecystitis

C. Acute cholecystitis

D. Hyalinizing cholecystitis

Correct Answer: A. Porcelain gallbladder

■ *Listen (English)*

■ *Listen (Hindi)*

Explanation: Porcelain gallbladder is characterized by extensive dystrophic calcification of the gallbladder wall. This condition is associated with chronic cholecystitis and may lead to an increased risk of gallbladder carcinoma. Porcelain gallbladder (Option A) Hyalinizing cholecystitis (Option D) Characterized by extensive dystrophic calcification of the gallbladder wall. Characterized by complete replacement of the gallbladder wall and mucosa by dense fibrosis, with or without calcification. Associated with chronic cholecystitis and an increased risk of gallbladder carcinoma



References:

Robbins and Cotran, Pathological Basis of Disease, 10th Edition, Page 876

↑ *Back to this question in Part A*

@Neet_pg_bot

• [10_Liver_ Biliary System and Pancreas] 046 Hepatic Tumors And Pancreas

« Back to Folder Directory

[10_Liver_ Biliary System and Pancreas] 046 Hepatic Tumors And Pancreas — Quick Jump

Q1 (p. 2067) *Q2 (p. 2068)* *Q3 (p. 2069)* *Q4 (p. 2070)* *Q5 (p. 2071)* *Q6 (p. 2071)*
Q7 (p. 2073) *Q8 (p. 2074)* *Q9 (p. 2075)* *Q10 (p. 2076)* *Q11 (p. 2077)* *Q12 (p. 2079)*
Q13 (p. 2080)

Q1: Which of the following is the most common benign tumor of the liver? (Q845809)

A. Cavernous hemangioma

B. Hepatoblastoma

C. Klatskin tumor

D. Hepatic adenoma

Correct Answer: A. Cavernous hemangioma

■ *Listen (English)*

■ *Listen (Hindi)*

Explanation: Cavernous hemangioma is the most common benign tumor of the liver Benign hepatic tumors : Cavernous hemangioma (most common) > focal nodular hyperplasia (FNH) >hepatocellular adenoma (rare) M/C benign hepatic tumour Cavernous hemangioma M/C hepatic tumour in children Hepatoblastoma (Option B) M/C Primary liver malignancy Hepatocellular carcinoma M/C cancer, which metastasis to the liver Colon carcinoma M/C sarcoma Angiosarcoma Klatskin tumor (Option C): Occurs at the junction of the right and left hepatic ducts meet, primarily a duct tumor. Hepatic Adenoma (Option D): Benign tumor of the liver, commonly associated with prolonged OCP usage in females.



References:

Robbins and Cotran, Pathological Basis of Disease, 10th Edition, Page 866, 871
https://www.ncbi.nlm.nih.gov/books/NBK470283/

↑ *Back to this question in Part A*

@Neet_pg_bot

Q2: A 30-year-old woman presents to the emergency department with severe abdominal pain and signs of hypovolemic shock. She has a history of long-term contraceptive pill use. Imaging studies reveal a large hepatic mass with evidence of haemorrhage. Laboratory tests show elevated liver enzymes. What is the likely diagnosis based on her clinical presentation and medical history? (Q845810)

A. Angiosarcoma

B. Hepatic adenoma

C. Hepatoblastoma

D. Cholangiocarcinoma

Correct Answer: B. Hepatic adenoma

■ *Listen (English)*

■ *Listen (Hindi)*

Explanation: Based on the patients gender, history of use of OCP and clinical presentation, she most likely has a hepatic adenoma Hepatocellular adenoma is a benign neoplasm that typically occurs in young women. Strong association with the use of oral contraceptives Estrogen is known to promote the growth of hepatic adenomas by stimulating hepatocyte proliferation. On imaging - well-circumscribed and encapsulated discrete mass, sometimes with associated hemorrhage - giving heterogenous appearance (fat+ hemorrhage) . The molecular subtypes of hepatic adenoma based on bordeaux classification are Hepatocyte nuclear factor 1-alpha (HNF1α) -inactivated hepatocellular adenoma which are multiple and presents in young patients Inflammatory hepatocellular adenoma - Most common to present with hemorrhage β-Catenin –activated hepatocellular adenoma

References:

Robbins and Cotran, Pathological Basis of Disease, 10th Edition, Page 867-872 https://www.ncbi.nlm.nih.gov/pmc/articles/PMC3125451/ https://www.ncbi.nlm.nih.gov/books/NBK513264/ https://www.aasld.org/liver-fellow-network/core-series/pathology-pearls/pathology-pearls-hepatocellular-adenoma

↑ *Back to this question in Part A*

@Neet_pg_bot

Q3: A 25-year-old sexually active woman who has been on OCP for the past 4 years comes to the ER with severe abdominal pain and features of hypovolemic shock. Ultrasound reveals a large hemorrhagic hepatic mass and fluid in the peritoneum. What is the most probable diagnosis? (Q845811)

A. Hepatocyte nuclear factor 1-alpha (HNF1α)-inactivated hepatocellular adenoma

B. β-Catenin–activated hepatocellular adenoma

C. Nodular regenerative hyperplasia (NRH).

D. Focal Nodular Hyperplasia

Correct Answer: B. β-Catenin–activated hepatocellular adenoma

■ *Listen (English)*

■ *Listen (Hindi)*

Explanation: The risk of malignant depends on the molecular subtypes : (HNF1α)-inactivated hepatocellular adenoma- minimal risk Inflammatory hepatocellular adenoma(most common) - moderate risk β-Catenin–activated hepatocellular adenoma - high risk unclassfied β-Catenin-–activated hepatocellular adenoma is strongly associated with OCP and anabolic steroid use. Resection is recommended for β-catenin–activated tumours and tumours that are 5 cm or larger due to the risk of malignant transformation and haemorrhage. Incorrect options:

HNF1α-inactivated Hepatocellular Adenoma (option A) Subtype of hepatic adenoma, often steatotic, usually smaller, asymptomatic, and rarely ruptures. Patient has acute hemorrhage, which is more typical of classic OCP-associated hepatic adenoma. Nodular Regenerative Hyperplasia (NRH) (option C) Diffuse hepatic nodularity without true fibrosis; usually asymptomatic or causes portal hypertension. Does not present as a large hemorrhagic mass or cause acute hemoperitoneum. Focal Nodular Hyperplasia (FNH) (option D) Benign liver lesion, often in young women, usually asymptomatic. Rarely bleeds or ruptures, and hemorrhagic presentation is unusual.

References:

Robbins and Cotran, Pathological Basis of Disease, 10th Edition, Page 865-866

↑ *Back to this question in Part A*

@Neet_pg_bot

Q4: Which of the following conditions presents with a central stellate scar? (Q845812)

A. Metastatic liver lesion

B. Focal Nodular Hyperplasia

C. Liver abscess

D. Liver Cirrhosis

Correct Answer: B. Focal Nodular Hyperplasia

■ *Listen (English)*

■ *Listen (Hindi)*

Explanation: Focal Nodular Hyperplasia is a benign, non-neoplastic lesion which presents with a central stellate scar and is most common in women. It occurs due to altered blood flow , which causes hyperplastic changes in hepatocytes. It is usually asymptomatic and is incidentally seen on imaging. Hallmark: Central Stellate Scar Appearance: On imaging (CT or MRI), it appears as a star-shaped fibrous area in the center of the lesion. Contents: Unlike a true scar, it contains large anomalous arteries that show intense enhancement during the arterial phase of imaging. Histology: The scar contains bile duct proliferation and inflammatory cells, but lacks the normal organized venous drainage of the liver. Conditions showing Central Stellate Scar: Liver: Focal Nodular Hyperplasia (FNH) : benign Fibrolamellar Hepatocellular Carcinoma (HCC): malignant Kidney: Oncocytoma: benign . Chromophobe Renal Cell Carcinoma (RCC): malignant Pancreas: Serous Cystadenoma (microcystic adenoma): benign Breast: Radial Scar (Complex Sclerosing Lesion): benign , mimics carcinoma Metastatic liver lesion (Option A): These usually present as multiple "umbilicated" nodules (central necrosis) rather than a stellate scar. They are typically poorly circumscribed and lack the organized hyperplastic growth seen in FNH. Liver abscess (Option C): This is a localized collection of pus caused by bacterial, parasitic, or fungal infection. Imaging shows a fluid-filled cavity with "rim enhancement" and surrounding edema, not a solid fibrous scar. Liver Cirrhosis (Option D): While cirrhosis involves extensive scarring, it is diffuse throughout the entire organ. It is characterized by regenerative nodules surrounded by bands of collagen, rather than a single localized lesion with a central star-shaped scar.

References:

Robbins and Cotran Pathologic Basis of Disease, 10th Edition, Page 865

↑ *Back to this question in Part A*

@Neet_pg_bot

Q5: All of the following increases the risk of Hepatocellular carcinoma, except? (Q845813)

A. Alcohol

B. NASH (Non-Alcoholic Steatohepatitis)

C. Hemochromatosis

D. Gilbert's syndrome

Correct Answer: D. Gilbert's syndrome

■ *Listen (English)*

■ *Listen (Hindi)*

Explanation: Gilbert's Syndrome is a benign condition associated with mild unconjugated hyperbilirubinemia and does not cause liver damage or increase the risk of HCC. The most common risk factors are Viral infections (chronic hepatitis B and hepatitis C) Toxic (Alcohol (Option A) and Aflatoxins) Metabolic (Diabetes and NASH (Option B) , Hemochromatosis (Option C) , Wilson's syndrome) Immune-related (Primary biliary cirrhosis and autoimmune hepatitis)

References:

Robbins and Cotran, Pathologic Basis of Disease, 10th Edition, Pages 850, 868-870

↑ *Back to this question in Part A*

@Neet_pg_bot

Q6: Which of the following is true regarding the fibrolamellar variant of hepatocellular carcinoma ? (Q845814)

A. Not associated with Hepatitis B, C

B. Increased AFP levels

C. Hematogenous spread

D. Poor prognosis

Correct Answer: A. Not associated with Hepatitis B, C

- *Listen (English)*
- *Listen (Hindi)*

Explanation: Fibrolamellar variant of hepatocellular carcinoma(HCC), where the malignant hepatocytes are separated by dense bundles of collagen is not associated with Hepatitis B, C Fibrolamellar variant Classical HCC Age Adolescents and young adults Older adults Gender Male=Female Male>Female Predisposing condition None Hepatitis B and C, Alcohol, NASH, Hemochromatosis AFP levels Normal (Option B) Increased Gene mutation DNAJB1-PRKACA TERT, Beta-catenin, TP53 Spread Lymphatic Hematogenous (Option C) Prognosis Good (Option D) Poor Serum markers Neurotensin B AFP, PIVKA II, Osteopontin, Glycipan 3, HepPar 1 Histology pathology

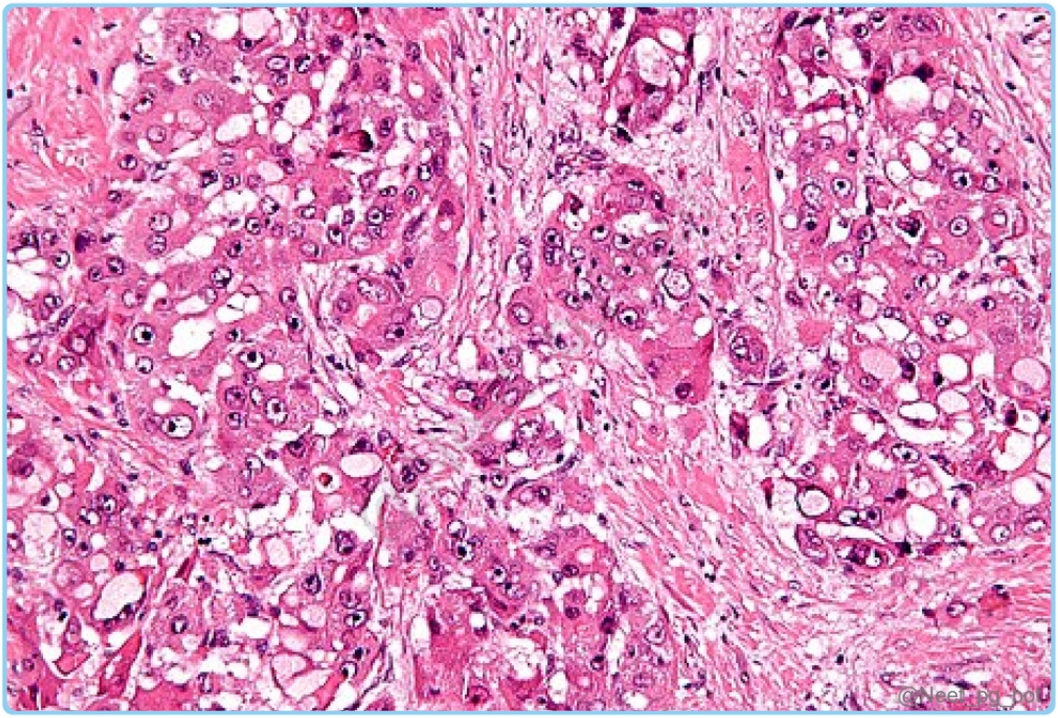

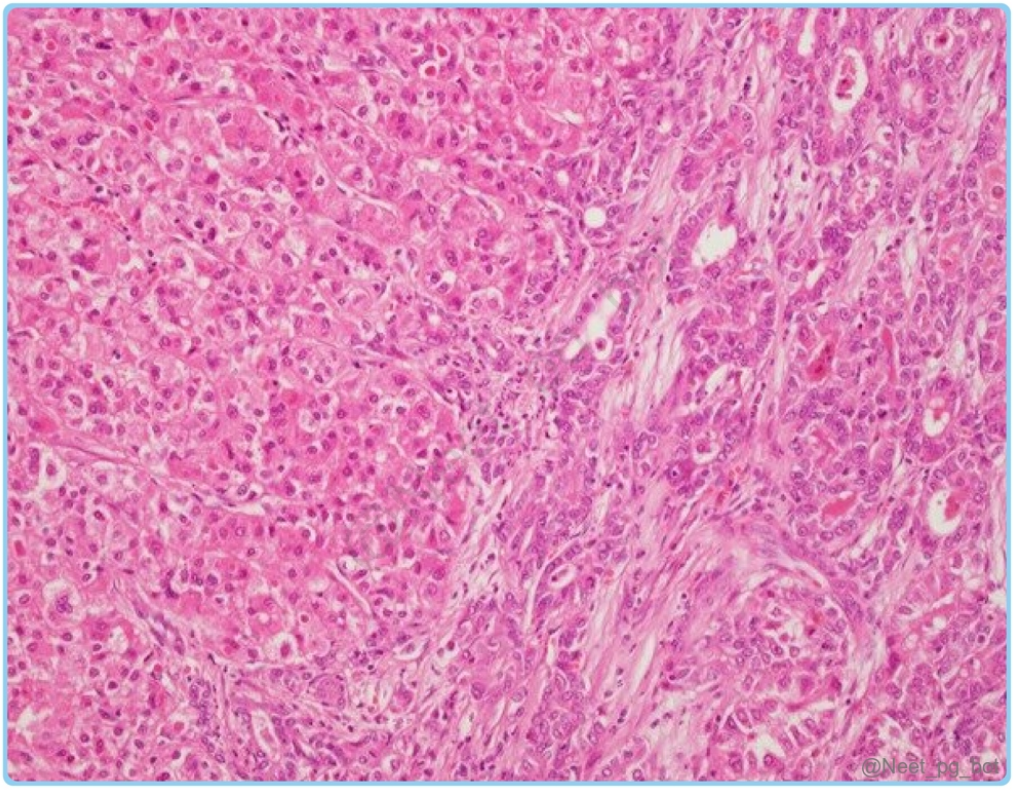

References:

Robbins and Cotran, Pathologic Basis of Disease, 10th Edition, Page 869,870.

↑ *Back to this question in Part A*

@Neet_pg_bot

Q7: A patient with a longstanding history of alcoholism is admitted with jaundice, abdominal distension & weight loss. A liver biopsy done during his previous admission showed the following changes, and suspicion of malignant transformation is raised now. Elevation of which of the following markers will support the differential? HepPar-1 Alpha-fetoprotein (AFP) Glypican-3 (GPC3) CA 15-3 Tissue polypeptide antigen (Q845816)

A. 1, 2 and 4

B. 1, 2 and 3

C. 2, 4 and 5

D. 2, 3 and 4

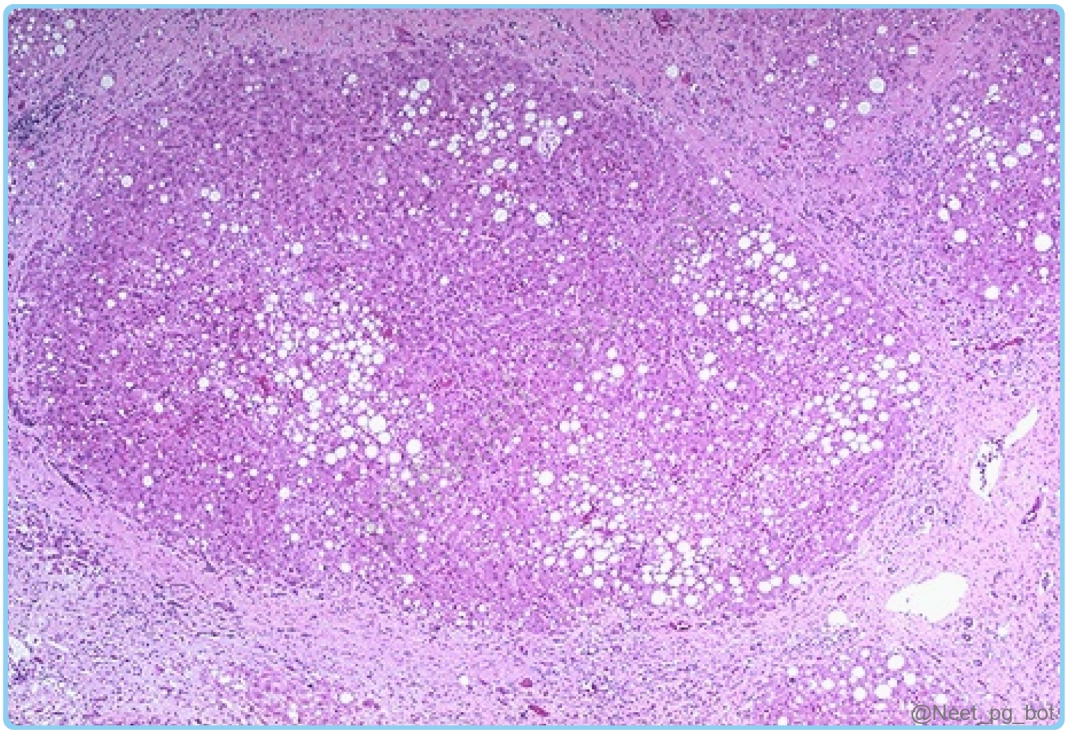

Correct Answer: B. 1, 2 and 3

■ *Listen (English)*

■ *Listen (Hindi)*

Explanation: The following markers will be elevated in case of hepatocellular carcinoma : HepPar-1 (Statement 1) Alpha-fetoprotein (AFP) (Statement 2) Glypican-3 (GPC3) (Statement 3) Neurotensin Arginase-1 CA-19-9 Chronic liver disease with cirrhosis is the major cause of transformation into hepatocellular carcinoma, and some of the common causes are listed below : Alcohol (as given in the above scenario) Chronic hepatitis B & C Metabolic diseases Non-alcoholic steatohepatitis Aflatoxins from Aspergillus

References:

Robbins and Cotran, Pathologic Basis of Disease, 10th Edition, Page 868-870

↑ *Back to this question in Part A*

@Neet_pg_bot

Q8: A 2-year-old child presented with progressive jaundice for the past 2 months. Initial investigations were done, and subsequent histopathological examination of liver biopsy showed changes consistent with hepatoblastoma. Which of the following additional biomarkers will be elevated in this child? (Q845817)

A. CA 19-9

B. AFP

C. Neurotensin

D. CEA

Correct Answer: B. AFP

■ *Listen (English)*

■ *Listen (Hindi)*

Explanation: Alpha-fetoprotein will be elevated in a patient with hepatoblastoma. Hepatoblastoma is the most common liver tumour of childhood. Activation of the Wnt signalling pathway is characteristic of hepatoblastoma, leading to nuclear β-catenin and increased expression of Wnt target genes such as glutamine synthetase in nearly all cases Hepatoblastoma: M/c primary malignant tumor seen in children (< 3 yrs of age) WNT pathway activation (APC pathway defect) FAP - Gardners syndrome → Hepatoblastoma Beckwith-Wiedemann syndrome (Wilms Tumor)- WT-2 gene mutation ↑ AFP , also seen in: YST (Yolk Sac Tumor), HCC classical T/t: Surgery, Chemotherapy Prognosis is better than HCC Due to Pure fetal histology (Blastemal Cells - Blue). CA 19-9 and Neurotensin markers are elevated in Heptatocellular carcinoma. (Options A and C) CEA is a tumor marker for colorectal carcinoma. (Option D)

References:

Robbins and Cotran Pathologic Basis of Disease, 10th Edition, Pages 867 - 868

↑ *Back to this question in Part A*

@Neet_pg_bot

Q9: Which of the following is not a genetic mutation associated with hereditary pancreatitis? (Q845818)

A. PRSS1

B. SPINK1

C. CFTR

D. BRCA1

Correct Answer: D. BRCA1

■ *Listen (English)*

■ *Listen (Hindi)*

Explanation: BRCA 1 mutation is most commonly associated with hereditary breast and ovarian cancer in women, whereas PRSS1, SPINK1, and CFTR are linked to hereditary pancreatitis. Hereditary Pancreatitis: Recurrent

severe acute pancreatitis attacks, often beginning in childhood due to a defect that increases trypsin activity in the gut. Gene Features PRSS1 (trypsinogen 1 gene) (Option B) Most common cause for hereditary pancreatitis. Autosomal dominant inheritance Gain-of-function mutation make trypsin resistant to self-inactivation Increased risk of developing chronic pancreatitis and pancreatic cancer. SPINK1 (Option C) Autosomal recessive inheritance Loss of function mutation encoding a trypsin inhibitor CFTR (cystic fibrosis transmembrane conductance regulator) (Option D) Loss of CFTR leads to abnormal secretions Promote plugging and duct obstruction Associated conditions: recurrent sinopulmonary infections, intestinal obstruction, diabetes, and male infertility. CASR (Calcium-sensing receptor): Mutation alters calcium concentrations and activates trypsin. CTRC (Chymotrypsin C): Responsible for protecting pancreas from trypsin-related injury. CPA1 (Carboxypeptidase A1): Acts as exopeptidase, regulating zymogen activation.

References:

Robbins and Cotran, Pathologic Basis of Disease, 10th Edition, Page 884

↑ *Back to this question in Part A*

@Neet_pg_bot

Q10: Which of the following factors is most strongly associated with the development of acute pancreatitis in adult males? (Q845819)

A. Gallstone disease

B. Alcohol

C. Trauma

D. HIV infection

Correct Answer: B. Alcohol

■ *Listen (English)*

■ *Listen (Hindi)*

Explanation: Acute pancreatitis is characterized by abdominal pain, associated with excessive alcohol intake, pancreatic duct obstruction, genetic factors, trauma, medications, infections, hypercalcemia, and ischemia. While gallstones are the leading cause of acute pancreatitis in the general population (especially in women), alcohol consumption is the most strongly associated factor and the most common cause in adult males . Most Common Cause (General Population): Gallstones (Option A). They account for about 40% of cases. Gallstones block the common bile duct, causing a backup of digestive enzymes. Most Common Cause (Adult Males): Alcohol (Option B). In many demographic studies, chronic heavy alcohol use is the primary driver for pancreatitis in men, accounting for roughly 30% of cases and often leading to recurrent or chronic issues. The "Strongest Association": In the context of male patients, the correlation between high-volume alcohol intake and pancreatic inflammation is the most consistent clinical finding. Trauma (Option C): A known cause (often blunt force, like a steering wheel injury), but far less common than alcohol or stones. HIV Infection (Option D): Not a primary cause of pancreatitis itself, though medications used to treat HIV (like didanosine) or opportunistic infections can sometimes trigger it.

References:

Robbins and Cotran Pathologic Basis of Disease, 10th Edition, Page 882

↑ *Back to this question in Part A*

@Neet_pg_bot

Q11: A 45-year-old female presented with a history of type-2 diabetes and hypertension presented to hospital with a 3 day history of generalized weakness, diffuse abdominal pain and altered mental status. Upon examination, her GCS was 10 with diffuse abdominal tenderness. Investigations showed elevated glucose, creatinine, lipase, and calcium levels. Histopathological examination suggests which of the following associated findings in this patient? (Q845820)

A. Pancreatic hyperplasia

B. Destruction of pancreatic beta cells

C. Intracellular activation of enzymes

D. Fibrosis of pancreatic ducts

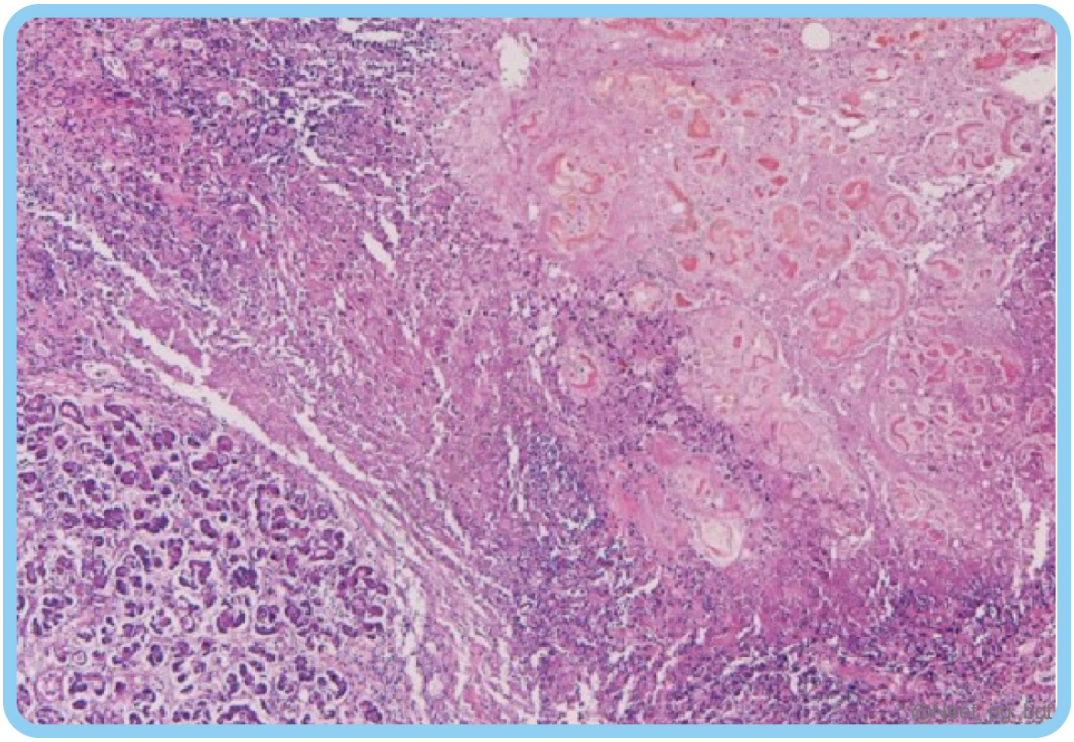

Correct Answer: C. Intracellular activation of enzymes

Explanation: The patient's clinical findings, including abdominal pain, elevated lipase, and calcium, with microscopic image findings, suggest hypercalcemia-induced acute pancreatitis due to intracellular enzyme activation, a morphological hallmark of pancreatitis. Gross : Fat and parenchymal necrosis with saponification. Microscopic : interstitial inflammation, edema, fat necrosis, vessel wall damage, and hemorrhage. (image). Hypercalcemia Induced Acute Pancreatitis: Increased calcium influx causes inappropriate activation of digestive enzymes with intracellular trypsin autoactivation causing acinar cell injury. Elevated calcium levels are linked to encephalopathy and acute kidney failure. Possible causes of hypercalcemia: malignancy, hyperparathyroidism, hypervitaminosis D, granulomatous diseases. Acute Pancreatitis: Feature Details Common Causes G allstones, E thanol (Alcohol), T rauma, S teroids, M umps, A utoimmune, S corpion sting, H ypertriglyceridemia/Hypercalcemia, E RCP, D rugs. Pathophysiology Inappropriate activation of trypsinogen to trypsin within the pancreas, leading to inflammation and necrosis. Clinical Presentation Sudden, severe epigastric pain radiating to the back ; nausea and vomiting; pain partially relieved by leaning forward. Physical Exam Signs Cullen’s sign (periumbilical ecchymosis) or Grey Turner’s sign (flank ecchymosis) indicating hemorrhagic pancreatitis. Diagnosis Requires 2 of 3: Typical abdominal pain, Serum lipase or amylase >3 × upper limit of normal, Characteristic findings on CT/MRI. Management Aggressive fluid resuscitation (isotonic crystalloids), pain control, and nutritional support.

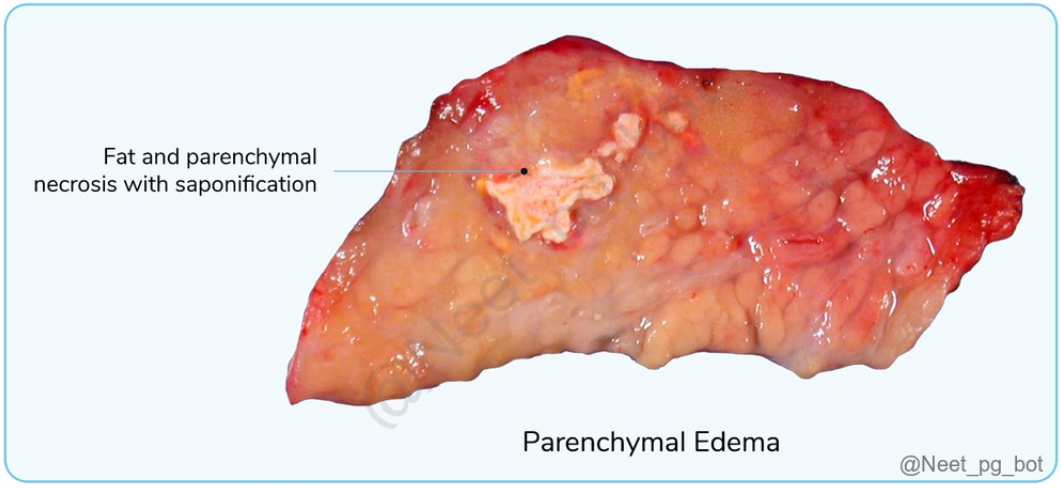

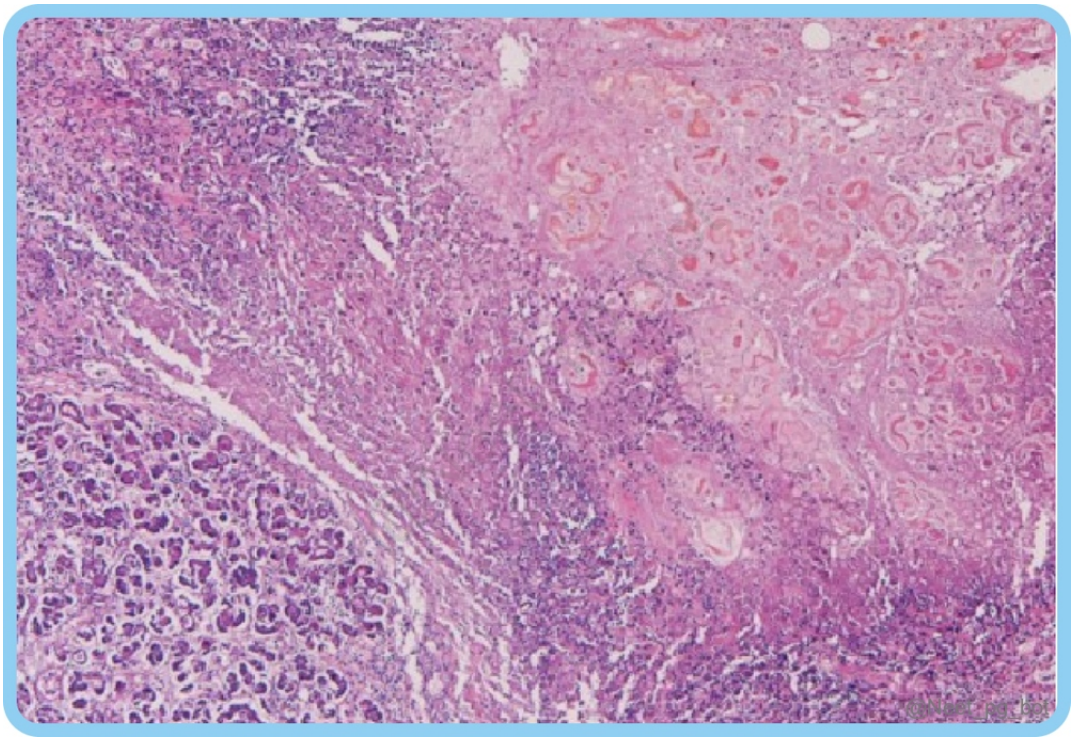

References:

Robbins and Cotran, Pathological Basis of Disease, 10th Edition, Pages 883,884, 887

https://www.sciencedirect.com/topics/nursing-and-health-professions/pancreas-islet-cell-hyperplasia

https://pathology.jhu.edu/type1-diabetes/under-the-microscope

↑ *Back to this question in Part A*

@Neet_pg_bot

Q12: A female patient presents with progressive jaundice and weight loss for the past six months. She also complains of low grade upper abdominal pain. Lab investigation revealed a random blood sugar of 320mg/dL and a raised serum Ig-G4 levels and a USG scan showed a mass like lesion over the head of pancreas. Based on these findings which of the following is the most likely finding in the histopathological examination ? (Q846627)

A. Pleomorphic cuboidal to columnar epithelial cells

B. Necrotic changes in the acini and ducts

C. Honeycombing appearance with cuboidal epithelium

D. Swirling fibrosis with inflammation of veins

Correct Answer: D. Swirling fibrosis with inflammation of veins

■ *Listen (English)*

■ *Listen (Hindi)*

Explanation: Based on the clinical presentation, history, raised blood glucose and serum Ig-G4, along with a mass-like lesion in the pancreas points towards Autoimmune pancreatitis and histopathological examination of the pancreatic specimen will show characteristic swirling/storiform fibrosis with inflammation of veins Treatment Excellent response to steroids Azathioprine for relapsing disease Raised Ig-G4 and the characteristic histological appearance help differentiate autoimmune pancreatitis from carcinoma pancreas since they both present with almost similar clinical features, and a mass-like lesion can be seen while imaging both. Pleomorphic cuboidal to columnar epithelial cells (Option A) are seen in carcinoma pancreas Necrotic changes in the acini and ducts (Option B) are seen in acute necrotising pancreatitis Honeycombing appearance with cuboidal epithelium (Option C) is seen in serous cystadenoma of the pancreas.

References:

Robbins and Cotran Pathological Basis of Disease, 10th Edition, Pages 886, 887

↑ *Back to this question in Part A*

@Neet_pg_bot

Q13: Which of the following statements about pancreatic cystic neoplasms is true? (Q846628)

A. Serous cystadenomas are commonly malignant.

B. Mucinous cystic neoplasms (MCNs) occur predominantly in males.

C. Intraductal papillary mucinous neoplasms (IPMNs) have a risk of malignant transformation.

D. Mucinous cystic neoplasms typically have a central scar on imaging.

Correct Answer: C. Intraductal papillary mucinous neoplasms (IPMNs) have a risk of malignant transformation.

■ *Listen (English)*

■ *Listen (Hindi)*

Explanation: Intraductal papillary mucinous neoplasms (IPMNs), especially those involving the main duct or mixed type, have a risk of malignant transformation. Features Serous cystadenoma (Option A) Mucinous cystic neoplasm Intraductal Papillary Mucinous Neoplasm (IPMN) (Option C) Demographics Females > males Females > males (Option B ruled out) Males = females Location Head of pancreas Body or tail of pancreas Anywhere in pancreas Morphology Microcystic , honeycombing appearance with central scar Macrocystic, multilocular, no central scar (Option D ruled out) Dilated ducts with papillary projections Malignancy risk Low High High (main

duct> mixed> branch duct) Histology Glycogen rich cuboidal cells Ovarian like stroma with mucin secreting epithelium Papillary architecture with mucin secreting epithelium Serum markers N/A CEA and CA 19-9 CEA Symptoms Usually asymptomatic Abdominal pain due to mass effect Weight loss Recurrent pancreatitis or jaundice Imaging Microcystic with central scar and stellate calcification Thin septation Unilocular or multilocular Dilated pancreatic duct or cystic lesion

References:

Robbins and Cotran, Pathological Basis of Disease, 10th Edition, Page 888-890

↑ *Back to this question in Part A*

@Neet_pg_bot

• [10_Liver_ Biliary System and Pancreas] 047 Previous Year Questions

« Back to Folder Directory

[10_Liver_ Biliary System and Pancreas] 047 Previous Year Questions — Quick Jump

Q1 (p. 2082)	*Q2 (p. 2082)*	*Q3 (p. 2085)*	*Q4 (p. 2085)*	*Q5 (p. 2086)*	*Q6 (p. 2087)*
Q7 (p. 2088)	*Q8 (p. 2088)*	*Q9 (p. 2089)*	*Q10 (p. 2091)*	*Q11 (p. 2093)*	*Q12 (p. 2094)*
Q13 (p. 2097)	*Q14 (p. 2098)*	*Q15 (p. 2099)*	*Q16 (p. 2101)*		

Q1: A 58-year-old male with history of multiple sexual partners presented with anorexia and jaundice. The biopsy shows ground-glass opacity in the cells. What is the most probable diagnosis? (Q866753)

A. Hepatitis A

B. Hepatitis B

C. Hepatitis C

D. Hepatitis D

Correct Answer: B. Hepatitis B

Explanation: Hepatitis B This clinical scenario of a male with a promiscuous sexual history and ground-glass opacities on biopsy points to Hepatitis B infection. In chronic Hepatitis B infection , hepatocytes can appear pale and finely granular on histology, called ground-glass hepatocytes . This appearance is due to the accumulation of Hepatitis B surface antigen (HBsAg) within the endoplasmic reticulum of infected hepatocytes. Common in chronic carriers and chronic hepatitis B patients. Risk factor- Multiple sexual partners, high risk of sexually transmitted infections, including HBV. Hepatitis A (Option A): Feco–oral transmission (contaminated food/water), not sexually transmitted in most cases. Does not produce ground-glass hepatocytes. Histology: hepatocyte ballooning degeneration, Councilman bodies in acute hepatitis. Hepatitis C (Option C): Transmitted mainly via blood (IV drug use, transfusions). Histology shows lymphoid aggregates in portal tracts, steatosis, and no ground-glass appearance. Hepatitis D (Option D: Histology changes depend on concurrent HBV changes; ground-glass cells still come from the HBV component.)

↑ *Back to this question in Part A*

@Neet_pg_bot

Q2: A cut section of liver is shown below. What is the likely diagnosis? (Q866392)

A. Hepatic adenoma

B. Hepatocellular carcinoma

C. Focal nodular hyperplasia

D. Hemangioma

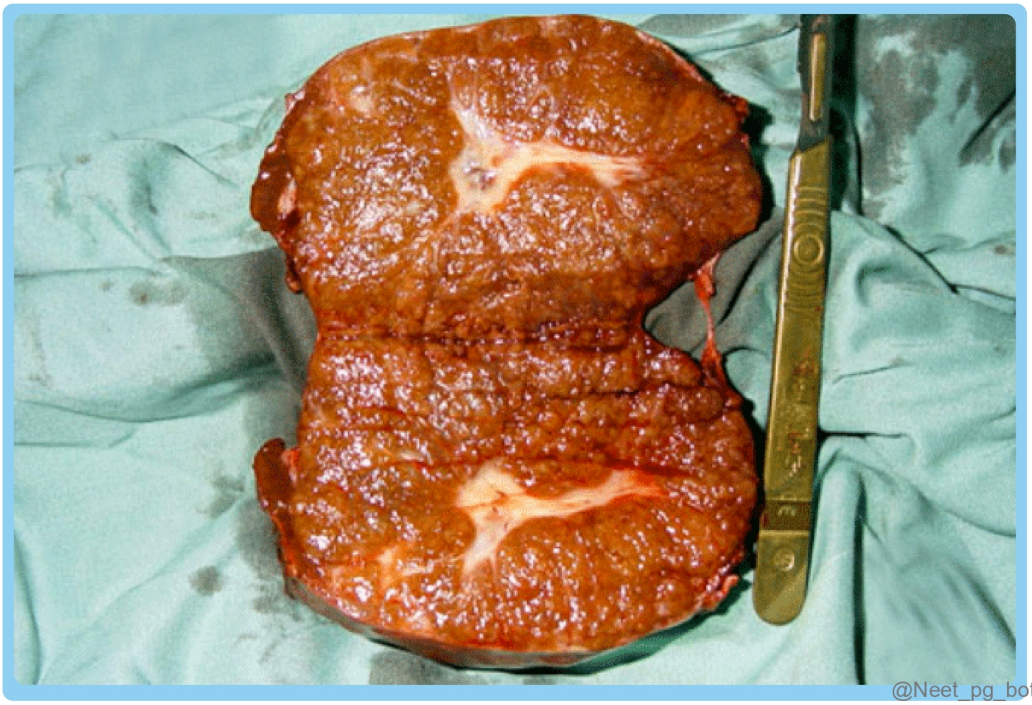

Correct Answer: C. Focal nodular hyperplasia

Explanation: A well-demarcated liver lesion with a central stellate scar on gross examination is characteristic of Focal Nodular Hyperplasia (FNH) . It is a benign, non-neoplastic lesion that is most common in women. It occurs due to altered blood flow, which causes hyperplastic changes in hepatocytes. Multifocal FNH can occur in Hepatic or extrahepatic hemangioma Vascular malformations Brain tumours (meningioma, astrocytoma) Histopathology It is less than 5 cm in diameter, well-circumscribed, lacks a capsule, and has a central stellate scar. Microscopically, fibrous septa radiating from the central scar divide the hepatic parenchyma into nodules. A large central artery is usually present. The image shows fibrous septae dividing the parenchyma. USG: It is incidentally seen on imaging. A USG of the liver indicating a mass with a central stellate scar Incorrect Options: Hepatic adenoma (Option A): Usually solitary, lacks central scar, associated with oral contraceptives. Hepatocellular carcinoma (HCC) (Option B): Malignant tumor; often shows hemorrhage, necrosis, no central scar. Hemangioma (Option D): Cavernous vascular lesion, red-blue on cut section, no central scar.

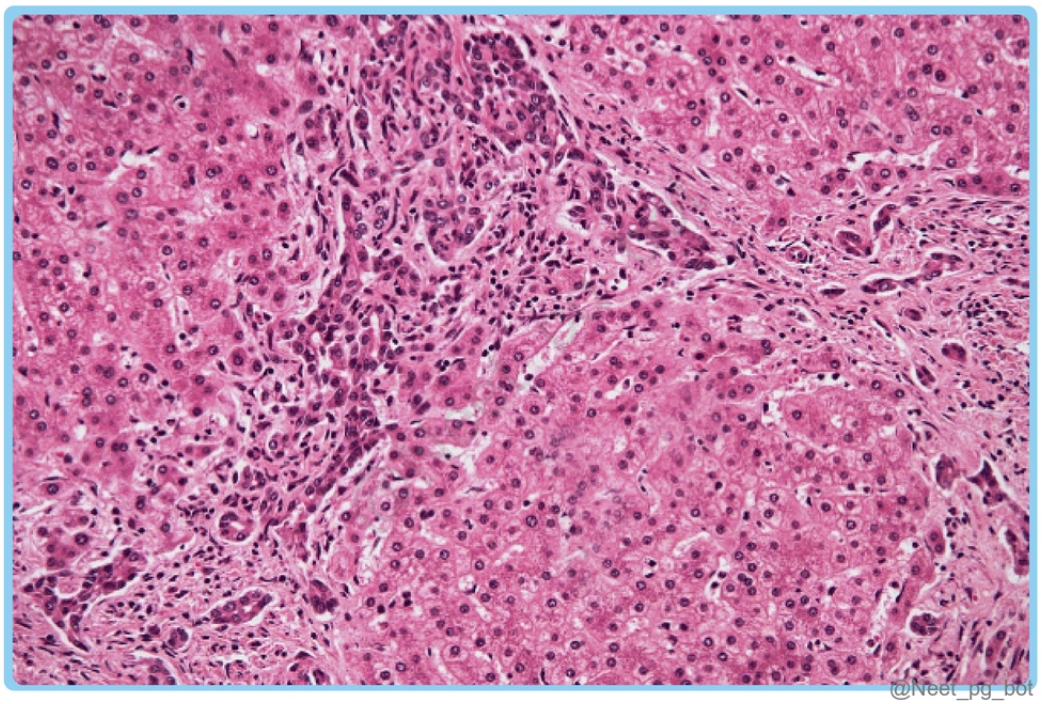

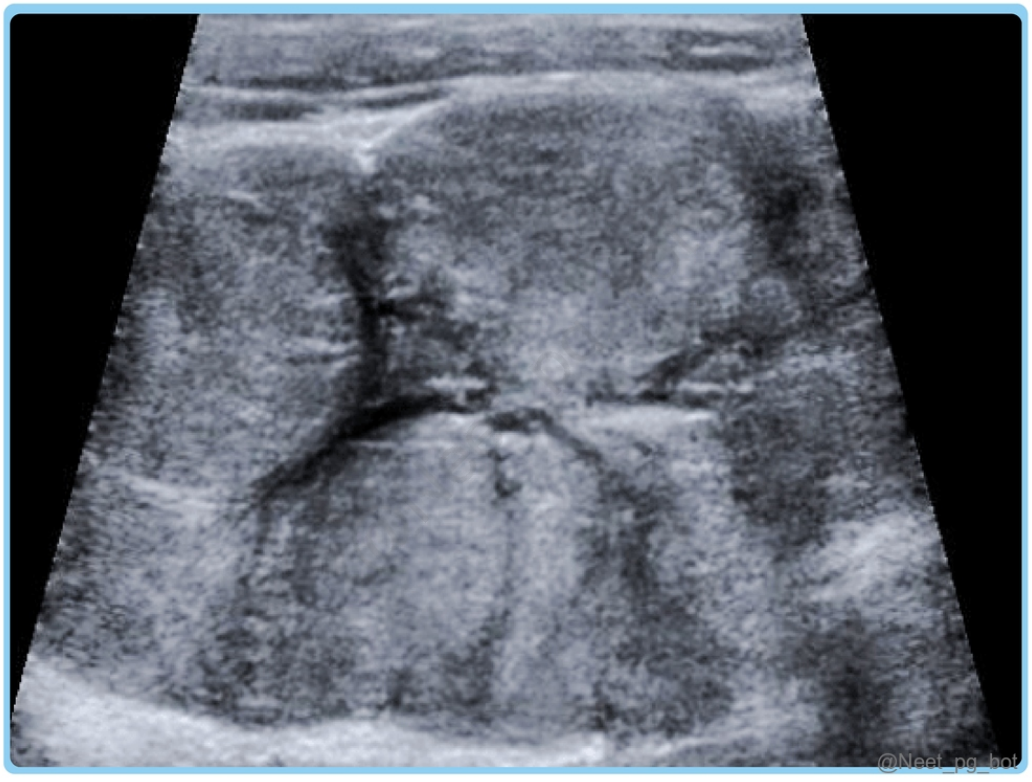

References:

.

↑ *Back to this question in Part A*

@Neet_pg_bot

Q3: An alcoholic patient presents with lower back pain and fever. During history-taking, he mentions experiencing similar episodes in the past with elevated amylase levels. Which type of necrosis is likely to be present in the peri-pancreatic fat? (Q860168)

A. Fibrinoid necrosis

B. Fat necrosis

C. Coagulative necrosis

D. Liquefactive necrosis

Correct Answer: B. Fat necrosis

Explanation: History of alcoholism and recurrent pancreatitis (elevated amylase) indicates pancreatic inflammation. In acute pancreatitis, pancreatic enzymes (especially lipase) leak into surrounding fat. These enzymes digest the peri-pancreatic fat, leading to saponification-calcium binds free fatty acids forming chalky deposits. This is called fat necrosis, a type of enzymatic necrosis. Most commonly affects peri-pancreatic fat, but can also occur in breast or subcutaneous tissue. Microscopically, ghost outlines of fat cells with basophilic calcium deposits are seen. Clinically associated with epigastric/back pain, fever, and elevated pancreatic enzymes. Incorrect Options: Option A) Fibrinoid necrosis: Seen in immune-mediated vascular injury, not pancreatitis. Option C) Coagulative necrosis: Typical of ischemic solid organs like heart or kidney. Option D) Liquefactive necrosis: Occurs in brain infarcts or abscesses, not in peri-pancreatic fat.

References:

Robbins and Cotran Pathologic Basis of Disease, 10th Edition, Page 882-885.

↑ *Back to this question in Part A*

@Neet_pg_bot

Q4: Which of the following is associated with conjugated hyperbilirubinemia? (Q860186)

A. Crigler Najar -1 syndrome

B. Crigler Najar -2 syndrome

C. Gilbert syndrome

D. Dubin-Johnson syndrome

Correct Answer: D. Dubin-Johnson syndrome

Explanation: Dubin-Johnson Syndrome is associated with conjugated hyperbilirubinemia. It is an autosomal recessive disorder. It is characterised by impaired excretion of conjugated bilirubin into bile due to a defect in the MRP2 transporter, leading to conjugated hyperbilirubinemia. Darkly pigmented liver (accumulation of epinephrine metabolite). Syndromes of Unconjugated hyperbilirubinemia Disorder Defect Severity of Unconjugated hyperbilirubinemia Crigler-Najjar syndrome type 1 (Option A ruled out) Complete deficiency of UGT Severe Crigler-Najjar syndrome type 2 (Option B ruled out) Partial deficiency of UGT Mild to moderate Gilbert syndrome (Option C ruled out) Very mild deficiency of UGT Mild, asymptomatic Syndromes of Conjugated hyperbilirubinemia Disorder Defect Gross Feature of liver Dubin Johnson syndrome (Option D) Defect in canalicular MRP2 protein. Pigmented liver (due to epinephrine metabolite). Rotor syndrome Defective ATP-dependent biliary excretion. Non-pigmented liver.

References:

Robbins & Cotran Pathologic Basis of Disease, 10th Edition, Page 853.

↑ *Back to this question in Part A*

@Neet_pg_bot

Q5: A 45-year-old patient with a history of chronic liver disease presents with symptoms of nausea, vomiting, edema, and ascites. On examination, his liver function tests are severely deranged. Further investigation reveals a diagnosis of hepatocellular carcinoma. The pathogenesis of this condition is most likely related to: (Q820599)

A. Benzol

B. Arsenic

C. Aflatoxin

D. Vinyl chloride

Correct Answer: C. Aflatoxin

Explanation:

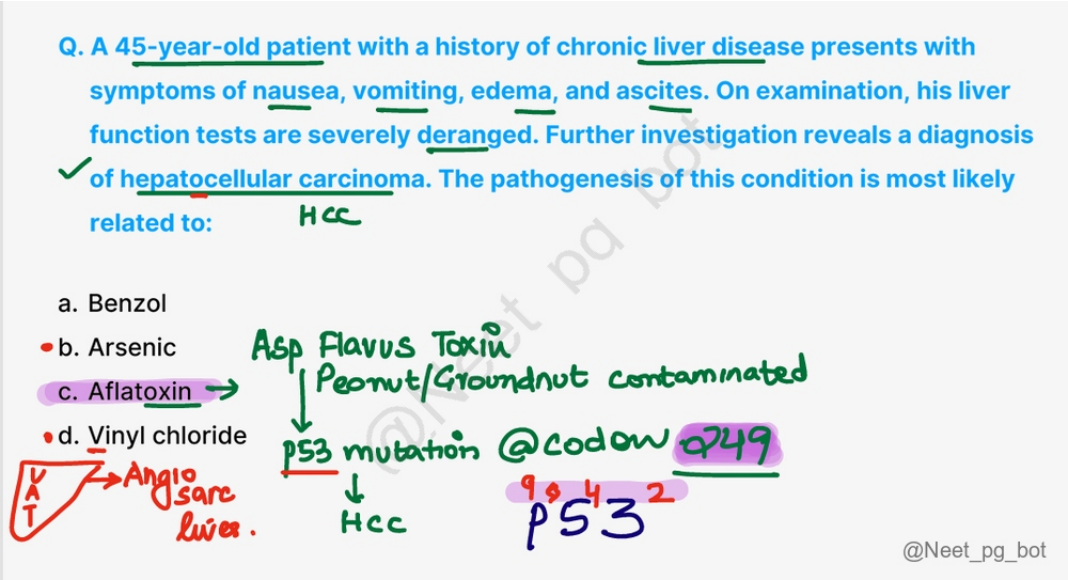

↑ *Back to this question in Part A*

@Neet_pg_bot

Q6: What is the most likely diagnosis for a 25-year-old male who presented with fever and has the following viral marker results: HBsAg: Positive and IgM anti-HBc antibody: Positive (Q830720)

A. Acute hepatitis

B. Chronic hepatitis

C. Window period

D. Persistent infection

Correct Answer: A. Acute hepatitis

Explanation: Correct Option A - Acute hepatitis: HBsAg is the surface antigen of the Hepatitis B virus and indicates current infection. IgM anti-HBc antibodies are specific to acute infection and indicate recent exposure to the virus. Incorrect Options: Option B - Chronic hepatitis : Chronic hepatitis B is characterized by the persistence of HBsAg for more than six months. The presence of IgM anti-HBc antibody indicates an acute or recent infection, making chronic hepatitis less likely. Option C - Window period: The window period refers to the time between infection and the appearance of detectable markers. In this context, the presence of both HBsAg and IgM anti-HBc antibody suggests an active infection rather than a window period. Option D - Persistent infection: Persistent infection could be considered for cases with prolonged presence of HBsAg, but the presence of IgM anti-HBc antibody indicates an ongoing immune response, which is more consistent with acute infection.

↑ *Back to this question in Part A*

@Neet_pg_bot

Q7: Which of the following is the best serum marker for alcoholic liver disease? (Q854711)

A. SGPT

B. SGOT

C. Carbohydrate-deficient transferrin (CDT)

D. Serum Bilirubin

Correct Answer: C. Carbohydrate-deficient transferrin (CDT)

Explanation: Best serum marker for alcoholic liver disease Elevated in people consuming ≥ 40–60 g alcohol/day for 1–2 weeks More reliable than AST, ALT, or bilirubin Not heavily influenced by liver disease severity Alcoholic liver disease LFT AST/ SGOT (Option B ruled out) Non-specific ; ↑ (<300-400) This is a liver enzyme that rises in conditions causing liver damage, including alcohol-induced liver injury, but it is also elevated in a variety of non-liver conditions, like muscle injury or cardiac events. ALT/ SGPT (Option A ruled out) Specific for liver injury ; ↑ (<300-400) This is another liver enzyme that primarily indicates liver cell injury , but it is less specific for alcohol-related liver disease compared to GGT. AST/ALT ratio: ≥ 2: 1 Specific for ALD ALP (Alkaline phosphatase) Elevated in bile duct pathologies GGT (γ-glutamyl transferase) Non-specific marker of ALD 5'-Nucleotidase Specific marker for bile duct pathologies S.Bilirubin (Option D ruled out) Usually normal/mildly ↑ S.Albumin ↓ in chronic liver disease (cirrhosis) Carbohydrate-deficient transferrin (CDT) Best serum marker for alcoholic liver disease.

References:

Robbins and Cotran Pathologic Basis of Disease, 10th Edition, Pages 842- 846

↑ *Back to this question in Part A*

@Neet_pg_bot

Q8: Which of the following cells plays a key role in phagocytosis and chronic inflammation in the liver? (Q858141)

A. Hepatocytes

B. Ito cells

C. Sinusoidal endothelial cells

D. Kupffer cells

Correct Answer: D. Kupffer cells

Explanation: Kupffer cells are specialised macrophages found in sinusoids of the liver and play a key role in phagocytosis and chronic inflammation . They are responsible for clearing pathogens, debris, and old red blood cells from the blood as it passes through the liver. Incorrect Options: Hepatocyte s (Option A) are vital liver cells responsible for various metabolic functions but are not directly responsible for phagocytosis. Ito cells (Option B), also called Hepatic stellate cells, are pericytes located in the space of Disse , between hepatocytes and sinusoidal endothelial cells in the liver that store vitamin A and regulate sinusoidal blood flow. Upon liver injury, they activate into myofibroblast-like cells, releasing TGFβ and promoting fibrosis through excessive collagen production. Sinusoidal endothelial cells (Option C) line the liver's sinusoids and facilitate material exchange between blood and liver cells. While they are not primarily involved in phagocytosis, their unique fenestrated structure enables them to filter blood and regulate molecule movement.

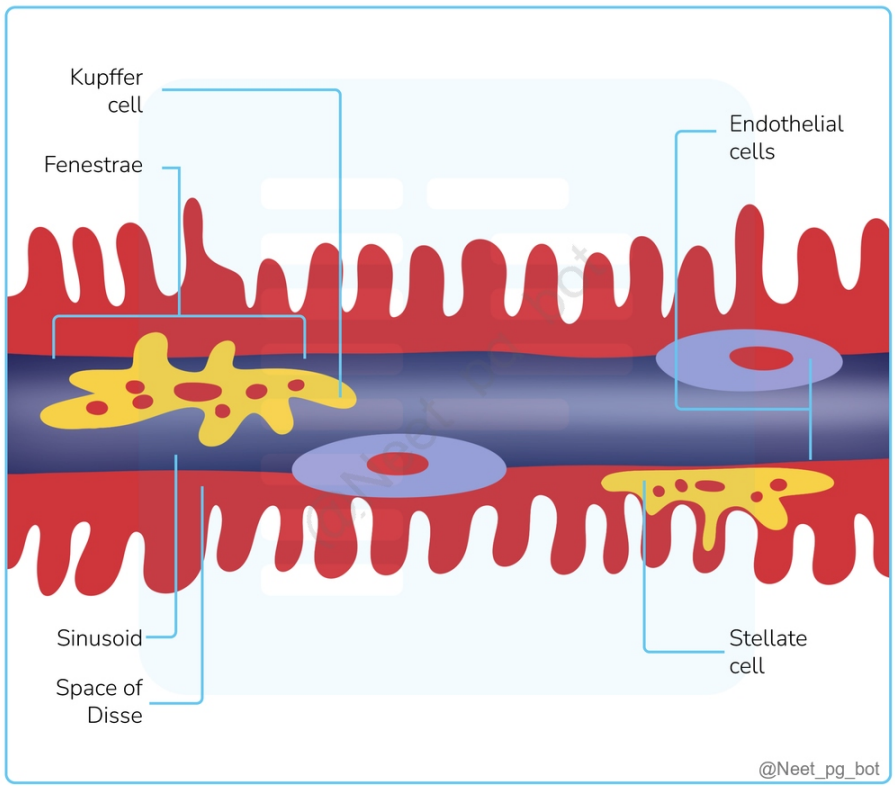

References:

Robbins & Cotran Pathologic Basis of Disease, 10th Edition, Page 824 NIH Link

↑ *Back to this question in Part A*

@Neet_pg_bot

Q9: A patient suffering from cholelithiasis underwent cholecystectomy. The image of the specimen is shown below. Which of the following is the correct diagnosis? (Q855934)

A. Chronic cholecystitis

B. Gallbladder cholesterol polyp

C. Carcinoma gallbladder

D. Strawberry gallbladder



@Neet_pg_bot

Correct Answer: B. Gallbladder cholesterol polyp

Explanation: The image shows a characteristic finding of a gallbladder cholesterol polyp , which typically presents as a raised, pedunculated lesion on the gallbladder mucosa. They are often benign and can be composed of cholesterol, adenomas, or inflammatory tissue. Gall bladder polyp is a pre-malignant condition presenting with cholecystitis & biliary colic. Types Cholesterol polyp (More common) Adenomatous polyp (Has malignant potential) Risk factors for malignancy in adenomatous polyp: Coexistence of gallstones Age > 60 years Increase in size Size > 10 mm Chronic cholecystitis (Option A) :– Thickened wall, stones, fibrotic mucosa, inflammation Strawberry gallbladder" (Option C), it occurs when cholesterol deposits accumulate in the gallbladder wall, giving it a speckled, yellowish appearance. {{caption_text}} Adenocarcinoma of the gallbladder (Option C) is the most common form of gallbladder cancer, arising from glandular cells and often associated with chronic cholecystitis, gallstones, and older age. It is more common in women. Early stages are usually asymptomatic, but as the tumour progresses, symptoms like right upper quadrant pain, jaundice, and weight loss may occur. HER2/neu overexpression and elevated CA 19-9 levels can aid in diagnosis and prognosis.



References:

Bailey & Love's Short Practice of Surgery, 27th Edition, Page 1201,1209-1211

Robbins & Cotran Pathologic Basis of Disease, 10th Edition, Page 876, 877

↑ *Back to this question in Part A*

@Neet_pg_bot

Q10: What is the gene mutation seen in hemochromatosis? (Q857113)

A. HFE

B. PTEN

C. ATP7B gene

D. MRP2 protein

Correct Answer: A. HFE

Explanation: Hereditary hemochromatosis is due to an HFE gene mutation on chromosome 6p that causes excess iron absorption, leading to increased iron deposition. This results in the classic triad of cirrhosis , secondary

diabetes mellitus , and bronze skin. Hereditary Hemochromatosis: Laboratory findings: High ferritin, high serum iron and low TIBC. Liver biopsy: Golden-yellow hemosiderin granules in periportal hepatocytes that appear blue with a Prussian blue stain followed by a micronodular pattern of cirrhosis. Other findings: dilated cardiomyopathy (M/C cardiac manifestation). Increased risk of hepatocellular carcinoma {{caption_text}} In Hemochromatosis, skin colour changes due to the deposition of excessive melanin >> iron in the skin. It is also known as "bronze diabetes" due to skin discolouration and associated pancreatic disease & typically manifests after 20 g of stored iron has accumulated in the body. Organs affected Clinical features Liver Hepatomegaly, elevated liver enzymes, risk of HCC Pancreas Iron-induced damage of beta cells - diabetes mellitus Heart Cardiomyopathy, arrhythmias, congestive heart failure Skin Hyperpigmentation (bronze skin due to melanin and iron deposition) Joints Arthropathy and joint pain CNS Rarely - Memory issues, depression and fatigue Hemochromatosis is of two types: Types of hemochromatosis Features Hereditary hemochromatosis HFE -related: It is the classic form of hereditary hemochromatosis that is inherited in an autosomal recessive (chromosome 6p) HAMP gene mutation-related HJV gene mutation (juvenile hemochromatosis Acquired/secondary hemochromatosis Repeated blood transfusion Excessive oral intake or iron PTEN (Option B) is a tumour suppressor gene linked to certain cancers and is not associated with hemochromatosis. ATP7B gene (Option C) mutations cause Wilson's disease , which involves copper accumulation, not iron overload, as in hemochromatosis. MRP2 protein (Option D) is involved in bile excretion and is related to Dubin-Johnson syndrome , not hemochromatosis.

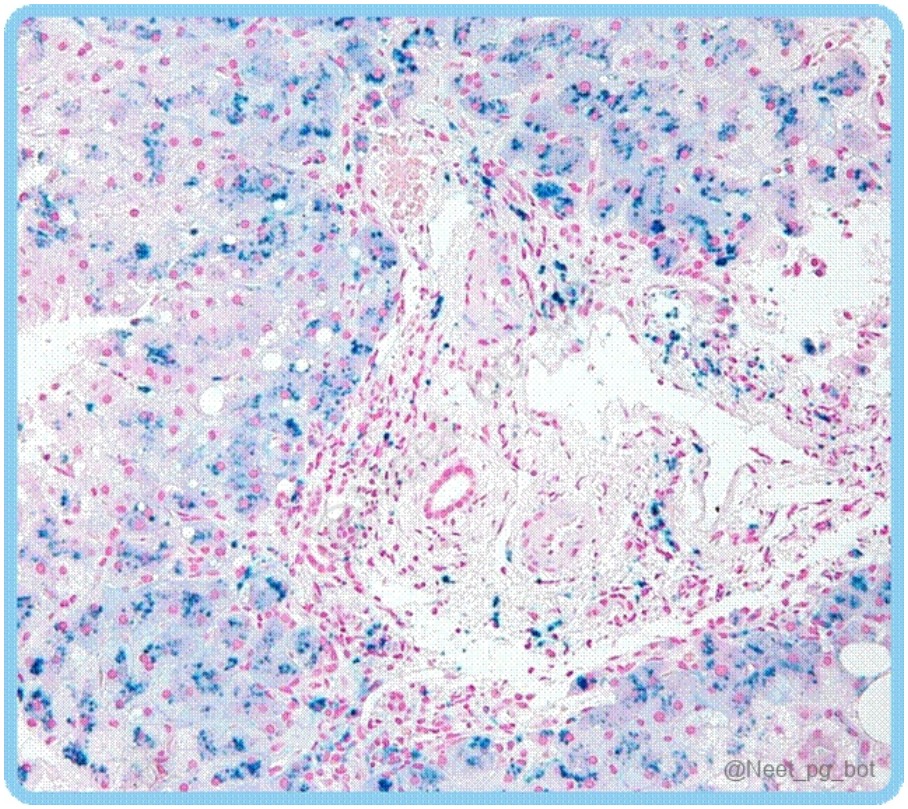

References:

Robbins & Cotran Pathologic Basis of Disease, 10th Edition, Page 848-850

↑ *Back to this question in Part A*

@Neet_pg_bot

Q11: A 30-year-old female presenting with an unsteady gait, forgetfulness, labile moods, and Kayser-Fleischer rings was diagnosed with Wilson’s disease. Which of the following options correctly indicates the gene mutated in this condition and its location? (Q857558)

A. ATP7B gene on chromosome 13

B. ATP7A gene on chromosome X (Xq21.1)

C. ATP7B gene on chromosome 17

D. ATP7A gene on chromosome 17

Correct Answer: A. ATP7B gene on chromosome 13

Explanation: Wilson’s disease is caused by mutations in the ATP7B gene located on chromosome 13 . The ATP7A gene on chromosome X (Xq21.1) is associated with Menkes disease . Wilson’s disease It is a genetic disorder caused by ATP7B gene mutations, leading to impaired copper transport and accumulation in the liver, brain, and other organs. Clinical Features: Kayser-Fleischer Rings: These are characteristic brownish-green rings seen in the cornea due to copper deposition and are a hallmark feature of Wilson's disease. Serum copper is raised, while ceruloplasmin levels (a copper-binding protein) are decreased in Wilson's disease. Increased urinary copper excretion is a characteristic finding. {{caption_text}} Findings: Low levels of Serum Ceruloplasmin. Increased 24-hour Urinary Copper Excretion (Most specific) . Liver Function Tests (LFTs) may show abnormalities. Kayser-Fleischer Rings Examination: Greenish-brown rings in the cornea. Genetic Testing: For ATP7B gene mutations, confirming diagnosis. Liver Biopsy (Gold standard): Demonstrates hepatic copper accumulation. Brain Imaging: MRI to assess neurological involvement.

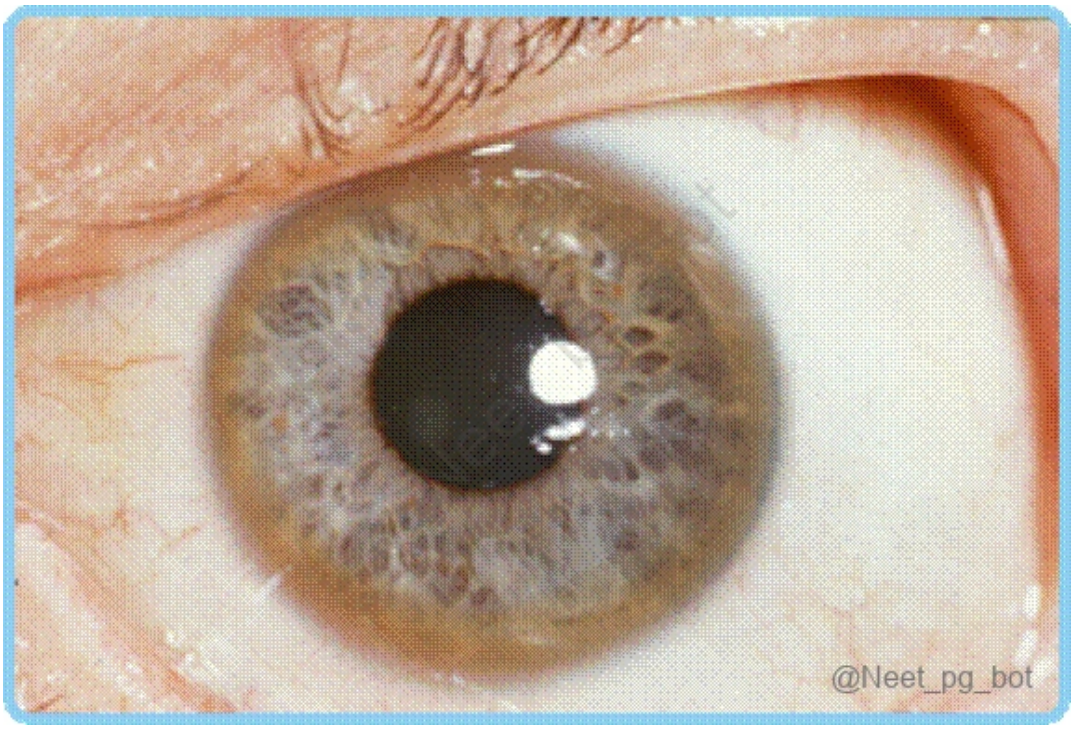

References:

Robbins & Cotran Pathologic Basis of Disease, 10th Edition, Page 850

↑ *Back to this question in Part A*

@Neet_pg_bot

Q12: A patient with cirrhosis and ascites presented to you. The gross appearance of his liver is shown below. Which of the following is true about it? (Q855403)

A. Dark areas represent necrosis, white areas represent viable liver

B. Dark areas represent viable liver tissue, white areas represent necrosis

C. White areas represent central hepatocytes

D. Dark areas represent peri-portal hepatocytes

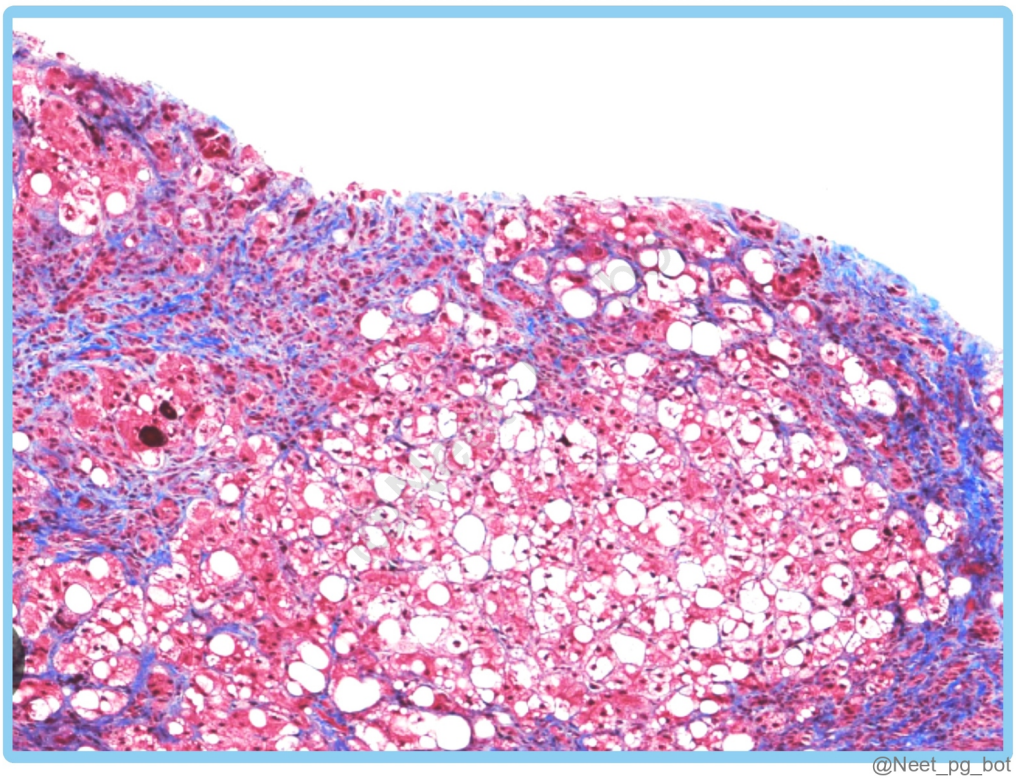

Correct Answer: A. Dark areas represent necrosis, white areas represent viable liver

Explanation: The scenario of Cirrhosis and ascites, along with the image, shows dark areas indicating necrosis and white areas representing viable liver tissue. It is a chronic liver disease characterized by fibrosis and nodular regeneration of the liver parenchyma. Causes: Chronic alcohol abuse, viral hepatitis, or metabolic disorders. The liver undergoes significant remodelling, destroying its normal architecture and the formation of fibrous bands. The dark areas indicate necrosis (cellular damage and blood congestion), while the white areas represent viable liver tissue with functional hepatocytes. (Option B, C, and D ruled out) {{caption_text}} {{caption_text}} Microscopy: Thick bands of collagen separate rounded cirrhotic nodules (Masson's trichrome stain is commonly used to visualise collagen fibres). {{caption_text}}


@Neet_pg_bot


@Neet_pg_bot

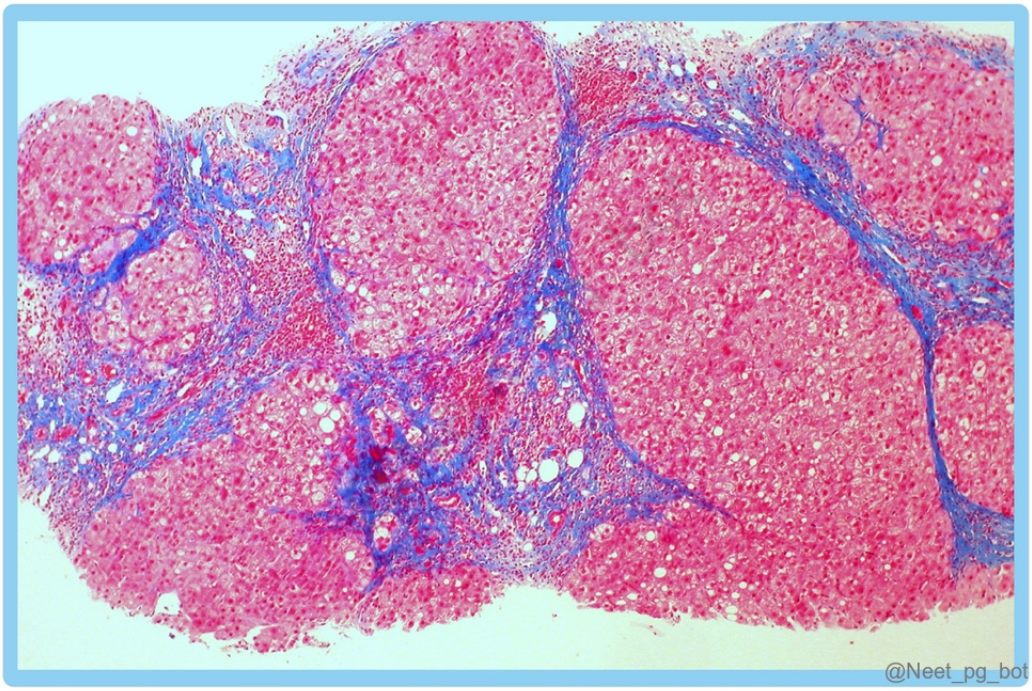

References:

Robbins & Cotran Pathologic Basis of Diseases, 10th Edition, Page 828-829

↑ *Back to this question in Part A*

@Neet_pg_bot

Q13: Which of the following is associated with hepatic angiosarcoma? (Q859271)

A. Iron

B. Copper

C. Zinc

D. Arsenic

Correct Answer: D. Arsenic

Explanation: Arsenic is a well-established carcinogen for hepatic angiosarcoma. Chronic arsenic exposure leads to DNA damage and promotes endothelial cell malignancy. It also notes that vinyl chloride , Thorotrast , and arsenic are the most frequently implicated agents in hepatic angiosarcoma development. Incorrect Options: Iron (Option A) overload (e.g., in hereditary hemochromatosis) is primarily associated with an increased risk of hepatocellular carcinoma (HCC) , not hepatic angiosarcoma. Copper (Option B) accumulation in Wilson's disease is linked to hepatocyte damage and cirrhosis but is not associated with angiosarcoma development. Zinc (Option C) is

essential for normal cellular function and is not carcinogenic.

References:

Robbins & Cotran Pathologic Basis of Disease, 10th Edition, Page 872

↑ *Back to this question in Part A*

@Neet_pg_bot

Q14: Macrophages play an important role in phagocytosis and chronic inflammation. Which of the following cells perform the same function in the liver? (Q859301)

A. Hepatocytes

B. Merkel cells

C. Sinusoid all cells

D. Kupffer cells

Correct Answer: D. Kupffer cells

Explanation: Kupffer cells are specialised macrophages located within the liver sinusoids. They play a crucial role in phagocytosis, removing pathogens, damaged cells, and cellular debris from the bloodstream. They are also involved in the regulation of immune responses and the promotion of chronic inflammation when necessary. Therefore, Kupffer cells in the liver perform similar functions to macrophages, including phagocytosis and participation in chronic inflammation. {{caption_text}} Incorrect Options: Hepatocytes (Option A) are the main functional cells of the liver responsible for various metabolic functions, such as detoxification, synthesis of proteins, and storage of nutrients. While hepatocytes are involved in many liver functions, they do not primarily perform phagocytosis and chronic inflammation. Merkel cells (Option B) are specialised cells found in the skin and are involved in the sensation of touch and tactile discrimination. They are not present in the liver or involved in phagocytosis or chronic inflammation. Sinusoidal cells (Option C) refer to the cells lining the sinusoids in the liver, which are specialised blood vessels.

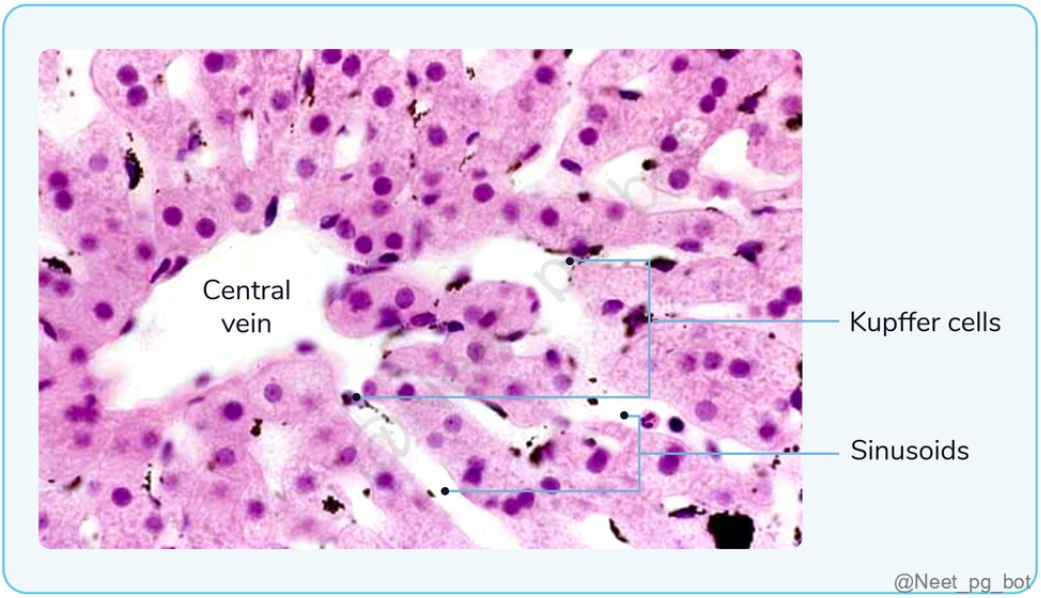

References:

Robbins and Cotrans Pathological Basis of Diseases, 10th Edition, Pages 97, 98

↑ *Back to this question in Part A*

@Neet_pg_bot

Q15: A 55-year-old man is found to have hepatomegaly on physical examination. He also complains of having dark tan skin despite avoiding sun exposure . His liver microscopy is given on the slide below. What is this patient most likely suffering from? (Q793776)

A. Wilson’s disease

B. Autoimmune hepatitis

C. α-1 antitrypsin deficiency

D. Hemochromatosis

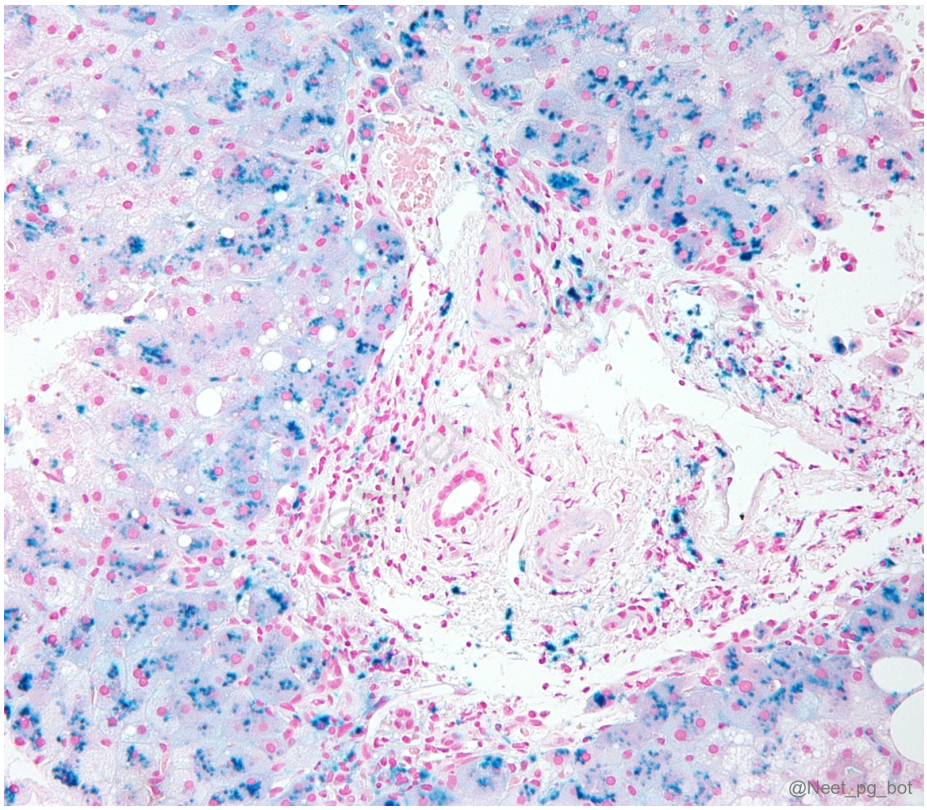

Correct Answer: D. Hemochromatosis

Explanation: Correct Option D - Hemochromatosis: The patient's presentation with dark tan skin and histopathological findings showing iron deposition in liver cells is suggestive of hemochromatosis. Hemochromatosis is a hereditary disorder characterized by the accumulation of iron in the body, which can lead to damage to various organs, including the liver, heart, and pancreas. Incorrect Options: Option A - Wilson's disease: Wilson's disease is an inherited disorder that causes copper to accumulate in various organs, including the liver, brain, and eyes. The symptoms of Wilson's disease usually begin in childhood or early adulthood and can include neurological symptoms such as tremors, dystonia, and difficulty with coordination. The liver damage associated with Wilson's disease can lead to hepatomegaly, as well as signs of liver disease such as jaundice, ascites, and elevated liver enzymes. Option B - Autoimmune hepatitis: Autoimmune hepatitis is a chronic autoimmune disorder that causes inflammation and damage to the liver. The symptoms of autoimmune hepatitis can include fatigue, joint pain, skin rashes, and abdominal pain. Liver damage can lead to hepatomegaly, as well as signs of liver disease such as jaundice, ascites, and elevated liver enzymes. Option C - α-1 antitrypsin deficiency: α-1 antitrypsin deficiency is a genetic disorder that affects the production of a protein called α-1 antitrypsin, which plays a role in protecting the lungs and liver from damage. The symptoms of α-1 antitrypsin deficiency can include respiratory symptoms such as shortness of breath and coughing, as well as liver diseases such as hepatomegaly and elevated liver enzymes.

References:

Prepladder Notes

↑ *Back to this question in Part A*

@Neet_pg_bot

Q16: A health care worker has been found to be seropositive for HBsAg, HBeAg, and anti-HBc IgM, indicating an acute HBV infection with high infectivity. A liver biopsy in such cases is likely to show all the following except: (Q793793)

A. Ballooning change of hepatocytes

B. Ground glass hepatocytes

C. Focal or spotty necrosis

D. Confluent necrosis of hepatocytes

Correct Answer: B. Ground glass hepatocytes

Explanation: Correct Option B - Ground glass hepatocytes: Ground glass hepatocytes are hepatocytes with a granular, eosinophilic cytoplasm. This appearance is due to the accumulation of hepatitis B surface antigen (HBsAg) within the endoplasmic reticulum of hepatocytes. This feature is more characteristic of chronic HBV infection rather than acute infection. It reflects ongoing viral replication and chronicity. Incorrect Options: Options A, C, and D A. Ballooning change of hepatocytes : Common in acute hepatitis. C. Focal or spotty necrosis : Common in acute hepatitis. D. Confluent necrosis of hepatocytes : Seen in severe acute hepatitis.

References:

Prepladder Notes

↑ *Back to this question in Part A*

@Neet_pg_bot

• [11_Renal System] 048 Basics Of Renal Pathology

« Back to Folder Directory

[11_Renal System] 048 Basics Of Renal Pathology — Quick Jump

Q1 (p. 2102)	*Q2 (p. 2104)*	*Q3 (p. 2107)*	*Q4 (p. 2111)*	*Q5 (p. 2114)*	*Q6 (p. 2117)*
Q7 (p. 2119)	*Q8 (p. 2124)*	*Q9 (p. 2126)*	*Q10 (p. 2127)*	*Q11 (p. 2128)*	*Q12 (p. 2129)*
Q13 (p. 2129)	*Q14 (p. 2130)*	*Q15 (p. 2131)*	*Q16 (p. 2132)*		

Q1: Which of the following statements regarding the glomerular basement membrane (GBM) is true? (Q845679)

A. The GBM is primarily composed of collagen type I and elastin.

B. The GBM is a selective barrier between the glomerular capillaries and Bowman's capsule.

C. Thickening of the GBM is a characteristic feature of minimal change disease.

D. The GBM is impermeable to large molecules such as albumin.

Correct Answer: B. The GBM is a selective barrier between the glomerular capillaries and Bowman's capsule.

■ *Listen (English)*

■ *Listen (Hindi)*

Explanation: GBM forms the semipermeable barrier between the glomerular capillaries (inside) and the Bowman’s capsule (outside). The Glomerular filtration barrier GFB acts as a highly specialized "sieve" that allows water and small solutes to pass into the Bowman's space while retaining blood cells and large proteins. Filtration membrane: 3-layered structure: 1. Fenestrated Capillary Endothelium Structure: The innermost layer, containing pores (fenestrae) roughly 70–100 nm in diameter. Function: It prevents the passage of blood cells (RBCs, WBCs, platelets) but is too "leaky" to stop most plasma proteins. 2. Glomerular Basement Membrane (GBM): Composition: Primarily Type IV collagen , laminin, nidogen, and heparan sulfate proteoglycans. Function: It acts as a physical meshwork and a charge barrier . The heparan sulfate molecules provide a strong negative charge , which electrostatically repels negatively charged proteins like albumin. 3. Podocytes (visceral epithelial cells of Bowman’s capsule): Structure: Specialized cells with "foot processes" (pedicels) that wrap around the capillaries. Slit Diaphragm: Between these foot processes are narrow gaps called filtration slits , bridged by a protein zipper known as the slit diaphragm (composed of proteins like nephrin and podocin). Function: This is the final and finest physical filter. Selectivity: The barrier filters based on two main criteria: Feature Description Size Selectivity Molecules with a radius < 1.8 nm are filtered freely; those > 4 nm (like albumin) are restricted by the physical "pore" size. Charge Selectivity All three layers (especially the GBM and podocyte coat) are coated with polyanions (negative charges). Since most plasma proteins are negatively charged, they are repelled even if they are small enough to fit through the physical gaps. The GBM is primarily composed of collagen type I and elastin (Option A): GBM primarily comprises collagen type IV, laminins, proteoglycans, and other glycoproteins.

Thickening of the GBM is a characteristic feature of minimal change disease (Option C): The hallmark of Minimal Change Disease (MCD) is effacement of podocyte foot processes (visceral epithelium of the Bowman's capsule). The GBM is impermeable to large molecules such as albumin (Option D): GBM is permeable to small molecules but is a selective barrier to larger molecules such as albumin. {{caption_text}}

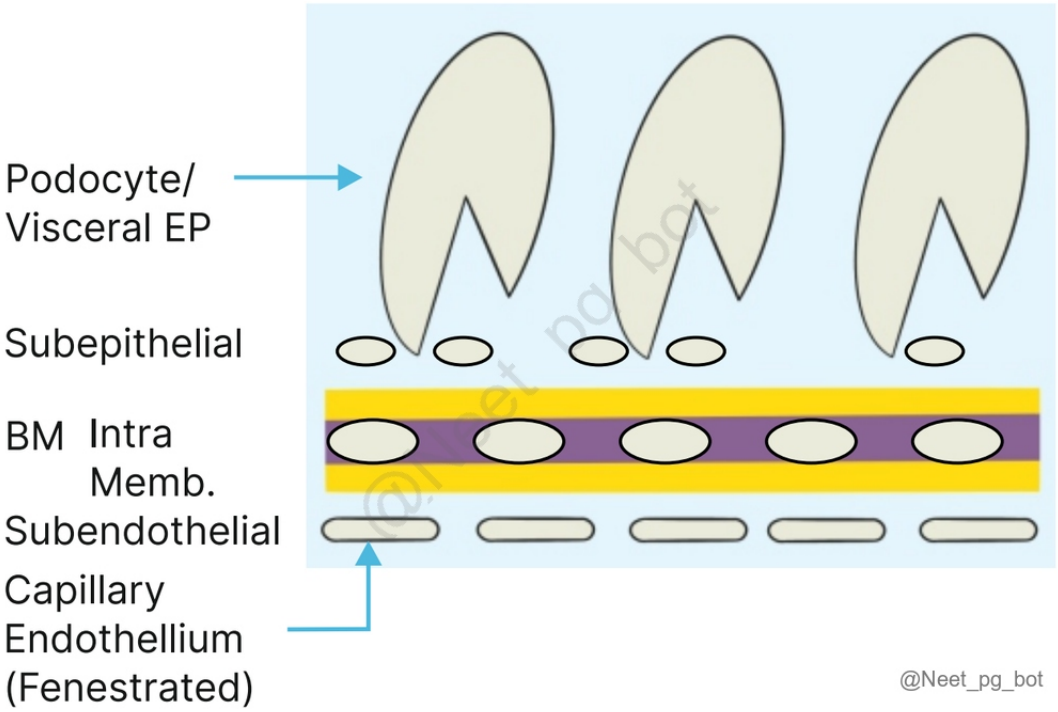

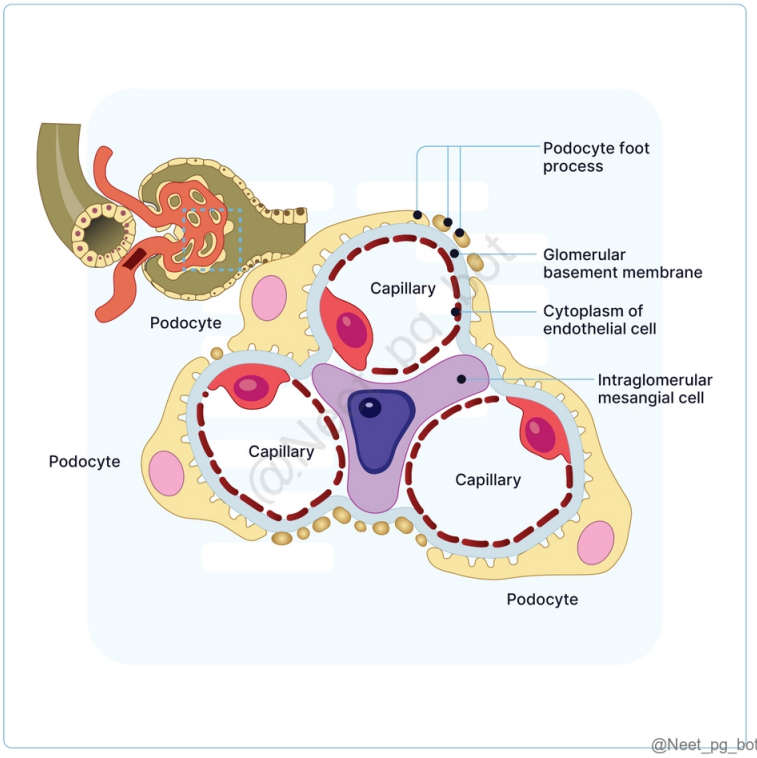

References:

Ganong’s Review of Medical Physiology, 26th edition, Page 661

↑ *Back to this question in Part A*

@Neet_pg_bot

Q2: Which of the following kidney findings will be seen in malignant hypertension? (Q845680)

A. Putty kidney

B. Leather grain kidney

C. Flea-bitten kidney

D. Waxy kidney

Correct Answer: C. Flea-bitten kidney

■ *Listen (English)*

■ *Listen (Hindi)*

Explanation: Flea-bitten kidney is defined as pinpoint petechial hemorrhages on the renal surface, caused by rupture of small glomerular or arteriolar vessels due to severe vascular damage. Mnemonic for differential diagnosis of flea-bitten kidney: We HaTe PSM We - We gener's granulomatosis. H a T e - H enoch Schonlein purpura, H US, T TP. P - P oststreptococcal glomerulonephritis, P olyarteritis nodosa. S - S ubacute bacterial endocarditis, S LE. M - M alignant hypertension. {{caption_text}} Putty kidney is seen in renal tuberculosis. (Option A) {{caption_text}} A leather-grain kidney appearance is seen in benign hypertension . (Option B) {{caption_text}} A Waxy kidney is seen in amyloidosis ..(Option D) {{caption_text}}


@Neet_pg_bot

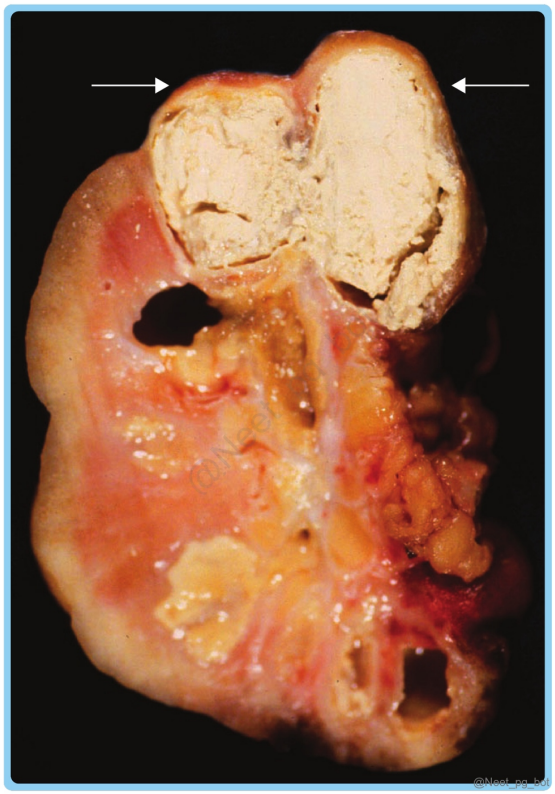
@Neet_pg_bot


@Neet_pg_bot

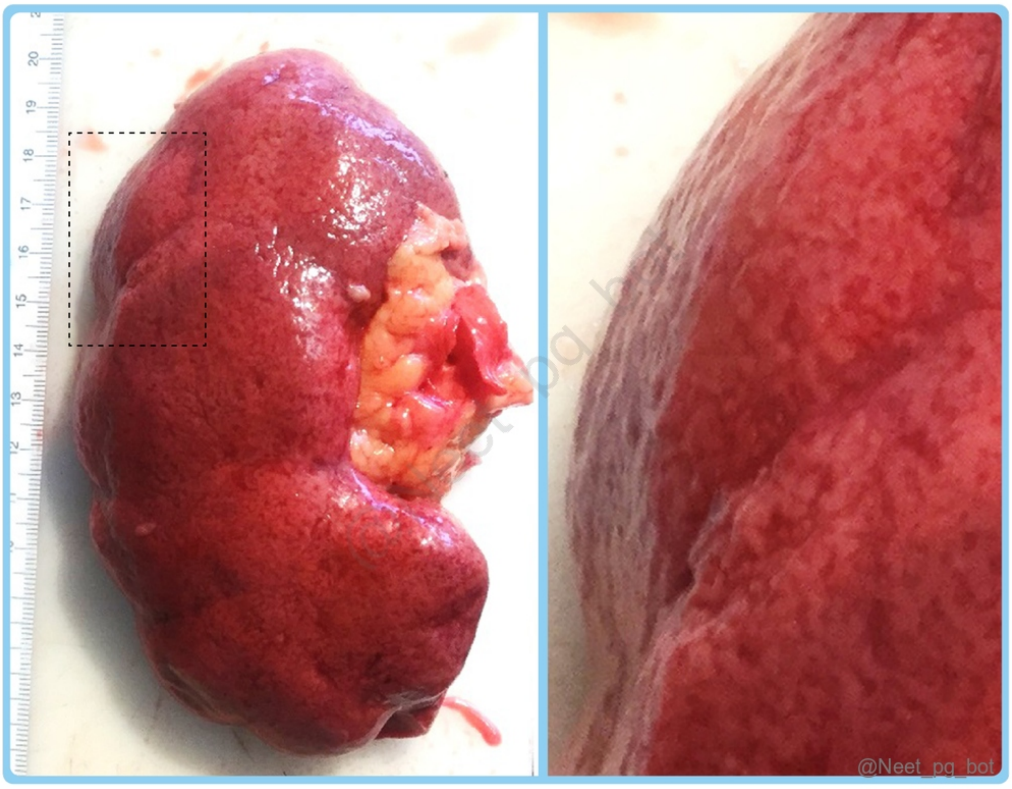
@Neet_pg_bot



References:

Robbins and Cotran Pathologic Basis of Disease, 10th Edition, Page 939

↑ *Back to this question in Part A*

@Neet_pg_bot

Q3: A 60-year-old female presents with a history of recurrent urinary tract infections and lower abdominal pain. Upon physical examination, palpable masses are noted in the pelvis. Urinalysis reveals persistent pyuria. A biopsy was done on the bladder lesions, which is shown below. Which of the following conditions is most likely responsible for the patient's presentation? (Q845681)

A. Bladder carcinoma

B. Malakoplakia

C. Schistosomiasis

D. Tuberculous cystitis

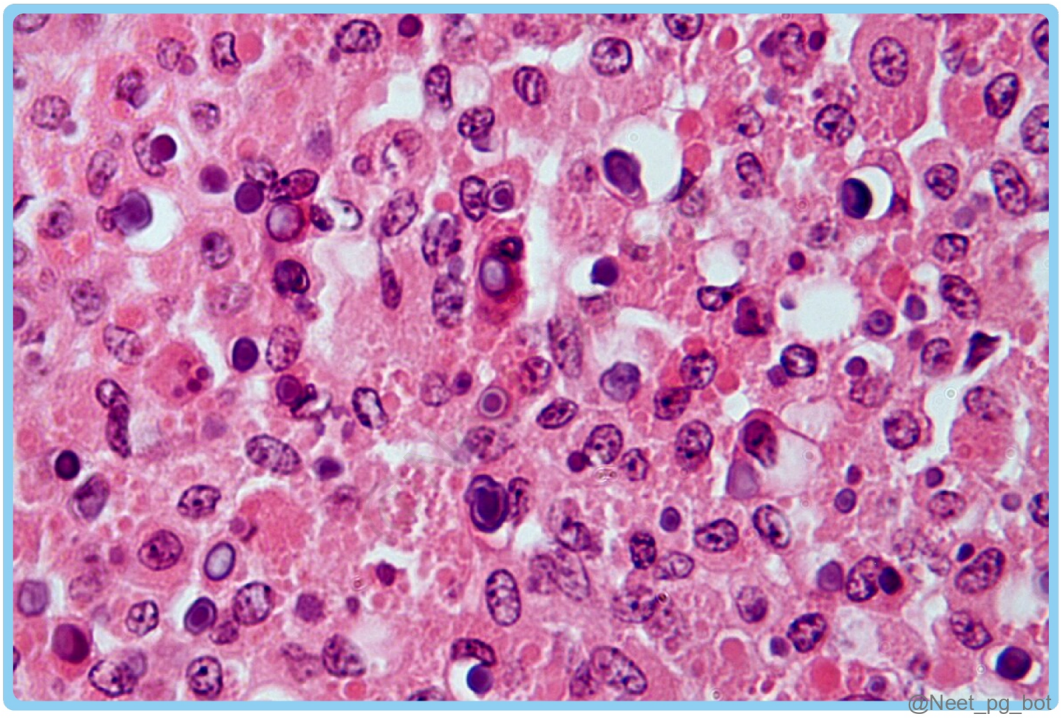

Correct Answer: B. Malakoplakia

- *Listen (English)*
- *Listen (Hindi)*

Explanation: Malakoplakia : Presentation: Patients may present with recurrent urinary tract infections and a bladder or pelvic mass, which can strongly mimic cancer. However, histopathology does not reveal malignant pleomorphic mitotic cells. Histology: The characteristic finding is bluish (basophilic) concretions known as Michaelis–Gutmann bodies, which are calcium deposits over bacterial remnants. These bodies are found within macrophages called Von Hansemann cells. Pathogenesis: Due to defective phagocytosis, macrophages engulf bacteria but fail to kill them. The most common causative organism is E. coli. Because the bacteria are not destroyed, calcium and iron gradually deposit over them, forming Michaelis–Gutmann bodies . Michaelis–Gutmann bodies : Basophilic calcium deposits within macrophages. {{caption_text}} Bladder carcinoma (Option A): Mass and UTI-like symptoms, but biopsy would show pleomorphic, atypical, mitotically active malignant cells Schistosomiasis (Option C): can cause chronic granulomatous inflammation in the bladder wall, leading to fibrosis and calcification. {{caption_text}} Tubercular cystitis reveals caseating granulomas with Langhans giant cells and epithelioid cells.(Option D)

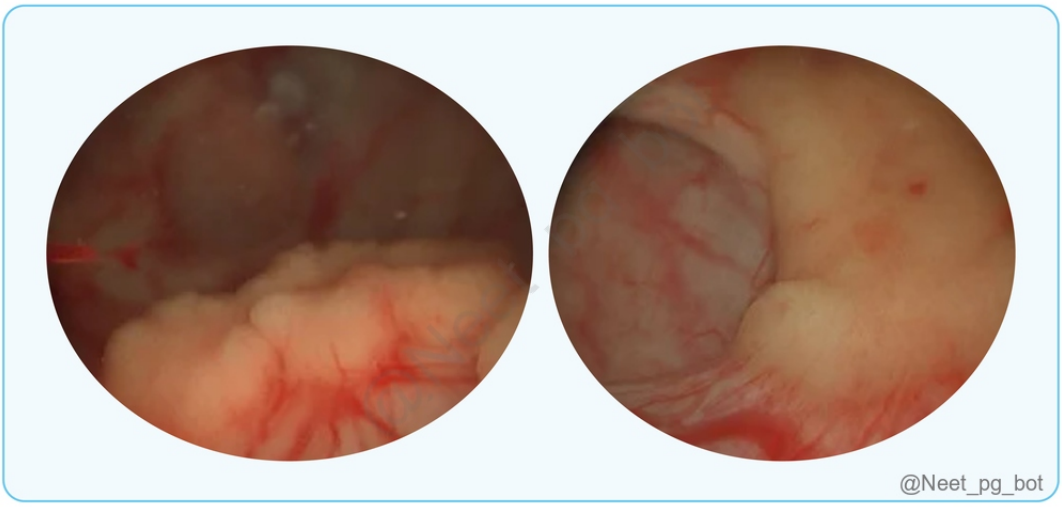
@Neet_pg_bot

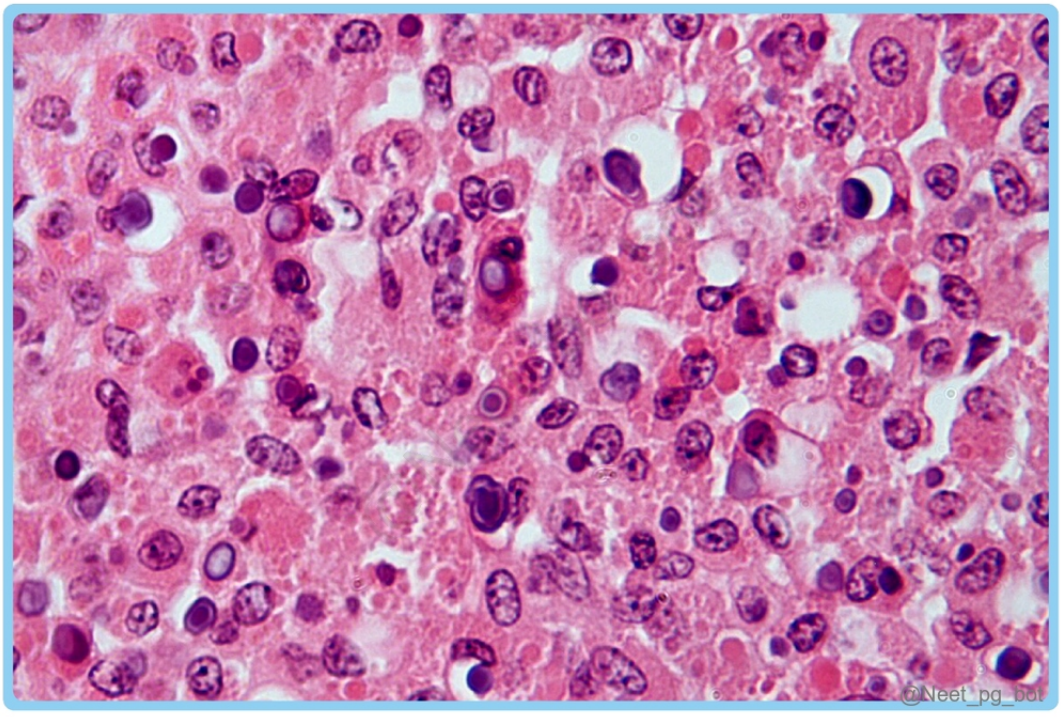
@Neet_pg_bot

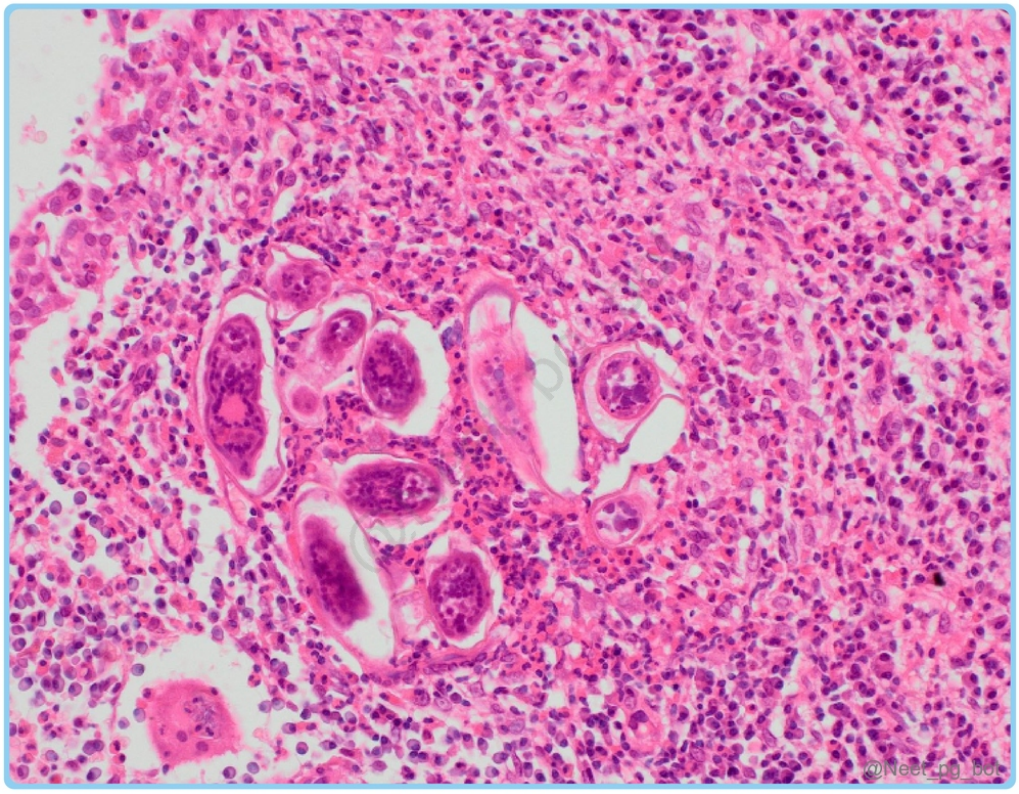

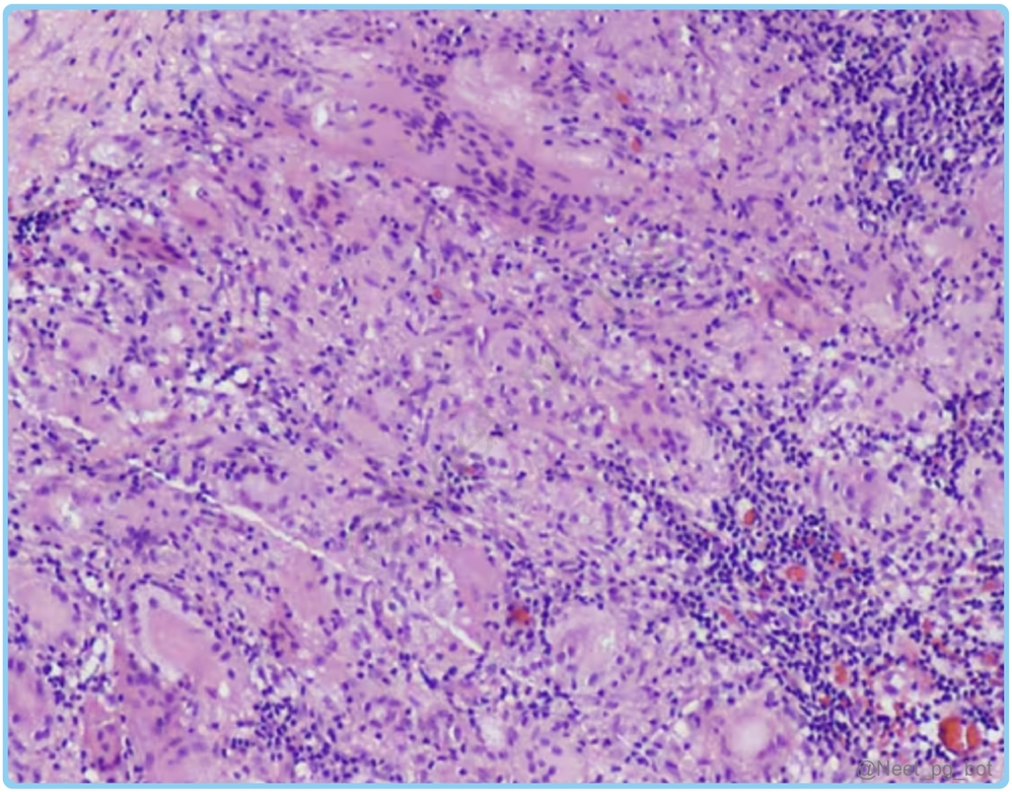

References:

Robbins and Cotran Pathologic Basis of Disease, 10th edition, page. 956

↑ *Back to this question in Part A*

@Neet_pg_bot

Q4: Which of the following statements are true regarding autosomal dominant polycystic kidney disease? 1) The gene associated with this condition is seen on chromosome 6. 2) The affected protein is fibrocystin. 3) It is associated with cyst formation in other organs. 4) The most common cause of death in these patients is hypertensive heart disease. (Q845682)

A. 1,2,3,4

B. 3,4

C. 2,3

D. 2,3,4

Correct Answer: B. 3,4

■ *Listen (English)*

■ *Listen (Hindi)*

Explanation: Characteristics ADPKD ARPKD Affected age group Adults (Males>Females) Children Cysts Are present in both outer and inner surfaces. Liver and pancreas as also affected other than the kidneys. (Statement 3) Present only on the inner surface. Involved gene PKD 1 on chromosome 16 PKD 2 on chromosome 4 PKHD on chromosome 6 (Statement 1) Protein affected polycystin Fibrocystin (Statement 2) Histology {{caption_text}} {{caption_text}} Complications Coronary or hypertensive heart disease (40%). (Statement 4) Infection (25%). Ruptured berry aneurysm or hypertensive intracerebral haemorrhage (15%). Neonatal period: Respiratory failure due to pulmonary hypoplasia. Renal failure. Childhood and adolescence: Progressive renal failure leading to ESRD. Complications of CKD. Complications from hepatic fibrosis. Images {{caption_text}} {{caption_text}}

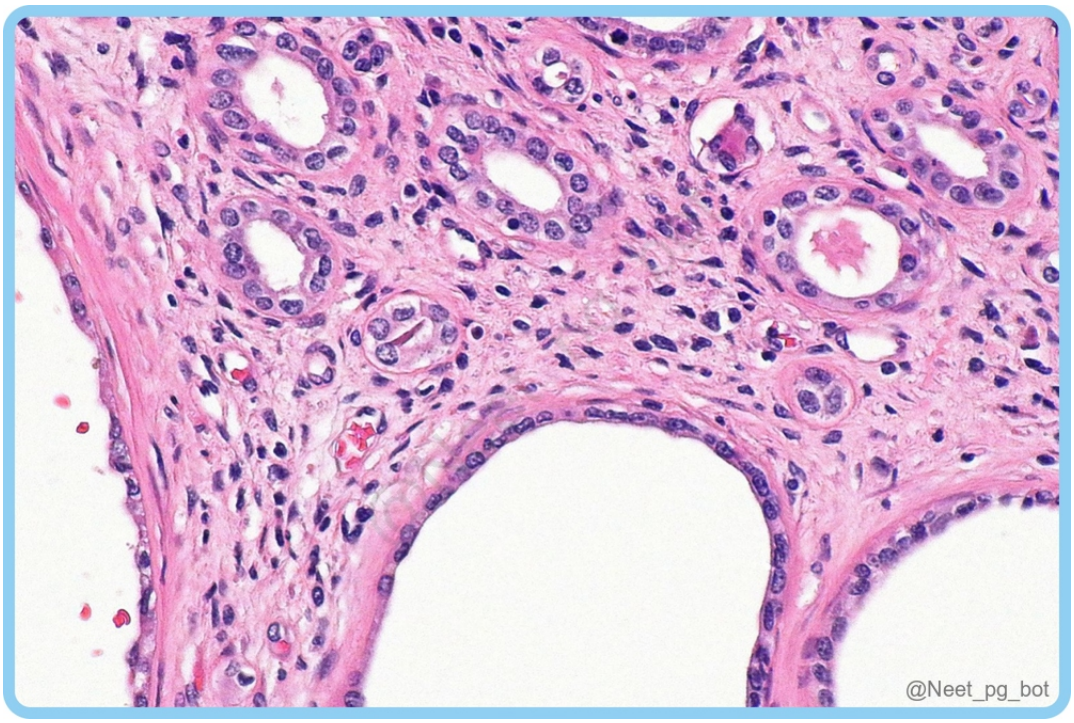
@Neet_pg_bot

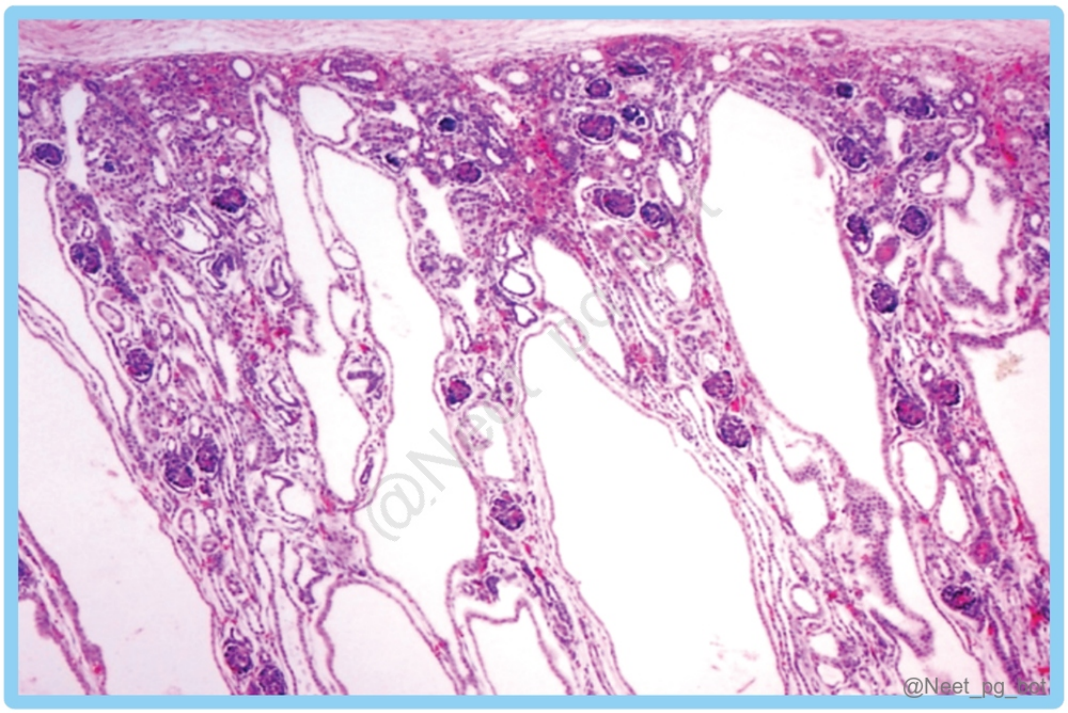
@Neet_pg_bot

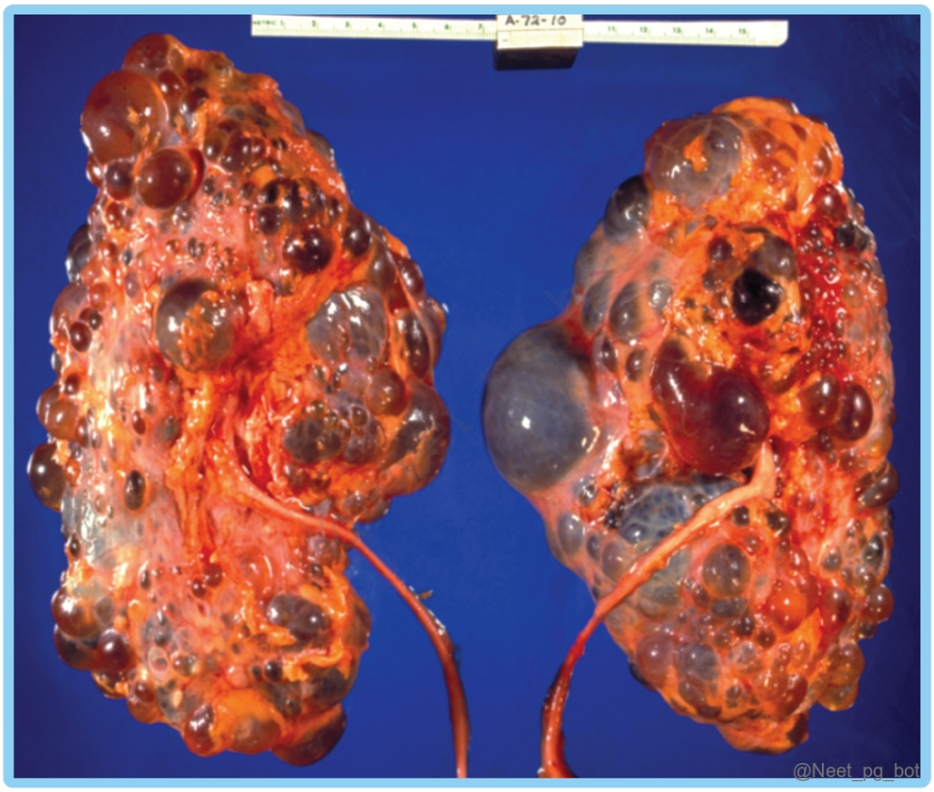

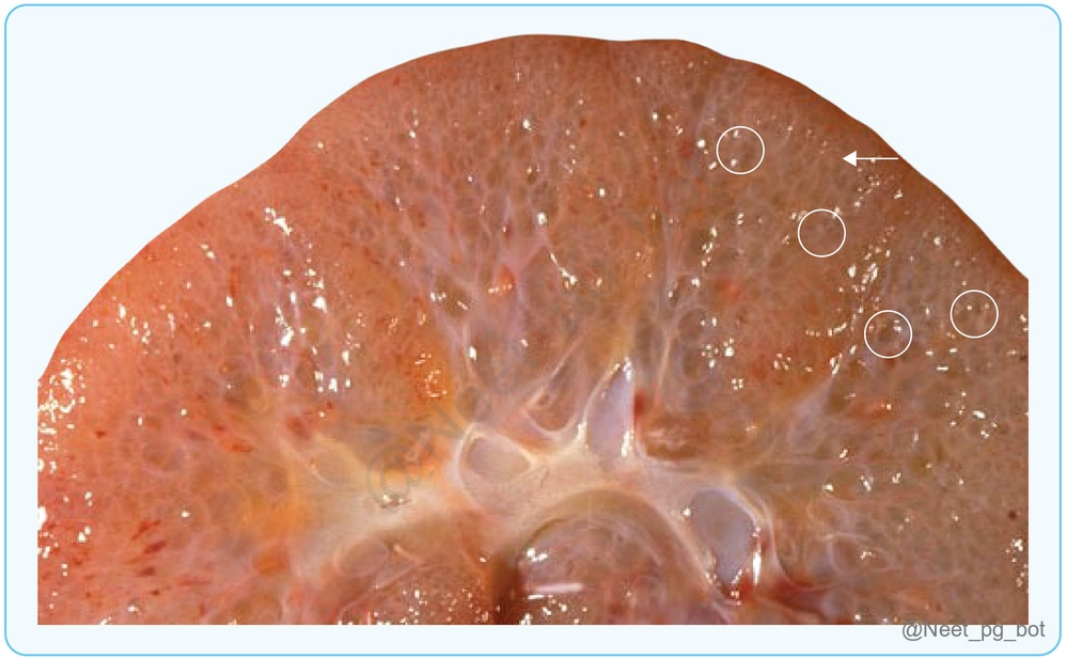

References:

Robbins and Cotran Pathologic Basis of Disease, 10th edition, Pages 941-944.

↑ *Back to this question in Part A*

@Neet_pg_bot

Q5: Match the following types of renal crystals with their characteristics Types of Renal Crystals Characteristics 1. Calcium Oxalate Monohydrate A. Coffin lid-shaped crystals, commonly found in alkaline urine 2.. Uric Acid B. Rhomboid-shaped crystals, typically seen in acidic urine. 3. Cystine C. Dumbbell or ovoid-shaped crystals are often colourless in acidic urine. 4. . Struvite (Magnesium Ammonium Phosphate) D. Hexagonal plates, often associated with acidic urine (Q845683)

A. 1-D, 2-B, 3-C, 4-A

B. 1-A, 2-B, 3-D, 4-C

C. 1-C, 2-B, 3-D, 4-A

D. 1-C, 2-D, 3-B, 4-A

Correct Answer: C. 1-C, 2-B, 3-D, 4-A

■ *Listen (English)*

■ *Listen (Hindi)*

Explanation: The microscopic appearance of various types of crystals and their descriptions are given below: Struvite/ Staghorn stones: Triple phosphate crystal (Magnesium Ammonium Phosphate) Radioopaque. Seen in alkaline urine. Rectangular/coffin lid appearance. Associated with urea-splitting organisms. Cystine Stones Radiopaque. Seen in acidic urine. Hexagonal Shaped. Very hard stones. Calcium Oxalate Monohydrate stones Radiopaque/colourless. Seen in acidic urine. Dumbbell or ovoid-shaped. Most common type of renal calculi. Uric Acid crystals Radiolucent. Seen in acidic urine. Rhomboids or parallelograms. Ammonium Urate crystals Radiolucent. Associated with laxative abuse.


@Neet_pg_bot


@Neet_pg_bot

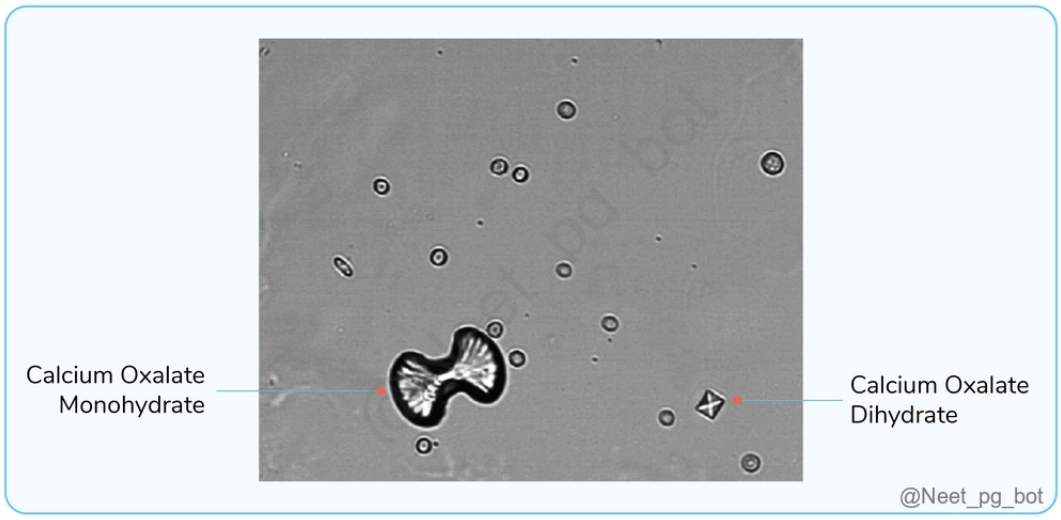
Calcium Oxalate
Monohydrate
Calcium Oxalate
Dihydrate
@Neet_pg_bot

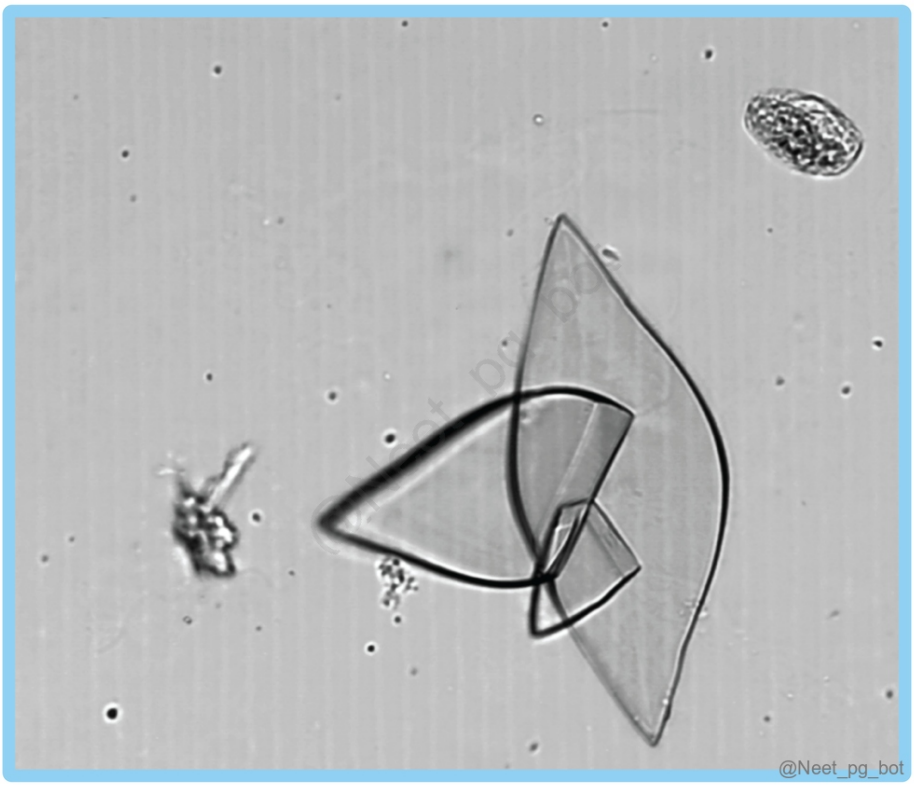
@Neet_pg_bot

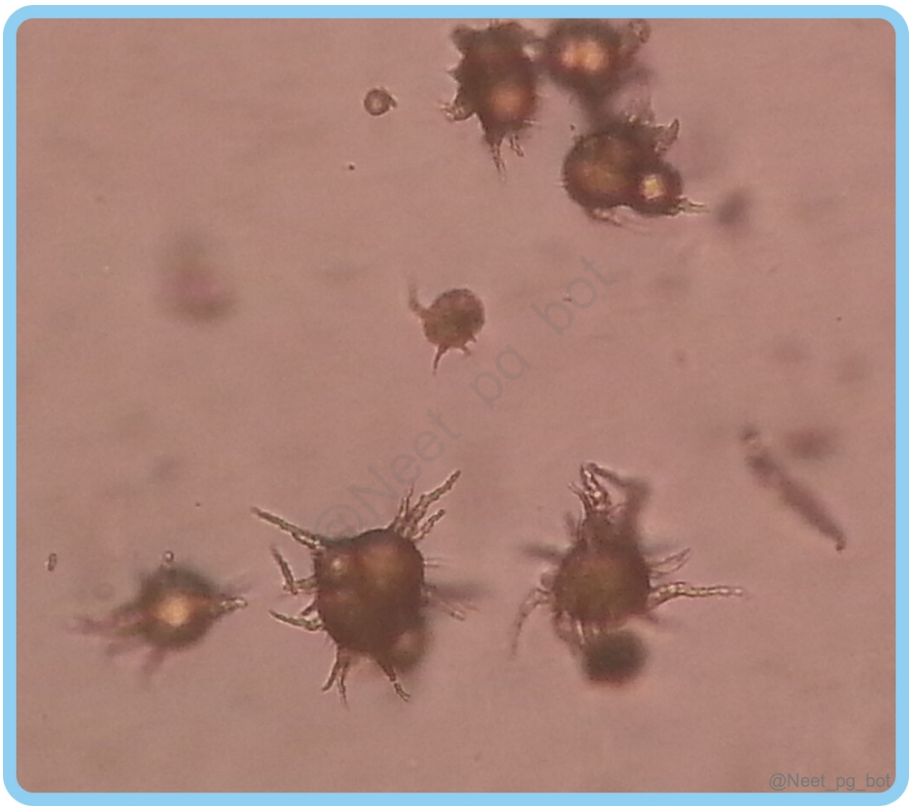

References:

Robbins and Cotran Pathologic Basis of Disease, 10th edition, page 947

↑ *Back to this question in Part A*

@Neet_pg_bot

Q6: A 45-year-old woman presents with complaints of severe lower abdominal pain, dysuria, and hematuria. She has a history of recurrent urinary tract infections (UTIs). Urinalysis reveals a high pH of 8.5 and the presence of white blood cells. Microscopic examination of the urine sediment shows the following finding. Which of the following is the most likely underlying cause of the patient's current presentation? (Q845684)

A. Hypercalcemia

B. Hyperuricemia

C. Infection with urease-producing bacteria

D. Cystinuria



Correct Answer: C. Infection with urease-producing bacteria

- *Listen (English)*
- *Listen (Hindi)*

Explanation: Triple phosphate stones, also known as struvite stones, are composed of magnesium ammonium phosphate (Triple phosphate crystal). They typically form in alkaline urine due to urinary tract infections caused by urease-producing bacteria- Protease . Struvite stones are characterised by their "coffin lid" appearance under a microscope. They can grow rapidly and fill the renal pelvis, leading to complications like infection and obstruction. Hypercalcemia, Hyperuricemia and Cystinuria are seen with acidic urine.



References:

Robbins and Cotran Pathologic Basis of Disease, 10th Edition, Page 947

↑ *Back to this question in Part A*

@Neet_pg_bot

Q7: Match the following renal casts with the conditions they are associated with: Renal Cast Type Condition Associated 1. Hyaline casts A. Nephrotic syndrome 2. Muddy Granular casts B. Chronic Renal Failure 3. Waxy casts C. Acute tubular necrosis 4. Fatty casts D. Fever (Q845685)

A. 1-C, 2-A, 3-B, 4-D

B. 1-B, 2-D, 3-C, 4-A

C. 1-D, 2-C, 3-B, 4-A

D. 1-D, 2-A,3-C, 4-B

Correct Answer: C. 1-D, 2-C, 3-B, 4-A

■ *Listen (English)*

■ *Listen (Hindi)*

Explanation: All casts are composed of Tamm-Horsfall protein produced in the thick ascending limb of loop of Henle . Various casts seen on urine examination are as follows. Renal Cast Type Condition Associated Images Hyaline casts Normal conditions, Fever, Pregnancy. Composed of Tamm-Horsfall protein which is normally produced by loop of Henle. Increase in number of these cast can cause Fever or dehydration Muddy Brown/ granular casts Acute tubular necrosis, It is suggestive of cell death following which occurs following poisoning, like ethylene glycol or mercury poisoning. Waxy casts Chronic renal failure Fatty casts Nephrotic syndrome, associated with lipidurea RBC casts Glomerulonephritis WBC casts Pyelonephritis, interstitial nephritis Epithelial casts Renal epithelial injury {{caption_text}} Broad casts Chronic renal disease

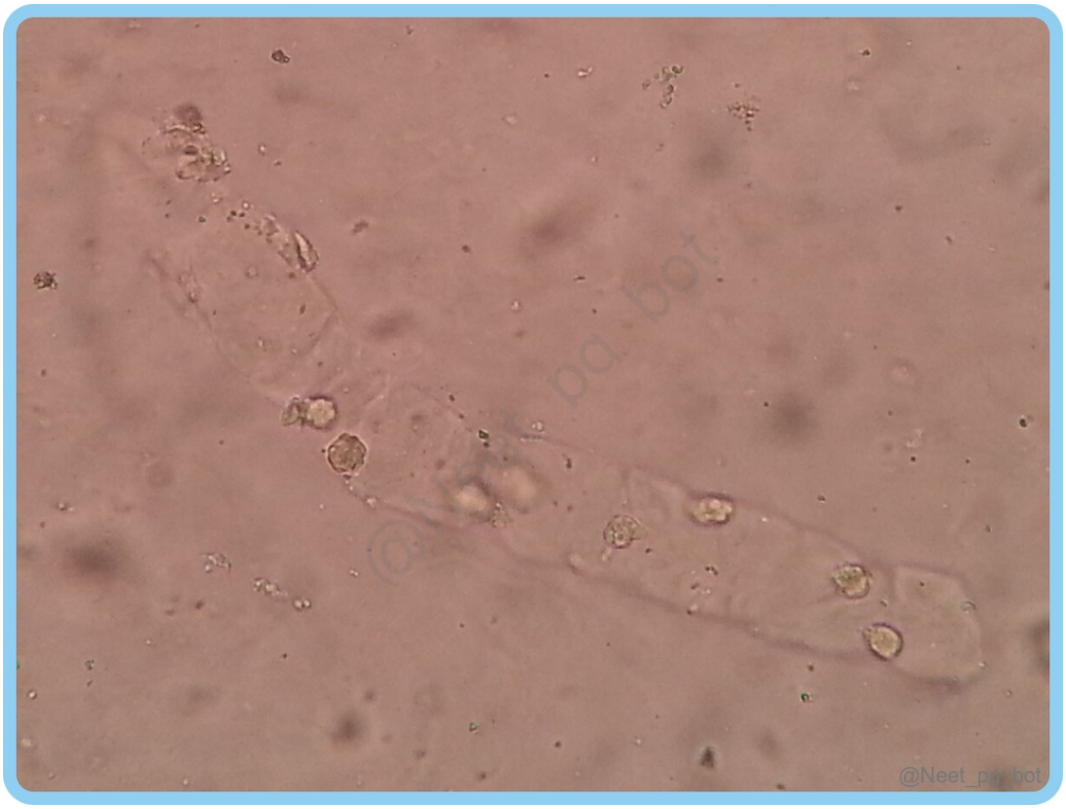


@Neet_pg_bot

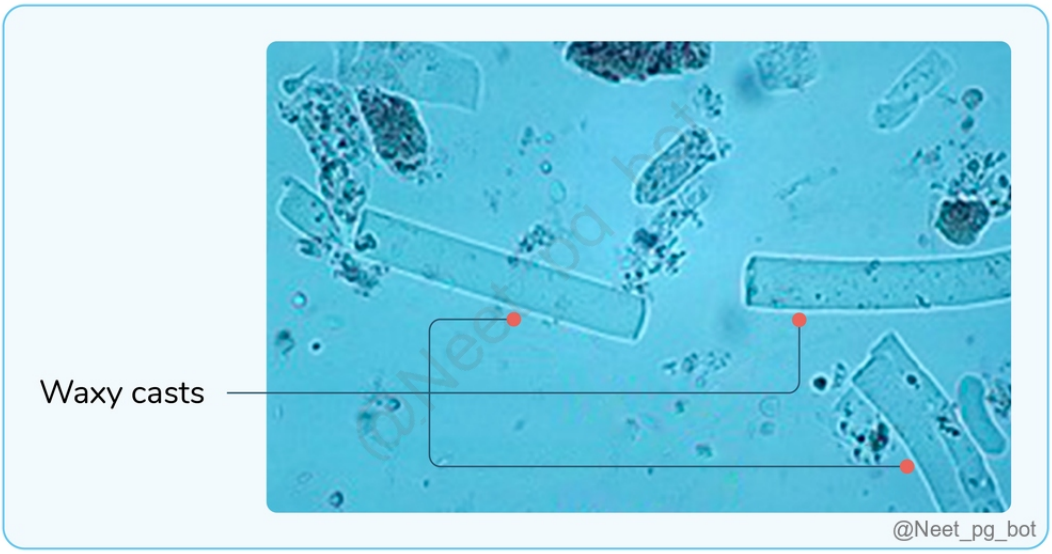

@Neet_pg_bot

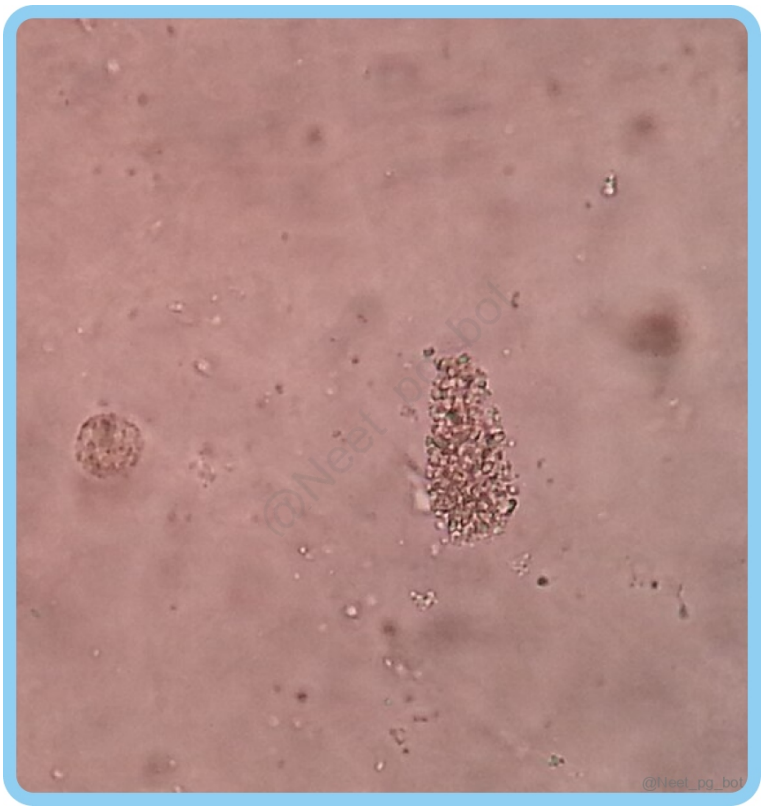
@Neet_pg_bot

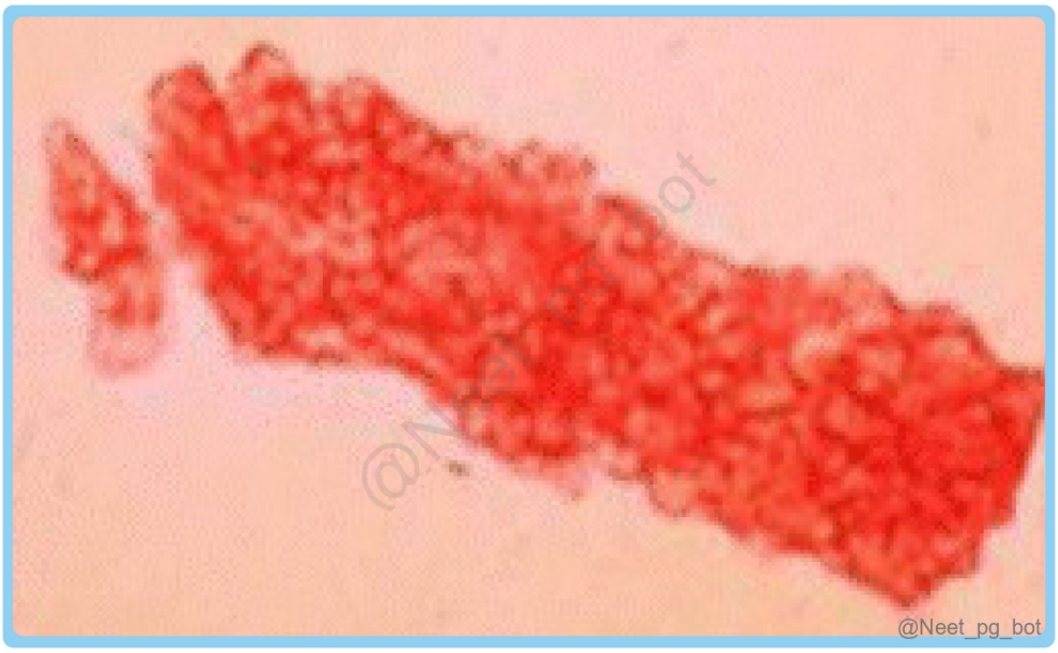
@Neet_pg_bot


@Neet_pg_bot


@Neet_pg_bot

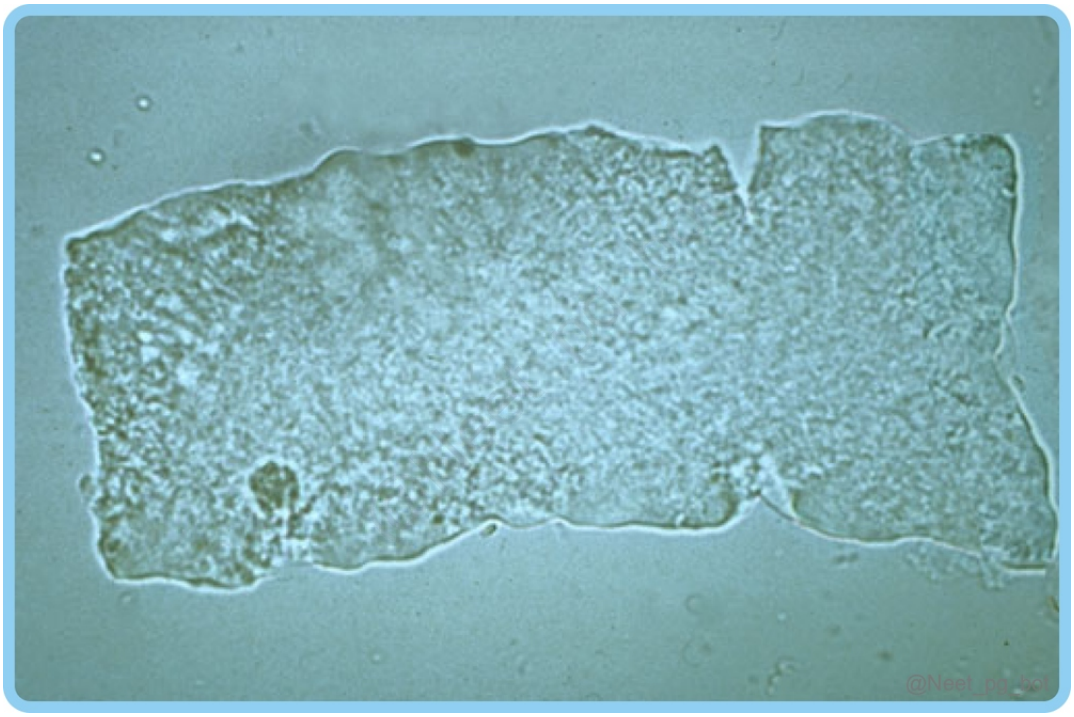

References:

Robbins and Cotran Pathologic Basis of Disease, 10th edition, page 947

↑ *Back to this question in Part A*

@Neet_pg_bot

Q8: A 45-year-old male presents with confusion, nausea, and abdominal pain after consuming antifreeze due to stress. Urinalysis reveals elevated BUN and creatinine. Microscopic examination is shown below. Identify the type of cast. (Q845687)

A. Hyaline casts

B. Granular casts

C. Waxy casts

D. Muddy brown casts



Correct Answer: D. Muddy brown casts

- *Listen (English)*
- *Listen (Hindi)*

Explanation: The clinical vignette of a patient with a history of anti-freeze consumption presenting with confusion, nausea, abdominal pain, elevated BUN and creatinine is suggestive of ethylene glycol poisoning . Muddy brown casts will be seen in this condition. Muddy brown casts: They are often seen in patients with ethylene glycol poisoning, leading to acute tubular necrosis (ATN). Ethylene glycol metabolites can damage renal tubules, resulting in the formation of muddy brown casts in urine sediment. Hyaline casts (Option A): Seen normally and are also increased during fever and dehydration. Granular casts (Option B): Seen due to degenerated cells. Waxy casts (Option C): Seen in chronic renal failure



References:

Robbins and Cotran Pathologic Basis of Disease, 10th Edition, Page 947

↑ *Back to this question in Part A*

@Neet_pg_bot

Q9: All of the following are true about medullary sponge kidney except: (Q845692)

A. It is more common in adults.

B. It is characterised by dilated collecting ducts in the renal medulla.

C. It is caused by an autoimmune destruction of renal tubules.

D. Cysts are lined by cuboidal epithelium.

Correct Answer: C. It is caused by an autoimmune destruction of renal tubules.

■ *Listen (English)*

■ *Listen (Hindi)*

Explanation: Medullary Sponge Kidney (MSK) is a congenital developmental anomaly. There is no immune mediated tubule destruction involved. Medullary Sponge Kidney: The term medullary sponge kidney is restricted to multiple cystic dilations of the collecting ducts in the medulla. The condition occurs in adults. (Option A) .

Renal function is usually normal. On gross inspection, the papillary ducts in the medulla are dilated (Option B) and small cysts may be present. The cysts are lined by cuboidal epithelium or occasionally by transitional epithelium. (Option D).

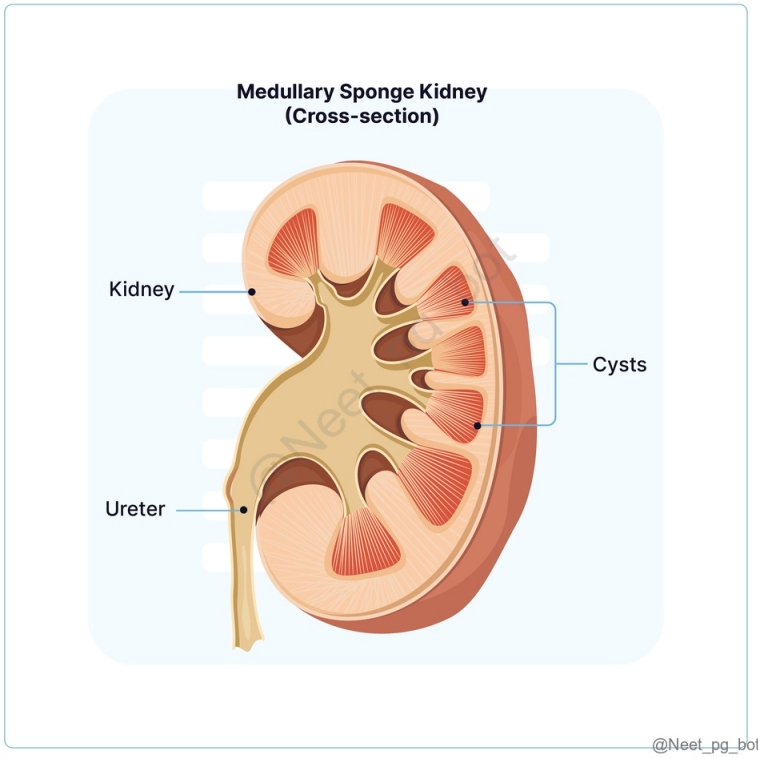

MEDULLARY CYSTIC KIDNEY	MEDULLARY SPONGE KIDNEY

• Cysts are present at the corticomedullary junction
• Types
  ○ Autosomal dominant
  ○ Autosomal recessive / Familial juvenile nephronophthisis
  → Salt wasting
  → Polyuria
	• Medullary cysts
	• Cortex is normal
	• Renal stones +

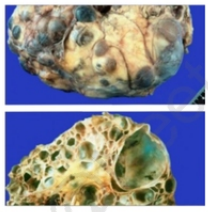

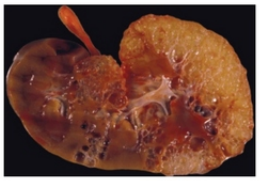

@Neet_pg_bot

References:

Robbins and Cotran Pathologic Basis of Disease, 10th Edition, Page 944

↑ *Back to this question in Part A*

@Neet_pg_bot

Q10: A 45-year-old man presents with generalised oedema and frothy urine. Laboratory evaluation shows hypoalbuminemia and hyperlipidemia. Urinalysis

reveals heavy proteinuria. What is the minimum daily urinary protein loss required to define nephrotic syndrome in adults? (Q889840)

A. 2.5 g/day

B. 3 g/day

C. 3.5 g/day

D. 4 g/day

Correct Answer: C. 3.5 g/day

Explanation: Nephrotic syndrome in adults is defined by proteinuria ≥3.5 g/day. Nephrotic syndrome: Increased permeability of the glomerular capillary wall Leads to excessive loss of plasma proteins in urine Core features: Massive proteinuria: ≥ 3.5 g/day (less in children) Hypoalbuminemia: Serum albumin < 3 g/dL Generalized edema Hyperlipidemia Lipiduria

References:

Robbins, Cotran & Kumar, Pathologic Basis of Disease, 11th Edition, Page 827

↑ *Back to this question in Part A*

@Neet_pg_bot

Q11: Which of the following mutations are associated with nephrotic syndrome? Nephrin Podocin ACTN4 INF2 TRPC6 (Q889842)

A. 1 and 2 only

B. 1, 2 and 5 only

C. 1, 2, 3 and 4 only

D. 1, 2, 3, 4 and 5

Correct Answer: D. 1, 2, 3, 4 and 5

Explanation: All listed mutations are associated with nephrotic syndrome , primarily through disruption of podocyte structure and slit diaphragm integrity . NPHS1 (Nephrin) : Encodes nephrin , a vital component of the slit diaphragm. Mutations lead to congenital nephrotic syndrome of the Finnish type . Characterised by minimal change disease-like glomerulopathy and extensive foot process effacement. NPHS2 (Podocin) : Encodes podocin , an intracellular protein associated with the slit diaphragm. Mutations cause autosomal recessive FSGS , typically presenting as steroid-resistant nephrotic syndrome in children. ACTN4 & INF2 : Encode actin-binding proteins α-actinin-4 and inverted formin-2 . Associated with autosomal dominant FSGS . Features an insidious onset with a

high risk of progression to renal insufficiency. TRPC6 : Found in families with adult-onset FSGS . Mutations are thought to disrupt podocyte function by increasing calcium flux in the cells.

References:

Robbins, Cotran & Kumar, Pathologic Basis of Disease, 11th Edition, Page 831

↑ *Back to this question in Part A*

@Neet_pg_bot

Q12: A 42-year-old man with nephrotic syndrome presents with generalised oedema and frothy urine. Laboratory tests reveal hypoalbuminemia and marked hyperlipidemia. He is noted to have an increased risk of thrombosis. Which of the following plasma proteins is increased in nephrotic syndrome? (Q889844)

A. Antithrombin III

B. Albumin

C. Fibrinogen

D. Immunoglobulin G

Correct Answer: C. Fibrinogen

Explanation: The liver increases the synthesis of fibrinogen and other coagulation factors to compensate for the low plasma oncotic pressure. Nephrotic syndrom e is characterized by massive urinary loss of plasma proteins due to increased glomerular permeability. In response to reduced plasma oncotic pressure, the liver increases synthesis of several proteins, including: Fibrinogen Other coagulation factors Lipoproteins Elevated fibrinogen levels contribute to the hypercoagulable state seen in nephrotic syndrome, increasing the risk of venous thrombosis (e.g., renal vein thrombosis). Antithrombin III (Option A): Lost in the urine and decreased in plasma, contributing to thrombosis risk. Albumin (Option B): Lost in large amounts in urine. Although hepatic synthesis increases, plasma albumin levels remain low (hypoalbuminemia). Immunoglobulin G (Option D): Lost in urine, leading to decreased plasma levels and increased susceptibility to infections.

References:

https://pubmed.ncbi.nlm.nih.gov/9453016/

↑ *Back to this question in Part A*

@Neet_pg_bot

Q13: A 40-year-old man presents with nephrotic-range proteinuria. Renal biopsy shows focal and segmental glomerulosclerosis. You are reviewing conditions associated with secondary FSGS. Which of the following is not associated with FSGS? (Q889847)

A. Reflux nephropathy

B. Sickle cell disease

C. ACTN4 mutation

D. Minimal change disease

Correct Answer: D. Minimal change disease

Explanation: Minimal change disease is a distinct primary podocytopathy characterised by diffuse foot process effacement without segmental sclerosis. It is not classified under FSGS. Focal Segmental Glomerulosclerosis (FSGS): Classification: Primary: Idiopathic Secondary: Viral & Toxic Injury: Caused by infections (HIV, SARS-CoV-2), heroin addiction, sickle cell disease (Option B) , or other direct toxicities. Adaptive Changes: Reduced renal mass (nephrectomy, reflux nephropathy (Option A) , agenesis) Obesity, advanced CKD Mechanism: glomerular hypertension → podocyte loss → sclerosis Inherited Forms: Uncommon mutations in slit diaphragm- and actin cytoskeleton-associated proteins. NPHS1 (nephrin) → congenital nephrotic syndrome (Finnish type) NPHS2 (podocin) → steroid-resistant childhood nephrotic syndrome ACTN4 (Option C) → autosomal dominant FSGS INF2 → autosomal dominant FSGS TRPC6 → adult-onset FSGS APOL1 Risk Alleles Secondary Scarring: IgA nephropathy ANCA-associated vasculitis

References:

Robbins, Cotran & Kumar, Pathologic Basis of Disease, 11th Edition, Page 831

↑ *Back to this question in Part A*

@Neet_pg_bot

Q14: Which of the following FSGS variants is associated with the best prognosis, and which is associated with the worst prognosis? (Q889849)

A. Hilar variant - Best; Cellular variant - Worst

B. Tip lesion variant - Best; Collapsing variant - Worst

C. Collapsing variant - Best; Tip lesion variant - Worst

D. Cellular variant - Best; Hilar variant - Worst

Correct Answer: B. Tip lesion variant - Best; Collapsing variant - Worst

Explanation: Tip lesion variant is associated with the best prognosis. It often responds well to corticosteroid therapy and has more favorable renal outcomes. Collapsing variant has the worst prognosis. It is characterized by collapse of glomerular capillary loops with podocyte proliferation and is associated with rapid progression to renal failure. Focal Segmental Glomerulosclerosis (FSGS): Focal : some glomeruli Segmental : part of tuft Primary podocytopathy → podocyte loss → sclerosis Clinical features: Nephrotic syndrome (often nonselective proteinuria) Hematuria, hypertension, ↓ GFR are common Poor steroid response ~50% → ESKD in 10 years 25–50% recurrence post-transplant Variants: Collapsing glomerulopathy (poor prognosis) Cellular variant Hilar lesion Tip lesion (better prognosis) Not otherwise specified (NOS)

References:

Robbins, Cotran & Kumar, Pathologic Basis of Disease, 11th Edition, Page 831

Harrison’s Principles of Internal Medicine, 21st Edition, Page 2342

↑ *Back to this question in Part A*

@Neet_pg_bot

Q15: Which of the following conditions is characterised by the absence of mesangial immune complex deposits? (Q889850)

A. IgA nephropathy

B. Lupus nephritis (Class II)

C. Henoch-Schönlein Purpura

D. Anti-GBM disease

Correct Answer: D. Anti-GBM disease

Explanation: Anti-GBM disease is characterized by linear deposition of IgG along the glomerular basement membrane on immunofluorescence. It is a type II hypersensitivity reaction , in which antibodies bind directly to GBM antigens. It does not involve immune complex deposition in the mesangium. Conditions showing mesangial deposits: IgA Nephropathy (Berger's Disease) (Option A) : Granular mesangial IgA deposition. Membranoproliferative Glomerulonephritis (MPGN) (Types I and II) C3 Glomerulopathy (Dense Deposit Disease and C3 Glomerulonephritis) Lupus Nephritis (specifically Classes I and II) (Option B): Mesangial immune complex deposition with “full house” immunofluorescence. Henoch-Schönlein-Purpura (IgA-Vasculitis) (Option C) : IgA-mediated vasculitis with mesangial IgA deposits.

References:

Robbins, Cotran & Kumar, Pathologic Basis of Disease, 11th Edition, Pages 821, 824, 826

↑ *Back to this question in Part A*

Q16: A child with nephrotic syndrome undergoes serum protein electrophoresis. Which protein is increased? (Q889852)

A. Albumin

B. α1-antitrypsin

C. α2-macroglobulin

D. IgG

Correct Answer: C. α2-macroglobulin

Explanation: α2-macroglobulin is increased in nephrotic syndrome. In nephrotic syndrome, there is massive urinary loss of low molecular weight proteins such as albumin and IgG. In response to decreased oncotic pressure, the liver increases the synthesis of various proteins. α2-macroglobulin is a very large molecule that: Is not filtered through the damaged glomerulus Is retained in plasma Increases in concentration Produces a rise in the α2-globulin fraction on serum electrophoresis Serum electrophoresis in nephrotic syndrome: Pattern: ↓ Albumin ↑ α2-globulin fraction ↓ γ-globulin (IgG) Albumin (Option A): Decreased due to heavy urinary loss. α1-antitrypsin (Option B): May be lost in urine and is not characteristically elevated. IgG (Option D): Lost in urine, leading to decreased levels and increased infection risk.

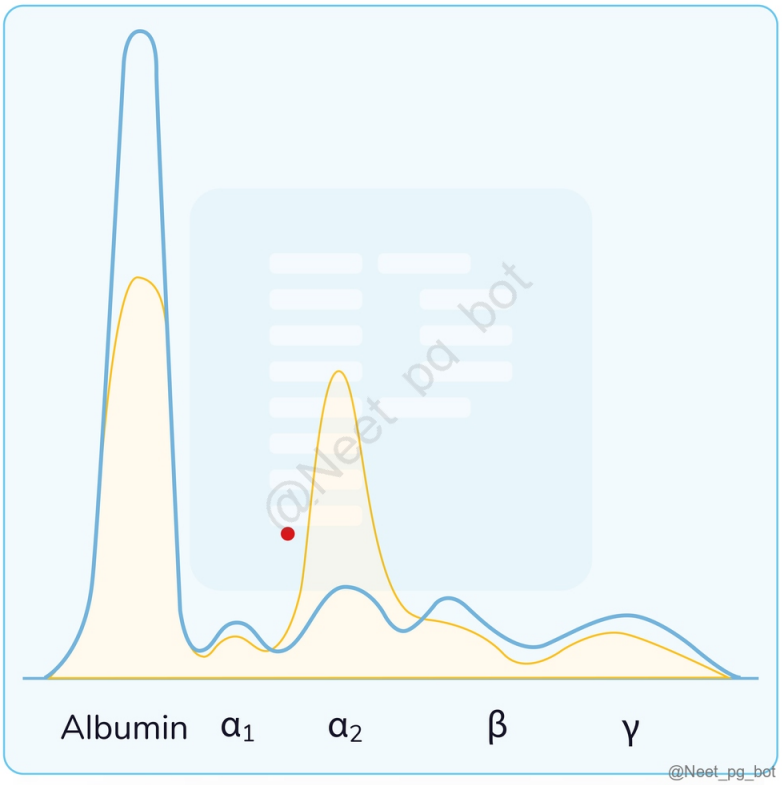

References:

https://pubmed.ncbi.nlm.nih.gov/9690220/

↑ *Back to this question in Part A*

@Neet_pg_bot

• [11_Renal System] 049 Nephritic And Nephrotic Syndromes

« Back to Folder Directory

[11_Renal System] 049 Nephritic And Nephrotic Syndromes — Quick Jump

Q1 (p. 2134)	*Q2 (p. 2135)*	*Q3 (p. 2139)*	*Q4 (p. 2142)*	*Q5 (p. 2145)*	*Q6 (p. 2147)*
Q7 (p. 2149)	*Q8 (p. 2150)*	*Q9 (p. 2152)*	*Q10 (p. 2153)*	*Q11 (p. 2156)*	*Q12 (p. 2157)*
Q13 (p. 2158)	*Q14 (p. 2160)*	*Q15 (p. 2161)*	*Q16 (p. 2164)*	*Q17 (p. 2166)*	*Q18 (p. 2168)*

Q1: A 9-year-old boy is brought to the clinic with swelling around the eyes, dark "tea-colored" urine, and decreased urine output. His mother reports that he had a skin infection (impetigo) about 3 weeks ago. On examination, he has mild periorbital edema and elevated blood pressure. Urinalysis shows RBC casts and mild proteinuria. Serum studies reveal low C3 complement levels. A renal biopsy is performed, and electron microscopy reveals following changes. Which of the following is the most likely diagnosis? (Q845704)

A. IgA nephropathy

B. Post-streptococcal glomerulonephritis

C. Membranous nephropathy

D. Minimal change disease

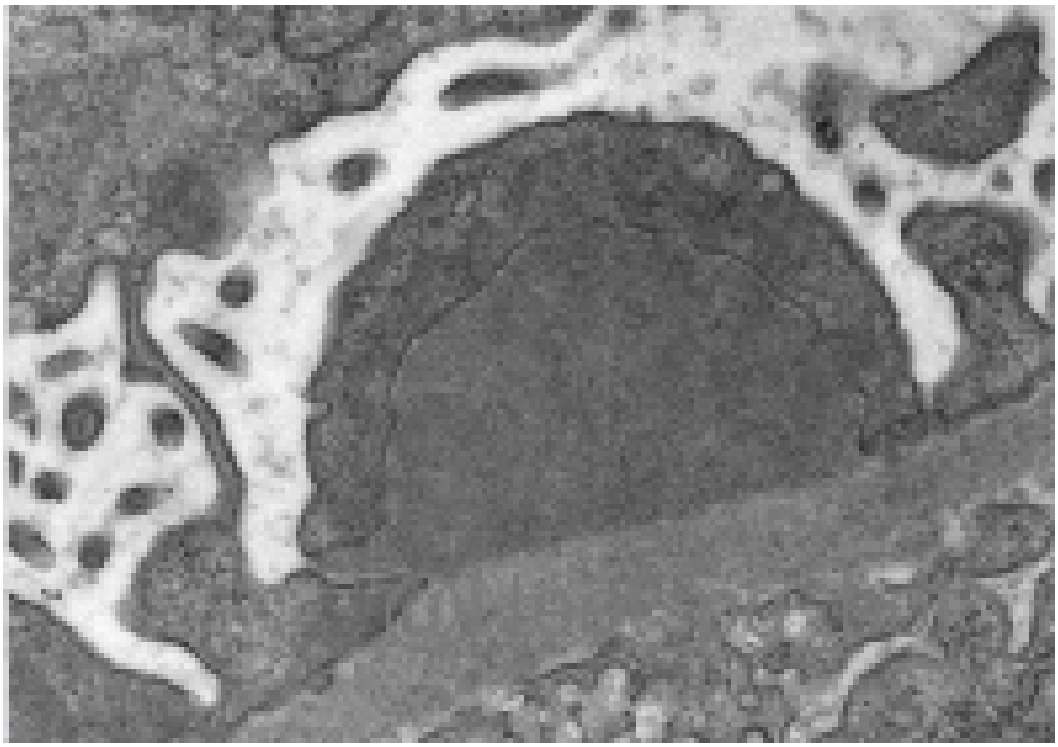

Correct Answer: B. Post-streptococcal glomerulonephritis

■ *Listen (English)*

■ *Listen (Hindi)*

Explanation: This child has the classic triad of PSGN: 1. Recent Streptococcal Infection Occurs 1–3 weeks after pharyngitis or impetigo (as in this case). 2. Clinical Features Periorbital edema Cola/tea-colored urine Hypertension RBC casts (nephritic syndrome) 3. Lab Findings Low C3 complement Normal C4 Anti-streptolysin O (ASO) may be elevated (more after pharyngitis than impetigo) 4. Electron Microscopy Subepithelial “hump-shaped” electron-dense deposits → pathognomonic IgA nephropathy (Option A) Typically occurs 1–2 days after a URI (synpharyngitic). Complement levels are usually normal. Deposits are mesangial, not subepithelial "humps." Membranous nephropathy (Option C) Presents with nephrotic syndrome, not nephritic. EM shows subepithelial spikes (“spike and dome”), not humps. Minimal change disease (Option D) Presents with nephrotic syndrome (massive proteinuria, edema). EM: effacement of podocyte foot processes, no immune deposits.

References:

Robbins and Cotran Pathologic Basis of Disease, 10th Edition, Page 909

↑ *Back to this question in Part A*

@Neet_pg_bot

Q2: A 12-year-old male child presents to the clinic with a history of progressive hearing loss, blurred vision, and recurrent episodes of hematuria over the past few

months.Electron microscopy reveals the ‘basketweave’ appearance of GBM. Which of the following morphological findings is responsible for this appearance? (Q846662)

A. Effacement of podocyte foot processes

B. Thickening of the glomerular basement membrane with subepithelial electron-dense deposits

C. Irregular thickening, thinning, and splitting of the glomerular basement membrane

D. Mesangial expansion with GBM thickening and eosinophilic nodular glomerulosclerosis

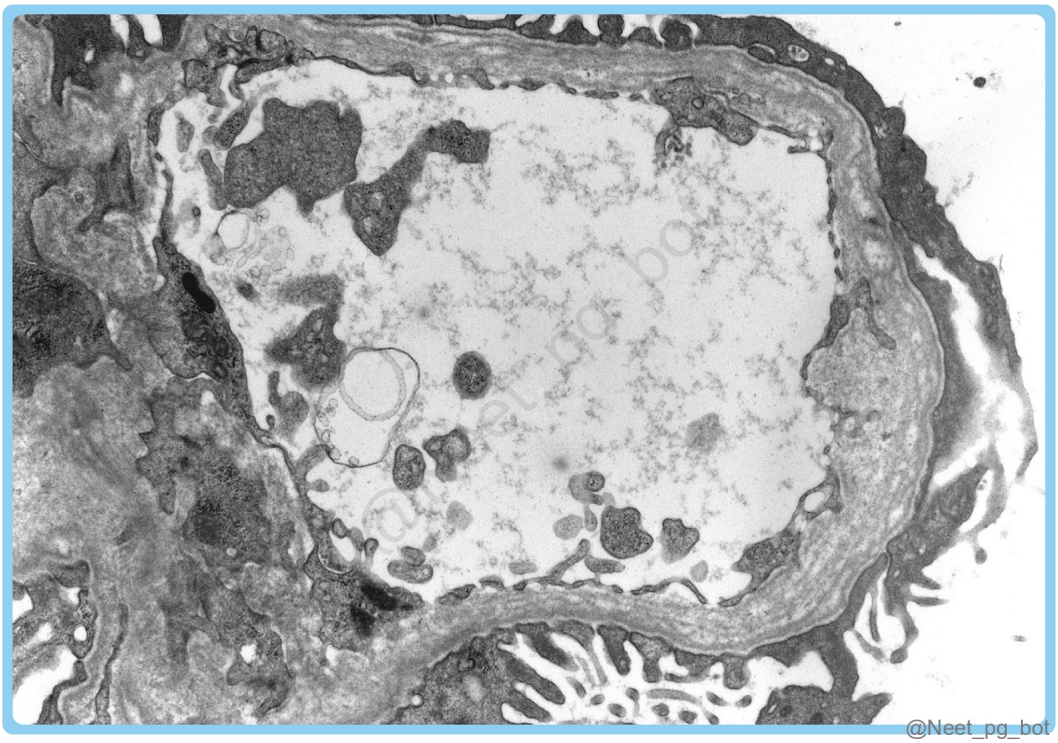

Correct Answer: C. Irregular thickening, thinning, and splitting of the glomerular basement membrane

■ *Listen (English)*

■ *Listen (Hindi)*

Explanation: The clinical presentation and EM findings of the characteristic basket-weave appearance of GBM suggest Alport syndrome. Alport syndrome arises due to mutations affecting Type IV collagen , specifically the α 5 chain (in X-linked cases) or the α3 and α4$ chains. This results in hematuria progressing to chronic renal insufficiency. Inheritance: Most commonly X-linked dominant (COL4A5), but can also be Autosomal Recessive or Dominant (COL4A3/4). Clinical Presentation: It presents alongside sensorineural hearing impairment and various ocular manifestations, including lens subluxation, posterior subcapsular cataracts, and corneal dystrophy. Histologically , Alport syndrome shows distinct electron microscopic features: GBM exhibits irregular areas of thickening interspersed with thinning. Splitting and layering of the lamina densa (basket-weave appearance of GBM) Effacement of podocyte foot processes (Option A): Effacement of podocytes is characteristically seen in Minimal change disease, not the Alport syndrome. Thickening of the glomerular basement membrane with

subepithelial electron-dense deposits (Option B): Membranous nephropathy shows the thickening of the glomerular basement membrane without hypercellularity on light microscopy, while electron microscopy shows the ‘spike and dome’ appearance of subepithelial deposits. Mesangial expansion with GBM thickening and eosinophilic nodular glomerulosclerosis (Option D): Diabetic glomerulonephropathy shows mesangial expansion with GBM thickening and eosinophilic nodular glomerulosclerosis (Kimmelstiel-Wilson lesions)

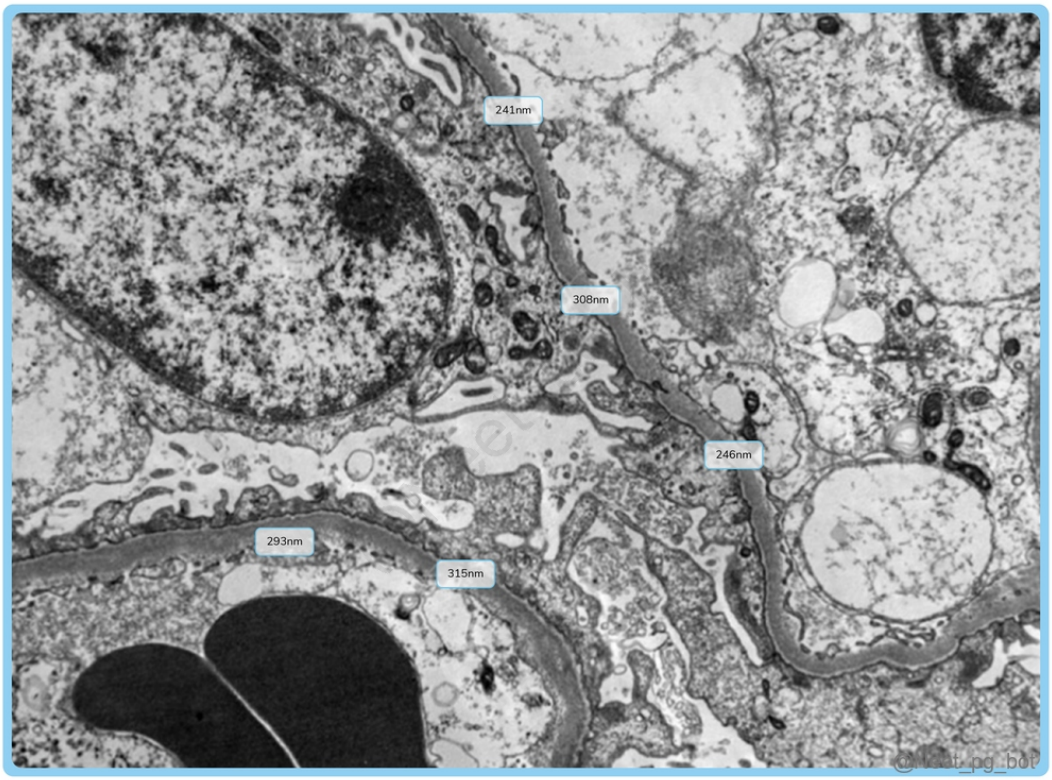

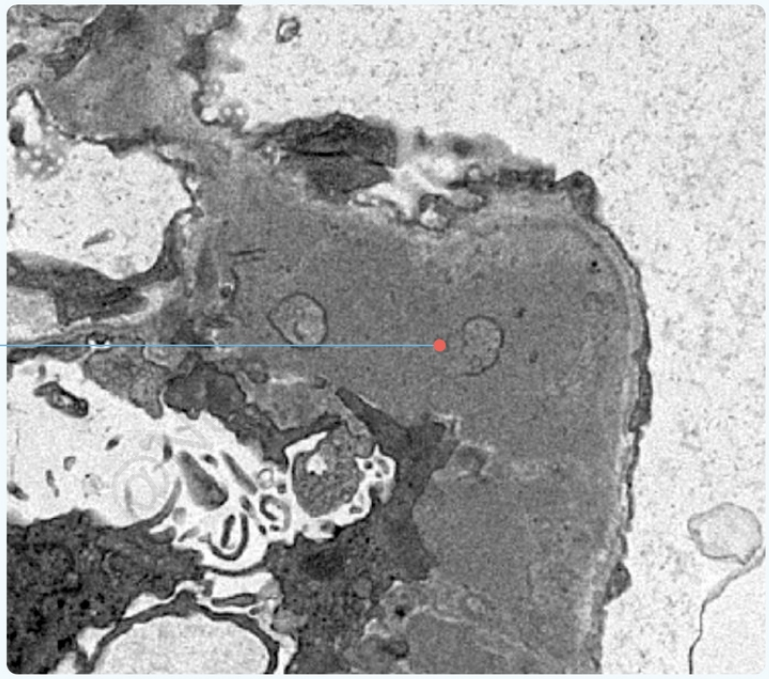

@Neet_pg_bot

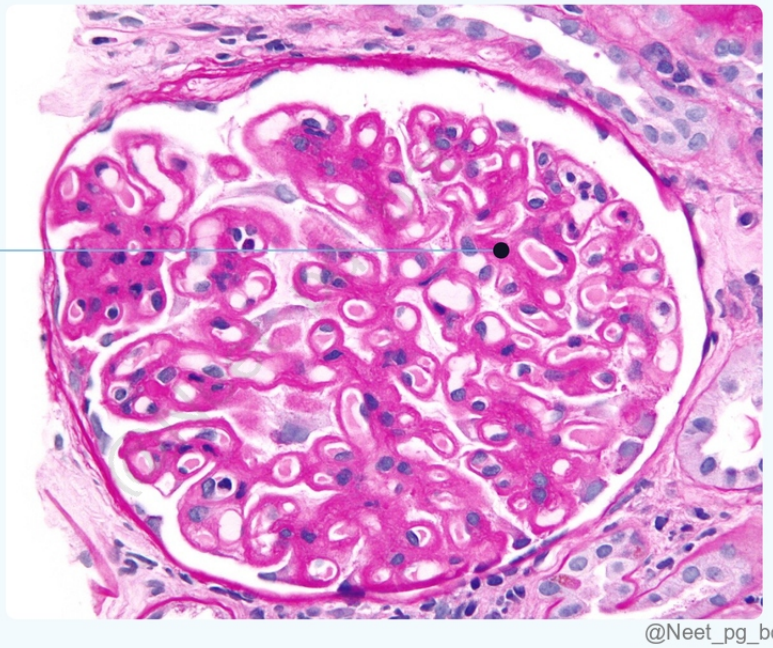

@Neet_pg_bot

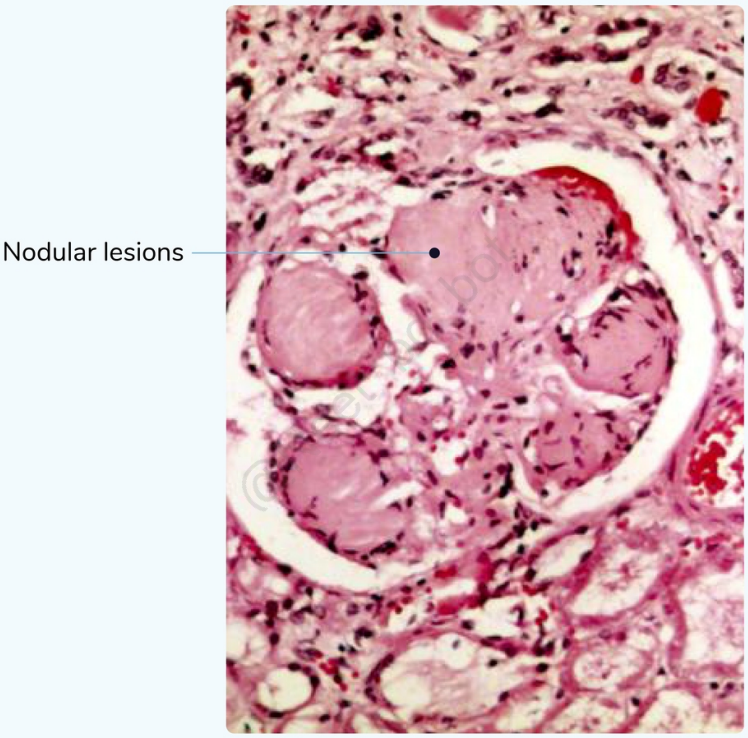

References:

Robbins and Cotran Pathologic Basis of Disease, 10th Edition, Pages 897-903 & 922-923.

↑ *Back to this question in Part A*

@Neet_pg_bot

Q3: A 55-year-old patient with a history of poorly controlled diabetes presents with worsening kidney function. Upon examination, renal biopsy reveals glomerular changes consistent with diabetic nephropathy. Which histological findings would be least likely to be observed in the glomeruli of this patient's kidney biopsy? (Q846670)

A. Kimmelstiel-Wilson nodule

B. Diffuse glomerulosclerosis

C. Arteriolar hyalinosis

D. Armani-Ebstein lesion

Correct Answer: D. Armani-Ebstein lesion

■ *Listen (English)*

■ *Listen (Hindi)*

Explanation: In uncontrolled diabetes, glucosuria causes glycogen accumulation in the proximal tubular cells (not in the glomerulus), known as Armanni-Ebstein cells. This pathological finding is more commonly associated with diabetic ketoacidosis (DKA) than with diabetic nephropathy. Kimmelstiel-Wilson nodule (Option A) Kimmelstiel-Wilson nodules (aka Nodular glomerulosclerosis) are a hallmark of diabetic nephropathy. They are ovoid or spherical, PAS-positive nodules found in the mesangial core of glomeruli. They are often accompanied by mesangiolysis and sometimes surrounded by dilated capillary loops. Diffuse glomerulosclerosis (Option B) Diffuse glomerulosclerosis refers to a diffuse increase in the mesangial matrix and thickening of GBM. It correlates with deteriorating renal function and increasing proteinuria. This is the most common histopathological finding of diabetic nephropathy. Arteriolar hyalinosis (Option C) Arteriolar hyalinosis involves the accumulation of hyaline material in the walls of both afferent and efferent arterioles, contributing to ischemia and kidney damage in diabetes. Hyaline material accumulated in capillary loops is known as “fibrin caps” in Bowman’s capsule, it is called “capsular drops.”

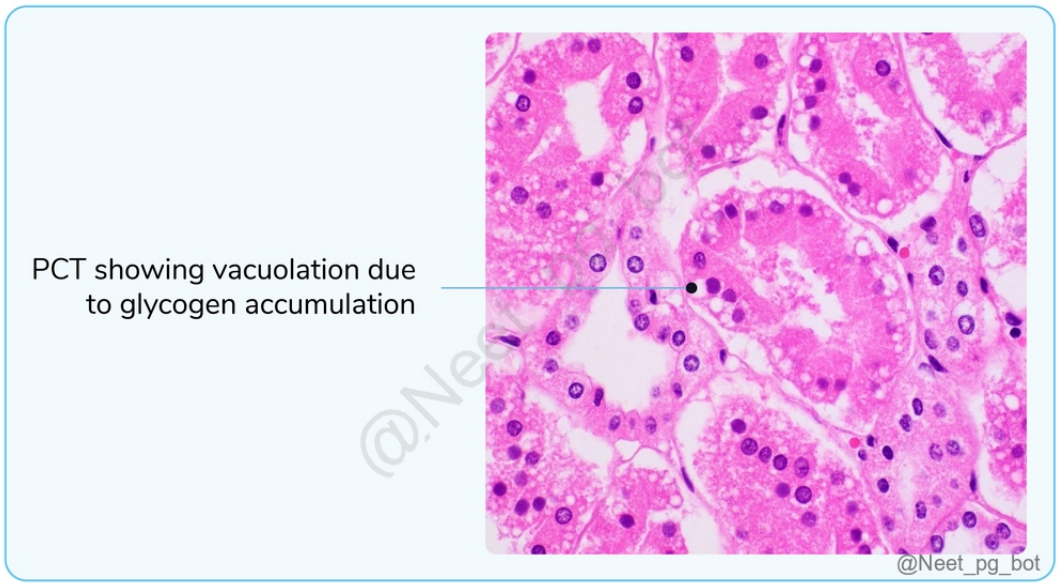



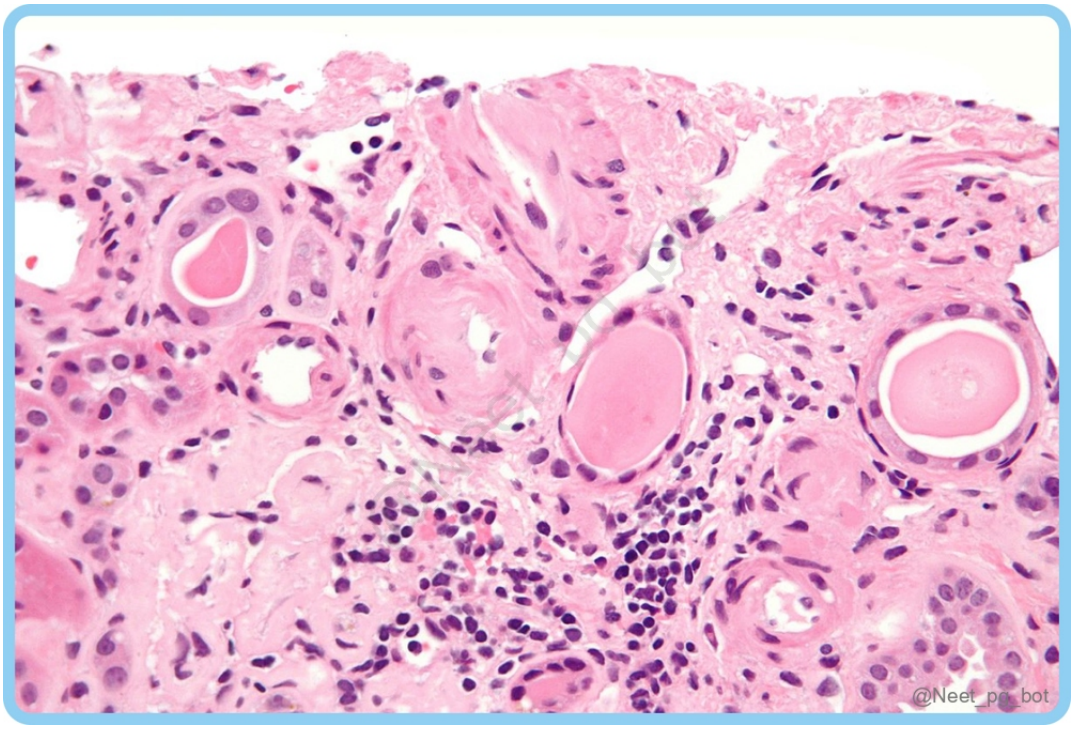

References:

Robbins and Cotran Pathologic Basis of Disease, 10th edition, page 1110, 1111

↑ *Back to this question in Part A*

Q4: A 32-year-old female presents with a history of joint pain, skin rash, and recent onset of shortness of breath. Lab investigations reveal elevated anti-double-stranded DNA antibodies and low complement levels. A kidney biopsy shows >50% involvement of glomeruli with wire loop lesions on light microscopy. Which type of lupus nephritis is most likely observed in the biopsy findings? (Q846669)

A. Class III

B. Class IV

C. Class V

D. Class VI

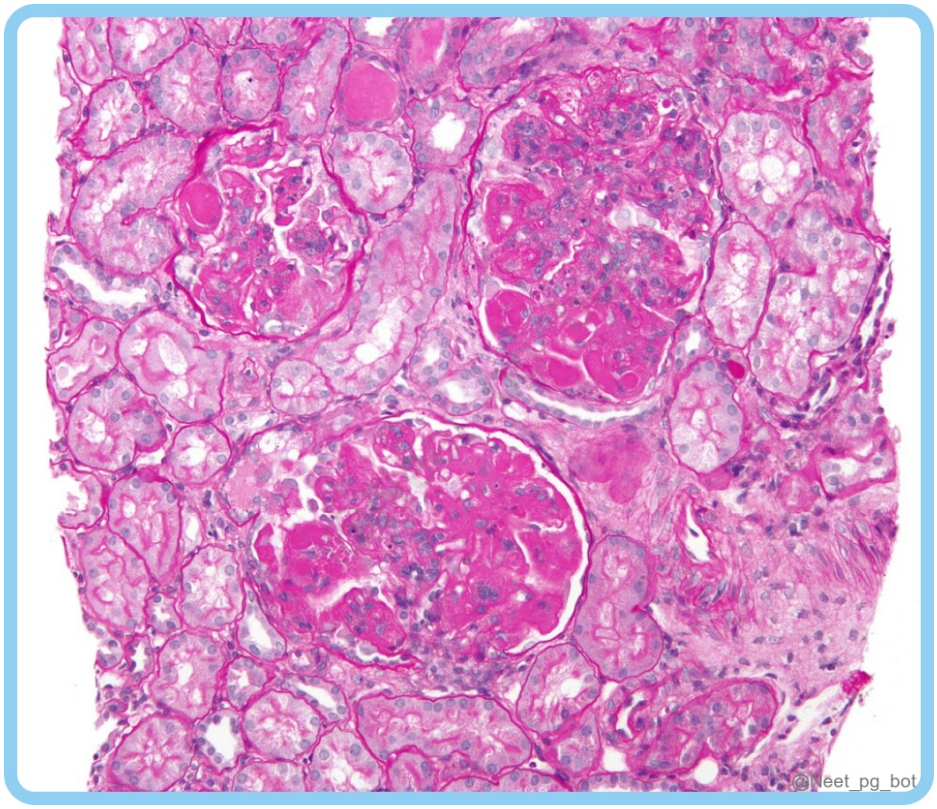

Correct Answer: B. Class IV

■ *Listen (English)*

■ *Listen (Hindi)*

Explanation: Based on the clinical scenario and lab results, the patient likely has systemic lupus erythematosus (SLE) with renal involvement. The kidney biopsy revealing >50% glomerular involvement with wire loop lesions indicates class IV lupus nephritis, the most common and severe form. Classification of Lupus Nephritis (LN): Class I Minimal Mesangial LN Class II Mesangial proliferative LN Class III (Option A) Focal LN (<50% glomeruli) Class IV Diffuse LN (>50% glomeruli) Class V (Option C) Membranous LN Class VI (Option D) Advanced Sclerosing LN Light microscopy: Subendothelial immune complex deposits can result in the circumferential thickening of the capillary wall, leading to the formation of "wire loop" structures, which are observed in Class III, IV (maximum) and V. Electron microscopy: Thumbprint/ fingerprint sign (alternating areas of electron-dense deposits and lucent regions in GBM, indicating immune complex deposition) Immunofluorescence: Full House Effect (IgG, IgA, IgM, C1, C3 get deposited in the kidney)

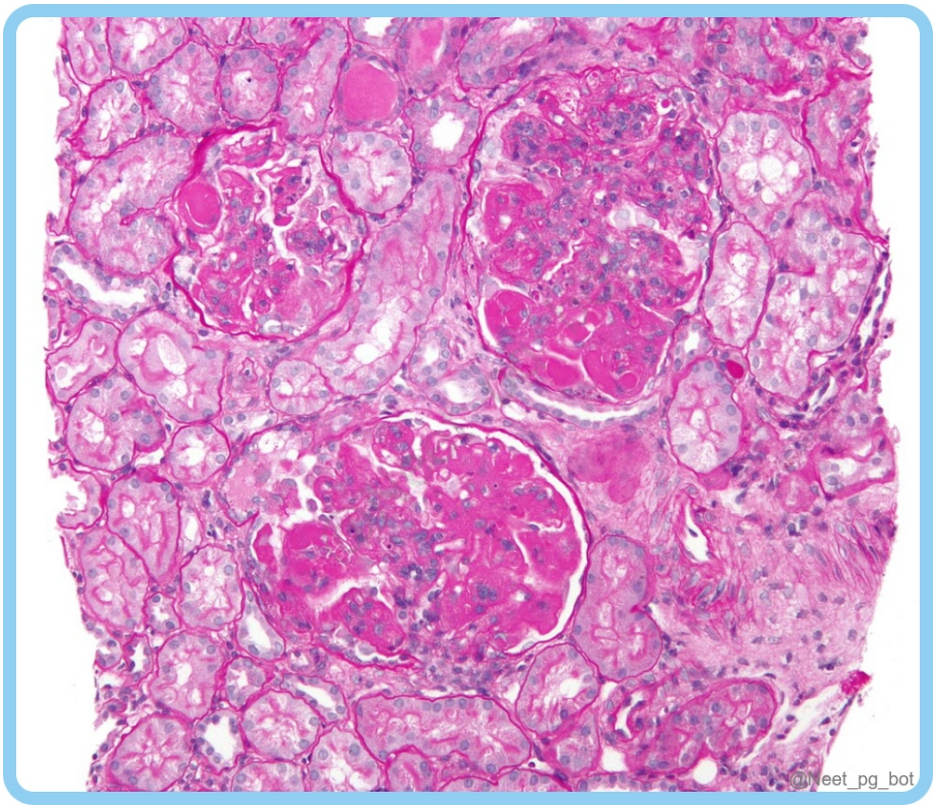



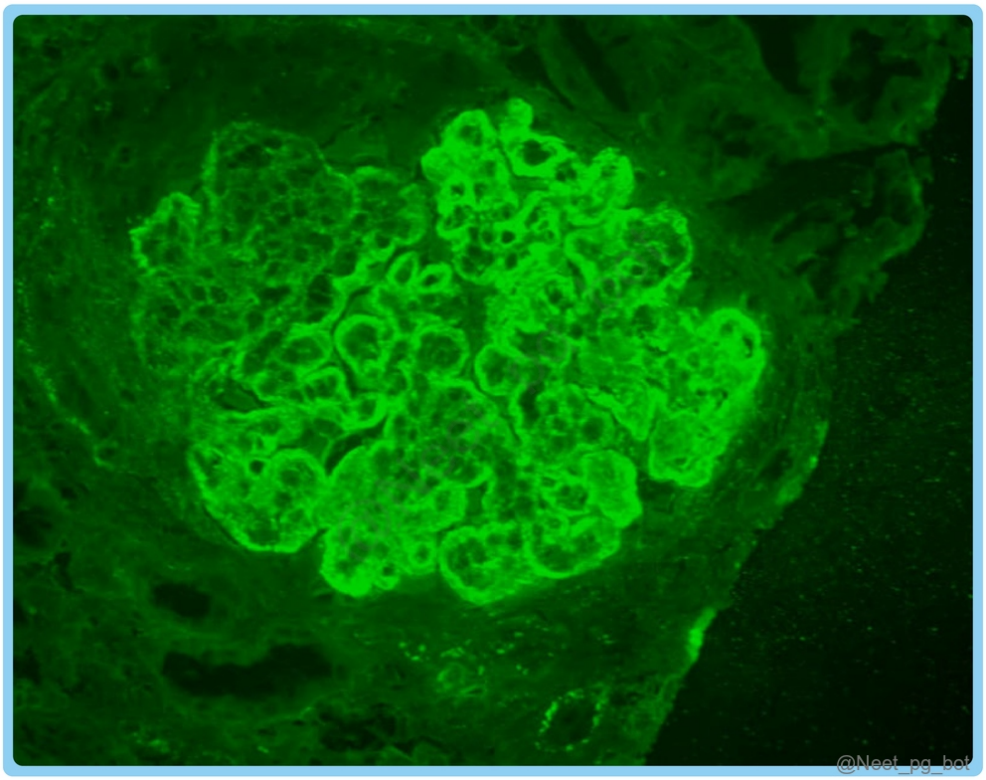

References:

Robbins and Cotran Pathologic Basis of Disease, 10th edition, page
https://link.springer.com/article/10.1007/s13730-019-00412-5/figures/3

↑ *Back to this question in Part A*

@Neet_pg_bot

Q5: A 45-year-old male presents with generalised oedema and frothy urine. Laboratory investigations reveal significant proteinuria and hypoalbuminemia. A kidney biopsy reveals diffuse thickening of GBM, a spike and dome pattern on the silver stain and subepithelial deposits on electron microscopy. Which of the following genetic mutations is most likely associated with this condition? (Q846668)

A. Mutation in PLA2R

B. Mutation in LAMB2 gene

C. Mutations in APOL1 gene

D. Mutations in CFH gene

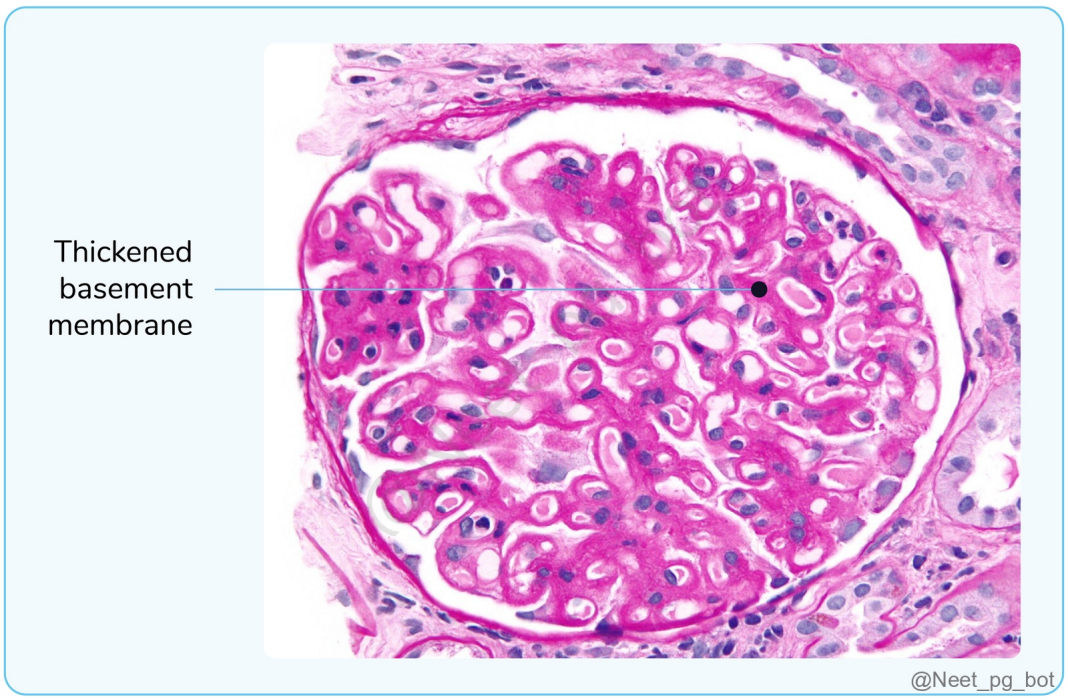

Correct Answer: A. Mutation in PLA2R

■ *Listen (English)*

■ *Listen (Hindi)*

Explanation: The clinical presentation, along with the histological findings of diffuse thickening of GBM, a spike and dome pattern on the silver stain, and subepithelial deposits on electron microscopy, suggest Membranous nephropathy , the most common cause of nephrotic syndrome in elderly patients. In primary membranous nephropathy, antibodies primarily target the M-type phospholipase A2 receptor (PLA2R) located on the basal surface of podocytes. This triggers complement activation and subepithelial immune complex deposition, resembling Heymann nephritis lesions. Other less common target antigens include THSD7A and neutral endopeptidase (CD10). The presence of anti-PLA2R antibodies is crucial for diagnosing the disease. Secondary → drugs (gold, penicillamine, NSAIDs), infections (HBV, syphilis), lupus, solid tumor and diabetes mellitus

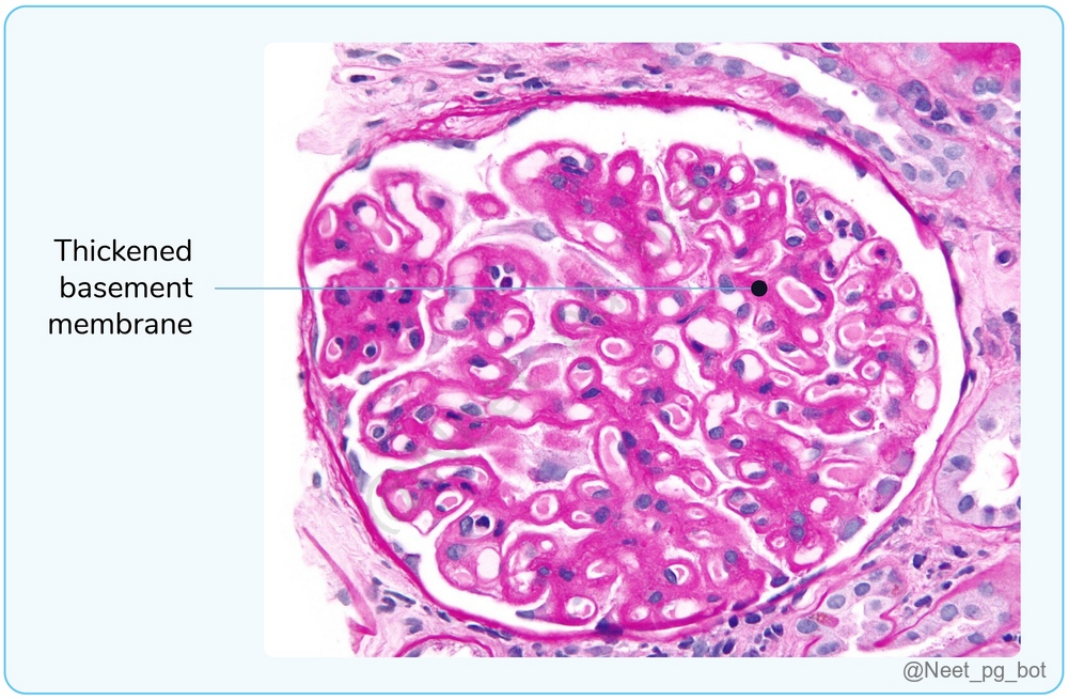

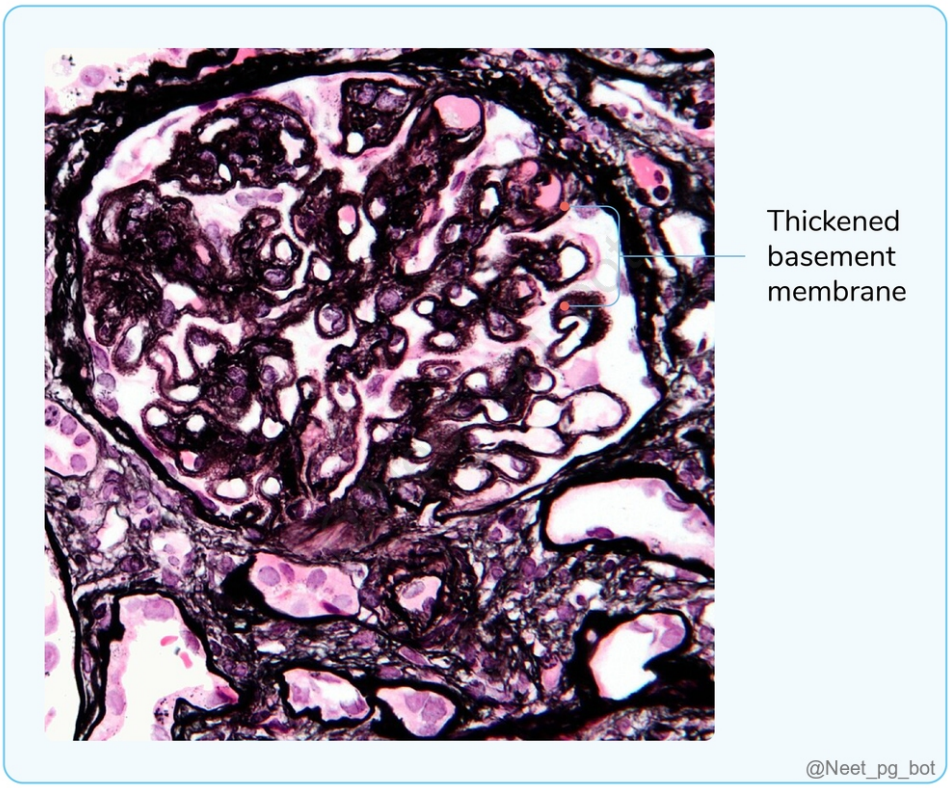

References:

Robbins and Cotran Pathologic Basis of Disease, 10th Edition, Pages 912-914

↑ *Back to this question in Part A*

@Neet_pg_bot

Q6: A 25-year-old female presents with edema, hypertension, significant proteinuria, and hematuria. Kidney biopsy reveals mesangial and endocapillary hypercellularity with mesangial and subendothelial electron-dense deposits, tram track appearance on silver stains and granular staining for IgG and C3 on Immunofluorescence. What is the most likely diagnosis? (Q846667)

A. Type I Membranoproliferative Glomerulonephritis

B. Type II Membranoproliferative Glomerulonephritis

C. Membranous Nephropathy

D. Focal Segmental Glomerulosclerosis

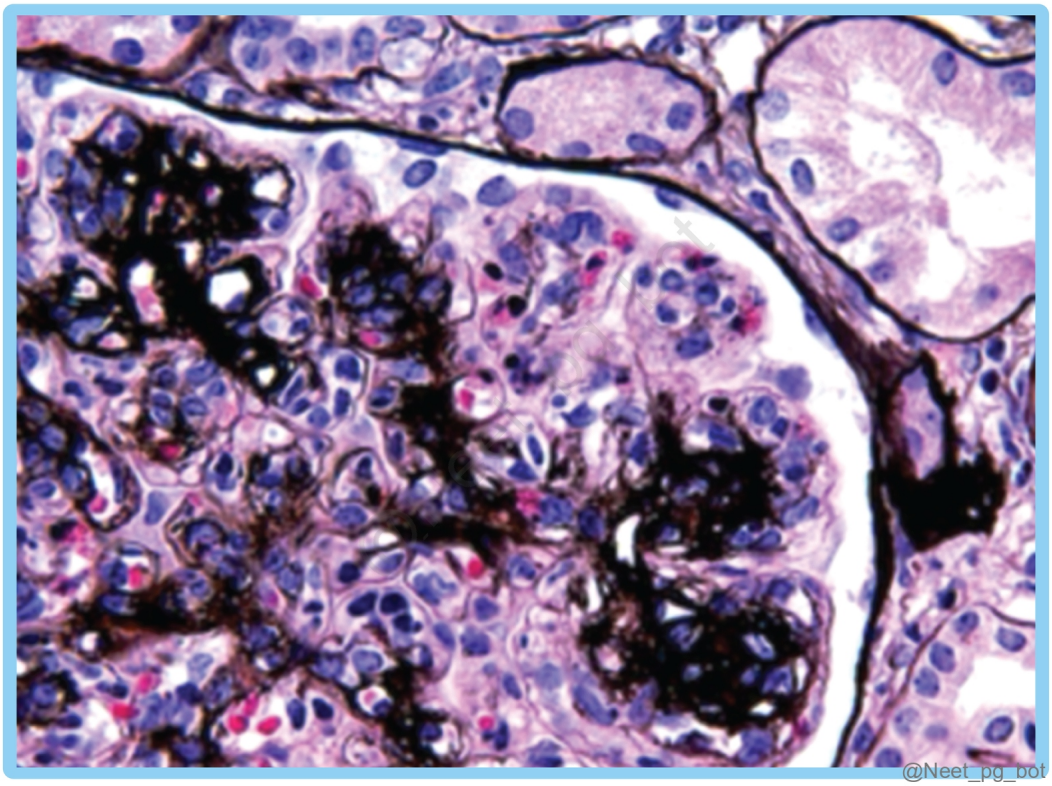

Correct Answer: A. Type I Membranoproliferative Glomerulonephritis

- *Listen (English)*
- *Listen (Hindi)*

Explanation: Tram track or double contour appearance due to splitting of GBM Pathology Primary Causes / Associations Light Microscope Electron Microscope Immunofluorescence Type I MPGN (Option A) Hepatitis C , Hepatitis B, SLE, Cryoglobulinemia, or Chronic Infections Mesangial proliferative or membranoproliferative patterns of proliferation; GBM thickening and Splitting. (Double-contour or tram track appearance) Subendothelial and mesangial deposits IgG ++ C3 (C1q ++ C4 may also present) Type II MPGN (Dense Deposit Disease) (Option B) C3 Nephritic Factor (C3NeF) ; Factor H deficiency; Alternative complement pathway dysregulation Dense intramembranous deposits C3; no C1q or C4 Membranous Nephropathy (Option C) Primary (anti-PLA2R); Secondary (NSAIDs, Malignancy, HBV, SLE) Diffuse capillary wall thickening Subepithelial deposits Granular IgG and C3; diffuse Focal Segmental Glomerulosclerosis (FSGS) (Option D) HIV, Heroin use, Obesity, Sickle Cell Disease, or Primary/Idiopathic Focal and segmental sclerosis and hyalinosis Effacement of foot processes; epithelial denudation Focal; IgM + C3 in many cases

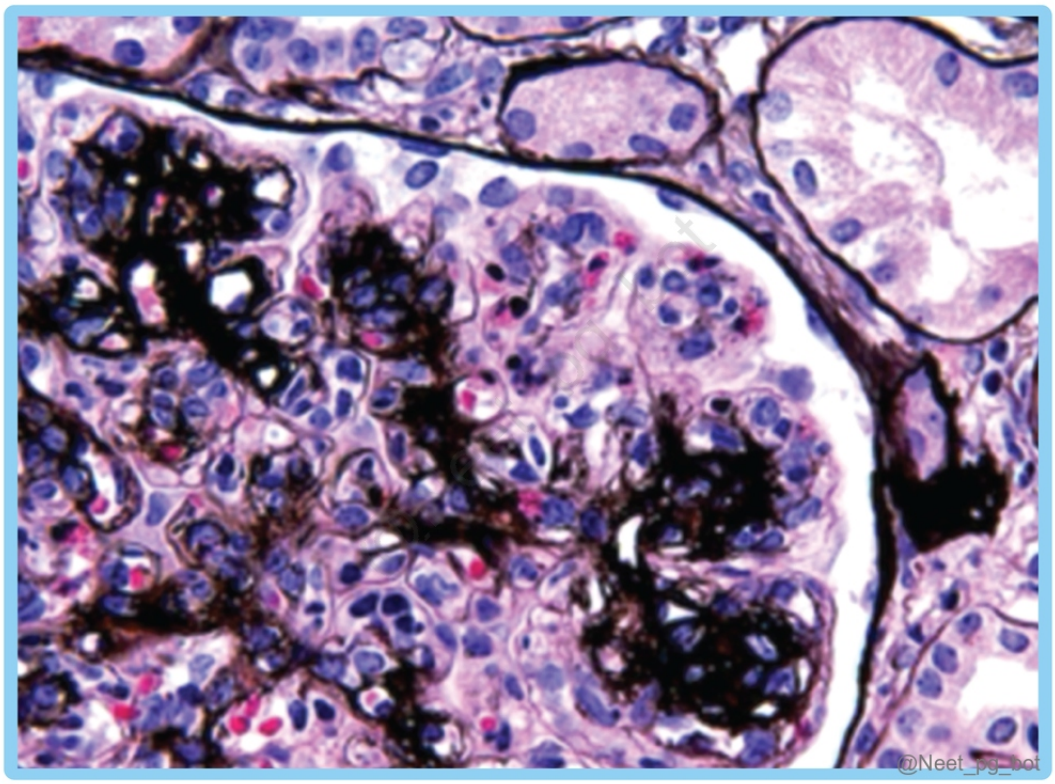

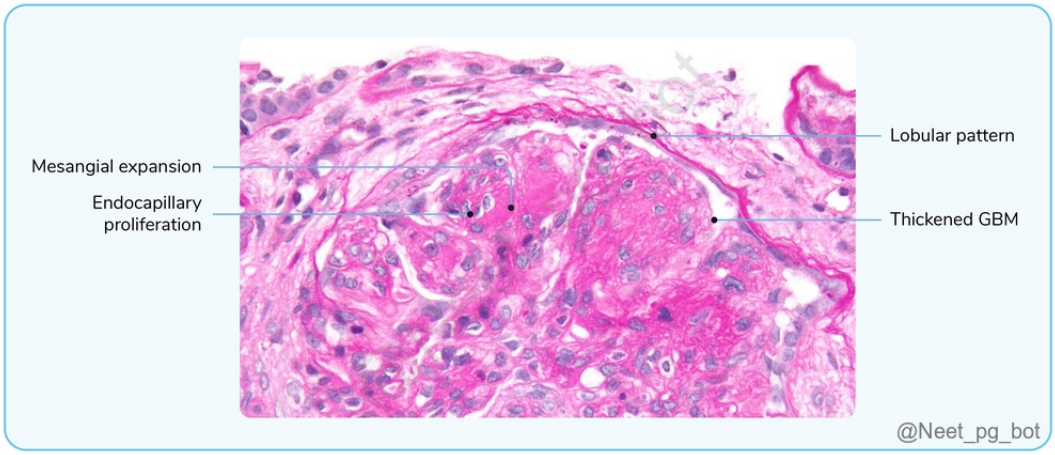

References:

Robbins and Cotran Pathologic Basis of Disease, 10th Edition, Pages 917-920

↑ *Back to this question in Part A*

@Neet_pg_bot

Q7: Which genetic mutation is responsible for a syndrome of steroid-resistant nephrotic syndrome of childhood onset? (Q846666)

A. NPHS1

B. NPHS2

C. α-actinin 4

D. TRPC6

Correct Answer: B. NPHS2

Explanation: The above clinical scenario points towards the diagnosis of steroid-resistant nephrotic syndrome, which is defined as the absence of remission despite 4 weeks of therapy with daily prednisone at a dose of 2 mg/kg/d. Mutations in the NPHS2 gene lead to this syndrome, typically manifesting in childhood. The NPHS2 gene is located on chromosome 1q25–q31. The NPHS2 gene encodes the protein product known as podocin which is localised to the slit diaphragm within the kidney. Patients typically present from birth to 6 years of age have a steroid-resistant course and reach End-stage Renal Disease (ESRD) before the end of their first decade. NPHS1 (Option A): NPHS1 mutations are associated with congenital nephrotic syndrome of the Finnish type. α-actinin 4 (Option C): Mutations in the gene encoding the podocyte actin-binding protein α-actinin 4 (ACTN4) underlie some cases of autosomal dominant focal segmental glomerulosclerosis (FSGS), which tends to have a high rate of progression to renal insufficiency. TRPC6 (Option D): Mutations in the TRPC6 gene, which encodes a calcium-permeable ion channel in podocytes , have been identified in some cases of familial FSGS. However, TRPC6 mutations are not typically linked to childhood-onset steroid-resistant nephrotic syndrome.

References:

Robbins and Cotran Pathologic Basis of Disease, 10th Edition, Page 915

↑ *Back to this question in Part A*

@Neet_pg_bot

Q8: A 35-year-old man presents with swelling around his eyes, ankles, and abdomen, along with frothy urine. Urinalysis shows proteinuria, elevated serum creatinine, and BUN levels. Image of renal biopsy is given below. Which of the following is not an established cause of this condition? (Q846665)

A. Diabetes mellitus

B. HIV infection

C. Hypertension

D. Sickle cell anaemia

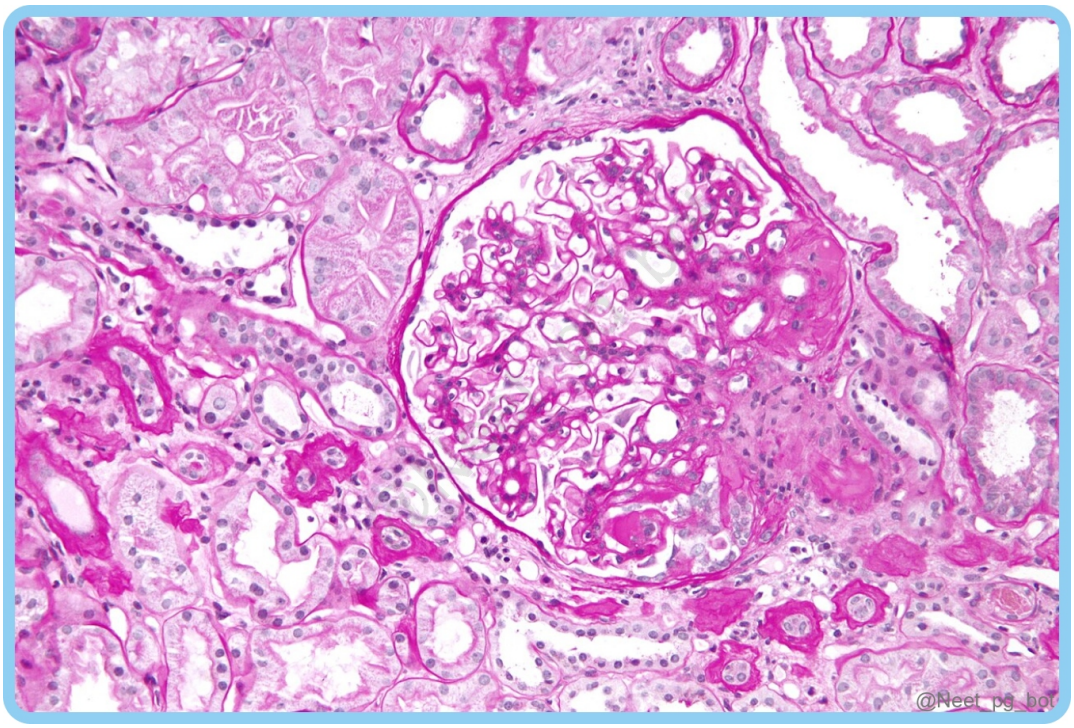

Correct Answer: A. Diabetes mellitus

■ *Listen (English)*

■ *Listen (Hindi)*

Explanation: Based on the given clinical scenario and HPE image (segmental sclerosis, glomerular hyalinosis, and tubular atrophy, with negative immunofluorescence), the most likely diagnosis is Focal Segmental Glomerulosclerosis (FSGS), the most common cause of nephrotic syndrome in adults. Diabetes mellitus primarily causes diabetic nephropathy, characterised by diffuse glomerulosclerosis rather than the focal and segmental pattern seen in FSGS. Causes of FSGS: 1. Primary (Idiopathic) FSGS. 2. Secondary FSGS: Mnemonic- H3R3S1 H ypertension (Option C) H IV associated nephropathy (Option B) H eroine drug abuse R eflux nephropathy R enal tissue loss S ickle cell anaemia (Option D) 3. Inherited forms: Genetic mutations affecting slit diaphragm proteins like nephrin, podocin, α-actinin 4, and TRPC6.

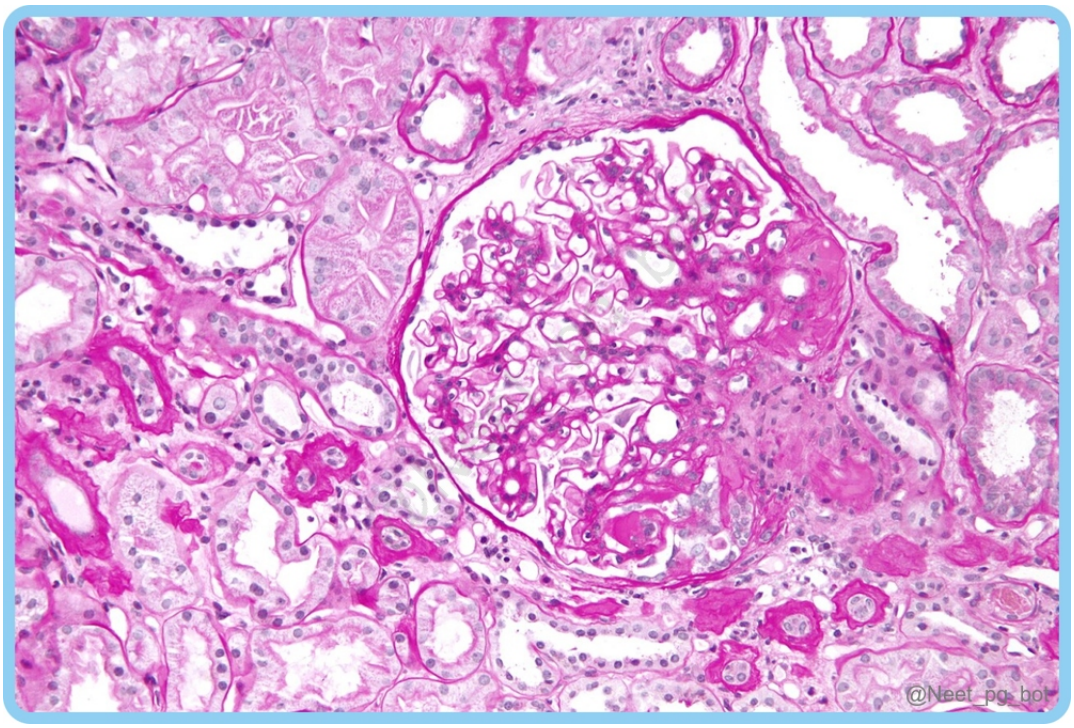

References:

Robbins and Cotran Pathologic Basis of Disease, 10th Edition, Page 914, 915, 1110, 1111

↑ *Back to this question in Part A*

@Neet_pg_bot

Q9: A 6-year-old boy presents with sudden generalised oedema and frothy urine. Urinalysis reveals heavy proteinuria without hematuria. Renal biopsy widespread effacement of podocyte foot processes on electron microscopy. Which of the following is true regarding this condition? (Q846664)

A. Lipid deposition within glomerular capillaries (tubular cells)

B. Immunofluorescence microscopy reveals granular deposition of IgG and C3 in the glomeruli.

C. Good response to corticosteroid therapy

D. Non-selective proteinuria

Correct Answer: C. Good response to corticosteroid therapy

■ *Listen (English)*

■ *Listen (Hindi)*

Explanation: The clinical and electron microscope findings suggest the diagnosis as Minimal Change Disease (MCD) , characterised by diffuse effacement of foot processes of podocytes in glomeruli. It primarily affects children aged 2-6 years. MCD typically responds rapidly to corticosteroid therapy, especially in children (>90%), leading to complete remission of proteinuria and resolution of symptoms. Lipid deposition within glomerular capillaries (Option A): Lipid deposition within glomerular capillaries is not observed in MCD. Instead, protein and lipid deposition may occur in the proximal tubules due to tubular reabsorption of lipoproteins passing through diseased glomeruli, leading to the historical term "lipoid nephrosis" for this disease. Immunofluorescence microscopy reveals granular deposition of IgG and C3 in the glomeruli (Option B) Immunofluorescence studies in MCD typically show no significant immune complex deposition or granular staining patterns. This distinguishes MCD from immune complex-mediated glomerular diseases like IgA nephropathy or lupus nephritis, where IgG and C3 deposits are commonly observed. Non-selective proteinuria (Option D) Minimal Change Disease (MCD) typically presents with highly selective proteinuria , mostly albumin . Renal function remains good despite massive proteinuria, with no hypertension or hematuria commonly.

References:

Robbins and Cotran Pathologic Basis of Disease, 10th Edition, Page 914

↑ *Back to this question in Part A*

@Neet_pg_bot

Q10: A 7-year-old girl with a recent upper respiratory tract infection presents with generalised swelling and reduced urine output. Urinalysis reveals proteinuria without blood cells or casts. Electron microscopy findings show flattening, retraction, and swelling of podocytes. Which light microscopy findings is characteristic of this condition? (Q846663)

A. Glomerulosclerosis

B. Normal glomeruli

C. Fibrinoid necrosis in glomeruli

D. Wire looping of capillaries

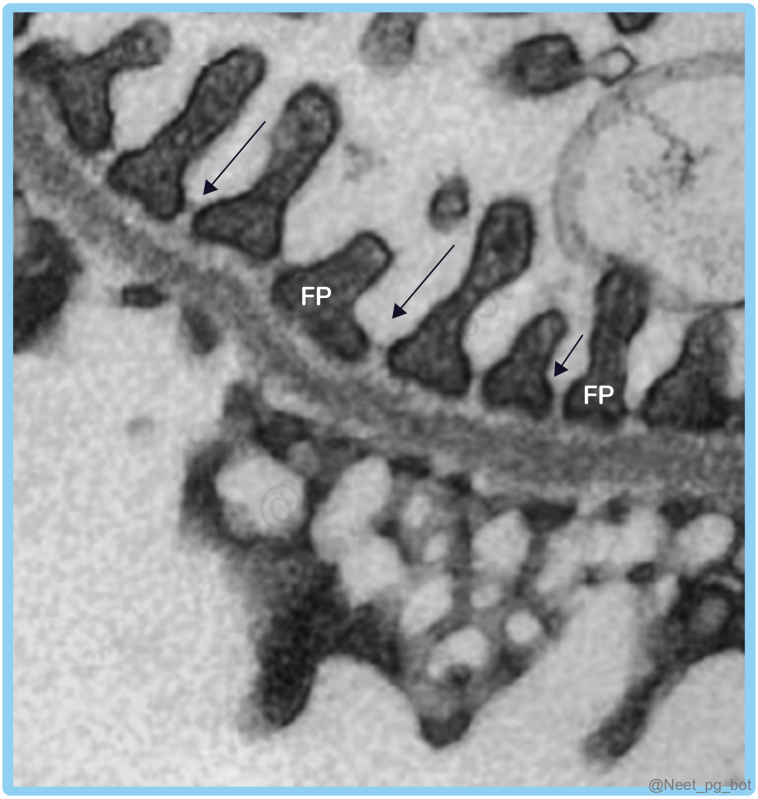

Correct Answer: B. Normal glomeruli

Explanation: The above clinical presentation and EM finding of podocyte effacement is characteristic of Minimal change disease. It is marked by the widespread flattening of podocytes, seen only on electron microscopy, while light microscopy shows normal glomeruli with lipids in proximal tubules. This alteration in podocyte structure leads to increased permeability of the glomerular filtration barrier, resulting in the loss of large amounts of protein in the urine. Glomerulosclerosis (Option A) Observed in diabetic nephropathy. Diffuse glomerulosclerosis Diffuse glomerulosclerosis Focal segmental glomerulosclerosis Fibrinoid necrosis in the glomeruli (Option C) : Vasculitis or immune complex-mediated glomerulonephritis. Wire looping of capillaries (Option D) : Wire looping of capillaries is seen in diffuse proliferative glomerulonephritis, often due to SLE (lupus nephritis).

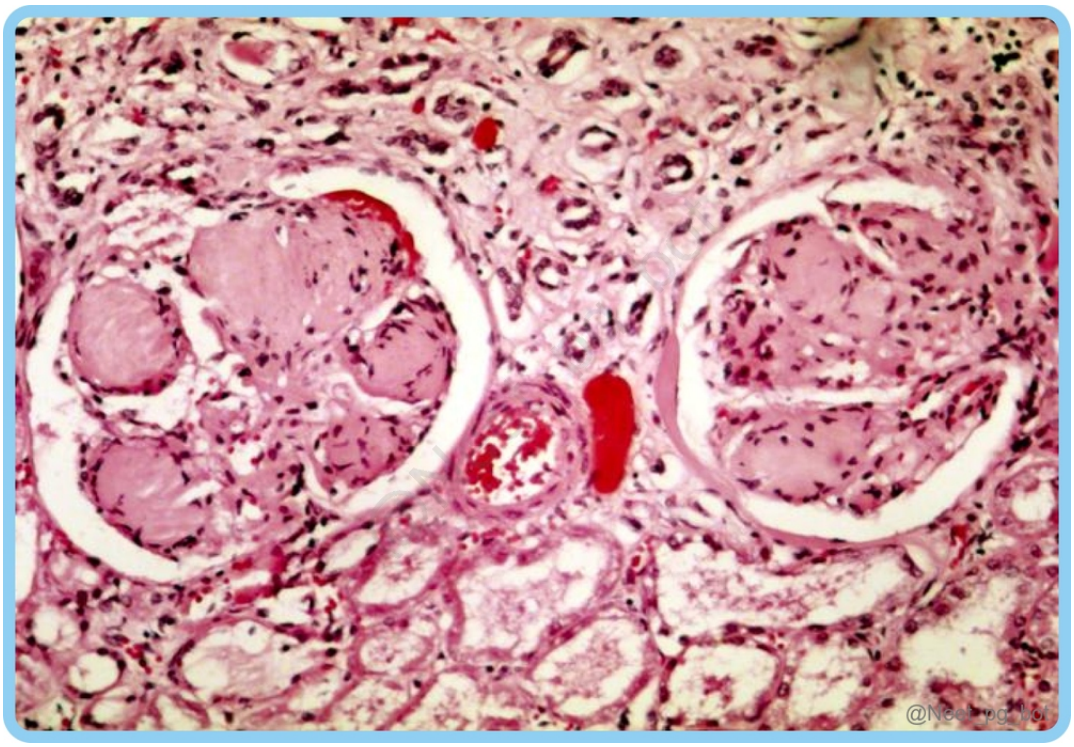
@Neet_pg_16

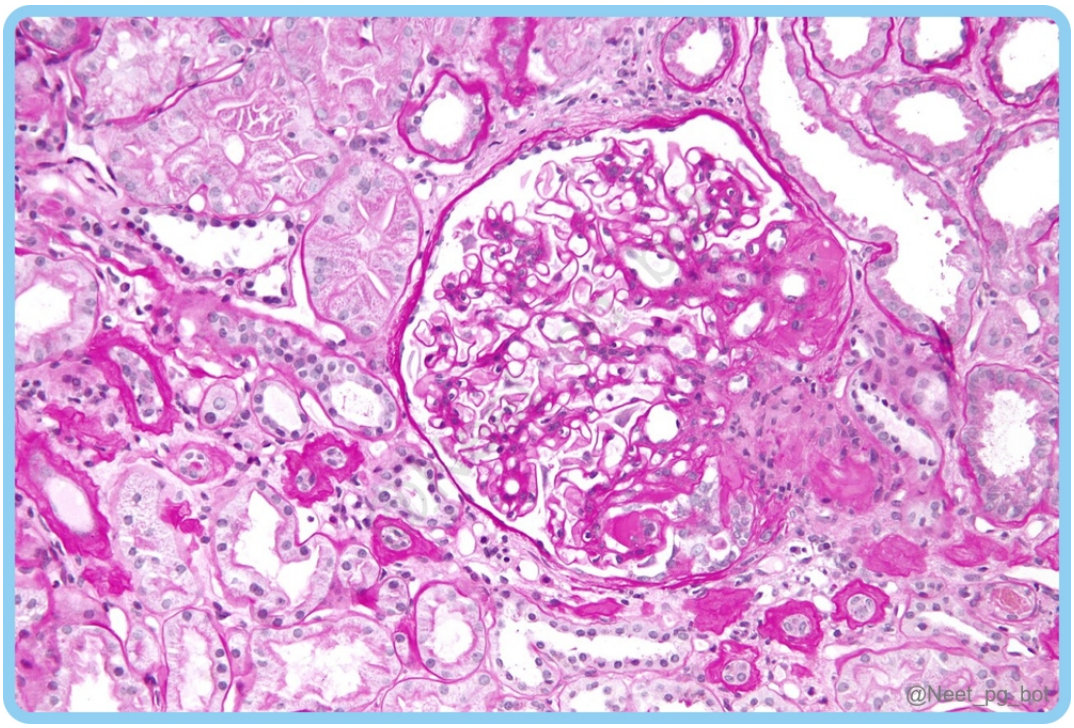
@Neet_pg_bot

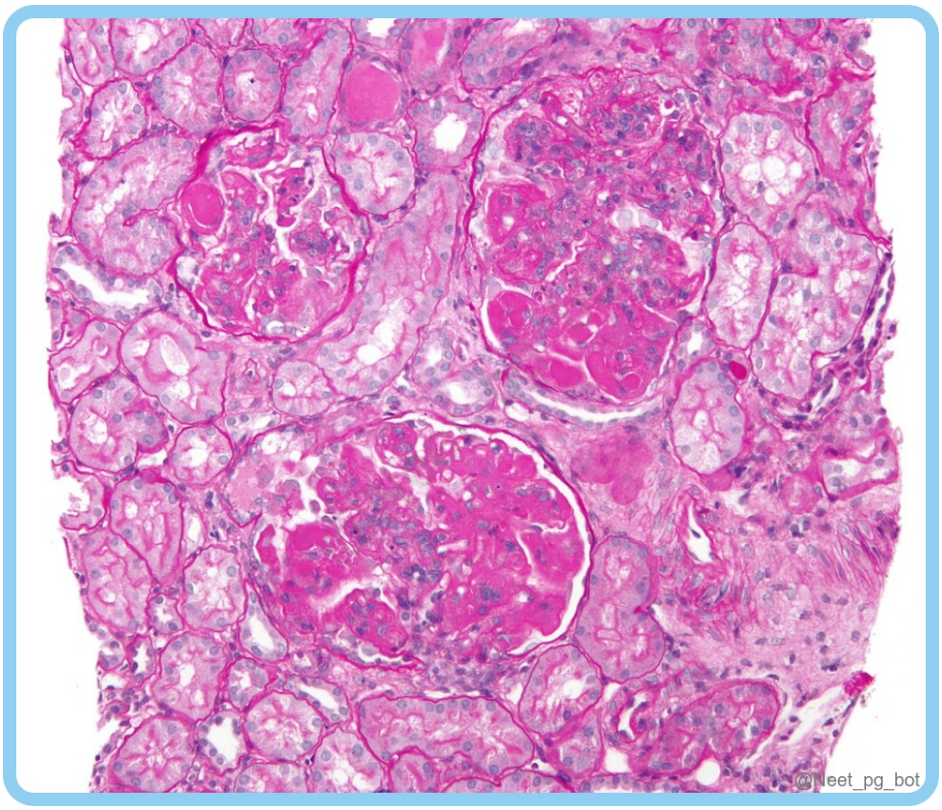

References:

Robbins and Cotran Pathologic Basis of Disease, 10th Edition, Pages 911-920

↑ *Back to this question in Part A*

@Neet_pg_bot

Q11: A 15-year-old boy presents with complaints of blurred vision, hearing loss, and recurrent episodes of hematuria. Genetic testing reveals a mutation in Type 4 collagen. Which of the following genetic mutations is observed in the patient? (Q846661)

A. COL4A3 gene

B. COL4A4 gene

C. COL4A5 gene

D. All of the above

Correct Answer: C. COL4A5 gene

■ *Listen (English)*

■ *Listen (Hindi)*

Explanation: This is the classic X- linked Alport syndrome COL4A5 has X-linked dominant trait - males are affected more severely whereas females have milder form of disease Alport syndrome is caused by defective COL4A3, COL4A4, and COL4A5 genes, which lead to impaired production and deposition of the Type 4 collagen α345 chain network in the basement membranes of the glomerulus, cochlea, and eyes. COL4A3, COL4A4 has autosomal recessive trait - both males and females are affected (Option A, B) It has a triad of symptoms. Blurred vision due to Anterior lenticonus, lens dislocation, posterior cataracts, and corneal dystrophy. Recurrent hematuria can lead to renal failure. Bilateral sensorineural hearing loss.

References:

Robbins and Cotran Pathologic Basis of Disease, 10th edition, page 922 Alport Syndrome-PMC(NIH.gov) https://www.ncbi.nlm.nih.gov/books/NBK470419/

↑ *Back to this question in Part A*

@Neet_pg_bot

Q12: A 32-year-old male presents with painless hematuria post-upper respiratory infections, normal vital signs, and no oedema. Urinalysis reveals red blood cell casts and further investigation shows elevated serum creatinine and mild proteinuria. Renal biopsy confirms glomerulonephritis. What is the most common type of glomerulonephritis in this case? (Q846660)

A. IgA nephropathy

B. Post-Streptococcal glomerulonephritis

C. Minimal change disease

D. Membranous nephropathy

Correct Answer: A. IgA nephropathy

■ *Listen (English)*

■ *Listen (Hindi)*

Explanation: IgA nephropathy, or Berger’s disease , is the most common type of glomerulonephritis in adults and worldwide. It presents with gross hematuria in adults, usually 2-3 days after an upper respiratory infection. It can progress to acute renal failure, causing ankle oedema, facial puffiness, and hypertension. It occurs due to the formation of aberrant IgA molecules that deposit in the mesangial regions. Post-streptococcal glomerulonephritis (Option B) It is the most common type of glomerulonephritis in children and presents with fever, oliguria, hypertension, periorbital oedema, and hematuria. It usually occurs 1 to 2 weeks after recovery from an upper respiratory infection, which causes an inflammatory response (type III hypersensitivity reaction). Minimal change

disease (Option C) It is the most common type of nephrotic syndrome in children. It presents with massive proteinuria(>3.5g/24hrs) due to immunological damage to epithelial cells. Membranous nephropathy (Option D) It is the most common type of nephrotic syndrome in the elderly. It is immune complex-mediated and can be caused by malignancy(colon, lung, melanoma), infections(malaria, hepatitis B, C, syphilis, schistosomiasis), drugs(gold, penicillamine), or autoimmune conditions(SLE).

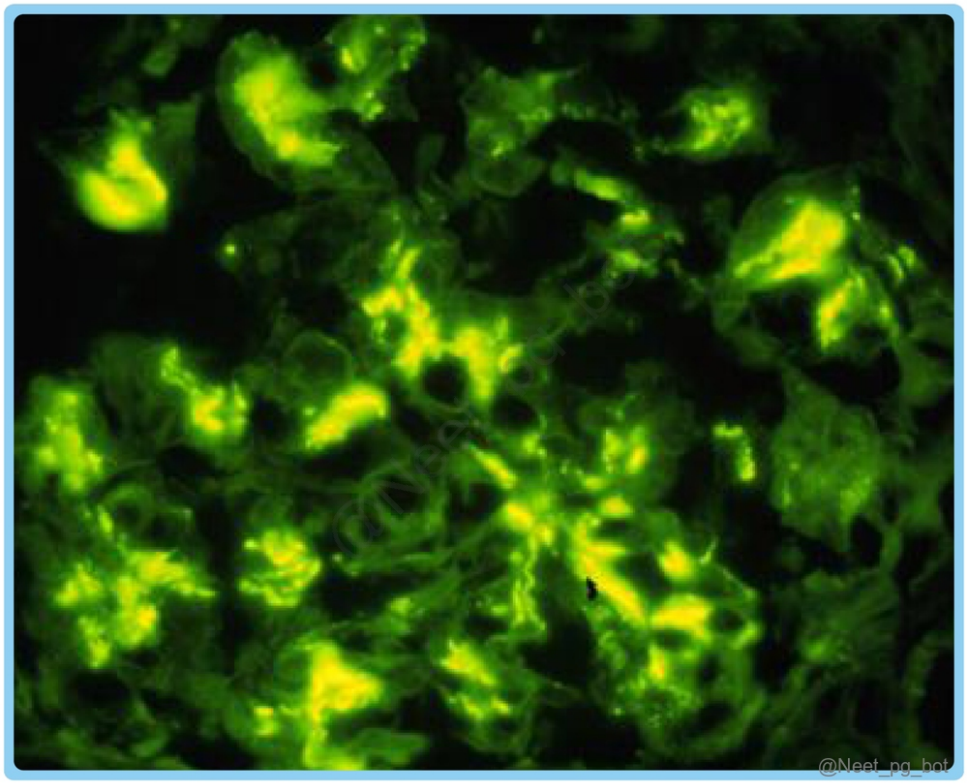

References:

Robbins and Cotran Pathologic Basis of Disease, 10th edition, pages 920-922, 912, 914, 909 IgA Nephropathy (Berger Disease)-PMC(NIH.gov) https://www.ncbi.nlm.nih.gov/books/NBK538214/

↑ *Back to this question in Part A*

@Neet_pg_bot

Q13: A 45-year-old male presents with recurrent hematuria following upper respiratory infections and intermittent proteinuria. Renal biopsy shows mesangial IgA deposits on immunofluorescence and electron-dense deposits in the mesangium on electron microscopy. What is the most likely diagnosis? (Q846659)

A. Berger's Disease

B. Alport syndrome

C. Membranous nephropathy

D. Buerger's Disease

Correct Answer: A. Berger’s Disease

■ *Listen (English)*

■ *Listen (Hindi)*

Explanation: The clinical and histopathological findings suggest the diagnosis of Berger’s disease or IgA nephropathy , characterised by the deposition of IgA antibodies in the mesangial regions of the glomeruli, leading to recurrent episodes of hematuria. Electron microscopy reveals electron-dense deposits predominantly localised in the mesangium. The characteristic immunofluorescent picture shows mesangial deposition of IgA , often with C3 and properdin and lesser amounts of IgG or IgM. Alport syndrome (Option B) It is a genetic disorder characterised by abnormalities in type IV collagen, leading to progressive kidney disease, hearing loss, and eye abnormalities. Electron microscopy reveals irregular thickening of the glomerular basement membrane with lamellation and splitting. Membranous nephropathy (Option C) It is caused by the deposition of immune complexes (primarily IgG and C3) on the outer (subepithelial) side of the glomerular basement membrane. Buerger's Disease (Option D) It is also called Thromboangiitis obliterans, it is a vascular disease causing extremity ischemia and is unrelated to renal involvement or immune deposits in the kidney. It does not present with hematuria or proteinuria.

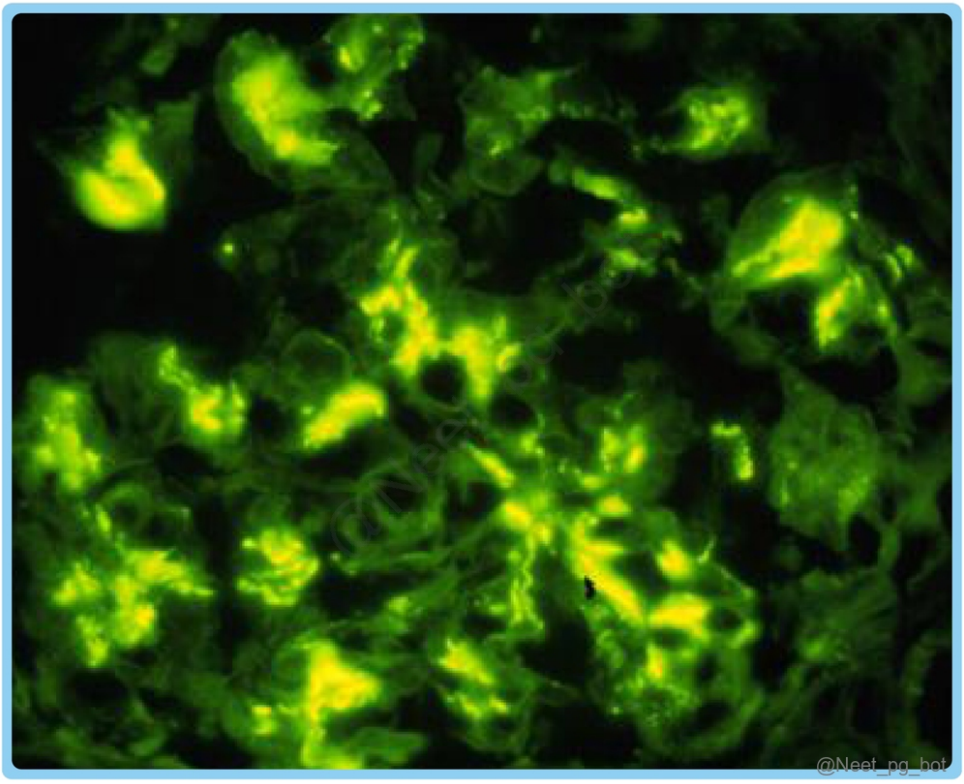

References:

Robbins and Cotran Pathologic Basis of Disease, 10th edition, page 920

↑ *Back to this question in Part A*

@Neet_pg_bot

Q14: A 30-year-old male presents with increasing shortness of breath and hemoptysis. Lab tests show elevated serum creatinine and hematuria. Renal biopsy reveals linear immunofluorescence along the glomerular basement membrane and subepithelial and intramembranous electron-dense deposits on electron microscopy. Which of the following statements regarding the diagnosis is not true? (Q846658)

A. It is a Type III hypersensitivity reaction

B. Defective α3 chain of collagen IV

C. Linear immunofluorescence is due to IgG deposition

D. The most common cause of death is uremia.

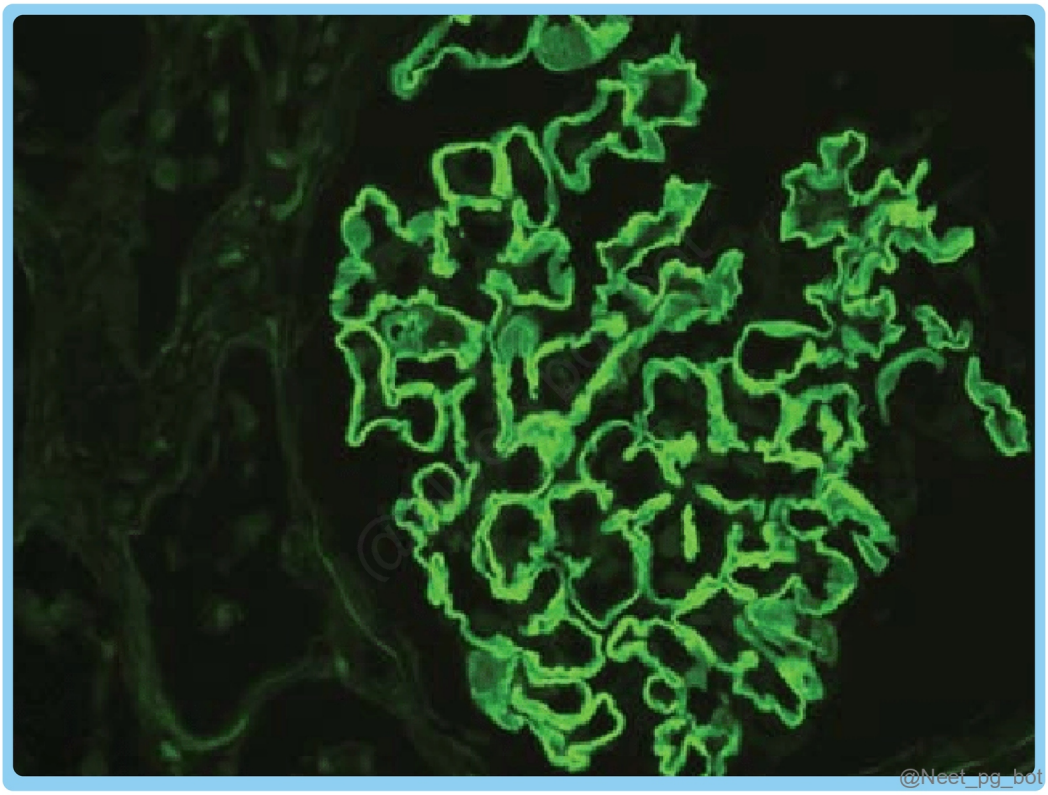

Correct Answer: A. It is a Type III hypersensitivity reaction

■ *Listen (English)*

■ *Listen (Hindi)*

Explanation: Above mentioned scenario is a case of Goodpasture Syndrome It can be learnt as 1, 2, 3, 4 It is RPGN type 1 It is hypersensitivity type II and 4. Caused due to antibiotics against alpha 3 chain of type IV collagen. Immunofluorescence shows linear deposit of IgG and C3. (Picture below) Electron microscopy shows rupture and wrinkling of the basement membrane. Clinical Features: Lung involvement- haemoptysis, Renal involvement- haematuria. Most common cause of death: Uremia.

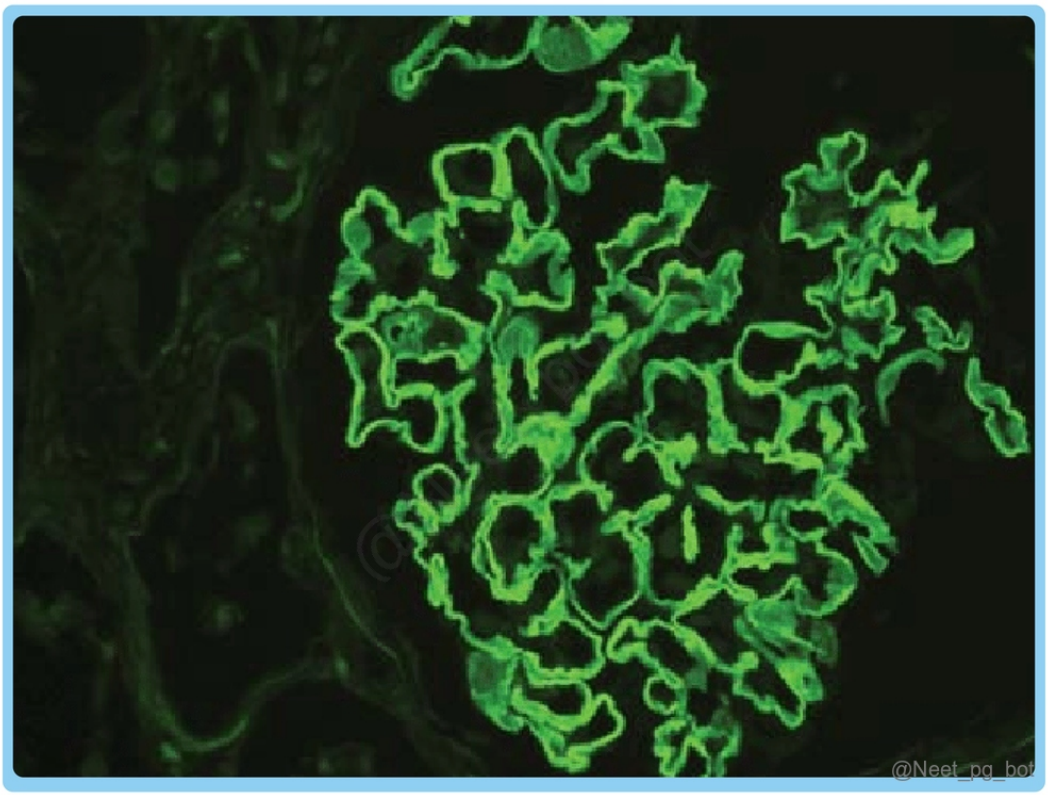

References:

Robbins and Cotran Pathologic Basis of Disease, 10th Edition, Page 909

↑ *Back to this question in Part A*

@Neet_pg_bot

Q15: A 9-year-old boy presents with a recent sore throat, dark urine, fatigue, eye puffiness, and mild limb swelling. Urinalysis reveals hematuria, proteinuria, and red blood cell casts. Serum creatinine levels are slightly elevated. A renal biopsy shows the immunofluorescence image provided below. Which condition is not typically associated with this pattern of rapidly progressive glomerulonephritis? (Q846657)

A. Wegeners granulomatosis

B. Henoch-Schonlein purpura

C. Systemic lupus erythematosus

D. Ig A Nephropathy

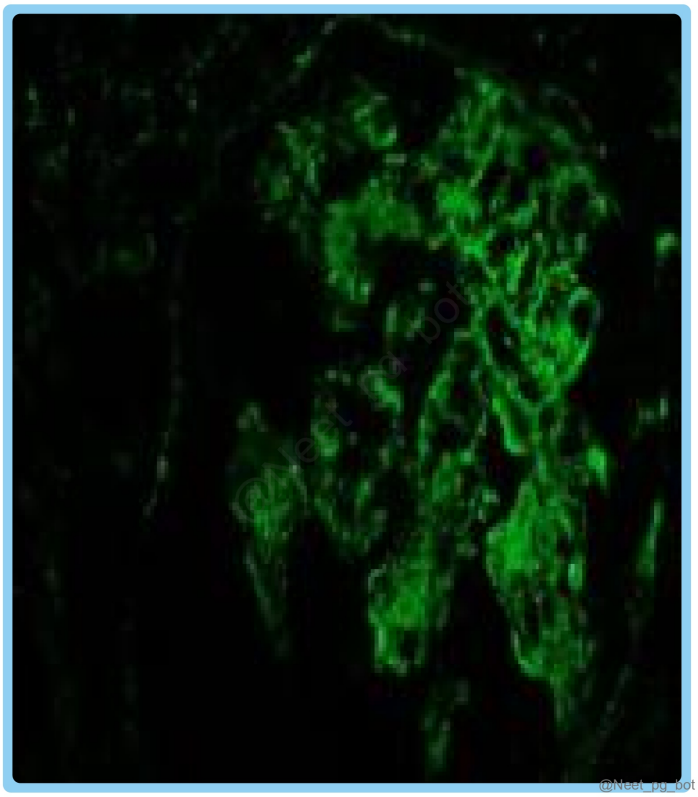

Correct Answer: A. Wegeners granulomatosis

■ *Listen (English)*

■ *Listen (Hindi)*

Explanation: The clinical scenario indicates post-streptococcal glomerulonephritis (PSGN), a Type 2 RPGN (Rapidly progressive glomerulonephritis) associated with granular immunofluorescence. Wegener's granulomatosis is Type 3 RPGN , characterised by pauci-immune glomerulonephritis with no immune deposits. Type I RPGN (Anti-GBM antibody-mediated) Type II RPGN (Immune complex-mediated) Type III RPGN (Pauci-immune) (M/C type) Includes: Idiopathic Goodpasture syndrome Includes: Idiopathic Postinfectious glomerulonephritis Lupus (SLE) nephritis Henoch-Schönlein purpura IgA nephropathy Includes: ANCA-associated Idiopathic Granulomatosis with polyangiitis (formerly Wegener granulomatosis) Microscopic polyangiitis IF finding: Linear/ribbon pattern (Linear GBM deposits of IgG and C3) IF finding: Lumpy Bumpy/ Granular/ Starry Sky/Garland Pattern (granular antibody deposits) IF finding: No deposits Electron microscopy: R PGN causes R upture and w R inkling of GBM

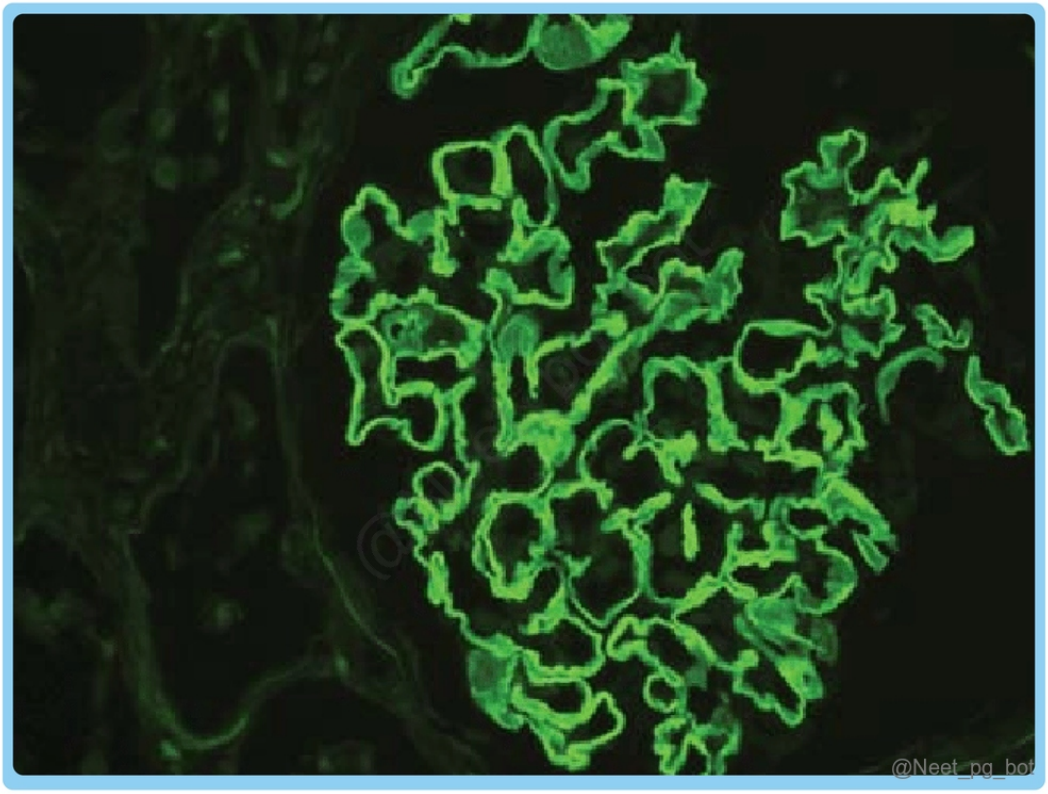
@Neet_pg_bot

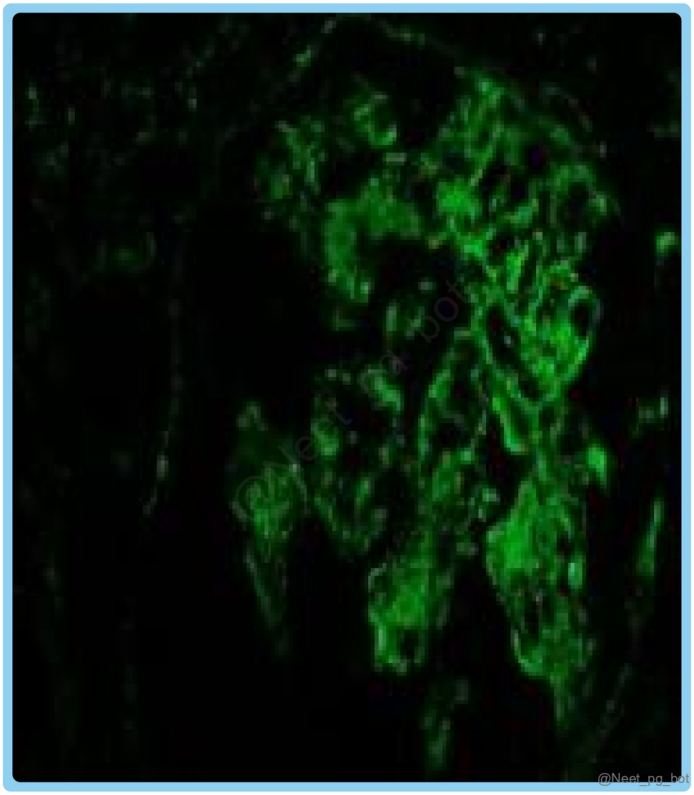
@Neet_pg_bot

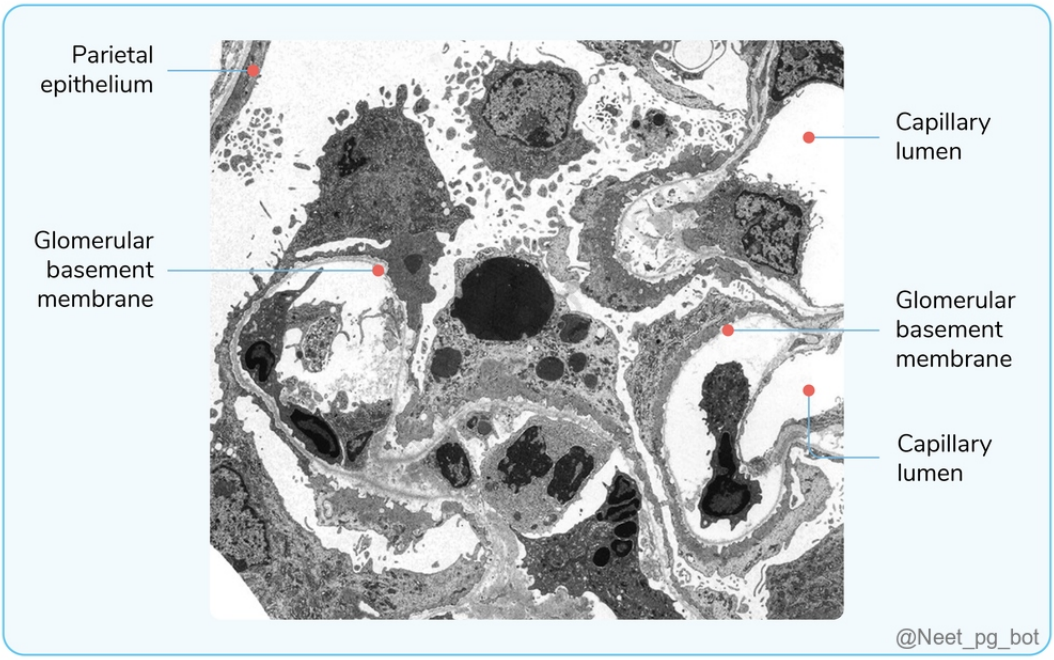

References:

Robbins and Cotran Pathologic Basis of Disease, 10th edition, pages 909, 910

↑ *Back to this question in Part A*

@Neet_pg_bot

Q16: A 32-year-old woman with a history of SLE presents with fatigue, decreased urine output, and facial swelling. Lab tests show elevated serum creatinine, proteinuria, and hematuria. A renal biopsy is performed, and the histopathological examination image is attached. Which statement is true regarding this condition? (Q846656)

A. >50% of glomeruli showing crescents is diagnostic.

B. More the number of crescents, better the prognosis.

C. Crescents are composed solely of endothelial cells.

D. Primarily caused by bacterial infections.

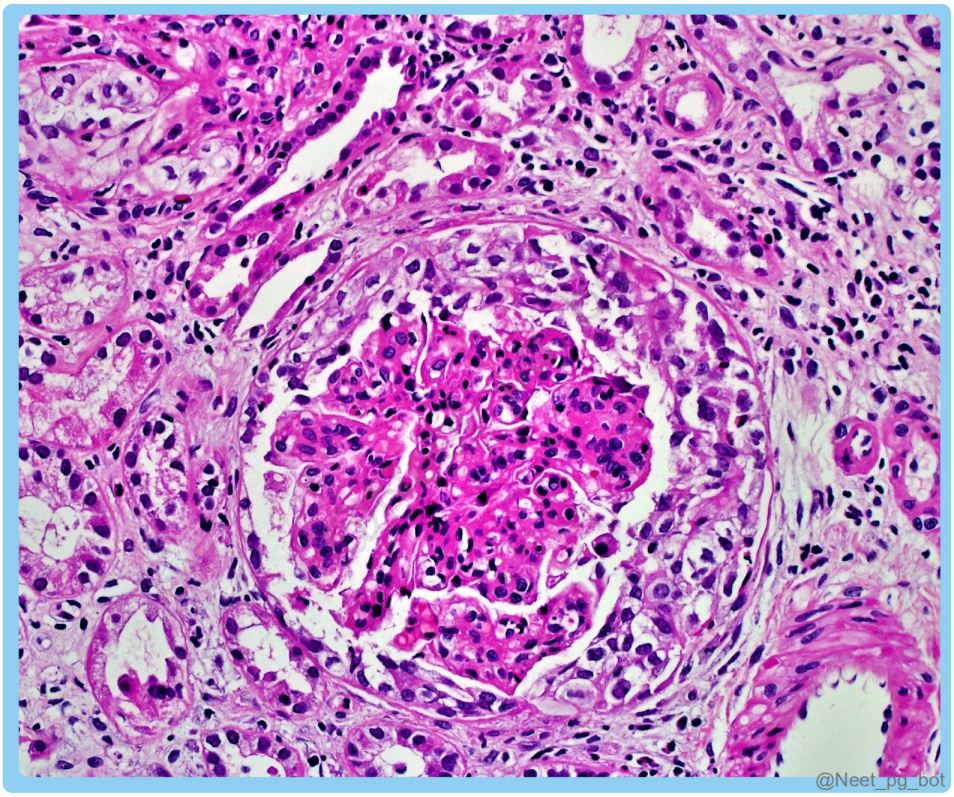

Correct Answer: A. >50% of glomeruli showing crescents is diagnostic.

- *Listen (English)*
- *Listen (Hindi)*

Explanation: The provided clinical scenario and the histopathological image suggest a Rapidly Progressive Glomerulonephritis (RPGN) diagnosis in a patient with systemic lupus erythematosus (SLE). Crescentic glomerulonephritis (or RPGN) is characterised by the presence of crescents in more than 50% of glomeruli on renal biopsy. More the number of crescents, the better the prognosis (Option B): In RPGN, more crescents generally indicate a poor prognosis Crescents are composed solely of endothelial cells (Option C) : Crescents are composed of fibrin, leucocytes, parietal and visceral layers of Bowman capsule. Primarily caused by bacterial infections (Option D) : RPGN Type I, II, III can be due to varied causes.

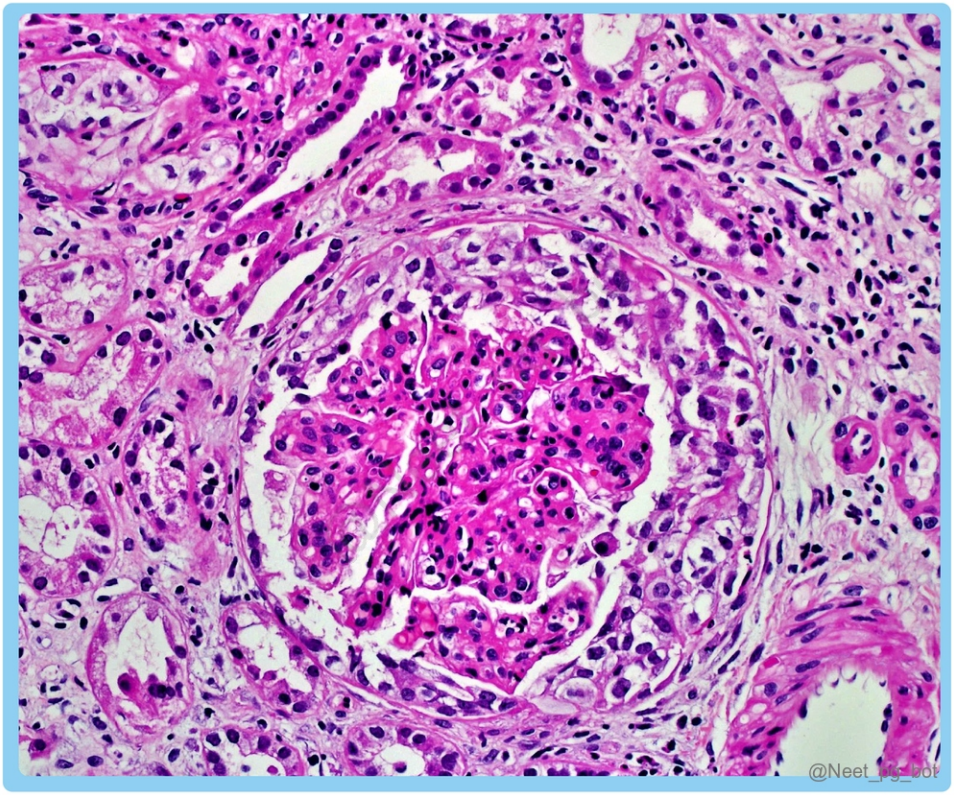

References:

Robbins and Cotran Pathologic Basis of Disease, 10th Edition, Pages 909 - 910

↑ *Back to this question in Part A*

@Neet_pg_bot

Q17: A 10-year-old boy presents with dark-coloured urine and puffiness around his eyes following a recent sore throat and skin infection. Laboratory tests show elevated serum creatinine, hematuria, and proteinuria. Renal biopsy image is given below. Which condition is most likely associated with these findings? (Q846655)

A. IgA nephropathy

B. Membranoproliferative glomerulonephritis

C. Post-streptococcal glomerulonephritis

D. Alport syndrome

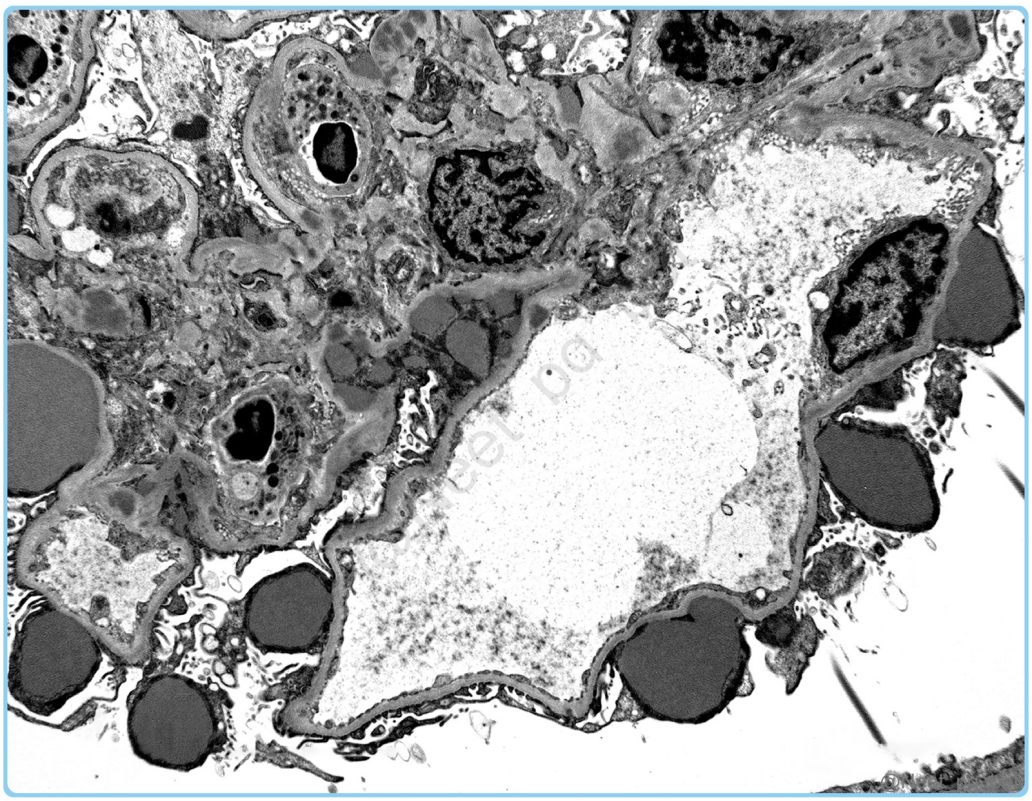

Correct Answer: C. Post-streptococcal glomerulonephritis

- *Listen (English)*
- *Listen (Hindi)*

Explanation: Pathological findings in PSGN Grossly Kidneys appear speckled or mottled due to numerous small haemorrhages (Flea-bitten appearance). Light microscopy Hypercellular glomeruli are caused by infiltration by leukocytes (neutrophils and monocytes) and the proliferation of endothelial and mesangial cells. Electron microscope ‘Subepithelial electron-dense humps’ due to immune complex deposition beneath the epithelial cells of the glomerular basement membrane. Immunofluorescence Characteristic 'Starry sky appearance' by immune complex deposition. Condition Findings in microscopy IgA Nephropathy (Option A) Mesangial deposition of IgA Membranoproliferative glomerulonephritis (Option B) Mesangial & subendothelial immune deposits are seen Alport Syndrome (Option D) Basket Weave Appearance of GBM

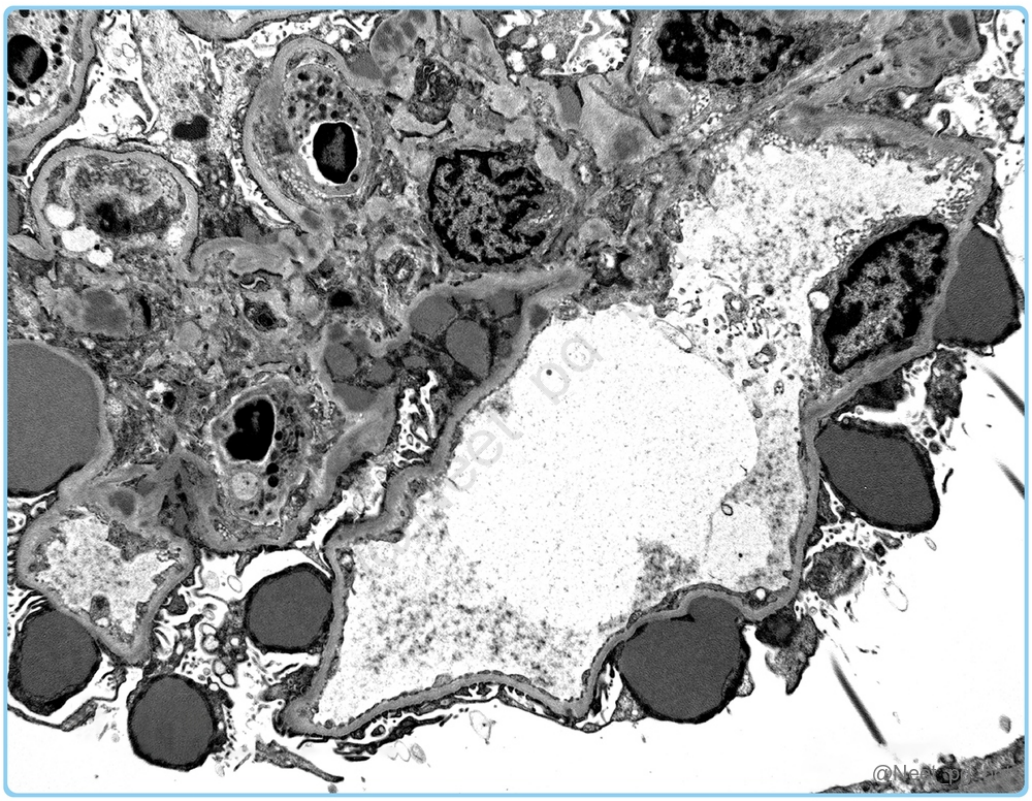

References:

Robbins and Cotran Pathologic Basis of Disease, 10th Edition, Page 909

↑ *Back to this question in Part A*

@Neet_pg_bot

Q18: A 45-year-old patient presents with complaints of frothy urine, as shown below, and severe generalised oedema. On physical examination, there is marked swelling in the legs and abdomen. Laboratory tests reveal significant proteinuria (3+ on dipstick) and hypoalbuminemia. Which of the following findings can be typically observed in this patient? {{caption_text}} (Q846653)

A. Azotemia

B. Hyperlipidemia

C. Red cell casts in the urine

D. Hypertension



Correct Answer: B. Hyperlipidemia

- *Listen (English)*
- *Listen (Hindi)*

Explanation: Feature Nephritic Syndrome Nephrotic Syndrome Primary Characteristic Inflammation of glomeruli Increased permeability of glomerular basement membrane Proteinuria Mild to moderate (< 1 g/day) Severe (> 3.5 g/day) Hematuria Present (visible blood in urine or microscopic hematuria) Absent or very minimal Edema Mild, usually in the face and eyes Severe, generalised (anasarca) Blood Pressure Elevated (Hypertension) (Option D) Normal or slightly elevated Serum Albumin Slightly decreased or normal Markedly decreased (hypoalbuminemia) Lipid Levels Normal or slightly elevated Hyperlipidemia (Option B) Renal Function Often reduced (Azotemia) (Option A) Usually normal or slightly impaired Urine findings Red cell casts (Option C), granular casts Fatty casts, oval fat bodies & Maltese cross appearance (lipiduria) Common Causes Post-streptococcal glomerulonephritis IgA nephropathy Minimal change disease Membranous nephropathy Focal segmental glomerulosclerosis Symptoms Oliguria, hematuria (cola-colour urine), hypertension, thrombotic events (Loss of AT III via urine) {{caption_text}} Frothy urine, severe oedema {{caption_text}}





References:

Robbins and Cotran Pathologic Basis of Disease, 10th edition, pages 906-920

↑ *Back to this question in Part A*

@Neet_pg_bot

• [11_Renal System] 050 Renal Urinary Tract Tumors

« Back to Folder Directory

[11_Renal System] 050 Renal Urinary Tract Tumors — Quick Jump

Q1 (p. 2172) *Q2 (p. 2175)* *Q3 (p. 2176)* *Q4 (p. 2178)* *Q5 (p. 2178)* *Q6 (p. 2179)*
Q7 (p. 2180) *Q8 (p. 2182)* *Q9 (p. 2185)* *Q10 (p. 2186)* *Q11 (p. 2189)* *Q12 (p. 2190)*
Q13 (p. 2191) *Q14 (p. 2192)* *Q15 (p. 2193)* *Q16 (p. 2194)*

Q1: A 65-year-old diabetic male presented to the hospital complaining of chronic abdominal discomfort and unexplained weight loss over the past few months. A palpable firm mass was detected on the left upper quadrant upon physical examination. Ultrasound revealed a large mass in the left upper pole of the kidney. Due to suspicion of renal malignancy, the patient underwent a left nephrectomy. Based on the specimen obtained, what is the most likely diagnosis? {{caption_text}} (Q845695)

A. Renal oncocytoma

B. Epithelioid angiomyolipoma

C. Clear cell carcinoma

D. Urothelial carcinoma

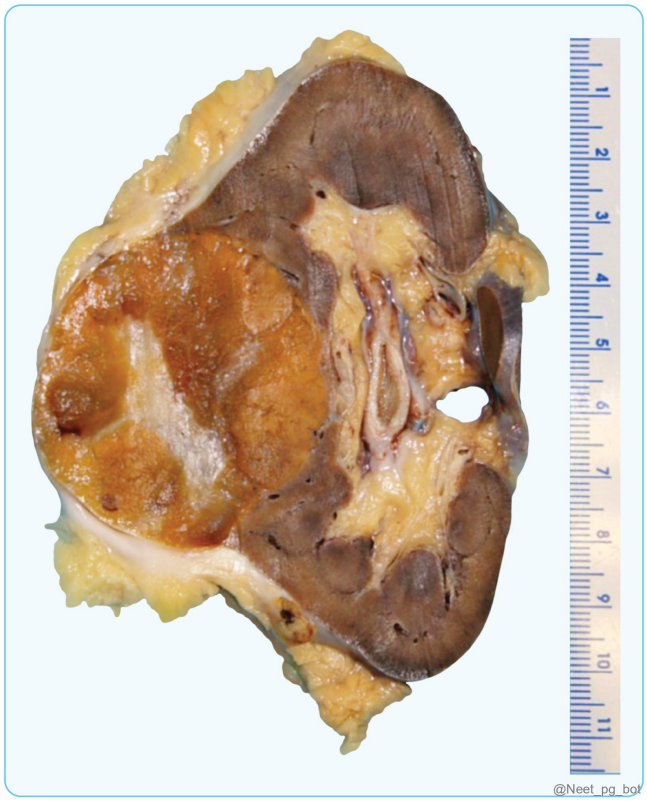

Correct Answer: A. Renal oncocytoma

- *Listen (English)*
- *Listen (Hindi)*

Explanation: Renal Oncocytoma: It is a benign tumor most commonly seen in > 50-year-old adults. It arises from the intercalated cells of the collecting ducts. Gross appearance: A well-circumscribed tumot which has classical tan or mahogany brown colour , with a central whitish scar called as Central stellate scar. Microscopy: Composed of dense, pink eosinophilic cells with small, round, benign-appearing nuclei. Electron microscope: Numerous mitochondria (granular appearance) Chromophobe RCC is a very close mimicker of renal oncocytoma because it also shows a central stellate scar. Chromophobe RCC shows classical plant cells, while Renal oncocytomas show benign-looking oncotic cells. {{caption_text}} {{caption_text}} {{caption_text}} Epithelioid angiomyolipoma (Option B) is a rare variant of angiomyolipoma composed of smooth muscle cells, fat, and blood vessels. Clear cell carcinoma (Option C) would typically present with more aggressive features like hematuria, anemia, and vascular invasion. This patient's presentation along with a well-circumscribed mass is more typical of a benign tumor. Urothelial carcinoma (Option D) is a bladder cancer and not a renal cancer.

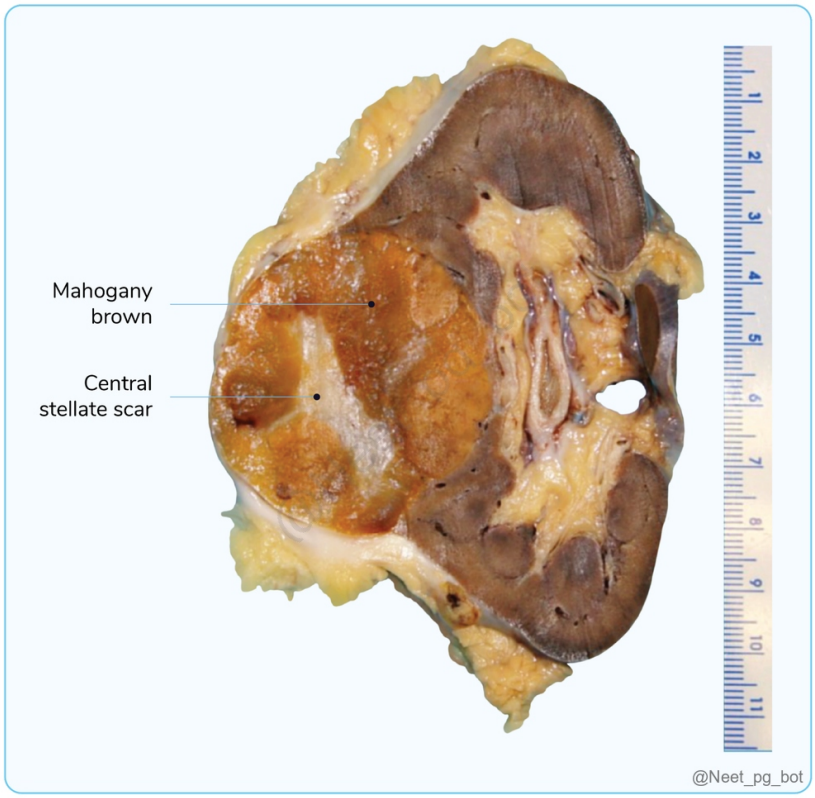
Mahogany brown
Central stellate scar
@Neet_pg_bot

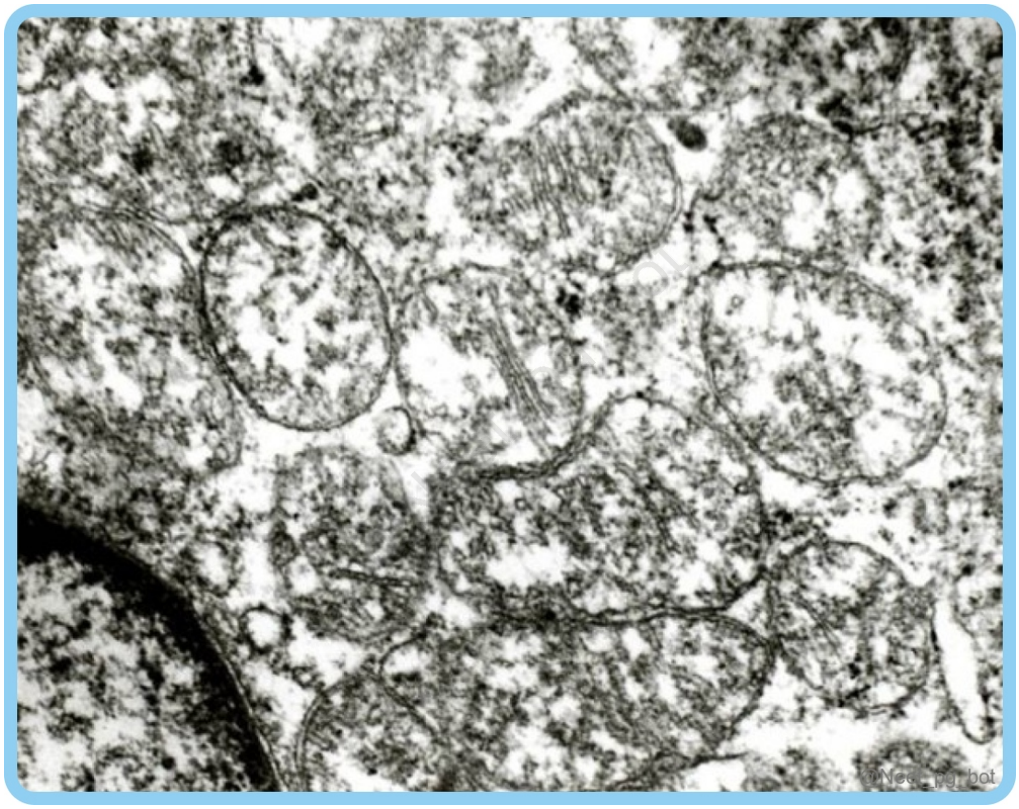
@Neet_pg_bot

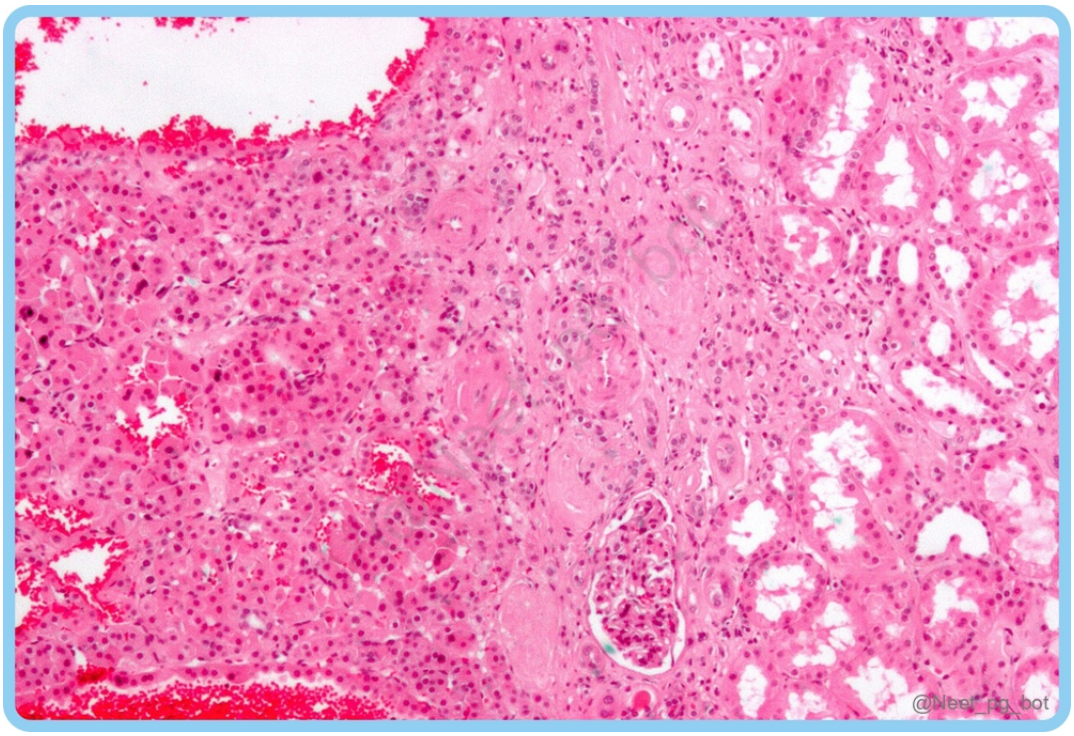

References:

Robbins and Cotran, Pathologic Basis of Disease, 10th Edition, Page 948

↑ *Back to this question in Part A*

@Neet_pg_bot

Q2: A child presents with hematuria and fever for the past 4 months. On examination, a mass-like structure was felt at the right flank. Which of the following features is not associated with this condition? (Q845709)

A. Gonadal dysgenesis and renal failure

B. Cryptorchidism and absent iris

C. Bilateral malar and mandibular hypoplasia

D. Adrenal cytomegaly and macroglossia

Correct Answer: C. Bilateral malar and mandibular hypoplasia

■ *Listen (English)*

■ *Listen (Hindi)*

Explanation: The given clinical vignette of a child with fever, hematuria, and abdominal mass in the right flank is suggestive of Wilm’s tumour or nephroblastoma. Bilateral malar and mandibular hypoplasia are characteristic of Treacher-Collins syndrome (not Wilms tumour). Wilm's tumor is the most common pediatric renal tumor. Clinical triad of Wilm's tumor: Mass in the flank Hematuria Fever Syndromes associated with Wilm’s tumour are : Mutation Syndrome Features WT1 WAGR syndrome Wilms tumour. Aniridia (absent iris) (Option B) . Gonadal anomalies (like cryptorchidism) (Option B) . Intellectual disability. Denys-Drash syndrome Gonadal dysgenesis (male pseudohermaphroditism) (Option A) . Early-onset nephropathy (leading to renal failure) (Option A) . WT2 Beckwith-Widemann syndrome Organomegaly. Macroglossia (Option D) . Hemihypertrophy. Omphalocele. Abnormal large cells in the adrenal cortex (adrenal cytomegaly) (Option D) .

References:

Robbins and Cotran, Pathologic Basis of Disease, 10th Edition, Page 481

↑ *Back to this question in Part A*

@Neet_pg_bot

Q3: A renal biopsy specimen has to be examined under microscopy for the presence of nephroblastoma. Presence of which of the following findings is less likely suggestive of the same? (Q845713)

A. Neuropils

B. Small blue cells

C. Adipose tissue

D. Myxoid stroma

Correct Answer: A. Neuropils

■ *Listen (English)*

■ *Listen (Hindi)*

Explanation: Neuropils are pinkish coloured eosinophilic fibrillary material surrounded by concentric groups of tumour cells (Homer-Wright pseudorosettes) commonly seen in brain tumors such as medulloblastoma. They are not seen in Wilm’s tumour/Nephroblastoma. Wilm's tumor is a triphasic tumor because it shows 3 things under the microscope: Epithelial: Cells like glomeruli or tubules. Mesenchymal: Adipose tissue and myxoid stroma are seen Blastemal: Blue cells Characteristics Wilms Tumor Neuroblastoma Location Kidney Most common abdominal tumor in childhood Common site: adrenal medulla, Also seen in abdomen, pelvis & neck. Most common primary renal tumor in childhood. Histological features Blastemal : Small blue cells. (Option B ruled out) Epithelial : Abortive tubules/glomeruli. Stromal : Fibroblastic or myxoid. (Option D ruled out) Small blue cells with neuroblasts, neurofibrils (neuropils) (Option A) , and mature ganglion cells Pseudo-rosettes (arrangements of small, round neuroblastic cells around a central fibrillary core) Histological image {{caption_text}} {{caption_text}}

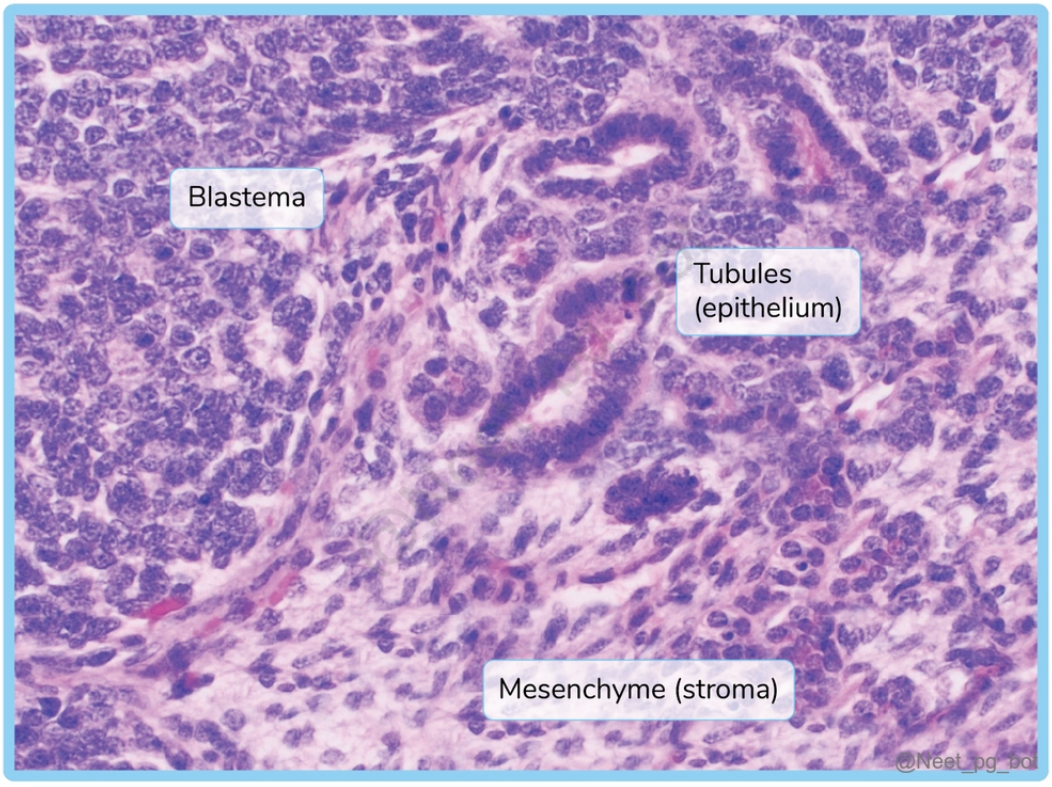

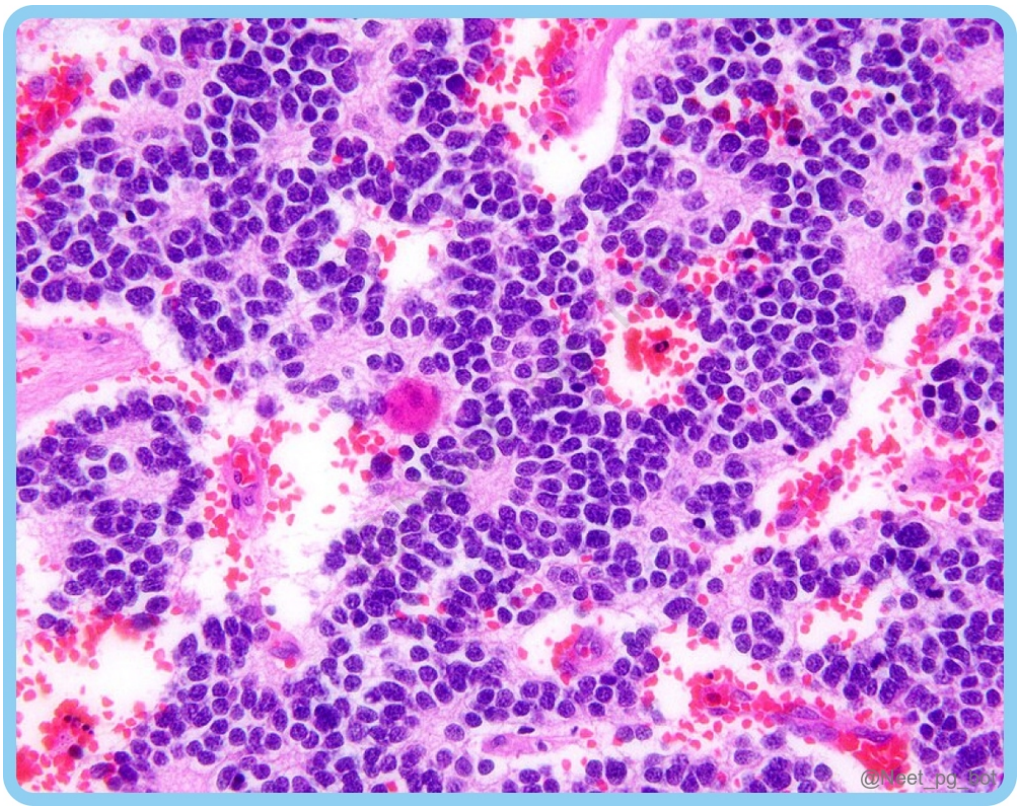

References:

Robbins and Cotran, Pathologic Basis of Disease, 10 Edition, Page 482.

↑ *Back to this question in Part A*

@Neet_pg_bot

Q4: A histopathological report of renal biopsy done on a child states, “tumour cells suggestive of nephroblastoma along with adjacent sclerotic rests”. What is the risk associated with the presence of such sclerotic rests? (Q845744)

A. Presence of anaplasia

B. Pulmonary metastasis

C. Contralateral tumour

D. Associated lymphoma

Correct Answer: C. Contralateral tumour

■ *Listen (English)*

■ *Listen (Hindi)*

Explanation: Nephrogenic rests if present along with Wilms tumours in the same kidney will indicate occurence of the tumor in same kidney previously also. Hence, It is important to document the presence of nephrogenic rests in the resected specimen because these patients are at an increased risk of developing Wilms tumours in the contralateral kidney and require frequent and regular surveillance for many years.

References:

Robbins and Cotran, Pathologic Basis of Disease, 10th Edition, Page 482

↑ *Back to this question in Part A*

@Neet_pg_bot

Q5: Which of the following statements regarding renal cell carcinoma is false? (Q845745)

A. Clear cell RCC is the most common type overall.

B. Papillary RCC is most commonly associated with dialysis patients.

C. Medullary RCC is commonly seen in sickle cell trait patients.

D. Papillary RCC has the best prognosis.

Correct Answer: D. Papillary RCC has the best prognosis.

■ *Listen (English)*

■ *Listen (Hindi)*

Explanation: Clear cell RCC is the most common type overall and is associated with deletion of chromosome 3p, known as Von Hippel-Lindau (VHL) syndrome. (Option A) Papillary RCC is most commonly associated with dialysis patients. (Option B) It can also be associated with: Trisomy 7, trisomy 17 and loss of chromosome Y. Medullary RCC is commonly seen in sickle cell trait patients and in black patients. (Option C) Chromophobe RCC has the best prognosis. Bellini duct or collecting duct RCC has the worst prognosis. Renal cell carcinoma: Age group Most common in the 6th and 7th decades. Male: Female ratio 2:1 Site of origin Proximal convoluted tubule. Risk factors Cigarette smoking (most important). Obesity (particularly in women) and hypertension. Unopposed estrogen therapy. Exposure to asbestos, petroleum products, and heavy metals. End-stage renal disease. Chronic kidney disease. Acquired cystic disease. Tuberous sclerosis. Classification Sporadic: Most common type. Hereditary: Autosomal dominant, young age affected. Von-Hippel-Lindau syndrome. Hereditary leiomyomatosis & renal cell cancer syndrome. Hereditary papillary carcinoma. Birt-Hogg-Dube syndrome. Histological classification: Clear cell carcinoma (most common type) (Option A ruled out) . Papillary cell carcinoma (associated with dialysis patients) (Option B ruled out) . Chromophobe carcinoma (best prognosis) (Option D) . Bellini duct (collecting duct) carcinoma. Xp11 translocation carcinoma. Medullary carcinoma (seen in patients with sickle cell trait) (Option C ruled out) .

References:

Robbins and Cotran, Pathologic Basis of Disease, 10th Edition, Pages 948-952

↑ *Back to this question in Part A*

@Neet_pg_bot

Q6: A 45-year-old female died within a few months after being diagnosed with renal cell carcinoma. The autopsy revealed a yellowish, spherical neoplasm in one pole of the kidney. The tumour cells invaded the renal vein and inferior vena cava. Histopathology is shown below. What is the most likely diagnosis? {{caption_text}} (Q845896)

A. Collecting duct RCC

B. Papillary RCC

C. Clear cell RCC

D. Chromophobe RCC

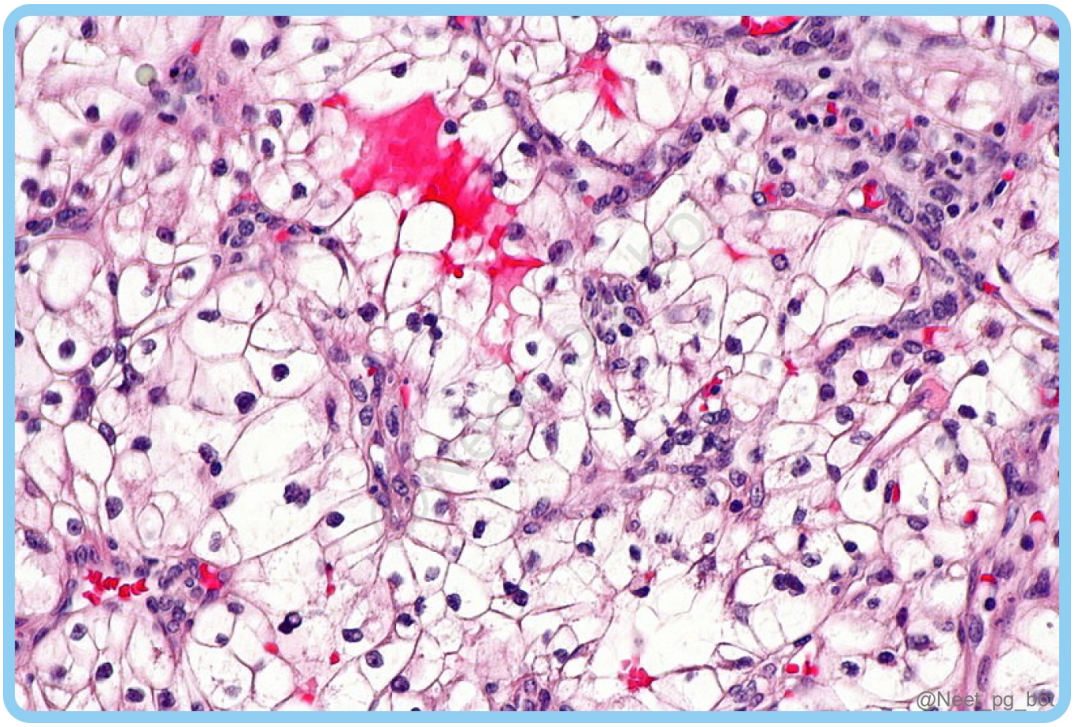

Correct Answer: C. Clear cell RCC

■ *Listen (English)*

■ *Listen (Hindi)*

Explanation: The clinical scenario and the histopathology image is suggestive of Clear cell carcinoma Clear cell carcinoma: Classical clearing of cells is due to the accumulation of glycogen and lipids. It is a yellowish neoplasm due to prominent lipid accumulation. It is the most common renal cell carcinoma and is associated with the deletion of chromosome 3p which leads to Von Hippel-Lindau (VHL) syndrome

References:

Robbins and Cotran, Pathologic Basis of Disease, 10th Edition, Page 952

↑ *Back to this question in Part A*

@Neet_pg_bot

Q7: A 36-year-old woman presents with intermittent flank pain and occasional gross hematuria. Laboratory tests show normal renal function. A renal biopsy of a mass lesion reveals a mixture of mature adipose tissue, thick-walled blood vessels, and bundles of smooth muscle cells. All are true regarding this condition except: {{caption_text}} (Q846649)

A. Commonly associated with tuberous sclerosis

B. More prevalent in males than females

C. Mostly a benign tumor

D. High susceptibility to spontaneous hemorrhage

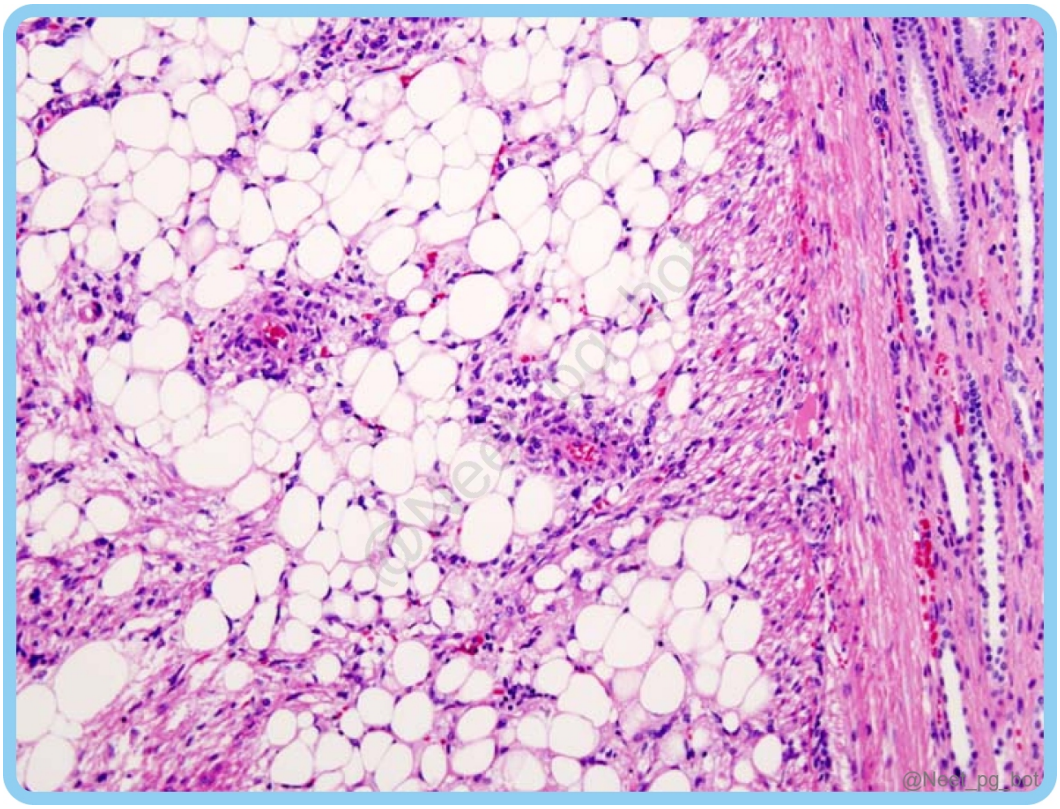

Correct Answer: B. More prevalent in males than females

Explanation: The history, findings and image point to a diagnosis of renal angiomyolipoma. Renal angiomyolipoma : Benign neoplasm consists of vessels, smooth muscle, and fat originating from perivascular epithelioid cells (Option C) . It is most often detected incidentally and has a female preponderance (Option B ruled out) . They are present in 25% to 50% of patients with tuberous sclerosis (Option A) . It has a high susceptibility for bleeding (can present as loin pain) (Option D) . Marker: HMB-45 positive Histology: Circular blood vessels, muscles, and fat; perivascular epithelioid cells with dense eosinophilic cytoplasm and mitotic figures.
{{caption_text}}

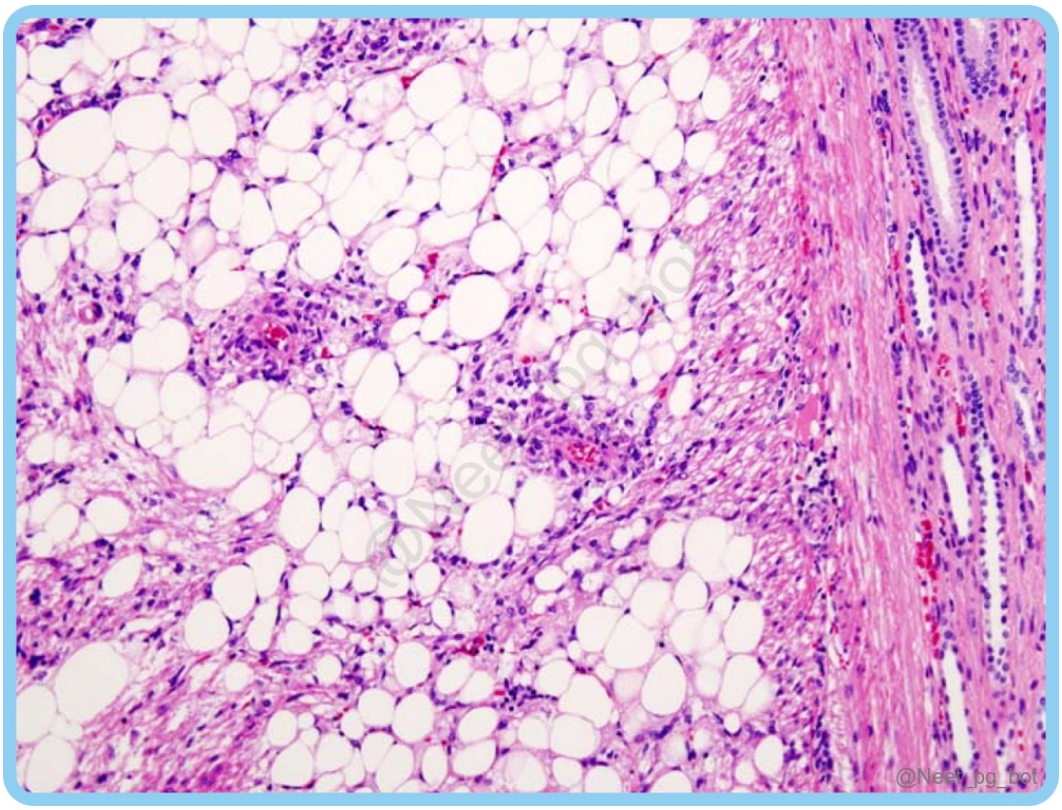

References:

Robbins and Cotran Pathologic Basis of Disease, 10th Edition, Page 948

Bailey and Love Short Practice of Surgery, 28th Edition, Page 1481

www.ncbi.nlm.nih.gov/books/NBK585104/

↑ *Back to this question in Part A*

@Neet_pg_bot

Q8: Hobnail nuclei are seen in which type of renal cell carcinoma? (Q846650)

A. Clear cell renal cell carcinoma.

B. Papillary renal cell carcinoma.

C. Chromophobe renal cell carcinoma.

D. Collecting duct carcinoma.

Correct Answer: D. Collecting duct carcinoma.

■ *Listen (English)*

■ *Listen (Hindi)*

Explanation: Hobnail nuclei are a characteristic feature of collecting duct carcinoma/ Bellini duct carcinoma. Hobnail nuclei: Nuclei are seen projecting out of the cell or into the lumen. It's the renal cell carcinoma with the worst prognosis. {{caption_text}} Clear cell renal cell carcinoma. (Option A): Shows white clear cells. Papillary renal cell carcinoma (Option B): Shows papillary projections along with psammoma bodies. {{caption_text}} Chromophobe renal carcinoma (Option C): Shows plant cells. {{caption_text}}

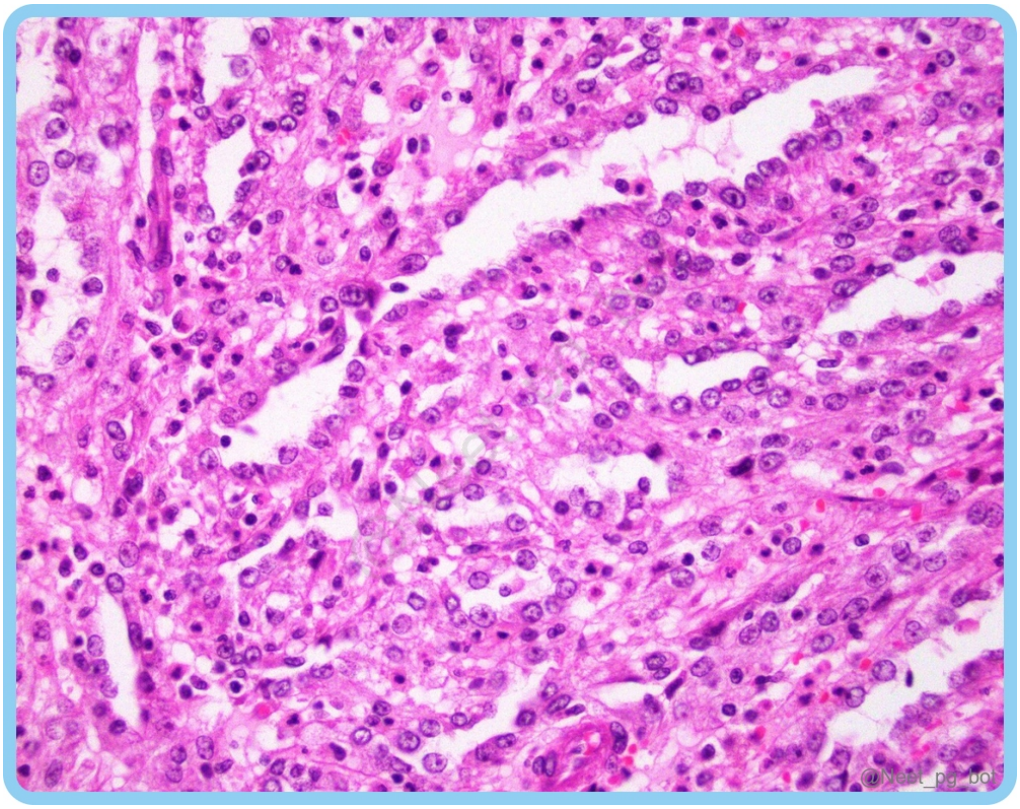

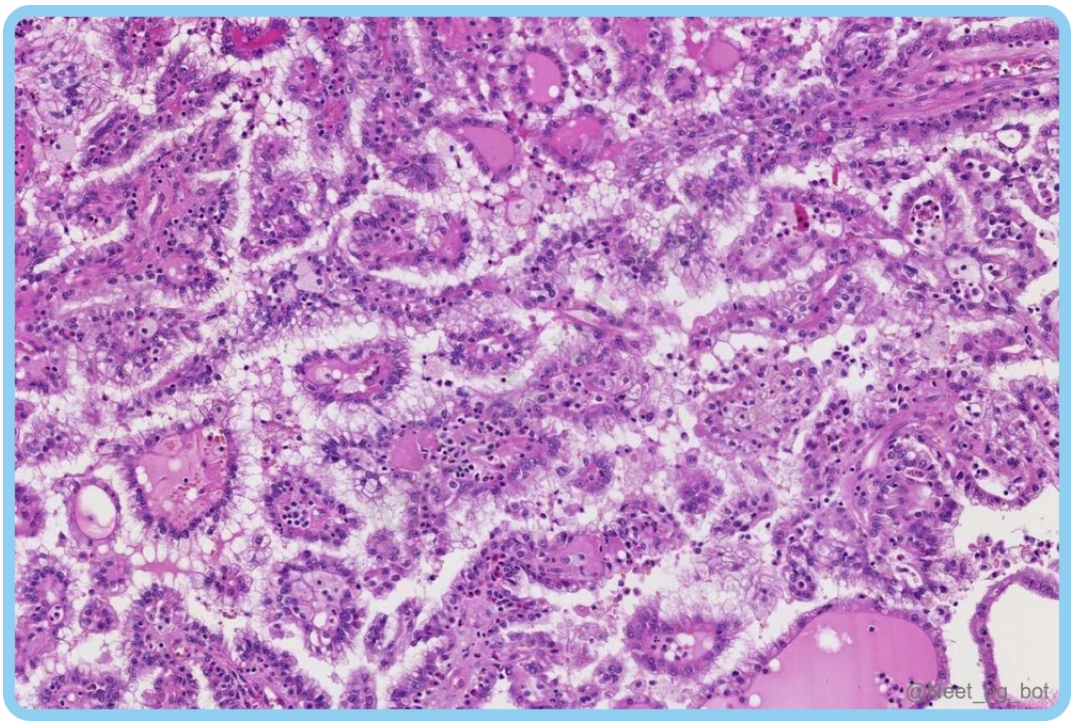

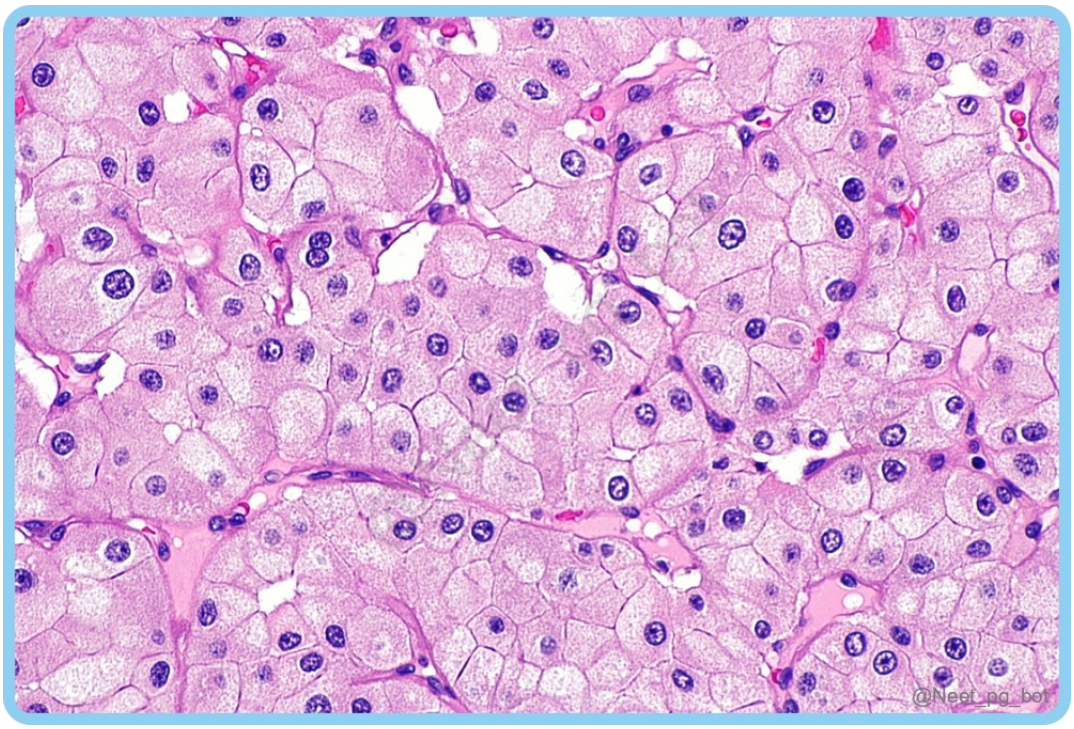

References:

Robbins and Cotran, Pathologic Basis of Disease, 10th Edition, Page 952

↑ *Back to this question in Part A*

@Neet_pg_bot

Q9: On histological examination, which of the following types of renal cell carcinoma shows large cells with a plant-cell-like appearance with a perinuclear halo? (Q846651)

A. Papillary RCC

B. Clear cell RCC

C. Chromophobe RCC

D. Medullary RCC

Correct Answer: C. Chromophobe RCC

■ *Listen (English)*

■ *Listen (Hindi)*

Explanation: Chromophobe renal cell carcinoma shows large cells having plant-cell-like appearance with a perinuclear halo. These are positive for Hale's Colloidal iron. Plant cells: Have a very well-defined outline and nucleus is shriveled like a raisin, known as raisinoid nucleus . A pernuclear halo is present around the nucleus. Special stain: Hale's Colloidal iron Among renal cell carcinomas, chromophobe renal cell carcinoma has the best prognosis. The histological image of chromophobe renal cell carcinoma:

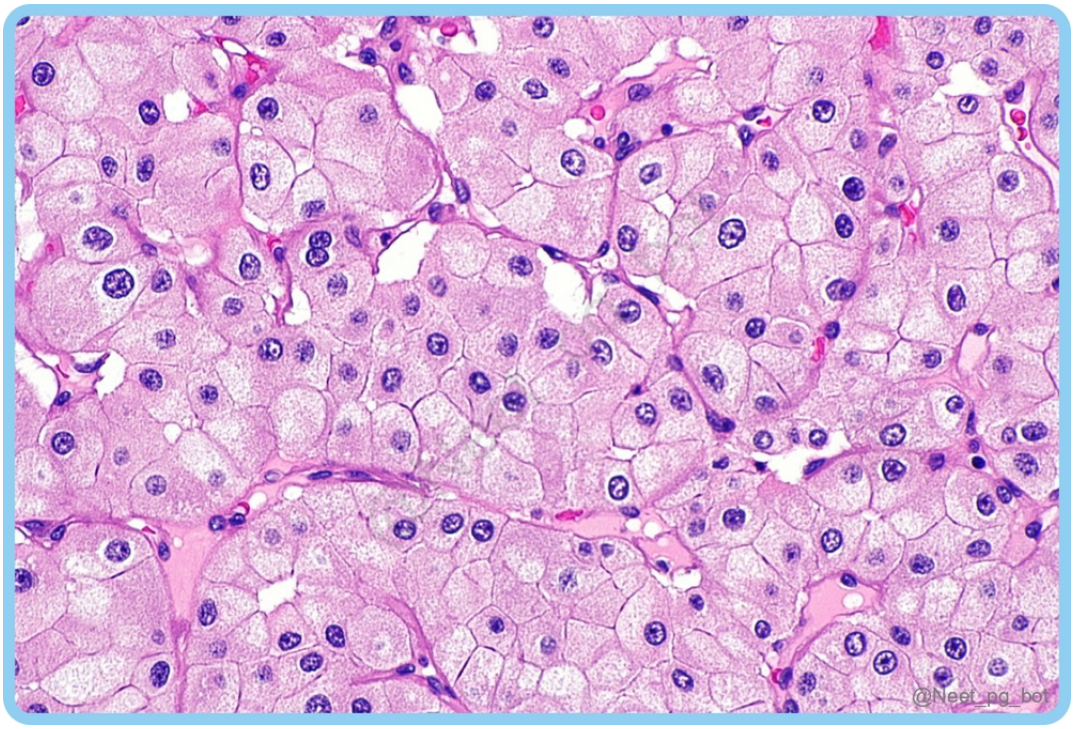

References:

Robbins and Cotran, Pathologic Basis of Disease, 10th Edition, Page 952

↑ *Back to this question in Part A*

Q10: Multiple losses of entire chromosomes are seen in which type of Renal Cell Carcinoma? (Q846652)

A. Papillary RCC

B. Clear cell RCC

C. Chromophobe RCC

D. Collecting duct RCC

Correct Answer: C. Chromophobe RCC

■ *Listen (English)*

■ *Listen (Hindi)*

Explanation: Chromophobe RCC: Mnemonic: Chromo: Chromosome Phobe : Phobia There are multiple chromosome losses seen in chromophobe RCC. It is associated with Birt-Hogg-Dubé syndrome. Gross appearance: Shows a central stellate scar Microscopic appearance: Shows plant cells (Cells having very well-defined outlines, raisinoid nucleus and a perinuclear halo) Stain positive for RCC is Hale's colloidal iron . Among renal cell carcinomas, chromophobe renal cell carcinoma has the best prognosis. Subtypes of renal cell carcinoma: Type of RCC Causes Microscopy Features Clear Cell RCC (Option B) Associated with mutations in the VHL gene (von Hippel-Lindau syndrome) Cells with clear cytoplasm due to the accumulation of glycogen and lipids {{caption_text}} Papillary RCC (Option A) Associated with- MET gene mutations Hereditary Leiomyomatosis RCC Dialysis-related cystic disease Loss of Y Psammoma bodies may be present {{caption_text}} Chromophobe RCC Associated with Birt-Hogg-Dubé syndrome Loss of multiple chromosomes (Option C) (hypodiploidy) Cells with pale, eosinophilic cytoplasm, Perinuclear halos- Plant cells Hale’s colloidal iron +ve {{caption_text}} Collecting Duct (Bellini Duct) RCC Associated with mutations in multiple genes, including SMARCB1 Hobnail cells seen. Worst prognosis. {{caption_text}} Medullary RCC Strongly associated with sickle cell trait. Poorly differentiated cells {{caption_text}}

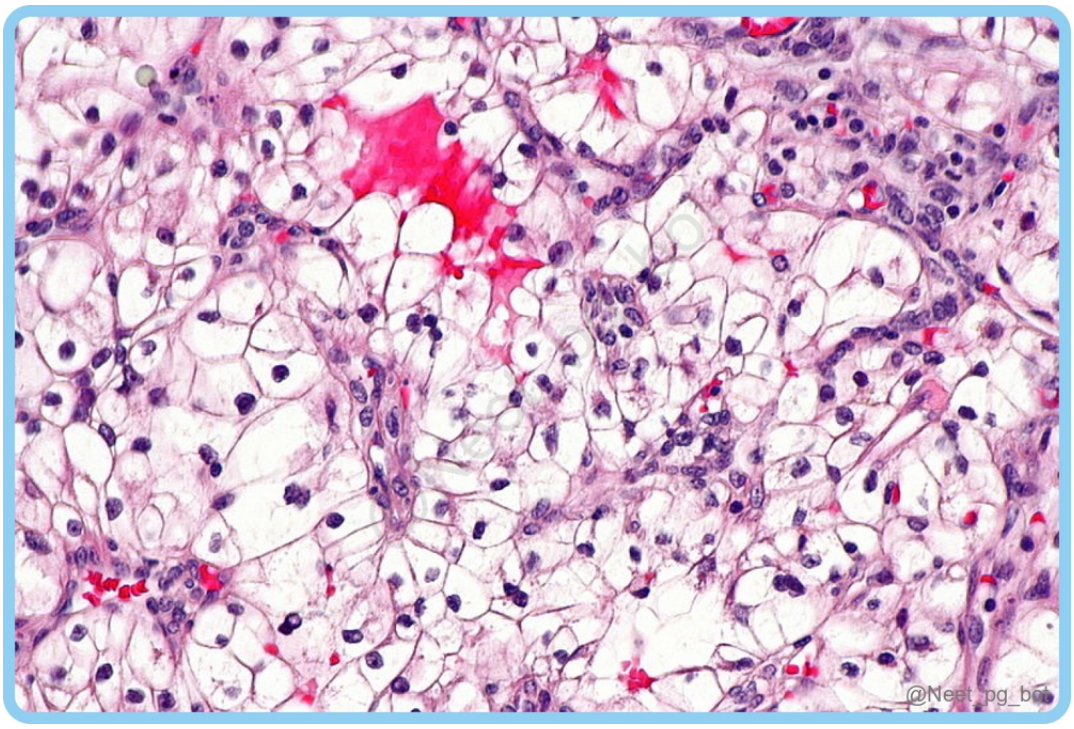
@Neet_pg_bot

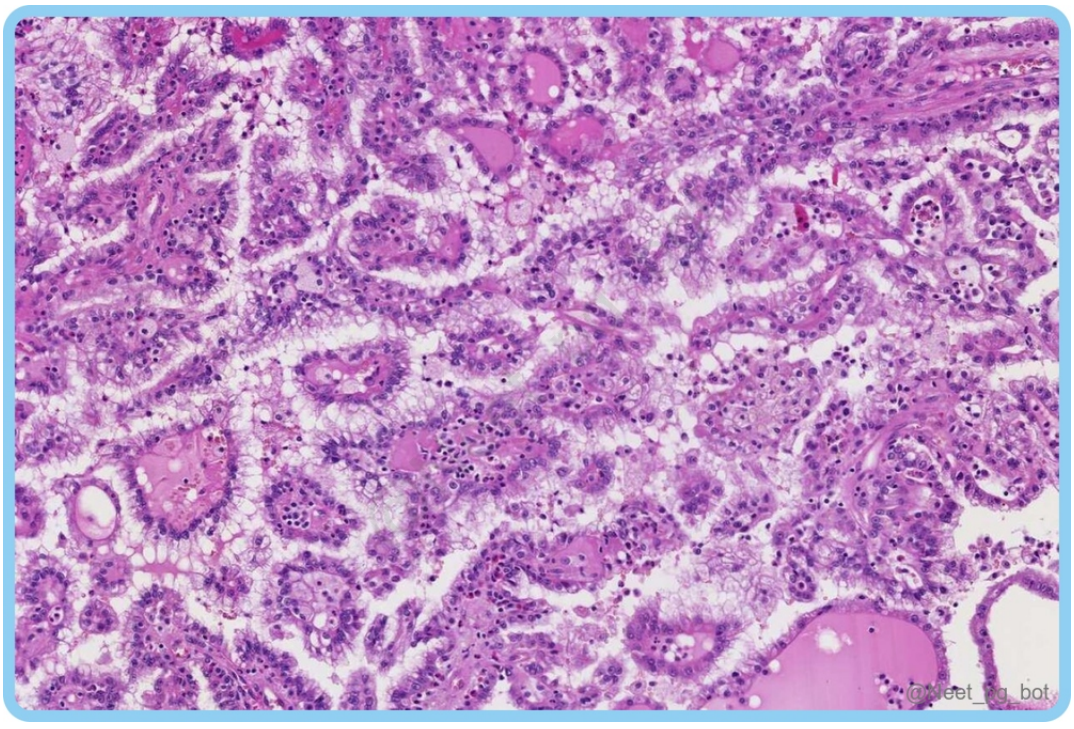
@Neet_pg_bot

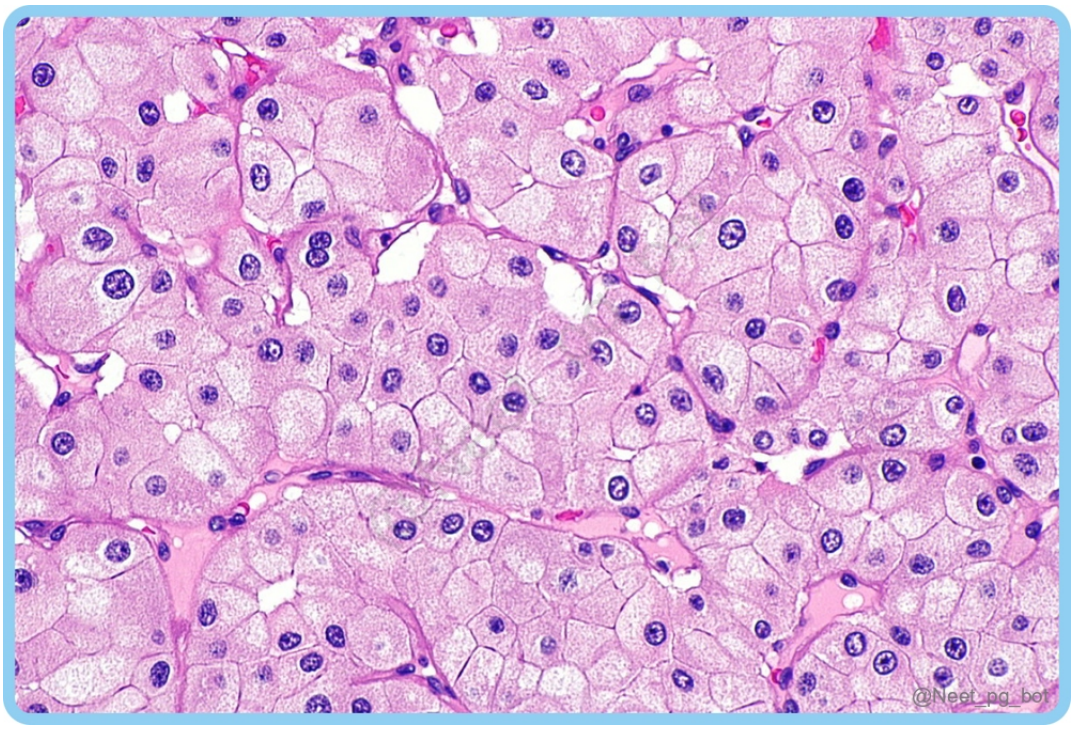
@Neet_pg_bot

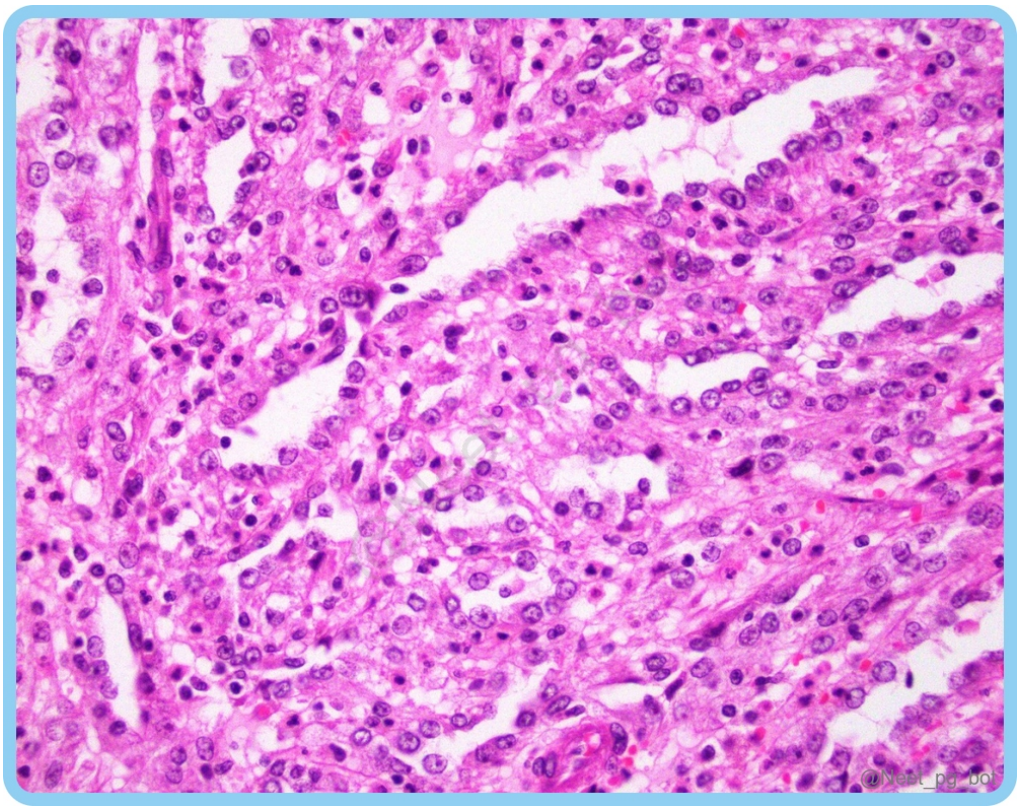
@Neet_pg_bot

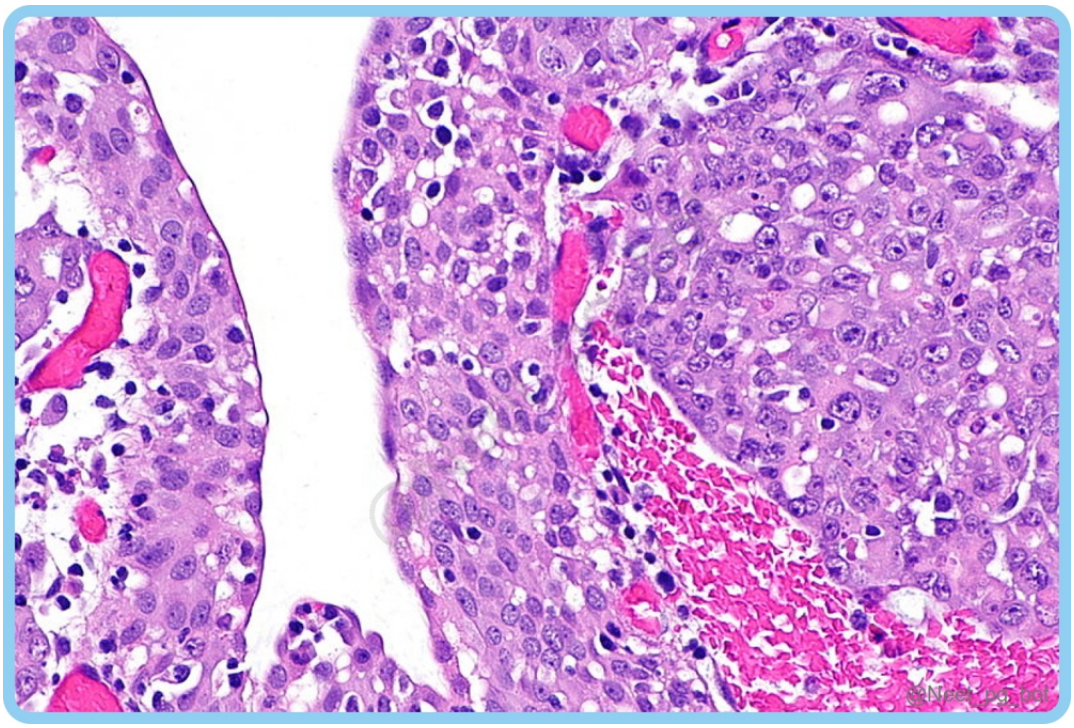

References:

Robbins and Cotran, Pathologic Basis of Disease, 10th Edition, Page 955

↑ *Back to this question in Part A*

@Neet_pg_bot

Q11: Which of the following statements regarding Wilms' tumour is incorrect? (Q889878)

A. It is associated with WAGR syndrome

B. Associated with triphasic morphology

C. The most common renal tumour in children

D. WT1 mutations are present in >80% of sporadic cases

Correct Answer: D. WT1 mutations are present in >80% of sporadic cases

Explanation: WT1 mutations occur in only ~10% of sporadic Wilms tumours, not the majority. Wilms Tumour (Nephroblastoma): The most common renal tumour in children (Option D) Peak: 2-5 years Cure rate ≈ 90% Associated syndromes: Syndrome Key Features Genetic Basis WAGR (Option A) W ilms, A niridia, G enitourinary anomalies, R etardation Germline deletion of 11p13 (WT1 & PAX6) Denys-Drash Gonadal dysgenesis, early-onset nephropathy Point mutation in WT1 (dominant-negative) Beckwith-Wiedemann

Organomegaly, macroglossia, hemihypertrophy 11p15.5 (WT2) ; IGF2 over-expressio Morphology (Triphasic) (Option B): Blastemal - small, round, blue cells Epithelial - abortive tubules/glomeruli Stromal - fibroblastic/myxoid ± skeletal muscle

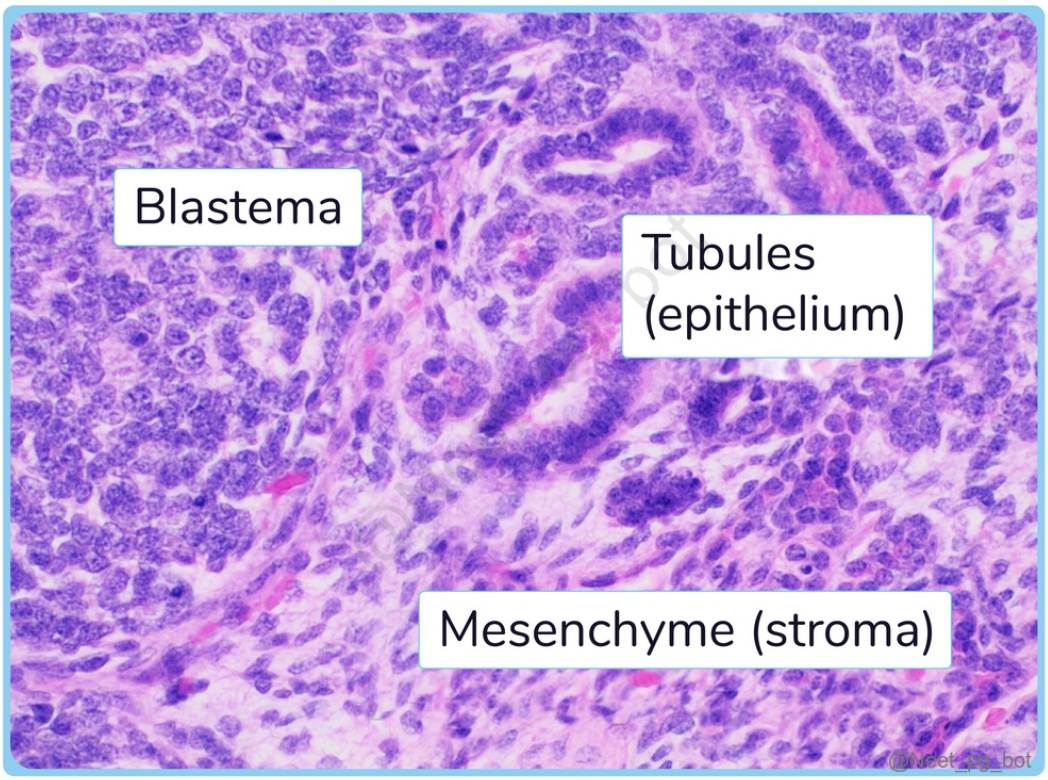

References:

Robbins, Cotran & Kumar, Pathologic Basis of Disease, 11th Edition, Pages 437 - 439

↑ *Back to this question in Part A*

@Neet_pg_bot

Q12: A 4-year-old child undergoes nephrectomy for a Wilms tumour. Histology shows large hyperchromatic pleomorphic nuclei with abnormal mitotic figures. The tumour shows a poor response to preoperative chemotherapy. Which of the following best explains the chemotherapy resistance in this tumour? (Q889881)

A. Gain-of-function mutation in β-catenin

B. Loss of the WT1 tumour suppressor gene

C. Mutation of TP53 leading to defective apoptosis

D. IGF2 overexpression due to an imprinting abnormality

Correct Answer: C. Mutation of TP53 leading to defective apoptosis

Explanation: The histological description of large hyperchromatic pleomorphic nuclei with abnormal mitotic figures indicates anaplastic Wilms tumour , an uncommon but clinically important variant associated with poor prognosis and resistance to chemotherapy . Most cases of anaplastic Wilms tumour harbour mutations in the TP53 gene . The p53 protein normally acts as a tumour suppressor by inducing cell cycle arrest or apoptosis in response to DNA damage , including damage caused by cytotoxic chemotherapy. When TP53 is mutated , this apoptotic response is impaired, allowing tumour cells to survive despite chemotherapy , resulting in treatment resistance and a worse prognosis. Gain-of-function mutation in β-catenin (Option A): Mutations in the CTNNB1 gene (β-catenin) occur in a subset of Wilms tumours and contribute to tumour development through abnormal WNT signalling Loss of the WT1 tumour suppressor gene (Option B): WT1 mutations are involved in the initiation of Wilms tumour and are seen in conditions such as WAGR syndrome and Denys-Drash syndrome IGF2 overexpression due to an imprinting abnormality (Option D): IGF2 overexpression occurs in Beckwith-Wiedemann syndrome due to abnormalities at chromosome 11p15 , contributing to tumour growth

References:

Robbins, Cotran & Kumar, Pathologic Basis of Disease, 11th Edition, Page 438

↑ *Back to this question in Part A*

@Neet_pg_bot

Q13: A 4-year-old child is diagnosed with Wilms tumour. Histology and genetic studies are reviewed to assess prognosis. Which of the following is not associated with poor prognosis in Wilms tumour? (Q889883)

A. Anaplastic histology

B. Loss of heterozygosity at chromosomes 1p and 16q

C. Gain of chromosome 1q

D. Triphasic histology

Correct Answer: D. Triphasic histology

Explanation: The classic triphasic histology of Wilms tumour consists of blastemal, epithelial, and stromal components . When this pattern occurs without anaplasia , it represents favourable histology , which is associated with a good response to therapy and an excellent prognosis . Most children with favourable histology Wilms tumour have survival rates approaching 90% or higher with modern treatment. In contrast, several histological and genetic features are associated with poor prognosis : Anaplastic histology (Option A): This is the most important adverse prognostic factor in Wilms tumour. Anaplasia is characterised by marked nuclear enlargement, hyperchromasia, and abnormal mitotic figures , and is often associated with TP53 mutations and chemotherapy

resistance . Loss of heterozygosity at chromosomes 1p and 16q (Option B): This genetic abnormality is associated with increased risk of relapse and poorer survival , and it is used in risk stratification in modern treatment protocols. Gain of chromosome 1q (Option C): Gain of 1q is one of the most common cytogenetic abnormalities in Wilms tumour and is also associated with higher relapse rates and worse outcomes .

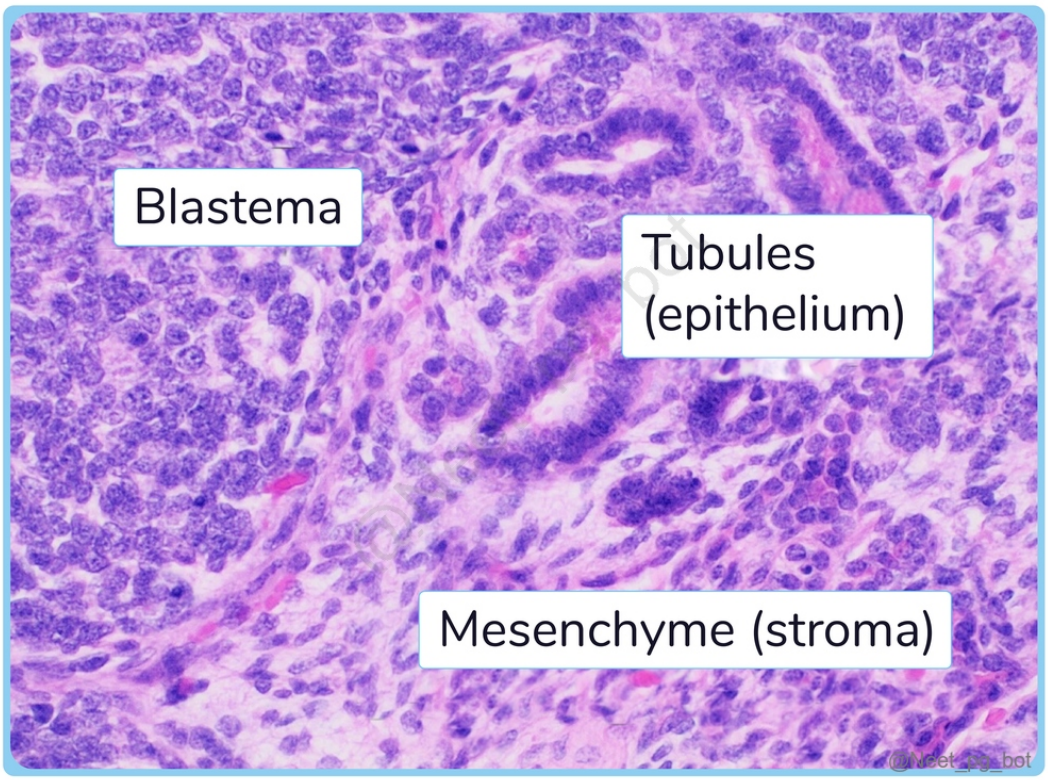

References:

Robbins, Cotran & Kumar, Pathologic Basis of Disease, 11th Edition, Page 439

↑ *Back to this question in Part A*

@Neet_pg_bot

Q14: Which of the following most reliably differentiates renal papillary adenoma from papillary renal cell carcinoma? (Q889885)

A. Presence of papillary architecture

B. Low-grade nuclear features

C. Tumour size cut-off

D. Presence of psammoma bodies

Correct Answer: C. Tumour size cut-off

Explanation: The most reliable criterion used to distinguish renal papillary adenoma from papillary renal cell carcinoma (pRCC) is the maximum tumour size . According to the WHO classification , papillary renal tumours measuring ≤ 1.5 cm are classified as papillary adenomas , while lesions > 1.5 cm are considered papillary renal cell carcinomas . Histologically and cytogenetically, these lesions are often very similar, suggesting that papillary adenomas may represent precursor lesions of papillary RCC . Both papillary adenomas and papillary RCC show papillary architecture (Option A) Both may exhibit low-grade nuclear features (Option B) , so these characteristics cannot reliably distinguish the two. Similarly, psammoma bodies (Option D) may be present in papillary tumours but are not specific for carcinoma . Both papillary adenomas and papillary RCC frequently show similar cytogenetic abnormalities, particularly trisomy of chromosomes 7 and 17 and loss of the Y chromosome , further supporting their biological relationship. Papillary renal cell carcinoma is the second most common subtype of renal cell carcinoma , accounting for approximately 15-20% of RCC cases . Two major histologic patterns are recognised: Type 1: Papillae lined by a single layer of small basophilic cells with low-grade nuclei. Type 2: Larger eosinophilic cells with higher nuclear grade , generally associated with more aggressive behaviour and poorer prognosis.

References:

https://pmc.ncbi.nlm.nih.gov/articles/PMC9394504/

https://radiopaedia.org/articles/renal-papillary-adenoma

↑ *Back to this question in Part A*

@Neet_pg_bot

Q15: A 50-year-old man with recurrent pneumothorax and multiple facial fibrofolliculomas is found to have bilateral renal masses. Genetic testing reveals an FLCN mutation. Which renal cell carcinoma (RCC) is most commonly associated with the most probable condition? (Q889889)

A. Clear cell RCC

B. Papillary RCC

C. Chromophobe RCC

D. Collecting duct carcinoma

Correct Answer: C. Chromophobe RCC

Explanation: The clinical features described - recurrent pneumothorax, facial fibrofolliculomas, and renal tumours with an FLCN mutation are characteristic of Birt-Hogg-Dubé syndrome , an autosomal dominant disorder caused by mutations in the FLCN gene (folliculin) . This syndrome is associated with a characteristic triad: Skin lesions: fibrofolliculomas, trichodiscomas, and acrochordons Pulmonary manifestations: lung cysts and spontaneous

pneumothorax Renal tumours: most commonly chromophobe RCC and hybrid oncocytic/chromophobe tumours Chromophobe Renal Cell Carcinoma (ChRCC): Origin: Intercalated cells of the collecting duct Cytogenetics: Multiple chromosome losses (e.g., 1, 2, 6, 10, 13, 17, 21) Prognosis: Better than clear cell RCC Histology: Composed of pale eosinophilic cells Prominent perinuclear halo Arranged in solid sheets Tendency for larger cells to cluster around blood vessels Distinct cell borders → “plant cell-like” appearance Cytoplasm may show reticular clearing Clear cell renal cell carcinoma (Option A) : Most common sporadic RCC and classically associated with Von Hippel-Lindau disease , not Birt-Hogg-Dubé syndrome. Papillary renal cell carcinoma (Option B) : More commonly linked to Hereditary papillary renal carcinoma due to MET proto-oncogene mutations. Collecting duct carcinoma (Option D) : A rare, aggressive RCC subtype not characteristically associated with Birt-Hogg-Dubé syndrome.

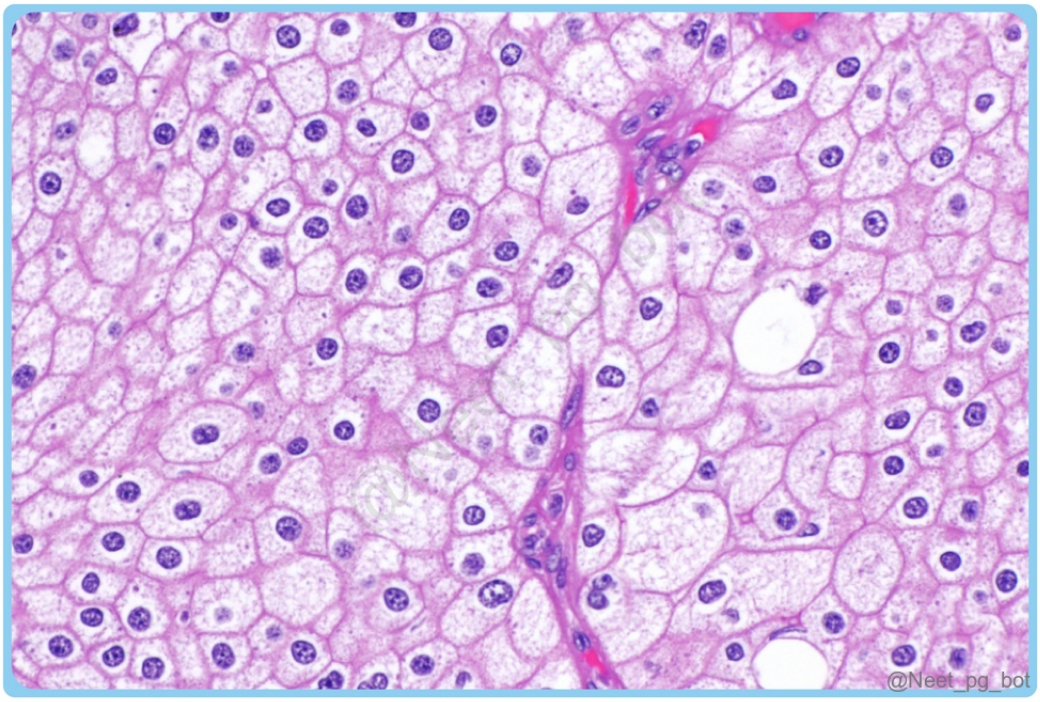

References:

Robbins, Cotran & Kumar, Pathologic Basis of Disease, 11th Edition, Page 863

https://pmc.ncbi.nlm.nih.gov/articles/PMC6942440/

↑ *Back to this question in Part A*

@Neet_pg_bot

Q16: A 13-year-old girl presents with painless hematuria. Imaging shows a renal mass. Biopsy reveals nested and tubulopapillary architecture. Immunostaining is positive for TFE3. What is the most likely diagnosis? (Q889892)

A. Clear cell renal cell carcinoma

B. Papillary renal cell carcinoma

C. Chromophobe renal cell carcinoma

D. Xp11 translocation renal cell carcinoma

Correct Answer: D. Xp11 translocation renal cell carcinoma

Explanation: The most likely diagnosis is Xp11 translocation renal cell carcinoma, because this subtype commonly occurs in children and young patients , shows nested, solid, or tubulopapillary architecture , and is defined by TFE3 gene rearrangements , leading to positive TFE3 immunostaining . Xp11 Translocation Renal Cell Carcinoma (TFE3-Rearranged RCC): Genetically distinct subtype of RCC characterised by TFE3 gene rearrangement . Common in children and young adults Genetics: Translocation involving TFE3 gene at Xp11.2 Fusion with various partner genes Leads to the overexpression of the TFE3 transcription factor Morphology: Variable (depends on fusion partner) Patterns include: Nested Solid Tubulopapillary Clear cell renal cell carcinoma (Option A) : Associated with VHL gene mutation and chromosome 3p deletion. It typically shows clear cytoplasm with rich vascularity and is more common in adults. Papillary renal cell carcinoma (Option B) : Commonly associated with trisomy 7 and 17 and MET mutations. Although papillary architecture may be present, it lacks TFE3 rearrangement and usually occurs in older adults. Chromophobe renal cell carcinoma (Option C) : Characterised by pale eosinophilic cells with perinuclear halos and multiple chromosome losses; not associated with TFE3 translocation.

References:

Robbins, Cotran & Kumar, Pathologic Basis of Disease, 11th Edition, Page 864

↑ *Back to this question in Part A*

@Neet_pg_bot

• [11_Renal System] 051 Previous Year Questions

« Back to Folder Directory

[11_Renal System] 051 Previous Year Questions — Quick Jump

Q1 (p. 2196)	*Q2 (p. 2198)*	*Q3 (p. 2199)*	*Q4 (p. 2202)*	*Q5 (p. 2205)*	*Q6 (p. 2208)*
Q7 (p. 2214)	*Q8 (p. 2216)*	*Q9 (p. 2217)*	*Q10 (p. 2218)*	*Q11 (p. 2219)*	*Q12 (p. 2220)*
Q13 (p. 2224)	*Q14 (p. 2224)*	*Q15 (p. 2225)*	*Q16 (p. 2226)*	*Q17 (p. 2227)*	

Q1: A 48-year-old man presents with facial puffiness, frothy urine, hypertension, a history of hepatitis B infection, and microscopic hematuria. A kidney biopsy reveals a spike and dome pattern. What is the most likely diagnosis? (Q855413)

A. Minimal change disease

B. Membranous nephropathy

C. Focal segmental glomerulosclerosis

D. PSGN-associated disease

Correct Answer: B. Membranous nephropathy

Explanation: The combination of frothy urine, hypertension, and the biopsy finding points to the diagnosis of Membranous nephropathy, which is a common cause of nephrotic syndrome in adults. It is often associated with hepatitis B and is characterised by the spike and dome pattern on kidney biopsy due to subepithelial immune complex deposition (primarily IgG and C3) . Membranous Nephropathy: M/C cause of nephrotic syndrome in elderly patients. It is immune complex-mediated and can be caused by malignancy (colon, lung, melanoma), infections(malaria, hepatitis B, C, syphilis, schistosomiasis), drugs (gold, penicillamine), or autoimmune conditions (SLE). {{caption_text}} {{caption_text}} In primary membranous nephropathy, antibodies primarily target the M-type phospholipase A2 receptor (PLA2R) located on the basal surface of podocytes. This triggers complement activation and subepithelial immune complex deposition , resembling Heymann nephritis lesions. Other less common target antigens include THSD7A and neutral endopeptidase (CD10) . The presence of anti-PLA2R antibodies is crucial for diagnosing the disease. Pathology Light Microscope Electron Microscope Immunofluorescence Membranous Nephropathy Diffuse capillary wall thickening Subepithelial deposits Granular IgG and C3; diffuse

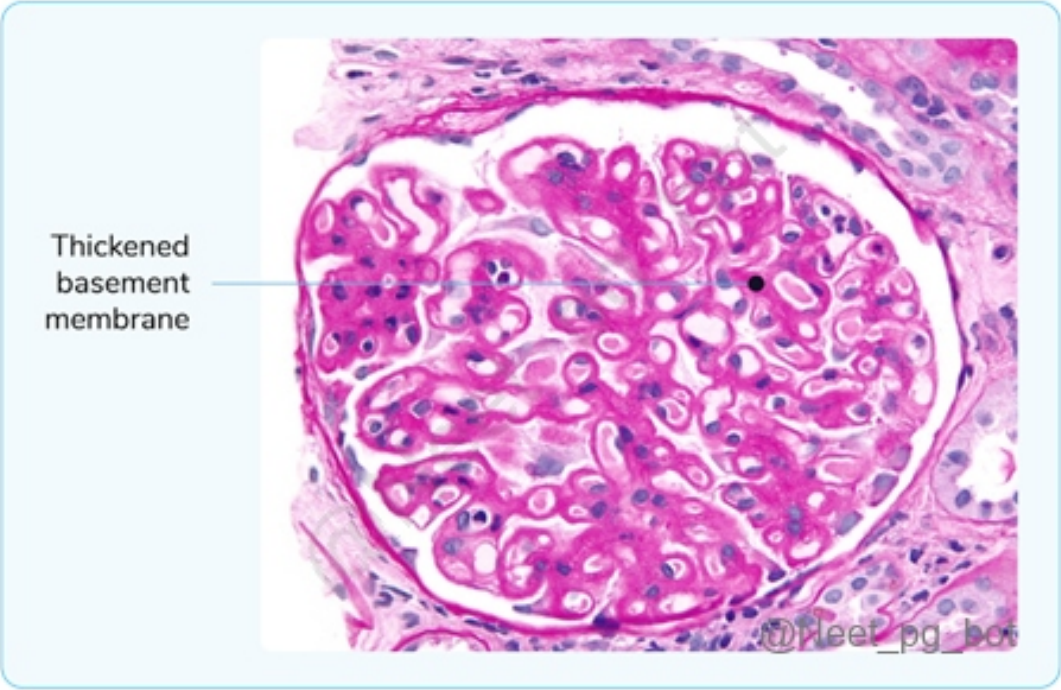

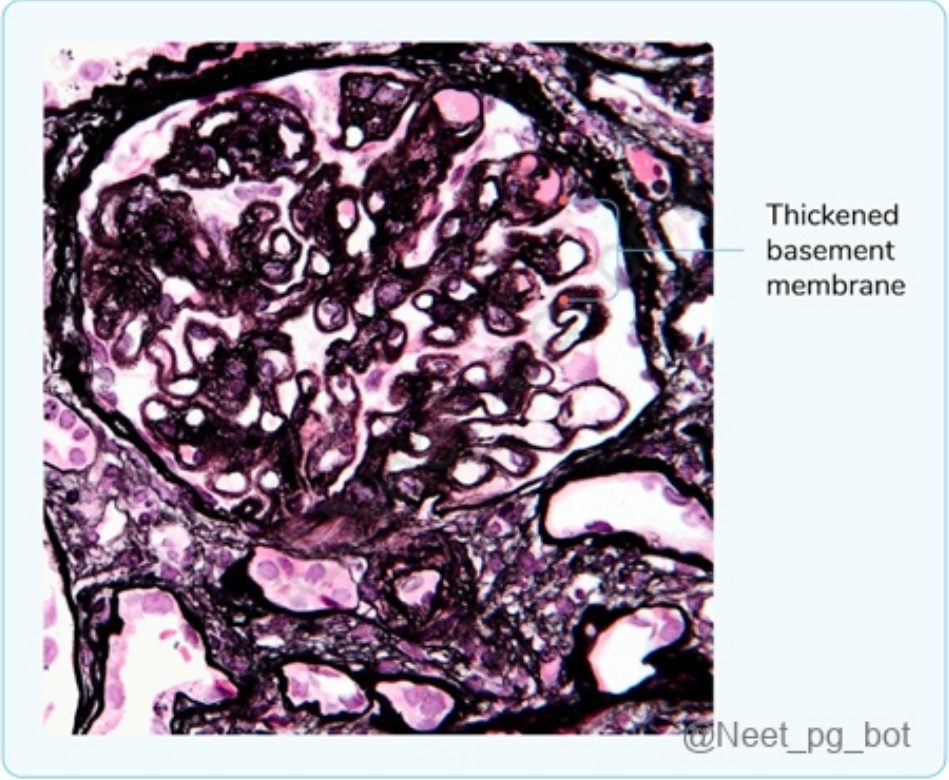

References:

Robbins and Cotran Pathologic Basis of Disease, 10th Edition, Page 912-914

↑ *Back to this question in Part A*

@Neet_pg_bot

Q2: A 40-year-old man has been diagnosed with solid cancer of the bowel. He also experienced massive proteinuria a few months after the initial diagnosis of cancer. What do you think is the likely cause of the development of urinary findings? (Q859258)

A. Membranous nephropathy

B. Focal segmental glomerulosclerosis

C. Membranoproliferative glomerulonephritis

D. Dense deposit disease

Correct Answer: A. Membranous nephropathy

Explanation: Characteristic Features of Membranous Nephropathy Feature Description Primary Cause Autoantibodies against phospholipase A2 receptor (PLA2R) on podocytes (most common in idiopathic cases). Secondary Causes Autoimmune diseases (SLE), infections (Hepatitis B/C), drugs (NSAIDs, penicillamine), and malignancies (lung, breast, colon cancer). Nephrotic Syndrome Features Massive proteinuria (>3.5 g/day), hypoalbuminemia, oedema, hyperlipidemia, lipiduria. Risk of Thrombosis Renal vein thrombosis is a known complication. Light Microscopy Diffuse thickening of the glomerular basement membrane (GBM) without hypercellularity. Electron Microscopy (EM) Subepithelial immune deposits create a "spike and dome" appearance . Immunofluorescence Granular IgG and C3 deposits along the GBM. PLA2R Antibodies Specific for primary membranous nephropathy and helps differentiate from secondary causes. Treatment ACE inhibitors/ARBs (reduce proteinuria), steroids + immunosuppressants (cyclophosphamide, rituximab) for severe cases. Prognosis ■ spontaneous remission, ■ persistent proteinuria, ■ progress to ESRD. {{caption_text}} Focal segmental glomerulosclerosis (Option B) (FSGS) is characterised by scarring and sclerosis of the glomeruli. While FSGS can occur in the setting of cancer, it is not commonly associated with solid cancer of the bowel. Membranoproliferative glomerulonephritis (Option C) (MPGN) is characterised by the thickening of the glomerular basement membrane and the proliferation of cells within the glomeruli.MPGN is not associated with solid cancer of the bowel. Dense deposit disease (Option D) , also known as C3 glomerulopathy, is characterised by the abnormal accumulation of complement component C3 within the glomeruli.Dense deposit disease is not associated with solid cancer of the bowel.

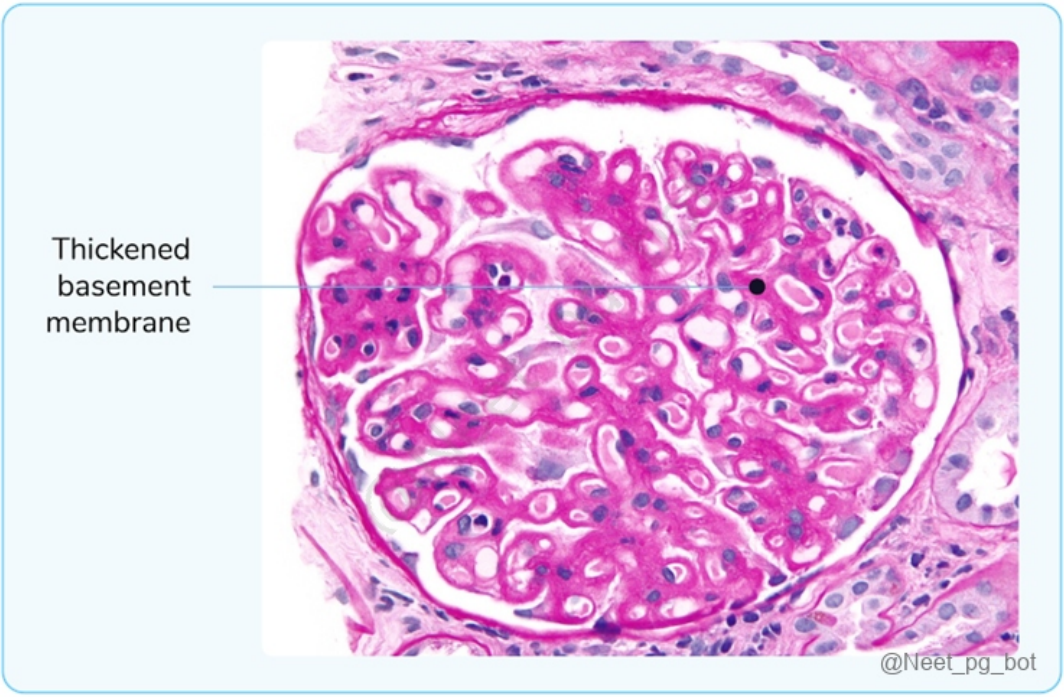

References:

Robbins & Cotran Pathologic Basis of Disease, 10th Edition, Pages 912 to 914

↑ *Back to this question in Part A*

@Neet_pg_bot

Q3: Effacement of podocyte foot processes is seen in which of the following diseases? (Q858521)

A. Steroid-resistant glomerulonephritis

B. Minimal change disease

C. Rapidly progressive glomerulonephritis

D. Chronic glomerulonephritis

Correct Answer: B. Minimal change disease

Explanation: Effacement of podocyte foot processes refers to the flattening or loss of the foot processes of podocytes, specialized cells located in the kidney's glomerulus. This structural change is a hallmark of minimal change disease (also called minimal change nephrotic syndrome) . It presents with severe proteinuria, hypoalbuminemia, edema, and lipiduria. While the glomeruli appear normal under light microscopy, the characteristic finding of podocyte foot process effacement can only be observed under electron microscopy. It is

the most common cause of nephrotic syndrome in children (2-6 years) and responds well to corticosteroid therapy. {{caption_text}} Steroid-resistant glomerulonephritis (Option A) does not typically show effacement of podocyte foot processes. Instead, it may show more severe glomerular damage. Rapidly progressive glomerulonephritis (RPGN) (Option C) is marked by crescent formation in the glomeruli and is not typically associated with podocyte effacement. {{caption_text}} Chronic glomerulonephritis (Option D) is associated with sclerosis and fibrosis in the glomeruli, and effacement of podocyte foot processes is not a characteristic finding. {{caption_text}}

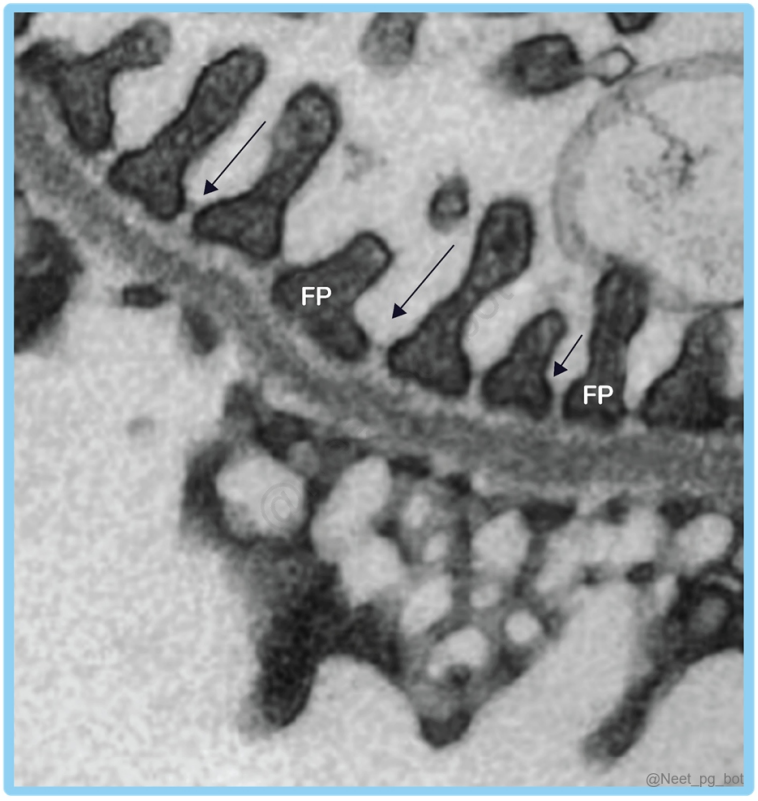

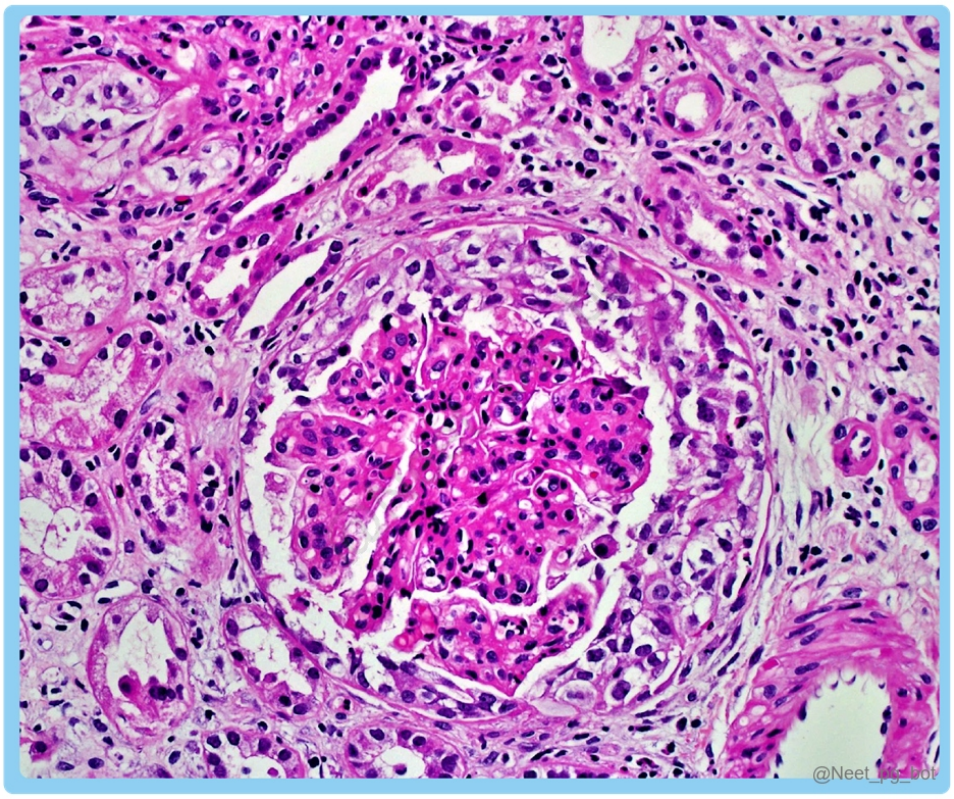

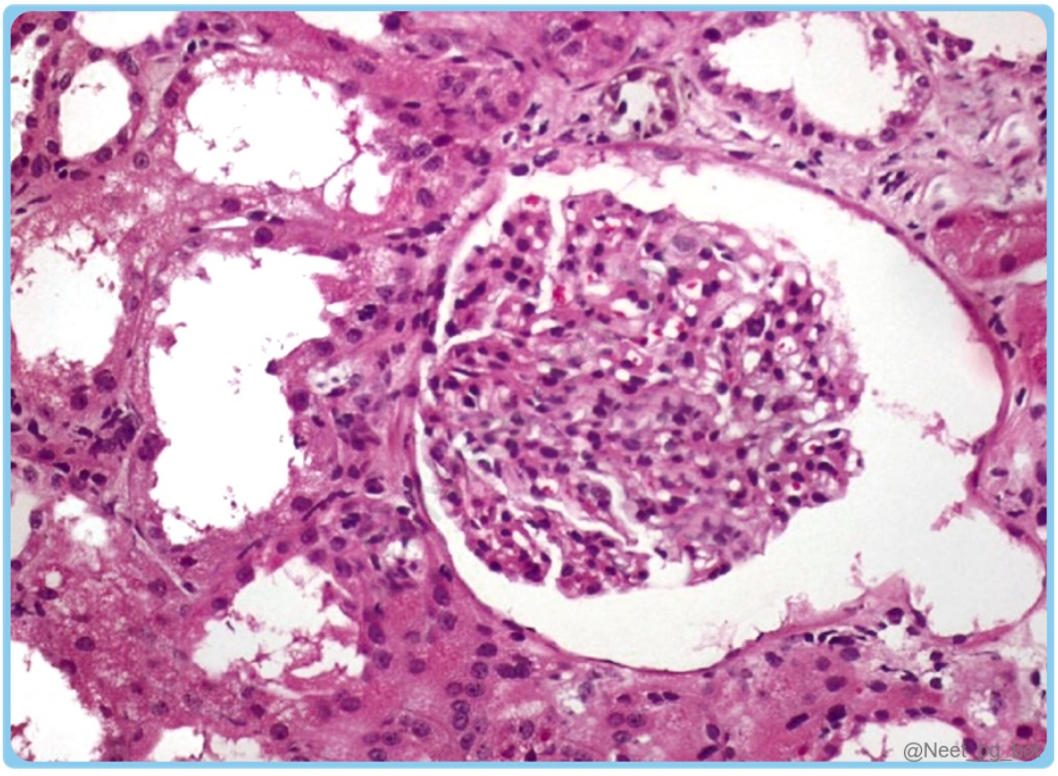

References:

Robbins & Cotran Pathologic Basis of Disease, 10th Edition, Page 911-920

↑ *Back to this question in Part A*

@Neet_pg_bot

Q4: A 51-year-old male patient presents with complaints of hematuria. On examination, he is normotensive and has pedal edema. Investigations reveal that the patient has no glycosuria and a creatinine level of 9. His renal biopsy finding is given below. Which of the following investigations should be done to identify the disease? (Q854838)

A. ANA

B. Anti-GBM antibodies

C. HIV RNA

D. Urine immunoelectrophoresis

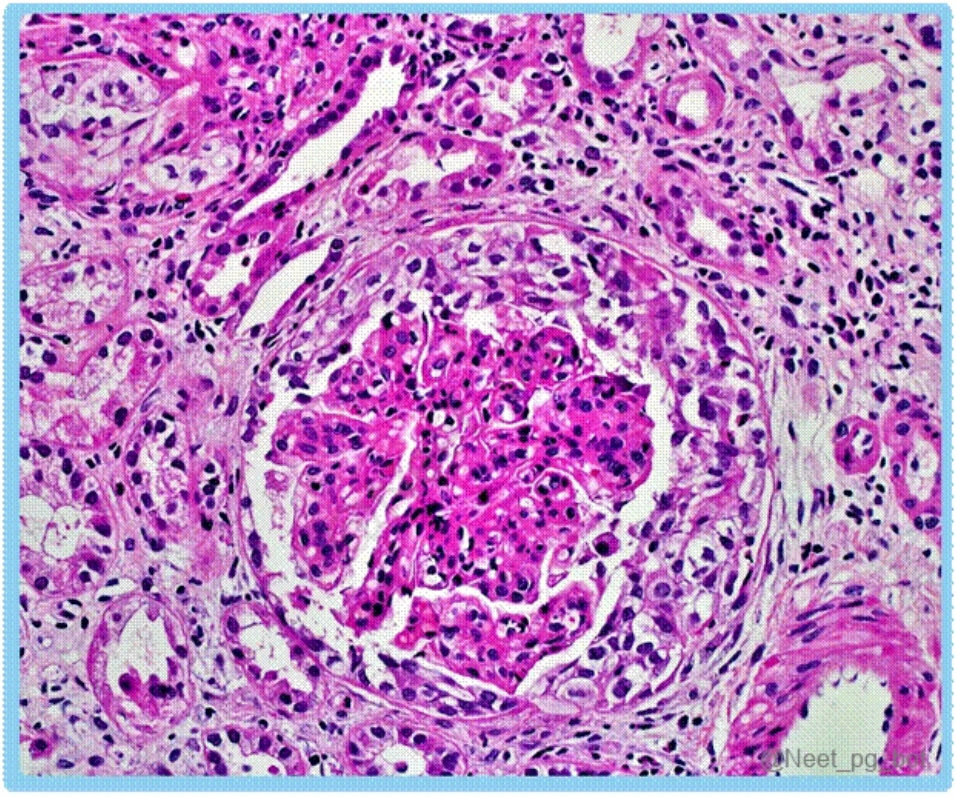

Correct Answer: B. Anti-GBM antibodies

Explanation: The presence of crescents on the renal biopsy & clinical presentation suggests rapidly progressive glomerulonephritis (RPGN) . This condition can be caused by an anti-glomerular basement membrane

(Anti-GBM) . Anti-GBM antibodies are used to confirm the diagnosis of Goodpasture syndrome , a form of RPGN. Rapidly progressive glomerulonephritis (RPGN): Type I RPGN (Anti-GBM Ab-mediated) Type II RPGN (Immune complex-mediated) Type III RPGN (Pauci-immune) (M/C type) Includes: Idiopathic Goodpasture syndrome Includes: Idiopathic Postinfectious glomerulonephritis Lupus (SLE) nephritis Henoch-Schönlein purpura IgA nephropathy Includes: ANCA-associated Idiopathic Granulomatosis with polyangiitis (formerly Wegener granulomatosis) Microscopic polyangiitis IF finding: Linear/ribbon pattern (Linear GBM deposits of IgG and C3) {{caption_text}} IF finding: Lumpy Bumpy/ Granular/ Starry Sky/Garland Pattern (granular antibody deposits) {{caption_text}} IF finding: No deposits Electron microscopy: R PGN causes R upture and w R inkling of GBM {{caption_text}} Antinuclear antibodies (ANA) (Option A) are typically associated with systemic autoimmune diseases such as SLE. While SLE can cause glomerulonephritis and affect the kidneys, the presence of crescents on the renal biopsy suggests a more acute and rapidly progressive disease, making SLE a less likely diagnosis in this case. HIV RNA (Option C): HIV infection can cause renal complications, including HIV-associated nephropathy, which is typically characterised by collapsing focal segmental glomerulosclerosis (FSGS) on renal biopsy. However, the patient’s presentation with hematuria, pedal oedema, and crescent formation on the renal biopsy makes Goodpasture syndrome (anti-GBM disease) a more likely diagnosis than HIV-associated nephropathy in this case. Urine immunoelectrophoresis (Option D) detects monoclonal immunoglobulins in conditions like multiple myeloma and amyloidosis. However, the biopsy findings suggest Goodpasture syndrome, which is better diagnosed with tests such as anti-GBM antibodies.

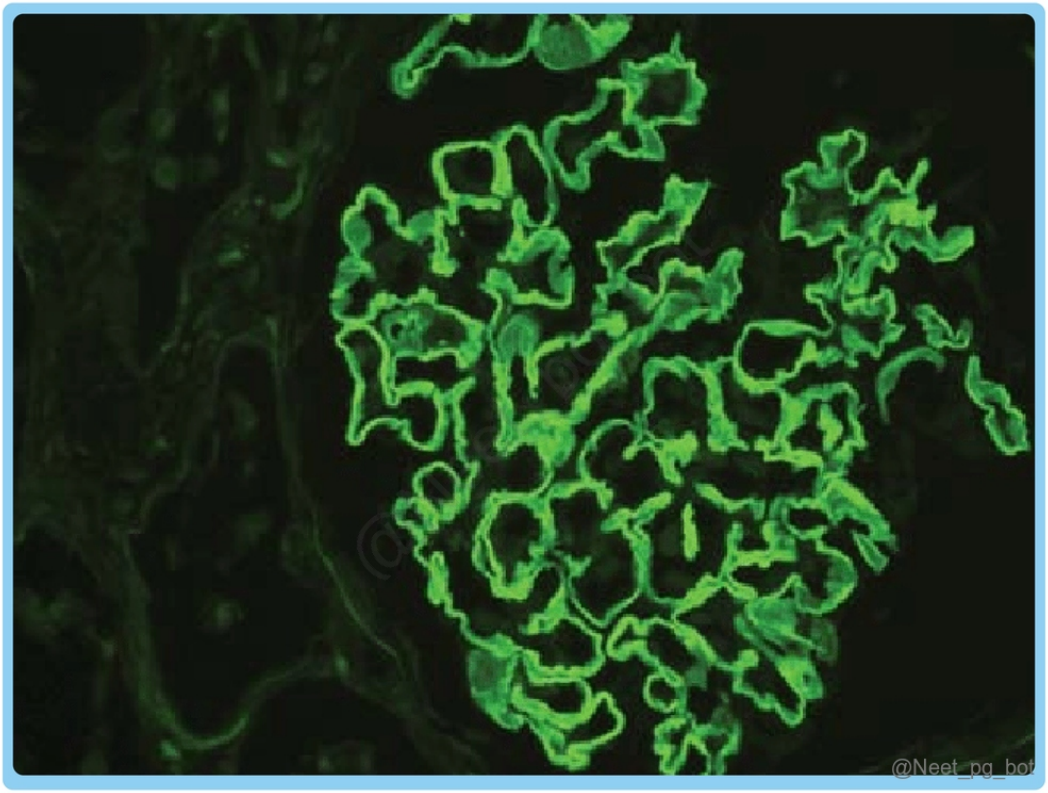

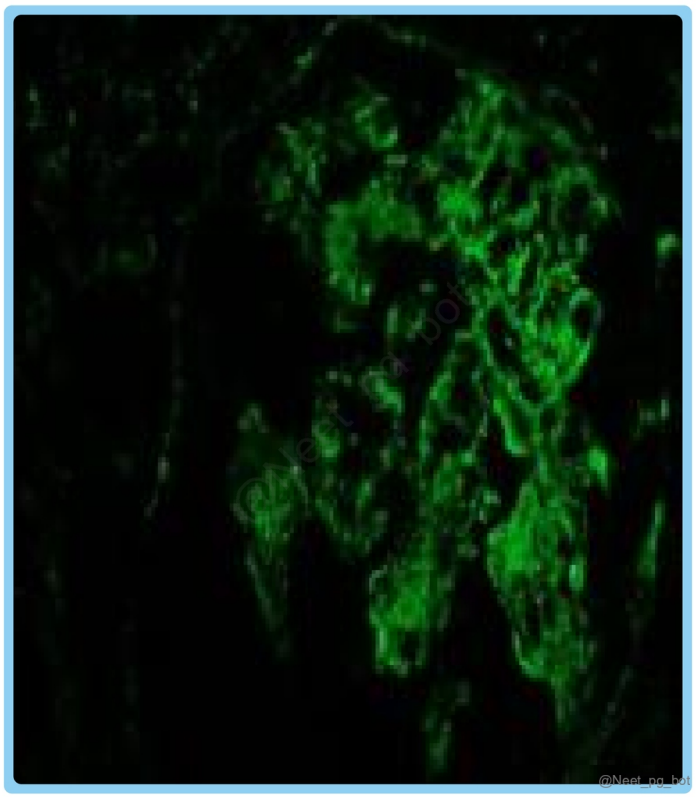

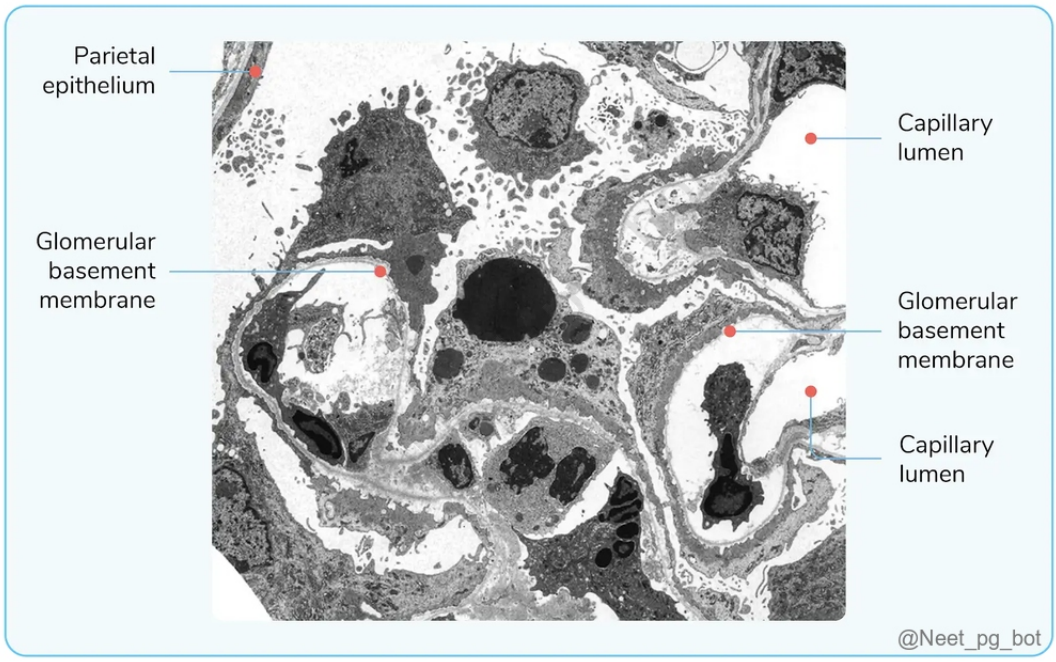

References:

Robbins & Cotran Pathologic Basis of Disease, 10th Edition, Page 909,910

↑ *Back to this question in Part A*

@Neet_pg_bot

Q5: Membranoproliferative glomerulonephritis is seen in which of the following conditions? HIV SLE CLL Hepatitis B (Q856912)

A. 1, 2, 3

B. 1, 2, 3, 4

C. 2, 3, 4

D. 1, 2

Correct Answer: B. 1, 2, 3, 4

Explanation: Membranoproliferative glomerulonephritis can be associated with human immunodeficiency virus (HIV), systemic lupus erythematosus (SLE), chronic lymphocytic leukaemia (CLL), and hepatitis B virus (HBV). Causes of MPGN: Primary MPGN: Idiopathic Secondary Membranoproliferative Glomerulonephritis (MPGN) (typically type I) is more common in adults and occurs in the following conditions: Chronic immune complex disorders, including SLE, hepatitis B and C infections (especially with cryoglobulinemia), endocarditis, infected ventriculoatrial shunts, chronic visceral abscesses, HIV infection , and schistosomiasis. α1-Antitrypsin deficiency. Malignant diseases, particularly lymphoid tumours, like chronic lymphocytic leukaemia . Pathology Light Microscope Electron Microscope Immunofluorescence Type I MPGN Mesangial proliferative or membranoproliferative patterns of proliferation; GBM thickening and Splitting. (Double-contour or tram track appearance). {{caption_text}} Subendothelial and mesangial deposits. {{caption_text}} IgG ++ C3 (C1q ++ C4 may also present) Type II MPGN (Dense Deposit Disease) Dense intramembranous deposits. C3; no C1q or C4 Membranous Nephropathy Diffuse capillary wall thickening. {{caption_text}} Subepithelial deposits. {{caption_text}} Granular IgG and C3; diffuse Focal Segmental Glomerulosclerosis (FSGS) Focal and segmental sclerosis and hyalinosis. {{caption_text}} Effacement of foot processes; epithelial denudation. Focal; IgM + C3 in many cases

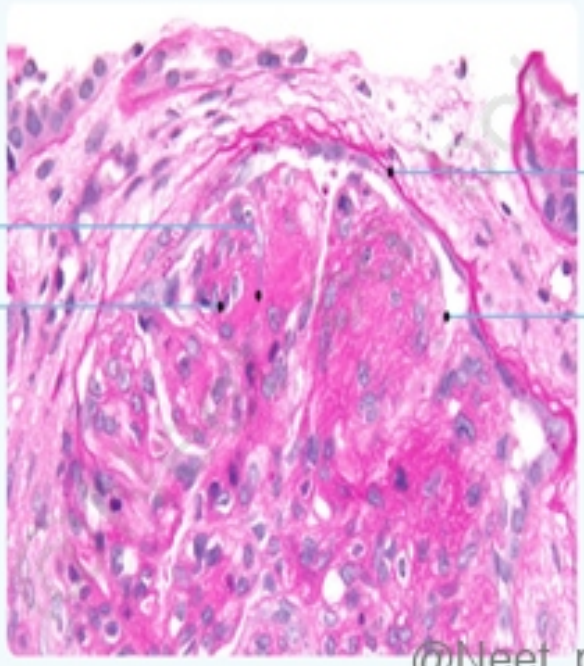

@Neet_pg_bot

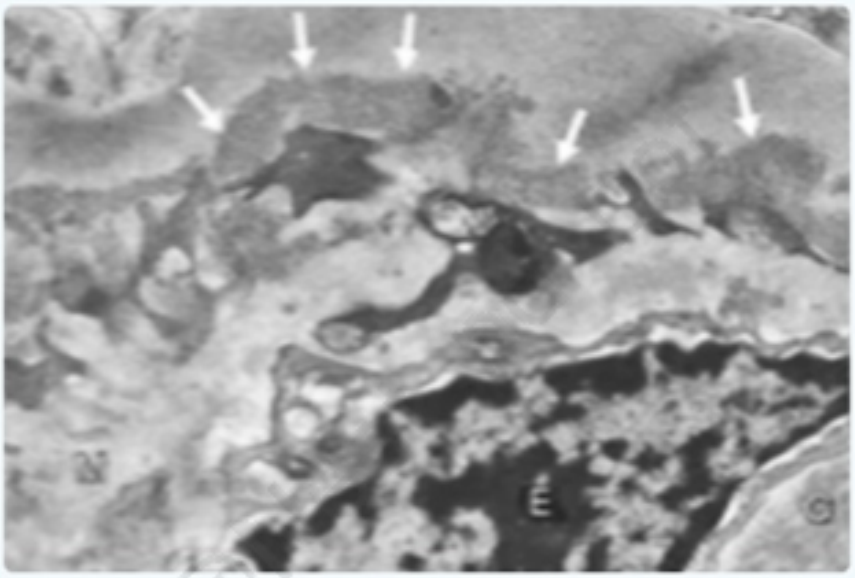

Numerous subendothelial deposits (arrows) between the duplicated basement membrane that extend into the mesangium (M) : C, capillary lumen ; E, endothelial cell nucleus.

@Neet_pg_bot

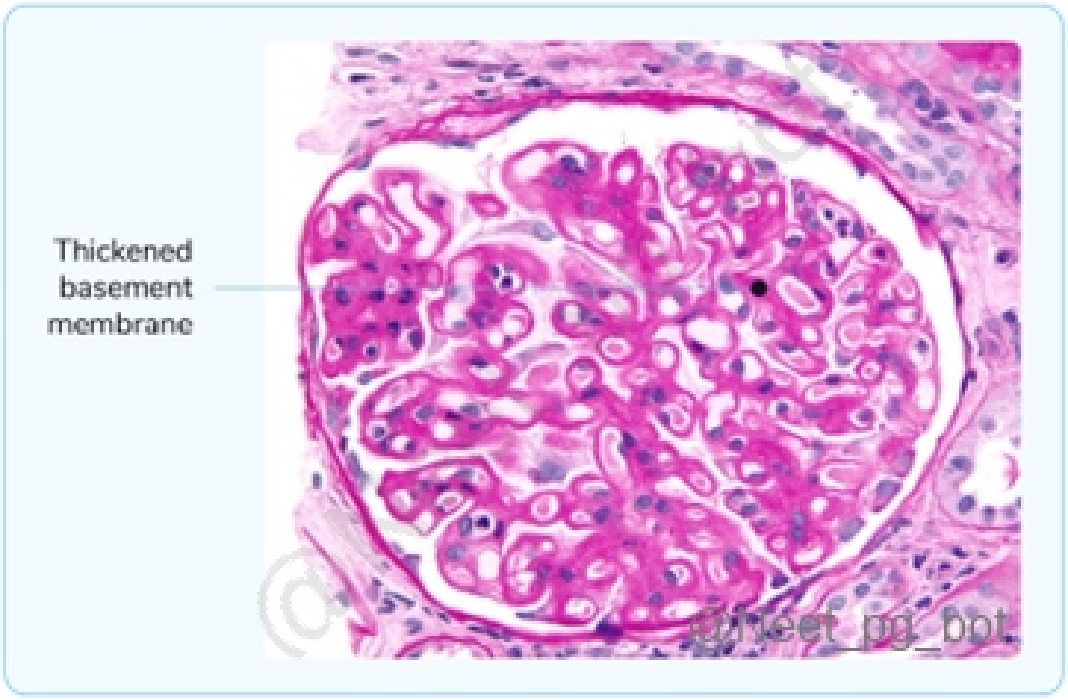
Thickened
basement
membrane

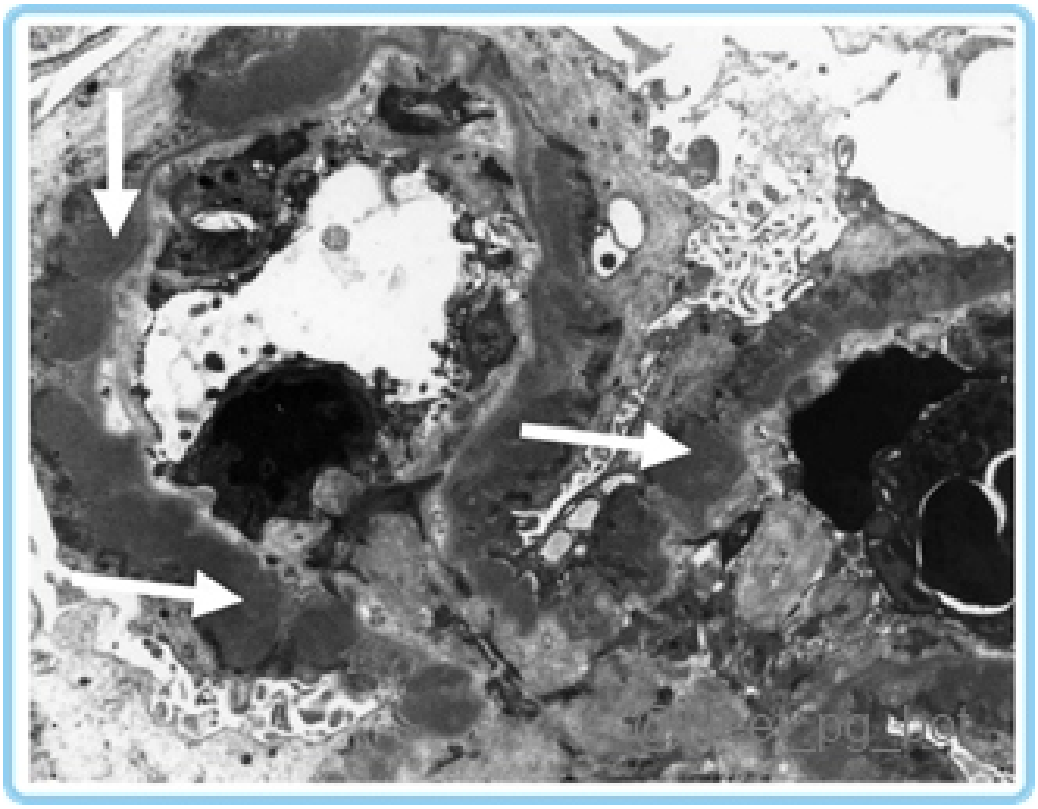

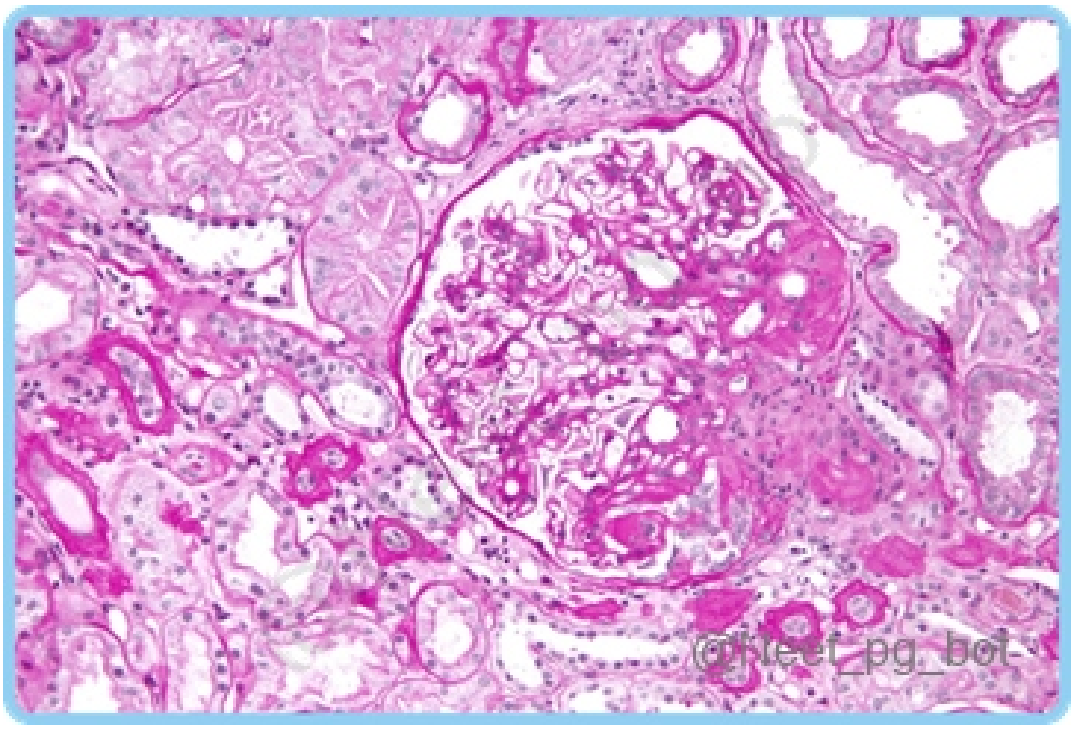

References:

Robbins & Cotran Pathologic Basis of Disease, 10th Edition, Page 918.

↑ *Back to this question in Part A*

@Neet_pg_bot

Q6: What type of urinary casts would you expect in a patient diagnosed with Fabry's disease? (Q856895)

A. Waxy cast

B. RBC cast

C. WBC cast

D. Maltese cross cast

Correct Answer: D. Maltese cross cast

Explanation: Fabry's disease is a rare genetic disorder caused by alpha-galactosidase A deficiency , leading to globotriaosylceramide (Gb3) accumulation in tissues, including the kidneys. {{caption_text}} A characteristic finding in the urinalysis of patients with Fabry's disease is the presence of Maltese cross casts, also referred to as "corneal-shaped" or "glycolipid" casts. These casts form when Gb3 precipitates within the renal tubules and appear as refractile, yellowish-brown structures with a cross-like pattern when observed under polarized light. Renal Cast

Type Condition Associated Images Hyaline casts Normal conditions, Fever, Pregnancy {{caption_text}} Muddy Brown casts Acute tubular necrosis {{caption_text}} Waxy casts Chronic renal failure {{caption_text}} Fatty casts Nephrotic syndrome {{caption_text}} RBC casts Glomerulonephritis {{caption_text}} WBC casts Pyelonephritis, interstitial nephritis {{caption_text}} Epithelial casts Renal epithelial injury {{caption_text}} Broad casts Chronic renal disease {{caption_text}}



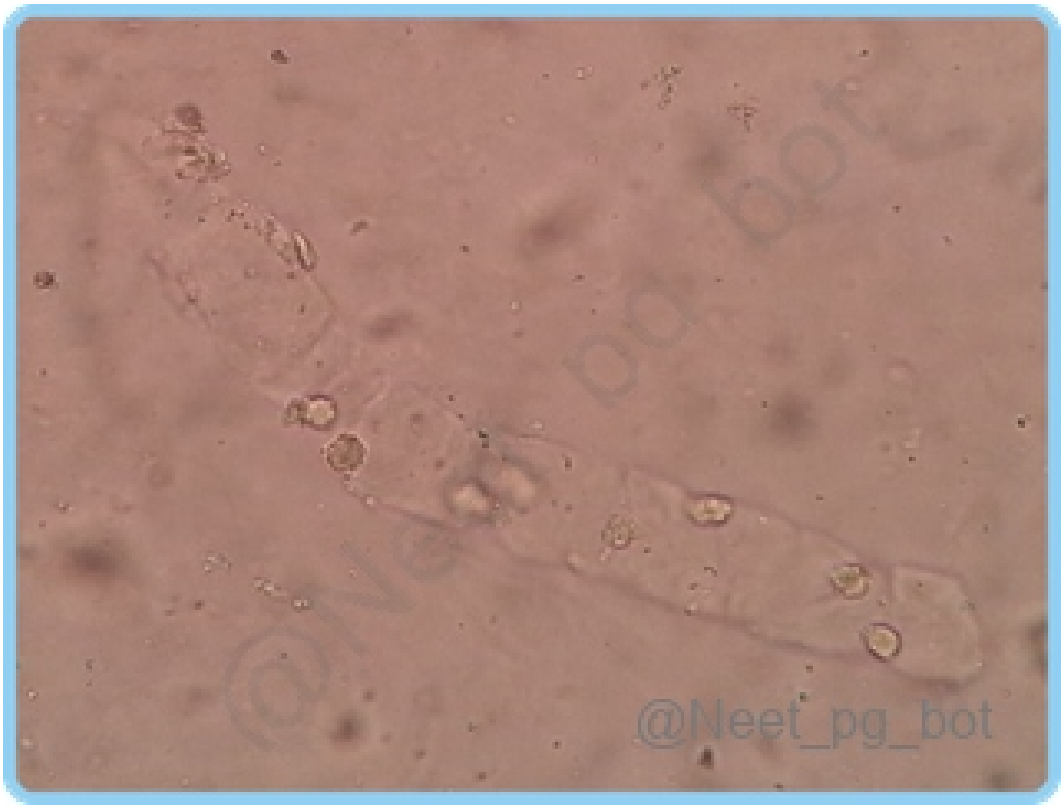
@Neet_pg_bot

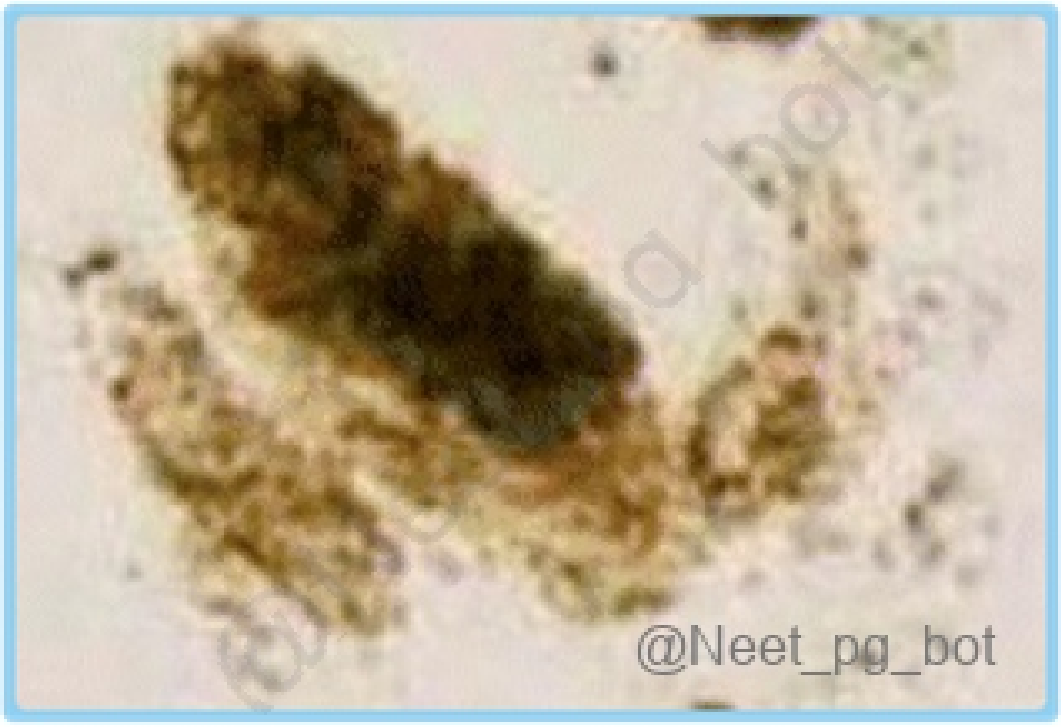
@Neet_pg_bot

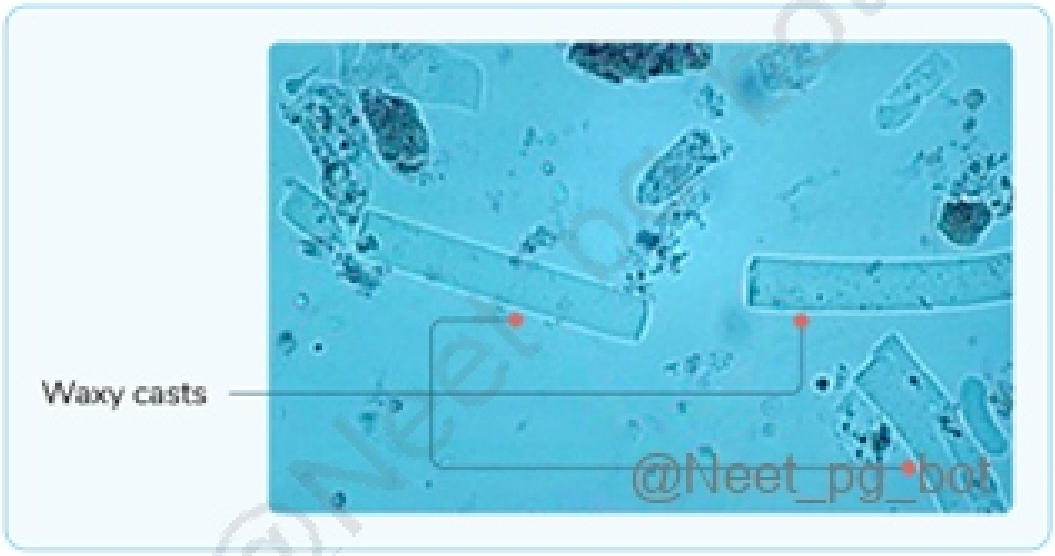
Waxy casts
@Neet_pg_bot

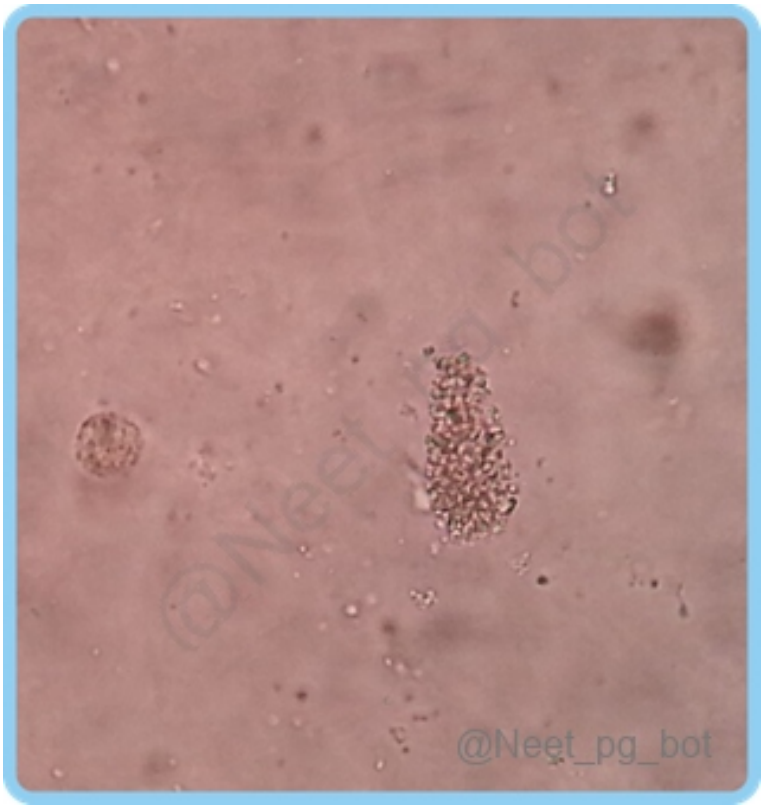
@Neet_pg_bot

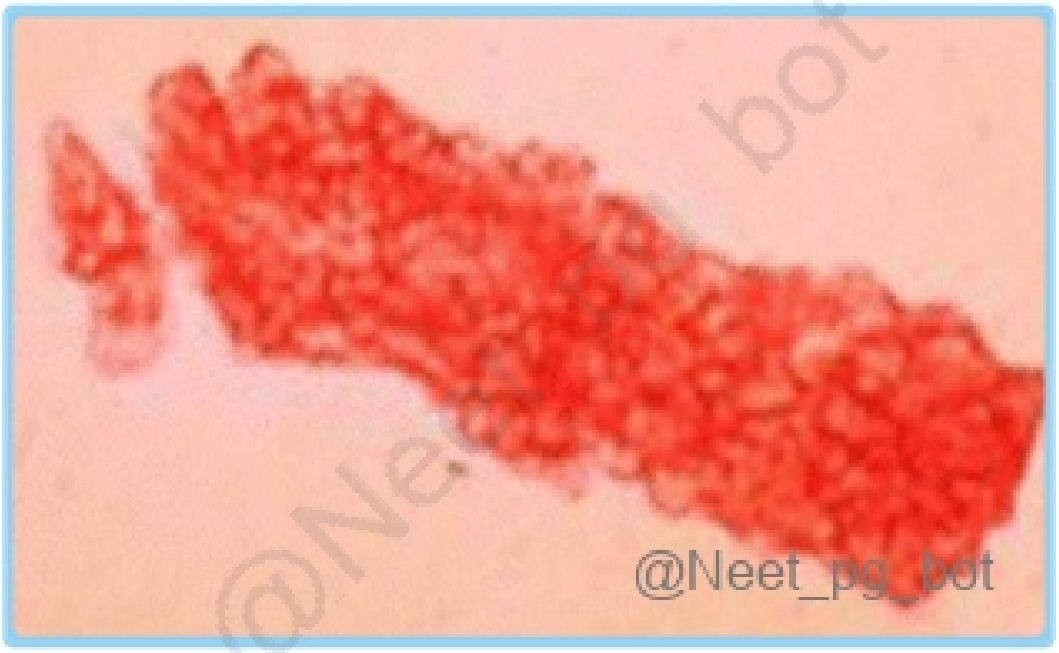
@Neet_pg_bot

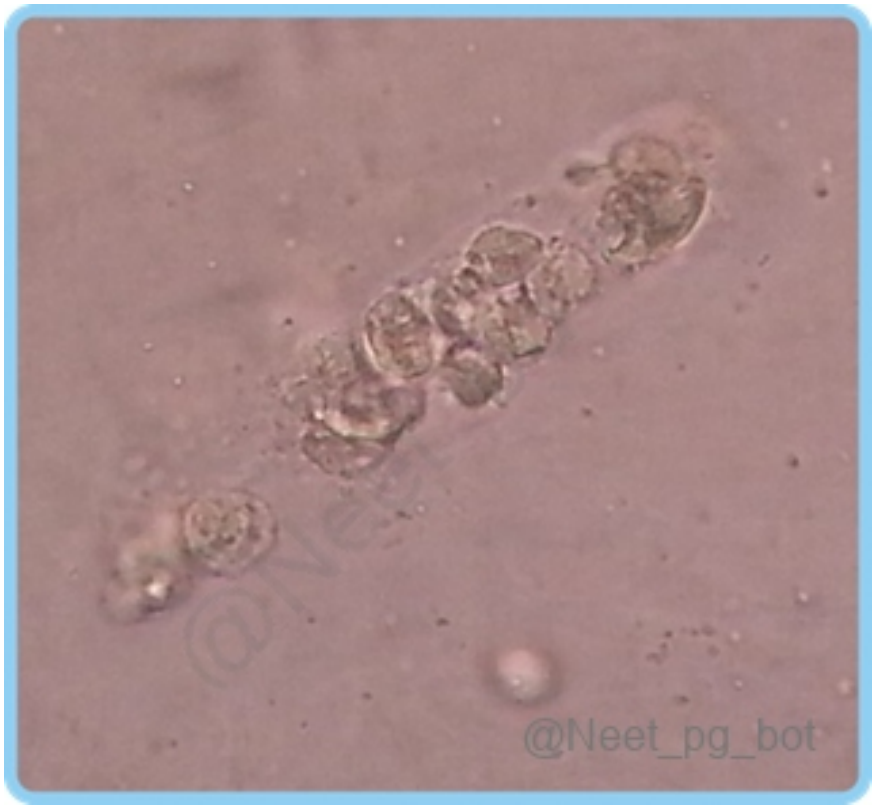
@Neet_pg_bot



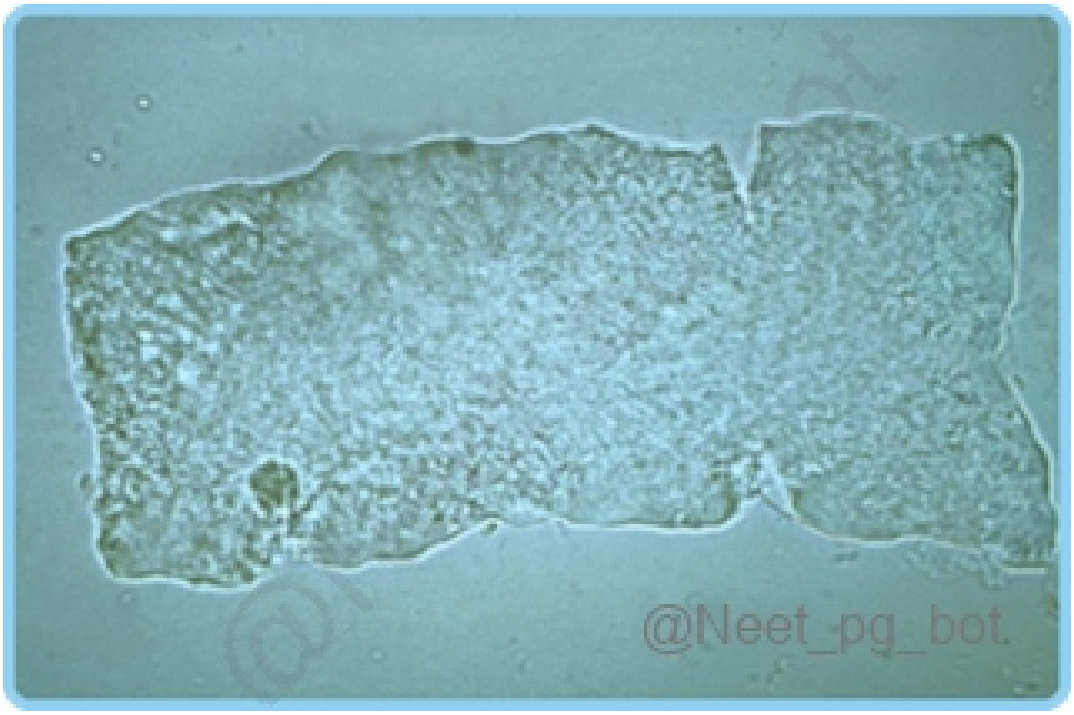

References:

Robbins & Cotran Pathologic Basis of Disease, 10th Edition, Page 947

Harrison’s Principles of Internal Medicine, 21st Edition, Page 2346

↑ *Back to this question in Part A*

@Neet_pg_bot

Q7: What is the most characteristic feature of diabetic nephropathy, as shown below? {{caption_text}} (Q857168)

A. Kimmelstiel Wilson nodules

B. Armanni Ebstein change

C. Aschoff nodule

D. Anitschkow cell

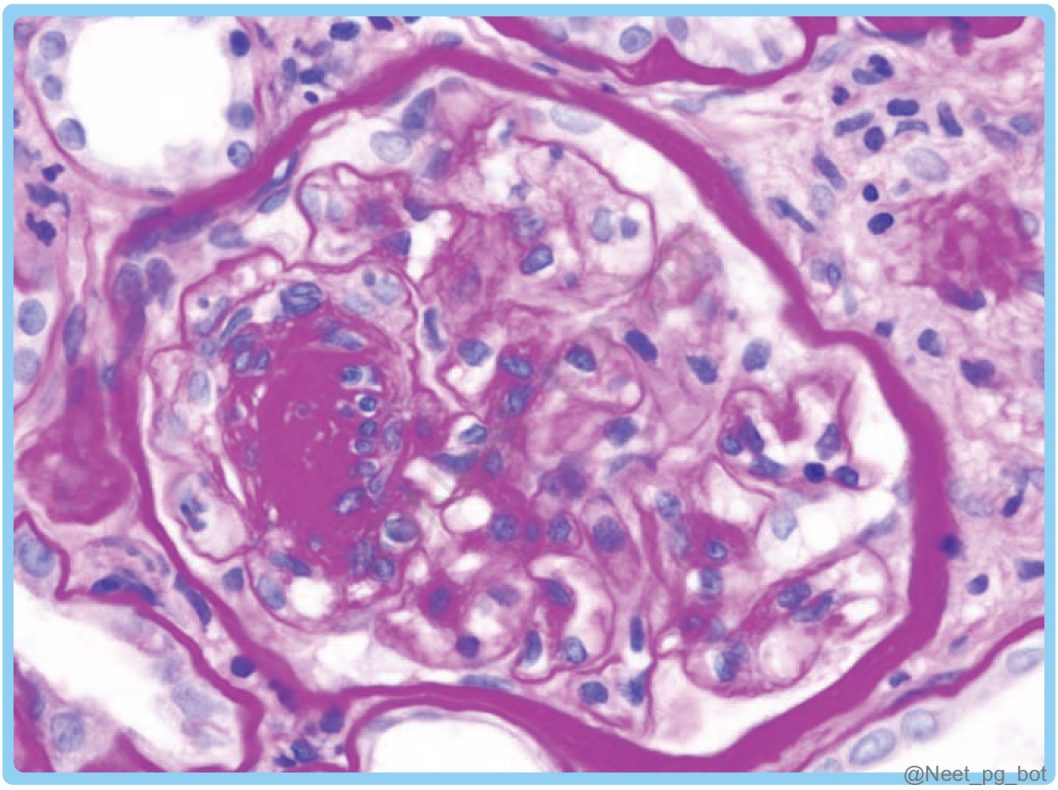

Correct Answer: A. Kimmelstiel Wilson nodules

Explanation: Kimmelstiel-Wilson nodules (aka Nodular glomerulosclerosis) are a hallmark of diabetic nephropathy. They are ovoid or spherical , PAS-positive nodules found in the mesangial core of glomeruli. They are often accompanied by mesangiolysis and sometimes surrounded by dilated capillary loops. {{caption_text}} {{caption_text}} Armanni Ebstein change (Option B) refers to glycogen accumulation in renal tubular epithelial cells, seen in severe or poorly controlled diabetes, but it is not specific to diabetic nephropathy. Aschoff nodule (Option C) is a histological hallmark of rheumatic fever, typically found in the myocardium. Anitschkow cell

(Option D) is a macrophage with a characteristic caterpillar-like nucleus, seen in rheumatic fever, not diabetic nephropathy.

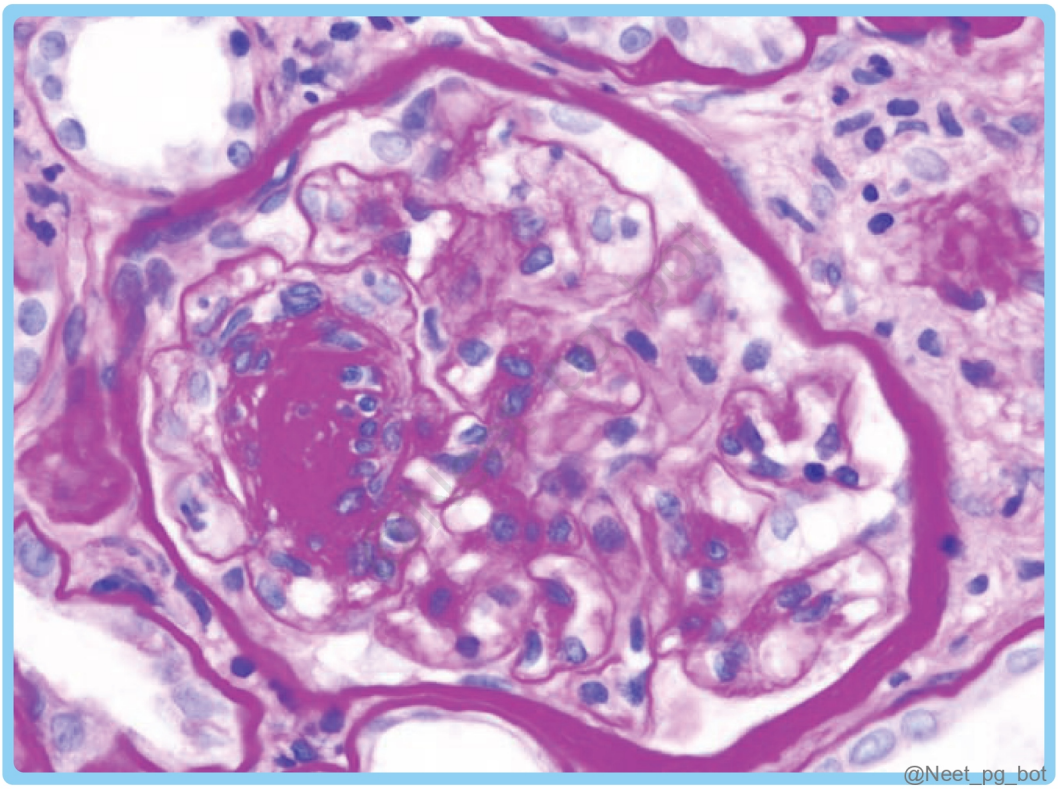



References:

Robbins and Cotrans Pathologic Basis of Disease 10th Edition, Pages 1110, 1111

https://pubmed.ncbi.nlm.nih.gov/21805374/#:~:text=The%20Armanni%2DEbstein%20lesion%20is,been%20reported%20to%20contain%20glycogen.

https://www.researchgate.net/figure/Kidney-autopsy-finding-Armanni-Ebstein-lesion-Diffuse-subnuclear-lipid-vacuolization_fig1_260914551

↑ *Back to this question in Part A*

@Neet_pg_bot

Q8: Which of the following statements is/are true regarding clear cell carcinoma of the kidney? Most common primary renal malignancy Associated with the loss of the short arm of chromosome 3 Not associated with paraneoplastic syndrome The classic triad of flank pain, palpable mass, and hematuria is seen. (Q855070)

A. 1, 2, 4

B. 2, 3

C. 1, 3

D. 1, 4

Correct Answer: A. 1, 2, 4

Explanation: Clear cell carcinoma is associated with paraneoplastic syndromes, including hypercalcemia, erythrocytosis, and hypertension. Clear cell carcinoma: Prevalence : Accounts for 70% to 80% of renal cell cancers. (Most common) Tumour Characteristics : Composed of cells with clear or granular cytoplasm and a nonpapillary pattern. Familial vs. Sporadic : Primarily sporadic (95%), but can also be familial. Genetic Alterations : Loss of sequences on the short arm of chromosome 3 in 98% of cases. The VHL gene, located in this region, is a key tumour suppressor gene. Classic triad of flank pain, palpable mass, and hematuria is commonly observed in kidney tumours, although it may not be present in all cases. Morphology: Origin : Arises from proximal tubular epithelium. Gross Appearance : Bright yellow-gray-white spherical masses. Yellow colour due to lipid accumulation in tumour cells. It may have areas of necrosis, haemorrhage, and cystic regions. Histopathology: {{caption_text}} Most tumours are well-differentiated & some may show nuclear atypia, bizarre nuclei, and giant cells. The growth pattern varies from solid to trabecular (cordlike) or tubular (resembling tubules). The tumour cells have a rounded or polygonal shape and abundant clear or granular cytoplasm containing glycogen and lipids. The tumours have delicate branching vasculature and may show cystic and solid areas.

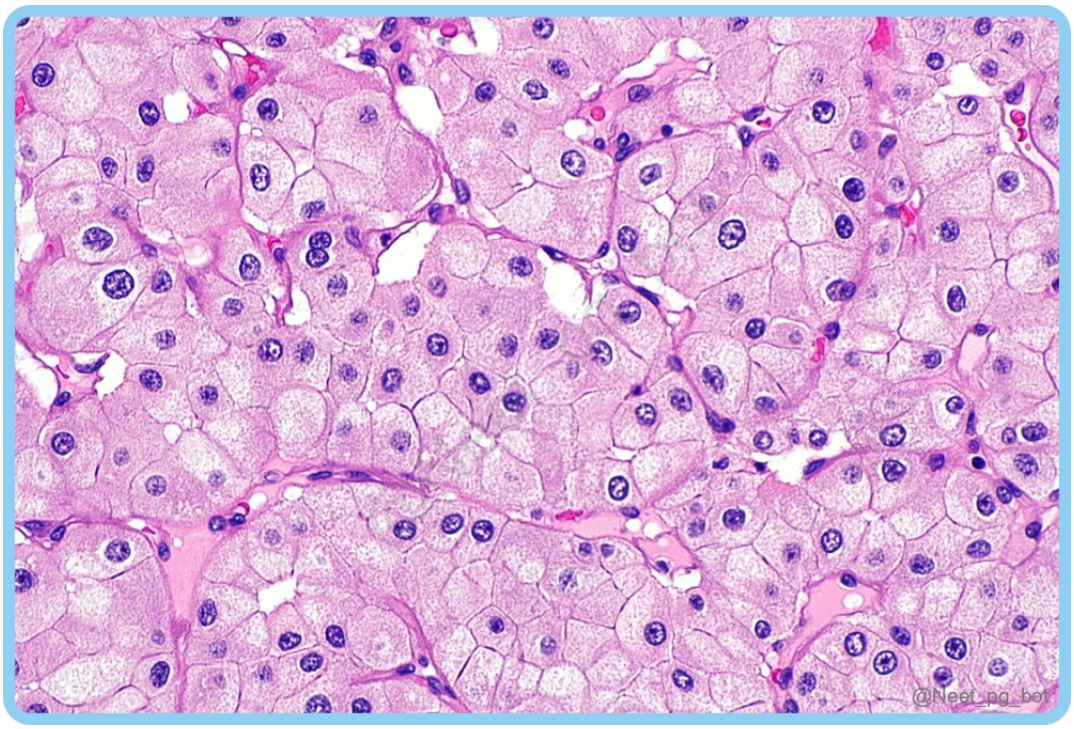

References:

Robbins & Cotran Pathologic Basis of Disease, 10th Edition, Page 952

https://pubmed.ncbi.nlm.nih.gov/8946620/

↑ *Back to this question in Part A*

@Neet_pg_bot

Q9: Tamm-Horsfall protein is a major component of which of the following? (Q858118)

A. Mural thrombi

B. Curschmann spirals

C. Renal casts

D. Bence-Jones proteins

Correct Answer: C. Renal casts

Explanation: Tamm-Horsfall protein, produced in the ascending limb of the loop of Henle, is the most abundant protein in normal urine and serves as a marker of tubular function. It plays a key role in preventing urinary tract infections and is the primary component of hyaline casts, the most common type of urinary casts. Incorrect

Options: Mural thrombi (Option A) are blood clots that stick to the walls of blood vessels or the heart. They are not related to the Tamm-Horsfall protein , which is specific to renal tubular function and not involved in thrombus formation. Curschmann spirals (Option B) are mucus plugs found in the sputum of patients with asthma or other obstructive pulmonary diseases. Bence-Jones proteins (Option D) are free immunoglobulin light chains found in urine and are linked to multiple myeloma. Unlike the Tamm-Horsfall protein, which is a normal renal protein involved in renal casts, Bence-Jones proteins are abnormal products resulting from plasma cell malignancies.

References:

Harrison's Principles of Internal Medicine, 21st Edition, Volume I, Page 2304. 686

↑ *Back to this question in Part A*

@Neet_pg_bot

Q10: A patient with renal disease undergoes a biopsy. On Congo red staining, the deposits show apple-green birefringence under polarised light. What is the most likely diagnosis? (Q866678)

A. Amyloidosis

B. Minimal change disease

C. Diabetic nephropathy

D. Membranous nephropathy

Correct Answer: A. Amyloidosis

Explanation: The clinical presentation of a patient with renal disease undergoing a biopsy and on Congo red staining, the deposits showing apple-green birefringence under polarized light points towards a diagnosis of AA amyloidosis , where chronic inflammation leads to the production of SAA , resulting in amyloid deposition in various organs. The most appropriate staining technique for confirming the diagnosis in this patient is by Congo red stain. Investigations in amyloidosis: The diagnosis depends on the histologic demonstration of amyloid deposits in tissues. The most common sites biopsied are the kidney when renal manifestations are present or rectal or gingival tissues in patients suspected of having systemic amyloidosis. Examination of abdominal fat aspirates stained with Congo red can also be used for the diagnosis of systemic amyloidosis. Staining: Stains/technique Appearance Congo red Most widely used and specific. Light microscopy: Salmon pink/red stains. Polarizing microscopy: Apple-green birefringence. H & E Eosin & hematoxylin staining on light microscopy. Amorphous , eosinophilic , extracellular substance. Thioflavin T Fluorescent stain. Yellow color under UV light. Electron microscopy Non-branching fibrils of indefinite length. Diameter: 7.5-10 nm. X-ray crystallography & infrared spectroscopy Cross-β-pleated sheet conformation. Methyl violet Crystal violet PAS Amyloid positive. Abdominal fat aspiration is preferred over rectal biopsy. In suspected cases of AL amyloidosis, serum and urine protein electrophoresis and immunoelectrophoresis should be performed. Bone marrow aspirates in such cases often show monoclonal plasmacytosis , even in the absence of overt multiple myeloma. Scintigraphy with radiolabeled serum amyloid P component is a rapid and specific test since it binds to the amyloid deposits and reveals their presence.

It also gives a measure of the extent of amyloidosis and can be used to follow patients undergoing treatment. The given images below show Congo red staining in amyloidosis. Incorrect Options: Minimal change disease (Option B): normal light microscopy; EM shows foot process effacement; Congo red negative. Diabetic nephropathy (Option C): nodular glomerulosclerosis (Kimmelstiel–Wilson lesions); no Congo red positivity. Membranous nephropathy (Option D): thickened GBM and subepithelial immune deposits; Congo red negative.

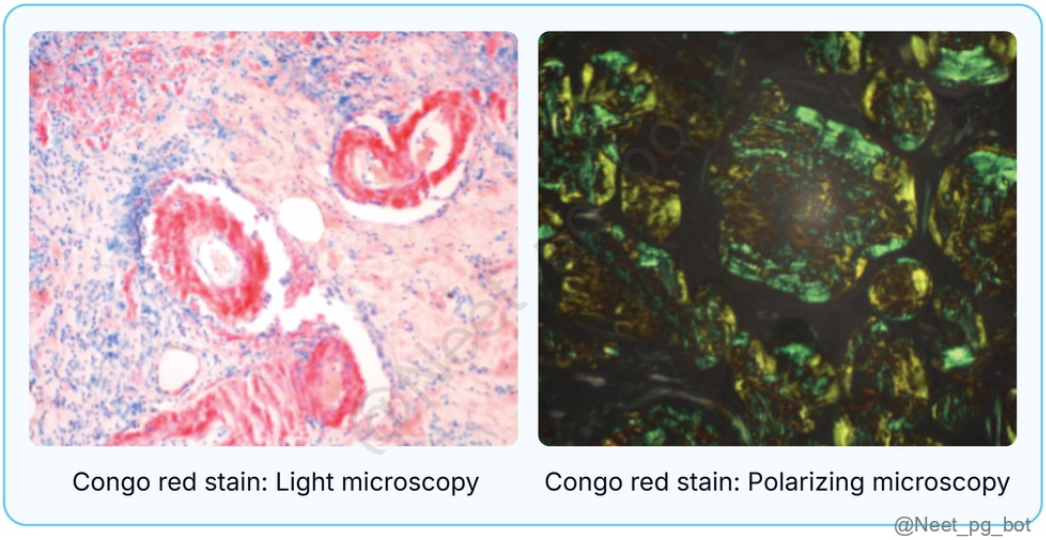

Congo red stain: Light microscopy

Congo red stain: Polarizing microscopy

@Neet_pg_bot

References:

.

↑ *Back to this question in Part A*

@Neet_pg_bot

Q11: Which of the following will increase in size on electrophoresis in Nephrotic syndrome? (Q854702)

A. Gamma globulin

B. Alpha 2 globulin

C. Beta globulin

D. Albumin

Correct Answer: B. Alpha 2 globulin

Explanation: Nephrotic syndrome is characterized by proteinuria , hypoalbuminemia , edema , and hyperlipidemia, and the electrophoresis shows decreased albumin levels and increased levels of alpha-2 globulin. The increase in alpha-2 globulin is due to an increase in macroglobulin, which is a larger protein , and its increase in the

bloodstream serves as a compensatory mechanism in nephrotic syndrome to counteract the loss of albumin . Gamma globulin (Option A) does not increase significantly . An increase in gamma globulins is seen in conditions like multiple myeloma or chronic inflammatory conditions , not in nephrotic syndrome. Beta globulin (Option C) increases, but this increase is typically modest compared to the marked rise in alpha-2 globulins . Albumin (Option D) is the major protein that decreases in size on electrophoresis in nephrotic syndrome due to its significant loss in the urine, leading to hypoalbuminemia .

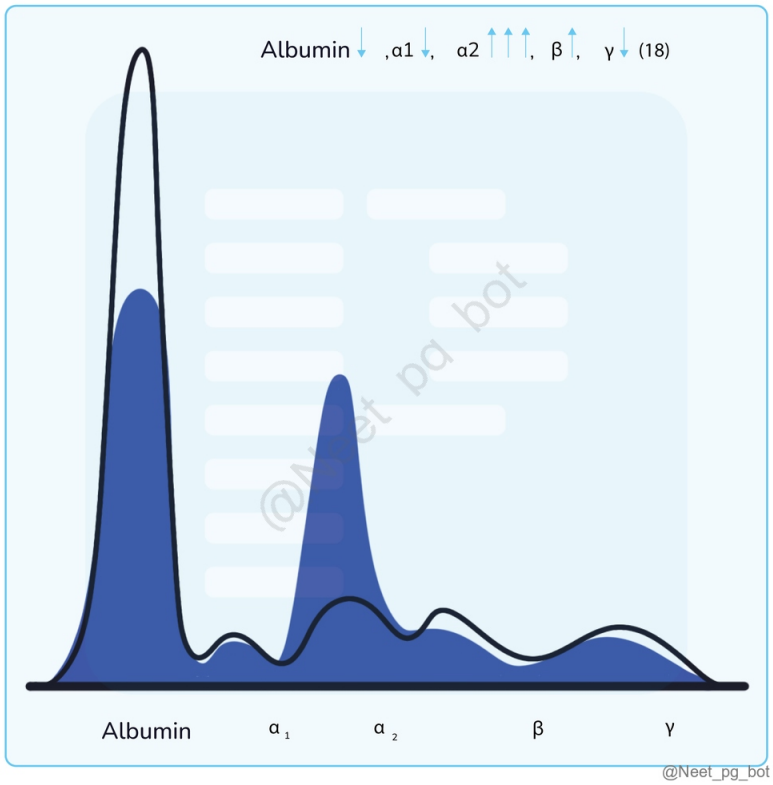

References:

Harper’s Illustrated Biochemistry, 32nd Edition, Page 636 NIH Link

↑ *Back to this question in Part A*

@Neet_pg_bot

Q12: A 47-year-old male with 400 ml urine output per 24 hrs. On histology, he had RPGN with Pauci immune glomerulonephritis with crescents. What is the main etiology? (Q854698)

A. Anti GBM

B. ANCA

C. Anti PLA2R

D. ANA

Correct Answer: B. ANCA

Explanation: The clinical presentation of RPGN with pauci-immune glomerulonephritis and crescents on histology strongly suggests an ANCA-associated vasculitis . Pauci-immune means that there are few immune complexes present in the glomeruli, which is typical of ANCA-associated vasculitis. ANCA are commonly associated with granulomatosis with polyangiitis (Wegener's) , microscopic polyangiitis , and Churg-Strauss syndrome , which can lead to pauci-immune RPGN . Type I RPGN (Anti-GBM antibody-mediated) Type II RPGN (Immune complex-mediated) Type III RPGN (Pauci-immune) (M/C type) Includes: Idiopathic Goodpasture syndrome- the presence of Anti GBM. (Option A ruled out) Includes: Idiopathic Postinfectious glomerulonephritis Lupus (SLE) nephritis - ANA positive (Option D ruled out) Henoch-Schönlein purpura IgA nephropathy Includes: ANCA-associated Idiopathic Granulomatosis with polyangiitis (formerly Wegener granulomatosis) Microscopic polyangiitis IF finding: Linear/ribbon pattern (Linear GBM deposits of IgG and C3) {{caption_text}} IF finding: Lumpy Bumpy/ Granular/ Starry Sky/Garland Pattern (granular antibody deposits) {{caption_text}} IF finding: No deposits Electron microscopy: R PGN causes R upture and w R inkling of GBM {{caption_text}} Anti PLA2R (Option C) antibody is primarily associated with membranous nephropathy, which presents with nephrotic syndrome, not RPGN. The histological findings do not align with membranous nephropathy , which typically shows thickening of the glomerular basement membrane without hypercellularity on light microscopy and a "spike and dome" appearance of subepithelial deposits on electron microscopy. glomerulonephritis in an infant. Saudi journal of kidney diseases and transplantation : an official publication of the Saudi Center for Organ Transplantation, Saudi Arabia. 24. 546-8. 10.4103/1319-2442.111061. " data-hash="" data-license="CC BY-NC-SA 4.0" data-source="" data-tags="" height="3476" src="" width="4167" /> {{caption_text}} {{caption_text}}

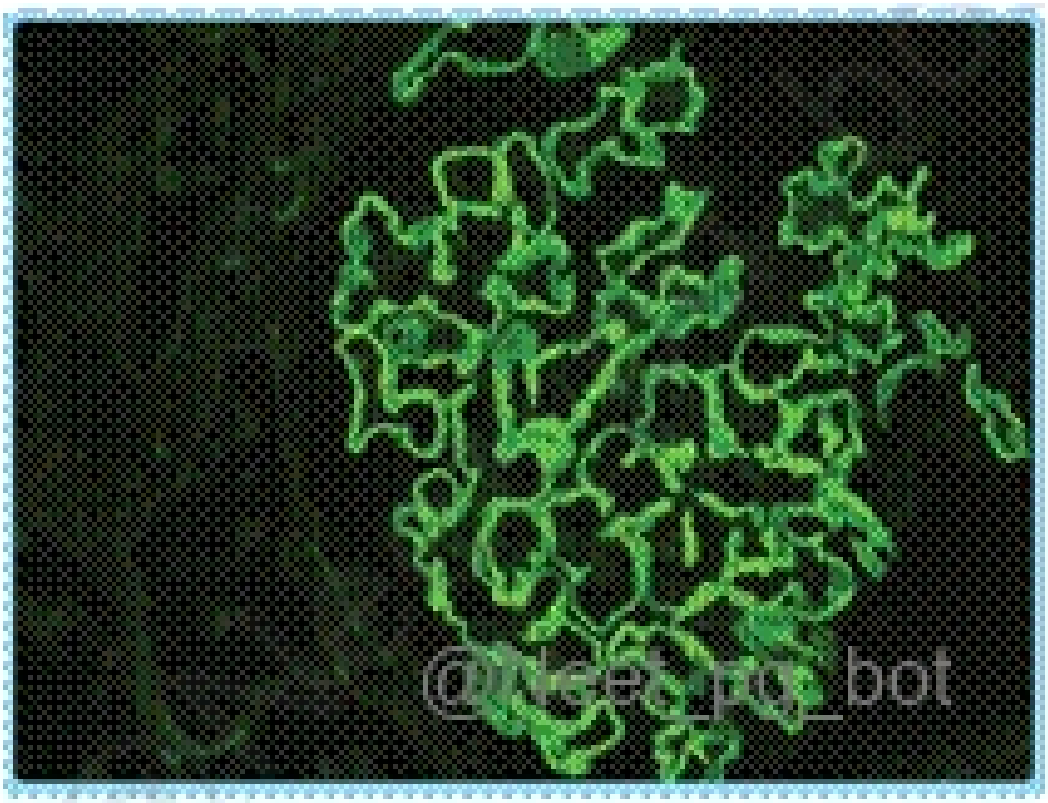

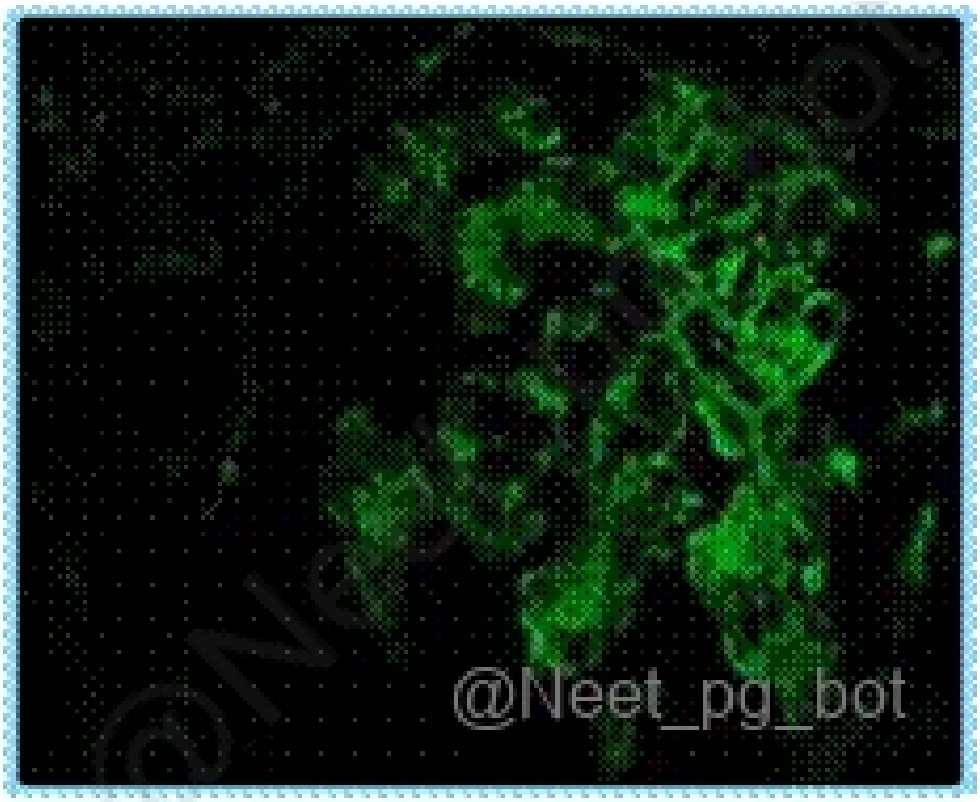
@Neet_pg_bot

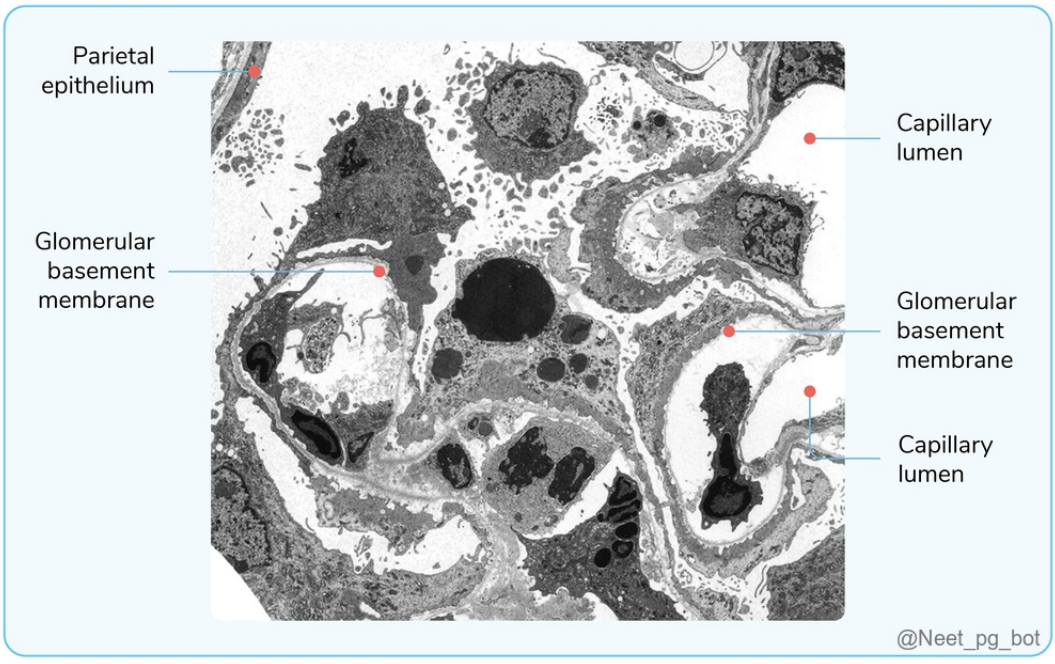
Parietal epithelium
Glomerular basement membrane
Capillary lumen
Glomerular basement membrane
Capillary lumen
@Neet_pg_bot

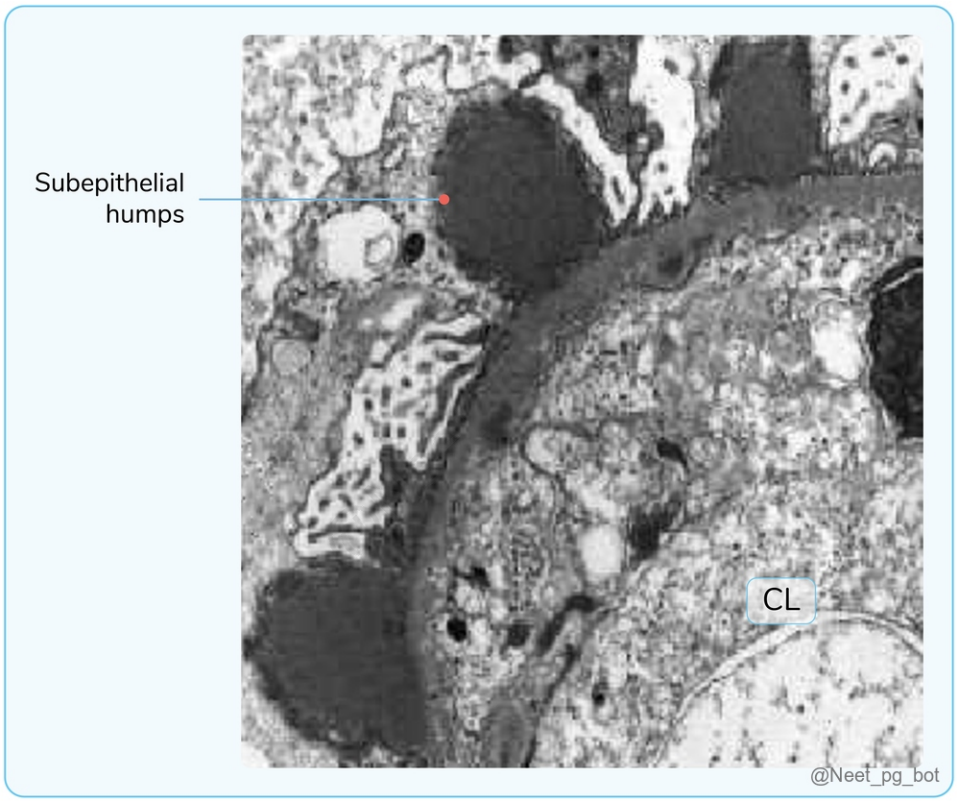

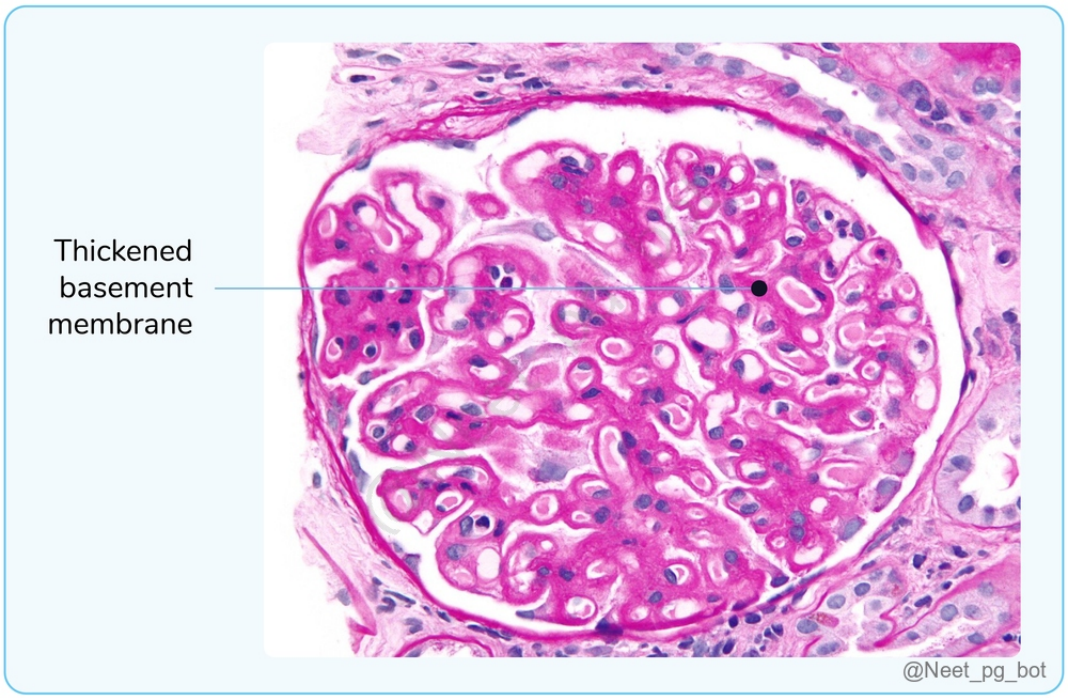

References:

Robbins and Cotran Pathologic Basis of Disease, 10th edition, pages 909, 910

↑ *Back to this question in Part A*

@Neet_pg_bot

Q13: What is the most likely diagnosis for a 9-year-old boy who presents with hematuria, hypertension, facial puffiness for 3 days, and a recent history of throat infection two weeks ago, with urine examination showing albumin positivity? (Q830713)

A. Group B beta-hemolytic streptococci

B. Staphylococcus aureus

C. Group A beta-hemolytic streptococci

D. Staphylococcus epidermidis

Correct Answer: C. Group A beta-hemolytic streptococci

Explanation: Correct Option C - Group A beta-hemolytic streptococci: This is the correct option. Group A streptococci, particularly Streptococcus pyogenes, are known to cause post-streptococcal glomerulonephritis, which can manifest with symptoms like hematuria, hypertension, and facial puffiness following a throat infection. It's a classic scenario for post-streptococcal glomerulonephritis(PSGN). Incorrect Options: Option A - Group B beta-hemolytic streptococci: While Group B streptococci are associated with various infections, including neonatal sepsis and meningitis, they are not typically linked to post-streptococcal glomerulonephritis, which is a more common presentation in the scenario described. Option B - Staphylococcus aureus: Staphylococcus aureus is a bacterium responsible for various infections, such as skin and soft tissue infections, but it is not a common cause of post-streptococcal glomerulonephritis. Option D - Staphylococcus epidermidis: Staphylococcus epidermidis is a bacterium commonly associated with medical device-related infections and biofilm formation. It is not typically linked to post-streptococcal glomerulonephritis.

↑ *Back to this question in Part A*

@Neet_pg_bot

Q14: A patient presents with hematuria and flank pain. A renal mass is shown in the image provided. What is the likely diagnosis? (Q844158)

A. Clear cell carcinoma

B. Papillary renal cell carcinoma

C. Chromophobe renal cell carcinoma

D. Bellini duct carcinoma

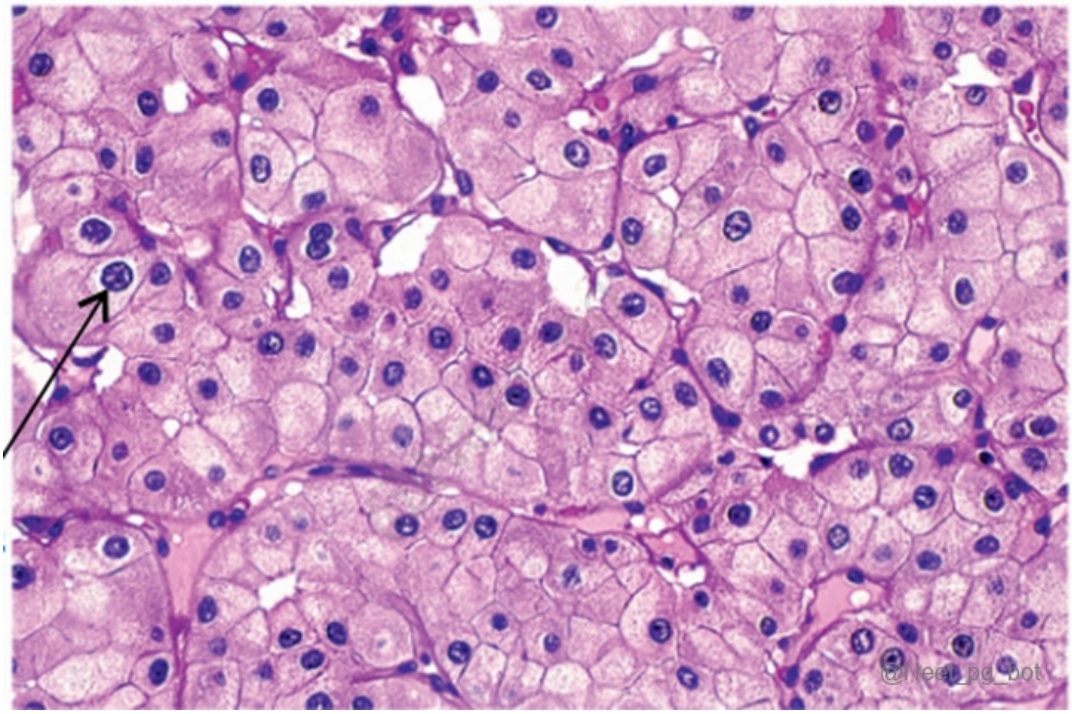

Correct Answer: C. Chromophobe renal cell carcinoma

Explanation: Correct Option C - Chromophobe renal cell carcinoma: Chromophobe RCC has a distinct histological appearance, which shows plant cells, perinuclear halos, and raisinoid nuclei. It also shows positivity with Hale's colloidal iron stain and has a better prognosis compared to other RCC types. Incorrect Options: Options A, B, and D do not show plant cells.

References:

.

↑ *Back to this question in Part A*

@Neet_pg_bot

Q15: A patient presents with a cerebellar mass and a renal tumor, along with a similar family history. Which of the following is responsible for his findings? (Q844087)

A. VHL disease

B. NF

C. TSC

D. Li Fraumeni syndrome

Correct Answer: A. VHL disease

Explanation: VHL is an autosomal dominant disorder. Classic tumors include cerebellar hemangioblastomas and renal cell carcinoma (clear cell type). Pheochromocytomas and pancreatic cysts can also occur. Family history of similar tumors is typical due to the dominant inheritance. On imaging, cerebellar masses are usually hemangioblastomas. Early diagnosis allows surveillance for RCC and CNS tumors. VHL gene mutation on chromosome 3p25-26 is responsible. Incorrect Options: Option B) Neurofibromatosis (NF): NF1: café-au-lait spots, neurofibromas, optic gliomas. NF2: bilateral vestibular schwannomas, meningiomas. Not associated with RCC or cerebellar hemangioblastomas. Option C) Tuberous sclerosis complex (TSC): Causes cortical tubers, subependymal giant cell astrocytomas, cardiac rhabdomyomas, renal angiomyolipomas. Does not cause cerebellar hemangioblastomas or clear cell RCC. Option D) Li-Fraumeni syndrome: Predisposes to breast cancer, sarcomas, leukemia, brain tumors (medulloblastoma, gliomas). Cerebellar hemangioblastomas and RCC are not typical.

References:

.

↑ *Back to this question in Part A*

@Neet_pg_bot

Q16: A female presents to the OPD with complaints of dysuria. Based on the microscopic examination, what is the most likely diagnosis? (Q844068)

A. HSV

B. CMV

C. HPV

D. Trichomonas

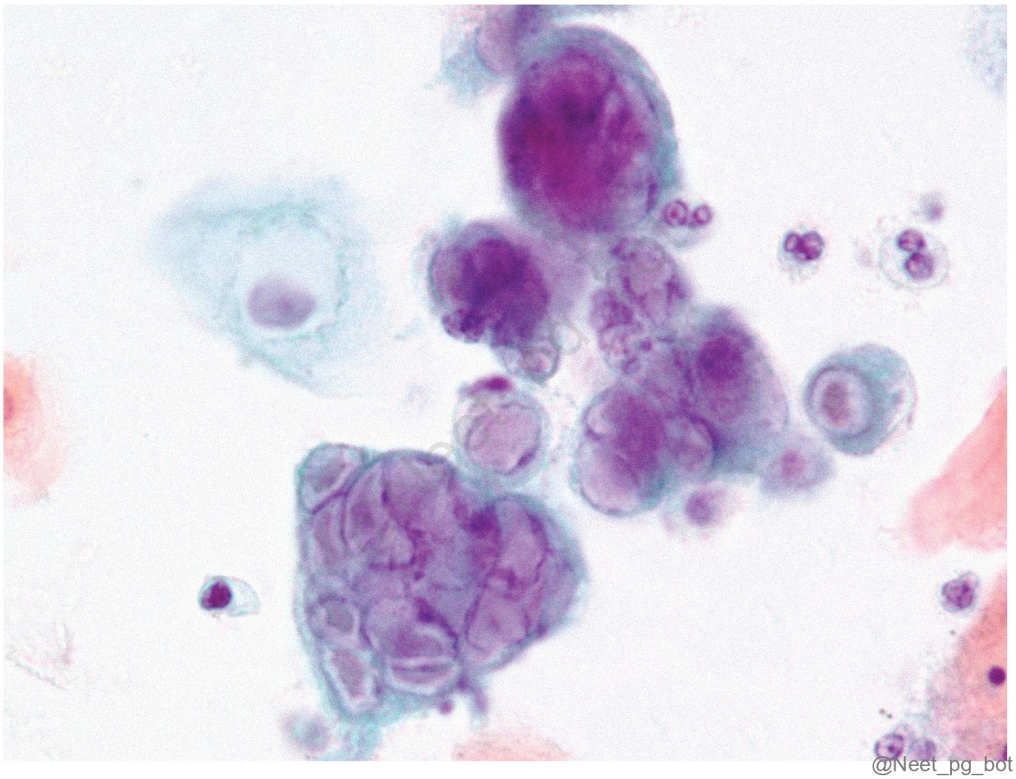

Correct Answer: A. HSV

Explanation: Correct Option A – HSV: The given image shows herpes simplex virus giant cells as they show: Multinucleated Moulding of nuclei Margination of the nucleus Incorrect Options: Options B, C, and D are not consistent with the microscopic examination findings.

References:

.

↑ *Back to this question in Part A*

@Neet_pg_bot

Q17: A pediatric patient presents with cola-coloured urine, high blood pressure, and periorbital oedema. Laboratory tests reveal a creatinine level of 2.5 mg/dL, which rises to 4.5 mg/dL after 3 weeks despite treatment. What electron microscopic finding is most likely in this patient? (Q855409)

A. Subendothelial deposits

B. Subepithelial deposits

C. Crescent formation

D. Mesangial deposits

Correct Answer: B. Subepithelial deposits

Explanation: The clinical presentation, including cola-coloured urine , hypertension , edema , and rising creatinine levels, is highly suggestive of acute glomerulonephritis , particularly post-streptococcal glomerulonephritis (PSGN). Subepithelial deposits are characteristic of PSGN in electron microscopy. Pathological findings in PSGN Grossly Kidneys appear speckled or mottled due to numerous small haemorrhages (Flea-bitten appearance) . {{caption_text}} Light microscopy Hypercellular glomeruli are caused by infiltration by leukocytes (neutrophils and monocytes) and the proliferation of endothelial and mesangial cells . Electron microscope ‘Subepithelial electron-dense humps’ due to immune complex deposition beneath the epithelial cells of the glomerular basement membrane. {{caption_text}} Immunofluorescence Characteristic 'Starry sky appearance' by immune complex deposition. {{caption_text}} {{caption_text}} Incorrect Options: Given the worsening renal function (rising creatinine levels) over time and the risk of progression to Rapidly Progressive Glomerulonephritis (RPGN), a finding of crescent formation (Option C) in the glomeruli would be expected, but it is a histopathological finding & not an electron microscope finding. Subendothelial deposits (Option A) are typically seen in systemic lupus erythematosus (SLE) or membranoproliferative glomerulonephritis (MPGN) , not in post-streptococcal glomerulonephritis (PSGN) . Mesangial deposits (Option D) are often seen in conditions like IgA nephropathy , membranoproliferative glomerulonephritis (MPGN) , or diabetic nephropathy , but not typically in PSGN .



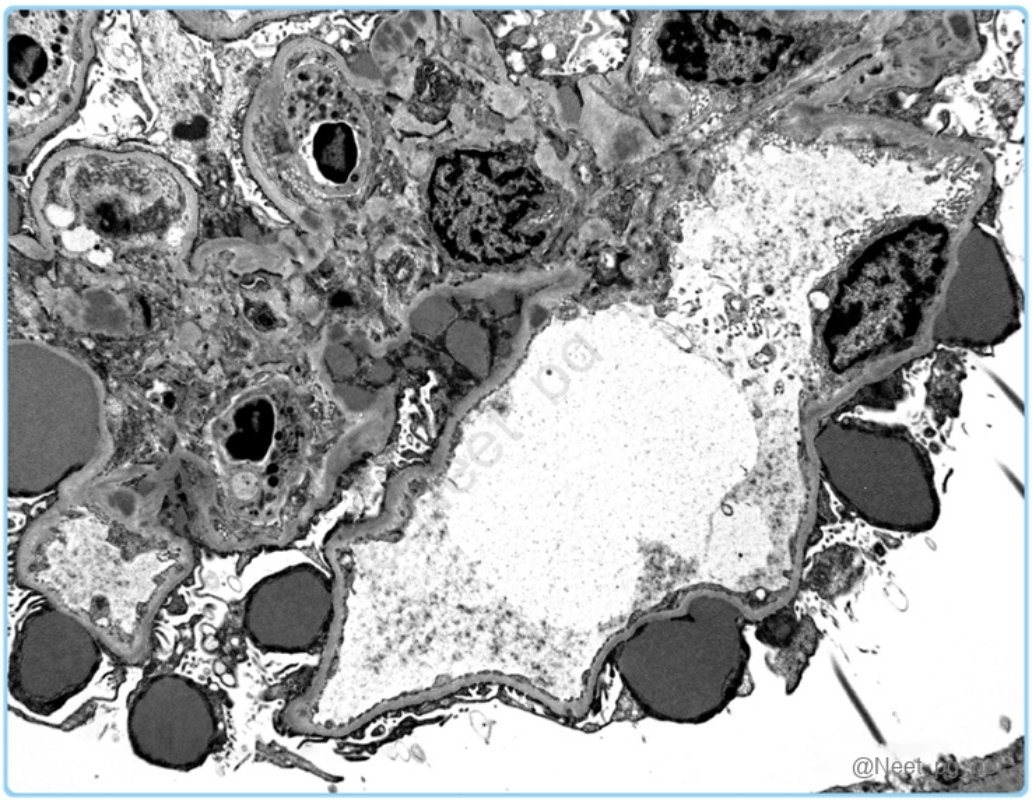

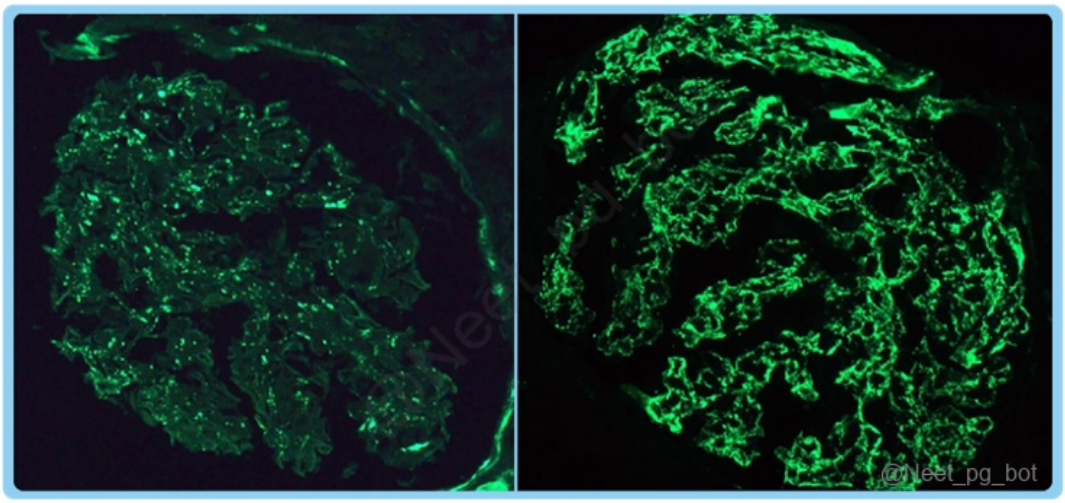

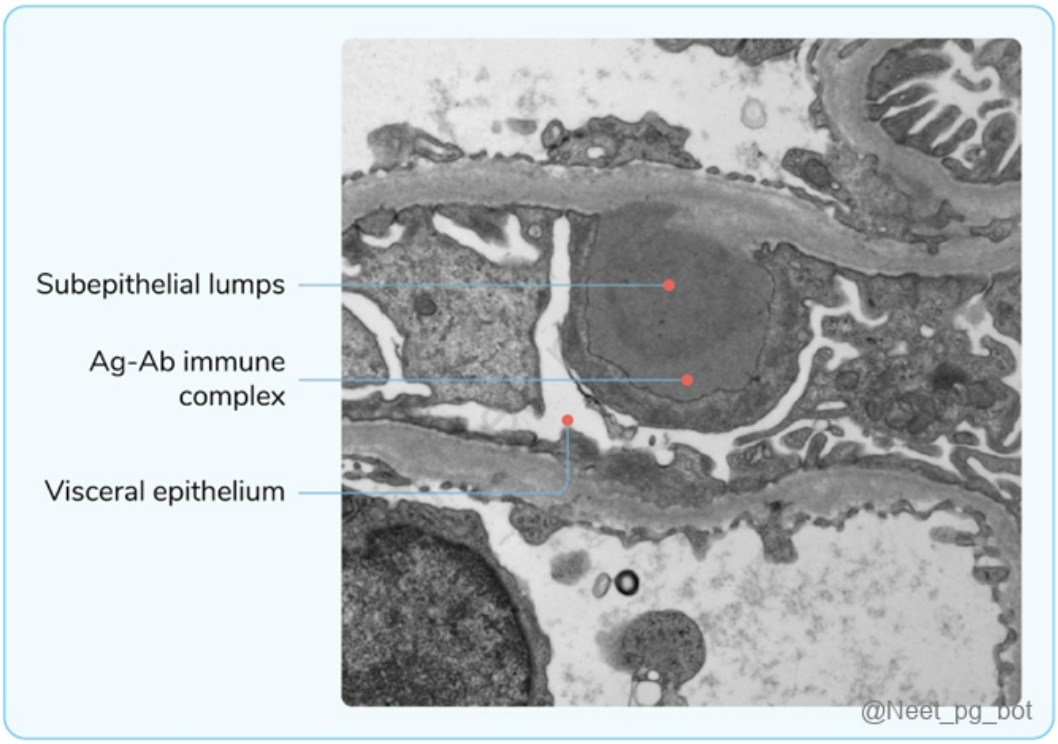

References:

Robbins and Cotran Pathologic Basis of Disease, 10th Edition, Page 909

↑ *Back to this question in Part A*

@Neet_pg_bot

• [12_Genital System] 052 Pathology Of Male Genital Tract

« Back to Folder Directory

[12_Genital System] 052 Pathology Of Male Genital Tract — Quick Jump

Q1 (p. 2231) *Q2 (p. 2233)* *Q3 (p. 2235)* *Q4 (p. 2236)* *Q5 (p. 2237)* *Q6 (p. 2237)*
Q7 (p. 2238) *Q8 (p. 2239)* *Q9 (p. 2240)* *Q10 (p. 2241)* *Q11 (p. 2243)* *Q12 (p. 2244)*
Q13 (p. 2247) *Q14 (p. 2248)* *Q15 (p. 2249)* *Q16 (p. 2251)* *Q17 (p. 2252)*

Q1: A 42-year-old male presents with testicular pain and swelling. Physical examination reveals a palpable mass. Subsequent biopsy of the mass provides important diagnostic insights. Which of the following statements regarding sex cord-stromal tumours in males are true? A) They are classified into three main subtypes: Leydig cell and Sertoli cell tumours and yolk sac tumours. B) Sertoli cell tumours are commonly associated with hormonal abnormalities. C) Histologically, Leydig cell tumors demonstrate golden pigment with reinke crystals with eosinophilic cytoplasmic inclusions. D) Sertoli cell tumours are often associated with Carney's complex and are typically malignant. (Q845855)

A. A, B, C

B. A, C, D

C. C

D. A, B, C, D

Correct Answer: C. C

■ *Listen (English)*

■ *Listen (Hindi)*

Explanation: Sex cord-stromal tumours have two major subtypes: Leydig cell and Sertoli cell tumour. Yolk sac tumours are germ cell tumours. (Statement A ruled out) Pathological features correlating with malignancy include large size, necrosis, infiltrative borders, anaplasia, mitotic activity, vascular-lymphatic invasion, and extratesticular extension. Leydig cell tumour Sertoli cell tumour Hormonal involvement It often involves androgens, oestrogens, and corticosteroids. Hormonally silent. (Statement B ruled out) Conditions associated with Klinefelter syndrome. Cryptorchidism. Renal cell carcinoma. Carney complex. (Statement D ruled out) Peutz-Jeghers syndrome. Familial adenomatous polyposis. Histology The tumour cells resemble their normal counterparts. They are large in size and have round or polygonal cell outlines , abundant granular eosinophilic cytoplasm , and a round central nucleus. The cytoplasm frequently contains lipid droplets , vacuoles , or lipofuscin pigment and, most characteristically, rod-shaped Reinke crystalloids (25% of the tumours). The tumour cells are arranged in

distinctive trabeculae that tend to form cord-like structures and tubules. Image

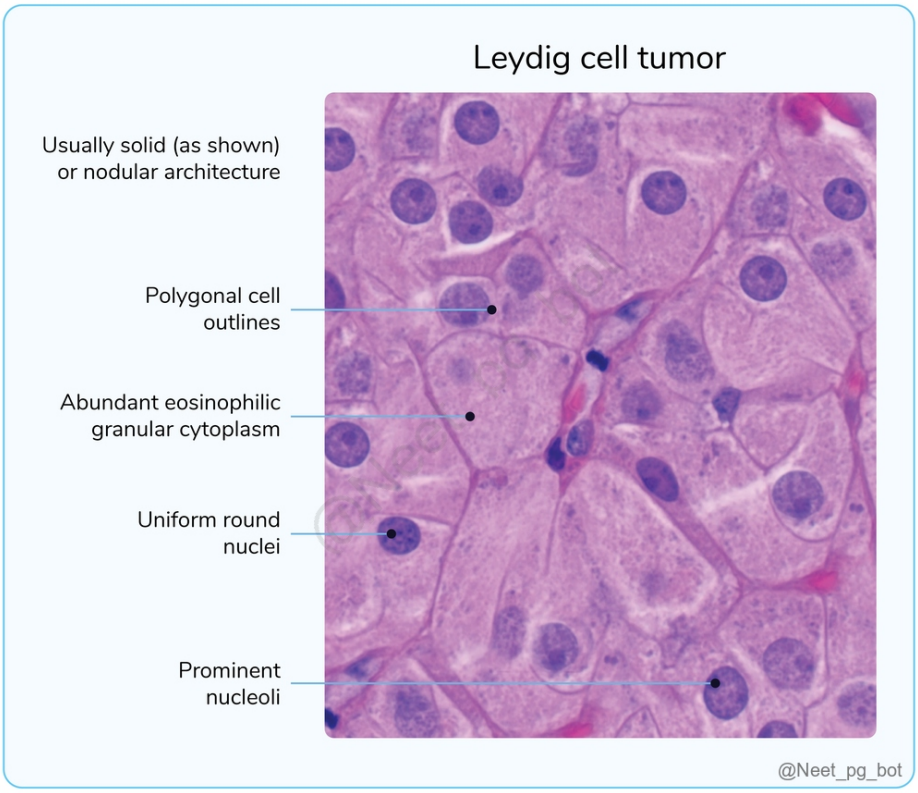

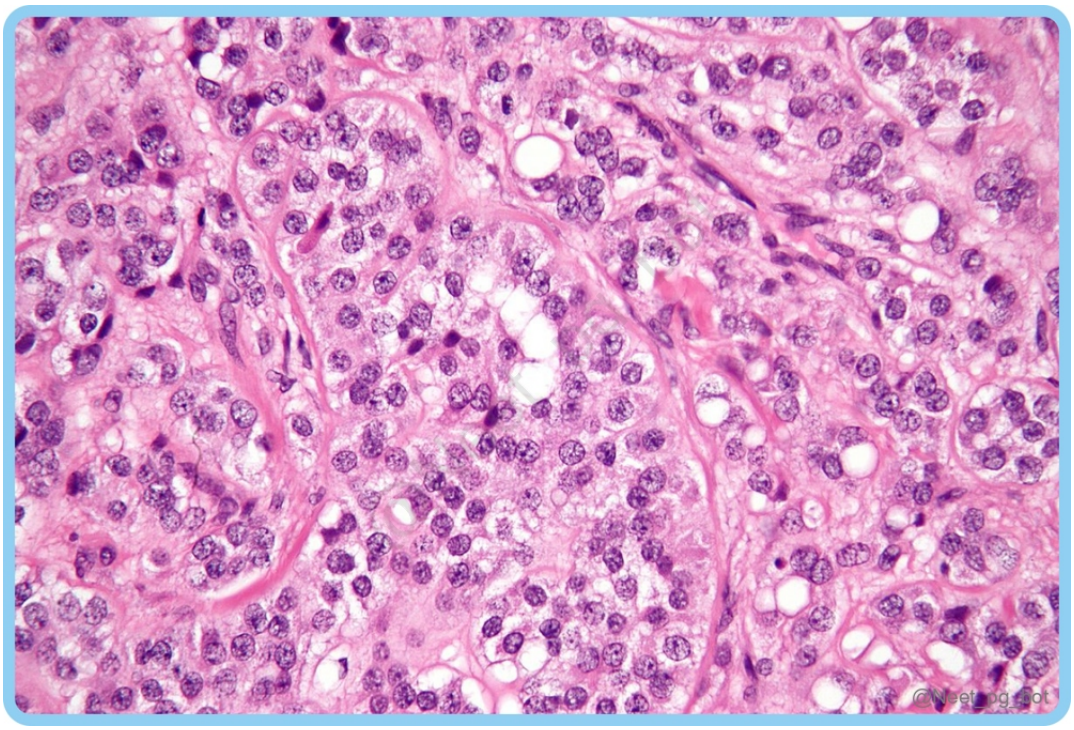

References:

Robbins and Cotran, Pathologic basis of disease, 10th edition, Page 974

↑ *Back to this question in Part A*

@Neet_pg_bot

Q2: A 32-year-old male presents with multiple, small, flesh-coloured growths on the shaft of his penis. A biopsy is performed, and histopathology reveals hyperkeratosis, acanthosis, and koilocytosis. Which of the following is the most likely causative agent of his condition? (Q845863)

A. HPV 6 and 11

B. Treponema pallidum

C. HSV 2

D. Chlamydia trachomatis

Correct Answer: A. HPV 6 and 11

■ *Listen (English)*

■ *Listen (Hindi)*

Explanation: Condyloma acuminatum: It is a benign sexually transmitted wart caused by human papillomavirus (HPV). Low risk HPV serotypes (HPV 6 and, less frequently, HPV 11) are the most frequent cause. (Option A) Histopathology: Hyperkeratosis: increased production of stratum corneum or keratin. Acanthosis: increased epidermal thickness Koilocytosis: shriveled (“raisinoid”) nucleus + perinuclear halo (whitish clearing around nucleus) Treponema pallidum (Option B) causes syphilis, which can present with a painless genital ulcer (chancre). HSV type 2 (Option C) typically causes genital herpes, characterized by painful vesicles and ulcers on the genitalia. Chlamydia trachomatis (Option D): "Chlamydia trachomatis serovars L1, L2, and L3 cause lymphogranuloma venereum. It results in painless genital ulcer and painful swelling of the inguinal lymph nodes, known as buboes."

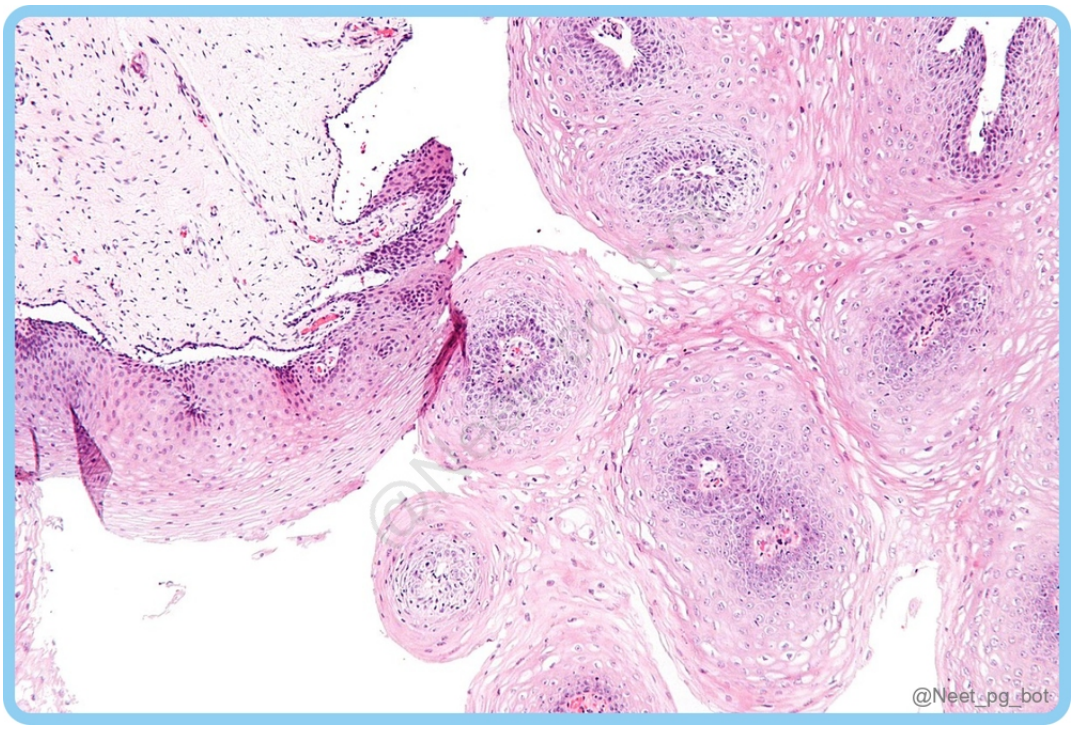



References:

Robbins and Cotran, Pathologic Basis of Disease, 10th edition, Page 964.

↑ *Back to this question in Part A*

Q3: A 65-year-old male presents with difficulty in urination and frequent nocturia. Digital rectal examination reveals a firm, irregular prostate. A subsequent prostate-specific antigen (PSA) test shows elevated levels. A transrectal ultrasound-guided prostate biopsy is performed, and the pathology report provides a Gleason score. Which of the following statements regarding the Gleason score in prostate cancer diagnosis is correct for this patient? (Q845862)

A. The Gleason score indicates the stage of prostate cancer.

B. A Gleason score of 6 suggests a poorly differentiated tumor with a high risk of metastasis.

C. The Gleason score is determined by adding the two least common Gleason grades found in the tumor.

D. The Gleason score is irrelevant in determining the treatment approach for prostate cancer.

Correct Answer: A. The Gleason score indicates the stage of prostate cancer.

■ *Listen (English)*

■ *Listen (Hindi)*

Explanation: The Gleason score is a grading system used to evaluate the aggressiveness and prognosis of prostate cancer based on the microscopic appearance of tumor cells observed in biopsy samples. Multistep approach that we follow in Gleason score in the order of: Pattern → Score → Grade (Ruled out Option C) Grade group Score Description 1 ≤6 Only individual discrete well-formed glands. 2 3 + 4 Predominantly well-formed glands with a lesser component of poorly formed, fused or cribriform glands 3 4 + 3 Predominantly poorly formed/fused/cribriform glands with a lesser component of well-formed glands 4 (4 + 4/3 + 5/5 + 3) Only poorly formed/fused/cribriform glands or predominantly mix of well-formed glands and lack of glands 5 (4 + 5/5 + 4/5 + 5) Lack gland formation (or with necrosis) with or without poorly formed/fused/cribriform glands A Gleason score of 6 suggests a poorly differentiated tumor with a high risk of metastasis (Option B): It does not indicate a poorly differentiated tumor. The Gleason score is irrelevant in determining the treatment approach for prostate cancer (Option D): On biopsy we give Gleason score and grade based on which treatment modality is decided.

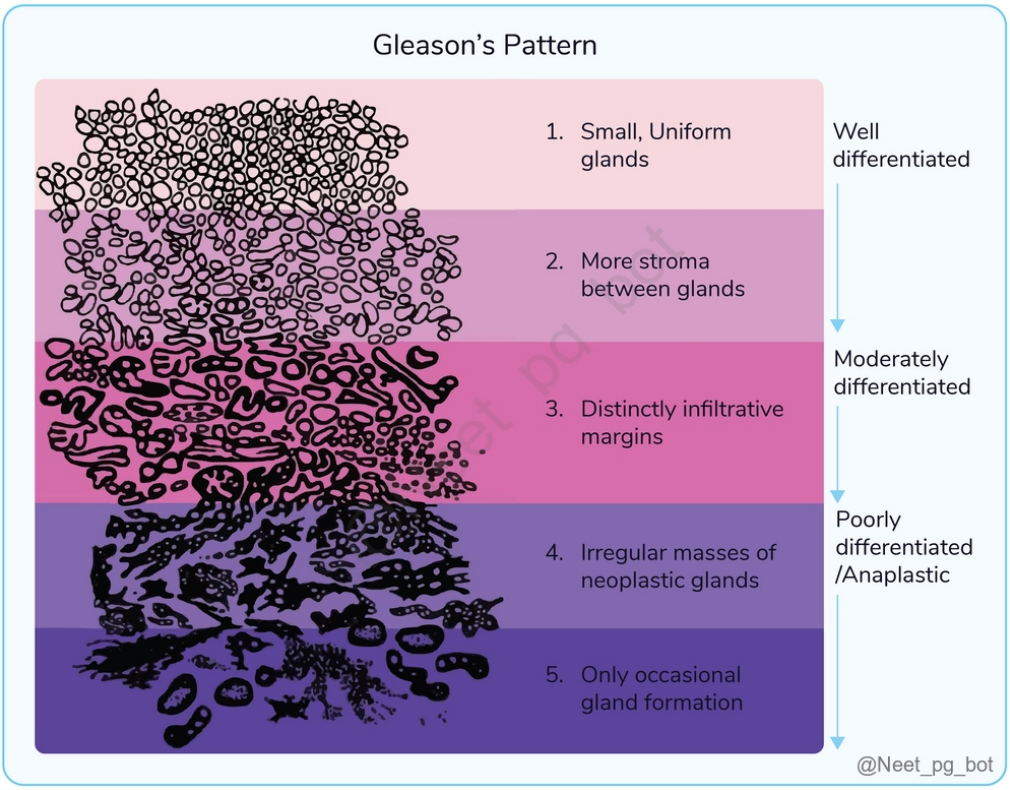

References:

Robbins and Cotran, Pathologic basis of disease, 10th edition, Page 976

↑ *Back to this question in Part A*

@Neet_pg_bot

Q4: A 60-year-old male presents with increased frequency, nocturia, and weak urine stream. DRE reveals a firm nodule. A prostate biopsy is performed, and the histology image shows complex, branching papillary structures lined by pseudostratified columnar epithelium.What is the most likely diagnosis? (Q845861)

A. Benign Prostatic Hyperplasia (BPH)

B. Prostate Adenocarcinoma-Ductal Type

C. Prostatic Intraepithelial Neoplasia (PIN)

D. Chronic Prostatitis

Correct Answer: B. Prostate Adenocarcinoma-Ductal Type

Explanation: The biopsy shows complex, arborizing papillary structures with branching architecture, characteristic of prostatic ductal adenocarcinoma. The papillae are lined by tall pseudostratified columnar epithelial cells, which is a hallmark of this aggressive variant. Unlike usual acinar adenocarcinoma with small crowded glands, ductal carcinoma forms papillary and cribriform patterns. It commonly arises in the periurethral region and can present with urinary obstruction symptoms. This morphology is distinct and diagnostic. Incorrect Options: Option A) BPH : Shows large, well-formed glands with papillary infolding but never pseudostratified malignant epithelium. Option C) PIN : Can show stratified epithelium but retains the basal cell layer and lacks complex papillary architecture. Option D) Chronic Prostatitis : Shows dense inflammatory infiltrates, not complex papillary tumor structures

References:

Robbins and Cotran, Pathologic basis of disease, 10th Edition, Page 976

↑ *Back to this question in Part A*

@Neet_pg_bot

Q5: Which of the following is a new biomarker used in Prostatic Cancer? (Q845860)

A. NMP22

B. Thymidine kinase

C. NKX 3.1

D. PLAP

Correct Answer: C. NKX 3.1

■ *Listen (English)*

■ *Listen (Hindi)*

Explanation: NKX3.1 is primarily expressed in the prostate, and its expression is regulated by androgens. It is involved in the maintenance of prostate epithelial cell differentiation, growth regulation, and suppression of cellular proliferation. Therefore, NKX3.1 is elevated in prostate cancer. Tumour markers for carcinoma of prostate: Prostate specific antigen (PSA). Prostatic acid phosphatase (PAP). PCA3. NKX 3.1.

References:

Robbins and Cotran, Pathologic basis of disease, 10th edition, Page 97

↑ *Back to this question in Part A*

@Neet_pg_bot

Q6: Which of the following is a protective factor associated with prostate cancer? (Q845859)

A. Age over 60 years

B. Family history of prostate cancer

C. High intake of red meat

D. Adequate levels of vitamin D

Correct Answer: D. Adequate levels of vitamin D

■ *Listen (English)*

■ *Listen (Hindi)*

Explanation: Adequate levels of vitamin D are considered a protective factor for prostate cancer. Protective factors Risk factors Vitamin D Selenium Lycopene Soy products Age >60 years High fat diet Racial preponderance (Blacks > Whites) Intake of red meat Family history of Prostate CA Genetic factors BRCA 2 gene mutation (Chromosome 13). Hypermethylation of glutathione S-transferase. Chromosomal rearrangement juxtaposes TMPRSS-2 with ETS fusion gene.

References:

Robbins and Cotran, Pathologic basis of disease, 10th edition, Page 97

↑ *Back to this question in Part A*

@Neet_pg_bot

Q7: A 65-year-old man presents with complaints of increased frequency and urgency of urination, particularly at night. He also mentions a feeling of incomplete bladder emptying and a weak urine stream. The patient's PSA level is within normal limits. The histopathology image is given below. Based on the diagnosis, which of the following is true? (Q845858)

A. Infiltration of lymphocytes

B. Presence of atypical cells with high mitotic activity

C. Increased number of stromal and epithelial cells

D. Dysplastic changes in the glandular architecture

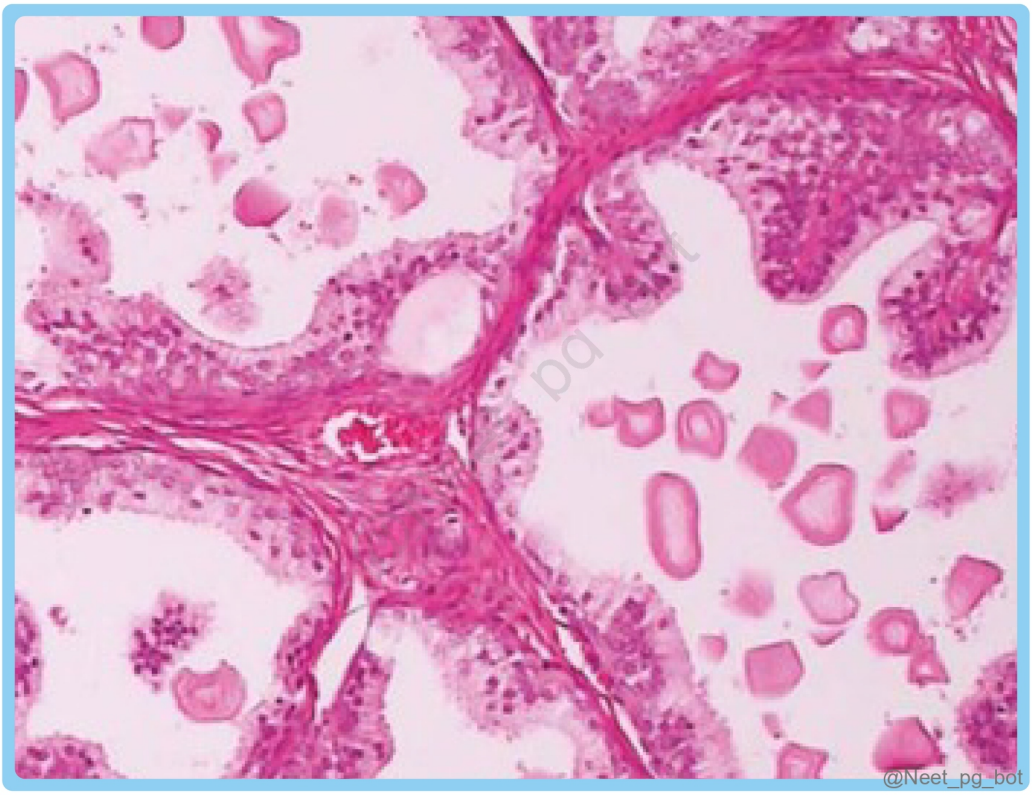

Correct Answer: C. Increased number of stromal and epithelial cells

■ *Listen (English)*

■ *Listen (Hindi)*

Explanation: Characteristic features of the histopathology of Benign Prostatic Hyperplasia (BPH) include: Hyperplasia (increase in the number of cells) of both stromal and epithelial components of the prostate gland, forming small bulbous papillary projections. The stromal cells include fibroblasts and smooth muscle cells, while the epithelial cells line the glandular structures of the prostate. Pink secretions (corpora amylacea) are also present in the lumen. BPH occurs due to the influence of dihydrotestosterone (DHT) .

References:

Robbins and Cotran, Pathologic basis of disease, 10th edition, Page 976

↑ *Back to this question in Part A*

@Neet_pg_bot

Q8: Which zone of the prostate is primarily affected by benign prostatic hyperplasia (BPH), and which zone is more commonly associated with prostate cancer? (Q845857)

A. Central zone & Peripheral zone

B. Peripheral zone & Transitional zone

C. Transitional zone & Peripheral zone

D. Peripheral zone & Central zone

Correct Answer: C. Transitional zone & Peripheral zone

■ *Listen (English)*

■ *Listen (Hindi)*

Explanation: Benign Prostatic Hyperplasia (BPH / Nodular Hyperplasia of prostate): The zone involved in BPH is the Transitional Zone. The transitional zone is closest to the urethra, and nodular hyperplasia compresses the urethra, which leads to early lower urinary tract symptoms (LUTS) such as frequency, urgency, nocturia, weak stream, and hesitancy. Prostate cancer: The zone involved in prostate cancer is the Peripheral Zone, which lies posteriorly. Because this zone is farther from the urethra, urethral symptoms appear late. Prostate cancer metastasizes early, commonly to bones such as the lumbar spine, pelvis, and ribs through Batson's venous plexus. Diseases Prostate zones Prostate cancer (adenocarcinoma) Peripheral Prostatic intraepithelial neoplasia Peripheral Prostatitis Central Benign prostatic hyperplasia Transitional

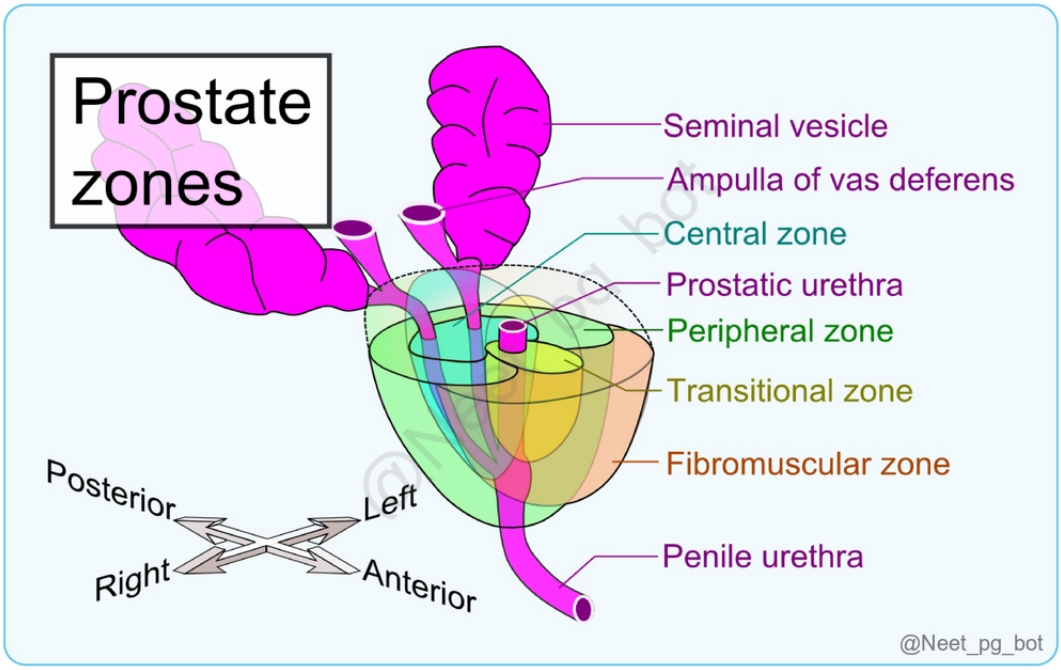

References:

Robbins and Cotran, Pathologic basis of disease, 10th edition, Page 976

↑ *Back to this question in Part A*

@Neet_pg_bot

Q9: Match the following tumour markers (Column A) with the corresponding testicular tumour types (Column B). Column A (Tumor Markers) Column B (Testicular Tumor Types) 1. Alpha-fetoprotein (AFP) A. Seminoma 2. Beta-human chorionic gonadotropin (β-hCG) B. Embryonal Carcinoma 3. CD-30 C. Yolk sac tumour 4. Placental alkaline phosphatase (PLAP) D. Choriocarcinoma 5. Cytokeratin E. Teratoma (Q845856)

A. 1-A, 2-B, 3-C, 4-D, 5-E

B. 1-C, 2-D, 3-A, 4-B, 5-E

C. 1-C, 2-D, 3-B, 4-A, 5-E

D. 1-B, 2-A, 3-D, 4-C, 5-B

Correct Answer: C. 1-C, 2-D, 3-B, 4-A, 5-E

■ *Listen (English)*

■ *Listen (Hindi)*

Explanation: The various testicular tumours and their markers are given below: Testicular Tumour Corresponding Tumor Markers Seminoma Placental alkaline phosphatase (PLAP) HCG LDH Newer markers: Oct 3/4, Nanog, CD117, SALL4 Embryonal Carcinoma CD-30 Yolk sac tumour Alpha-fetoprotein (AFP) Alpha-1 antitrypsin Choriocarcinoma Beta-human chorionic gonadotropin (β-hCG) Teratoma Cytokeratin

References:

Robbins and Cotran, Pathologic basis of disease, 10th edition, Page 969

↑ *Back to this question in Part A*

@Neet_pg_bot

Q10: The histological examination of a normal testis is given in the image below. Which of the following callouts is responsible for maintaining the blood testis barrier? (Q845847)

A. 1

B. 2

C. 3

D. 4

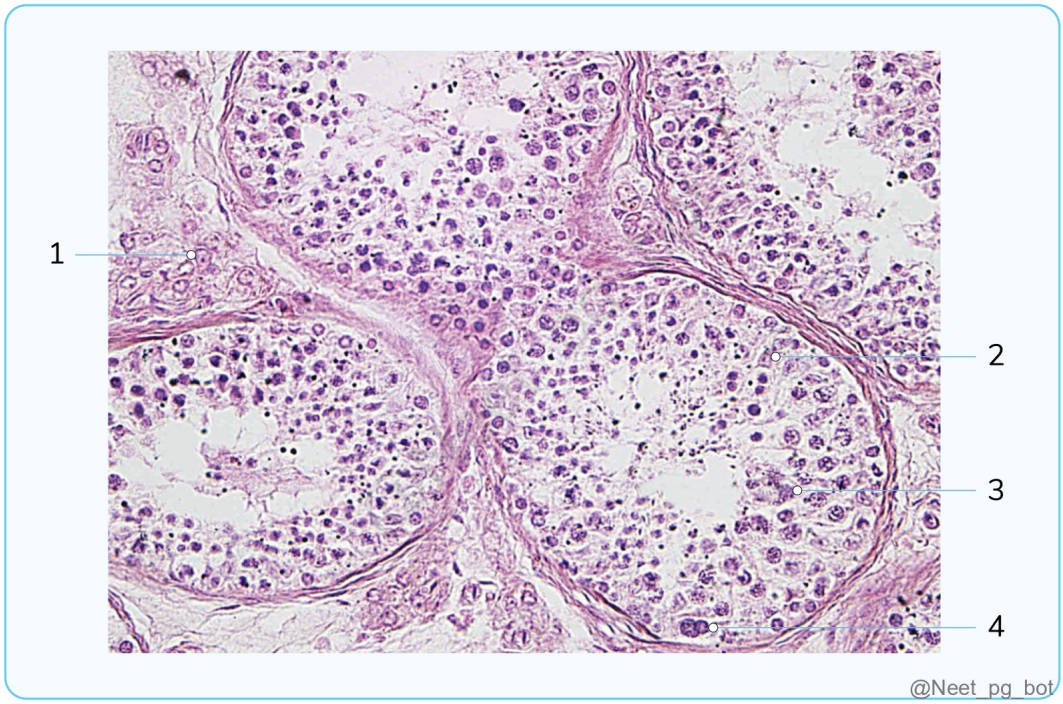

Correct Answer: B. 2

- *Listen (English)*
- *Listen (Hindi)*

Explanation: The callouts given in the illustration correspond to the following. 1- Interstitial cell of Leydig : Responsible for hormones production 2- Sertoli/sustentacular cell : Provides nutrition and makes blood-testicular barrier 3- Spermatocyte (Mature spermatogonium) 4- Spermatogonium .

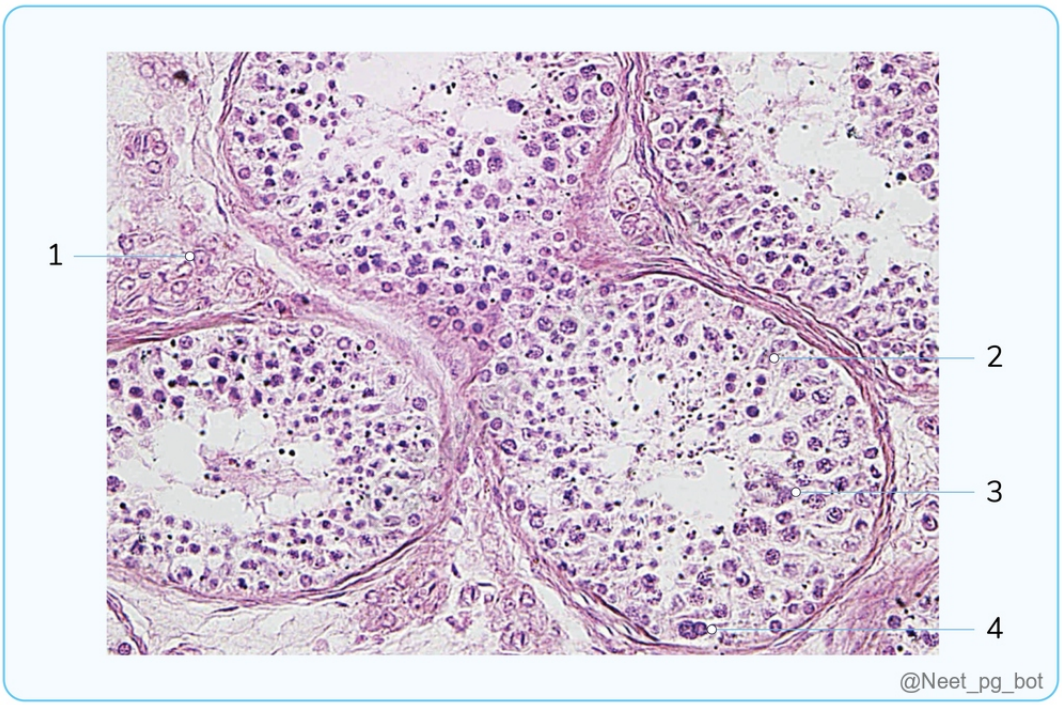

References:

Inderbir Singh Histology, 9th edition, Pages 550-552, 882.

↑ *Back to this question in Part A*

@Neet_pg_bot

Q11: A 10-month-old boy was referred to the hospital with non-palpable right testes. The physical examination revealed no jaundice, palpable left testes, or right-sided abdominal mass. Subsequent surgical excision of the mass revealed a cystic mass with keratinous debris, and a biopsy image of the specimen was obtained. All of the following statements regarding this condition are true except? (Q845854)

A. Typically present as well-defined, encapsulated masses with cystic and solid components.

B. Often associated with areas of haemorrhage and necrosis.

C. Histologically, it contains differentiated cells or organoid structures embedded in a fibrous or myxoid stroma.

D. Demonstrate homogeneous appearance and are mostly found malignant in young children.

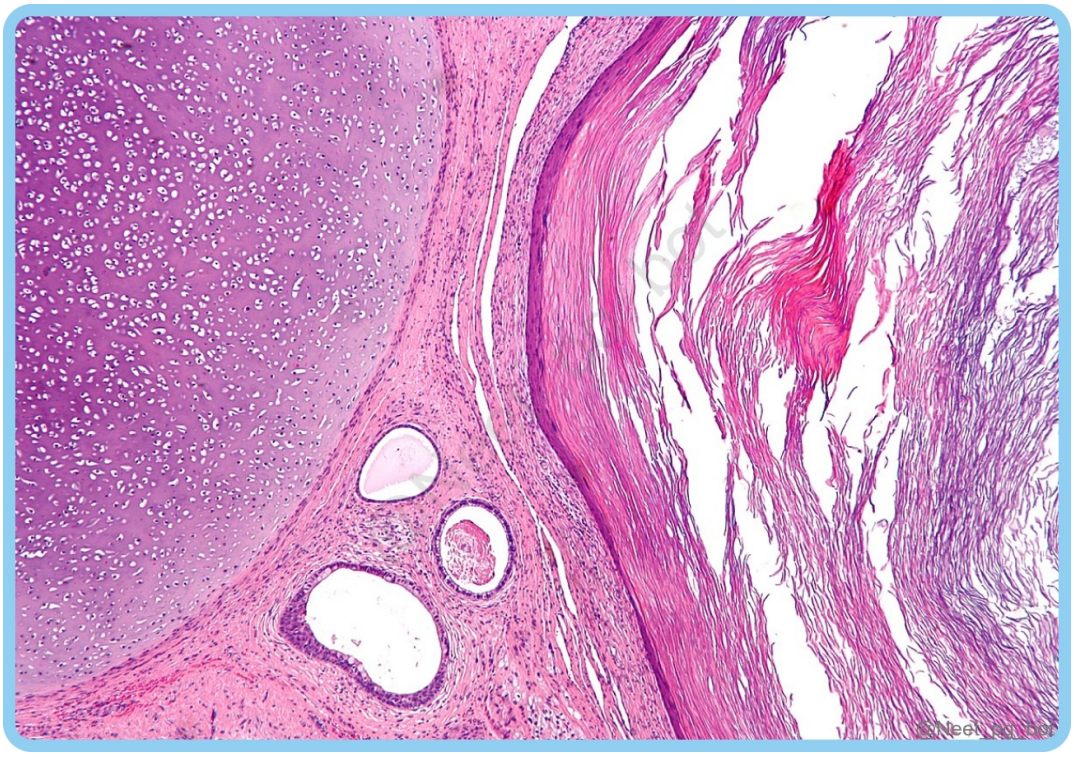

Correct Answer: D. Demonstrate homogeneous appearance and are mostly found malignant in young children.

■ *Listen (English)*

■ *Listen (Hindi)*

Explanation: Dermoid cyst/Teratoma : Germ cell tumours (GCTs) having various organoid components derived from multiple germ layers. Prepubertal teratoma: Pure teratomas are common in infants and very young children. Mostly benign, resembling normal tissue. (Option D). Can present as undescended testicular teratoma. Postpubertal adult teratomas: Malignant transformation to squamous cell carcinoma, adenocarcinoma, or sarcoma. Histopathology: Gross: Heterogeneous appearance with a well-defined encapsulated mass containing solid, cartilaginous, and cystic areas. (Option A). Associated with foci of haemorrhage and necrosis. (Option B). Microscopy: Differentiated cells or organoid structures, such as neural tissue, muscle, cartilage, epidermal-like surfaces, thyroid gland, and intestinal wall or brain substance embedded in a fibrous or myxoid stroma. (Option C) Special types include dermoid cysts containing hair, teeth, and skin.

References:

Robbins and Cotran, Pathologic Basis of Disease, 10th edition, Pages 966-67

↑ *Back to this question in Part A*

@Neet_pg_bot

Q12: A 30-year-old male presents with a rapidly enlarging testicular mass associated with testicular pain and gynecomastia. He reports associated mild hemoptysis for the last 4 days. A biopsy of the mass is performed, and both gross and microscopic images are obtained. What is the most likely diagnosis based on the clinical presentation? (Q845853)

A. Choriocarcinoma

B. Embryonal Carcinoma

C. Seminoma

D. Yolk Sac Tumor

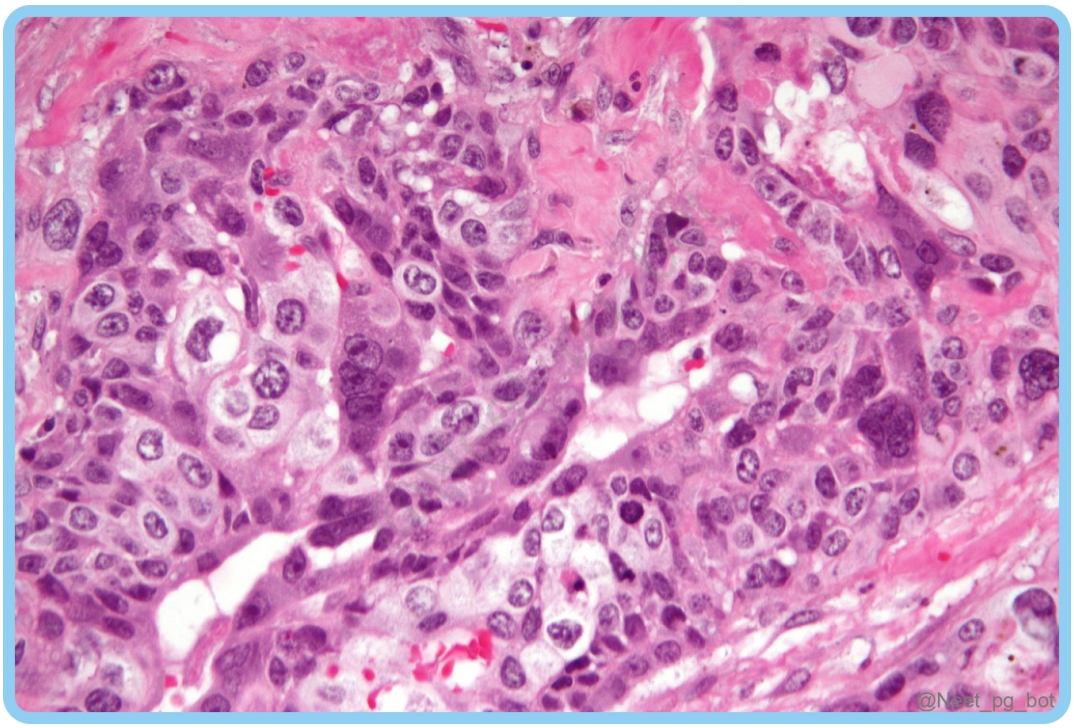



Correct Answer: A. Choriocarcinoma

■ *Listen (English)*

■ *Listen (Hindi)*

Explanation: Choriocarcinoma: It is a very aggressive and highly malignant type of GCT. Tumor marker: Elevated serum beta HCG (human chorionic gonadotropin). Histopathology: Gross: Haemorrhage and necrosis at involved sites. Microscopy: Composed of two cell types- syncytiotrophoblasts and cytotrophoblasts. Syncytiotrophoblasts: Large multinucleated cells. Cytotrophoblasts: Regular, polygonal. mononuclear cells. Widespread metastasis: Hematogenous metastasis to lungs (cannonball appearance).

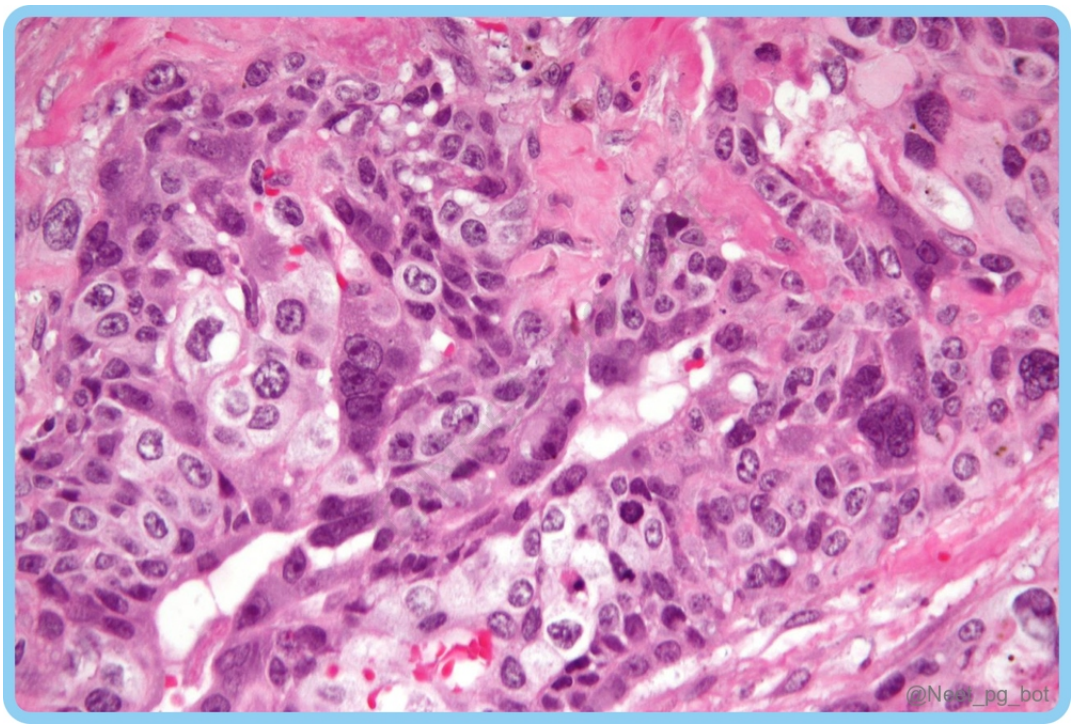



References:

Robbins and Cotran, Pathologic basis of disease, 10th edition, Page 972

↑ *Back to this question in Part A*

@Neet_pg_bot

Q13: A 10-year-old male with a painless testicular mass for the past few months. On examination, the right testis was enlarged and the transillumination test was negative. A biopsy of the mass was performed and is shown below. What is the most likely diagnosis? (Q845852)

A. Hydrocoele

B. Yolk Sac tumour

C. Choriocarcinoma

D. Germ Cell tumour

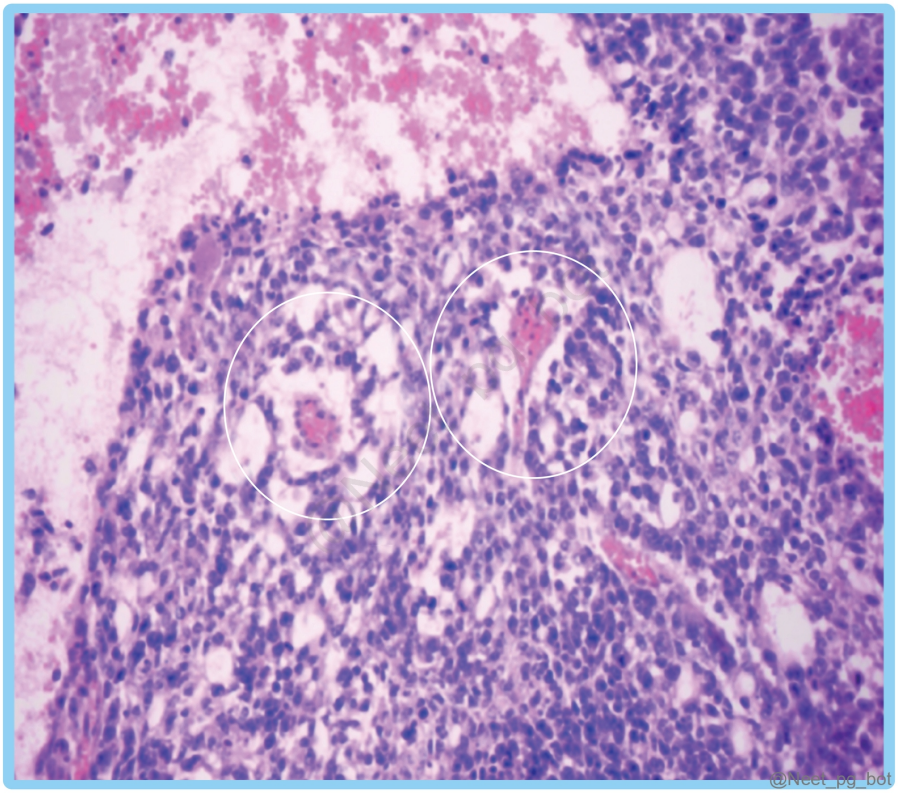

Correct Answer: B. Yolk Sac tumour

■ *Listen (English)*

■ *Listen (Hindi)*

Explanation: Yolk Sac Tumour or Endodermal Sinus Tumour: Common in infants and children. Biopsy finding: Schiller-Duval or glomerular bodies: At centre, it has a reddish blood vessel which is surrounded by two rows of tumor cells, and there is space between these two rows. Because of this appearance they start looking as a gromerulus and hence the name glomerular bodies. Glomerular bodies are seen in 2 tumors: Yolk sac tumor in genitals Glioblastoma in brain.

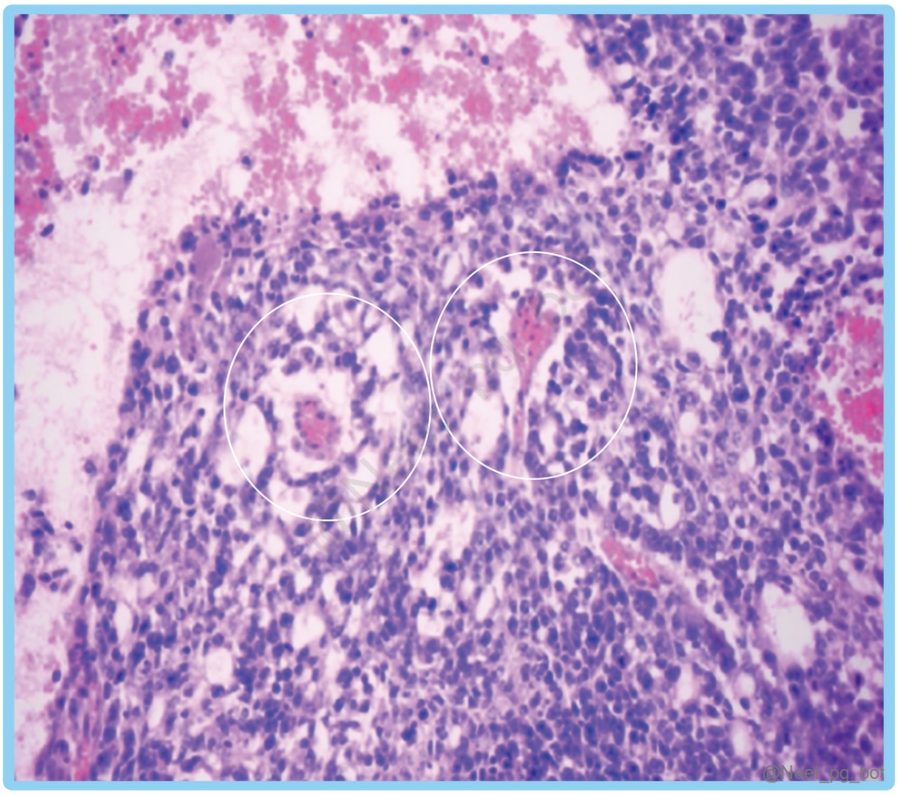

References:

Robbins and Cotran, Pathologic basis of disease, 10th edition, Page 97

↑ *Back to this question in Part A*

@Neet_pg_bot

Q14: A 65-year-old male presents to the hospital with a painless scrotal mass. Ultrasound scan reveals a solid testicular mass suspicious for a spermatocytic tumour. Upon further examination, the following histological findings are identified except? (Q845851)

A. Associated with gain of function mutation

B. Presence of inflammatory infiltrates and syncytiotrophoblasts

C. Presence of three intermixed cell distinct cell populations on microscopy

D. Low risk of metastasis following surgical resection

Correct Answer: B. Presence of inflammatory infiltrates and syncytiotrophoblasts

■ *Listen (English)*

■ *Listen (Hindi)*

Explanation: Spermatocytic seminoma : Testicular germ cell neoplasm. Associated with gain of chromosome 9q (Option A). It is a slow-growing tumour and doesn't metastasise (Option D). Histopathology: Microscopy (Option C): Smaller cells with dense chromatin and a narrow eosinophilic cytoplasm rim resembling secondary spermatocytes. Medium-sized cells containing a round nucleus, spireme-type chromatin with occasional nucleoli, and eosinophilic cytoplasm. Scattered giant cells , large multinucleated cells. Presence of inflammatory infiltrates and syncytiotrophoblasts (Option B): Cytotrophoblasts and syncytiotrophoblasts indicate gestational trophoblastic diseases are seen in choriocarcinoma.

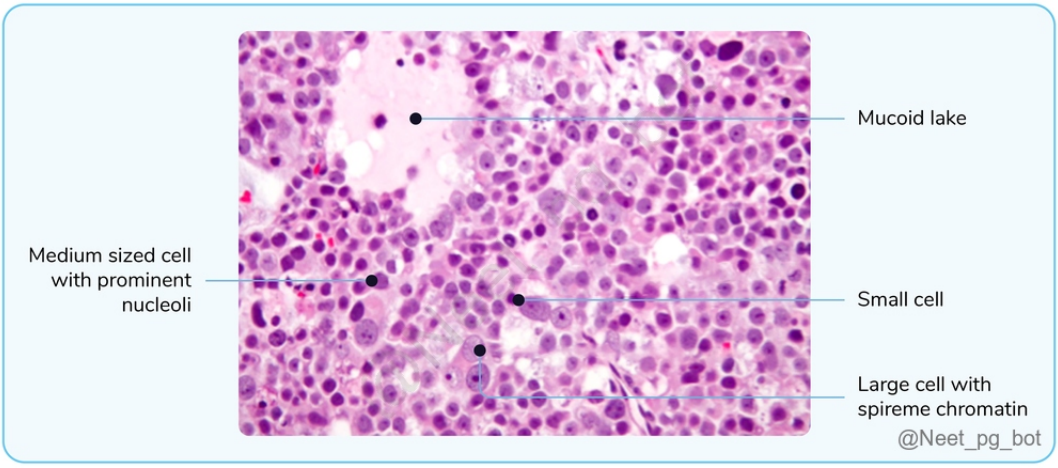

References:

Robbins and Cotran, Pathologic basis of disease, 10th edition, Page 970.

↑ *Back to this question in Part A*

@Neet_pg_bot

Q15: A patient underwent unilateral orchiectomy for a swelling in the right testis. The specimen is sent for histopathological examination, and its microscopic appearance is depicted in the image below. Which of the following statements is true regarding the diagnosis? (Q845850)

A. 3 different sizes of tumour cells are seen

B. Schiller-Duval bodies are present

C. Tumor cells are arranged in sheets

D. Tumor cells have a watery-clear cytoplasm

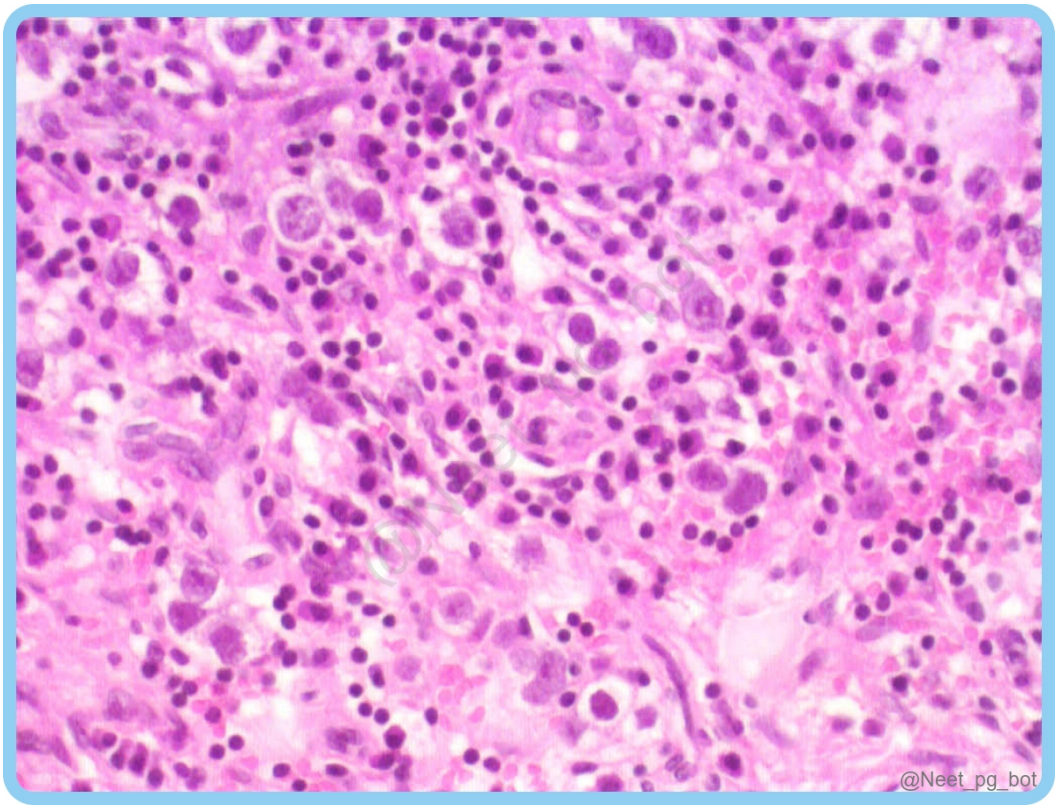

Correct Answer: D. Tumor cells have a watery-clear cytoplasm

■ *Listen (English)*

■ *Listen (Hindi)*

Explanation: The given histopathological image shows features suggestive of testicular seminoma. Histology of seminoma: The tumor shows cells with watery, clear cytoplasm (described as a “fried-egg” or clear cell appearance) due to glycogen accumulation, which is PAS positive. The tumor cells are arranged in nests separated by fibrous septa, and within these septa there is lymphocytic and plasma cell infiltration. This triad of clear cytoplasm, nests of tumor cells, and lymphoplasmacytic infiltrate is characteristic of seminoma . 3 different sizes of tumour cells (small, medium and giant cells) are seen in a case of spermatocytic seminoma. (Option A) Endodermal sinuses-like structures called Schiller-Duval bodies are present in the case of a yolk sac tumour. (Option B) Tumor cells arranged in sheets are typical of embryonal carcinoma, whereas in seminoma, tumor cells are arranged in nests with intervening fibrous septa. (Option C)

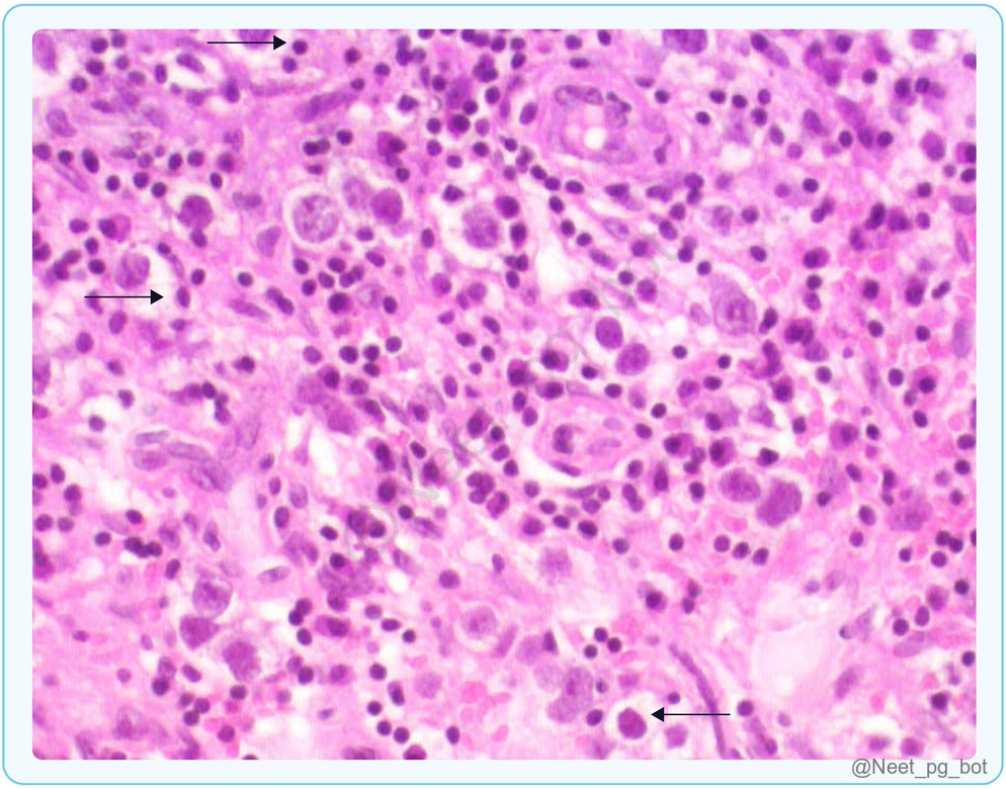

References:

Robbins and Cotran, Pathologic basis of disease, 10th edition, Page 970.

↑ *Back to this question in Part A*

@Neet_pg_bot

Q16: Which of the following is not a germ cell tumour? (Q845849)

A. Teratoma

B. Embryonal carcinoma

C. Spermatocytic seminoma

D. Sertoli cell tumour

Correct Answer: D. Sertoli cell tumour

■ *Listen (English)*

■ *Listen (Hindi)*

Explanation: The classification of testicular tumours is given in the table below. Germ cell tumours Sex cord-stromal tumours Mixed Seminomatous: Seminoma (Most common) Spermatocytic seminoma. Sertoli cell tumour. Leydig cell tumour. Pure tumours. Gonadoblastoma. Non-seminomatous: Embryonal carcinoma. Choriocarcinoma. Yolk sac tumour. Teratoma.

References:

Robbins and Cotran, Pathologic basis of disease, 10th edition. Page 969

↑ *Back to this question in Part A*

@Neet_pg_bot

Q17: A 1-year-old boy is brought to the pediatric clinic by his parents, who are concerned about the absence of his left testicle in the scrotum. On physical examination, the right testicle is palpable in the scrotum, but the left is not. All are true regarding this condition except? (Q845848)

A. It can occur in association with hypospadias.

B. The most common site of arrest of descent is the inguinal canal.

C. It is very commonly associated with a well-defined hormonal disorder.

D. The Leydig cells appear prominent.

Correct Answer: C. It is very commonly associated with a well-defined hormonal disorder.

■ *Listen (English)*

■ *Listen (Hindi)*

Explanation: Cryptorchidism: It is a complete or partial failure of the intra-abdominal testes to descend into the scrotal sac , associated with testicular dysfunction and an increased risk of testicular cancer. It usually occurs as an isolated anomaly but may be accompanied by other genitourinary tract malformations, such as hypospadias. (Option A) The normal descent of the testes occurs in two phases: Transabdominal phase: Mediated by Mullerian inhibiting substance. Inguinoscrotal phase: Mediated by the androgen-induced release of calcitonin-related gene peptide. Any problem in any of these descents can lead to cryptorchidism. Sites of arrest of descent: Inguinal canal (most common). (Option B) Abdomen (uncommon). When the testis fails to descend into the scrotum, it is deprived of the temperature needed for spermatogenesis. As a result, sperm production does not occur, and the seminiferous tubules contain only Sertoli cells (Sertoli cell–only syndrome). Leydig cells outside the tubules may appear prominent—not from true hypertrophy or hyperplasia, but due to the absence of germ cells—though this prominence is often mistakenly reported as Leydig cell hyperplasia . (Option D)

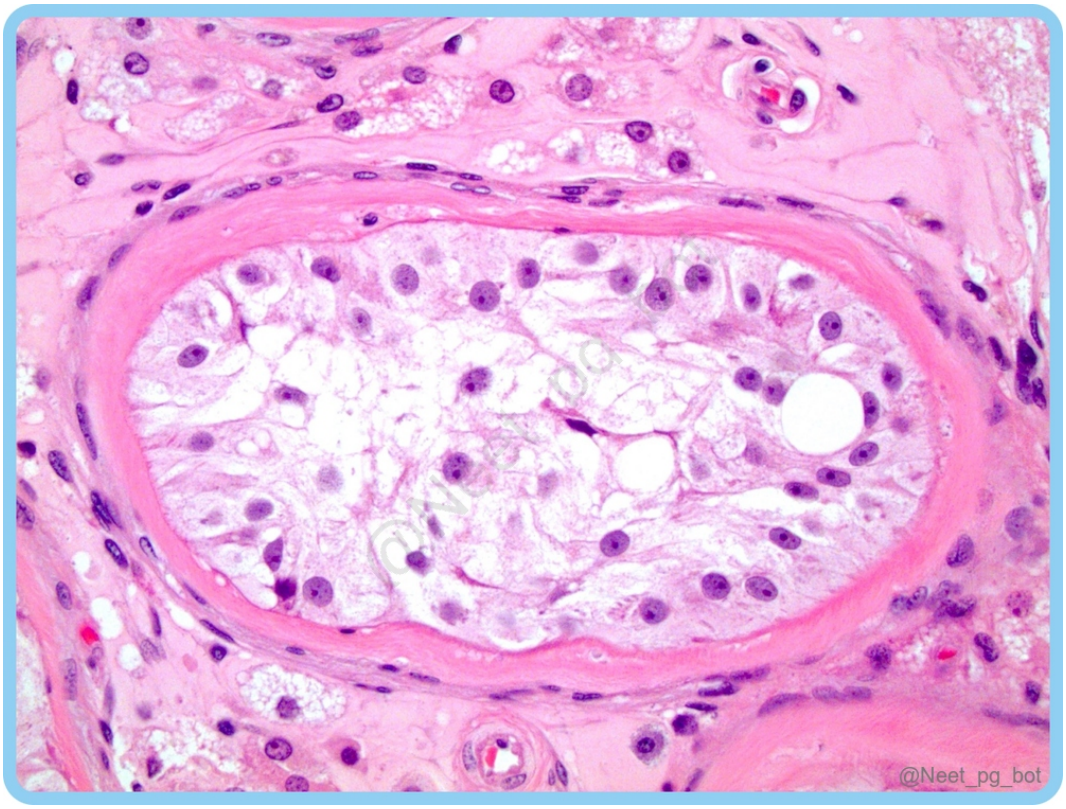

References:

Robbins and Cotran, Pathologic Basis of Disease, 10th Edition, Pages 966-67.

↑ *Back to this question in Part A*

@Neet_pg_bot

• [12_Genital System] 053 Pathology Of Female Genital Tract-I

« Back to Folder Directory

[12_Genital System] 053 Pathology Of Female Genital Tract-I — Quick Jump

Q1 (p. 2254) *Q2 (p. 2255)* *Q3 (p. 2258)* *Q4 (p. 2261)* *Q5 (p. 2264)* *Q6 (p. 2265)*
Q7 (p. 2267) *Q8 (p. 2267)* *Q9 (p. 2269)* *Q10 (p. 2270)* *Q11 (p. 2273)* *Q12 (p. 2274)*

Q1: Which of the following is not a part of the vaginal epithelium? (Q845578)

A. Superficial squamous cells

B. Intermediate squamous cells

C. Columnar cells

D. Parabasal cells

Correct Answer: C. Columnar cells

■ *Listen (English)*

■ *Listen (Hindi)*

Explanation: Vaginal epithelium consists of Non keratinized Stratified squamous epithelium. Layers of vaginal epithelium: Basal layer Parabasal layer Intermediate layer Superficial layer

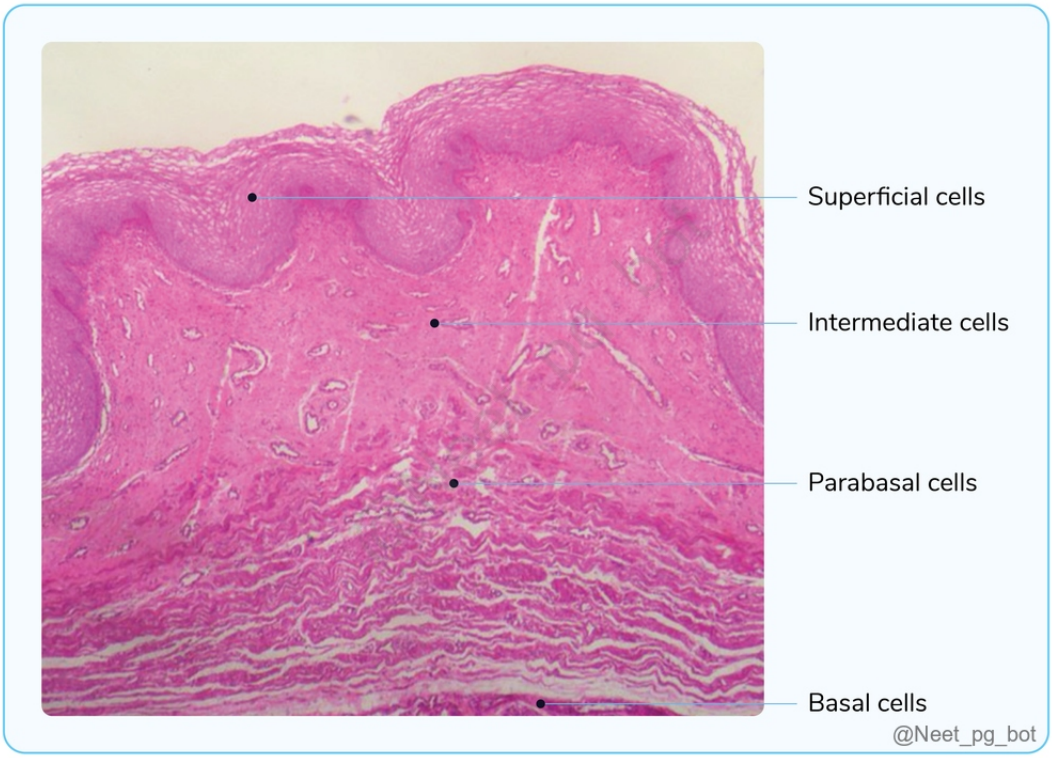

References:

Robbins and Cotran, Pathologic Basis of Disease, 10th Edition, Page 991.

Organoids of the female reproductive tract PMC(NIH.gov)https://pubmed.ncbi.nlm.nih.gov/33580825/

↑ *Back to this question in Part A*

@Neet_pg_bot

Q2: Which strain of the HPV virus is responsible for causing Condyloma acuminatum? (Q845605)

A. HPV 6 & 11

B. HPV 16 & 18

C. HPV 6 & 16

D. HPV 11 & 18

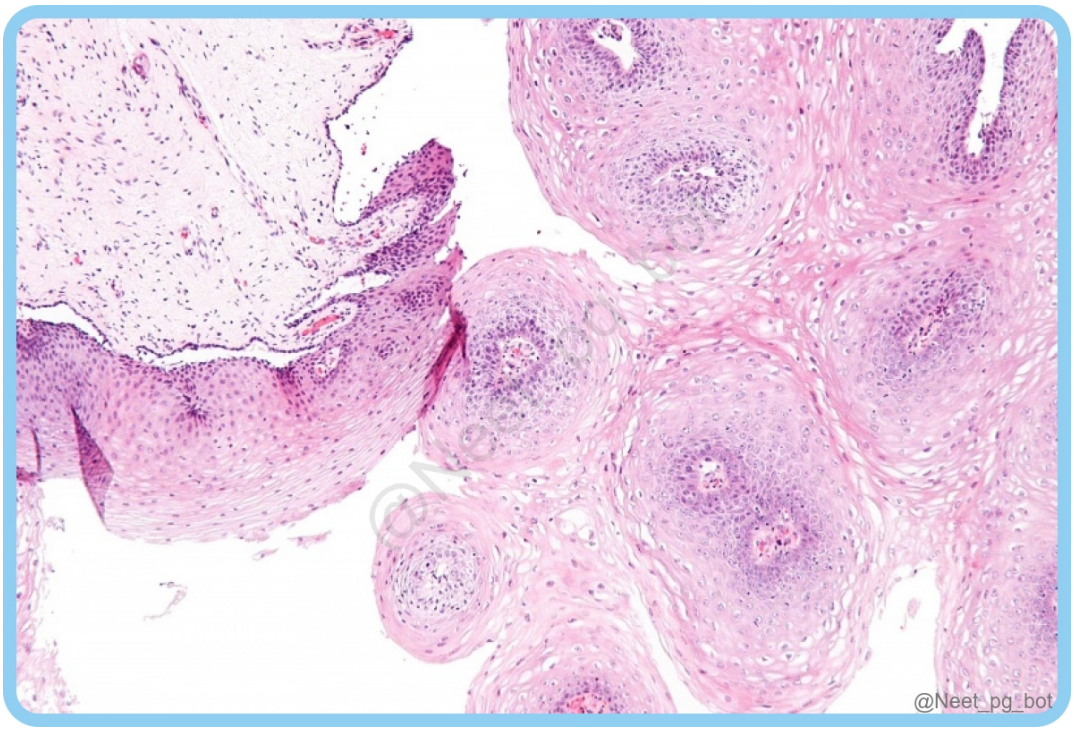

Correct Answer: A. HPV 6 & 11

■ *Listen (English)*

■ *Listen (Hindi)*

Explanation: Histopathology image suggests Condylomata acuminata, which are benign genital warts caused by low-risk HPV 6 and 11, a double-stranded DNA virus that infects differentiated squamous epithelial cells. Condyloma acuminata are cauliflower-like, dry, and bulky, typically found in the squamous mucosa of the anal canal. Lots of hyperkeratosis and acanthosis are seen. {{caption_text}} HPV 16 and 18 (Option B): HPV 16 and 18 are high-risk strains responsible for cervical carcinoma, vulvar intraepithelial neoplasia (VIN) and vulvar carcinoma.



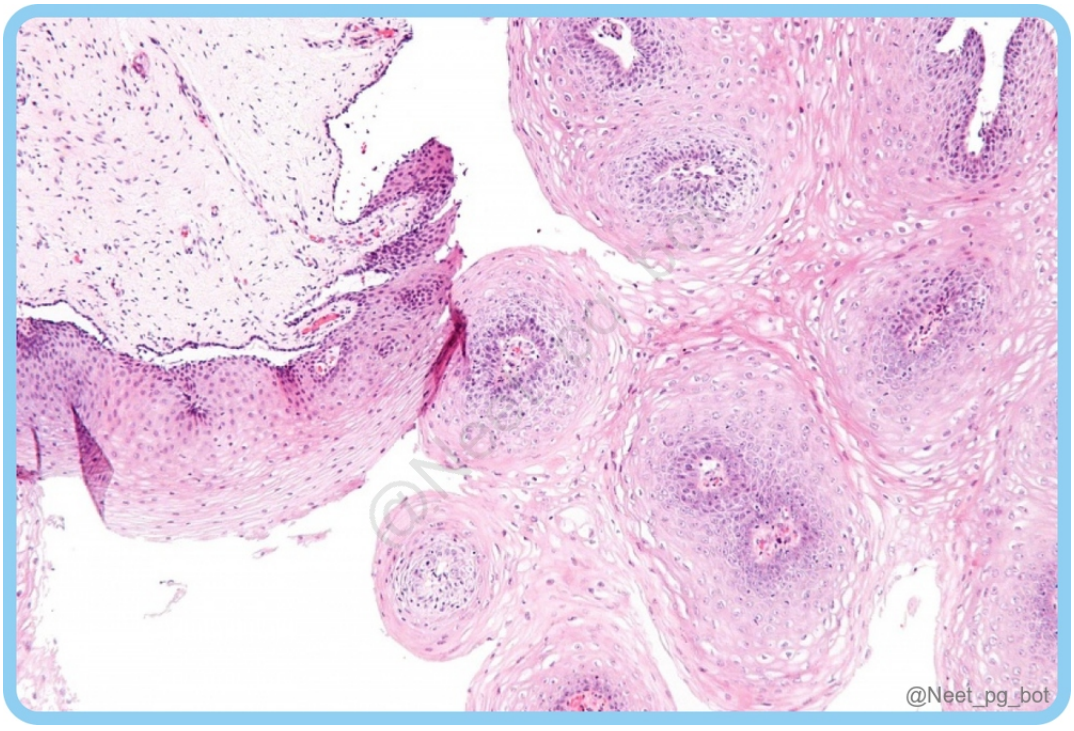

References:

Robbins and Cotran, Pathologic Basis of Disease, 10th Edition, Page 991.

Human Papillomavirus and Cervical Cancer-PMC(NIH.gov)https://www.ncbi.nlm.nih.gov/pmc/articles/PMC145302/

↑ *Back to this question in Part A*

@Neet_pg_bot

Q3: A 25-year-old sexually active female presents with foul-smelling vaginal discharge and dysuria. Upon examination of the cervix, the following appearance is noted. Wet mount microscopy reveals the findings shown in the image below. Which of the following is most likely responsible for this presentation? (Q845606)

A. Trichomonas vaginalis

B. Candida

C. Herpes simplex virus

D. Human Papilloma virus



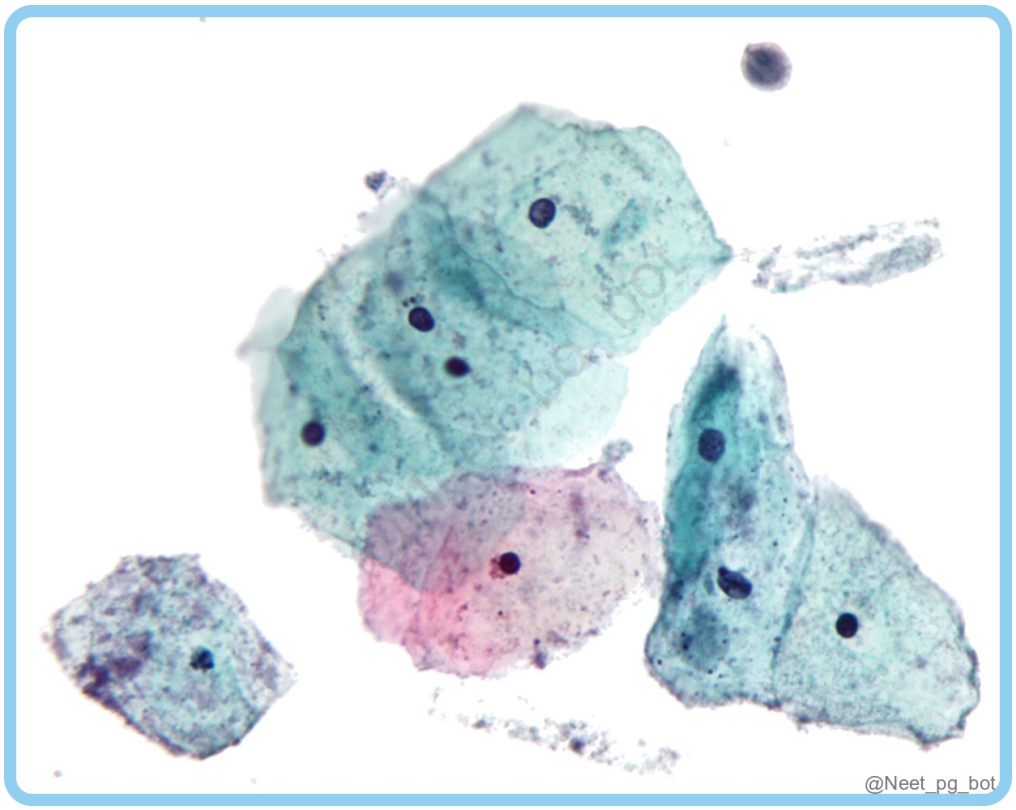

Correct Answer: A. Trichomonas vaginalis

- *Listen (English)*
- *Listen (Hindi)*

Explanation: The clinical presentation, examination, and microscopy findings suggest Trichomonas vaginalis infection, a large, flagellated ovoid protozoan transmitted by sexual contact. Patients may present with greenish, frothy vaginal discharge, vulvovaginal discomfort, dysuria (painful urination) dyspareunia (painful intercourse). The vaginal and cervical mucosa has a fiery-red appearance, with dilation of cervical mucosal vessels resulting in a “strawberry cervix.” Wet mount microscopy of the discharge reveals motile pear-shaped Trichomonas vaginalis with flagella. Trophozoite form of Trichomonas vaginalis Treatment: Metronidazole + Partner's treatment also. Candida (Option B): Pap smear: shish kebab effect {{caption_text}} Herpes simplex virus (Option C) Microscopy: squamous cell nuclei exhibit 3Ms : Multinucleation, molding and margination Human Papillomavirus (Option D) Microscopy: Koilocytes are seen.

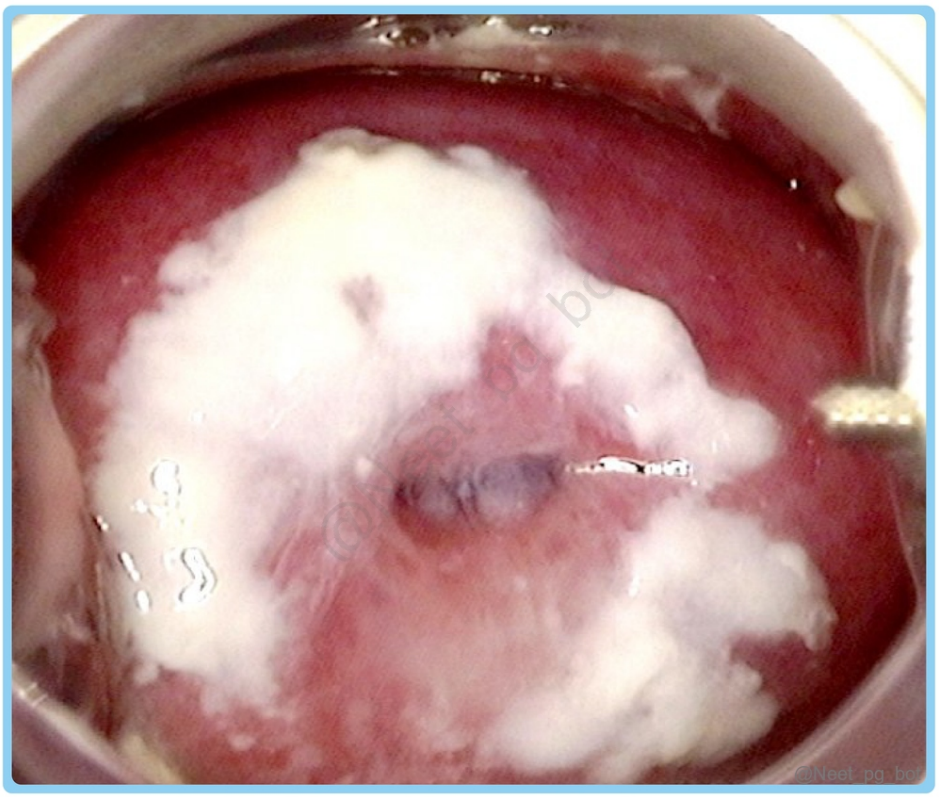
@Neet_pg_bot

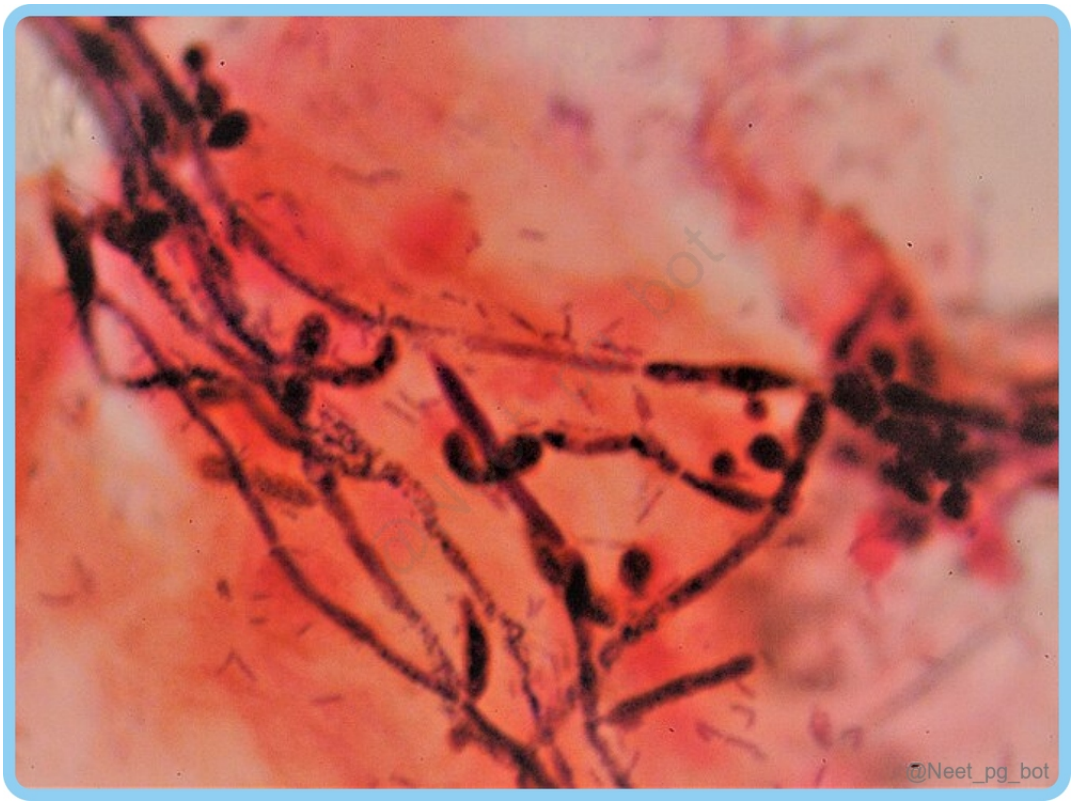
@Neet_pg_bot

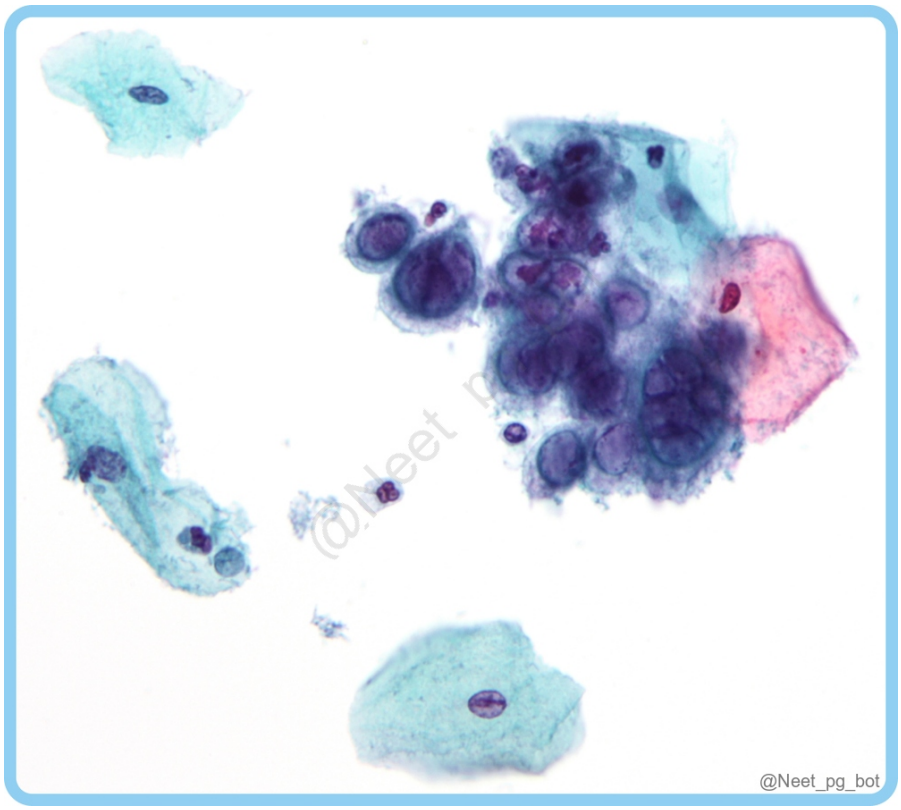

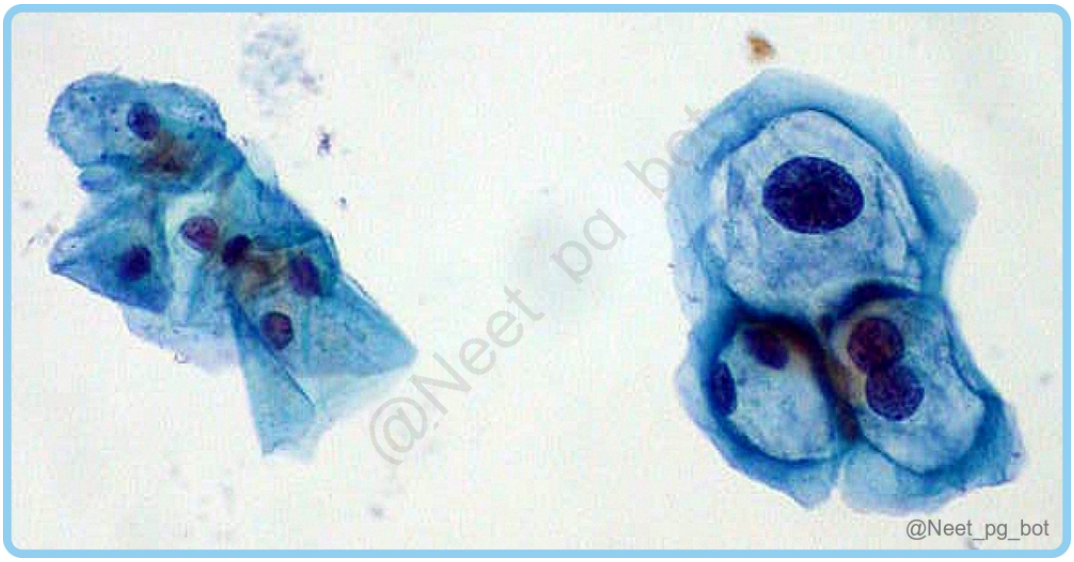

References:

Robbins and Cotran, Pathologic Basis of Disease, 10th Edition, Pages 988, 384, 991.

↑ *Back to this question in Part A*

@Neet_pg_bot

Q4: A 58-year-old woman complains of persistent itching and redness in her vulvar area. On examination, well-defined, erythematous plaques with an eczematous appearance are noted. A biopsy reveals large cells with pale cytoplasm and positive staining for mucopolysaccharides. Immunohistochemical analysis shows positive staining for cytokeratin 7. Based on these findings, what is the most likely diagnosis? (Q845607)

A. Bowen's disease of the vulva

B. Extramammary Paget's disease

C. Papillary Hidradenoma

D. Squamous cell carcinoma



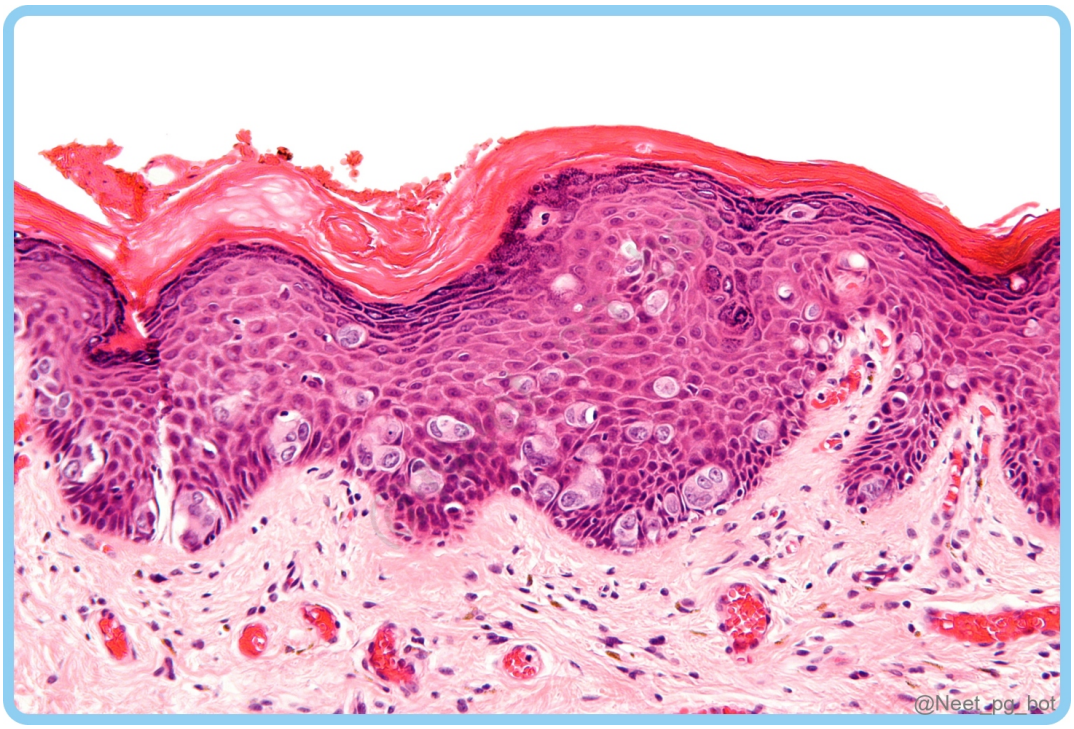

Correct Answer: B. Extramammary Paget's disease

■ *Listen (English)*

■ *Listen (Hindi)*

Explanation: 2 types of Paget's: Mammary Paget's (Paget's disease of breast): A condition with underlying cancer like ductal carcinoma in situ or ductal cancer and these cancer cells are spreading to the overlying skin, resulting in Paget cells (Clear looking cells) Extramammary Paget's (Paget's disease of vulva): It is typically not associated with underlying malignancy and is confined to the vulvar epidermis. Biopsy findings commonly reveal large, round cells, known as Paget cells, within the epidermis. These cells have pale cytoplasm containing mucopolysaccharide that stains with PAS, Alcian blue, or mucicarmine stains. Immunohistochemistry staining often shows positivity for cytokeratin (CK) 7.

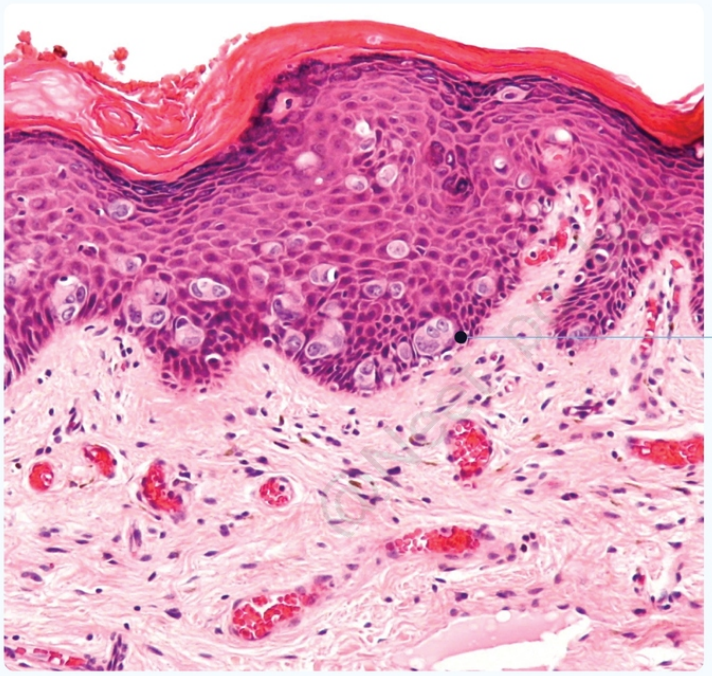

Extramammary Paget's disease of vulva

@Neet_pg_bot

References:

Robbins and Cotran, Pathologic Basis of Disease, 10th Edition, Pages 991, 993

↑ *Back to this question in Part A*

@Neet_pg_bot

Q5: Which of the following has a strong association with clear cell adenocarcinoma of the vagina? (Q845608)

A. Male partner who has multiple sexual partners

B. In utero exposure to diethylstilbestrol

C. HPV infection

D. Sexual activity at a young age

Correct Answer: B. In utero exposure to diethylstilbestrol

■ *Listen (English)*

■ *Listen (Hindi)*

Explanation: The clinical presentation and biopsy findings suggest Clear cell adenocarcinoma of the vagina, characterized histologically by cells with clear cytoplasm and hobnail cells and is strongly associated with in-utero exposure to diethylstilbestrol (DES). Vaginal adenosis (precursor lesion for clear cell adenocarcinoma) refers to the presence of glandular columnar epithelium in the proximal vagina. Diethylstilbestrol is a synthetic non-steroidal estrogen that was historically widely used to prevent potential miscarriages by stimulating the synthesis of estrogen and progesterone in the placenta. Side effect of Diethylstilbestrol: Girls born to mothers who were taking this drug during pregnancy were found to have clear cell cancers of female genital tract (vagina, cervix or ovary).

References:

Robbins and Cotran, Pathologic Basis of Disease, 10th Edition, Page 994

↑ *Back to this question in Part A*

@Neet_pg_bot

Q6: A 4-year-old girl presents to the pediatric clinic with complaints of vaginal bleeding and a visible mass protruding from her vagina. On examination, a polypoid mass with a "grape-like" appearance is observed. A biopsy is taken, and immunohistochemical staining is positive for desmin. Which of the following will show as a biopsy finding? (Q845609)

A. Cells with small protrusions of cytoplasm from one end

B. Marked atypia of cells with numerous keratin pearls

C. Columnar mucinous epithelium

D. Fibrous stroma covered by mucus-secreting endocervical glands



Correct Answer: A. Cells with small protrusions of cytoplasm from one end

- *Listen (English)*
- *Listen (Hindi)*

Explanation: The clinical presentation and IHC findings suggest Sarcoma botryoides , a rare type of Embryonal rhabdomyosarcoma, characterised by polypoid,rounded, bulky masses that have the appearance and consistency of grapelike clusters, commonly found in infants and children younger than 5 years of age. Embryonal rhabdomyosarcoma: Embryonal: Very young children; Rhabdomyosarcoma: Skeletal muscle differentiation. Histologically characterised by cells with small and oval nuclei with small protrusions of cytoplasm resembling a tennis racket/strap (Strap cells/Tennis racket cells/ Tadpole cells) and rarely cytosolic striations (indicative of muscle differentiation) can be seen.

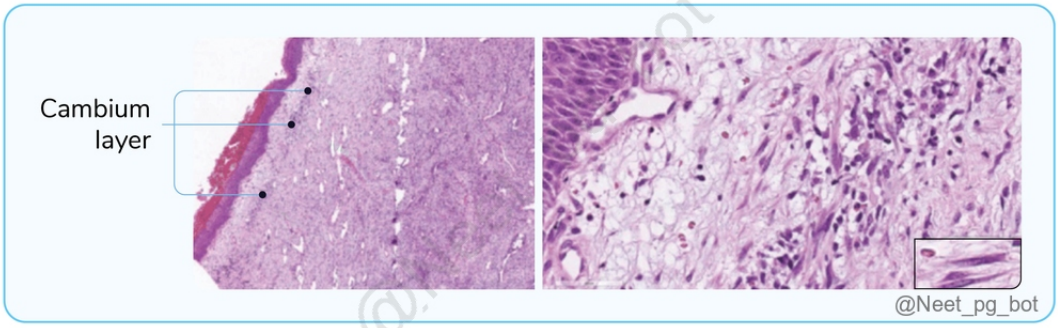

References:

Robbins and Cotran, Pathologic Basis of Disease, 10th Edition, Page 995

↑ *Back to this question in Part A*

@Neet_pg_bot

Q7: Which of the following is an advantage of liquid-based cytology (LBC) over the conventional Pap smear? (Q845610)

A. Cost-effective

B. More widely available in resource-limited settings

C. Adequacy of 8,000-12,000 epithelial cells

D. Allows simultaneous HPV testing

Correct Answer: D. Allows simultaneous HPV testing

■ *Listen (English)*

■ *Listen (Hindi)*

Explanation: Aspect Conventional Cervical Screening (Pap Smear) Liquid-Based Cytology (LBC) Sample Collection Cells are collected using a spatula or brush and smeared directly onto a glass slide. Cells are collected using a brush and then rinsed into a vial containing a preservative solution. Processing Time Typically longer due to manual preparation and staining. Faster automated processing and staining. Sensitivity and Specificity Lower sensitivity and specificity compared to LBC. Higher sensitivity and specificity for detecting abnormalities. Cost Generally lower cost. Higher cost due to specialized equipment and supplies. (Option A) Follow-up Testing Additional sample collection may be needed if the initial sample is inadequate. Usually provides enough samples for additional tests (e.g., HPV testing) without recollection. (Option D) Adequacy of cells 8000-12000 epithelial cells/ 10 hpf (Option C) 5000 epithelial cells/10 hpf Resource limited setting Available in resource-limited settings (Option B) Specialized equipment and infrastructure are needed

References:

Robbins and Cotran, Pathologic Basis of Disease, 10th Edition, Pages 1000,1001

https://www.ncbi.nlm.nih.gov/pmc/articles/PMC6022377/

↑ *Back to this question in Part A*

@Neet_pg_bot

Q8: A 45-year-old woman comes to the OPD for regular Pap smear screening. The smear suggests a low-grade squamous intraepithelial lesion. Which of the following abnormal cell types was most likely seen on the smear? {{caption_text}} (Q845611)

A. Doderlein cells

B. Hobnail cells

C. Arias-Stella reaction cells

D. Koilocytes

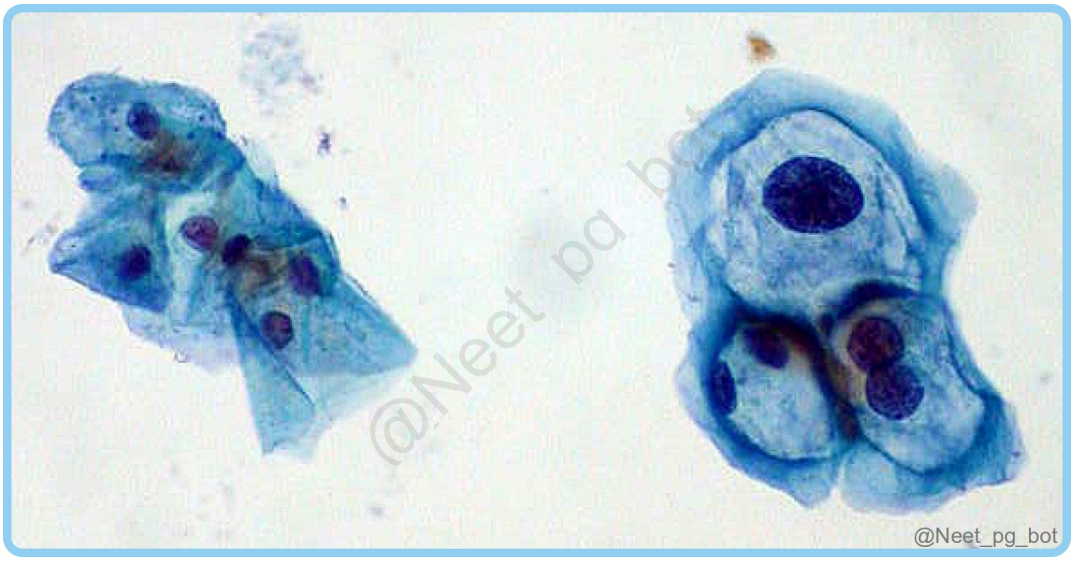

Correct Answer: D. Koilocytes

■ *Listen (English)*

■ *Listen (Hindi)*

Explanation: Koilocytes are abnormal cervical cells seen on pap smears, indicative of HPV infections of the cervix. They are squamous epithelial cells with nuclear enlargement, coarse chromatin, perinuclear cavitation, and irregular nuclear membranes. A rim of condensed cytoplasm often surrounds the perinuclear cavitation, giving the cell a "halo" appearance. Doderlein cells (Option A): Doderlein cells are large, glycogen-rich squamous epithelial cells in the vaginal epithelium, associated with Lactobacillus species. A reduction or absence of Doderlein cells can indicate pathological conditions such as bacterial vaginosis. Hobnail cells (Option B): Hobnail cells are found in clear cell carcinoma of the ovary. Arias-Stella reaction cells (Option C): Arias-Stella reaction cells are a type of glandular epithelial cell found in the endometrium during pregnancy, ectopic pregnancy, or pathological conditions like gestational trophoblastic disease.

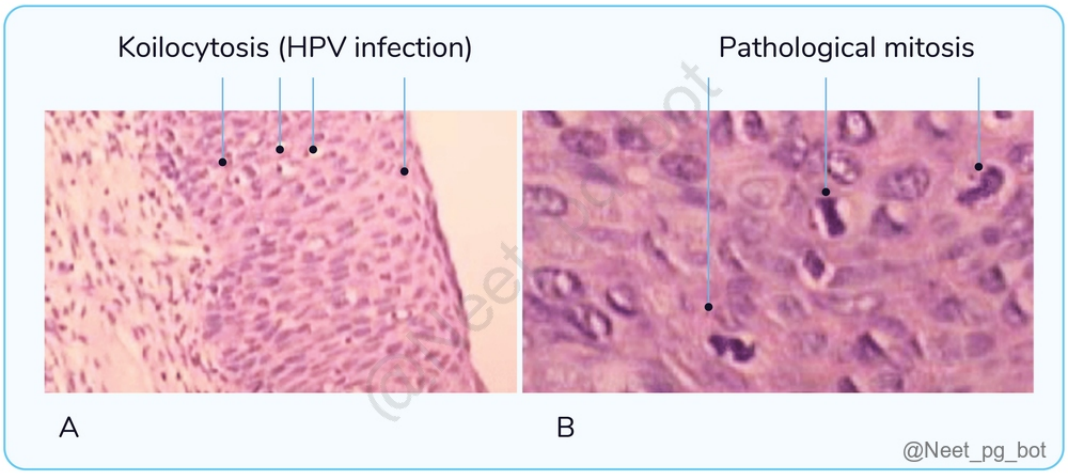

References:

Robbins and Cotran, Pathologic Basis of Disease, 10th Edition, Pages 996-997

↑ *Back to this question in Part A*

@Neet_pg_bot

Q9: Which of the following risk factors is not typically associated with cervical cancer? (Q845612)

A. Smoking

B. Multiple sexual partners

C. Oral contraceptive pill use

D. Nulliparity

Correct Answer: D. Nulliparity

■ *Listen (English)*

■ *Listen (Hindi)*

Explanation: Nulliparity is not a risk factor for cervical cancer. Multiparity is a risk factor for cervical cancer. Nulliparity is a risk factor for breast and ovarian cancer. Risk factors for cervical cancer include: Human papillomavirus (HPV) infection, particularly High-risk HPVs, is the most important factor in the development of cervical cancer Multiple sexual partners (Option B) or early sexual activity Smoking (Option A) Weak immune system Long-term use of oral contraceptives (OCP) (Option C) High parity Lack of regular cervical screening (Pap tests) Family history of cervical cancer Socioeconomic factors

References:

Robbins and Cotran, Pathologic Basis of Disease, 10th Edition, Page 996

https://www.ncbi.nlm.nih.gov/books/NBK431093/

↑ *Back to this question in Part A*

@Neet_pg_bot

Q10: A 32-year-old woman undergoes a routine gynecological examination. Abnormalities are detected on her pap smear, and colposcopy-guided biopsy reveals dysplastic changes involving two-thirds of the cervical epithelium. What is the most likely diagnosis? {{caption_text}} (Q845613)

A. Cervical intraepithelial neoplasia 1

B. Cervical intraepithelial neoplasia 2

C. Cervical intraepithelial neoplasia 3

D. Invasive cervical carcinoma

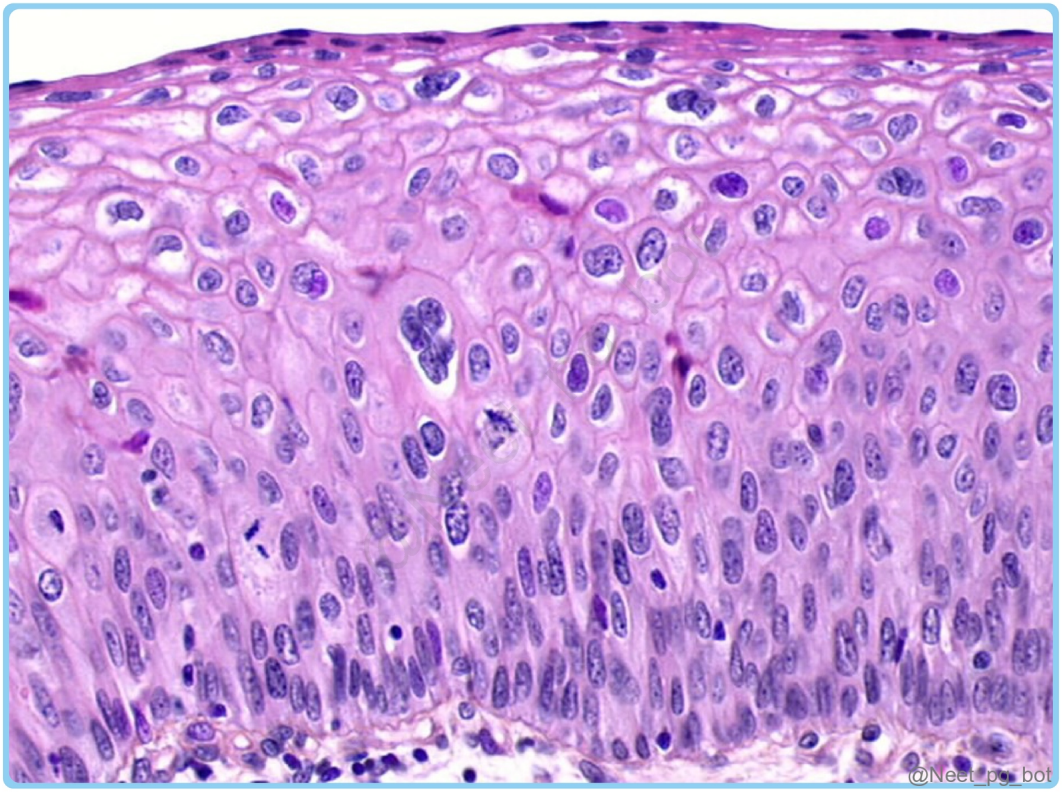

Correct Answer: B. Cervical intraepithelial neoplasia 2

■ *Listen (English)*

■ *Listen (Hindi)*

Explanation: Grade HPE Features CIN 1 Low-grade squamous intraepithelial lesion of cervical intraepithelial neoplasia with koilocytic atypia showing atypical cells in the lower 1/3rd of the epithelium . CIN 2 {{caption_text}} High-grade squamous intraepithelial lesion (HSIL) with progressive atypia and expansion of the immature basal cells in the lower 2/3rd of the epithelial thickness CIN 3 HSIL with diffuse atypia, loss of maturation, and expansion of the immature basal cells to almost the entire length of the epithelial surface. Carcinoma in situ (CIS): The entire thickness of the cervical surface lining is made up of abnormal, dysplastic cells, but these cells have not yet spread or invaded deeper tissues. Invasive cervical carcinoma (Option D): Invasive cervical carcinoma presents with invasion beyond the basement membrane of the cervical epithelium.

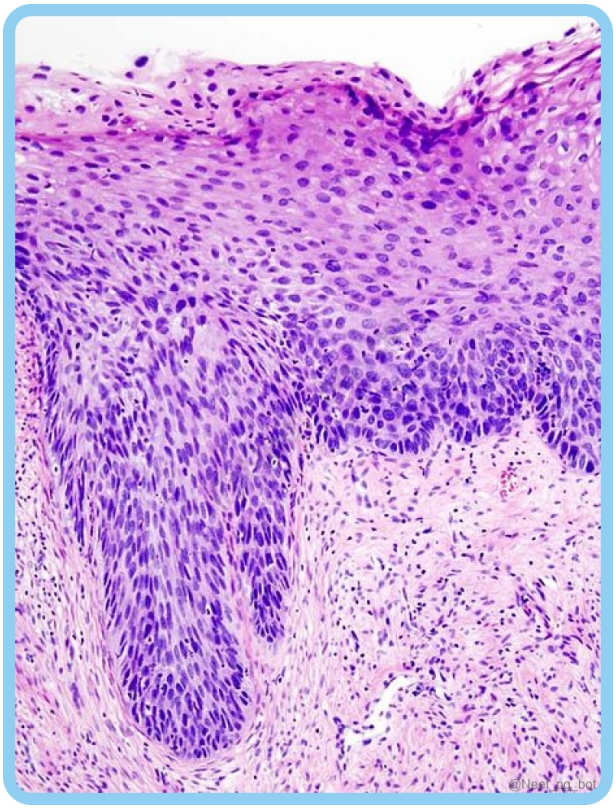

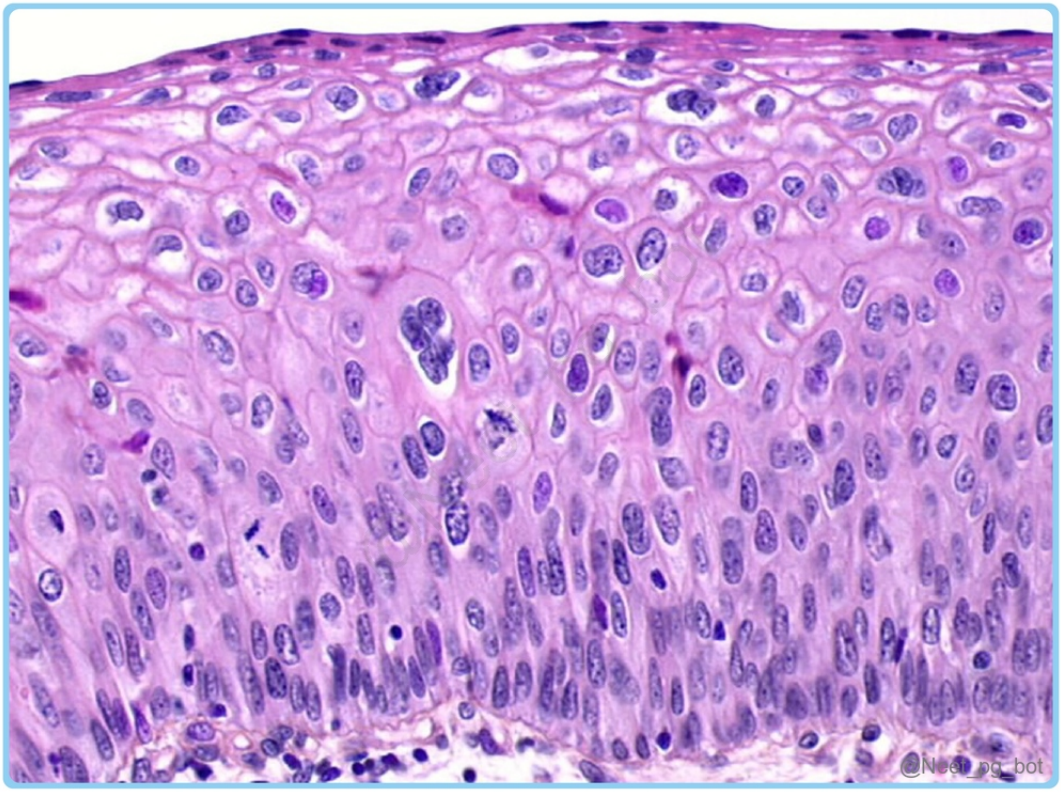

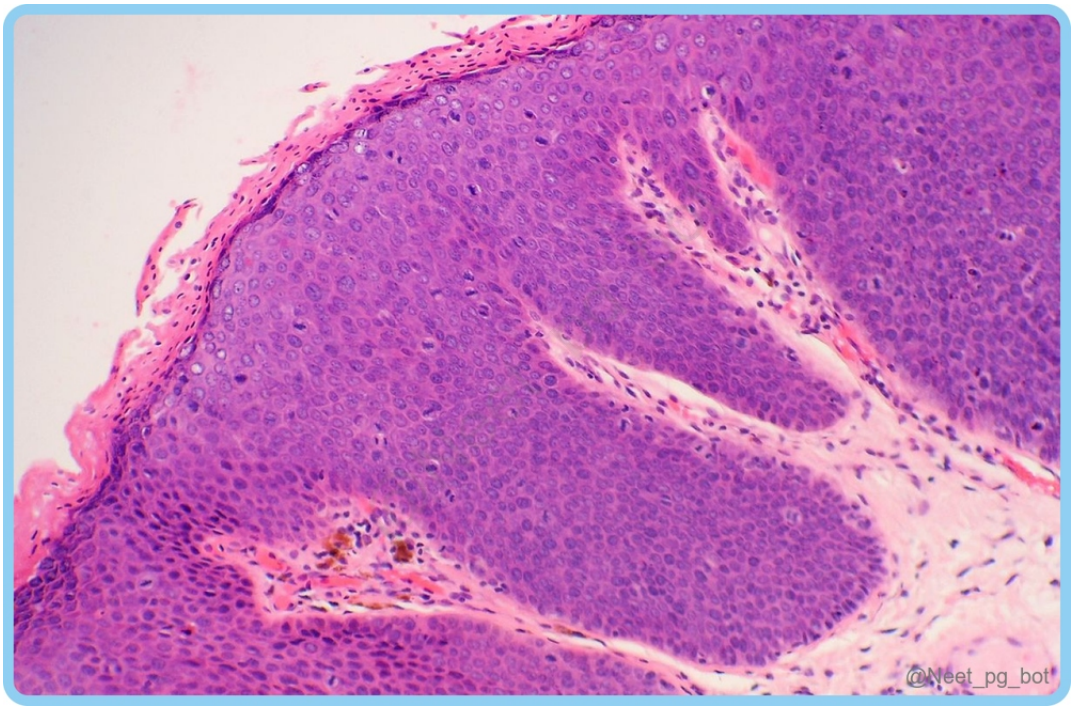

References:

Robbins and Cotran, Pathologic Basis of Disease, 10th Edition, Page 998

↑ *Back to this question in Part A*

@Neet_pg_bot

Q11: Which of the following statements is true regarding the squamous cell carcinoma of the cervix? HPV types 16 and 18 are the most common HPV types identified in invasive cervical cancer. The most common site of metastasis is the lungs. E6 protein interferes with the activity of the tumor suppressor proteins p53. Squamous cell carcinoma is the most common histologic subtype. (Q845614)

A. 1,2,3,4

B. 1,2,3

C. 1,3,4

D. Only 1

Correct Answer: A. 1,2,3,4

■ *Listen (English)*

■ *Listen (Hindi)*

Explanation: Cervical Carcinoma: Squamous cell carcinoma (80%) and adenocarcinoma (15%) are the main cervical cancer subtypes caused by high-risk HPVs (HPV16 and 18). HPV's E6 and E7 proteins disrupt p53 and Rb tumor suppressors, respectively. Lung metastasis is common and indicates poor prognosis. Squamous cell carcinoma is the most common histologic subtype. Squamous cell carcinoma:

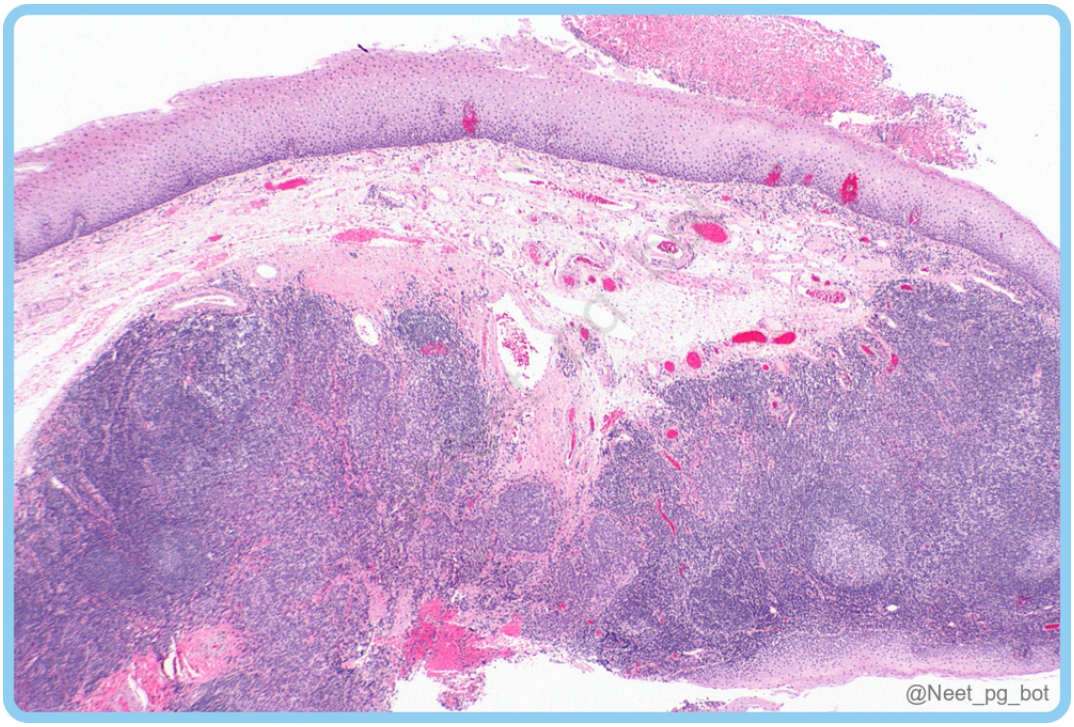

References:

Robbins and Cotran, Pathologic Basis of Disease, 10th Edition, Page 998-1000

https://www.ncbi.nlm.nih.gov/pmc/articles/PMC7414489/

↑ *Back to this question in Part A*

@Neet_pg_bot

Q12: Which of the following is most likely associated with basaloid vulvar carcinomas? (Q846624)

A. Not associated with HPV

B. Arise from differentiated vulvar intraepithelial neoplasia

C. Keratinising morphology

D. High-risk HPV

Correct Answer: D. High-risk HPV

Explanation: The given clinical presentation and biopsy findings suggest Basaloid or warty carcinoma of the vulva, which is highly associated with high-risk HPV, most commonly HPV-16. Types of Vulval Carcinoma: Features Basaloid or Warty carcinoma Keratinising Squamous cell carcinoma Prevalence Less common (30% of cases) More common (70% of cases) HPV association Related to high-risk HPVs, most commonly HPV-16. (Option D) Unrelated to HPV infection. (Option A) Precursor lesion Develop from classic vulvar intraepithelial neoplasia (VIN) Arise from differentiated vulvar intraepithelial neoplasia (differentiated VIN) (Option B) Histological features Basaloid and warty morphology Keratinizing morphology (Option C) Other features No association with lichen sclerosis Often associated with long-standing lichen sclerosis or squamous cell hyperplasia and TP53 mutations.

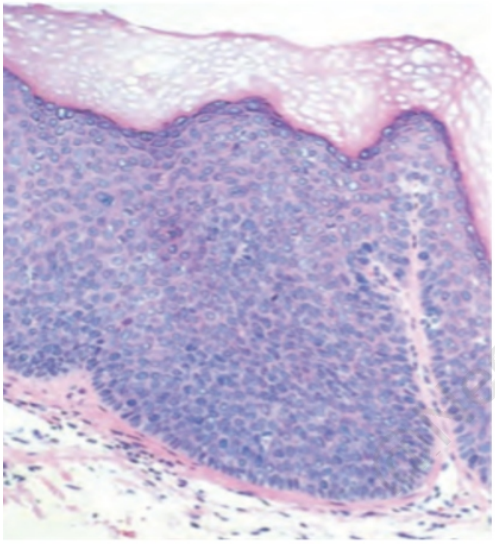

Classic vulvar intraepithelial neoplasia (HPV positive)

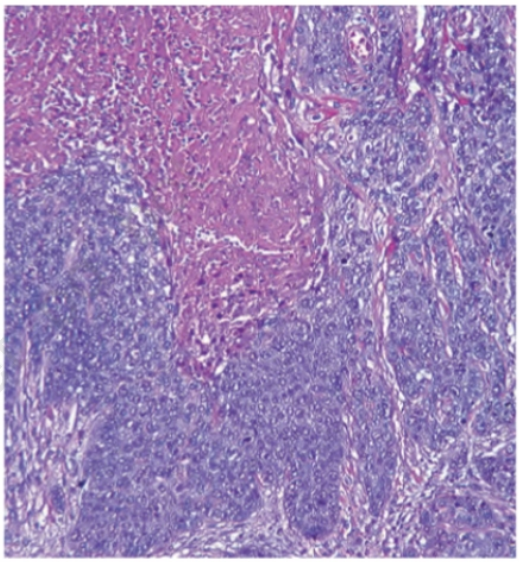

Basaloid vulvar carcinoma with foci of necrosis (red) (HPV positive)

@Neet_pg_bot

A

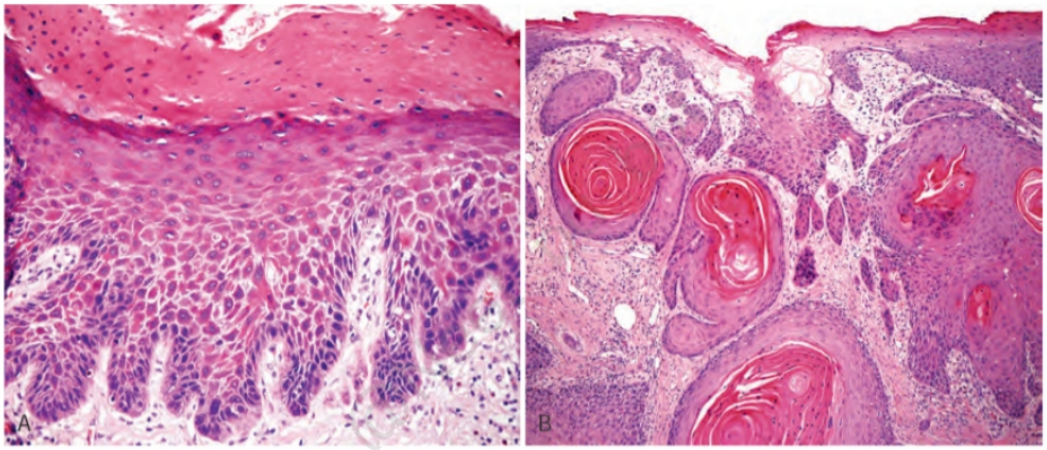

Differentiated vulvar intraepithelial neoplasia (HPV negative)

Keratinizing squamous cell carcinoma of the vulva (HPV negative)

@Neet_pg_bot

References:

Robbins and Cotran, Pathologic Basis of Disease, 10th Edition, Pages 991- 993

↑ *Back to this question in Part A*

@Neet_pg_bot

• [12_Genital System] 054 Pathology Of Female Genital Tract-Ii

« Back to Folder Directory

[12_Genital System] 054 Pathology Of Female Genital Tract-Ii — Quick Jump

Q1 (p. 2276) *Q2 (p. 2278)* *Q3 (p. 2279)* *Q4 (p. 2280)* *Q5 (p. 2283)* *Q6 (p. 2284)*
Q7 (p. 2286) *Q8 (p. 2287)* *Q9 (p. 2289)* *Q10 (p. 2290)* *Q11 (p. 2294)* *Q12 (p. 2296)*
Q13 (p. 2297) *Q14 (p. 2300)* *Q15 (p. 2301)* *Q16 (p. 2303)* *Q17 (p. 2305)* *Q18 (p. 2305)*
Q19 (p. 2306) *Q20 (p. 2307)*

Q1: A 52-year-old woman presents with abdominal bloating, discomfort, and increased abdominal girth. Ascites and a palpable pelvic mass are noted on examination. Histopathological examination shows papillary structures with atypical epithelial cells containing psammoma bodies and elevated CA-125 levels. What is the likely diagnosis? {{caption_text}} (Q845717)

A. Mucinous cystadenocarcinoma

B. Endometrioid carcinoma

C. Serous cystadenocarcinoma

D. Clear cell carcinoma

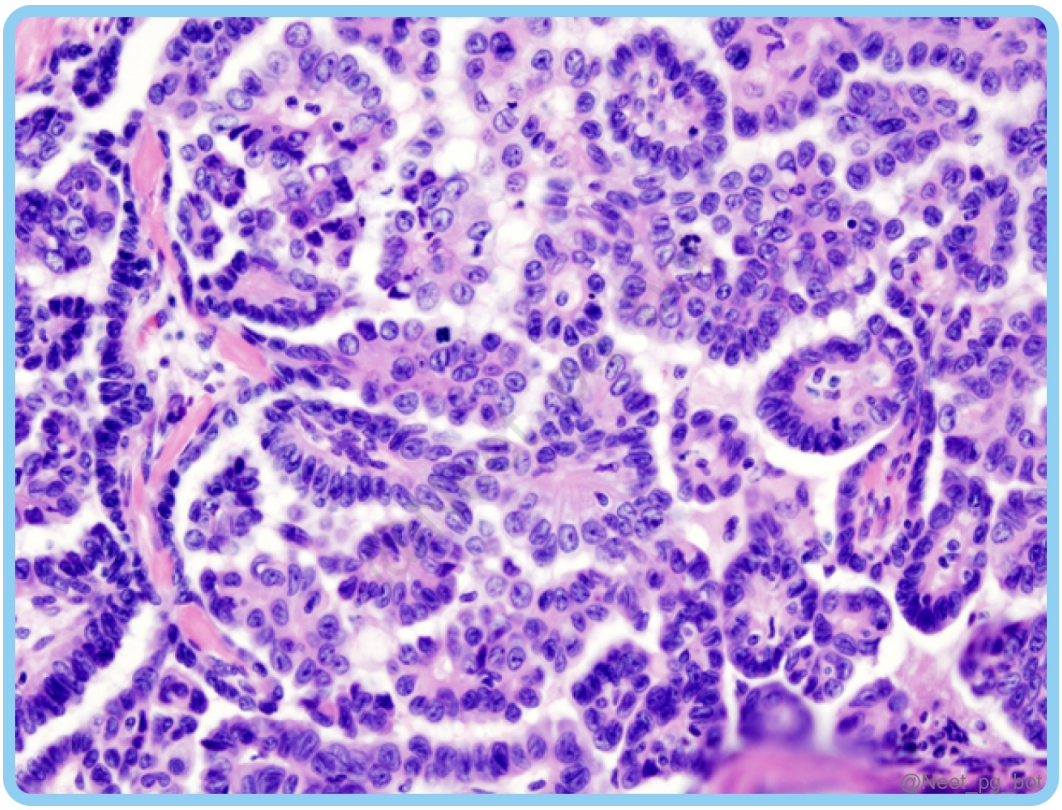

Correct Answer: C. Serous cystadenocarcinoma

- *Listen (English)*
- *Listen (Hindi)*

Explanation: The given clinical presentation and histopathological findings point towards diagnosing Serous cystadenocarcinoma of the ovary, characterised by complex papillary structures, psammoma bodies, and atypical epithelial cells with evidence of stromal invasion. Psammoma bodies in the ovaries are always suggestive of serous ovarian tumors and the tumor marker is CA-125. Serous ovarian tumors can be benign or malignant (Serous cystadenocarcinoma) Gross morphology shows larger areas of solid or papillary growth, irregularity, and capsule nodularity. {{caption_text}}

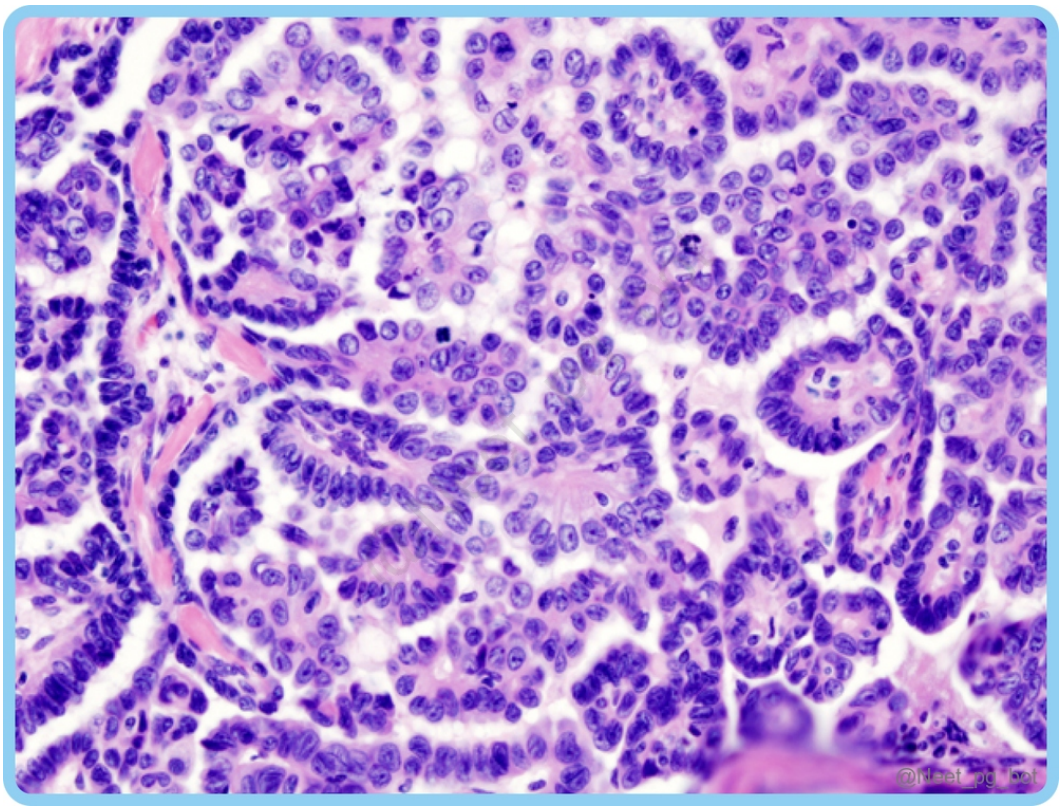

References:

Robbins and Cotran, Pathologic Basis of Disease, 10th Edition, Page 1019

↑ *Back to this question in Part A*

@Neet_pg_bot

Q2: What is the extent of nonsquamous growth present in Grade 2 endometrial carcinoma? (Q846626)

A. 5% or less nonsquamous solid growth pattern

B. 6 - 50% nonsquamous solid growth pattern

C. > 50% nonsquamous solid growth pattern

D. >75% nonsquamous solid growth pattern

Correct Answer: B. 6 - 50% nonsquamous solid growth pattern

■ *Listen (English)*

■ *Listen (Hindi)*

Explanation: FIGO Grading of endometrial carcinoma Grade 1 5% or less nonsquamous solid growth pattern (well-differentiated) with preserved glandular architecture (Option A) Grade 2 6 - 50% nonsquamous solid growth pattern (moderately differentiated) (Option B) Grade 3 > 50% nonsquamous solid growth pattern (poorly differentiated) (Option C)

References:

Robbin's Pathology, 10th edition, pg 1010-1012

https://www.pathologyoutlines.com/topic/uterusendometrioid.html

↑ *Back to this question in Part A*

@Neet_pg_bot

Q3: A 32-year-old woman presents with irregular vaginal bleeding and passage of grape-like clusters at ten weeks of gestation. Ultrasound reveals a heterogeneous pattern with fetal parts. On histopathology, some villi appear enlarged, and there is a presence of fetal tissue admixed with abnormal placental tissue. Which of the following is true regarding this condition? (Q846625)

A. High risk of invasive mole

B. Resulting from androgenetic fertilisation

C. Immunostaining for p57 is negative

D. High risk of malignancy

Correct Answer: A. High risk of invasive mole

■ *Listen (English)*

■ *Listen (Hindi)*

Explanation: This clinical scenario strongly suggests a diagnosis of partial mole, commonly associated with a high risk of invasive mole. A partial mole has bot villi and fetal components, while a complete mole shows only molar villi with no fetal component present. The villi from a partial mole can invade into the myometrium, leading to a condition known as an invasive mole. This feature can be seen in association with a partial hydatidiform mole. Resulting from androgenetic fertilisation (Option B): A partial mole occurs when an ovum is fertilized by more than one sperm, resulting in a triploid or sometimes tetraploid conceptus, depending on the number of sperms involved. Therefore, it is not an example of androgenetic fertilization. Androgenetic fertilization, on the other hand, is seen in a complete mole. In this situation, the ovum is empty and has lost all of its DNA material, leaving it without chromosomes. When such an empty ovum is fertilized by a sperm carrying 23 chromosomes, the product cannot survive with just 23. Therefore, the sperm replicates its chromosomal material to make it diploid (46), which is the characteristic mechanism of a complete mole. Immunostaining for p57 is negative (Option C): Partial mole shows P57 Positivity. High risk of malignancy (Option D): Complete mole has a higher risk of

malignancy, not partial mole.

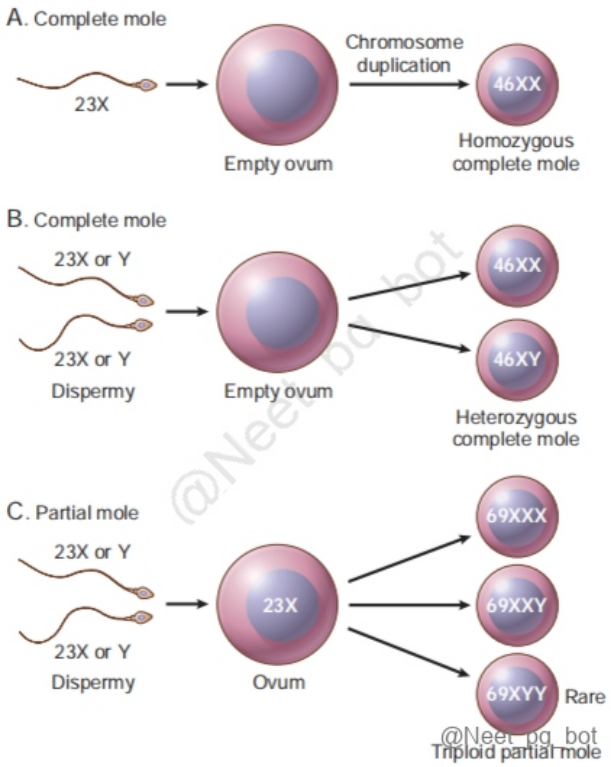

References:

Robbin's Pathology, 10th edition, pg 1033, 1034

↑ *Back to this question in Part A*

@Neet_pg_bot

Q4: A 29-year-old woman at 11 weeks of gestation presents with vaginal bleeding and passage of grape-like clusters. Ultrasound shows a "snowstorm" appearance without fetal parts. On histopathology, most villi are enlarged with central cistern formation and the absence of fetal tissue. Which of the following is characteristic of this condition? (Q845739)

A. Presence of fetal tissue and partially developed placenta

B. Diploid karyotype, typically 46, XX or 46, XY, with no fetal tissue

C. Triploid karyotype, typically 69, XXX or 69, XXY, with some fetal tissue

D. Normal-sized chorionic villi with no trophoblastic proliferation

Correct Answer: B. Diploid karyotype, typically 46, XX or 46, XY, with no fetal tissue

■ *Listen (English)*

■ *Listen (Hindi)*

Explanation: Clinical scenario points to a diagnosis of a complete mole based on the combination of vaginal bleeding, "snowstorm" appearance on ultrasound, absence of fetal tissue, and histopathology showing diffuse trophoblastic proliferation with hydropic villi . A complete mole forms when the ovum loses all its DNA material and has no chromosomes. When such an ovum is fertilized by a sperm carrying 23 chromosomes, the sperm duplicates its genetic material to restore diploidy. As a result, the karyotype of a complete mole is diploid, with 46 chromosomes. (46, XX or 46, XY). Features of complete mole: It has a diploid karyotype . It is only going to have the villi and the mole components. It does not have any fetal part but exhibit extensive trophoblastic proliferation (Diffuse and circumferential). {{caption_text}} {{caption_text}} {{caption_text}}



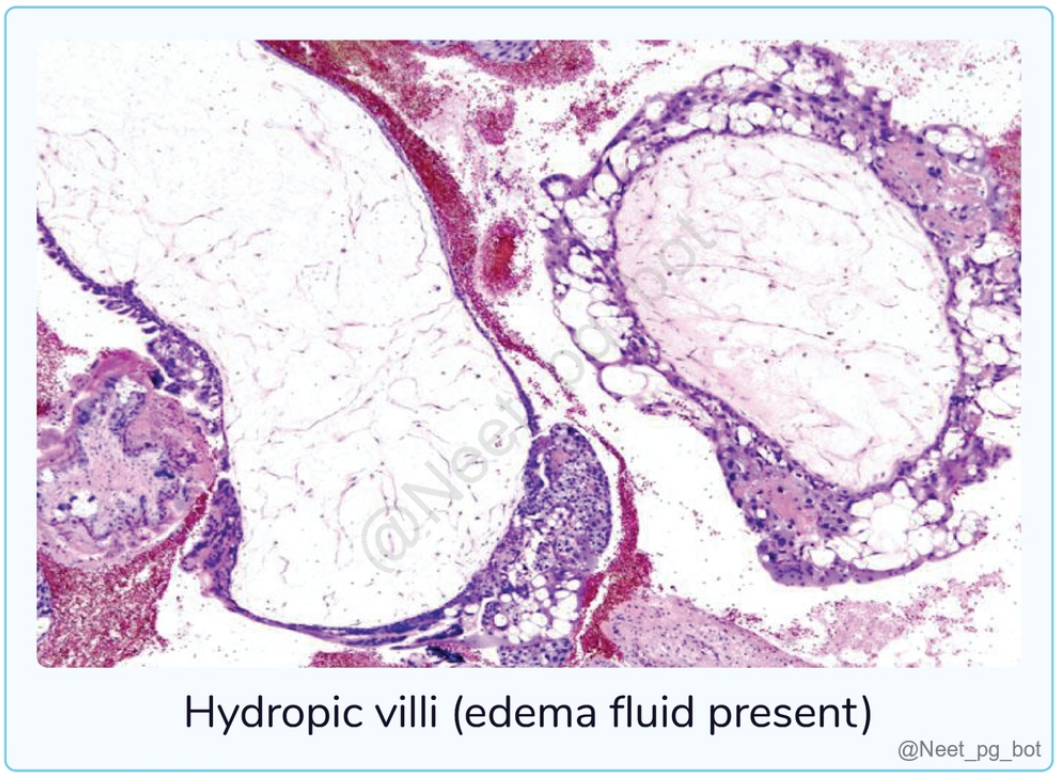

Hydropic villi (edema fluid present)

@Neet_pg_bot

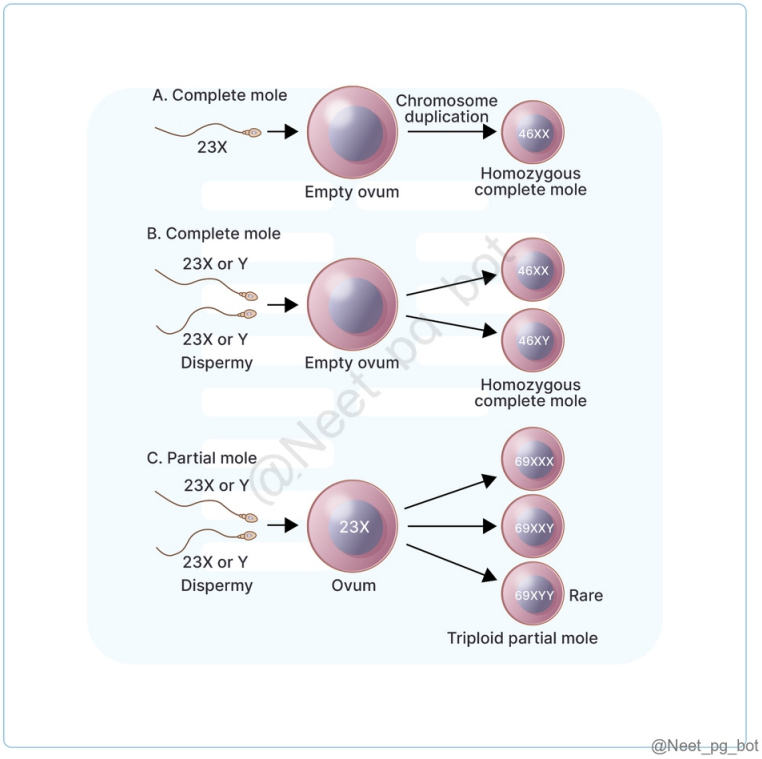

@Neet_pg_bot

References:

Robbins and Cotran, Pathologic Basis of Disease, 10th Edition, Page 1033, 1034

↑ *Back to this question in Part A*

@Neet_pg_bot

Q5: A 58-year-old postmenopausal woman presents with progressive abdominal distension, shortness of breath, and pelvic pain. Physical examination reveals ascites and a right-sided pleural effusion. Imaging reveals a solid ovarian mass. A biopsy of the mass shows benign ovarian fibroma. Which of the following is the most likely diagnosis? (Q845737)

A. Meigs syndrome

B. Pseudo Meigs syndrome

C. Fitz-Hugh-Curtis syndrome

D. Mayer-Rokitansky-Küster-Hauser syndrome

Correct Answer: A. Meigs syndrome

■ *Listen (English)*

■ *Listen (Hindi)*

Explanation: Meigs syndrome is characterised by the triad of a benign ovarian fibroma , ascites , and pleural effusion/hydrothorax (commonly right-sided). Features of Meigs syndrome: In pelvis: Ovarian fibroma In abdomen: Ascites In chest or mediastinum: Pleural effusion or hydrothorax (commonly right-sided) Pseudo Meigs syndrome (Option B): Pseudo-Meigs syndrome is characterised by the triad of ascites, pleural effusion , and pelvic mass other than an ovarian tumor. Fitz-Hugh-Curtis syndrome (Option C): Fitz-Hugh-Curtis syndrome is a chronic manifestation of pelvic inflammatory disease (PID), characterised by inflammation of the liver capsule (perihepatitis) without the involvement of liver parenchyma. {{caption_text}} Mayer-Rokitansky-Küster-Hauser (MRKH) syndrome (Option D): MRKH syndrome is a congenital condition characterised by the failure of the development of mullerian ducts leading to the absence of the uterus,fallopian tube and upper part of the vagina in otherwise phenotypically normal females with normal ovarian function.

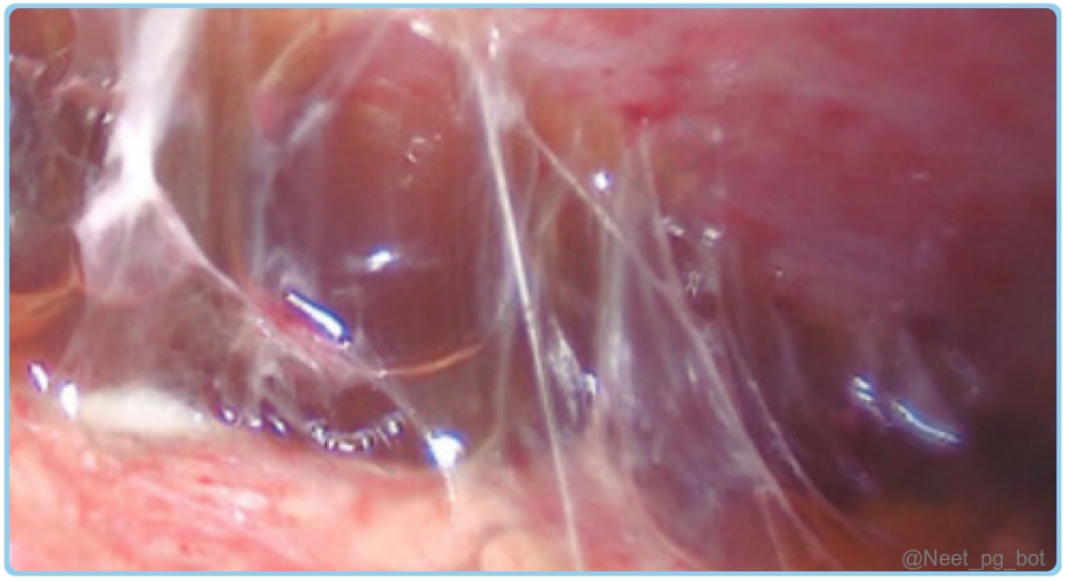

References:

Robbins and Cotran, Pathologic Basis of Disease, 10th Edition, Page 1027

https://www.ncbi.nlm.nih.gov/pmc/articles/PMC7489329/

↑ *Back to this question in Part A*

@Neet_pg_bot

Q6: Which of the following tumours is typically NOT associated with coffee bean nuclei? {{caption_text}} (Q845736)

A. Chondroblastoma

B. Granulosa cell tumour

C. Brenner tumour

D. Yolk sac tumour

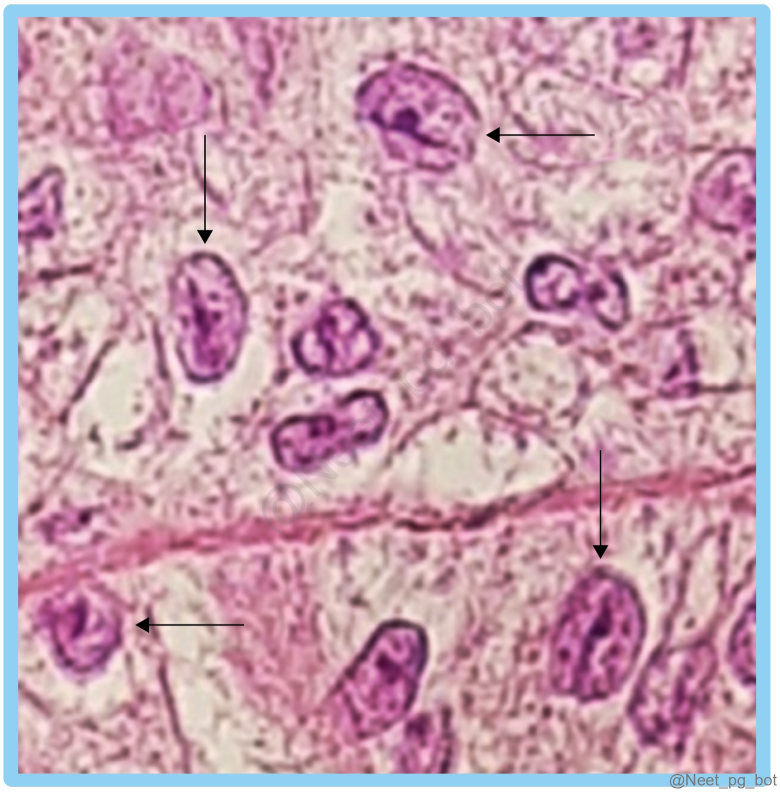

Correct Answer: D. Yolk sac tumour

- *Listen (English)*
- *Listen (Hindi)*

Explanation: Yolk sac tumor shows Schiller-Duval bodies and not coffee bean nuclei. Coffee bean nuclei are characterised by their distinctive longitudinal groove , seen in several tumours, including: Chondroblastoma: Bone tumour (Option A) Granulosa cell tumour: Ovarian tumour (Option B) Brenner tumour: Ovarian tumour (Option C) Langerhans cell histiocytosis: Skin tumour (LCH) Papillary carcinoma thyroid {{caption_text}}

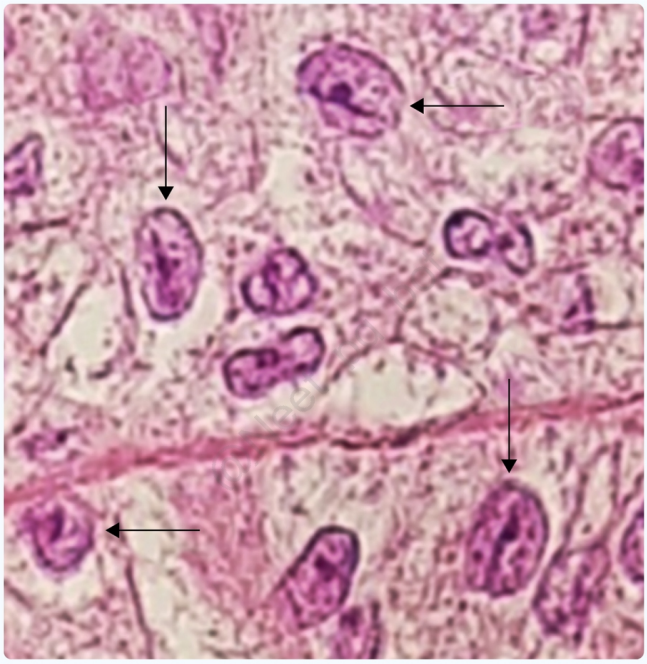

Coffee bean nuclei
(Longitudinal nuclear grooves)

@Neet_pg_bot

References:

Robbins and Cotran, Pathologic Basis of Disease, 10th Edition, Page 1025

↑ *Back to this question in Part A*

@Neet_pg_bot

Q7: A 55-year-old postmenopausal woman presents with abnormal uterine bleeding and a pelvic mass. An ultrasound reveals a solid ovarian mass. The mass is surgically removed, and the HPE shows small, follicle-like structures filled with eosinophilic material. Which histological feature is most likely associated with this ovarian tumour? (Q845732)

A. Spindle cells with lipid droplets

B. Call-Exner bodies

C. Reinke crystalloids

D. Signet ring cells

Correct Answer: B. Call-Exner bodies

■ *Listen (English)*

■ *Listen (Hindi)*

Explanation: The clinical presentation and histopathological findings are consistent with a Granulosa cell tumour , a sex cord-stromal tumour. Granulosa cell tumors are typically seen in postmenopausal women and secrete large amounts of estrogen, leading to a hyperestrogenic state. Increased estrogen levels cause endometrial hyperplasia, which leads to abnormal uterine bleeding. 2 microscopic features of Granulosa cell tumors: Call-Exner bodies: These are small, follicle-like structures filled with pinkish eosinophilic material in the lumen of the follicles. Coffee bean nuclei Tumor marker: Inhibin and CD99 positivity Spindle cells with lipid droplets (Option A): It descrives Fibrothecoma which is an ovarian tumor Reinke crystalloids (Option C): Seen in Leydig cell tumor. Signet ring cells (Option D): Seen in Krukenberg tumor. {{caption_text}}

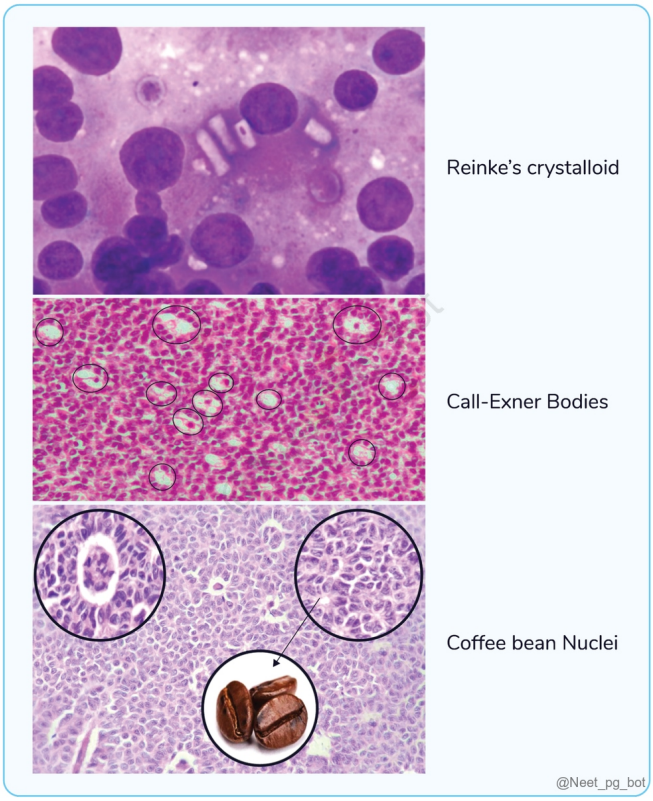

References:

Robbins and Cotran, Pathologic Basis of Disease, 10th Edition, Page 1026-1028

↑ *Back to this question in Part A*

@Neet_pg_bot

Q8: A 19-year-old woman presents with lower abdominal pain and a rapidly enlarging pelvic mass. Imaging reveals a solid and cystic ovarian tumour. A biopsy of the mass

shows immature neural elements and other embryonic-like tissues, indicating a high risk of malignancy. What is the most likely diagnosis? (Q845729)

A. Mature teratoma

B. Immature teratoma

C. Carcinoid tumour

D. Monodermal teratoma

Correct Answer: B. Immature teratoma

■ *Listen (English)*

■ *Listen (Hindi)*

Explanation: Types of Teratoma: Mature Teratoma (aka Dermoid cyst) : Benign ovarian tumour comprising tissues from all three germ layers. {{caption_text}} Immature Teratoma: Ovarian tumour with immature or embryonic-like tissues associated with an increased risk of malignancy. {{caption_text}} Monodermal Teratoma: Tumor primarily consists of a single tissue type, like thyroid tissue in struma ovarii or neuroendocrine cells in carcinoid tumours.



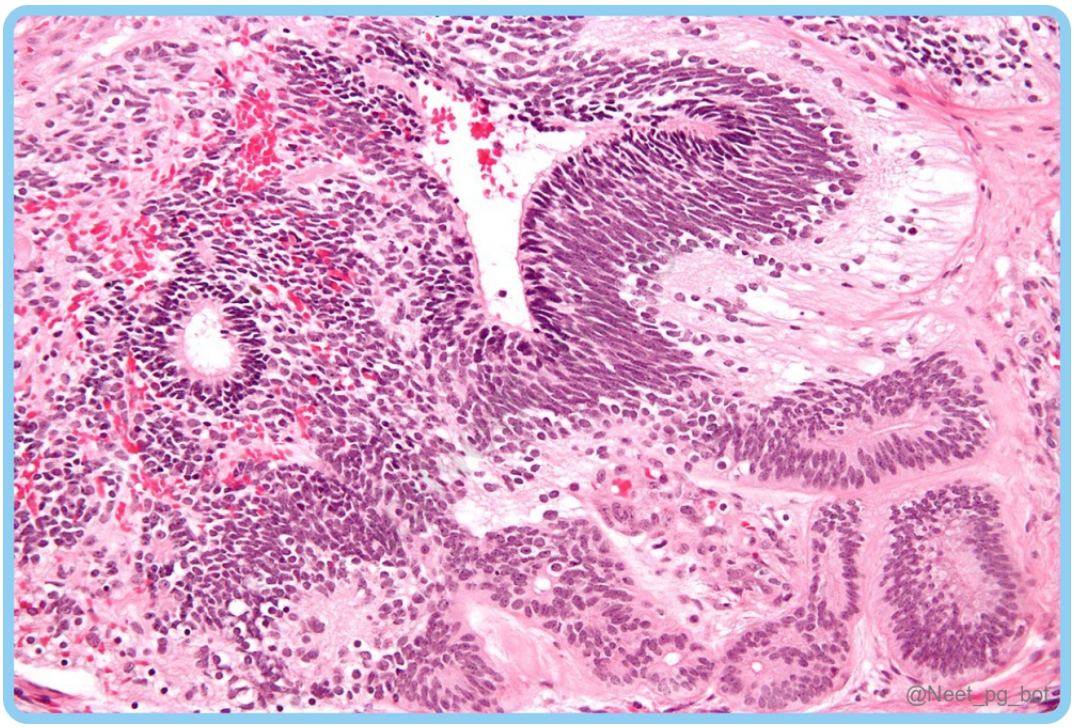

References:

Robbins and Cotran, Pathologic Basis of Disease, 10th Edition, Page 1025

↑ *Back to this question in Part A*

@Neet_pg_bot

Q9: A 28-year-old woman presents with severe vaginal bleeding and lower abdominal pain six months postpartum. USG reveals a heterogeneous uterine mass with haemorrhage and necrosis, raising suspicion of choriocarcinoma. What tumour marker is most likely elevated in her condition? (Q845724)

A. CA-125

B. LDH

C. AFP

D. HCG

Correct Answer: D. HCG

■ *Listen (English)*

■ *Listen (Hindi)*

Explanation: Choriocarcinoma is a gestational trophoblastic disease. Tumor Marker Associated Tumors AFP Yolk sac tumor (Option C) β-hCG Choriocarcinoma LDH and PLAP Dysgerminoma of ovary (Counterpart of Seminoma in testes) (Option B) CA-125 Surface epithelial tumours of ovary (e.g., Serous carcinoma) (Option A)

References:

Robbins and Cotran, Pathologic Basis of Disease, 10th Edition, Page 1024

↑ *Back to this question in Part A*

@Neet_pg_bot

Q10: A 16-year-old female presents with abdominal pain, distension, and a large pelvic mass accompanied by ascites. Elevated serum alpha-fetoprotein levels are detected. Surgical resection of the mass reveals histopathological findings depicted in the image. What is the probable diagnosis? {{caption_text}} (Q845718)

A. Endodermal sinus tumor

B. Dysgerminoma

C. Choriocarcinoma

D. Teratoma

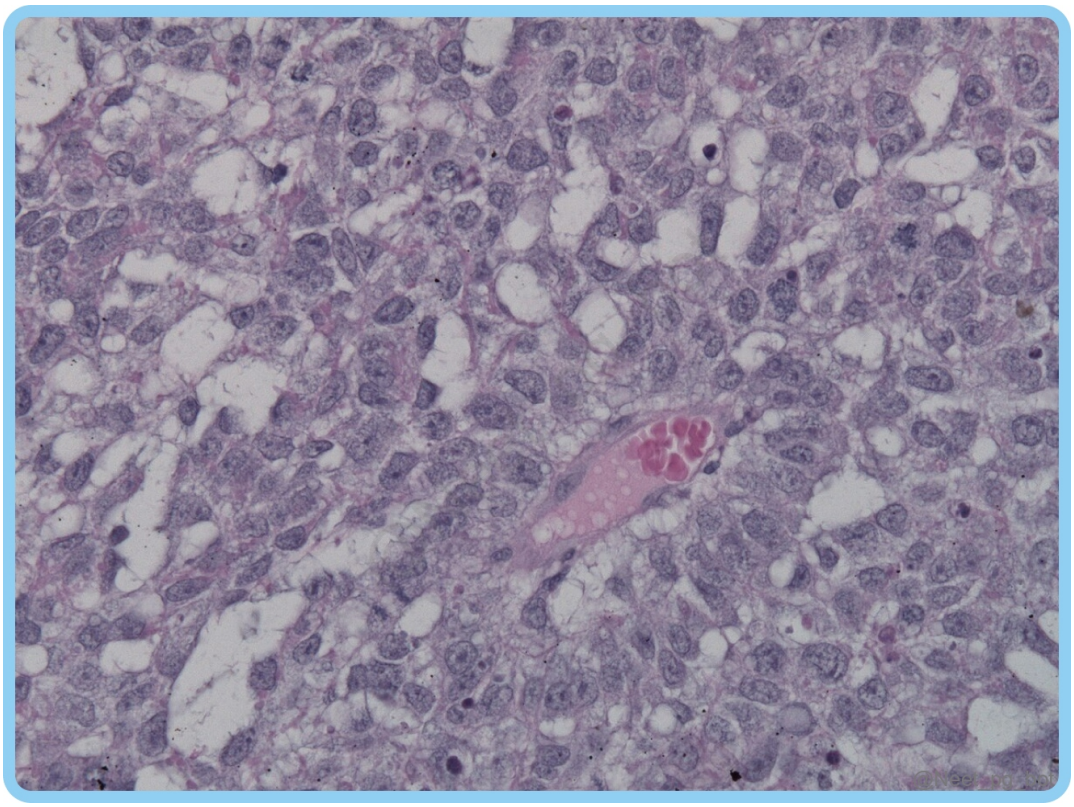

Correct Answer: A. Endodermal sinus tumor

- *Listen (English)*
- *Listen (Hindi)*

Explanation: Given clinical presentation of 16 year old female with abdominal pain and ascites along with elevated serum AFP and HPE showing shiller duval bodies points towards Endodermal sinus tumor/Yolk sac tumor . Shiller duval bodies: It is characterized by a central blood vessel surrounded by a row of tumor cells, a clear space, and another outer row of tumor cells. Classification of Germ cell tumours: Tumour type Histological feature Endodermal Sinus Tumour Presence of Schiller-Duval bodies. {{caption_text}} Dysgerminoma ‘Fried egg appearance’ (large cells with clear cytoplasm and central nuclei). Lymphocytic infiltration in the fibrous septa. {{caption_text}} Choriocarcinoma Consists of cytotrophoblasts and syncytiotrophoblasts. It may show haemorrhage and necrosis. {{caption_text}} Teratoma They comprise tissues from all three germ cell layers (ectoderm, mesoderm, and endoderm), such as skin, hair,teeth, and neural tissue. {{caption_text}}

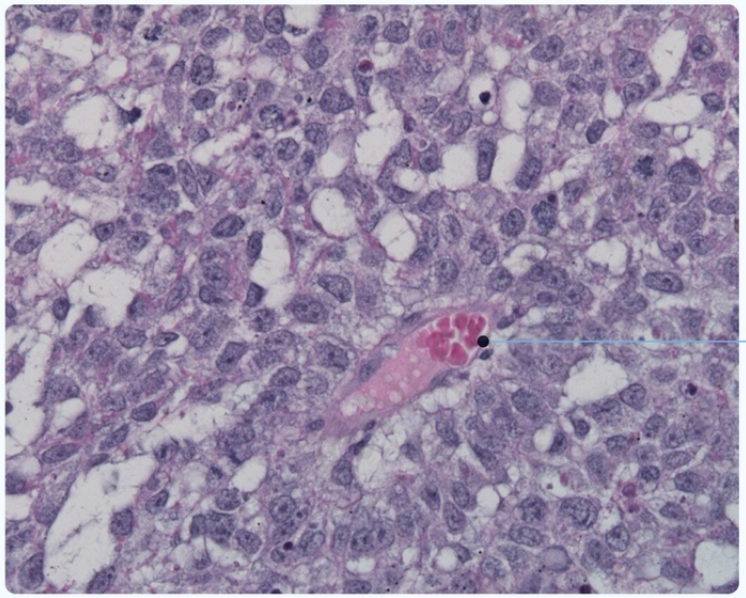

@Neet_pg_bot

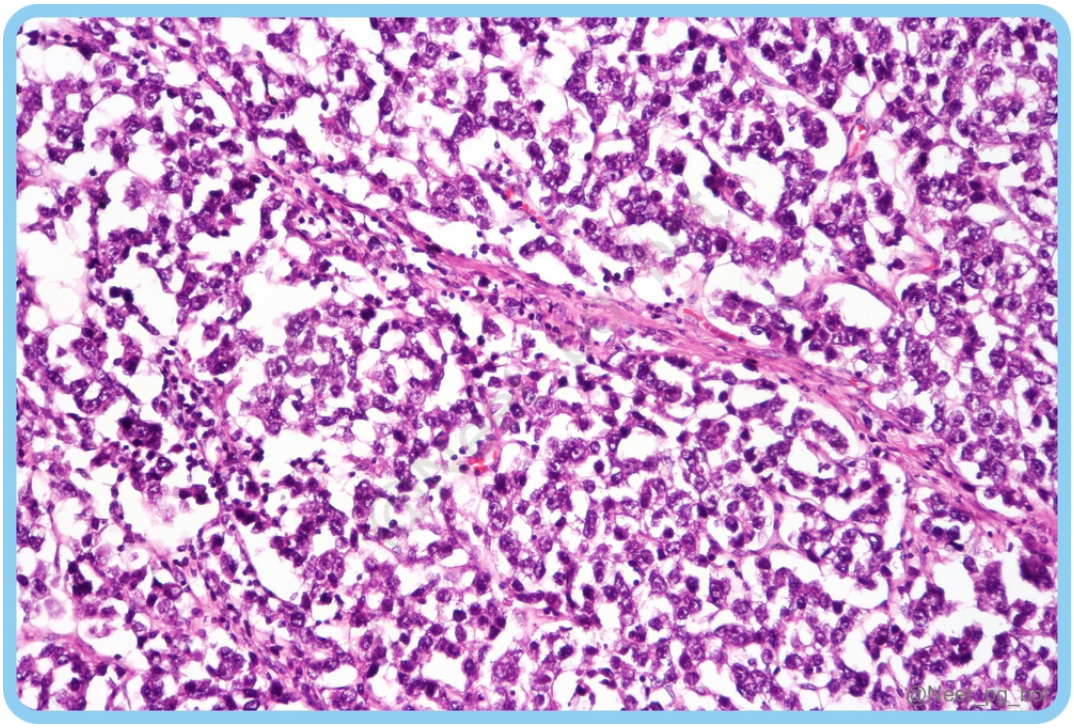

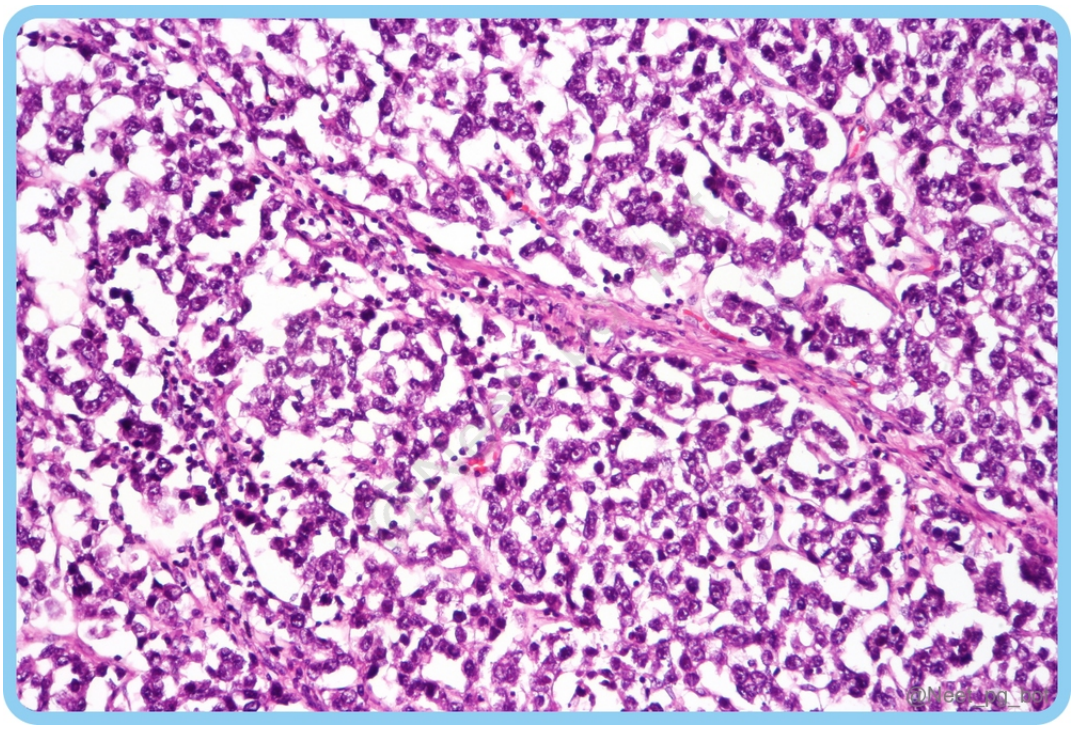



References:

Robbins and Cotran, Pathologic Basis of Disease, 10th Edition, Page 1025

↑ *Back to this question in Part A*

Q11: A 34-year-old woman with irregular menstrual cycles and difficulty conceiving undergoes an endometrial biopsy. HPE reveals glands with tall columnar epithelial cells with subnuclear vacuoles. Which phase of the endometrial cycle is most likely being discussed here? (Q845664)

A. Proliferative phase

B. Early secretory phase

C. Late secretory phase

D. Menstrual phase

Correct Answer: B. Early secretory phase

■ *Listen (English)*

■ *Listen (Hindi)*

Explanation: Phase Day Morphological changes Proliferative phase (Option A) Day 5-14 The rapid growth of glands and stroma from the basalis layer and tall columnar cells with numerous mitotic figures are seen. Absence of mucus secretion or vacuolation. Stroma is composed of spindle cells with minimal cytoplasm. {{caption_text}} Ovulatory phase Day 14 Mature follicle rupture and releases oocyte. Watery mucus is produced in the cervix, which facilitates sperm passage Secretory phase Day 14-28 Early secretory phase: Presence of subnuclear vacuolation in the glandular epithelium. (Option B) {{caption_text}} Late secretory phase: Basal vacuoles gradually move to the apical surface (supranuclear vacuolation) and are shed off later. Glands become tortuous. (Serrated or Sawtooth appearance) Stromal changes include stromal cell hypertrophy infiltration of neutrophils and lymphocytes. (Option C) {{caption_text}} Menstrual phase Day 1-5 Breakdown of the corpus luteum and the subsequent drop in progesterone levels. The functional layer of the endometrium breaks down, leading to bleeding within the stroma and the start of the next menstrual cycle. (Option D)

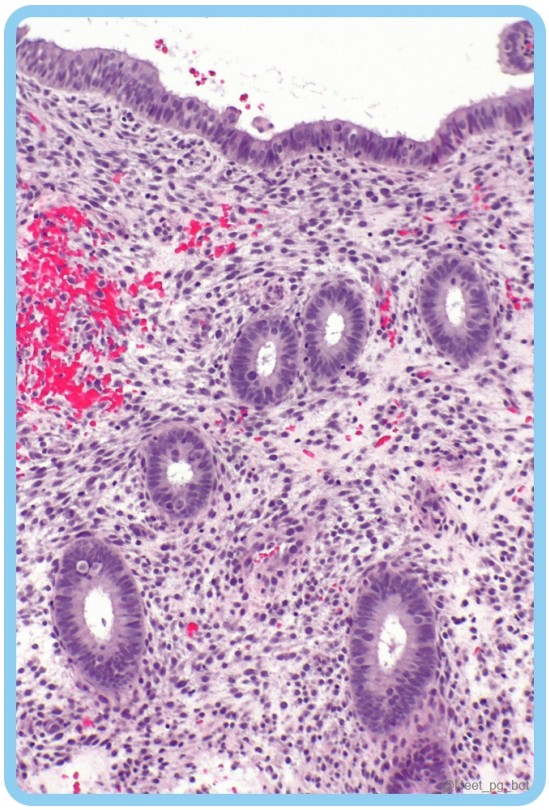
@Neet_pg_bot

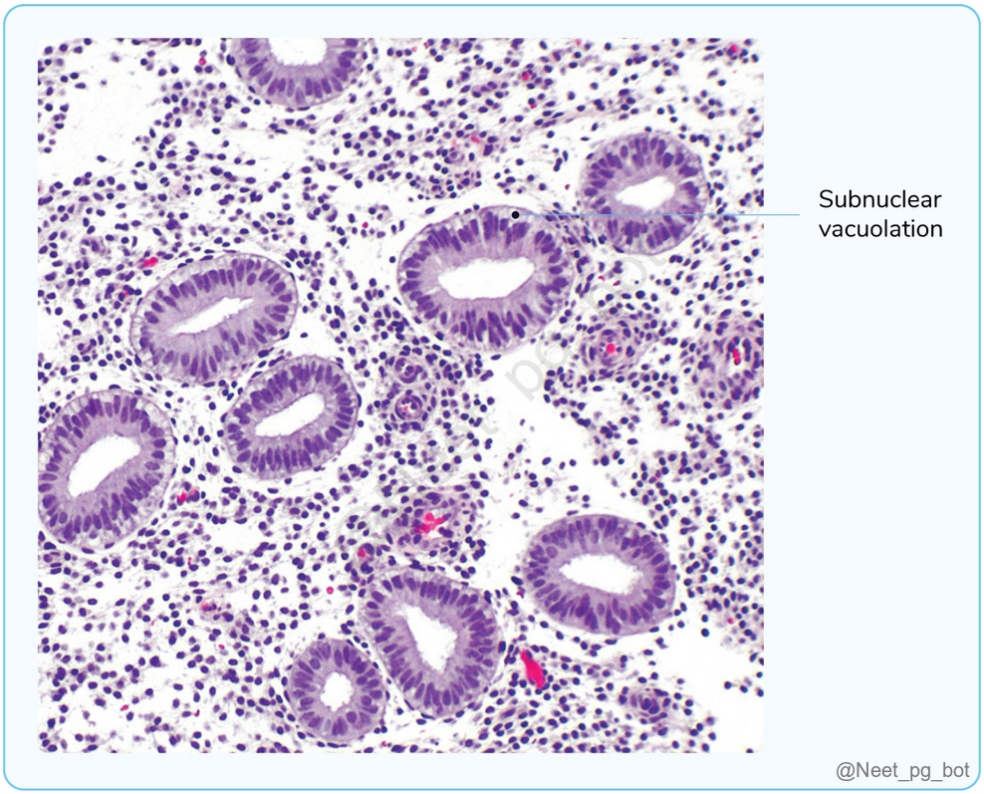
Subnuclear
vacuolation
@Neet_pg_bot

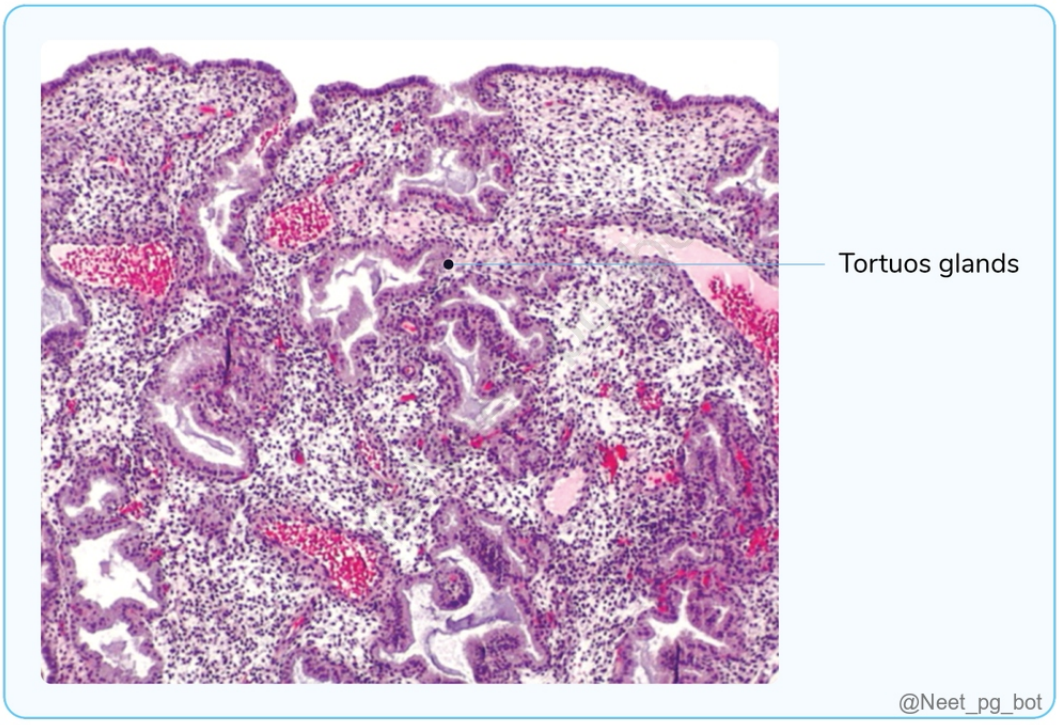

References:

Robbins and Cotran, Pathologic Basis of Disease, 10th Edition, Page 1001-1002

https://www.ncbi.nlm.nih.gov/books/NBK500020/

↑ *Back to this question in Part A*

@Neet_pg_bot

Q12: Match the following. Tumors Genetic Mutation a) Serous tumors 1) PIK3CA b) Mucinous tumors 2) KRAS proto-oncogene c) Endometrioid carcinomas 3) PTEN d) Clear cell carcinomas 4) BRCA1 and BRCA2 (Q845715)

A. a-4,b-1,c-2,d-3

B. a-4,b-2,c-3,d-1

C. a-3,b-4,c-1,d-2

D. a-2,b-1,c-3,d-4

Correct Answer: B. a-4,b-2,c-3,d-1

■ *Listen (English)*

■ *Listen (Hindi)*

Explanation: Surface Epithelial Tumor of Ovary Genetic association Serous tumours Mutations in BRCA1 and BRCA2 Mucinous tumours Mutations in KRAS Endometrioid carcinomas Mutations in PTEN gene on chromosome 10. In endometrium and uterus, PTEN gene mutation causes endometria hyperplasia and endometrial carcinoma. In ovary, PTEN gene mutation causes endometriod type ovarian cancers. Clear cell carcinomas Mutations in PIK3CA Types of Ovarian tumours based on origin: {{caption_text}}

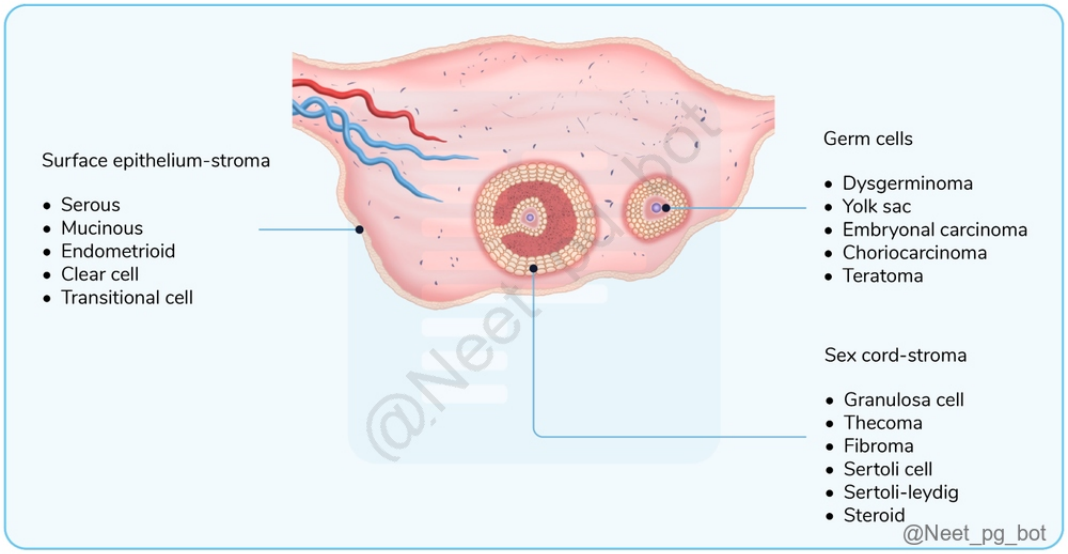

References:

Robbins and Cotran, Pathologic Basis of Disease, 10th Edition, Page 1016-1018

↑ *Back to this question in Part A*

@Neet_pg_bot

Q13: A 25-year-old woman presents with persistent dull lower abdominal pain and increased urinary frequency. A uterine ultrasound reveals a heterogeneous vascular mass with areas of necrosis. Biopsy results show spindle cells with significant atypia, high mitotic activity, and necrosis. What is the most likely diagnosis? {{caption_text}} (Q845699)

A. Endometriosis

B. Endometrial carcinoma

C. Leiomyoma

D. Leiomyosarcoma

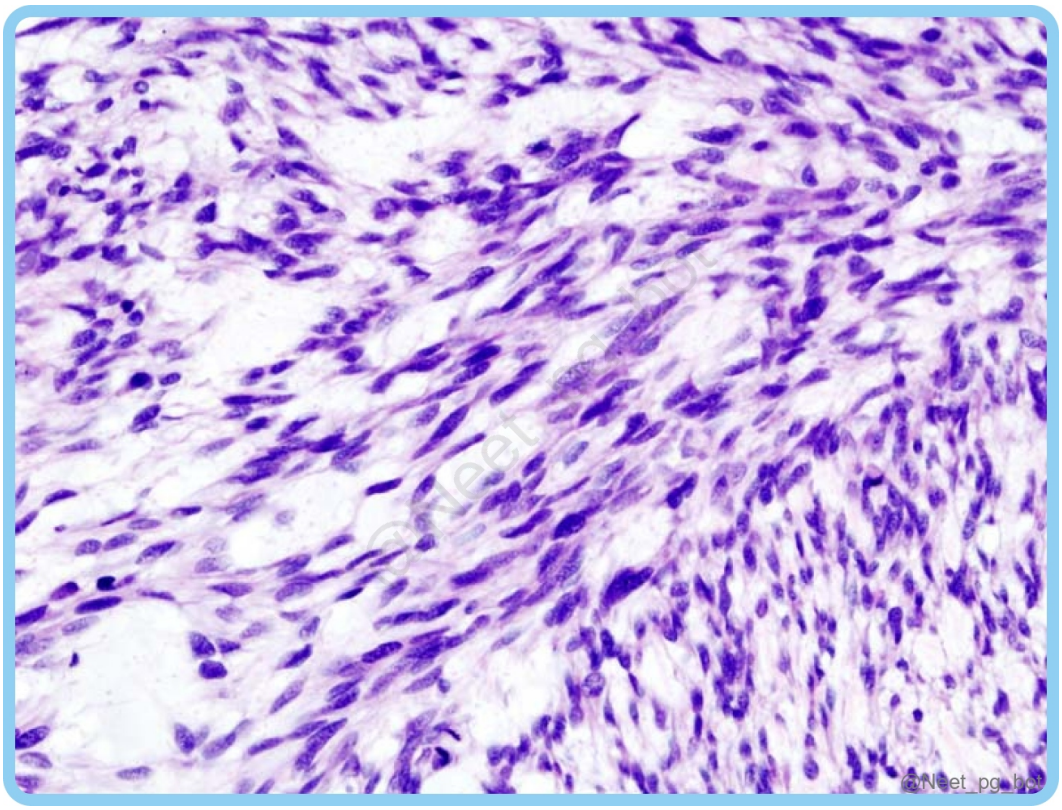

Correct Answer: D. Leiomyosarcoma

- *Listen (English)*
- *Listen (Hindi)*

Explanation: The patient most likely has uterine leiomyosarcoma, a malignant smooth muscle tumour of the myometrium. Characteristic Leiomyoma (Fibroid) (Option C) Leiomyosarcoma (Option D) Type Benign smooth muscle tumour of the myometrium. Malignant smooth muscle tumour of the myometrium. Gene mutations MED12 gene Highly variable Cellular Atypia Minimal to absent Prominent Mitotic Activity Rare to absent Increased, >10/10 hpf Gross Pattern Well-defined, encapsulated, whorled, firm, grey-white tumours varying in size Bulky masses that invade the uterine wall OR Polypoid masses that project into the lumen Microscopic Features Uniform bundles of smooth muscle cells with cigar-shaped nuclei. {{caption_text}} Characterised by spindle shaped smooth muscle cells with nuclear atypia , high mitotic index and tumour necrosis. {{caption_text}} Necrosis Absent Often present Risk of Metastasis Virtually absent Can metastasise, particularly to the lungs Endometriosis (Option A): This is not a tumor, Endometrial cancer (Option B): It is an epithelial tumor which shows glands and not spindles. {{caption_text}}

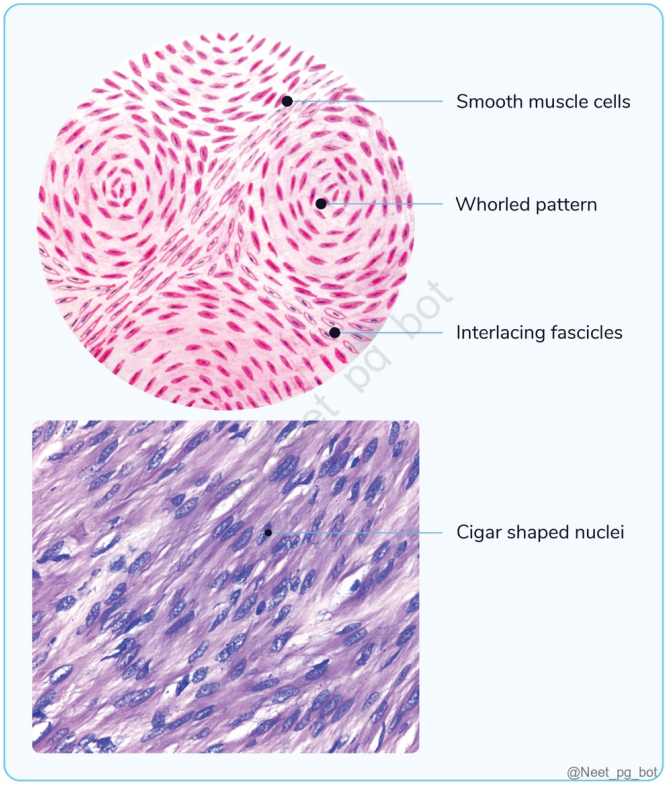
Smooth muscle cells
Whorled pattern
Interlacing fascicles
Cigar shaped nuclei
@Neet_pg_bot

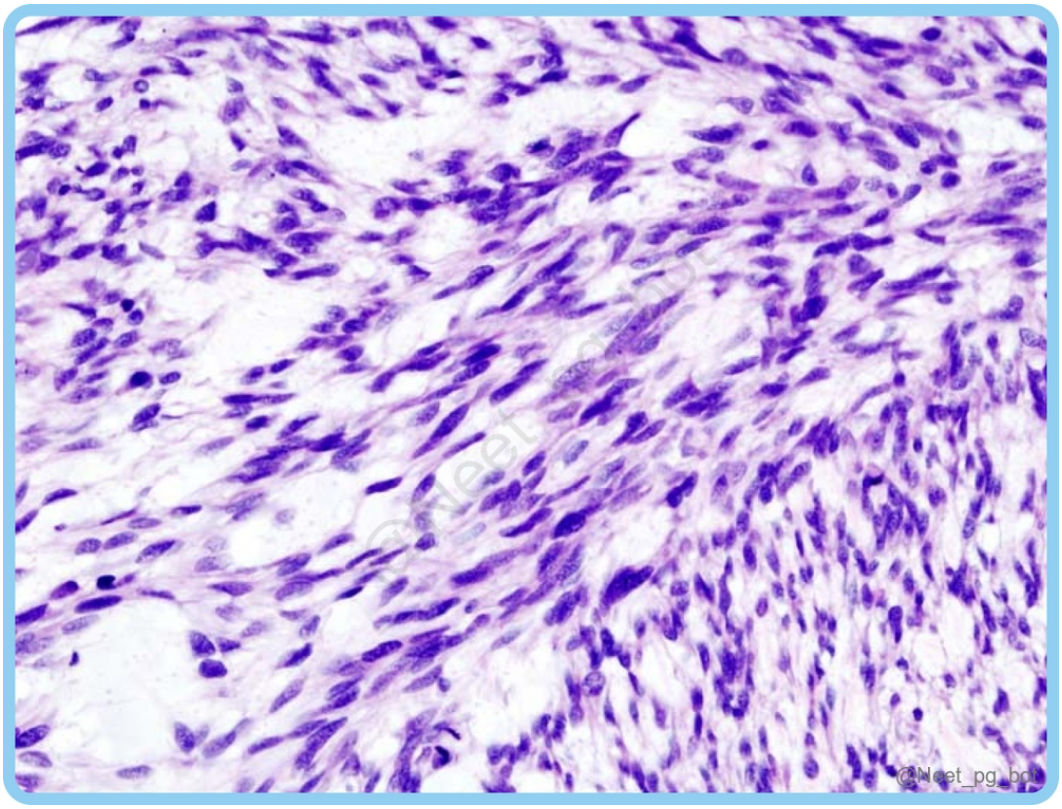
@Neet_pg_bot

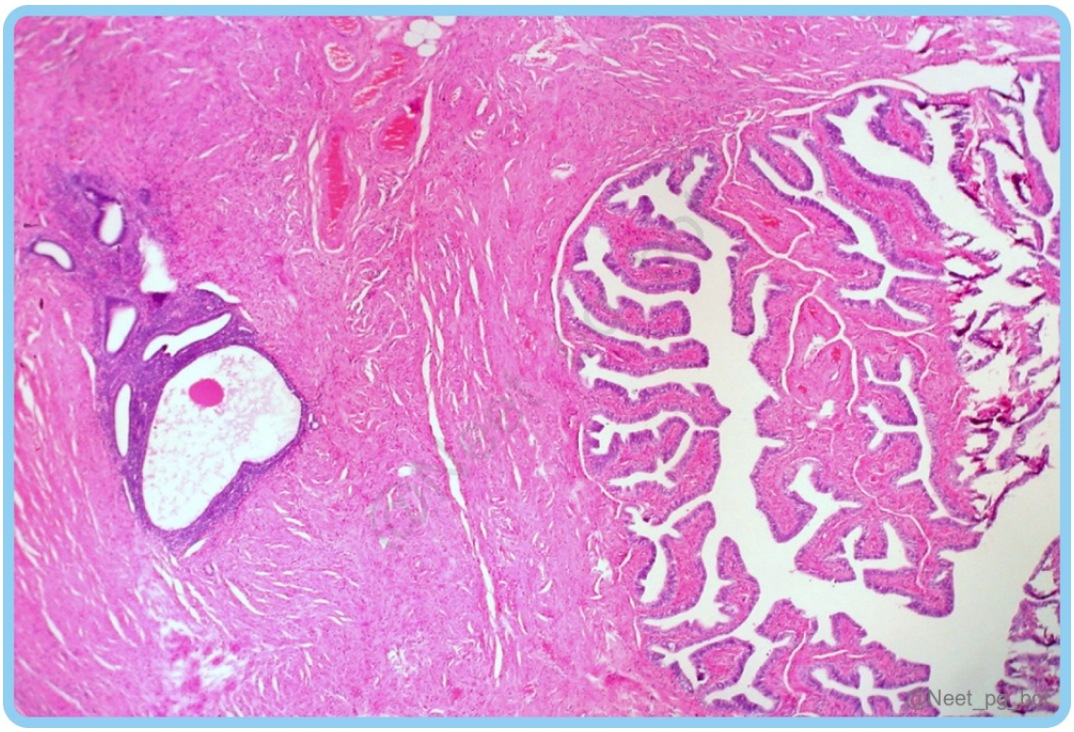

References:

Robbins and Cotran, Pathologic Basis of Disease, 10th Edition, Page 1014, 1015

https://www.flickr.com/photos/euthman/4771220585

https://commons.wikimedia.org/wiki/File:Cutaneous_leiomyosarcoma_-_high_mag.jpg

↑ *Back to this question in Part A*

@Neet_pg_bot

Q14: A 30-year-old pregnant woman at 20 weeks gestation presents with acute onset of severe abdominal pain. On examination, she has a tender, firm uterine mass. Ultrasound shows a fibroid with heterogeneous echotexture and increased vascularity. What type of degeneration is most likely occurring in the fibroid? (Q845698)

A. Hyaline degeneration

B. Calcific degeneration

C. Red degeneration

D. Myxoid degeneration

Correct Answer: C. Red degeneration

■ *Listen (English)*

■ *Listen (Hindi)*

Explanation: The patient most likely has red degeneration of fibroid/leiomyoma, characterised by prominent blood vessels and haemorrhage due to inadequate blood supply to the fibroid due to its sudden, rapid growth. Red degeneration of fibroid/leiomyoma: Occurs commonly in pregnant women. Appears beefy red in colour. Symptoms: Nausea, vomiting and high-grade fever. Degenerations seen in fibroids: Hyaline degeneration (Most common) Ca;cific degeneration Red degeneration (Omly degeneration of fibroids seen in pregnancy) Myxoid degeneration

References:

Robbins and Cotran, Pathologic Basis of Disease, 10th Edition, Page 1014 https://www.uptodate.com/contents/uterine-fibroids-leiomyomas-epidemiology-clinical-features-diagnosis-and-natural-history#H3784133710

↑ *Back to this question in Part A*

@Neet_pg_bot

Q15: A 40-year-old woman presents with heavy menstrual bleeding, pelvic discomfort, and increased urinary frequency. Examination reveals an enlarged, irregular uterus, and imaging shows well-defined, solid myometrial masses.Which of the following genetic rearrangements is seen in leiomyomas? (Q845694)

A. MED12

B. KIT

C. p53

D. BRAF

Correct Answer: A. MED12

■ *Listen (English)*

■ *Listen (Hindi)*

Explanation: The clinical scenario points towards Leiomyoma , (aka fibroid) a benign smooth muscle tumour of the myometrium causing symptoms like heavy menstrual bleeding, pelvic discomfort, and increased urinary frequency, caused by rearrangements in the MED12 gene on chromosomes 12q and 6p. Rearrangements in the MED12 gene can cause 3 conditions in female body: Fibroid/Leiomyoma in the uterus Fibroadenoma of the breast Phyllodes tumor in the breast Leiomyoma are well-defined, whorled, firm, grey-white tumours varying in size. {{caption_text}} Microscopically, there are uniform bundles of smooth muscle cells arranged in whorls with cigar-shaped nuclei. {{caption_text}}



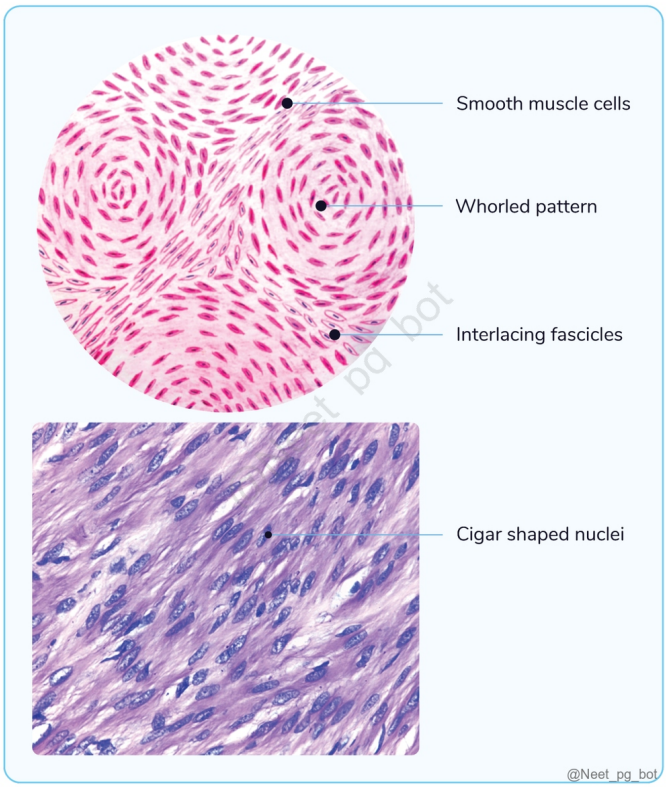

References:

Robbins and Cotran, Pathologic Basis of Disease, 10th Edition, Page1014, 1015, 1009

↑ *Back to this question in Part A*

@Neet_pg_bot

Q16: A 55-year-old postmenopausal woman presents with abnormal uterine bleeding and pelvic discomfort. On examination, her uterus is mildly enlarged, and an endometrial biopsy reveals hyperplasia with atypia. Further investigation suggests endometrial carcinoma.Which of the following genes is not responsible for the pathogenesis of Endometrial carcinoma? (Q845691)

A. PTEN

B. KRAS

C. CTNNB-1

D. ETV1

Correct Answer: D. ETV1

Explanation: ETV1 gene overexpression is seen in prostate carcinoma and is androgen-dependent. The clinical presentation suggests endometrial carcinoma, which arises from endometrial hyperplasia due to increased estrogen. This leads to excessive gland growth and myometrial invasion. The genes involved in the pathogenesis of endometrial carcinoma (Type I) are: PTEN (Option A) MLH1 KRAS (Option B) B-Catenin (CTNNB-1) (Option C) PIK3CA. P53 is involved in Type II endometrial carcinoma. Pathogenesis of Endometrial Carcinoma {{caption_text}} Type 2 Endometrial carcinoma {{caption_text}}

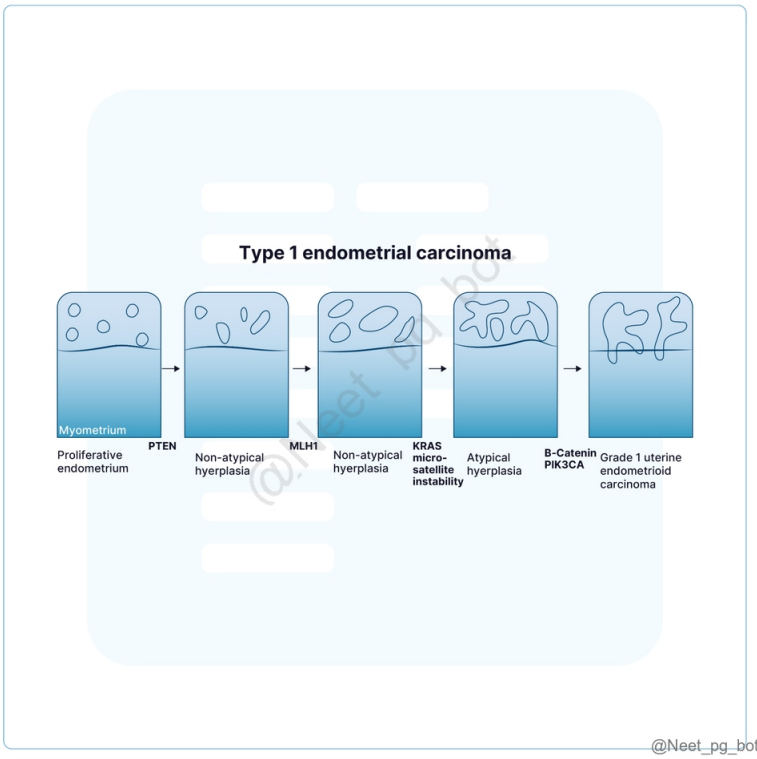

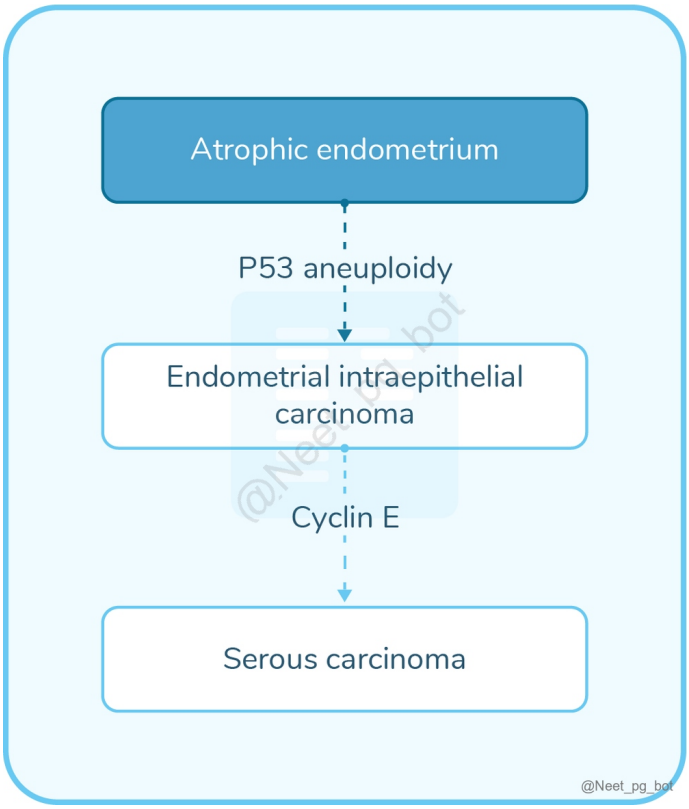

References:

Robbins and Cotran, Pathologic Basis of Disease, 10th Edition, Page 1009, 1014

↑ *Back to this question in Part A*

@Neet_pg_bot

Q17: A 49-year-old nulliparous woman with a history of irregular menses and breast cancer treated with tamoxifen presents with vaginal bleeding. Transvaginal ultrasound indicates irregular endometrial thickening, while biopsy confirms complex endometrial hyperplasia with atypia progressing to endometrioid carcinoma. Which of the following is not a risk factor for the above condition? (Q845690)

A. Thin physique

B. Diabetes mellitus

C. Tamoxifen

D. Unopposed estrogenic stimulation of the uterus

Correct Answer: A. Thin physique

■ *Listen (English)*

■ *Listen (Hindi)*

Explanation: Features Type 1 Endometrial Carcinoma Type 2 Endometrial Carcinoma Age 55-65 years of age More than 65 years of age Patient profile Obese; Perimenopausal woman Thin; Postmenopausal Risk factors Unopposed estrogen activity like: Nulliparity (Option D) Obesity (Overweight) PCOS Hypertension Diabetes No such risk factor Morphology Endometrioid Serous; Clear cell; Mixed Mullerian Precursor Endometrial hyperplasia Serous endometrial intraepithelial carcinoma. Associated Gene mutation PTEN ARID IA (regulator of chromatin) KRAS PIK3CA POLE MLH1,MSH2,and MSH6 mutations associated with Lynch syndrome TP53 Aneuploidy PIK3CA BRCA 1 and 2 Spread Indolent; spreads via lymphatics Better prognosis Aggressive intraperitoneal and lymphatic spread

References:

Robbins and Cotran, Pathologic Basis of Disease, 10th Edition, Page 1006-1008

↑ *Back to this question in Part A*

@Neet_pg_bot

Q18: Which of the following genetic mutations is associated with Endometrial hyperplasia? (Q845689)

A. BRCA 1 gene

B. PTEN gene

C. TP53 gene

D. BRCA 2 gene

Correct Answer: B. PTEN gene

■ *Listen (English)*

■ *Listen (Hindi)*

Explanation: PTEN gene is associated with endometrial hyperplasia. Germline mutation of PTEN, present on chromosome 10, is known as Cowden syndrome. Later on, endometrial hyperplasia can convert into endometrial carcinoma type-1. Another gene associated with endometrial hyperplasia and cancer is the ARID1A gene. BRCA1 (Option A)/BRCA2 (Option D): Breast, Ovarian, Prostate, Pancreatic, Uterine Serous Adenocarcinoma (Type 2) TP53 (Option C): Breast, Colorectal, Ovarian, Uterine Serous Adenocarcinoma (Type 2)

References:

Robbins and Cotran, Pathologic Basis of Disease, 10th Edition, Page 1006-1008

https://www.ncbi.nlm.nih.gov/pmc/articles/PMC2827900/

https://www.ncbi.nlm.nih.gov/books/NBK532286/

↑ *Back to this question in Part A*

@Neet_pg_bot

Q19: Which of the following statements is NOT true about Adenomyosis? (Q845688)

A. It presents with abnormal uterine bleeding.

B. Ectopic endometrial tissue is found at least 2.5 cm from the endometrial junction.

C. It is seen in pre-menopausal women.

D. Biopsy shows irregular nests of endometrial stroma arranged within the myometrium.

Correct Answer: B. Ectopic endometrial tissue is found at least 2.5 cm from the endometrial junction.

■ *Listen (English)*

■ *Listen (Hindi)*

Explanation: Adenomyosis is the presence of endometrial tissue within the myometrium at least 2.5 mm away from the endometrial / endomyometrial junction (not 2.5 cm). It is typically seen in pre-menopausal, multiparous

women in their 30-40’s (Option C) and is associated with a history of prior uterine surgery like C-section and increased exposure to estrogen. Clinical presentation includes: Irregular and heavy menstrual bleeding (menometrorrhagia) (Option A) Crampy menstrual pain (dysmenorrhea) Pain during intercourse (dyspareunia) Pelvic discomfort, particularly before menstruation. HPE shows irregular nests of endometrial stroma arranged within the myometrium (Option D) Adenomyosis MRI : can show salt and pepper appearance. {{caption_text}}

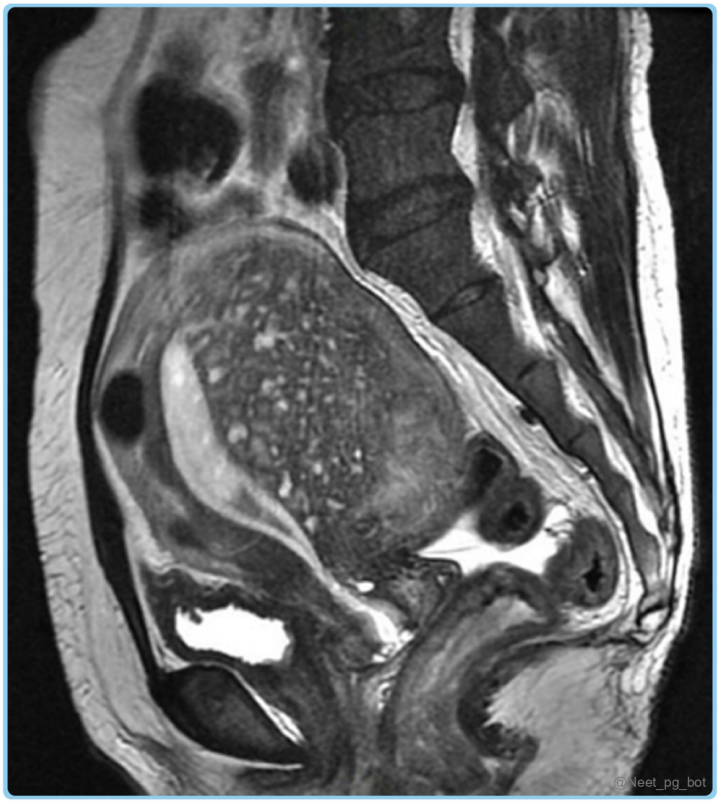

References:

Robbins and Cotran, Pathologic Basis of Disease, 10th Edition, Page 1006

https://www.ncbi.nlm.nih.gov/books/NBK539868/

↑ *Back to this question in Part A*

@Neet_pg_bot

Q20: A 28-year-old woman with chronic pelvic pain worsened during menstrual periods and accompanied by heavy bleeding, was found to have a 'chocolate' brown cyst on her ovaries during a laparoscopy. What is the most commonly accepted theory for the pathogenesis of this condition? (Q845686)

A. Benign metastasis theory

B. Metaplastic theory

C. Extrauterine stem/progenitor cell theory

D. Regurgitation theory

Correct Answer: D. Regurgitation theory

■ *Listen (English)*

■ *Listen (Hindi)*

Explanation: The clinical presentation and presence of a chocolate brown cyst on the ovaries suggest Endometriosis . Endometriosis is a condition in which endometrial glands and stroma are located at sites other than the endometrium. When the endometrial glands are present in the ovary, as in this case, the ovary develops a chocolate brown color , which occurs because the endometrial tissue within the ovary undergoes menstruation every month, leading to the accumulation of old, altered blood that gives the ovary its characteristic appearance.. The Regurgitation theory (Sampson's theory) proposes that endometriosis is caused by the backward flow of menstrual blood through the fallopian tubes into the pelvic cavity. In this theory, endometrial cells carried in the menstrual blood implant on pelvic surfaces, such as the ovaries, and then proliferate to form endometriotic lesions. Other theories for the pathogenesis of endometriosis: Benign metastasis theory (Halban's theory) (Option A) Metaplastic theory (Meyer and Ivanoff's theory) (Option B) Extrauterine stem/progenitor cell theory (Option C)

References:

Robbins and Cotran, Pathologic Basis of Disease, 10th Edition, Page 1004-1006

https://www.ncbi.nlm.nih.gov/books/NBK567777/

↑ *Back to this question in Part A*

@Neet_pg_bot

• [12_Genital System] 055 Previous Year Questions

« Back to Folder Directory

[12_Genital System] 055 Previous Year Questions — Quick Jump

Q1 (p. 2309) *Q2 (p. 2310)* *Q3 (p. 2311)* *Q4 (p. 2313)* *Q5 (p. 2314)* *Q6 (p. 2315)*
Q7 (p. 2319) *Q8 (p. 2319)* *Q9 (p. 2323)* *Q10 (p. 2326)* *Q11 (p. 2330)* *Q12 (p. 2331)*
Q13 (p. 2332)

Q1: A patient presents with ascites and omental caking. Imaging reveals solid components in an adnexal mass, and there is a long-standing history of symptoms. CA-125 is positive. What is the most probable diagnosis? (Q865380)

A. Serous ovarian tumor

B. Mucinous ovarian tumor

C. Endometroid tumor

D. Granulosa cell tumor

Correct Answer: A. Serous ovarian tumor

Explanation: The presence of ascites, omental caking, a solid adnexal mass, elevated CA-125, and chronic vague symptoms strongly points to serous ovarian tumor. Types of Epithelial Ovarian Tumor: Type of Epithelial Ovarian Tumor Characteristics Clinical Presentation Serous Tumors Serous Cystadenoma: Benign, unilateral, cystic spaces with serous epithelium. Large cystic mass, unilateral. Serous Cystadenocarcinoma: Malignant, often bilateral, cystic and solid components. Bilateral involvement in 30%, elevated CA-125. Mucinous Tumors Mucinous Cystadenoma: Benign, unilateral, filled with mucinous fluid. Large, unilateral mass. Mucinous Cystadenocarcinoma: Malignant, unilateral, mucinous epithelial lining. May rupture and spread to the peritoneum. Endometrioid Tumors (Option C ruled out) Endometrioid Carcinoma: Arises from endometrial-like tissue, solid and cystic. Solid and cystic components, associated with endometriosis. Clear Cell Tumors Clear Cell Carcinoma: Clear cytoplasm due to glycogen accumulation. Advanced stage, associated with endometriosis. Brenner Tumors (Transitional Cell) Brenner Tumor: Transitional epithelial cells resembling urinary tract epithelium. Rare, usually benign. Mucinous ovarian tumor (Option B) typically presents as a large, unilateral, multiloculated cystic mass and is less commonly associated with peritoneal spread or omental caking. CA-125 elevation is not as prominent unless the disease is advanced, and it lacks the classic imaging and spread pattern seen in serous carcinoma. Granulosa cell tumors (Option D) are sex cord-stromal tumors that secrete estrogen and often cause hormonal symptoms like abnormal uterine bleeding; they rarely cause ascites or omental caking, and CA-125 is typically not elevated.

References:

Shaw’s Textbook of Gynaecology, 17th Edition, Page 442.

↑ *Back to this question in Part A*

@Neet_pg_bot

Q2: A histopathological image of an ovarian mass in a lady is shown below. Which of the following statements are true regarding this condition? Sex cord stromal tumor Call-Exner bodies are seen CA125 is high Inhibin is a marker (Q865416)

A. 1, 2, 3

B. 1, 2, 4

C. 2, 4

D. 1, 4

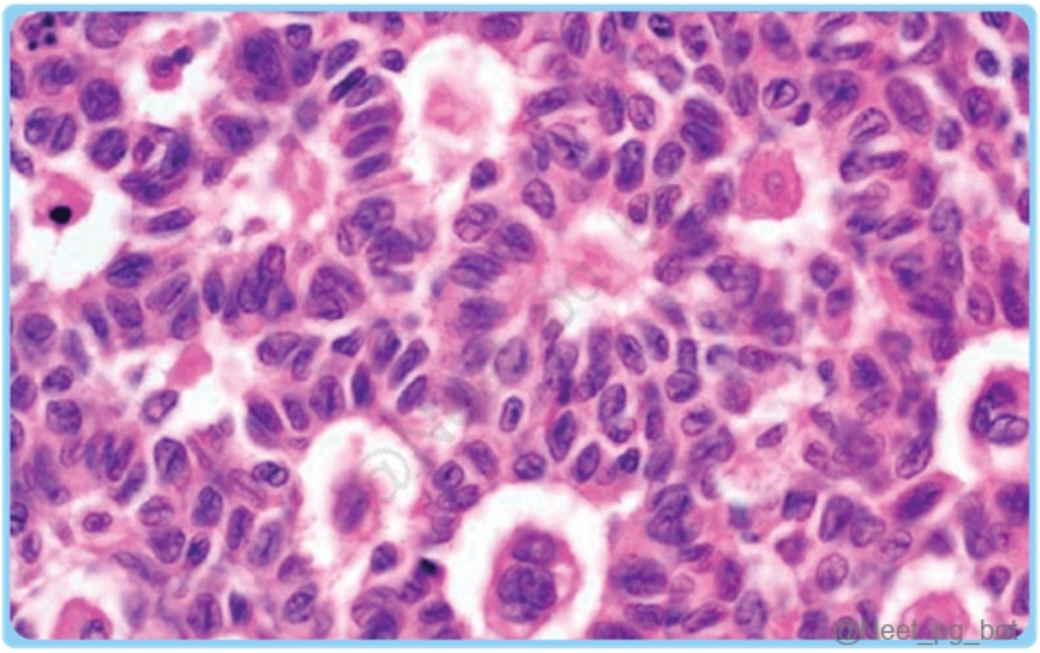

Correct Answer: B. 1, 2, 4

Explanation: The ovarian tumor showing Call-Exner bodies on histopathology is most consistent with a Granulosa Cell Tumor, a type of Sex Cord-Stromal Tumors , for which inhibin serves as an important diagnostic marker. Feature Sertoli-Leydig tumour, Pure Leydig tumour (or Hilus cell tumour) Fibroma, Thecoma, Fibrothecoma Granulosa Cell Tumor Derived from Sertoli or Leydig cells Ovarian stroma Granulosa cells of ovarian follicle Age of Occurrence Second and third decades Any age Postmenopausal (adult type), any age (juvenile type) Associated symptoms Abnormal sexual development or Virilization Associated with Meigs syndrome and basal nevus syndrome Precocious sexual development in juveniles or abnormal uterine bleeding, endometrial hyperplasia (carcinoma) in adults Histological features Reinke crystalloids (in pure Leydig cell tumours) Well-differentiated

fibroblasts (fibroma), plump spindle cells with lipid droplets (thecomas) Call-Exner bodies, Coffee bean nuclei (Statement 2) Mutations & Markers Mutations in DICER1 (which encodes endonuclease) Vimentin +, Thecoma: Oil Red O +ve Fibroma: Oil Red O -ve Elevated inhibin levels, CD99+, and FOXL2 mutations (in adult cases) (Statement 4) Prognosis Low recurrence or metastasis rate (<5%) Benign; Rarely malignant (fibrosarcomas) Potentially malignant with unpredictable behaviour; 10-year survival rate 85%

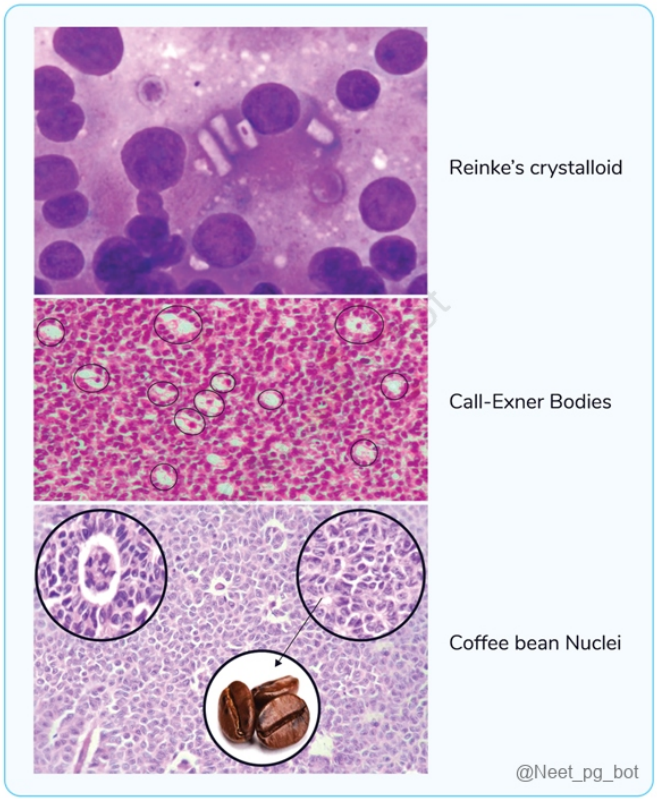

References:

Textbook of Robbin and Cotran's Pathological Basis of Diseases, 10th Edition, Page 1026-1028.

↑ *Back to this question in Part A*

@Neet_pg_bot

Q3: A 30-year-old man presents with a painless testicular mass. An ultrasound shows a well-circumscribed, homogeneous, non-hemorrhagic testicular tumour. Which of the following is the most likely diagnosis? (Q866364)

A. Yolk sac tumour

B. Choriocarcinoma

C. Teratoma

D. Seminoma

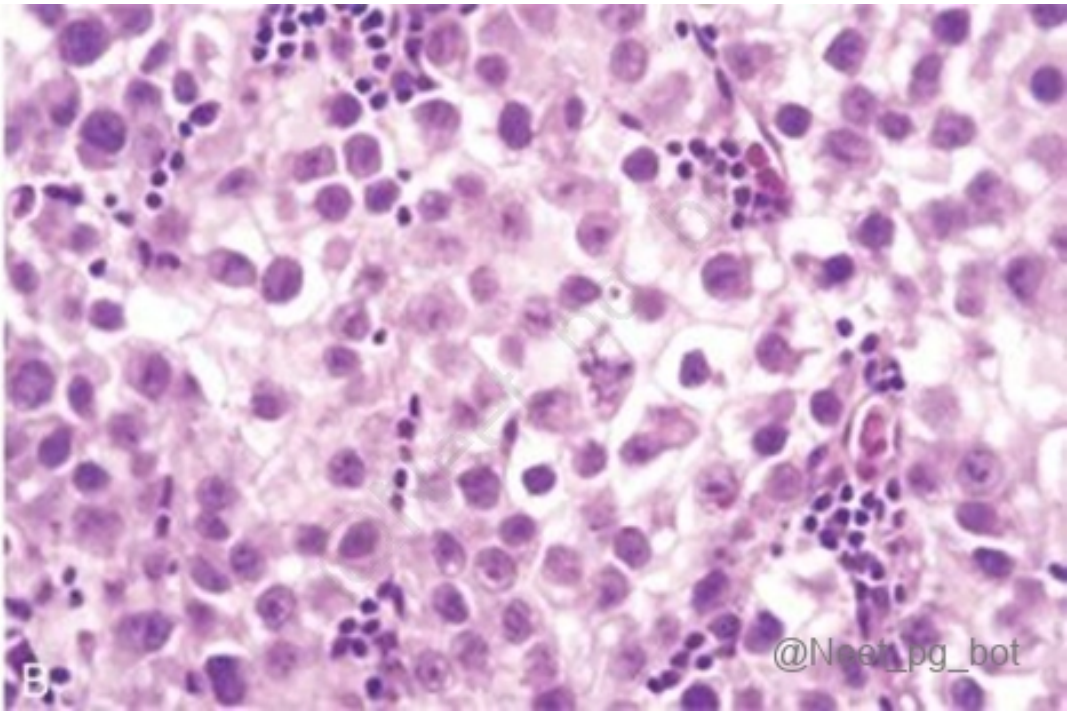

Correct Answer: D. Seminoma

Explanation: The given histopathological image shows features suggestive of testicular seminoma. Histology of seminoma: Sheets of monomorphic cells. The sheets are divided into poorly demarcated lobules by the septa of the fibrous tissue. The septa show lymphocytic infiltration (T lymphocytes). The classic seminoma cell is large and round to polyhedral with a distinct cell membrane and a large, central nucleus with one or two prominent nucleoli. The cytoplasm is clear or watery appearing and contains glycogen . The arrows in the image below show seminomatous tumour cells. Seminoma: It is the most common germ cell tumour of the testis. A similar presentation in the ovary is called dysgerminoma , and germinoma is present in the pineal gland . Incidence: Peak incidence in the fourth decade. Genetics: Seminomas contain isochromosome 12p and express OCT3/4 & NANOG. Gross: Seminoma has a homogeneous, grey-white, lobulated cut surface, usually devoid of haemorrhage or necrosis . Generally, the tunica albuginea is not penetrated, but extension to the epididymis, spermatic cord, or scrotal sac occasionally occurs.

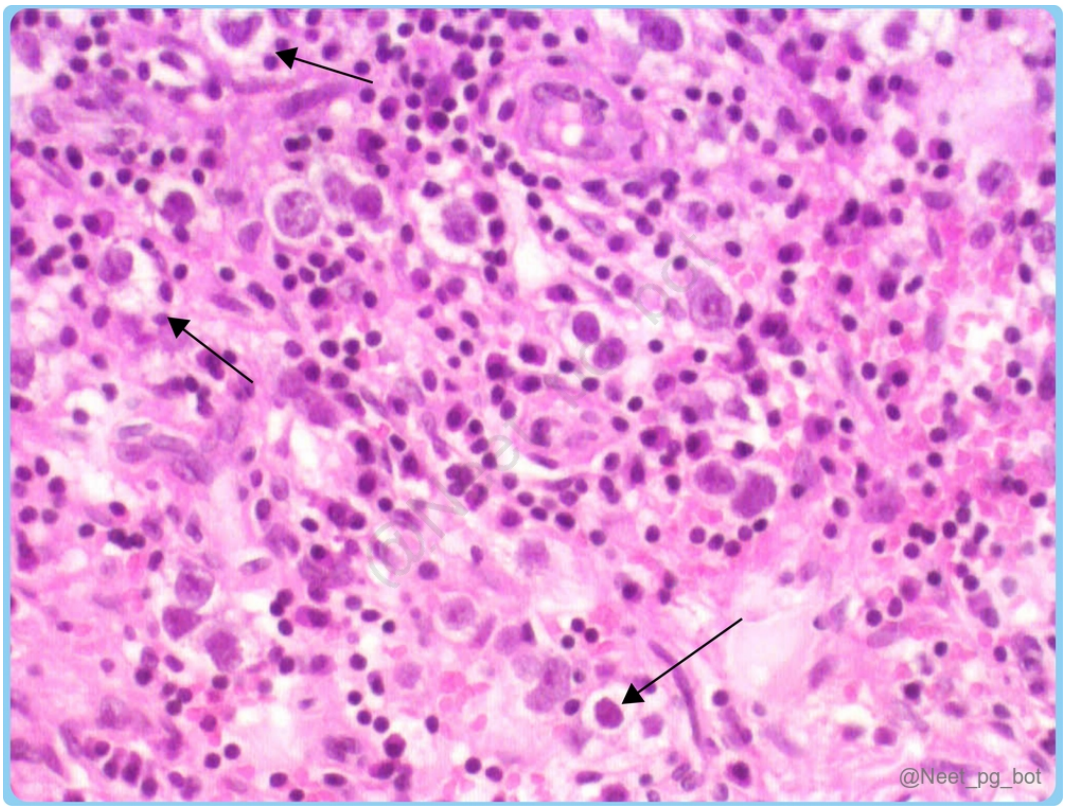

References:

.

↑ *Back to this question in Part A*

@Neet_pg_bot

Q4: A patient presents with an ovarian mass that is multiloculated and has a serum CA-125 level >1000 U/mL. What is the most likely diagnosis? (Q866385)

A. Serous cystadenoma

B. Mature teratoma

C. Granulosa cell tumor

D. Serous cystadenocarcinoma



Correct Answer: D. Serous cystadenocarcinoma

Explanation: Serous cystadenocarcinoma is the most common malignant epithelial ovarian tumour , often bilateral, and tends to be multiloculated with papillary projections. CA-125 is a tumour marker for epithelial ovarian cancers, especially serous and endometrioid types . A very high CA-125 (>1000 U/mL) is far more suggestive of malignancy than benign lesions. Patients often present with abdominal distension, ascites, and an adnexal mass. Incorrect Options: Serous cystadenoma (Benign epithelial tumour) (Option A): Usually unilocular or mildly multilocular, with thin walls and clear serous fluid. CA-125 levels may be normal or only mildly elevated, not usually >1000. There is no invasive growth, and it occurs in younger women compared to cystadenocarcinoma Mature teratoma (Dermoid cyst) (Option B): Benign germ cell tumour containing ectodermal derivatives like hair, teeth, and sebaceous material. It usually occurs in younger women (teens to early adulthood). CA-125 is not a typical marker; instead, you might find elevated AFP or β-hCG in other germ cell tumours (not teratomas). On imaging, it often has fat-fluid levels or calcifications, not a multiloculated cystic appearance. Granulosa cell tumour (Sex cord–stromal tumour) (Option C): Often estrogen-producing may cause precocious puberty in children or postmenopausal bleeding in older women. Serum marker: Inhibin (not CA-125). Usually, a solid or cystic-solid mass, not a multiloculated cyst with such high CA-125.

↑ *Back to this question in Part A*

@Neet_pg_bot

Q5: What is the role of inhibin? (Q860564)

A. Stimulates the release of FSH

B. Inhibits the secretion of FSH

C. Inhibition of PRL

D. Stimulation of PRL

Correct Answer: B. Inhibits the secretion of FSH

Explanation: Inhibin from the granulosa cells inhibits FSH secretion. It is a hormone primarily produced by the ovaries (in females) and testes (in males). It regulates the reproductive system by inhibiting the secretion of FSH (Follicle-Stimulating Hormone) from the anterior pituitary gland. Inhibin suppresses the FSH Inhibin B: Before ovulation Inhibin A: After ovulation Stimulates the secretion of FSH (Option A): Inhibin does not stimulate FSH release; instead, it inhibits it. FSH is involved in the growth and maturation of reproductive cells, but inhibin reduces its secretion once the follicle or sperm production reaches sufficient levels. Inhibition of PRL (Option C) and Stimulation of PRL (Option D): Inhibin does not directly regulate prolactin (PRL), a hormone involved in milk production. PRL levels are primarily controlled by dopamine from the hypothalamus and other factors, not by inhibin. Therefore, inhibin neither inhibits nor stimulates PRL production.

References:

Ganong's Review of Medical Physiology, 26th Edition, pg 401-403.

↑ *Back to this question in Part A*

@Neet_pg_bot

Q6: In the cervical smear below, which of the following stains are used (Q857417)

A. Papanicolaou stain

B. H & E stain

C. Giemsa stain

D. Toluidine blue

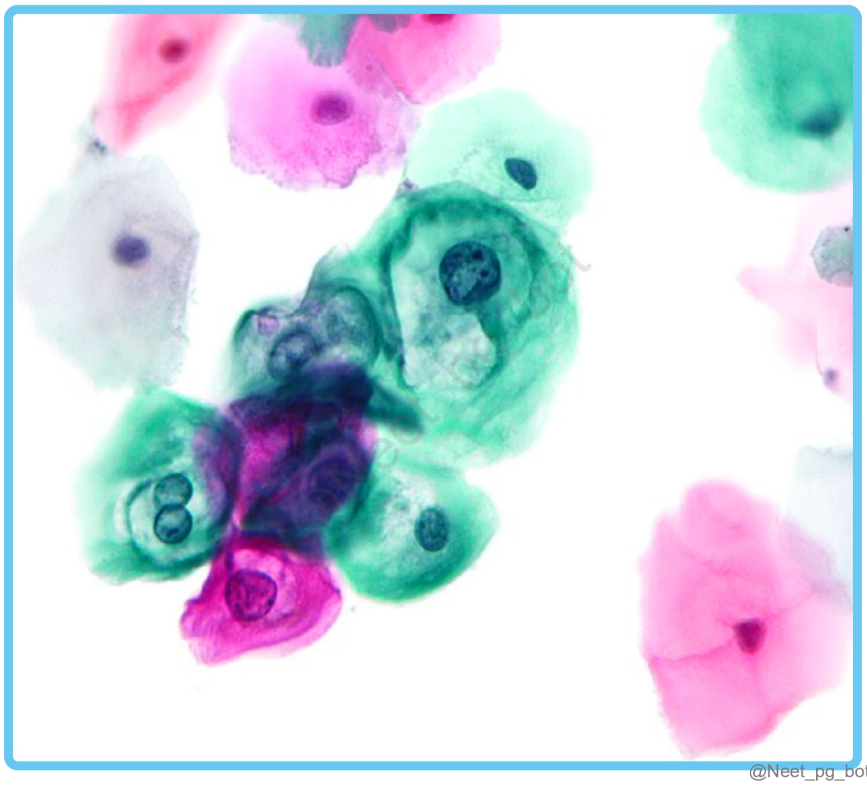

Correct Answer: A. Papanicolaou stain

Explanation: Papanicolaou stain is the standard stain used in cervical smears to detect cellular abnormalities. {{caption_text}} The Pap stain results in: Well-stained nuclear chromatin Differential polychromatic counterstaining of the cytoplasm Cytoplasmic transparency H & E stain (Option B) (hematoxylin and eosin) staining procedure uses two dyes to stain tissue samples, making it easier to see cell structure under a microscope; this is commonly used for histopathological tissue sections , not for cervical smears. {{caption_text}} Giemsa stain (Option C) is used to stain blood and bone marrow smears, as well as some parasites, but it is not used in cervical cytology. {{caption_text}} Toluidine blue (Option D) is a basic metachromatic dye primarily used to stain acidic components of tissues, such as nucleic acids and mast cell granules. It is not used for routine cervical cytology. {{caption_text}}

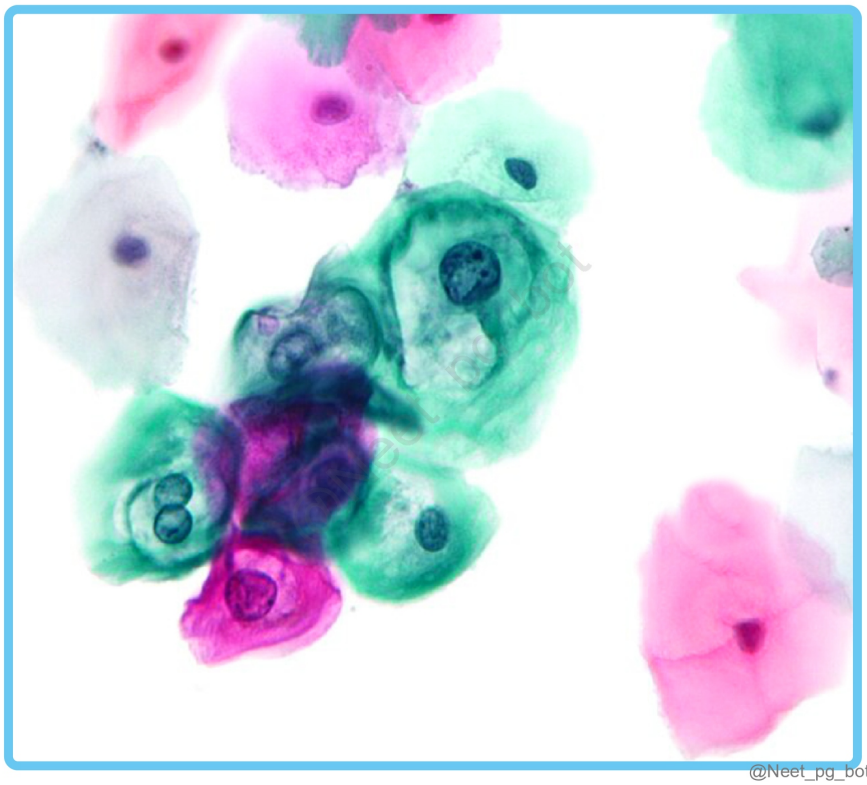

@Neet_pg_bot

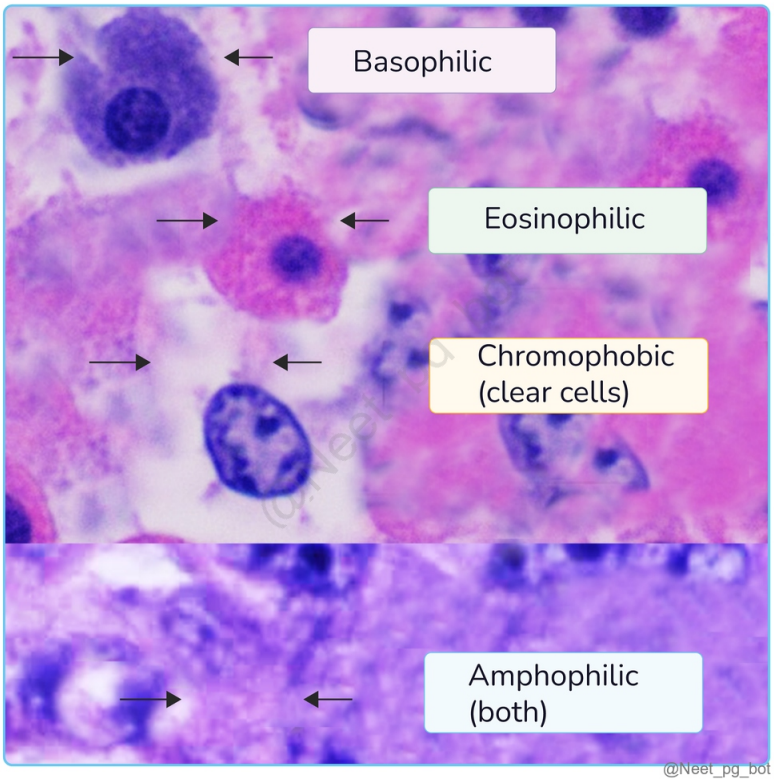

@Neet_pg_bot



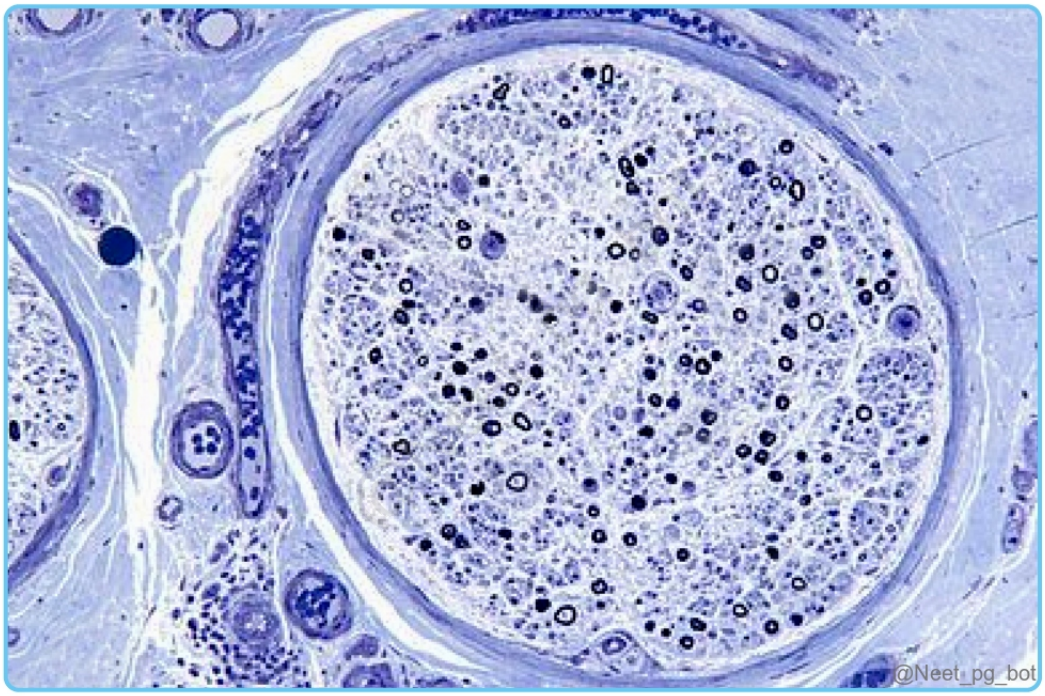

References:

Robbins and Cotran Pathologic Basis of Disease, 10th Edition, Pages 62, 63
https://pmc.ncbi.nlm.nih.gov/articles/PMC9345133/

↑ *Back to this question in Part A*

@Neet_pg_bot

Q7: Which of the following tumour markers are positive for seminoma? PLAP OCT3/4 NANOG HCG (Q854709)

A. 1 only

B. 1 and 2

C. 1, 2 and 3

D. 1, 2, 3 and 4

Correct Answer: D. 1, 2, 3 and 4

Explanation: Seminomas are characterized by specific tumour markers like PLAP (Placental alkaline phosphatase) HCG LDH Newer markers: OCT ¾ NANOG CD117 SALL4 Seminoma is the most common germ cell tumour of the testis. A similar presentation in the ovary is called dysgerminoma , and germinoma is present in the pineal gland . Incidence: Peak incidence in the fourth decade. Gross: Seminoma has a homogeneous, grey-white, lobulated cut surface, usually devoid of haemorrhage or necrosis .

References:

Robbins and Cotran Pathologic Basis of Disease, 10th Edition, Pages 969, 970

↑ *Back to this question in Part A*

@Neet_pg_bot

Q8: Which of the following conditions is NOT caused by high-risk strains of human papillomavirus (HPV)? (Q855950)

A. Cervical cancer

B. Anal cancer

C. Oropharyngeal cancer

D. Laryngeal papillomatosis

Correct Answer: D. Laryngeal papillomatosis

Explanation: Laryngeal papillomas are benign lesions primarily associated with HPV serotypes 6 and 11 . These serotypes are known to cause condyloma acuminatum and are commonly associated with laryngeal lesions, particularly in children and young adults Types of HPV Cutaneous involvement HPV 1, 2, 3 (low risk) Filiform wart Verruca Plantaris HPV 5, 8 (high risk) Epidermodysplasia Verruciformis Mucosal involvement HPV 6, 11

(low risk) Condyloma Acuminatum Recurrent laryngeal papillomas HPV 16, 18, 31, 33, 35 (high risk) Squamous cell carcinoma HPV 16 (High risk) LSIL, HSIL, Carcinoma cervix Vulval carcinoma Oropharyngeal SCC HPV 18 (High risk) LSIL, HSIL, Carcinoma cervix Anogenital carcinoma Cutaneous involvement Benign Warts Common Skin Warts (Verruca Vulgaris) : Small, hard, rough growths on the skin; commonly seen in children (associated with serotypes 2, 4, 27, 57). Flat Warts (Verruca Plana) : Also prevalent among children. Plantar Warts (Verruca Plantaris) : Benign lesions commonly found in adolescents (linked to serotype 1). {{caption_text}} {{caption_text}} Epidermodysplasia Verruciformis Rare autosomal recessive conditions may progress to squamous cell carcinoma, especially in sun-exposed areas. Associated with serotypes 5, 8 , 9, 12, 17, 20, 36, and 47. {{caption_text}} Mucosal involvement Anogenital Warts It is also known as Condyloma Acuminatum. A sexually transmitted infection in adults, associated with HPV serotypes 6 and 11. {{caption_text}} Head and Neck Lesions Benign : Recurrent laryngeal papillomas , especially in children (serotypes 6, 11). Malignant : Laryngeal and esophageal carcinomas (serotypes 16, 18) {{caption_text}} Carcinoma Cervix Mainly squamous cell carcinoma , linked to high-risk serotypes like 16, 18, 31, 33, and others . Serotype 16 alone accounts for ~50% of cases, while serotypes 16 & 18 together cause ~70% of cervical cancers.




@Neet_pg_bot


@Neet_pg_bot



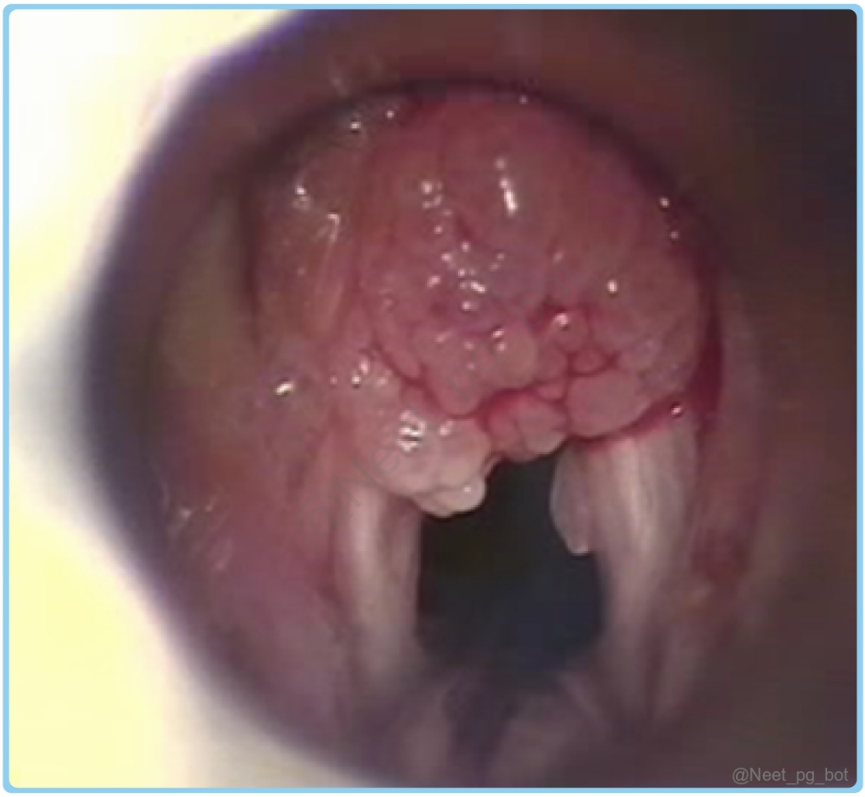

References:

Murray Medical Microbiology, 8th Edition, Page 413

Apurba S Sastry’s Essentials of Microbiology, 3rd Edition, Page 804

↑ *Back to this question in Part A*

@Neet_pg_bot

Q9: What is the most probable tumour that a 22-year-old woman with a sizable growth in her right ovary, which has been determined to originate from all three germ layers based on histopathology, is experiencing? (Q857106)

A. Dysgerminoma

B. Teratoma

C. Thecoma

D. Theca lutein cyst

Correct Answer: B. Teratoma

Explanation: Teratomas are tumours that originate from all three germ layers (ectoderm, mesoderm, and endoderm) and are commonly found in the ovaries. They are often seen in young women and can contain a variety of tissue types, such as hair, teeth, and muscle, which reflects their origin from all three germ layers. {{caption_text}} Immature teratoma: Bulky, solid ovarian tumours that contain immature neuroepithelium, cartilage, bone, and muscle, with areas of necrosis and haemorrhage. They grow rapidly, often spreading beyond the ovary. They are seen in young females and have a high risk of malignancy. They have small, round blue cells (Immature neural components). {{caption_text}} Mature teratoma Mature teratomas, or dermoid cysts , are common benign ovarian tumours found in young women. They are bilateral in 10-15% of cases. They contain tissues from all three germ layers, including skin, hair, and teeth, and can rarely undergo malignant transformation to squamous cell carcinoma. Grossly, they are unilocular cysts with a thin wall and hair; microscopically, they have stratified squamous epithelium and sebaceous glands. Monodermal teratoma: Monodermal teratomas consist predominantly of a single type of tissue, such as thyroid tissue in struma ovarii or neuroendocrine cells in carcinoid tumours. They lack immature or embryonic-like tissues and typically do not have a high risk of malignancy. Dysgerminoma (Option A) is also a type of germ cell tumour (GCT) that typically secretes beta hCG. {{caption_text}} Thecoma (Option C) is a rare benign tumour originating from the ovarian stroma, accounting for less than 1% of all ovarian tumours. It is most commonly found in perimenopausal and postmenopausal women. {{caption_text}} Theca lutein cysts (Option D) are rare benign cystic lesions caused by hypertrophy of the theca interna layer due to excessive stimulation by hCG. {{caption_text}}

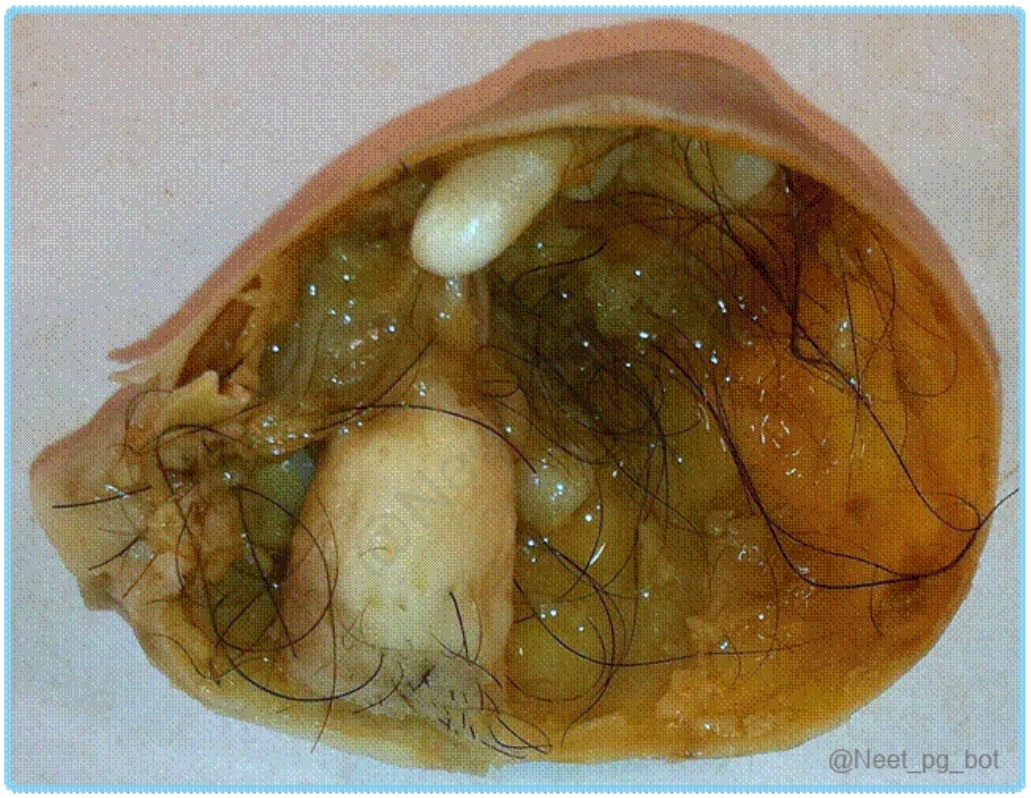
@Neet_pg_bot

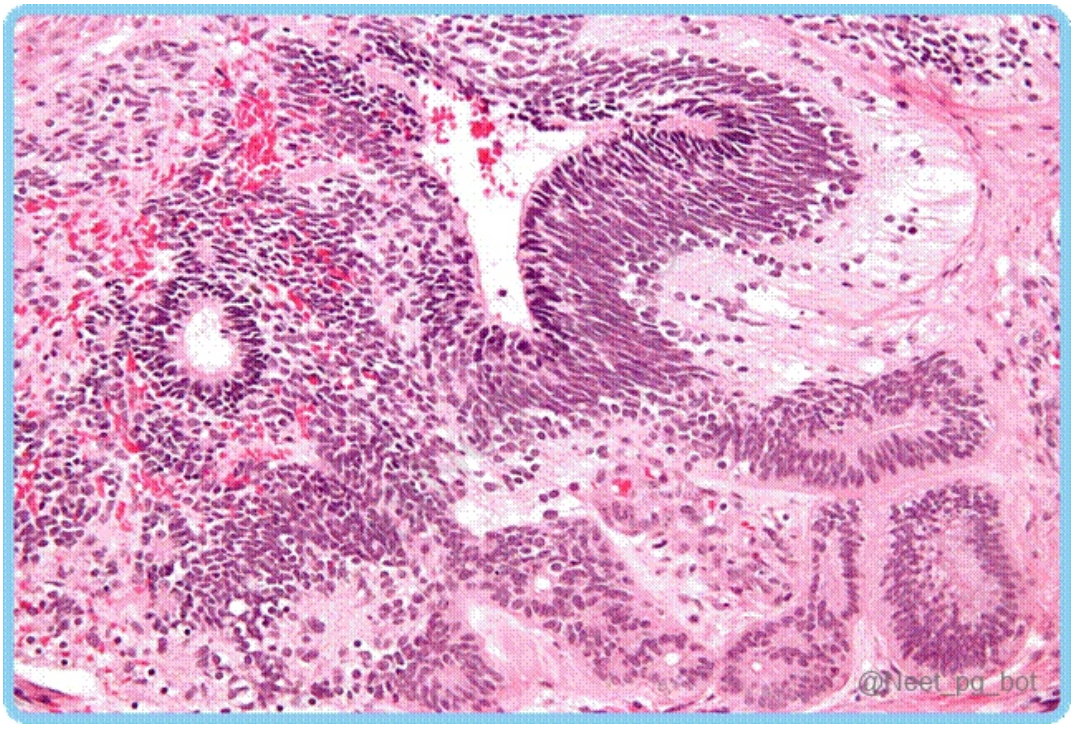
@Neet_pg_bot

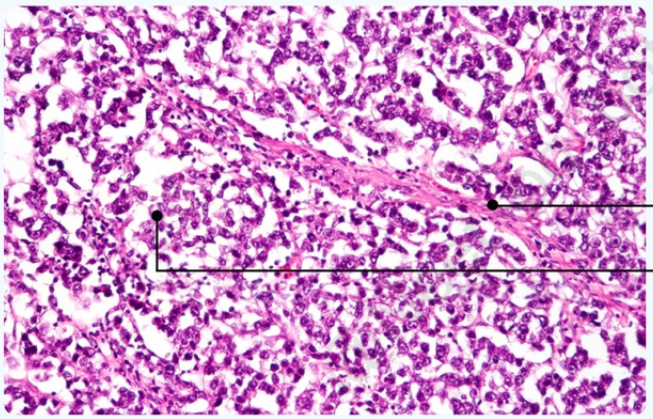

@Neet_pg_bot

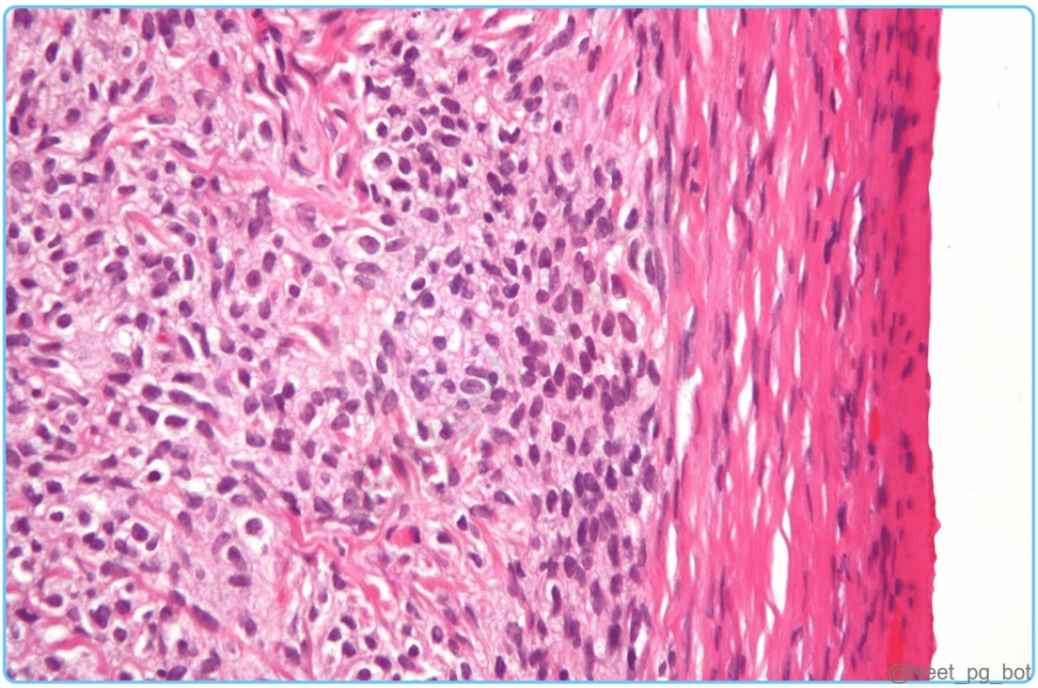

@Neet_pg_bot

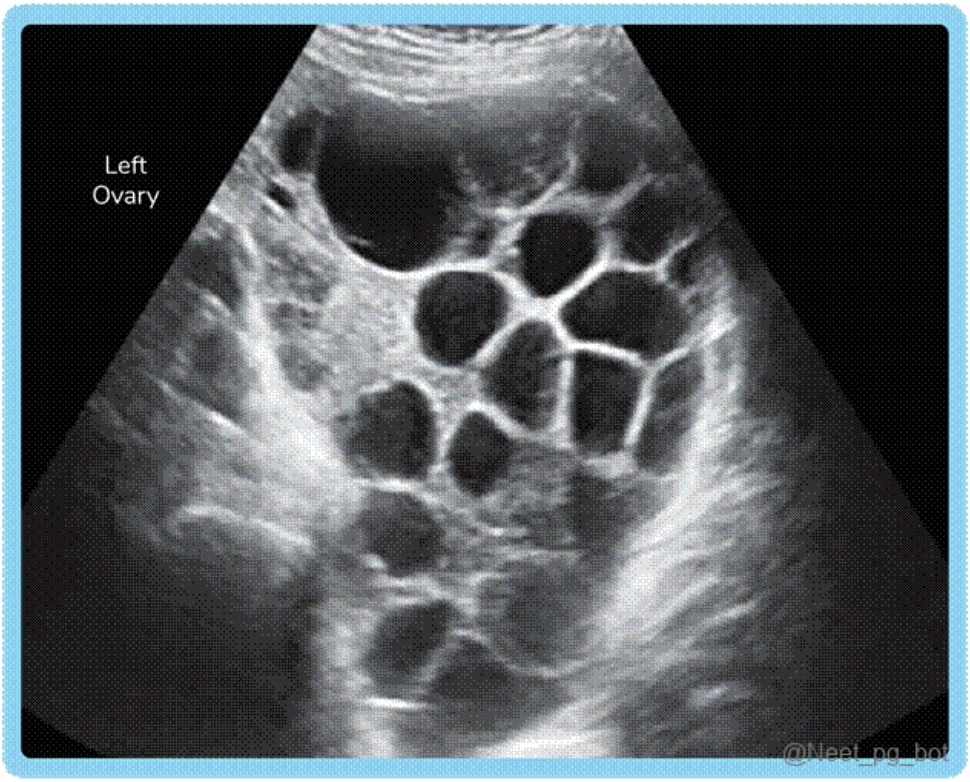

References:

Robbins & Cotran Pathologic Basis of Disease, 10th Edition, Page 1025

↑ *Back to this question in Part A*

@Neet_pg_bot

Q10: What is the most likely diagnosis for a 48-year-old patient who came with scrotal swelling, had elevated LDH levels but normal AFP levels on tests for testicular tumours, and exhibited a specific histological picture after orchidectomy? (Q857111)

A. Yolk sac tumor

B. Teratoma

C. Seminoma

D. Embryonal carcinoma

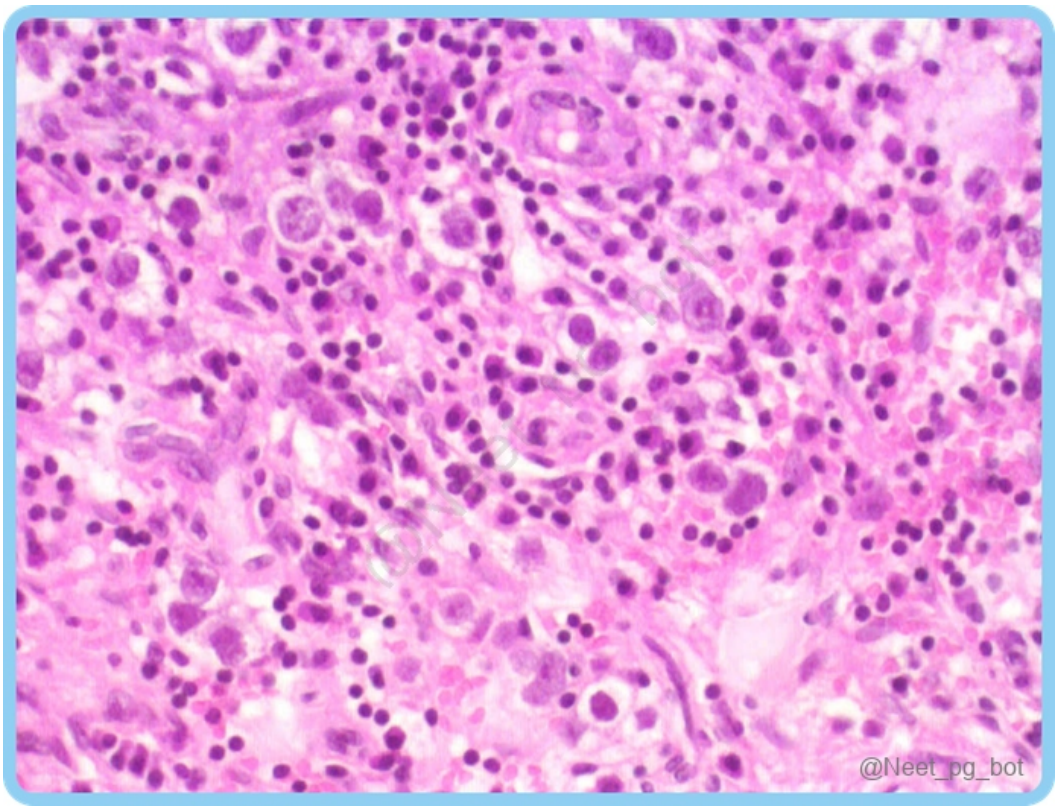

Correct Answer: C. Seminoma

Explanation: The clinical presentation and histopathological findings suggest testicular seminoma. Seminomas elevate LDH levels, while AFP remains normal. Histology shows large, uniform cells with clear cytoplasm and prominent nucleoli. Seminoma: It is the most common germ cell tumour of the testis. A similar presentation in the ovary is called dysgerminoma , and germinoma is present in the pineal gland . Incidence: Peak incidence in the fourth decade. Genetics: Seminomas contain isochromosome 12p and express OCT3/4 & NANOG. Morphology: Seminoma has a homogeneous, grey-white, lobulated cut surface, usually devoid of haemorrhage or necrosis . Histology of seminoma: Sheets of monomorphic cells. The sheets are divided into poorly demarcated lobules by the septa of the fibrous tissue. The septa show lymphocytic infiltration (T lymphocytes). The classic seminoma cell is large and round to polyhedral with a distinct cell membrane and a large, central nucleus with one or two prominent nucleoli. The cytoplasm is clear or watery appearing and contains glycogen . The arrows in the image below show seminomatous tumour cells. {{caption_text}} Source: Testicular Tumour Corresponding Tumor Markers Seminoma Placental alkaline phosphatase (PLAP) HCG LDH Newer markers: Oct 3/4, Nanog, CD117, SALL4 Embryonal Carcinoma {{caption_text}} CD-30 Yolk sac tumour {{caption_text}} Alpha-fetoprotein (AFP) Alpha-1 antitrypsin Choriocarcinoma Beta-human chorionic gonadotropin (β-hCG) Teratoma {{caption_text}} Cytokeratin

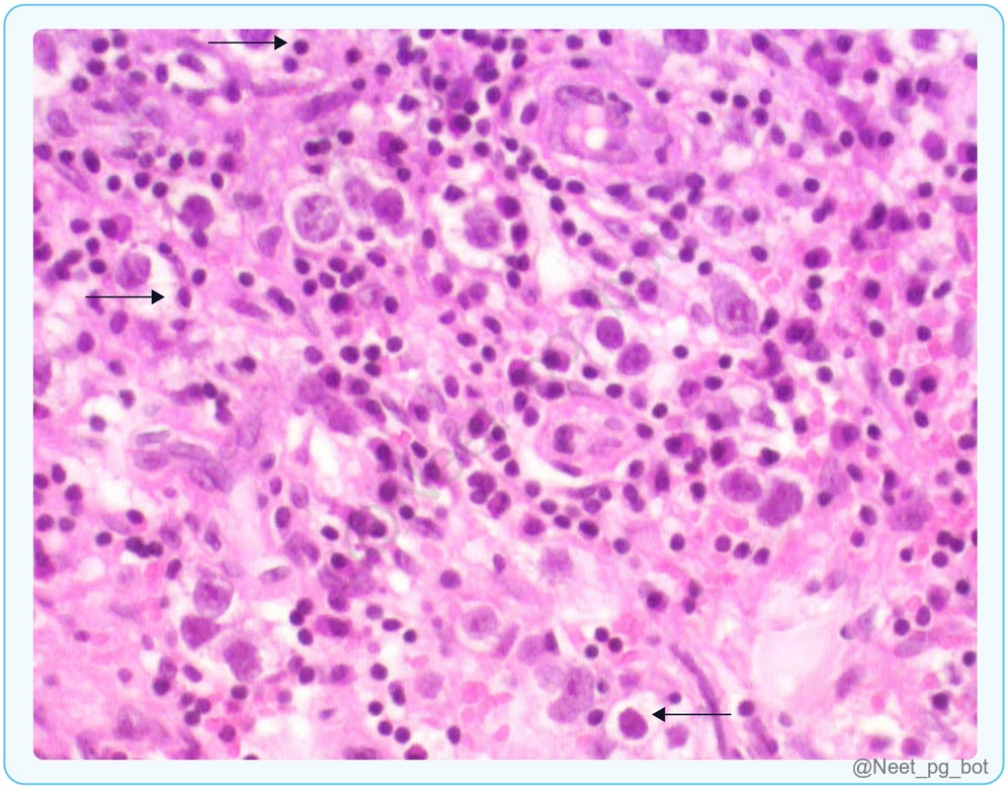
@Neet_pg_bot

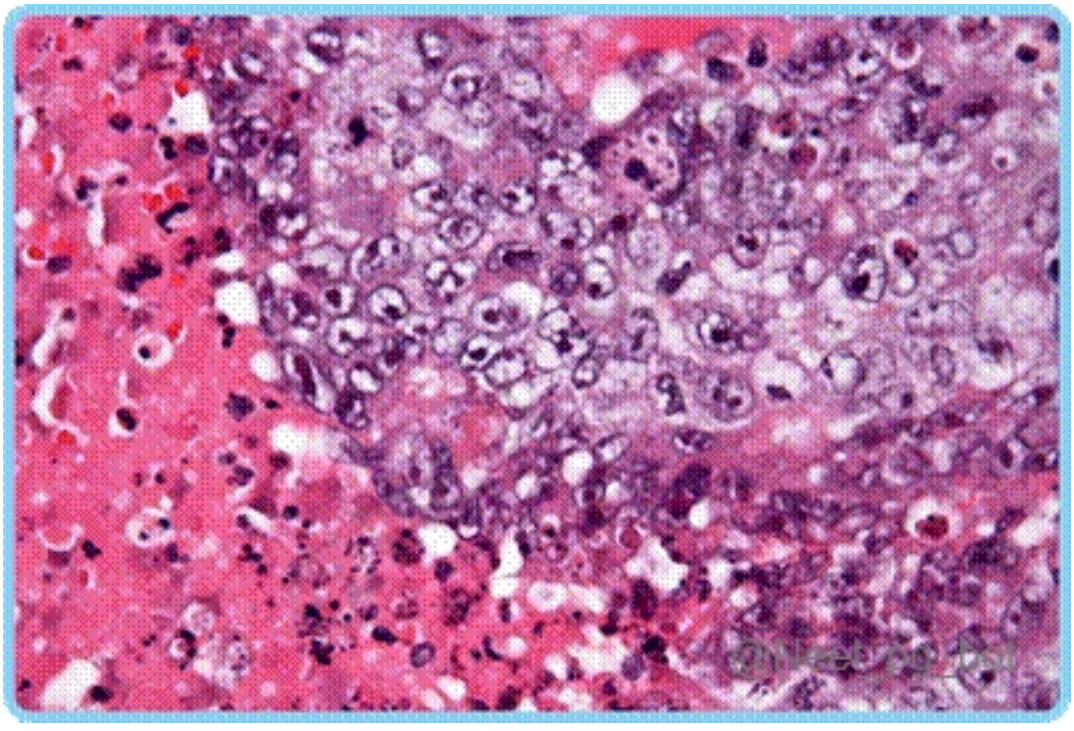

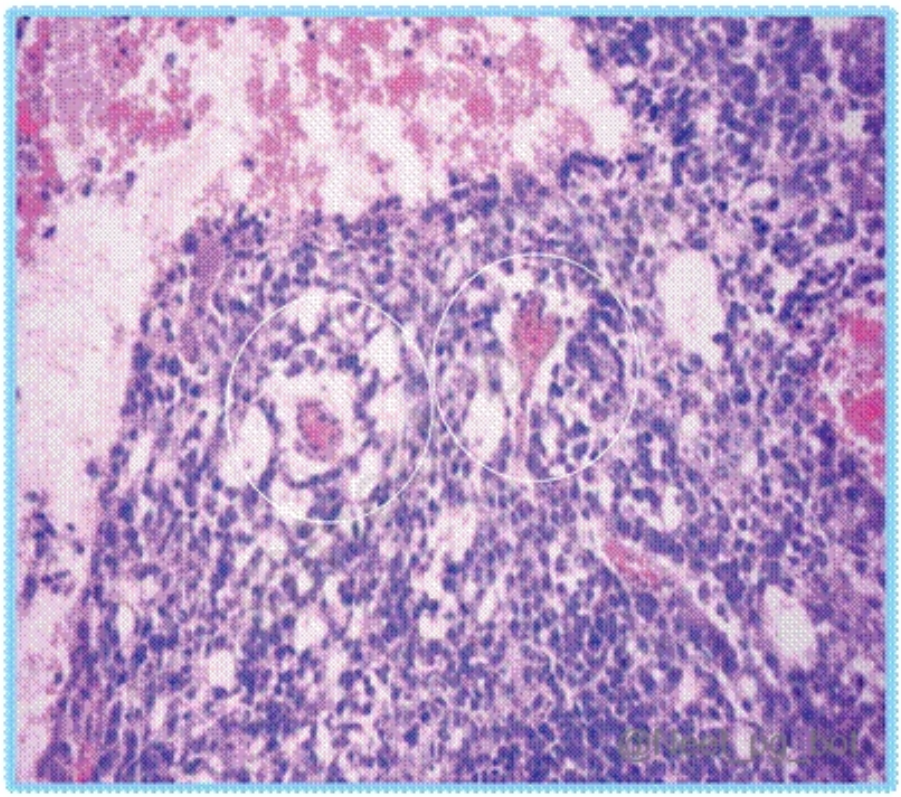

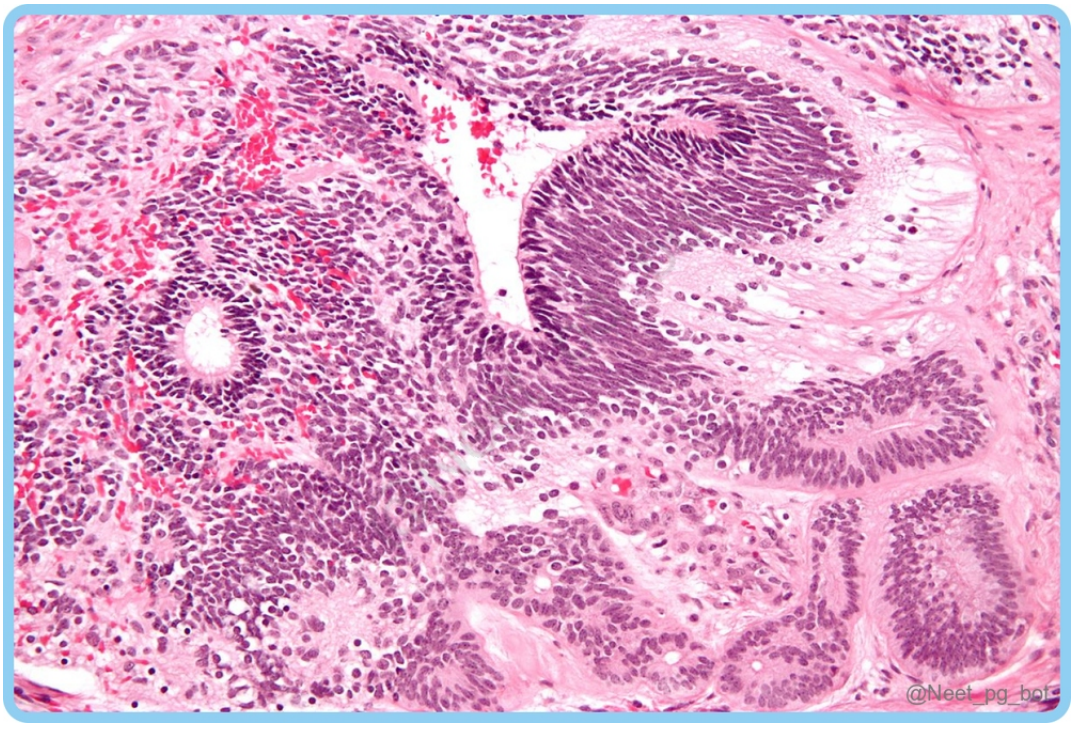

References:

Robbins & Cotran Pathologic Basis of Disease, 10th Edition, Page 970

↑ *Back to this question in Part A*

Q11: Which of the following is not a component of Meigs syndrome? (Q857125)

A. Ascites

B. Right-sided hydrothorax

C. Fibromas of ovary

D. Dysgerminoma of ovary

Correct Answer: D. Dysgerminoma of ovary

Explanation: Dysgerminoma is a type of germ cell tumour and is not part of Meigs syndrome. Meigs Syndrome: Meigs syndrome is a condition characterised by a triad of: Ovarian fibroma (fibrothecoma) Ascites Hydrothorax (pleural effusion) {{caption_text}} {{caption_text}}

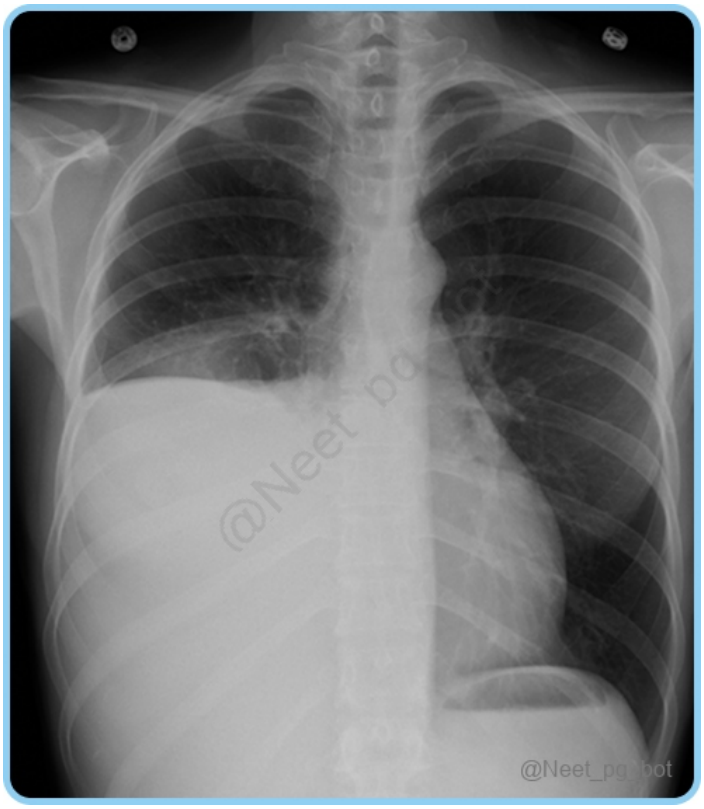



References:

Robbins & Cotran Pathologic Basis of Disease, 10th Edition, Page 1027

↑ *Back to this question in Part A*

@Neet_pg_bot

Q12: Which of the following statements is accurate concerning liquid-based cytology? (Q856890)

A. Urine specimen is used

B. Sanger sequencing is used

C. Study of fluid in the tumor microenvironment

D. DNA is collected in microvessels

Correct Answer: A. Urine specimen is used

Explanation: Liquid-based cytology is often used to collect specimens, including urine, and study cells for various diagnostic purposes. Liquid-based cytology: It is a technique to collect and prepare cell samples for microscopic

analysis. It involves gathering cells from various body fluids, such as cervical or vaginal fluids, respiratory secretions, or urine, depending on the diagnostic goal. This method is commonly used for cervical cancer screening. Cells collected from the cervix with a brush or spatula are suspended in a preservative solution. This suspension is used to prepare slides for cytological examination to detect abnormalities or disease. Advantages of Liquid-Based Cytology (LBC): Improved slide preparation: LBC creates a thin-layer or monolayer slide preparation, providing better quality and clarity than conventional Papanicolaou (Pap) smears. Enhanced cell preservation: The collection fluid used in LBC fixes, homogenizes, and rinses the cells, ensuring better preservation for microscopic examination. Reduced sample contamination: The homogenization process minimizes the presence of non-representative material, such as blood or mucus, leading to a more accurate analysis of the collected cells. Increased diagnostic accuracy: With improved sample quality, LBC enhances the sensitivity and specificity of cervical cancer screening, allowing for more reliable detection of abnormalities. Disadvantage: Although cervical cytological screening has proven effective in reducing the incidence and mortality of cervical cancer, the conventional Pap test is less sensitive than commonly thought. The false-negative rate of the conventional Pap test has been reported to reach as high as 50%.

References:

https://www.gfmer.ch/GFMER_members/pdf/Liquid-based-cytology-Abd-El-Hafez-2010.pdf

↑ *Back to this question in Part A*

@Neet_pg_bot

Q13: Which of the following is not a constituent of the Papanicolaou stain? (Q856892)

A. Light green SF

B. Orange G

C. Eosin B

D. Hematoxylin

Correct Answer: C. Eosin B

Explanation: Eosin B is not a constituent of the Papanicolaou stain. Eosin is a different type of stain typically used for general histology to highlight cytoplasm in tissues, but it is not used in the Papanicolaou (Pap) stain. The Papanicolaou (Pap) stain is a widely used technique for examining cells from the cervix to screen for cervical cancer and other abnormalities. It uses a combination of multiple dyes to differentiate cellular components: Hematoxylin - Stains the cell nuclei, allowing for clear visualization of nuclear structure. Orange G - Stains keratinized cells orange, highlighting squamous cells. Eosin A - Second counterstain & a polychrome mixture of Eosin Y and Light Green (stains cytoplasm and helps differentiate between various cell types). {{caption_text}}

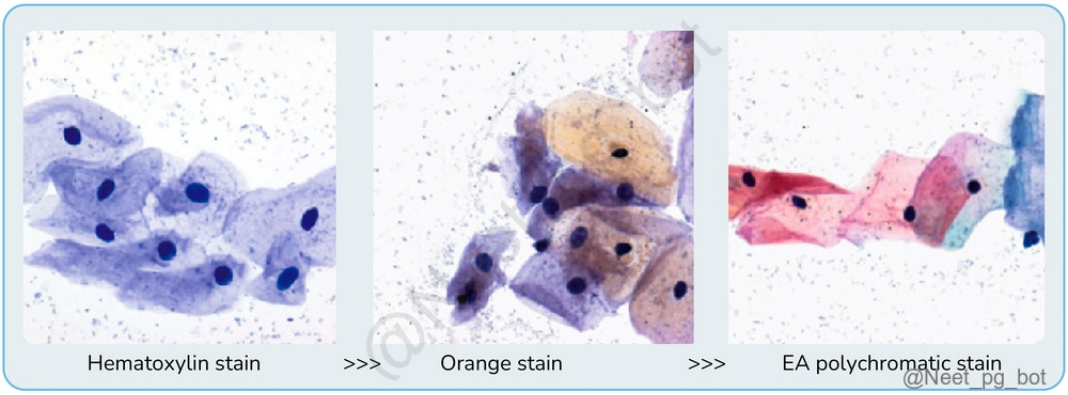

References:

Bancroft's Theory and Practice of Histological Techniques, 8th Edition, Page 132

↑ *Back to this question in Part A*

@Neet_pg_bot

• [13_Endocrinology] 056 Thyroid Gland

« Back to Folder Directory

[13_Endocrinology] 056 Thyroid Gland — Quick Jump

Q1 (p. 2334) *Q2 (p. 2339)* *Q3 (p. 2340)* *Q4 (p. 2342)* *Q5 (p. 2343)* *Q6 (p. 2343)*
Q7 (p. 2344) *Q8 (p. 2345)* *Q9 (p. 2346)* *Q10 (p. 2347)* *Q11 (p. 2348)* *Q12 (p. 2350)*
Q13 (p. 2351) *Q14 (p. 2353)* *Q15 (p. 2354)* *Q16 (p. 2357)* *Q17 (p. 2358)* *Q18 (p. 2359)*
Q19 (p. 2359) *Q20 (p. 2361)* *Q21 (p. 2362)* *Q22 (p. 2364)*

Q1: A 40-year-old patient presents with a nodule in the anterior neck and lymphadenopathy. The tumour is found to have spread to the lymphatics. Histopathological examination shows characteristic findings. What is the most likely diagnosis? (Q845553)

A. Follicular thyroid carcinoma

B. Medullary thyroid carcinoma

C. Papillary thyroid carcinoma

D. Anaplastic thyroid carcinoma

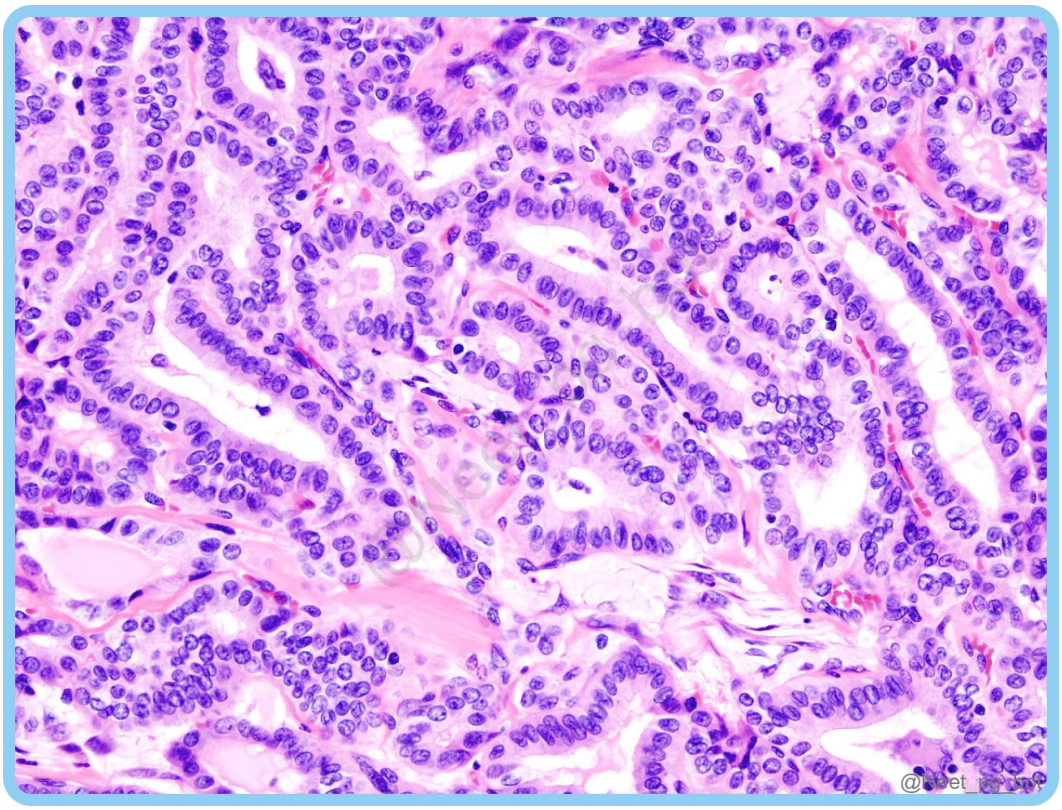

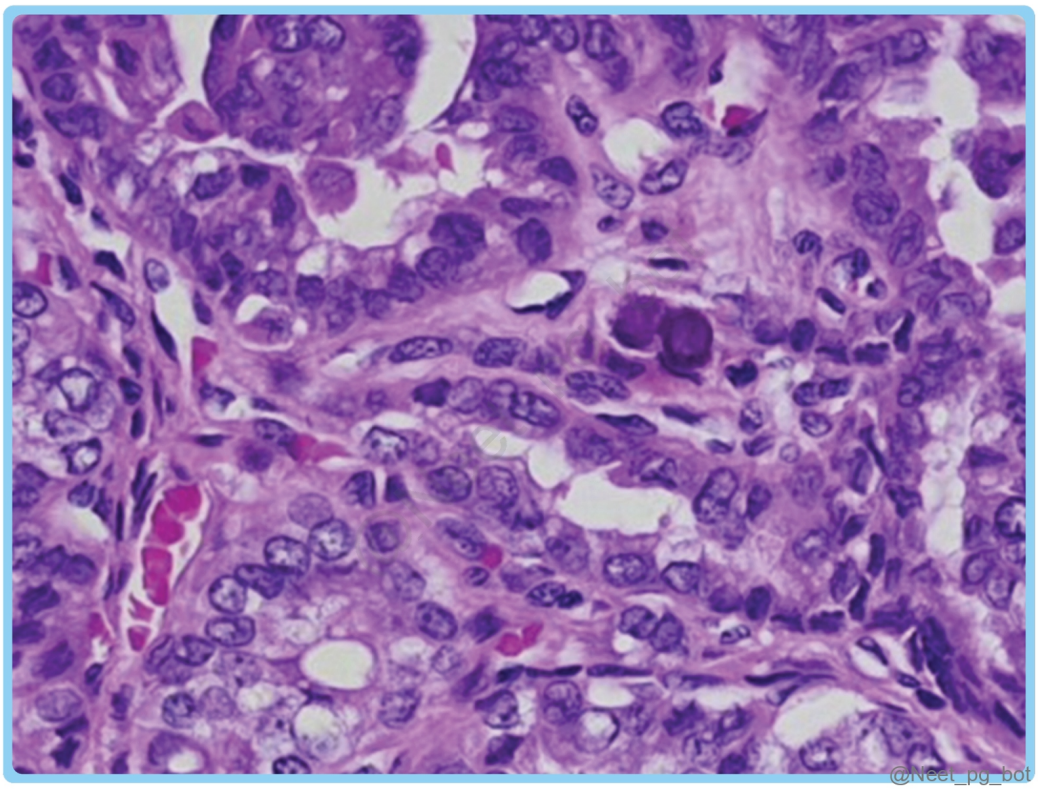

Correct Answer: C. Papillary thyroid carcinoma

■ *Listen (English)*

■ *Listen (Hindi)*

Explanation: The above features and HPE showing psammoma bodies, nuclear grooves, and " Orphan Annie eye" nucle i are indicative of papillary thyroid carcinoma. This is the most common type of thyroid cancer and is characterised by lymphatic spread. Clinical features: Thyroid nodule + Lymphadenopathy Microscopy (Biopsy): True papilla Fibrovascular core Fingerlike projections with central core of fibrovascular tissue. (Image 1) Psammoma bodies (Dystrophic calcification) Blue colour bodies (Image 2) Orphan Annie eye nucleus Optically clear nucleus Formalin artifact Seen on biopsy Not seen on FNAC INCI - Intranuclear cytoplasmic inclusion Nuclear groove/Coffee bran nucleus Microscopy (FNAC): Chewing gum colloid

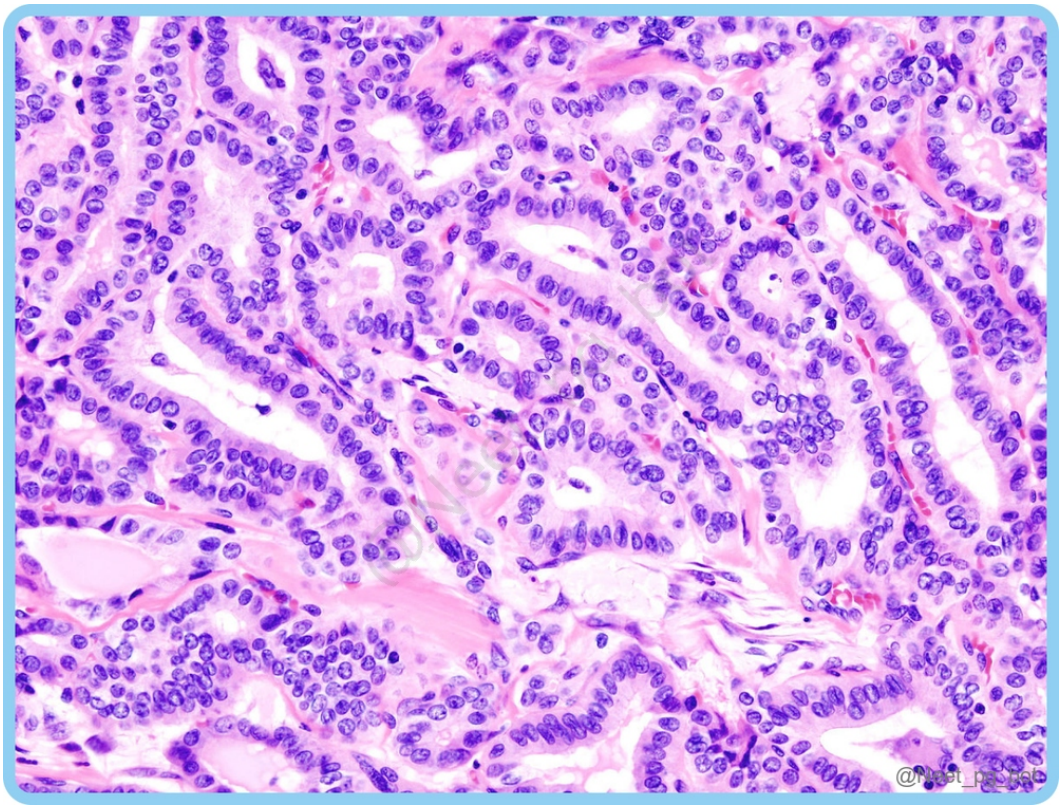

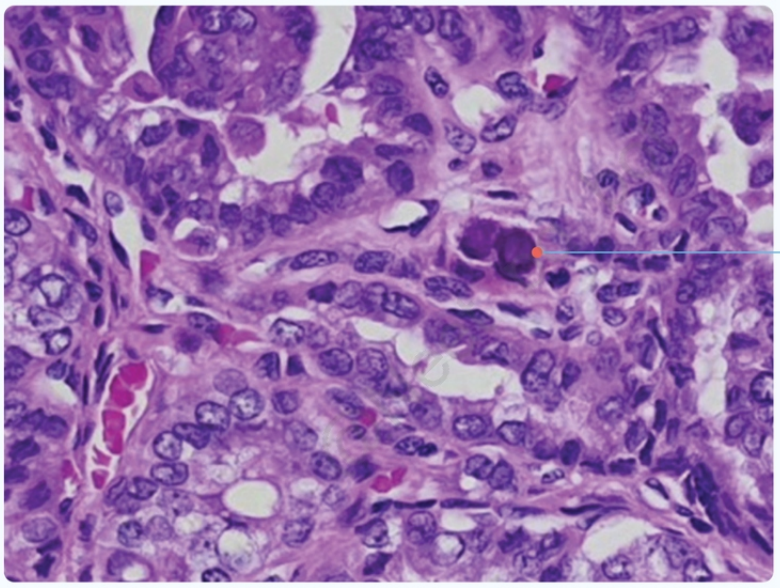

@Neet_pg_bot

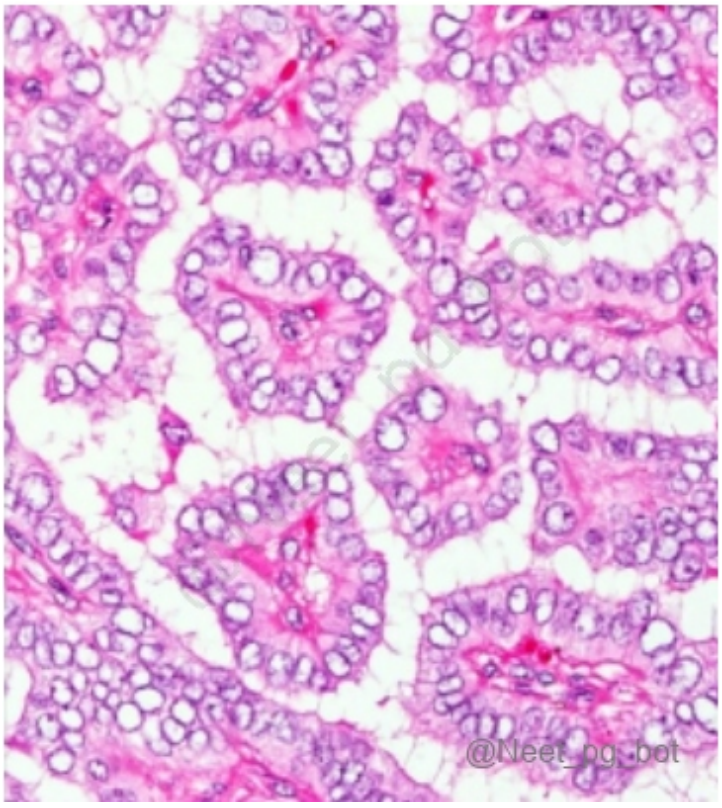

@Neet_pg_bot

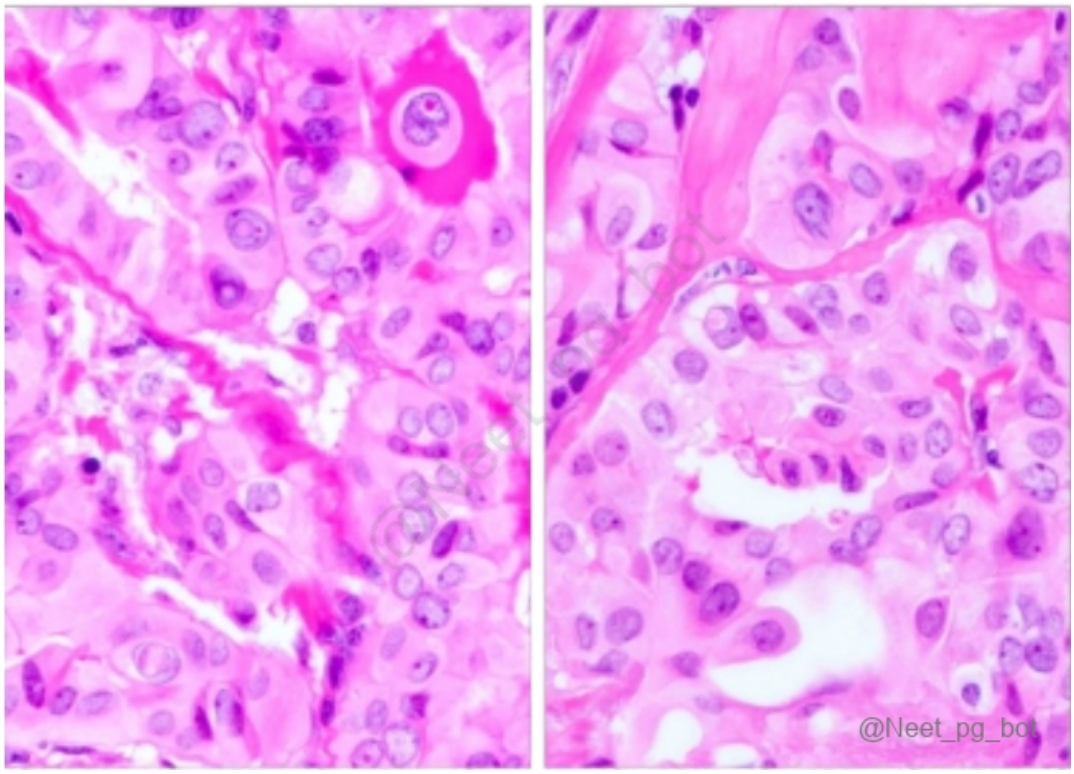
@Neet_pg_bot

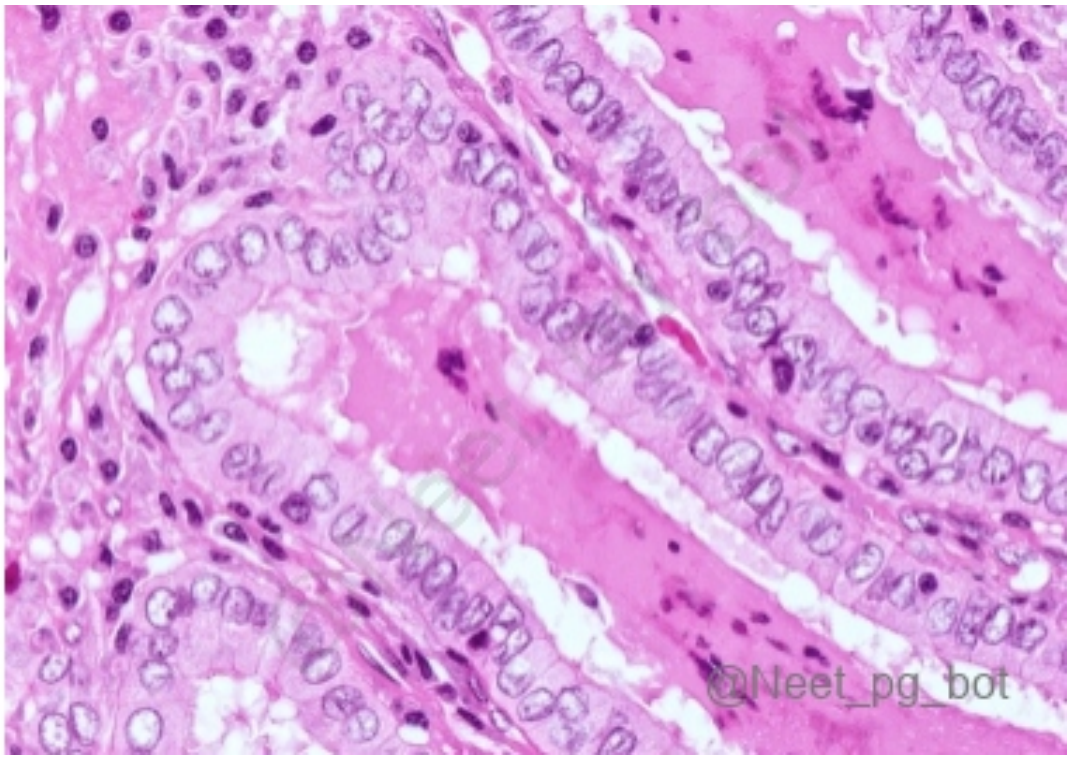
@Neet_pg_bot

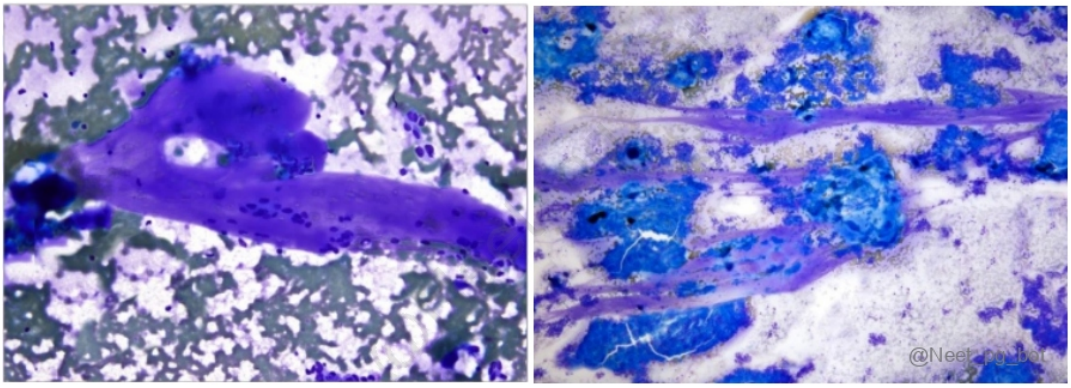

References:

Robbins & Cotran Pathologic Basis of Disease, 10th Edition, Page 1088.

↑ *Back to this question in Part A*

@Neet_pg_bot

Q2: A 35-year-old patient is diagnosed with papillary thyroid carcinoma. Which of the following statements about papillary thyroid carcinoma is true? (Q890473)

A. Not associated with radiation exposure

B. Hot nodule on scintigraphy

C. Accounts for 85% of thyroid cancers

D. Has a poor prognosis

Correct Answer: C. Accounts for 85% of thyroid cancers

Explanation: Papillary thyroid carcinoma (PTC) is the most common thyroid cancer , representing approximately 85% of cases . Papillary Thyroid Carcinoma (PTC): Most common thyroid cancer (~85%) Age: 25-50 years Strongly associated with prior ionising radiation (Option A) Morphology: Gross: Solitary/multifocal, cystic, may calcify Microscopic: Branching papillae, Orphan Annie nuclei , nuclear grooves, pseudoinclusions, psammoma bodies , lymphatic invasion common Clinical features: Usually asymptomatic nodule or cervical lymphadenopathy Advanced: hoarseness, dysphagia, cough, dyspnea Diagnosis: FNA cytology reliable Cold nodule on scintigraphy (Option B) Molecular testing for indeterminate cytology Prognosis/Management: 10-year survival >95% (Option D) Lobectomy for low-risk; total thyroidectomy + radioactive iodine for high-risk Recurrence 5-20%; distant metastases 10-15% Poor prognosis: age >55, extrathyroidal extension, metastases

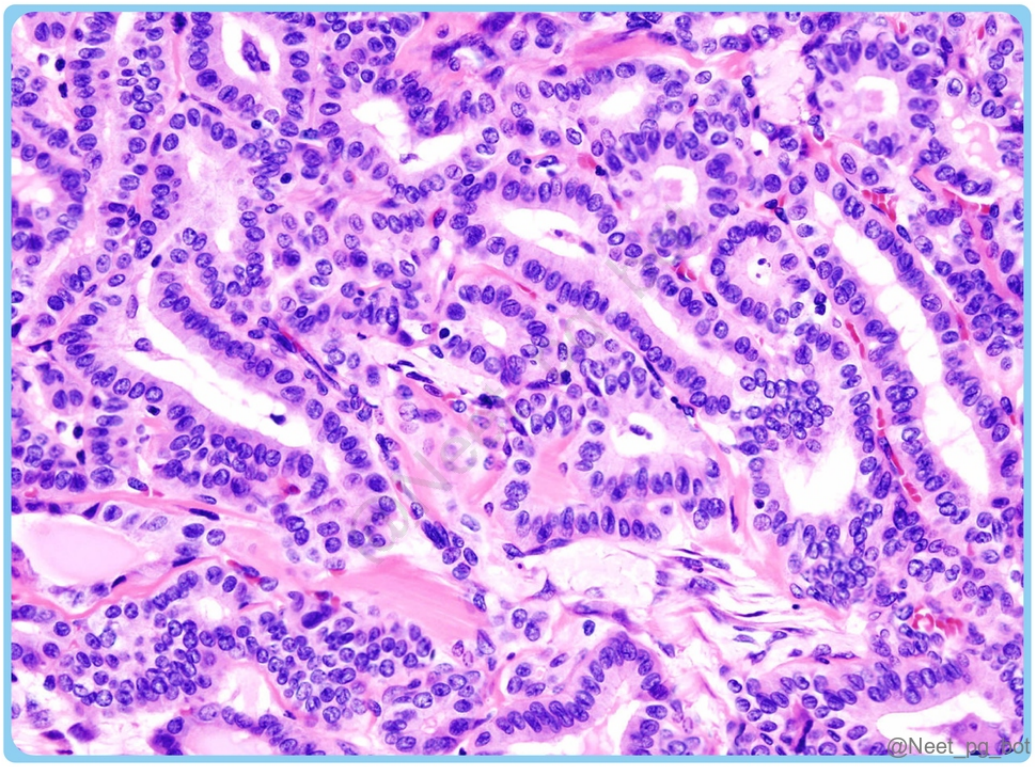

References:

Robbins, Cotran & Kumar, Pathologic Basis of Disease, 11th Edition, Pages 989, 990

↑ *Back to this question in Part A*

@Neet_pg_bot

Q3: A 32-year-old woman presents with a midline neck swelling that moves with deglutition and tongue protrusion. The swelling has been present since childhood but has recently increased in size. Surgical excision is performed. Histopathological examination reveals the following findings. What is the most likely diagnosis? (Q890469)

A. Follicular carcinoma

B. Papillary carcinoma

C. Medullary carcinoma

D. Anaplastic carcinoma

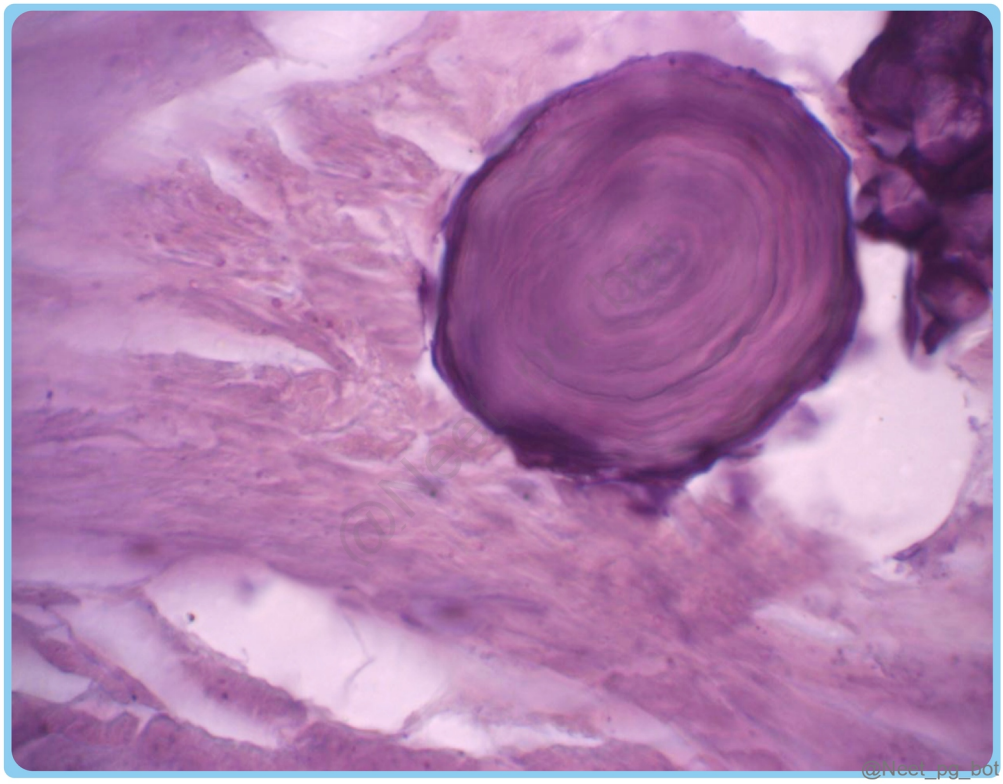

Correct Answer: B. Papillary carcinoma

Explanation: The image shows a psammoma body , characterised by concentric lamellated calcification . Psammoma bodies are a characteristic feature of papillary thyroid carcinoma (PTC) and are commonly found within papillary structures or adjacent stroma. The clinical presentation of a midline neck swelling that moves with tongue protrusion suggests a thyroglossal cyst , which may contain ectopic thyroid tissue . Papillary carcinoma can arise in this ectopic thyroid tissue Papillary Thyroid Carcinoma (PTC): Most common thyroid cancer (~85%) Age: 25-50 years Strongly associated with prior ionising radiation Microscopic features: Branching papillae with fibrovascular cores Orphan Annie eye nuclei (clear nuclei with finely dispersed chromatin) Nuclear grooves and intranuclear pseudoinclusions Psammoma bodies (concentric calcifications) Lymphatic invasion is common, vascular invasion is uncommon Clinical features: Usually asymptomatic thyroid nodule May present with an enlarged cervical lymph node Advanced disease: hoarseness, dysphagia, dyspnea Follicular carcinoma (Option A): Characterised by follicular architecture with capsular and vascular invasion; lacks the nuclear features of papillary carcinoma. Medullary carcinoma (Option C): Arises from parafollicular (C) cells and produces calcitonin; does not show papillary structures or characteristic nuclear features. Anaplastic carcinoma (Option D): Highly aggressive, undifferentiated tumour in elderly patients; shows marked pleomorphism without papillary architecture or nuclear features.

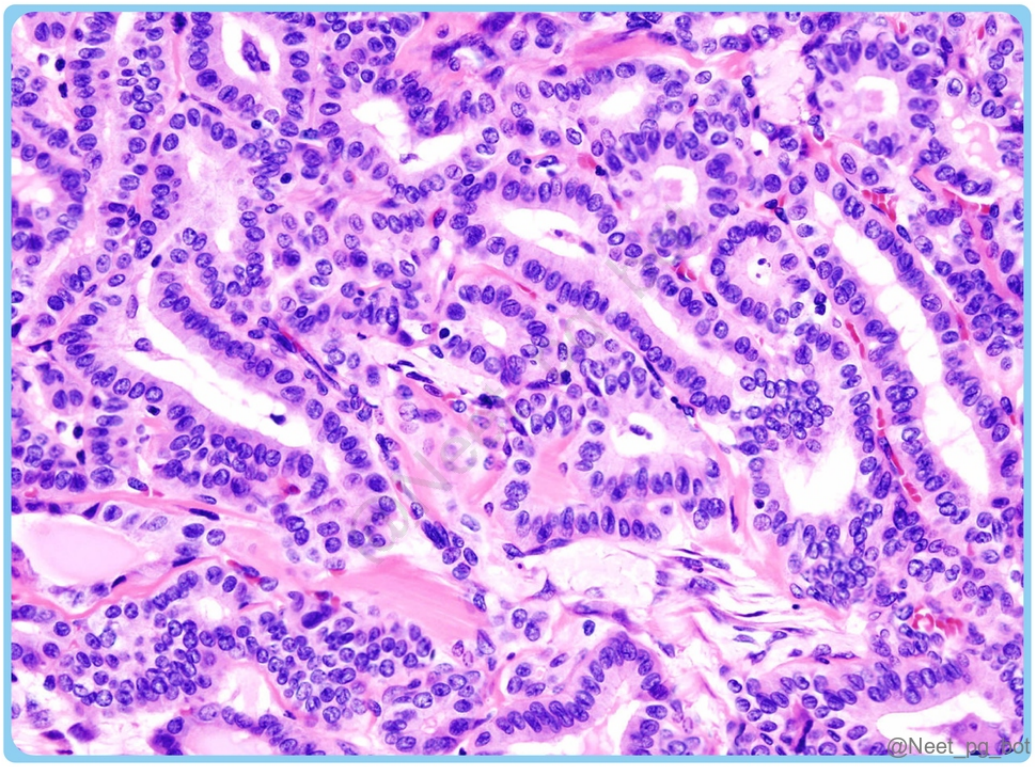

References:

Robbins, Cotran & Kumar, Pathologic Basis of Disease, 11th Edition, Pages 989, 990

↑ *Back to this question in Part A*

@Neet_pg_bot

Q4: Which of the following correctly represents the most common and least common thyroid carcinomas, respectively? (Q890467)

A. Papillary carcinoma - Anaplastic carcinoma

B. Follicular carcinoma - Medullary carcinoma

C. Medullary carcinoma - Papillary carcinoma

D. Anaplastic carcinoma - Papillary carcinoma

Correct Answer: A. Papillary carcinoma - Anaplastic carcinoma

Explanation: Papillary thyroid carcinoma (~85%) is the most common , whereas anaplastic carcinoma (<1%) is the least common and most aggressive thyroid cancer. Thyroid Carcinomas: Major Subtypes & Frequency: Papillary thyroid carcinoma (PTC) (~85% of cases) Follicular or oncocytic thyroid carcinoma (~5-15% of cases) High-grade

differentiated and poorly differentiated carcinoma (~5% of cases) Anaplastic (undifferentiated) carcinoma (~1% of cases) Medullary thyroid carcinoma (a neoplasm of C cells) (<5% of cases)

References:

Robbins, Cotran & Kumar, Pathologic Basis of Disease, 11th Edition, Page 988

↑ *Back to this question in Part A*

@Neet_pg_bot

Q5: Which of the following is the correct statement regarding a solitary thyroid nodule? (Q890465)

A. Most often malignant

B. Incidence decreases with age

C. Rare in the general population

D. Higher risk of malignancy than multiple nodules

Correct Answer: D. Higher risk of malignancy than multiple nodules

Explanation: A solitary thyroid nodule is more likely to be neoplastic and has a higher risk of malignancy compared with multinodular goitre. However, most nodules are still benign , and the incidence increases with age and they are relatively common . Solitary Thyroid Nodule: A solitary thyroid nodule (STN) is a clinically palpable, discrete swelling in the thyroid gland, although many such nodules are actually part of multinodular disease on ultrasonography . Present in up to 50% (autopsy studies) (Option C) Incidence increases with age (Option B) Clinical significance: Primary concern: malignancy Most nodules are benign (Option A) (multinodular goitre, cysts, thyroiditis, follicular adenoma) Risk factors for malignancy: Male sex Extremes of age (<20 or >60 years) History of head & neck radiation Rapid growth, hard nodule, cervical lymphadenopathy

References:

Robbins, Cotran & Kumar, Pathologic Basis of Disease, 11th Edition, Page 987

↑ *Back to this question in Part A*

@Neet_pg_bot

Q6: A 45-year-old woman presents with painful enlargement of the thyroid following an upper respiratory infection. Laboratory tests show ↑ T3/T4, ↓ TSH, and low radioactive iodine uptake. What is the most likely diagnosis? (Q890464)

A. Hashimoto thyroiditis

B. Graves disease

C. Subacute granulomatous thyroiditis

D. Riedel thyroiditis

Correct Answer: C. Subacute granulomatous thyroiditis

Explanation: The most likely diagnosis is subacute granulomatous thyroiditis , suggested by a painful thyroid enlargement following a viral upper respiratory infection , with transient thyrotoxicosis (↑T3/T4, ↓TSH) and low radioactive iodine uptake , due to release of preformed thyroid hormones from damaged follicles. Subacute Granulomatous Thyroiditis (de Quervain): Age: 40-50 years F:M = 4:1 Etiology: Post-viral (URTI) Viruses: Coxsackie, SARS-CoV-2, mumps, measles, adenovirus Pathology: Granulomatous inflammation Multinucleated giant cells around colloid Damaged/collapsed follicles Later fibrosis Clinical features: The most common cause of painful thyroid Transient thyrotoxicosis (2-6 weeks) ↑T3/T4, ↓TSH Low radioactive iodine uptake May have a temporary hypothyroid phase Recovery in 6-8 weeks Hashimoto thyroiditis (Option A) : Painless autoimmune hypothyroidism with lymphocytic infiltration and Hürthle cells. Graves disease (Option B) : Hyperthyroidism with diffuse goiter and increased radioactive iodine uptake . Riedel thyroiditis (Option D) : Extensive fibrosis producing a hard, fixed thyroid mass that may mimic carcinoma.

References:

Robbins, Cotran & Kumar, Pathologic Basis of Disease, 11th Edition, Page 983

↑ *Back to this question in Part A*

@Neet_pg_bot

Q7: Which of the following is the most common cause of hypothyroidism in iodine-sufficient areas? (Q890463)

A. Hashimoto thyroiditis

B. Wolff-Chaikoff effect

C. Pituitary failure

D. Thyroid agenesis

Correct Answer: A. Hashimoto thyroiditis

Explanation: Hashimoto thyroiditis is the most common cause of hypothyroidism in iodine-sufficient regions. It is an autoimmune disease characterised by destruction of thyroid follicles and the presence of anti-thyroid peroxidase and anti-thyroglobulin antibodies . Hypothyroidism: ↓ thyroid hormone production due to dysfunction of the

thyroid, pituitary, or hypothalamus 10× more common in females Primary Hypothyroidism (Most common): Due to intrinsic thyroid disease Causes: Hashimoto thyroiditis - most common in iodine-sufficient areas Iodine deficiency Post-ablative (thyroid surgery, radioiodine, irradiation) Drugs: lithium, amiodarone, thionamides Congenital defects Thyroid agenesis/hypoplasia Dyshormonogenesis Secondary (Central) Hypothyroidism: Due to pituitary failure → ↓ TSH Tertiary Hypothyroidism: Due to hypothalamic disease → ↓ TRH Wolff-Chaikoff effect (Option B): The Wolff-Chaikoff effect refers to a temporary inhibition of thyroid hormone synthesis following exposure to large amounts of iodine. Although it may cause transient hypothyroidism in certain situations, it is not the most common cause of hypothyroidism. Pituitary failure (Option C): Pituitary failure leads to secondary (central) hypothyroidism due to decreased secretion of thyroid-stimulating hormone (TSH). However, central hypothyroidism is much less common than primary hypothyroidism caused by thyroid gland disorders. Thyroid agenesis (Option D): Thyroid agenesis is a congenital absence of the thyroid gland and is an important cause of congenital hypothyroidism , but it is rare and not the most common cause of hypothyroidism in the general population.

References:

Robbins, Cotran & Kumar, Pathologic Basis of Disease, 11th Edition, Pages 980, 981, 983

↑ *Back to this question in Part A*

@Neet_pg_bot

Q8: Which of the following histopathological features is not typically seen in Hashimoto thyroiditis? (Q890447)

A. Lymphoid follicles with germinal centres

B. Hürthle (oncocytic) cell change

C. Fibrosis extending beyond the thyroid capsule

D. Dense mononuclear inflammatory infiltrate

Correct Answer: C. Fibrosis extending beyond the thyroid capsule

Explanation: Fibrosis extending beyond the thyroid capsule is characteristic of Riedel thyroiditis and is not seen in Hashimoto thyroiditis. In Hashimoto thyroiditis, fibrosis may be present but remains confined within the gland. Hashimoto Thyroiditis - Morphology: Thyroid gland: Diffusely enlarged, well-demarcated Cut surface: Pale, yellow-tan, firm, slightly nodular Microscopy: Dense mononuclear inflammatory infiltrate (Option D) Lymphocytes Plasma cells Lymphoid follicles with germinal centres (Option A) Atrophic thyroid follicles Hürthle (Oncocytic) Cell Change: (Option B) Follicular epithelial cells with abundant eosinophilic granular cytoplasm Represents metaplastic response to chronic injury On FNAC: oncocytes + mixed lymphocytes → characteristic Fibrosis: Increased interstitial connective tissue Does not extend beyond the thyroid capsule (unlike Riedel thyroiditis)

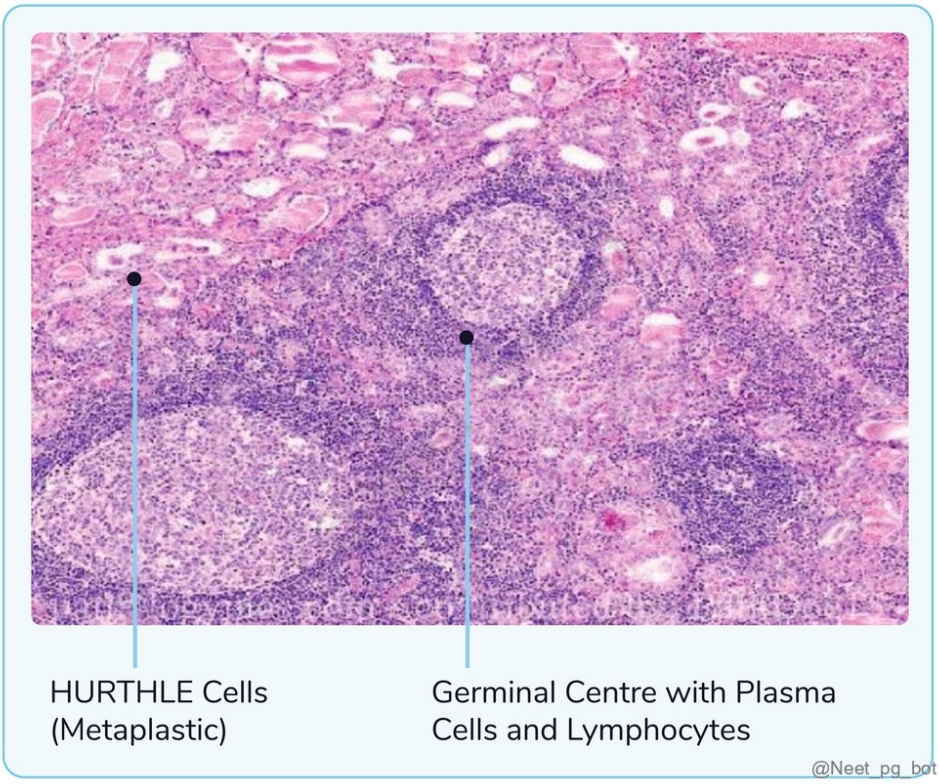

References:

Robbins, Cotran & Kumar, Pathologic Basis of Disease, 11th Edition, Page 982

↑ *Back to this question in Part A*

@Neet_pg_bot

Q9: Which of the following statements regarding hyperthyroidism is correct? (Q890446)

A. Graves' disease is the most common cause of hyperthyroidism.

B. Serum TSH levels are increased in primary hyperthyroidism.

C. Osteoporosis is not a complication

D. Constipation is a typical feature of hyperthyroidism.

Correct Answer: A. Graves' disease is the most common cause of hyperthyroidism.

Explanation: Graves' disease accounts for approximately 85% of cases of hyperthyroidism and is the most common cause. It results from autoantibodies that stimulate the TSH receptor, leading to increased thyroid

hormone production. Hyperthyroidism: Hyperthyroidism: thyrotoxicosis due to thyroid gland hyperfunction Common causes: Graves' disease (~85%) Toxic multinodular goitre Toxic adenoma Rare: TSH-secreting pituitary tumor Other Causes (without ↑ hormone production): Subacute thyroiditis Painless thyroiditis Struma ovarii Factitious thyrotoxicosis Clinical features: Weight loss despite ↑ appetite Heat intolerance, sweating Warm, flushed skin Tachycardia, palpitations, atrial fibrillation Tremor, anxiety, insomnia Hyperdefecation (Option D) Lid lag, staring gaze Proptosis (Graves disease) Complications: Osteoporosis (Option C) Thyroid storm (life-threatening) Apathetic hyperthyroidism in the elderly Lab findings: Primary: ↓ TSH, ↑ T4 (Option B) T3 toxicosis: ↑ T3 only Secondary: normal/↑ TSH

References:

Robbins, Cotran & Kumar, Pathologic Basis of Disease, 11th Edition, Pages 979, 980

↑ *Back to this question in Part A*

@Neet_pg_bot

Q10: A 45-year-old patient presents with a painless lump on the front of the neck, bone pain, fatigue, and episodes of flushed skin. Genetic studies reveal a mutation in the RET gene. Which type of amyloid is typically deposited in this condition? (Q845555)

A. A-β

B. A-CAL

C. A-L

D. A-TTR

Correct Answer: B. A-CAL

■ *Listen (English)*

■ *Listen (Hindi)*

Explanation: The given scenario and mutation are associated with medullary thyroid carcinoma, which has amyloid deposition derived from calcitonin, known as A-CAL. Medullary carcinoma of the thyroid is a neuroendocrine tumour arising from parafollicular C cells. In this condition, excess calcitonin is secreted (a hormone that regulates calcium levels), leading to facial flushing and bone pain. When calcitonin is converted into amyloid, it is known as A-CAL type of amyloid. Types and mutation: Familial syndrome Sporadic: RET gene TEN (On chromosome 10) MED - Medullary carcinoma thyroid MEN (II a& II b) Tumor marker: ↑ Calcitonin → ACaL Microscopic examination: Pink extracellular ACaL Congo red stain: Apple green birefringence on polarizing microscopy Markers: Neuroendocrine markers + Medullary thyroid carcinoma with amyloid deposition:

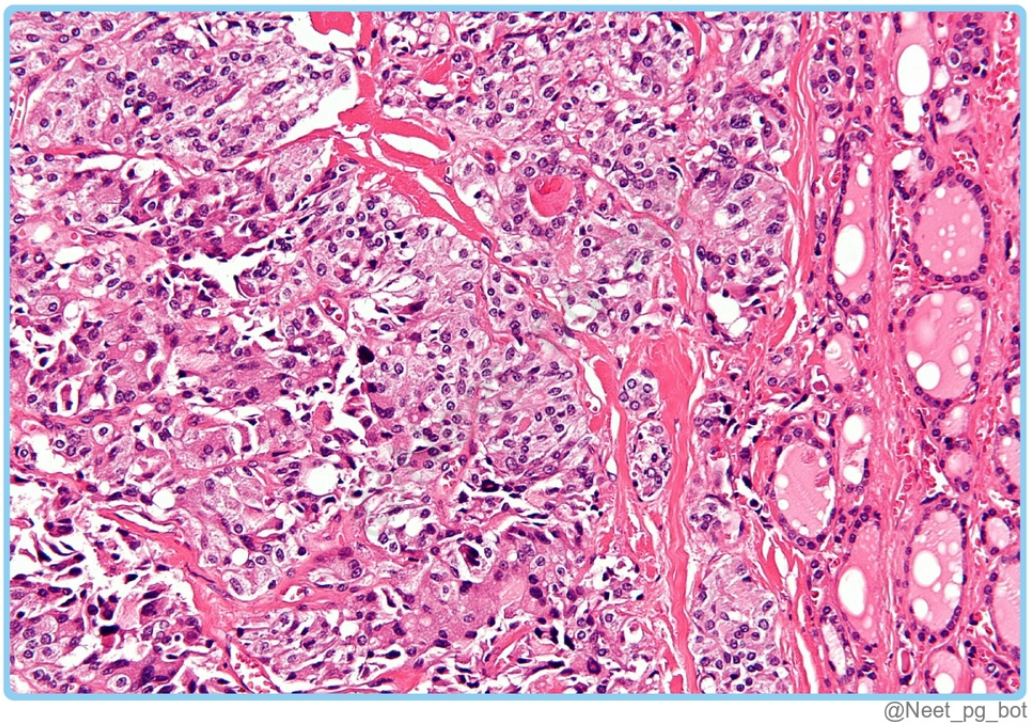

References:

Robbins & Cotran Pathologic Basis of Disease, 10th Edition, Pages 261, 1091.

↑ *Back to this question in Part A*

@Neet_pg_bot

Q11: Which of the following is not a common feature of follicular carcinoma of thyroid? (Q845554)

A. Second most common thyroid malignancy

B. Has a Hurthle cell variant

C. Commonly spreads by lymphatic route

D. FNAC is not helpful in diagnosis

Correct Answer: C. Commonly spreads by lymphatic route

■ *Listen (English)*

■ *Listen (Hindi)*

Explanation: Spread by lymphatic route is not a common feature of follicular carcinoma as they commonly spread by hematogenous route. It spreads through the hematogenous route, affecting bones and producing lytic lesions in the skull as well as other parts of the body. Follicular carcinoma of thyroid is the second common malignancy of thyroid following papillary carcinoma. Both follicular adenoma and carcinoma has a huethle cell variant. They are commonly associated with K-RAS mutation Capsular and vascular invasion on biopsy is a diagnostic feature of follicular carcinoma. FNAC is not helpful in diagnosis of follicular carcinomas because we cannot see capsular and vascular invasions by it. Capsular invasion: Vascular Invasion:

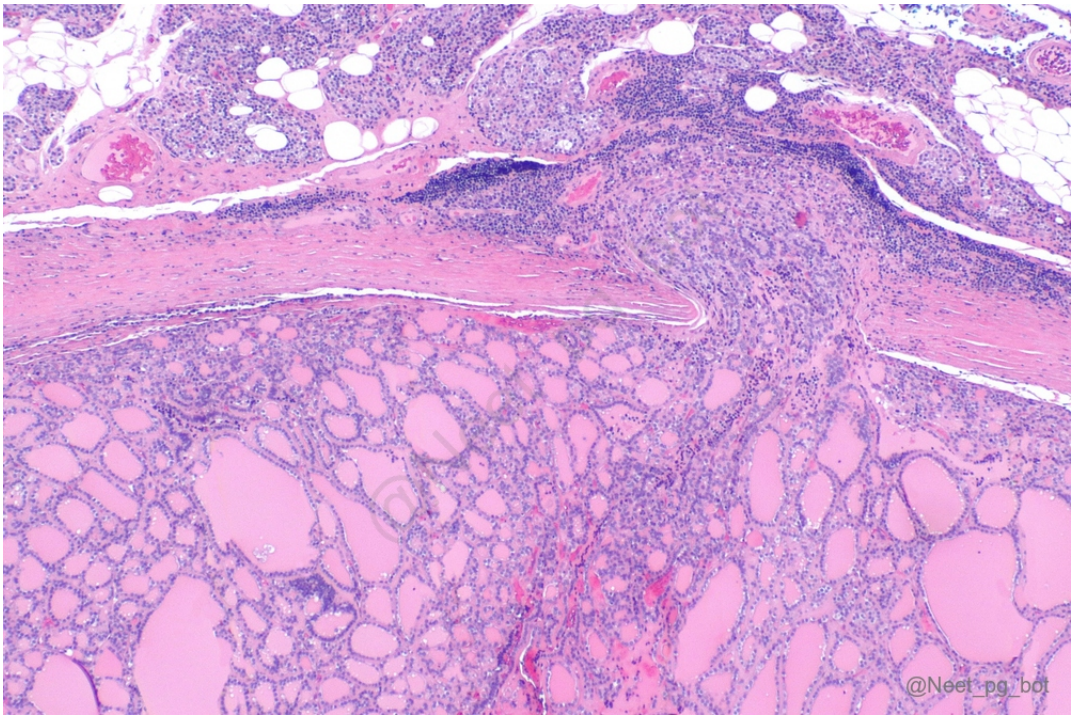

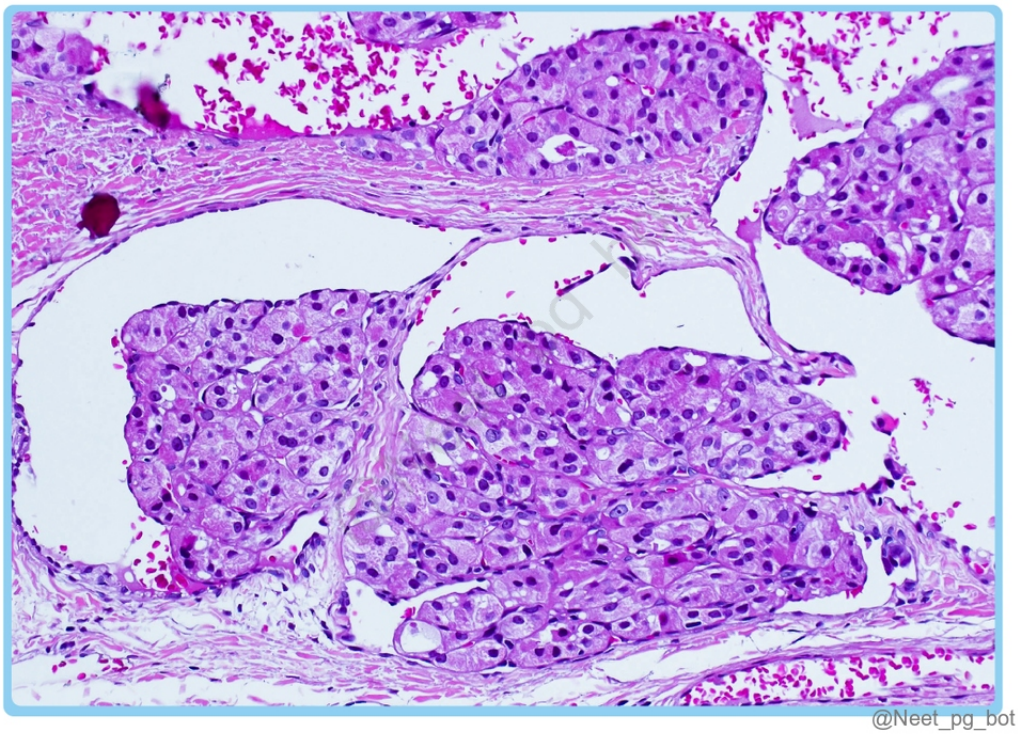

References:

Robbins & Cotran Pathologic Basis of Disease, 10th Edition, Page 1059-1090.

↑ *Back to this question in Part A*

@Neet_pg_bot

Q12: Which system is widely used for reporting thyroid cytopathology? (Q845542)

A. TIRADS

B. Gleason System

C. Bethesda System

D. Duke Classification

Correct Answer: C. Bethesda System

■ *Listen (English)*

■ *Listen (Hindi)*

Explanation: The Bethesda System for Reporting Thyroid Cytopathology (TBSRTC) is a standardised reporting system designed to classify thyroid Fine-Needle Aspiration Cytology (FNAC) biopsy results. The Bethesda system

is used to report: Thyroid FNAC Cervical cytology (pap smears or cervical smears) Breast FNAC Adequacy criteria of FNAC: ≥ 6 cell clusters ≥ 10 follicular cells /cluster Exception: Cancer cells Colloid cysts (↑↑ colloid) Inflammatory disorder (Hashimoto's thyroiditis) Bethesda system categories: Bethesda Category Diagnostic Category Risk of Malignancy (Approx.) Usual Management I Nondiagnostic / Unsatisfactory 5–10% Repeat FNA with ultrasound guidance II Benign 0–3% Clinical follow-up (Ultrasound) III AUS / FLUS (Atypia/Follicular Lesion of Undetermined Significance) 10–30% Repeat FNA, molecular testing, or lobectomy IV Follicular Neoplasm (or Suspicious for FN) 25–40% Surgical lobectomy V Suspicious for Malignancy 50–75% Near-total thyroidectomy or lobectomy VI Malignant 97–99% Thyroidectomy TIRADS (Thyroid Imaging Reporting and Data System) (Option A) is a classification system for reporting thyroid ultrasound findings, not cytopathology. Guides which nodules need FNA , but doesn't interpret cytology results Uses nodule features (composition, echogenicity, margins, calcifications, shape) to assign TR1-TR5 scores The Point System: Points are awarded for 5 features: Composition (solid vs. cystic), Echogenicity (darkness), Shape (taller than wide), Margins (irregular), and Echogenic Foci (calcifications). Categories: TR1/TR2: Benign/Not suspicious; no biopsy needed. TR3: Mildly suspicious; biopsy if ≥ 2.5 cm. TR4: Moderately suspicious; biopsy if ≥ 1.5 cm. TR5: Highly suspicious; biopsy if ≥ 1.0 cm. Gleason’s System (Option B) is used to grade prostate cancer based on histological patterns. Unlike Bethesda (which uses categories), Gleason uses a "Score" based on architectural patterns: A pathologist looks for the most common pattern (Primary) and the second most common (Secondary). Each is graded 1 to 5. The Score: Expressed as a sum (e.g., 3 + 4 = 7). Grade 1-2: Glands look nearly normal. Grade 3: Well-formed, discrete glands. Grade 4: Fused, "cribriform," or ill-defined glands. Grade 5: No glands; sheets or nests of cells. Duke Classification (Option D) is a system for staging colorectal cancer. Duke A: Limited to the bowel wall (mucosa/submucosa). Duke B: Through the muscle layer of the bowel, but no lymph nodes. Duke C: Any depth of invasion with lymph node involvement. Duke D: Distant metastasis (e.g., to the liver or lungs).

References:

The Bethesda System for Reporting Thyroid Cytopathology, 3rd Edition, Page 4

↑ *Back to this question in Part A*

@Neet_pg_bot

Q13: Match each type of thyroid tumour with its most commonly associated risk factor: Thyroid Carcinoma Risk Factors: 1. Papillary thyroid carcinoma A. Iodine deficiency 2. Follicular thyroid carcinoma B. RET proto-oncogene mutations 3. Medullary thyroid carcinoma C. Radiation exposure 4. Anaplastic thyroid carcinoma D. History of a well-differentiated follicular neoplasm (Q845552)

A. 1-C, 2-A, 3-B, 4-D

B. 1-B, 2-C, 3-D, 4-A

C. 1-A, 2-D, 3-C, 4-B

D. 1-D, 2-B, 3-A, 4-C

Correct Answer: A. 1-C, 2-A, 3-B, 4-D

■ *Listen (English)*

■ *Listen (Hindi)*

Explanation: Feature Papillary Thyroid Carcinoma (PTC) Follicular Thyroid Carcinoma (FTC) Medullary Thyroid Carcinoma (MTC) Anaplastic Thyroid Carcinoma (ATC) Frequency Most common (85%) Second most common 5–10% Rarest (<2%) Origin Cell Follicular cell Follicular cell Parafollicular C-cells Follicular cell Common Age 30–50 years 40–60 years 40–60 (Sporadic) Elderly (>65 years) Risk Factors Radiation exposure (especially in childhood) Family history of thyroid cancer Hashimoto thyroiditis Thyroglossal cyst Iodine deficiency Long-standing Goiter. RET proto-oncogene mutations. Family history (e.g., MEN2 syndrome) Older age ¼ th of patients have a past history of a well-differentiated follicular neoplasm Previous radiation exposure Genetic Key Most common mutation: BRAFV600E Gene fusion: RET/PTC gene fusion RAS / PAX8-PPAR γ RET mutation p53 mutation Spread Path Lymphatic (Cervical) Hematogenous (Bone/Lung) Lymphatic & Hemato Local invasion (Aggressive) Tumor Marker Thyroglobulin Thyroglobulin Calcitonin / CEA None (Undifferentiated) Prognosis Excellent Good Variable Very Poor (<6 months) Histopathology Orphan Annie eye nuclei Nuclear grooves Intranuclear inclusions Psammoma bodies Uniform follicles Capsular invasion Vascular invasion Amyloid stroma (Congo red positive) Polygonal cells Calcitonin positive Giant cells Spindle cells Highly pleomorphic Necrosis

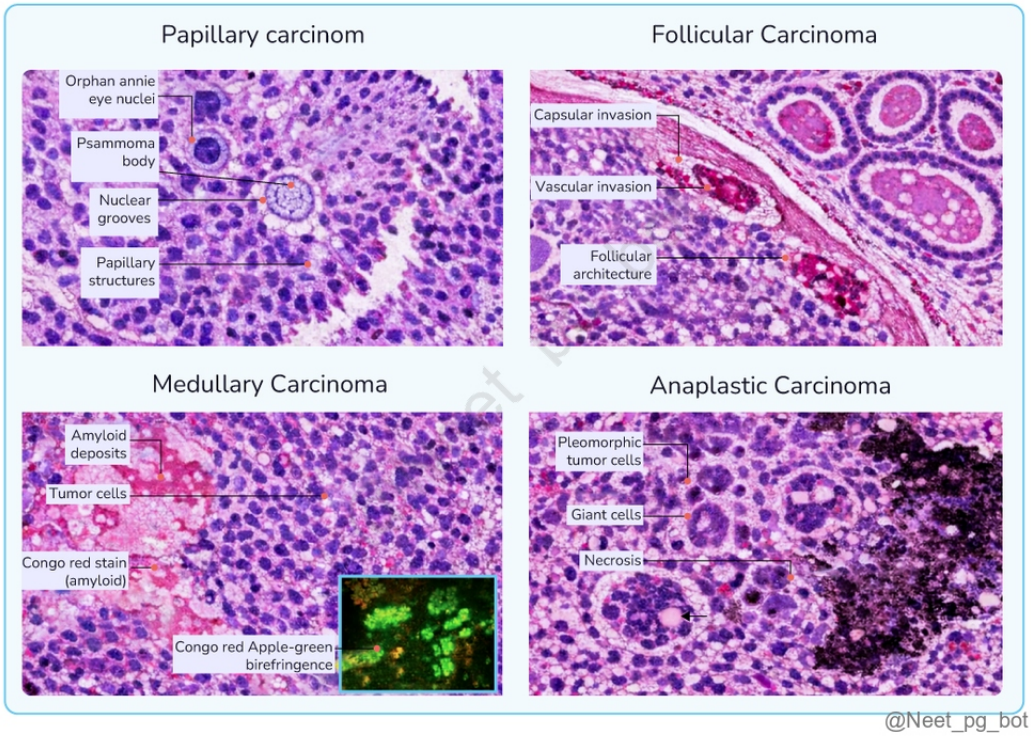

References:

Robbins and Cotran Pathologic basis of disease, 10th Edition, Pages 1086-91.

https://www.mayoclinic.org/diseases-conditions/thyroid-cancer/symptoms-causes/syc-20354161

https://www.ncbi.nlm.nih.gov/pmc/articles/PMC4052185/

↑ *Back to this question in Part A*

@Neet_pg_bot

Q14: A 55-year-old patient presents with a solitary thyroid nodule. The patient also reports difficulty swallowing, with no complaints of weight loss, fatigue, or heat intolerance. An excisional biopsy reveals >75% of the following characteristic cells. Which genetic mutation is most commonly associated with this type of thyroid tumour? {{caption_text}} (Q845551)

A. BRAF

B. GNAS

C. RAS

D. PTEN

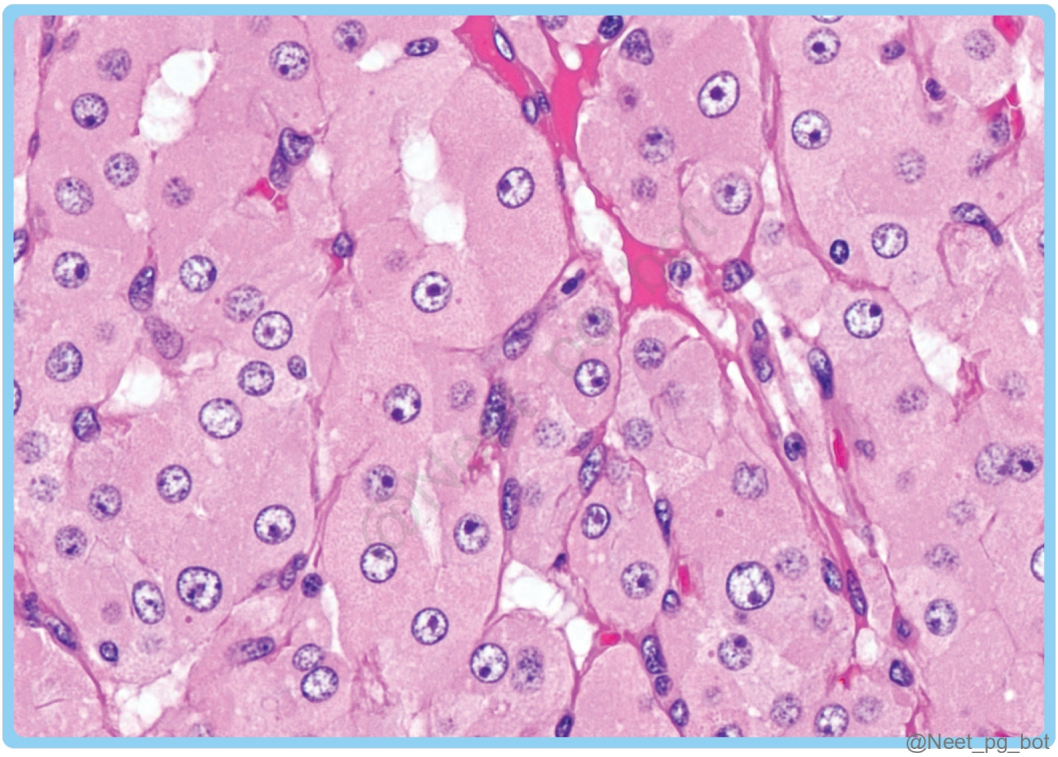

Correct Answer: C. RAS

■ *Listen (English)*

■ *Listen (Hindi)*

Explanation: The above image shows cells with abundant pinkish eosinophilic cytoplasm and small regular nuclei, suggesting Hurthle cells. The presence of >75% of these cells indicates a Hurthle cell adenoma , a rare thyroid neoplasm of follicular cell origin associated with RAS mutation. Hurthle cell adenomas are variants of follicular adenoma, and the presence of more than 75% of Hurthle cells is a key diagnostic feature. {{caption_text}} Thyroid Malignancy Mutations/Genetic Alterations Follicular Thyroid Adenoma (Benign Condition) RAS Papillary Thyroid Carcinoma (PTC) BRAF V600E RET/PTC rearrangements Follicular Thyroid Carcinoma (FTC) RAS PAX8-PPARγ rearrangements PIK3CA Medullary Thyroid Carcinoma (MTC) RET Anaplastic Thyroid Carcinoma (ATC) TP53

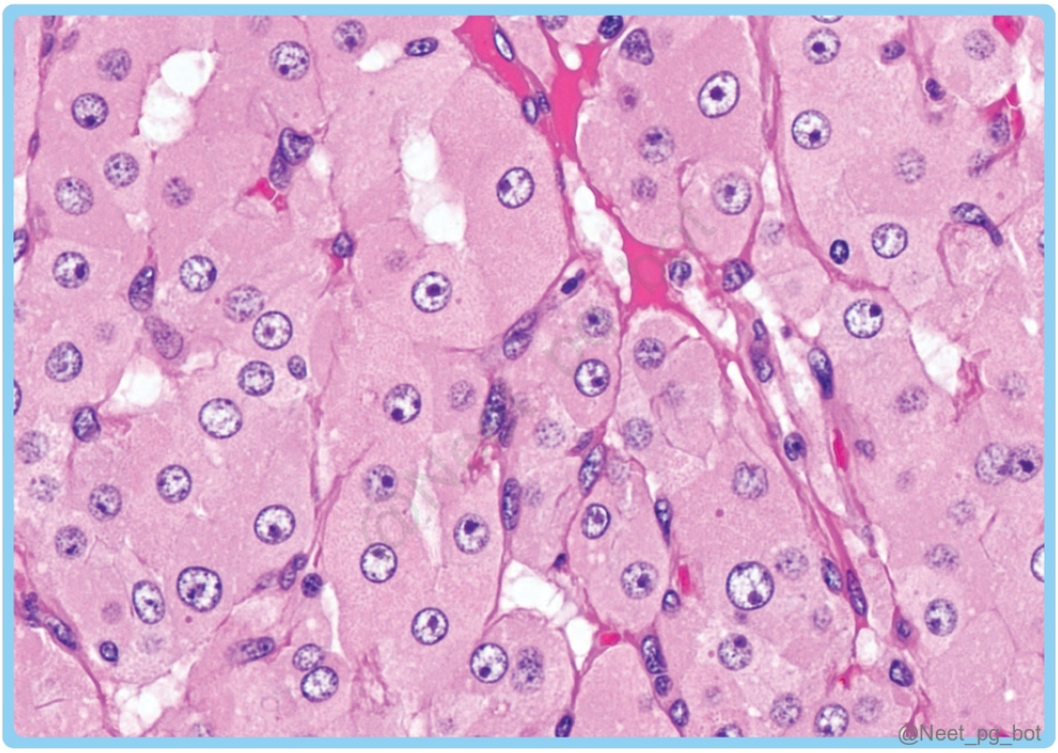

References:

Robbins and Cotran Pathologic basis of disease, 10th Edition, Page 1086. Hurthle cell tumours of the thyroid. Personal experience and review of the literature - PMC (nih.gov) https://www.ncbi.nlm.nih.gov/pmc/articles/PMC9312840/table/biomedicines-10-01515-t001/?report=objectonly https://www.ncbi.nlm.nih.gov/pmc/articles/PMC3228182/

↑ *Back to this question in Part A*

@Neet_pg_bot

Q15: What is the finding in the histopathological examination of a biopsy specimen from a patient with De Quervain Thyroiditis? (Q845550)

A. Extensive stromal fibrosis extending beyond the thyroid capsule

B. Follicular hyperplasia with scalloping colloid

C. Mononuclear infiltration with well-developed germinal centres

D. Mixed cellular infiltration with occasional multinucleated giant cells

Correct Answer: D. Mixed cellular infiltration with occasional multinucleated giant cells

■ *Listen (English)*

■ *Listen (Hindi)*

Explanation: Painful enlargement of the thyroid gland following a viral infection such as mumps or adenovirus infection is suggestive of De Quervain thyroiditis/Granulomatouus thyroiditis.. The microscopic findings include: Large multinucleated giant cells Giant cells with engulfed colloid Mixed cellular infiltration Extensive stromal fibrosis extending beyond the thyroid capsule (Option A): Seen in Riedel thyroiditis Follicular hyperplasia with scalloping colloid (Option B) is a feature of hyperthyroidism seen in Grave's disease. Mononuclear infiltration with well-developed germinal centres (Option C): Seen in lymphocytic or hashimotos's thyroiditis.

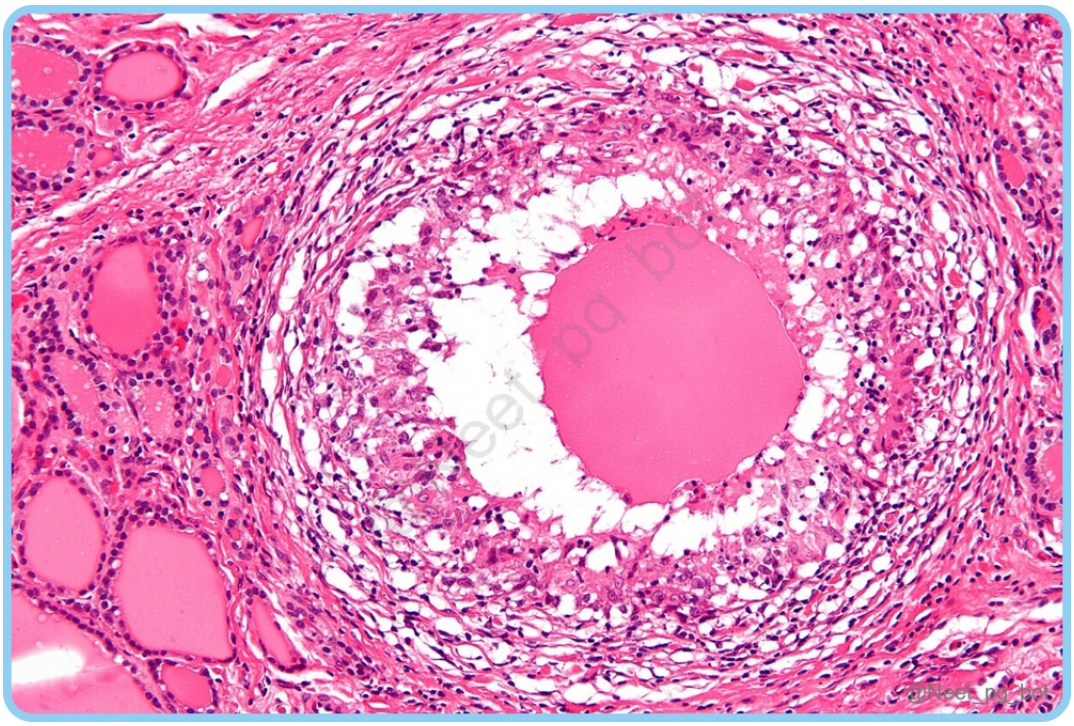

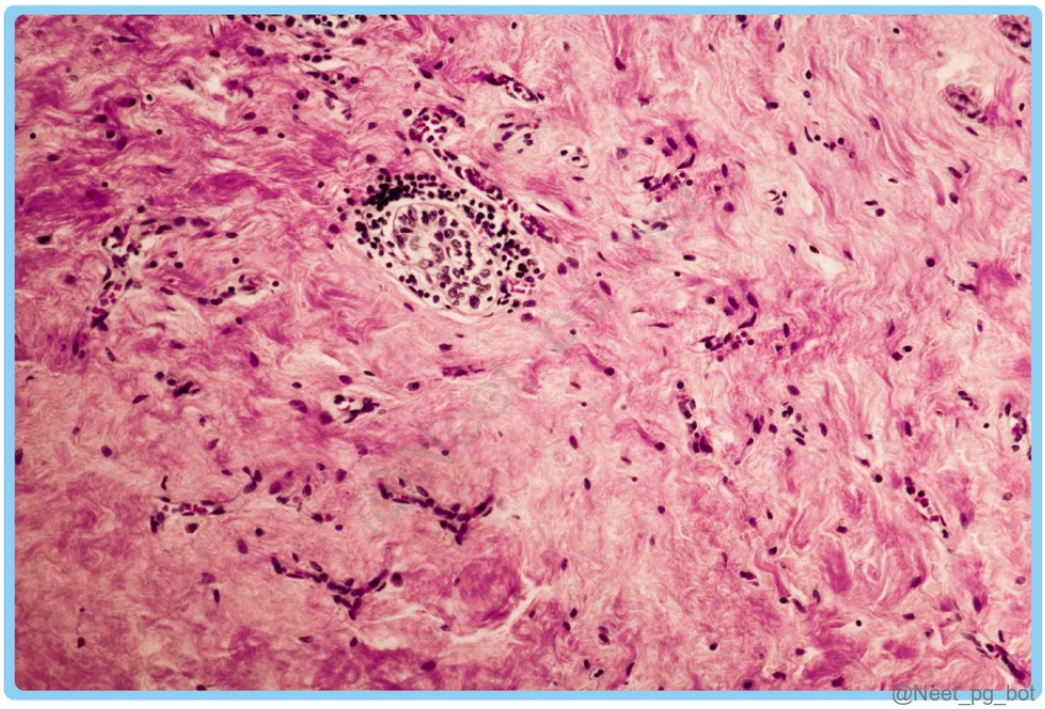
@Neet_pg_bot

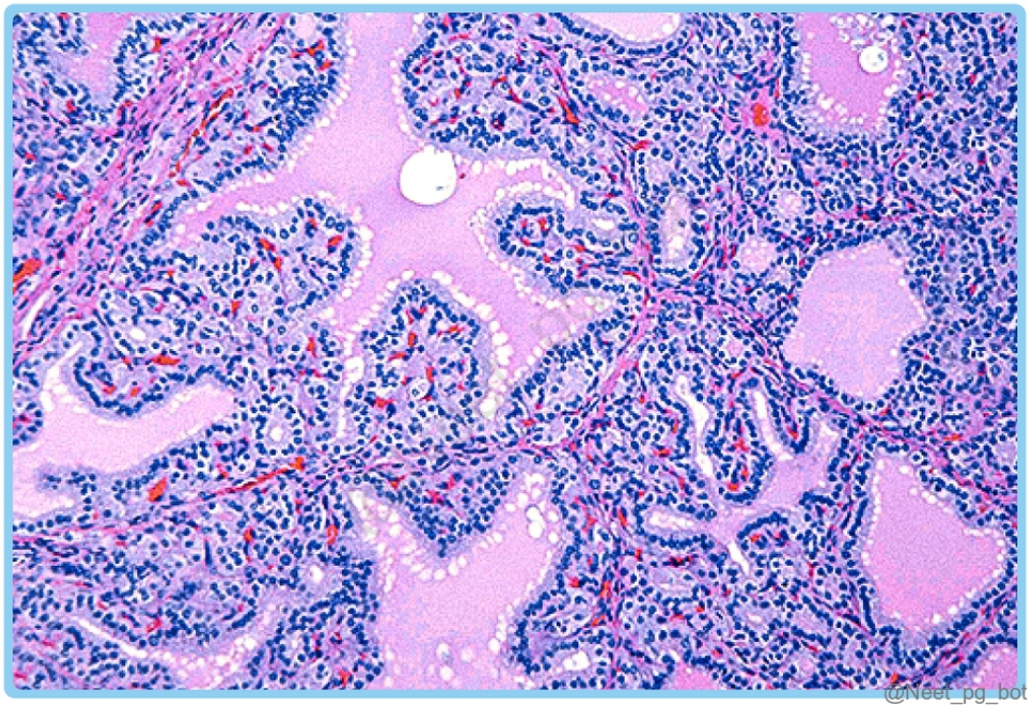
@Neet_pg_bot

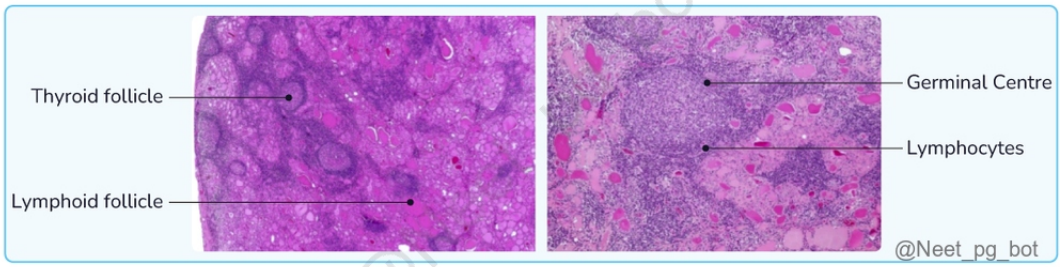

References:

www.ncbi.nlm.nih.gov/books/NBK526066/

↑ *Back to this question in Part A*

@Neet_pg_bot

Q16: Which of the following is not a feature of subacute lymphocytic thyroiditis? (Q845549)

A. Also called postpartum thyroiditis

B. Usually presents as a painful enlargement of the thyroid

C. Self-limiting condition

D. Lymphocytic inflammation in the thyroid

Correct Answer: B. Usually presents as a painful enlargement of the thyroid

■ *Listen (English)*

■ *Listen (Hindi)*

Explanation: Subacute lymphocytic thyroiditis is also know as Postpartum thyroiditis because it is seen in postpartum women. (Option A) It is a self-limiting condition does not usually require treatment (Option C) It is characterised by lymphocytic inflammation in the thyroid. (Option D) Subacute lymphocytic thyroiditis is typically a painless enlargement of the thyroid. The only painful thyroiditis is De Quervain thyroiditis or granulomatous thyroiditis, ■■■■■■which is usually seen following a viral infection. hyroiditis: 4 types: Hashimoto's Thyroiditis / Chronic Lymphocytic Thyroiditis: Autoimmune M/c cause of hypothyroidism in iodine sufficient areas Associated with HLA-DR3, DR5, PTPN22, CTLA Antibodies: Anti-TG antibody (antithyroglobulin antibody), Anti-TSH antibody Investigations: ↓T3, ↓T4, ↑TSH RAIU - radioactive iodine uptake: < 5% Feature - Painless diffuse enlargement of thyroid Microscopy: Hurthle cell/Askanazy cell/Oncocytic cell/Oxyphilic cell De Quervain’s Thyroiditis / Granulomatous Thyroiditis / Subacute Thyroiditis: Cause - HLA B5 mutation, post-viral Painful enlargement of the thyroid M/c cause of thyroid pain High ESR and low iodine uptake Subacute Lymphocytic Thyroiditis / Silent Thyroiditis / Painless Thyroiditis : ■■■■■■■ Painless Seen in postpartum females Self-limiting Transient thyrotoxicosis followed by hypothyroidism Riedel's Thyroiditis /

Invasive Fibrous Thyroiditis : ■■■■■■■ Stony/woody hard thyroid - Due to fibrosis Mimics cancer

References:

Robbins and Cotran Pathologic basis of disease, 10th Edition, Page 1080

↑ *Back to this question in Part A*

@Neet_pg_bot

Q17: Which of the following best describes the gross morphology of Riedel's thyroiditis? (Q845548)

A. Localised nodule within the gland

B. Diffusely enlarged thyroid gland

C. Mobile and well-circumcised mass

D. Stony and hard consistency

Correct Answer: D. Stony and hard consistency

■ *Listen (English)*

■ *Listen (Hindi)*

Explanation: Riedel's Thyroiditis belongs to an IgG4-related disease that causes extensive fibrosis. Fibrosis causes the thyroid to become stony and hard. It also attaches the thyroid to the adjacent tissues, muscles, and vessels implying the mass is fixed and does not move with deglutition. So it behaves like/mimics a cancer. IgG4-related diseases: Disease Fibrosis Mikulicz syndrome Salivary gland and lacrimal gland Kuttner syndrome Submandibular gland Ormond disease Retroperitoneal Riedel's thyroiditis Thyroid Thyroiditis: 4 types: Hashimoto's Thyroiditis / Chronic Lymphocytic Thyroiditis: Autoimmune M/c cause of hypothyroidism in iodine sufficient areas Associated with HLA-DR3, DR5, PTPN22, CTLA Antibodies: Anti-TG antibody (antithyroglobulin antibody), Anti-TSH antibody Investigations: ↓T3, ↓T4, ↑TSH RAIU - radioactive iodine uptake: < 5% Feature - Painless diffuse enlargement of thyroid Microscopy: Hurthle cell/Askanazy cell/Oncocytic cell/Oxyphilic cell De Quervain's Thyroiditis / Granulomatous Thyroiditis / Subacute Thyroiditis: Cause - HLA B5 mutation, post-viral Painful enlargement of the thyroid M/c cause of thyroid pain High ESR and low iodine uptake Subacute Lymphocytic Thyroiditis / Silent Thyroiditis / Painless Thyroiditis : ■■■■■■■■■■■■■■■ Painless Seen in postpartum females Self-limiting Transient thyrotoxicosis followed by hypothyroidism Riedel's Thyroiditis / Invasive Fibrous Thyroiditis : ■■■■■■■ Stony/woody hard thyroid - Due to fibrosis Mimics cancer

References:

Robbins and Cotran Pathologic basis of disease, 10th Edition, Page 1081

↑ *Back to this question in Part A*

@Neet_pg_bot

Q18: A 28-year-old woman comes to the office due to progressively worsening eye irritation and double vision over the last two months. She also reports unintentional weight loss, mood swings, diarrhoea, and palpitations. Physical examination shows tachycardia and bilateral proptosis. What is the pathophysiology causing proptosis? (Q845547)

A. Increased activity of orbital fibroblasts

B. Increased breakdown of hyaluronic acid

C. Increased synthesis of thyroid hormones

D. Increase in sympathetic activity

Correct Answer: A. Increased activity of orbital fibroblasts

■ *Listen (English)*

■ *Listen (Hindi)*

Explanation: This patient with hyperthyroidism (weight loss, palpitations, tachycardia) and significant ophthalmopathy (proptosis, diplopia) has Graves disease with ophthalmopathy, which is due to increased activity of orbital fibroblasts. Triad in Graves: Hyperthyroidism Pretibial myxoedema: infiltrative dermopathy due to thickening of the dermis due to deposition of glycosaminoglycans and lymphocyte infiltration. Proptosis: Increased activity of orbital fibroblasts leads to bulging of the eyeballs (proptosois).

References:

Robbins and Cotran Pathologic basis of disease, 10th Edition, Pages 1081-1082

↑ *Back to this question in Part A*

@Neet_pg_bot

Q19: A 29-year-old lady has been experiencing loss of appetite, profuse sweating, and palpitations for the past three months. Laboratory tests conclude increased T3 and T4 levels with decreased TSH levels. A representative HPE of this condition is shown below. The most common antibodies in this condition target which of the following? {{caption_text}} (Q845546)

A. TSH receptor

B. Thyroid peroxidase

C. Thyroglobulin

D. Dermal fibroblasts

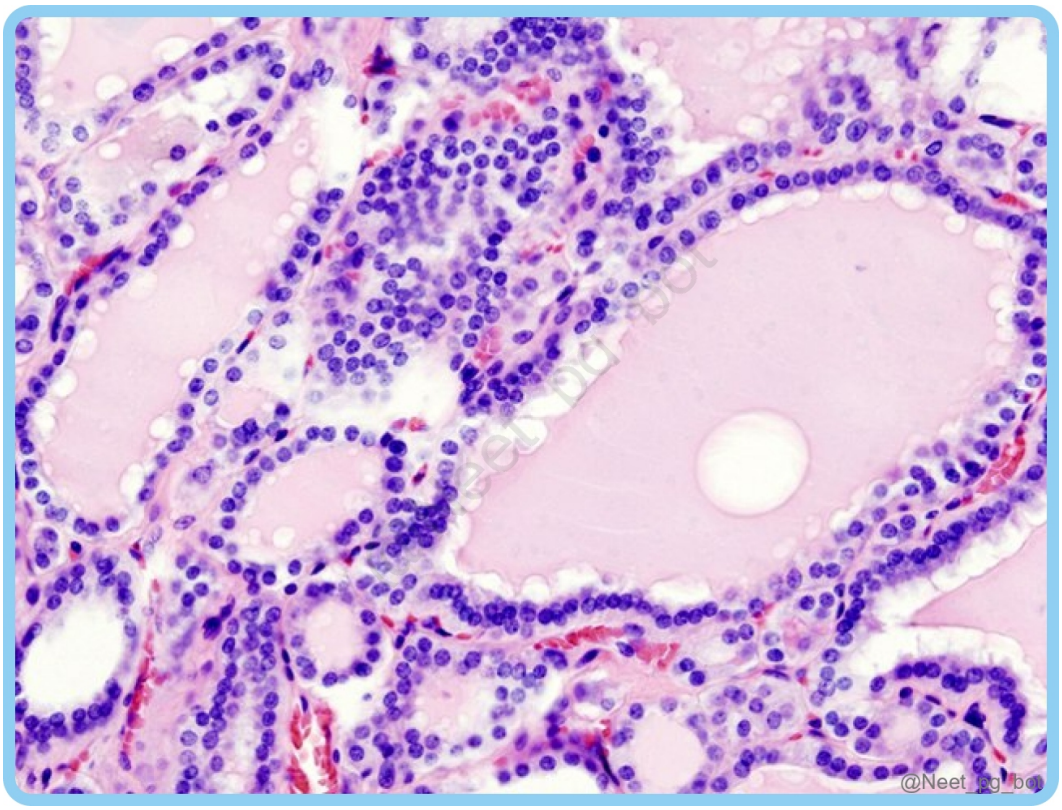

Correct Answer: A. TSH receptor

■ *Listen (English)*

■ *Listen (Hindi)*

Explanation: The HPE image demonstrates features of Grave’s disease, most commonly due to long-acting thyroid stimulator antibodies that bind to and activate the TSH receptor. Antibodies in Graves disease: TSI - Thyroid-stimulating immunoglobulin■■■: When these antibodies bind to the TSH receptor, they stimulate production of T3 and T4, leading to hyperthyroidism. The classical finding of Graves' disease on HPE is scalloping of colloids.

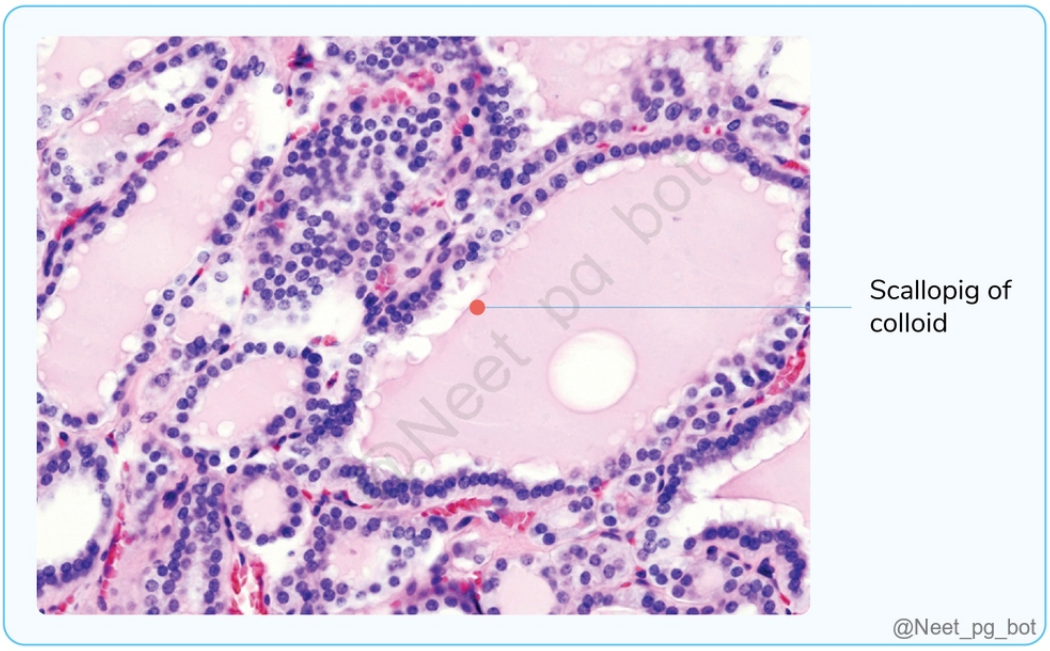

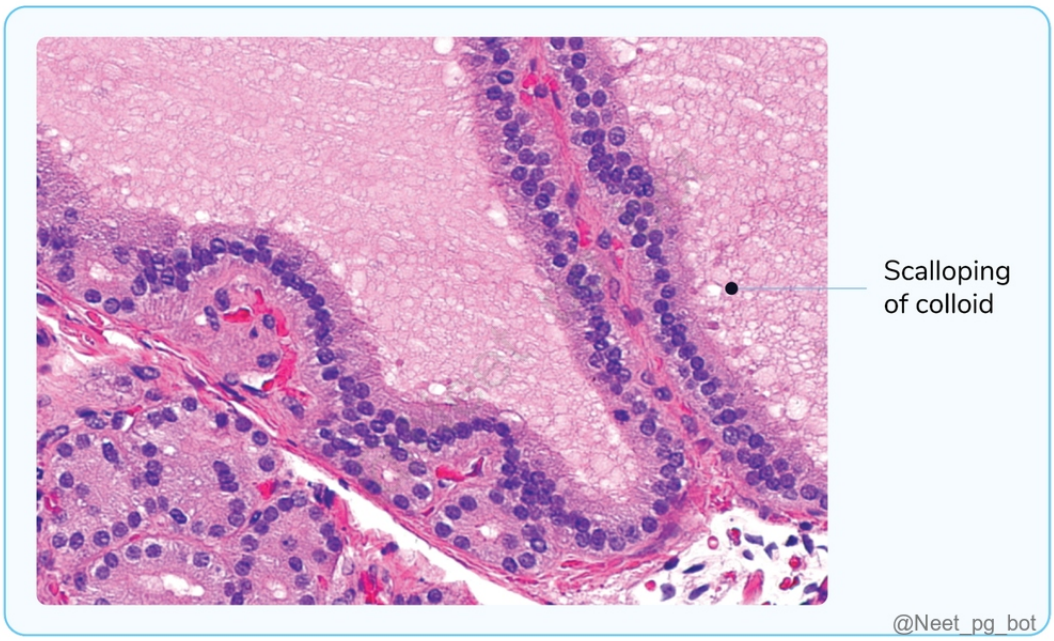

References:

Robbins and Cotran Pathologic basis of disease, 10th Edition, Page 1081

↑ *Back to this question in Part A*

@Neet_pg_bot

Q20: Which of the following antibodies are elevated in a patient of Hashimoto's thyroiditis? (Q845545)

A. Thyroid-stimulating immunoglobulins (TSI)

B. Anti-thyroid peroxidase antibodies (Anti-TPO)

C. Anti-thyroid stimulating hormone receptor antibodies (Anti-TSHR)

D. Anti-thyroid hormone antibodies (Anti-T3/T4)

Correct Answer: B. Anti-thyroid peroxidase antibodies (Anti-TPO)

■ *Listen (English)*

■ *Listen (Hindi)*

Explanation: Hashimoto's thyroiditis is an autoimmune disorder in which autoantibodies target the thyroid gland, leading to reduced production of T3 and T4 and resulting in hypothyroidism. The autoantibodies responsible for Hashimoto's thyroiditis include: Anti-Thyroid Peroxidase (TPO) Antibodies Anti-Thyroglobulin(Tg) Antibodies In Graves' disease, thyroid-stimulating immunoglobulins (TSI) are found, which cause hyperthyroidism. (Option A)

References:

Robbins and Cotran Pathologic basis of disease, 10th Edition, Pages 1077 , 1078 , 1079

Harrison’s principle of internal medicine, 21st Edition, Page 2934

↑ *Back to this question in Part A*

@Neet_pg_bot

Q21: A 35-year-old female presents with fatigue, weight gain, and cold intolerance. On physical examination, she has diffuse goitre and dry skin. Histopathological examination shows lymphoid infiltration, atrophic thyroid follicles lined in many areas by epithelial cells with abundant eosinophilic, granular cytoplasm as shown below. What is the likely diagnosis? {{caption_text}} (Q845544)

A. Grave’s disease

B. Thyroid nodule

C. Papillary carcinoma

D. Hashimoto thyroiditis

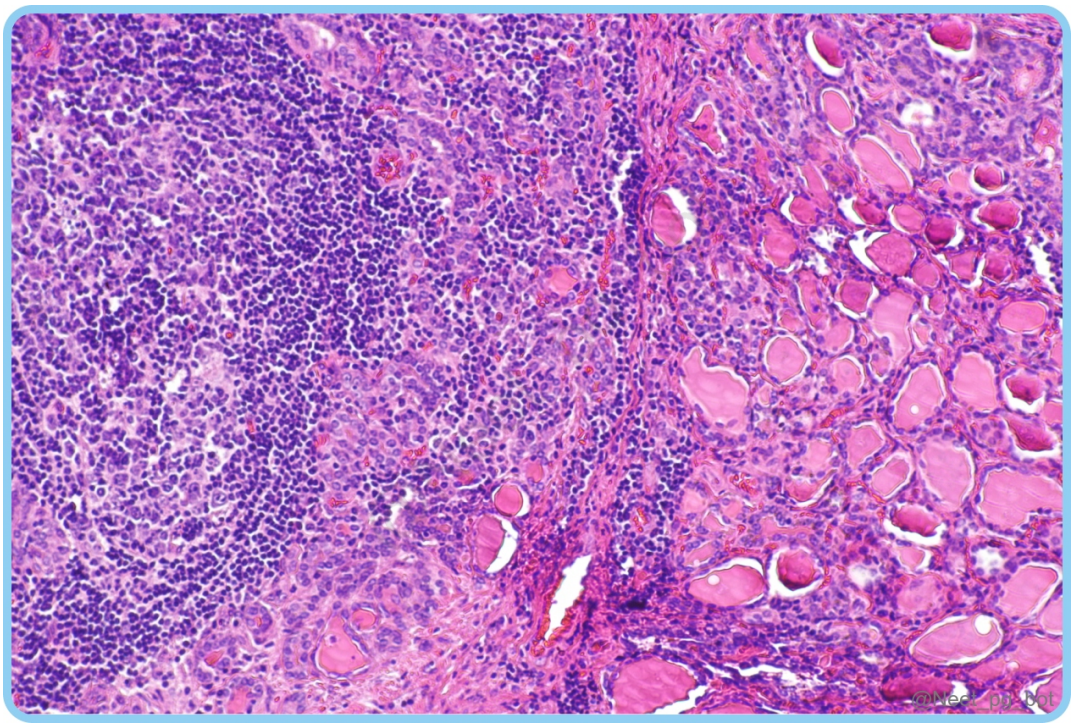

Correct Answer: D. Hashimoto thyroiditis

- *Listen (English)*
- *Listen (Hindi)*

Explanation: The above scenario and HPE findings suggest a diagnosis of Hashimoto's thyroiditis/Lymphocytic thyroiditis.. It is the most common cause of hypothyroidism in iodine-sufficient areas. In histopathology, there is extensive lymphocytic infiltration with well-developed germinal centres. The thyroid follicles are atrophic and are lined in many areas by epithelial cells with abundant eosinophilic, granular cytoplasm, termed Hürthle cells (hallmark feature of Hashimoto's thyroiditis) . It is an autoimmune condition, so on hematological testing we see autoantibodies like Anti-TSH receptor antibody, antithyroglobulin antibody, and anti-TPO antibodies. Genetic cause of Hashimoto's thyroiditis is HLA-DR3 and HLA-DR5 polymorphisms. Long standing Hashimoto's thyroiditis can give rise to some cancers like: Papillary carcinoma thyroid Maltoma (a marginal zone lymphoma) {{caption_text}}

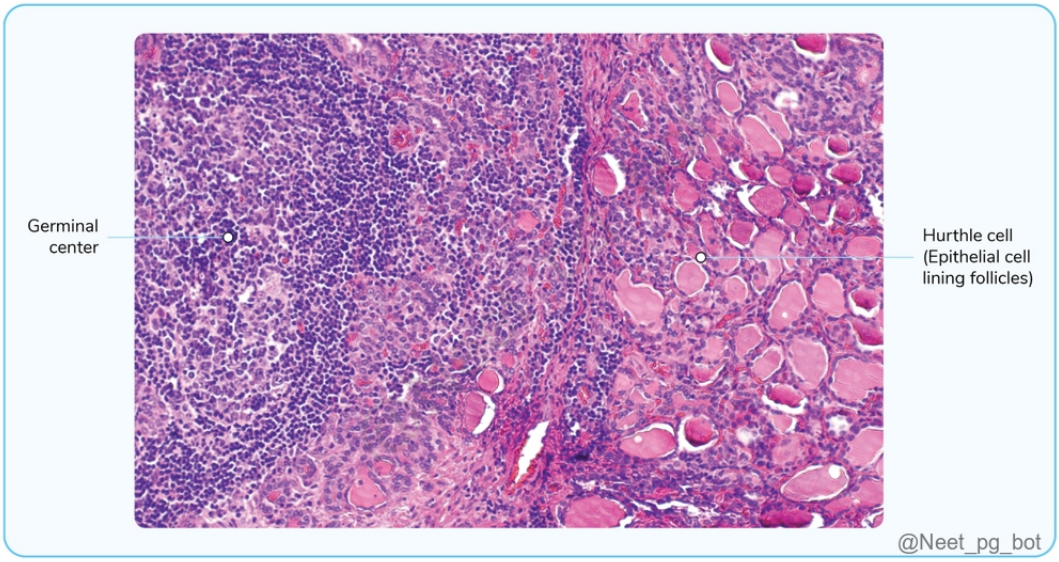

References:

Robbins and Cotran Pathologic basis of disease, 10th Edition, Page 1079

↑ *Back to this question in Part A*

@Neet_pg_bot

Q22: You are examining a high-resolution microscopic image of thyroid tissue. Which of the following depicts cells responsible for the secretion of calcitonin? {{caption_text}} (Q845543)

A. A

B. B

C. C

D. D

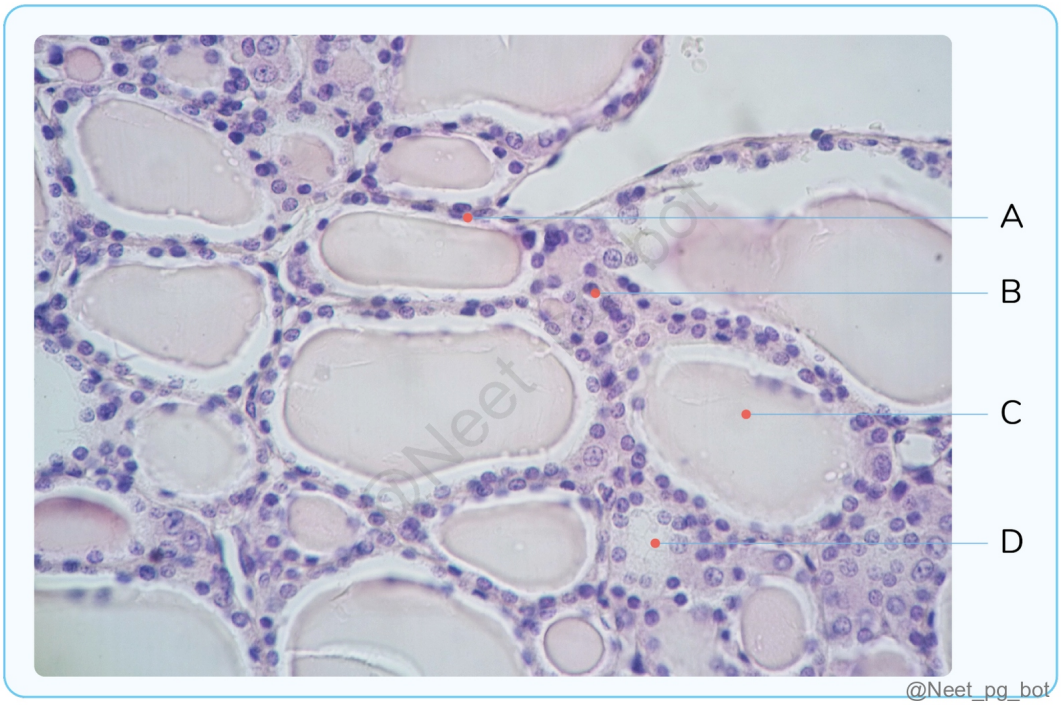

Correct Answer: B. B

■ *Listen (English)*

■ *Listen (Hindi)*

Explanation: Parafollicular C-cells responsible for calcitonin secretion are indicated by ‘B’ in the given image. Parafollicular C-cells, located between the thyroid follicles, secrete the hormone calcitonin (Hypocalcemic Hormone). Follicular Cells (Option A) have a round nucleus and basophilic cytoplasm. Their function is to synthesize thyroid hormones. Colloid (Option C) is a gel-like substance that appears pinkish and homogeneous in the follicles and serves as a reservoir for thyroid hormones. Stromal Cells (Option D) fill up spaces between the follicles and connective tissue, capillaries, and stroma.

References:

Victor P. Eroschenko - Atlas of Histology with Functional Correlations, 13th Edition, Page 771.

↑ *Back to this question in Part A*

@Neet_pg_bot

• [13_Endocrinology] 057 Parathyroid Pituitary And Adrenal Glands - I

« Back to Folder Directory

[13_Endocrinology] 057 Parathyroid Pituitary And Adrenal Glands - I — Quick Jump

Q1 (p. 2366) *Q2 (p. 2367)* *Q3 (p. 2368)* *Q4 (p. 2372)* *Q5 (p. 2374)* *Q6 (p. 2376)*
Q7 (p. 2377) *Q8 (p. 2378)* *Q9 (p. 2379)* *Q10 (p. 2380)* *Q11 (p. 2381)* *Q12 (p. 2383)*
Q13 (p. 2385) *Q14 (p. 2387)*

Q1: Which of the following cell types are typically found in the anterior lobe of the pituitary gland, and which are stained pink and purple, respectively? (Q845580)

A. Sommatotrophs and lactotrophs

B. Lactotrophs and thyrotrophs

C. Corticotrophs and gonadotrophs

D. Gonadotrophs and somatotrophs

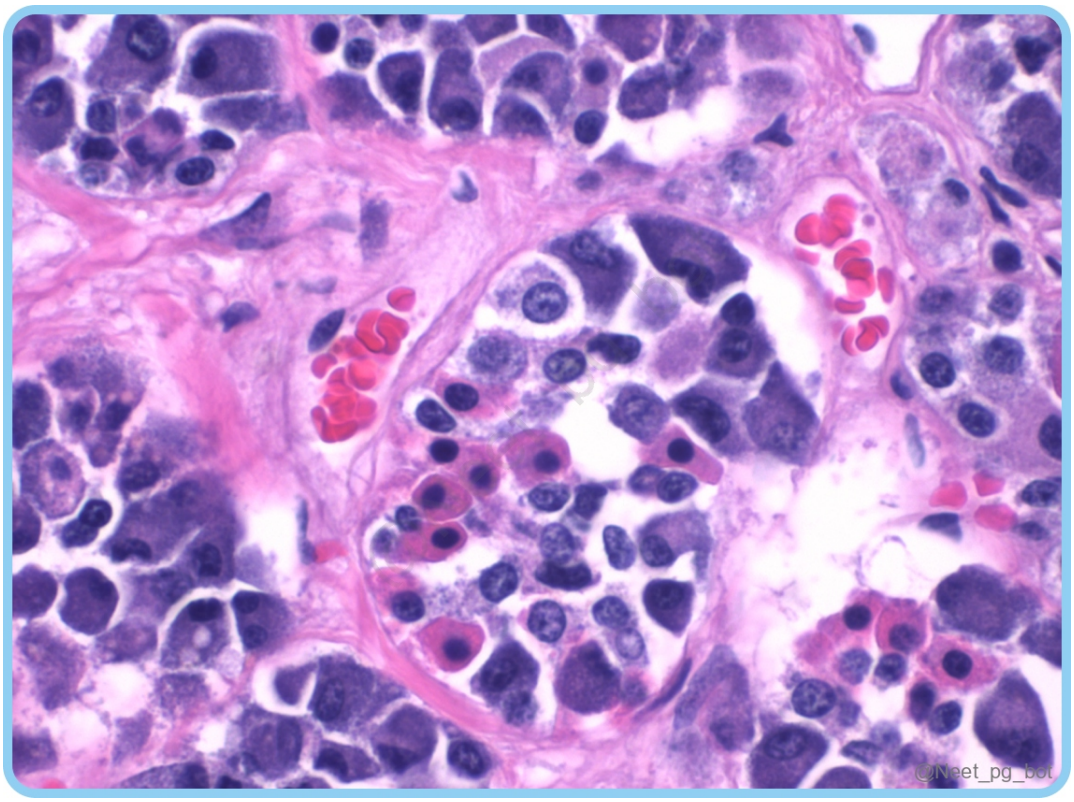

Correct Answer: B. Lactotrophs and thyrotrophs

■ *Listen (English)*

■ *Listen (Hindi)*

Explanation: The scenario suggests acidophils and basophils seen in the anterior pituitary. Lactotrophs and thyrotrophs are examples of cells found respectively with these staining. The pituitary consists of 2 lobes. The Anterior pituitary/ Adenohypophysis c ontains many hormone-producing cells. These cells can be acidophilic, basophilic or poorly staining based on the staining pattern. Acidophils- Eosinophilic/pink colored- Sommatotrophs and lactotrophs Basophils- Basophilic/blue colored- Corticotrophs, thyrotrophs, and gonadotrophs Chromophobe cells- poorly staining cytoplasm

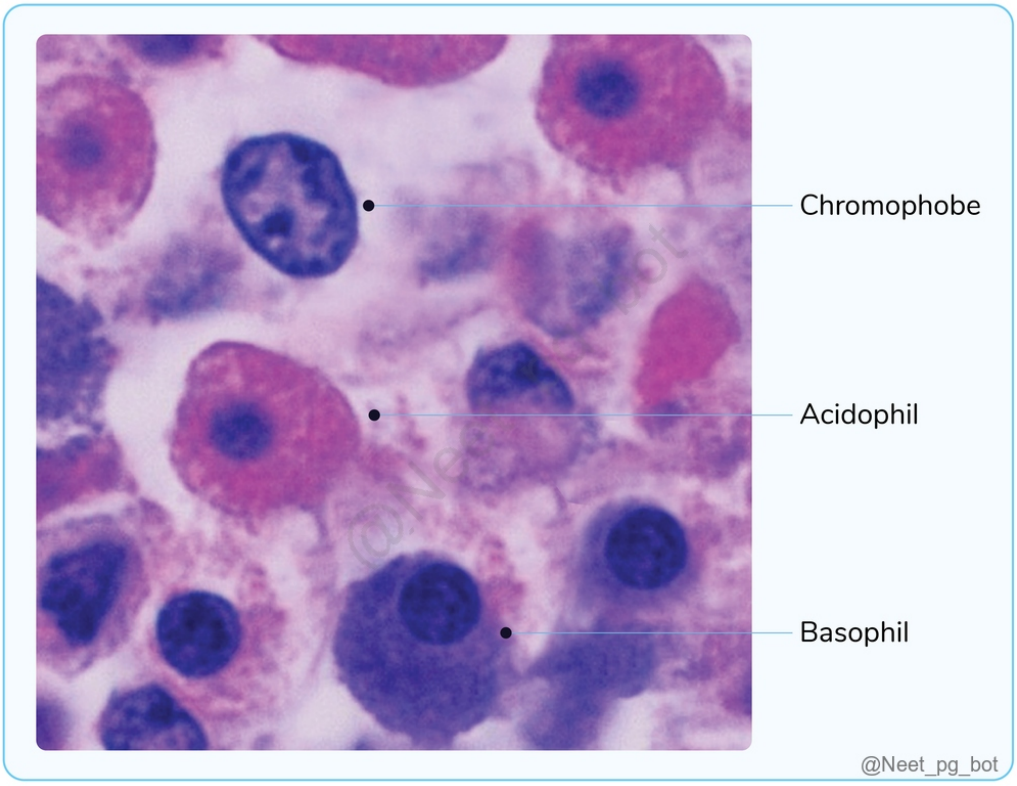

References:

Robbins and Cotran Pathologic basis of disease, 10th edition, Page 1066

↑ *Back to this question in Part A*

@Neet_pg_bot

Q2: Pituitary adenomas are often classified based on the hormones they secrete. Which of the following statements correctly matches the type of pituitary adenoma with its primary hormone secretion and associated syndrome? (Q845581)

A. Prolactinoma – Secretes prolactin – Causes Cushing's disease

B. Somatotroph adenoma – Secretes growth hormone – Causes acromegaly

C. Corticotroph adenoma – Secretes thyroid-stimulating hormone – Causes hyperthyroidism

D. Gonadotroph adenoma – Secretes adrenocorticotropic hormone (ACTH) – Causes Addison's disease

Correct Answer: B. Somatotroph adenoma – Secretes growth hormone – Causes acromegaly

■ *Listen (English)*

■ *Listen (Hindi)*

Explanation: Adenoma type Hormone secreted Associated condition Prolactinoma Prolactin Hyperprolactinemia Somatotroph Adenoma Growth Hormone Gigantism (Children), Acromegaly (Adults) Corticotroph Adenoma Adrenocorticotropic hormone (ACTH) Cushings disease Gonadotroph Adenoma Gonadotropins (LH and FSH) Often asymptomatic , may cause hypogonadism

References:

Robbins and Cotran Pathologic basis of disease, 10th edition, Page 1068

↑ *Back to this question in Part A*

@Neet_pg_bot

Q3: A pathologist examines a surgically resected pituitary tumour under a microscope. The tumour comprises sheets of monomorphic, round to polygonal cells with central nuclei and sparse to absent reticulin network. What is the most likely diagnosis? (Q845582)

A. Pituitary adenoma

B. Pituitary carcinoma

C. Craniopharyngioma

D. Schwannoma

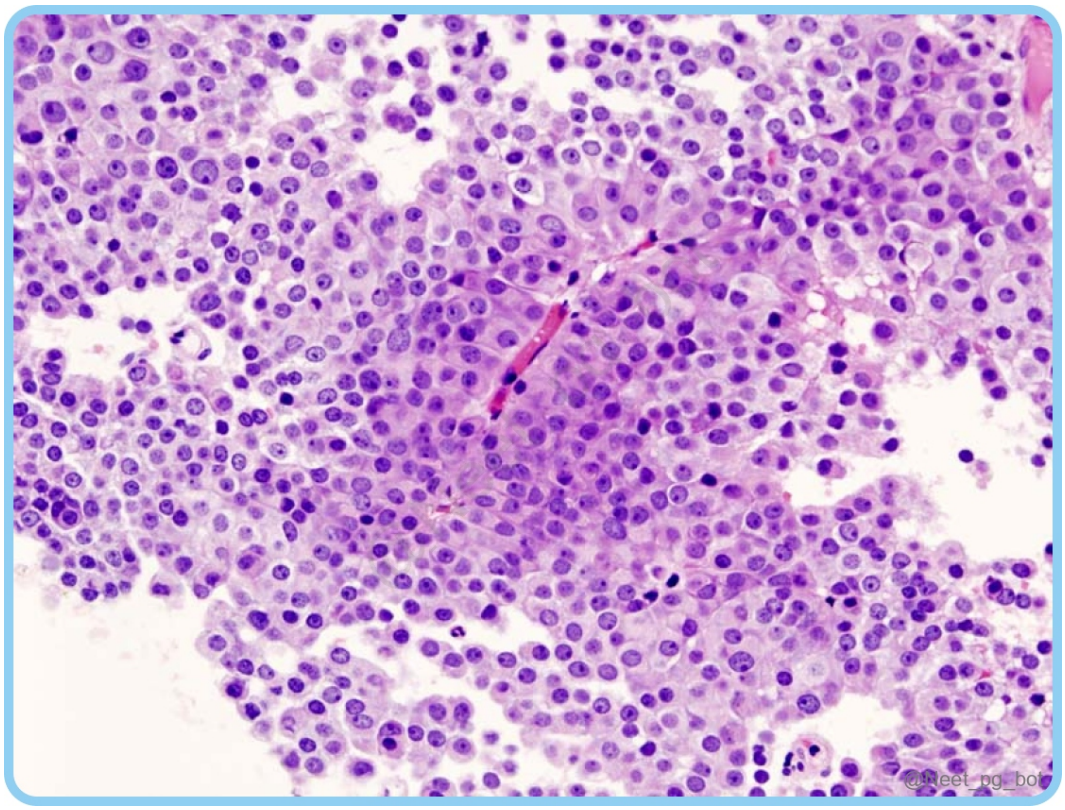

Correct Answer: A. Pituitary adenoma

Explanation: Pituitary adenoma: Pituitary adenomas are benign tumors that arise from the pituitary gland and are characterized by sheets of monomorphic, round to polygonal cells with central nuclei and a sparse to absent reticulin network Cellular monomorphism and the absence of a significant reticulin network distinguish pituitary adenomas from normal anterior pituitary parenchyma. ■They are well-circumscribed and encapsulated. ■They are the most common type of pituitary tumor and can be classified based on size as follows. Pituitary carcinoma (Option B) : Is very rare and have malignant cells showing nuclear pleomorphism along with invasive growth and metastasis. Schwannoma (Option D) : Schwannomas are tumors of Schwann cells found along peripheral nerves. They display spindle-shaped cells in a palisading pattern and stain positive for S-100 protein. They do not arise in the pituitary gland. Craniopharyngioma (Option C): Origin: Rathke's pouch Site: Suprasellar location (compression of optic chiasm) Age: Children Clinical feature: Vision disturbance & headaches Radiology: Calcification Microscopic Examination: Adamantinomatous Palisading nuclei Stellate reticulum Wet keratin on gross examination: Machine oil appearance ■■■■■■■ Papillary

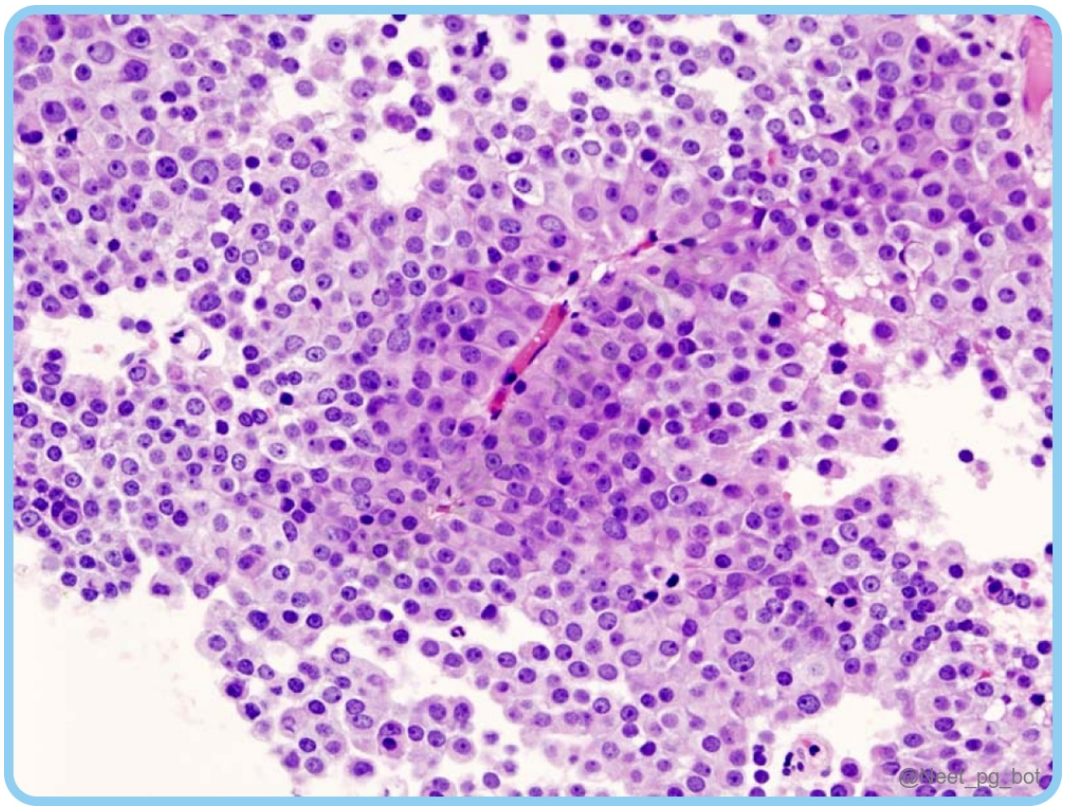
@Neet_pg_bot

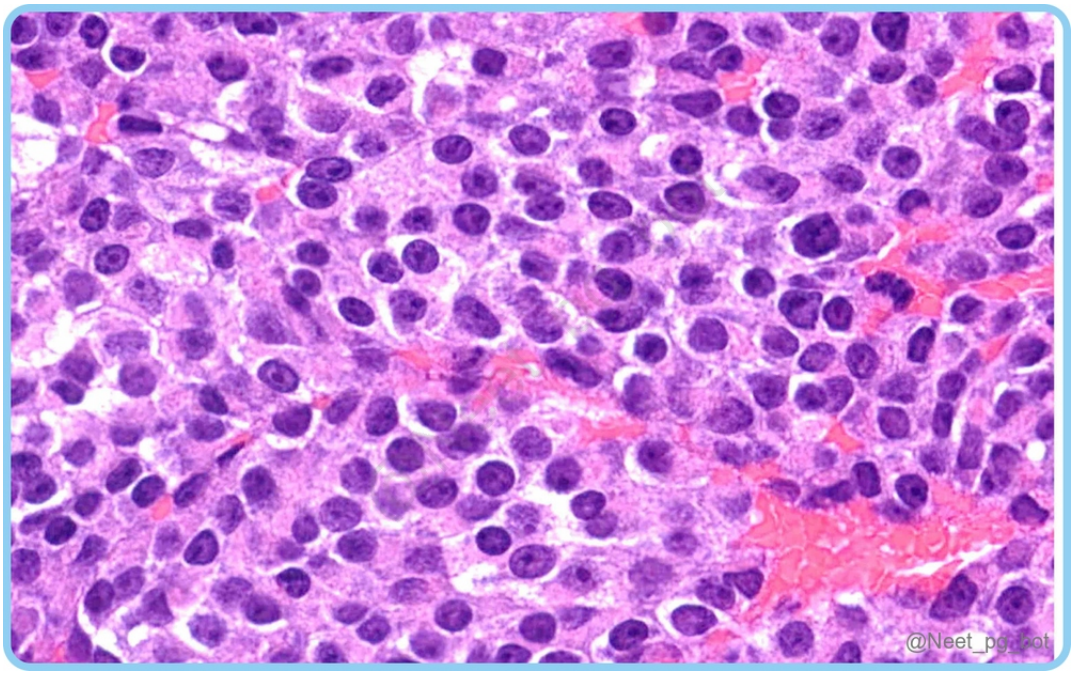
@Neet_pg_bot

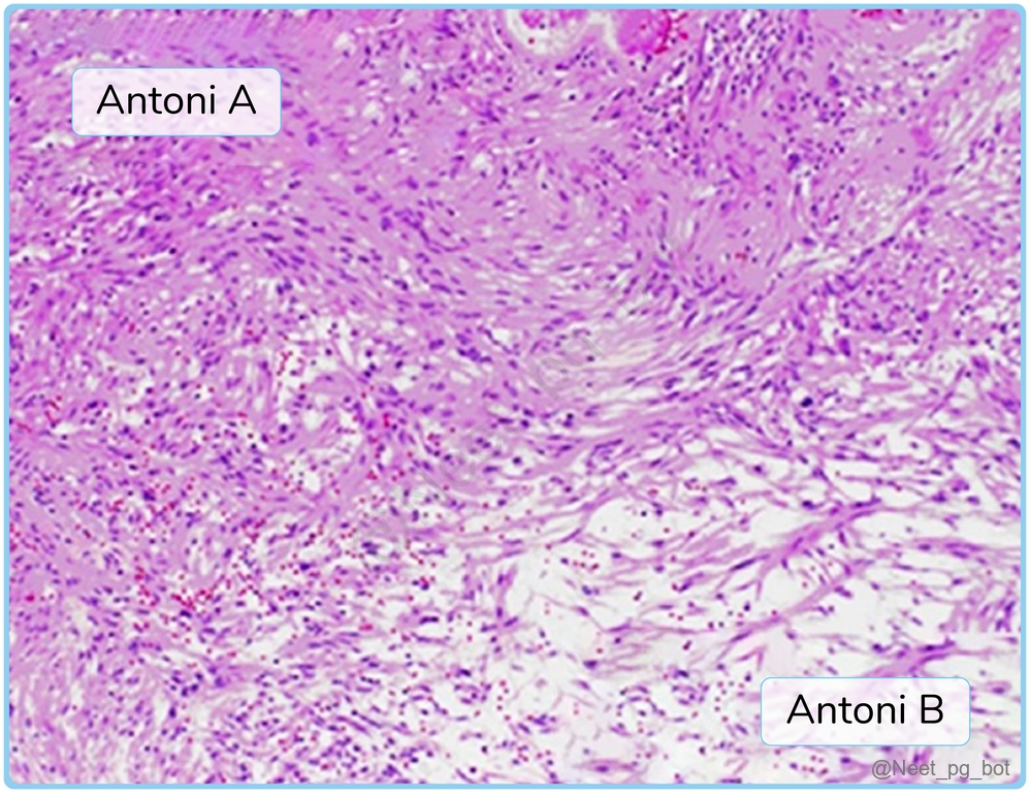
Antoni A
Antoni B
@Neet_pg_bot

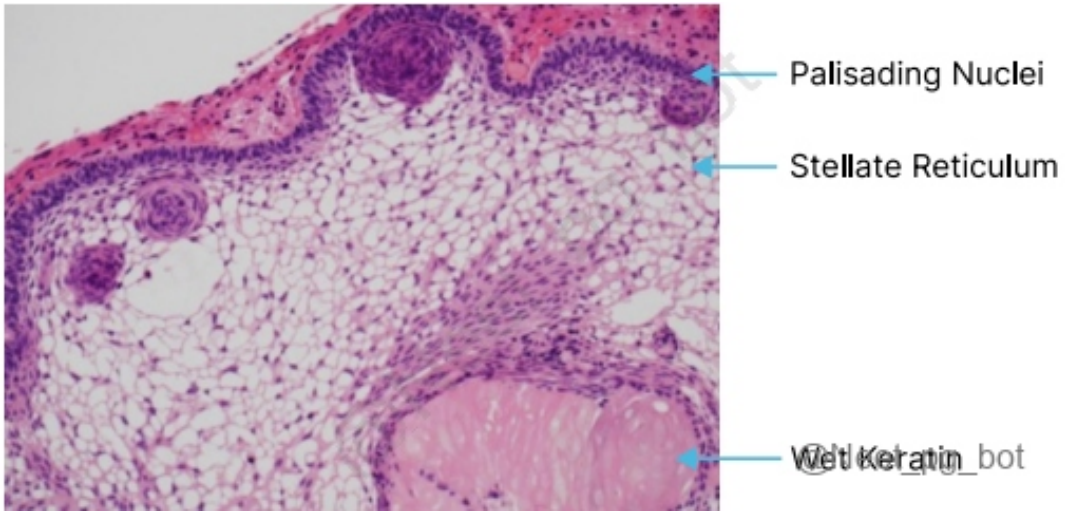
Palisading Nuclei
Stellate Reticulum
Wet Keratin
@Neet_pg_bot


Palisading Nuclei
Wet Keratin
Stellate Reticulum
@Neet_pg_bot

References:

Robbins and Cotran Pathologic basis of disease, 10th Edition, Page 1067

↑ *Back to this question in Part A*

@Neet_pg_bot

Q4: A 12-year-old child presents with headaches, visual disturbances, and delayed growth. An MRI of the brain reveals a 3 cm cystic mass with calcifications. The growth was found to be encapsulated and multiloculated. What is the most likely diagnosis? (Q845583)

A. Oligodendroglioma

B. Meningioma

C. Craniopharyngioma

D. Pituitary adenoma

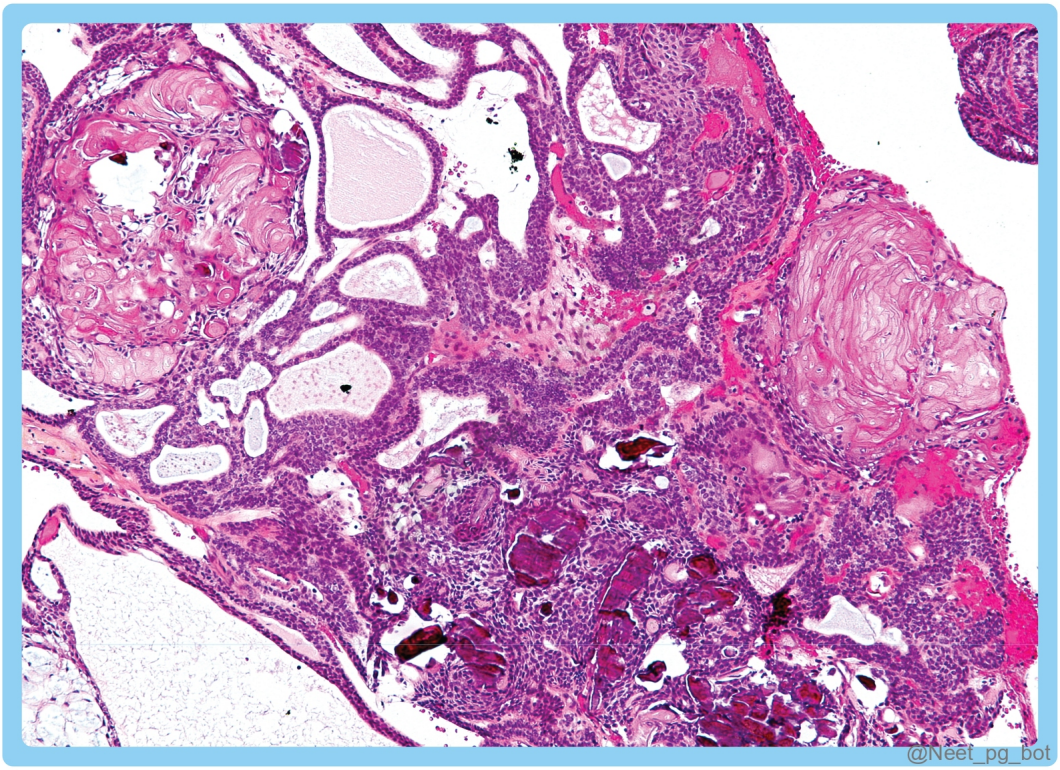

Correct Answer: C. Craniopharyngioma

■ *Listen (English)*

■ *Listen (Hindi)*

Explanation: Craniopharyngiomas are benign tumours arising from vestigial remnants of the Rathke pouch. They commonly occur in the suprasellar region and often present as encapsulated and multiloculated cystic masses with calcifications. The cysts contain cholesterol-rich, thick brownish-yellow fluid (compared to machine oi). It has 2 histological variants: Adamantinomatous and papillary. The common presentations include headaches and visual disturbances like bitemporal hemianopia due to optic chiasma compression, while children present with growth retardation due to pituitary hypofunction and GH deficiency. Oligodendroglioma (Option A): Typically affects adults (30–50 years old). Commonly located in the cerebral hemispheres , not suprasellar. Calcifications can be present, but they are intra-axial and not cystic or multiloculated. Endocrine symptoms are rare . Meningioma (Option B): Rare in children; typically seen in middle-aged to older adults . Usually extra-axial , solid , may calcify but are not cystic or multiloculated. Often found incidentally unless very large. It does not cause hormonal dysfunction in children. Pituitary Adenoma(Option D): Unlikely in a child. Pituitary adenomas are rare in children. Typically, adenomas cause endocrine symptoms, but visual changes in children from adenomas are uncommon. Less likely to be calcified or multiloculated. Usually, solid tumours are not cystic.

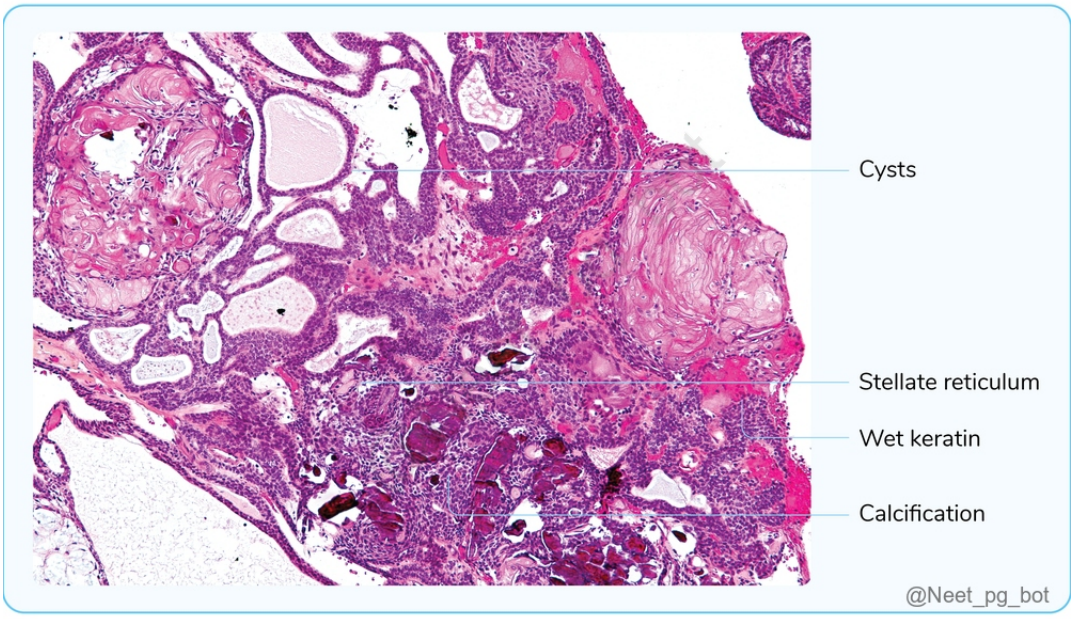

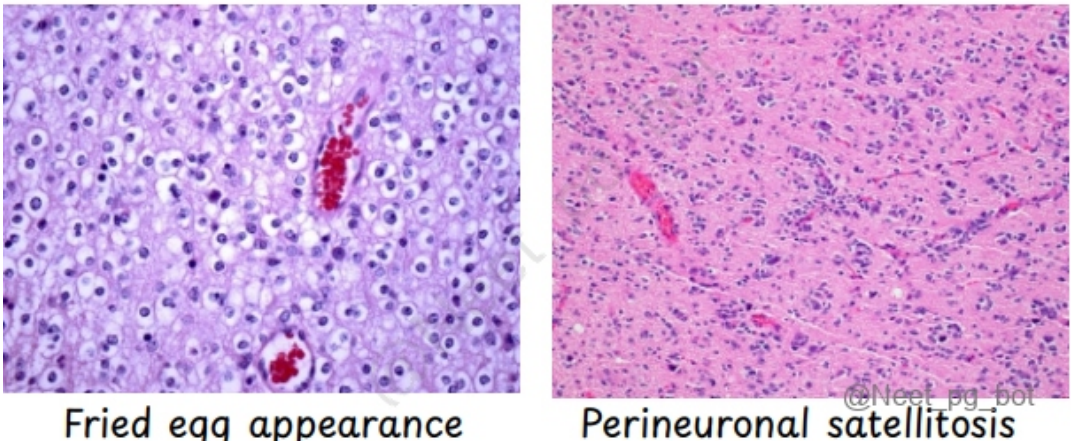

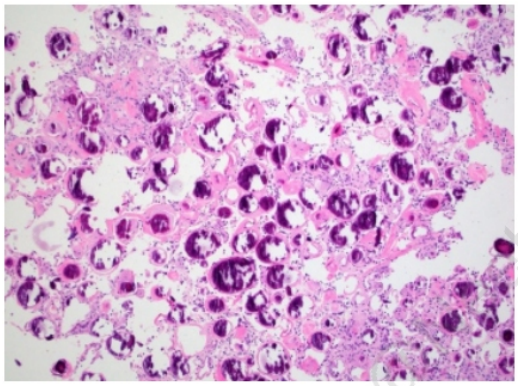

Psammoma Bodies

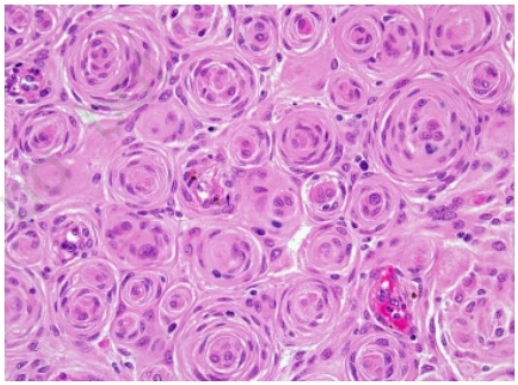

Whorling of tumor cells

@Neet_pg_bot

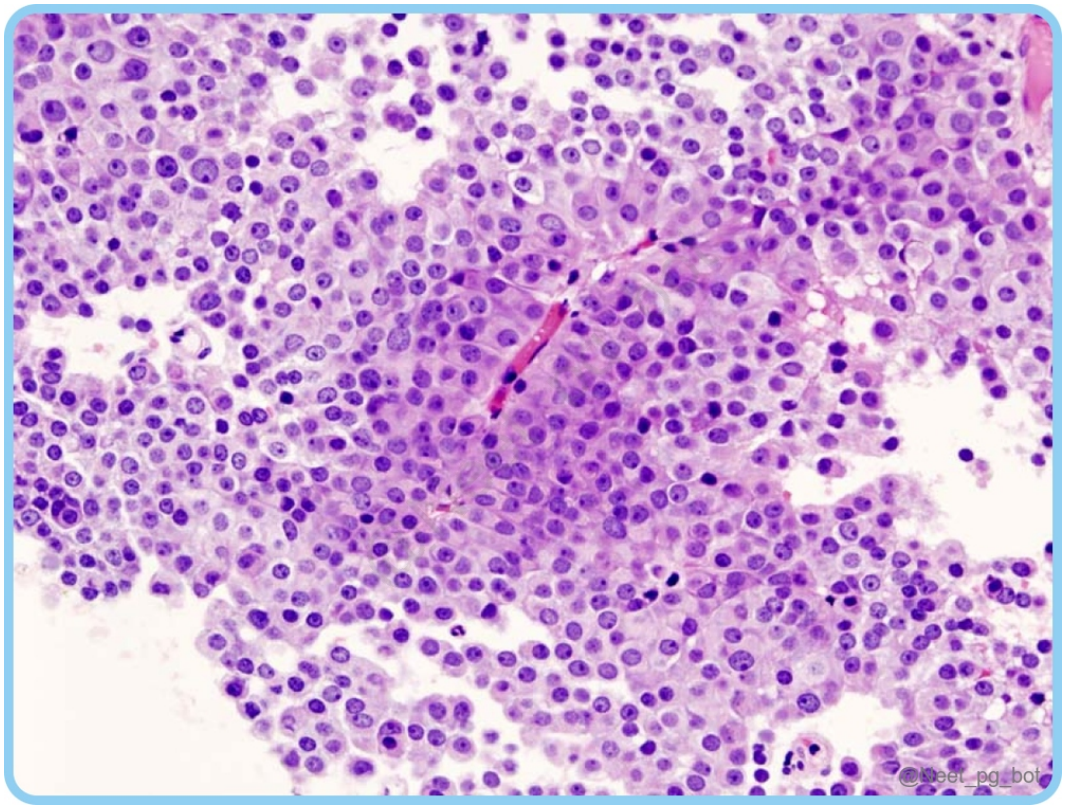

@Neet_pg_bot

References:

Robbins and Cotran Pathologic basis of disease, 10th Edition, Page 1074, 1296, 1300

↑ *Back to this question in Part A*

@Neet_pg_bot

Q5: A 35-year-old male presents with a history of recurrent kidney stones, hypercalcemia, and a recent diagnosis of a pituitary adenoma. Which of the following

syndromes is most likely associated with his clinical presentation? (Q845584)

A. MEN 2A syndrome

B. MEN 2B syndrome

C. MEN 4 syndrome

D. MEN 1 syndrome

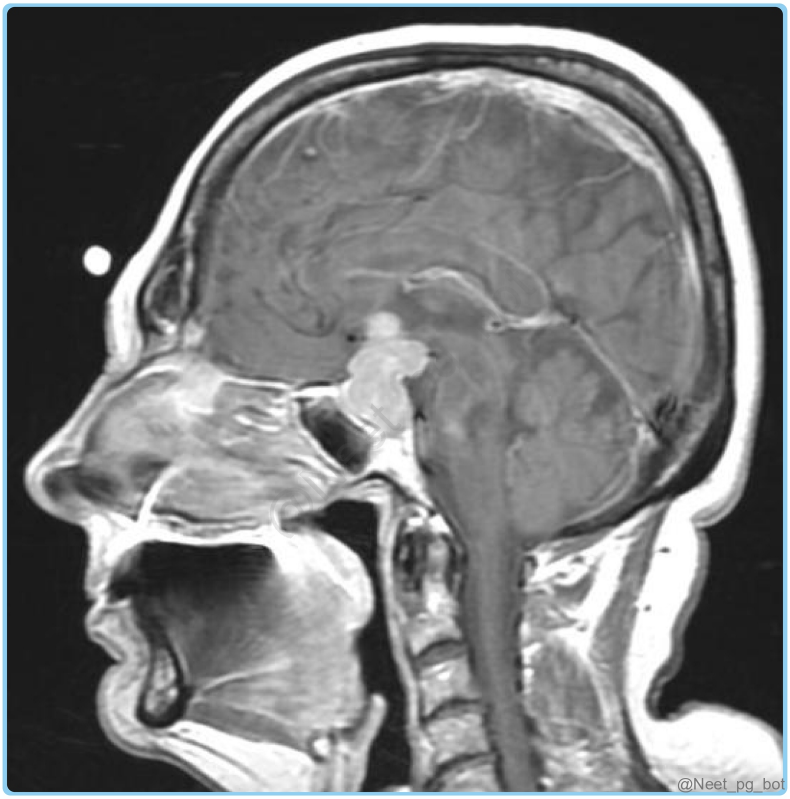

Correct Answer: D. MEN 1 syndrome

Explanation: The given clinical scenario of hypercalcemia and radiological finding of pituitary adenoma is suggestive of MEN1 Genetics: Autosomal dominant; MEN1 mutation on chromosome 11q13. Common Tumors: Anterior Pituitary: Prolactinoma. Parathyroid Adenoma: Most common. Pancreatic Tumors: Gastrinoma (MC, often in the duodenum). Other Associations: Angiofibroma, collagenoma, lipoma, meningioma, VIPoma, foregut carcinoid. Clinical features often include primary hyperparathyroidism (leading to hypercalcemia and recurrent kidney stones), pituitary adenomas, hypoglycemia due to insulinomas, and peptic ulcers in Zollinger-Ellison syndrome. MEN 2A syndrome (Option A) : Associated with mutations in the RET proto-oncogene. Its clinical features include medullary thyroid carcinoma, pheochromocytomas, and parathyroid hyperplasia. MEN 2B syndrome (Option B): Also associated with mutations in the RET proto-oncogene. The clinical features include medullary thyroid carcinoma, pheochromocytomas, mucosal neuromas, and Marfanoid habitus. MEN 4 syndrome (Option D): Caused by mutations in the CDKN1B gene. It is similar to MEN 1 but can include additional features such as tumors of adrenal, kidneys, and reproductive organs.

MEN I	MEN IIa	MEN IIb	MEN IV
Wermer's syndrome	Sipple syndrome		
MENIN mutation	RET mutation	CDKN1B mutation	
• Pituitary adenoma • Parathyroid Hyperplasia • Pancreatic tumor	• Parathyroid Hyperplasia • Medullary carcinoma thyroid • Pheochromocytoma	• Mucosal neuroma • Marfanoid habitus • Medullary carcinoma • Pheochromocytoma	Similar to MEN 1

@Neet_pg_bot

References:

Robbins and Cotran Pathologic basis of disease, 10th Edition, Page 1129-1130

↑ *Back to this question in Part A*

@Neet_pg_bot

Q6: Which mutation is associated with pituitary carcinoma? (Q845585)

A. AIP

B. CDKN I B

C. HRAS

D. MEN 1

Correct Answer: C. HRAS

■ *Listen (English)*

■ *Listen (Hindi)*

Explanation: Pituitary adenoma treated with surgery, radiation therapy, and subsequent symptoms that include adjacent structure invasion point to a diagnosis of pituitary carcinoma which has HRAS mutation. HRAS mutation is a somatic activating mutation affecting mitogenic signaling cell growth and survival. HRAS → Proto-oncogene; mutations seen in bladder, thyroid, head & neck cancers . KRAS → Most common RAS mutation; in colon, pancreatic, lung adenocarcinoma ; resistant to EGFR inhibitors. NRAS → Mutations mainly in melanoma and hematologic malignancies (AML, ALL, MDS). Genetic alterations in pituitary tumors Gene affected Commonly associated tumour AIP PRKAR1A Somatotroph or lactotroph adenoma CDKN1 B USP8 Corticotroph adenoma GNAS Somatotroph adenoma HRAS Pituitary carcinoma DICER1 Pituitary blastoma MEN 1 Somatotroph, lactotroph, or corticotroph adenoma

References:

Robbins and Cotran Pathologic basis of disease, 10th edition, Page 1069

↑ *Back to this question in Part A*

@Neet_pg_bot

Q7: Identify the marked cells in the histology of the parathyroid below. (Q845586)

A. Oxyphil cells

B. Chief cells

C. Adipocytes

D. Parafollicular cells

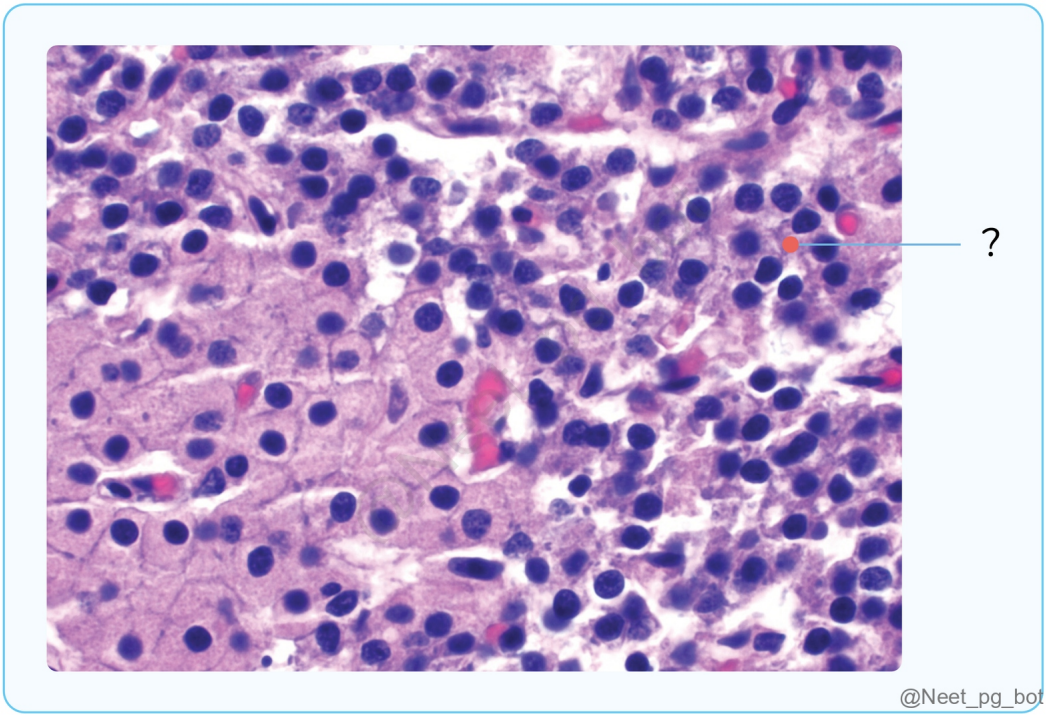

Correct Answer: B. Chief cells

■ *Listen (English)*

■ *Listen (Hindi)*

Explanation: The marked cells with light pink cytoplasm and centrally placed nuclei in the histology of the parathyroid gland are called chief cells. Oxyphil cells (Option A) are dark pink, and have eosinophilic granular cytoplasm. Adipocytes (Option C) are fat cells with clear cytoplasm due to the dissolution of fat content during tissue processing. Parafollicular cells (Option D) are seen in the thyroid gland, interspersed between thyroid follicles, and stain pale.

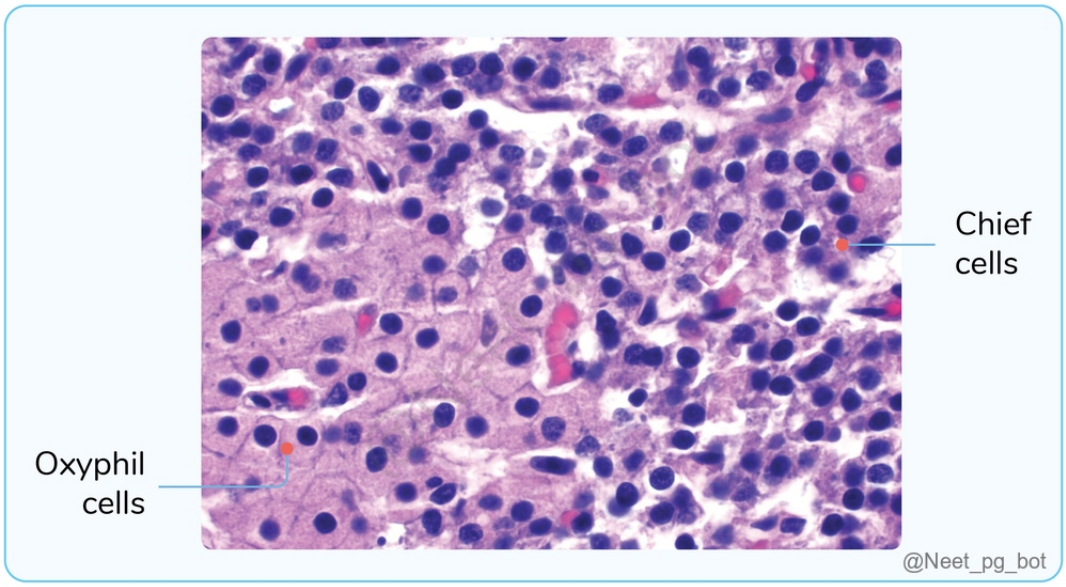

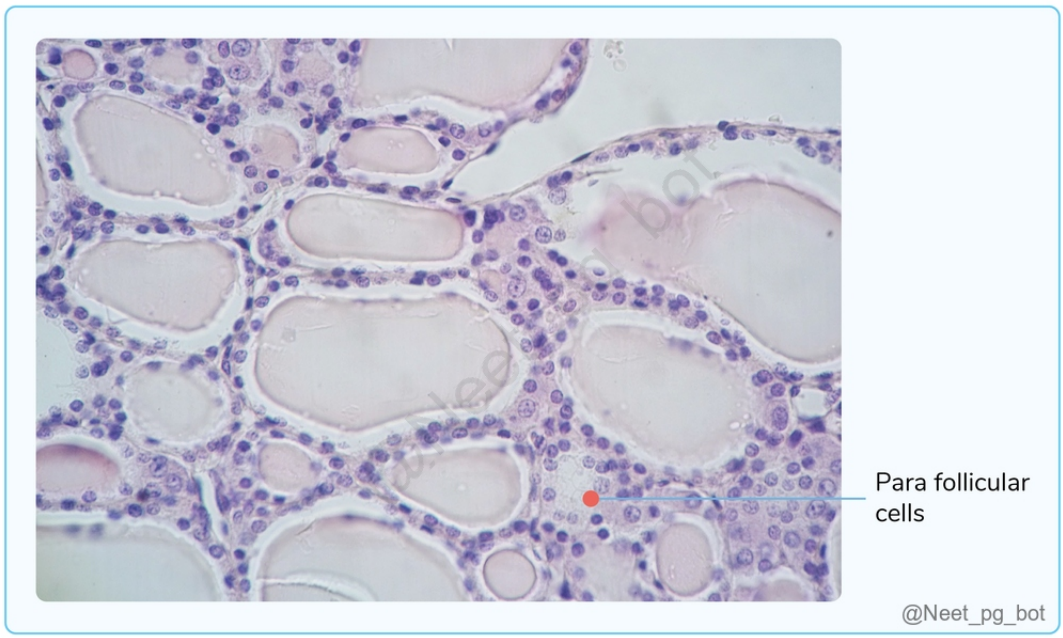

References:

Robbins and Cotran Pathologic basis of disease, 10th edition, Page 1094

↑ *Back to this question in Part A*

@Neet_pg_bot

Q8: Which of the following microscopic features is most indicative of a parathyroid adenoma rather than parathyroid hyperplasia? (Q845587)

A. Diffuse hyperplasia of chief cells throughout the parathyroid gland

B. Stromal fat infiltration within the parathyroid tissue

C. Intranuclear cytoplasmic inclusions within chief cells

D. Difficult to distinguish on microscopy

Correct Answer: D. Difficult to distinguish on microscopy

■ *Listen (English)*

■ *Listen (Hindi)*

Explanation: Parathyroid adenoma and parathyroid hyperplasia are microscopically identical and difficult to differentiate. All microscopic features mentioned are seen in both parathyroid adenoma and parathyroid hyperplasia. Diffuse hyperplasia of chief cells throughout the parathyroid gland Stromal fat infiltration within the parathyroid tissue Intranuclear cytoplasmic inclusions within chief cells Grossly, parathyroid adenoma occurs as a distinct nodule within a capsule and parathyroid hyperplasia classically affects all four glands. Syndromes associated with parathyroid adenomas: MEN-1 MEN-2 MEN-4 Familial hypocalciuric hypercalcemia (rare)

References:

Robbins and Cotran Pathologic basis of disease, 10th edition, Page 1094 Parathyroid hyperplasia - an overview | ScienceDirect Topics

↑ *Back to this question in Part A*

@Neet_pg_bot

Q9: Which of the following genetic mutations is most commonly associated with pheochromocytoma? (Q845588)

A. Gain of function mutation in n-Myc gene

B. Gain of function mutation in RET gene

C. Loss of function mutation in the RET gene

D. Loss of function mutation in MEN 1 gene

Correct Answer: B. Gain of function mutation in RET gene

■ *Listen (English)*

■ *Listen (Hindi)*

Explanation: The genetic mutation most commonly associated with pheochromocytoma is the Gain of function mutation in the RET gene. Genetics of pheochromocytoma 25% familial Rule of TENS-1/10 patients with pheochromocytoma it is malignant, in 1/10 of cases the tumor is bilateral, in 1/10 extra-adrenal and in 1/10

familial RET(Chromosome 10) EPAS 1 VHL(deletion of chromosome 3p) NF1 SDH B, C, D

References:

Robbins and Cotran Pathologic basis of disease, 10th Edition, Page 1127

↑ *Back to this question in Part A*

@Neet_pg_bot

Q10: The 4-year-old kid is brought with complaints of periorbital ecchymosis, miosis, and ptosis. CT scan reveals a tumour on the right kidney with calcifications. A biopsy reveals small, dark blue cells with scanty cytoplasm. Which mutation is most likely connected to this mass? (Q845589)

A. ALK gene mutation

B. RET gene mutation

C. L-MYC gene mutation

D. VHL gene mutation

Correct Answer: A. ALK gene mutation

■ *Listen (English)*

■ *Listen (Hindi)*

Explanation: Neuroblastoma Neural crest cell origin Most common extracranial solid tumors of childhood. Pathogenesis N-Myc amplification, and ALK gene mutation Involves adrenal medulla, sympathetic chain Clinical features Age < 4 years Abdominal mass Opsoclonus myoclonus syndrome Periorbital ecchymoses (orbital metastases) Spinal cord compression from epidural invasion (horner syndrome) Diagnostic findings N-MYC gene amplification Microscopy: small round blue cells with scanty cytoplasm, Homer Wright rosettes. Labs: elevated catecholamines Gene Role Notes ALK Proto-oncogene Most common familial neuroblastoma mutation (~50% of familial cases), sporadic cases also occur RET (option B) Medullary thyroid carcinoma / MEN2 Not associated with neuroblastoma L-MYC (option C) Oncogene Primarily associated with Small Cell Lung Cancer (SCLC) ; amplification is rarely the primary driver in neuroblastoma compared to N-MYC. N-MYC Oncogene Amplification associated with poor prognosis in neuroblastoma, but mutation not the primary driver VHL (option B) Von Hippel–Lindau disease Associated with renal cell carcinoma, pheochromocytoma; not neuroblastoma Wilm's tumor: Wilms tumor (Nephroblastoma) is the most common primary renal malignancy of childhood, typically presenting in children aged 2–5 years . Feature Description Origin Derived from nephrogenic rests (primitive metanephric blastema). Presentation Large, palpable, unilateral flank mass ; usually smooth and firm. Associated Signs Hematuria (25%), hypertension (due to increased renin), and abdominal pain. Imaging CT/Ultrasound shows a mass that does NOT cross the midline (displaces the kidney). Histology Triphasic pattern : Blastemal (small blue cells), Stromal (fibrocystic), and Epithelial (tubules/glomeruli).

References:

Robbins and Cotran Pathologic basis of disease, 10th Edition, Page 477, 478

↑ *Back to this question in Part A*

@Neet_pg_bot

Q11: A 2-year-old boy is brought with complaints of abdominal lump for 2 months. HPE of the mass is shown below. Which of the following conditions is not associated with a similar finding? (Q845590)

A. Neuroblastoma

B. Medulloblastoma

C. Retinoblastoma

D. Primitive neuroectodermal tumors

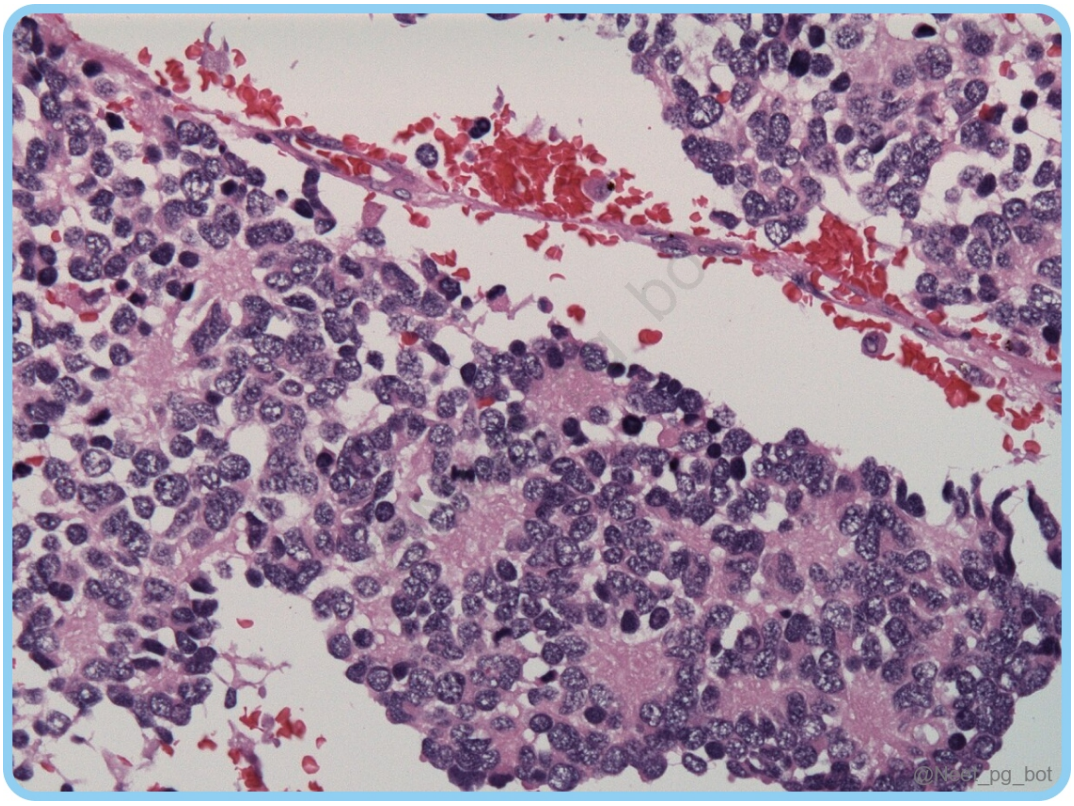

Correct Answer: C. Retinoblastoma

■ *Listen (English)*

■ *Listen (Hindi)*

Explanation: Homer Wright rosettes are also seen in Neuroblastoma, Medulloblastoma and primitive neuroectodermal tumors.

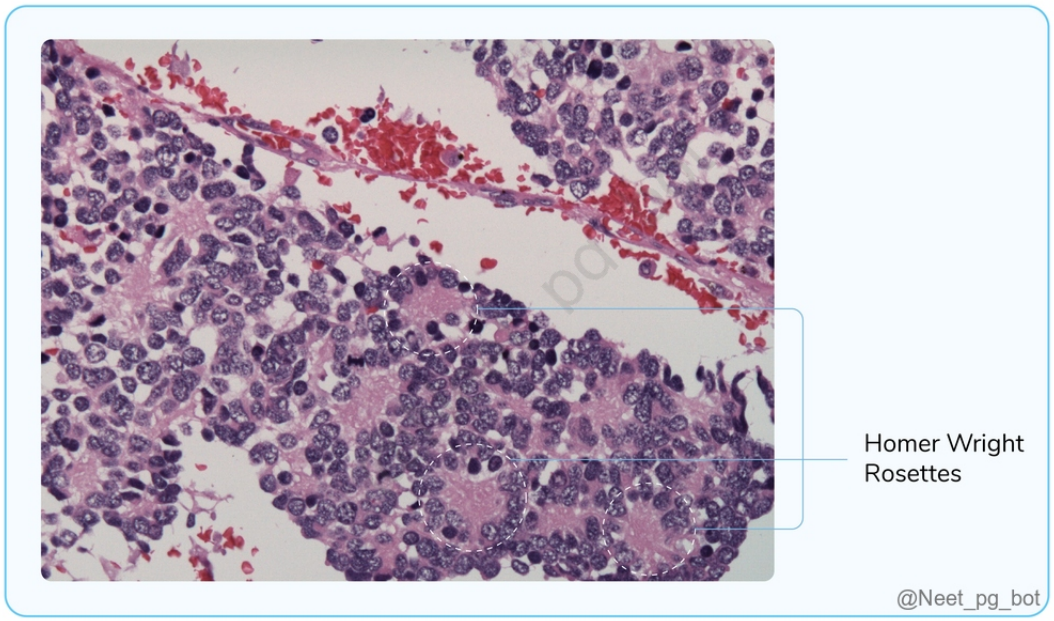

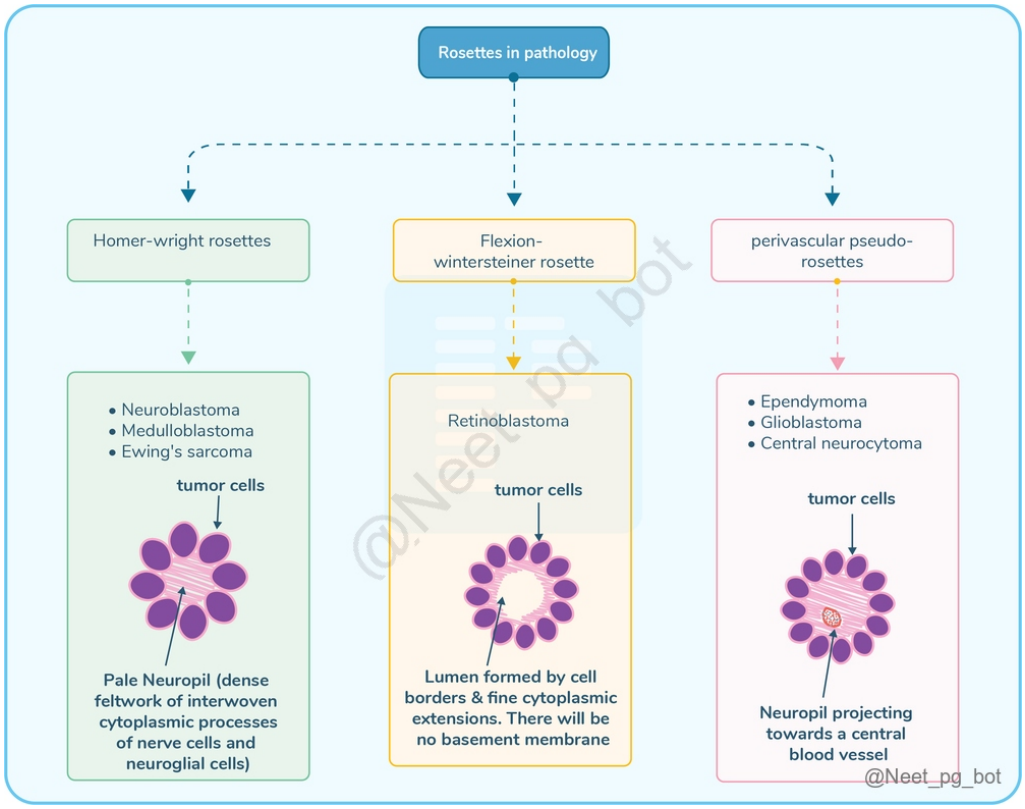

References:

Robbins and Cotran Pathologic basis of disease, 10th edition, 478, 1298, 1193, 723

↑ *Back to this question in Part A*

@Neet_pg_bot

Q12: This histology finding is seen in all these tumors except? (Q845591)

A. Pheochromocytoma

B. Carotid body tumor

C. Neuroblastoma

D. Medullary carcinoma of the thyroid

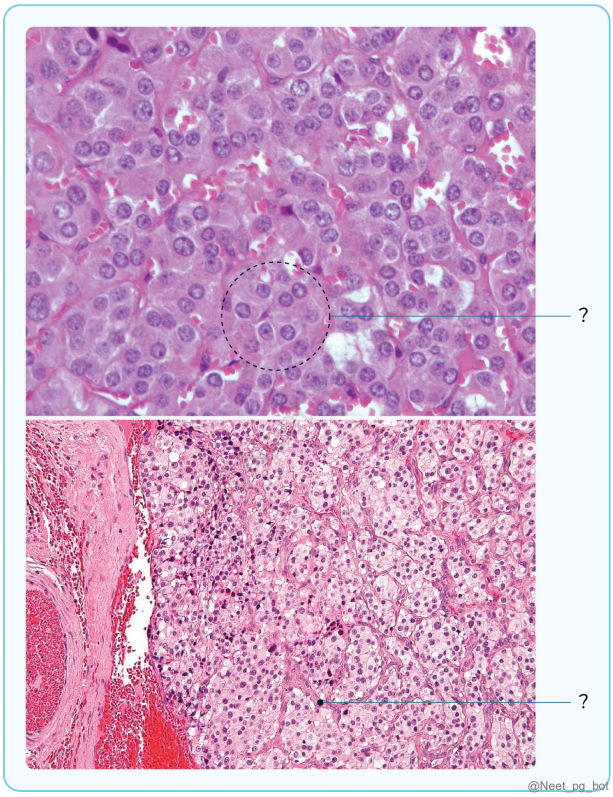

Correct Answer: C. Neuroblastoma

■ *Listen (English)*

■ *Listen (Hindi)*

Explanation: The image shows nests (Zellballen) of round to oval chief cells with abundant, clear, or granular, eosinophilic cytoplasm and uniform, round nuclei surrounded by delicate vascular septae. The nuclei show a stippled “salt-and-pepper” chromatin that is characteristic of tumors like: Pheochromocytoma (Option A) Carotid body tumour (Option B) Medullary carcinoma of the thyroid (Option D) Small cell carcinoma of the lungs Neuroblastoma (Option C) on histology has small round blue cells with scanty cytoplasm. These cells resemble a

rosette which means ‘flower-like’ called Homer-Wright rosettes.

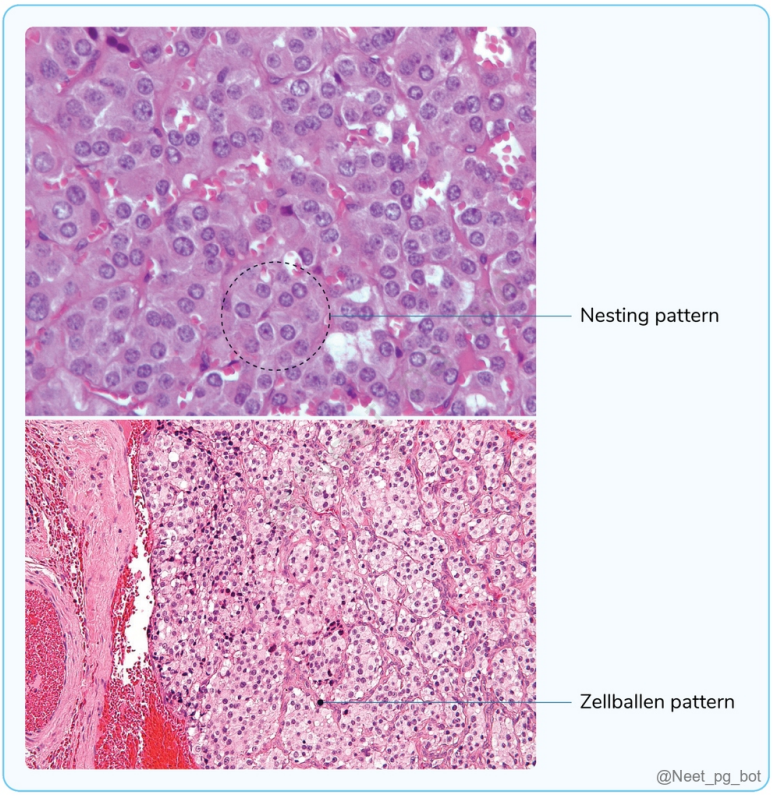

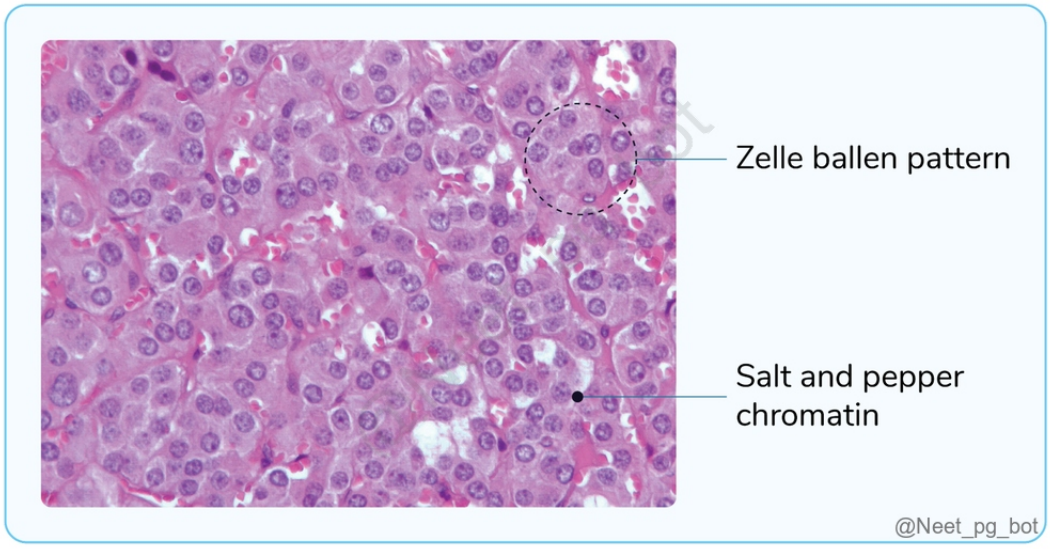

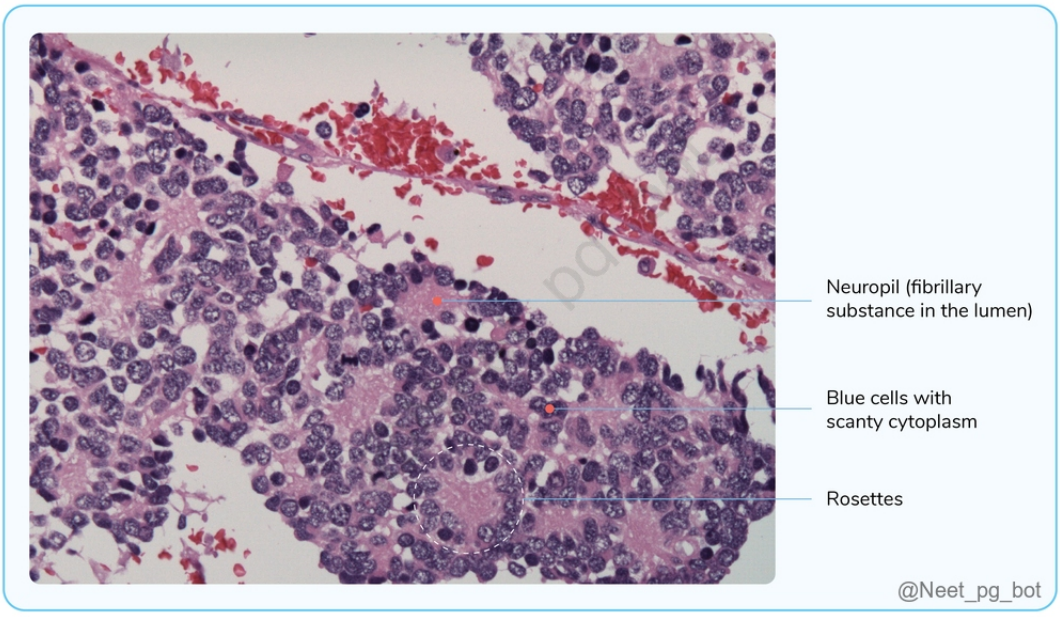

References:

Robbins and Cotran Pathologic Basis of Disease, 10th Edition, Pages 746 & 1128.

↑ *Back to this question in Part A*

@Neet_pg_bot

Q13: A 40-year-old woman has been evaluated for intermittent headaches, insomnia, diaphoresis, and unintentional weight loss over the past several months. The patient is found to have a neoplastic mass producing excessive hormones causing symptoms. Histopathology of the same is shown below. These cells marked below stain positive for which of the following immunohistochemical markers? (Q845592)

A. Synaptophysin

B. Chromogranin

C. Neuron-specific enolase

D. S-100

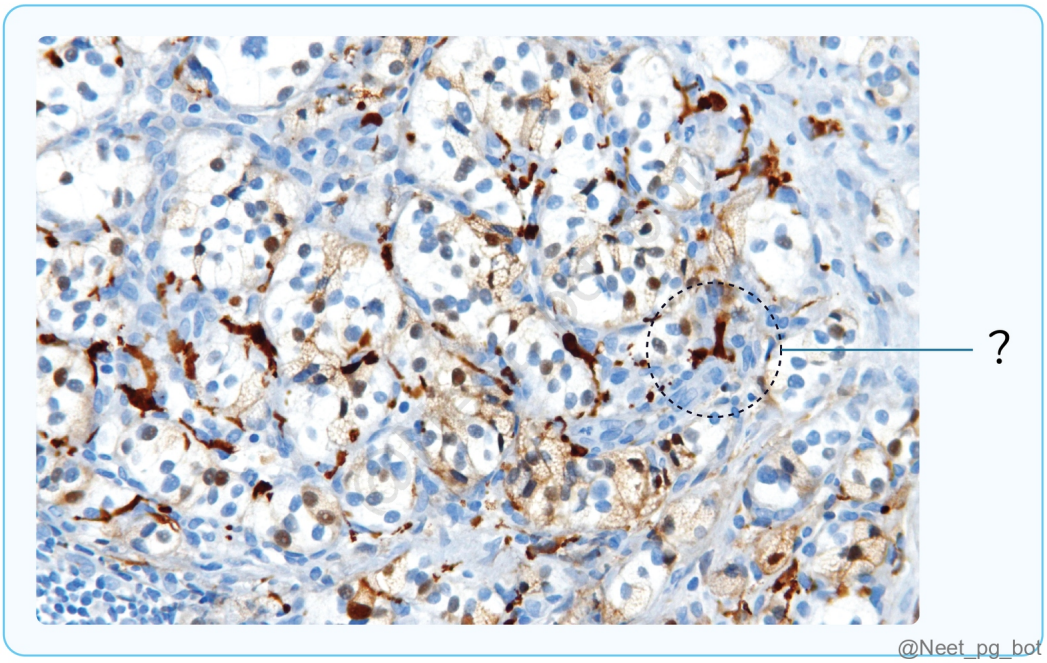

Correct Answer: D. S-100

■ *Listen (English)*

■ *Listen (Hindi)*

Explanation: The given scenario and HPE is suggestive of pheochromocytoma with a marked structure containing sustentacular cells that stain positive for S-100 protein . Pheochromocytoma is a tumour of the chromaffin cells or the chief cells of the adrenal medulla. The diagnosis is confirmed by histology showing a highly vascular tumor with nests of spindle-shaped or polygonal cells (zelleballen pattern). The chief cells are neuroendocrine in origin and stain strongly for synaptophysin, chromogranin, and neuron-specific enolase(NSE). The supporting network of spindle-shaped stromal cells, collectively called sustentacular cells stain positive for S-100 protein a calcium-binding protein expressed by a variety of mesenchymal cell types. (Option D) .

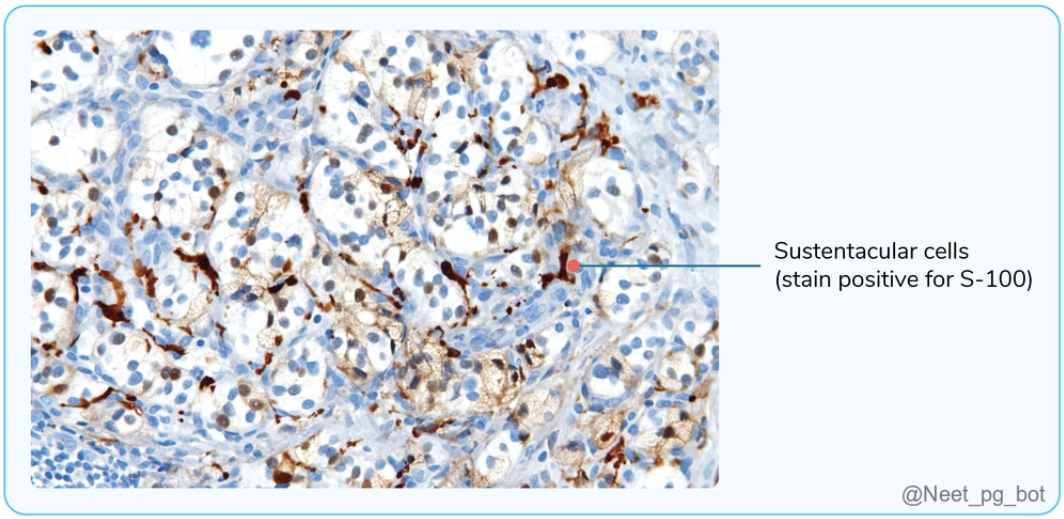

References:

Robbins and Cotran Pathologic basis of disease, 10th Edition, Page 1128

↑ *Back to this question in Part A*

@Neet_pg_bot

Q14: A 40-year-old woman presents to her primary care physician with a recent diagnosis of medullary thyroid carcinoma (MTC). She reports no significant family history of endocrine disorders. Laboratory investigations show elevated levels of serum calcium and plasma catecholamines and metanephrines. What is the most likely diagnosis in this patient? (Q845593)

A. MEN 1 syndrome

B. MEN 2 A syndrome

C. MEN 2 B syndrome

D. Neurofibromatosis type 1

Correct Answer: B. MEN 2 A syndrome

Explanation: The most likely diagnosis in this patient is MEN 2 A syndrome, which is characterized by medullary thyroid carcinoma (MTC), primary hyperparathyroidism and pheochromocytoma. Elevated serum calcium → suggests primary hyperparathyroidism Elevated plasma catecholamines and metanephrines → suggests pheochromocytoma

MEN I	MEN IIa	MEN IIb	MEN IV
Wermer's syndrome	Sipple syndrome		
MENIN mutation	RET mutation	CDKN1B mutation	
• Pituitary adenoma • Parathyroid Hyperplasia • Pancreatic tumor	• Parathyroid Hyperplasia • Medullary carcinoma thyroid • Pheochromocytoma	• Mucosal neuroma • Marfanoid habitus • Medullary carcinoma • Pheochromocytoma	Similar to MEN 1

@Neet_pg_bot

References:

Robbins and Cotran Pathologic basis of disease, 10th Edition, Page 1130

↑ *Back to this question in Part A*

@Neet_pg_bot

• [13_Endocrinology] 058 Previous Year Questions

« Back to Folder Directory

[13_Endocrinology] 058 Previous Year Questions — Quick Jump

Q1 (p. 2388) *Q2 (p. 2388)* *Q3 (p. 2389)* *Q4 (p. 2390)* *Q5 (p. 2391)* *Q6 (p. 2393)*
Q7 (p. 2394) *Q8 (p. 2395)* *Q9 (p. 2395)* *Q10 (p. 2398)* *Q11 (p. 2402)* *Q12 (p. 2403)*
Q13 (p. 2404) *Q14 (p. 2406)* *Q15 (p. 2408)*

Q1: Mutation in which of the following genes is most commonly associated with medullary thyroid carcinoma? (Q866734)

A. RAS

B. BRAF

C. RET

D. TP53

Correct Answer: C. RET

Explanation: Medullary thyroid carcinomas are associated with RET proto-oncogene mutation. Medullary carcinoma of the thyroid a neuroendocrine tumour arising from parafollicular C cells. They secrete calcitonin, which regulates calcium levels and is also a marker for diagnosis and postoperative follow-up. Carcinoembryonic antigen (CEA) is a marker in whom calcitonin is negative. They can be sporadic or associated with familial syndromes like MEN 2. Both have associated RET mutations. Sporadic tumors usually present with solitary nodules whereas familial are characterized by bilaterality and multicentricity, and can have features of other associated tumors. A biopsy would show amyloid deposits (Acal) derived from calcitonin polypeptides. Thyroid Malignancy Mutations/Genetic Alterations Follicular Thyroid Adenoma (Benign Condition) RAS (Option A) Papillary Thyroid Carcinoma (PTC) BRAF V600E (Option B) RET/PTC rearrangements Follicular Thyroid Carcinoma (FTC) RAS (Option A) PAX8-PPARγ rearrangements PIK3CA Medullary Thyroid Carcinoma (MTC) RET (Option C) Anaplastic Thyroid Carcinoma (ATC) TP53 (Option D)

↑ *Back to this question in Part A*

@Neet_pg_bot

Q2: A patient presents with a mass in the front of the neck, along with odynophagia and dyspnea. Histopathology reveals tumour cells positive for TTF-1, synaptophysin, and chromogranin, and there is evidence of amyloid deposition. What is the most

likely diagnosis? (Q866374)

A. Papillary thyroid carcinoma

B. Follicular thyroid carcinoma

C. Medullary thyroid carcinoma

D. Anaplastic thyroid carcinoma

Correct Answer: C. Medullary thyroid carcinoma

Explanation: The given clinical scenario with IHC positive for TTF-1, synaptophysin, and chromogranin and evidence of amyloid deposition is all suggestive of medullary thyroid carcinoma, which has amyloid deposition derived from calcitonin, known as A-CAL. 1. Clinical Features Origin: Parafollicular C cells of the thyroid (neuroendocrine cells). Hormone secreted: Calcitonin (does not cause hypocalcemia in most cases). Presentations: Neck mass: Firm, non-tender, may be solitary or multiple. Local compressive symptoms: Odynophagia (painful swallowing) Dyspnea (tracheal compression) Hoarseness (recurrent laryngeal nerve involvement) Systemic symptoms Diarrhea and flushing (due to hormone secretion like calcitonin, serotonin, VIP in some cases) Family history: MEN 2A or 2B syndromes (pheochromocytoma, parathyroid hyperplasia in 2A; mucosal neuromas and Marfanoid habitus in 2B). 2. Investigations A. Laboratory tests Serum calcitonin: Elevated (marker for diagnosis and follow-up). Carcinoembryonic antigen (CEA): Often elevated; used for prognosis. RET proto-oncogene mutation testing: In patients and first-degree relatives. B. Imaging Neck ultrasound: Hypoechoic solid nodule, may show cervical lymphadenopathy. CT/MRI: For extent and metastasis assessment. Radioiodine scan: Usually negative (C cells do not take up iodine). C. Histopathology Tumour cells: Polygonal/spindle-shaped, arranged in nests/trabeculae. Amyloid deposition in stroma (derived from calcitonin). Immunohistochemistry: TTF-1 → confirms thyroid origin Synaptophysin & chromogranin → confirm neuroendocrine nature Calcitonin positive in tumour cells. 3. Diagnosis Definitive diagnosis : Fine-needle aspiration (FNA) cytology → suspicious for MTC. Confirmed by immunohistochemistry for calcitonin and neuroendocrine markers + histologic amyloid. Elevated serum calcitonin strongly supports the diagnosis.

↑ *Back to this question in Part A*

@Neet_pg_bot

Q3: Identify the gene commonly involved in the carcinoma shown in the image below: (Q843990)

A. RAS

B. PAX8–PPARγ

C. BRAF V600

D. P53

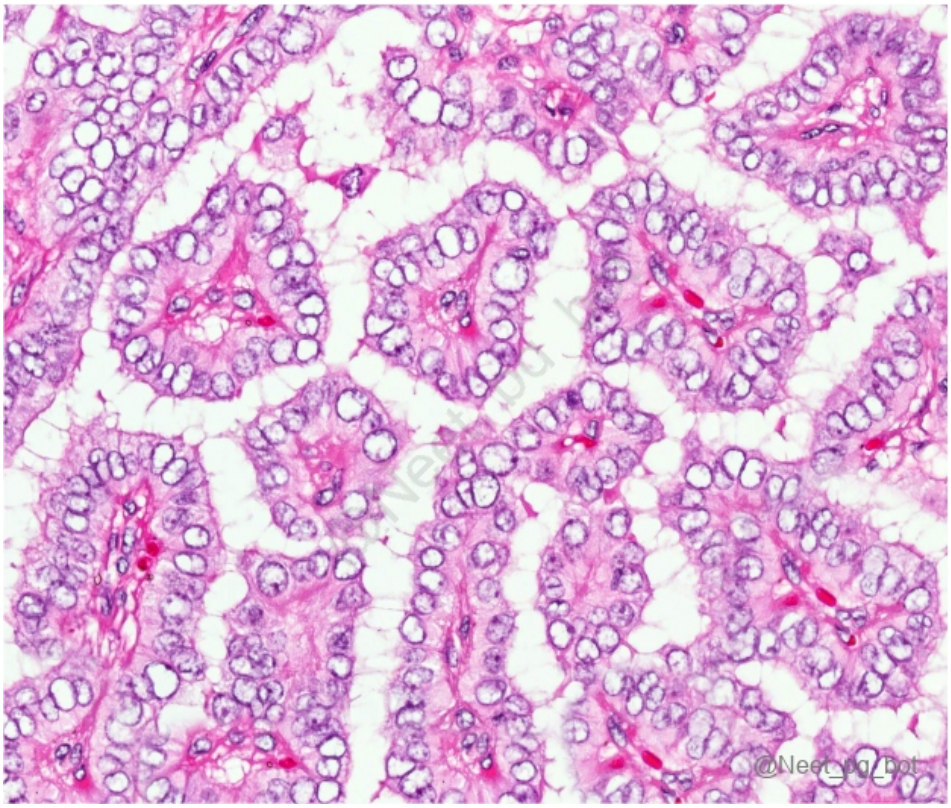

Correct Answer: C. BRAF V600

Explanation: Correct Option C - BRAF V600: The image shows Orphan Annie's eye nucleus, which is seen in papillary thyroid cancer. It is associated with BRAF V600 mutation. Orphan Annie Eye Nuclei These nuclei appear empty, clear, and ground-glass–like. Caused by chromatin clearing. Highly characteristic of papillary thyroid carcinoma (PTC). Other nuclear features in PTC: Nuclear grooves, Intranuclear cytoplasmic inclusions Overlapping nuclei, Psammoma bodies BRAF V600E Mutation One of the most common mutations in PTC, especially the classical and tall-cell variant. Leads to constitutive activation of the MAPK pathway, driving tumor growth. Mutation associated with: More aggressive disease Extrathyroidal extension Lymph node metastasis Higher recurrence risk Incorrect Options: Options A, B, and D are not associated with papillary thyroid cancer.

References:

Prepladder notes

↑ *Back to this question in Part A*

@Neet_pg_bot

Q4: A patient presents with headaches, palpitations, and hypertension. On laboratory examination, urine VMA is positive. His biopsy findings are given below. Which of the following is a correct statement? (Q844236)

A. Mostly malignant

B. Mostly in children

C. Mostly bilateral

D. Associated with MEN2A

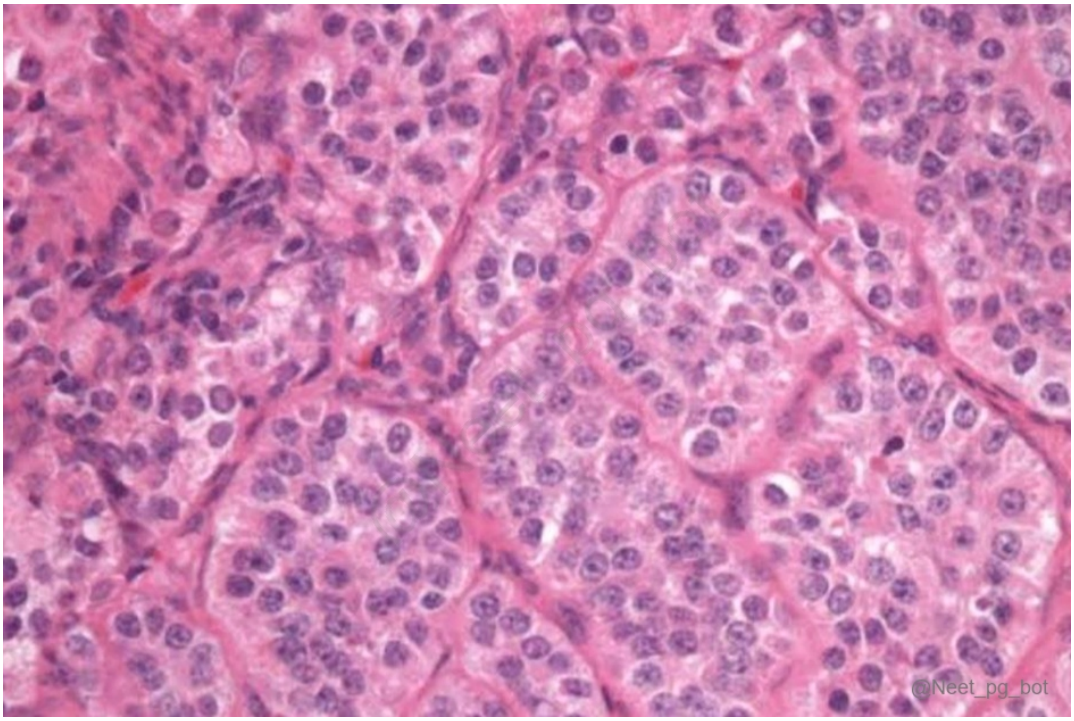

Correct Answer: D. Associated with MEN2A

Explanation: Correct Option D - Associated with MEN2A: The given biopsy shows a nesting pattern or Zellballen pattern, which is suggestive of pheochromocytoma. It is associated with Multiple Endocrine Neoplasia type 2A (MEN2A). Incorrect Options: Option A - Mostly malignant: Pheochromocytomas are mostly benign, only 10% malignant. Option B - Mostly in children: Pheochromocytomas are more common in adults; only 10% occur in children. Option C - Mostly bilateral: Pheochromocytomas are mostly unilateral, and only 10% are bilateral.

References:

.

↑ *Back to this question in Part A*

@Neet_pg_bot

Q5: Which hormone is secreted by the structure marked with an arrow? (Q860565)

A. Glucocorticoid

B. DHEA

C. Androgens

D. Mineralocorticoid

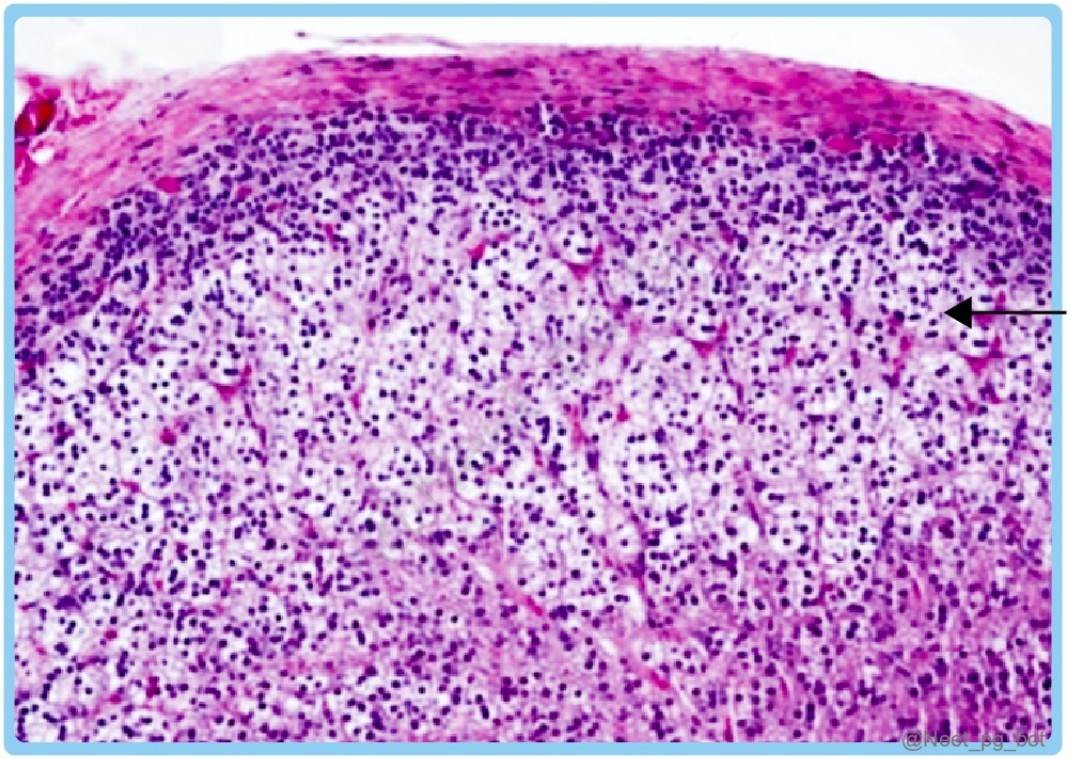

Correct Answer: A. Glucocorticoid

Explanation: The marked portion is Zona Fasciculata , which releases glucocorticoids. {{caption_text}} Layers of Adrenal Gland Adrenal Cortex Zones of the cortex Hormones produced Main function Morphology of Zone Zona Glomerulosa Mineralocorticoid (Option D ruled out) Aldosterone(main) Deoxycorticosterone Maintenance of sodium balance Small clumps of cells Zona fasciculata Glucocorticoids (Option A) Cortisol Corticosterone Maintenance of sugars Columnar cells that form long cords Zona reticularis Sex steroids Dehydroepiandrosterone (DHEA) (Option B ruled out) Androstenedione (Option C ruled out) Maintenance of sexual functioning Network of intercalated cells Adrenal medulla Medulla Catecholamines: Norepinephrine Epinephrine Small amounts of dopamine Carbohydrate and fat metabolisms Fight or flight responses Specialised sympathetic ganglion Clumps and strands of chromaffin cells

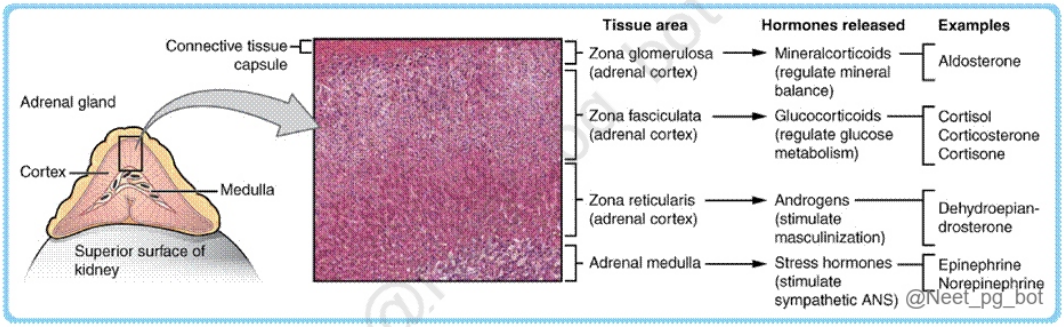

References:

Ganong's Review of Medical Physiology, 26th Edition, Page 329-333.

Textbook of Physiology, G. K Pal, 1st Edition, Page 507.

↑ *Back to this question in Part A*

@Neet_pg_bot

Q6: Which of the following is a new intranuclear immunohistochemistry marker for neuroendocrine tumors? (Q840013)

A. Synaptophysin

B. Chromogranin

C. INSM1

D. NCAM1/ CD56

Correct Answer: C. INSM1

Explanation: INSM1 (Insulinoma-associated protein 1) is a newer intranuclear marker used in pathology for identifying neuroendocrine tumors (NETs). It stains the nucleus, unlike older markers which are cytoplasmic or membranous. INSM1 has high sensitivity and specificity for NETs including carcinoid tumors, small-cell carcinoma, medullary thyroid carcinoma, and pheochromocytoma. Because of its strong and clear nuclear staining, it is now widely adopted as a modern, reliable NET marker. Incorrect Options: Option A) Synaptophysin – A cytoplasmic neuroendocrine marker; not intranuclear. Option B) Chromogranin – A cytoplasmic secretory granule marker; not new and not intranuclear. Option D) NCAM1 / CD56 – A cell surface adhesion molecule; less specific and not intranuclear.

References:

.

↑ *Back to this question in Part A*

Q7: A patient presents with neck swelling with compression of the trachea and esophagus. Histopathological assessment shows cell nest and pink extracellular amyloid stroma. What is the origin of the tumor? (Q840079)

A. Parafollicular C cells

B. Hurthle cell

C. Follicular cells

D. Askanazy cells

Correct Answer: A. Parafollicular C cells

Explanation: Correct Option A - Parafollicular C cells: The presence of an amyloid stroma and nesting pattern suggests the likelihood of medullary carcinoma of the thyroid. It originates from the Parafollicular C cells. Incorrect Options: Options B & D - Hurthle cells & Askanazy cells: Hurthle cells or Askanazy cells are seen in Hashimoto's thyroiditis. They are not associated with medullary carcinoma. Option C - Follicular cells: Follicular cells give rise to papillary, follicular, and anaplastic thyroid carcinomas but not medullary carcinoma.

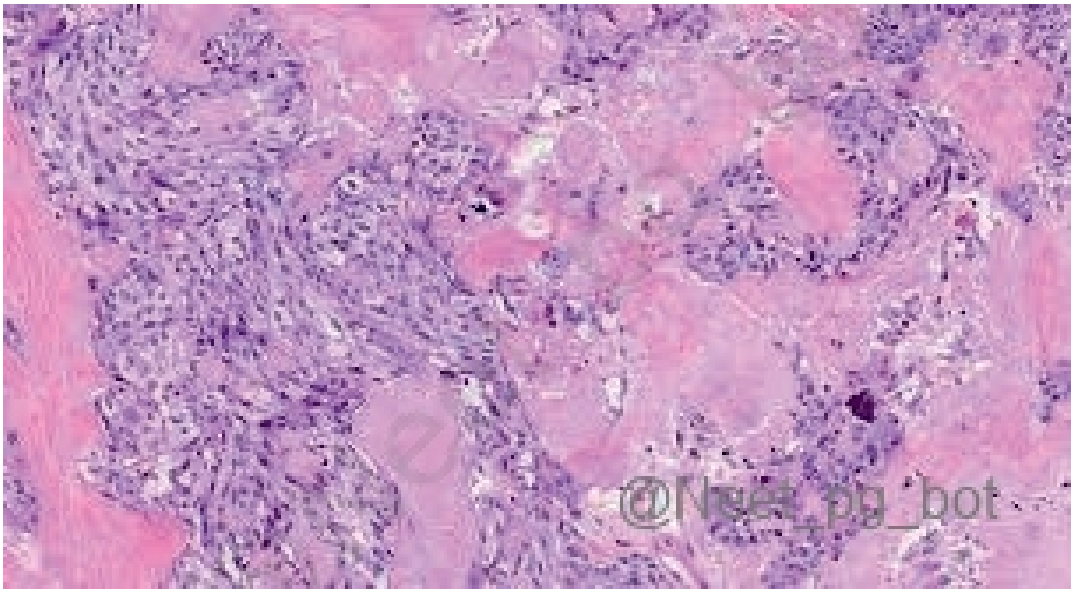

References:

.

↑ *Back to this question in Part A*

Q8: A 26-year-old female patient presents with a palpable thyroid nodule and occasional neck discomfort. She has no history of radiation exposure to the neck. On physical examination, a solitary, firm, non-tender thyroid nodule is noted. Ultrasound reveals a hypoechoic nodule with microcalcifications. Fine-needle aspiration biopsy is performed, and histological analysis reveals characteristic nuclear changes. What is the most common thyroid cancer in this patient? (Q820517)

A. Papillary carcinoma

B. Follicular carcinoma

C. Medullary carcinoma

D. Anaplastic carcinoma

Correct Answer: A. Papillary carcinoma

Explanation: Correct Option A - Papillary carcinoma: This is the most common type of thyroid cancer, especially in young adults. It often presents as a solitary thyroid nodule, and its characteristics on ultrasound, such as hypoechoic appearance and microcalcifications, along with the patient's demographic and clinical profile, are consistent with the case described. Papillary carcinoma is known for its characteristic nuclear changes, including nuclear grooves and pseudoinclusions. It usually has an excellent prognosis with a high survival rate. Incorrect Options: Option B - Follicular carcinoma: This type of thyroid cancer also presents as a thyroid nodule. However, it is less common than papillary carcinoma. Fine-needle aspiration biopsy alone might not be able to distinguish between follicular adenoma and follicular carcinoma. Histopathological examination of the tumor capsule and vascular invasion is required to make the distinction. Option C - Medullary carcinoma: Medullary carcinoma arises from parafollicular C cells and is associated with calcitonin production. It is typically not associated with microcalcifications on ultrasound and does not have the characteristic nuclear changes mentioned in the case. It's less common than papillary carcinoma and is often familial or associated with multiple endocrine neoplasia syndromes. Option D - Anaplastic carcinoma: This is an aggressive and rare type of thyroid cancer. It usually presents with rapid growth, hoarseness, dyspnea (difficulty breathing), and is commonly seen in older patients. It is not associated with the characteristic nuclear changes mentioned in the case and does not typically present with microcalcifications.

References:

.

↑ *Back to this question in Part A*

@Neet_pg_bot

Q9: A 19-year-old female presents with a neck swelling that shifts during swallowing. Ultrasound reveals a 2 cm x 2 cm mass in the left lobe of the thyroid, reaching the strap muscles. Histopathology shows findings as shown in the image. What is the most probable diagnosis? (Q855119)

A. Medullary CA thyroid

B. Follicular CA thyroid

C. Thyroglossal cyst

D. Papillary CA thyroid

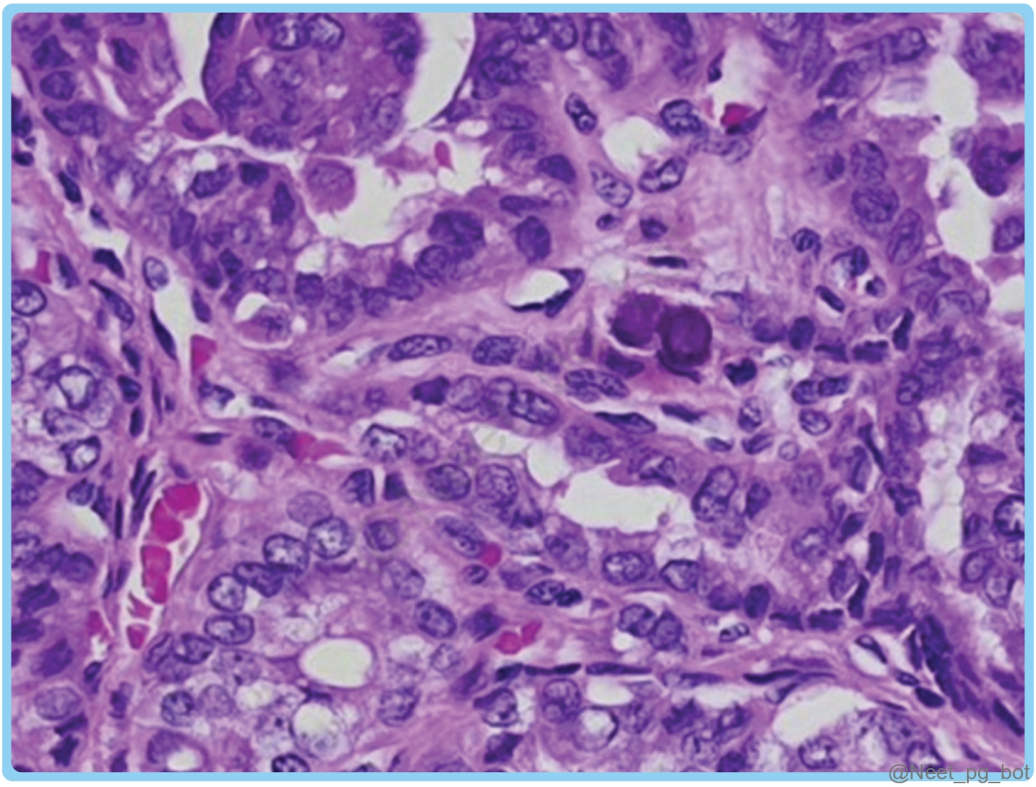

Correct Answer: D. Papillary CA thyroid

Explanation: The clinical presentation with neck swelling that shifts during swallowing, along with the ultrasound findings of a mass in the thyroid reaching the strap muscles, raises suspicion for a thyroid pathology. The histopathology showing papillae lined with overlapping nuclei and the characteristic " Orphan Annie eye" nuclei is highly indicative of papillary carcinoma of the thyroid . Papillary carcinoma of the thyroid: This is the most common type of thyroid cancer and is characterized by lymphatic spread. It often presents with a nodule in the anterior neck and lymphadenopathy. Associated with BRAF mutations and RET-PTC fusion HPE shows: True papillae: Fingerlike projections with fibrovascular core. Orphan Annie eye nuclei: Optically clear nucleus produced due to artefact. Intranuclear cytoplasmic inclusions (INCI). Nuclear groove or coffee bean nucleus. Presence of psammoma bodies: Dystrophic calcifications {{caption_text}} {{caption_text}} It has the best

prognosis among thyroid malignancies. Medullary Carcinoma of the Thyroid (Option A) arises from the parafollicular C cells , which produce calcitonin. The provided histopathology does not show the typical features of medullary carcinoma, such as nests or clusters of polygonal cells with amyloid deposits. Follicular Carcinoma of the Thyroid (Option B) arises from the thyroid follicular cells. The histopathology image does not display the characteristic features of follicular carcinomas, such as invasion of the tumour capsule or blood vessels. Thyroglossal Cyst (Option C) is a congenital anomaly resulting from the persistence of thyroglossal duct remnants. It typically presents as a midline neck swelling that moves during swallowing. However, the histopathology does not show features typical of a thyroglossal cyst, such as a cystic structure lined by stratified squamous or columnar epithelium.

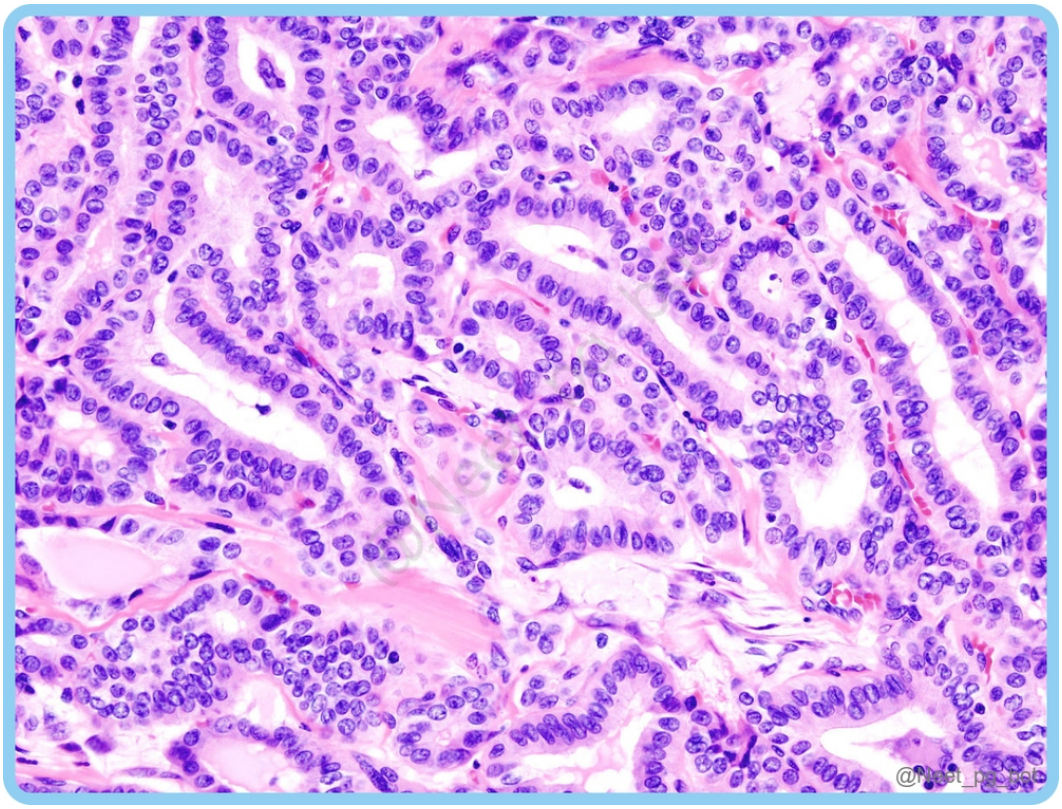

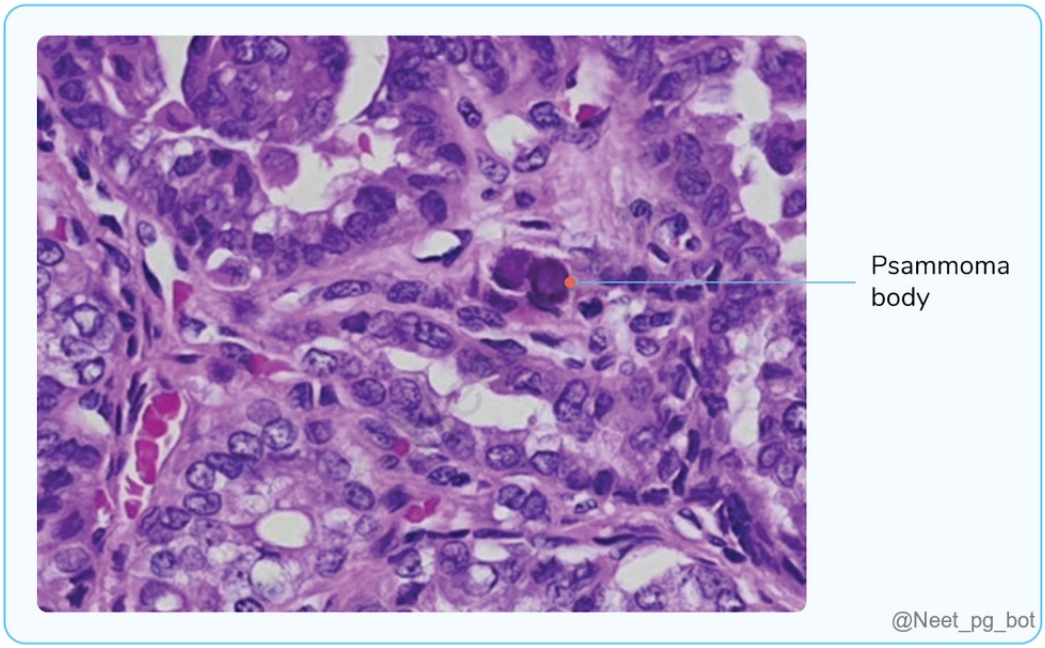

References:

Robbins & Cotran Pathologic Basis of Disease, 10th Edition, Page 1088

↑ *Back to this question in Part A*

@Neet_pg_bot

Q10: What is the likely diagnosis for a patient who presents with a swelling in the midline of the neck, based on the biopsy findings, which reveal orphan Annie's eye nuclei as depicted in the image provided? (Q857571)

A. Follicular carcinoma

B. Papillary carcinoma

C. Toxic nodular goiter

D. Medullary carcinoma

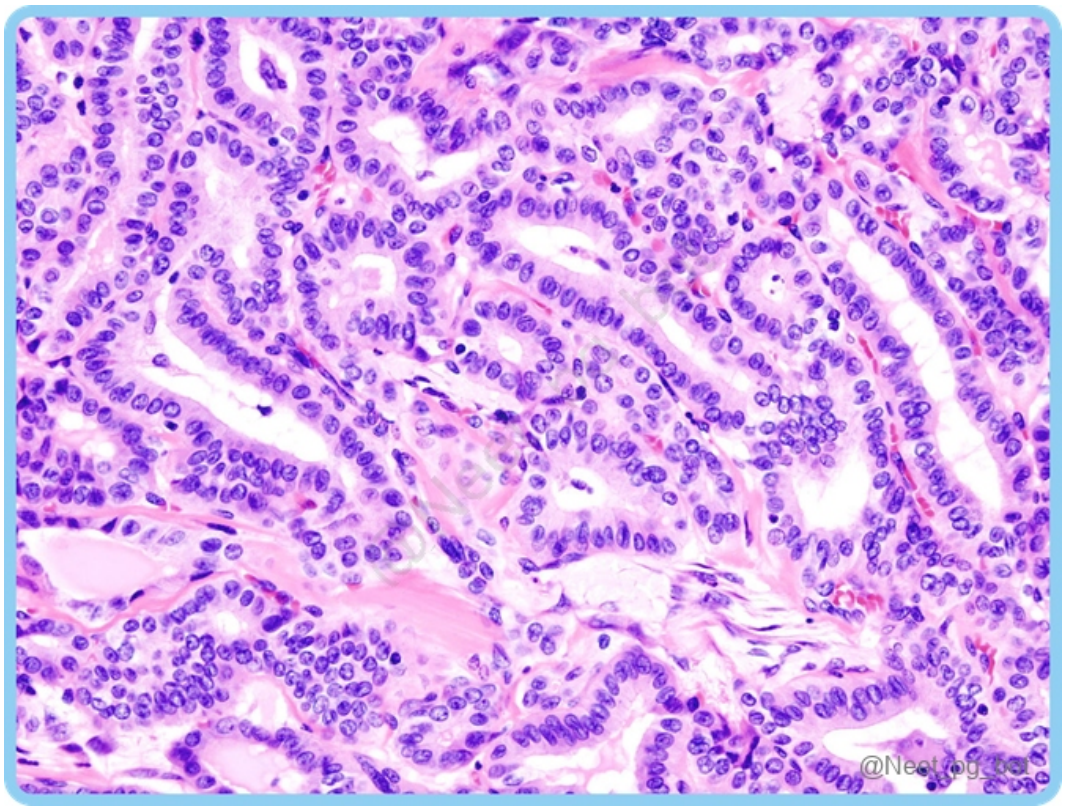

Correct Answer: B. Papillary carcinoma

Explanation: Papillary thyroid carcinoma, the most common thyroid cancer, is characterised by "orphan Annie's eye" nuclei, which appear empty with a pale, ground-glass appearance under microscopy. Papillary carcinoma thyroid: It is the most common type of thyroid cancer and is characterised by lymphatic spread. It often presents with a nodule in the anterior neck and lymphadenopathy. Associated with BRAF mutations and RET-PTC fusion. HPE shows True papillae: Fingerlike projections with fibrovascular core. Orphan Annie eye nuclei: Optically clear nucleus produced due to artefact. Intranuclear cytoplasmic inclusions (INCI). Nuclear groove or coffee bean nucleus. Presence of psammoma bodies: Dystrophic calcifications It has the best prognosis among thyroid malignancies. {{caption_text}} {{caption_text}} Follicular carcinoma (Option A) is a malignant thyroid tumour of follicular cells lacking papillary carcinoma's distinctive features. It typically affects older individuals and presents as a solitary thyroid mass or, less commonly, as bone metastases. It is more cellular, with a thick, irregular capsule, necrosis, and frequent mitotic activity. {{caption_text}} Toxic nodular goitre (Option C) , also known as Plummer disease or a toxic multi-nodular goitre (MNG), is characterised by a hormonally active and leads to hyperthyroidism. Treatment often includes radioactive iodine, which is absorbed by the thyroid and destroys hormone-producing cells, reducing or eliminating hormone production and potentially decreasing the size of the goitre. {{caption_text}} Medullary carcinoma (Option D) of the thyroid (MTC), a neuroendocrine tumour, originates from the C cells of the thyroid, which produce calcitonin. MTC accounts for less than 5% of all thyroid cancers. Unlike other thyroid cancers, MTC does not accumulate radioiodine but secretes calcitonin. Symptoms may include a lump in the throat, hoarseness due to vocal cord involvement, or difficulty breathing if the tumour obstructs the windpipe. {{caption_text}}

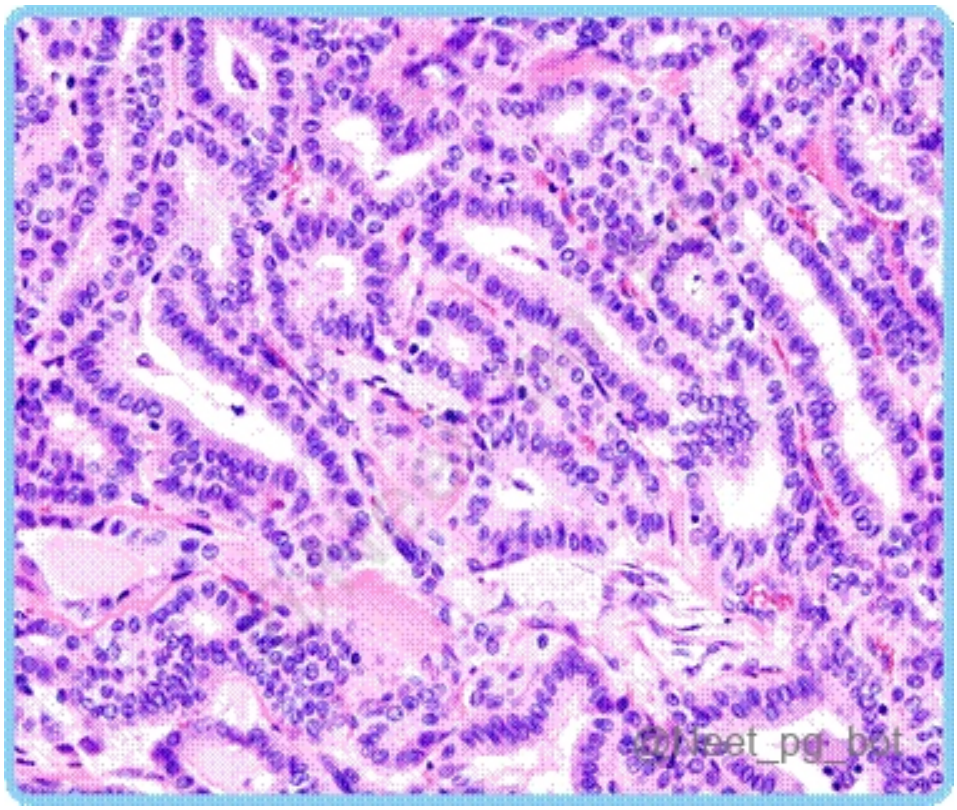
@Neet_pg_bot

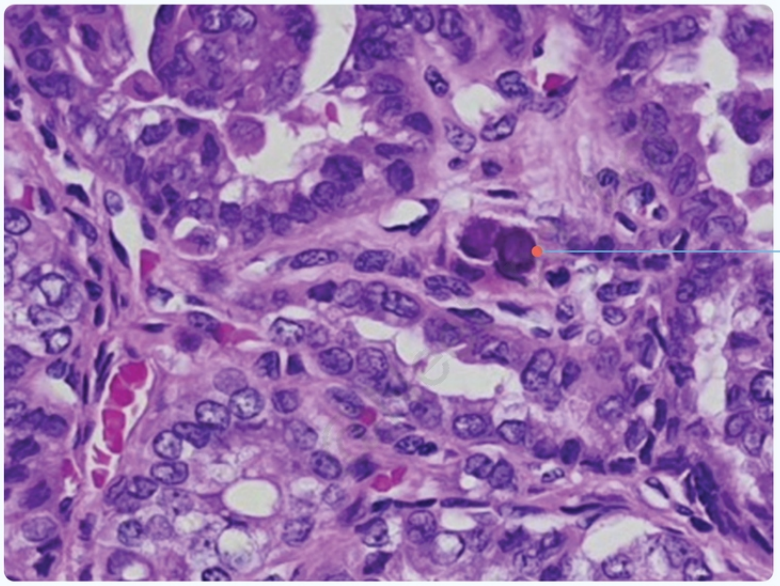
Psammoma body
@Neet_pg_bot

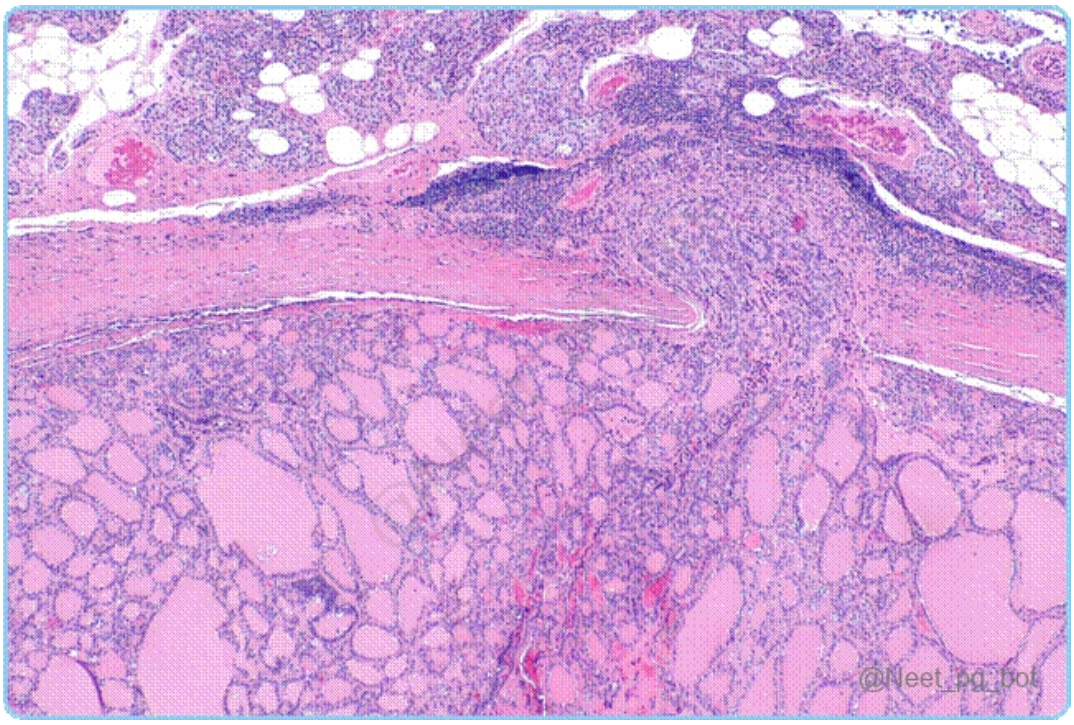
@Neet_pg_bot

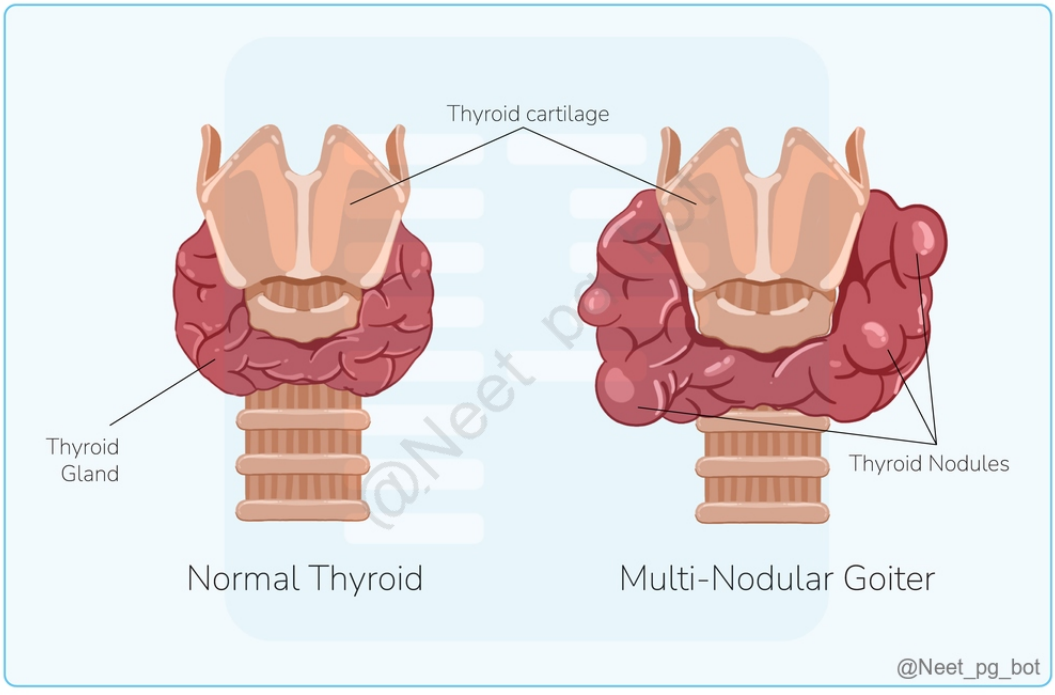
Thyroid cartilage
Thyroid
Gland
Thyroid Nodules
Normal Thyroid
Multi-Nodular Goiter
@Neet_pg_bot

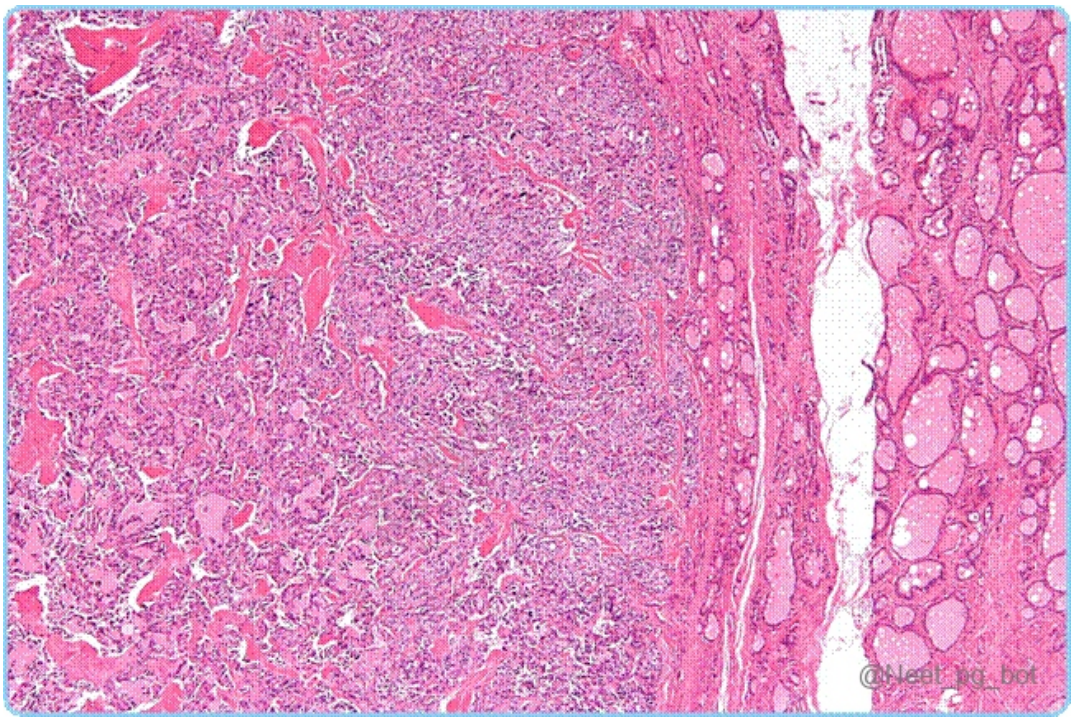

References:

Robbins & Cotran Pathologic Basis of Disease, 10th Edition, Page 1088.

↑ *Back to this question in Part A*

@Neet_pg_bot

Q11: A patient presented to the OPD with long hands and feet and a protruding lower jaw. Which of the following genes is most likely implicated in this scenario? (Q856900)

A. GATA1

B. PIT1

C. TPIT

D. SF1

Correct Answer: B. PIT1

Explanation: The features of long hands and feet, along with a protruding lower jaw, are characteristic of acromegaly , often caused by overproduction of growth hormone (GH). The gene most commonly implicated in this condition is PIT1 (Pituitary-specific gene), a transcription factor that regulates the development and function of pituitary cells responsible for GH production, particularly: Somatotrophs (Growth hormone-producing cells) Lactotrophs (Prolactin-producing cells) Thyrotrophs (TSH-producing cells). PIT1 is essential for the

differentiation of specific pituitary cell types during embryonic development. Its mutations or dysregulation can lead to abnormal pituitary function, causing excess growth hormone production and acromegaly.

References:

Robbins & Cotran Pathologic Basis of Disease, 10th Edition, Page 1066, 1068.

↑ *Back to this question in Part A*

@Neet_pg_bot

Q12: What is the minimum biopsy specimen requirement for an adequate sample in the case of a thyroid biopsy? (Q856910)

A. 15 follicular cell clusters containing 10-12 cells

B. 10 follicular cell clusters containing 6-8 cells

C. 3 follicular cell clusters containing 10-15 cells

D. 6 follicular cell clusters containing 10-15 cells

Correct Answer: D. 6 follicular cell clusters containing 10-15 cells

Explanation: For an adequate thyroid biopsy, the specimen should ideally contain at least 6 follicular cell clusters, each having 10-15 cells. Fine Needle Aspiration Cytology (FNAC) is a minimally invasive diagnostic procedure to evaluate abnormalities in various tissues, including thyroid nodules. Provides cytological details but not the Architecture. It is useful in papillary/medullary (amyloid)/anaplastic carcinomas, colloid nodules, and autoimmune or granulomatous thyroiditis. A 23G needle is used. Suspicious solitary/multiple nodules/ dominant nodules should be aspirated. A minimum of six aspirations should be done. An adequate FNAC smear should have six aspirations with six groups of cells, each containing 20 cells. USG-guided aspiration is better. Diagnostic accuracy of FNAC is 95%; sensitivity 85%; specificity 94%. Classification of FNAC reports: Thy 1 Non-diagnostic Thy 1c Non-diagnostic cystic Thy 2 Non-neoplastic Thy 3 Follicular Thy 4 Suspicion of malignancy Thy 5 Malignant Limitations of FNAC: Follicular Neoplasms: FNAC cannot differentiate between follicular adenoma and follicular carcinoma because it does not provide information about the capsule or vascular invasion . A further biopsy is needed for a definitive diagnosis. Riedel’s Thyroiditis: In this, the thyroid gland is replaced by fibrous tissue, which can result in a poor yield of cells, reducing the effectiveness of FNAC. Thyroid Lymphoma: FNAC may not provide sufficient information to diagnose thyroid lymphoma accurately. A biopsy is required to obtain tissue samples for specific markers and a more comprehensive diagnosis.

References:

Bailey & Love’s Short Practice of Surgery, 28th Edition, Page 866

SRB’s Manual of Surgery, 6th Edition, Page 449

↑ *Back to this question in Part A*

Q13: A patient presents with a midline swelling in the neck. A biopsy reveals Orphan Annie's eye nuclei, as shown in the image below. What is the diagnosis? (Q854832)

A. Follicular carcinoma

B. Papillary carcinoma

C. Toxic nodular goitre

D. Medullary carcinoma

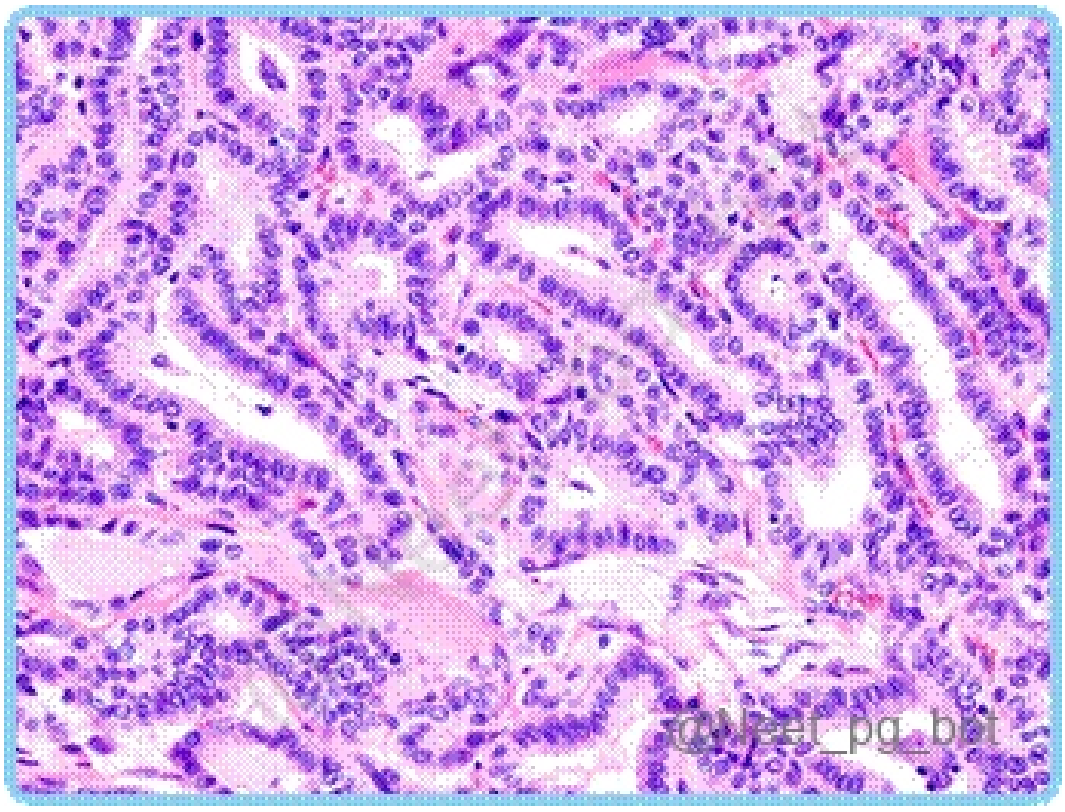

Correct Answer: B. Papillary carcinoma

Explanation: The above features and HPE showing psammoma bodies, nuclear grooves, and "Orphan Annie eye" nuclei indicate papillary thyroid carcinoma, the most common type of thyroid cancer & characterised by lymphatic spread. It often presents with a nodule in the anterior neck and lymphadenopathy. Associated with BRAF mutations and RET-PTC fusion. Histopathological Features: True papillae- Fingerlike projections with fibrovascular core. Orphan Annie eye nuclei - Optically clear nucleus produced due to artefact. Intranuclear cytoplasmic inclusions (INCI). Nuclear groove or coffee bean nucleus. Presence of psammoma bodies- dystrophic calcifications {{caption_text}} {{caption_text}} It has the best prognosis among thyroid malignancies.

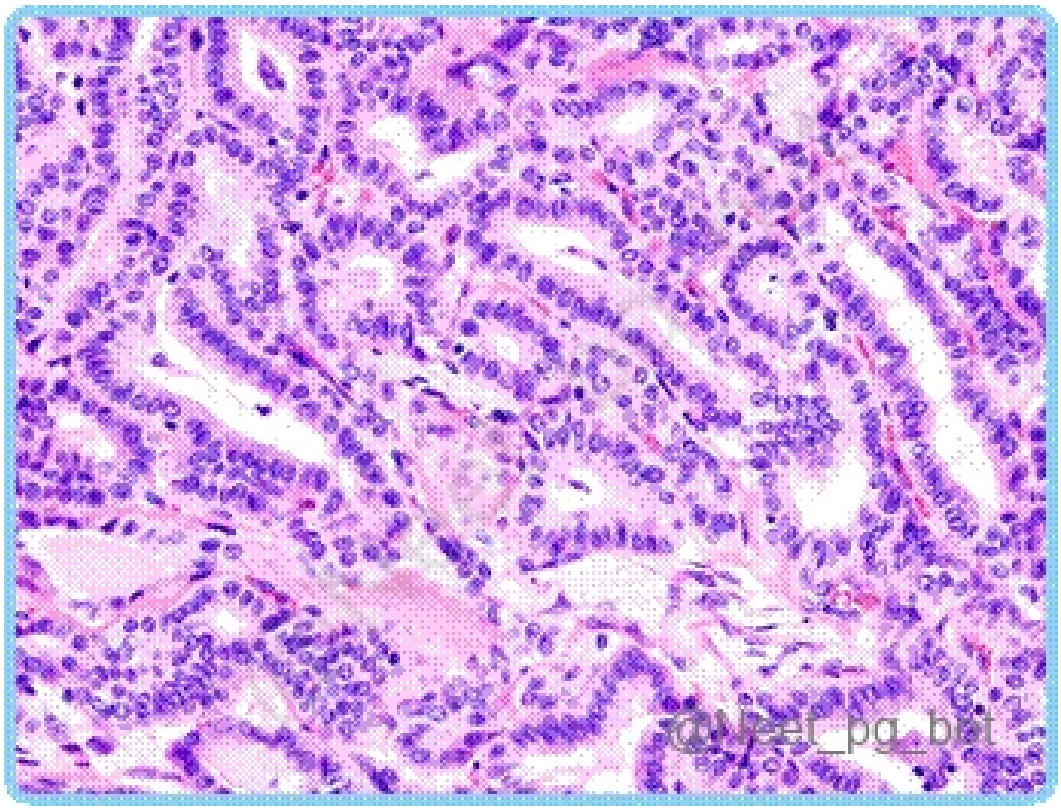

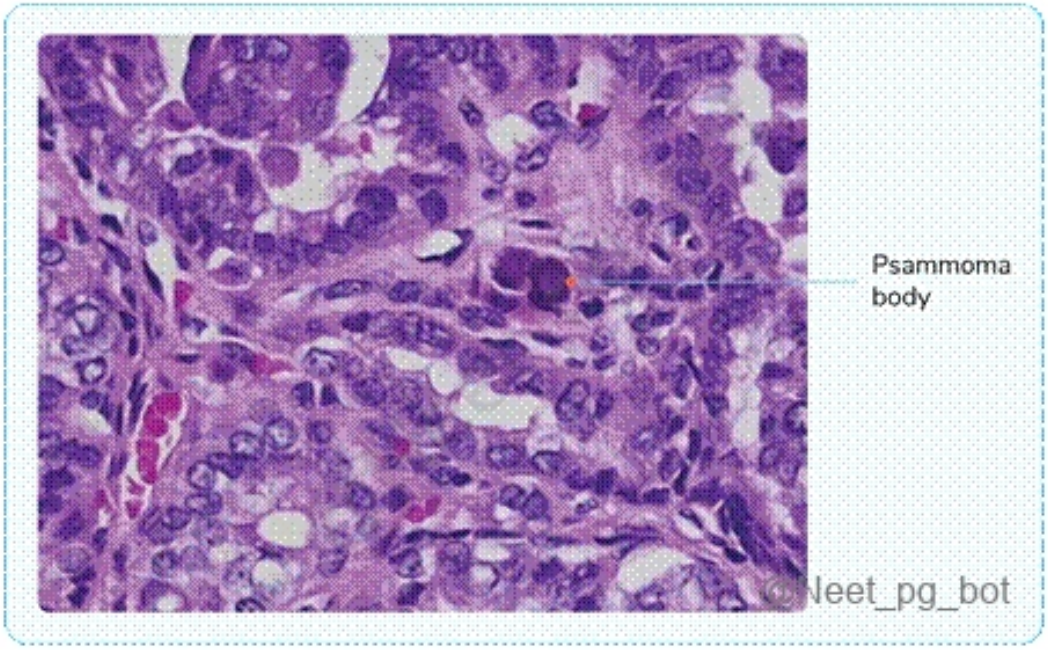

References:

Robbins & Cotran Pathologic Basis of Disease, 10th Edition, Page 1088

↑ *Back to this question in Part A*

@Neet_pg_bot

Q14: A middle-aged woman presents with thyroid swelling. Blood tests show elevated TSH levels and the presence of thyroid peroxidase antibodies. Histopathological examination revealed the presence of Hurthle cells. What is the most likely diagnosis? (Q854852)

A. Hashimoto thyroiditis

B. Graves’ disease

C. Follicular carcinoma of thyroid

D. Medullary carcinoma of thyroid

Correct Answer: A. Hashimoto thyroiditis

Explanation: The clinical scenario with thyroid swelling and elevated TSH levels & presence of thyroid peroxidase antibodies along with the presence of hurthle cells points towards Hashimoto thyroiditis. Hashimoto thyroiditis: An autoimmune disorder that causes chronic inflammation of the thyroid gland. It is the most common cause of hypothyroidism. The characteristic features include elevated TSH levels (due to thyroid failure) and the presence of thyroid peroxidase (TPO) antibodies , which attack the thyroid tissue. It is the most common cause of hypothyroidism in iodine-sufficient areas. It is characterised by painless enlargement of the thyroid, commonly in middle-aged women. The enlargement of the gland is generally symmetric and diffuse. In histopathology, there is extensive lymphocytic infiltration with well-developed germinal centres. The thyroid follicles are atrophic and are lined in many areas by epithelial cells with abundant eosinophilic, granular cytoplasm, termed Hürthle cells, that represent a metaplastic response of the normally low cuboidal follicular epithelium to chronic injury. {{caption_text}} The thyroid parenchyma contains a dense lymphocytic infiltrate with germinal centres. Graves' disease (Option B) is an autoimmune disorder leading to hyperthyroidism, characterised by low TSH levels and the presence of thyroid-stimulating immunoglobulins (TSI), not thyroid peroxidase antibodies. Hurthle cells are not a feature of Graves’ disease. Follicular carcinoma of the thyroid (Option C) is a malignant tumour of the thyroid, usually presenting with a solitary nodule and not typically associated with Hurthle cells or elevated TSH levels. Histopathologically, it features follicular cells arranged in a follicular pattern , with capsular and vascular invasion . {{caption_text}} Medullary carcinoma of the thyroid (Option D) is a neuroendocrine cancer arising from the C-cells of the thyroid, and it is associated with elevated calcitonin levels. Histopathologically, it features polygonal or spindle-shaped cells arranged in nests or follicles , with amyloid deposits often present. {{caption_text}}

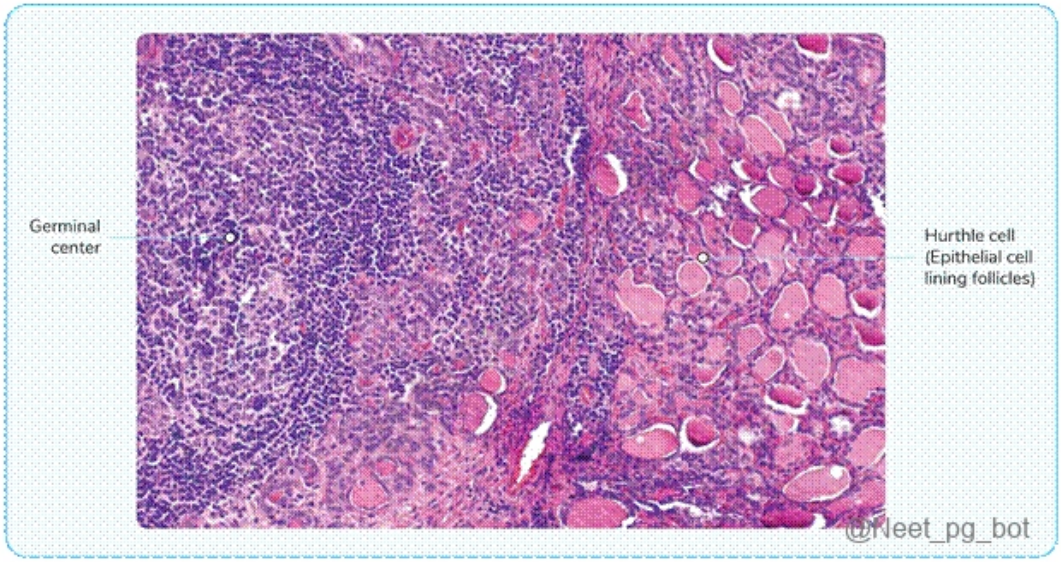
Germinal center
Hurthle cell (Epithelial cell lining follicles)
@Neet_pg_bot

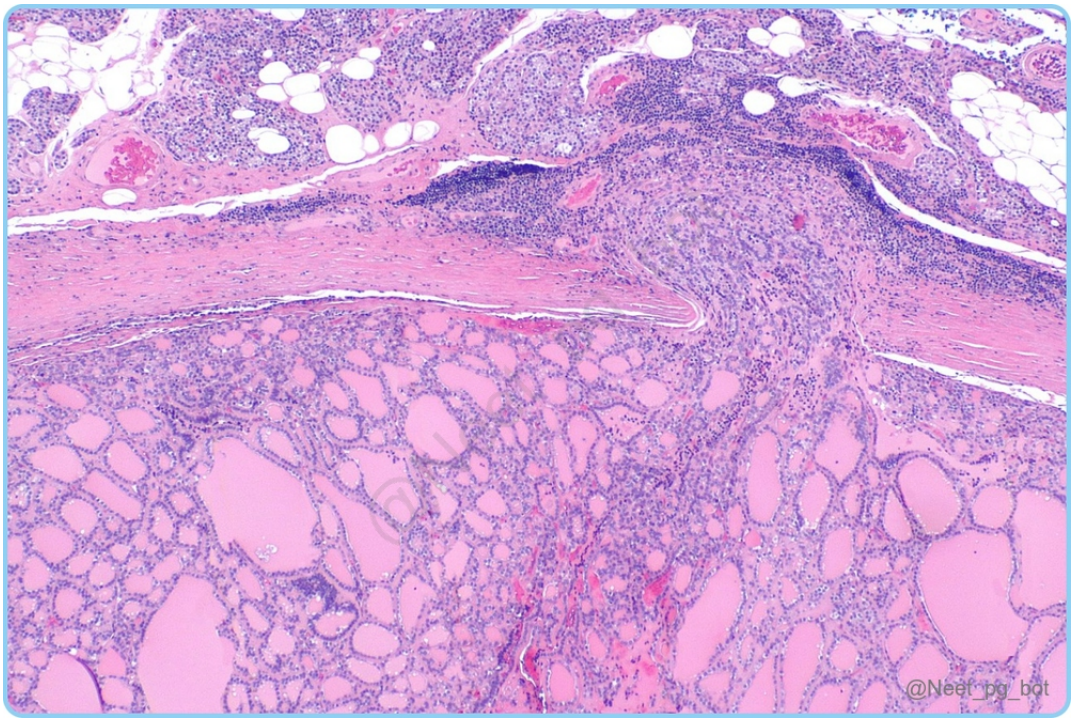
@Neet_pg_bot

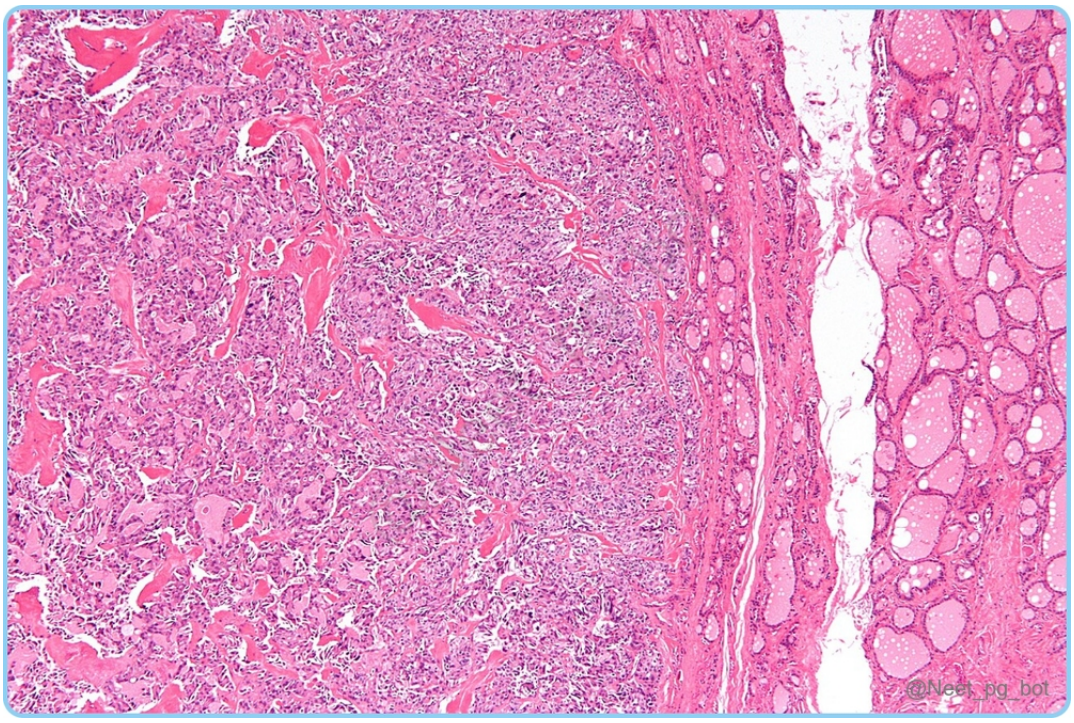

References:

Robbins & Cotran Pathologic Basis of Disease, 10th Edition, Page 1079

↑ *Back to this question in Part A*

@Neet_pg_bot

Q15: What is the probable diagnosis for a patient who has swelling in the middle of their neck, along with weight loss, and a thyroid biopsy showing the presence of 'Orphan Annie eye nuclei? (Q859243)

A. Follicular thyroid carcinoma

B. Papillary thyroid carcinoma

C. Anaplastic thyroid carcinoma

D. Medullary thyroid carcinoma

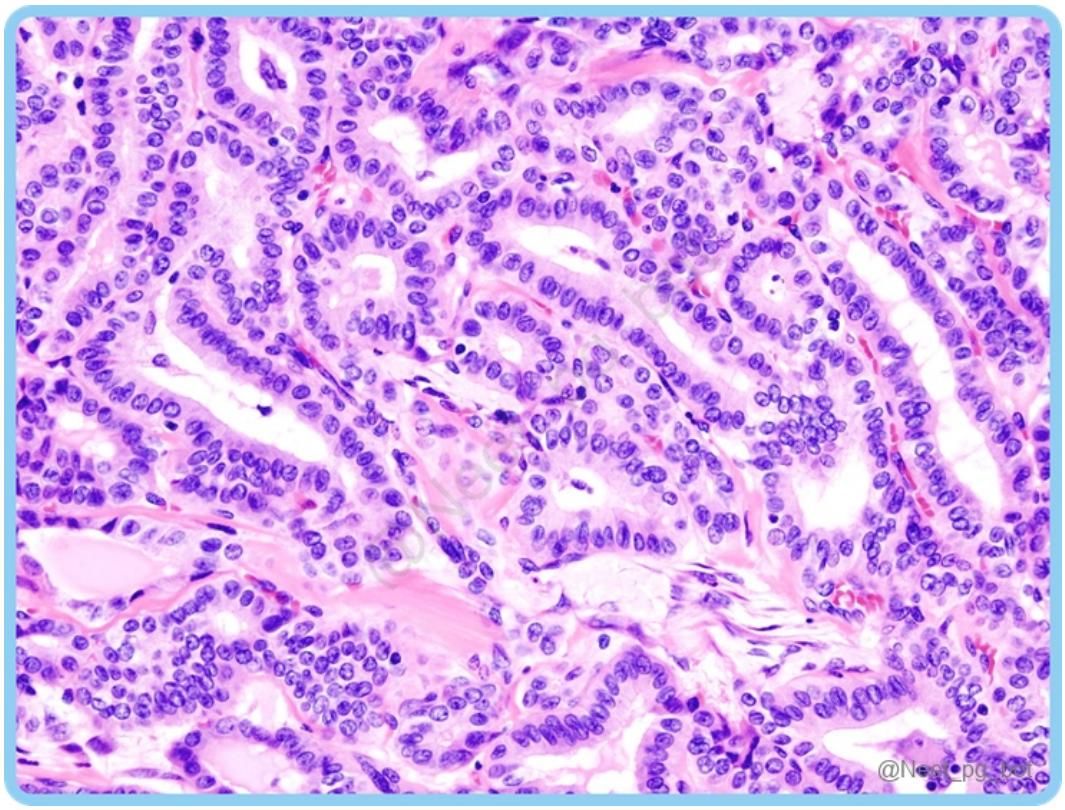

Correct Answer: B. Papillary thyroid carcinoma

Explanation: The histopathological features of psammoma bodies, nuclear grooves, and "Orphan Annie eye" nuclei are indicative of papillary thyroid carcinoma. It is the most common type of thyroid cancer and is characterised by lymphatic spread. It often presents with a nodule in the anterior neck and lymphadenopathy. Associated with BRAF mutations and RET-PTC fusion HPE shows True papillae: Fingerlike projections with fibrovascular core. Orphan Annie eye nuclei: Optically clear nucleus produced due to artefact. Intranuclear cytoplasmic inclusions (INCI). Nuclear groove or coffee bean nucleus. Presence of psammoma bodies: Dystrophic calcifications. It has the best prognosis among thyroid malignancies. {{caption_text}} {{caption_text}} Follicular thyroid carcinoma (Option A) typically does not exhibit "Orphan Annie eye nuclei." Instead, it is characterised by follicular cell differentiation and the presence of follicular patterns. {{caption_text}} Anaplastic thyroid carcinoma (Option C) is a highly aggressive and undifferentiated form of thyroid cancer. It typically does not exhibit "Orphan Annie eye nuclei." Instead, it is characterised by marked cellular pleomorphism and loss of cellular differentiation. {{caption_text}} Medullary thyroid carcinoma (Option D) arises from the parafollicular C cells of the thyroid gland and is associated with the production of calcitonin. {{caption_text}}

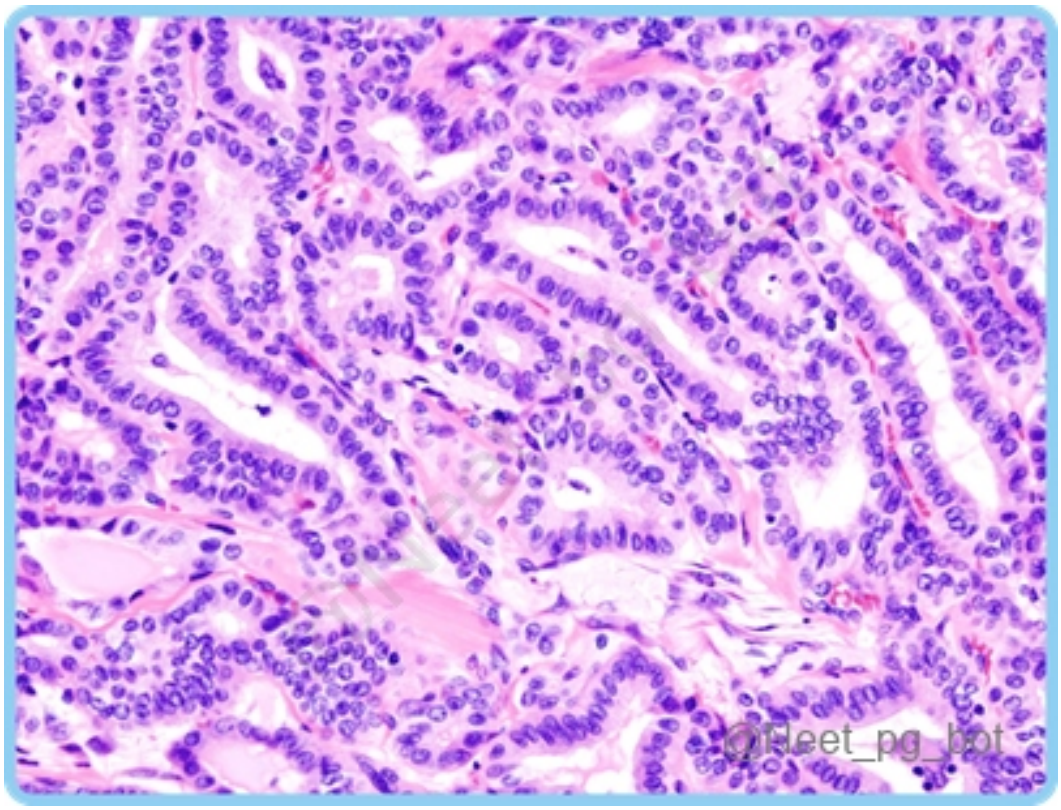
@Neet_pg_bot

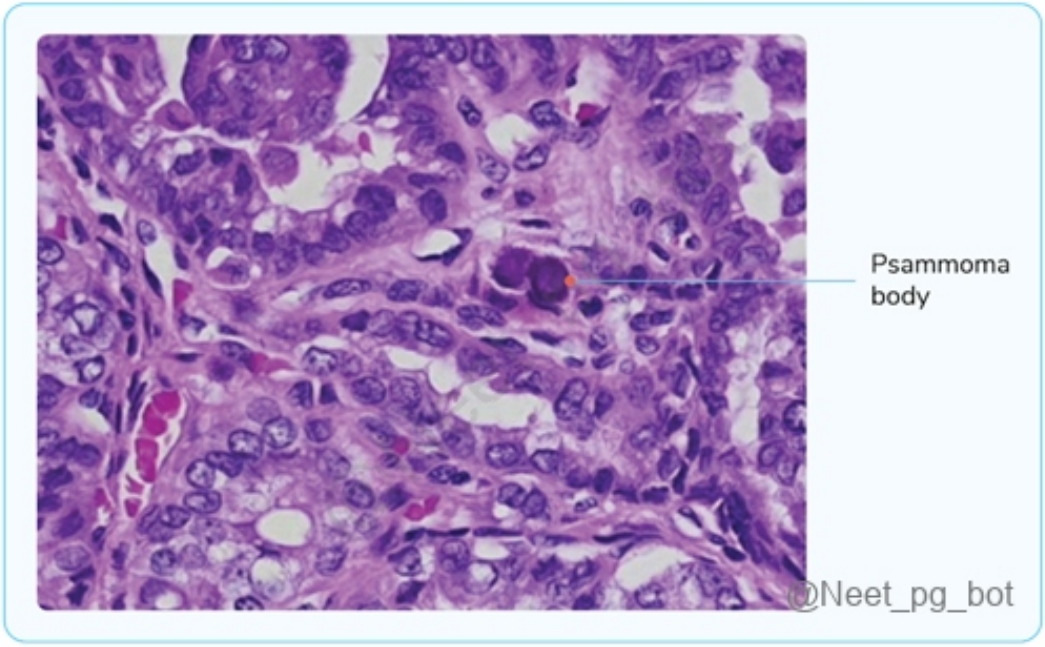
Psammoma body
@Neet_pg_bot

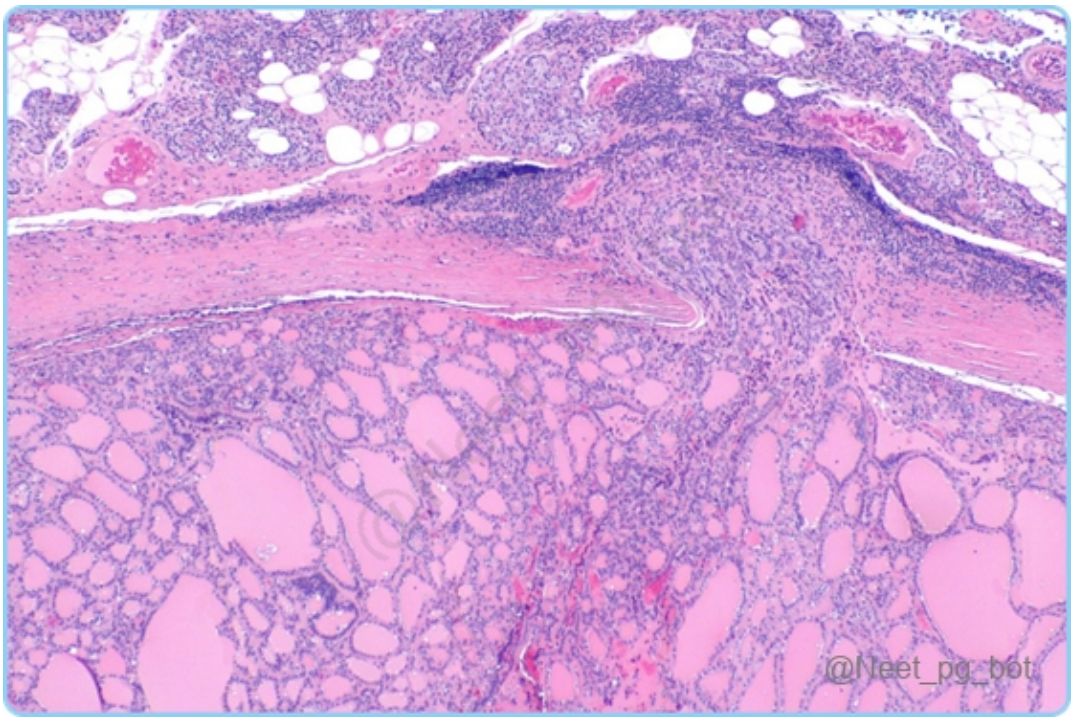
@Neet_pg_bot

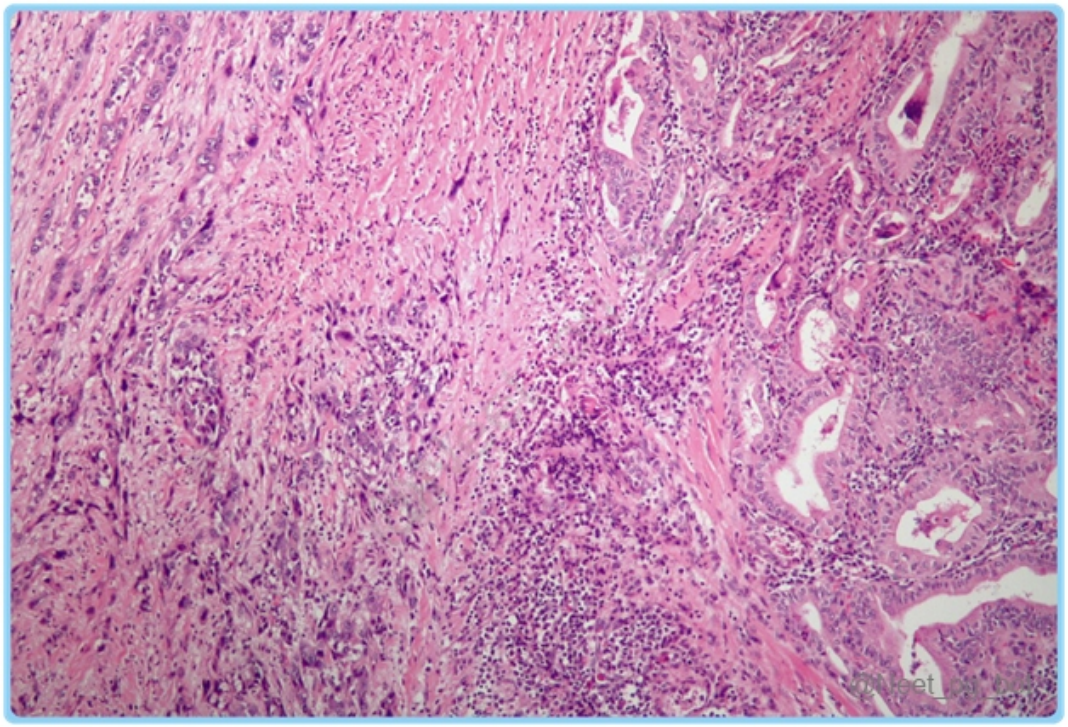
@Neet_pg_bot

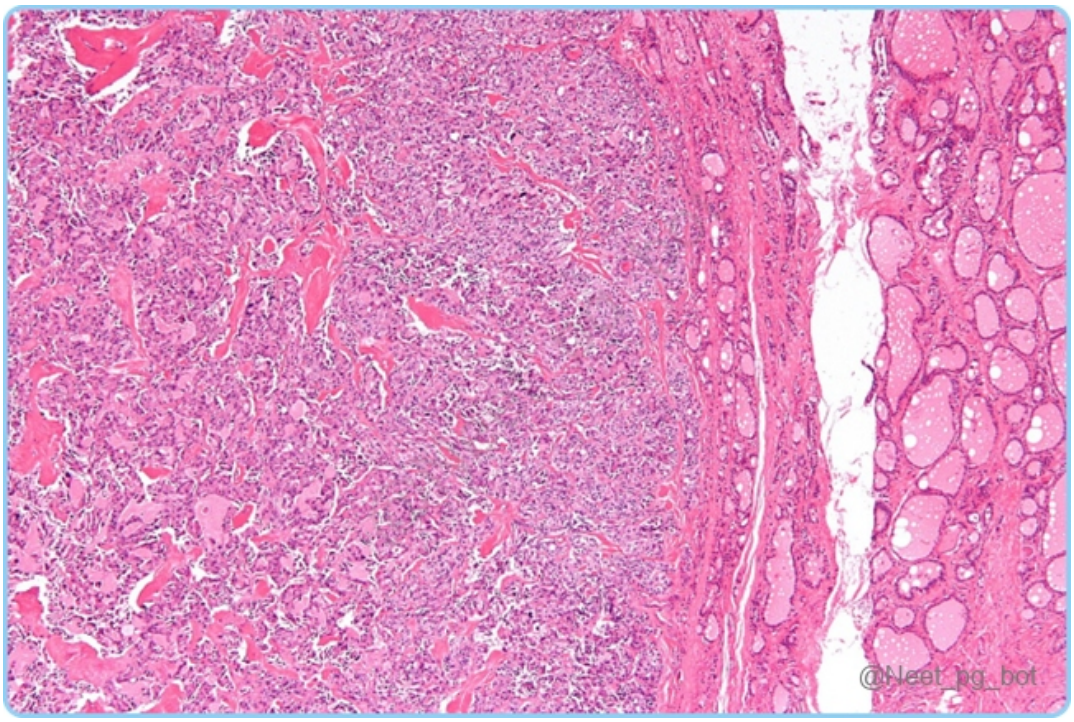

References:

Robbins & Cotran Pathologic Basis of Disease, 10th Edition, Page 1088.

↑ *Back to this question in Part A*

@Neet_pg_bot

• [14_Breast Pathology] 059 Benign Breast Lesions

« Back to Folder Directory

[14_Breast Pathology] 059 Benign Breast Lesions — Quick Jump

Q1 (p. 2413)	*Q2 (p. 2419)*	*Q3 (p. 2421)*	*Q4 (p. 2422)*	*Q5 (p. 2422)*	*Q6 (p. 2423)*
Q7 (p. 2424)	*Q8 (p. 2425)*	*Q9 (p. 2426)*	*Q10 (p. 2426)*	*Q11 (p. 2428)*	*Q12 (p. 2429)*
Q13 (p. 2431)	*Q14 (p. 2431)*	*Q15 (p. 2433)*	*Q16 (p. 2434)*	*Q17 (p. 2435)*	*Q18 (p. 2437)*
Q19 (p. 2439)	*Q20 (p. 2442)*	*Q21 (p. 2442)*	*Q22 (p. 2443)*	*Q23 (p. 2445)*	*Q24 (p. 2445)*
Q25 (p. 2446)	*Q26 (p. 2448)*				

Q1: Which of the following breast lesions are correctly paired with their histopathological characteristics? 1. Fibrocystic changes 2. Duct ectasia 3. Phyllodes tumor 4. Invasive Ductal Carcinoma (Q846606)

A. 1, 2, 3

B. 2, 3, 4

C. 1, 3, 4

D. 1, 2, 3, 4

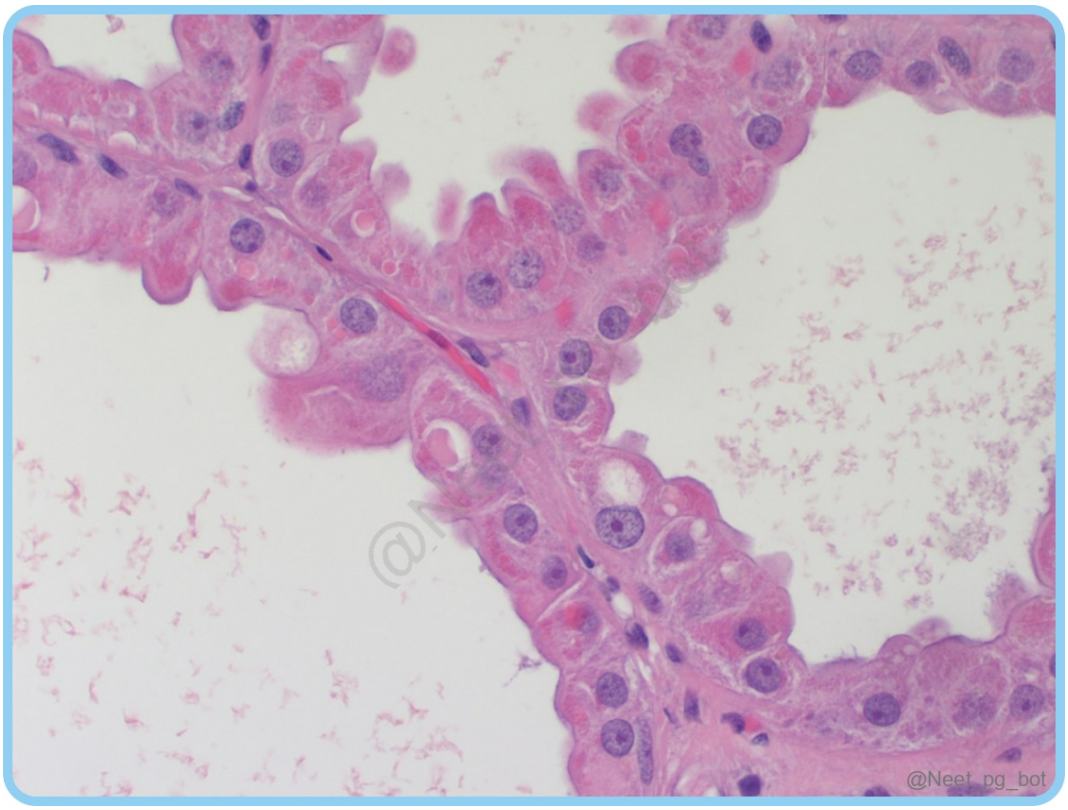
@Neet_pg_bot

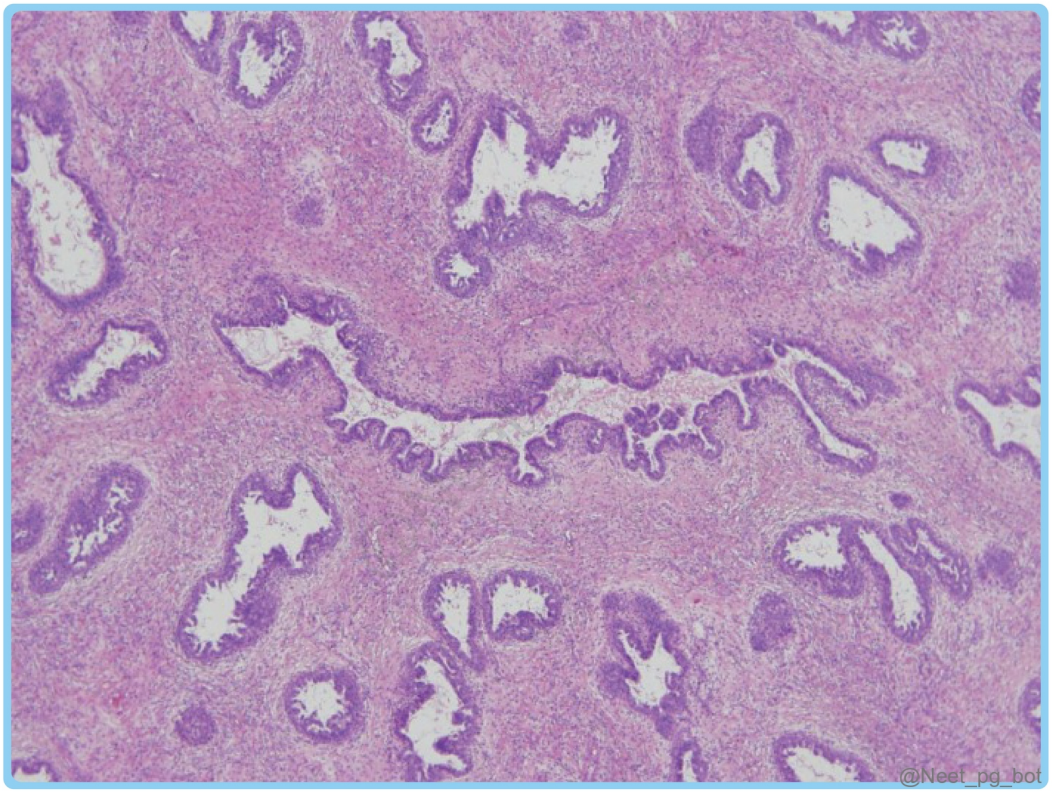
@Neet_pg_bot

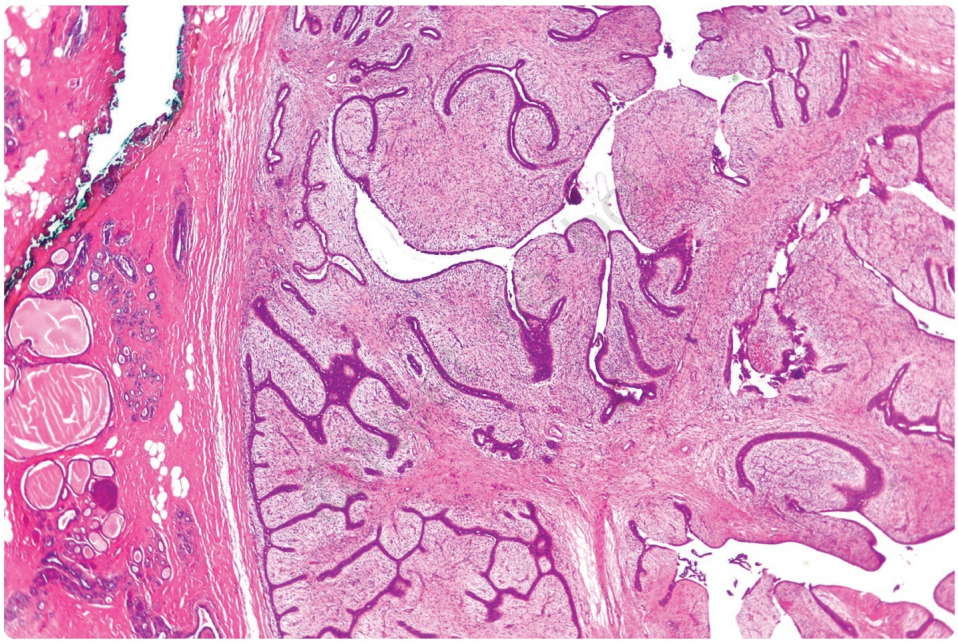

@Neet_pg_bot

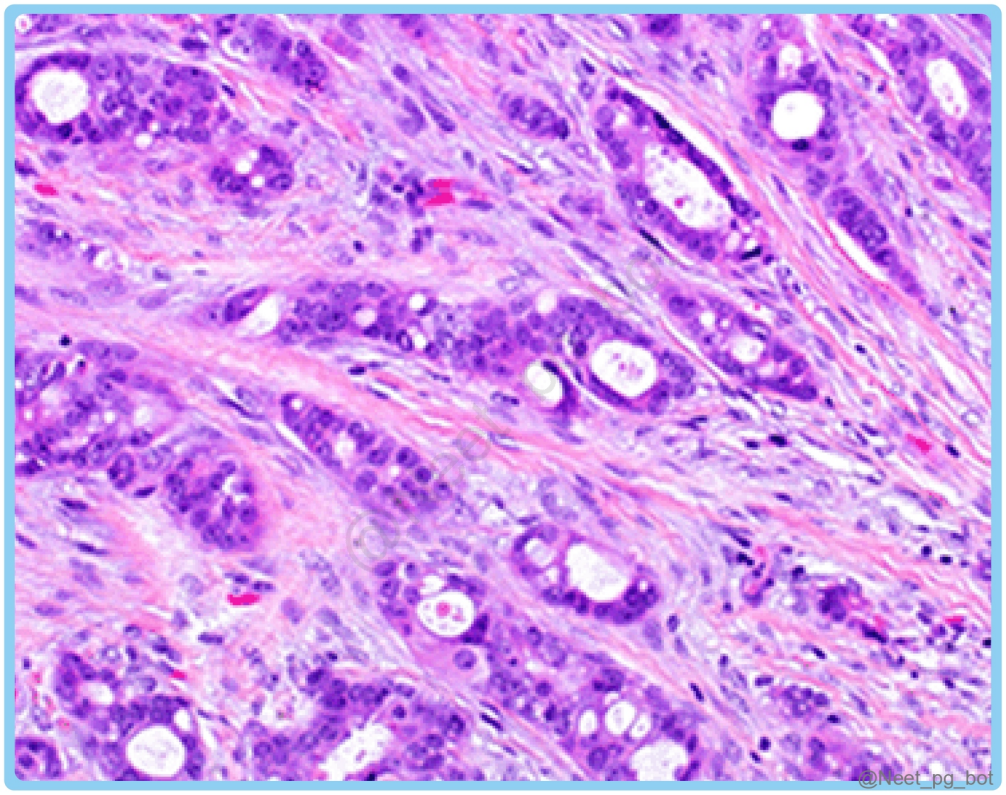

@Neet_pg_bot

Correct Answer: C. 1, 3, 4

■ *Listen (English)*

■ *Listen (Hindi)*

Explanation: Breast tumors with their histopathological findings: Fibrocystic changes Cysts: Fluid-filled sacs within the breast tissue, often surrounded by fibrous tissue. Fibrosis: Thickening and scarring of breast tissue, which may result in palpable lumps or areas of increased density on imaging studies. Apocrine Metaplasia: Transformation of ductal epithelial cells into apocrine-like cells, characterized by abundant eosinophilic cytoplasm and apical snouts. Duct ectasia A lot of foamy macrophages, periductal lymphocytic infiltrates can be observed. Phyllodes tumor Increased stromal cellularity and overgrowth, giving rise to the typical leaf-like architecture. Ductal Carcinoma In Situ (DCIS) Types of DCIS: Micropapillary tumors : Additional epithelial cells within the lumen. Cribriform tumors: Ducts filled with cells that form multiple lumena. Solid tumors: Completely filled ducts. Comedo tumors: Solid with a necrotic core Invasive Ductal Carcinoma (IDC) Shows more mucin both extracellular and intracellular with signet ring cells. Fibroadenoma Well-defined borders due to a fibrous capsule , with proliferating stroma potentially compressing and distorting glandular components. Intracanalicular fibroadenoma - Ducts are compressed. Pericanalicular fibroadenoma - Ducts are open.

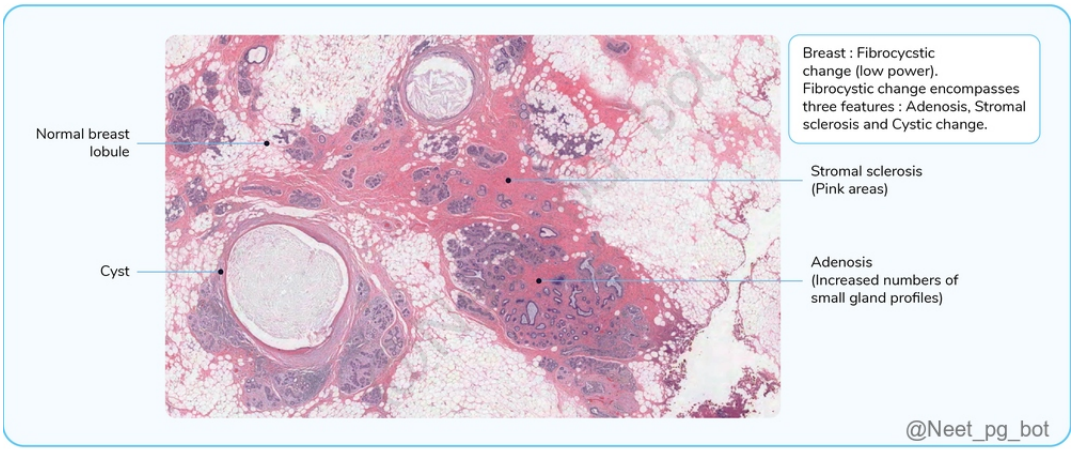

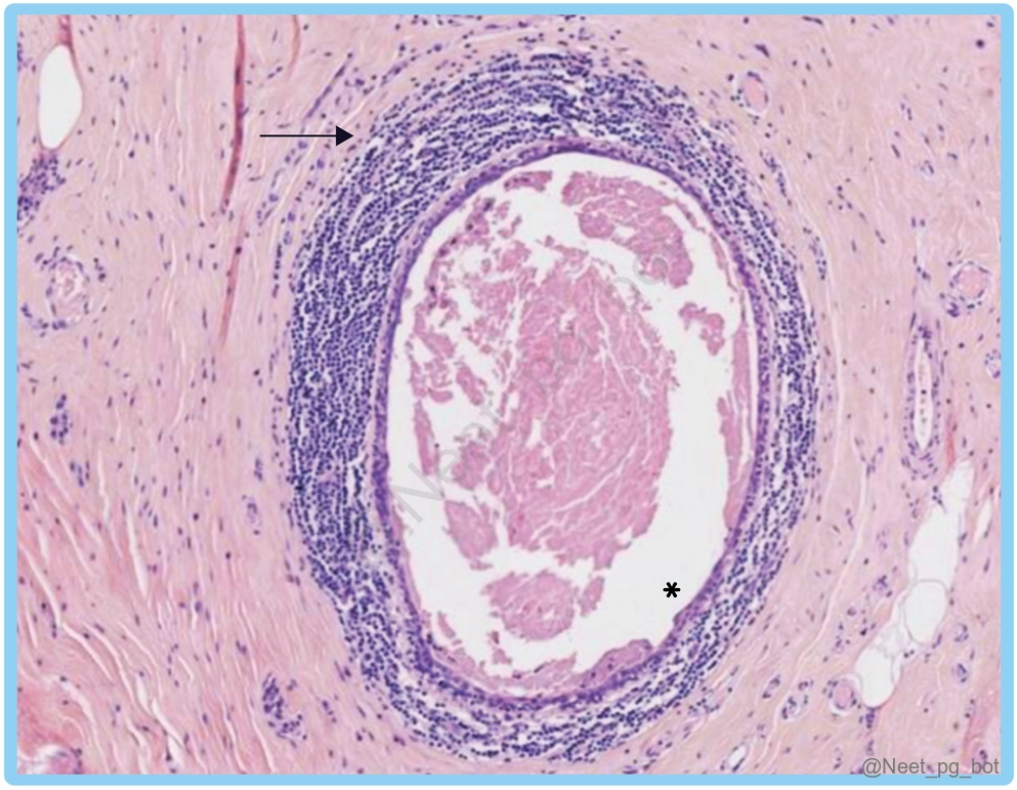

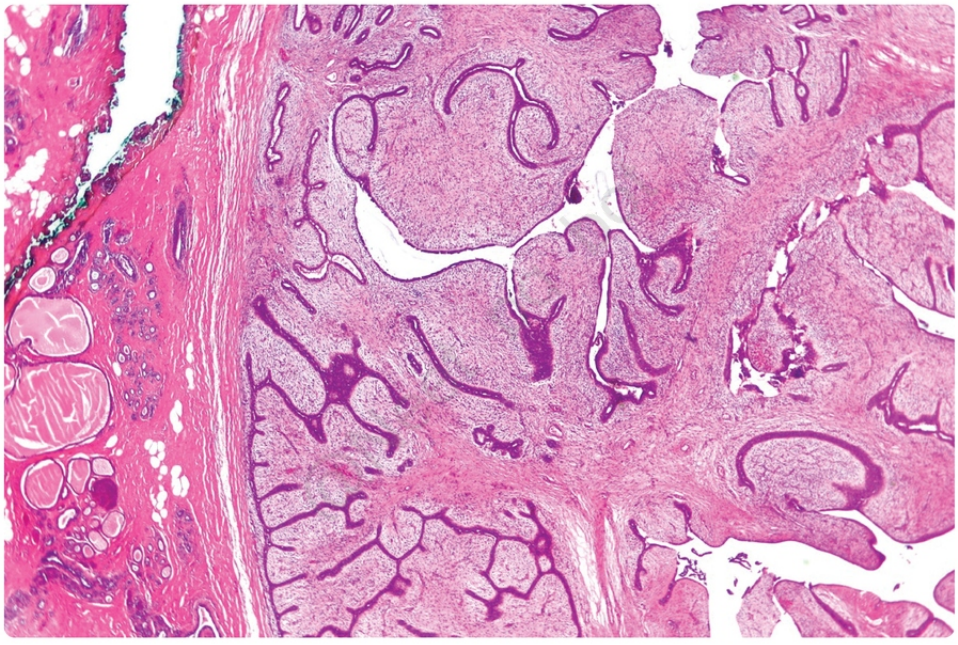

@Neet_pg_bot

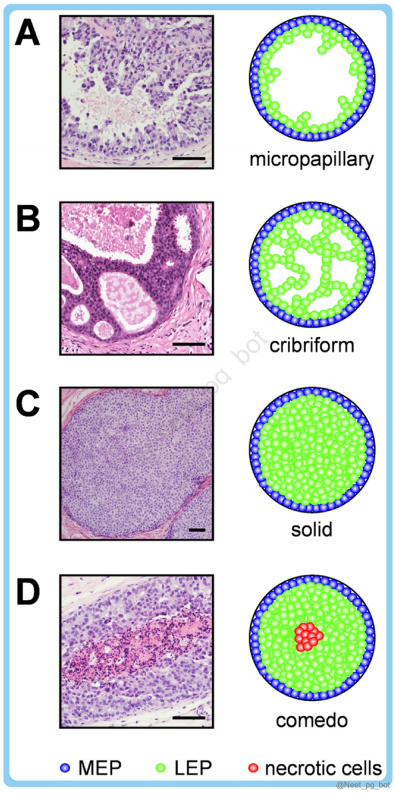
A
micropapillary
B
cribriform
C
solid
D
comedo
MEP
LEP
necrotic cells

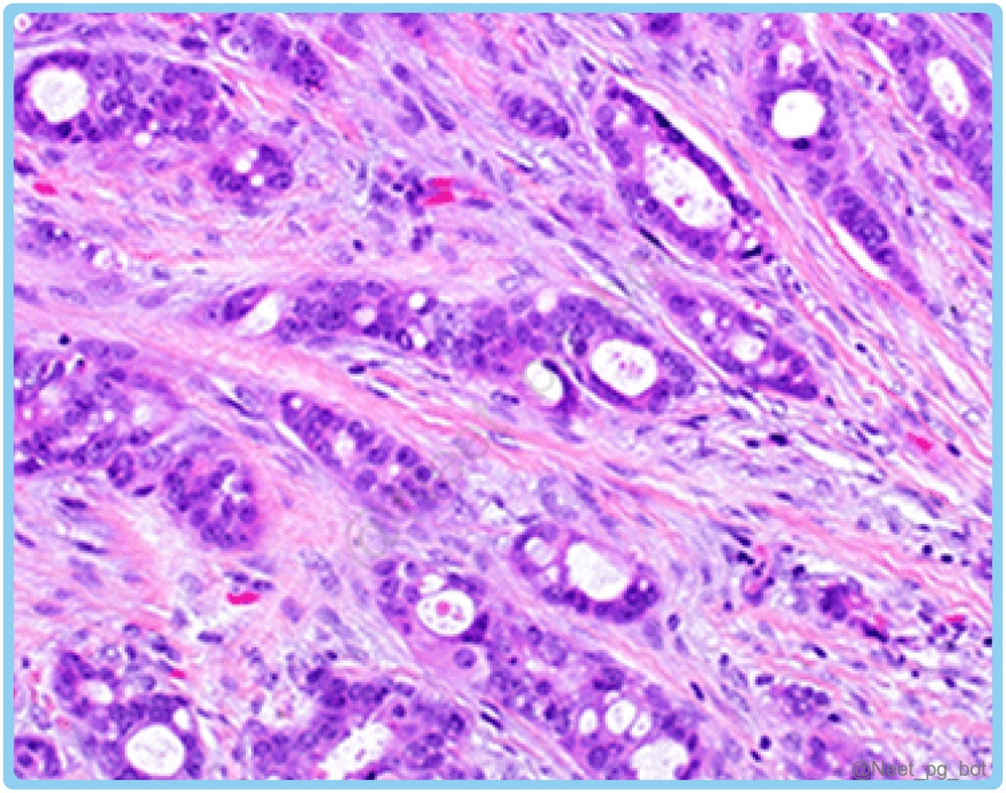

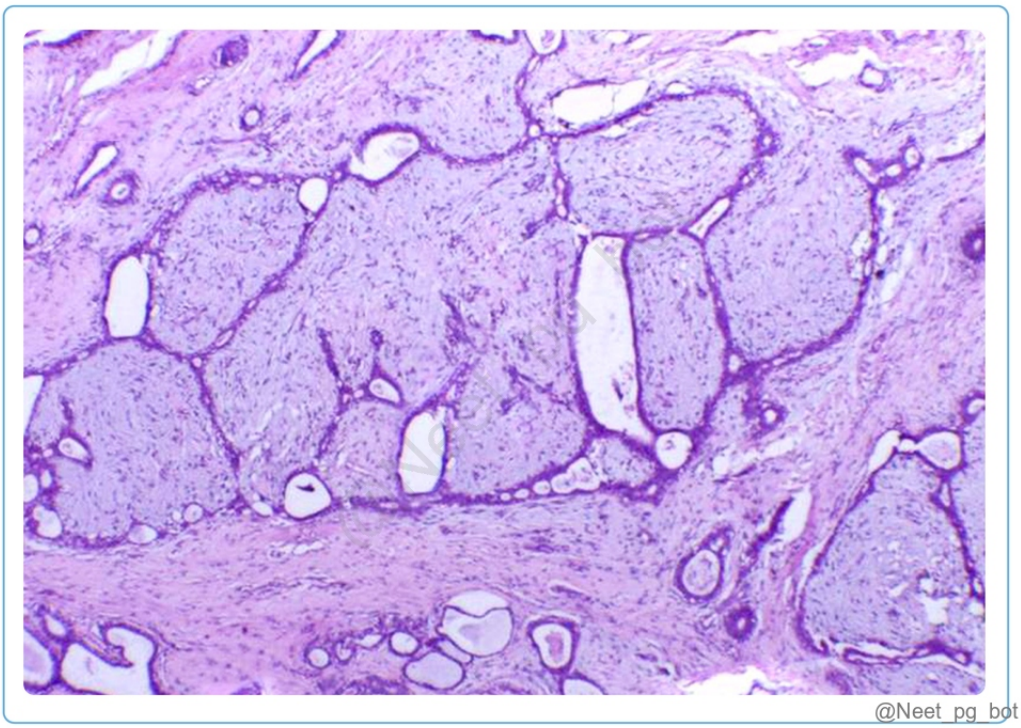

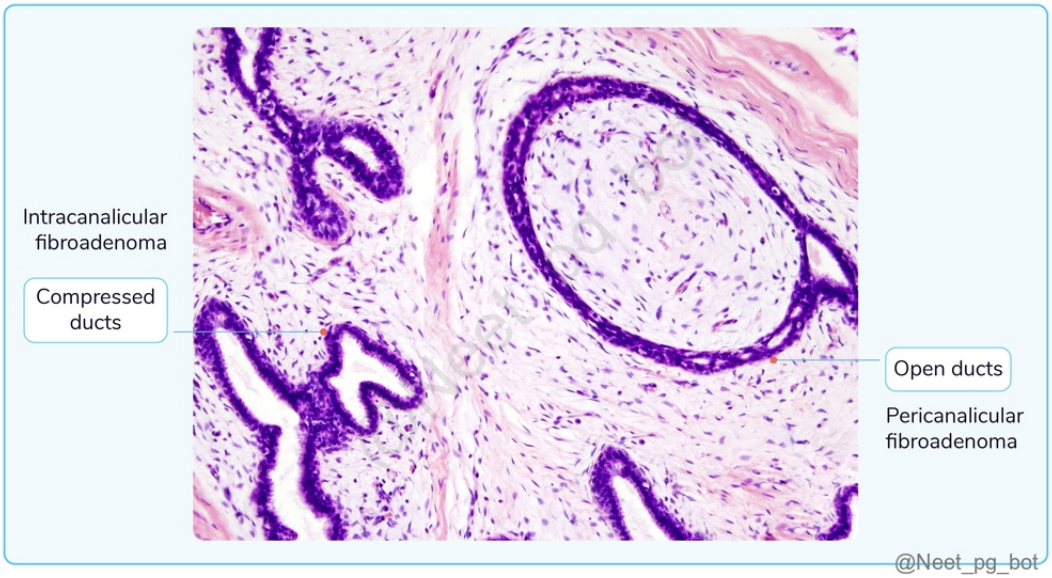

References:

Robbins & Cotran Pathologic Basis of Disease, 10th Edition, Page No, 1041, 1042, 1050.

↑ *Back to this question in Part A*

@Neet_pg_bot

Q2: A 58-year-old woman has a eczematous lesion of the nipple not responding to treatment. Histopathology is shown. What is the most likely diagnosis? (Q890380)

A. Commonly associated with underlying DCIS

B. Malignant cells are present within the nipple epidermis

C. Shows CK7 positivity

D. It commonly presents as a bilateral nipple lesion

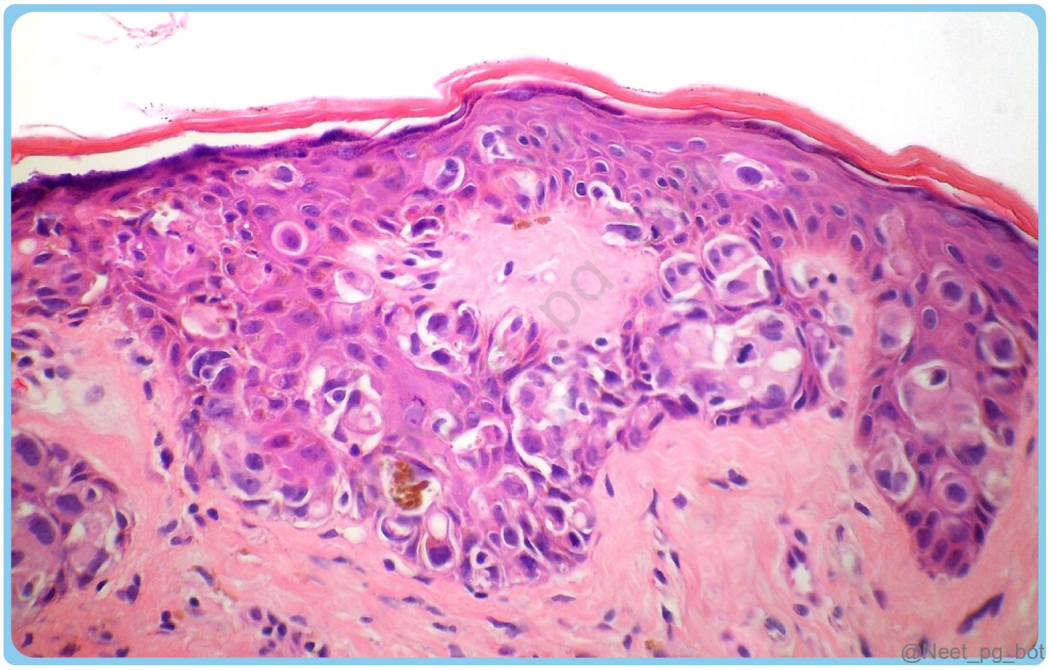

Correct Answer: D. It commonly presents as a bilateral nipple lesion

Explanation: A treatment-resistant nipple eczema with histology showing large pale intraepidermal malignant cells (Paget cells) is diagnostic of Mammary Paget's disease. It typically presents as a unilateral eczematous lesion of the nipple and is usually associated with underlying DCIS or invasive ductal carcinoma . Mammary Paget Disease: Rare manifestation of breast cancer (~1-4% of cases). Clinical features: Unilateral erythematous, scaly crusted lesion of the nipple Pruritus common Often mistaken for eczema Pathogenesis: Malignant Paget cells spread from ductal carcinoma in situ (DCIS) through lactiferous ducts/sinuses into the nipple epidermis (Option B) Tumour cells disrupt the epithelial barrier , causing serous fluid exudation on the nipple surface. Associated lesions: DCIS (most common) (Option A) Invasive ductal carcinoma IHC: Positive: CK7 (Option C) , HER2/neu, EMA, CEA Negative: S100 Diagnosis: Nipple biopsy

References:

Robbins, Cotran & Kumar, Pathologic Basis of Disease, 11th Edition, Page 952

https://www.ncbi.nlm.nih.gov/books/NBK563228/

↑ *Back to this question in Part A*

@Neet_pg_bot

Q3: A 56-year-old woman presents with persistent unilateral erythematous, scaly crusting of the nipple associated with itching for 3 months. Topical treatment for eczema has not improved the lesion. What is the next step in management? (Q890379)

A. Repeat topical corticosteroids

B. Fine-needle aspiration of the breast mass

C. Nipple biopsy

D. Reassurance and follow-up



Correct Answer: C. Nipple biopsy

Explanation: The patient has a persistent unilateral erythematous, scaly, crusted lesion of the nipple with pruritus that does not respond to eczema treatment , which is classic for Paget disease of the breast . The next step in management is a nipple biopsy to identify Paget cells within the epidermis , which confirms the diagnosis. Paget's disease of the nipple: Rare manifestation of breast cancer (~1-4% of cases). Clinical features: Unilateral erythematous, scaly, crusted lesion of the nipple Pruritus common Often mistaken for eczema Pathogenesis: Malignant Paget cells spread from underlying ductal carcinoma in situ (DCIS) through lactiferous ducts/sinuses into the nipple epidermis Tumour cells disrupt the epithelial barrier , causing serous fluid exudation on the nipple surface. Diagnosis: Nipple biopsy Cytology of nipple discharge/exudate Repeat topical corticosteroids (Option A) : Persistent unilateral nipple eczema unresponsive to treatment requires biopsy , not further topical therapy.

Fine-needle aspiration of the breast mass (Option B) : FNA is useful only if a palpable mass exists , but diagnosis of Paget disease requires biopsy of the nipple lesion . Reassurance and follow-up (Option D) : Inappropriate because the lesion may represent underlying breast carcinoma .

References:

Robbins, Cotran & Kumar, Pathologic Basis of Disease, 11th Edition, Page 952

↑ *Back to this question in Part A*

@Neet_pg_bot

Q4: Which of the following markers is most useful for distinguishing invasive carcinoma from DCIS? (Q890364)

A. p53

B. p63

C. Cytokeratin 7

D. Estrogen receptor (ER)

Correct Answer: B. p63

Explanation: p63 is a nuclear myoepithelial marker used to distinguish ductal carcinoma in situ (DCIS) from invasive carcinoma. Myoepithelial cells normally surround ducts and lobules and maintain basement membrane integrity. In DCIS , the myoepithelial layer is preserved → p63 shows continuous nuclear staining around ducts. In invasive carcinoma , the myoepithelial layer is lost → absence of p63 staining supports invasion . However, p63 should not be used in isolation , as focal positivity may occasionally be seen in invasive lesions. Therefore, interpretation is done in conjunction with morphology and a panel of myoepithelial markers. Myoepithelial Markers in Breast Lesions: P63 Calponin α-Smooth Muscle Actin (α-SMA) Smooth Muscle Myosin (SMM)

References:

https://jcp.bmj.com/content/64/7/644.full

https://pmc.ncbi.nlm.nih.gov/articles/PMC4630168/

↑ *Back to this question in Part A*

@Neet_pg_bot

Q5: Which of the following findings does not indicate a low risk for breast cancer? (Q890362)

A. Cysts with apocrine metaplasia

B. Fibrosis

C. Adenosis

D. Florid hyperplasia

Correct Answer: D. Florid hyperplasia

Explanation: Nonproliferative fibrocystic changes are associated with low breast cancer risk . Florid hyperplasia is a proliferative lesion with significant epithelial overgrowth → higher risk of breast cancer. Nonproliferative Breast Changes (Fibrocystic Changes): Common breast alterations in women aged 30–50 , often linked to hormonal changes during menstruation . Principal Morphologic Features: Cysts: Formed by lobular dilation , may coalesce into larger cysts. Contain turbid, brown/blue fluid ("blue-dome cysts"). Lined by flattened atrophic epithelium or apocrine metaplasia . Apocrine change (Option A) : abundant granular eosinophilic cytoplasm, resembling sweat gland epithelium. Calcifications are common. Solitary, firm cysts may mimic tumours; diagnosis confirmed by fnac . Fibrosis: (Option B) Occurs when cysts rupture , releasing secretory material into the stroma. Leads to chronic inflammation and palpable nodularity . Adenosis: (Option C) Increase in acini per lobule . Lined by columnar epithelial cells . Calcifications may be present.

References:

Robbins, Cotran & Kumar, Pathologic Basis of Disease, 11th Edition, Pages 947, 948

↑ *Back to this question in Part A*

@Neet_pg_bot

Q6: A 52-year-old man presents with a painless swelling of the breast as seen in the image. Which of the following conditions are associated with the development of this condition? Liver cirrhosis Marijuana use Klinefelter syndrome Classical Seminoma (Q890352)

A. 1 and 3 only

B. 1, 2 and 3 only

C. 1, 3 and 4 only

D. 1, 2, 3 and 4



Correct Answer: B. 1, 2 and 3 only

Explanation: The image shows gynecomastia , the most common benign lesion of the male breast, characterized by subareolar enlargement due to proliferation of ductal tissue . Classical seminomas are non–hormone-producing germ cell tumors Gynecomastia results from an increased estrogen-to-androgen ratio : Estrogens → stimulate breast tissue growth Androgens → inhibit estrogenic effects Associations: Liver cirrhosis → impaired estrogen metabolism Drugs: Alcohol, Marijuana & Heroin Antiretroviral therapy Anabolic steroids Klinefelter syndrome (47, XXY) Functioning testicular tumors Leydig cell tumor Sertoli cell tumor

References:

Robbins, Cotran & Kumar, Pathologic Basis of Disease, 11th Edition, Page 948

↑ *Back to this question in Part A*

@Neet_pg_bot

Q7: Which of the following conditions is most commonly associated with bloody nipple discharge? (Q890350)

A. Intraductal papilloma

B. Mammary duct ectasia

C. Fibrocystic change

D. Sclerosing adenosis

Correct Answer: A. Intraductal papilloma

Explanation: The most common cause of bloody nipple discharge (especially when it is spontaneous and coming from a single duct) is intraductal papilloma . Intraductal Papilloma: Benign papillary tumour arising within a dilated breast duct Composed of multiple branching fibrovascular cores Associated changes: Usual ductal hyperplasia Apocrine metaplasia Large Duct Papilloma (Central): Located in the lactiferous sinuses near the nipple Usually solitary >80% cause nipple discharge Often bloody (due to stalk torsion and infarction) May be serous Small Duct Papillomas (Peripheral): Occurs in the peripheral ductal system Often multiple Usually clinically silent May present as: Small palpable mass Mammographic density or calcification Mammary duct ectasia (Option B) : Usually causes thick, sticky green or brown nipple discharge , not typically bloody. Fibrocystic change (Option C) : Presents with breast pain, nodularity, and cysts , not bloody discharge. Sclerosing adenosis (Option D) : A proliferative breast lesion without atypia that may mimic carcinoma but rarely causes nipple discharge.

References:

Robbins, Cotran & Kumar, Pathologic Basis of Disease, 11th Edition, Page 948

↑ *Back to this question in Part A*

@Neet_pg_bot

Q8: Which of the following is a non-proliferative change of the breast? (Q890349)

A. Sclerosing adenosis

B. Radial scar

C. Adenosis

D. Atypical ductal hyperplasia

Correct Answer: C. Adenosis

Explanation: Adenosis is one of the three principal morphologic features of non-proliferative breast change , defined as an increase in the number of acini per lobule . Non-Proliferative Breast Changes: Cysts Fibrosis Adenosis Proliferative Breast Disease Without Atypia: Usual ductal hyperplasia Sclerosing adenosis (Option A) Radial scar (complex sclerosing lesion) (Option B) Intraductal papilloma Proliferative Breast Disease With Atypia: Atypical ductal hyperplasia (ADH) (Option D) Atypical lobular hyperplasia (ALH)

References:

Robbins, Cotran & Kumar, Pathologic Basis of Disease, 11th Edition, Pages 947-950

↑ *Back to this question in Part A*

@Neet_pg_bot

Q9: Which of the following is not a proliferative breast lesion? (Q890348)

A. Intraductal papilloma

B. Sclerosing adenosis

C. Radial scar

D. Cystic change with apocrine metaplasia

Correct Answer: D. Cystic change with apocrine metaplasia

Explanation: Cystic change with apocrine metaplasia is part of non-proliferative fibrocystic breast change . Non-Proliferative Breast Changes: Cysts Fibrosis Adenosis Proliferative Breast Disease Without Atypia: Usual ductal hyperplasia Sclerosing adenosis (Option B) Radial scar (complex sclerosing lesion) (Option C) Intraductal papilloma (Option A) Proliferative Breast Disease With Atypia: Atypical ductal hyperplasia (ADH) Atypical lobular hyperplasia (ALH)

References:

Robbins, Cotran & Kumar, Pathologic Basis of Disease, 11th Edition, Pages 947-950

↑ *Back to this question in Part A*

@Neet_pg_bot

Q10: A 36-year-old woman presents with a painful subareolar mass and recurrent nipple discharge. Examination reveals nipple inversion, and histology shows keratinising squamous metaplasia of lactiferous ducts with keratin plugging. Which of the following is the most important risk factor for this condition? (Q890347)

A. Cigarette smoking

B. Alcohol

C. Nulliparity

D. Family history of breast carcinoma

Correct Answer: A. Cigarette smoking

Explanation: >90% of cases of squamous metaplasia of lactiferous ducts (periductal mastitis) occur in smokers. Smoking may cause relative vitamin A deficiency , leading to abnormal squamous differentiation of duct epithelium and keratin plugging. Squamous Metaplasia of Lactiferous Ducts (Periductal mastitis, Recurrent subareolar abscess, Zuska disease): A condition involving keratinising squamous metaplasia of lactiferous ducts leading to duct obstruction, inflammation, and recurrent abscess formation . Painful erythematous subareolar mass May mimic a bacterial abscess Recurrent cases → fistula tract opening near the areola Nipple inversion due to inflammation and scarring Occurs in women and occasionally in men Major risk factor: Smoking (>90% of cases) Morphology: ■ ■■ Keratinising squamous metaplasia of lactiferous duct epithelium Keratin plugs in the ducts Duct dilation and rupture Chronic granulomatous periductal inflammation

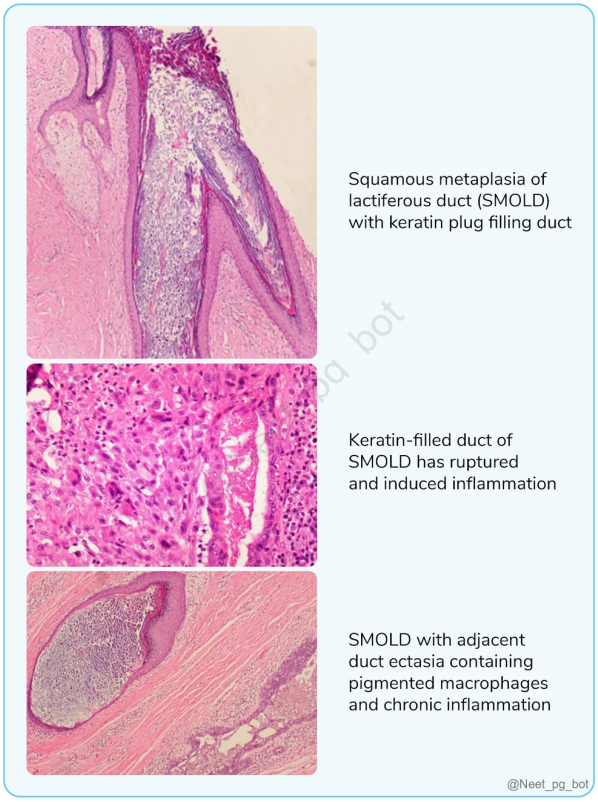



References:

Robbins, Cotran & Kumar, Pathologic Basis of Disease, 11th Edition, Page 946

↑ *Back to this question in Part A*

@Neet_pg_bot

Q11: Which of the following conditions involves the large ducts of the breast? Mammary duct ectasia Large duct papilloma Paget disease of the nipple Atypical lobular hyperplasia Sclerosing adenosis (Q890346)

A. 1, 2, 3

B. 2, 3, 4

C. 1, 2, 3, 4

D. 2, 4, 5

Correct Answer: A. 1, 2, 3

Explanation: Large duct (subareolar/lactiferous duct) involvement is seen in mammary duct ectasia, large duct papilloma, and Paget disease of the nipple. Mammary duct ectasia: Dilatation of major ducts near the nipple with periductal inflammation and fibrosis → presents with nipple discharge and subareolar mass Large duct papilloma (central papilloma): Benign tumor arising in major ducts → commonly causes serous or bloody nipple discharge Paget disease of nipple: Intraepidermal spread of malignant ductal cells from underlying DCIS via lactiferous ducts Atypical lobular hyperplasia: Proliferative lesion arising from the terminal duct lobular unit (TDLU) ; associated with increased breast cancer risk. Sclerosing adenosis: TDLU lesion characterized by increased acini per lobule with stromal fibrosis; may mimic carcinoma.

References:

Robbins, Cotran & Kumar, Pathologic Basis of Disease, 11th Edition, Page 948

https://www.ncbi.nlm.nih.gov/books/NBK563228/

https://www.ncbi.nlm.nih.gov/books/NBK557665/

↑ *Back to this question in Part A*

@Neet_pg_bot

Q12: Which of the following conditions does not arise from the terminal duct lobular unit? (Q890345)

A. DCIS

B. Sclerosing adenosis

C. Intraductal papilloma

D. Mammary duct ectasia

Correct Answer: D. Mammary duct ectasia

Explanation: Mammary duct ectasia primarily involves large subareolar ducts near the nipple , not the terminal duct lobular unit. It is characterised by dilatation of major ducts with periductal inflammation and fibrosis , often presenting with nipple discharge and subareolar mass . Therefore, it does not originate from the TDLU . Terminal Duct Lobular Unit (TDLU): Formed by the terminal duct + lobule . It is the structural and functional unit of the breast . ■ ■■ Conditions Arising from the Terminal Duct Lobular Unit (TDLU): Non-Proliferative Breast Changes (Fibrocystic Changes): Cysts Apocrine metaplasia Fibrosis Adenosis Lactational adenoma Proliferative Breast Disease Without Atypia: Usual ductal hyperplasia Sclerosing adenosis (Option B) Radial scar (complex sclerosing lesion) Intraductal papilloma (Option C) Proliferative Breast Disease With Atypia: Columnar cell lesions Flat epithelial atypia Atypical ductal hyperplasia (ADH) Atypical lobular hyperplasia (ALH) Ductal carcinoma in situ (DCIS) (Option A) Lobular carcinoma in situ (LCIS)

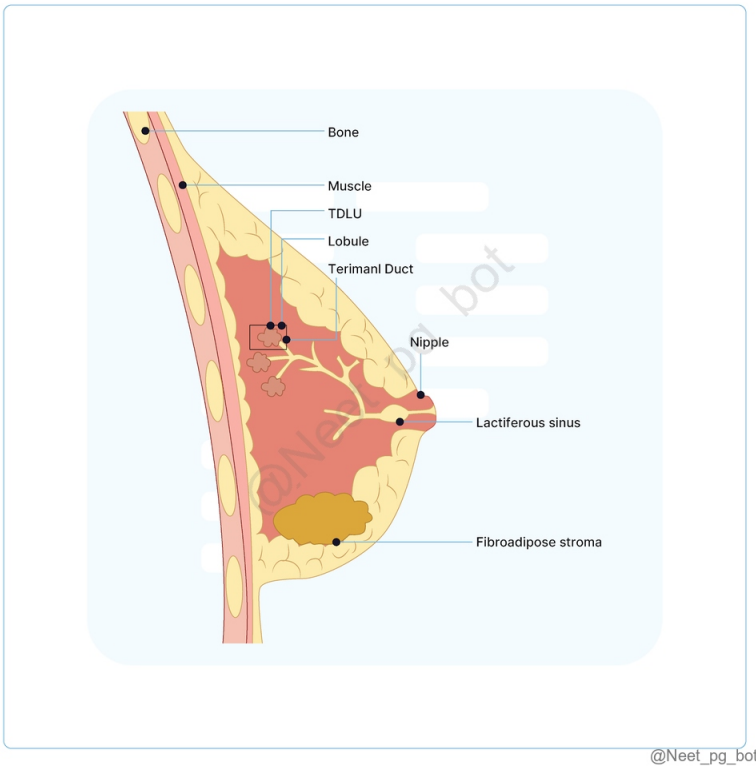



References:

Robbins, Cotran & Kumar, Pathologic Basis of Disease, 11th Edition, Pages 944, 947, 949, 953

↑ *Back to this question in Part A*

@Neet_pg_bot

Q13: A 24-year-old with a 2-month-old infant presents to the OPD with pain in her left breast. The baby is exclusively breastfed. On examination, the nipple is tender and erythematous with a fluctuant mass beneath the areola. Which of the following is the most common cause of this condition? (Q846611)

A. Pseudomonas aeruginosa

B. Staphylococcus aureus

C. Streptococcus sp.

D. Listeria monocytogenes

Correct Answer: B. Staphylococcus aureus

Explanation: The clinical scenario suggests acute breast abscess from lactational mastitis which is commonly caused by Staphylococcus aureus . It is caused by a local infection through cracks and fissures in the nipples that occur commonly during the 1st month of breastfeeding. It is often preceded by either engorgement or a focally blocked duct. Patients can develop a focal area of erythema, pain, fever, and swelling. This can further develop into single or multiple abscesses. Streptococcus pyogenes, Escherichia coli, Bacteroides species, and coagulase-negative Staphylococci are other organisms that cause mastitis.

References:

Robbins and Cotran Pathological Basis of Disease, 10th Edition, Pg 1040

↑ *Back to this question in Part A*

@Neet_pg_bot

Q14: The terminal duct lobular unit (TDLU) is the functional unit of the breast. Which of the following is not a part of the TDLU? (Q845782)

A. Intralobular terminal duct

B. Extralobular terminal duct

C. Lactiferous duct

D. Ductules

Correct Answer: C. Lactiferous duct

■ *Listen (English)*

■ *Listen (Hindi)*

Explanation: Lactiferous ducts are not a part of the TDLU. The morpho-functional unit of the breast is the terminal duct lobular unit(TDLU). TDLU is a grapelike cluster of small alveoli that comprises lobule and terminal duct. A lobule is a collection of multiple ductules, which are epithelial structures that produce milk during lactation. Terminal ducts consist of 2 parts: Intralobular terminal duct: A portion of the terminal duct located within the lobule. Extralobular terminal duct is the portion connecting the lobule to the lactiferous duct.

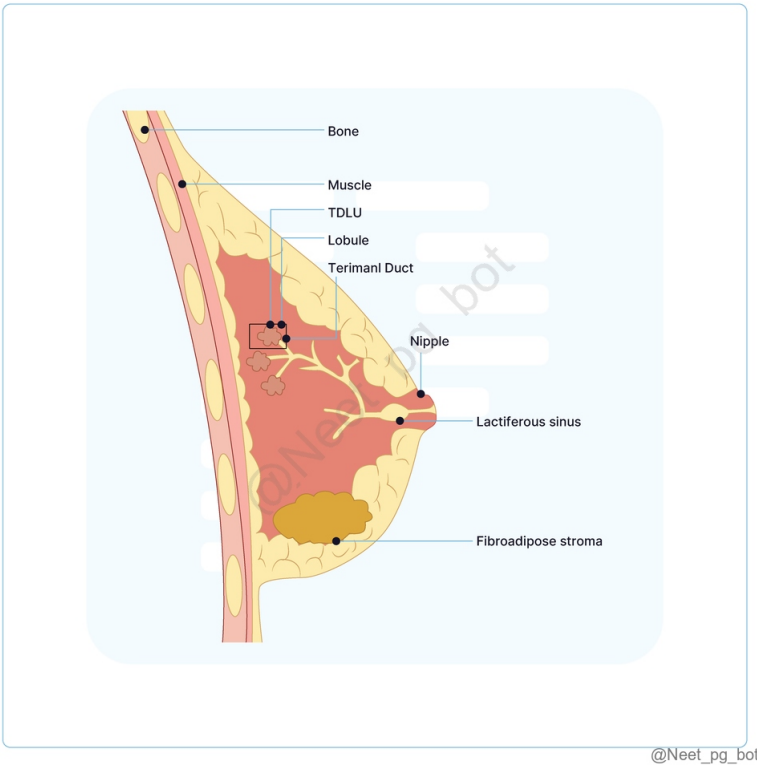

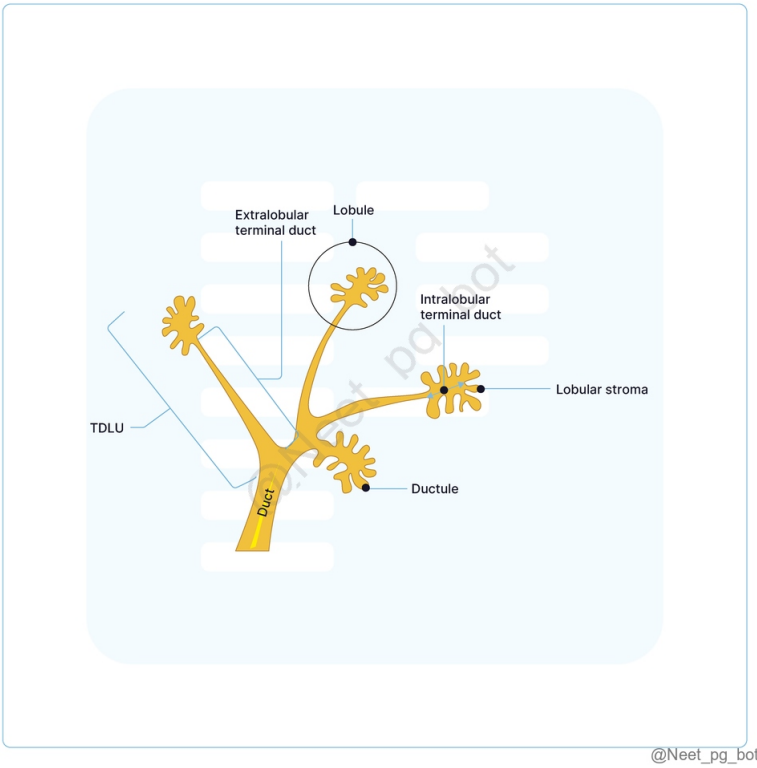

@Neet_pg_bot

References:

Syed A. Hoda Rosen's Diagnosis of Breast Pathology, Page 55. Curcumin: the spicy modulator of breast carcinogenesis | Journal of Experimental & Clinical Cancer Research | Full Text (biomedcentral.com) Terminal duct lobular unit | Radiology Reference Article | Radiopaedia.org

↑ *Back to this question in Part A*

@Neet_pg_bot

Q15: Which of the following statements about phyllodes tumors of the breast is incorrect? (Q845804)

A. They originate in the connective tissue of the breast

B. Often present as rapidly growing breast masses

C. They vary in size from a few centimeters to massive lesions

D. These lesions are always benign

Correct Answer: D. These lesions are always benign

■ *Listen (English)*

■ *Listen (Hindi)*

Explanation: The clinical features and HPE showing increased stromal cellularity and overgrowth, giving rise to the typical leaf-like architecture, suggests phyllodes tumor. It is a rapidly growing tumor, varying in size, ranging from few centimeter to massive lesions. It can be benign or malignant. Genetics: Gain of 1q MED12 mutations TERT mutations The incorrect statement is that these lesions are always benign. Since phylloides tumour can be benign, borderline or malignant, depending on the overgrowth of stroma and the mitotic activity. Criteria (Based on stroma) Benign Borderline Malignant Stromal cellularity and atypia Minimal Moderate Marked Stromal overgrowth Minimal Moderate Marked Mitoses (Definitive criteria) 0-4 mitosis per 10 hpf 5-9 per 10 hpf ≥ 10 per 10 hpf Mitosis ≥ 10/10 hpf (Seen in only 2 condition) Malignant phyllodes Leiomyosarcoma uterus

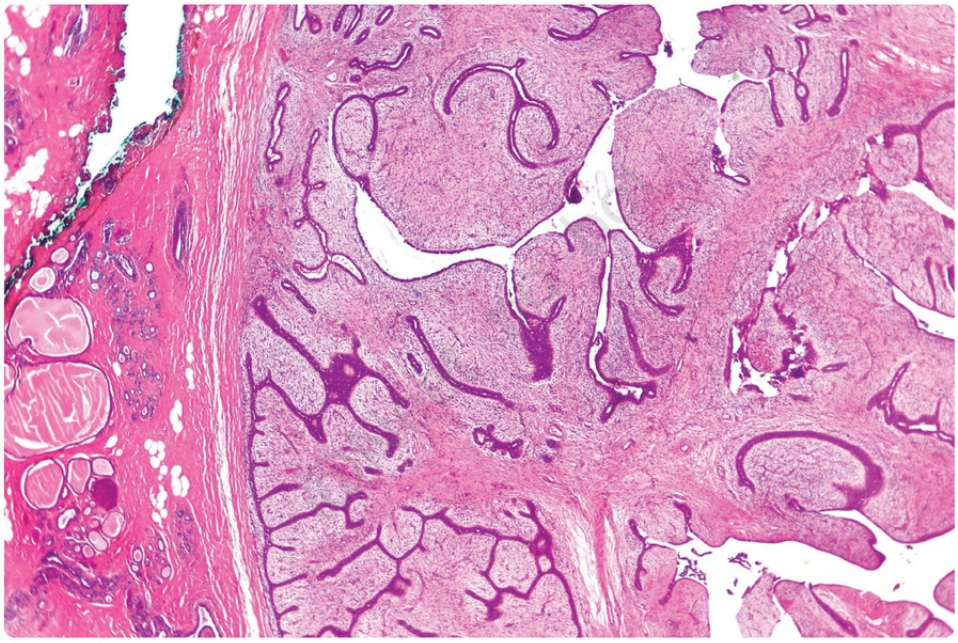

@Neet_pg_bot

References:

Robbins & Cotran Pathologic Basis of Disease, 10th Edition, Pages 1062-1063

↑ *Back to this question in Part A*

@Neet_pg_bot

Q16: Which of the following is not a feature of complex fibroadenoma? (Q845803)

A. Cysts larger than 0.3cm

B. Sclerosing adenosis

C. Nodules of proliferating stroma forming bulbous protrusions

D. Papillary apocrine change

Correct Answer: C. Nodules of proliferating stroma forming bulbous protrusions

■ *Listen (English)*

■ *Listen (Hindi)*

Explanation: Complex fibroadenoma is an example of epithelial proliferative breast lesions without atypia. Fibroadenoma with complex features has a risk of malignancy, whereas, without complexity, it does not. Complex features include, Cysts > 0.3cm Sclerosing adenosis (sclerosis + increase in the acini cells per lobule i.e, adenosis) Epithelial calcifications Papillary apocrine change (metaplastic change in breast tissue)

References:

Robbins & Cotran Pathologic Basis of Disease, 10th Edition, Pages 1063, 1045

↑ *Back to this question in Part A*

@Neet_pg_bot

Q17: A 34-year-old woman comes to the clinic due to a mass in her right breast. A 2-cm nodule is noted on breast examination, and the patient is referred for biopsy. Histologic evaluation of the tissue specimen is shown in the image below. What is the most likely diagnosis? (Q845802)

A. Ductal Carcinoma In Situ

B. Intracanalicular Fibroadenoma

C. Sclerosing adenosis

D. Pericanalicular Fibroadenoma

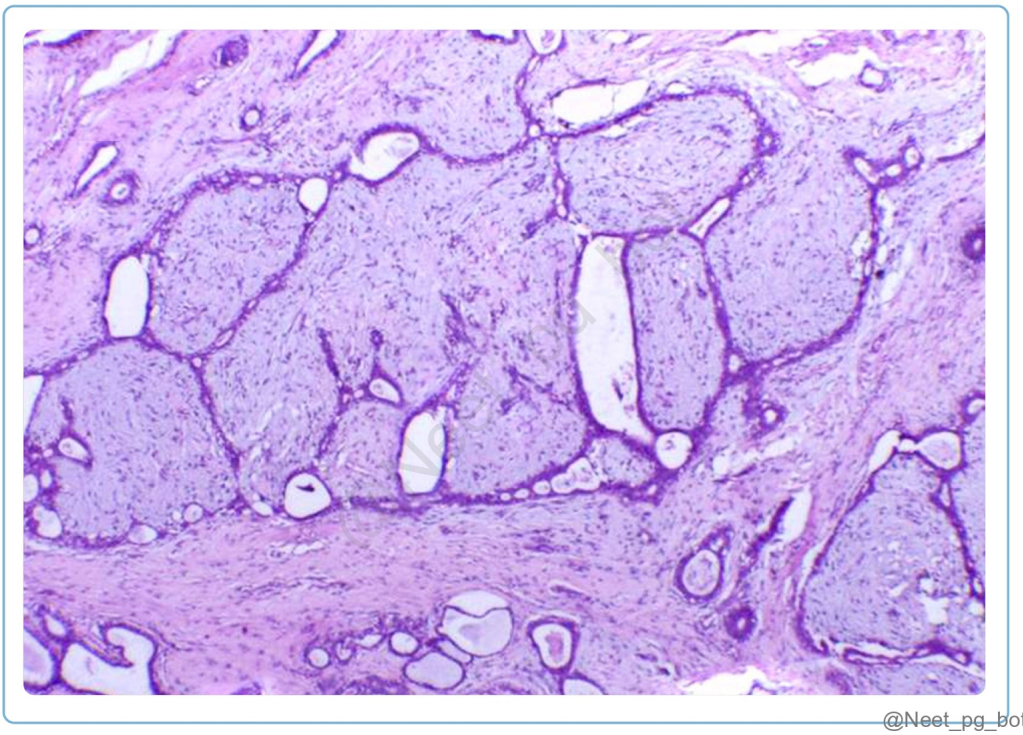

Correct Answer: B. Intracanalicular Fibroadenoma

- *Listen (English)*
- *Listen (Hindi)*

Explanation: The histopathology image shows epithelial ducts compressed and distorted by surrounding stroma which is characteristic of an intracanalicular fibroadenoma. Fibroadenoma is of 2 types: Intracanalicular - Epithelial ducts compressed due to surrounding stroma Pericanalicular - Ducts would be slightly open Both types have similar prognosis.

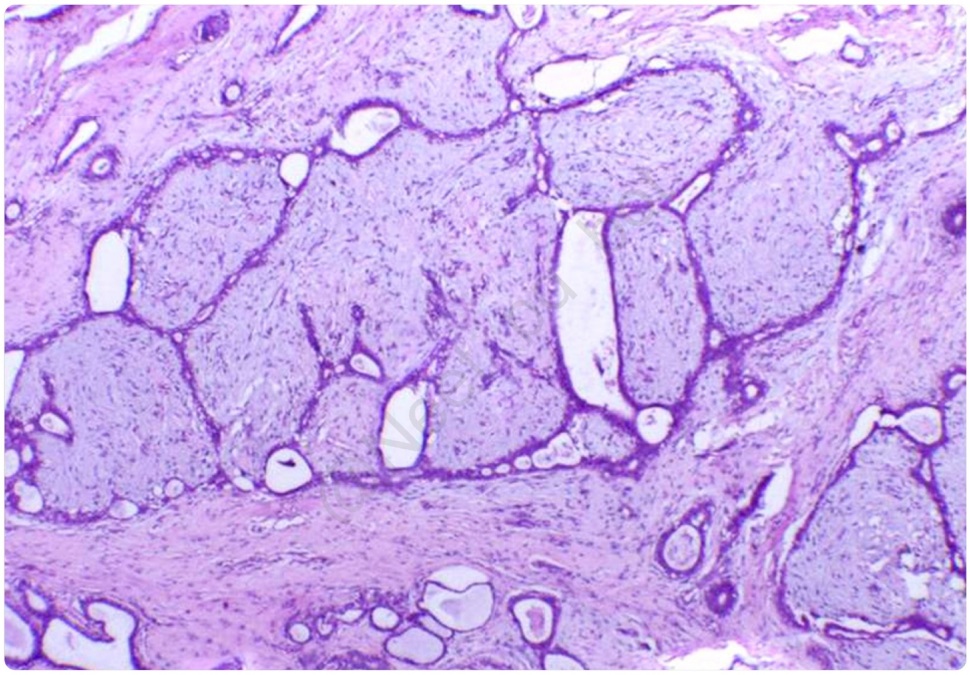

References:

Robbins & Cotran Pathologic Basis of Disease, 10th Edition, Page No. 1062 Liquid-Based Cytology in Fine-Needle Aspiration of Breast Lesions: A Review | Acta Cytologica | Karger Publishers

↑ *Back to this question in Part A*

@Neet_pg_bot

Q18: A 38-year-old woman presents with cyclical breast pain, most severe in the week before her period. She also notices her breasts feeling lumpy and swollen around the time of her period, which subsides later. She denies any fever, nipple discharge, or lumps. What is the most likely finding seen in this pathology? (Q845801)

A. Peau d'orange appearance of the skin

B. Nipple retraction and bloody discharge

C. Blue dome of Bloodgood cyst

D. Eczematous changes of the nipple and areola

Correct Answer: C. Blue dome of Bloodgood cyst

■ *Listen (English)*

■ *Listen (Hindi)*

Explanation: The above features of cyclical pain and breast changes are suggestive of fibrocystic breast disease, which has a blue dome of Bloodgood cyst. Fibrocystic changes of the breast is a benign condition characterized by the development of cysts, fibrosis (thickening and scarring of tissue), and other benign alterations in the breast tissue. Symptoms Breast pain (mastalgia) or tenderness that fluctuates with menstruation Mastalgia (or mastodynia) can be cyclic (with menses, due to premenstrual edema) or noncyclic (localized to one area of the breast and may be caused by ruptured cysts, physical injury, and infections). Breast lumps or nodules Swelling or enlargement of the breasts Fluid-filled cysts with varying size Nipple discharge Gross Features: Blue-domed cyst of Bloodgood- Large cysts that contain turbid, semitranslucent brown or blue-colored fluid which imparts a blue color onto the intact cyst. They are typically fluid-filled and may vary in size. Histopathological Features: Cysts: Fluid-filled sacs within the breast tissue, often surrounded by fibrous tissue. Fibrosis: Thickening and scarring of breast tissue, which may result in palpable lumps or areas of increased density on imaging studies. Apocrine Metaplasia: Transformation of ductal epithelial cells into apocrine-like cells, characterized by abundant eosinophilic cytoplasm and apical snouts. Peau d'orange appearance of the skin (Option A): This describes skin thickening and "orange peel" pitting caused by lymphatic obstruction , a classic sign of Inflammatory Breast Cancer , not cyclical hormonal changes. Nipple retraction and bloody discharge (Option B): These are "red flag" symptoms typically associated with Intraductal Papilloma or an Invasive Carcinoma that has tethered the ducts or Cooper's ligaments. Eczematous changes of the nipple and areola (Option D): Scaly, itchy, or ulcerated skin on the nipple is the hallmark of Paget’s Disease of the Breast , representing malignant cells that have migrated to the epidermis from an underlying cancer.

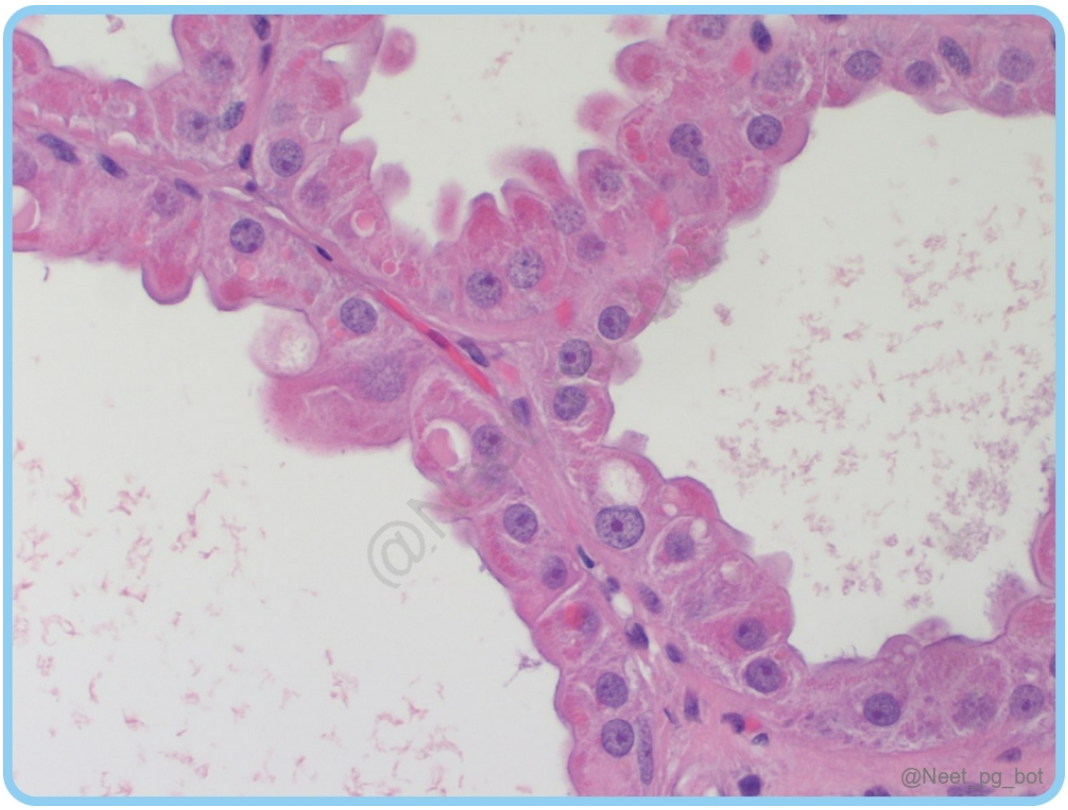

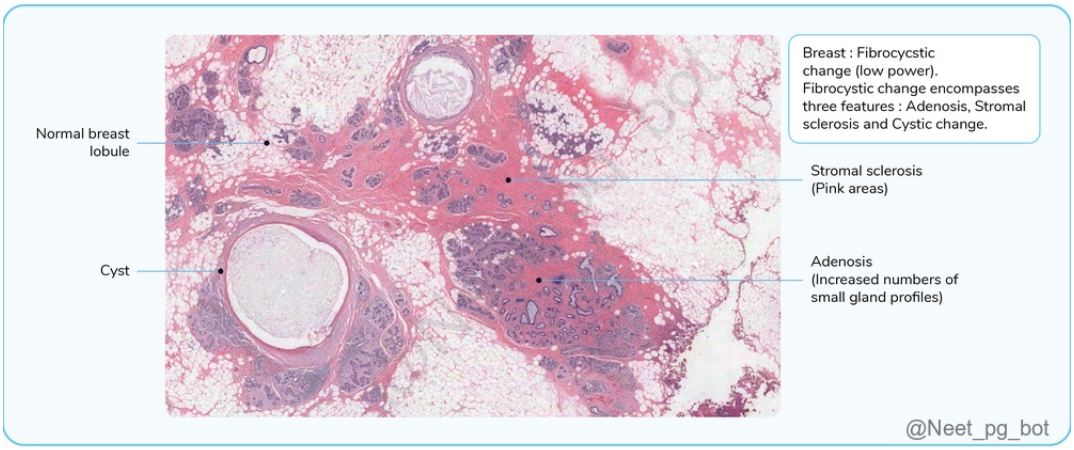

References:

Robbins & Cotran Pathologic Basis of Disease, 10th Edition, Page No. 1042.

www.ncbi.nlm.nih.gov/pmc/articles/PMC4261351/

↑ *Back to this question in Part A*

@Neet_pg_bot

Q19: A 38-year-old woman presents with a firm, irregular mass that has been slowly increasing in size over the past few months. Histopathological examination shows the following, what is the most likely diagnosis? (Q845798)

A. Sclerosing adenosis

B. Radial scar

C. Papilloma

D. Paget’s disease

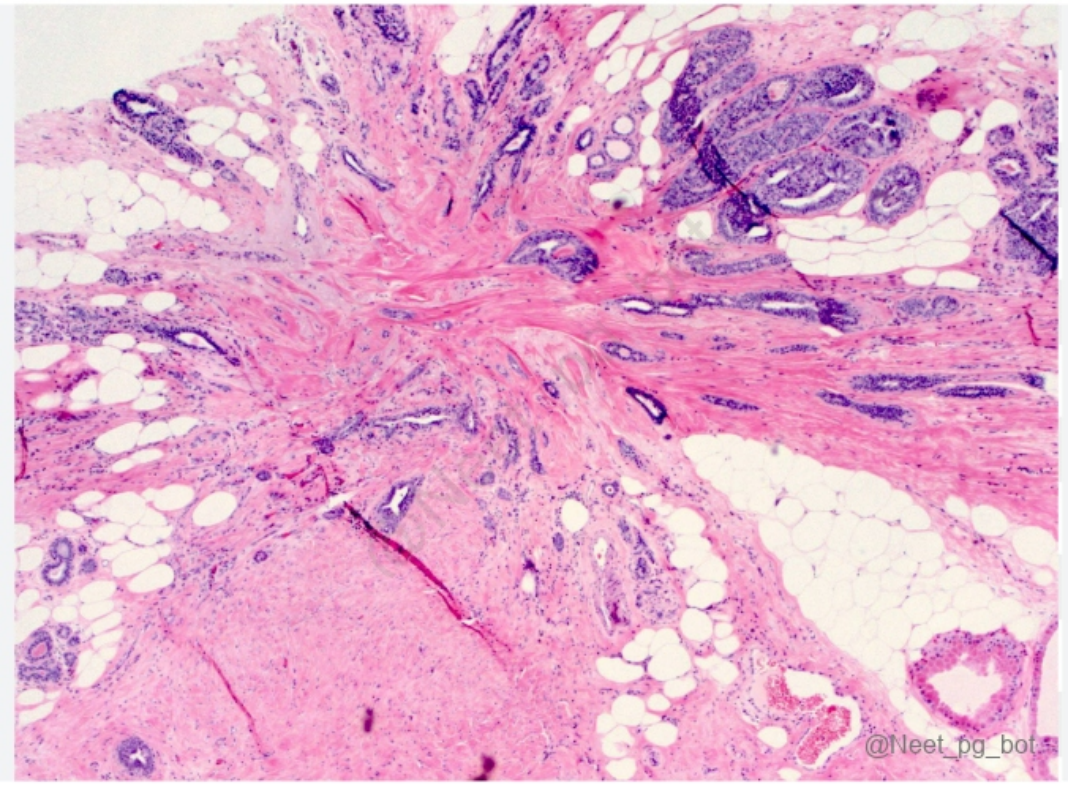

Correct Answer: B. Radial scar

- *Listen (English)*
- *Listen (Hindi)*

Explanation: The clinical features and HPE showing central sclerosis with fibroelastotic stroma and entrapped glands radiating outwards with hyperplasia are suggestive of radial scar. Radial scars, also known as complex sclerosing lesions , are benign proliferative breast lesions that can mimic breast cancer clinically and radiologically but look like scars when viewed under a microscope. They are characterized by a spiculated appearance on imaging, with a translucent, low-density center. Grossly, a whitish scar is present at the center (central stellate scar). {{caption_text}} HPE shows glands entrapped in a hyalinised stroma surrounded by long radiating projections containing epithelium. Sclerosing adenosis (Option A): While this is often a part of a radial scar, it typically presents as an increased number of distorted acini bundled together in a lobular pattern. It lacks the prominent, centralized "sunburst" fibroelastotic core seen here. Papilloma (Option C): This would show finger-like projections (papillae) with fibrovascular cores growing inside a dilated duct. The image provided shows a solid, radiating stromal process, not an intraductal growth. Paget’s disease (Option D): This involves the nipple epidermis . On Histology: Large, pale malignant cells (Paget cells) infiltrating the skin of the nipple are seen (our image shows deep breast tissue with fat (adipocytes) and ducts, not the skin surface.).

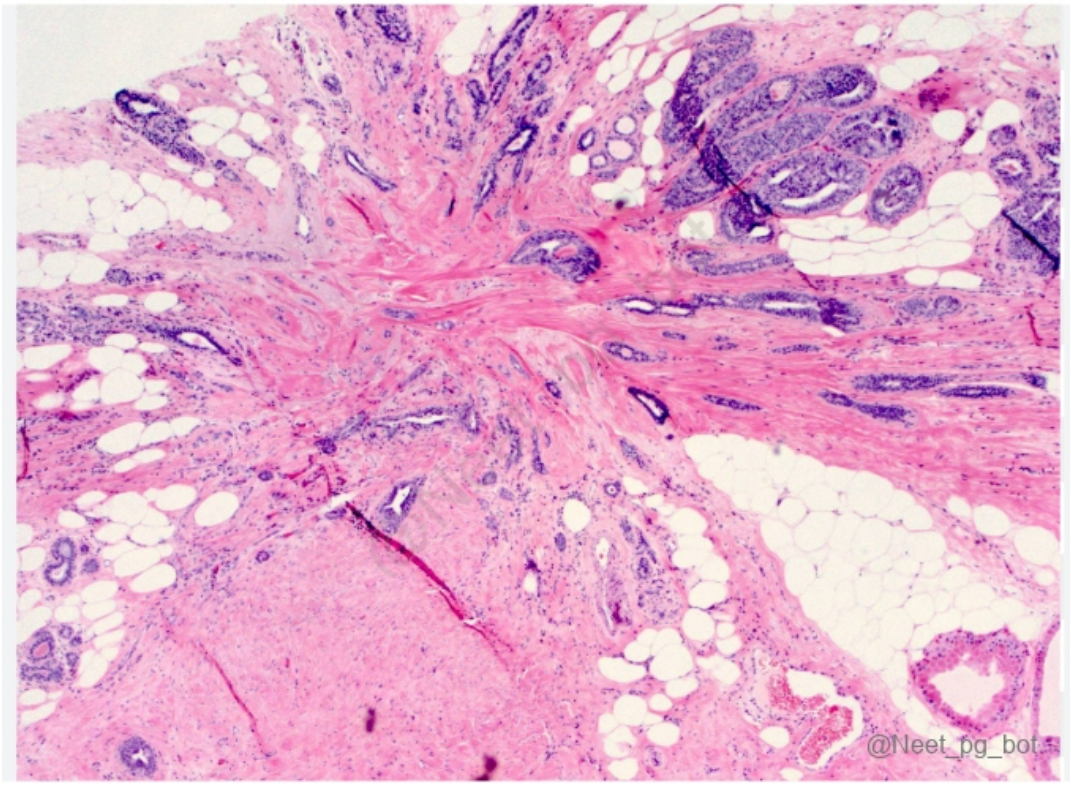



References:

Robbins & Cotran Pathologic Basis of Disease, 10th Edition, Page 1044

↑ *Back to this question in Part A*

@Neet_pg_bot

Q20: What is the absolute risk of a fibrocystic lesion of the breast converting to malignancy? (Q845797)

A. <1%

B. 3%

C. 5-7%

D. 13-17%

Correct Answer: B. 3%

■ *Listen (English)*

■ *Listen (Hindi)*

Explanation: Fibrocystic disease presents as “lumpy bumpy” breasts on palpation. Patients present with cyclical pain (Pain during menstrual cycle). They are included in the category of non-proliferative breast changes with a relative risk: of 1% and an absolute risk: of 3% of developing invasive carcinoma. Category Diseases/disorders Relative risk and absolute lifetime risk Non-proliferative breast changes Mild hyperplasia, duct ectasia, cysts, apocrine metaplasia, adenosis, fibroadenoma without complex features Relative risk: 1% Absolute risk: 3% Proliferative diseases without atypia Moderate or florid hyperplasia, sclerosing adenosis, complex sclerosing lesion, fibroadenoma with complex features Relative risk: 1.5-2% (2%) Absolute risk: 5-7% (6%) Proliferative breast diseases with atypia Atypical ductal hyperplasia Atypical lobular hyperplasia Relative risk: 4-5% (4%) Absolute risk: 13-17% (>12%) Carcinoma in situ Precancerous condition Relative risk: 8-10 (8%) Absolute risk: 25-30% (>24%)

References:

Robbins & Cotran Pathologic Basis of Disease, 10th Edition, Page 1045

↑ *Back to this question in Part A*

@Neet_pg_bot

Q21: Match the following Category Diseases/disorders 1. Non-proliferative breast changes a) Sclerosing adenosis 2. Proliferative diseases without atypia b) Mild hyperplasia 3. Proliferative breast diseases with atypia c) Precancerous condition 4. Carcinoma in situ d) Atypical ductal hyperplasia (Q845795)

A. 1- b, 2-d, 3-c, 4-a

B. 1- b, 2-a, 3-d, 4-c

C. 1- d, 2-a, 3-b, 4-c

D. 1- d, 2-c, 3-a, 4-b

Correct Answer: B. 1- b, 2-a, 3-d, 4-c

■ *Listen (English)*

■ *Listen (Hindi)*

Explanation: Category Diseases/disorders Non-proliferative breast changes Mild hyperplasia, duct ectasia, cysts, apocrine metaplasia, adenosis, fibroadenoma without complex features Proliferative diseases without atypia Moderate or florid hyperplasia, sclerosing adenosis, complex sclerosing lesion, fibroadenoma with complex features Proliferative breast diseases with atypia Atypical ductal hyperplasia Atypical lobular hyperplasia Carcinoma in situ Precancerous condition

References:

Robbins & Cotran Pathologic Basis of Disease, 10th Edition, Page 1045

↑ *Back to this question in Part A*

@Neet_pg_bot

Q22: A 38-year-old woman presents with a firm, immobile mass in her right breast for the past few days. 2 weeks ago, she bruised her breast while exercising. A mammogram reveals scattered punctate calcifications within the lump. What is the most likely diagnosis? (Q845794)

A. Mastitis

B. Breast abscess

C. Fat Necrosis

D. Inflammatory Breast Cancer

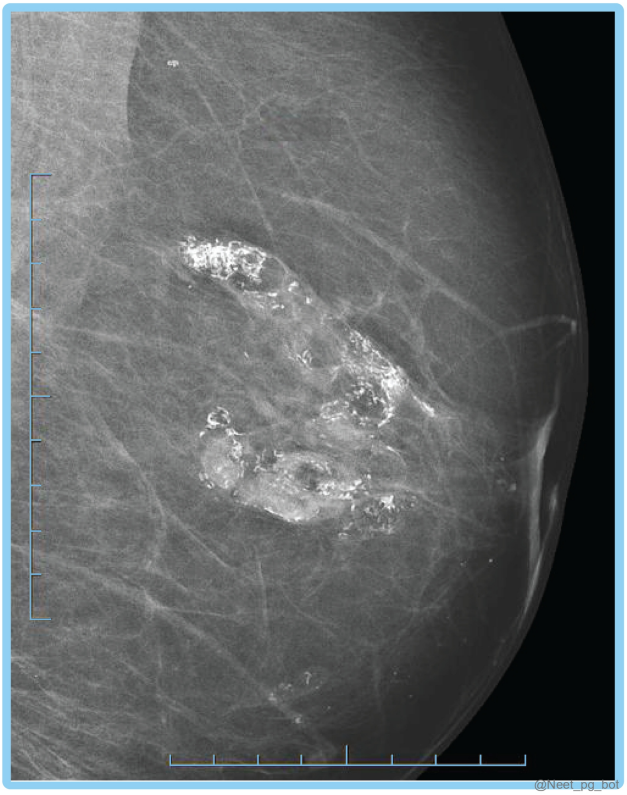

Correct Answer: C. Fat Necrosis

■ *Listen (English)*

■ *Listen (Hindi)*

Explanation: The most likely diagnosis in this patient with recent trauma and calcification could be fat necrosis. Breast fat necrosis is caused by injured or ischemic breast tissue that is replaced with scar tissue and presents as a palpable nodule. It is commonly caused by breast trauma and breast surgical procedures. It presents as a mammographic density , a painless palpable lump, skin thickening, or deposits of calcium. Fat necrosis can manifest in a variety of ways that closely resemble cancer like irregular breast mass, usually fixed to the dermis, with possible skin tethering and/or nipple retraction as a result of fibrotic bands between necrotic tissue and skin. Calcifications can sometimes occur in fat necrosis, particularly in older lesions. These are typically punctate (tiny dots) and scattered throughout the lump, unlike some cancers (differentiated by biopsy). Mastitis(Option A): This is an infection of breast tissue, often caused by bacteria entering through milk ducts during breastfeeding. It can cause inflammation, redness, pain, fever, and chills, which are absent in this case. Breast Abscess(Option B) This is a localized collection of pus within the breast tissue, often caused by a bacterial infection. It presents with fever, chills, and a more fluctuant (fluid-filled) mass compared to the firm mass often felt with fat necrosis. Inflammatory Breast Cancer(Option D): It typically presents with additional symptoms like skin thickening, peau d'orange (skin resembling an orange peel), and rapid progression.

References:

Robbins & Cotran Pathologic Basis of Disease, 10th Edition, Page 1041. Breast Fat Necrosis - StatPearls - NCBI Bookshelf (nih.gov)

↑ *Back to this question in Part A*

@Neet_pg_bot

Q23: Which of the following conditions is most likely to cause a sticky, green, or black discharge from the nipple? (Q845793)

A. Duct Papilloma

B. Paget's Disease

C. Duct Ectasia

D. Breast Cancer

Correct Answer: C. Duct Ectasia

■ *Listen (English)*

■ *Listen (Hindi)*

Explanation: Duct Ectasia: This is a benign (non-cancerous) condition where the milk ducts in the breast widen and thicken. This can cause a blockage and a build-up of fluid, which often appears as a sticky, green, black, or grey discharge from the nipple. Discharge Colour Disorders Clear or Milky Hormonal fluctuations, Pregnancy, Breastfeeding Yellow, Green, or Brown Duct Ectasia, Infection Bloody Duct Papilloma, Paget's Disease, Breast Cancer White or Cloudy Infection

References:

Robbins & Cotran Pathologic Basis of Disease, 10th Edition, Page 1041 Bailey and Love's Short Practice of Surgery, 28th Edition, Page 925

↑ *Back to this question in Part A*

@Neet_pg_bot

Q24: Which of the following statements regarding Zuska’s disease is incorrect? (Q845789)

A. There is squamous metaplasia of the lactiferous duct

B. Characterized by the formation of keratin plug

C. Presents as subareolar abscess

D. Alcohol is a major risk factor

Correct Answer: D. Alcohol is a major risk factor

■ *Listen (English)*

■ *Listen (Hindi)*

Explanation: Smoking is a major risk factor in Zuska's disease Zuska's disease is also known as Squamous metaplasia of lactiferous ducts(SMOLD), recurrent subareolar abscess, or periductal mastitis. The risk factors include a deficiency of vitamin A associated with smoking(90% of cases). This leads to k eratinizing squamous metaplasia of the ductal epithelium, which is cuboidal. Keratin released from these cells blocks the ductal system. This leads to the formation of subareolar abscess, dilation, and eventually, the rupture of the duct, causing fistulas.

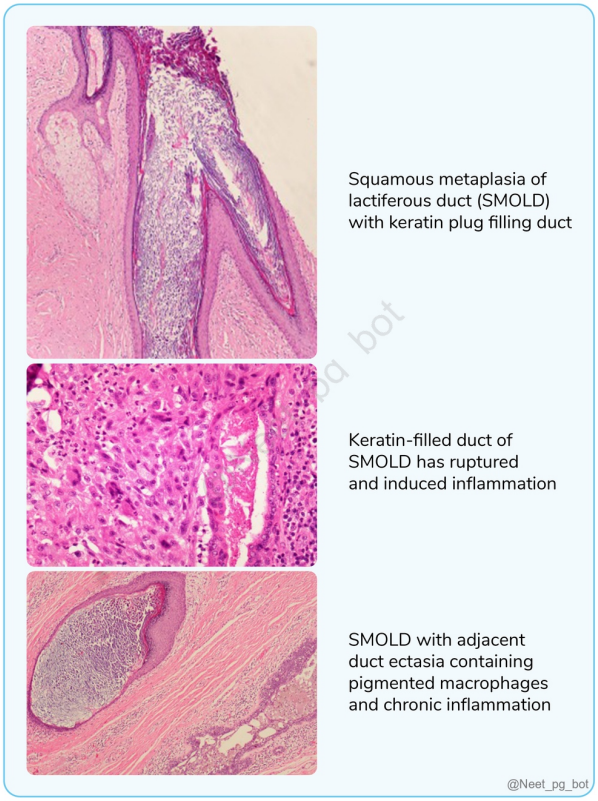

References:

Robbins & Cotran Pathologic Basis of Disease, 9th Edition, Page No. 1040-1041

↑ *Back to this question in Part A*

@Neet_pg_bot

Q25: A 48-year-old woman presents with pain in her left breast and associated nipple discharge for the past few weeks. She denies any fever, chills, or recent lactation. On examination, a small ovoid, well-defined subareolar mass is felt. What is the most likely diagnosis? (Q845788)

A. Acute mastitis

B. Duct ectasia

C. Ductal carcinoma in situ

D. Fibroadenoma

Correct Answer: B. Duct ectasia

■ *Listen (English)*

■ *Listen (Hindi)*

Explanation: The patient presenting with breast pain, nipple discharge, and palpable subareolar mass most likely has duct ectasia. Mammary duct ectasia is a benign, non-proliferative breast disease that affects large ducts. It is most common in women who are nearing menopause, typically between the ages of 45 and 55. The breast ducts become clogged with thick secretion and debris, leading to dilation of the duct. Symptoms Nipple discharge, which can be clear, green, brown, or bloody Breast tenderness or pain , especially around the nipple A tender lump in the subareolar or periareolar region of a breast Inward retraction of the nipple due to repeated episodes and scarring A transverse slit-like or fish-mouth-like retraction of the nipple is classically seen in periductal mastitis but circumferential retraction may indicate a carcinoma. Ductal ectasia is often diagnosed during a routine mammogram or breast exam and managed by excision. If a lump is found, a biopsy may be needed to rule out cancer. Acute mastitis (Option A): This is primarily an inflammatory/infectious condition seen in women who are currently breastfeeding (lactational mastitis). It presents with systemic signs (fever, chills) and a red, swollen, diffuse area of infection rather than a localized, well-defined mass. Key Pathogen: Usually Staphylococcus aureus. Ductal carcinoma in situ (Option C): DCIS is a non-invasive cancer where abnormal cells are found in the lining of a breast duct. It is typically asymptomatic and non-palpable. It is almost always detected as microcalcifications on a mammogram rather than a distinct well-defined mass and discharge. Fibroadenoma (Option D): This is the most common benign breast tumor. It is most common in younger women (ages 15–35). While they are well-defined, they are "rubbery" and highly mobile ("breast mice"). They do not cause nipple discharge .

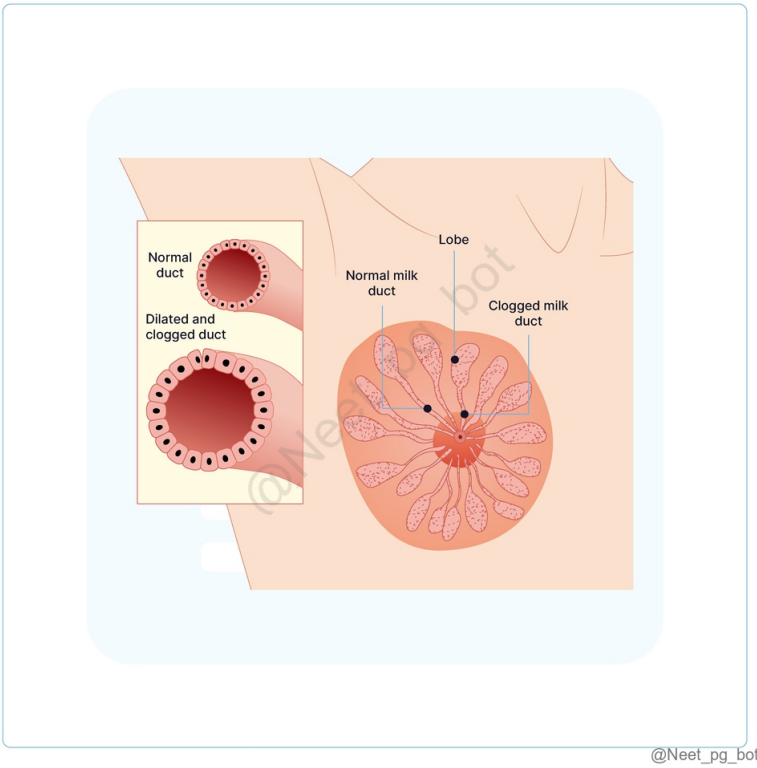

@Neet_pg_bot

References:

Robbins & Cotran Pathologic Basis of Disease, 10th Edition, Page No. 1041.

www.ncbi.nlm.nih.gov/books/NBK557665/

↑ *Back to this question in Part A*

@Neet_pg_bot

Q26: A 24-year-old with a 2-month-old infant presents to the OPD with pain in her left breast. The baby is exclusively breastfed. On examination, the nipple is tender and erythematous with a fluctuant mass beneath the areola. Which of the following is the most common cause of this condition? (Q845786)

A. Pseudomonas aeruginosa

B. Staphylococcus aureus

C. Streptococcus sp.

D. Listeria monocytogenes

Correct Answer: B. Staphylococcus aureus

■ *Listen (English)*

■ *Listen (Hindi)*

Explanation: The clinical scenario suggests acute breast abscess from lactational mastitis which is commonly caused by Staphylococcus aureus . It is caused by a local infection through cracks and fissures in the nipples that occur commonly during the 1st month of breastfeeding. It is often preceded by either engorgement or a focally blocked duct. Patients can develop a focal area of erythema, pain, fever, and swelling. This can further develop into single or multiple abscesses. Streptococcus pyogenes, Escherichia coli, Bacteroides species, and coagulase-negative Staphylococci are other organisms that cause mastitis. Treatment: I&D (Incision and Drainage) + Antibiotics First line agent: Cloxacillin/ Dicloxacillin for 10-14 days



References:

Robbins and Cotran Pathological Basis of Disease, 10th Edition, Pg 1040

↑ *Back to this question in Part A*

@Neet_pg_bot

• [14_Breast Pathology] 060 Malignant Breast Lesions

« Back to Folder Directory

[14_Breast Pathology] 060 Malignant Breast Lesions — Quick Jump

Q1 (p. 2450)	*Q2 (p. 2450)*	*Q3 (p. 2451)*	*Q4 (p. 2452)*	*Q5 (p. 2453)*	*Q6 (p. 2454)*
Q7 (p. 2456)	*Q8 (p. 2456)*	*Q9 (p. 2457)*	*Q10 (p. 2458)*	*Q11 (p. 2459)*	*Q12 (p. 2461)*
Q13 (p. 2462)	*Q14 (p. 2462)*	*Q15 (p. 2463)*	*Q16 (p. 2464)*	*Q17 (p. 2465)*	*Q18 (p. 2467)*
Q19 (p. 2468)	*Q20 (p. 2470)*	*Q21 (p. 2472)*	*Q22 (p. 2473)*	*Q23 (p. 2476)*	*Q24 (p. 2477)*
Q25 (p. 2481)					

Q1: A 52-year-old woman presents with a painless palpable breast mass detected during self-examination. Imaging and biopsy confirm carcinoma of the breast. Which of the following is the most common location for breast carcinoma? (Q890381)

A. Upper outer quadrant

B. Upper inner quadrant

C. Lower outer quadrant

D. Lower inner quadrant

Correct Answer: A. Upper outer quadrant

Explanation: reast carcinoma most commonly arises in the upper outer quadrant (~50%) , which contains the greatest volume of glandular breast tissue , including the axillary tail (tail of Spence) —a common site of tumor origin. This region is also clinically significant because tumors here may present with early axillary lymph node involvement due to proximity to lymphatic drainage pathways. Distribution of Breast Carcinoma Upper outer quadrant ~50% Central/subareolar ~20% Other quadrants ~10% each

References:

Robbins, Cotran & Kumar, Pathologic Basis of Disease, 11th Edition, Page 945

↑ *Back to this question in Part A*

@Neet_pg_bot

Q2: Which of the following cancers are commonly associated with the BRCA2 mutation? Male breast cancer Ovarian carcinoma Pancreatic carcinoma Prostate

carcinoma Colorectal carcinoma (Q890407)

A. 1, 2, 3, 4

B. 1, 2, 5

C. 1, 2, 4, 5

D. 2, 3, 5

Correct Answer: A. 1, 2, 3, 4

Explanation: Colorectal carcinoma is not a classic cancer associated with BRCA2 mutations. It is more commonly linked to: Lynch syndrome (MMR genes) APC mutations (FAP) BRCA1 and BRCA2 are tumor suppressor genes involved in homologous recombination repair of DNA double-strand breaks . Mutations lead to genomic instability and increased cancer risk. BRCA2-associated cancers Male breast cancer (strong association; hallmark) Ovarian carcinoma Pancreatic carcinoma Prostate carcinoma BRCA1-associated cancers Breast carcinoma (often triple-negative) Ovarian carcinoma (higher risk than BRCA2) Also associated with pancreatic and prostate cancers (less prominently)

References:

https://www.ncbi.nlm.nih.gov/books/NBK1247/

↑ *Back to this question in Part A*

@Neet_pg_bot

Q3: Which of the following is the most common stromal malignancy of the breast? (Q890406)

A. Fibrosarcoma

B. Angiosarcoma

C. Liposarcoma

D. Leiomyosarcoma

Correct Answer: B. Angiosarcoma

Explanation: The most common stromal malignancy of the breast is Breast angiosarcoma , a rare malignant vascular tumour arising from endothelial cells . Angiosarcoma of the Breast: Most common malignant stromal tumour of the breast. Primary (Sporadic): Occurs in the breast parenchyma Young women (mean age ~35 years) Poor prognosis Secondary (Therapy-related): Occurs in older women Associated with: Radiation therapy Stewart–Treves syndrome (chronic lymphedema) MYC amplification in >90% Incidence after radiation: ~0.3%

Develops 5-10 years after treatment Fibrosarcoma (Option A): Extremely rare in the breast and not the most common stromal malignancy. Liposarcoma (Option C): Occurs very rarely in the breast and is less common than angiosarcoma among stromal malignancies. Leiomyosarcoma (Option D): A rare smooth muscle tumour of the breast and not the most frequent stromal malignancy.

References:

Robbins, Cotran & Kumar, Pathologic Basis of Disease, 11th Edition, Pages 968, 969

↑ *Back to this question in Part A*

@Neet_pg_bot

Q4: 60-year-old woman presents with a rapidly enlarging breast mass. Histology shows findings as shown. Which of the following statements regarding the most probable condition is incorrect? (Q890404)

A. Most tumours are benign

B. Metastases contain only the stromal component

C. Arises from the intralobular stroma

D. Local recurrence is rare

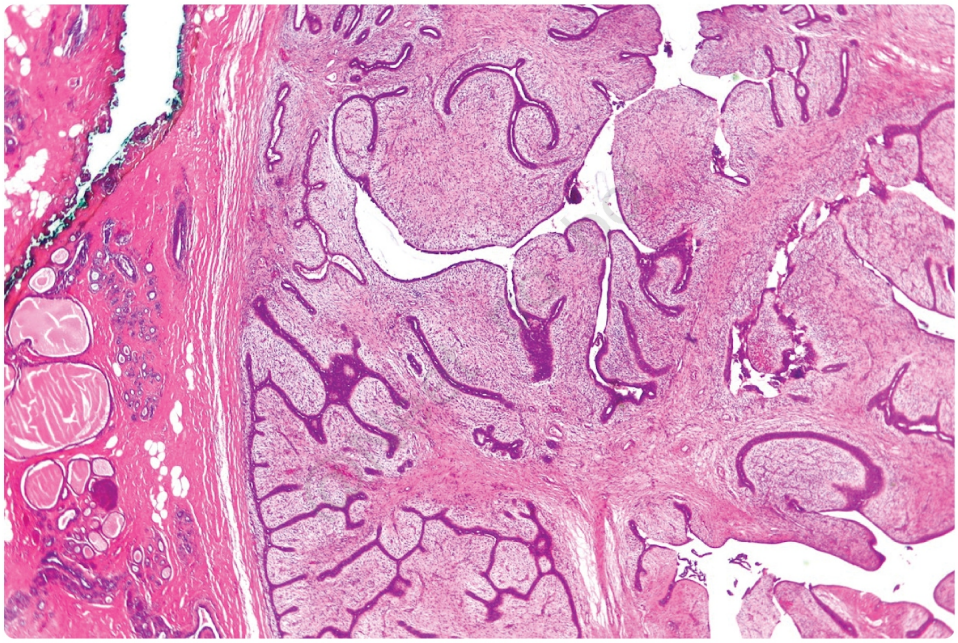

@Neet_pg_bot

Correct Answer: D. Local recurrence is rare

Explanation: The most probable diagnosis is Phyllodes tumour , a fibroepithelial breast tumour characterised by leaf-like stromal projections lined by epithelium . Phyllodes tumours commonly show local recurrence , especially borderline and malignant tumours , and margin status is the most important predictor of recurrence . Phyllodes tumour: Fibroepithelial tumour arising from intralobular stroma (Option C) ~ 2.5% of fibroepithelial breast lesions Mutations: MED12, RARA ; additional TERT, TP53, RB Morphology: Large palpable breast mass Leaf-like stromal projections lined by epithelium May form cystic spaces Clinical features: Peak age: ~6th decade (later than fibroadenoma) ~75% benign (Option A) Local recurrence is common ; margin status predicts recurrence Metastasis: Lymphatic spread rare → no axillary dissection Malignant tumours metastasise hematogenously (~1/3) Metastases contain only the stromal component (Option B)

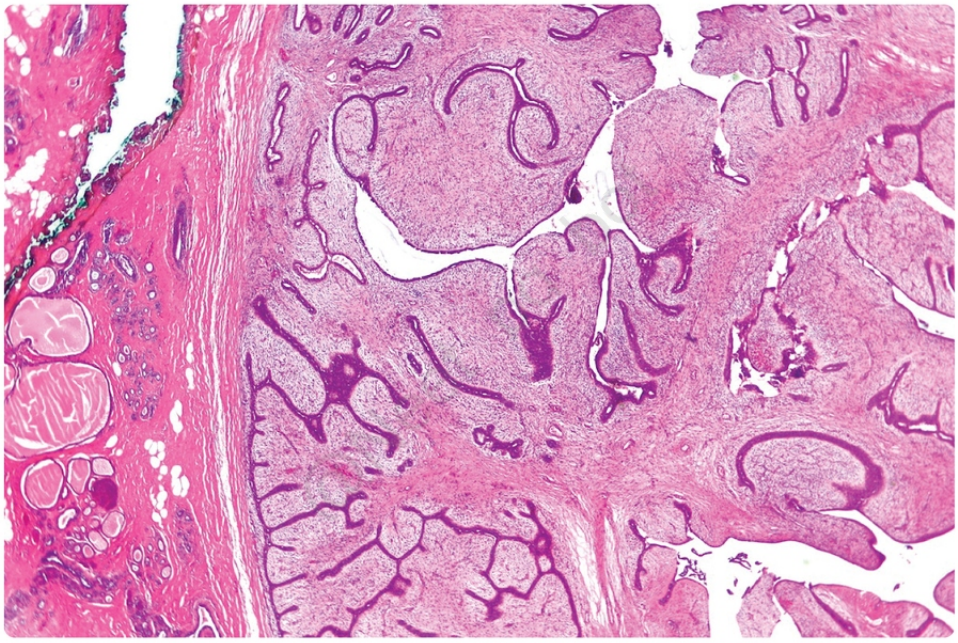

@Neet_pg_bot

References:

Robbins, Cotran & Kumar, Pathologic Basis of Disease, 11th Edition, Page 968

↑ *Back to this question in Part A*

@Neet_pg_bot

Q5: A 55-year-old woman is diagnosed with invasive breast carcinoma. Several tumour characteristics are evaluated to determine prognosis and guide therapy. Which of the following is considered a good prognostic marker in breast cancer?

(Q890402)

A. HER2 overexpression

B. ER positivity

C. Presence of BRCA mutation

D. Basal-type breast cancer

Correct Answer: B. ER positivity

Explanation: Tumours that express estrogen receptors (ER-positive) generally have a better prognosis and respond well to endocrine therapies such as tamoxifen or aromatase inhibitors . ER positivity is therefore considered an important, favourable prognostic and predictive marker in breast cancer. Breast cancer - Prognostic factor: Disease factors that influence prognosis Histologic Subtypes Invasive Ductal Carcinoma (IDC): Prognosis varies by grade and molecular markers. Invasive Lobular Carcinoma (ILC): Intermediate prognosis. Tubular and Mucinous Carcinomas: Best prognosis. Basal-like Breast Cancer (Option D) : Aggressive, triple-negative, no targeted treatments. Other Subtypes: Medullary, cribriform, papillary, adenoid cystic, and metaplastic carcinomas, vary in prognosis. Tumour Size & Lymph Node Larger tumours (>2cm) and positive lymph nodes = worse prognosis. Molecular Markers Hormone Receptors (ER, PR): ER-positive = better prognosis . HER-2 Status: HER-2 positive = aggressive (Option A) but treatable with targeted therapies. Patient factors that influence prognosis Age Younger, particularly premenopausal women, may have higher local recurrence rates post-surgery, but radiation therapy can reduce this risk. BRCA Mutation (Option C) Associated with aggressive phenotype Family History A strong family history may indicate inherited susceptibility and potentially worse prognosis.

References:

Sabiston Textbook of Surgery, 21st Edition, Pages 828, 829, 831, 832, 835, 839, 847, 851

Bailey & Love's Short Practice of Surgery, 28th Edition, Page 942

↑ *Back to this question in Part A*

@Neet_pg_bot

Q6: Which of the following IHC requires confirmation with fluorescence in situ hybridisation (FISH) for HER2 gene amplification? (Q890397)

A. D

B. C

C. B

D. A

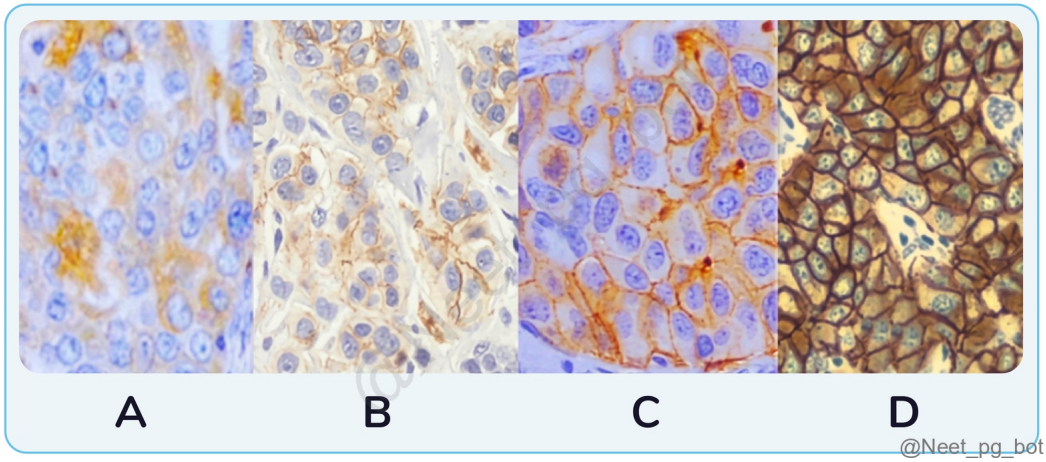

Correct Answer: B. C

Explanation: HER2 immunohistochemistry (IHC) scoring determines when fluorescence in situ hybridisation (FISH) is required to confirm HER2 gene amplification . Image C (IHC 2+) is considered Equivocal (borderline). Because the protein expression is unclear, guidelines require confirmation using Fluorescence In Situ Hybridisation (FISH) to look for actual gene amplification. Image Interpretation: A: No significant membrane staining → Score 0 B: Faint incomplete staining → Score 1+ C: Moderate complete membrane staining → Score 2+ (Equivocal) D: Strong circumferential staining → Score 3+ Her2 IHC interpretation: Score IHC Pattern Interpretation FISH Needed 0 No staining or faint, incomplete membrane staining Negative No 1+ Faint/incomplete membrane staining in >10% cells Negative No 2+ Weak–moderate complete membrane staining in >10% cells Equivocal Yes 3+ Strong circumferential membrane staining Positive No

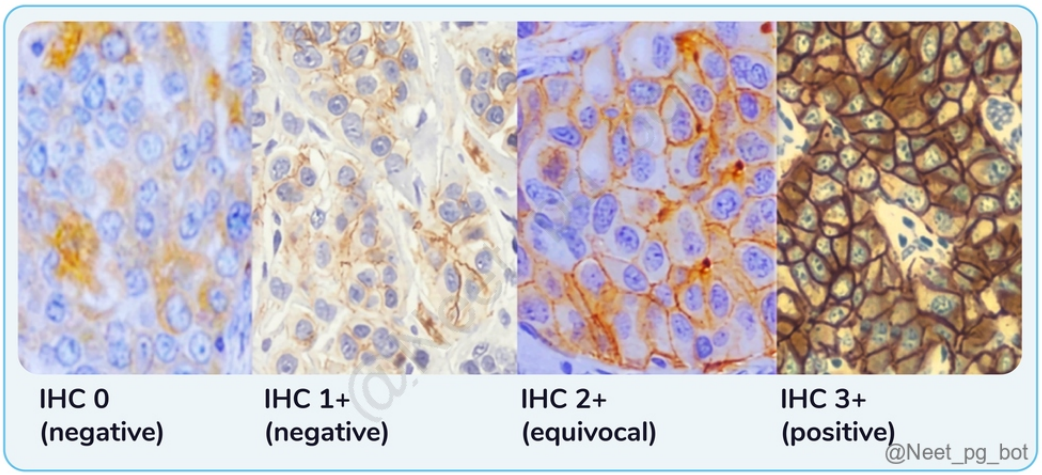

References:

Robbins, Cotran & Kumar, Pathologic Basis of Disease, 11th Edition, Pages 960, 961

https://pmc.ncbi.nlm.nih.gov/articles/PMC5938719/

↑ *Back to this question in Part A*

@Neet_pg_bot

Q7: A breast carcinoma is classified as T4d in the TNM staging system. Which of the following features is not characteristic of this stage? (Q890396)

A. Diffuse breast erythema and oedema

B. Peau d'orange appearance of the skin

C. Tumour emboli within dermal lymphatic vessels

D. Prominent neutrophilic inflammatory infiltrate in the dermis

Correct Answer: D. Prominent neutrophilic inflammatory infiltrate in the dermis

Explanation: A breast carcinoma classified as T4d corresponds to inflammatory breast carcinoma , which is characterised by tumour emboli within dermal lymphatic vessels leading to lymphatic obstruction . Despite the term inflammatory, true inflammatory cell infiltrates are usually absent Inflammatory Breast Carcinoma (IBC): Not a special histologic type; refers to a distinct clinical presentation. Caused by tumour emboli obstructing dermal lymphatic vessels. (Option C) Clinical features: Diffuse breast erythema (Option A) Breast swelling Skin thickening Peau d'orange (orange-peel appearance) (Option B) Dermal oedema + tethering by Cooper ligaments → skin dimpling. Usually high-grade, diffusely infiltrative carcinoma Often no discrete palpable mass



References:

Robbins, Cotran & Kumar, Pathologic Basis of Disease, 11th Edition, Page 963

↑ *Back to this question in Part A*

@Neet_pg_bot

Q8: Which of the following is the most common clinical presentation of occult breast carcinoma? (Q890395)

A. Palpable breast lump with nipple retraction

B. Axillary lymphadenopathy due to metastatic carcinoma

C. Bloody nipple discharge

D. Diffuse breast skin thickening resembling peau d’orange

Correct Answer: B. Axillary lymphadenopathy due to metastatic carcinoma

Explanation: The most common presentation of occult breast carcinoma is isolated axillary lymph node metastasis , where patients present with painless axillary lymphadenopathy and the primary breast lesion remains undetectable. Occult breast carcinoma (OBC) is a breast malignancy that presents with metastatic disease (most commonly axillary lymph node metastasis) without a detectable primary tumour in the breast on clinical examination or imaging. Rare entity: ~0.1–1% of all breast cancers . Most common presentation: Isolated axillary lymphadenopathy due to metastatic carcinoma. Diagnosis: Histologically proven metastatic carcinoma (usually adenocarcinoma) in lymph nodes. No identifiable breast tumour on: Clinical examination Mammography Ultrasound MRI (often used for detection). Palpable breast lump with nipple retraction (Option A): Indicates a detectable primary breast carcinoma, whereas occult breast carcinoma presents without an identifiable primary lesion. Bloody nipple discharge (Option C): Seen in conditions with a primary ductal lesion such as intraductal papilloma or carcinoma, not in occult breast carcinoma. Diffuse breast skin thickening resembling peau d’orange (Option D): Characteristic of inflammatory breast carcinoma with overt breast involvement, not occult disease where the primary tumor is not detectable.

References:

https://pmc.ncbi.nlm.nih.gov/articles/PMC9568768/

↑ *Back to this question in Part A*

@Neet_pg_bot

Q9: A breast tumour shows strong ER positivity, PR positivity, HER2 negativity, and a low Ki-67 proliferation index. Which of the following histologic types of breast carcinoma is not associated with this subtype? (Q890394)

A. Tubular carcinoma

B. Papillary carcinoma

C. Mucinous carcinoma

D. Secretory carcinoma

Correct Answer: D. Secretory carcinoma

Explanation: The IHC profile indicates Luminal A breast carcinoma , which typically shows ER/PR positivity, HER2 negativity, and low proliferation . Secretory carcinoma is not associated with Luminal A; it is usually triple-negative . Molecular classification of breast cancer: Classification Hormone receptor HER2/Neu Others Luminal A Positive (either or both ER/PR) Negative Ki-67 low Luminal B Positive (either or both ER/PR) + or - Ki-67 high Basal type (triple -ve) Negative Negative Ki-67 usually high HER2/neu enriched Negative Positive Ki-67 high Claudin low Negative Negative Claudin low Luminal A (Low proliferation rate) Tubular carcinoma (Option A) Papillary carcinoma (Option B) Mucinous carcinoma (Option C) Low-grade ILC Luminal B (High proliferation rate) High-grade ILC. HER2/Neu rich Apocrine carcinoma. Micropapillary carcinoma. Triple-negative Medullary carcinoma Metaplastic carcinoma Secretory carcinoma Adenoid cystic carcinoma

References:

Robbins, Cotran & Kumar, Pathologic Basis of Disease, 11th Edition, Page 960

Robbins and Cotran, Pathologic Basis of Disease, 10th Edition. Pages 1049, 1056-1058

Bailey and Love, Short Practice of Surgery, 28th Edition, Page 931

↑ *Back to this question in Part A*

@Neet_pg_bot

Q10: A 50-year-old woman is diagnosed with an aggressive breast carcinoma. Immunohistochemistry shows findings as shown. Which of the following histologic types of breast carcinoma is not associated with this subtype? (Q890386)

A. Medullary carcinoma

B. Metaplastic carcinoma

C. Adenoid cystic carcinoma

D. Mucinous carcinoma

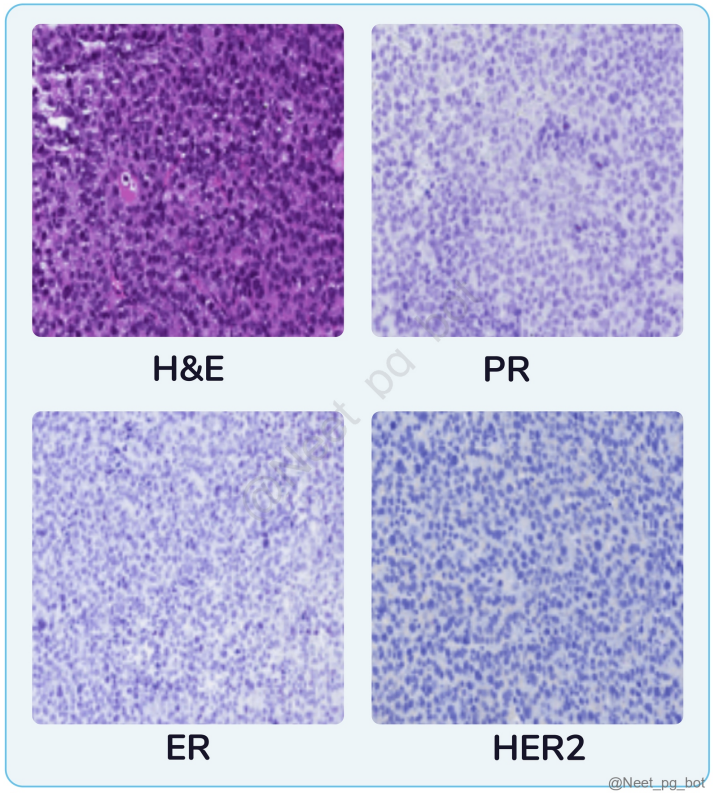

Correct Answer: D. Mucinous carcinoma

Explanation: Based on the findings in the IHC, the most likely subtype is TNBC. Triple-negative breast cancers (TNBC) lack ER, PR, and HER2 expression. Mucinous carcinoma is not associated with TNBC; it is usually ER-positive and part of the luminal A subtype . Molecular classification of breast cancer: Classification Hormone receptor HER2/Neu Others Luminal A Positive (either or both ER/PR) Negative Ki-67 low Luminal B Positive (either or both ER/PR) + or - Ki-67 high Basal type (triple -ve) Negative Negative Ki-67 usually high HER2/neu enriched Negative Positive Ki-67 high Claudin low Negative Negative Claudin low Luminal A (Low proliferation rate) Tubular carcinoma Papillary carcinoma Mucinous carcinoma Low-grade ILC Luminal B (High proliferation rate) High-grade ILC. HER2/Neu rich Apocrine carcinoma. Micropapillary carcinoma. Triple-negative Medullary carcinoma (Option A) Metaplastic carcinoma (Option B) Secretory carcinoma Adenoid cystic carcinoma (Option C)

References:

Robbins, Cotran & Kumar, Pathologic Basis of Disease, 11th Edition, Page 960

Robbins and Cotran, Pathologic Basis of Disease, 10th Edition. Pages 1049, 1056-1058

Bailey and Love, Short Practice of Surgery, 28th Edition, Page 931

↑ *Back to this question in Part A*

@Neet_pg_bot

Q11: A 54-year-old woman undergoes a biopsy for a breast mass. Immunohistochemistry shows findings as shown. Which of the following is not a feature of the most probable molecular subtype? (Q890384)

A. Well differentiated

B. Strong luminal gene expression

C. Best prognosis

D. 1q loss

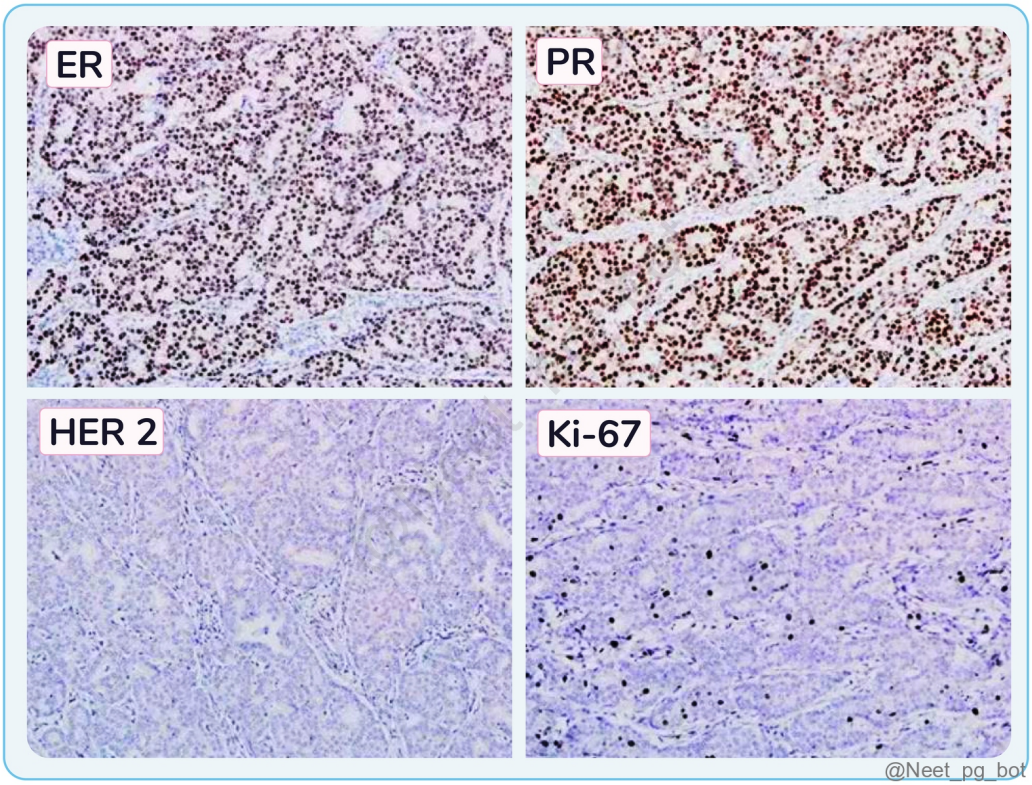

Correct Answer: D. 1q loss

Explanation: The findings suggest Luminal A breast carcinoma , which is characterised by ER/PR positivity, HER2 negativity, low proliferation, and well-differentiated tumours with strong luminal gene expression and a favourable prognosis . Luminal A tumours usually show 1q gain , not loss. Luminal A Breast Cancer: ER positive PR positive HER2 negative Low Ki-67 / low proliferation rate Well-differentiated tumours (Option A) Strong luminal (estrogen-regulated) gene expression (Option B) Common genomic changes: 1q gain 16q loss PIK3CA mutations Best prognosis among molecular subtypes of breast cancer. (Option C) Molecular classification of breast cancer: Subtype ER Status PR Status HER2 Status Ki-67 Status Characteristics Luminal A + + - Low Generally low grade, better prognosis, responsive to hormonal therapy. Luminal B + + or - + or - High Higher grade, poor prognosis compared to Luminal A, may require targeted HER2 therapy following status. HER2-enriched - - + High Aggressive, higher grade, poor prognosis, requires targeted HER2 therapy. Basal-like - - - High Includes triple-negative breast cancer (TNBC), which is highly aggressive and has no targeted hormonal

therapy. Claudin-low - - + or - Often High Often associated with poor prognosis and aggressive behaviour, typically lacks response to hormonal therapy.

References:

Robbins, Cotran & Kumar, Pathologic Basis of Disease, 11th Edition, Pages 958, 959

Bailey & Love's Short Practice of Surgery, 28th Edition, Page 931.

SRB's Manual of Surgery, 6th Edition, Page 533.

↑ *Back to this question in Part A*

@Neet_pg_bot

Q12: A 48-year-old woman is diagnosed with an aggressive breast carcinoma. Molecular testing reveals a mutation in the TP53 gene, which is the most common genetic alteration seen in this tumor subtype. Which of the following types of breast carcinoma is most likely present? (Q890383)

A. Luminal A breast carcinoma

B. Luminal B breast carcinoma

C. HER2-enriched carcinoma

D. Triple-negative breast carcinoma

Correct Answer: D. Triple-negative breast carcinoma

Explanation: Triple-negative breast carcinoma most commonly harbours TP53 mutations and typically presents as an aggressive, high-grade tumour lacking ER, PR, and HER2 expression . Triple-Negative Breast Cancer (TNBC): Morphology: Most tumours are high-grade with: Solid growth Nuclear pleomorphism Necrosis High proliferation Genetics: TP53 mutation - most common mutation BRCA1 / BRCA2 defects in familial cases Sporadic TNBC: BRCA1 is often epigenetically silenced Molecular classification of breast cancer: Subtype ER Status PR Status HER2 Status Ki-67 Status Characteristics Luminal A (Option A) + + - Low Generally low grade, better prognosis, responsive to hormonal therapy. Luminal B (Option B) + + or - + or - High Higher grade, poor prognosis compared to Luminal A, may require targeted HER2 therapy following status. HER2-enriched (Option C) - - + High Aggressive, higher grade, poor prognosis, requires targeted HER2 therapy. Basal-like - - - High Includes triple-negative breast cancer (TNBC), which is highly aggressive and has no targeted hormonal therapy. Claudin-low - - + or - Often High Often associated with poor prognosis and aggressive behaviour, typically lacks response to hormonal therapy.

References:

Robbins, Cotran & Kumar, Pathologic Basis of Disease, 11th Edition, Pages 960, 961

Bailey & Love's Short Practice of Surgery, 28th Edition, Page 931.

SRB's Manual of Surgery, 6th Edition, Page 533.

↑ *Back to this question in Part A*

@Neet_pg_bot

Q13: A 38-year-old woman with a strong family history of early-onset breast and ovarian cancer undergoes genetic testing. Which of the following correctly states the chromosomal locations of BRCA1 and BRCA2? (Q890382)

A. BRCA1 - 17q21; BRCA2 - 13q12.3

B. BRCA1 - 13q12.3; BRCA2 - 17q21

C. BRCA1 - 11p15; BRCA2 - 17p13

D. BRCA1 - 9p21; BRCA2 - 10q23

Correct Answer: A. BRCA1 - 17q21; BRCA2 - 13q12.3

Explanation: BRCA1 is located on chromosome 17q21, while BRCA2 is located on chromosome 13q12.3. These tumour suppressor genes are involved in DNA double-strand break repair through homologous recombination , and their mutations significantly increase the risk of hereditary breast and ovarian cancers. BRCA Genes: BRCA1 (chromosome 17q21) BRCA2 (chromosome 13q12.3) Responsible for 80-90% of single-gene familial breast cancers Account for 3-6% of all breast cancers Most female carriers develop cancer before age 70 Male breast cancer risk ↑ (especially BRCA2) Associated cancers: Ovarian carcinoma Prostate carcinoma Pancreatic carcinoma

References:

Robbins, Cotran & Kumar, Pathologic Basis of Disease, 11th Edition, Page 957

↑ *Back to this question in Part A*

@Neet_pg_bot

Q14: A 35-year-old woman comes to the clinic presenting with swelling in the upper quadrant of her left breast. She reports changes in the skin and surrounding nipple areola complex as well. All of the following are risk factors for this condition except? (Q845693)

A. Alcohol

B. Early menarche

C. Age

D. Multiparity

Correct Answer: D. Multiparity

■ *Listen (English)*

■ *Listen (Hindi)*

Explanation: Multiparity is not a risk factor for breast carcinoma. The clinical presentation of a 35-year-old female with swelling in the upper quadrant of her breast with skin changes in the skin and the surrounding nipple-areola complex is highly suggestive of carcinoma of the breast. Risk factors for breast carcinoma : Risk factors Relative risk Female gender. Increasing age. (Option C) Germline mutations of high penetrance. Strong family history (>1 first-degree relative, young age, multiple cancers). Personal history of breast cancer. High breast density. >4.0 Germline mutations of moderate penetrance. High-dose radiation to the chest at a young age. Family history (1 first-degree relative). 2.1-4.0 Early menarche (age <12 years). (Option B) Late menopause (age >55 years). Late first pregnancy (age >35 years). Nulliparity . Absence of breastfeeding. Exogenous hormone therapy. Postmenopausal obesity. Physical inactivity. High alcohol consumption. (Option A) 1.1-2.0 Relative risk is the likelihood of developing invasive carcinoma compared to women without any risk factors. Protective factors Early full term pregnancy Multiparity Lactation and breastfeeding Late menarche and early menopause

References:

Robbins and Cotran Textbook of Pathology, 10th Edition, Page 1047

↑ *Back to this question in Part A*

@Neet_pg_bot

Q15: Which of the following parameters is not assessed in the Bloom-Richardson scoring system? (Q845723)

A. Nuclear size

B. Tubule formation

C. Size of the tumor

D. Mitotic count

Correct Answer: C. Size of the tumor

■ *Listen (English)*

■ *Listen (Hindi)*

Explanation: The size of the tumor is a part of the Van Nuys Prognostic Index and it is not assessed in the BLoom-Richardson scoring ssystem Bloom-Richardson scoring system (Also known as Nottingham grading system): The parameters include: Tubule formation (Option B) , which assesses the degree of glandular formation in tumor tissue. Nuclear pleomorphism (Option A) refers to variations in the size and shape of cell nuclei. Mitotic count (Option D) indicates the number of actively dividing cells per high-power field. Each parameter is assigned from 1 to 3 points according to the degree of deviation from normal breast epithelium. Score Grade 3-5 I 6 or 7 II 8 or 9 III Van Nuys Prognostic Index (VNPI): It predicts the risk of local recurrence for DCIS (non-invasive breast cancer) to guide treatment. Factor 1 Point (Low Risk) 2 Points (Medium Risk) 3 Points (High Risk) Tumor Size ≤ 15 mm 16 - 40 mm > 40 mm Margin Width ≥ 10 mm 1 - 9 mm < 1 mm Pathologic Class Low/Intermediate grade, no necrosis Low/Intermediate grade with necrosis High grade (Grade 3) Patient Age > 60 years 40 - 60 years < 40 years Treatment Recommendations: 4, 5, or 6 (Low Risk): Surgery only (lumpectomy). 7, 8, or 9 (Intermediate Risk): Surgery + Radiation. 10, 11, or 12 (High Risk): Mastectomy generally recommended.

References:

Bailey & Love's Short Practice of Surgery, 28th edition, Page 872.

www.ncbi.nlm.nih.gov/pmc/articles/PMC5161065/

↑ *Back to this question in Part A*

@Neet_pg_bot

Q16: A biopsy taken from a patient's breast lump is subjected to histopathological examination. Upon staining, it is found to be a luminal breast carcinoma with a high proliferative rate. Overexpression of which of the following cellular proteins has led to this interpretation? (Q845721)

A. Alpha catenin

B. Arp-2/3

C. Ki-67

D. Vimentin

Correct Answer: C. Ki-67

■ *Listen (English)*

■ *Listen (Hindi)*

Explanation: Ki-67 is a nuclear protein associated with cellular proliferation . Luminal A: ER and PR positive, HER2 negative, Ki-67 < 14% (low proliferation rate). Luminal B: ER and PR positive, HER2 negative/positive, Ki-67 > 14% (high proliferation rate). Alpha catenin (Option A): This protein is involved in cell-to-cell adhesion; its loss (along with E-cadherin) is a hallmark of lobular carcinoma rather than an indicator of proliferative speed.

Arp-2/3 (Option B): This complex regulates the actin cytoskeleton and is associated with cell motility and metastasis (forming lamellipodia), but it is not used to quantify the proliferation rate in a standard biopsy.
Vimentin (Option D): his is a marker for mesenchymal cells ; in breast cancer, it is often expressed in "triple-negative" or metaplastic carcinomas undergoing epithelial-mesenchymal transition (EMT), not specifically "luminal" types.

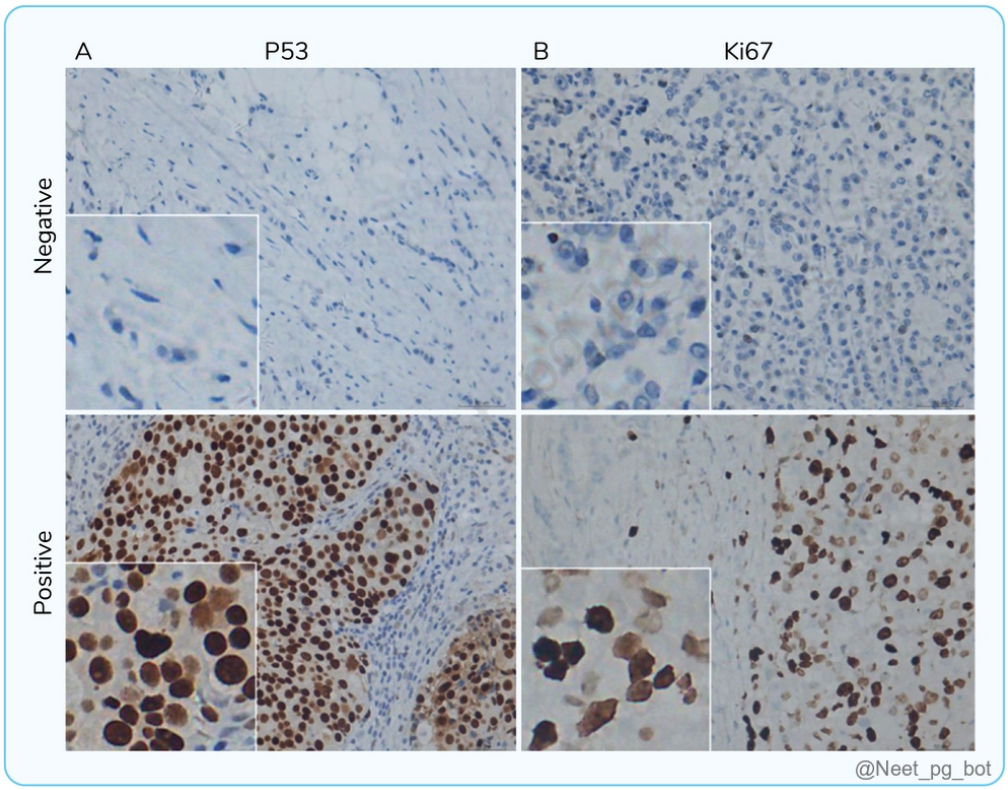

References:

Robbins and Cotran, Pathologic Basis of Disease, 10th Edition, Page 1048

↑ *Back to this question in Part A*

@Neet_pg_bot

Q17: A patient with a lump in her left breast is subjected to a biopsy. Subsequent immunohistochemistry was done and the image is given below. After an MDT discussion, a decision was made to prescribe Trastuzumab as the appropriate management for this patient. What would have been the diagnosis based on the above clinical scenario? (Q845716)

A. Apocrine carcinoma

B. Medullary carcinoma

C. Tubular carcinoma

D. Papillary carcinoma

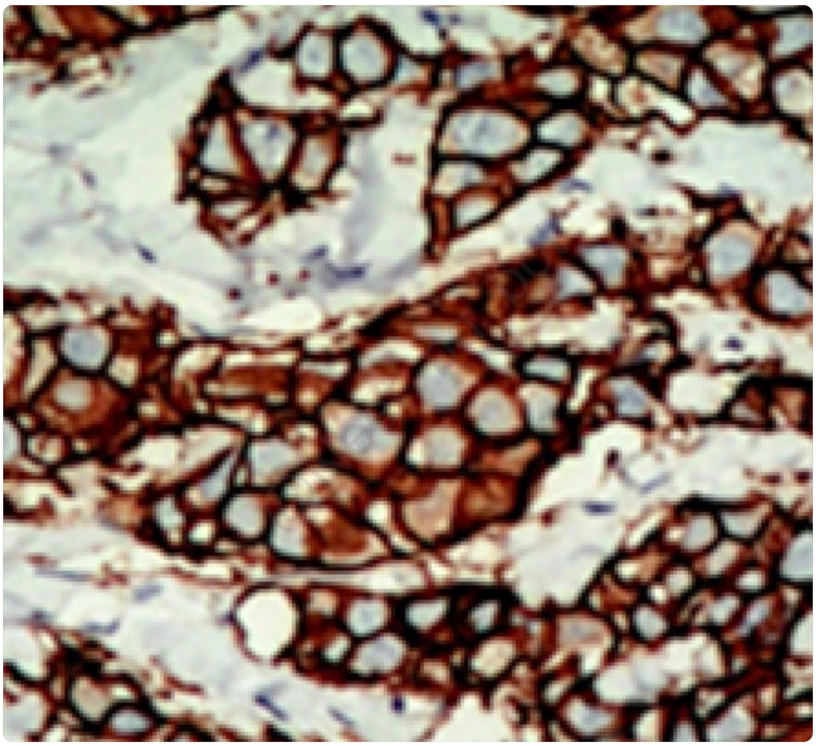

Correct Answer: A. Apocrine carcinoma

■ *Listen (English)*

■ *Listen (Hindi)*

Explanation: The given clinical vignette along with the immunohistochemical finding that shows staining of membranes rather than the nucleus suggest the diagnosis of a HER2 receptor-rich breast carcinoma. In breast biopsy, we test for three important markers: ER (estrogen receptor), PR (progesterone receptor), and HER2/neu Apocrine carcinoma is one of the two most common HER2 receptor-rich subtypes of invasive breast carcinoma, the other one being micropapillary carcinoma. Trastuzumab is a monoclonal antibody that acts by inhibiting the HER2 receptors and prevents further growth of the tumor, since HER2 receptor rich tumors respond well to HER2 inhibitor therapy. Medullary carcinoma (Option B) is a triple-negative subtype. Tubular and papillary carcinomas (Option C and D) are ER/PR positive subtypes hence considered Luminal A. Molecular classification of breast cancer : Classification Hormone receptor HER2/Neu Proliferative marker Luminal A Positive (either or both ER/PR) Negative Ki-67 <14% (low) Luminal B (triple +ve) Positive (either or both ER/PR) Negative / Positive Ki-67 >14% (high) Basal type (triple -ve) Negative Negative Ki-67 usually high HER2/neu enriched Negative Positive Ki-67 high Claudin low (triple -ve) Negative Negative Claudin low Luminal A (Low proliferation rate) Tubular carcinoma Papillary carcinoma Mucinous carcinoma Low-grade ILC Luminal B (High proliferation rate) High-grade ILC HER2/Neu rich Apocrine carcinoma Micropapillary carcinoma Triple-negative Medullary carcinoma Metaplastic carcinoma Secretory carcinoma Adenoid cystic carcinoma

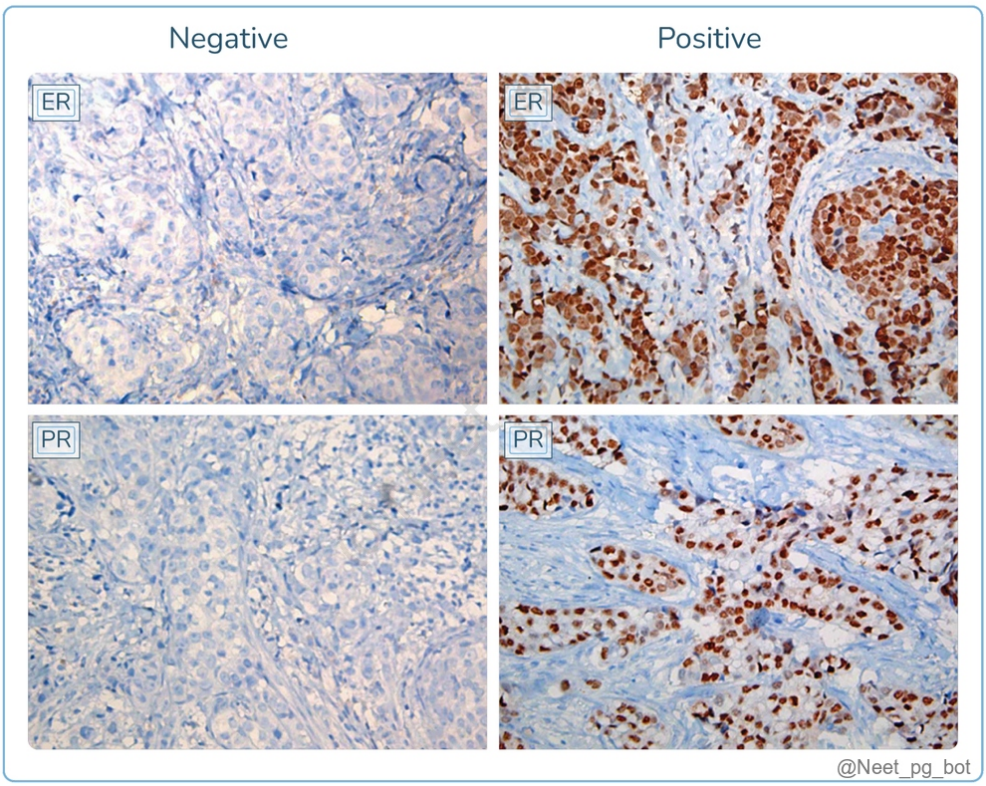

References:

Robbins and Cotran, Pathologic Basis of Disease, 10th Edition, Pages 1048, 1053, 1058.

↑ *Back to this question in Part A*

@Neet_pg_bot

Q18: You are provided with results of receptor status from the biopsy obtained from a patient's breast lump. You realize that her molecular subtype carries a low proliferative rate and a better prognosis. Which of the following will not be the likely histological subtype in this patient? (Q845714)

A. Tubular carcinoma

B. Medullary carcinoma

C. Papillary carcinoma

D. Mucinous carcinoma

Correct Answer: B. Medullary carcinoma

■ *Listen (English)*

■ *Listen (Hindi)*

Explanation: The biopsy results obtained from a patient’s breast lump carrying a low proliferative rate (better prognosis) is indicative of a luminal type A malignancy. Among the given options, medullary carcinoma of the breast does not belong to luminal type A; rather it is a luminal type B malignancy. Molecular classification of breast cancer is based on the results of receptor status such as ER, PR and HER2. Molecular classification of breast cancer : Classification Hormone receptor HER2/Neu Proliferative marker Luminal A Positive (either or both ER/PR) Negative Ki-67 <14% (low) Luminal B (triple +ve) Positive (either or both ER/PR) Negative / Positive Ki-67 >14% (high) Basal type (triple -ve) Negative Negative Ki-67 usually high HER2/neu enriched Negative Positive Ki-67 high Claudin low (triple -ve) Negative Negative Claudin low Luminal A (Low proliferation rate) Tubular carcinoma (Option A ruled out). Papillary carcinoma (Option C ruled out). Mucinous carcinoma (Option D ruled out). Low-grade ILC. Luminal B (High proliferation rate) High-grade ILC. HER2/Neu rich Apocrine carcinoma. Micropapillary carcinoma. Triple-negative Medullary carcinoma. (Option B) Metaplastic carcinoma. Secretory carcinoma. Adenoid cystic carcinoma.

References:

Robbins and Cotran, Pathologic Basis of Disease, 10th Edition, Pages 1049, 1056-1058.

Bailey and Love, Short Practice of Surgery, 28th Edition, Page 931

↑ *Back to this question in Part A*

@Neet_pg_bot

Q19: Consider the following statements about Paget's disease of the breast? 1. It is an in-situ cancer. 2. Presence of Paget cells is needed for diagnosis. 3. Underlying carcinoma is usually LCIS. 4. Immunostaining is positive for carcinoembryonic antigen (CEA). Which of the above are true statements? (Q845712)

A. 1,3, and 4

B. 1,2, and 4

C. 1,2, and 3

D. All of the above

Correct Answer: B. 1,2, and 4

■ *Listen (English)*

■ *Listen (Hindi)*

Explanation: Paget’s disease Mammary Paget's: Paget's disease of the breast. (Most common) Extramammary Paget's: Paget's disease of the vulva. Clinically, the patient usually tends to visit the dermatology department because the skin over the breast and the nipple–areola region becomes reddened and encrusted , so the patient

mistakes this as a dermatological disorder. There is a cancer sitting underneath , and that cancer is usually a ductal carcinoma in situ (DCIS) . From this underlying cancer, the malignant process spreads to the overlying skin . (Statement 3) Clear cancer cells can be seen within the epidermis, called as Paget cells . Paget cells must be seen in the skin for diagnosis (Statement 2) On immunohistochemistry: Cytokeratin (CK) positivity Indicates that the cells are derived from an epithelial cancer . Carcinoembryonic antigen (CEA) positive. It is an in-situ cancer . (Statement 1) Immunostaining is positive for CEA. (Statement 4)



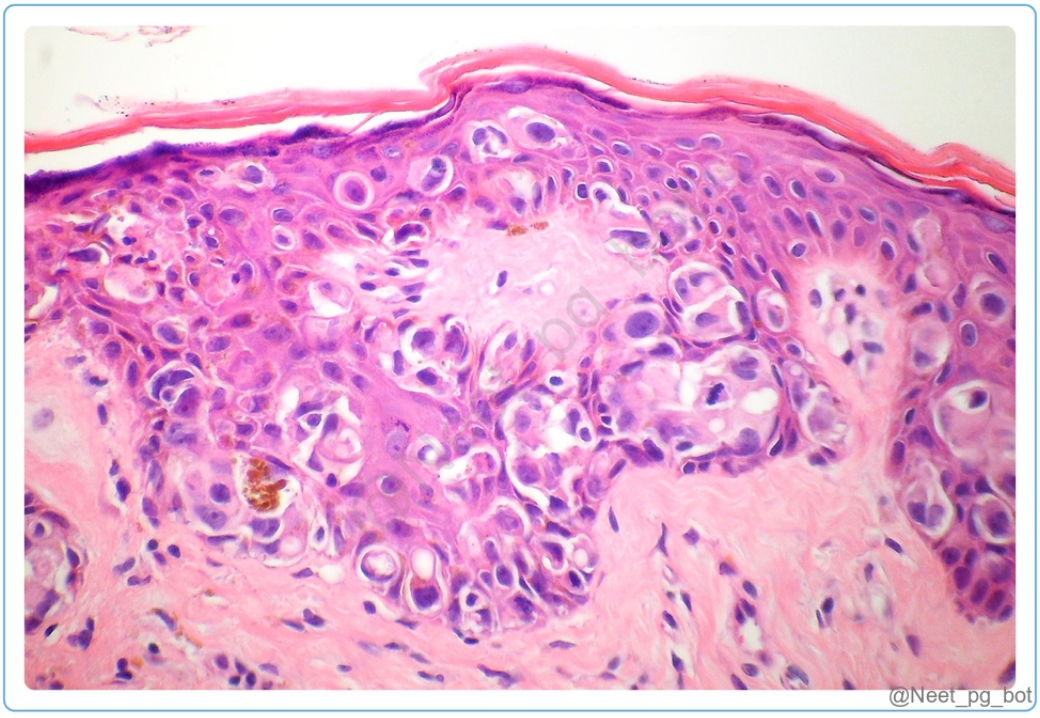

References:

Sabiston textbook of surgery, 20th edition, Page no 883

Bailey & Love's Short Practice of Surgery, 28th edition, Page no 924

↑ *Back to this question in Part A*

@Neet_pg_bot

Q20: A 60-year-old woman presents with a newly diagnosed left-sided breast mass on routine mammography. Core needle biopsy shows the following findings. Further molecular study revealed the involvement of the CDH1 gene. Which of the following statements are incorrect concerning this type of breast cancer? 1) Increased E-cadherin expression is observed in tumor cells. 2) Minimal desmoplasia and fibrosis were observed on microscopy. 3) A contralateral breast examination is usually required due to bilateral involvement. 4) It is associated with a poor prognosis compared to other types of breast cancer. 5) Metastatic spread affects leptomeninges and retroperitoneum. (Q845710)

A. 1, 2, 3, 4

B. 1, 2, 3

C. 1, 4

D. 1, 2, 4, 5

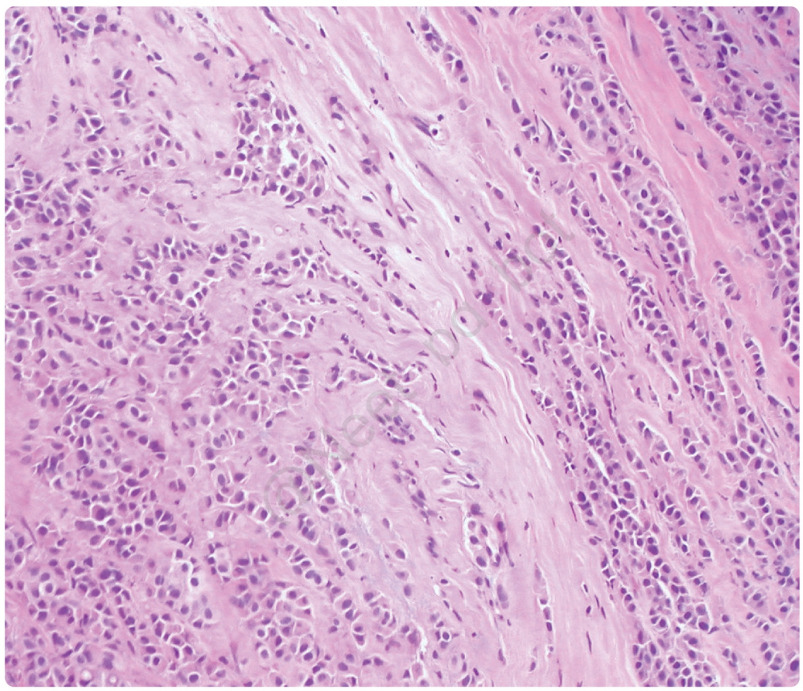

@Neet_pg_bot

Correct Answer: C. 1, 4

- *Listen (English)*
- *Listen (Hindi)*

Explanation: Invasive lobular breast carcinoma: CDH1 gene mutation : Decreased E-cadherin levels (also seen in signet ring gastric adenocarcinoma). (Statement 1) Clinically: Bilateral and multicentric lesions; if one breast has ILC, both breasts should be examined. (Statement 3) Microscopy Features: The tumor cells are dyscohesive, present back to back, and are called Indian file pattern. Shows minimal desmoplasia and fibrosis. (Statement 2) Metastatic spread to the retroperitoneum and leptomeninges is called carcinomatous meningitis. (Statement 5) Excellent prognosis because it usually belongs to Luminal A and B categories. (Statement 4)

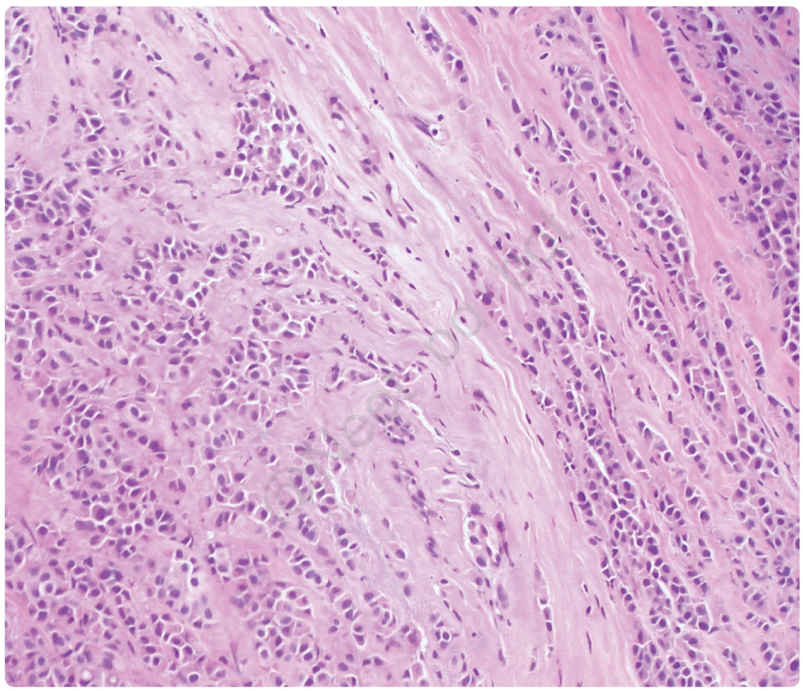

@Neet_pg_bot

References:

Robbins and Cotran, Pathologic Basis of Disease, 10th edition, Page 1053- 57.

↑ *Back to this question in Part A*

@Neet_pg_bot

Q21: Which of the following is associated with the worst prognosis? (Q845707)

A. Paget’s disease

B. Metaplastic carcinoma

C. Medullary carcinoma

D. Inflammatory carcinoma

Correct Answer: D. Inflammatory carcinoma

■ *Listen (English)*

■ *Listen (Hindi)*

Explanation: Inflammatory breast carcinoma has a poor prognosis, with extensive invasion of subdermal lymphovascular channels. Inflammatory Breast Carcinoma: It presents as breast erythema, swelling, and skin thickening. Edematous skin is tethered to the breast by Cooper ligaments and mimics orange peel or peau d'orange because cancer has spread into subdermal lymphatics. Usually high grade with very poor prognosis.



References:

Robbins and Cotran, Pathologic Basis of Disease, 10th edition, Page 1058

↑ *Back to this question in Part A*

@Neet_pg_bot

Q22: A 50-year-old woman presents with discomfort in her left breast. Mammography reveals a suspicious mass. Ultrasound-guided core needle biopsy is performed. Based on the histopathological findings, what is the most likely diagnosis? (Q845703)

A. Lobular carcinoma

B. Ductal carcinoma in situ

C. Medullary carcinoma

D. Mucinous carcinoma

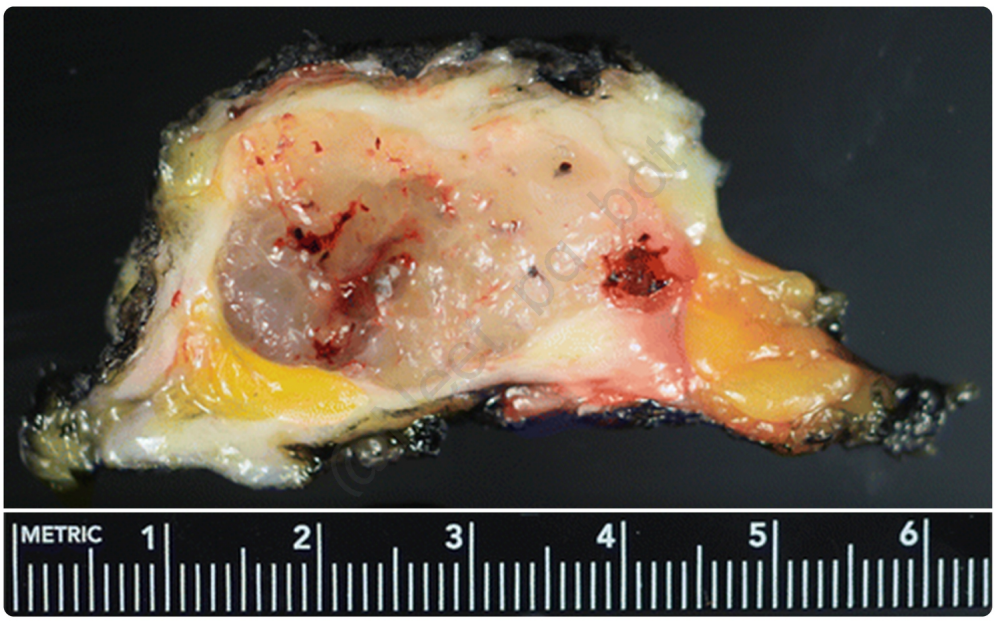

@Neet_pg_bot

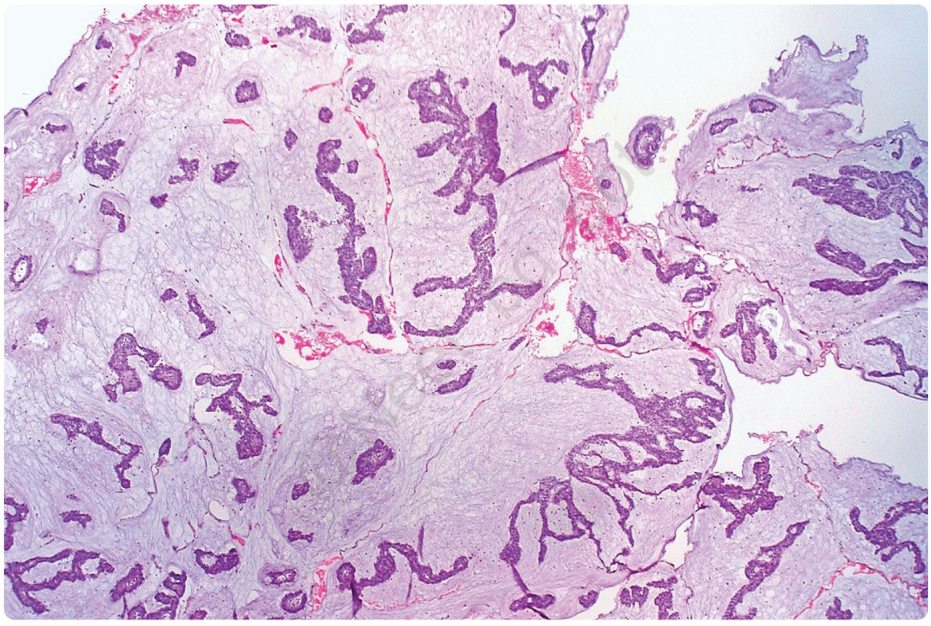

@Neet_pg_bot

Correct Answer: D. Mucinous carcinoma

- *Listen (English)*
- *Listen (Hindi)*

Explanation: Mucinous or Colloid Carcinoma: A subtype of infiltrating ductal carcinoma with Excellent prognosis. Clinical findings: Soft to firm lump due to mucilage. It may be mistaken for a benign tumor.

Histopathology: Gross: Soft, shiny, rubbery texture with pale gelatinous/jelly consistency. Microscopy: Tumor cells arranged in clusters or islands with pools of mucin extracellularly and may be intracellularly (called signet ring cell). FNAC: Chicken wire blood vessels (blood vessels get entangled in FNAC needle because of presence of mucin) . Chicken wire blood vessels is also seen in Oligodendroglioma, which is a brain tumor showing fried egg appearance on biopsy and Chicken wire blood vessels. Lobular carcinoma (Option A): It is characterized by "single-file" (Indian file) rows of small, discohesive cells invading a fibrous stroma. It lacks extracellular mucin pools and typically doesn't form a well-circumscribed gelatinous mass. Ductal carcinoma in situ (Option B): Neoplastic cells are confined within the basement membrane of the ducts, often with a "comedo" (central necrosis) or cribriform (Swiss cheese) pattern. Medullary carcinoma (Option C): Characterized by large, pleomorphic cells growing in "syncytial" sheets with a prominent lymphoplasmacytic (white blood cell) infiltrate. Medullary carcinoma is "fleshy" and solid, not gelatinous

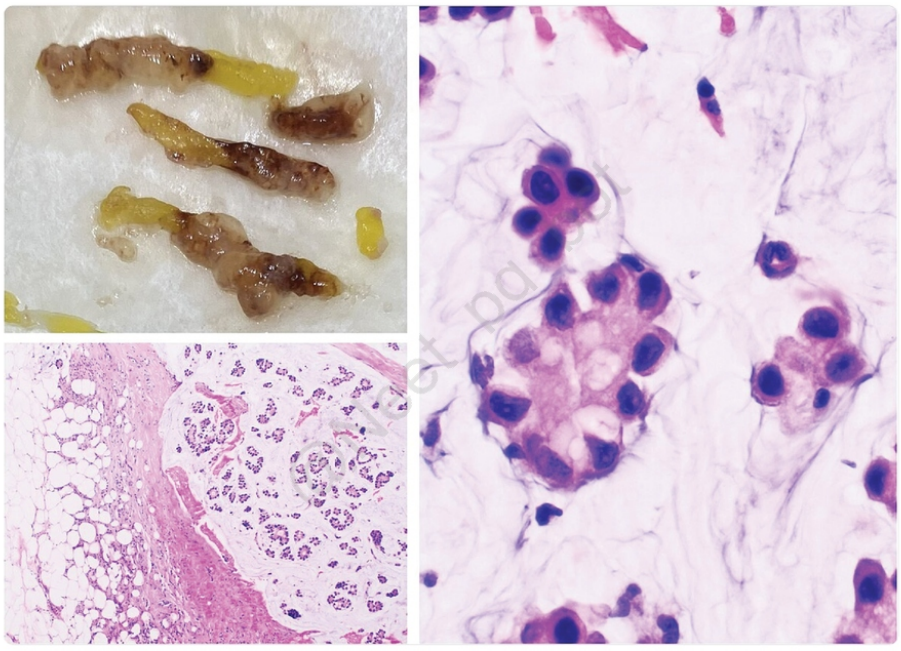

@Neet_pg_bot

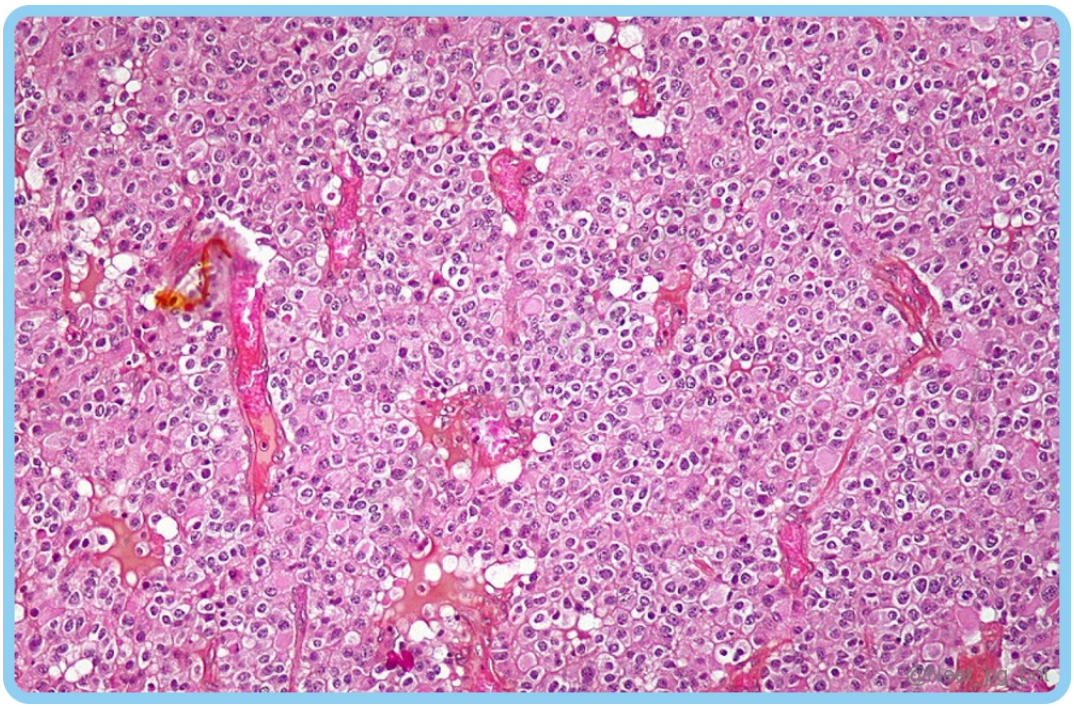

References:

Robbins and Cotran, Pathologic Basis of Disease, 10th Edition, Pages 1053- 1058

↑ *Back to this question in Part A*

@Neet_pg_bot

Q23: A 45-year-old woman presented with a palpable breast lump detected during a routine self-examination. A biopsy confirmed the diagnosis of infiltrating ductal carcinoma (IDC). Which of the following is not a subtype of IDC? 1. Tubular carcinoma 2. Medullary carcinoma 3. Colloid carcinoma 4. Lobular carcinoma 5. Papillary carcinoma 6. Apocrine carcinoma 7. Secretory carcinoma 8. Myofibroblastoma 9. Angiosarcoma (Q845701)

A. 3, 4, 8, 9

B. 4, 6, 8

C. 2, 4, 7, 9

D. 4, 8, 9

Correct Answer: D. 4, 8, 9

■ *Listen (English)*

■ *Listen (Hindi)*

Explanation: Lobular carcinoma, myofibroblastoma, and angiosarcoma are not subtypes of infiltrating ductal carcinoma (IDC). Carcinoma: Epithelial origin tumor Lobular carcinoma (Option 4) Myofibroblastoma (Option 8) : Mesenchymal tumor Angiosarcoma (Option 9) : Blood vessel cancer Infiltrating ductal carcinoma: Special Types of IDC: Tubular carcinoma: Good prognosis. Mucinous or Colloid Carcinoma- Signet ring cells on biopsy and FNAC: Chicken wire blood vessels. Medullary carcinoma- Lymphoplasmacytic infiltrate. Apocrine carcinoma. Metaplastic carcinoma. Papillary carcinoma Secretary carcinoma: Occurs in younger females. Inflammatory carcinoma- Peau d'orange appearance with Poor prognosis

References:

Robbins and Cotran Textbook of Pathology, 10th Edition, Page 1055-58

↑ *Back to this question in Part A*

@Neet_pg_bot

Q24: A 52-year-old woman presents for her routine mammogram, which reveals microcalcifications in the right breast. She has no significant family history of breast cancer and is asymptomatic. A core needle biopsy is performed, and the histopathological image is shown below. Based on histopathology, what is the most likely diagnosis? (Q845697)

A. Invasive Ductal Carcinoma

B. Lobular Carcinoma in Situ

C. Ductal Carcinoma in Situ

D. Fibroadenoma

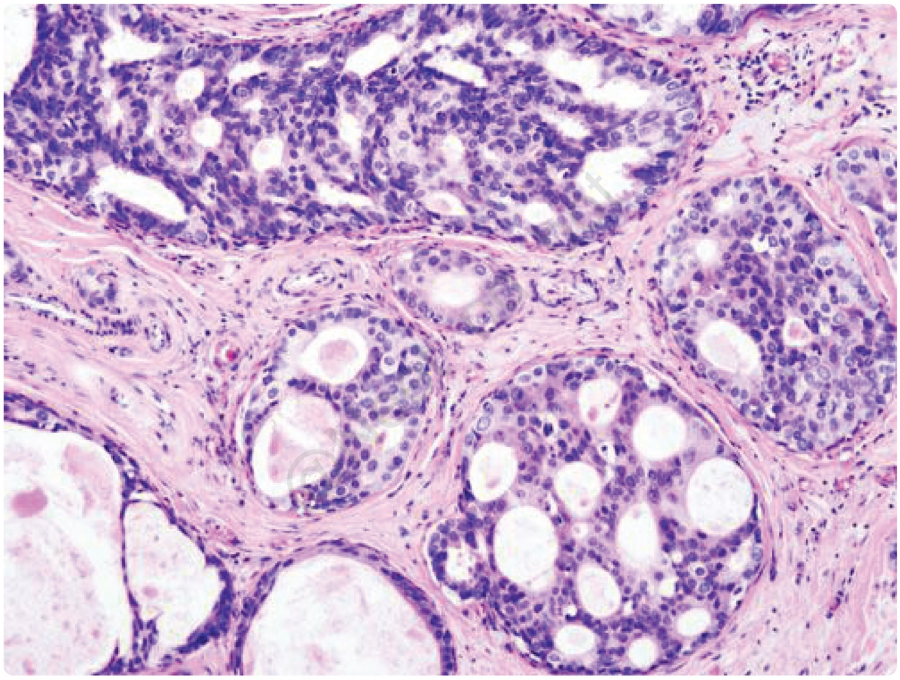

@Neet_pg_bot

Correct Answer: C. Ductal Carcinoma in Situ

- *Listen (English)*
- *Listen (Hindi)*

Explanation: The histopathological image shows features consistent with ductal carcinoma in situ (DCIS), including malignant cells confined within the ductal system without invasion into surrounding tissue. This correlates with the clinical scenario of microcalcifications detected on mammography, a common presentation of DCIS. The image shows cribriform variant of DCIS: In this duct, multiple small white spaces can be seen, which gives it the cribriform pattern . he most high-grade DCIS is comedo necrosis DCIS , because it has the highest chance of converting into invasive ductal carcinoma . Types of DCIS : Comedo It may occasionally produce a vague nodularity but is often detected as clustered or linear and branching areas of calcification. There is necrotic, dirty material inside the duct . Two features define it: Tumor cells with pleomorphic, high-grade nuclei. Areas of central necrosis. Cribriform It has rounded (cookie cutter–like) spaces, often filled with calcified secretory material. Micropapillary It produces complex bulbous protrusions without fibrovascular cores. Shows small papillary projections inside the duct. Papillary It produces true papillae with fibrovascular cores that lack a myoepithelial cell layer and shows proper finger-like papillary projections . Solid The duct is full of cells and becomes solid. Histological images of types of DCIS: Comedo DCIS: Cribriform DCIS: Micropapillary DCIS: Papillary DCIS:

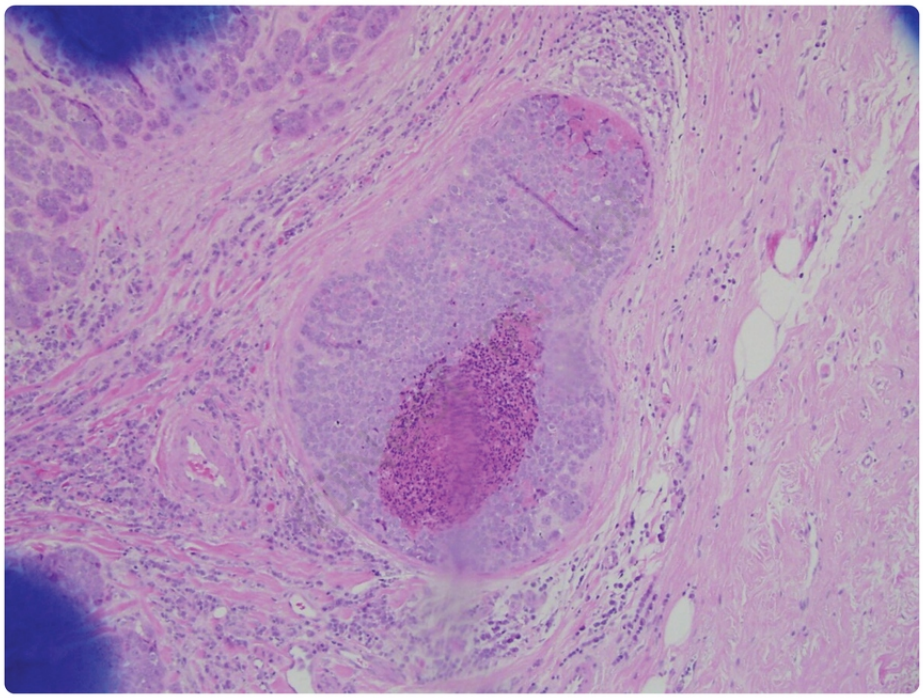

@Neet_pg_bot

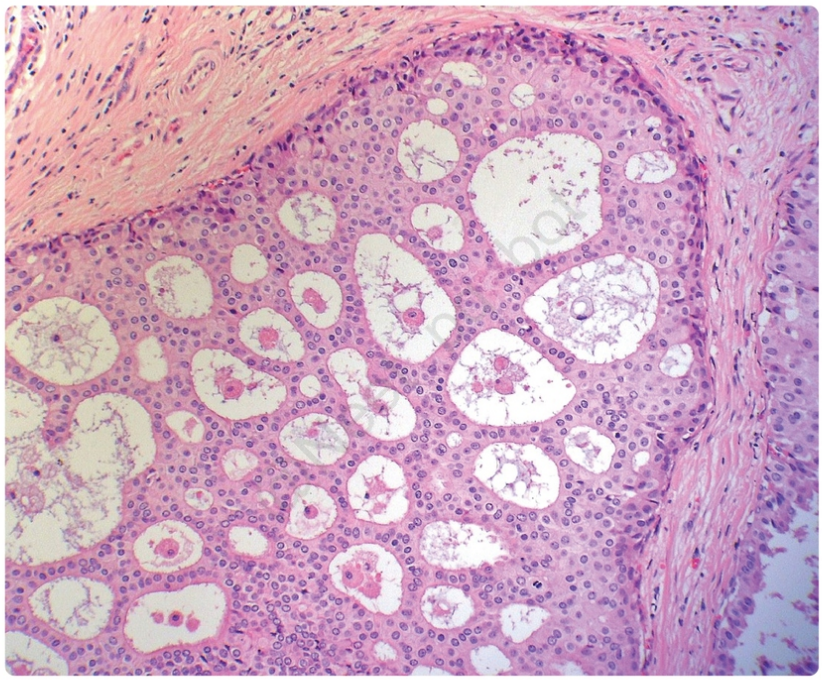

@Neet_pg_bot

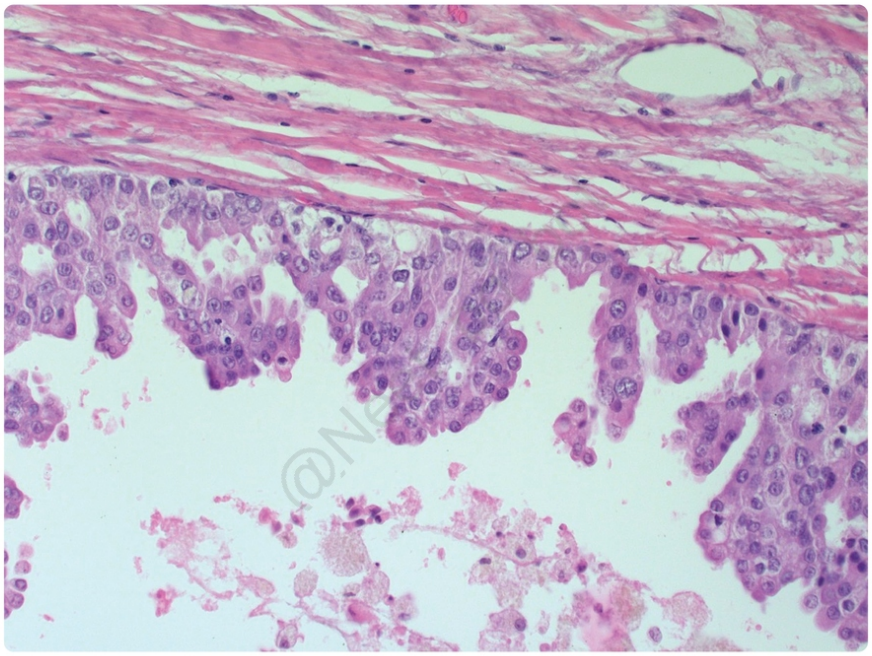

@Neet_pg_bot

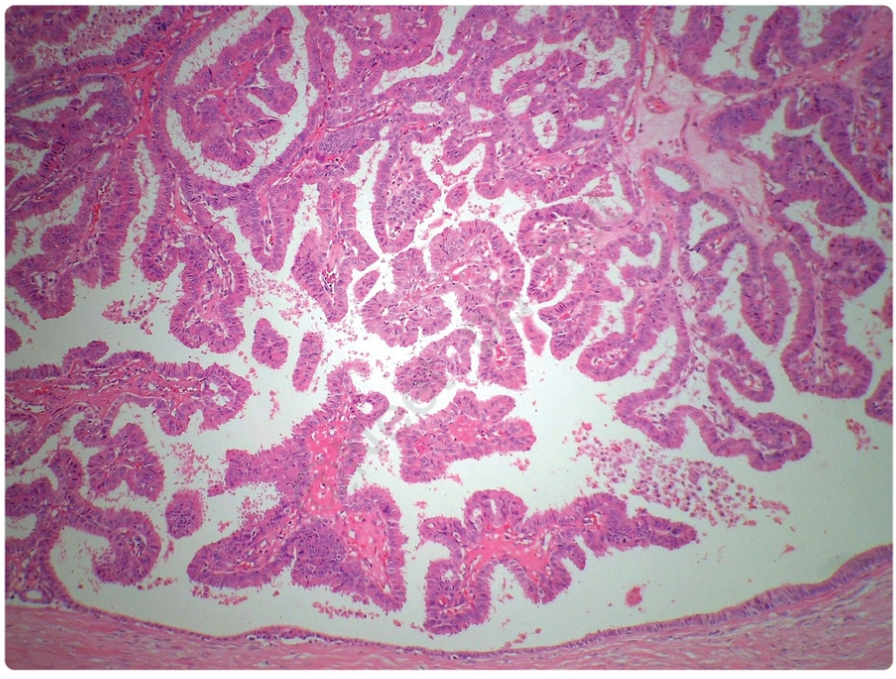

@Neet_pg_bot

References:

Robbins and Cotran Textbook of Pathology, 10th Edition, Page 1053

↑ *Back to this question in Part A*

@Neet_pg_bot

Q25: Mutations in which of the following genes is not associated with breast cancer? (Q845696)

A. BRCA1

B. STK11

C. CDH1

D. CHEK1

Correct Answer: D. CHEK1

■ *Listen (English)*

■ *Listen (Hindi)*

Explanation: The CHEK1 gene mutation is not linked to breast cancer, whereas the CHEK2 mutation is associated with radiation-induced breast cancer. BRCA1 and BRCA2 are the most common genes associated with hereditary breast cancer. (Option A) STK11 gene (Option B): Associated with hereditary breast cancer and Peutz-Jeghers syndrome. CDH1 (E-cadherin) gene (Option C): Associated with lobular carcinoma breast. Gene Frequency Tumors BRCA1 (Chromosome 17) (M/c cause of familial breast cancer) 55% Breast cancer Ovarian cancer Prostate cancer BRCA2 (Chromosome 13) (2nd M/c cause of familial breast cancer) 35% Breast cancer Ovarian cancer Prostate cancer (BRCA2 > BRCA1) Associated with male breast cancer P53 (M/c cause of sporadic breast cancer) <1% Li Fraumeni syndrome Autosomal Dominant B reast carcinoma B rain cancer B one cancer B lood cancer PTEN (Chromosome 10) <1% Cowden syndrome P olyps, Breast cancer T hyroid cancer, Trichilemmoma EN dometrial cancer STK11 <1% Peutz-Jegher's Syndrome CDH1 (Chromosome 16) <1% E-cadherin → Cell Adhesion Molecule Mutation: (Mnemonic- Go Lu) Diffuse g astric cancer Invasive lo bular carcinoma PALPB2 (Newer) (Monoallelic loss) <1% P ancreatic cancer P rostate cancer B reast cancer - Monoallelic loss (Fanconi anemia- Biallelic loss) ATM gene 5% Breast cancer Ataxia Telangiectasia CHEK2 5% Radiation induced

References:

Robbins and Cotran Textbook of Pathology, 10th Edition, Page 1049

↑ *Back to this question in Part A*

@Neet_pg_bot

• [14_Breast Pathology] 061 Previous Year Questions

« Back to Folder Directory

[14_Breast Pathology] 061 Previous Year Questions — Quick Jump

Q1 (p. 2482) *Q2 (p. 2484)* *Q3 (p. 2485)* *Q4 (p. 2486)* *Q5 (p. 2487)* *Q6 (p. 2490)*

Q1: A 27-year-old woman discovers a well-defined mobile and rubbery breast lump measuring 4x7 cm on self-examination. The lesion is painless and has been stable over several months. What is the most likely diagnosis? (Q860560)

A. Acute mastitis

B. Fibroadenoma

C. Ductal ectasia

D. Sclerosing adenosis

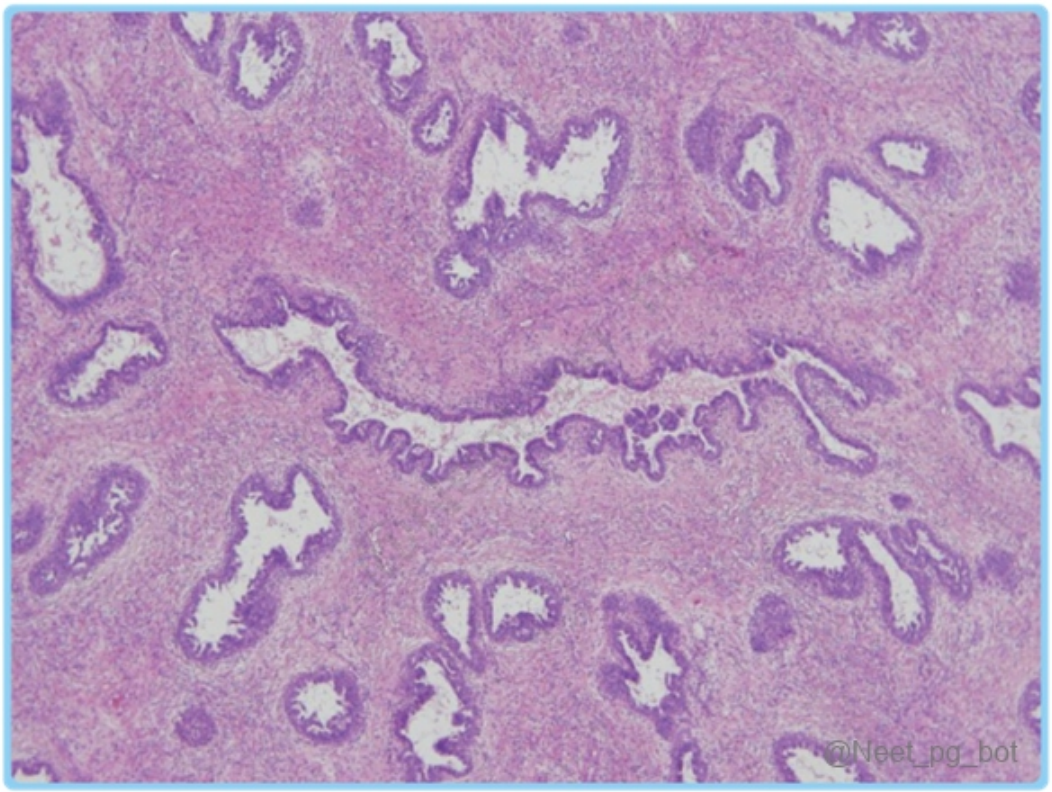

Correct Answer: B. Fibroadenoma

Explanation: The clinical presentation along with histopathology showing epithelial ducts compressed and distorted by surrounding stroma, is characteristic of an intracanalicular Fibroadenoma. Fibroadenoma Definition Benign tumours arising from the proliferation of glandular tissue in the breast Prevalence Most common in women aged 15-25 years. Aetiology Believed to be influenced by hormonal fluctuations during reproductive years Molecular alteration: Alterations in MED12 gene. Clinical Presentation Painless, firm, rubbery, and mobile lumps Described as feeling like a "marble in the breast." Histopathology Well-defined borders due to a fibrous capsule, with proliferating stroma potentially compressing and distorting glandular components. The epithelium may be of 2 patterns: Pericanalicular Pattern: Surrounded by stroma Intracanalicular Pattern: Compressed and distorted by it. {{caption_text}} Mammogram Popcorn calcification on mammogram {{caption_text}} Diagnosis Triple Assessment: Clinical examination, radiological imaging (ultrasound), tissue sampling (core-needle biopsy) Ultrasound: Helps distinguish fibroadenomas from cysts Core-Needle Biopsy: Provides definitive diagnosis Treatment Conservative Management: Watchful waiting, regular monitoring Surgical Excision: For larger fibroadenomas, those causing symptoms, or uncertain diagnosis Giant Fibroadenomas: Over 5 cm, may require excision through submammary incision Prognosis Benign , does not increase the risk of breast cancer Growth can vary, influenced by hormonal changes Recurrence is uncommon Relationship to ANDI Categorised according to ANDI as: Normal: Small fibroadenomas (≤1 cm) Disorder: Larger fibroadenomas (≤3 cm) Disease: Giant fibroadenomas (>3 cm), multiple fibroadenomas Acute mastitis (Option A) is a breast infection, common in lactating women, presenting with pain, redness, swelling, and fever. It is caused by a bacterial infection but is unlikely here due to the absence of pain and inflammation. Ductal ectasia (Option C) is a benign condition in older women, causing nipple discharge, nipple retraction, and breast tenderness. It does not present as a well-defined, mobile, painless lump, making it an unlikely diagnosis here. Sclerosing adenosis (Option D) is a benign breast condition causing firm, palpable lumps, often associated with pain and calcifications. It is not typically mobile or rubbery, making it a less likely diagnosis.

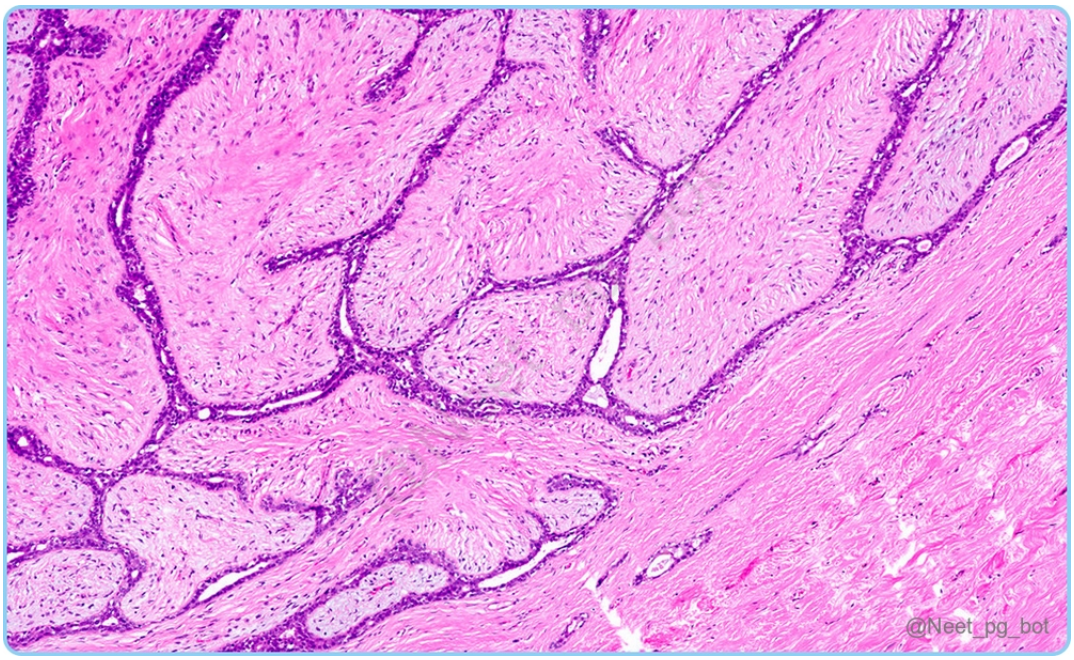



References:

Robbins and Cotran Pathologic Basis of Disease, 10th Edition, Page 1062.

Bailey & Love's Short Practice of Surgery, 28th Edition, Page 922.

↑ *Back to this question in Part A*

@Neet_pg_bot

Q2: What does luminal type A tumour refer to? (Q857445)

A. ER+ / HER2 neu- ; mild to moderate proliferation

B. ER+ / HER2 neu+

C. ER- / HER2 neu-

D. ER+ / HER2 neu- ; high proliferation

Correct Answer: A. ER+ / HER2 neu- ; mild to moderate proliferation

Explanation: Luminal type A tumours refer to a subtype of breast cancer with ER-positive, HER2 neu negative and mild to moderate proliferation. These tumours tend to grow slowly and have a better prognosis compared to other

subtypes. Molecular classification of breast cancer is based on the results of receptor status such as ER, PR and HER2. Molecular classification of breast cancer Classification Hormone receptor HER2/Neu Others Luminal A Positive (either or both ER/PR) Negative Ki-67 low (mild to moderate proliferation) Luminal B (Options A & D ruled out) Positive (either or both ER/PR) Negative/ positive Ki-67 high (high proliferation) Basal type (triple -ve) (Option C ruled out) Negative Negative Ki-67 usually high HER2/neu enriched Negative Positive Ki-67 high Claudin low Negative Negative Claudin low

References:

Robbins and Cotran Pathologic Basis of Disease, 10th Edition, Pages 1049, 1056-1058

↑ *Back to this question in Part A*

@Neet_pg_bot

Q3: A woman presents with a firm and irregular lump in the upper outer quadrant of her breast. The histopathological slide of the mass sample is provided. What is the most likely diagnosis? f (Q830822)

A. Phyllodes tumor

B. Inflammatory breast carcinoma

C. Invasive lobular carcinoma

D. Fibroadenoma

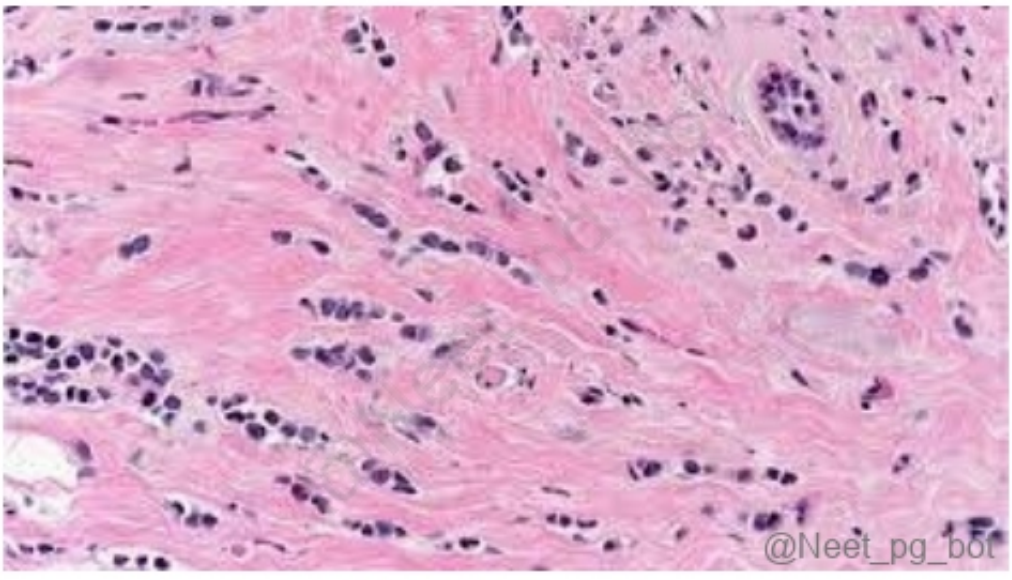

Correct Answer: C. Invasive lobular carcinoma

Explanation: Correct Option C - Invasive lobular carcinoma: Invasive lobular carcinoma originates from the terminal duct lobular units and develops only in the female breast. It is mostly multicentric and bilateral Increased risk of cancer is in both breasts Calcifications associated with Invasive lobular carcinoma typically occur in adjacent tissues (neighborhood calcification) The histologic hallmark of Invasive lobular carcinoma is the tendency of tumor cells to invade in linear strands (Indian file pattern) Incorrect Options: Option A - Phyllodes tumor: It is mostly a benign tumor. It is characterized by Leaf-like (phyllode) epithelial pattern formed by an exaggerated intracanalicular pattern. Option B - Inflammatory breast carcinoma: It causes skin changes in the involved breast. It presents as a red and swollen breast, mimics mastitis. It is characterized by dermal lymphatic invasion by tumor cells on a skin punch biopsy of the affected breast. Option D - Fibroadenoma: It usually occurs in young women and regresses after menopause. The tumor consists of proliferating epithelial and mesenchymal components. Stroma proliferates around tubular ducts (pericanalicular pattern) or compressed cleft-like ducts (Intracanalicular pattern).

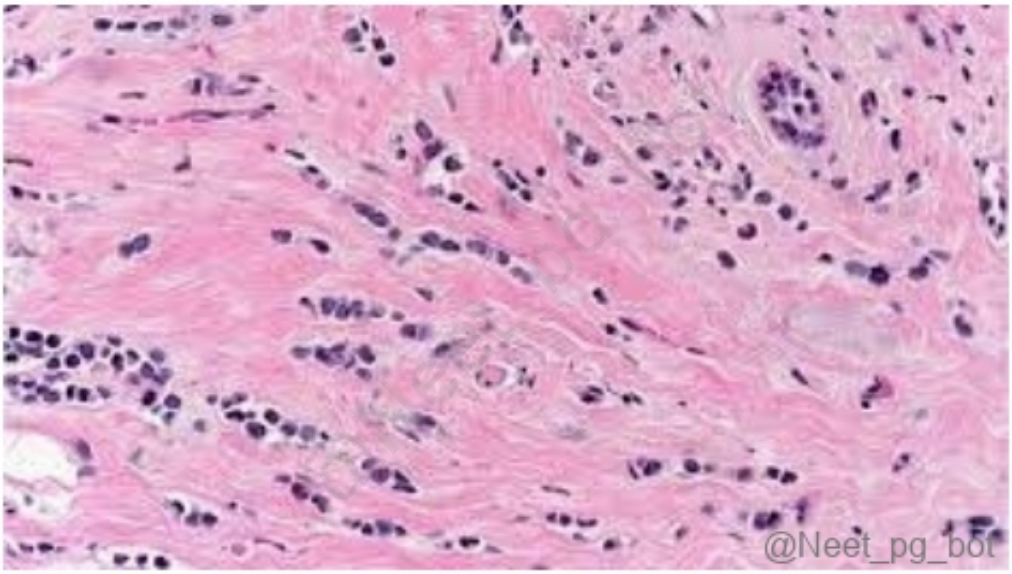

↑ *Back to this question in Part A*

@Neet_pg_bot

Q4: Which of the following is NOT a favorable prognostic marker for a middle-aged woman diagnosed with breast carcinoma presenting with a lump in her right breast? (Q793798)

A. Luminal subtype

B. Low Ki67 /MIB 1 index

C. Her2 overexpression

D. Mucinous carcinoma

Correct Answer: C. Her2 overexpression

Explanation: HER2 overexpression is a biological phenomenon that occurs when there is an excessive expression of the human epidermal growth factor receptor 2 (HER2) protein on the surface of a cell. HER2 is a type of receptor that is involved in the regulation of cell growth and division. It is overexpressed in approximately 15-30% of breast cancer cases, as well as in other types of cancer. Incorrect choices: Option a. The Luminal subtype is a molecular classification of breast cancer, which is determined based on the genes expressed by the cancer cells. This subtype is defined by the presence of hormone receptors - estrogen receptors (ER) and/or progesterone receptors (PR). The Luminal subtype is further divided into two subtypes: Luminal A and Luminal B. Option b. Ki-67 is a protein that is associated with cell proliferation and is often used as a prognostic marker in breast cancer. A higher Ki-67 index is generally associated with a more aggressive form of cancer. Option d. Mucinous carcinoma is a type of cancer that starts in cells that produce mucus, called mucin. It is a relatively rare subtype of invasive cancer and can occur in many different organs or tissues, including the breast, colon, and ovaries. Mucinous carcinoma is defined by the presence of extracellular mucin that fills more than 50% of the tumor volume.

References:

Harrisons principle of internal medicine 22nd edition-page 632

↑ *Back to this question in Part A*

@Neet_pg_bot

Q5: A 35-year-old woman presents with a lump in the upper outer quadrant of her breast. Histopathological examination of the mass shows cells in mucin pools and faint nuclei. What is the most likely diagnosis? (Q858517)

A. Colloid carcinoma

B. Papillary carcinoma

C. Medullary carcinoma

D. Lobular carcinoma

Correct Answer: A. Colloid carcinoma

Explanation: Colloid carcinoma , also known as mucinous carcinoma , is characterised by malignant cells surrounded by mucin pools. Mucinous or Colloid Carcinoma: A subtype of infiltrating ductal carcinoma. Location: Upper outer quadrant (most common). Clinical findings: Soft to firm lump due to mucilage. It may be mistaken for a benign tumour. Histopathology: Gross: Soft, rubbery texture with pale gelatinous/jelly consistency. Microscopy: Tumour cells arranged in clusters or islands with pools of mucin extracellularly and may be intracellularly (called signet ring cell). FNAC: Chicken wire blood vessels. {{caption_text}} Gross pathology (upper left) of biopsies of

mucinous carcinoma shows gelatinous areas (which are transparent compared to normal yellow fatty tissue). Histopathology shows clusters or nests of tumour cells floating in pools of extracellular mucin. Excellent prognosis. Papillary carcinoma (Option B) is defined by the presence of papillary structures within the tumor. The tumour cells typically show elongated nuclei with nuclear grooves and intranuclear pseudo inclusions, which are distinct features not seen in colloid carcinoma. {{caption_text}} Medullary carcinoma (Option C) is a type of invasive breast carcinoma that presents with sheets of poorly differentiated tumour cells. These cells have large, pleomorphic nuclei and prominent nucleoli, which is different from the mucin-filled appearance in colloid carcinoma. {{caption_text}} Lobular carcinoma (Option D) originates from the lobular units of the breast and is characterised by tumour cells infiltrating in a single-file pattern, known as the Indian file pattern. The cells may exhibit signet ring morphology but do not form mucin pools, as seen in colloid carcinoma.

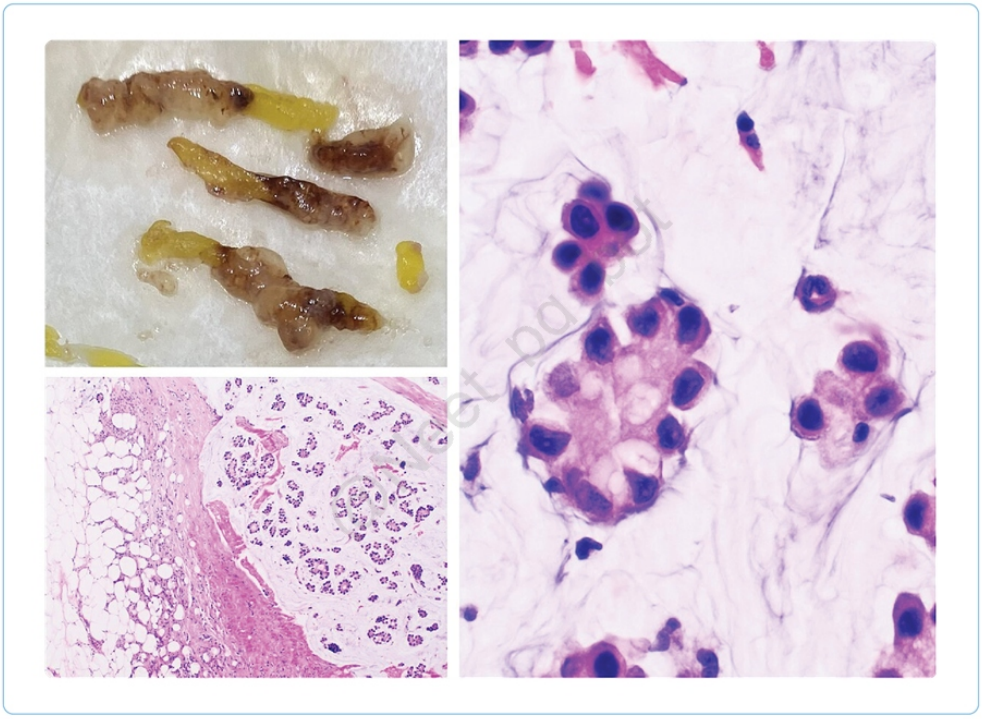

@Neet_pg_bot

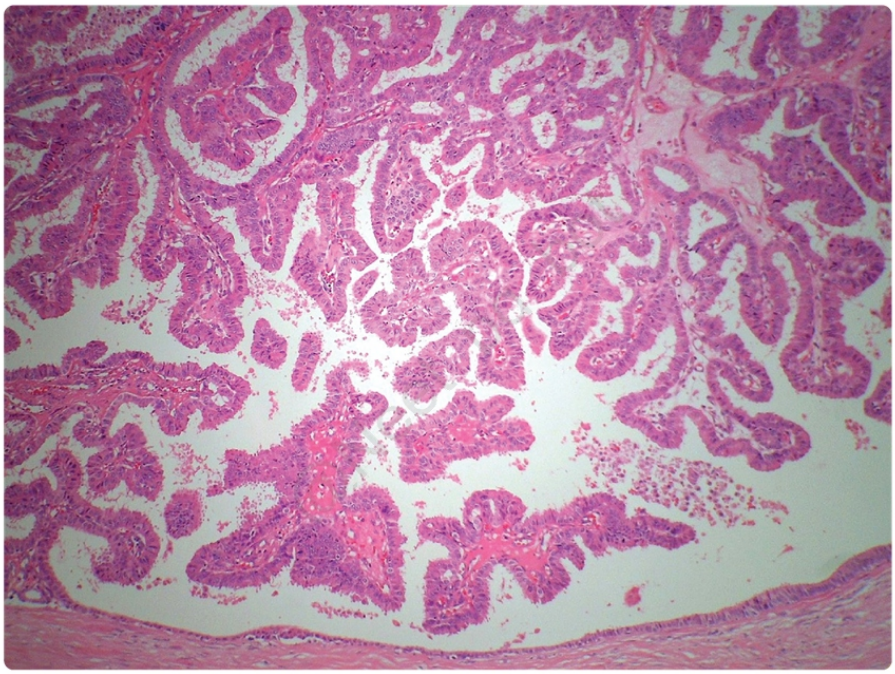

@Neet_pg_bot

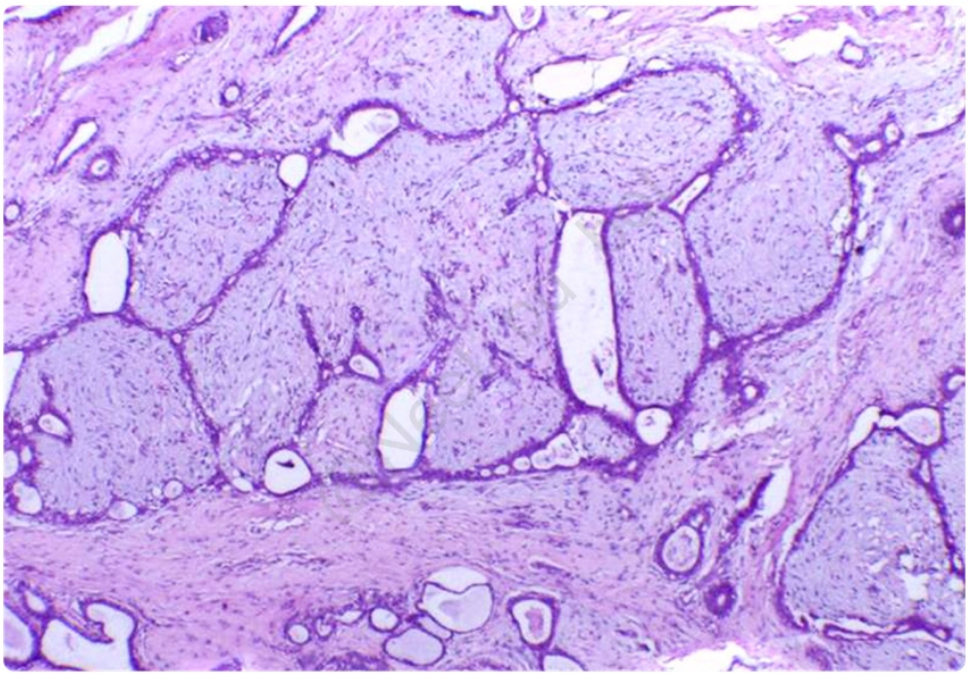

@Neet_pg_bot

References:

Robbins & Cotran Pathologic Basis of Disease, 10th Edition, Page 1053-1058

↑ *Back to this question in Part A*

Q6: A 35-year-old female presents with a lump in the upper outer part of her breast. Histopathological analysis of the mass reveals a signet ring appearance. What is the probable diagnosis? (Q857606)

A. Colloid carcinoma

B. Papillary carcinoma

C. Medullary carcinoma

D. Phyllodes tumour

Correct Answer: A. Colloid carcinoma

Explanation: Colloid carcinoma, or mucinous carcinoma, is characterised by extracellular mucin and signet ring cells, where mucin pushes the nucleus to one side, creating a ring-like appearance. This carcinoma typically occurs in older women and presents as a soft, mobile mass. Mucinous or Colloid Carcinoma: A subtype of infiltrating ductal carcinoma. Location: Upper outer quadrant (most common). Clinical findings: Soft to firm lump due to mucilage. It may be mistaken for a benign tumour. Histopathology: Gross: Soft, rubbery texture with pale gelatinous/jelly consistency. Microscopy: Tumour cells arranged in clusters or islands with pools of mucin extracellularly and may be intracellularly (called signet ring cell). FNAC: Chicken wire blood vessels. Excellent prognosis. {{caption_text}} Source: Gross pathology (upper left) of biopsies of mucinous carcinoma shows gelatinous areas (which are transparent compared to normal yellow fatty tissue). Histopathology shows clusters or nests of tumour cells floating in pools of extracellular mucin. Papillary carcinoma (Option B) of the breast accounts for about 0.5% of all breast cancers, primarily affecting postmenopausal women aged 60 to 80. It generally has a favorable prognosis. Clinically, it may be asymptomatic or present with bloody nipple discharge or a palpable mass. On mammography, it appears as a high-density mass with circumscribed margins, sometimes accompanied by satellite nodules, microcalcifications, or a dilated ductal pattern. {{caption_text}} Medullary carcinoma (Option C) of the breast is typically well-circumscribed, moderately firm, and has a fleshy grey-tan cut surface, often appearing lobular or nodular with areas of haemorrhage, necrosis, or cystic degeneration. Tumours are usually smaller than 3 cm, with a median size of 2 to 3 cm. Patients commonly present with a palpable mass in the upper outer quadrant, which is well-defined clinically and on imaging. Axillary lymphadenopathy may also be present, indicating potential metastatic involvement. {{caption_text}} Phyllodes tumour (Option D) is a rare fibroepithelial neoplasm with a spectrum from benign to malignant, classified by the WHO based on nuclear atypia, stromal cellularity, mitotic activity, tumour margins, and stromal overgrowth. These tumours typically present as nodular masses with clear boundaries, although some may be ill-defined due to surrounding tissue invasion. The tumour is lobulated, solid, and firm, with a grey or grey-yellow colour, often containing narrow gaps or cavities filled with a clear, bloody, or jelly-like fluid. {{caption_text}}

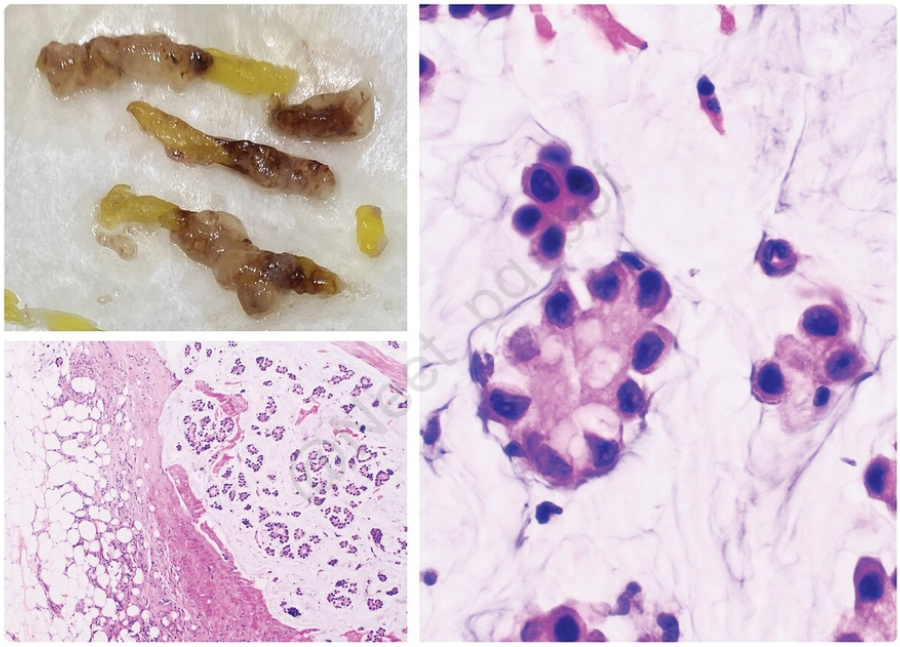

@Neet_pg_bot

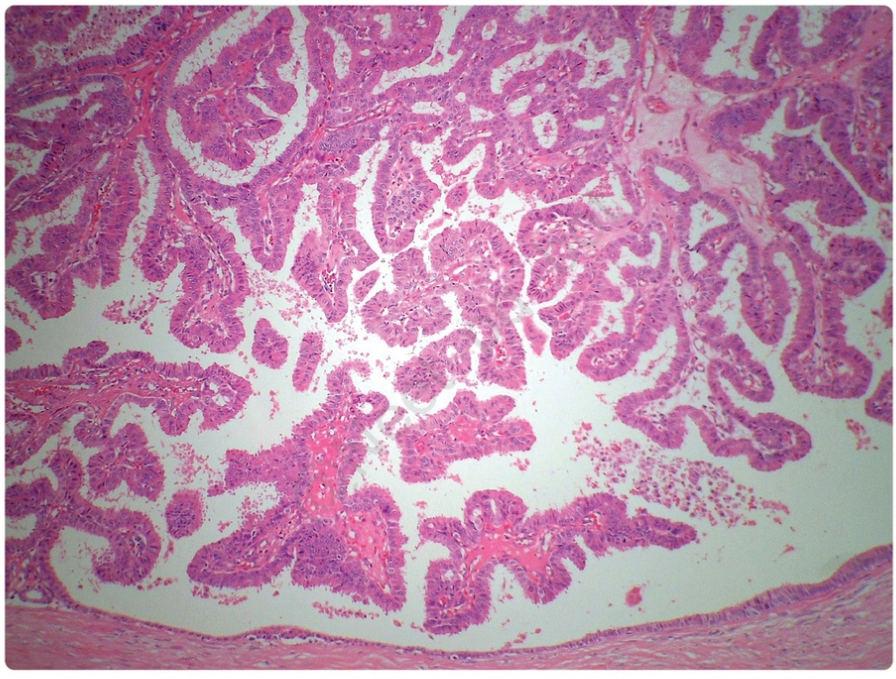

@Neet_pg_bot

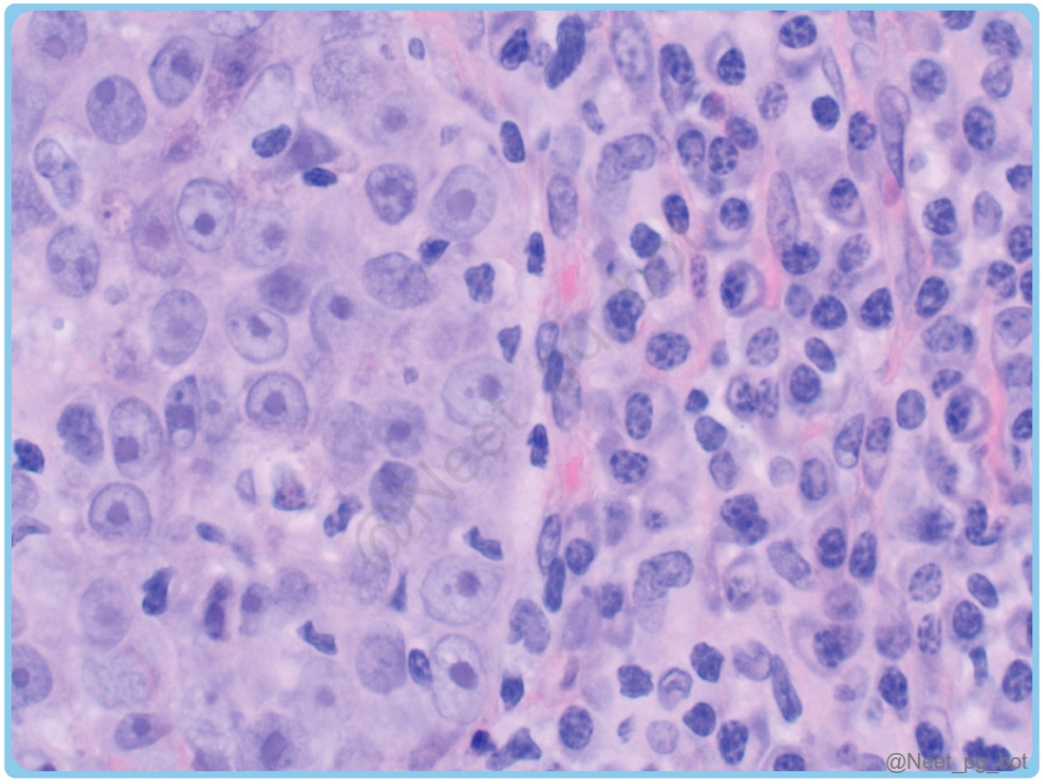

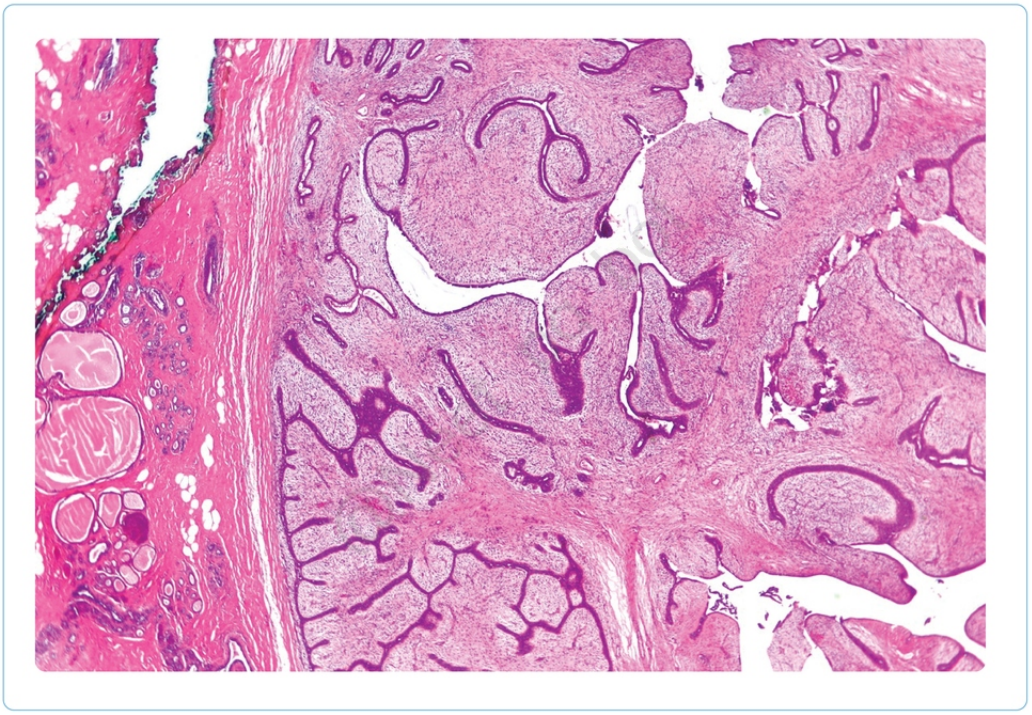

References:

Robbins & Cotran Pathologic Basis of Disease, 10th Edition, Page 1053-1058

↑ *Back to this question in Part A*

@Neet_pg_bot

• [15_Central Nervous System] 062 Cns Pathology

« Back to Folder Directory

[15_Central Nervous System] 062 Cns Pathology — Quick Jump

Q1 (p. 2494)	*Q2 (p. 2494)*	*Q3 (p. 2497)*	*Q4 (p. 2498)*	*Q5 (p. 2499)*	*Q6 (p. 2501)*
Q7 (p. 2502)	*Q8 (p. 2505)*	*Q9 (p. 2510)*	*Q10 (p. 2511)*	*Q11 (p. 2515)*	*Q12 (p. 2516)*
Q13 (p. 2517)	*Q14 (p. 2518)*	*Q15 (p. 2523)*	*Q16 (p. 2526)*	*Q17 (p. 2527)*	*Q18 (p. 2528)*

Q1: Q1. A 40-year-old woman presents with headache and undergoes evaluation for a brain tumor/ cerebellopontine angle. Histopathological examination reveals a tumor composed of Antoni A and Antoni B areas. Which of the following is the most sensitive immunohistochemical marker for this tumor? (Q882188)

A. S-100 protein

B. Glial fibrillary acidic protein (GFAP)

C. Epithelial membrane antigen (EMA)

D. c-KIT

Correct Answer: A. S-100 protein

Explanation: Correct Option : A. Schwannomas characteristically show Antoni A (hypercellular) and Antoni B (hypocellular) areas on histology. These tumors arise from Schwann cells , which show strong and diffuse positivity for S-100 protein , making it the most sensitive immunohistochemical marker . Cerebellopontine angle location further supports this diagnosis. Incorrect Options: Opiton B: Glial fibrillary acidic protein (GFAP) GFAP is a marker of astrocytic and glial tumors, such as astrocytomas and glioblastomas, not Schwann cell tumors. Option C: Epithelial membrane antigen (EMA) EMA is typically positive in meningiomas, which can also occur at the cerebellopontine angle but lack Antoni A and B areas. Option D: c-KIT c-KIT (CD117) is commonly associated with gastrointestinal stromal tumors (GISTs) and some hematologic malignancies, not schwannomas.

↑ *Back to this question in Part A*

@Neet_pg_bot

Q2: A 38-year-old woman has a new onset of recurrent seizures. MRI detects a frontal lobe mass. A biopsy of the mass shows cells with a perinuclear halo, as shown in the image. What is the most likely diagnosis? {{caption_text}} (Q845168)

A. Oligodendroglioma

B. Glioblastoma multiforme

C. Meningioma

D. Ependymoma

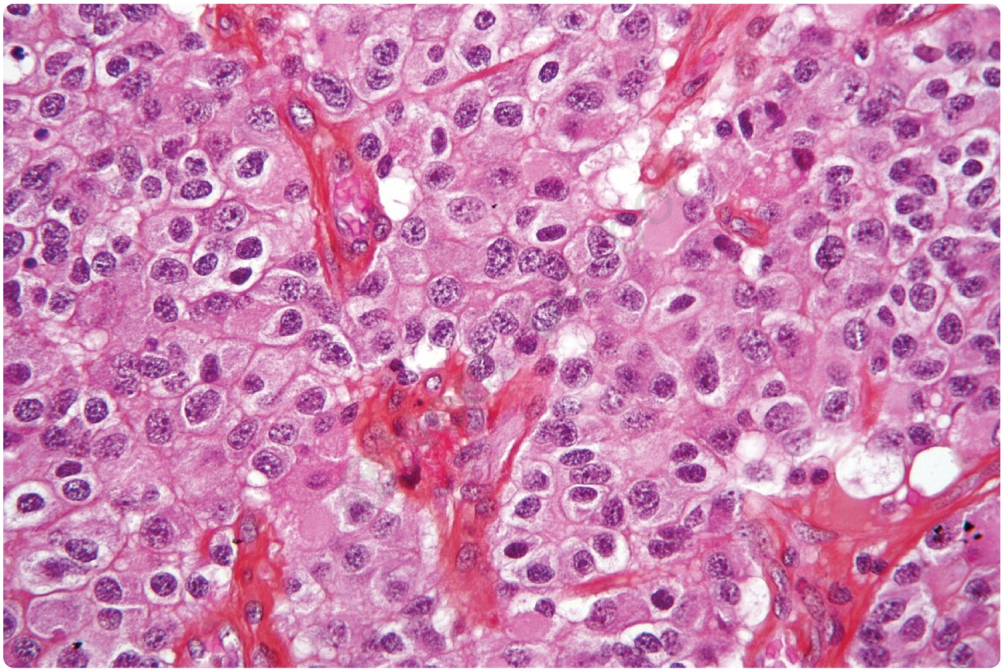

@Neet_pg_bot

Correct Answer: A. Oligodendroglioma

■ *Listen (English)*

■ *Listen (Hindi)*

Explanation: Oligodendroglioma: Site: Frontal Lobe Gross: Calcification (Mneumonic: COM) C raniopharyngioma O ligodendroglioma M eningioma Microscopy: Fried egg appearance: Perinuclear halo Chicken wire appearance of blood vessel Perineuronal satellitosis: Spread Mutation: IDH mutation: Most common Co-deletion 1p/19q: Good response to chemotherapy Fried egg appearance Chicken wire appearance Brain - Oligodendroglioma Bone marrow biopsy - Hairy cell leukemia Testes/Ovary - Seminoma/ Dysgerminoma Microbiology colonies: Malassezia furfur Mycoplasma Blood vessels: Oligodendroglioma Breast FNAC - (Mucinous/ colloid carcinoma breast) Fibrosis: Alcoholic Liver Disease Calcification: Chondroblastoma Tumor Morphology Histology Oligodendroglioma (Option A) Gelatinous, grey mass with calcification +/- cysts, focal hemorrhages. Fried egg appearance (perinuclear halo) Chicken wire vessels Calcification Perineuronal satellitosis Glioblastoma (GBM) (Option B) Butterfly Glioma Serpentine necrosis Pseudopalisading of tumor cells Glomeruloid bodies Meningioma (Option C) Rubbery dural mass that compresses the underlying brain but can easily be separated from it. Whorled pattern Psammoma bodies Ependymoma (Option D) Arises from the ependyma-lined ventricular system: Floor of 4th ventricle (children) Spinal cord (adults) Perivascular

pseudorosettes Medulloblastoma Cerebellar mass in children Homer-Wright rosettes (cells around a fibrillar center). Schwannoma Often affects the 8th cranial nerve (Vestibular Schwannoma) Antoni A & B areas Verocay bodies (palisaded nuclei) S100 positivity Pilocytic Astrocytoma Cerebellum (Children/Young Adults) Rosenthal fibers (thick eosinophilic corkscrews) Cystic appearance Hemangioblastoma Cerebellum (Adults) Foam cells High vascularity {{caption_text}} {{caption_text}} {{caption_text}}

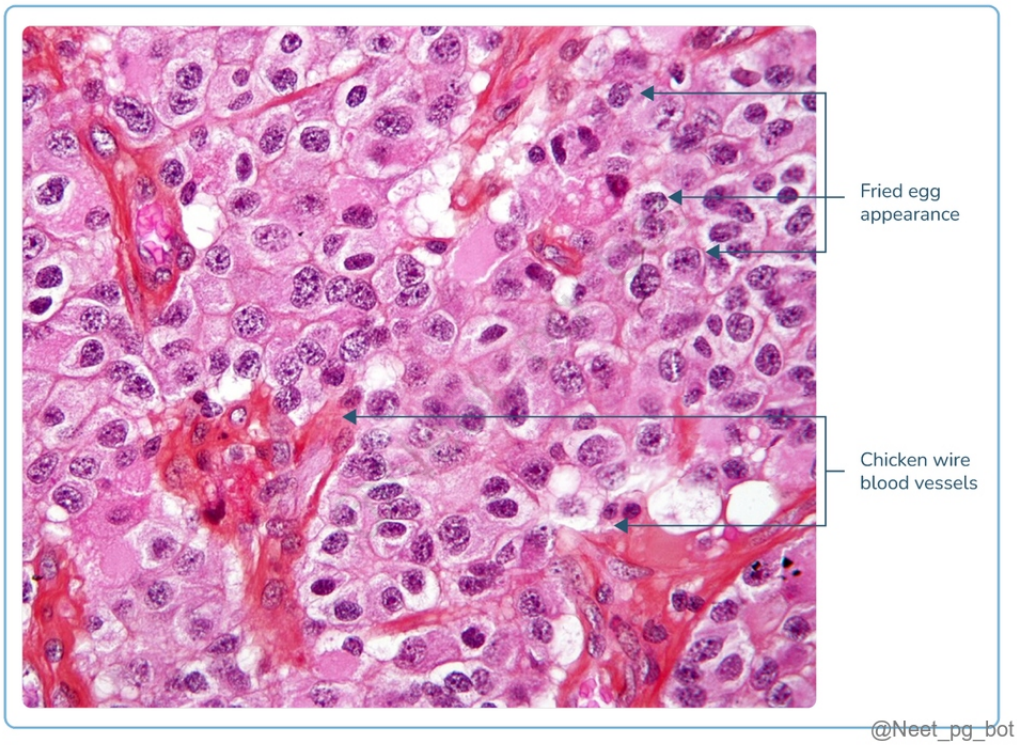

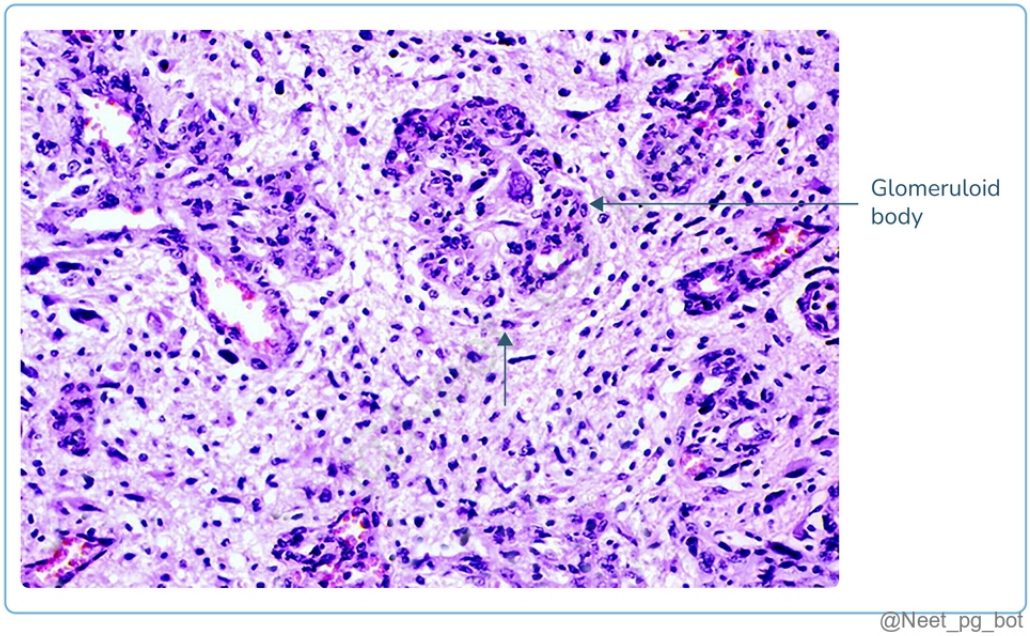

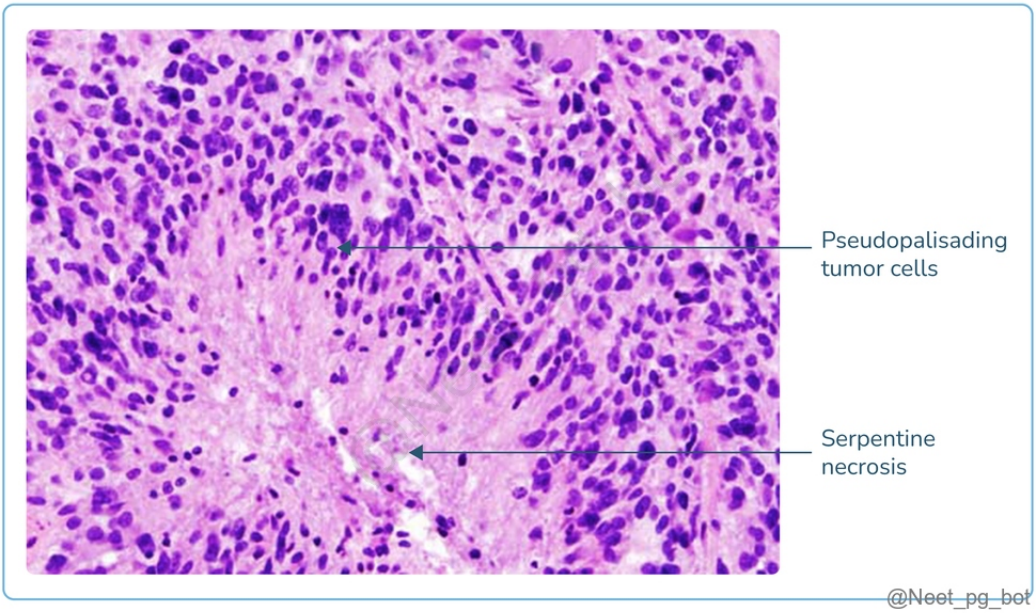

References:

Robbin’s and Cotran Pathologic Basis of Disease, 10th edition, Pages 1293-1301

https://www.ncbi.nlm.nih.gov/books/NBK559042/

https://www.ncbi.nlm.nih.gov/books/NBK559184/

↑ *Back to this question in Part A*

@Neet_pg_bot

Q3: Which genetic mutation is associated with multiple bilateral renal cysts and cerebellar hemangioblastomas and a family history of renal cell carcinoma? (Q845175)

A. VHL gene mutation

B. TSC 1 gene mutation

C. APC gene mutation

D. PTCH gene mutation

Correct Answer: A. VHL gene mutation

■ *Listen (English)*

■ *Listen (Hindi)*

Explanation: Syndromes associated with CNS tumours : Syndrome Mutation CNS manifestation Von-Hippel Lindau (VHL) (Option A) VHL gene mutation on chromosome 3. Autosomal dominant disease. Hemangioblastomas of the CNS (cerebellum and retina) Cysts of the pancreas, liver, and kidneys Renal cell carcinomas Pheochromocytomas. Tuberous sclerosis (Option B) TSC1 (Hamartin) and TSC2 (Tuberin) gene mutations. Autosomal dominant disease. Brain-Subependymal nodules, cortical tubers, subependymal giant cell astrocytoma. Skin- Ash-leaf macules, Shagreen patches Renal-angiomyolipoma Heart-rhabdomyoma Lung-Lymphangioleiomyomatosis Turcot syndrome (Option C) APC gene mutation Medulloblastoma FAP Gorlin syndrome (Option D) Autosomal dominant disorder. PTCH gene mutation. Multiple basal cell carcinomas Medulloblastomas Ovarian fibromas Odontogenic keratocysts Neurofibromatosis Type I (NF-I) NF1 gene (Neurofibromin) on chromosome 17. Autosomal dominant. Skin: Café-au-lait spots, Lisch nodules (iris hamartomas), Neurofibromas. CNS: Optic pathway gliomas. Skeletal: Sphenoid dysplasia, pseudoarthrosis. Neurofibromatosis Type II (NF-II) NF2 gene (Merlin) on chromosome 22. Autosomal dominant. Classic: Bilateral vestibular schwannomas ("acoustic neuromas"). CNS: Multiple meningiomas, ependymomas. Eyes: Juvenile posterior subcapsular lenticular opacities. Cowden Syndrome PTEN gene mutation. Autosomal dominant. Skin: Trichilemmomas, papillomatous papules. Organs: High risk of Breast, Thyroid (follicular), and Endometrial cancers. CNS: Lhermitte-Duclos disease (dysplastic cerebellar gangliocytoma). Li-Fraumeni Syndrome TP53 gene mutation. Autosomal dominant. SBLA Syndrome: Sarcomas, Breast cancer, Leukemia, Adrenal cortical carcinoma. Early onset of various malignancies. Constitutional Mismatch Repair Deficiency (CMMRD) Biallelic MSH6/MLH1/PMS2/MSH2 ■ High-grade gliomas, medulloblastomas, supratentorial PNETs ■ Rhabdoid Tumor Predisposition SMARCB1/SMARCA4 (SWI/SNF chromatin remodeling, AD) ■ Atypical teratoid/rhabdoid tumors (ATRT)

References:

Robbin’s and Cotran Pathologic Basis of Disease, 10th Edition, Pages 809, 1302, 1147

↑ *Back to this question in Part A*

@Neet_pg_bot

Q4: Which of the following is true regarding primary CNS lymphoma? (Q845174)

A. Caused by EB Virus (EBV)

B. Caused by underexpression of PDL1 gene

C. Leptomeningeal spread is common

D. Typically arises from meningeal layers.

Correct Answer: A. Caused by EB Virus (EBV)

■ *Listen (English)*

■ *Listen (Hindi)*

Explanation: Primary CNS lymphoma It is caused by the Epstein-Barr virus in immunosuppressed cases and PDL1 gene overexpression in others. These diffuse large B-cell lymphomas present as multiple, aggressive, grey-white

masses in deep brain regions, often spreading in the periventricular areas . The cells are angiocentric and have areas of necrosis, expressing CD20. {{caption_text}} Primary CNS lymphoma where the malignant B cells show angiocentric hooping patterns.

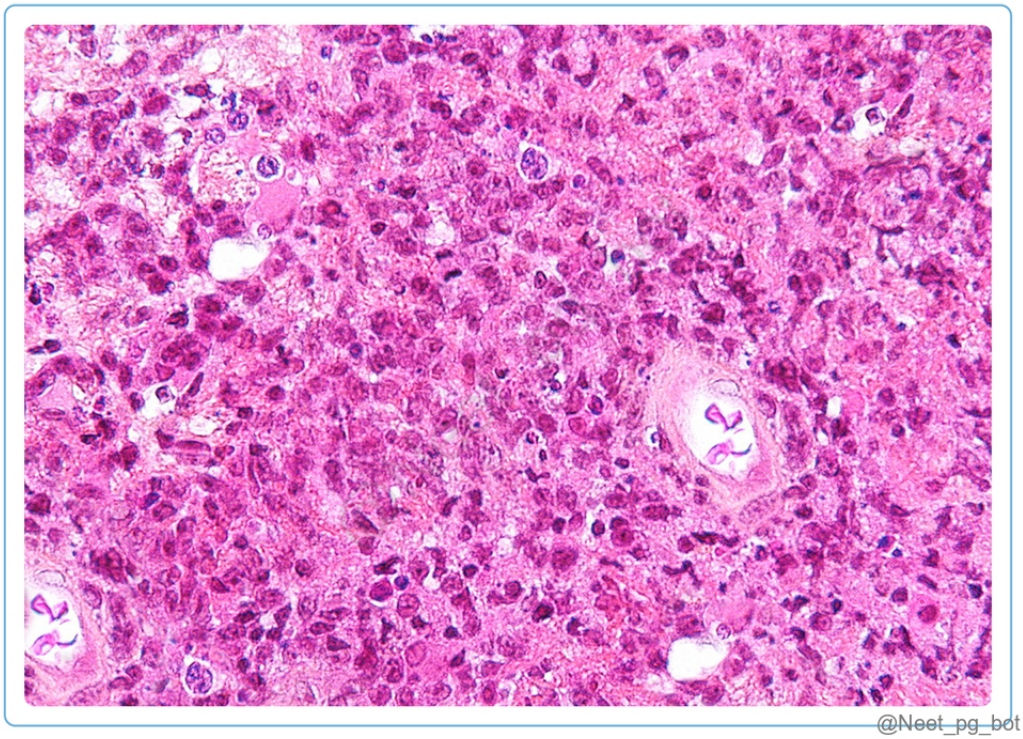

References:

Robbin's and Cotran Pathologic Basis of Disease, 10th Edition, Pages 1299, 1300, 1237, 1296.

↑ *Back to this question in Part A*

@Neet_pg_bot

Q5: A 45-year-old woman with right-sided hearing loss, tinnitus, and vertigo has an MRI showing a mass at the right cerebellopontine angle from the vestibulocochlear nerve. Biopsy reveals encapsulated tissue with areas of dense cellularity and loose myxoid regions, as depicted in the image below. Which of the following statements is NOT true regarding this condition? (Q845173)

A. Associated with NF-1 gene mutation

B. Typically exhibit verocay bodies

C. Expresses Merlin

D. Immunoreactivity for S-100

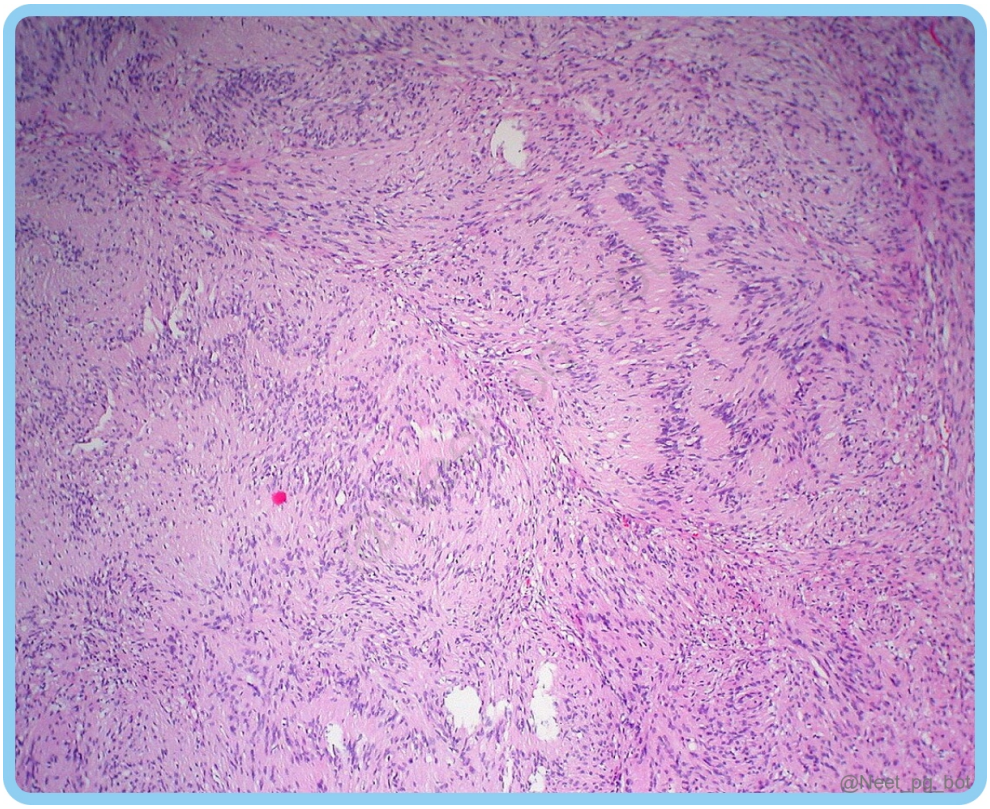

Correct Answer: A. Associated with NF-1 gene mutation

- *Listen (English)*
- *Listen (Hindi)*

Explanation: NF1 (Neurofibromatosis type 1) Gene: NF1 gene on chromosome 17 Protein: Neurofibromin (tumor suppressor) Features: Multiple café-au-lait spots Cutaneous neurofibromas Lisch nodules (iris hamartomas) Optic gliomas Diagnostic Criteria (NIH, ≥2 required): ≥6 café-au-lait macules (>5 mm prepubertal). ≥2 neurofibromas or 1 plexiform neurofibroma. Axillary/inguinal freckling. Optic pathway glioma. ≥2 Lisch nodules (iris hamartomas). Distinctive bony lesion (sphenoid dysplasia, tibial pseudarthrosis). 1st-degree relative with NF1. Complications : Scoliosis, learning disability, hypertension (pheo/renal artery stenosis), MPNST (malignant transformation). Management : Annual ophthalmic exam, whole-body MRI for plexiform Nfs, MEK inhibitors (selumetinib) for inoperable plexiforms. NF2 (Neurofibromatosis type 2) Gene: NF2 gene on chromosome 22 Protein: Merlin (schwannomin) Inheritance : Autosomal Dominant Features: Bilateral vestibular (acoustic) schwannomas – 8th cranial nerve Meningiomas, ependymomas Diagnostic Criteria (Manchester): Bilateral vestibular schwannomas (classic), OR 1st-degree relative + unilateral VS, OR ≥2 meningiomas, OR ≥1 glioma/schwannoma/ependymoma, OR ≥2 CNS meningiomas. Histology : S100+ (neural crest marker); NF2 schwannomas show dense vs loose hypocellular areas (Antoni A/B). Complications : Hearing loss, balance issues, cataracts (juvenile posterior subcapsular), young age at tumor onset. Management : Serial MRI brain/spine, auditory evoked potentials, bevacizumab or HSCT for tumor control. Histology & IHC of Schwannoma Antoni A and B areas : dense cellular vs loose hypocellular regions Verocay bodies : parallel rows of palisaded nuclei with fibrillary processes between → characteristic of schwannoma S100 positivity : marker of neural crest origin (seen in schwannomas & neurofibromas

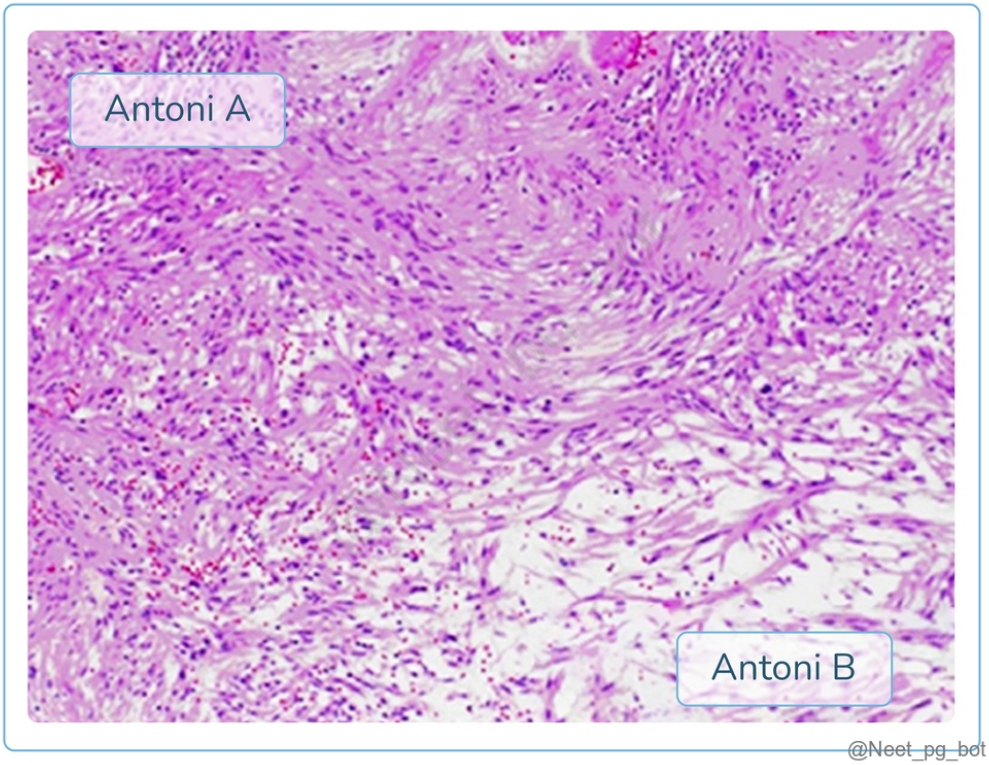

References:

Robbin’s and Cotran Pathologic Basis of Disease, 10th Edition, Page 1237, 1297, 1298

↑ *Back to this question in Part A*

@Neet_pg_bot

Q6: A 35-year-old female presents with persistent headaches and weakness in her right upper limbs. Imaging reveals a brain tumor that is PR+. Biopsy reveals psammoma bodies with necrosis, cellular atypia, mitosis >4/hpf, and invasion of brain parenchyma. What is the most likely diagnosis? {{caption_text}} (Q845172)

A. Typical meningioma

B. Atypical meningioma

C. Anaplastic meningioma

D. Papillary meningioma

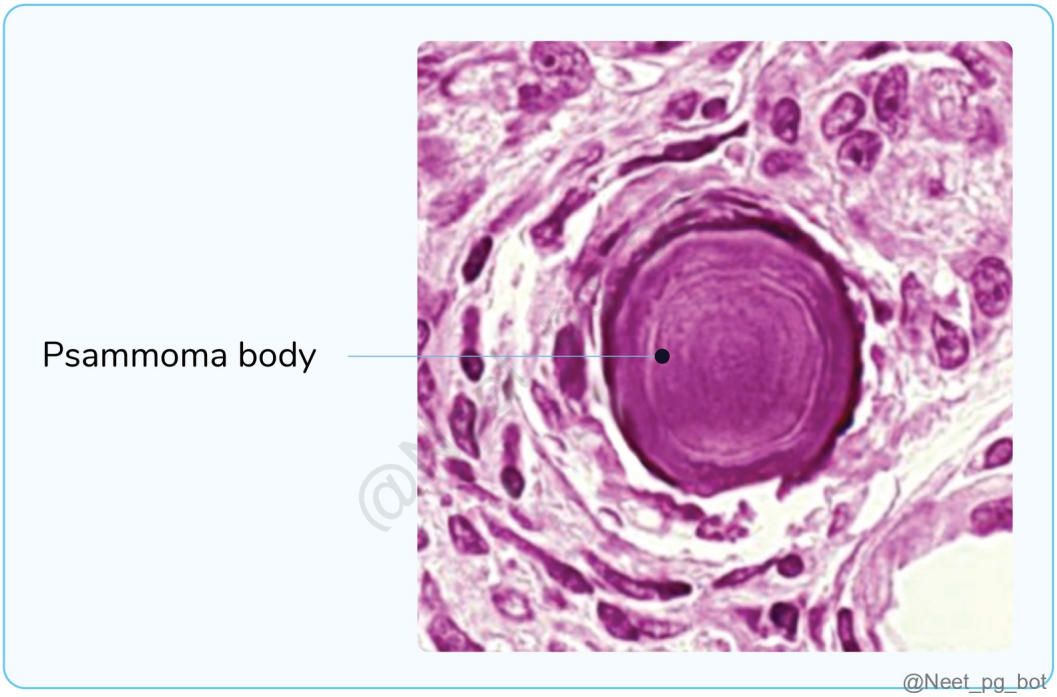

Correct Answer: B. Atypical meningioma

■ *Listen (English)*

■ *Listen (Hindi)*

Explanation: The clinical presentation and biopsy features suggest Atypical meningiomas characterized by the presence of psammoma bodies with areas of necrosis, cellular atypia, mitosis >4/hpf, and invasion of brain parenchyma. They arise from the meningothelial cells of the arachnoid and are attached to the dura. These PR+ tumors of adults are locally aggressive and are associated with higher recurrence rates. They are distinguished from lower-grade meningiomas by having Increased mitotic index (>4/hpf and <20/hpf) Brain invasion Cellular atypia Areas of necrosis Prominent nucleoli High N: C ratio Disorganised growth Typical Meningioma (Option A): A typical meningioma is characterized by slow growth, well-defined borders, and low mitotic activity. It is a benign dural masses that compress the underlying brain but are easily separated from it. They are PR+, non-aggressive, and do not invade the underlying brain parenchyma. Anaplastic meningioma (Option C): Anaplastic meningioma is a highly aggressive malignant tumor that often resembles a carcinoma or sarcoma. It's Mitotic index is >20/hpf. Papillary meningioma (Option D): Papillary meningioma is a variant of anaplastic meningioma and is also highly aggressive with a mitotic index of >20/hpf.

References:

Robbin's and Cotran Pathologic Basis of Disease, 10th edition, Pages 1300,1301

↑ *Back to this question in Part A*

@Neet_pg_bot

Q7: A 28-year-old gravid woman comes to the ODP due to a severe headache that started during her pregnancy. Investigations reveal the following. Which of the following statements is not true for the above condition? {{caption_text}} (Q845171)

A. Progesterone receptor-positive

B. Risk factors include exposure to radiation

C. Associated with NF2 gene mutation

D. HPE shows perivascular pseudorosettes

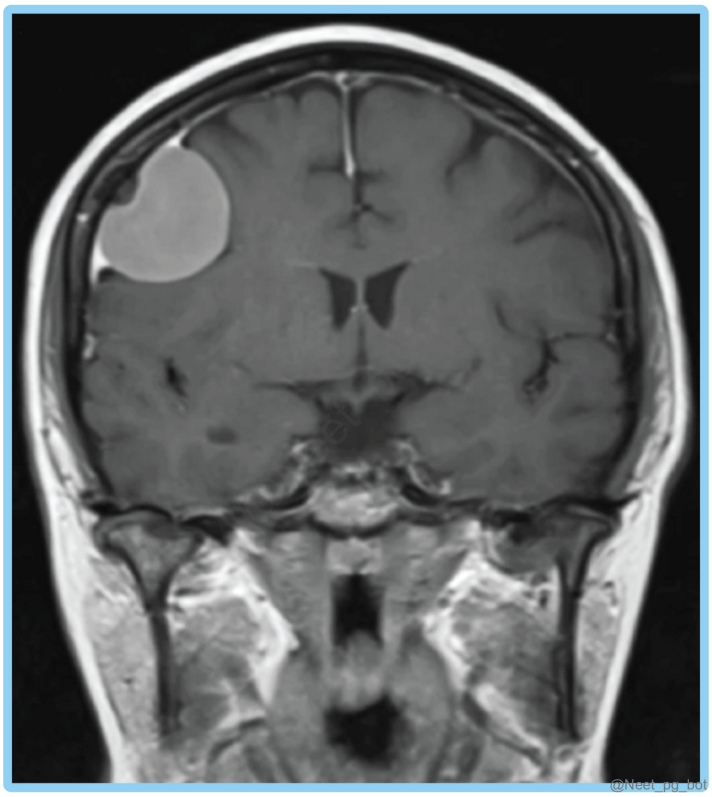

Correct Answer: D. HPE shows perivascular pseudorosettes

■ *Listen (English)*

■ *Listen (Hindi)*

Explanation: Perivascular pseudo-rosette is seen in Ependymomas. The clinical presentation suggests Meningiomas, which are mostly benign tumors found in adults. They originate from meningothelial cells of the arachnoid layer and are typically connected to the dura mater. More common in women and has increased risk with pregnancy, exposure to radiation (Option B) , and NF2 gene mutation (Option C) . Tumors typically exhibit a rubbery dural mass, compressing the brain, yet easily separable. Histopathologically, they present with a whorled pattern of cells and psammoma bodies and are progesterone receptor-positive (Option A) . {{caption_text}} {{caption_text}}

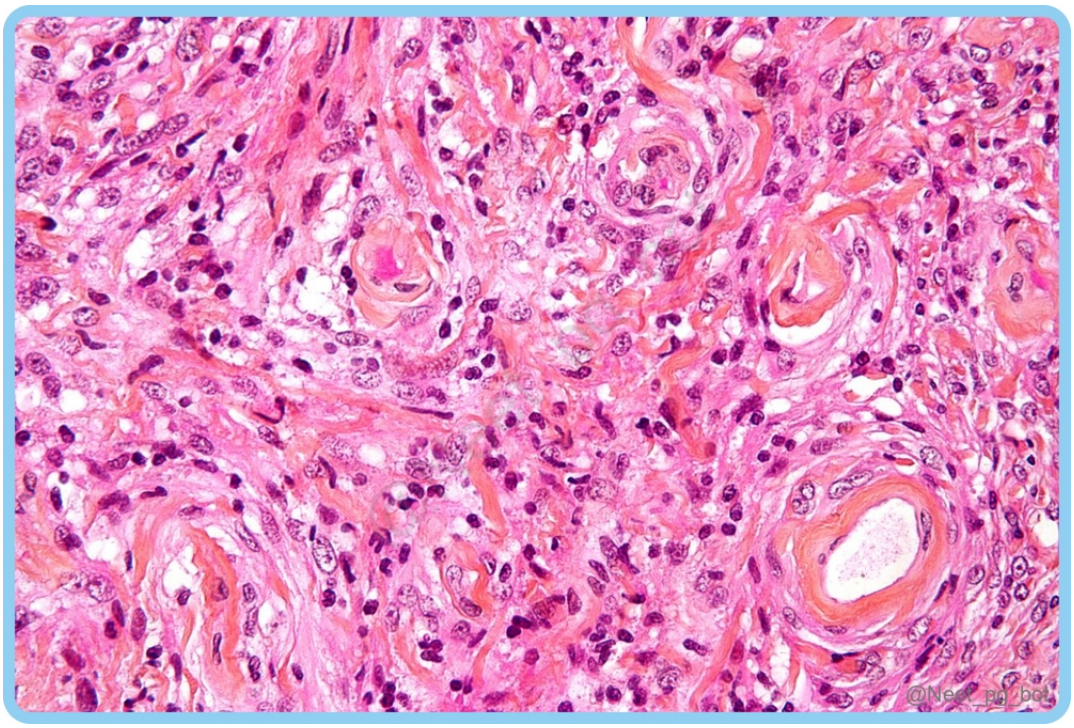

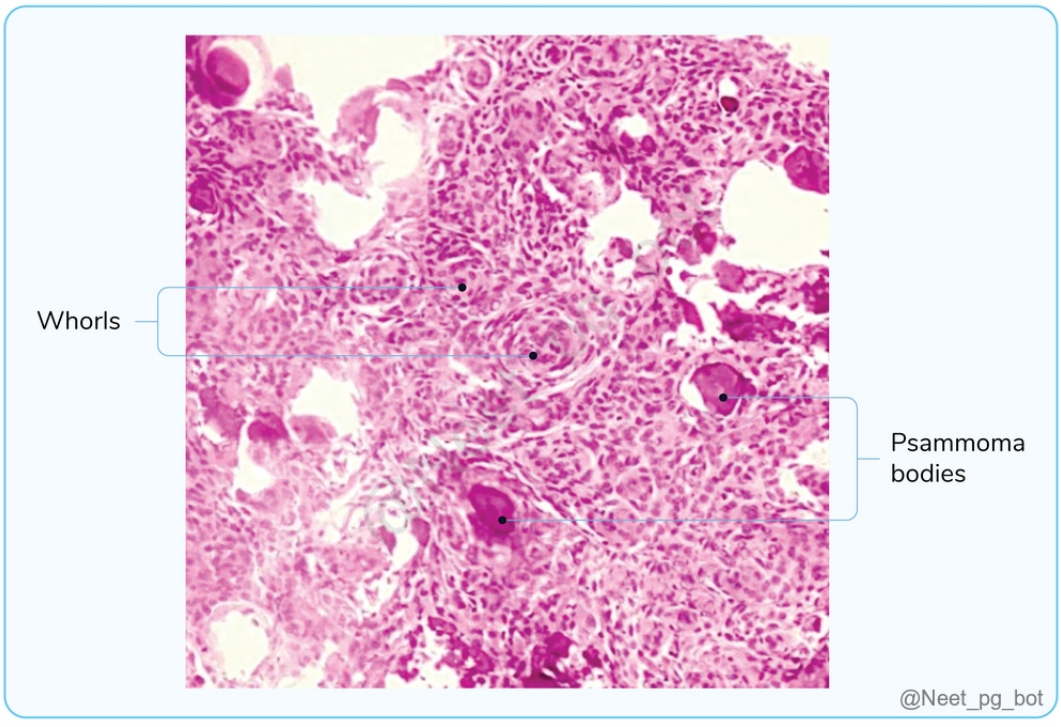

References:

Robbin’s and Cotran Pathologic Basis of Disease, 10th Edition, Page 1300-1301

↑ *Back to this question in Part A*

@Neet_pg_bot

Q8: A 7-year-old boy presents with a history of persistent morning headaches, vomiting, and difficulty with coordination for the past two months. MRI shows a mass in the cerebellum, and HPE shows Homer Wright's rosette. What is the most common route of metastasis? {{caption_text}} (Q845170)

A. Lymphatics

B. Hematogenous

C. Drop metastasis

D. All of the above

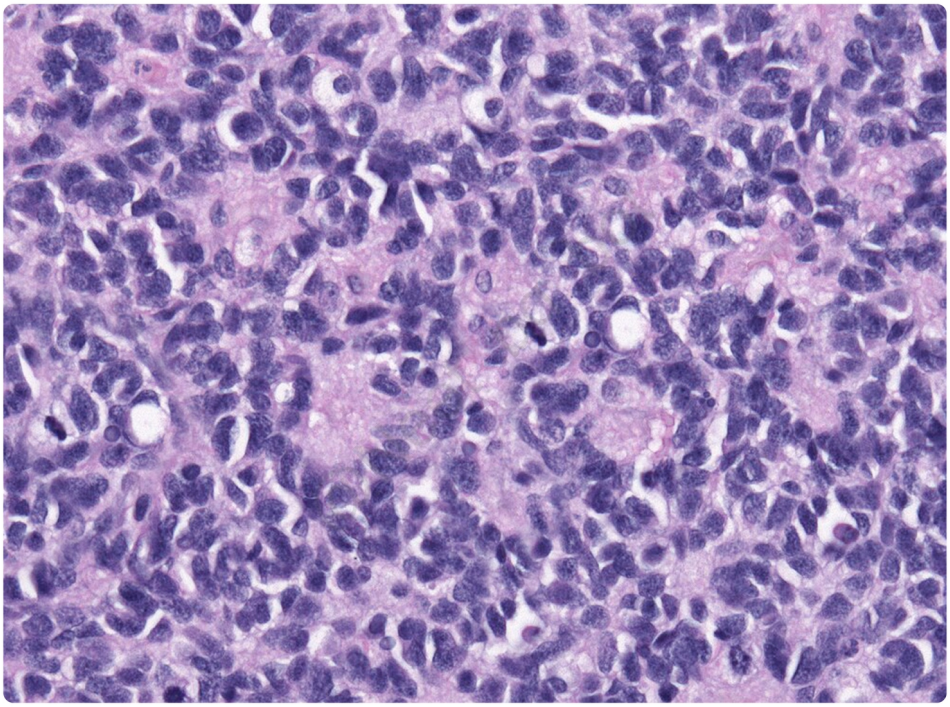

@Neet_pg_bot

Correct Answer: C. Drop metastasis

■ *Listen (English)*

■ *Listen (Hindi)*

Explanation: Medulloblastoma is a malignant embryonal tumor that occurs mainly in children, exclusively in the cerebellum. It is a WHO-grade IV tumor with poor prognosis. Metastasis occurs via CSF-Drop metastasis from the cerebellum to the spinal cord. Histology reveals small round blue cells with scanty cytosol and Homer Wright rosettes Neuropathology Rosettes and Diagnostic Patterns; Pattern Type Central Feature Associated Tumor(s) Key Pathological Significance Image Homer-Wright Rosette Neuropil/Fibrillar hub (no lumen) Medulloblastoma ,

Neuroblastoma, PNET Pathognomonic for "small round blue cell" tumors. Flexner-Wintersteiner Rosette Central Lumen (clear space) Retinoblastoma , Pineoblastoma Indicates primitive photoreceptor differentiation. Perivascular Pseudorosette Blood Vessel Ependymoma , Glioblastoma Tumor cells radiate processes toward a central vessel. Pineocytomatous Rosette Large, irregular Fibrillar hub Pineocytoma Larger and more irregular than Homer-Wright rosettes. Pseudopalisading Necrosis Necrotic core Glioblastoma (GBM) Cells "picket fence" around dead tissue; indicates Grade 4 malignancy. Verocay Bodies Acellular fibrillary zone Schwannoma Parallel rows of palisading nuclei in Antoni A areas. Psammoma Bodies Laminated Calcification Meningioma , Papillary Thyroid CA Concentric calcified whorls.

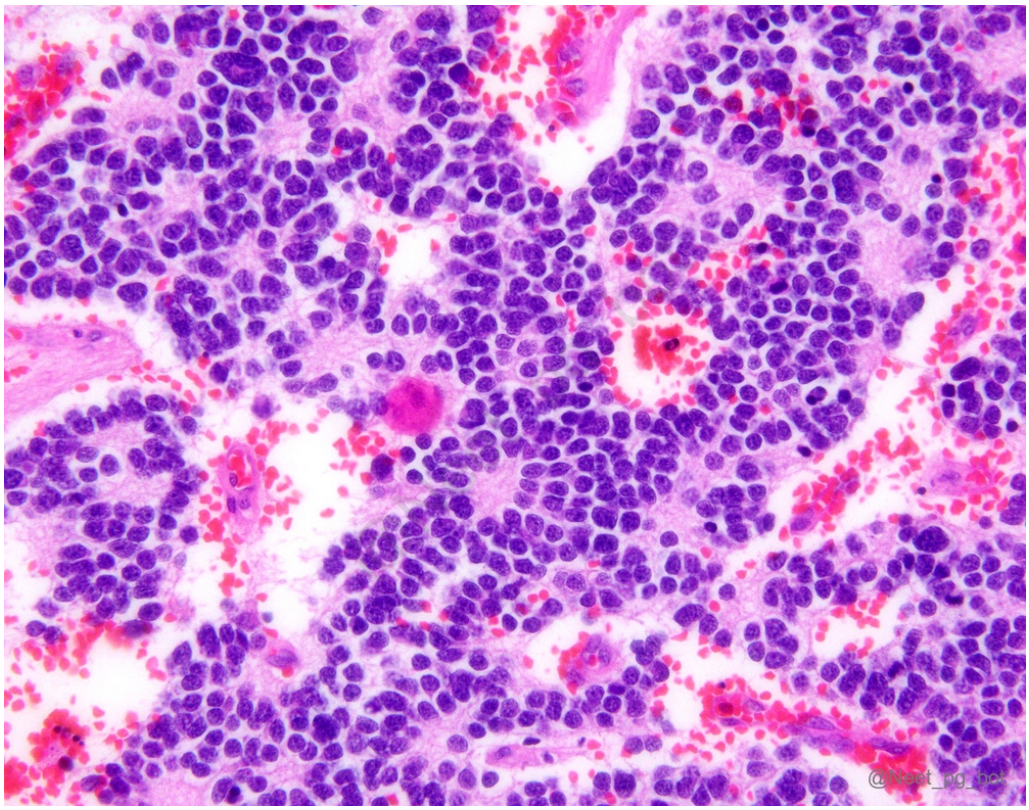

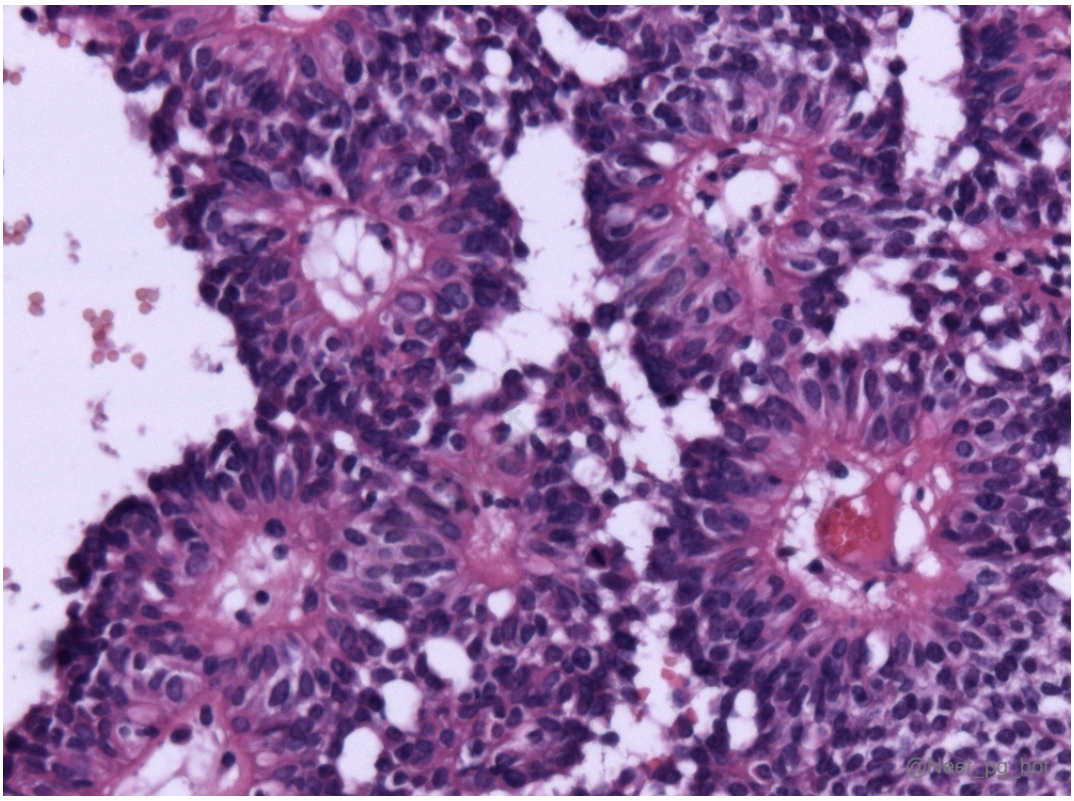
@Neet_pg_bot

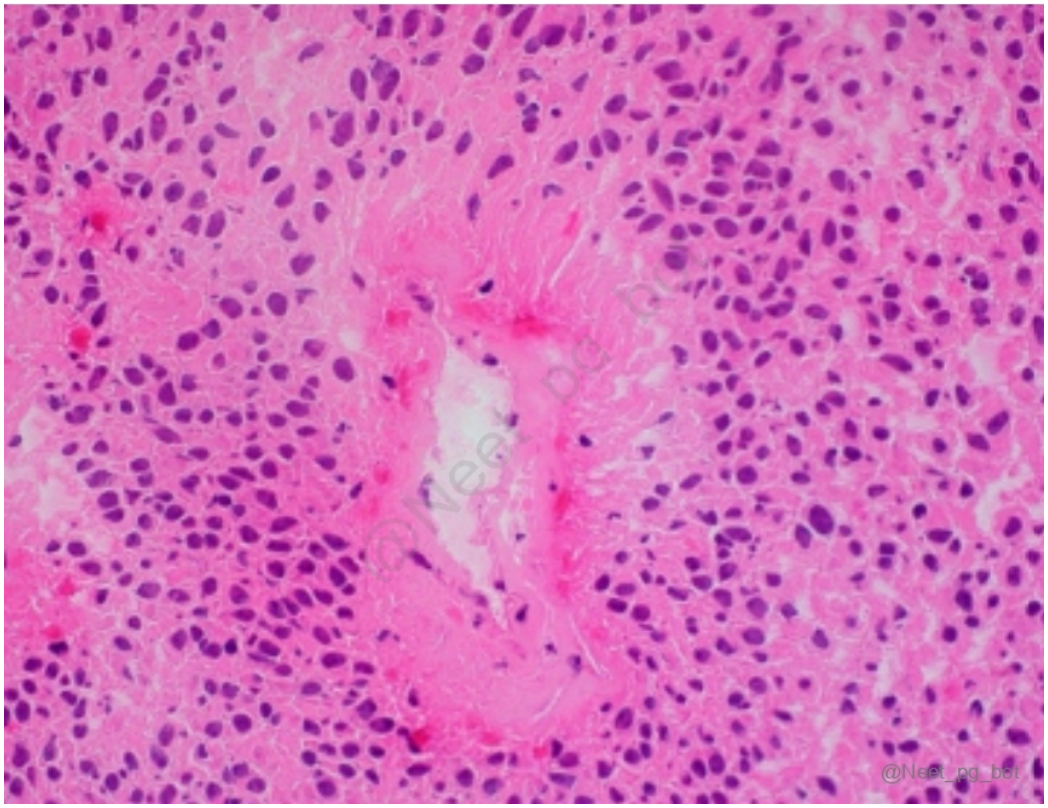
@Neet_pg_bot

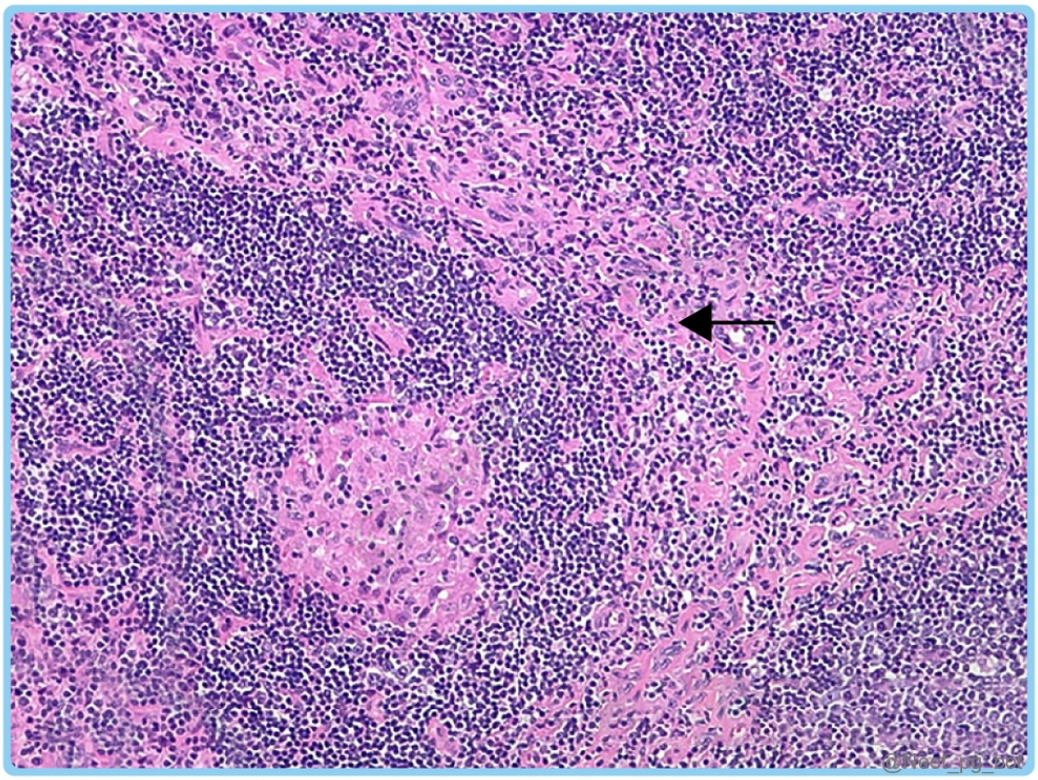
@Neet_pg_bot

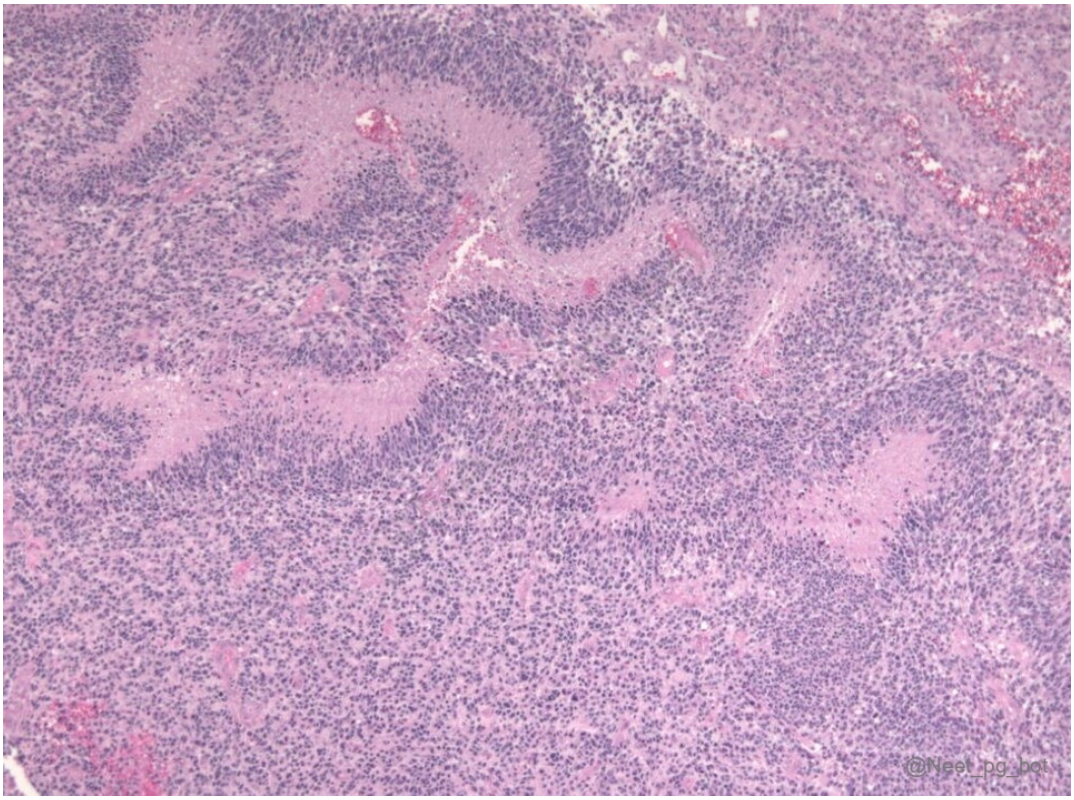
@Neet_pg_bot

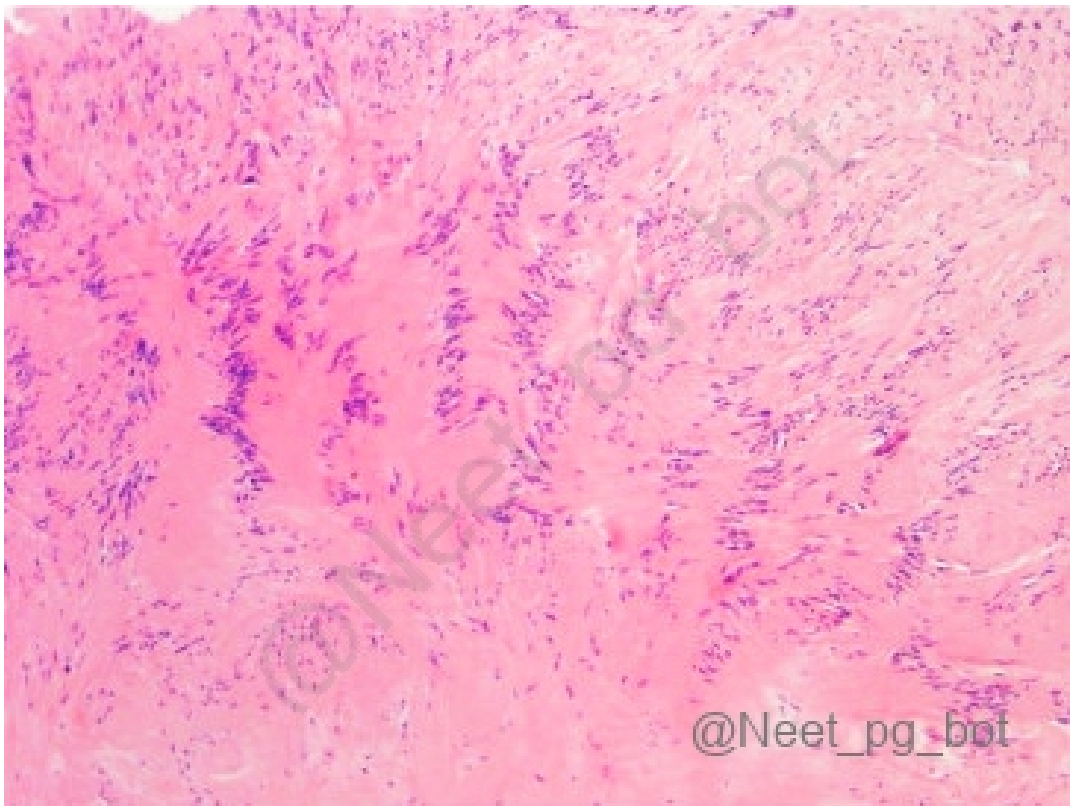

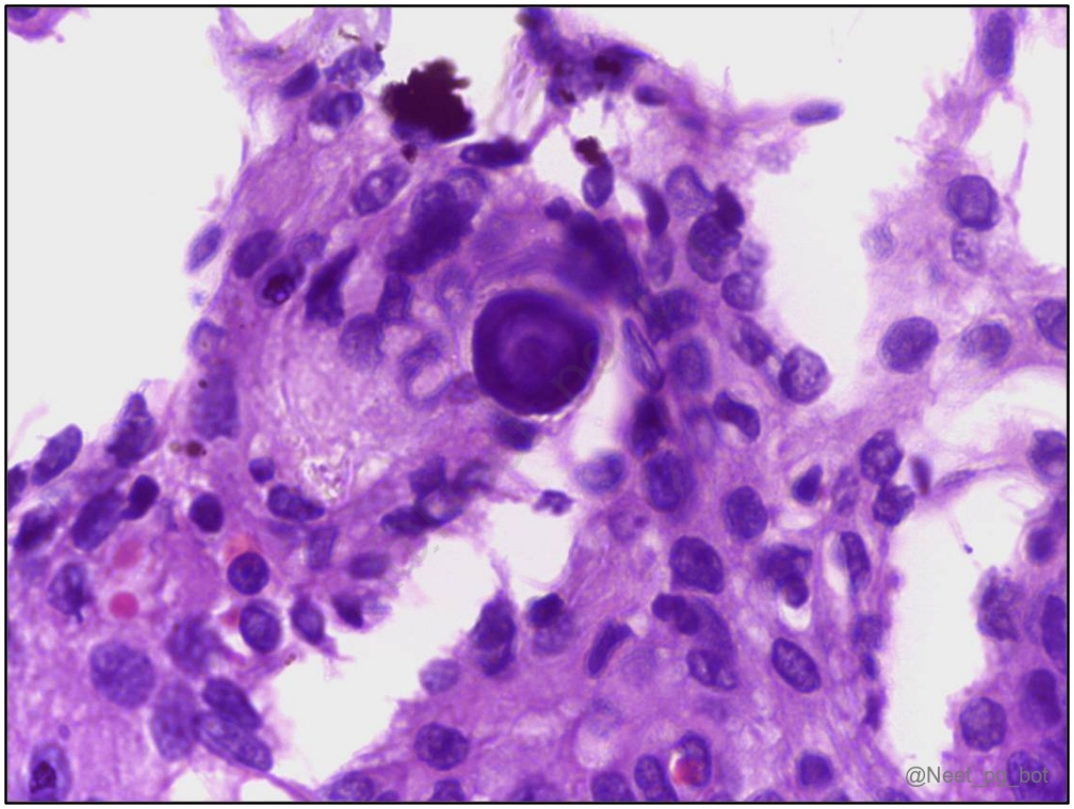

References:

Robbin’s and Cotran Pathologic Basis of Disease, 10th Edition, Page 1298

https://www.cancer.gov/rare-brain-spine-tumor/tumors/medulloblastoma#

↑ *Back to this question in Part A*

@Neet_pg_bot

Q9: A 28-year-old man comes to the OPD due to a severe headache and blurring of vision. MRI indicates an intraventricular mass in the posterior fossa obstructing the CSF flow. Following surgical resection, which histopathological finding is most probable on examination? (Q845169)

A. Perivascular pseudorosette

B. Perinuclear halo

C. Psammoma bodies

D. Homer Wright rosettes

Correct Answer: A. Perivascular pseudorosette

■ *Listen (English)*

■ *Listen (Hindi)*

Explanation: Ependymomas are tumors that typically develop near the ependyma-lined ventricular system. They frequently obstruct CSF flow, leading to obstructive hydrocephalus. It most commonly arises from the floor of the 4th ventricle in children and in adults, spinal cord tumors are most common, especially in those with neurofibromatosis type 2 (NF2). Characteristic histopathological features of ependymomas include perivascular pseudorosettes, cells with fibrillary processes, and round to oval nuclei. {{caption_text}} Perinuclear halo (Option B): Oligodendroglioma Psammoma bodies (Option C): Meningioma Homer Wright rosettes (Option D): Neuroblastoma, medulloblastoma, primitive neuroectodermal tumor

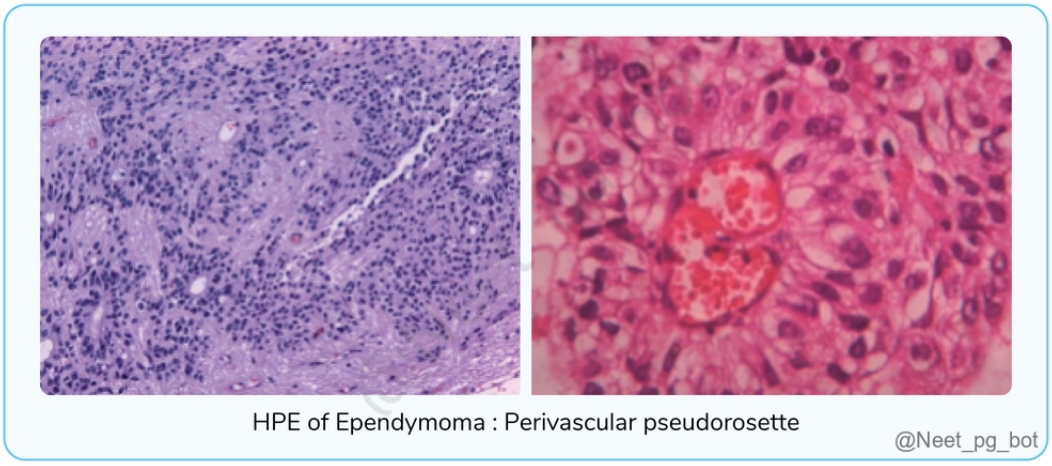

References:

Robbin’s and Cotran Pathologic Basis of Disease, 10th edition, Page 1296

https://www.ncbi.nlm.nih.gov/pmc/articles/PMC5700879/

https://pubmed.ncbi.nlm.nih.gov/19373908/

↑ *Back to this question in Part A*

@Neet_pg_bot

Q10: Identify the following CNS cells and match them with their specific roles: 1.Fibrous astrocytes A.It is found primarily in white matter and maintains the blood-brain barrier Star-shaped cells Functions: Formation of Blood Brain Barrier (BBB) Involved in repair mechanism IHC stain: Glial Fibrillary Acidic Protein (GFAP) marker 2. Oligodendrocyte B. Line the brain's ventricles and assist in producing cerebrospinal fluid (CSF). Function: Formation of myelin in CNS Perinuclear halo Special stain for Myelin: Luxol fast blue 3. Ependymal cell C. Produce myelin sheath for fast impulse conduction in the CNS. Present in ventricles of the brain Helps in formation of Cerebrospinal fluid (CSF) 4. Protoplasmic astrocytes D. Phagocytize pathogens in CNS and are physiologically and embryologically unrelated to other neural cell types. Location: Found in the grey matter. Help maintain the appropriate concentration of neurotransmitters. 5.Microglia E. They are found in the grey matter and help maintain the appropriate concentration of neurotransmitters. Phagocytize pathogens in the CNS. Origin: Physiologically and embryologically unrelated to other neural cell types (Q845147)

A. 1- A, 2-B, 3-C, 4-D, 5-E

B. 1- A, 2-C, 3-B, 4-E, 5-D

C. 1- B, 2-C, 3-A, 4-E, 5-D

D. 1- E, 2-C, 3-A, 4-B, 5-D

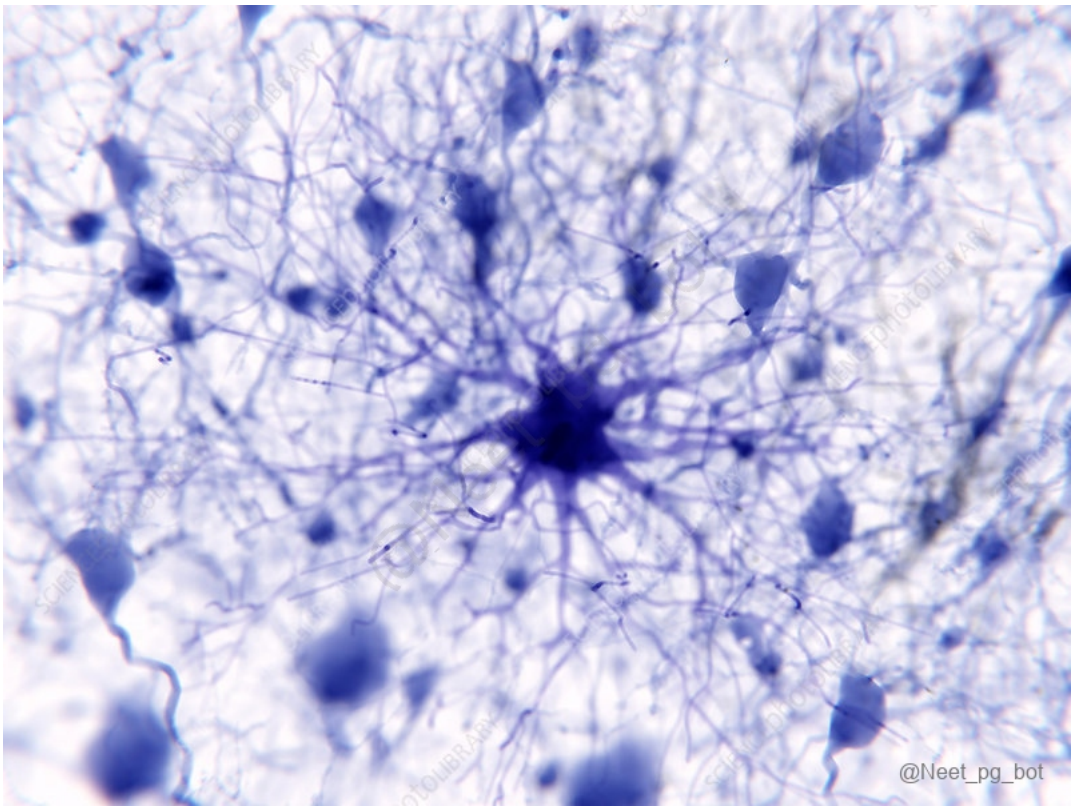
@Neet_pg_bot

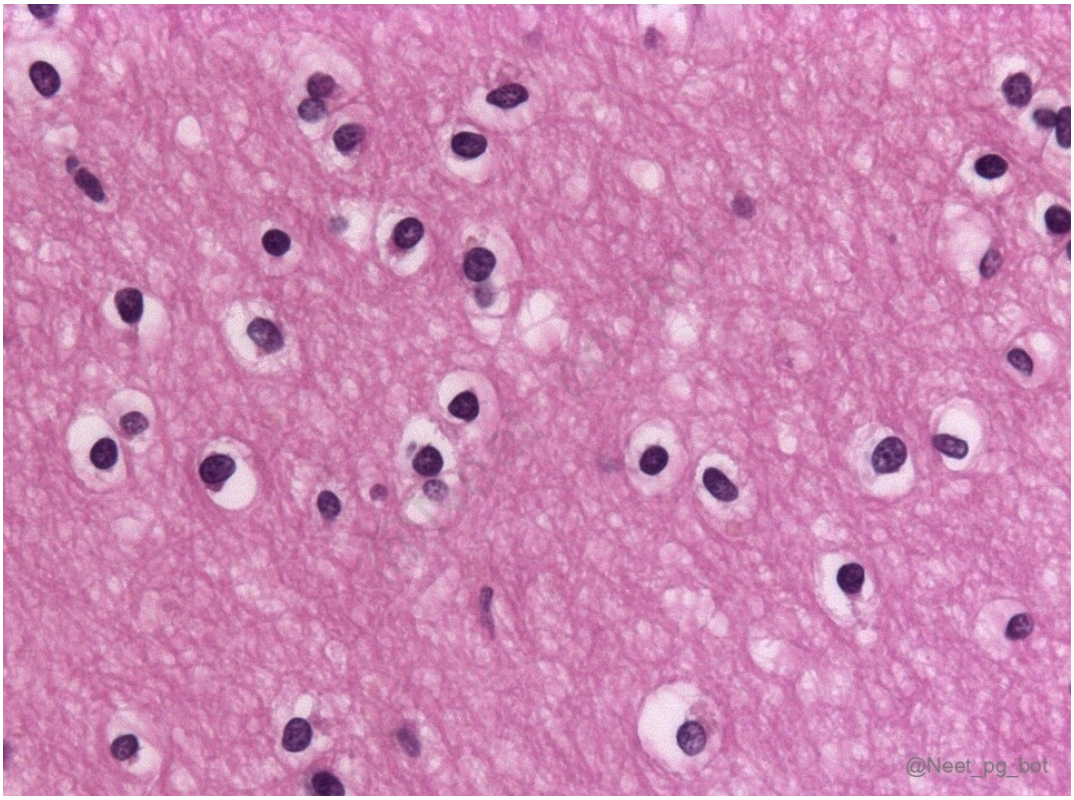
@Neet_pg_bot

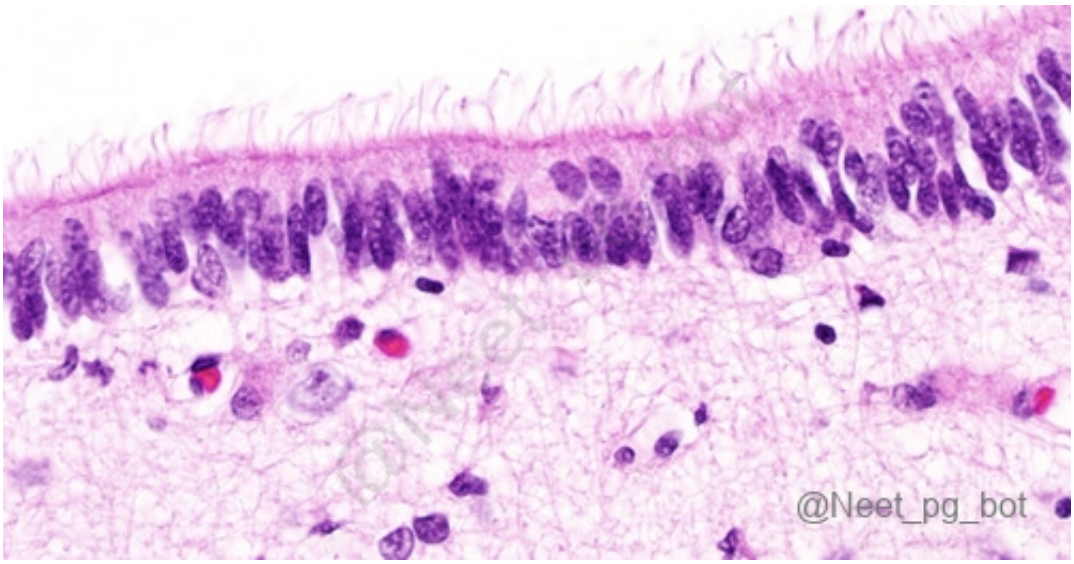
@Neet_pg_bot

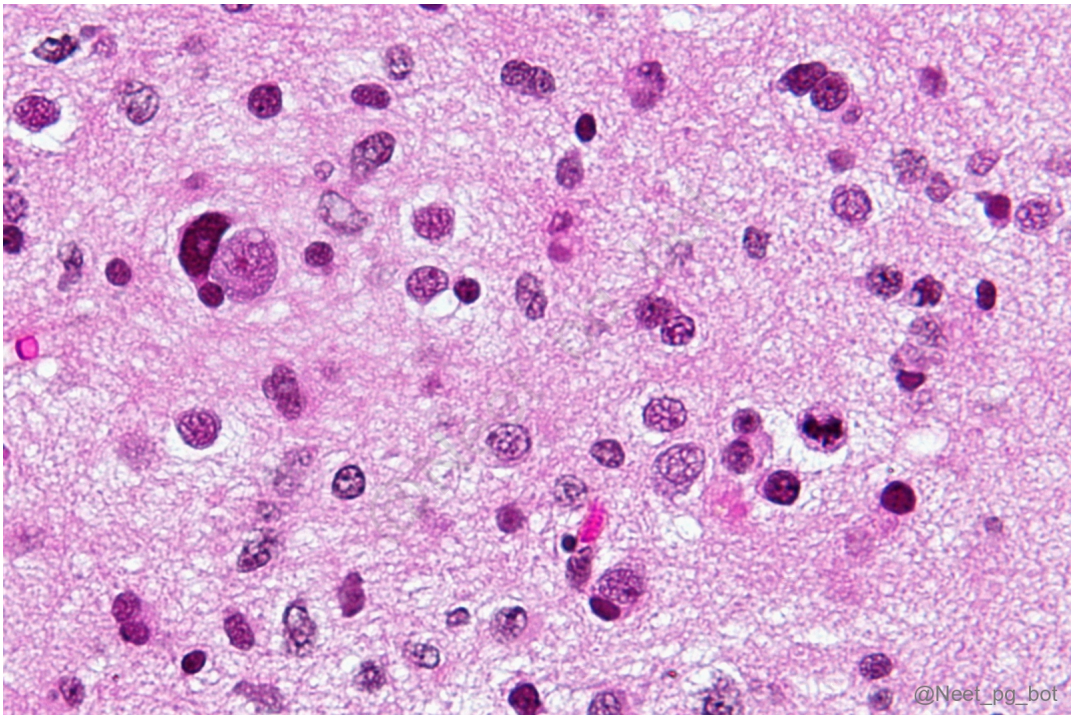
@Neet_pg_bot

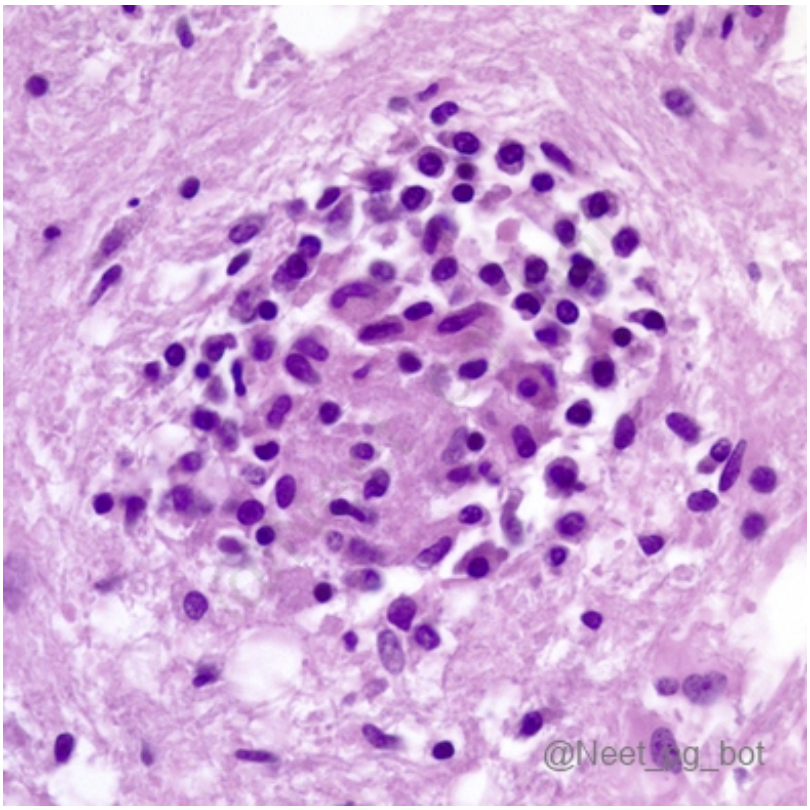

Correct Answer: B. 1- A, 2-C, 3-B, 4-E, 5-D

- *Listen (English)*
- *Listen (Hindi)*

Explanation: Cells of the central nervous system Glial cells: Astrocytes Oligodendrocytes Ependymal cells Star-shaped cells. Immunohistochemistry stain: Glial Fibrillary Acidic Protein (GFAP) marker. Functions: Formation of the blood-brain barrier, structural support, and repair mechanism. Types: Fibrous astrocytes: Found in white matter and contain intermediate filaments. (A) Protoplasmic astrocytes: Found in grey matter and have granular cytoplasm. Maintain appropriate concentration of ions and neurotransmitters. (E) Form myelin on neighboring axons. Helps in the fast conduction of impulses in the CNS. (B) Associated diseases: Guillain–Barré syndrome. Multiple sclerosis. Charcot-MarieTooth disease. Myelin stain: Luxol fast blue. Present in ventricles of the brain. Production and circulation of CSF. (C) Astrocytes and their cell processes around capillaries (brown). {{caption_text}} Microglia: Scavenger cells arise from macrophages outside the nervous system. (D)

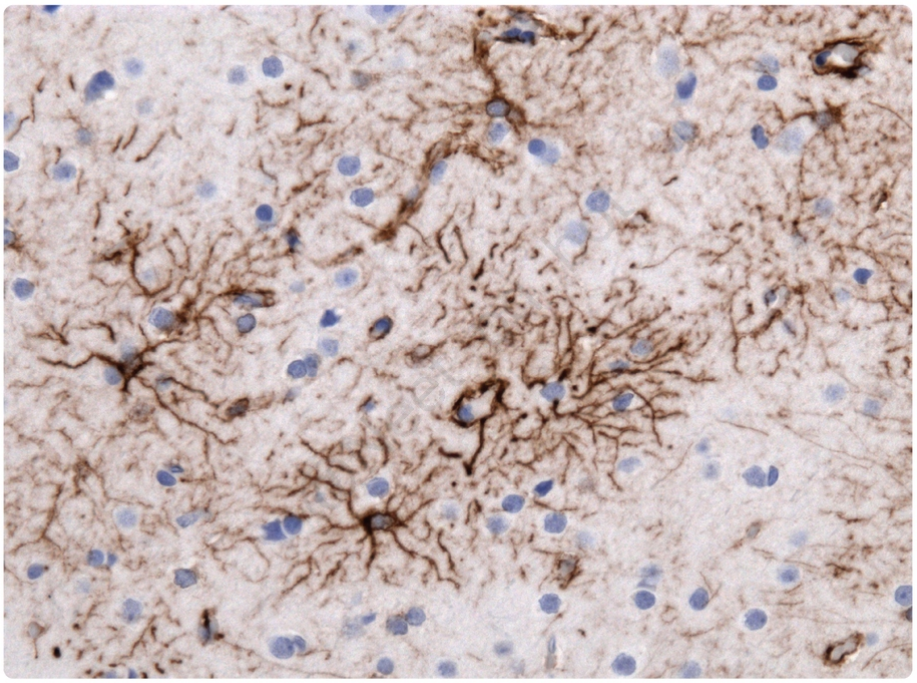

References:

Robbin’s and Cotran Pathologic Basis of Disease, 10th Edition, Page 970

Ganong’s Review of Medical Physiology, 26th Edition, Pages 92-94

↑ *Back to this question in Part A*

@Neet_pg_bot

Q11: A 10-year-old child presents with a history of headaches and balance difficulties over the past few months. Histopathological examination of the biopsy shows bipolar cells with long, thin hairlike processes, dense fibrillary meshwork, and characteristic eosinophilic corkscrew-shaped inclusions. Which inclusion bodies are involved in this type of tumor? (Q845167)

A. Rosenthal fibers

B. Glomeruloid bodies

C. Negri bodies

D. Lewy bodies

Correct Answer: A. Rosenthal fibers

■ *Listen (English)*

■ *Listen (Hindi)*

Explanation: The given clinical scenario and histopathological findings point towards diagnosing Pilocytic astrocytoma, low-grade brain tumors commonly found in children and young adults. They are characterized by their slow growth and relatively benign behavior. The histopathology shows bipolar cells with elongated processes and characteristic eosinophilic inclusions like Rosenthal fibers and mulberry bodies (eosinophilic granular bodies) These tumors are often well-demarcated and cystic , with a contrast-enhancing mural nodule seen on imaging. {{caption_text}} Glomeruloid bodies (Option B) : Glomeruloid bodies are a characteristic feature of Glioblastoma multiforme (GBM). Negri bodies (Option C) : Negri bodies are eosinophilic, inclusion bodies typically found in neurons infected with the rabies virus Lewy bodies (Option D): Lewy bodies are eosinophilic cytoplasmic inclusions composed primarily of alpha-synuclein protein. They are characteristic pathological features of Parkinson's disease.

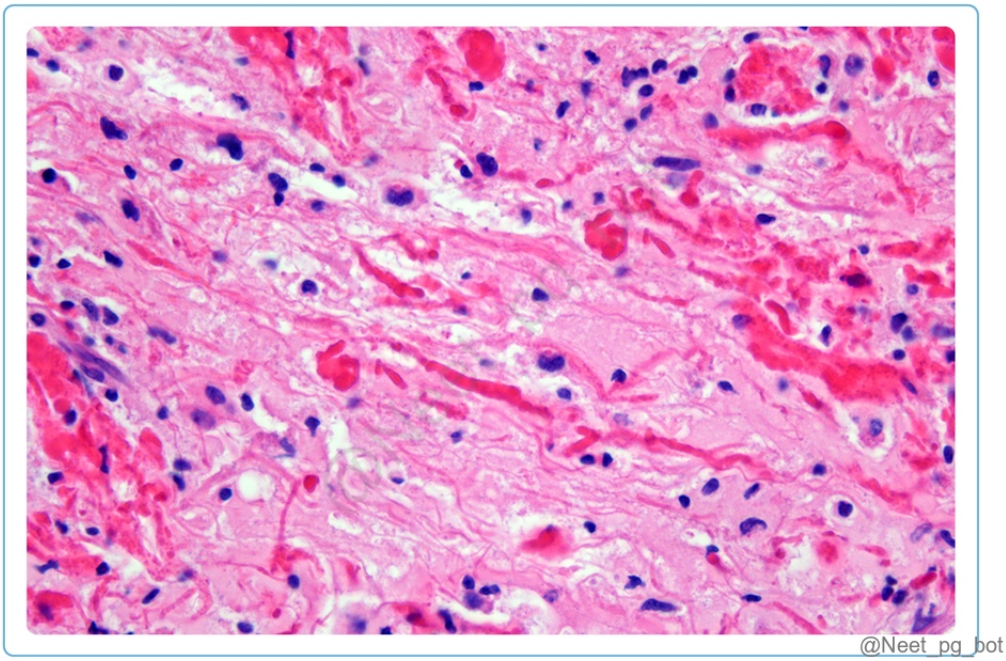

References:

Robbin’s and Cotran Pathologic Basis of Disease, 10th edition, Page 1296

www.researchgate.net/figure/Glomeruloid-vascular-proliferation-in-a-human-glioblastoma-multiforme-bioptic-specimen_fig2_359611477

↑ *Back to this question in Part A*

@Neet_pg_bot

Q12: According to the Anne Mayo grading system, what grade would be assigned to the tumor showing hypercellularity, nuclear atypia, and mitotic activity but no evidence of microvascular proliferation or necrosis? (Q845166)

A. Grade 1

B. Grade 2

C. Grade 3

D. Grade 4

Correct Answer: C. Grade 3

■ *Listen (English)*

■ *Listen (Hindi)*

Explanation: The St. Anne-Mayo grading system is a 4 tiered system and uses the presence of 4 morphologic criteria (AMEN) to assign a grade: Nuclear A typia M itosis E ndothelial proliferation - 'piled-up' endothelial cells. (NOT hypervascularity) N ecrosis The grade then depends on the accumulation of these criteria as follows: Grade 1 (Good prognosis): No AMEN Grade 2: Only atypia Grade 3: Atypia and mitosis Grade 4 (Poor prognosis): Atypia, mitosis, endothelial proliferation ± Necrosis Grade Tumor Types Characteristics Low grade Grade I Craniopharyngioma Chordomas Ganglioma Gangliocytoma Pilocytic astrocytoma Possibly curable via surgery alone Long-term survival Least malignant (benign) Non-infiltrative Grade II Pineocytoma "Diffuse" astrocytoma Pure oligodendroglioma Slight infiltrative Relatively slow-growing Can recur as a higher grade High grade Grade III Anaplastic ependymoma Anaplastic astrocytoma Anaplastic oligodendroglioma Malignant Infiltrative Tend to recur as higher grade. Grade IV Glioblastoma multiforme (GBM) Medulloblastoma Ependymoblastoma Pineoblastoma Most malignant Rapidly growing and aggressive Widely infiltrative Recurrence Tendency for necrosis

References:

Robbin’s and Cotran Pathologic Basis of Disease, 10th edition, Page 1293

https://www.ncbi.nlm.nih.gov/pmc/articles/PMC5709890/

↑ *Back to this question in Part A*

@Neet_pg_bot

Q13: A 45-year-old patient presents with new-onset headaches, seizures, and progressive unilateral weakness. Brain MRI reveals a cerebral mass with irregular borders and heterogeneous contrast enhancement. Biopsy shows GFAP-positive glial cells. What is the possible diagnosis? (Q845165)

A. Astrocytoma

B. Neurocytoma

C. Medulloblastoma

D. Meningioma

Correct Answer: A. Astrocytoma

■ *Listen (English)*

■ *Listen (Hindi)*

Explanation: The clinical presentation and biopsy showing GFAP (Glial Fibrillary Acidic Protein) positivity indicates a Glial cell tumor, Astrocytoma, the most common primary brain tumor in children. Classification of Brain tumors based on origin: Origin Tumors Glial Cell Astrocytoma (Option A) , ependymoma, oligodendroglioma Undifferentiated Cell Medulloblastoma (Option C) Neuronal Cell Neurocytoma (Option B) , Ganglioglioma, Ganglioneuroma Meningeal Cell Meningioma (Option D)

References:

Robbin’s and Cotran Pathologic Basis of Disease, 10th edition, Page 1293

↑ *Back to this question in Part A*

@Neet_pg_bot

Q14: Match the following: 1. Neuronophagia a) 2. Rabies b) 3. Microglial nodules c) 4. Globoid bodies d) (Q845164)

A. 1-b,2-c,3-a,4-d

B. 1-a,2-c,3-b,4-d

C. 1-a,2-b,3-d,4-c

D. 1-b,2-d,3-a,4-c

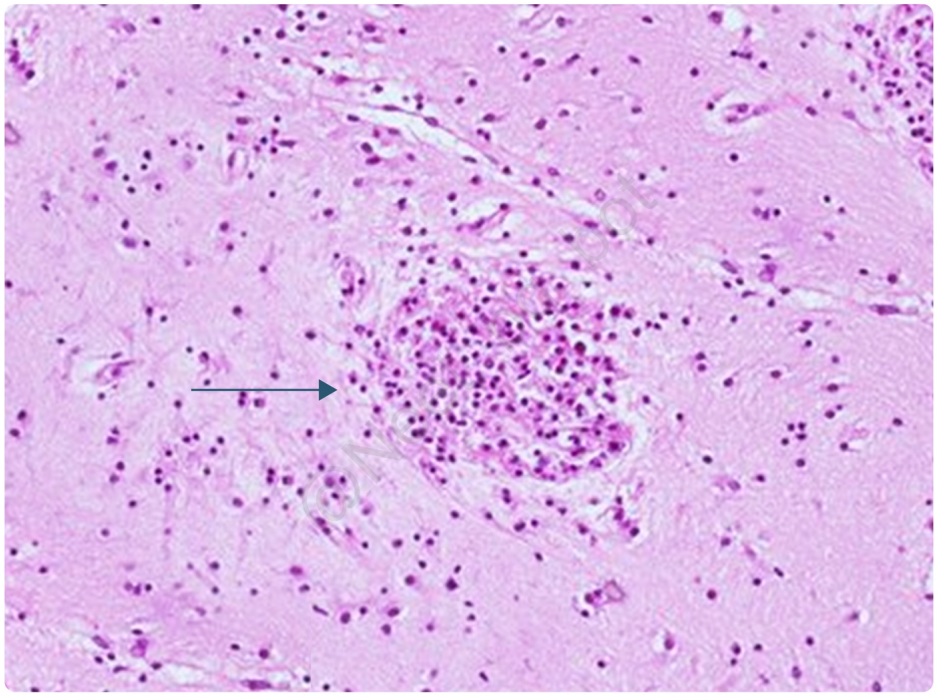

@Neet_pg_bot

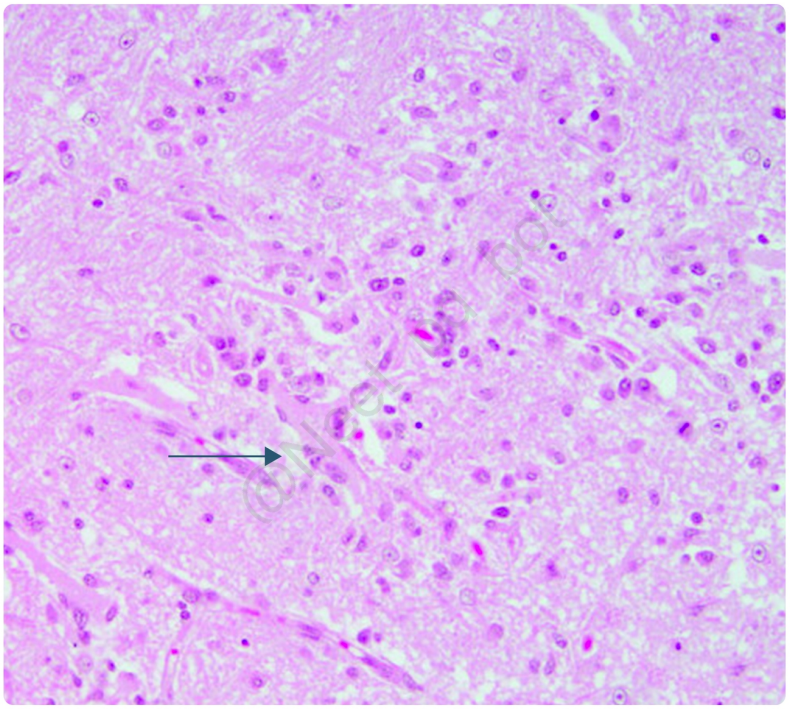

@Neet_pg_bot

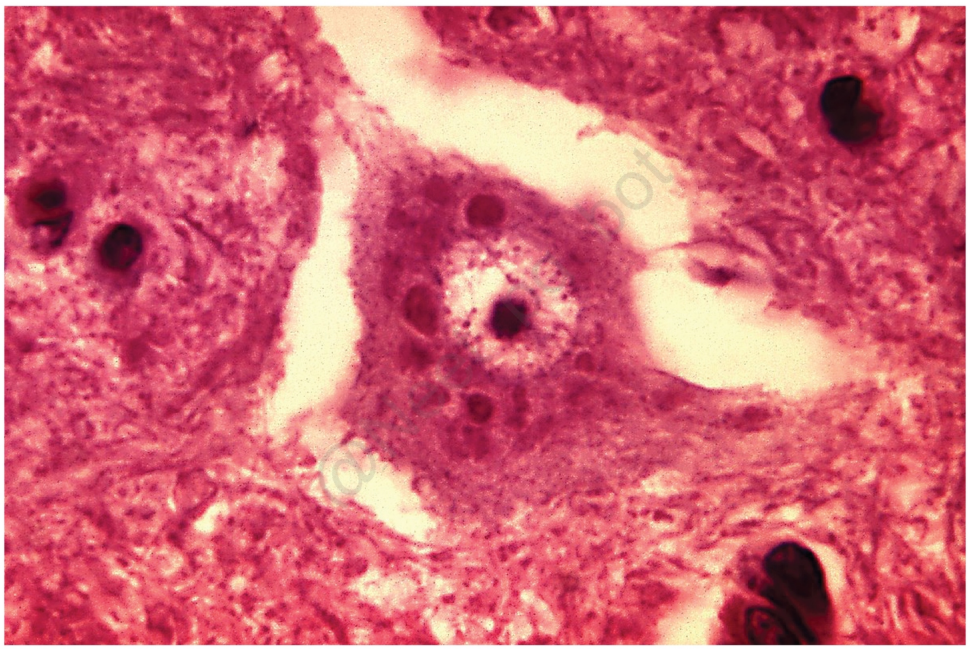

@Neet_pg_bot

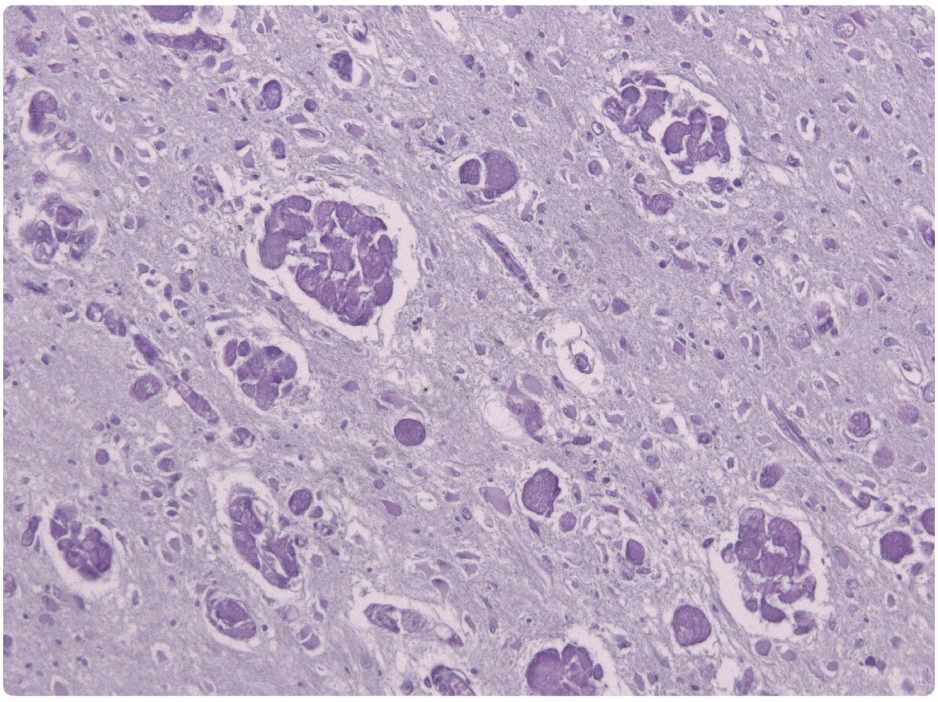

@Neet_pg_bot

Correct Answer: A. 1-b,2-c,3-a,4-d

■ *Listen (English)*

■ *Listen (Hindi)*

Explanation: Neuronophagia: Neuronophagia is a reaction of the microglial cells to injury. There are congregating cell bodies of dying neurons. It is seen in infections such as polio and rabies {{caption_text}} Rabies: Negri bodies , the pathognomonic microscopic finding, are cytoplasmic , inclusions found in pyramidal neurons of the hippocampus and Purkinje cells of the cerebellum {{caption_text}} Microglial nodules: They are seen in HIV infection of the brain. {{caption_text}} Krabbe's disease: Krabbe disease is an autosomal recessive leukodystrophy resulting from a deficiency of galactocerebroside β-galactosidase . The unique and diagnostic feature is the aggregation of engorged macrophages (globoid cells) in the brain parenchyma {{caption_text}}

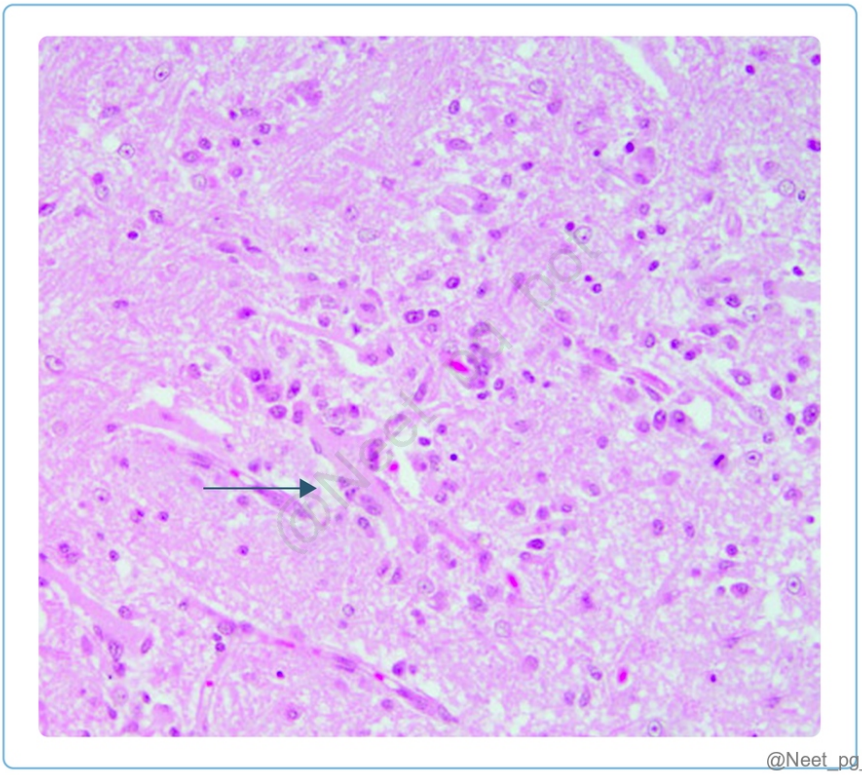

Negri bodies

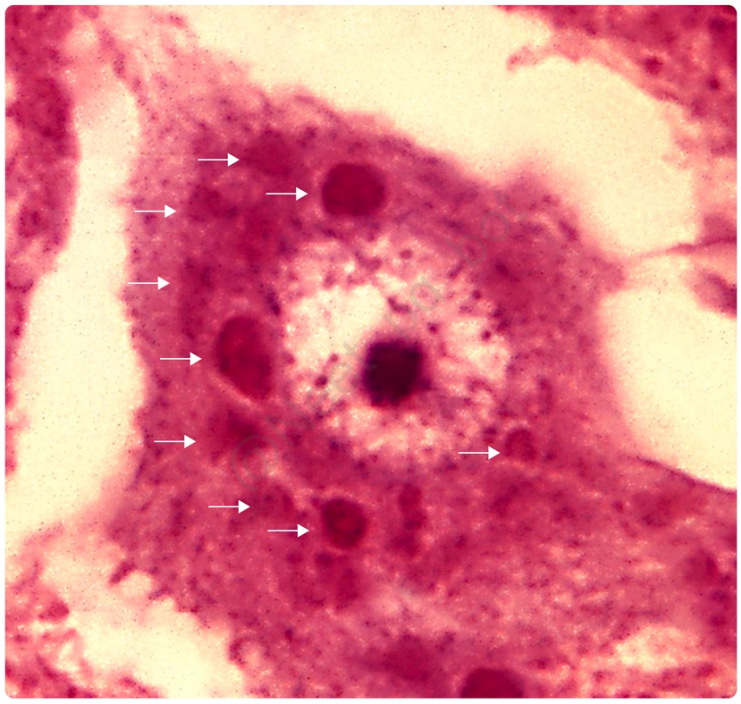

@Neet_pg_bot

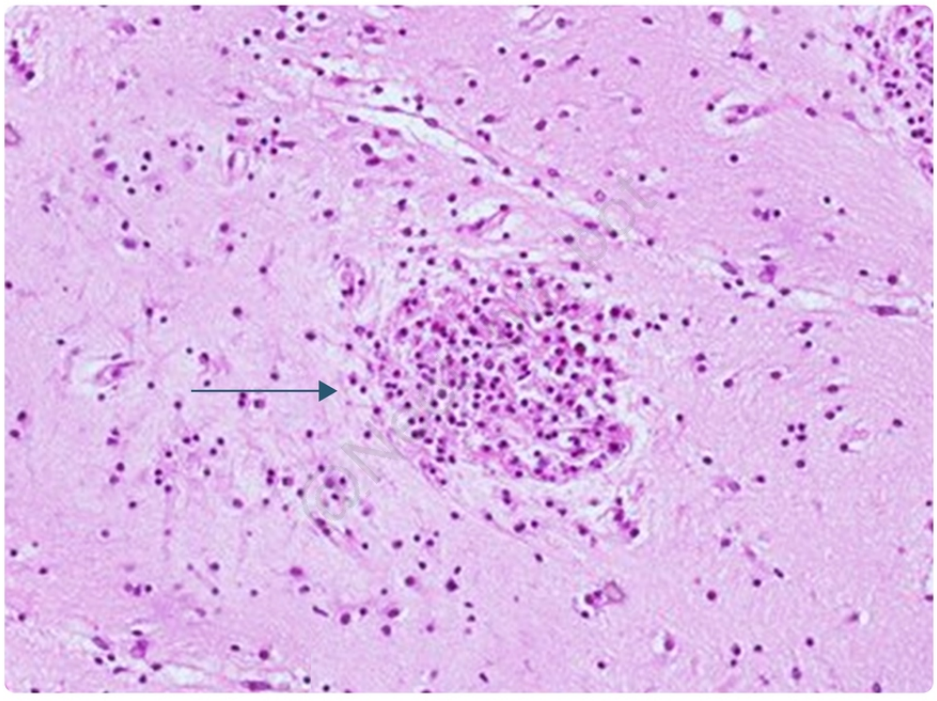

@Neet_pg_bot

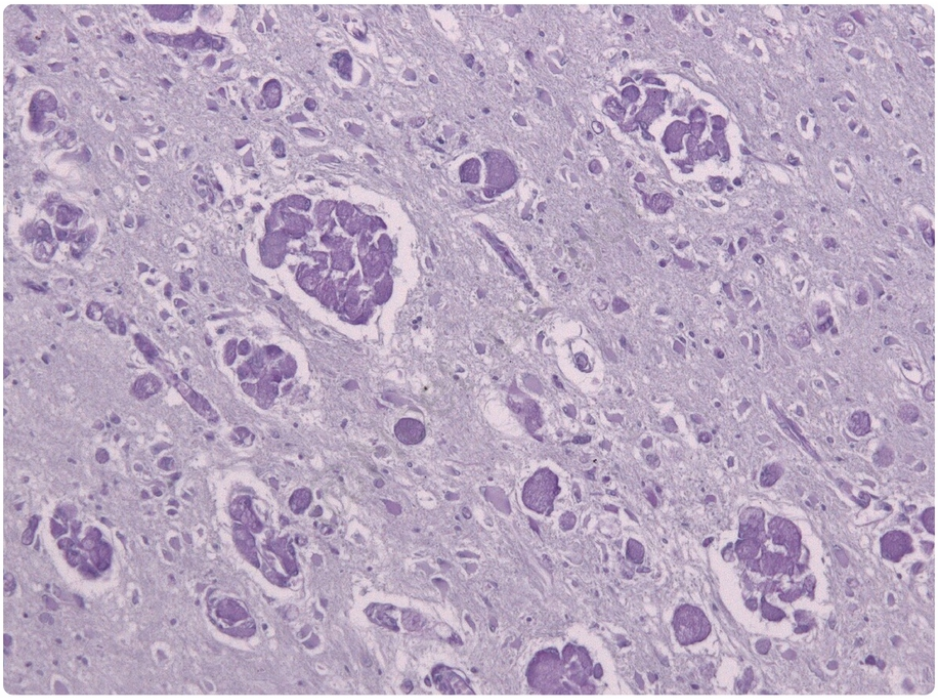

References:

Robbin’s and Cotran Pathologic Basis of Disease, 10th Edition, Pages 1275, 1287, 1290

↑ *Back to this question in Part A*

@Neet_pg_bot

Q15: Which of the following features are not seen in Alzheimer’s Disease? (Q845163)

A. Bunina bodies

B. Neuritic plaques

C. Neurofibrillary tangles

D. Hirano bodies

Correct Answer: A. Bunina bodies

■ *Listen (English)*

■ *Listen (Hindi)*

Explanation: Bunina bodies are seen in amyotrophic lateral sclerosis (ALS). They are PAS-positive cytoplasmic inclusions , which appear to be remnants of autophagic vacuoles . They contain two proteins, cystatin, and transferrin , and are considered a hallmark of ALS. Histology of Alzheimer’s disease: Plaques Deposits of Aβ peptides in the neuropil. Neuritic plaques contain both Aβ 40 and Aβ 42. Tangles Aggregates of the microtubule-binding protein tau. Demonstrated by silver (Bielschowsky) staining. Hirano bodies Composed of Actin (intracellular inclusions) Granulovacuolar degeneration Formation of small, clear vacuoles within the neurons. {{caption_text}} Plaques {{caption_text}} Neurofibrillary tangles {{caption_text}} Hirano bodies {{caption_text}} Granulovacuolar degeneration

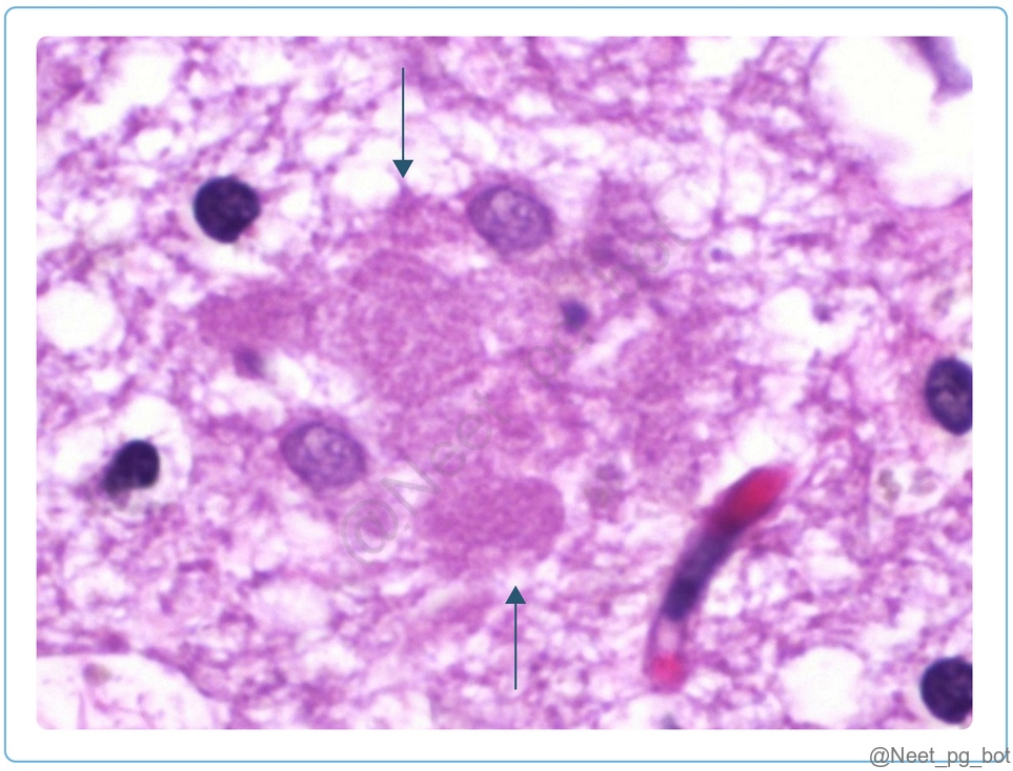

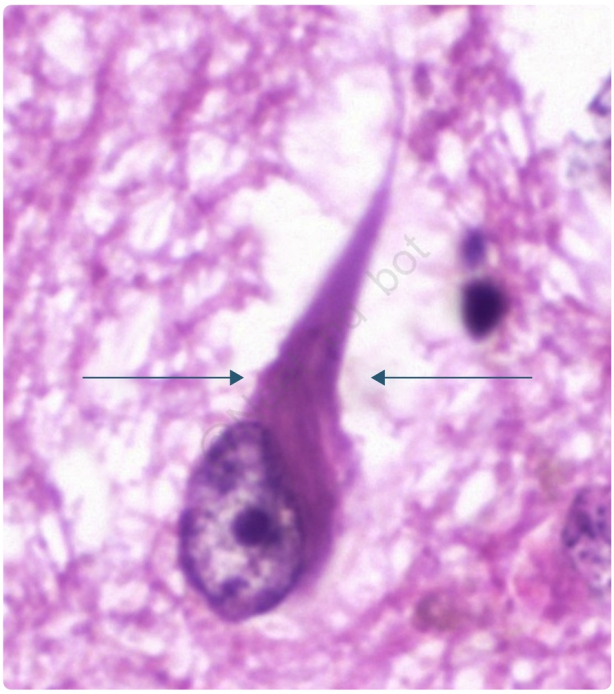

@Neet_pg_bot

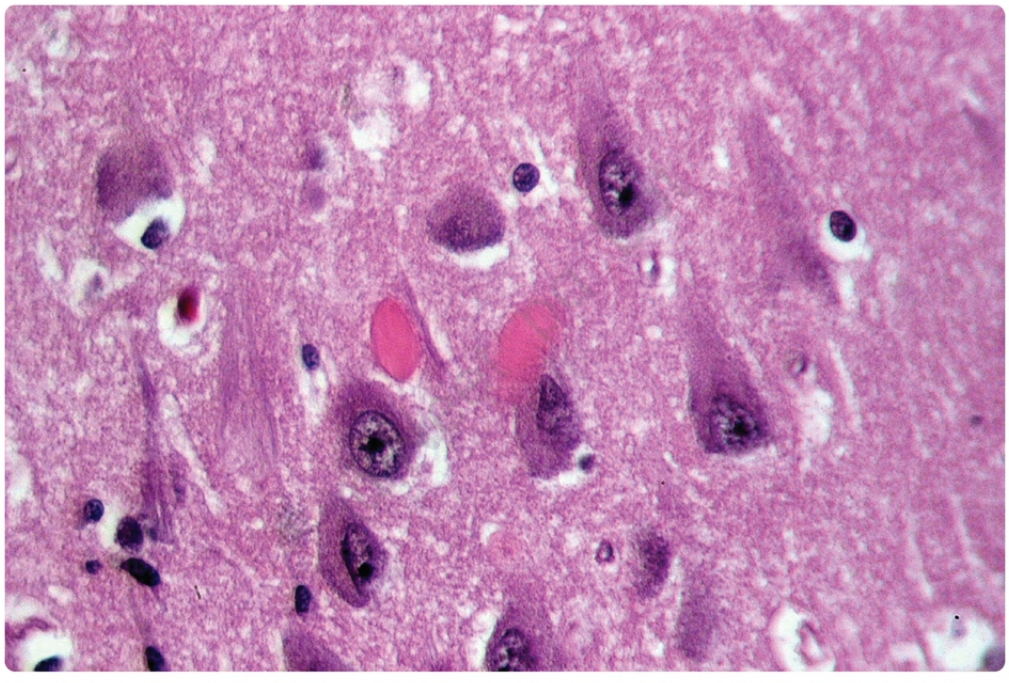

@Neet_pg_bot

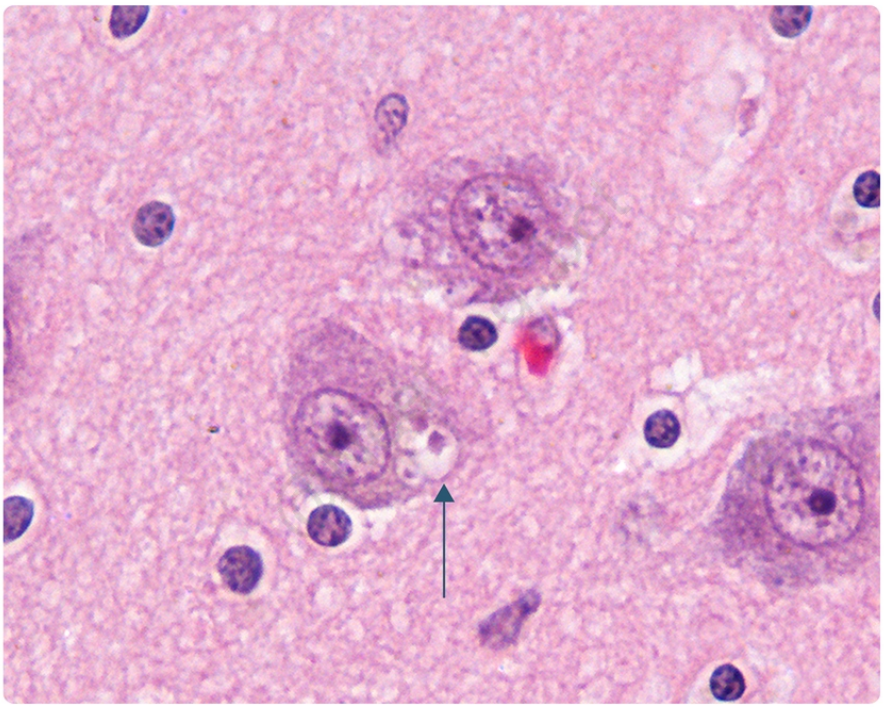

References:

Robbin’s and Cotran Pathologic Basis of Disease, 10th Edition, Page 1278

↑ *Back to this question in Part A*

@Neet_pg_bot

Q16: Which of the following statements about Alzheimer’s Disease is/are correct? 1) Due to the mutation of the APP gene on Chromosome 21 2) Alpha and Gama secretase pathways are involved 3) APOE2 is a risk factor 4) Affects the frontal, parietal, and temporal lobes. (Q845162)

A. 2,3

B. 2,4

C. 1,3

D. 1,4

Correct Answer: D. 1,4

Explanation: Alzheimer's disease is a progressive neurological disorder causing memory loss, cognitive decline, and personality changes. Alzheimer's Disease is the most common cause of dementia in the elderly. It affects the frontal, parietal, and temporal lobes (Statement 4). It occurs due to the mutation of the APP gene on Chromosome 21 (Statement 1). If APP is processed by alpha and gamma-secretase pathways, products are soluble and do not deposit in the brain, and there is no disease. (Statement 2). If the beta-secretase pathway processes APP, it produces amyloid products, which are pathogenic. APOE2 is considered a protective factor for Alzheimer's Disease (Statement 3). Genetics of Alzheimer's Disease: Gene Chromosome Features APP 21 Trisomy 21 (Down's syndrome): ↑ APP → Presenile Alzheimer's disease Presenilin 1 14 γ-secretase complex generates increased amounts of Aβ, particularly Aβ42. Presenilin 2 1 APOE4 19 Early-onset Alzheimer's disease.

References:

Robbin's and Cotran Pathologic Basis of Disease, 10th Edition, Pages 1275-1277.

↑ *Back to this question in Part A*

@Neet_pg_bot

Q17: A 65-year-old male presents with a 6-month history of resting tremor in his right hand, which improves with movement. He reports increasing slowness in daily activities and stiffness, particularly in the morning. He has had occasional falls due to unsteadiness while walking. Physical examination reveals a shuffling gait and cogwheel rigidity. All of the following are true statements regarding this condition except? (Q845161)

A. A key pathological feature in the substantia nigra neurons is observed.

B. This condition can occur due to mitochondrial dysfunction.

C. Mutations in LRRK2 are the most common cause of autosomal dominant disease.

D. Homozygous mutation of glucocerebrosidase is an important risk factor for this condition.

Correct Answer: D. Homozygous mutation of glucocerebrosidase is an important risk factor for this condition.

■ *Listen (English)*

■ *Listen (Hindi)*

Explanation: The clinical vignette of resting tremors, early morning stiffness, unsteadiness, shuffling gait, and cogwheel rigidity is suggestive of Parkinson's disease. Homozygous mutations in glucocerebrosidase cause Gaucher's disease , a lysosomal storage disorder. Parkinson's Disease (PD): Autosomal dominant PD is SNCA , a gene that encodes α-synuclein . This protein is a major component of the Lewy body, which is the diagnostic hallmark of PD. Autosomal recessive forms of PD, are caused by gene mutations that encode the proteins DJ-1, PINK1, and parkin (Option B) . Mutations in the gene encoding LRRK2 (leucine-rich repeat kinase 2) are the most common cause of autosomal dominant PD (Option C) . Clinical Features: Triad of tremor, rigidity, and

bradykinesia. Morphology: A characteristic gross finding in PD is pallor of the substantia nigra Lewy bodies are usually single or multiple, cytoplasmic, eosinophilic, round to elongated inclusions. They have a dense core surrounded by a pale halo. Ultrastructurally, they are composed of fine filaments (composed of α-synuclein) {{caption_text}}

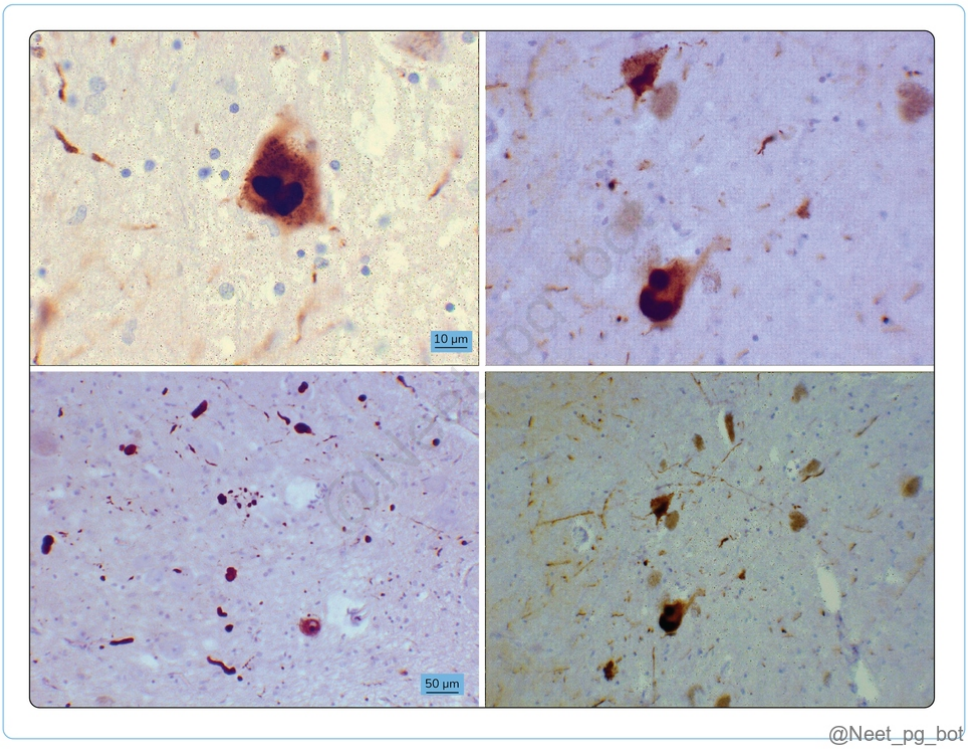

References:

Robbin's and Cotran Pathologic Basis of Disease, 10th Edition, Pages 1282-1283

↑ *Back to this question in Part A*

@Neet_pg_bot

Q18: A 55-year-old male presented with behavioral changes and involuntary movements over the past several weeks. Neurological examination revealed ataxia and myoclonus. He passed away after 4 months, and biopsy findings of the brain tissue are shown below. Based on these findings, which of the following statements is false regarding this condition? Proteinaceous particles with single-stranded RNA cause it. It results from the misfolding of PrPsc to PrPc. Spongiform transformation is a characteristic histopathological feature It is associated with a good prognosis if diagnosed early. Familial forms are associated with specific genetic mutations.

(Q845160)

A. 1, 2 and 4

B. 1, and 4

C. 2 and 4

D. 3, 4 and 5

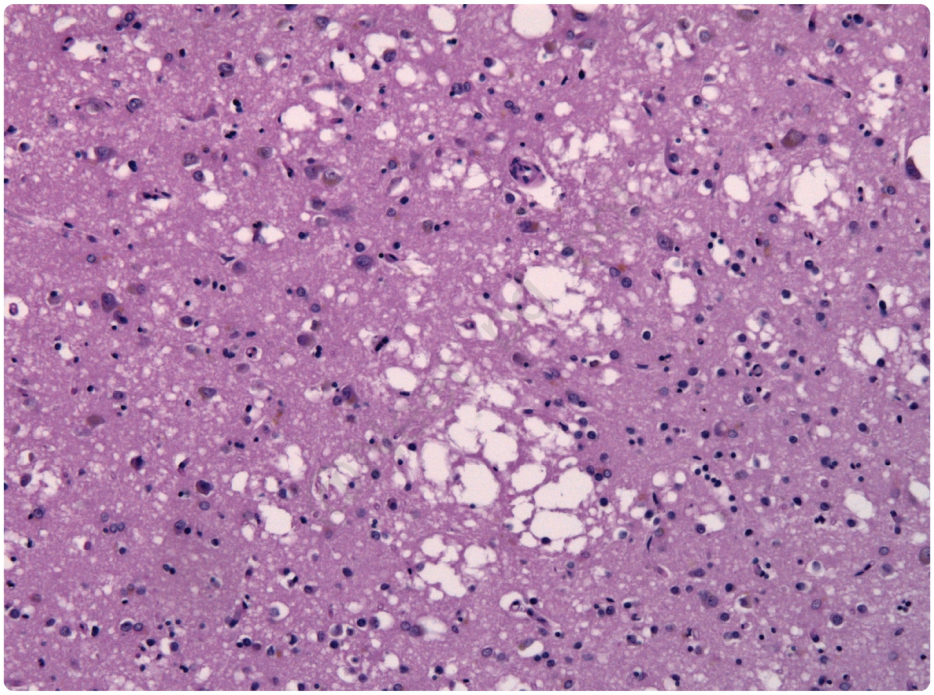

Correct Answer: A. 1, 2 and 4

■ *Listen (English)*

■ *Listen (Hindi)*

Explanation: The most likely diagnosis in this clinical presentation is Creutzfeldt-Jakob disease (CJD), a prion disease. Prion Disease or Transmissible Spongiform Encephalopathy (TSE): Prions are proteinaceous infectious particles with no RNA/DNA . Pathogenesis: Misfolding of normal prion protein (PrPc) to form beta-pleated configuration (PrPSc). Common Symptoms: ■■■■■■■ Rapidly progressing dementia (memory loss, confusion). Ataxia (difficulty walking and loss of balance). Myoclonus (sudden, involuntary muscle jerks). Insomnia (specifically severe in the Fatal Familial Insomnia variant). Mood changes (depression, anxiety, or personality shifts). Histopathology: Spongiform vacuolisation inside the cell. Diagnosis: DWI (Diffusion-Weighted Imaging): Most sensitive sequence for early diagnosis. It identifies restricted diffusion as bright hyperintense signals. ADC Map (Apparent Diffusion Coefficient): Used to confirm "true" restricted diffusion. Affected areas in prion disease typically appear dark (hypointense) on the ADC map. FLAIR (Fluid-Attenuated Inversion Recovery): Shows hyperintensities in similar regions as DWI but is generally less

sensitive in the earliest stages. T1-weighted MRI: Usually appears normal or shows non-specific brain shrinkage (atrophy) as the disease reaches the end stage. Types of prion disease 1. Creutzfeldt-Jakob disease (M/C) Genetic: Familial form caused by PRNP mutation. Transmission: Iatrogenic Symptoms: Dementia. Associated pronounced involuntary jerking muscle contractions on sudden stimulation (startle myoclonus) and cerebellar dysfunction (ataxia). Histopathogenesis: Spongiform transformation of the cerebral cortex. Prognosis: Uniformly fatal with average survival < 7 months after the onset of symptoms. 2. Kuru disease PAS & Congo: red positive. Kuru plaques: Extracellular aggregated abnormal PrP. 3. Fatal familial insomnia 4. Bovine spongiform encephalopathy Comparison of radiological findings in different types of prions diseases: Feature Sporadic CJD (sCJD) Variant CJD (vCJD) Genetic Forms (FFI/GSS) Primary Location Cortex and Basal Ganglia Thalamus (Pulvinar/Dorsomedial) Thalamic atrophy (FFI); variable cortical/limbic signs Key Sign Cortical Ribboning Pulvinar/Hockey Stick Sign Thalamic degeneration DWI vs. FLAIR DWI > FLAIR FLAIR is highly sensitive Routine MRI is often normal

References:

Robbin’s and Cotran Pathologic Basis of Disease, 10th Edition, Pages 1273-1275

↑ *Back to this question in Part A*

@Neet_pg_bot

• [15_Central Nervous System] 063 Previous Year Questions

« Back to Folder Directory

[15_Central Nervous System] 063 Previous Year Questions — Quick Jump

Q1 (p. 2531)	*Q2 (p. 2534)*	*Q3 (p. 2534)*	*Q4 (p. 2537)*	*Q5 (p. 2539)*	*Q6 (p. 2540)*
Q7 (p. 2541)	*Q8 (p. 2542)*	*Q9 (p. 2543)*	*Q10 (p. 2544)*	*Q11 (p. 2544)*	*Q12 (p. 2545)*
Q13 (p. 2547)	*Q14 (p. 2547)*	*Q15 (p. 2549)*	*Q16 (p. 2551)*	*Q17 (p. 2552)*	

Q1: A 40-year-old female presents with frequent headaches. The investigation reveals raised intracranial pressure and the presence of a dural-based tumour. Which of the following histological findings correlates with the diagnosis? (Q858139)

A. Fried-egg appearance

B. Flexner-Wintersteiner rosettes

C. Psammoma bodies with whorling of tumor cells

D. Homer-Wright rosettes

Correct Answer: C. Psammoma bodies with whorling of tumor cells

Explanation: The patient’s presentation of a dural-based tumour with raised intracranial pressure suggests a diagnosis of meningioma, and the histological feature of psammoma bodies with whorling of tumour cells is a characteristic finding. They originate from meningothelial cells of the arachnoid layer and are typically connected to the dura mater. More common in women and has increased risk with pregnancy , exposure to radiation and NF2 gene mutation. Tumours typically exhibit a rubbery dural mass, compressing the brain, yet easily separable. Histopathologically, they present with a whorled pattern of cells and psammoma bodies and are progesterone receptor-positive . {{caption_text}} {{caption_text}} Incorrect Options: Fried-egg appearance (Option A) is characteristic of oligodendrogliomas along with chicken wire vessels, calcification and perineuronal satellitosis. {{caption_text}} Flexner-Wintersteiner rosettes (Option B) are composed of an ‘empty’ lumen surrounded by columnar cells and are seen in retinoblastomas , along with Homer-Wright rosettes , undifferentiated tumour cells and areas of necrosis and calcification. {{caption_text}} Homer-Wright rosettes (Option D) are pseudo-rosettes and consist of cells surrounding a central lumen made up of their processes. They are commonly seen in neuroblastomas.

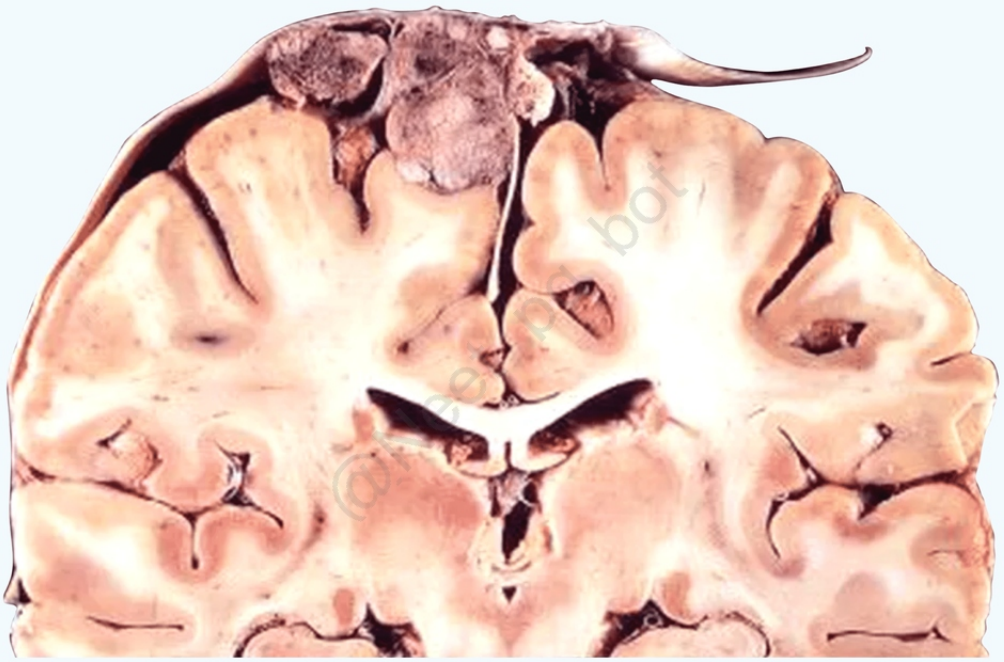

@Neet_pg_bot

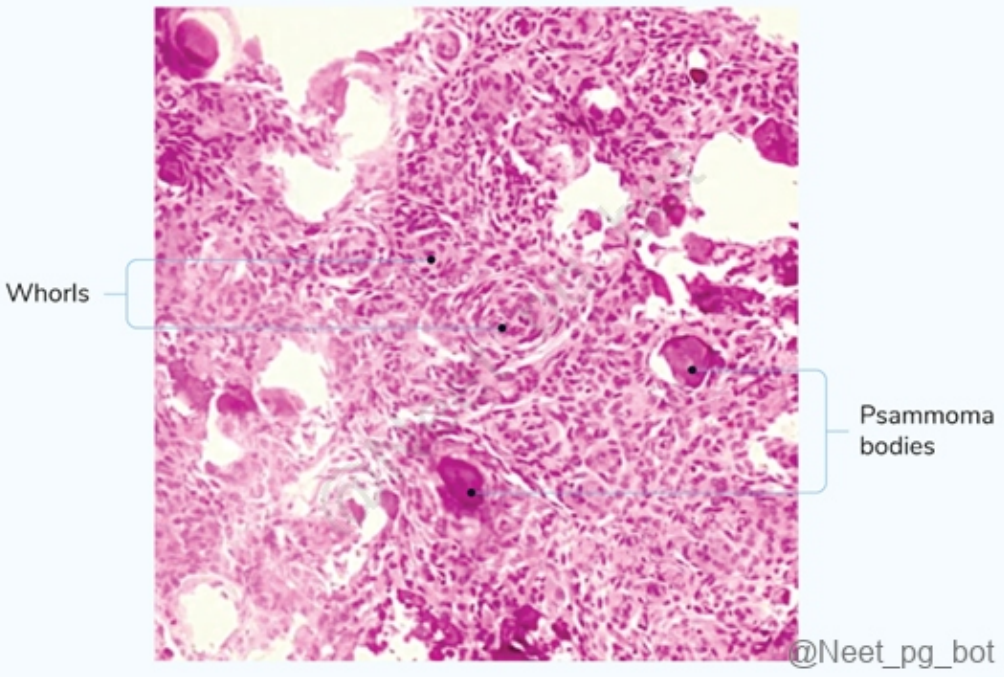

@Neet_pg_bot

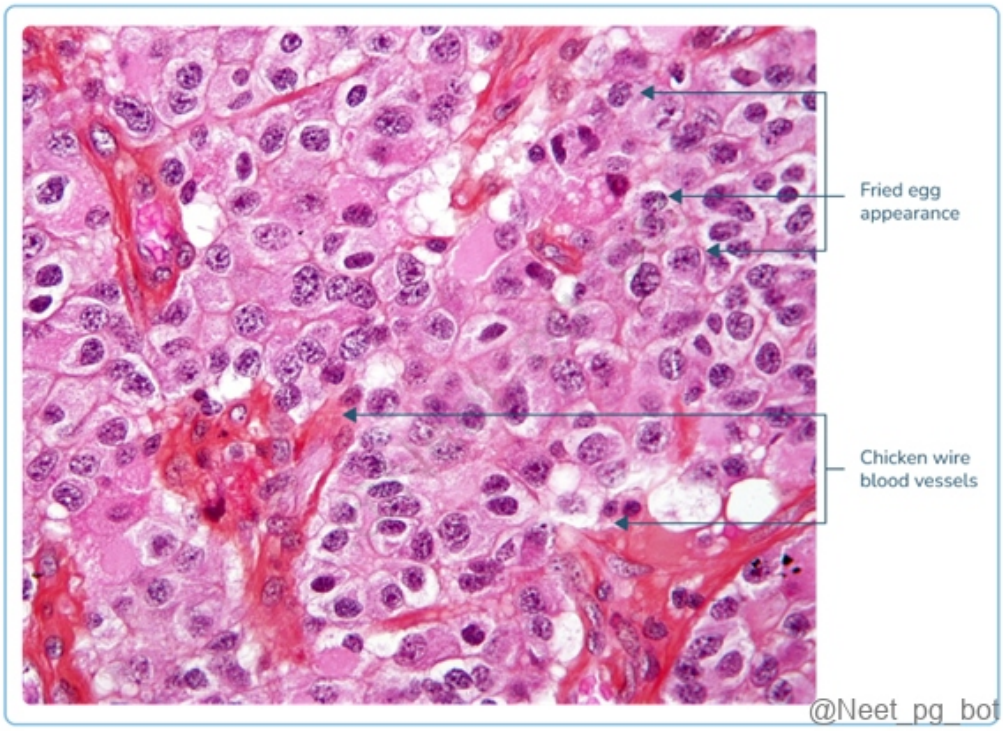

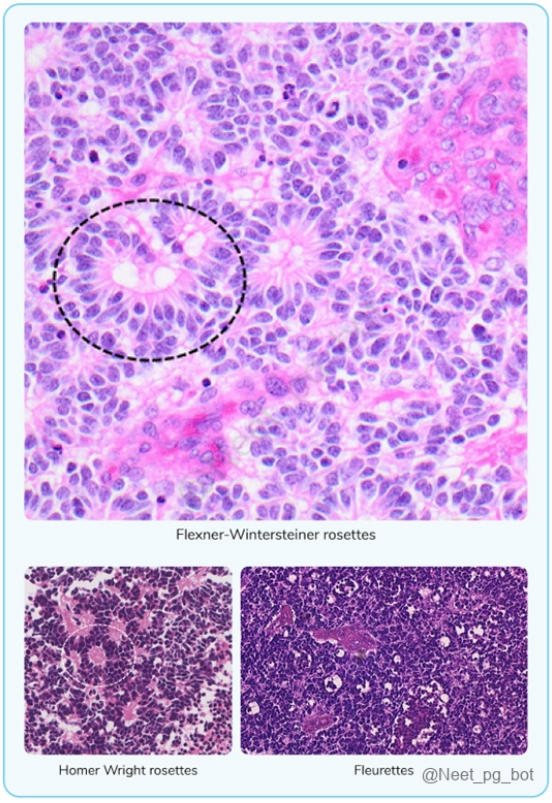

References:

Robbins & Cotran, Pathologic Basis of Disease, 10th Edition, Pages 1293 - 1301

↑ *Back to this question in Part A*

@Neet_pg_bot

Q2: What is the most common cause of berry aneurysm? (Q859895)

A. Endothelial injury of the vessel due to hypertension

B. Muscle intimal elastic lamina layer defect

C. Muscle and adventitial layer defect

D. Adventitia defect

Correct Answer: B. Muscle intimal elastic lamina layer defect

Explanation: Berry aneurysms , also known as saccular aneurysms or intracranial aneurysms, most commonly occur due to a defect in the muscle intimal elastic lamina layer of the blood vessel wall. This defect weakens the vessel wall, leading to the formation of a small outpouching or sac-like dilation. These aneurysms are frequently found in the arteries at the base of the brain, particularly at the branching points of the major cerebral arteries. Endothelial injury of vessels due to hypertension (Option A): While hypertension can contribute to the development and progression of aneurysms, it is not the most common cause of berry aneurysms. Muscle and adventitial layer defect (Option C) and Adventitia defect (Option D) : Berry aneurysms primarily involve the defect in the muscle intimal elastic lamina layer.

References:

Robbins & Cotran Pathologic Basis of Disease, 10th Edition, Pages 487- 506, 1259

↑ *Back to this question in Part A*

@Neet_pg_bot

Q3: Tau protein inclusions are involved in: (Q859856)

A. Alzheimer’s disease

B. Huntington's disease

C. Amyotrophic lateral sclerosis

D. CNS lymphoma

Correct Answer: A. Alzheimer’s disease

Explanation: The fundamental abnormality in Alzheimer’s disease is the accumulation of two proteins (Aβ and tau) in specific brain regions in the form of plaques and tangles. Morphology of Alzheimer’s disease: Gross: Cortical atrophy (narrowed gyri and widened sulci) is predominant in the frontal, temporal, and parietal lobes. Histology: Plaques Deposits of Aβ peptides in the neuropil. They are of two types: Diffuse and neuritic (senile). Neuritic plaques contain both Aβ 40 and Aβ 42. Diffuse plaques are predominantly made up of Aβ 42 and seen in trisomy 21 patients. Tangles Aggregates of the microtubule-binding protein tau. Demonstrated by silver (Bielschowsky) staining. Commonly found in cortical neurons, especially in the entorhinal cortex, and in other sites such as pyramidal cells of the hippocampus, amygdala, basal forebrain, and raphe nuclei. Hirano bodies Intracellular eosinophilic inclusions are typically found in conditions like Alzheimer's disease and Creutzfeldt–Jakob disease. Granulovacuolar degeneration Formation of small, clear vacuoles within the neurons. {{caption_text}} Plaques {{caption_text}} Neurofibrillary tangles {{caption_text}} Hirano bodies {{caption_text}} Granulovacuolar degeneration Huntington's Disease (Option B) is characterised by toxic gain-of-function of mutant huntingtin protein and neuronal loss in the striatum. Amyotrophic Lateral Sclerosis (ALS) (Option C) involves the degeneration of motor neurons, often linked to superoxide dismutase 1 (SOD1) mutations or TDP-43 protein inclusions. CNS Lymphoma (Option D) is a type of brain tumour originating from lymphocytes (B cells) and is unrelated to tau protein.

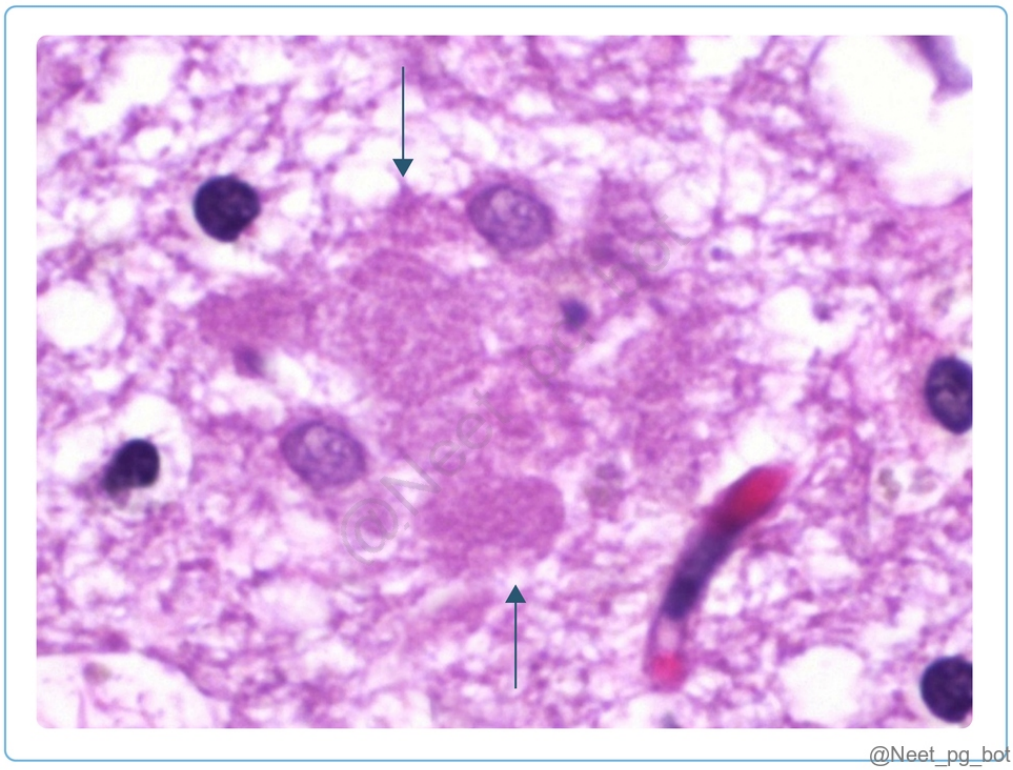

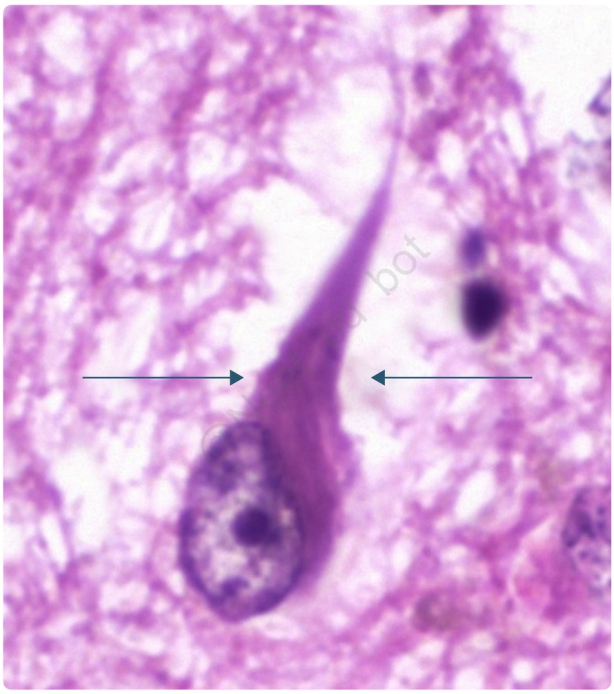

@Neet_pg_bot

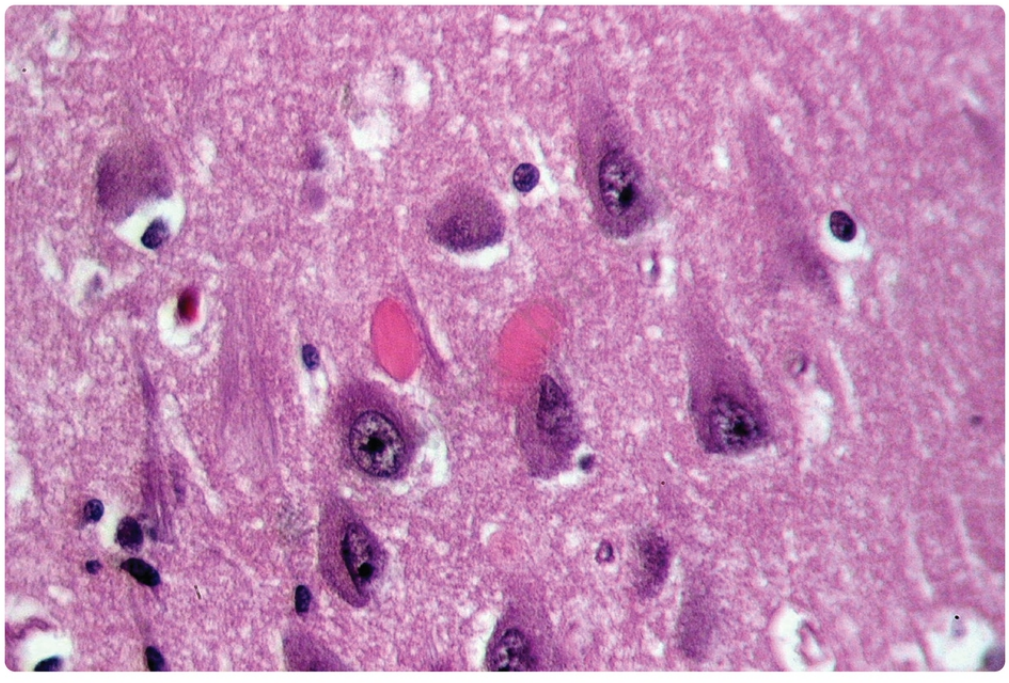

@Neet_pg_bot

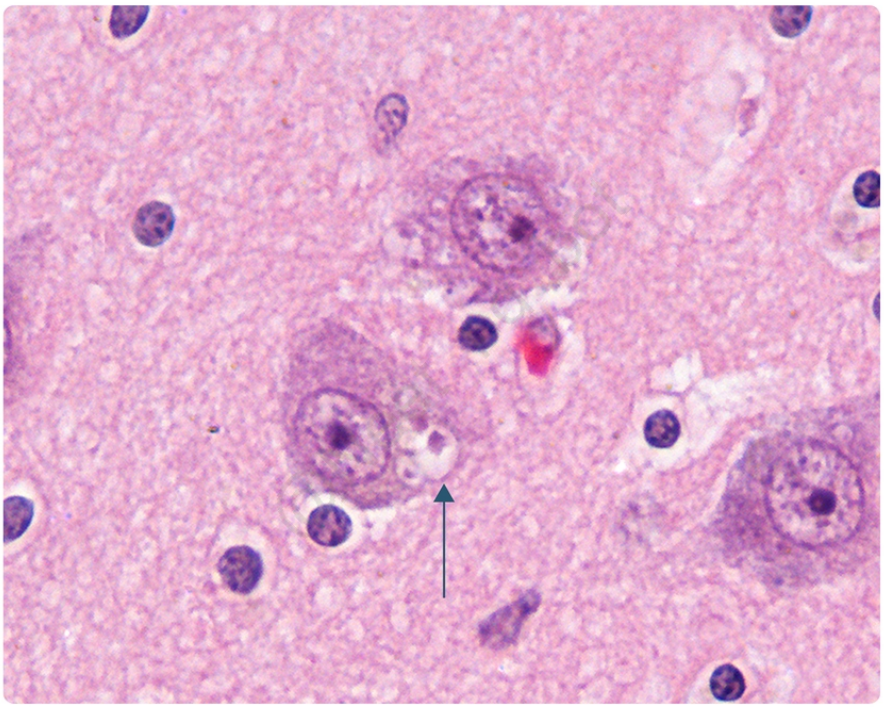

References:

Robbins & Cotran Pathologic Basis of Disease, 10th Edition, Page 1278

↑ *Back to this question in Part A*

@Neet_pg_bot

Q4: A 40-year-old female presents with the development of seizures, for which a CT-guided biopsy was done. The histopathological image showed the presence of psammoma bodies. What is the most likely diagnosis? (Q859262)

A. Astrocytoma

B. Medulloblastoma

C. Meningioma

D. Ependymoma

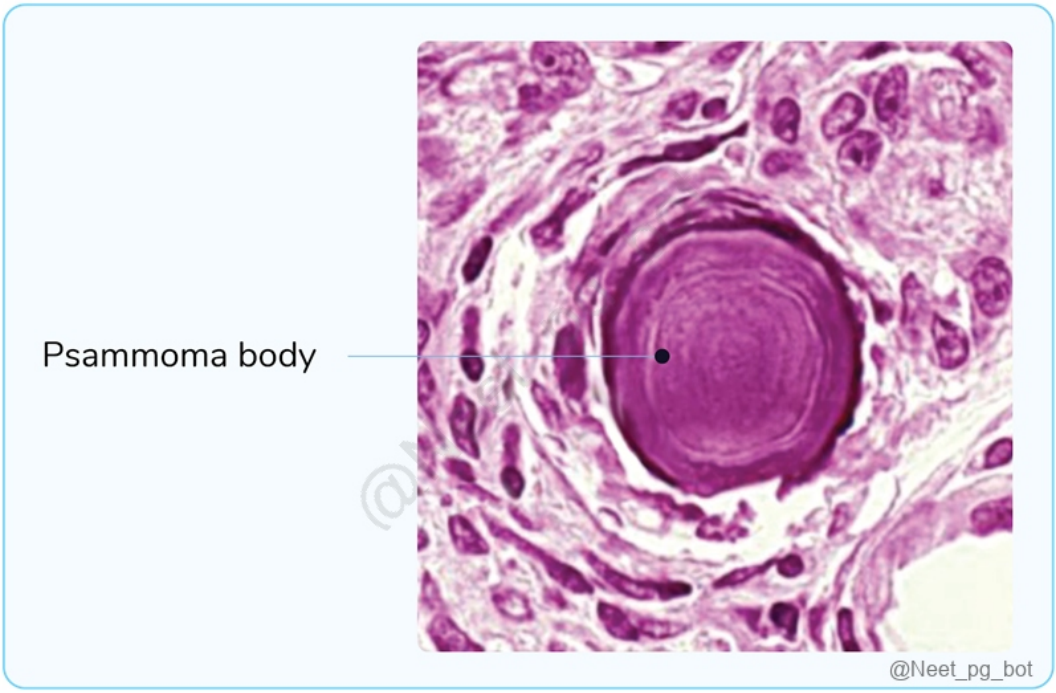

Correct Answer: C. Meningioma

Explanation: Meningiomas are tumours originating from the meninges , the protective membranes covering the brain and spinal cord. They are not derived from glial cells but rather from the arachnoid cap cells of the meninges . Incorrect Options: Astrocytoma (Option A) is a GFAP-positive glial cell tumour and the most common primary brain tumour in children. Histologically, it features densely packed elongated cells with round to oval nuclei and prominent nucleoli. Medulloblastoma (Option B) are embryonal tumours that develop from undifferentiated neuroepithelial cells in the cerebellum . They are not derived from glial cells but instead from primitive neuroectodermal cells . It is the most common malignant tumour in children. Ependymoma (Option D) arises from ependymal cells lining the ventricular system or spinal cord. It is commonly seen in the fourth ventricle in children and in the spinal cord in adults . Histologically, it is characterised by perivascular pseudorosettes , where tumour cells are arranged around blood vessels, and ependymal rosettes , where cells form true rosettes with a central lumen. {{caption_text}}

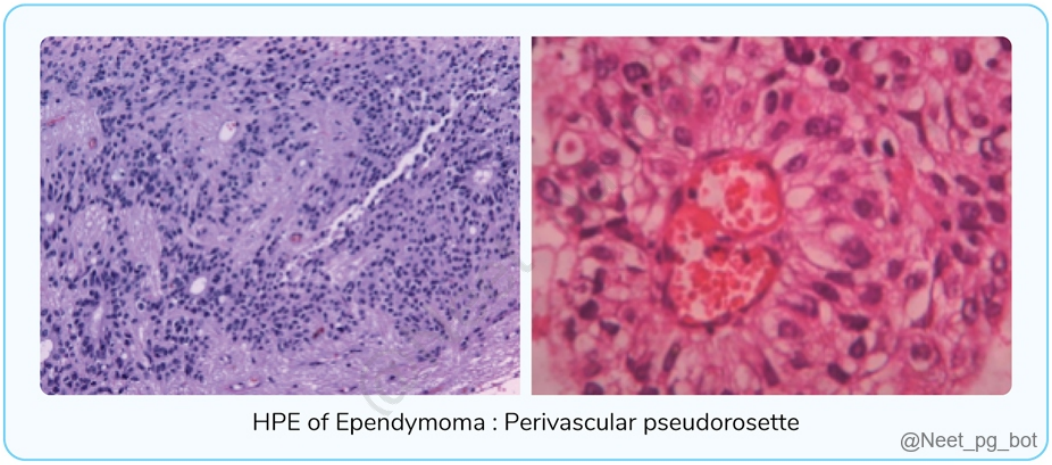

References:

Robbins & Cotran Pathologic Basis of Disease, 10th Edition, Page 1293

↑ *Back to this question in Part A*

@Neet_pg_bot

Q5: A 24-year-old patient presented with swelling in the wrist joint. Histopathological examination of the swelling revealed spindle cells with palisading of the nuclei and Verocay bodies. Which of the following is the most likely condition? (Q854862)

A. Schwannoma

B. Neurofibroma

C. Neuroma

D. Glioma

Correct Answer: A. Schwannoma

Explanation: Schwannoma is a benign tumour of the peripheral nerve sheath, characterised by spindle-shaped cells with palisading nuclei and Verocay bodies, which are pathognomonic. Schwannomas are benign tumours originating from Schwann cells, often linked to mutations in the NF2 gene. These tumours are well-circumscribed, encapsulated, and typically attached loosely to nerves, allowing for surgical removal without damaging nerve function. They appear as firm, grey masses. Histology: Antoni A areas : Dense eosinophilic regions with spindle cells in intersecting fascicles. Antoni B areas : Looser, hypocellular regions with a myxoid extracellular matrix. Verocay bodies : Structures with central "nuclear-free zones" surrounded by palisading nuclei. Schwann cells show spindle-shaped nuclei and immunoreactivity for S-100. {{caption_text}} Degenerative changes: Nuclear pleomorphism, xanthomatous change, and necrosis can occur. Malignant transformation is rare, but large mitotically active schwannomas can resemble sarcomas. Other features: Schwannomas may recur if incompletely resected but rarely transform malignantly. They can arise from sensory nerves, including branches of the trigeminal nerve or dorsal roots, and can occur both within and outside the nerve trunk. Surgical removal is typically curative. Neurofibroma (Option B) are benign tumours that develop from peripheral nerves. They are composed of a mix of Schwann cells, fibroblasts, and other cellular components. Histologically, neurofibromas have a more varied appearance than schwannomas, with multiple cell types and no presence of Verocay bodies. Neuroma (Option C) is an abnormal growth of nerve tissue caused by nerve injury or trauma. They are characterised by disorganised nerve fibres and can lead to symptoms such as pain, tingling, and sensory disturbances. Glioma (Option D) are tumours that arise from glial cells in the central nervous system.

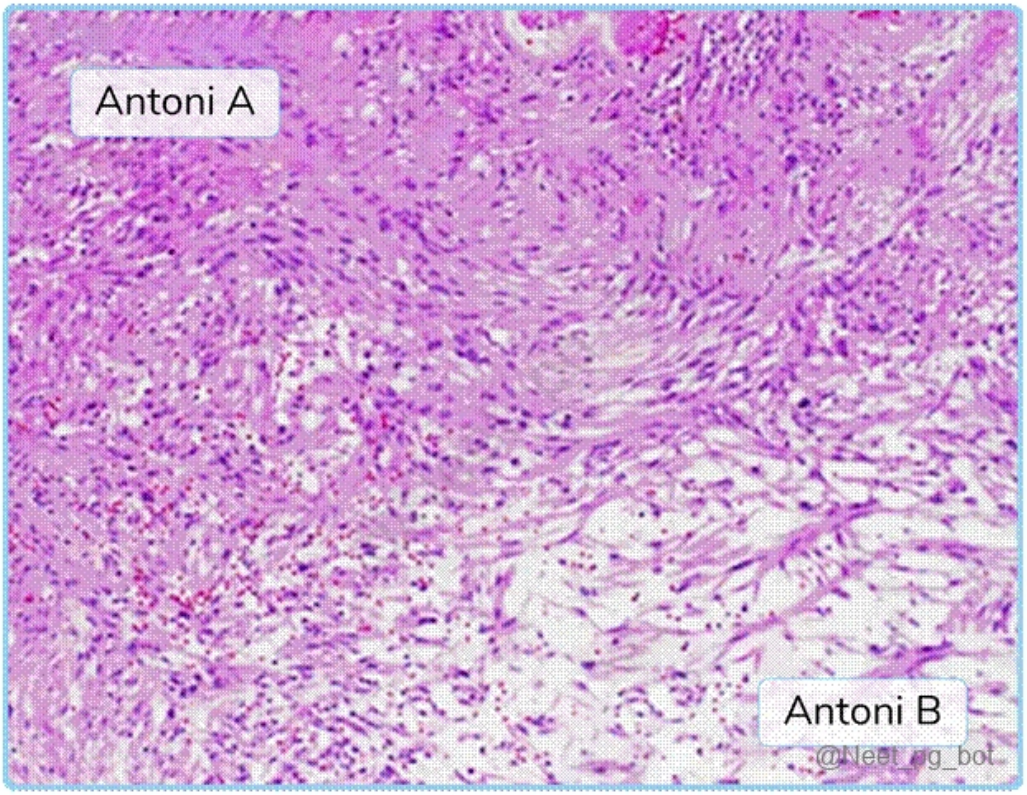

References:

Robbins & Cotran Pathologic Basis of Disease, 10th Edition, Page 1237

↑ *Back to this question in Part A*

@Neet_pg_bot

Q6: All of the following conditions are related to the same core pathology, except: (Q856486)

A. Parkinson’s disease

B. Alzheimer’s disease

C. Lewy body dementia

D. Multisystem atrophy

Correct Answer: B. Alzheimer’s disease

Explanation: Parkinson's disease, Lewy body dementia, and multisystem atrophy are all associated with alpha-synuclein pathology, specifically the formation of Lewy bodies in the brain. In contrast, Alzheimer's disease

is primarily characterized by the accumulation of amyloid plaques and neurofibrillary tangles of tau protein, representing a different core pathology. Parkinson’s Disease (PD): Genetic Basis: Autosomal Dominant PD: Caused by mutations in SNCA, which encodes α-synuclein, the key component of Lewy bodies. Autosomal Recessive PD: Linked to mutations in DJ-1, PINK1, and Parkin. Most Common Autosomal Dominant Mutation: LRRK2 (Leucine-Rich Repeat Kinase 2). Clinical Features: Triad of Tremor, rigidity, and bradykinesia. Morphology: Gross pathology: Pallor of the substantia nigra due to neuronal loss. Microscopic features: Lewy bodies: Cytoplasmic, eosinophilic inclusions, either single or multiple. Structure: Dense core surrounded by a pale halo. Ultrastructure: Composed of fine filaments of α-synuclein. {{caption_text}} Protein Associated Disease(s) Aβ (Amyloid-beta) Alzheimer disease Tau Alzheimer's disease, Frontotemporal lobar degeneration LRRK2 mutations Parkinson disease α-synuclein Parkinson's disease, Multiple system atrophy TPD-43 Frontotemporal lobar degeneration, Amyotrophic lateral sclerosis FUS Frontotemporal lobar degeneration, Amyotrophic lateral sclerosis Polyglutamine aggregates Huntington's disease, Some forms of spinocerebellar ataxia, Spinal bulbar muscular atrophy Tau (with other symptoms) Progressive supranuclear palsy, Corticobasal degeneration, Chronic traumatic encephalopathy

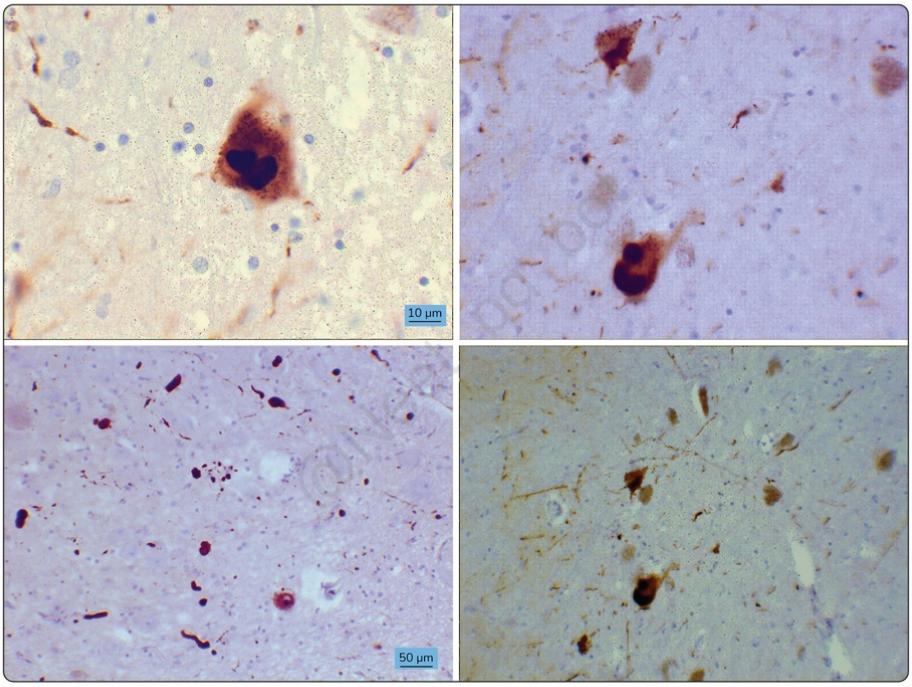

References:

Robbins & Cotran Pathologic Basis of Disease, 10th Edition, Page 1274

↑ *Back to this question in Part A*

@Neet_pg_bot

Q7: What is the most common cause of berry aneurysm? (Q857610)

A. Endothelial injury of the vessel due to hypertension

B. Muscle intimal elastic lamina layer defect

C. Muscle and adventitial layer defect

D. Adventitia defect

Correct Answer: B. Muscle intimal elastic lamina layer defect

Explanation: Berry aneurysms , also known as saccular aneurysms or intracranial aneurysms, most commonly occur due to a defect in the muscle intimal elastic lamina layer of the blood vessel wall. This defect weakens the vessel wall, leading to the formation of a small outpouching or sac-like dilation. These aneurysms are frequently found in the arteries at the base of the brain, particularly at the branching points of the major cerebral arteries. Endothelial injury of vessels due to hypertension (Option A): While hypertension can contribute to the development and progression of aneurysms, it is not the most common cause of berry aneurysms. Muscle and adventitial layer defect (Option C) and Adventitia defect (Option D) : Berry aneurysms primarily involve the defect in the muscle intimal elastic lamina layer.

References:

Robbins & Cotran Pathologic Basis of Disease, 10th Edition, Pages 487- 506, 1259.

↑ *Back to this question in Part A*

@Neet_pg_bot

Q8: A mutation in the SOD1 gene is most commonly associated with which of the following conditions? (Q866751)

A. Huntington's disease

B. Multiple sclerosis

C. Amyotrophic lateral sclerosis (ALS)

D. Parkinson's disease

Correct Answer: C. Amyotrophic lateral sclerosis (ALS)

Explanation: The SOD1 gene encodes superoxide dismutase 1, an enzyme responsible for breaking down harmful superoxide radicals into oxygen and hydrogen peroxide. This protects cells from oxidative damage. SOD1 and ALS: Condition: Amyotrophic lateral sclerosis (ALS), also known as Lou Gehrig’s disease. Type: SOD1 mutations account for about 20% of familial ALS cases (familial ALS ~10% of all ALS cases). Mechanism: Mutant SOD1 misfolds → gains toxic properties → causes oxidative stress and mitochondrial dysfunction. This leads to degeneration of both upper motor neurons (in motor cortex) and lower motor neurons (in brainstem and

spinal cord). Clinical Features of ALS: Mixed UMN and LMN signs: UMN: Spasticity, hyperreflexia, Babinski sign. LMN: Fasciculations, muscle atrophy, weakness. Progressive, usually fatal within 3–5 years (respiratory failure common). Sensation and cognition are usually preserved (helps differentiate from MS or other neuropathies). Huntington's disease (Option A): CAG trinucleotide repeat expansion in the HTT gene (chromosome 4). Multiple sclerosis (Option B): Autoimmune demyelination, not linked to SOD1. Parkinson's disease (Option C): Often linked to mutations in SNCA, LRRK2, PARK genes, not SOD1.

↑ *Back to this question in Part A*

@Neet_pg_bot

Q9: A 45-year-old patient presents with severe headaches, seizures, and progressive neurological deficits. Imaging reveals a large mass with areas of necrosis and irregular borders in the brain. The biopsy confirms the diagnosis of a malignant tumor. Which of the following options represents the most common type of brain tumor in adults? (Q820559)

A. Medulloblastoma

B. Meningioma

C. Retinoblastoma

D. Glioblastoma

Correct Answer: D. Glioblastoma

Explanation: Correct Option D - Glioblastoma: Glioblastoma, also known as glioblastoma multiforme, is the most common and aggressive type of malignant brain tumor in adults. It originates from glial cells, which are supportive cells in the brain. Glioblastomas often have a rapid growth rate and infiltrative behavior and tend to be resistant to conventional treatments. The symptoms mentioned in the question, such as severe headaches, seizures, and progressive neurological deficits, are characteristic of glioblastoma due to its invasive nature and effect on brain function. Glioblastoma accounts for about 80% of primary brain tumors in adults. Incorrect Options: Option A - Medulloblastoma: Medulloblastoma is a type of malignant brain tumor, but it is more commonly found in children rather than adults. It usually arises in the cerebellum, which is the part of the brain responsible for coordinating movement. Option B - Meningioma: Meningiomas are generally benign tumors that arise from the meninges, which are the protective layers surrounding the brain and spinal cord. While they can occur in adults, they are usually slow-growing and tend to be less aggressive than glioblastomas. Option C - Retinoblastoma: Retinoblastoma is a rare type of eye cancer that primarily affects young children. It originates in the retina, which is the light-sensitive tissue at the back of the eye. It does not typically present as a brain tumor and is not commonly seen in adults

References:

Robbins Ed 10 Pg 1293

↑ *Back to this question in Part A*

@Neet_pg_bot

Q10: A 70-year-old patient presents with progressive memory loss, cognitive decline, and behavioral changes. Imaging reveals characteristic amyloid plaques and neurofibrillary tangles in the brain. On further investigation, the accumulation of a specific protein is found to be a hallmark of this disease. What is the protein responsible for the amyloidosis seen in Alzheimer's disease? (Q820521)

A. Amyloid beta protein

B. ATTR

C. Amyloid beta 2 protein

D. Acal

Correct Answer: A. Amyloid beta protein

Explanation: Correct Option A - Amyloid beta protein: In Alzheimer's disease, there is an accumulation of abnormal proteins, including beta-amyloid plaques and tau protein neurofibrillary tangles, in the brain. These amyloid plaques are primarily composed of beta-amyloid protein, which is derived from the amyloid precursor protein (APP). The accumulation of beta-amyloid protein is a hallmark feature of Alzheimer's disease and is believed to play a role in the pathogenesis of the condition. Incorrect Options: Option B - ATTR (Transthyretin Amyloidosis): Transthyretin amyloidosis is a disease characterized by the buildup of abnormal transthyretin proteins, primarily in the nerves and heart, not in the brain. It is not associated with Alzheimer's disease. Option C - Amyloid Beta 2 Protein: Amyloid beta protein is typically referred to as amyloid beta (Aβ) or amyloid beta protein 1-42 (Aβ42) in the context of Alzheimer's disease. There isn't a commonly recognized "Amyloid beta 2" protein associated with Alzheimer's disease. Option D - Acal: Acal does not correspond to any known protein associated with Alzheimer's disease or amyloidosis.

References:

.

↑ *Back to this question in Part A*

@Neet_pg_bot

Q11: Which of the following is the disorder associated with hexanucleotide repeat? (Q860225)

A. Fragile X syndrome

B. Huntington disease

C. Myotonic dystrophy

D. Frontotemporal dementia

Correct Answer: D. Frontotemporal dementia

Explanation: The disorder associated with hexanucleotide repeat is Frontotemporal dementia or Frontotemporal Lobar Degeneration (FTLD). These are a heterogeneous group of disorders associated with focal degeneration of frontal and/or temporal lobes. They are associated with cellular inclusions comprised of specific proteins; the two most common patterns are: Features FTLD-tau FTLD-TDP Inclusions Cytoplasmic tau inclusions Inclusions contain TDP-43 (RNA-binding protein) Associated mutations Associated with mutations in the MAPT gene (encoding tau) Expansion of a hexanucleotide repeat in the 5′ region of C9orf72 . Mutations in the TARDBP gene (encoding TDP-43) Mutations in the GRN gene The below-mentioned disorders are Trinucleotide Repeat Disorders, where there is excessive repetition of trinucleotides. In Introns/Non-coding region: Fragile X syndrome: CGG (Option A ruled out) Friedreich ataxia: GAA Myotonic dystrophy: CTG (Option C ruled out) In Exons/ Coding region: Huntington's disease: CAG (Mnemonic- Hunter in a Cage) (Option B ruled out)

References:

Robbins and Cotrans Pathological Basis of Diseases, 10th Edition, Page 174, 1280-1282.

↑ *Back to this question in Part A*

@Neet_pg_bot

Q12: A 5-year-old child presents with a lesion in the right eye. Histopathology reveals the presence of Flexner-Wintersteiner rosettes. What is the likely diagnosis? (Q860515)

A. Retinoblastoma

B. Optic nerve glioma

C. Rhabdomyosarcoma

D. Ocular melanoma

Correct Answer: A. Retinoblastoma

Explanation: The presence of a lesion in the right eye and histopathological findings of Flexner-Wintersteiner rosettes strongly suggest a diagnosis of Retinoblastoma . Retinoblastoma It is caused by the inactivation of both alleles of the RB1 tumour suppressor gene. Types Heritable (germline): It frequently leads to bilateral retinoblastoma and is caused by a germline mutation in the RB1 gene in all cells, followed by a somatic mutation

in the retinal cells. Affected individuals are also at increased risk for developing non-ocular tumours, such as osteosarcoma. Non-heritable (sporadic): This form typically presents as a unilateral tumour and results from two somatic mutations in the retinal cells occurring after embryonic development, without a germline mutation. It is not inherited and does not carry an increased risk of developing non-ocular tumours. Clinical features Occurs in young children, usually before 5 years of age (most common ocular neoplasm in children). Leukocoria: White pupillary reflex (most common presenting sign of retinoblastoma). Strabismus Painful red eye Poor vision Asymptomatic Fundus examination A white, elevated mass in the retina is characteristic of retinoblastoma Genetic testing RB1 gene mutation on chromosome 13q14 Histopathology Flexner-Wintersteiner rosettes (highly specific) : These are composed of an ‘empty’ lumen surrounded by columnar cells. Homer-Wright rosettes : These are pseudo-rosettes and consist of cells surrounding a central lumen made up of their processes. Undifferentiated tumour cells. Areas of necrosis and calcification. {{caption_text}} Optic nerve glioma (Option B) is a benign tumour that arises from the glial cells of the optic nerve. It is most commonly seen in children and is often associated with neurofibromatosis type 1. Symptoms may include vision loss, proptosis, and visual field defects. It typically occurs along the optic nerve and does not exhibit Flexner-Wintersteiner rosettes. Rhabdomyosarcoma (Option C) is a malignant soft tissue sarcoma that originates from skeletal muscle cells or their precursors. It is most common in children and can occur in various locations, including the head and neck, genitourinary tract, and extremities. Symptoms depend on the tumour's location but often include a painless mass or swelling. It affects the eye but does not show these characteristic rosettes. Ocular melanoma (Option D) is a rare malignant tumour that develops in the pigment-producing cells (melanocytes) of the eye, most commonly in the choroid (part of the eye's vascular layer). It is more common in adults and can lead to symptoms like vision changes, dark spots in the field of vision, and proptosis.

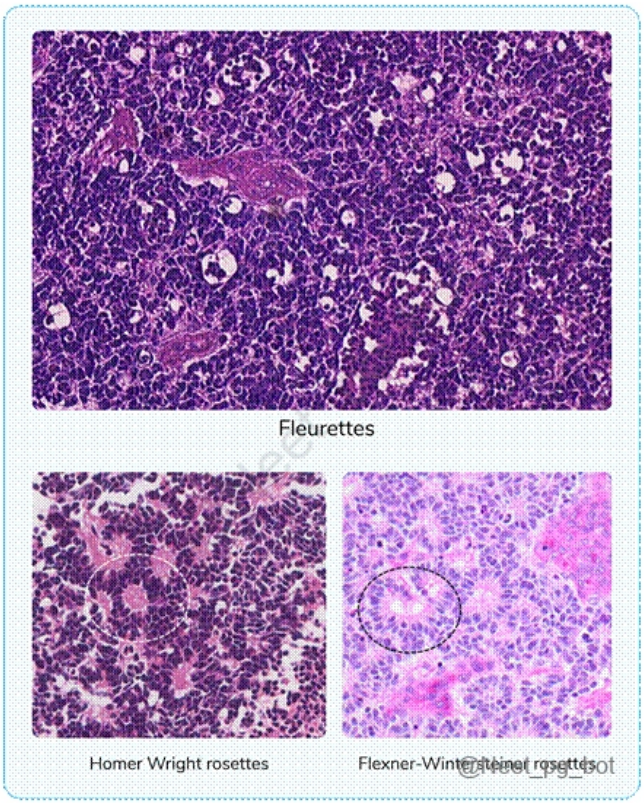

References:

Robbins & Cotran Pathologic Basis of Disease, 10th Edition, Page 1324-1325.

Kanski’s Clinical Ophthalmology, 9th Edition, Page 861.

↑ *Back to this question in Part A*

@Neet_pg_bot

Q13: Which of the following is a marker of Alzheimer’s disease? (Q844213)

A. Synuclein

B. Aβ **40 and 42**

C. Polyglutamine

D. FUS

Correct Answer: B. Aβ **40 and 42**

Explanation: Correct Option B - Aβ 40 and 42: αβ 40 and 42 are amyloid-beta peptides that are deposited in the brains of patients with Alzheimer's disease, forming plaques. Incorrect Options: Option A - Synuclein: This is associated with Parkinson's disease and Lewy body dementia. Option C - Polyglutamine: This is associated with Huntington's disease. Option D - FUS: This is associated with frontotemporal lobar degeneration.

↑ *Back to this question in Part A*

@Neet_pg_bot

Q14: A patient presents with a hand lesion, and the histopathology of the lesion is provided. Which of the following statements is incorrect? (Q853372)

A. It originates from the peripheral nerve

B. Verrocay bodies are seen in light microscopy

C. Associated with neurofibromatosis

D. It is malignant and often metastasizes

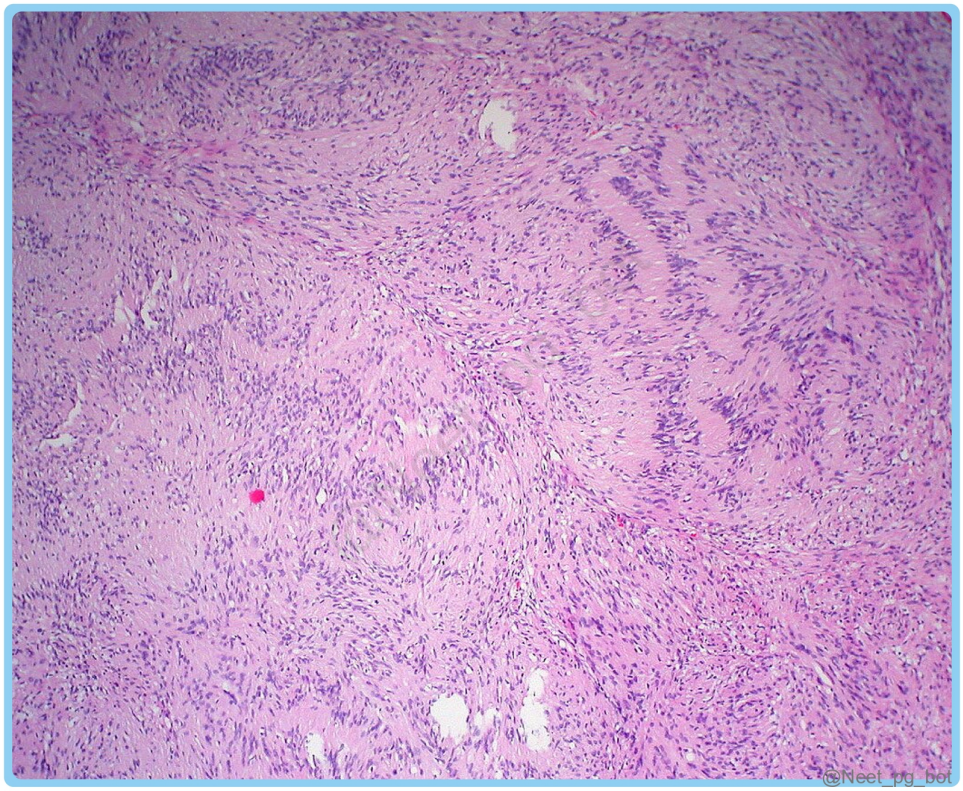

Correct Answer: D. It is malignant and often metastasizes

Explanation: The described scenario, featuring a hand lesion and histopathological findings of encapsulated tissue with areas of dense cellularity and loose myxoid regions, suggests a diagnosis of Schwannoma . Schwannomas are benign tumours exhibiting Schwann cell differentiation and originate directly from peripheral nerves. (Option A) It is associated with NF2 mutations on chromosome 22 , producing merlin . (Option C) Most common location: Cerebellopontine angle Microscopically, they are comprised of: Antoni A area: Dense eosinophilic areas containing spindle cells are arranged into intersecting fascicles, leading to nuclei palisading. The resulting structures with central “nuclear-free zones” are called Verocay bodies . (Option B) Antoni B area: Loose, hypocellular areas where a myxoid extracellular matrix spreads apart the spindle cells. It typically shows immunoreactivity to S-100 . Clinical features: Cause symptoms by local compression of the involved nerve or adjacent structures (e.g., brainstem or spinal cord). Mostly occurs at the cerebellopontine angle (attached to the vestibular branch of the 8th nerve). Presents with tinnitus and hearing loss Sensory nerves are involved (trigeminal nerve and dorsal roots). They can arise in association with large nerve trunks or as soft tissue lesions (extradural) Management: Surgical removal is curative.

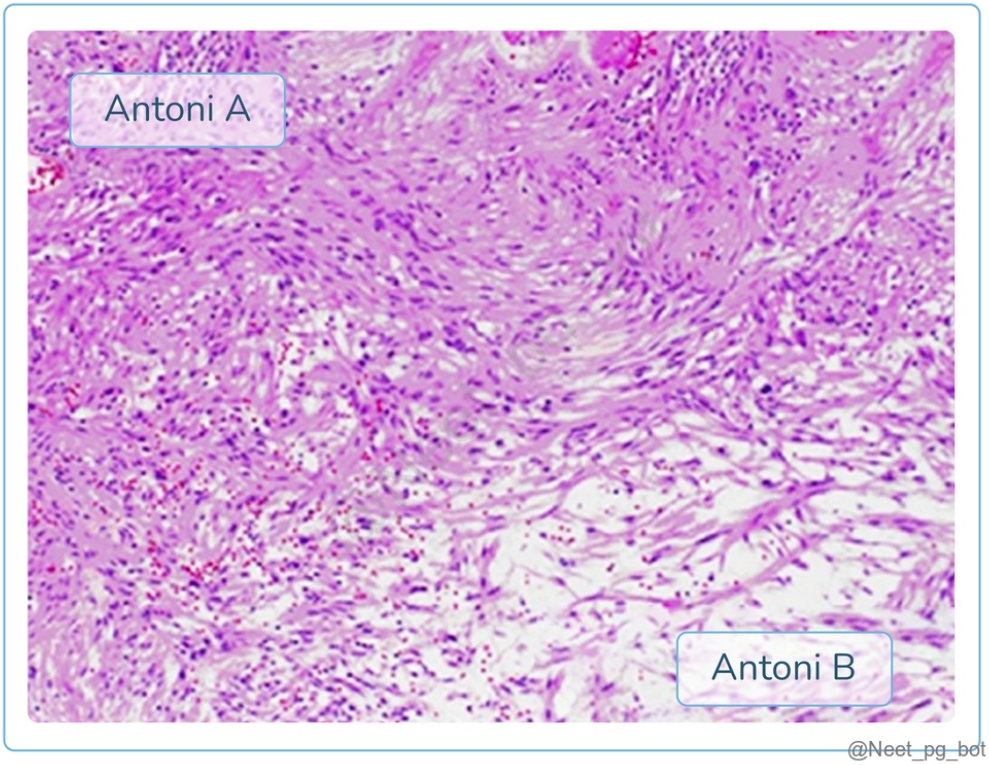

References:

Robbin’s and Cotran Pathologic Basis of Disease, 10th Edition, Page 1237, 1297-1298.

↑ *Back to this question in Part A*

@Neet_pg_bot

Q15: A child presents with visual disturbances and delayed growth. Imaging reveals a suprasellar mass, and histopathology shows the presence of "wet keratin" (compact, eosinophilic anucleate keratin). What is the most likely diagnosis? (Q866366)

A. Craniopharyngioma

B. Medulloblastoma

C. Glioma

D. Pituitary adenoma

Correct Answer: A. Craniopharyngioma

Explanation: The above history of a child presenting with visual disturbances and delayed growth with imaging features of a suprasellar mass, and histopathology showing the presence of "wet keratin" is suggestive of Craniopharyngioma. Rare, benign CNS tumour Often partly cystic in nature Occurs in the sellar/suprasellar region Pathophysiology: It can compress normal pituitary tissue and result in pituitary deficiencies, particularly of the anterior pituitary hormones. It can also compress the optic chiasm and also present with hydrocephalus secondary to third ventricle compression. Clinical Features: Headaches: Due to increased intracranial pressure or meningeal irritation. Visual Disturbances: Temporal hemianopsia is common due to optic chiasm compression. Endocrine Deficiencies: Growth hormone (GH) deficiency. Gonadotroph, ACTH, TSH, and vasopressin deficiencies. Other Symptoms: Hydrocephalus, nausea, vomiting, and possible cranial nerve palsies. Microscopic Examination: Adamantinomatous Craniopharyngioma (ACP): More common in children. Solid and cystic components. Characterised by squamous epithelium, "wet keratin," and calcifications. Papillary Craniopharyngioma (PCP): More common in adults. Predominantly solid, with well-differentiated squamous epithelium. Calcifications are rare. Imaging: MRI: Preferred modality for detailed evaluation. ACP: Heterogeneous with cystic areas and calcifications. PCP: Solid and less commonly cystic or calcified. CT: Best for identifying calcifications. Treatment: Surgery is the mainstay of treatment. Incorrect Options: Medulloblastoma (Option B): Typical location: Midline cerebellum (vermis) in children, not suprasellar. Presentation : Ataxia, gait disturbance, signs of increased intracranial pressure (due to 4th ventricle obstruction) like headache, vomiting, papilledema. Histology: Small, round, blue cells with Homer–Wright rosettes — no wet keratin. This child’s mass is suprasellar, causing visual and endocrine symptoms, which medulloblastomas do not. Glioma (Option C): Typical types relevant to the optic–hypothalamic region: Optic pathway gliomas, often in children (sometimes with NF1). Presentation: Progressive visual loss, proptosis, and sometimes endocrine dysfunction if the hypothalamus is involved. Histology: Glial fibrillary acidic protein (GFAP)–positive spindle cells, eosinophilic Rosenthal fibres (in pilocytic astrocytoma type) — no wet keratin. While location could overlap, the hallmark histologic finding is completely different. Pituitary Adenoma (Option D): Epidemiology: Very rare in children; it mostly affects adults. Presentation: Endocrine syndromes (hyperprolactinemia, Cushing’s disease, acromegaly), bitemporal hemianopia from optic chiasm compression. Histology: Uniform polygonal pituitary cells in nests or cords; no keratin debris. Age is atypical, histology doesn’t match, and pituitary adenomas don’t show “wet keratin.”

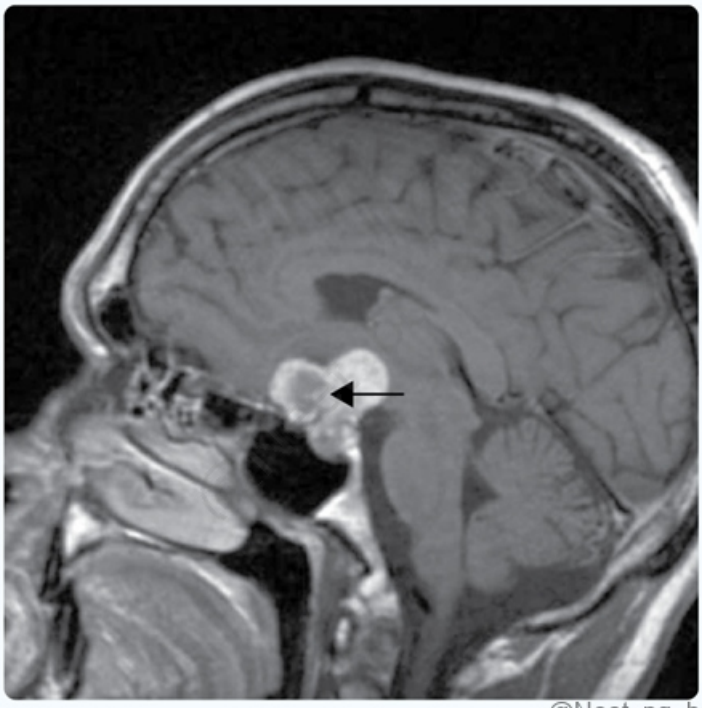

References:

.

↑ *Back to this question in Part A*

@Neet_pg_bot

Q16: In the WHO grading of astrocytoma, which grade does glioblastoma fall under? (Q793781)

A. I

B. II

C. III

D. IV

Correct Answer: D. IV

Explanation: Correct Option D - IV: In the WHO classification of astrocytoma, glioblastoma falls under Grade IV. This is the highest grade, and it means that the tumor is very bad and growing quickly. Glioblastoma is also called

a grade IV astrocytoma. Incorrect Options: Options A, B, and C are incorrect.

References:

Prepladder Notes

↑ *Back to this question in Part A*

@Neet_pg_bot

Q17: An electron microscopic picture of a cut section of a nerve fibre is given. Identify the area that will be affected by the most common variant of Guillain-Barre syndrome. (Q855395)

A. 1

B. 2

C. 3

D. 4

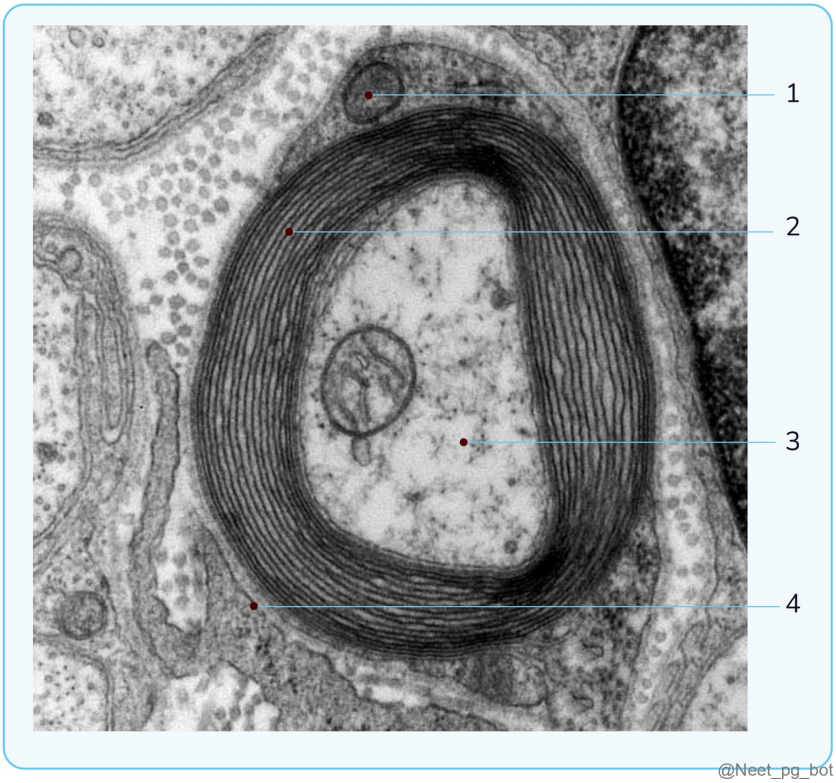

Correct Answer: B. 2

Explanation: The myelin sheath labelled "2" is the most common variant affected in Guillain-Barré Syndrome (GBS). Guillain-Barré Syndrome (GBS) A group of immune-mediated disorders causing acute paralysis, clinically characterized by weakness starting in the distal limbs and quickly progressing to involve proximal muscle function, resulting in "ascending paralysis". Variants Acute Inflammatory Demyelinating Polyneuropathy (AIDP) The most common variant is in Europe & North America. Patchy segmental demyelination of spinal cord and peripheral nerves Antibodies seen: IgG Anti GM1 IgG Anti GQ1b Axonal Variants Often associated with Campylobacter jejuni infection. More prevalent in China and Japan. Miller Fisher Syndrome Best-recognised variant. Associated with anti-GQ1b antibodies. Presents with internal and external ophthalmoplegia, ataxia, and areflexia Clinical features Motor Symptoms: Progressive ascending paralysis (distal to proximal) Areflexia Weakness in legs causing rubbery legs and instability to stand Truncal paralysis, quadriplegia, neck floppiness Bilateral 7th nerve palsy Bulbar palsy Difficulty in handling secretions leading to aspiration pneumonia A leading cause of death due to pulmonary involvement. Diaphragmatic paralysis Ventilatory support is required in 30% of cases. Increased carbon dioxide levels. Sensory Symptoms: Glove-and-stocking distribution paresthesias Proprioception loss Difficulty in climbing stairs Pain in the neck/arm/shoulder is similar to over-exercised muscle Sensory manifestations can occur before or along with motor manifestations. Autonomic Symptoms: Autonomic dysregulation (e.g., orthostatic hypotension, bladder/bowel sparing/transient involvement) Wide fluctuations of blood pressure, arrhythmias, postural hypotension Reduced heart rate and blood pressure, neurogenic shock. Investigations Lumbar Puncture CSF protein: 100-1000 mg/dL Elevated CSF protein but normal WBC count (albuminocytologic dissociation) CSF Study Timing Normal CSF findings (<48 hours) Maximum rise of protein seen by 7 days Electrodiagnostic Testing Prolonged F-wave latencies Earliest finding in AIDP (Acute Inflammatory Demyelinating Polyneuropathy) 1 (Option A) indicates Schwann cells, which are the supporting cells of the peripheral nervous system and play a crucial role in forming the myelin sheath around the axons. While Schwann cells can be involved in GBS, they are not the primary site of damage in the most common variant, acute inflammatory demyelinating polyradiculoneuropathy (AIDP). 3 (Option C) indicates an axon, whose damage can occur in GBS. It is more commonly associated with variants such as acute motor axonal neuropathy (AMAN) or acute motor-sensory axonal neuropathy (AMSAN). In the most common AIDP variant, the primary pathology is focused on the myelin sheath rather than the axon itself. 4 (Option D) indicates mesaxon, i.e., the region where the inner and outer layers of the Schwann cell membrane meet. It is involved in the formation of the myelin sheath. Although the mesaxon can be affected in GBS, it is not the primary area of damage in the most common AIDP variant.

References:

Robbins & Cotran Pathological Basis of Diseases, 10th Edition, Page, 1220-1221.

Harrison's Principle of Internal Medicine, 21st Edition, Page, 3501-3503.

↑ *Back to this question in Part A*

@Neet_pg_bot

• [16_Skin and Musculoskeletal] 064 Previous Year Questions

« Back to Folder Directory

[16_Skin and Musculoskeletal] 064 Previous Year Questions — Quick Jump

Q1 (p. 2554) *Q2 (p. 2554)* *Q3 (p. 2555)* *Q4 (p. 2561)* *Q5 (p. 2562)* *Q6 (p. 2565)*
Q7 (p. 2566) *Q8 (p. 2570)*

Q1: A child presents with skin eruptions upon exposure to sunlight and is diagnosed with a DNA repair defect. Which type of repair defect is most likely responsible? (Q844175)

A. Nucleotide excision repair defect

B. Base excision repair defect

C. Mismatch repair defect

D. Recombination repair defect

Correct Answer: A. Nucleotide excision repair defect

Explanation: Correct Option A - Nucleotide excision repair defect: Xeroderma pigmentosa is caused by a defect in nucleotide excision repair, leading to an inability to repair UV-induced DNA damage, which results in extreme sensitivity to sunlight and a high risk of skin cancers. Incorrect Options: Options B, C, and D do not cause xeroderma pigmentosa.

↑ *Back to this question in Part A*

@Neet_pg_bot

Q2: Identify the diagnosis based on the image provided: (Q844180)

A. Tuberculosis (TB)

B. Malakoplakia

C. Pyoderma gangrenosum

D. Squamous cell carcinoma (SCC)

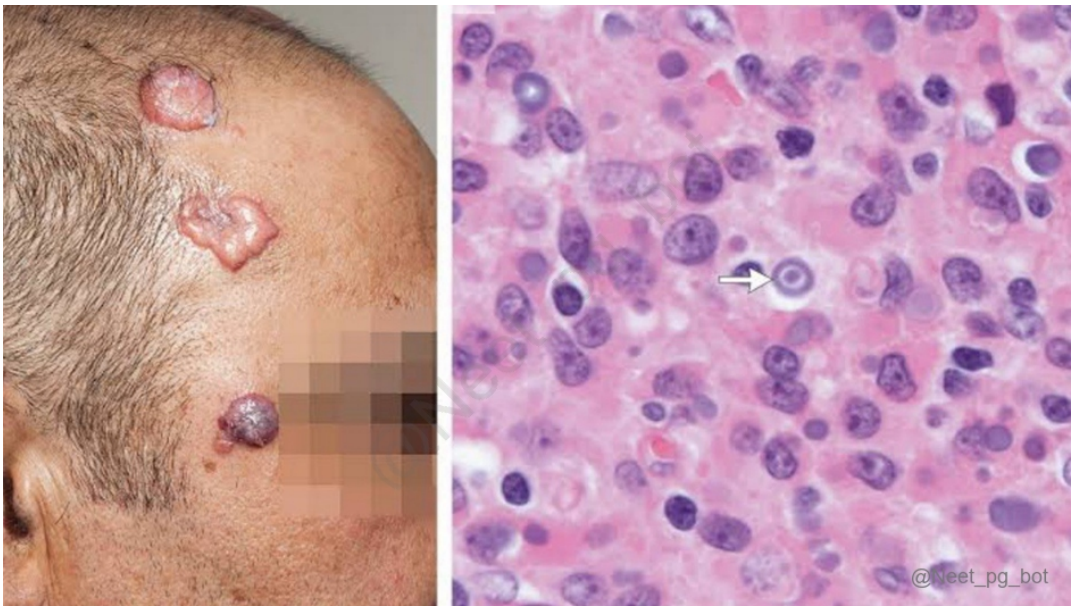

Correct Answer: B. Malakoplakia

Explanation: Correct Option B – Malakoplakia: The given microscopy image reveals Michaelis Guttman bodies, along with cutaneous malakoplakia on the scalp region. Incorrect Options: Options A, C, and D do not show Michaelis Guttman's bodies.

References:

.

↑ *Back to this question in Part A*

@Neet_pg_bot

Q3: Identify the given condition. (Q856687)

A. Pemphigus Vulgaris

B. Leprosy

C. Mycosis fungoides

D. Visceral leishmaniasis

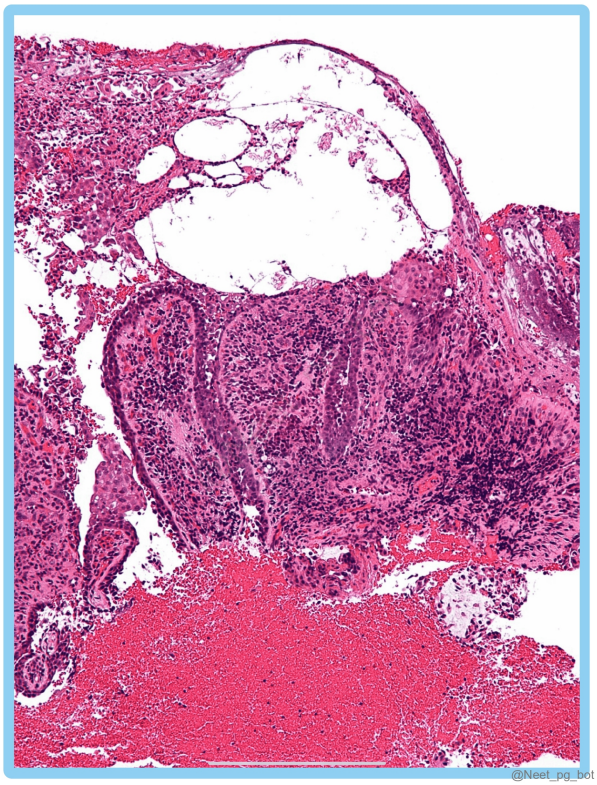

Correct Answer: A. Pemphigus Vulgaris

Explanation: The histopathological image shows Pemphigus Vulgaris (PV) , with intraepidermal cleavage and acantholysis in the suprabasal layer, along with a "row of tombstones" appearance due to the separation of basal keratinocytes at the basement membrane zone. It is the most common chronic autoimmune blistering disease caused by antibodies against desmosomal adhesion proteins. The target antigens for PV are most commonly Desmoglein 3 and sometimes Desmoglein 1. Clinical features: Flaccid blisters filled with clear fluid present on normal skin or an erythematous base. The blisters rupture, producing painful erosion. {{caption_text}} Mucosal involvement is a very important and one of the distinguishing features of PV. {{caption_text}} {{caption_text}} Histopathology: Intraepidermal cleavage with acantholysis (detached keratinocytes) primarily localized to the suprabasal region. Separation of basal keratinocytes along the basement membrane zone, resulting in an appearance that resembles a "row of tombstones". {{caption_text}} Leprosy (Option B) , also known as Hansen's disease , is a chronic infection caused by Mycobacterium leprae , affecting the skin, peripheral nerves, and mucous membranes. Tuberculous leprosy shows granulomatous lesions similar to tuberculosis, while lepromatous leprosy features lipid-laden macrophages (lepra cells) containing "globi" of acid-fast bacilli. {{caption_text}} {{caption_text}} Mycosis fungoides (Option C) is the most common type of cutaneous T-cell lymphoma. It presents with a variety of skin lesions, including patches, plaques, and tumours. Histologically, the epidermis and upper dermis are infiltrated by neoplastic T cells, which often have a cerebriform appearance due to marked infolding of the nuclear membrane. {{caption_text}} Visceral leishmaniasis (Option D) , also known as kala-azar, is a systemic parasitic infection caused by Leishmania species. It is characterized by granulomatous inflammation, phagocytosed parasites, hyperplasia of the reticuloendothelial system, necrosis with fibrosis, and hemophagocytosis, where macrophages engulf red blood cells, white blood cells, or platelets. {{caption_text}}


@Neet_pg_bot


@Neet_pg_bot


@Neet_pg_bot

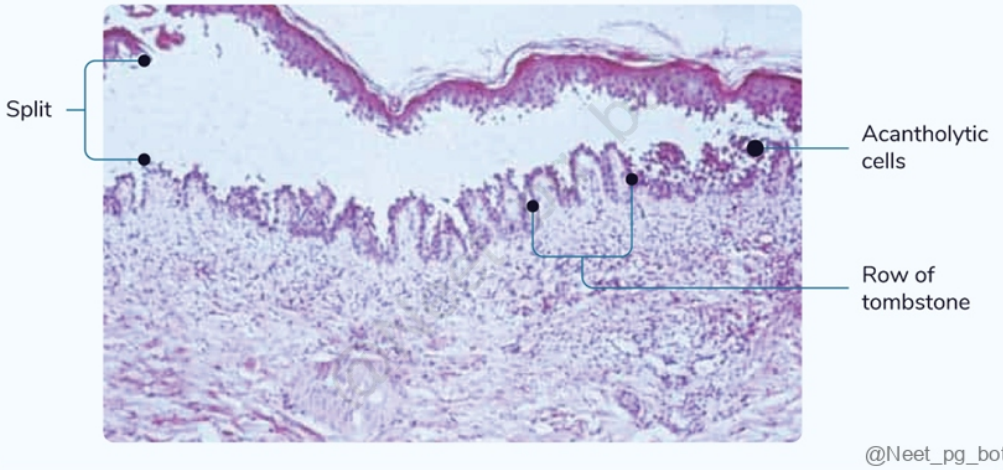
Split
Acantholytic cells
Row of tombstone
@Neet_pg_bot

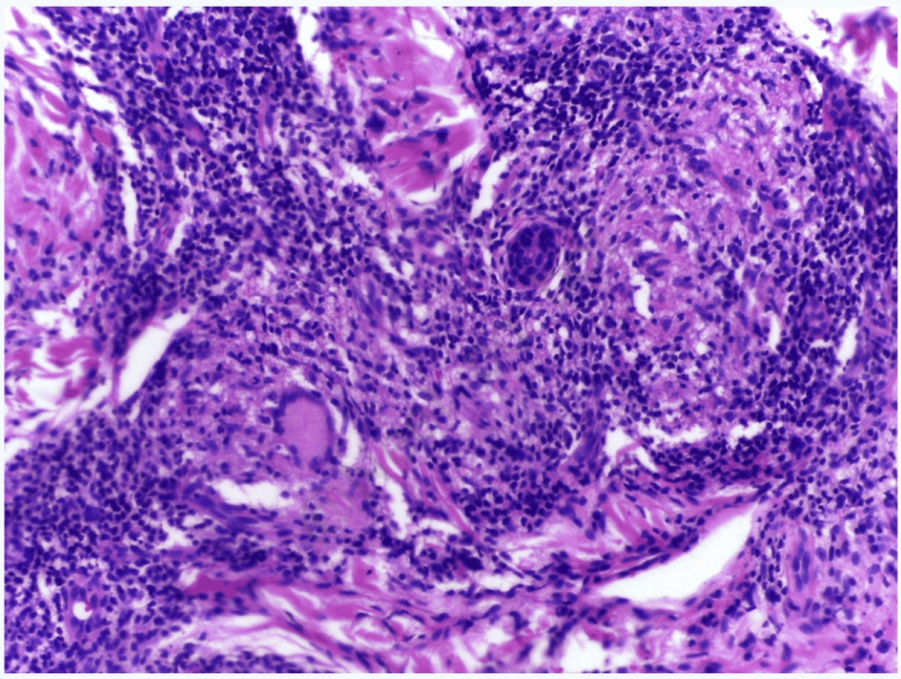

Tuberculoid Leprosy

@Neet_pg_bot

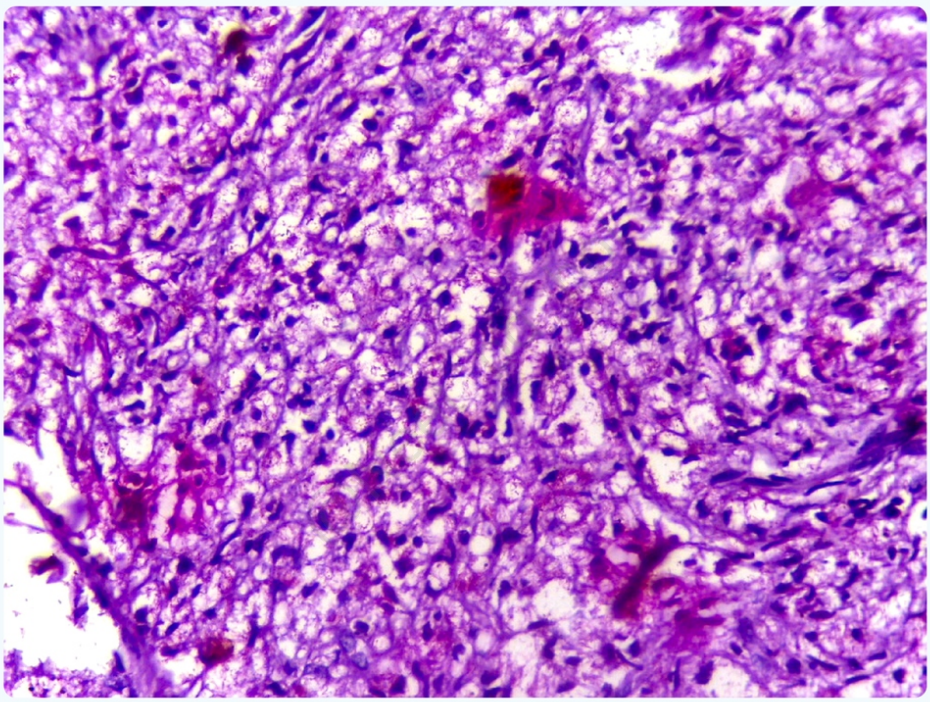

Lepromatous Leprosy

@Neet_pg_bot

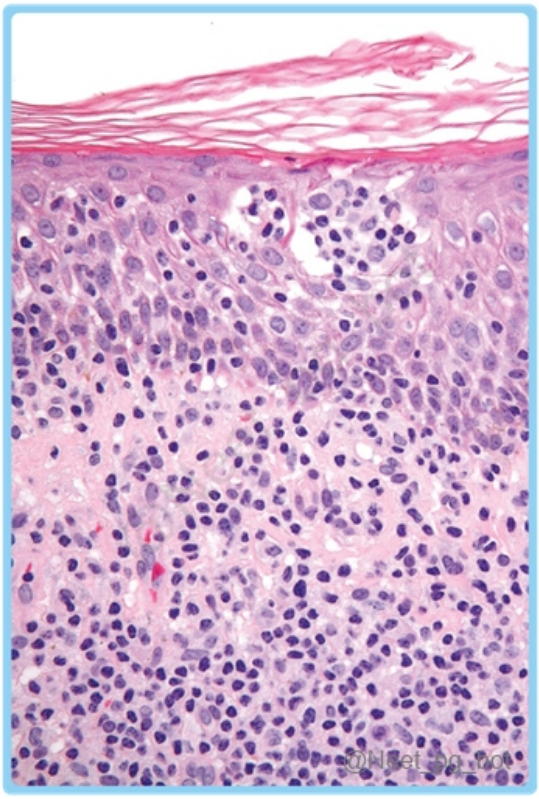

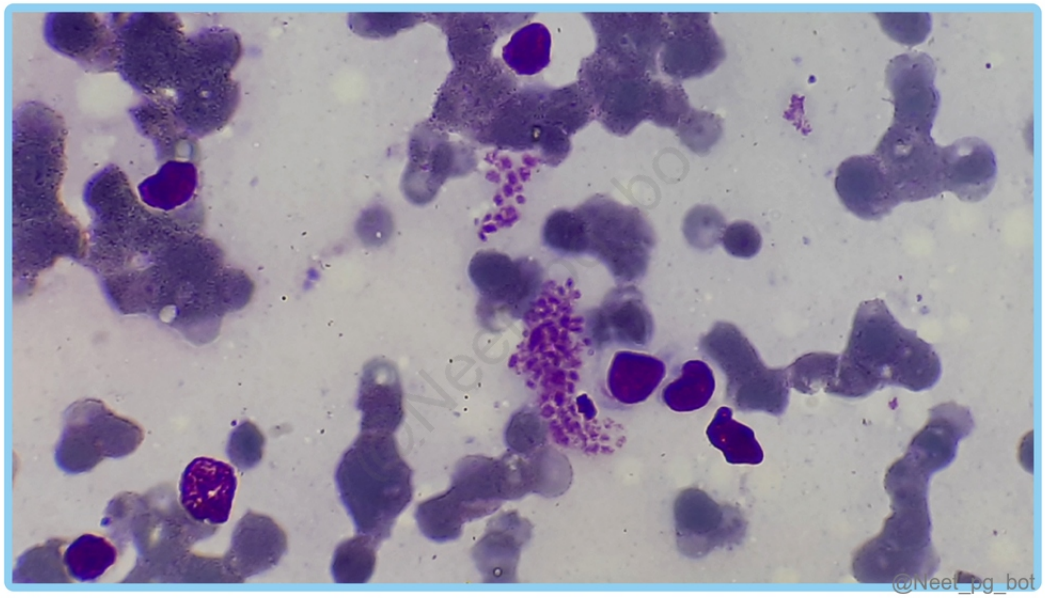

References:

Robbins and Cotran, Pathologic Basis of Disease, 10th Edition, Page 1159-1162.

Rooks Textbook of Dermatology, 9th Edition, Page, 50.1-50.4.

↑ *Back to this question in Part A*

@Neet_pg_bot

Q4: A 5-year-old child who presented with proptosis of one of the eyes was found to have a desmin-positive tumour. What is the probable diagnosis? (Q856705)

A. Ewing’s sarcoma

B. Embryonal rhabdomyosarcoma

C. Leukaemia

D. Retinoblastoma

Correct Answer: B. Embryonal rhabdomyosarcoma

Explanation: The clinical presentation of a 5-year-old child with proptosis and a desmin-positive tumour suggests embryonal rhabdomyosarcoma (RMS). Desmin is a marker for muscle differentiation, and rhabdomyosarcoma, a malignant tumour of skeletal muscle origin, is common in children and can present with proptosis if it involves the orbit. Rhabdomyosarcoma (RMS) Origin A malignant tumour arising from skeletal muscle progenitors Types Embryonal rhabdomyosarcoma. Alveolar rhabdomyosarcoma. Pleomorphic rhabdomyosarcoma. Spindle cell/sclerosing rhabdomyosarcoma Clinical features It is the most common soft tissue sarcoma in children and adolescents. It commonly presents in the extremities. Pediatric rhabdomyosarcomas mostly arise in the sinuses, head and neck, and genitourinary tract. IHC Positive Markers Desmin Myogenin MyoD1 Muscle-specific actin Gross appearance The tumours are often large, soft, and infiltrative, with areas of necrosis and haemorrhage. Microscopy Small, round to spindle-shaped cells with hyperchromatic nuclei and scant cytoplasm, sometimes with a myxoid stroma, are also seen. {{caption_text}} Ewing’s sarcoma (Option A) is a malignant tumour typically affecting bones or soft tissues, often seen in children and adolescents. It is characterized by a specific genetic translocation (t(11;22)) and is usually not associated with desmin positivity, which is more typical of rhabdomyosarcoma. Ewing's sarcoma may cause localized swelling or pain but rarely presents with proptosis unless it involves the orbit or surrounding tissues. It is composed of sheets of uniform, small, round cells with scant cytoplasm that may be clear due to abundant glycogen. Leukaemia (Option C) is a type of cancer that affects the blood and bone marrow, leading to the uncontrolled production of abnormal white blood cells. It typically doesn't present with localized tumours or proptosis. However, in cases of leukemic infiltration of the orbit, proptosis may occur, though it's relatively rare. Retinoblastoma (Option D) is a malignant eye tumour that primarily affects young children, often before the age of 5. While it can cause proptosis due to orbital involvement, it is typically not associated with a desmin-positive tumour. Retinoblastoma usually presents with a white reflex in the pupil (leukocoria) and can cause vision problems or strabismus.

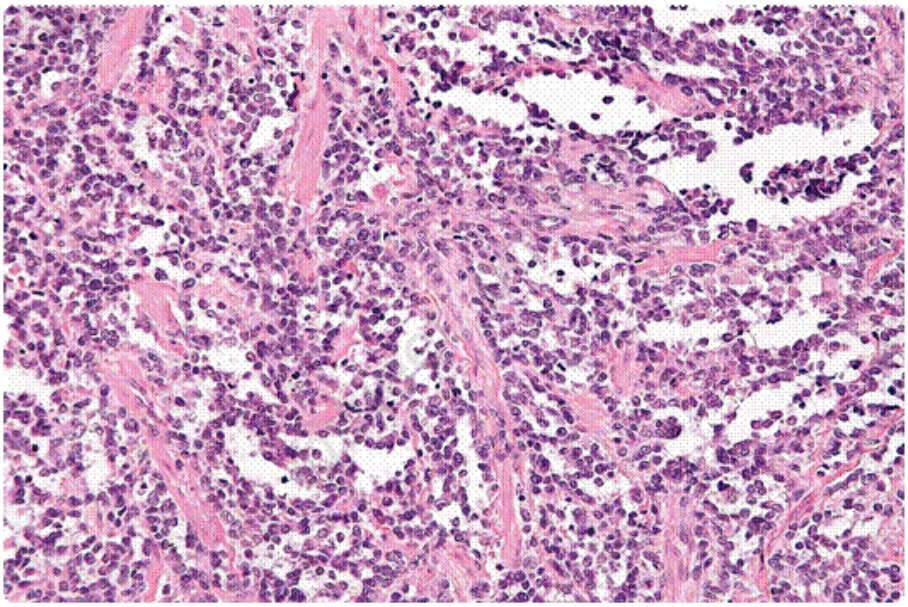

References:

Robbins and Cotran Pathologic Basis of Disease, 10th Edition, Page 1212.

↑ *Back to this question in Part A*

@Neet_pg_bot

Q5: A patient underwent surgery for lipoma 5 weeks ago and now presents with a scar at the incision site, which is limited to the original wound boundaries. What is the most likely diagnosis? (Q857162)

A. Keloid

B. Exuberant granulation

C. Hypertrophic scar

D. Granulation tissue

Correct Answer: C. Hypertrophic scar

Explanation: The most likely diagnosis is a hypertrophic scar, characterised by a raised scar confined to the original wound boundaries, unlike keloids that extend beyond the wound. It is marked by excess collagen, rapid

growth, and the presence of myofibroblasts. Hypertrophic scars tend to regress over time and recur less frequently than keloids. {{caption_text}} Keloid: (Option A) Scar grows beyond the original wound boundaries and doesn’t regress. More common among African Americans. Develops after deep dermal injuries. {{caption_text}} Exuberant Granulation Tissue: (Option B) {{caption_text}} Excessive granulation tissue above skin level. Blocks reepithelialisation (also called "proud flesh"). Requires cauterisation or surgical excision for healing Contractures: {{caption_text}} Abnormal tightening of the wound and surrounding tissues. Common in palms, soles, and chest. Seen in severe burns, it may impair joint movement.







@Neet_pg_bot



References:

Robbins & Cotran Pathologic Basis of Disease, 10th Edition, Page 110,111

↑ *Back to this question in Part A*

@Neet_pg_bot

Q6: An 8-year-old boy presents with progressive muscle weakness and walking difficulties. On examination, pseudohypertrophy of the calf muscles was noted. Which of the following is true regarding this condition? (Q858113)

A. Abnormal collagen

B. Absent dystrophin

C. Expansions of CAG triplet repeats

D. Defective fibrillin

Correct Answer: B. Absent dystrophin

Explanation: The patient described is likely suffering from Duchenne muscular dystrophy (DMD) , a genetic disorder characterised by progressive muscle weakness, particularly in the lower limbs, with pseudohypertrophy of the calf muscles . This condition is caused by a mutation in the dystrophin gene , resulting in the absence or severe deficiency of dystrophin , a protein that helps anchor the muscle cell membrane. Aspect Duchenne Muscular Dystrophy (DMD) Type of Mutation Frameshift mutations lead to a disrupted reading frame Dystrophin Protein Dystrophin deficient Truncated and unstable (< 3% of normal) Clinical Severity Severe, early onset, rapid progression Inheritance Pattern X-linked recessive. Age of onset Early childhood (Before 5 years) Incorrect Options: Abnormal collagen (Option A) would be more consistent with conditions like Ehlers-Danlos syndrome or osteogenesis imperfecta , which involve defective collagen synthesis. Dystrophinopathies, like DMD, do not primarily involve collagen. Expansion of CAG triplet repeats (Option C) can cause Huntington's disease or fragile X syndrome, but DMD is caused by a mutation in the dystrophin gene , not CAG repeats. Defective fibrillin (Option D) is the cause of Marfan syndrome , which affects connective tissue and is characterized by features like tall stature, long limbs, and aortic dissection, but it is not involved in muscle degeneration like DMD.

References:

Nelson Textbook of Pediatrics, 21st Edition, Page 3283

↑ *Back to this question in Part A*

@Neet_pg_bot

Q7: A farmer has a lesion on the shoulder. What is the most likely diagnosis based on the histopathological image of the lesion given below? (Q860532)

A. SCC

B. BCC

C. Molluscum contagiosum

D. Verrucous carcinoma

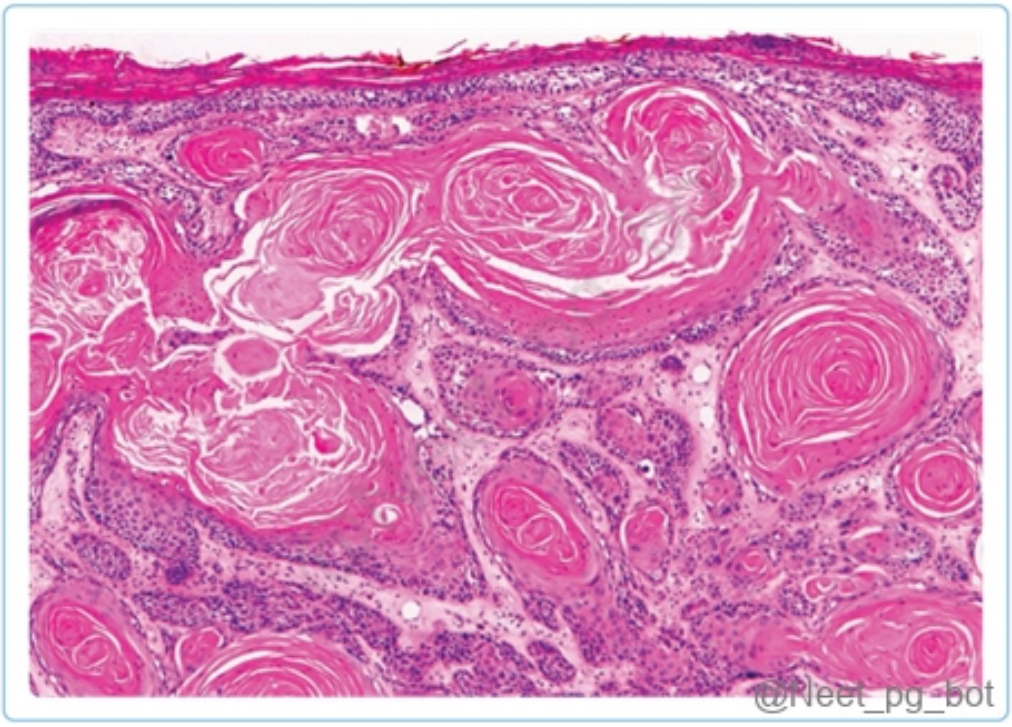

Correct Answer: A. SCC

Explanation: The histopathological image showing keratin pearls on histopathology is suggestive of Squamous Cell Carcinoma (SCC) . It is a malignant tumour originating from epidermal keratinocytes. It is the second most common skin tumour after basal cell carcinoma (BCC). SCC is notably the most common skin tumour in immunocompromised individuals . Predisposing factors include UV exposure, immunosuppression, and conditions like xeroderma pigmentosum, albinism, LP, and DLE, which can rarely progress into SCC. Clinical features: It typically exhibits a lower rate of local, regional, and distant spread compared to other skin malignancies. Associated with immunocompromised states such as HIV infection and renal transplant recipients. It presents as papules, nodules, or plaques with induration and signs of photodamage like crusting and scaling. {{caption_text}} Histopathological examination reveals characteristic keratin pearls . {{caption_text}} Treatment: Primary treatment involves wide surgical excision with margins. Advanced cases may require radiation or chemotherapy. BCC (Basal Cell Carcinoma) (Option B) is the most common type of skin cancer , originating from the basal cells in the epidermis. It is typically slow-growing, often appearing as a painless, pearly nodule with telangiectasias on sun-exposed areas like the face. Histologically, BCC is characterised by nests of basaloid cells with a palisading pattern at the periphery, fibrotic stroma, and clefting between the tumour and surrounding tissue. {{caption_text}} Molluscum contagiosum (Option C) is a viral skin infection causing small, flesh-coloured lesions with central umbilication, often in children and immunocompromised individuals. Histologically, it shows epidermal hyperplasia, ballooning keratinocytes, and Henderson-Patterson (HP) bodies in cup-shaped spaces. {{caption_text}} Verrucous carcinoma (Option D) is a rare, low-grade squamous cell carcinoma often found in areas with chronic irritation (e.g., oral cavity, genitals). It presents as a slow-growing, wart-like lesion and is associated with HPV infection. Histopathologically, it shows exophytic growth, thick keratinisation, well-differentiated squamous cells, and pushing borders with minimal atypia. {{caption_text}}


@Neet_pg_bot

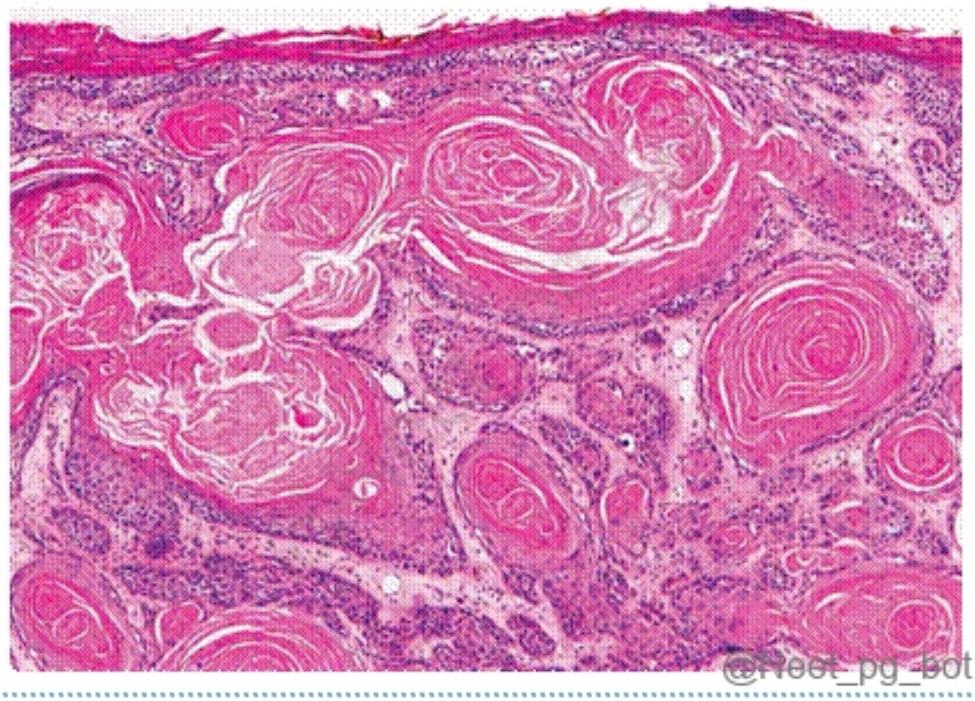
@Neet_pg_bot

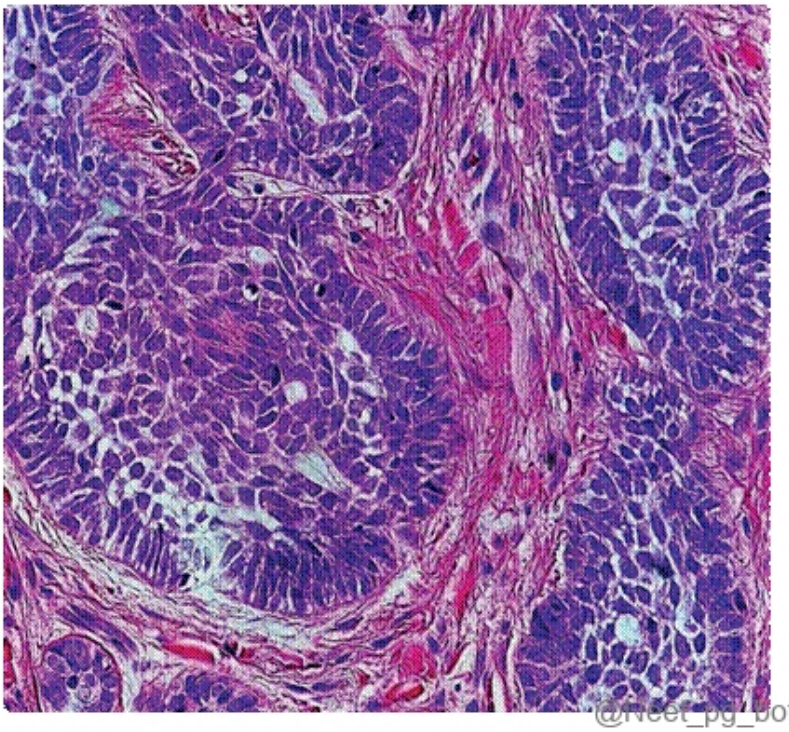
@Neet_pg_bot

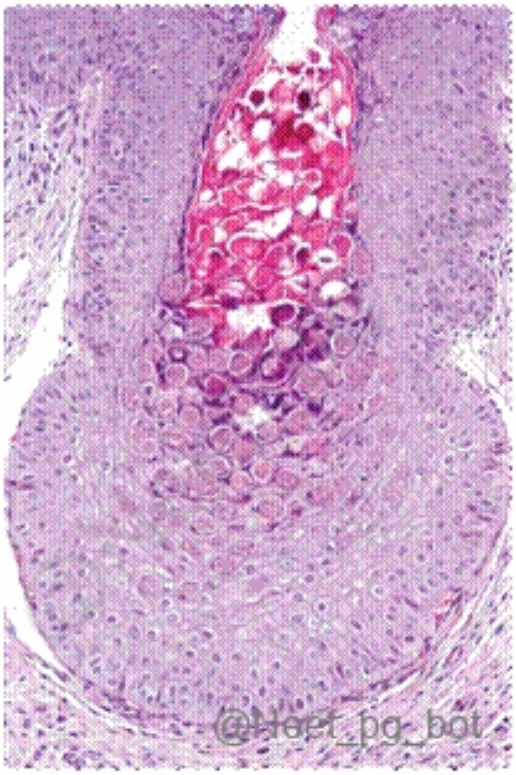
@Neet_pg_bot

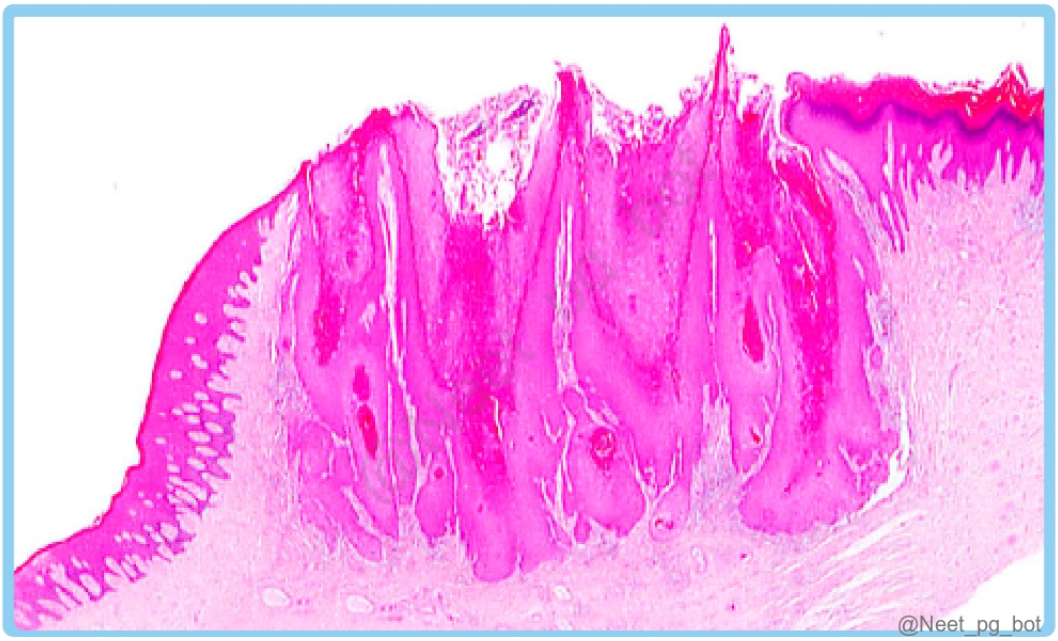

References:

Robbins and Cotran, Pathologic Basis of Diseases, 10th Edition, Page 271.

Rook’s Textbook of Dermatology, 9th Edition, Page 142.10.

↑ *Back to this question in Part A*

@Neet_pg_bot

Q8: Identify the histopathological image. (Q860535)

A. Basal cell carcinoma

B. Squamous cell carcinoma

C. Adenocarcinoma

D. Malignant melanoma

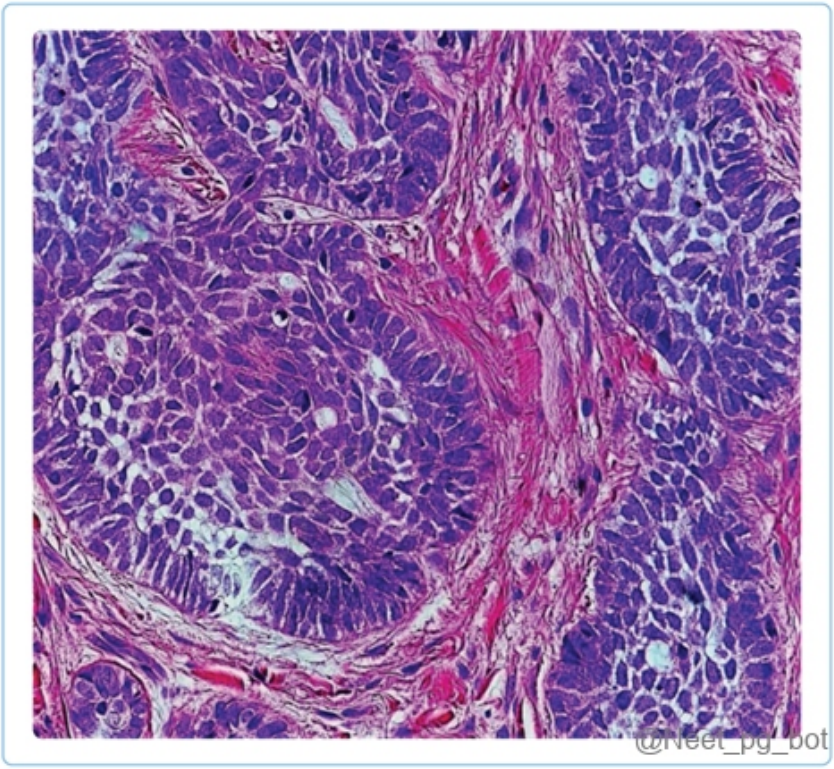

Correct Answer: A. Basal cell carcinoma

Explanation: The histopathological image of the skin biopsy reveals nests of basaloid cells with peripheral palisading and a distinctive stromal retraction artefact, characteristic of Basal Cell Carcinoma (BCC), also known as Rodent Ulcer. It is the most common type of skin cancer and is typically seen in sun-exposed areas of the skin. It is a slow-growing, locally invasive tumour, and it rarely metastasises. Origin: Arises from pluripotent cells within the basal layer of the epidermis or follicular structures. Pathogenesis: Site: Face, Around eyes, Nose Clinical Features It presents initially small, scaly plaque. They present as pearly papules containing dilated blood vessels (telangiectasias) They may ulcerate locally and invade the underlying bone or facial sinuses (rodent ulcers). Slow progressive course of peripheral extension. {{caption_text}} Histologically: The tumour cells are basophilic cells with hyperchromatic nuclei (basaloid cells) arranged in clusters with a palisading pattern . The stroma sometimes retracts from the malignant cells. {{caption_text}} Treatment Medical: Imiquimod, 5-FU,Intralesional interferon α-2b Hedgehog pathway inhibitors:(Vismodegib) Surgical: Mohs micrographic surgery, Done in recurrent BCCs. Squamous cell Carcinoma (Option B) typically exhibits keratin pearls and intercellular bridges, features not present in the image provided. Additionally, the cells are generally larger and have more abundant cytoplasm, unlike the smaller basaloid cells seen in BCC. {{caption_text}} Adenocarcinoma (Option C) arises from glandular epithelium and shows glandular structures or mucin production. {{caption_text}} Malignant Melanoma (Option D) is characterised by atypical melanocytes, which can be seen in various configurations, such as nests or single cells within the epidermis and dermis. These cells often contain melanin pigment. {{caption_text}}

In basal cell carcinoma

Mutated PTCH receptor

↓

Permanently activated SMO protein

↓

Activates the transcription factor GLI1

↓

Unregulated cell division and growth

↓

Basal cell carcinoma

@Neet_pg_bot



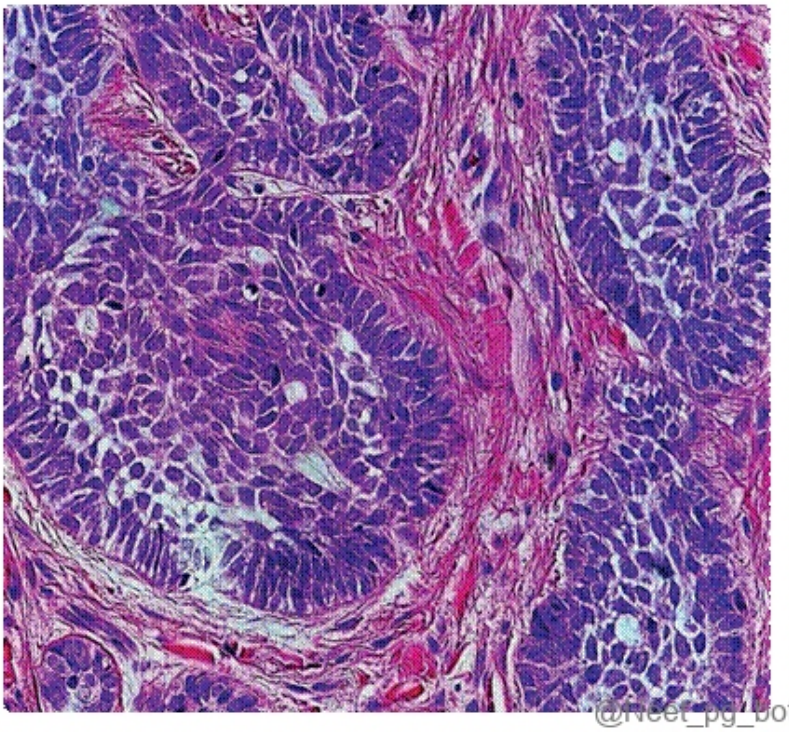
@Neet_pg_bot


@Neet_pg_bot

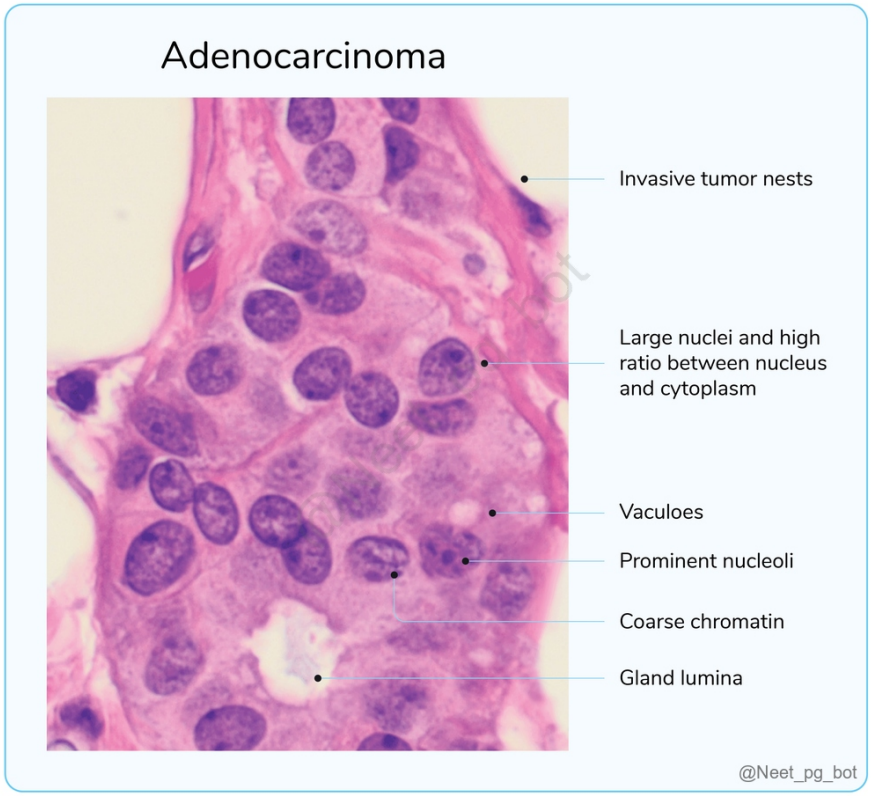

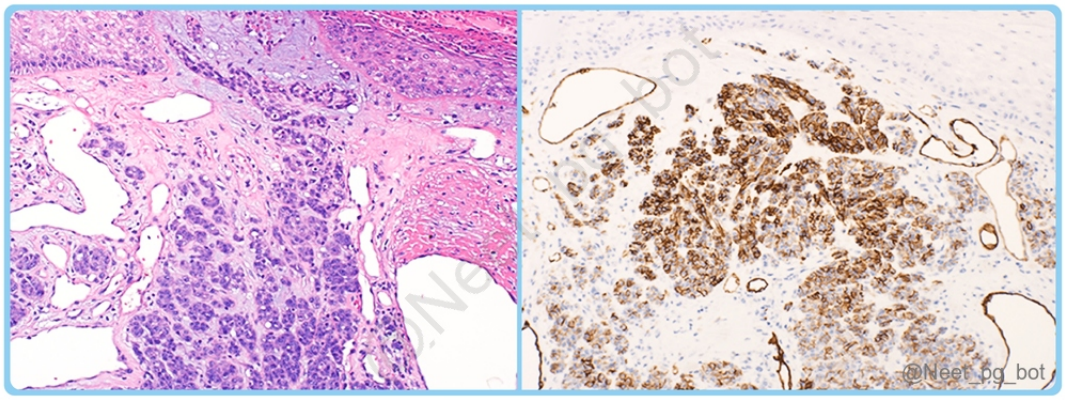

References:

Robbins and Cotran, Pathologic Basis of Diseases, 10th Edition, Page 292, 1147-1149.

Rooks Textbook of Dermatology, 9th Edition, Page 141.4-141.6.

↑ *Back to this question in Part A*

@Neet_pg_bot

• [17_Hematology_ Red Blood Cells] 065 Introduction To Hematology

« Back to Folder Directory

[17_Hematology_ Red Blood Cells] 065 Introduction To Hematology — Quick Jump

Q1 (p. 2575)	*Q2 (p. 2576)*	*Q3 (p. 2577)*	*Q4 (p. 2577)*	*Q5 (p. 2578)*	*Q6 (p. 2579)*
Q7 (p. 2579)	*Q8 (p. 2583)*	*Q9 (p. 2583)*	*Q10 (p. 2584)*	*Q11 (p. 2585)*	*Q12 (p. 2585)*
Q13 (p. 2586)	*Q14 (p. 2587)*	*Q15 (p. 2590)*	*Q16 (p. 2591)*	*Q17 (p. 2592)*	*Q18 (p. 2593)*
Q19 (p. 2594)	*Q20 (p. 2595)*				

Q1: What is the most common reason for an elevated reticulocyte count among the conditions? (Q846639)

A. Aplastic anemia

B. Hemolytic anemia

C. Megaloblastic anemia

D. Myelophthisic anemia

Correct Answer: B. Hemolytic anemia

■ *Listen (English)*

■ *Listen (Hindi)*

Explanation: Normal reticulocyte count is 0.5–2.5%. When red blood cells are destroyed, as in hemolytic anemia, a signal is sent to the bone marrow to increase red blood cell production. In response, the bone marrow releases more reticulocytes into circulation, which explains the elevated reticulocyte count seen in hemolytic anemia. Aplastic anemia (Option A): This means bone marrow failure. If the bone marrow is not producing red blood cells, the reticulocyte count will be low. Megaloblastic anemia (Option C): This occurs due to vitamin B12 or folic acid deficiency, where nuclear-cytoplasmic asynchrony impairs proper cell maturation, resulting in a low reticulocyte count. Myelophthisic anemia (Option D): This situation arises when the bone marrow is infiltrated, such as by cancer metastasis or a tubercular granuloma. The infiltration disrupts normal cellular production and alters the types of cells produced, leading to a decreased reticulocyte count.

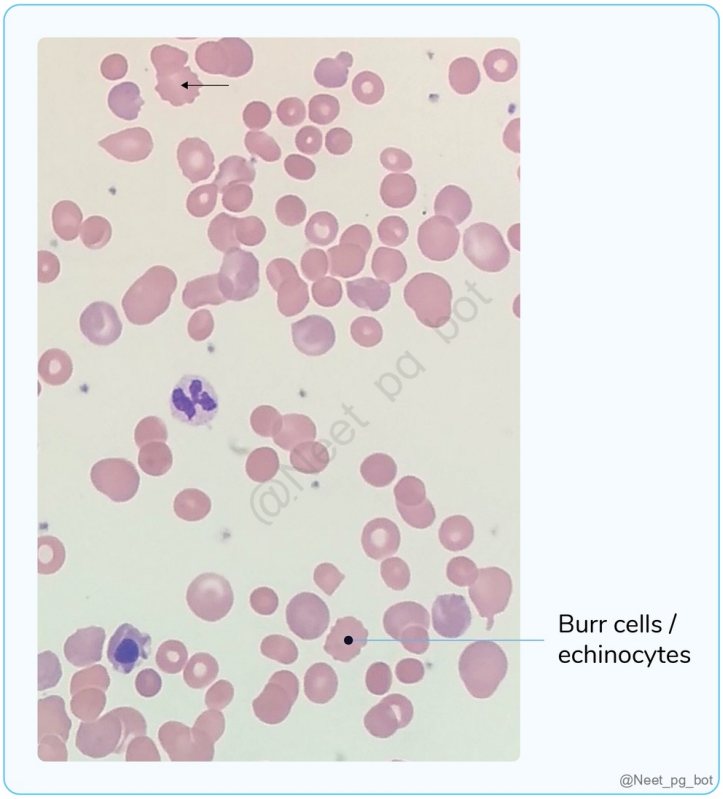

References:

Robbins & Cotran Pathologic Basis of Disease, 10th Edition, Page 636, 659, 661

↑ *Back to this question in Part A*

@Neet_pg_bot

Q2: What is the most likely interpretation if Hemoglobin is 9 g/dL, MCV is 104 fL, MCH is 22 pg, and MCHC is 31 g/dL? (Q846648)

A. Microcytic Hypochromic Anaemia

B. Normocytic Normochromic Anaemia

C. Macrocytic Hypochromic Anaemia

D. Microcytic Normochromic Anaemia

Correct Answer: C. Macrocytic Hypochromic Anaemia

■ *Listen (English)*

■ *Listen (Hindi)*

Explanation: Parameter Values Normal Range Interpretation Haemoglobin (Hb) 9 g/dL 12-16 g/dL Low Mean Corpuscular Volume (MCV) 104 fL 80-100 fL High (Macrocytic) Mean Corpuscular Hemoglobin (MCH) 22 pg 27-32 pg Low (Hypochromic) Mean Corpuscular Hemoglobin Concentration (MCHC) 31 g/dL 32-36 g/dL Low (Hypochromic) Examples of Macrocytic anemia: Liver diseases Hypothyroidism Megaloblastic anemia (Vitamin B12 and folic acid deficiency) Chemotherapeutic drugs use

References:

Robbins & Cotran Pathologic Basis of Disease, 10th Edition, Page 635 Dacie and Lewis Practical Haematology, 12th Edition, Page 35 https://www.ncbi.nlm.nih.gov/books/NBK470252/

↑ *Back to this question in Part A*

@Neet_pg_bot

Q3: What is the Mean Corpuscular Hemoglobin Concentration (MCHC) using Hemoglobin (Hb) level is 15 g/dL and Hematocrit (Hct) is 45%? (Q846647)

A. 33.3 g/dL

B. 34.0 g/dL

C. 32.0 g/dL

D. 30.0 g/dL

Correct Answer: A. 33.3 g/dL

Explanation: MCHC indicates the amount of haemoglobin per unit volume. In contrast to MCH, MCHC correlates the haemoglobin content with the volume of the cells. It is expressed as g/dl of red blood cells or as a percentage value. MCHC (g/dl) = Hb x 100/ PCV or Hematocrit Given: Hemoglobin (Hb) = 15 g/dL; Hematocrit (Hct) = 45% Using the formula for MCHC: MCHC(g/dL)=Hemoglobin (g/dL)×100/Hematocrit (%) MCHC=15×100/45 MCHC=1500/45 MCHC=33.3 g/dL

References:

Dacie and Lewis Practical haematology 12th edition, Page 35 https://www.ncbi.nlm.nih.gov/books/NBK260/

↑ *Back to this question in Part A*

@Neet_pg_bot

Q4: A 45-year-old male patient presents for a routine check-up. His laboratory results show that his Hemoglobin (Hb) level is 14 g/dL, and his RBC count is 4.7 million

cells/µL. Using these values, calculate the Mean Corpuscular Hemoglobin (MCH). (Q846646)

A. 29.8 pg

B. 29.0 pg

C. 30.0 pg

D. 28.5 pg

Correct Answer: A. 29.8 pg

Explanation: MCH (Mean Corpuscular Hemoglobin) measures the average hemoglobin amount per red blood cell, expressed in picograms (pg). It helps diagnose and classify anemia by assessing hemoglobin content in individual red blood cells. MCH (pg) = Hb x 10/ RBC count Given: Hemoglobin (Hb) = 14 g/dL; RBC count = 4.7 million cells/µL Using the formula for MCH: MCH(pg)=Hemoglobin (g/dL)×10/RBC count (millions/µL) MCH=14 ×10/4.7 MCH=140/4.7■ MCH=29.8 pg

References:

Dacie and Lewis Practical haematology 12th edition,pg 35 https://www.ncbi.nlm.nih.gov/books/NBK260/

↑ *Back to this question in Part A*

@Neet_pg_bot

Q5: Calculate MCV in a patient where RBC count is 4.5 million cells per microliter (cells/µL), Hb 9gm/dl and Hematocrit is 30% (Q846645)

A. 65.7 fL

B. 66.7 fL

C. 67.7 fL

D. 68.7 fL

Correct Answer: B. 66.7 fL

Explanation: Mean corpuscular volume (MCV) measures the average size of red blood cells in femtoliters (fL) and helps diagnose anemia. It is calculated by dividing the hematocrit (%) by the red blood cell count and multiplying by 10. MCV (fL) = PCV x 10/ RBC count Given: RBC count: 4.5 million cells/µL; Hematocrit/ PCV: 40% Using the formula for MCV: MCV (in fL) = (Hematocrit %)×10/(RBC×10 12 /L) MCV (fL) = Hematocrit(%)×10/RBC count(millions/µL) MCV = 30×10/4.5 MCV = 300/4.5■ MCV = 66.7 fL From the calculated MCV, the patient is likely to have Microcytic anaemia.

References:

Dacie and Lewis Practical Haematology, 12th Edition, Page 35 https://pubmed.ncbi.nlm.nih.gov/31424859/

↑ *Back to this question in Part A*

@Neet_pg_bot

Q6: RBC indices Definitions 1. MCV a) Indicates the variation in the size of red blood cells. 2. MCH b) Reflects the average volume of a red blood cell. 3. MCHC c) Measures the average amount of haemoglobin in a single red blood cell. 4. RDW d) Represents the amount of haemoglobin per unit volume of red blood cells. (Q846644)

A. 1-b, 2-c, 3-d, 4-a

B. 1-c, 2-a, 3-b, 4-d

C. 1-d, 2-a, 3-c, 4-b

D. 1-b, 2-d, 3-c, 4-a

Correct Answer: A. 1-b, 2-c, 3-d, 4-a

■ *Listen (English)*

■ *Listen (Hindi)*

Explanation: RBC INDICES DEFINITION MCV (Mean Corpuscular Volume) Reflects the average volume of a red blood cell (size of RBC) and is expressed as femtoliters (fl) or cubic microns (μm³). MCH (Mean Corpuscular Hemoglobin) Measures the average amount of haemoglobin in a single red blood cell, expressed in picograms (pg). MCHC (Mean Corpuscular Hemoglobin Concentration) Represents the average concentration of haemoglobin in a given volume of red blood cells, expressed as grams per deciliter (g/dl). RDW (Red Cell Distribution Width) Indicates the variation in the size of red blood cells (Anisocytosis) , expressed as a percentage.

References:

Dacie and Lewis Practical Haematology, 12th Edition, Page 35 http://www.ncbi.nlm.nih.gov/books/NBK260/

↑ *Back to this question in Part A*

@Neet_pg_bot

Q7: A 5-year-old child presented with a fever and his blood sample was taken to measure ESR using the Wintrobe tube. What are the advantages of the instrument (A) over instrument (B)? (Q846643)

A. The test is more sensitive

B. Does not need anticoagulant

C. Useful for estimation of both PCV and ESR

D. More volume of the tube

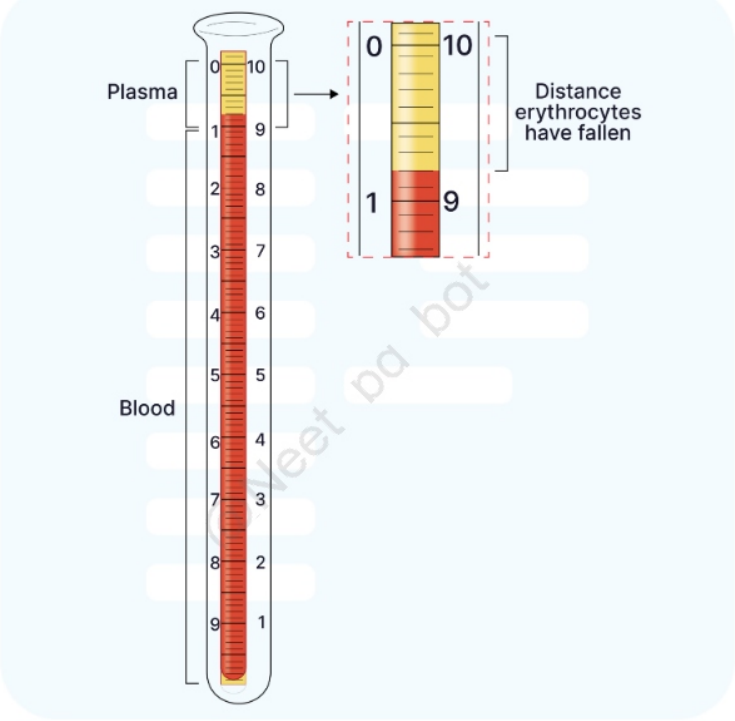

A

@Neet_pg_bot

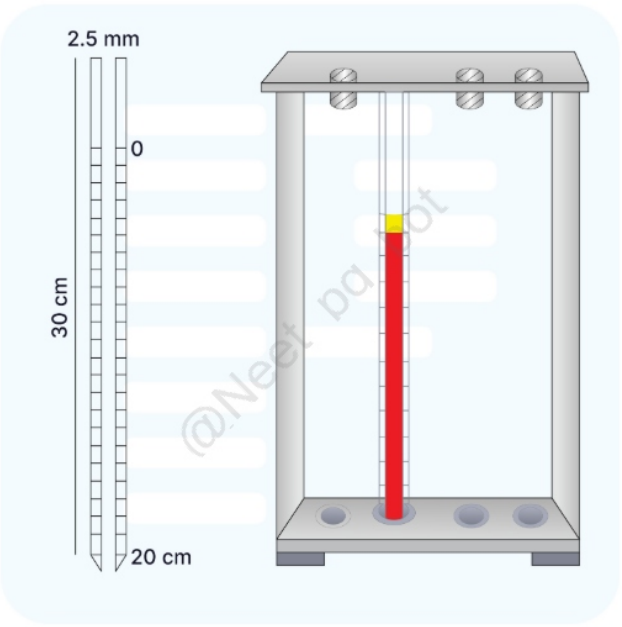

Correct Answer: C. Useful for estimation of both PCV and ESR

- *Listen (English)*
- *Listen (Hindi)*

Explanation: Features Wintrobe (A) Westergren (B) Structure Tube - closed and curved at lower end Pipette - open at both ends Length 11cm 30cm Diameter 2.5mm 2.5mm Volume (Option D) Less volume More volume Anticoagulant (Option B) EDTA (Purple vacutainer) Trisodium citrate (Light blue vacutainer) Uses (Option C) PCV, ESR estimation, buffy coat smear preparation ESR estimation Sensitivity (Option A) Less More Image

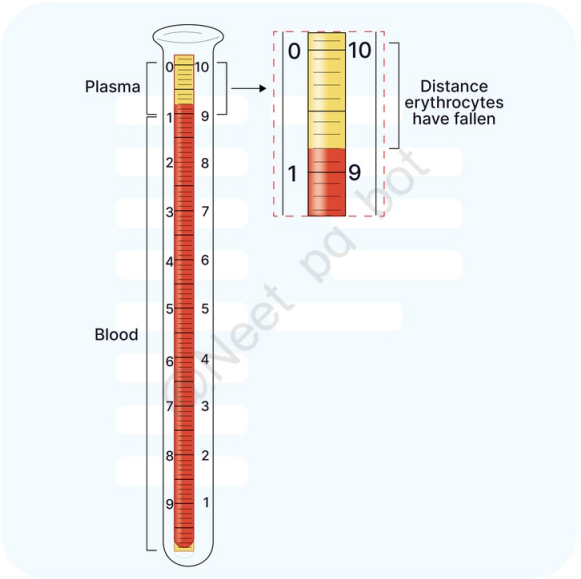

@Neet_pg_bot

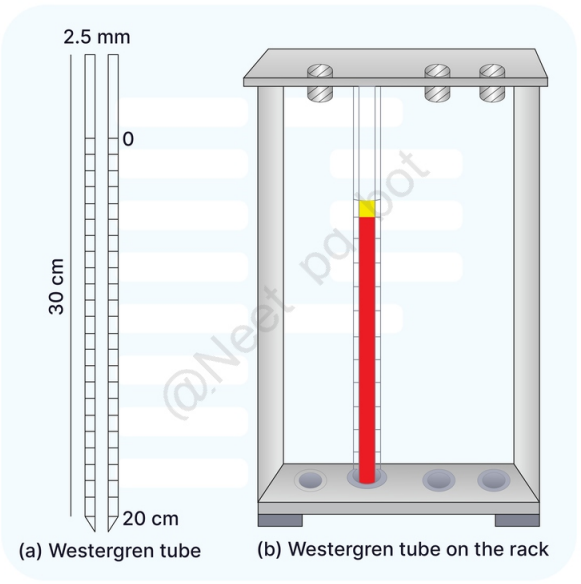

@Neet_pg_bot

References:

Wintrobes's Clinical Hematology,13th edition, Page 02, 35

↑ *Back to this question in Part A*

@Neet_pg_bot

Q8: Which statement accurately describes ESR (Erythrocyte Sedimentation Rate)? (Q846642)

A. Non-specific marker of inflammation

B. Proportion of red blood cells in the total blood volume

C. Reflects the oxygen-carrying capacity of the blood

D. Reported in percentage

Correct Answer: A. Non-specific marker of inflammation

■ *Listen (English)*

■ *Listen (Hindi)*

Explanation: ESR (Erythrocyte Sedimentation Rate) PCV (Packed Cell Volume) / Hematocrit Definition It measures the rate at which red blood cells (erythrocytes) settle at the bottom of a test tube over a specified period, usually one hour. PCV, also known as hematocrit, measures the proportion of blood volume occupied by red blood cells. (Option B) Significance Non-specific marker of inflammation No specific role in inflammation. Increases in Inflammation, fever, pregnancy, cancer Polycythemia Decreases in Sickle cell disease, polycythemia, hypoproteinemia Anemia Reported in Millimetre per hour percentage % (Option D) Reference range Male ≤15 mm/hr Female ≤ 20 mm/hr Child ≤10 mm/h Male = 40% to 54% Female = 36% to 48%.

References:

Wintrobes’s Clinical Haematology, 13th Edition, Page 35, 1360
https://www.ncbi.nlm.nih.gov/books/NBK557485/

↑ *Back to this question in Part A*

@Neet_pg_bot

Q9: A 48-year-old man presents to the clinic with fatigue, palpitations, and shortness of breath. Examination reveals pallor. Using the following values, calculate the reticulocyte production index: Reticulocyte count: 5% Hemoglobin: 9 g/dL Hematocrit: 28% (Q846641)

A. 1.8

B. 1.5

C. 2.5

D. 2.0

Correct Answer: B. 1.5

Explanation: The reticulocyte production index (RPI) is a calculated value that adjusts the reticulocyte count for anemia severity and reticulocyte maturation time to assess bone marrow response. RPI = CRC / maturation time in peripheral blood in days CRC = Observed reticulocyte count x Patient's haemoglobin / standard haemoglobin. Reticulocyte maturation time: Hematocrit Maturation time ≥ 40% 1 Day 30-40% 1.5 Days 20-30% 2 Days < 20% 2.5 Days From the given Clinical scenario, Reticulocyte count: 5%; Hemoglobin: 9 g/dL; Hematocrit: 28% CRC = 5 x 9 / 15 = 3.0 RPI = CRC / 2= 1.5

References:

Wintrobes's Clinical Haematology, 13th Edition, Page 1367,1368

↑ *Back to this question in Part A*

@Neet_pg_bot

Q10: A 30-year-old man presents to the OPD with fatigue, weakness, and breathlessness. He shows pallor and icterus on examination. Given his hemogram results, reticulocyte count of 5%, haemoglobin of 9 g/dL, and hematocrit of 28%, calculate his corrected reticulocyte count. (Q846640)

A. 4.0

B. 5.1

C. 4.5

D. 3.0

Correct Answer: D. 3.0

■ *Listen (English)*

■ *Listen (Hindi)*

Explanation: Normal reticulocyte count is 0.5-1.5%. Corrected reticulocyte count (CRC) is the correction for the degree of anaemia, and it's calculated using the following formula. Calculation of CRC using Haemoglobin: CRC= Observed reticulocyte count x Patient's haemoglobin / Standard haemoglobin Standard hemoglobin for men= 15g/dl; for women=13g/dl For the the above patient: CRC = 5 x 9 / 15 = 3.0 Calculation of CRC using Hematocrit: CRC= Observed reticulocyte count x Patient's hematocrit / Standard hematocrit Normal adult hematocrit= 45%

References:

Wintrobes’s Clinical Haematology, 13th edition, Page 1367-1368

https://www.ncbi.nlm.nih.gov/pmc/articles/PMC8490160/

↑ *Back to this question in Part A*

@Neet_pg_bot

Q11: At which site does erythropoiesis primarily occur in an adult human? (Q845922)

A. Bone marrow of long bones

B. Bone marrow of all bones

C. Yolk sac

D. Liver

Correct Answer: A. Bone marrow of long bones

■ *Listen (English)*

■ *Listen (Hindi)*

Explanation: Primary Sites of Erythropoiesis 1st trimester: Yolksac (Option C) 2nd trimester onwards: Liver (Option D) Children: Bone marrow of almost all bones (Option B) After puberty and in adults: Only in the bone marrow of the long bones (e.g., femur, tibia), as well as in the pelvis, vertebrae, and sternum.

References:

Robbins & Cotran Pathologic Basis of Disease, 10th Edition, Page 28

↑ *Back to this question in Part A*

@Neet_pg_bot

Q12: What is the approximate maturation time for reticulocytes in the bloodstream to form mature red blood cells? (Q846637)

A. 1-2 days

B. 2-5 days

C. 6-7 days

D. 8-10 days

Correct Answer: A. 1-2 days

■ *Listen (English)*

■ *Listen (Hindi)*

Explanation: Reticulocytes are the first cell in erythropoiesis that comes out of the bone marrow and starts circulating in the peripheral blood. Reticulocytes have a reticulum of RNA in them. Reticulocytes need 1-2 days to form mature red blood cells. Over 1–2 days, reticulocytes repeatedly pass through the spleen, where the spleen removes their extra RNA, thereby maturing them into mature red blood cells.

References:

Robbins & Cotran Pathologic Basis of Disease, 10th Edition, Page 584 Guyton and Hall Textbook of Medical Physiology, 14th Edition, Page 441

↑ *Back to this question in Part A*

@Neet_pg_bot

Q13: What is the normal range for reticulocyte count in adults? (Q846636)

A. 0.5-2%

B. 2-6%

C. 2-3%

D. 0-0.1%

Correct Answer: A. 0.5-2%

■ *Listen (English)*

■ *Listen (Hindi)*

Explanation: Reticulocytes are RBC precursors with no nucleus. 0.5-2.5% is the normal range of reticulocyte count in adults. In umbilical cord's blood sample, normal reticulocyte count is 2-6%

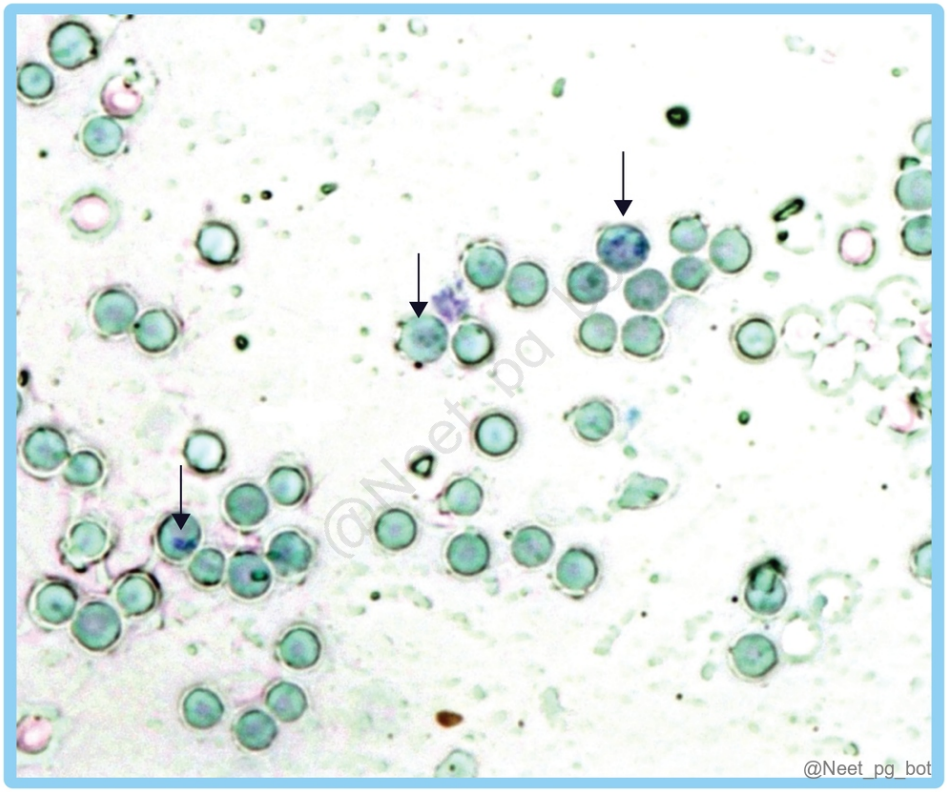

References:

Robbins & Cotran Pathologic Basis of Disease, 10th Edition, Page 584 Guyton and Hall Textbook of Medical Physiology, 14th Edition, Page 441 https://emedicine.medscape.com/article/2086146-overview?form=fpf

↑ *Back to this question in Part A*

@Neet_pg_bot

Q14: A 25-year-old woman experiences ongoing fatigue and weakness, appearing pale upon examination. Laboratory investigations reveal low haemoglobin levels, and a peripheral blood smear is ordered. Which stain is most effective for visualising reticulocytes in peripheral blood smears? (Q846635)

A. Prussian Blue

B. New Methylene Blue

C. Periodic acid-Schiff (PAS) stain

D. Wright stain

Correct Answer: B. New Methylene Blue

■ *Listen (English)*

■ *Listen (Hindi)*

Explanation: The presence of anaemia typically triggers the body's response by increasing erythropoiesis, releasing reticulocytes into circulation early as part of the compensatory mechanism to replenish red blood cells and enhance tissue oxygenation. New Methylene blue is used to visualise reticulocytes in peripheral blood smears. It is a supravital stain that stains living states like the RNA in reticulocytes. Normal reticulocyte count in peripheral blood is 0.5% to 2.5% . Prussian blue (Option A): It is also known as Pearl stain and is used to stain iron. PAS Stain (Option C): It stains polysaccharides such as glycogen, glycoproteins, glycolipids, and mucin in tissues a pink color. Wright's stain (Option D): It comes under the Romanowsky stain family which is usual/routine stain used in haematology.

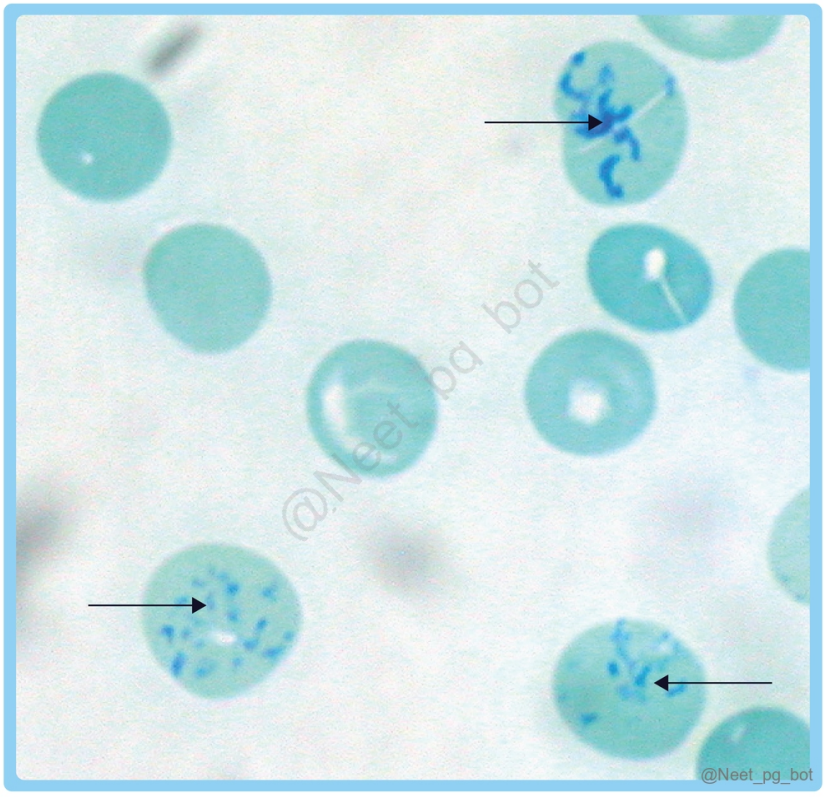

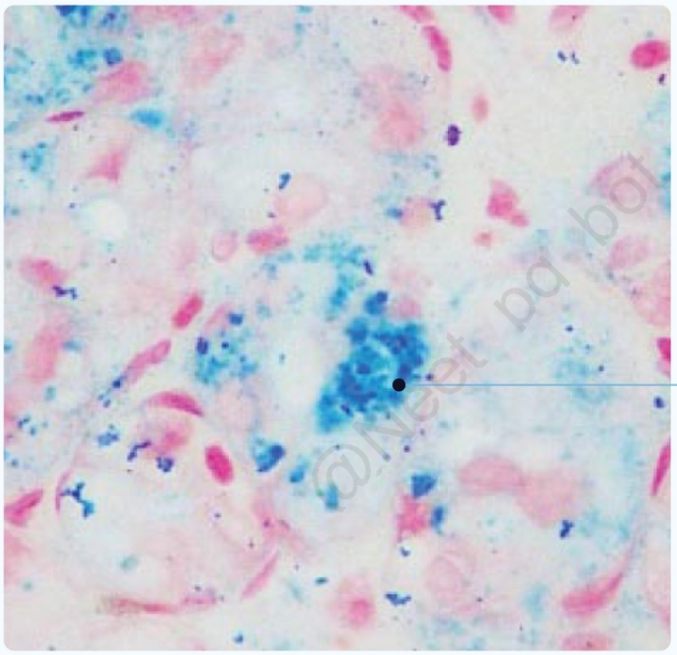

Hemosiderin containing cell

@Neet_pg_bot

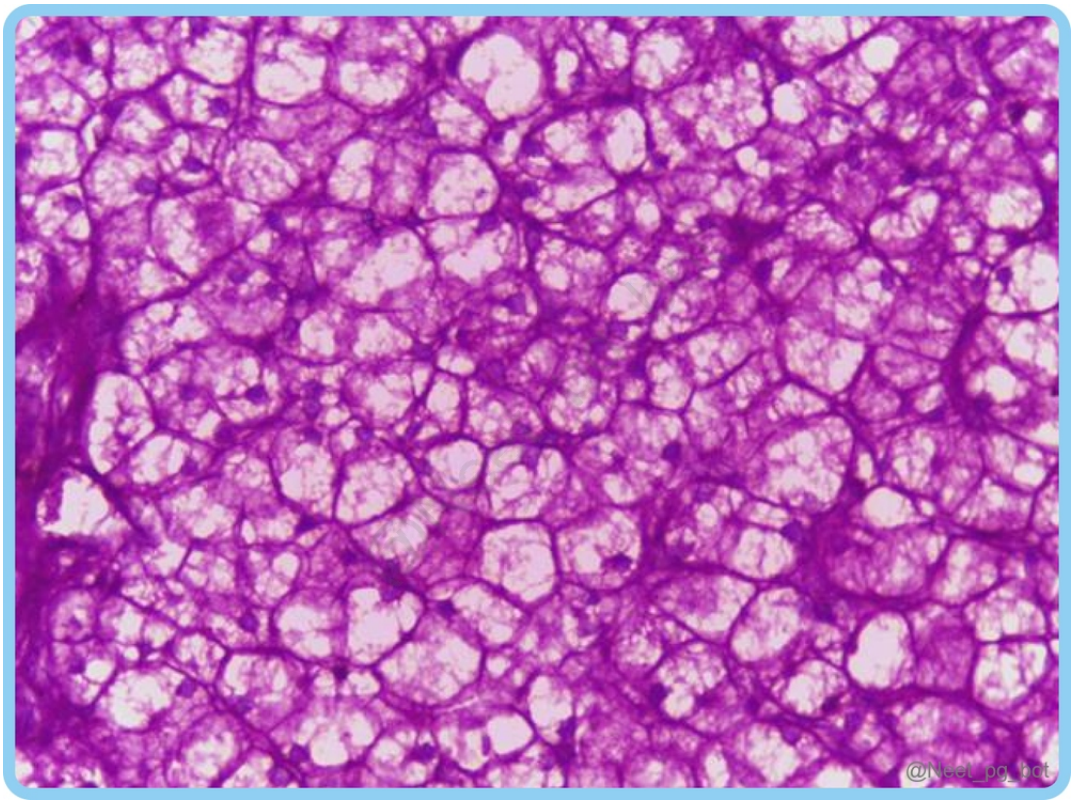

@Neet_pg_bot

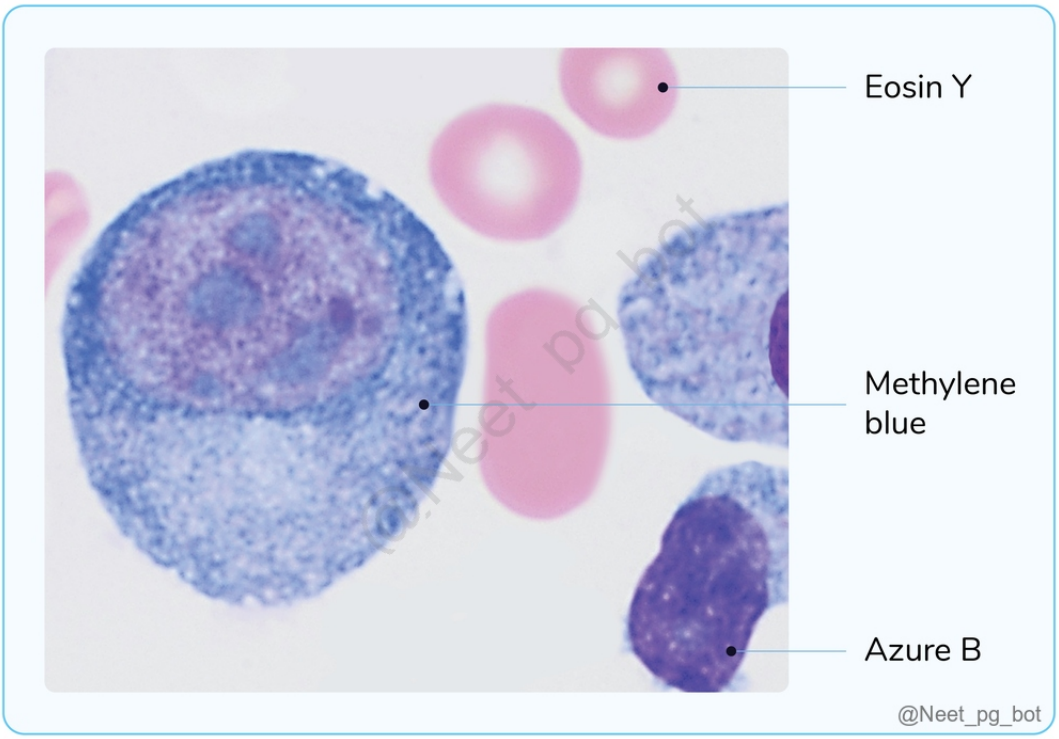

References:

Robbins & Cotran Pathologic Basis of Disease, 10th Edition, Page 655

https://www.ncbi.nlm.nih.gov/pmc/articles/PMC9681839/

https://www.ncbi.nlm.nih.gov/pmc/articles/PMC4821094/

↑ *Back to this question in Part A*

@Neet_pg_bot

Q15: Which stage of erythropoiesis is characterised by the expulsion of the nucleus, resulting in a smaller, pyknotic cell with increased haemoglobin content? (Q846634)

A. Reticulocyte

B. Normoblast

C. Basophilic erythroblast

D. Proerythroblast

Correct Answer: A. Reticulocyte

■ *Listen (English)*

■ *Listen (Hindi)*

Explanation: Reticulocytes are smaller pyknotic cells with increased haemoglobin content and have no nucleus. Stages of Erythropoiesis It starts with Hematopoietic stem cells(HSC)→Common Myeloid Progenitor cells(CMP)→Proerythroblasts. As the erythroid lineage progresses from the earliest precursor to the mature red blood cell, the overall cell size gradually decreases. In erythropoiesis, every stage that includes the term “blast” retains a nucleus, which applies to the proerythroblast, early normoblast, intermediate normoblast, and late normoblast stages. Reticulocyte: ■■■■■■■ It is the first cell in the erythropoietic lineage that does not have a nucleus . It is the first cell that comes out of the bone marrow and starts circulating in the peripheral blood . The normal reticulocyte count in peripheral blood is 0.5% to 2.5% .

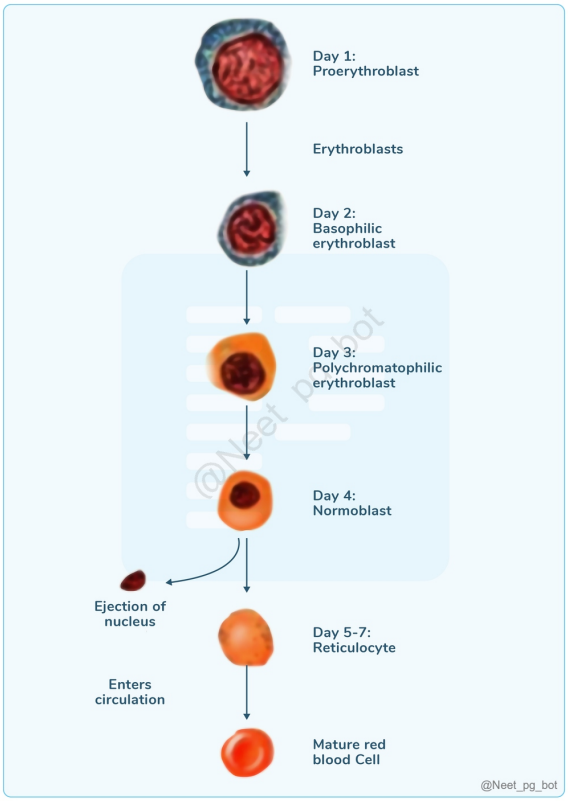

References:

Robbins & Cotran Pathologic Basis of Disease, 10th Edition, Page 584

↑ *Back to this question in Part A*

@Neet_pg_bot

Q16: Which condition is NOT typically associated with a dry tap during bone marrow aspiration? (Q846633)

A. Aplastic anaemia

B. Hairy cell leukemia

C. Myelofibrosis

D. Chronic Myeloid Leukemia

Correct Answer: D. Chronic Myeloid Leukemia

■ *Listen (English)*

■ *Listen (Hindi)*

Explanation: Chronic Myeloid Leukemia (CML) is a myeloproliferative neoplasm characterised by the presence of the Philadelphia chromosome, resulting in the abnormal proliferation of myeloid cells. The marrow in CML is hypercellular due to increased numbers of matured cells. It typically does not cause significant fibrosis or hypocellularity, the primary factor contributing to dry taps. Causes of Dry Tap: Aplastic anaemia: Because of the bone marrow's failure, it is unable to produce new cells. Hairy cell Leukemia: Hairy cell's release mediators like TGF-β and PDGF which leads to bone marrow fibrosis and dry tap. Myelofibrosis: Marrow has undergone fibrosis, and on putting a needle, nothing will be aspirated. Myelophthisic anaemia AML-M7

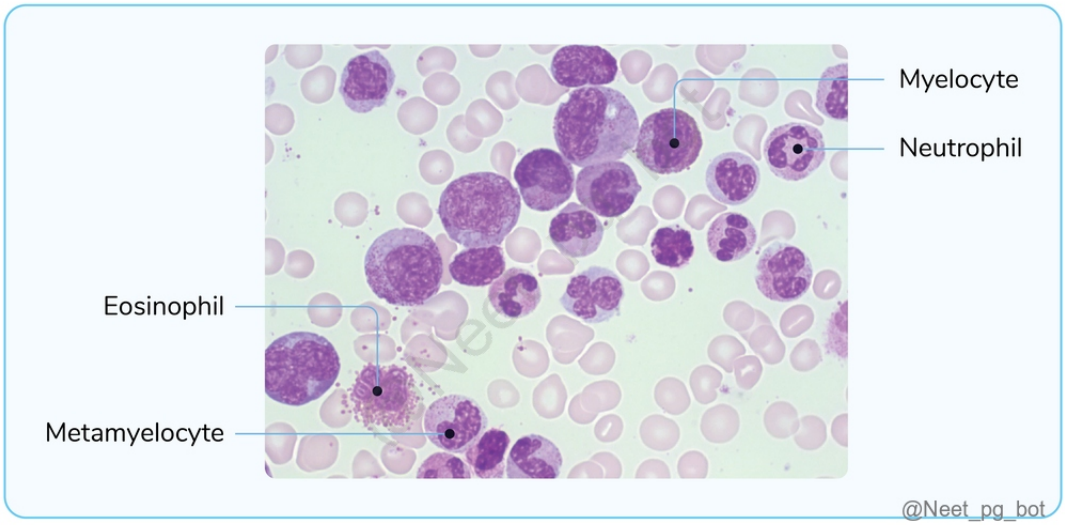

References:

Robbins & Cotran Pathologic Basis of Disease, 10th Edition, Page 622, 623, 660, 661

↑ *Back to this question in Part A*

@Neet_pg_bot

Q17: If a person is 45 years old, what would be the expected percentage of cellularity in their bone marrow biopsy? (Q845972)

A. 45%

B. 55%

C. 65%

D. 75%

Correct Answer: B. 55%

■ *Listen (English)*

■ *Listen (Hindi)*

Explanation: The expected percentage of cellularity in a bone marrow biopsy can be estimated using the formula: Expected bone marrow cellularity =100 – age of the patient So, for a 45-year-old person: Cellularity = 100 – 45 = 55% Therefore, the expected percentage of cellularity in their bone marrow biopsy would be 55%. n a healthy adult, the expected bone marrow cellularity is about 1:1, meaning roughly 50% is composed of hematopoietic cells and the other 50% of fat (adipose) cells.

References:

https://clinicalgate.com/normal-bone-marrow-histology/

↑ *Back to this question in Part A*

@Neet_pg_bot

Q18: A 35-year-old man undergoes a bone marrow biopsy, which shows a composition of cells and fat. What is the ratio of hematopoietic cells to fat cells expected in an adult? (Q845971)

A. 1:1

B. 1:3

C. 2:3

D. 3:1

Correct Answer: A. 1:1

■ *Listen (English)*

■ *Listen (Hindi)*

Explanation: Two primary constituents within the bone marrow are hematopoietic cells and fat cells . This ratio tends to be more evenly distributed in adults , with around 50% of each cell type present. (1:1) (Option A) A child's marrow typically consists of 75% hematopoietic cells and 25% fat cells (3:1) for more production ability.

(Option D) An elderly individual's marrow cosists of 25% hematopoietic cells and 75% fat cells (1:3) because the production capability of body decreases with age (Option B)

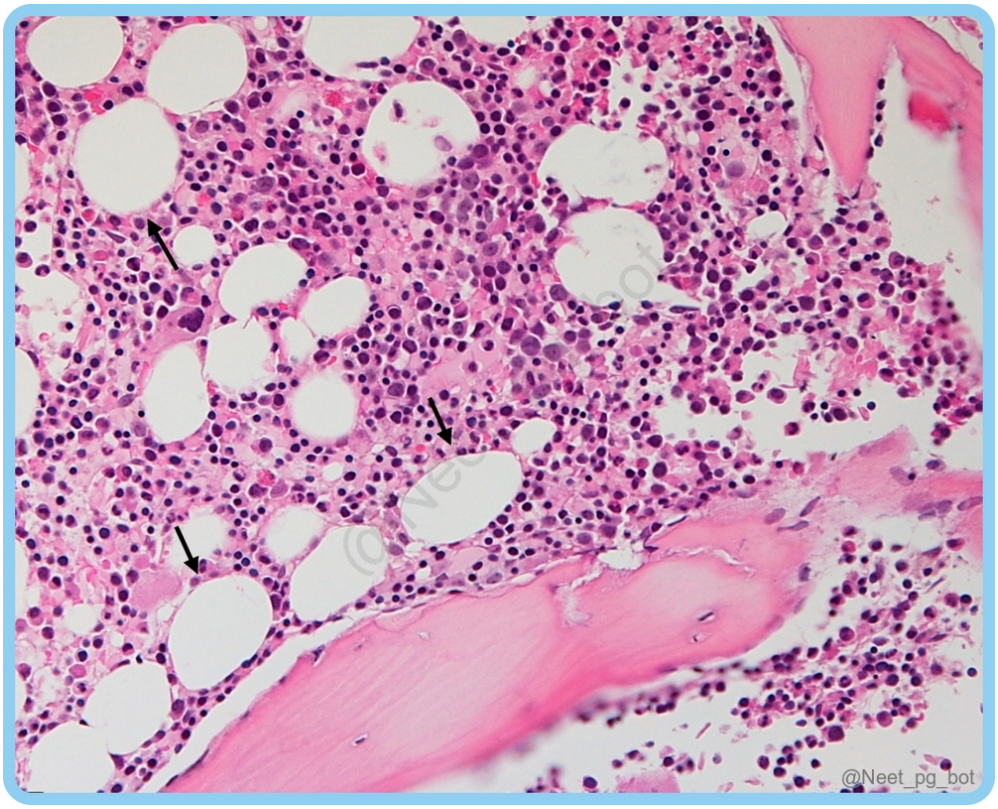

References:

Atlas of Clinical Hematology, Chapter 4, Page 69

↑ *Back to this question in Part A*

@Neet_pg_bot

Q19: A 56-year-old male presents with pancytopenia and is scheduled for a bone marrow biopsy to determine the underlying cause. What is the most common site for performing a bone marrow biopsy in this patient? (Q845946)

A. Anterior Superior Iliac spine

B. Posterior Superior Iliac spine

C. Proximal femur

D. Proximal tibia

Correct Answer: B. Posterior Superior Iliac spine

■ *Listen (English)*

■ *Listen (Hindi)*

Explanation: The posterior superior iliac spine (PSIS) is the preferred site for obtaining bone marrow in adults because it contains the most cellular marrow, there are no vital organs in close proximity, and it is a non-weight-bearing structure. If patient is obese and PSIS is difficult to palpate and locate then we can perform a bone marrow biopsy from Anterior Superior iliac spine (ASIS). In children, upper end of tibia is also commonly used for bone marrow biopsy.

References:

Atlas of Clinical Hematology Page 4

↑ *Back to this question in Part A*

@Neet_pg_bot

Q20: Identify the instrument shown in the image below. (Q845945)

A. Salah needle

B. Klima needle

C. Jamshidi needle

D. Quincke needle



Correct Answer: C. Jamshidi needle

- *Listen (English)*
- *Listen (Hindi)*

Explanation: The Jamshidi Needle (T-shaped needle) is the most commonly used needle for bone marrow biopsy due to its design, which allows for minimal trauma and obtaining an intact core biopsy. The most common site for obtaining a sample for any bone marrow study is the Posterior superior iliac spine (PSIS). Salah needle (Option A) : This needle is used for only bone marrow aspiration and not for biopsy. Klima needle (Option B): The Klima needle is also used for bone marrow aspiration . It functions similarly to the Salah needle in aspirating bone marrow cells but is not the primary tool for obtaining a core biopsy Quincke needle (Option D): The Quincke needle is used primarily for lumbar puncture procedures (spinal taps) to collect cerebrospinal fluid (CSF). It is not used for bone marrow biopsies.


@Neet_pg_bot


@Neet_pg_bot





References:

Atlas of Clinical Hematology, Page 4

↑ *Back to this question in Part A*

@Neet_pg_bot

• [17_Hematology_ Red Blood Cells] 066 Hemolytic Anemia-I

« Back to Folder Directory

[17_Hematology_ Red Blood Cells] 066 Hemolytic Anemia-I — Quick Jump

Q1 (p. 2599) *Q2 (p. 2600)* *Q3 (p. 2601)* *Q4 (p. 2602)* *Q5 (p. 2607)* *Q6 (p. 2608)*
Q7 (p. 2609) *Q8 (p. 2610)* *Q9 (p. 2611)* *Q10 (p. 2613)* *Q11 (p. 2614)* *Q12 (p. 2616)*
Q13 (p. 2616) *Q14 (p. 2619)* *Q15 (p. 2620)* *Q16 (p. 2623)* *Q17 (p. 2624)*

Q1: A 30-year-old male presents with severe fatigue, shortness of breath, and dark urine after eating fava beans. He has a history of recurrent hemolytic anemia. On examination, he appears pale and jaundiced. Which statement correctly describes the pathogenesis of his condition? (Q845845)

A. Deficiency in an enzyme leads to oxidative stress-induced hemolysis.

B. Excessive production of glutathione leads to the destruction of red blood cells.

C. Decreased levels of reactive oxygen species (ROS) lead to decreased oxidative damage.

D. The severity is not influenced by environmental factors or dietary triggers like fava beans.

Correct Answer: A. Deficiency in an enzyme leads to oxidative stress-induced hemolysis.

■ *Listen to Audio 1*

Explanation: The clinical scenario is suggestive of glucose-6-phosphate dehydrogenase deficiency that leads to oxidative stress-induced hemolysis Glucose-6-phosphate dehydrogenase (G6PD) deficiency is an X-linked recessive disorder characterised by a deficiency in the G6PD enzyme, which protects red blood cells from oxidative damage. This reduces the ability to generate NADPH via the pentose phosphate pathway and impairs glutathione regeneration, exacerbating oxidative stress and hemolysis. (Option B) When exposed to oxidative stressors, there is an imbalance between the production of reactive oxygen species (ROS) and antioxidants that neutralize them. This leads to oxidative damage to red blood cell membranes and proteins, resulting in hemolysis. (Option C) It presents with episodes of acute hemolytic anemia triggered by oxidative stressors such as infections, certain medications (e.g., antimalarials, sulfonamides), or ingestion of certain foods (e.g., fava beans). (Option D) Clinical manifestations include fatigue, pallor, jaundice, and dark urine (due to hemoglobinuria). The severity of hemolysis varies depending on the degree of enzyme deficiency and the magnitude of the oxidative insult, with some individuals experiencing life-threatening hemolytic crises. G6PD deficiency causes both intra and extravascular hemolysis.

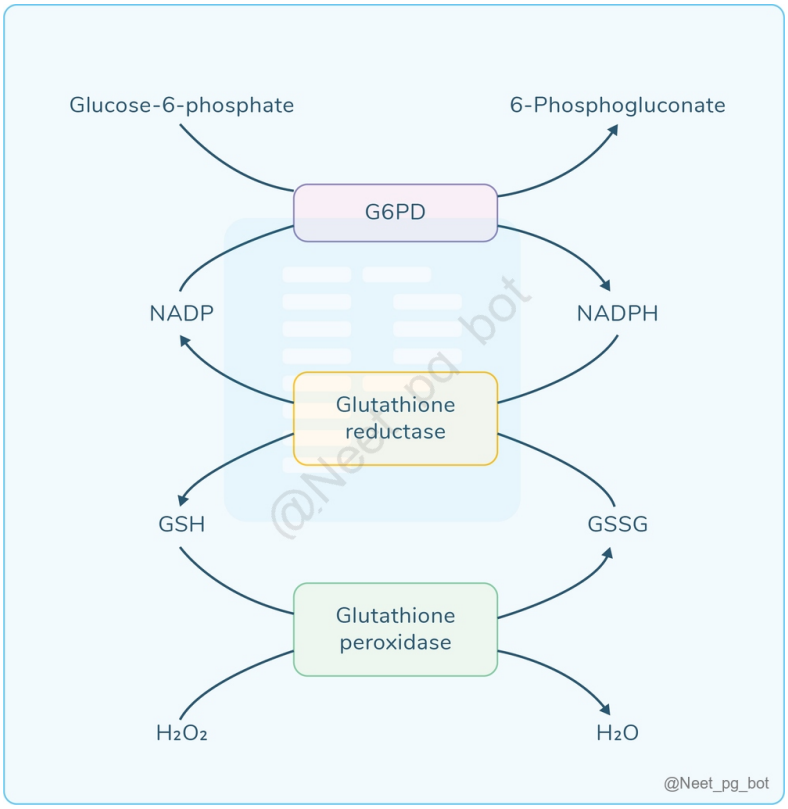

References:

Robbins & Cotran Pathologic Basis of Disease, 10th Edition, Page 640.

↑ *Back to this question in Part A*

@Neet_pg_bot

Q2: Which investigation is considered the most definitive for confirming the diagnosis of paroxysmal nocturnal hemoglobinuria (PNH)? (Q890597)

A. Ham’s acid hemolysis test

B. Bone marrow biopsy

C. High-performance liquid chromatography (HPLC)

D. Flow cytometry

Correct Answer: D. Flow cytometry

Explanation: Flow cytometry detects the absence or deficiency of GPI-anchored proteins (CD55, CD59) on RBCs and WBCs, providing a highly sensitive and specific diagnosis of PNH. It is considered the gold standard test.

Ham’s acid hemolysis test (Option A): This older test detects complement-mediated lysis and is not as sensitive or specific. Bone marrow biopsy (Option B): Useful to evaluate marrow failure or exclude other causes, but not diagnostic of PNH. High-performance liquid chromatography (HPLC) (Option C): Used for hemoglobinopathies, not PNH diagnosis.

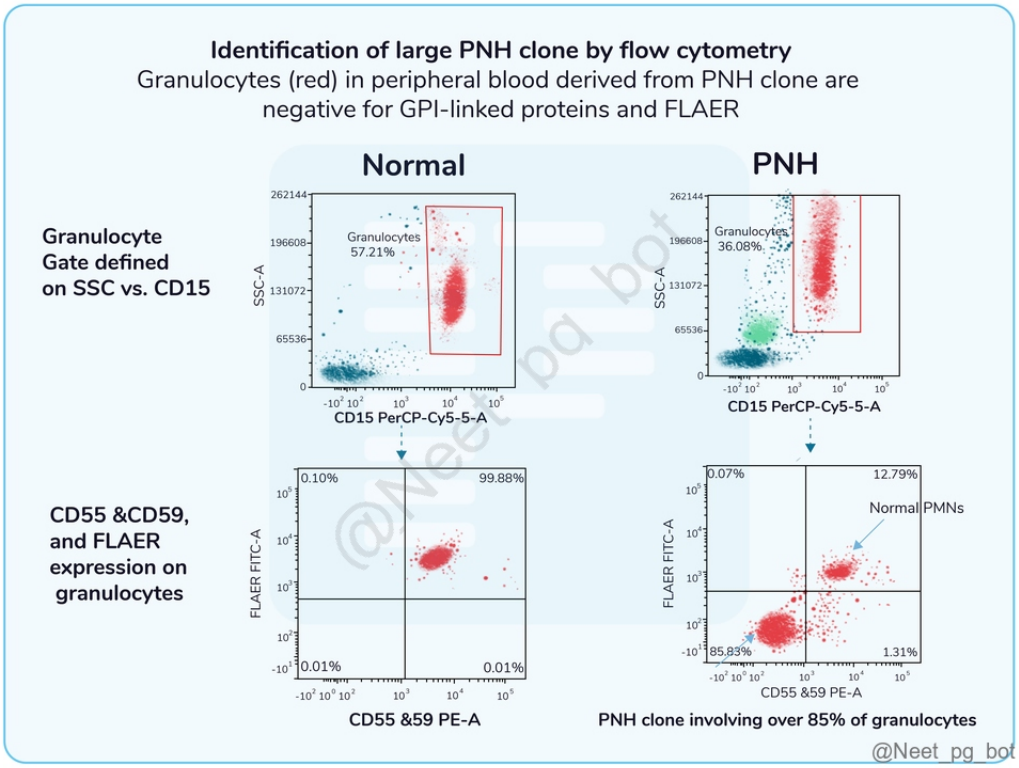

References:

Robbins and Cotran, Pathologic Basis of Disease, 11th Edition, Pages 589-590.

↑ *Back to this question in Part A*

@Neet_pg_bot

Q3: A 12-year-old girl presents for a regular health maintenance visit. There are no active complaints, and she has been feeling well. She has no chronic medical conditions and does not take any medications. She has a positive family history of thalassemia. Which of the following best confirms the diagnosis of thalassemia trait? (Q882123)

A. Elevated HbA2

B. Reticulocytosis

C. NESTROFT

D. Peripheral smear

Correct Answer: A. Elevated HbA2

Explanation: Option A: Elevated HbA 2 Elevated levels of HbA 2 are a specific feature of the thalassemia trait. The levels of HbF are relatively normal. Prominently increased levels of HbF are a particular feature of thalassemia major . Option B: Reticulocytosis Increased formation of reticulocytes occurs secondary to almost all hemolytic anaemias and is a very non-specific sign. It has no role in confirming the diagnosis of thalassemia trait. Option C: NESTROFT NESTROFT [Naked Eye Single Tube Red Cell Osmotic Fragility Test] is useful in screening thalassemia trait. Option D: Peripheral smear The peripheral smear findings can sometimes be used for screening purposes But these have no role in the confirmation of the thalassemia trait.

References:

Robbins 10th edition, pg-644-47

↑ *Back to this question in Part A*

@Neet_pg_bot

Q4: Match the following histopathological findings with their correct diagnosis: 1. A. Sickle Cell Anemia 2. B. Hereditary Spherocytosis 3. C. G6PD deficiency 4. D. Thalassemia (Q845892)

A. 1-C, 2-D, 3-A, 4-B

B. 1-D, 2-C, 3-B, 4-A

C. 1-B, 2-A, 3-D, 4-C

D. 1-A, 2-B, 3-C, 4-D

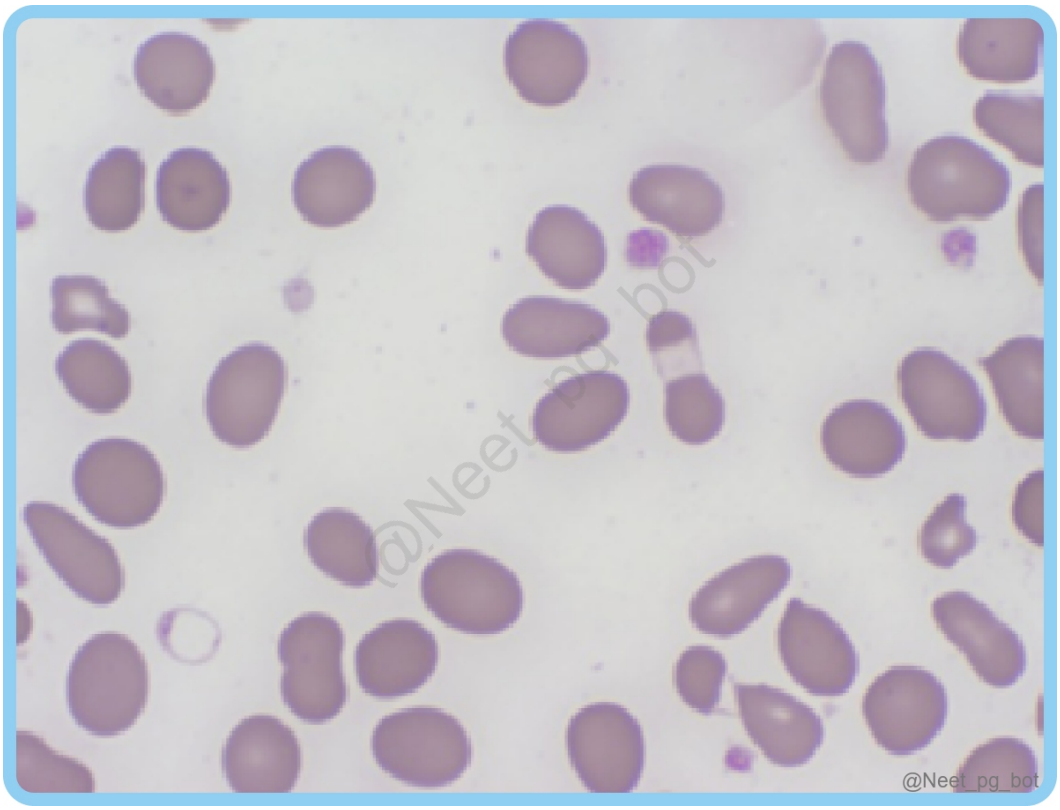
@Neet_pg_bot

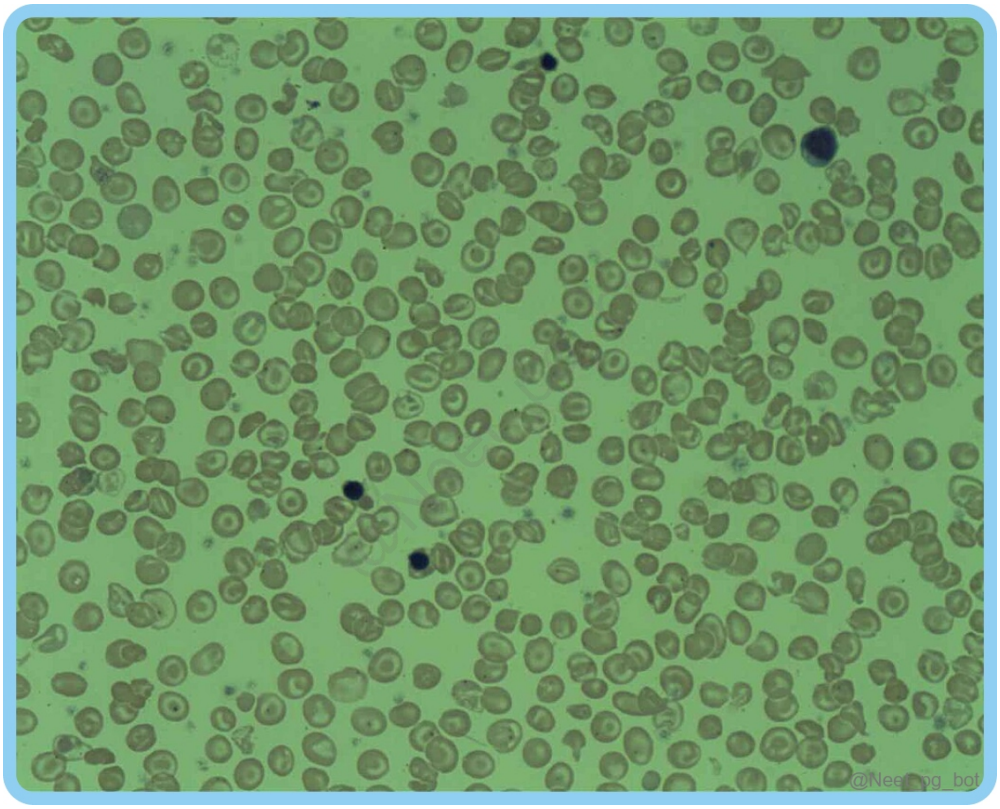
@Neet_pg_bot

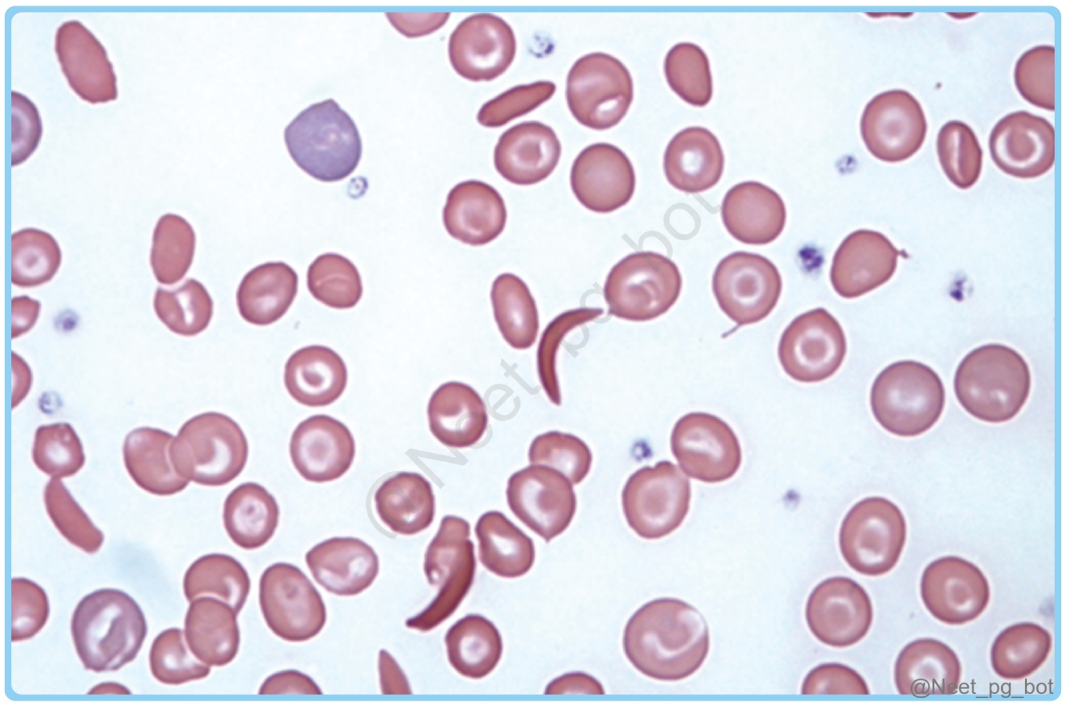

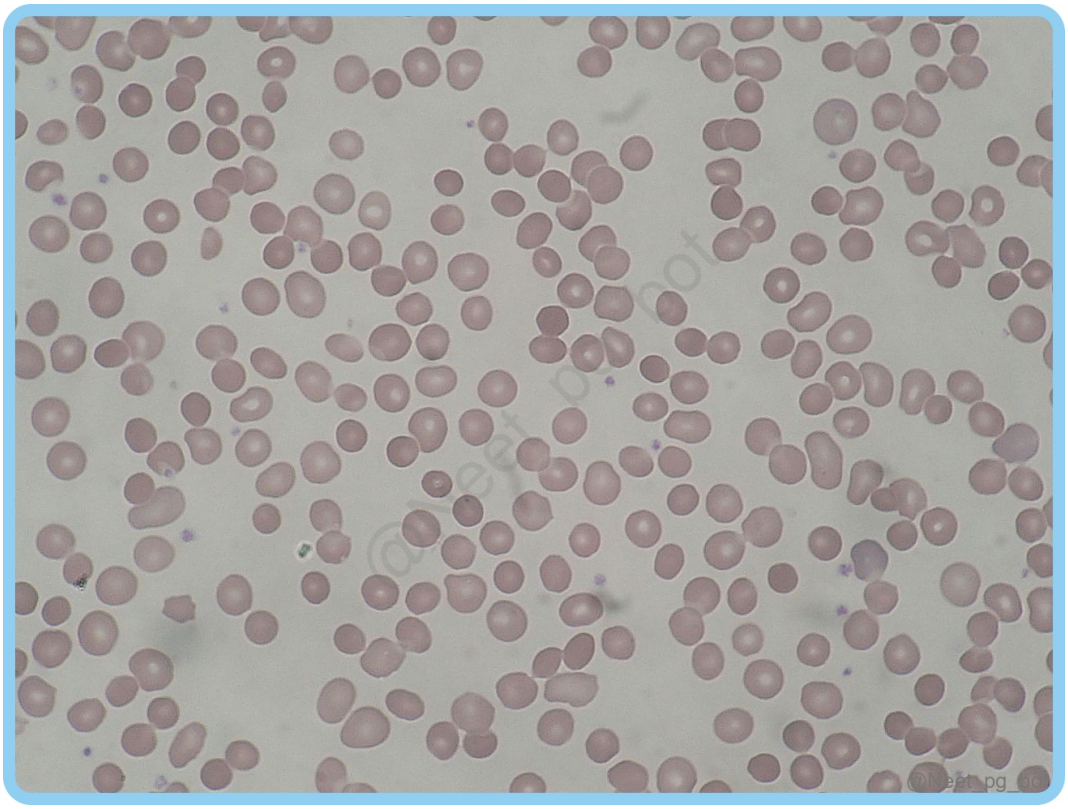

Correct Answer: A. 1-C, 2-D, 3-A, 4-B

■ *Listen to Audio 1*

Explanation: Red Blood Cell Abnormality Condition Reason 1. Bite cells C. G6PD deficiency Oxidative stress leads to denaturation of hemoglobin → Heinz bodies 2. Target cells D. Thalassemia ↓ Hemoglobin content in

RBCs → ↓ RBC volume → Surface area relatively unchanged → ↑ Surface area to volume ratio→ Altered lipid composition → ↑ Formation of membrane protrusions→ ↑ Membrane instability → ↓ Hemoglobin accumulation in certain membrane areas → Central area with hemoglobin, clear zone, outer ring Uneven distribution of hemoglobin and lipids → Characteristic "bull's-eye" appearance of Target cells 3. Sickle-shaped red blood cells A. Sickle Cell Anemia Abnormal Hemoglobin (HbS) →HbS molecules polymerize under low oxygen→RBCs become rigid and assume a sickle shape. 4. Spherocytes B. Hereditary Spherocytosis Genetic defect in RBC membrane protein(spectrin) ■ Loss of membrane surface area ■ RBCs become spherical

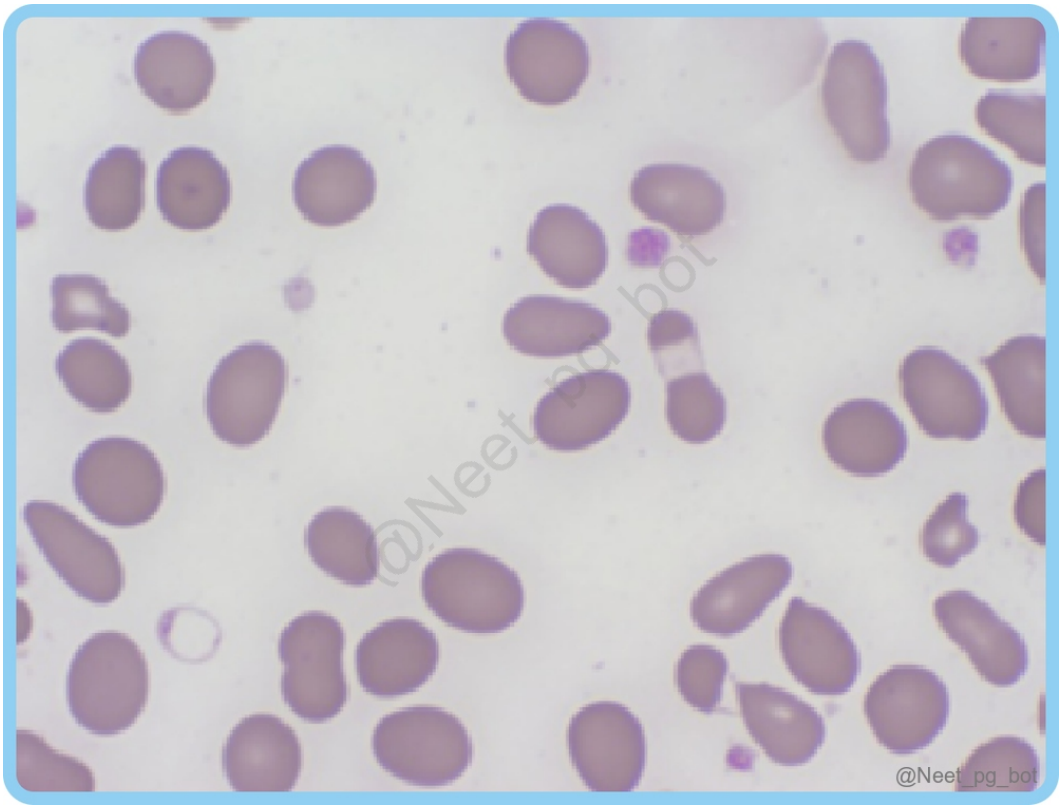

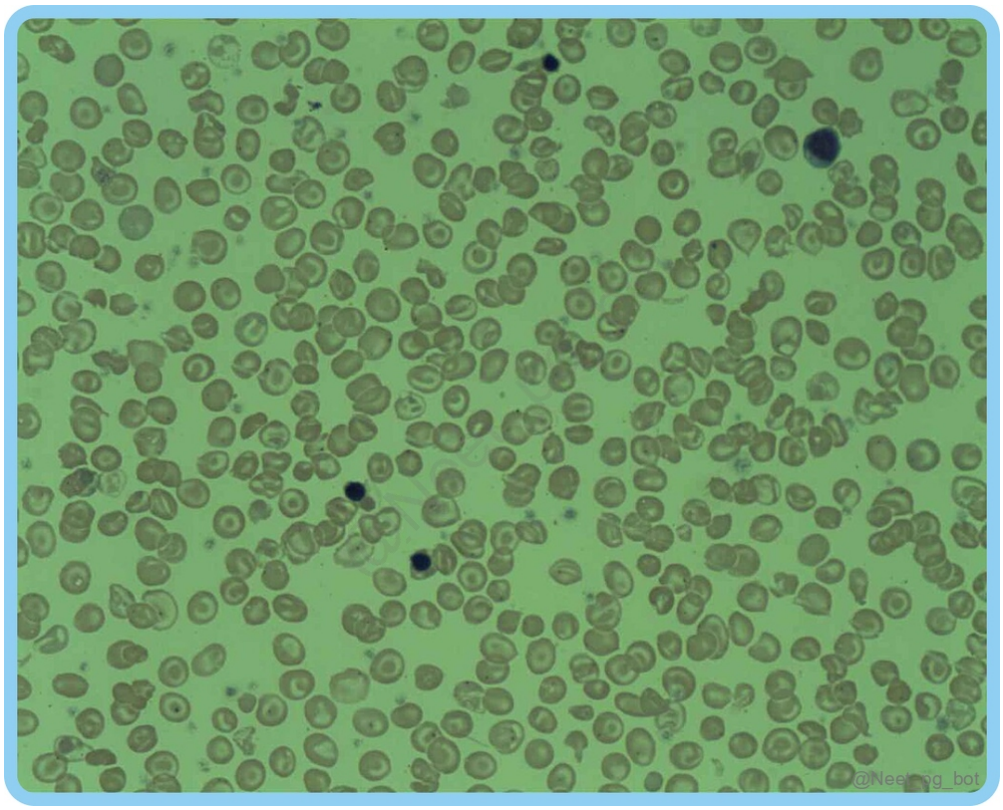
@Neet_pg_bot

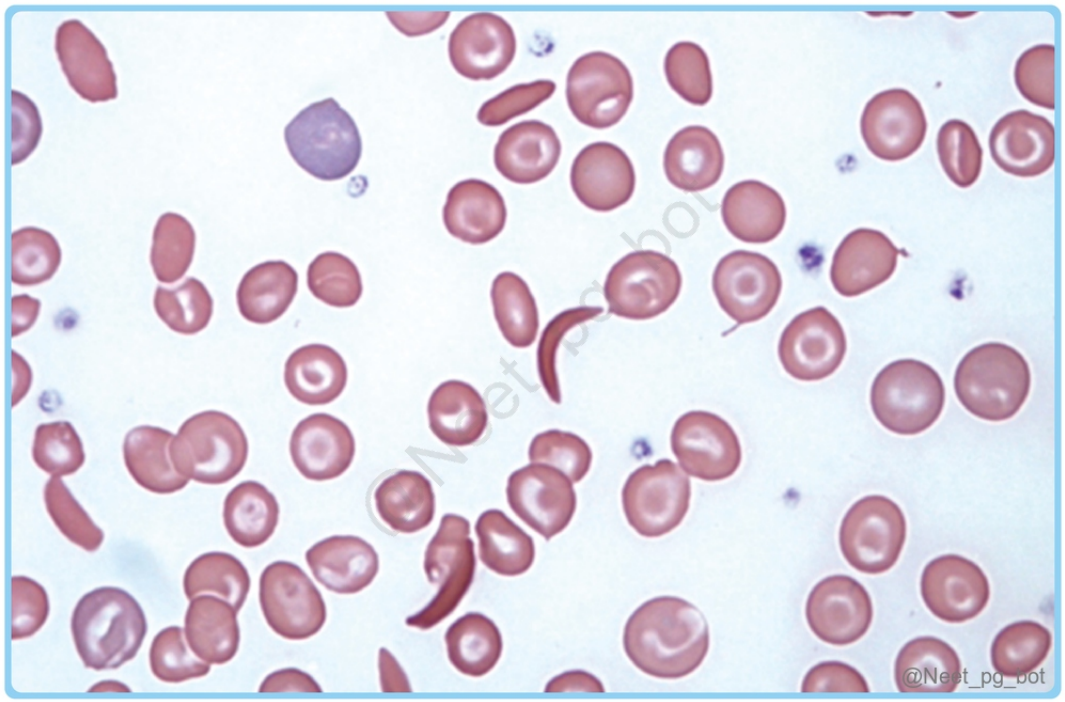
@Neet_pg_bot

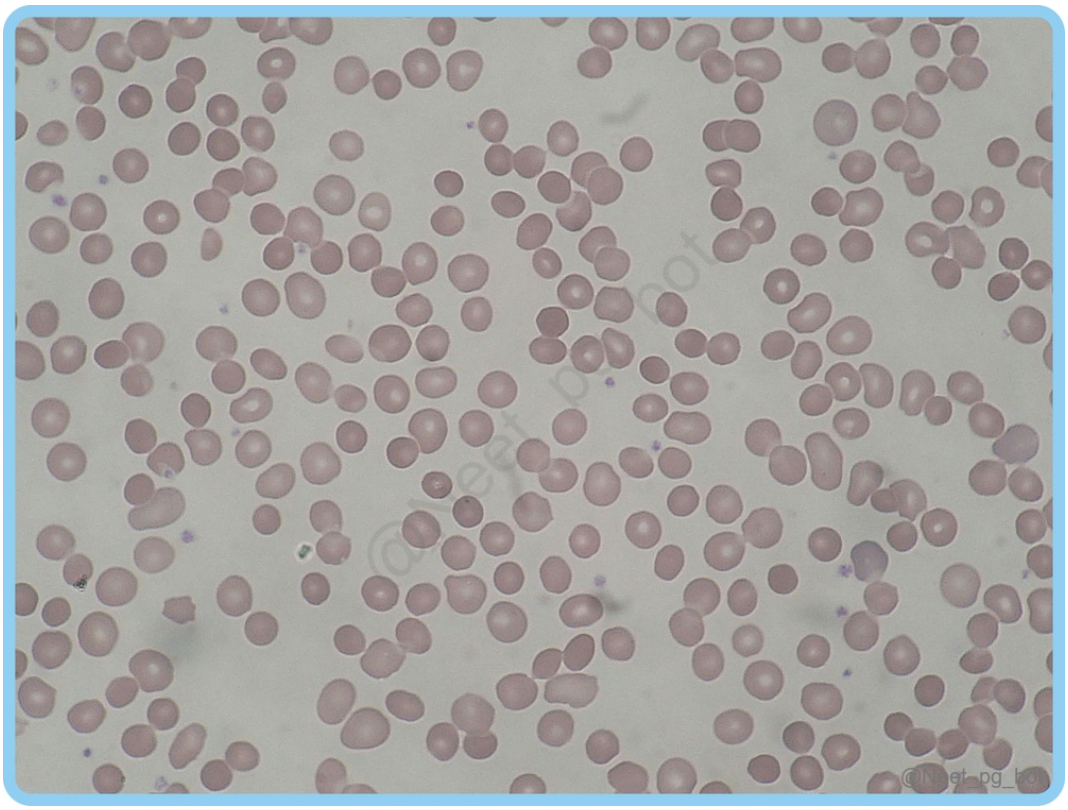

References:

Robbins & Cotran Pathologic Basis of Disease, 10th Edition, Page 639, 641, 650

↑ *Back to this question in Part A*

@Neet_pg_bot

Q5: Which of the following treatments is commonly used for Paroxysmal Nocturnal Hemoglobinuria? (Q845891)

A. Rituximab

B. Bevacizumab

C. Eculizumab

D. Trastuzumab

Correct Answer: C. Eculizumab

Explanation: Monoclonal antibody-Eculizumab is commonly used for Paroxysmal Nocturnal Hemoglobinuria. Mechanism of action: By binding to C5, eculizumab blocks the enzymatic activity of the C5 convertase, which is

responsible for cleaving C5 into two fragments, C5a and C5b. Inhibition of C5 cleavage prevents the formation of (Membrane Attack Complex), which is involved in cell lysis. It also lowers the risk of thrombosis by up to 90% Drawback: Increased risk of serious or fatal meningococcal infection The only cure is hematopoietic stem cell transplantation. Monoclonal Antibody Disorders Mechanism of Action Eculizumab Paroxysmal Nocturnal Hemoglobinuria (PNH) Inhibits complement protein C5, preventing terminal complement activation and reducing hemolysis. Rituximab (Option A) Non-Hodgkin lymphoma Chronic lymphocytic leukemia (CLL) Rheumatoid arthritis Idiopathic thrombocytopenic purpura (ITP) Targets CD20 antigen on B cells, leading to B cell depletion and modulation of immune response. Bevacizumab (Option B) Colorectal cancer Lung cancer Renal cell carcinoma Age-related macular degeneration Targets vascular endothelial growth factor (VEGF), inhibiting angiogenesis and tumor growth. Trastuzumab (Option D) Breast cancer Gastric cancer Targets HER2/neu receptor on cancer cells, inhibiting cell proliferation and promoting antibody-dependent cellular cytotoxicity.

References:

Robbins & Cotran Pathologic Basis of Disease, 10th Edition, Page 649
https://www.ncbi.nlm.nih.gov/pmc/articles/PMC7551545/table/antibodies-09-00034-t001/?report=objectonly

↑ *Back to this question in Part A*

@Neet_pg_bot

Q6: Which of the following is the most common cause of death in Paroxysmal Nocturnal Hemoglobinuria? (Q845890)

A. Pancytopenia

B. Acute Myeloid Leukemia

C. Hepatic vein thrombosis

D. Myelodysplastic syndrome

Correct Answer: C. Hepatic vein thrombosis

Explanation: Hepatic vein thrombosis is the most common cause of death in PNH. Paroxysmal nocturnal hemoglobinuria (PNH) is a disease that results from acquired mutations in the phosphatidylinositol glycan complementation group A gene (PIGA), an enzyme that is essential for the synthesis of certain membrane-associated complement regulatory proteins. PNH blood cells are deficient in three GPI-linked proteins that regulate complement activity: (1) decay-accelerating factor, or CD55; (2) membrane inhibitor of reactive lysis, or CD59; and (3) C8-binding protein Of these factors, the most important is CD59, a potent inhibitor of C3 convertase that prevents the spontaneous activation of the alternative complement pathway. Clinical Features: Hemolysis at night (slight decrease in blood pH during sleep, which increases the activity of complement) Anemia - usually mild to moderate in severity. Complications: Thrombosis is the leading cause of disease-related death in individuals with PNH. About 40% of patients suffer from venous thrombosis, often involving the hepatic, portal, or cerebral veins. Diagnosis: Flow cytometry - for detecting red cells that are deficient in GPI-linked proteins such as CD59. Treatment: Eculizumab (prevents the conversion of C5 to C5a) Drawbacks: high cost and an increased

risk of serious or fatal meningococcal infection Definitive treatment: Hematopoietic stem cell transplantation Complications of PNH Bone marrow failure Pancytopenia (Option A) Aplastic anemia Thrombosis (Most common cause of death in PNH) Cerebral vein thrombosis Hepatic and portal vein thrombosis - Budd Chiari Syndrome Clonal expansion Acute Myeloid Leukemia(AML). (Option B) Myelodysplastic syndrome (Option D)

References:

Robbins & Cotran Pathologic Basis of Disease, 10th Edition, Pages 643, 648.

https://www.uptodate.com/contents/clinical-manifestations-and-diagnosis-of-paroxysmal-nocturnal-hemoglobinuria

https://www.ncbi.nlm.nih.gov/pmc/articles/PMC8672449/

↑ *Back to this question in Part A*

@Neet_pg_bot

Q7: Which of the following defects is seen in paroxysmal nocturnal hemoglobinuria? (Q845889)

A. Spectrin

B. CD 45 and CD 95

C. G6PD enzyme

D. PIGA gene

Correct Answer: D. PIGA gene

Explanation: Paroxysmal nocturnal hemoglobinuria is due to a mutation in the PIGA gene. Pathogenesis of PNH: PNH is caused by an acquired mutation in the PIGA gene leading to defective synthesis of (GPI) anchors. GPI anchors are essential for attaching certain proteins to the cell surface, including CD55 (decay-accelerating factor), CD59 (membrane inhibitor of reactive lysis), and C8-binding protein. (Option B) These proteins regulate the complement system and inhibit the formation of the membrane attack complex (MAC) that leads to cell lysis. In PNH, the deficiency of these regulators increases susceptibility to complement-mediated hemolysis. Subsequent lysis by the MAC leads to intravascular hemolysis Hemoglobin from lysed RBCs appears in the urine (hemoglobinuria) and is more pronounced during periods of increased complement activation, such as at night (Nocturnal) or stress. Clinical manifestations: Fatigue, weakness, dyspnea Pallor due to anemia Hemoglobinuria may cause urine to appear dark or cola-colored. Abdominal pain, thrombosis (due to platelet activation and endothelial injury)

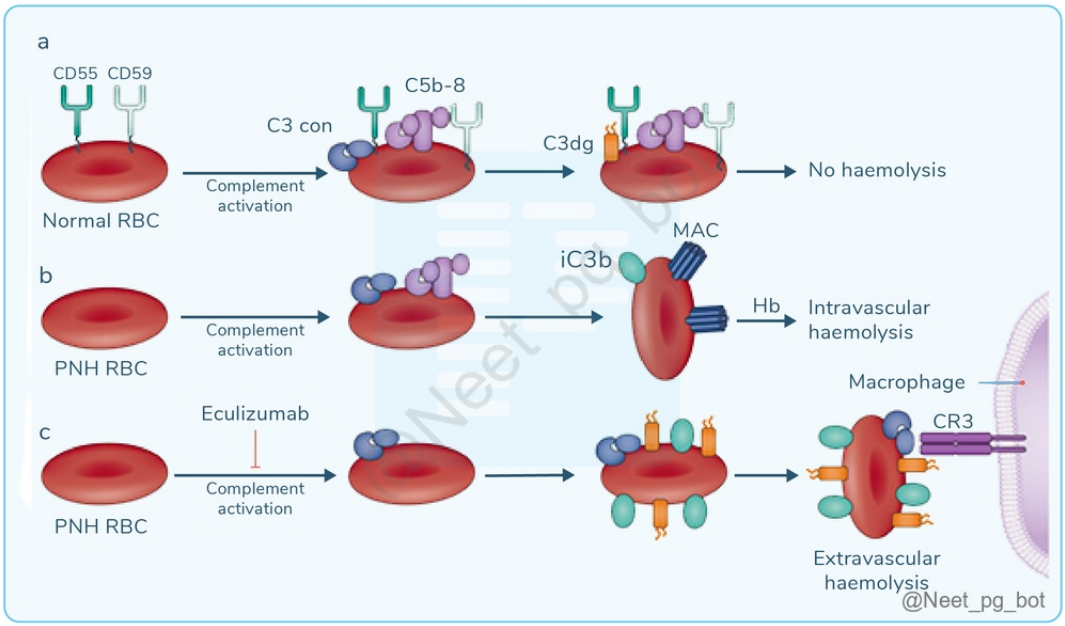

References:

Robbins & Cotran Pathologic Basis of Disease, 10th Edition, Page 638, 640, 648.

↑ *Back to this question in Part A*

@Neet_pg_bot

Q8: Which of the following statements regarding Paroxysmal Nocturnal Hemoglobinuria (PNH) is true? (Q845888)

A. Causes extravascular hemolysis

B. Splenectomy would be beneficial

C. Causes hemolysis only at night

D. Acquired intracorpuscular defect

Correct Answer: D. Acquired intracorpuscular defect

Explanation: The true statement regarding PNH is that it is an acquired intracorpuscular defect. PNH is the "ONLY" acquired intracorpuscular defect (defect within the RBCs) among hemolytic anemia, making them susceptible to destruction by the complement system. It causes intravascular hemolysis due to complement activation that attacks RBCs. (Option A) Hence, splenectomy, which would be beneficial in some cases of extravascular hemolysis, would not be of any use in PNH. (Option B) Contrary to the name, only 25% of cases show paroxysmal and nocturnal hemolysis. (Option C) Red cell lysis at night is explained by a slight decrease in blood pH during sleep, which increases complement activation. Chronic hemolysis without dramatic

hemoglobinuria is more typical.

References:

Robbins & Cotran Pathologic Basis of Disease, 10th Edition, Page 636, 648

↑ *Back to this question in Part A*

@Neet_pg_bot

Q9: A 45-year-old male presents to the emergency department with symptoms of acute hemolytic anemia. A methemoglobin reduction test is performed, revealing a delayed rate of methemoglobin reduction. What is the underlying principle of the above-mentioned screening test used to diagnose G6PD deficiency? (Q845846)

A. Measures the levels of methemoglobin in red blood cells.

B. Evaluates the ability of red blood cells to reduce methemoglobin back to haemoglobin.

C. Detects G6PD activity by measuring the rate of reduction of a fluorescent dye.

D. Measures the actual activity levels of the G6PD enzyme.

Correct Answer: B. Evaluates the ability of red blood cells to reduce methemoglobin back to haemoglobin.

■ *Listen to Audio 1*

Explanation: Purpose of Methemoglobin Reduction Test : Used to detect glucose-6-phosphate dehydrogenase (G6PD) deficiency. Measures the ability of red blood cells to convert methemoglobin back to hemoglobin. Helps assess the enzymatic activity crucial for protecting cells from oxidative stress. Mechanism in G6PD Deficiency : Individuals with G6PD deficiency have reduced enzyme activity. Red blood cells are more vulnerable to oxidative damage. Impaired reduction of methemoglobin indicates decreased G6PD function. Testing Procedure : The blood sample is exposed to a chemical that induces methemoglobin formation. The rate of reduction back to hemoglobin is measured. The slower reduction compared to normal suggests G6PD deficiency. Clinical Application : Used to confirm diagnosis in patients suspected of having G6PD deficiency. Helps guide management decisions in conditions where oxidative stress can trigger hemolysis. Provides insight into the enzymatic function critical for maintaining red blood cell integrity. Other tests used for screening include: Fluorescent Spot Test (FST): This is a quick screening test that detects G6PD activity by measuring the rate of reduction of a fluorescent dye. (Option C) NADPH is autofluorescent In normal cases: fluorescence is seen. In G6PD deficiency: Fluorescence not seen Quantitative Enzyme Assays: These tests measure the actual activity levels of G6PD enzyme in the blood. They provide a more accurate assessment but are often more expensive and time-consuming. (Option D)

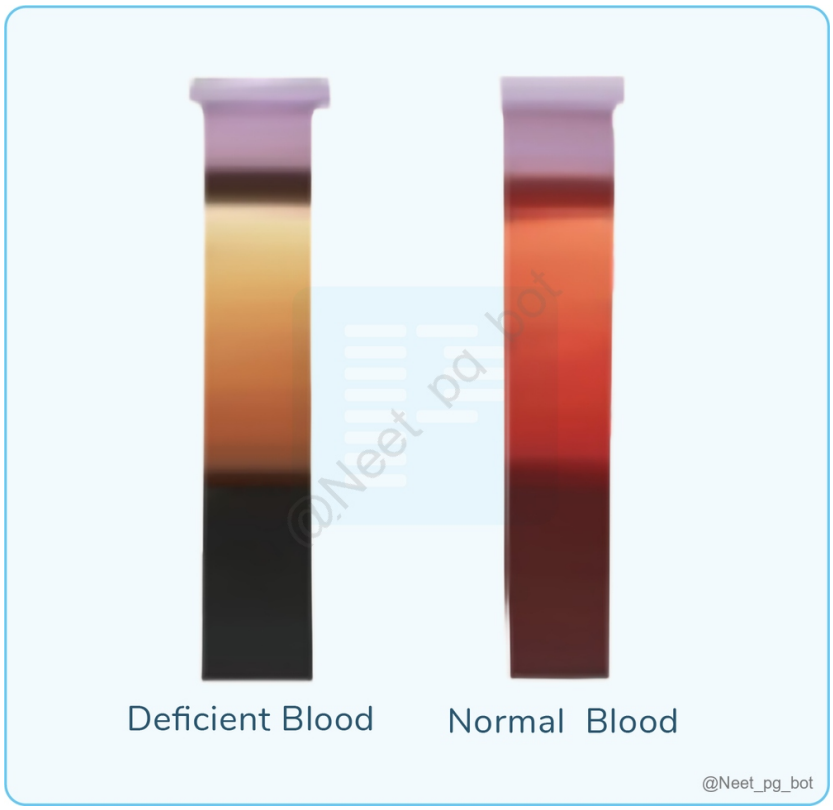



References:

https://www.ncbi.nlm.nih.gov/pmc/articles/PMC2555344/

↑ *Back to this question in Part A*

@Neet_pg_bot

Q10: Which of the following sequences correctly represents the progression of hemoglobin handling in the body during intravascular hemolysis (IVH)? A. Hemoglobin binds to albumin, forming meth albuminemia B. Hemoglobin combines with haptoglobin C. Haptoglobin saturation and hemoglobin binding to hemopexin. D. RBC lysis causes hemoglobin to leak out. (Q845837)

A. D → B → C→ A

B. D → B → A → C

C. D → C → A → B

D. D → C → B → A

Correct Answer: A. D → B → C→ A

■ *Listen to Audio 1*

Explanation: Intravascular hemolysis involves the destruction of RBCs within blood vessels. Hemoglobin(Hb) is released and free Hb in the blood is toxic. Several mechanisms come into play to sequester this free Hb as shown below. Clinical and laboratory findings include: Hemoglobinemia Hemoglobinuria Hemosiderinuria - Hemoglobin filtered into the urine → absorbed by renal tubular cells → broken down to iron→ accumulated as hemosiderin→ shedding of tubular cells → hemosiderinuria. Decreased serum haptoglobin Increased LDH

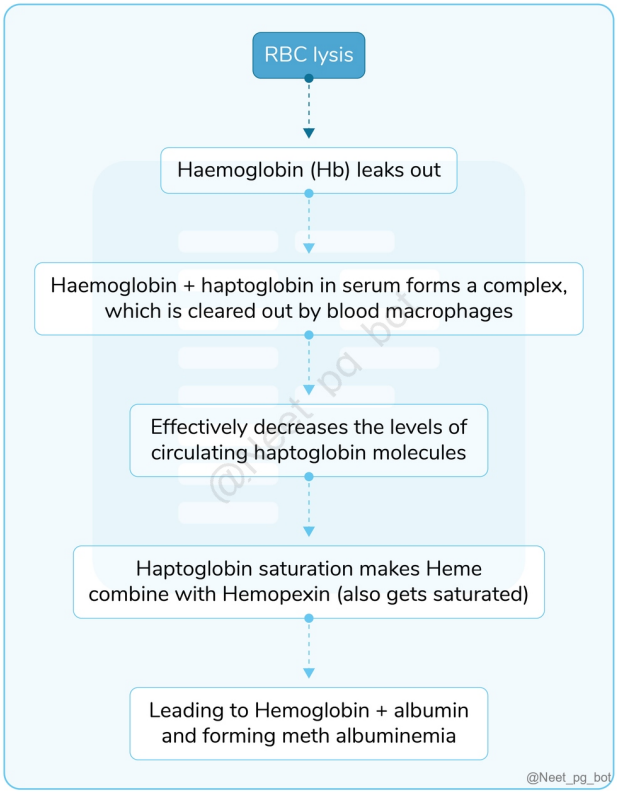

References:

Robbins & Cotran Pathologic Basis of Disease, 10th Edition, Page 637

Hemolysis, free hemoglobin toxicity, and scavenger protein therapeutics - PMC (nih.gov)

https://nopr.niscpr.res.in/bitstream/123456789/3501/1/IJBB%2042(1)%207-12.pdf

↑ *Back to this question in Part A*

@Neet_pg_bot

Q11: A 6-year-old child presents with a history of recurrent episodes of jaundice, fatigue, and abdominal pain. Physical examination reveals splenomegaly. The child's blood work shows the presence of spherocytes on the peripheral blood smear. An osmotic fragility test is performed. Identify the correct statement about this test. (Q845844)

A. It is a diagnostic test.

B. In thalassemia patients, low osmotic fragility leads to a right shift on the graph.

C. In HS patients, high osmotic fragility leads to a right shift on the graph.

D. Normally, RBC lysis begins at 0.7% NaCl.

Correct Answer: C. In HS patients, high osmotic fragility leads to a right shift on the graph.

■ *Listen to Audio 1*

Explanation: The correct statement regarding the osmotic fragility test is high osmotic fragility leads to a right shift on the graph in patients with HS. Osmotic Fragility Test : The osmotic fragility test measures the resistance of RBCs to hemolysis in hypotonic saline . It is mainly used to diagnose membrane disorders , especially Hereditary spherocytosis . Principle: When RBCs are placed in hypotonic saline , water enters → cells swell → burst (hemolysis). Spherocytes → burst early → ↑ osmotic fragility Target cells / thalassemia → burst late → ↓ osmotic fragility Steps of an osmotic fragility test: Prepare serial dilutions of NaCl (0.85% → 0.0%) Add equal amount of patient blood to each tube Incubate ~30 minutes Centrifuge tubes Measure hemolysis (supernatant Hb color / spectrophotometer) Plot graph: % hemolysis vs NaCl concentration In the osmotic fragility curve, the x-axis represents NaCl concentration and the y-axis represents % Hemolysis Normal Curve: Hemolysis starts at 0.45% NaCl and completes at 0.30% NaCl (OptionD) Right Shift (Increased Fragility): Cells lyse earlier (at higher NaCl concentration) due to decreased RBC surface area Seen in Hereditary spherocytosis (Option C) , Autoimmune hemolytic anemia Left Shift (Decreased Fragility): Cells lyse later (at lower NaCl concentration) due to increased RBC surface area Seen in Thalassemia (Option B) , Iron deficiency anemia, Sickle cell anemia and Liver disease However, this test is just a screening method, and the Eosin-5-maleimide (EMA) binding test is the gold standard for diagnosing hereditary spherocytosis. (Option A)

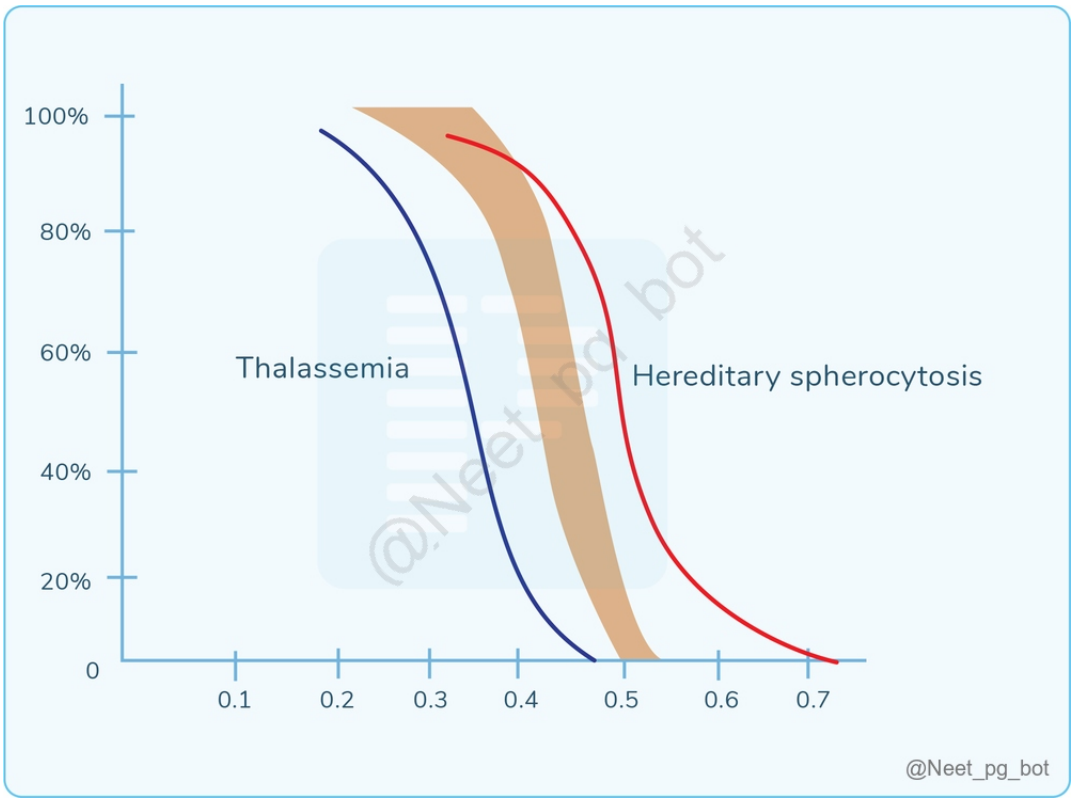

References:

https://www.sciencedirect.com/topics/immunology-and-microbiology/osmotic-fragility

https://emedicine.medscape.com/article/2085814

↑ *Back to this question in Part A*

@Neet_pg_bot

Q12: Which of the following is not a typical change in blood indices in patients with hereditary spherocytosis? (Q845843)

A. MCV decreases

B. MCHC increases

C. RDW decreases

D. Hemoglobin decreases

Correct Answer: C. RDW decreases

■ *Listen to Audio 1*

Explanation: The RDW (red cell distribution width) increases, not decreases, in hereditary spherocytosis due to anisocytosis- a heterogeneous population of red blood cells, including both normal-sized and smaller, denser spherocytes. The MCV decreases due to the presence of smaller, more dense red blood cells (spherocytes). (Option A) The MCHC increases due to dehydration of RBCs, leading to a higher concentration of hemoglobin per unit volume of the cell. (Option B) Hemoglobin levels may decrease in hereditary spherocytosis due to the hemolysis, but they do not increase. (Option D) Blood indices in hereditary spherocytosis: Reduced Hemoglobin Reduced MCV Normal or increased MCH Increased MCHC due to water loss Increased RDW (variation in size) Increased reticulocyte count

References:

Robbins & Cotran Pathologic Basis of Disease, 10th Edition, Page 638-639
https://www.ncbi.nlm.nih.gov/books/NBK539797/

↑ *Back to this question in Part A*

@Neet_pg_bot

Q13: A 10-year-old child presents with a history of recurrent episodes of jaundice, fatigue, and abdominal pain. Physical examination reveals splenomegaly, and peripheral blood smear shows the following picture. Coomb's test is negative. What is the most likely diagnosis? (Q845842)

A. Hereditary spherocytosis

B. Autoimmune hemolytic anemia

C. Glucose-6-phosphate dehydrogenase (G6PD) deficiency

D. Thalassemia

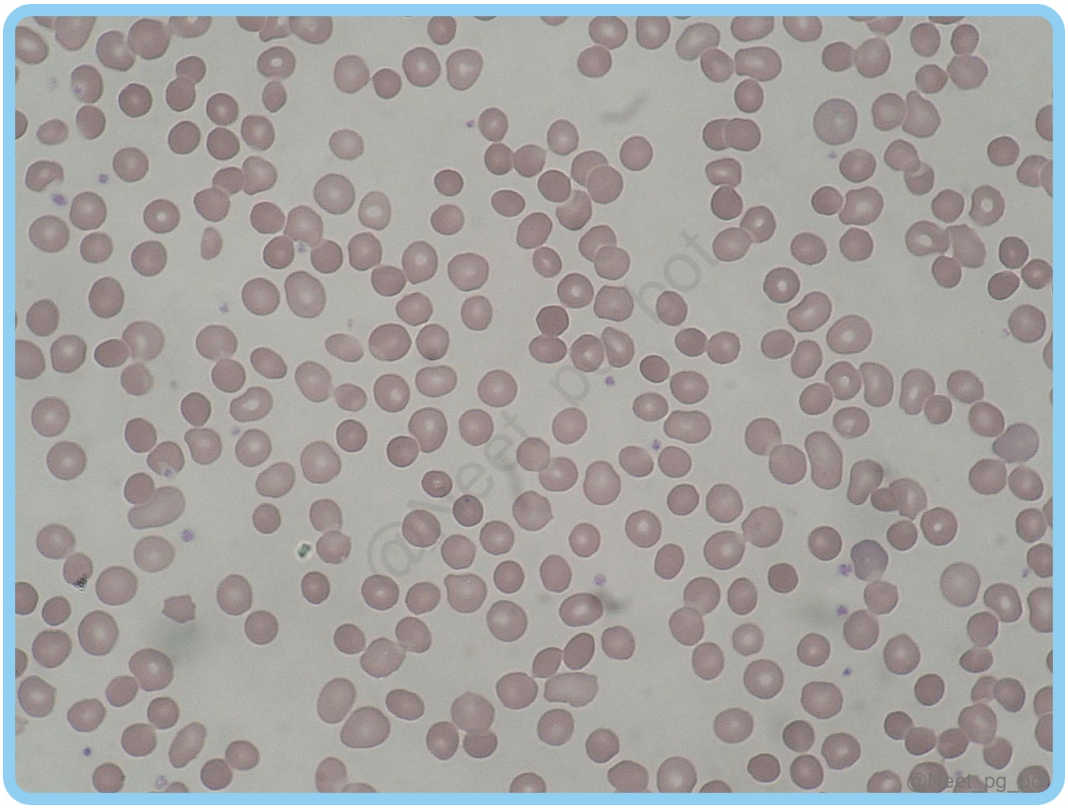

Correct Answer: A. Hereditary spherocytosis

Listen to Audio 1

Explanation: The given clinical scenario and peripheral smear showing spherocytes most likely suggest a diagnosis of hereditary spherocytosis. Hereditary spherocytosis (HS) is an inherited disorder caused by intrinsic defects in the red cell membrane skeleton that render red cells spheroid, less deformable, and vulnerable to splenic sequestration and destruction. It has an autosomal dominant inheritance(75%) characterized by ankyrin mutation and an autosomal recessive inheritance characterized by spectrin mutation. Pathophysiology of hereditary spherocytosis: The most specific morphologic finding is spherocytosis: Dark-staining (hyperchromic) spherocytes lacking the central zone of pallor. Other features include reticulocytosis. The characteristic clinical features are anemia, splenomegaly, jaundice, and an increased risk of gallstones. Severity ranges from asymptomatic to severe hemolytic anemia requiring transfusions. Early complications include neonatal jaundice and hemolytic crises. Late complications include gallstones and rarely iron overload. Autoimmune hemolytic anemia (AIHA) (Option B): AIHA involves antibodies targeting red blood cells and typically has a positive Coombs test, which is not mentioned. It usually presents with acute rather than recurrent hemolysis. Glucose-6-phosphate dehydrogenase (G6PD) deficiency (Option C): It is characterized by bite cells, not hyperchromic spherocytes lacking a central pallor. Thalassemia (Option D): It is characterized by target cells rather than sperocytes on peripheral smear.

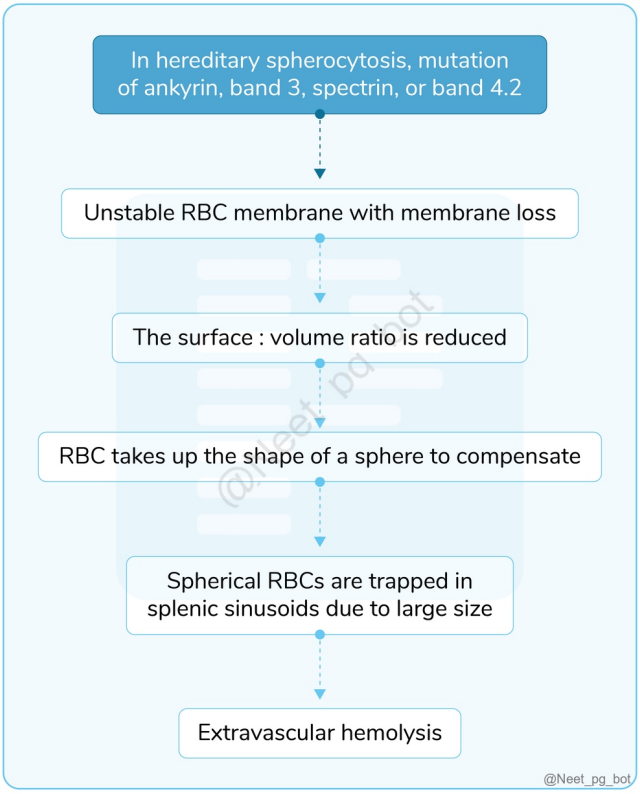

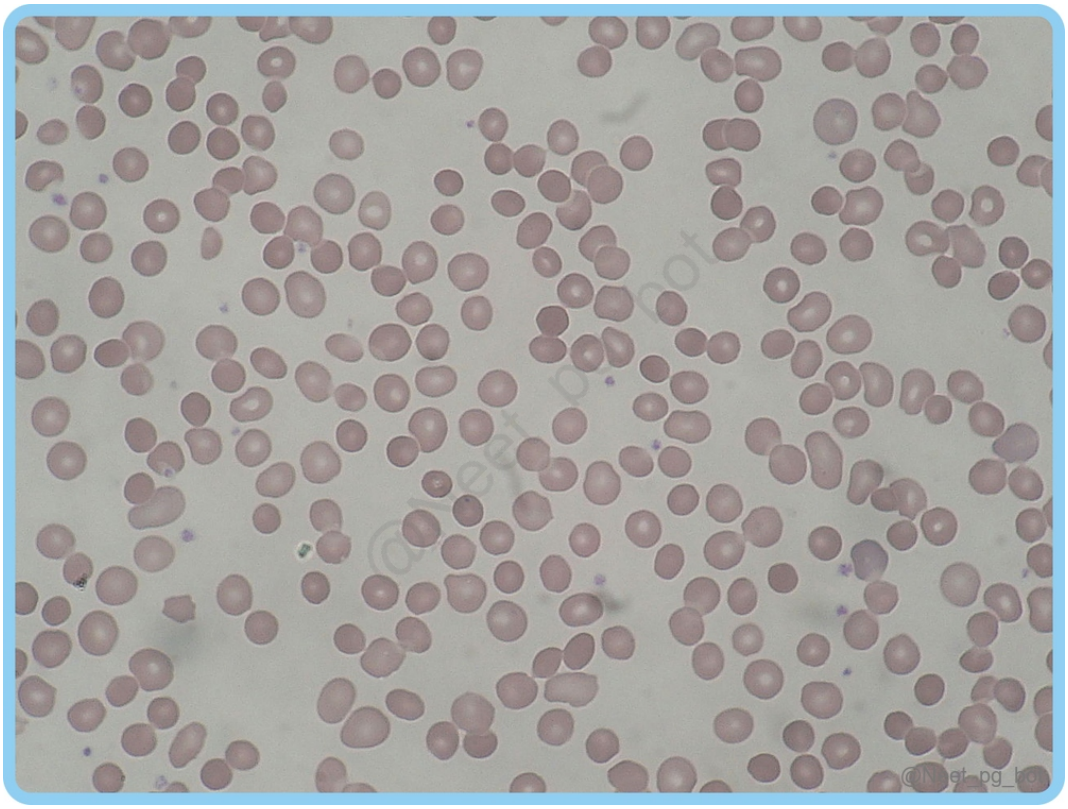

References:

Robbins & Cotran Pathologic Basis of Disease, 10th Edition, Page 638-639

↑ *Back to this question in Part A*

@Neet_pg_bot

Q14: A 28-year-old male presents with fatigue, jaundice, splenomegaly, and anemia with elevated MCHC. A peripheral smear is done which is shown below. What is the most common protein defect in this condition? (Q845841)

A. Spectrin

B. Band 3 protein

C. Ankyrin

D. Glycophorin A

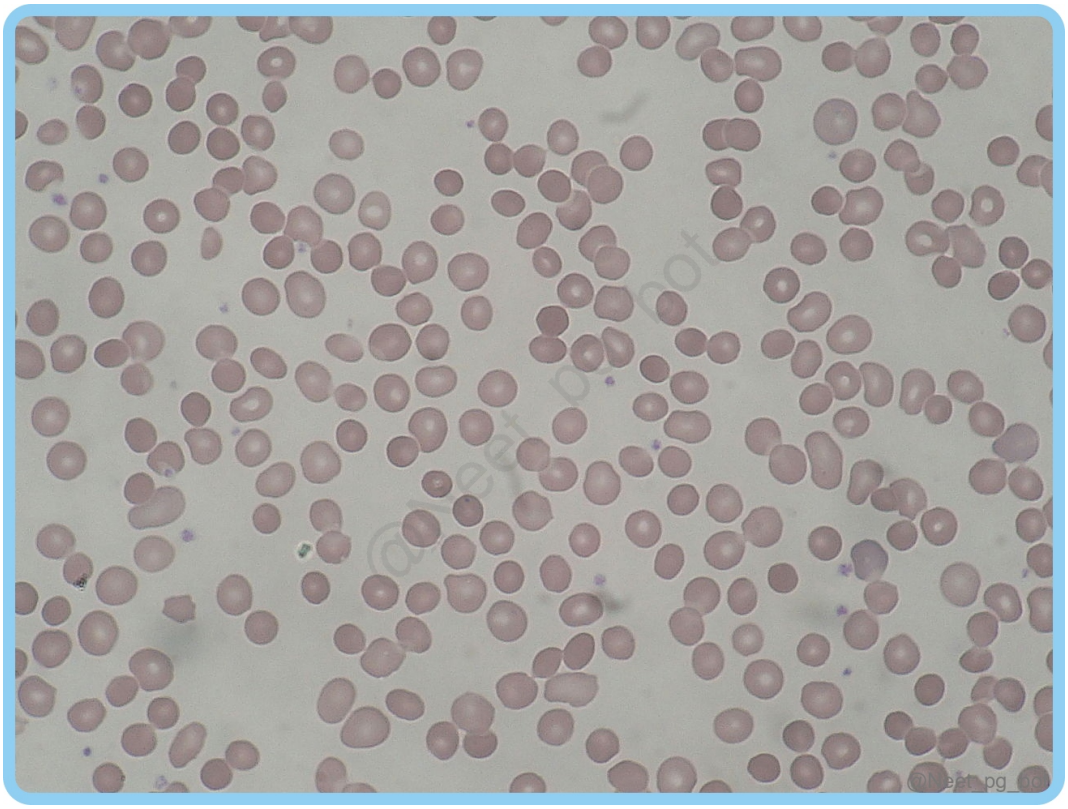

Correct Answer: C. Ankyrin

■ *Listen to Audio 1*

Explanation: The peripheral smear in this scenario indicates hereditary spherocytosis, and ankyrin is the most common or important protein defective in hereditary spherocytosis. IMPORTANT PROTEINS IN RBC MEMBRANE: Spectrin: Responsible for RBC stability and biconcave shape (Option A) Ankyrin: The most important or common protein defective in hereditary spherocytosis. Band 3 protein (Option B) Glycophorin A:

The most abundant protein present in the RBC membrane , rarely(almost never) undergoes mutation in hereditary spherocytosis (Option D) Actin, Band 4.1, and Band 4.2 Proteins present at the head end of spectrin: Ankyrin, Band 4.2, Band 3 Proteins present at the tail end of spectrin: Actin, Band 4.1, Glycophorin A

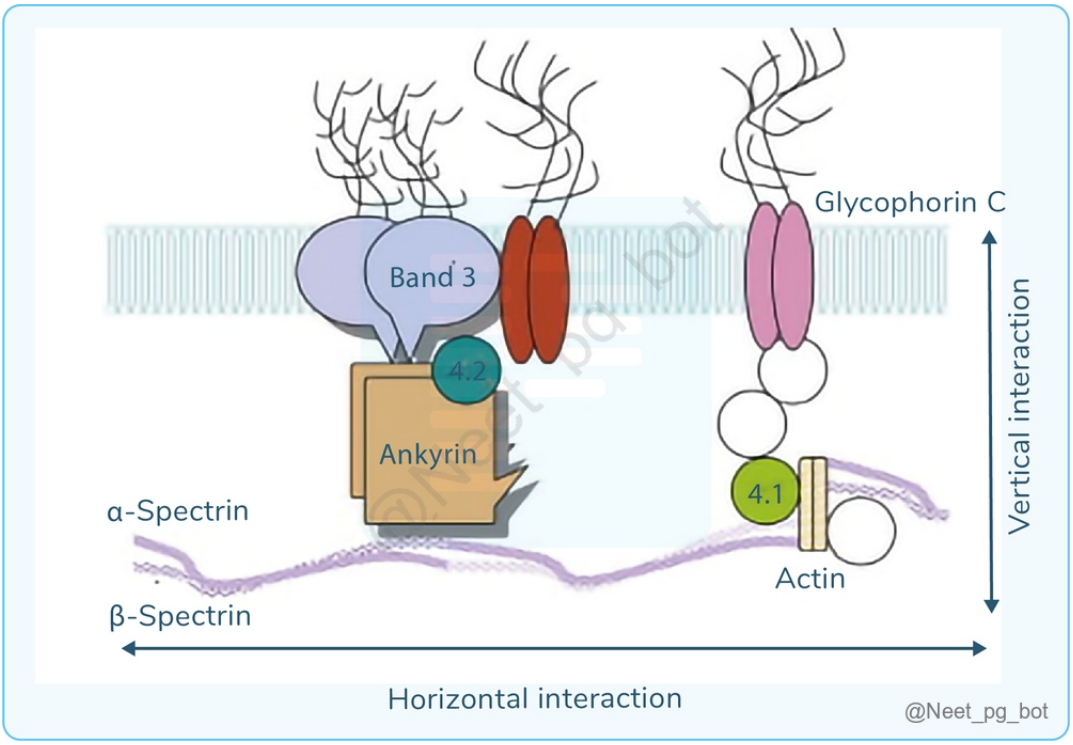

References:

Robbins & Cotran Pathologic Basis of Disease, 10th Edition, Page 638

https://pmc.ncbi.nlm.nih.gov/articles/PMC8267758/

↑ *Back to this question in Part A*

@Neet_pg_bot

Q15: Examine the provided histopathology image of a blood smear containing two types of abnormal red blood cells. Identify the diseases associated with each cell type. (Q845840)

A. a: Pyruvate kinase deficiency, burns, and uremia; b: Abetalipoproteinemia, liver disease, and vitamin E deficiency.

B. a: Abetalipoproteinemia, liver disease, and vitamin E deficiency; b: Pyruvate kinase deficiency, burns, and uremia.

C. a: Abetalipoproteinemia and burns; b: Pyruvate kinase deficiency and uremia.

D. a: Pyruvate kinase deficiency and liver disease; b: Abetalipoproteinemia and vitamin E deficiency.

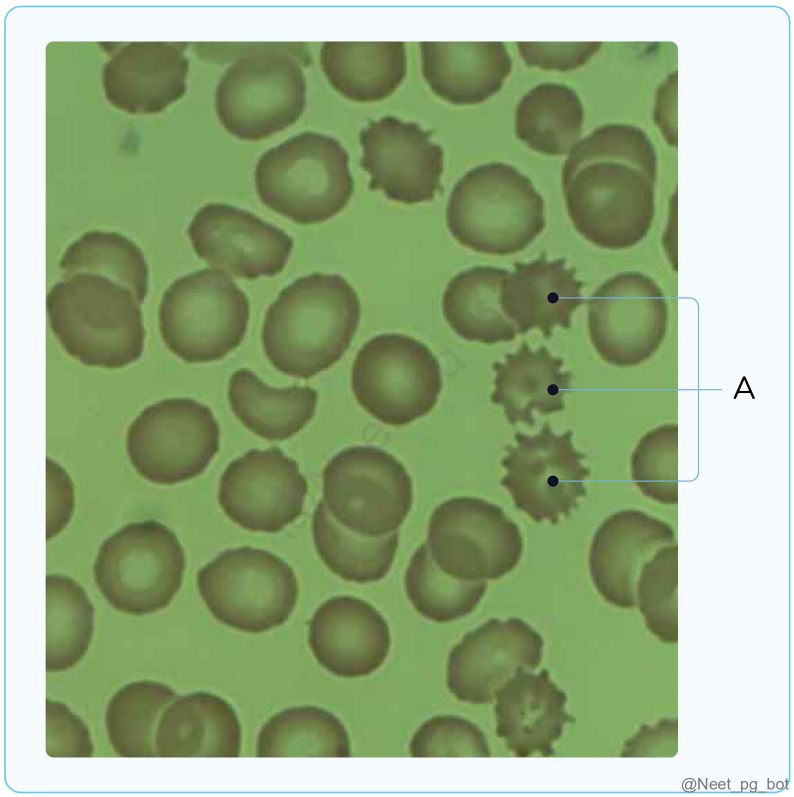

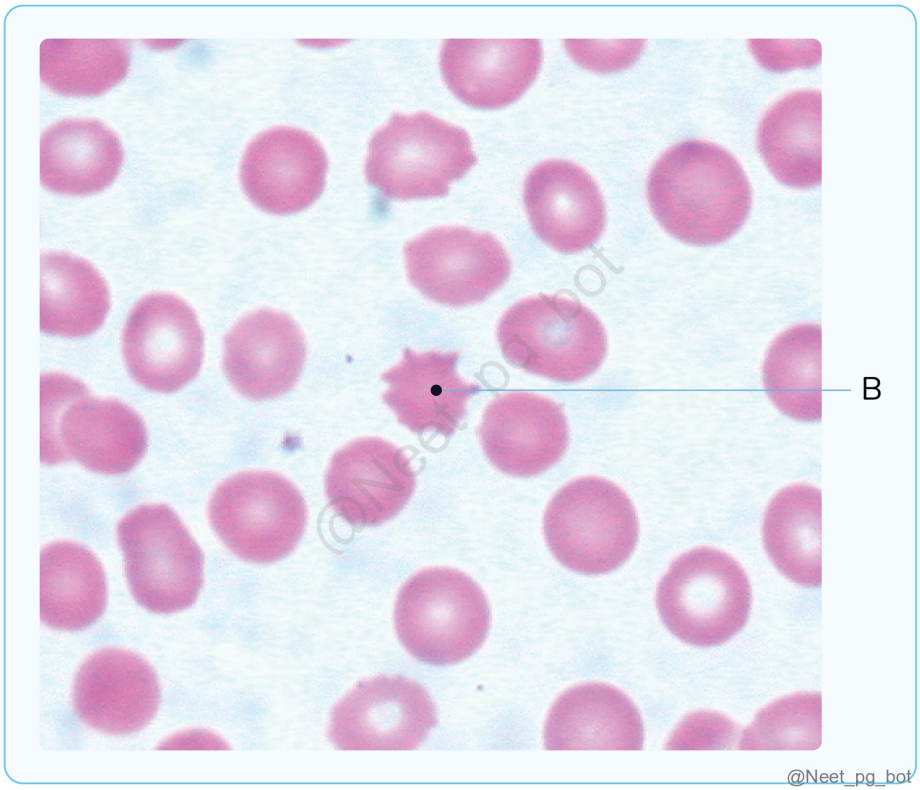

Correct Answer: A. a: Pyruvate kinase deficiency, burns, and uremia; b: Abetalipoproteinemia, liver disease, and vitamin E deficiency.

■ *Listen to Audio 1*

Explanation: The structure marked A is an echinocyte seen in pyruvate kinase deficiency, burns, and uremia and B is an acanthocyte seen in abetalipoproteinemia, liver disease, and vitamin E deficiency. Echinocytes (aka Burr cells) Acanthocytes (aka Spur cells) Description Echinocytes are red blood cells with uniformly spaced , short projections over the cell surface Acanthocytes are red blood cells with irregularly spaced , spiky projections of varying lengths Associated conditions Pyruvate kinase deficiency Burns Liver disease Uremia Abetalipoproteinemia Liver Disease Vitamin E Deficiency



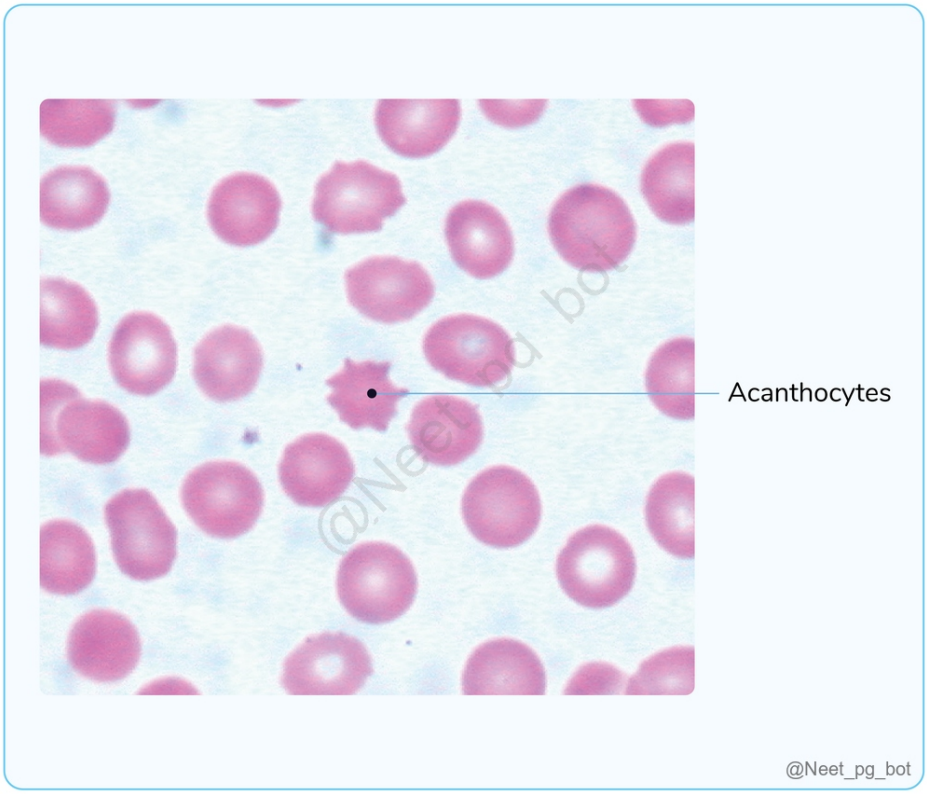

References:

https://www.ncbi.nlm.nih.gov/books/NBK549788/

https://www.ncbi.nlm.nih.gov/books/NBK562141/

↑ *Back to this question in Part A*

@Neet_pg_bot

Q16: Match the following causes of hemolysis with their corresponding categories. Categories Causes of hemolysis a. Intracorpuscular defect b. Extracorpuscular defect 1. Hereditary Spherocytosis (HS) 2. G6PD Deficiency 3. Thrombotic Thrombocytopenic Purpura (TTP) 4. Hemoglobin C Disease 5. Hemolytic Uremic Syndrome (HUS) 6. Sickle Cell Anemia (Q845839)

A. 1-a, 2-b, 3-b, 4-a, 5-a, 6-b

B. 1-b, 2-a, 3-b, 4-a, 5-a, 6-a

C. 1-a, 2-a, 3-b, 4-a, 5-b, 6-a

D. 1-a, 2-b, 3-a, 4-b, 5-a, 6-a

Correct Answer: C. 1-a, 2-a, 3-b, 4-a, 5-b, 6-a

■ *Listen to Audio 1*

Explanation: Hemolytic anemias can be classified based on defects in RBCs. Intracorpuscular defect : Refer to abnormalities in the red blood cell itself. Extracorpuscular defects: Refer to defects that are influenced by external factors, including mechanical, immune-mediated, or infectious causes. Intracorpuscular defect Extracorpuscular defect Inherited : membrane, enzymes or hemoglobin defects Membrane defects: Hereditary spherocytosis (HS), Hereditary elliptocytosis Enzyme defects: G6PD deficiency, Pyruvate kinase deficiency, Hexokinase deficiency Hemoglobinopathies: Sickle cell anemias, Thalassemias, HbC disease, and HbD disease. Acquired : PNH (Paroxysmal Nocturnal Hemoglobinuria) AIHA (Autoimmune hemolytic anemia) MAHA (Microangiopathic hemolytic anemia)-HUS, TTP, DIC (leads to clotting) Malaria (Blackwater fever) March Hemoglobinuria (capillaries present in the heels of soldiers break down)

References:

Robbins & Cotran Pathologic Basis of Disease, 10th Edition, Page 637

https://www.ncbi.nlm.nih.gov/books/NBK558904/

www.ncbi.nlm.nih.gov/pmc/articles/PMC3999811/

↑ *Back to this question in Part A*

@Neet_pg_bot

Q17: Which of the following conditions can cause intravascular hemolysis (IVH)? Select all that apply. a. Paroxysmal Nocturnal Hemoglobinuria (PNH) b. Glucose-6-Phosphate Dehydrogenase (G6PD) deficiency c. Hereditary spherocytosis d. Paroxysmal Cold Hemoglobinuria (PCH) e. Hemolytic Uremic Syndrome (HUS) f. Thrombotic Thrombocytopenic Purpura (TTP) (Q845838)

A. b, c, d, e and f

B. a, b, d, e, and f

C. a, b, c, e, and f

D. a, b, c, d, and f

Correct Answer: B. a, b, d, e, and f

■ *Listen to Audio 1*

Explanation: Among the given options, Paroxysmal Nocturnal Hemoglobinuria (PNH), Paroxysmal Cold Hemoglobinuria (PCH) , Hemolytic Uremic Syndrome (HUS), and Thrombotic Thrombocytopenic Purpura (TTP) cause intravascular hemolysis. Causes of hemolytic anemia: Extravascular Hemolysis Intravascular hemolysis

Hereditary spherocytosis Sickle cell anemia Thalassemia G6PD deficiency Warm autoimmune hemolytic anemia (AIHA) Cold agglutinin type AIHA Paroxysmal Nocturnal Hemoglobinuria (PNH) Microangiopathic Hemolytic Anemia (MAHA)- HUS, TTP, DIC Paroxysmal cold hemoglobinuria/Cold hemolysin type AIHA G6PD deficiency

References:

Robbins & Cotran Pathologic Basis of Disease, 10th Edition, Page 637

↑ *Back to this question in Part A*

@Neet_pg_bot

• [17_Hematology_ Red Blood Cells] 067 Hemolytic Anemia-Ii

« Back to Folder Directory

[17_Hematology_ Red Blood Cells] 067 Hemolytic Anemia-Ii — Quick Jump

Q1 (p. 2626)	*Q2 (p. 2627)*	*Q3 (p. 2627)*	*Q4 (p. 2628)*	*Q5 (p. 2630)*	*Q6 (p. 2630)*
Q7 (p. 2632)	*Q8 (p. 2633)*	*Q9 (p. 2634)*	*Q10 (p. 2635)*	*Q11 (p. 2636)*	*Q12 (p. 2639)*
Q13 (p. 2639)	*Q14 (p. 2641)*	*Q15 (p. 2642)*	*Q16 (p. 2643)*		

Q1: A 1-year-old boy, previously healthy until five months ago, presents with a three-hour history of severe swelling and tenderness of hands and feet. The family history is significant for an older brother who had transfusion-dependent anaemia and died of pneumococcal sepsis at the age of 6. Which haemoglobin molecule composition protected him from developing symptoms until recently? (Q845914)

A. α2γ2

B. α2β2

C. α2δ2

D. α2ε2

Correct Answer: A. α2γ2

■ *Listen to Audio 1*

Explanation: The given scenario is most likely suggestive of sickle cell anaemia. This child did not present with the disease earlier because of the presence of fetal haemoglobin (HbF) containing α2γ2 HbF has a high oxygen affinity, which helps maintain oxygen concentration and prevent hypoxia. (Sickle cells are formed during hypoxia) HbF inhibits the polymerisation of HbS more effectively than HbA , so infants with sickle cell disease typically remain asymptomatic until 5 or 6 months of age when HbF levels naturally decline. Normal Adult Hemoglobin: HbA (α■β■): ~95% of total Hb HbA■ (α■δ■): <3% of total Hb HbF (α■γ■): Fetal hemoglobin, normally <1% in adults Hydrops fetalis (Hb Barts) – α■-thalassemia: Cause: Deletion of all four α-globin genes → no α chains. Effect: Fetal hemoglobin (α■γ■) cannot form. Compensation: Excess γ chains form γ■ tetramer (Hb Barts) . Consequence: High oxygen affinity → poor tissue oxygen delivery → hydrops fetalis. α■β■ & α■δ■: Variants of normal adult Hb (Options B & C) α■ε■ (Hb Gower-1) & ζ■ε■ (Hb Gower-2): Embryonal hemoglobins (Option D)

References:

Robbins & Cotran Pathologic Basis of Disease, 10th Edition, Page 645
https://www.sciencedirect.com/topics/neuroscience/hemoglobin-chain

↑ *Back to this question in Part A*

@Neet_pg_bot

Q2: Which of the following points best describes the pathogenesis of sickle cell disease (SCD)? Select all that apply. Nonsense point mutation in 6th position of β-globin chain Mutation promotes the polymerization of oxygenated hemoglobin Glutamic acid is changed to valine at the 6th position of β-globin chain Presence of HbF and HbS is protective against SCD. Patients heterozygous for HbS have more severe diseases than homozygous HbS. Individuals with coexistent α-thalassemia have less severe disease. (Q845915)

A. 1, 5, 4, and 6

B. 3, 4, and 6

C. 2, 5, and 6

D. 1, 2, 5, and 6

Correct Answer: B. 3, 4, and 6

Explanation: Sickle cell disease is caused by a missense mutation in the 6th position of the β-globin chain. This mutation replaces glutamic acid with valine, promoting polymerization of deoxygenated hemoglobin. Heterozygous individuals (HbAS) have about 40% HbS and the rest HbA, reducing polymerization and disease severity. Homozygous individuals have more HbS and more severe disease. HbF inhibits HbS polymerization better than HbA, keeping infants asymptomatic until 5-6 months of age. Intracellular parasites consume oxygen and lower pH, promoting sickling and rapid clearance of infected HbAS cells, reducing parasite load. Coexistent α-thalassemia reduces Hb synthesis, resulting in milder disease.

References:

Robbins & Cotran Pathologic Basis of Disease, 10th Edition, Page 641- 642

↑ *Back to this question in Part A*

@Neet_pg_bot

Q3: Which of the following conditions does not lead to sickling of RBCs in patients with sickle cell disease? (Q845917)

A. Dehydration

B. Hypoxia

C. Increased pH

D. Decreased HbF

Correct Answer: C. Increased pH

■ *Listen (English)*

■ *Listen (Hindi)*

Explanation: Among the given options, increased pH/alkalosis does not lead to sickling, but rather decreased pH or acidosis. Factors affecting sickling: Dehydration - Higher HbS concentrations and increased MCHC due to intracellular dehydration enhance the likelihood of HbS aggregation and polymerization during deoxygenation, facilitating sickling. Hypoxia - Hypoxia induces sickling of cells Less pH (acidic environment) : A decrease in pH reduces hemoglobin's oxygen affinity, increasing deoxygenated HbS and enhancing the tendency for sickling. Decreased fetal hemoglobin (HbF) - HbF has high affinity for oxygen. Decrease in HbF will cause hypoxia, leading to sickling. Amount of HbS : Homozygous>heterozygous Interaction of HbS with the other types of hemoglobin : HbSC> HbSA/HbSA2 > HbSF (Fetal hemoglobin has more affinity towards oxygen, thus reducing sickling)

References:

Robbins & Cotran Pathologic Basis of Disease, 10th Edition, Page 641 - 642

↑ *Back to this question in Part A*

@Neet_pg_bot

Q4: A 28-year-old man who has received blood transfusions on some occasions and has experienced severe pain in his hands and legs came to follow up. He is currently fine with no complaints and has been receiving treatment that has increased his HbF levels for the past 5 years. Which of the following would be seen in the peripheral smear of this patient? (Q845919)

A. Bite cells

B. Heinz bodies

C. Howell-Jolly bodies

D. Spherocytes

Correct Answer: C. Howell-Jolly bodies

Explanation: Howell-Jolly bodies are nuclear remnants seen in red cells when the spleen is nonfunctional or absent, as in sickle cell disease with autosplenectomy caused by repeated infarctions. Bite cells and Heinz bodies indicate G6PD deficiency, not sickle cell disease. (Options A and B) . Spherocytes are typical of autoimmune hemolytic anemia or hereditary spherocytosis. (Option D) . RBC Shape Defects (Poikilocytosis): RBC Shape Morphology Associated Conditions Spherocytes Small, round, no central pallor Hereditary spherocytosis, Autoimmune hemolytic anemia Elliptocytes / Ovalocytes Elliptical/oval cells Hereditary elliptocytosis, Iron deficiency anemia Target cells (Codocytes) Central Hb with ring Thalassemia, Liver disease, Sickle cell disease Sickle cells Crescent-shaped Sickle cell disease Schistocytes Fragmented RBCs Disseminated intravascular coagulation, Thrombotic thrombocytopenic purpura, Hemolytic uremic syndrome Acanthocytes (spur cells) Irregular spiky projections Liver disease, Abetalipoproteinemia Echinocytes (burr cells) Regular projections Uremia, CKD Tear drop cells (Dacrocytes) Tear-shaped Myelofibrosis, marrow infiltration Bite cells “Bite-like” defects Glucose-6-phosphate dehydrogenase deficiency Helmet cells RBC fragments Microangiopathic hemolysis Stomatocytes Slit-like central pallor Hereditary stomatocytosis, liver disease Rouleaux formation Stacked RBCs Multiple myeloma, chronic inflammation WBC Disorders (Morphology and Functional Abnormalities): Disorder Morphology Associated Condition Hypersegmented neutrophils >5 lobes Megaloblastic anemia Hyposegmented neutrophils (Pelger-Huët anomaly) Bilobed nucleus Congenital or acquired (MDS) Toxic granulation Prominent granules Severe infection Döhle bodies Blue cytoplasmic inclusions Infection, burns Leukemoid reaction Marked neutrophilia Severe infection Neutropenia ↓ neutrophils Drugs, infections, aplastic anemia

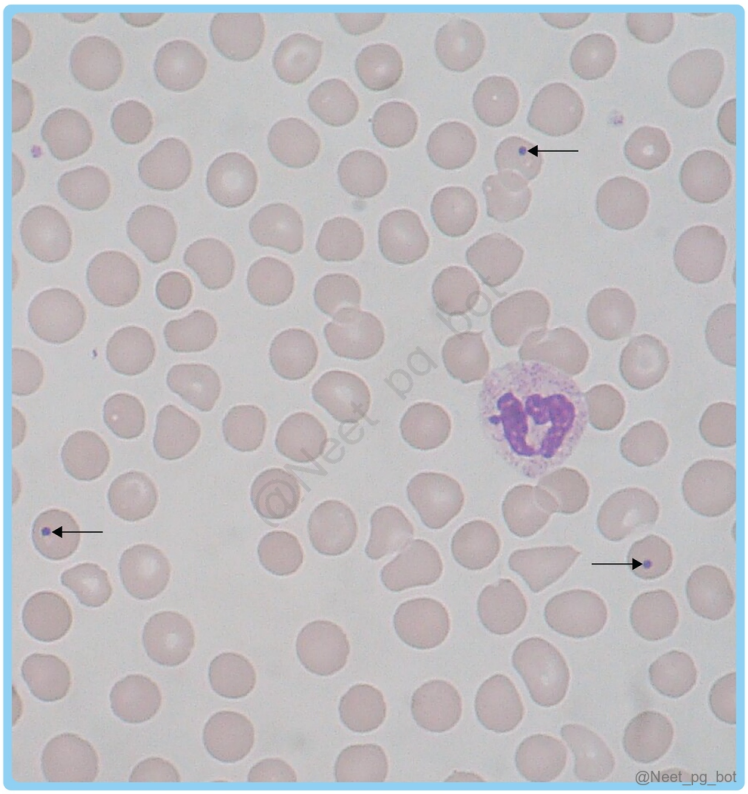

References:

Robbins & Cotran Pathologic Basis of Disease, 10th Edition, Page 642

https://sso.uptodate.com/contents/clinical-features-evaluation-and-management-of-fever-in-patients-with-impaired-splenic-function

↑ *Back to this question in Part A*

@Neet_pg_bot

Q5: Match the complications of sickle cell disease (SCD) with their corresponding crises: Complications Crises 1. Acute chest syndrome A. Vaso-occlusive crises 2. Parvovirus B19 infection B. Aplastic crises 3. Splenic enlargement C. Sequestration crisis 4. Splenic fibrosis (Q845921)

A. 1-A, 2-B, 3-C, 4-C

B. 1-A, 2-B, 3-C, 4-A

C. 1-A, 2-A, 3-B, 4-C

D. 1-A, 2-C, 3-B, 4-A

Correct Answer: B. 1-A, 2-B, 3-C, 4-A

■ *Listen (English)*

■ *Listen (Hindi)*

Explanation: Vaso-occlusive crises include: Splenic fibrosis: Because the blood supply is hampered by sickle cells, the spleen undergoes repeated infarctions. Over time, this causes progressive shrinkage of the spleen (autosplenectomy), with normal splenic tissue being replaced by fibrosis. Acute chest syndrome: Affecting the lungs, it presents with fever, cough, chest pain, and pulmonary infiltrates, potentially leading to life-threatening hypoxemia. Bone crises Renal papillary necrosis Cerebrovascular accident Priapism Autosplenectomy Aplastic crisis in SCD Cause: Parvovirus B19 infects erythroid precursors → temporarily halts RBC production Occurs in: Patients with pre-existing hemolytic anemia (HS, sickle cell, thalassemia) Lab features: Severe anemia, reticulocytopenia , WBC/platelets normal or slightly low, peripheral smear shows underlying hemolysis Sequestration crisis in SCD - Sequestration crisis affects children with intact spleens, characterized by significant trapping of sickled red cells, resulting in swift splenic enlargement , hypovolemia, and occasionally shock.

References:

Robbins & Cotran Pathologic Basis of Disease, 10th Edition, Page 641- 642

https://www.uptodate.com/contents/overview-of-the-clinical-manifestations-of-sickle-cell-disease

↑ *Back to this question in Part A*

@Neet_pg_bot

Q6: A 12-year-old girl presents to her primary care physician with complaints of fatigue, pallor, and jaundice. Peripheral smear showed sickling of RBCs. What is the most likely electrophoretic pattern seen in this patient? (Q845923)

A. A

B. B

C. C

D. D

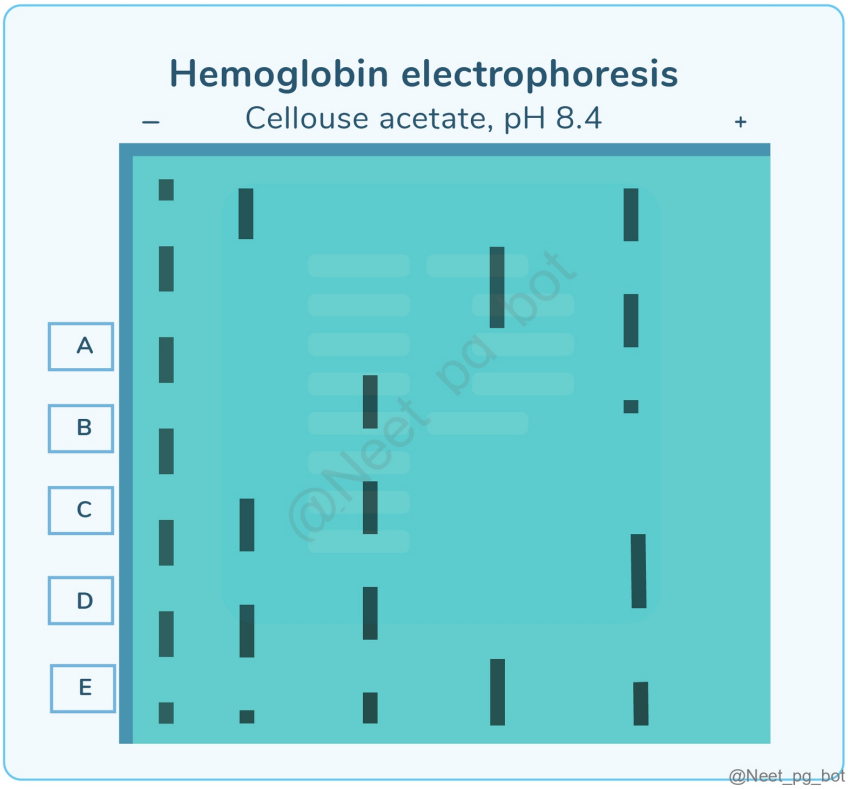

Correct Answer: B. B

Explanation: The patient's clinical presentation with fatigue, pallor, jaundice, and the presence of sickle cells on peripheral blood smear are consistent with sickle cell anemia . The electrophoretic pattern seen in this patient would be B. Electrophoresis is a technique that separates hemoglobin variants based on their electric charge and solubility in different media. It is performed using cellulose acetate at alkaline pH (8.4) and citrate agar at acidic pH (6.0–6.2). High-performance liquid chromatography (HPLC) is the gold standard for diagnosing hemoglobinopathies.

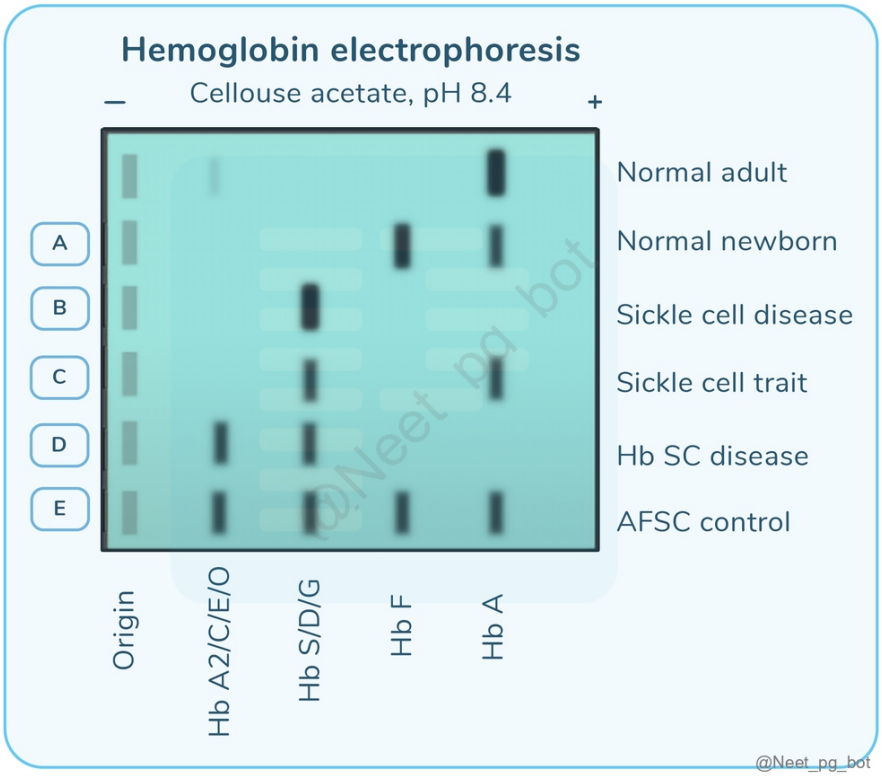

References:

https://openi.nlm.nih.gov/gridquery?q=hb%20electrophoresis&it=xg&lic=by&m=1&n=100

↑ *Back to this question in Part A*

@Neet_pg_bot

Q7: Which of the following statements regarding the different types of thalassemia is correct? Thalassemia major - mutations in both alleles of the HBB gene - impaired production of beta-globin chains. Beta-thalassemia trait - mutations in one allele of the HBB gene - reduced beta-globin chain synthesis. Alpha-thalassemia trait - deletions in one or more alpha-globin genes - decreased production of alpha-globin chains. Thalassemia intermedia - mutations affecting both alpha and beta-globin genes - severe anemia requiring regular blood transfusions (Q845925)

A. 1, 2, and 4

B. 2, 3, and 4

C. 1, 3 and 4

D. 1, 2, and 3

Correct Answer: D. 1, 2, and 3

■ *Listen (English)*

■ *Listen (Hindi)*

Explanation: Statements 1, 2, & 3 are correct. Statement 4 is wrong as thalassemia intermedia does not require regular blood transfusions. A thalassemia is a group of inherited blood disorders characterized by abnormal hemoglobin production, leading to anemia. Genetic defects in thalassemia involve mutations, insertions, or deletions in the genes responsible for producing hemoglobin chains This results in either decreased or absent production of alpha or beta-globin chains. These defects are inherited in an autosomal recessive manner. There are two main types: alpha-thalassemia and beta-thalassemia. 1. Alpha-thalassemia: Deletion of one or more genes out of the total four genes, which leads to decreased production of alpha-globin chains. 2. Beta-thalassemia: Arising from mutations in the beta-globin gene located on chromosome 11. Subtypes include: Beta-thalassemia minor (trait): Reduced beta-globin chain production due to mutations in one allele of the HBB gene. Beta-thalassemia major: Mutations in both alleles of the HBB gene, leading to severe anemia requiring lifelong transfusions and treatment. Thalassemia intermedia: Milder variants and unusual forms of β-thalassemia, also include alpha globin defects in some cases. But the cases does not require regular blood transfusions

References:

Robbins & Cotran Pathologic Basis of Disease, 10th Edition, Page 644-647

↑ *Back to this question in Part A*

@Neet_pg_bot

Q8: A 25-year-old male presents with fatigue, jaundice, and splenomegaly. Laboratory investigations reveal microcytic hypochromic anemia with increased levels of serum iron and ferritin. Further genetic analysis reveals a mutation in the HBB gene. Upon histopathological examination of the bone marrow, there is evidence of erythroid hyperplasia with ineffective erythropoiesis. Which mutation in the HBB gene is most likely responsible for the patient's presentation? (Q845927)

A. Substitution of cytosine for guanine at position 8 in the promoter region of the HBB gene.

B. Substitution of one nucleotide at position +8 in the coding region of the HBB gene.

C. Splicing mutation resulting in the removal of intervening sequence-IVS1-5 G-> C in the HBB gene.

D. Insertion of a nucleotide at position 54 in the coding region of the HBB gene

Correct Answer: C. Splicing mutation resulting in the removal of intervening sequence-IVS1-5 G-> C in the HBB gene.

■ *Listen (English)*

■ *Listen (Hindi)*

Explanation: Among the given options, Splicing mutation resulting in the removal of intervening sequence-IVS1-5 G-> C in the HBB gene leads to β-thalassemia: This mutation affects the splicing process by altering the consensus splice site, leading to aberrant splicing and abnormal mRNA transcripts, contributing to β-thalassemia. Beta-thalassemia mutations are diverse and can occur throughout the HBB gene, which encodes the beta-globin subunit of hemoglobin. These mutations can affect various aspects of beta-globin production, including transcription, splicing (most common) , mRNA stability, and translation. Splicing is removal of non-coding part or intron (intervening sequence) from gene. Most common splicing mutation resulting in beta thalassemia is IVS1-5 G-> C. (IVS = Intervening sequence) These mutations disrupt normal hemoglobin synthesis, leading to reduced or absent beta-globin production and the characteristic clinical features of beta-thalassemia. 3-types of beta thalassemia: FEATURE THALASSEMIA MAJOR THALASSEMIA INTERMEDIA THALASSEMIA MINOR Beta chain production No beta chain production. Little chains present. One beta chain is normal. Others are defective. Clinically Pallor Jaundice Splenomegaly Pallor Jaundice Splenomegaly Asymptomatic Hb (gm/dl) 3 to 5 (more severe) 5 to 8 >8 Iron profile Increased Normal Normal

References:

Robbins & Cotran Pathologic Basis of Disease, 10th Edition, Page 646-648
https://www.ncbi.nlm.nih.gov/pmc/articles/PMC10147086/

↑ *Back to this question in Part A*

@Neet_pg_bot

Q9: A 35-year-old woman with beta-thalassemia major presents to the cardiology clinic with complaints of increasing shortness of breath on exertion and swelling in her ankles. She has been undergoing regular blood transfusions since childhood. She dies after a few days of hospitalization. What is the most common condition leading to her death? (Q845930)

A. Anemia

B. Liver disease

C. Infections

D. Heart failure

Correct Answer: D. Heart failure

■ *Listen (English)*

■ *Listen (Hindi)*

Explanation: The above scenario of heart failure is the most common cause of death in beta-thalassemia major. Cardiac disease resulting from progressive iron overload and secondary hemochromatosis is the most common cause of death in patients with beta-thalassemia major They must be treated with iron chelators to prevent this complication. Other complications include growth retardation, splenomegaly, leg ulcers, hepatic disease, lung disease/pulmonary hypertension, thromboembolism, endocrinopathies, and bone disease. Hematopoietic stem cell transplantation is the only therapy offering a cure in these patients.

References:

Harrison's Principles of Internal Medicine, 21st Edition, Page 763

↑ *Back to this question in Part A*

@Neet_pg_bot

Q10: A 25-year-old woman presents to the clinic for routine prenatal care. She has no significant past medical history. Her initial lab work reveals a microcytic, hypochromic anemia. Which of the following statements is most accurate in differentiating between iron deficiency anemia (IDA) and beta-thalassemia minor in this patient? (Q845932)

A. RDW is typically elevated in IDA compared to beta-thalassemia minor

B. RDW is typically lower in IDA compared to beta-thalassemia minor

C. Mentzer index is >13 in beta-thalassemia minor

D. RDW is typically normal in both IDA and beta-thalassemia minor

Correct Answer: A. RDW is typically elevated in IDA compared to beta-thalassemia minor

■ *Listen (English)*

■ *Listen (Hindi)*

Explanation: RDW is significantly higher in patients with IDA compared to those with beta-thalassemia minor or coexistent IDA and beta-thalassemia traits. This is because in IDA, the erythropoiesis process is disrupted, leading to a more varied size of red blood cells and thus an increased RDW (Red cell distribution width). Normal RDW = 11.5 to 14.5% In contrast, RDW tends to be lower in beta-thalassemia minor as most cells are just microcytic and hypochromic due to uniformly reduced hemoglobin synthesis. The Mentzer index, which is the MCV divided by the RBC count, is more useful in distinguishing between IDA and beta-thalassemia minor, with a lower Mentzer index (<13) indicating beta-thalassemia minor. Therefore, an elevated RDW favors a diagnosis of IDA over beta-thalassemia minor in this patient with microcytic, hypochromic anemia. Confirmatory testing with hemoglobin electrophoresis to detect elevated HbA2 levels (>3.5%) is required to diagnose beta-thalassemia minor. Feature Iron Deficiency Anemia Beta Thalassemia Minor Type Microcytic hypochromic anemia Microcytic hypochromic anemia RBC Less More MCV Normal to low Low RDW(size variance) More Normal Mentzer index: MCV/RBC >13 <13 Reticulocyte count Low Normal to slightly increased HbA2 - confirmatory

test <3.5% >3.5%

References:

https://www.uptodate.com/contents/diagnosis-of-thalassemia-adults-and-children

https://www.ncbi.nlm.nih.gov/pmc/articles/PMC6151350/

↑ *Back to this question in Part A*

@Neet_pg_bot

Q11: A hematologist is reviewing the peripheral blood smears of three patients diagnosed with different types of thalassemia. Patient A has severe anemia, target cells, and nucleated red blood cells (NRBCs). Patient B has mild anemia with microcytosis and hypochromia but no NRBCs. Patient C has mild anemia with microcytosis and hypochromia but also shows a small number of NRBCs and some hemoglobin H inclusions. Based on the peripheral smear findings, which of the following correctly matches the patients with their thalassemia types? (Q845933)

A. Patient A: β-thalassemia major, Patient B: β-thalassemia minor, Patient C: α-thalassemia

B. Patient A: β-thalassemia minor, Patient B: α-thalassemia, Patient C: β-thalassemia major

C. Patient A: α-thalassemia, Patient B: β-thalassemia minor, Patient C: β-thalassemia major

D. Patient A: β-thalassemia major, Patient B: α-thalassemia, Patient C: β-thalassemia minor

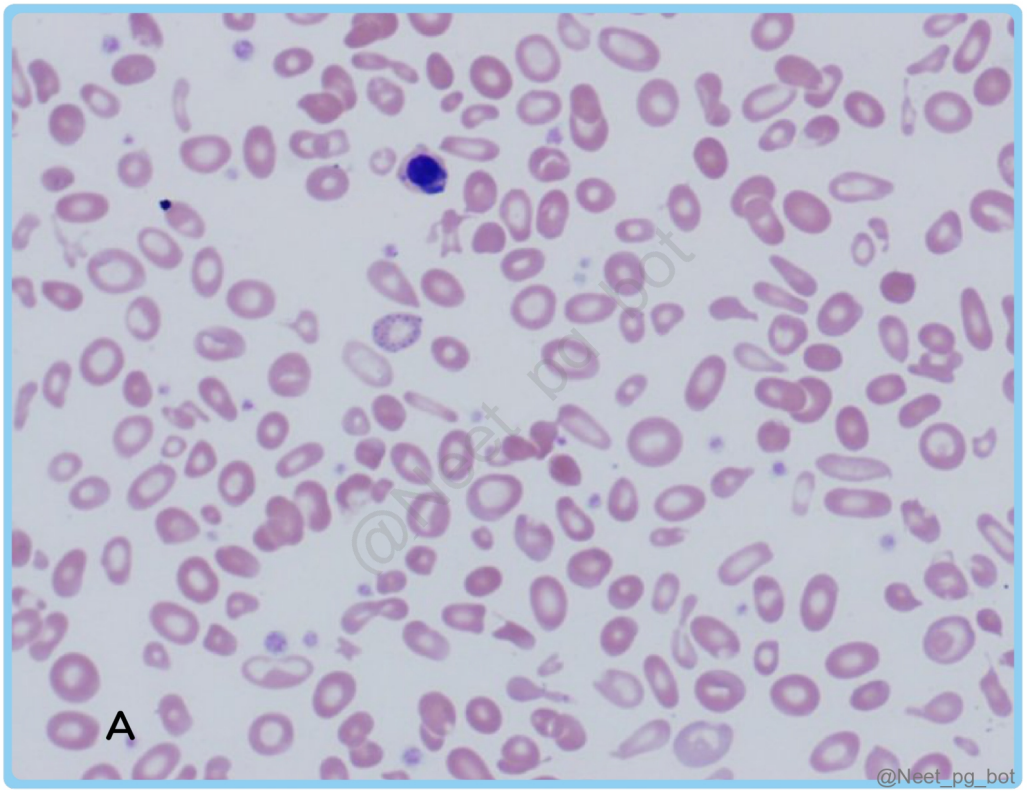
A
@Neet_pg_bot

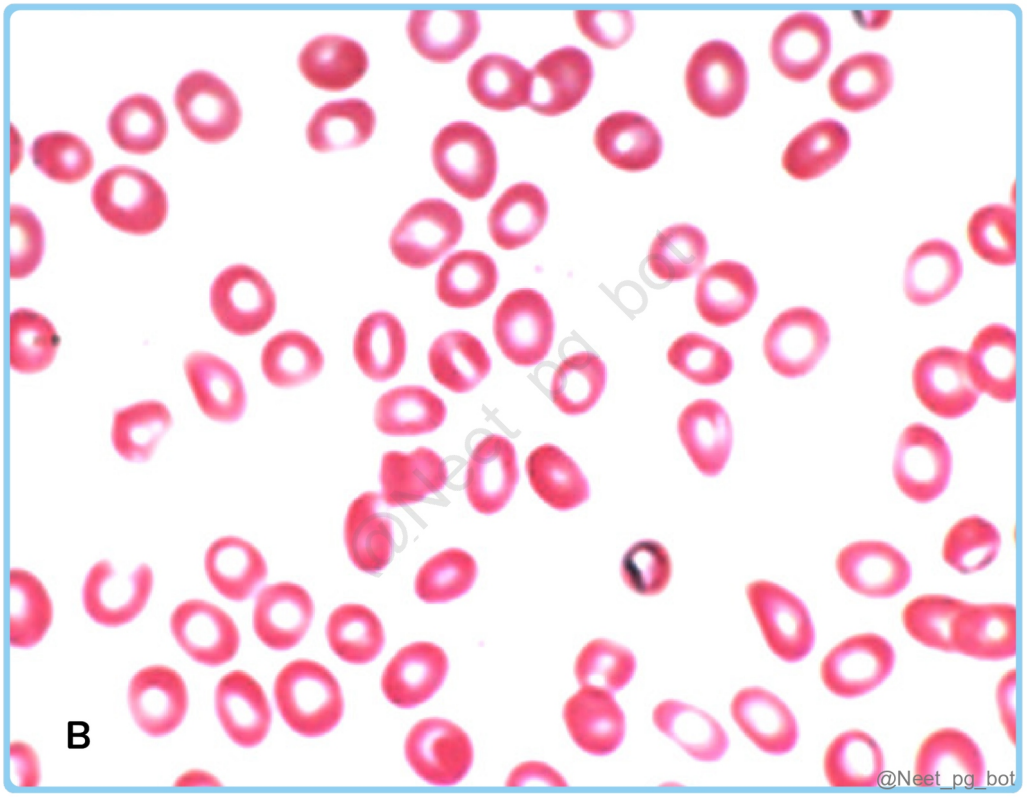
B
@Neet_pg_bot

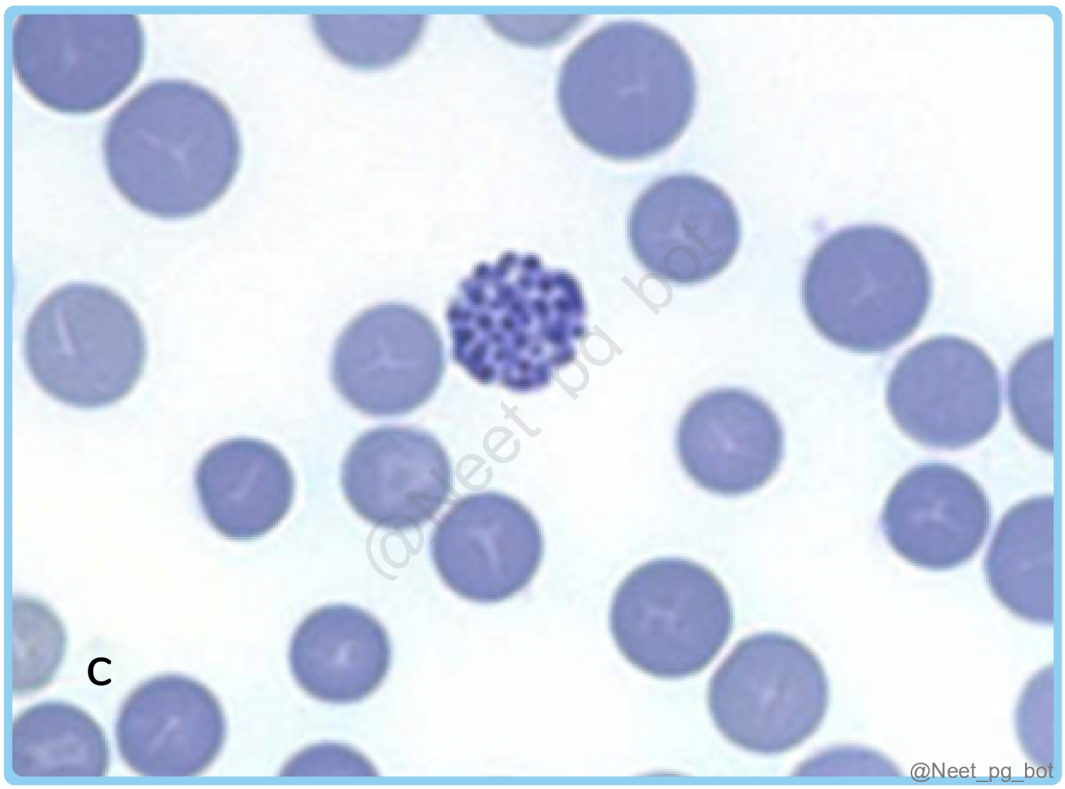

Correct Answer: A. Patient A: β-thalassemia major, Patient B: β-thalassemia minor, Patient C: α-thalassemia

■ *Listen (English)*

■ *Listen (Hindi)*

Explanation: The peripheral smear findings can help distinguish between different types of thalassemia: β-thalassemia major (Patient A): This condition is characterized by severe anemia . The peripheral smear typically shows significant abnormalities, including target cells , nucleated red blood cells (NRBCs) , microcytosis, hypochromia, and anisopoikilocytosis. These findings are consistent with the severe hemolytic anemia and ineffective erythropoiesis seen in β-thalassemia major. β-thalassemia minor/β-thalassemia trait (Patient B): This condition usually presents with mild anemia. The peripheral smear shows microcytosis and hypochromia but generally lacks significant numbers of NRBCs. α-thalassemia (Patient C): This condition can vary in severity. The peripheral smear of a patient with α-thalassemia trait may show mild anemia , microcytosis, and hypochromia. In cases of HbH disease (a form of α-thalassemia), the smear can also show NRBCs and hemoglobin H inclusions (golf ball cells), which are not seen in β-thalassemia minor. Hemoglobin H inclusions are seen in α-thalassemia patients when there are 3 out of 4 alpha genes deletions.

References:

Robbins & Cotran Pathologic Basis of Disease, 10th Edition, Page 647.

https://www.ncbi.nlm.nih.gov/books/NBK545151/

↑ *Back to this question in Part A*

@Neet_pg_bot

Q12: Which of the following findings is most consistent with β thalassemia major when compared to β thalassemia minor? (Q845934)

A. Decrease in HbA, slight increase in HbA2, and normal HbF; HPLC: HbA2: 6%, HbF: 2%

B. Decrease in HbA, increase in HbA2, and marked increase in HbF; HPLC: HbA2: 6%, HbF: 90%

C. Absent HbA, slight increase in HbA2, and moderate increase in HbF; HPLC: HbA2: 4%, HbF: 20%

D. Decrease in HbA, normal HbA2, and normal HbF; HPLC: HbA2: 2%, HbF: 2%

Correct Answer: B. Decrease in HbA, increase in HbA2, and marked increase in HbF; HPLC: HbA2: 6%, HbF: 90%

Explanation: β thalassemia major is characterised by decrease in HbA, increase in HbA2, and marked increase in HbF; HPLC: HbA2: 6%, HbF: 90% In β-thalassemia major, adult hemoglobin (HbA) is severely reduced, often to 0–5%. Fetal hemoglobin (HbF) compensates, rising above 90%. HbA2 may be normal or slightly elevated around 5%. Decrease in HbA, slight increase in HbA2, and normal HbF; HPLC: HbA2: 6%, HbF: 2% (Option A): These findings indicate β-thalassemia trait, characterized by decreased adult hemoglobin (HbA), normal HbF, and increased HbA2 levels. Absent HbA, slight increase in HbA2, and moderate increase in HbF; HPLC: HbA2: 4%, HbF: 20% (Option C): This is seen in sickle cell anemia with absent HbA, presence of sickle hemoglobin HbS >75%, HbA2: 4% and HbF: 20% Decrease in HbA, normal HbA2, and normal HbF; HPLC: HbA2: 2%, HbF: 2% (Option D): These findings indicate sickle cell trait, with HbA levels around 60-70%, HbS about 30%, and normal HbA2 and HbF levels.

References:

Robbins & Cotran Pathologic Basis of Disease, 10th Edition, Page 647 Harrison's Principles of Internal Medicine, 21st edition, Page 757, 762 https://www.ncbi.nlm.nih.gov/books/NBK545151/

↑ *Back to this question in Part A*

@Neet_pg_bot

Q13: A pregnant woman is a silent carrier for α-thalassemia (α-/αα) and is concerned about the risk of her child inheriting α-thalassemia. Her partner has the α-thalassemia trait (αα/--). What is the probability that their child will have Hemoglobin H (HbH) disease? (Q845937)

A. 0%

B. 25%

C. 50%

D. 75%

Correct Answer: B. 25%

■ *Listen (English)*

■ *Listen (Hindi)*

Explanation: This couple will have a 25% chance of their child being affected with Hemoglobin H Disease. α-Thalassemia: Autosomal recessive condition, caused by deletions of 1–4 α-globin genes Severity of disease correlates with the number of genes deleted – more deletions lead to more severe clinical manifestations Hemoglobin H (HbH) disease is caused by α-thalassemia, with the deletion of 3 α-globin genes, leaving only 1 α-gene remaining. Effect: Insufficient α chains; excess β chains form β■ tetramers (HbH) . Pathophysiology: HbH is unstable → extravascular hemolysis → inclusion bodies on brilliant cresyl blue staining . Clinical features: Anemia, jaundice, splenomegaly, mild hemolysis. The α-globin gene is located on chromosome 16, and each individual has two copies of this gene on each chromosome, for a total of four α-globin genes (αα/αα). Parent Genotypes: Mother (Silent carrier): α-/αα Father (α-thalassemia trait): αα/– Interpretation of Results: α-/αα (Silent carrier)- 25% αα/αα (Normal)- 25% α-/-- (HbH disease)- 25% αα/-- (α-thalassemia trait)- 25% When 2 carriers get married: Chance of child having the disease = 25% Chance of child of being a carrier = 50%

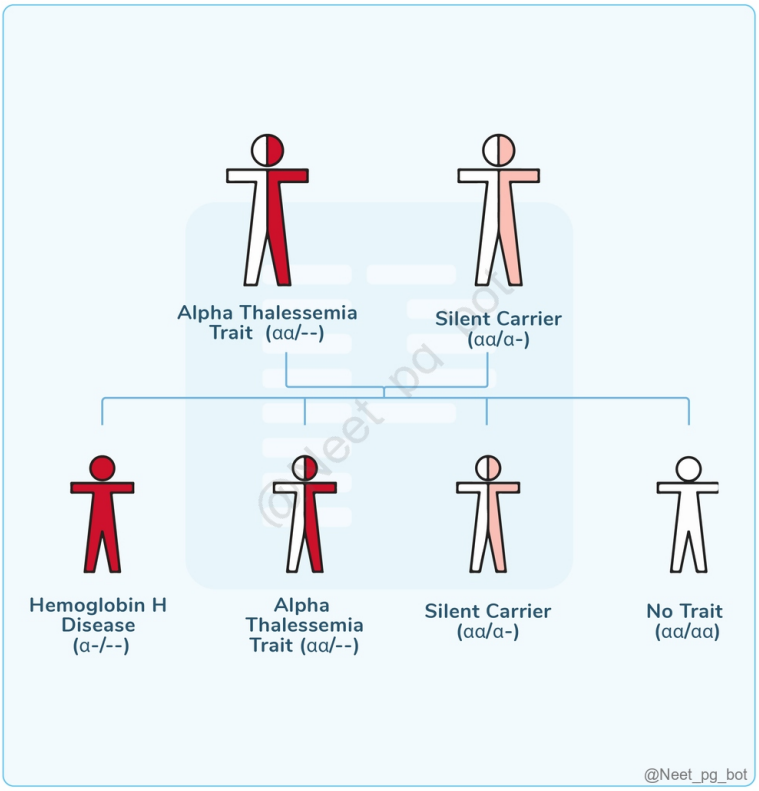

References:

Robbins & Cotran Pathologic Basis of Disease, 10th Edition, Page 646, 647.
https://www.stjude.org/treatment/disease/sickle-cell-disease/diagnosing-sickle-cell/alpha-thalassemia-trait.html

↑ *Back to this question in Part A*

@Neet_pg_bot

Q14: The medical team, aware of the prevalence of genetic disorders in the village decides to implement a screening process using NESTROFT for beta thalassemia. They plan to test the result by observing the solution turning clear by checking the visibility of a black line behind the test and control tubes. Which of the following on Nestrof test would be indicative of a positive result? (Q845940)

A. Black line visible in both tubes

B. Black line visible in only control tubes

C. Black line not visible in only test tubes

D. No black line visible in any of the tubes

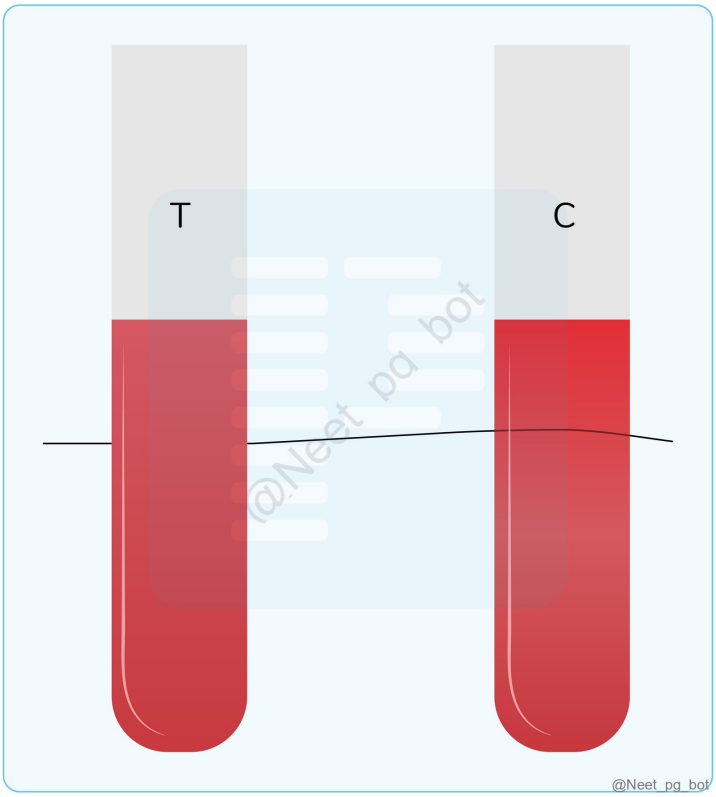

Correct Answer: C. Black line not visible in only test tubes

Explanation: A black line not visible only in the test tubes containing blood sample mixed with a 0.36 buffered solution is suggestive of a positive Nestrof test. NESTROFT (Naked Eye Single Tube Red Cell Osmotic Fragility Test) Screening test for beta thalassemia and sickle cell trait carriers. Take 5 ml of 0.35% hypotonic saline in two tubes Add patient's blood (test) and a normal person's blood (control) A white paper with black lines is placed behind both tubes after half an hour RBCs of a normal person's blood break due to hypotonic saline - black line is visible Thalassemia cells do not break - line is not visible

References:

https://pediatrics.medresearch.in/index.php/ijpr/article/view/142/281

↑ *Back to this question in Part A*

@Neet_pg_bot

Q15: Match the following diseases with their respective antibodies and target antigens on red blood cells (RBCs): 1. Cold Agglutinin Disease 2. Cold Hemolytic Disease Antibody Target Antigen on RBCs A IgM I antigen B IgG P antigen C IgG I antigen D IgM P antigen Select the correct matching pairs: (Q845943)

A. 1-A, 2-C

B. 1-C, 2-D

C. 1-A, 2-B

D. 1-B, 2-D

Correct Answer: C. 1-A, 2-B

■ *Listen (English)*

■ *Listen (Hindi)*

Explanation: Cold Agglutinin Disease is associated with IgM antibodies against the I antigen on RBCs. Cold Hemolytic Disease involves IgG Donath-Landsteiner antibodies against the P antigen on RBCs. Feature Cold Agglutinin Disease (CAD) Cold Hemolytic Disease (CHD) / Paroxysmal Cold Haemoglobinuria(PCH) Antibody Type IgM antibodies against the I antigen on RBCs. IgG Donath-Landsteiner antibodies against the P antigen on RBCs. Temperature Sensitivity Bind avidly at low temperatures (0°C to 4°C), but not at 37°C Bind in cool peripheral regions, but complement-mediated lysis occurs at warm core Causes Associated with certain infections (Mycoplasma pneumoniae, Epstein-Barr virus, cytomegalovirus, influenza virus, HIV), B-cell neoplasms, or idiopathic Often seen in children following viral infections Hemolysis Intravascular hemolysis is usually not seen; extravascular hemolysis due to phagocytosis after release of IgM Complement-mediated intravascular hemolysis and hemoglobinuria Clinical Symptoms Pallor, cyanosis, Raynaud phenomenon in cold-exposed body parts Hemoglobinuria, intravascular hemolysis

References:

Robbins & Cotran Pathologic Basis of Disease, 10th Edition, Page 650

↑ *Back to this question in Part A*

@Neet_pg_bot

Q16: Which of the following statements is false regarding warm antibody-mediated autoimmune hemolytic anemia (AIHA)? (Q845944)

A. It is commonly mediated by IgG antibodies active at 37°C.

B. It can be associated with the intake of drugs like alpha-methyldopa and quinine.

C. It typically involves the destruction of red blood cells primarily in the liver.

D. A positive direct Coombs test is often used to confirm the diagnosis.

Correct Answer: C. It typically involves the destruction of red blood cells primarily in the liver.

■ *Listen (English)*

■ *Listen (Hindi)*

Explanation: The incorrect statement regarding warm AIHA is that it involves the destruction of red blood cells primarily in the liver, rather than in the spleen. Warm Antibody-Mediated Autoimmune Hemolytic Anemia (AIHA): Feature Description Antibody Type IgG Optimal Temperature for Activity 37°C (body temperature) (Option A) Common Symptoms Fatigue, pallor, jaundice, shortness of breath, dark urine, splenomegaly Mechanism of Hemolysis IgG antibodies bind to RBCs, leading to phagocytosis primarily in the spleen (Option C) Diagnosis Positive direct Coombs test (direct antiglobulin test) (Option D) Hemolysis Location Primarily in the spleen Associated Conditions Autoimmune diseases (e.g., SLE), lymphoproliferative disorders (e.g., CLL), infections Drug-Induced Causes Alpha-methyldopa, quinine, penicillin, and cephalosporins (Option B) Laboratory Findings Anemia, elevated reticulocyte count, increased LDH, Decreased haptoglobin, spherocytes on blood smear Type of AIHA Warm AIHA (WAIHA) Cold AIHA (CAIHA) Most Common Antibody Ig G Ig M Frequency Most common type (approx. 70-80% of cases) Less common Optimal Reaction Temperature 37°C (Body temperature) Below 37°C (usually 4°C)

References:

Robbins & Cotran Pathologic Basis of Disease, 10th Edition, Page 649

↑ *Back to this question in Part A*

@Neet_pg_bot

• [17_Hematology_ Red Blood Cells] 068 Microcytic Hypochromic Anemia

« Back to Folder Directory

[17_Hematology_ Red Blood Cells] 068 Microcytic Hypochromic Anemia — Quick Jump

Q1 (p. 2644)	*Q2 (p. 2645)*	*Q3 (p. 2645)*	*Q4 (p. 2646)*	*Q5 (p. 2646)*	*Q6 (p. 2647)*
Q7 (p. 2648)	*Q8 (p. 2650)*	*Q9 (p. 2654)*	*Q10 (p. 2655)*	*Q11 (p. 2656)*	*Q12 (p. 2657)*
Q13 (p. 2659)	*Q14 (p. 2660)*	*Q15 (p. 2661)*	*Q16 (p. 2661)*	*Q17 (p. 2662)*	*Q18 (p. 2663)*
Q19 (p. 2663)	*Q20 (p. 2666)*	*Q21 (p. 2667)*	*Q22 (p. 2668)*	*Q23 (p. 2669)*	*Q24 (p. 2670)*
Q25 (p. 2671)	*Q26 (p. 2672)*	*Q27 (p. 2674)*			

Q1: Which of the following conditions is least likely to result in iron deficiency anemia? (Q880000)

A. A young 5-year-old suffering from hookworm infection

B. An elderly 60-year-old male diagnosed with carcinoma of the cecum

C. A middle-aged 54-year-old woman who has undergone Billroth II gastrectomy

D. A 25-year-old female consuming a diet predominantly based on maize

Correct Answer: D. A 25-year-old female consuming a diet predominantly based on maize

Explanation: Maize-based diets are least likely to cause iron deficiency anemia on their own. While maize is low in bioavailable iron and contains absorption inhibitors, iron deficiency anemia usually requires other risk factors, such as poor overall nutrition or blood loss. Iron fortification may also lessen deficiency risk. Condition Likelihood of Iron Deficiency Anemia Reason Hookworm infection (5 years old) High (Ruled out Option A) Blood loss from intestinal parasites Carcinoma of the cecum (60-year-old male) High (Ruled out Option B) Chronic gastrointestinal bleeding Billroth II gastrectomy (54-year-old woman) High (Ruled out Option C) Malabsorption from altered GI anatomy and acid secretion Maize-based diet (25-year-old female) Least Likely (Option D) Iron bioavailability is low, but anemia is less likely without additional causes

References:

Robbins and Cotran, Pathologic Basis of Disease, 11th Edition, Page 596.

↑ *Back to this question in Part A*

@Neet_pg_bot

Q2: In the human body, where is the majority of biologically active iron located? (Q879988)

A. Hemoglobin

B. Myoglobin

C. Catalase enzymes

D. Ferritin

Correct Answer: A. Hemoglobin

Explanation: About 70% of total body iron is bound in hemoglobin within red blood cells, responsible for oxygen transport. Incorrect Options: Myoglobin (Option B): Myoglobin contains iron but represents a small fraction compared to hemoglobin. Catalase enzymes (Option C): Catalase enzymes contain iron but constitute a minor portion. Ferritin (Option D): Ferritin is an iron storage protein that stores iron in an inactive form, not the most biologically active iron.

References:

Robbins and Cotran, Pathologic Basis of Disease, 11th Edition, Page 59.

↑ *Back to this question in Part A*

@Neet_pg_bot

Q3: A patient is found to have a mean corpuscular volume (MCV) of 109 fL. Which of the following conditions is least commonly associated with this laboratory finding? (Q879982)

A. Hypothyroidism

B. Vitamin B12 deficiency

C. Orotic aciduria

D. Anemia of chronic disease

Correct Answer: D. Anemia of chronic disease

Explanation: Anemia of chronic disease usually causes normocytic or mildly microcytic anemia. Macrocytosis is uncommon in this condition. Incorrect Options: Hypothyroidism (Option A): Hypothyroidism frequently causes mild macrocytosis due to decreased erythropoiesis. Vitamin B12 deficiency (Option B): Hypothyroidism

frequently causes mild macrocytosis due to decreased erythropoiesis. Orotic aciduria (Option C): Orotic aciduria is a rare cause of macrocytic anemia with increased MCV.

References:

Robbins and Cotran, Pathologic Basis of Disease, 11th Edition, Page 577.

↑ *Back to this question in Part A*

@Neet_pg_bot

Q4: All of the following anemias arise from reduced red cell production, except: (Q879974)

A. Iron deficiency anemia

B. Hereditary spherocytosis

C. Megaloblastic anemia

D. Aplastic anemia

Correct Answer: B. Hereditary spherocytosis

Explanation: Hereditary spherocytosis is a hemolytic anemia caused by increased red cell destruction, not reduced production. Incorrect Options: Iron deficiency anemia (Option A): Iron deficiency anemia arises from reduced red cell production due to insufficient iron for hemoglobin synthesis. Megaloblastic anemia (Option C): Megaloblastic anemia results from impaired DNA synthesis leading to defective red cell production. Aplastic anemia (Option D): Aplastic anemia is caused by bone marrow failure leading to decreased production of all blood cells.

References:

Robbins and Cotran, Pathologic Basis of Disease, 11th Edition, Page 578.

↑ *Back to this question in Part A*

@Neet_pg_bot

Q5: In individuals living with HIV infection, which hematologic abnormality is observed most commonly? (Q879969)

A. Thrombocytopenia

B. Neutropenia

C. Lymphocytosis

D. Anemia

Correct Answer: D. Anemia

Explanation: Anemia is the most common blood abnormality and can be caused by chronic disease, bone marrow suppression (from HIV or medications like zidovudine), opportunistic infections, and nutritional deficiencies. Incorrect Options: Thrombocytopenia (Option A): Common in HIV but less frequent than anemia. Caused by immune destruction and marrow suppression. Neutropenia (Option B): Seen, especially in advanced disease or related to medication side effects, but less common than anemia. Lymphocytosis (Option C): Not typical; more often, lymphopenia occurs due to CD4+ T-cell depletion.

References:

Robbins and Cotran, Pathologic Basis of Disease, 11th Edition, Page 219.

↑ *Back to this question in Part A*

@Neet_pg_bot

Q6: What is considered the most significant inflammatory mediator in the pathophysiology of anemia of chronic disease (AOCD)? (Q845881)

A. Interleukin-6

B. Transferrin

C. Interleukin-10

D. Interferon-γ

Correct Answer: A. Interleukin-6

■ *Listen (English)*

■ *Listen (Hindi)*

Explanation: Interleukin-6 is the most important inflammatory mediator linked to the pathogenesis of anemia of chronic disease (AOCD). In chronic conditions, Interleukin-6 will increase and act on the liver. Releases Hepcidin (master regulator) Inhibits Fe absorption. Serum iron levels and transferrin saturation are decreased. Inhibits the release of Fe from ferritin. Therefore, ferritin levels increase. This leads to a decrease in TIBC. Interleukin-10 (Option C) is an anti-inflammatory cytokine, which supports erythropoiesis and maintains iron homeostasis. It reduces the impact of chronic inflammation on RBC production. Interferon-γ (Option D) is produced by activated Th1 cells. It promotes the immune-mediated destruction of stem cells and leads to bone marrow failure and pancytopenia in aplastic anemia.

References:

Robbins & Cotran Pathologic Basis of Disease, 10th Edition, Page 655-660

↑ *Back to this question in Part A*

@Neet_pg_bot

Q7: A 5-year-old child presents to the clinic with symptoms of irritability, abdominal pain, and vomiting. The physician suspects lead poisoning and orders a complete blood count along with a peripheral blood smear. Which of the following findings would most likely be seen on the peripheral blood smear in lead poisoning? (Q845895)

A. Schistocytes

B. Spherocytes

C. Basophilic stippling

D. Bite cells

Correct Answer: C. Basophilic stippling

■ *Listen (English)*

■ *Listen (Hindi)*

Explanation: Basophilic stippling is a characteristic finding seen in lead poisoning. The retained rRNA appears as small blue granules on a stained peripheral blood smear, leading to the characteristic basophilic stippling seen on blood smears. The accumulation of ribosomal RNA in lead poisoning is a consequence of disrupted heme synthesis, leading to ineffective red blood cell maturation and the retention of rRNA in developing erythrocytes. Schistocytes (Option A): These fragmented red blood cells are typically seen in microangiopathic hemolytic anaemia caused by conditions such as thrombotic thrombocytopenic purpura (TTP) or disseminated intravascular coagulation (DIC), not in lead poisoning. Spherocytes (Option B): These are round cells with no central pallor, associated with hereditary spherocytosis Bite cells (Option D): Bite cells are seen in G6PD deficiency. In G6PD deficiency, oxidative stress leads to the denaturation of haemoglobin, resulting in the formation of Heinz bodies (aggregates of denatured haemoglobin). Macrophages in the spleen recognize and remove these Heinz bodies, creating a characteristic bite-shaped appearance. Morphological Defects in Blood Cell Lineages and Their Causes 1. RBC Morphological Defects (Size, Shape, Color, Inclusions) Morphological Defect Description Causes / Associated Diseases Microcytosis Small RBCs (↓ MCV) Iron deficiency anemia, Thalassemia, anemia of chronic disease, sideroblastic anemia Macrocytosis Large RBCs Megaloblastic anemia (B12/folate deficiency), liver disease, alcoholism Hypochromia ↓ Hb, large central pallor Iron deficiency anemia, Thalassemia Spherocytes Round RBCs, no central pallor Hereditary spherocytosis, Autoimmune hemolytic anemia Elliptocytes Elliptical RBCs Hereditary elliptocytosis, Iron deficiency anemia Target cells Bull’s eye appearance Thalassemia, liver disease, Sickle cell disease Schistocytes Fragmented RBCs Disseminated intravascular coagulation, Thrombotic thrombocytopenic purpura, Hemolytic uremic syndrome Sickle cells Crescent-shaped RBCs Sickle cell anemia Tear drop cells Tear-shaped RBCs Myelofibrosis, marrow infiltration Acanthocytes Spur cells Liver disease, abetalipoproteinemia Echinocytes Burr cells Uremia, CKD Rouleaux formation Stacked RBCs Multiple myeloma

Howell-Jolly bodies Nuclear remnants Splenectomy, megaloblastic anemia Basophilic stippling Ribosomal RNA Lead poisoning, thalassemia Heinz bodies Denatured Hb Glucose-6-phosphate dehydrogenase deficiency Cabot rings Mitotic spindle remnants Megaloblastic anemia 2. WBC Morphological Defects and Causes Neutrophil Abnormalities: Morphological Defect Description Causes Hypersegmented neutrophils >5 lobes Megaloblastic anemia Pelger-Huët anomaly Bilobed nucleus Congenital, Myelodysplastic syndrome Toxic granulation Coarse granules Severe bacterial infection Döhle bodies Blue cytoplasmic inclusions Infection, burns, inflammation Vacuolated neutrophils Cytoplasmic vacuoles Sepsis Auer rods Needle-like inclusions Acute myeloid leukemia Smudge cells Fragile lymphocytes Chronic lymphocytic leukemia Atypical lymphocytes Large reactive lymphocytes Infectious mononucleosis 3. Platelet Morphological Defects and Causes: Morphological Defect Description Causes Giant platelets Large platelets Bernard-Soulier syndrome, ITP Small platelets Small platelets Wiskott-Aldrich syndrome Platelet clumping Platelet aggregates EDTA artifact Hypogranular platelets ↓ granules Myelodysplastic syndrome Gray platelets Gray appearance Gray platelet syndrome Thrombocytopenia ↓ platelets ITP, aplastic anemia, leukemia Thrombocytosis ↑ platelets Myeloproliferative disorders

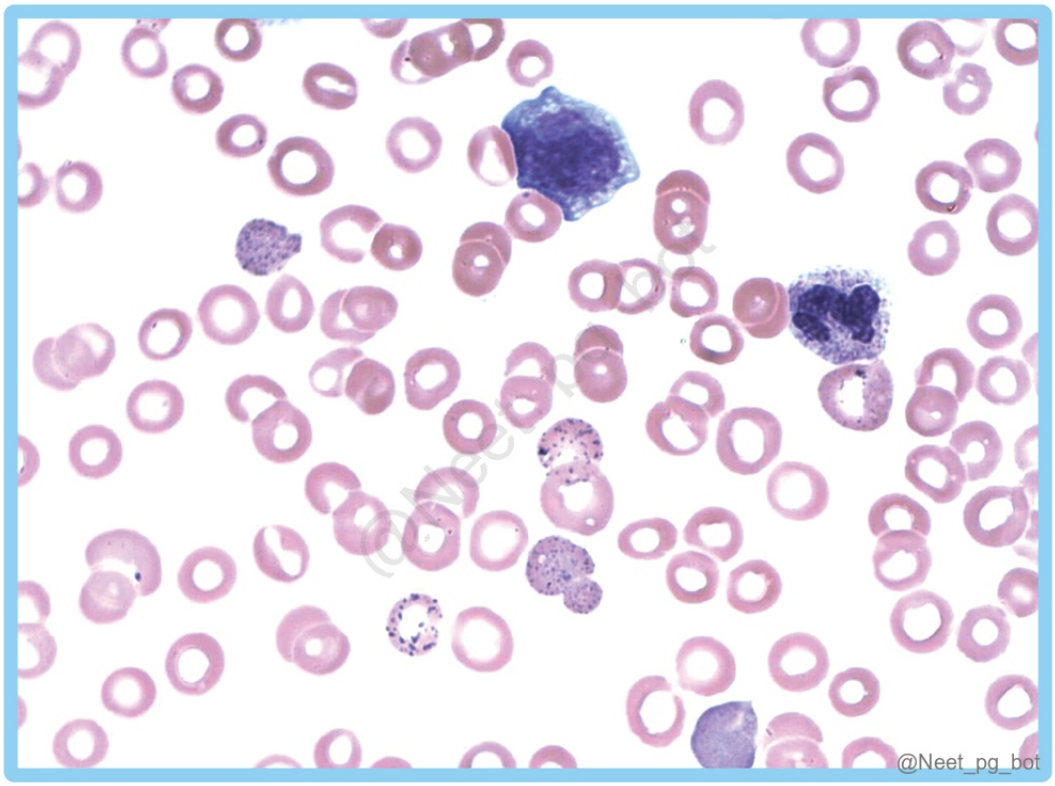

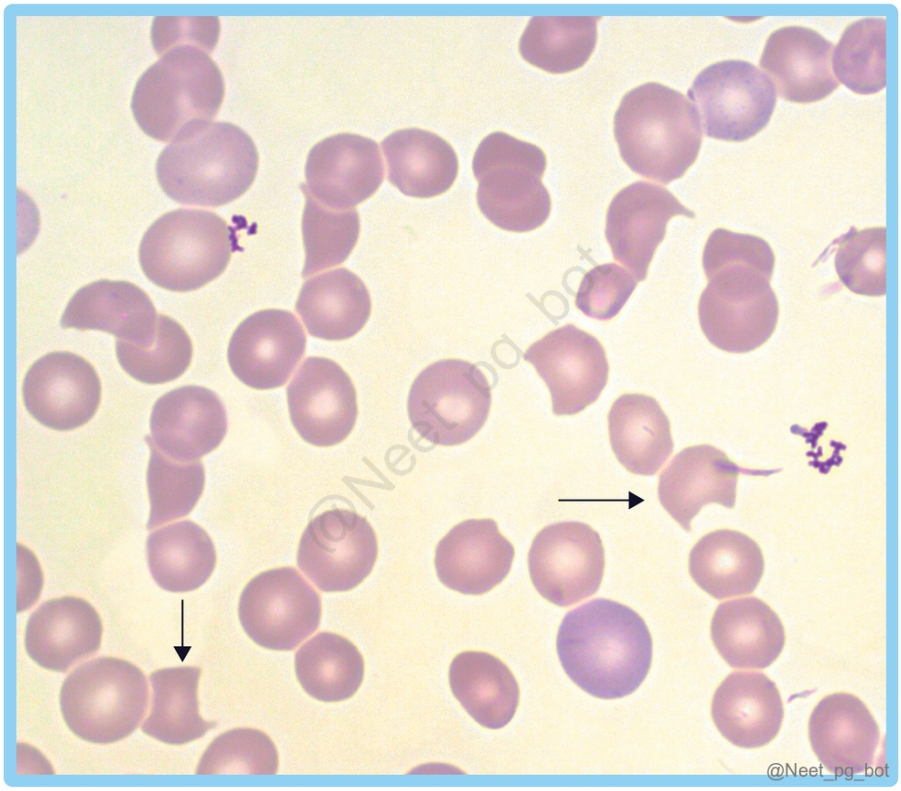

References:

Robbins & Cotran Pathologic Basis of Disease, 10th Edition, Page 620, 621

↑ *Back to this question in Part A*

@Neet_pg_bot

Q8: A peripheral blood smear revealed basophilic granules with Prussian blue stain. Which of the following bone marrow cells are associated with this condition? (Q845894)

A. Sideroblast

B. Siderocyte

C. Reticulocyte

D. Bite cells

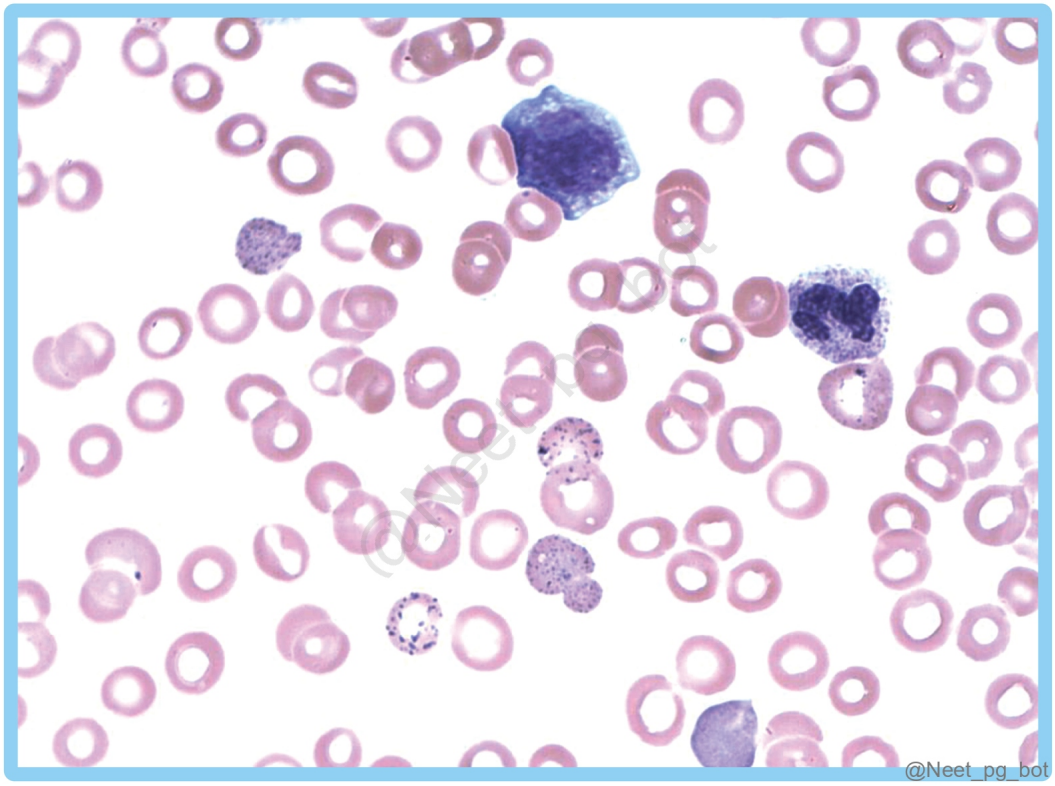

Correct Answer: A. Sideroblast

- *Listen (English)*
- *Listen (Hindi)*

Explanation: The patient's peripheral smear reveals numerous basophilic iron granules, resembling Pappenheimer bodies in sideroblastic anemia, which has ringed sideroblasts on the bone marrow smear. Findings of sideroblastic anemia: Peripheral Smear: Pappenheimer bodies Bone Marrow: Ringed Sideroblasts Multiple basophilic iron aggregates Stain blue with Perl's/ Prussian blue Seen in sideroblastic anemia, lead poisoning, or hemochromatosis Blue granules form full or partial ring Blasts have a nucleus Iron is present in mitochondria in the perinuclear region. Stain blue on Perl's/Prussian blue. Seen with Sideroblastic anemia and Myelodysplastic syndrome. Associated with SF3B1 mutation Siderocyte (Option B) Red blood cells containing non hemoglobin ferric iron called siderotic granules on peripheral smear Seen in patients with absent spleen, sideroblastic anemia and hemolytic anemia Reticulocyte (Option C) Immature red blood cells produced in the bone marrow and released into the peripheral blood Brilliant cresyl blue stain Seen in hemolytic anemia, erythroblastosis fetalis and pregnancy. Bite Cells (Degmacytes) (Option D) Bite cells are erythrocytes with irregular membrane due to G6PD deficiency

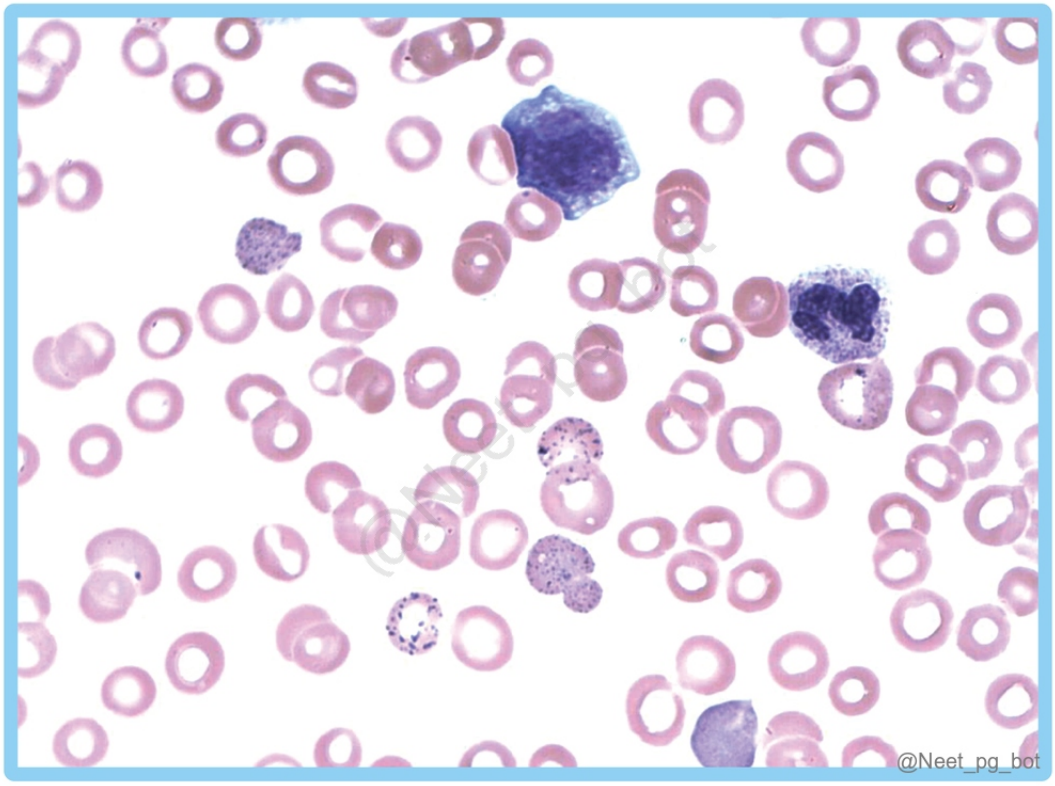
@Neet_pg_bot

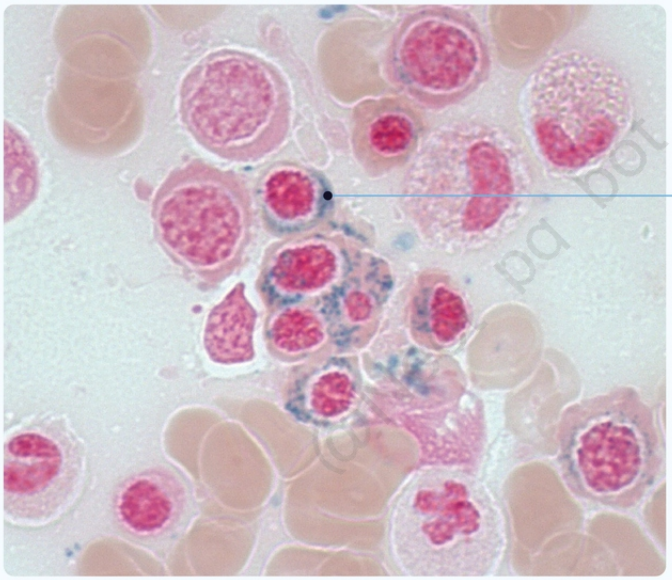

@Neet_pg_bot

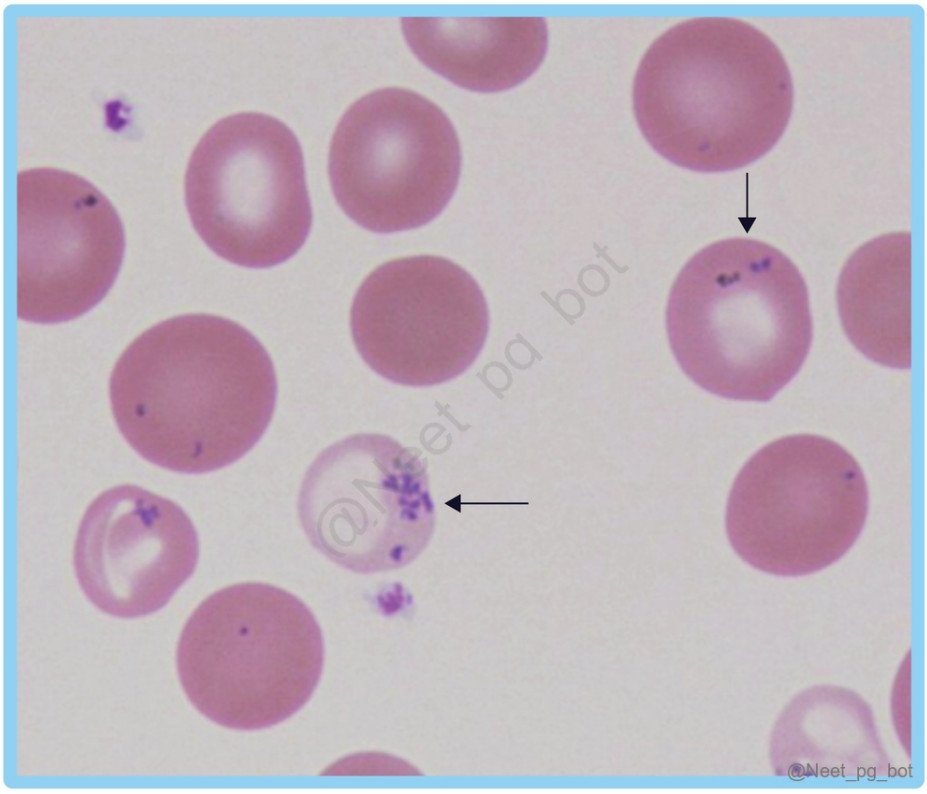
@Neet_pg_bot

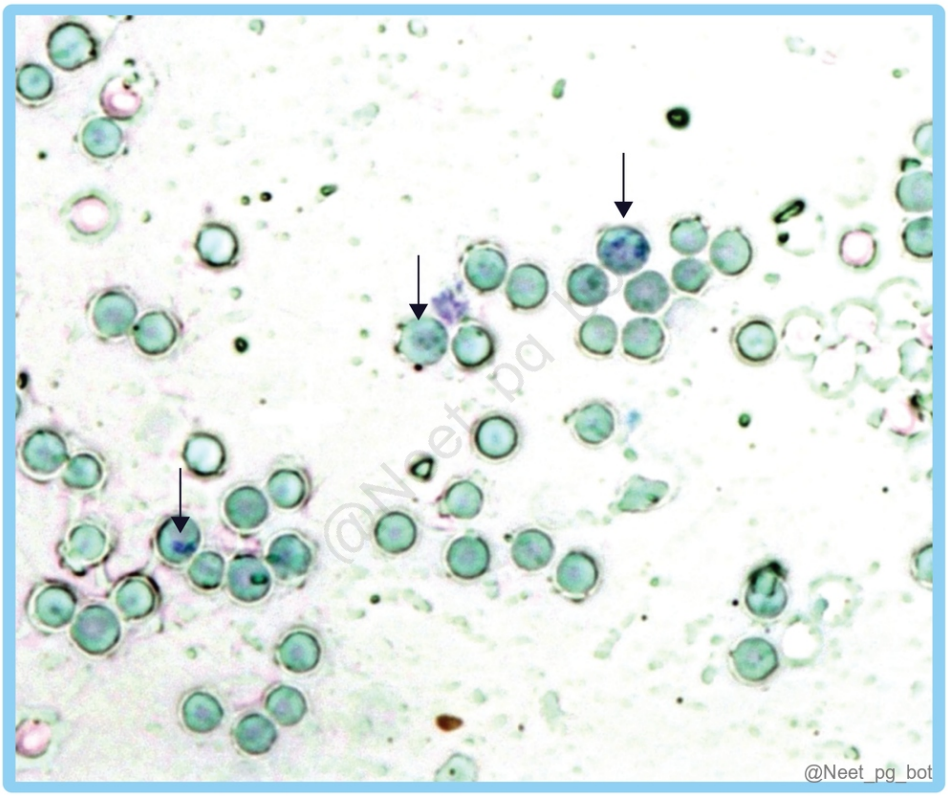
@Neet_pg_bot

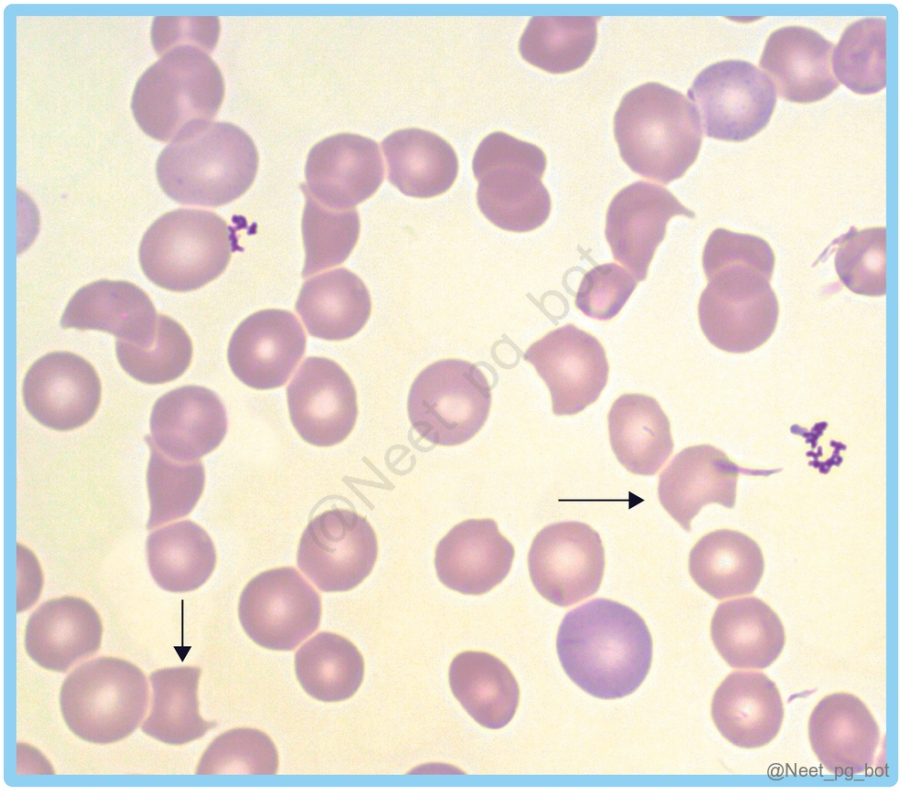

References:

Robbins & Cotran Pathologic Basis of Disease, 10th Edition, Page 620-621

↑ *Back to this question in Part A*

@Neet_pg_bot

Q9: A 7-year-old girl presents to the clinic with complaints of fatigue, weakness, and pale skin. Her mother mentions that she has developed cravings for ice (pica). Laboratory tests reveal microcytic anaemia, and her serum ferritin levels are significantly low. Which of the following is the most likely infectious cause of her condition? (Q845887)

A. Giardia lamblia

B. Ancylostoma

C. Diphyllobothrium latum

D. Enterobius vermicularis

Correct Answer: B. Ancylostoma

■ *Listen (English)*

■ *Listen (Hindi)*

Explanation: The clinical presentation (fatigue, pallor, and pica) and laboratory findings (microcytic anaemia, and low serum ferritin levels) in this patient point towards iron deficiency anaemia. Lab Parameters Iron Deficiency Anemia (IDA) Ferritin Low Transferrin saturation Low Serum Iron Low TIBC High Hookworm (Ancylostoma) infection is a well-known cause of iron deficiency anaemia, particularly in children. Hookworms attach to the intestinal wall to feed on the host's blood, leading to chronic blood loss. This results in microcytic anaemia due to iron deficiency, especially in children with limited dietary iron intake. Giardia lamblia (Option A): This protozoan parasite causes giardiasis, which primarily leads to malabsorption and chronic diarrhoea with fatty stools. Diphyllobothrium latum (Option C): This fish tapeworm causes megaloblastic anaemia(macrocytic) due to vitamin B12 deficiency rather than iron deficiency anaemia. Enterobius vermicularis (Option D): Commonly known as pinworm, this parasite primarily causes anal itching and discomfort, particularly in children. It does not lead to significant blood loss or iron deficiency anaemia.

References:

Robbins & Cotran Pathologic Basis of Disease, 10th Edition, Page 658

↑ *Back to this question in Part A*

@Neet_pg_bot

Q10: Which of the following vitamin deficiencies is most commonly associated with sideroblastic anemia? (Q845886)

A. Vitamin B1 (Thiamine)

B. Vitamin B9 (Folic Acid)

C. Vitamin B6 (Pyridoxine)

D. Vitamin B12 (Cobalamin)

Correct Answer: C. Vitamin B6 (Pyridoxine)

■ *Listen (English)*

■ *Listen (Hindi)*

Explanation: Sideroblastic anaemia is characterized by defective heme synthesis, leading to the accumulation of iron in the form of ringed sideroblasts in the bone marrow. Causes of sideroblastic anaemia: Congenital causes Due to enzyme deficiencies like ALA synthase, ferrochelatase, etc. Acquired causes Vitamin B6 deficiency Drugs like isoniazid and chloramphenicol Lead and alcohol poisoning Vitamin B6 (Pyridoxine) is a cofactor for the enzyme Aminolevulinic Acid Synthase (ALAS), which catalyses the first step in the heme biosynthetic pathway. Deficiency of vitamin B6 leads to the development of sideroblastic anaemia. Vitamin B1 (Thiamine)(Option A) :

Thiamine is important for carbohydrate metabolism and nerve function. Its deficiency leads to conditions such as Wernicke-Korsakoff syndrome and beriberi but is not associated with sideroblastic anaemia. Folic acid and vitamin B12 are vital for DNA synthesis and red blood cell production. Their deficiencies lead to megaloblastic anaemia, but not sideroblastic anaemia and vitamin B12 deficiency also causes neurological issues(Subacute Combined Degeneration) (Options C and D).

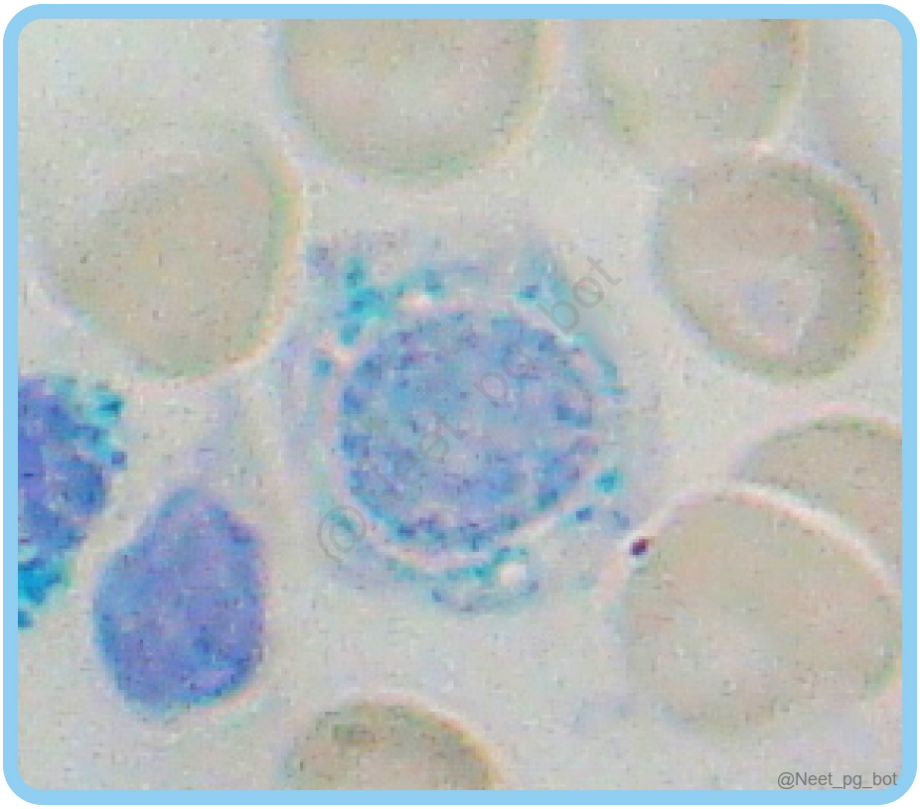

References:

Robbins & Cotran Pathologic Basis of Disease, 10th Edition, Page 620, 621

↑ *Back to this question in Part A*

@Neet_pg_bot

Q11: Which of the laboratory findings are suggestive of sideroblastic anemia? Serum Iron Transferrin saturation Serum Ferritin TIBC A. High High High Low B. Low Low Low High C. Low Low High Low D. High Low High Low (Q845885)

A. A

B. B

C. C

D. D

Correct Answer: A. A

■ *Listen (English)*

■ *Listen (Hindi)*

Explanation: Iron overload is a hallmark of sideroblastic anemia, as seen by elevated blood iron, low TIBC value, high transferrin saturation, and ferritin levels in laboratory tests. Serum Iron Transferrin saturation Serum Ferritin TIBC Sideroblastic Anemia High High High Low Iron Deficiency Anemia (Option B) Low Low Low High Anemia of Chronic Disease (Option C) Low Low High Low Hemolytic Anemia (Option D) High Low High Low

References:

Robbins & Cotran Pathologic Basis of Disease, 10th Edition, Page 620-621, 655, 659

↑ *Back to this question in Part A*

@Neet_pg_bot

Q12: A 40-year-old female with a history of treatment for latent tuberculosis presents with fatigue. Physical examination reveals pallor and mild jaundice. Bone marrow smear revealed the following findings.which of the following is the most likely diagnosis? Options: (Q845884)

A. Iron deficiency anemia

B. Megaloblastic anemia

C. Sideroblastic anemia

D. Hemolytic anemia

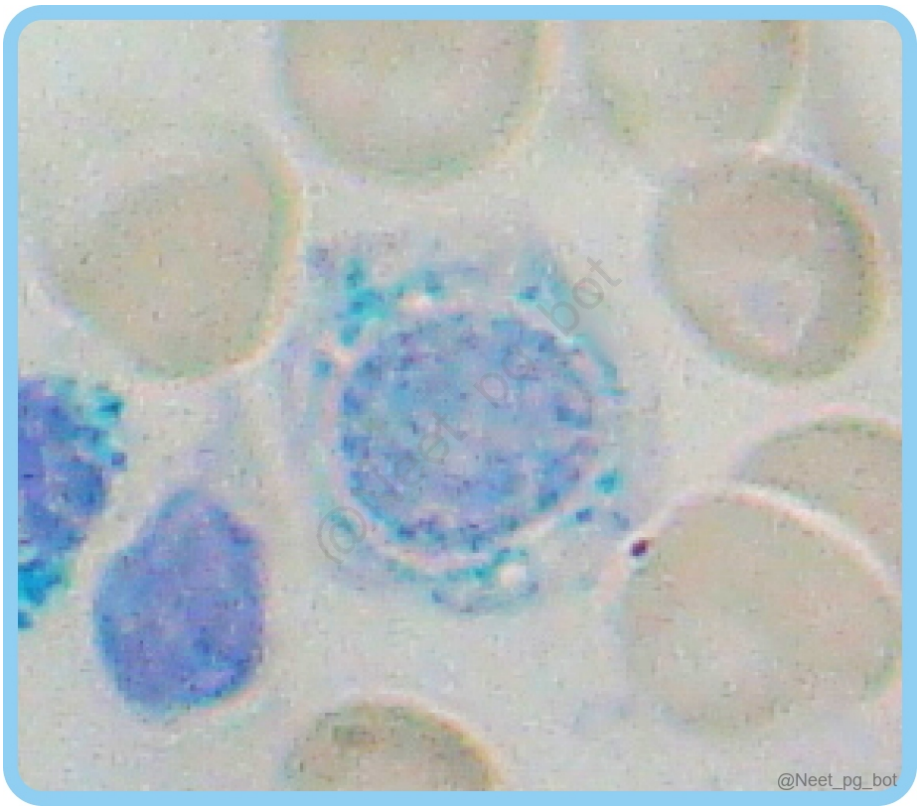

Correct Answer: C. Sideroblastic anemia

- *Listen (English)*
- *Listen (Hindi)*

Explanation: This patient’s history of treatment for latent tuberculosis with a bone marrow smear showing ringed sideroblasts suggests isoniazid induced sideroblastic anemia. Causes of sideroblastic anemia: Congenital causes Due to enzyme deficiencies like ALA synthase, ferrochelatase, etc. Acquired causes Vitamin B6 deficiency Drugs like isoniazid and chloramphenicol Lead and alcohol poisoning

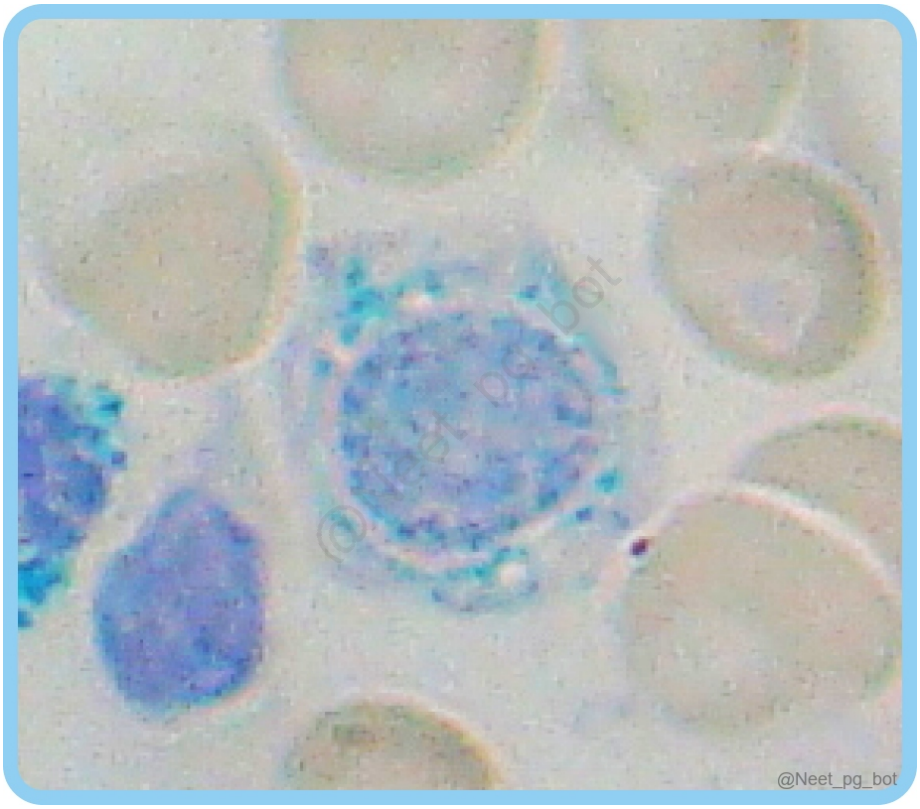

References:

Robbins & Cotran Pathologic Basis of Disease, 10th Edition, Page 620-621

↑ *Back to this question in Part A*

@Neet_pg_bot

Q13: Which of the following new parameters has high specificity for differentiating anemia of chronic disease (ACD) from iron deficiency anemia (IDA)? (Q845883)

A. Serum transferrin receptor (sTfR)/log - ferritin index >1.5

B. Serum transferrin receptor (sTfR)/log - ferritin index <1.5

C. Reduced reticulocyte index

D. Blood film morphology

Correct Answer: B. Serum transferrin receptor (sTfR)/log - ferritin index <1.5

■ *Listen (English)*

■ *Listen (Hindi)*

Explanation: The sTfR/log ferritin score was greater than 1.5 in all cases of IDA and ACD with concurrent IDA, while less than 1.5 in pure ACD patients. Parameter Finding Serum transferrin receptor (sTfR)-ferritin index sTfR reflects erythropoiesis, and ferritin describes iron stores. sTfR/log ferritin index > 1.5 in all cases of IDA and ACD with coexisting IDA. (Option A) sTfR/log ferritin index < 1.5 in pure ACD Reticulocyte index (Option C) Normal = 0.5-2.5% Reduced in IDA and AOCD Increased in hemolytic anemia. Blood film morphology (Option D) Predominantly: normocytic and normochromic anemia. Less commonly: microcytic and hypochromic anemia (also in IDA).

References:

https://eurjmedres.biomedcentral.com/articles/10.1186/s40001-022-00922-6

https://pubmed.ncbi.nlm.nih.gov/20091370/

↑ *Back to this question in Part A*

@Neet_pg_bot

Q14: A 52-year-old female complains of fatigue, joint pain, and stiffness, especially in the mornings. Physical examination reveals swollen and tender joints in her wrists with ulnar deviation at metacarpophalangeal joints. Which of the following lab findings is not associated with this condition? (Q845882)

A. Low serum iron

B. Low transferrin saturation

C. High ferritin

D. High total iron-binding capacity (TIBC)

Correct Answer: D. High total iron-binding capacity (TIBC)

■ *Listen (English)*

■ *Listen (Hindi)*

Explanation: The clinical presentation described in the scenario is suggestive of rheumatoid arthritis. Rheumatoid arthritis is associated with Anemia of chronic disease. Laboratory parameters in IDA and AOCD: Lab Parameters AOCD Iron Deficiency Anemia (IDA) Ferritin High (Option C) Low Transferrin saturation Low (Option B) Low Serum Iron Low (Option A) Low TIBC Low (characteristic) High

References:

Robbins & Cotran Pathologic Basis of Disease, 10th Edition, Page 655-659

↑ *Back to this question in Part A*

@Neet_pg_bot

Q15: Which of the following investigations is the least helpful in determining the underlying cause of anemia? (Q845864)

A. MCV

B. MCH

C. Peripheral smear

D. Reticulocyte count

Correct Answer: B. MCH

■ *Listen (English)*

■ *Listen (Hindi)*

Explanation: The least useful investigation in determining the underlying cause of anemia is MCH (Mean Corpuscular Hemoglobin). MCH measures the average amount of hemoglobin per red blood cell. MCH can be valuable when used together with MCV to refine the classification of anemia but it does not independently yield as much diagnostic information regarding the underlying causes of anemia as other tests MCV (Option A) categorizes anemia by measuring the red blood cell size: microcytic (<80 fL), normocytic (80-100 fL), and macrocytic (>100 fL), aiding in identifying underlying causes such as iron deficiency or vitamin B12 deficiency. Peripheral smear (Option C) is used to assess the morphology of red blood cells, white blood cells, and platelets, crucial in identifying abnormalities such as hypochromia , microcytosis , or macrocytosis ,. Reticulocyte count (Option D) measures the percentage of reticulocytes in the blood and can indicate the bone marrow's response to anemia. It helps differentiate between causes of anemia related to decreased production or increased destruction or loss of red blood cells.

References:

Robbins & Cotran Pathologic Basis of Disease, 10th Edition, Page 655

↑ *Back to this question in Part A*

@Neet_pg_bot

Q16: A 65-year-old female with a history of breast cancer presents with fatigue and pallor. Laboratory results indicate a hemoglobin level of 9.7 g/dL, low serum iron, elevated ferritin, and low total iron-binding capacity (TIBC). All of the following are true regarding this condition except? Anemia is caused by reduced erythroid progenitor proliferation and iron uptake. Causes include chronic infections,

autoimmune disorders and lymphoma. Peripheral smear does not show microcytic hypochromic anemia. All the patients benefit from erythropoietin administration. (Q845880)

A. 1, 3, 4

B. 3, 4

C. 4 only

D. 3 only

Correct Answer: B. 3, 4

Explanation: Anemia of chronic disease Caused by reduced erythroid progenitors and impaired iron utilization (statement 1) . Common cause of anemia due to chronic diseases (statement 2) , including Microbial infections: Osteomyelitis, bacterial endocarditis, lung abscess Immune disorders: Rheumatoid arthritis, inflammatory bowel disease Neoplasms: Lung, breast, and Hodgkin lymphoma Blood smear: Normocytic and normochromic (mostly), or hypochromic and microcytic (like IDA) (statement 3) . Management: Treat the underlying condition; some benefit with erythropoietin administration (statement 4) .

References:

Robbins & Cotran Pathologic Basis of Disease, 10th Edition, Page 658-659

↑ *Back to this question in Part A*

@Neet_pg_bot

Q17: Which of the following statements correctly describes the principle of Prussian blue stain? (Q845879)

A. Ferrocyanide to ferricyanide

B. Ferrocyanide to ferric ferrocyanide

C. Ferroferric cyanide to ferrocyanide

D. Ferrocyanide to ferrocyanide

Correct Answer: B. Ferrocyanide to ferric ferrocyanide

■ *Listen (English)*

■ *Listen (Hindi)*

Explanation: The Prussian blue stain is a histological stain used primarily to detect ferric iron (Fe^{3}■) in tissues, cells, and blood smears. It works based on the reaction of potassium ferrocyanide with ferric ions to form an insoluble blue compound called Prussian blue (Ferric ferro cyanide) which stains blue and is insoluble in water.

References:

Robbins & Cotran Pathologic Basis of Disease, 10th Edition, Page 655

↑ *Back to this question in Part A*

@Neet_pg_bot

Q18: A 24-year-old female with severe anemia started on parenteral iron. Which of the following would occur first in this patient as a response to therapy? (Q845878)

A. Increase in serum iron level

B. Erythroid hyperplasia in bone marrow

C. Increase in MCV

D. Increase in reticulocyte count

Correct Answer: A. Increase in serum iron level

Explanation: One of the earliest responses to the correction of iron deficiency anemia is increase in serum iron level Responses after initiation of treatment: 12 to 24 hours Replenishment of intracellular iron enzymes, decreased irritability; increased appetite, increase in serum iron. (Option A) 36 to 48 hours Erythroid hyperplasia in bone marrow (Option B ruled out) 48 to 72 hours Reticulocytosis, peaking at 5-7 days (Option D ruled out) 4 to 30 days Increase in hemoglobin level, increase in ferritin, increase in MCV (Option C ruled out) 1 to 3 months Repletion of stores

References:

Nelson’s Textbook of Pediatrics, 21st Edition, Page 2325

Harrison Principles of Internal Medicine, 20th Edition, Page 687

↑ *Back to this question in Part A*

@Neet_pg_bot

Q19: A 28-year-old female presented with easy fatigability and dyspnea on exertion. She was found to have a hemoglobin of 6 g/dL. What will be most likely finding in the peripheral blood smear of this patient? (Q845877)

A. Macrocytic red cells

B. Cabot ring

C. Hypersegmented neutrophils

D. Microcytic and hypochromic red cells

Correct Answer: D. Microcytic and hypochromic red cells

■ *Listen (English)*

■ *Listen (Hindi)*

Explanation: Microcytosis (smaller than normal red cells) and hypochromia are classic findings in iron deficiency anemia, which is consistent with the patient's symptoms and low hemoglobin. In iron deficiency anemia (IDA), a peripheral blood smear can reveal characteristic changes. Hypochromic Red Blood Cells: The RBCs appear pale due to decreased hemoglobin content. Microcytic Red Blood Cells: RBCs are smaller than normal due to decreased hemoglobin synthesis. Anisocytosis: There is significant variation in the size of RBCs. Poikilocytosis: RBCs may show abnormal shapes, such as pencil cells, target cells (codocytes), and occasionally, elliptocytes. Macrocytic red cells (Option A): Macrocytosis typically indicates a deficiency in vitamin B12 or folate, not iron. Cabot rings (Option B): Appear as thin, thread-like structures that form a loop or figure-eight shape within RBCs. It is composed of remnants of the nuclear material remnants from erythroblasts or megakaryocytes. Associated with megaloblastic anemia. Hypersegmented neutrophils (Option C): These have more than 5 lobes in their nucleus. This condition is often associated with vitamin B12 deficiency or folate deficiency.

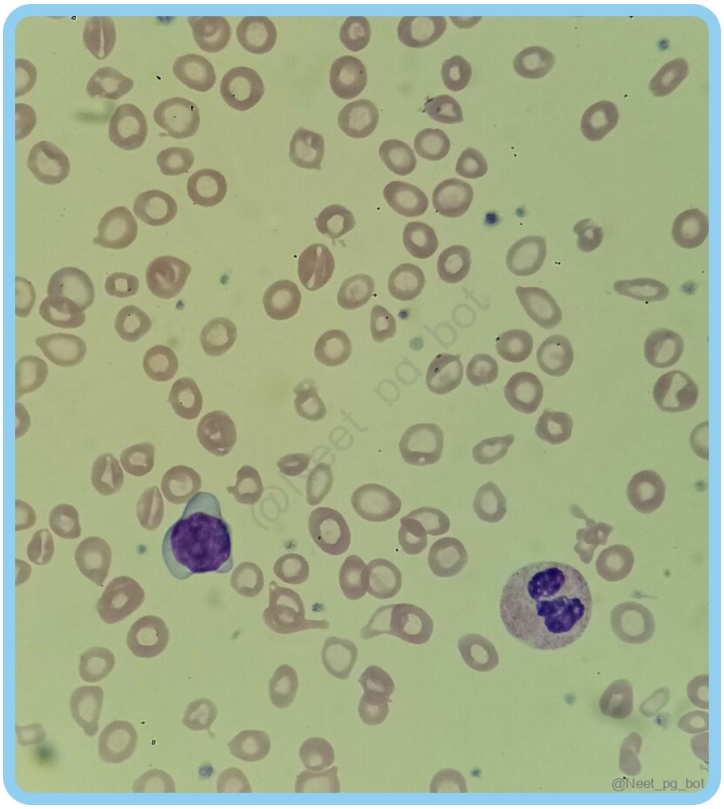

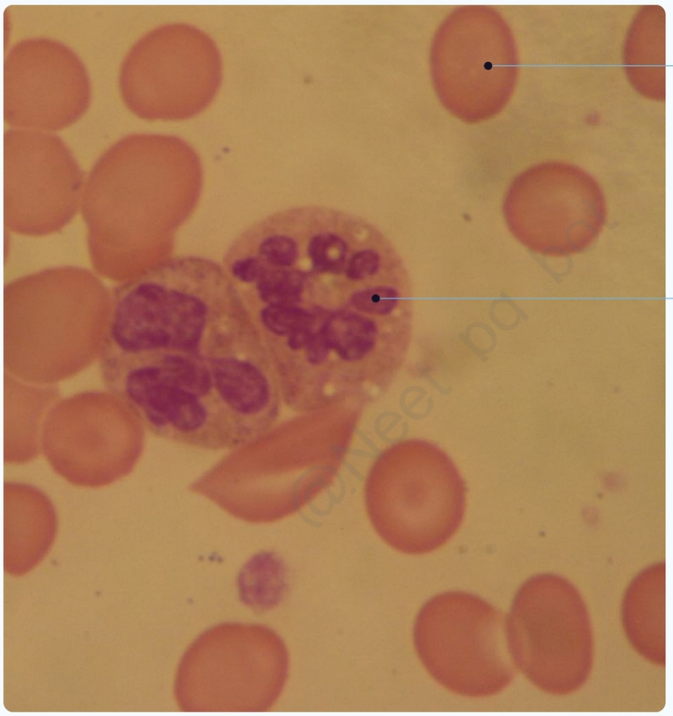
Oval shaped
macrocytes
Hypersegmented
neutrophil
@Neet_pg_bot

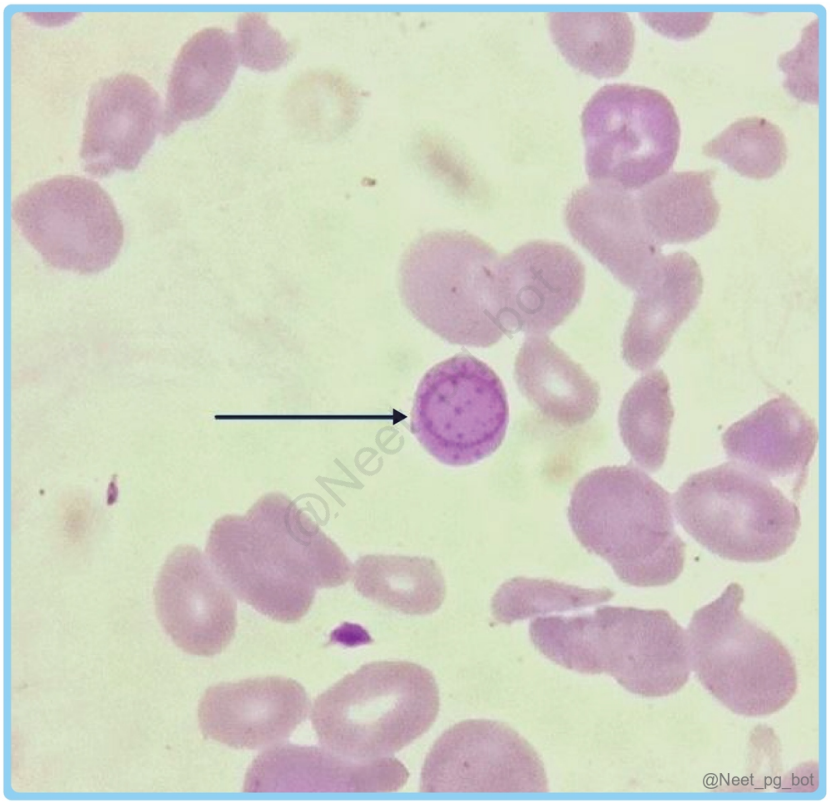
@Neet_pg_bot

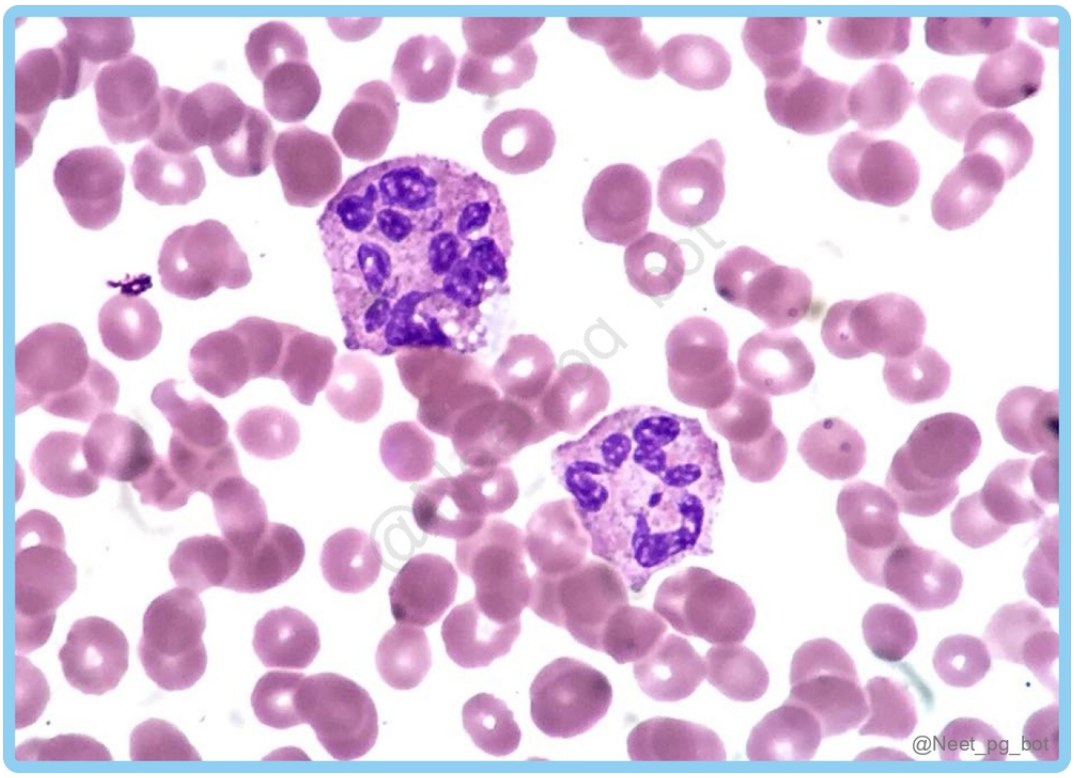

References:

Robbins & Cotran Pathologic Basis of Disease, 10th Edition, Page 658

↑ *Back to this question in Part A*

@Neet_pg_bot

Q20: A 32-year-old female diagnosed with iron deficiency anemia is prescribed oral iron supplements. Foods containing which of the following can she take to increase iron absorption? (Q845876)

A. Ascorbate

B. Oxalate

C. Carbonate

D. Phosphate

Correct Answer: A. Ascorbate

■ *Listen (English)*

■ *Listen (Hindi)*

Explanation: Ascorbate (Vitamin C) enhances the absorption of non-heme iron (the type of iron found in plant-based foods and supplements) by reducing ferric iron (Fe^{3}■) to the more soluble ferrous form (Fe^{2}■), which is more readily absorbed in the duodenum. Factors affecting iron absorption: Enhancers Inhibitors Ascorbic acid Tannins Citric acid Carbonate Amino acid Oxalate Sugars in the diet Phosphate

References:

Robbins & Cotran Pathologic Basis of Disease, 10th Edition, Page 657

https://www.ncbi.nlm.nih.gov/pmc/articles/PMC9219084/

↑ *Back to this question in Part A*

@Neet_pg_bot

Q21: In a patient diagnosed with iron deficiency anemia, the values of all of the following increase except? (Q845875)

A. Total iron binding capacity

B. RBC protoporphyrin

C. Transferrin saturation

D. Transferrin receptor

Correct Answer: C. Transferrin saturation

■ *Listen (English)*

■ *Listen (Hindi)*

Explanation: Transferrin saturation decreases in iron deficiency anemia. It is the serum iron to TIBC ratio and reflects the percentage of transferrin saturated with iron. In iron deficiency, less iron is available for binding to transferrin, leading to a decreased saturation. Total iron binding capacity (TIBC) (Option A) is increased in iron deficiency anemia. It represents the maximum amount of iron that can be bound to transferrin. RBC protoporphyrin (Option B) is a precursor to heme, and in the absence of sufficient iron, protoporphyrin accumulates. Transferrin receptor (TfR) (Option D) expression on cells increases to enhance cellular uptake of iron when iron stores are low.



References:

Robbins & Cotran Pathologic Basis of Disease, 10th Edition, Page 656

↑ *Back to this question in Part A*

@Neet_pg_bot

Q22: A 10-year-old girl presented with fatigue, weakness and reduced exercise tolerance. Her mother reports that she has pica, frequently eating chalk and ice and the child also complains of brittle nails and occasional glossitis. Her laboratory results show reduced hemoglobin, MCV 75 fl, MCH 22 pg and RDW 28. What is the most likely diagnosis? (Q845874)

A. Iron deficiency anemia

B. Megaloblastic anemia

C. Sideroblastic anemia

D. Thalassemia major

Correct Answer: A. Iron deficiency anemia

■ *Listen (English)*

■ *Listen (Hindi)*

Explanation: The given clinical presentation and investigation points towards the diagnosis of Iron deficiency anemia. Iron deficiency anemia typically presents with microcytic (low MCV) and hypochromic (low MCH) red blood cells. The elevated RDW suggests a wide variation in red blood cell sizes, which is characteristic of iron deficiency anemia. Iron deficiency anemia can result from dietary lack, impaired absorption, increased iron requirement (e.g., during pregnancy), or chronic blood loss (e.g., gastrointestinal bleeding). Clinical features include Koilonychia, alopecia, atrophic glossitis, and esophageal webs, pica and intestinal malabsorption, affecting overall nutritional status Megaloblastic anemia (Option B) usually presents with macrocytic anemia due to deficiencies in vitamin B12 or folate. Sideroblastic anemia (Option C) can also present with microcytosis, but it is usually associated with ringed sideroblasts in the bone marrow and RDW is usually normal or mildly elevated, not as high as 28. Thalassemia major (Option D) usually presents in infancy or early childhood with severe anemia, failure to thrive, and a need for regular blood transfusions. This patient's high RDW (28) suggests iron deficiency anemia, as thalassemia typically shows a normal RDW due to uniformly small red cells. There's no mention of classic features of thalassemia major, such as hepatosplenomegaly or bone deformities. Lastly, the MCV of 75 fL is low but not as profoundly low as usually seen in thalassemia major.

References:

Robbins & Cotran Pathologic Basis of Disease, 10th Edition, Page 655

↑ *Back to this question in Part A*

@Neet_pg_bot

Q23: A 45-year-old male patient was diagnosed with iron deficiency anemia. Which of the following is true about the intracellular regulation of iron in the above condition? IRP- Iron regulatory protein IRE- Iron response elements (Q845873)

A. Ferritin translation is increased by binding IRP to IRE.

B. Ferritin translation is decreased by binding IRP to IRE.

C. Transferrin receptor 1 translation is unaffected by binding IRP to IRE.

D. Transferrin receptor 1 translation is decreased by binding IRP to IRE.

Correct Answer: B. Ferritin translation is decreased by binding IRP to IRE.

Explanation: In iron deficiency anemia, ferritin translation is decreased by binding iron regulatory protein to iron response elements. Iron regulatory mechanism: IRP: Binds to IREs in specific mRNAs' untranslated regions (UTRs) to control the translation of proteins involved in iron metabolism. IRE: These are sequences found in the mRNAs of proteins involved in iron metabolism, such as ferritin and transferrin receptor 1 Ferritin: Ferritin stores iron inside cells. When iron levels are low, IRPs bind to IREs in the 5' UTR of ferritin mRNA, preventing its

translation to conserve iron. Transferrin receptor 1 (TfR1): TfR1 imports iron into cells. When iron levels are low, IRPs bind to IREs in the 3' UTR of TfR1 mRNA , stabilizing it and increasing its translation to enhance iron uptake.

References:

https://www.ncbi.nlm.nih.gov/pmc/articles/PMC2932529/

↑ *Back to this question in Part A*

@Neet_pg_bot

Q24: Which transport molecule facilitates the absorption of Fe2+ into enterocytes in the small intestine? (Q845872)

A. Ferroportin

B. Hephaestin

C. DMT-1

D. Hepcidin

Correct Answer: C. DMT-1

■ *Listen (English)*

■ *Listen (Hindi)*

Explanation: DMT-1 is a transmembrane protein that facilitates the transport of divalent metal ions, primarily ferrous iron (Fe 2+), across the apical membrane of enterocytes in the duodenum. Heme iron enters the intestinal cells directly through a heme transporter. Non-heme iron (Fe^{3}■) is first reduced to Fe^{2}■ by duodenal cytochrome B, then Fe^{2}■ enters the cells via the DMT-1 transporter (Option C) . Inside the duodenal cell, Fe^{2}■ can either be stored as mucosal iron or transported into the bloodstream. Fe^{2}■ exits the cell through ferroportin (Option A) . In the blood, Fe^{2}■ is oxidized to Fe^{3}■ by hephaestin (Option B) and ceruloplasmin. Fe^{3}■ binds to transferrin for delivery to the bone marrow, where it is stored as ferritin; in cases of hemolysis, ferritin aggregates to form hemosiderin. The liver secretes hepcidin (Option D) , a protein that regulates iron absorption. When iron stores are adequate, hepcidin downregulates ferroportin expression, reducing iron absorption.

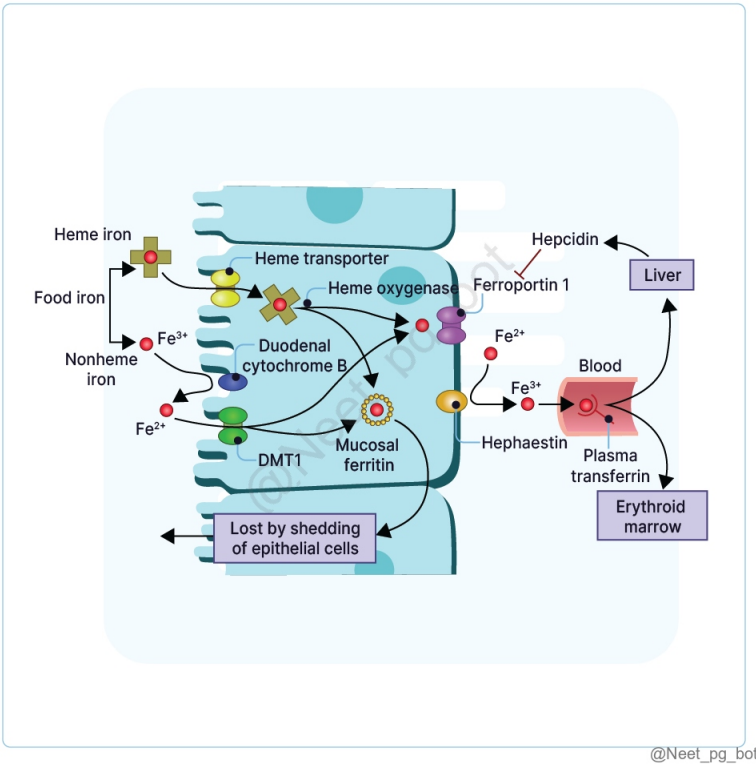

@Neet_pg_bot

References:

Robbins & Cotran Pathologic Basis of Disease, 10th Edition, Page 656

↑ *Back to this question in Part A*

@Neet_pg_bot

Q25: A 28-year-old woman presents with fatigue and pallor. Lab tests show hemoglobin of 9 g/dL and MCV of 68 fL. Peripheral smear reveals microcytic and hypochromic red blood cells. Her symptoms and laboratory findings are consistent with iron deficiency anemia. Which of the following statements regarding iron deficiency anemia (IDA) is correct? (Q845871)

A. Serum ferritin levels are elevated.

B. Serum ferritin is the gold standard investigation

C. Decreased serum ferritin levels

D. Serum ferritin levels are not affected.

Correct Answer: C. Decreased serum ferritin levels

■ *Listen (English)*

■ *Listen (Hindi)*

Explanation: Serum ferritin is a key marker used in diagnosing iron deficiency anemia. In iron deficiency, ferritin levels are decreased because ferritin stores decrease as iron stores deplete. (Option A and D) Serum ferritin levels below 30 ng/mL are generally considered indicative of depleted iron stores and are a reliable marker for iron deficiency. Serum ferritin is the gold standard investigation (Option B): While serum ferritin is commonly used as a marker for iron stores, it is not considered the gold standard test for diagnosing iron deficiency. A bone marrow aspirate to directly assess iron stores is the gold standard for diagnosing iron deficiency.

References:

Robbins & Cotran Pathologic Basis of Disease, 10th Edition, Page 655

↑ *Back to this question in Part A*

@Neet_pg_bot

Q26: A 35-year-old woman has been experiencing fatigue, pallor, and shortness of breath for the past six months. Laboratory tests reveal a Hb of 6 gm/dl. Red cell distribution width is increased. Peripheral smear is shown below. Where is the likely site of absorption of the micronutrient deficient in this patient? (Q845870)

A. Jejunum

B. Ileum

C. Duodenum

D. Colon

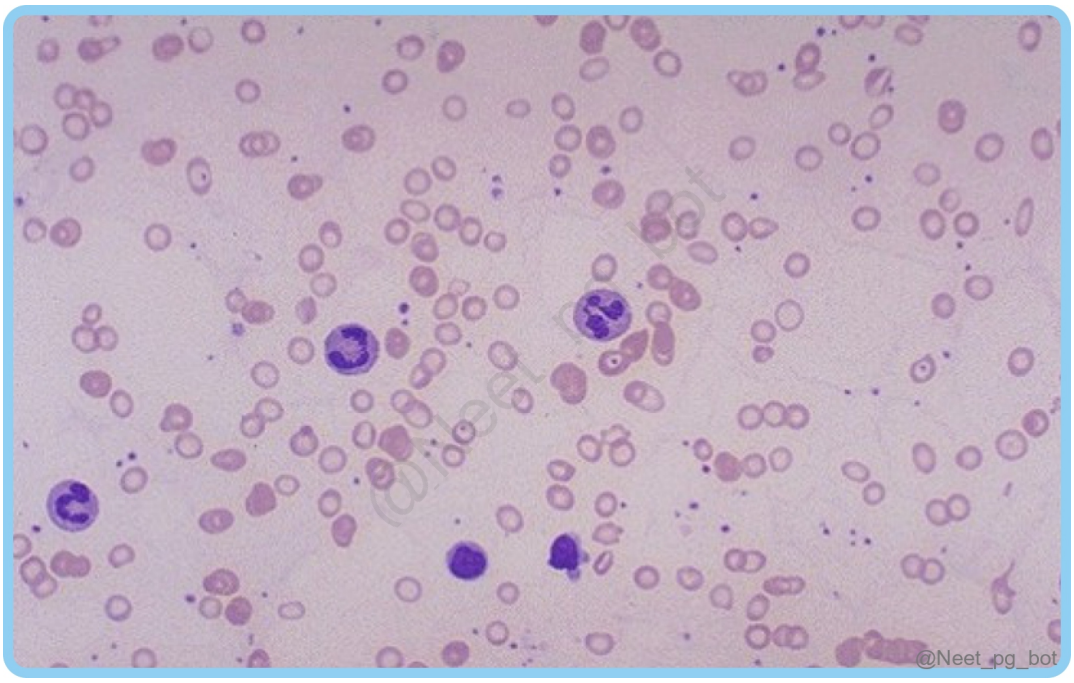

Correct Answer: C. Duodenum

- *Listen (English)*
- *Listen (Hindi)*

Explanation: The given clinical presentation of low hemoglobin, increased RDW, and microcytic hypochromic red cells on peripheral smear, points towards the diagnosis of Iron deficiency anemia . Iron is primarily absorbed through the duodenal mucosa , making duodenum the most likely site of absorption. Metabolism of iron: Iron from the diet (heme and non-heme) is converted to ferrous form in the stomach. Heme iron is primarily found in animal-based foods, while non heme iron is found in plant-based foods and iron-fortified foods. In the duodenum, ferrous iron is absorbed via DMT1 and transported into enterocytes. Inside, it binds to ferritin or enters the bloodstream via ferroportin. Iron binds to transferrin in the blood, facilitating its delivery to tissues for functions like hemoglobin synthesis. Hepcidin, a peptide hormone produced by the liver, plays a crucial role in regulating iron homeostasis. Jejunum (Option A) absorbs nutrients like amino acids, glucose, fatty acids, and folic acid. Ileum (Option B) completes nutrient absorption, including bile salts, vitamin B12 , and remaining nutrients, before the material enters the colon. Colon (Option D) focuses on absorbing water, electrolytes like sodium and chloride, and some vitamins from gut bacteria, such as vitamin K and biotin.

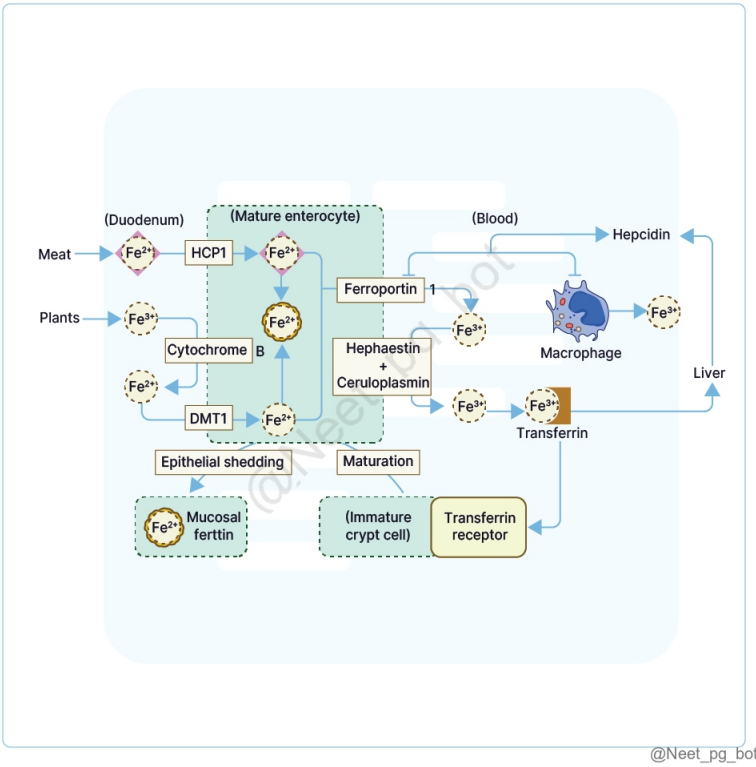

@Neet_pg_bot

References:

Robbins & Cotran Pathologic Basis of Disease, 10th Edition, Page 655

↑ *Back to this question in Part A*

@Neet_pg_bot

Q27: All of the following are causes of microcytic hypochromic anemia except? (Q845869)

A. Iron deficiency anemia

B. Sideroblastic anemia

C. Thalassemia

D. Hereditary spherocytosis

Correct Answer: D. Hereditary spherocytosis

■ *Listen (English)*

■ *Listen (Hindi)*

Explanation: Microcytic Anaemia Normocytic Anaemia Macrocytic Anaemia S ideroblastic anemia. I ron deficiency anemia. T halassemia. A nemia of chronic disease. L ead poisoning. (Mnemonic- SITAL) Acute Blood Loss Hemolytic Anaemia (hereditary spherocytosis) Anemia of Chronic Disease Bone Marrow Disorders (e.g., Aplastic Anaemia) Renal Disease Endocrine Disorders (e.g., Hypothyroidism) Early stages of Iron Deficiency Anemia Vitamin B12 Deficiency Folate Deficiency Alcohol Abuse Liver Disease Hypothyroidism Myelodysplastic Syndrome

References:

https://pubmed.ncbi.nlm.nih.gov/1578956/#:~:text=Microcytic%20anemia%20is%20d

↑ *Back to this question in Part A*

@Neet_pg_bot

• [17_Hematology_ Red Blood Cells] 069 Macrocytic Hypochromic Normocytic Anemia

« Back to Folder Directory

[17_Hematology_ Red Blood Cells] 069 Macrocytic Hypochromic Normocytic Anemia — Quick Jump

Q1 (p. 2676)	*Q2 (p. 2677)*	*Q3 (p. 2677)*	*Q4 (p. 2678)*	*Q5 (p. 2679)*	*Q6 (p. 2679)*
Q7 (p. 2680)	*Q8 (p. 2681)*	*Q9 (p. 2682)*	*Q10 (p. 2683)*	*Q11 (p. 2685)*	*Q12 (p. 2686)*
Q13 (p. 2687)	*Q14 (p. 2688)*	*Q15 (p. 2689)*	*Q16 (p. 2690)*	*Q17 (p. 2693)*	*Q18 (p. 2695)*
Q19 (p. 2697)					

Q1: A 72-year-old male complains of increasing tiredness and generalised weakness. On examination, a firm 1-cm nodule is palpated in the prostate gland. Laboratory studies show anemia with a normocytic, normochromic blood picture. Peripheral smear demonstrates occasional myelocytes, tear-drop erythrocytes, and about 2 nucleated red cells per 100 leukocytes. Which diagnosis best explains these findings? (Q880071)

A. Myelodysplastic syndrome

B. Myelophthisic anemia

C. Primary myelofibrosis

D. Myeloproliferative neoplasm

Correct Answer: B. Myelophthisic anemia

Explanation: Myelophthisic anemia results from bone marrow replacement by metastatic cancer, granulomas, or fibrosis. In this case, the firm prostate nodule suggests prostate carcinoma with marrow infiltration, while tear-drop cells, nucleated RBCs, and immature myeloid cells on smear indicate a leukoerythroblastic picture, which is classical for this condition. Incorrect Options: Myelodysplastic syndrome (Option A): Causes cytopenias with dysplastic marrow cells; smear shows abnormal morphology, not tear-drop cells or leukoerythroblastic picture. Primary myelofibrosis (Option C) also shows tear-drop cells and a leukoerythroblastic picture, but the marrow fibrosis is due to a myeloproliferative neoplasm, not metastatic tumor, and there is no prostate nodule in this condition. Prior exposure to radiation (Option D): Includes CML, PV, ET, PMF; causes abnormal blood counts but not typically due to marrow replacement by metastasis.

References:

Robbins and Cotran, Pathologic Basis of Disease, 11th Edition, Page 601.

↑ *Back to this question in Part A*

@Neet_pg_bot

Q2: Myelophthisic anemia typically arises when normal bone marrow is replaced by abnormal tissue. Among the following, which is the leading cause? (Q880070)

A. Granulomatous disorders

B. Secondary deposits from malignant tumours

C. Myeloproliferative disorders

D. Prior exposure to radiation

Correct Answer: B. Secondary deposits from malignant tumours

Explanation: The most common cause of myelophthisic anemia is bone marrow infiltration by metastatic cancers (commonly breast, prostate, lung, kidney, thyroid), which replace normal hematopoietic tissue and lead to anemia or pancytopenia. Disrupted marrow function produces characteristic blood smear findings such as teardrop cells and immature precursors (leukoerythroblastosis). Incorrect Options: Granulomatous disorders (Option A) cause marrow infiltration by inflammatory granulomas but are less common than tumour metastases. Myeloproliferative disorders (Option C) can cause marrow fibrosis leading to anemia, but rarely cause the marrow replacement seen in myelophthisic anemia. Prior exposure to radiation (Option D): Radiation can damage bone marrow and cause aplasia, but does not typically cause the marrow replacement pattern seen in myelophthisic anemia.

References:

Robbins and Cotran, Pathologic Basis of Disease, 11th Edition, Page 601.

↑ *Back to this question in Part A*

@Neet_pg_bot

Q3: Which of the following conditions are known to cause pure red cell aplasia? 1. Parvovirus B19 infection 2. Thymoma 3. Chronic neutrophilic leukaemia 4. Diamond–Blackfan anemia 5. Rifampicin use (Q880069)

A. 1, 2

B. 2, 3, 5

C. 1, 4

D. 1, 2, 4

Correct Answer: D. 1, 2, 4

Explanation: Parvovirus B19 infection , Thymoma , and Diamond-Blackfan anaemia are known to cause pure red cell aplasia (PRCA). Parvovirus B19 infection: Parvovirus B19 is the most common viral cause, destroying erythroid precursors and leading to transient or chronic PRCA, particularly in immunocompromised patients or those with chronic hemolytic anemia. Thymoma: Tumors of the thymus are strongly associated with PRCA, possibly due to autoimmune mechanisms where abnormal T cells attack red cell precursors. Chronic neutrophilic leukemia: It is not a known cause of PRCA. Diamond–Blackfan anemia: This is a congenital (inherited) pure red cell aplasia affecting children, characterized by failure of erythroid progenitors from birth. Rifampicin use: Drug-induced PRCA is rare but recognized with certain medications; rifampicin is not commonly implicated.

References:

Robbins and Cotran, Pathologic Basis of Disease, 11th Edition, Page 601.

↑ *Back to this question in Part A*

@Neet_pg_bot

Q4: Aplastic anemia has the potential to evolve into certain hematologic malignancies or disorders over time. Which of the following are known possible transformations? 1. Acute myeloid leukaemia 2. Acute lymphoblastic leukaemia 3. Chronic myeloid leukaemia 4. Chronic lymphocytic leukaemia 5. Myelodysplastic syndrome (Q880036)

A. 2, 3, 4

B. 1, 2

C. 1, 5

D. 1, 3, 5

Correct Answer: C. 1, 5

Explanation: Aplastic anemia can evolve into acute myeloid leukemia (AML) or myelodysplastic syndrome (MDS) due to clonal evolution of hematopoietic stem cells or as a consequence of immunosuppressive therapy. Acute myeloid leukemia (AML): Aplastic anemia can evolve into AML, particularly after immunosuppressive therapy, as clonal evolution of hematopoietic stem cells leads to malignant transformation. Myelodysplastic syndrome (MDS): MDS is a clonal bone marrow disorder characterized by ineffective hematopoiesis and risk of progression to AML. It can develop in patients previously diagnosed with aplastic anemia, representing a clonal evolution. Acute lymphoblastic leukaemia (ALL) , chronic myeloid leukaemia (CML) , and chronic lymphocytic leukaemia (CLL) : These lymphoid or chronic myeloproliferative leukaemias are not typically reported secondary transformations of aplastic anemia.

References:

Robbins and Cotran, Pathologic Basis of Disease, 11th Edition, Pages 599-600.

↑ *Back to this question in Part A*

@Neet_pg_bot

Q5: Which of the following represents the most common known cause of aplastic anemia? (Q880030)

A. Drugs

B. Autoimmune disorders

C. Infections

D. Radiation exposure

Correct Answer: A. Drugs

Explanation: Some drugs, such as antibiotics (like chloramphenicol), anti-inflammatory drugs, and chemotherapy agents, can damage the bone marrow and lead to aplastic anemia. This is the most commonly identified cause when a specific cause is found, but overall, many cases are idiopathic (unknown cause). Incorrect Options: Autoimmune disorders (Option B): The autoimmune destruction of hematopoietic stem cells is a common underlying cause of aplastic anaemia, particularly in idiopathic cases, and often responds to immunosuppressive therapy. Infections (Option C): Viral infections such as hepatitis, EBV, HIV, and parvovirus B19 may cause aplastic anemia. Radiation exposure (Option D): High doses of ionising radiation can cause bone marrow aplasia, usually seen in cancer therapy or radiation accidents.

References:

Robbins and Cotran, Pathologic Basis of Disease, 11th Edition, Page 599.

↑ *Back to this question in Part A*

@Neet_pg_bot

Q6: A 55-year-old female with a history of rheumatoid arthritis on long-term therapy presents with dizziness on standing. Clinical examination reveals pallor and koilonychia. Considering the type of anemia associated with chronic inflammatory states, which of the following statements is correct? (Q880025)

A. Both serum iron and tissue iron are within normal limits

B. The anemia may present as normocytic and normochromic

C. Hepcidin production is suppressed

D. Total iron-binding capacity (TIBC) is increased

Correct Answer: B. The anemia may present as normocytic and normochromic

Explanation: Anemia of chronic disease (ACD) typically presents as a mild to moderate normocytic, normochromic anemia, especially early in the disease. It may become microcytic over time. Incorrect Options: Both serum iron and tissue iron are within normal limits (Option A): In anemia of chronic disease (ACD), serum iron is low due to hepcidin-induced iron sequestration, but total body iron stores (tissue iron) are normal or increased. Hepcidin production is suppressed (Option C): Hepcidin production is increased in ACD, causing decreased iron absorption and release from macrophages. Total iron-binding capacity (TIBC) is increased (Option D): TIBC decreases in ACD since transferrin (the main iron-binding protein) synthesis is suppressed by inflammatory cytokines.

References:

Robbins and Cotran, Pathologic Basis of Disease, 11th Edition, Page 599.

↑ *Back to this question in Part A*

@Neet_pg_bot

Q7: With respect to antibodies associated with pernicious anemia, which of the following descriptions is incorrect? (Q880019)

A. Type I antibody can be detected in both serum and gastric secretions

B. Type I antibody interferes with the attachment of vitamin B12 to intrinsic factor

C. Type II antibody blocks the interaction of the intrinsic factor–B12 complex with ileal receptors

D. Type III antibody targets haptocorrin

Correct Answer: D. Type III antibody targets haptocorrin

Explanation: Haptocorrin binds vitamin B12 in the stomach to protect it from acid degradation, but is not the target of autoimmune antibodies in pernicious anemia. Incorrect Options: Binding of cobalamin to haptocorrin in the stomach (Option A): Type I antibody (“blocking antibody”) can be detected in serum and gastric secretions and prevents the binding of vitamin B12 to intrinsic factor. Transport of cobalamin via transcobalamin II (Option B): Type I antibody inhibits vitamin B12 from binding to intrinsic factor, preventing intrinsic factor-vitamin B12 complex formation. Interaction of vitamin B12 with intrinsic factor (Option C): Type II antibody (“binding antibody”) binds to the intrinsic factor-vitamin B12 complex and blocks its uptake in the terminal ileum.

References:

Robbins and Cotran, Pathologic Basis of Disease, 11th Edition, Page 594.

↑ *Back to this question in Part A*

@Neet_pg_bot

Q8: A 28-year-old woman who underwent ileal resection for Crohn's disease presents with features of megaloblastic anemia. Which step in vitamin B12 absorption and transport is most likely impaired in her case? (Q880008)

A. Cubilin receptor–mediated uptake

B. Binding of cobalamin to haptocorrin

C. Transport of cobalamin via transcobalamin II

D. Interaction of vitamin B12 with intrinsic factor

Correct Answer: A. Cubilin receptor–mediated uptake

Explanation: Vitamin B12 absorption occurs mainly in the terminal ileum, where the intrinsic factor–vitamin B12 complex binds to the cubilin receptor on the ileal enterocyte surface for absorption. Extensive ileal resection, as in Crohn's disease surgery, impairs this step, leading to B12 deficiency and megaloblastic anemia. Incorrect Options: Binding of cobalamin to haptocorrin in the stomach (Option B): Binding of vitamin B12 to haptocorrin occurs in the stomach; this step is unaffected by ileal resection. Transport of cobalamin via transcobalamin II (Option C): Transcobalamin II transports vitamin B12 in the plasma after absorption; this process is not impaired by ileal resection. Interaction of vitamin B12 with intrinsic factor (Option D): Vitamin B12 binds intrinsic factor in the duodenum; this early step remains intact in ileal resection.

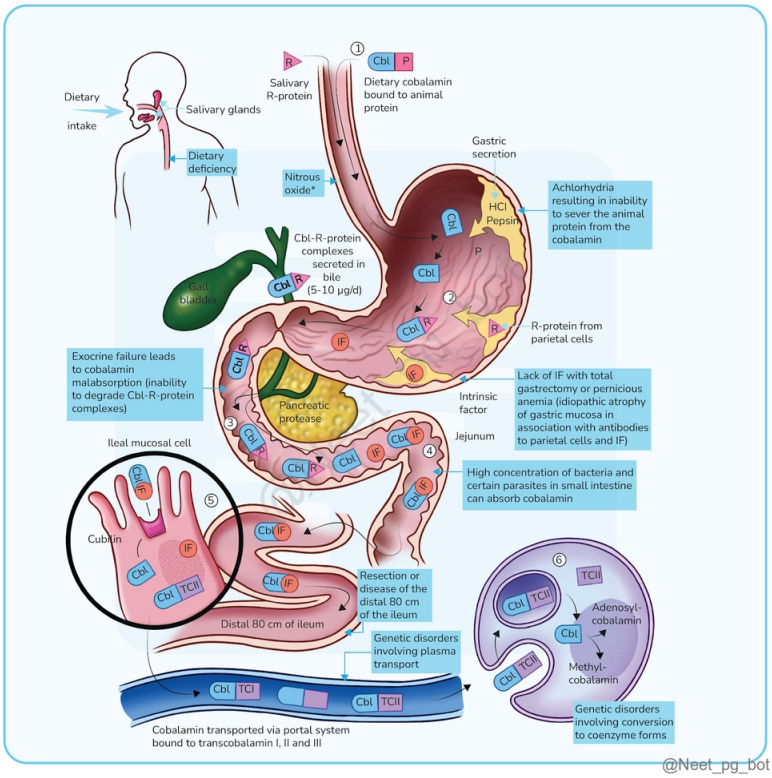

@Neet_pg_bot

References:

Robbins and Cotran, Pathologic Basis of Disease, 11th Edition, Page 593.

↑ *Back to this question in Part A*

@Neet_pg_bot

Q9: A patient presents with inflammation of the mouth and tongue. He is a non-vegetarian. As part of the evaluation, a Schilling test was done and found unremarkable. Which of the following investigations could lead to the aetiology behind this presentation? (Q845910)

A. Serum folate levels

B. Peripheral blood smear

C. Anti-IF antibody levels

D. Serum Vitamin B12 levels

Correct Answer: A. Serum folate levels

■ *Listen (English)*

■ *Listen (Hindi)*

Explanation: It is a scenario of possible megaloblastic anaemia due to folate deficiency. Hence, serum/red cell folate can lead to the aetiology behind this presentation. Schilling test is done by orally administering the patient with radioactive vitamin B12 and checking its presence in the urine. If present, as with this case, it is understood that there is no problem with the absorption. In addition to an unremarkable Schilling test, the fact that vitamin B12 deficiency is uncommon among non-vegetarians suggests a diagnosis of folate-deficient megaloblastic anaemia. Stage of test 24-hour urinary excretion of radiolabelled B12 Inference Stage 1: Oral radiolabelled B12 + IM dose of unlabelled B12 (to saturate liver stores) >10% (Normal) Malnutrition <10% Stage 2 of the test is done Stage 2: Oral radiolabelled B12 + Intrinsic factor >10% Pernicious anaemia <10% Stage 3 of the test is done Stage 3: Oral radiolabelled B12 + Antibiotics (5-day course) >10% Small intestinal bacterial overgrowth <10% Stage 4 of the test is done Stage 4: Oral radiolabelled B12 + Recombinant pancreatic enzymes >10% Pancreatic insufficiency (Cystic fibrosis, chronic pancreatitis) <10% Consider other ileal diseases Peripheral blood smear (Option B) may exhibit megalocytes with hyper-segmented neutrophils suggestive of megaloblastic anaemia, but the aetiology cannot be identified based on this. Anti-IF (intrinsic factor) antibodies (Option C) are found in patients with pernicious anaemia, and since the Schilling test is unremarkable, it can be ruled out.

References:

Robbins and Cotran, Pathological Basis of Disease, 10th Edition, Page 654, 655

Harrison’s Principles of Internal Medicine, 21st Edition, Page 771

↑ *Back to this question in Part A*

@Neet_pg_bot

Q10: A group of scientists is studying the mechanisms involved in the pathogenesis of megaloblastic Anaemia secondary to vitamin deficiencies. The final study results demonstrate a "folate trap" as one of the likely pathophysiologic mechanisms of megaloblastic Anaemia. Which of the following is closely associated with the "folate trap"? (Q875986)

A. Normal serum tetrahydrofolate

B. Reduced serum methyltetrahydrofolate

C. Normal serum B12

D. Reduced serum vitamin B12

Correct Answer: D. Reduced serum vitamin B12

Explanation: Option D: Reduced Serum Vitamin B12 Megaloblastic Anaemia is caused by a deficiency of vitamin B12 or folic acid. Vitamin B12 or methylcobalamin is required for the conversion of homocysteine to methionine

by methionine synthase. In this reaction, methylcobalamin recovers a methyl group from N 5 -methyltetrahydrofolate (N 5 -methyl FH 4), which is the principal form of folic acid in plasma. N 5 - methyl FH 4 is converted to tetrahydrofolic acid (FH 4) during this process. Tetrahydrofolic acid is crucial for DNA synthesis because its derivative N 5,10 -methylene FH 4 is required to convert deoxyuridine monophosphate (dUMP) to deoxythymidine monophosphate (dTMP). The " methyl tetrahydrofolate trap " hypothesis has been proposed to explain the cause of impaired DNA synthesis in vitamin deficiencies. Folic acid deficiency can occur due to vitamin B12 deficiency due to an impairment of methionine synthase resulting in the trapping of folate as methyltetrahydrofolate whereby methyl THFA accumulates in serum leading to folate trap phenomenon and increased urinary excretion of folate. Conversion of methyl FH4 [tetrahydrofolate] to FH4 requires Vita min B12. Hence in Vitamin B12 deficiency, this conversion is impaired & most of the folate remains trapped as methyl FH4 ("folate trap"). Methylene FH4 required for the synthesis of dTMP is thus not generated (functional folate deficiency), ultimately leading to defective synthesis of DNA. Option A: Normal Serum Tetrahydrofolate In "the folate trap," most of the folic acid is trapped in the form of methyltetrahydrofolat e, as its conversion to tetrahydrofolate requires vitamin B12 during the conversion of homocysteine to methionine. The serum levels of tetrahydrofolate would therefore be reduced in vitamin B12 deficiency. Option B: Reduced Serum Methyltetrahydrofolate Vitamin B12 is required to convert methyltetrahydrofolate to tetrahydrofolate during the reaction involving the conversion of homocysteine to methionine. Serum methyltetrahydrofolate levels would be increased in vitamin B12 deficiency because of the trapping of the folic acid as methyltetrahydrofolate. Option C: Normal Serum Vitamin B12 Megaloblastic Anaemia is characterised by a "folate trap" secondary to vitamin B12 deficiency. The serum levels of vitamin B12 would therefore be reduced than normal.

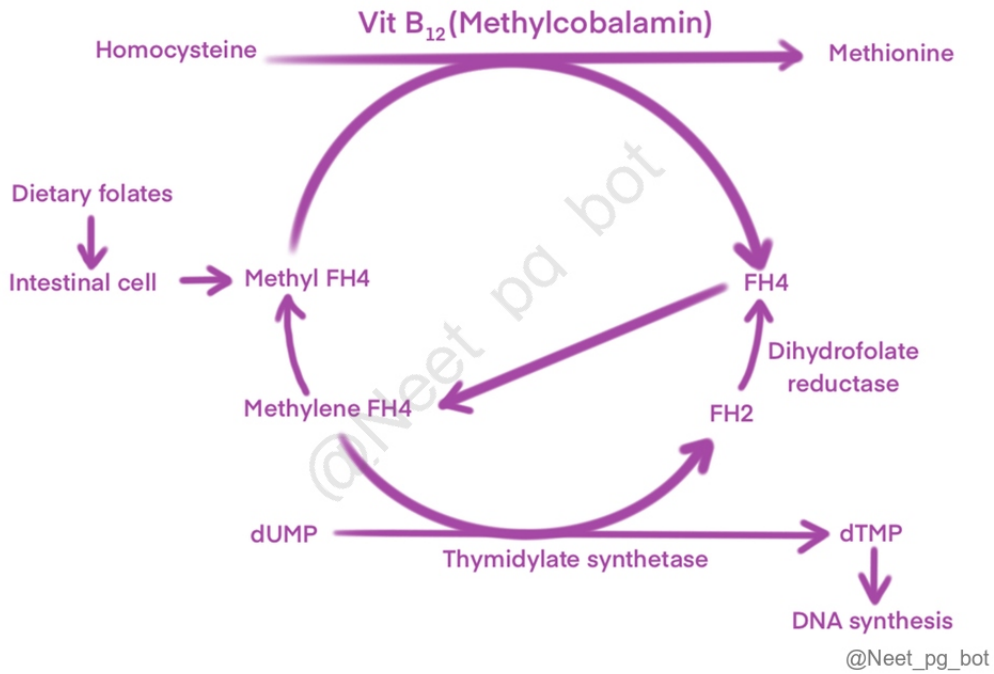

References:

Robbins & Cotran Pathologic Basis of Disease 10th edition, page 653

↑ *Back to this question in Part A*

@Neet_pg_bot

Q11: Which of the following statements is correct regarding the normal metabolism of vitamin B12? A. Haptocorrin from salivary glands binds to B12 in the stomach. B. It is absorbed in the duodenum with the help of intrinsic factor and transcobalamin II. C. Gastric enzymes play an important role in splitting of haptocorrin-B12 complex. D. It is stored primarily in the liver and has a large reserve capacity. E. It acts as a cofactor for converting homocysteine to methionine and methylmalonyl-CoA to succinyl-CoA. (Q845897)

A. A, B, C, and D

B. A, D, and E

C. A and C

D. C and D

Correct Answer: B. A, D, and E

■ *Listen (English)*

■ *Listen (Hindi)*

Explanation: Vitamin B12 Absorption and Transport: Vitamin B12 is absorbed in the terminal ileum (Option B). Haptocorrin , secreted by the salivary gland , binds to B12 in the stomach and enters the duodenum (Option A) . Haptocorrin is separated from B12 by pancreatic enzymes and binds to IF (Option C) . Absorbed B12 is transported by transcobalamin II (Option B) . Stored primarily in the liver and has a large reserve capacity to last several years (Option D) . Vitamin B12 is a cofactor for: (Option E) Conversion of homocysteine to methionine. Methyl malonyl-CoA to succinyl-CoA.

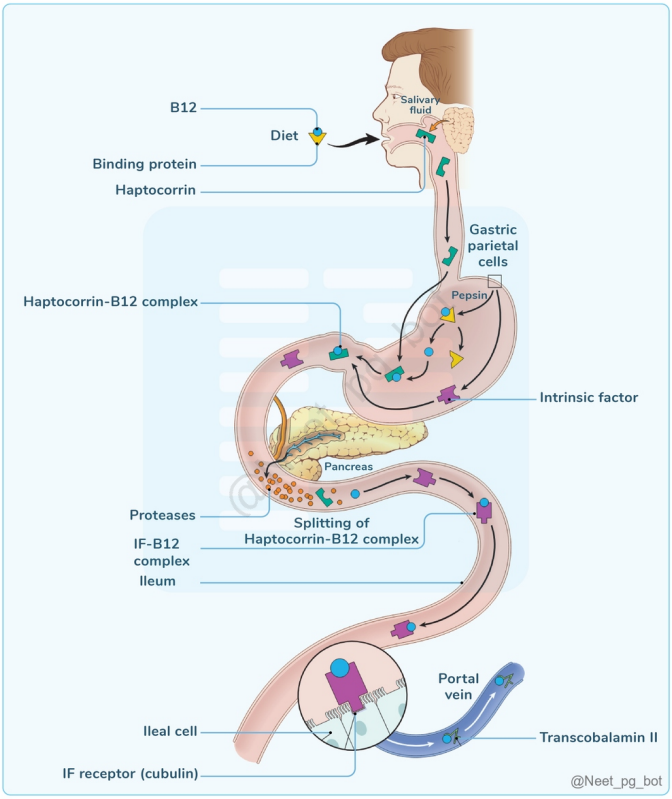

References:

Robbins and Cotran, Pathological Basis of Disease, 10th Edition, Page 651-653

↑ *Back to this question in Part A*

@Neet_pg_bot

Q12: Which of the following is true when increased urinary formiminoglutamic acid is detected in a patient to whom histidine is given? (Q845907)

A. Presence of antibodies against intrinsic factor

B. Deficiency of folic acid is present

C. Neurological symptoms are common

D. Presence of worm infestation

Correct Answer: B. Deficiency of folic acid is present

■ *Listen (English)*

■ *Listen (Hindi)*

Explanation: Elevated urinary levels of formiminoglutamic acid (FIGlu) in a patient to whom histidine is given suggests the presence of folic acid deficiency . This is called the FIGlu test. Folic acid is normally required in its tetrahydrofolate form to regulate DNA synthesis and the production of methionine, glutamate, etc. Formiminoglutamic acid derived from histidine will be converted to glutamate in the presence of folic acid. If there is a folic acid deficiency, this conversion will not occur, leading to elevated urinary formiminoglutamic acid. Presence of antibodies against intrinsic factor (Option A): Antibodies to intrinsic factor will be seen in pernicious anaemia in which there will be vitamin B12 deficiency. Neurological symptoms are common (Option C): Neurological symptoms will be seen in Vitamin B12 deficiency , not folate deficiency.

References:

Robbins and Cotran, Pathological Basis of Disease, 10th Edition, Page 653

Harper's Illustrated Biochemistry, 32nd Edition, Page 545

↑ *Back to this question in Part A*

@Neet_pg_bot

Q13: Which of the following helps differentiate megaloblastic anaemia caused by vitamin B12 deficiency, not folate? (Q845905)

A. Reduced plasma homocysteine levels

B. Neurological symptoms improve after folate administration

C. Raised urinary methylmalonic acid levels

D. Anaemia doesn't improve after folate administration

Correct Answer: C. Raised urinary methylmalonic acid levels

■ *Listen (English)*

■ *Listen (Hindi)*

Explanation: Plasma and urinary methylmalonic acid levels will be elevated in case of vitamin B12 deficiency but not with folate deficiency. This is because the enzyme methylmalonyl coenzyme A mutase's isomerisation of methylmalonyl coenzyme A to succinyl coenzyme A requires adenosylcobalamin (a form of vitamin B12) as a cofactor. A deficiency of vitamin B12 thus leads to increased plasma and urine levels of methylmalonic acid. Vitamin B12 is key in converting homocysteine to methionine; hence, its deficiency will lead to elevated homocysteine levels (Option A) rather than reduction. Neurological symptoms will remain the same, if not worsen, after folate administration in case of Vitamin B12 deficient megaloblastic anaemia (Option B) . Improvement in symptoms and reduction in megaloblastic count occur after folate administration, even if the anaemia is due to Vitamin B12 deficiency (Option D) .

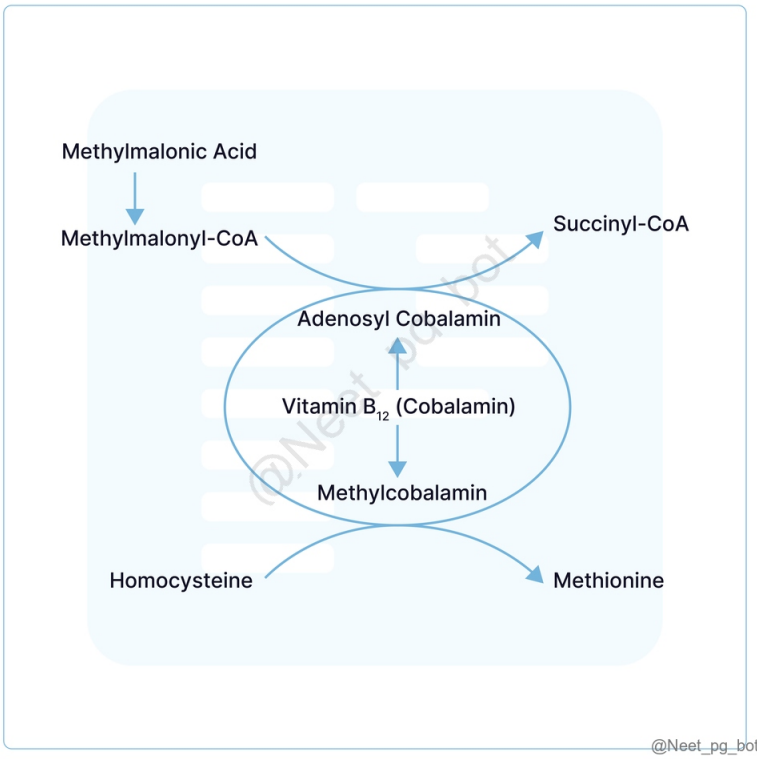

References:

Robbins and Cotran, Pathological Basis of Disease, 10th Edition, Page 653, 654

↑ *Back to this question in Part A*

@Neet_pg_bot

Q14: A patient presents with tiredness and myalgia for the past 3 months. She has hypertension, psoriasis and hyperuricemia, for which she is on multiple medications. A peripheral blood smear is done which is given in the image below. Which of her following medications would have caused these symptoms? (Q845903)

A. Hydrochlorothiazide

B. Adalimumab

C. Methotrexate

D. Colchicine

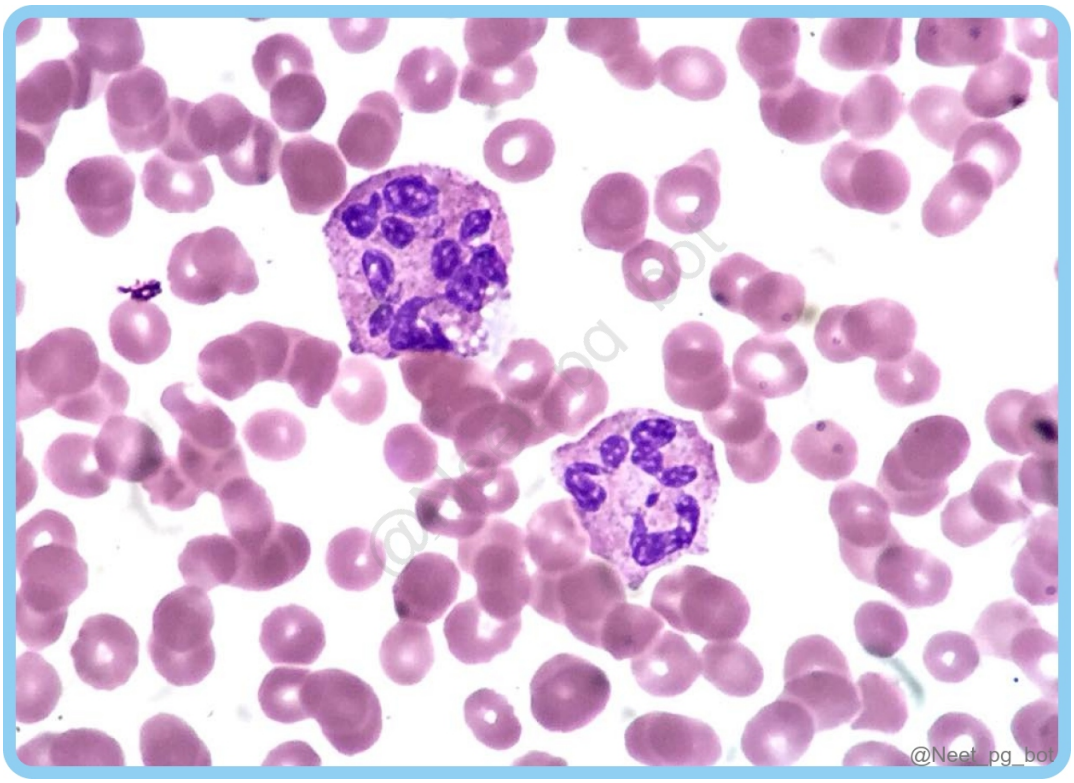

Correct Answer: C. Methotrexate

■ *Listen (English)*

■ *Listen (Hindi)*

Explanation: The peripheral blood smear shows enlarged oval-shaped red blood cells (macro-ovalocytes) with hyperchromia and hypersegmented neutrophils. This suggests megaloblastic anaemia , which in this scenario would be due to folate deficiency caused by methotrexate. Common causes of folate deficiency are given below : Decreased intake Inadequate diet. Alcoholism. Infancy. Impaired absorption Malabsorption states. Intrinsic intestinal disease. Anticonvulsants, oral contraceptives. Increased loss Haemodialysis. Increased requirement Pregnancy. Infancy. Disseminated cancer. Markedly increased hematopoiesis. Impaired utilisation Folic acid antagonists (Methotrexate).

References:

Robbins and Cotran Pathologic Basis of Disease, 10th Edition, Page 651

↑ *Back to this question in Part A*

@Neet_pg_bot

Q15: All the following findings are seen in vitamin B12 deficiency except? (Q845902)

A. Myeloid/erythroid ratio is 3:1

B. Sieve-like chromatin on bone marrow smear

C. Increased LDH levels

D. Increased bilirubin levels

Correct Answer: A. Myeloid/erythroid ratio is 3:1

■ *Listen (English)*

■ *Listen (Hindi)*

Explanation: The normal myeloid: erythroid ratio is 3:1. In vitamin B12 deficiency, a reversal of myeloid: erythroid ratio is seen (1:3). Important Laboratory findings associated with Vitamin B12 deficiency: Bone Marrow Biochemical Tests Hypercellular bone marrow Erythroid Hyperplasia Sieve-like chromatin (Option: B) . Hypersegmented neutrophils Reversal of myeloid: erythroid ratio 1:1 or less (Normal: 3:1) (Option A) Nuclear-cytoplasmic asynchrony Serum bilirubin: Increases (Option: D) . Serum LDH: Increases (Option: C) . Vitamin B12: Decreases Folic acid: Decreases Anti-Intrinsic Factor (IF) antibody: Present (Pernicious anemia) Methylmalonyl CoA: Increases Homocysteine: Increases Schilling Test: Assess cause of B12 deficiency.

References:

Robbins and Cotran, Pathological Basis of Disease, 10th Edition, Page 651-655

↑ *Back to this question in Part A*

@Neet_pg_bot

Q16: Which of the following is not a finding on a peripheral blood smear in vitamin B12 deficiency? (Q845901)

Correct Answer: Unknown

■ *Listen (English)*

■ *Listen (Hindi)*

Explanation: Acanthocytes/Spur cells: Spiculated red blood cells with multiple irregularly shaped and randomly distributed cytoplasmic projections. Associated conditions: Abetalipoproteinemia. Cirrhosis. Chronic hepatitis. Renal failure. Peripheral blood smear findings in megaloblastic anaemia: Blood Smear Findings Associated Disease Macrocytosis (Option A) Enlarged oddly shaped RBC MCV > 100fL Alcoholism Megaloblastic anaemia Pregnancy Aplastic anemia Hypothyroidism. Cabot ring (Option B) Arginine-rich mitotic spindle Figure of 8" shaped inclusions Basophilic stippling in the erythrocyte. Thalassaemia Megaloblastic anaemia Lead poisoning Howell-Jolly body (Option C) DNA or nuclear remnants in the erythrocyte. Megaloblastic anaemia Post-splenectomy Hemolytic anaemia


@Neet_pg_bot

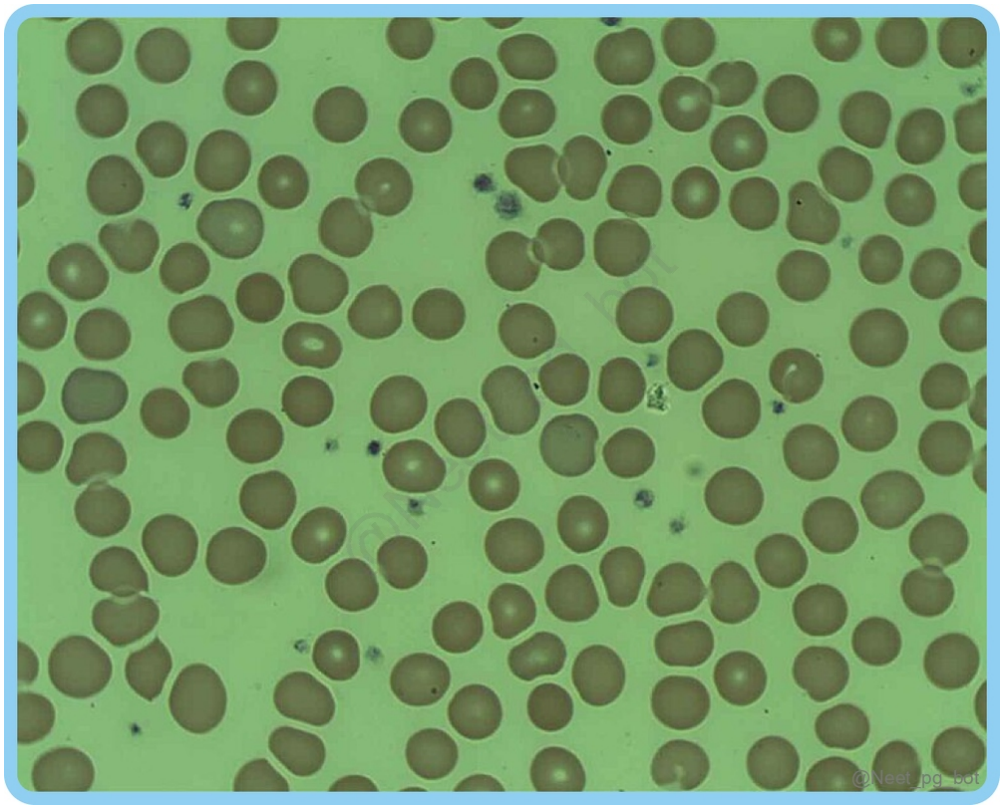
@Neet_pg_bot

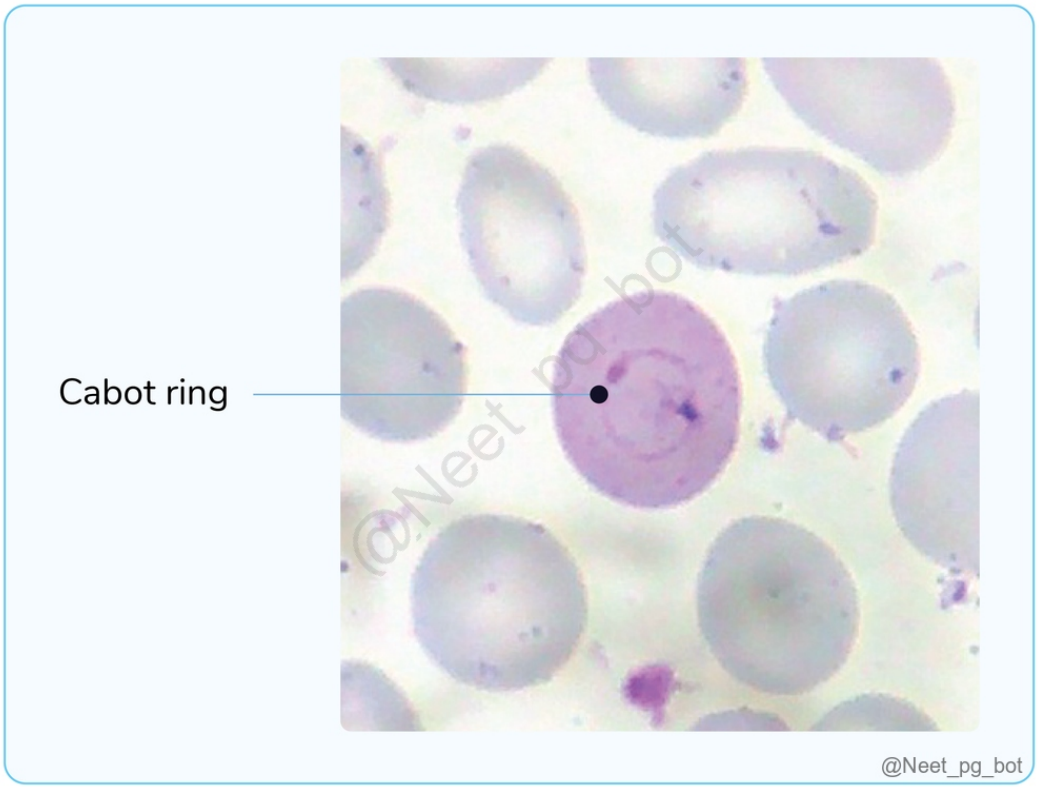



References:

Robbins and Cotran, Pathological Basis of Disease, 10th Edition, Page 651-655

↑ *Back to this question in Part A*

@Neet_pg_bot

Q17: Match the following laboratory findings with the most likely diagnosis. a. Microcytic anaemia, normal homocysteine and methylmalonic acid levels. 1. Vitamin B12 Deficiency b. Macrocytic anaemia, elevated homocysteine and methylmalonic acid levels. 2. Iron Deficiency Anemia (IDA) c. Macrocytic anaemia, elevated homocysteine and normal methylmalonic acid levels. 3. Anaemia of Chronic Disease (ACD) d. Normocytic anaemia, normal homocysteine and methylmalonic acid levels. 4. Folate Deficiency (Q845900)

A. a-2, b-1, c-4, d-3

B. a-1, b-2, c-4, d-3

C. a-2, b-1, c-3, d-4

D. a-3, b-4, c-1, d-2

Correct Answer: A. a-2, b-1, c-4, d-3

■ *Listen (English)*

■ *Listen (Hindi)*

Explanation: Disease Lab Findings Blood Smear Vitamin B12 Deficiency RBC Indices: Hemoglobin(Hb): low. MCV: high (> 100fL). MCH: high. MCHC: normal. Homocysteine: High Methylmalonic acid: High. Macrocytic hyperchromic anemia. Folate Deficiency RBC Indices: Hemoglobin(Hb): low. MCV: high (> 100fL). MCH: high. MCHC: normal. Homocysteine: High Methylmalonic acid: Normal. Iron deficiency anaemia & anaemia of chronic disease (AOCD): Microcytic hypochromic anaemia is seen (AOCD: Normocytic normochromic > microcytic hypochromic). Homocysteine & methylmalonic acid levels are normal.

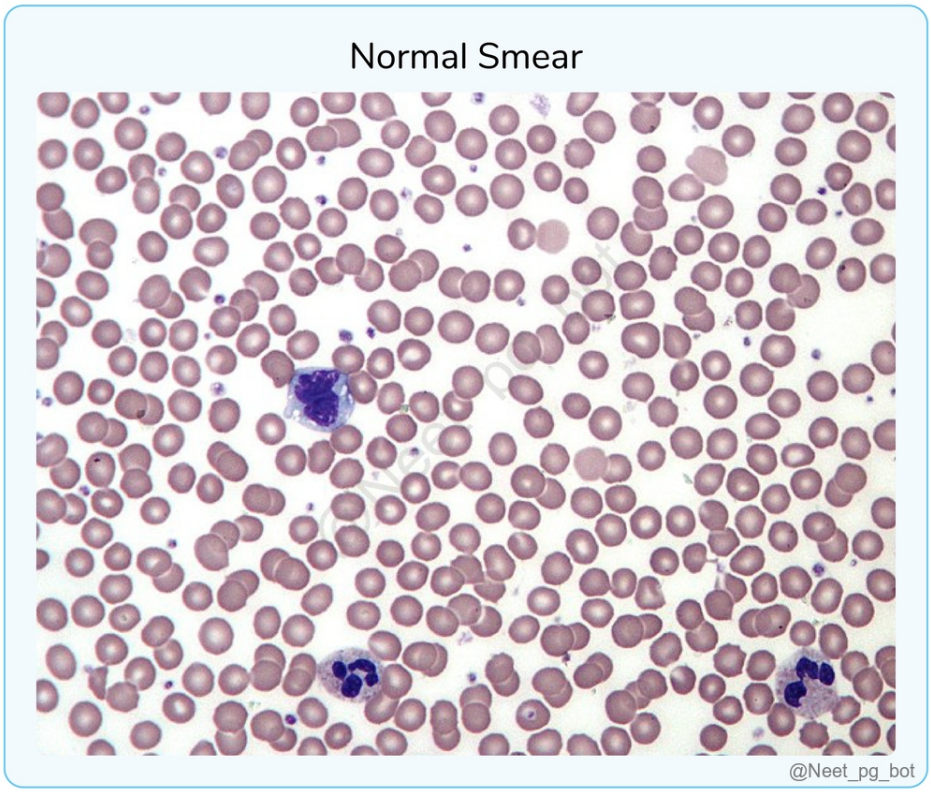

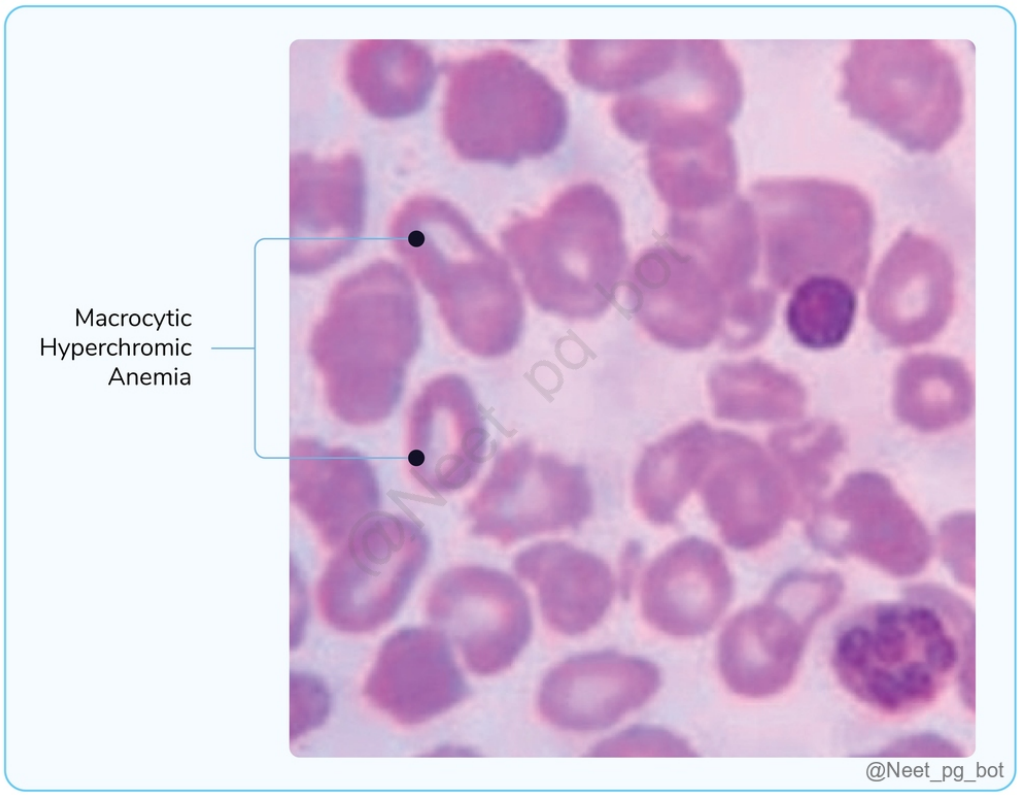

References:

Robbins and Cotran, Pathological Basis of Disease, 10th Edition, Page 655-659

↑ *Back to this question in Part A*

@Neet_pg_bot

Q18: A 60-year-old female presents with chronic fatigue, shortness of breath, tingling and numbness in her hands and feet, bloating, and epigastric pain after meals. She has a history of occasional heartburn and nausea. On examination, she is pale, has a smooth, enlarged tongue with the following findings on the hand. Lab investigations show haemoglobin to be 9.6 g% and MCV 112. What is the most likely diagnosis? (Q845899)

A. Iron deficiency anaemia

B. Folate deficiency

C. Pernicious anaemia

D. Thalassemia



Correct Answer: C. Pernicious anaemia

■ *Listen (English)*

■ *Listen (Hindi)*

Explanation: Pernicious anaemia is the likely diagnosis due to macrocytic anaemia (high MCV), chronic fatigue, neurological symptoms (tingling and numbness), and gastrointestinal issues (bloating and epigastric pain). The physical signs of pallor and a smooth, enlarged tongue, along with the image of knuckle hyperpigmentation further indicate vitamin B12 deficiency, characteristic of pernicious anaemia. Pernicious Anemia: Pernicious anaemia is a specific form of megaloblastic anaemia caused by autoimmune gastritis that impairs the production of the intrinsic factor required for vitamin B12 uptake from the gut. Three types of antibodies: Type 1: Inhibit B12 binding to intrinsic factor . Type 2: Inhibit B12-IF binding to iliac cubilin receptors. Type 3: Target parietal cells. Clinical features : Fatigue and pallor. Hyperpigmentation : Mainly on knuckles and interphalangeal areas. Atrophic glossitis (beefy red smooth tongue). Atrophic gastritis (due to antibodies against parietal cells). Increased gastric adenocarcinoma risk. Neurological manifestations: Subacute combined degeneration of the spinal tract. Both sensory and motor loss (combined degeneration) Headache, fatigue , impaired balance , paresthesia, muscle weakness and neuropathy . Blood smear: Iron deficiency anaemia typically presents with microcytic anaemia (Option A) . Folate deficiency can present with macrocytic anaemia but is less likely to cause neurological symptoms and knuckle hyperpigmentation (Option B) . Thalassemia presents with microcytic anaemia and is not associated with hyperpigmentation or neurological symptoms (Option C) .

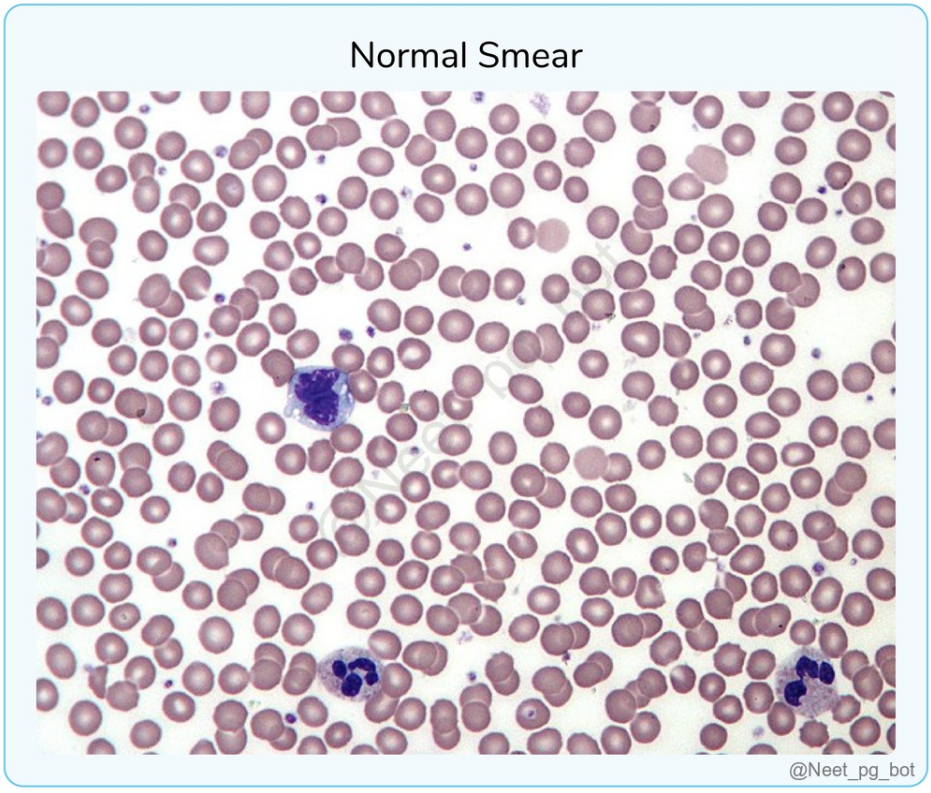

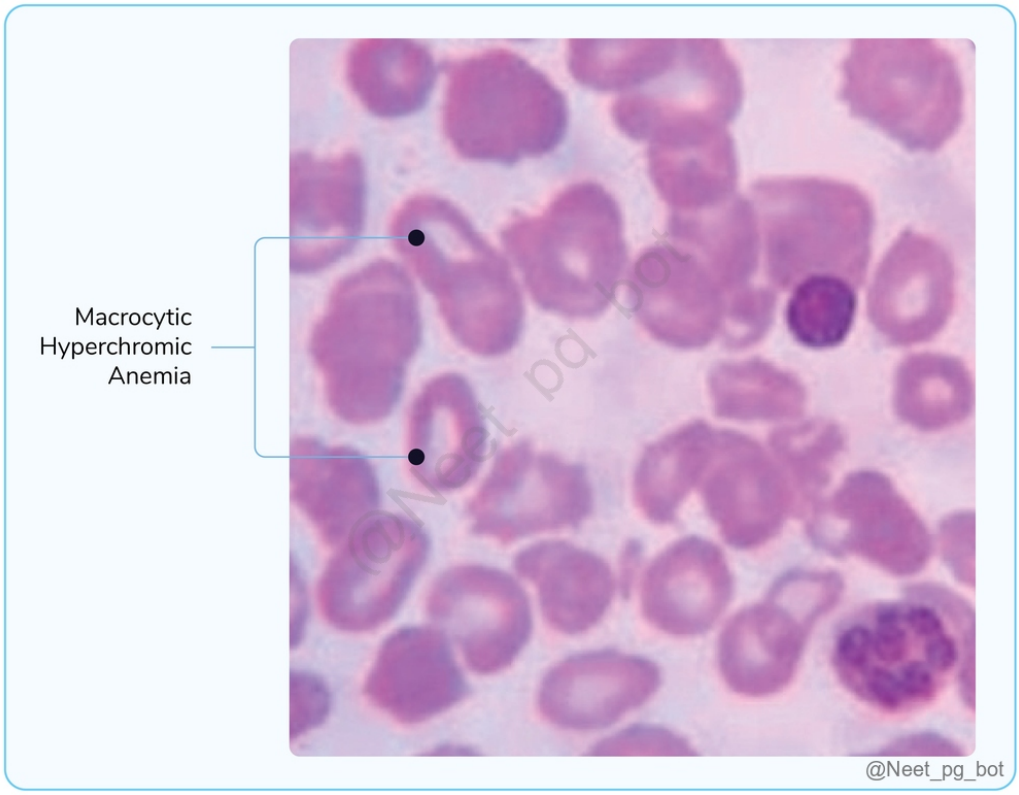

References:

Robbins and Cotran, Pathological Basis of Disease, 10th Edition, Page 652-654

↑ *Back to this question in Part A*

@Neet_pg_bot

Q19: All of the following are the causes of anaemia due to vitamin B12 deficiency, except? (Q845898)

A. Pernicious anemia

B. Chronic alcoholism

C. Diphyllobothrium latum infection

D. Gastric resection

Correct Answer: B. Chronic alcoholism

■ *Listen (English)*

■ *Listen (Hindi)*

Explanation: Chronic alcoholism causes megaloblastic anaemia due to folate deficiency. Causes of Vitamin B12 deficiency: Reduced Dietary Intake Increased demand Impaired Absorption Vegetarian diet Pregnancy Lactation Growing child Pernicious anemia (Option A) Infections- Diphyllobothrium latum (Option C) Gastrectomy (Option:D) Ileal disorders Malabsorption Ileal resection Diverticula of bowel

References:

Robbins and Cotran, Pathological Basis of Disease, 10th Edition, Page 651

↑ *Back to this question in Part A*

@Neet_pg_bot

• [17_Hematology_ Red Blood Cells] 070 Previous Year Questions

« Back to Folder Directory

[17_Hematology_ Red Blood Cells] 070 Previous Year Questions — Quick Jump

Q1 (p. 2699)	*Q2 (p. 2700)*	*Q3 (p. 2701)*	*Q4 (p. 2702)*	*Q5 (p. 2703)*	*Q6 (p. 2703)*
Q7 (p. 2704)	*Q8 (p. 2705)*	*Q9 (p. 2705)*	*Q10 (p. 2707)*	*Q11 (p. 2708)*	*Q12 (p. 2709)*
Q13 (p. 2710)	*Q14 (p. 2711)*	*Q15 (p. 2712)*	*Q16 (p. 2713)*	*Q17 (p. 2714)*	*Q18 (p. 2716)*
Q19 (p. 2717)	*Q20 (p. 2720)*	*Q21 (p. 2721)*	*Q22 (p. 2722)*	*Q23 (p. 2724)*	*Q24 (p. 2724)*
Q25 (p. 2726)	*Q26 (p. 2729)*	*Q27 (p. 2730)*	*Q28 (p. 2731)*	*Q29 (p. 2735)*	*Q30 (p. 2736)*
Q31 (p. 2738)	*Q32 (p. 2742)*	*Q33 (p. 2744)*	*Q34 (p. 2746)*	*Q35 (p. 2749)*	*Q36 (p. 2750)*
Q37 (p. 2753)	*Q38 (p. 2756)*	*Q39 (p. 2757)*	*Q40 (p. 2757)*	*Q41 (p. 2758)*	*Q42 (p. 2759)*
Q43 (p. 2760)	*Q44 (p. 2762)*	*Q45 (p. 2763)*	*Q46 (p. 2765)*	*Q47 (p. 2765)*	*Q48 (p. 2767)*
Q49 (p. 2770)	*Q50 (p. 2772)*	*Q51 (p. 2775)*	*Q52 (p. 2778)*	*Q53 (p. 2779)*	*Q54 (p. 2782)*
Q55 (p. 2783)	*Q56 (p. 2785)*	*Q57 (p. 2786)*	*Q58 (p. 2786)*	*Q59 (p. 2787)*	*Q60 (p. 2788)*
Q61 (p. 2790)	*Q62 (p. 2791)*	*Q63 (p. 2792)*	*Q64 (p. 2793)*	*Q65 (p. 2794)*	*Q66 (p. 2796)*
Q67 (p. 2797)	*Q68 (p. 2798)*	*Q69 (p. 2798)*	*Q70 (p. 2799)*	*Q71 (p. 2800)*	*Q72 (p. 2800)*
Q73 (p. 2802)	*Q74 (p. 2803)*	*Q75 (p. 2804)*	*Q76 (p. 2806)*	*Q77 (p. 2807)*	*Q78 (p. 2808)*
Q79 (p. 2810)	*Q80 (p. 2811)*	*Q81 (p. 2814)*	*Q82 (p. 2817)*	*Q83 (p. 2818)*	*Q84 (p. 2821)*
Q85 (p. 2822)	*Q86 (p. 2823)*	*Q87 (p. 2823)*	*Q88 (p. 2824)*	*Q89 (p. 2825)*	*Q90 (p. 2825)*
Q91 (p. 2826)	*Q92 (p. 2827)*	*Q93 (p. 2827)*	*Q94 (p. 2828)*	*Q95 (p. 2829)*	*Q96 (p. 2829)*
Q97 (p. 2830)					

Q1: Caspase-1 is primarily involved in which type of programmed cell death? (Q865391)

A. Apoptosis

B. Pyroptosis

C. Necroptosis

D. Necrosis

Correct Answer: B. Pyroptosis

Explanation: Caspase-1 plays a central role in Pyroptosis , a form of programmed cell death associated with inflammation. It is a form of apoptosis in which there is release of the fever-inducing cytokine IL-1. Microbial products entering infected cells are recognized by cytoplasmic receptors, activating the multiprotein complex

inflammasome. This complex activates caspase 1 which converts the inactive IL-1 to active IL-1, causing fever, inflammation and leucocyte recruitment. (Option B) Pyroptosis is the mechanism by which some microbes cause the death of infected cells and trigger local inflammation. Apoptosis (Option A) is a controlled, non-inflammatory cell death involving caspases-8, -9, -3, and -7, but not caspase-1, and serves to remove damaged cells without triggering an immune response. Necroptosis (Option C) is a programmed inflammatory cell death triggered when apoptosis is blocked, involving RIPK1, RIPK3, and MLKL—but not caspase-1, distinguishing it from pyroptosis. Necrosis (Option D) is an uncontrolled, non-programmed cell death due to injury (e.g., trauma or ischemia), causing inflammation without involving caspases, including caspase-1.

References:

Textbook of Robbin and Cotran's Pathological Basis of Diseases, 10th Edition, Page 46-48.

↑ *Back to this question in Part A*

@Neet_pg_bot

Q2: A 24-year-old male was brought to the emergency department after suffering severe injuries in a motorcycle accident. His blood pressure was 80/60 mm Hg, and he was tachycardic with cold, clammy skin. An ultrasound examination revealed a ruptured spleen. Arterial blood gas analysis was suggestive of metabolic acidosis. Which of the following conditions most likely caused the patient to suffer? (Q857122)

A. Cardiogenic shock

B. Septic shock

C. Hypovolemic shock

D. Neurogenic shock

Correct Answer: C. Hypovolemic shock

Explanation: Hypovolemic shock occurs due to significant blood or fluid loss, leading to reduced blood volume and inadequate tissue perfusion. This patient's low blood pressure, tachycardia, cold, clammy skin, and metabolic acidosis suggest shock caused by blood loss from the ruptured spleen. Shock is a state of circulatory failure that impairs tissue perfusion and leads to cellular hypoxia. Initially, cellular injury is reversible, but prolonged shock can cause irreversible tissue damage and may be fatal. It can result from various conditions, such as severe haemorrhage, extensive trauma, burns, myocardial infarction, pulmonary embolism, and microbial sepsis. The causes of shock can be categorised into three main types: Cardiogenic shock: (Option A) Caused by low cardiac output due to myocardial pump failure. This may result from intrinsic myocardial damage (e.g., infarction), ventricular arrhythmias, extrinsic compression (e.g., cardiac tamponade), or outflow obstruction (e.g., pulmonary embolism). Hypovolemic shock: Occurs due to low blood volume, often from massive haemorrhage or fluid loss (e.g., severe burns). This leads to reduced cardiac output and impaired tissue perfusion. Septic shock: (Option B) Sepsis : Life-threatening organ dysfunction due to a dysregulated host response to infection. Septic Shock : A

subset of sepsis with profound circulatory, cellular, and metabolic abnormalities that increase mortality risk. Systemic Inflammatory Response Syndrome (SIRS) : A sepsis-like condition triggered by non-microbial insults, such as burns, trauma, or pancreatitis. Both SIRS and septic shock are marked by a massive release of inflammatory mediators, causing arterial vasodilation, vascular leakage, and venous blood pooling, leading to tissue hypoperfusion, cellular hypoxia, and organ dysfunction. Neurogenic Shock (Option D) : Occurs following spinal cord injury, leading to acute vasodilation and hypotension. Anaphylactic Shock : Caused by an IgE-mediated hypersensitivity reaction, resulting in acute vasodilation, hypotension, and tissue hypoperfusion.

References:

Robbins & Cotran Pathologic Basis of Disease, 10th Edition, Page 134,135

↑ *Back to this question in Part A*

@Neet_pg_bot

Q3: Which of the following is true regarding sirtuins? Increases insulin sensitivity and glucose metabolism Promotes genes that increase longevity They are of 7 types They are one of the types of histone deacetylases (Q855087)

A. 1, 2, 3

B. 1, 2, 3, 4

C. 2, 3

D. 2, 4

Correct Answer: B. 1, 2, 3, 4

Explanation: Sirtuins are NAD-dependent protein deacetylases. (Statement 4) Seven types (Statement 3) of sirtuins exist in mammals, each with unique functions. They help the body adapt to environmental stresses like food deprivation and DNA damage . Longevity : Sirtuins promote genes that increase longevity (Statement 2) , reduce metabolism, inhibit apoptosis, and protect against oxidative damage. Sirtuins enhance insulin sensitivity and glucose metabolism (Statement 1) Caloric restriction : Increases sirtuin activity, reducing IGF-1 signalling, leading to slower cell growth, reduced metabolism, and cellular damage. Sirtuin-6 : Plays a key role in metabolic adaptations and DNA repair by activating repair enzymes. Anti-ageing : Sirtuins are linked to anti-ageing effects. Red wine : A compound in red wine is believed to activate sirtuins, potentially contributing to increased lifespan.

References:

Robbins & Cotran Pathologic Basis of Disease, 10th Edition, Page 68

↑ *Back to this question in Part A*

@Neet_pg_bot

Q4: Cell-in-cell appearance is seen in which of the following? (Q855076)

A. Necrosis

B. Apoptosis

C. Necroptosis

D. Entosis

Correct Answer: D. Entosis

Explanation: Entosis refers to the process where one cell is engulfed by another, leading to a "cell-in-cell" appearance. Entosis : It refers to a homotypic process where one epithelial cell invades the cytoplasm of another epithelial cell. The host cell forms a vacuole around the internalized cell, which deforms its organelles, including the nucleus. The inner cell may survive within the host cell for up to 12 hours or longer, eventually being digested by the outer cell through an autophagosomal mechanism, or it may escape. {{caption_text}} Necrosis (Option A) is an uncontrolled form of cell death characterized by cell swelling, rupture, and inflammation. Apoptosis (Option B) is a controlled, programmed cell death where cells shrink and fragment into apoptotic bodies. Necroptosis (Option C) is a form of regulated cell death that mimics necrosis but is genetically controlled. Unlike apoptosis, it is associated with inflammation and occurs via receptor-interacting protein kinases (RIPK1 and RIPK3), leading to membrane rupture and the release of intracellular contents.

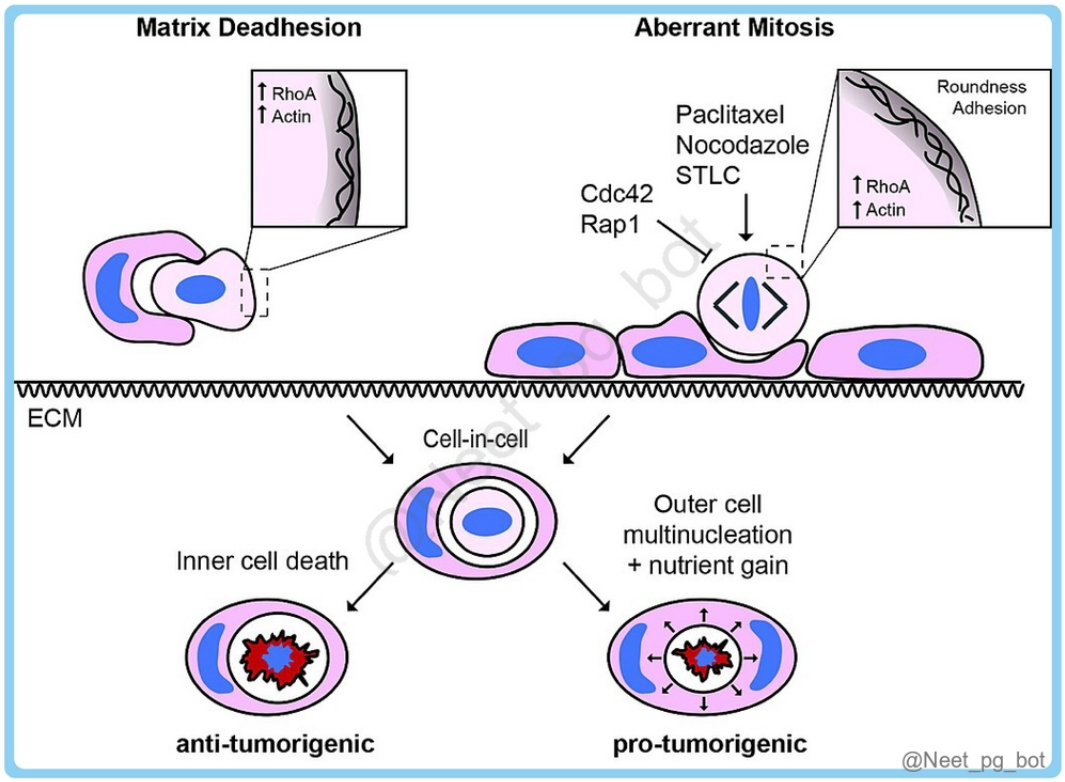

References:

https://pmc.ncbi.nlm.nih.gov/articles/PMC9102690/

↑ *Back to this question in Part A*

@Neet_pg_bot

Q5: Senile atrophy occurs due to which of the following? (Q856024)

A. Denervation

B. Decreased nutrition

C. Decreased workload

D. Reduced blood supply

Correct Answer: D. Reduced blood supply

Explanation: Chronic ischemia from progressive arterial occlusion leads to tissue atrophy. In older adults, reduced cerebral blood flow due to atherosclerosis causes senile atrophy of the brain. Loss of innervation (denervation atrophy) (Option A) : Skeletal muscle metabolism and function rely on nerve supply. Damage to the nerves results in atrophy of the muscle fibres they innervate. Inadequate nutrition (Option B) : Severe protein-calorie malnutrition, such as marasmus , causes the breakdown of skeletal muscle proteins for energy after fat stores are depleted, leading to muscle wasting (cachexia) . This is common in chronic inflammatory diseases and cancer. In cachectic states, excessive TNF production contributes to appetite suppression and lipid depletion, further exacerbating muscle atrophy. Decreased workload (disuse atrophy) (Option C) : Immobilization of bones, such as through a plaster cast or prolonged bed rest, leads to rapid muscle atrophy. Initially, the decrease in cell size is reversible upon resumption of activity. However, with prolonged disuse, muscle fibres shrink in size and number (due to apoptosis), and muscle atrophy may be accompanied by increased bone resorption, resulting in disuse osteoporosis.

References:

Robbins & Cotran Pathologic Basis of Disease, 10th Edition, Page 60

↑ *Back to this question in Part A*

@Neet_pg_bot

Q6: Which among the following is less related to irreversible cell injury? (Q820573)

A. Blebs formation

B. Karyolysis

C. Amorphous densities

D. Pyknotic nucleus

Correct Answer: A. Blebs formation

Explanation: Correct Option A - Blebs formation: Blebs formation is actually a characteristic feature of reversible cell injury, not irreversible injury. Blebs formation is less related to irreversibility when compared to other features given in the options. Blebs are small, bubble-like protrusions on the cell membrane that result from cytoskeletal and membrane alterations. They can be observed in conditions like ischemia and toxic injury. Reversibility implies that the cell can recover its normal structure and function when the damaging stimulus is removed. Incorrect Options: Option B - Karyolysis: Karyolysis refers to the dissolution of the cell nucleus due to DNA degradation. This is indeed a feature of irreversible cell injury. In irreversible injury, the cell's nuclear structure and DNA integrity are compromised beyond repair, leading to processes like karyolysis. Option C - Amorphous Densities: The presence of amorphous densities is often associated with irreversible cell injury. These densities can be observed under electron microscopy and represent aggregates of denatured or altered proteins, lipids, and other cellular components. They are a sign of severe damage and cell death. Option D - Pyknotic Nucleus: Pyknosis is the irreversible condensation of chromatin within the nucleus, resulting in a small, darkly stained and shrunken nucleus. This is indeed a feature of irreversible cell injury. Pyknotic nuclei indicate severe cellular damage that cannot be reversed, leading to cell death.

References:

.

↑ *Back to this question in Part A*

@Neet_pg_bot

Q7: Which of the following is an anti-apoptotic gene? (Q857450)

A. BAK

B. MCL1

C. PUMA

D. BAD

Correct Answer: B. MCL1

Explanation: MCL1 is an anti-apoptotic gene and part of the BCL-2 family. Apoptosis is a key process for maintaining cell balance and eliminating damaged cells, regulated by the interplay between pro-apoptotic and anti-apoptotic genes. MCL1 inhibits apoptosis by preventing the activation of pro-apoptotic proteins, thereby promoting cell survival. Apoptotic genes: Anti Apoptotic genes :- BCL-2 , BCL-XL , MCL-1 Pro Apoptotic genes:- BAX and BAK (Option A ruled out) Apoptosis initiators:- BAD, BIM, BID, Noxa and Puma (Option C & D ruled out)

References:

Robbins and Cotran Pathologic Basis of Disease, 10th edition, pages 44, 45

↑ *Back to this question in Part A*

@Neet_pg_bot

Q8: Which of the following diseases is caused by abnormal folding of proteins? (Q857433)

A. Creutzfelt Jakob disease

B. Cirrhosis

C. Nephritic syndrome

D. Sickle cell anemia

Correct Answer: A. Creutzfelt Jakob disease

Explanation: Creutzfeldt-Jakob disease (CJD) is a type of prion disease caused by the abnormal folding of proteins, specifically prion proteins (PrP), which leads to neurodegeneration. It is irreversible and fatal . The disease progresses quickly, and death usually occurs within a year. It is characterised by Rapidly progressive dementia Myoclonus Ataxia Visual disturbances Diagnosis: It is confirmed via MRI (increased signal in basal ganglia) and EEG findings Cirrhosis (Option B) is liver scarring typically caused by chronic liver diseases (e.g., hepatitis, alcoholism), not protein misfolding. Nephritic syndrome (Option C) is a kidney disorder involving inflammation, typically due to immune complex deposition, not protein misfolding. Sickle cell anaemia (Option D) is caused by a genetic mutation in the haemoglobin gene (HbS) that leads to abnormal haemoglobin, but not a misfolding of proteins in the same sense as prion diseases.

References:

Harper’s Illustrated Biochemistry, 32nd Edition, Page 42

Kaplan and Sadock’s Synopsis of Psychiatry, 12th Edition, Pages 763, 764, 765

↑ *Back to this question in Part A*

@Neet_pg_bot

Q9: Which nuclear change of cell injury is being shown in the image? (Q857432)

A. Pyknosis

B. Karyorrhexis

C. Karyolysis

D. Normal nucleus

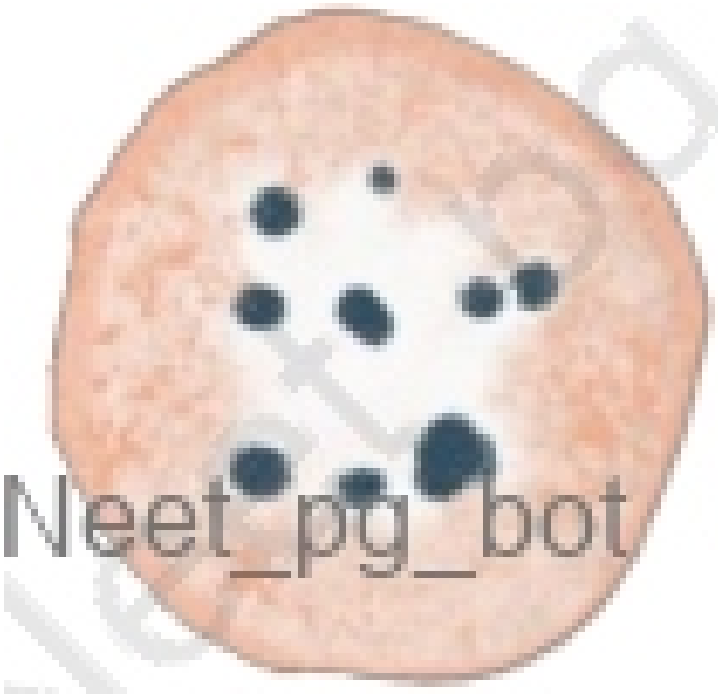

Correct Answer: B. Karyorrhexis

Explanation:

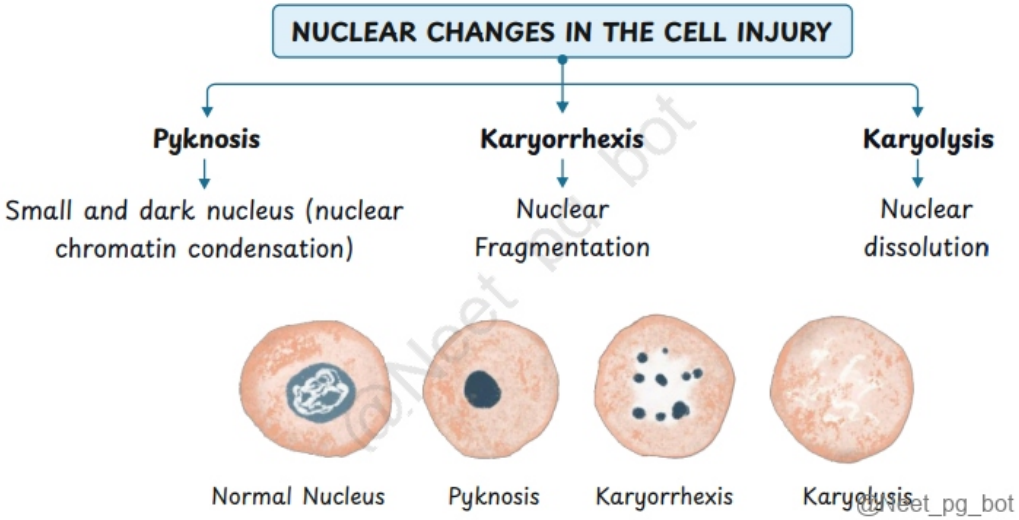

References:

Prepladder notes

↑ *Back to this question in Part A*

@Neet_pg_bot

Q10: Identify the correct statements regarding amyloidosis. Amyloidosis is called so because it looks like the deposition of starch. Beta-pleated sheets are seen. AL is a type of secondary amyloidosis. It is an extracellular protein. (Q857424)

A. 1, 2 and 3

B. 1, 4

C. 2, 3 and 4

D. 1, 2 and 4

Correct Answer: D. 1, 2 and 4

Explanation: Amyloidosis is a group of disorders characterized by the extracellular deposition of amyloid fibrils that are produced by the aggregation of misfolded proteins. (Statement 4) The presence of abundant charged sugar groups in these adsorbed proteins gives the deposits staining characteristics that were thought to resemble starch (amylose). Therefore, the deposits were called amyloid (Statement 1). 95% of amyloid consists of fibril proteins, with the remaining 5% being glycosaminoglycans (dermatan sulfate and heparan sulfate) and plasma proteins, notably serum amyloid P . AL amyloidosis is a primary form of amyloidosis, whereas secondary form can be caused by various etiologies and is associated with characteristic amyloid deposition (Statement 3). Physical nature of amyloid: Light microscopy with H & E stains: Amyloid is an amorphous , eosinophilic , hyaline , and extracellular substance. Electron microscopy: All types of amyloid, regardless of clinical setting or chemical composition, consist of continuous, nonbranching fibrils with a diameter of approximately 7.5 to 10 nm. X-ray crystallography and infrared spectroscopy: Characteristic cross-β-pleated sheet conformation, which is responsible for the distinctive Congo-red staining and apple-green birefringence of the amyloid. (Statement 2)

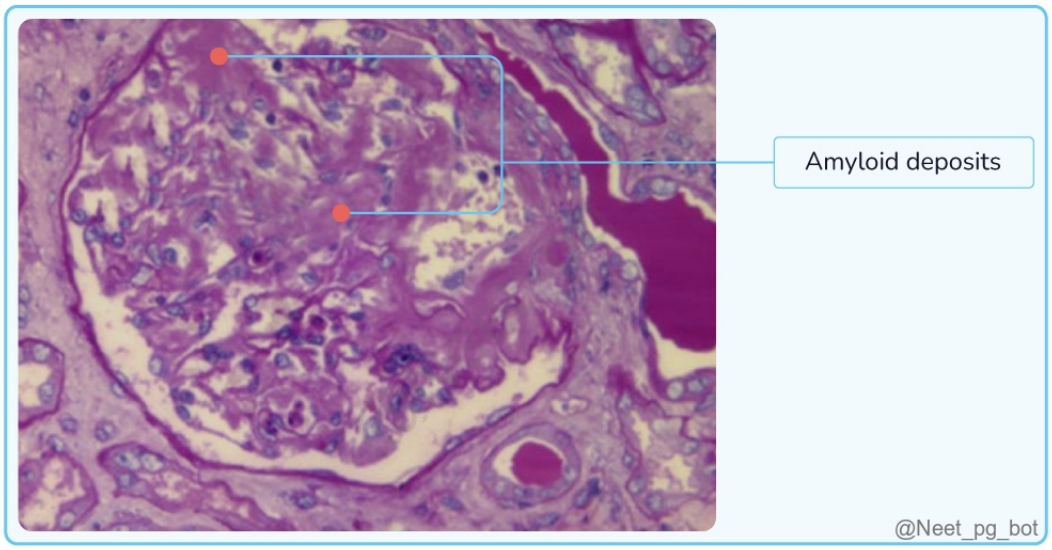

References:

Robbins and Cotran Pathologic Basis of Disease, 10th Edition.

↑ *Back to this question in Part A*

@Neet_pg_bot

Q11: Apoptotic bodies comprise of? (Q860513)

A. Include cytoplasm + intranuclear material + organelle

B. Cytoplasm + organelle

C. Organelle + intranuclear material

D. Only organelle

Correct Answer: A. Include cytoplasm + intranuclear material + organelle

Explanation: Apoptotic bodies are comprised of cytoplasm, intranuclear material and cellular organelles. Apoptosis (caspase-dependent programmed cell death): It is a type of cell death that is induced by a tightly regulated suicide program in which cells destined to die activate intrinsic enzymes that degrade the cells' genomic DNA and nuclear and cytoplasmic proteins. It is an active process. It eliminates cells that are injured beyond repair without eliciting a host reaction, thus limiting collateral tissue damage. Apoptosis results from the activation of enzymes called caspases, which leads to DNA fragmentation. The process of apoptosis may be divided into: Initiation phase: Caspases 8,9,10 become catalytically active and unleash a cascade of other caspase Execution phase: During which the terminal caspases 3,6,7 trigger cellular fragmentation. Morphological features:- Cell shrinkage Chromatin condensation Formation of cytoplasmic blebs and apoptotic bodies (cytoplasm and tightly packed organelles, with or without nuclear fragments) (Option A) Phagocytosis of apoptotic bodies, usually by

macrophages. Histopathology: The apoptotic cell appears as a round or oval mass of intensely eosinophilic cytoplasm with fragments of dense nuclear chromatin. {{caption_text}} The cell is reduced in size and contains brightly eosinophilic cytoplasm and a condensed nucleus. Types: Apoptosis occurs in two broad contexts: Physiological apoptosis. Pathological apoptosis. Physiological Apoptosis Pathological Apoptosis The removal of supernumerary cells (in excess of the required number) during development. Involution of hormone-dependent tissues on hormone withdrawal, such as endometrial cell breakdown during the menstrual cycle. Elimination of potentially harmful self-reactive lymphocytes to prevent immune reactions against one's own tissues. Death of host cells that have served their useful purpose, such as neutrophils in an acute inflammatory response and lymphocytes at the end of an immune response. DNA damage. Accumulation of misfolded proteins Apoptosis can be induced during certain infections- as in adenovirus and HIV infections and viral hepatitis. It may also contribute to pathologic atrophy in parenchymal organs after duct obstruction, such as occurs in the pancreas, parotid gland, and kidney.

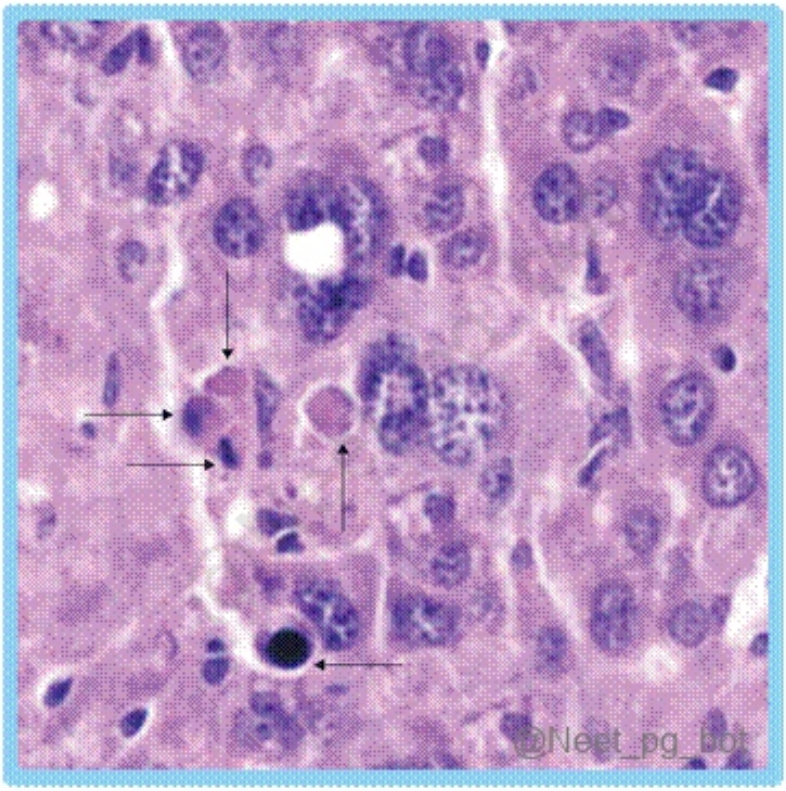

References:

Robbins & Cotran Pathologic Basis of Disease, 10th Edition, Page, 42-43.

↑ *Back to this question in Part A*

@Neet_pg_bot

Q12: Which of the following types of cell death involves activation of caspase enzymes? (Q866340)

A. Necrosis and Apoptosis

B. Apoptosis and Pyroptosis

C. Apoptosis and necroptosis

D. Apoptosis only

Correct Answer: B. Apoptosis and Pyroptosis

Explanation: Apoptosis and Pyroptosis involves activation of caspase enzymes. Apoptosis A tightly regulated suicide program where cells activate enzymes to degrade their DNA and proteins. It's an active process eliminating irreparably damaged cells without causing inflammation or tissue damage. Driven by activation of caspases that cause DNA fragmentation Phases: (Option B) Initiation phase: Activation of caspases 8, 9, 10 triggers a cascade. Execution phase: Terminal caspases 3, 6, 7 lead to cellular breakdown. Morphological features: Cell shrinkage Chromatin condensation Cytoplasmic blebs and formation of apoptotic bodies Phagocytosis of apoptotic bodies by macrophages Histopathology: Apoptotic cells appear as round/oval with intensely eosinophilic cytoplasm and dense nuclear chromatin fragments. Pyroptosis It is a form of programmed cell death involving release of IL-1, a fever-inducing cytokine. Microbial products in cells activate the inflammasome complex. Inflammasome activates caspase-1, which converts inactive IL-1 to active IL-1. (Option B) Active IL-1 causes fever, inflammation, and leukocyte recruitment. Pyroptosis helps eliminate infected cells and triggers local inflammation. Necrosis (Option A) is a form of accidental cell death that does not involve caspases. Necroptosis (Option C) is a programmed form of necrosis that occurs independently of caspases.

↑ *Back to this question in Part A*

@Neet_pg_bot

Q13: Supravital stains are used in the identification of all except? (Q857588)

A. Reticulocytes

B. Copper in tissue

C. Heinz bodies

D. Ribosomal RNA

Correct Answer: B. Copper in tissue

Explanation: Supravital stains are typically used to identify cellular components such as reticulocytes (immature red blood cells), Heinz bodies (denatured haemoglobin), and ribosomal RNA (which is seen in reticulocytes as a network). However, copper in tissue is not identified using supravital stains; it requires special staining techniques like rhodanine stains. {{caption_text}}

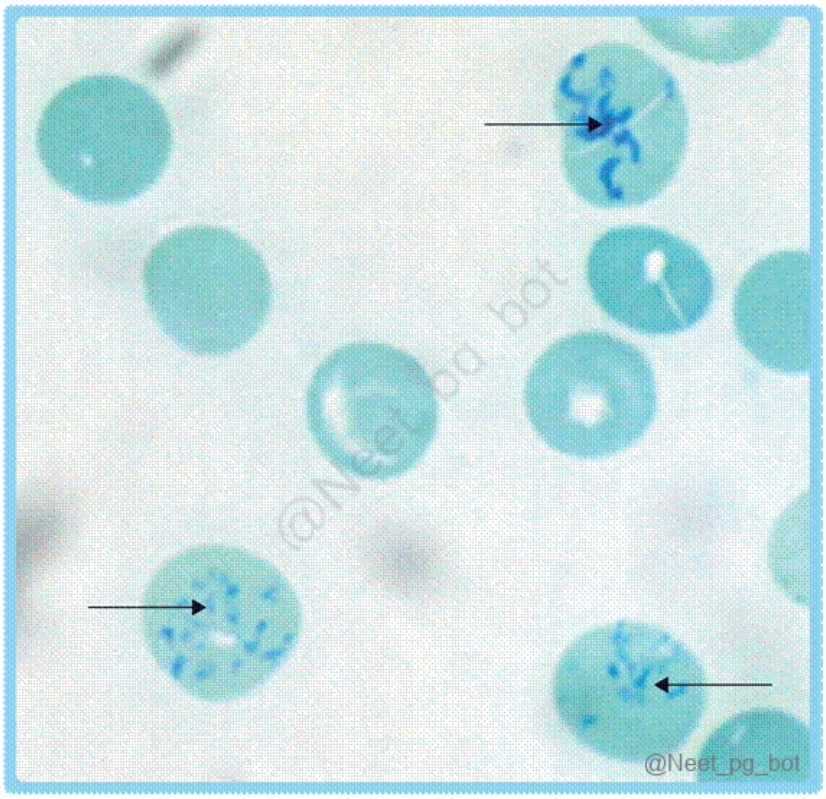

References:

Robbins & Cotran Pathologic Basis of Disease, 10th Edition, Page 641

↑ *Back to this question in Part A*

@Neet_pg_bot

Q14: A diabetic male presented with seizures. Radiological examination shows a lesion. Histopathological examination shows liquefactive necrosis. What is the most important mechanism responsible for this? (Q866754)

A. Enzymatic degradation

B. Mechanical

C. Ischemic

D. Pressure

Correct Answer: A. Enzymatic degradation

Explanation: Diabetic patient with seizures → raises suspicion for a brain lesion (possibly abscess, infarct, or infection-related pathology). Histopathology: liquefactive necrosis → classic type of necrosis seen in brain tissue. Liquefactive necrosis in brain is mainly due to hydrolytic enzyme action breaking down tissue. In the CNS, ischemia or infection activates microglia and infiltrating neutrophils. These cells release lysosomal hydrolytic enzymes. Brain tissue is rich in lipids and has little structural stroma, so enzymatic digestion quickly converts tissue into a liquid mass. Mechanism: enzymatic degradation > structural breakdown → liquefactive necrosis. Mechanical (Option B): Trauma can cause hemorrhage or contusion, but necrosis type is not primarily from mechanical injury alone, here histology points to enzymatic breakdown. Ischemic (Option C): Ischemia in most organs causes coagulative necrosis, except in the brain, where it still leads to liquefactive necrosis, but the mechanism is enzymatic digestion, not ischemia per se. Pressure (Option D): Increased intracranial pressure can cause herniation or atrophy, not liquefactive necrosis by itself.

↑ *Back to this question in Part A*

@Neet_pg_bot

Q15: Which of the following is pro-apoptotic? (Q866665)

A. Bcl-2

B. Bcl-xL

C. Mcl-1

D. Bax

Correct Answer: D. Bax

Explanation: The correct answer is Bax , because it is a pro-apoptotic member of the Bcl-2 protein family. The Bcl-2 family regulates the intrinsic (mitochondrial) apoptosis pathway. Members are divided into: Anti-apoptotic : Bcl-2, Bcl-xL, Mcl-1 → preserve mitochondrial membrane integrity, prevent cytochrome c release. Pro-apoptotic : Bax, Bak, Bok → promote mitochondrial outer membrane permeabilisation (MOMP), allowing cytochrome c release and caspase activation. Mnemonic: "Bax and Bak Break" (break the mitochondrial membrane) → pro-apoptotic. "Bcl and Bcl-xL Build" (preserve the membrane) → anti-apoptotic.

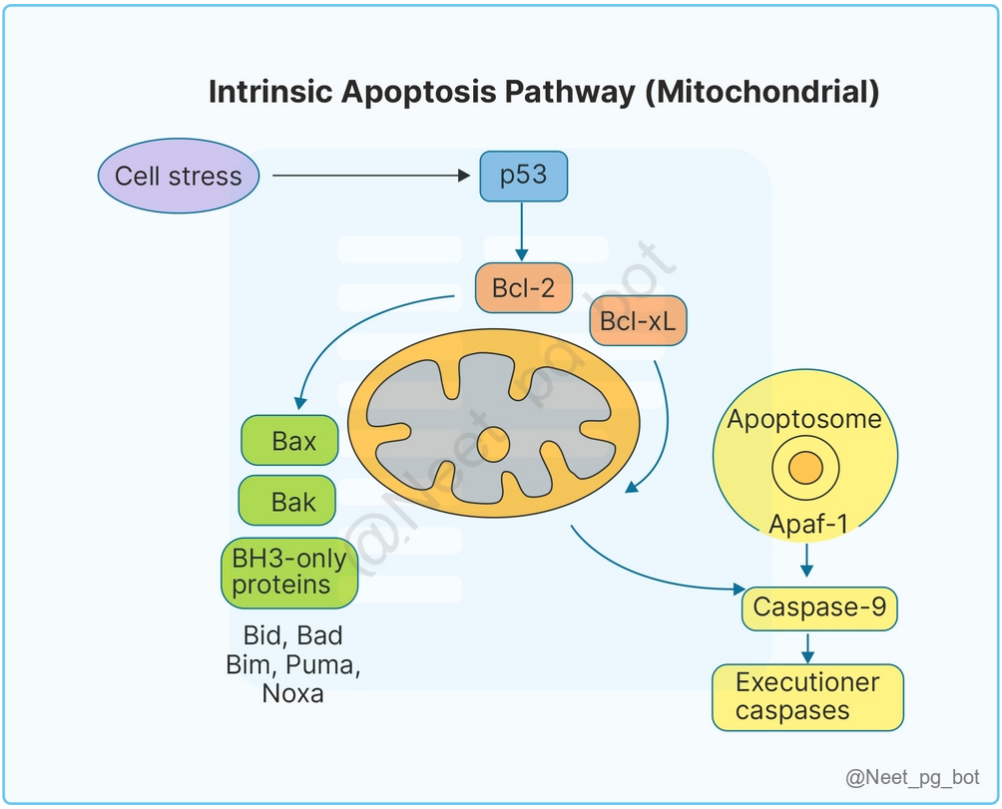

References:

.

↑ *Back to this question in Part A*

@Neet_pg_bot

Q16: A female patient presented with fatigue and a history of piles. Routine complete blood count analysis showed a hemoglobin of 8.5 g/dL, an MCV of 65 fL, and an RBC count of 3.2 million and RDW is increased. A peripheral smear is given below. Which of the following is the next best investigation for this patient? (Q855974)

A. HbA2 levels

B. Serum ferritin levels

C. Serum folate levels

D. Serum homocysteine levels

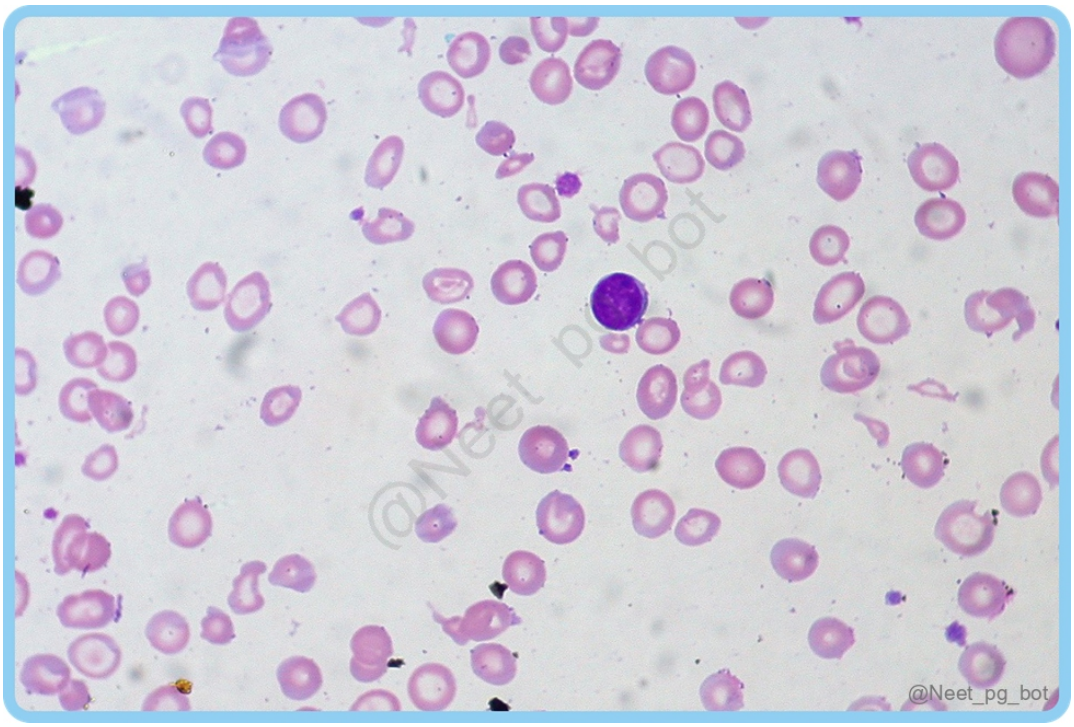

Correct Answer: B. Serum ferritin levels

Explanation: : Folate deficiency causes macrocytic anemia , not microcytic anemia. The MCV here is low , making folate levels less relevant. Serum homocysteine levels (Option D) : This would be more relevant for vitamin B12 or folate deficiency , which typically causes macrocytic anemia , not microcytic anemia.

References:

Robbins and Cotran Pathologic Basis of Disease, 10th Edition, Pages 620, 621, 655, 658, 659

↑ *Back to this question in Part A*

@Neet_pg_bot

Q17: An elderly patient presents with anemia and hemoglobinuria. Investigations reveal increased bilirubin and lactate dehydrogenase. The peripheral smear image is given below. Which of the following is associated with this? (Q855931)

A. Splenomegaly

B. Mechanical second heart valve

C. Increased HbA2

D. Goitre

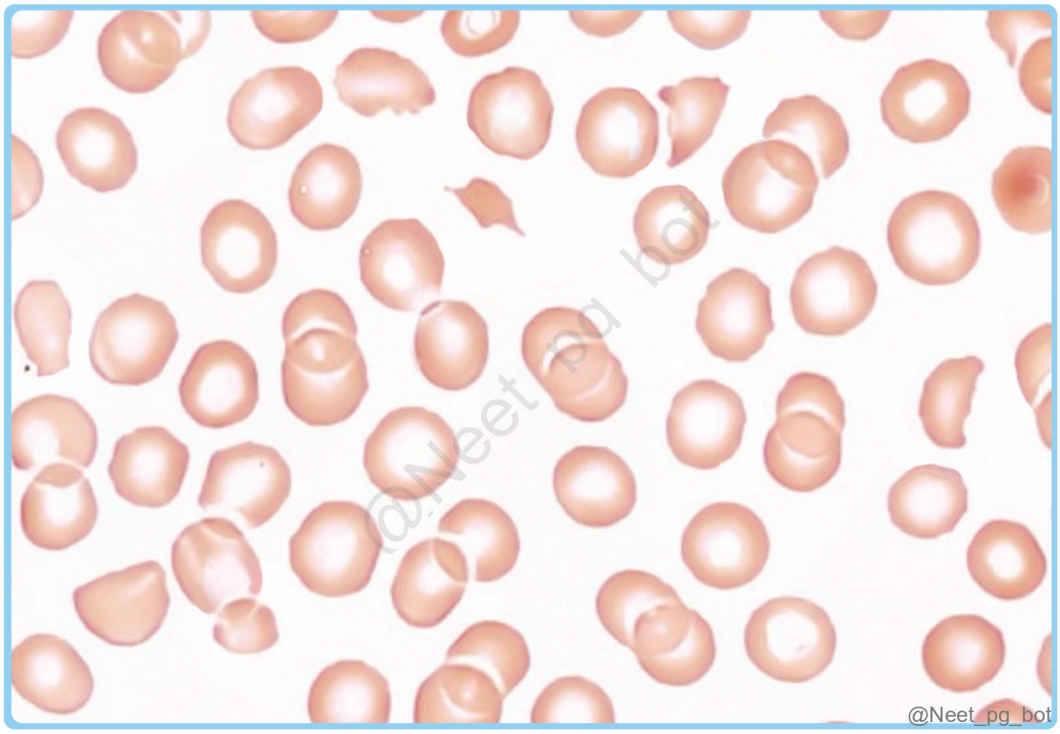

Correct Answer: B. Mechanical second heart valve

Explanation: refers to an enlarged thyroid gland , and it is typically associated with thyroid disorders. The patient's symptoms and lab results point toward a haematological problem, specifically hemolysis , which would not be linked to a thyroid disorder like goitre.

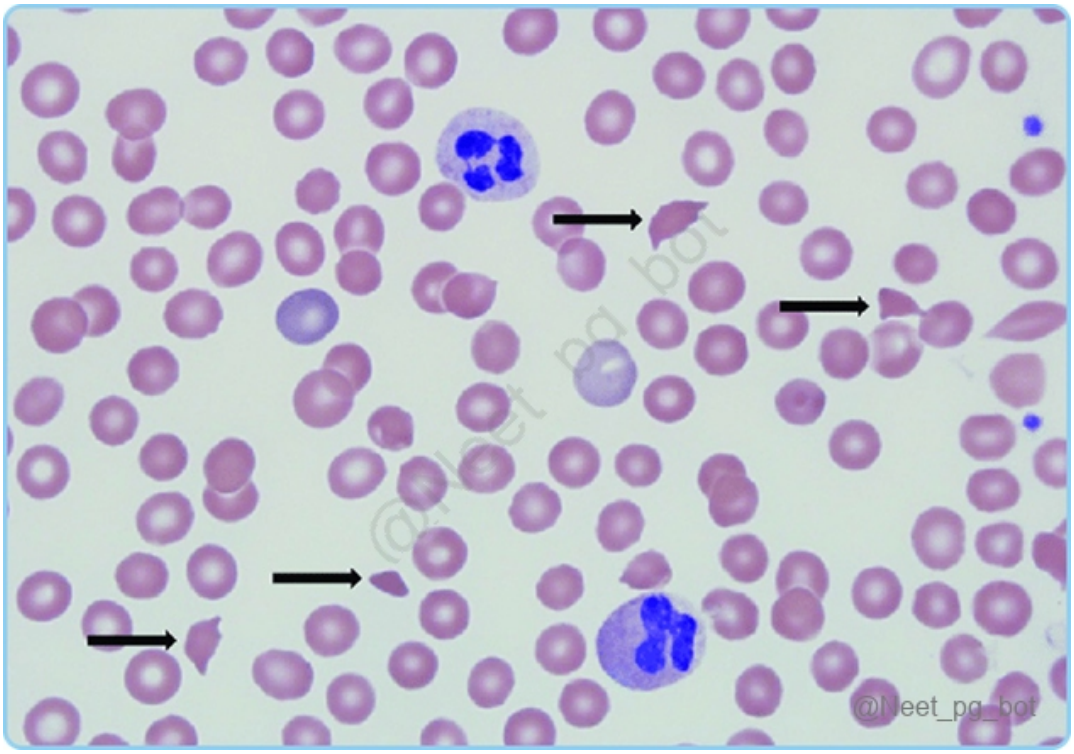

References:

Robbins and Cotran, Pathologic Basis of Disease, 10th edition, Pages 566, 637,

MedscapeLink

↑ *Back to this question in Part A*

@Neet_pg_bot

Q18: A child presents with recurrent chest infections and abdominal pain. There is a history of delayed growth and bone problems causing facial changes. On examination, he had icterus and mild splenomegaly. Peripheral smear shows following finding. What is the likely diagnosis? (Q855920)

A. Beta thalassemia

B. HbC disease

C. Sickle cell disease

D. Acute coronary disease



Correct Answer: A. Beta thalassemia

Explanation: The clinical presentation described, with recurrent chest infections, abdominal pain, delayed growth, bone problems, icterus, and mild splenomegaly, points towards a hemoglobinopathy, and the peripheral smear showing target cells is also consistent with Beta-thalassemia. Thalassemia is a genetic disorder affecting haemoglobin production and causing microcytic, hypochromic anemia. Hemoglobin consists of two alpha (α) and two beta (β) chains, and mutations in the genes responsible for these chains lead to alpha or beta thalassemia, inherited in an autosomal recessive pattern. Beta thalassemia is caused by mutations in the HBB gene on chromosome 11, affecting β chain production. The severity depends on whether one or both β genes are mutated: Beta Thalassemia Trait (β-thalassemia minor) (1 mutated gene) Beta Thalassemia Intermedia (2 mutated genes with partial function) Beta Thalassemia Major (β0-thalassemia) (2 mutated genes, with complete absence of β chain production) Beta Thalassemias Major (Transfusion-dependent) Intermedia (Non-transfusion-dependent) Minor (Trait or Carrier) Genotype Homozygous: β■/β■ β■/β■ β■/β■ Variable: β■/β■ or β■/β■ or β■/β or β■/β Heterozygous: β■/β or β■/β Laboratory Findings Severe microcytic anemia with target cells (Hb 3–4 g/dL) Moderate microcytic anemia Mild microcytic anemia Hemoglobin Electrophoresis HbA■ (5% or more); HbF (up to 95%); No HbA HbA■ (4% or more); HbF (up to 50%) HbA■ (4% or more); HbF (up to 5%) Incorrect options: HbC disease (Option B) results in mild hemolysis splenomegaly and usually presents with milder symptoms compared to beta-thalassemia . Electrophoresis in HbC disease would reveal elevated levels of HbC, not HbA, and affected individuals generally experience normal growth and development. Sickle cell disease (Option C) is caused by a mutation in the beta-globin gene , leading to the production of HbS (sickle haemoglobin). The electrophoresis in this condition would show a predominant HbS peak. Acute coronary disease (Option D) is a cardiovascular condition that primarily affects adults. This condition would present with chest pain, shortness of breath, and EKG changes rather than jaundice, splenomegaly, and bone deformities. The patient described here is a child, making ACS an unlikely diagnosis.

References:

Robbins and Cotran Pathologic Basis of Disease, 10th Edition, Pages 644 - 647

↑ *Back to this question in Part A*

@Neet_pg_bot

Q19: A 9-month-old boy presents with progressive pallor and abdominal distention. On examination, hepatosplenomegaly and malar eminence are observed. Laboratory investigations reveal a low hemoglobin level, and the Mentzer index is less than 13. Considering these findings, what is the most likely diagnosis for this patient? (Q859851)

A. Megaloblastic anemia

B. Iron deficiency anaemia

C. Thalassemia

D. Pernicious anemia

Correct Answer: C. Thalassemia

Explanation: Beta-thalassemia major typically presents in infants between 6 and 24 months with symptoms like progressive pallor due to severe anemia, abdominal distention from hepatosplenomegaly, and characteristic facial bone changes (malar eminence) caused by marrow expansion. The low Mentzer index (<13) supports the diagnosis of a microcytic hypochromic anemia like thalassemia rather than iron deficiency. Early diagnosis is crucial for management, including regular blood transfusions to improve survival and growth. Thalassemia Major (β-Thalassemia Major) Features Description Definition A severe form of β-thalassemia caused by homozygous or compound heterozygous mutations in the β-globin gene (HBB) on chromosome 11, leading to absent or markedly reduced β-globin chain production. Genetics Autosomal recessive disorder, caused by mutations in the β-globin gene leading to defective hemoglobin synthesis. Pathophysiology Reduced or absent β-globin chains lead to excess α-globin chains, which form unstable precipitates, causing ineffective erythropoiesis, hemolysis, and severe anaemia. Clinical Features Symptoms appear around 6 months of age (as fetal haemoglobin declines); severe anaemia, growth retardation, hepatosplenomegaly, skeletal deformities (crew-cut appearance on skull X-ray, frontal bossing), jaundice, and delayed puberty. Hematological Findings Peripheral smear : Microcytic hypochromic anaemia, target cells, anisopoikilocytosis, nucleated RBCs. Bone marrow : Erythroid hyperplasia with expansion of marrow cavities. Hemoglobin Electrophoresis Absent or very low HbA, markedly increased HbF (>90%), variable HbA2. Complications Iron overload (due to repeated transfusions leading to secondary hemochromatosis) Cardiac failure (due to iron deposition) E ndocrinopathies (diabetes, hypothyroidism, hypogonadism) Osteopenia/osteoporosis I ncreased infection risk (especially from Yersinia and viral infections). Diagnosis Blood tests (CBC, peripheral smear), Hb electrophoresis/HPLC , Serum ferritin (for iron overload), Genetic testing (HBB gene mutations), Prenatal diagnosis (chorionic villus sampling or amniocentesis). Treatment Regular blood transfusions , iron chelation therapy (deferoxamine, deferasirox, deferiprone), splenectomy (in refractory cases), and hematopoietic stem cell transplantation (HSCT) (only curative option). Prevention Carrier screening, genetic counselling, prenatal diagnosis, preimplantation genetic diagnosis (PGD) in high-risk couples. The Mentzer index (MCV/RBC count) helps distinguish IDA from beta-thalassemia minor , with a value <13 suggesting beta-thalassemia minor . An elevated RDW favours IDA in microcytic, hypochromic anaemia. Confirmatory test: Hemoglobin electrophoresis showing HbA■ >3.5% confirms beta-thalassemia minor. Megaloblastic anaemia (Option A) The main causes are folate and vitamin B12 deficiency. Peripheral blood shows hypersegmented neutrophils and macroovalocytes as early changes. Bone marrow is hypercellular, with numerous megaloblasts and giant metamyelocytes. {{caption_text}} Iron deficiency anemia (Option B) is the most common nutritional deficiency in the world. Diagnostic criteria include anaemia, hypochromic and microcytic red cell indices, low serum ferritin and iron levels, low transferrin saturation, and increased total iron-binding capacity. {{caption_text}} Pernicious anaemia (Option D): The most common cause of vitamin B12 deficiency, resulting from autoimmune destruction of gastric mucosa, leading to intrinsic factor deficiency.

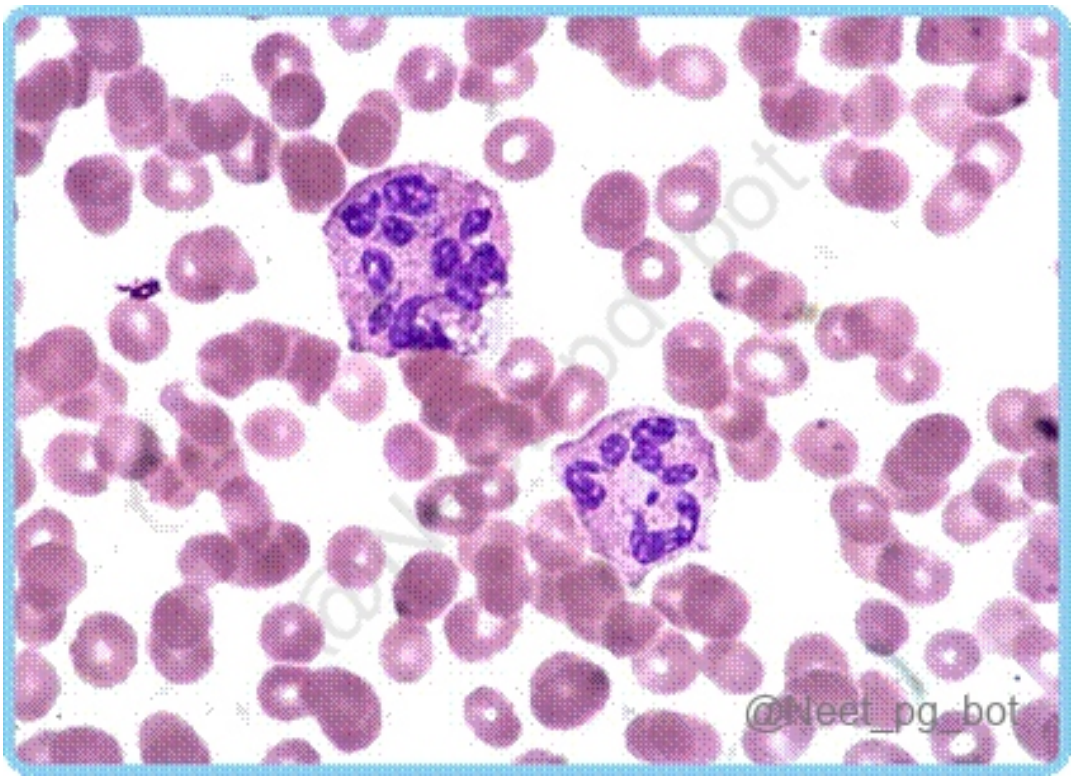

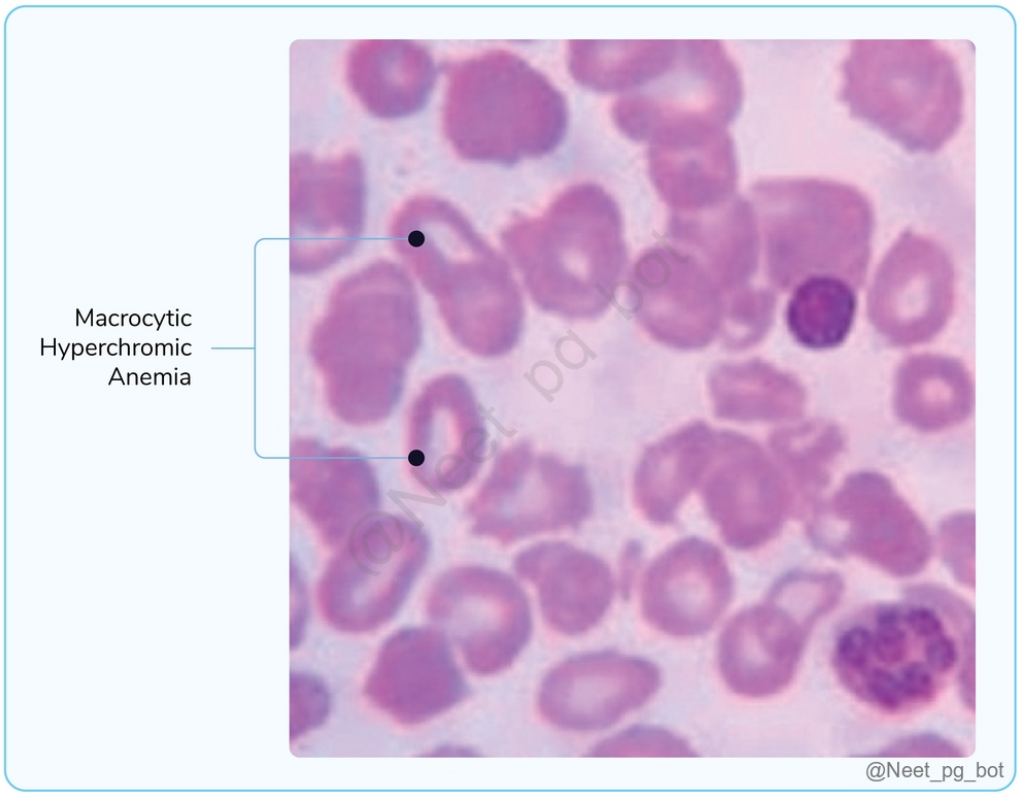

References:

Diagnosis of thalassemia (adults and children) - UpToDate

https://www.ncbi.nlm.nih.gov/pmc/articles/PMC6151350/

↑ *Back to this question in Part A*

@Neet_pg_bot

Q20: A 23-year-old male patient presented with a history of fatigue and tiredness. On investigation, he was found to have Hb = 9 g/dl and MCV = 101 FL. A peripheral smear examination showed macrocytic RBC and hypersegmented neutrophils. Which of the following is the most likely etiology? (Q858518)

A. Lead poisoning

B. Iron deficiency anaemia

C. Hemolytic anemia

D. Chronic alcoholism

Correct Answer: D. Chronic alcoholism

Explanation: The patient presents with macrocytic anemia (MCV = 101 fL) and peripheral smear findings of macrocytic RBCs and hypersegmented neutrophils, which strongly indicate megaloblastic anemia. This condition is most commonly caused by deficiencies in vitamin B12 or folate , often due to poor dietary intake, malabsorption, or chronic alcohol use. Chronic alcohol consumption is a well-known cause of macrocytic anemia, either due to direct toxic effects on hematopoiesis or through the development of folate deficiency , a key cause of megaloblastic anemia. {{caption_text}} Lead poisoning (Option A) typically causes microcytic anemia due to interference with heme synthesis. Iron deficiency anemia (Option B) is characterised by microcytic, hypochromic anaemia resulting from reduced haemoglobin production. Hemolytic anemia (Option C) may cause mild macrocytosis due to increased reticulocyte production; hypersegmented neutrophils are not seen. The hallmark findings of hemolysis (e.g., jaundice, reticulocytosis) are absent in this case.



References:

Robbins & Cotran Pathologic Basis of Disease, 10th Edition, Page 651

↑ *Back to this question in Part A*

@Neet_pg_bot

Q21: A 52-year-old male patient comes with complaints of abdominal pain, nausea, and vomiting. A peripheral blood smear reveals macrocytes and hypersegmented neutrophils, and an endoscopy reveals atrophic gastritis. Which of the following conditions is likely to be seen in this patient? (Q854855)

A. Vitamin B12 deficiency

B. Folate deficiency

C. Pyridoxine deficiency

D. Niacin deficiency

Correct Answer: A. Vitamin B12 deficiency

Explanation: Vitamin B12 deficiency is commonly associated with macrocytic anemia, which is characterized by the presence of macrocytes and hypersegmented neutrophils on the peripheral blood smears. {{caption_text}} It can be caused by atrophic gastritis , which leads to impaired absorption of B12 due to reduced intrinsic factor production. Atrophic gastritis is frequently seen in pernicious anemia , a common cause of vitamin B12 deficiency. Causes of Vitamin B12 deficiency: Reduced Dietary Intake Increased demand Impaired Absorption Vegetarian diet Pregnancy Lactation Growing child Pernicious anemia (Option A) Infections- Diphyllobothrium latum (Option C) Gastrectomy (Option:D) Ileal disorders Malabsorption Ileal resection Diverticula of bowel Folate deficiency (Option B) can cause macrocytic anemia and hypersegmented neutrophils. However, it is less commonly associated with atrophic gastritis, and the absence of other features like neural tube defects (in pregnancy) makes it less likely in this case. Pyridoxine deficiency (Option C) (Vitamin B6) deficiency causes microcytic anemia and not macrocytic anemia and is unlikely to explain the findings of macrocytes and hypersegmented neutrophils. Niacin deficiency (Option D) (Vitamin B3) deficiency causes pellagra , which is characterised by the "three D's": dermatitis, diarrhea, and dementia. It does not cause macrocytic anemia or hypersegmented neutrophils.



References:

Robbins & Cotran Pathologic Basis of Disease, 10th Edition, Page 651-654

↑ *Back to this question in Part A*

@Neet_pg_bot

Q22: What does the vacutainer tube depicted in the provided image contain? (Q856491)

A. Na-EDTA

B. Trisodium citrate

C. NAF-heparin

D. Clot activator



Correct Answer: D. Clot activator

Explanation: Clot activator is found in red-top vacutainer tubes and is used to promote blood clotting, which is needed for serum separation in various tests. Vacutainer Color Additive Purple/Lavender Na-EDTA (Option A) Blue Trisodium Citrate (Option B) Green Heparin (NAF-heparin) (Option C) Red No additive or Clot activator Yellow Acid citrate dextrose Gray Sodium fluoride, Potassium oxalate

References:

https://www.ncbi.nlm.nih.gov/books/NBK555991/

↑ *Back to this question in Part A*

@Neet_pg_bot

Q23: The JAK2 mutation is most commonly associated with: (Q856485)

A. Polycythemia vera

B. Essential thrombocytosis

C. Chronic myelogenous leukemia (CML)

D. Primary myelofibrosis (PMF)

Correct Answer: A. Polycythemia vera

Explanation: In polycythemia vera (>95% cases) , the JAK2 mutation leads to the persistent activation of the JAK-STAT signalling pathway, resulting in the uncontrolled proliferation and survival of red blood cell precursors. This overproduction increases red blood cell count in the bloodstream, leading to blood thickening and potential complications like thrombosis. Essential thrombocytosis (Option B) is characterized by the overproduction of platelets in the bone marrow, increasing the risk of abnormal blood clotting. Although JAK2 mutations can occur in essential thrombocytosis, they are less frequent compared to polycythemia vera. Chronic myelogenous leukaemia (CML) (Option C) is primarily associated with the Philadelphia chromosome, which results from a reciprocal translocation between chromosomes 9 and 22. This translocation leads to the creation of the BCR-ABL fusion gene, which causes uncontrolled proliferation of myeloid cells. Primary myelofibrosis (PMF) (Option D) involves the excessive production of abnormal blood cells, often leading to fibrosis (scarring) of the bone marrow. JAK2 mutations can also occur in primary myelofibrosis, though they are less common than in polycythemia vera.

References:

Robbins & Cotran Pathologic Basis of Disease, 10th Edition, Page 622

↑ *Back to this question in Part A*

@Neet_pg_bot

Q24: A 16-year-old boy presents with jaundice and splenomegaly. His father had a similar illness during adolescence. The MCHC was high. What is the most likely diagnosis? (Q866370)

A. IDA

B. Hereditary spherocytosis

C. Thalassemia major

D. AIHA

Correct Answer: B. Hereditary spherocytosis

Explanation: Hereditary Spherocytosis (HS) An inherited disorder caused by intrinsic defects in the red blood cell membrane skeleton, leading to spheroid, less deformable red cells vulnerable to splenic sequestration and destruction. 75% of cases are autosomal dominant . Remaining cases often involve severe forms due to compound heterozygosity (inheritance of two different defects). Etiopathogenesis HS is marked by a loss of membrane surface area relative to the intracellular volume, leading to spherical red blood cells with reduced or absent central pallor . Spherocytes have decreased deformability , resulting in their retention and destruction in the spleen , causing hemolysis. spectrin , ankyrin, AE1(band 3) , protein 4.2 that weakens the vertical connections between the cytoskeletal framework and lipid bilayer. The ANK1 gene on chromosome 8p produces Ankyrin . Two proposed mechanisms for membrane loss: In cells with spectrin/ankyrin deficiency . Reduced AE1/protein . Clinical features 60-70% of patients present with moderate disease, typically in infancy or childhood. Common findings in children include: Anaemia may be asymptomatic, Jaundice is usually intermittent and acholuric (unconjugated hyperbilirubinemia). >75% show palpable splenomegaly . Family history. Complications Gallbladder Disease : Chronic hemolysis can lead to bilirubinate gallstones . Crisis Events : Hemolytic Crisis : Commonly associated with viral illnesses in childhood; typically mild and self-resolving. Aplastic Crisis : Rare but may cause severe anaemia and require hospitalisation, often linked to parvovirus infection. Typically lasts 10–14 days and may reveal undiagnosed HS in asymptomatic patients. Megaloblastic Crisis : Occurs in patients with increased folate needs, preventable by supplementation. Other rare complications may include leg ulcers , chronic dermatitis, and skeletal abnormalities. HS has been associated with increased risks of hematologic malignancies and thrombotic events post-splenectomy. Incorrect Options: Iron deficiency anaemia (Option A): Usually microcytic, hypochromic anaemia with low MCHC, no jaundice, no splenomegaly, and no strong family history. Thalassemia minor (Option C): Presents in infancy with severe anaemia, failure to thrive, hepatosplenomegaly, and bone deformities; MCHC is not elevated, and family history often shows transfusion-dependent anaemia. AIHA (Option D): Can also have spherocytes and jaundice, but is typically acquired, not familial, and the Coombs test is positive . It is often acute/subacute onset, not a chronic familial condition.

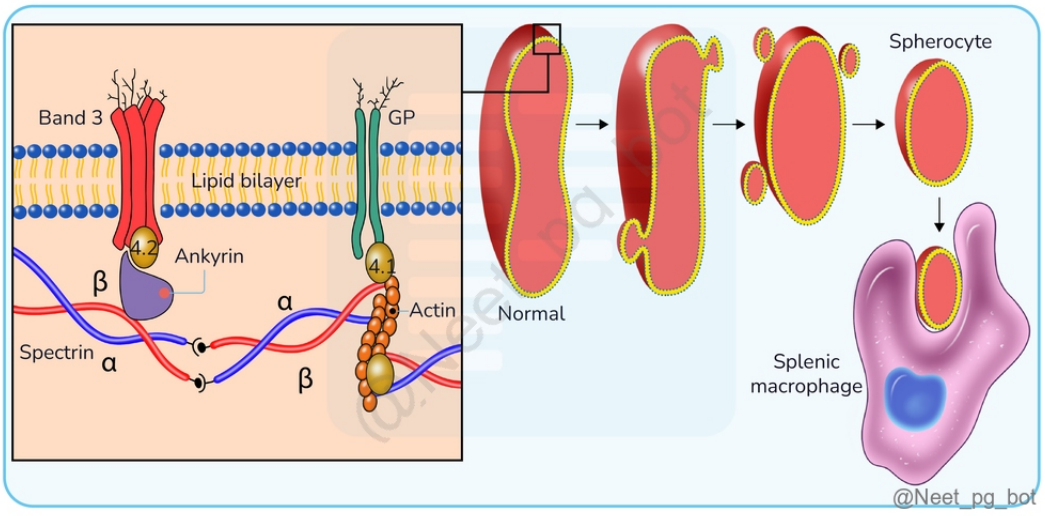

References:

.

↑ *Back to this question in Part A*

Q25: A phlebotomist is asked to collect blood samples for a patient undergoing multiple tests. Which of the following is the correct order of blood collection to avoid contamination of the samples based on the additives in the collection tubes? (Q854685)

A. Light blue → Lavender → Red → Grey

B. Grey → Red → Light blue → Lavender

C. Light blue → Red → Lavender → Grey

D. Red → Lavender → Grey → Light blue

Correct Answer: C. Light blue → Red → Lavender → Grey

Explanation: The correct order here is Light blue → Red → Lavender → Grey In blood collection, it's crucial to follow the correct order to prevent contamination between tubes with different additives. The correct order of drawing the blood in vacutainers is Blood culture → Light blue → Red or Yellow → Green → Lavender → Grey Vacutainer colour Additive Uses Blood culture Broth media (aerobic/anaerobic) For detecting bacterial and fungal infections Light blue {{caption_text}} Trisodium citrate For coagulation tests Red or Yellow {{caption_text}} {{caption_text}} No additive (Red) / Gel separator (Yellow) For serum collection (serology, chemistry) Green Heparin For plasma collection (chemistry tests) Lavender {{caption_text}} EDTA For haematology tests (e.g., CBC, blood smears) Pink EDTA For blood bank tests (e.g., crossmatch, blood type Grey {{caption_text}} Potassium Oxalate + Sodium Fluoride For glucose, lactate, and alcohol tests


BD Vacutainer®
Buff. Na Citrate
0.109M, 3.2%
REF 363083
LOT 21241322 2013-02
@Neet_pg_bot


Surname
First Name
6 ml
20101H



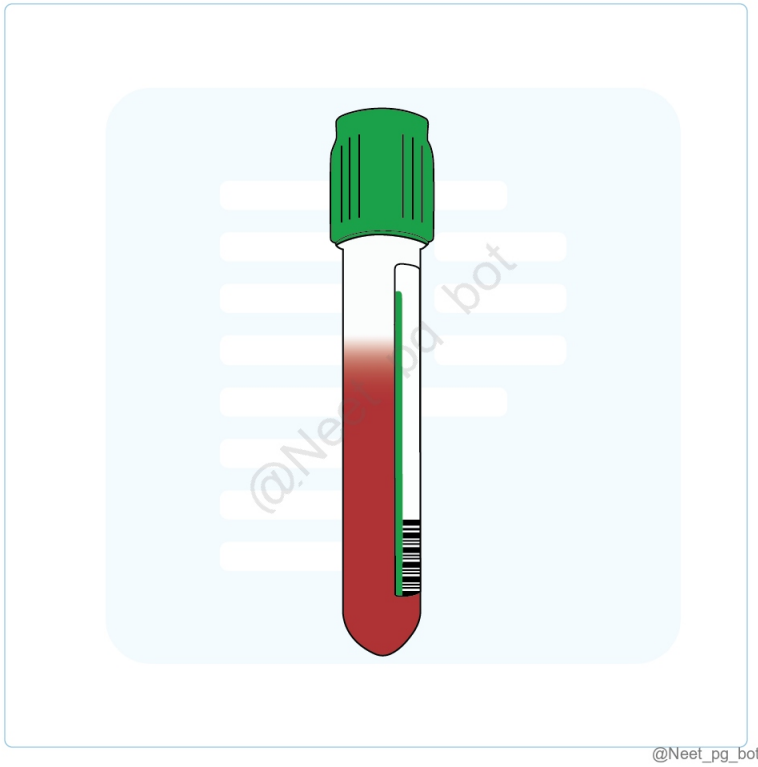

@Neet_pg_bot

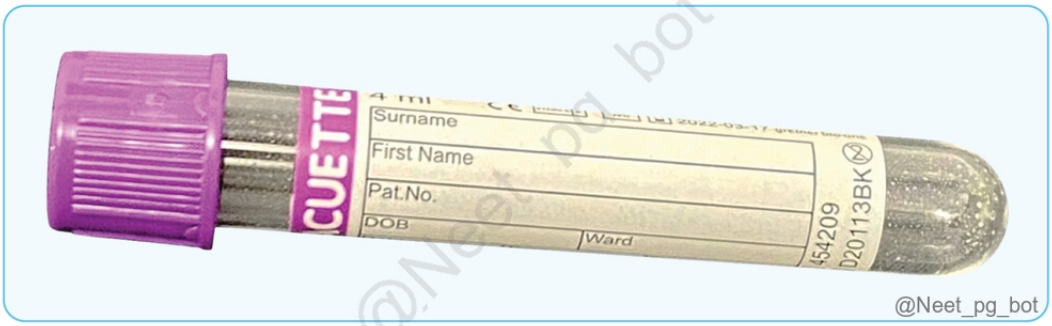



References:

Online source - Link , Link , Link

↑ *Back to this question in Part A*

@Neet_pg_bot

Q26: Which of the following causes microcytic anemia? Iron deficiency Thalassemia Lead poisoning Vitamin B12 deficiency (Q879228)

A. 1, 2, 3

B. 1, 2

C. 1, 3

D. 1, 2, 3, 4

Correct Answer: A. 1, 2, 3

Explanation: Microcytic anemia is characterised by decreased mean corpuscular volume (MCV < 80 fL) due to defective haemoglobin synthesis . This can result from a deficiency of iron , defective globin chain production , or impaired heme synthesis . Microcytic Anaemia Normocytic Anaemia Macrocytic Anaemia S ideroblastic anemia. I ron deficiency anemia (Option 1) T halassemia (Option 2) A nemia of chronic disease L ead poisoning (Option 3) (Mnemonic- SITAL) Acute Blood Loss Hemolytic Anaemia (hereditary spherocytosis) Anemia of Chronic Disease Bone Marrow Disorders (e.g., Aplastic Anaemia) Renal Disease Endocrine Disorders (e.g., Hypothyroidism) Early stages of iron deficiency anemia Vitamin B12 Deficiency Folate Deficiency Alcohol Abuse Liver Disease Hypothyroidism Myelodysplastic Syndrome Vitamin B12 deficiency (Option 4) causes macrocytic (megaloblastic) anemia due to impaired DNA synthesis, not microcytic anemia.

References:

Microcytic anemia. Differential diagnosis and management of iron deficiency anemia - PubMed .

↑ *Back to this question in Part A*

@Neet_pg_bot

Q27: A patient presents with microcytic hypochromic anemia (MCV: 70–79 fL) and a Mentzer index of 11 with increased RBC count. Peripheral blood smear reveals target cells. Which of the following investigations is the most appropriate for establishing the diagnosis? (Q879222)

A. Bone marrow examination

B. Hb electrophoresis

C. Serum ferritin

D. Serum iron and TIBC

Correct Answer: B. Hb electrophoresis

Explanation: This patient’s features - microcytic hypochromic anemia, low Mentzer index (<13), increased RBC count, and target cells - strongly suggest thalassemia trait rather than iron deficiency anemia. The investigation of choice for confirmation is hemoglobin electrophoresis , which quantifies Hb fractions (HbA, HbA■, HbF). Incorrect Options: Bone marrow examination (Option A): Unnecessary for thalassemia trait, as peripheral smear and hemoglobin studies are sufficient. Serum ferritin (Option C): Normal in thalassemia trait; low ferritin indicates

iron deficiency, not thalassemia. Serum iron and TIBC (Option D): Typically normal in thalassemia trait and mainly used to assess iron deficiency anemia.

References:

Thalassemia - StatPearls - NCBI Bookshelf

↑ *Back to this question in Part A*

@Neet_pg_bot

Q28: The vacutainer tube shown in the given image contains the following: (Q855434)

A. EDTA

B. Trisodium citrate

C. NAF - heparin

D. Clot activator



Correct Answer: D. Clot activator

Explanation: The vacutainer tube shown in the image contains a clot activator, which is a substance designed to accelerate the blood clotting process. It promotes quicker coagulation of the blood sample. This type of tube is typically used to collect serum samples for various laboratory tests. Colour Anti-coagulants Uses Purple/Lavender {{caption_text}} EDTA (Ca2+ chelating anticoagulant) (Option A ruled out) CBC, Peripheral Smear, ESR, HbA1c Light Blue {{caption_text}} Trisodium Citrate (Ca2+ chelating anticoagulant) (Option B ruled out) ESR, PT, aPTT Red {{caption_text}} No anti-coagulant is added. Clot activator without gel (Option D) Serum studies (Proteins, enzymes, hormones) Yellow {{caption_text}} Clot activator/Gel separator Serum studies (Proteins, enzymes, hormones) Grey {{caption_text}} Sodium Fluoride Blood Glucose Green {{caption_text}} Heparin (Option C ruled out) ABG, Osmotic fragility, flow cytometry, immunophenotyping

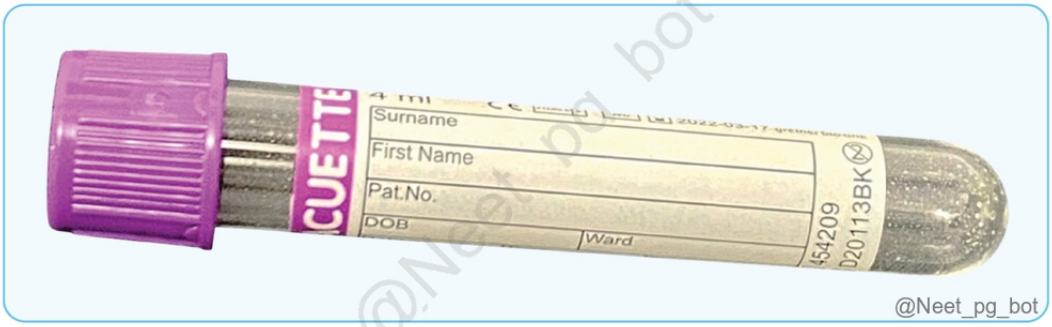




Surname
First Name
Pat.No.


5 ml
Surname
First Name
Pat.No.



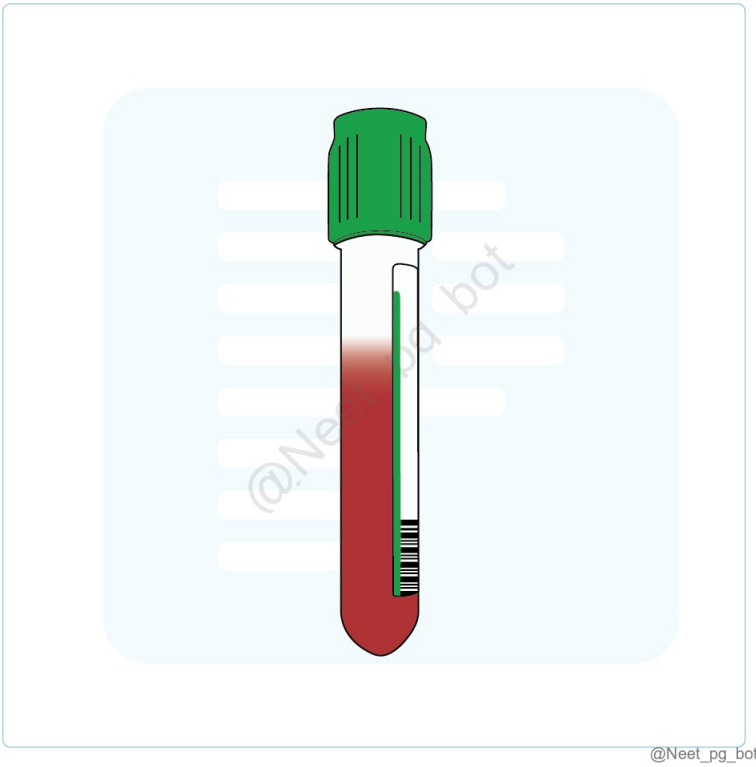

@Neet_pg_bot

References:

Atlas of Clinical Hematology, Chapter 1, Page 4

Laboratory tube collection

↑ *Back to this question in Part A*

@Neet_pg_bot

Q29: Which of the following oil red O stain is used? (Q855393)

A. Formalin fixation

B. Frozen section

C. Alcohol fixation

D. Glutaraldehyde fixation

Correct Answer: B. Frozen section

Explanation: Oil Red O stain is commonly used in frozen sections to detect the presence of lipids, particularly neutral lipids such as triglycerides. It is a lipophilic dye that selectively stains lipids within cells or tissues. It binds to the neutral lipid droplets and produces a bright red colour when examined under a microscope. {{caption_text}} This stain is particularly useful in identifying lipid accumulation in various tissues and organs, including adipose tissue, liver, muscle, and atherosclerotic plaques. Frozen sections are typically used for rapid intraoperative diagnosis or for research purposes. Formalin fixation (Option A) refers to the preservation of tissue samples using formaldehyde solutions, leading to the cross-linking of proteins and modification of lipid structures, which may interfere with the staining properties of Oil Red O. Alcohol fixation (Option C) involves the preservation of tissues using alcohol-based solutions, such as ethanol or methanol. It can also alter the structure of lipids, affecting the staining properties of Oil Red O. Glutaraldehyde fixation (Option D) is typically used for electron microscopy studies. It may lead to changes in lipid composition and affect the staining properties of Oil Red O.

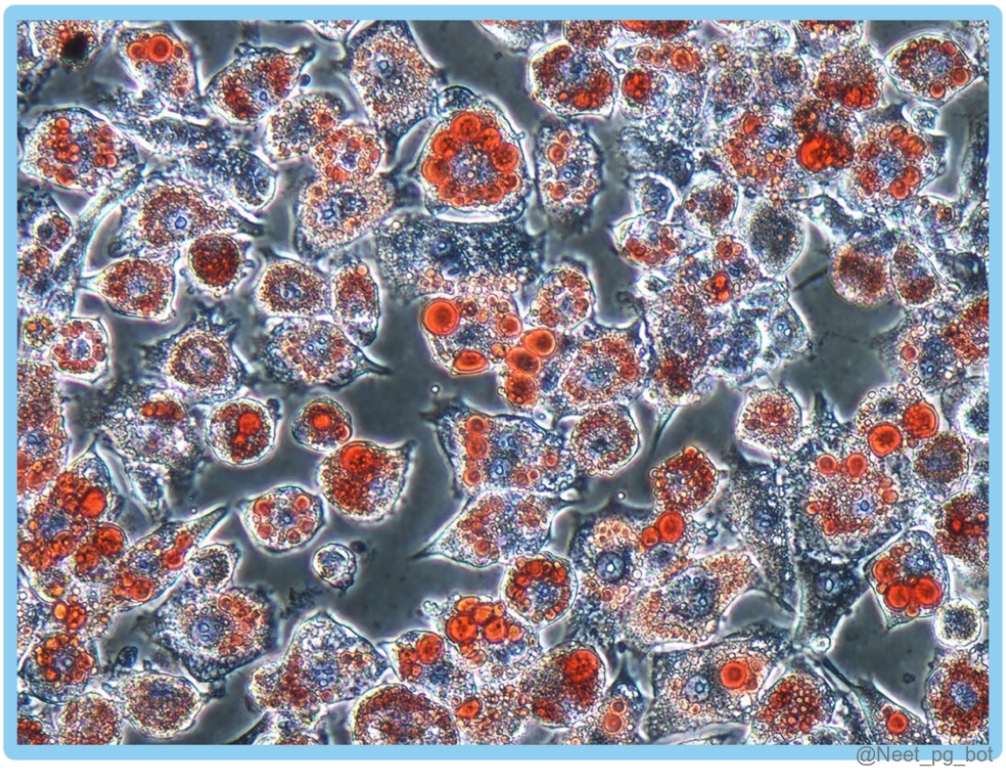

References:

Oil Red O - Wikipedia

An optimized method for Oil Red O staining with the salicylic acid ethanol solution

↑ *Back to this question in Part A*

@Neet_pg_bot

Q30: Which of the following needles is commonly used for bone marrow biopsy? (Q855114)

A. Klima needle

B. Salah needle

C. Jamshidi needle

D. Islam needle

Correct Answer: C. Jamshidi needle

Explanation: The Jamshidi needle is the most widely used needle for bone marrow aspiration and biopsy. It has a hollow, beveled tip designed to obtain a core of bone marrow with minimal trauma. Common sites for biopsy using this needle are the posterior superior iliac spine and sternum (for aspiration only). It allows both aspiration of liquid marrow and core biopsy for histology in the same procedure. The needle is preferred for its ease of use, safety, and high-quality sample retrieval. {{caption_text}} Incorrect Options: Option A) Klima needle: Rarely used; mainly historical, not standard for marrow biopsy. Option B) Salah needle: Not a standard or recognized needle for bone marrow procedures. ■ Option D) Islam needle: Not used for bone marrow biopsy; no clinical standard. {{caption_text}}



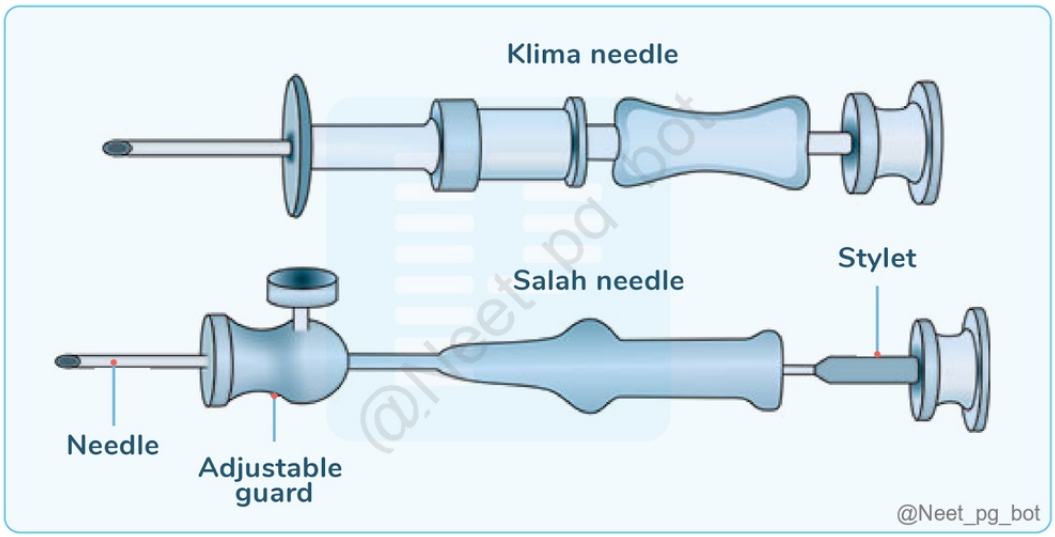



@Neet_pg_bot

References:

Dacie and Lewis Practical Hematology, 12th Edition, Page 115,120,121,122

https://www.cancer.gov/publications/dictionaries/cancer-terms/def/jamshidi-needle

https://pmc.ncbi.nlm.nih.gov/articles/PMC1860622/

↑ *Back to this question in Part A*

@Neet_pg_bot

Q31: A child presents with multiple skin lesions over the inner thigh and genital areas. Initially, the lesions started as macules and later developed into nodules. Some of the nodules have a central umbilication. The histology of the lesion is shown below. What would be found on a biopsy? (Q855108)

A. Multinucleate giant cells (Tzanck cells)

B. Donovan bodies

C. Henderson-Patterson bodies

D. Koilocytes

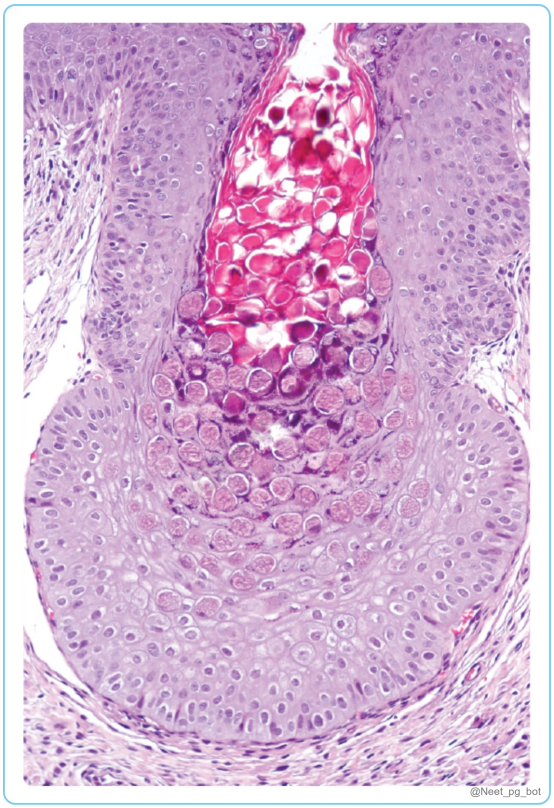

Correct Answer: C. Henderson-Patterson bodies

Explanation: The given clinical scenario and image are diagnostic of Molluscum contagiosum lesions, which show intracytoplasmic inclusion bodies called Henderson-Patterson bodies /molluscum bodies. Molluscum Contagiosum: Caused by: Poxvirus (MCV-1 to MCV-4) MCV-1 is the most common. MCV-2 is often sexually transmitted. Common in: Children (2-12 years): Spread through direct contact or shared items (e.g., towels) Adults: Typically sexually transmitted, affecting genitals, lower abdomen, buttocks, and inner thighs Incubation period: Approximately 6 weeks Clinical Features: Pearly, dome-shaped papules (1-5 mm in diameter) with a dimpled centre. The central waxy core contains cytoplasmic viral inclusions. Common sites in children: Trunk, arms, and legs Common sites in adults: Genitals, lower abdomen, buttocks, and inner thighs Microscopic examination: Lesion characteristics: Cup-like, verrucous epidermal hyperplasia. Diagnostic structure : Molluscum body : Large (up to 35 µm), ellipsoid, homogeneous cytoplasmic inclusion. Found in the stratum granulosum and stratum corneum . Eosinophilic in the stratum granulosum. Pale blue hue in the stratum corneum. {{caption_text}} Multinucleate giant cells (Tzanck cells) (Option A) are typically seen in herpesvirus infections (like herpes simplex or varicella-zoster), not in molluscum contagiosum. They are large cells with multiple nuclei, and their presence is a hallmark of herpesvirus infections. {{caption_text}} Donovan bodies (Option B) are characteristic of granuloma inguinale , caused by Klebsiella granulomatis . The bodies are intracellular and appear in macrophages. They are unrelated to molluscum contagiosum. {{caption_text}} Koilocytes (Option D) are cells with a characteristic perinuclear halo and are associated with human papillomavirus (HPV) infections, such as warts. {{caption_text}}

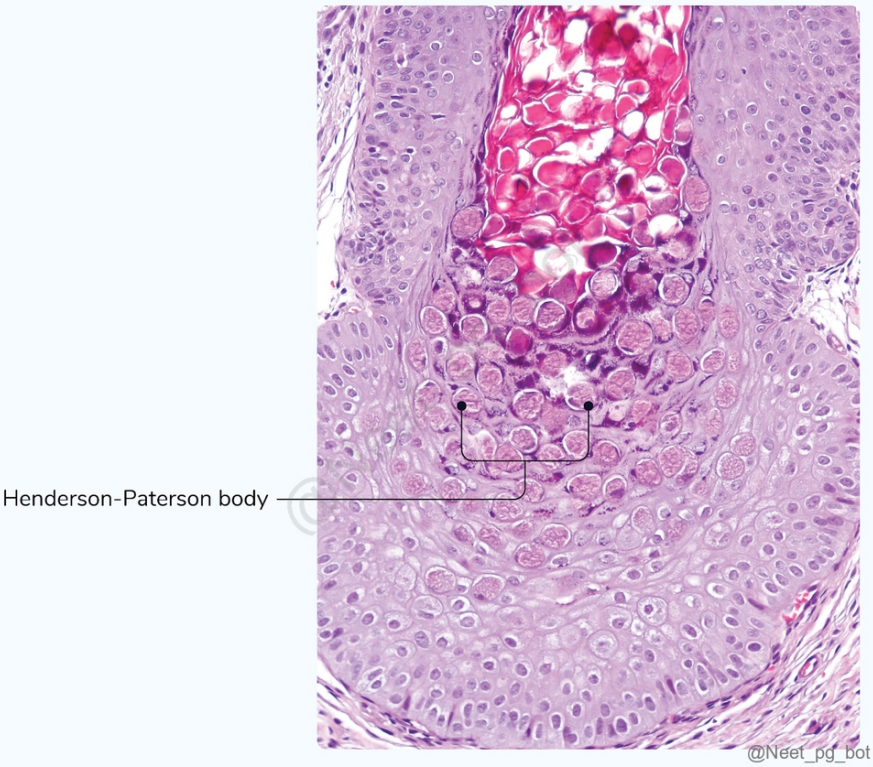

@Neet_pg_bot

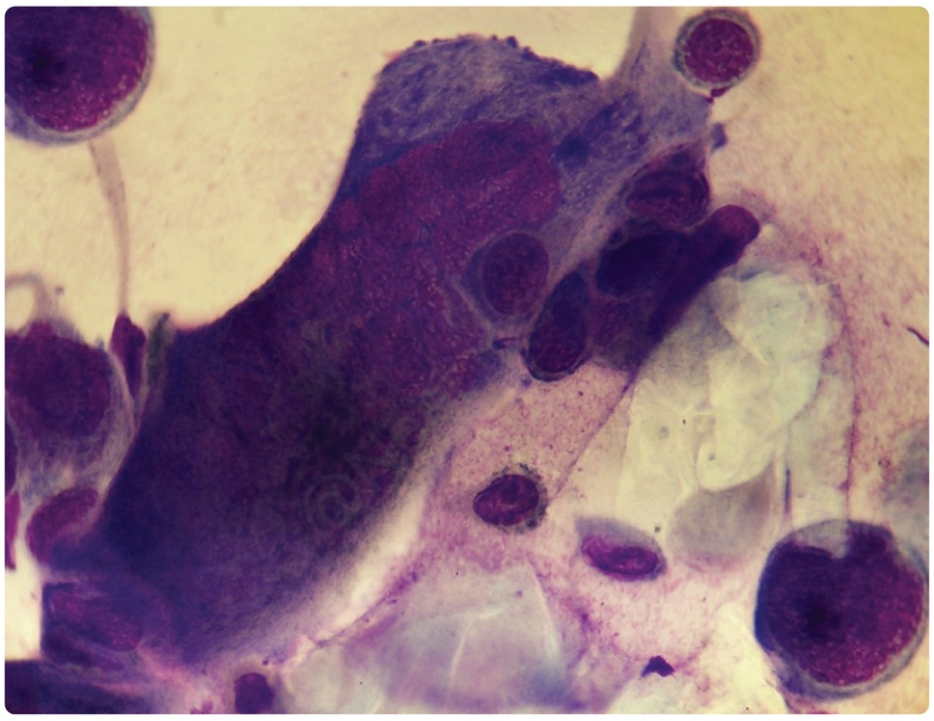
@Neet_pg_bot

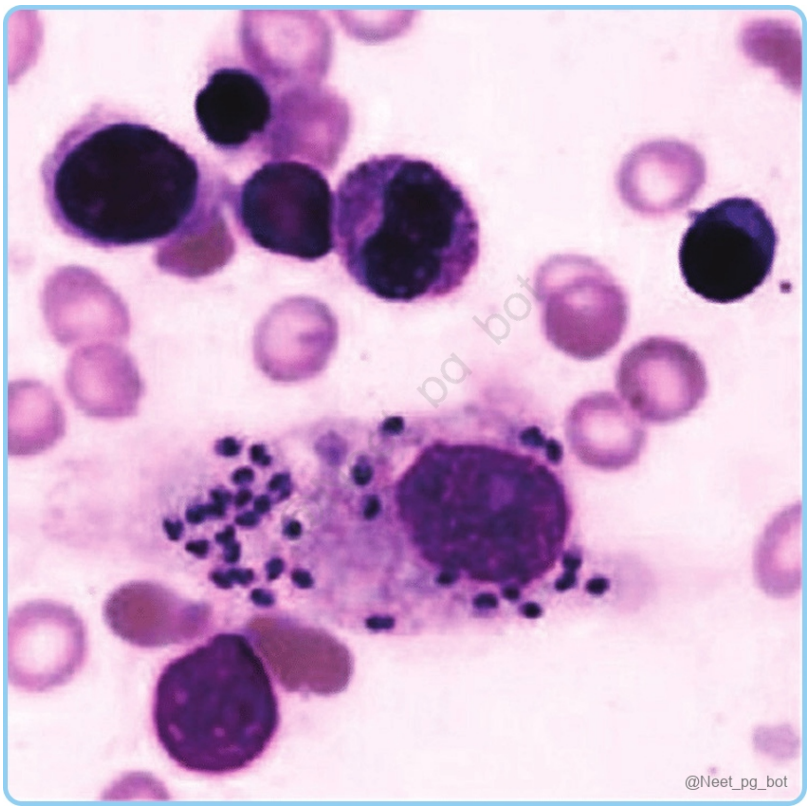



References:

Robbins & Cotran Pathologic Basis of Disease, 10th Edition, Page 987, 988

↑ *Back to this question in Part A*

Q32: Pair the stains with their corresponding options Stain Corresponding Option 1. Prussian blue stain a. Iron 2. PAS stain b. Glycogen 3. Congo red stain c. Leprosy 4. Fite-Faraco stain d. Amyloid (Q855085)

A. 1-d, 2-c, 3-b, 4-a

B. 1-c, 2-a, 3-b, 4-d

C. 1-a, 2-b, 3-d, 4-c

D. 1-b, 2-a, 3-c, 4-d

Correct Answer: C. 1-a, 2-b, 3-d, 4-c

Explanation: Stain Corresponding Option Images Prussian blue stain Iron {{caption_text}} PAS stain Glycogen {{caption_text}} Congo red stain Amyloid {{caption_text}} Fite-Faraco stain Leprosy {{caption_text}}

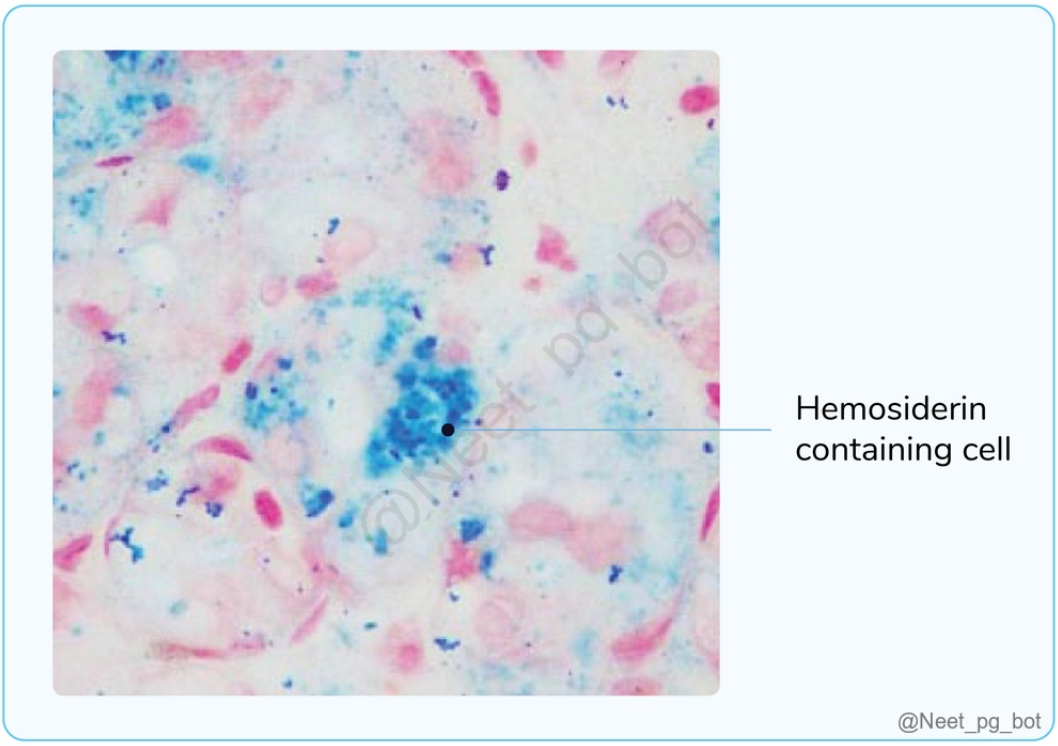

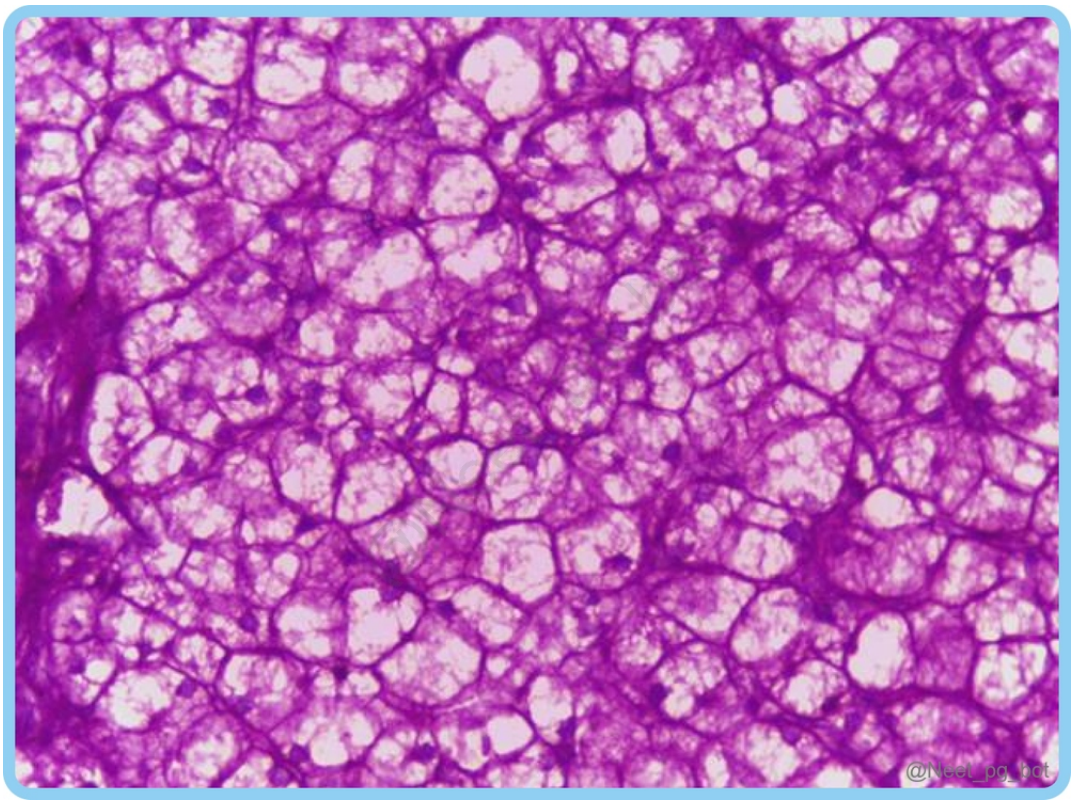
@Neet_pg_bot

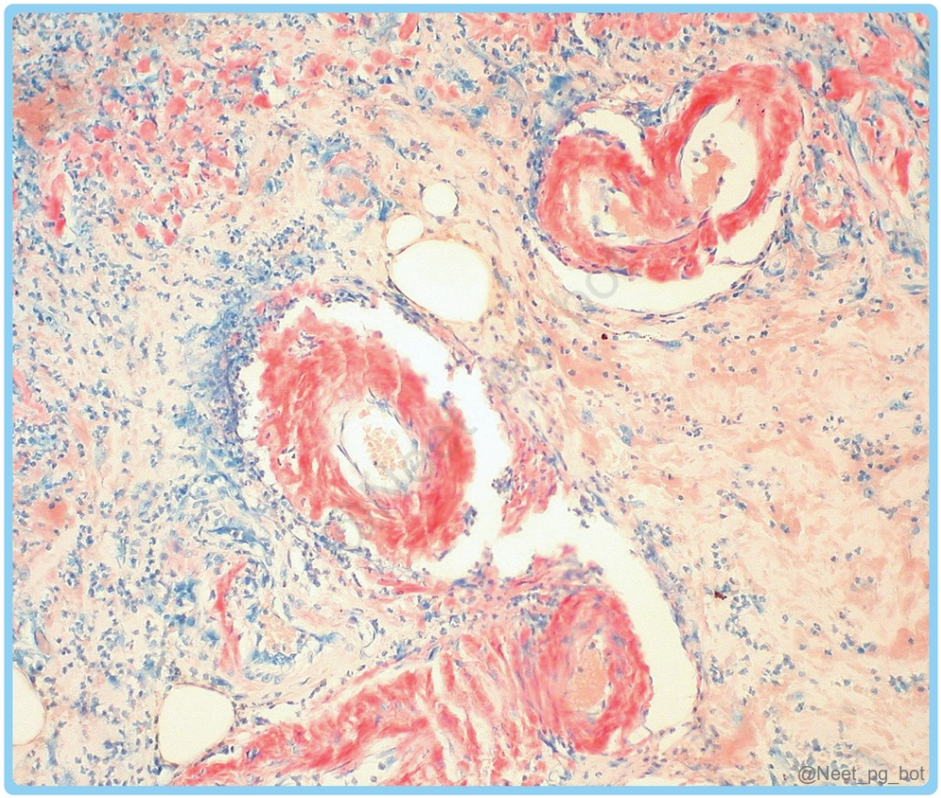
@Neet_pg_bot

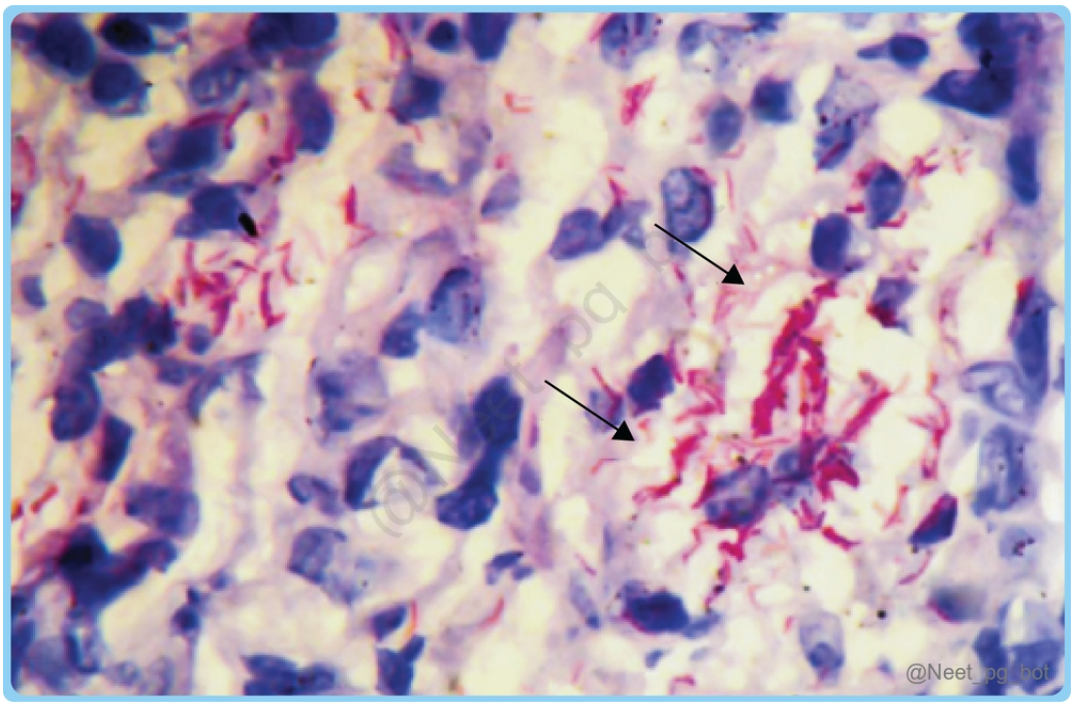

References:

Robbins & Cotran Pathologic Basis of Disease, 10th Edition, Page 259, 260, 574, 655, 768, 848.

↑ *Back to this question in Part A*

@Neet_pg_bot

Q33: A woman presents with nodular lesions, 4-6 mm in size, on the inner thighs and peri-anal region. The lesions appear pale, and histopathological examination reveals multiple intracytoplasmic inclusion bodies consistent with Henderson-Patterson bodies. What is the most likely diagnosis? (Q855907)

A. Trichodysplasia spinulosa

B. Condyloma acuminata

C. Molluscum contagiosum

D. Donovanosis

Correct Answer: C. Molluscum contagiosum

Explanation: The patient's presentation of pale, nodular lesions on the inner thighs and peri-anal region, along with the presence of Henderson-Patterson bodies, is characteristic of Molluscum contagiosum . Henderson-Patterson bodies are eosinophilic inclusion bodies that are diagnostic for Molluscum contagiosum virus (MCV) infection.

The virus primarily infects the skin, causing characteristic lesions that are typically described as pearl-like, dome-shaped, and umbilicated. The lesions are generally painless and self-limiting, though they can persist for months or even years. {{caption_text}} Molluscum Contagiosum: Caused by: Poxvirus (MCV-1 to MCV-4) MCV-1 is the most common. MCV-2 is often sexually transmitted. Common in: Children (2-12 years): Spread through direct contact or shared items (e.g., towels). Adults: Typically sexually transmitted, affecting genitals, lower abdomen, buttocks, and inner thighs. Incubation period: Approximately 6 weeks. Clinical Features: Pearly, dome-shaped papules with a dimpled centre. Papules are 1-5 mm in diameter. The central waxy core contains cytoplasmic viral inclusions. Common sites in children: Trunk, arms, and legs. Common sites in adults: Genitals, lower abdomen, buttocks, and inner thighs. Microscopic examination: Lesion Characteristics: Cup-like, verrucous epidermal hyperplasia. Diagnostic Structure : Molluscum body , a large (up to 35 µm), ellipsoid, homogeneous cytoplasmic inclusion. Found in the stratum granulosum and stratum corneum . Eosinophilic in the stratum granulosum. Pale blue hue in the stratum corneum. Trichodysplasia Spinulosa (Option A) is a viral infection that predominantly affects immunocompromised individuals, especially organ transplant recipients. It typically manifests as follicular papules and spiny nodules on the face, neck, and upper extremities. Histologically, it shows hyperkeratosis, follicular plugging, and hair shaft abnormalities. Condyloma acuminata (Option B) , or genital warts, is caused by the human papillomavirus (HPV) and is a sexually transmitted infection. These warts usually appear as flesh-coloured, cauliflower-like growths in the genital and perianal regions. Histologically, they are characterized by hyperkeratosis, acanthosis, and koilocytosis, where squamous cells exhibit a clear halo around the nucleus. {{caption_text}} Donovanosis (Option D), also called granuloma inguinale, is a bacterial infection caused by Klebsiella granulomatis . It presents as painless nodules or ulcers in the genital and perianal regions. Histologically, it shows granulomatous inflammation with Donovan bodies, which are large, rod-shaped, intracytoplasmic bacteria

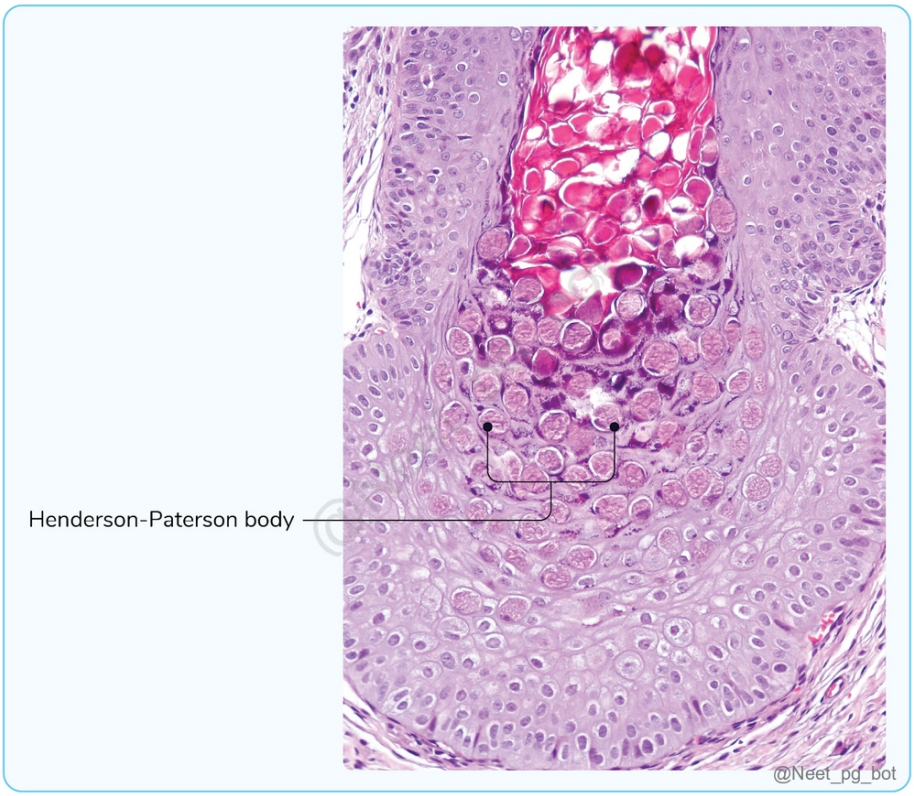

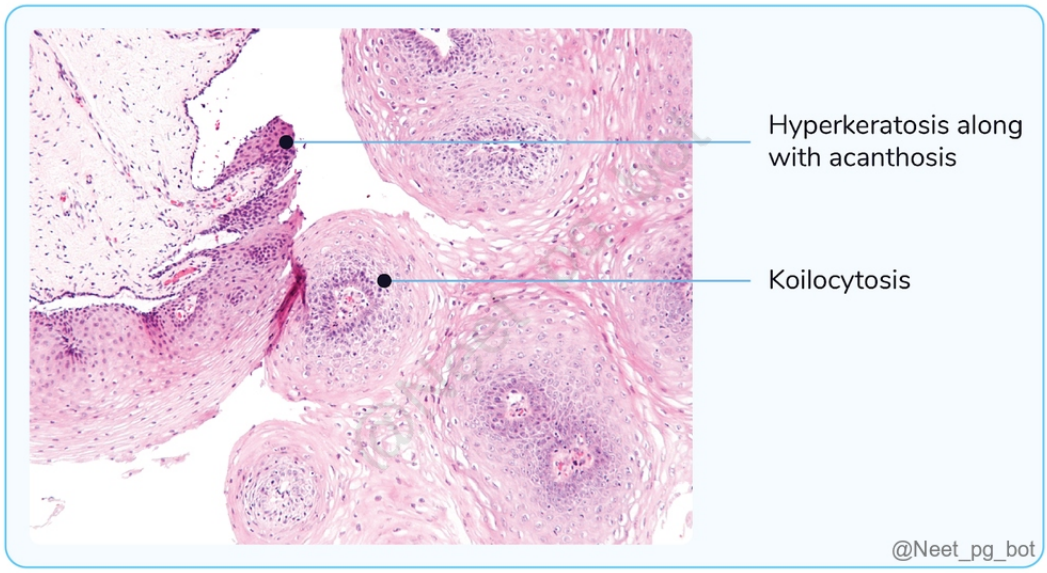

References:

Robbins & Cotran Pathologic Basis of Disease, 10th Edition, Page 987,988

↑ *Back to this question in Part A*

@Neet_pg_bot

Q34: Which of the following methods is iron in tissues stained? (Q855899)

A. Masson’s trichrome

B. Prussian blue

C. PAS

D. Fite-Faraco

Correct Answer: B. Prussian blue

Explanation: Iron in tissues is stained using Prussian blue. This staining technique relies on the reaction between Fe3+ ions and ferrocyanide ions to form an insoluble blue pigment. When tissue sections are treated with a solution of potassium ferrocyanide and hydrochloric acid, any iron present in the tissue reacts with the ferrocyanide, producing the blue pigment. This stain is specific for iron and is frequently employed to detect iron deposition in conditions like hemochromatosis and hemosiderosis. Prussian blue stain Iron {{caption_text}} Masson Trichrome Differentiate Collagen & muscle fibers {{caption_text}} Fite-Faraco stain Leprosy {{caption_text}} PAS stain Glycogen {{caption_text}}

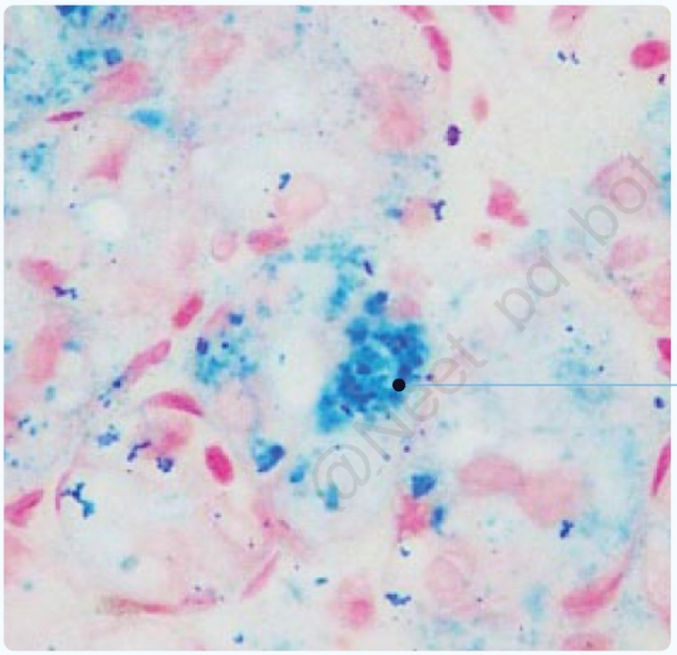

Hemosiderin containing cell

@Neet_pg_bot

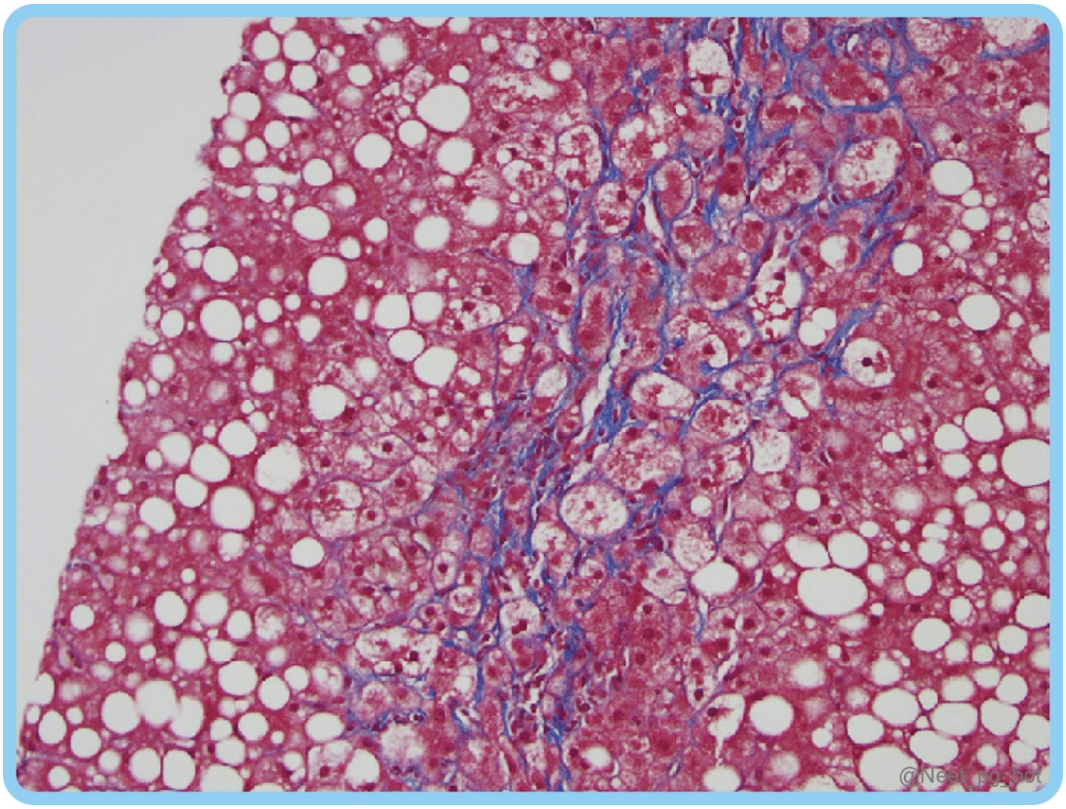

@Neet_pg_bot

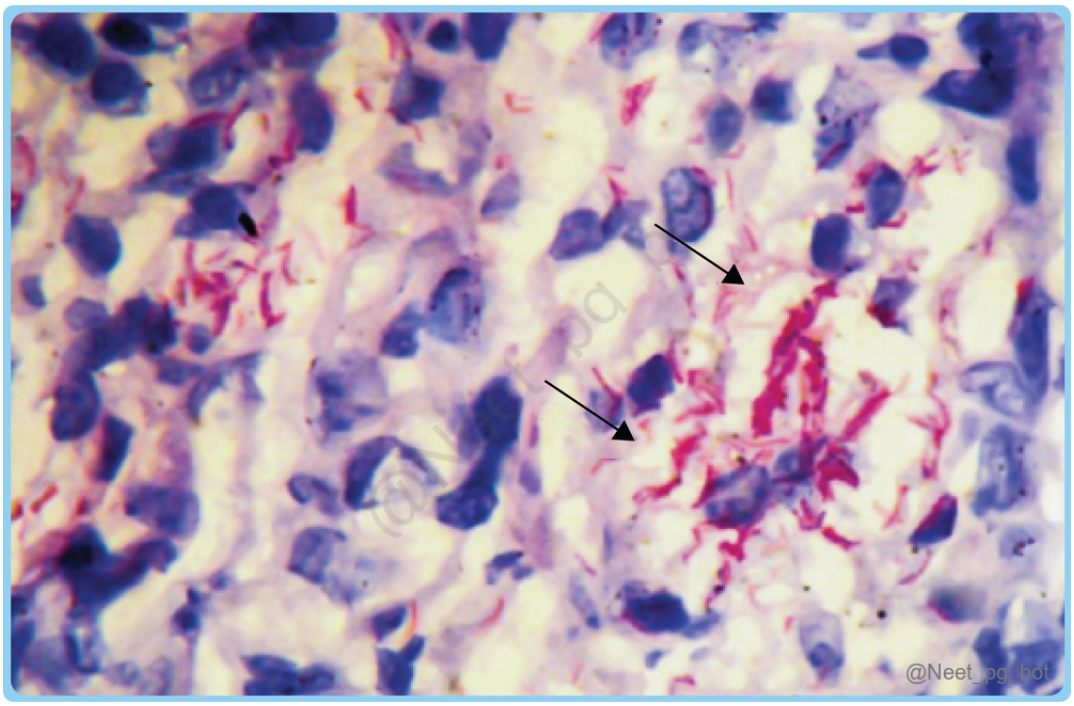

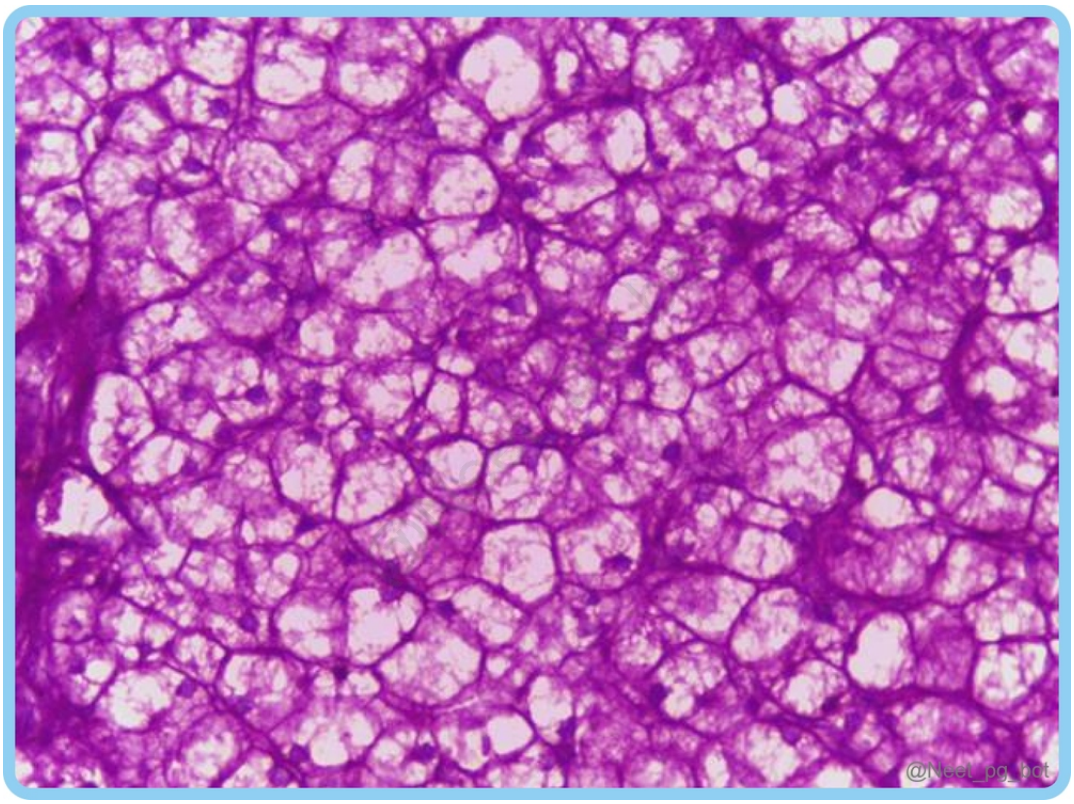

References:

Robbins & Cotran Pathologic Basis of Disease, 10th Edition, Page 259, 260, 574, 655, 768, 848

↑ *Back to this question in Part A*

@Neet_pg_bot

Q35: The following image shows an instrument used to estimate haemoglobin levels. What does it measure? (Q855893)

A. Alkaline hematin

B. Acid hematin

C. Oxyhemoglobin

D. Deoxyhemoglobin



@Neet_pg_bot

Correct Answer: B. Acid hematin

Explanation: The image depicts a device known as the Sahli hemoglobinometer, which is used to estimate haemoglobin levels in blood. The hemoglobinometer works by adding a dilute acid to a small sample of blood, causing the formation of acid hematin , a derivative of haemoglobin formed when haemoglobin reacts with an acid. This acid hematin is then compared to a standard colour chart to determine the haemoglobin concentration.

References:

https://pmc.ncbi.nlm.nih.gov/articles/PMC2536237/

↑ *Back to this question in Part A*

Q36: The given inclusion bodies are characteristic of which of the following organisms? (Q858119)

A. Human papillomavirus

B. Cytomegalovirus

C. Epstein-Barr virus

D. Herpes simplex virus

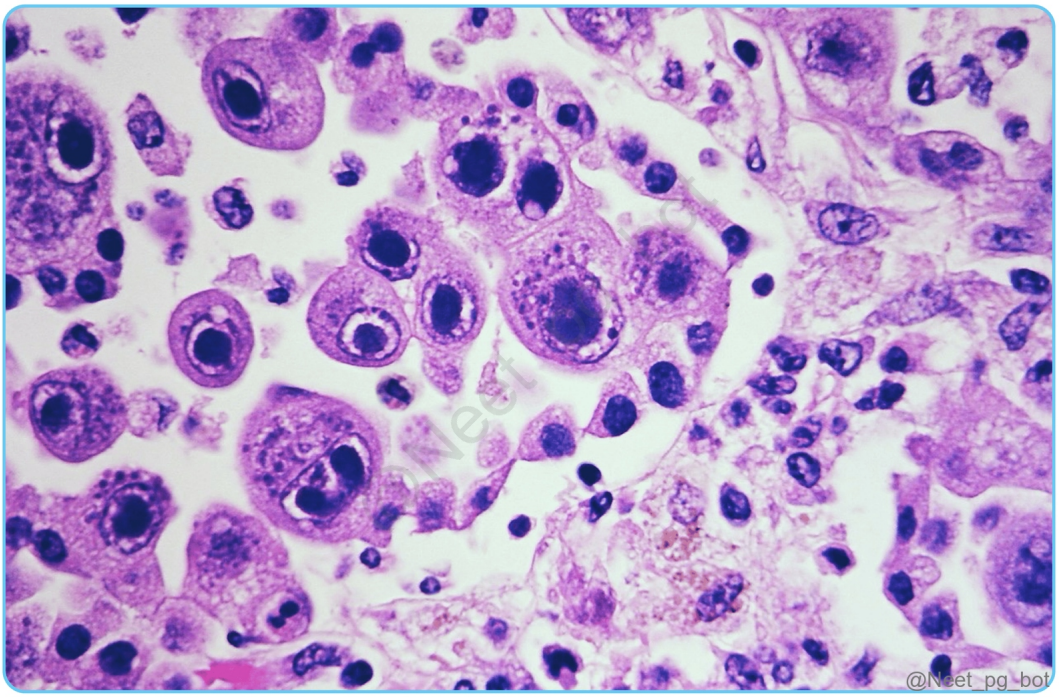

Correct Answer: B. Cytomegalovirus

Explanation: The presence of inclusion bodies, which gives the characteristic “Owl-eye appearance,” suggests Cytomegalovirus. CMV infection Modes of transmission Oral route, respiratory & body secretions (most common) Vertical transmission Sexual transmission Organ transplantation Blood transfusion Investigations Peripheral smear Owl’s eye appearance of inclusion bodies {{caption_text}} Virus isolation It is done by Human fibroblast cell line culture Shell vial culture Antigen detected PP65 Antibody detection It is done by ELISA, and the antibodies detected are CMV IgM antibodies. CMV IgG antibodies. Against PP150 and PP65. Against the PP52. PCR Used in detecting CMV DNA. Quantitative nucleic acid testing (QNAT) by PCR is the most sensitive and specific testing. Treatment Ganciclovir (drug of choice) Foscarnet (in Ganciclovir resistance) CMV immunoglobulins and Ganciclovir are given to bone marrow transplant patients. Incorrect Options: Human papillomavirus (Option A) is a sexually transmitted virus, including low-risk strains 6 & 11, causing benign

genital warts, and high-risk strains 16 & 18 , linked to cervical carcinoma, vulvar intraepithelial neoplasia (VIN) and vulvar carcinoma. It is characterised by the presence of enlarged, hyperchromatic nuclei with perinuclear halos (koilocytes) in the superficial layers of the epithelium. {{caption_text}} Epstein-Barr virus (Option C) is primarily associated with infectious mononucleosis and certain lymphoproliferative disorders. It is characterised by ‘ Downey cells’, i.e. atypical lymphocytes (large, vacuolated) and Ballerina skirt appearance. {{caption_text}} Herpes simplex virus (Option D) causes vesicular lesions and is characterised by intranuclear inclusion bodies in infected cells. It is characterised by multinucleated giant cells with faceted nuclei and homogeneously stained 'ground-glass' chromatin (Tzanck cells) in the Tzanck smear and the formation of Lipschutz bodies (Cowdry type A). {{caption_text}}

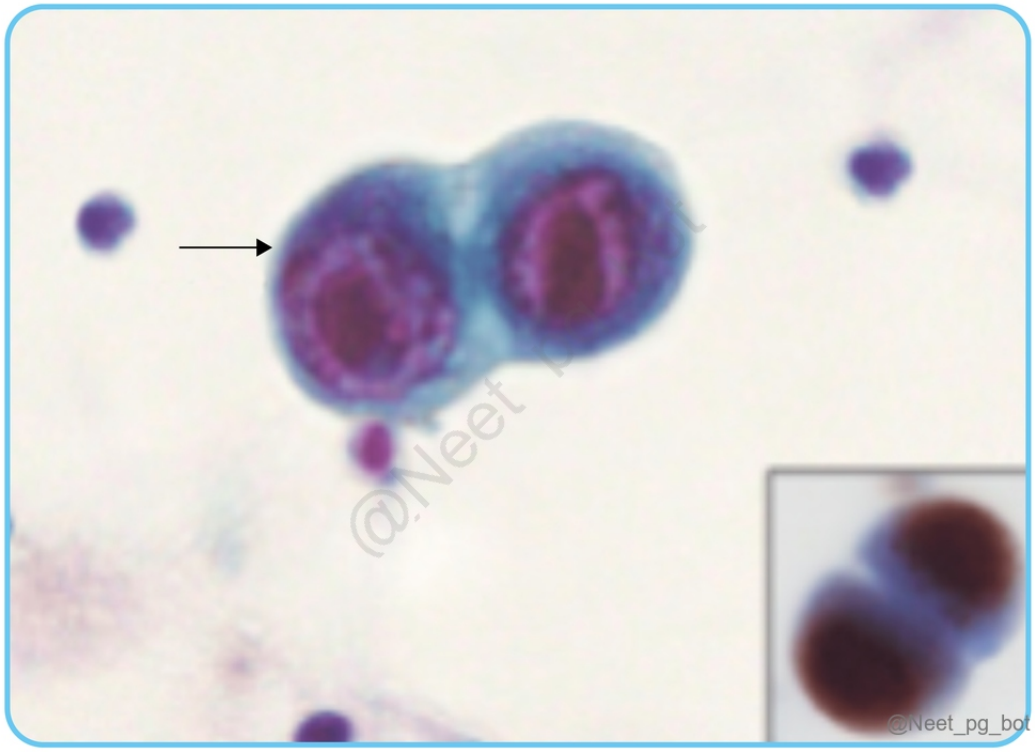

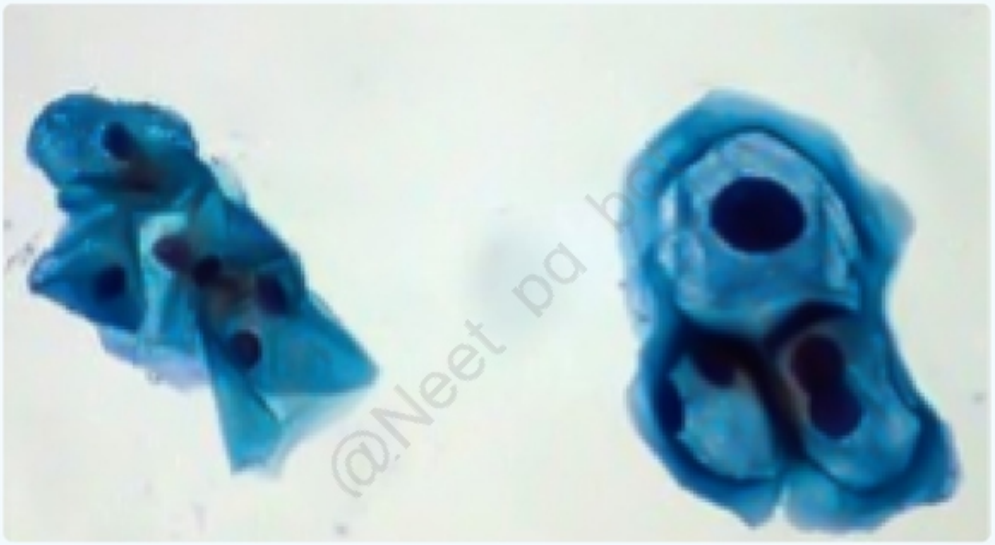

Koilocytes showing perinuclear halo on pap smear

@Neet_pg_bot

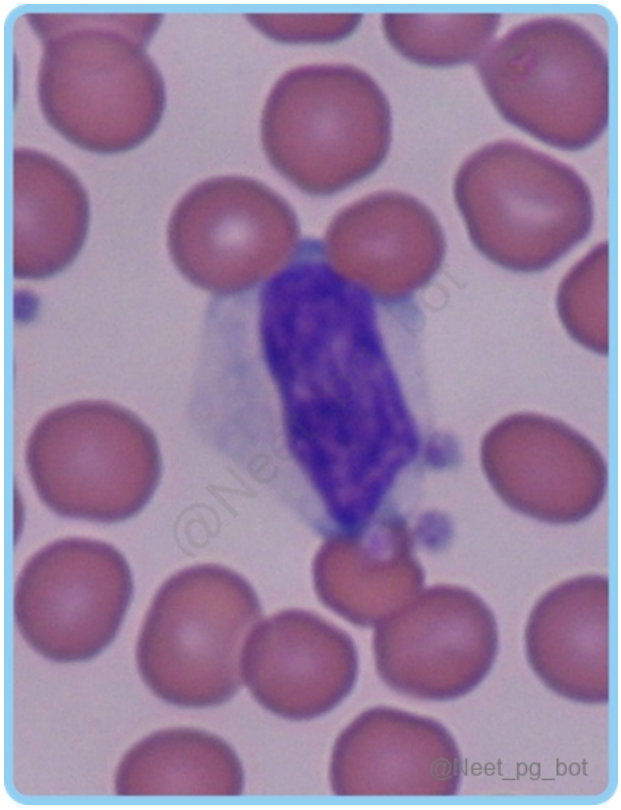

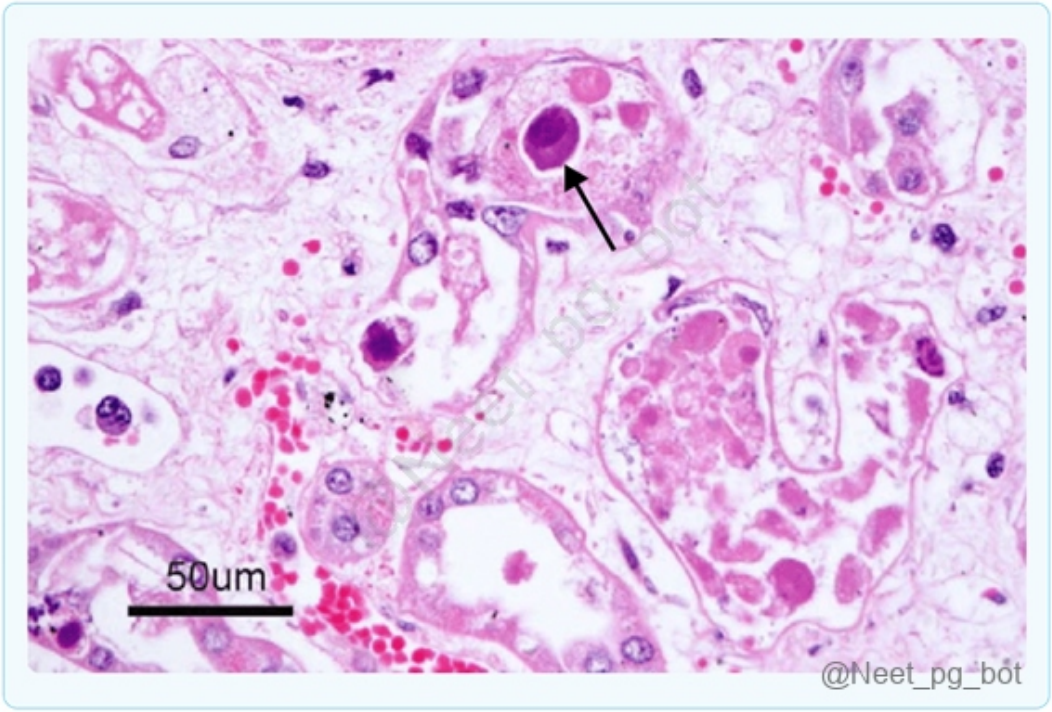

References:

Apurba S Sastry's Essentials of Medical Microbiology, 3rd Edition, Page 795, 796, 797

↑ *Back to this question in Part A*

@Neet_pg_bot

Q37: A 20-year-old female with easy fatiguability and pallor presented to the OPD. The image of her hand is shown below. What is the most likely diagnosis? (Q856480)

A. Aplastic anemia

B. Vitamin B12 deficiency

C. Iron deficiency anaemia

D. Hypoalbuminemia



Correct Answer: C. Iron deficiency anaemia

Explanation: The image shows koilonychia, a concave nail deformity with raised edges, commonly seen in iron deficiency anaemia. The patient's fatigue and pallor further support this diagnosis. Iron deficiency anaemia: Iron deficiency anaemia can result from dietary lack, impaired absorption, increased iron requirement (e.g., during pregnancy), or chronic blood loss (e.g., gastrointestinal bleeding). Clinical features include Koilonychia , alopecia, atrophic glossitis, oesophagal webs, pica and intestinal malabsorption, affecting overall nutritional status. Characteristic changes seen in peripheral smear: Hypochromic: The RBCs appear pale due to decreased haemoglobin content. Microcytic: RBCs are smaller than normal due to decreased haemoglobin synthesis. {{caption_text}} Anisocytosis: There is significant variation in the size of RBCs. Poikilocytosis: RBCs may show abnormal shapes, such as pencil cells, target cells (codocytes), and occasionally, elliptocytes. Iron Study Interpretation in Iron Deficiency Anemia Serum Ferritin Low (< 30 ng/mL) indicates depleted iron stores. Serum Iron (Fe) Low levels are seen in iron deficiency anaemia. Total Iron Binding Capacity (TIBC) Increased TIBC reflects the increased capacity of transferrin to bind iron in response to low iron stores. Red Cell Distribution Width (RDW) Increased RDW is often seen in iron deficiency anaemia Bone Marrow Aspiration and Iron Staining Confirmatory test Aplastic anaemia (Option A) is a condition where the bone marrow fails to produce enough blood cells, resulting in a reduction of red blood cells, white blood cells, and platelets. Vitamin B12 deficiency (Option B) leads to megaloblastic anaemia and is often accompanied by neurological symptoms such as numbness and tingling. Hypoalbuminemia (Option D) is characterized by low blood albumin levels. It is associated with Muehrcke's lines , which appear as paired, narrow white bands on the fingernails. {{caption_text}}

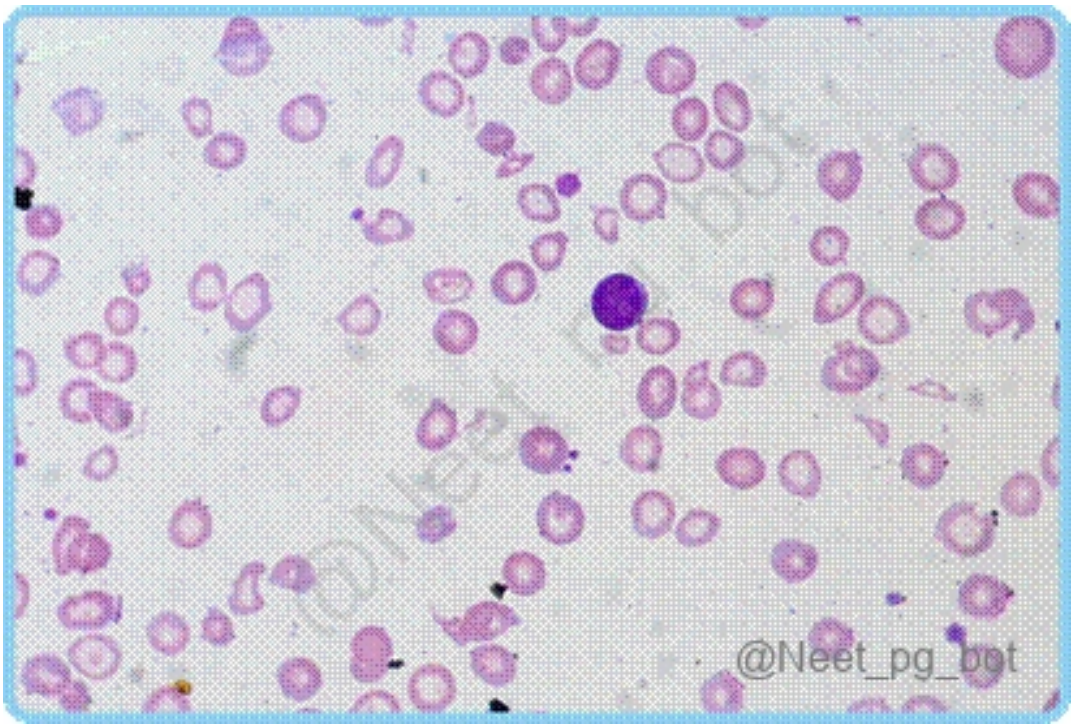



References:

Robbins & Cotran Pathologic Basis of Disease, 10th Edition, Page 655, 658

↑ *Back to this question in Part A*

@Neet_pg_bot

Q38: The image below represents the presence of HER2 neu cells in a patient with breast carcinoma. What agent is used to produce this characteristic discolouration? (Q854670)

A. FITC

B. Phycoerythrin

C. Cyanate dye

D. Diaminobenzidine

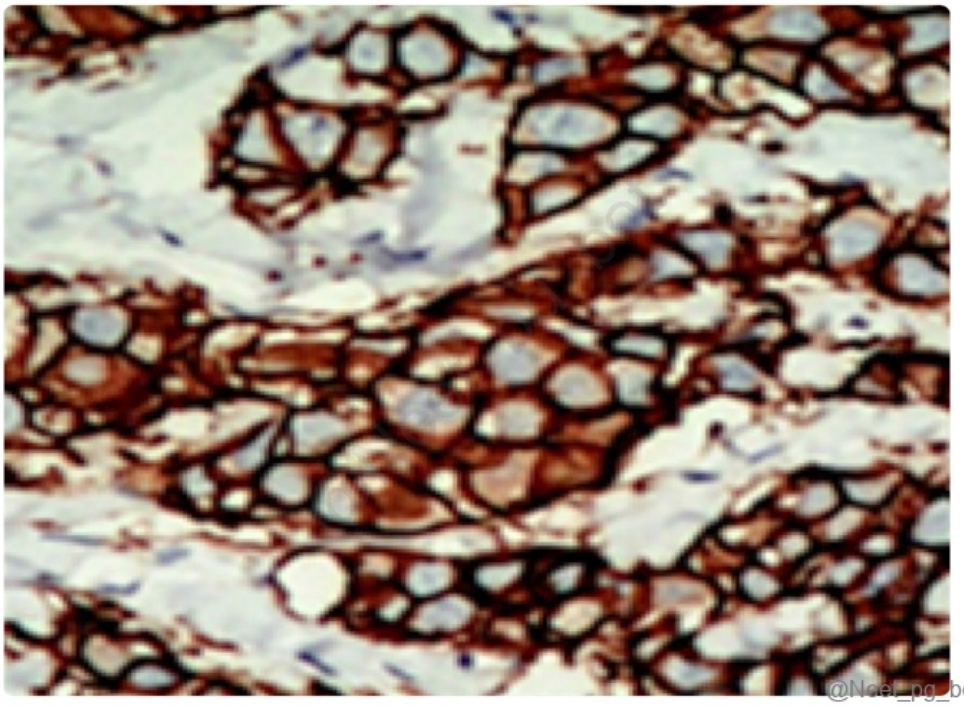

Correct Answer: D. Diaminobenzidine

Explanation: 3,3′-Diaminobenzidine (DAB) is a commonly used chromogen in immunohistochemistry (IHC) to detect HER2 overexpression in certain breast cancers. It serves as a substrate for a peroxidase enzyme coupled to a primary or secondary antibody. It is oxidised and converted to an insoluble polymer, precipitating as a dark brown pigment, which allows visualisation of the target molecule. FITC (Fluorescein Isothiocyanate) (Option A) is a fluorescent dye that is used in fluorescence microscopy to detect specific antigens but does not produce a brown colour. It would instead produce a green fluorescence. Phycoerythrin (Option B) is another fluorescent dye often used in flow cytometry and fluorescence microscopy but does not produce a brown colouration. It fluoresces red-orange and is used for labelling antibodies. Cyanate dye (Option C) is commonly used in fluorescence-based applications such as fluorescent labelling of biomolecules in biological and biochemical research. These dyes are known for their high sensitivity and photostability.

References:

NIH Link , Link

↑ *Back to this question in Part A*

@Neet_pg_bot

Q39: CD markers can be detected by which of the following tests? (Q866390)

A. Cytogenetics

B. Next-generation sequencing

C. Flow cytometry

D. Karyotype

Correct Answer: C. Flow cytometry

Explanation: CD markers (Cluster of Differentiation) are surface proteins used to identify and classify immune cells, and they are typically detected using Flow Cytometry , which employs fluorescent-labeled antibodies. Principle : Detects physical and chemical characteristics of individual cells in a fluid stream using laser-based technology. Detects : CD markers (surface antigens) using fluorescent-labeled antibodies. Cell size, granularity, and fluorescence. Used in : Immunophenotyping (e.g., leukemia/lymphoma classification) Stem cell enumeration Monitoring HIV (CD4 count) Output : Dot plots or histograms showing expression of specific markers. Incorrect Options: Cytogenetics (Option A): Detects chromosomal abnormalities, not surface markers. Next-generation sequencing (NGS) (Option B): Detects gene mutations, not surface proteins. Karyotype (Option D): Analyzes chromosome structure and number, not proteins.

↑ *Back to this question in Part A*

@Neet_pg_bot

Q40: In Pap smear cytology, which of the following is the most appropriate fixative used to preserve cellular details immediately after smearing? (Q866744)

A. 50% formaldehyde

B. 95% ethanol

C. 70% ethanol

D. 10% buffered formalin

Correct Answer: B. 95% ethanol

Explanation: 95% ethanol is the fixative used in a conventional pap smear. Fixatives are chemicals that preserve biological tissues by stabilizing cellular structures and preventing decay or degradation. The goal is to maintain the tissue in a life-like state as much as possible for microscopic examination. Fixation helps maintain the tissue's integrity by preventing autolysis (self-digestion) and putrefaction (bacterial decay). Crosslinking Fixatives: These fixatives work by forming covalent bonds between the proteins and other cellular structures, effectively "locking" them in place. This preserves the tissue's structural integrity. Formaldehyde: Most commonly used in the form of 10% neutral-buffered formalin. (Option D) Glutaraldehyde : Often used for electron microscopy due to its ability to preserve fine cellular structures. Osmium tetroxide : Used primarily for electron microscopy, particularly for preserving lipids and membranes. Precipitating Fixatives: These work by precipitating proteins and other cellular components, which makes them less soluble and helps preserve their structure. Methanol Ethanol Additive Fixatives: They chemically bind to tissue components, such as proteins or nucleic acids, and stabilise them. They are typically more gentle and produce better preservation of ultrastructure. Formaldehyde (Option A) Glutaraldehyde Non-Additive Fixatives: Alcohol Acetone Pap smear Site The transformation zone of the cervix, where the squamous epithelium (ectocervix) and columnar epithelium (endocervix) meet. This is the most common site for cervical cancer to develop. Instruments Ayre spatula collects cells from the ectocervix Cervical broom (also called a cytobrush) from the transition zone Endocervical brush from the endocervix Procedure Conventional Pap smear : Cells are collected with a spatula or brush, smeared onto a slide, and immediately fixed with a spray fixative or by immersing in 95% ethanol with/without ether Liquid-based cytology : Cells are collected and then rinsed into a liquid fixative vial. This is considered more sensitive than the conventional Pap smear as it provides a more uniform distribution of cells.

↑ *Back to this question in Part A*

@Neet_pg_bot

Q41: Which of the following measures is associated with an increased life span? (Q855961)

A. Regular moderate exercise for 30 min

B. Decrease stress

C. Decreasing calorie intake by 30%

D. Pharmacological intervention with proton pump inhibitors

Correct Answer: C. Decreasing calorie intake by 30%

Explanation: aloric restriction has increased lifespan across various species, including nonhuman primates and humans. This is linked to two key neurohormonal circuits regulating metabolism: Insulin and IGF-1 Signaling IGF-1, produced in response to growth hormone, mimics insulin signalling, promoting an anabolic state, cell growth, and replication. Sirtuins These are NAD-dependent deacetylases that help adapt to stressors like food deprivation and DNA damage. They promote longevity by regulating genes that reduce metabolic activity, apoptosis, and oxidative damage. Sirtuins also improve insulin sensitivity and glucose metabolism. Caloric

restriction reduces IGF-1 signalling, which may reduce cellular damage while simultaneously increasing sirtuins, particularly sirtuin-6 , to promote DNA repair and metabolic adaptation. Hence, caloric restriction, particularly a reduction in calories by about 20-30%, can reduce IGF-1 signalling and increase sirtuin activity, which together is thought to extend lifespan. Regular moderate exercise for 30 min (Option A) is associated with numerous health benefits, like improved cardiovascular health, better metabolic function, and reduced risk of chronic diseases. While it may increase health span , it is not as directly proven to increase lifespan compared to caloric restriction. Decrease stress (Option B): Chronic stress is associated with a range of negative health effects, all of which can reduce lifespan. Stress management techniques can help improve health and increase longevity, but this relationship is more indirect and variable. Pharmacological intervention with proton pump inhibitors (Option D) : PPIs are used to reduce stomach acid and treat conditions like GERD and peptic ulcers. While they are effective for symptom relief, they are not associated with increased lifespan.

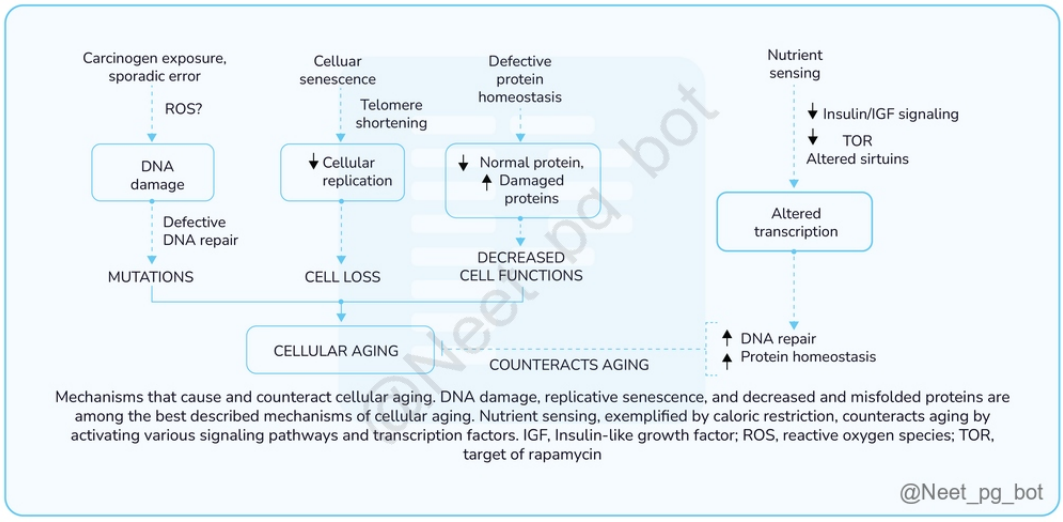

Mechanisms that cause and counteract cellular aging. DNA damage, replicative senescence, and decreased and misfolded proteins are among the best described mechanisms of cellular aging. Nutrient sensing, exemplified by caloric restriction, counteracts aging by activating various signaling pathways and transcription factors. IGF, Insulin-like growth factor; ROS, reactive oxygen species; TOR, target of rapamycin

@Neet_pg_bot

References:

Robbins and Cotran Pathologic Basis of Disease, 10th Edition, Page 80

↑ *Back to this question in Part A*

@Neet_pg_bot

Q42: Choose the correct statement regarding the telomerase theory of ageing: (Q855914)

A. Telomere stability is associated with ageing

B. Abnormal telomerase activation is associated with ageing

C. Decreased telomere length is associated with ageing

D. Increased telomere length is associated with ageing

Correct Answer: C. Decreased telomere length is associated with ageing

Explanation: : Telomere stability refers to maintaining the length of telomeres, which are protective caps at the ends of chromosomes. As we age, telomeres shorten rather than remain stable, which is a key factor in cellular ageing, not stability. Abnormal telomerase activation is associated with ageing (Option B): Abnormal telomerase activation is more commonly associated with cancer (where cells avoid normal ageing and continue to divide) rather than the ageing process itself. In ageing, telomerase activity tends to decline, not increase.

References:

Robbins and Cotran, Pathologic Basis of Disease, 10th Edition, Pages 67, 68

↑ *Back to this question in Part A*

@Neet_pg_bot

Q43: The body of an 82-year-old man has been seen for a post-mortem to determine the cause of death. You are examining a histopathological slide containing a section of his cardiac tissue where you notice some pigmentation. Which is the substance that is seen in the image given below? (Q859859)

A. Melanin

B. Lipofuscin

C. Hemosiderin

D. Iron

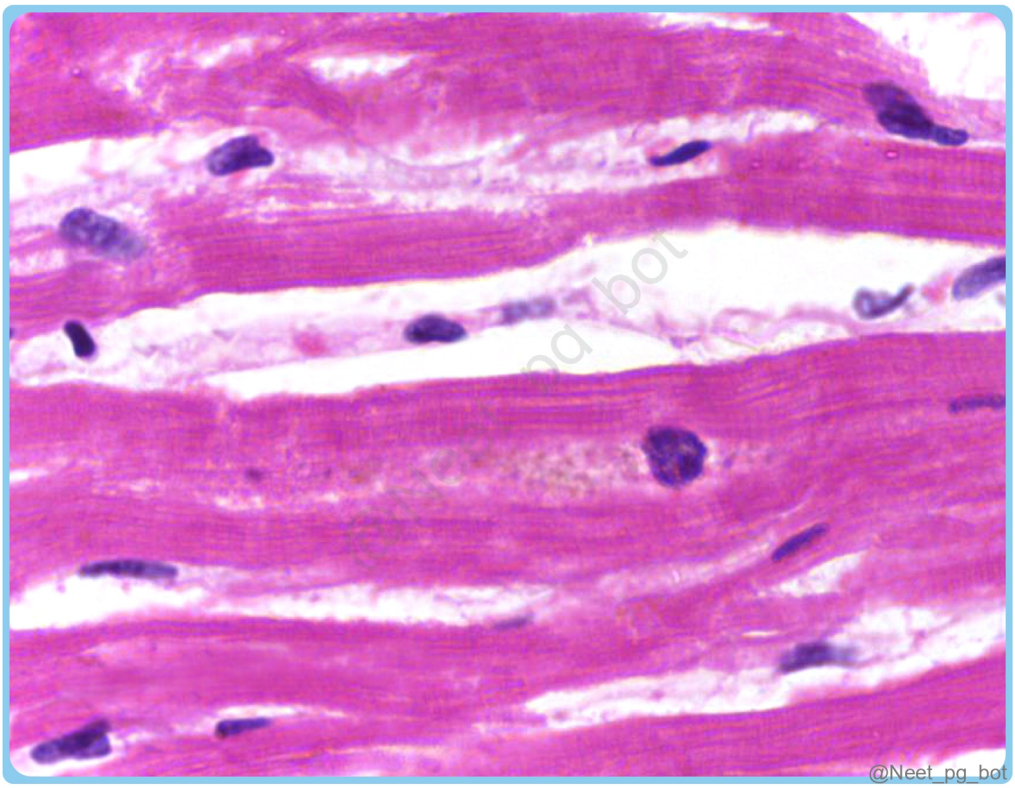

Correct Answer: B. Lipofuscin

Explanation: The histopathological image shows lipofuscin in the section of cardiac tissue. Lipofuscin is a yellow to red-brown pigment found in cardiac muscle cells, particularly around the nucleus in the hearts of elderly, debilitated people. {{caption_text}} Melanin (Option A) is a black or brown pigment found in skin, hair, and certain brain areas, not typically seen in cardiac tissue. Hemosiderin (Option C) is an iron-storage complex resulting from the breakdown of haemoglobin, typically associated with conditions like haemorrhage or hemochromatosis. Iron (Option D) : Elemental iron deposition in tissues is pathological and associated with diseases like hemochromatosis or chronic blood transfusions. Staining with Prussian blue would help confirm iron presence.

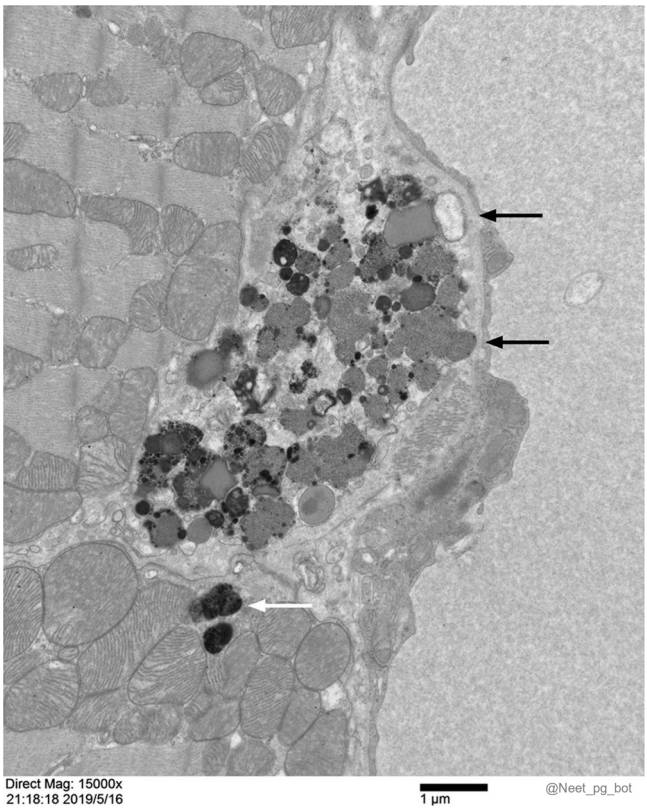

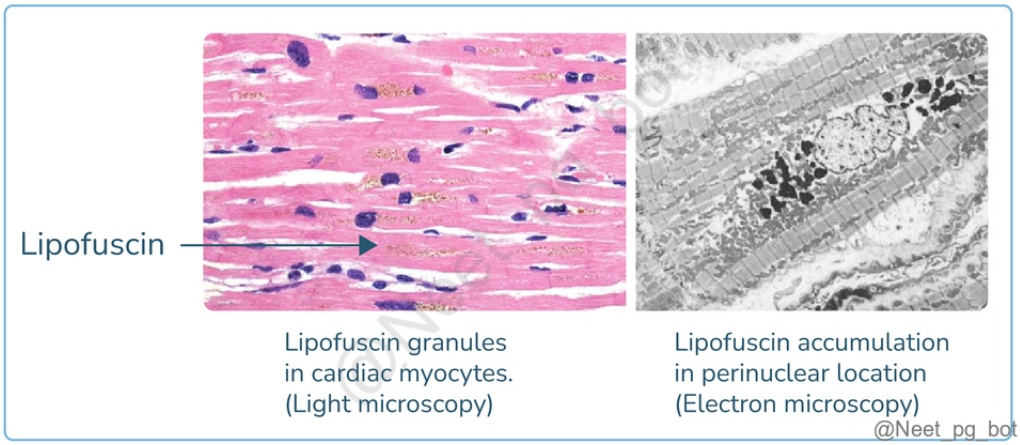

References:

Robbins & Cotran Pathologic Basis of Disease, 10th Edition, Pages 64, 65

↑ *Back to this question in Part A*

@Neet_pg_bot

Q44: Among the following, which molecule is required for the presentation of the antigens by the APCs to TH2 cells? (Q859298)

A. NK cells

B. G-protein coupled receptor

C. MHC

D. Lectin receptor

Correct Answer: C. MHC

Explanation: Antigen-presenting cells (APCs) such as dendritic cells, macrophages, and B cells play a crucial role in the adaptive immune response by presenting antigens to T-helper (TH2) cells . This process requires Major Histocompatibility Complex (MHC) Class II molecules , which are essential for the activation of CD4+ T cells, including TH2 cells. MHC Molecule Role : APCs process antigens and present them on their surface bound to MHC Class II molecules. MHC Class II molecules interact with the T-cell receptor (TCR) on CD4+ T cells. This interaction is critical for the differentiation and activation of TH2 cells, which secrete cytokines to mediate humoral immunity. Incorrect Options: NK cells (Option A) are part of the innate immune system and do not present antigens or directly interact with TH2 cells. G-protein coupled receptors (Option B) are involved in cell signalling but are not involved in antigen presentation to T cells. Lectin receptors (Option D) are involved in innate immune recognition, particularly of carbohydrate molecules, but they do not mediate antigen presentation to TH2 cells.

References:

Robbins and Cotran Pathologic Basis of Disease, 10th Edition, Page 192-200.

↑ *Back to this question in Part A*

@Neet_pg_bot

Q45: Which of the following caspases binds to Cyt c and the APAF-1 complex? (Q856488)

A. Caspase 1

B. Caspase 8

C. Caspase 9

D. Caspase 4

Correct Answer: C. Caspase 9

Explanation: In the intrinsic apoptotic pathway , the release of cytochrome c (Cyt c) from the mitochondria triggers the formation of the apoptosome, a complex consisting of Cyt c, apoptotic protease-activating factor 1 (APAF-1), and procaspase 9. This complex is essential for initiating the caspase cascade that leads to cell death.

Apoptosis (Caspase-dependent programmed cell death): Apoptosis is a type of cell death that is induced by a tightly regulated suicide program in which cells destined to die activate intrinsic enzymes that degrade the cells' genomic DNA and nuclear and cytoplasmic proteins. It is an active process. It eliminates cells that are injured beyond repair without eliciting a host reaction, thus limiting collateral tissue damage. Apoptosis results from activating enzymes called caspases, leading to DNA fragmentation. The process of apoptosis may be divided into an initiation phase , during which caspases 8,9,10 become catalytically active and unleash a cascade of other caspases, and an execution phase , during which the terminal caspases 3,6,7 trigger cellular fragmentation. Morphological features:- Cell shrinkage Chromatin condensation Formation of cytoplasmic blebs and apoptotic bodies Phagocytosis of apoptotic bodies, usually by macrophages. Histopathology: In H&E-stained tissue, the apoptotic cell appears as a round or oval mass of intensely eosinophilic cytoplasm with fragments of dense nuclear chromatin. {{caption_text}} The above image shows apoptosis of an epidermal cell in an immune reaction. The cell is reduced in size and contains brightly eosinophilic cytoplasm and a condensed nucleus Types: Apoptosis occurs in two broad contexts: Physiological apoptosis. Pathological apoptosis. Apoptosis in physiological conditions Apoptosis in pathological conditions 1. The removal of supernumerary cells (in excess of the required number) during development. 2. Involution of hormone-dependent tissues on hormone withdrawal, such as endometrial cell breakdown during the menstrual cycle. 3. Elimination of potentially harmful self-reactive lymphocytes to prevent immune reactions against one's own tissues. 4. Death of host cells that have served their useful purpose, such as neutrophils in an acute inflammatory response and lymphocytes at the end of an immune response. 1. DNA damage. 2. Accumulation of misfolded proteins 3. Apoptosis can be induced during infections such as adenovirus , HIV , and viral hepatitis . 4. It may also contribute to pathologic atrophy in parenchymal organs after duct obstruction, such as occurs in the pancreas, parotid gland, and kidney

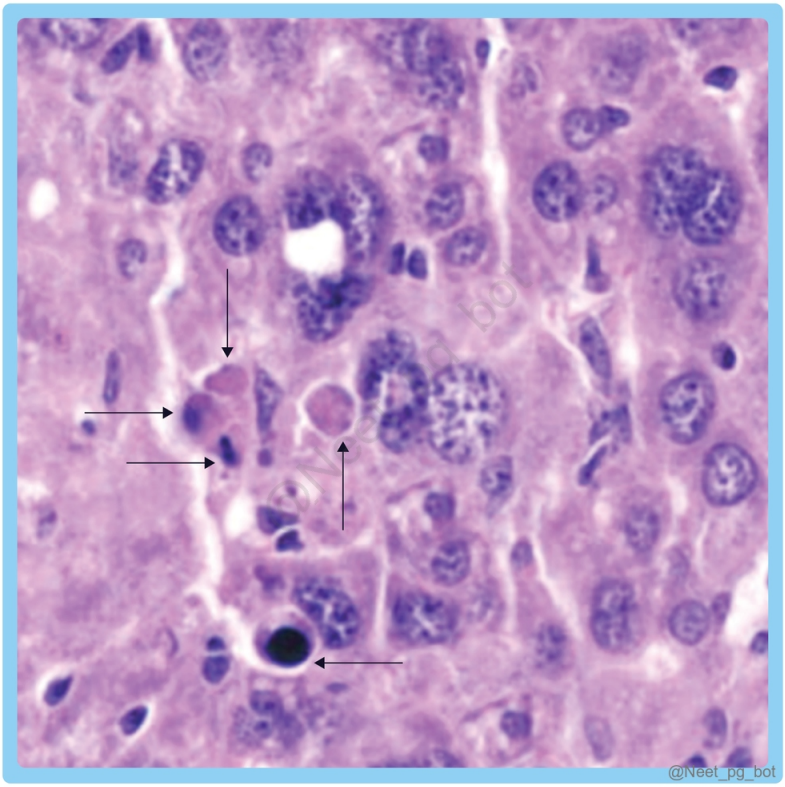

References:

Robbins & Cotran Pathologic Basis of Disease, 10th Edition, Page 42,43

↑ *Back to this question in Part A*

@Neet_pg_bot

Q46: All of the following are crosslinking fixatives except? (Q856893)

A. Glutaraldehyde

B. Formaldehyde

C. Methanol

D. Osmium tetroxide

Correct Answer: C. Methanol

Explanation: Methanol is not a crosslinking fixative. It is a dehydrant coagulant fixative. Fixatives are chemicals that preserve biological tissues by stabilizing cellular structures and preventing decay or degradation. The goal is to maintain the tissue in a life-like state as much as possible for microscopic examination. Fixation helps maintain the tissue's integrity by preventing autolysis (self-digestion) and putrefaction (bacterial decay). Crosslinking Fixatives: These fixatives work by forming covalent bonds between the proteins and other cellular structures, effectively "locking" them in place. This preserves the tissue's structural integrity. Formaldehyde (Option B) : Most commonly used in the form of 10% neutral-buffered formalin. Glutaraldehyde (Option A) : Often used for electron microscopy due to its ability to preserve fine cellular structures. Osmium tetroxide (Option D) : Used primarily for electron microscopy, particularly for preserving lipids and membranes. Precipitating Fixatives: These work by precipitating proteins and other cellular components, which makes them less soluble and helps preserve their structure. Methanol Ethanol Additive Fixatives: They chemically bind to tissue components, such as proteins or nucleic acids, and stabilize them. They are typically more gentle and produce better preservation of ultrastructure. Formaldehyde Glutaraldehyde Non-Additive Fixatives: Alcohol Acetone

References:

Bancroft's Theory and Practice of Histological Techniques, 8th Edition, Page 40-44.

↑ *Back to this question in Part A*

@Neet_pg_bot

Q47: A chronic alcoholic patient presented with increasing abdominal girth. On examination, shifting dullness was present, and the liver span was less than 7cm. Histopathological examination revealed the presence of intracytoplasmic eosinophilic inclusions in hepatocytes. What is the content of these inclusions? (Q856152)

A. Intermediate filaments

B. Actin

C. Microtubules

D. Fibronectin

Correct Answer: A. Intermediate filaments

Explanation: The presence of intracytoplasmic eosinophilic inclusions in hepatocytes is a key finding in alcoholic liver disease. Mallory-Denk bodies or Mallory hyaline bodies are eosinophilic , intracytoplasmic inclusions composed of intermediate filaments, particularly cytokeratin 8 and 18, commonly seen in hepatocytes in conditions such as alcoholic liver disease. Conditions where Mallory Hyaline bodies are seen are (Mnemonic: N ew Indian WATCH) N on-alcoholic fatty liver disease (NAFLD) Indian childhood cirrhosis W ilson's disease A lpha-1 antitrypsin deficiency ; A lcoholic Liver Disease T umor of the liver (Hepatocellular carcinoma) Chronic C holestatic conditions H epatic or Primary Biliary cirrhosis (not seen in Secondary biliary cirrhosis) {{caption_text}} Actin (Option B) is a structural protein found in microfilaments but does not typically form eosinophilic inclusions in alcoholic liver disease. Microtubules (Option C) are involved in intracellular transport and cell division but do not form eosinophilic inclusions in hepatocytes. Fibronectin (Option D) is an extracellular matrix protein , and although it plays a role in tissue repair and scarring , it is not associated with the formation of intracytoplasmic inclusions in liver cells, especially in alcoholic liver disease.

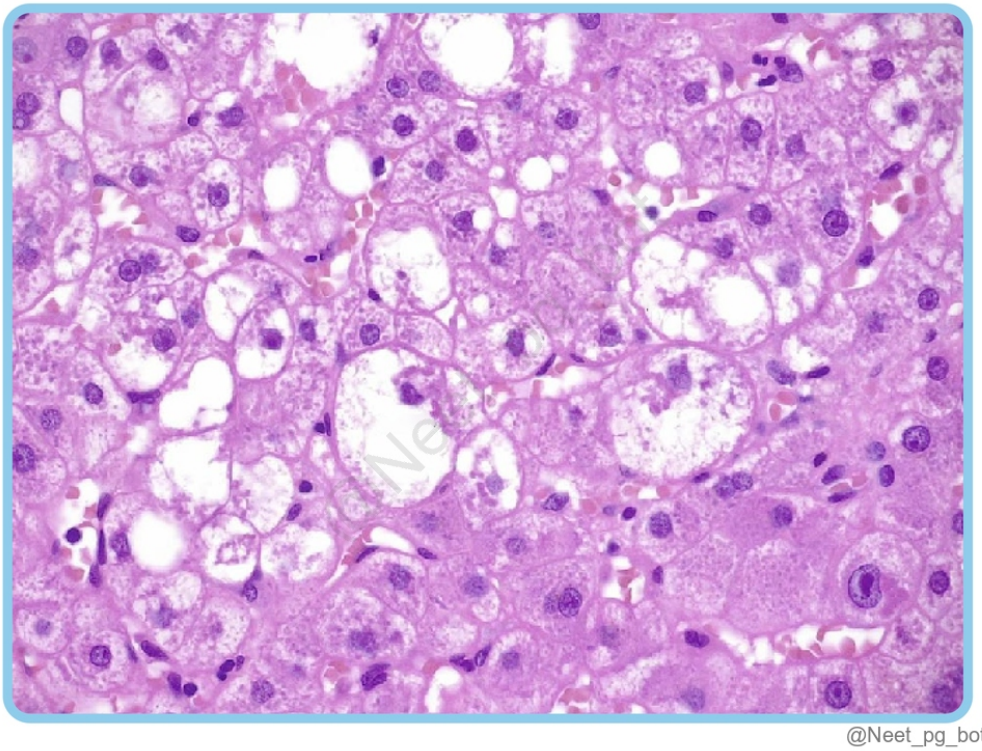

References:

Robbins and Cotran Pathologic Basis of Disease, 10th Edition, Page 843, 1116

↑ *Back to this question in Part A*

@Neet_pg_bot

Q48: A 70-year-old patient presented with cough, fatigue, and weight loss. He was diagnosed with squamous cell carcinoma on bronchoscopy. The resected specimen had a hilar lymph node that was 1 cm in size and showed a black pigment. What is the black pigment likely to be? (Q856097)

A. Anthracotic pigment

B. Melanin

C. Lipochrome

D. Hemosiderin

Correct Answer: A. Anthracotic pigment

Explanation: Anthracotic pigment is a black, carbon-based pigment commonly seen in lymph nodes and lungs, as well as in individuals with chronic smoking or environmental pollution exposure. These particles are engulfed by macrophages in the lungs and then transported to nearby lymph nodes, often leading to anthracosis . HPE shows carbon-laden macrophages. In patients with lung cancer , particularly squamous cell carcinoma , the presence of hilar lymphadenopathy and black pigment is a common finding due to the direct proximity of the lungs and lymphatic drainage of carbon particles. {{caption_text}} Melanin (Option B) is responsible for skin and hair pigmentation and protects against UV radiation. While it can sometimes be found in melanomas (a type of skin cancer), it is not typically found in the lungs or lymph nodes. {{caption_text}} Lipochrome (Option C) is a group of yellow to brown pigments that arise from the breakdown of lipids (fats). On microscopy, it appears as a yellow-brown, finely granular cytoplasmic pigment, often deposited in the perinuclear location. These pigments can be found in various tissues but are not typically associated with lung diseases or lymph node involvement . {{caption_text}} Hemosiderin (Option D) is an iron-containing pigment derived from the breakdown of hemoglobin . While hemosiderin can appear brown, it does not appear as a black pigment in the context of smoking-related lung disease or cancer . {{caption_text}}

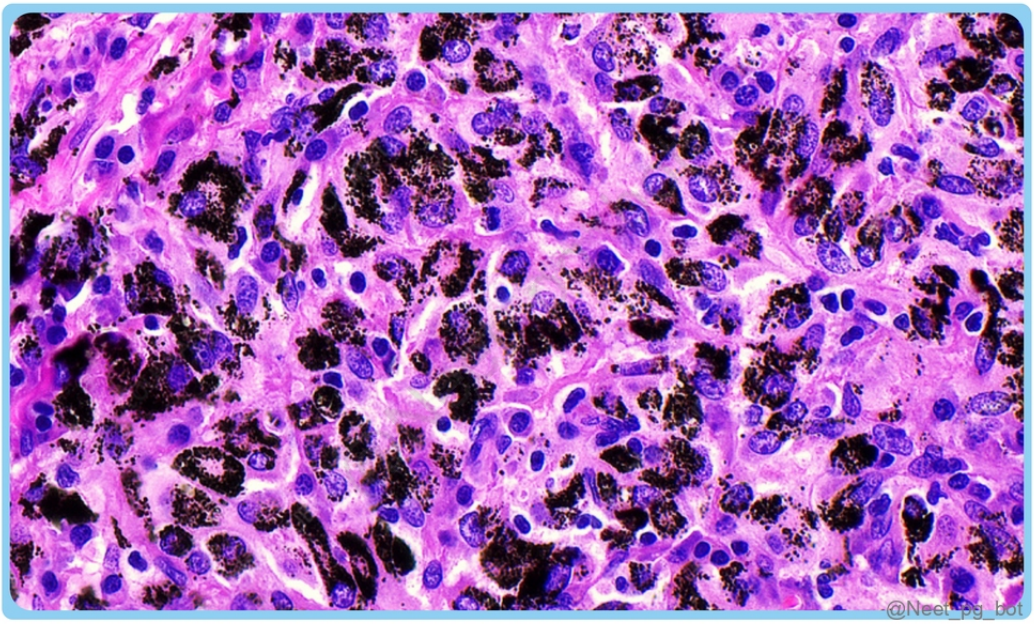
@Neet_pg_bot


Melanin representing
blackish color with
Masson fontasa stain
@Neet_pg_bot

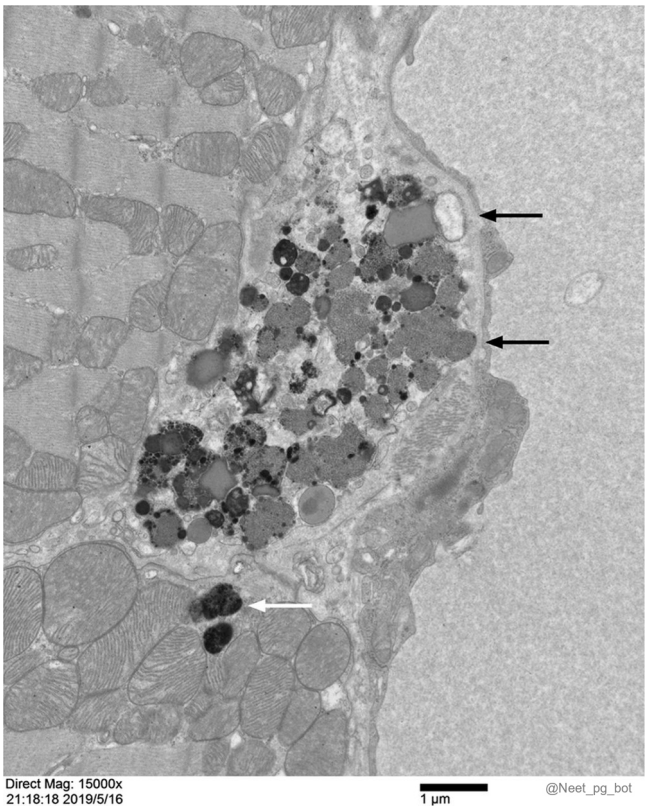
Direct Mag: 15000x
21:18:18 2019/5/16
1 µm
@Neet_pg_bot

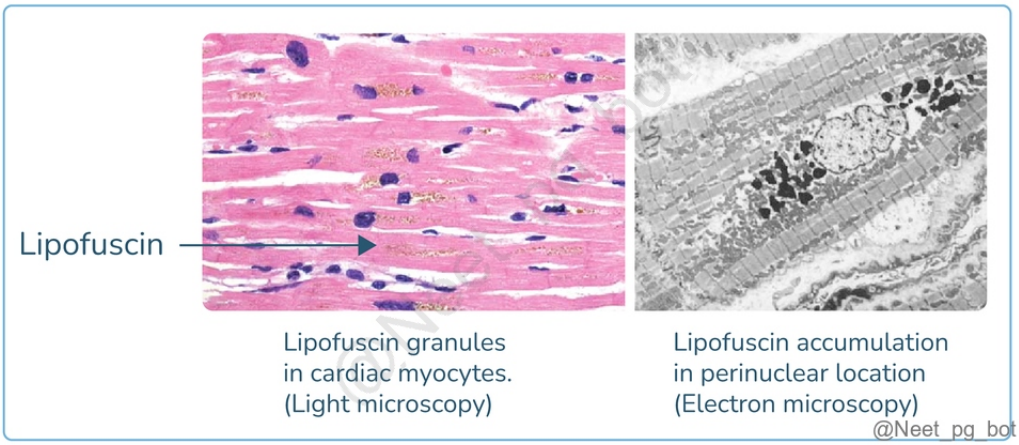
Lipofuscin
Lipofuscin granules
in cardiac myocytes.
(Light microscopy)
Lipofuscin accumulation
in perinuclear location
(Electron microscopy)
@Neet_pg_bot

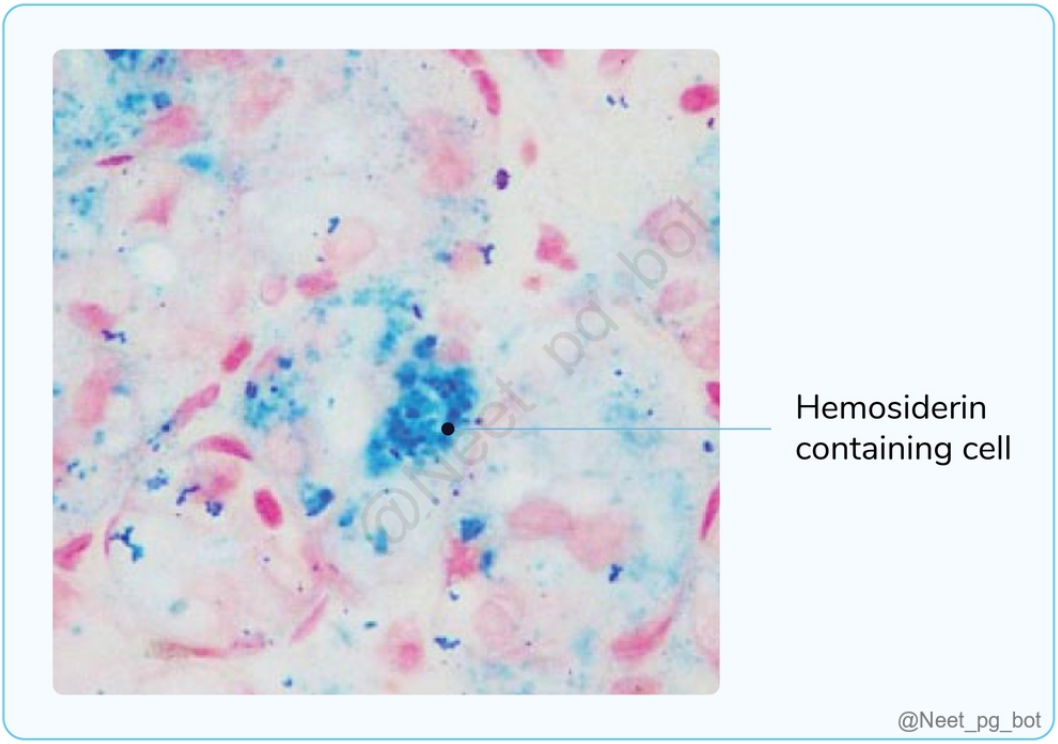

References:

Robbins and Cotran Pathologic Basis of Disease, 10th Edition, Pages 76, 77

Park's Textbook of Preventive and Social Medicine, 27th Edition, Pages 933, 934

↑ *Back to this question in Part A*

@Neet_pg_bot

Q49: A 20-year-old female who is a known case of sickle cell anaemia was rushed to the emergency department with a complaint of extreme pain in the legs and fingers for the past 4 hours. Further examination revealed pain and tenderness in the right upper quadrant, and investigations showed sickle cells on peripheral blood smear and high bilirubin(indirect). What is the diagnosis? (Q860284)

A. IDA

B. Thalassemia

C. Anaemia of chronic disease

D. Sickle cell crisis

Correct Answer: D. Sickle cell crisis

Explanation: The patient, a known case of sickle cell anaemia, presenting with severe leg and finger pain for the past 4 hours, right upper quadrant tenderness, sickle cells on the peripheral blood smear, and elevated indirect bilirubin is likely undergoing a vaso-occlusive crisis (type of sickle cell crisis) , a common complication of Sickle Cell Disease (SCD) . Complications Acute Painful Episodes (Vaso-Occlusive Crisis) Characterised by unprovoked, severe, symmetrical pain often requiring strong opioids The most common acute event in sickle cell disease. Lasting from days to weeks. Sudden death during acute pain episodes can occur, possibly due to arrhythmias or pulmonary embolism. Acute Chest Syndrome: Symptoms include chest pain, cough, fever, hypoxia, and pulmonary infiltrates on x-ray. It can be mild in children (e.g., due to viral infections) or severe with multiple lobes affected. Thrombocytopenia, leukocytosis, and rapid anaemia suggest severe complications like acute respiratory distress syndrome (ARDS) and multiorgan failure. Osteonecrosis: Involves the hips bilaterally . Chronic pain can progress to severe disability; MRI detects early stages, while X-rays are less sensitive. Leg ulcer: Ulcers range from small and superficial to deep, covering most of the lower leg. Painful and difficult to treat if recurrent, long-standing and large ulcer. Other Complications: Priapism Stroke and silent infarction Gallstones/Surgery Hepatic disease Nephropathy Lung/pulmonary hypertension Retinopathy Aplastic crisis: Caused by parvovirus B19 infection Multiorgan failure IDA (Iron Deficiency Anemia) (Option A) presents with microcytic hypochromic anaemia, not sickle cells on the smear. It also lacks acute pain crises and indirect hyperbilirubinemia. Thalassemia (Option B) causes chronic anaemia with target cells, not acute vaso-occlusive pain. It is also associated with ineffective erythropoiesis rather than hemolysis-induced hyperbilirubinemia. Anaemia of chronic disease (ACD) (Option C) is linked to chronic inflammation and cytokine-mediated iron sequestration, typically presenting with normocytic or microcytic anaemia without acute pain crises or hemolysis.

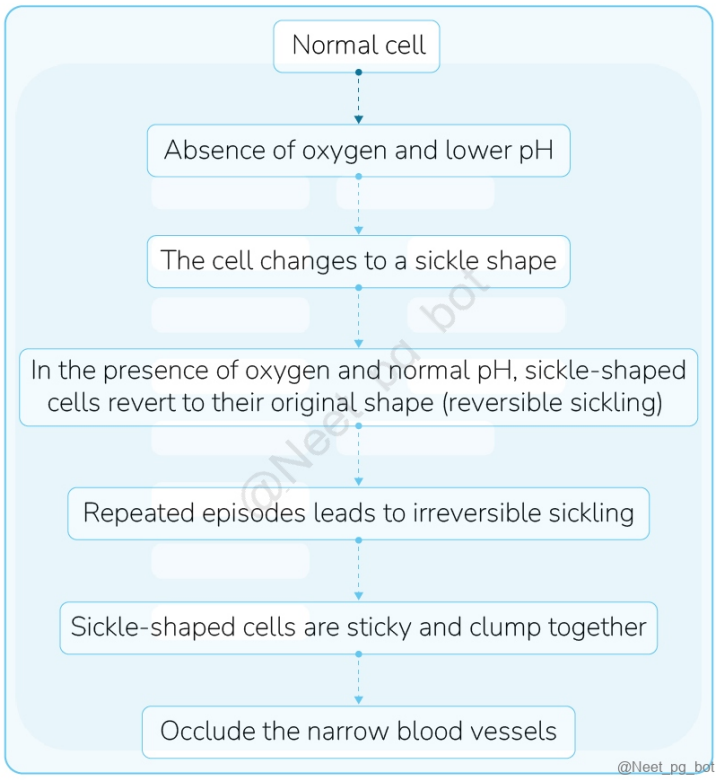

References:

Robbins & Cotran Pathological Basis of Diseases, 10th Edition, Page 643-644.

Harrison’s Principles of Internal Medicine, 21st Edition, Page 758-760.

↑ *Back to this question in Part A*

@Neet_pg_bot

Q50: Investigations of a patient being evaluated for leukaemia revealed a WBC count of 450,000/μL, with eosinophilia and basophilia. What is the likely diagnosis in this case? (Q855989)

A. Acute Lymphoblastic Leukemia (ALL)

B. Chronic Myelogenous Leukemia (CML)

C. Chronic Lymphocytic Leukemia (CLL)

D. Acute Myelogenous Leukemia (AML)

Correct Answer: B. Chronic Myelogenous Leukemia (CML)

Explanation: A very high WBC count (450,000/microliter) with eosinophilia and basophilia is suggestive of Chronic Myelogenous Leukemia (CML) . Chronic Myeloid Leukemia (CML) Category Description Genetics Philadelphia chromosome t(9;22) Origin Myeloid lineage Etiopathogenesis BCR-ABL fusion gene from t(9;22) increases tyrosine kinase activity, leading to uncontrolled myeloid proliferation. Radiation exposure is a risk factor. Clinical Features Affects adults. Presents with splenomegaly, fatigue, weight loss, night sweats, and abdominal discomfort. It can progress to blast crisis, resembling acute leukaemia. Diagnosis Bone marrow aspirate to confirm. FISH detects the BCR-ABL fusion gene. Bone Marrow aspirate findings. Presence of scattered macrophages with abundant wrinkled, green-blue cytoplasm, called sea-blue histiocytes or pseudo-Gaucher cells. The marrow is markedly hypercellular due to massively increased numbers of maturing granulocytic precursors (elevated eosinophils and basophils) Increased megakaryocytes, commonly with small, dysplastic forms called dwarf megakaryocytes. Normal or slightly decreased erythroid progenitors (increased myeloid: erythroid ratio). Increased deposition of reticulin fibres. Management Tyrosine kinase inhibitors (TKIs) like Imatinib. {{caption_text}} Acute Lymphoblastic Leukemia (ALL) (Option A): Lymphoblasts in bone marrow >=20% Cytoplasmic vacuolations They contain fat (Oil Red O Positive) Hand mirror-shaped cells {{caption_text}} Acute Myeloid Leukemia (AML) (Option D) : Blasts ≥ 20% Myeloblasts with AuerRods {{caption_text}} Chronic Lymphocytic Leukemia (CLL) (Option C) : Smudge cells (or parachute/basket cell): Due to the fragility of lymphocytes during slide preparation Convent girl appearance : Lot of homogenous, small, mature-like, round lymphocytes with scant cytoplasm {{caption_text}} Chronic Myeloid Leukemia (CML): Leukocytosis Cell Types: Neutrophils(multilobed nucleus), metamyelocytes (indented nucleus), myelocytes (D-shaped nucleus), and eosinophils (orange cells) College girl/garden party appearance : Due to the variety of cell appearances Shift to the Left: Presence of immature cell types, mainly immature neutrophils, in the blood.

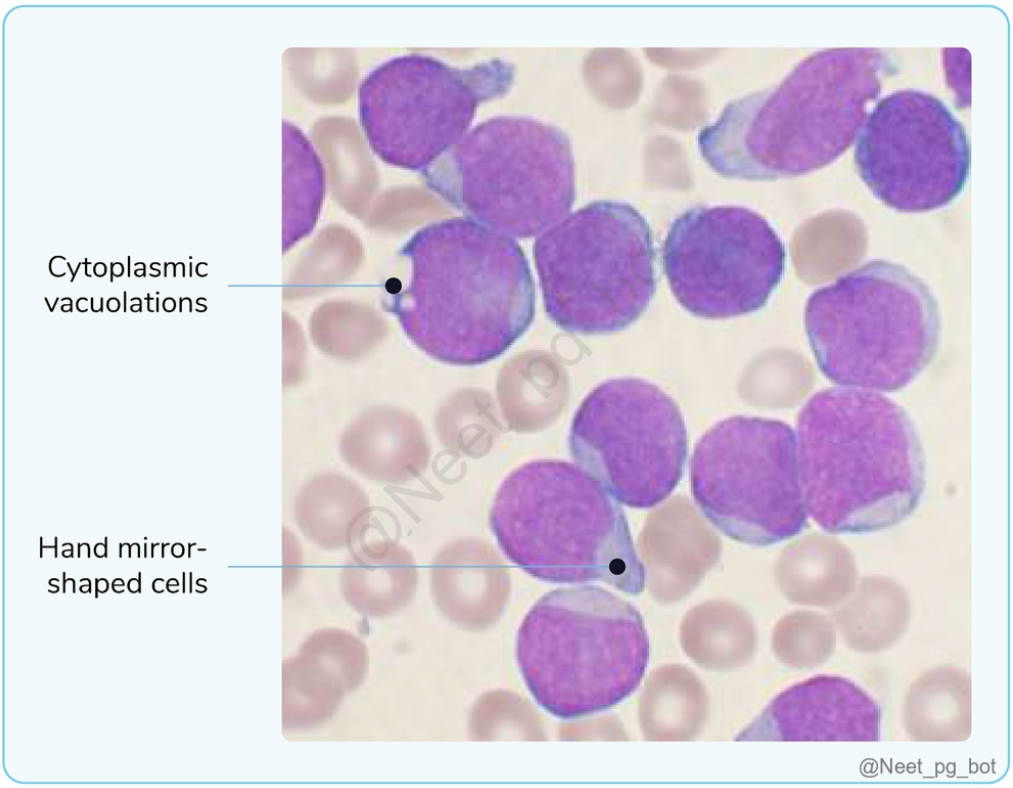
Cytoplasmic vacuolations
Hand mirror-shaped cells
@Neet_pg_bot

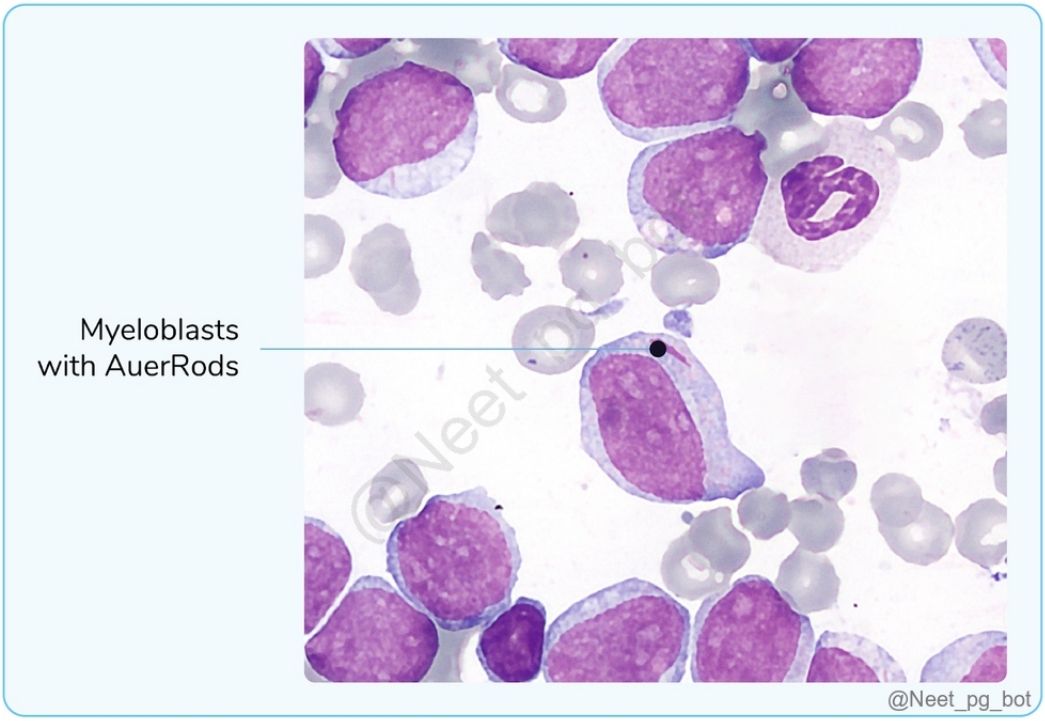
Myeloblasts with AuerRods
@Neet_pg_bot

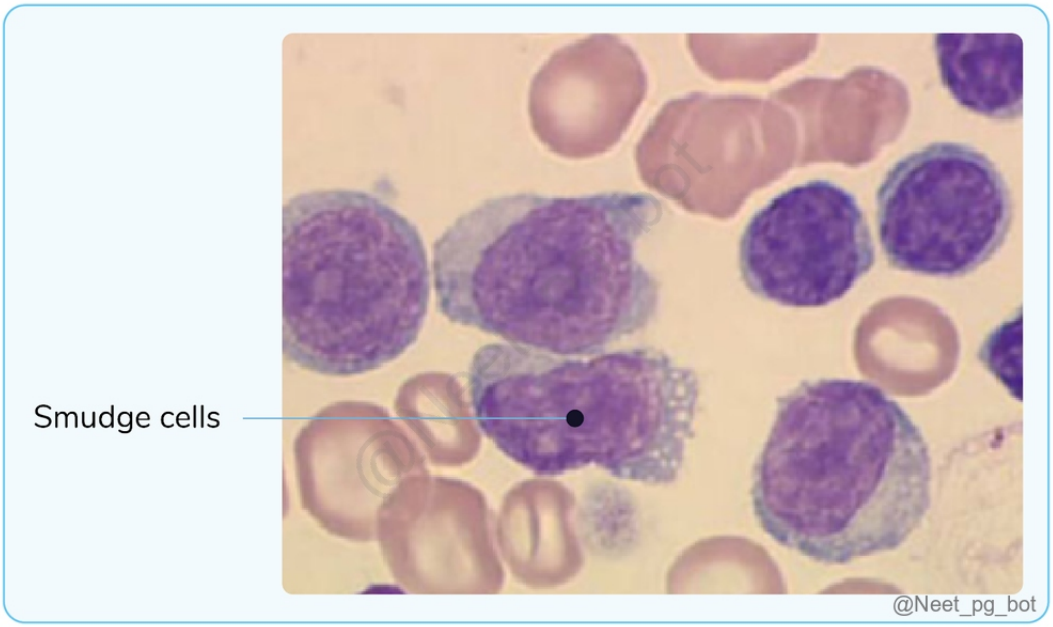

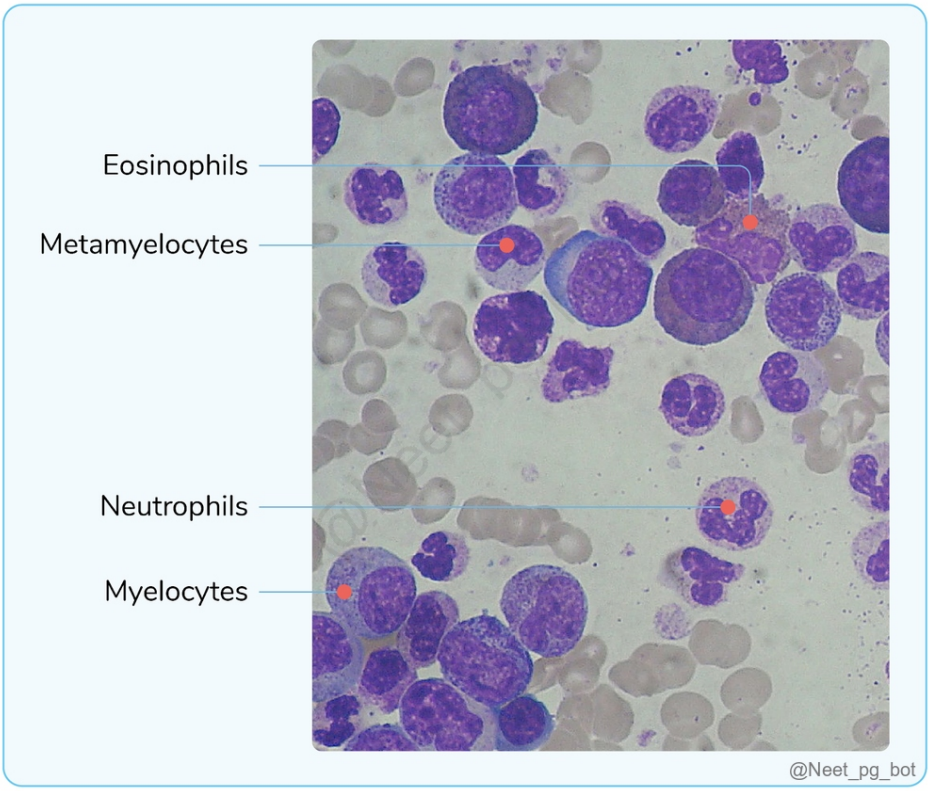

References:

Robbins & Cotran Pathologic Basis of Disease, 10th Edition, Page 622, 597, 619

https://onlinelibrary.wiley.com/doi/10.1155/2021/7488025

↑ *Back to this question in Part A*

@Neet_pg_bot

Q51: Which of the following is true regarding glucose-6-phosphate dehydrogenase (G6PD) deficiency? (Q856478)

A. Spectrin defect

B. Bite cells are present

C. Cells do not lyse in a hypotonic solution

D. Cells lyse in hypertonic solution

Correct Answer: B. Bite cells are present

Explanation: In glucose-6-phosphate dehydrogenase deficiency , oxidative stress leads to the formation of bite cells (also called degmacytes) due to the removal of damaged portions of the cell membrane. Glucose-6-phosphate dehydrogenase (G6PD) deficiency is an inherited enzyme affecting red blood cells. Caused by a lack of the G6PD enzyme, which protects red blood cells from oxidative damage. Oxidative stress makes red blood cells vulnerable, leading to hemolysis. A characteristic feature is the presence of bite cells (degmacytes). Heinz bodies, formed from denatured haemoglobin, are not visible with Romanowsky stains. When Romanowsky stains are used, the denatured haemoglobin may not be detected, resulting in the appearance of bite cells. Abnormality Condition Reason Bite cells {{caption_text}} G6PD deficiency Oxidative stress leads to cross-linking of sulfhydryl groups in haemoglobin → Denaturation of haemoglobin → Heinz bodies. RBCs with Heinz bodies pass through the spleen → Splenic macrophages try to pluck these Heinz bodies → Membrane loss → Bite cells . Target cells {{caption_text}} Thalassemia ↓ Haemoglobin content in RBCs → ↓ RBC volume → Surface area relatively unchanged → ↑ Surface area to volume ratio→ Altered lipid composition → ↑ Formation of membrane protrusions→ ↑ Membrane instability → ↓ Hemoglobin accumulation in certain membrane areas → Central area with haemoglobin, clear zone, outer ring. Uneven distribution of haemoglobin and lipids → Characteristic "bull's-eye" appearance of Target cells Sickle-shaped RBC {{caption_text}} Sickle Cell Anemia Abnormal Hemoglobin (HbS) → HbS molecules polymerize under low oxygen → RBCs become rigid and assume a sickle shape. Spherocytes {{caption_text}} Hereditary Spherocytosis Genetic defect in RBC membrane protein(spectrin) ■ Loss of membrane surface area ■ RBCs become spherical. Spectrin defect (Option A) is a structural protein that maintains the shape and flexibility of red blood cells. Deficiency of spectrin is seen in hereditary spherocytosis , not G6PD deficiency. Cells do not lyse in hypotonic solution (Option C): In G6PD deficiency, red blood cells are more likely to lyse in hypotonic solutions due to their increased vulnerability to oxidative stress. Cells lyse in hypertonic solution (Option D): Red blood cells do not typically lyse in hypertonic solutions; instead, they undergo crenation. The lysis occurs more readily in hypotonic solutions, especially in G6PD deficiency.

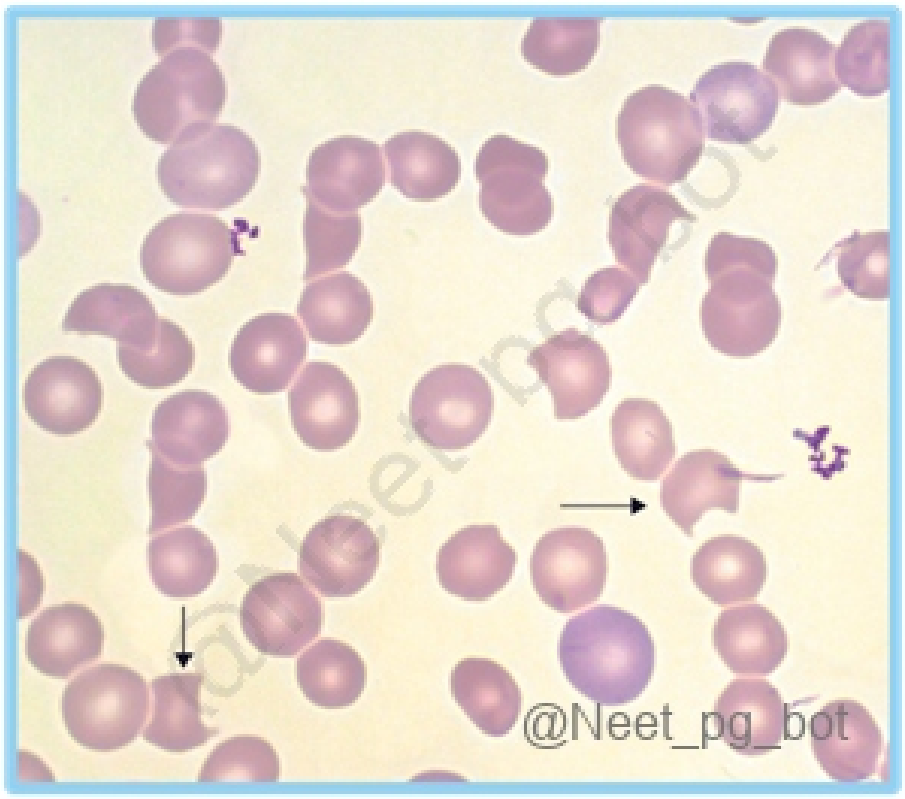
@Neet_pg_bot

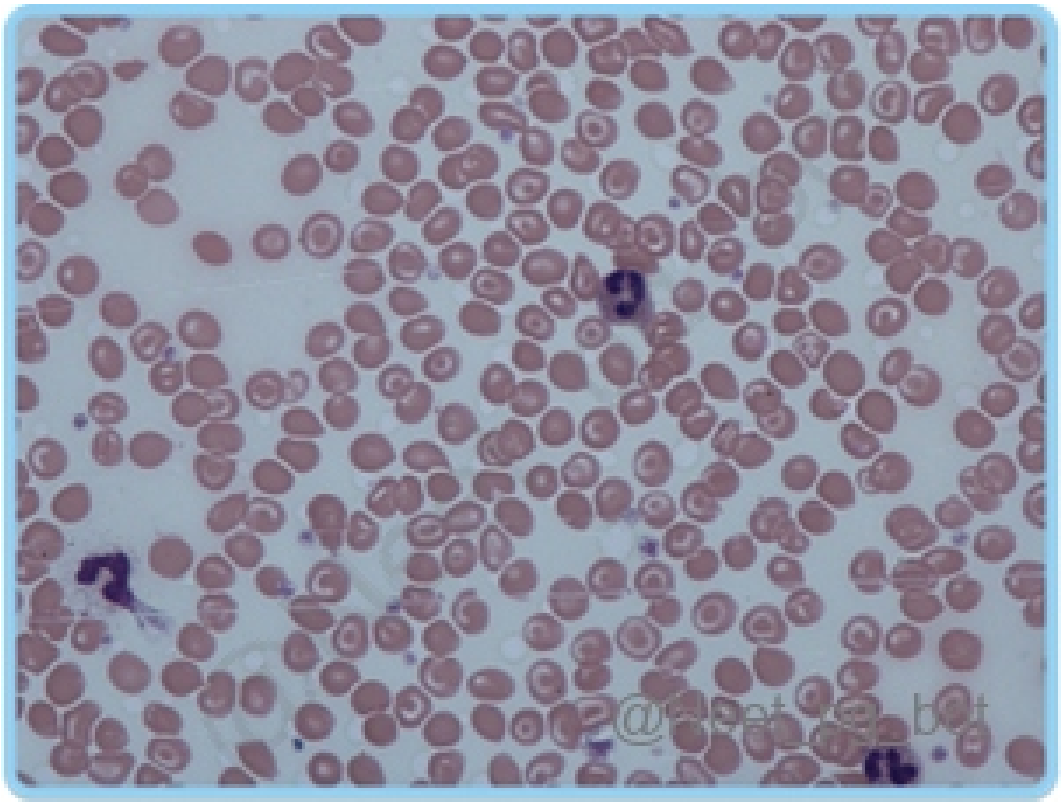

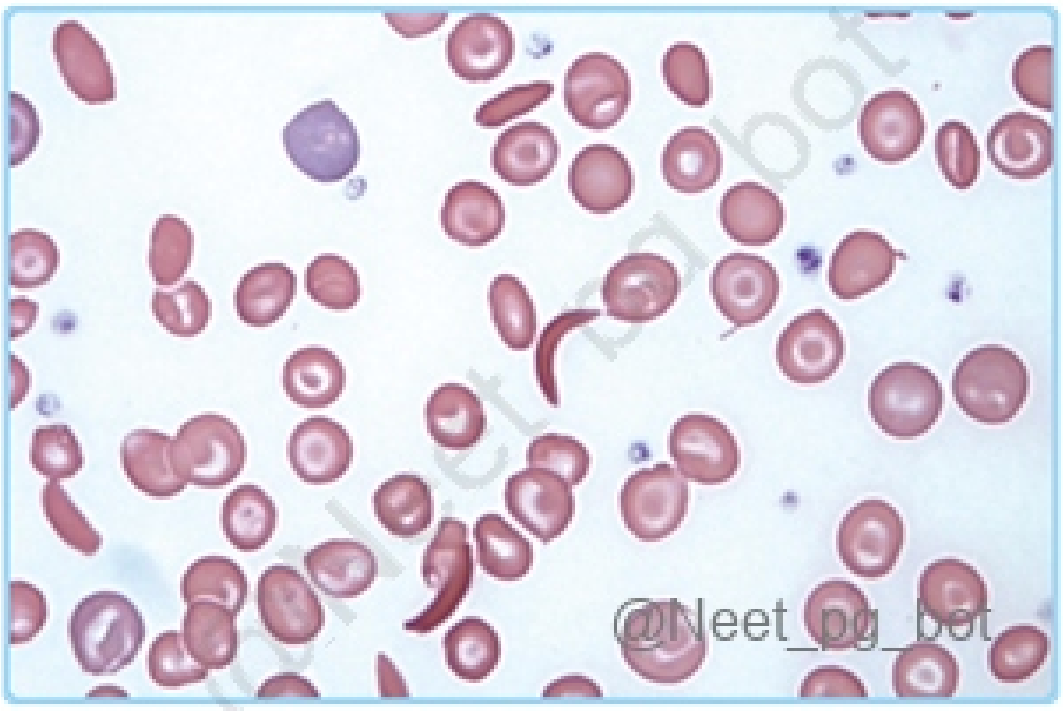

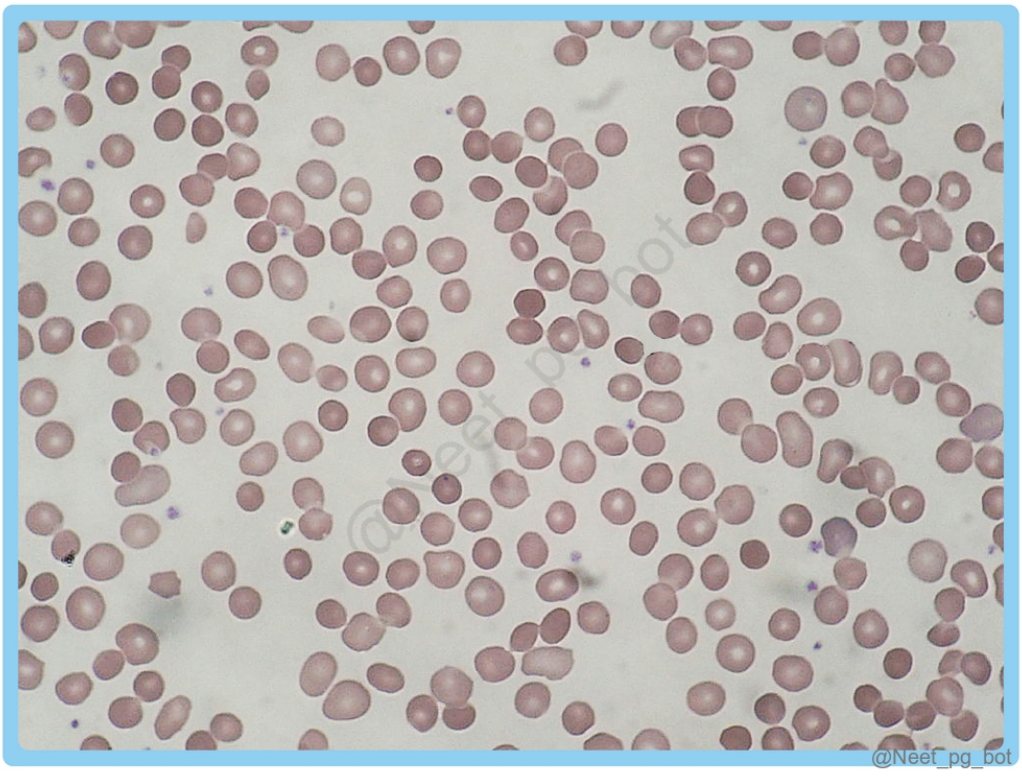

References:

Robbins & Cotran Pathologic Basis of Disease, 10th Edition, Page 640

↑ *Back to this question in Part A*

Q52: A 35-year-old woman presents with fatigue. Investigations reveal the following: Hemoglobin (Hb): 5 gm%, low mean corpuscular haemoglobin (MCH), and low mean corpuscular volume (MCV). The peripheral smear shows microcytic hypochromic red blood cells. What is the most likely diagnosis? {{caption_text}} (Q855889)

A. Megaloblastic anaemia

B. Iron deficiency anaemia

C. Thalassemia major

D. Essential thrombocytosis

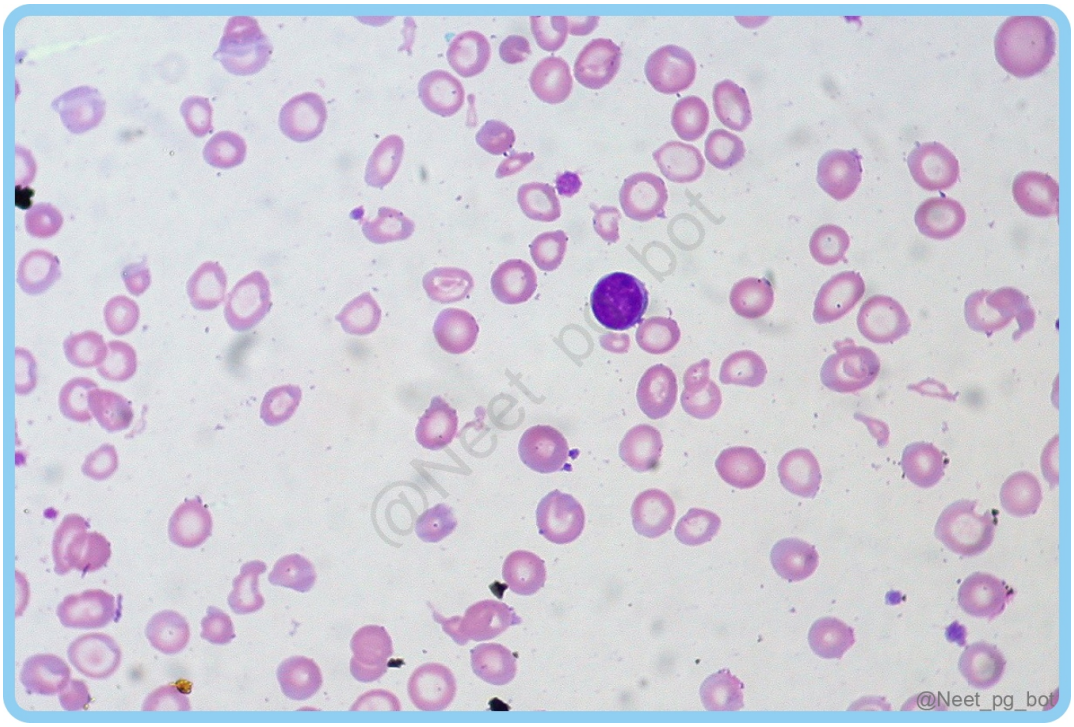

Correct Answer: B. Iron deficiency anaemia

Explanation: The laboratory findings and peripheral smear indicate iron deficiency anaemia, characterized by microcytic, hypochromic RBCs, anisocytosis, and poikilocytosis. Iron deficiency anaemia can result from dietary lack, impaired absorption, increased iron requirement (pregnancy), or chronic blood loss (gastrointestinal bleeding). Clinical features include Koilonychia, alopecia, atrophic glossitis, oesophagal webs, pica and intestinal malabsorption, affecting overall nutritional status. Iron studies commonly used in the diagnosis of iron deficiency anaemia (IDA): Iron Study Interpretation in Iron Deficiency Anemia Serum Ferritin Low (< 30 ng/mL) indicates depleted iron stores. Serum Iron (Fe) Low levels are seen in iron deficiency anaemia. Total Iron Binding Capacity

(TIBC) Increased TIBC reflects the increased capacity of transferrin to bind iron in response to low iron stores. Red Cell Distribution Width (RDW) Increased RDW is often seen in iron deficiency anaemia Bone Marrow Aspiration and Iron Staining Confirmatory test Learning Objective: Microcytic Anaemia Normocytic Anaemia Macrocytic Anaemia S ideroblastic anemia. I ron deficiency anaemia. T halassemia. A naemia of chronic disease. L ead poisoning. (Mnemonic- SITAL) Acute Blood Loss Hemolytic Anaemia(hereditary spherocytosis) Anaemia of Chronic Disease Bone Marrow Disorders (e.g., Aplastic Anaemia) Renal Disease Endocrine Disorders (e.g., Hypothyroidism) Early stages of iron deficiency anaemia Vitamin B12 Deficiency Folate Deficiency Alcohol Abuse Liver Disease Hypothyroidism Myelodysplastic Syndrome

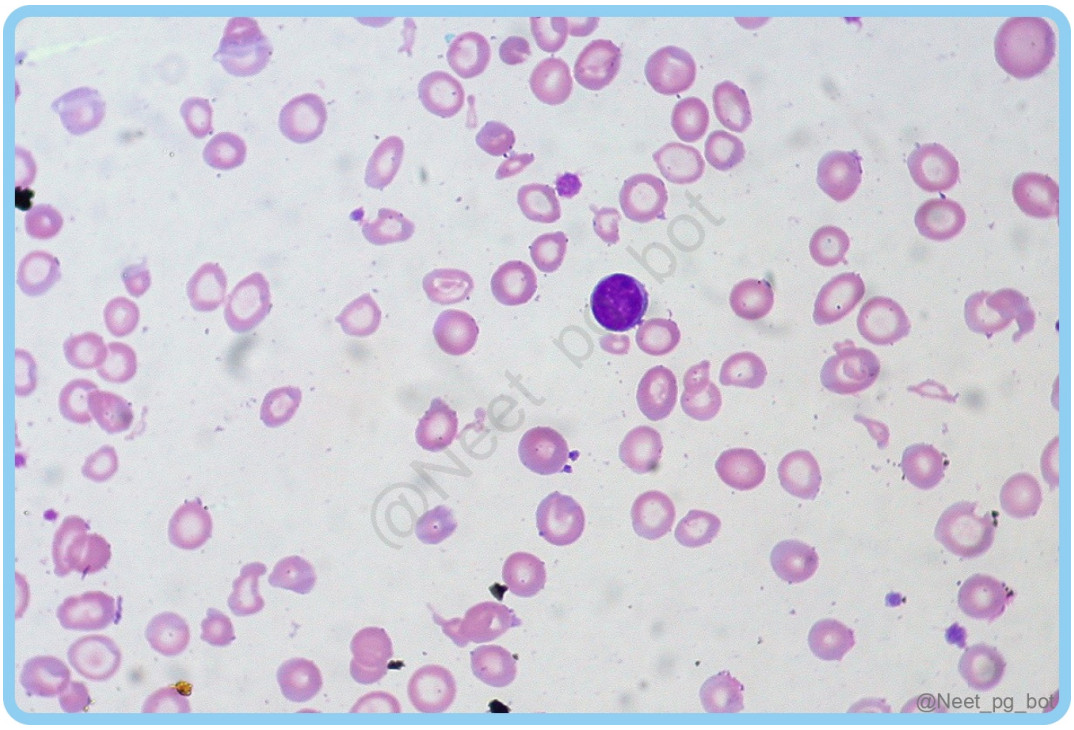

References:

Robbins & Cotran Pathologic Basis of Disease, 10th Edition, Page 655

↑ *Back to this question in Part A*

@Neet_pg_bot

Q53: Match the following cell types with their associated malignancy: Cell Type Associated Malignancy 1. Popcorn cell a. Acute promyelocytic leukemia 2. Faggot cell b. Lymphocyte-predominant Hodgkin's lymphoma 3. Cerebriform nuclei c. Burkitt lymphoma 4. Starry sky appearance d. Sezary syndrome (Q855885)

A. 1-b, 2-a, 3-d, 4-c

B. 1-a, 2-d, 3-c, 4-b

C. 1-b, 2-c, 3-a, 4-c

D. 1-a, 2-b, 3-d, 4-c

Correct Answer: A. 1-b, 2-a, 3-d, 4-c

Explanation: Cell Type Associated Malignancy Popcorn cell Lymphocyte-predominant Hodgkin’s lymphoma Faggot cell Acute promyelocytic leukemia Cerebriform nuclei Sezary syndrome Starry sky appearance Burkitt lymphoma Popcorn cells are characteristic of lymphocyte-predominant Hodgkin's lymphoma . These cells have a distinctive appearance with irregular nuclei and are found in the background of reactive lymphocytes. Popcorn cells {{caption_text}} Cells with multiple infolded nuclear membranes, small nucleoli, fine chromatin, and abundant pale cytoplasm. Seen in Nodular lymphocyte-Predominant Hodgkin lymphoma. Faggot cells are seen in acute promyelocytic leukaemia (APL) . These are abnormal promyelocytes that appear as bundles of rods (also called Auer rods) within the cells. AML-M3 Acute promyelocytic leukemia t(15:17) - PML-RAR■ fusion Blocks promyelocyte → myelocyte transformation Bone marrow: Auer rods form criss-cross called faggot cell {{caption_text}} Can cause DIC PAS+ Cerebriform nuclei are a feature of Sezary syndrome , a type of cutaneous T-cell lymphoma. The nuclei have a convoluted, brain-like appearance, which is a key histological finding. {{caption_text}} Starry sky appearance is associated with Burkitt lymphoma . It refers to darkly stained tumour cells with numerous bright spots representing macrophages engulfing apoptotic tumour cells. {{caption_text}}

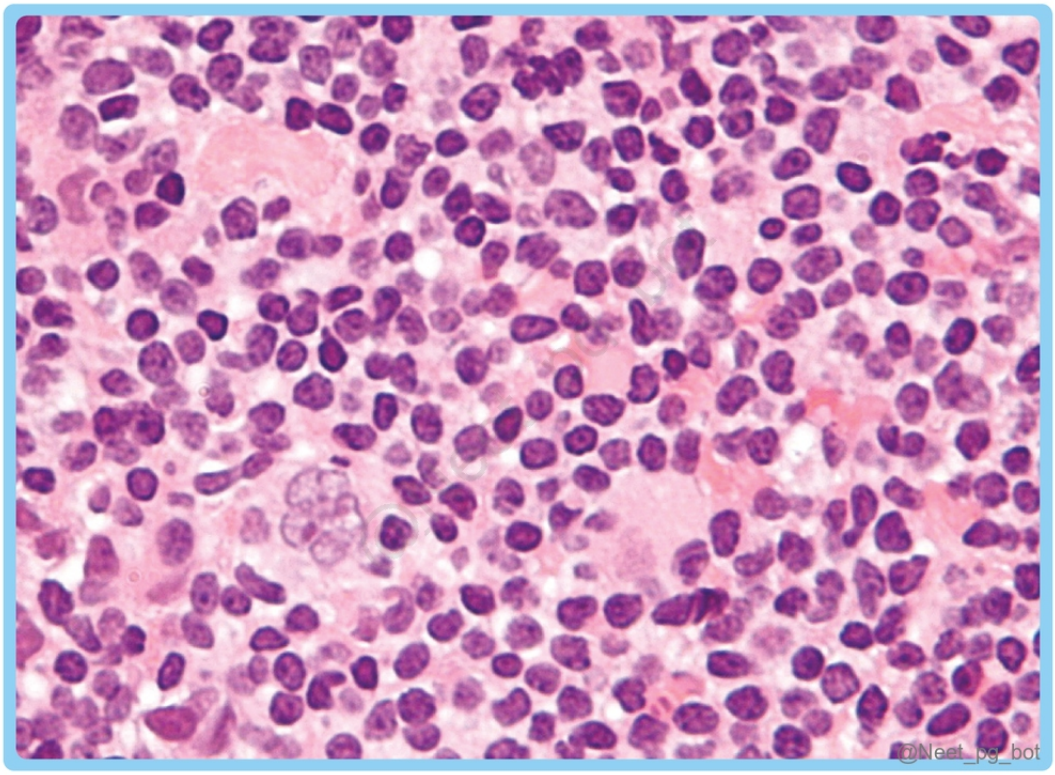

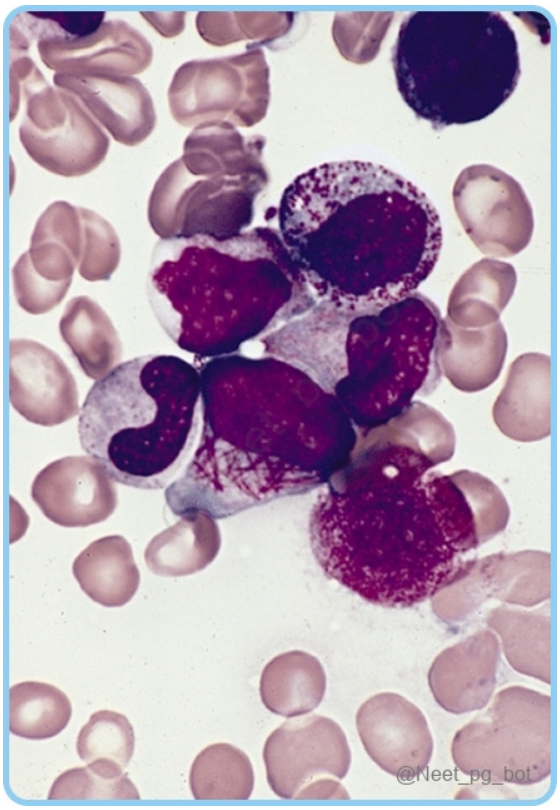
@Neet_pg_bot

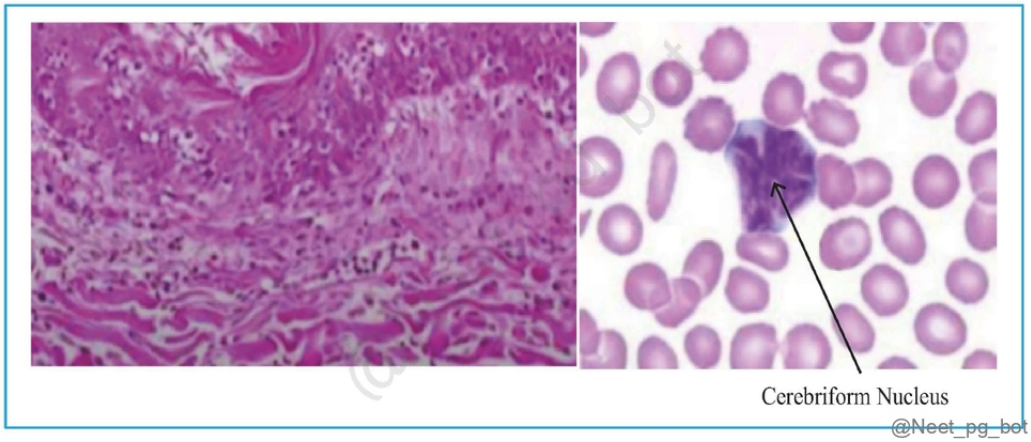

@Neet_pg_bot

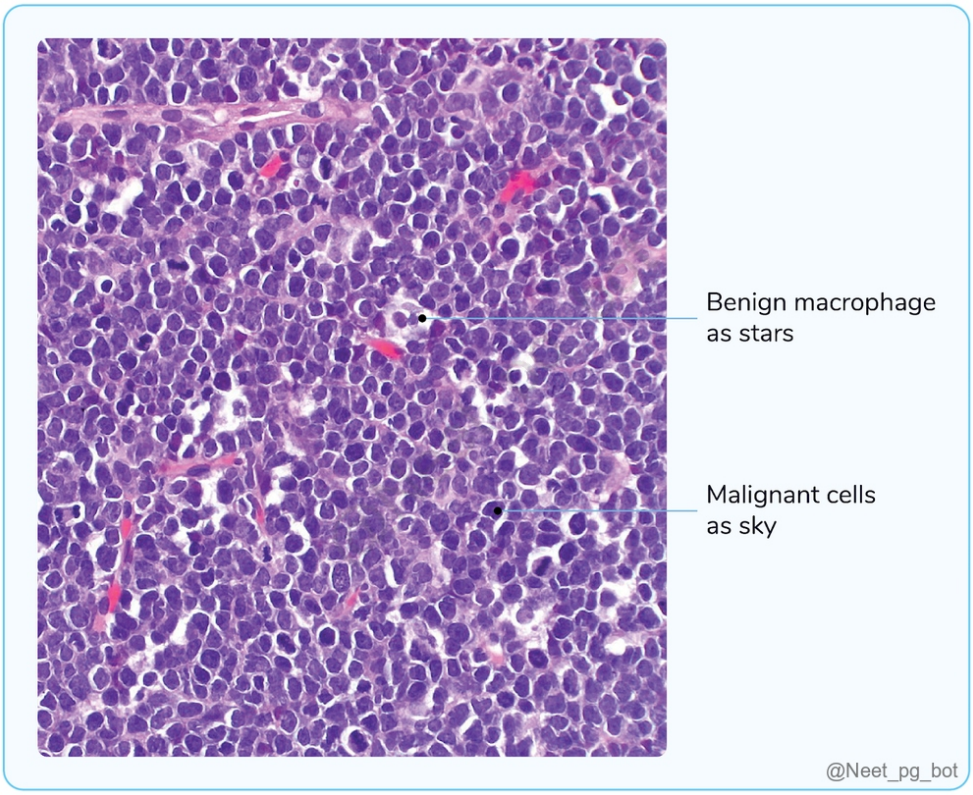

References:

Robbins & Cotran Pathologic Basis of Disease, 10th Edition, Page 601, 602, 606, 608, 614, 618

↑ *Back to this question in Part A*

@Neet_pg_bot

Q54: Which of the following is a feature of hemolytic anaemia? (Q858116)

A. Increased haptoglobin

B. Neutropenia

C. Reticulocytopenia

D. Decreased haptoglobin

Correct Answer: D. Decreased haptoglobin

Explanation: Decreased haptoglobin is a hallmark of hemolytic anaemia and helps distinguish it from other types of anaemia. In hemolytic anaemia, the destruction of RBCs increases the amount of free haemoglobin in the blood, which binds to haptoglobin. Other conditions where haptoglobin is reduced are (intravascular hemolysis): Paroxysmal Nocturnal Hemoglobinuria (PNH) Microangiopathic Hemolytic Anemia (MAHA)- HUS, TTP, DIC

Paroxysmal cold hemoglobinuria/Cold hemolysin type AIHA G6PD deficiency Neutropenia (Option B) refers to a low number of neutrophils, a type of white blood cell, which is not directly associated with hemolytic anaemia . Hemolytic anaemia primarily involves RBC destruction, not neutrophil abnormalities. Reticulocytopenia (Option C) : In hemolytic anaemia , the body responds to RBC destruction by producing more reticulocytes (immature red blood cells) as part of the compensatory mechanism. Thus, you would typically see reticulocytosis , not reticulocytopenia .

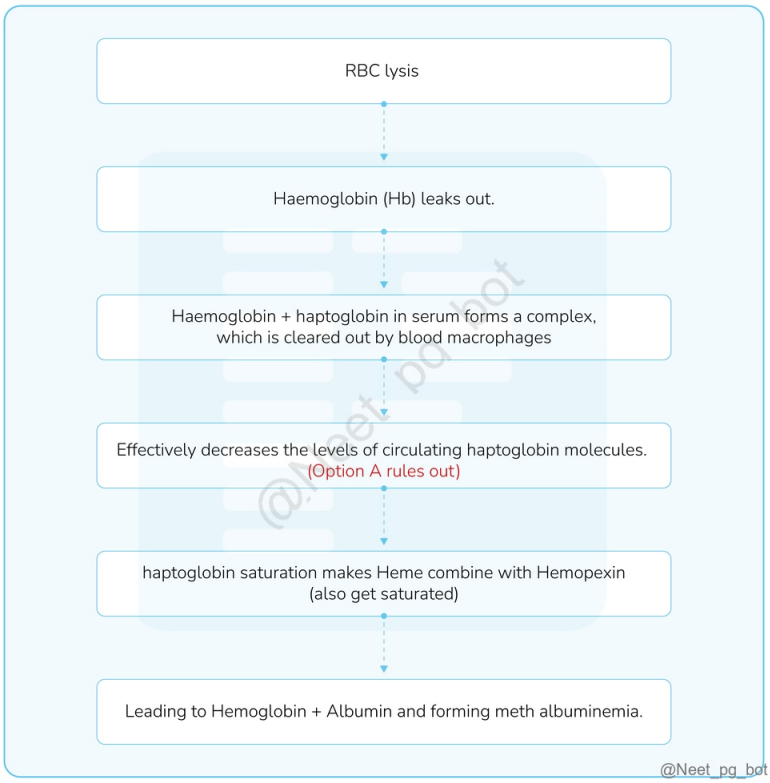

References:

Robbins and Cotran Pathologic Basis of Disease, 10th Edition, Page 637

↑ *Back to this question in Part A*

@Neet_pg_bot

Q55: A child presents with intermittent jaundice and splenomegaly. There is a history of similar complaints in the elder brother. A peripheral smear shows the following findings. Which of the following is the most appropriate diagnostic test for this condition? (Q855398)

A. Osmotic fragility test - Hereditary spherocytosis

B. Coombs test - Autoimmune hemolytic anaemia

C. Genetic testing - G6PD deficiency

D. Flow cytometry - Paroxysmal nocturnal hemoglobinuria

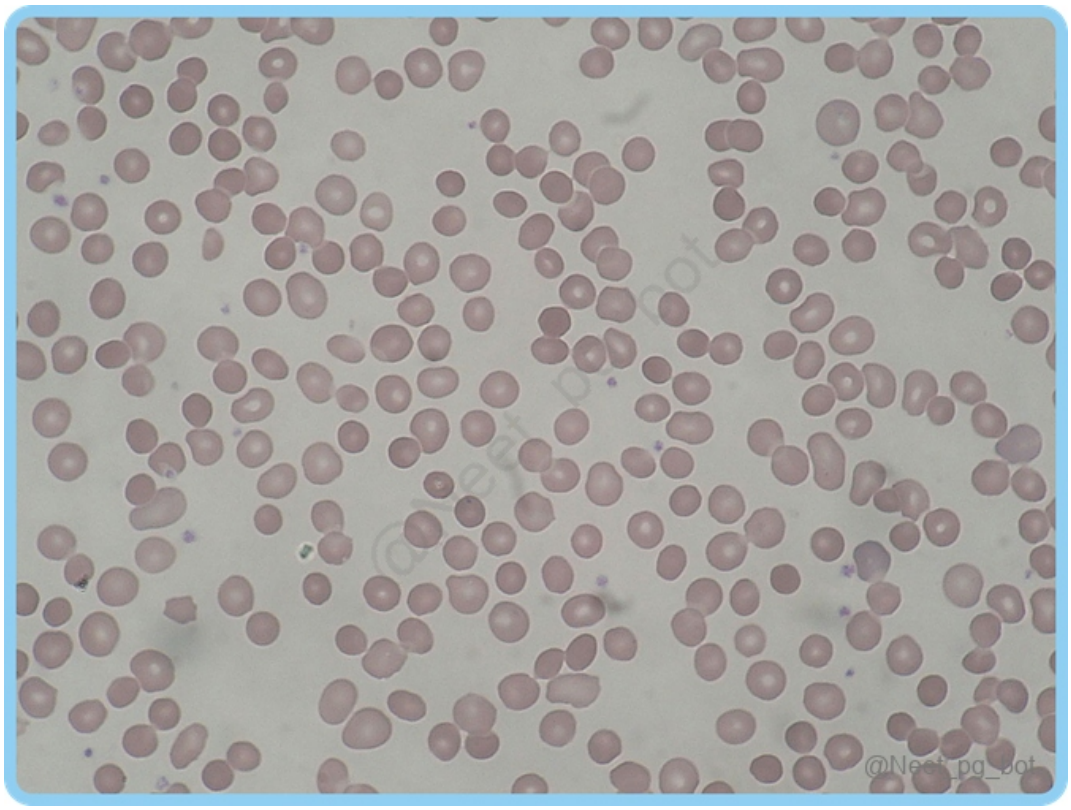

Correct Answer: A. Osmotic fragility test - Hereditary spherocytosis

Explanation: The given clinical scenario and peripheral smear showing spherocytes most likely suggest a diagnosis of hereditary spherocytosis. The osmotic fragility test is used to diagnose hereditary spherocytosis, as spherocytes are more fragile and lyse in hypotonic solutions. Hereditary spherocytosis (HS) is an inherited disorder caused by intrinsic defects in the red cell membrane skeleton that render red cells spheroid, less deformable, and vulnerable to splenic sequestration and destruction. It has an autosomal dominant inheritance(75%) characterised by ankyrin mutation and an autosomal recessive inheritance characterised by spectrin mutation. Pathophysiology of hereditary spherocytosis: Mutations of ankyrin, band 3, spectrin, or band 4.2 ↓ Unstable RBC membrane with membrane loss ↓ The surface: volume ratio is reduced ↓ RBC takes up the shape of a sphere to compensate ↓ Spherical RBCs are trapped in splenic sinusoids due to large size ↓ Extravascular hemolysis {{caption_text}} The most specific morphologic finding is spherocytosis: Dark-staining (hyperchromic) spherocytes lacking the central zone of pallor. Other features include reticulocytosis. The characteristic clinical features are anemia, splenomegaly, jaundice, and an increased risk of gallstones. Severity ranges from asymptomatic to severe hemolytic anemia requiring transfusions. Early complications include neonatal jaundice and hemolytic crises. Late complications include gallstones and rarely iron overload.

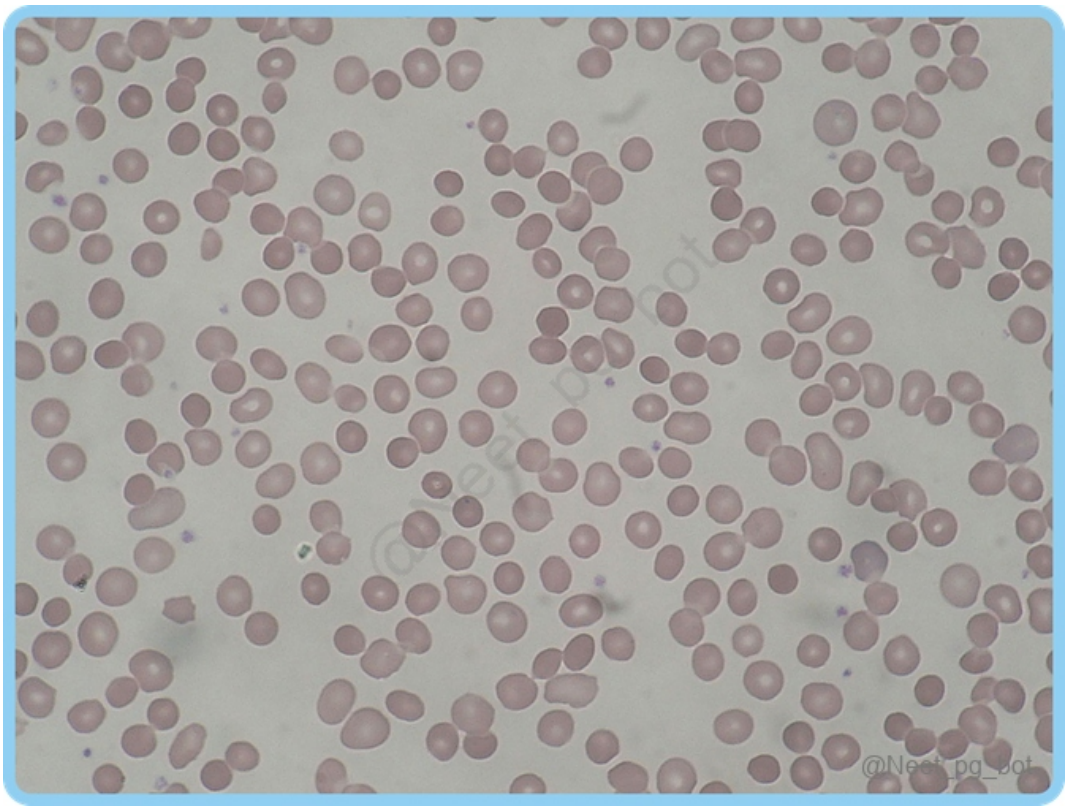

References:

Robbins and Cotran Pathologic Basis of Disease, 10th Edition, Page 638,639

↑ *Back to this question in Part A*

@Neet_pg_bot

Q56: Serum transferrin saturation level is low. What is the most likely condition? (Q854695)

A. Iron Deficiency Anemia

B. Hemochromatosis

C. Sideroblastic anemia

D. Pernicious anemia

Correct Answer: A. Iron Deficiency Anemia

Explanation: Serum transferrin saturation is a key marker of iron status in the body. Low serum transferrin saturation indicates low iron stores , which is commonly seen in iron deficiency anaemia. Investigations for IDA

Iron Study Interpretation in Iron Deficiency Anemia Serum Ferritin Low (< 30 ng/mL) indicates depleted iron stores. Serum Iron (Fe) Low levels are seen. Total Iron Binding Capacity (TIBC) Increased TIBC reflects the increased capacity of transferrin to bind iron in response to low iron stores. Transferrin saturation Is decreased, which refers to the percentage of transferrin that is bound to iron Red Cell Distribution Width (RDW) Increased RDW is often seen in iron deficiency anaemia Bone Marrow Aspiration and Iron Staining Confirmatory test Type of Anemia Serum Iron Transferrin saturation Serum Ferritin TIBC Sideroblastic Anemia (Option C ruled out) High High High Low Iron Deficiency Anemia Low Low Low High Hemochromatosis (Option B ruled out) High High High Low Pernicious anaemia (Option D) is an autoimmune condition that occurs when the body can't absorb enough vitamin B12. It does not primarily affect iron metabolism, and transferring saturation levels would not be low in this condition.

References:

Robbins and Cotran Pathologic Basis of Disease, 10th Edition, Pages 620, 621, 655, 658, 659

↑ *Back to this question in Part A*

@Neet_pg_bot

Q57: Which of the following for Sickle cell anaemia is correct? (Q854687)

A. Low mechanical fragility, high osmotic fragility

B. High mechanical fragility, high osmotic fragility

C. Low mechanical fragility, low osmotic fragility

D. High mechanical fragility, low osmotic fragility

Correct Answer: D. High mechanical fragility, low osmotic fragility

Explanation: Sickle cell disease (SCD) is a hemoglobinopathy characterized by the presence of abnormal haemoglobin, known as haemoglobin S (HbS). Under low oxygen conditions, HbS polymerizes, causing RBCs to assume a sickle shape. Sickle-shaped RBCs are more rigid and less deformable, leading to high mechanical fragility , making them more likely to rupture under stress. Unlike normal RBCs, sickle-shaped RBCs have low osmotic fragility , meaning they are less prone to hemolysis in hypotonic solutions.

References:

Robbins and Cotran Pathologic Basis of Disease, 10th Edition, Pages 641, 642

↑ *Back to this question in Part A*

@Neet_pg_bot

Q58: A 45-year-old male patient with a history of chronic inflammatory conditions presents with fatigue, weakness, and pallor. Laboratory investigations reveal microcytic hypochromic anemia. Further evaluation suggests an underlying disorder affecting iron metabolism. Which cytokine is most likely inhibiting the activity of ferroportin in this patient? (Q820595)

A. IL-1

B. IL-6

C. IFN-gamma

D. TNF-Alpha

Correct Answer: B. IL-6

Explanation: Correct Option B - IL-6: IL-6 stands for Interleukin-6, which is a cytokine that plays a crucial role in inflammation and immune responses. In this scenario, the patient presents with microcytic hypochromic anemia, which is often caused by iron deficiency. Ferroportin is a protein that functions as an iron exporter, allowing iron to exit from cells into the bloodstream, where it can be utilized for various physiological processes including red blood cell production. When ferroportin is inhibited, it leads to reduced iron export from cells and contributes to iron retention within the cells.In chronic inflammatory conditions, such as the one mentioned in the question, there is an increased production of IL-6. IL-6 has been shown to stimulate the production of hepcidin, a peptide hormone synthesized in the liver. Hepcidin regulates iron homeostasis by binding to ferroportin and causing its internalization and degradation. This action reduces iron export from cells, leading to decreased iron availability for erythropoiesis (red blood cell production). Consequently, chronic inflammation-induced elevation of IL-6 and subsequent increase in hepcidin levels result in reduced iron absorption and availability for red blood cell formation, leading to microcytic hypochromic anemia. Incorrect Options: Option A - IL-1: Interleukin-1 is also involved in inflammation and immune responses, but it does not have a direct role in inhibiting ferroportin. It can contribute to inflammation-induced systemic responses. Option C - IFN-gamma: Interferon-gamma (IFN-gamma) is primarily involved in immune responses and has not been directly implicated in the inhibition of ferroportin. Option D - TNF-Alpha: Tumor Necrosis Factor-alpha (TNF-alpha) is another cytokine involved in inflammation. It does contribute to the inflammatory response, but it is not the primary cytokine responsible for inhibiting ferroportin.

References:

.

↑ *Back to this question in Part A*

@Neet_pg_bot

Q59: A 25-year-old female patient presents to the clinic with complaints of fatigue, weakness, and pale skin. On further investigation, her complete blood count reveals a

microcytic anemia. What is the likely diagnosis for this patient? (Q820581)

A. Alcoholism

B. Chronic Kidney disease

C. Hemolytic anemia

D. Iron deficiency anemia

Correct Answer: D. Iron deficiency anemia

Explanation: Correct Option D - Iron deficiency anemia: Iron deficiency anemia is characterized by a deficiency of iron, a key component required for hemoglobin synthesis in red blood cells. Microcytic anemia, where the red blood cells are smaller than normal, is a hallmark of iron deficiency. The patient's symptoms of fatigue, weakness, and pale skin are classic signs of anemia. Iron deficiency can be caused by inadequate dietary intake, chronic blood loss (such as from menstruation or gastrointestinal bleeding), or poor iron absorption. Based on the patient's presentation of microcytic anemia along with the symptoms of fatigue, weakness, and pale skin, the most likely diagnosis is D. Iron deficiency anemia. Incorrect Options: Option A - Alcoholism: Alcoholism can lead to various health issues, including anemia. However, in this case, the patient's presentation of fatigue, weakness, and pale skin along with microcytic anemia suggests a more specific cause related to iron deficiency. Option B - Chronic Kidney Disease: Chronic kidney disease can cause anemia due to reduced production of erythropoietin (a hormone that stimulates red blood cell production) by the kidneys. However, anemia caused by chronic kidney disease is usually normocytic or normochromic rather than microcytic. Option C - Hemolytic Anemia: Hemolytic anemia results from the destruction of red blood cells at a rate that exceeds their production. It can lead to a variety of symptoms, including fatigue and pale skin. However, microcytic anemia is typically associated with conditions related to impaired hemoglobin synthesis, like iron deficiency anemia, rather than hemolysis

References:

.

↑ *Back to this question in Part A*

@Neet_pg_bot

Q60: A patient reports to the outpatient department with complaints of fatigue. Investigation results indicate a Hb of 5.9, increased RDW and TIBC, and low ferritin. What is the most likely diagnosis? (Q860296)

A. Sideroblastic anemia

B. IDA

C. Anaemia of chronic disease

D. Hemolytic anemia

Correct Answer: B. IDA

Explanation: The patient's presentation with fatigue and investigations showing low haemoglobin, increased RDW, high TIBC, and low ferritin are consistent with a diagnosis of Iron Deficiency Anemia (IDA) . It results in inadequate haemoglobin synthesis. Causes: Dietary lack Impaired absorption Increased requirement Chronic blood loss Pathogenesis: Iron deficiency initially depletes iron stores (low ferritin) while maintaining normal serum iron and transferrin saturation. As depletion progresses, serum iron declines, leading to reduced haemoglobin synthesis. Hypochromic microcytic anaemia develops once iron stores are exhausted, with low serum iron, ferritin, and transferrin saturation, while total iron-binding capacity (TIBC) increases. Clinical features include koilonychia, alopecia, atrophic glossitis, esophageal webs, pica, malabsorption, fatigue, pale skin, shortness of breath, dizziness, headaches, tachycardia, cold extremities, and restless leg syndrome. Histopathology: Bone marrow aspiration: Increased erythroid progenitors and a lack of stainable iron in macrophages, best assessed by Prussian blue staining. Peripheral blood smears: Red cells are small (microcytic) and pale (hypochromic). {{caption_text}} Diagnosis: Iron Study Interpretation in Iron Deficiency Anemia Serum Ferritin Low (< 30 ng/mL) (depleted iron stores). Serum Iron (Fe) Low levels Total Iron Binding Capacity (TIBC) Increased TIBC (increased capacity of transferrin to bind iron in response to low iron stores). Red Cell Distribution Width (RDW) Increased RDW (Red Cell Distribution Width) Bone Marrow Aspiration and Iron Staining Confirmatory test Lab parameters in various anaemia: Serum Iron Transferrin saturation Serum Ferritin TIBC Sideroblastic Anemia (Option A ruled out) High High High Low Iron Deficiency Anemia (Option B) Low Low Low High Anaemia of Chronic Disease (Option C ruled out) Low Low High Low Hemolytic Anemia (Option D ruled out) High Low High Low

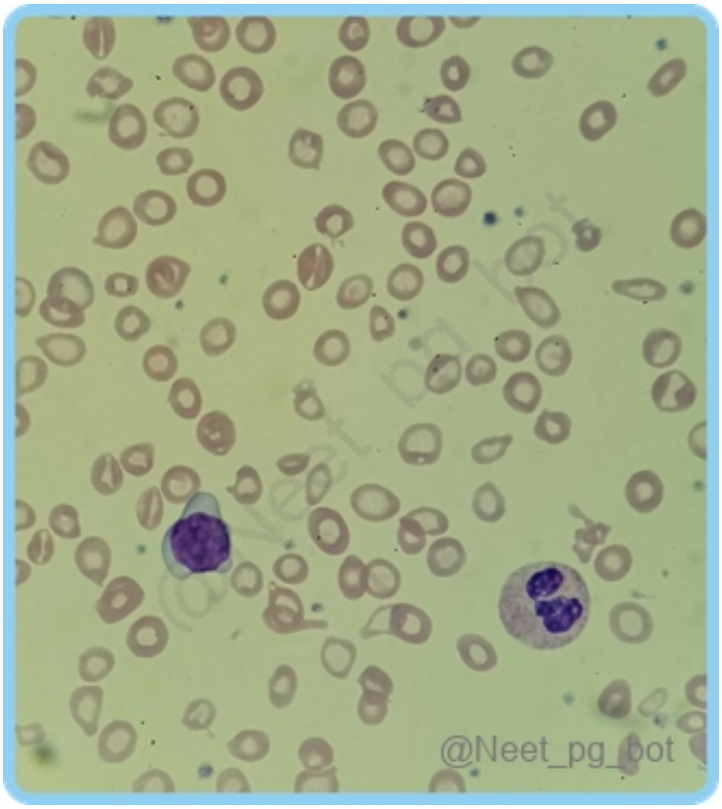

References:

Robbins & Cotran Pathologic Basis of Disease, 10th Edition, Page 655-658.

↑ *Back to this question in Part A*

@Neet_pg_bot

Q61: A 60-year-old woman presents with complaints of fatigue and dyspnea for 2 weeks. On examination, pallor is noted, and haemoglobin is found to be 6 gm/dL. What is the likely finding seen on the peripheral smear? (Q855962)

A. Poikilocytes

B. Microcytic hypochromic cells

C. Macrocytic cells

D. Target cells

Correct Answer: B. Microcytic hypochromic cells

Explanation: An elderly woman with fatigue, dyspnea, and severe anaemia (Hb 6 g/dL) suggests iron deficiency anaemia (IDA) . The peripheral smear typically shows microcytic hypochromic cells , the hallmark of IDA. While poikilocytosis can be present, microcytosis and hypochromia are more characteristic. Iron deficiency anaemia can result from dietary lack, impaired absorption, the increased iron requirement (pregnancy), or chronic blood loss (gastrointestinal bleeding). Clinical features: Koilonychia, alopecia, atrophic glossitis, oesophagal webs, pica and intestinal malabsorption, affecting overall nutritional status {{caption_text}} In iron deficiency anaemia (IDA), a peripheral blood smear can reveal characteristic changes. Hypochromic Red Blood Cells: The RBCs appear pale due to decreased haemoglobin content. Microcytic Red Blood Cells: RBCs are smaller than normal due to decreased haemoglobin synthesis. Anisocytosis: There is significant variation in the size of RBCs. Poikilocytosis: RBCs may show abnormal shapes, such as pencil cells, target cells (codocytes), and occasionally, elliptocytes.

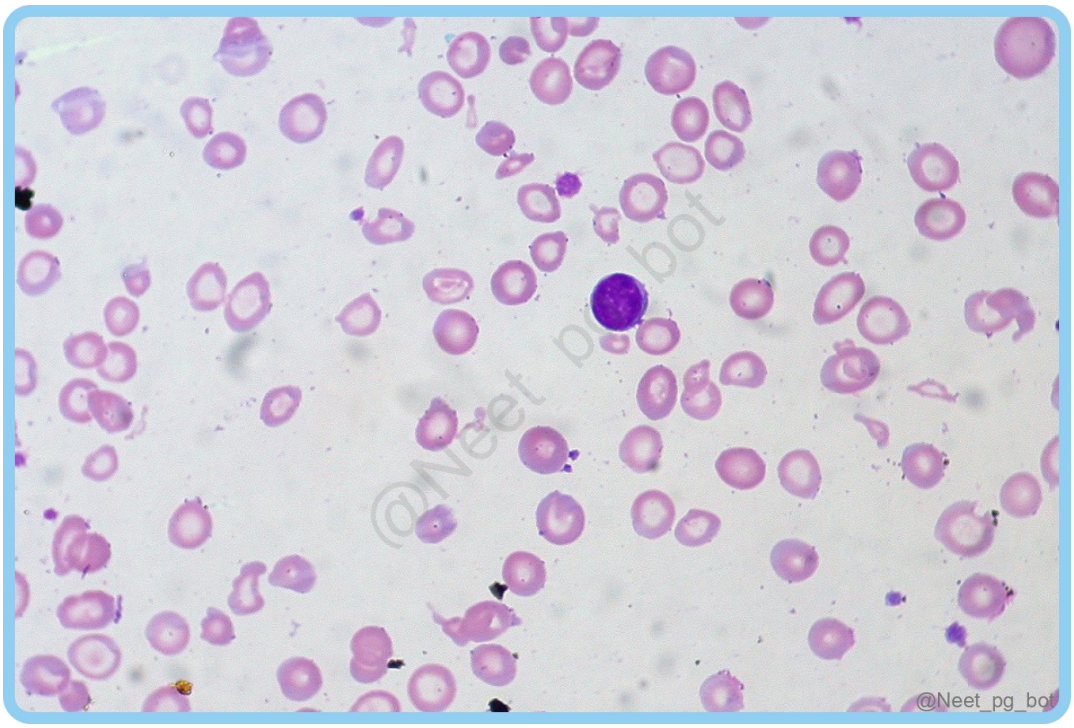

References:

Robbins & Cotran Pathologic Basis of Disease, 10th Edition, Page 655,658

↑ *Back to this question in Part A*

@Neet_pg_bot

Q62: Which of the following cells are located in the centre of the lumen in a venule? (Q860262)

A. Lymphocytes

B. RBCs

C. Neutrophils

D. Platelets

Correct Answer: B. RBCs

Explanation: Red blood cells (RBCs) are located in the centre of the lumen in a venule. In venules with normal blood flow, red blood cells remain in the central axial column , while leukocytes are displaced toward the vessel wall . They are responsible for transporting oxygen from the lungs to the tissues and returning carbon dioxide from the tissues to the lungs. Lymphocytes (Option A) are white blood cells essential for immunity, comprising B cells (antibody production), T cells (immune regulation), and Natural Killer cells (targeting infected or cancerous cells).

They originate in the bone marrow, circulate in the blood and lymph, and typically adhere to the endothelium of blood vessels rather than residing within the venous lumen. Neutrophils (Option C) are white blood cells essential for bacterial defence . Produced in the bone marrow , they rapidly migrate to infection sites and eliminate pathogens via phagocytosis . During inflammation , like lymphocytes , they tend to localize near vessel walls rather than the lumen. Platelets (Option D) are small cell fragments produced in the bone marrow that play a key role in blood clotting. They aggregate at injury sites to form clots and stop bleeding, typically found near vessel walls rather than in the centre of the lumen.

References:

Robbins & Cotran Pathological Basis of Diseases, 10th Edition, Page 77.

↑ *Back to this question in Part A*

@Neet_pg_bot

Q63: A 65-year-old patient presents with anaemia. Investigations show low serum iron and ferritin levels, along with increased TIBC. Which of the following is most likely to be present? (Q860216)

A. Iron Deficiency Anemia (IDA)

B. Myelodysplastic Syndrome

C. Aplastic Anemia

D. Anaemia of Chronic Disease

Correct Answer: A. Iron Deficiency Anemia (IDA)

Explanation: The pattern of low serum iron and ferritin levels, along with increased TIBC (total iron-binding capacity), is characteristic of Iron Deficiency Anemia (IDA) . It is the most common nutritional disorder in the world . It results in inadequate haemoglobin synthesis. Causes: Dietary lack Impaired absorption Increased requirement Chronic blood loss Pathogenesis: Iron deficiency initially depletes iron stores (low ferritin) while maintaining normal serum iron and transferrin saturation. As depletion progresses, serum iron declines, leading to reduced haemoglobin synthesis. Hypochromic microcytic anaemia develops once iron stores are exhausted, with low serum iron, ferritin, and transferrin saturation, while total iron-binding capacity (TIBC) increases. Clinical features include koilonychia, alopecia, atrophic glossitis, oesophagal webs, pica, malabsorption, fatigue, pale skin, shortness of breath, dizziness, headaches, tachycardia, cold extremities, and restless legs syndrome. Histopathology: Bone marrow aspiration: increased erythroid progenitors and a lack of stainable iron in macrophages, best assessed by Prussian blue staining. Peripheral blood smears: Red cells are small (microcytic) and pale (hypochromic). {{caption_text}} Diagnosis: Iron Study Interpretation in Iron Deficiency Anemia Serum Ferritin Low (< 30 ng/mL) (depleted iron stores). (Option A) Serum Iron (Fe) Low levels (Option A) Total Iron Binding Capacity (TIBC) Increased TIBC (increased capacity of transferrin to bind iron in response to low iron stores). (Option A) Red Cell Distribution Width (RDW) Increased RDW Bone Marrow Aspiration and Iron Staining Confirmatory test Myelodysplastic Syndrome (MDS) (Option B) is a group of disorders where the bone

marrow produces dysfunctional blood cells, leading to cytopenias (anaemia, leukopenia, thrombocytopenia). It typically presents with multiple cytopenias, severe symptoms like infections or bleeding, and abnormal blood cell production. MDS often shows normal or elevated ferritin, not low iron and ferritin with high TIBC. Aplastic Anemia (Option C) is a rare condition where the bone marrow fails to produce enough blood cells, leading to pancytopenia (low red and white blood cells and platelets). It typically presents with pancytopenia, not just anaemia, and ferritin is usually normal or slightly elevated, not low with high TIBC. Anaemia of Chronic Disease (ACD) (Option D) occurs in chronic infections, inflammation, or kidney disease and is caused by impaired iron use and reduced red blood cell production. It typically presents with low serum iron and ferritin, but TIBC is decreased, not increased, due to iron sequestration and impaired utilisation in chronic inflammation.

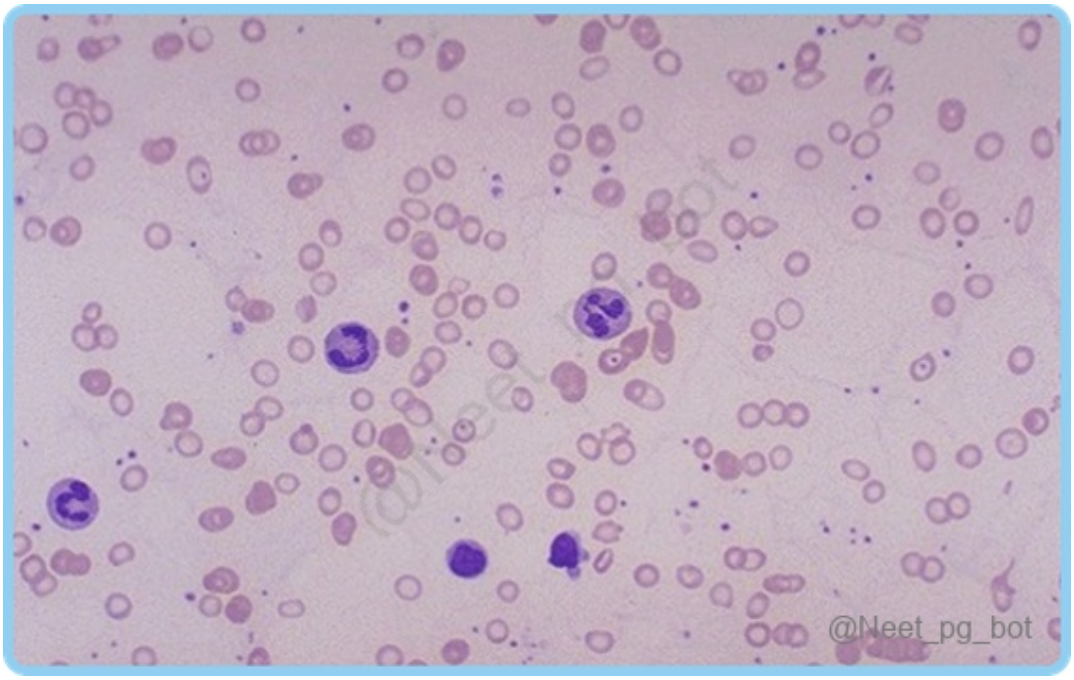

References:

Robbins & Cotran Pathologic Basis of Disease, 10th Edition, Page 655-658.

↑ *Back to this question in Part A*

@Neet_pg_bot

Q64: A 45-year-old patient visits a haematologist with symptoms of weakness and fatigue. Laboratory tests show low haemoglobin, a low reticulocyte count, and normal WBC and platelet counts. The bone marrow analysis reveals a selective reduction in erythroid precursors. What is the likely diagnosis? (Q860156)

A. Aplastic anemia

B. Pure red cell aplasia

C. Iron deficiency anaemia

D. Pernicious anemia

Correct Answer: B. Pure red cell aplasia

Explanation: The scenario of weakness, fatigue, low haemoglobin, low reticulocyte count, normal WBC and platelet counts, and bone marrow showing a selective reduction in erythroid precursors is consistent with Pure Red Cell Alasia (PRCA) , which is characterized by a marked reduction or absence of red blood cell precursors while other hematopoietic cell lines remain normal. It is a primary marrow disorder in which only erythroid progenitors are suppressed (red cell progenitors are completely absent in severe cases). Causes: Associated with neoplasms (thymoma and large granular lymphocytic leukaemia) Drug exposures Autoimmune disorders Parvovirus infection Clinical features: Fatigue, weakness, pallor, frequent infections, easy bruising or bleeding, and shortness of breath due to insufficient production of red blood cells, white blood cells, and platelets. It features a marked reduction or absence of red blood cell precursors while other hematopoietic cell lines remain normal . Aplastic anaemia (Option A) is a rare condition where the bone marrow fails to produce sufficient red blood cells, white blood cells, and platelets, leading to fatigue, infections, and bleeding. It can be caused by autoimmune diseases, infections, medications, or toxins. It involves a reduction in all hematopoietic cell lines and a hypocellular marrow with increased fat content on bone marrow biopsy. Iron deficiency anaemia (Option C) is a common type of anaemia caused by insufficient iron, leading to reduced haemoglobin production. Symptoms include fatigue, pallor, and weakness. It presents with low haemoglobin, low MCH, low MCV, low MCV, and high reticulocyte count , and it often shows signs of microcytic anaemia on blood smears. Pernicious anaemia (Option D) is a type of vitamin B12 deficiency anaemia caused by impaired absorption of B12 due to a lack of intrinsic factors. It leads to symptoms like fatigue, weakness, and neurological issues. It features low haemoglobin, high MCV, high MCH, and Erythroid hyperplasia on bone marrow biopsy .

References:

Robbins and Cotran Pathologic Basis of Diseases, 10th Edition, Page 661.

↑ *Back to this question in Part A*

@Neet_pg_bot

Q65: A patient reports to the outpatient department with complaints of fatigue. Investigation results indicate a Hb of 5.9, increased RDW and TIBC, and low ferritin. What is the most likely diagnosis? (Q860499)

A. Sideroblastic anemia

B. IDA

C. Anaemia of chronic disease

D. Hemolytic anemia

Correct Answer: B. IDA

Explanation: The patient's presentation with fatigue and investigations showing low haemoglobin, increased RDW, high TIBC, and low ferritin are consistent with a diagnosis of Iron Deficiency Anemia (IDA) . It results in inadequate haemoglobin synthesis. Causes: Dietary lack Impaired absorption Increased requirement Chronic blood loss Pathogenesis: Iron deficiency initially depletes iron stores (low ferritin) while maintaining normal serum iron and transferrin saturation. As depletion progresses, serum iron declines, leading to reduced haemoglobin synthesis. Hypochromic microcytic anaemia develops once iron stores are exhausted, with low serum iron, ferritin, and transferrin saturation, while total iron-binding capacity (TIBC) increases. Clinical features include koilonychia, alopecia, atrophic glossitis, esophageal webs, pica, malabsorption, fatigue, pale skin, shortness of breath, dizziness, headaches, tachycardia, cold extremities, and restless leg syndrome. Histopathology: Bone marrow aspiration: Increased erythroid progenitors and a lack of stainable iron in macrophages, best assessed by Prussian blue staining. Peripheral blood smears: Red cells are small (microcytic) and pale (hypochromic). {{caption_text}} Diagnosis: Iron Study Interpretation in Iron Deficiency Anemia Serum Ferritin Low (< 30 ng/mL) (depleted iron stores). Serum Iron (Fe) Low levels Total Iron Binding Capacity (TIBC) Increased TIBC (increased capacity of transferrin to bind iron in response to low iron stores). Red Cell Distribution Width (RDW) Increased RDW (Red Cell Distribution Width) Bone Marrow Aspiration and Iron Staining Confirmatory test Lab parameters in various anaemia: Serum Iron Transferrin saturation Serum Ferritin TIBC Sideroblastic Anemia (Option A ruled out) High High High Low Iron Deficiency Anemia (Option B) Low Low Low High Anaemia of Chronic Disease (Option C ruled out) Low Low High Low Hemolytic Anemia (Option D ruled out) High Low High Low

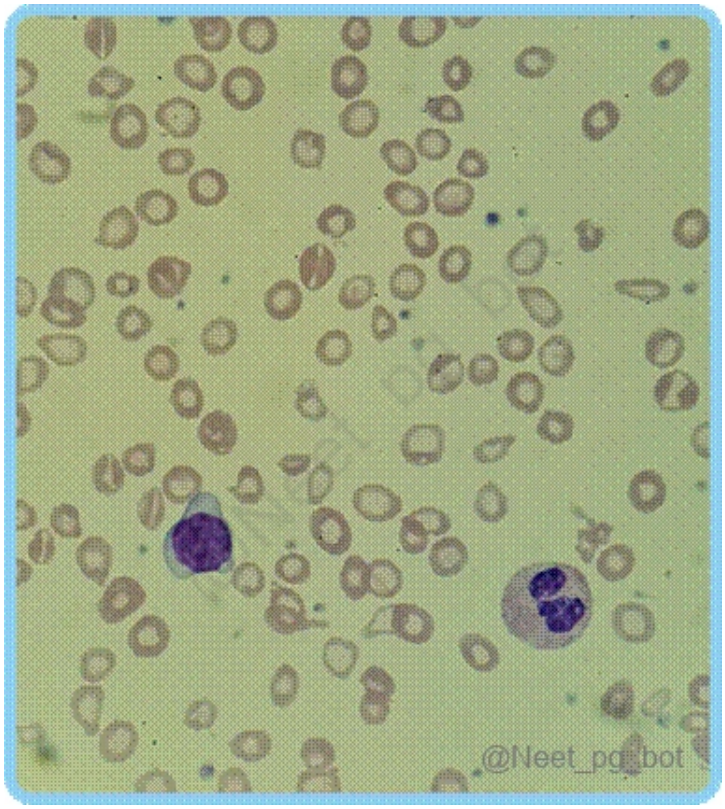

References:

Robbins & Cotran Pathologic Basis of Disease, 10th Edition, Page 655-658.

↑ *Back to this question in Part A*

Q66: A 20-year-old female who is a known case of sickle cell anaemia was rushed to the emergency department with a complaint of extreme pain in the legs and fingers for the past 4 hours. Further examination revealed pain and tenderness in the right upper quadrant, and investigations showed sickle cells on peripheral blood smear and high bilirubin(indirect). What is the diagnosis? (Q860485)

A. IDA

B. Thalassemia

C. Anaemia of chronic disease

D. Sickle cell crisis

Correct Answer: D. Sickle cell crisis

Explanation: The patient, a known case of sickle cell anaemia, presenting with severe leg and finger pain for the past 4 hours, right upper quadrant tenderness, sickle cells on the peripheral blood smear, and elevated indirect bilirubin is likely undergoing a vaso-occlusive crisis (type of sickle cell crisis) , a common complication of Sickle Cell Disease (SCD) . Complications Acute Painful Episodes (Vaso-Occlusive Crisis) Characterised by unprovoked, severe, symmetrical pain often requiring strong opioids The most common acute event in sickle cell disease. Lasting from days to weeks. Sudden death during acute pain episodes can occur, possibly due to arrhythmias or pulmonary embolism. Acute Chest Syndrome: Symptoms include chest pain, cough, fever, hypoxia, and pulmonary infiltrates on x-ray. It can be mild in children (e.g., due to viral infections) or severe with multiple lobes affected. Thrombocytopenia, leukocytosis, and rapid anaemia suggest severe complications like acute respiratory distress syndrome (ARDS) and multiorgan failure. Osteonecrosis: Involves the hips bilaterally . Chronic pain can progress to severe disability; MRI detects early stages, while X-rays are less sensitive. Leg ulcer: Ulcers range from small and superficial to deep, covering most of the lower leg. Painful and difficult to treat if recurrent, long-standing and large ulcer. Other Complications: Priapism Stroke and silent infarction Gallstones/Surgery Hepatic disease Nephropathy Lung/pulmonary hypertension Retinopathy Aplastic crisis: Caused by parvovirus B19 infection Multiorgan failure IDA (Iron Deficiency Anemia) (Option A) presents with microcytic hypochromic anaemia, not sickle cells on the smear. It also lacks acute pain crises and indirect hyperbilirubinemia. Thalassemia (Option B) causes chronic anaemia with target cells, not acute vaso-occlusive pain. It is also associated with ineffective erythropoiesis rather than hemolysis-induced hyperbilirubinemia. Anaemia of chronic disease (ACD) (Option C) is linked to chronic inflammation and cytokine-mediated iron sequestration, typically presenting with normocytic or microcytic anaemia without acute pain crises or hemolysis.

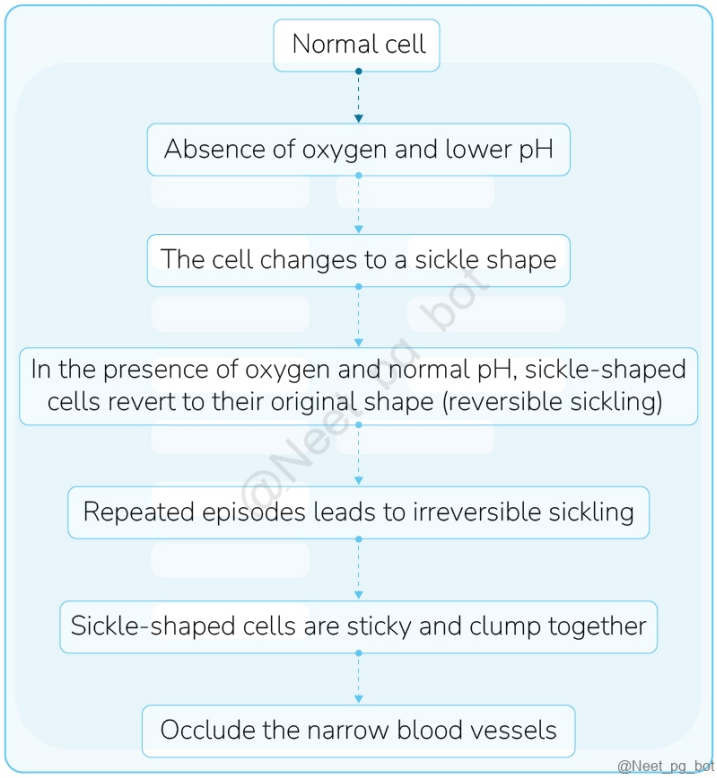

References:

Robbins & Cotran Pathological Basis of Diseases, 10th Edition, Page 643-644.

Harrison's Principles of Internal Medicine, 21st Edition, Page 758-760.

↑ *Back to this question in Part A*

@Neet_pg_bot

Q67: Which of the following is not seen after ileal resection? (Q844209)

A. Nuclear cytological asynchrony

B. Neurological manifestations

C. Microcytic hypochromic anemia

D. Reversible dementia

Correct Answer: C. Microcytic hypochromic anemia

Explanation: Ileal resection primarily affects vitamin B12 and bile acid absorption, since the terminal ileum is responsible for their absorption. Deficiency of vitamin B12 leads to megaloblastic anemia, nuclear-cytoplasmic

asynchrony, neurological manifestations (paresthesia, ataxia), and reversible dementia in severe cases. Microcytic hypochromic anemia (iron deficiency) is not typical, because iron is absorbed in the duodenum and proximal jejunum, which are not resected. Incorrect Options: Option A) Nuclear cytological asynchrony: Seen due to B12 deficiency affecting DNA synthesis. Option B) Neurological manifestations: Due to B12 deficiency, e.g., peripheral neuropathy. Option D) Reversible dementia: Severe B12 deficiency can lead to cognitive decline.

References:

.

↑ *Back to this question in Part A*

@Neet_pg_bot

Q68: How is transferrin saturation affected by iron deficiency anemia? (Q844208)

A. Increased

B. Decreased

C. Normal

D. Dynamic

Correct Answer: B. Decreased

Explanation: Correct Option B – Decreased Transferrin saturation is decreased in iron deficiency anemia because there is less iron available to bind to transferrin despite increased transferrin levels. Incorrect Options: Options A, C, and D are incorrect.

FEATURE	IDA	AOCD	SIDEROBLASTIC ANEMIA
Serum iron	↓	↓	↑
Transferrin saturation	↓	↓	↑
Ferritin	↓	↑↑	↑
TIBC	↑	↓	↓

@Neet_pg_bot

References:

Prepladder notes

↑ *Back to this question in Part A*

@Neet_pg_bot

Q69: Which of the following statement is correct regarding Paroxysmal Nocturnal Hemoglobinuria? (Q844193)

A. Sucrose lysis test is used for confirmation

B. Flow cytometry is the best investigation

C. Most common cause of death is heart failure

D. It is an inherited disorder

Correct Answer: B. Flow cytometry is the best investigation

Explanation: Correct Option B - Flow cytometry is the best investigation: Flow cytometry is the confirmatory test for diagnosing Paroxysmal Nocturnal Hemoglobinuria (PNH). It detects the absence or reduction of GPI-anchored proteins like CD55 and CD59 on the surface of red blood cells. Incorrect Options: Option A - Sucrose lysis test is used for confirmation: Sucrose lysis testb is no longer the preferred diagnostic test. Option C - Most common cause of death is heart failure: Most common cause of death is heart failure: The most common cause of death in PNH is thrombosis, not heart failure. Option D - It is an inherited disorder: It is an inherited disorder: PNH is an acquired disorder, not inherited.

References:

.

↑ *Back to this question in Part A*

@Neet_pg_bot

Q70: In a patient of hereditary spherocytosis, which of the following organisms is likely to attack progenitor cells, resulting in aplastic anemia? (Q844045)

A. CMV

B. EBV

C. Parvovirus B19

D. HSV

Correct Answer: C. Parvovirus B19

Explanation: Correct Option C - Parvovirus B19: Parvovirus B19 is responsible for causing aplastic crisis in hereditary spherocytosis. Incorrect Options: Options A, B, and D will not precipitate aplastic anemia.

↑ *Back to this question in Part A*

@Neet_pg_bot

Q71: All are hereditary causes of thrombosis except: (Q853369)

A. PNH

B. Protein S deficiency

C. Antithrombin deficiency

D. Homocystinuria

Correct Answer: A. PNH

Explanation: Paroxysmal nocturnal hemoglobinuria (PNH) is a rare acquired condition marked by clonal expansion of hematopoietic stem cells lacking GPI anchor proteins and is not a hereditary cause of thrombosis. PNH blood cells are deficient in three GPI-linked proteins that regulate complement activity: CD55 (decay-accelerating factor) CD59 (membrane inhibitor of reactive lysis) C8-binding protein. Pathogenesis: It results from acquired mutations in the phosphatidylinositol glycan complementation group A gene (PIGA), an enzyme that is essential for the synthesis of certain membrane-associated complement regulatory proteins. Clinical features: It causes intravascular haemolysis and anaemia Haemoglobinuria (red-brown colour) (most noticeable in early morning urine) Hypoplastic bone marrow failure, aplastic anaemia and myelodysplastic syndrome Management Transfusion Folate supplements Prophylaxis or treatment of thrombosis Anti-complement C5 monoclonal antibody. Incorrect Options: Protein S deficiency (Option B) is a genetic disorder that increases the risk of abnormal blood clotting (thrombosis). Protein C and its co-factor protein S are vitamin K-dependent natural anticoagulants involved in switching off coagulation factor activation (factors Va and VIIIa) and thrombin generation. Deficiency can lead to deep vein thrombosis (DVT), pulmonary embolism (PE), and other thrombotic events. Antithrombin deficiency (Option C) is an autosomal dominant inherited disorder that heightens the risk of abnormal blood clotting (thrombosis). Antithrombin (AT) is a serine protease inhibitor (SERPIN) that inactivates activated coagulation factors IIa, IXa, Xa, and XIa. A deficiency in AT can result in deep vein thrombosis (DVT), pulmonary embolism (PE), and other thrombotic events. Heparins and fondaparinux enhance AT activity to exert their therapeutic effects. Homocystinuria (Option D) is an autosomal recessive disorder caused by mutations in the CBS gene, leading to cystathionine β-synthase deficiency that results in the accumulation of homocysteine and methionine in the blood. Symptoms include lens dislocation (ectopia lentis), intellectual disability, seizures, skeletal abnormalities similar to Marfan's syndrome, osteoporosis, thrombosis, and hyperpigmentation.

References:

Robbins & Cotran Pathologic Basis of Diseases, 10th Edition, Page 648-649. Davidson’s Principles and Practice of Medicine, 24th Edition, Page 950-951.

↑ *Back to this question in Part A*

@Neet_pg_bot

Q72: A patient presents with fever, night sweats, and weight loss for 2 months. On examination, non-tender rubbery nodes are palpable in the supraclavicular and inguinal regions on both sides. A peripheral smear shows the presence of binucleated cells. Which of the following markers will be seen in this condition? CD15 CD30 CD19 CD3 (Q856019)

A. 1, 2, 4

B. 2, 3, 4

C. 2, 3

D. 1, 2

Correct Answer: D. 1, 2

Explanation: The clinical presentation of fever, night sweats, weight loss, and non-tender rubbery lymph nodes suggests Hodgkin lymphoma , supported by the presence of binucleated Reed-Sternberg cells in the peripheral smear. CD15 and CD30 are specific markers for Reed-Sternberg cells in Hodgkin lymphoma . {{caption_text}} CD19 and CD3 are typically markers for B cells and T cells , respectively, and are not characteristic of Hodgkin lymphoma. Hodgkin lymphoma typically spreads in an orderly, contiguous manner from one lymph node group to the next adjacent group without skipping areas. Feature Hodgkin Lymphoma (HL) Non-Hodgkin Lymphoma (NHL) Age of presentation Bimodal distribution peaks in young adults (15-35 years) and older adults (over 55). It is more common in older adults but can occur at any age. Localisation More often localised to a single axial group of nodes (cervical, mediastinal, para-aortic) More frequent involvement of multiple peripheral nodes. Pattern of Spread Orderly spread by contiguity. Non Contiguous spread Involvement of Mesenteric Nodes and Waldeyer Ring Mesenteric nodes and Waldeyer ring are rarely involved. Waldeyer ring and mesenteric nodes are commonly involved. Extranodal Presentation Extranodal presentation is rare. Extranodal presentation is common. WHO Classification of Hodgkin lymphoma: 1. Classical Hodgkin Lymphoma (CHL) Nodular Sclerosis Hodgkin Lymphoma Mixed Cellularity Hodgkin Lymphoma Lymphocyte-Rich Hodgkin Lymphoma Lymphocyte-Depleted Hodgkin Lymphoma 2. Non-classical lymphoma: Nodular Lymphocyte-Predominant Hodgkin Lymphoma (NLPHL) (CD20, CD45, and BCL-6 are expressed in Non-classical Nodular Lymphocyte-Predominant Hodgkin Lymphoma.

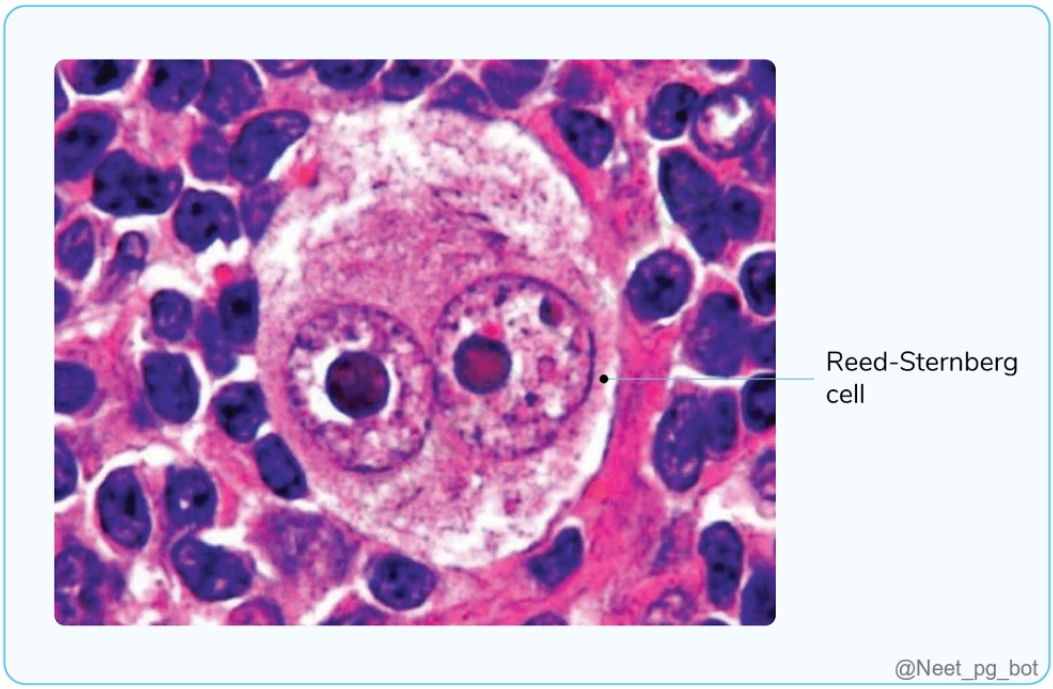

References:

Robbins & Cotran Pathologic Basis of Disease, 10th Edition, Page 611

↑ *Back to this question in Part A*

@Neet_pg_bot

Q73: Which of the following is not true about stem cells? (Q856476)

A. They can differentiate

B. They can replicate

C. They can divide without any regulatory stimulus

D. They can regenerate damaged tissues

Correct Answer: C. They can divide without any regulatory stimulus

Explanation: Stem cells can differentiate into various cell types, replicate, and regenerate damaged tissues. However, they do not divide uncontrollably or without regulatory stimuli. Their division is tightly regulated by signalling pathways to ensure proper function and prevent uncontrolled cell proliferation, which could lead to issues like cancer. Stem cells: Dual property: Stem cells can self-renew (Option B) and differentiate (Option A) into various cell types. Totipotent stem cells: Found during development, can generate all cell types in the body. Adult stem cells: Present in tissues, maintain cell populations, and repair damage (Option D) . Limited

differentiation capacity, typically producing cells within their respective tissues. Main types: Embryonic stem (ES) cells: Totipotent, can differentiate into all cell types. Adult (Tissue) stem cells: Limited to differentiating into specific tissue types, regulated by stem cell niches . Examples: Hematopoietic stem cells: Replenish blood cells in bone marrow, used in clinical treatments like leukaemia. Mesenchymal stem cells: Found in bone marrow and fat, they can differentiate into stromal cells (cartilage, bone, fat, muscle) and aid tissue regeneration.

References:

Robbins & Cotran Pathologic Basis of Disease, 10th Edition, Page 28

↑ *Back to this question in Part A*

@Neet_pg_bot

Q74: Identify the cells marked in the given image: (Q856905)

A. Lymphocyte-1, Monocyte-4, Eosinophil-2, Basophil-3

B. Lymphocyte-2, Monocyte-4, Eosinophil-1, Basophil-3

C. Lymphocyte-1, Monocyte-2, Eosinophil-3, Basophil-4

D. Lymphocyte-2, Monocyte-1, Eosinophil-3, Basophil-4

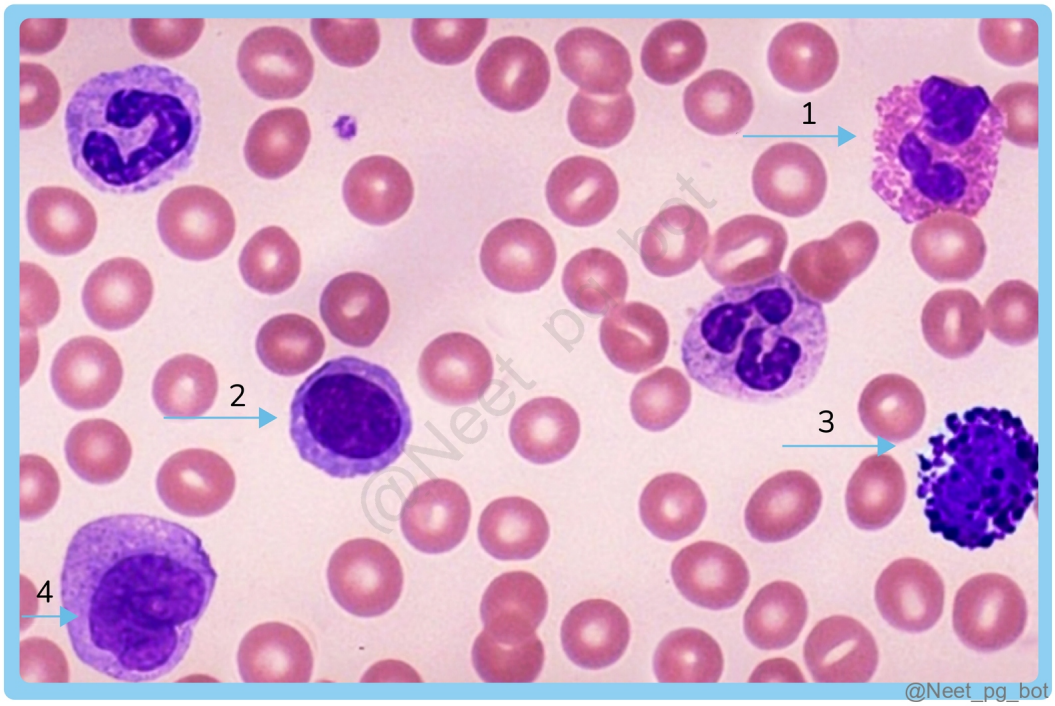

Correct Answer: B. Lymphocyte-2, Monocyte-4, Eosinophil-1, Basophil-3

Explanation: {{caption_text}} Neutrophils are granulocytes with a multilobed nucleus and pale cytoplasm containing fine pinkish granules. They are the most abundant white blood cells and play a key role in innate immunity through phagocytosis and enzyme release. Lymphocytes have a large, round nucleus, a small amount of cytoplasm & no granules. Monocytes are the largest cells with a kidney-shaped nucleus and a substantial cytoplasm. Eosinophils are granulocytes with a bilobed nucleus and prominent brick-red granules in their cytoplasm. Basophils are a type of granulocyte with a segmented nucleus and large bluish granules in their cytoplasm.

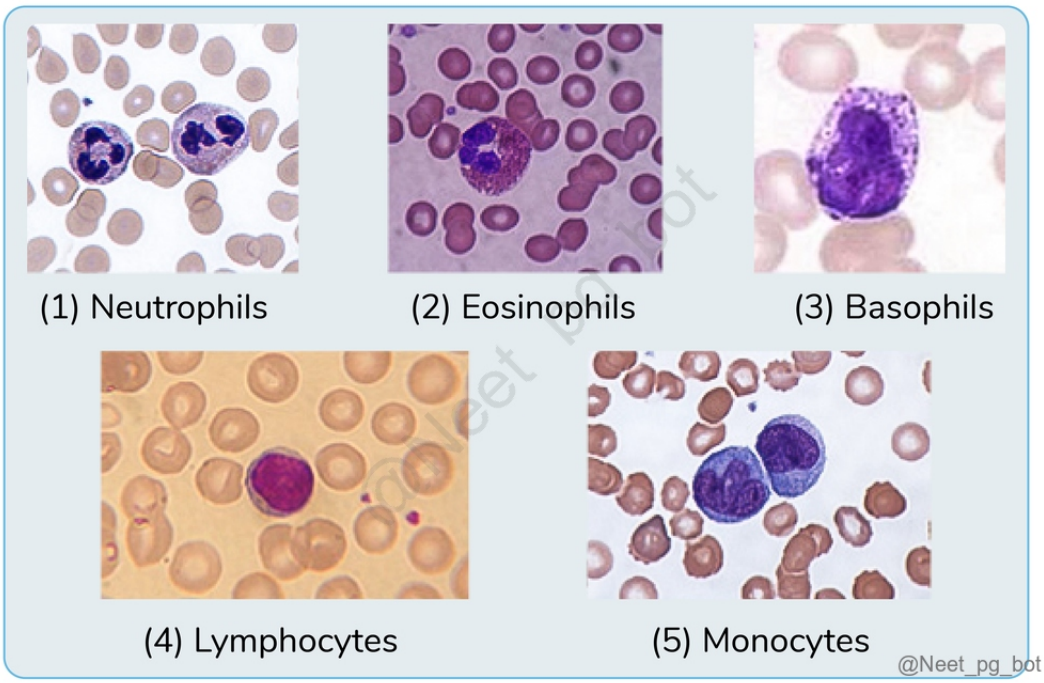

References:

Robbins & Cotran Pathologic Basis of Disease, 9th Edition, Page 580

↑ *Back to this question in Part A*

@Neet_pg_bot

Q75: What is your diagnosis with respect to the findings shown in the peripheral smear: (Q856901)

A. Iron deficiency anaemia

B. Vitamin B12 deficiency

C. Hereditary spherocytosis

D. Acute myeloid leukemia

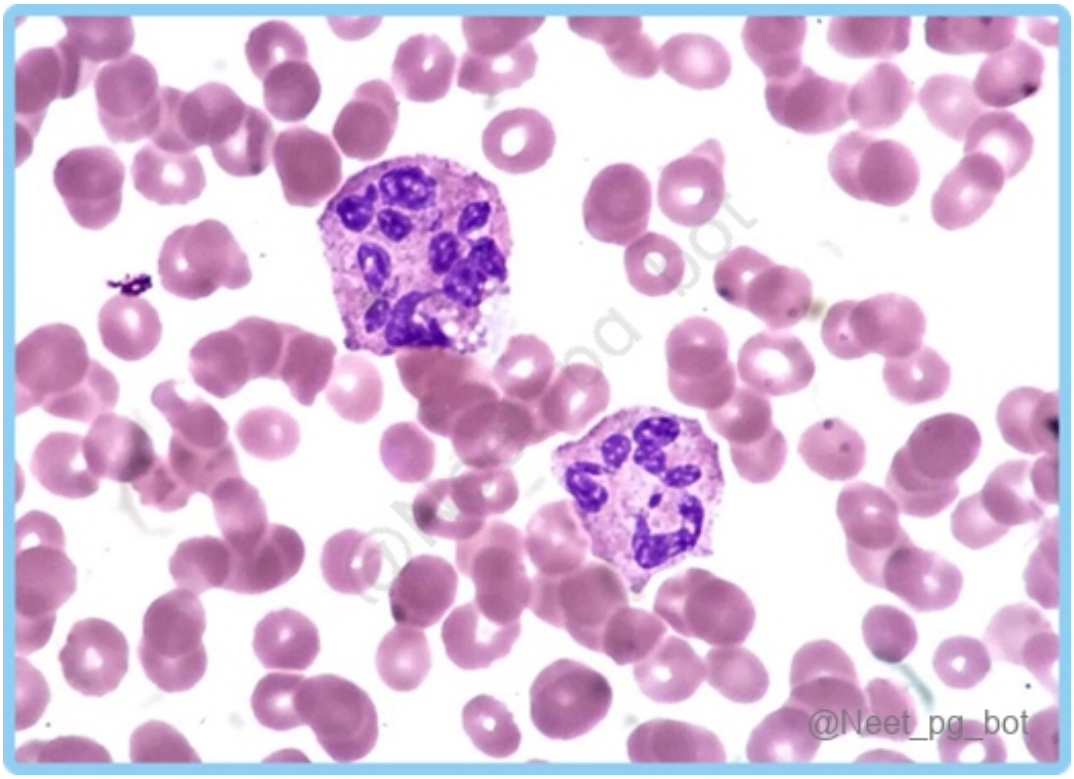

Correct Answer: B. Vitamin B12 deficiency

Explanation: The peripheral blood smear shows enlarged oval-shaped red blood cells (macro-ovalocytes) with hyperchromia and hypersegmented neutrophils , suggesting megaloblastic anaemia caused by B12 deficiency or folic acid deficiency. Causes of megaloblastic anaemia: Vitamin B12 deficiency Folate deficiency Other causes: Orotic aciduria, thiamine-responsive megaloblastic anaemia, arsenic poisoning, nitrous oxide inhalation, chemotherapy Lab findings in B12 deficiency: Bone Marrow Biochemical Tests Hypercellular bone marrow Erythroid Hyperplasia Sieve-like chromatin Hypersegmented neutrophils Reversal of myeloid: erythroid ratio 1:1 or less (Normal: 3:1) Nuclear-cytoplasmic asynchrony. {{caption_text}} Serum bilirubin: Increases Serum LDH: Increases Vitamin B12: Decreases Folic acid: Decreases Anti-intrinsic factor (IF) antibody: Present (Pernicious anaemia) Methylmalonyl CoA: Increases Homocysteine: Increases Schilling Test: Assess the cause of B12 deficiency.

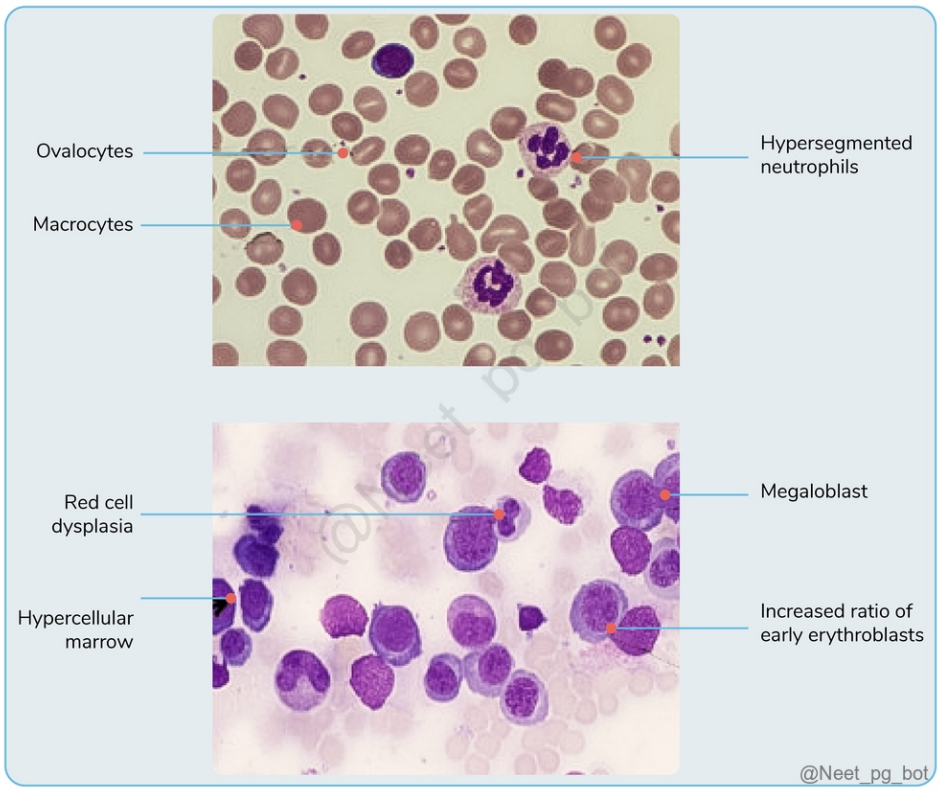

References:

Robbins & Cotran Pathologic Basis of Disease, 10th Edition, Page 651-655

↑ *Back to this question in Part A*

@Neet_pg_bot

Q76: Rees and Ecker diluting fluid is used in: (Q856896)

A. Wintrobe tube

B. WBC pipette

C. RBC pipette

D. Hemoglobin pipette

Correct Answer: C. RBC pipette

Explanation: Rees and Ecker diluting fluid is used in the RBC pipette for platelet counting. Composition of Rees and Ecker diluting fluid : Components Value Sodium citrate 3.8g Formaldehyde (40%) 0.2ml Brilliant cresyl blue 0.1g Distilled water 100ml

References:

https://www.sciencedirect.com/science/article/pii/S0032579119560291/pdf?md5=2a83111960f94586877200f392b69797&pid=1-s2.0-S0032579119560291-main.pdf

https://pmc.ncbi.nlm.nih.gov/articles/PMC3706762/

↑ *Back to this question in Part A*

@Neet_pg_bot

Q77: An 18-year-old male presented to the outpatient department with gum bleeding and fever for the past 2 months. The general examination showed pallor, and the systemic examination was unremarkable. Laboratory examination revealed a Hb level of 3 g/dl, a TLC of 1500/microL, and a platelet count of 15,000/microL. A peripheral smear shows macrocytes, and the reticulocyte count is 0.5%. A bone marrow examination revealed fatty streaks and absent megakaryocytes with no immature cells. What is the likely diagnosis? (Q856143)

A. Idiopathic acquired aplastic anaemia

B. Paroxysmal nocturnal hemoglobinuria

C. Myelodysplastic syndrome

D. Tuberculosis

Correct Answer: A. Idiopathic acquired aplastic anaemia

Explanation: The clinical presentation of gum bleeding, fever, pallor, severe anaemia, leukopenia, and thrombocytopenia, along with the findings of peripheral smear and bone marrow biopsy, strongly point toward idiopathic acquired aplastic anaemia (AAA). Aplastic Anemia is characterised by bone marrow failure, where the bone marrow does not produce enough blood cells, leading to Pancytopenia. In severe cases, the bone marrow may become hypocellular , making it difficult to aspirate sufficient material, leading to a dry tap. {{caption_text}} The absence of immature cells and the presence of fatty streaks in the bone marrow suggests bone marrow failure , typical of aplastic anemia, where normal hematopoiesis is replaced by fat. Paroxysmal nocturnal hemoglobinuria (Option B) is a rare disorder that causes red blood cells to prematurely break down by the complement system. It is characterised by hemolytic anemia and hemoglobinuria. The peripheral smear shows evidence of hemolysis, which is not the case here. Myelodysplastic syndrome (Option C) is a group of disorders characterised by ineffective hematopoiesis and dysplastic cells in the bone marrow. While MDS can cause pancytopenia, it would typically show dysplastic features in the marrow, including abnormal shapes of cells, which is not the case here. Tuberculosis (Option D) is an infectious disease caused by Mycobacterium tuberculosis that is not commonly associated with severe pancytopenia, fatty marrow, or absence of megakaryocytes. TB-related bone marrow suppression would usually have other findings like granulomas .

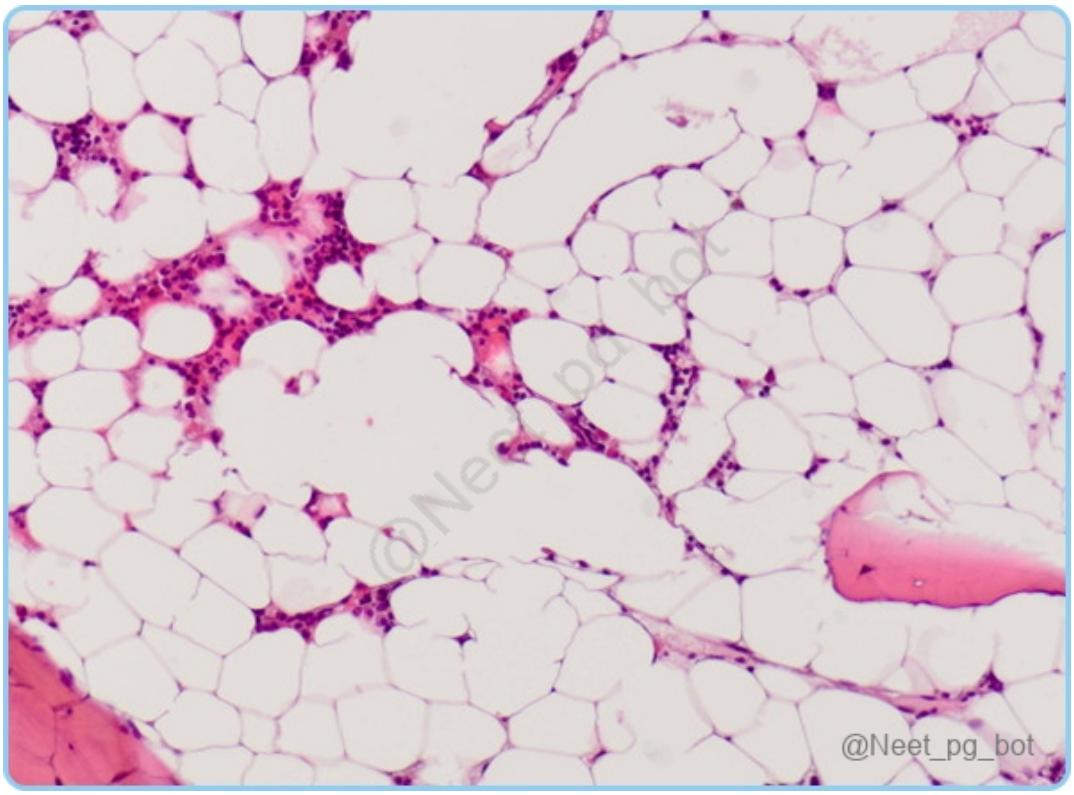

References:

Robbins and Cotran, Pathologic Basis of Disease, 10th Edition, Page 648

NIHLink

↑ *Back to this question in Part A*

@Neet_pg_bot

Q78: Which of the following is used in treating sideroblastic anaemia? (Q855432)

A. Vitamin B12

B. Vitamin B6

C. Vitamin B1

D. Iron

Correct Answer: B. Vitamin B6

Explanation: The treatment of Sideroblastic Anemia involves the use of vitamin B6 (pyridoxine). Sideroblastic Anemia It is a condition characterized by defective heme synthesis in the bone marrow, leading to the

accumulation of iron within the mitochondria of red blood cell precursors (sideroblasts). Causes Congenital causes: Due to enzyme deficiencies like ALA synthase, ferrochelatase, etc. Acquired causes Vitamin B6 deficiency Drugs like isoniazid and chloramphenicol Lead and alcohol poisoning Pathogenesis Vitamin B6 is crucial for the proper function of enzymes in heme synthesis. As a cofactor for aminolevulinic acid synthase, it aids in the first step of heme production. Ensuring sufficient vitamin B6 restores enzyme activity, supports heme synthesis, and helps alleviate symptoms of sideroblastic anaemia. Microscopy Peripheral Smear: Pappenheimer bodies Multiple basophilic iron aggregates Stain blue with Perl's/ Prussian blue Seen in sideroblastic anaemia, lead poisoning, or hemochromatosis {{caption_text}} Bone Marrow: Ringed Sideroblasts Blue granules form a full or partial ring Blasts have a nucleus Iron is present in mitochondria in the perinuclear region. Stain blue on Perl's/Prussian blue. Seen with Sideroblastic anemia and Myelodysplastic syndrome. Associated with SF3B1 mutation {{caption_text}} Vitamin B1 (Option C), or thiamine, plays a key role in carbohydrate metabolism and nerve function. Its deficiency causes conditions like Wernicke-Korsakoff syndrome and Beriberi, but it is not linked to sideroblastic anaemia. Vitamin B12 (Option A) deficiency causes megaloblastic anaemia and neurological symptoms. It results from poor diet, malabsorption, or lack of intrinsic factors. In sideroblastic anaemia, vitamin B6 is used instead of vitamin B12 because it helps correct the heme synthesis defect, while B12 is not involved in this process. Iron (Option D) deficiency presents with symptoms like pale skin, shortness of breath, dizziness or lightheadedness, brittle nails, headaches, restless legs syndrome, etc. In sideroblastic anaemia, treatment focuses on addressing the underlying cause, as the main issue is impaired heme synthesis. Iron supplementation is generally ineffective and may worsen the condition by increasing iron accumulation in tissues.

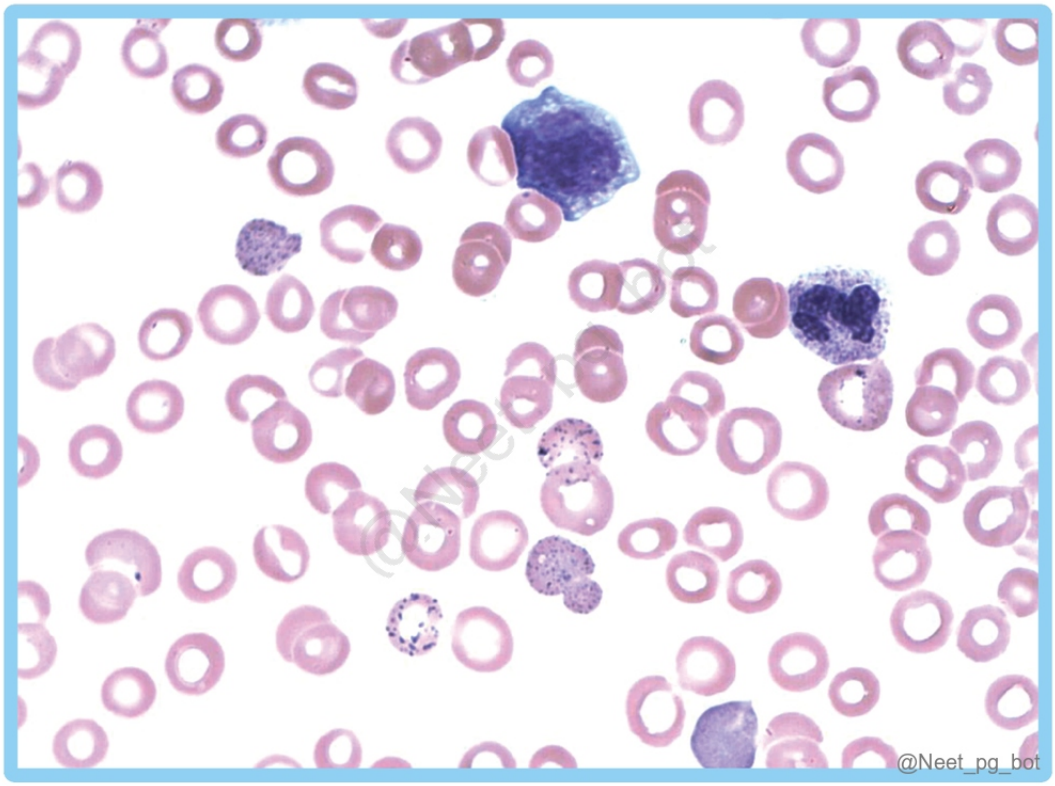

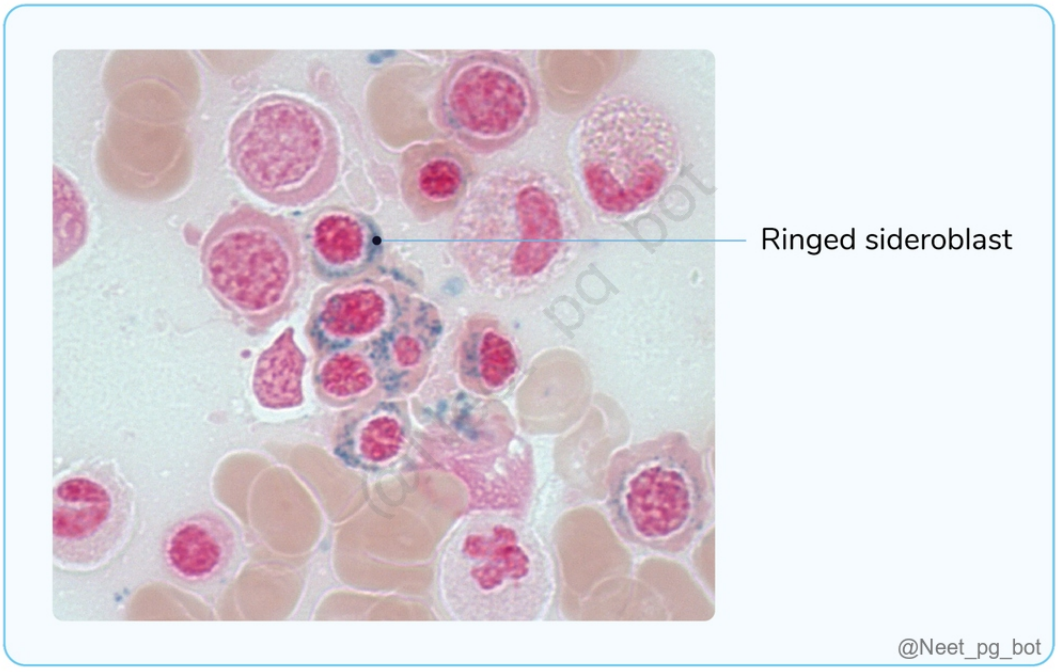

References:

Robbins & Cotran Pathological Basis of Diseases, 10th Edition, Page, 620-621.

↑ *Back to this question in Part A*

@Neet_pg_bot

Q79: Which of the following statements regarding the effect of glucose-6-phosphate dehydrogenase deficiency is correct? Decrease in reduced glutathione Decrease NADPH Decreased lipid peroxidation Decreased RBC membrane damage (Q855416)

A. Only 1 is correct

B. 1 & 2 are correct

C. 2 & 3 are correct

D. 1, 2 & 4 are correct

Correct Answer: B. 1 & 2 are correct

Explanation: 1 & 2 statements are correct regarding Glucose-6-phosphate Dehydrogenase (G6PD) Deficiency. It is an X-linked recessive disorder. Pathogenesis: It is characterized by a deficiency in the G6PD enzyme, which protects red blood cells from oxidative damage. This reduces the ability to generate NADPH (Statement 2) via the pentose phosphate pathway and impairs glutathione regeneration (Statement 1), exacerbating oxidative stress and

hemolysis. When exposed to oxidative stressors, there is an imbalance between the production of reactive oxygen species (ROS) and antioxidants that neutralize them. This leads to oxidative damage to red blood cell membranes and proteins, resulting in hemolysis. (Statement 4) {{caption_text}} Clinical features: Episodes of acute hemolytic anaemia triggered by oxidative stressors such as infections, certain medications (e.g., antimalarials, sulfonamides), or ingestion of certain foods (e.g., fava beans). Fatigue, pallor, jaundice, and dark urine (due to hemoglobinuria). The severity of hemolysis varies depending on the degree of enzyme deficiency and the magnitude of the oxidative insult, with some individuals experiencing life-threatening hemolytic crises. G6PD deficiency causes both intra and extravascular hemolysis. Decreased lipid peroxidation (Statement 3): G6PD deficiency does not directly lead to a reduction in lipid peroxidation. On the contrary, it can increase susceptibility to oxidative stress and the production of reactive oxygen species (ROS). The reduced levels of NADPH and glutathione in G6PD deficiency impair the cell's antioxidant defence mechanisms, resulting in enhanced lipid peroxidation and oxidative damage.

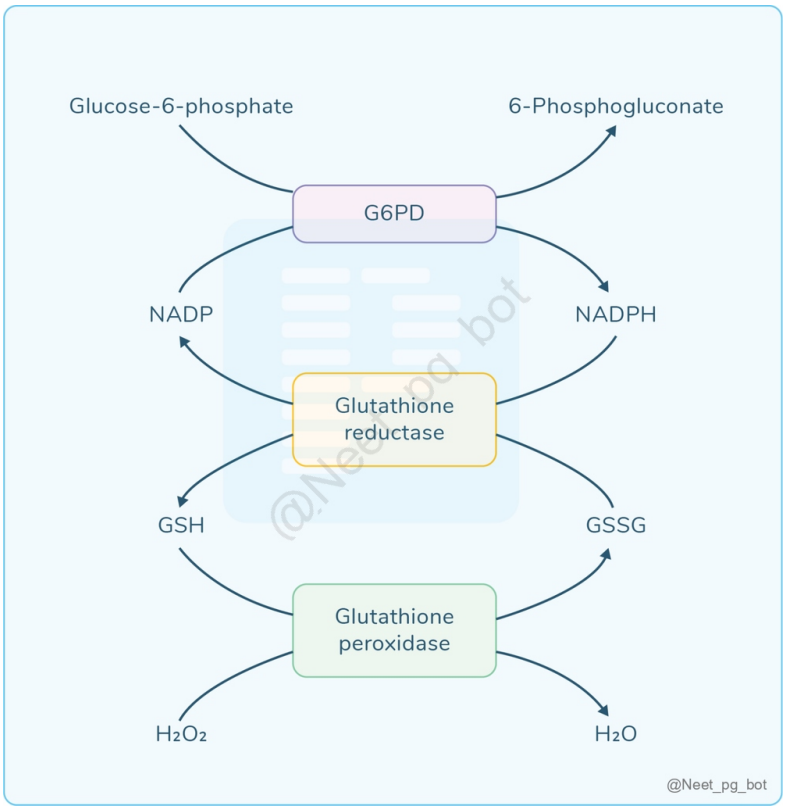

References:

Robbins & Cotran Pathologic Basis of Diseases, 10th Edition, Page 640.

↑ *Back to this question in Part A*

@Neet_pg_bot

Q80: A child presented with bilateral proptosis. From the peripheral smear, he was suspected to have chloroma. What is the next investigation of choice? (Q855410)

A. Platelet count

B. WBC count

C. Flow cytometry

D. Bone marrow biopsy

Correct Answer: D. Bone marrow biopsy

Explanation: The next investigation of choice for a child suspected to have Chloroma (also known as Granulocytic Sarcoma or Myeloblastoma) is a bone marrow biopsy. It is a localized extramedullary myeloid tumour composed of immature myeloid cells, which can occur in patients with acute myeloid leukaemia (AML) or myelodysplastic syndrome (MDS). It is not a benign tumour, but it has a greenish colour. Site: Soft tissue involvement in orbit leads to proptosis. Associated with AML M2 and M5. Bone marrow biopsy: Confirms the diagnosis by revealing the presence of abnormal myeloid cells infiltrating the bone marrow. (Option D) {{caption_text}} Peripheral smear findings: Myeloblasts. Arbiskov cells: Atypical monocytes/macrophages. Markers: MPO (green colour), CD 43, CD 45 and Lysozyme. {{caption_text}} {{caption_text}} Platelet count (Option A), WBC count (Option B) and Flow cytometry (Option C) might be done but they do not confirm the diagnosis of chloroma.

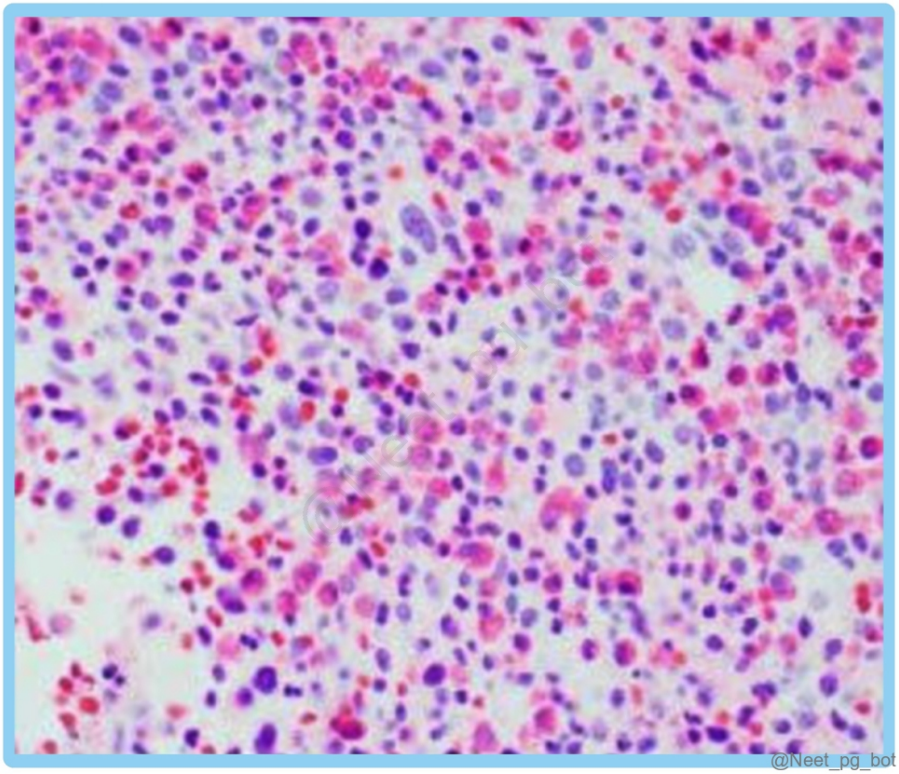

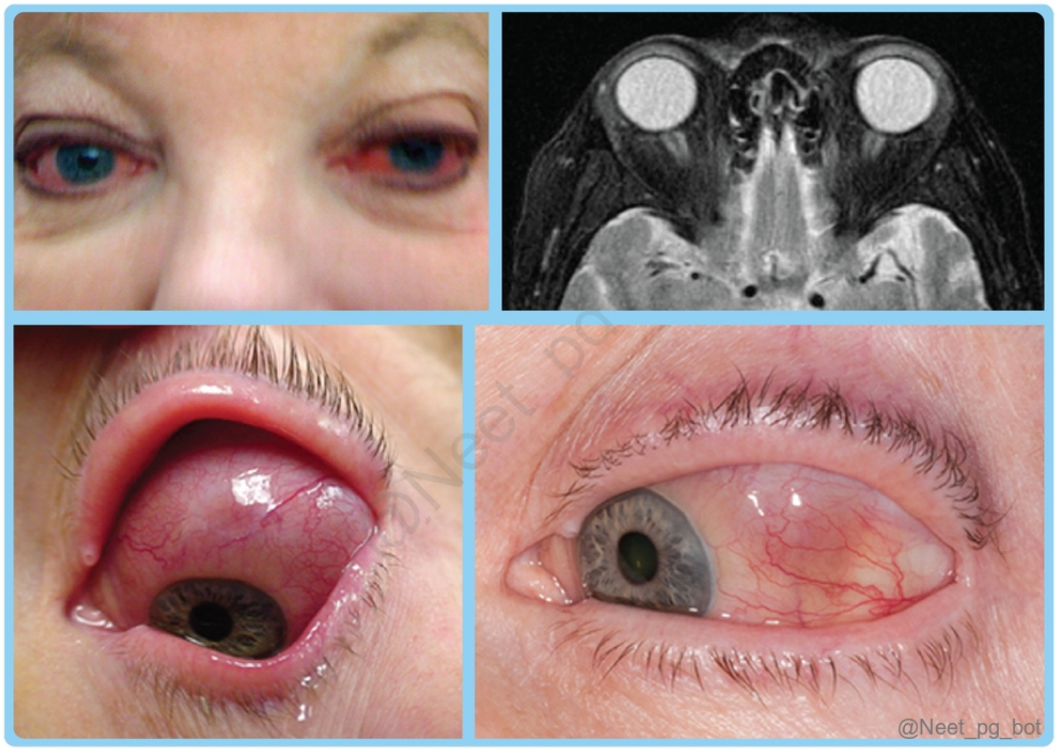

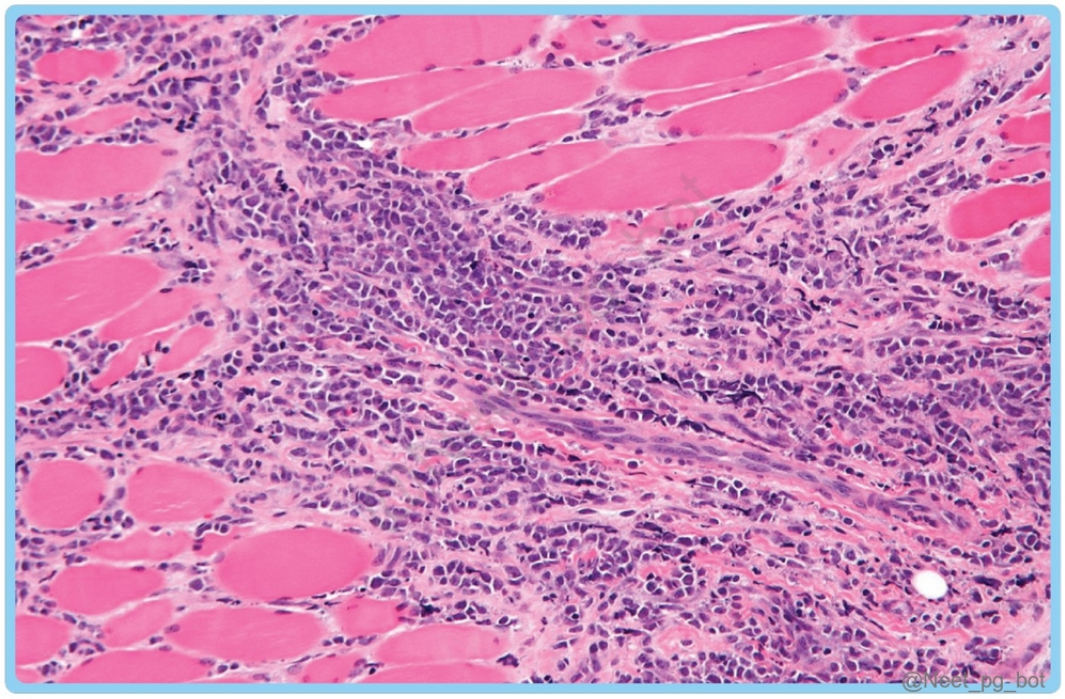

References:

Robbins & Cotran Pathologic Basis of Diseases, 10th Edition, Page 618-620.

↑ *Back to this question in Part A*

@Neet_pg_bot

Q81: All of the following are associated with massive splenomegaly, except: (Q855400)

A. Chronic myeloid leukemia

B. Aplastic anemia

C. Hairy cell leukemia

D. Lymphoma

Correct Answer: B. Aplastic anemia

Explanation: Massive splenomegaly, often linked to haematological disorders, is not typically associated with Aplastic Anemia, a bone marrow failure condition characterized by reduced production of blood cells. Aplastic Anemia It refers to a syndrome of chronic primary hematopoietic failure and attendant pancytopenia. Cause Acquired Idiopathic Acquired stem cell defects Immune-mediated Chemical agents Dose-related (Alkylating agents, antimetabolites, benzene, chloramphenicol, inorganic arsenicals) Idiosyncratic (Chloramphenicol, phenylbutazone, organic arsenicals, methylphenylethylhydantoin, carbamazepine, penicillamine, gold salts) Physical agents Whole-body irradiation Viral infections Hepatitis (unknown virus) Cytomegalovirus infections Epstein-Barr virus infections Herpes zoster (varicella zoster) Inherited Fanconi anemia Telomerase defects Pathogenesis The pathogenesis of aplastic anaemia is not fully understood. However, two major etiologies have been invoked: Extrinsic (immune-mediated suppression of marrow progenitors) Intrinsic (abnormality of stem cells) Clinical features Onset: Insidious. Pancytopenia Anaemia (progressive weakness, pallor, and dyspnea) Thrombocytopenia (petechiae and ecchymoses) Neutropenia (frequent and persistent infections or the sudden onset of chills, fever, and prostration). Splenomegaly is absent (Option B) The red cells are usually slightly macrocytic and normochromic. Microscopy Hypocellular bone marrow is largely devoid of hematopoietic cells; often, only fat cells, fibrous stroma, and scattered lymphocytes and plasma cells remain. Marrow aspirates often yield little material (a “dry tap”). {{caption_text}} Chronic myeloid leukaemia (Option A): Extensive extramedullary hematopoiesis often results in significant splenomegaly. Bone marrow findings typically include hypercellularity, an increased myeloid-to-erythroid ratio, and the presence of dwarf megakaryocytes. Additionally, sea-blue histiocytes, also known as pseudo-Gaucher cells, may be observed in the marrow. {{caption_text}} {{caption_text}} {{caption_text}} Hairy cell leukaemia (Option C) presents with fatigue, recurrent infections, easy bruising, and symptoms related to splenomegaly, such as early satiety and abdominal discomfort, along with pancytopenia. Peripheral smear typically shows "hairy cells" with round, oblong, or reniform nuclei and pale blue cytoplasm. Bone marrow findings often reveal hypocellular or fibrotic marrow with "hairy cells" and a characteristic "fried egg" appearance. {{caption_text}} Lymphoma (Option D) is cancer that originates in the lymphatic system, part of the immune system, and involves the uncontrolled growth of lymphocytes (a type of white blood cell). It can present with splenomegaly. The two main types are Hodgkin lymphoma (HL), characterized by Reed-Sternberg cells, and Non-Hodgkin lymphoma (NHL).

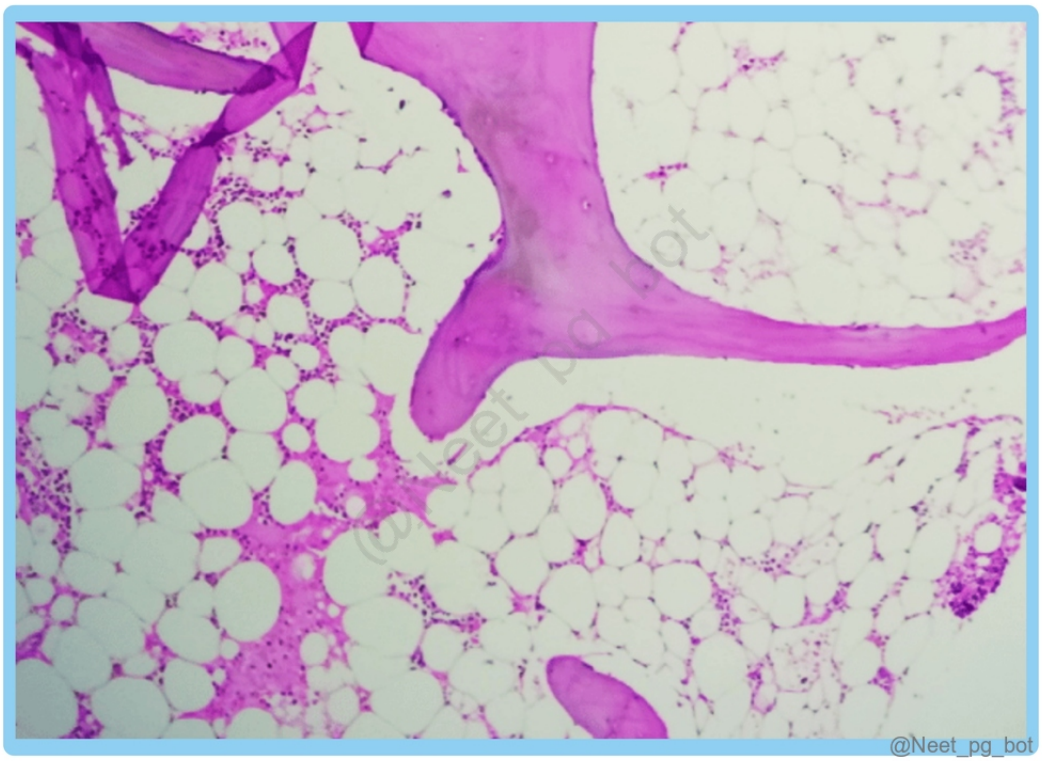
@Neet_pg_bot

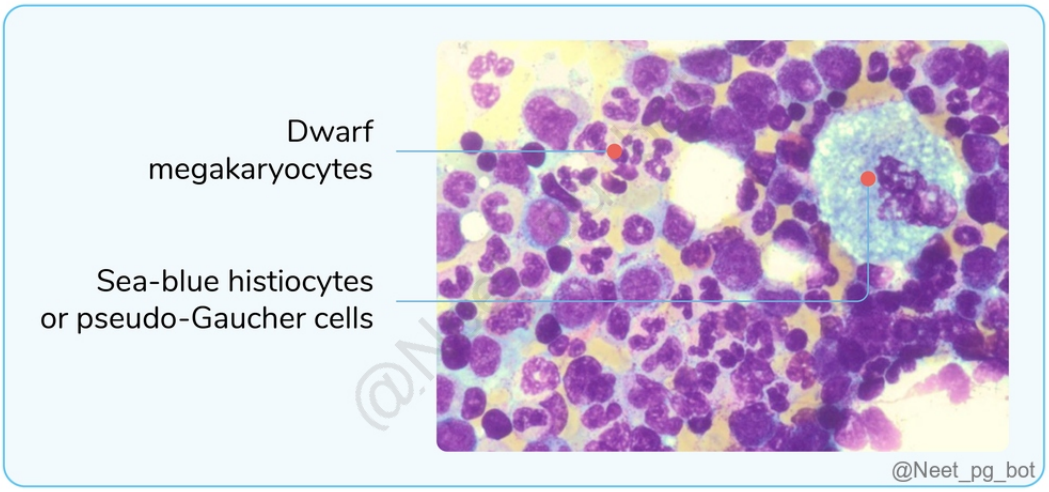
Dwarf
megakaryocytes
Sea-blue histiocytes
or pseudo-Gaucher cells
@Neet_pg_bot

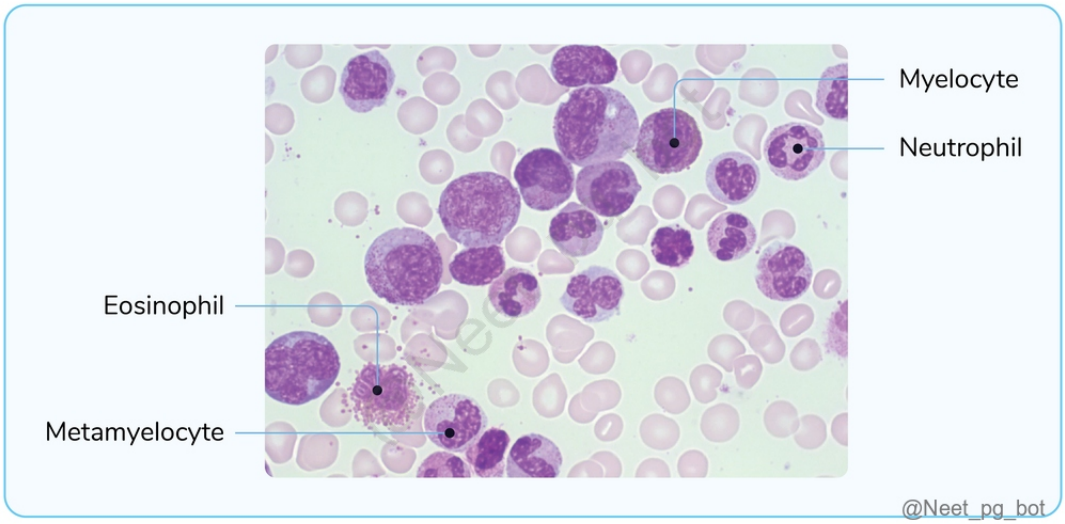
Myelocyte
Neutrophil
Eosinophil
Metamyelocyte
@Neet_pg_bot

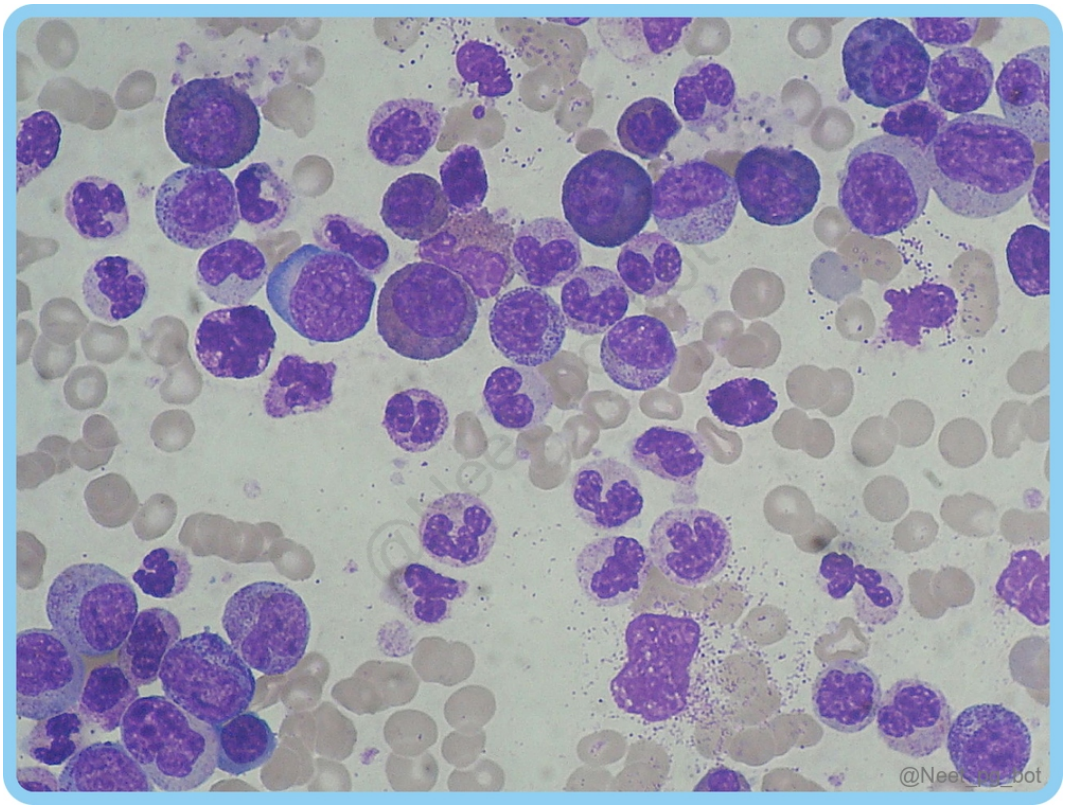
@Neet_pg_bot

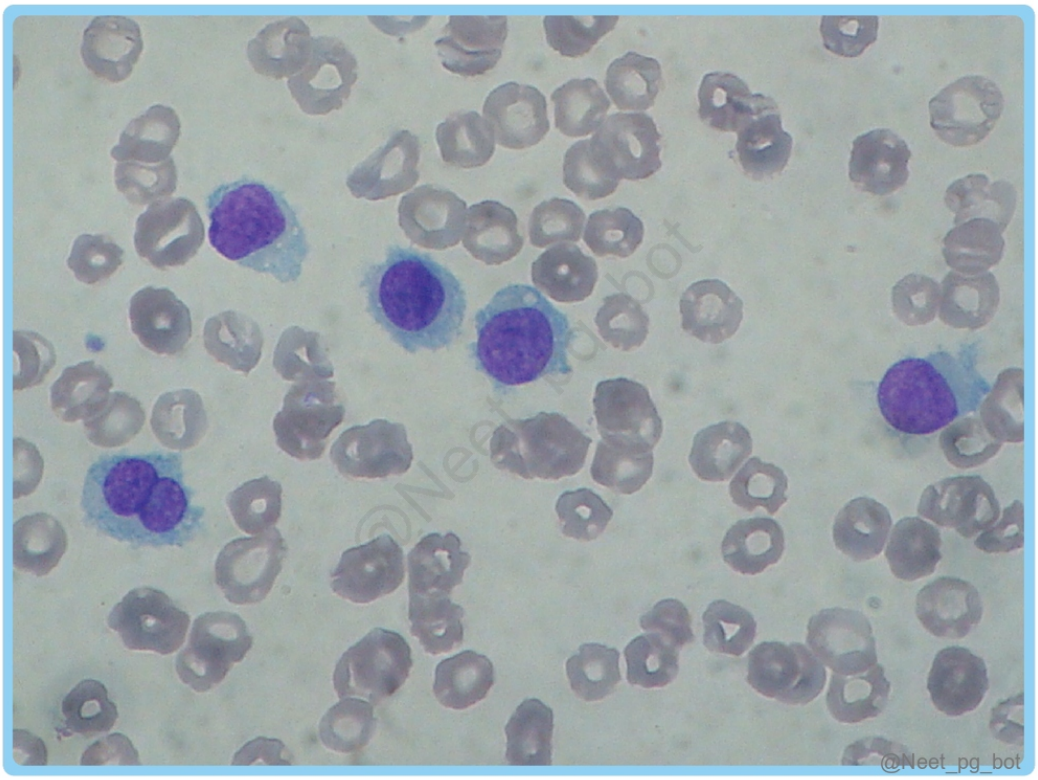

References:

Robbins & Cotran Pathologic Basis of Diseases, 10th Edition, Page 659-661.

↑ *Back to this question in Part A*

@Neet_pg_bot

Q82: A 45-year-old male patient was diagnosed with iron deficiency anaemia. Which of the following is true about the intracellular regulation of iron in iron deficiency anaemia? (Q855399)

A. Ferritin translation is increased by binding IRP to IRE

B. Ferritin translation is decreased by binding IRP to IRE

C. Transferrin receptor 1 translation is unaffected by binding IRP to IRE

D. Transferrin receptor 1 translation is decreased by binding IRP to IRE

Correct Answer: B. Ferritin translation is decreased by binding IRP to IRE

Explanation: Iron deficiency state → intracellular iron is low Iron regulatory proteins (IRPs) are key to maintaining iron homeostasis. When iron levels are low, IRPs bind to iron response elements (IREs) located in the untranslated regions (UTRs) of specific messenger RNAs (mRNAs) Ferritin regulation Ferritin mRNA has IRE in the 5′ UTR The binding of IRP to this 5' IRE physically blocks the ribosome from initiating translation, thus decreasing ferritin production . This action helps conserve the limited iron available by preventing its storage. Transferrin receptor 1 (TfR1) regulation TfR1 mRNA has IREs in the 3′ UTR The binding of IRP to the 3' IRE protects the mRNA from degradation, thereby increasing its stability and translation. This leads to increased production of TfR1 , which enhances iron uptake into the cells to compensate for the deficiency. Ferritin translation is increased by binding IRP to IRE (Option A) : Opposite of true; IRP binding inhibits ferritin translation Transferrin receptor 1 translation is unaffected by binding IRP to IRE (Option C): IRP binding increases TfR1 translation by stabilizing mRNA Transferrin receptor 1 translation is decreased by binding IRP to IRE (Option D): IRP binding actually enhances TfR1 expression

References:

Harrison’s Principle of Internal Medicine, 21st Edition, Page 748-750.

Intracellular Iron Transport and Storage: From Molecular Mechanisms to Health Implications - PMC

↑ *Back to this question in Part A*

@Neet_pg_bot

Q83: A 24-year-old male patient presents with anaemia. Both his father and paternal aunt experienced similar illnesses and were effectively treated with splenectomy. The patient's peripheral blood smear resembles the one depicted in the accompanying illustration, showing spherocytes. What other abnormalities can be anticipated? (Q857592)

A. Decreased osmotic fragility

B. Decreased reticulocytes

C. Heinz bodies

D. Howell-Jolly bodies

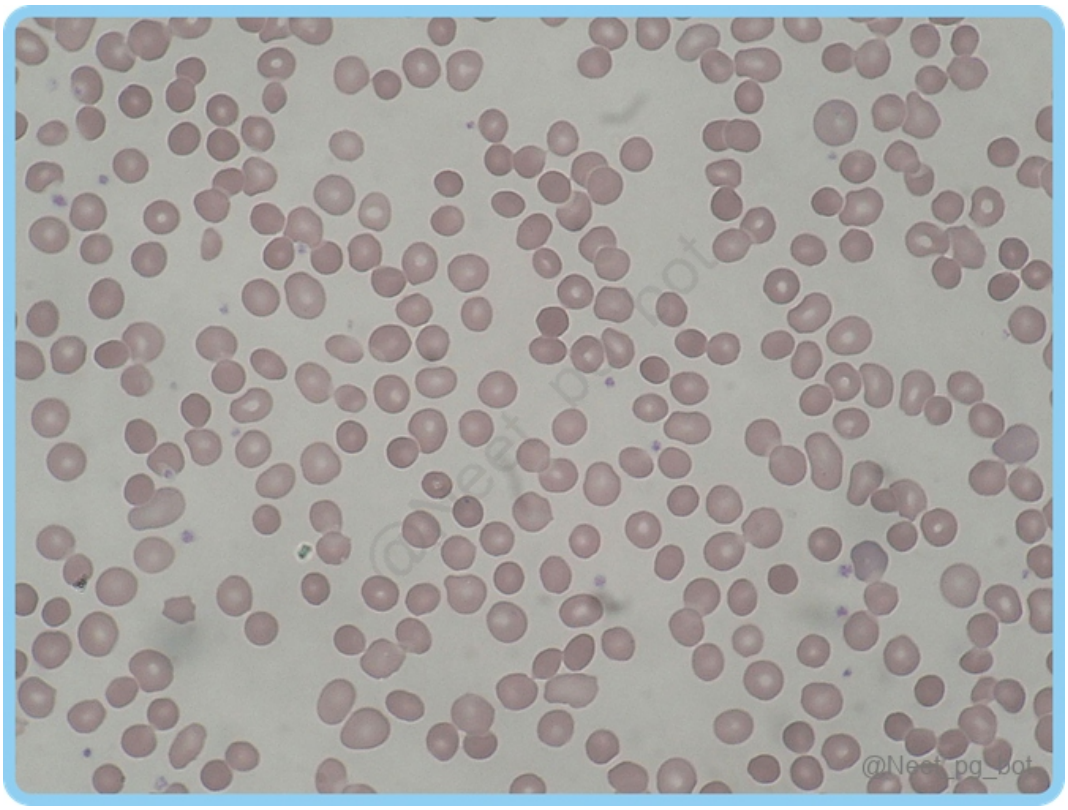

Correct Answer: D. Howell-Jolly bodies

Explanation: The clinical presentation, along with microscopic findings, indicates hereditary spherocytosis. Howell-Jolly bodies, remnants of nuclear material normally removed by the spleen, persist in red blood cells in splenectomised patients and can be seen on a peripheral blood smear. Hereditary spherocytosis (HS) is an inherited disorder caused by intrinsic defects in the red cell membrane skeleton that render red cells spheroid, less deformable, and vulnerable to splenic sequestration and destruction. It has an autosomal dominant inheritance(75%) characterised by ankyrin mutation and an autosomal recessive inheritance characterised by spectrin mutation. Pathophysiology of hereditary spherocytosis: {{caption_text}} {{caption_text}} The most specific morphologic finding is spherocytosis: Dark-staining (hyperchromic) spherocytes lacking the central zone of pallor. Other features include reticulocytosis. The characteristic clinical features are anaemia, splenomegaly, jaundice, and an increased risk of gallstones. Severity ranges from asymptomatic to severe hemolytic anaemia requiring transfusions. Early complications include neonatal jaundice and hemolytic crises. Late complications include gallstones and rarely iron overload. Decreased osmotic fragility (Option A): In hereditary spherocytosis, osmotic fragility increases , not decreases. Red blood cells are more prone to bursting in hypotonic solutions. Decreased reticulocytes (Option B): Reticulocyte count is typically increased in hereditary spherocytosis, especially in cases of hemolysis, as the bone marrow compensates by producing more immature red blood cells. Heinz bodies (Option C) are formed due to oxidative damage to haemoglobin and are typically seen in G6PD deficiency or other conditions involving hemoglobinopathy.

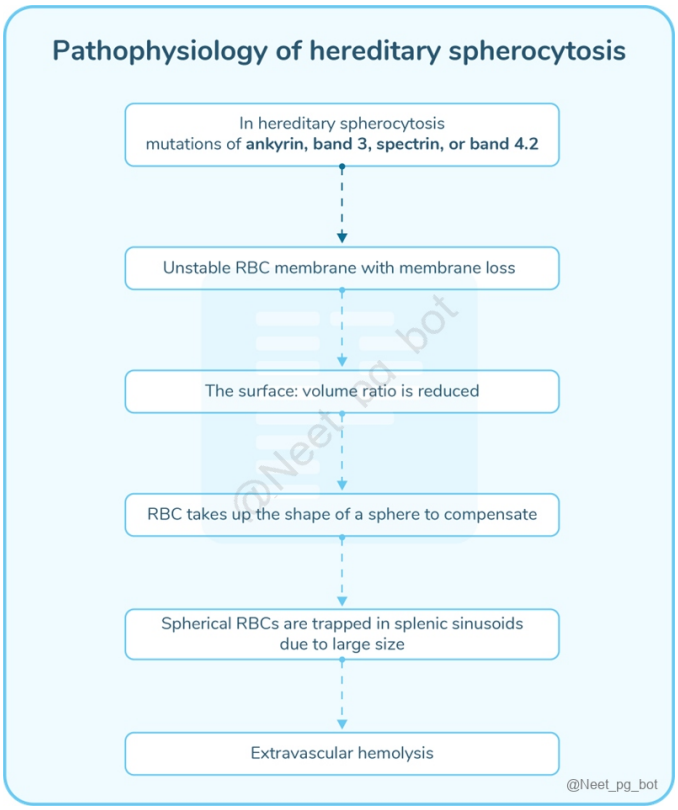

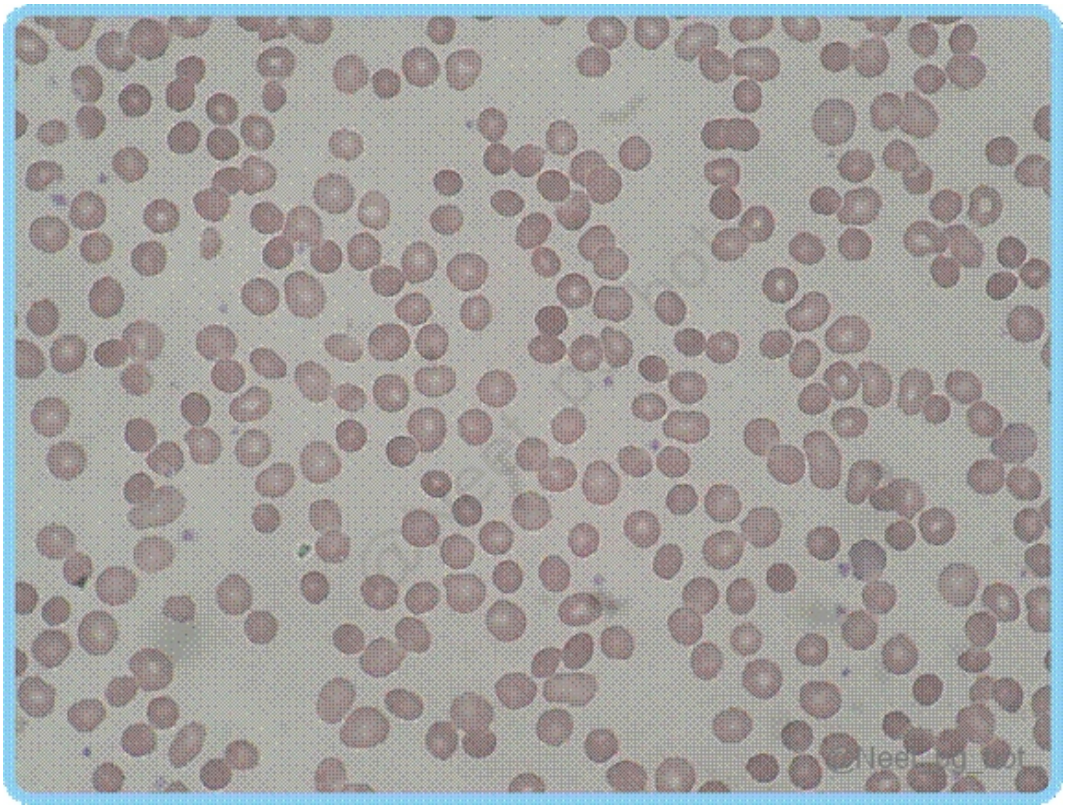

References:

Robbins and Cotran Pathologic Basis of Disease, 10th Edition, Page 638, 639

↑ *Back to this question in Part A*

@Neet_pg_bot

Q84: What is the most likely diagnosis for an 18-year-old male with gum bleeding, fever for two months, pallor, low haemoglobin (3 gm/dL), low TLC (1500/microL), low platelet count (15000/microL), macrocytes on peripheral smear, 0.5% reticulocyte count, and bone marrow examination showing fatty streaks and a lack of megakaryocytes but no immature cells? (Q857108)

A. Idiopathic acquired aplastic anemia

B. Paroxysmal nocturnal hemoglobinuria

C. Myelodysplastic syndrome

D. Tuberculosis

Correct Answer: A. Idiopathic acquired aplastic anemia

Explanation: The patient presents with gum bleeding, prolonged fever, pallor, and pancytopenia. Bone marrow examination shows fatty streaks, a lack of megakaryocytes, and no immature cells, suggesting idiopathic acquired aplastic anemia, where bone marrow failure leads to hematologic abnormalities. Aplastic anaemia is a condition of primary hematopoietic failure resulting in pancytopenia (anaemia, neutropenia, thrombocytopenia), often due to autoimmune mechanisms or inherited/acquired abnormalities in hematopoietic stem cells. Etiology: Common causes: Chemical and drug exposure (e.g., chemotherapy, benzene) Viral infections (e.g., hepatitis, linked to 5% of cases) Radiation exposure (e.g., therapeutic or nuclear accidents) Genetic causes: Fanconi anaemia : Rare autosomal recessive disorder with congenital anomalies (kidney, spleen hypoplasia, bone anomalies). Telomerase defects : Found in 5-10% of adult-onset cases, causing premature exhaustion of hematopoietic stem cells. Idiopathic cases: No identifiable cause in ~65% of cases. Morphology: Bone Marrow: Hypocellular marrow with fat cells, fibrous stroma, and scattered lymphocytes/plasma cells. "Dry tap" on marrow aspirates (due to lack of hematopoietic cells). Peripheral Blood: Macrocytic , normochromic red cells with reticulocytopenia . Granulocytopenia (leading to infections) and thrombocytopenia (leading to bleeding). Clinical features: Onset: Insidious, with progressive pancytopenia. Anaemia : Weakness, pallor, dyspnea. Thrombocytopenia : Petechiae, ecchymosis. Neutropenia : Frequent infections, chills, fever. Splenomegaly : Generally absent. Red Cells : Slightly macrocytic and normochromic. Diagnosis: Based on bone marrow biopsy , showing hypocellularity . Must differentiate from other causes of pancytopenia, like leukaemia or myelodysplastic syndrome, where the marrow is typically hypercellular. Paroxysmal nocturnal hemoglobinuria (PNH) (Option B) is a rare acquired disorder where red blood cells are destroyed by complement. It often presents with hemolysis and episodes of dark urine, especially at night. The peripheral smear in PNH shows evidence of hemolysis and pancytopenia, but bone marrow findings would not show fatty streaks with a lack of megakaryocytes, as in this case. Myelodysplastic syndrome (MDS) (Option C) typically presents with cytopenias and abnormal blood cell morphology. Bone marrow findings in MDS often show dysplastic changes in blood cells, which would not correlate with the lack of immature cells seen here. Additionally, the absence of megakaryocytes and the presence of fatty streaks suggest aplasia rather

than dysplastic hematopoiesis. Tuberculosis (TB) (Option D): While TB can cause systemic symptoms like fever and weight loss, it is not typically associated with pancytopenia, macrocytic anaemia, and bone marrow findings of fatty streaks with a lack of megakaryocytes. TB may affect bone marrow in disseminated forms, but the presentation and lab findings here point more to an intrinsic hematopoietic failure like aplastic anaemia.

References:

Robbins & Cotran Pathologic Basis of Disease, 10th Edition, Page 659-661

↑ *Back to this question in Part A*

@Neet_pg_bot

Q85: A 10-year-old boy presents with fatigue. Investigations reveal the following: Hemoglobin: 9 g/dL MCV: 80 fL MCH: 29 pg Serum ferritin: 185 µg/L TLC: Elevated with predominant lymphocytes and neutrophils. What is the likely diagnosis for this patient? (Q855124)

A. Thalassemia

B. Anemia of chronic disorder

C. Iron deficiency anaemia

D. Sickle cell anemia

Correct Answer: B. Anemia of chronic disorder

Explanation: The patient has normocytic, normochromic anaemia with normal MCV (80 fL) and MCH (29 pg). Elevated serum ferritin (185 µg/L) suggests adequate iron stores, ruling out iron deficiency anaemia. The elevated TLC with predominant lymphocytes and neutrophils indicates an underlying chronic inflammatory or infectious condition consistent with anaemia of chronic disease (ACD). Serum Iron Transferrin saturation Serum Ferritin TIBC Sideroblastic Anemia High High High Low Iron Deficiency Anemia Low Low Low High Anemia of Chronic Disease Low Low High Low Hemolytic Anemia High Low High Low Thalassemia (Option A) typically presents with microcytic anaemia and reduced MCV, which is not seen here. Iron deficiency anaemia (Option C) typically presents with low ferritin levels, which is not consistent with the patient's ferritin level. Sickle cell anaemia (Option D) usually results in normocytic anaemia but would typically show sickle-shaped cells on a peripheral blood smear, which is not described in this case.

References:

Robbins & Cotran Pathologic Basis of Disease, 10th Edition, Page 620,621,655,659

↑ *Back to this question in Part A*

@Neet_pg_bot

Q86: All of the following are seen in the anaemia of chronic disease, except: (Q855067)

A. High serum hepcidin

B. Low serum ferritin

C. Chronic infection

D. Normal iron stores

Correct Answer: B. Low serum ferritin

Explanation: In anaemia of chronic disease, ferritin levels are typically normal or elevated due to the inflammatory response, while hepcidin levels are increased, leading to impaired iron absorption and reduced availability of iron for erythropoiesis. Anaemia of Chronic Disease (AOCD): Interleukin-6 is the most important inflammatory mediator linked to the pathogenesis of anaemia of chronic disease (AOCD). In chronic conditions, Interleukin-6 will increase and act on the liver. Releases Hepcidin (Master regulator of Iron metabolism) Inhibits Fe absorption. Serum iron levels and transferrin saturation are decreased. Inhibits the release of Fe from ferritin. Therefore, ferritin levels increase . This leads to a decrease in TIBC. Anemia Serum Iron Transferrin saturation Serum Ferritin TIBC Sideroblastic Anemia High High High Low Iron Deficiency Anemia Low Low Low High Anaemia of Chronic Disease Low Low High Low Hemolytic Anemia High Low High Low

References:

Robbins & Cotran Pathologic Basis of Disease, 10th Edition, Page 620, 621, 655, 659

↑ *Back to this question in Part A*

@Neet_pg_bot

Q87: A patient is diagnosed with B-cell leukaemia. Which of the following are poor prognostic factors? Hyperdiploidy Age <1 year t(9:22) t(4:11) (Q856031)

A. A, C, D

B. C, D

C. A, B, C, D

D. B, C, D

Correct Answer: D. B, C, D

Explanation: Hyperdiploidy is generally associated with a better prognosis in B-cell leukaemia, particularly in acute lymphoblastic leukaemia (ALL) Prognostic factors in ALL: Favorable Prognostic factors Unfavorable

prognostic factors Age: 1-10 years Leucocyte count < 50000/µl Hyperploidy t (12:21) L1 ALL Response to treatment Early Pre B-cell ALL Female Extreme age group : <1 year or >10 years Hypoploidy t(9:22) and t(4:11) L2 and L3 ALL and mature B cell ALL Total leukocyte count >50,000/cubic.mm Black males Organomegaly CNS Leukemia Absence of CD10 Remission> 14 days

References:

Harrison's Principles of Internal Medicine, 21st Edition, Page 830

↑ *Back to this question in Part A*

@Neet_pg_bot

Q88: Which of the following is true about hereditary spherocytosis? (Q856004)

A. Gallstones develop by 4-5 years of age

B. Splenectomy does not protect against developing gallstones

C. Around 75% of cases show an autosomal dominant pattern

D. High MCH is pathognomonic of HS

Correct Answer: C. Around 75% of cases show an autosomal dominant pattern

Explanation: Hereditary spherocytosis (HS) is an inherited disorder caused by intrinsic defects in the red cell membrane skeleton that render red cells spheroid, less deformable, and vulnerable to splenic sequestration and destruction. It has an autosomal dominant inheritance (75%) characterized by ankyrin mutation and an autosomal recessive inheritance characterized by spectrin mutation . Gallstones develop by 4-5 years of age (Option A): Pigment gallstones form due to chronic hemolysis (excessive red blood cell breakdown). While a common complication, they usually appear in adolescence or adulthood , not as early as 4-5 years old. Splenectomy does not protect against developing gallstones (Option B): Splenectomy is performed precisely to stop the chronic hemolysis . By eliminating the major site of red blood cell destruction, it halts the overproduction of bilirubin and does protect against the formation of new bilirubin (pigment) gallstones. High MCH is pathognomonic of HS (Option D): The characteristic finding is a high MCHC, not MCH. This high MCHC occurs because the spherocytes lose cell membrane and cytoplasm, becoming dehydrated and "concentrating" the hemoglobin inside. Even a high MCHC is not pathognomonic. It is highly suggestive, but it can also be seen in other conditions, such as autoimmune hemolytic anemia.

References:

Robbins & Cotran Pathologic Basis of Disease, 10th Edition, Page 638, 639

↑ *Back to this question in Part A*

@Neet_pg_bot

Q89: Which of the following is not likely to be seen in a patient with paroxysmal nocturnal hemoglobinuria (PNH)? (Q855389)

A. Aplastic anemia

B. Leukaemia

C. Thrombosis

D. Hemolysis

Correct Answer: B. Leukaemia

Explanation: Leukaemia is not likely to be seen in a patient with Paroxysmal Nocturnal Hemoglobinuria (PNH). It is a rare acquired hematopoietic stem cell disorder characterized by a deficiency of glycosylphosphatidylinositol (GPI)-anchored proteins on the surface of blood cells, particularly red blood cells. PNH blood cells are deficient in three GPI-linked proteins that regulate complement activity: CD55 (decay-accelerating factor) CD59 (membrane inhibitor of reactive lysis) C8-binding protein. Pathogenesis: It results from acquired mutations in the phosphatidylinositol glycan complementation group A gene (PIGA), an enzyme that is essential for the synthesis of certain membrane-associated complement regulatory proteins. Clinical features: It causes intravascular hemolysis and anaemia. (Option D ruled out) Haemoglobinuria (red-brown colour) (most noticeable in early morning urine) Hypoplastic bone marrow failure, aplastic anaemia (Option A ruled out), thrombosis (Option C ruled out), and myelodysplastic syndrome Management Transfusion Folate supplements Prophylaxis or treatment of thrombosis Anti-complement C5 monoclonal antibody.

References:

Robbins & Cotran Pathologic Basis of Diseases, 10th Edition, Page 648-649.

Davidson’s Principles and Practice of Medicine, 24th Edition, Page 950-951.

↑ *Back to this question in Part A*

@Neet_pg_bot

Q90: Which of the following are features describing necrosis? Cell swelling Disrupted cell membrane Induces inflammation Physiological (Q857443)

A. 1 and 2

B. 1, 2 and 4

C. 1, 2 and 3

D. 1 and 3

Correct Answer: C. 1, 2 and 3

Explanation: Necrosis is a form of pathological cell death (Statement 4 ruled out) , often occurring due to various injuries, such as physical trauma, ischemia, infection, or exposure to toxic substances. It is characterized by cell swelling, membrane rupture, organelle damage, and nuclear changes (Pyknosis, Karyorrhexis, Karyolysis). Cell swelling occurs because of the loss of cellular integrity and failure of ion pumps (such as the Na+/K+ ATPase pump), leading to an influx of water into the cell. In necrosis, the plasma membrane of the cell is disrupted , allowing the release of intracellular contents. The released substances trigger an immune response, leading to an inflammatory reaction, which is a characteristic of necrosis.

References:

Robbins and Cotran Pathologic Basis of Disease, 10th Edition, Page 42

↑ *Back to this question in Part A*

@Neet_pg_bot

Q91: In which of the following conditions is macrocytic anemia seen? (Q793648)

A. Thalassemia

B. Anemia of chronic disease

C. Sideroblastic anemia

D. Liver disease

Correct Answer: D. Liver disease

Explanation: Correct Option D - Liver disease: There are several potential pathological mechanisms of macrocytic anemia associated with liver disease. First, patients with liver disease are more likely to have vitamin B12 or folate deficiencies, which directly result in macrocytic anemia. Vitamin B12 and folate coenzymes are required for thymidylate and purine synthesis; thus, their deficiencies result in retarded DNA synthesis and eventually will develop into macrocytic anemia. Second, macrocytic anemia in liver disease may be due to an increased deposition of cholesterol on the membranes of circulating RBCs. This deposition effectively increases the surface area of the erythrocyte. Incorrect Options: In options A, B, and C, macrocytic anemia is not seen.

References:

Prepladder Notes

↑ *Back to this question in Part A*

@Neet_pg_bot

Q92: Which of the following stains is used for the detection of hemosiderin deposits? (Q793650)

A. Mason-Fontana stain

B. Oil Red O

C. Sudan black

D. Perls Prussian blue

Correct Answer: D. Perls Prussian blue

Explanation: Correct Option D - Perls Prussian Blue: Hemosiderin is an iron-containing pigment that is produced by the breakdown of hemoglobin. It is commonly found in macrophages and can accumulate in various tissues in the body under certain conditions, such as hemorrhage, inflammation, and iron overload disorders. Perls Prussian blue stain is a commonly used stain for the detection of hemosiderin. The stain is based on the reaction of potassium ferrocyanide and hydrochloric acid with iron in hemosiderin, which produces a blue color. The staining is often performed on tissue sections from biopsy or autopsy specimens. Incorrect Options: Option A - Mason-Fontana stain: This stain is based on the oxidation of melanin by potassium permanganate, which results in the formation of brown or black pigment. The stain is commonly used for the detection of melanin pigment in tissues, such as the skin, hair, and eyes. Option B - Oil Red O: This stain is a lipophilic dye that is used to detect lipids, such as triglycerides and cholesterol esters. The dye binds to the lipid droplets in tissues, producing a bright red color. The stain is commonly used for the detection of fat in frozen sections of tissue samples. Option C - Sudan black: This stain is a lipophilic dye that is used to detect lipids in tissues. The stain binds to the lipid droplets in tissues, producing a dark blue-black color. The stain is commonly used for the detection of fat in frozen sections of tissue samples.

References:

Prepladder Notes

↑ *Back to this question in Part A*

@Neet_pg_bot

Q93: In iron deficiency anaemia, all of the following are increased except: (Q856136)

A. Transferrin saturation

B. RBC protoporphyrin

C. Total iron binding capacity

D. Ferritin soluble receptors

Correct Answer: A. Transferrin saturation

Explanation: Transferrin saturation is decreased in iron deficiency anaemia. This is because although TIBC is elevated, there is not enough iron to saturate the transferrin molecules, leading to low transferrin saturation. Iron Study Interpretation in Iron Deficiency Anemia Serum Ferritin Low (< 30 ng/mL) Serum Iron (Fe) Low Serum transferrin saturation (Option A) Low Total Iron Binding Capacity (TIBC) (Option C ruled out) Increased: TIBC reflects the increased capacity of transferrin to bind iron in response to low iron stores. Red Cell Distribution Width (RDW) Increased Ferritin soluble receptors (sTfR)(Option D ruled out) Increased RBC protoporphyrin (Option B ruled out) Increased Bone Marrow Aspiration and Iron Staining Confirmatory test for Iron deficiency anaemia.

References:

Robbins and Cotran Pathologic Basis of Disease, 10th Edition, Page 655

↑ *Back to this question in Part A*

@Neet_pg_bot

Q94: A child visited the hospital with her mother with complaints of severe fatigue, lethargy, pallor, and irritation. She has a known case of iron deficiency anemia and is on oral iron supplements. On reviewing the child, the physician in charge plans to start IV iron supplementation. What is the next best test to be done in assessing this child? (Q793752)

A. Blood hemoglobin

B. Total iron binding capacity

C. Serum ferritin

D. Hematocrit

Correct Answer: C. Serum ferritin

Explanation: Correct Option C - Serum ferritin: Serum ferritin is considered the most sensitive and specific test for the diagnosis of iron deficiency anemia. It reflects the amount of iron stored in the body and is considered an indirect measure of iron stores. A low serum ferritin level is the earliest indicator of iron deficiency anemia, and it can be used to monitor the effectiveness of iron therapy. Incorrect Options: Options A, B, and D are not specific to iron deficiency anemia.

References:

Prepladder Notes

↑ *Back to this question in Part A*

@Neet_pg_bot

Q95: A software engineer presents to the outpatient department with easy fatiguability. He gives a history of sitting in front of the computer for 12-14 hours. He consumes a lot of junk food with very few fruits and vegetables. Hb is 9 g/dl, and MCV is 80 fl. What is the most likely cause of this patient's anemia? (Q856150)

A. Cyanocobalamin deficiency

B. Iron deficiency

C. Folic acid deficiency

D. Hereditary spherocytosis

Correct Answer: B. Iron deficiency

Explanation: This patient's symptoms with a history of poor dietary habits and laboratory findings of Hb 9 g/dL with an MCV of 80 fl (microcytic anaemia) strongly suggest iron deficiency anaemia . Iron deficiency anaemia can result from dietary lack, impaired absorption, increased iron requirement (e.g., during pregnancy), or chronic blood loss (e.g., gastrointestinal bleeding). Clinical features include Koilonychia, alopecia, atrophic glossitis, esophageal webs, pica and intestinal malabsorption, affecting overall nutritional status. Cyanocobalamin deficiency (Option A) causes megaloblastic anemia , which typically presents with macrocytic anemia (elevated MCV), not the microcytic anemia seen in this patient. Folic acid deficiency (Option B) also causes megaloblastic anemia , which presents with macrocytic anemia (high MCV), not microcytic anemia . Hereditary spherocytosis (Option D) is a condition where red blood cells are abnormally shaped (spherocytes), leading to hemolysis and normocytic anemia (normal MCV).

References:

Robbins and Cotran Pathologic Basis of Disease, 10th Edition, Page 655

↑ *Back to this question in Part A*

@Neet_pg_bot

Q96: Which of the following is not routinely screened before conducting a blood transfusion? (Q793763)

A. Hepatitis A

B. Hepatitis B

C. Hepatitis C

D. HIV 1 / HIV 2

Correct Answer: A. Hepatitis A

Explanation: of the correct answer.

References:

Prepladder Notes

↑ *Back to this question in Part A*

@Neet_pg_bot

Q97: Metastatic calcification occurs in all except ? (Q793597)

A. Kidney

B. Fundus of the stomach

C. Pulmonary veins

D. Atheroma

Correct Answer: D. Atheroma

Explanation: Correct Option D - Atheroma: The type of calcification seen in atheroma is dystrophic calcification. Metastatic calcification: Metastatic calcification is caused by increased calcium phosphate in the blood and may result from hypercalcemia, hyperphosphatemia, or both. It is commonly associated with hyperparathyroidism, sarcoidosis, metastatic disease, and myeloma. Dystrophic calcification: The deposition of calcium salt in degenerated tissues in the absence of a systemic imbalance is called dystrophic calcification. It is mostly associated with trauma, inflammation, or infection. ■■■■■■■ Incorrect Options: Metastatic calcification occurs in options A, B, and C .

References:

.

↑ *Back to this question in Part A*

@Neet_pg_bot

• [18_Hematology_ White Blood Cells] 071 Cml And Cll

« Back to Folder Directory

[18_Hematology_ White Blood Cells] 071 Cml And Cll — Quick Jump

Q1 (p. 2831) *Q2 (p. 2832)* *Q3 (p. 2833)* *Q4 (p. 2833)* *Q5 (p. 2839)* *Q6 (p. 2840)*
Q7 (p. 2842) *Q8 (p. 2843)* *Q9 (p. 2844)* *Q10 (p. 2845)* *Q11 (p. 2846)* *Q12 (p. 2847)*
Q13 (p. 2848)

Q1: A 45-year-old male complained of fatigue and weakness in daily activities associated with intermittent fever. A blood workup revealed ↑ TLC, ↑ Platelets, and↑ Differential leukocyte count. On further investigations, Chronic Myeloid Leukemia is diagnosed. Which of the following is correct regarding CML? (Q882174)

A. Philadelphia chromosome is present in a minority of cases

B. Tyrosine kinase inhibitors (TKIs) are the drug of choice

C. Most cases present in the blast phase

D. Methotrexate is the drug of choice for AML

Correct Answer: B. Tyrosine kinase inhibitors (TKIs) are the drug of choice

Explanation: Tyrosine kinase inhibitors (TKIs) are the drug of choice CML is the most common myeloproliferative neoplasm. It is caused by a reciprocal translocation between the long arms of chromosomes 9 & 22 [t(9;22)] , giving rise to shortened chromosome 22, which is referred to as the Philadelphia chromosome (Ph chromosome). CML progresses in three phases: 1) Chronic phase: Leukocytosis, < 10% blast cells, basophils <20% and monocytosis < 3% 2) Accelerated phase: 10%-19% blasts, ≥ 20% basophils in the peripheral blood or bone marrow Persistent or increasing WBC (>10 × 10^9/L) and splenomegaly, unresponsive to therapy Persistent thrombocytosis (>1000 × 10^9/L), unresponsive to therapy Persistent thrombocytopenia (<100 × 10^9/L) unrelated to therapy This phase often leads to the terminal blast crisis within 6-12 months 3) Blast Crisis: ≥20% blasts in peripheral blood or bone marrow In 50% of patients, the blast crisis occurs abruptly without an accelerated phase Extensive extramedullary hematopoiesis occurs to compensate for CML and leads to significant splenomegaly Transformation into AML is more predominant than ALL Patient present with hyperleukocytosis , massive splenomegaly Bone marrow is hypercellular with granulocytic hyperplasia. Sea-blue histiocytes can be seen. After a variable period, some patients may transform into an accelerated phase or blast crisis. Tyrosine kinase inhibitors are the drug of choice, e.g., Imatinib, Dasatinib, etc. Generation Drugs Activity 1st generation Imatinib BCR-ABL inhibitor 2nd generation Dasatinib, Nilotinib, Bosutinib More potent, used in resistance 3rd generation Ponatinib Active against T315I mutation Option A: Philadelphia chromosome is present in a minority of cases CML is caused by the reciprocal translocation between long arms of chromosomes 9 & 22 [t(9;22)] , giving rise to shortened chromosome 22, which is referred to as the Philadelphia chromosome (Ph chromosome). It is present in more than 90% of patients with CML. The presence of the Philadelphia chromosome confirms CML .

Option C: Most cases present in the blast phase Some patients with CML progress to blast crises in which the CML acts as acute leukaemia. It is the terminal phase of CML. Most patients with CML present with splenomegaly and are in the chronic phase of the disease. Option D: Methotrexate is the drug of choice for AML Methotrexate is a nucleotide synthesis inhibitor. It is used for the treatment of psoriasis, rheumatoid arthritis, breast cancer, and certain acute leukaemias.

References:

Robbins & Cotran Pathologic Basis of Disease 10th ed pgs 622, 623

↑ *Back to this question in Part A*

@Neet_pg_bot

Q2: A 65-year-old woman presents with fatigue, night sweats and unintentional weight loss over the past few months. Physical examination reveals palpable lymph nodes and enlarged spleen. Lab tests show significant lymphocytosis (>20,000/μL) with small, mature-appearing lymphocytes. What is true regarding the origin and risk factors of the patient's condition? (Q842739)

A. B cells, no exposure to radiation

B. B-cells, exposure to radiation

C. Myeloid cells; BTK gene mutation

D. Myeloid cells; Philadelphia chromosome

Correct Answer: A. B cells, no exposure to radiation

■ *Listen (English)*

■ *Listen (Hindi)*

Explanation: Based on the above scenario, the patient is most likely suffering from Chronic Lymphocytic Leukemia. CLL is one of the cancers not associated with radiation exposure and originates from B cells. Chronic Lymphocytic Leukemia Genetics: Trisomy 12, deletion 13q14 , and others Origin: Post–germinal center memory B cell or naive B Cells in the mantle zone of the lymph node (Option A) Etiopathogenesis Antiapoptotic protein BCL2 overexpression. CLL cell growth depends on Bruton Tyrosine kinase (BTK) activity. No association with radiation exposure (Options A and B) Myeloid cells and Philadelphia chromosomes are seen in Chronic Myeloid Leukemia (Options C and D) .

References:

Robbin's and Cotran Pathological Basis of Disease, 10th Edition, Page 597

↑ *Back to this question in Part A*

@Neet_pg_bot

Q3: A 65-year-old male presents with generalised fatigue and night sweats. Lab tests reveals Hemoglobin (Hb) 12 g/dL Platelet count 150,000/µL Absolute lymphocyte count (ALC) 45,000/µL Total leukocyte count (TLC) 70,000/µL Differential leukocyte count (DLC) 70% lymphocytes, 20% neutrophils, 5% monocytes, and 5% eosinophils Based on these lab findings, what is the most likely diagnosis? (Q842740)

A. ALL

B. AML

C. CML

D. CLL

Correct Answer: D. CLL

■ *Listen (English)*

■ *Listen (Hindi)*

Explanation: The diagnosis is CLL due to the following laboratory findings: Absolute lymphocyte count (ALC) is significantly elevated (45,000/µL), a characteristic finding in CLL. Diagnostic ALC >5000/mm3. Total leukocyte count (TLC) is elevated (70,000/µL), consistent with leukemia. The differential leukocyte count (DLC) shows 70% lymphocytes, further supporting the CLL diagnosis. In CLL, there is a proliferation of mature-appearing lymphocytes. Definitive criterias for confirmation of CLL: Persistent lymphocytosis> 5000/µL On flow cytometry: Dual positivity for CD5 and CD23 On bone marrow examination: Lymphocyte count > 30% ALL (Option A): ALL is characterised by the presence of a high blast count in the peripheral blood. AML (Option B): AML involves the rapid proliferation of myeloid blasts in the bone marrow, often leading to high leukocyte counts. CML (Option C): CML is characterised by the presence of the Philadelphia chromosome and the overproduction of mature and immature granulocytes.

References:

Robbin’s and Cotran Pathological Basis of Disease, 10th Edition, Pages 595-598, 617

↑ *Back to this question in Part A*

@Neet_pg_bot

Q4: Match the following peripheral smear images with the respective diagnosis: A. 1. Acute Myeloid Leukemia (AML) B. 2. Chronic Myeloid Leukemia (CML) C. 3. Acute Lymphoblastic Leukemia (ALL) D. 4. Chronic Lymphocytic Leukemia (CLL)

(Q842741)

A. 1-B, 2-A, 3-D, 4-C

B. 1-B, 2-C, 3-D, 4-A

C. 1-C, 2-D, 3-B, 4-A

D. 1-D, 2-C, 3-A, 4-B

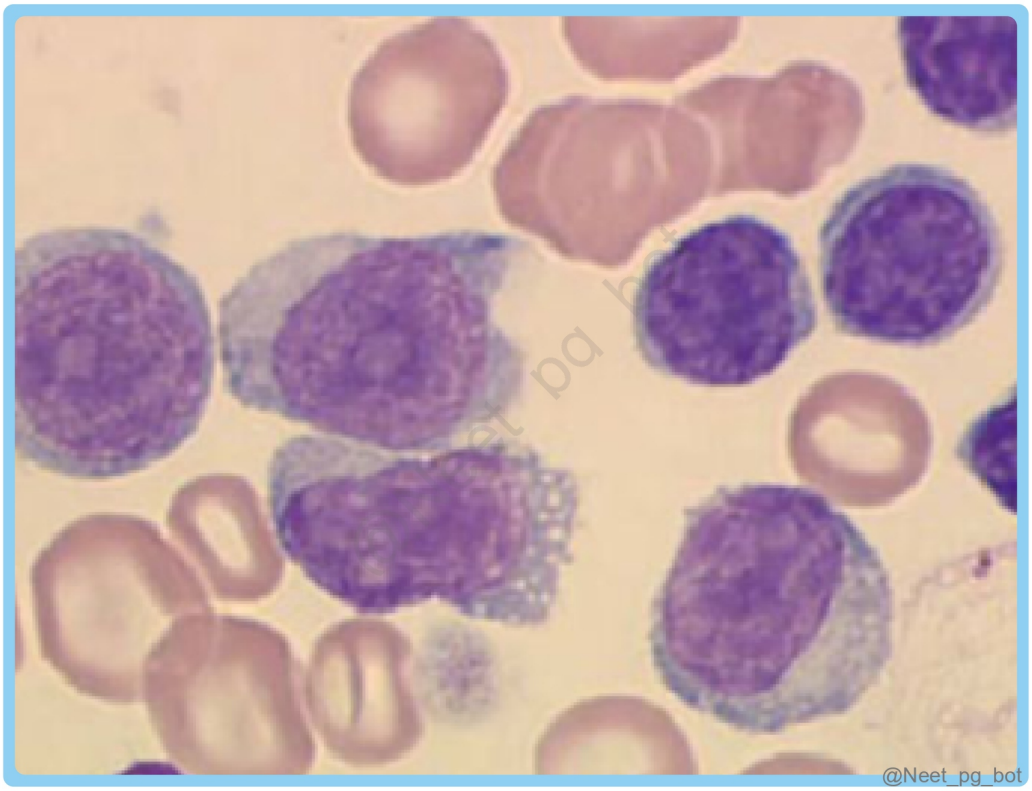

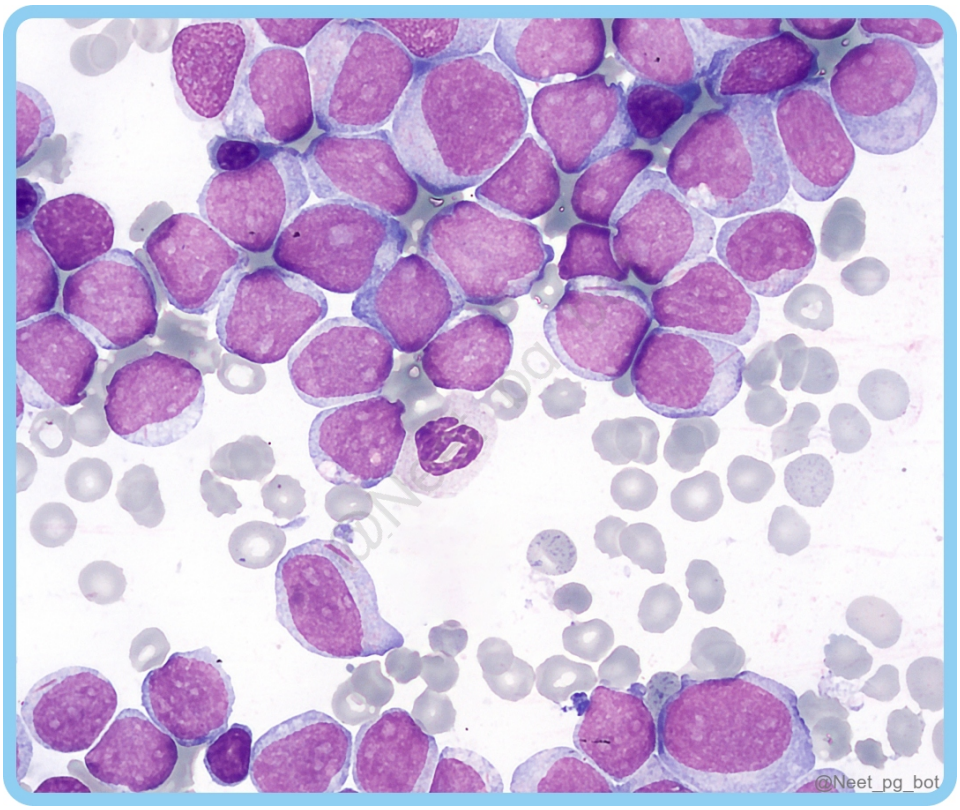
@Neet_pg_bot

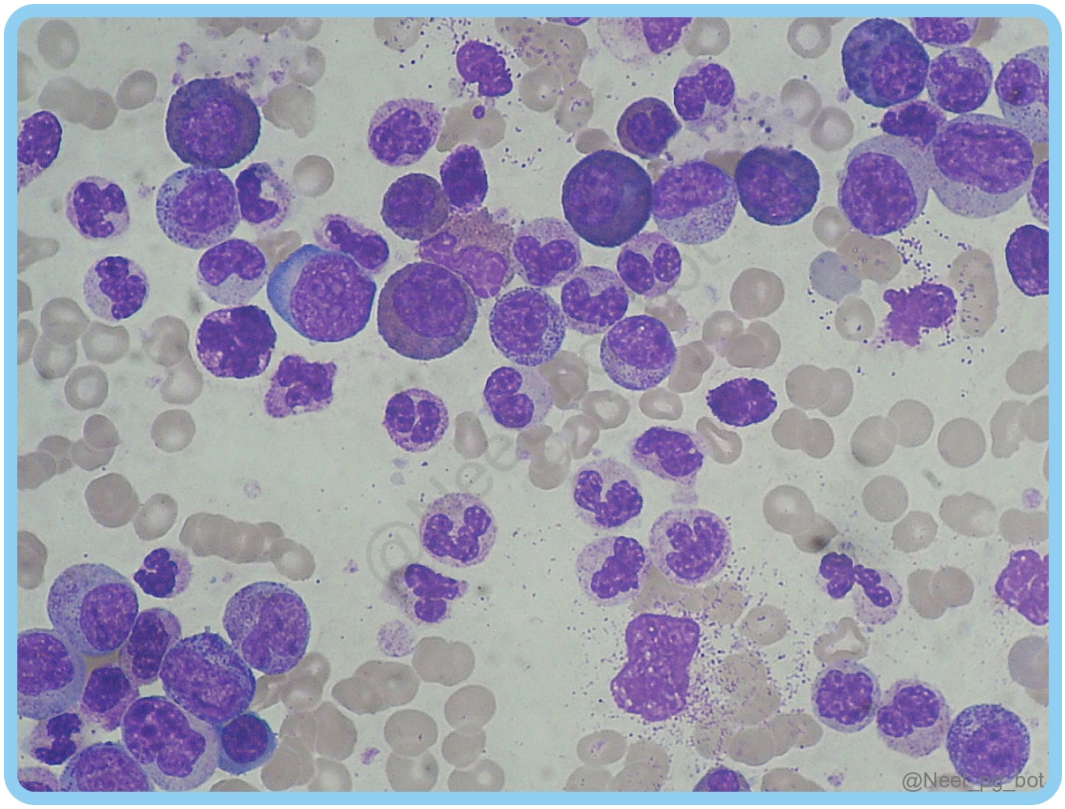
@Neet_pg_bot

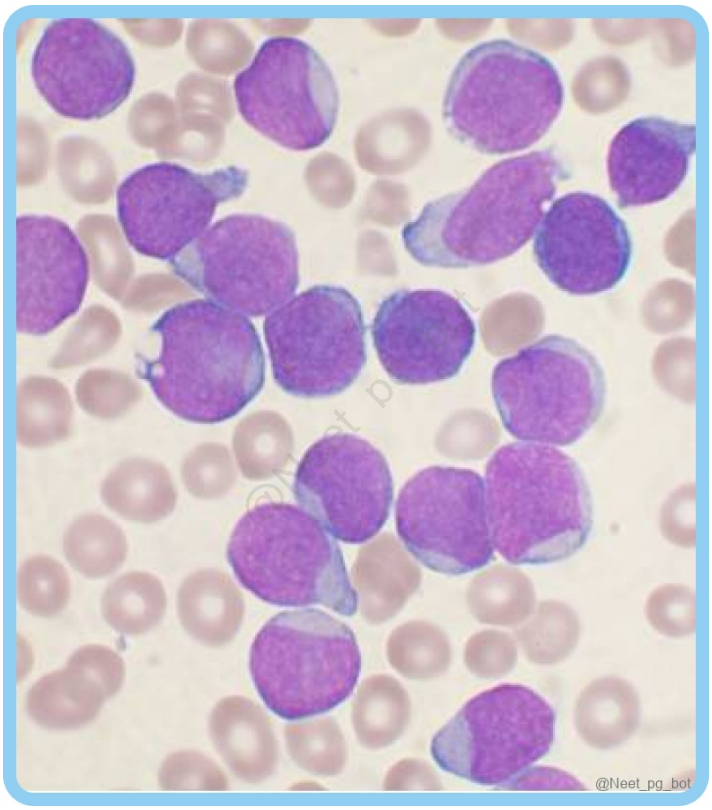

Correct Answer: B. 1-B, 2-C, 3-D, 4-A

- *Listen (English)*
- *Listen (Hindi)*

Explanation: 1. Acute Lymphoblastic Leukemia (ALL): Lymphoblasts in bone marrow ≥ 20% Cytoplasmic vacuolations They contain fat (Oil Red O Positive) Hand mirror -shaped cells 2. Acute Myeloid Leukemia (AML): Blasts ≥ 20% Myeloblasts with Auer Rods in cytoplasm. 3. Chronic Lymphocytic Leukemia (CLL): Smudge cells (or parachute/basket cell): Due to the fragility of lymphocytes during slide preparation Convent Girl Appearance: Lot of homogenous, small, mature-like, round lymphocytes with scant cytoplasm 4. Chronic Myeloid Leukemia (CML): Leukocytosis Cell Types: Neutrophils(multilobed nucleus), metamyelocytes (indented nucleus), myelocytes (D-shaped nucleus), and eosinophils (orange cells) College girl/garden party appearance: Due to the variety of cell appearances Shift to the Left: Presence of immature cells, mainly immature neutrophils types in the blood.

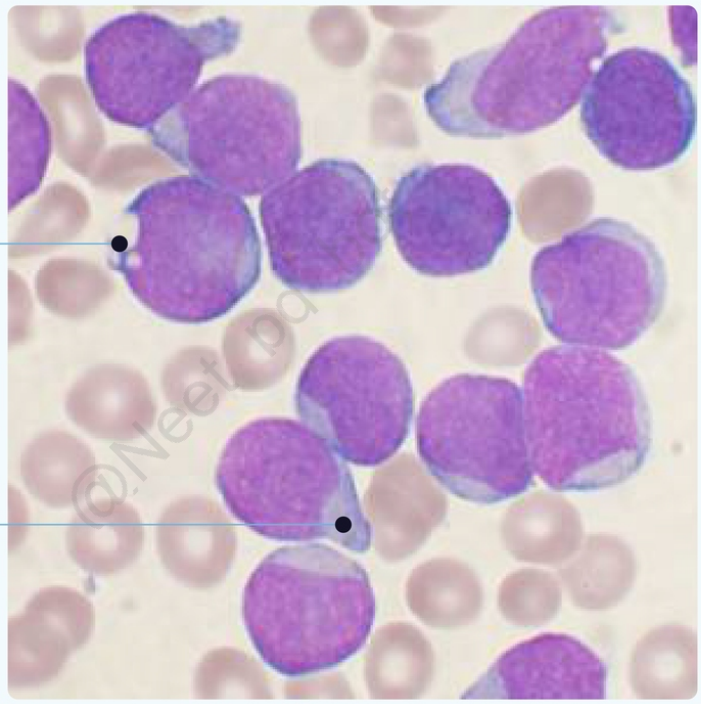

@Neet_pg_bot

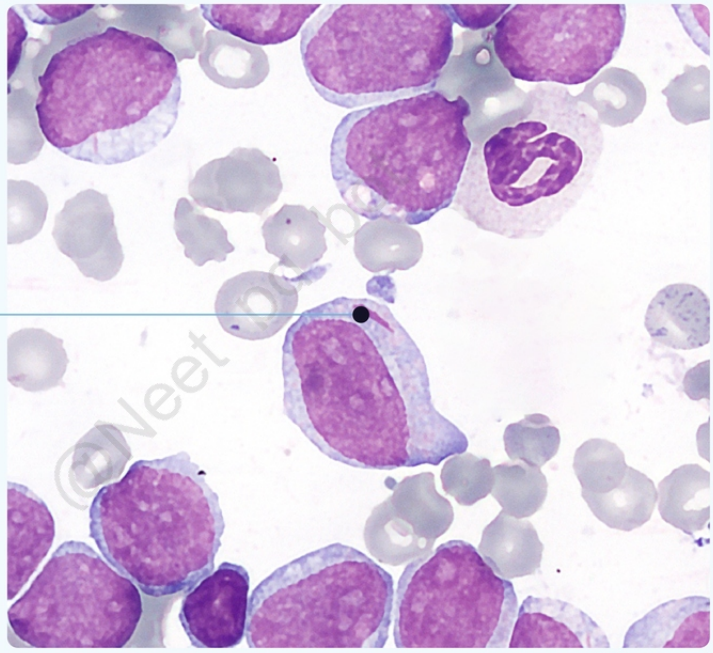

@Neet_pg_bot

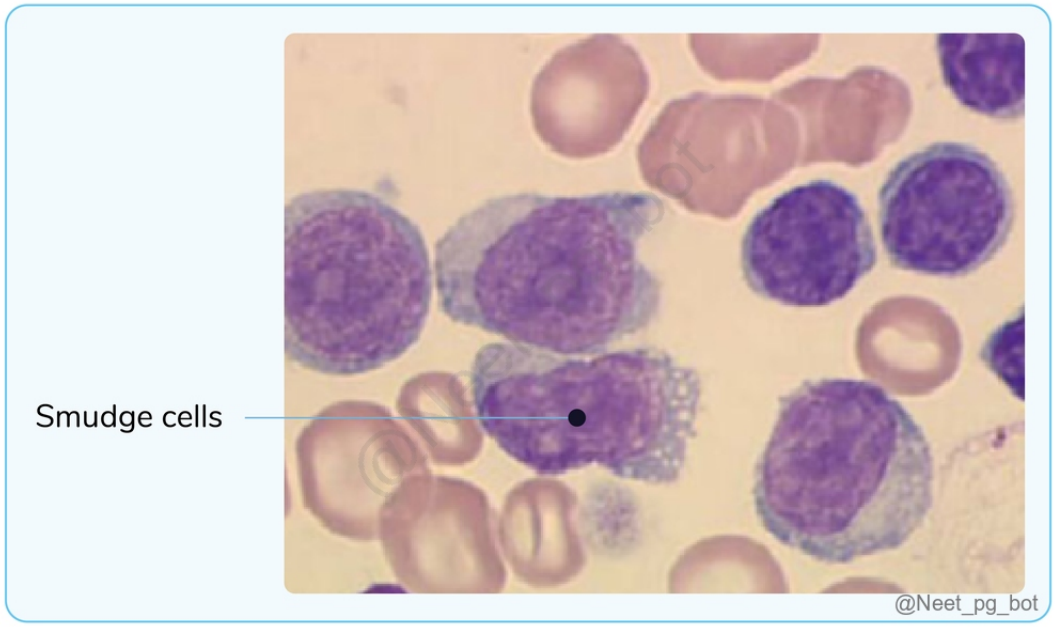

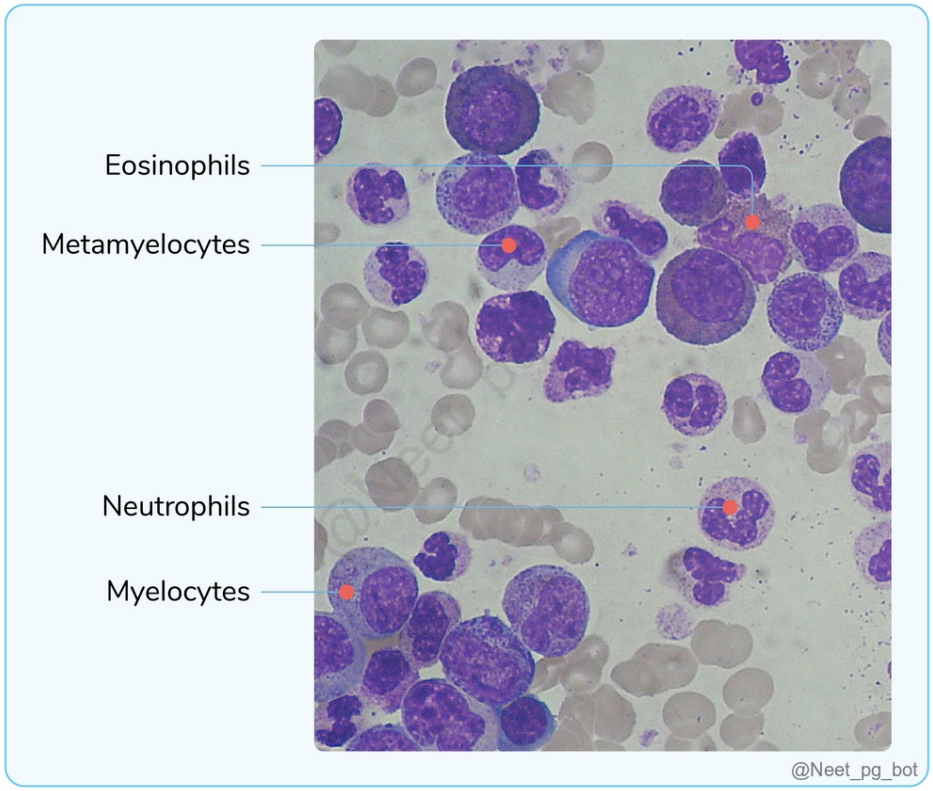

References:

https://onlinelibrary.wiley.com/doi/10.1155/2021/7488025

↑ *Back to this question in Part A*

@Neet_pg_bot

Q5: A 60-year-old man presents with fatigue, night sweats, and unintentional weight loss over the past several months. Examination reveals generalised lymphadenopathy and mild splenomegaly. Peripheral blood smear is shown below. Which of the following is not typically associated with the patient's condition? (Q842742)

A. Autoimmune hemolytic anemia (AIHA)

B. Evan’s syndrome

C. Richter’s syndrome

D. Di Guglielmo Disease

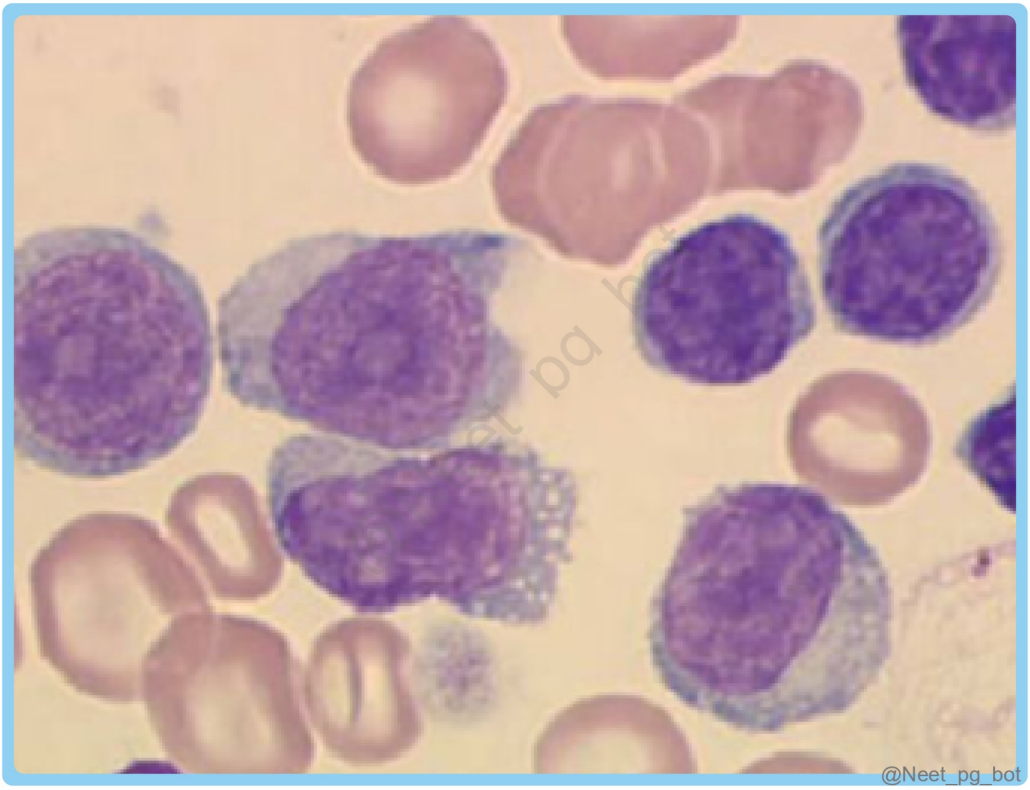

Correct Answer: D. Di Guglielmo Disease

■ *Listen (English)*

■ *Listen (Hindi)*

Explanation: Based on the clinical presentation, laboratory findings, and HPE image, the patient's diagnosis is Chronic Lymphocytic Leukemia (CLL). CLL is not associated with Di Guglielmo Disease. Di Guglielmo Disease, or acute erythroid leukemia, represents a subtype of acute myeloid leukemia (AML-M6 in FAB classification.) characterised by the proliferation of erythroid precursors in the bone marrow. ≥50% erythroid precursors in bone marrow ≥20% myeloblasts among non-erythroid cells Autoimmune hemolytic anemia (AIHA) (Option A): AIHA

is associated with CLL, sometimes occurring independently or in Evan’s syndrome, along with immune thrombocytopenia. Peripheral smear may reveal spherocytes (round, hyperchromatic RBCs). Evan’s syndrome (Option B): Evan’s syndrome is associated with CLL. In Evan's syndrome, RBCs, WBCs and Platelets are affected in bone marrow: RBCs: Autoimmune hemolytic anemia (AIHA) (Coomb’s positive) WBCs: CLL Platelets: Immune thrombocytopenic purpura (ITP) Richter’s syndrome (Option C): Richter’s syndrome is associated with CLL and occurs when CLL transforms to small lymphocytic lymphoma (SLL) in the lymph nodes. The transition from SLL to diffuse large B-cell lymphoma (DLBCL) is known as Richter's syndrome.

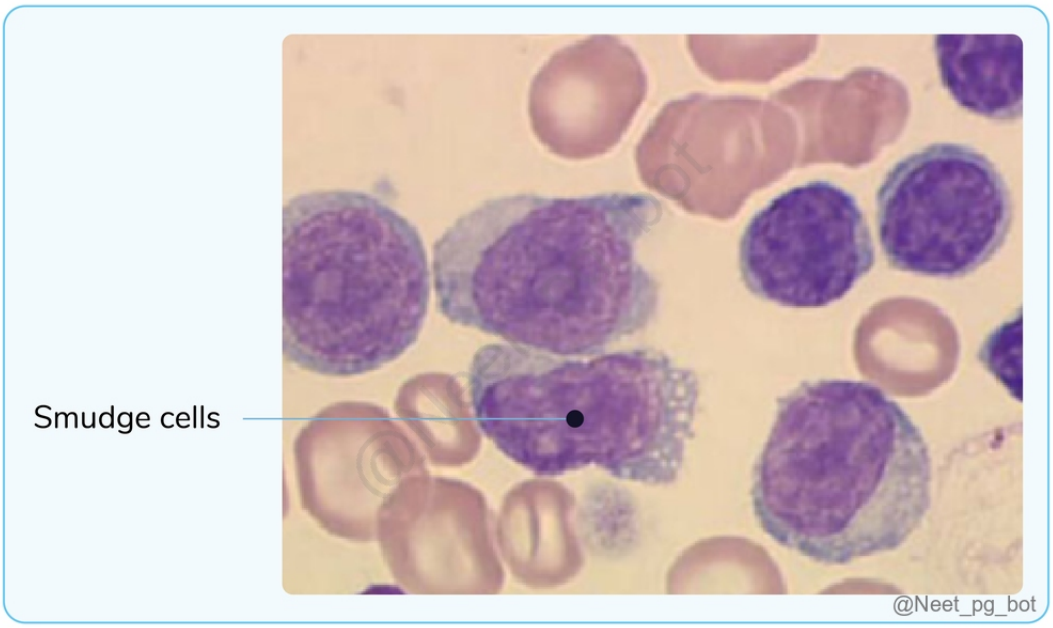

References:

Robbin’s and Cotran Pathological Basis of Disease, 10th Edition, Pages 597-598

https://www.ncbi.nlm.nih.gov/books/NBK519015/

https://www.ncbi.nlm.nih.gov/pmc/articles/PMC7049379/

↑ *Back to this question in Part A*

@Neet_pg_bot

Q6: A 52-year-old male presents with complaints of fatigue, abdominal fullness, and night sweats. His complete blood count shows WBC count of 120,000/μL. A peripheral blood smear shows an increased number of granulocytes at different stages of maturation. A bone marrow aspirate is shown below. Which of the following features can be seen in this condition? (Q842743)

A. Diffusely effaced lymph node architecture with proliferation centres

B. Presence of Reed-Sternberg cells

C. Normal marrow cellularity with increased blast cells

D. Hypercellular bone marrow with decreased erythroid precursors

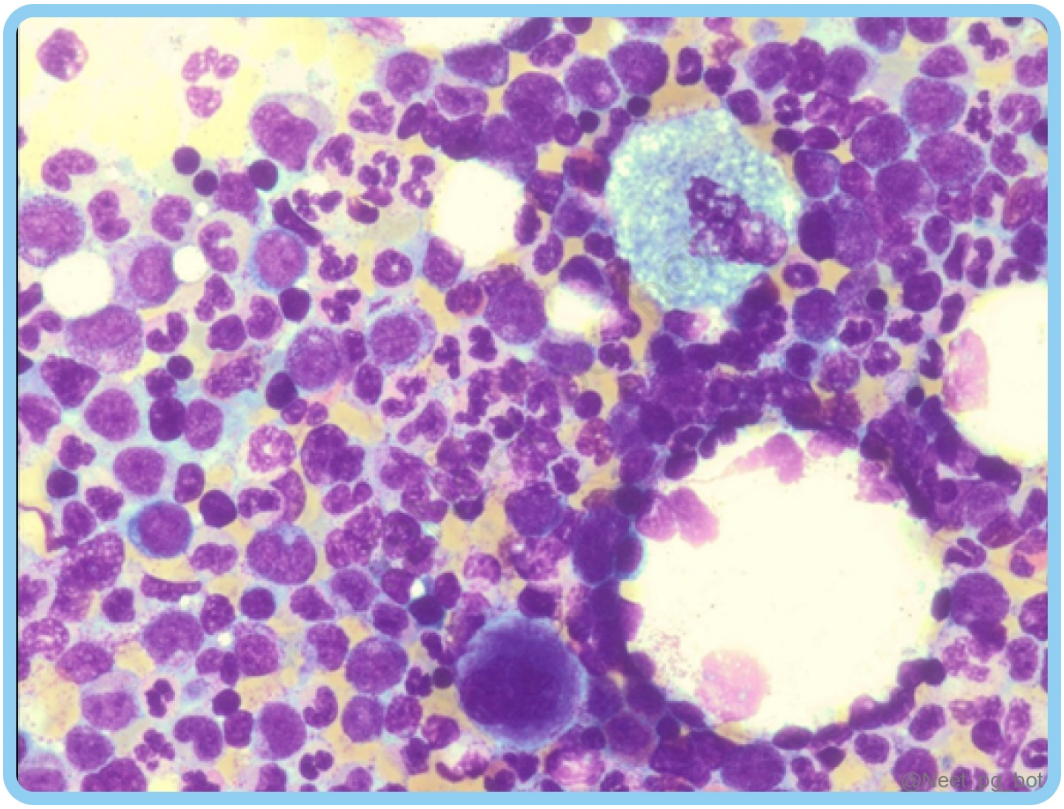

Correct Answer: D. Hypercellular bone marrow with decreased erythroid precursors

■ *Listen (English)*

■ *Listen (Hindi)*

Explanation: The features described in the scenario are consistent with Chronic Myeloid Leukemia (CML). CML typically presents with splenomegaly, high white blood cell counts, and a characteristic peripheral blood smear showing increased granulocytes at different stages of maturation. Bone Marrow aspirate findings of CML: Presence of scattered macrophages with abundant wrinkled, green-blue cytoplasm, called sea-blue histiocytes or pseudo-Gaucher cells . The marrow is markedly hypercellular due to massively increased numbers of maturing granulocytic precursors (elevated eosinophils and basophils) Increased megakaryocytes, commonly with small, dysplastic forms called dwarf megakaryocytes. Normal or slightly decreased erythroid progenitors (increased myeloid: erythroid ratio). Increased deposition of reticulin fibers.

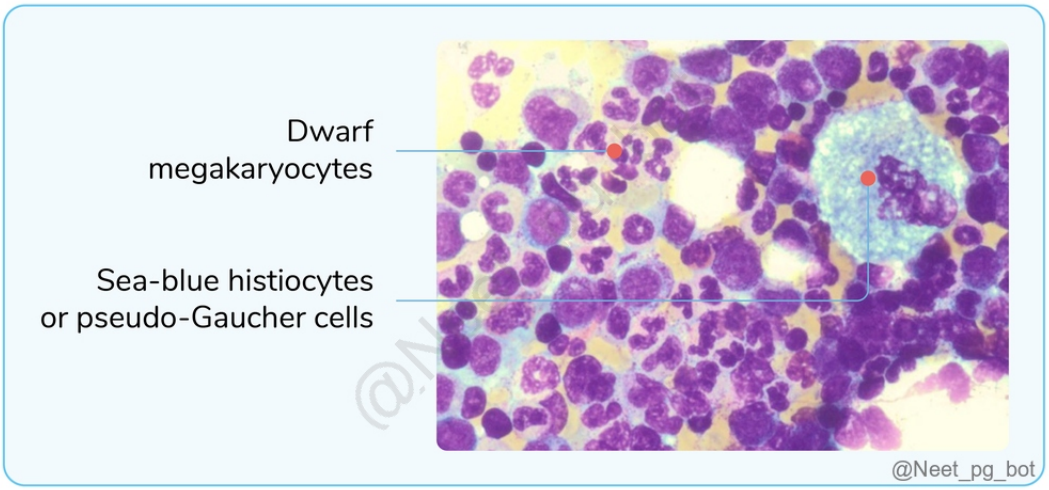

References:

Robbin's and Cotran Pathological Basis of Disease, 10th Edition, Pages 622, 597, 619.
https://pubmed.ncbi.nlm.nih.gov/28102226/

↑ *Back to this question in Part A*

@Neet_pg_bot

Q7: A 62-year-old woman presents with fatigue, unintentional weight loss, and occasional night sweats over the past few months. On physical examination, cervical lymphadenopathy is noted. A complete blood count reveals leukocytosis with an absolute lymphocyte count of 10,000/mm3. Which of the following flow cytometry marker profiles is most consistent with this form of leukemia? (Q842744)

A. CD5+, CD19+, CD23+, CD10-

B. CD20+, CD79a+, CD5+, CD25-

C. CD3+, CD5+, CD19+, CD20-

D. CD10+, CD19+, CD22+, CD23-

Correct Answer: A. CD5+, CD19+, CD23+, CD10-

■ *Listen (English)*

■ *Listen (Hindi)*

Explanation: Lab investigations with CBC showing leukocytosis with ALC >=5000/mm3 points towards diagnosis of Chronic Lymphocytic Leukemia (CLL). It is seen in elderly and is characterised by specific cell surface markers detected via flow cytometry: CLL shows dual positivity for CD5 and CD23. The typical CLL immunophenotype

includes CD5+, CD10-, CD19+, CD20+ (with dim expression), and CD23+. CD19 and CD20 are B-cell markers, with CD20 typically appearing dim in CLL. CD23 is also commonly found on CLL cells. CD20+, CD79a+, CD5+, CD25-: Seen in Mantle cell lymphoma, along with other CD markers such as SIgD, CD 5, cyclin D1 (Option B) . CD3+, CD5+, CD19+, CD20-: CD3 indicates a T-cell lineage, CD 19+ denotes B-cell lineage, seen in Mixed Phenotype Acute Leukemia (MPAL) (Option C) . CD10+, CD19+, CD22+, CD23-: CD10 and CD22 expression is more typical of precursor B-cell lymphoblastic leukemia/lymphoma (Option D) . Cell Type CD Markers Common lymphoid progenitor cell CD 34, HLA DR Pro-B cell CD 19, CD 34, HLA DR, PAX 5 Pre-B cell CD 10 (CALLA antigen), Tdt, CD 19, CD 20, CD 21, CD 22, CD 79a, CD 79b Immature B cell CD 19, CD 20, CD 21, CD 22, CD79a, CD 79b, SIgM Naive B cell CD 19, CD 20, CD 21, CD 22, CD 79a, CD 79b, SIgM, +/- CD5 Polyclonal Plasma cell CD 19, CD 38, CD 138 Chronic Lymphocytic Leukemia CD 19, CD 20, CD 21, CD 22, CD 79a, CD 79b, SIgM, CD 5, CD 23 Mantle Cell Lymphoma CD 19, CD 20, CD 21, CD 22, CD 79a, CD 79b, SIgM, SIgD, CD 5, cyclin D1 Diffuse Large B-cell Lymphoma CD 19, CD 20, CD 21, CD 22, CD 79a, CD 79b, SIgM, SIgD, CD 10, CD 23, BCL-6 Burkitt's Lymphoma CD 19, CD 20, CD 21, CD 22, CD 79a, CD 79b, SIgM, SIgD, CD 10, CD 23, BCL-6 Follicular Lymphoma CD 19, CD 20, CD 21, CD 22, CD 79a, CD 79b, SIgM, SIgD, CD 10, CD 23, BCL-2 Marginal Zone Lymphoma CD 19, CD 20, CD 21, CD 22, CD 79a, CD 79b, SIgM, SIgD T-cell CD 3 Anaplastic Large Cell Lymphoma CD 3, CD 30

References:

Robbin's and Cotran Pathological Basis of Disease, 10th Edition, Pages 597, 604

↑ *Back to this question in Part A*

@Neet_pg_bot

Q8: Which of the following are the good prognostic factors of CLL? (Q842745)

A. NOTCH1 mutations

B. CD38+

C. Expression of Zap 70

D. Expression of MiR-15/16

Correct Answer: D. Expression of MiR-15/16

■ *Listen (English)*

■ *Listen (Hindi)*

Explanation: Most common deletion occuring in CLL is deletion of chromosome 13 which has a good prognosis. Good prognostic factors Poor prognostic factors Deletion of MicroRNA15 and 16 (acts as tumor suppressors) (Option D) Deletion of 13q14 Post GC B cell Naive B-cell NOTCH 1 mutation (commonly associated with Trisomy 12) (Option A) Deletion of 11q, 17p Richter's transformation (DLBCL transformation) Expression of ZAP 70 (Option C) Increased CD38 expression High β2-microglobulin levels Lack of somatic hypermutation High LDH levels

References:

Robbin’s and Cotran Pathological Basis of Disease, 10th Edition, Page 597

Harrison’s Principles of Internal Medicine, 21st Edition, Page 835

https://www.ncbi.nlm.nih.gov/pmc/articles/PMC3128231/

↑ *Back to this question in Part A*

@Neet_pg_bot

Q9: A 45-year-old man presents with purulent nasal discharge, headache, sore throat, and nonproductive cough. He has maxillary sinus tenderness, pharyngeal erythema, and tender anterior cervical lymphadenopathy. Laboratory results are as follows: Leukocytes 58,000/mm3 Neutrophils 42% Myelocytes 30% Metamyelocytes 8% Band forms 1% Blast cells 1% Eosinophils 6% Basophils 4% The leukocyte alkaline phosphatase score is low. Which of the following is the most likely diagnosis and its appropriate management/drug for treatment? (Q842746)

A. Leukemoid reaction and Amoxicillin

B. CML and Imatinib mesylate

C. ALL and vincristine

D. AML and stem cell transplant

Correct Answer: B. CML and Imatinib mesylate

■ *Listen (English)*

■ *Listen (Hindi)*

Explanation: This scenario is suggestive of chronic myelogenous leukemia (CML) as the patient has a markedly elevated white blood cell (WBC) count, increased myeloid precursor forms , basophilia, and eosinophilia in the peripheral blood smear, and a low LAP score . CML Genetics: Philadelphia chromosome (t(9;22)) Origin: Myeloid lineage Etiopathogenesis: BCR-ABL fusion gene, due to t(9;22), causes tyrosine kinase activity much above normal Radiation exposure Clinical features: Occurs in adults. Often presents with splenomegaly, fatigue, weight loss, night sweats, and abdominal discomfort. Can progress to a blast crisis with features of acute leukemia. Diagnosis: Bone marrow aspirate to confirm diagnosis FISH - presence of BCR ABL fusion gene product. Management: Tyrosine kinase inhibitors such as Imatinib mesylate (Option B) Generation Drugs Target Details 1st Generation Imatinib BCR-ABL First-line in CML 2nd Generation Dasatinib, Nilotinib, Bosutinib BCR-ABL resistant mutations More potent than imatinib 3rd Generation Ponatinib T315I mutation Used in resistant CML 4th Generation Asciminib STAMP inhibitor (ABL myristoyl pocket) Used in resistant disease Leukemoid reaction (Option A): LAP score is increased in leukemoid reaction, and basophilia is not seen. It is usually due to

underlying infections and treated with antibiotics. ALL and vincristine (Option C): Typically, acute lymphoblastic leukemia, which is more common in young children, is characterised by having over 20% bone marrow lymphoblasts and is treated with chemotherapy. AML and stem cell transplant (Option D): Most patients present with a WBC count of approximately 15,000-20,000/mm³ and a significant increase in blast cells (e.g., >20%), unlike the 1% seen in this patient and treated with stem cell transplant. Types of Philadelphia Chromosome based on breakpoint: Type Fusion Protein Associated Disease p210 BCR-ABL p210 CML (most common) p190 BCR-ABL p190 ALL (especially B-ALL) p230 BCR-ABL p230 Chronic neutrophilic leukemia (rare)

References:

https://pubmed.ncbi.nlm.nih.gov/28273028/

https://www.ncbi.nlm.nih.gov/pmc/articles/PMC6415732/

↑ *Back to this question in Part A*

@Neet_pg_bot

Q10: A 55-year-old man who is a known case of chronic phase CML presents with increasing fatigue, weight loss, and abdominal discomfort. His physical examination reveals splenomegaly. Lab tests show a persistent decline in platelet counts, increased circulating basophils, and a blast count of 12%. What is the most likely explanation for the patient's clinical presentation and laboratory findings? (Q842747)

A. Progression to accelerated phase CML

B. Development of acute lymphoblastic leukemia

C. Entry into the blast crisis phase of CML

D. Development of secondary myelofibrosis

Correct Answer: A. Progression to accelerated phase CML

■ *Listen (English)*

■ *Listen (Hindi)*

Explanation: This patient's increasing anemia and thrombocytopenia, accompanied by a rise in the number of basophils in the blood and a blast percentage of 12%, is consistent with the accelerated phase of CML. The 3 phases of CML and their characteristics are: 1) Chronic phase: Leukocytosis, < 10% blast cells , basophils <20% and monocytosis < 3% 2) Accelerated phase: 10%-19% blasts , ≥ 20% basophils in the peripheral blood or bone marrow Persistent or increasing WBC (>10 × 10^9/L) and persistent splenomegaly , unresponsive to therapy Persistent thrombocytosis (>1000 × 10^9/L), unresponsive to therapy Persistent thrombocytopenia (<100 × 10^9/L) unrelated to therapy This phase often leads to the terminal blast crisis within 6-12 months 3) Blast Crisis: ≥20% blasts in peripheral blood or bone marrow In 50% of patients, the blast crisis occurs abruptly without an accelerated phase Extensive extramedullary hematopoiesis occurs to compensate for CML and leads to significant

splenomegaly Transformation into AML is more predominant than ALL

References:

Robbin’s and Cotran Pathological Basis of Disease, 10th Edition, Page 623

https://doi.org/10.1182/blood-2016-03-643544

https://www.sciencedirect.com/science/article/pii/S0006497120301567

↑ *Back to this question in Part A*

@Neet_pg_bot

Q11: A 50-year-old male presents with fatigue, abdominal discomfort, and splenomegaly. Lab tests reveal a markedly elevated WBC count with a left shift and increased myeloid precursor forms on peripheral blood smear. Which of the following statements regarding the leukocyte (neutrophil) alkaline phosphatase (LAP) score in this condition is correct? (Q842748)

A. Normal LAP score

B. Increased due to excessive myeloid cell production

C. Decreased due to cytochemical abnormal WBCs

D. LAP score is relevant only in acute leukemia

Correct Answer: C. Decreased due to cytochemical abnormal WBCs

■ *Listen (English)*

■ *Listen (Hindi)*

Explanation: The leukocyte (neutrophil) alkaline phosphatase (LAP/NAP) score is typically decreased in CML . This is because the WBCs in CML are abnormal, which are formed after philadelphia chromosome mutation, reducing LAP activity. Nomal LAP count: 40-100 neutrophils Alkaline phosphatase activity is found predominantly in mature segmented neutrophils. Conditions with Increased and Decreased LAP Score: Increased LAP score Decreased LAP score Leukemoid reaction Neutrophilia / Sepsis Pregnancy OCP Down’s syndrome Chronic Myeloid leukemia Paroxysmal nocturnal hemoglobinuria

References:

https://www.ncbi.nlm.nih.gov/books/NBK531464/

↑ *Back to this question in Part A*

@Neet_pg_bot

Q12: A 55-year-old patient presents with fatigue, weight loss, and abdominal discomfort. Labs reveal a markedly elevated WBC count with a left shift and increased myeloid precursor forms on peripheral blood smear as shown below. Which of the following is the investigation of choice to confirm the diagnosis? (Q842749)

A. Bone Marrow Aspiration and Biopsy

B. Flow Cytometry Analysis of Peripheral Blood

C. Fluorescent in situ hybridisation (FISH)

D. Serum Lactate Dehydrogenase (LDH) Levels

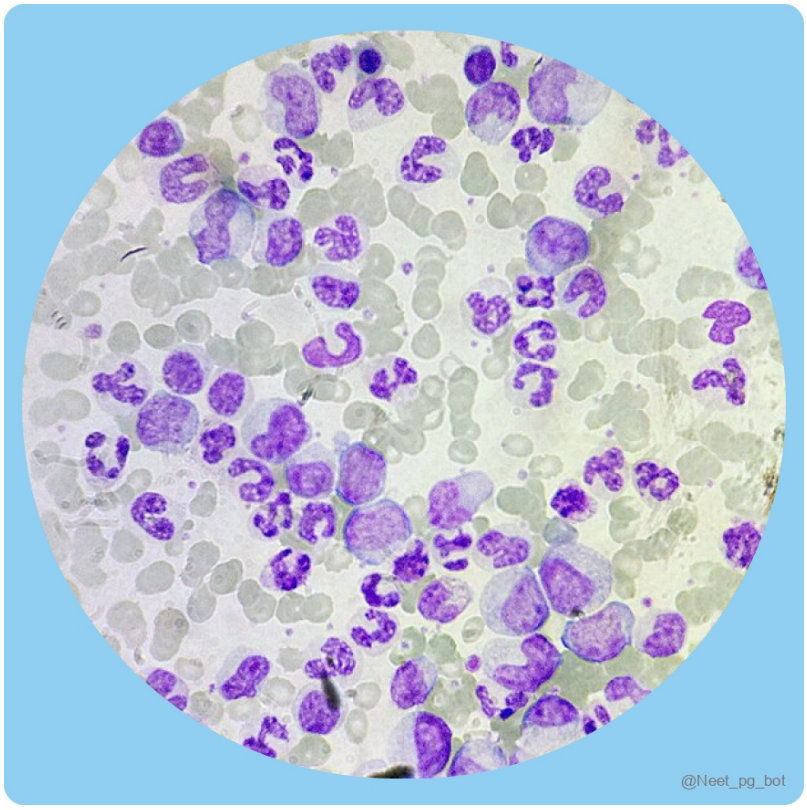

Correct Answer: C. Fluorescent in situ hybridisation (FISH)

■ *Listen (English)*

■ *Listen (Hindi)*

Explanation: The investigation of choice to confirm the diagnosis of Chronic Myelogenous Leukemia is Fluorescence In-Situ Hybridisation (FISH) , which makes a cytogenetic analysis of the Philadelphia chromosome. CML shows garden party/college girl appearance. The presence of the Philadelphia chromosome, resulting from the reciprocal translocation between chromosomes 9 and 22 [t(9;22)(q34;q11)], or detection of the BCR-ABL1

fusion gene on mRNA, confirms the diagnosis of CML. Fluorescence In-Situ Hybridisation (FISH): Uses fluorescently labeled DNA probes that bind to specific chromosomal sequences to detect translocations, deletions and amplifications, done in Interphase cells (vs. metaphase in karyotyping). Types of FISH: Type of FISH Probe Design Detects Classic Example Dual fusion FISH Two probes on different chromosomes Translocations BCR-ABL in CML Break-apart FISH Probes flanking a gene Gene rearrangements ALK in lymphoma Centromeric (CEP) FISH Targets centromere Aneuploidy Trisomy detection Locus-specific FISH Targets a specific gene Deletion/amplification HER2 in breast cancer Telomeric FISH Targets chromosome ends Structural abnormalities Rarely used Multicolor FISH (M-FISH/SKY) Whole chromosome painting Complex karyotypes Complex leukemias Bone Marrow Aspiration and Biopsy (Option A) : Showing myeloid cells at different stages of maturation can support the diagnosis, it is not the investigation of choice for confirming the diagnosis. Flow Cytometry Analysis of Peripheral Blood (Option B) : can help characterise the immunophenotypic features of leukemic cells (cell surface markers) but is not the primary investigation for confirming the diagnosis of CML. Serum Lactate Dehydrogenase (LDH) Levels (Option D) : Not specific for the diagnosis. It is used more as a marker of disease activity rather than a diagnostic tool .

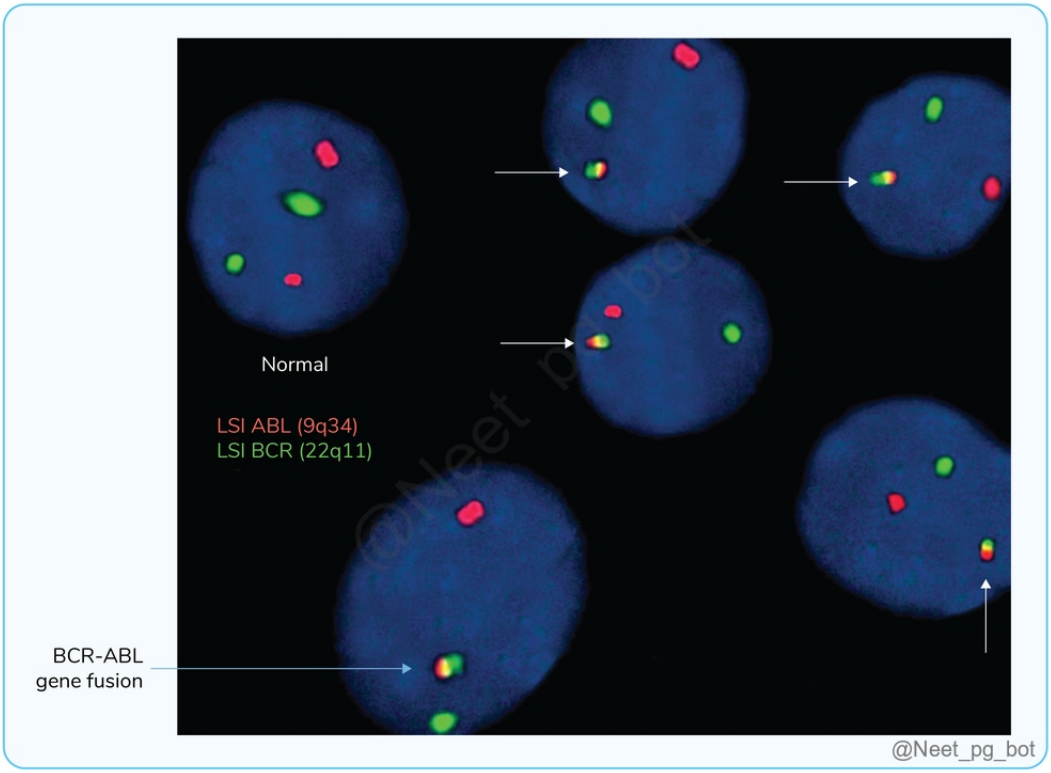

References:

https://www.ncbi.nlm.nih.gov/pmc/articles/PMC5656269/

↑ *Back to this question in Part A*

@Neet_pg_bot

Q13: A 60-year-old male presents with fatigue and abdominal discomfort. Laboratory investigations reveal a markedly elevated WBC count with a left shift and increased myeloid precursor forms on peripheral blood smear. Which of the following features would help differentiate Chronic Myelogenous Leukemia (CML) from a leukemoid reaction? (Q842750)

A. Massive splenomegaly

B. High LAP score

C. History of recent antibiotic use

D. Resolution of neutrophilia after treating the underlying cause

Correct Answer: A. Massive splenomegaly

■ *Listen (English)*

■ *Listen (Hindi)*

Explanation: Extensive extramedullary hematopoiesis in CML frequently leads to significant splenomegaly, with the spleen often containing infarcts of various ages. In contrast, leukemoid reaction does not cause splenomegaly. Differences between leukemoid reaction and CML: Characteristics CML (Blood cancer) Leukemoid Reaction (Leukaemia-like reaction) Cause t (9:22) BCR/ABL fusion gene Sepsis Spleen Massive Splenomegaly No splenomegaly TLC High High but not as high as CML LAP score (Normal: 40-100) Decreased (Option B) Increased Basophils > 20% in accelerated phase (Basophilia) No basophilia Peripheral smear Garden party appearance _

References:

Robbin’s and Cotran Pathological Basis of Disease, 10th Edition, Page 623

https://pubmed.ncbi.nlm.nih.gov/16962944/

https://www.ncbi.nlm.nih.gov/books/NBK531459/

↑ *Back to this question in Part A*

@Neet_pg_bot

• [18_Hematology_ White Blood Cells] 072 Plasma Cell Disorders

« Back to Folder Directory

[18_Hematology_ White Blood Cells] 072 Plasma Cell Disorders — Quick Jump

Q1 (p. 2850) *Q2 (p. 2852)* *Q3 (p. 2853)* *Q4 (p. 2855)* *Q5 (p. 2855)* *Q6 (p. 2861)*
Q7 (p. 2862) *Q8 (p. 2863)* *Q9 (p. 2864)* *Q10 (p. 2865)* *Q11 (p. 2866)* *Q12 (p. 2866)*
Q13 (p. 2867) *Q14 (p. 2868)* *Q15 (p. 2869)*

Q1: Which of the following images shows the typical features of a plasma cell in a histopathological examination (HPE) of bone marrow? (Q845746)

Correct Answer: Unknown

■ *Listen (English)*

■ *Listen (Hindi)*

Explanation: HPE image

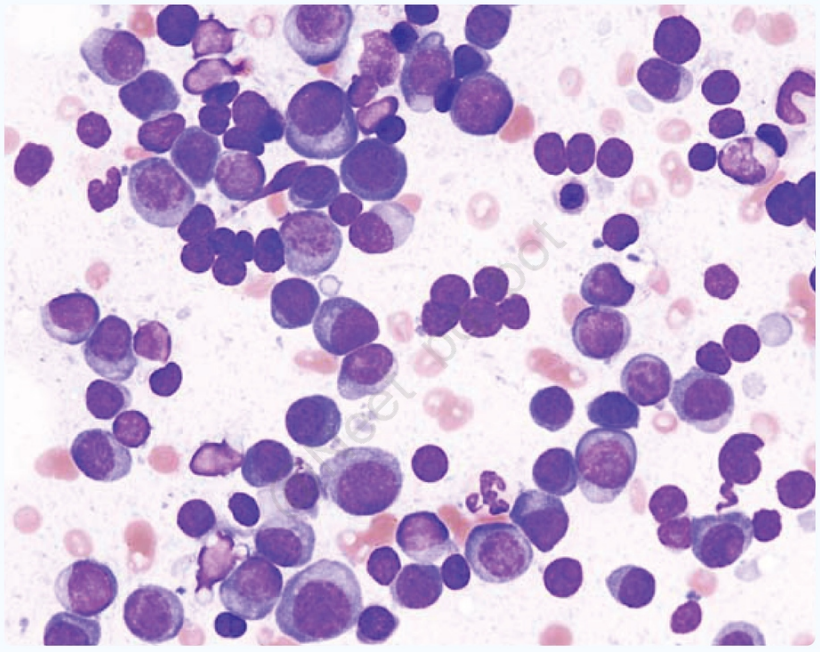

An HPE image of plasma cell, identified by its eccentrically located nucleus, a clear perinuclear zone and a basophilic cytoplasm

@Neet_pg_bot

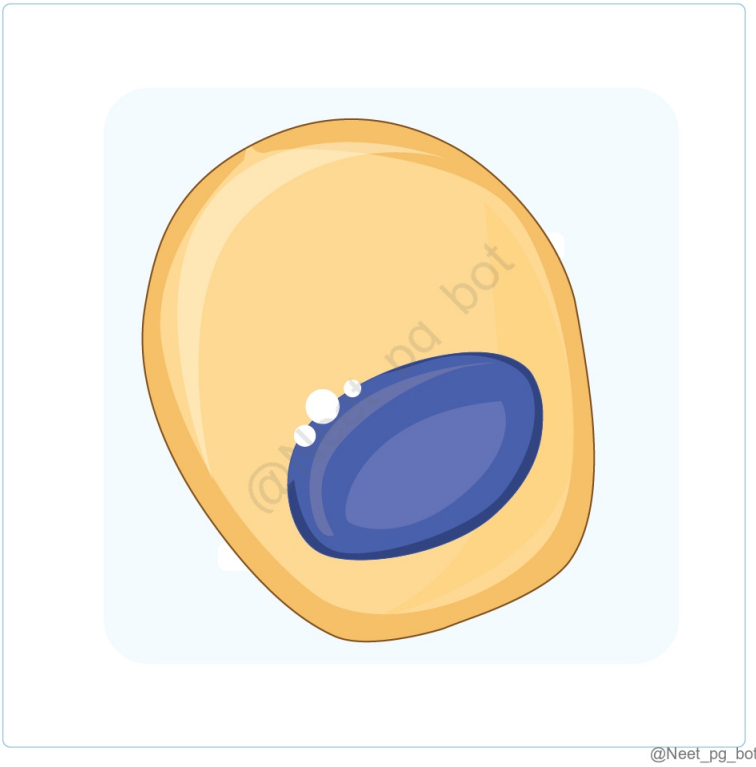

@Neet_pg_bot

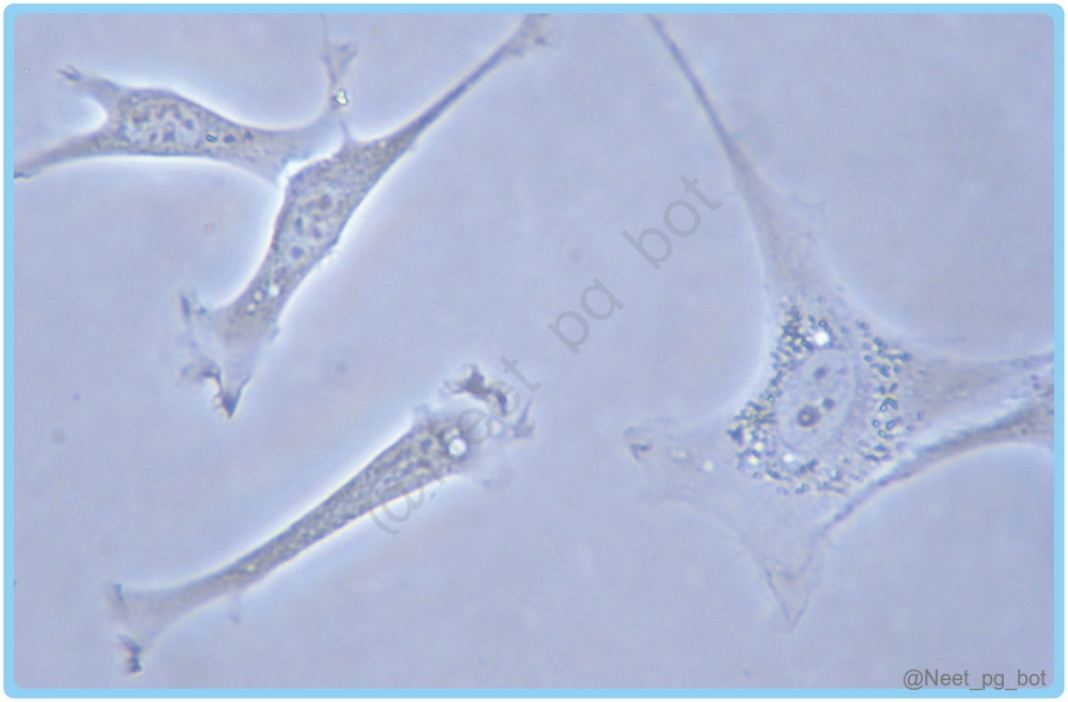

@Neet_pg_bot

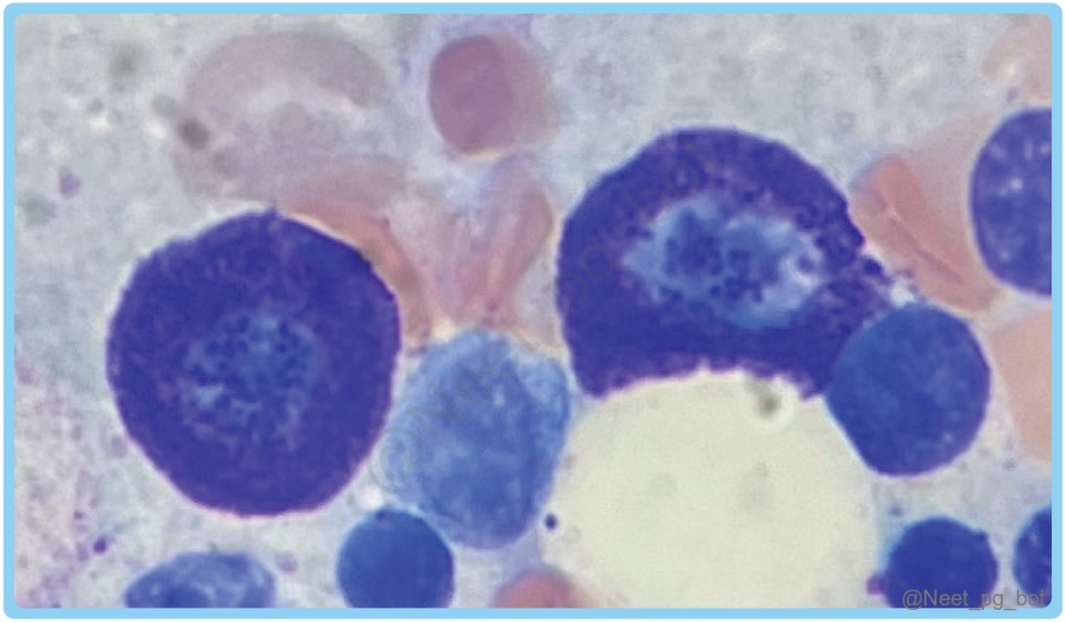

References:

Robbins and Cotran Pathological Basis of Disease, 10th Edition, Page 607, 608

Wheater Functional Histology, 6th Edition, Page 81

www.ncbi.nlm.nih.gov/books/NBK499904/

www.ncbi.nlm.nih.gov/pmc/articles/PMC3329689/

www.ncbi.nlm.nih.gov/books/NBK556082/

↑ *Back to this question in Part A*

@Neet_pg_bot

Q2: A 55-year-old woman presents with 6 months of persistent fatigue, lower back pain and recurrent infections. Laboratory tests show hypercalcemia, elevated creatinine, and normocytic anemia. Serum protein electrophoresis indicates a monoclonal spike. Bone marrow biopsy shows atypical plasma cells with eccentric nuclei and perinuclear halos, as shown in the image below. Which of the following cytogenetic abnormalities is not typically associated with this condition? (Q845747)

A. Deletion of chromosome 13q

B. Translocation t(11;14)

C. Trisomy 21

D. Deletion of chromosome 17p

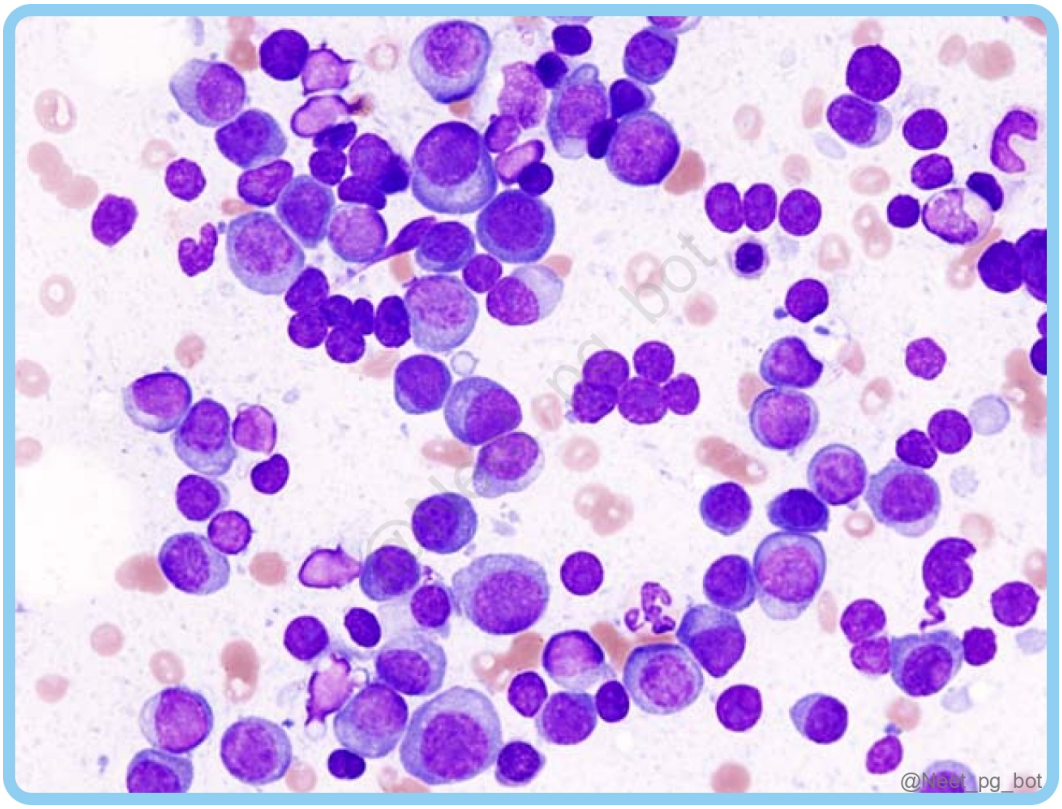

Correct Answer: C. Trisomy 21

■ *Listen (English)*

■ *Listen (Hindi)*

Explanation: The patient most likely has Multiple myeloma (MM) , a plasma cell neoplasm associated with hyper c alcemia, r enal failure, a naemia, lytic b one lesions (CRAB features) and immune abnormalities. Trisomy 21 is associated with Down's syndrome and not multiple myeloma. It is seen in patients 60-70 years of age. There are 3 main cytogenetic abnormalities seen in MM. Deletion of chromosome 13q (also seen in CLL) (Option A) Translocation t (11;14) (also seen in mantle cell lymphoma) (Option B) Deletion of chromosome 17p (TP53) (Option D) IL-6 essential for plasma cell growth , elevated IL-6 linked to poor prognosis. Risk Stratification in Multiple Myeloma: Standard Risk Intermediate Risk High Risk Trisomies (Hyperdiploidy) t(4;14) 17p deletion t(11;14) Gain 1q21 t(14;16) t(6;14) t(14;20)

References:

Robbins and Cotran, Pathological Basis of Disease, 10th Edition, Page 607, 608

↑ *Back to this question in Part A*

@Neet_pg_bot

Q3: A 68-year-old man presents with complaints of persistent bone pain, particularly in his lower back and ribs, along with fatigue and recurrent infections over the past few months. Further workup demonstrates Bence Jones proteinuria. What temperature does it precipitate at? (Q845748)

A. 100°C

B. 60°C

C. 0°C

D. 30°C

Correct Answer: B. 60°C

■ *Listen (English)*

■ *Listen (Hindi)*

Explanation: The clinical presentation and Bence Jones proteinuria are consistent with Multiple myeloma Multiple myeloma cells produce excess free light chains, either alongside complete immunoglobulins or independently. Due to their small size, free light chains (Bence Jones proteins) can pass through the glomeruli of the kidneys and appear in urine. This is a diagnostic marker for multiple myeloma. Bence Jones Proteinuria: The presence of Bence Jones proteins in urine contributes to myeloma kidney, a form of renal damage. These light chains exert toxic effects on renal tubular epithelial cells, leading to renal impairment. It is a kappa or lambda light chain immunoglobulin that precipitates in the urine at 40-60°C . When boiling, it disappears and reappears when cooling. Urine and serum electrophoresis show a characteristic M spike due to increased levels of monoclonal IgG.

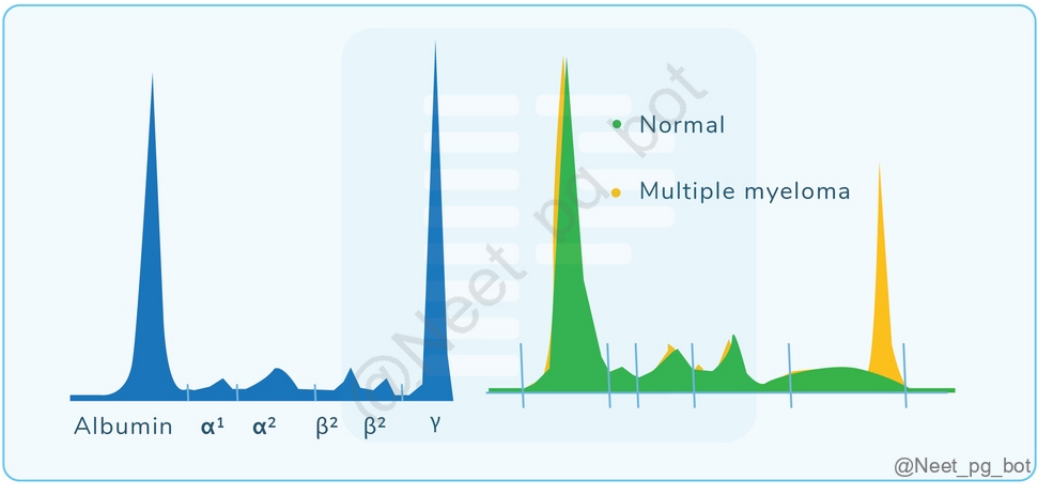

References:

Robbins and Cotran, Pathological Basis of Disease, 10th Edition, Page 609

↑ *Back to this question in Part A*

@Neet_pg_bot

Q4: A 55-year-old woman presents with bone pain, recurrent infections, elevated serum calcium levels, renal dysfunction, and anaemia. Laboratory tests reveal an M spike on serum protein electrophoresis and the presence of Bence Jones proteins in the urine. Based on this presentation, which of the following is not a criterion for a myeloma-defining event in the diagnostic criteria for this condition? (Q845749)

A. Hypercalcemia

B. Anemia

C. Renal failure

D. Bence jones proteinuria

Correct Answer: D. Bence jones proteinuria

■ *Listen (English)*

■ *Listen (Hindi)*

Explanation: The clinical scenario is consistent with Multiple myeloma in which Bence jones proteinuria is not a diagnostic criterion for a myeloma-defining event according to the current diagnostic criteria for the condition Diagnostic Criteria for Multiple Myeloma: ≥10% clonal bone marrow plasma cells (or) a biopsy-proven bony or extra medullary plasmacytoma + (PLUS) Evidence of one or more multiple myeloma defining events (MDE): (CRAB features) Hyper C alcemia (S.Ca2+ >11g/dl) (Option A) R enal failure (S. Creatinine >2mg/dl) (Option C) A naemia (Hb <10gm) (Option B) Lytic B one lesions are attributable to the plasma cell disorder. (OR) One or more biomarkers of malignancy (SLIM criteria) Bone marrow clonal plasmacytosis ≥60% (S ixty per cent) Serum involved/uninvolved free Li ght chain (FLC) ratio ≥ 100 (provided involved FLC is ≥100 mg/L) >1 focal lesion on M RI.

References:

Robbins and Cotran Pathological Basis of Disease, 10th Edition, Page 609

www.ncbi.nlm.nih.gov/pmc/articles/PMC9387011/

↑ *Back to this question in Part A*

@Neet_pg_bot

Q5: A 70-year-old woman is being evaluated for monoclonal gammopathy. Bone marrow examination showed abnormal proliferation of plasma cells with evidence of certain microscopic features. Match the following structures with corresponding

histopathological images regarding this condition. 1. Flame Cell a) 2. Mott cell b) 3. Russel bodies c) 4. Dutcher bodies d) (Q845750)

A. 1-d; 2-a; 3-c; 4-b

B. 1-d; 2-c; 3-a; 4-b

C. 1-c; 2-d; 3-a; 4-b

D. 1-c; 2-d; 3-b; 4-a

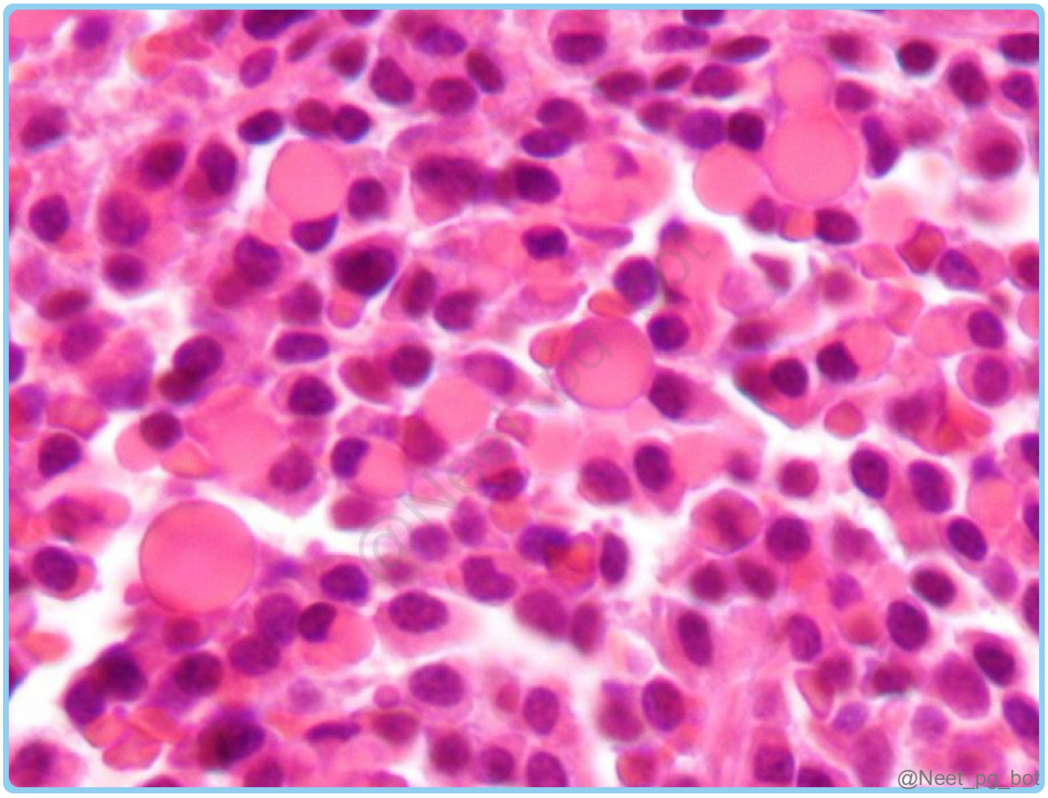

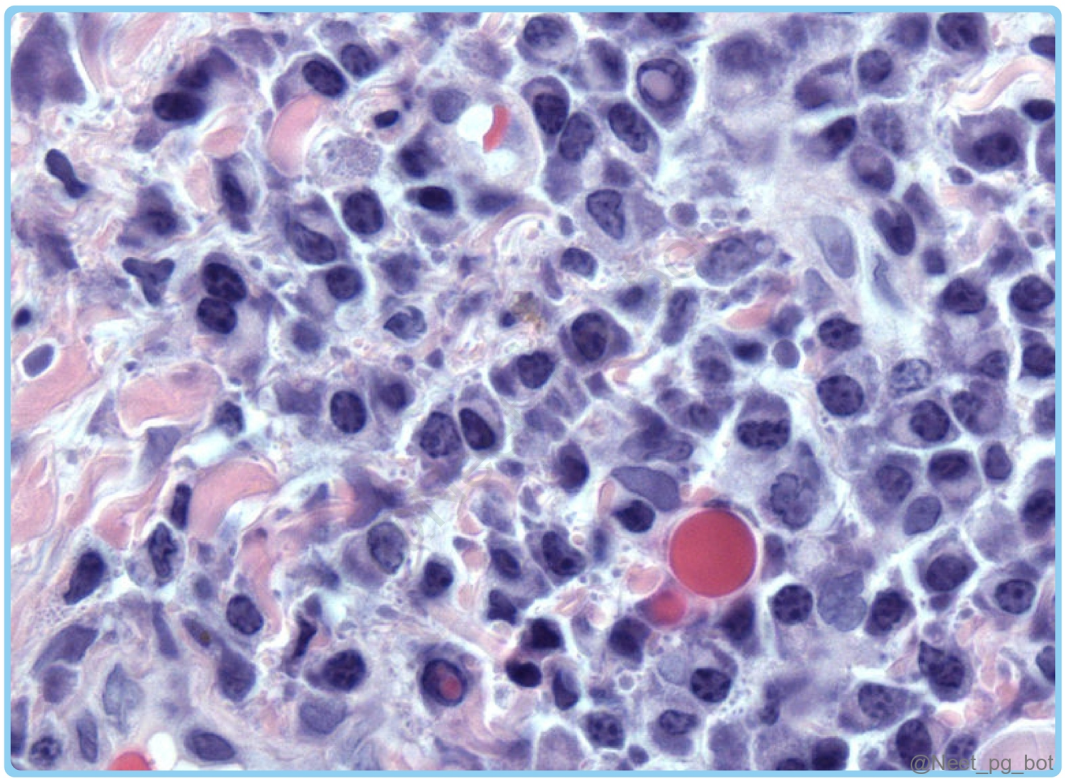
@Neet_pg_bot

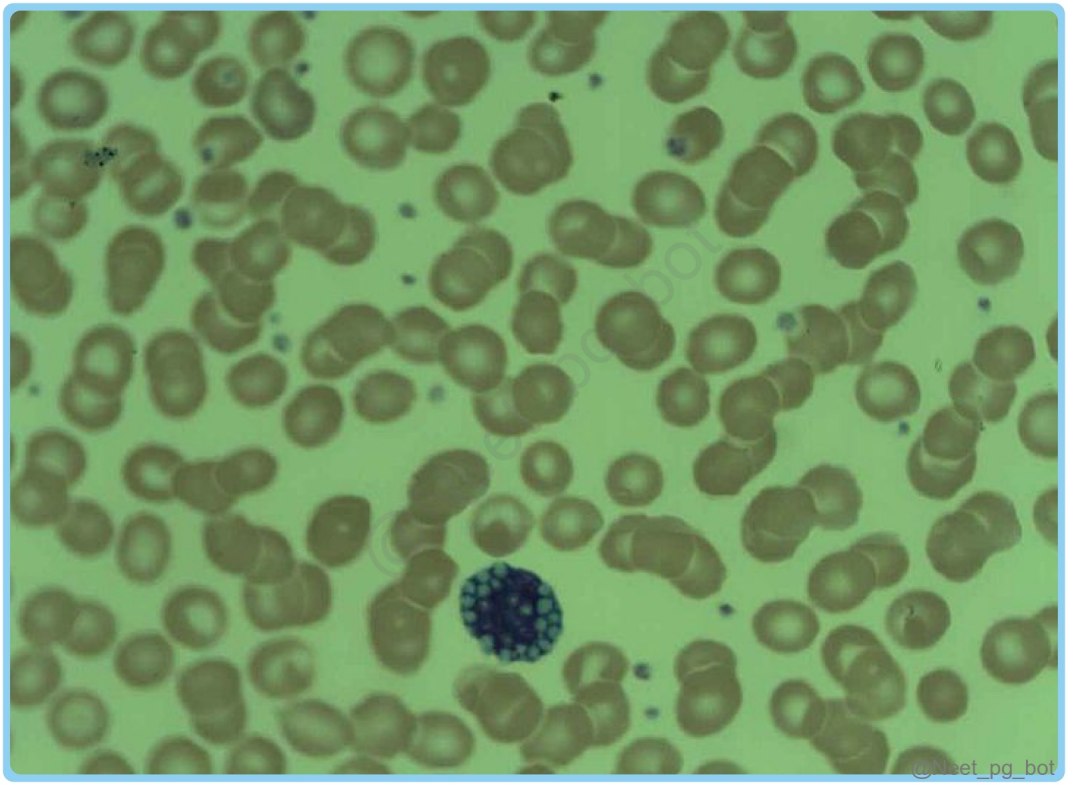
@Neet_pg_bot

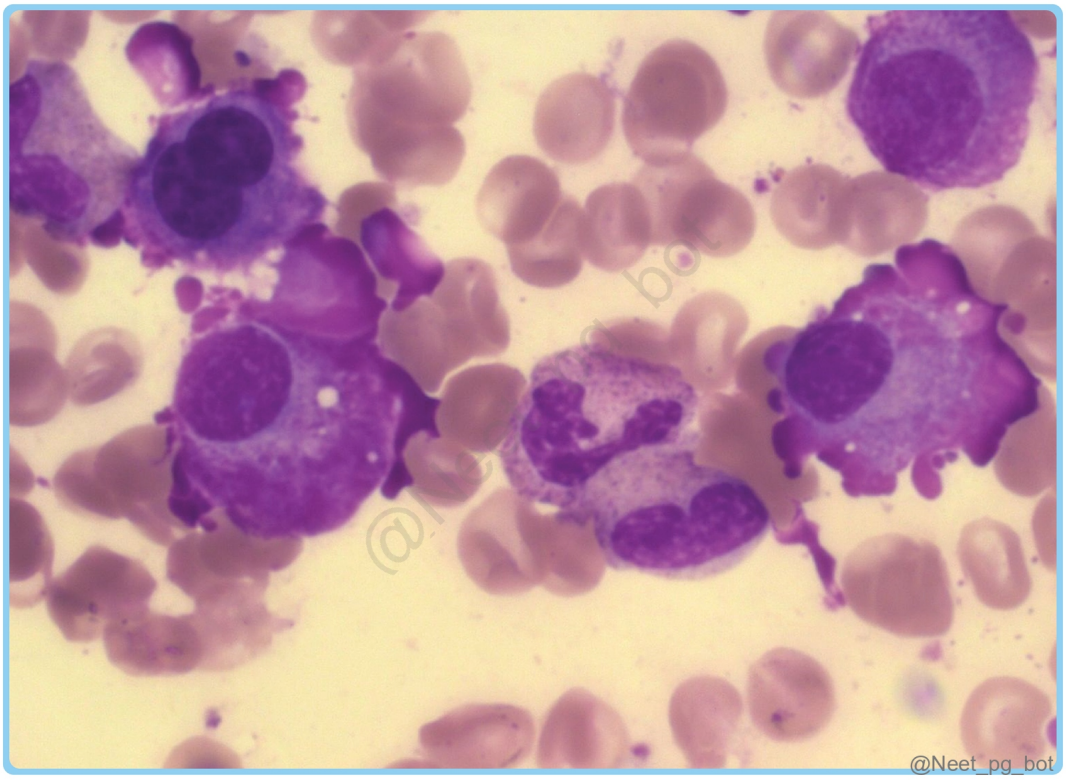

Correct Answer: B. 1-d; 2-c; 3-a; 4-b

- *Listen (English)*
- *Listen (Hindi)*

Explanation: The patient most likely has multiple myeloma, a plasma cell neoplasm, and can present with characteristic histopathological features such as: INCLUSION BODIES SEEN IN MULTIPLE MYELOMA Russel bodies Location: Intracytoplasmic Composition: Eosinophilic Round Dilated endoplasmic reticulum cisternae filled with condensed immunoglobulin. . Dutcher bodies Location: Intranuclear. Composition: Globular inclusions containing accumulated immunoglobulin. PLASMA CELL VARIANTS IN MULTIPLE MYELOMA Mott cells Contain Grape-like cytoplasmic droplets. Composition: Inclusion bodies, fibrils, crystalline rods, and globules. Flame cells Appearance : Fiery red cytoplasm. Cause : High concentration of immunoglobulin as bright red granules within the cytoplasm. Often seen in IgA subtype myeloma.

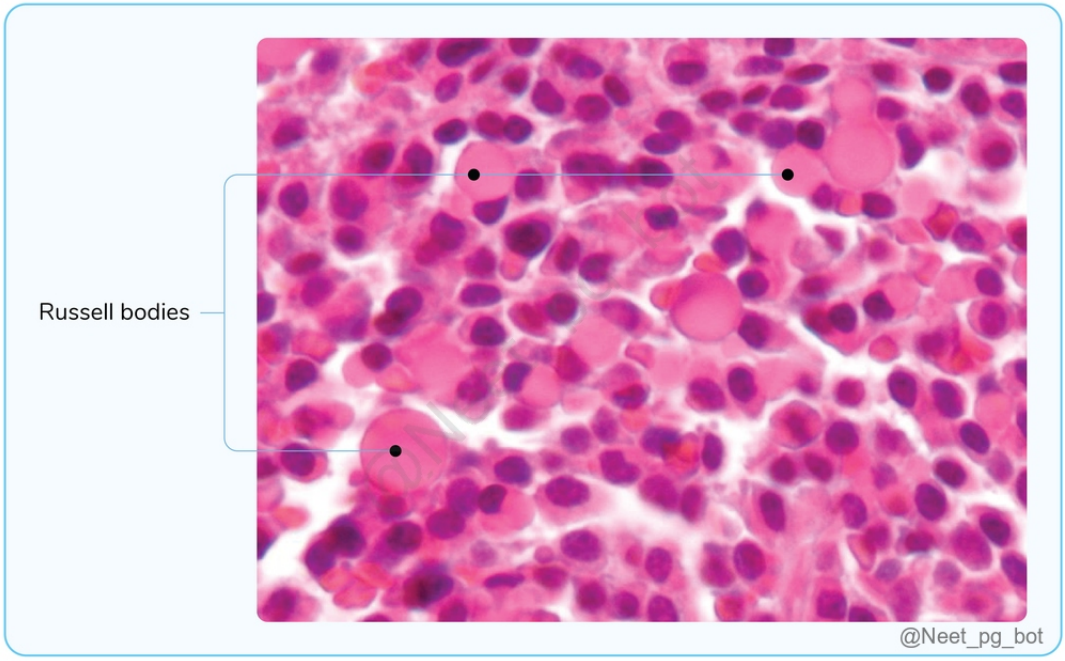
Russell bodies
@Neet_pg_bot

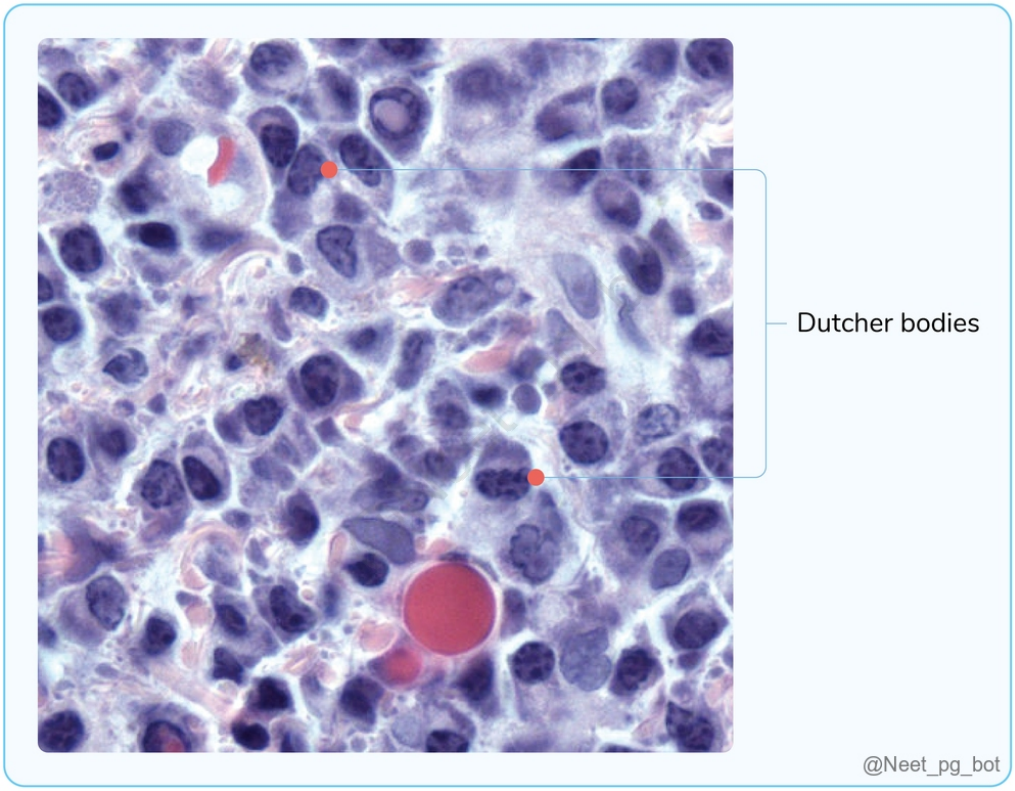
Dutcher bodies
@Neet_pg_bot

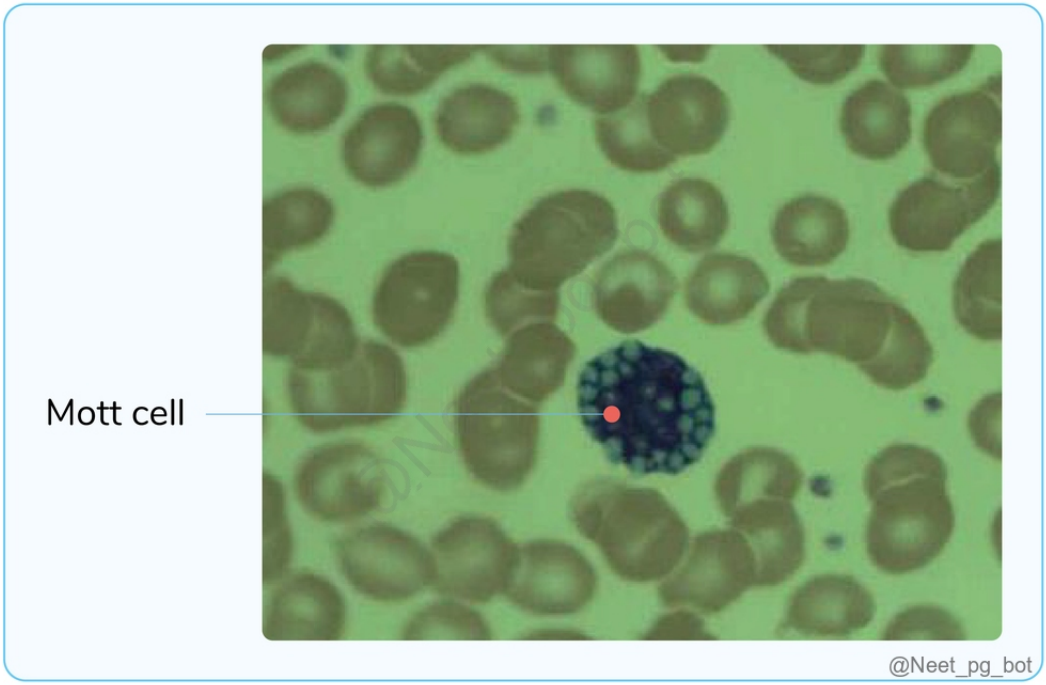
Mott cell
@Neet_pg_bot

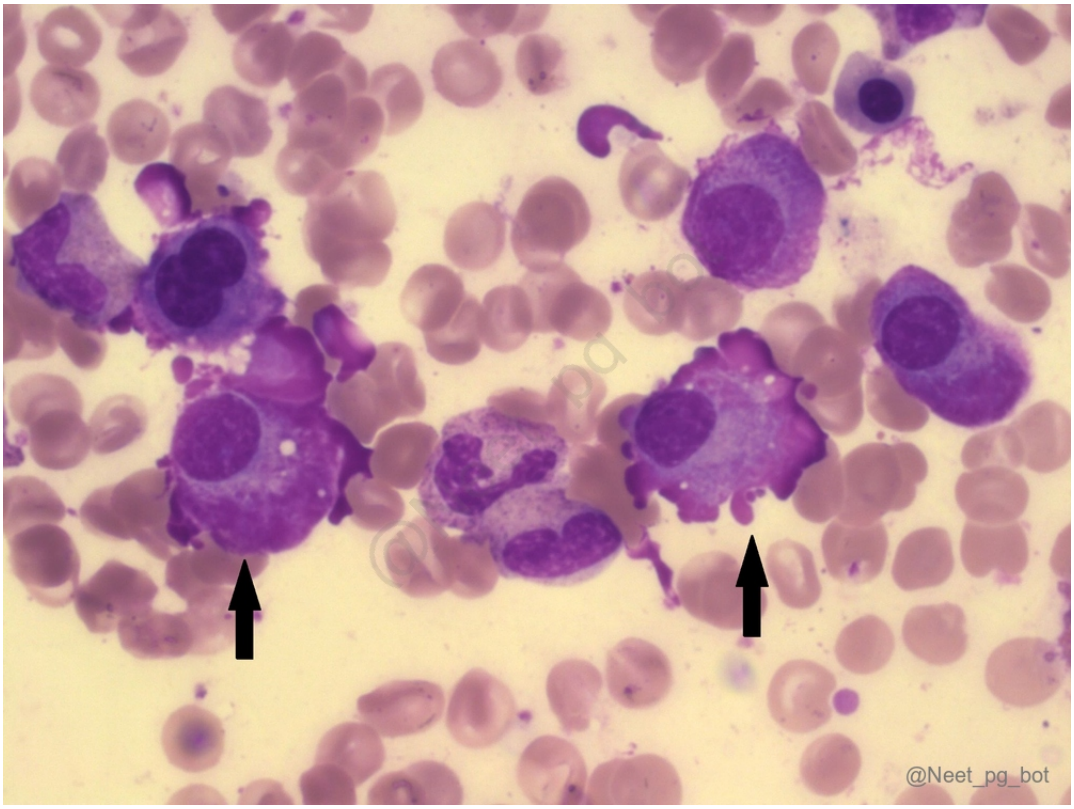
@Neet_pg_bot

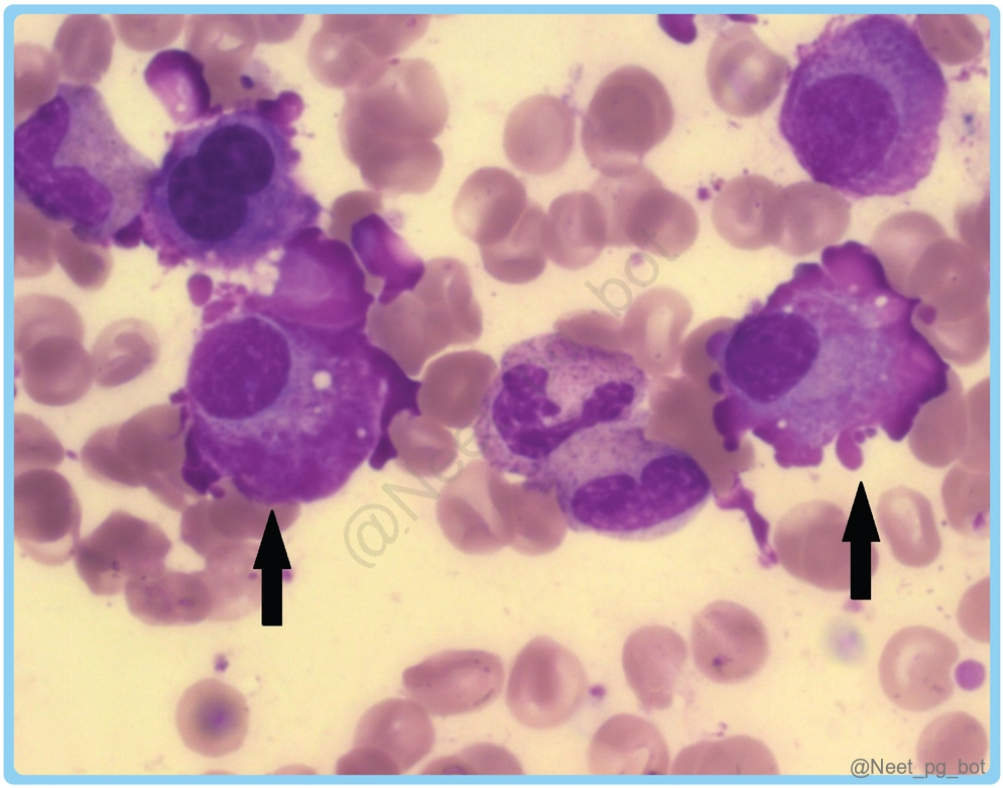

References:

Robbins and Cotran Pathological Basis of Disease, 10th Edition, Page 607, 608, 609

Multiple myeloma cells with asurophillic granules

↑ *Back to this question in Part A*

@Neet_pg_bot

Q6: A 65-year-old male presents with fatigue, bone pain, and recurrent infections. Laboratory tests show elevated IL-6 and beta-2 microglobulin levels, while imaging reveals multiple lytic bone lesions. Bone marrow biopsy showed a high percentage of plasma cells, and cytogenetic analysis revealed a deletion of chromosome 17p. Flow cytometry is performed to distinguish abnormal plasma cells from normal ones in this patient. Which marker commonly shows increased expression on plasma cells in multiple myeloma, aiding in this differentiation? (Q845751)

A. CD19

B. CD38

C. CD56

D. CD117

Correct Answer: C. CD56

■ *Listen (English)*

■ *Listen (Hindi)*

Explanation: The clinical scenario is consistent with Multiple myeloma with poor prognosis. CD56 is a marker commonly overexpressed on plasma cells in multiple myeloma, and it helps to differentiate malignant cells from normal plasma cells. Prognostic factors of Multiple myeloma Good prognostic factors Poor prognostic factors ↓ Beta-2 Microglobulin Level Normal Lactate Dehydrogenase (LDH) Levels Low Serum Free Light Chain Ratio Chromosomal abnormalities like t(11;14) ↑ Beta-2 Microglobulin Level ↑ IL-6 ↑ Lactate Dehydrogenase (LDH) Levels High Serum Free Light Chain Ratio Deletions of chromosome 17p Flow cytometry Markers Normal plasma cells Multiple myeloma plasma cells CD19 + - CD45 + - CD 38 + + CD138 (Syndecan-1) + + CD56 - + CD19 (Option A): It is a pan-B cell marker, absent on malignant plasma cells in multiple myeloma but may be expressed on normal plasma cells. CD 38 (Option B): A marker highly expressed on plasma cells, both normal and malignant. High levels of CD38 are a characteristic feature of multiple myeloma plasma cells. However, CD38 is also found on other cells, so it is combined with other markers like CD138 to identify malignant plasma cells specifically. CD 117 (Option D): CD117, or c-kit, is a receptor tyrosine kinase that is sometimes expressed on hematopoietic stem cells and progenitor cells. CD117 can be expressed in multiple myeloma and is associated with a poorer prognosis. However, its presence is less common than CD56 in multiple myeloma cells. When positive, it can indicate a more aggressive disease course.

References:

Robbins and Cotran Pathological Basis of Disease, 10th Edition, Page 608

Normal plasma cells vs myeloma cells

Multiple myeloma prognosis

Multiple myeloma prognosis- NCBI

↑ *Back to this question in Part A*

@Neet_pg_bot

Q7: A 68-year-old man presents with fatigue, bone pain, and recurrent infections. Laboratory tests reveal hypercalcemia and increased beta-2 microglobulin; imaging shows multiple lytic bone lesions. Which biochemical test is most commonly used to assess renal function and evaluate kidney damage in patients with multiple myeloma? (Q845752)

A. Serum protein electrophoresis (SPEP)

B. Serum creatinine levels

C. Serum calcium levels

D. Urine protein electrophoresis

Correct Answer: B. Serum creatinine levels

■ *Listen (English)*

■ *Listen (Hindi)*

Explanation: The patient presents with multiple myeloma features in which renal involvement is common due to factors like hypercalcemia and the deposition of monoclonal light chains in the renal tubules (light chain cast nephropathy). Serum creatinine levels are the most commonly used biochemical test to assess renal function and detect kidney damage. Biochemical tests useful in the diagnosis of Multiple Myeloma Serum Protein Electrophoresis (SPEP): Detects and measures M-proteins in blood, aiding in multiple myeloma diagnosis and monitoring. But does not help in assessing kidney damage. (Option A) Urine Protein Electrophoresis (UPEP): Identifies Bence Jones proteins in urine, supporting multiple myeloma diagnosis. (Option D) Serum Free Light Chain Assay: Measures free kappa and lambda light chains, useful for diagnosis and treatment monitoring. Serum creatinine: Elevated levels indicate renal impairment. Serum calcium: Commonly elevated due to bone resorption. But does not assess renal function (Option C) CBC: Look for anaemia, leukopenia, or thrombocytopenia. Albumin to globulin ratio - reversed Serum Beta 2 microglobulin - Increased Peripheral blood: Rouleaux formation due to high serum protein (M-protein), red blood cells stack like coins in a roll.

References:

Robbins and Cotran Pathological Basis of Disease, 10th Edition, Page 609

↑ *Back to this question in Part A*

@Neet_pg_bot

Q8: A 62-year-old male with a routine health check-up is found to have a serum M protein level of 3.5 g/dL and plasma cells making up 25% of the marrow cellularity. He reports no bone pain, normal kidney function, normal calcium levels, and no lytic bone lesions on imaging. What is the most likely diagnosis? (Q845753)

A. Monoclonal Gammopathy of Undetermined Significance (MGUS)

B. Plasma Cell Leukemia

C. Multiple Myeloma

D. Smouldering Myeloma

Correct Answer: D. Smouldering Myeloma

■ *Listen (English)*

■ *Listen (Hindi)*

Explanation: The clinical findings suggest Smouldering Myeloma . It is a precursor condition to multiple myeloma, lying between Monoclonal Gammopathy of Undetermined Significance (MGUS) and symptomatic multiple myeloma. It is characterised by the presence of monoclonal protein in the absence of end-organ damage , with bone marrow plasma cell infiltration of ≥10% and <30% without myeloma-defining events. Plasma cell leukemia (Option B) is a rare and aggressive form of multiple myeloma associated with myc gene mutations. Criteria MGUS (most common plasma cell abnormality) (Option A) Plasma Cell Leukemia (Option B) Multiple Myeloma (Option C) Smouldering Myeloma (Option D) Serum M Protein Level Typically < 3 g/dL Variable Variable, often > 3 g/dL > 3 g/dL Plasma Cells in Bone Marrow < 10% Variable Variable, often > 10% 10% to 30% Symptoms Absent Present Present (bone pain, anemia, hypercalcemia) Absent Organ Damage Absent Present Present (renal impairment, bone lesions) Absent

References:

Robbins and Cotran Pathological Basis of Disease, 10th Edition, Page 610

↑ *Back to this question in Part A*

@Neet_pg_bot

Q9: A 70-year-old male presents with blurred vision, dizziness, and epistaxis. Physical examination reveals engorged retinal veins and signs of haemorrhage. Laboratory tests show an elevated serum viscosity. Serum protein electrophoresis reveals a monoclonal IgM spike. What is the most likely cause of the patient's symptoms? (Q845754)

A. Multiple Myeloma

B. Chronic Lymphocytic Leukemia

C. IgA Myeloma

D. Waldenstrom’s Macroglobulinemia

Correct Answer: D. Waldenstrom’s Macroglobulinemia

■ *Listen (English)*

■ *Listen (Hindi)*

Explanation: The clinical presentation suggests Waldenstrom’s macroglobulinemia, a lymphoproliferative disorder characterised by the presence of monoclonal IgM antibodies . Waldenström Macroglobulinemia (WM) is due to increased association with Lymphoplasmacytic Lymphoma (LPL) associated with: MYD88 Mutation: Present in >90% of Waldenström patients (a high-yield molecular marker). CD40-CD40L Interaction: The interaction between CD40 on B-cells and CD40L (CD154) on T-cells drives B-cell proliferation and class-switching.

Aberrant signaling here contributes to the lymphoplasmacytic expansion. Patients may present with symptoms of hyperviscosity syndrome , such as blurred vision, dizziness, and bleeding tendencies. It is d iagnosed by the monoclonal IgM gammopathy seen on serum protein electrophoresis (SPEP) or immunofixation electrophoresis (IFE). Multiple Myeloma (Option A): Multiple myeloma is characterised by the presence of monoclonal IgG or IgA antibodies, not IgM . Chronic Lymphocytic Leukemia (Option B): CLL is a B-cell malignancy characterised by the accumulation of monoclonal B lymphocytes and not IgM antibodies. IgA Myeloma (Option C): A subtype of multiple myeloma that primarily produces monoclonal IgA. While it can cause hyperviscosity syndrome, it is not characterised by an IgM spike.

References:

Robbins and Cotran Pathological Basis of Disease, 10th Edition, Page 607

www.ncbi.nlm.nih.gov/pmc/articles/PMC3659998/

↑ *Back to this question in Part A*

@Neet_pg_bot

Q10: A 55-year-old male presents with recurrent infections and fatigue. Palatal edema is noted. Laboratory tests show hypogammaglobulinemia and serum protein electrophoresis reveals an absence of normal immunoglobulins but a monoclonal spike in the gamma region. Bone marrow biopsy reveals large lymphoid cells with intracytoplasmic inclusions. Which type of heavy chain disease is most likely causing the patient's symptoms? (Q845755)

A. Alpha Heavy Chain Disease

B. Gamma Heavy Chain Disease

C. Mu Heavy Chain Disease

D. Delta Heavy Chain Disease

Correct Answer: B. Gamma Heavy Chain Disease

■ *Listen (English)*

■ *Listen (Hindi)*

Explanation: The clinical scenario is consistent with Gamma heavy chain disease (Franklin’s Disease). Heavy-chain diseases are rare monoclonal gammopathies characterized by the production and secretion of free heavy-chain fragments. These diseases can be associated with various disorders, including: Lymphoplasmacytic Lymphoma Small Bowel Marginal Zone Lymphoma Gamma heavy chain disease (Franklin's disease): (Option B) Present with systemic symptoms & sometimes palatal and uvular swelling. Involves the production of abnormal monoclonal gamma heavy chains without associated light chains , resulting in hypogammaglobulinemia and recurrent infections. Serum protein electrophoresis (SPEP) reveals a monoclonal spike in the gamma region. Alpha

heavy chain disease (Seligmann's Disease) (Option A): The most common type. Often presents as a gastrointestinal immunoproliferative small intestinal disease (IPSID). Mu heavy chain disease (Option C): A very rare subtype that resembles chronic lymphocytic leukaemia/small lymphocytic leukaemia Delta heavy chain disease (Option D): Extremely rare subtype.

References:

Robbins and Cotran Pathological Basis of Disease, 10th Edition, Page 607

www.uptodate.com/contents/the-heavy-chain-diseases

↑ *Back to this question in Part A*

@Neet_pg_bot

Q11: Which of the following represents the normal serum free κ:λ light chain ratio? (Q889647)

A. 0.01 - 0.10

B. 0.26 - 1.65

C. 1.65 - 3.50

D. 3.50 - 5.00

Correct Answer: B. 0.26 - 1.65

Explanation: 0.26 - 1.65 is the normal reference range for the serum free κ:λ light chain ratio . This range reflects balanced polyclonal production of κ and λ light chains by plasma cells. A high ratio suggests excess κ light chain production (e.g., κ-restricted monoclonal gammopathy). A low ratio suggests excess λ light chain production. Marked deviations from the normal range raise suspicion for monoclonal plasma cell disorders , such as multiple myeloma, MGUS, or light chain amyloidosis.

References:

https://pmc.ncbi.nlm.nih.gov/articles/PMC1895159/

↑ *Back to this question in Part A*

@Neet_pg_bot

Q12: A 67-year-old man presents with back pain and anaemia. Skull radiograph shows multiple punched-out lytic lesions. He is diagnosed with multiple myeloma. Which of the following is the most common location of lytic bone lesions in multiple

myeloma? (Q889652)

A. Vertebral column

B. Femur

C. Skull

D. Pelvis

Correct Answer: A. Vertebral column

Explanation: Multiple myeloma characteristically involves the axial skeleton , with the vertebral column being the most commonly affected site . Vertebral involvement frequently leads to back pain and compression fractures , which are common presenting features. Bone destruction in myeloma occurs due to: Increased osteoclast activity (via RANKL and cytokine stimulation) Suppressed osteoblast function (mediated by inhibitors such as DKK1) This imbalance produces the classic “punched-out” lytic lesions seen on radiographs. Commonly affected bones include the vertebrae, ribs, skull, pelvis, and proximal long bones .

References:

Robbins, Cotran & Kumar, Pathologic Basis of Disease, 11th Edition, Page 553

↑ *Back to this question in Part A*

@Neet_pg_bot

Q13: A 66-year-old man with multiple myeloma presents with bone pain and hypercalcemia. Imaging shows multiple punched-out lytic lesions. The increased bone resorption in this condition is primarily mediated by which of the following factors produced by neoplastic plasma cells? (Q889654)

A. Interleukin-2

B. MIP-1α

C. Erythropoietin

D. Transforming growth factor-β

Correct Answer: B. MIP-1α

Explanation: In multiple myeloma, bone destruction results from an imbalance between osteoclast activation and osteoblast suppression. Neoplastic plasma cells produce MIP-1α (macrophage inflammatory protein-1 alpha, also known as CCL3) , which is a key mediator of osteoclast differentiation and activation . MIP-1α stimulates osteoclast precursors and enhances osteoclast formation, leading to increased bone resorption and the

characteristic punched-out lytic lesions . The resulting bone breakdown also contributes to hypercalcemia . Although additional factors such as RANKL (from stromal cells) and DKK1 (which inhibits osteoblast differentiation) participate in myeloma bone disease, MIP-1α is a principal osteoclast-activating factor produced directly by myeloma cells. Interleukin-2 (Option A): Primarily promotes T-cell proliferation and is not involved in osteoclast activation in multiple myeloma. Erythropoietin (Option C): Stimulates erythroid progenitor cells in the bone marrow and does not mediate bone resorption. Transforming growth factor-β (Option D): Involved in tissue remodelling and fibrosis, but is not the primary mediator of osteoclast-driven bone destruction in multiple myeloma.

References:

Robbins, Cotran & Kumar, Pathologic Basis of Disease, 11th Edition, Page 553

↑ *Back to this question in Part A*

@Neet_pg_bot

Q14: Excessive production of which of the following proteins is most commonly associated with hyperviscosity in multiple myeloma? (Q889661)

A. IgG3

B. IgG

C. IgM

D. IgG2

Correct Answer: A. IgG3

Explanation: IgG3 is the immunoglobulin subtype among the given options most strongly associated with hyperviscosity in multiple myeloma. Hyperviscosity syndrome results from markedly elevated levels of monoclonal immunoglobulin (M protein), which increases plasma viscosity and impairs microcirculation. In multiple myeloma, hyperviscosity is most commonly associated with IgA myeloma because IgA forms dimers and polymers that significantly increase serum viscosity. However, since IgA is not listed in the options, IgG3 is the best answer among those provided. IgG3 has a long hinge region and a greater tendency for self-aggregation , increasing its effective molecular size and its contribution to plasma viscosity compared to other IgG subclasses. Clinical features of hyperviscosity include: Headache Blurred vision Mucosal bleeding Retinal venous engorgement Neurological symptoms IgG (Option B): Although IgG is the most common immunoglobulin subtype in multiple myeloma overall, it is less strongly associated with hyperviscosity compared to IgG3. IgM (Option C): IgM is the classic cause of hyperviscosity in Waldenström macroglobulinemia , not multiple myeloma. IgG2 (Option D): Does not demonstrate the aggregation tendency seen with IgG3 and is less associated with hyperviscosity.

References:

Robbins, Cotran & Kumar, Pathologic Basis of Disease, 11th Edition, Page 554

↑ *Back to this question in Part A*

@Neet_pg_bot

Q15: Which type of multiple myeloma is most commonly associated with a higher risk of renal insufficiency? (Q889663)

A. IgG myeloma

B. IgA myeloma

C. IgD myeloma

D. IgE myeloma

Correct Answer: C. IgD myeloma

Explanation: IgD myeloma is most commonly associated with a higher risk of renal insufficiency. IgD myeloma characteristically produces large amounts of free light chains (Bence Jones proteins) . These light chains are filtered by the kidneys and precipitate within renal tubules, leading to light chain cast nephropathy (myeloma kidney) . Tubular obstruction and inflammation result in progressive renal dysfunction. IgD myeloma is rare but often presents with high tumour burden and advanced renal impairment at diagnosis. Renal injury in multiple myeloma is primarily mediated by excessive free light chain production. IgG myeloma (Option A): Most common subtype of multiple myeloma; renal failure may occur, but is not disproportionately associated compared to IgD myeloma. IgA myeloma (Option B): Second most common subtype; can cause renal involvement but is less frequently associated with severe renal insufficiency compared to IgD myeloma. IgE myeloma (Option D): Extremely rare subtype and not classically associated with a higher incidence of renal failure.

References:

https://pmc.ncbi.nlm.nih.gov/articles/PMC9727151/

↑ *Back to this question in Part A*

@Neet_pg_bot

• [18_Hematology_ White Blood Cells] 073 Wbc Basics And Instruments

« Back to Folder Directory

[18_Hematology_ White Blood Cells] 073 Wbc Basics And Instruments — Quick Jump

Q1 (p. 2870) *Q2 (p. 2873)* *Q3 (p. 2874)* *Q4 (p. 2877)* *Q5 (p. 2878)* *Q6 (p. 2883)*
Q7 (p. 2884) *Q8 (p. 2887)* *Q9 (p. 2891)*

Q1: A 50-year-old man presents with complaints of fatigue, easy bruising, and recurrent nosebleeds over the past month. Laboratory investigations reveal leukopenia and thrombocytopenia. Peripheral blood smear examination demonstrates the presence of cells with Auer rods. In which stage of myelopoiesis are Auer rods typically found? (Q845756)

A. Myeloblast

B. Myelocyte

C. Metamyelocyte

D. Monoblast

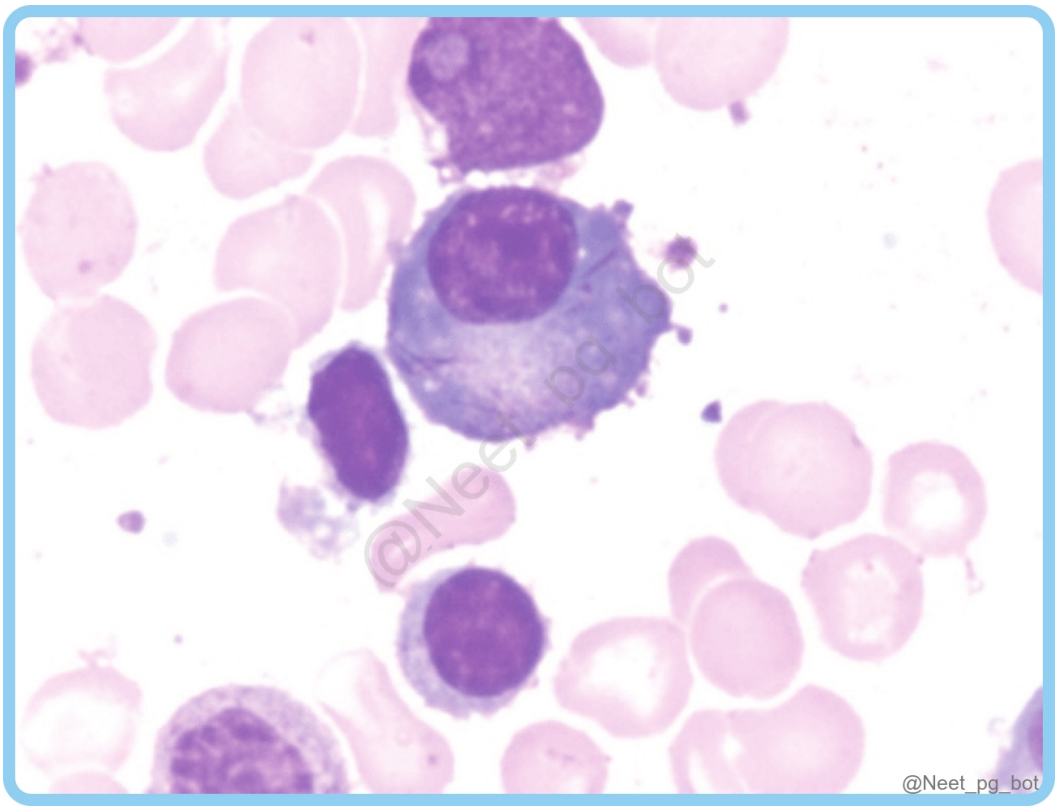

Correct Answer: A. Myeloblast

- *Listen (English)*
- *Listen (Hindi)*

Explanation: The patient most likely has Acute Myeloid Leukemia (AML) , characterised by Myeloblasts with Auer rods, which are needle-like granules in the cytoplasm. Because they are formed from the fusion of primary granules (azurophilic granules), they can also be found in promyelocytes . Myelopoiesis is the process of WBC formation, which starts with the Pluripotent Stem Cells, which are CD34+.

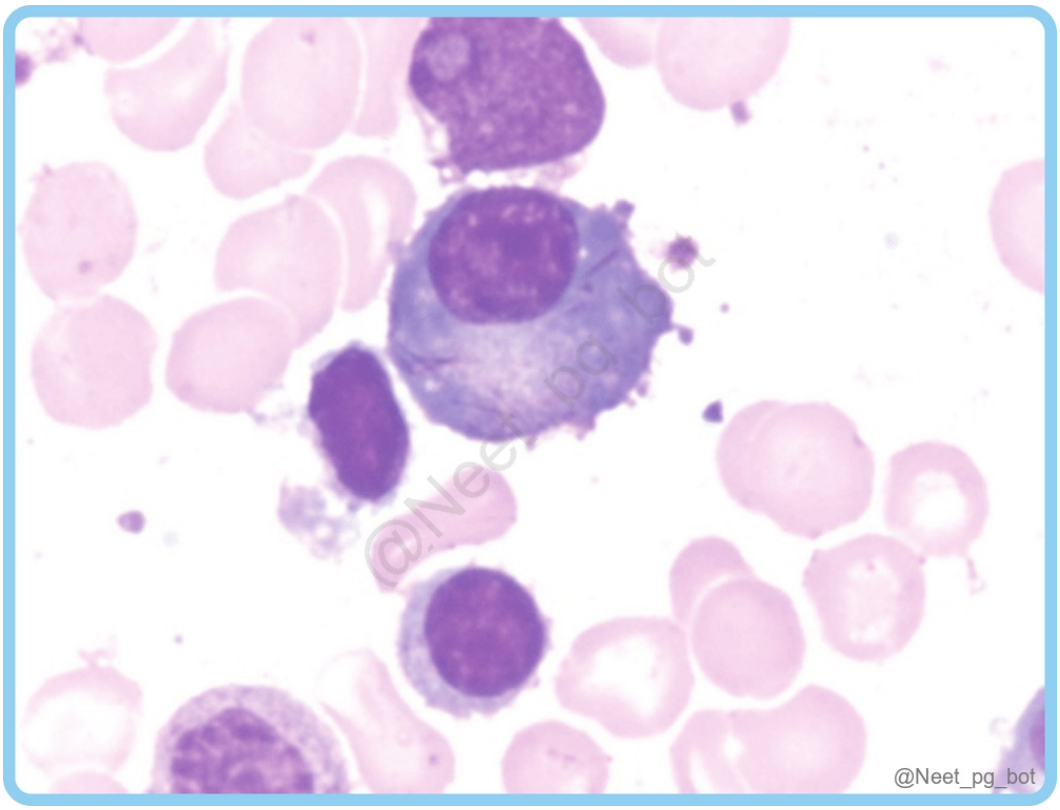

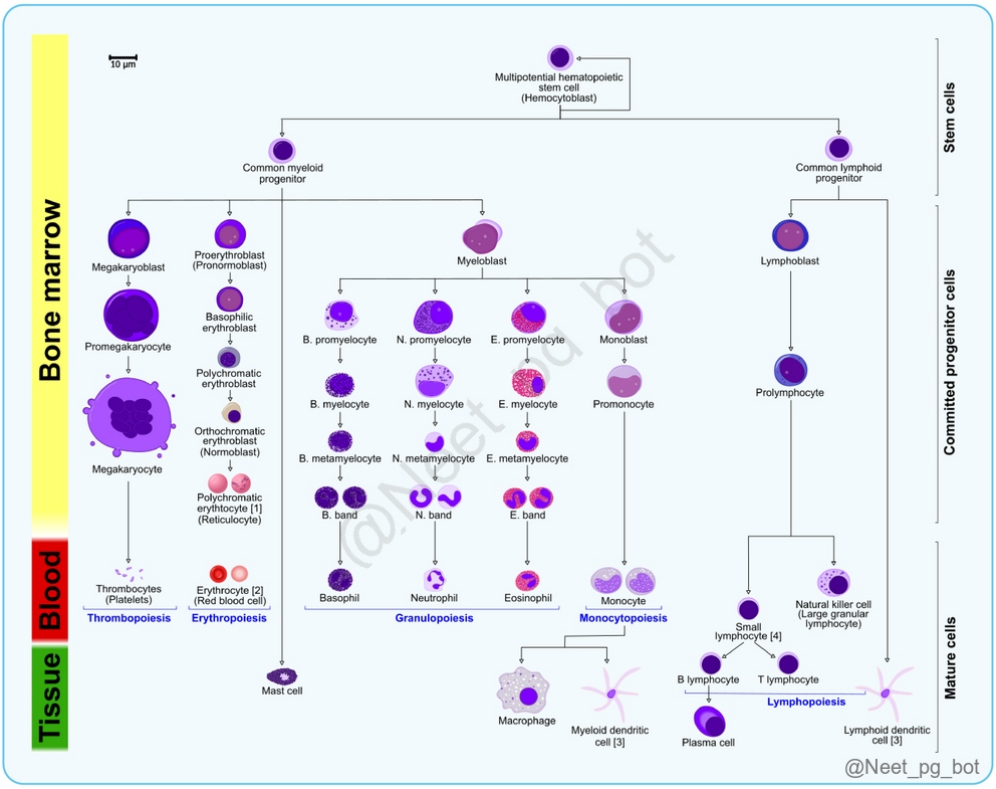

References:

Robbins and Cotran, Pathological Basis of Disease, 10th Edition, Page 585

Guyton and Hall Textbook of Medical Physiology, 14th edition, Page 449-450.

www.sciencedirect.com/topics/medicine-and-dentistry/auer-rod

https://commons.wikimedia.org/wiki/File:Band_neutrophil_%2816694694661%29.jpg

↑ *Back to this question in Part A*

@Neet_pg_bot

Q2: A 45-year-old man presents with complaints of persistent fever, chills, and generalized weakness for the past week. Lab reports revealed leukocytosis with a left shift, and peripheral blood smear examination shows cells with kidney-shaped nuclei and parasites in ring forms inside RBCs. What is the cell called? (Q845757)

A. Monocyte

B. Neutrophil

C. Basophil

D. Eosinophil

Correct Answer: A. Monocyte

■ *Listen (English)*

■ *Listen (Hindi)*

Explanation: The patient most likely has malaria which presents initially with fever, chills and weakness. On smear examination, there is monocytosis (cells with kidney-shaped nuclei) and parasites in ring forms within RBCs. Different types of WBC a) Granulocytes Neutrophils: 3-5 lobes and are involved in the acute inflammatory response to bacterial infection and the removal of the bacteria by phagocytosis. (Option B) Eosinophils : They have orange-red granules and a bilobed nucleus and are involved in chronic inflammation, allergic reactions, and host defence against parasitic infections. (Option D) Basophils: They have blue-black granules and their primary function is inflammation and allergic reaction. They act similar to Mast cells. (Option C) b) Agranulocytes Lymphocytes: They are part of the adaptive immune system. They are circulating immunocompetent cells that develop the ability to recognise and react to antigens. Monocytes: They have a kidney-shaped nucleus. In tissues, they differentiate into phagocytes , such as macrophages, osteoclasts and Kupffer cells and phagocytose bacteria, cells, and debris and function as antigen-presenting cells.

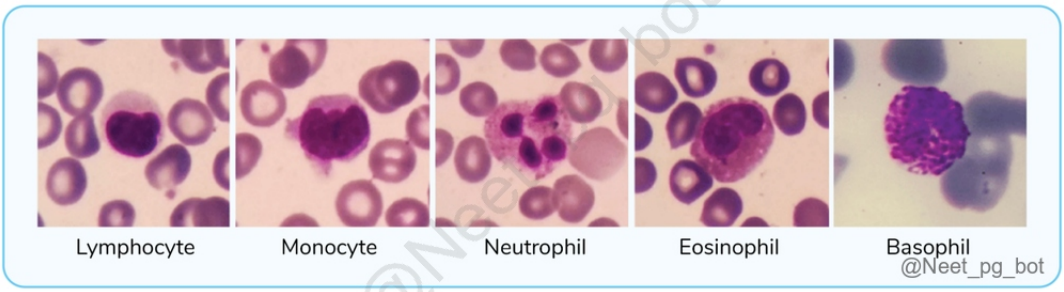

References:

Robbins and Cotran, Pathological Basis of Disease, 10th Edition, Page 586

Guyton and Hall, Textbook of Medical Physiology, 14th Edition, Page 450.

www.ncbi.nlm.nih.gov/books/NBK563148/

www.researchgate.net/figure/fig1_358024806

↑ *Back to this question in Part A*

@Neet_pg_bot

Q3: A 6-year-old child is brought up due to concerns about persistent fever, fatigue, and frequent infections over the past few weeks. There is generalised lymphadenopathy. Laboratory investigations reveal leukocytosis with lymphoblasts on peripheral smear examination. Which of the following stains are used to visualise lymphoblasts? (Q845758)

A. Periodic Acid Schiff (PAS) stain

B. Myeloperoxidase stain

C. Sudan Black stain

D. Wright stain

Correct Answer: A. Periodic Acid Schiff (PAS) stain

■ *Listen (English)*

■ *Listen (Hindi)*

Explanation: The child most likely has Acute lymphoblastic leukemia (ALL) which is a neoplasm composed of immature B or T cells, referred to as Lymphoblasts which is visualised by Periodic Acid Schiff (PAS) stain. ALL lymphoblasts show a block or coarse granular positivity. Symptoms related to depression of marrow function and neoplastic infiltration include fatigue (anaemia), fever(infections due to neutropenia), bleeding

(thrombocytopenia), generalised lymphadenopathy, splenomegaly, and hepatomegaly, most of which are seen in this patient. Features Lymphoblast Myeloblast Monoblasts Cell Features No Auer rods Auer rods present Lobulated nuclei differentiate it from myeloblasts. Stains Periodic Acid Schiff (PAS) stain Acid phosphatase for T-lymphoblasts Myeloperoxidase stain (Option B) Sudan Black stain (Option C) HPE Nucleus with clumped, dark purple chromatin Nucleus with opened up, homogeneous, lighter chromatin Wright's stain (Option D): Wright’s stain is a mixture of eosin (red) and methylene blue dyes and is used in blood smears and bone marrow aspirates to detect RBCs, WBCs and platelet abnormalities.

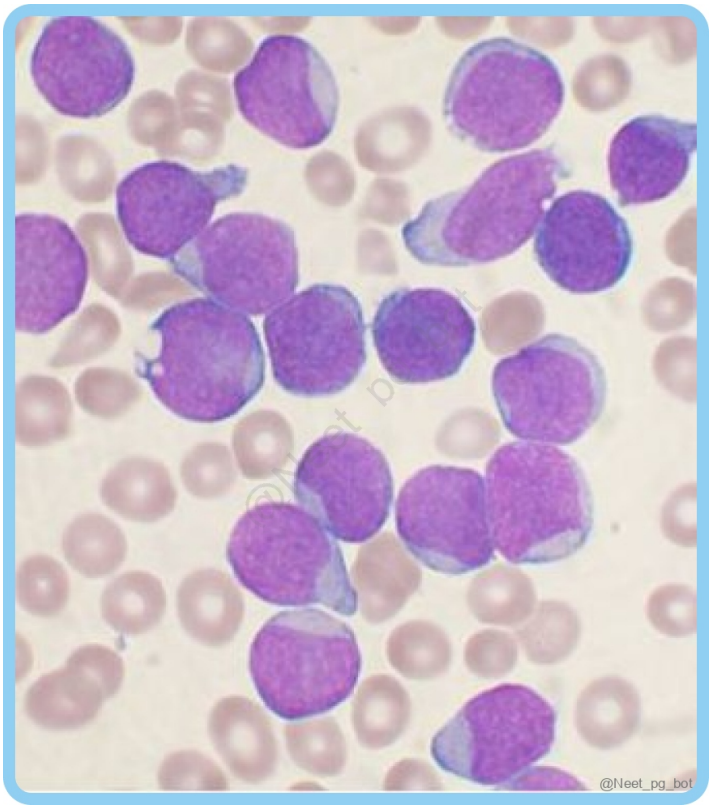

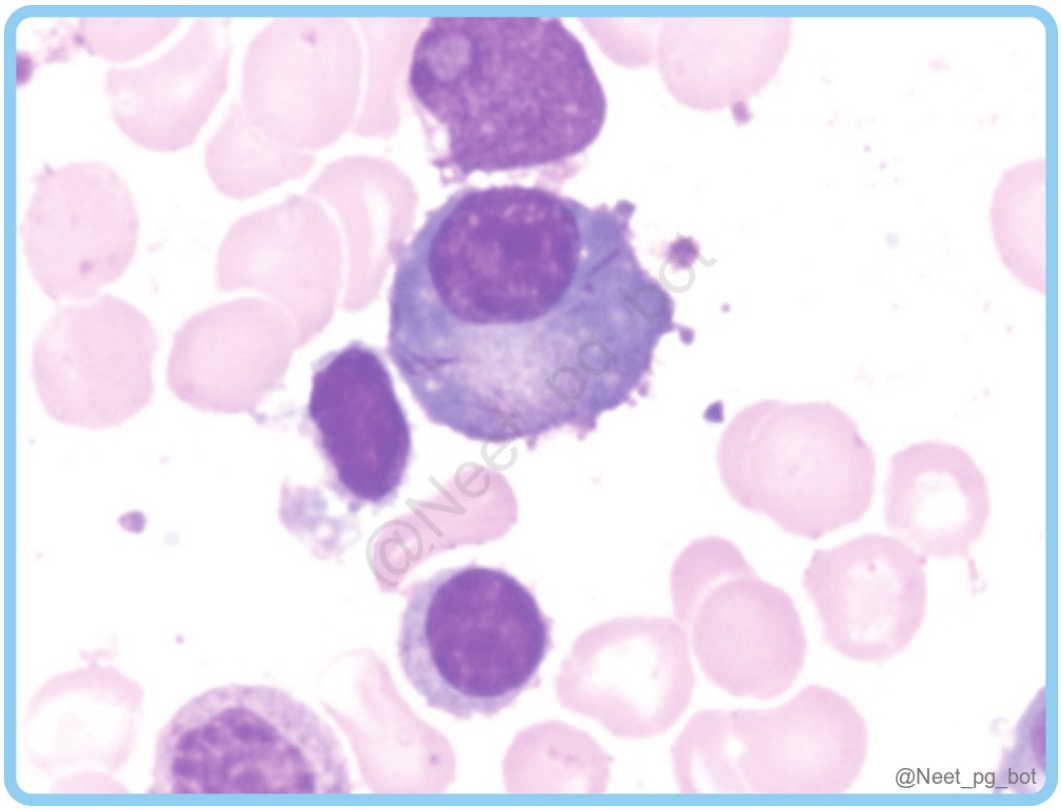

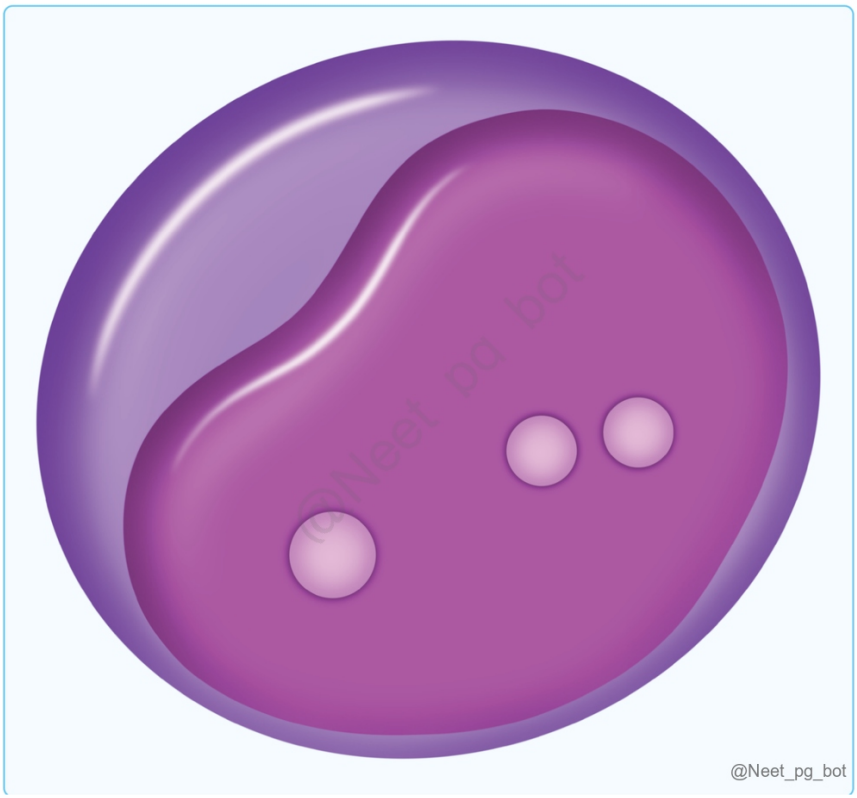

References:

Robbins and Cotran, Pathological Basis of Disease, 10th Edition, Page 594, 596

www.sciencedirect.com/topics/biochemistry-genetics-and-molecular-biology/monoblast

www.ncbi.nlm.nih.gov/pmc/articles/PMC9681839/

www.ncbi.nlm.nih.gov/books/NBK537237/

↑ *Back to this question in Part A*

@Neet_pg_bot

Q4: A 55-year-old male presents with persistent fatigue, significant weight loss, and night sweats over the past few months. Examination revealed massive splenomegaly. CBC shows elevated white blood cell count. A bone marrow biopsy confirms the diagnosis of CML. Which of the following types of leukocytosis is most commonly associated with this condition? (Q845760)

A. Neutrophilia

B. Eosinophilia

C. Lymphocytosis

D. Basophilia

Correct Answer: D. Basophilia

Explanation: Chronic Myeloid Leukemia (CML) is a myeloproliferative neoplasm characterised by the unregulated proliferation of myeloid cells. It is defined by the presence of the Philadelphia chromosome, a balanced translocation t(9;22)(q34;q11), which creates the BCR-ABL1 fusion gene. While a generalised increase in myeloid cells (neutrophilia) is always present, the presence of basophilia is a distinct, high-yield, and classic peripheral blood finding in CML. Clinical and Laboratory Pointers: Splenomegaly: Massive splenic enlargement is common due to extramedullary hematopoiesis and sequestration of cells. Peripheral Blood: Shows a wide spectrum of myeloid precursors (the "leukemic hiatus" is absent) and frequently includes an absolute increase in basophils and eosinophils. Basophilia: A characteristic feature that helps distinguish CML from other causes of reactive neutrophilia. Disease Course: Typically progresses from a chronic phase to an accelerated phase and eventually to a terminal blast crisis, resembling acute leukemia. Neutrophilia (Option A): While CML does present with neutrophilia, it is a non-specific finding seen in various reactive states, infections, and other malignancies. Eosinophilia (Option B): While eosinophilia can occur in CML, it is less consistent and less diagnostic than basophilia. Lymphocytosis (Option C): Lymphocytosis is characteristic of lymphoid malignancies like Chronic Lymphocytic Leukemia (CLL).

References:

Robbins and Cotran, Pathological Basis of Disease, 10th Edition, Page 588

↑ *Back to this question in Part A*

Q5: Match the following cells with their respective images a) Hypersegmented neutrophil 1) b) Hyposegmented neutrophil 2) c) Dohle bodies 3) d) Alder Reilly anomaly 4) (Q845761)

A. a-3, b-4, c-1, d-2

B. a-2, b-1, c-4, d-3

C. a-4, b-3, c-1, d-2

D. a-2, b-3, c-4, d-1

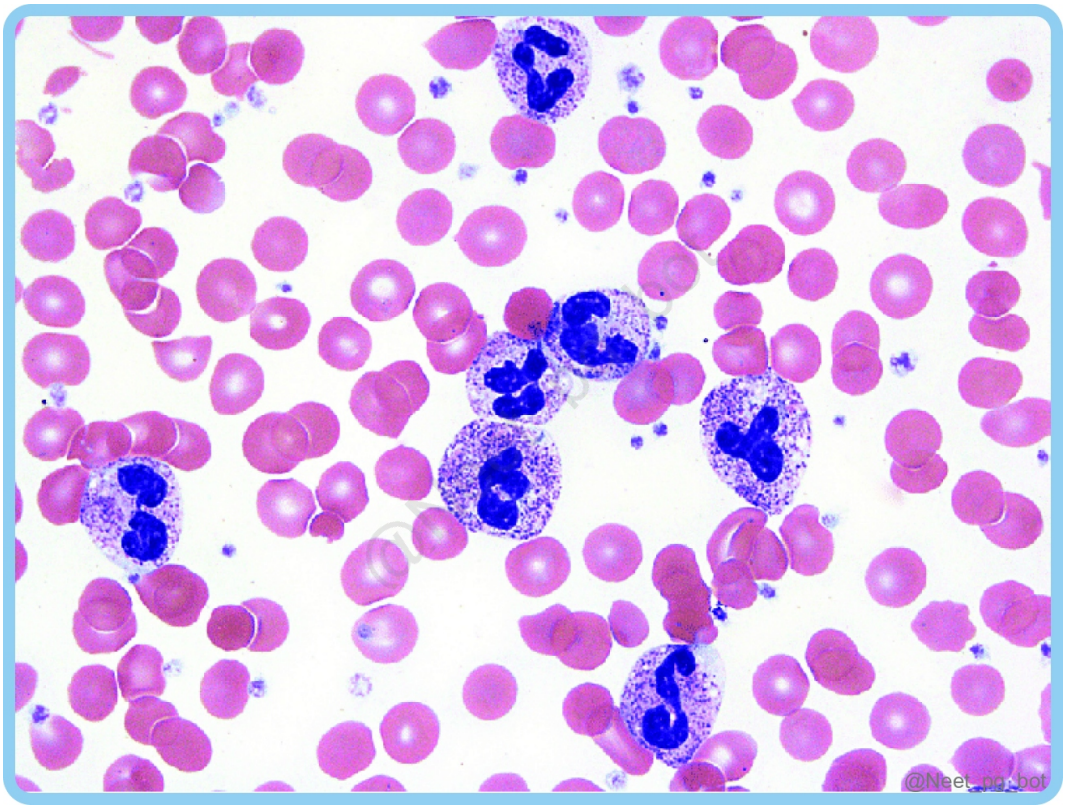

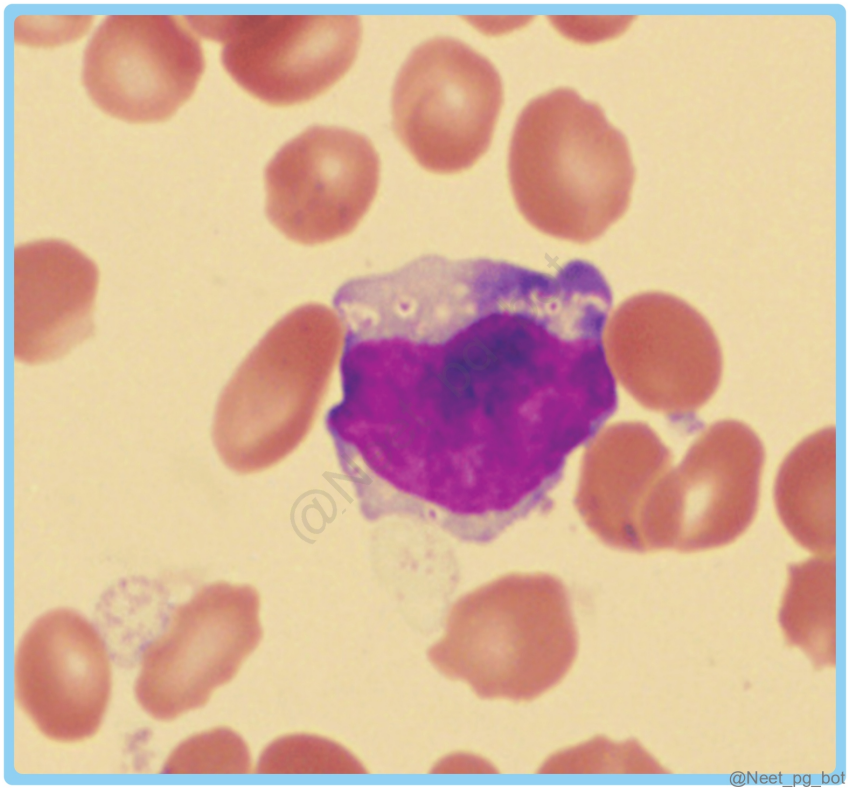
@Neet_pg_bot

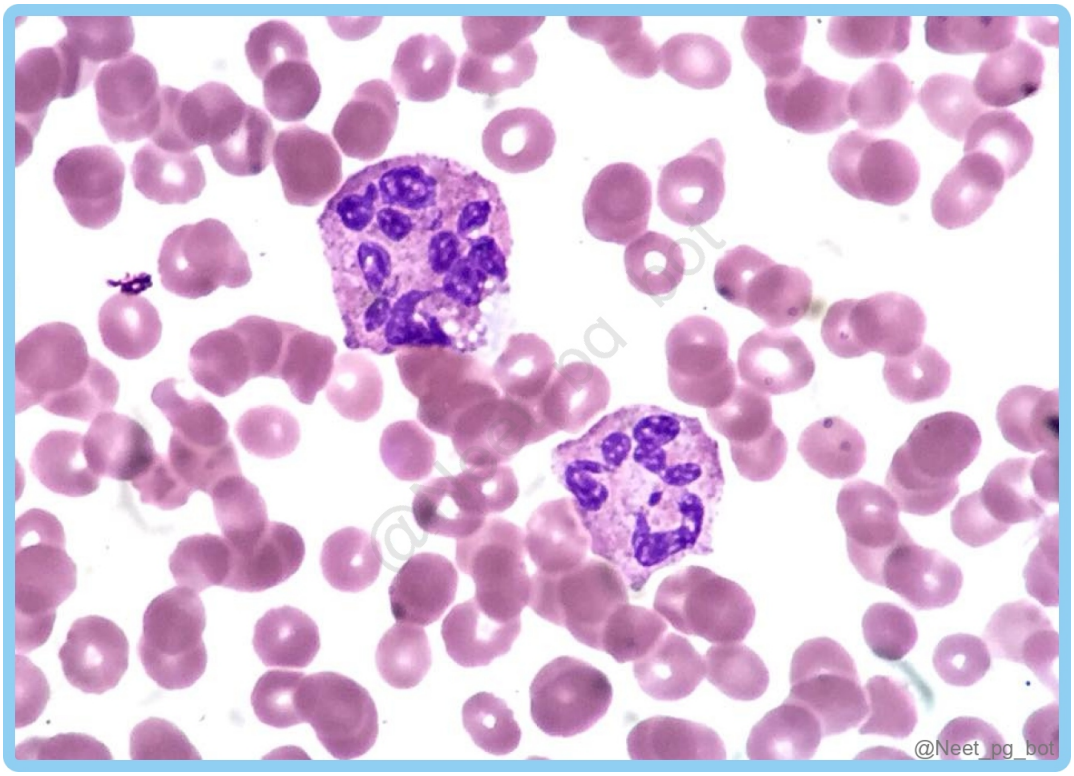
@Neet_pg_bot

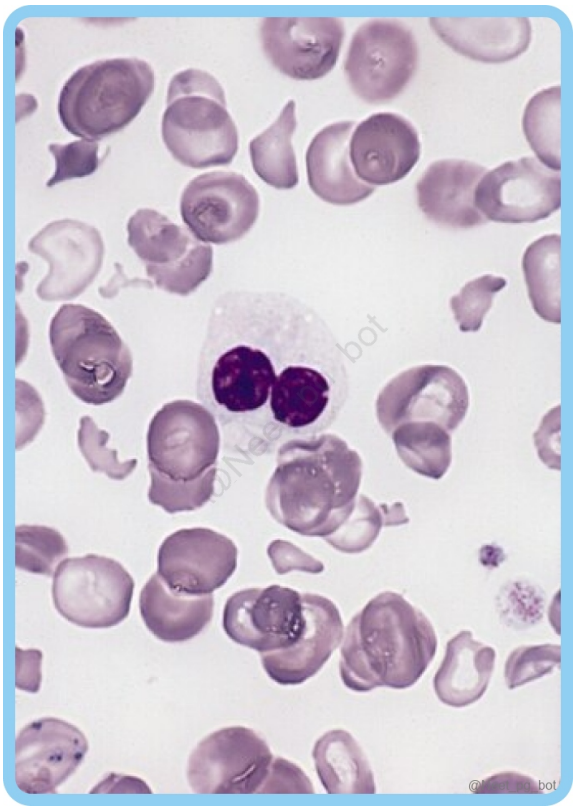

Correct Answer: A. a-3, b-4, c-1, d-2

- *Listen (English)*
- *Listen (Hindi)*

Explanation: Pathological features

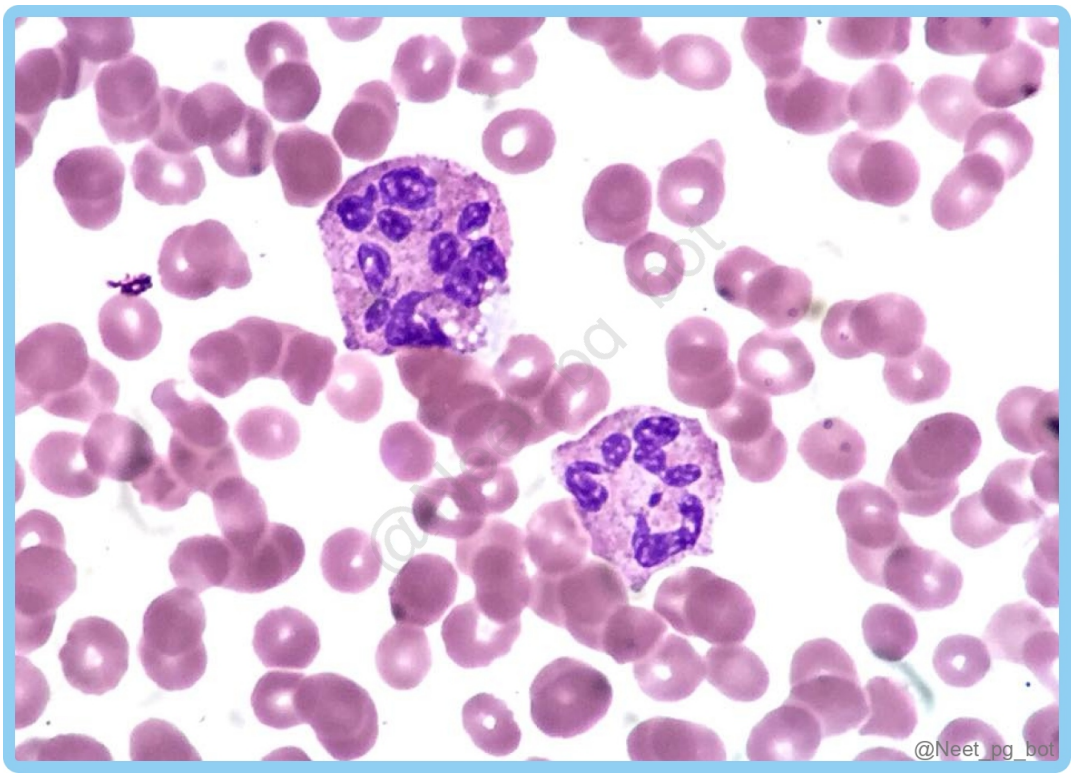
@Neet_pg_bot

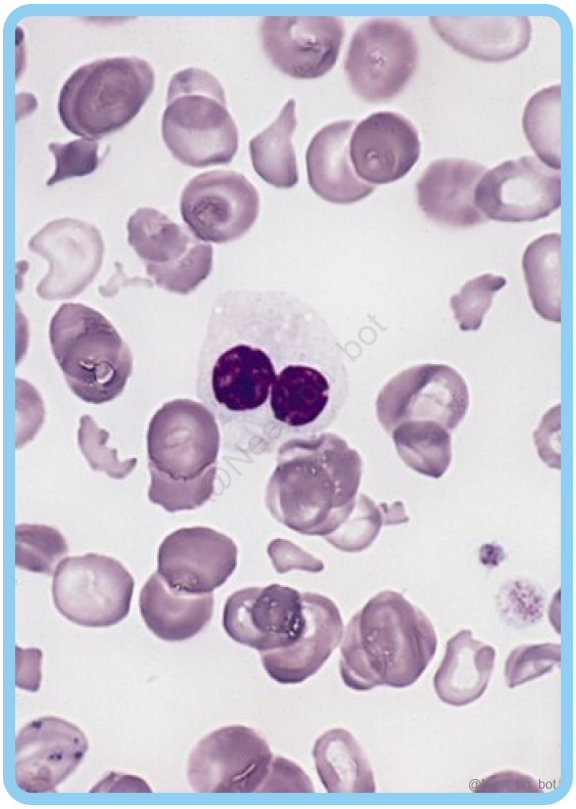

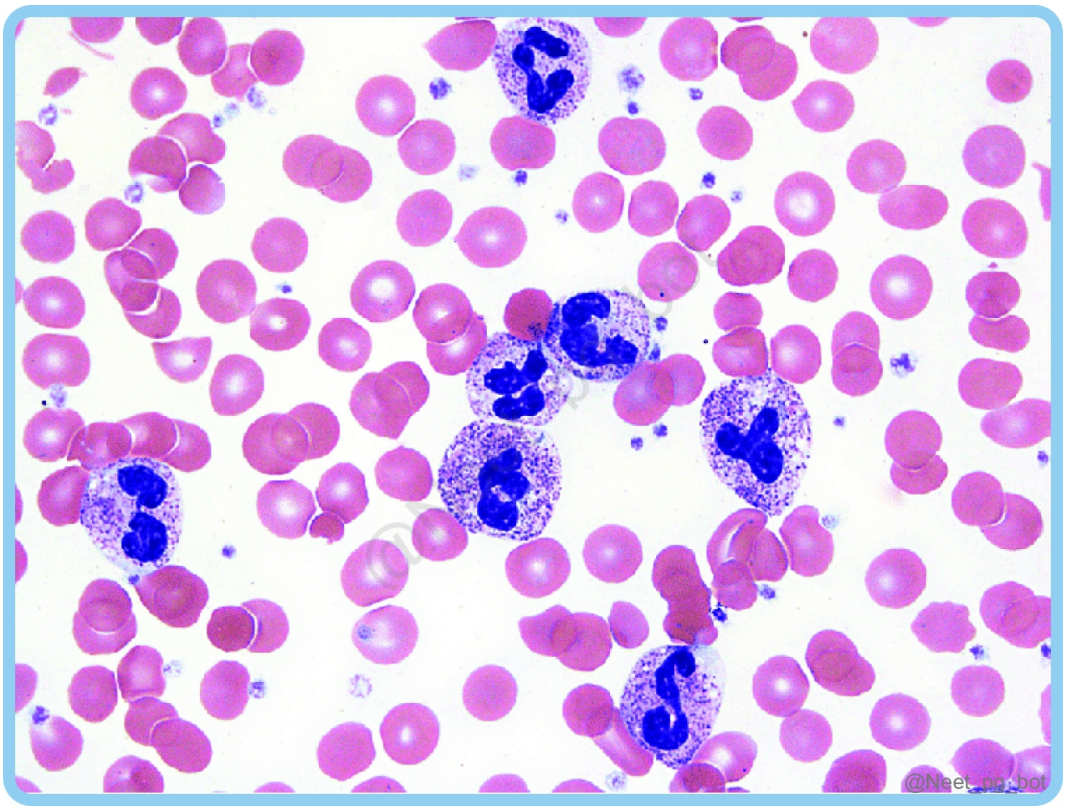

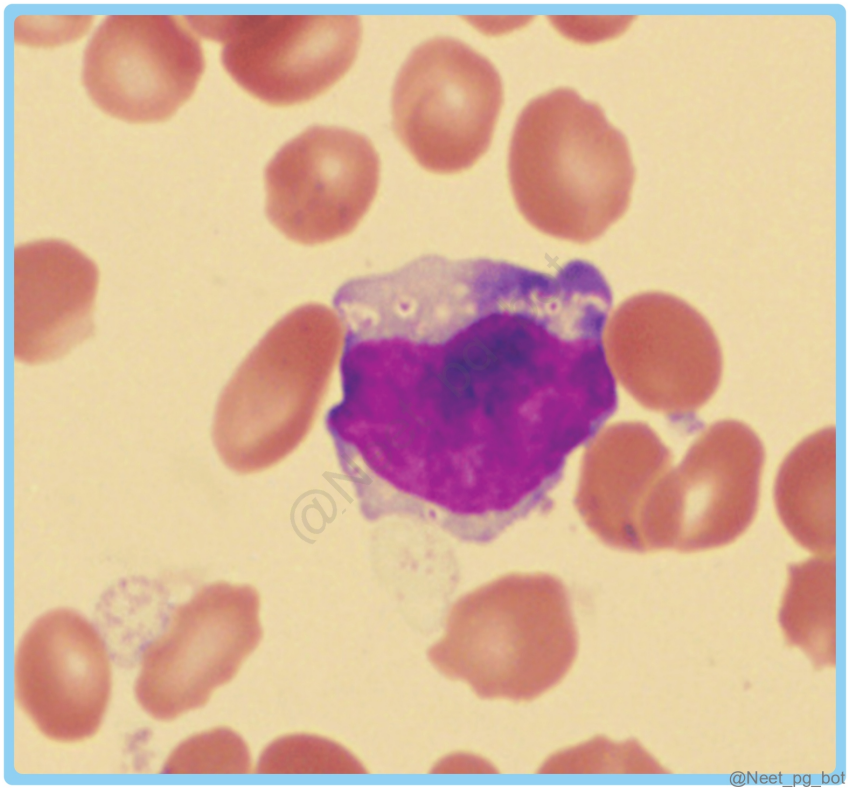

References:

Robbins and Cotran, Pathological Basis of Disease, 10th Edition, Page 688

pubmed.ncbi.nlm.nih.gov/27684937/

www.ncbi.nlm.nih.gov/pmc/articles/PMC3710559/

↑ *Back to this question in Part A*

@Neet_pg_bot

Q6: A 17-year-old boy presented with complaints of a sore throat, fever, and extreme fatigue for the past two weeks. On examination, he has enlarged cervical lymph nodes and an enlarged spleen. A complete blood count reveals lymphocytosis with atypical lymphocytes and is diagnosed as infectious mononucleosis. Which of the following statements is NOT correct? (Q845762)

A. Caused by Epstein-Barr Virus (EBV)

B. The Monospot test is a common diagnostic tool

C. Downey cells are characteristic histopathological features.

D. Also known as Haemophagocytic Lymphohistiocytosis.

Correct Answer: D. Also known as Haemophagocytic Lymphohistiocytosis.

■ *Listen (English)*

■ *Listen (Hindi)*

Explanation: Hemophagocytic lymphohistiocytosis (HLH) is a reactive condition marked by cytopenias and systemic inflammation due to macrophage activation. It is a Cytokine Storm syndrome. EBV-induced HLH occurs when the immune system (T-cells/NK cells) becomes hyper-activated but ineffective, causing macrophages to phagocytose blood elements (RBCs, WBCs, platelets). Epstein-Barr virus infection is a common trigger. Clinical features include acute febrile illness, splenomegaly, hepatomegaly, anaemia, thrombocytopenia, elevated ferritin and IL-2 receptor levels, and liver dysfunction. Types: Primary (Familial): Usually caused by genetic defects in cytotoxic T-cell/NK cell function (e.g., PRF1, UNC13D genes). Secondary (Acquired): Triggered by infections (most commonly EBV), malignancies, or rheumatological conditions. Diagnostic Criteria (HLH-2004): Requires 5 out of 8: Fever. Splenomegaly. Cytopenias (affecting ≥ 2 cell lines). Hypertriglyceridemia and/or hypofibrinogenemia. Hemophagocytosis in bone marrow, spleen, or lymph nodes. Low/absent NK-cell activity. Ferritin >500 µg/L. Soluble CD25 (sIL-2 receptor) >2400 U/mL. Infectious mononucleosis, primarily caused by Epstein-Barr Virus (Option A), presents with fever, sore throat, lymphadenopathy, and splenomegaly, predominantly affecting late adolescents and young adults. Diagnosis relies on lymphocytosis with atypical lymphocytes, known as Downey cells (Ballerina skirt appearance) (Option C), which are activated CD8 T lymphocytes responding to EBV-infected cells. Positive heterophile antibody reaction (Monospot test) (Option B) and rising specific antibodies for EBV antigens aid in diagnosis.



References:

Robbins and Cotran, Pathological Basis of Disease, 10th Edition, Page 358

↑ *Back to this question in Part A*

@Neet_pg_bot

Q7: A 58-year-old patient presents with fatigue, night sweats, and significant weight loss. Physical examination reveals generalized lymphadenopathy and splenomegaly. Blood tests show a markedly elevated white blood cell count. Based on the clinical scenario, which diagnosis is most likely if the bone marrow biopsy reveals over 20% blasts? (Q845763)

A. Chronic Lymphocytic Leukemia (CLL)

B. Acute Myeloid Leukemia (AML)

C. Hodgkin’s Lymphoma (HL)

D. Non-Hodgkin’s Lymphoma (NHL)

Correct Answer: B. Acute Myeloid Leukemia (AML)

■ *Listen (English)*

■ *Listen (Hindi)*

Explanation: Based on the clinical scenario and the bone marrow findings, the most likely diagnosis is Acute Myeloid Leukemia (AML). Blasts in the bone marrow are a pivotal factor in diagnosing different types of leukaemia. When the bone marrow contains over 20% blasts, it indicates acute leukaemia rather than a chronic condition. Acute Myeloid Leukemia (AML) is characterised by the rapid proliferation of abnormal myeloid blasts (Myeloblasts are identified by the presence of Auer rods), crowding out normal cells and leading to the symptoms observed. Chronic Lymphocytic Leukemia (CLL) (Option A): CLL typically presents with mature lymphocytes , not blasts, in the bone marrow, distinguishing it from AML. Histopathology reveals smudge cells. The elevated blast count seen in the bone marrow biopsy is not characteristic of CLL. Hodgkin's Lymphoma (Option C): HL is diagnosed via lymph node biopsy revealing Reed-Sternberg cells , not through a bone marrow biopsy showing high blast counts. The hallmark of HL is the presence of specific large abnormal lymphocytes, not blasts.HL primarily involves lymph nodes, with systemic symptoms such as night sweats and weight loss. Non-Hodgkin's Lymphoma (NHL) (Option D): The diagnosis of NHL involves malignant lymphoid cells in affected tissues, not an increased blast percentage in the bone marrow.

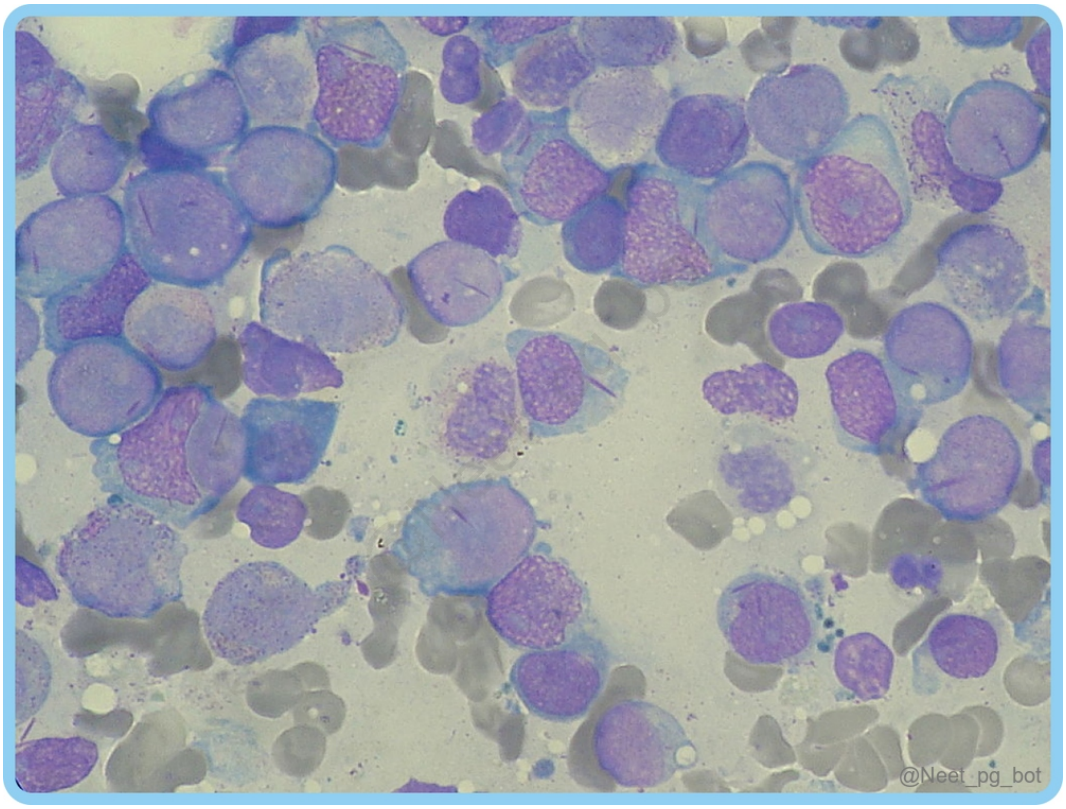

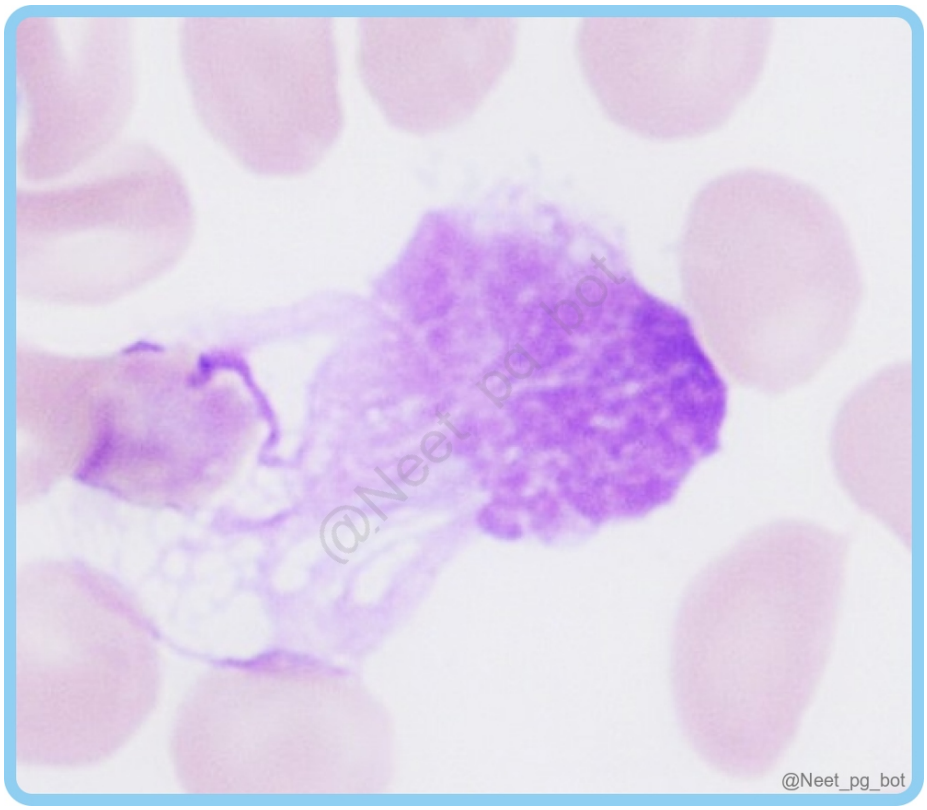
@Neet_pg_bot

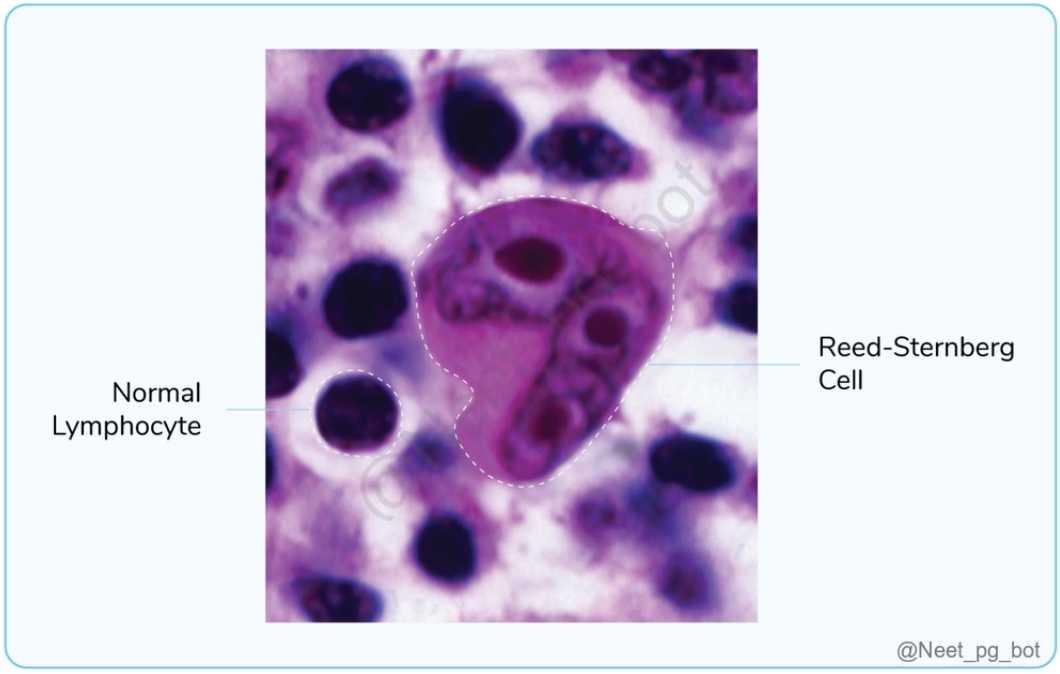
Normal
Lymphocyte
Reed-Sternberg
Cell
@Neet_pg_bot

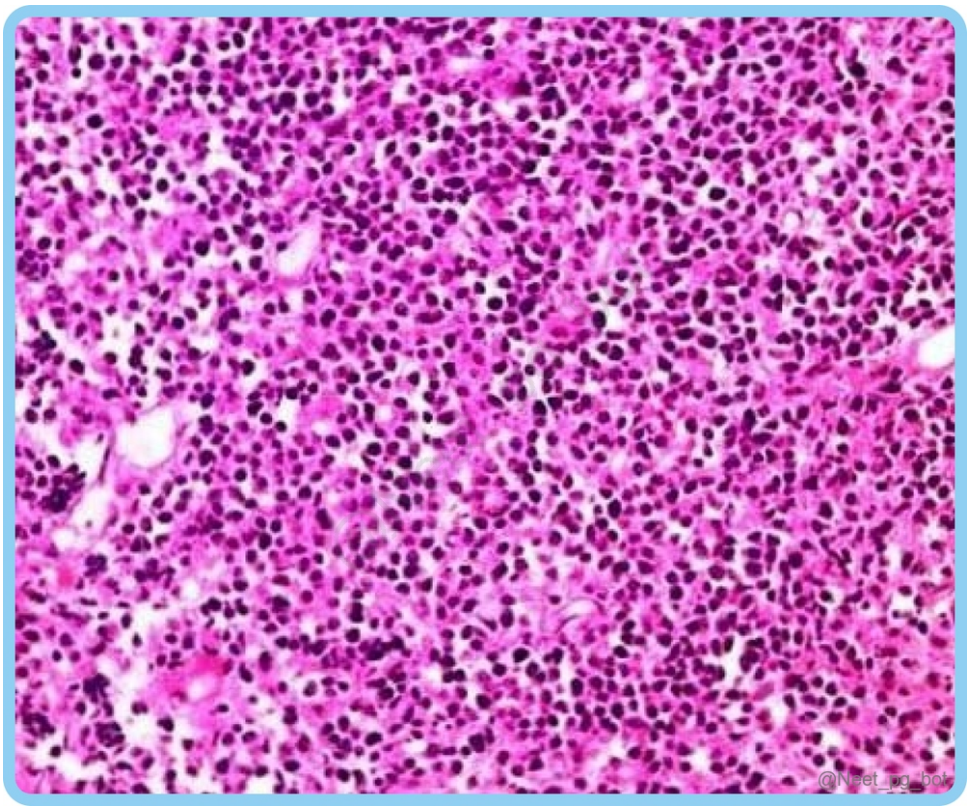

References:

Robbins and Cotran, Pathological Basis of Disease, 10th Edition, Page 617

↑ *Back to this question in Part A*

@Neet_pg_bot

Q8: A 45-year-old female is undergoing routine blood work. The laboratory technician uses different Vacutainers for various tests. Which Vacutainer colour is used for coagulation studies, such as PT and aPTT? (Q845764)

Correct Answer: Unknown

■ *Listen (English)*

■ *Listen (Hindi)*

Explanation: The light blue Vacutainer contains sodium citrate as an anticoagulant and is specifically used for coagulation studies, such as Prothrombin Time (PT) and Activated Partial Thromboplastin Time (aPTT) . The anticoagulant preserves the coagulation factors for accurate testing. Colour Anti-coagulants Uses Purple/Lavender (Option D) EDTA (Ca2+ chelating anticoagulant) CBC, Peripheral Smear, ESR Light Blue (Option B) Citrate (Ca2+ chelating anticoagulant) ESR, PT, aPTT Red (Option A) No anti-coagulant is added Serum studies (Proteins, enzymes, hormones) Yellow Clot activator/Gel separator Serum studies (Proteins, enzymes, hormones)

Grey Sodium Fluoride Blood Glucose Green (Option C) Heparin ABG, Osmotic fragility, flow cytometry, immunophenotyping

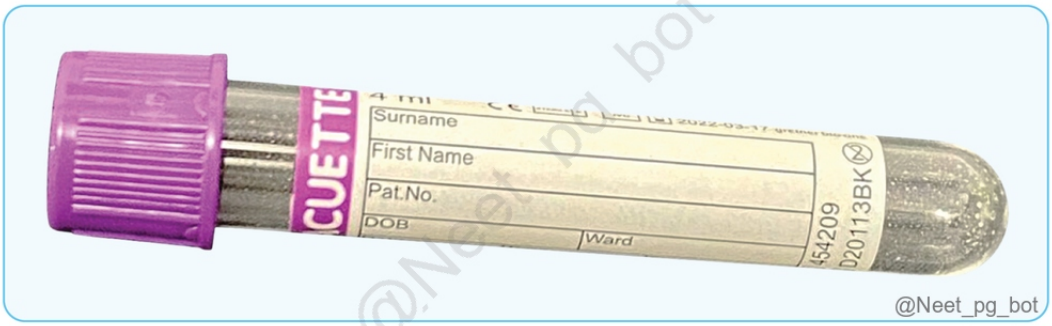




6 ml
Surname
First Name
Pat.No.
2013-07
56089
120101H


5 ml
Surname
First Name
Pat.No.
2022-02-12
greiner bio-one
018
103BM



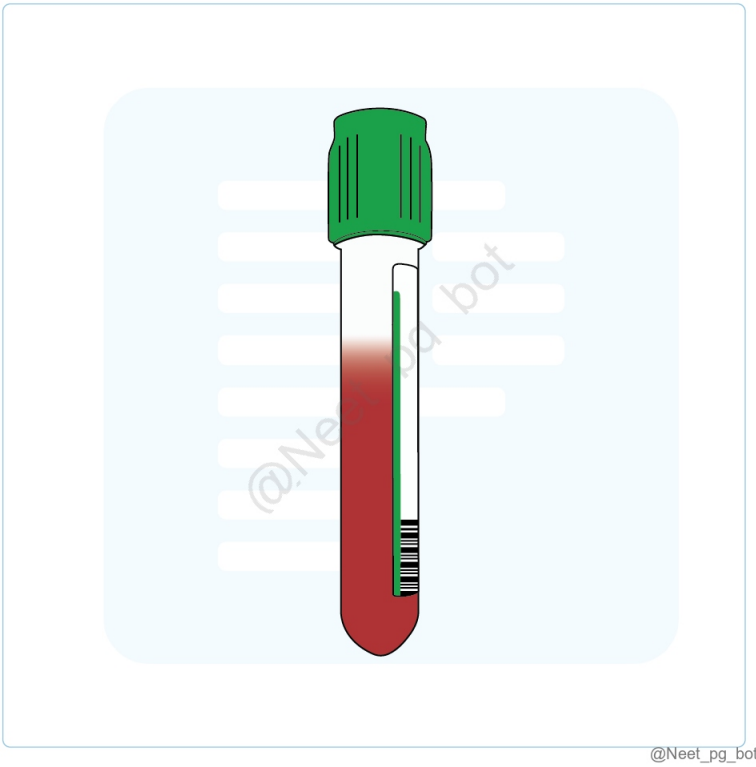

@Neet_pg_bot

References:

Atlas of Clinical Hematology, Chapter 1, Page 4

www.ncbi.nlm.nih.gov/books/NBK555991/

↑ *Back to this question in Part A*

@Neet_pg_bot

Q9: Which of the following diluting fluids correctly matches its specific use in haematology? (Q845767)

A. Turk's Solution - Platelets

B. Hayem's Solution - WBCs

C. Gower's Solution - RBCs

D. 1% Ammonium Oxalate - WBCs

Correct Answer: C. Gower's Solution - RBCs

Explanation: Gower's solution is specifically designed for the counting of RBCs. It provides a suitable environment for diluting blood samples while preserving the integrity and morphology of red blood cells. This solution ensures accurate counting of RBCs under a microscope without altering their appearance or function. Turk's Solution - Platelets (Option A): Turk's solution causes hemolysis of red blood cells and stains white blood cells for microscopic examination, not for platelet counting. Hayem's Solution - WBCs (Option B): Hayem’s solution is used for RBC counting rather than WBC due to its isotonicity preventing hemolysis, fixation, maintaining cell shape, and prevention of agglutination, with a longer shelf life. 1% Ammonium Oxalate - WBCs (Option D): Ammonium oxalate is used to prevent clotting in blood collection tubes and does not directly aid in white blood cell count in haematology.

References:

Atlas of Clinical Hematology, Chapter 3

↑ *Back to this question in Part A*

@Neet_pg_bot

• [18_Hematology_ White Blood Cells] 074 All And Aml

« Back to Folder Directory

[18_Hematology_ White Blood Cells] 074 All And Aml — Quick Jump

Q1 (p. 2892) *Q2 (p. 2892)* *Q3 (p. 2894)* *Q4 (p. 2895)* *Q5 (p. 2896)* *Q6 (p. 2897)*
Q7 (p. 2898) *Q8 (p. 2899)* *Q9 (p. 2900)* *Q10 (p. 2903)* *Q11 (p. 2904)* *Q12 (p. 2905)*
Q13 (p. 2906) *Q14 (p. 2907)*

Q1: As per FAB classification, what percentage of blast cells in bone marrow biopsy is required to diagnose a patient with acute leukaemia? (Q845765)

A. 10

B. 20

C. 25

D. 30

Correct Answer: D. 30

Explanation: According to the FAB classification , 30% of blast cells must be present in the bone marrow and peripheral smear to diagnose acute leukaemia. Classification for diagnosis of acute lymphoblastic leukaemia: WHO classification FAB (French-American-British) classification Basis of classification It incorporates genetics, immunophenotypic, and morphological features. It is primarily based on morphology and cytochemistry Subtypes B-cell ALL, NOS (not otherwise specified). B-cell ALL with recurrent genetic abnormalities. T-cell ALL. ALL-L1- small uniform cells ALL-L2- large cells with irregular nuclei ALL-L3- large cells with regular nuclei Clinical utility Used for diagnosis, treatment, and prognostication. Less commonly used in clinical practice and more historical. Diagnosis threshold >20% blasts in the bone marrow. >30% blasts in the bone marrow.

References:

WHO Classification of Tumors of Haematopoietic and Lymphoid Tissues 2017, Page 77

↑ *Back to this question in Part A*

@Neet_pg_bot

Q2: Which is not included in the FAB classification of acute lymphoblastic leukaemia (ALL) L3 subtype? (Q845766)

A. Presence of lymphoblasts with vacuoles and cytoplasmic blebs

B. Expression of surface immunoglobulins

C. Association with Epstein-Barr virus (EBV)

D. t(9;22) Philadelphia chromosome

Correct Answer: B. Expression of surface immunoglobulins

■ *Listen (English)*

■ *Listen (Hindi)*

Explanation: Unlike Burkitt lymphoma cells, which typically express surface immunoglobulins, the lymphoblasts in ALL L3 subtype do not express surface immunoglobulins. Instead, they express other markers, such as CD10 and CD19. Immunoglobulin and Monoclonality are fetures of B-ceels and Plasma cells seen in Multiple myeloma. ALL-L3 is similar to Burkitt's lymphoma. The image below shows the FAB types of ALL. Presence of lymphoblasts with vacuoles and cytoplasmic blebs (Option A): The presence of lymphoblasts with vacuoles and cytoplasmic blebs is a characteristic feature of L3 subtype ALL. Association with Epstein-Barr virus (Option C): Burkitt lymphoma is strongly associated with Epstein-Barr Virus (EBV) infection. However, while EBV infection may be present in some ALL cases, it is not a defining characteristic of the ALL L3 subtype. t(9;22) Philadelphia chromosome (Option D): The Philadelphia chromosome, resulting from the translocation t(9;22), is associated with a different subtype of ALL (Philadelphia chromosome-positive ALL, or Ph+ ALL) rather than the L3 subtype. Ph+ ALL is characterised by the BCR-ABL1 fusion gene. If weight of BCR-ABL1 fusion gene protein is 190 kDa: ALL If weight of BCR-ABL1 fusion gene protein is 210 kDa: CML FAB classification of ALL: L1 L2 L3 Occurrence More common - Less common Morphology Small homogenous blasts Large heterogenous blasts Large homogenous blasts Cytoplasm Scant blue Moderately weak basophilic Abundant basophilic with prominent vacuoles Nucleus Regular Irregular nuclear outlines - Nucleoli Small & indistinct Prominent - Chromatin Coarse & dark purple Pink - Prognosis Best - Poor

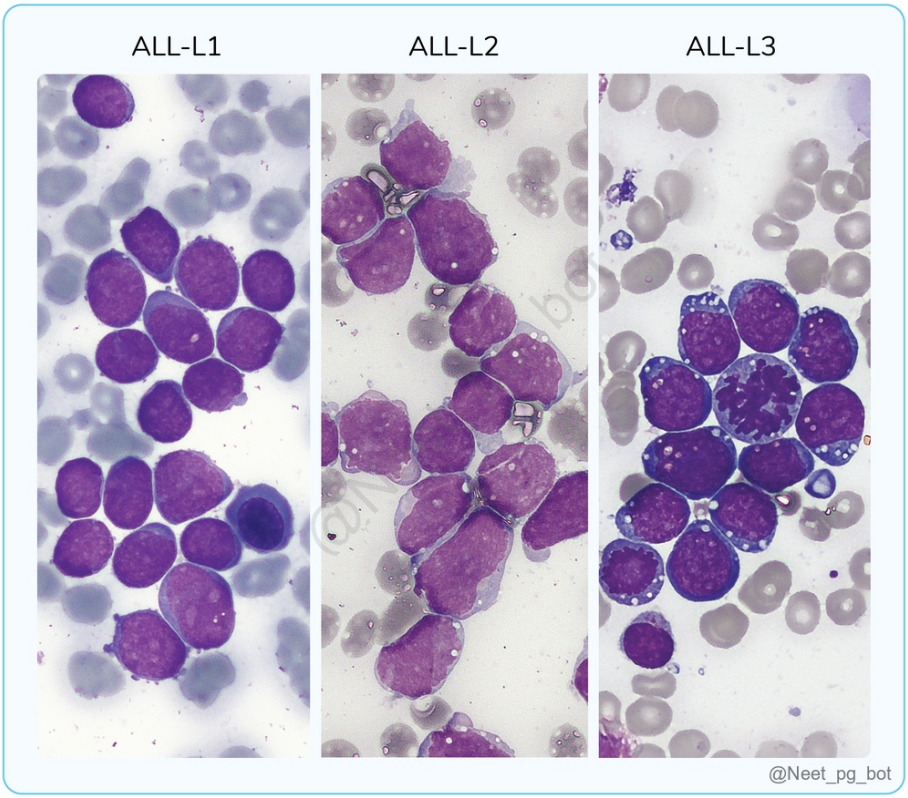

References:

www.ncbi.nlm.nih.gov/pmc/articles/PMC4235437/

↑ *Back to this question in Part A*

@Neet_pg_bot

Q3: Which of the following is not associated with acute lymphoblastic leukaemia (ALL) regarding chromosomes? (Q845768)

A. t(9;22)

B. t(12;21)

C. t(1;19)

D. t(15;17)

Correct Answer: D. t(15;17)

■ *Listen (English)*

■ *Listen (Hindi)*

Explanation: t(15;17) translocation is not associated with ALL; rather, it is seen in acute promyelocytic leukaemia (APML) , a type of acute myeloid leukaemia , where t(15;17) translocation leads to the formation of a PML-RAR■ fusion protein (Option D) . Genetic abnormalities associated with ALL: Most common genetic abnormality seen in ALLs is Hyperdiploidy. B-cell ALL with recurrent cytogenetic abnormalities: t(12;21): ETV6-RUNX1 (Option B ruled out) . t(5,11) (KMT2A-MLL). t(9;22): BCR-ABL1 (Option A ruled out) . It produces a 190 kDa fusion protein. t(5;14): IgH-IL3. B-cell ALL with hyperdiploidy. B-cell ALL with hypodiploidy. B-cell ALL t(1;19): TCF3-PBX1. (Option C ruled out) . T-cell ALL: NOTCH1 mutations are most common (50-70% of the cases).

References:

Robbins & Cotran Pathologic Basis of Disease, 10th Edition, Pages 594, 595

WHO Classification of Tumours of Lymphoid and Hematopoietic Tissues, 4th Edition, Volume 2, Pages 203-208.

↑ *Back to this question in Part A*

@Neet_pg_bot

Q4: A 4-year-old male presents with fever, bleeding gums, and fatigue for 5 days. CBC shows Hb of 8g%, TLC 30,000/µL, and platelet count of 40,000/µL. A differential count shows an increased number of immature white blood cells. A bone marrow aspiration is done, as shown below. What is the most likely diagnosis? (Q845769)

A. Chronic myeloid leukaemia.

B. Acute lymphoblastic leukaemia.

C. Acute promyelocytic leukaemia.

D. Aplastic anaemia

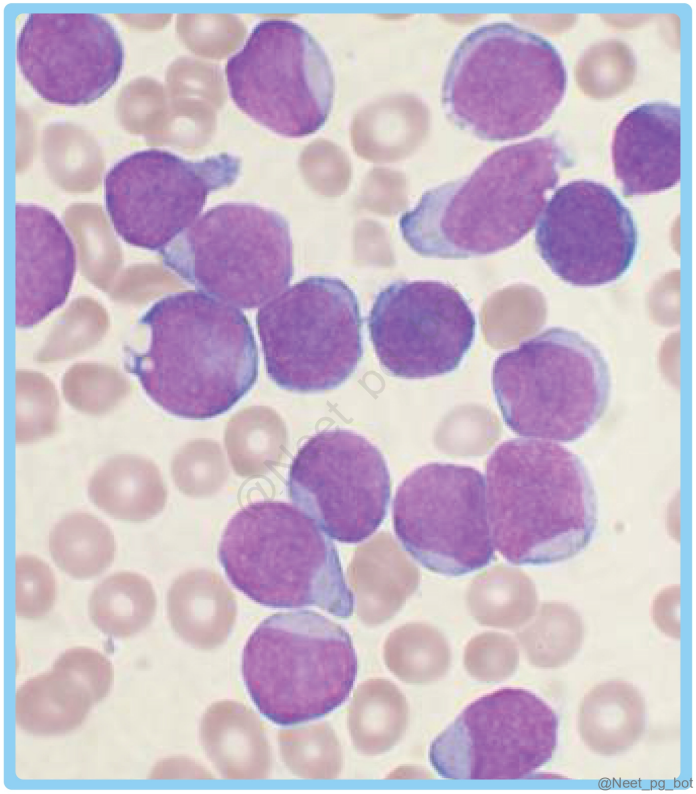

Correct Answer: B. Acute lymphoblastic leukaemia.

■ *Listen (English)*

■ *Listen (Hindi)*

Explanation: The clinical presentation of fatigue , fever , and bleeding gums , along with anaemia , thrombocytopenia , leukocytosis with a high proportion of immature white blood cells , and bone marrow aspirate showing lymphoblasts is indicative of acute lymphoblastic leukaemia (ALL) . Acute lymphoblastic leukaemia: It is the most common cancer among children. Symptoms Due to decline in normal marrow function. Fatigue - anaemia. Infections - neutropenia. Bleeding - thrombocytopenia Mass effects Bone pain. Generalised lymphadenopathy. Hepatosplenomegaly. Testicular enlargement. Mediastinal mass in T-ALL (Superior mediastinal syndrome). CNS manifestations Headache. Vomiting. Nerve palsies. Morphology : Hypercellular bone marrow. Lymphoblasts show characteristic Hand-mirror morphology where the cytoplasm extends out like the handle of a hand-mirror.

References:

Robbins and Cotran, Pathologic Basis of Disease, 10th Edition, Pages 594-596.

↑ *Back to this question in Part A*

@Neet_pg_bot

Q5: Which of the following markers will be negative on immunophenotyping of a patient with early pre-B acute leukaemia? (Q845770)

A. TdT

B. DR

C. CD19

D. CD10

Correct Answer: D. CD10

Explanation: CD10 is negative in early pre-B acute leukaemia. Immunophenotyping of Acute Lymphocytic Leukemia (ALL): Type of ALL Immunophenotype Early Pre-B ALL TdT, DR, CD19, CD24 Pre-B ALL TdT, DR, CD10, CD19, CD20, CD24, Cy Ig Common ALL CD19+, CD10+/CALLA+ Mature B ALL DR, CD19 CD20, CD24, Surface Ig Pro-T ALL CD3, CD7 Pre-T ALL TdT, CD2, CD3, CD4, CD5, CD7, CD8, CD34 Mature T ALL CD2, CD7, TdT

References:

Robbins & Cotran Pathologic Basis of Disease, 10th Edition, Pages 593, 596.

↑ *Back to this question in Part A*

@Neet_pg_bot

Q6: Which of the following statements is incorrect regarding the prognosis of ALL? Adults have a worse prognosis as compared to children aged 2-9 years. White females have a good survival rate as compared to black males. The Philadelphia chromosome (t(9;22)) is associated with a favourable prognosis. Higher white blood cell counts at diagnosis are associated with a better prognosis. Hypodiploidy in B-ALL is associated with a better prognosis. (Q845771)

A. 3, 4 and 5

B. 2, 3 and 4

C. 1, 4 and 5

D. 4 and 5

Correct Answer: A. 3, 4 and 5

■ *Listen (English)*

■ *Listen (Hindi)*

Explanation: Prognostic factors associated with ALL: Determinants Favourable Unfavourable WBC/µL <10,000 >1,00,000 (Statement D) Age 2-9 years <1 year, >10 years (Statement A) Gender Female Male Ethnicity White (Statement B) Black Lymph node, liver, spleen enlargement Absent Present Testicular enlargement Absent Present CNS involvement Absent Present FAB morphologic features L1, early pre-B cell ALL L3, Pre-B cell & mature B-cell ALL Ploidy Hyperdiploidy (Most common) Hypodiploidy (Statement E) Cytogenetic markers Trisomy 4, 10, 17, t(12;21) t(9;22), t(4;11) (Statement C) Remission states <14 days >14 days

References:

Robbins and Cotran Pathologic Basis of Disease, 10th Edition, Pages 594-596

Wintrobe's Clinical Haematology, 13th Edition, Page 1561

↑ *Back to this question in Part A*

@Neet_pg_bot

Q7: A 9-year-old boy presents with fever, fatigue, and worsening shortness of breath. On examination, he has a large anterior mediastinal mass causing respiratory distress . Laboratory findings shows leukocytosis and blasts on peripheral smear. Flow cytometry of blasts reveals the positivity for CD3, CD5, CD7 along with variable expression of CD10. What is the most likely diagnosis? (Q845772)

A. Acute Myeloid Leukemia (AML)

B. T cell Acute Lymphoblastic Leukemia

C. B cell Acute Lymphoblastic Leukemia

D. Chronic Lymphocytic Leukemia (CLL)

Correct Answer: B. T cell Acute Lymphoblastic Leukemia

■ *Listen (English)*

■ *Listen (Hindi)*

Explanation: T cells mature in thymus located in anterior mediastinum This young boy with mass in anterior mediastinum is classic for T-cell acute lymphocytic leukaemia (ALL). CD3 - definitive pan T cell marker, CD5,7 - T cell marker, CD10- may be expressed in early T-cell precursors Important features of different types of leukaemia: ALL AML (Option A) CML (Option D) B cell -ALL (Option C) T cell -ALL (Option B) Most common Less common (15%) M2 (M/C) - Age Children Teenagers Adults (15-40 years) Middle-Elderly Mutation Loss of function PAX5, E2A, EBF Gain of function NOTCH1 t(15:17) in M3, t (8:21) in M2 t(9:22) BCR-ABL fusion gene. Prognosis Good Poor Good Good Organ Involvement No tissue involvement T-ALL shows tissue infiltration: CNS Mediastinum Testes Bone pain Hepatosplenomegaly, gum hyperplasia, chloroma Massive splenomegaly, hepatomegaly Stain PAS+ Acid Phosphatase MPO+, NSE + Decreased NAP/LAP score Markers

CD 19,20,21 CD 1,2, 3 , 5 ,7, 10 (CALLA antigen) CD 13, 33, and 117 CD 25

References:

Robbins and Cotran, Pathologic Basis of Disease, 10th Edition, Pages 594-597

↑ *Back to this question in Part A*

@Neet_pg_bot

Q8: Which of the following statements regarding the M4 subtype of AML based on FAB classification is true? (Q845773)

A. It is associated with t(8:21), called AML with maturation.

B. It is associated with t(15:17), called acute promyelocytic leukaemia

C. It is associated with CBF-MYH fusion, called acute myelomonocytic leukaemia

D. It is associated with MPO positivity, called AML without maturation.

Correct Answer: C. It is associated with CBF-MYH fusion, called acute myelomonocytic leukaemia

■ *Listen (English)*

■ *Listen (Hindi)*

Explanation: Acute myelocytic leukemia (M4) type, also called acute myelomonocytic leukaemia, is associated with the CBF-MYH fusion gene. FAB classification of AML Subtype Name Features AML-M0 AML undifferentiated MPO negative AML-M1 AML without maturation (Option D) MPO + AML-M2 AML with maturation (Option A) Most common t(8:21) RUNX1-RUNX1T1 fusion Associated with chloroma. AML-M3 Acute promyelocytic leukaemia (Option B) t(15:17) - PML-RAR■ fusion Blocks promyelocyte → myelocyte transformation Bone marrow: Auer rods form criss-cross called faggot cell Can cause DIC PAS+ AML-M4 Acute myelomonocytic leukaemia (Option C) Associated with inversion 16 chromosome and CBF-MYH fusion gene (CBF = Core binding factor) Gums - gum hypertrophy Skin - leukaemia cutis MPO+, NSE + AML-M5 Acute monocytic leukaemia Gums - gum hypertrophy Skin - leukaemia cutis MPO-, NSE + AML-M6 Acute erythroid leukaemia Also called DI Guglielmo Disease Diffuse PAS+, CD71 AML-M7 Acute megakaryocytic leukaemia Bone Marrow aspiration gives a dry tap PAS+, CD41 and CD61

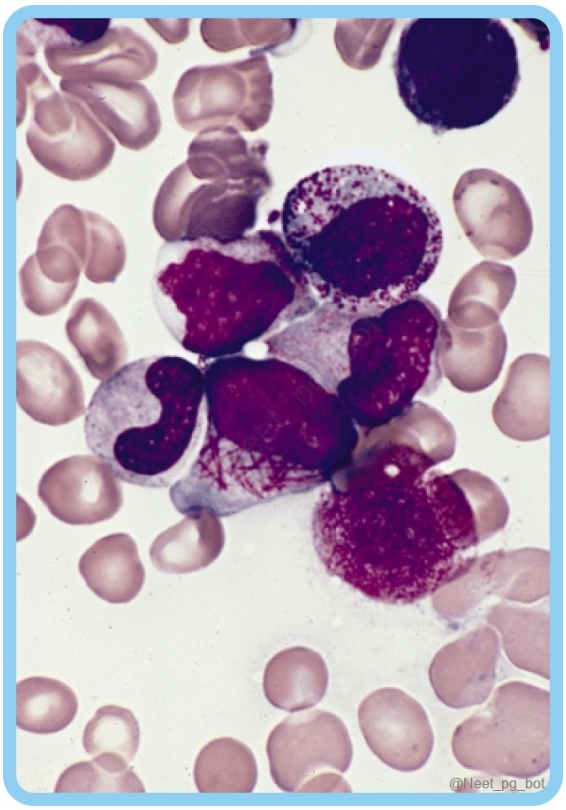

References:

Robbins and Cotran, Pathologic Basis of Disease, 10th Edition, Pages 617-620

↑ *Back to this question in Part A*

@Neet_pg_bot

Q9: A 12-year-old boy presents with fatigue, bruising, and intermittent fevers for the past few weeks. Physical examination reveals the following findings. Immunophenotyping of the biopsy specimen shows CD43 and MPO positivity. What is the most likely diagnosis? (Q845774)

A. Acute Lymphoblastic Leukemia (ALL)

B. AML with maturation

C. Acute promyelocytic leukaemia

D. Non-Hodgkin Lymphoma

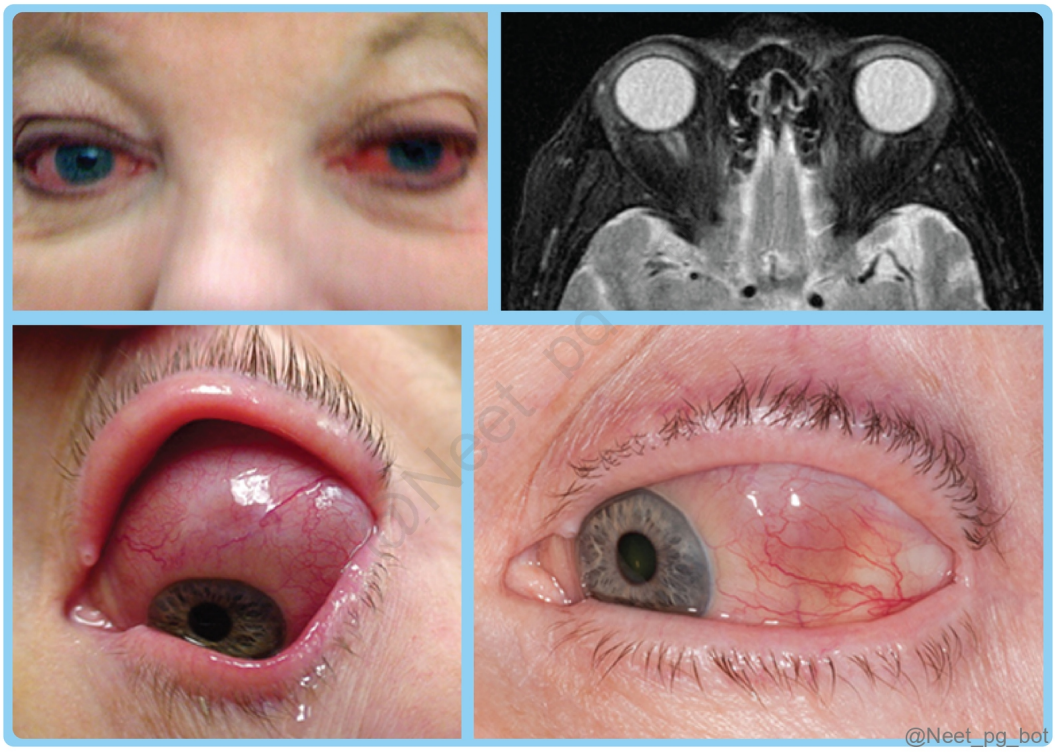

Correct Answer: B. AML with maturation

- *Listen (English)*
- *Listen (Hindi)*

Explanation: This young child with nonspecific systemic symptoms, MPO positivity, and an image showing orbital swelling and proptosis suggests chloroma associated with AML with maturation (AML-M2). Chloroma : A.k.a Myeloblastoma/Granulocytic Sarcoma. It is not a benign tumour, but it has a greenish colour. Site: Soft tissue involvement in orbit leads to proptosis. Associated with AML M2 and M5 . Peripheral smear findings: Myeloblasts . Arbiskov cells: Atypical monocytes/macrophages. Markers: MPO (green colour), CD 43, CD 45 and Lysozyme .

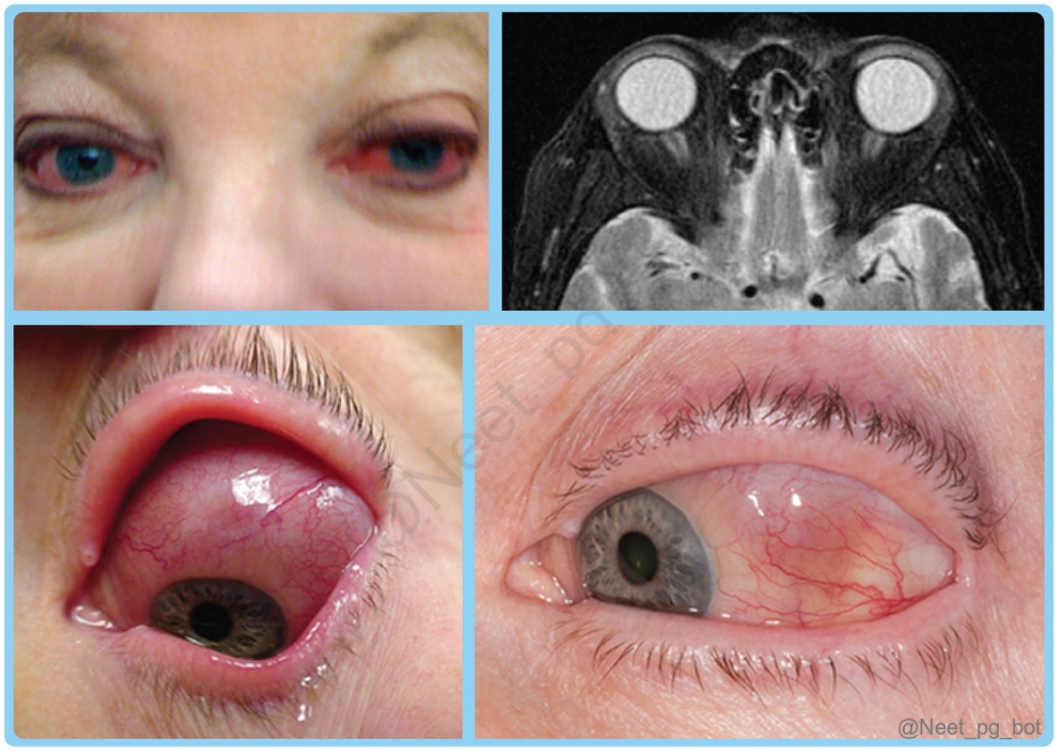

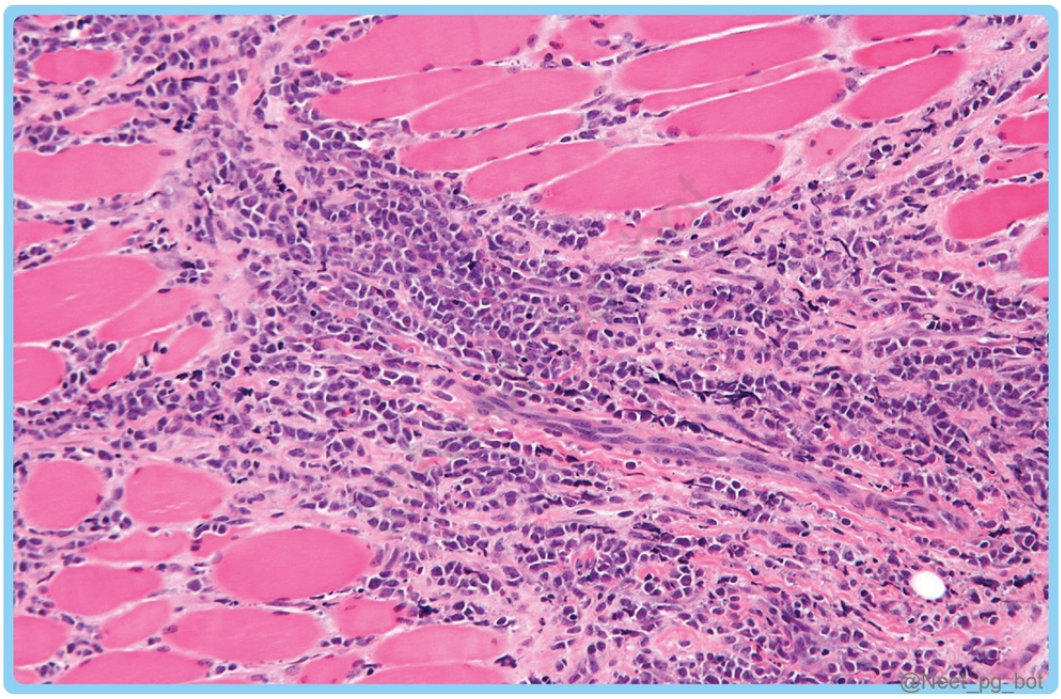

References:

Robbins and Cotran Pathologic Basis of Disease, 10th Edition, Pages 618-620

↑ *Back to this question in Part A*

@Neet_pg_bot

Q10: A 28-year-old female was admitted to the hospital with complaints of frequent nosebleeds, reports of sudden onset chest pain and dyspnea. On examination, she has petechiae and ecchymoses on her skin. Laboratory tests revealed WBC 15,000/µL, haemoglobin 8 g/dL, platelets 20,000/µL and elevated prothrombin time. A peripheral blood smear shows the following findings. Further testing confirms which of the following associated conditions? (Q845775)

A. t(12:21) translocation

B. t(15:17) translocation

C. t(9:22) translocation

D. t(8:21) translocation

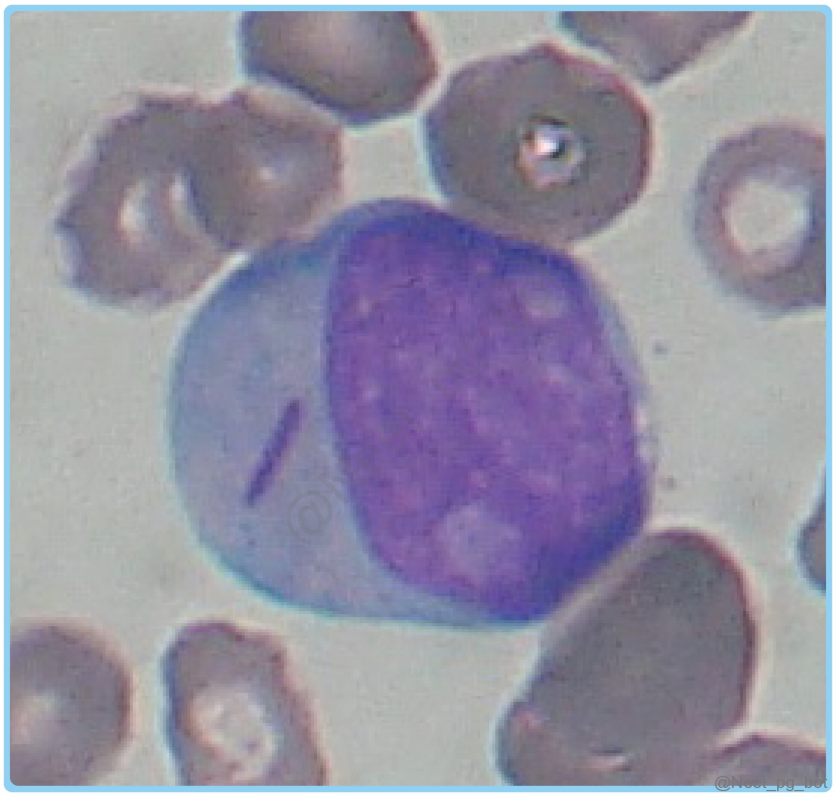

Correct Answer: B. t(15:17) translocation

■ *Listen (English)*

■ *Listen (Hindi)*

Explanation: This patient's history of sudden onset symptoms with pancytopenia, high prothrombin time, and Auer-rods on blood smear suggests disseminated intravascular coagulation secondary to acute promyelocytic leukaemia (AML M3) associated with t(15:17) translocation . A key morphological feature is the presence of faggot cells , which are promyelocytes containing bundles of Auer rods . Genetics of M3 AML/ Acute promyelocytic leukemia: t(15:17) translocation causes PML-RARA (retinoic acid receptor alpha) fusion protein formation. Blocks promyelocyte → myelocyte maturation. Accumulation of abnormal promyelocytes with procoagulant granules. These granules trigger DIC , which is the most common cause of early mortality Diagnosis of choice: FISH Management ATRA (All-trans retinoic acid): Drug of choice; start immediately (even before confirmation) Induces differentiation of promyelocytes → reverses coagulopathy Arsenic Trioxide: Used with ATRA Promotes apoptosis of leukemic cells Improves survival significantly t(12:21) translocation (Option A) is seen in ALL and has a good prognosis. They are negative for auer rods. t(9:22) translocation (Option C): Philadelphia chromosome associated with CML and ALL (worse prognosis). ALL (Acute Lymphoblastic Leukemia) : t(9;22) results in a BCR-ABL fusion protein of 190 kDa CML (Chronic Myeloid Leukemia) : t(9;22) results in a BCR-ABL fusion protein of 210 kDa . CNL (Chronic Neutrophilic Leukemia) : t(9;22) results in a BCR-ABL fusion protein of 230 kDa t(8:21) translocation (Option D): t(8:21) translocation is seen in the M2 subtype of AML (most common).

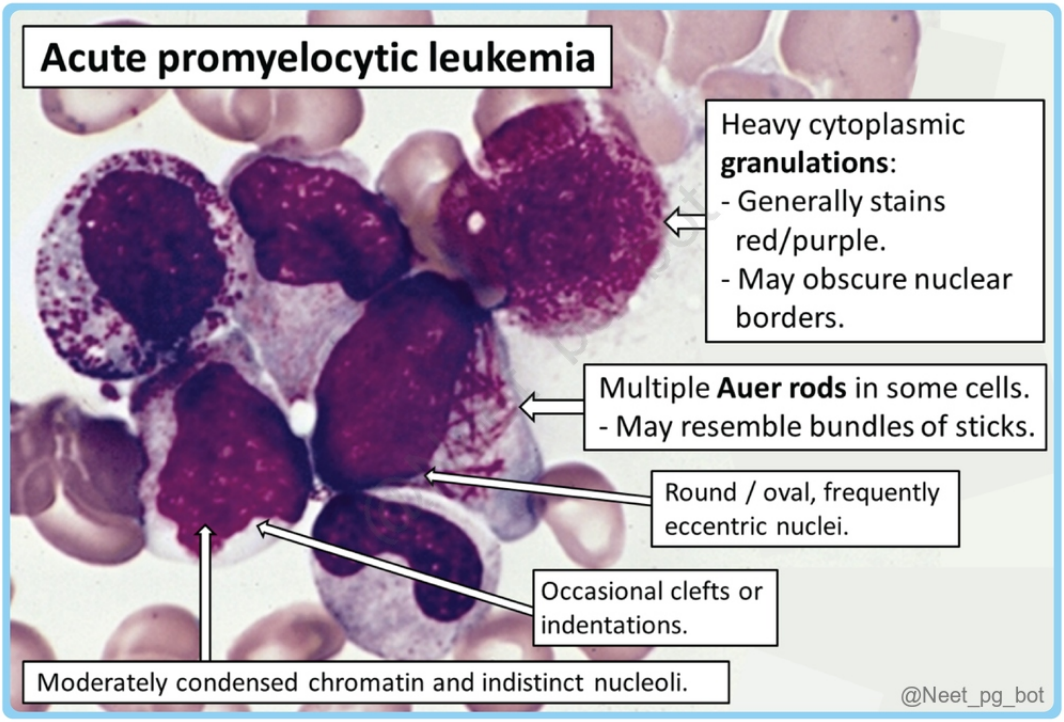

References:

Robbins and Cotran Pathologic Basis of Disease, 10th Edition, Pages 617-620

↑ *Back to this question in Part A*

@Neet_pg_bot

Q11: Which of the following types of AML, according to the FAB classification, is associated with Down's syndrome? (Q845776)

A. Acute erythroid leukaemia

B. Acute myelomonocytic leukaemia

C. Acute megakaryocytic leukaemia

D. Acute monocytic leukaemia

Correct Answer: C. Acute megakaryocytic leukaemia

■ *Listen (English)*

■ *Listen (Hindi)*

Explanation: Acute megakaryoblastic leukaemia (AML M7) is notably associated with Down's syndrome. Down's syndrome associated disorders: Overall most common leukemia associated with Down's syndrome is ALL . In less than 3 years old child, most common leukemia associated with Down's syndrome is AML-M7 . Most common haematological abnormality associated with Down's syndrome is TAM (Transient Abnormal Myelopoiesis) Transient: Lasts for only a few months Abnormal Myelopoiesis: Some abnormal WBC lineage cells are found circulating in bone marrow and peripheral blood. Reduced incidence of: Breast cancer Lung cancer Prostate cancer Neuroblastoma Medulloblastoma

References:

Robbins and Cotran Pathologic Basis of Disease, 10th Edition, Page 618

↑ *Back to this question in Part A*

@Neet_pg_bot

Q12: Which of the following is associated with a good prognosis according to WHO classification of AML? (Q845777)

A. AML: Therapy-related

B. AML with MDS-like features

C. AML with recurrent genetic abnormality

D. AML not otherwise specified

Correct Answer: C. AML with recurrent genetic abnormality

■ *Listen (English)*

■ *Listen (Hindi)*

Explanation: AML defined by specific genetic abnormalities are associated with a good prognosis due to the presence of targetable mutations and the availability of specific therapies, such as ATRA for APL. AML having good prognosis: t(8;21): AMLM2 t(15;17): AMLM3 inv(16): AMLM4 WHO Classification of AML: AML with Recurrent Genetic Abnormalities (good prognosis): t(8;21)(q22;q22.1); RUNX1-RUNX1T1 inv(16) (CBFB-MYH11) t(15;17)(q24.1;q21.1); PML-RARA. t(1;22) AML with Myelodysplasia-Related Changes (bad prognosis) Therapy-Related Myeloid Neoplasms (bad prognosis) AML, Not Otherwise Specified (NOS) (bad prognosis) AML with minimal differentiation AML without maturation AML with myelocytic maturation AML with myelomonocytic maturation. AML with monocytic maturation. AML with erythroid maturation. AML with megakaryocytic maturation. AML associated with Down's syndrome - AMLM7.

References:

Robbins and Cotran Pathologic Basis of Disease, 10th Edition, Page 617

↑ *Back to this question in Part A*

@Neet_pg_bot

Q13: What is the most likely immunophenotype associated with the condition indicated by the peripheral blood smear shown below? (Q845778)

A. CD13+, CD33+, CD34+, HLA-DR+

B. CD19+, CD20-, CD22+, CD79a-

C. CD3+, CD4+, CD8+, CD5-

D. CD10+, CD19+, CD20+, CD22-

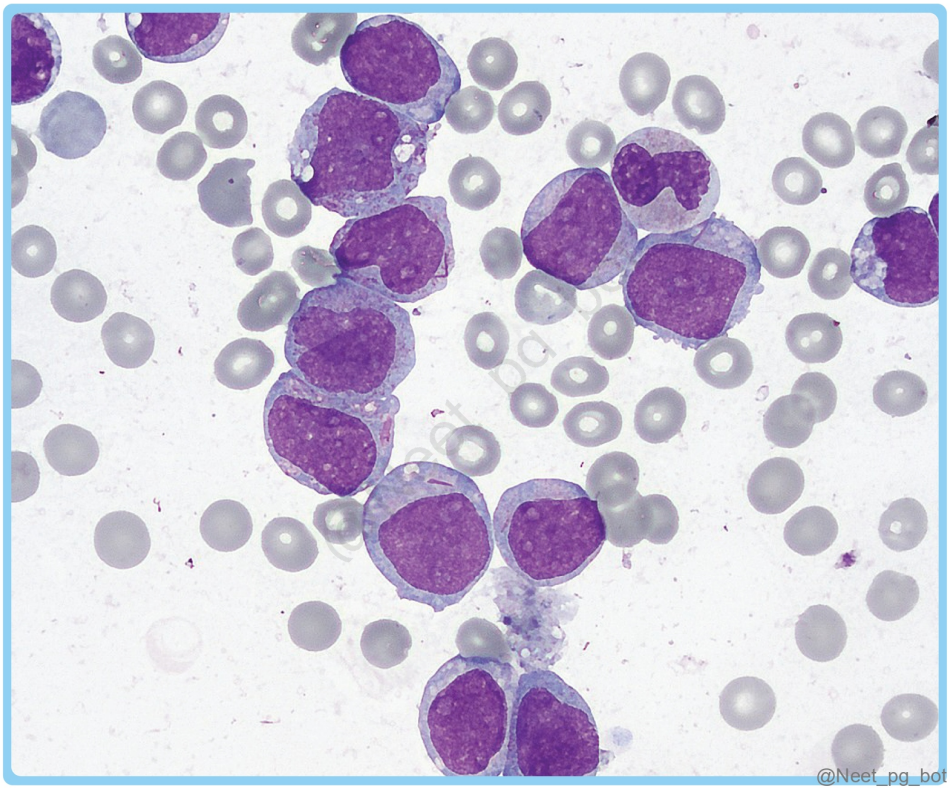

Correct Answer: A. CD13+, CD33+, CD34+, HLA-DR+

■ *Listen (English)*

■ *Listen (Hindi)*

Explanation: The peripheral smear shows myeloblasts (large, irregularly shaped cells with prominent nuclei and moderately granular cytoplasm), and needle-like inclusions in the cytoplasm of blasts (Auer rods) , suggesting acute myeloid leukaemia (AML). The immunophenotype associated with AML is CD13+, CD33+, CD34+, and HLA-DR+. AML is characterised by the presence of myeloid lineage markers. Myeloid lineage markers: Myeloperoxidase, CD13 , and CD33 . TdT, HLA-DR , and CD34 are expressed on AML blasts.. CD19+, CD20-, CD22+, CD79a- (Option B): Suggestive of B-cell ALL. CD3+, CD4+, CD8+, CD5- (Option C): Suggestive of T-cell ALL. CD10+, CD19+, CD20+, CD22- (Option D): Suggestive of B-cell Chronic Lymphocytic Leukemia (B-CLL).

References:

Robbins and Cotran Pathologic Basis of Disease, 10th Edition, Pages 593-619

↑ *Back to this question in Part A*

@Neet_pg_bot

Q14: A 55-year-old female presented with fatigue, easy bruising, and recurrent infections over the past few months. On examination, there is mild splenomegaly, but

no lymphadenopathy is noted. Laboratory tests reveal pancytopenia. A peripheral blood smear shows normocytic normochromic red blood cells and bone marrow shows blast count >20%. What is the most likely diagnosis? (Q845779)

A. Aplastic anemia

B. Myelodysplasia

C. Aleukemic leukaemia

D. Myeloproliferative disorder

Correct Answer: C. Aleukemic leukaemia

Explanation: The patient shows pancytopenia, fatigue, bruising, and infections with no lymphadenopathy, mild splenomegaly, >20% blast count in bone marrow, indicating aleukemic leukemia. Aplastic anemia (Option A): Aplastic anemia causes pancytopenia from bone marrow failure with no splenomegaly. Myelodysplasia (Option B): Myelodysplastic syndrome (MDS) has <20% blasts by definition Myeloproliferative disorder (Option D): Myeloproliferative disorders (MPDs) typically has features of elevated blood counts, only late spent phase causes cytopenias with <20% blast counts

References:

www.ncbi.nlm.nih.gov/pmc/articles/PMC7233898/

↑ *Back to this question in Part A*

@Neet_pg_bot

• [18_Hematology_ White Blood Cells] 075 Myeloid Disorders

« Back to Folder Directory

[18_Hematology_ White Blood Cells] 075 Myeloid Disorders — Quick Jump

Q1 (p. 2909) *Q2 (p. 2910)* *Q3 (p. 2911)* *Q4 (p. 2912)* *Q5 (p. 2914)* *Q6 (p. 2915)*
Q7 (p. 2919) *Q8 (p. 2921)* *Q9 (p. 2922)* *Q10 (p. 2923)* *Q11 (p. 2924)* *Q12 (p. 2925)*
Q13 (p. 2926) *Q14 (p. 2926)*

Q1: A 45-year-old female presents with complaints of occasional headaches and blurred vision. Laboratory tests reveal isolated thrombocytosis without significant leukocytosis or erythrocytosis. Bone marrow biopsy shows increased megakaryocytes. Which of the following types of myeloproliferative neoplasm (MPN) is most likely to be diagnosed based on these findings? (Q845780)

A. Polycythemia Vera (PV)

B. Essential Thrombocytosis (ET)

C. Chronic Myeloid Leukemia (CML)

D. Primary Myelofibrosis (PMF)

Correct Answer: B. Essential Thrombocytosis (ET)

■ *Listen (English)*

■ *Listen (Hindi)*

Explanation: Essential thrombocytosis is a type of myeloproliferative neoplasm which is characterized by isolated thrombocytosis without any without significant leukocytosis or erythrocytosis , along with increased megakaryocytes in bone marrow biopsy It is asymptomatic in more than half of the cases and is usually diagnosed incidentally Less than 50% patients have symptoms related to thrombosis or hemorrhage Symptoms include Bleeding tendency Microvascular occlusion Thrombosis of major arteries (leading to CVA and transient ischemic attacks), and vasomotor symptoms such as headache, visual disturbances, and syncope. Mild splenomegaly and rarely hepatomegaly and lymphadenopathy Diagnosis Criteria for Early/Prefibrotic ET Sustained platelet count ≥ 450 x 10^9/L Megakaryocyte proliferation Absence of criteria for other myeloid neoplasms Absence of JAK2, CALR, or MPL mutation Bone Marrow: Shows megakaryocytic hyperplasia with large, hyperlobulated (staghorn) megakaryocytes in clusters. Polycythemia Vera (PV) (Option A): It is characterized by increased red blood cell mass, leading to erythrocytosis. Associated with JAK2 mutation Symptoms : headaches, dizziness, and pruritus due to hyperviscosity. Laboratory findings typically include elevated hemoglobin and hematocrit levels, leukocytosis, and thrombocytosis. Bone marrow biopsy shows hypercellularity with increased erythropoiesis Chronic Myeloid Leukemia (Option C): CML is characterized by the Philadelphia chromosome (BCR-ABL fusion gene). Patients present with leukocytosis, predominantly neutrophils, and may have splenomegaly. Laboratory

findings- elevated white blood cell count, left-shifted granulocytes, and basophilia. Treatment often involves tyrosine kinase inhibitors targeting the BCR-ABL fusion protein. Primary Myelofibrosis (PMF) (Option D): It is characterized by bone marrow fibrosis, leading to cytopenias and splenomegaly. Symptoms- fatigue, weight loss, and abdominal discomfort due to splenomegaly. Laboratory findings: anemia, leukoerythroblastosis, and teardrop-shaped red blood cells (dacrocytes) on peripheral smears. JAK2 mutation is commonly found in PMF Bone marrow biopsy shows fibrosis with increased megakaryocytes.

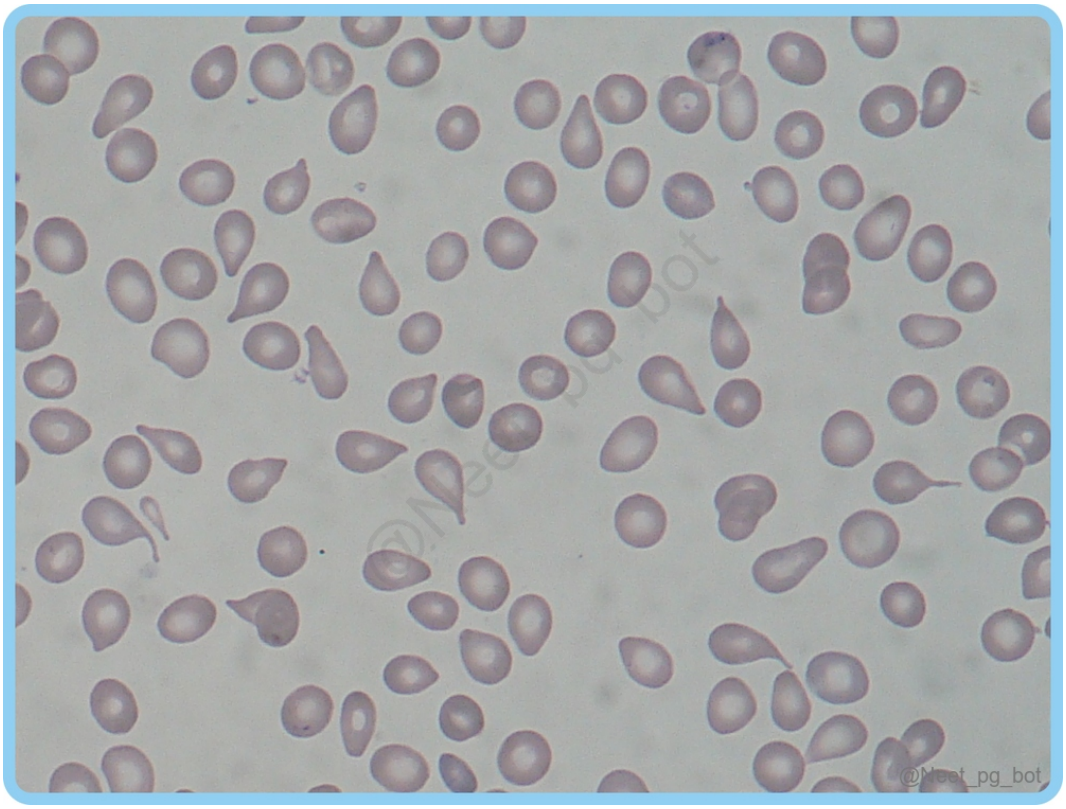

References:

Robbins and Cotran, Pathological Basis of Disease, 10th Edition, Page 625

↑ *Back to this question in Part A*

@Neet_pg_bot

Q2: A 50-year-old male presents with complaints of headaches, dizziness, and pruritus. Physical examination reveals a plethora and splenomegaly. Laboratory tests show elevated hemoglobin and hematocrit levels. Which of the following criteria are consistent with the Polycythemia Vera (PV) diagnosis? (Q845781)

A. Sustained platelet count ≥ 450 x 10^9/L

B. Increased red blood cell mass

C. Presence of JAK2 mutation

D. Presence of CALR or MPL mutation

Correct Answer: B. Increased red blood cell mass

Explanation: Diagnostic Criteria of Polycythemia Vera: Major criteria: Hb: > 16.5 g/dL in men and 16 g/dL in women. Hct: > 49% in men and > 48% in women. BM Trilineage myeloproliferative with pleomorphic megakaryocytes. Presence of JAK2 mutation. Minor Criteria: Subnormal serum erythropoietin level. Clinical features: Increased Hb causes stasis and neurological abnormalities. Increased TLC causes itching after a hot water bath and flushing. A high platelet count causes bleeding tendencies. Hepatosplenomegaly. Sustained platelet count ≥ 450 x 10^9/L (Option A): This criterion is not indicative of polycythemia vera (PV). Instead, it is a characteristic of Essential Thrombocytosis (ET), which is characterized by isolated thrombocytosis without significant erythrocytosis or leukocytosis. Presence of JAK2 mutation (Option C): While the presence of JAK2 mutation is a major diagnostic criterion for PV, it is not the only criterion. The presence of JAK2 mutations may also be observed in other myeloproliferative neoplasms like Essential Thrombocythemia (ET) or Primary Myelofibrosis (PMF). Presence of CALR or MPL mutation (Option D): CALR and MPL mutations are typically associated with other myeloproliferative neoplasms, such as Essential Thrombocythemia (ET) or Primary Myelofibrosis (PMF), and are not specific to Polycythemia Vera (PV).

References:

Robbins and Cotran, Pathological Basis of Disease, 10th Edition, Page 624

↑ *Back to this question in Part A*

@Neet_pg_bot

Q3: A 55-year-old female presents to the clinic with complaints of frequent headaches, dizziness, and occasional burning pain in her hands and feet. Examination reveals splenomegaly. Her complete blood count shows a platelet count of 12,00,000/µL. The peripheral blood smear shows marked thrombocytosis with giant platelets. Which of the following is not true regarding this condition? (Q845783)

A. Characterized by the presence of megakaryocytic hyperplasia.

B. Associated with JAK2, CALR, or MPL mutations.

C. Bone marrow biopsy typically shows increased reticulin fibrosis.

D. Increased risk of thrombotic and hemorrhagic events.

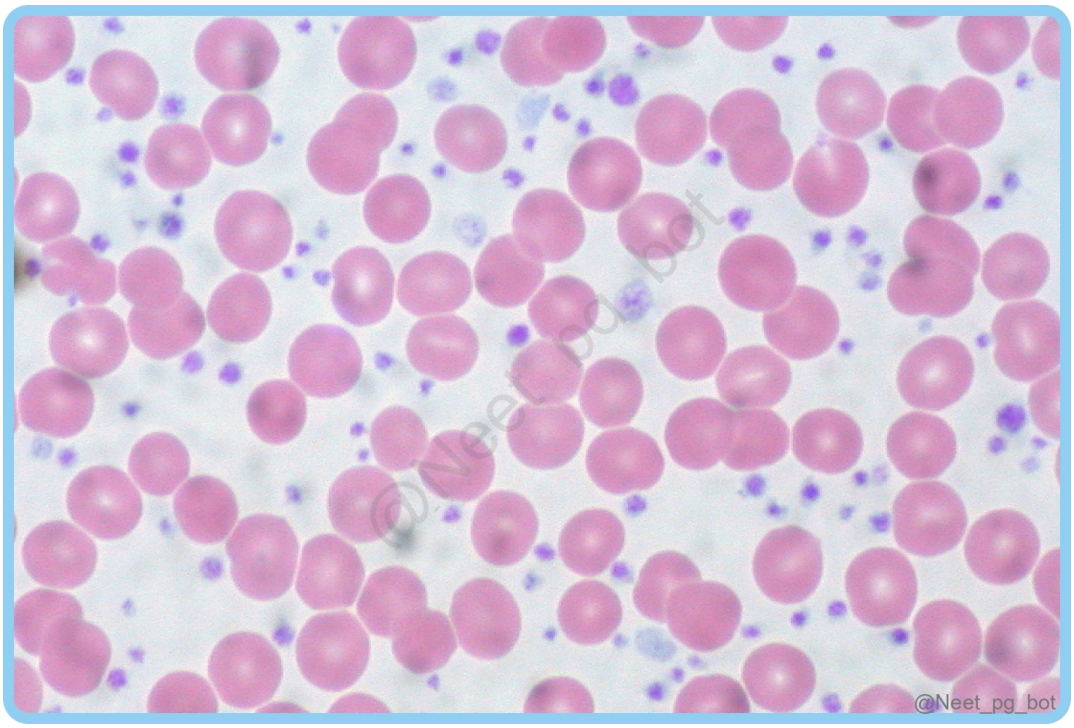

Correct Answer: C. Bone marrow biopsy typically shows increased reticulin fibrosis.

■ *Listen (English)*

■ *Listen (Hindi)*

Explanation: The clinical presentation is consistent with Essential Thrombocytosis, which typically does not show a significant increase in reticulin fibers in the bone marrow at diagnosis. Increased reticulin fibrosis is more characteristic of primary myelofibrosis. WHO diagnostic criteria of Essential thrombocytosis Major criteria Platelet count greater than or equal to 450,000/microliter. Bone marrow biopsy Shows proliferation, mainly of the megakaryocytic lineage, with an increase in enlarged mature megakaryocytes. (Option A) No significant increase or left shift in neutrophil granulopoiesis or erythropoiesis is present, Very rarely a minor increase in reticulin fibers. (Option C) The presentation does not meet WHO criteria for BCR-ABL1 +ve CML, PCV, myelofibrosis, MDS, or other myeloid neoplasms. Presence of JAK2, CALR, or MPL mutation. (Option B) Minor criteria: Presence of a clonal marker or absence of evidence of reactive thrombocytosis. Clinical features Thrombotic or hemorrhagic symptoms such as Bleeding tendency Microvascular occlusion Thrombosis of major arteries (leading to CVA and transient ischemic attacks), and vasomotor symptoms such as headache, visual disturbances, and syncope. Mild splenomegaly and rarely hepatomegaly and lymphadenopathy

References:

Robbins and Cotran, Pathological Basis of Disease, 10th Edition, Page 625

https://www.ncbi.nlm.nih.gov/books/NBK539709/

↑ *Back to this question in Part A*

@Neet_pg_bot

Q4: A 65-year-old man presents with progressive fatigue and significant weight loss for the past six months. Examination reveals a markedly enlarged spleen. Peripheral blood smear shows teardrop-shaped red cells. Bone marrow biopsy confirms the diagnosis of primary myelofibrosis. Which of the following statements regarding the diagnosis is true? 1) It is characterized by extensive marrow fibrosis. 2) Diagnostic criteria include the presence of JAK2, CALR, or MPL mutations. 3) Pathogenesis involves the inappropriate release of fibrogenic factors like PDGF and TGF-β. (Q845784)

A. All statements are true

B. 1,2

C. Only 3

D. 2,3

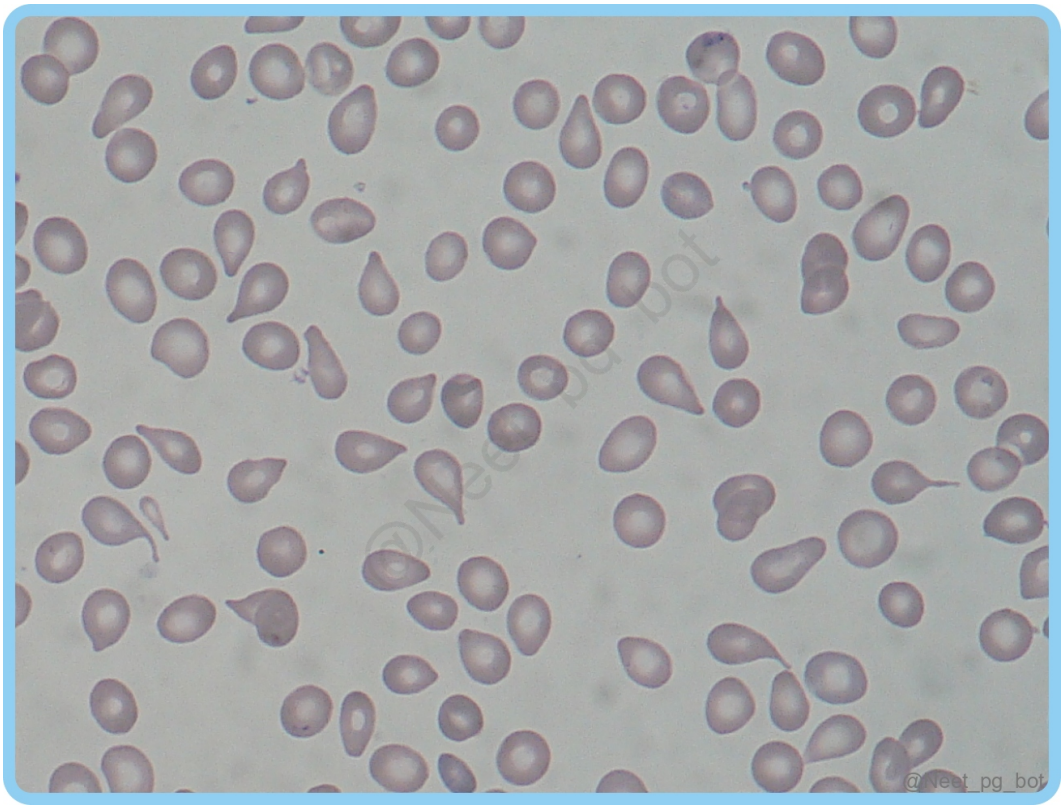

Correct Answer: A. All statements are true

- *Listen (English)*
- *Listen (Hindi)*

Explanation: Primary myelofibrosis (PMF) is a chronic myeloproliferative neoplasm characterized by the development of extensive marrow fibrosis, which impairs normal hematopoiesis. (Statement 1) This fibrosis is

driven by the inappropriate release of fibrogenic factors, such as platelet-derived growth factor and TGF-β, from neoplastic megakaryocytes. (Statement 3) Clinically, PMF presents with progressive anemia, splenomegaly, and symptoms like fatigue and weight loss. WHO diagnostic criteria: Major criteria Megakaryocyte proliferation and atypia, usually with reticulin or collagen fibrosis. Not meeting WHO criteria for BCR-ABL1 + CML, PV, ET, MDS, or other myeloid neoplasm Presence of JAK2, CALR, or MPL mutation or in the absence of these mutations, presence of other clonal markers or absence of minor reactive BM reticulin fibrosis. (Statement 2) Minor criteria: Leukocytosis ≥ 11 × 10 9 /L. Increased Serum Lactate Dehydrogenase (LDH). Anemia not attributed to another condition. Palpable Splenomegaly.

References:

Robbins and Cotran, Pathological Basis of Disease, 10th Edition, Page 626

https://www.ncbi.nlm.nih.gov/pmc/articles/PMC5807384/

↑ *Back to this question in Part A*

@Neet_pg_bot

Q5: A 60-year-old man presents with complaints of increasing fatigue, early satiety, and unintentional weight loss over the past few months. On examination, there is palpable splenomegaly. Laboratory reports reveal pancytopenia with dacrocytes on the peripheral smear. Which of the following is not associated with Myelofibrosis? (Q845785)

A. Dry tap

B. Leukoerythroblastic blood picture

C. Dacrocytes

D. Myeloblasts

Correct Answer: D. Myeloblasts

■ *Listen (English)*

■ *Listen (Hindi)*

Explanation: Myeloblasts are seen in AML and are not associated with myelofibrosis. Myelofibrosis is the development of obliterative marrow fibrosis. Replacement of the marrow by fibrous tissue reduces bone marrow hematopoiesis, leading to cytopenias and extensive extramedullary hematopoiesis. Investigations include CBC-pancytopenia due to obliterative bone marrow fibrosis Peripheral smear reveals a leukoerythroblastic blood picture where the distortion of the marrow leads to the premature release of immature erythroid and granulocyte (Option B) Teardrop-shaped red cells (dacrocytes) that are damaged during the birthing process in the fibrotic marrow (Option C) Bone marrow aspirate may reveal a dry tap. (Option A) May reveal thickening and distortion of bony trabeculae and deposition of reticulin and collagen fibers.

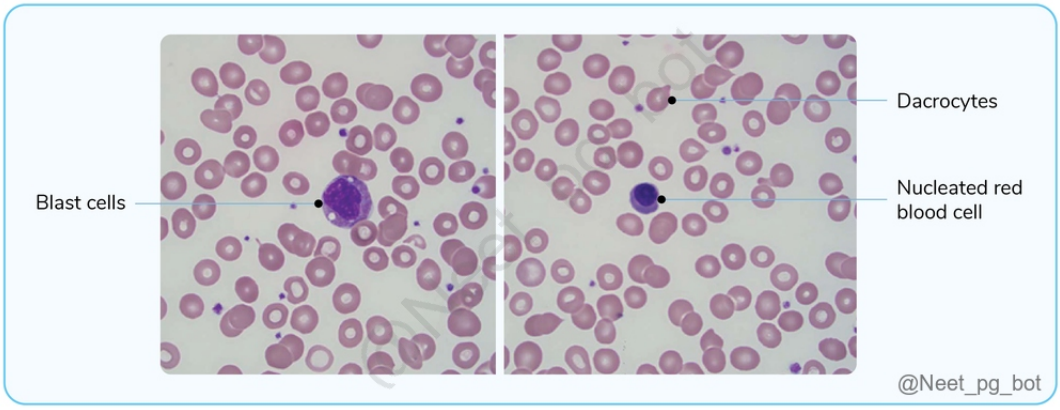

References:

Robbins and Cotran, Pathological Basis of Disease, 10th Edition, Page 626

https://www.ncbi.nlm.nih.gov/pmc/articles/PMC5013940/

↑ *Back to this question in Part A*

@Neet_pg_bot

Q6: A 75-year-old man presents with increasing fatigue, weakness, and easy bruising over the past few months. Labs show pancytopenia. Peripheral blood smear reveals dysplastic differentiation in the erythroid, granulocytic, monocytic, and megakaryocytic lineages. Which condition does this suggest? (Q845787)

A. Hyperlobated megakaryocyte

B. Leukoerythroblastic picture

C. Increased proliferation of RBCs

D. Pawn ball megakaryocyte

Correct Answer: D. Pawn ball megakaryocyte

Explanation: Pawn ball megakaryocytes is associated with Myelodysplastic syndrome. Myelodysplastic Syndrome (MDS) is a group of clonal stem cell disorders characterized by maturation defects and ineffective hematopoiesis with a risk transformation to AML Bone marrow replaced by clonal progeny of a neoplastic multipotent stem cell Leading to ineffective and disordered differentiation Can cause cytopenias and potential malignancy Genetic Causes Adults: Deletion of 5q chromosome Children: Monosomy 7 Types Primary (idiopathic) Secondary (due to genotoxic drugs or radiation therapy) Peripheral Smear Findings: Dysplastic differentiation of erythroid, granulocytic, monocytic, and megakaryocytic lineages Ring sideroblasts Erythroblasts with iron-laden mitochondria (visible as perinuclear granules in Prussian blue stain) Neutrophils with decreased secondary

granules Döhle bodies PseudoPelger–Hüet cells (neutrophils with two nuclear lobes) Megakaryocytes with Single nuclear lobes Multiple separate nuclei (Pawnball megakaryocytes) Ringed sideroblasts: Döhle bodies: PseudoPelger–Hüet cells: Hyperlobated megakaryocytes (Option A): These are seen in Essential thrombocytosis, where peripheral smears reveal abnormally large platelets and marked thrombocytosis. It is characterized by erythromelalgia, a throbbing and burning of hands and feet caused by the occlusion of small arterioles by platelet aggregates. Leukoerythroblastic picture (Option B): This is seen in Myelofibrosis, which causes obliterative marrow fibrosis, decreasing hematopoiesis and causing cytopenias, with extensive extramedullary hematopoiesis. Increased proliferation of RBCs (Option C): It is seen in Polycythemia Vera due to JAK2 mutation. Patients present with symptoms such as headaches, dizziness, and pruritus due to hyperviscosity. Bone marrow biopsy shows hypercellularity with increased erythropoiesis.

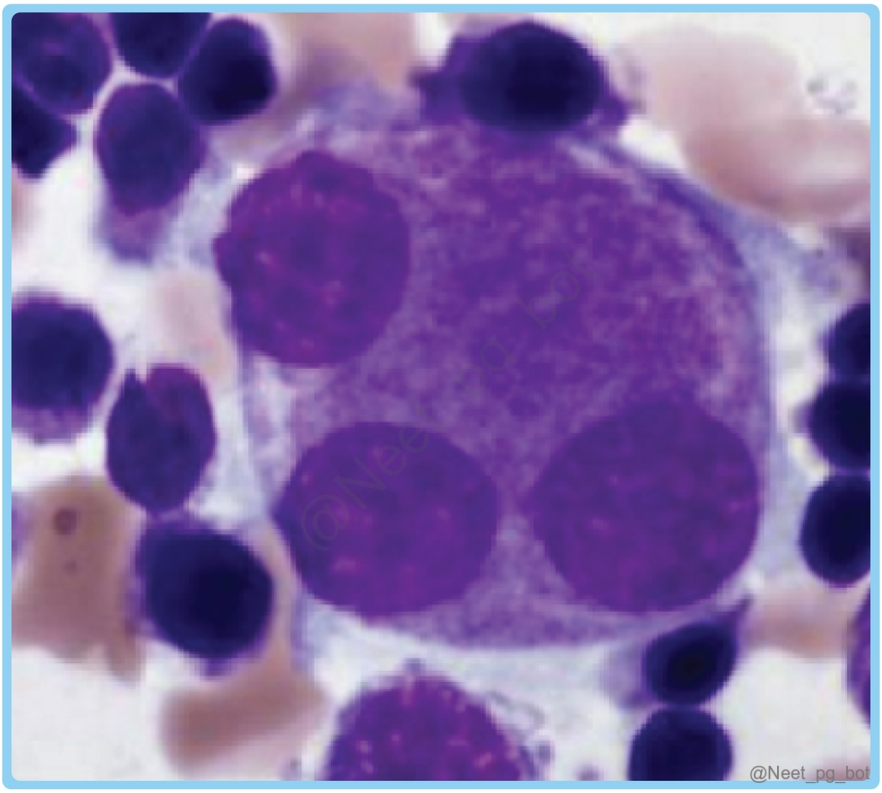

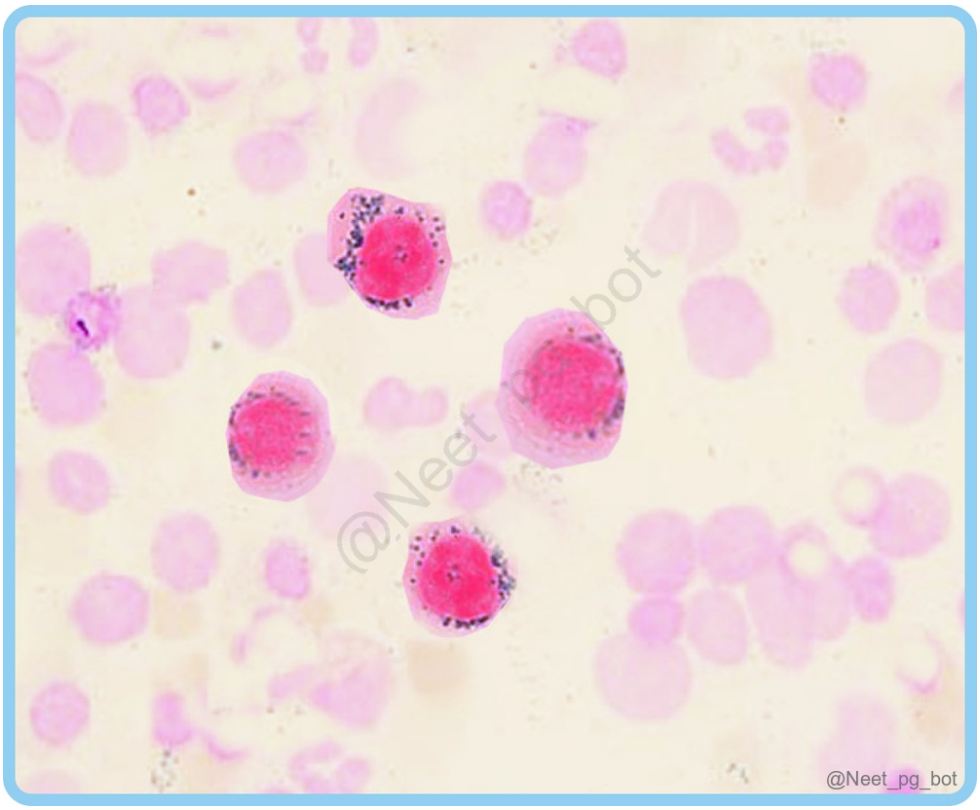
@Neet_pg_bot

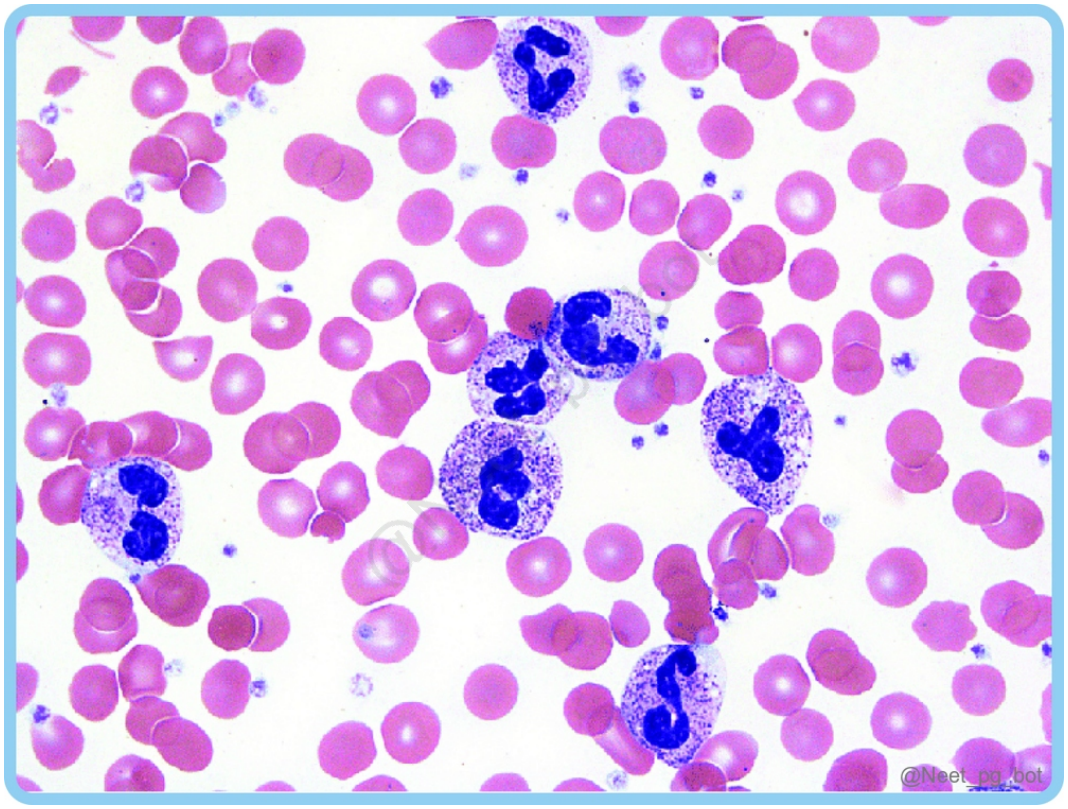
@Neet_pg_bot

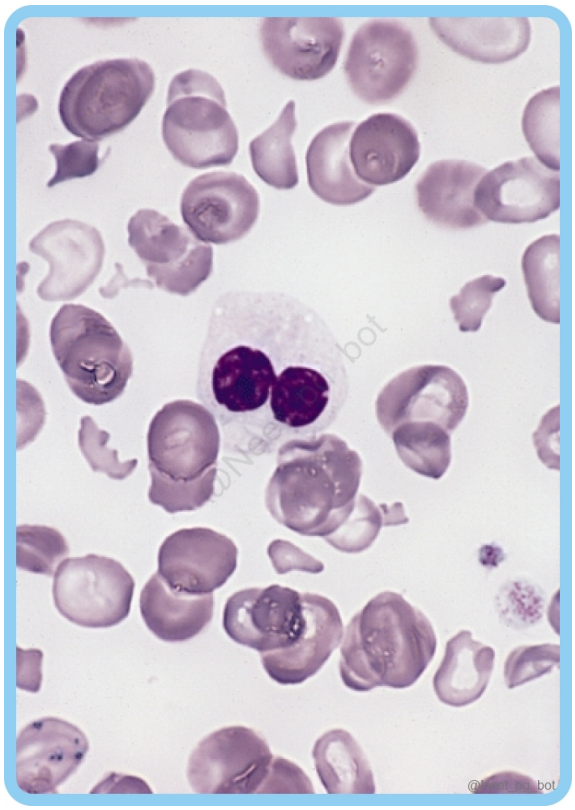

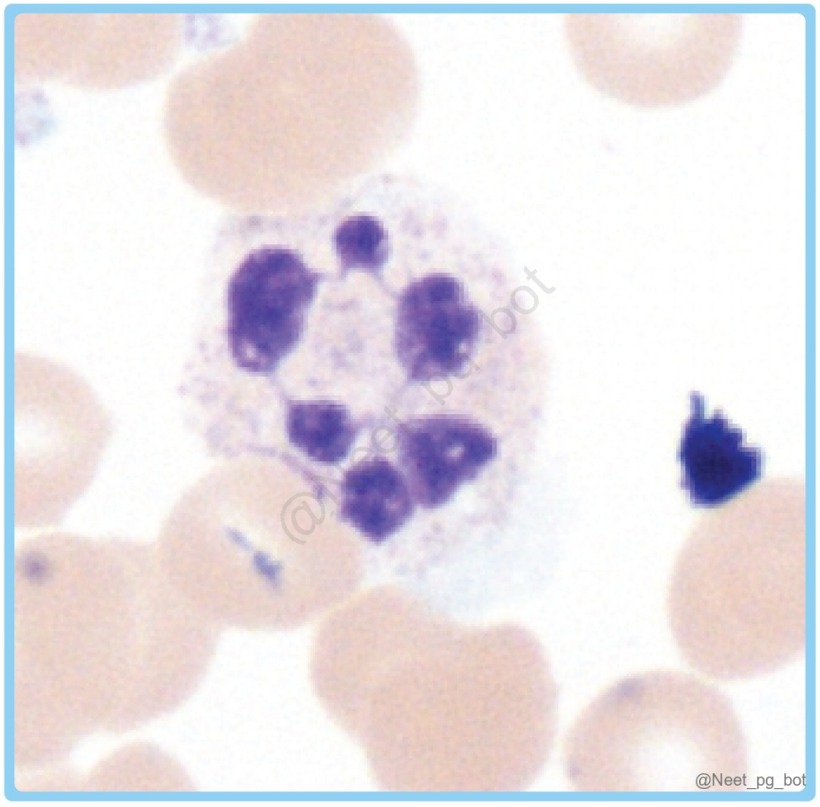
@Neet_pg_bot

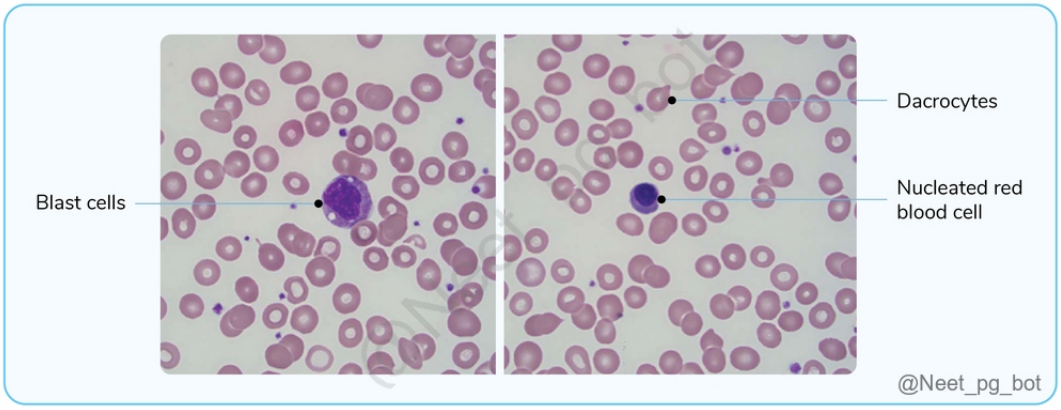

References:

Robbins and Cotran, Pathological Basis of Disease, 10th Edition, Page 620, 621, 624, 625
https://ashpublications.org/blood/article/133/10/1071/272739/Genetic-predisposition-to-MDS-clinical-features

↑ *Back to this question in Part A*

@Neet_pg_bot

Q7: A 5-year-old child presents with a skin rash, recurrent ear infections, bone pain, and polyuria. Imaging revealed lytic bone lesions and a biopsy of one of the lesions showed CD1a and S-100 positive Langerhans cells. Which of the following types of Langerhans cell histiocytosis (LCH) is characterized by multifocal uni system involvement? (Q845790)

A. Eosinophilic granuloma

B. Hand-Schüller-Christian disease

C. Letterer-Siwe disease

D. Both A and C

Correct Answer: B. Hand-Schüller-Christian disease

Explanation: Langerhans Cell Histiocytosis (LCH) is a rare inflammatory and neoplastic condition that involves myeloid dendritic cells Genetic Mutation: BRAF V600E mutation found in the majority of cases BRAF gene encodes B-Raf, part of the MAPK pathway Mutation establishes the neoplastic nature of LCH Categories: Unisystem: Unifocal Multifocal Multisystem Types of langerhan histiocytosis: Eosinophilic granuloma (Option A) Hand-Schuller-Christian disease (Option B) Letterer-Siwe disease (Option C) Unifocal involvement. Primarily involves lytic bone lesions. Seen in young children. Multifocal involvement. It is characterized by a triad of symptoms such as: Bony lesions in a calvarial defect. Diabetes insipidus and Exophthalmos. It is a more severe, disseminated form of LCH with multisystem involvement. It is characterized by lytic bony lesions and seborrheic

dermatitis. LCH Diagnosis: Light Microscopy Eosinophils appear as orange-looking cells Nuclei have a coffee bean appearance Immunohistochemistry (IHC): Positive markers: CD1a, CD207 (langerin), S100, HLA-DR Electron Microscopy:(Gold standard for diagnosis) Reveals tennis racket appearance of Birbeck granules

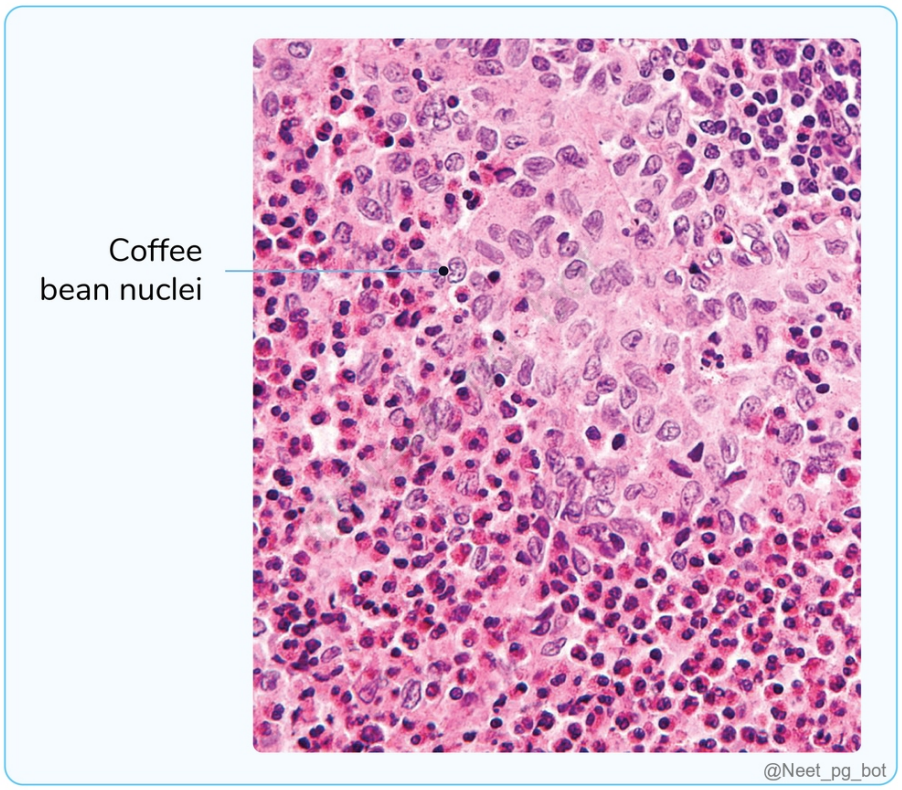

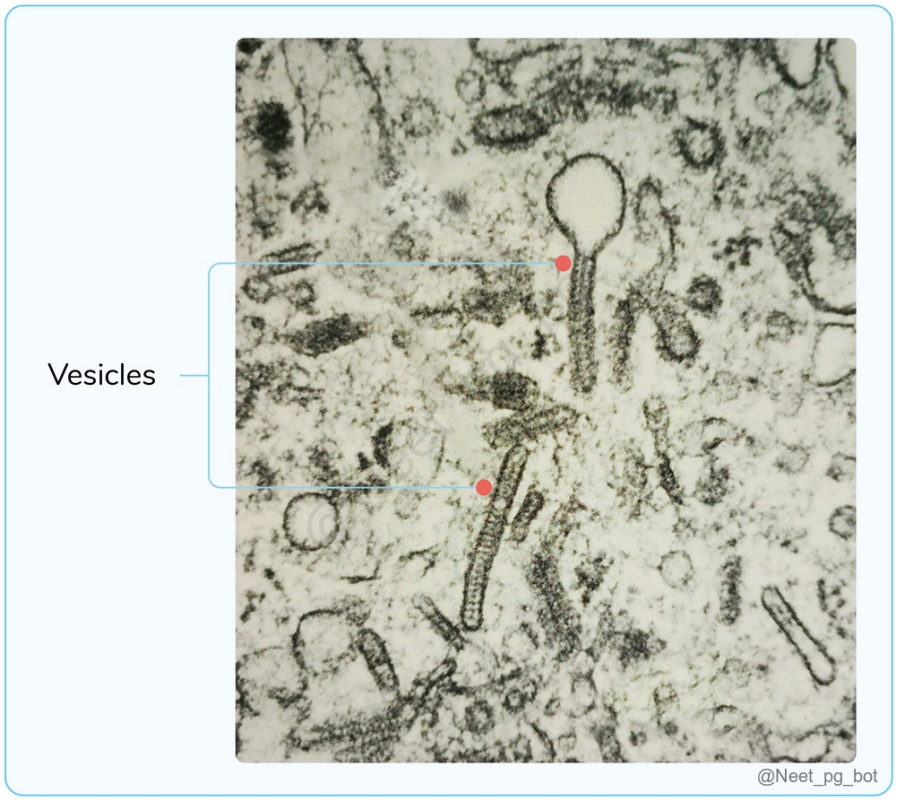

References:

Robbins and Cotran, Pathological Basis of Disease, 10th Edition, Page 627-628

↑ *Back to this question in Part A*

@Neet_pg_bot

Q8: Pseudo-Gaucher cells are commonly seen in which of the following conditions? (Q889668)

A. Gaucher disease

B. Chronic myeloid leukaemia

C. Hairy cell leukaemia

D. Multiple myeloma

Correct Answer: B. Chronic myeloid leukaemia

Explanation: Pseudo-Gaucher cells are macrophages with cytoplasm resembling true Gaucher cells , seen in conditions associated with high cell turnover , particularly chronic myeloid leukaemia (CML) . In CML, rapid myeloid proliferation leads to increased breakdown of leukocytes, resulting in the accumulation of glucocerebroside within marrow macrophages. Unlike true Gaucher cells, these cells occur without β-glucocerebrosidase deficiency . They are termed “pseudo” because they resemble Gaucher cells morphologically but do not represent a lysosomal storage disorder. Gaucher disease (Option A): Characterised by true Gaucher cells caused by β-glucocerebrosidase deficiency , leading to glucocerebroside accumulation in macrophages. Hairy cell leukaemia (Option C): Characterised by TRAP-positive B cells , marrow fibrosis, and “fried-egg” appearing cells; pseudo-Gaucher cells are not a typical feature. Multiple myeloma (Option D): Although rare pseudo-Gaucher-like cells have been reported in high cell turnover states, multiple myeloma is primarily characterised by clonal plasma cell proliferation , not by classic pseudo-Gaucher cells.

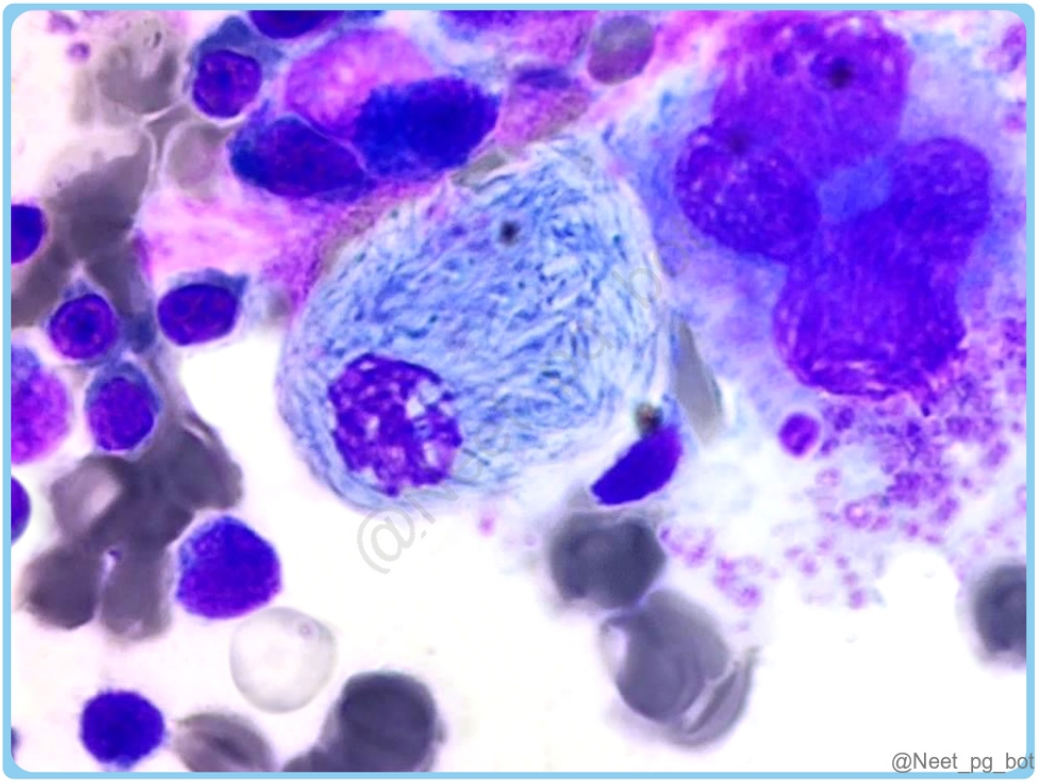

References:

https://pubmed.ncbi.nlm.nih.gov/9083517/

↑ *Back to this question in Part A*

@Neet_pg_bot

Q9: Which of the following findings is least likely to be seen in polycythemia vera (PCV)? (Q889669)

A. Low serum erythropoietin

B. Basophilia

C. Budd-chiari syndrome

D. Lymphocytosis

Correct Answer: D. Lymphocytosis

Explanation: Lymphocytosis is not a feature of PCV because the disease arises from a myeloid progenitor , not the lymphoid lineage. Polycythemia Vera (PCV): Myeloproliferative neoplasm → ↑ RBCs, granulocytes, platelets

(panmyelosis) Symptoms are mainly from erythrocytosis Pathogenesis: JAK2 V617F mutation → constitutive JAK/STAT → growth factor-independent hematopoiesis Low EPO (Option A) , hyperviscosity → thrombosis & bleeding Morphology: Hypercellular marrow, ↑ erythroid/granulocyte/megakaryocyte precursors ↑ basophils (Option B) , giant/abnormal platelets Mild organomegaly; fibrosis & extramedullary hematopoiesis in spent phase Clinical features: Middle-aged adults; plethoric, cyanotic, pruritus, headache, dizziness, GI symptoms Complications: thrombosis (DVT, MI, stroke, Budd-Chiari (Option C)), bleeding, gout Management: Phlebotomy + low-dose aspirin JAK2 inhibitors Progression: 10-20% → myelofibrosis, ~2% → AML

References:

Robbins, Cotran & Kumar, Pathologic Basis of Disease, 11th Edition, Pages 568, 569

↑ *Back to this question in Part A*

@Neet_pg_bot

Q10: Which of the following conditions is most likely associated with a leucoerythroblastic blood film? (Q889671)

A. Iron deficiency anaemia

B. Vitamin B12 deficiency

C. Primary myelofibrosis

D. Thalassemia

Correct Answer: C. Primary myelofibrosis

Explanation: Primary myelofibrosis disrupts normal marrow architecture due to progressive marrow fibrosis , leading to a leucoerythroblastic blood film characterised by nucleated RBCs , tear-drop cells (dacrocytes) , and early myeloid precursors in the peripheral blood. Leucoerythroblastic Blood Film / Anaemia: Presence of immature blood cells in peripheral blood - nucleated RBCs along with early myeloid precursors (myelocytes, metamyelocytes). Significance : Pathological in adults ; indicates marrow infiltration, fibrosis, or severe marrow stress . It may clinically resemble leukaemia due to circulating immature cells and splenomegaly, though marked leukocytosis is more typical of leukaemia. Common causes: Marrow infiltration: metastatic carcinoma, myelofibrosis Severe systemic stress: sepsis, severe infections (e.g., tuberculosis) Other marrow stress: acute blood loss, severe haemolysis, marrow recovery phase Iron deficiency anaemia (Option A): Causes microcytic, hypochromic RBCs but does not disrupt marrow architecture; therefore, a leucoerythroblastic blood film is uncommon. Vitamin B12 deficiency (Option B): Causes megaloblastic anaemia with hypersegmented neutrophils . Although severe cases may show occasional nucleated RBCs, a true leucoerythroblastic picture with myeloid precursors is not typical. Thalassemia (Option D): Shows microcytosis , target cells , and marked erythroid hyperplasia. Severe forms may show nucleated RBCs, but true leucoerythroblastosis with early myeloid precursors is uncommon, as the marrow is hyperactive rather than infiltrated.

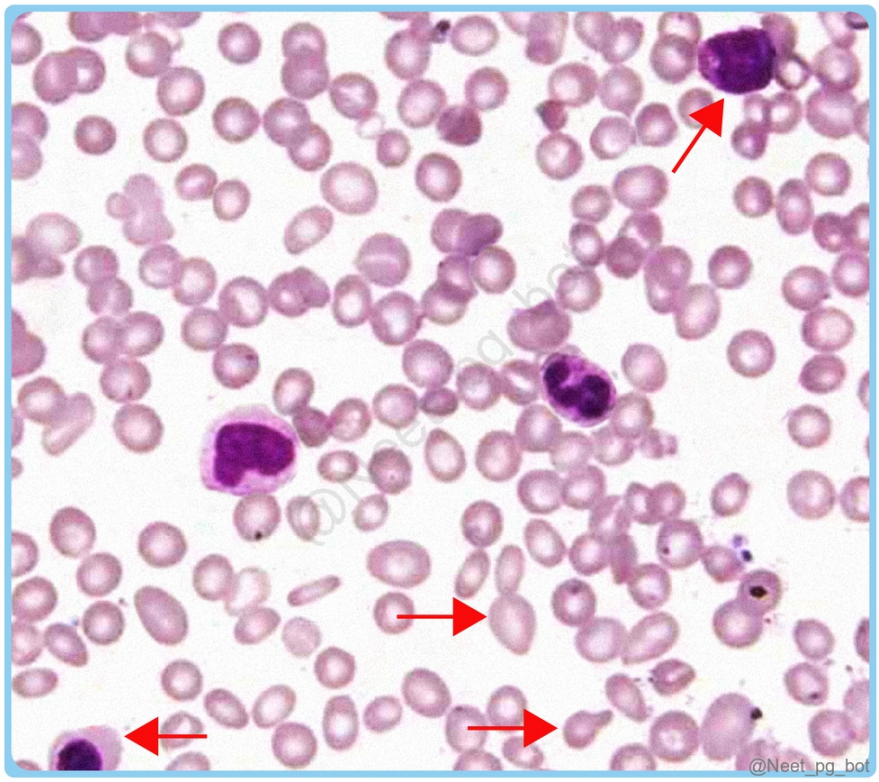

References:

https://pmc.ncbi.nlm.nih.gov/articles/PMC4276592/

https://www.rcpa.edu.au/Manuals/RCPA-Manual/Clinical-Presentations-and-Diagnoses/L/Leucoerythroblastic-blood-film-anaemia

↑ *Back to this question in Part A*

@Neet_pg_bot

Q11: Which of the following is not part of the WHO 2022 diagnostic criteria for CMML? (Q889674)

A. Persistent absolute (≥0.5 × 10■/L) and relative (≥10%) peripheral blood monocytosis

B. Blasts constitute <20% in blood and bone marrow

C. Presence of Philadelphia chromosome (BCR::ABL1 fusion)

D. Dysplasia involving ≥1 myeloid lineage

Correct Answer: C. Presence of Philadelphia chromosome (BCR::ABL1 fusion)

Explanation: The presence of the Philadelphia chromosome (BCR::ABL1 fusion) establishes a diagnosis of chronic myeloid leukaemia (CML) and therefore excludes chronic myelomonocytic leukaemia (CMML). According to WHO 2022, CMML requires exclusion of BCR::ABL1-positive CML and other defined myeloproliferative neoplasms. CMML (WHO 2022) - Diagnostic Criteria: Prerequisite Criteria (all must be present): Persistent peripheral blood monocytosis (Option A) Absolute monocyte count ≥ 0.5 × 10■/L Relative monocytes ≥ 10% of leukocytes Blasts < 20% in peripheral blood and bone marrow (Option B) Does not meet criteria for: Chronic myeloid leukaemia (BCR::ABL1-positive) Other myeloproliferative neoplasms (MPNs) Myeloid/lymphoid neoplasms with eosinophilia and defining gene rearrangements (e.g., PDGFRA, PDGFRB, FGFR1, JAK2) Supporting criteria: Dysplasia in ≥1 myeloid lineage (Option D) Acquired clonal cytogenetic or molecular abnormality Abnormal distribution of peripheral blood monocyte subsets Requirements for Diagnosis: If absolute monocytosis ≥ 1 × 10■/L: At least one supporting criterion (dysplasia, clonal abnormality, or abnormal monocyte subsets) must be present. If absolute monocytosis 0.5-<1 × 10■/L: Both dysplasia and an acquired clonal cytogenetic/molecular abnormality must be demonstrated. Subtyping Based on WBC: MD-CMML (Myelodysplastic type): WBC < 13 × 10■/L MP-CMML (Myeloproliferative type): WBC ≥ 13 × 10■/L Subgrouping Based on Blasts (including promonocytes): CMML-1: <5% blasts in peripheral blood <10% in bone marrow CMML-2: 5-19% blasts in peripheral blood 10-19% in bone marrow

References:

https://www.mll.com/en/myelodysplastic-myeloproliferative-neoplasm-mds-mpn/chronic-myelomonocytic-leukemia-cmml

↑ *Back to this question in Part A*

@Neet_pg_bot

Q12: Which of the following findings is not typically present in juvenile myelomonocytic leukaemia (JMML)? (Q889678)

A. Peripheral blood monocytosis ≥1 × 10■/L

B. Blasts <20% in blood and marrow

C. BCR::ABL1 fusion gene

D. Splenomegaly

Correct Answer: C. BCR::ABL1 fusion gene

Explanation: The presence of the BCR::ABL1 fusion gene establishes a diagnosis of chronic myeloid leukaemia (CML) and excludes juvenile myelomonocytic leukaemia (JMML). JMML requires the absence of BCR::ABL1. Diagnostic Criteria for JMML: Category Requirements Key Details 1. Clinical & Laboratory All Required Peripheral blood monocyte count ≥1 × 10■/L (Option A) Blasts/promonocytes <20% (blood & bone marrow) (Option B) Evidence of organ infiltration (splenomegaly) (Option D) Absence of BCR::ABL1 fusion gene Absence of KMT2A rearrangement 2. Genetic Criteria Any 1 Sufficient Canonical RAS pathway variant: PTPN11, KRAS, or NRAS (somatic); NF1 or CBL (with loss of heterozygosity) Noncanonical RAS variant: (e.g.,

RRAS, RRAS2) or fusions activating upstream genes (ALK, PDGFRB, ROS1) 3. Other Criteria 2+ Required* Circulating myeloid and erythroid precursors Increased Haemoglobin F for age Thrombocytopenia with hypercellular bone marrow GM-CSF hypersensitivity (myeloid progenitor cells) *(If no defining genetic mutation identified - at least two required)

References:

https://www.ncbi.nlm.nih.gov/books/NBK602741/table/CDR0000810728__2008/

↑ *Back to this question in Part A*

@Neet_pg_bot

Q13: Which of the following numbered conditions are histiocytic and dendritic cell neoplasms? Langerhans Cell Histiocytosis (LCH) Chronic Lymphocytic Leukaemia (CLL) Rosai-Dorfman Disease (RDD) Juvenile Xanthogranuloma (JXG) Erdheim-Chester Disease (ECD) (Q889681)

A. 1, 3, 4, 5

B. 2, 3, 4

C. 1, 2, 5

D. 2, 4, 5

Correct Answer: A. 1, 3, 4, 5

Explanation: Histiocytic & Dendritic Cell Neoplasms are a group of rare neoplasms originating from cells of the mononuclear phagocyte system, including histiocytes (macrophage■like cells) and dendritic cells (antigen■presenting cells). Langerhans Cell Histiocytosis (LCH) Langerhans Cell Sarcoma Indeterminate Dendritic Cell Histiocytosis Juvenile Xanthogranuloma (JXG) Rosai-Dorfman Disease (RDD) Histiocytic Sarcoma Interdigitating Dendritic Cell Sarcoma Erdheim-Chester Disease (ECD) ALK-Positive Histiocytosis Blastic Plasmacytoid Dendritic Cell Neoplasm (BPDCN)

References:

https://www.ncbi.nlm.nih.gov/books/NBK586208/

↑ *Back to this question in Part A*

@Neet_pg_bot

Q14: Which of the following conditions is typically not characterised by pancytopenia? (Q889685)

A. Vitamin B12 deficiency

B. Hairy cell leukaemia

C. Hypocellular myelodysplastic syndrome

D. Immune thrombocytopenic purpura (ITP)

Correct Answer: D. Immune thrombocytopenic purpura (ITP)

Explanation: Immune thrombocytopenic purpura (ITP) is characterised by isolated immune-mediated platelet destruction, with normal red cell and white cell counts. Therefore, pancytopenia is not typical. Pancytopenia with Hypocellular Bone Marrow: Acquired aplastic anaemia Constitutional aplastic anaemia (e.g., Fanconi anaemia, dyskeratosis congenita) Hypocellular myelodysplastic syndrome (Option C) Rare aleukemic leukaemia Some acute lymphoid leukaemias Rare lymphomas of bone marrow Copper deficiency Pancytopenia with Cellular Bone Marrow: Primary bone marrow diseases: Myelodysplastic syndromes Paroxysmal nocturnal hemoglobinuria (PNH) Myelofibrosis Aleukemic leukemia Myelophthisis Bone marrow lymphoma Hairy cell leukaemia (Option B) Secondary to systemic diseases: Systemic lupus erythematosus (SLE) Hypersplenism Vitamin B■■ or folate deficiency (Option A) Copper deficiency Alcohol HIV infection Brucellosis Sarcoidosis Tuberculosis Leishmaniasis Sepsis

References:

Harrison’s Principles of Internal Medicine, 21st Edition, Page 793

↑ *Back to this question in Part A*

@Neet_pg_bot

• [18_Hematology_ White Blood Cells] 076 Hodgkin S And Non-Hodgkin S Lymphoma

« Back to Folder Directory

[18_Hematology_ White Blood Cells] 076 Hodgkin S And Non-Hodgkin S Lymphoma — Quick Jump

Q1 (p. 2928)	*Q2 (p. 2929)*	*Q3 (p. 2929)*	*Q4 (p. 2930)*	*Q5 (p. 2931)*	*Q6 (p. 2932)*
Q7 (p. 2933)	*Q8 (p. 2934)*	*Q9 (p. 2935)*	*Q10 (p. 2936)*	*Q11 (p. 2936)*	*Q12 (p. 2939)*
Q13 (p. 2940)	*Q14 (p. 2941)*	*Q15 (p. 2941)*	*Q16 (p. 2942)*	*Q17 (p. 2944)*	*Q18 (p. 2945)*
Q19 (p. 2946)	*Q20 (p. 2947)*	*Q21 (p. 2947)*	*Q22 (p. 2949)*	*Q23 (p. 2949)*	*Q24 (p. 2950)*
Q25 (p. 2953)	*Q26 (p. 2954)*	*Q27 (p. 2955)*	*Q28 (p. 2958)*	*Q29 (p. 2959)*	*Q30 (p. 2960)*
Q31 (p. 2961)	*Q32 (p. 2963)*	*Q33 (p. 2964)*	*Q34 (p. 2966)*	*Q35 (p. 2968)*	*Q36 (p. 2971)*
Q37 (p. 2972)	*Q38 (p. 2973)*	*Q39 (p. 2974)*	*Q40 (p. 2979)*	*Q41 (p. 2980)*	*Q42 (p. 2982)*

Q1: A 64-year-old man presents with persistent lymphocytosis on routine blood work. Flow cytometry shows a clonal B-cell population consistent with CLL/SLL. What absolute lymphocyte count (ALC) is required to diagnose CLL rather than SLL? (Q884880)

A. >1,500/mm³

B. >3,000/mm³

C. >5,000/mm³

D. >10,000/mm³

Correct Answer: C. >5,000/mm³

Explanation: An ALC >5,000/mm³ is required to diagnose Chronic Lymphocytic Leukemia. If the count is lower with predominant nodal disease, it is classified as Small Lymphocytic Lymphoma. Chronic Lymphocytic Leukemia / Small Lymphocytic Lymphoma: Same disease entity Differ only by degree of peripheral blood lymphocytosis CLL: Absolute lymphocyte count > 5,000/mm³ SLL: Minimal/no peripheral blood lymphocytosis Epidemiology: Most common adult leukemia in Western countries Median age at diagnosis: ~60 years Male predominance: 2:1

References:

Robbins, Cotran & Kumar, Pathologic Basis of Disease, 11th Edition, Page 543

↑ *Back to this question in Part A*

@Neet_pg_bot

Q2: Which of the following genetic alterations represents the central pathogenic event in classic Hodgkin lymphoma? (Q884843)

A. Loss-of-function mutation of IKBα (NFKBIA)

B. Activation of NF-κB

C. Loss-of-function mutation of TNFAIP3 (A20)

D. Copy number gain of the REL proto-oncogene

Correct Answer: B. Activation of NF-κB

Explanation: In classic Hodgkin lymphoma, multiple genetic alterations converge to cause constitutive activation of NF-κB , the central pathogenic driver of Reed-Sternberg cell survival. NF-κB Activation (Central Event): Promotes RS cell growth & survival. Mechanisms: EBV (LMP-1) - mediated activation Loss-of-function mutations in: IκB TNFAIP3 (A20) REL proto-oncogene (2p) copy gain Loss-of-function mutation of IKBα (NFKBIA) (Option A) : IKBα is a negative regulator of NF-κB. Its loss leads to NF-κB activation, but this is a mechanism causing the central event, not the event itself. Loss-of-function mutation of TNFAIP3 (A20) (Option C) : TNFAIP3 is another negative regulator of NF-κB. Mutation results in increased NF-κB signalling, but it is one of several contributing genetic alterations. Copy number gain of the REL proto-oncogene (Option D) : REL enhances NF-κB activity. Its amplification contributes to pathway activation but is not the defining central event.

References:

Robbins, Cotran & Kumar, Pathologic Basis of Disease, 11th Edition, Page 557

↑ *Back to this question in Part A*

@Neet_pg_bot

Q3: A patient with classic Hodgkin lymphoma undergoes cytogenetic analysis. The Reed-Sternberg cells show a recurrent copy number gain on chromosome 2p, contributing to increased NF-κB activity. Which gene is most likely amplified? (Q884845)

A. TNFAIP3

B. NFKBIA

C. REL

D. PD-L1

Correct Answer: C. REL

Explanation: Copy number gain on chromosome 2p in classic Hodgkin lymphoma commonly involves the REL proto-oncogene , enhancing NF-κB signalling. TNFAIP3 (Option A) : Located on chromosome 6; loss-of-function mutation (not amplification) increases NF-κB activity. NFKBIA (Option B) : Encodes IκBα, a negative regulator of NF-κB; typically inactivated, not amplified. PD-L1 (Option D) : Located on chromosome 9p; copy number gain causes immune evasion, not direct NF-κB activation.

References:

Robbins, Cotran & Kumar, Pathologic Basis of Disease, 11th Edition, Page 557

↑ *Back to this question in Part A*

@Neet_pg_bot

Q4: Reed-Sternberg-like cells (RSLC) are seen in which of the following conditions? Infectious mononucleosis Non-Hodgkin lymphoma Solid tumors Classic Hodgkin lymphoma (Q884847)

A. 1, 2 only

B. 1, 2, 3 only

C. 4 only

D. 1, 2, 3, 4

Correct Answer: B. 1, 2, 3 only

Explanation: Classic Hodgkin lymphoma (cHL) is characterised by true Reed-Sternberg (RS) cells , not Reed-Sternberg-like cells. Correct Answer: B) 1, 2, 3 only



References:

https://pmc.ncbi.nlm.nih.gov/articles/PMC9754675/

https://www.nature.com/articles/modpathol201270

↑ *Back to this question in Part A*

@Neet_pg_bot

Q5: A 28-year-old man presents with a 3-month history of painless cervical lymphadenopathy. He reports sharp pain in the neck nodes within minutes of drinking small amounts of alcohol, which resolves spontaneously. He also has intermittent low-grade fever and night sweats. Which of the following is the most likely diagnosis? (Q884849)

A. Non-Hodgkin lymphoma

B. Metastatic squamous cell carcinoma

C. Hodgkin lymphoma

D. Tuberculous lymphadenitis

Correct Answer: C. Hodgkin lymphoma

Explanation: Hodgkin lymphoma is classically associated with alcohol-induced pain in involved lymph nodes , a rare but highly suggestive symptom. The presence of painless lymphadenopathy, B symptoms (fever, night sweats), and alcohol-triggered nodal pain strongly supports this diagnosis. The pathogenesis is thought to involve alcohol-induced vasodilation and inflammatory mediator release within diseased lymph nodes.

References:

https://pmc.ncbi.nlm.nih.gov/articles/PMC3652965/

↑ *Back to this question in Part A*

@Neet_pg_bot

Q6: Which subtype of Hodgkin lymphoma is associated with biphasic incidence? (Q884854)

A. Nodular sclerosis

B. Mixed cellularity

C. Lymphocyte-rich

D. Nodular lymphocyte predominant

Correct Answer: B. Mixed cellularity

Explanation: Mixed cellularity Hodgkin lymphoma shows a biphasic age distribution and is often EBV-associated. Mixed Cellularity Hodgkin Lymphoma: Biphasic incidence (young adults & >55 years) More common in males ~70% EBV associated Morphology: Numerous classic Reed–Sternberg cells Mixed inflammatory background (T lymphocytes, eosinophils, plasma cells, macrophages) ■ Immunophenotype: CD15+, CD30+

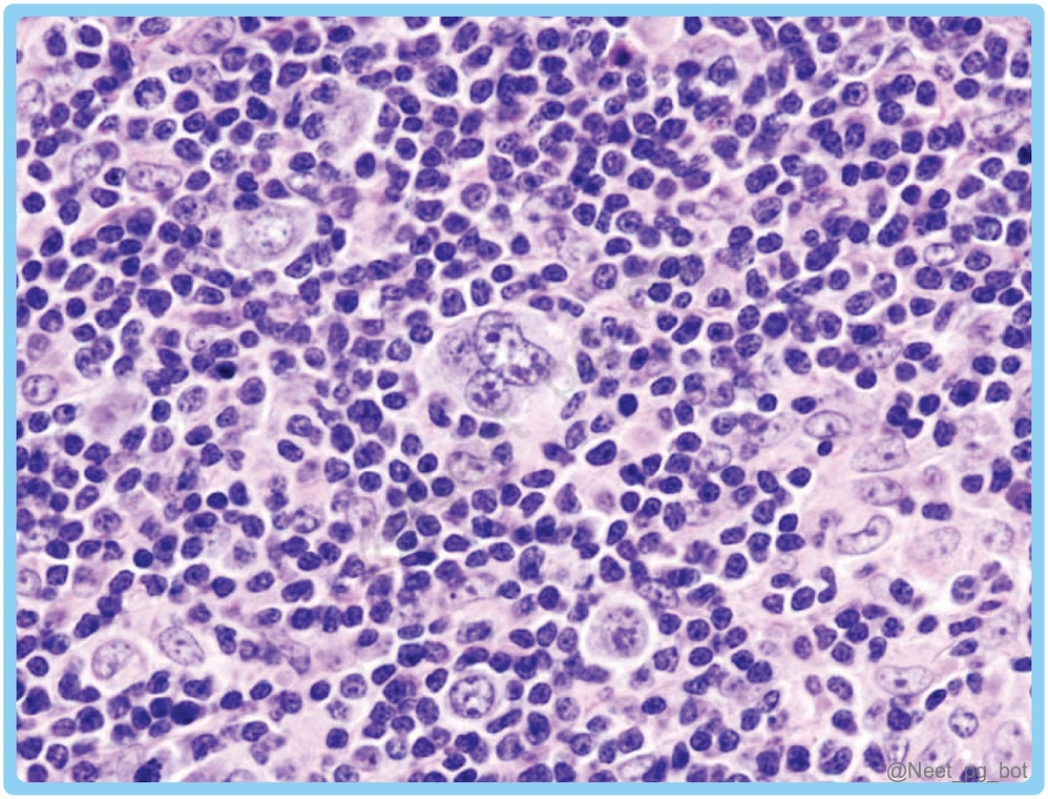

References:

Robbins, Cotran & Kumar, Pathologic Basis of Disease, 11th Edition, Page 558

↑ *Back to this question in Part A*

@Neet_pg_bot

Q7: A 65-year-old man presents with fever, weight loss, and generalized lymphadenopathy (Stage III). Lymph node biopsy shows numerous classic Reed–Sternberg cells in a mixed inflammatory background. Which of the following statements regarding this subtype of hodgkin lymphoma is incorrect? (Q884858)

A. It often presents at advanced stage.

B. EBV positivity is seen in approximately 70% of cases.

C. It accounts for about 20–25% of Hodgkin lymphoma cases.

D. It most commonly presents as a mediastinal mass in young females.

Correct Answer: D. It most commonly presents as a mediastinal mass in young females.

Explanation: The clinical description provided—a 65-year-old man with fever, weight loss, and a biopsy showing Reed–Sternberg cells in a "mixed inflammatory background"—identifies this subtype as Mixed Cellularity Hodgkin Lymphoma (MCHL) . Presenting as a mediastinal mass in young females is the classic clinical hallmark of Nodular Sclerosis Hodgkin Lymphoma (NSHL) , not the Mixed Cellularity subtype. Mixed Cellularity Hodgkin Lymphoma: ~20–25% of Hodgkin lymphoma cases (Option C) Morphology: Diffuse effacement of lymph node Mixed inflammatory "list-style-type:square" aria-level="3">T cells, eosinophils, plasma cells, macrophages Numerous classic Reed–Sternberg cells and mononuclear variants ~70% EBV positive (Option B) Clinical features: More common in males Often older patients Frequently presents with B symptoms (fever, night sweats, weight loss) More likely advanced stage at diagnosis (Option A) Overall prognosis remains very good.

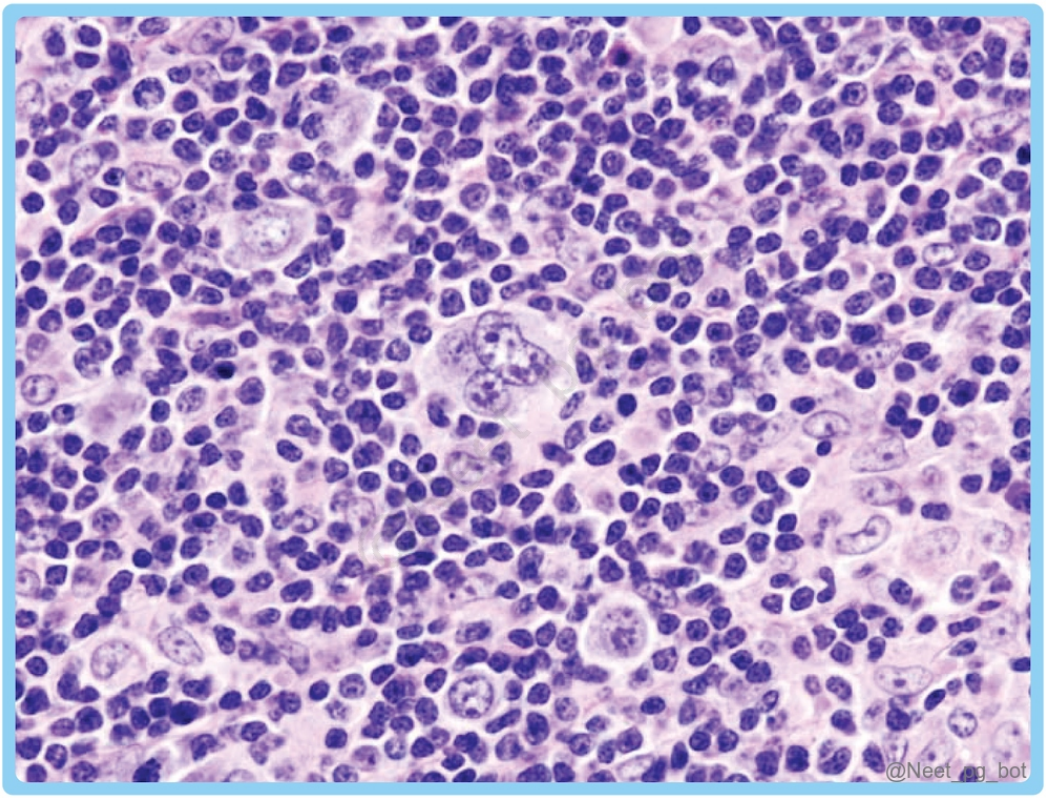

References:

Robbins, Cotran & Kumar, Pathologic Basis of Disease, 11th Edition, Page 557

↑ *Back to this question in Part A*

@Neet_pg_bot

Q8: A lymph node biopsy shows a ring of tightly packed small B lymphocytes surrounding a germinal center and displaced outward by it. Which zone is being described? (Q884865)

A. Germinal center

B. Mantle zone

C. Marginal zone

D. Paracortex

Correct Answer: B. Mantle zone

Explanation: The mantle zone consists of tightly packed small naïve B lymphocytes that form a ring around the germinal center and are pushed outward by it. Germinal Centre: (Option A) Round/oval zone containing pale-staining cells surrounded by darker cells Predominantly B lymphocytes Centroblasts (dark zone) Centrocytes (light zone) Scattered follicular T helper (Tfh) cells and T regulatory cells Tingible body macrophages Follicular dendritic cells (FDCs) Mantle zone: Tightly packed small naïve B lymphocytes Surrounds and is pushed outward by the germinal centre Marginal zone: (Option C) Loosely arranged small B lymphocytes with more cytoplasm Located at the outer rim of the mantle zone Contains: Post-follicular memory B cells (T-cell dependent responses) Naïve B cells Often poorly developed in the lymph nodes Paracortex (Option D) : The region between the follicles and the medulla, primarily populated by T lymphocytes and high endothelial venules.

References:

https://www.pathologyoutlines.com/topic/lymphnodesanatomy.html

https://pmc.ncbi.nlm.nih.gov/articles/PMC9985168/

↑ *Back to this question in Part A*

@Neet_pg_bot

Q9: Which of the following is a T-cell neoplasm? (Q884874)

A. Follicular lymphoma

B. Mantle cell lymphoma

C. Anaplastic large-cell lymphoma

D. Burkitt lymphoma

Correct Answer: C. Anaplastic large-cell lymphoma

Explanation: Anaplastic large-cell lymphoma is a T-cell lymphoma (often CD30+). WHO classification of lymphoid neoplasms: Precursor B-cell neoplasm: B-cell acute lymphoblastic leukaemia/lymphoma (B-ALL) Peripheral B-cell neoplasm: Chronic lymphocytic leukaemia/small lymphocytic lymphoma B-cell prolymphocytic leukaemia Lymphoplasmacytic lymphoma Splenic and nodal marginal zone lymphomas Extranodal marginal zone lymphoma Mantle cell lymphoma (Option B) Follicular lymphoma (Option A) Marginal zone lymphoma Hairy cell leukaemia Plasmacytoma/plasma cell myeloma Diffuse large B-cell lymphoma Burkitt lymphoma (Option D) Precursor T-cell neoplasm T-cell acute lymphoblastic leukaemia/lymphoma (T-ALL) Peripheral T-cell and

NK-cell neoplasms T-cell prolymphocytic leukaemia Large granular lymphocytic leukaemia Mycosis fungoides/Sézary syndrome Peripheral T-cell lymphoma, unspecified Anaplastic large-cell lymphoma Angioimmunoblastic T-cell lymphoma Enteropathy-associated T-cell lymphoma Panniculitis-like T-cell lymphoma Hepatosplenic γδ T-cell lymphoma Adult T-cell leukaemia/lymphoma Extranodal NK/T-cell lymphoma NK-cell leukaemia Hodgkin's lymphoma: Classic subtypes Nodular sclerosis Mixed cellularity Lymphocyte-rich Lymphocyte depletion Nodular lymphocyte predominant

References:

Robbins, Cotran & Kumar, Pathologic Basis of Disease, 11th Edition, Page 538

↑ *Back to this question in Part A*

@Neet_pg_bot

Q10: Which of the following is the most common site of primary extranodal non-Hodgkin lymphoma? (Q884877)

A. Skin

B. Gastrointestinal tract

C. Central nervous system

D. Bone marrow

Correct Answer: B. Gastrointestinal tract

Explanation: The gastrointestinal tract is the most common site of primary extranodal non-Hodgkin lymphoma. Primary Extranodal Lymphoma (pENL): Lymphoma arising in tissues other than lymph nodes. Most common site: Gastrointestinal Tract - specifically the stomach, followed by the small and large bowel. Other sites: Head/Neck (nasopharynx), Testis, Uterus/Ovary, Thyroid, and CNS. Most common subtype: Diffuse Large B-cell Lymphoma (DLBCL) .

References:

https://pmc.ncbi.nlm.nih.gov/articles/PMC5686961/

↑ *Back to this question in Part A*

@Neet_pg_bot

Q11: A 65-year-old man presents with lymphadenopathy and lymphocytosis. Lymph node biopsy & peripheral smear findings are as shown. Which feature is

pathognomonic for this condition? (Q884878)

A. Smudge cells

B. Diffuse lymph node effacement

C. Proliferation centres

D. Bone marrow involvement

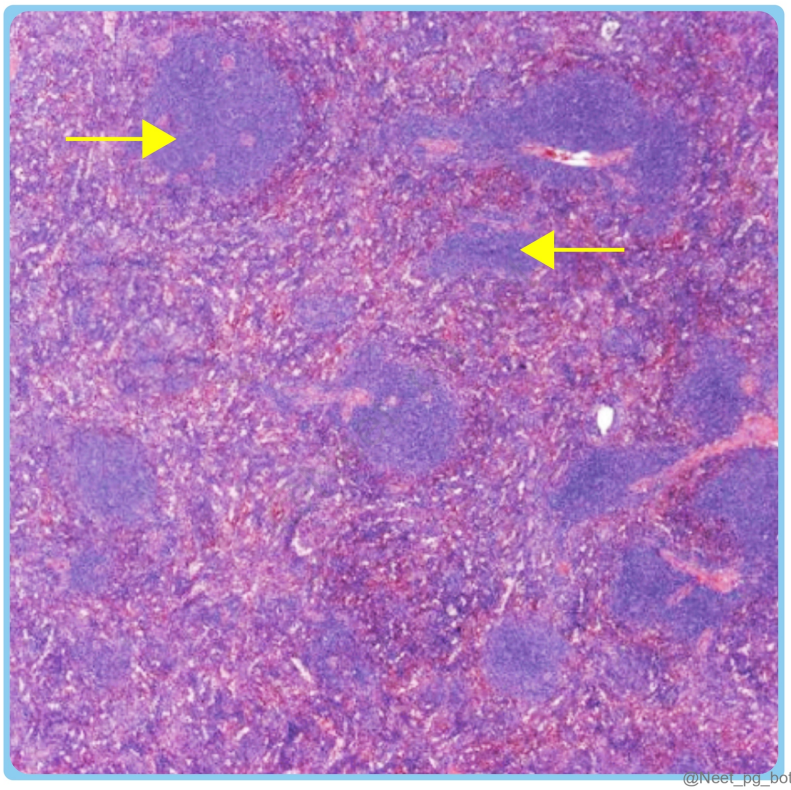

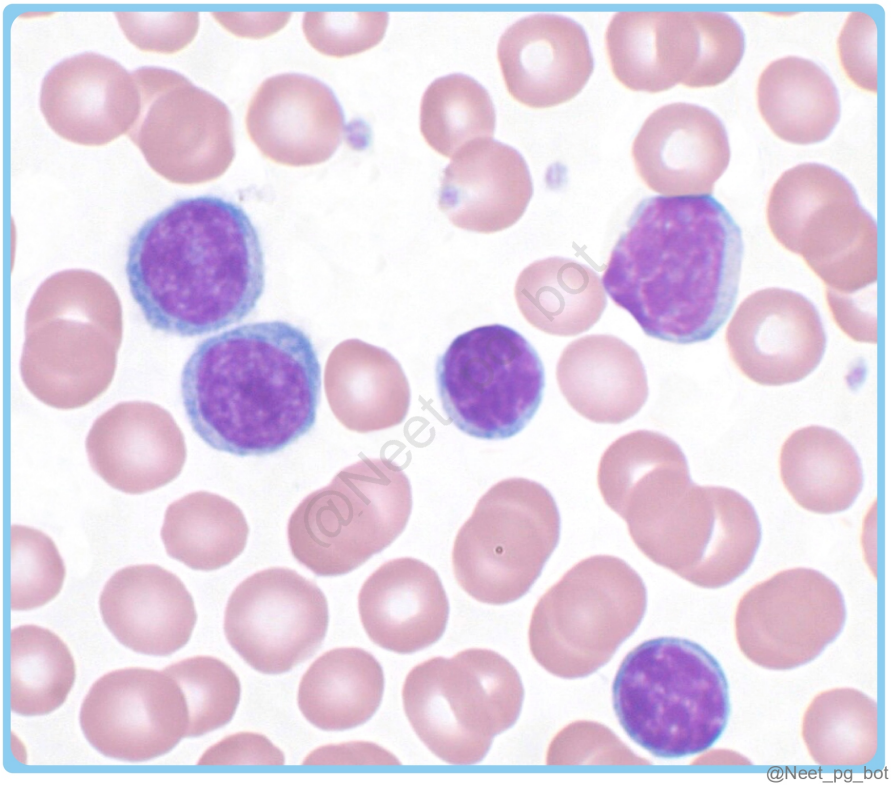

Correct Answer: C. Proliferation centres

Explanation: Lymph node biopsy shows diffuse sheets of small lymphocytes with scattered pale nodular aggregates of larger activated cells, and the Peripheral smear shows smudge cells. The clinical presentation described (65-year-old male, lymphadenopathy, lymphocytosis, and smudge cells) is classic for Chronic Lymphocytic Leukaemia (CLL) / Small Lymphocytic Lymphoma (SLL) . Proliferation centres are pathognomonic for Chronic Lymphocytic Leukaemia / Small Lymphocytic Lymphoma. Chronic Lymphocytic Leukaemia / Small Lymphocytic Lymphoma (CLL/SLL): Lymph node findings: Diffuse effacement of lymph node architecture Predominantly small lymphocytes (6-12 µm) Round to slightly irregular nuclei Condensed (clumped) chromatin Scant cytoplasm Proliferation centres (pseudofollicles) present: Aggregates of larger activated lymphocytes Contain mitotically active cells Pathognomonic for CLL/SLL Smudge cells (Option A): These are fragile lymphocytes seen on peripheral smear in CLL, but they are not specific and therefore not pathognomonic . Diffuse lymph node effacement (Option B): Although seen in CLL/SLL, diffuse effacement can occur in many other lymphomas , so it is not diagnostic . Bone marrow involvement (Option D): Bone marrow infiltration is common in CLL/SLL, but it is not unique to this disease and therefore not pathognomonic .

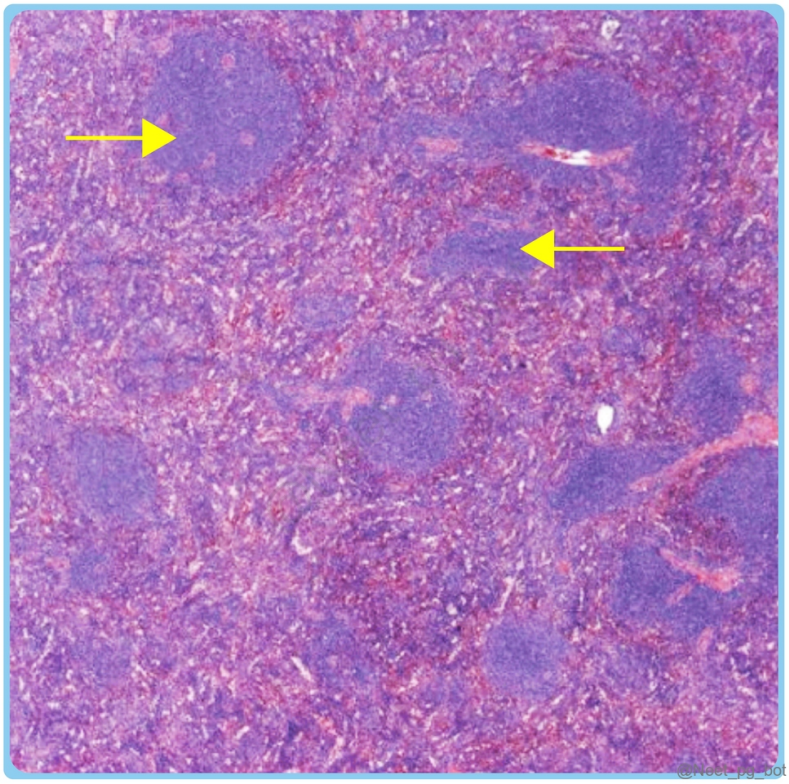

References:

Robbins, Cotran & Kumar, Pathologic Basis of Disease, 11th Edition, Page 543

↑ *Back to this question in Part A*

@Neet_pg_bot

Q12: What is the most common subtype of Hodgkin lymphoma? (Q884841)

A. Lymphocyte-rich

B. Mixed cellularity

C. Nodular sclerosis

D. Lymphocyte-depleted

Correct Answer: C. Nodular sclerosis

Explanation: The most common subtype of Hodgkin lymphoma is Nodular sclerosis . Nodular Sclerosis Hodgkin Lymphoma (NSHL): Most common subtype (65–70%) Histology: ■■ Lacunar Reed–Sternberg cells Collagen bands → nodular appearance Mixed inflammatory background Immunophenotype markers: Positive: PAX5, CD15, CD30 Negative: CD45, other B/T markers Clinical: Adolescents & young adults Equal M:F Cervical,

supraclavicular, mediastinal nodes EBV: Uncommon association Prognosis: Excellent Lymphocyte-rich (Option A) : Uncommon subtype; characterised by predominance of reactive lymphocytes with few classic Reed–Sternberg cells; very good prognosis. Mixed cellularity (Option B) : Second most common (20–25%); diffuse pattern with numerous RS cells; frequently EBV-associated; more common in older males. Lymphocyte-depleted (Option D) : Least common (<5%); numerous pleomorphic RS cells with paucity of lymphocytes; associated with HIV, elderly patients, advanced stage; poorer prognosis.

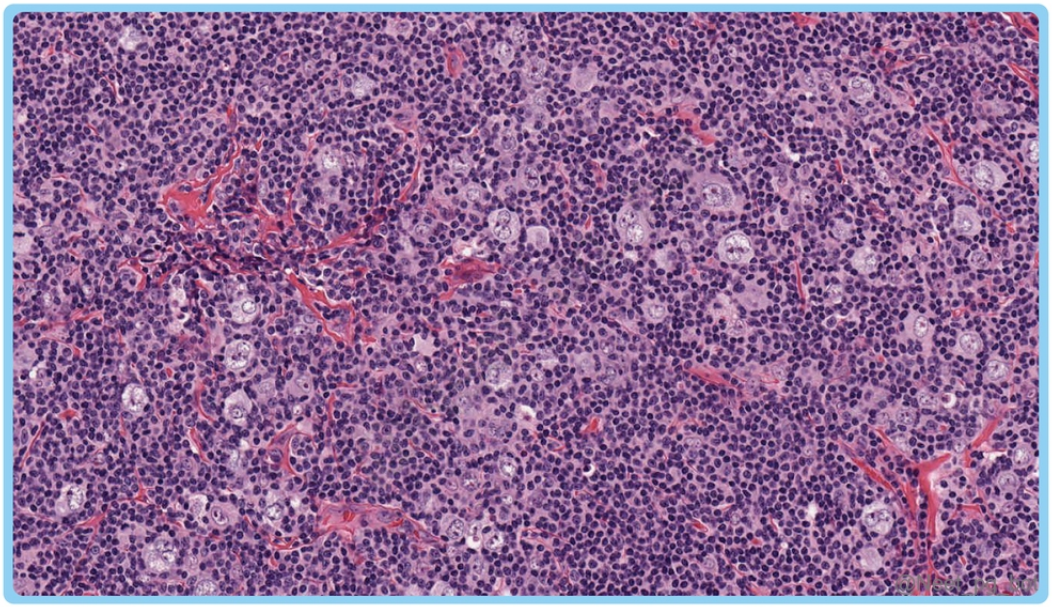

References:

Robbins, Cotran & Kumar, Pathologic Basis of Disease, 11th Edition, Page 557

↑ *Back to this question in Part A*

@Neet_pg_bot

Q13: Which of the following statements about extranodal marginal zone (MALT) lymphoma is correct? (Q884881)

A. t(11;18) translocation makes it antigen-dependent

B. Spreads systemically early

C. May regress if inciting agent is removed

D. Not associated with chronic inflammation

Correct Answer: C. May regress if inciting agent is removed

Explanation: Extranodal MALT lymphoma often develops in chronically inflamed tissues (e.g., H. pylori gastritis) and can regress if the triggering antigen is eliminated. Extranodal MZL (MALToma): Triggers: Chronic inflammation (autoimmune or infection) Salivary gland – Sjögren syndrome Thyroid – Hashimoto thyroiditis Stomach – H. pylori gastritis Features: Localized disease for long periods (Option B) May regress if trigger removed Pathogenesis: Reactive Phase: Begins as polyclonal lymphoid hyperplasia due to chronic antigenic stimulation. Early Neoplastic Phase: Emergence of a monoclonal B-cell population Still antigen-dependent Tumor may regress if antigen is removed Antigen-Independent Phase: (Option A) Chromosomal translocations (t(11;18), t(14;18), t(1;14)) These upregulate BCL10 or MALT1 Activation of NF-κB pathway → promotes B-cell survival and proliferation Advanced Disease: Systemic spread Possible transformation to Diffuse Large B-Cell Lymphoma (DLBCL)

References:

Robbins, Cotran & Kumar, Pathologic Basis of Disease, 11th Edition, Pages 548, 549

↑ *Back to this question in Part A*

@Neet_pg_bot

Q14: Marginal zone lymphoma primarily arises from which type of B cell? (Q884882)

A. Naïve B cells

B. Memory B cells

C. Plasma cells

D. Pre-B cells

Correct Answer: B. Memory B cells

Explanation: Marginal zone lymphomas originate from memory B cells , often showing somatic hypermutation. Sites: Lymph nodes, spleen, extranodal (MALT)

References:

Robbins, Cotran & Kumar, Pathologic Basis of Disease, 11th Edition, Page 548

↑ *Back to this question in Part A*

@Neet_pg_bot

Q15: Extranodal marginal zone (MALT) lymphoma is commonly associated with which of the following conditions? Sjögren syndrome Hashimoto thyroiditis Helicobacter pylori gastritis (Q884884)

A. 1 and 2 only

B. 2 and 3 only

C. 1 and 3 only

D. 1, 2, and 3

Correct Answer: D. 1, 2, and 3

Explanation: Extranodal Marginal Zone (MALT) Lymphoma is fundamentally a malignancy that arises in the context of chronic persistent inflammation . This inflammation can be triggered by either autoimmune disorders or chronic infections, which provide the stimulus for B-cell proliferation. Extranodal MZL (MALToma): Triggers: Chronic inflammation (autoimmune or infection) Salivary gland - Sjögren syndrome Thyroid - Hashimoto thyroiditis Stomach - H. pylori gastritis Features: Localized disease for long periods May regress if trigger removed

References:

Robbins, Cotran & Kumar, Pathologic Basis of Disease, 11th Edition, Page 548,549

↑ *Back to this question in Part A*

@Neet_pg_bot

Q16: A 62-year-old man presents with generalized exfoliative erythroderma and intense pruritus. Examination reveals diffuse lymphadenopathy. Peripheral blood smear shows findings as shown. Skin biopsy demonstrates dermal infiltration by atypical CD4■ T cells. What is the most likely diagnosis? (Q884885)

A. Sézary syndrome

B. Mycosis fungoides

C. Peripheral T-cell lymphoma

D. Adult T-cell leukemia/lymphoma

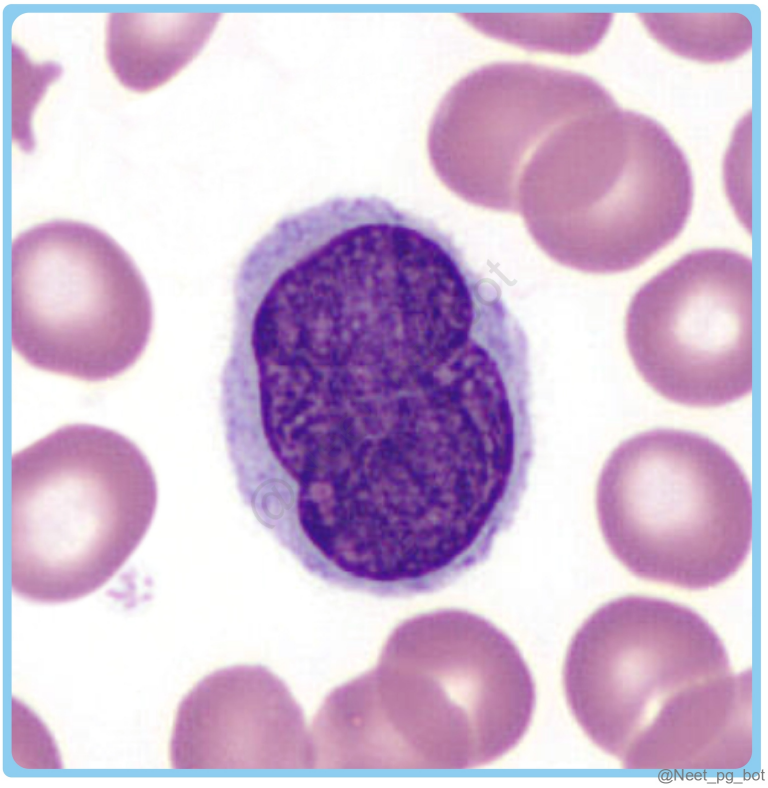

Correct Answer: A. Sézary syndrome

Explanation: The most likely diagnosis is B. Sézary syndrome. It presents with the triad of generalized erythroderma, lymphadenopathy, and circulating malignant T cells (Sézary cells) with cerebriform nuclei in peripheral blood (leukemic phase). Sezary syndrome: Generalized exfoliative erythroderma Leukemia of Sézary cells (cerebriform nuclei) Generalized lymphadenopathy Skin lesions rarely form tumors Prognosis: More aggressive than MF Poorer survival (minority alive at 5 years) Mycosis fungoides (Option A) : Typically presents with patch/plaque/tumor stages confined mainly to skin early; leukemic involvement is not a defining early feature. Peripheral T-cell lymphoma (Option C) : Usually presents with nodal/systemic disease without characteristic erythroderma and circulating Sézary cells. Adult T-cell leukemia/lymphoma (Option D) : Associated with HTLV-1 infection and commonly presents with hypercalcemia and systemic disease rather than classic erythroderma with Sézary cells.

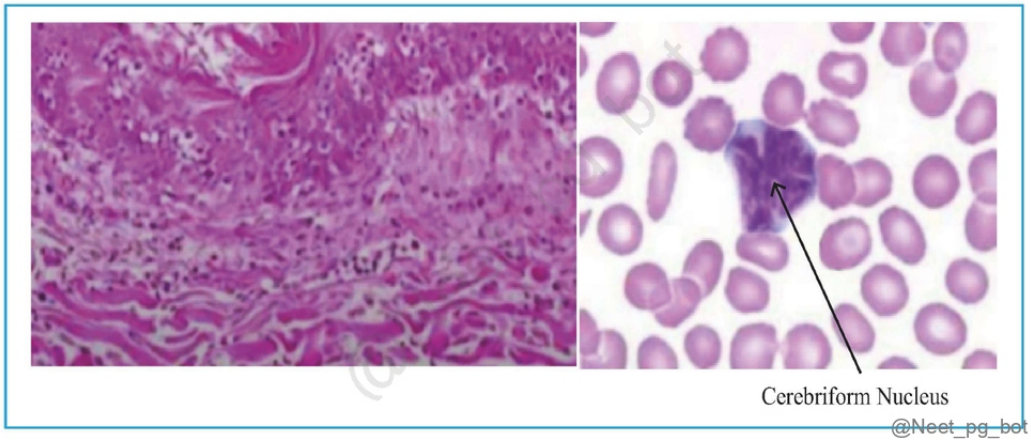

References:

Robbins, Cotran & Kumar, Pathologic Basis of Disease, 11th Edition, Pages 551, 552

↑ *Back to this question in Part A*

@Neet_pg_bot

Q17: A 60-year-old woman with rheumatoid arthritis presents with recurrent infections. She has splenomegaly and neutropenia. Peripheral smear shows large lymphocytes with azurophilic granules. Cells are CD3■. What is the most likely diagnosis? (Q884888)

A. Chronic lymphocytic leukemia

B. Hairy cell leukemia

C. Large granular lymphocytic leukemia

D. Sézary syndrome

Correct Answer: C. Large granular lymphocytic leukemia

Explanation: The most likely diagnosis is Large granular lymphocytic (LGL) leukemia . It classically presents in adults with rheumatoid arthritis (Felty-like association), neutropenia, splenomegaly, and large granular CD3■ T lymphocytes with azurophilic granules on peripheral smear. Large Granular Lymphocytic (LGL) Leukemia: Types: T-cell (CD3■) - more common, indolent NK-cell (CD3■, CD56■) - more aggressive Age: Adults Key Mutation: STAT3 mutation (30–40%) → cytokine-independent activation Morphology: Large lymphocytes Pale cytoplasm with azurophilic granules Clinical features: Neutropenia (common) Anemia ± pure red cell aplasia Splenomegaly Strong association with autoimmune disorders (e.g., Felty syndrome) Clonal cytotoxic T/NK-cell proliferation → prominent cytopenias + autoimmunity. Chronic lymphocytic leukemia (Option A) : Characterized

by small mature lymphocytes with smudge cells, not large granular cells. Hairy cell leukemia (Option B) : Shows cells with cytoplasmic “hairy” projections and marked pancytopenia with massive splenomegaly. Sézary syndrome (Option D) : Presents with erythroderma and circulating cerebriform T cells, not granular cytotoxic lymphocytes.

References:

Robbins, Cotran & Kumar, Pathologic Basis of Disease, 11th Edition, Page 552

↑ *Back to this question in Part A*

@Neet_pg_bot

Q18: A 70-year-old man presents with fever, weight loss, and rapidly enlarging lymph nodes. Biopsy shows diffuse sheets of large CD20+ B cells. EBER in situ hybridisation is positive in tumour cells. What is the most likely diagnosis? (Q884909)

A. Epstein-Barr virus-positive diffuse large B-cell lymphoma

B. Classic Hodgkin lymphoma

C. Burkitt lymphoma

D. Angioimmunoblastic T-cell lymphoma

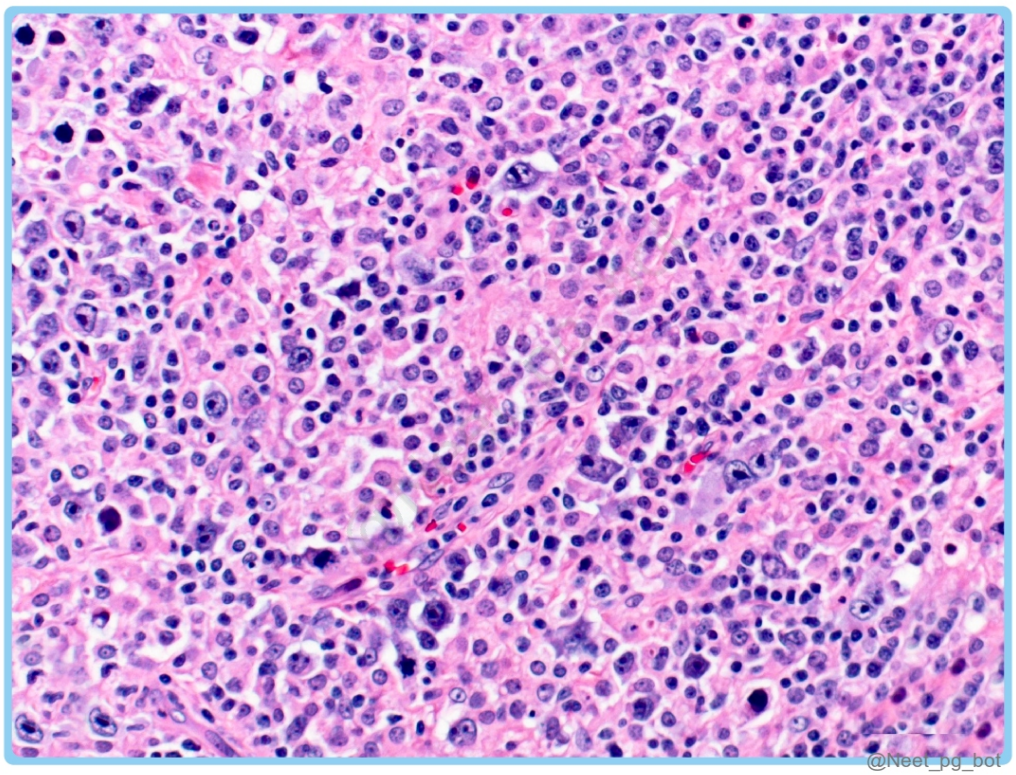

Correct Answer: A. Epstein-Barr virus-positive diffuse large B-cell lymphoma

Explanation: The most likely diagnosis is Epstein-Barr virus-positive diffuse large B-cell lymphoma (EBV+ DLBCL) . The patient has an aggressive large B-cell lymphoma (CD20 positive) with strong EBER positivity, indicating EBV-driven disease. The activated B-cell phenotype and presentation in an older adult with B symptoms are characteristic. Epstein-Barr virus-positive diffuse large B-cell lymphoma (EBV+ DLBCL) : A subtype of Diffuse Large B-Cell Lymphoma associated with Epstein–Barr virus (EBV). Occurs in both elderly and younger patients ~2–14% of DLBCL cases. More common in older adults. Slight male predominance. Pathogenesis: EBV infects B cells → viral proteins (e.g., LMP1) activate the NF-κB pathway. Usually shows an activated B-cell (ABC) phenotype. Most cases exhibit the EBV latency II pattern. Clinical features: Rapid lymphadenopathy. B symptoms (fever, weight loss, night sweats). Often advanced stage with extranodal involvement. Diagnosis: Lymph node biopsy. EBV detection by EBER in situ hybridisation. Treatment: Treated with standard R-CHOP–based chemotherapy. Response may be inferior to EBV-negative DLBCL. Prognosis: Generally poorer than EBV-negative DLBCL. High EBV load may indicate a worse outcome. Classic Hodgkin lymphoma (Option B) : Reed–Sternberg cells (CD15+, CD30+), not diffuse CD20+ sheets. Burkitt lymphoma (Option C) : MYC translocation, starry-sky pattern, very high Ki-67. Angioimmunoblastic T-cell lymphoma (Option D) : T-cell (CD3+) neoplasm, not B-cell.

References:

https://www.ncbi.nlm.nih.gov/books/NBK578250/

↑ *Back to this question in Part A*

@Neet_pg_bot

Q19: A 62-year-old man is newly diagnosed with diffuse large B-cell lymphoma. The clinician plans to calculate the International Prognostic Index (IPI) score to assess prognosis. Which of the following are included in the IPI score? Age >60 years Elevated serum lactate dehydrogenase (LDH) Presence of B symptoms ECOG performance status ≥2 More than one extranodal site (Q884910)

A. 1, 2, 3

B. 1, 2, 4, 5

C. 2, 3, 4

D. 1, 3, 5

Correct Answer: B. 1, 2, 4, 5

Explanation: The International Prognostic Index (IPI) includes five clinical variables: Age > 60 years Ann Arbor Stage III or IV disease Serum LDH above the upper limit of normal ECOG Performance Status ≥ 2 >1 extranodal site of involvement

References:

https://pmc.ncbi.nlm.nih.gov/articles/PMC10620582/

↑ *Back to this question in Part A*

@Neet_pg_bot

Q20: A 70-year-old man with a 5-year history of chronic lymphocytic leukaemia develops rapidly enlarging lymph nodes, fever, weight loss, and elevated LDH. Lymph node biopsy shows diffuse large B-cell lymphoma. What is the most likely diagnosis? (Q884911)

A. Progressive CLL

B. Richter syndrome

C. Prolymphocytic transformation

D. Hodgkin lymphoma

Correct Answer: B. Richter syndrome

Explanation: The most likely diagnosis is Richter syndrome (also known as Richter transformation). An important factor affecting survival in chronic lymphocytic leukaemia / small lymphocytic lymphoma (CLL/SLL) is its ability to transform into a more aggressive malignancy. Most common transformation: Transformation to Diffuse Large B-Cell Lymphoma (DLBCL) Known as Richter syndrome Occurs in approximately 5–10% of patients with CLL/SLL Associated with rapid clinical deterioration (Most survive < 2 years) Markedly worse prognosis compared to typical CLL Progressive CLL (Option A) : Shows gradual progression, not transformation to DLBCL. Prolymphocytic transformation (Option C) : Characterised by increased circulating prolymphocytes, not DLBCL. Hodgkin lymphoma (Option D) : Rare transformation variant; biopsy would show Reed-Sternberg cells.

References:

Robbins, Cotran & Kumar, Pathologic Basis of Disease, 11th Edition, Page 544

↑ *Back to this question in Part A*

@Neet_pg_bot

Q21: A 15-year-old boy presents with painless lymphadenopathy. Biopsy shows findings as shown. Tumour cells are CD30 positive and ALK positive. What is the most likely diagnosis? (Q884912)

A. Diffuse large B-cell lymphoma

B. Classical Hodgkin lymphoma

C. Anaplastic large-cell lymphoma

D. Adult T-cell leukaemia/lymphoma

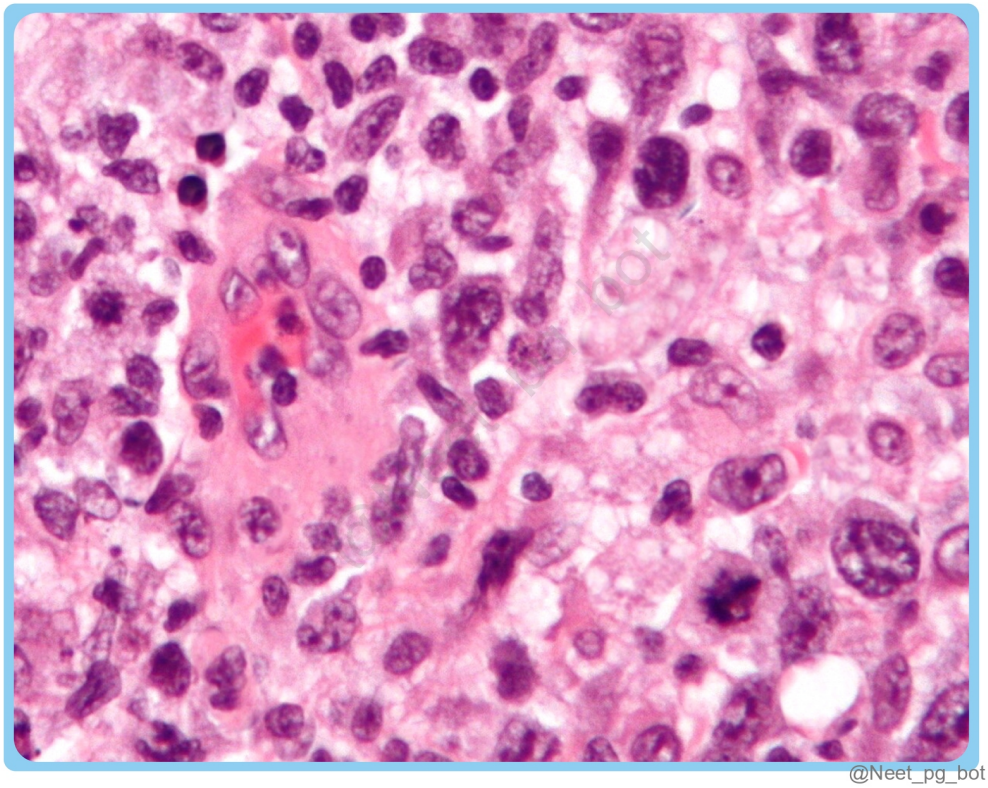

Correct Answer: C. Anaplastic large-cell lymphoma

Explanation: The most likely diagnosis is Anaplastic large-cell lymphoma (ALCL) . The image showing large cells with horseshoe-shaped or kidney-shaped nuclei is the definitive morphological feature of ALCL. Anaplastic large cell lymphoma: Caused by ALK gene rearrangement (2p23) → ALK fusion protein Constitutive tyrosine kinase activation → RAS & JAK/STAT signalling IHC: ALK positive, CD30 positive Morphology: Large anaplastic cells Characteristic “hallmark cells” : Horseshoe / embryoid nuclei Abundant cytoplasm Tumour cells may cluster around venules Can mimic metastatic carcinoma Common in children & young adults Often involves lymph nodes and soft tissues Prognosis: Good prognosis Cure rate with chemotherapy: 75-80% ALK inhibitors are effective in refractory cases ALK-negative type: Occurs in older adults Worse prognosis Also CD30 positive Lacks ALK rearrangement Diffuse large B-cell lymphoma (Option A) : Typically CD20 positive (B-cell markers) and ALK negative; lacks hallmark cells. Classical Hodgkin lymphoma (Option B) : CD30 positive but ALK negative; shows Reed-Sternberg cells. Adult T-cell leukaemia/lymphoma (Option D) : Associated with HTLV-1 infection and does not show ALK positivity or hallmark cells.

References:

Robbins, Cotran & Kumar, Pathologic Basis of Disease, 11th Edition, Page 551

↑ *Back to this question in Part A*

@Neet_pg_bot

Q22: Match the following lymphomas with their cell of origin. Lymphoma/leukaemia Cell of origin 1. Diffuse large B-cell lymphoma a. Memory B-cell 2. Mantle cell lymphoma b. Germinal/post germinal center B cell 3. Hairy cell lymphoma c. Helper T-cell 4. Mycosis fungoides d. Naive B cell (Q845823)

A. 1-b, 2-a, 3-c, 4-d

B. 1-a, 2-b, 3-d, 4-c

C. 1-d, 2-a, 3-d, 4-c

D. 1-b, 2-d, 3-a, 4-c

Correct Answer: D. 1-b, 2-d, 3-a, 4-c

■ *Listen (English)*

■ *Listen (Hindi)*

Explanation: Neoplasm Cell of origin Description Diffuse large B-cell lymphoma (Statement 1) Germinal/post-germinal center B cells Most common NHL. Associated with BCL6 gene rearrangement If CLL transforms into DLBCL, it is called Richter's Syndrome. Hairy cell leukemia (Statement 3) Memory B cells More common in boys. BRAF V600E Mutation + It presents with massive splenomegaly affecting the red pulp of the spleen. Mantle cell lymphoma (Statement 2) Naive B cell Translocation t(11:14). Associated with GIT polyps. Cyclin D1 and SOX11 +ve, Mycosis Fungoides (Statement 4) Helper T cells Cutaneous T-cell NHL. presents with erythema and pruritus. If it affects the blood vessels, it is known as Sezary syndrome.

References:

Robbin’s and Cotran, Pathological Basis of Disease, 10th Edition, Pages 594-595

↑ *Back to this question in Part A*

@Neet_pg_bot

Q23: In the WHO classification of Hodgkin lymphoma, which marker is typically expressed in classical Hodgkin lymphoma? (Q845792)

A. CD20

B. CD15

C. CD45

D. BCL-6

Correct Answer: B. CD15

■ *Listen (English)*

■ *Listen (Hindi)*

Explanation: The CD15 marker is typically expressed by Reed-Sternberg cells in classical Hodgkin lymphoma, aiding in its identification and diagnosis. WHO Classification of Hodgkin lymphoma: 1. Classical Hodgkin Lymphoma (CHL) Nodular Sclerosis Hodgkin Lymphoma Mixed Cellularity Hodgkin Lymphoma Lymphocyte-Rich Hodgkin Lymphoma Lymphocyte-Depleted Hodgkin Lymphoma 2. Non-classical lymphoma: Nodular Lymphocyte-Predominant Hodgkin Lymphoma (NLPHL) CD20, CD45, and BCL-6 are expressed in Non-classical Nodular Lymphocyte-Predominant Hodgkin Lymphoma. (Option A,C,D)

References:

Robbin's and Cotran, Pathological Basis of Disease,10th Edition, Page 611

↑ *Back to this question in Part A*

@Neet_pg_bot

Q24: Match the following characteristic cells with their corresponding histopathological variant of Hodgkin lymphoma: Cells A) Popcorn cells B) Lacunar cells C) Mononuclear cells D) Reed-Sternberg cells Histopathology 1. Classical Hodgkin Lymphoma (general type) 2.Mixed Cellularity Classical Hodgkin Lymphoma 3. Nodular Sclerosis Classical Hodgkin Lymphoma 4. Nodular Lymphocyte Predominant Hodgkin Lymphoma (Q845796)

A. A-4, B-3, C-2, D-1

B. A-1, B-4, C-3, D-2

C. A-3, B-2, C-1, D-4

D. A-4, B-1, C-2, D-3

Correct Answer: A. A-4, B-3, C-2, D-1

Explanation: Cells Histopathological variants of Hodgkin's Lymphoma Mononuclear cells (Option C) Single nucleus with a large, inclusion-like nucleolus with abundant cytoplasm. Seen in Mixed Cellularity Hodgkin Lymphoma Popcorn cells (Option A) Cells with multiple infolded nuclear membranes, small nucleoli, fine

chromatin, and abundant pale cytoplasm. Seen in Nodular lymphocyte - Predominant Hodgkin lymphoma. Reed-sternberg cell (Option D) It is characterised by two nuclear lobes, large inclusion-like nucleoli, and abundant cytoplasm and is typically surrounded by lymphocytes, macrophages, and an eosinophil. Classic Hodgkin Lymphoma (general type) Lacunar cells (Option B) Typically found in the nodular sclerosis subtype. Nuclei are more delicate, folded, or multilobate. Abundant pale cytoplasm often gets disrupted during sectioning, creating an appearance where the nucleus sits in an empty space (lacuna).

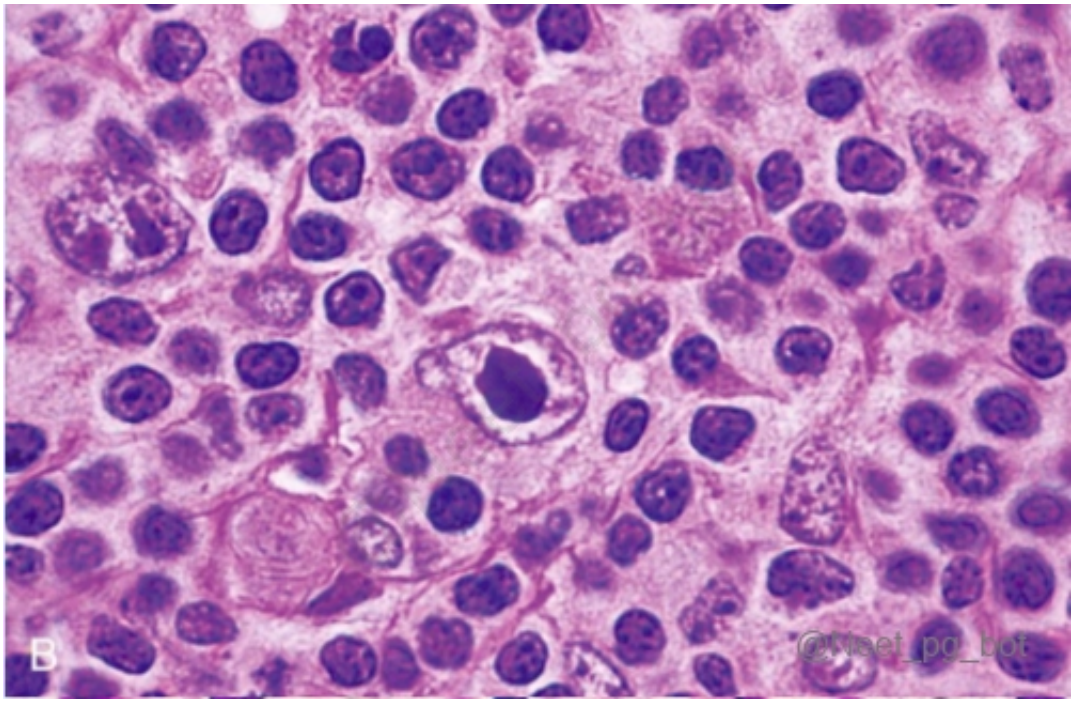

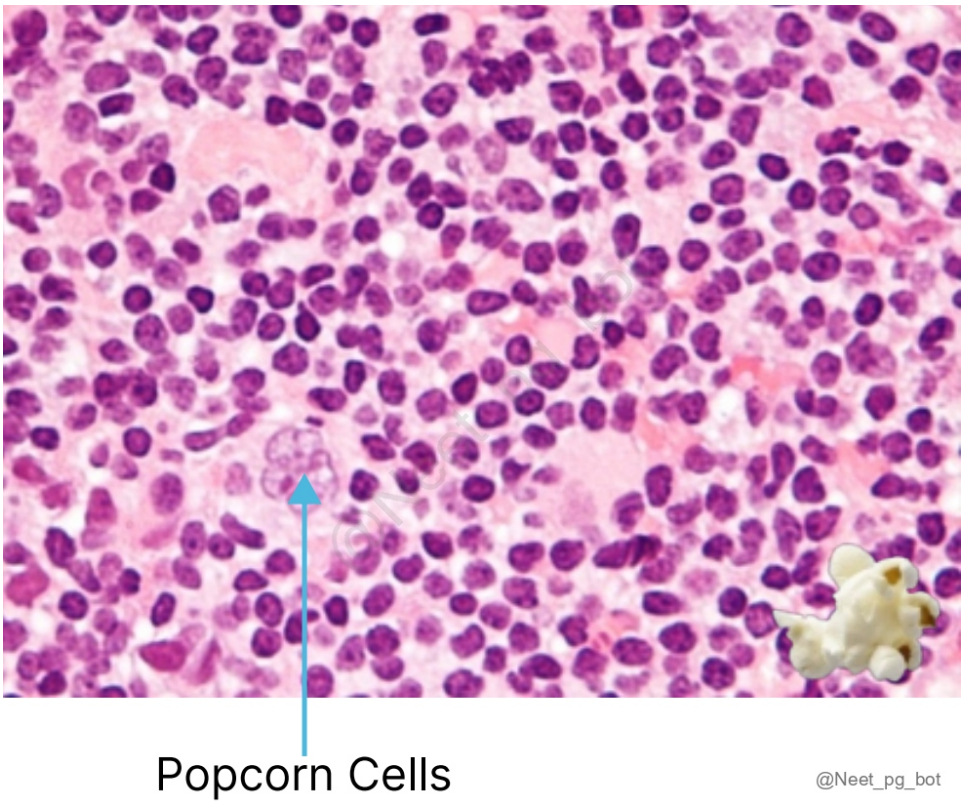

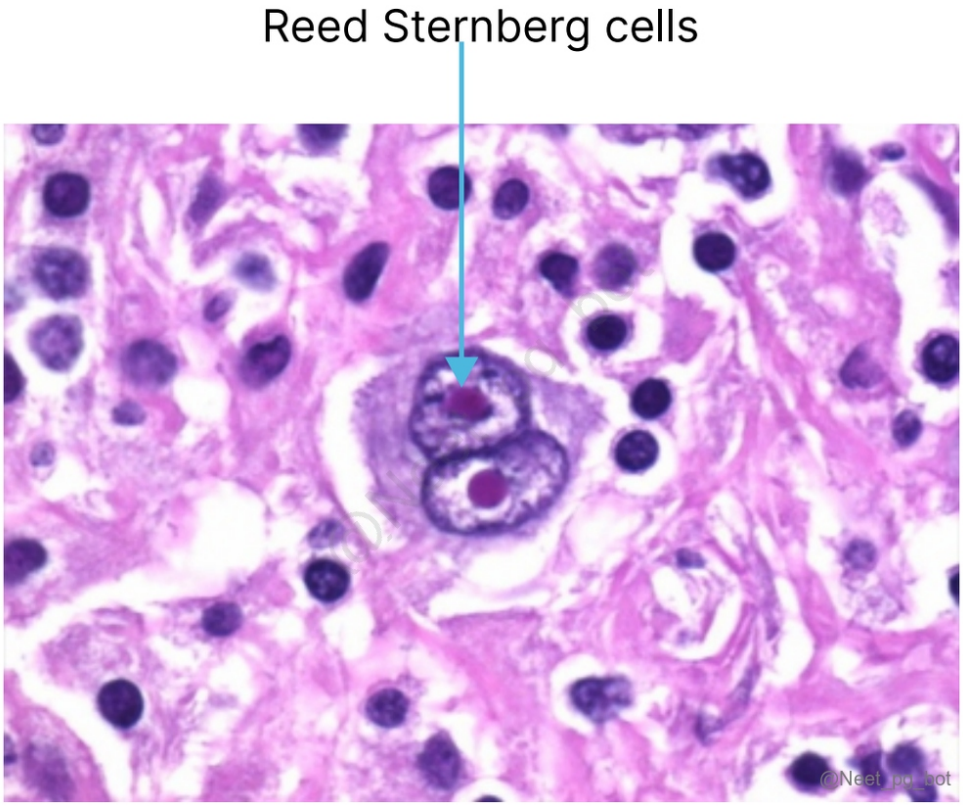

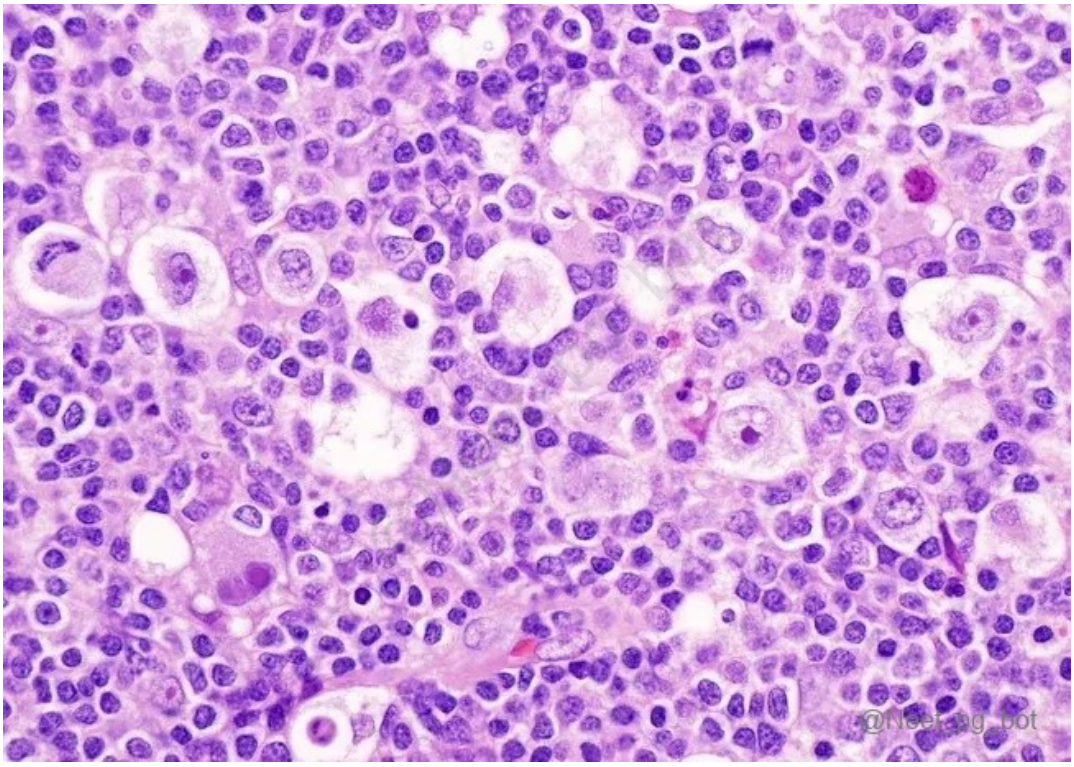

References:

Robbin’s and Cotran Pathological Basis of Disease, 10th Edition, Page 612

↑ *Back to this question in Part A*

@Neet_pg_bot

Q25: A 28-year-old female presents with painless swelling in her neck and shortness of breath. Imaging studies reveal a large mediastinal mass. A biopsy of the lymph node shows frequent lacunar cells and Reed-Sternberg cells. The RS cells are positive for CD15 and CD30 and usually negative for EBV. Which subtype of Hodgkin's lymphoma is most likely? (Q845799)

A. Nodular Sclerosis Classical Hodgkin Lymphoma

B. Nodular Lymphocyte-Predominant Hodgkin Lymphoma

C. Lymphocyte-Rich Classical Hodgkin Lymphoma

D. Lymphocyte-depleted classical Hodgkin Lymphoma

Correct Answer: A. Nodular Sclerosis Classical Hodgkin Lymphoma

■ *Listen (English)*

■ *Listen (Hindi)*

Explanation: The given clinical scenario points towards diagnosing Nodular Sclerosis type of Classical Hodgkin Lymphoma which features characteristic Lacunar variant Reed-Sternberg cells and collagen deposition in lymph nodes. Its background includes T cells, eosinophils, plasma cells, and macrophages, with occasional diagnostic Reed-Sternberg cells, which express PAX5, CD15, and CD30. Spread may involve spleen, liver, and bone marrow, infrequently associated with Epstein-Barr virus. Occurring equally in males and females, it commonly affects lower cervical, supraclavicular, and mediastinal lymph nodes in adolescents or young adults and has an excellent prognosis. Nodular Lymphocyte-Predominant Hodgkin Lymphoma (Option B) is characterised by a background of follicular dendritic cells and reactive B cells, with frequent lymphocyte-rich (Popcorn cell) variants, typically does not express CD15 or CD30 and is usually EBV-negative. Lymphocyte-Rich Classical Hodgkin Lymphoma (Option C) is characterised by a background infiltrate rich in T lymphocytes, with frequent mononuclear and diagnostic RS cells. RS cells of this type typically express CD15 and CD30 and are usually EBV-negative. Lymphocyte-Depleted Classical Hodgkin Lymphoma (Option D) has a paucity of background reactive cells and frequent diagnostic RS cells. RS cells in lymphocyte-depleted classical Hodgkin lymphoma typically express CD15 and CD30 and are usually EBV-positive. It often presents with advanced disease.

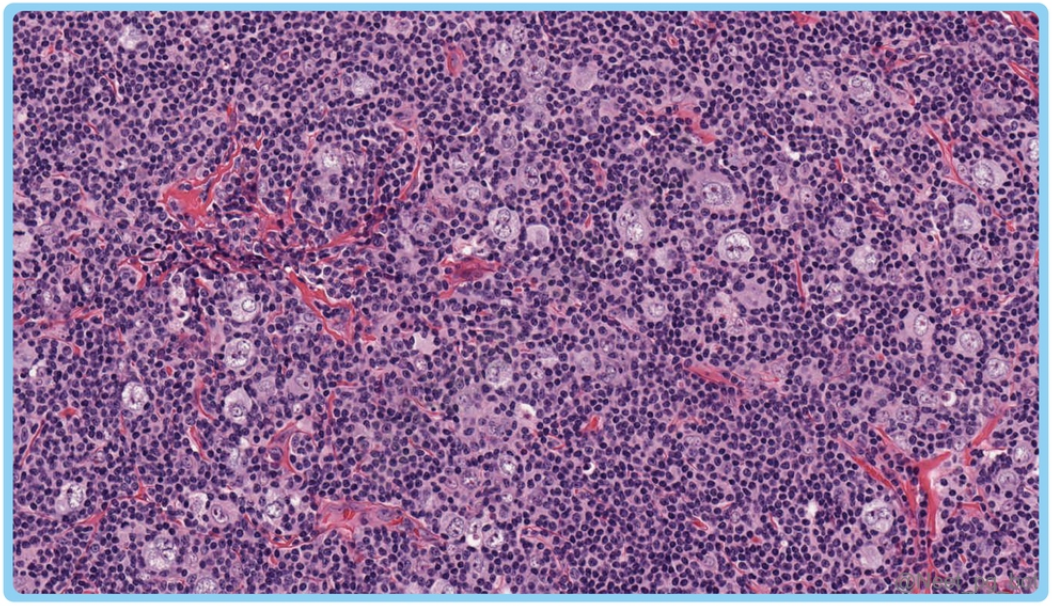

References:

Robbin’s and Cotran, Pathological Basis of Disease, 10th Edition, Page 612

↑ *Back to this question in Part A*

@Neet_pg_bot

Q26: A 35-year-old male presents with painless swelling of multiple lymph nodes, fever, night sweats, and weight loss. A biopsy of the affected lymph node reveals the presence of Reed-Sternberg cells. Which of the following options regarding Mixed cellularity type Hodgkin’s Lymphoma is not true? (Q845800)

A. It is characterised by frequent mononuclear and diagnostic Reed-Sternberg (RS) cells.

B. RS cells in this subtype typically express CD15 and CD30.

C. More than 70% of cases are Epstein-Barr virus (EBV) positive.

D. It is usually associated with a better prognosis than other subtypes of Hodgkin’s lymphoma.

Correct Answer: D. It is usually associated with a better prognosis than other subtypes of Hodgkin’s lymphoma.

■ *Listen (English)*

■ *Listen (Hindi)*

Explanation: Mixed Cellularity Hodgkin's Lymphoma often presents at an advanced stage (III or IV), which is generally associated with a worse prognosis compared to the Nodular Sclerosis subtype, which typically presents at an earlier stage (I or II) and has a relatively better prognosis. Mixed-Cellularity Hodgkin Lymphoma (MCHL) accounts for 20% to 25% of cases and features lymph nodes diffusely effaced by a heterogeneous cellular infiltrate, including T cells, eosinophils, plasma cells, and macrophages, along with abundant Reed-Sternberg and mononuclear variants. (Option A) Approximately 70% of Reed-Sternberg cells are EBV-positive. (Option B) RS cells are CD15+, CD30+ (Option C) MCHL is more prevalent in males and is more likely to be associated with systemic symptoms such as night sweats and weight loss.

References:

Robbin's and Cotran, Pathological Basis of Disease, 10th Edition, Page 612

↑ *Back to this question in Part A*

@Neet_pg_bot

Q27: A 32-year-old male presents with painless lymphadenopathy in the cervical region. A biopsy reveals the presence of numerous small lymphocytes with scattered large mononuclear Hodgkin and Reed-Sternberg cells, which are CD20 positive and CD15/CD30 negative. Which subtype of Hodgkin's lymphoma is most consistent with these findings? (Q845805)

A. Nodular sclerosis Hodgkin lymphoma

B. Mixed cellularity Hodgkin lymphoma

C. Nodular Lymphocyte-predominant Hodgkin lymphoma

D. Lymphocyte-depleted Hodgkin lymphoma

Correct Answer: C. Nodular Lymphocyte-predominant Hodgkin lymphoma

■ *Listen (English)*

■ *Listen (Hindi)*

Explanation: ■■■■■■■ Histological Features: Nodular Lymphocyte-predominant Hodgkin lymphoma is characterised by a predominance of reactive lymphocytes with relatively few Reed-Sternberg (RS) cells. Immunophenotype: The RS cells are typically positive for CD20 and negative for CD15 and CD30 , distinguishing it from other subtypes of Hodgkin lymphoma. Clinical Presentation: Patients often present with painless lymphadenopathy, commonly in peripheral lymph nodes rather than mediastinal involvement. Prognosis: This subtype generally has a favourable prognosis compared to other types of Hodgkin lymphoma due to its lower aggressiveness and higher responsiveness to treatment. Nodular sclerosis Hodgkin lymphoma (Option A) is the most common subtype, characterised by the presence of lacunar Reed-Sternberg cells and fibrous bands that divide the lymphoid tissue into nodules. These cells are usually positive for CD15 and CD30 but negative for CD20. Mixed cellularity Hodgkin lymphoma (Option B) features a heterogeneous mixture of cells, including

Reed-Sternberg cells, lymphocytes, eosinophils, neutrophils, and plasma cells. These cells are typically CD15 and CD30 positive but negative for CD20. Lymphocyte-depleted Hodgkin lymphoma (Option D) is the least common subtype and is characterised by a paucity of lymphocytes and a high number of pleomorphic, often bizarre Reed-Sternberg cells. These cells are usually CD15 and CD30 positive but negative for CD20 and associated with a poorer prognosis

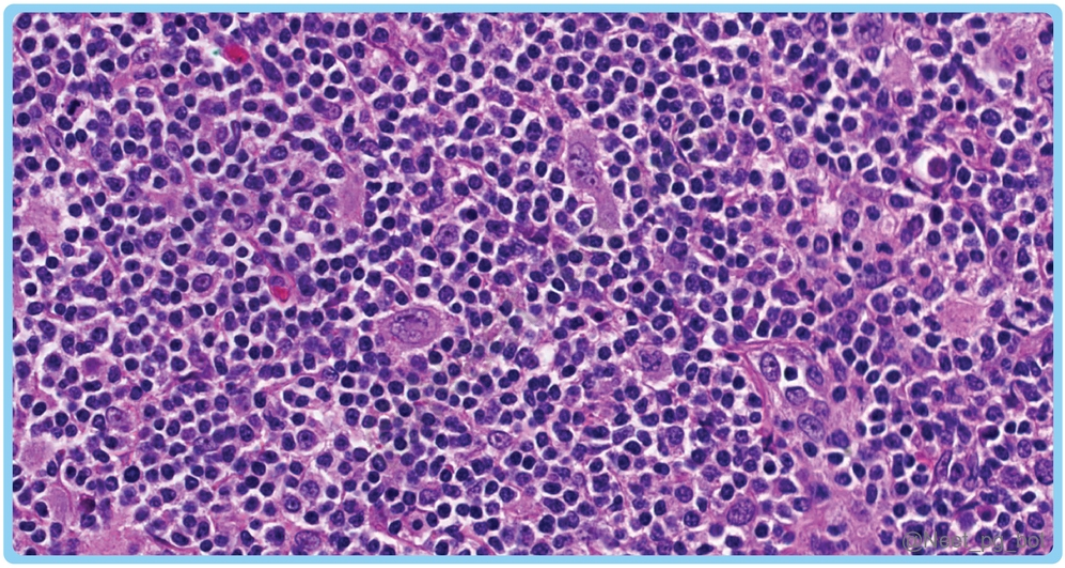

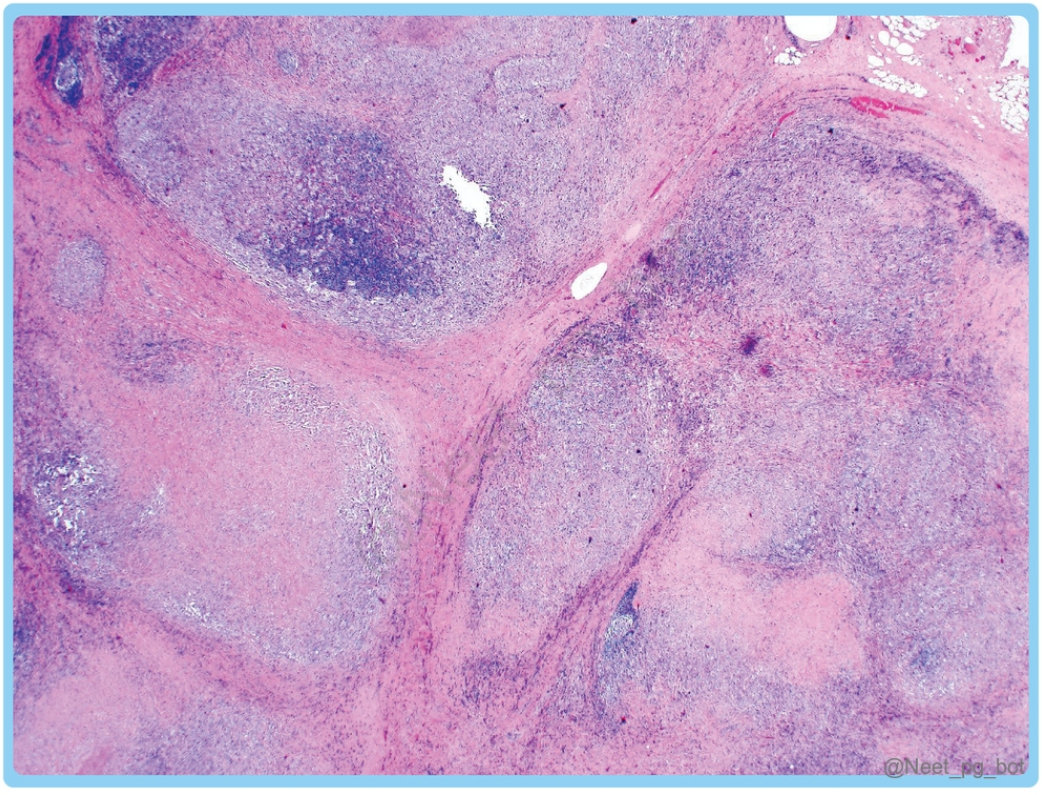

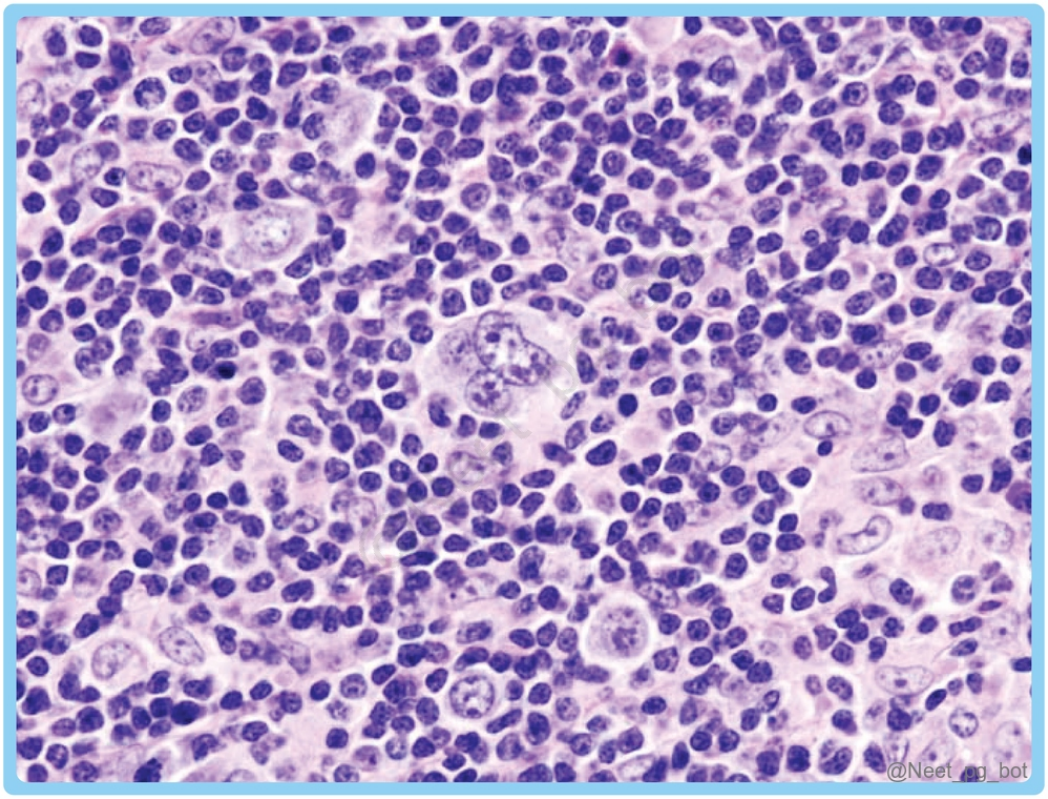

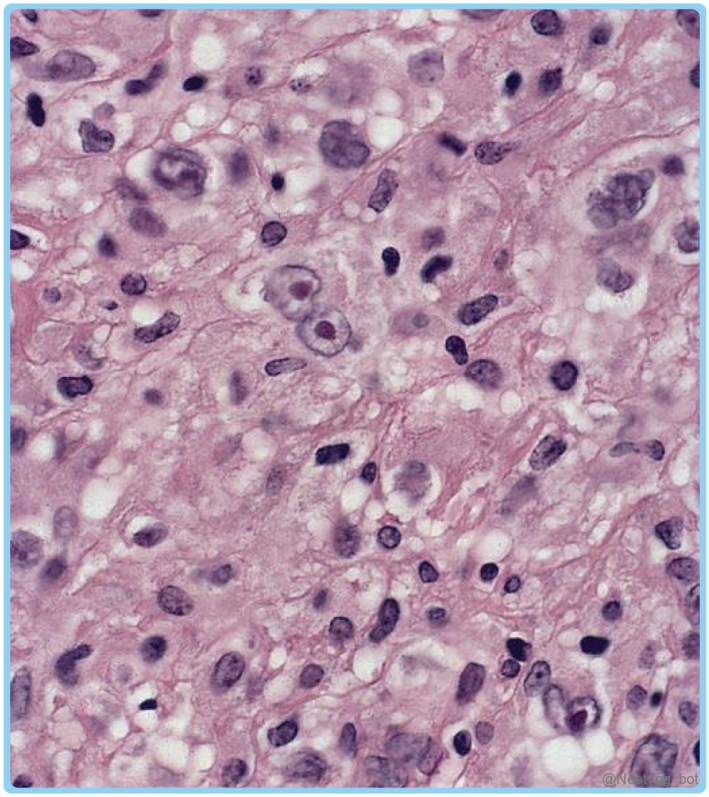

References:

Robbin’s and Cotran, Pathological Basis of Disease, 10th Edition, Page 613

↑ *Back to this question in Part A*

@Neet_pg_bot

Q28: A 65-year-old male with a history of HIV presents with fever, night sweats, and weight loss. A lymph node biopsy was done. Immunohistochemical staining shows these cells are CD15 and CD30 positive but CD20 negative. He was diagnosed with Lymphocyte-depleted Hodgkin's lymphoma. Which of the following features is characteristic of lymphocyte-depleted Hodgkin's lymphoma? (Q845806)

A. Presence of fibrous bands

B. Abundance of reactive lymphocytes

C. High number of Reed-Sternberg cells

D. Predominance of nodular growth pattern

Correct Answer: C. High number of Reed-Sternberg cells

■ *Listen (English)*

■ *Listen (Hindi)*

Explanation: Lymphocyte-depleted Hodgkin's lymphoma Histological Features: LDHL is characterised by a scarcity of lymphocytes and many pleomorphic, often bizarre Reed-Sternberg (RS) cells. The cellular environment is typically rich in fibrosis or necrosis. Presence of fibrous bands (Option A) it is characteristic of nodular sclerosis Hodgkin's lymphoma, not LDHL. Nodular sclerosis is marked by the presence of fibrous bands that divide the lymph node into nodules. Abundance of reactive lymphocytes (Option B) it is typical of lymphocyte-rich Hodgkin's lymphoma, a subtype characterised by an abundance of small, reactive lymphocytes and relatively few Reed-Sternberg cells. Predominance of nodular growth pattern (Option D) it is associated with nodular lymphocyte-predominant Hodgkin's lymphoma (NLPHL), not LDHL. It is characterised by a nodular growth pattern and the presence of "popcorn" or lymphocyte-predominant cells,

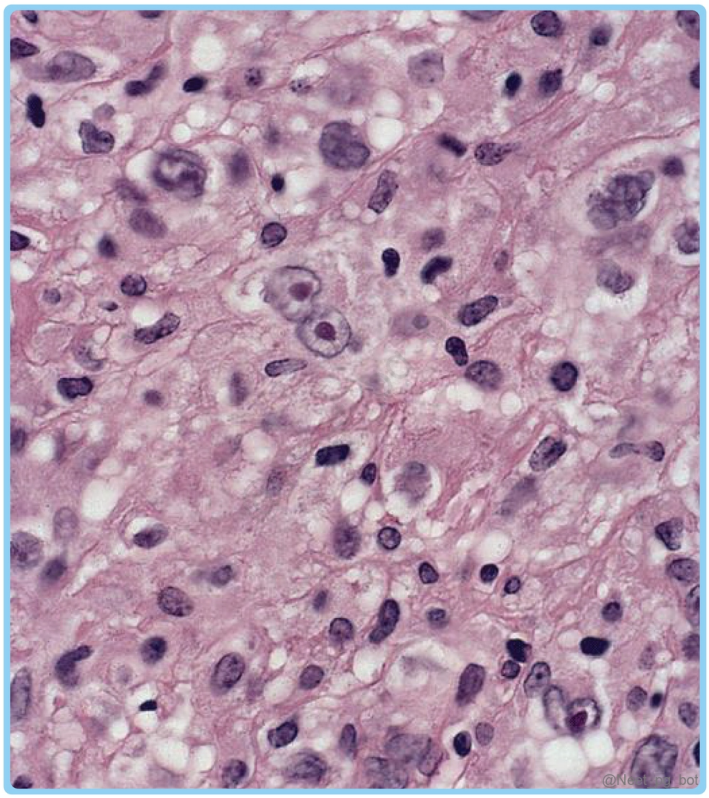

References:

Robbin’s and Cotran, Pathological Basis of Disease, 10th Edition, Page 614

↑ *Back to this question in Part A*

@Neet_pg_bot

Q29: A 35-year-old male presents with painless enlargement of cervical lymph nodes, accompanied by fever, night sweats, and weight loss. Biopsy reveals large, atypical cells with prominent nucleoli and a mixed inflammatory background. Immunohistochemical staining shows these cells are negative for CD15 and CD30. Which marker is most likely to be positive in these cells? (Q845807)

A. CD20

B. CD3

C. CD15

D. CD30

Correct Answer: A. CD20

■ *Listen (English)*

■ *Listen (Hindi)*

Explanation: Predominant (Non-Classical) Hodgkin Lymphoma: Histological Features: Predominant (Non-Classical) Hodgkin Lymphoma is characterised by large, atypical cells with prominent nucleoli and a mixed inflammatory background. Immunophenotype: The atypical cells in this subtype typically lack expression of CD15 and CD30 but are positive for CD20 and CD45 markers, distinct from classical Hodgkin lymphoma. Clinical Presentation: painless lymphadenopathy, fever, night sweats, and weight loss, similar to classical Hodgkin lymphoma Prognosis: overall survival rates may be lower compared to classical Hodgkin lymphoma. Epidemiology: Less common than classical Hodgkin lymphoma and may occur in younger and older adults. CD3 (Option B) is a marker of mature T lymphocytes and is not typically expressed by the large, atypical cells seen in Predominant (Non-Classical) Hodgkin's lymphoma CD15 and CD 30 (Option C) and (Option D) are markers commonly expressed on Reed-Sternberg cells in classical Hodgkin's lymphoma but is typically negative in predominantly (Non-Classical) Hodgkin's lymphoma

References:

Robbin's and Cotran, Pathological Basis of Disease, 10th Edition, Page 611

↑ *Back to this question in Part A*

@Neet_pg_bot

Q30: A 45-year-old male presents with painless swelling of multiple lymph nodes in his neck and groin. He denies experiencing fever, night sweats, or weight loss. Physical examination reveals bilateral cervical and inguinal lymphadenopathy. Based on the Ann Arbor classification, what is this patient's most likely stage of disease? (Q845808)

A. Stage I

B. Stage II

C. Stage III

D. Stage IV

Correct Answer: C. Stage III

■ *Listen (English)*

■ *Listen (Hindi)*

Explanation: Based on the Ann Arbor classification, Stage III involves lymph node regions on both sides of the diaphragm , corresponding to the presentation of bilateral cervical and inguinal lymphadenopathy in this patient. Clinical Staging of Hodgkins Lymphoma (Ann Arbor Classification) STAGE DISTRIBUTION OF DISEASE I Involvement of a single lymph node region (I) or a single extra lymphatic organ or site (IE). II Involvement of two

or more lymph node regions on the same side of the diaphragm alone (II) or localised involvement of an extra lymphatic organ or site (IIE). III Involvement of lymph node regions on both sides of the diaphragm without (III) or with (IIIE) localised involvement of an extra lymphatic organ or site. IV Diffuse involvement of one or more extra lymphatic organs or sites with or without lymphatic involvement. All stages are further divided based on the absence (A) or presence (B) of the following symptoms: unexplained fever, drenching night sweats, and/or unexplained weight loss of greater than 10% of normal body weight. Lugano Classification for Non-Hodgkins Lymphoma: Ann Arbor applies to both Hodgkin and non-Hodgkin lymphomas, but Lugano (2014 update) refines it with PET-CT emphasis and similar stage definitions. Lugano stage III: Nodes or spleen on both diaphragm sides. Key similarity: Diaphragm divides stages II/III; Lugano adds "bulky" for large masses >10 cm. Stage Description I One node or group of adjacent nodes (single site). IE Single extranodal lesion without nodal involvement. II ≥2 nodal groups, same side of diaphragm; may include limited contiguous extranodal (IIE). II bulky Stage II with mass ≥10 cm (or mediastinal >1/3 thoracic diameter). III Nodes/spleen on both sides of diaphragm. IV Noncontiguous extranodal sites (e.g., liver, bone marrow).

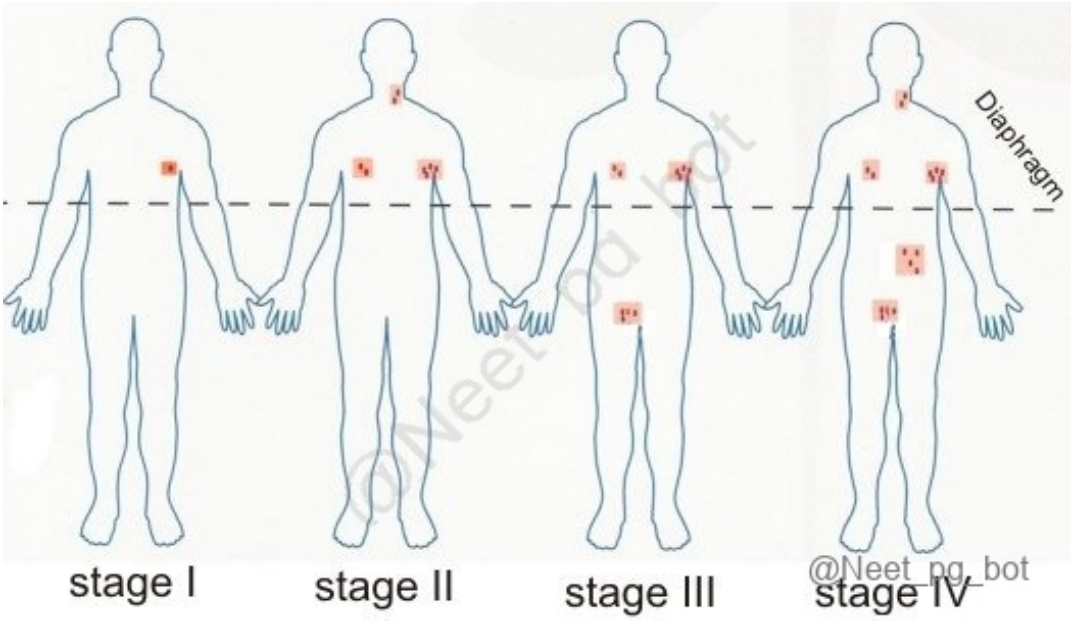

References:

Robbin’s and Cotran, Pathological Basis of Disease, 10th Edition, Page 615

↑ *Back to this question in Part A*

@Neet_pg_bot

Q31: A 40-year-old male presents with a palpable lump in his right axilla. Physical examination reveals a mobile, non-tender, and rubbery lymph node. FNAC is performed, and the sample is examined under the microscope. Which of the following histological features is characteristic of a normal lymph node? (Q845821)

A. Presence of large pleomorphic cells

B. Disorganized architecture with fibrosis

C. Distorted germinal centres and absence of sinuses

D. Distinct cortex and medulla with germinal centres and sinuses

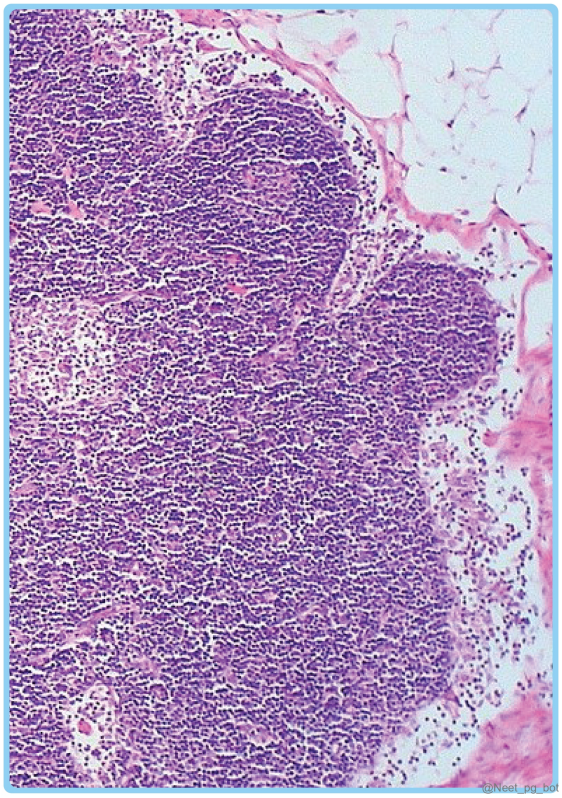

Correct Answer: D. Distinct cortex and medulla with germinal centres and sinuses

Explanation: Normal Lymph Node Histology: A normal lymph node is divided into distinct regions known as the cortex and medulla. Cortical Region: The cortex contains lymphoid follicles, which consist of densely packed B lymphocytes surrounding germinal centres. These germinal centres are sites of B cell proliferation and differentiation. Paracortex: Located between the cortex and medulla, the paracortex contains high concentrations of T lymphocytes and is involved in initiating cellular immune responses. Medullary Sinuses: The medulla contains medullary sinuses, which are spaces lined by endothelial cells and filled with lymph, serve as conduits for lymph drainage from the cortex to efferent lymphatic vessels. Medullary Cords: Interspersed between the medullary sinuses are medullary cords, which contain plasma cells, macrophages, and lymphocytes. These structures filter lymph and remove foreign particles and antigens. Afferent and Efferent Lymphatic Vessels: Lymph enters the lymph node through afferent lymphatic vessels and exits through efferent lymphatic vessels, allowing lymphocytes and antigen-presenting cells to interact with antigens and participate in immune responses. Presence of large pleomorphic cells (Option A) : These cells often indicate malignancy or infection rather than normal lymph node architecture. Disorganised architecture with fibrosis (Option B): Disorganised architecture with fibrosis is typically associated with pathological conditions, such as chronic inflammation or lymphoproliferative disorders. Distorted germinal centres and absence of sinuses (Option D): Distorted germinal centres and absence of sinuses may suggest pathological changes, such as lymphadenitis or lymphoma, rather than

normal histology.

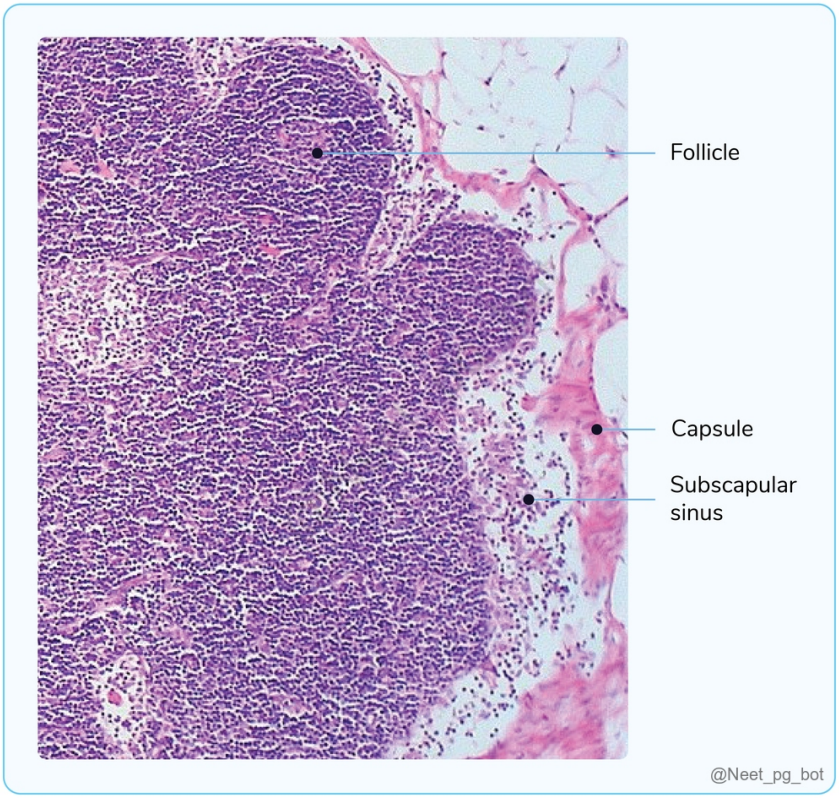

References:

Robbin's and Cotran Pathological Basis of Disease, 10th edition, Page 587

↑ *Back to this question in Part A*

@Neet_pg_bot

Q32: A 35-year-old woman came with complaints of chronic fatigue and a palpable nodular mass in her axilla. Further investigations reveal a B-cell neoplasm. Which of the following is the least likely diagnosis? (Q845822)

A. Follicular lymphoma

B. Marginal zone lymphoma

C. Hairy cell leukemia

D. Anaplastic large cell lymphoma

Correct Answer: D. Anaplastic large cell lymphoma

■ *Listen (English)*

■ *Listen (Hindi)*

Explanation: Anaplastic Large-cell lymphoma is a type of peripheral T-cell lymphoma, not a B-cell neoplasm. Peripheral B-cell neoplasm Chronic lymphocytic leukemia/small lymphocytic lymphoma B-cell prolymphocytic leukemia Lymphoplasmacytic lymphoma Splenic and nodal marginal zone lymphomas Extranodal marginal zone lymphoma Mantle cell lymphoma Follicular lymphoma (Option A) Marginal zone lymphoma (Option B) Hairy cell leukemia (Option C) Plasmacytoma/plasma cell myeloma Diffuse large B-cell lymphoma Burkitt lymphoma Peripheral T-Cell and NK-Cell Neoplasms T-cell prolymphocytic leukemia Large granular lymphocytic leukemia Mycosis fungoides/Sézary syndrome Peripheral T-cell lymphoma, unspecified Anaplastic large-cell lymphoma Angioimmunoblastic T-cell lymphoma Enteropathy-associated T-cell lymphoma Panniculitis-like T-cell lymphoma Hepatosplenic γδ T-cell lymphoma Adult T-cell leukemia/lymphoma Extranodal NK/T-cell lymphoma NK-cell leukemia

References:

Robbin’s and Cotran, Pathological Basis of Disease, 10th Edition, Page 592

↑ *Back to this question in Part A*

@Neet_pg_bot

Q33: A 30-year-old female presents with painless swelling of the neck, intermittent fever, night sweats and significant weight loss over the past three months. On examination, enlarged cervical and mediastinal lymph nodes are noted. A biopsy reveals the presence of characteristic cells, as shown in the image below. Which of the following about the described condition is NOT true? (Q845791)

A. More often localised to a single axial group of nodes

B. Typically, it spreads in a contiguous manner.

C. Mesenteric nodes and Waldeyer ring involvement are rare.

D. Extranodal presentation is common.

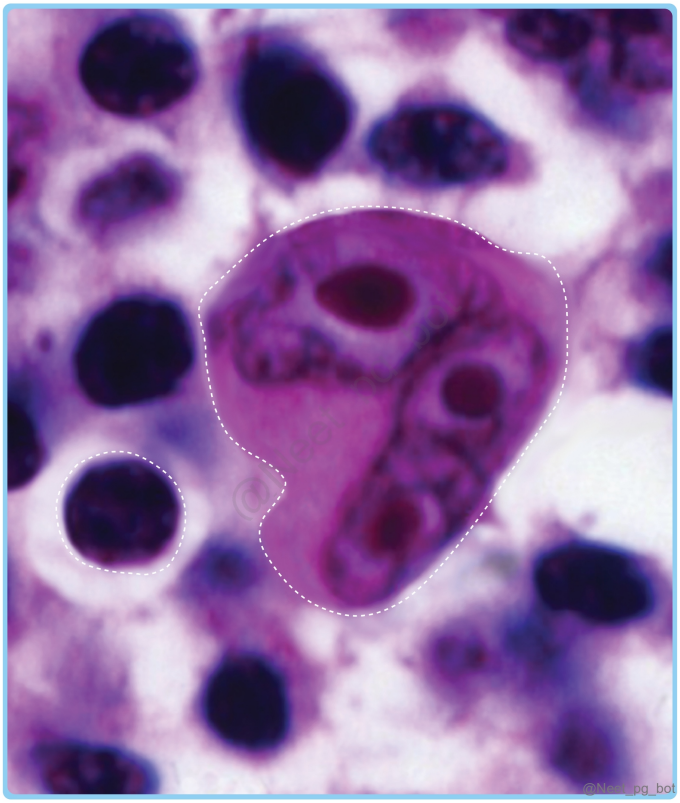

Correct Answer: D. Extranodal presentation is common.

- *Listen (English)*
- *Listen (Hindi)*

Explanation: The given clinical scenario and histopathological findings suggest a diagnosis of Hodgkin lymphoma, and the HPE reveals the presence of characteristic Reed-Sternberg cells. Hodgkin lymphoma typically spreads in an orderly, contiguous manner from one lymph node group to the next adjacent group without skipping areas. Feature Hodgkin Lymphoma (HL) Non-Hodgkin Lymphoma (NHL) Age of presentation Bimodal distribution peaks in young adults (15-35 years) and older adults (over 55). More common in older adults but can occur at any age. Localisation More often localised to a single axial group of nodes (cervical, mediastinal, para-aortic) (Option A) More frequent involvement of multiple peripheral nodes Pattern of Spread Orderly spread by contiguity Non Contiguous spread (Option B) Involvement of Mesenteric Nodes and Waldeyer Ring Mesenteric nodes and Waldeyer ring are rarely involved. (Option C) Waldeyer ring and mesenteric nodes are commonly involved. Extranodal Presentation Extranodal presentation is rare. Extranodal presentation is common. (Option D)

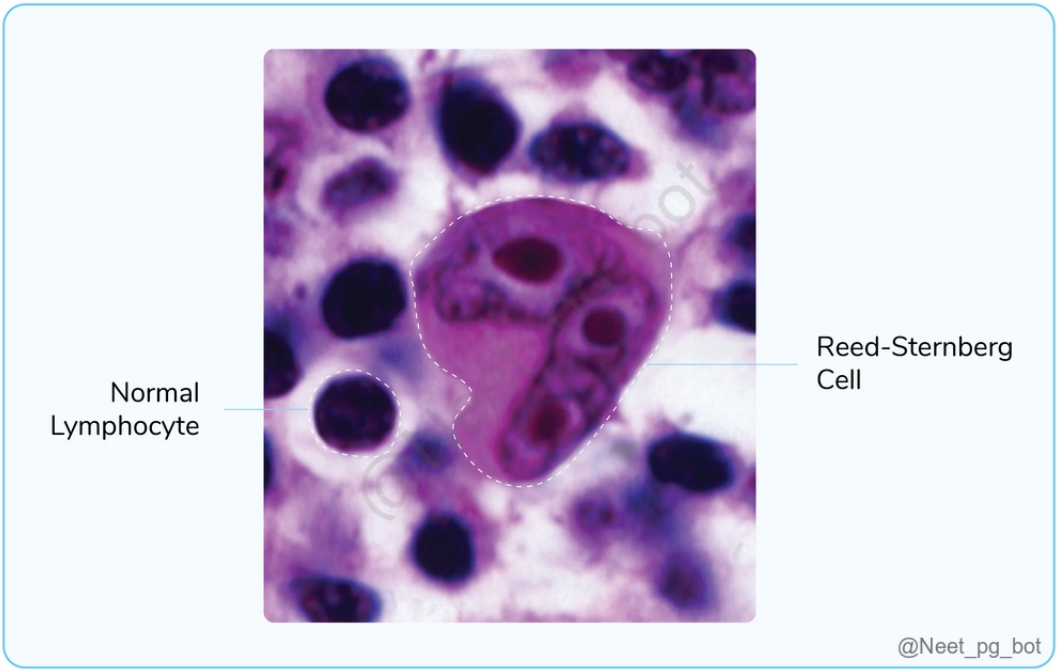

References:

Robbin's and Cotran, Pathological Basis of Disease,10th Edition, Page 611

↑ *Back to this question in Part A*

@Neet_pg_bot

Q34: An 8-year-old boy presents with a large mass over the mandible. On the HPE of the lesion, a 'starry sky pattern' is seen, similar to the image below. This condition is associated with which of the following genetic abnormalities? (Q845824)

A. MYC gene

B. BCL2 gene

C. Cyclin-D1

D. BCL6 gene

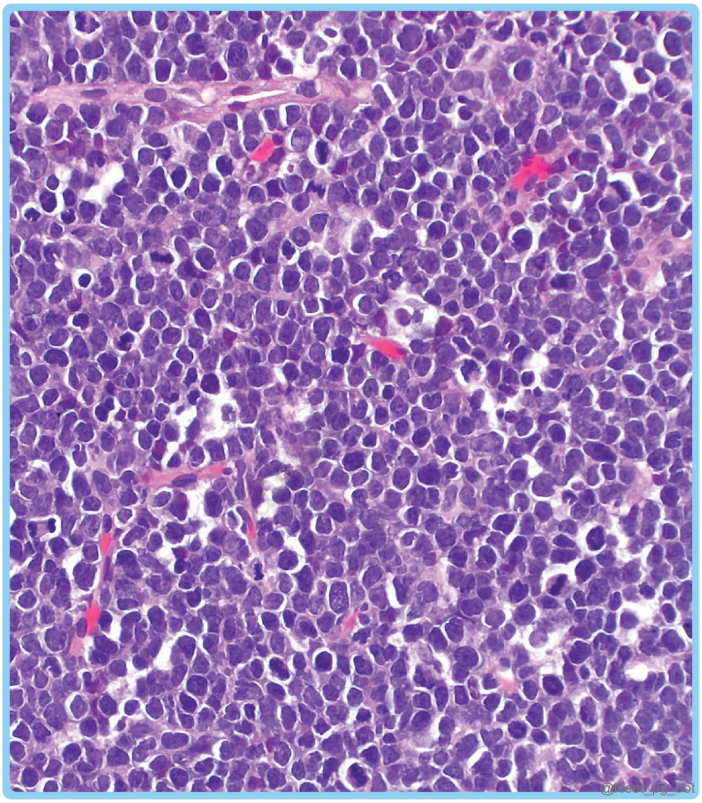

Correct Answer: A. MYC gene

- *Listen (English)*
- *Listen (Hindi)*

Explanation: The clinical presentation with mandibular mass and a starry sky appearance on HPE are characteristic of Burkitt’s lymphoma, which is associated with the translocation of the MYC gene on chromosome 8, thus leading to overexpression of the MYC protein. All forms of Burkitt’s lymphoma (Endemic, Sporadic and HIV associated) are associated with such translocations. The most common translocations are t (8:2), t(8:14), and t(8:22). Endemic Burkitt's lymphoma: Strong association with Epstein-Barr Virus Infection (~95%) Common in African children Jaw/facial bone involvement (very characteristic) Often involves kidneys, ovaries, and CNS Rx: Intensive short-course combination chemotherapy (e.g., CODOX-M/IVAC) Sporadic Burkitt's lym phoma: Seen worldwide (children & young adults) EBV association less common (~20–30%) Predominantly involves abdomen (ileocecal region) Presents with abdominal mass ± intussusception Rx: Aggressive multi-agent chemotherapy Immunodeficiency-associated Burkitt's lymphoma : Occurs in HIV Infection or post-transplant patients Intermediate EBV association (~30–40%) Commonly involves lymph nodes and bone marrow More aggressive; may present with systemic (B) symptoms Rx: Combination chemotherapy (dose-adjusted regimens), add Rituximab (anti-CD20) Ki-67 Index: Near 100% (indicates the fastest-growing human tumor). BCL2 gene (Option B) translocation is associated with follicular lymphoma. The most common is t(14;18), leading to the juxtaposition of the IGH locus (Ch 14) with the BCL2 locus(Ch 18), leading to overexpression of BCL2. Cyclin-D1 (Option C) gene translocation is associated with all mantle cell lymphoma. There is a translocation of the cyclin D1 locus on chromosome 11 and IGH locus on chromosome 14; t(11;14), which results in overexpression of cyclin D1, thus promoting G1 to S-phase progression in the cell cycle. BCL6 gene (Option D) dysregulation is associated with Diffuse large B cell lymphoma. It can occur due to translocations or promoter sequence mutations of the BCL6 gene on Chr. 3q27.

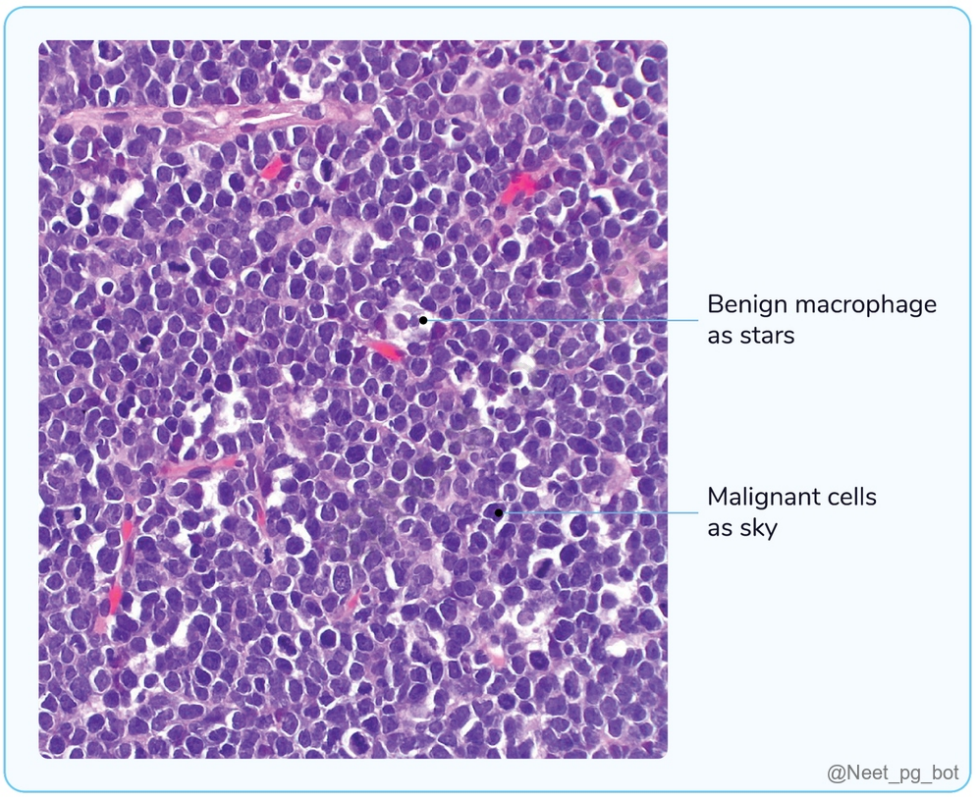

References:

Robbin's and Cotran, Pathological Basis of Disease, 10th Edition, Pages 598-603

↑ *Back to this question in Part A*

@Neet_pg_bot

Q35: A 30-year-old man presents to the outpatient department with an axillary mass and complaints of low-grade fever, weight loss, and night sweats for the past 6 months. Histopathological examination (HPE) of a biopsy sample from the mass reveals diffuse follicular growth with centrocytes with cleaved nuclei and centroblasts. Immunohistochemistry shows BCL2 stain positive, CD19, CD20, and CD10 positive, and CD5 negative. What is the most likely diagnosis? (Q845827)

A. Follicular hyperplasia

B. Mantle cell lymphoma

C. Follicular lymphoma

D. Burkitt's lymphoma

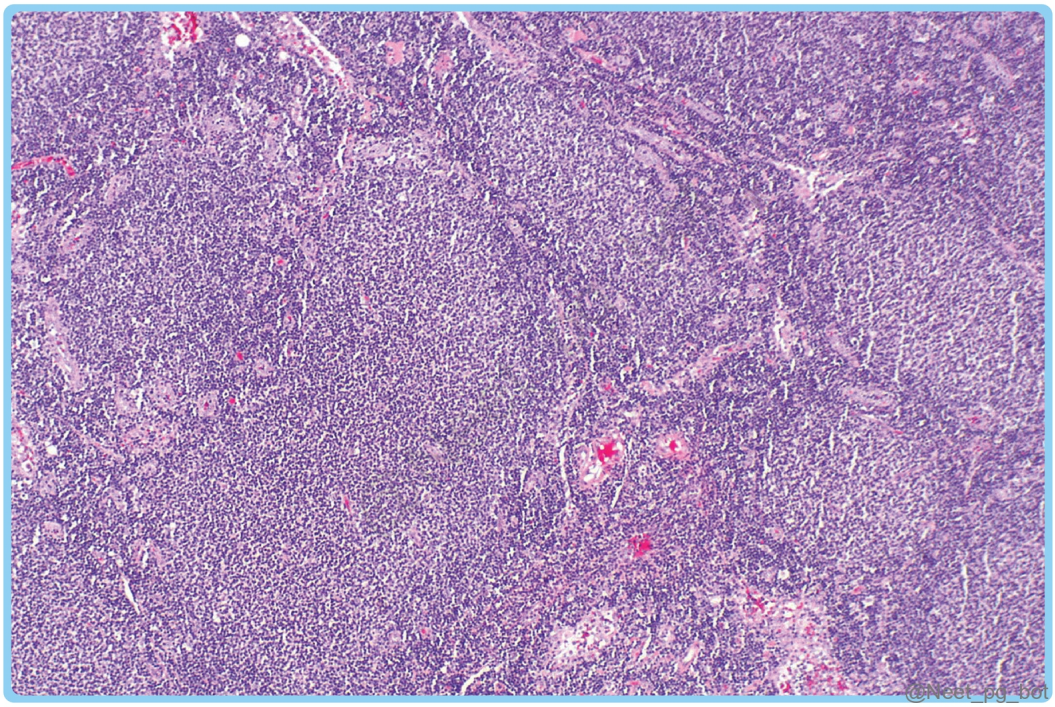

Correct Answer: C. Follicular lymphoma

- *Listen (English)*
- *Listen (Hindi)*

Explanation: The given scenario, along with HPE and IHC, is consistent with Follicular lymphoma, which is associated with BCL2- gene translocation; t(14:18) Follicular lymphoma (FL) is a malignant neoplasm originating from germinal center B-cells, characterized by the t(14;18) translocation leading to overexpression of BCL2. Clinically, it presents with painless lymphadenopathy and may include systemic symptoms. Histopathologically, FL exhibits a nodular growth pattern with centrocytes (Small cells with cleaved nuclei and scanty cytosol) and centroblasts(Larger cells with open nuclear chromatin, several nucleoli) Immunohistochemistry shows positivity for CD10/19/20, BCL2, and BCL6, and negativity for CD5. Management focuses on palliative approaches due to its indolent but incurable nature. Follicular hyperplasia (Option A) is benign, featuring reactive B cell proliferation in lymph nodes with preserved architecture, characterized by CD10/20 positivity and absence of BCL2 expression. Mantle cell lymphoma (Option B) Immunohistochemistry shows positivity for Cyclin D1, CD19, CD20, surface immunoglobulins (usually IgM and IgD), and CD5, but CD23 is negative and HPE shows small lymphoid cells with irregular nuclear outlines, condensed chromatin, and scanty cytoplasm Burkitt’s lymphoma (Option D) Histopathological examination reveals numerous mitotic and apoptotic cells, nuclear remnants phagocytosed by benign macrophages with abundant clear cytoplasm, creating a characteristic "starry sky" pattern. Immunohistochemistry shows positivity for IgM, CD19, CD20, CD10, and BCL6, but negativity for BCL2.

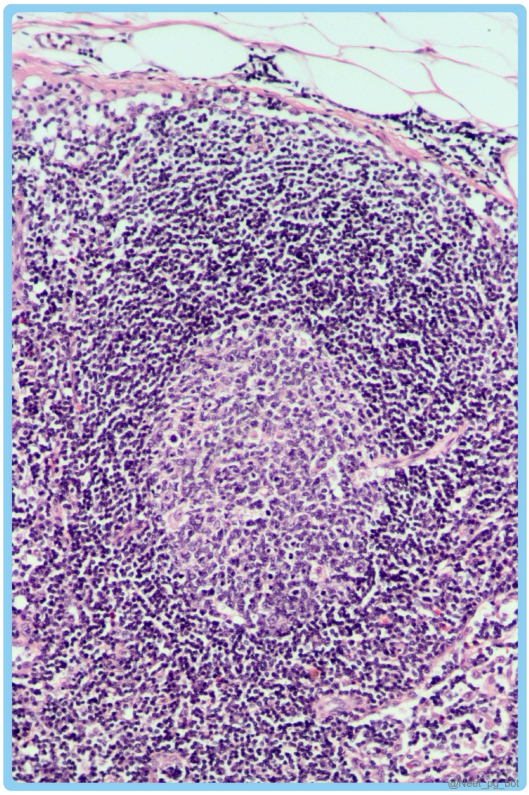
@Neet_pg_bot

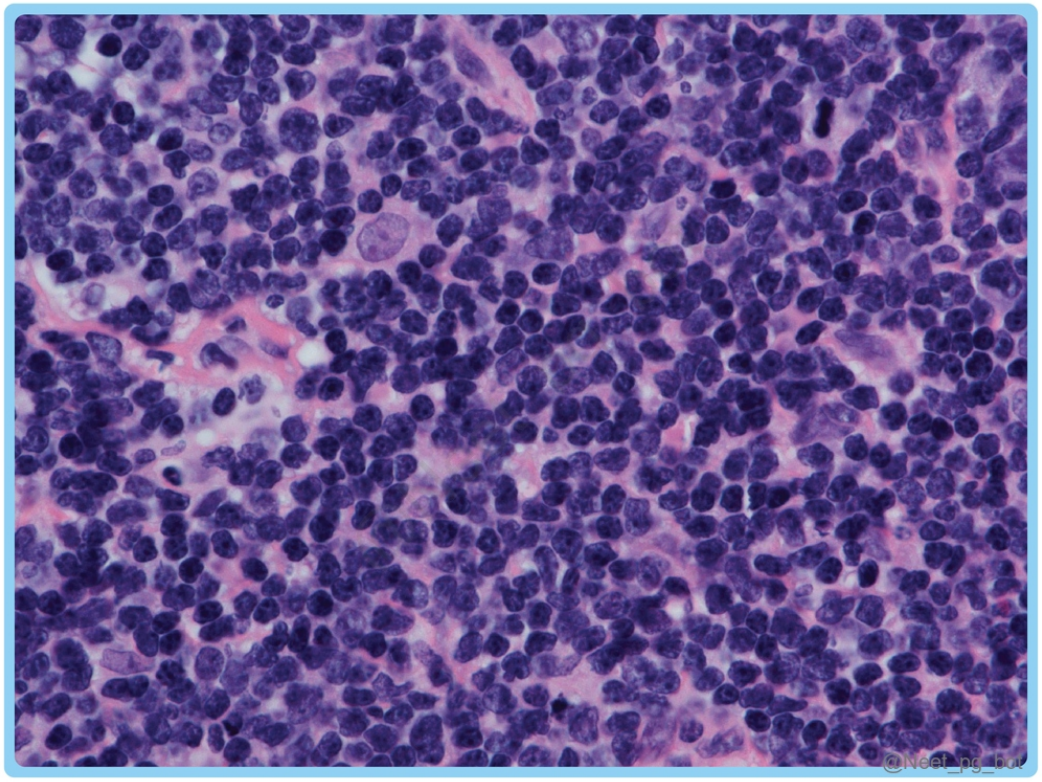
@Neet_pg_bot

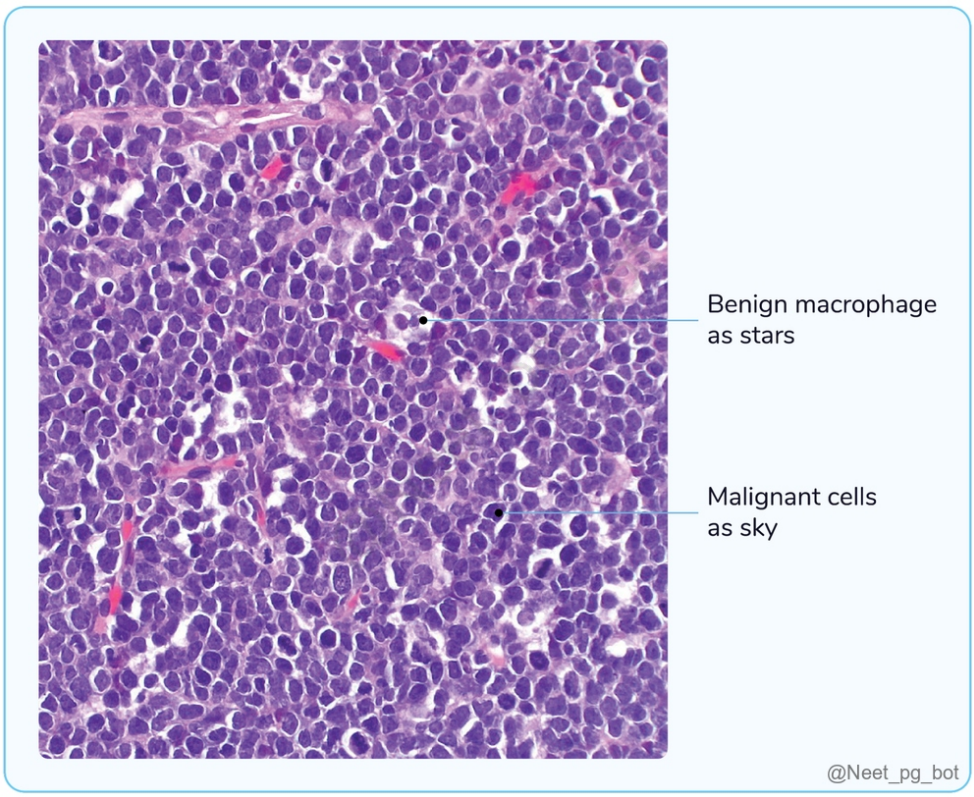

References:

Robbin’s and Cotran, Pathological Basis of Disease, 10th Edition, Pages 589, 599-603

↑ *Back to this question in Part A*

@Neet_pg_bot

Q36: Match the following neoplasm with its appropriate genetic mutation. Neoplasia Genetic mutation 1. Mantle cell lymphoma A. BCL6 gene 2. Burkitt’s lymphoma B. Cyclin D1 gene 3. Diffuse large B cell lymphoma C. BCL10 / MALT1 4. Marginal zone lymphoma D. MYC gene (Q845828)

A. 1-B, 2-D, 3-A, 4-C

B. 1-B, 2-A ,3-C ,4-D

C. 1-A ,2-C ,3-D,4- B

D. 1-C ,2-D ,3-A ,4- B

Correct Answer: A. 1-B, 2-D, 3-A, 4-C

■ *Listen (English)*

■ *Listen (Hindi)*

Explanation: NEOPLASIA GENETIC MUTATION Other points Burkitt’s lymphoma (Statement 2) t(8:14) c-MYC gene Associated with EBV and HIV. 3 types: Endemic, Sporadic and HIV associated. HPE shows ‘starry sky’ appearance DLBCL (Statement 3) BCL6 rearrangement Most common NHL If CLL transforms into DLBCL, it is called Richter's Syndrome. Extranodal marginal zone lymphoma (Statement 4) t(11:18) - API2-MLT fusion t(1:14) - BCL10 - IGH fusion t(14:18) - MALT1-IGH fusion Associated with H.pylori infection Sjogran's Syndrome Hashimoto's Disease. Mantle cell lymphoma (Statement 1) t(11:14) - Cyclin-D1 IGH fusion Associated with GIT polyps

References:

Robbin’s and Cotran, Pathological Basis of Disease, 10th Edition, Page 595

↑ *Back to this question in Part A*

@Neet_pg_bot

Q37: A 14-year-old boy from Bihar presents with a low-grade fever, weight loss, and abdominal pain for the past 2 months. Investigation reveals a mass involving the ileocecal region, with histopathological examination showing a 'starry sky' appearance, immunohistochemistry positive for CD10, CD19, CD20, and BCL6, and FISH indicating a (8:14) translocation involving the MYC gene. This type of presentation is common in which condition? (Q845829)

A. Endemic Burkitt’s lymphoma

B. Sporadic Burkitt’s lymphoma

C. HIV-associated Burkitt’s lymphoma

D. All of the above

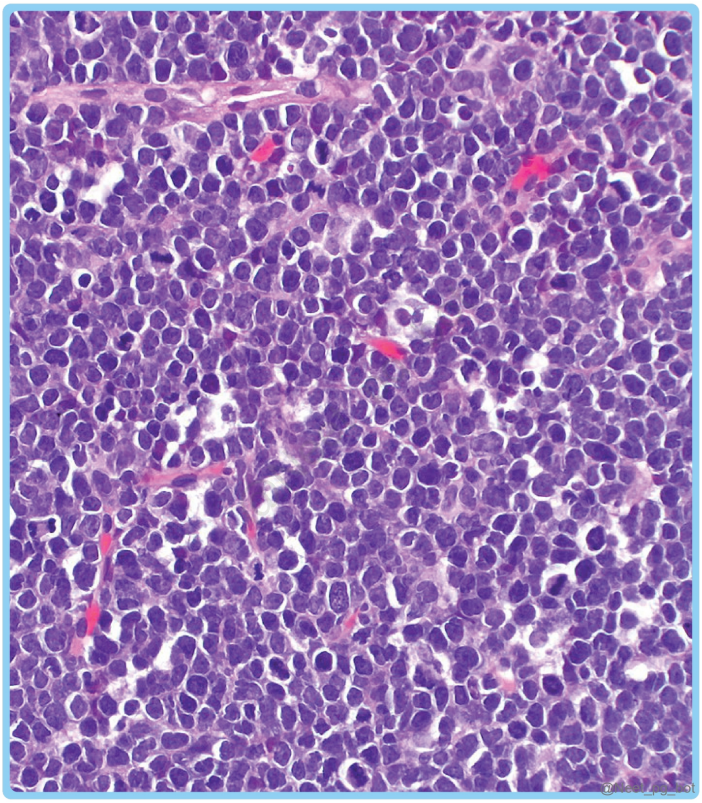

Correct Answer: B. Sporadic Burkitt’s lymphoma

■ *Listen (English)*

■ *Listen (Hindi)*

Explanation: In the above case, the patient is from a non-endemic region, and the lesion mainly affects the abdomen. Based on the HPE and IHC findings, it is suggestive of sporadic Burkitt’s lymphoma. Burkitt's lymphoma is a highly aggressive B-cell non-Hodgkin lymphoma associated with the translocations of the c-MYC gene on chromosome 8, t(8:14). It has three primary subtypes: Endemic Burkitt's lymphoma (Option A): Strong association with Epstein-Barr Virus Infection (~95%) Common in African children Jaw/facial bone involvement (very characteristic) Often involves kidneys, ovaries, and CNS Sporadic Burkitt's lym phoma (Option B): Seen worldwide (children & young adults) EBV association less common (~20–30%) Predominantly involves abdomen (ileocecal region) Presents with abdominal mass ± intussusception Immunodeficiency-associated Burkitt's lymphoma (Option C): Occurs in HIV Infection or post-transplant patients Intermediate EBV association (~30–40%) Commonly involves lymph nodes and bone marrow More aggressive; may present with systemic (B) symptoms

References:

Robbin’s and Cotran, Pathological Basis of Disease, 10th Edition, Pages 601, 602

↑ *Back to this question in Part A*

@Neet_pg_bot

Q38: Which of the following statements correctly differentiates between Primary Effusion Lymphoma (PEL) and Immunodeficiency-associated Large B-cell Lymphoma? (Q845830)

A. PEL presents with lymphomatous masses in solid organs, while Immunodeficiency-associated Large B-cell Lymphoma presents as effusions.

B. PEL is associated with EBV , whereas Immunodeficiency-associated Large B-cell Lymphoma is linked to HHV-8.

C. PEL presents as Effusions and is associated with HHV-8, whereas Immunodeficiency-associated Large B-cell Lymphoma is linked to EBV.

D. Both are predominantly found in immunocompetent individuals without any viral association.

Correct Answer: C. PEL presents as Effusions and is associated with HHV-8, whereas Immunodeficiency-associated Large B-cell Lymphoma is linked to EBV.

■ *Listen (English)*

■ *Listen (Hindi)*

Explanation: Subtypes of DLBCL: Characteristic Primary Effusion Lymphoma (PEL) Immunodeficiency-associated Large B-cell Lymphoma Presentation Malignant pleural or ascitic effusion Solid or nodal tumours , or extranodal involvement, often in immunocompromised individuals. Patient Demographics Mostly in patients with advanced HIV infection or in older adults Seen in patients with advanced HIV infection and recipients of organ or HSC transplants. Appearance of Tumor Cells Anaplastic in appearance, Typically, do not express surface B- or T-cell markers Neoplastic B cells Viral Association With Pathogenesis HHV-8 infection appears to have a causal role HIV EBV infection plays a critical pathogenic role

References:

Robbin’s and Cotran, Pathological Basis of Disease, 10th Edition, Page 601.

Primary effusion lymphoma

↑ *Back to this question in Part A*

@Neet_pg_bot

Q39: Match each lymphoma or leukaemia type with its corresponding histopathological finding. Lymphoma/Leukemia Type Histopathological Finding 1.Follicular Lymphoma A) 2. Burkitt's Lymphoma B) 3. Diffuse Large B-Cell Lymphoma (DLBCL) C) 4. Hairy Cell Leukemia D) (Q845833)

A. 1-C, 2-B, 3-A, 4-D

B. 1-B, 2-A, 3-D, 4-C

C. 1-D, 2-C, 3-B, 4-A

D. 1-A, 2-D, 3-C, 4-B

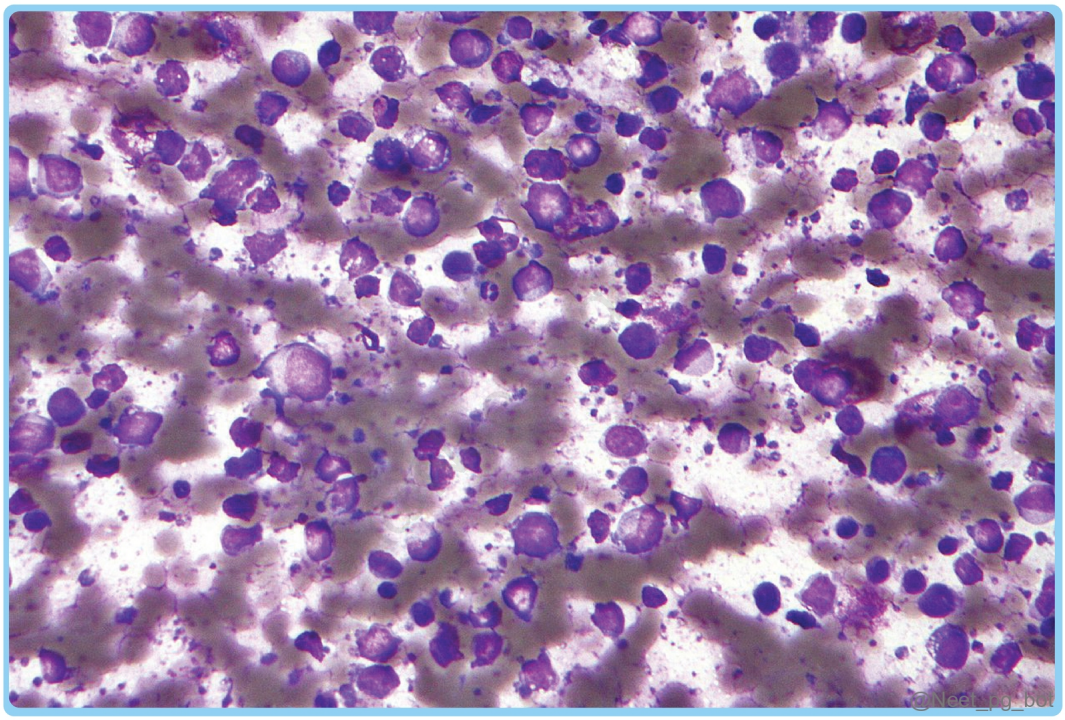

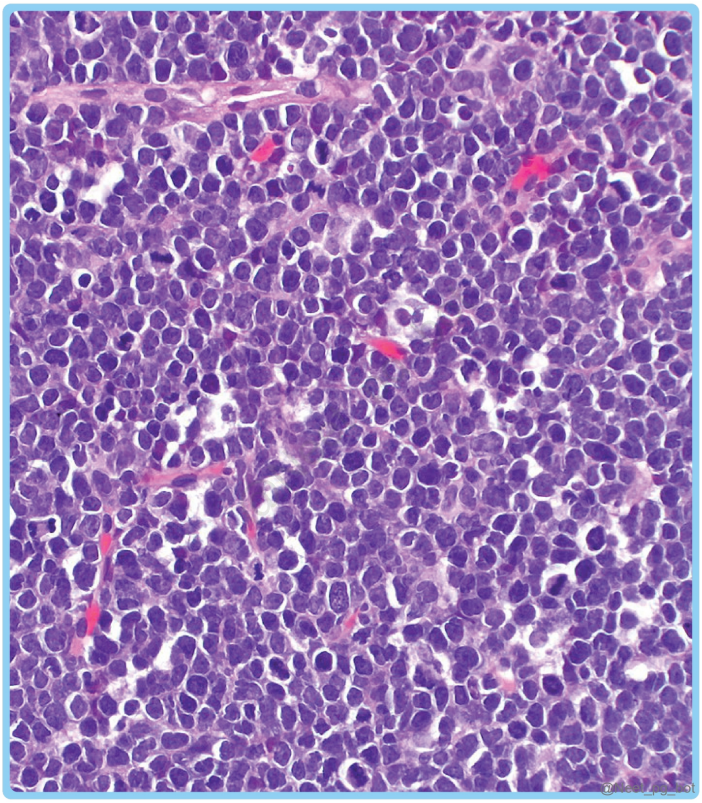

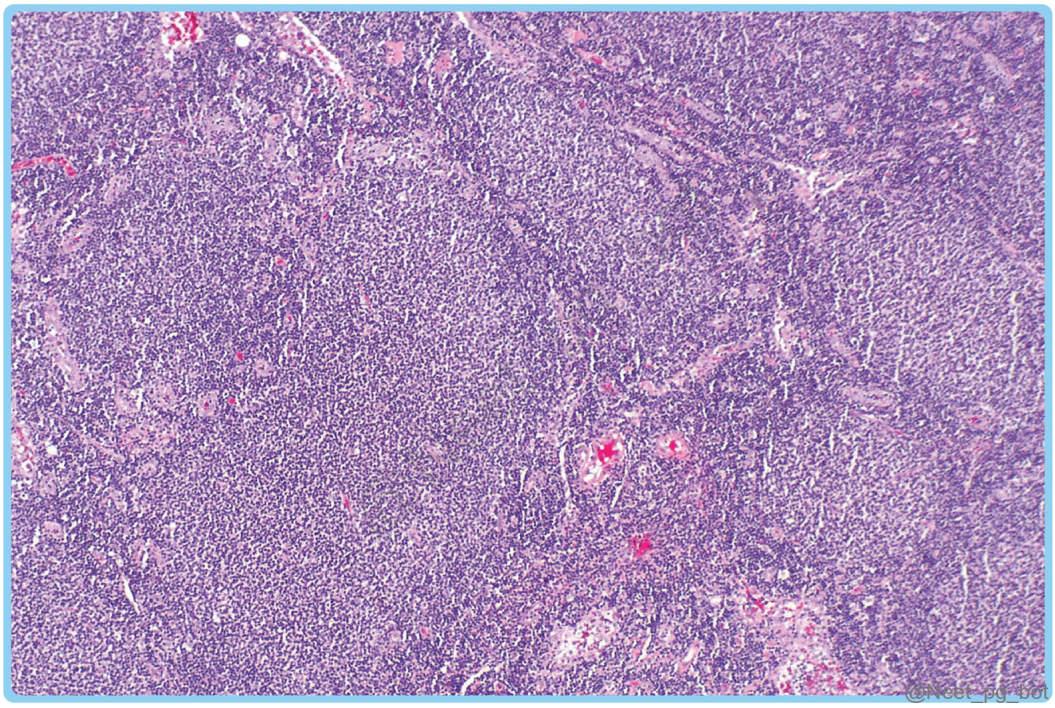

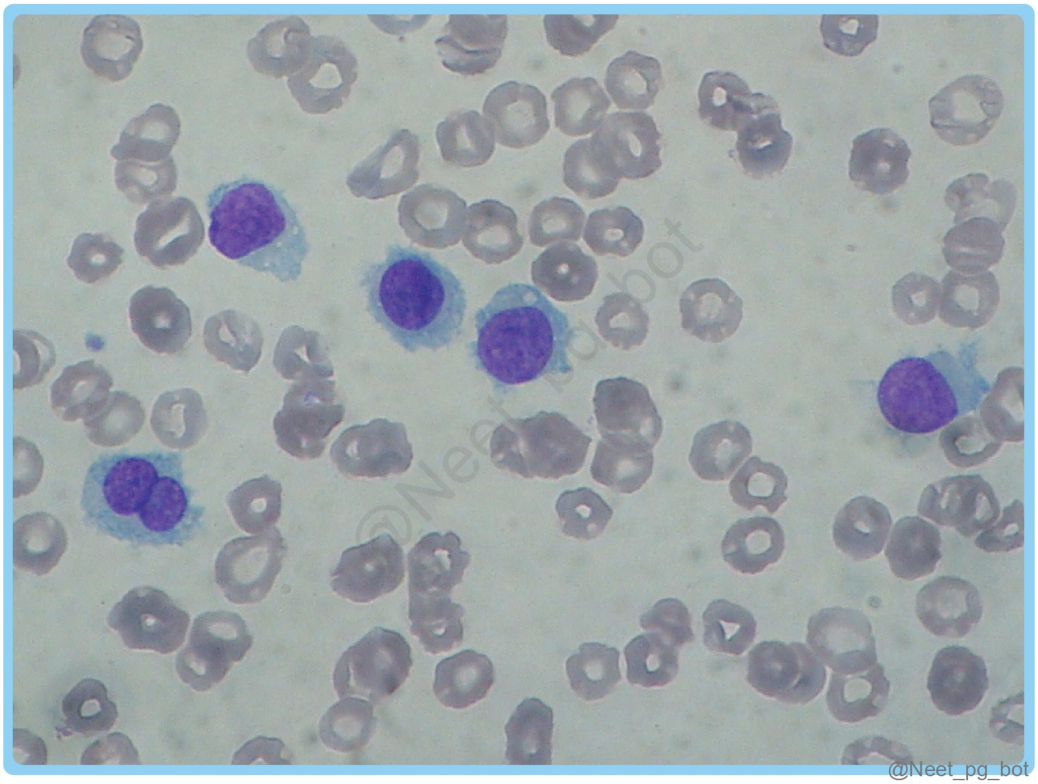

Correct Answer: A. 1-C, 2-B, 3-A, 4-D

■ *Listen (English)*

■ *Listen (Hindi)*

Explanation: Lymphoma/Leukemia Type Histopathological Finding HPE image 1. Follicular lymphoma Cleaved lymphocytes. 2. Burkitt’s Lymphoma "Starry sky" appearance with interspersed macrophages. 3. DLBCL Large lymphoid cells with vesicular nuclei and prominent nucleoli. 4. Hairy cell leukemia Cells with fine hair-like projections.

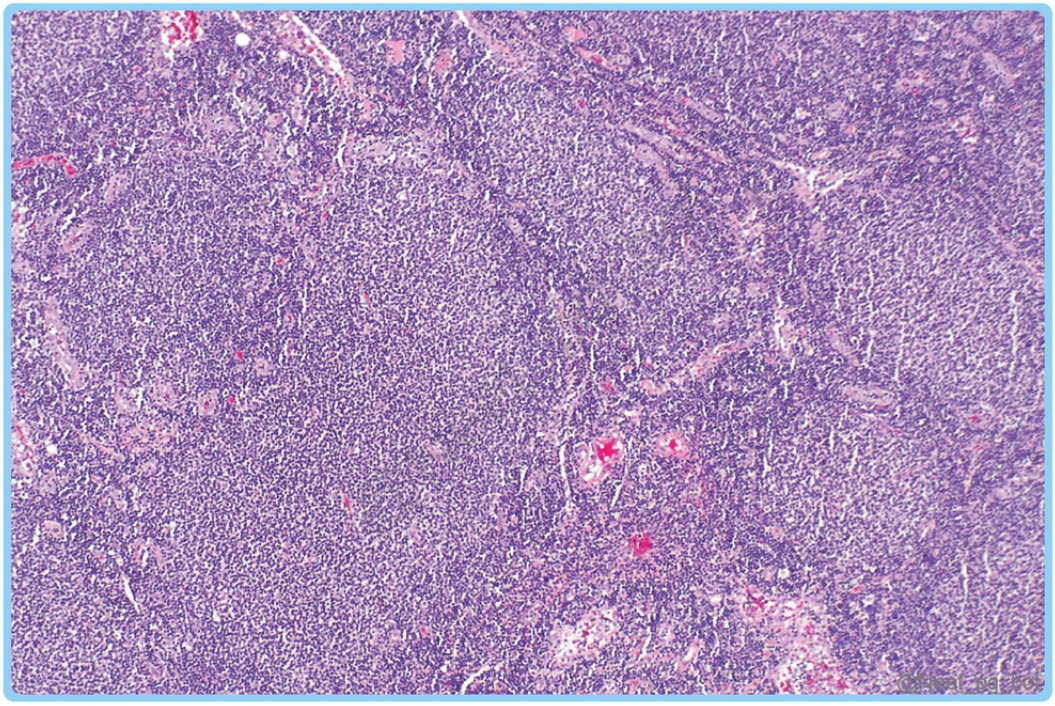

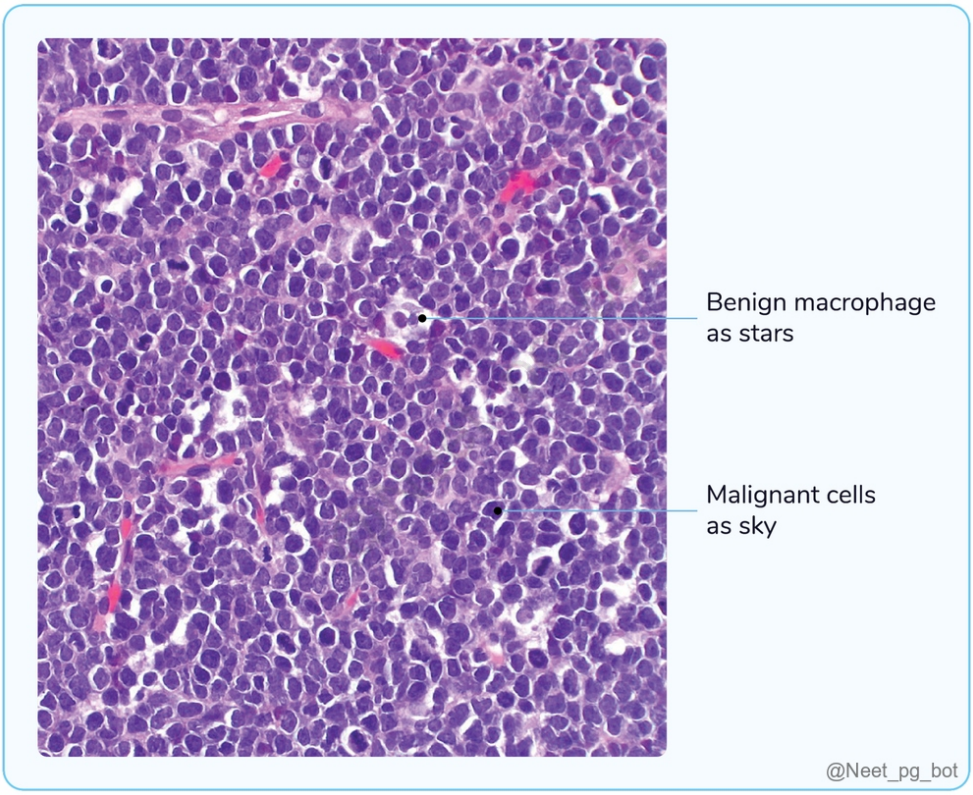

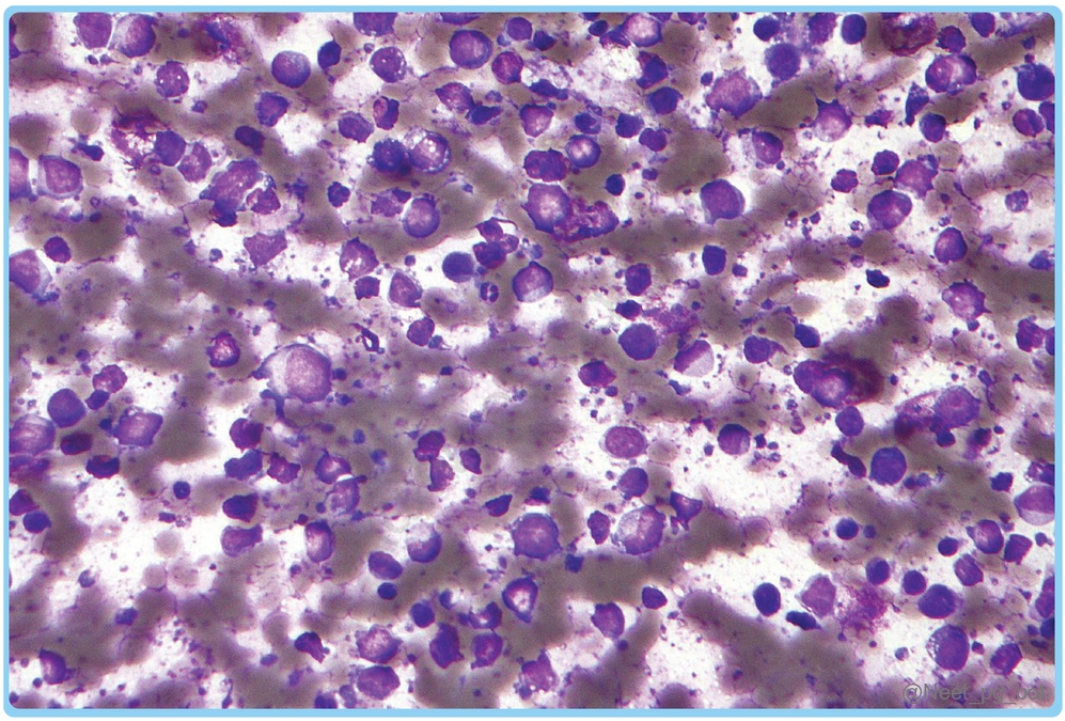

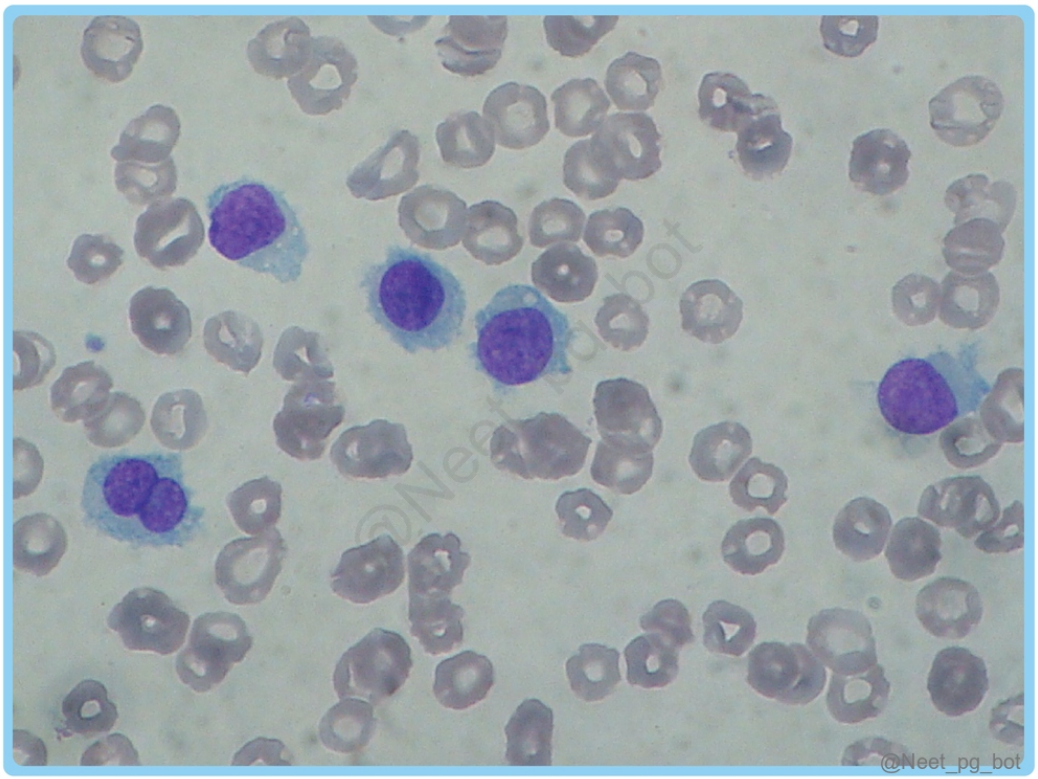

References:

Robbin’s and Cotran, Pathological Basis of Disease, 10th Edition, Pages 599-601 & 604.

↑ *Back to this question in Part A*

Q40: A 45-year-old male has been complaining of persistent fatigue, recurrent infections, and easy bruising over the past few months. On physical examination, he has a noticeable abdominal mass. A peripheral smear shows the presence of atypical lymphoid cells with cytoplasmic projections, as shown in the image below. Which of the following statements is not true regarding the patient's condition? (Q845834)

A. Associated with the BRAF V600E mutation.

B. Massive splenomegaly is a common clinical feature.

C. The pathogenesis involves the proliferation of immature myeloid cells

D. Typically present with fatigue, infections, and pancytopenia.

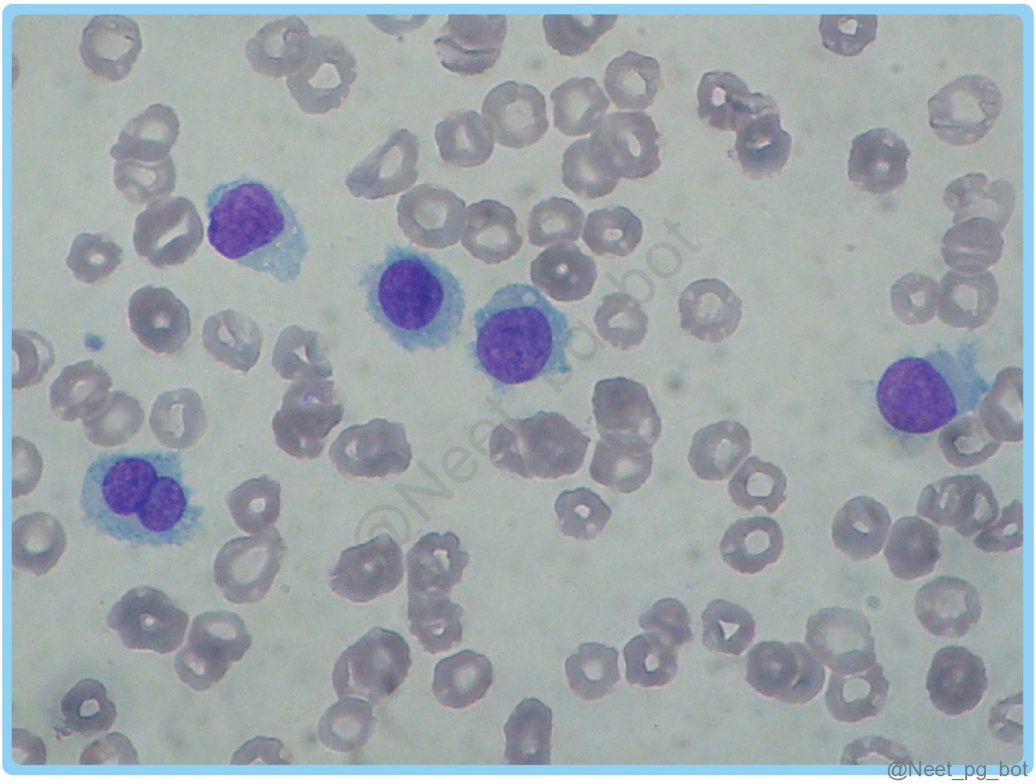

Correct Answer: C. The pathogenesis involves the proliferation of immature myeloid cells

■ *Listen (English)*

■ *Listen (Hindi)*

Explanation: The clinical presentation and peripheral smear findings suggest Hairy cell leukemia, which involves abnormal proliferation of Mature B cells. Mutations BRAF V600E (Option A ruled out) Pathogenesis Mutation of BRAF V600E gene → Activation of the BRAF protein → MAPK/ERK signalling pathway → Uncontrolled proliferation and survival of mature B-cells (Hairy cells). Clinical Presentation Presents with fatigue, recurrent infections, easy bruising, (e.g., early satiety, abdominal discomfort), pancytopenia (Option D ruled out) and symptoms related to splenomegaly (Option B ruled out)

References:

Robbin's and Cotran, Pathological Basis of Disease, 10th Edition, Page 604

↑ *Back to this question in Part A*

@Neet_pg_bot

Q41: A 55-year-old male presents with persistent fatigue, splenomegaly, and pancytopenia. Peripheral blood smear shows leukocytosis with mature lymphocytes displaying hairy projections. Flow cytometry confirms the presence of CD11c and CD25 positive cells. Which of the following is the most specific biomarker commonly useful in the diagnosis of condition? (Q845835)

A. CD 20

B. Annexin V

C. Annexin A1

D. Apolipoprotein A1

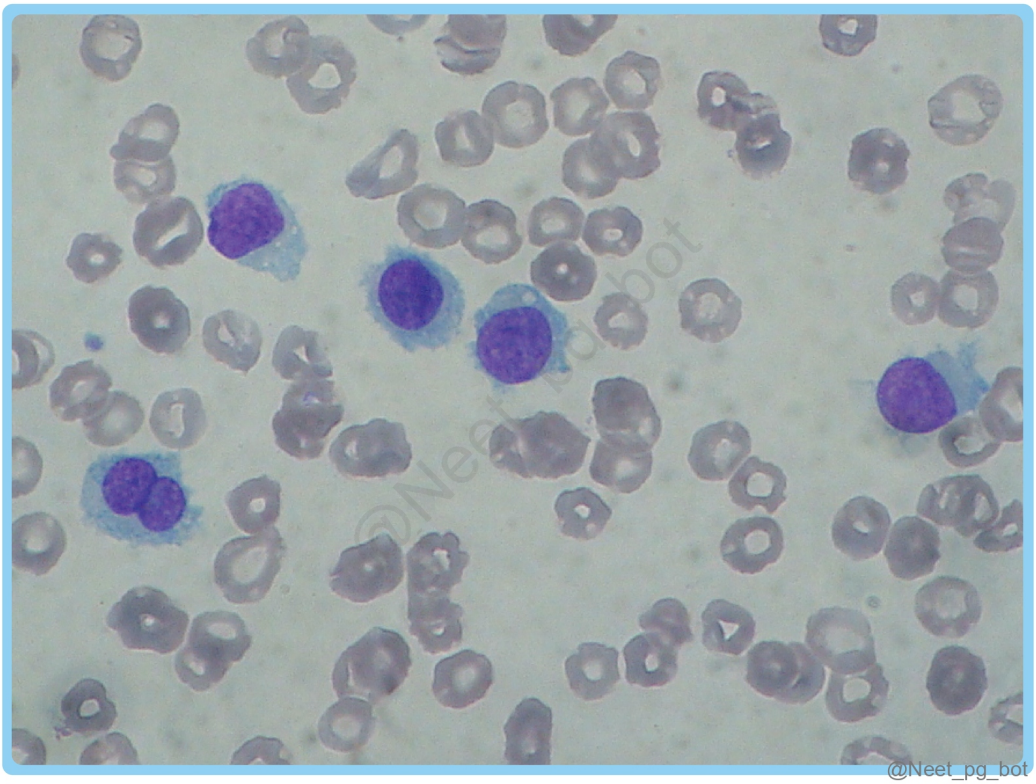

Correct Answer: C. Annexin A1

■ *Listen (English)*

■ *Listen (Hindi)*

Explanation: The clinical presentation and peripheral smear findings are consistent with Hairy Cell Leukemia (HCL). Annexin A1 is a protein specifically expressed on the surface of hairy cells in Hairy Cell Leukemia. It is characterized by a distinctive genetic mutation (BRAF V600E in >90% of cases) and expression of specific B-cell markers Clinical presentation include persistent fatigue, splenomegaly, and pancytopenia and increased susceptibility to infections.. Peripheral smear shows Leukocytosis with mature lymphocytes displaying hairy projections. Marrow exhibits diffuse interstitial infiltrates Flow cytometry markers: The cells in HCL typically expressCD19, CD20, surface Ig (usually IgG), CD11c, CD25, CD103, and annexin A1. CD20 (Option A) is a surface marker present on most B cells and is commonly expressed in a variety of B-cell lymphomas and leukemias. While CD20 can be positive, it is not specific to HCL and is found in many other B-cell neoplasms. Annexin A5 (Option B) is a protein involved in the cellular processes related to apoptosis and phospholipid binding. It is used as a marker to detect apoptotic cells. Apolipoprotein A1 (Option D) is a marker for germ cell neoplasms.

References:

Robbin’s and Cotran, Pathological Basis of Disease, 10th Edition, Page 604

https://www.cancer.gov/publications/dictionaries/cancer-terms/def/cd20-antigen

https://www.ncbi.nlm.nih.gov/pmc/articles/PMC4007141/

↑ *Back to this question in Part A*

Q42: A 45-year-old male presents with a three-year history of pruritic, erythematous plaques on his trunk and extremities. Physical examination reveals widespread erythematous patches and plaques with a "cerebriform" appearance. Peripheral smear findings reveal the presence of abnormal lymphocytes with convoluted nuclei and abundant cytoplasm. Which of the following is the most likely diagnosis? (Q845836)

A. Mycosis fungoides

B. Adult T-cell leukemia

C. Anaplastic large cell lymphoma

D. Hairy cell leukemia

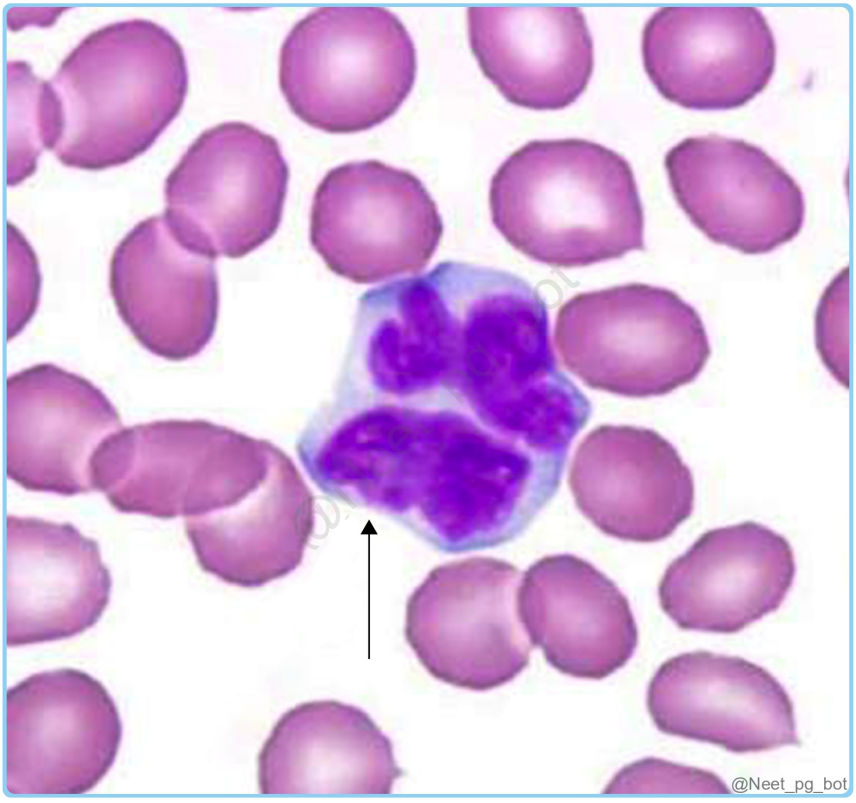

Correct Answer: A. Mycosis fungoides

■ *Listen (English)*

■ *Listen (Hindi)*

Explanation: The clinical presentation and peripheral findings is consistent with Mycosis fungoides, a Cutaneous T-cell lymphoma, characterized by pruritic erythematous patches and plaques. Cutaneous lesion : Erythematous plaque with fungal-like appearance → but not fungal. Type : It is a cutaneous T-cell Non-Hodgkin's lymphoma (NHL) . Histology (skin biopsy) : Malignant T-cell collections in epidermis → Pautrier's microabscesses . Blood finding : Atypical lymphocytes with cerebriform nuclei → Sezary cells . Terminology : Skin involvement only → Mycosis fungoides . When cells spill into blood → Sezary syndrome Clinical Stages: Patch (scaly/erythematous) Plaque (elevated/indurated) Tumor (nodular/ulcerated) Erythroderma (Sezary Syndrome: >80% body surface area involved + leukemia). Treatment: Topical corticosteroids, phototherapy (PUVA/UVB), or topical mechlorethamine. Systemic therapy (Interferon, Vorinostat) for advanced stages.

References:

Robbin's and Cotran, Pathological Basis of Disease, 10th Edition, Pages 605, 606

↑ *Back to this question in Part A*

@Neet_pg_bot

• [18_Hematology_ White Blood Cells] 077 Previous Year Questions

« Back to Folder Directory

[18_Hematology_ White Blood Cells] 077 Previous Year Questions — Quick Jump

Q1 (p. 2984)	*Q2 (p. 2985)*	*Q3 (p. 2989)*	*Q4 (p. 2992)*	*Q5 (p. 2994)*	*Q6 (p. 2995)*
Q7 (p. 2996)	*Q8 (p. 2997)*	*Q9 (p. 3001)*	*Q10 (p. 3003)*	*Q11 (p. 3003)*	*Q12 (p. 3005)*
Q13 (p. 3005)	*Q14 (p. 3006)*	*Q15 (p. 3008)*	*Q16 (p. 3009)*	*Q17 (p. 3010)*	*Q18 (p. 3011)*
Q19 (p. 3012)	*Q20 (p. 3014)*	*Q21 (p. 3016)*	*Q22 (p. 3017)*	*Q23 (p. 3018)*	*Q24 (p. 3019)*
Q25 (p. 3020)	*Q26 (p. 3023)*	*Q27 (p. 3025)*	*Q28 (p. 3030)*	*Q29 (p. 3030)*	*Q30 (p. 3031)*
Q31 (p. 3032)	*Q32 (p. 3034)*	*Q33 (p. 3036)*	*Q34 (p. 3037)*	*Q35 (p. 3039)*	*Q36 (p. 3044)*
Q37 (p. 3044)	*Q38 (p. 3048)*	*Q39 (p. 3048)*	*Q40 (p. 3049)*	*Q41 (p. 3050)*	*Q42 (p. 3051)*
Q43 (p. 3053)	*Q44 (p. 3057)*	*Q45 (p. 3059)*	*Q46 (p. 3060)*	*Q47 (p. 3062)*	*Q48 (p. 3062)*
Q49 (p. 3063)					

Q1: Which of the following is not true about nodular lymphocyte-predominant Hodgkin lymphoma (NLPHL)? (Q856479)

A. EBV negative

B. CD 30 negative

C. CD 20 positive

D. Poor prognosis compared to classical HL

Correct Answer: D. Poor prognosis compared to classical HL

Explanation: Nodular lymphocyte-predominant Hodgkin lymphoma (NLPHL) typically has a more favourable prognosis compared to classical Hodgkin lymphoma (HL). It is usually EBV negative, CD30 negative, and CD20 positive , characteristic features of NLPHL. However, it does not generally have a poorer prognosis than classical HL. {{caption_text}} Subtypes and features of Hodgkin's lymphoma: Subtype Morphology and Immunophenotype Typical Clinical Features Nodular Sclerosis Frequent lacunar cells and occasional diagnostic Reed-Sternberg (RS) cells. Background infiltrate includes T lymphocytes, eosinophils, macrophages, and plasma cells. Fibrous bands divide cellular areas into nodules. RS cells: CD15+, CD30+; usually EBV negative. Most common subtype, typically stage I or II with mediastinal involvement . Equal occurrence in males and females . Common in young adults . Mixed Cellularity Frequent mononuclear and diagnostic RS cells. Background infiltrate rich in T lymphocytes, eosinophils, macrophages, and plasma cells. RS cells: CD15+, CD30+; 70% EBV positive . More than 50% present as stage III or IV . More common in males . Biphasic incidence peaks in young adults and those >55 years . Lymphocyte-Rich Frequent mononuclear and diagnostic RS cells. Background infiltrate rich in T

lymphocytes. RS cells: CD15+, CD30+; 40% EBV positive. Uncommon , more frequent in males . Typically seen in older adults . Lymphocyte Depletion Reticular variant with numerous RS cells and few background reactive cells. RS cells: CD15+, CD30+ , most EBV positive . Rare , more common in older men , HIV-infected individuals , and low-income regions . Often presents with advanced disease . Nodular Lymphocyte-Predominant Frequent L&H (popcorn) cell variants in a background of follicular dendritic cells and reactive B cells. RS cells: CD20+, CD15–, CD30–; EBV negative . Uncommon , typically in young males . Presents with cervical/axillary lymphadenopathy . Rarely involves the mediastinum .

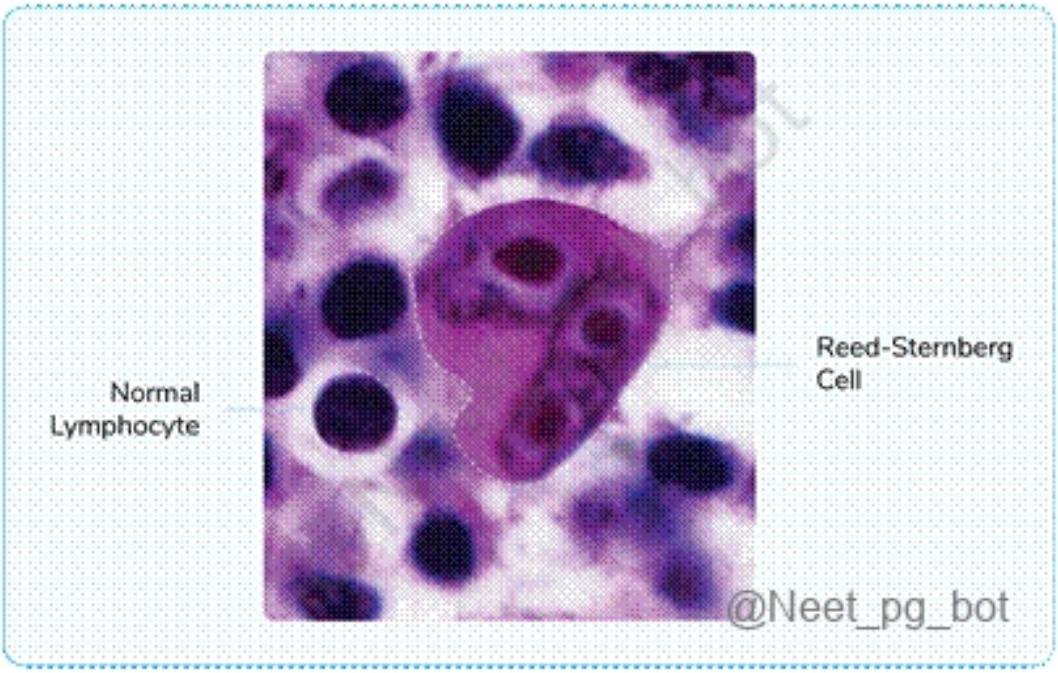

References:

Robbins & Cotran Pathologic Basis of Disease, 10th Edition, Page 613

↑ *Back to this question in Part A*

@Neet_pg_bot

Q2: What is the most likely diagnosis for a 5-year-old boy who has weight loss, fever, and a painless swelling in his jaw area, with anaemia and lymphocytosis revealed by a CBC and biopsy findings shown in the accompanying image?\ (Q857579)

A. Hodgkin’s disease

B. Acute lymphocytic leukemia

C. Chloroma

D. Burkitt’s lymphoma

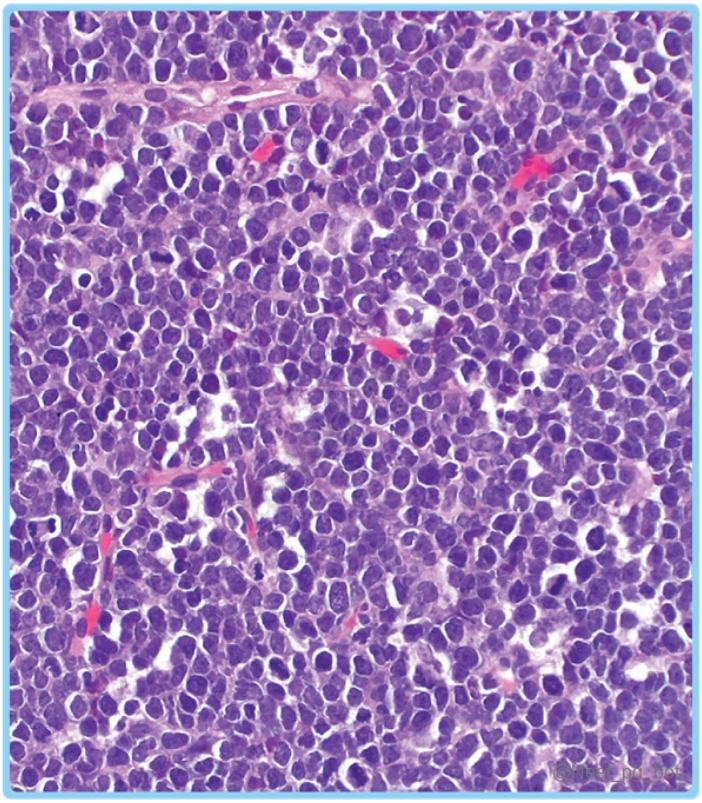

Correct Answer: D. Burkitt’s lymphoma

Explanation: The clinical presentation of weight loss, fever, painless jaw swelling, along with a starry sky appearance on histology and anaemia with lymphocytosis on CBC, strongly suggests Burkitt’s lymphoma. It is an aggressive B-cell non-Hodgkin lymphoma, typically associated with Epstein-Barr virus (EBV) infection, HIV, and chromosomal translocations leading to c-myc oncogene overexpression. It is classified into three clinical groups: endemic, sporadic, and immunodeficiency-related. Clinical symptoms include: Painless swelling : The most common symptom is the presence of one or more painless, rapidly enlarging masses, typically involving lymph nodes. Heavy night sweating Intermittent high fever Significant weight loss (more than 10% of body weight) Associated with the translocations of the MYC gene on chromosome 8, t(8:14). It has three primary subtypes: Endemic Burkitt's lymphoma: Commonly affects children in malaria-endemic areas of Africa, often presenting with tumours in the jaw or facial bones. Sporadic Burkitt's lymphoma: More frequently seen in non-endemic regions and usually involving the ileocaecal region and peritoneum Immunodeficiency-associated Burkitt's lymphoma: Found in patients with conditions such as HIV/AIDS or other forms of immunodeficiency. {{caption_text}} Hodgkin's disease (Option A) is a cancer of the lymphatic system, characterised by uncontrolled proliferation of lymphocytes. It often presents with painless swollen lymph nodes, but the hallmark feature is the presence of Reed-Sternberg cells (large, abnormal lymphocytes with two nuclei resembling "owl eyes"). HL is treated with chemotherapy, radiation, and stem-cell transplantation. {{caption_text}} Acute lymphocytic leukaemia (ALL) (Option B) is a malignancy of the blood and bone marrow characterised by the rapid production of immature white blood cells. Common symptoms include fatigue, pallor, frequent infections, and unusual bleeding, but it does not typically present with localised swelling, as seen in Burkitt’s lymphoma . {{caption_text}} Chloroma (Option C) , also known as granulocytic sarcoma or myeloid sarcoma , is a rare tumour composed of myeloblasts, usually associated with acute myeloid leukaemia (AML). It can form in various tissues such as the bones, skin, lymph nodes, and central nervous system, but it does not present with the

distinctive symptoms or patterns of Burkitt's lymphoma, such as the characteristic jaw swelling. Chloromas are often nonspecific and can include symptoms like fatigue, weight loss, and pain. {{caption_text}}

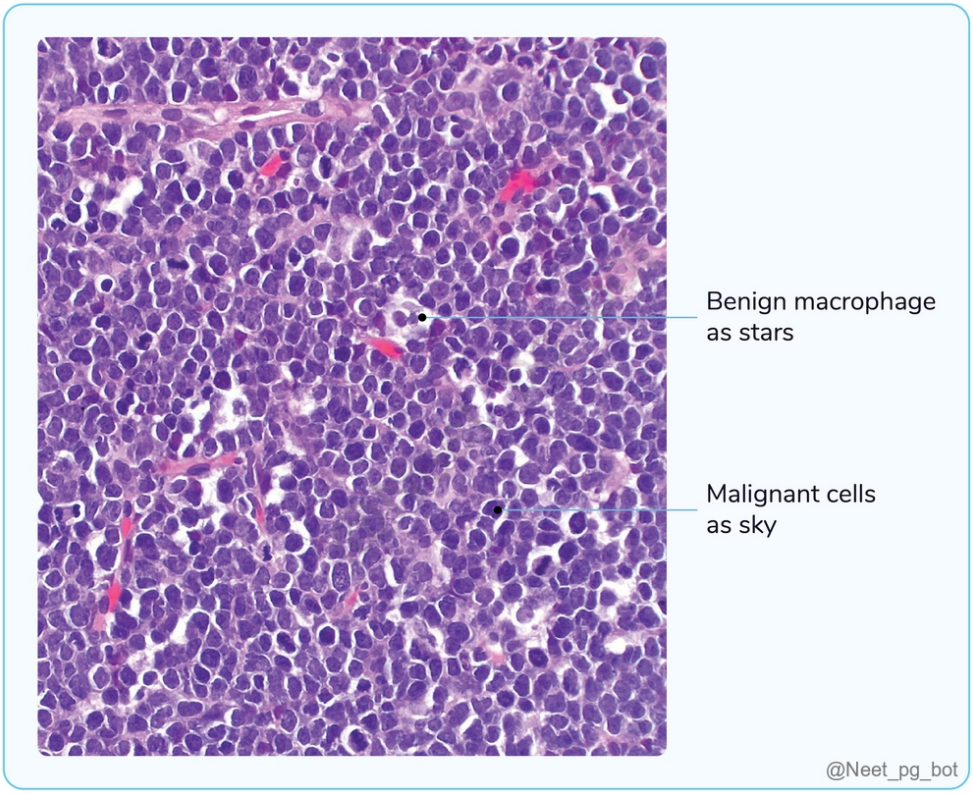

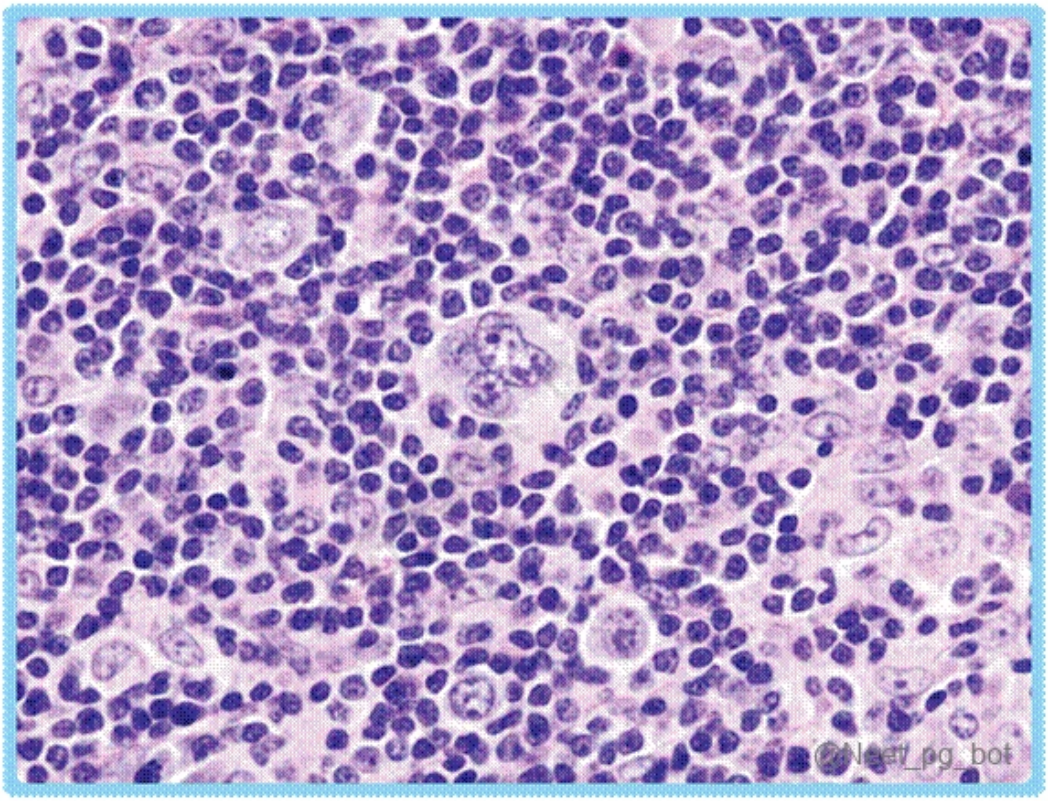

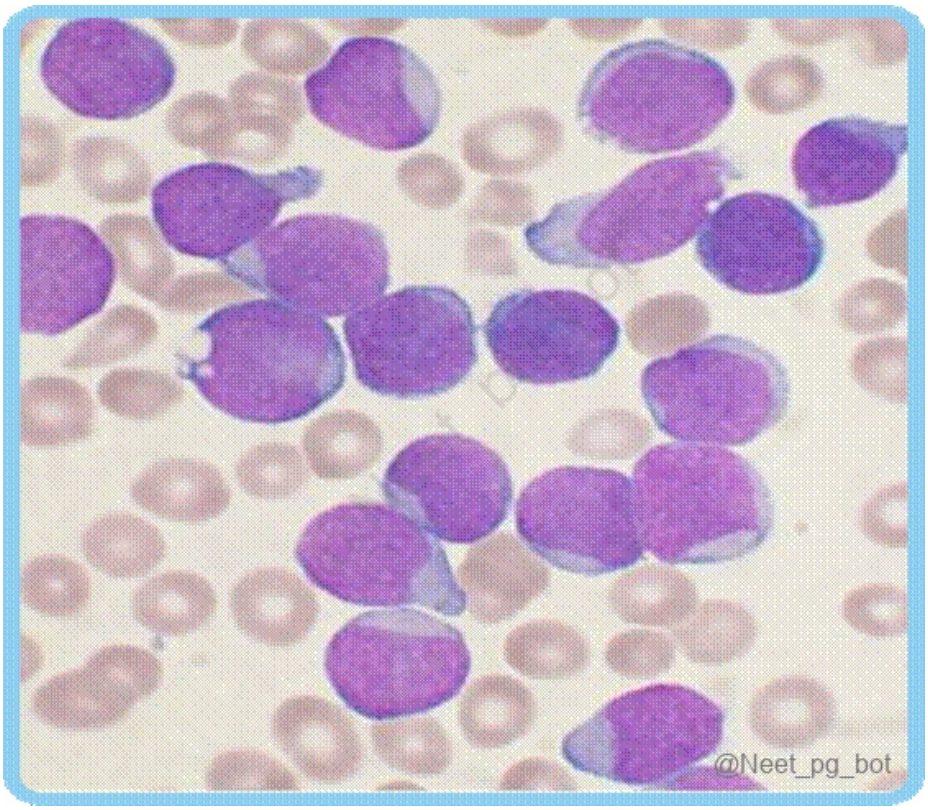

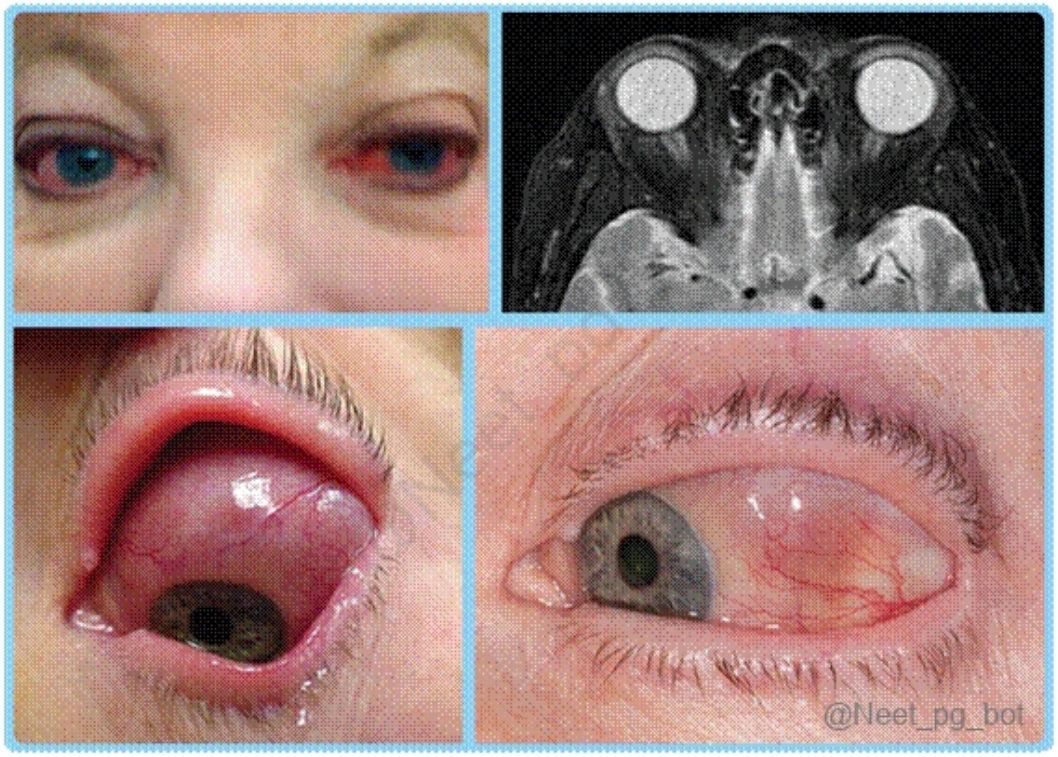

References:

Robbins & Cotran Pathologic Basis of Disease, 10th Edition, Page 598-603

↑ *Back to this question in Part A*

@Neet_pg_bot

Q3: A 60-year-old male presents with easy fatigability, back pain, and multiple lytic lesions in the skull. The bone marrow biopsy finding is given below. What is the most probable diagnosis? (Q857582)

A. CML (Chronic Myelogenous Leukemia)

B. CLL (Chronic Lymphocytic Leukemia)

C. Multiple Myeloma

D. Hairy Cell Leukemia

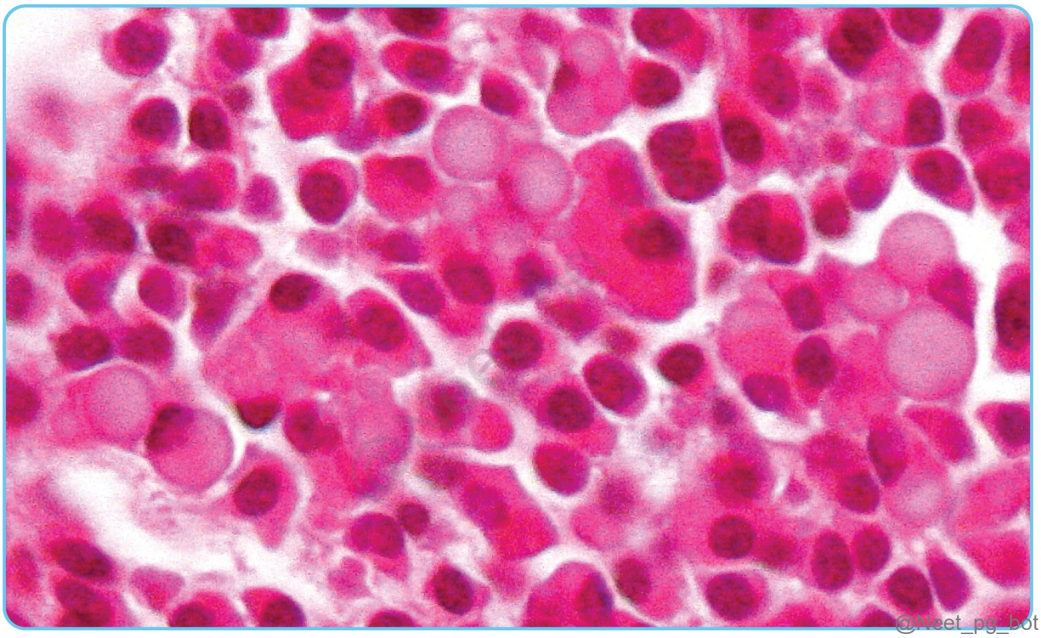

Correct Answer: C. Multiple Myeloma

Explanation: The clinical presentation of easy fatigability, back pain, and skull lytic lesions, along with Russell bodies in bone marrow biopsy, strongly suggests multiple myeloma, which commonly causes bone pain and elevated serum proteins. Multiple myeloma is a cancer of plasma cells, which normally produce antibodies to fight infections. In this disease, malignant plasma cells proliferate uncontrollably in the bone marrow, crowding out healthy blood cells and producing abnormal proteins that cause complications. Early symptoms may be absent, but when present, they include: Bone pain, especially in the spine or chest Nausea Constipation Loss of appetite Confusion or mental fogginess Fatigue Frequent infections Weight loss Weakness or numbness in the legs Excessive thirst CML (Chronic Myelogenous Leukemia) (Option A) is a blood and bone marrow cancer that leads to an overproduction of white blood cells. In its chronic phase, the disease can often go unnoticed until detected by

a blood test. Symptoms include: Weakness Fatigue Shortness of breath with daily activities Fever Bone pain Unexplained weight loss Pain or fullness in the left side of the abdomen due to an enlarged spleen Night sweats {{caption_text}} CLL (Chronic Lymphocytic Leukemia) (Option B) is a slow-progressing blood and bone marrow cancer, typically occurring in older adults. It may not cause symptoms in the early stages and is often discovered during a routine blood test. Later symptoms include: Painless swelling of lymph nodes Weakness or fatigue Feeling full due to spleen or liver enlargement Fever and frequent infections Easy bruising or bleeding Unexplained weight loss Drenching night sweats {{caption_text}} Hairy Cell Leukemia (Option D) is a cancer of the B lymphocytes (a type of white blood cell). The leukaemia cells in this condition look "hairy" under a microscope. Symptoms may be absent or include: A feeling of fullness in the abdomen, making it difficult to eat large meals Fatigue Easy bruising Frequent infections Weakness Unintentional weight loss {{caption_text}}

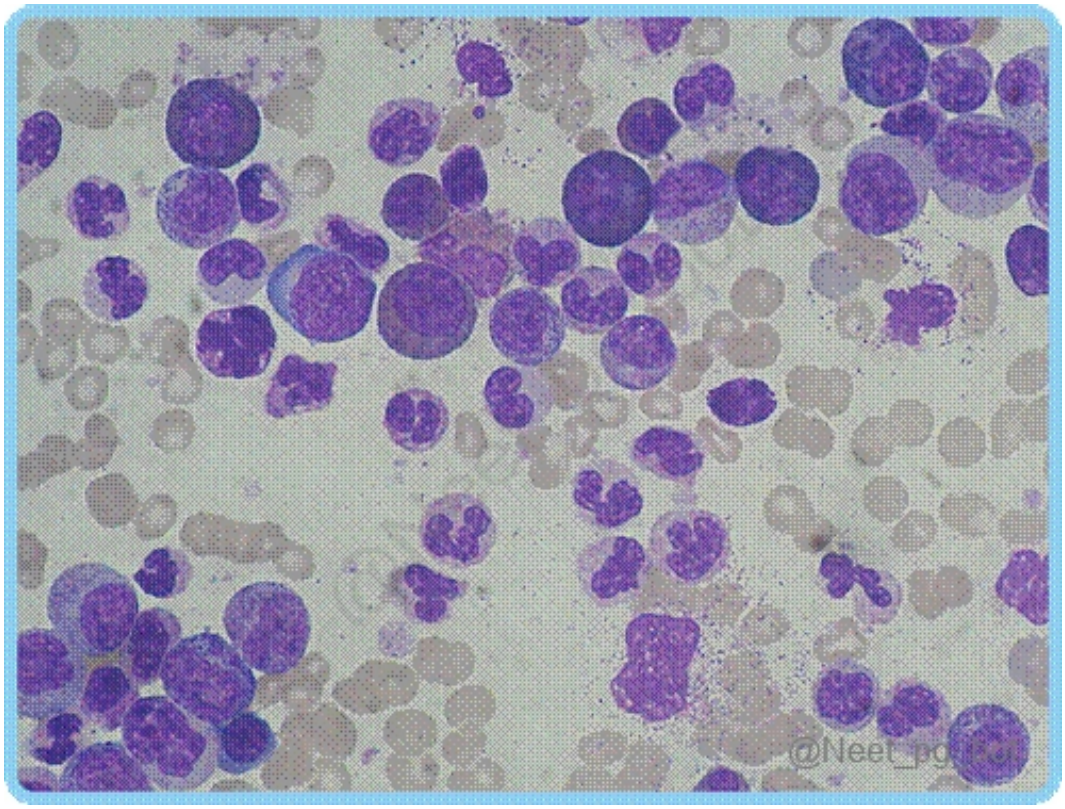

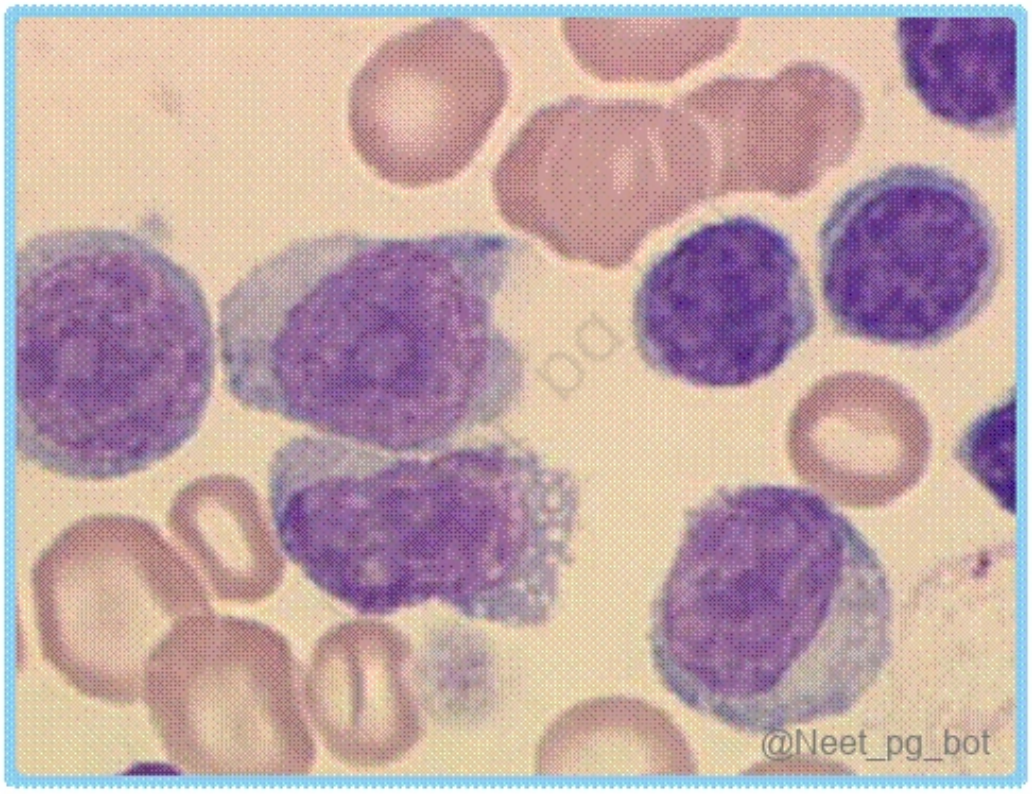

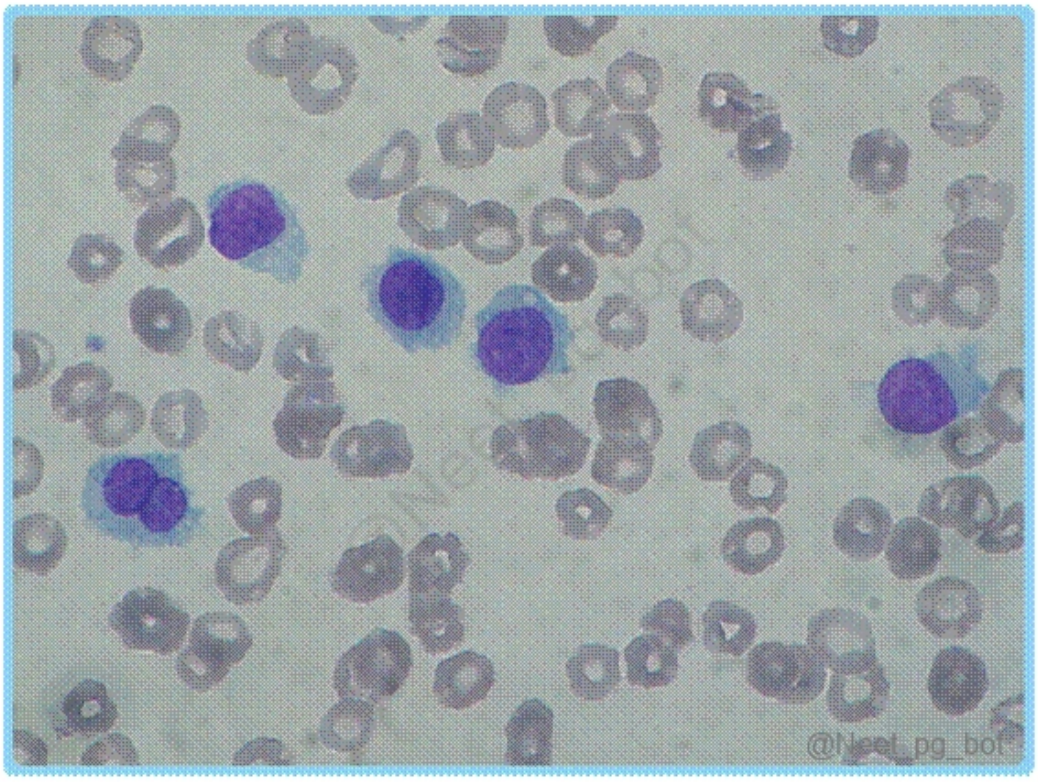

References:

Robbins & Cotran Pathologic Basis of Disease, 10th Edition, Page 607-609

↑ *Back to this question in Part A*

@Neet_pg_bot

Q4: What is the likely diagnosis for a 10-year-old boy with Down syndrome who presents with a mediastinal mass (SVC-like syndrome), based on the provided bone marrow histology shown below? (Q857605)

A. AML (Acute Myeloid Leukemia)

B. Aplastic anemia

C. ALL (Acute Lymphoblastic Leukemia)

D. Juvenile Myelomonocytic Leukemia (JMML)

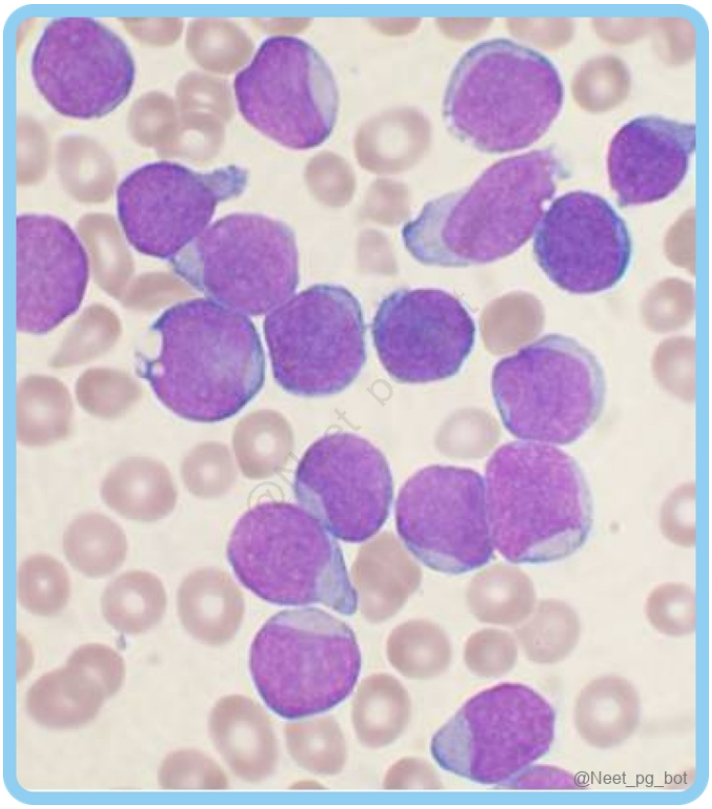

Correct Answer: C. ALL (Acute Lymphoblastic Leukemia)

Explanation: Acute Lymphoblastic Leukemia (ALL) is the most common leukemia and cancer in children, often seen in patients with Down syndrome. It is a clonal malignancy where lymphoblasts, early lymphoid precursors, proliferate abnormally, replacing normal hematopoietic cells in the bone marrow. Bone marrow in ALL shows lymphoblasts with condensed nuclear chromatin, small nucleoli, and scant agranular cytoplasm, which are characteristic of lymphoblastic leukemia. Precursor B-cell ALL shows large purple malignant lymphoblasts on

bone marrow aspirate smears. Normal lymphoblasts mature into B-cells or T-cells that fight infections, but in ALL, they fail to mature properly. T-cell ALL may present as a mediastinal mass, potentially causing superior vena cava (SVC) syndrome. Both peripheral blood and bone marrow in ALL show increased lymphoblasts. ALL has a poorer prognosis in adults compared to children. {{caption_text}} Acute Lymphoblastic Leukemia (ALL) Lymphoblasts in bone marrow >=20% Cytoplasmic vacuolations They contain fat (Oil Red O Positive) Hand mirror-shaped cells {{caption_text}} Acute Myeloid Leukemia (AML) Blasts ≥ 20% Myeloblasts with AuerRods AML (Acute Myeloid Leukemia) (Option A) is a blood and bone marrow cancer primarily affecting adults caused by the uncontrolled proliferation of myeloblasts (immature white blood cells). It is characterised by an abundance of abnormal cells that fail to mature into healthy blood cells, leading to symptoms like infections, anaemia, and easy bleeding. Common in infants and children < 3yrs with Down syndrome (M7 subtype), not 10-year-olds. Aplastic Anemia (Option B) is a serious condition where the bone marrow fails to produce enough blood cells, leading to low blood counts and symptoms like easy bruising, heavy menstrual bleeding, shortness of breath, fatigue, and frequent infections. It can be inherited or acquired, with acquired cases often linked to immune system dysfunction. Juvenile Myelomonocytic Leukemia (JMML) (Option D) is a rare blood cancer in young children, characterised by abnormal development of monocytes and myelocytes (types of white blood cells). Treatment often involves chemotherapy followed by a bone marrow transplant. Unlike ALL, JMML does not typically present with lymphoblasts.

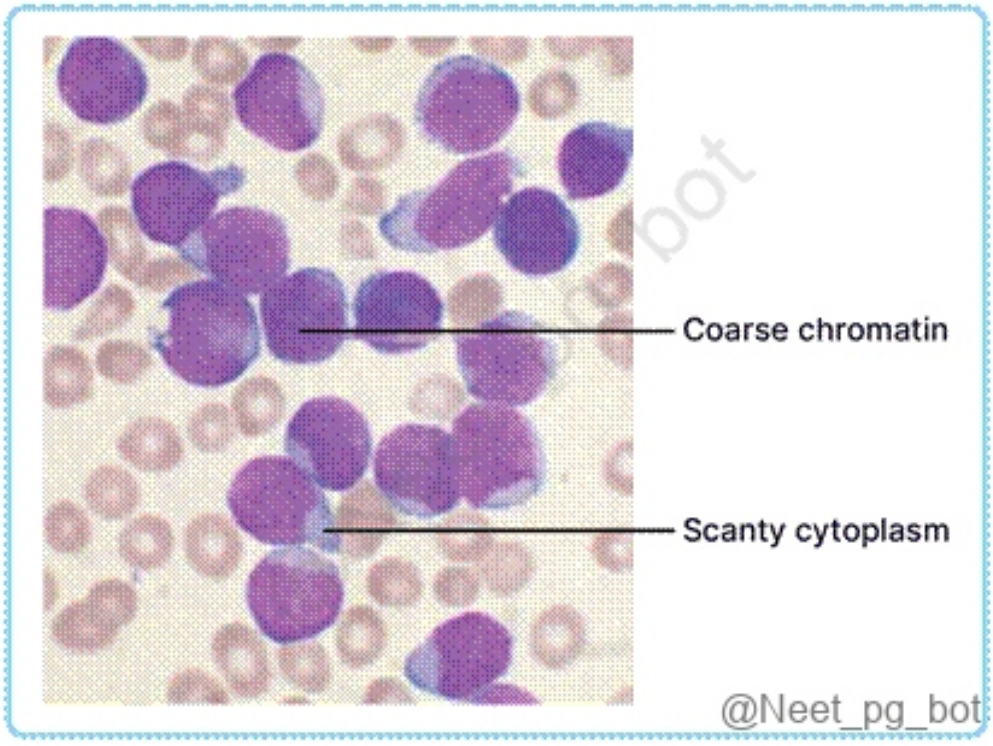

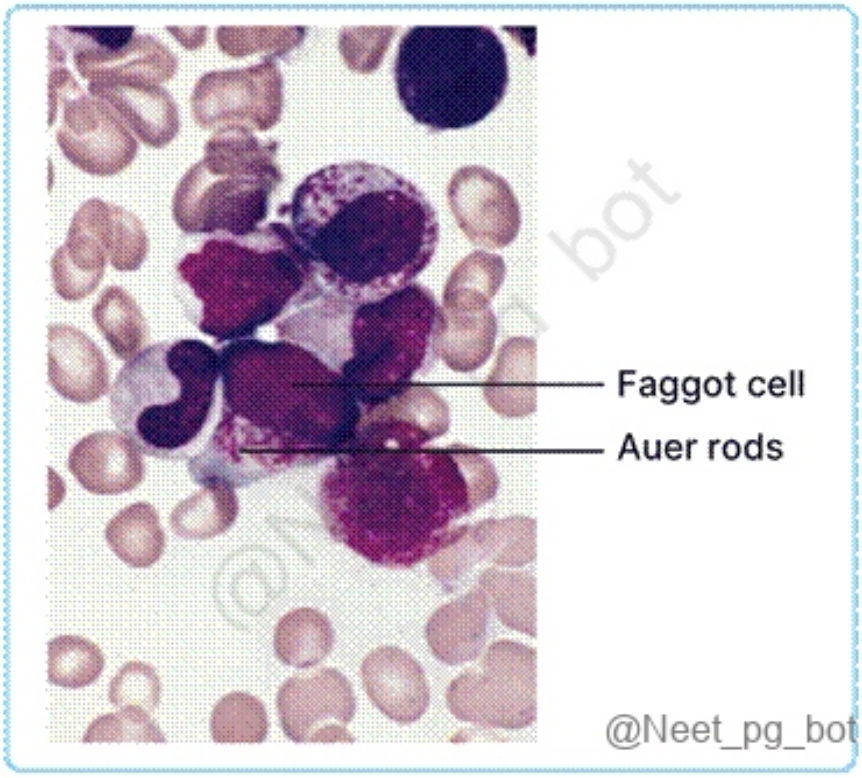

References:

Robbins & Cotran Pathologic Basis of Disease, 10th Edition, Page 414, 415, 594-597, 618, 622

https://onlinelibrary.wiley.com/doi/10.1155/2021/7488025

↑ *Back to this question in Part A*

@Neet_pg_bot

Q5: A 60-year-old patient presented with scrotal swelling and ataxia. Which among the following could likely be a cause? (Q856695)

A. Glioblastoma multiforme

B. Hodgkin lymphoma

C. Non-Hodgkin lymphoma

D. Non seminomatous germ cell tumor

Correct Answer: C. Non-Hodgkin lymphoma

Explanation: The case scenario of a 60-year-old man with scrotal swelling and ataxia is likely diagnosed as Non-Hodgkin Lymphoma (NHL) , where lymphatic obstruction causes scrotal swelling, and CNS involvement leads to ataxia. It is a type of cancer originating from lymphocytes and is characterized by the growth of lymphoid tissue. Clinical features: Asymptomatic Palpable Lymphadenopathy is the hallmark (neck, armpits, or groin). Lymphadenopathy is not rapidly progressive. B Symptoms (Fever, Night sweats, and Weight loss) Extranodal involvement Ileocecal region (abdominal pain or changes in bowel habits). Lymphomatoid polyposis. The oropharynx, especially Waldeyer's ring (sore throat or difficulty swallowing). Bone marrow involvement (cytopenias-anemia, leukopenia, and thrombocytopenia). Splenomegaly (abdominal discomfort and a sensation of fullness). Hodgkin lymphoma (Option B ruled out) Non-Hodgkin lymphoma (Option C) Age of presentation Bimodal distribution peaks in young adults (15-35 years) and older adults (over 55). More common in older adults but can occur at any age. Localization More often localised to a single axial group of nodes (cervical, mediastinal, para-aortic) More frequent involvement of multiple peripheral nodes Malignant cells Reed-Sternberg cells (owl eye cells) - B cells - induce inflammation and fibrosis Lymphoid cells - many subtypes - most are B cells than T cells Mass composition Inflammatory cells and fibrosis (reactive cells) Lymphoid cells Clinical Painless lymphadenopathy B symptoms Painless lymphadenopathy Mesenteric nodes and Waldeyer ring are involved. Spread Contiguous (touching); rarely extranodal Diffuse; often extranodal Staging Guides therapy Radiation mainstay treatment Limited importance Leukemic phase Doesn't occur Occurs Glioblastoma multiforme (Option A) is a type of brain tumour that arises from glial cells. It typically does not cause scrotal swelling or ataxia. The symptoms associated with glioblastoma multiforme are typically related to the location of the tumour within the brain. Non-seminomatous germ cell tumours (Option D) are a type of testicular cancer that arise from germ cells in the testicles. While they can cause scrotal swelling, ataxia is not a typical presentation of this type of tumour.

References:

Robbins & Cotran Pathologic Basis of Disease, 10th Edition, Page 611.

↑ *Back to this question in Part A*

@Neet_pg_bot

Q6: Which cell is the origin of chronic lymphocytic leukaemia / small lymphocytic lymphoma? (Q856721)

A. Naive B cells

B. Mature T cells

C. Progenitor T cells

D. Granulocytes

Correct Answer: A. Naive B cells

Explanation: The cells of origin of Chronic Lymphocytic Leukemia (CLL) and Small Lymphocytic Lymphoma (SLL) are mature B cells. Genetics: Trisomy 12, deletion 13q14, and others Origin: Post–germinal centre memory B cell or naive B Cells in the mantle zone of the lymph node (Option A) Etiopathogenesis Antiapoptotic protein

BCL2 overexpression. CLL cell growth depends on Bruton Tyrosine kinase (BTK) activity. No association with radiation exposure Clinical Presentation Most common Leukemia in the elderly. Frequently asymptomatic at diagnosis. May present with fatigue, lymphadenopathy, hepatosplenomegaly, or infection due to immunosuppression. Associated with autoimmune hemolytic anaemia- Spherocytes can be seen on peripheral smear It can lead to hypogammaglobulinemia due to abnormal B cells, which impair normal antibody production. Infection is the M/C/C of death in CLL Laboratory diagnosis: Absolute lymphocyte count (ALC) > 5000/mm3 Bone marrow lymphocytes >30% Surface markers using flow cytometry were positive for CD5, CD23, CD19 CD20. CLL co-expresses both T cell (CD5) and B cell (CD20, CD19) markers Mature T cells (Option B) can give rise to several cancers, including Peripheral T-cell lymphoma (PTCL), Cutaneous T-cell lymphoma (CTCL), Adult T-cell leukaemia/lymphoma (ATLL) (associated with HTLV-1), Anaplastic large cell lymphoma (ALCL), and T-cell prolymphocytic leukaemia (T-PLL). Progenitor T cells (Option C) can give rise to cancers such as T-cell acute lymphoblastic leukaemia (T-ALL) and T-cell lymphoblastic lymphoma (T-LBL). Both of these are aggressive hematologic malignancies that involve the malignant transformation of immature T cells (or T-cell precursors), characterized by rapid proliferation of immature T lymphocytes. Granulocytes (Option D) can give rise to acute myelogenous leukaemia (AML), where immature myeloid cells, including granulocyte precursors, proliferate rapidly, and chronic myelogenous leukaemia (CML), characterized by uncontrolled production of mature granulocytes due to the Philadelphia chromosome. Both cancers stem from the malignant transformation of myeloid progenitor cells.

References:

Robbins & Cotran Pathologic Basis of Disease,10th Edition, Page 597-598.

↑ *Back to this question in Part A*

@Neet_pg_bot

Q7: A patient with lytic lesions on the skull is suspected of a diagnosis of Langerhans cell histiocytosis. Which of the following is a characteristic finding of electron microscopy? (Q856725)

A. Histiocytes

B. Birbeck granules

C. Eosinophils

D. Giant cells

Correct Answer: B. Birbeck granules

Explanation: A characteristic finding on electron microscopy in Langerhans cell histiocytosis (LCH) is the presence of Birbeck Granules . These are rod-shaped, tennis racket-like structures that have a central linear striation. {{caption_text}} They are considered to be specific ultrastructural markers for Langerhans cells. These are thought to be derived from the endosomal compartment and are composed of a protein called langerin (CD207), a unique marker for Langerhans cells and is involved in antigen presentation and immune response

regulation. Histiocytes (Option A) are a type of immune cell that plays a key role in the body's defence mechanisms. They are specialized macrophages or dendritic cells found in tissues, where they function to engulf pathogens, dead cells, and foreign substances. Histiocytic disorders can give rise to cancers such as histiocytic sarcoma and Langerhans cell histiocytosis (LCH). Eosinophils (Option C) are a type of white blood cell involved in immune responses, particularly in allergic reactions and parasitic infections. They can give rise to cancers such as eosinophilic leukaemia and eosinophilic lymphoma, which are rare disorders characterized by the uncontrolled proliferation of eosinophils, leading to symptoms like organ infiltration, tissue damage, and inflammation. Giant cells (Option D) are large, multinucleated cells that can arise in response to chronic inflammation or certain infections. They can be found in various cancers, such as giant cell tumours of bone (a benign but locally aggressive tumour) and osteoclast-like giant cell tumours in soft tissues. Additionally, giant cells are often seen in granulomatous diseases like tuberculosis and sarcoidosis, where they form part of the immune response.

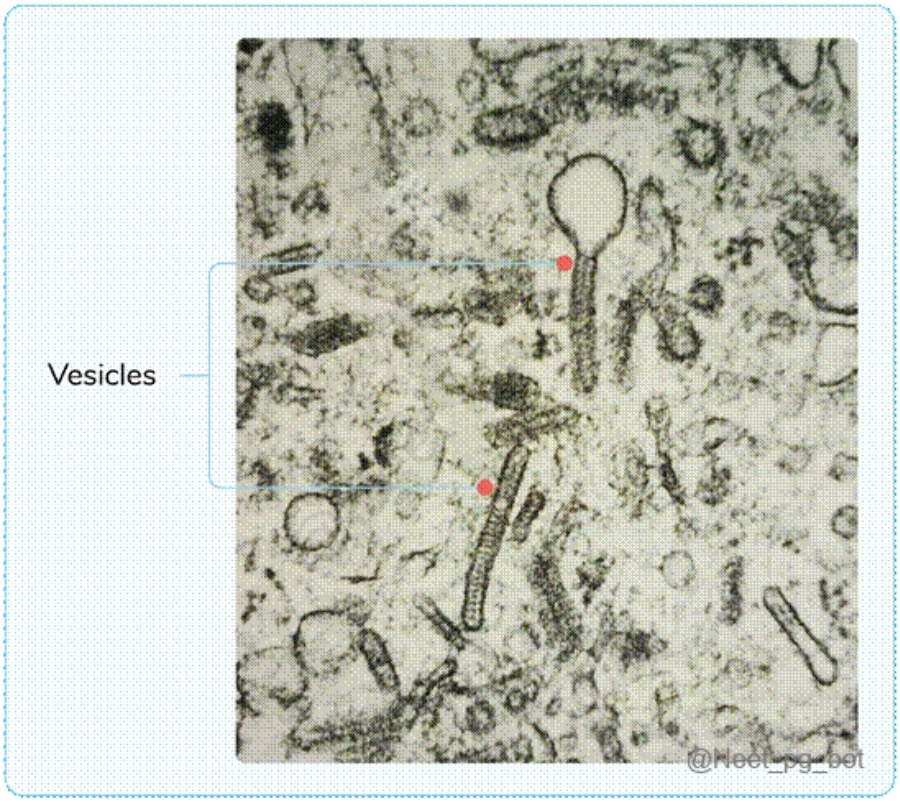

References:

Robbins & Cotran Pathologic Basis of Disease,10th Edition, Page 627.

↑ *Back to this question in Part A*

@Neet_pg_bot

Q8: A 6-year-old boy came with bilateral cervical lymphadenopathy. What is the probable diagnosis, cell, and virus associated with the image given below? RS cell: Reed Stemberg cell HIV: Human immunodeficiency virus CMV: Cytomegalovirus

EBV: Epstein–Barr virus (Q856726)

A. Non-Hodgkin’s lymphoma, RS cell, EBV

B. Kaposi sarcoma, Giant cell, HIV

C. Hodgkin’s lymphoma, RS cell, EBV

D. Infectious mononucleosis, RS cell, CMV

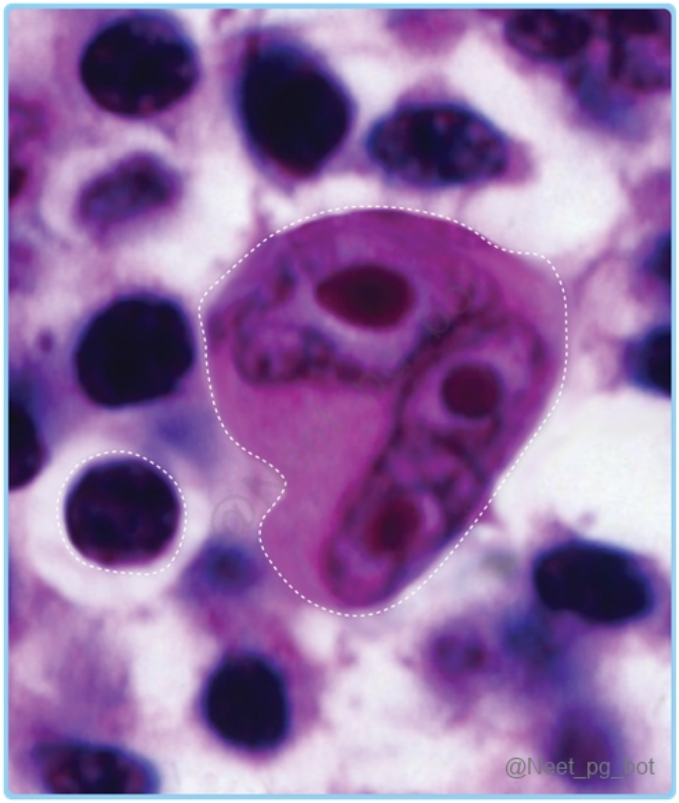

Correct Answer: C. Hodgkin’s lymphoma, RS cell, EBV

Explanation: The histopathological image reveals Reed-Sternberg cells , indicating Hodgkin's Lymphoma (HL) , which is associated with EBV (Epstein-Barr virus). Hodgkin's Lymphoma (HL) Etiology M ore common in whites & Males. Bimodal age distribution with peaks in the 20s and 80s. It is not a part of AIDS-defining lymphoma. Risk Factors : HIV infection is a major risk factor. Epstein-Barr virus (EBV). (Option C) Reed-Sternberg (HRS) Cells (Option C) HRS cells are derived from the germinal centre or post-germinal centre B cells (mature B cells in peripheral lymph nodes). Diagnostic of HL. Large, with abundant cytoplasm, bilobed or multinucleated. Typically positive for PAX-5, CD15, and CD30. {{caption_text}} NF-κB Activation Common in cHL, promoting RS cell growth and survival. EBV+ Tumors : Express latent membrane protein-1 (LMP-1) , which activates NF-κB. EBV– Tumors : NF-κB activation may result from loss-of-function mutations in IκB or loss-of-function mutation of TNF-α–induced protein 3, both of which normally inhibit NF-κB. NF-κB activation may rescue "crippled" B cells that can't express Ig, preventing apoptosis and enabling further mutations that form RS cells. Immune Evasion Genetic abnormalities at the PD-L1 locus on chromosome 9p24.1 lead to PD-L1 overexpression, which helps the tumour evade immune detection. Non-Hodgkin’s lymphoma, RS cell, EBV (Option A) : Non-Hodgkin's

lymphoma (NHL) is a diverse group of hematologic cancers marked by lymphoid tissue proliferation, often linked to HIV but not typically associated with Reed-Sternberg cells or EBV. Kaposi sarcoma, Giant cell, HIV (Option B): Kaposi sarcoma is marked by the proliferation of spindle-shaped cells that express markers of both endothelial (vascular or lymphatic) and smooth muscle cells, and is linked to human herpesvirus 8 (HHV-8) , but is not typically associated with Reed-Sternberg cells or EBV. {{caption_text}} Infectious mononucleosis, RS cell, CMV (Option D) : Infectious mononucleosis, a benign and self-limited lymphoproliferative disorder caused by Epstein-Barr virus (EBV), is characterized histopathologically by atypical lymphocytes—large, irregularly shaped cells with abundant cytoplasm and prominent nuclei. It is not typically associated with Reed-Sternberg cells. {{caption_text}}

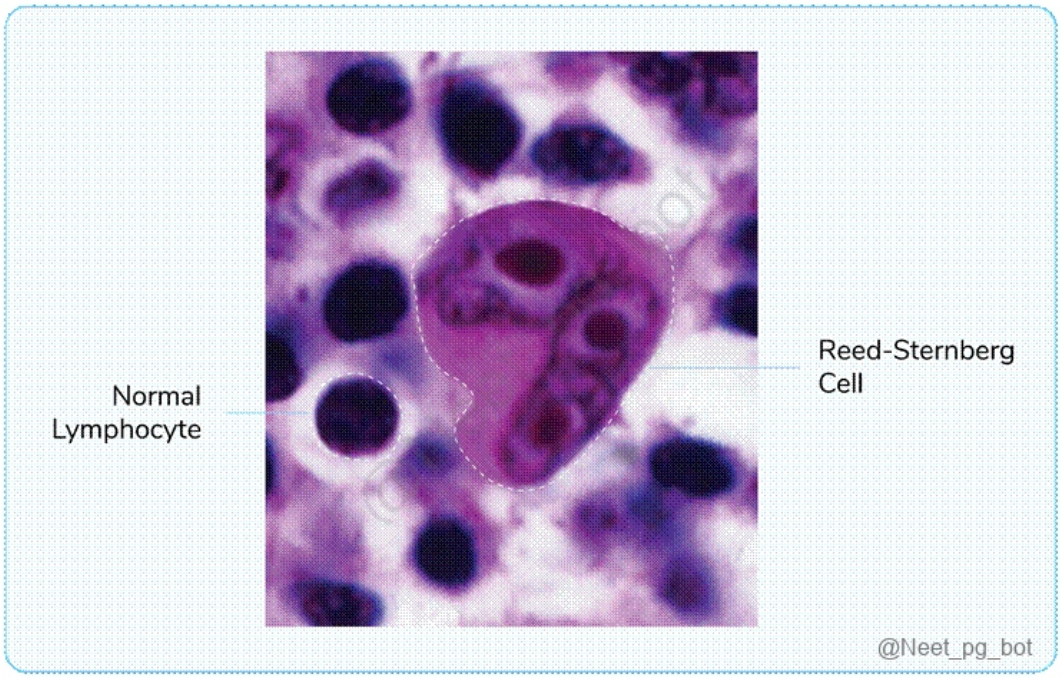

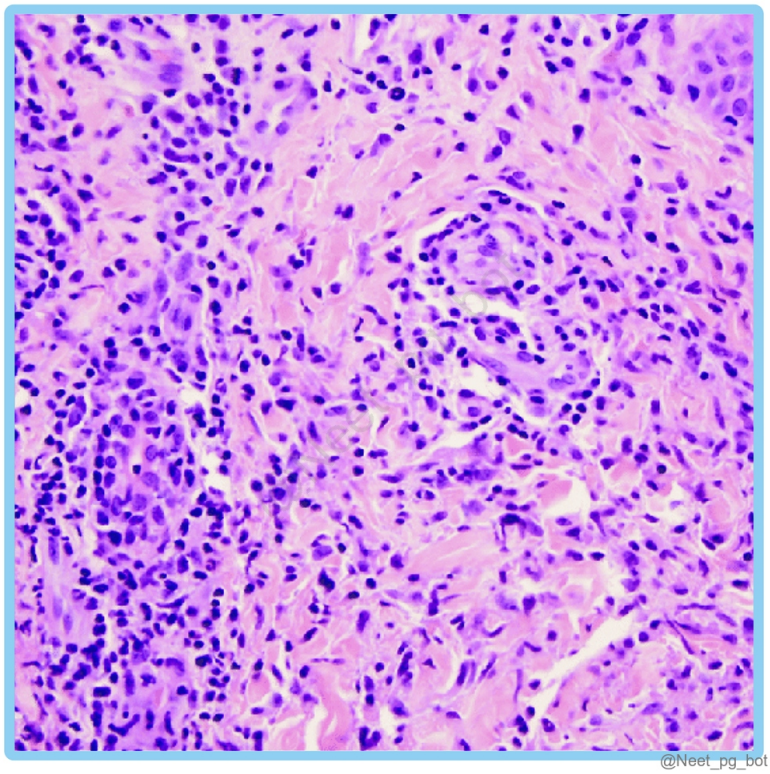

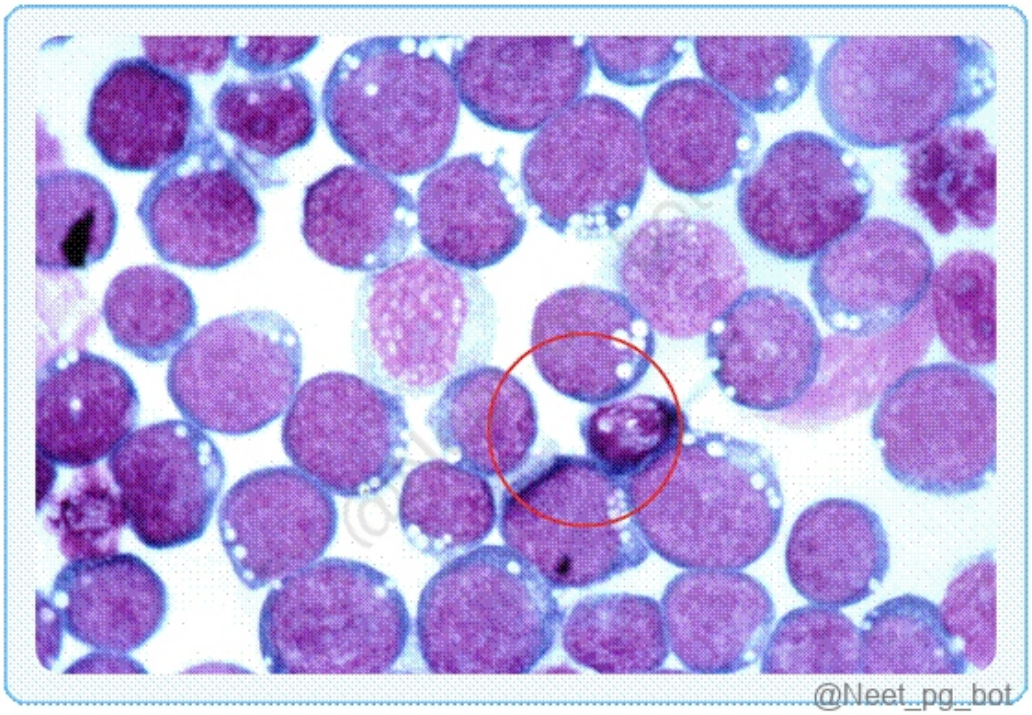

References:

Robbins & Cotran Pathologic basis of disease, 10th Edition, Page 611, 612.

Harrison’s Principles of Internal Medicine, 21st Edition Page 852.

↑ *Back to this question in Part A*

@Neet_pg_bot

Q9: A 30-year-old male has been complaining of fatigue for the past year. The examination revealed massive splenomegaly. His blood workup shows the presence of anemia, TLC 150,000/microL, and PBS shows 60% neutrophils, 6% basophils, 4% eosinophils, myeloblasts, myelocytes, and metamyelocytes. The myeloid-to-erythroid ratio was 18:1. Which of the following is the most sensitive investigation in this case? (Q856102)

A. Immunophenotyping

B. LAP score

C. FISH and PCR

D. Flow cytometry

Correct Answer: C. FISH and PCR

Explanation: The clinical presentation with massive splenomegaly, anaemia, and a markedly elevated TLC with myeloblasts, myelocytes, and basophils is highly suggestive of Chronic Myelogenous Leukemia (CML), and the most sensitive test for diagnosing CML is FISH and PCR . Investigations to find CML CBC Normal RBC + Elevated TLC + Elevated platelets Peripheral smear Left shift with predominant segmented neutrophils, myelocytes, and metamyelocytes. College girl/garden party appearance. Bone marrow aspirate Increased Myeloid: Erythroid ratio. Dwarf megakaryocytes. Sea blue histiocytes (blue-coloured cytoplasm) Pseudo Gaucher cells {{caption_text}} NAP/LAP score The leukocyte alkaline phosphatase (LAP) score is low in CML and can be used to differentiate it from other leukaemias, but it’s not the most sensitive test. (Option B ruled out) FISH (IOC) Confirms t(9:22) translocation. Analysis to quantify Philadelphia chromosome-positive cells. Estimates the tumour load. {{caption_text}} PCR To quantify BCR-ABL-1. It can be a false negative or a false positive. False negative: Early part of the disease. Immunophenotyping (Option A) can be useful for characterising cell surface markers in hematologic malignancies, but it is not the most sensitive test for CML . It is more helpful in identifying acute leukaemias or lymphoproliferative disorders but does not directly detect the genetic mutation responsible for CML. Flow cytometry (Option D) is primarily used to analyse the immunophenotype of hematologic cells and is useful for detecting acute leukaemias and lymphoproliferative disorders . However, it does not directly detect the Philadelphia chromosome or the BCR-ABL fusion gene , which are key to diagnosing CML.

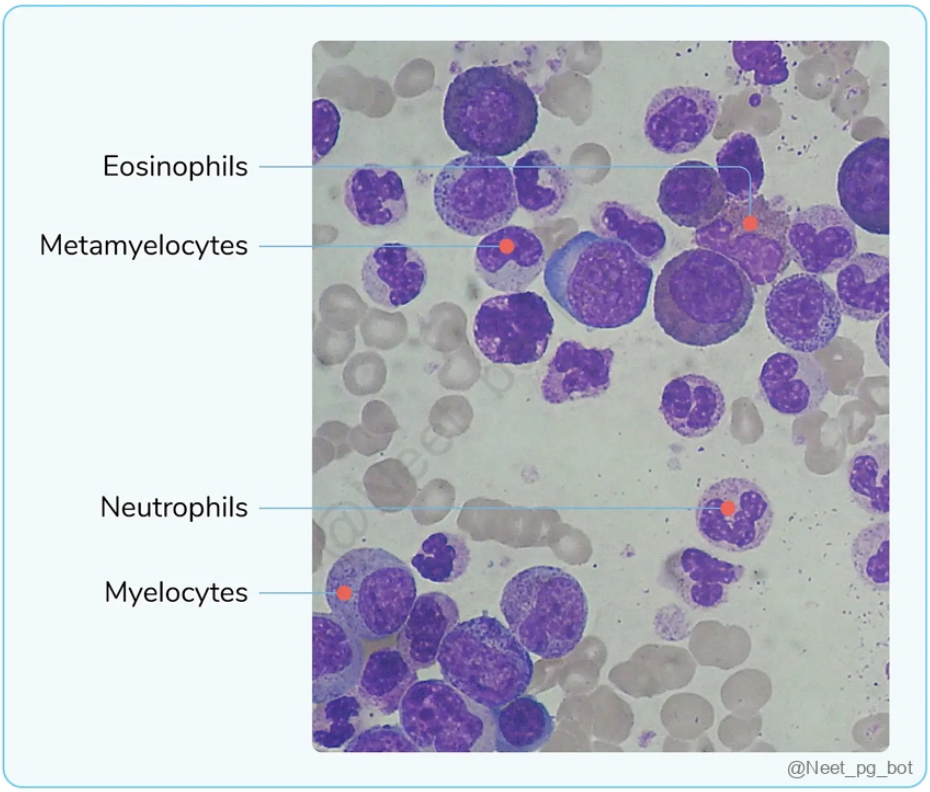

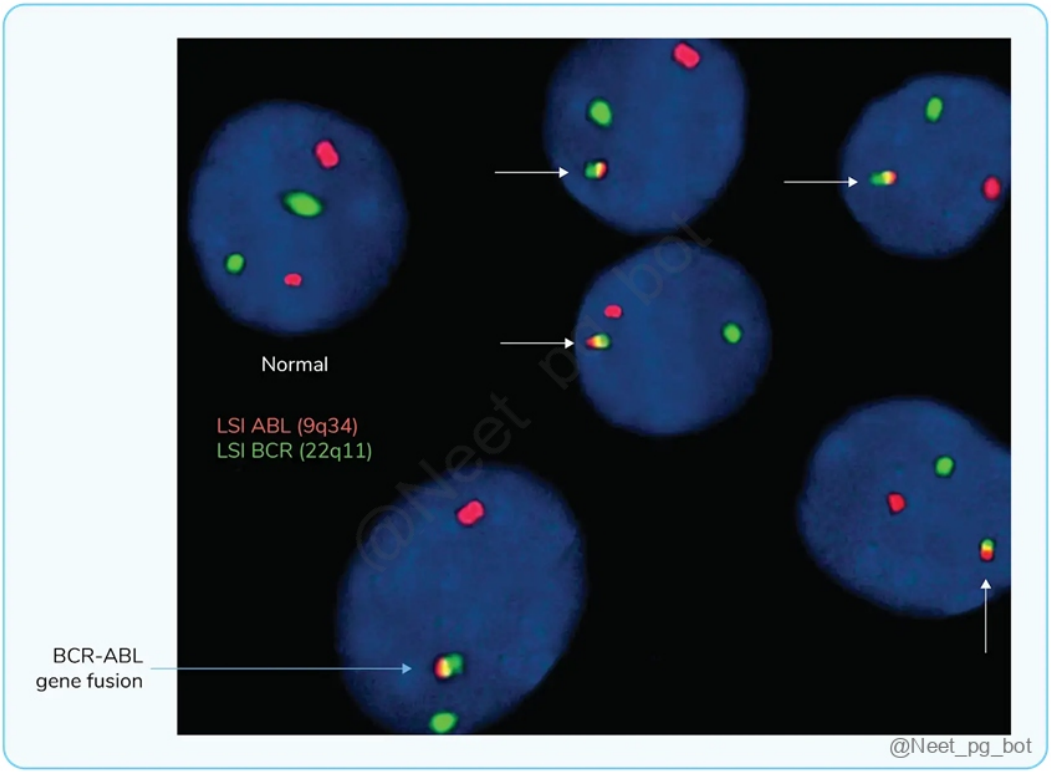

References:

Robbins and Cotran Pathologic Basis of Disease, 10th edition, Page 622

↑ *Back to this question in Part A*

@Neet_pg_bot

Q10: Which of the following is a poor prognostic marker of multiple myeloma? (Q856140)

A. β-2 microglobulin

B. Calcium levels

C. Serum creatinine

D. Protein levels

Correct Answer: A. β-2 microglobulin

Explanation: In multiple myeloma , one of the most significant poor prognostic markers is β-2 microglobulin. Elevated levels of β-2 microglobulin correlate with a higher tumour burden and more aggressive disease Prognosis of Multiple Myeloma is determined by: Durie-Salmon staging system (earlier) International Staging System (ISS): Three-stage system to predict survival based on: β2-microglobulin Albumin levels Calcium levels (Option B) : Hypercalcemia is a common marker in multiple myeloma, but it is often a late-stage complication and does not directly indicate poor prognosis compared to β-2 microglobulin . Serum creatinine (Option C) , when elevated, indicates renal impairment , which is a common complication of multiple myeloma. While kidney function is important for prognosis, serum creatinine is not a prognosis indicator compared to β-2 microglobulin . Protein levels (Option D) are commonly elevated and serve as disease markers, but they do not directly indicate a poor prognosis.

References:

Harrison’s Principles of Internal Medicine, 21st Edition, Page 871

↑ *Back to this question in Part A*

@Neet_pg_bot

Q11: A 54-year-old patient presents to the outpatient department with fatigue, tiredness, and cervical lymphadenopathy. The TLC and DLC were normal, with no immature cells. A lymph node biopsy showed diffuse effacement of the lymph node architecture and cells with an indented nucleus and prominent nucleolus that are atypical. CD10 and BCL2 are positive. What is the likely diagnosis? (Q856147)

A. Follicular lymphoma

B. Burkitt lymphoma

C. Mycosis fungoides

D. Chronic myeloid leukaemia

Correct Answer: A. Follicular lymphoma

Explanation: Given the lymphadenopathy , the findings on lymph node biopsy (indented nuclei, BCL2 positivity), and the normal blood counts (no immature cells), Follicular lymphoma is the most likely diagnosis. Follicular lymphoma (FL) is a malignant neoplasm originating from germinal centre B-cells, characterised by the t(14;18) translocation leading to overexpression of BCL2. Clinically, it presents with painless lymphadenopathy and may include systemic symptoms. Histopathologically, FL exhibits a nodular growth pattern with centrocytes(Small cells with cleaved nuclei and scanty cytosol) and centroblasts(Larger cells with open nuclear chromatin and several nucleoli) Immunohistochemistry shows positivity for CD10/19/20, BCL2, and BCL6, and negativity for CD5. Management focuses on palliative approaches due to their indolent but incurable nature. {{caption_text}} Burkitt lymphoma (Option B) is a type of B-cell lymphoma characterised by rapidly growing tumours , typically extranodal , most commonly in the abdomen or jaw . It often presents as large masses rather than just cervical lymphadenopathy . It has a "starry sky" pattern on histology due to macrophages phagocytosing apoptotic tumour cells, which was not noted in the biopsy here. Mycosis fungoides (Option C) is a cutaneous T-cell lymphoma that primarily affects the skin and presents as patches, plaques , or tumours . It does not typically present with lymphadenopathy as a primary feature; its main involvement is in the skin rather than the lymph nodes. Chronic myeloid leukemia (Option D) is a myeloproliferative disorder that is marked by the presence of the Philadelphia chromosome (t(9;22) translocation), which leads to the production of the BCR-ABL fusion gene .

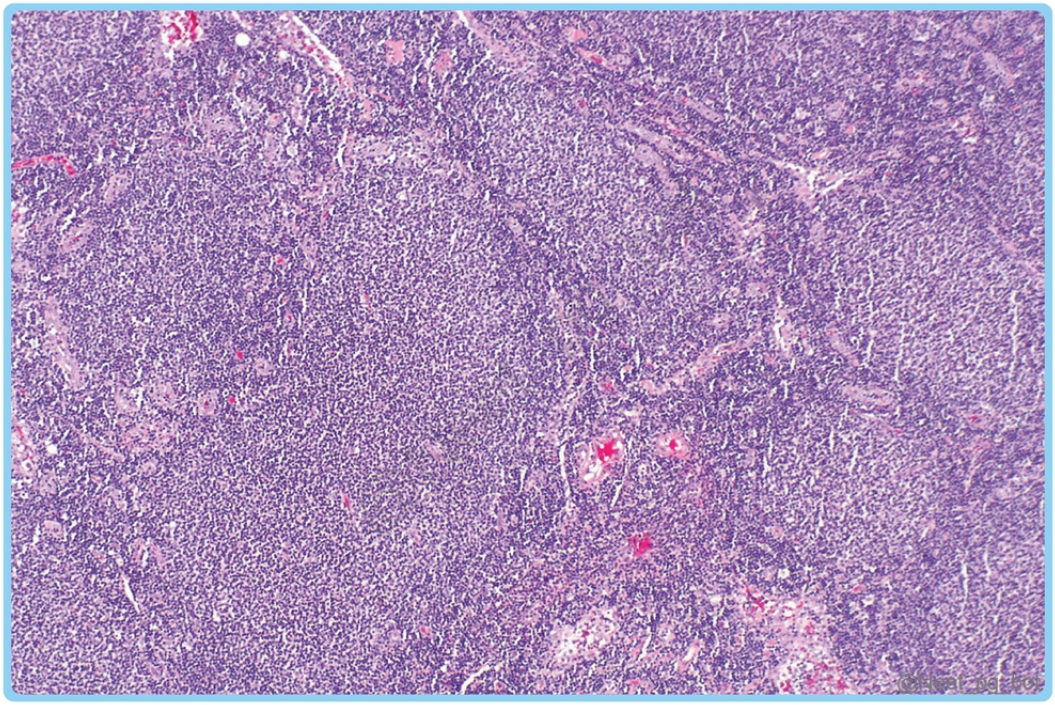

References:

Robbins and Cotran Pathologic Basis of Disease, 10th Edition, Pages 589, 599 - 603

↑ *Back to this question in Part A*

@Neet_pg_bot

Q12: Which of the following is a possible explanation for the presence of pancytopenia as indicated by the blood examination results? A. Megaloblastic anemia B. Hairy cell leukemia C. MDS with hypocellular BM D. APML (Q856922)

A. B, D

B. A, B, C

C. B, C, D

D. A, B, D

Correct Answer: B. A, B, C

Explanation: Megaloblastic anaemia is caused by impaired DNA synthesis, leading to the production of abnormally large and immature red blood cells (megaloblasts). Pancytopenia occurs due to reduced production of red blood cells, white blood cells, and platelets. Hairy cell leukaemia is a rare form of chronic lymphocytic leukaemia characterized by abnormal B lymphocytes with hair-like projections on their surface. It can lead to pancytopenia by infiltrating the bone marrow with these atypical cells, which disrupt normal blood cell production. MDS with hypocellular bone marrow : Myelodysplastic syndromes (MDS) are a group of disorders marked by ineffective blood cell production. In some cases, MDS leads to a hypocellular bone marrow, where the number of blood-forming cells is lower than usual, resulting in pancytopenia due to a reduction in the production of all types of blood cells. Causes of pancytopenia in hypocellular marrow: Hypocellular MDS Some Lymphomas and ALL Copper deficiency Acquired aplastic anemia Causes of pancytopenia in cellular bone marrow: Myelodysplastic syndromes (MDS) Systemic Lupus Erythematosus (SLE) Megaloblastic anemia Hairy cell leukemia Myelofibrosis Paroxysmal Nocturnal Hemoglobinuria (PNH) Sarcoidosis, HIV, Brucellosis,Leishmaniasis Hypersplenism Bone marrow lymphoma

References:

Robbins & Cotran Pathologic Basis of Disease, 10th Edition, Page 392, 604, 661,830

↑ *Back to this question in Part A*

@Neet_pg_bot

Q13: 2-year-old with fever, lymphadenopathy and H&E has hallmark cells. The diagnosis of anaplastic large cell lymphoma was made. Most likely translocation? (Q866673)

A. t(8;14)

B. t(8;22)

C. t(2;5)

D. t(14;18)

Correct Answer: C. t(2;5)

Explanation: Anaplastic Large Cell Lymphoma (ALCL) is most often associated with the t(2;5) translocation. t(2;5) → creates the NPM-ALK fusion gene NPM - nucleophosmin (chromosome 5) ALK - anaplastic lymphoma kinase (chromosome 2) This fusion leads to constitutive activation of ALK tyrosine kinase, driving uncontrolled cell growth. ALCL histology shows hallmark cells, large pleomorphic cells with horseshoe- or kidney-shaped nuclei and abundant cytoplasm. Incorrect Options: t(8;14) (Option A): Seen in Burkitt lymphoma . MYC gene on chromosome 8 translocates to Ig heavy chain locus on chromosome 14 → MYC overexpression. It is a very aggressive B-cell lymphoma; common in children in malaria-endemic areas. t(8;22) (Option B) : Variant of Burkitt lymphoma involving MYC and Ig lambda light chain locus (chromosome 22). t(14;18) (Option D): Seen in Follicular lymphoma. BCL2 gene (chromosome 18) translocates to Ig heavy chain locus (chromosome 14) → BCL2 overexpression → apoptosis inhibition. It usually has an indolent course.



References:

.

↑ *Back to this question in Part A*

@Neet_pg_bot

Q14: Identify the correct statement regarding immune surveillance. (Q856493)

A. Anti-CTLA-4 Ab is a new modality in the treatment of advanced cancers

B. Mutation of tumour suppressor genes decreases antigen toxicity

C. PD1/PDL1 activation leading to tumour suppression

D. Binding of CD28 leads to immune tolerance

Correct Answer: A. Anti-CTLA-4 Ab is a new modality in the treatment of advanced cancers

Explanation: Anti-CTLA-4 antibody (Ab) is an emerging treatment in immunotherapy, especially in advanced cancers. It works by blocking the CTLA-4 receptor , enhancing T-cell activation and immune response against tumour cells. Immune surveillance: Immune surveillance refers to the immune system's ability to detect and eliminate cancerous cells, thereby preventing cancer development and progression. CTLA-4 (cytotoxic T-lymphocyte-associated protein 4) is a checkpoint protein that negatively regulates T-cell activation. Immunotherapeutic agents, such as ipilimumab , target CTLA-4 to enhance T-cell activation, boosting the immune response against tumours and showing promising results in treating advanced cancers. Mutations in tumour suppressor genes typically increase tumorigenicity and antigenicity (Option B) , not decrease antigen toxicity. PD1/PDL1 activation generally inhibits immune responses (Option C) , leading to immune evasion by tumours, not suppression. Binding of CD28 to CD80/86 enhances immune activation, not tolerance (Option D) . Immune tolerance is more associated with inhibitory signals like CTLA-4.

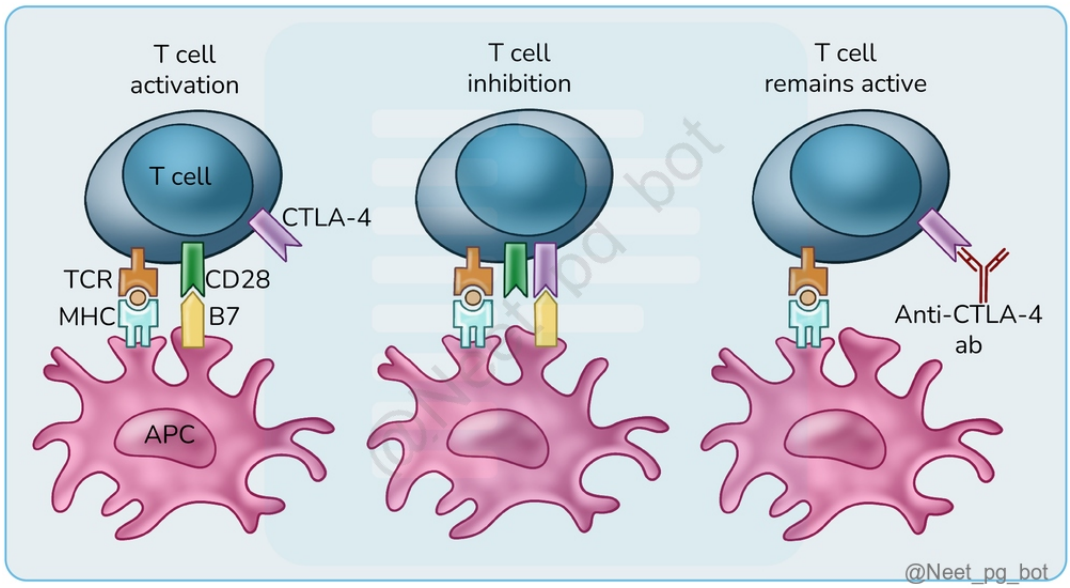

References:

Robbins & Cotran Pathologic Basis of Disease, 10th Edition, Page 312

↑ *Back to this question in Part A*

@Neet_pg_bot

Q15: All-trans retinoic acid (ATRA) is used in the treatment of tumours associated with which of the following genetic aberrations? (Q854879)

A. PML-RARA

B. BCR-ABL

C. cMYC

D. RUNX1-ETO

Correct Answer: A. PML-RARA

Explanation: All-trans retinoic acid (ATRA) is specifically used in the treatment of acute promyelocytic leukaemia (APL) , which is associated with the genetic fusion of PML (promyelocytic leukaemia gene) and RARA (retinoic acid receptor alpha) genes. The fusion disrupts the normal differentiation of promyelocytes, and ATRA helps reverse this block by promoting differentiation. M3 AML/ Acute promyelocytic leukaemia: Genetics : t(15:17) translocation causes PML-RARA (retinoic acid receptor alpha) fusion protein formation. Blocks promyelocyte → myelocyte maturation. Diagnosis of choice: FISH Smear findings: Increased promyelocytes. Auer Rods : Fused granules in promyelocytes Faggot Cells: Auer rods with a crisscross pattern. Laboratory : Low haemoglobin and platelets. > 20% blasts on peripheral and bone marrow smear Stain: PAS + CD markers: CD 13, 33 + Complication : Disseminated intravascular coagulation therefore, chemotherapy is not recommended. Treatment : ATRA (All-trans-retinoic-acid) + As 2 O 3 (arsenic trioxide) Best prognosis among all AML. {{caption_text}} BCR-ABL (Option B) fusion gene is characteristic of chronic myelogenous leukemia (CML) . The treatment for CML typically involves tyrosine kinase inhibitors (e.g., imatinib) rather than ATRA. cMYC (Option C) is an oncogene often implicated in Burkitt lymphoma and other cancers, but it is not treated with ATRA. Treatment for cMYC-related tumours typically involves chemotherapy and targeted therapy based on the specific malignancy. RUNX1-ETO (Option D) fusion gene is associated with acute myeloid leukemia (AML) , but it does not respond to ATRA treatment. Treatment for AML often includes chemotherapy and other agents.

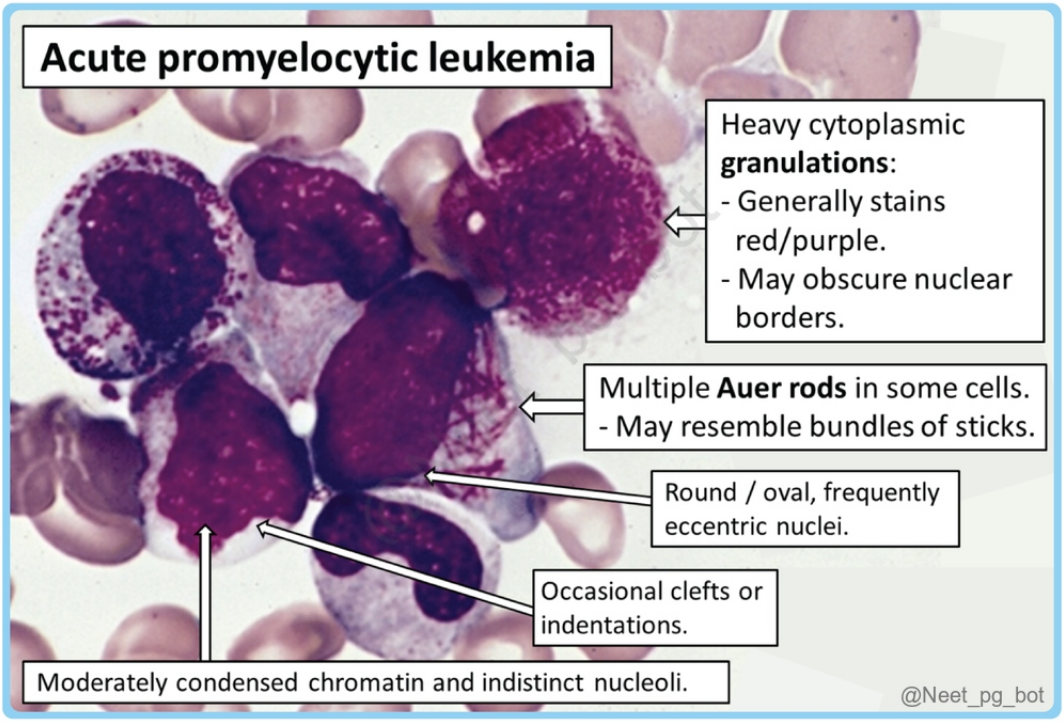

References:

Robbins & Cotran Pathologic Basis of Disease, 10th Edition, Page 617-620

↑ *Back to this question in Part A*

@Neet_pg_bot

Q16: A 70-year-old man has presented with chronic lower back pain, fatigue, and headaches for the last few weeks. On examination, he has pallor and bony tenderness. Lab investigations revealed an increased ESR, and his skull radiograph revealed several punched-out lytic lesions. Which of the following is the best investigation for this patient among the following options? (Q859274)

A. Serum electrophoresis showing IgG

B. Serum levels of CA 15-3

C. Whole-body scan

D. CT head with contrast

Correct Answer: A. Serum electrophoresis showing IgG

Explanation: The patient's pain, fatigue, multiple punched-out lytic lesions on X-ray, and elevated ESR suggest Multiple myeloma. The best investigation is serum electrophoresis , which detects monoclonal immunoglobulins, such as IgG, confirming the diagnosis and quantifying the abnormal proteins. Incorrect Options: Serum levels of CA 15-3 (Option B): CA 15-3 is a tumour marker primarily used for monitoring breast cancer. Whole-body scan (Option C) : While imaging studies such as whole-body scans may be useful in assessing the extent of multiple myeloma involvement, they are not typically the initial investigation for diagnosis. CT head with contrast (Option D) is not necessary for multiple myeloma.

References:

Robbins & Cotran Pathologic Basis of Disease, 10th Edition, Pages 607- 610

↑ *Back to this question in Part A*

@Neet_pg_bot

Q17: A 65-year-old male underwent a bone marrow examination, which revealed the presence of the following findings, as shown in the image. What is the likely diagnosis of this patient? (Q859279)

A. Multiple myeloma

B. ALL

C. Tuberculosis

D. Sickle cell disease

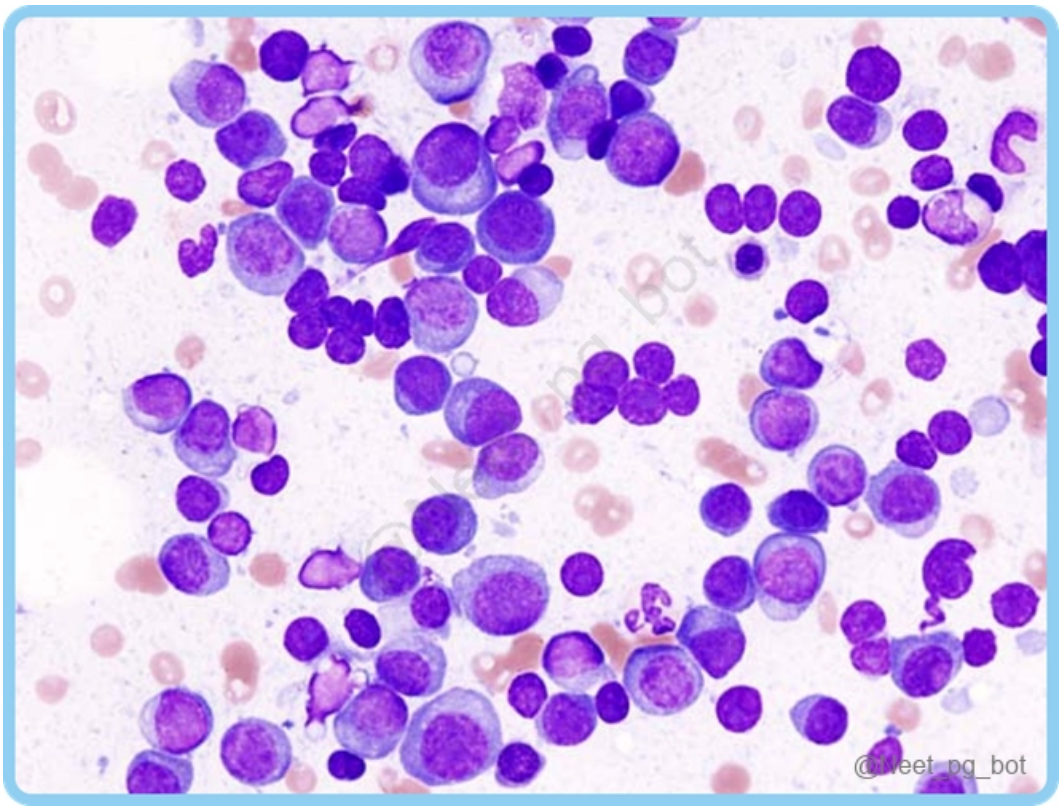

Correct Answer: A. Multiple myeloma

Explanation: Multiple myeloma is a plasma cell malignancy characterised by the uncontrolled proliferation of clonal plasma cells in the bone marrow. Bone Marrow Examination: Presence of ≥10% clonal plasma cells in bone marrow. Atypical plasma cells with features such as binucleation, prominent nucleoli, and perinuclear hof (Golgi clearing). Serum and Urine Electrophoresis: Detection of monoclonal (M) protein in serum or urine (commonly IgG or IgA). Free light chains may be detected in urine (Bence Jones proteins). CRAB Criteria (End-Organ Damage): Calcium elevation (hypercalcemia). Renal dysfunction (elevated creatinine). Anaemia (normocytic, normochromic). Bone lesions (osteolytic lesions on skeletal imaging). Incorrect Options: ALL (Acute Lymphoblastic Leukemia) (Option B) is characterised by increased bone marrow and peripheral blood lymphoblasts but lacks the plasma cell morphology seen in multiple myeloma. Tuberculosis (Option C) of the bone marrow usually shows granulomas with caseous necrosis, not plasma cells. Sickle Cell Disease (Option D): Bone marrow findings in sickle cell disease may show erythroid hyperplasia and abnormal erythrocytes, but plasma cells are not a feature.

References:

Robbins and Cotran Pathologic Basis of Disease, 10th Edition, Page 607, 608, 609

↑ *Back to this question in Part A*

@Neet_pg_bot

Q18: A 10-year-old boy with Down syndrome presents with mediastinal mass (presenting as SVC-like syndrome), and Peripheral blood and bone marrow have increased lymphoblasts. What is the probable diagnosis? (Q859296)

A. Acute myeloblastic leukemia

B. Chronic lymphoblastic leukemia

C. Acute lymphoblastic leukemia

D. Chronic myeloid leukemia

Correct Answer: C. Acute lymphoblastic leukemia

Explanation: The diagnosis is based on the presence of increased lymphoblasts in peripheral blood and bone marrow, along with a mediastinal mass causing SVC-like syndrome, a characteristic feature of T-cell Acute Lymphoblastic Leukaemia (ALL). The strong association with Down syndrome further supports the diagnosis. Common in children, with a worse prognosis in adults. T-cell ALL often presents with a mediastinal mass. Immunophenotyping: TdT+ (a marker of pre-T and pre-B cells), CD10+ (a marker of pre-B cells). Incorrect Options: Acute Myeloblastic Leukemia (AML) (Option A) typically presents with symptoms such as fatigue, recurrent infections, bleeding tendencies, and bone pain. It is less commonly associated with hepatosplenomegaly and sternal tenderness. Chronic Lymphoblastic Leukemia (CLL) (Option B) usually occurs in older individuals and is characterised by lymphocytosis, lymphadenopathy, and splenomegaly. It is less likely to present with hepatomegaly, sternal tenderness, and petechiae in a 10-year-old patient. Chronic Myeloid Leukemia (CML) (Option D) typically presents in adults and is characterised by an elevated white blood cell count, splenomegaly, and a characteristic genetic abnormality called the Philadelphia chromosome. It is less common in children and may not present with the described symptoms.

References:

Robbins and Cotran Pathologic Basis of Disease, 10th Edition, Pages 594-596.

↑ *Back to this question in Part A*

@Neet_pg_bot

Q19: What is the diagnosis for a 5-year-old boy who has weight loss, fever, and a painless swelling in his jaw area? CBC results indicate anaemia and lymphocytosis. The image below shows biopsy findings from the swelling. (Q859847)

A. Kikuchi disease

B. Infectious mononucleosis

C. Hodgkins lymphoma

D. Burkitt lymphoma

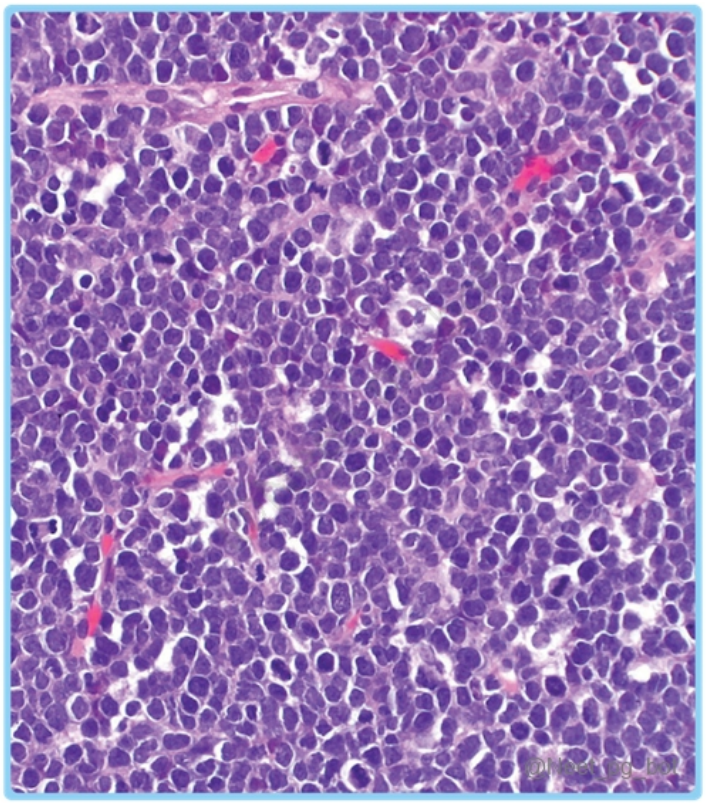

Correct Answer: D. Burkitt lymphoma

Explanation: The histopathological picture is of a Classical Burkitt Lymphoma involving a lymph node. The most characteristic finding is a “starry sky” pattern. At high-power magnification, the neoplastic cells are of intermediate size, similar to the size of benign histiocyte nuclei. The neoplastic cells have round nuclear contours, multiple nucleoli, frequent mitoses, and basophilic cytoplasm. Macrophages with engulfed pyknotic nuclei and nuclear debris are also present. Burkitt's lymphoma Aspects Description Definition An aggressive form of non-Hodgkin lymphoma characterised by the proliferation of mature B-cells. Epidemiology Endemic (African) form : Common in children, associated with Epstein-Barr virus (EBV) infection. Sporadic form : Worldwide distribution, more common in children and young adults. Immunodeficiency-related : Often seen in HIV/AIDS patients. Etiology Strong association with EBV (especially in the endemic form). Translocations involving the MYC gene (chromosome 8). Genetic Abnormality t(8;14): MYC gene translocated next to the IgH locus (most common). t(2;8) or t(8;22) : Less common, involving MYC and Ig light chain loci. Clinical Features Endemic form : Presents with jaw or facial bone tumours. Sporadic form : Often involves the abdomen (e.g., ileum, cecum) and may cause bowel obstruction. Systemic symptoms : Fever, night sweats, weight loss. Pathology Histology : "Starry-sky" appearance due to numerous apoptotic cells and macrophages. Tumor cells are medium-sized with round nuclei, coarse chromatin, and high mitotic activity. Immunophenotype Positive for CD19 , CD20 (B-cell markers), and CD10 . Expresses surface IgM . High proliferation index (Ki-67 > 95%). Diagnosis Biopsy : Histological examination showing "starry-sky" appearance. Cytogenetics : Detection of MYC translocations. Immunohistochemistry : Positive for B-cell markers (CD19, CD20). Prognosis Highly aggressive but potentially curable with prompt treatment. Favorable response to chemotherapy in many cases. Treatment Chemotherapy : Intensive regimens like cyclophosphamide, doxorubicin, vincristine, and methotrexate (CODOX-M) . CNS prophylaxis : Methotrexate or cytarabine. Supportive care for tumour lysis syndrome. Complications Risk of

tumour lysis syndrome due to rapid tumour breakdown. It may progress to involve bone marrow or CNS if untreated. Differential Diagnosis Diffuse large B-cell lymphoma. Other high-grade B-cell lymphomas. Lymphoblastic lymphoma. Hodgkin lymphoma (rarely resembles). Kikuchi disease (Option A) is a subacute necrotising lymphadenopathy affecting young adults, predominantly women, especially in Japan and neighbouring Asian countries. It presents with painless lymphadenopathy, moderate fever, chills, myalgia, sore throat, and skin rashes . Histopathology reveals necrotising lymphadenitis with histiocyte proliferation and reactive germinal centres. Infectious mononucleosis (Option B) presents with a triad of fever, pharyngitis, and cervical or generalised lymphadenopathy. Histopathology reveals Paracortical hyperplasia with a mottled ("moth-eaten") lymph node architecture. Hodgkin lymphoma (HL) (Option C) is characterised by a heterogeneous cellularity comprising a minority of specific neoplastic cells—the Hodgkin cells, the Reed-Sternberg cells, and a majority of reactive non-neoplastic cells. {{caption_text}}

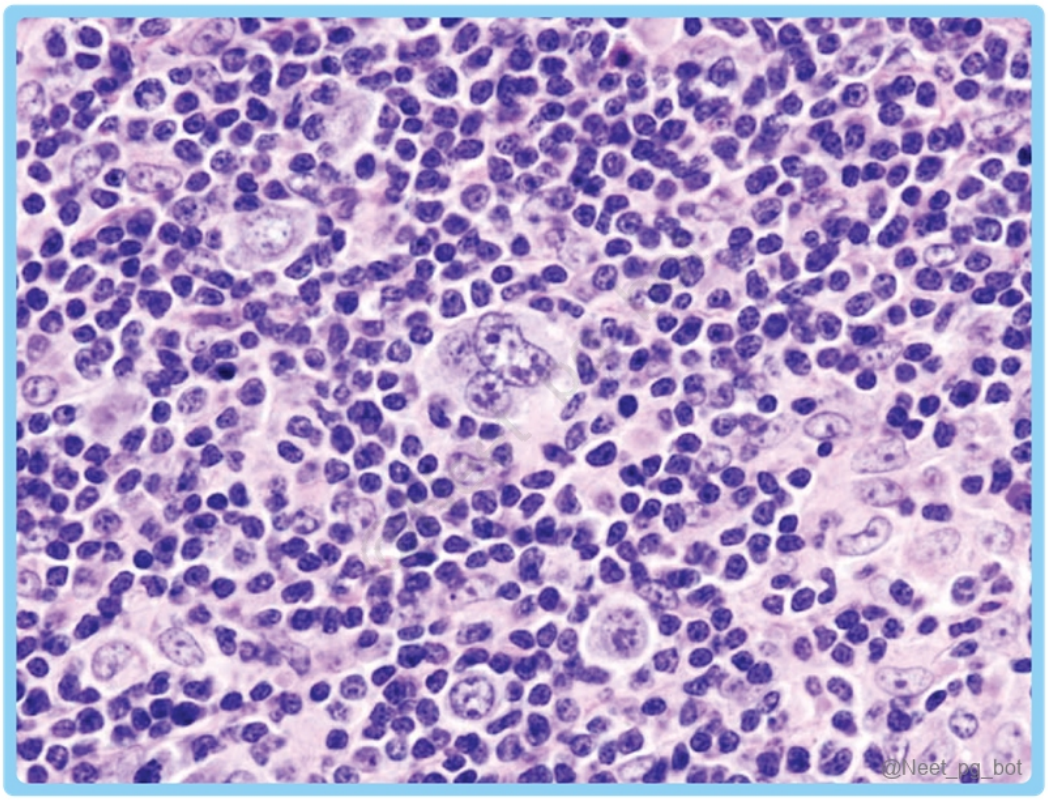

References:

Robbins & Cotran Pathologic Basis of Disease, 10th Edition, Pages 601, 602

↑ *Back to this question in Part A*

@Neet_pg_bot

Q20: A 60-year-old male patient presented with anaemia and hepatosplenomegaly. A peripheral smear showed teardrop cells, nucleated RBCs, and giant abnormal platelets. A biopsy showed marrow fibrosis and a few characteristics, as given below.

The most likely diagnosis is: (Q859854)

A. Polycythemia vera

B. Essential thrombocythemia

C. Primary myelofibrosis

D. Chronic myeloid leukemia

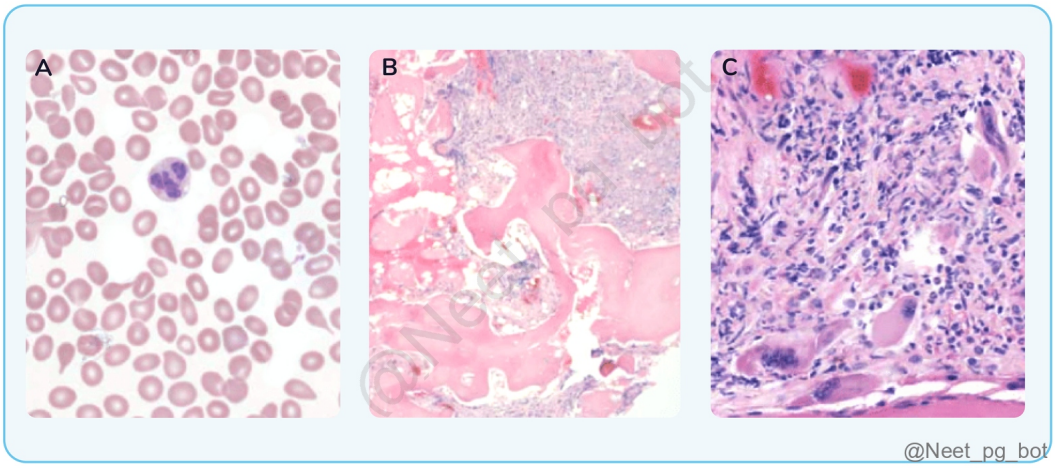

Correct Answer: C. Primary myelofibrosis

Explanation: Primary myelofibrosis (PMF) is a chronic myeloproliferative neoplasm characterised by the development of extensive marrow fibrosis , which impairs normal hematopoiesis. This fibrosis is driven by the inappropriate release of fibrogenic factors, such as platelet-derived growth factor and TGF-β, from neoplastic megakaryocytes. Clinically, PMF presents with progressive anaemia, splenomegaly, and symptoms like fatigue and weight loss. {{caption_text}} WHO diagnostic criteria: Major criteria: Megakaryocyte proliferation and atypia, usually with reticulin or collagen fibrosis. Not meeting WHO criteria for BCR-ABL1 + CML, PV, ET, MDS, or other myeloid neoplasm. Presence of JAK2, CALR, or MPL mutation or in the absence of these mutations, presence of other clonal markers, or absence of minor reactive BM reticulin fibrosis. Minor criteria: Leukocytosis ≥ 11 × 10 9 /L. Increased Serum Lactate Dehydrogenase (LDH). Anaemia is not attributed to another condition. Palpable Splenomegaly. Polycythemia vera (Option A) : Given that the patient presents with anaemia, the diagnosis is unlikely to be polycythemia vera. Essential thrombocythemia (Option B): In Essential thrombocythemia, patients usually present erythromelalgia and elevated platelet count, and there is an absence of marrow fibrosis. Chronic myeloid leukaemia (Option D): Though CML presents with anaemia and splenomegaly, bone marrow aspirate in CML is likely to show dwarf megakaryocyte and characteristic garden party appearance.

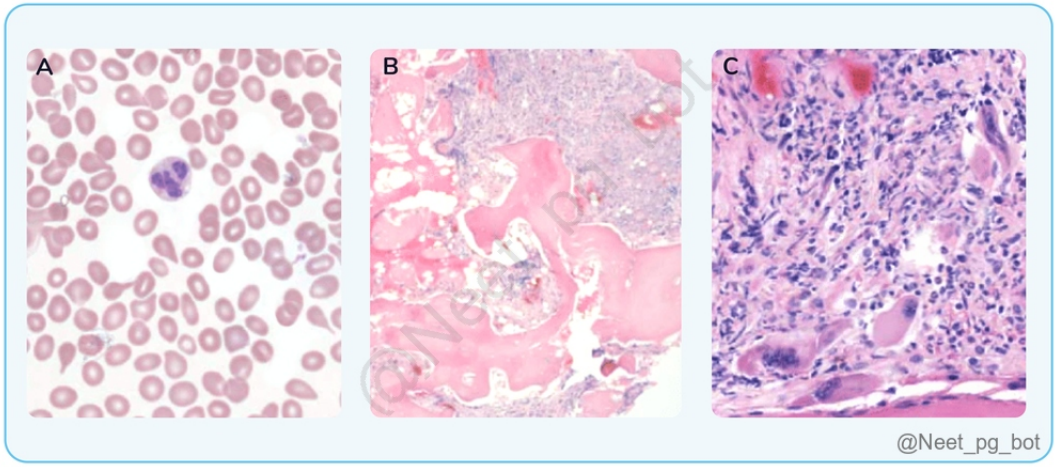

References:

Robbins & Cotran Pathologic Basis of Disease, 10th Edition, Page 626

https://www.ncbi.nlm.nih.gov/pmc/articles/PMC5807384/

↑ *Back to this question in Part A*

@Neet_pg_bot

Q21: A 35-year-old man presents with nosebleeds, bleeding gums, and multiple ecchymoses. Lab investigations show: Haemoglobin: 8.5 g/dL Platelet count: 12,000 platelets/mm3 Total leucocyte count: 52,000 cells/mm3 with 83% blasts, as seen below. The blasts are CD33 +ve. The most likely diagnosis is: (Q859860)

A. Acute myeloid leukemia

B. Acute lymphoblastic leukemia

C. Chronic lymphocytic leukemia

D. Myelodysplastic syndrome

Correct Answer: A. Acute myeloid leukemia

Explanation: The patient's presentation with nosebleeds, bleeding gums, and multiple ecchymoses with anaemia, thrombocytopenia, and leukocytosis with 83% blast, which is CD33+ve, and peripheral smear showing myeloblasts is suggestive of acute myeloid leukemia. AML arises due to genetic mutations in hematopoietic stem cells, leading to the accumulation of immature myeloblasts in the bone marrow, resulting in marrow failure. Patients often present with pancytopenia-related symptoms, including easy bruising (due to thrombocytopenia), fatigue (due to anaemia), and infections (due to leukopenia with dysfunctional blasts). Acute Lymphoblastic Leukemia (Option B): In ALL, the lymphoblasts are CD33-ve and myeloperoxidase-ve. Chronic Lymphocytic

Leukemia (Option C) : Smudge cells characteristic of CLL are CD33-ve, CD20+ve, and CD5+ve. Myelodysplastic Syndrome (Option D) is a heterogeneous group of hematologic neoplasms classically described as a clonal disorder of hematopoietic stem cells leading to dysplasia and ineffective hematopoiesis in the bone marrow. Some patients with MDS may have a transformation into acute myeloid leukemia.

References:

Robbins and Cotran, Pathologic Basis of Disease, 10th Edition, Page 594-597

↑ *Back to this question in Part A*

@Neet_pg_bot

Q22: What is the type of cell from which the cell displayed below originates? (Q859892)

A. NK cells

B. CD4 cells

C. B cells

D. CD8 cells

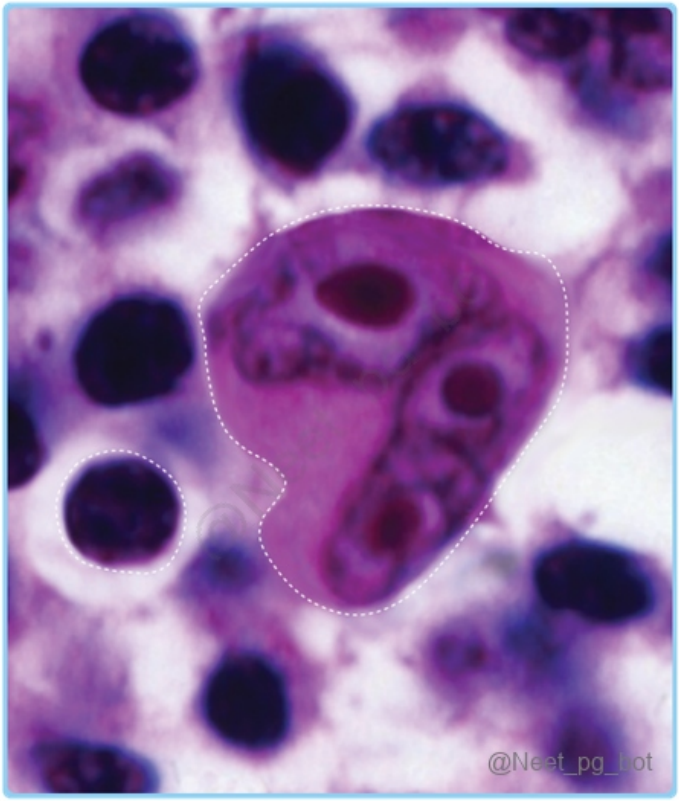

Correct Answer: C. B cells

Explanation: B cells express CD19, CD20, and CD21 markers. When activated, they differentiate into plasma cells , which have an eccentric nucleus, basophilic cytoplasm, and a perinuclear halo (indicative of the Golgi apparatus involved in antibody production). Plasma cells secrete immunoglobulins (IgG, IgA, etc.) , essential for humoral immunity. Incorrect options: NK (Natural Killer) (Option A) cells are innate immune cells. NK cells are lymphocytes that arise from the same common lymphoid progenitor that gives rise to T lymphocytes and B lymphocytes. CD4 (Option B) and CD8 (Option D) are expressed on distinct T-cell subsets and act as coreceptors during T-cell activation.CD4 is expressed in 50% to 60% of T cells, whereas CD8 is expressed in about 40% of T cells. The CD4- and CD8-expressing T cells—called CD4+ and CD8+ cells, respectively

References:

Robbins and Cotran Pathologic Basis of Disease, 10th Edition, Pages 611 to 613

↑ *Back to this question in Part A*

@Neet_pg_bot

Q23: A 56-year-old man presents with dragging pain in the abdomen. On examination, there is a massive splenomegaly. A peripheral smear shows leukocytosis with increased myelocytes, metamyelocytes, and basophils. Which of the following translocations is seen in this condition? (Q855983)

A. t(9;22)

B. t(8;21)

C. t(15;17)

D. t(8;14)

Correct Answer: A. t(9;22)

Explanation: one marrow aspirate to confirm diagnosis Peripheral smear: shows many mature neutrophils, some metamyelocytes, and myelocytes. {{caption_text}} On FISH - the presence of BCR ABL fusion gene product can be seen. Management Tyrosine kinase inhibitors such as Imatinib. t(8;21) (Option B) translocation results in the RUNX1-RUNX1T1 fusion gene , which is commonly seen in acute myeloid leukemia (AML) . t(15;17) (Option C) translocation results in the PML-RARA fusion gene, which is also characteristic of AML. t(8;14) (Option D) translocation involves the MYC gene on the chromosome, which is characteristic of Burkitt lymphoma.

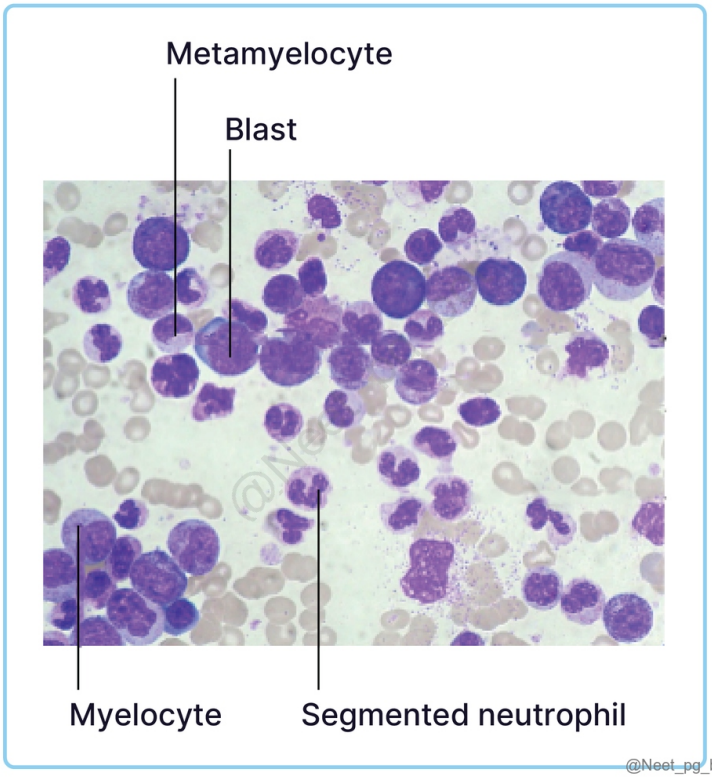

References:

Robbins and Cotran Pathologic Basis of Disease, 10th Edition, Pages 152, 600,

NIHLink,Link

↑ *Back to this question in Part A*

@Neet_pg_bot

Q24: A 62-year-old man presents with generalised lymphadenopathy and splenomegaly. Peripheral smear shows small to medium-sized lymphoid cells with irregular nuclear contours. Cytogenetic analysis demonstrates a t(11;14) (q13;q32) translocation. Which of the following markers is most closely associated with the pathogenesis? Cyclin D SOX 11 CD -200 D CD10 (Q879203)

A. 1, 2, 3

B. 1, 2

C. 1, 2, 4

D. 2, 3, 4

Correct Answer: B. 1, 2

Explanation: The described case is Mantle Cell Lymphoma (MCL) - characterised by t(11;14)(q13;q32) translocation → overexpression of Cyclin D1 . Cyclin D1 : Directly involved in pathogenesis via cell cycle dysregulation (G1→S transition). (Option 1) SOX11 : A diagnostic marker often co-expressed with Cyclin D1, helping confirm MCL, especially in Cyclin D1-negative variants. (Option 2) Conditions Surface IHC marker Follicular Lymphoma CD5 -ve, CD10+ve, CD19+ve, CD20+ve, BCL2+ve, BCL6+ve, Surface Ig+ve Follicular Hyperplasia CD3+ve, CD10+ve, CD20+ve, BCL2 -ve, BCL6+ve Mantle Cell Lymphoma Cyclin D1+ve, CD19+ve, CD20+ve, Surface Ig (usually IgM and IgD) +ve, CD5+ve, CD23 -ve Burkitt's Lymphoma IgM+ve, CD19+ve, CD20+ve, CD10+ve, BCL6+ve, BCL2 -ve CD200 (Option 3) is seen in CLL, not MCL. CD23 (Option 4) is negative in MCL but positive in CLL/SLL.

References:

Robbins & Cotran, Pathologic Basis of Diseases, 10th Edition, Page 602,603

↑ *Back to this question in Part A*

@Neet_pg_bot

Q25: A 30-year-old male presents with fatigue for the past year. Examination reveals massive splenomegaly. His blood workup shows the following findings: Anemia Total leukocyte count (TLC): 150,000/microliter Peripheral smear: 60% neutrophils, 6% basophils, 4% eosinophils, myeloblasts, myelocytes, and metamyelocytes Myeloid to erythroid ratio: 18:1 What is the most likely diagnosis? (Q857164)

A. Acute Lymphoblastic Leukemia (ALL)

B. Acute Myeloid Leukemia (AML)

C. Chronic Myelogenous Leukemia (CML)

D. Chronic Lymphocytic Leukemia (CLL)

Correct Answer: C. Chronic Myelogenous Leukemia (CML)

Explanation: Chronic Myelogenous Leukemia (CML) is the most likely diagnosis due to: Massive splenomegaly , which is a hallmark of CML. Marked leukocytosis (TLC of 150,000/microliter) with a predominance of neutrophils and the presence of immature myeloid cells (myeloblasts, myelocytes, metamyelocytes) on the peripheral smear. These are key features of CML. Basophilia (6%) and the myeloid-to-erythroid ratio of 18:1 , characteristic of CML, further support this diagnosis. Here is the revised table: Aspect Details Genetics Philadelphia chromosome (t(9;22)) Origin Myeloid lineage Etiopathogenesis BCR-ABL fusion gene causes overactive tyrosine kinase activity and is associated with radiation exposure. Clinical Features Common in adults, presenting with splenomegaly, fatigue, weight loss, night sweats, and abdominal discomfort. It can progress to a blast crisis with acute leukaemia features. Diagnosis Bone marrow aspirate to confirm diagnosis FISH to detect

BCR-ABL fusion gene product Management Tyrosine kinase inhibitors (e.g., Imatinib) The 3 phases of CML and their characteristics are: 1) Chronic phase: Leukocytosis, < 10% blast cells, basophils <20% and monocytosis < 3% 2) Accelerated phase: 10%-19% blasts, ≥ 20% basophils in the peripheral blood or bone marrow Persistent or increasing WBC (>10 × 10^9/L) and splenomegaly, unresponsive to therapy Persistent thrombocytosis (>1000 × 10^9/L), unresponsive to therapy Persistent thrombocytopenia (<100 × 10^9/L) unrelated to therapy This phase often leads to the terminal blast crisis within 6-12 months. 3) Blast Crisis: ≥20% blasts in peripheral blood or bone marrow In 50% of patients, the blast crisis occurs abruptly without an accelerated phase. Extensive extramedullary hematopoiesis occurs to compensate for CML and leads to significant splenomegaly. Transformation into AML is more predominant than ALL. {{caption_text}} Acute Lymphoblastic Leukemia (ALL) Lymphoblasts in bone marrow >=20% Cytoplasmic vacuolations They contain fat (Oil Red O Positive) Hand mirror-shaped cells {{caption_text}} Acute Myeloid Leukemia (AML) Blasts ≥ 20% Myeloblasts with AuerRods {{caption_text}} 3. Chronic Lymphocytic Leukemia (CLL): Smudge cells (or parachute/basket cell): Due to the fragility of lymphocytes during slide preparation Convent Girl Appearance: Lot of homogenous, small, mature-like, round lymphocytes with scant cytoplasm {{caption_text}} Chronic Myeloid Leukemia (CML) Leukocytosis Cell Types: Neutrophils(multilobed nucleus), metamyelocytes (indented nucleus), myelocytes (D-shaped nucleus), and eosinophils (orange cells) College girl/garden party appearance: Due to the variety of cell appearances Shift to the Left: Presence of immature cell types, mainly immature neutrophils, in the blood.

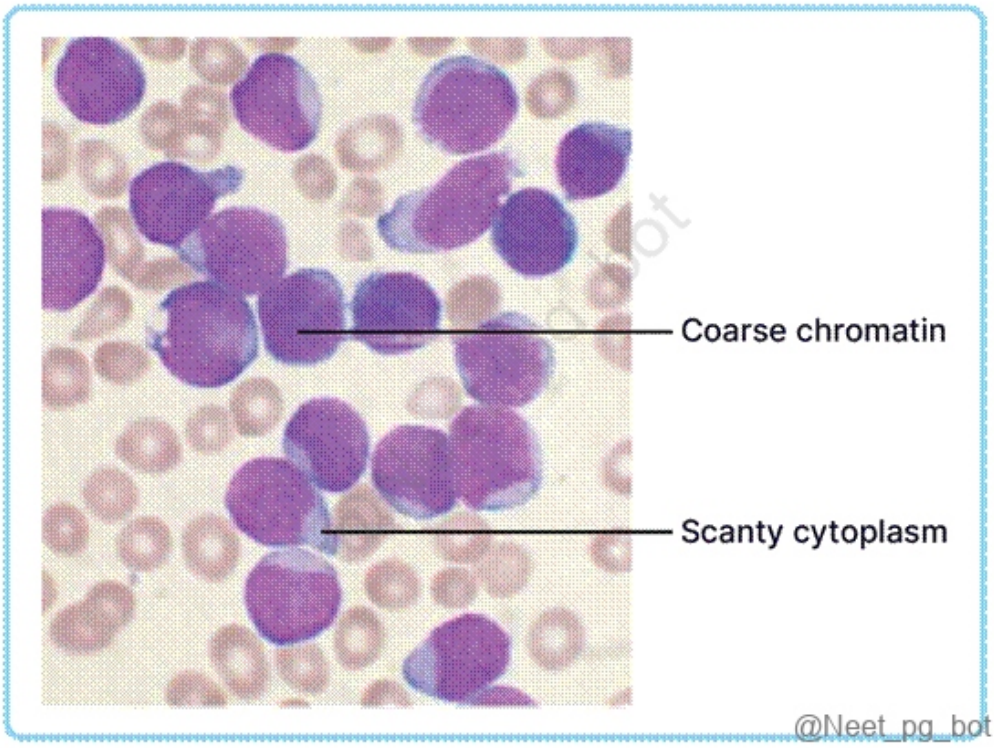

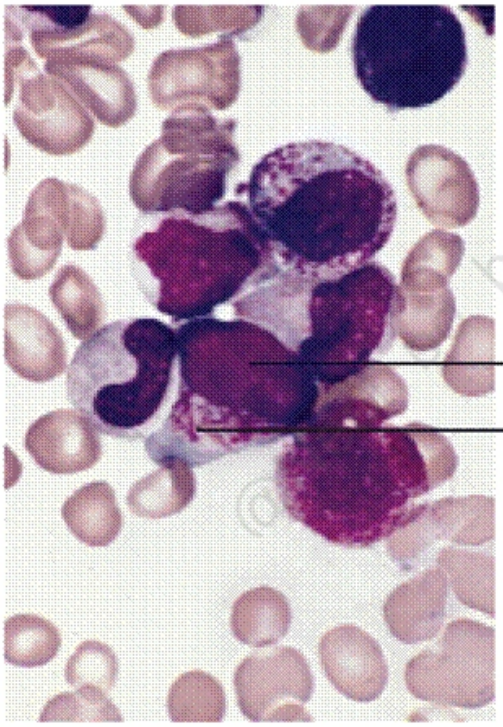

@Neet_pg_bot

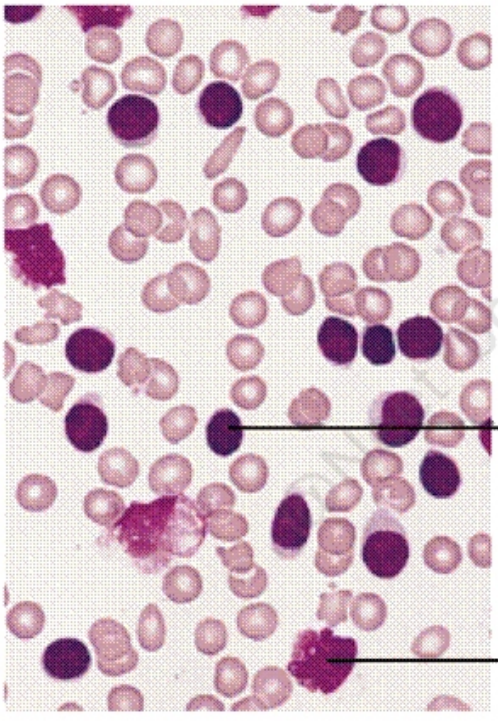

@Neet_pg_bot

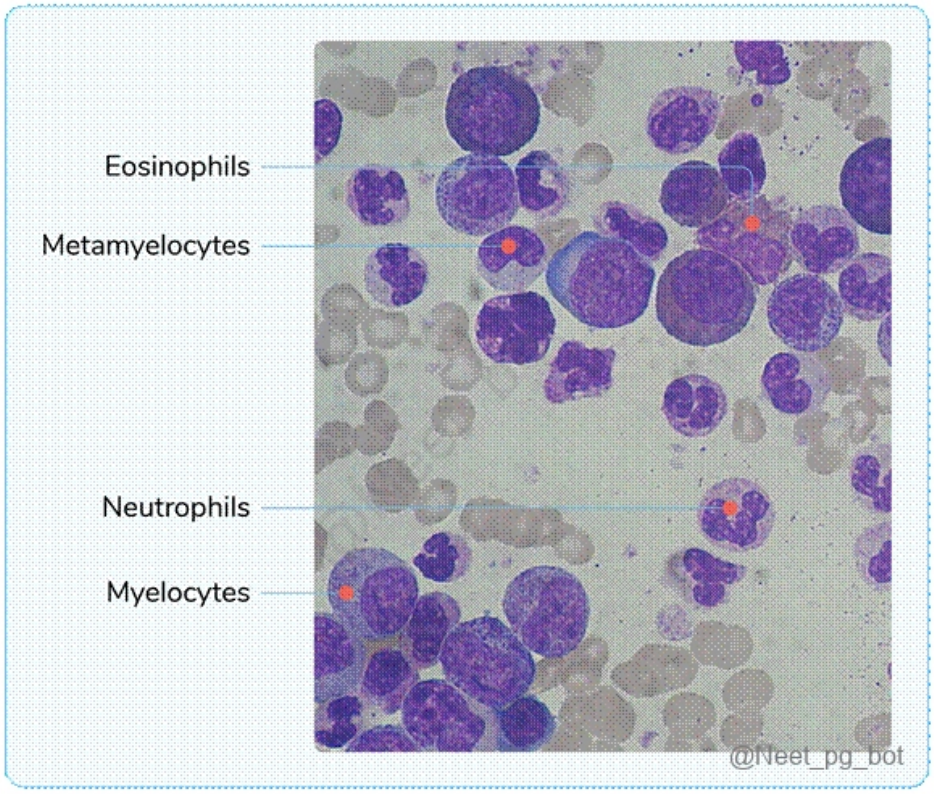

References:

Robbins & Cotran Pathologic Basis of Disease, 10th Edition, Page 623

https://www.ncbi.nlm.nih.gov/pmc/articles/PMC5656269/

↑ *Back to this question in Part A*

@Neet_pg_bot

Q26: A 68-year-old man presents with bleeding manifestations. The peripheral smear shows the presence of the cells shown below. Which of the following is the most common chromosomal abnormality seen in this condition? (Q866343)

A. t(8:21)

B. t(15:17)

C. t(14:18)

D. Inv(16)

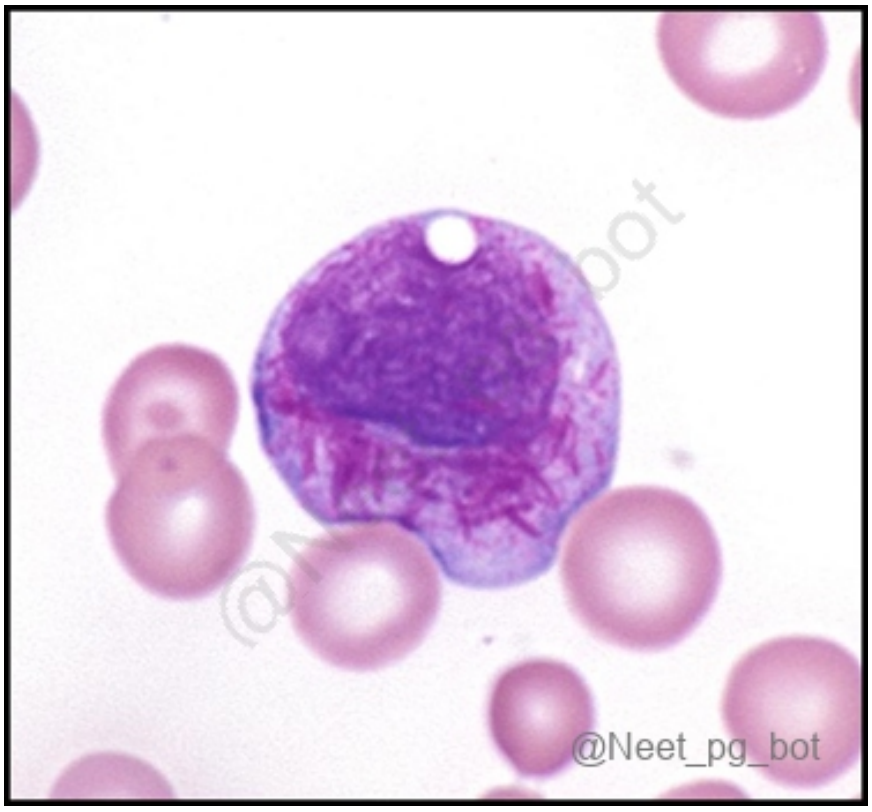

Correct Answer: B. t(15:17)

Explanation: This patient's history of 68 year old man with bleeding manifestations and Auer-rods on blood smear suggests disseminated intravascular coagulation secondary to acute promyelocytic leukaemia associated with t(15:17) translocation. M3 AML/ Acute promyelocytic leukaemia: Genetics: t(15:17) translocation causes PML-RARA (retinoic acid receptor alpha) fusion protein formation. Blocks promyelocyte → myelocyte maturation. Diagnosis of choice: FISH Smear findings: Increased promyelocytes. Auer Rods : Fused granules in promyelocytes Faggot Cells: Auer rods with a crisscross pattern. Laboratory: Low haemoglobin and platelets. > 20% blasts on peripheral and bone marrow smear Stain: PAS + CD markers: CD 13, 33 + Complication: Disseminated intravascular coagulation; therefore, chemotherapy is not recommended. Treatment: ATRA (All-trans-retinoic-acid) + As 2 O 3 (arsenic trioxide) Best prognosis among all AML. Incorrect Options: t(8 : 21) (Option A): AML with maturation (FAB M2); often associated with large myeloblasts and abundant Auer rods, but not the classic multiple “faggot cell” picture of APL. It is associated with Chloroma. t(14 : 18) (Option C): Follicular lymphoma; involves BCL2 gene rearrangement, unrelated to AML. inv(16) (Option D): Associated with AML with abnormal eosinophils (FAB M4Eo), not APL.

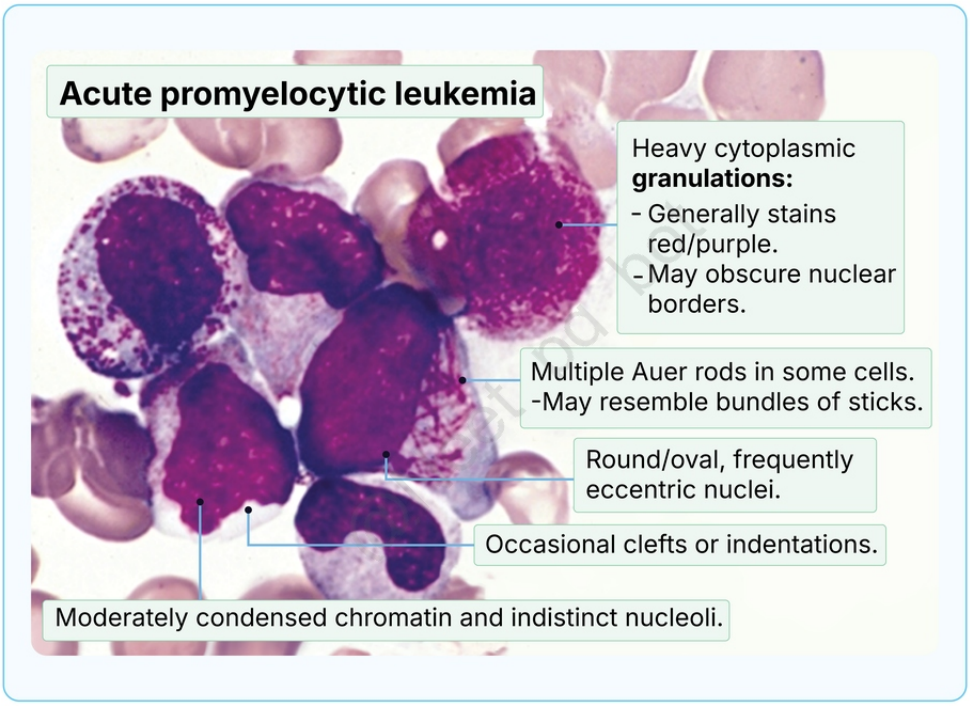

@Neet_pg_bot

References:

.

↑ *Back to this question in Part A*

@Neet_pg_bot

Q27: A young child presents with bleeding gums and bruising for the past two weeks. Bone marrow biopsy and flow cytometry have been performed. What is the diagnosis? (Q853374)

A. Acute myeloid leukemia

B. CLL

C. ALL: B Phenotype

D. ALL: T Phenotype

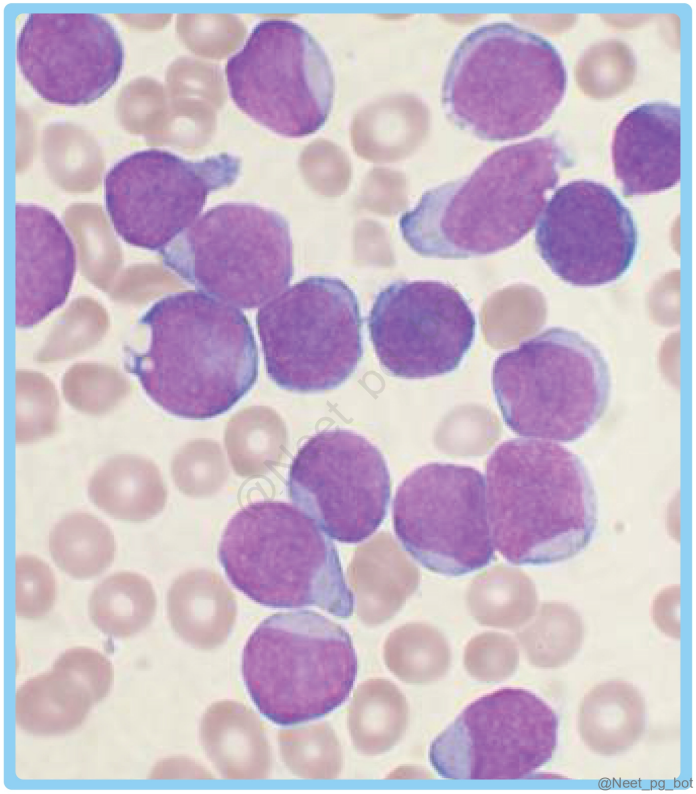

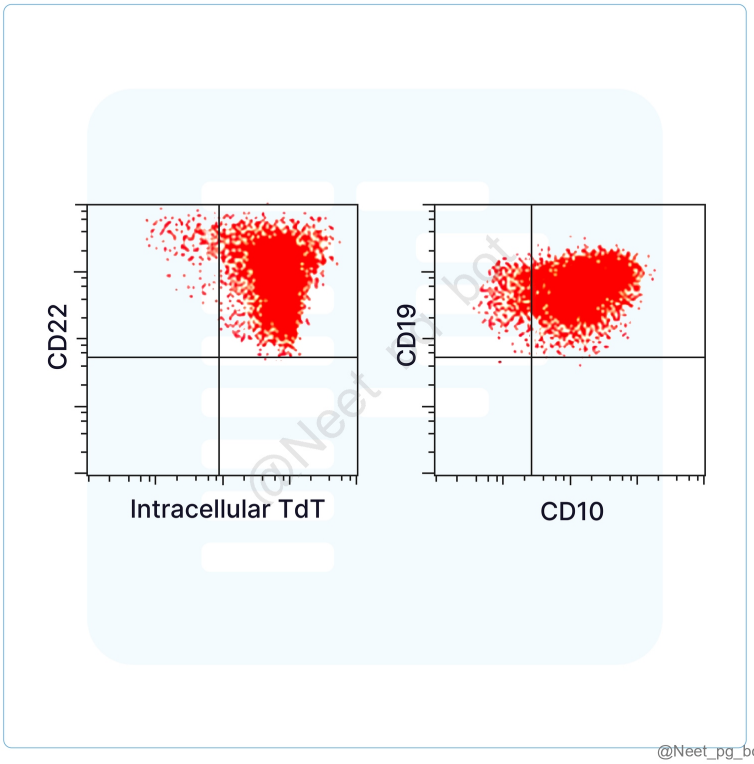

Correct Answer: C. ALL: B Phenotype

Explanation: The clinical presentation, along with histopathological and flow cytometry findings, confirms a diagnosis of Acute Lymphoblastic Leukemia (ALL) with a B-cell phenotype based on the following results: Histopathological examination reveals lymphoblasts with condensed nuclear chromatin, small nucleoli, and scant agranular cytoplasm. Flow cytometry analysis: Image B: The lymphoblasts (indicated by red dots) expressing terminal deoxynucleotidyl transferase (TdT) and the B-cell marker CD22. Image C: The cells test positive for two other markers, CD10 and CD19, commonly found on pre-B lymphoblasts. Acute Lymphoblastic Leukemia (ALL) ALL is an acute-onset blood and bone marrow malignancy of B and T lymphoblasts characterised by the uncontrolled proliferation of abnormal and immature lymphocytes Clinical features Age : 2-8 years (Fast disease progression), adults: > 50 years. Weight loss, Night sweats Anemia : Easy fatigability and pallor Bleeding : Epistaxis, easy bruising. Leucocytopenia : Recurrent infections Bone Marrow proliferation : Bone pain, sternal tenderness Hepatosplenomegaly, Lymphadenopathy CNS leukemia : Raised ICP, vomiting, and 6th nerve palsy T cell tumors : Mediastinal and testicular mass. Diagnosis CBC is the first investigation performed while suspecting ALL: Hemoglobin (Hb) : Decreased, indicating normocytic normochromic anemia. Hyperleukocytosis : TLC >100,000/µL can lead to leukostasis (more common in AML than ALL) with >20% Blasts. Elderly Presentation : TLC often remains low throughout ALL. Thrombocytopenia may be present. Peripheral smear: The smear shows a high percentage of lymphoblasts , which are larger than normal lymphocytes and have a high nucleus-to-cytoplasm ratio. They often have a scant amount of cytoplasm and may exhibit nucleoli. Bone Marrow aspiration shows blasts >20% . It is also used to classify morphological types into L1, L2, and L3 in the FAB classification system. FISH- Fluorescent in situ hybridization shows translocation of genes/chromosomes. t(9:22) - ALL associated with the Philadelphia chromosome . t(8:14) - Associated with Burkitt's leukemia t(4:11) t(1:19) Flow cytometry: CD10, also known as common acute lymphoblastic leukaemia antigen (CALLA), is a cell surface marker commonly used in the classification and diagnosis of leukaemias and lymphomas, particularly acute lymphoblastic leukaemia (ALL). B cell type - CD19+, CD79a+. (Option C) T cell type - CD3+ (Option D ruled out) Acute myeloid leukaemia (Option A) is a malignancy of hematopoietic progenitors caused by oncogenic mutations that prevent differentiation, leading to the accumulation of immature myeloid blasts. These blasts have delicate chromatin, two to four nucleoli, and more cytoplasm than lymphoblasts, often containing peroxidase-positive azurophilic granules. Auer rods , needle-like azurophilic granules, are also commonly present. CLL (Chronic Lymphocytic Leukemia) (Option B) is characterised by lymph node infiltration with small lymphocytes featuring condensed chromatin and scant cytoplasm, along with larger activated lymphocytes forming proliferation centres, which are pathognomonic for CLL/SLL. The blood shows small lymphocytes and smudge cells, while the bone marrow, spleen, and liver are typically involved to varying degrees.

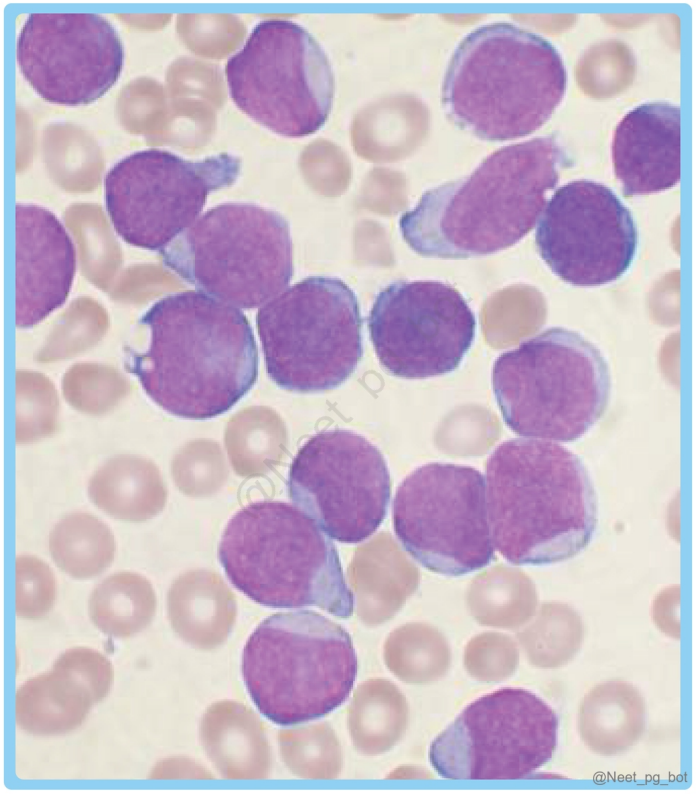

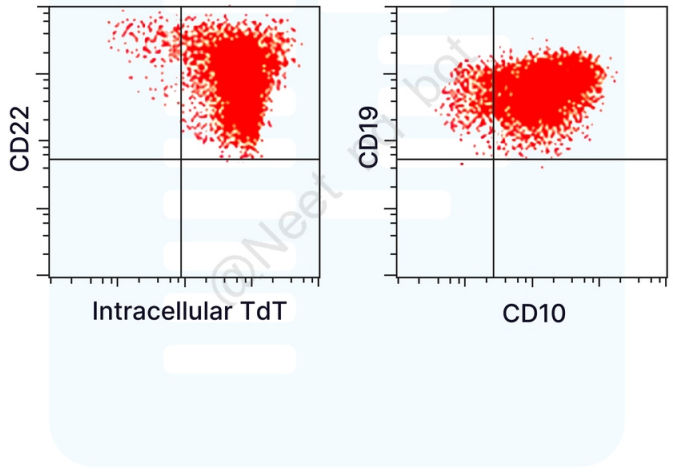

@Neet_pg_bot

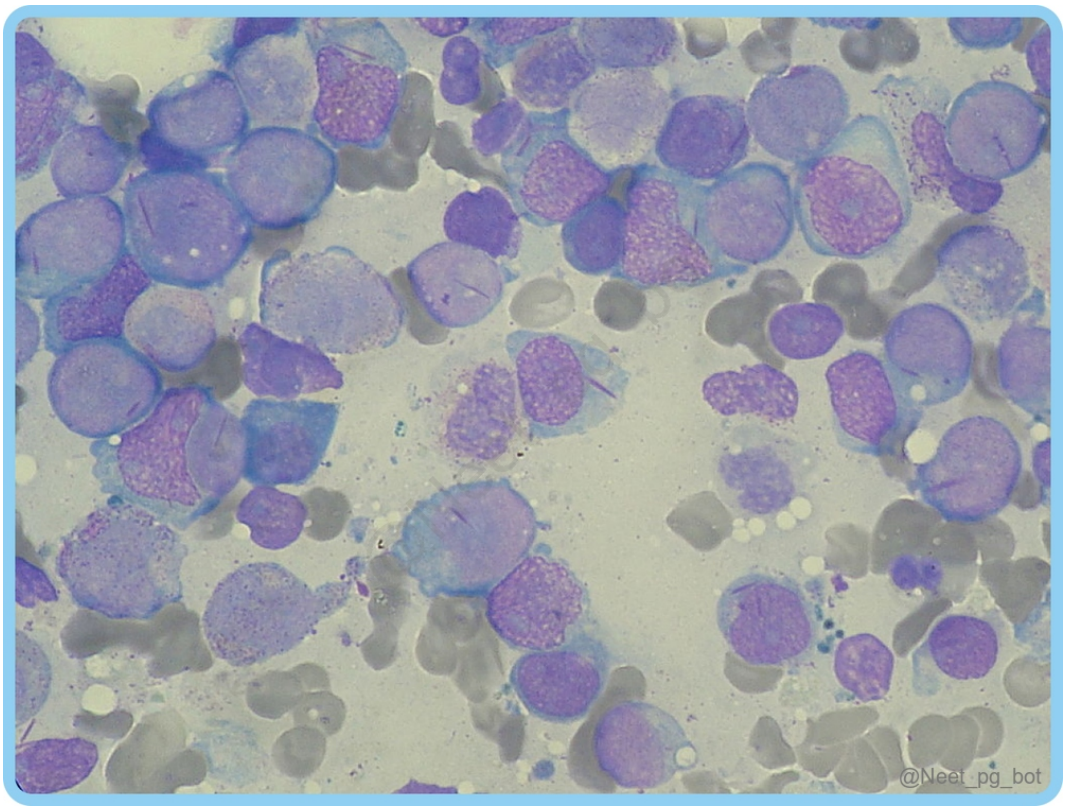

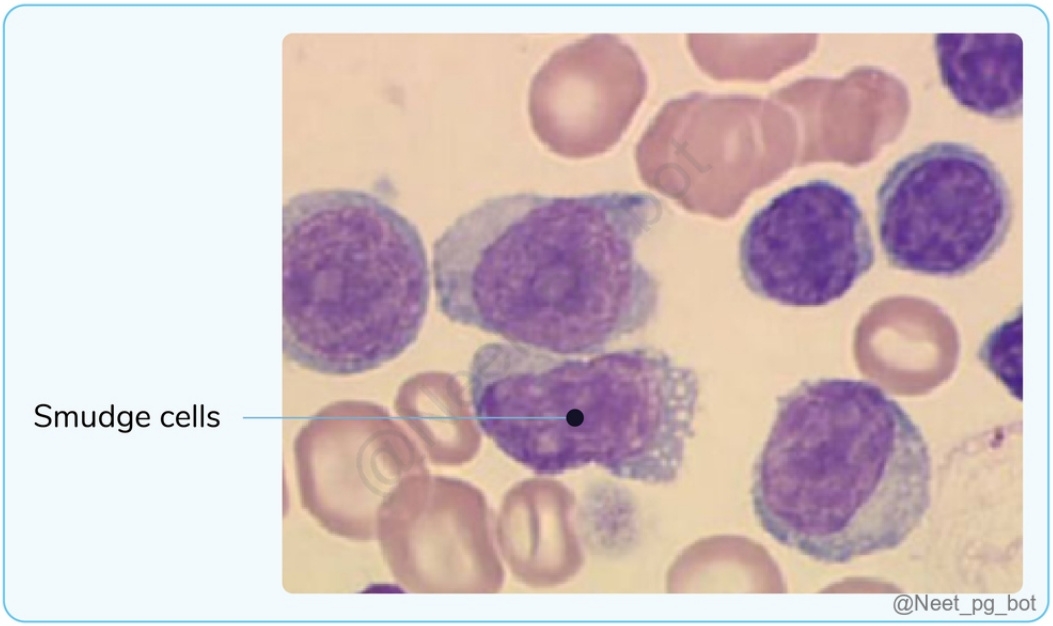

References:

Robbins and Cotran Pathologic Basis of Diseases, 10th Edition, Page 594-597.

↑ *Back to this question in Part A*

@Neet_pg_bot

Q28: Which gene mutation is most commonly associated with Burkitt's lymphoma? (Q852602)

A. C-myc

B. P-21

C. Rb

D. p53

Correct Answer: A. C-myc

Explanation: Burkitt's lymphoma is a highly aggressive B-cell non-Hodgkin lymphoma that is strongly associated with a translocation involving the C-myc oncogene. Burkitt’s lymphoma. Burkitt's lymphoma is a highly aggressive B-cell non-Hodgkin lymphoma associated with the translocations of the MYC gene on chromosome 8, t(8:14). It has three primary subtypes: Endemic Burkitt's lymphoma: Commonly affects children in malaria-endemic areas of Africa, often presenting with tumours in the jaw or facial bones. Sporadic Burkitt's lymphoma: More frequently seen in non-endemic regions and usually involving the ileocaecal region and peritoneum. Immunodeficiency-associated Burkitt's lymphoma: Found in patients with conditions such as HIV/AIDS or other forms of immunodeficiency. P-21 (Option B): P-21 (CDKN1A) is a cyclin-dependent kinase inhibitor that regulates the cell cycle by inhibiting cyclin-CDK complexes. It plays a role in cell cycle arrest but is not primarily associated with Burkitt's lymphoma. Rb (Option C) : The Retinoblastoma (Rb) gene is a tumor suppressor that controls the G1/S checkpoint of the cell cycle. Its mutations are primarily associated with retinoblastoma and osteosarcoma , not Burkitt's lymphoma. p53 (Option D): The p53 gene (TP53) is a tumor suppressor involved in DNA repair and apoptosis. While TP53 mutations are found in various cancers, they are not the characteristic mutation seen in Burkitt's lymphoma.

References:

Robbin’s Pathology, 10th edition, pg 601-602

↑ *Back to this question in Part A*

@Neet_pg_bot

Q29: A 34-year-old female presents with low hemoglobin, platelet count of 25,000/mm 3 , and raised PT and APTT. The peripheral smear image is shown below. Which of the following fusion genes is likely affected? (Q843988)

A. PML-RARA

B. RUNX1-RUNX1T1

C. INV 16

D. IGH-NSD2

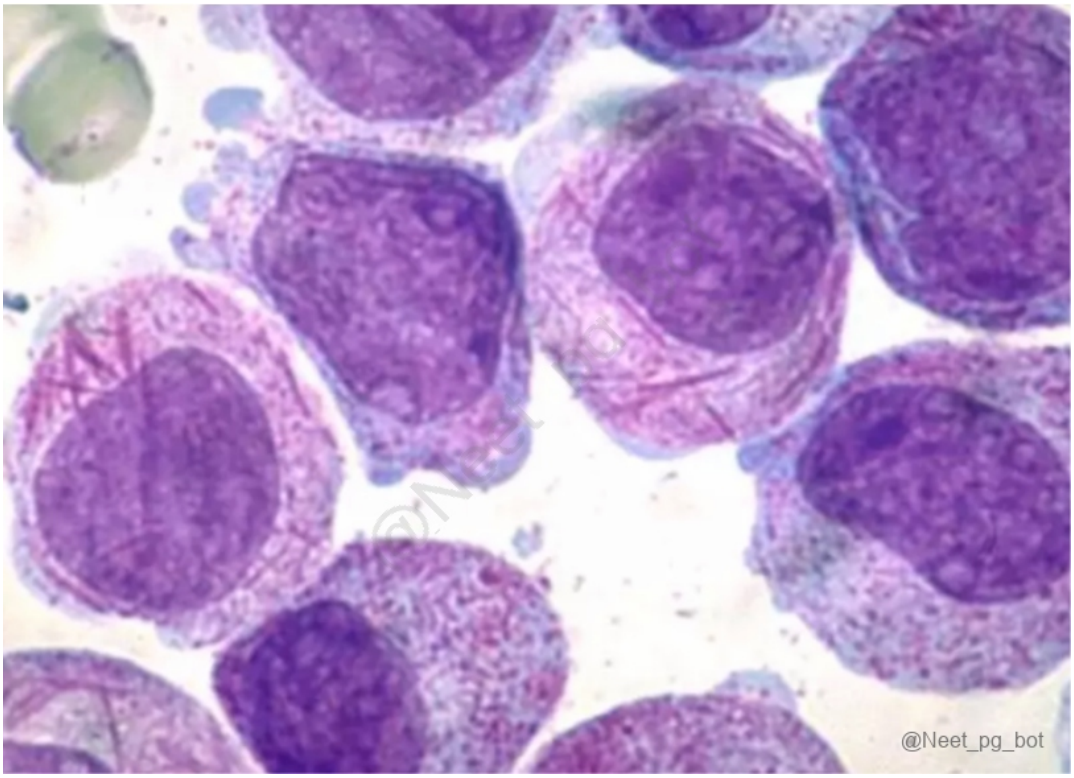

Correct Answer: A. PML-RARA

Explanation: Correct Option A - PML-RARA: The given image shows faggot cells containing Auer rods, which is a characteristic feature of Acute myeloid leukemia M3. In AML M3, t(15:17) - PML-RARA fusion gene is affected. Incorrect Options: Options B, C, and D are not affected in AML M3.

References:

.

↑ *Back to this question in Part A*

@Neet_pg_bot

Q30: A patient presents with fever, hepatosplenomegaly, abdominal pain, and WBC count > 50,000/mm 3 . Which of the following genetic abnormalities is involved? (Q844072)

A. t(9;22)

B. del(1q)

C. t(15;17)

D. del 3q

Correct Answer: A. t(9;22)

Explanation: Correct Option A - t(9;22): The given clinical features are suggestive of chronic myeloid leukemia, and the genetic abnormality associated with it is translocation of t(9;22). Incorrect Options: Options B, C, and D are not associated with CML.

↑ *Back to this question in Part A*

@Neet_pg_bot

Q31: An elderly patient presents with elevated calcium levels, increased serum creatinine levels, and decreased hemoglobin. Electrophoresis reveals a monoclonal spike. Her immunofixation test findings are given below. Which of the following best describes her condition? (Q844198)

A. Multiple myeloma with increased IgG

B. Multiple myeloma with increased IgM

C. Multiple myeloma with increased IgA

D. Monoclonal gammopathy of unknown significance

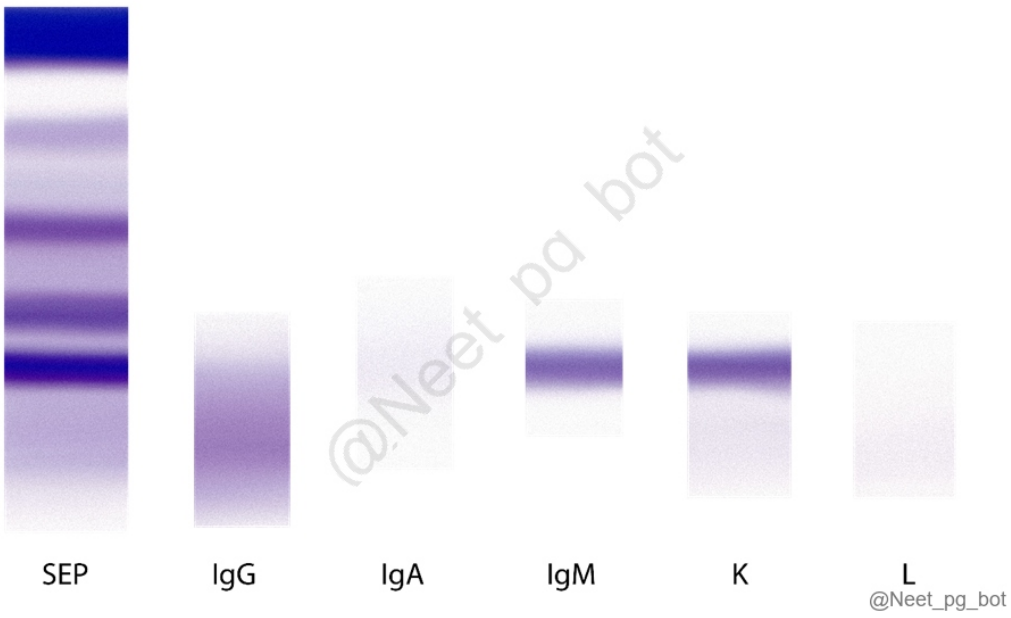

Correct Answer: B. Multiple myeloma with increased IgM

Explanation: Multiple myeloma is characterized by a monoclonal spike on electrophoresis, and the immunofixation test revealed increased IgM levels (a distinct band can be seen, whereas the smear pattern without any band formation above IgG is insignificant) Serum Protein Electrophoresis in Multiple Sclerosis: The gamma (Ig) will increase and show a spike an M spike - monoclonal or myeloma spike Immunofixation - will tell the type of immunoglobulin Immunofixation of Multiple myeloma with increased IgG Incorrect Options: Multiple myeloma with increased IgG (Option A): Smear pattern without any bands, so its not IgG Multiple myeloma with increased IgA (Option C) : No protein fixation, so its not IgA MGUS (Option D): In MGUS, gammaglobulins levels are <3gm/dL

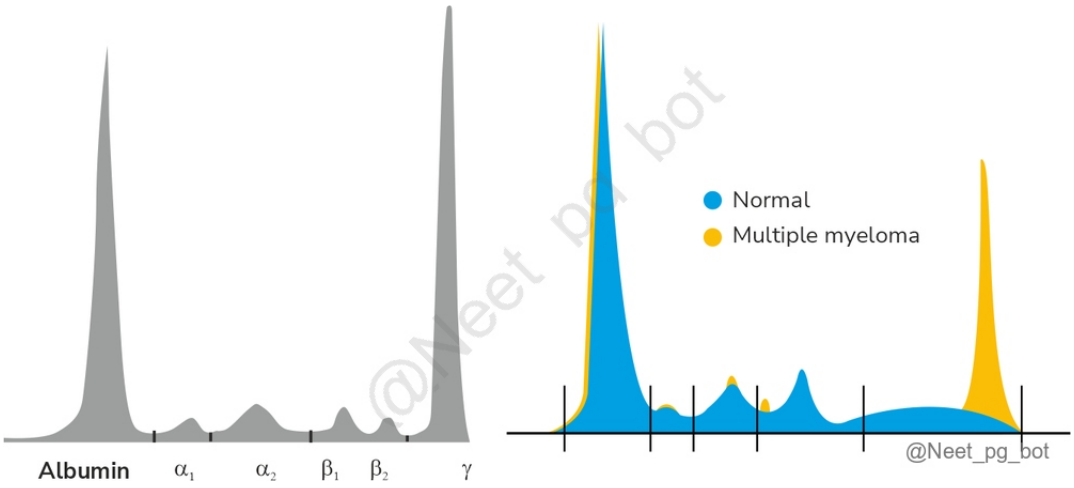

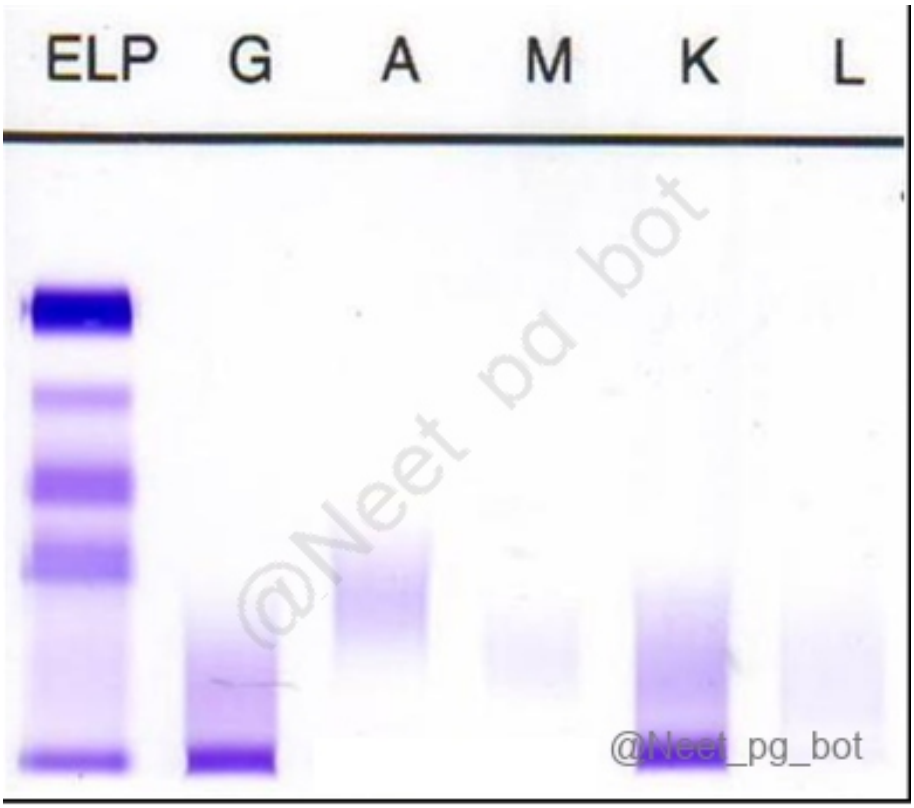

References:

.

↑ *Back to this question in Part A*

@Neet_pg_bot

Q32: Which of the following is the investigation of choice for CML? (Q860526)

A. LAP score

B. FISH

C. Karyotyping

D. Reciprocal translocation

Correct Answer: B. FISH

Explanation: Fluorescence in situ hybridisation (FISH) is the choice of investigation for detecting the Philadelphia chromosome in CML. It makes a cytogenetic analysis of the Philadelphia chromosome. The presence of the Philadelphia chromosome, resulting from the reciprocal translocation between chromosomes 9 and 22 [t(9;22)(q34;q11)], or detection of the BCR-ABL1 fusion gene on mRNA , confirms the diagnosis of CML. Diagnosis of Chronic Myeloid Leukemia (CML) CBC Normal RBC + Elevated TLC + Elevated platelets Peripheral smear Left shift with predominant segmented neutrophils, myelocytes, and metamyelocytes. College girl/garden party appearance: Due to non-uniform appearance (every cell appears different). {{caption_text}} Bone marrow aspirate Increased Myeloid: Erythroid ratio. Dwarf megakaryocytes. Sea blue histiocytes (blue-coloured cytoplasm) Pseudo Gaucher cells {{caption_text}} The image shows Pseudo-Gaucher cells NAP (Neutrophil Alkaline Phosphatase)/LAP score (Leukocyte Alkaline Phosphatase) (Option A ruled out) Decreased FISH (IOC) (Option B) Confirms t(9:22) translocation. Analysis to quantify Philadelphia chromosome-positive cells. Estimates the tumour load. {{caption_text}} The image shows BCR-ABL gene fusion (red + green) in fluorescence in-situ hybridisation (FISH; the ABL gene is red, and the BCR gene is green). PCR To quantify BCR-ABL-1 It can be a false negative or false positive False negative: Early part of the disease Karyotyping (Option C) examines chromosomes to detect abnormalities like Down syndrome or the Philadelphia chromosome in CML. While it can identify chromosomal abnormalities, it is less sensitive than FISH for detecting the Philadelphia chromosome. Reciprocal translocation (Option D) is a chromosomal abnormality where segments of two chromosomes are exchanged, such as the Philadelphia chromosome in CML. It results in the BCR-ABL fusion gene, detectable by FISH or karyotyping, but is not an independent diagnostic test.

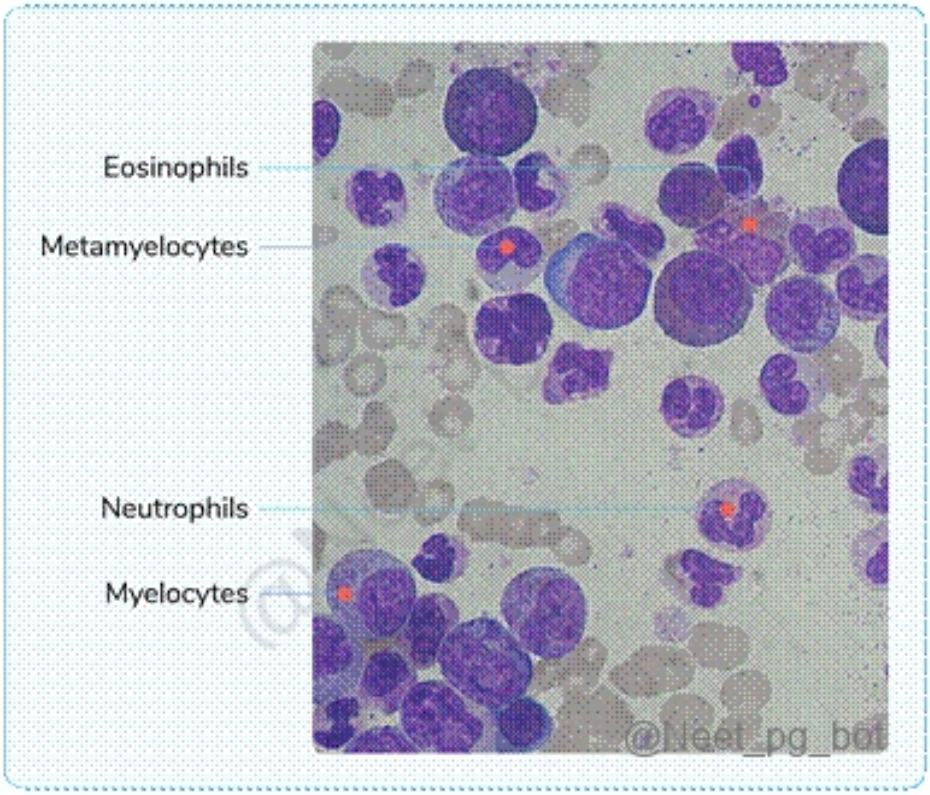
Eosinophils
Metamyelocytes
Neutrophils
Myelocytes
@Neet_pg_bot

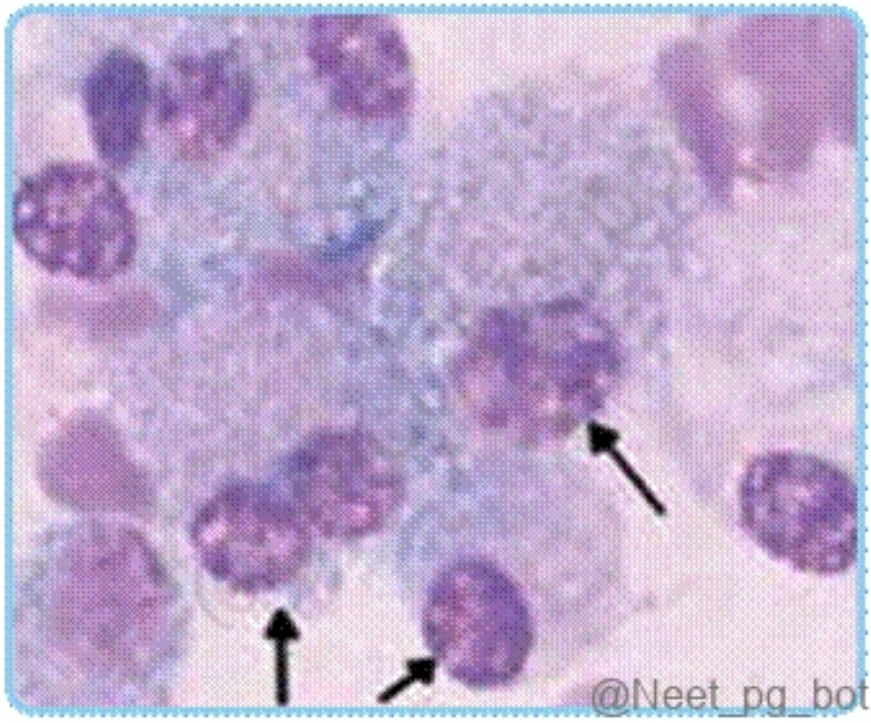
@Neet_pg_bot

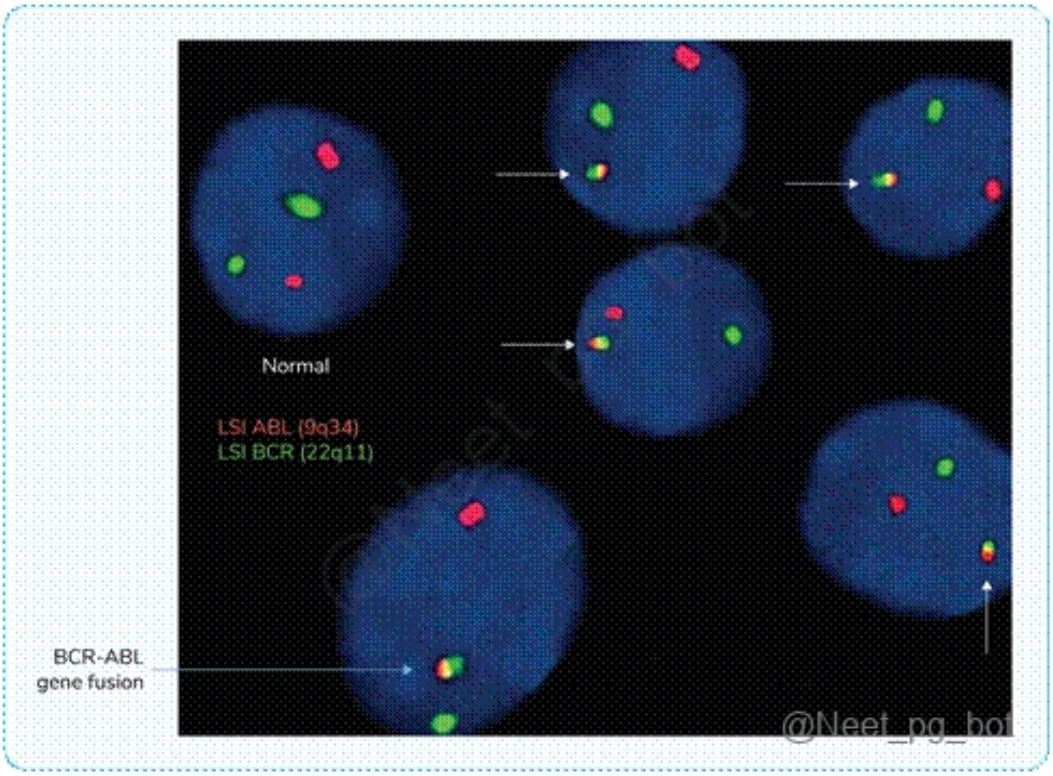

References:

Robbins & Cotran Pathologic Basis of Disease, 10th Edition, Page 622.

Harrison’s Principles of Internal Medicine, 21st Edition, Page 801.

↑ *Back to this question in Part A*

@Neet_pg_bot

Q33: Mark the incorrect statement regarding Hodgkin Lymphoma: (Q840028)

A. Reed Sternberg cells are of B-cell origin

B. Waldeyer's ring is involved

C. Nodular sclerosing is the most common subtype and involves mediastinum

D. CD 15, 30 Positivity in Reed Sternberg cells

Correct Answer: B. Waldeyer's ring is involved

Explanation: Correct Option B - Waldeyer's ring is involved Waldeyer’s ring involvement is rare in classical Hodgkin lymphoma. HL more commonly involves cervical, mediastinal, and supraclavicular lymph nodes.

Primary Waldeyer’s ring involvement is unusual and more typical of non-Hodgkin lymphoma. Incorrect Options: Option A - Reed Sternberg cells are of B-cell origin: True; derived from germinal center B cells. Option C - Nodular sclerosing is the most common subtype and involves mediastinum: Most common HL subtype, frequently involves mediastinum, especially in young adults. Option D - CD 15, 30 Positivity in Reed Sternberg cells: Classic immunophenotype of Reed-Sternberg cells in classical HL.

References:

.

↑ *Back to this question in Part A*

@Neet_pg_bot

Q34: A patient with elevated calcium and normal alkaline phosphatase undergoes a skull X-ray. What is the likely diagnosis? (Q860163)

A. Grave’s disease

B. Paget’s disease

C. Multiple myeloma

D. CML



Correct Answer: C. Multiple myeloma

Explanation: The clinical scenario of a patient with elevated calcium, normal alkaline phosphatase, and osteolytic lesions on a skull X-ray suggests Multiple Myeloma . It is a plasma cell neoplasm associated with (Mnemonic: CRAB features with immune abnormalities) C - Hyper c alcemia R - R enal failure A - A naemia B - Lytic b one lesions, and Immune abnormalities. Antibodies in Multiple Myeloma: Monoclonal Immunoglobulins Free Light Chains IgG: Most common (55% of patients). IgA: Seen in 25% of cases. IgM, IgD, IgE: Less common. Often produced in excess, these are called Bence Jones proteins . It can cause myeloma kidney (renal disease). Pathogenesis of Multiple Myeloma: There are 3 main cytogenetic abnormalities seen in MM. Deletion of chromosome 13q (also seen in CLL). Translocation t (11;14) (also seen in mantle cell lymphoma). Deletion of chromosome 17p (TP53). IL-6 is essential for plasma cell growth , and its elevated levels are linked to poor prognosis. Clinical features: It is seen in patients 60-70 years of age. Increased osteoclastic activity leads to bone resorption hypercalcemia and lytic punched-out lesions. Decreased osteoblastic activity (Normal or ↓ ALP levels). {{caption_text}} Multiple Punched-out Osteolytic Lesions on the Lateral Skull Radiograph in a patient with Multiple Myeloma Grave's disease (Option A) is an autoimmune disorder that causes hyperthyroidism, characterised by an overactive thyroid gland. It results in symptoms like weight loss, heat intolerance, tremors, and bulging eyes (exophthalmos). It is caused by autoantibodies that stimulate the thyroid-stimulating hormone (TSH) receptor. It involves thyroid hormone imbalance and does not typically cause hypercalcemia or specific bone lesions on X-ray. Paget's disease (Option B) is a bone disorder marked by abnormal bone remodelling, leading to enlarged and weakened bones. It causes bone pain, deformities, and fractures with elevated alkaline phosphatase levels. It typically causes elevated alkaline phosphatase due to abnormal bone remodelling. Chronic myeloid leukaemia (CML) (Option D) is a bone marrow cancer characterised by excessive white blood cell production and the presence of the Philadelphia chromosome . It typically causes fatigue, weight loss, and splenomegaly but does not present with hypercalcemia or lytic bone lesions .

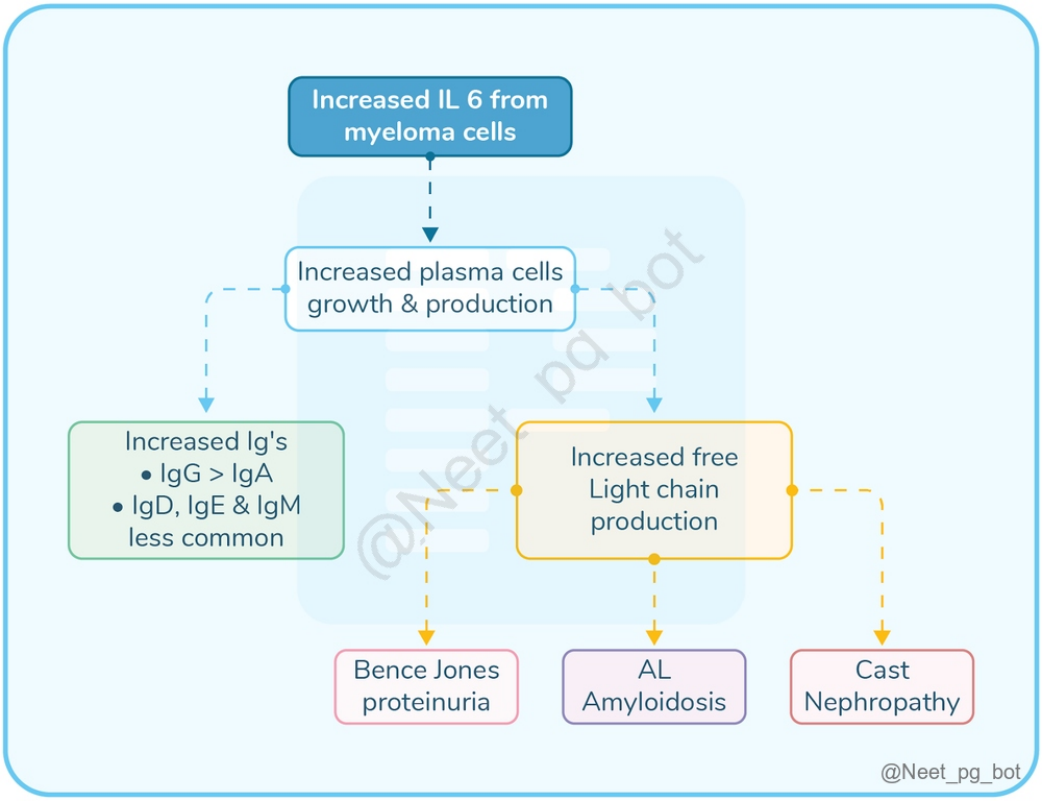

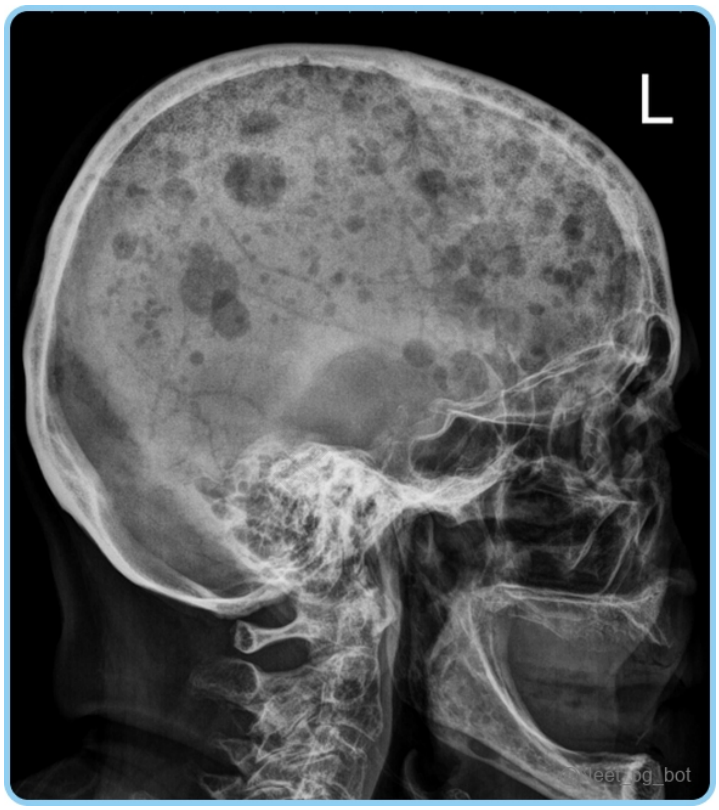

References:

Robbins and Cotran Pathologic Basis of Disease, 10th Edition, Page 607, 608. Harrison's Principles of Internal Medicine, 21st Edition, Page 871.

↑ *Back to this question in Part A*

@Neet_pg_bot

Q35: A 50-year-old male complains of lower back pain with a 1-1.5 mm osteolytic lesion at the T10 vertebra. Histopathological findings are given below. Which of the following options is correct regarding this condition? (Q860232)

A. Presence of Bence-Jones proteinuria

B. Absence of Rouleaux formation

C. Absence of free light chains

D. Decreased Calcium levels in the blood

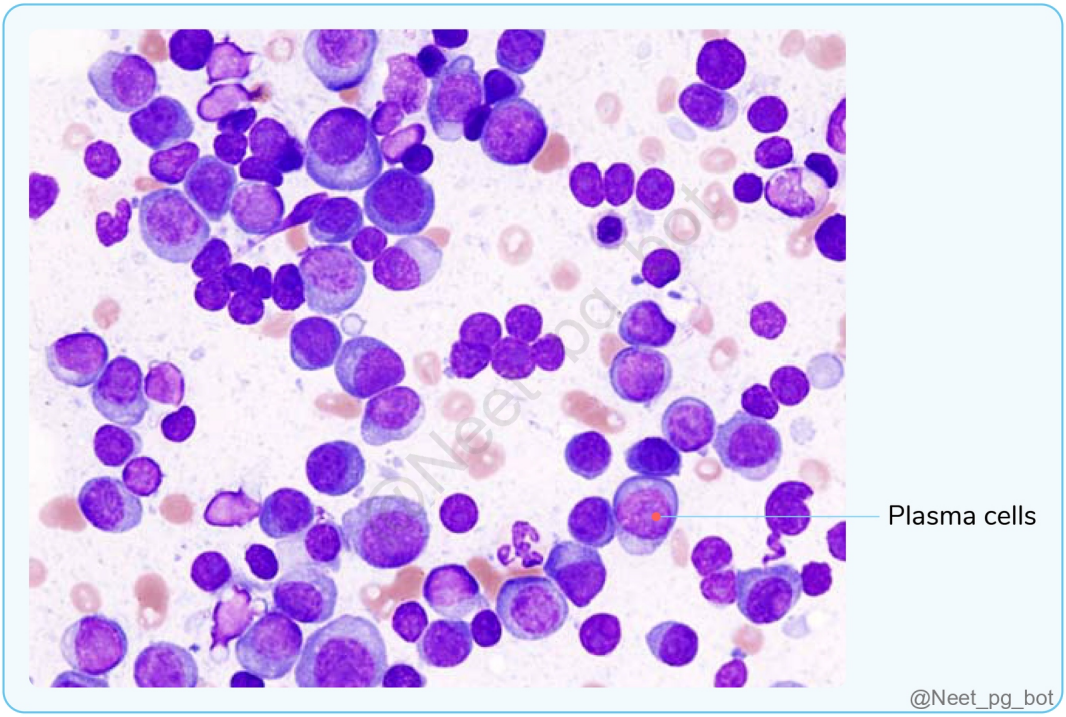

Correct Answer: A. Presence of Bence-Jones proteinuria

Explanation: The scenario describing lower back pain with a 1-1.5 mm osteolytic lesion at the T10 vertebra and a histopathological image showing intracytoplasmic inclusions (Russell bodies) suggests Multiple Myeloma , which is characterised by the presence of Bence-Jones proteinuria. It is caused by increased antibody production. It is a plasma cell neoplasm associated with (Mnemonic: CRAB features with immune abnormalities) C - Hyper c alcemia (Option D ruled out) R - R enal failure A - A naemia B - Lytic b one lesions, and Immune abnormalities. The cells produce excess free light chains, either alongside complete immunoglobulins or independently. (Option C ruled out) Due to their small size, free light chains (Bence Jones proteins) can pass through the glomeruli of the kidneys and appear in the urine. This is a diagnostic marker for multiple myeloma. Inclusion Bodies Seen In Multiple Myeloma Russel bodies: {{caption_text}} Location: Intracytoplasmic Composition: Eosinophilic Round Dilated endoplasmic reticulum cisternae filled with condensed immunoglobulin. . Dutcher bodies {{caption_text}} Location: Intranuclear. Composition: Globular inclusions containing accumulated immunoglobulin. Plasma Cell Variants In Multiple Myeloma Mott cells {{caption_text}} Contain Grape-like cytoplasmic droplets. Composition: Inclusion bodies, fibrils, crystalline rods, and globules. Flame cells {{caption_text}} Appearance : Fiery red cytoplasm. Cause : High concentration of immunoglobulin as bright red granules within the cytoplasm. Often seen in IgA subtype myeloma. Rouleaux formation {{caption_text}} High levels of M protein in the blood cause red cells to stick to one another in linear arrays in smears, a finding referred to as rouleaux formation. (Option B ruled out) It is also seen in s lupus erythematosus and early HIV infection.

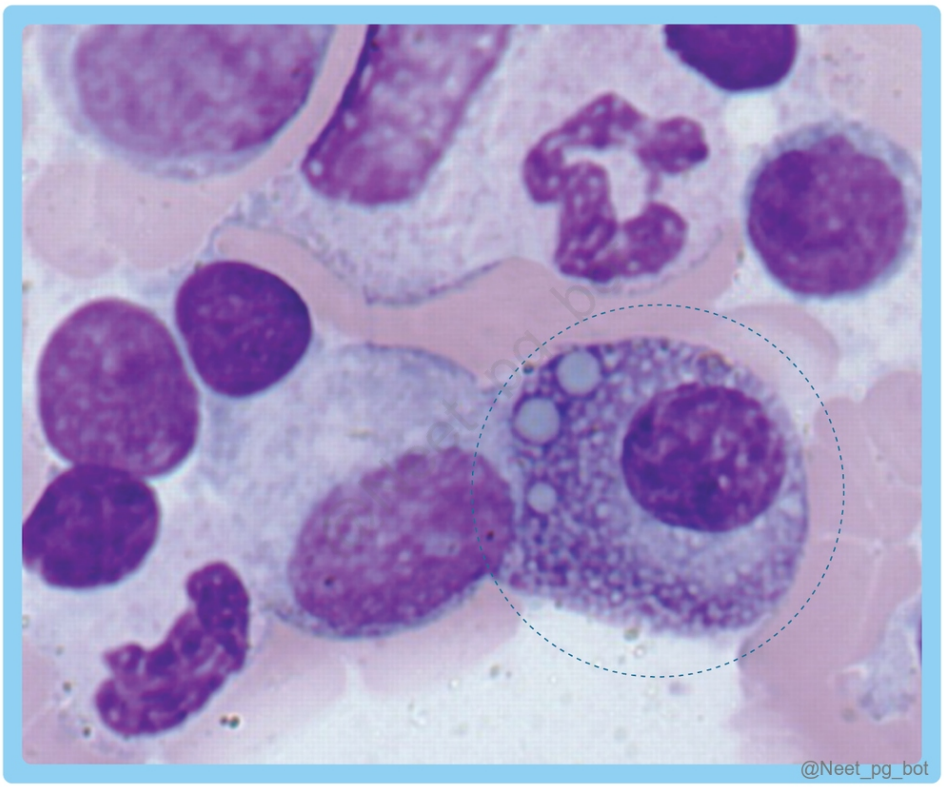
@Neet_pg_bot

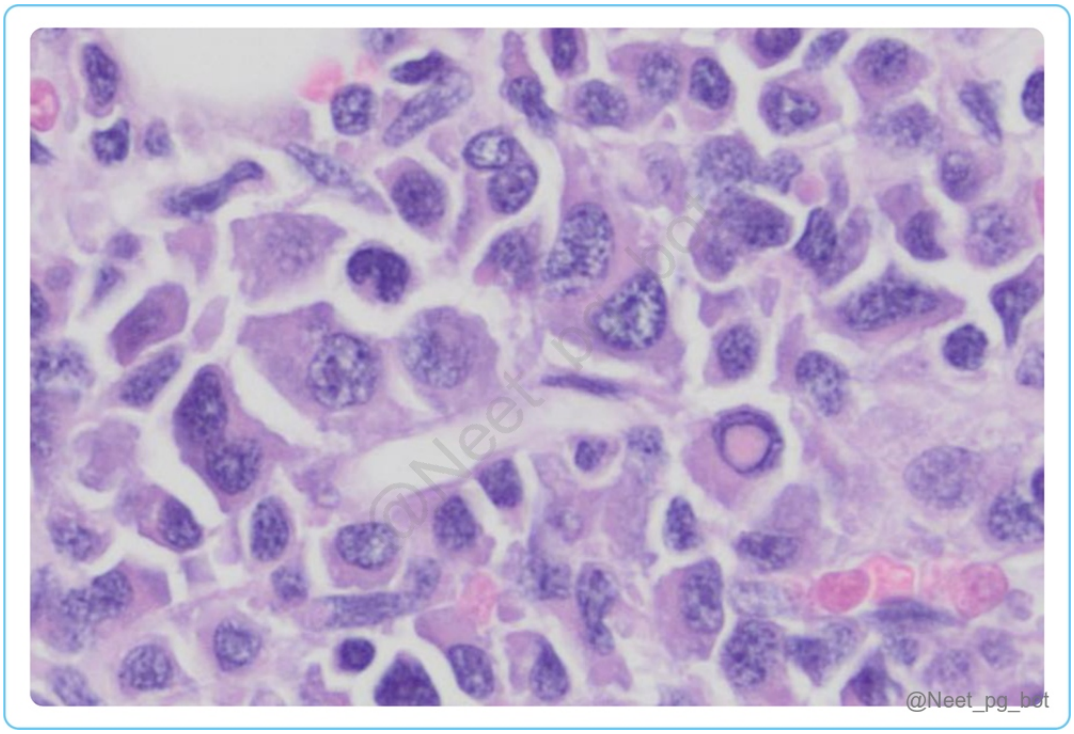
@Neet_pg_bot

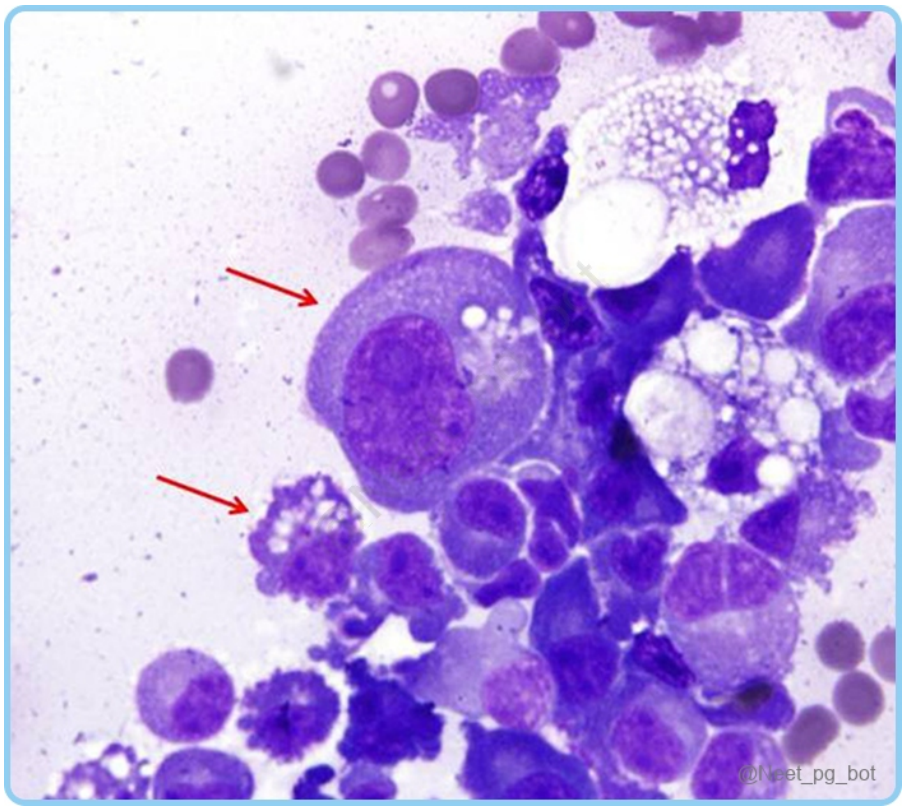
@Neet_pg_bot

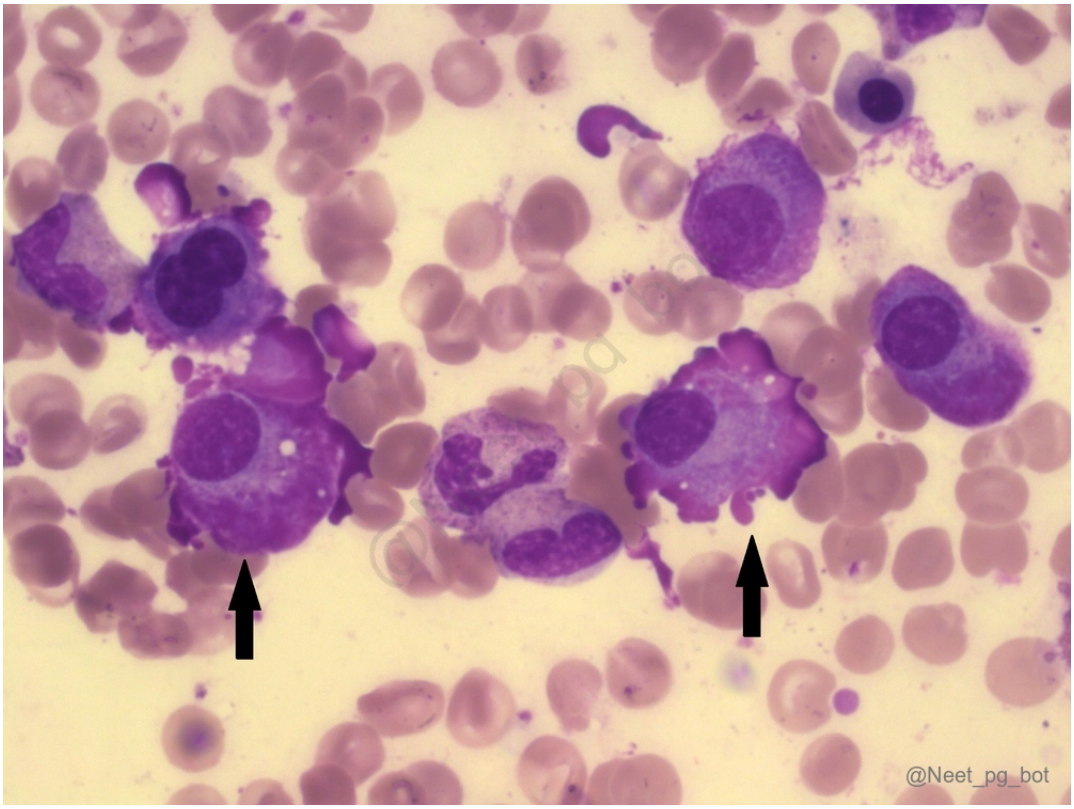
@Neet_pg_bot

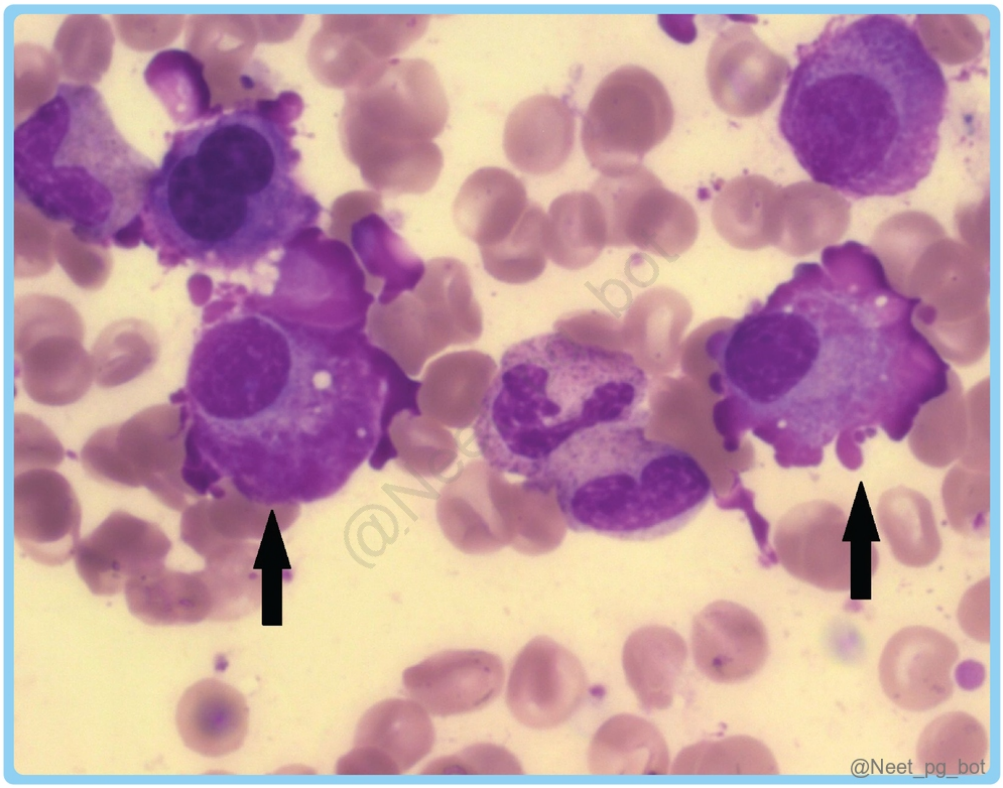

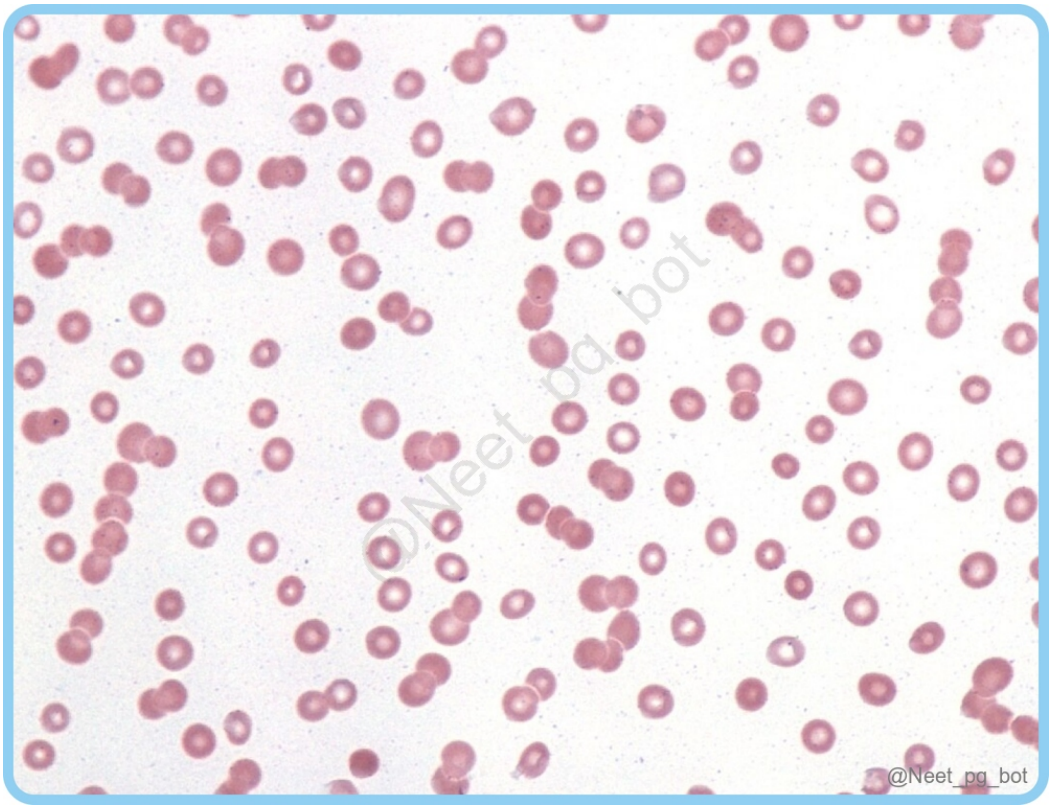

References:

Robbins and Cotran, Pathological Basis of Disease, 10th Edition, Page 607, 608.

Harrison’s Principles of Internal Medicine, 21st Edition, Page 871.

↑ *Back to this question in Part A*

@Neet_pg_bot

Q36: Which among the following is associated with Cryoglobulinemia? (Q860258)

A. Hepatitis C infection

B. Ovarian cancer

C. Diabetes

D. Leukaemia

Correct Answer: A. Hepatitis C infection

Explanation: Hepatitis C infection is associated with Cryoglobulinemia . Cryoglobulinemia : Cryoglobulins are proteins that precipitate from serum or plasma at low temperatures (<37°C). They can be a mixture of immunoglobulin and complement components or immunoglobulins alone. They deposit in medium and large-sized blood vessels throughout the body, causing endothelial injury and end-organ damage known as cryoglobulinemia. It is often associated with Hepatitis C virus infection Hepatitis B virus infection HIV Autoimmune diseases (mainly SLE and Sjogren’s syndrome) Lymphoproliferative disorders. Ovarian cancer (Option B) is a type of cancer that begins in the ovaries (female reproductive organs). It often goes undiagnosed in the early stages due to vague symptoms like abdominal bloating, pelvic pain, and early satiety. Risk factors include age, family history, and genetic mutations (such as BRCA1 and BRCA2). Diabetes (Option C) is a chronic condition where the body can't properly regulate blood sugar. Type 1 is insulin deficiency due to an autoimmune response, while Type 2 is caused by insulin resistance, often linked to obesity. Symptoms include thirst, frequent urination, and fatigue. Treatment involves lifestyle changes and medication, with long-term risks to organs like the heart and kidneys. Leukaemia (Option D) is a type of cancer that affects the blood and bone marrow, leading to the abnormal production of white blood cells. It is classified into acute and chronic forms, with acute leukaemia progressing rapidly and chronic leukaemia developing more slowly. Symptoms include fatigue, fever, frequent infections, easy bruising, and weight loss.

References:

Robbins & Cotran Pathological Basis of Diseases, 10th Edition, Page 837.

↑ *Back to this question in Part A*

@Neet_pg_bot

Q37: Which of the following cells is shown in the given image? (Q857427)

A. Hairy cell

B. Gaucher cell

C. Sickle cell

D. Target cell

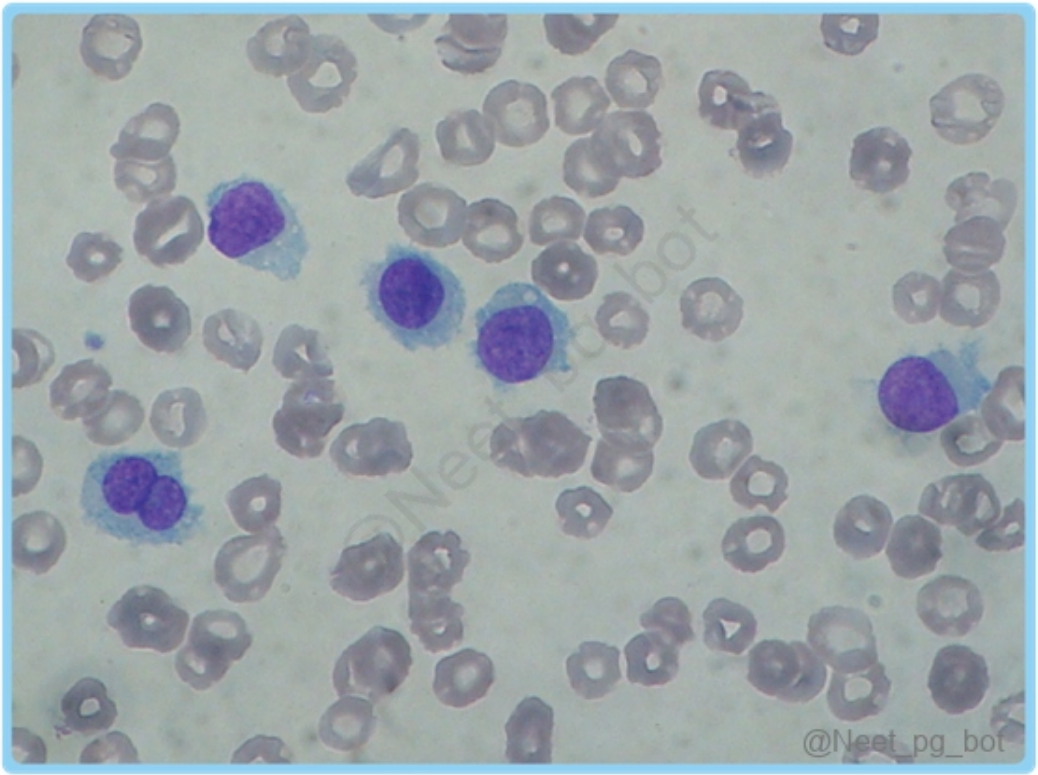

Correct Answer: A. Hairy cell

Explanation: The given image depicts a Hairy cell, which is characterised by the presence of fine, hair-like projections on the surface of the cell. It is a characteristic type of cell found in Hairy Cell Leukemia, which involves abnormal proliferation of Mature B cells. These cells have a round, oblong, or reniform nucleus and pale blue cytoplasm. Gaucher cells (Option B) are lipid-laden macrophages found in Gaucher's disease , an autosomal recessive disorder caused by mutations in the GBA1 gene, resulting in deficient glucocerebrosidase enzyme activity. These cells appear as foamy macrophages with a crumpled tissue-paper appearance due to the accumulation of glucocerebroside in the cytoplasm. {{caption_text}} Crinkled paper macrophages in the marrow space Sickle cells (Option C) are abnormally shaped red blood cells that resemble a crescent or sickle due to the presence of abnormal haemoglobin (haemoglobin S) . These cells are not characterized by cytoplasmic projections like hairy cells. {{caption_text}} Target cells (Option D) are red blood cells that have a bull's-eye appearance due to an increase in cell membrane relative to the volume of the cytoplasm. This condition can occur in several disorders, such as thalassemia , but they do not have the cytoplasmic projections seen in hairy cells. {{caption_text}}

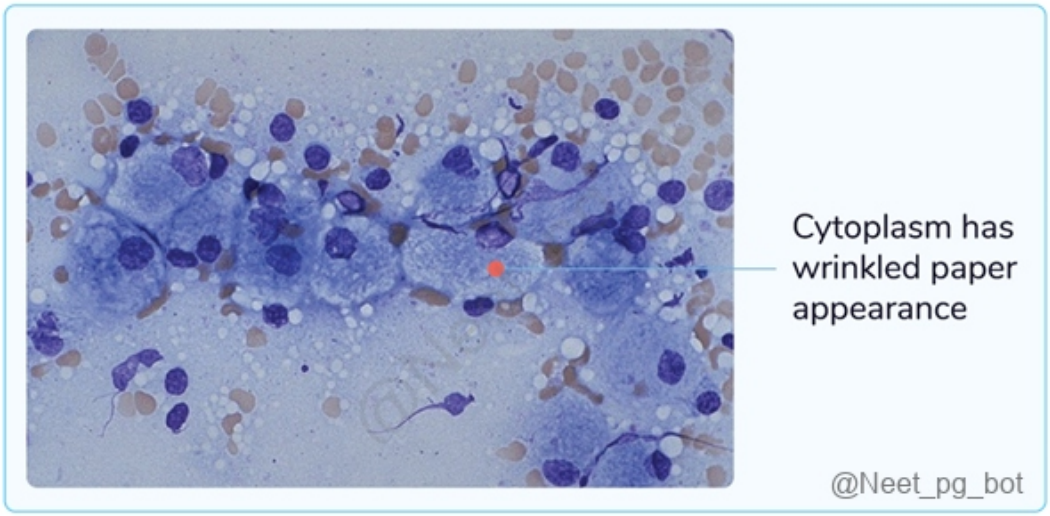
Cytoplasm has wrinkled paper appearance
@Neet_pg_bot

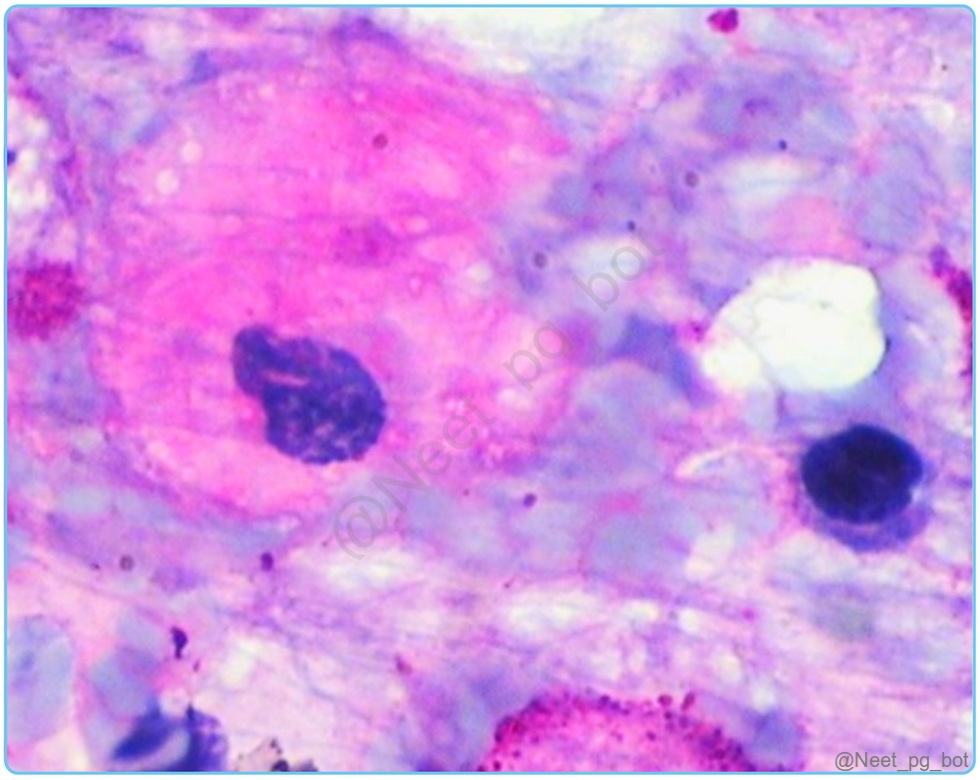
@Neet_pg_bot

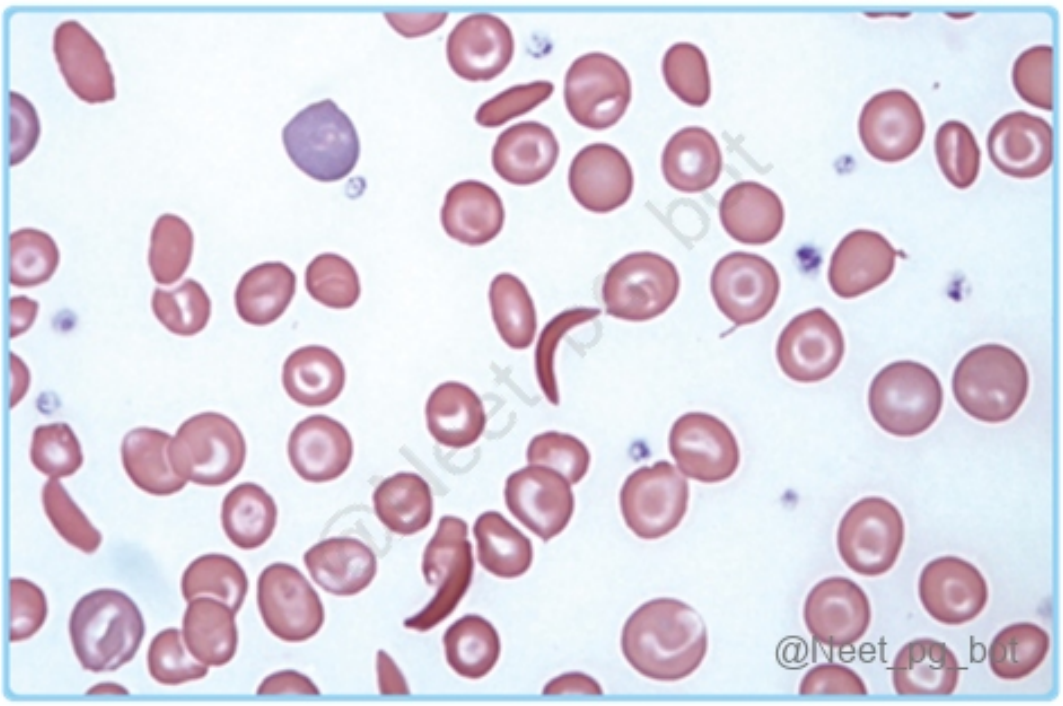

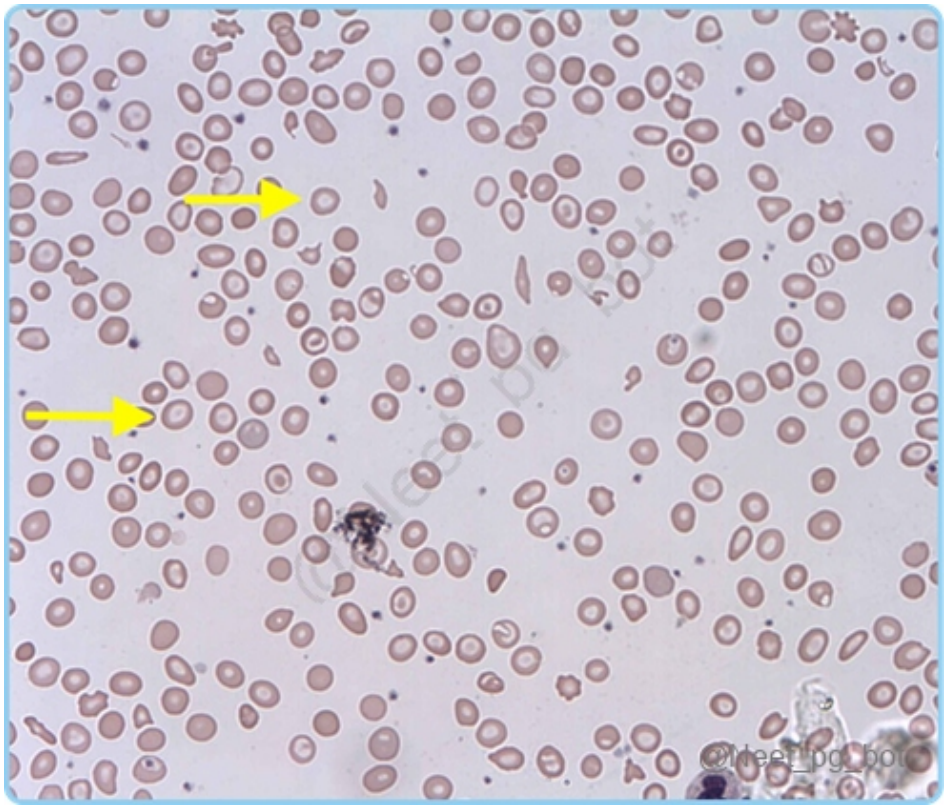

References:

Robbins and Cotran Pathologic Basis of Disease, 10th Edition, Page 604

↑ *Back to this question in Part A*

Q38: A 70 year old male presents with low back ache and progressive pallor. On work up: KFT is deranged, LFT is normal with normal level of albumin and gamma globulin increased disproportionately. X-ray spine shows multiple lytic lesions. Which of the following is the most probable diagnosis? (Q820525)

A. Multiple myeloma

B. MGUS

C. Immunoglobulin light chain amyloidosis (AL)

D. Solitary plasmacytoma.

Correct Answer: A. Multiple myeloma

Explanation: Correct Option A - Multiple myeloma: Multiple myeloma is a malignancy of plasma cells, a type of white blood cell that produces antibodies. It is characterized by the presence of abnormal plasma cells in the bone marrow, which can lead to bone destruction and the release of monoclonal (abnormal) immunoglobulins or light chains into the bloodstream. The clinical presentation of low back ache, progressive pallor (anemia), deranged kidney function tests (KFT), disproportionately increased gamma globulin levels, and lytic lesions on X-ray spine are all consistent with multiple myeloma. Incorrect Options: Option B - MGUS (Monoclonal Gammopathy of Undetermined Significance): MGUS is a benign condition where a small amount of abnormal plasma cells produce a monoclonal protein (usually immunoglobulin) in the blood. It is generally asymptomatic and does not cause significant organ damage. The patient in the scenario has more severe symptoms and findings that are not typical for MGUS. Option C - Immunoglobulin Light Chain Amyloidosis (AL) : AL amyloidosis is a rare condition where abnormal light chain proteins are deposited as amyloid in various organs, including the kidneys. This can lead to organ dysfunction. While AL amyloidosis can cause kidney involvement and abnormal levels of light chains, the lytic bone lesions seen on X-ray and the disproportionately increased gamma globulin levels are not characteristic of AL amyloidosis. Option D - Solitary Plasmacytoma: Solitary plasmacytoma is a localized tumor of plasma cells that typically presents as a single mass in bone or soft tissue. It is less likely in this case because the patient has multiple lytic lesions on X-ray spine, which indicates widespread bone involvement. Solitary plasmacytoma typically doesn't show this pattern of multiple bone lesions.

References:

.

↑ *Back to this question in Part A*

Q39: A 55-year-old male patient presents with fever, night sweats, and pleural effusion. On further investigation, he is diagnosed with Primary Effusion Lymphoma. What is the most likely causative agent responsible for this condition? (Q820628)

A. HHV-8

B. EBV

C. HPV

D. HIV

Correct Answer: A. HHV-8

Explanation: Correct Option A - HHV-8 (Human Herpesvirus 8): This is the most likely causative agent responsible for Primary Effusion Lymphoma (PEL), a rare and aggressive form of non-Hodgkin lymphoma. PEL primarily affects immunocompromised individuals, such as those with advanced HIV infection. HHV-8 is also known as Kaposi's sarcoma-associated herpesvirus (KSHV) and is strongly associated with both Kaposi's sarcoma and Primary Effusion Lymphoma Incorrect Options: Option B - EBV (Epstein-Barr Virus) : Epstein-Barr virus is associated with several types of lymphomas, including Burkitt lymphoma, Hodgkin lymphoma, and some cases of non-Hodgkin lymphoma. However, it is not typically associated with Primary Effusion Lymphoma. Option C - HPV (Human Papillomavirus) : Human Papillomavirus is known to cause cervical cancer and is not associated with Primary Effusion Lymphoma. Option D - HIV (Human Immunodeficiency Virus) : While HIV infection can lead to immunosuppression and an increased risk of certain infections and cancers, including Primary Effusion Lymphoma, it is not the direct causative agent. The underlying infection in this case would be HHV-8.

↑ *Back to this question in Part A*

@Neet_pg_bot

Q40: What further test should be conducted for a 60-year-old male patient who has presented with widespread lymph node enlargement, elevated white blood cell count, and smudge cells observed on peripheral smear? (Q854682)

A. Cytogenic study

B. Bone marrow biopsy

C. Flow cytometry from peripheral blood

D. X-ray crystallography

Correct Answer: C. Flow cytometry from peripheral blood

Explanation: The given clinical presentation of a 60-year-old male with lymph node enlargement, elevated WBC, and smudge cells (characteristic cells) on the peripheral smear strongly suggests Chronic Lymphocytic Leukemia (CLL). Flow cytometry is a highly sensitive technique used to identify the specific cell surface markers on the abnormal lymphocytes in CLL. It helps distinguish CLL from other types of lymphoma and leukaemia. Flow cytometry markers of CLL include CD 5+, CD10-, CD19+, CD20+, CD 23+ and CD 200+ Cytogenic studies (Option A), including Fluorescence In Situ Hybridization (FISH) , are helpful in identifying specific genetic mutations associated with CLL, which have prognostic implications. However, flow cytometry is a more immediate and critical step for diagnosis, as it directly assesses the immunophenotype of the cells. Bone marrow biopsy (Option B) might be performed later to evaluate marrow involvement or disease progression , but it is not the first-line investigation for CLL. Given the peripheral smear findings, Flow cytometry helps to assess the immunophenotype of the lymphocytes. X-ray crystallography (Option D) is a technique used to determine the atomic and molecular structure of crystals. It is irrelevant in the context of diagnosing CLL.

References:

Robbins and Cotran Pathologic Basis of Disease, 10th Edition, Pages 597, 604

↑ *Back to this question in Part A*

@Neet_pg_bot

Q41: An African child is found to have a mass in the jaw. A biopsy of the mass was done, and it appears as shown in the image below. The child also has a translocation, t(8;14). What is the probable diagnosis? (Q855405)

A. Acute myeloid leukemia

B. Follicular lymphoma

C. Multiple myeloma

D. Burkitt lymphoma

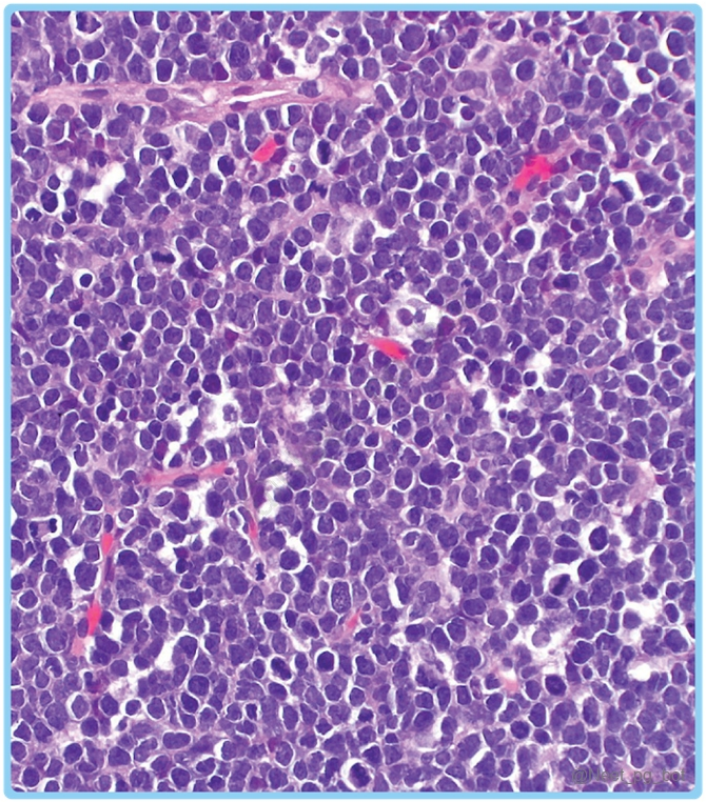

Correct Answer: D. Burkitt lymphoma

Explanation: The "starry sky" appearance and t(8;14) translocation are characteristic of Burkitt lymphoma , a high-grade B-cell lymphoma. The translocation involves the MYC gene on chromosome 8, leading to uncontrolled cell proliferation. All forms of Burkitt’s lymphoma (Endemic, Sporadic, and HIV associated) are associated with such translocations. The most common translocations are t (8:2), t(8:14) , and t(8:22) Burkitt's lymphoma is a highly aggressive B-cell non-Hodgkin lymphoma associated with the translocations of the MYC gene on chromosome 8, t(8:14). It has three primary subtypes: Endemic Burkitt's lymphoma: Commonly affects children in malaria-endemic areas of Africa, often presenting with tumours in the jaw or facial bones. Sporadic Burkitt's lymphoma: More frequently seen in non-endemic regions and usually involving the ileocaecal region and peritoneum. Immunodeficiency-associated Burkitt's lymphoma: Found in patients with conditions such as HIV/AIDS or other forms of immunodeficiency.

References:

Robbins and Cotran Pathologic Basis of Disease, 10th Edition, Page 598-603

↑ *Back to this question in Part A*

@Neet_pg_bot

Q42: A 25-year-old male presented with low haemoglobin, a platelet count of 25,000/mL, gum bleeding, and raised PT and aPTT. The image of his peripheral

smear is shown below. What is the likely diagnosis? (Q855440)

A. AML with t(8;21)

B. AML with inv(16)

C. AML with t(15;17)

D. AML with t(11;22)

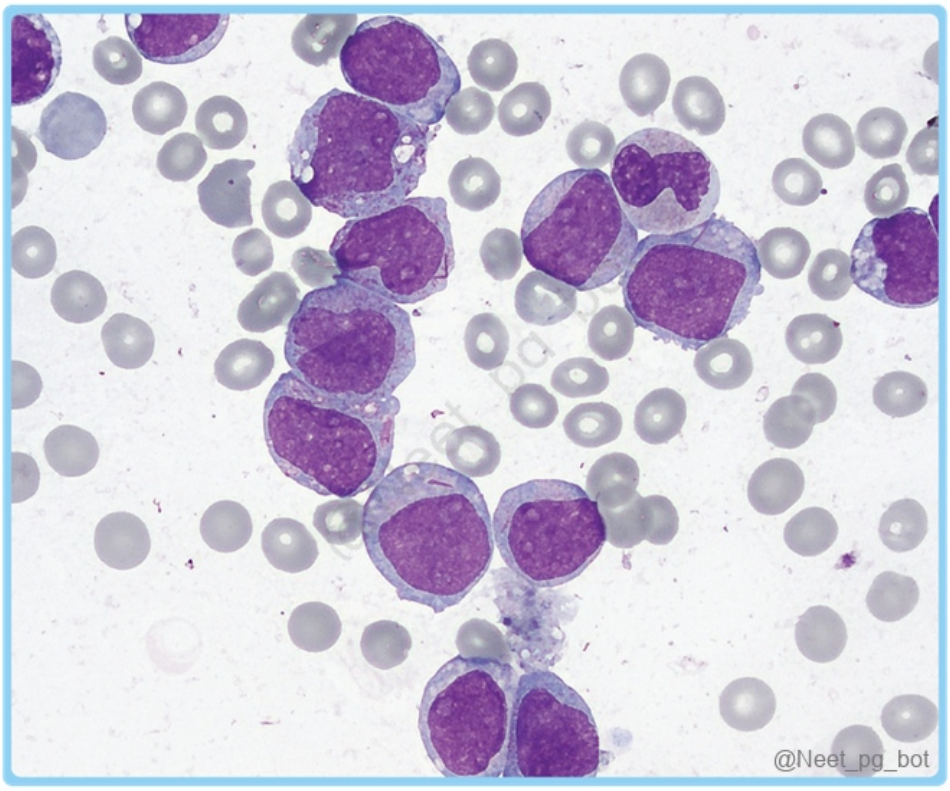

Correct Answer: C. AML with t(15;17)

Explanation: AML with t(15;17) is characteristic of acute promyelocytic leukaemia (APML) , which typically presents with Auer rods on the peripheral smear. The patient also exhibits typical features like low haemoglobin , low platelet count , gum bleeding , and prolonged PT and aPTT , which are seen in this condition due to disseminated intravascular coagulation (DIC). M3 AML/ Acute promyelocytic leukaemia: Genetics : t(15:17) translocation causes PML-RARA (retinoic acid receptor alpha) fusion protein formation. Blocks promyelocyte → myelocyte maturation. Diagnosis of choice: Fluorescence In Situ Hybridization (FISH) Smear findings: Increased promyelocytes. Auer Rods : Fused granules in promyelocytes Faggot Cells: Auer rods with a crisscross pattern. Laboratory : Low haemoglobin and platelets. > 20% blasts on peripheral and bone marrow smear Stain: PAS + CD markers: CD 13, 33 + Complication : Disseminated intravascular coagulation therefore, chemotherapy is not recommended. Treatment : ATRA (All-trans-retinoic-acid) + As 2 O 3 (arsenic trioxide) Best prognosis among all AML. FAB classification of AML Subtype Name Features AML-M0 AML undifferentiated MPO negative AML-M1 AML without maturation MPO + AML-M2 AML with maturation Most common t(8:21) RUNX1-RUNX1T1 fusion Associated with chloroma. AML-M3 Acute promyelocytic leukemia t(15:17) -

PML-RAR■ fusion Blocks promyelocyte → myelocyte transformation. Bone marrow: Auer rods form criss-cross called faggot cell. {{caption_text}} Can cause disseminated intravascular coagulation (DIC) PAS+ AML-M4 Acute myelomonocytic leukemia (Option C) Associated with inv 16 and CBF-MYH fusion gene Gums: Gum hypertrophy Skin: Leukaemia cutis MPO+, NSE + AML-M5 Acute monocytic leukemia Gums: Gum hypertrophy Skin: Leukaemia cutis MPO-, NSE + AML-M6 Acute erythroid leukemia Also called Di Guglielmo Disease Diffuse PAS+, cd71 AML-M7 Acute megakaryocytic leukemia Bone Marrow aspiration gives a dry tap PAS+, cd41 and cd61

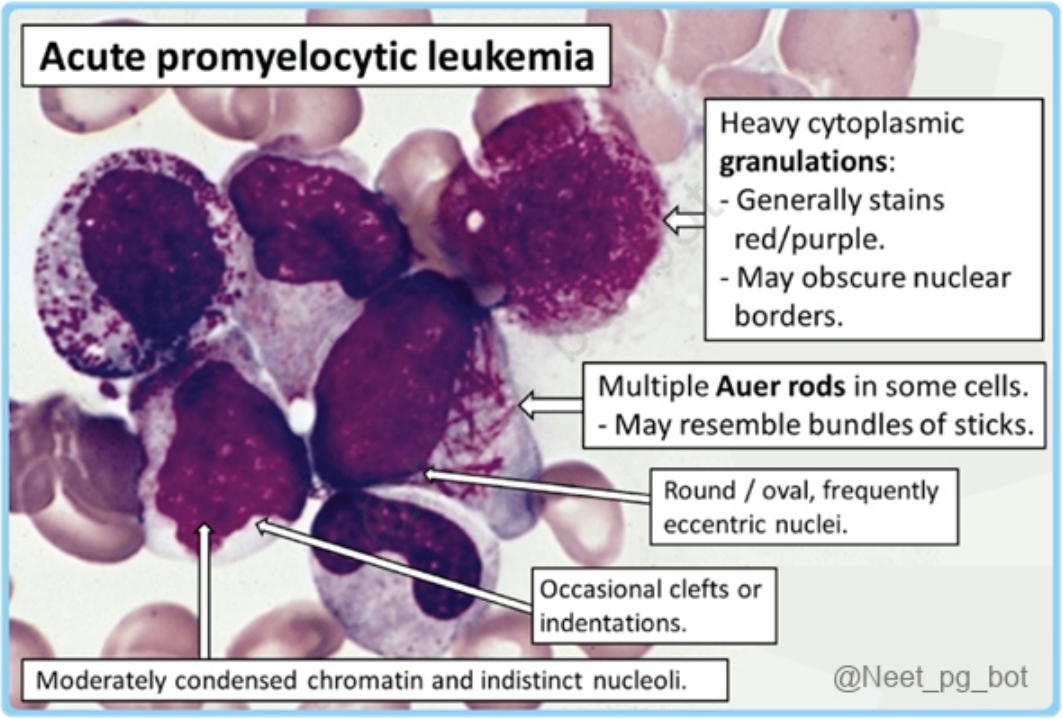

References:

Robbins and Cotran Pathologic Basis of Diseases, 10th Edition, Page 617-620

↑ *Back to this question in Part A*

@Neet_pg_bot

Q43: Which of the following leukaemias is associated with the given peripheral smear? (Q855099)

A. Acute lymphoblastic leukemia

B. Chronic lymphocytic leukemia

C. Acute myeloid leukemia

D. Chronic myelogenous leukemia

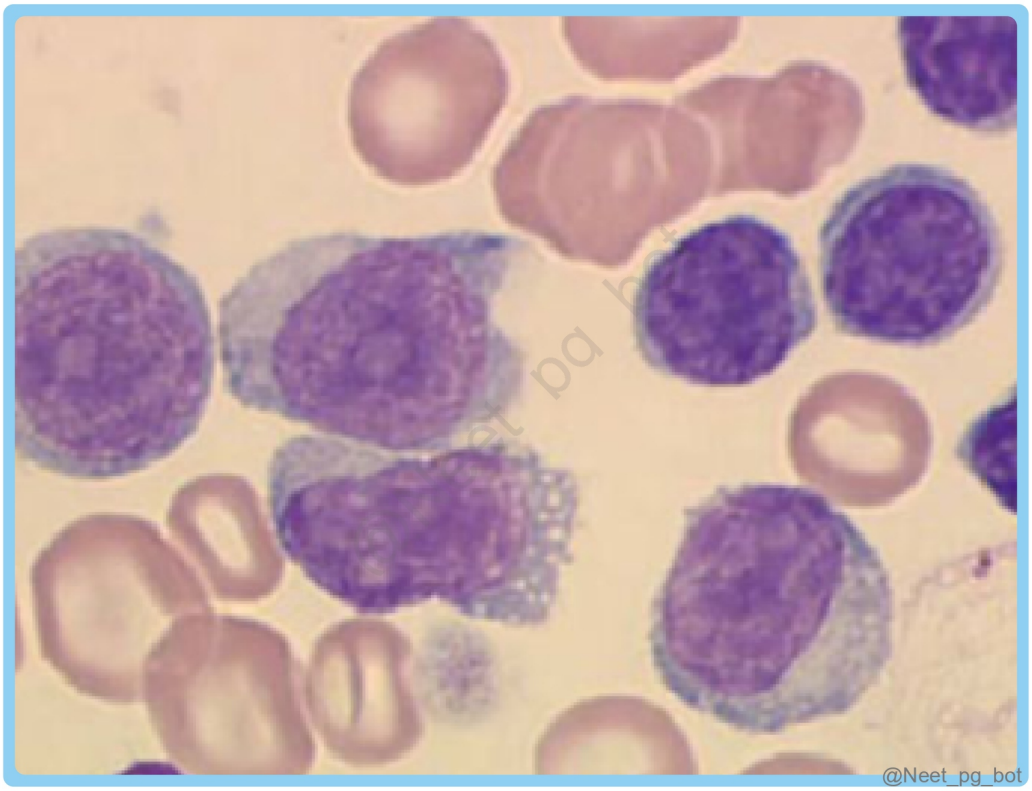

Correct Answer: B. Chronic lymphocytic leukemia

Explanation: The peripheral smear showing an increased number of small, mature lymphocytes with a characteristic smudge appearance is indicative of Chronic lymphocytic leukaemia (CLL) . {{caption_text}} Acute Lymphoblastic Leukemia (ALL): (Option A) Lymphoblasts in bone marrow >=20% Cytoplasmic vacuolations They contain fat (Oil Red O Positive) Hand mirror-shaped cells {{caption_text}} Acute Myeloid Leukemia (AML) (Option C) Blasts ≥ 20% Myeloblasts with Auer rods {{caption_text}} Chronic Lymphocytic Leukemia (CLL): Smudge cells (or parachute/basket cell): Due to the fragility of lymphocytes during slide preparation Convent Girl Appearance: Lot of homogenous, small, mature-like, round lymphocytes with scant cytoplasm {{caption_text}} Chronic Myeloid Leukemia (CML) (Option D) Leukocytosis Cell Types: Neutrophils(multilobed nucleus), metamyelocytes (indented nucleus), myelocytes (D-shaped nucleus), and eosinophils (orange cells) College girl/garden party appearance: Due to the variety of cell appearances Shift to the Left: Presence of immature cell types, mainly immature neutrophils, in the blood.

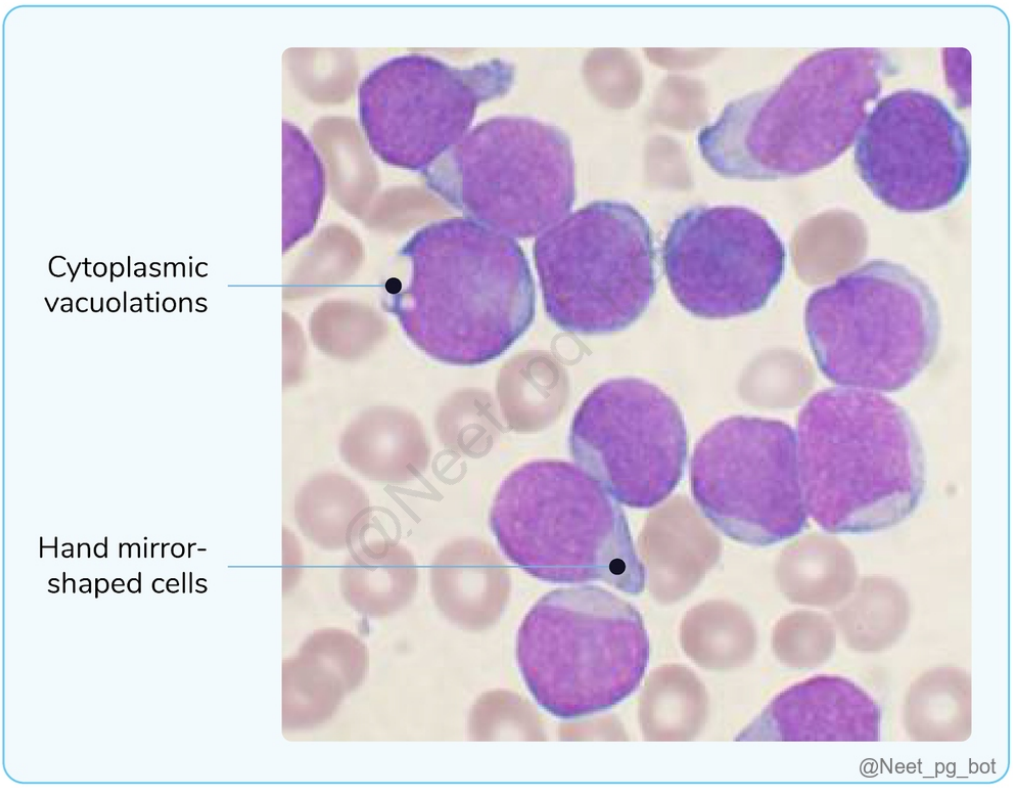
Cytoplasmic vacuolations
Hand mirror-shaped cells
@Neet_pg_bot

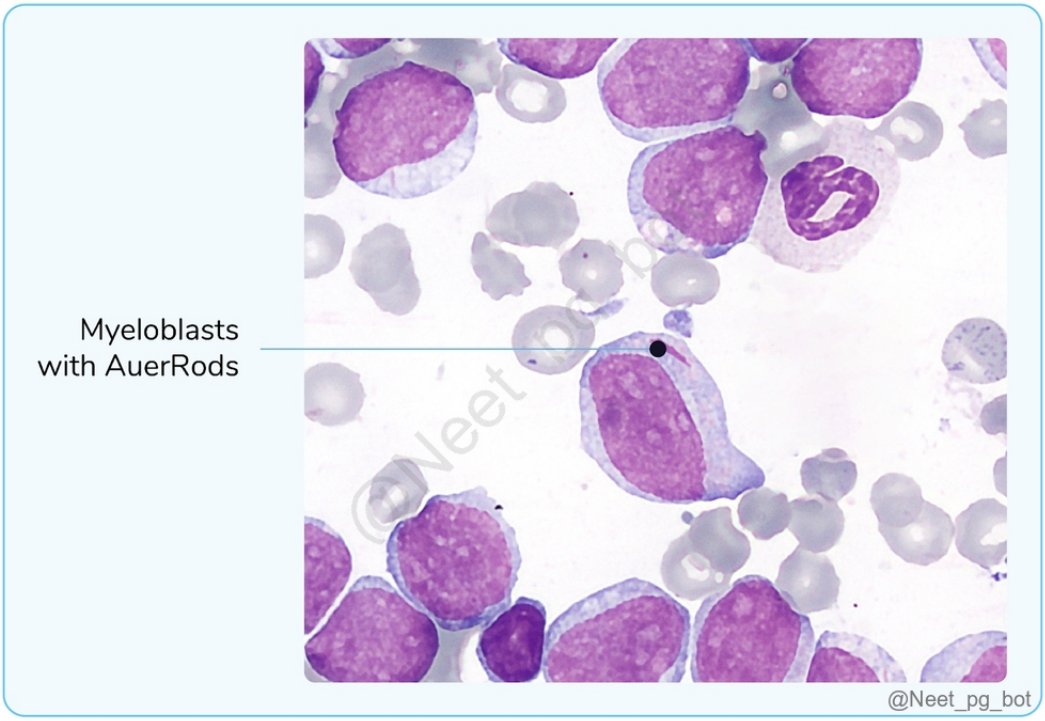
Myeloblasts with AuerRods
@Neet_pg_bot

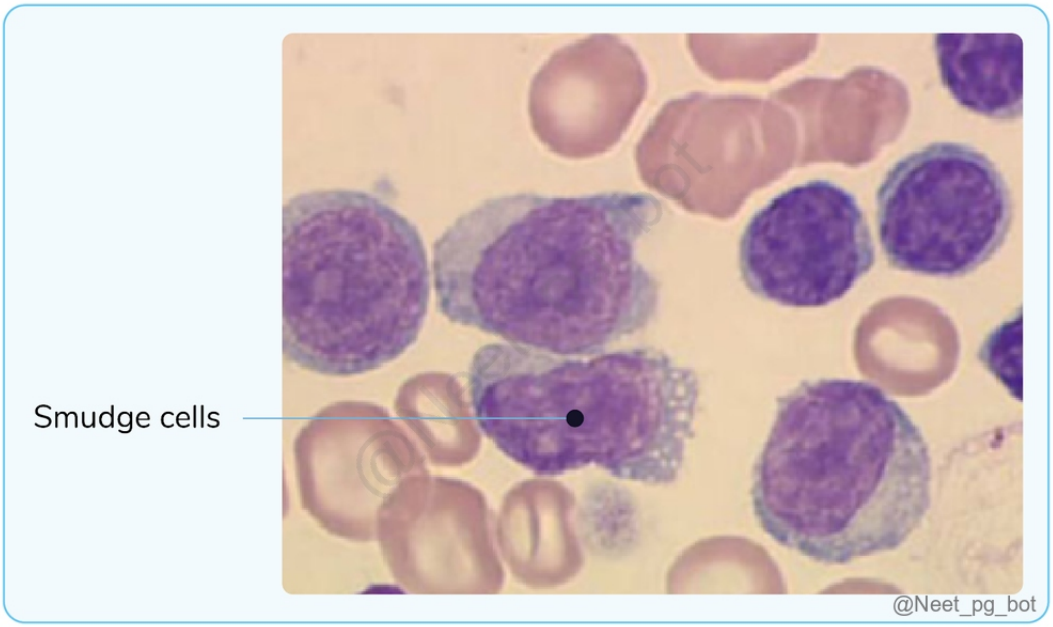

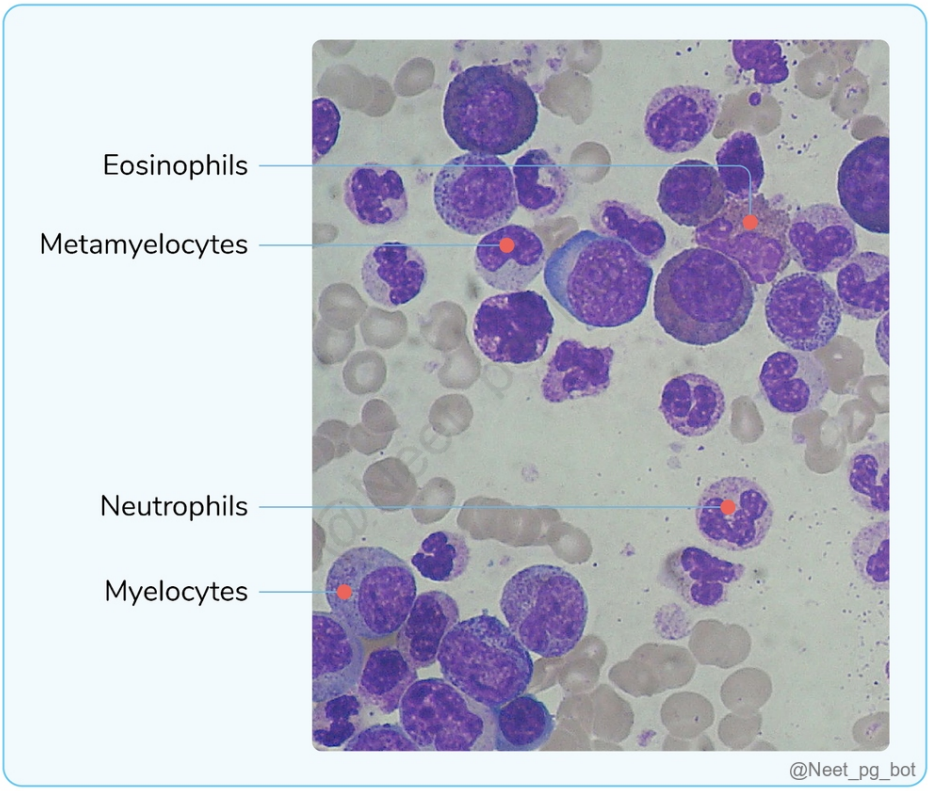

References:

Robbins & Cotran Pathologic Basis of Disease, 10th Edition, Page 414,415,594-597,618,622

https://onlinelibrary.wiley.com/doi/10.1155/2021/7488025

↑ *Back to this question in Part A*

@Neet_pg_bot

Q44: Identify the cell in the image below: (Q855101)

A. Mast cell

B. Macrophage

C. Plasma cell

D. Fibroblast

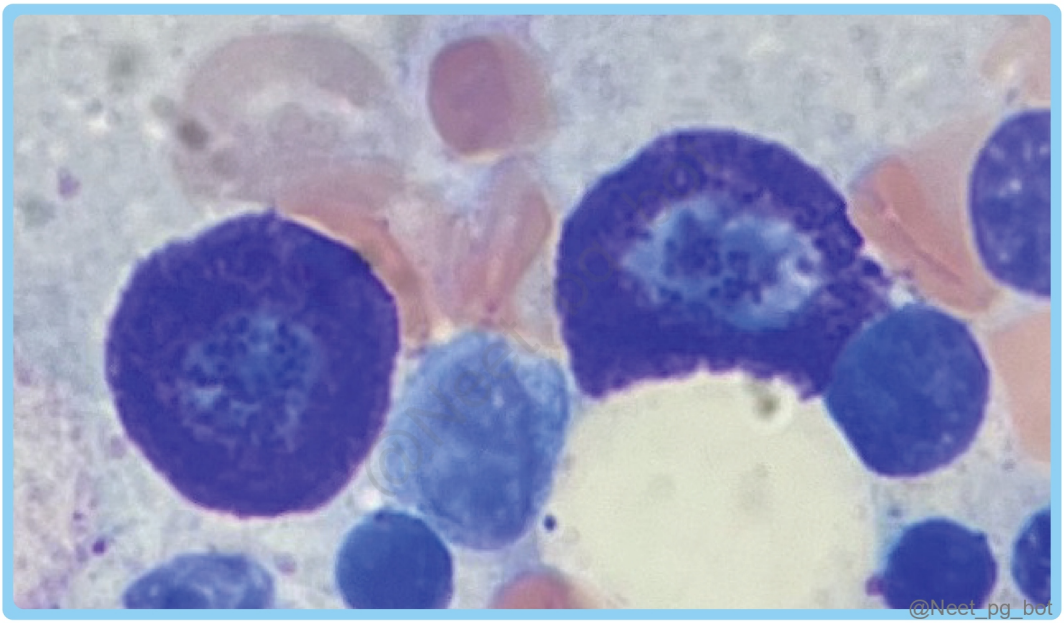

Correct Answer: A. Mast cell

Explanation: The given image shows mast cells stained with toluidine blue. It contains the acid proteoglycan that binds basic blue. Mast cells are characterized by the presence of large granules & stains with toluidine blue, giving them a distinct purple-blue colour. It plays a crucial role in allergic reactions and inflammation by releasing histamine and other mediators from their granules. Macrophages (Option B) are large phagocytic cells with abundant cytoplasm and a kidney-shaped nucleus. They lack metachromatic granules and do not stain with toluidine blue. {{caption_text}} Plasma cells (Option C) have an eccentric nucleus with a clock-face chromatin pattern and a perinuclear hof due to the prominent Golgi apparatus; they produce antibodies but lack granules. {{caption_text}} Fibroblasts (Option D) are spindle-shaped cells involved in collagen and extracellular matrix synthesis, lacking granules and immune functions. Histopathologically, they appear as elongated, fusiform cells with a pale, slightly granular cytoplasm and a single, elongated nucleus. {{caption_text}}

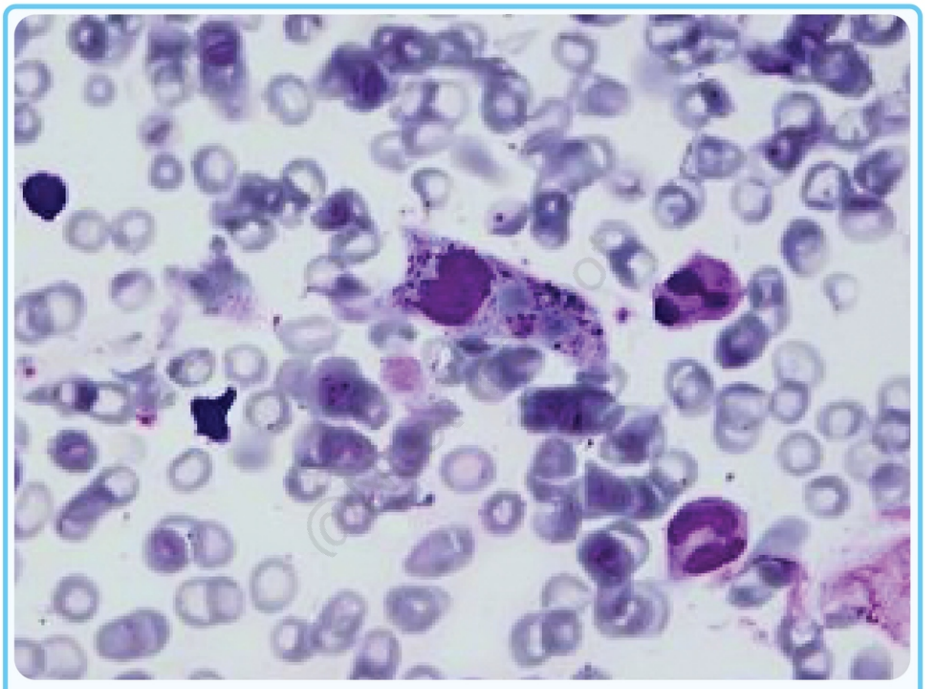

A macrophage with phagocytosis of red blood cells and platelets

@Neet_pg_bot

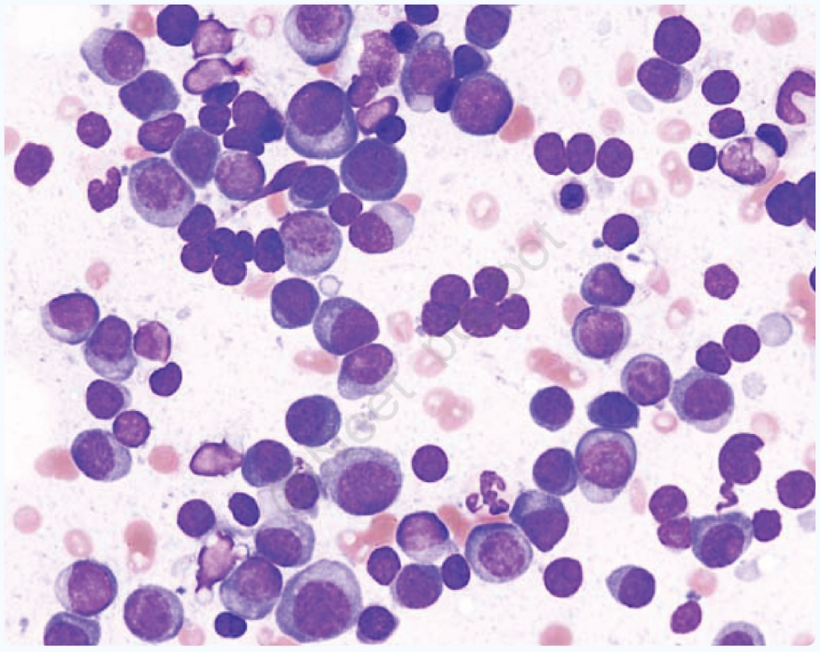

An HPE image of plasma cell, identified by its eccentrically located nucleus, a clear perinuclear zone and a basophilic cytoplasm

@Neet_pg_bot

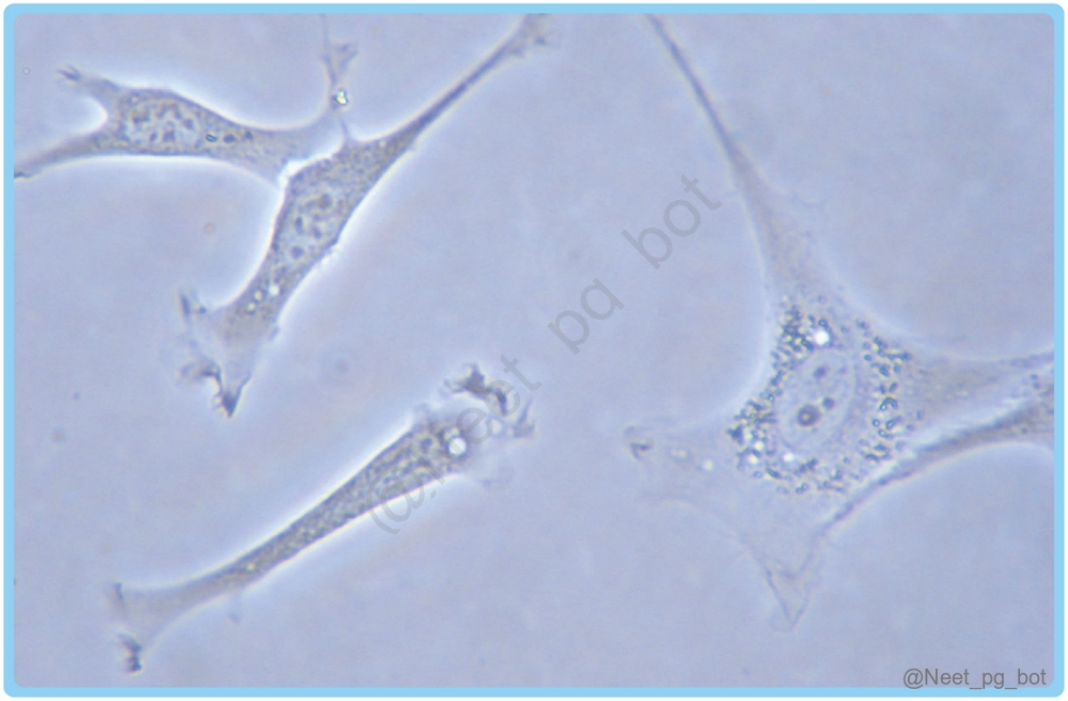

References:

Robbins & Cotran Pathologic Basis of Disease, 10th Edition, Page 206,1152

↑ *Back to this question in Part A*

@Neet_pg_bot

Q45: A patient with cervical lymphadenopathy has a positive t(11;14) translocation. Which of the following markers should be used to confirm the diagnosis? A. CD10 B. CD200 C. SOX11 D. Cyclin D1 (Q856913)

A. A, B

B. B, D

C. A, C

D. C, D

Correct Answer: D. C, D

Explanation: The t(11;14) translocation is a characteristic feature of mantle cell lymphoma. Immunohistochemistry for Cyclin D1 is crucial to confirm the diagnosis, as it is overexpressed in mantle cell lymphoma due to this translocation. SOX11 is another marker commonly expressed in mantle cell lymphoma and

can help in diagnosis. Neoplasm Cell of origin Description Diffuse large B-cell lymphoma Germinal/post-germinal center B cells Most common NHL. Associated with BCL6 gene rearrangement If CLL transforms into DLBCL, it is called Richter's Syndrome. Hairy cell leukemia Memory B cells More common in boys. BRAF V600E Mutation + It presents with massive splenomegaly affecting the red pulp of the spleen. Mantle cell lymphoma Naive B cell Translocation t(11:14). Associated with GIT polyps. Cyclin D1 and SOX11 +ve Mycosis Fungoides Helper T cells Cutaneous T-cell NHL . Presents with erythema and pruritus. If it affects the blood vessels, it is known as Sezary syndrome. CD10, also known as CALLA (Common Acute Lymphoblastic Leukemia Antigen), is a cell surface marker commonly used in the diagnosis of follicular lymphoma and Burkitt lymphoma, as well as other B-cell lymphomas. However, CD10 is not typically expressed in mantle cell lymphoma. CD200 is more commonly associated with other lymphoproliferative disorders, such as chronic lymphocytic leukaemia (CLL) , rather than mantle cell lymphoma.

References:

Robbins & Cotran Pathologic Basis of Disease, 10th Edition, Page 594, 595

↑ *Back to this question in Part A*

@Neet_pg_bot

Q46: An elderly male presents for a routine medical examination. Laboratory investigations reveal a very high total leukocyte count (TLC). The peripheral smear shows findings as shown in the image. What is the appropriate next step for this patient? (Q855433)

A. Stem cell transplantation

B. Bone marrow biopsy

C. Flow cytometry

D. Start high-dose chemotherapy

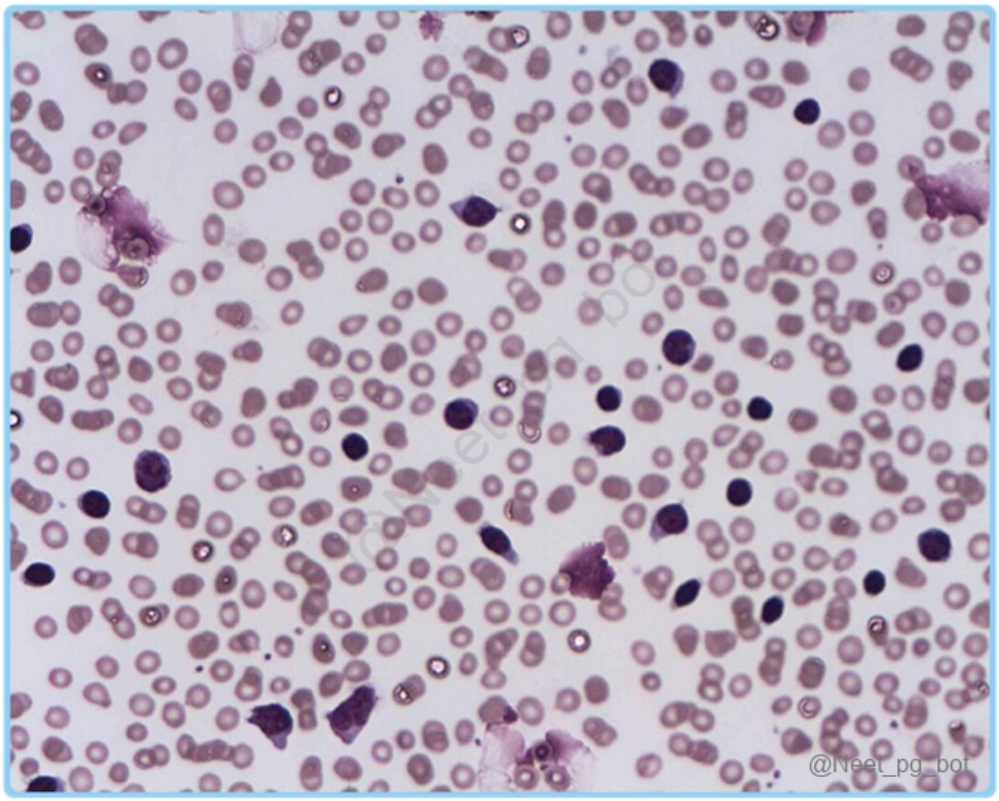

Correct Answer: C. Flow cytometry

Explanation: An elderly male with a high total leukocyte count (TLC) and the presence of smudge cells on the peripheral smear is likely to have Chronic Lymphocytic Leukemia (CLL) . The next appropriate step for confirming the diagnosis is flow cytometry , which analyses cell surface markers and helps identify abnormal lymphocytes characteristic of CLL. Chronic Lymphocytic Leukemia Genetics: Trisomy 12, deletion 13q14 , and others Origin: Post–germinal centre memory B cell or naive B Cells in the mantle zone of the lymph node. Etiopathogenesis Antiapoptotic protein BCL2 overexpression. CLL cell growth depends on Bruton Tyrosine kinase (BTK) activity. No association with radiation exposure Clinical Presentation Most common Leukemia in the elderly. Frequently asymptomatic at diagnosis. May present with fatigue, lymphadenopathy, hepatosplenomegaly, or infection due to immunosuppression. Associated with autoimmune hemolytic anemia-spherocytes can be seen on peripheral smear Can l/t Hypogammaglobulinemia(highlight)as B cells are abnormal - Infection is the M/C/C of death in CLL Laboratory diagnosis: Absolute lymphocyte count (ALC) > 5000/mm3 Bone marrow lymphocytes >30% Surface markers using flow cytometry were positive for CD5, CD23, CD19, and CD20. CLL co-expresses both T cell (CD5) and B cell (CD20, CD19) markers Incorrect Options: Stem cell transplantation (Option A) : This is not the first-line treatment for CLL. It is typically considered in more advanced or refractory cases, but the initial approach for most patients involves observation or targeted therapy. Bone marrow biopsy (Option B) : Although bone marrow biopsy can help in finding the extent of infiltration., it is not the first choice for diagnosing CLL. Flow cytometry usually confirms the diagnosis, which is more specific for CLL. High-dose chemotherapy (Option D) is generally not the first treatment for CLL. Most patients with early-stage CLL are observed without immediate chemotherapy. Treatment is usually initiated if there are symptoms or complications and targeted therapies are often used instead of high-dose chemotherapy.

References:

Robbins and Cotran Pathologic Basis of Diseases, 10th Edition, Page 597

↑ *Back to this question in Part A*

@Neet_pg_bot

Q47: A 38-year-old man presented with bleeding gums for 20 days. He has gingival hyperplasia and hepatosplenomegaly. On investigation, Hb-11 g/dL, platelet count-95,000 platelets/mm3, and WBC count-45000 cells/mm3. A bone marrow biopsy shows 100% cellularity, with many blast cells that are peroxidase-negative and non-specific esterase-positive . The most likely diagnosis is: (Q793658)

A. Acute myeloid leukemia M2 (AML M2)

B. Acute myeloid leukemia M0 (AML M0)

C. Acute myeloid leukemia M5 (AML M5)

D. Acute myeloid leukemia M7 (AML M7)

Correct Answer: C. Acute myeloid leukemia M5 (AML M5)

Explanation: Correct Option C - Acute myeloid leukemia M5 (AML M5): The patient's presentation with bleeding gums, gingival hyperplasia, hepatosplenomegaly, and bone marrow biopsy findings, which indicate 100% cellularity with many blast cells that are peroxidase negative and non-specific esterase positive, is suggestive of acute myeloid leukemia M5 (AML M5). Acute myeloid leukemia M5 (AML M5) is also known as acute monocytic leukemia. Incorrect Options: Option A - Acute Myeloid Leukemia M2 (AML M2): It is characterized by the presence of abnormal promyelocytes in the bone marrow and blood. Option B - Acute Myeloid Leukemia M0 (AML M0): It is characterized by the absence of surface markers on the blast cells. Option D - Acute Myeloid Leukemia M7 (AML M7): It is characterized by the presence of abnormal megakaryocytes in the bone marrow, which can lead to thrombocytopenia and bleeding.

References:

Prepladder Notes

↑ *Back to this question in Part A*

@Neet_pg_bot

Q48: What is the most accurate test for evaluating the effectiveness of treatment in chronic myeloid leukemia (CML)? (Q857166)

A. ■■■

B. RT PCR

C. Cytogenetic test

D. FISH

Correct Answer: B. RT PCR

Explanation: RT-PCR is the most sensitive test for monitoring treatment response in chronic myeloid leukemía (CML). It accurately detects and quantifies the BCR-ABL1 fusion gene, allowing for precise assessment of treatment response and minimal residual disease (MRD) status in CML patients. Regular monitoring with RT-PCR guides treatment decisions for optimal patient outcomes. Chronic Myeloid Leukemia: It occurs due to the translocation of Philadelphia chromosome t (9:22) (q34.1, q11.2). BCR-ALB1 is a hybrid gene. It is a translocation with respect to the long arm of chromosome no. 9 to the long arm of chromosome no. 22 BCR : Breakpoint cluster region ALB1 : Abelson leukemia BCR-ALB1 results in the production of novel oncoproteins (Molecular weight: 210 kilodaltons) CBC (Complete Blood Count) (Option A): While CBC indicates changes in blood cell levels, it may not detect MRD or early treatment failure as sensitively as RT-PCR. Cytogenetic Test (Option B): Although cytogenetic tests reveal chromosomal abnormalities like the Philadelphia chromosome, they may not detect low levels of disease or MRD as effectively as molecular techniques like RT-PCR. FISH (Fluorescence In Situ Hybridization) (Option D): While FISH detects genetic sequences like the BCR-ABL1 fusion gene, it may not quantify residual disease or assess treatment response as accurately as RT-PCR.

References:

CML

↑ *Back to this question in Part A*

@Neet_pg_bot

Q49: Which CD markers are typically positive in Chronic Lymphocytic Leukaemia (CLL)? . (Q866672)

A. CD3, CD5, CD8

B. CD10, CD19, CD22

C. CD19, CD20, CD23, CD5

D. CD13, CD33, CD117

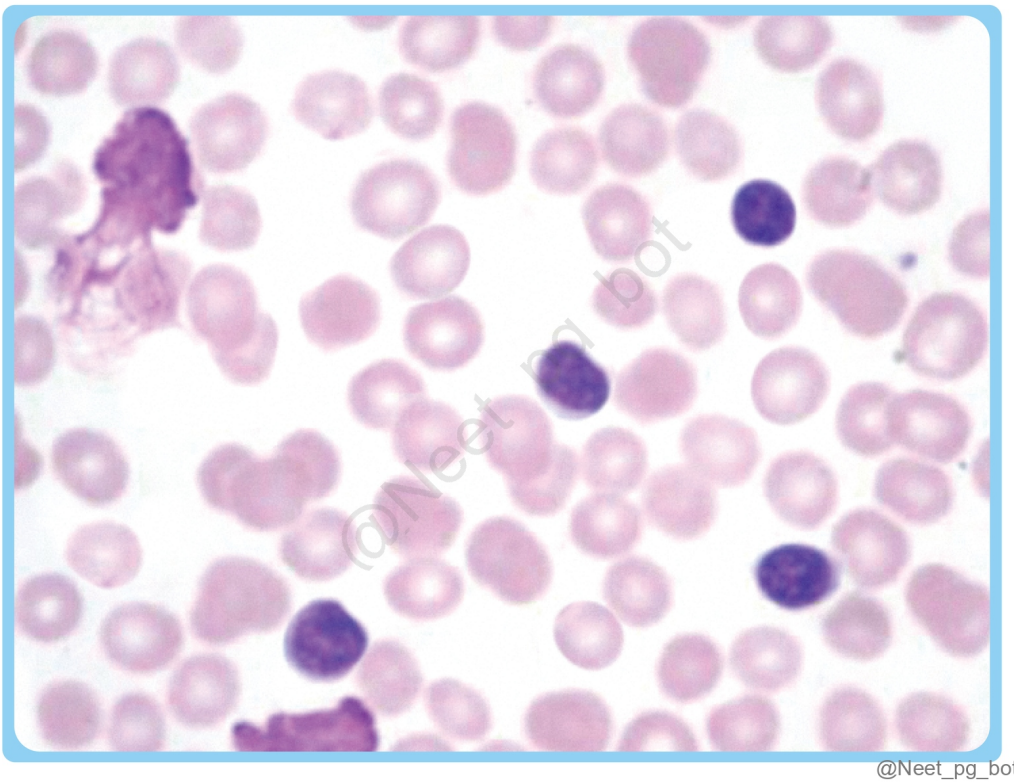

Correct Answer: C. CD19, CD20, CD23, CD5

Explanation: In Chronic Lymphocytic Leukaemia (CLL) , the hallmark immunophenotype is: B-cell markers: CD19, CD20, CD23 Aberrant co-expression of T-cell marker: CD5 (this is unusual for B-cells and is a diagnostic clue) CLL is a mature B-cell neoplasm → expresses typical B-cell surface antigens (CD19, CD20, CD23). Uniquely, it abnormally expresses CD5 , which is normally a T-cell marker, this feature helps distinguish CLL from other B-cell leukemias/lymphomas. Incorrect Options: CD3, CD5, CD8 (Option A): T-cell markers (CD8 = cytotoxic T cells), not CLL. CD10, CD19, CD22 (Option B): seen in precursor B-cell ALL (CD10 - CALLA antigen), not mature CLL. CD13, CD33, CD117 (Option D): myeloid lineage markers (seen in AML), not lymphoid.

References:

.

↑ *Back to this question in Part A*

@Neet_pg_bot

• [19_Platelet and Bleeding Disorders] 078 Platelet And Hemostasis Disorders

« Back to Folder Directory

[19_Platelet and Bleeding Disorders] 078 Platelet And Hemostasis Disorders — Quick Jump

Q1 (p. 3065)	*Q2 (p. 3066)*	*Q3 (p. 3068)*	*Q4 (p. 3069)*	*Q5 (p. 3071)*	*Q6 (p. 3073)*
Q7 (p. 3074)	*Q8 (p. 3075)*	*Q9 (p. 3076)*	*Q10 (p. 3077)*	*Q11 (p. 3078)*	*Q12 (p. 3081)*
Q13 (p. 3081)	*Q14 (p. 3084)*	*Q15 (p. 3085)*	*Q16 (p. 3086)*	*Q17 (p. 3087)*	*Q18 (p. 3088)*
Q19 (p. 3089)	*Q20 (p. 3090)*	*Q21 (p. 3091)*	*Q22 (p. 3092)*	*Q23 (p. 3093)*	

Q1: An 8-year-old girl has been brought to the pediatric clinic by her parents. She has been suffering from tiny cutaneous haemorrhages spread all over her body. She has been recovering for a week from a flu-like condition. Her Physical examination is unremarkable, and she is vitally stable. Her Laboratory investigations revealed a platelet count of 20,000/mL. The number of megakaryocytes in her bone marrow has increased. Which of the following is the most likely diagnosis for this girl? (Q882287)

A. Antiphospholipid antibody syndrome

B. Disseminated intravascular coagulation

C. Hemolytic-uremic syndrome

D. Idiopathic thrombocytopenic purpura

Correct Answer: D. Idiopathic thrombocytopenic purpura

Explanation: It is a quantitative disorder of platelets caused by antibodies directed against platelet or megakaryocytic antigens. Related to antibody-mediated immune destruction of platelets or their precursors. The peripheral blood smear in ITP exhibits numerous large platelets, and the bone marrow shows a compensatory increase in megakaryocytes. Clinical Features: Petechia Purpura Hemorrhagic bullae Gum bleeding Hematuria Melena Classification of ITP: ITP is primarily classified by duration and cause . By Duration: Newly Diagnosed: Less than 3 months since diagnosis. Persistent: Lasting 3 to 12 months from diagnosis. Chronic: Lasting more than 12 months (more common in adults). By Cause: Primary ITP: Occurs in isolation without an underlying trigger (accounts for 80% of cases). Secondary ITP: Associated with another condition, such as: Infections: HIV, Hepatitis C, H. pylori. Autoimmune diseases: Systemic Lupus Erythematosus (SLE). Malignancies: Chronic Lymphocytic Leukemia (CLL). Treatment of ITP: Phase Treatment Options Mechanism First-Line Corticosteroids (Prednisone/Dexamethasone) Suppress immune destruction of platelets. IVIG (Intravenous Immunoglobulin) "Distracts" the spleen from destroying platelets (fast-acting). Anti-D IG Only for Rh-positive, non-splenectomized

patients. Second-Line TPO-RAs (Eltrombopag, Romiplostim) Stimulate the bone marrow to produce more platelets. Rituximab Depletes B-cells that produce the auto-antibodies. Splenectomy Surgical removal of the primary site of platelet destruction. Emergency Platelet Transfusion + High-dose IVIG Used only in life-threatening bleeding (rarely used alone as the body destroys them quickly). Thrombocytopenia may be observed in the other choices but is usually associated with other systemic signs and symptoms. Option A: Anti-Phospholipid Antibody Syndrome The antiphospholipid antibody syndrome is the most common form of acquired thrombophilia. Antiphospholipid antibodies include lupus anticoagulant antibodies and anticardiolipin antibodies. They can occur as a manifestation of various conditions, such as systemic lupus erythematosus and other rheumatic disease, infections, and drug reactions. Women who sustain recurrent spontaneous abortions or a thromboembolic event during pregnancy should also undergo evaluation for the disorder Option B: Disseminated Intravascular Coagulation Disseminated intravascular coagulation is a rare but serious condition that causes abnormal blood clotting throughout the body's blood vessels. An infection usually follows it. It can present with any of the following: Bleeding at wound sites or from the nose, gums, or mouth Blood in the stool or urine Bruising in small dots or larger patches on the body Chest pain Pain, redness, warmth, and swelling of the leg Option C: Hemolytic Uremic Syndrome Hemolytic uremic syndrome (HUS) is a condition that affects the blood and blood vessels. It results in: destruction of blood platelets (cells involved in clotting) a low red blood cell count (Anemia) kidney failure due to damage to the tiny blood vessels of the kidneys However, in this case, the triad is not present

References:

Robbins & Cotran Pathologic Basis of Disease 10 th Edition Page No. 664-665

↑ *Back to this question in Part A*

@Neet_pg_bot

Q2: A 62-year-old hospitalized woman is evaluated for worsening skin lesions. She was admitted 6 days ago for total hip replacement surgery. The surgery was uncomplicated. She is receiving low-dose subcutaneous heparin for prophylaxis of DVT. O/E, there are several large purple/ black patches seen in the periumbilical region surrounded by erythema. Which of the following is true regarding heparin-induced thrombocytopenia (HIT)? (Q845960)

A. Type 1 is more common than type 2

B. Type 1 is due to antibodies against PF 4

C. HIT can lead to elevated fibrinogen levels

D. Type 2 occurs immediately after the initiation of heparin.



Correct Answer: A. Type 1 is more common than type 2

Explanation: This patient, who underwent a Total hip replacement seven days ago on low-dose subcutaneous heparin, now has purple/black-colored skin necrosis at the abdominal injection site. This is a classic thrombotic complication of Heparin-induced thrombotic thrombocytopenia, commonly observed following the administration of unfractionated heparin. Heparin Induced Thrombocytopenia is of 2 types: HIT type 1 HIT type 2 Epidemiology More common (Option A) Less common Timeline Occurs immediately Occurs 5 - 14 days after therapy (Option D) Prognosis Self-resolving Can lead to life-threatening arterial or venous thrombosis Pathogenesis This occurs due to the platelet aggregating effects of heparin Antibodies against PF4 that lead to platelet aggregation and thrombosis. (Option B) Heparin-induced thrombocytopenia type 2 (HIT type 2) is an immune-mediated adverse reaction where antibodies form against complexes of heparin and platelet factor 4 (PF4). These antibodies activate platelets, leading to their consumption and a pro-thrombotic state, resulting in both thrombocytopenia and an increased risk of thrombosis. Fibrinogen levels usually decrease due to clot formation and consumption. (Option C).



References:

Robbins and Cotran, Pathological Basis of Disease, 10th Edition, Page 127

↑ *Back to this question in Part A*

@Neet_pg_bot

Q3: A 45-year-old woman presents with easy bruising and recurrent nosebleeds. Laboratory investigations reveal a prolonged aPTT. A mixing study is performed, and the aPTT corrects after mixing with normal plasma. What is the most likely diagnosis? (Q845970)

A. Factor deficiency

B. Platelet dysfunction

C. Presence of lupus anticoagulant

D. Vitamin K deficiency

Correct Answer: A. Factor deficiency

Explanation: Mixing studies are done when there's a prolonged aPTT with normal BT and PT. This could be due to factor deficiency, like Factor VIII deficiency (hemophilia), or increased antibodies, as seen in Anti-phospholipid antibody syndrome (APLA), including lupus anticoagulant (LAC). Platelet dysfunction(Option B): Platelet dysfunction typically presents with symptoms such as easy bruising and recurrent nosebleeds. However, a prolonged aPTT typically indicates a defect in the coagulation cascade rather than platelet dysfunction. Vitamin K deficiency(Option D): Vitamin K is crucial for synthesizing coagulation factors II, VII, IX, and X. Its deficiency

can lead to prolonged PT and aPTT. However, in this case, the aPTT corrects after mixing with normal plasma, indicating that clotting factors are present. Hence, vitamin K deficiency is less likely.

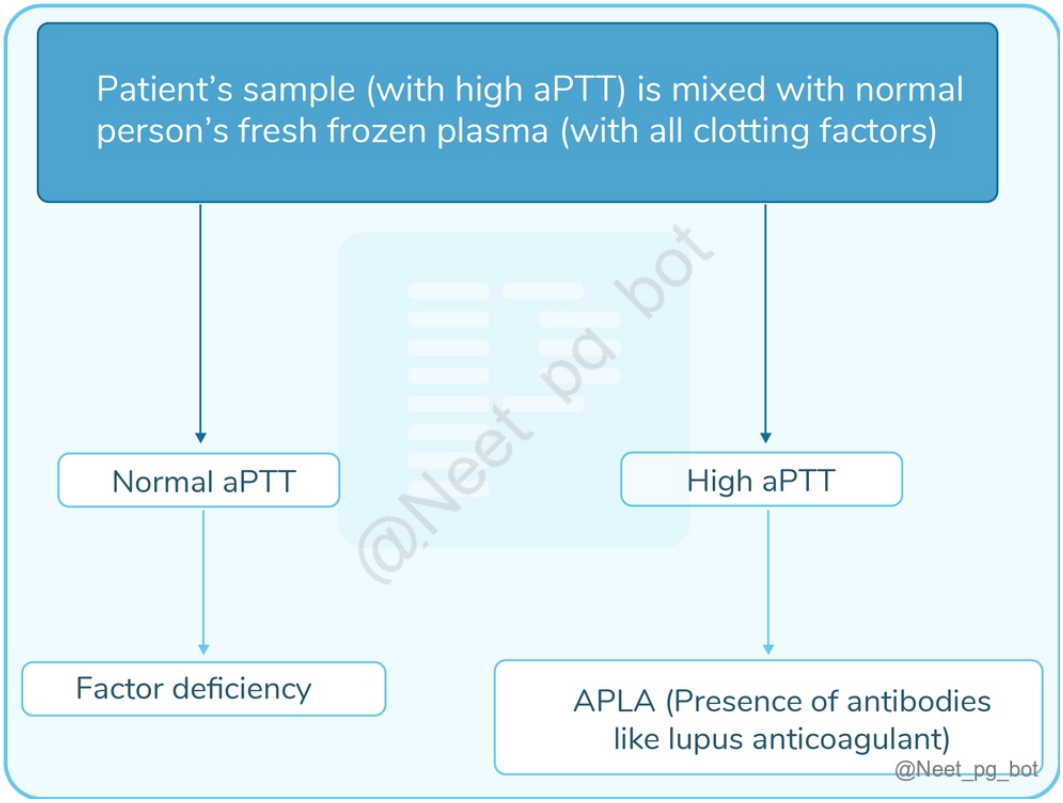

References:

www.pathologyoutlines.com/topic/coagulationmixingstudies.html

↑ *Back to this question in Part A*

@Neet_pg_bot

Q4: A 45-year-old male is admitted to the ICU following a road traffic accident. Upon arrival, he is hypotensive and tachycardic. Despite fluid resuscitation and transfusion of packed red blood cells, his condition deteriorates rapidly. Lab investigations show a sudden drop in platelet count and prolonged PT and aPTT. DIC is suspected. The thromboelastogram (TEG) graph is shown below: Which of the following is correct? (Q845969)

A. R time is more in Stage 1

B. K time is more in stage 2

C. Maximum amplitude is more in stage 2

D. Maximum amplitude is less in stage 1



Correct Answer: B. K time is more in stage 2

Explanation: K time is more in stage 2 of DIC due to the increased time for the clot to reach firmness, as there is fibrinogen dysfunction in this stage. Stages of DIC: Stage 1- Hypercoagulable state with multiple clots being formed in vessels throughout the body. The graph shows decreased R time (Option A) , decreased K time, higher maximum amplitude (Option C) , and higher LY30 from subsequent fibrinolysis. Stage 2- Widespread bleeding due to used-up clotting factors and platelets. The graph shows an increased R time, higher K time, lower maximum amplitude (Option D), and lower LY30. The image below depicts how a TEG graph is formed.



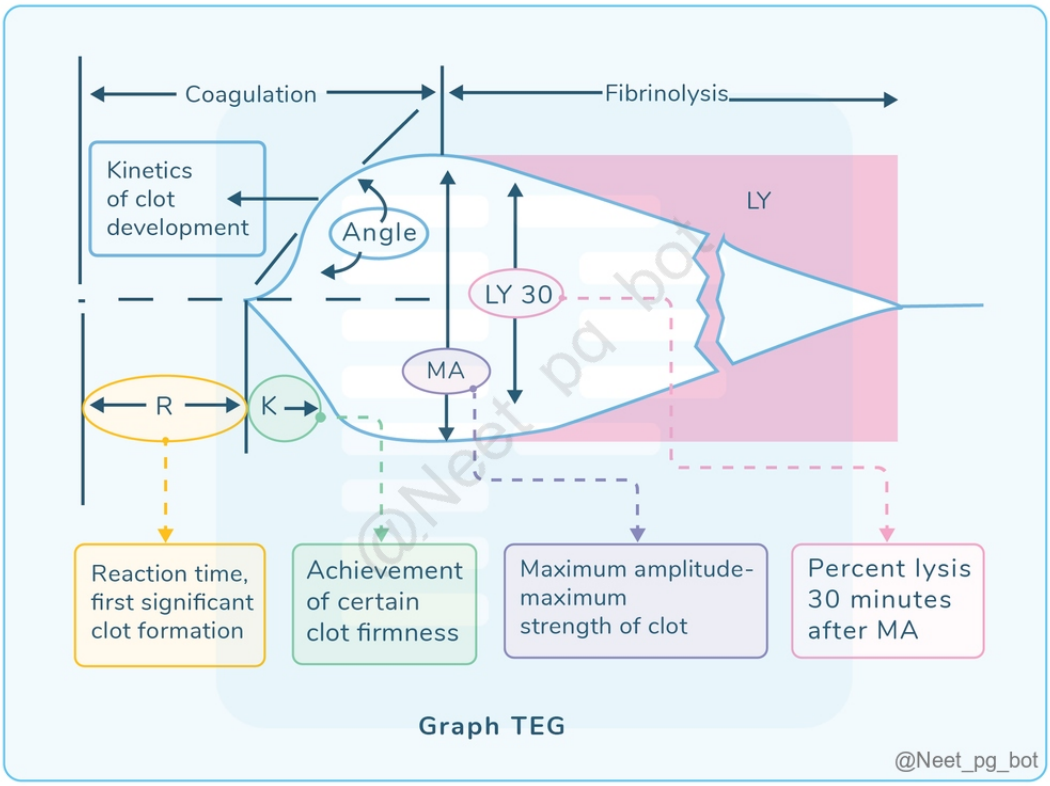

References:

www.nhlbi.nih.gov/health/disseminated-intravascular-coagulation#:~:text=In%20stage%20one%2C%20overactive%20clotting,help%20the%20blood%20to%20clot

↑ *Back to this question in Part A*

@Neet_pg_bot

Q5: A 60 y/o man is brought to the hospital following a high-speed head-on collision. O/E, BP is 80/50mmhg and HR is 130bpm. Laboratory studies indicate a significant drop in platelet count, prolonged PT, and aPTT. DIC is suspected, and a thromboelastogram is performed. What term represents the time from the initiation of the test until the initial formation of the clot? (Q845968)

A. R time

B. K Time

C. Maximum Amplitude (MA)

D. LY30

Correct Answer: A. R time

Explanation: A thromboelastogram is a test that studies the ability of blood to form a clot by studying its viscoelastic properties. Stages of Thromboelastogram (TEG): Definition Normal value Problem it indicates Treatment Reaction time (Option A) Time taken for the clot to start forming 7.5-15 mins Increased: Deficiency in clotting factors Decreased: Hypercoagulable states Fresh frozen plasma K time- clot firmness (Option B) Time for the clot to reach fixed strength 3-6 mins Fibrinogen dysfunction Cryoprecipitate Alpha angle Fibrin linking speed 45° and 55° Fibrinogen dysfunction Cryoprecipitate Maximum amplitude (Option C) The highest vertical amplitude of TEG 50-60 mm Platelets (most often) Clotting factors Platelets Lysis in 30 mins (Option D) Percentage of amplitude reduction 30 minutes after maximum amplitude 0-8% A high value indicates excess lysis of the clot Tranexamic acid

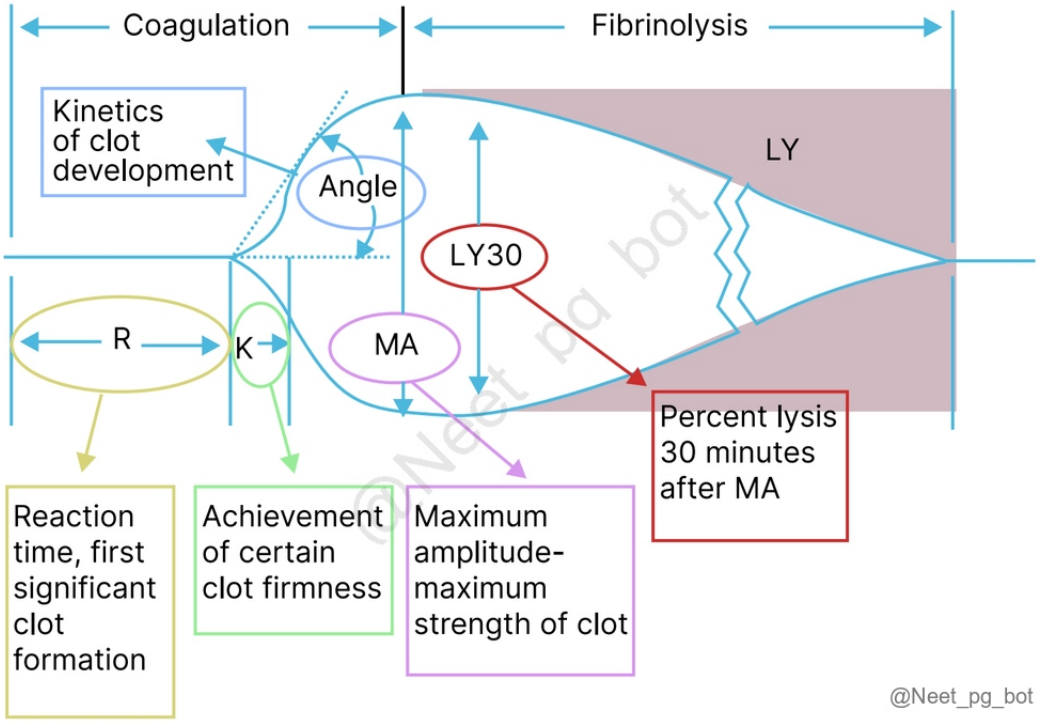

	Normal

	• ↑ R time
	  ○ Clotting factors deficiency
	  ○ Cause - hemophilia

	• Maximum amplitude ↓
	  ○ Primarily measure of platelets
	  ○ Cause - use of platelet blockers

	LY30 ↑ - case of fibrinolysis

	• Disseminated Intravascular coagulation
	  ○ Hypercoagulable state - stage 1
	  → R time ↓
	  → Maximum Amplitude is ↑
	  ○ Consumptive coagulopathy - stage 2
	  → platelets and clotting factors ↓
	  → R time ↑
	  → Maximum amplitude ↓

@Neet_pg_bot

References:

www.ncbi.nlm.nih.gov/pmc/articles/PMC4528385/#:~:text=The%20R%20time%2C%20K%20time,LY30%20measure%20the%20platelet%20contribution

↑ *Back to this question in Part A*

@Neet_pg_bot

Q6: A 10 y/o boy presents with a history of recurrent nosebleeds and easy bruising since early childhood. O/E, there are multiple petechiae and ecchymoses on his skin. Laboratory investigations reveal normal platelet count but markedly decreased platelet aggregation. Bernard-Soulier Syndrome is suspected. Which of the following features would commonly be observed in platelet aggregometry for this patient? (Q845967)

A. Normal aggregation with ristocetin

B. No aggregation with ristocetin

C. No aggregation with collagen

D. No aggregation with epinephrine

Correct Answer: B. No aggregation with ristocetin

Explanation: In platelet aggregometry, ristocetin enhances the binding of glycoprotein Ib/IX and von Willebrand factor, assessing platelet adhesion. In Bernard-Soulier Syndrome (glycoprotein Ib/IX complex deficiency) and von Willebrand disease (vWF deficiency), platelet aggregation in response to ristocetin is typically abnormal (Option A). In contrast, aggregation responses to ADP, collagen, and epinephrine are typically normal (Options C and D).

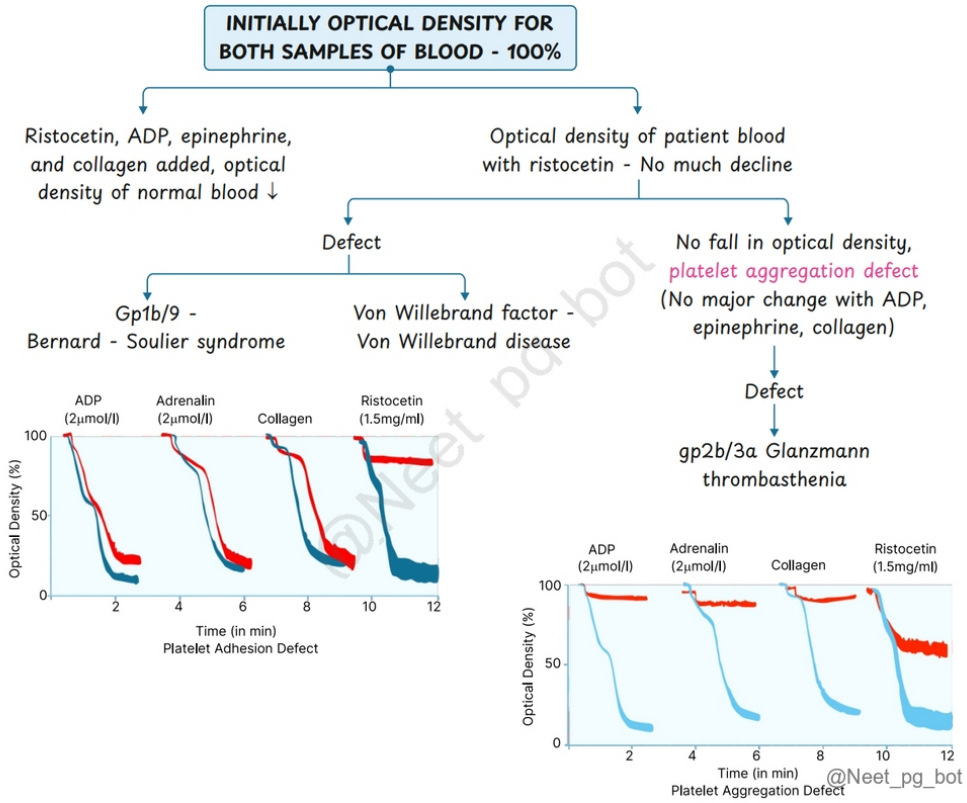

References:

Robbins and Cotran, Pathological Basis of Disease, 10th Edition, Page 666

www.ncbi.nlm.nih.gov/pmc/articles/PMC5578190/

↑ *Back to this question in Part A*

@Neet_pg_bot

Q7: A 6-year-old girl presents with persistent bleeding from minor cuts and bruises since early childhood. On examination, there are multiple bruises and petechiae on her limbs. Lab investigations reveal normal platelet count but markedly decreased platelet aggregation. Glanzmann thrombasthenia is suspected. Which of the following agonists will be able to demonstrate decreased platelet aggregation? (Q845966)

A. Adenosine diphosphate (ADP)

B. Collagen

C. Epinephrine

D. All of the above

Correct Answer: D. All of the above

Explanation: In Glanzmann thrombasthenia, platelet aggregation is impaired due to dysfunctional glycoprotein IIb/IIIa. During platelet aggregometry, ADP, epinephrine, and collagen are added to stimulate platelet aggregation by increasing the binding of glycoprotein IIb/IIIa. However, in Glanzmann thrombasthenia, platelets fail to aggregate in response to these agonists due to dysfunctional glycoprotein IIb/IIIa. Thus, Option D, "All of the above," is correct.

References:

Robbins and Cotran, Pathological Basis of Disease, 10th Edition, Page 666

↑ *Back to this question in Part A*

@Neet_pg_bot

Q8: A 45-year-old man presents with a history of easy bruising and recurrent nosebleeds. Laboratory investigations reveal normal platelet count but prolonged bleeding time. A Platelet aggregometry test is performed, showing a decrease in light transmission. What is the most likely interpretation of the platelet aggregometry results in this patient? (Q845965)

A. Platelet aggregation

B. No platelet aggregation

C. Increase in serum sodium

D. Increase in plasma fibrinogen

Correct Answer: B. No platelet aggregation

Explanation: The decrease in light transmission observed during platelet aggregometry indicates no platelet aggregation. This test measures platelet adhesion, secretion, and aggregation by passing light through platelet-rich plasma. Initially, light transmission is reduced as the cells are dispersed through plasma. Then we add a "clumping trigger" (Agonist). Common agonists include: ADP, Epinephrine, Collagen, or Arachidonic Acid. Ristocetin (unique because it tests the interaction between vWF and the GpIb receptor). Reaction: Normal Response: Platelet aggregation occurs → Plasma becomes clearer → Light transmission increases. (Option A). Abnormal Response:

Platelets aggregation does not occur → Plasma stays cloudy → Light transmission stays low (Option B) Serum sodium (Option C): Serum sodium levels are not directly assessed or measured during platelet aggregometry. Increase in plasma fibrinogen (Option D): Platelet aggregometry primarily assesses platelet function and aggregation, not plasma fibrinogen levels. Therefore, a decrease in light transmission during the test is unrelated to increased plasma fibrinogen.

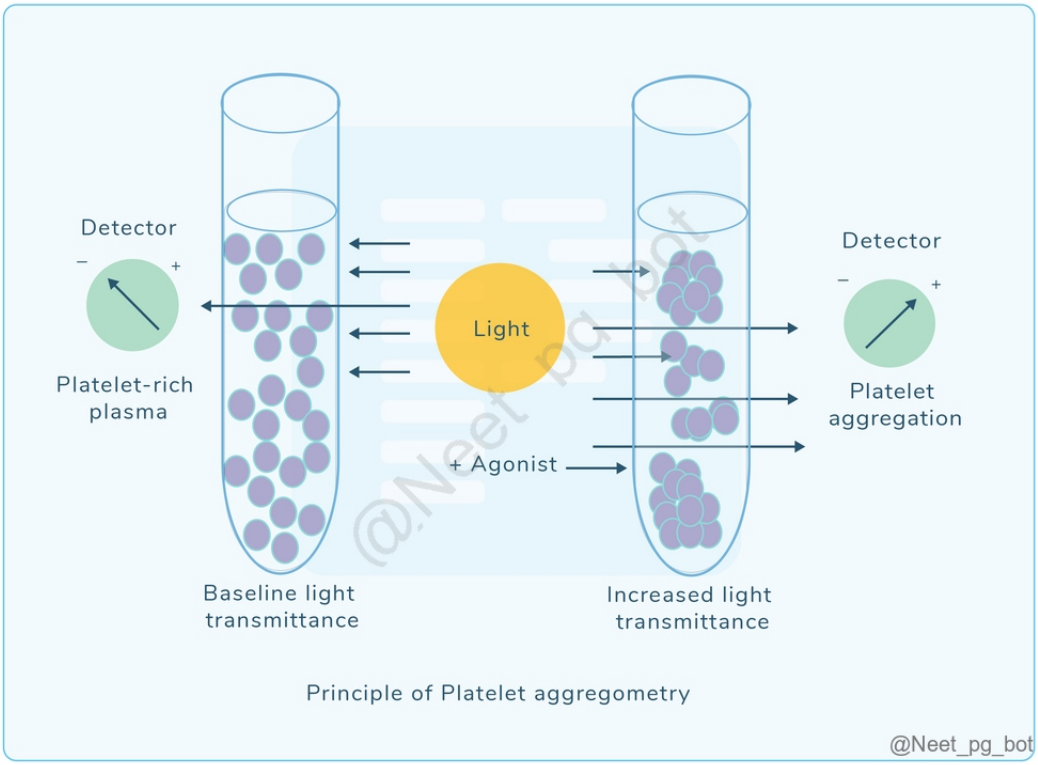

References:

www.ncbi.nlm.nih.gov/pmc/articles/PMC5578190/

↑ *Back to this question in Part A*

@Neet_pg_bot

Q9: A 12-year-old male presents with a history of frequent nosebleeds and easy bruising. His parents report that he has had these symptoms for several years, but they seem to be worsening recently. On examination, petechiae are noted on his skin, particularly over his legs, and laboratory investigations reveal prolonged bleeding time, elevated aPTT, and PT within normal range. His platelet count is normal. Which of the following is the most likely diagnosis? (Q845964)

A. Hemolytic Uremic Syndrome (HUS)

B. Hemophilia

C. Bernard Soulier syndrome

D. Von Willebrand Disease (vWD)

Correct Answer: D. Von Willebrand Disease (vWD)

■ *Listen (English)*

■ *Listen (Hindi)*

Explanation: The case scenario shows that the patient has an increased bleeding tendency. The laboratory results show normal platelet count, normal PT, prolonged bleeding time, and elevated aPTT, pointing to a diagnosis of von Willebrand disease . Disease Platelet count BT PT aPTT Bernard Soulier syndrome (Option C) Glanzman thrombasthenia (Both qualitative) Normal Elevated Normal Normal HUS/TTP (Option A) Low Elevated Normal Normal vWD Normal Elevated Normal Elevated DIC Low Elevated Elevated Elevated Hemophilia A (Option B) Hemophilia B Normal Normal Normal Elevated ITP Low Elevated Normal Normal

References:

Robbins and Cotran, Pathological Basis of Disease, 10th Edition, Page 665, 668, 669, 670

↑ *Back to this question in Part A*

@Neet_pg_bot

Q10: A 35-year-old mother underwent a C-section. On post-op day 1, she complains of shortness of breath and bleeding from catheter sites. Her vitals are unstable. Which of the following statements is false concerning her condition? (Q845963)

A. PT, and APTT are normal.

B. AMLM3 is associated with DIC

C. FDP & D-dimer levels are elevated

D. Meningococcemia is associated with DIC

Correct Answer: A. PT, and APTT are normal.

Explanation: This 35-year-old mother just delivered one day ago and is now having symptoms of Disseminated intravascular coagulation (DIC) . DIC is classified as an acute, subacute, or chronic thrombo-hemorrhagic illness characterized by excessive coagulation activation and microvascular thrombi formation. Common causes include sepsis, significant trauma, malignant neoplasms, and complications during pregnancy. Acute promyelocytic leukemia (AML M3) and adenocarcinomas of the stomach, colon, pancreas, and lung are frequently associated with DIC. (Option B) DIC is triggered by two main mechanisms: Extensive endothelial cell damage and Release of tissue factor or other procoagulants into the bloodstream. Additionally, widespread endothelial damage can

result from the deposition of antigen-antibody complexes, extremes in temperature, or infections like meningococci and rickettsiae (Option D). Signs and symptoms of DIC may include hemorrhage due to depleted hemostatic components, tissue hypoxia, and infarction due to microthrombi, or both. Diagnosis: ↓ platelet count, ↓ fibrinogen levels; ↑ PT, ↑ aPTT, and ↑ fibrin breakdown products, especially D-dimers (Option C).

References:

Robbins and Cotran, Pathological Basis of Disease, 10th Edition, Page 669.

↑ *Back to this question in Part A*

@Neet_pg_bot

Q11: A 4-year-old child is brought to the emergency department with a history of bloody diarrhea followed by pallor, fatigue, and reduced urine output. Laboratory investigations reveal anemia, thrombocytopenia, and elevated serum creatinine. A peripheral blood smear is done and is given below. What is the most likely cause of this child's diarrhea? (Q845962)

A. O157:H7

B. Defect in ADAM-TS 13

C. Mutation in TGF-beta

D. Prosthetic valves

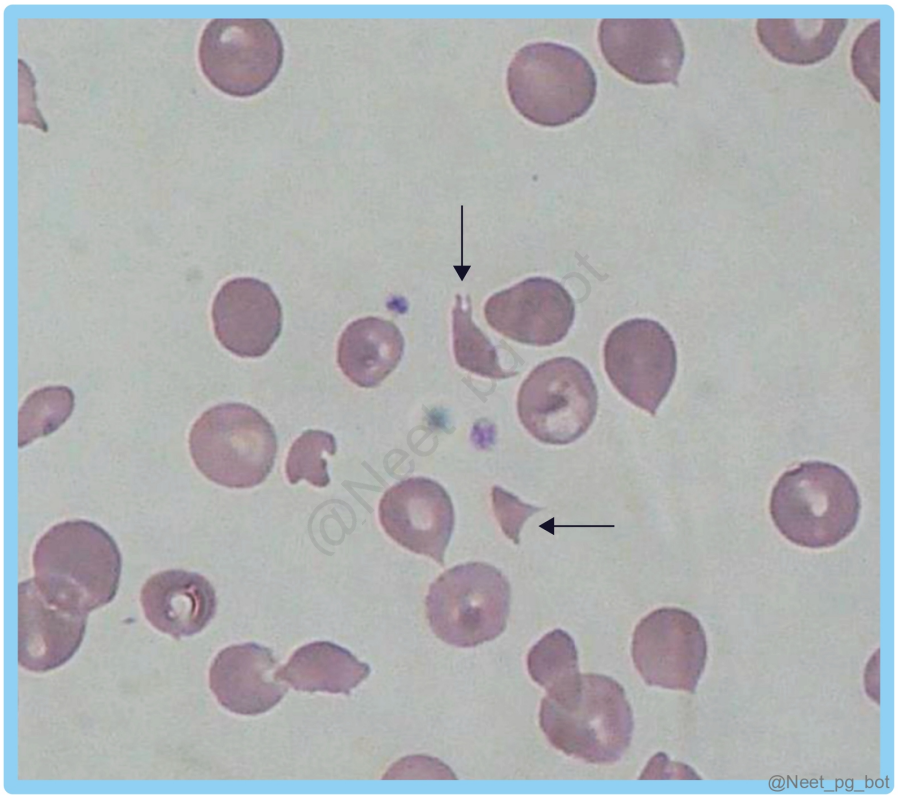

Correct Answer: A. O157:H7

- *Listen (English)*
- *Listen (Hindi)*

Explanation: This child with symptoms of bloody diarrhea followed by symptoms of renal failure, anemia, and thrombocytopenia has Hemolytic Uremic Syndrome (HUS) Types of HUS and its risk factors: Both types of HUS lead to endothelial injury, resulting in thrombus formation. The characteristic features include renal involvement, hemolytic anemia with schistocytes, thrombocytopenia, and elevated bleeding time. Defect in ADAM-TS 13 (Option B): A defect in ADAM TS 13 (breaks multimers of VWF) is seen in Thrombotic Thrombocytopenic Purpura (TTP). It usually presents as a pentad of fever, thrombocytopenia, microangiopathic hemolytic anemia, temporary neurologic impairments, and renal failure. Mutation in TGF-beta (Option C): .Osler-Weber-Rendu syndrome also known as hereditary hemorrhagic telangiectasia(HHT) is an autosomal dominant disorder characterized by multiple AV malformations in viscera and mucocutaneous structures such as the lips,tongue,buccal mucosa and fingertips. Prosthetic valves (Option D): Prosthetic heart valves can cause macroangiopathic hemolytic anemia due to mechanical stress, where red blood cells fracture from increased blood flow around the valve. The spleen removes damaged cells that do not hemolyse in circulation through extravascular hemolysis. However, this is not a specific risk factor for HUS.

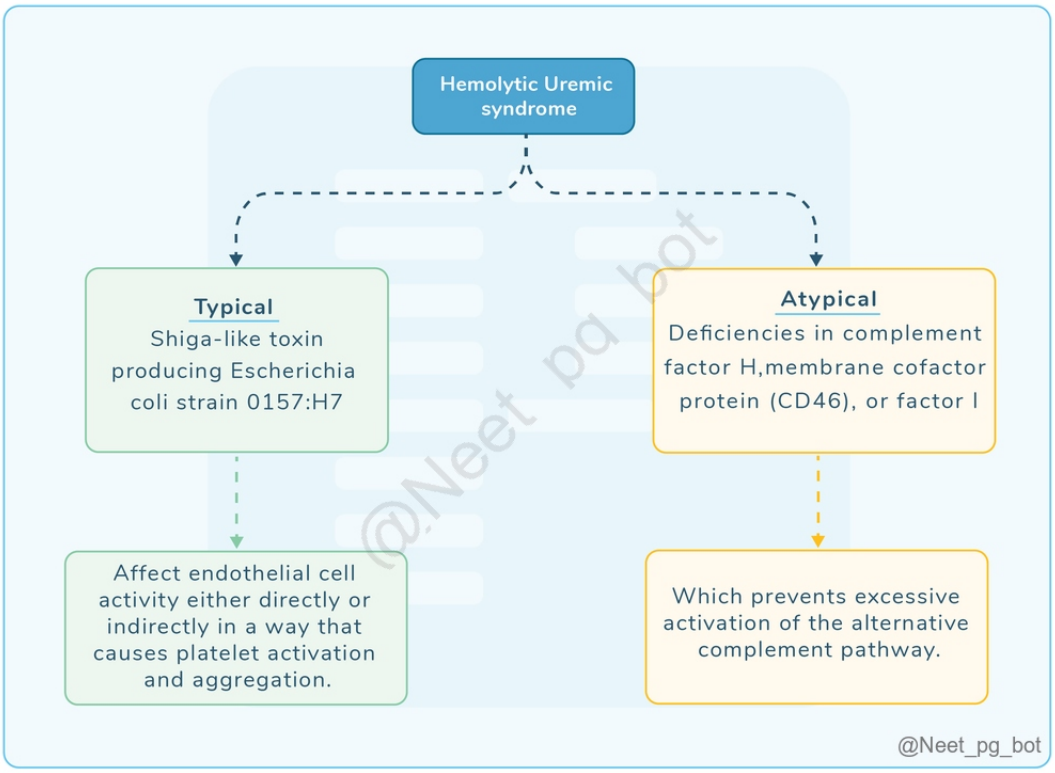

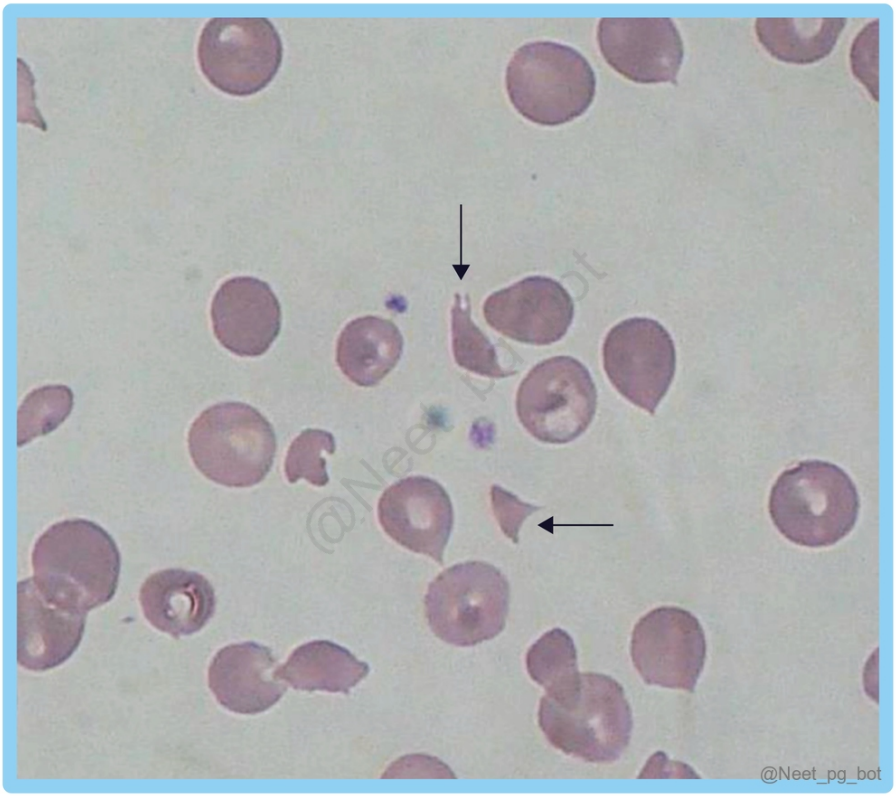

References:

Robbins and Cotran, Pathological Basis of Disease, 10th Edition, Page 665

↑ *Back to this question in Part A*

@Neet_pg_bot

Q12: A 5-year-old boy is brought to the clinic with recurrent episodes of spontaneous bleeding into his joints. Laboratory tests reveal a prolonged activated partial thromboplastin time (aPTT) and reduced factor VIII levels. Based on these findings, what is the most likely diagnosis? (Q845961)

A. Hemophilia A

B. Hemophilia B

C. Hemophilia C

D. Pseudohemophilia

Correct Answer: A. Hemophilia A

Explanation: This 5-year-old boy has Hemophilia A, caused by a factor VIII deficiency. Factor VIII is a necessary cofactor for factor IX in the coagulation cascade. Hemophilia is an X-linked recessive disorder. Hence, only males are affected. Aspect Hemophilia A (Option A) Hemophilia B (option B) Deficient factor Factor 8 deficiency Factor 9 deficiency Pathway affected in the cascade Intrinsic pathway defect APTT Elevated BT, PT, and TT Normal Treatment Cryoprecipitate, Recombinant factor 8 (Humate) Fresh frozen plasma (FFP) Hemophilia C (Option C): Hemophilia C is due to factor 11 deficiency, an autosomal recessive condition. Bleeding episodes are generally milder than in Hemophilia A and B, and hemarthrosis is rare. Pseudohemophilia (Option D): Pseudohemophilia, also termed von Willebrand disease (vWD), involves a deficiency or dysfunction of von Willebrand factor (vWF), crucial for platelet adhesion and factor VIII stabilization. Symptoms include prolonged aPTT and bleeding due to impaired platelet function and reduced facto

References:

Robbins and Cotran, Pathological Basis of Disease, 10th Edition, Page 668, 669

↑ *Back to this question in Part A*

@Neet_pg_bot

Q13: A 58-year-old woman presents with fatigue, early satiety, and left upper quadrant mass. Lab investigation reveals anemia and thrombocytopenia. Blood smear shows teardrop-shaped RBCs and nucleated RBCs. Bone marrow biopsy confirms myelofibrosis. Which megakaryocyte defect is characteristic in this condition?

(Q845949)

A. Dwarf Megakaryocyte

B. Staghorn megakaryocyte

C. Pawn ball megakaryocyte

D. Cloud-like megakaryocyte

Correct Answer: D. Cloud-like megakaryocyte

■ *Listen (English)*

■ *Listen (Hindi)*

Explanation: In myelofibrosis, cloud-like megakaryocytes are present, characterized by normal-sized megakaryocytes arranged in dense clusters, exhibiting small cytoplasm and hypolobated cloud-like nuclei. Megakaryocyte defect Description Seen in Dwarf Megakaryocyte/ Micromegakaryocyte (Option A) Small megakaryocytes with hypolobated nuclei Chronic myeloid leukemia (CML) Staghorn megakaryocyte (Option B) Large in size with hyperlobated staghorn-shaped nuclei, and abundant cytoplasm Essential thrombocytopenia Pawn ball megakaryocyte (Option C) Megakaryocytes with multiple dispersed nuclei Myelodysplastic syndrome (MDS) Cloud-like megakaryocyte (Option D) Normal-sized megakaryocytes with small cytoplasm and hyperchromatic, hypolobated cloud-like nuclei Myelofibrosis

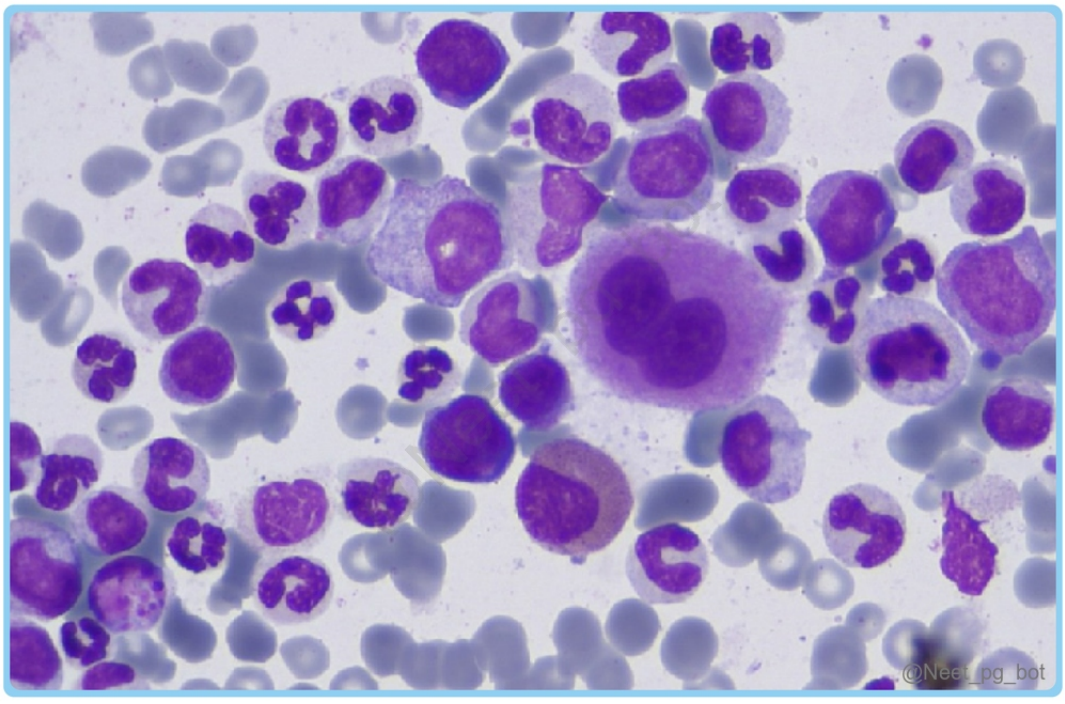

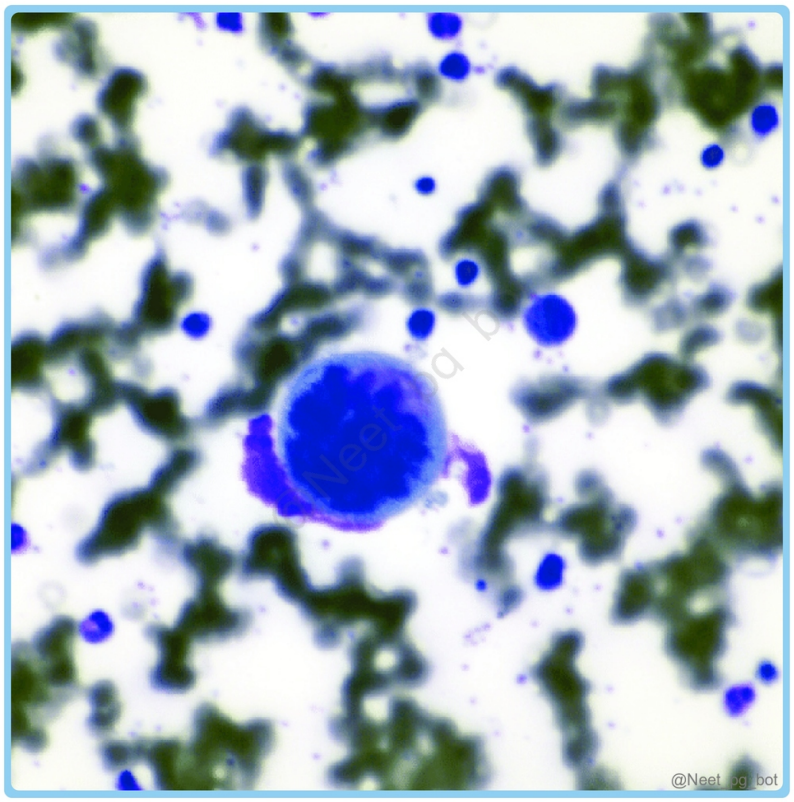
@Neet_pg_bot

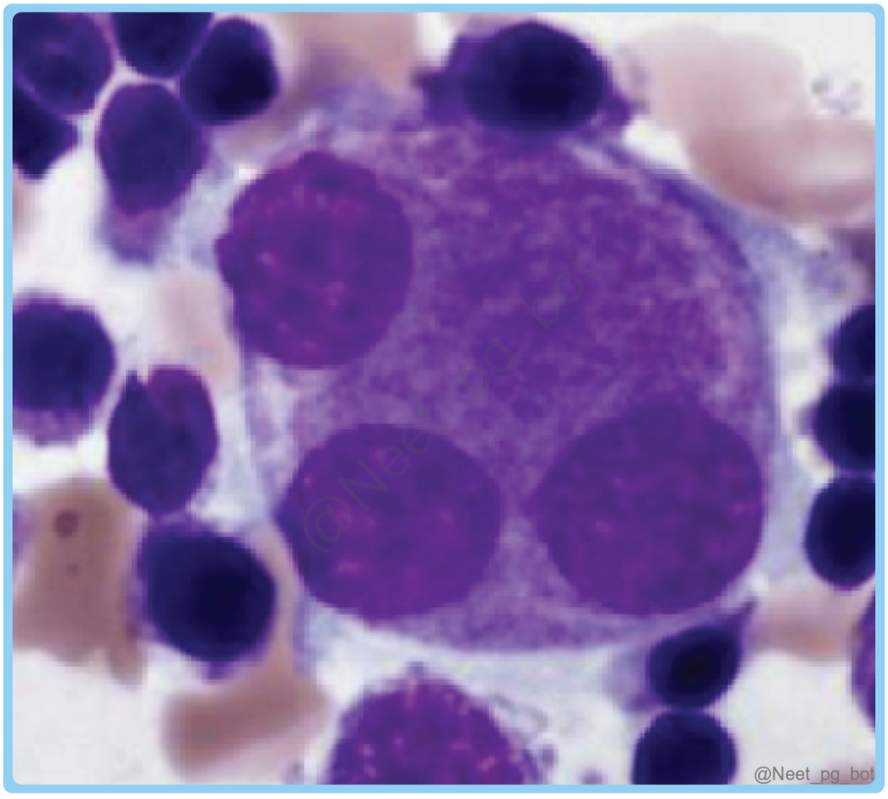
@Neet_pg_bot

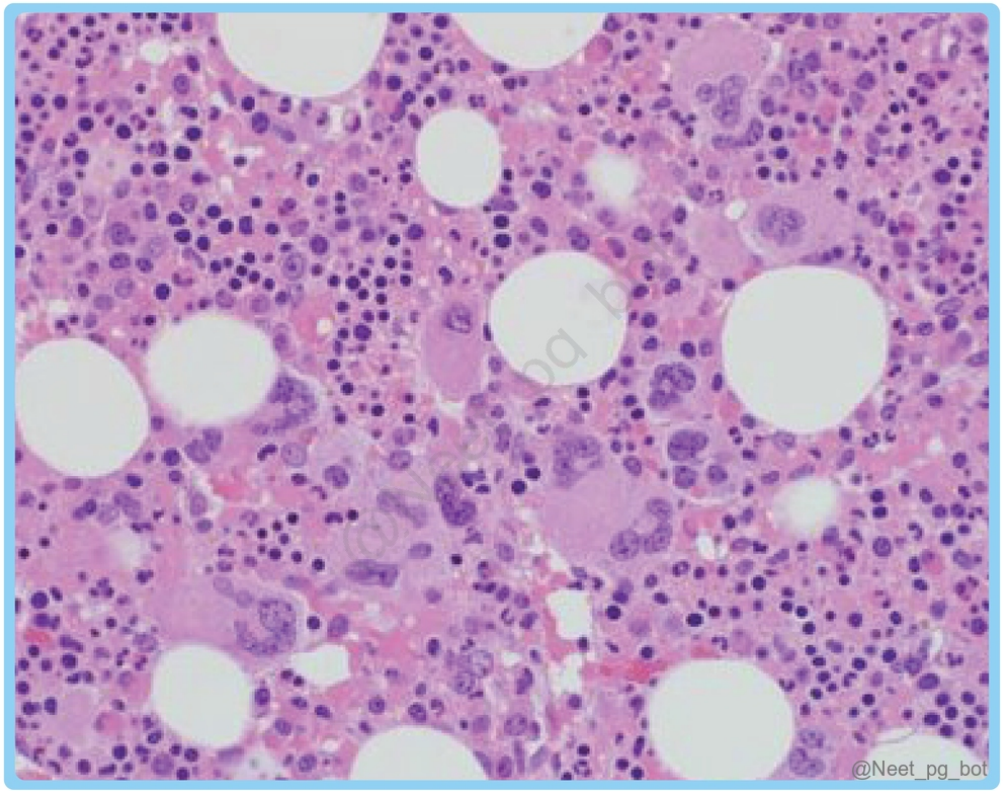

References:

Robbins and Cotran Pathological Basis of Disease, 10th Edition, Page 626. Megakaryocyte

↑ *Back to this question in Part A*

@Neet_pg_bot

Q14: Match the defect with the corresponding syndrome: Defect Syndrome 1. Gp1b/9 a. Hermanski pudlak syndrome 2. Alpha granules b. Bernard Soulier syndrome 3. Delta granules c. Glanzmann thrombasthenia 4. Gp2b/3a d. Gray platelet syndrome (Q845959)

A. 1-c, 2-a, 3-b, 4-b

B. 1-d, 2-c, 3-a, 4-b

C. 1-b, 2-a, 3-d, 4-c

D. 1-b, 2-d, 3-a, 4-c

Correct Answer: D. 1-b, 2-d, 3-a, 4-c

■ *Listen (English)*

■ *Listen (Hindi)*

Explanation: Defect Syndrome Gp1b/9 Bernard Soulier syndrome (shows big-sized platelets) Von Willebrand factor Von Willebrand disease Alpha granules Gray platelet syndrome (aged platelets) Delta granules Hermansky-Pudlak syndrome Gp2b/3a Glanzmann thrombasthenia Fibrinogen Afibrinogenemia

References:

Robbins and Cotran, Pathological Basis of Disease, 10th Edition, Page 120.

Hemansky-pudlak syndrome

Gray platelet syndrome

↑ *Back to this question in Part A*

@Neet_pg_bot

Q15: A 34-year-old man comes to the physician complaining of occasional dizziness and palpitations in crowded spaces. He is an executive who travels frequently and reports high-stress levels at work. Labs: Hb= 14.0 Platelets = 80,000 Leukocytes = 7,200 RBCs= 5 million Peripheral smear shows a reduced platelet count without clumping or malignant cells. Which of the following is the most appropriate next test for this patient? (Q845958)

A. EBV virus titers

B. Rapid plasma reagin test

C. Schilling test

D. HIV antibody test

Correct Answer: D. HIV antibody test

Explanation: Isolated thrombocytopenia without anemia or leukopenia suggests Immune Thrombocytopenic Purpura (ITP), diagnosed after excluding other causes. Thrombocytopenia may occur in chronic HIV infection; thus, HIV and hepatitis C testing are essential. ITP is a diagnosis of exclusion, requiring exclusion of other causes of thrombocytopenia. Pathogenesis: Autoantibodies (usually IgG) are formed against platelet membrane glycoproteins GpIIb/IIIa or GpIb/IX . Antibody-coated platelets are destroyed in the spleen → thrombocytopenia, increased megakaryocytes in marrow → large platelets in smear . Features Acute ITP Chronic ITP Age Child Adult (<40 yrs) Common in M=F Females Etiology Often follows viral infections Can be primary (idiopathic) or secondary to SLE, HIV, CLL Laboratory Findings Isolated thrombocytopenia (<20,000/μL), normal PT and aPTT, ↑BT Isolated thrombocytopenia (30,000-80,000/μL), normal PT and aPTT, ↑BT; Hypercellular marrow with megakaryocytic hyperplasia; Megathrombocytes in peripheral blood Autoantibodies IgG (short-lived and often

transient) IgG (persistent) Resolution Normal within 6 months > 6 months Treatment Often self-limited Steroids. Splenectomy in refractory cases. EBV virus titers (Option A) titers are useful for diagnosing infectious mononucleosis. Patients with infectious mononucleosis usually present with fatigue, sore throat, fever, palatal petechiae, posterior cervical lymphadenopathy, and splenomegaly. Labs show lymphocytosis and possible thrombocytopenia. This patient does not have findings of infectious mononucleosis. Rapid plasma reagin test (Option B) is a non-treponemal antigen test used to screen for syphilis. However, syphilis is not associated with thrombocytopenia. Schilling test (Option C) determines if vitamin B12 deficiency is due to pernicious anemia or a malabsorption syndrome. It is not used to diagnose ITP.

References:

Robbins and Cotran, Pathological Basis of Disease, 10th Edition, Page 664

↑ *Back to this question in Part A*

@Neet_pg_bot

Q16: A 14-year-old adolescent presents with recurrent episodes of unexplained swelling and pain following minor injuries or physical activity. Upon examination, there are signs of localized swelling and tenderness. Lab investigations reveal normal platelet counts and bleeding time, but clotting times are prolonged. Which symptom would strongly suggest a coagulation defect in this patient? (Q845957)

A. Petechiae

B. Purpura

C. Ecchymosis

D. Hemarthrosis

Correct Answer: D. Hemarthrosis

Explanation: Coagulation factor abnormalities, or defects in secondary hemostasis, may manifest as bleeding into soft tissues like muscles or joints. Hemarthrosis, characterized by bleeding into joints following minor trauma, is a specific feature associated with hemophilia. Clinical manifestation Platelet disorders Coagulation disorders Bleeding site Mucous membranes Muscles and joints Presentation Superficial bleeds like Petechia , purpura, mucosal bleeds; multiple sites Deep tissue bleeds like Hematoma , intracranial bleeds (most dangerous) , joint bleeds/ hemarthroses (most common); localized Bleeding onset Prolonged bleeding from cuts May be delayed at onset Family history Rare Common Treatment response Immediately Insidious Petechiae(Option A): Petechiae (minute 1 to 2-mm hemorrhages) arise due to a defect in platelet function. They occur as pinpoint hemorrhages in the dependent areas where the capillary pressure is higher. Purpura (Option B): Purpura are slightly larger than petechiae (>3 mm) and can be palpable. They are often seen in conditions like Henoch-Schonlein purpura. Ecchymoses(Option C): Ecchymoses, or bruises, are 1 to 2-cm hemorrhages. The volume of blood that has been extravasated in purpura and ecchymoses may be sufficient to form a palpable mass of blood called a hematoma.

References:

Robbins and Cotran, Pathological Basis of Disease, 10th Edition, Page 125.

↑ *Back to this question in Part A*

@Neet_pg_bot

Q17: A 22-year-old woman presents to the clinic with a history of frequent nosebleeds and heavy menstrual periods. She reports prolonged bleeding after minor cuts and has noticed easy bruising. On physical examination, multiple small bruises are on her arms and legs. Which of the following tests is most likely to be abnormal? (Q845956)

A. Bleeding Time (BT)

B. Clotting Time (CT)

C. Prothrombin Time (PT)

D. Activated Partial Thromboplastin Time (aPTT)

Correct Answer: A. Bleeding Time (BT)

Explanation: Based on the clinical presentation, the most likely diagnosis is von Willebrand Disease (vWD) , which is the most common inherited bleeding disorder. The patient's symptoms like mucocutaneous bleeding (nosebleeds, heavy periods, easy bruising) and prolonged bleeding after minor cuts, point toward a defect in primary hemostasis (platelet plug formation) rather than the coagulation cascade. Symptoms: Epistaxis, menorrhagia, and easy bruising are classic signs of platelet or vessel wall dysfunction. Pathophysiology: In vWD, there is a deficiency or dysfunction of von Willebrand Factor (vWF). vWF is essential for: Platelet Adhesion: It acts as a bridge between platelets and the damaged subendothelium. Factor VIII Stabilization: It protects Factor VIII from rapid degradation in the blood. Bleeding Time (BT): Prolonged when platelet number or function is reduced → best screening test for primary hemostasis defect. Clotting Time (CT) (Option B) : Measures overall clot formation (intrinsic + extrinsic); normal in isolated platelet defects. Normal CT: 8-15 mins. Prothrombin Time (PT) (Option C): Prolonged only in extrinsic pathway disorders (factor VII deficiency, warfarin therapy). Normal PT: 11-16 secs. Activated Partial Thromboplastin Time (aPTT) (Option D): Prolonged in intrinsic pathway defects (hemophilia A/B, heparin therapy). Normal aPTT: 25-30 secs.

References:

Robbins and Cotran, Pathological Basis of Disease, 10th Edition, Page 663

www.ncbi.nlm.nih.gov/books/NBK265/

↑ *Back to this question in Part A*

@Neet_pg_bot

Q18: A 2-week-old male infant is brought to the pediatrician by his parents because of prolonged bleeding from the umbilical stump. The parents report that the bleeding started soon after the umbilical cord fell off and has not stopped despite applying pressure. Laboratory tests show normal Prothrombin Time (PT), Activated Partial Thromboplastin Time (aPTT), and platelet count. Which of the following deficiencies is most likely causing the prolonged bleeding? (Q845955)

A. Factor VIII

B. Factor XIII

C. Factor IV

D. Factor IX

Correct Answer: B. Factor XIII

Explanation: Factor XIII is crucial for maintaining clot stability and promoting fibrin polymer cross-linking, ensuring effective hemostasis. Its deficiency can lead to prolonged bleeding from the umbilical stump in neonates, as seen in this case. Other symptoms include severe menstrual bleeding, hemarthrosis, repeated early pregnancy loss, and delayed postoperative bleeding. Unlike other factors, Factor XIII deficiency does not affect BT, CT, PT, aPTT, or platelet count. Diagnosis is confirmed with a urea clot solubility test, in which the clot dissolves if Factor XIII is deficient. Factor VIII deficiency (Option A): Hemophilia A, or Factor VIII deficiency is an X-linked disorder, characterized by elevated aPTT and causes deep tissue and joint bleeding. Von Willebrand factor (vWF) protects Factor VIII from degradation, and its deficiency can lead to reduced Factor VIII levels, resulting in a condition called pseudohemophilia. Factor IV deficiency (Option C): Factor IV (calcium) is essential for the coagulation cascade, activating Factor X in intrinsic and extrinsic pathways. However, calcium deficiency is extremely rare and not associated with umbilical stump bleeding; it typically causes widespread bleeding. Factor IX deficiency (Option D): Factor IX deficiency (Hemophilia B or Christmas disease) is an X-linked recessive disorder affecting the intrinsic pathway, causing elevated aPTT with normal PT. Like Hemophilia A, it primarily leads to deep tissue and joint bleeding.

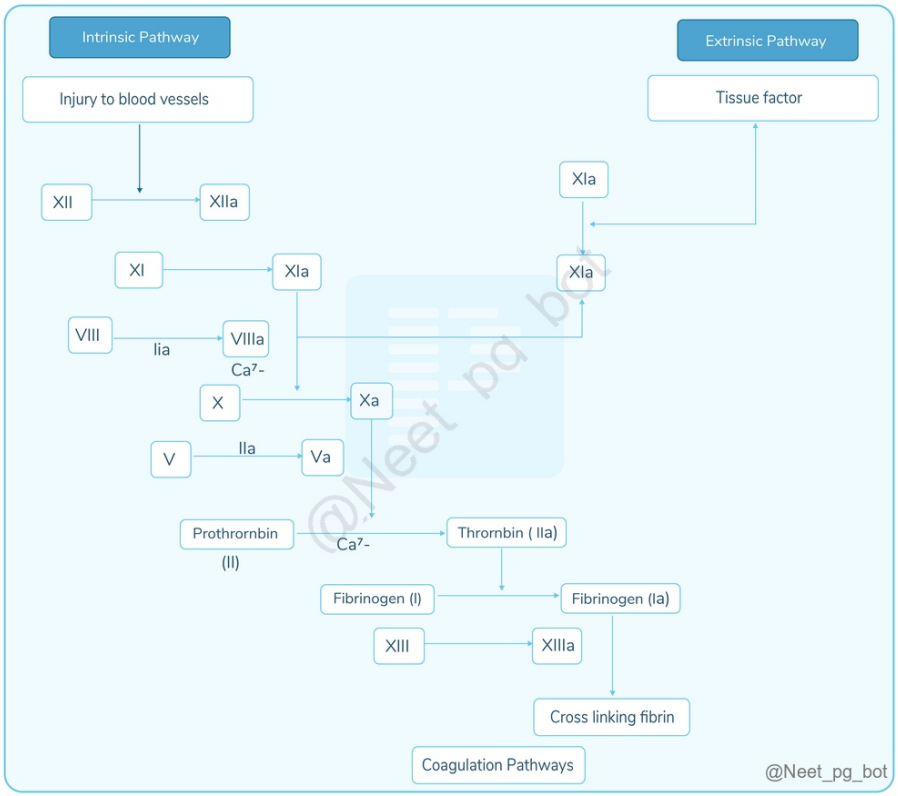

References:

Robbins and Cotran, Pathological Basis of Disease, 10th Edition, Page 667-669

www.ncbi.nlm.nih.gov/books/NBK557467/

↑ *Back to this question in Part A*

@Neet_pg_bot

Q19: A 30-year-old woman presents with excessive bleeding following a tooth extraction. She reports a history of recurrent nosebleeds and easy bruising since childhood. Lab tests show prolonged activated partial thromboplastin time (aPTT) and normal prothrombin time (PT). Further testing reveals decreased levels of a clotting factor's activity. Which of the following is not an intrinsic factor? (Q845954)

A. Factor XII

B. Factor VII

C. Factor XI

D. Factor IX

Correct Answer: B. Factor VII

Explanation: Factor VII is an extrinsic factor. Clotting cascade: Extrinsic factors Intrinsic factors Common pathway factors 3 (tissue factor), 7 12, 11, 9 (Options A, C , D), 8 10, 5, 2, 1, 13

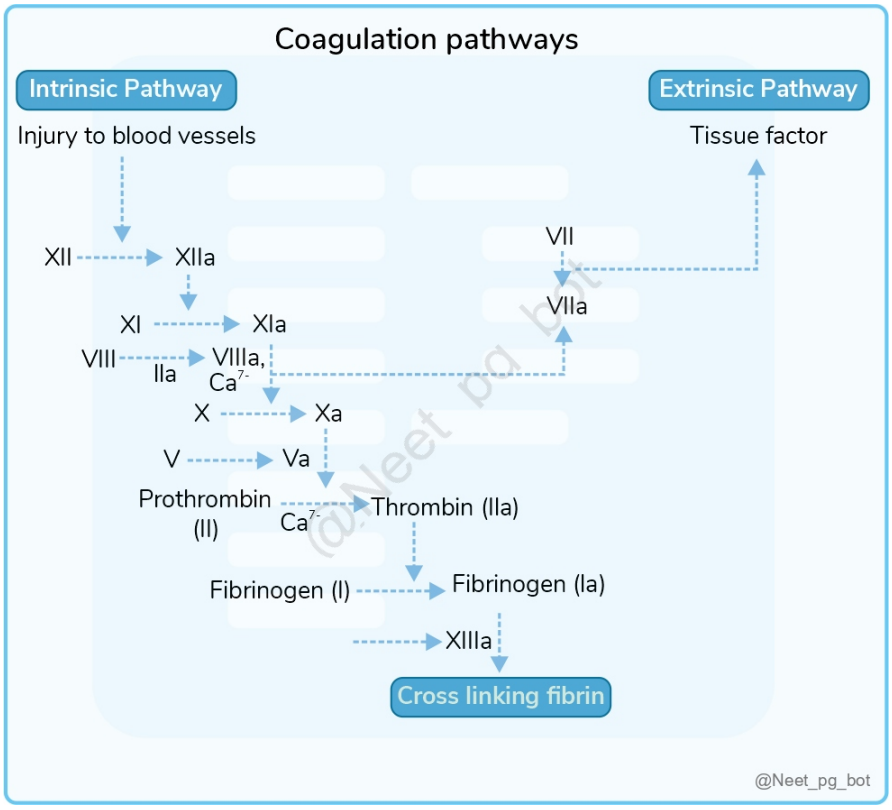

References:

Robbins and Cotran, Pathological Basis of Disease, 10th Edition, Page 121

↑ *Back to this question in Part A*

@Neet_pg_bot

Q20: A 55-year-old male patient presents with a history of recurrent episodes of uncontrolled bleeding from minor injuries and easy bruising. Lab investigations reveal prolonged prothrombin time (PT) and activated partial thromboplastin time (aPTT). Considering a potential vitamin K deficiency, which specific clotting factors should be evaluated to confirm the diagnosis in this patient? (Q845953)

A. Tissue thromboplastinLabile factor

B. Labile factor

C. Hageman factor

D. Stable factor

Correct Answer: D. Stable factor

Explanation: In the context of a potential vitamin K deficiency, clotting factors synthesized in the liver and dependent on vitamin K should be evaluated. Factors II (Prothrombin), VII (Stable factor), IX (Christmas factor), X (Stuart-Prower factor), and Protein C depend on vitamin K for synthesis in the liver. Vitamin K deficiency leads to reduced carboxylation of glutamate residues on clotting factors impairing blood clotting. Factors III (Tissue thromboplastin), V (Labile factor), and XII (Hageman factor) are not vitamin K-dependent factors (Options A, B, and C)

References:

Robbins and Cotran, Pathological Basis of Disease, 10th Edition, Page 122.

↑ *Back to this question in Part A*

@Neet_pg_bot

Q21: A 32-year-old woman presents with easy bruising, heavy menstrual bleeding, and prolonged bleeding after cuts and dental extraction. Lab tests show normal platelet counts but impaired platelet function. Which of the following substances, primarily released from alpha granules, might be deficient in this patient's platelets? (Q845952)

A. Serotonin

B. Epinephrine

C. ADP

D. P-selectin

Correct Answer: D. P-selectin

Explanation: P-selectin, primarily released from platelet alpha granules, plays a crucial role in platelet aggregation and adhesion. Its deficiency leads to easy bruising and prolonged bleeding. Alpha and delta granules in platelets and their contents: Alpha granules Delta/Dense granules P- selectin (Option D) PF4 (platelet factor 4) PDGF (platelet-derived growth factor) Factor V, VIII Fibrinogen (Mnemonic: all P things and all Factors) ADP (Option C) ATP Serotonin (Option A) Serum calcium Epinephrine (Option B)

References:

www.ncbi.nlm.nih.gov/pmc/articles/PMC2720568/

www.sciencedirect.com/topics/medicine-and-dentistry/dense-granule

www.ncbi.nlm.nih.gov/pmc/articles/PMC4452143/

↑ *Back to this question in Part A*

@Neet_pg_bot

Q22: A 22 y/o woman arrives at the clinic complaining of heavy menstrual flow and recurrent nosebleeds. Upon physical inspection, her arms and legs have several minor bruises. Coagulation studies show high BT, APTT, and normal PT. She is diagnosed with von Willibrand disease. Which type of vWD shows a decrease in binding between VWF and Gp 1b/9? (Q845951)

A. Type 1

B. Type 2a

C. Type 2b

D. Type 3

Correct Answer: B. Type 2a

Explanation: Von Willebrand disease is the most common inherited bleeding disorder. Clinically and molecularly, von Willebrand disease is heterogeneous, below are 3 identified kinds, each with a variety of phenotypes; vWD type 1 (Option A) vWD Type 2 vWD Type 3 (Option D) Autosomal dominant. The most common type. Mild to moderate vWF deficiency. Quantitative defect. point substitutions prevent the vWF protein from maturing or cause it to leave the plasma quickly Autosomal dominant. Qualitative defect. Types: 2A, 2B, 2M, 2N 2A (Most common) - Decrease in binding between vWF and Gp1b/9 (Option B) missense mutations cause faulty multimer formation → the most active forms of vWF, i.e. large- and intermediate-sized multimers are absent. 2B - Increase in binding between vWF and Gp1b/9 (Option C) 2M - VWF dependant platelet adhesion is decreased. There is impairment of VWF binding to platelets. Type 2M VWD typically has mild to moderate mucocutaneous bleeding 2N - There is marked decline in the binding affinity for factor VIII. The level of factor VIII is lower when compared to the VWF:Ag. This led to misdiagnosis as haemophilia A Autosomal recessive . Quantitative defect. produced by frameshift mutations or deletions affecting both alleles (autosomal recessive), which produce little or no vWF. Factor VIII levels are also lowered because vWF stabilizes factor VIII in the blood, and the resulting bleeding condition is severe.

References:

Robbins and Cotran, Pathological Basis of Disease, 10th Edition, Page 668

https://pmc.ncbi.nlm.nih.gov/articles/PMC3224412/

↑ *Back to this question in Part A*

Q23: A 30-year-old woman is diagnosed with von Willebrand Disease (vWD) after presenting with frequent nosebleeds and prolonged bleeding after minor cuts. Laboratory tests reveal a defect in the von Willebrand factor (vWF). Which of the following is also involved in the pathogenesis of this condition? (Q845950)

A. gp1b-IX

B. gpIIb-IIIa

C. Factor IX

D. Factor XIII

Correct Answer: A. gp1b-IX

■ *Listen to Audio 1*

Explanation: Gp1b-IX is a membrane complex in platelets that facilitates binding to the von Willebrand Factor, which is defective/deficient in von Willebrand disease. vWF is produced by endothelial cells (Weibel–Palade bodies) and megakaryocytes (α-granules of platelets). vWF stabilizes factor VIII in circulation, so its deficiency causes both platelet adhesion defect and a secondary factor VIII deficiency (hence bleeding resembles both platelet-type and hemophilia-like features). Defective platelet adhesion occurs because vWF mediates binding between platelets (GpIb receptor) and subendothelial collagen. gpIIb-IIIa (Option B): This glycoprotein complex is crucial for platelet aggregation, the final step in primary hemostasis. It binds fibrinogen and von Willebrand factor (vWF), aiding in the formation of platelet plugs. However, defects in gpIIb-IIIa are not associated with von Willebrand Disease (vWD). Factor IX (Option C): Factor IX (or Christmas factor) is a vitamin K-dependent clotting factor, part of the intrinsic clotting pathway. Factor IX deficiency is known as Hemophilia B, an X-linked recessive disorder. Factor XIII (Option D) stabilises fibrin by cross-linking and deficiency leads to severe bleeding.

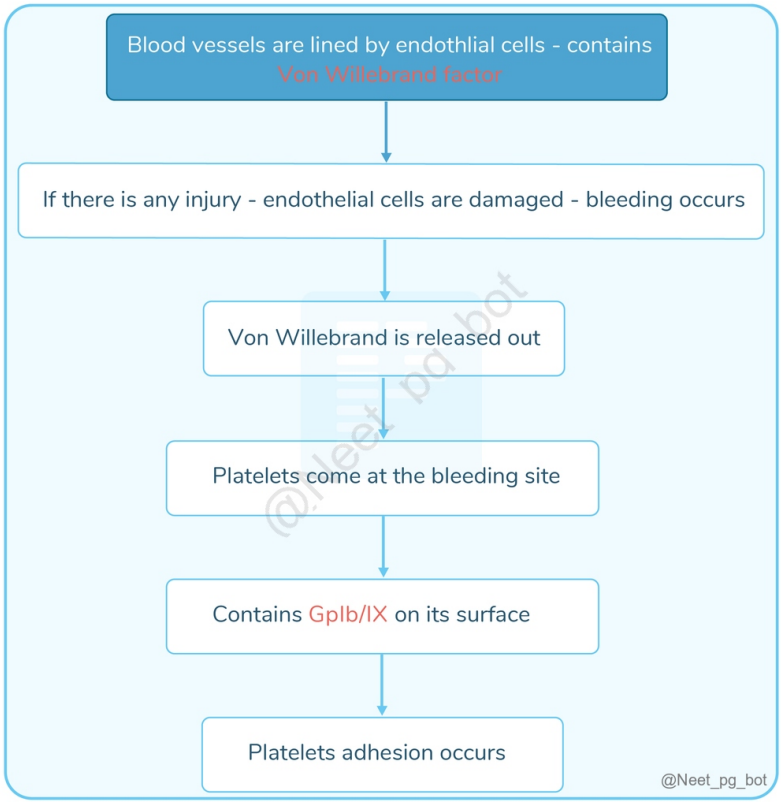

References:

Robbins and Cotran, Pathological Basis of Disease, 10th Edition, Page 668.

↑ *Back to this question in Part A*

@Neet_pg_bot

• [19_Platelet and Bleeding Disorders] 079 Previous Year Questions

« Back to Folder Directory

[19_Platelet and Bleeding Disorders] 079 Previous Year Questions — Quick Jump

Q1 (p. 3095)	*Q2 (p. 3096)*	*Q3 (p. 3097)*	*Q4 (p. 3100)*	*Q5 (p. 3104)*	*Q6 (p. 3107)*
Q7 (p. 3109)	*Q8 (p. 3110)*	*Q9 (p. 3111)*	*Q10 (p. 3111)*	*Q11 (p. 3112)*	*Q12 (p. 3112)*
Q13 (p. 3113)	*Q14 (p. 3114)*	*Q15 (p. 3115)*	*Q16 (p. 3116)*	*Q17 (p. 3116)*	*Q18 (p. 3119)*
Q19 (p. 3119)	*Q20 (p. 3121)*	*Q21 (p. 3122)*	*Q22 (p. 3123)*	*Q23 (p. 3123)*	*Q24 (p. 3124)*

Q1: A patient presents with a tingling sensation in both legs, polyuria, and weight loss. Based on the given bone marrow aspirate findings, what is the most likely diagnosis? (Q844224)

A. Multiple myeloma with renal failure

B. SACD with vitamin B12 deficiency

C. SACD with diabetes

D. Waldenstrom's Macroglobulinemia

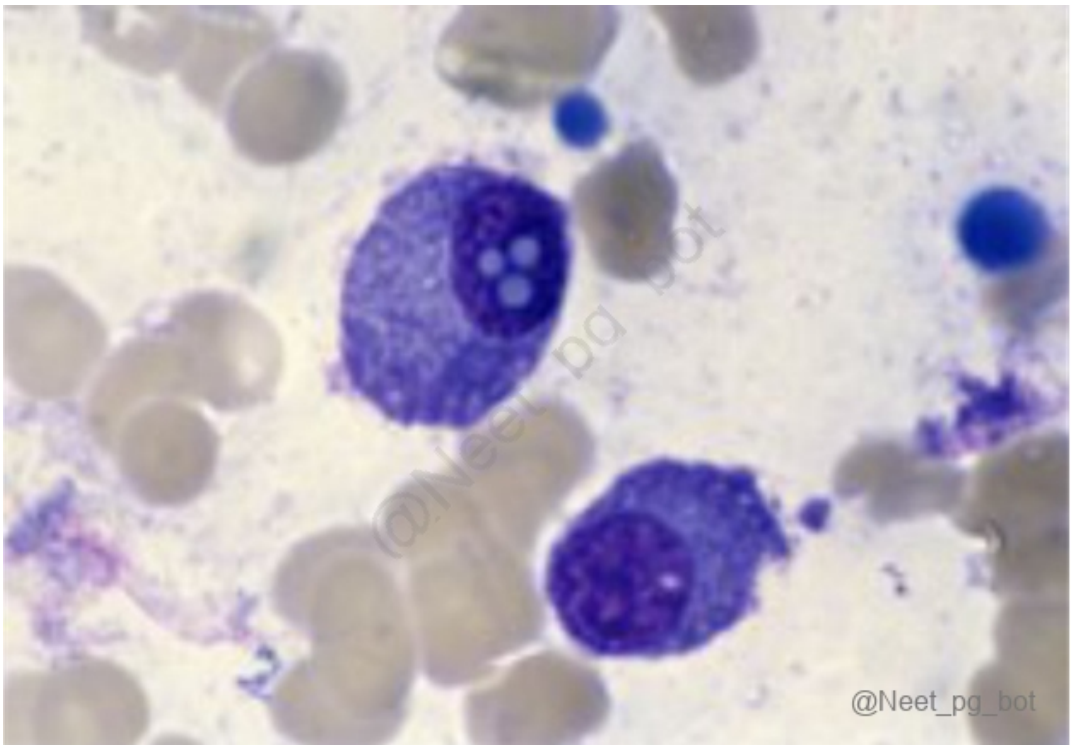

Correct Answer: A. Multiple myeloma with renal failure

Explanation: Correct Option A - Multiple myeloma with renal failure: The bone marrow aspirate shows intranuclear inclusions known as Dutcher's bodies, which are characteristic of multiple myeloma. Multiple myeloma often presents with renal failure, polyuria (due to hypercalcemia), and tingling sensations (due to amyloid deposition or hypercalcemia-related neuropathy). Incorrect Options: Options B, C, and D do not show Dutcher bodies on bone marrow biopsy.

References:

.

↑ *Back to this question in Part A*

@Neet_pg_bot

Q2: Most common cause of inherited coagulopathy is: (Q853370)

A. Factor V Leiden mutation

B. Antithrombin III deficiency

C. Protein C deficiency

D. Protein S deficiency

Correct Answer: A. Factor V Leiden mutation

Explanation: Factor V Leiden mutation is the most common cause of inherited coagulopathy among the given options. Hypercoagulability It refers to an increased tendency of the blood to clot, usually due to changes in coagulation factors. Types: Primary disorders (genetic) Secondary disorders (acquired) Among inherited causes, point mutations in the factor V and prothrombin genes are the most common. Primary disorders (Genetic) Secondary disorders (Acquired) Common Factor V mutation A single-nucleotide mutation (autosomal dominant inheritance) in the factor V gene makes factor V resistant to cleavage and inactivation by protein C. Prothrombin mutation A single nucleotide change (G20210A) in the 3′-untranslated region of the prothrombin gene is linked to hypercoagulability. Rare Antithrombin III deficiency (Option B) Protein C deficiency (Option C) Protein S deficiency (Option D) Very rare Fibrinolysis defects Homozygous homocystinuria (deficiency of cystathionine β-synthetase) Strong Risk Factors for Thrombosis Prolonged bed rest or immobilization Myocardial infarction Atrial fibrillation Tissue injury (surgery, fracture, burn) Cancer Prosthetic cardiac valves Disseminated intravascular coagulation Heparin-induced thrombocytopenia Antiphospholipid antibody syndrome Other Risk Factors for Thrombosis Cardiomyopathy Nephrotic syndrome Hyperestrogenic states (pregnancy and postpartum) Oral contraceptive use Sickle cell anemia Smoking

References:

Robbins & Cotran Pathologic Basis of Disease, 10th Edition, Page 126-127.

↑ *Back to this question in Part A*

@Neet_pg_bot

Q3: Which of the following diseases are correctly associated with their respective inclusion bodies? (Q853377)

A. Rabies - Lewy bodies

B. Parkinson’s disease - Dutcher bodies

C. Multiple myeloma - Negri bodies

D. Malakoplakia - Michaelis Gutmann bodies

Correct Answer: D. Malakoplakia - Michaelis Gutmann bodies

Explanation: Michaelis Gutmann bodies are seen in Malakoplakia. Disease Inclusion bodies Rabies Negri bodies are cytoplasmic, round to oval, eosinophilic inclusions found in pyramidal neurons of the hippocampus and Purkinje cells of the cerebellum , sites usually devoid of inflammation. Parkinson’s disease Lewy bodies These are single or multiple, cytoplasmic, eosinophilic, round to elongated inclusions that often have a dense core surrounded by a pale halo. They are composed of fine filaments, densely packed in the core but loose at the rim; these filaments are composed of α-synuclein. Multiple myeloma The globular inclusions are referred to as Russell bodies (if cytoplasmic) or Dutcher bodies (if nuclear). Malakoplakia Michaelis Gutmann bodies: Laminated mineralized concretions resulting from calcium deposition in enlarged lysosomes.

Negri bodies

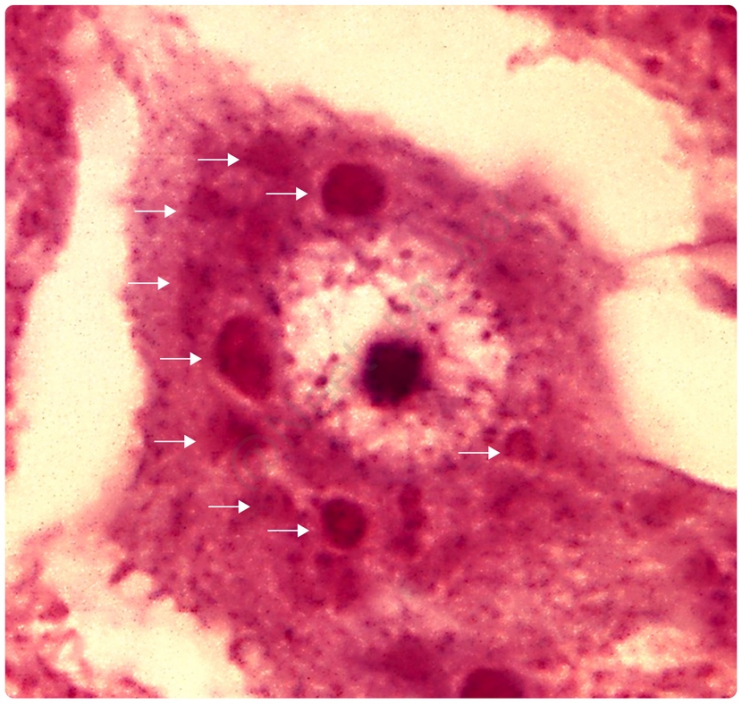

@Neet_pg_bot

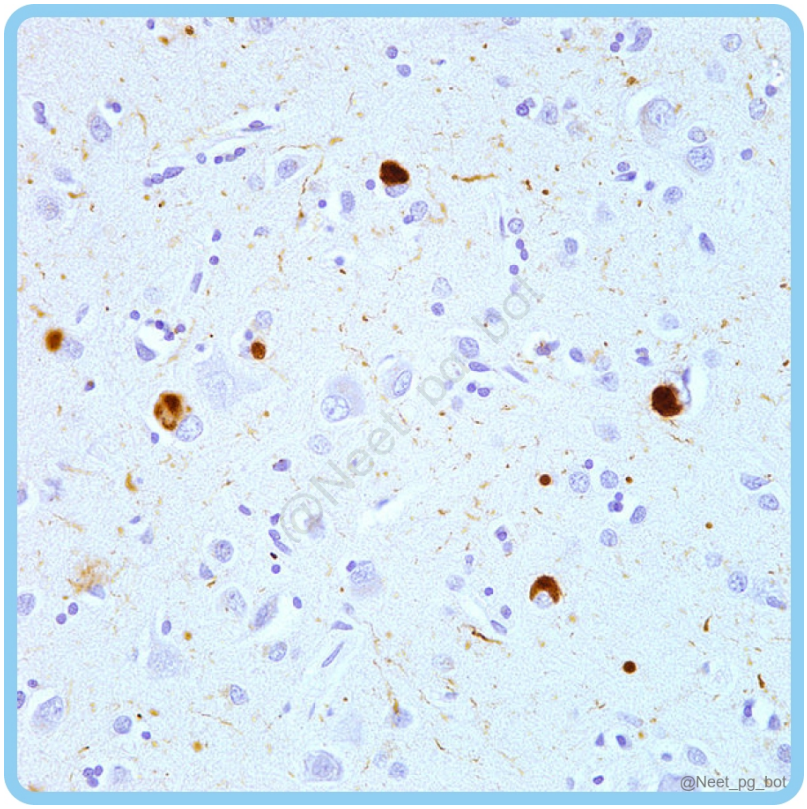

@Neet_pg_bot

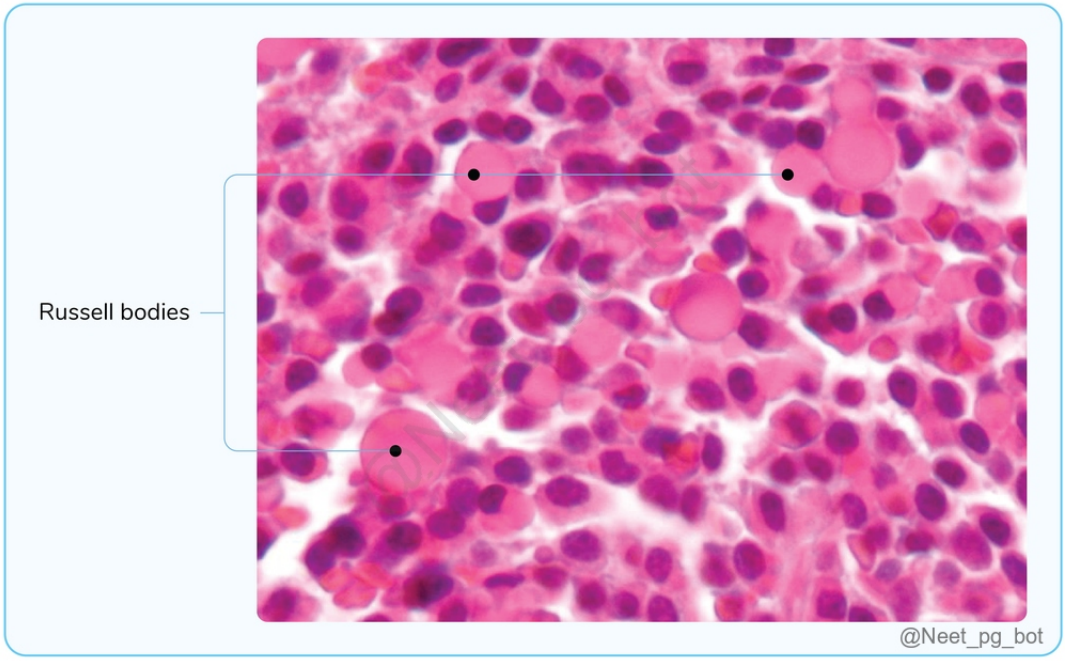
Russell bodies
@Neet_pg_bot

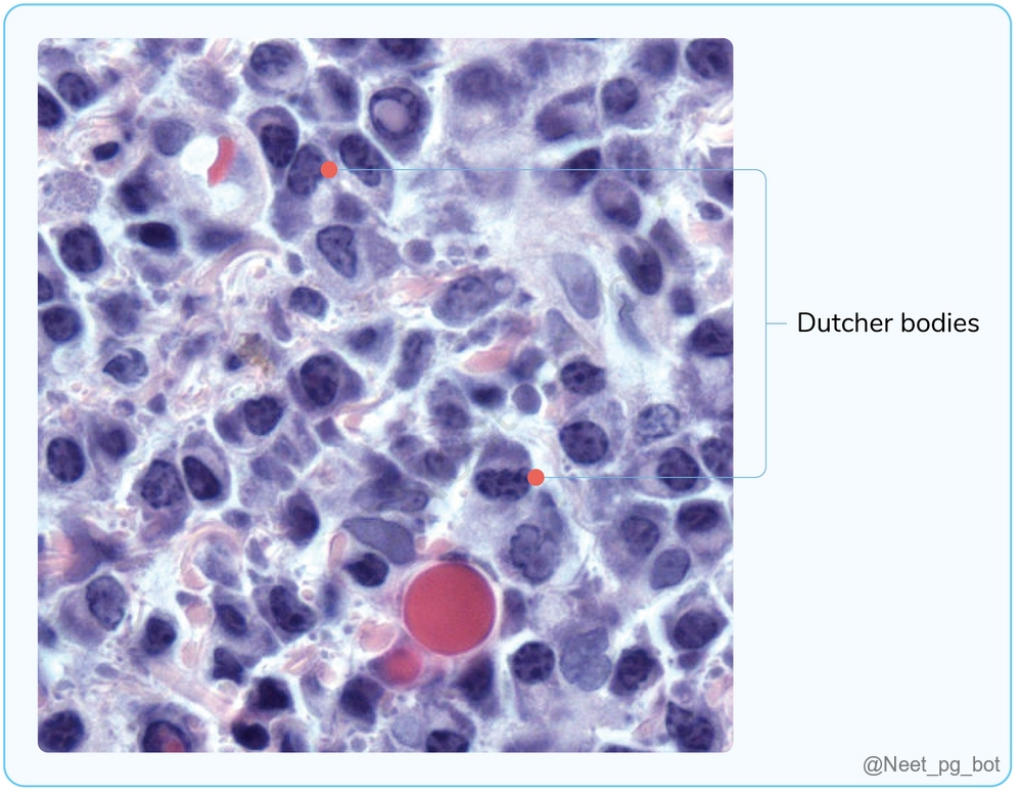
Dutcher bodies
@Neet_pg_bot

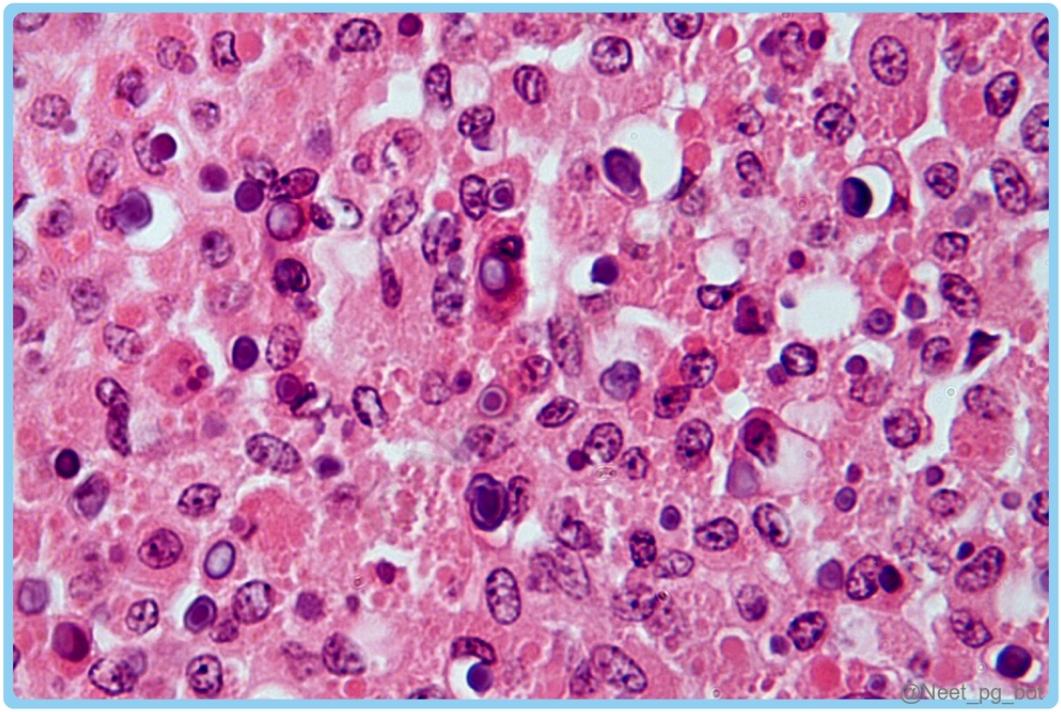

References:

Robbins and Cotran Pathological Basis of Diseases, 10th Edition, Page 607, 956, 1266, 1283.

↑ *Back to this question in Part A*

@Neet_pg_bot

Q4: Vacutainer used in serum electrolyte estimation: (Q853367)

A. Green

B. Lavender

C. Yellow

D. Grey

Correct Answer: A. Green

Explanation: The green-top vacutainer contains lithium heparin, which is routinely used for plasma electrolyte estimation because: Heparin prevents clotting without altering electrolyte levels. Plasma electrolytes remain stable and can be analyzed immediately. Types of Vacutainers Colour Anti-coagulants Uses Purple/Lavender (Option B ruled out) EDTA (Ca2+ chelating anticoagulant) CBC, Peripheral Smear, ESR, HbA1c. Light Blue Citrate (Ca2+ chelating anticoagulant) ESR, PT (Prothrombin Time), APTT (Activated Partial Thromboplastin Time), and INR

(International Normalized Ratio). Red No anti-coagulant is added. Serum studies (blood chemistry, serology, and blood bank testing). Yellow (Option C ruled out) Clot activator/Gel separator Serum tests, such as hormone tests, chemistry panels, and serological tests Grey (Option D ruled out) Sodium Fluoride Blood glucose. Green Heparin ABG, Osmotic fragility, flow cytometry, Serum electrolytes, immunophenotyping.

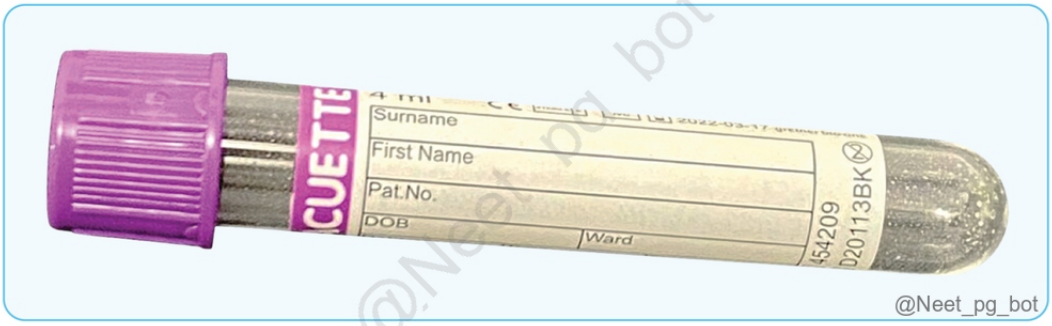




UETTE
6 ml
Surname
First Name
Pat.No.
56089
120101H


UETTE
5 ml
Surname
First Name
Pat.No.
2022-02-12
greiner bio-one
018
103BM



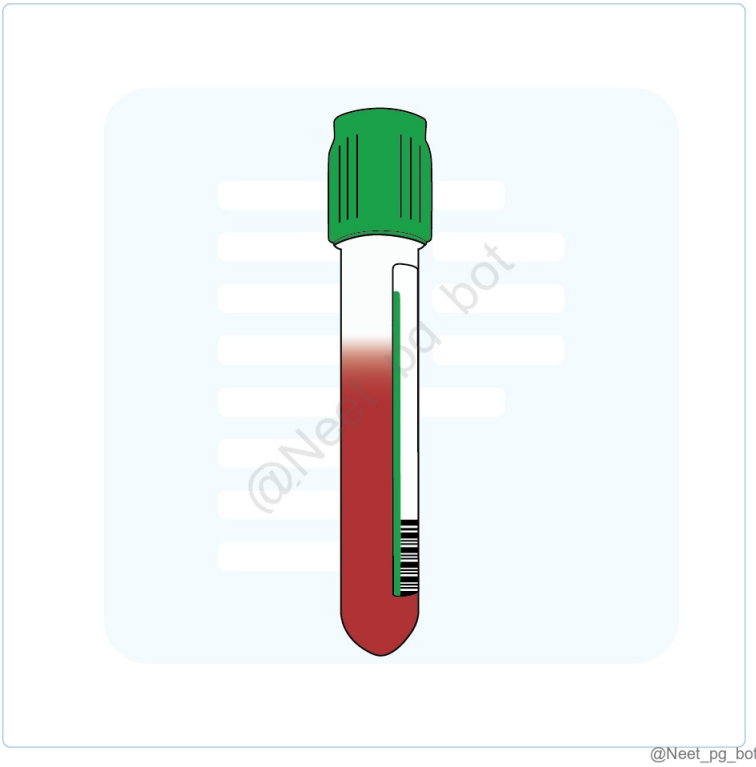

@Neet_pg_bot

References:

Atlas of Clinical Hematology, Chapter 1, Page 4 Laboratory tube collection

↑ *Back to this question in Part A*

@Neet_pg_bot

Q5: Anticoagulant used in the test tube for estimating HbA1c? (Q853366)

A. Warfarin

B. Sodium Fluoride

C. EDTA

D. Heparin

Correct Answer: C. EDTA

Explanation: EDTA (purple/lavender vacutainer) is the anticoagulant for estimating HbA1c. Vacutainers types Colour Anti-coagulants Uses Purple/Lavender EDTA (Ca2+ chelating anticoagulant) (Option C) CBC, Peripheral Smear, ESR, HbA1c. Light Blue Citrate (Ca2+ chelating anticoagulant). ESR, PT (Prothrombin Time), APTT (Activated Partial Thromboplastin Time), and INR (International Normalized Ratio) Red No anti-coagulant is added Serum studies (blood chemistry, serology, and blood bank testing) Yellow Clot activator/Gel separator Serum tests, such as hormone tests, chemistry panels, and serological tests (LFT, RFT, serum electrolytes) Grey Sodium Fluoride (Option B) Blood Glucose Green Heparin (Option D) ABG, Osmotic fragility, flow cytometry, immunophenotyping Warfarin (Option A) is not an anticoagulant in any vacutainer.

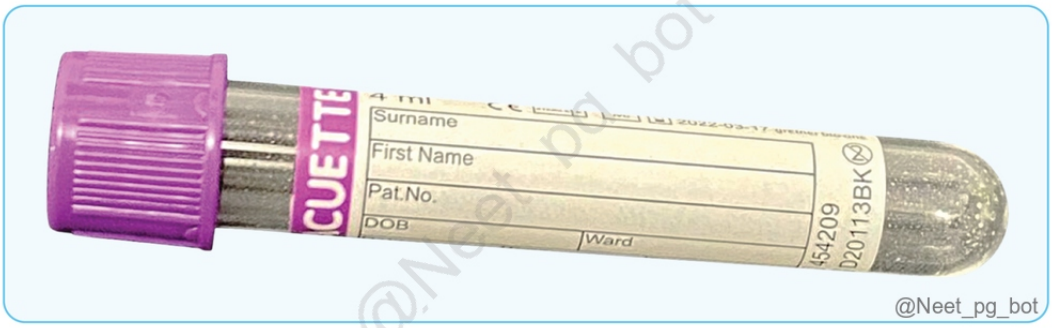


BD Vacutainer®
Buff. Na Citrate
0.109M, 3.2%
REF 363083
LOT 21241328 2013-02
@Neet_pg_bot


Surname
First Name
6 ml
20101H


UETTE
5 ml
Surname
First Name
Pat.No.
2022-02-12
greiner bio-one
018
103BM


UETTE
2 ml
Surname
First Name
Pat.No.
2022-05-03
greiner bio-one
238
101368

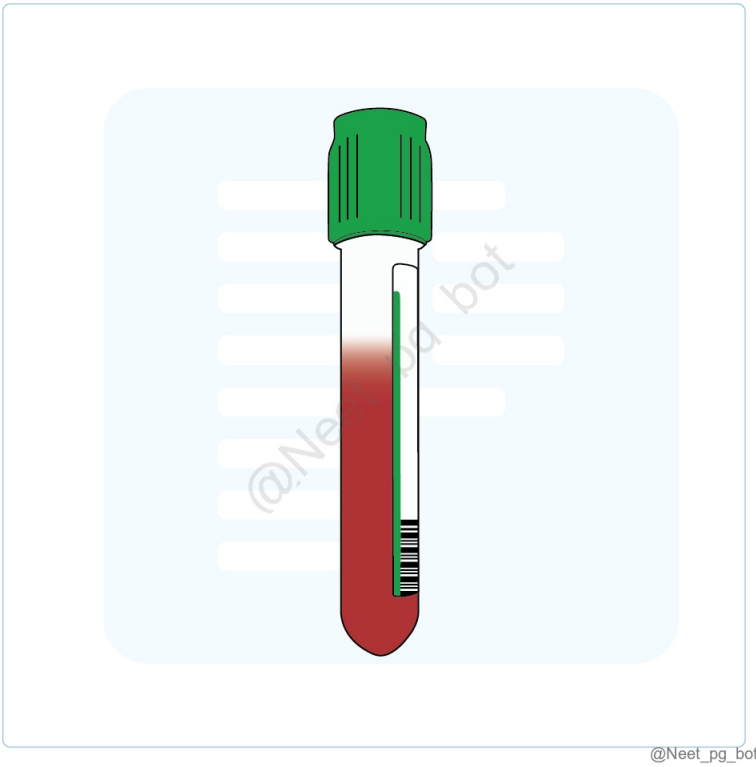

References:

Atlas of Clinical Hematology, Chapter 1, Page 4 Laboratory tube collection

↑ *Back to this question in Part A*

@Neet_pg_bot

Q6: A child is brought to the emergency department with a large lesion on his forearm. As a surgery resident, you decide to excise the lesion in the emergency operation theatre. Which of the following investigations will test the entire coagulation pathway? (Q856915)

A. Activated partial thromboplastin time

B. Prothrombin time

C. Thromboelastography

D. Bleeding time

Correct Answer: C. Thromboelastography

Explanation: Thromboelastography (TEG) is a coagulation test that evaluates the entire coagulation pathway, including both the intrinsic and extrinsic pathways and fibrinolysis. It offers a comprehensive assessment of clot formation, clot strength, and clot breakdown. Thromboelastography (TEG) is a diagnostic tool used to evaluate coagulation profiles and guide management with transfusions and hemostatic therapies. Studies show that TEG can reduce blood product usage by up to 40%, decrease postoperative length of stay, and lower the risk of reoperation. TEG measures the viscoelastic properties of blood as clotting occurs. The resulting data is plotted on a graph with time on the x-axis and amplitude (clot strength) on the y-axis. Key values include: Reaction time (R): The time it takes for the clot strength to reach an amplitude of 2 mm. Kinetics (K): The time from R to when the amplitude reaches 20 mm. α-angle: The angle formed by a line from R to the point where K intersects with the 20 mm amplitude mark. Maximum amplitude (MA): The highest amplitude reached. Lysis at 30 minutes (Ly30): The per cent decrease in amplitude 30 minutes after MA (or 60 minutes in some cases). Inference: A prolonged R time may indicate coagulation factor deficiency or anticoagulation. A decreased α-angle can result from hypofibrinogenemia Low MA can be due to thrombocytopenia or platelet dysfunction. Increased Ly30 indicates hyperfibrinolysis, often seen in severe trauma or with thrombolytic therapy. Based on the TEG findings, targeted blood products can be administered to normalize coagulation. For example: Fresh frozen plasma for prolonged R time Cryoprecipitate for decreased α-angle Platelets for decreased MA Tranexamic acid or aminocaproic acid for increased Ly30 Incorrect Options: Activated Partial Thromboplastin Time (aPTT) (Option A) primarily evaluates the intrinsic pathway of the coagulation cascade. Prothrombin Time (PT) (Option B) mainly assesses the extrinsic pathway of the coagulation cascade. Bleeding Time (Option D) measures the duration for bleeding to cease following a standardized skin incision. It primarily evaluates platelet function and primary hemostasis.

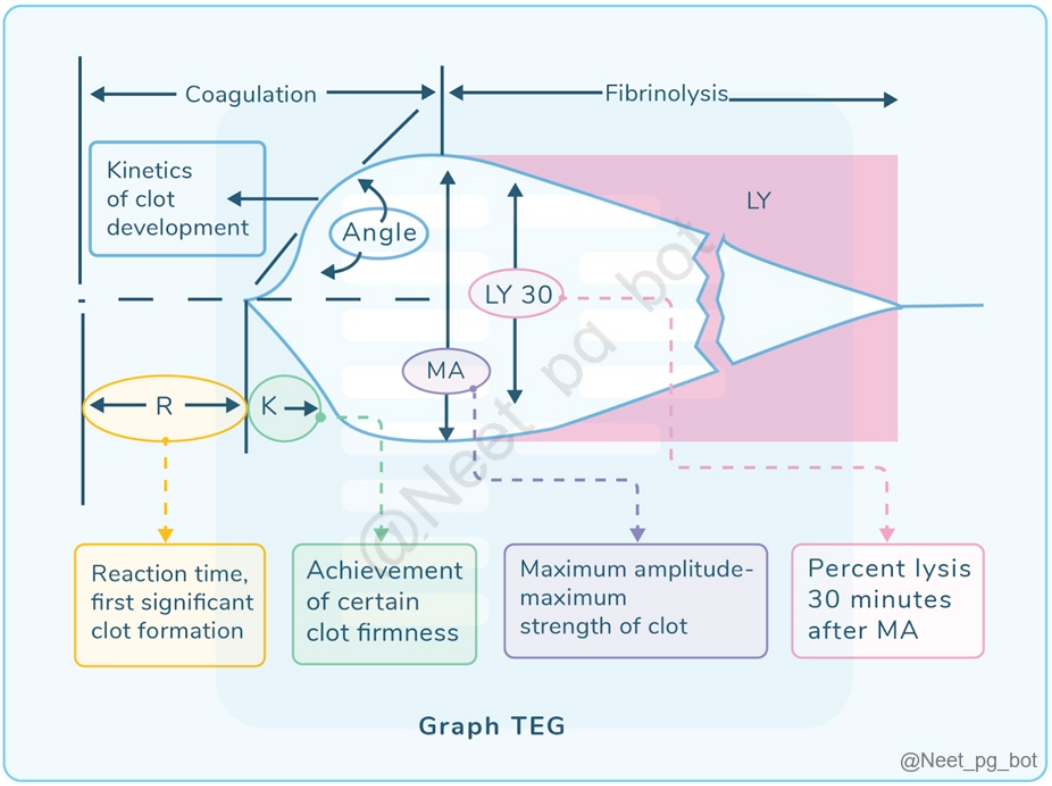

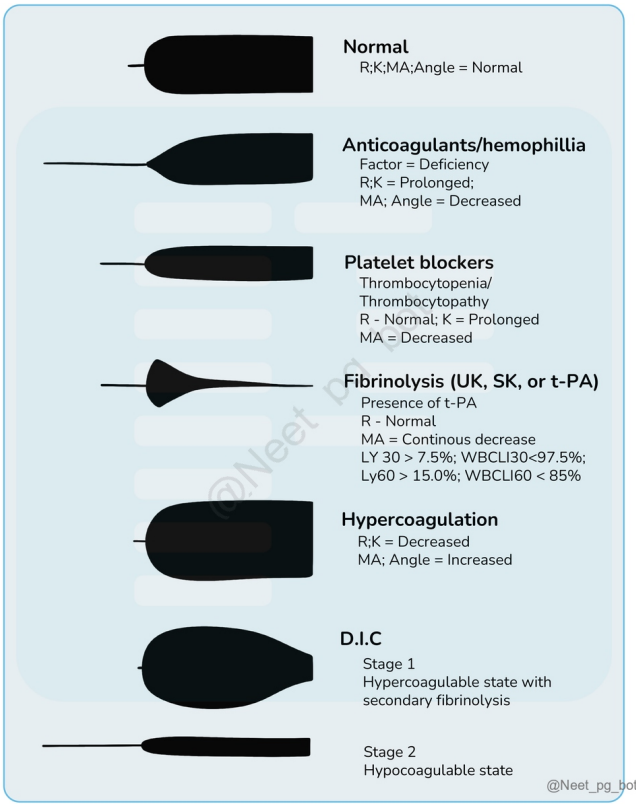

References:

Bailey & Love's Short Practice of Surgery, 27th Edition, Page 1161

https://pmc.ncbi.nlm.nih.gov/articles/PMC10117405/#:~:text=Thromboelastography%20(TEG)%20is%20a%20diagnostic,University%20of%20Heidelberg%20(1).

↑ *Back to this question in Part A*

@Neet_pg_bot

Q7: What is the commonest cause of a hypercoagulable state? (Q857441)

A. Antithrombin III deficiency

B. Protein C deficiency

C. Factor V Leiden mutation

D. G20210A prothrombin gene mutation

Correct Answer: C. Factor V Leiden mutation

Explanation: The most common inherited cause of a hypercoagulable state (predisposing to thrombosis) is the Factor V Leiden mutation . Mutation: Factor V becomes resistant to cleavage and inactivation by protein C, disrupting the antithrombotic pathway. Inheritance: Autosomal dominant. Primary causes of Hypercoagulable states Common causes Factor V mutation (Factor V Leiden) Prothrombin mutation (G20210A) - It is comparatively less common than Factor V mutation (Option D ruled out) Elevated factor levels (VIII, IX, XI, or fibrinogen) Rare causes Antithrombin III deficiency (Option A ruled out) Protein C deficiency (Option B ruled out) Protein S deficiency Very rare causes Fibrinolysis Defects Homozygous Homocystinuria Secondary causes of Hypercoagulable states Major risk factors Myocardial infarction Atrial fibrillation Tissue injury (surgery, fracture, burn) Cancer Prosthetic cardiac valves DIC Heparin-induced thrombocytopenia Prolonged rest or immobilisation Additional risk factors for thrombosis Cardiomyopathy Nephrotic syndrome Hyperestrogenic states (pregnancy and postpartum) Oral contraceptive use Sickle cell anemia Smoking

References:

Robbins and Cotran Pathologic Basis of Disease, 10th Edition, Pages 126, 127

↑ *Back to this question in Part A*

@Neet_pg_bot

Q8: How does Total plasma exchange help in the management of TTP (Q857426)

A. TPE removes the Von Willebrand factor

B. TPE removes the Antiplatelet antibodies

C. TPE removes Anti ADAMTS13 autoantibodies and thereby increases the ADAMTS protease activity

D. TPE replenishes the coagulation factor

Correct Answer: C. TPE removes Anti ADAMTS13 autoantibodies and thereby increases the ADAMTS protease activity

Explanation: Total plasma exchange (TPE) is a key treatment for thrombotic thrombocytopenic purpura (TTP); it removes the autoantibodies against ADAMTS13. (Option B ruled out) ADAMTS13 is a protease that cleaves von Willebrand factor, preventing the formation of large, thrombogenic von Willebrand factor multimers. (Option A ruled out) This helps restore normal ADAMTS13 activity and reduces the microvascular clotting that characterizes TTP. Treatment of TTP Plasma exchange (PEX) with high-dose corticosteroid therapy. It is the mainstay of treatment in TTP. Corticosteroids operate by decreasing the activity of the reticuloendothelial system as well as decreasing autoantibody production. Both the ultra-large VWF multimers and the ADAMTS13 autoantibodies are effectively removed from circulation by plasma exchange therapy. The recommended volume of exchange is one estimated plasma volume (usually 40 mL/kg of body weight) with each treatment. The recommended dose for corticosteroids is 1 mg/kg per day of prednisolone. Rituximab An anti-CD20 monoclonal antibody was found to help treat TTP refractory to PEX. It targets B-lymphocytes and has a good response rate in refractory and relapsed TTP. Caplacizumab It has a high potential for TTP. It is a humanized monoclonal antibody fragment (a bivalent, variable-domain-only fragment) that attacks the A1 section of VWF and prevents platelet adhesion. Others

Splenectomy, Vincristine, Cyclosporine and Cyclophosphamide. TPE replenishes the coagulation factor (Option D) : TPE does not replenish coagulation factors; instead, it removes harmful substances like autoantibodies against ADAMTS13 in TTP, where clotting issues stem from defective vWF cleavage, not coagulation factor deficiencies.

References:

NIH Link

↑ *Back to this question in Part A*

@Neet_pg_bot

Q9: Which of the following is not seen in a delayed hemolytic transfusion reaction? (Q840056)

A. Raised LDH

B. Raised indirect bilirubin

C. No improvement in Hb despite transfusion

D. Cola-colored urine after 2 hrs

Correct Answer: D. Cola-colored urine after 2 hrs

Explanation: Correct Option D - Cola-colored urine after 2 hrs Cola-colored urine is not a typical presentation in delayed hemolytic transfusion reactions. Instead, urine color typically ranges from red to brown during hemolysis. Additionally, delayed reactions typically occur after 2-3 days or even a few weeks. Incorrect Options: Options A, B & C: Raised LDH, Raised indirect bilirubin, and No improvement in Hb despite transfusion are all features of delayed hemolytic transfusion reactions.

↑ *Back to this question in Part A*

@Neet_pg_bot

Q10: In a trauma patient with an unknown blood group who is unstable and requires urgent blood transfusion, which type of blood should be transfused? (Q840032)

A. A positive

B. AB positive

C. O positive

D. O negative

Correct Answer: D. O negative

Explanation: O-negative red blood cells are called the universal donor for RBC transfusion. O blood group has no A or B antigens, and negative Rh (D) antigen avoids Rh sensitization in Rh-negative recipients. This is critical in trauma or emergency situations when there is no time to determine blood group. Allows rapid transfusion while minimizing risk of acute hemolytic transfusion reactions. After stabilizing the patient and determining the blood group, group-specific blood should be transfused. Incorrect Options: Option A) A positive: May cause hemolytic reaction if the patient is type B or O. Option B) AB positive: Contains A and B antigens; unsafe for most unknown recipients. Option C) O positive: Safe for Rh-positive patients, but can sensitize Rh-negative recipients.

References:

.

↑ *Back to this question in Part A*

@Neet_pg_bot

Q11: Which of the following is used in the treatment of Hemophilia B? (Q840031)

A. Factor 9

B. Cryoprecipitate

C. Factor 8

D. Tranexamic acid

Correct Answer: A. Factor 9

Explanation: Hemophilia B is caused by Factor IX deficiency (Christmas disease). Replacement therapy with Factor IX concentrate restores the intrinsic coagulation pathway and stops bleeding. It can be given prophylactically or during bleeding episodes or surgery. Incorrect Answers: Option B) Cryoprecipitate: Rich in Factor VIII, fibrinogen, and vWF, but contains minimal Factor IX. Not effective for Hemophilia B. Option C) Factor VIII: Used in Hemophilia A (Factor VIII deficiency). Does not correct Factor IX deficiency. Option D) Tranexamic acid : Antifibrinolytic; stabilizes formed clots. Supportive only, does not replace missing Factor IX.

References:

.

↑ *Back to this question in Part A*

@Neet_pg_bot

Q12: Match the following blood products with their shelf lives. a. 1-Granulocytes A- 5 days b. 2- PRBC B- 24 hours c. 3- SDP C- 42 days d. 4- CRYO D- 1 year (Q840026)

A. 1-A, 2-C, 3D, 4-B

B. 1-B, 2-D, 3-A, 4-C

C. 1-C, 2-A, 3-B, 4-D

D. 1-B, 2-C, 3-A, 4-D

Correct Answer: D. 1-B, 2-C, 3-A, 4-D

Explanation: Correct Option D - 1-B, 2-C, 3-A, 4-D: Granulocyte concentrate : They have a very short shelf life of 24 hours. PRBC (Packed Red Blood Cells) : Packed Red Blood cells have a shelf life of 35 to 42 days, depending on the anti-coagulant used: 21 days (ACD/CPD), 35 days (CPDA) and 42 days (SAGM). SDP (Single Donor Platelets) : Single Donor Platelets have a shelf life of 5 days, CRYO (Cryoprecipitate) : Cryoprecipitate has a shelf life of 1 year. Incorrect Options: Options A, B, and C are incorrectly matched.

References:

.

↑ *Back to this question in Part A*

@Neet_pg_bot

Q13: A young boy presents with joint swelling after a fall. Lab investigations show normal PT and raised aPTT. What is the most likely diagnosis? (Q866666)

A. Von Willebrand Disease

B. Hemophilia

C. Iron Deficiency Anaemia (IDA)

D. Platelet function disorder

Correct Answer: B. Hemophilia

Explanation: This presentation matches haemophilia because: Joint swelling after trauma → suggests hemarthrosis, which is typical of coagulation factor deficiencies, especially haemophilia. Normal PT → extrinsic pathway is intact. Prolonged aPTT → intrinsic pathway defect (Factors VIII, IX, XI). Haemophilia A = Factor VIII deficiency; Haemophilia B = Factor IX deficiency. Incorrect Options: Von Willebrand Disease (Option A): usually has prolonged aPTT (due to low factor VIII) and mucocutaneous bleeding (epistaxis, menorrhagia), not deep joint bleeds as the main feature. Iron Deficiency Anaemia (IDA) (Option C) : causes pallor and fatigue, not

isolated coagulation abnormalities. Platelet function disorder (Option D): causes mucosal bleeding and petechiae, not hemarthrosis; PT and aPTT are usually normal.

↑ *Back to this question in Part A*

@Neet_pg_bot

Q14: Which of the following is the most common inherited bleeding disorder? (Q865368)

A. Von Willebrand Disease

B. Disseminated Intravascular Coagulation

C. Factor V Deficiency

D. Hemophilia

Correct Answer: A. Von Willebrand Disease

Explanation: Von Willebrand Disease (VWD) is the most common inherited bleeding disorder. Types: vWD type 1 vWD Type 2 vWD Type 3 Autosomal dominant. The most common type. Mild to moderate vWF deficiency. Quantitative defect. point substitutions prevent the vWF protein from maturing or cause it to leave the plasma quickly Autosomal dominant. Qualitative defect. Types: 2A, 2B, 2M, 2N 2A (Most common) - Decrease in binding between vWF and Gp1b/9 missense mutations cause faulty multimer formation → the most active forms of vWF, i.e. large- and intermediate-sized multimers are absent. 2B - Increase in binding between vWF and Gp1b/9 2M - VWF dependant platelet adhesion is decreased. There is impairment of VWF binding to platelets. Type 2M VWD typically has mild to moderate mucocutaneous bleeding 2N - There is marked decline in the binding affinity for factor VIII. The level of factor VIII is lower when compared to the VWF:Ag. This led to misdiagnosis as haemophilia A Autosomal recessive . Quantitative defect. produced by frameshift mutations or deletions affecting both alleles (autosomal recessive), which produce little or no vWF. Factor VIII levels are also lowered because vWF stabilizes factor VIII in the blood, and the resulting bleeding condition is severe. Disseminated Intravascular Coagulation (DIC) (Option B) is an acquired (not inherited), secondary condition due to systemic activation of the clotting cascade (e.g., in sepsis, trauma, malignancy). Factor V Deficiency (Option C) is a rare inherited bleeding disorder, also known as parahemophilia. Far less common than vWD. Hemophilia (A or B) (Option D) is an inherited X-linked recessive disorder involving Factor VIII (A) or Factor IX (B) deficiency. More common in males but still less prevalent than von Willebrand disease.

References:

Textbook of Robbin and Cotran’s Pathological Basis of Diseases, 10th Edition, Page 668.

↑ *Back to this question in Part A*

@Neet_pg_bot

Q15: Which of the following clotting factor deficiencies will not affect clotting in vivo? (Q856490)

A. Factor VII

B. Factor V

C. Factor XII

D. Factor IX

Correct Answer: C. Factor XII

Explanation: Factor XII deficiency (Hageman factor) does not significantly affect clotting in vivo, as it primarily participates in the intrinsic pathway and is involved in the activation of the fibrinolytic system and the contact activation of the clotting cascade. Factor XII does not notably impair normal clotting, as other factors and pathways can compensate for its lack. In contrast, Factor VII, Factor V, and Factor IX deficiencies significantly impact the clotting cascade and lead to bleeding disorders. Factor VII (Option A) is a critical component of the extrinsic pathway of coagulation. Deficiency can lead to bleeding disorders, as it directly impacts the initiation of the clotting cascade in vivo. Factor V (Option B) is essential for the common pathway of coagulation, acting as a cofactor for Factor Xa in the conversion of prothrombin to thrombin. Its deficiency results in impaired clotting and increases the risk of bleeding. Factor IX (Option D) is involved in the intrinsic pathway of coagulation. Deficiency causes Hemophilia B, leading to impaired clot formation and increased bleeding risk in vivo.

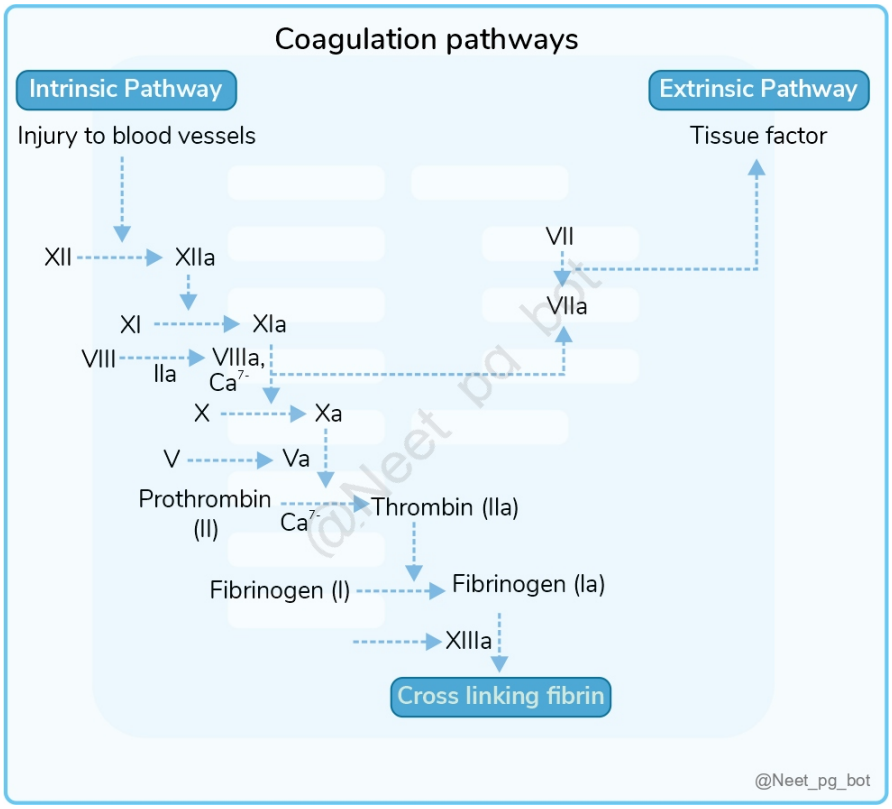

References:

Robbins & Cotran Pathologic Basis of Disease, 10th Edition, Page 121

↑ *Back to this question in Part A*

@Neet_pg_bot

Q16: Leiden mutation is of factor: (Q856167)

A. V

B. VIII

C. I

D. X

Correct Answer: A. V

Explanation: The Leiden mutation is a genetic alteration in Factor V , a protein essential for blood clotting. It has the autosomal dominant type of inheritance. The mutation makes factor V resistant to inactivation by protein C, disrupting an antithrombotic pathway and increasing the risk of thrombosis. Factor VIII (Option B) plays a key role in the intrinsic pathway of coagulation, where it activates Factor X to Xa, which then helps in the conversion of prothrombin to thrombin, leading to the formation of a blood clot. It is not associated with the Leiden mutation. Factor I (Option C) , also known as fibrinogen, is the precursor to fibrin, which forms the structural framework of a blood clot. When bleeding occurs, fibrinogen is converted to fibrin by the enzyme thrombin during the final steps of the coagulation cascade. It is not associated with the Leiden mutation. Factor X (Option D) , also known as the Stuart-Prower factor, is a key enzyme in the blood clotting process. It is activated to Factor Xa and plays a crucial role in converting prothrombin to thrombin, ultimately leading to the formation of a blood clot. It is not associated with the Leiden mutation.

References:

Robbins & Cotran Pathological Basis of Diseases, 10th Edition, Page 127.

↑ *Back to this question in Part A*

@Neet_pg_bot

Q17: Below is an image of the coagulation cascade activation following closed endothelial injury. Identify the factor ‘L’, which combines with tissue factor to activate factor IX. (Q856684)

A. Factor XII

B. Factor VII

C. Factor VIII

D. vWF

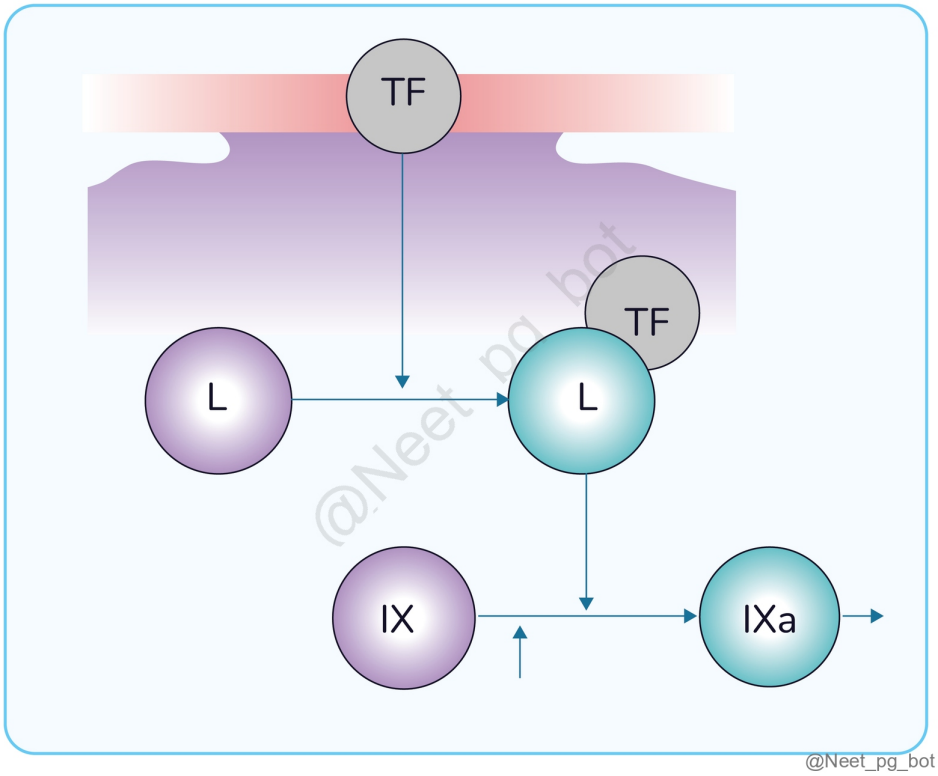

Correct Answer: B. Factor VII

Explanation: Factor VII (Proconvertin) combines with tissue factor to activate factor IX in the Coagulation Cascade following closed endothelial injury. When tissue factor is exposed due to endothelial injury, it forms a complex with Factor VII. This complex activates Factor IX by cleaving it to Factor IXa, which then participates in the coagulation cascade. Factor XII (Hageman factor) (Option A) is involved in the initiation of the intrinsic pathway of the coagulation cascade. It is not directly responsible for activating factor IX in response to closed endothelial injury. Factor VIII (antihemophilic factor A) (Option C) plays a crucial role in the intrinsic pathway of the coagulation cascade. However, it is not involved in the direct activation of factor IX in response to closed endothelial injury. vWF (von Willebrand factor) (Option D) is a glycoprotein that plays a vital role in platelet adhesion and aggregation. It is not directly involved in activating factor IX in the coagulation cascade following closed endothelial injury.

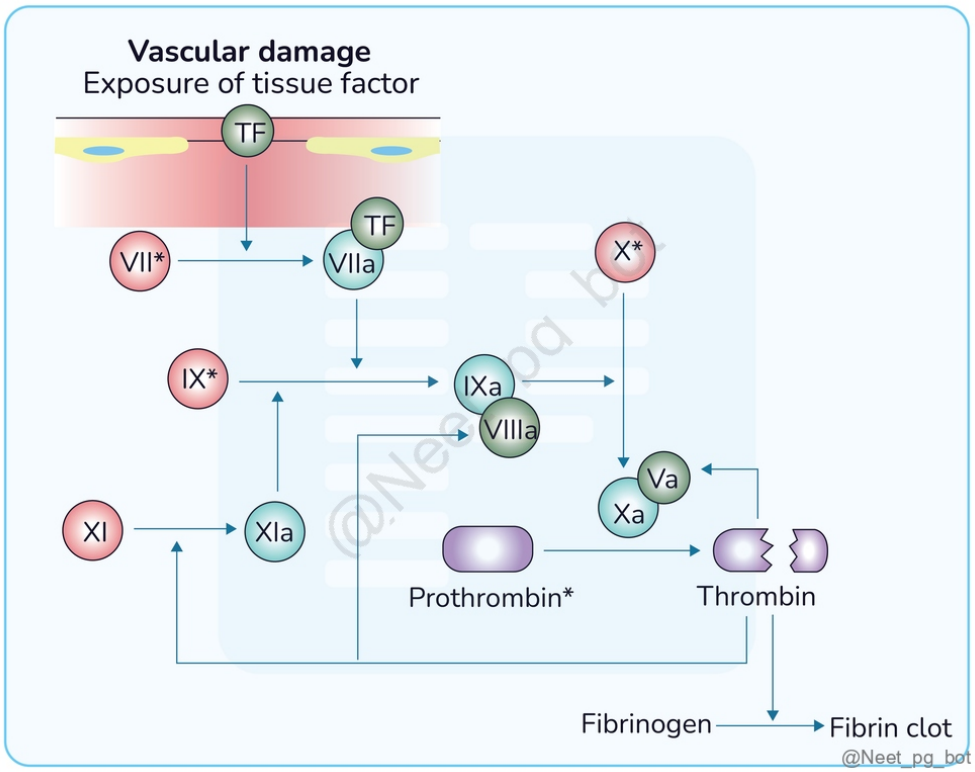

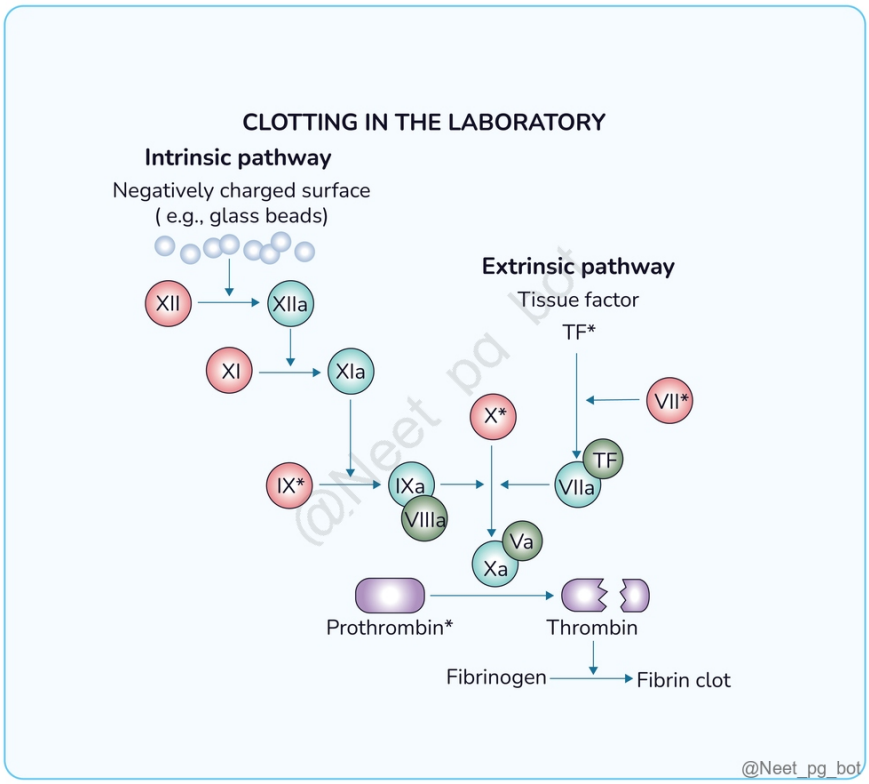

References:

Robbins and Cotran, Pathologic Basis of Disease, 10th Edition, Page 120-122.

↑ *Back to this question in Part A*

@Neet_pg_bot

Q18: Stellate granuloma is found in: (Q857169)

A. Cat scratch disease

B. Leprosy

C. Coccidomycosis

D. Histoplasmosis

Correct Answer: A. Cat scratch disease

Explanation: Stellate granulomas are irregular star-shaped granulomas commonly found in Cat Scratch Disease (CSD) , caused by Bartonella henselae . Causative agent: Bartonella henselae (transmitted via cat scratches/bites). Histology: Stellate-shaped granulomas with central necrosis and neutrophilic infiltrate. Symptoms: Painful lymphadenopathy (axillary, cervical) with fever. Resolves spontaneously in immunocompetent individuals. Leprosy (Option B) granulomas contain foamy macrophages (Virchow cells) and Langhans giant cells, not stellate granulomas. Coccidiomycosis (Option C) forms caseating granulomas , not stellate granulomas. Histoplasmosis (Option D) forms well-defined granulomas with caseation commonly found in the lungs .

References:

Robbins and Cotrans Pathologic Basis of Disease 10th Edition, Page 101

↑ *Back to this question in Part A*

@Neet_pg_bot

Q19: Which of the following shows maximum amplitude on thromboelastography? (Q856011)

A. Platelets

B. Intrinsic

C. Extrinsic

D. von Willebrand Disease (vWD)

Correct Answer: A. Platelets

Explanation: Thromboelastography (TEG) measures the viscoelastic properties of blood as it clots. The maximum amplitude (MA) on TEG reflects the strength of the clot, which is primarily determined by the number and function of platelets and the fibrinogen concentration. The platelets contribute most significantly to the clot's strength and the MA value. Thromboelastography (TEG) is a diagnostic tool used to evaluate coagulation profiles and guide management with transfusions and hemostatic therapies. Studies show that TEG can reduce blood product usage by up to 40%, decrease postoperative length of stay, and lower the risk of reoperation. TEG measures the viscoelastic properties of blood as clotting occurs. The resulting data is plotted on a graph with time on the x-axis and amplitude (clot strength) on the y-axis. Key values include: Reaction time (R): The time it takes for the clot strength to reach an amplitude of 2 mm. Kinetics (K): The time from R to when the amplitude reaches 20 mm. α-angle: The angle formed by a line from R to the point where K intersects with the 20 mm amplitude mark. Maximum amplitude (MA): The highest amplitude reached. Lysis at 30 minutes (Ly30): The per cent decrease in amplitude 30 minutes after MA (or 60 minutes in some cases). Inference: A prolonged R time may indicate coagulation factor deficiency or anticoagulation. A decreased α-angle can result from hypofibrinogenemia Low MA can be due to thrombocytopenia or platelet dysfunction. Increased Ly30 indicates hyperfibrinolysis, often seen in severe trauma or with thrombolytic therapy. Based on the TEG findings, targeted blood products can be administered to normalize coagulation. For example: Fresh frozen plasma for prolonged R time Cryoprecipitate for decreased α-angle Platelets for decreased MA Tranexamic acid or aminocaproic acid for increased Ly30.

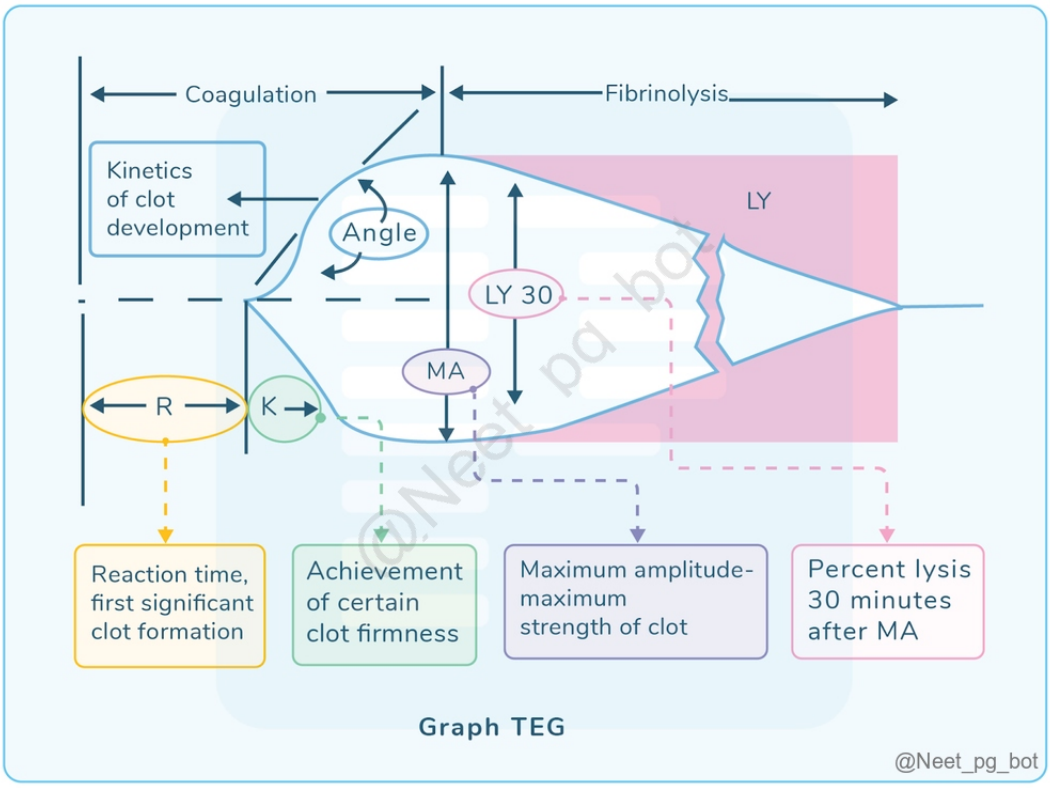



References:

Bailey & Love's Short Practice of Surgery, 27th Edition, Page 1161

https://pmc.ncbi.nlm.nih.gov/articles/PMC10117405/#:~:text=Thromboelastography%20(TEG)%20is%20a%20diagnostic,University%20of%20Heidelberg%20(1).

↑ *Back to this question in Part A*

@Neet_pg_bot

Q20: A young patient presents with a large retroperitoneal hemorrhage and a history of intermittent knee swelling during strenuous exercise. There is no history of mucosal bleeding. Which of the following deficiencies is responsible for this condition ? (Q855429)

A. Factors VIII and IX

B. GP1b/IX

C. Von Willebrand factor

D. Lupus anticoagulant

Correct Answer: A. Factors VIII and IX

Explanation: The clinical picture suggests hemarthroses (knee swelling after exertion) and deep soft tissue bleeding (retroperitoneal hemorrhage), classic for hemophilia. Hemophilia A is due to factor VIII deficiency, and Hemophilia B is due to factor IX deficiency. These are X-linked recessive disorders, typically presenting in males, without mucosal bleeding. Unlike platelet disorders or von Willebrand disease, hemophilia mainly causes joint and muscle bleeding. Large retroperitoneal hemorrhage in a young male strongly points toward severe factor VIII or IX deficiency. Incorrect Options: Option B) GP1b/IX – Deficiency causes Bernard-Soulier syndrome, characterized by mucosal bleeding and thrombocytopenia, not deep muscle/joint bleeds. Option C) Von

Willebrand factor – Deficiency causes mucocutaneous bleeding (nosebleeds, menorrhagia), not typically hemarthroses. Option D) Lupus anticoagulant – Causes thrombosis, not bleeding.

References:

Robbins and Cotran Pathologic Basis of Disease, 10th Edition, Page 668, 669

↑ *Back to this question in Part A*

@Neet_pg_bot

Q21: A 26-year-old female with a bleeding disorder following autosomal dominant inheritance. She gave the history of her father and sister having the same bleeding disorders. What is the most likely disorder? (Q854692)

A. Von Willebrand disease

B. Hemophilia A

C. Christmas disease

D. Factor X deficiency

Correct Answer: A. Von Willebrand disease

Explanation: Von Willebrand disease (VWD) is the most common inherited bleeding disorder caused by defective or deficient von Willebrand factor (vWF) . It follows an autosomal dominant inheritance pattern , affecting both males and females, with a 50% chance of passing the disorder to offspring. Von Willebrand disease is clinically and molecularly heterogeneous, with three identified types, each exhibiting a variety of phenotypes. vWD type 1 vWD Type 2 vWD Type 3 Autosomal dominant. The most common type. Mild to moderate vWF deficiency. Quantitative defect. Point substitutions prevent the vWF protein from maturing or cause it to leave the plasma quickly. Autosomal dominant. Qualitative defect. Types: 2A, 2B, 2M, 2N 2A (Most common) - Decrease in binding between vWF and Gp1b/9 Missense mutations cause faulty multimer formation → the most active forms of vWF, i.e. large- and intermediate-sized multimers are absent. 2B - Increase in binding between vWF and Gp1b/9 2M - VWF-dependent platelet adhesion is decreased. VWF binding to platelets is impaired. Type 2M VWD typically has mild to moderate mucocutaneous bleeding 2N - There is a marked decline in the binding affinity for factor VIII. The level of factor VIII is lower when compared to the VWF: Ag. This led to misdiagnosis as haemophilia A. Autosomal recessive . Quantitative defect. Produced by frameshift mutations or deletions affecting both alleles (autosomal recessive), which produce little or no vWF. Factor VIII levels are also lowered because vWF stabilizes factor VIII in the blood, and the resulting bleeding condition is severe. Hemophilia A (Option B) is an X-linked recessive disorder that mainly affects males, with females being carriers. This makes it an unlikely diagnosis for this patient, who has a family history involving females. Christmas disease (Option C) is an X-linked recessive disorder; hence, this condition is primarily seen in males, and it is less likely to be the cause of an autosomal dominant inheritance pattern. Factor X deficiency (Option D) is a rare bleeding disorder that can be inherited in autosomal recessive patterns, which causes the clotting process to take longer than normal.

References:

Robbins and Cotran Pathologic Basis of Disease, 10th Edition, Page 668 NIH Link .

↑ *Back to this question in Part A*

@Neet_pg_bot

Q22: Which of the following statements about Von Willebrand's disease is incorrect? (Q843976)

A. Type 2 von Willebrand disease is associated with a moderate bleeding tendency.

B. Type 3 von Willebrand disease is associated with a complete absence of von Willebrand factor.

C. Type 1 von Willebrand disease presents with severe bleeding since childhood.

D. Type 2 von Willebrand disease includes subtypes with varying defects in the von Willebrand factor.

Correct Answer: C. Type 1 von Willebrand disease presents with severe bleeding since childhood.

Explanation: Type 1 vWD is the most common type and involves a partial quantitative deficiency of vWF. It typically produces mild to moderate bleeding symptoms. Patients often remain asymptomatic until later childhood or adulthood. Severe bleeding from early childhood is not characteristic of Type 1. Such severe presentations are more typical of Type 3 vWD. Incorrect Options: Option A) Type 2 vWD is associated with a moderate bleeding tendency: True. Type 2 involves qualitative defects that cause moderate bleeding. Option B) Type 3 vWD is associated with a complete absence of vWF: True. Type 3 is the most severe form with near-total absence of vWF. Option D) Type 2 vWD includes subtypes with varying vWF defects: True. Subtypes 2A, 2B, 2M, and 2N each show specific qualitative abnormalities.

References:

.

↑ *Back to this question in Part A*

@Neet_pg_bot

Q23: A patient underwent ileal resection and subsequently developed anemia along with peripheral neuropathy and features of SACD. Laboratory findings show hemoglobin (Hb) of 9 g/dL and mean corpuscular volume (MCV) of 110 fL. What is the most likely cause of his anemia? (Q866386)

A. Iron deficiency anemia

B. Vitamin B12 deficiency

C. Folic acid deficiency

D. Sideroblastic anemia

Correct Answer: B. Vitamin B12 deficiency

Explanation: Ileal resection can lead to vitamin B12 deficiency, as the terminal ileum is the primary site for absorption of the vitamin B12–intrinsic factor complex; this deficiency commonly results in macrocytic anemia, reflected by an elevated MCV of 110 fL. Terminal ileum : Site of vitamin B12 absorption (B12–intrinsic factor complex). Ileal resection → impaired B12 absorption → Vitamin B12 deficiency. Vitamin B12 deficiency : Causes macrocytic (megaloblastic) anemia → MCV > 100 fL. May present with neurological symptoms (e.g., paresthesia, ataxia). Lab findings : ↓ Hemoglobin ↑ MCV (e.g., 110 fL) ↑ LDH, ↑ indirect bilirubin, ↓ reticulocyte count Incorrect Options: Iron deficiency anemia (Option A) is unlikely because it typically causes microcytic anemia (low MCV), not macrocytic anemia. Folic acid deficiency (Option C) causes macrocytic anemia, but folate is absorbed in the jejunum, not the ileum, making it less likely after ileal resection. Sideroblastic anemia (Option D) usually presents with microcytic or dimorphic anemia, and it's not related to ileal absorption.

↑ *Back to this question in Part A*

@Neet_pg_bot

Q24: Bernard-Soulier syndrome is caused by a defect in which of the following platelet glycoproteins? (Q866676)

A. GpIIb/IIIa

B. GpIb/IX complex

C. GpIa/IIa

D. GpIV

Correct Answer: B. GpIb/IX complex

Explanation: Bernard-Soulier syndrome is caused by a defect in the GpIb/IX complex on platelets. GpIb/IX complex is the receptor for von Willebrand factor (vWF) → mediates platelet adhesion to subendothelial collagen after vascular injury. In Bernard–Soulier syndrome, this adhesion step is impaired → defective platelet plug formation. Labs/Findings: Normal or low platelet count Prolonged bleeding time Giant platelets on peripheral smear Normal platelet aggregation with ADP, collagen, epinephrine, but absent aggregation with ristocetin (not corrected by adding normal plasma, unlike vWD). Incorrect Options: GpIIb/IIIa (Option A) : Function: Binds fibrinogen → platelet aggregation . Defect causes Glanzmann thrombasthenia , not BSS. Lab: Normal platelet count, defective aggregation with all agonists except ristocetin. GpIa/IIa (Option C): Function: Binds collagen

(supports platelet adhesion). Defects are rare and cause mild bleeding disorders, not the classic BSS picture. GpIV (Option D): Also called CD36; role in platelet adhesion and scavenger receptor function.

↑ *Back to this question in Part A*

@Neet_pg_bot

• [20_Blood Banking and Transfusion Medicine] 080 Blood Banking And Transfusion Pathology

« Back to Folder Directory

[20_Blood Banking and Transfusion Medicine] 080 Blood Banking And Transfusion Pathology — Quick Jump

Q1 (p. 3126) *Q2 (p. 3126)* *Q3 (p. 3127)* *Q4 (p. 3128)* *Q5 (p. 3129)* *Q6 (p. 3130)*
Q7 (p. 3131) *Q8 (p. 3132)* *Q9 (p. 3132)* *Q10 (p. 3133)* *Q11 (p. 3134)*

Q1: A pathologist is reviewing the chromosomal locations of blood group antigens. When considering the Rh blood group system, including the Rh antigen, which of the following chromosomes is involved? (Q845924)

A. Chr. 1

B. Chr. 9

C. Chr. 19

D. Chr. 13

Correct Answer: A. Chr. 1

■ *Listen (English)*

■ *Listen (Hindi)*

Explanation: The Rh antigen is denoted by the C, D, and E antigens , and these are located on chromosome 1 (Option A) . The ABO antigens are present on chromosome 9 . (Option B) All antigens and all blood groups are derived from a common precursor - H antigen or H substance , which is present on chromosome 19. (Option C)

References:

Guyton and Hall Textbook of Medical Physiology, 14th Edition, Page 472

↑ *Back to this question in Part A*

@Neet_pg_bot

Q2: A 32-year-old male requires a blood transfusion after a severe bike accident. He is known to have the Bombay phenotype. Before the transfusion, his blood sample is sent to the laboratory for compatibility testing. Based on his blood group, which of the

following statements is incorrect? (Q845926)

A. Lack of H, A and B antigens on RBCs

B. Lack of H, A and B substances in saliva

C. Lack of antigens of several blood group systems

D. H, A and B antibodies will always be present in the serum

Correct Answer: C. Lack of antigens of several blood group systems

■ *Listen (English)*

■ *Listen (Hindi)*

Explanation: People with the Bombay phenotype lack H, A, and B antigens on the red blood cells. (Option A ruled out) "Oh" phenotype denotes Bombay blood group. The antigens are absent in all body secretions including saliva. (Option B ruled out) As the antigens are not expressed, the serum will always present the H, A, and B antibodies. (Option D ruled out) Antigens from blood group systems other than ABO system (e.g., Rh, MNS, etc.) are still present on the RBC (Option C) This person can receive blood only from another Bombay blood group donor.

References:

Wintrobe’s Clinical Hematology, 12th Edition, Pages 635, 636

↑ *Back to this question in Part A*

@Neet_pg_bot

Q3: A 23-year-old individual is scheduled to donate blood for a local blood drive. To ensure the safety of the blood supply, the donor's blood will be screened for various infectious diseases. Among the following options, which one is typically not included in the routine screening for donated blood? (Q845928)

A. Malaria

B. Hepatitis B

C. HIV

D. Dengue fever

Correct Answer: D. Dengue fever

■ *Listen (English)*

■ *Listen (Hindi)*

Explanation: Dengue is a viral illness spread by Aedes mosquitoes, and routine blood donor screening isn't done since it's mainly mosquito-borne, not transfusi In India, the following five diseases are screened before blood transfusion: HIV-1 & 2 (Option C) . HBV (Option B) . HCV. Malaria (Option A) . Syphilis. The following infections can be transmitted by blood transfusion. Viral Bacterial Parasites Others Hepatitis (A, B, C, G). HIV (I & II). HTLV (I & II). CMV. EBV. Parvovirus B19. Syphilis Malaria Babesiosis Trypanosoma cruzi Creutzfeldt-Jakob disease

References:

Robbins and Cotrans, Pathological Basis of Diseases, 10th Edition, Page 672

Wintrobe's Clinical Hematology, 14th Edition, Page 1869-1876

https://www.ncbi.nlm.nih.gov/pmc/articles/PMC2937300/

https://pubmed.ncbi.nlm.nih.gov/21858015/

↑ *Back to this question in Part A*

@Neet_pg_bot

Q4: Which of the following can be used to store blood for up to 42 days? (Q845929)

A. ACD

B. CPD

C. CPDA

D. SAGM

Correct Answer: D. SAGM

■ *Listen (English)*

■ *Listen (Hindi)*

Explanation: Blood can be stored for up to 42 days in SAGM (Saline-Adenine-Glucose-Mannitol) Adenine: Gives energy to RBCs Glucose and Mannitol: Provides nutrition Additive solutions used for storage of blood products: Anticoagulant Full form Shelf Life ACD (Option A) Acid citrate dextrose 21 days / 3 weeks CPD (Option B) Citrate phosphate dextrose 21 days / 3 weeks CPDA (Option C) Citrate phosphate dextrose adenine 35 days / 5 weeks SAGM (Option D) Saline-adenine-glucose-mannitol 42 days / 6 weeks

References:

Wintrobe's Clinical Hematology, 13th Edition, Page 550

↑ *Back to this question in Part A*

@Neet_pg_bot

Q5: Based on the agglutination test shown below, what is the blood group? (Q845931)

A. B Positive

B. B negative

C. A positive

D. AB positive

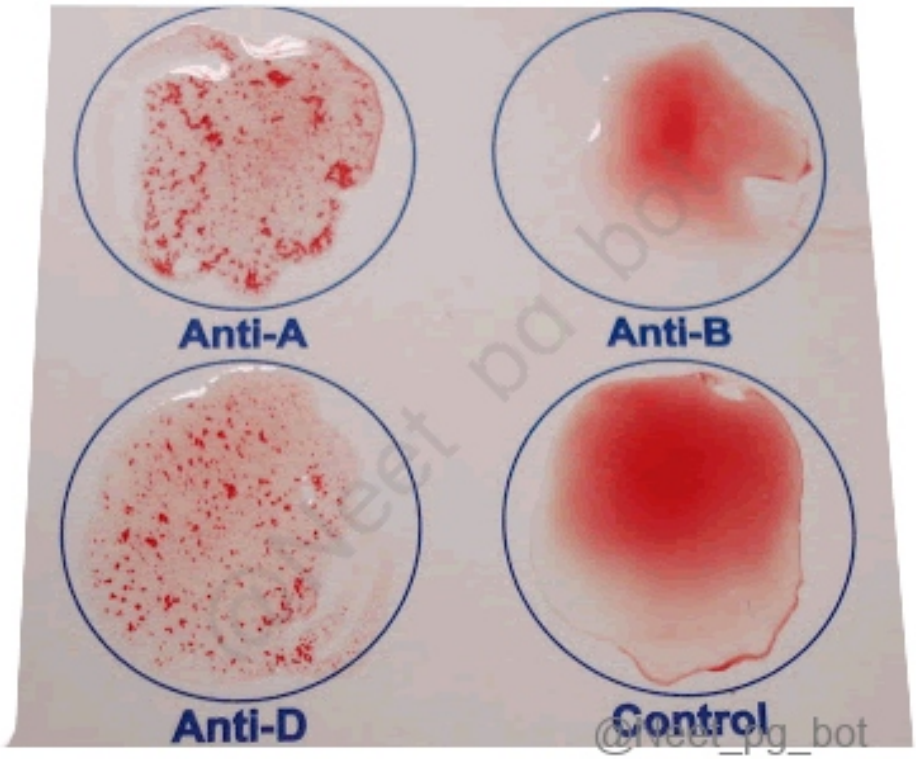

Correct Answer: C. A positive

■ *Listen (English)*

■ *Listen (Hindi)*

Explanation: The image shows a slide agglutination test to determine a person's blood group. It shows clotting with anti-A and anti-D , indicating the person has an A (+ve) blood group. During agglutination test for blood group determination, a control (only blood) is always added first to confirm proper sampling and ensure the blood hasn’t clotted. A drop of antibody is then added to the blood sample, and if antigen–antibody reaction causes agglutination (clumping), the site of agglutination indicates the blood group. Interpretation of results:

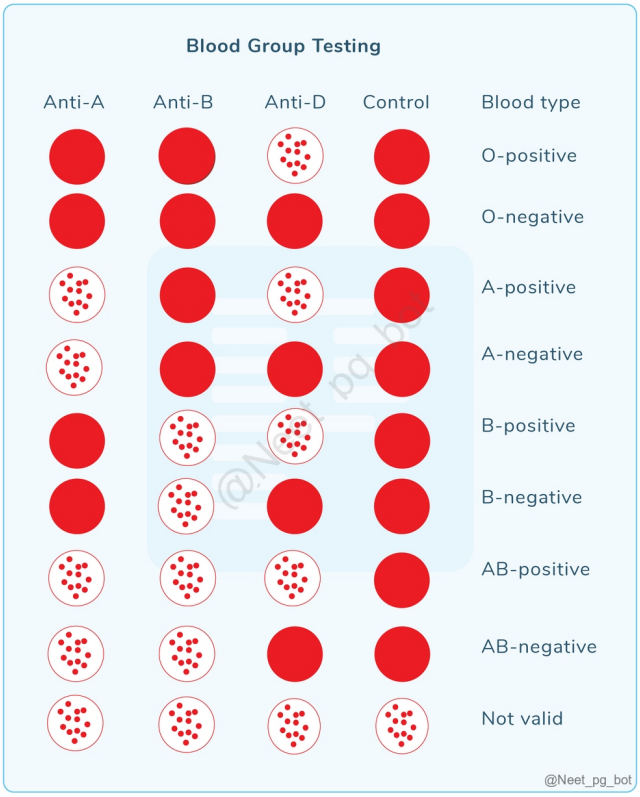

References:

Guyton and Hall Textbook of Medical Physiology, 13th Edition, Page 479

↑ *Back to this question in Part A*

@Neet_pg_bot

Q6: Match the following: Blood Products Shelf Life A Packed Red Blood Cells (PRBCs) in CPD-A i 1 year B Fresh Frozen Plasma (FFP) ii 35 days C Platelets iii 42 days D PRBC in SAGM iv 5 days (Q845935)

A. A-iii, B-i, C-iv, D-ii

B. A-i, B-iii, C-iv, D-ii

C. A-ii, B-i, C-iv, D-iii

D. A-ii, B-iii, C-i, D-iv

Correct Answer: C. A-ii, B-i, C-iv, D-iii

■ *Listen (English)*

■ *Listen (Hindi)*

Explanation: The blood products and their corresponding shelf life are: Blood Products Shelf Life Storage temperature Packed Red Blood Cells (PRBCs) in CPD-A 35 days / 5 weeks 1-6 °C Fresh Frozen Plasma (FFP) 1 year -30°C or colder Platelets 5 days 20–24°C (with continuous agitation) PRBC in SAGM 42 days / 6 weeks 1–6°C Cryoprecipitate 2 years –30°C

References:

Harmening, D. M. (2012). Modern Blood Banking & Transfusion Practices (6th ed.).

http://nbtc.naco.gov.in/assets/resources/training/8.pdf

↑ *Back to this question in Part A*

@Neet_pg_bot

Q7: A unit of packed red blood cells is issued from the blood bank for transfusion to a patient in the emergency department. Due to delays in setting up the IV line, the staff asks how long the unit can safely remain out of refrigeration before the transfusion must be completed.What is the maximum allowable time for transfusing this RBC unit after removal from cold storage? (Q845936)

A. 1 hour

B. 4 hour

C. 8 hour

D. 24 hour

Correct Answer: B. 4 hour

■ *Listen (English)*

■ *Listen (Hindi)*

Explanation: The recommended time frame for administering a unit of red blood cells (RBCs) once it has been removed from cold storage is within 4 hours. The unit must be removed from the refrigeration and the temperature must be brought up to the room temperature before transfusion Once a unit of RBCs is removed from the refrigerator, it should be transfused as soon as possible, ideally starting within 30 minutes. The entire unit should be infused within 4 hours as hemolysis occurs after 4 hours which can lead to metabolic abnormalities like hyperkalemia. Duration times for transfusion of blood and blood products: Blood product Start time End time Whole blood/PRBC Within 30 minutes of removing it from the refrigerator ≤ 4 hours Discard if this period is exceeded Platelets Immediately Within 30 minutes FFP Immediately Within 30 minutes Cryoprecipitate Immediately Within 30 minutes

References:

Harmening, D. M. (2012). Modern Blood Banking & Transfusion Practices (6th ed.)

↑ *Back to this question in Part A*

@Neet_pg_bot

Q8: Which of the following is the most common complication of blood transfusion? (Q845938)

A. TRALI

B. TACO

C. Delayed Hemolytic Reaction

D. Febrile Non-hemolytic reaction

Correct Answer: D. Febrile Non-hemolytic reaction

Explanation: Febrile non-hemolytic transfusion reactions (FNHTRs) are the most common complication of blood transfusions. These reactions typically occur when the recipient's immune system responds to the transfused blood product's white blood cells or cytokines. FNHTRs are characterised by fever and chills during or shortly after a transfusion. TRALI (Transfusion-related acute lung injury) (Option A) is a severe transfusion reaction causing acute non-cardiogenic pulmonary edema within 6 hours due to donor antibodies or bioactive substances. TACO (Transfusion-associated circulatory overload) (Option B) results from rapid or excessive transfusion, causing circulatory overload and pulmonary edema from raised pulmonary pressure. Delayed hemolytic reactions (Option C) arise days to weeks post-transfusion, causing mild fever, jaundice, and gradual hemoglobin drop.

References:

Harmening, D. M. (2012). Modern Blood Banking & Transfusion Practices (6th ed.).

↑ *Back to this question in Part A*

@Neet_pg_bot

Q9: Which of the following is defined as a massive blood transfusion? (Q845939)

A. Replacement of whole blood volume within 12 hours

B. Replacement of whole blood volume within 48 hours

C. Replacement of whole blood volume within 24 hours

D. Replacement of whole blood volume within 4 hours

Correct Answer: C. Replacement of whole blood volume within 24 hours

Explanation: Massive blood transfusion replaces a patient's total blood volume within 24 hours. This is usually around 10 units of red blood cells (RBCs) in adults. Massive transfusion is defined as: Transfusion of ≥1 blood volume (~10 units PRBC) in 24 hours ≥4 units PRBC in 1 hour with ongoing need >50% blood volume replaced within 3 hours Indications of Massive Transfusion: Trauma - Polytrauma, road traffic accidents Obstetric hemorrhage - PPH, placenta previa, abruption Surgical bleeding GI bleeding - Variceal bleed, peptic ulcer Coagulopathy - DIC, liver failure Balanced transfusion approach (Damage control resuscitation): PRBC, Fresh frozen plasma and Platelets in typical ratio of 1 : 1 : 1. Complications of Massive Blood Transfusion: Hematological Complications: Dilutional thrombocytopenia Dilutional coagulopathy Disseminated intravascular coagulation Metabolic Complications: Hypocalcemia - Citrate in blood binds Ca^{2}■ Hyperkalemia - Potassium leaks from stored RBCs Metabolic alkalosis - Citrate is converted into bicarbonate Metabolic acidosis - Poor perfusion, shock Temperature-related: Hypothermia - Cold stored blood (2–6°C) Respiratory Complications: Transfusion-related acute lung injury Transfusion-associated circulatory overload Immunological Complications: Acute hemolytic transfusion reaction - ABO incompatibility Febrile non-hemolytic reaction - Cytokine-mediated Allergic reactions - Urticaria, anaphylaxis

References:

Harmening, D. M. (2012). Modern Blood Banking & Transfusion Practices (6th ed.).

↑ *Back to this question in Part A*

@Neet_pg_bot

Q10: All of the following are complications of massive blood transfusion except? (Q845941)

A. Metabolic Alkalosis

B. Metabolic Acidosis

C. Hyperkalemia

D. Hypocalcemia

Correct Answer: B. Metabolic Acidosis

■ *Listen (English)*

■ *Listen (Hindi)*

Explanation: Metabolic acidosis can occur in the setting of shock and hypoperfusion rather than directly from the transfusion itself, so it is not likely seen in massive blood transfusion. In massive blood transfusion, the anticoagulant citrate is transfused along with blood. Citrate stimulates bicarbonate production, leading to metabolic alkalosis (Option A) . It also chelates calcium, causing hypocalcemia (Option D) . In stored blood, red

cell breakdown releases potassium, resulting in hyperkalemia (Option C) .

References:

Harmening, D. M. (2012). Modern Blood Banking & Transfusion Practices (6th ed.).

↑ *Back to this question in Part A*

@Neet_pg_bot

Q11: Which of the following is a characteristic feature of Transfusion-Related Acute Lung Injury (TRALI)? (Q845942)

A. Non-cardiogenic pulmonary edema within 6 hours of transfusion

B. Cardiogenic pulmonary edema within 24 hours of transfusion

C. Acute onset of fever and chills without respiratory symptoms

D. Gradual onset of jaundice and anemia several days after transfusion

Correct Answer: A. Non-cardiogenic pulmonary edema within 6 hours of transfusion

Explanation: TRALI is characterised by acute onset of respiratory distress and non-cardiogenic pulmonary edema occurring within 6 hours of a blood transfusion. It is caused by an immune reaction to donor antibodies or bioactive substances in the transfused blood. Characteristics: Onset: TRALI typically occurs within 6 hours of transfusion. Symptoms: Sudden onset of dyspnea (shortness of breath). Hypoxemia (low blood oxygen levels) Fever. Hypotension. Bilateral pulmonary infiltrates on a chest X-ray, indicating fluid accumulation in the lungs without cardiac cause. TACO is a transfusion reaction with respiratory distress and cardiogenic pulmonary edema within 24 hours due to circulatory fluid overload. (Option B) . Febrile non-hemolytic transfusion reactions present with acute fever and chills without respiratory distress. (Option C) Delayed hemolytic transfusion reactions present days to weeks later with gradual jaundice and anemia. (Option D) Note: Multigravida women develop anti-HLA antibodies during pregnancy due to exposure to fetal antigens. If such plasma is transfused, the antibodies react with recipient leukocytes and will lead to TRALI. Hence blood banks prefer male plasma donors and screen female donors for HLA antibodies. Thalassemia patients are at increased risk of immune-mediated reactions including TRALI, since they receive repeated transfusions and hence an increased exposure to donor antibodies

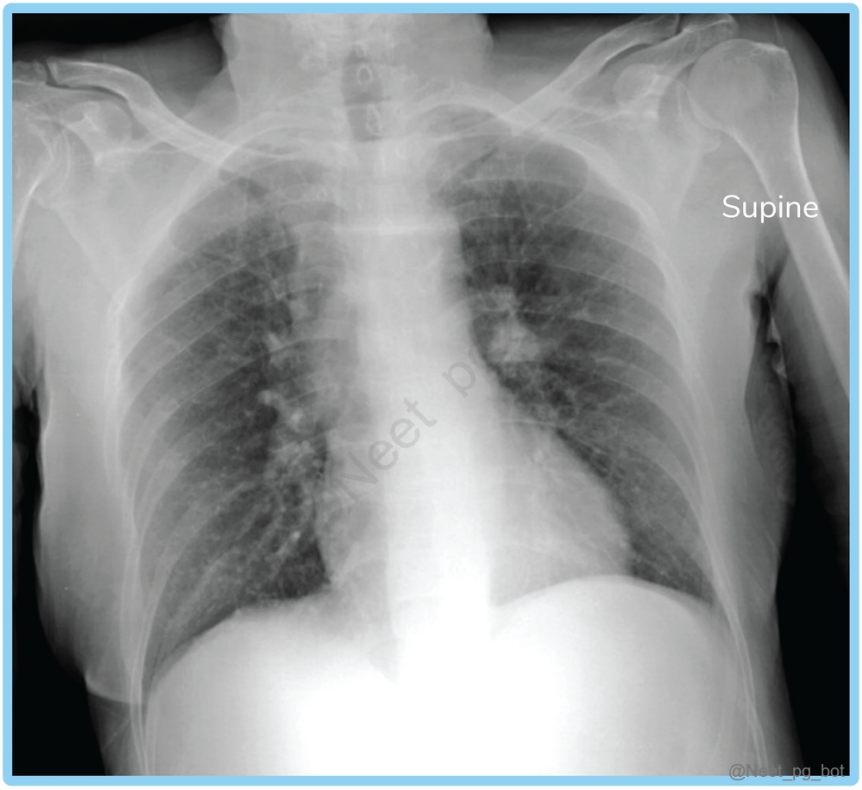

References:

Harmening, D. M. (2012). Modern Blood Banking & Transfusion Practices (6th ed.).

↑ *Back to this question in Part A*

@Neet_pg_bot

• [20_Blood Banking and Transfusion Medicine] 081 Previous Year Questions

« Back to Folder Directory

[20_Blood Banking and Transfusion Medicine] 081 Previous Year Questions — Quick Jump

Q1 (p. 3136) *Q2 (p. 3137)* *Q3 (p. 3138)* *Q4 (p. 3139)* *Q5 (p. 3139)* *Q6 (p. 3140)*

Q1: A 28-year-old woman with a known history of beta-thalassemia undergoes a blood transfusion. During the transfusion, she develops symptoms of anxiety, hypotension, and fever. What is the next appropriate step in the management of this patient? (Q860282)

A. Stop the blood transfusion and restart after stabilization

B. Continue the blood transfusion and perform an ECG

C. Investigate for clerical errors in the blood transfusion process

D. Administer corticosteroids and monitor vital signs

Correct Answer: A. Stop the blood transfusion and restart after stabilization

Explanation: In a woman with beta-thalassemia experiencing anxiety, hypotension, and fever during transfusion, the immediate step is to stop the transfusion and ensure stabilization. Transfusion Reactions: It refers to an adverse response to blood components, which can be Immunologically mediated (via WBC) Related to infections. It can either be immediate or delayed. Aspect Immediate Transfusion Reactions Delayed Transfusion Reactions Onset Time Within hours of transfusion Days to weeks after transfusion Cause Immunologic reactions, hemolytic or non-hemolytic Immune-mediated, often involving minor antigen sensitization Presentation Fever, chills, Dyspnea (TRALI, TACO), Acute respiratory distress (TRALI), Pulmonary oedema (TACO), hypothermia, electrolyte abnormalities, coagulopathy, acid-base disorders and hyperkalemia Fever, jaundice, Gradual decline in haemoglobin levels (hemolysis) Severity Can range from mild to life-threatening Generally less severe than immediate reactions Examples Febrile non-hemolytic reaction (FNHTR) Transfusion-related acute lung injury (TRALI) Transfusion-associated circulatory overload (TACO) Delayed hemolytic reaction Management Stop the blood transfusion. Supportive care. Three samples are to be collected Blood 1st sample: For BG/CM (blood grouping - cross matching) (EDTA vial) 2nd sample: Biochemical test for hemolysis (plain red vial) Urine Test for hemoglobinuria (hemolysis). Continue the blood transfusion and perform an ECG (Option B) : Continuing the transfusion could worsen the reaction. The first step in managing a suspected transfusion reaction is stopping the transfusion. Investigate for clerical errors in the blood transfusion process (Option C) : While clerical errors (e.g., blood type mismatch) are important to rule out, the immediate priority is to stop the transfusion and stabilize the patient before investigating further. Administer corticosteroids and monitor vital signs (Option D) : Corticosteroids may be used in certain reactions (such as allergic reactions), but the first step should be stopping the transfusion

and addressing any immediate complications (e.g., hypotension, fever). Corticosteroids are not the first-line treatment for most transfusion reactions.

References:

Robbins & Cotran Pathological Basis of Diseases, 10th Edition, Page 671-672.

Harrison's Principles of Internal Medicine, 21st Edition, Page 893-895.

Harmening, D. M. (2012). Modern Blood Banking & Transfusion Practices (6th ed.).

↑ *Back to this question in Part A*

@Neet_pg_bot

Q2: Blood transfusion requires screening of donor blood for all of the following infections except: (Q855917)

A. Hepatitis C virus

B. Dengue virus

C. HIV virus

D. Hepatitis B virus

Correct Answer: B. Dengue virus

Explanation: Dengue fever is a viral illness transmitted by Aedes mosquitoes . Unlike some other diseases listed, routine screening for dengue in donated blood is not typically performed. This is because mosquitoes primarily transmit dengue rather than through blood transfusions. Screening for transfusion-transmitted infections: The following infections can be transmitted by blood transfusion. Viral Bacterial Parasites Others Hepatitis (A, B, C, G) HIV (I & II) HTLV (I & II) CMV EBV Parvovirus B19 Syphilis Malaria Babesiosis Trypanosoma cruzi Creutzfeldt- Jakob disease Plasma processing methods have been shown to inactivate most recognized infectious organisms, except for non-lipid-enveloped viruses and prions. All clinically relevant blood components transmit prion disease following a single blood transfusion. Malaria can also be transmitted by most blood components (red cells, platelets, white-cell concentrates, cryoprecipitates, and frozen red cells after thawing and washing). Transmission from single-donor FFP has not been reported. In India, the following five diseases are screened: HBV (Option D) HCV (Option A) HIV (Option C) Malaria Syphilis Screening for the diseases mentioned above is mandatory , and transfusing unscreened blood is a medical offence.

References:

Robbins & Cotran Pathologic Basis of Disease, 10th Edition, Page 672

Wintrobe Haematology, 14th Edition, Page 1869-1876

https://www.ncbi.nlm.nih.gov/pmc/articles/PMC2937300/

https://pubmed.ncbi.nlm.nih.gov/21858015/

↑ *Back to this question in Part A*

@Neet_pg_bot

Q3: A patient has been brought with severe bleeding to your ER. His blood group is unknown. Fresh frozen plasma from which of the following blood groups can be given? (Q855120)

A. O

B. AB

C. B

D. A

Correct Answer: B. AB

Explanation: In the given scenario where the blood group is unknown, fresh frozen plasma from blood group AB can be safely administered to the patient. Blood group AB individuals are considered universal plasma donors because their plasma lacks both A and B antibodies, making it compatible with recipients of any ABO blood type without causing an ABO incompatibility reaction. The differences between Rh Blood Group and ABO Blood Group: Properties ABO system Rh system Blood groups A, B, AB, and O Rh-positive & negative Genetic loci On chromosome 9 On chromosome 1 Ag and Ab Group Antigen Antibody C, c, D, E, & e antigens. ‘d’ indicates the absence of D. Most important: Anti-D antibody. O H Anti-A & anti-B A A Anti-B B B Anti-A AB A & B None Antigens also seen on/in Endothelial & epithelial cells, plasma, saliva, and semen (not seen in CSF) No other cells Type of Ab IgM (naturally occurring). IgG (does not occur naturally). Clinical significance Anti-A & anti-B can cause severe intravascular haemolysis after incompatible transfusion. ABO-matching is required before the transplantation of solid organs. Rh -ve individuals make anti-D Ab if: Transfused with Rh +ve blood. Rh -ve pregnant women are exposed to Rh +ve fetal RBCs that have crossed the placenta.

References:

Harrison’s Principles of Internal Medicine, 21st Edition, Page 887.

Guyton and Hall Textbook of Medical Physiology, 14th Edition, Page 472.

Blood Safety and Matching - Hematology.org

Why is O+ blood often given in an emergency? - Bloodworks Northwest Blog

↑ *Back to this question in Part A*

@Neet_pg_bot

Q4: Which of the following can be prevented by transfusing irradiated RBCs? (Q856715)

A. Graft versus host disease

B. HLA alloimmunization

C. Immunomodulation

D. Nonhemolytic Febrile Transfusion Reactions

Correct Answer: A. Graft versus host disease

Explanation: Transfusion of irradiated red blood cells (RBCs) can prevent graft versus host disease (GVHD). Steps for Production of Red Blood Cell Concentrates (RBCC) from Whole Blood 1 Whole Blood Collection Blood is drawn into sterile bags with anticoagulants to prevent clotting. Each unit contains 450-500 mL. (First 20-30 ml is discarded due to skin flora contamination) 2 Slow Speed Centrifugation (Soft Spin) Separates Red Blood Cell Concentrate (RBCC) at the bottom and Platelet-Rich Plasma (PRP) at the top, with the buffy coat (white blood cells) in between. 3 RBCC Processing and Additive Solutions After removing plasma and buffy coat, additive solutions like SAGM (Saline, Adenine, Glucose, Mannitol) or CPD are added to preserve cell viability and extend shelf life. 4 Leukoreduction/ Deleucocytation Achieved by filtering RBCC to remove >99.9% of white blood cells. Purpose: Nonhemolytic Febrile Transfusion Reactions (NHFTRs) . (Option D ruled out) Alloimmunization and platelet transfusion refractoriness. (Option B ruled out) Transfusion-transmitted infections, such as cytomegalovirus (CMV). Immunomodulation risks from transfusions (Option C ruled out) Post-reduction leukocyte content: <1–5 x 10■ leukocytes/unit. 5 Irradiation (Optional) RBCC is irradiated with X-rays or gamma rays (25–35 Gy). Purpose: Prevents graft-versus-host disease (GVHD) by inactivating donor lymphocytes. (Option A) Use: RBCC must be transfused within 24 hours post-irradiation. 6 Plasma Reduction (Optional) Plasma proteins are removed to prevent allergic or anaphylactic reactions. Purpose: Useful for patients with a history of allergic transfusion reactions, reducing post-transfusion anaphylaxis risk. 7 Cryopreservation (Optional) RBCC is cryopreserved at -80°C, mainly for rare blood types. Purpose: Extends shelf life up to 30 years, increasing availability of rare blood groups.

References:

Harrison's Principles of Internal Medicine, 21st Edition, Page 884,885,886

Davidson's Principles and Practice of Medicine, 24th Edition, Page 930,931,932.

↑ *Back to this question in Part A*

@Neet_pg_bot

Q5: A 24-year-old man, after being involved in a road traffic accident (RTA), was brought to the casualty 6 hours later. His B.P. was 90/60 mm Hg, heart rate was

110/min, and SpO2 was 92%. A blood transfusion was administered. A few hours later, the patient becomes febrile and tachypneic and starts bleeding from the IV and NG tube sites. His SpO2 levels begin to drop. What is the likely cause? (Q856483)

A. Transfusion reaction

B. Acute adrenal crisis

C. Fat embolism

D. Hemorrhagic shock

Correct Answer: A. Transfusion reaction

Explanation: The patient's fever, tachypnea, bleeding from IV and NG tube sites, and declining SpO2 after transfusion suggest an acute transfusion reaction, likely due to an immune response causing hemolysis, shock, and DIC. Types of Transfusion reactions Aspect Immediate Transfusion Reactions Delayed Transfusion Reactions Onset Within hours of transfusion Days to weeks after transfusion Cause Immunologic reactions, hemolytic or non-hemolytic Immune-mediated, often involving minor antigen sensitization Presentation Fever, chills, dyspnea (TRALI, TACO), Acute respiratory distress (TRALI), Pulmonary oedema (TACO), hypothermia, electrolyte abnormalities, coagulopathy , acid-base disorders and hyperkalemia. Fever, jaundice, gradual decline in haemoglobin levels (hemolysis). Severity Can range from mild to life-threatening. Generally less severe than immediate reactions. Examples Febrile non-hemolytic reaction (FNHTR) Transfusion-related acute lung injury (TRALI) Transfusion-associated circulatory overload (TACO) Delayed hemolytic reaction Management Stop transfusion and manage symptoms. Supportive care (e.g., antipyretics, oxygen). Monitor for worsening anaemia and hemolysis. Consider further transfusion support if indicated.

References:

Robbins & Cotran Pathologic Basis of Disease, 10th Edition, Page 671, 672

Harmening, D. M. (2012). Modern Blood Banking & Transfusion Practices (6th ed.)

↑ *Back to this question in Part A*

@Neet_pg_bot

Q6: Which of the following statement regarding blood donation is incorrect? (Q858506)

A. Voluntary blood donation day - 1st october

B. People aged 18-65yrs with comorbidities can not donate blood

C. For people with body weight >55 kg, 49 ml of anticoagulant is required

D. All are correct

Correct Answer: C. For people with body weight >55 kg, 49 ml of anticoagulant is required

Explanation: For people with body weight >55 kg, 63 ml of anticoagulant is required For people with body weight 45-55 kg, 49 ml of anticoagulant is required

References:

Prepladder notes

↑ *Back to this question in Part A*

@Neet_pg_bot

• [21_Bone Disorders] 082 Bone And Soft Tissue Pathology - I

« Back to Folder Directory

[21_Bone Disorders] 082 Bone And Soft Tissue Pathology - I — Quick Jump

Q1 (p. 3142)	*Q2 (p. 3143)*	*Q3 (p. 3144)*	*Q4 (p. 3146)*	*Q5 (p. 3148)*	*Q6 (p. 3152)*
Q7 (p. 3156)	*Q8 (p. 3157)*	*Q9 (p. 3159)*	*Q10 (p. 3160)*	*Q11 (p. 3162)*	*Q12 (p. 3163)*
Q13 (p. 3165)	*Q14 (p. 3166)*	*Q15 (p. 3168)*	*Q16 (p. 3169)*	*Q17 (p. 3172)*	*Q18 (p. 3175)*
Q19 (p. 3176)	*Q20 (p. 3177)*				

Q1: A patient who presents with a painful, progressively enlarging growth from her left upper tibia is suspected to have chondrosarcoma and subjected to a biopsy and examination. The report states, “presence of osteoclast-type giant cells with intralesional bone formation”. Which of the following types of chondrosarcoma does this patient have? (Q845700)

A. Conventional

B. Mesenchymal

C. Clear cell

D. Dedifferentiated

Correct Answer: C. Clear cell

Explanation: The presence of osteoclast-type giant cells with intralesional bone formation is seen in clear-cell chondrosarcoma. Chondrosarcoma: Chondrosarcomas are malignant cartilage tumors, often with IDH1/IDH2 mutations, mainly affecting males over 40 usually arising in the axial skeleton (pelvis, shoulder, ribs) Clear cell and mesenchymal types occur in younger patients. Characteristic popcorn-like calcifications appear in the cartilage matrix, and histologically they are classified into 4 types: Conventional (Option A): Neoplastic cartilage invades marrow and surrounds bony trabeculae. Dedifferentiated (Option D): Low-grade chondrosarcoma can have a high-grade, non-cartilage-producing component. Clear-cell (Option C): Contains large malignant chondrocytes with clear cytoplasm, many osteoclast-like giant cells, and intralesional bone formation. Mesenchymal (Option B): Composed of islands of hyaline cartilage amid primitive small round cells.

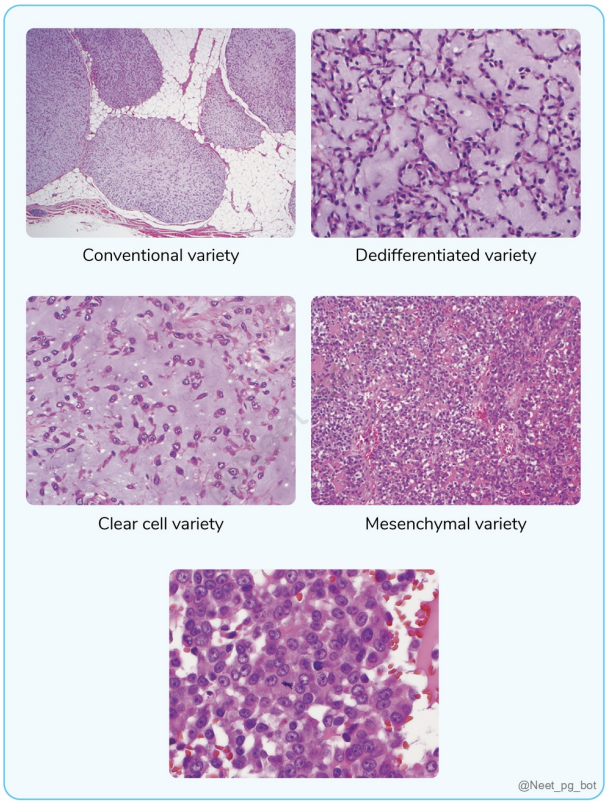

References:

Robbins and Cotran Pathologic Basis of Diseases 10th edition, page 1191,1192

↑ *Back to this question in Part A*

@Neet_pg_bot

Q2: Match the tumours in column A to their genetic alterations in Column B Tumor Translocation A) Ewing's Sarcoma 1) t(x;18) B) Rhabdomyosarcoma 2) t(12;16) C) Liposarcoma 3) t(1;13) D) Synovial Sarcoma 4) t(11;22) (Q845734)

A. A-4, B-2, C-3, D-1

B. A-4, B-3,C-1, D-2

C. A-4, B-3, C-2, D-1

D. A-3, B-4, C-1, D-2

Correct Answer: C. A-4, B-3, C-2, D-1

■ *Listen (English)*

■ *Listen (Hindi)*

Explanation: Tumour Translocation Ewing's Sarcoma t(11;22) Rhabdomyosarcoma t(1;13) t(2;13) Liposarcoma t(12;16) Synovial Sarcoma t(x;18) Tumor Translocation Fusion Gene / Molecular Event Pathogenesis / Key Details High-Yield Ewing's Sarcoma t(11;22)(q24;q12) EWSR1–FLI1 EWSR1 (Chr 22) fuses with FLI1 (Chr 11) → aberrant transcription factor → oncogenesis Most common Ewing fusion (~85%); CD99+, small round blue cell tumor Desmoplastic Small Round Cell Tumor t(11;22)(p13;q12) EWSR1–WT1 EWSR1 fused with WT1 → transcriptional dysregulation Polyphenotypic IHC; young males; peritoneal masses Extra-skeletal Myxoid Chondrosarcoma t(9;22) EWSR1–NR4A3 (CHN) Fusion activates transcription factor NR4A3 Myxoid matrix; indolent but metastatic potential Synovial Sarcoma t(X;18)(p11;q11) SS18–SSX1 / SSX2 SS18 (Chr 18) fuses with SSX (X-chr) → chromatin remodelling alteration Biphasic or monophasic; TLE1+; young adults Alveolar Soft Part Sarcoma t(X;17)(p11;q25) ASPSCR1–TFE3 TFE3 transcription factor overexpression PAS+ crystals; slow growing but highly metastatic Infantile Fibrosarcoma t(12;15) ETV6–NTRK3 Constitutive tyrosine kinase activation NTRK inhibitor sensitive (Larotrectinib) Myxoid Liposarcoma t(12;16)(q13;p11) FUS–DDIT3 (CHOP) Abnormal adipocytic differentiation Most common liposarcoma subtype Alveolar Rhabdomyosarcoma t(2;13) or t(1;13) PAX3–FOXO1 / PAX7–FOXO1 Fusion transcription factor → aggressive phenotype Worse prognosis vs embryonal type Dermatofibrosarcoma Protuberans t(17;22) COL1A1–PDGFB PDGFB overexpression → autocrine growth Imatinib responsive Nodular Fasciitis t(17;22) USP6 rearrangement USP6 activation → transient proliferation Self-limiting; reactive lesion mimic

References:

Robbins and Cotran, Pathologic Basis of Disease, 10th Edition, Pages 1192, 1209, 1212, 1213

↑ *Back to this question in Part A*

@Neet_pg_bot

Q3: A 55-year-old male, presents with a sudden onset of severe pain, redness, and swelling in his right big toe. The right big toe is red, swollen, and extremely tender to touch. There is no fever or other systemic symptoms. He enjoys red meat and seafood, and he drinks alcholol regularly. All of the following are true about his diagnosis except? (Q845728)

A. Deposition of monosodium urate crystals in joints.

B. Thiazide diuretics can precipitate attacks.

C. Rhomboid-shaped, weakly positively birefringent under polarised light confirms the diagnosis.

D. Elevated uric acid levels.

Correct Answer: C. Rhomboid-shaped, weakly positively birefringent under polarised light confirms the diagnosis.

■ *Listen (English)*

■ *Listen (Hindi)*

Explanation: Correct Option: C) Rhomboid-shaped, weakly positively birefringent under polarised light confirms the diagnosis. Explanaiton: The patient's presentation is suggestive of acute gout. Feature Gout Pseudogout Aetiology Deposition of monosodium urate (MSU) crystals in the joint. (Option A) Deposition of calcium pyrophosphate dihydrate (CPPD) crystals Commonly Affected Joints First metatarsophalangeal joint (big toe), ankles, knees Knees, wrists, hips, shoulders, elbows Crystal Characteristics Needle-shaped, negatively birefringent under polarised light Rhomboid-shaped, weakly positively birefringent under polarised light (Option 3) Serum Findings Elevated uric acid levels (Option D) Often, normal calcium and phosphorus levels Risk Factors High purine diet, alcohol consumption, obesity, diuretics (thiazides & loop diuretics) (Option B) , genetic predisposition Age, joint trauma, familial predisposition, metabolic disorders (e.g., hyperparathyroidism, hemochromatosis) Acute Attack Presentation Sudden, severe pain, redness, swelling, and warmth in the affected joint Sudden, severe pain, redness, swelling, and warmth in the affected joint



@Neet_pg_bot



References:

Robins and Cotran Pathologic Basis of Disease, 10th Edition, Page 1204

↑ *Back to this question in Part A*

@Neet_pg_bot

Q4: All of the following are true about rhabdomyosarcoma except? (Q845726)

A. It is the most common soft tissue sarcoma in children.

B. Positive IHC staining for desmin and myogenin.

C. It commonly presents in the extremities of children and adolescents.

D. It has a benign clinical course and rarely metastasizes.

Correct Answer: D. It has a benign clinical course and rarely metastasizes.

■ *Listen (English)*

■ *Listen (Hindi)*

Explanation: Rhabdomyosarcoma is also known as Sarcoma botryoids (Bunch of grapes)/Embryonal RMS It is a malignant tumour arising from skeletal muscle progenitors. It is the most common soft tissue sarcoma in children and adolescents (Option 1). It commonly presents in the extremities (Option 3). The tumours are often large, soft, and infiltrative, with areas of necrosis and haemorrhage. Microscopy: Small, round to spindle-shaped cells with hyperchromatic nuclei and scant cytoplasm , sometimes with a myxoid stroma are also seen. IHC Positive Markers: Desmin , myogenin , MyoD1 , and muscle-specific actin (Option 2). Rhabdomyosarcoma has an aggressive clinical course and can metastasise, particularly to the lungs, bone marrow, and lymph nodes. Common locations and symptoms: Head and Neck: Often presents as a painless lump, but can cause nasal congestion, ear discharge, or headaches. Orbit (Eye): Causes rapid bulging of the eye (proptosis), swelling, or double vision. Genitourinary: May cause hematuria, difficulty urinating, or a vaginal/scrotal mass. Extremities: Typically appears as a rapidly enlarging, firm, and sometimes painful mass on the arms or legs. Main subtypes: ■■■■■■■ Embryonal (ERMS): The most common type, usually affecting children under age 5. It often occurs in the head, neck, or pelvic organs Generally has a favorable prognosis . Alveolar (ARMS): More aggressive and common in teens/young adults. It often affects the trunk or limbs Frequently linked to specific gene fusions (PAX/FOXO1). Spindle Cell/Sclerosing: A rarer variant that can occur in both children (often paratesticular) and adults. Pleomorphic: Primarily affects adults over age 50 and is highly aggressive. Microscopic examination: Cambium layer (dense cellular layer) Strap cells (RMS)/Tennis racket appearance Tennis Racket: The image below shows alveolar rhabdomyosarcoma.

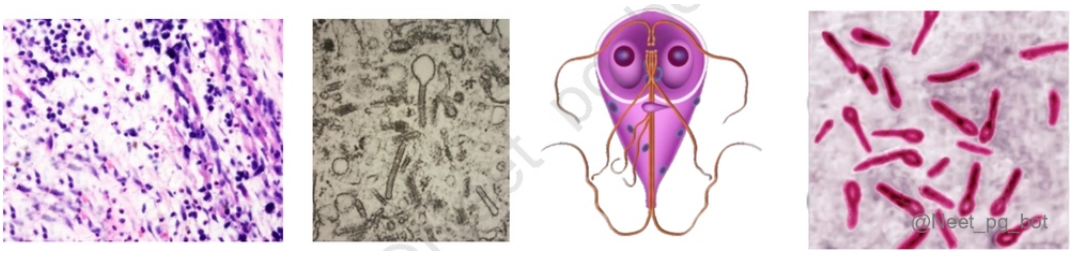

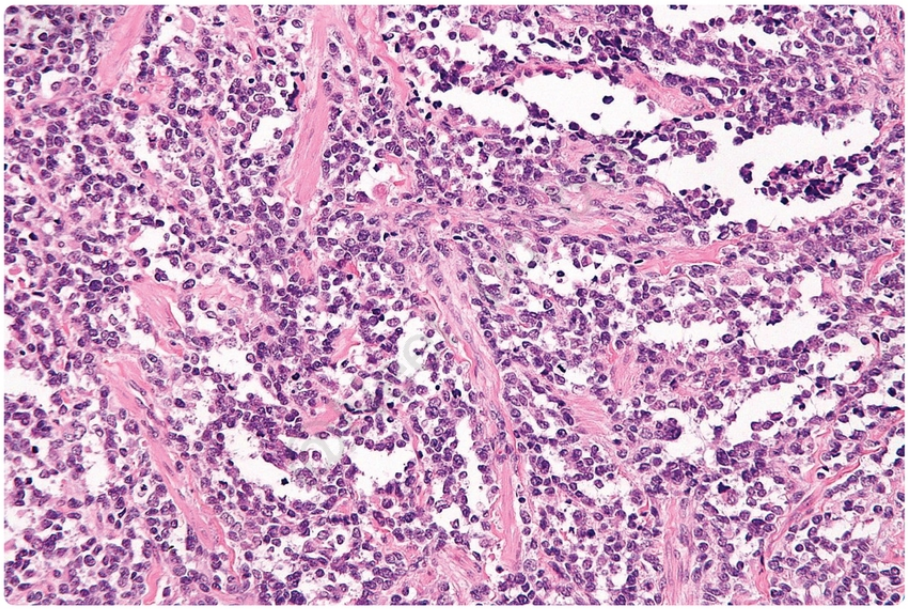

References:

Robins and Cotran Pathologic Basis of Disease, 10th Edition, Page1212

↑ *Back to this question in Part A*

@Neet_pg_bot

Q5: A 38-year-old female presents with a 6-month history of heavy menstrual bleeding and a sensation of pelvic pressure. She reports that her periods have become increasingly heavy. There is no significant past medical history, and she is not currently on any medication.Ultrasound reveals a heterogeneous, hypoechoic mass within the uterus. A histology image is given below. What is the most likely diagnosis? (Q845719)

A. Adenomyosis

B. Leiomyosarcoma

C. Endometrial carcinoma

D. Leiomyoma

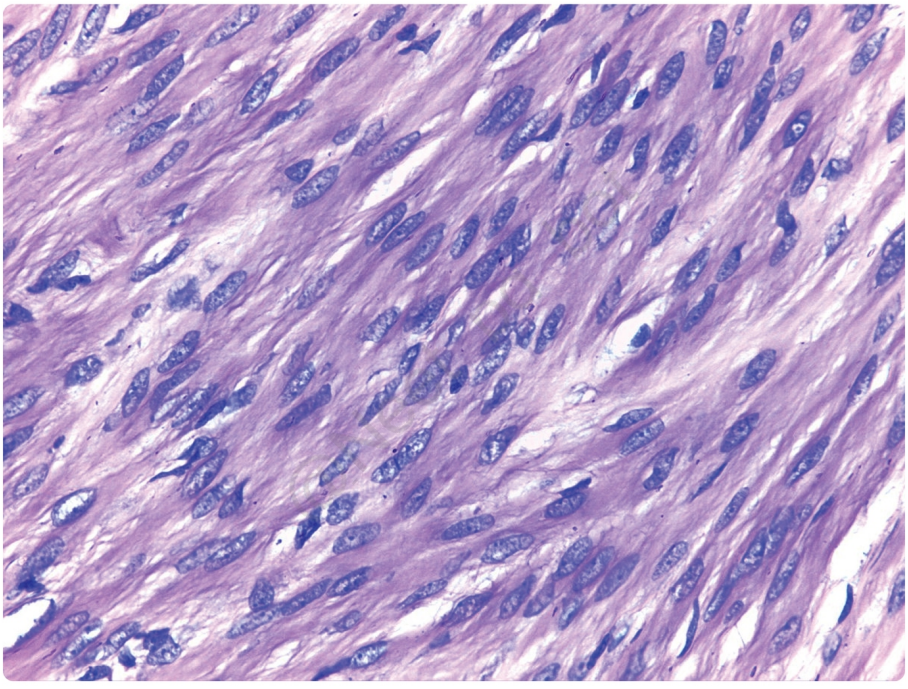

@Neet_pg_bot

Correct Answer: D. Leiomyoma

- *Listen (English)*
- *Listen (Hindi)*

Explanation: Leiomyoma, also known as a uterine fibroid , is a benign smooth muscle tumour that commonly occurs in the uterus. These tumors are composed of well-differentiated smooth muscle cells and are the most common benign tumours in women of reproductive age. Symptoms: Menorrhagia, pelvic pressure, and potential reproductive issues like infertility or miscarriage. Genetic Factors: Mutations in MED12 gene. Physical Exam: Presents as a firm, enlarged, irregularly shaped, non-tender uterus . Hormonal Influence: Their growth is highly influenced by estrogen and progesterone ; they typically regress after menopause. Leiomyomas have low mitotic activity. Degeneration: In pregnancy, fibroids may undergo Red (Carneous) Degeneration due to rapid growth outstripping blood supply, leading to acute pain. On biopsy: Spindle-shaped cells with blunt-ended nuclei (classical cigar-shaped nuclear appearance) are seen Cigar-shaped nuclei confirms a smooth muscle origin and can be seen in: Normal smooth muscle Benign smooth muscle tumors (leiomyoma) Malignant smooth muscle tumors (leiomyosarcoma) Distinction from Leiomyosarcoma: Unlike many other cancers, leiomyosarcomas typically arise de novo and not from a pre-existing benign fibroid. Malignancy is suspected if there is rapid post-menopausal growth or high mitotic figures on histology. Types of fibroids: Type Location High-Yield Clinical Points Submucosal Beneath the endometrium (protrudes into the uterine cavity). Most symptomatic: Associated with heavy/prolonged menstrual bleeding (menorrhagia) and infertility. Intramural Within the muscular wall (myometrium) of the uterus. Most common: Causes uterine enlargement and can lead to heavy bleeding or pelvic pressure. Subserosal Beneath the serosa (outer surface of the uterus). Pressure symptoms: Often asymptomatic regarding bleeding, but can cause frequent urination (bladder pressure) or constipation (rectal pressure). {{caption_text}} Adenomyosis (Option A): Typically presents with a uniformly enlarged, boggy uterus. Histologically shows endometrial glands and stroma within the myometrium, not just smooth muscle cells. Leiomyosarcoma (Option B): Histologically shows significant atypia, high mitotic rate, and areas of necrosis. Most important diagnostic criterion for leiomyosarcoma is the mitotic count and for diagnosis, we must see more than 10 mitoses per 10 high-power fields . Endometrial carcinoma (Option C): Typically presents with abnormal uterine bleeding, especially postmenopausal bleeding. Histology shows malignant endometrial glandular cells, not smooth muscle cells.


@Neet_pg_bot

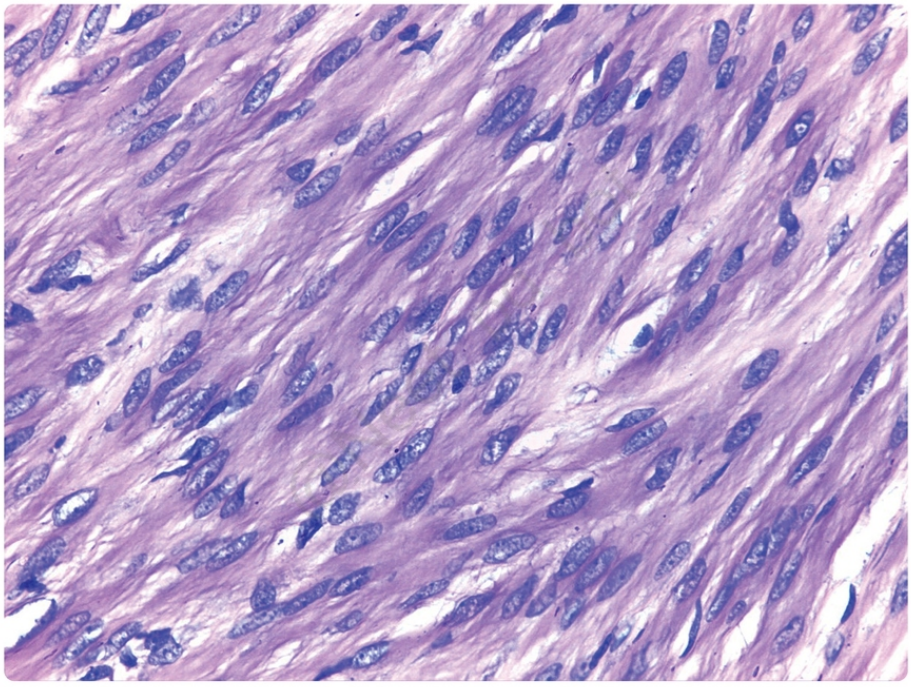
@Neet_pg_bot

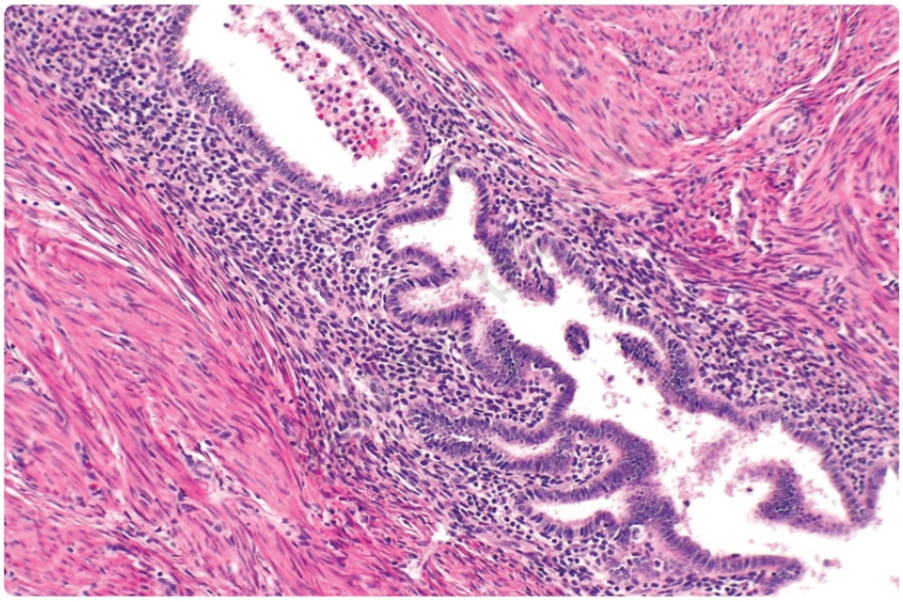

@Neet_pg_bot

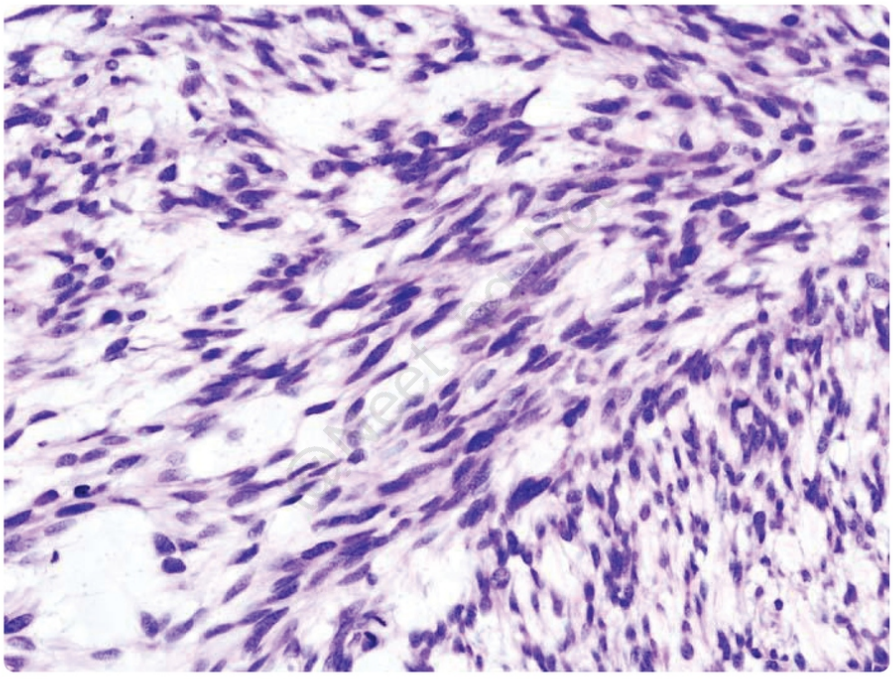

@Neet_pg_bot

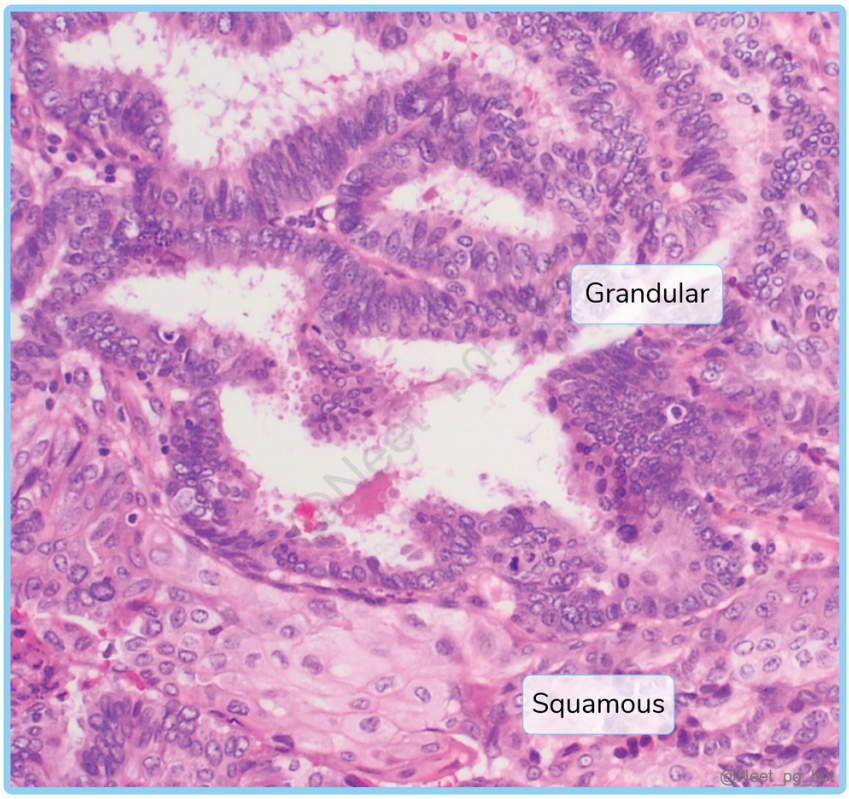

References:

Robins and Cotran Pathologic Basis of Disease, 10th Edition, Page 1014

↑ *Back to this question in Part A*

@Neet_pg_bot

Q6: A 65-year-old male presented with an enlarging mass in his left thigh for the last three months. Physical examination revealed a non-tender, palpable mass with indistinct borders. He has a prior history of mass excision in the same location. A biopsy of the lesion is obtained. Based on the presentation, which of the following is the most likely diagnosis? (Q845711)

A. Lipoma

B. Liposarcoma

C. Leiomyosarcoma

D. Rhabdomyosarcoma

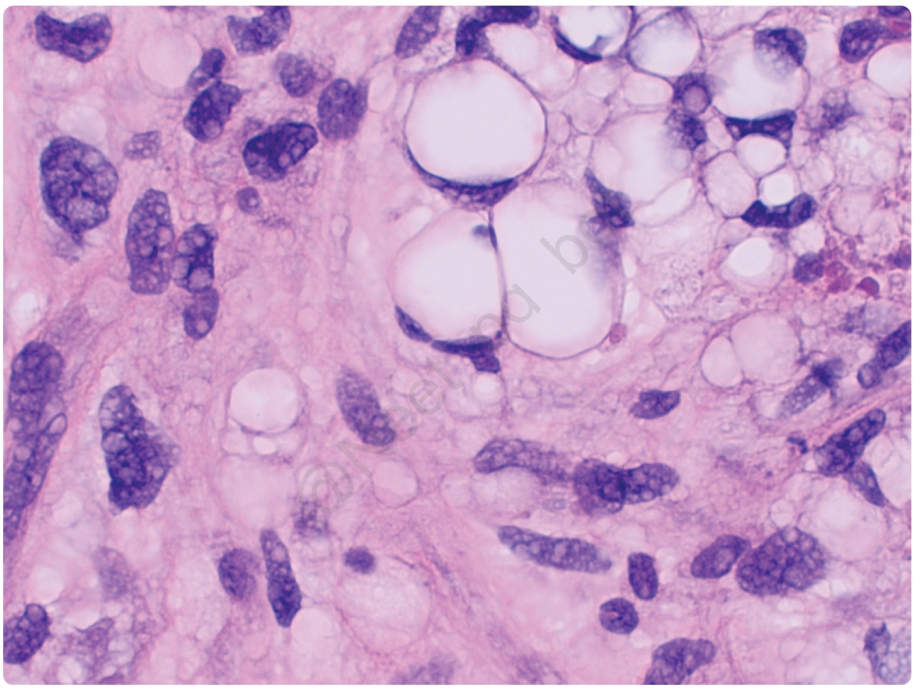

@Neet_pg_bot

Correct Answer: B. Liposarcoma

- *Listen (English)*
- *Listen (Hindi)*

Explanation: Liposarcoma: Malignant adipose tissue tumour. Most common adult sarcoma. Typically occur in the sixth and seventh decades. Develop in proximal extremities and retroperitoneum. Biopsy: The nucleus is very prominent and is indented to the corner by fatty vacuoles (lipoblasts). Subtype Genetic Feature Histological Hallmark Well-Differentiated MDM2 amplification (12q15) Looks like fat but has atypical stromal cells with enlarged nuclei. Myxoid t(12;16) (FUS-DDIT3) "Chicken-wire" capillary pattern and a myxoid (mucoid) matrix. Pleomorphic Complex karyotype High-grade, bizarre multinucleated giant cells; very aggressive. Lipoma (Option A): Lipoma is the benign soft tissue tumor of fat in adults and, upon biopsy, reveals clear cells (mature fat cells) with peripheral nuclei. Typically presents as a soft, mobile, painless mass in the subcutaneous tissue (back, neck, or proximal extremities). Gross Appearance: Well-circumscribed, encapsulated, bright yellow "greasy" mass. Histology: Consists of clusters of mature adipocytes that are indistinguishable from normal fat. They lack cellular atypia or increased mitotic activity. Genetics: Most common chromosomal abnormality involves 12q13-15 rearrangements. Leiomyosarcoma (Option C): Leiomyosarcomas are malignant, painless, firm masses arising from smooth muscle. These tumours are composed of eosinophilic spindle cells with blunt-ended, cigar shaped nuclei. Rhabdomyosarcoma (Option D): Fibrosarcoma is a malignant tumour of fibroblasts with a "herringbone" architecture.

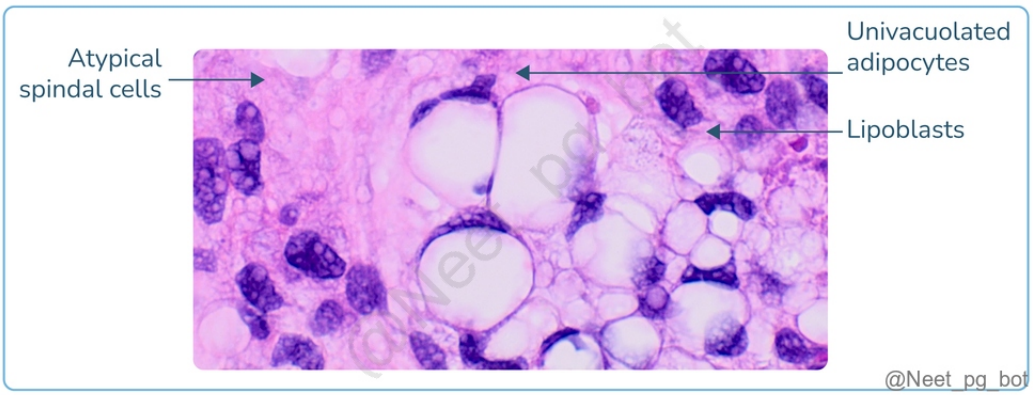
Atypical spindal cells
Univacuolated adipocytes
Lipoblasts
@Neet_pg_bot

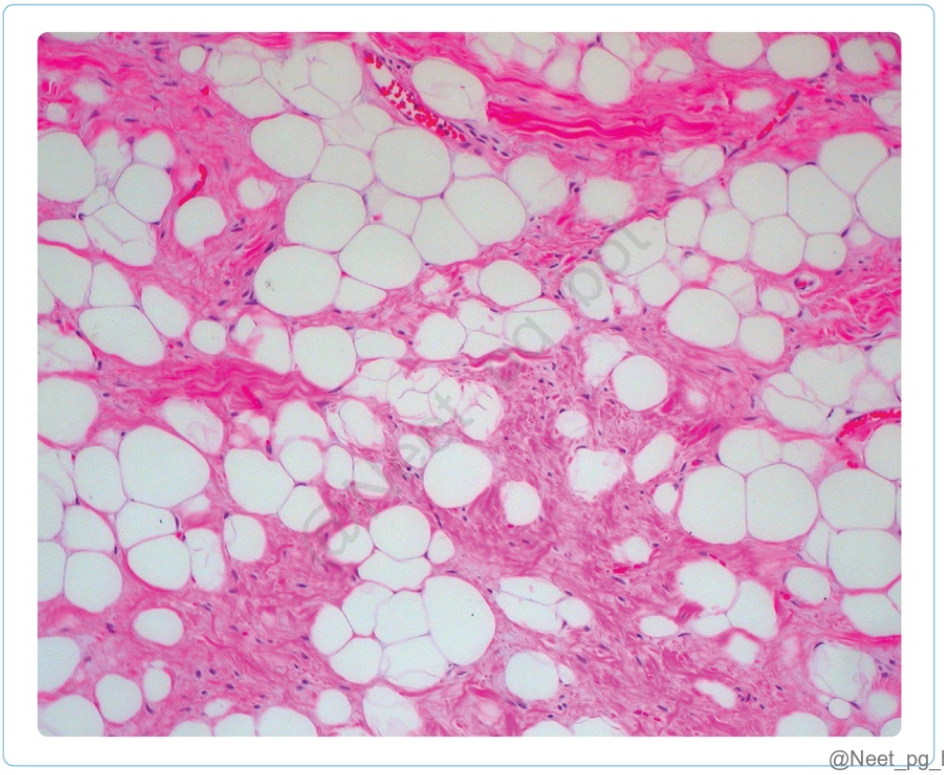
@Neet_pg_bot

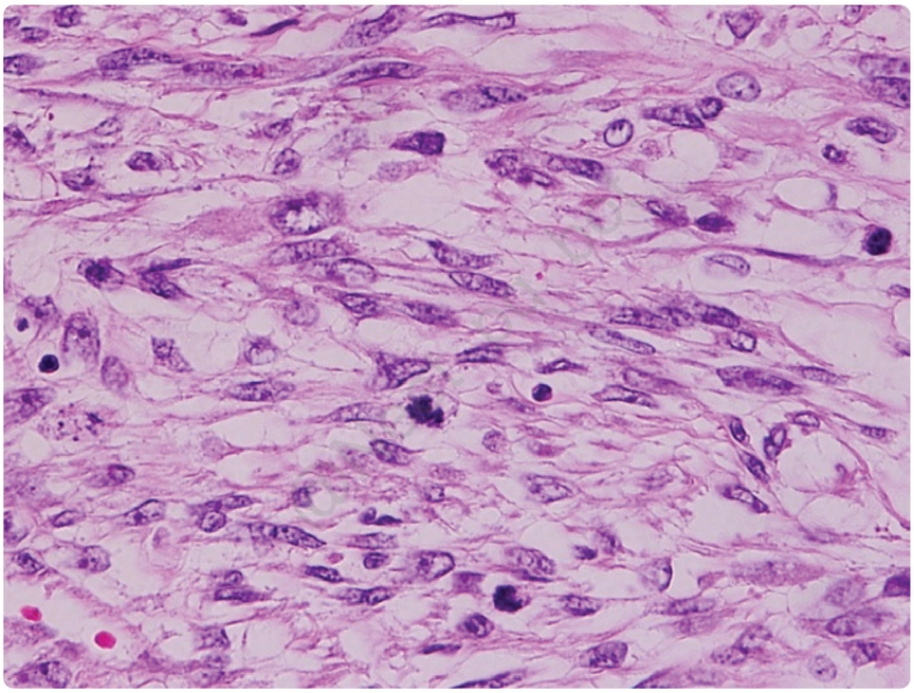

@Neet_pg_bot

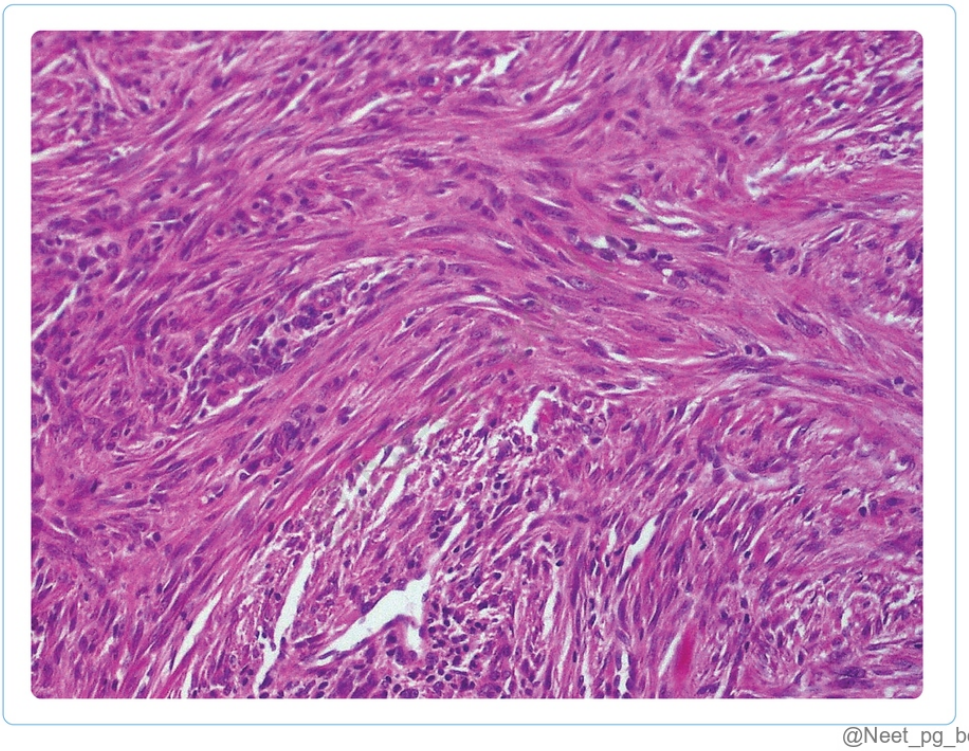

@Neet_pg_bot

References:

Robins and Cotran Pathologic Basis of Disease, 10th Edition, Page 1209-1210

↑ *Back to this question in Part A*

@Neet_pg_bot

Q7: A 17-year-old female presents with worsening pain in her right tibia over the past few months. On examination, there is tenderness and swelling over the proximal right tibia. Biopsy results show blood-filled cystic spaces lined by fibrous septa containing giant cells. All the following statements are true regarding this condition except? (Q845708)

A. Characterised by uniloculated blood-filled spaces with eggshell appearance on x-ray.

B. Often aggressively growing and are frequently discovered in vertebral bodies.

C. Majority cases are found associated with USP6 gene involvement in chromosome 17

D. Nearly one third patients have a distinctive basophilic metaplastic matrix known as blue bone

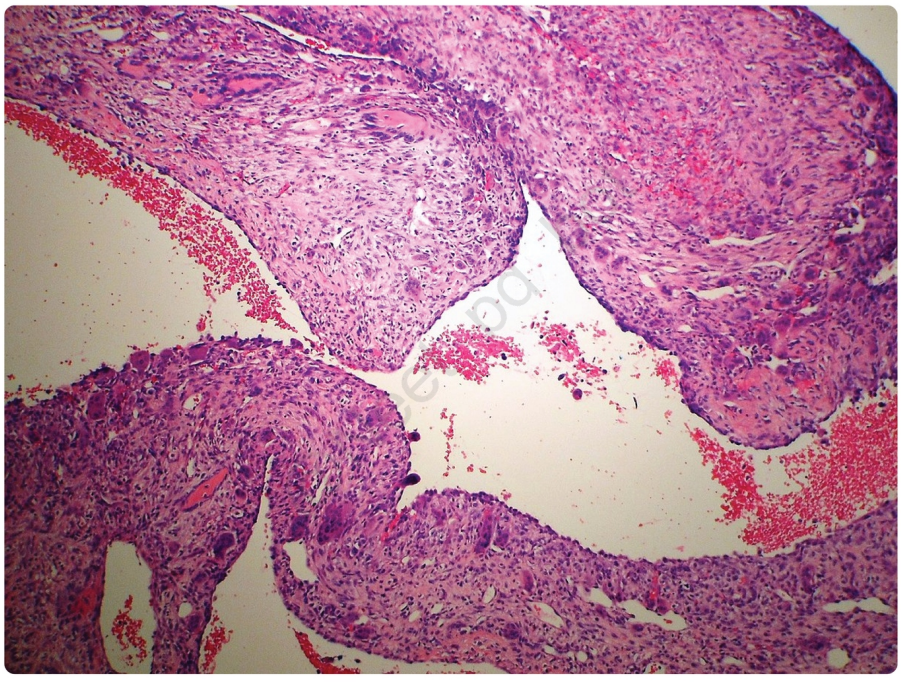

@Neet_pg_bot

Correct Answer: A. Characterised by uniloculated blood-filled spaces with eggshell appearance on x-ray.

Explanation: Aneurysmal Bone Cyst (ABC): Affects all age groups, with most cases in adolescence. Characterised by multiloculated blood-filled spaces (Option 1). Location: Femur, tibia, and posterior vertebral body (Option 2).

Genetics : Chromosome 17p13 rearrangements result in fusion of the USP6 coding region in 70% cases. (Option 3) Highly expressed osteoblast genes like CDH11. Biopsy: Blood-filled cystic spaces separated by thin, tan-white septa made up of spindle cells , osteoclast-like giant cells. Approximately one-third cases contain densely calcified, basophilic metaplastic matrix called blue bone (Option 4).

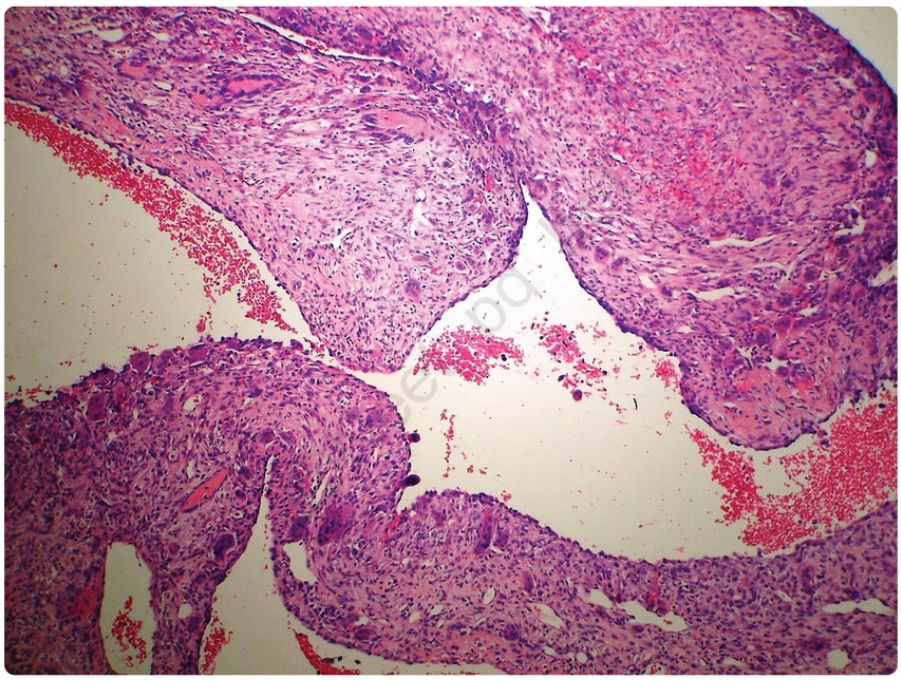

@Neet_pg_bot

References:

Robins and Cotran Pathologic Basis of Disease, 10th Edition, Page 1194-1195

↑ *Back to this question in Part A*

@Neet_pg_bot

Q8: A 14-year-old male presents with left knee pain for several months. Physical examination reveals tenderness and X-ray demonstrates metaphyseal lesion of the distal femur. A biopsy image of the lesion is shown. What is the most likely diagnosis? (Q845706)

A. Chondrosarcoma

B. Ewing sarcoma

C. Non-ossifying fibroma

D. Giant cell tumor of bone

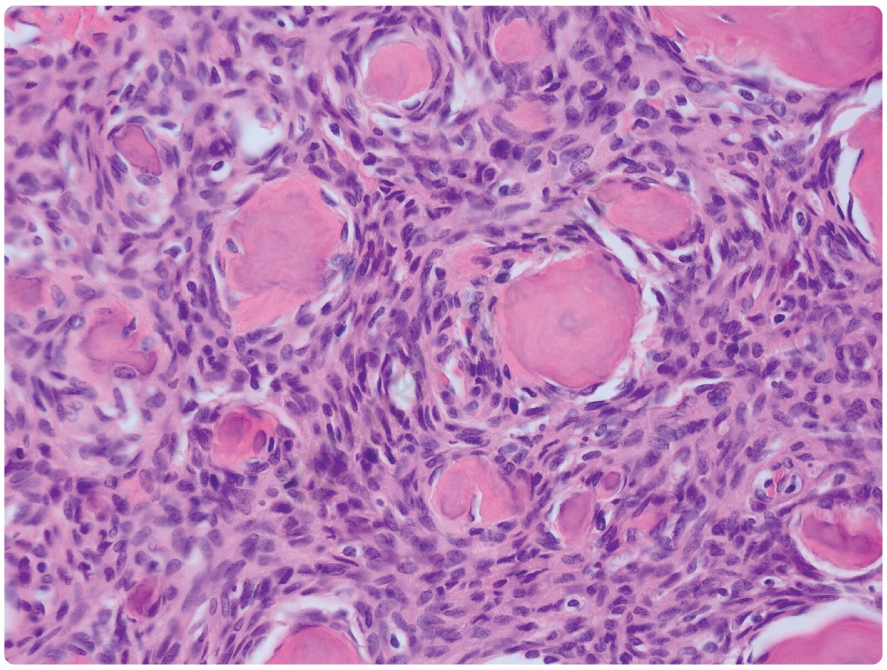

@Neet_pg_bot

Correct Answer: C. Non-ossifying fibroma

■ *Listen (English)*

■ *Listen (Hindi)*

Explanation: A non-ossifying fibroma is the most likely diagnosis. A biopsy finding suggestive of a storiform pattern made by benign spindle cells with scattered osteoclast-type giant cells. Non-Ossifying Fibroma: Developmental defect in which fibrous connective tissue replaces bone. It is a cartilagenous tumor that is commonly seen in children and adolescents. Arise eccentrically in the metaphysis of the distal femur and proximal tibia. Bony trabeculae that appear pink are seen on biopsy, and these trabeculae are lined by osteoblasts , a pattern referred to as osteoblastic rimming . Giant cell tumor of bone (Option D): It arises in the epiphysis rather than the metaphysis. Giant cells are seen on biopsy. Ewing sarcoma (Option B): It classically occurs in the diaphysis . Small round blue cells are seen on biopsy. Chondrosarcoma (Option A): It is a cartilaginous tumor. So histology reveals bluish cartilage matrix and cells showing chondrocytic differentiation .

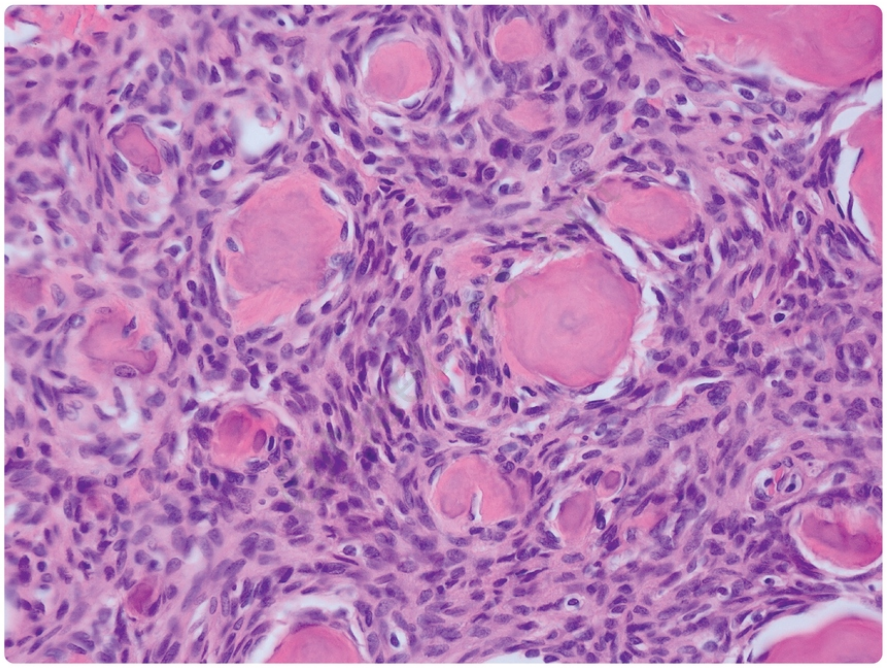

@Neet_pg_bot

References:

Robins and Cotran Pathologic Basis of Disease, 10th Edition, Page1192-1195

↑ *Back to this question in Part A*

@Neet_pg_bot

Q9: Which of the following statements are true regarding fibrous dysplasia? It is a malignant tumour with components of normal bone unable to differentiate into mature structures Associated with CSF 1 R gene mutation and soft tissue myxoma. Typically occurs in older individuals causing bones to become weak and easily fractured. Histopathological examination shows woven bone trabeculae with disorganised growth plates. Females commonly presents with precocious puberty and irregular dark skin lesions. (Q845705)

A. 1, 3 and 4

B. 2, 3 and 5

C. 3, 4 and 5

D. 4 and 5

Correct Answer: D. 4 and 5

■ *Listen (English)*

■ *Listen (Hindi)*

Explanation: Fibrous Dysplasia: It is a benign childhood tumour caused by GNAS1 mutations, characterised by immature normal bone components and disorganised growth plates, linked to McCune- Albright syndrome. (Statement 1 and 3 ruled out) McCuneAlbright Syndrome: Commonly presented as precocious sexual development, mainly in girls. (Statement 5) Polyostotic disease associated with café-au-lait skin pigmentations and endocrine abnormalities. Café-au-lait macules: dark large macules with irregular serpiginous borders on the same side of the body as the bone lesions. Microscopy: Curvilinear trabeculae of woven bone that lack conspicuous osteoblastic rimming in a background of fibrous tissue (Chinese letter pattern). (Statement 4) Statement 2: CSF 1 R gene mutation is seen in giant cell tumor of tendon sheath, but not in fibrous dysplasia.

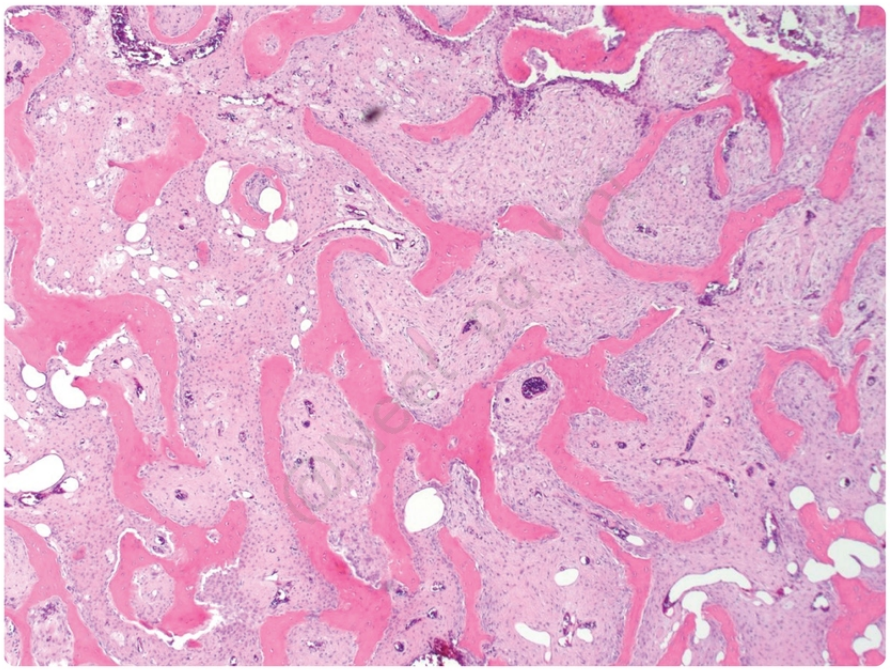

References:

Robins and Cotran Pathologic Basis of Disease, 10th Edition, Page 1195-1197

↑ *Back to this question in Part A*

@Neet_pg_bot

Q10: A 58-year-old male presents with worsening lower back pain and difficulty walking for the last few months. Molecular analysis revealed brachyury gene expression. A biopsy image of the lesion is shown. What is the most likely diagnosis? (Q845702)

A. Chordoma

B. Enchondroma

C. Ewing sarcoma

D. Chondrosarcoma

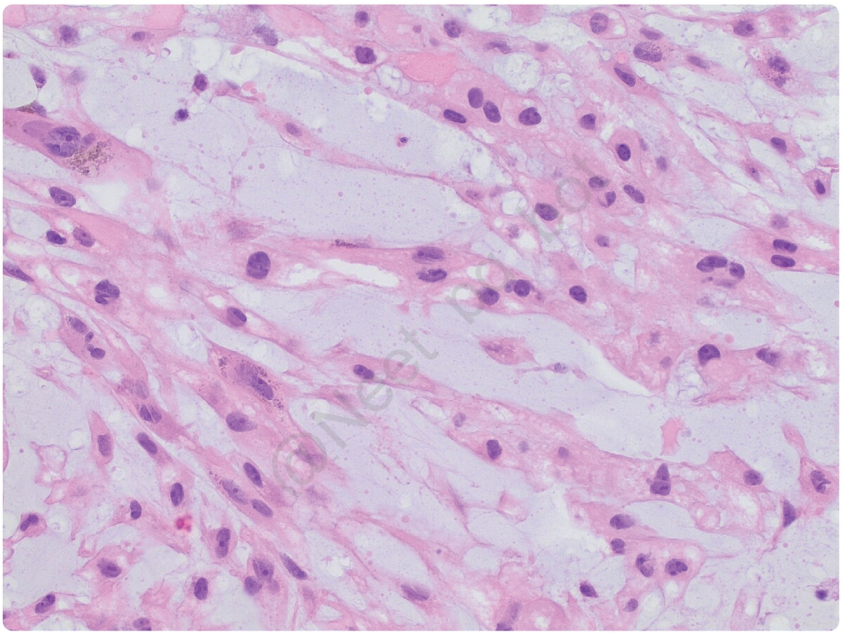

@Neet_pg_bot

Correct Answer: A. Chordoma

■ *Listen (English)*

■ *Listen (Hindi)*

Explanation: The clinical vignette of lower back pain, brachyury gene expression, and biopsy showing Physaliferous cells is suggestive of chordoma. Chordoma: It is a low-grade, slow-growing but locally invasive and locally aggressive tumour. They arise from the remnants of the notochord and occur along the midline spinal axis between the clivus and the sacrum , anterior to the spinal cord. Genetics: Brachyury gene mutation Morphology: Microscopy: Physaliferous cells (cells with bubbly or vacuolated appearance), abundant eosinophilic cytoplasm, cords of epithelioid cells, vacuoles, and extracellular myxoid matrix. Enchondroma (Option B) are benign cartilaginous tumors that typically occur in the small bones of the hands and feet , not the axial skeleton. They are

usually asymptomatic unless they cause a pathologic fracture. Histology: They consist of mature hyaline cartilage and do not express the brachyury gene . Ewing Sarcoma (Option C): This is a high-grade malignant tumor primarily seen in children and adolescents (typically ages 10–20), not 58-year-olds. Histology: It is characterized by sheets of Small Round Blue Cells . Molecular: It is defined by the t(11;22) translocation involving the EWS-FLI1 gene, not brachyury. Chondrosarcoma (Option D): While chondrosarcomas can occur in the axial skeleton of older adults, they lack the specific brachyury expression found in chordomas. Histology: They show malignant chondrocytes within a chondroid (cartilaginous) matrix , often with multiple cells per lacuna and nuclear pleomorphism. They do not contain physaliphorous cells.

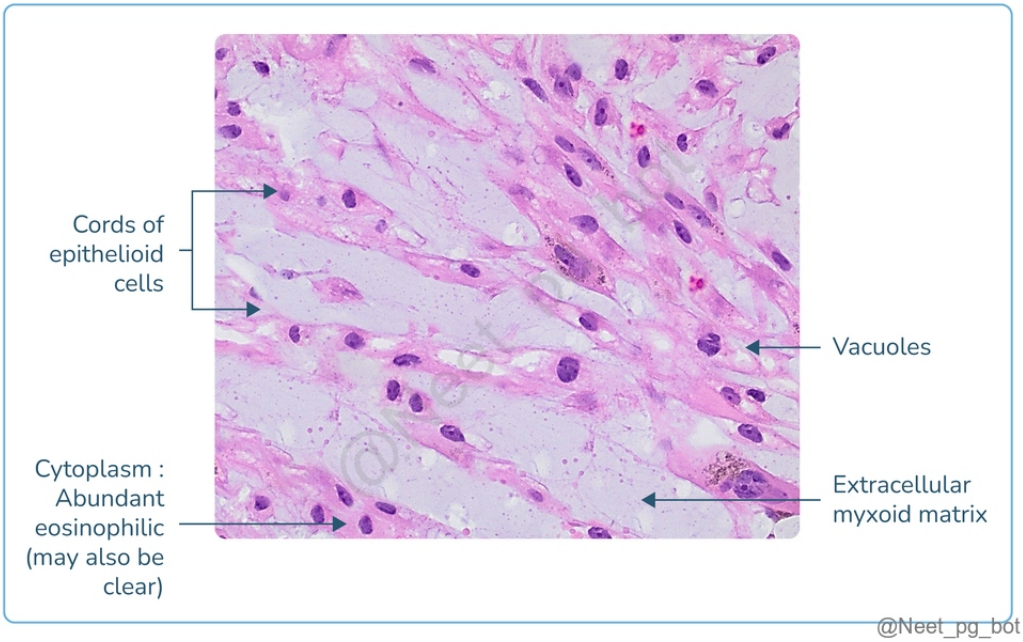

References:

https://www.ncbi.nlm.nih.gov/books/NBK430846/

↑ *Back to this question in Part A*

@Neet_pg_bot

Q11: Which of the following statements regarding normal bone and bone marrow are true? 1. Bone marrow contains a rich network of blood vessels, nerves, and lymphatics, supporting its role as a hematopoietic organ. 2. Osteoblasts are responsible for bone formation, while osteoclasts are involved in bone resorption. 3. Hematopoietic stem cells in the bone marrow give rise to some blood cell lineages. 4. Bone marrow lacks hematopoietic elements and serves primarily as a site for fat storage. 5. Bone remodelling is solely regulated by hormonal factors. (Q845574)

A. Statements 1 and 2 are correct

B. Statements 3 and 4 are correct

C. Statements 4 and 5 are correct

D. Statements 1 and 5 are correct

Correct Answer: A. Statements 1 and 2 are correct

■ *Listen (English)*

■ *Listen (Hindi)*

Explanation: Correct statements: Statement

References:

Robins and Cotran Pathologic Basis of Disease, 10th Edition, Page 1171 - 1173

↑ *Back to this question in Part A*

@Neet_pg_bot

Q12: Which of the following is incorrect about enchondromas? (Q845647)

A. Maffucci syndrome can also co-exist with brain glioma.

B. Mutations in isocitrate dehydrogenase enzyme genes are common.

C. Histology shows hyaline cartilage encased by reactive bone.

D. Ollier's disease presents as solitary juxta-cortical enchondromas.

Correct Answer: D. Ollier's disease presents as solitary juxta-cortical enchondromas.

■ *Listen (English)*

■ *Listen (Hindi)*

Explanation: Chondroma is a benign tumour of hyaline cartilage that occurs in bones of endochondral origin. Enchondromas: Tumours can arise within the medullary cavity, Juxtacortical chondromas: Tumors arising on the bone surface. Both Maffucci syndrome and Ollier’s disease are characterised by multiple enchondromas (not solitary). (Option D) Option A: Maffucci syndrome can be distinguished from Ollier’s disease by the presence of other neoplasms like spindle cell hemangioma, brain glioma, etc. Option B: Mutations in the IDH1 & IDH2 genes which code for isocitrate dehydrogenase enzyme are seen commonly in enchondromas. Option C: Radiograph shows a characteristic nodule of hyaline cartilage encased by reactive bone , which can also be confirmed by histopathological examination, as shown in the image. Benign Cartilage



@Neet_pg_bot

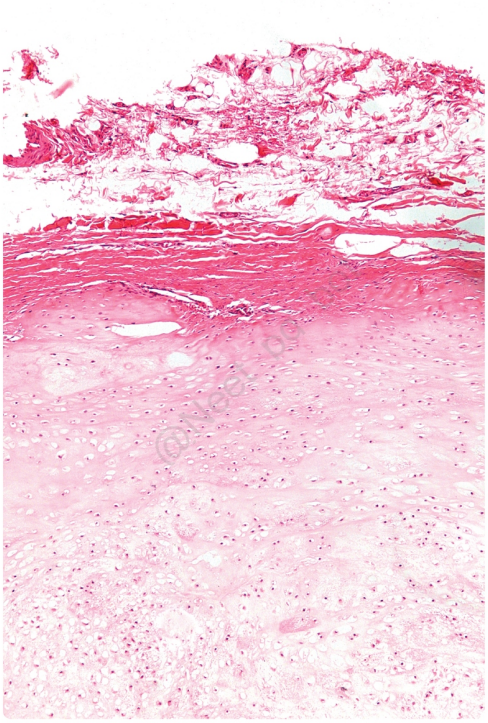

@Neet_pg_bot

References:

Robbins and Cotran Pathologic Basis of Disease, 10th Edition, Pages 1190 - 1191

↑ *Back to this question in Part A*

@Neet_pg_bot

Q13: A 14-year-old boy presents with a swelling on his left tibia. An X-ray of the leg shows a destructive process with indistinct borders and an onion-skin pattern of the periosteal bone. A biopsy was performed, as shown in the image below. Identify the true statements regarding this condition. It is a malignant tumour characterised by primitive round cells with obvious differentiation. It affects boys more than girls. More than 90% of the cases are caused due to t(11;22)(q24;q12) mutation. The presence of rounded cell clusters with a central fibrillary core indicates neuroectodermal differentiation. Chemotherapy-induced necrosis is a negative prognostic indicator. (Q845646)

A. 1, 2, 3

B. 2, 3, 4

C. 1, 3

D. 3, 4, 5

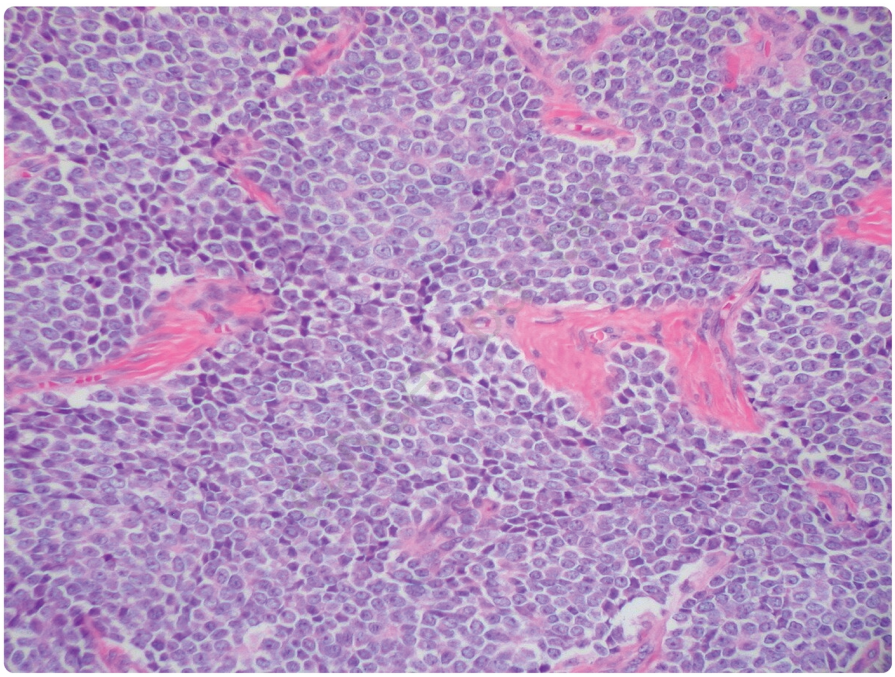

@Neet_pg_bot

Correct Answer: B. 2, 3, 4

■ *Listen (English)*

■ *Listen (Hindi)*

Explanation: The given clinical scenario suggests Ewing's sarcoma. The correct statements regarding this condition are 2, 3, 4. Ewing's sarcoma: It is a malignant bone tumour characterised by primitive round cells without obvious differentiation. (Statement 1) Approximately 80% of patients are younger than 20 years of age. Males are affected more often than Females. (Statement 2) It usually arises in the diaphysis of long tubular bones, especially the femur and in the flat bones of the pelvis and presents as a painful, enlarging mass. The most common mutation (>90% of the cases) is t(11;22)(q24;q12). (Statement 3) Morphology: It comprises sheets of uniform, small, round cells with scant cytoplasm that may be clear due to abundant glycogen. Homer-Wright rosettes (pseudorosettes) are rounded cell clusters with a central fibrillary core, their presence indicates neuroectodermal differentiation. (Statement 4) Specific markers: CD99+ (MIC2) positive. Chemotherapy-induced necrosis is a positive prognostic indicator. (Statement 5)

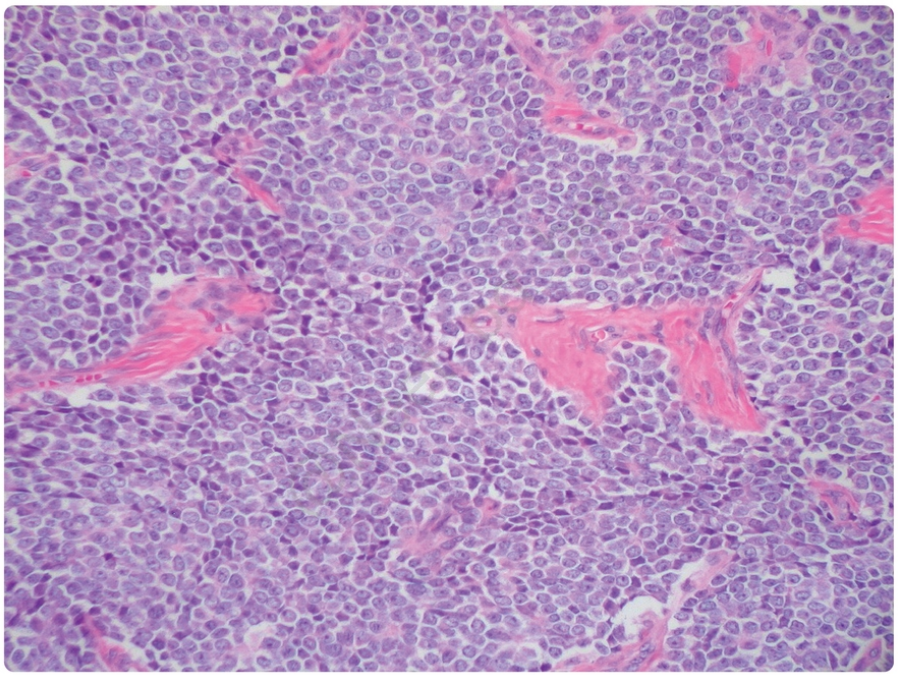

@Neet_pg_bot

References:

Robbins and Cotran, Pathologic Basis of Disease, 10th Edition, Pages 1192-1193

↑ *Back to this question in Part A*

@Neet_pg_bot

Q14: Histopathological examination of a lesion arising from the right distal femur is given as the image below with such characteristic cells. Which of the following is the most probable diagnosis? (Q845645)

A. Osteoclastoma

B. Chondrosarcoma

C. Osteochondroma

D. Ewing's sarcoma

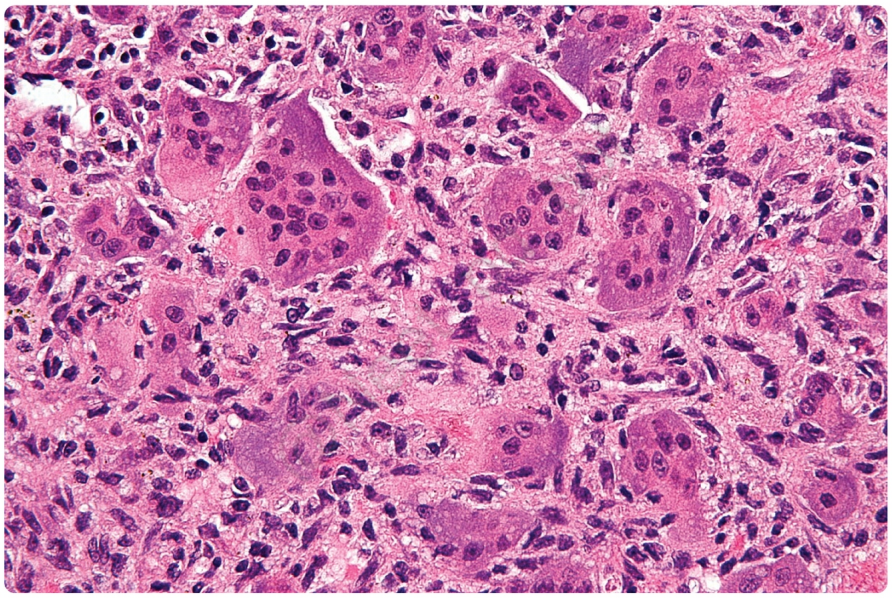

@Neet_pg_bot

Correct Answer: A. Osteoclastoma

■ *Listen (English)*

■ *Listen (Hindi)*

Explanation: The histopathological image shows numerous multinucleated giant cells , along with mononuclear cells scattered in the background in a bone lesion, suggesting osteoclastoma/giant cell tumour. Giant cell tumour (Osteoclastoma): It is a benign but locally aggressive tumour characterised by numerous multinucleated osteoclast-type giant cells. The neoplastic component is made up of the mononuclear cells , while the multinucleated giant cells are only a reactionary or secondary component . Giant cell tumours develop within the epiphysis and may extend into the metaphysis. Mostly located near the knee, involving the distal femur or proximal tibia. Although rare, they can metastasize to the lungs , but typically regress spontaneously and are rarely fatal. Morphology: Grossly, the tumours are large , red-brown masses that frequently undergo cystic degeneration. Chondrosarcoma (Option B): S hows malignant cartilage, which is recognised by the presence of multiple cartilage cells within a single lacuna, Osteochondroma (Option C): It classically shows both bone (osteo) and

cartilage components together. Ewing’s sarcoma (Option D): This belongs to the group of small round blue cell tumors . On histology, we would see sheets of small blue cells and the characteristic Homer Wright pseudorosettes , none of which are seen here.

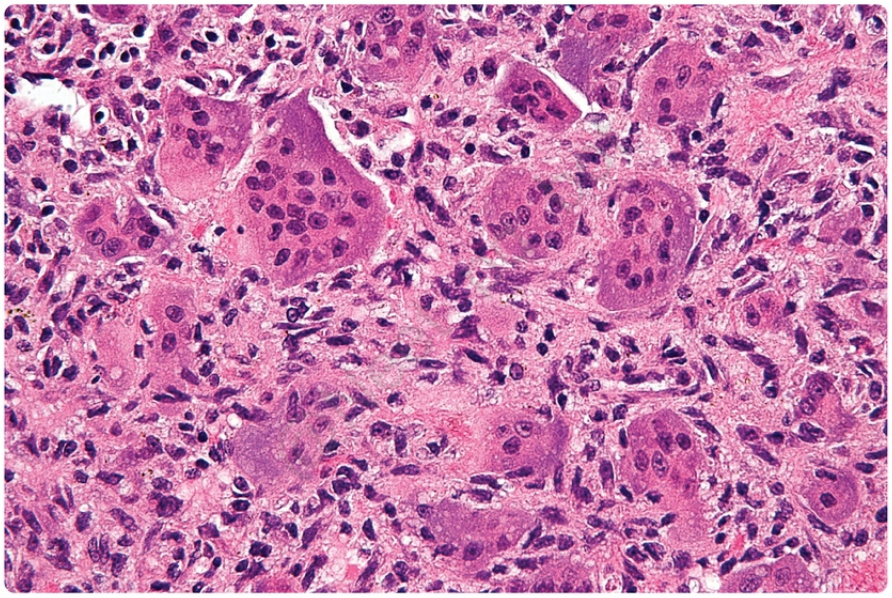

References:

Robbins and Cotran Pathologic Basis of Disease 10th Edition, Page 1193

↑ *Back to this question in Part A*

@Neet_pg_bot

Q15: A patient presented with a hard mass over the right tibia, and subsequent imaging revealed the presence of sessile growth in the bone. Biopsy is done later, which shows the presence of “cartilage cap” over the lesion. What is the most likely diagnosis? (Q845604)

A. Osteochondroma

B. Chondroblastoma

C. Enchondroma

D. Chondrosarcoma

Correct Answer: A. Osteochondroma

■ *Listen (English)*

■ *Listen (Hindi)*

Explanation: The clinical presentation is suggestive of osteochondroma, characterised by the presence of cartilage cap over the lesion and sessile growth in the bone, which means the lesion has both bone and cartilage elements together. Osteochondroma (Exostosis): Osteochondroma is one of the most common benign bone tumors , also called exosurface. It looks like a mushroom-like growth coming out of the bone and is in exact continuity with the underlying bone . In osteochondroma, the tumor's medulla is continuous with the bone medulla (inner part) and its cortex with the bone cortex (outer part), but it is covered by a cartilage cap, which distinguishes it and gives it the name osteochondroma. Histology: It resembles a disorganized growth plate , and they undergo enchondral ossification , with the newly formed bone making up the inner portion of the head and stalk.

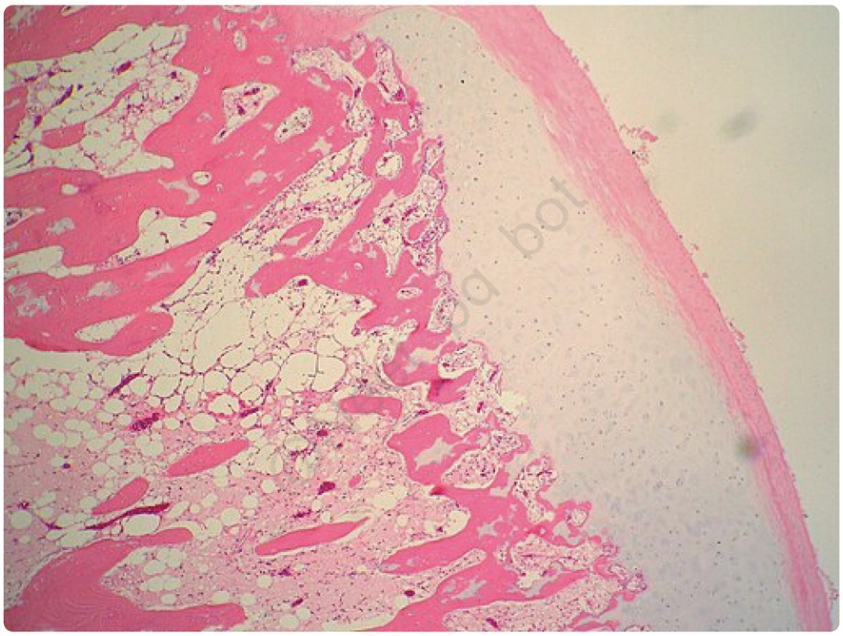

@Neet_pg_bot

References:

Robbins and Cotran Pathologic Basis of Diseases, 10th Edition, Pages 1189-1190

↑ *Back to this question in Part A*

@Neet_pg_bot

Q16: A 15-year-old male presents with persistent knee pain and swelling of two months duration. The pain is persistent, severe at night and not relieved by NSAIDs.

On examination there is a firm, tender mass around distal femur. X-ray shows destructive lesion with sunburst pattern and lifting of the perisoteum. A biopsy was performed, and it showed pleomorphism, large hyperchromatic nuclei, and bizarre giant cells producing unmineralised osteoid. What is the most likely diagnosis? (Q845601)

A. Osteoid osteoma

B. Osteoblastoma

C. Osteosarcoma

D. Osteoclastoma

Correct Answer: C. Osteosarcoma

■ *Listen (English)*

■ *Listen (Hindi)*

Explanation: The clinical presentation is suggestive of osteosarcoma, characterised by presence of pleomorphism, large hyperchromatic nuclei, and bizarre giant cells producing unmineralised osteoid Osteosarcoma : It is the most common primary malignant tumour of bone . Tumours usually arise in the metaphyseal region of the long bones (distal femur or proximal tibia). Genetic associations: RB gene (most common) TP53. CDKN2A (also known as INK4a). MDM2 and CDK4. Morphology: Osteosarcomas are bulky, gritty, grey-white tumours that often contain haemorrhage and cystic degeneration. Histology demonstrate pleomorphism , large hyperchromatic nuclei , bizarre tumour giant cells , and abundant mitoses. Extensive necrosis and intravascular invasion are also common. Diagnosis of osteosarcoma requires the presence of malignant tumour cells producing unmineralised osteoid or mineralised bone. Osteoid Osteoma (Option A): Small benign tumor. Severe night pain , but typically relieved by NSAIDs. Histology: woven bone and osteoblasts , but no marked pleomorphism or malignant features . No unmineralised osteoid with atypia Osteoblastoma (Option B): Benign , larger than osteoid osteoma. May cause chronic pain, less responsive to NSAIDs than osteoid osteoma. Histology: Similar to osteoid osteoma but larger, more vascular, no marked pleomorphism or malignant osteoid production Osteoclastoma (Option D):(Giant Cell Tumor): Typically occurs in young adults. Involves epiphysis of long bones, not metaphysis. Histology: multinucleated giant cells, but no malignant osteoid, and no pleomorphic malignant osteoblasts

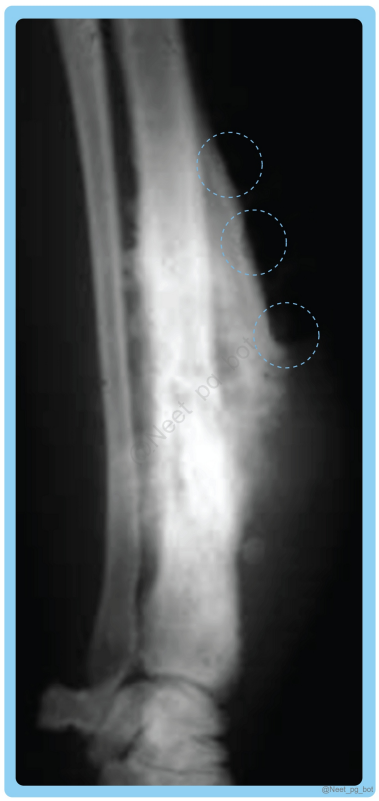

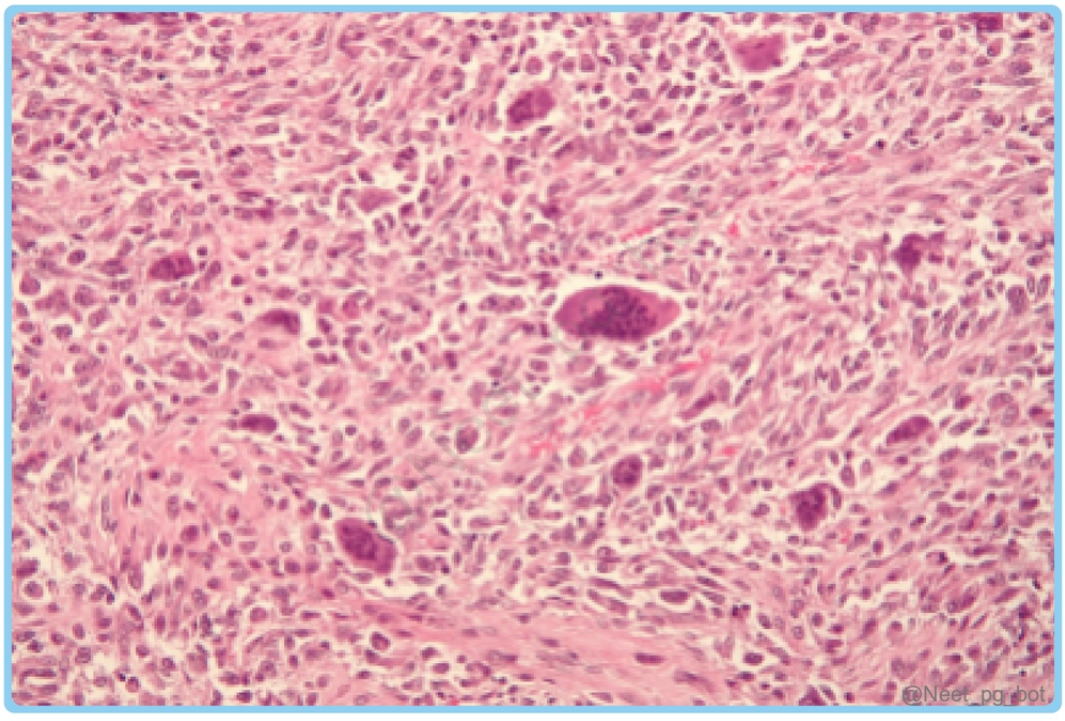

References:

Robins and Cotran Pathologic Basis of Disease, 10th Edition, Pages 1188, 1189

↑ *Back to this question in Part A*

Q17: A 25-year-old male presents with persistent pain in his right leg that worsens at night and is partially relieved by nonsteroidal anti-inflammatory drugs (NSAIDs). Imaging is given below. Based on the clinical presentation and imaging findings, which of the following is incorrect regarding this condition? (Q845596)

A. It has a predilection for the appendicular skeleton.

B. It is less than 2 cm in diameter.

C. It commonly affects the axial skeleton

D. Pain is relieved on taking aspirin



Correct Answer: C. It commonly affects the axial skeleton

■ *Listen (English)*

■ *Listen (Hindi)*

Explanation: The imaging shows a small, well-defined bone tumor, and the clinical presentation is consistent with osteoid osteoma , which is characterized by nocturnal pain. These are rarely found in the axial skeleton , with a much higher predilection for the appendicular skeleton (limbs). On X-ray, sclerotic bone at the periphery is seen in

both osteoid osteoma and osteoblastoma. The center of the lesion contains a nidus made of woven or spongy bone, surrounded by cortical bone that appears white on the X-ray. Features Osteoid Osteoma Osteoblastoma Size Less than 2 cm More than 2 cm Site Femur or Tibia (Appendicular skeleton) Spine (Axial skeleton) Pain Nocturnal pain Dull pain On treatment Relieved about taking aspirin Not relieved on taking aspirin Imaging The image below shows the histological features of osteoid osteoma, including spongy (woven) bone with dilated blood vessels.





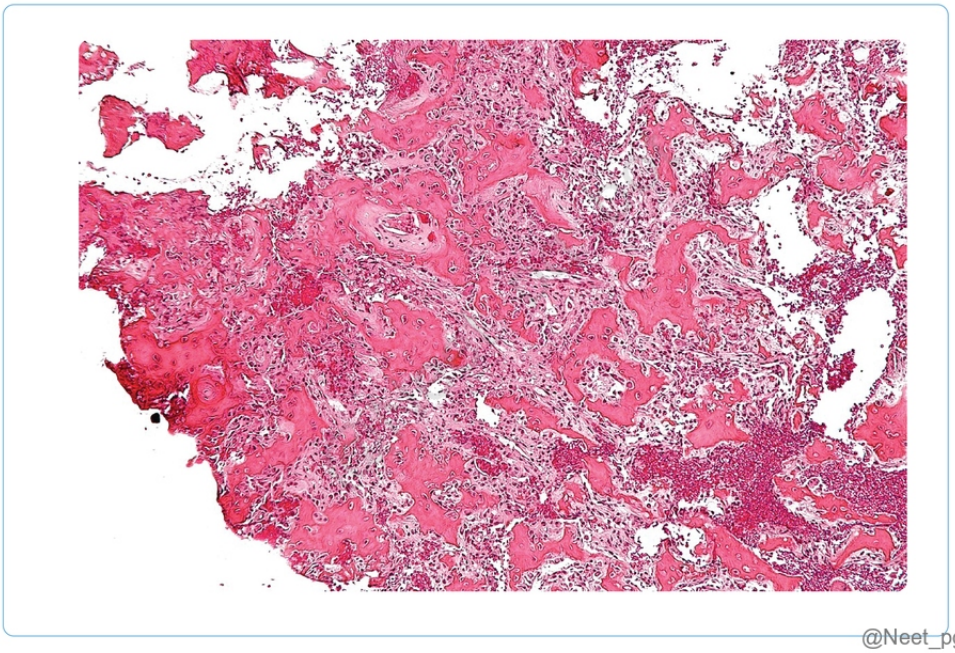

References:

Robins and Cotran Pathologic Basis of Disease, 10th Edition, Page 1188

↑ *Back to this question in Part A*

Q18: All of the following are associated with Gardner’s syndrome except? (Q845577)

A. Multiple osteoma

B. Colon polyps with risk of malignancy

C. Enchondroma

D. Supernumerary teeth

Correct Answer: C. Enchondroma

■ *Listen (English)*

■ *Listen (Hindi)*

Explanation: Gardner syndrome is an autosomal dominant phenotypic variant of familial adenomatous polyposis(FAP) , along with various extraintestinal manifestations. The patient has more than 100 polyps in the intestine (High risk of malignancy) Several extraintestinal manifestations are also seen, like: Skin – S ebaceous cysts . Below the skin (fibrous tissue) – Fibromas (Fibrous tumors) Below the fibrous tissue (bones) – Multiple osteomas (Bony tumors) , which are classically seen in the head and neck region of the bones . Spernumerary teeth . Familial Adenomatous Polyposis (FAP): It is an Autosomal dominant hereditary colorectal cancer. Genetic pathogenesis: APC gene: chr 5q21 Rare: NER gene defect 100% risk of cancer, usually >100 polyps (minimum) Types of FAP: 1. Classical FAP: This is the standard form of the disease caused by a germline mutation in the APC (Adenomatous Polyposis Coli) gene located on chromosome 5q21 . Clinical Presentation: Polyps typically begin to appear in the second or third decade of life. Leads to Congenital hypertrophy of RPE (Retinal Pigment Epithelium) The "100" Rule: A diagnosis usually requires the presence of at least 100 polyps in the large intestine. Pathophysiology: The APC gene is a tumor suppressor that regulates the Wnt signaling pathway . Mutation leads to the accumulation of β-catenin, which translocates to the nucleus and activates genes promoting cell proliferation. Management: Total proctocolectomy is generally recommended by age 20. 2. Gardner Syndrome: This variant combines the intestinal features of FAP with specific extracolonic manifestations. It is caused by the same APC mutation but with different phenotypic expression. Key Triad: Colonic Polyposis: >100 polyps in the large intestine. Osteomas: Benign bony growths, most commonly found in the mandible, skull, or long bones. Soft Tissue Tumors: Includes Desmoid tumors (aggressive fibromatosis), epidermoid cysts, and fibromas. Dental Abnormalities: Often presents with impacted or supernumerary (extra) teeth. 3. Turcot Syndrome: This variant involves the association of intestinal polyposis with Central Nervous System (CNS) tumors . It is often referred to as the "Brain-Turcot" association. A diagnosis usually requires the presence of at least 100 polyps in the large intestine. FAP-Associated Turcot: Specifically associated with Medulloblastoma . This is linked to the APC gene mutation. HNPCC (Lynch)-Associated Turcot: More commonly associated with Glioblastoma multiforme . This is linked to DNA mismatch repair gene mutations. 4. Attenuated FAP (AFAP): A milder version of the syndrome where the onset of polyps and cancer is delayed. Pore Count: Patients typically develop fewer than 100 polyps (average 30). Location: Polyps are more likely to be located in the proximal (right) colon . Cancer Risk: While delayed, the lifetime risk of colorectal cancer is still significantly high (~70%). 5. MUTYH-Associated Polyposis (MAP): While clinically similar to FAP, this variant has a different inheritance pattern and genetic cause.

Inheritance: Autosomal Recessive (unlike the dominant FAP). Gene: Mutation in the MUTYH gene, which is involved in base excision repair. Presentation: Typically presents with 10 to a few hundred polyps in the 40s or 50s. Variant Gene Polyp Number Age of Polyps CRC Risk/Age Extracolonic Features Classic FAP APC (5q) >100 10-15 yrs ~100% by 40 Gardner : osteomas, desmoids, dental anomalies, CHRPE Turcot : medulloblastoma Attenuated FAP (AFAP) APC (5' or 3' ends) 10-100 (R) colon > L 20-30 yrs 70% by 80 (delayed) Fewer/milder extracolonic MUTYH-associated polyposis (MAP) MUTYH (biallelic) 10-1000 20-40 yrs 80% lifetime Similar to AFAP; recessively inherited Gardner Syndrome APC (specific codons) >100 Same as classic Same as classic Osteomas (mandible), desmoid tumors (APC 1445), epidermoid cysts , supernumerary teeth Turcot Syndrome (Type 2) APC >100 Same as classic Same as classic Medulloblastoma (vs Type 1 = MMR genes + GBM)

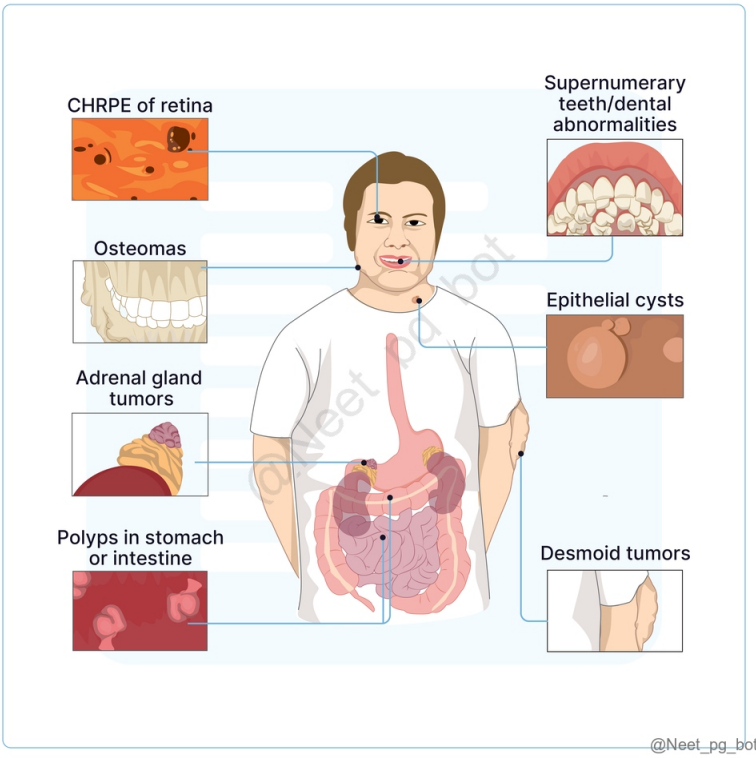

References:

https://www.ncbi.nlm.nih.gov/books/NBK482342/

↑ *Back to this question in Part A*

@Neet_pg_bot

Q19: Which of the following is not a metaphyseal tumour? (Q845576)

A. Osteosarcoma

B. Fibrous dysplasia

C. Giant cell tumour of the bone

D. Aneurysmal bone cyst

Correct Answer: C. Giant cell tumour of the bone

■ *Listen (English)*

■ *Listen (Hindi)*

Explanation: Classification of bone tumours: Epiphyseal tumours Metaphyseal tumours Diaphyseal tumours Giant cell tumour (GCT). Chondroblastoma. Clear cell chondrosarcoma. Simple bone cyst. Osteosarcoma. Fibrous dysplasia. Aneurysmal bone cyst. Osteochondroma. Chondrosarcoma Multiple myeloma. Adamantinoma. Ewing's Sarcoma. Osteoid Osteoma.

References:

Robins and Cotran Pathologic Basis of Disease, 10th Edition, Pages 1187-1194

↑ *Back to this question in Part A*

@Neet_pg_bot

Q20: A 6-year-old boy presents with a history of frequent fractures, bone pain, and difficulty walking. On examination, he has short stature and cranial nerve palsies. The radiograph is revealed below. Which of the following is the most likely diagnosis? (Q845575)

A. Osteogenesis imperfecta

B. Osteopetrosis

C. Rickets

D. Paget disease of the bone



Correct Answer: B. Osteopetrosis

- *Listen (English)*
- *Listen (Hindi)*

Explanation: The clinical presentation and radiography showing generalised sclerosis and a bone-within-bone appearance is suggestive of osteopetrosis. Osteopetrosis/Marble bone disease: Osteopetrosis is a defect in the osteoclasts . Because the osteoclasts are not functioning properly, bone remodelling and bone resorption are impaired. As a result, the patient ends up with brittle bones , which gives rise to this bone-in-bone appearance . It has multiple inheritance patterns , including autosomal dominant, autosomal recessive, and X-linked disorders . Morphologically, affected bones lack internal medullary canal leading to frequent features Osteogenesis imperfecta (Option A): Often called "Brittle Bone Disease" This is a genetic disorder where the "blueprint" for bone is flawed from the start. Cause: A mutation (usually in the COL1A1 or COL1A2 genes) that affects Type I collagen . Key Features: Frequent Fractures: Bones can break with minimal impact or even no trauma at all. Blue Sclera: The whites of the eyes appear blue because the underlying veins show through the abnormally thin collagen. Hearing Loss: Small bones in the ear (ossicles) can fracture or develop abnormally. Rickets (Option C): It is a childhood disease characterized by soft, weak bones. Cause: A severe deficiency in Vitamin D (Most common) , Calcium, or Phosphate . Without these, the bone cannot "mineralize" (harden). In adults, this same process is called Osteomalacia . Key Features: Bowed Legs: Since the bones are soft, they bend under the weight of the growing child. Rachitic Rosary: Visible bumps on the rib cage where bone meets cartilage. Growth Delays: Significant impact on height and dental development. Paget disease of the bone (Option D): Cause: The normal bone remodeling process goes out of control. Old bone is broken down too fast, and new bone is laid down too quickly and haphazardly. It is very uncommon at a young age and typically occurs in older individuals Key Features: Disorganized Structure: The new bone is large and thick, but mechanically weak and "shaggy." Bone Pain & Deformity: Commonly affects the skull, pelvis, and spine. If the skull enlarges, it can compress nerves,

leading to headaches or hearing loss. Increased Vascularity: The affected area often feels warm because of increased blood flow to the overactive bone.. It is also considered a pre-malignant condition with an increased risk of osteosarcoma.

References:

Robins and Cotran Pathologic Basis of Disease, 10th Edition, Pages 1176 - 1178

↑ *Back to this question in Part A*

@Neet_pg_bot

• [21_Bone Disorders] 083 Previous Year Questions

« Back to Folder Directory

[21_Bone Disorders] 083 Previous Year Questions — Quick Jump

Q1 (p. 3180) *Q2 (p. 3181)* *Q3 (p. 3183)* *Q4 (p. 3186)* *Q5 (p. 3189)*

Q1: Which HLA is associated with Reiter syndrome? (Q860540)

A. HLA-DR3

B. HLA-B27

C. HLA-DQ8

D. HLA- DR4

Correct Answer: B. HLA-B27

Explanation: Reiter Syndrome (also known as Reactive Arthritis) is associated with HLA-B27. It is defined by the triad of: Arthritis Nongonococcal urethritis or cervicitis Conjunctivitis Etiology: It occurs days to weeks after genitourinary (Chlamydia) or gastrointestinal (Shigella, Salmonella, Yersinia, Campylobacter, and Clostrdioides difficile) infections. HIV-positive patients may also be affected. Clinical features: Onset: Acute Enthesitis, oligoarthritis and/or spinal inflammation. Lower limb joints and entheses are predominantly affected. Systemic disturbances like fever and weight loss. Achilles insertional enthesitis/tendonitis or plantar fasciitis may also be present. The first attack of arthritis is usually self-limiting, but recurrent or chronic arthritis can develop. Low back pain and stiffness (due to enthesitis and osteitis) Sacroiliitis Extra-articular features: Circinate balanitis: Starts as vesicles on the coronal margin of the prepuce and glans penis, later rupturing to form superficial erosions with minimal surrounding erythema, some coalescing to give a circular pattern. Keratoderma blennorrhagica: Begins as discrete waxy, yellow-brown vesico-papules with desquamating margins, occasionally coalescing to form large crusty plaques on the palms and soles of the feet. Pustular psoriasis Nail dystrophy with subungual hyperkeratosis Mouth ulcers Conjunctivitis Uveitis HLA-DR3 (Option A) is associated with autoimmune diseases such as Systemic Lupus Erythematosus (SLE), Type 1 diabetes, and Graves' disease, but it is not linked to Reiter's Syndrome (Reactive Arthritis), which is specifically associated with HLA-B27. HLA-DQ8 (Option C) is associated with Celiac disease and some autoimmune disorders, such as Type 1 diabetes, but it is not linked to Reiter's Syndrome. HLA-DR4 (Option D) is associated with autoimmune conditions such as Rheumatoid Arthritis (RA) and Type 1 diabetes.

References:

Robbins and Cotran Pathologic Basis of Disease, 10th Edition, Page 1207.

Davidson’s Principles and Practice of Medicine, 21st Edition, Page 1031-1032.

↑ *Back to this question in Part A*

Q2: A 15-year-old boy presents with swelling in the upper diaphyseal part of the tibia. X-ray of the swelling showed a periosteal reaction. A histopathological image of the biopsy is given below. Immunohistochemistry was positive for synaptophysin and MIC2. What is the likely diagnosis? (Q855073)

A. Osteosarcoma

B. Ewing sarcoma

C. Metastatic neuroblastoma

D. Osteoclastoma

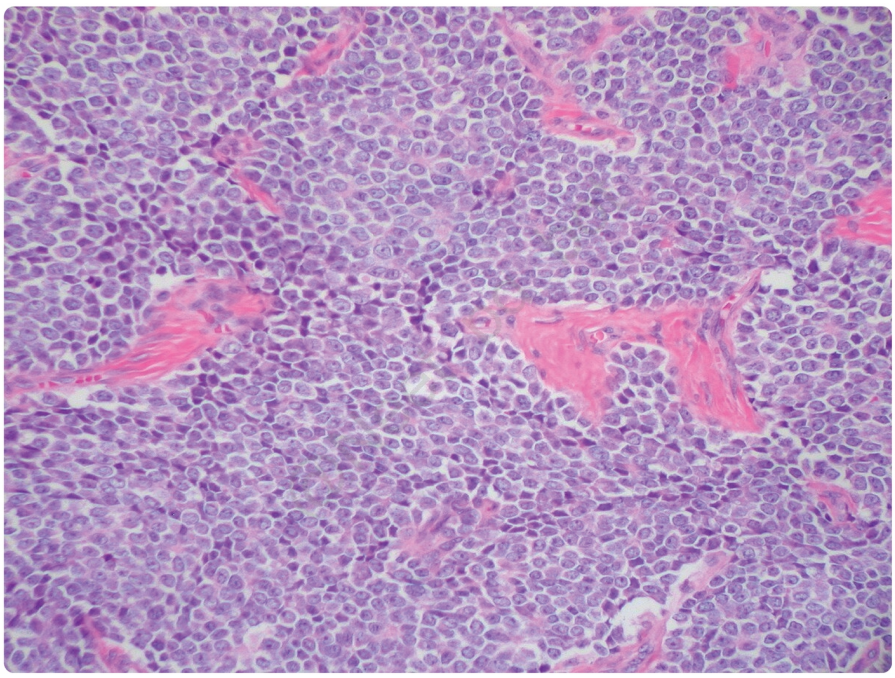

@Neet_pg_bot

Correct Answer: B. Ewing sarcoma

Explanation: The clinical scenario, along with the image showing small, round, uniform cells and positive immunohistochemistry for synaptophysin and MIC2 (CD99) in the diaphysis of long bones like the tibia, is characteristic of Ewing sarcoma. Ewing's sarcoma: It is a malignant bone tumour characterized by primitive round cells without obvious differentiation . Approximately 80% of patients are younger than 20 years of age. Males are affected slightly more often than Females. It usually arises in the diaphysis of long tubular bones, especially the

femur and in the flat bones of the pelvis, and presents as a painful, enlarging mass. The most common mutation (>90% of the cases) is t(11;22)(q24;q12) . Morphology: The tumour is soft , tan-white , and frequently contains areas of haemorrhage and necrosis. It comprises sheets of uniform, small, round cells with scant cytoplasm that may be clear due to abundant glycogen. Homer-Wright rosettes (pseudorosettes) are rounded cell clusters with a central fibrillary core; their presence indicates neuroectodermal differentiation. Specific markers: CD99+ (MIC2) positive. Fibrous septae may also be present, but there is little stroma. Geographic necrosis may be prominent. {{caption_text}} Chemotherapy-induced necrosis is a positive prognostic indicator. Osteosarcoma (Option A) is a type of bone cancer originating from cells that produce new bone tissue. It often presents with pain and swelling in the affected bone, and X-rays may show a characteristic "sunburst" or "spiculated" appearance . Histologically, osteosarcoma is characterized by the production of osteoid, a bone-like substance formed by the tumour cells. Metastatic Neuroblastoma (Option C) is a cancer that develops from immature nerve cells and most commonly occurs in young children. It can originate in areas like the adrenal glands or nerve tissues in the neck, chest, or abdomen. While it may metastasize to the bone and cause lytic lesions, it is not typically associated with a periosteal reaction or positive immunohistochemistry for synaptophysin and MIC2. Osteoclastoma (Option D), also known as a giant cell tumour of bone , is a benign tumour that mainly affects young adults. It is characterized by multinucleated giant cells and osteoclast-like cells. X-rays usually show a lytic lesion with a "soap bubble" appearance. However, it is not typically associated with a periosteal reaction or positive immunohistochemical findings for synaptophysin and MIC2.

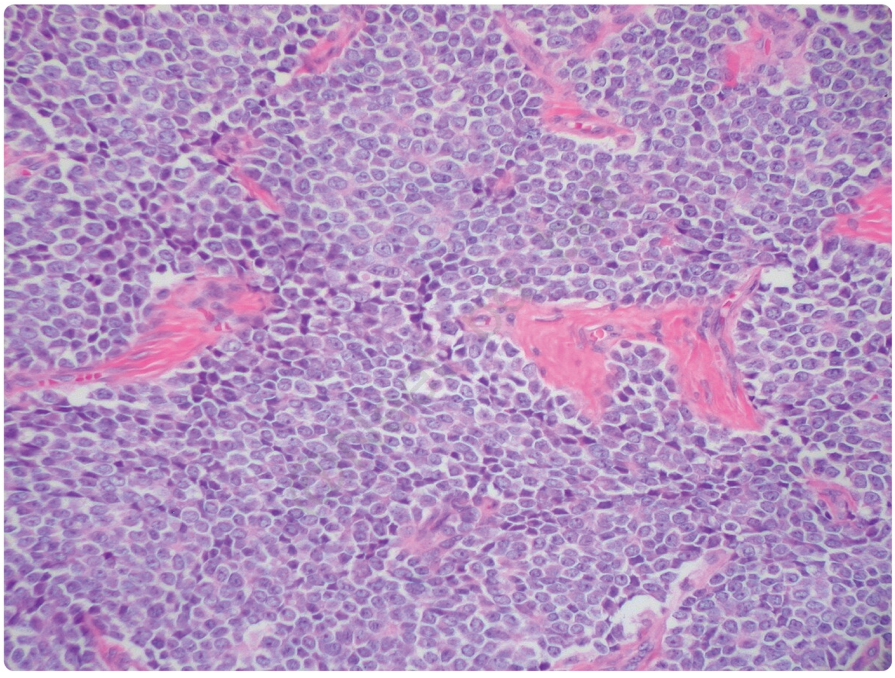

@Neet_pg_bot

References:

Robbins & Cotran Pathologic Basis of Disease, 10th Edition, Page 1192,1193

↑ *Back to this question in Part A*

@Neet_pg_bot

Q3: A 30-year-old woman has been experiencing left knee pain for one month. The knee is tender to touch, and an X-ray reveals a 5cm mass in the distal femoral epiphysis with a "soap bubble" appearance. Microscopy findings are provided below. What is the likely diagnosis? (Q857575)

A. Chondroblastoma

B. Osteoclastoma

C. Osteosarcoma

D. Osteochondroma

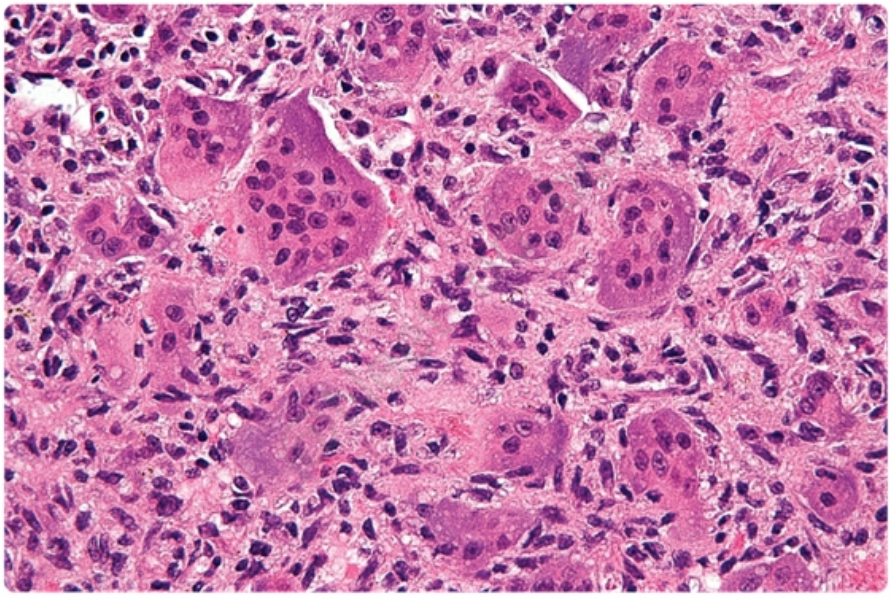

Correct Answer: B. Osteoclastoma

Explanation: The clinical presentation and histopathological image reveal numerous multinucleated giant cells within a bone lesion, which highly suggests Osteoclastoma (Giant cell tumour of bone). Giant cell tumour (Osteoclastoma): It is a benign but locally aggressive tumour, characterised by numerous multinucleated osteoclast-type giant cells. It occurs in the third to fifth decades of life. Pathogenesis: The neoplastic cells are primitive osteoblast precursors that express high levels of RANKL, promoting the proliferation of osteoclast precursors and their differentiation into mature osteoclasts. This increased activity of osteoclasts is responsible for the tumour being highly lytic and expansile due to uncontrolled bone resorption. Giant cell tumours develop within the epiphysis and may extend into the metaphysis. Mostly located near the knee, involving the distal femur or

proximal tibia. Although rare, they can metastasise to the lungs but typically regress spontaneously and are rarely fatal. Morphology: Grossly, the tumours are large , red-brown masses that frequently undergo cystic degeneration. Histologically, the tumours consist of uniform oval mononuclear tumour cells and abundant osteoclast-type giant cells with 100 or more nuclei. {{caption_text}} Chondroblastoma (Option A) is a benign, chondroid-producing tumour that usually arises in the epiphysis or apophysis of skeletally immature individuals. It is characterised by a sheet-like proliferation of chondroblasts and presents with pain, joint stiffness, and swelling. Chondroblastomas rarely show a soap bubble appearance on X-ray. {{caption_text}} Osteosarcoma (Option C) is a malignant bone tumour, typically found in the metaphysis of long bones. It is most common in children and young adults, particularly around sites of bone growth. It can present with bone pain, swelling, and fractures but does not typically exhibit the soap bubble appearance associated with giant cell tumours. {{caption_text}} Osteochondroma (Option D) is a benign bone tumour that forms on the surface of bones, usually near the growth plate. It comprises bone and cartilage and tends to stop growing after skeletal maturity. They do not present with a soap bubble appearance and are typically not located in the epiphysis. {{caption_text}}

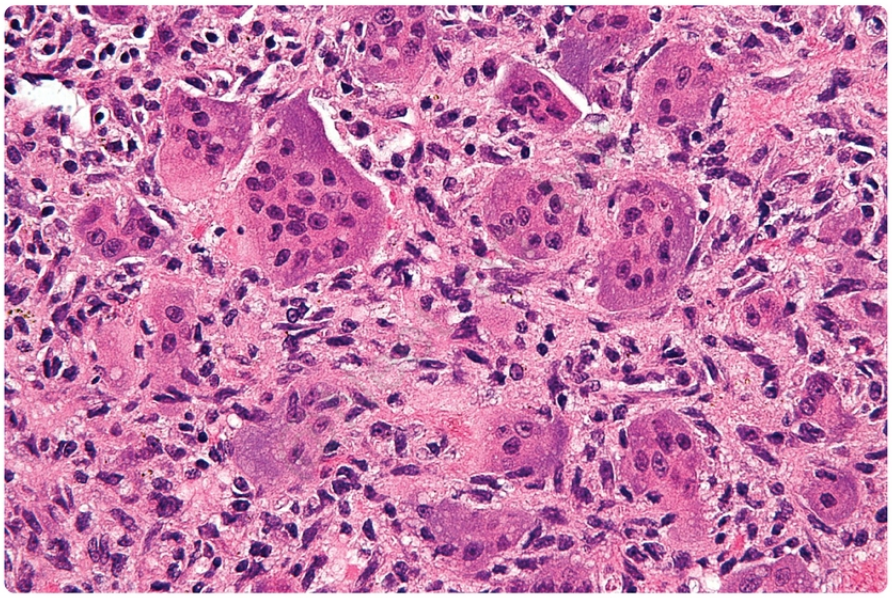

@Neet_pg_bot


Femur
Tibia
Chondroblastoma

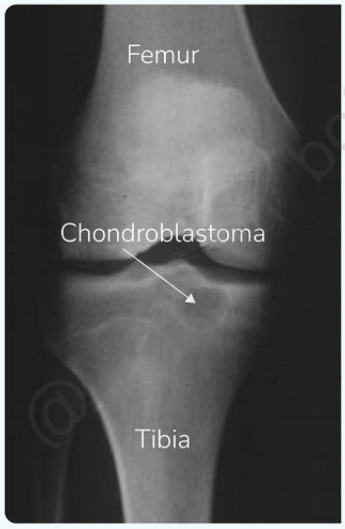
Femur
Chondroblastoma
Tibia


Chondroblastoma

@Neet_pg_bot

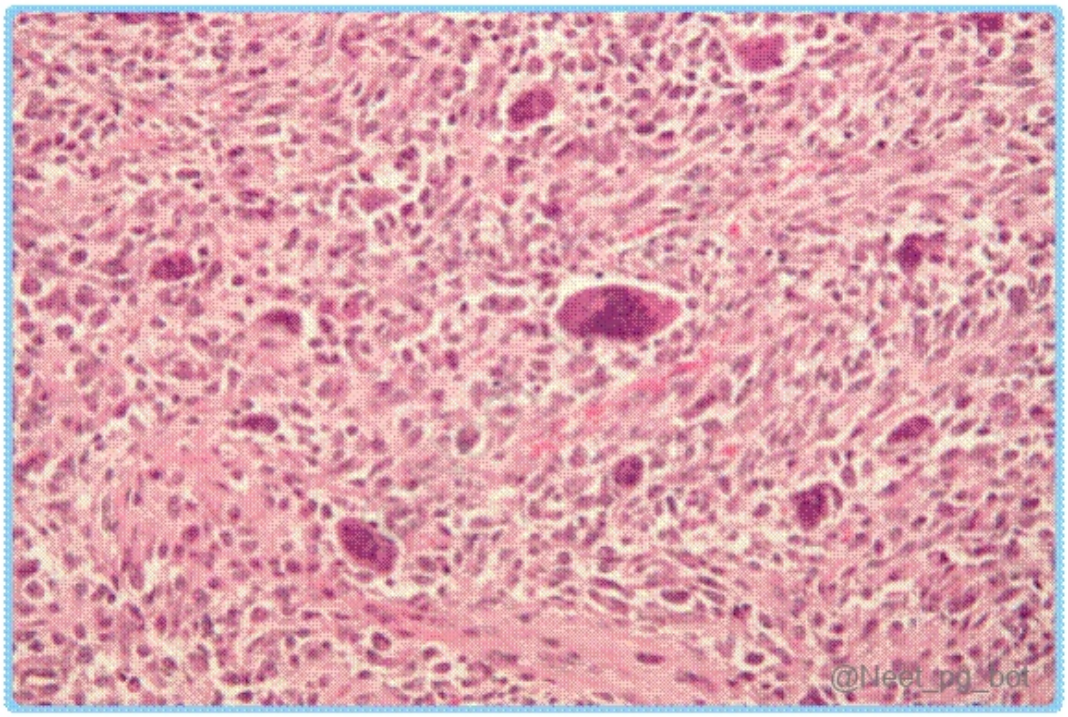
@Neet_pg_bot

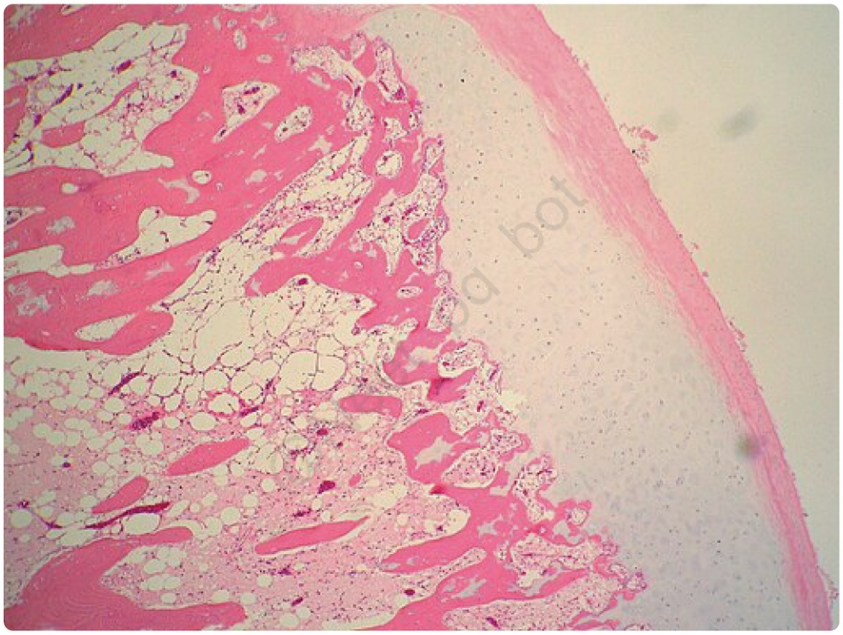

@Neet_pg_bot

References:

Robbins & Cotran Pathologic Basis of Disease, 10th Edition, Page 1193

↑ *Back to this question in Part A*

@Neet_pg_bot

Q4: A woman who had undergone total knee replacement surgery comes back with complaints of knee pain and loosening of implants. The following histopathological slide was obtained, showing foreign body giant cells and the appearance highlighted in the image below. What is your diagnosis? (Q856891)

A. Ochronosis

B. Metallosis

C. Malignant melanoma

D. Rosai-Dorfman disease

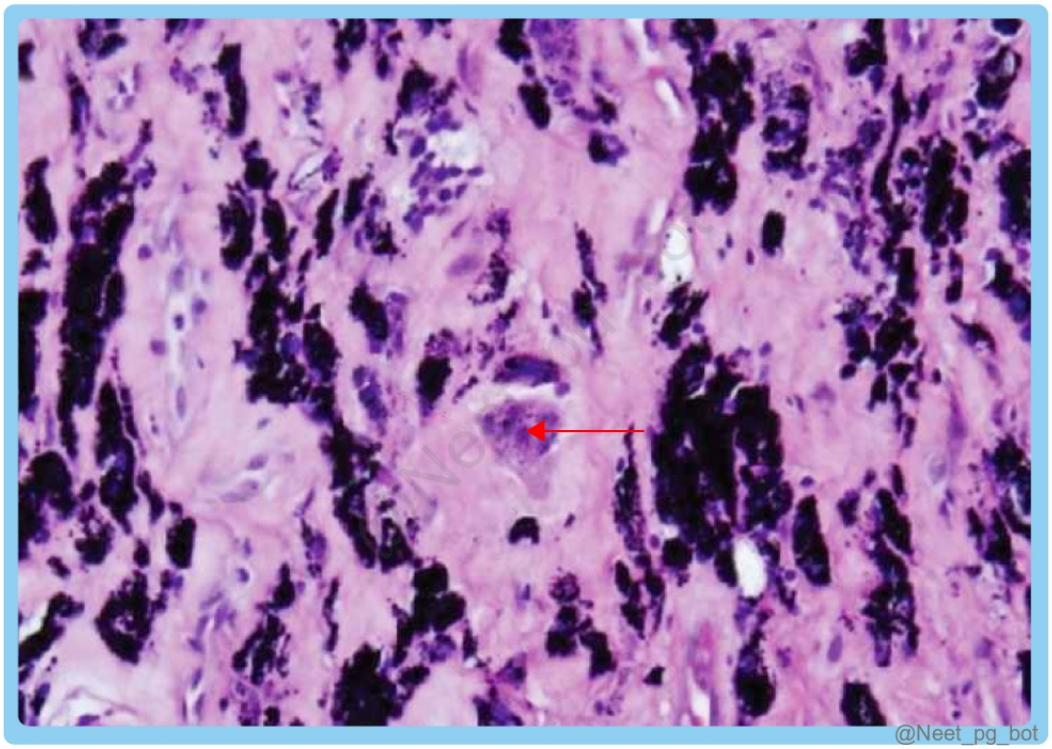

Correct Answer: B. Metallosis

Explanation: Metallosis refers to the accumulation of metal debris in tissues commonly associated with wear and corrosion of metal implants, such as those used in joint replacements. This causes inflammation, foreign body giant cells, and metallic debris, visible on histopathology. Metallosis: Definition: Aseptic fibrosis, local necrosis, and prosthetic loosening due to metal wear and corrosion in metal-on-metal (MoM) implants . Pathophysiology: Metallic debris (cobalt, chromium, titanium) triggers an inflammatory response , leading to foreign body giant cell reaction , cytokine release, and tissue necrosis . Systemic metal ion absorption may cause neuropathy, cardiomyopathy, and thyroid dysfunction . Clinical Features: Local : Chronic pain, swelling, pseudotumors, skin discolouration. Systemic : Neurological, cardiac, and endocrine toxicity. Diagnosis: Serum cobalt and chromium levels . MARS MRI (Metal Artifact Reduction Sequence) for pseudotumors. Histopathology : Pigmented macrophages, metal debris, necrosis. Management Regular monitoring of metal ion levels and symptoms. Revision surgery with non-metallic implants in symptomatic cases. Incorrect Options: Ochronosis (Option A) : A rare condition often associated with alkaptonuria, characterized by dark pigmentation in cartilage but not related to metal debris from implants. {{caption_text}} Malignant melanoma (Option C) is a type of skin cancer that arises from melanocytes. It typically presents as a pigmented skin lesion and does not cause the formation of foreign body giant cells or be associated with metal debris from joint replacements. {{caption_text}} Rosai-Dorfman disease (Option D) is a rare condition characterized by the accumulation of histiocytes (a type of white blood cell) in various organs, leading to lymphadenopathy and other systemic symptoms. It is not related to the inflammatory response caused by metal debris in metallosis. {{caption_text}}

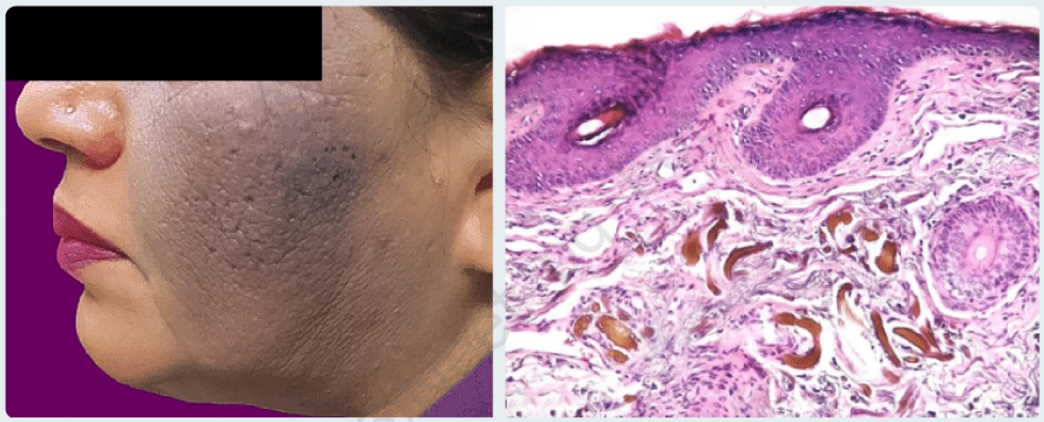

(A) Exogenous ochronosis with itchy, tender, and darkened macules
(B) Skin biopsy showing elongated yellow-brown deposits ("banana-like") of acellular material in the superficial dermis with associated solar elastosis

@Neet_pg_bot



@Neet_pg_bot

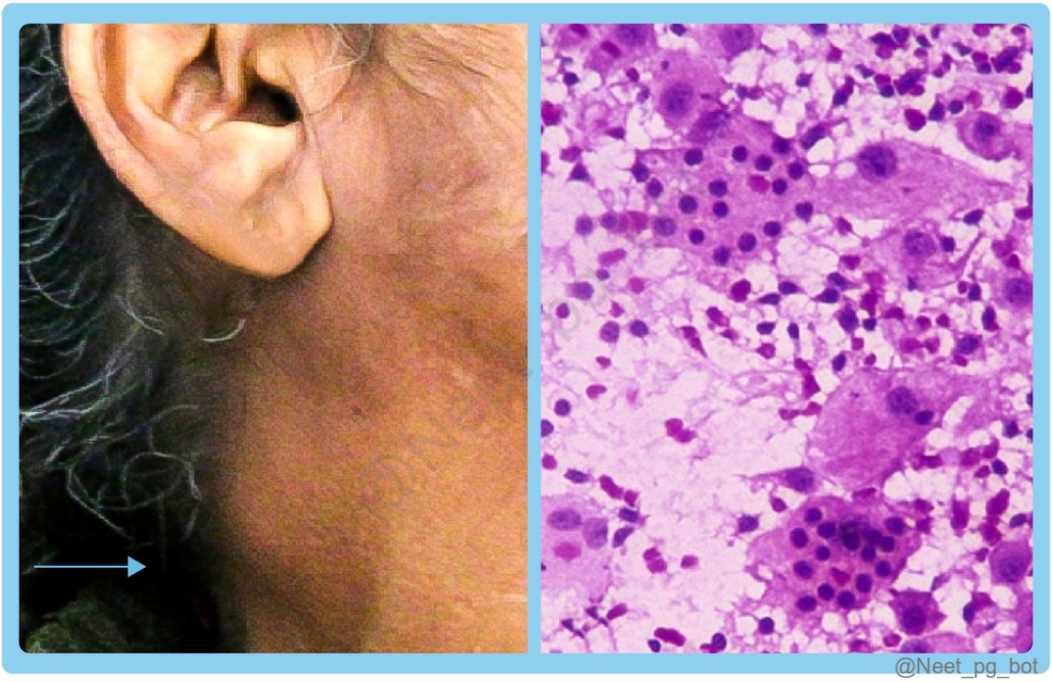

References:

https://pmc.ncbi.nlm.nih.gov/articles/PMC4750564/

https://pmc.ncbi.nlm.nih.gov/articles/PMC9075182/

↑ *Back to this question in Part A*

@Neet_pg_bot

Q5: Which of the following conditions will have the least chance of a dry bone marrow aspiration? (Q856898)

A. Hairy cell leukemia

B. Acute myeloid leukemia (AML)

C. Myelodysplastic syndrome

D. Follicular lymphoma

Correct Answer: D. Follicular lymphoma

Explanation: Follicular lymphoma is less likely to result in a dry bone marrow aspiration compared to the other conditions. In follicular lymphoma, the bone marrow may be infiltrated with lymphoma cells but typically retains enough cellularity for a successful aspiration. Conditions that can lead to a dry bone marrow aspiration (Dry tap):

Metastatic carcinoma infiltration (17%) Chronic myeloid leukemia (CML) (15%) Myelofibrosis (14%) Hairy cell leukemia (10%) Acute leukemia (10%) Lymphomas, including Hodgkin's disease. {{caption_text}} Hairy Cell Leukemia (HCL) (Option A) , Acute Myeloid Leukemia (AML) (Option B) (e.g., AML with myelofibrosis), and Myelodysplastic Syndrome (MDS) (Option C) can all cause dry bone marrow aspiration due to bone marrow fibrosis, increased reticulin deposition or dense cellular infiltration .

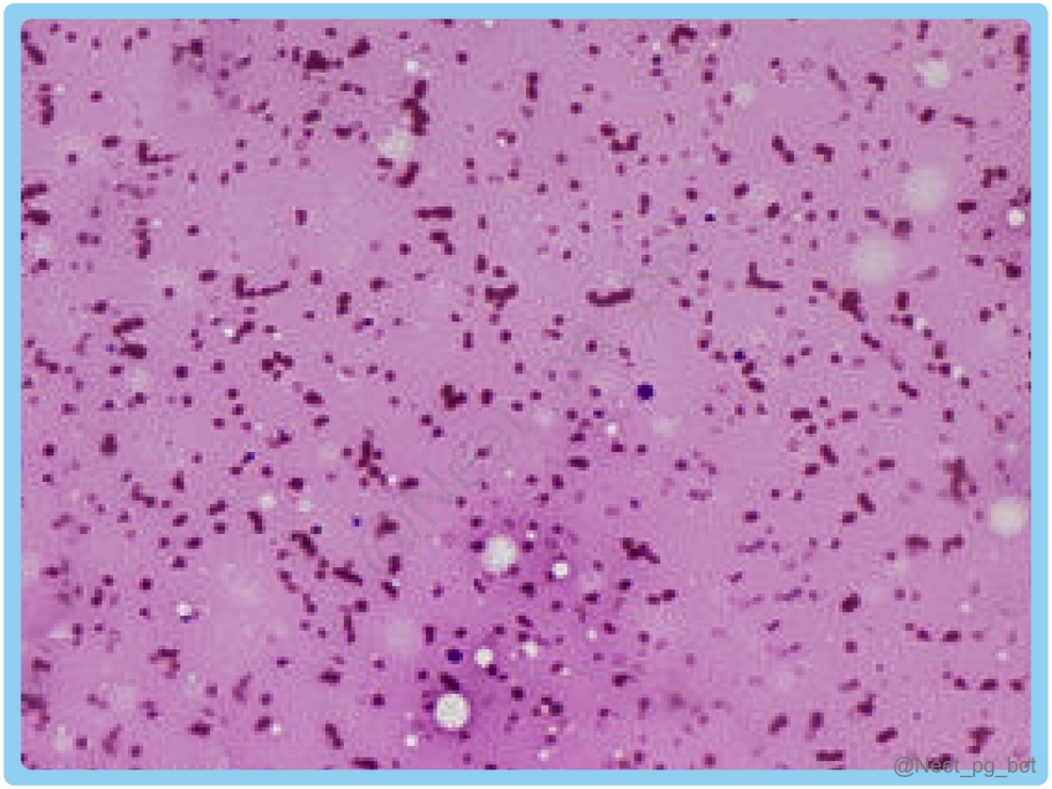

References:

Harrison's Principles of Internal Medicine, 21st Edition, Page 856

↑ *Back to this question in Part A*

@Neet_pg_bot

• [22_Techniques in Pathology] 084 Previous Year Questions

« Back to Folder Directory

[22_Techniques in Pathology] 084 Previous Year Questions — Quick Jump

Q1 (p. 3191) *Q2 (p. 3192)* *Q3 (p. 3195)* *Q4 (p. 3198)* *Q5 (p. 3202)* *Q6 (p. 3204)*
Q7 (p. 3205) *Q8 (p. 3209)* *Q9 (p. 3210)* *Q10 (p. 3213)* *Q11 (p. 3215)* *Q12 (p. 3219)*
Q13 (p. 3219)

Q1: The image below represents the presence of HER2 neu cells in a patient with breast carcinoma. What agent is used to produce this characteristic discolouration? (Q854670)

A. FITC

B. Phycoerythrin

C. Cyanate dye

D. Diaminobenzidine

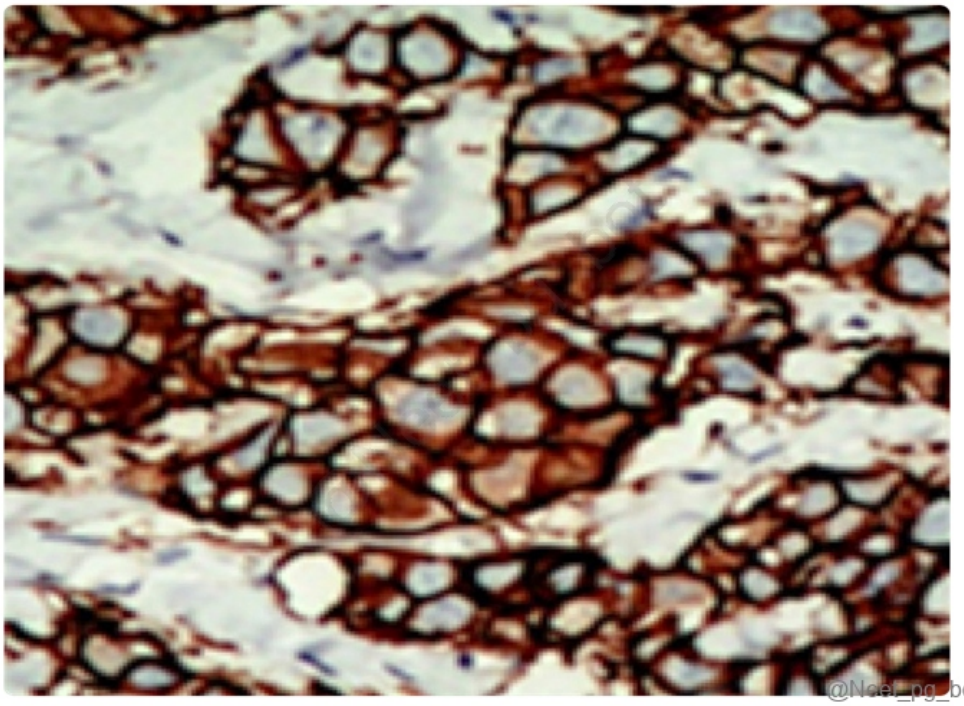

Correct Answer: D. Diaminobenzidine

Explanation: 3,3′-Diaminobenzidine (DAB) is a commonly used chromogen in immunohistochemistry (IHC) to detect HER2 overexpression in certain breast cancers. It serves as a substrate for a peroxidase enzyme coupled to a primary or secondary antibody. It is oxidised and converted to an insoluble polymer, precipitating as a dark brown pigment, which allows visualisation of the target molecule. FITC (Fluorescein Isothiocyanate) (Option A) is a fluorescent dye that is used in fluorescence microscopy to detect specific antigens but does not produce a brown colour. It would instead produce a green fluorescence. Phycoerythrin (Option B) is another fluorescent dye often used in flow cytometry and fluorescence microscopy but does not produce a brown colouration. It fluoresces red-orange and is used for labelling antibodies. Cyanate dye (Option C) is commonly used in fluorescence-based applications such as fluorescent labelling of biomolecules in biological and biochemical research. These dyes are known for their high sensitivity and photostability.

References:

NIH Link , Link

↑ *Back to this question in Part A*

@Neet_pg_bot

Q2: A phlebotomist is asked to collect blood samples for a patient undergoing multiple tests. Which of the following is the correct order of blood collection to avoid contamination of the samples based on the additives in the collection tubes? (Q854685)

A. Light blue → Lavender → Red → Grey

B. Grey → Red → Light blue → Lavender

C. Light blue → Red → Lavender → Grey

D. Red → Lavender → Grey → Light blue

Correct Answer: C. Light blue → Red → Lavender → Grey

Explanation: The correct order here is Light blue → Red → Lavender → Grey In blood collection, it's crucial to follow the correct order to prevent contamination between tubes with different additives. The correct order of drawing the blood in vacutainers is Blood culture → Light blue → Red or Yellow → Green → Lavender → Grey Vacutainer colour Additive Uses Blood culture Broth media (aerobic/anaerobic) For detecting bacterial and fungal infections Light blue {{caption_text}} Trisodium citrate For coagulation tests Red or Yellow {{caption_text}} {{caption_text}} No additive (Red) / Gel separator (Yellow) For serum collection (serology, chemistry) Green Heparin For plasma collection (chemistry tests) Lavender {{caption_text}} EDTA For haematology tests (e.g., CBC, blood smears) Pink EDTA For blood bank tests (e.g., crossmatch, blood type Grey {{caption_text}} Potassium Oxalate + Sodium Fluoride For glucose, lactate, and alcohol tests


BD Vacutainer®
Buff. Na Citrate
0.109M, 3.2%
REF 363083
LOT 21241322 2013-02
@Neet_pg_bot


Surname
First Name
6 ml
20101H



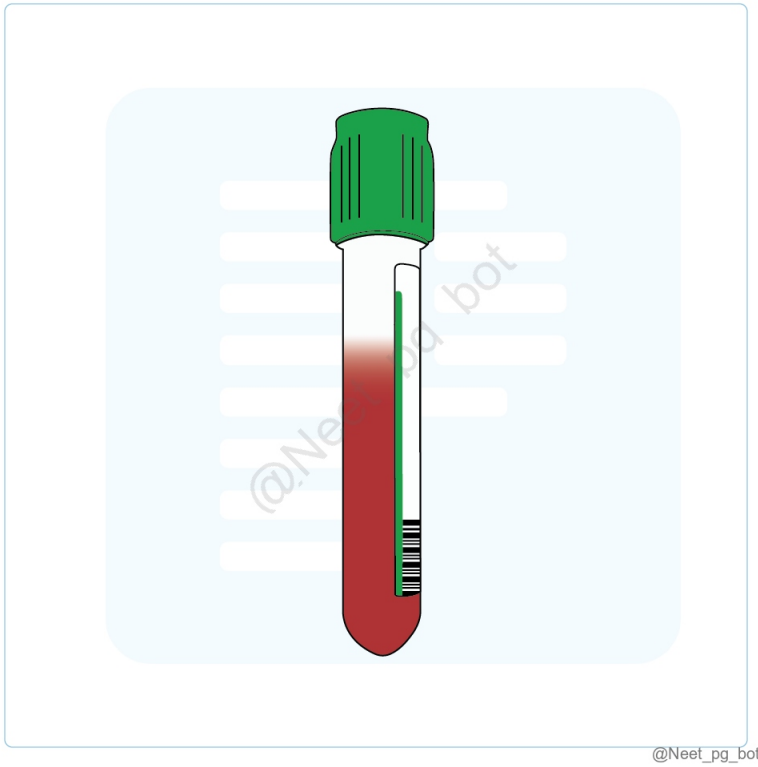

@Neet_pg_bot

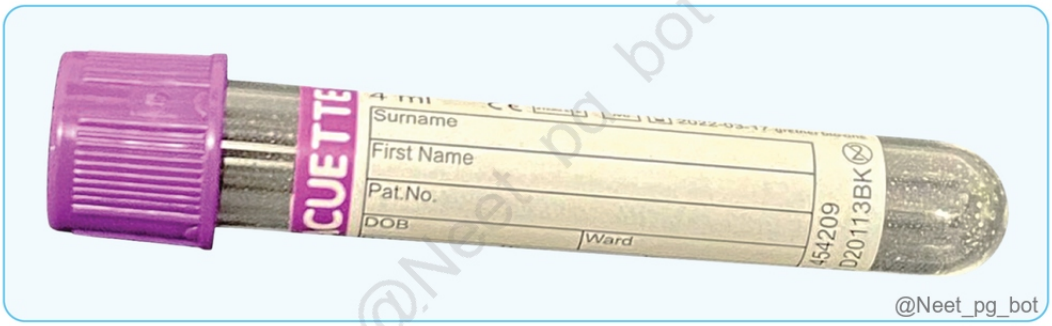



References:

Online source - Link , Link , Link

↑ *Back to this question in Part A*

@Neet_pg_bot

Q3: Pair the stains with their corresponding options Stain Corresponding Option 1. Prussian blue stain a. Iron 2. PAS stain b. Glycogen 3. Congo red stain c. Leprosy 4. Fite-Faraco stain d. Amyloid (Q855085)

A. 1-d, 2-c, 3-b, 4-a

B. 1-c, 2-a, 3-b, 4-d

C. 1-a, 2-b, 3-d, 4-c

D. 1-b, 2-a, 3-c, 4-d

Correct Answer: C. 1-a, 2-b, 3-d, 4-c

Explanation: Stain Corresponding Option Images Prussian blue stain Iron {{caption_text}} PAS stain Glycogen {{caption_text}} Congo red stain Amyloid {{caption_text}} Fite-Faraco stain Leprosy {{caption_text}}

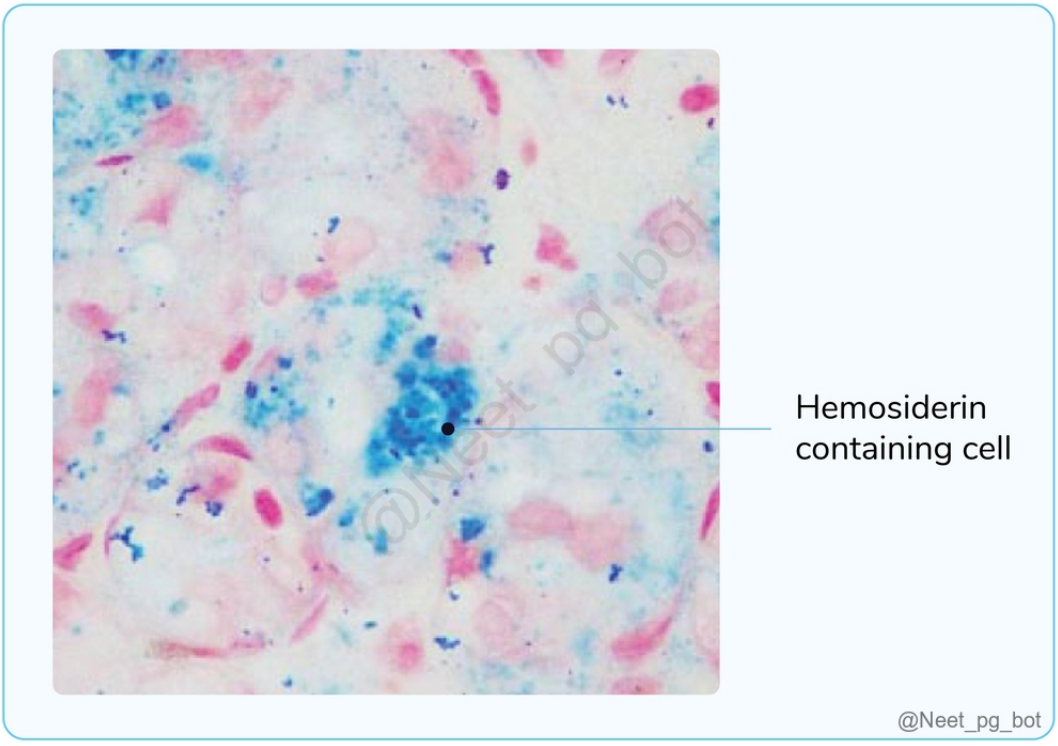

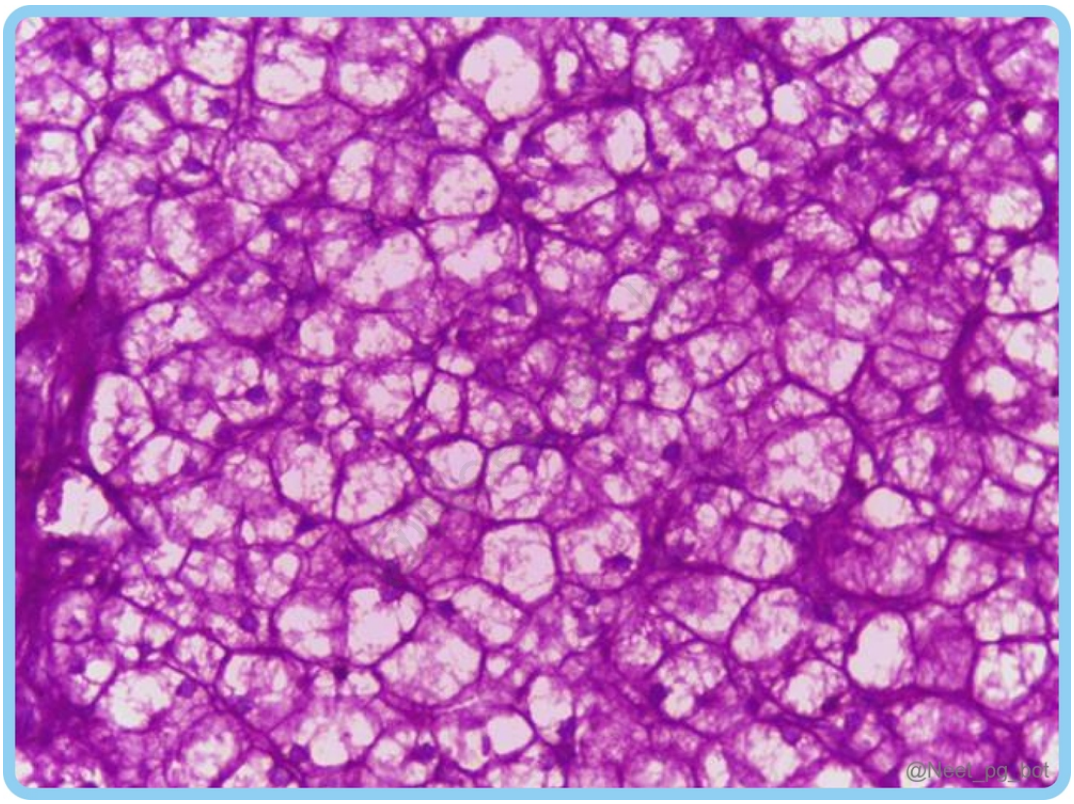
@Neet_pg_bot

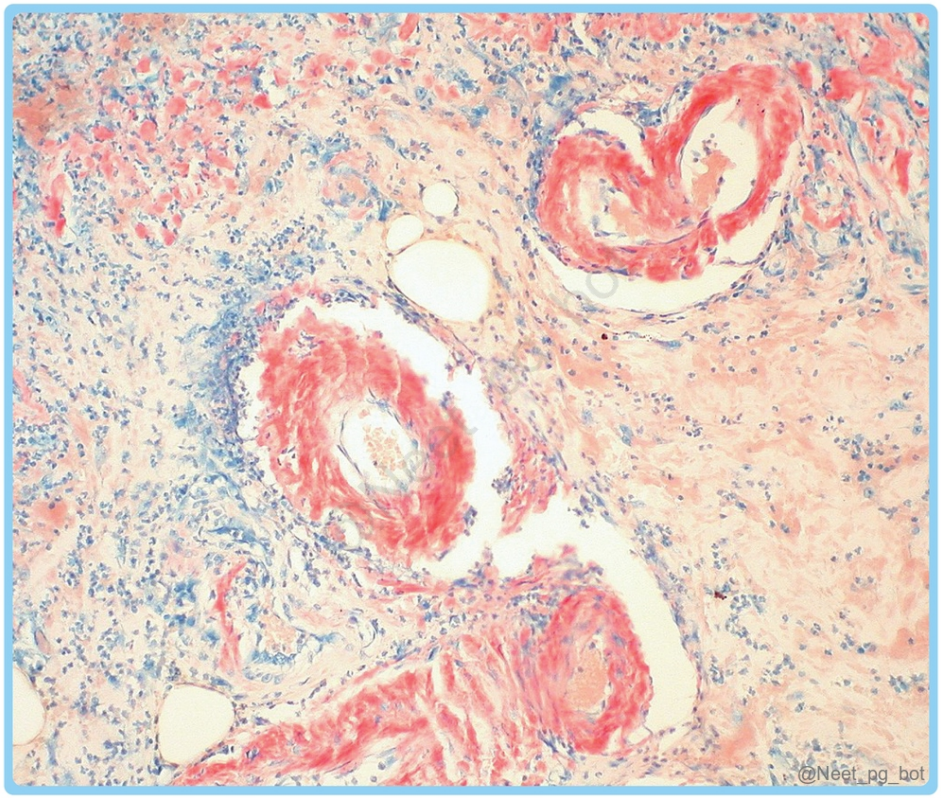
@Neet_pg_bot

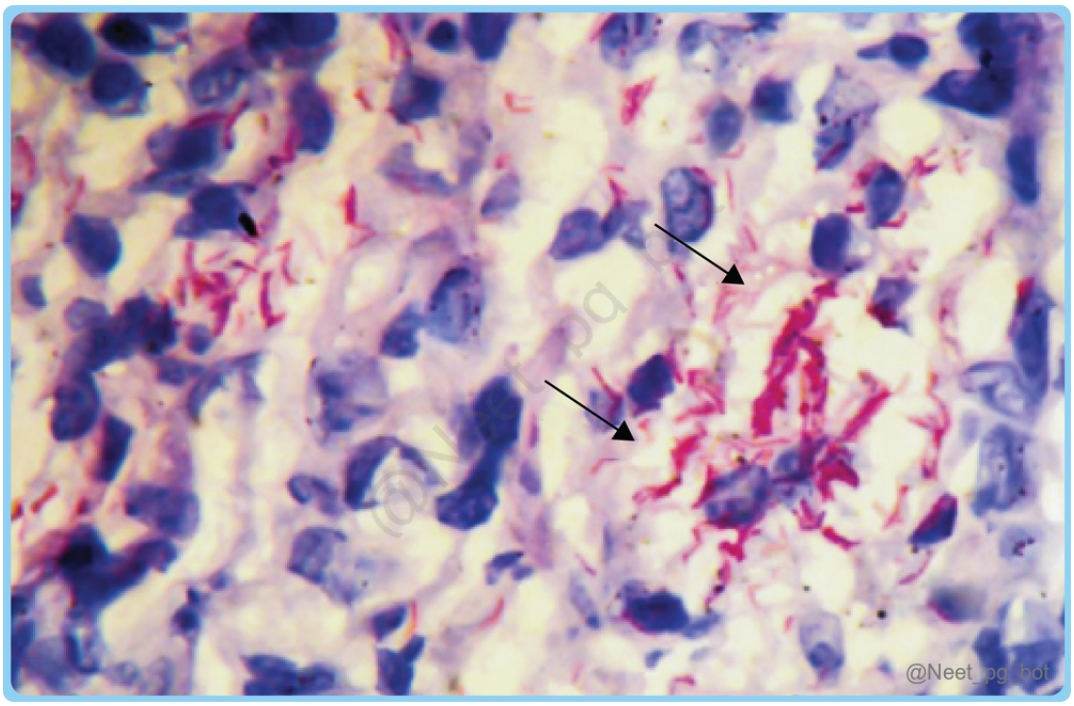

References:

Robbins & Cotran Pathologic Basis of Disease, 10th Edition, Page 259, 260, 574, 655, 768, 848.

↑ *Back to this question in Part A*

@Neet_pg_bot

Q4: A child presents with multiple skin lesions over the inner thigh and genital areas. Initially, the lesions started as macules and later developed into nodules. Some of the nodules have a central umbilication. The histology of the lesion is shown below. What would be found on a biopsy? (Q855108)

A. Multinucleate giant cells (Tzanck cells)

B. Donovan bodies

C. Henderson-Patterson bodies

D. Koilocytes

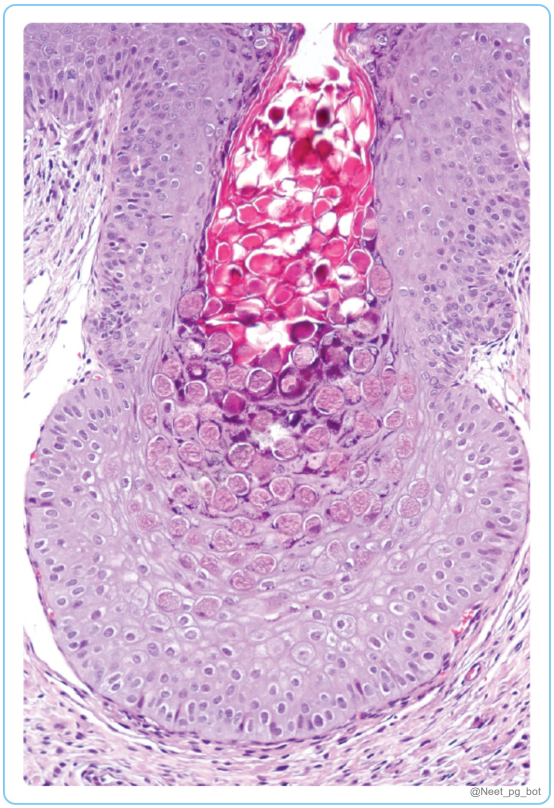

Correct Answer: C. Henderson-Patterson bodies

Explanation: The given clinical scenario and image are diagnostic of Molluscum contagiosum lesions, which show intracytoplasmic inclusion bodies called Henderson-Patterson bodies /molluscum bodies. Molluscum Contagiosum: Caused by: Poxvirus (MCV-1 to MCV-4) MCV-1 is the most common. MCV-2 is often sexually transmitted. Common in: Children (2-12 years): Spread through direct contact or shared items (e.g., towels) Adults: Typically sexually transmitted, affecting genitals, lower abdomen, buttocks, and inner thighs Incubation period: Approximately 6 weeks Clinical Features: Pearly, dome-shaped papules (1-5 mm in diameter) with a dimpled centre. The central waxy core contains cytoplasmic viral inclusions. Common sites in children: Trunk, arms, and legs Common sites in adults: Genitals, lower abdomen, buttocks, and inner thighs Microscopic examination: Lesion characteristics: Cup-like, verrucous epidermal hyperplasia. Diagnostic structure : Molluscum body : Large (up to 35 µm), ellipsoid, homogeneous cytoplasmic inclusion. Found in the stratum granulosum and stratum corneum . Eosinophilic in the stratum granulosum. Pale blue hue in the stratum corneum. {{caption_text}} Multinucleate giant cells (Tzanck cells) (Option A) are typically seen in herpesvirus infections (like herpes simplex or varicella-zoster), not in molluscum contagiosum. They are large cells with multiple nuclei, and their presence is a hallmark of herpesvirus infections. {{caption_text}} Donovan bodies (Option B) are characteristic of granuloma inguinale , caused by Klebsiella granulomatis . The bodies are intracellular and appear in macrophages. They are unrelated to molluscum contagiosum. {{caption_text}} Koilocytes (Option D) are cells with a characteristic perinuclear halo and are associated with human papillomavirus (HPV) infections, such as warts. {{caption_text}}

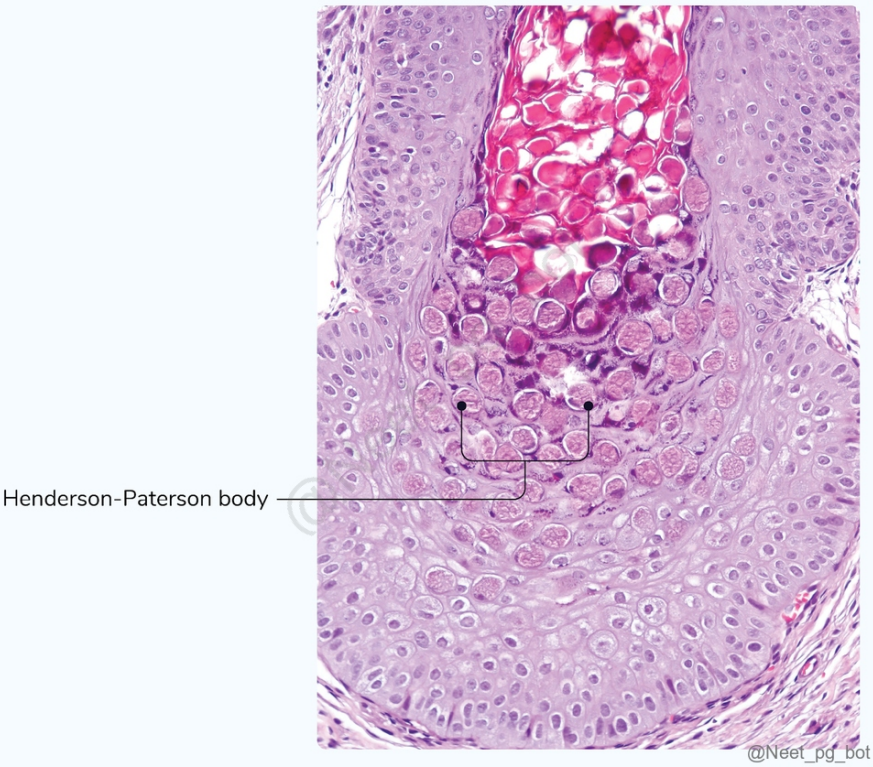

@Neet_pg_bot

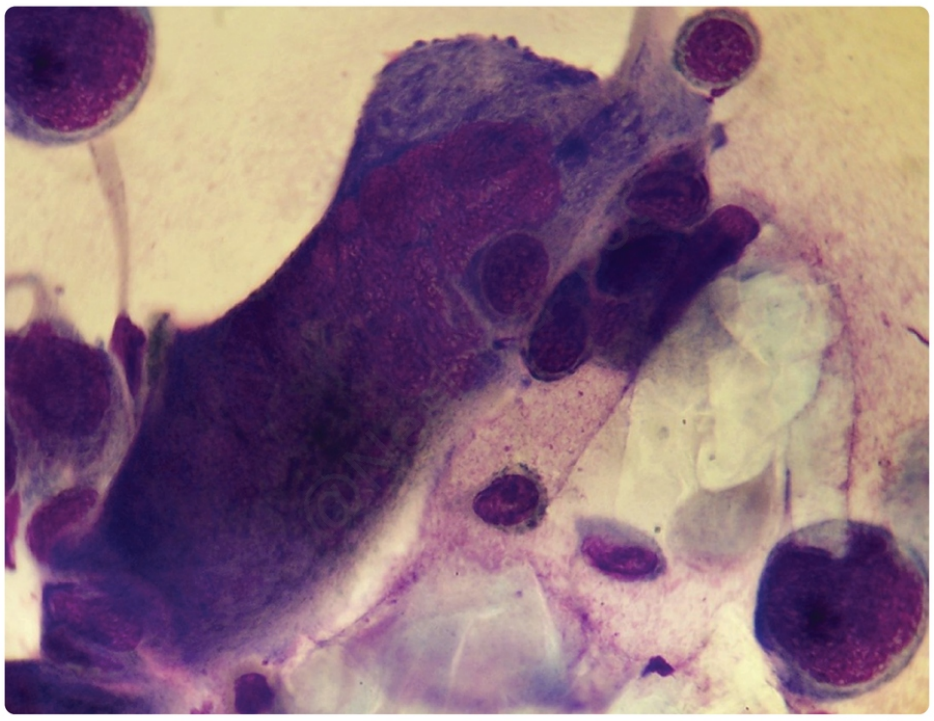
@Neet_pg_bot

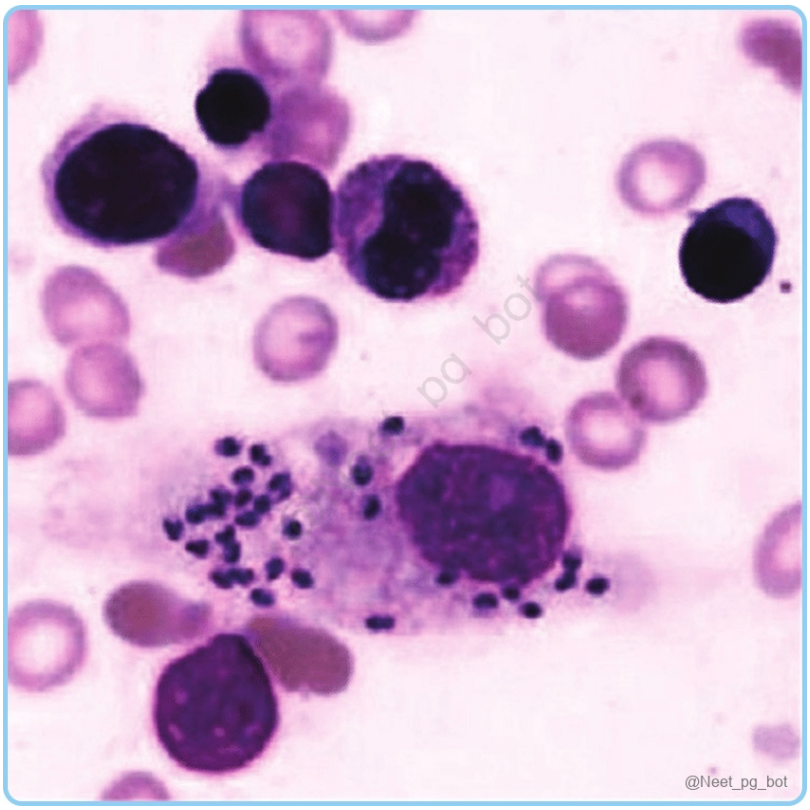



References:

Robbins & Cotran Pathologic Basis of Disease, 10th Edition, Page 987, 988

↑ *Back to this question in Part A*

Q5: Which of the following needles is commonly used for bone marrow biopsy? (Q855114)

A. Klima needle

B. Salah needle

C. Jamshidi needle

D. Islam needle

Correct Answer: C. Jamshidi needle

Explanation: The Jamshidi needle is the most widely used needle for bone marrow aspiration and biopsy. It has a hollow, beveled tip designed to obtain a core of bone marrow with minimal trauma. Common sites for biopsy using this needle are the posterior superior iliac spine and sternum (for aspiration only). It allows both aspiration of liquid marrow and core biopsy for histology in the same procedure. The needle is preferred for its ease of use, safety, and high-quality sample retrieval. {{caption_text}} Incorrect Options: Option A) Klima needle: Rarely used; mainly historical, not standard for marrow biopsy. Option B) Salah needle: Not a standard or recognized needle for bone marrow procedures. ■ Option D) Islam needle: Not used for bone marrow biopsy; no clinical standard. {{caption_text}}



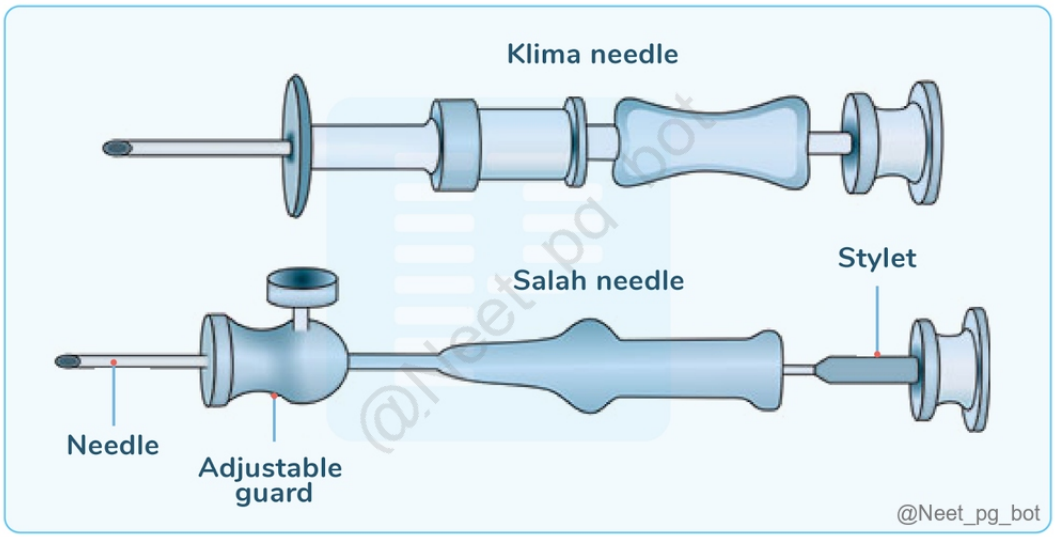



References:

Dacie and Lewis Practical Hematology, 12th Edition, Page 115,120,121,122

https://www.cancer.gov/publications/dictionaries/cancer-terms/def/jamshidi-needle

https://pmc.ncbi.nlm.nih.gov/articles/PMC1860622/

↑ *Back to this question in Part A*

@Neet_pg_bot

Q6: Which of the following oil red O stain is used? (Q855393)

A. Formalin fixation

B. Frozen section

C. Alcohol fixation

D. Glutaraldehyde fixation

Correct Answer: B. Frozen section

Explanation: Oil Red O stain is commonly used in frozen sections to detect the presence of lipids, particularly neutral lipids such as triglycerides. It is a lipophilic dye that selectively stains lipids within cells or tissues. It binds to the neutral lipid droplets and produces a bright red colour when examined under a microscope. {{caption_text}} This stain is particularly useful in identifying lipid accumulation in various tissues and organs, including adipose tissue, liver, muscle, and atherosclerotic plaques. Frozen sections are typically used for rapid intraoperative diagnosis or for research purposes. Formalin fixation (Option A) refers to the preservation of tissue samples using formaldehyde solutions, leading to the cross-linking of proteins and modification of lipid structures, which may interfere with the staining properties of Oil Red O. Alcohol fixation (Option C) involves the preservation of tissues using alcohol-based solutions, such as ethanol or methanol. It can also alter the structure of lipids, affecting the staining properties of Oil Red O. Glutaraldehyde fixation (Option D) is typically used for electron microscopy studies. It may lead to changes in lipid composition and affect the staining properties of Oil Red O.

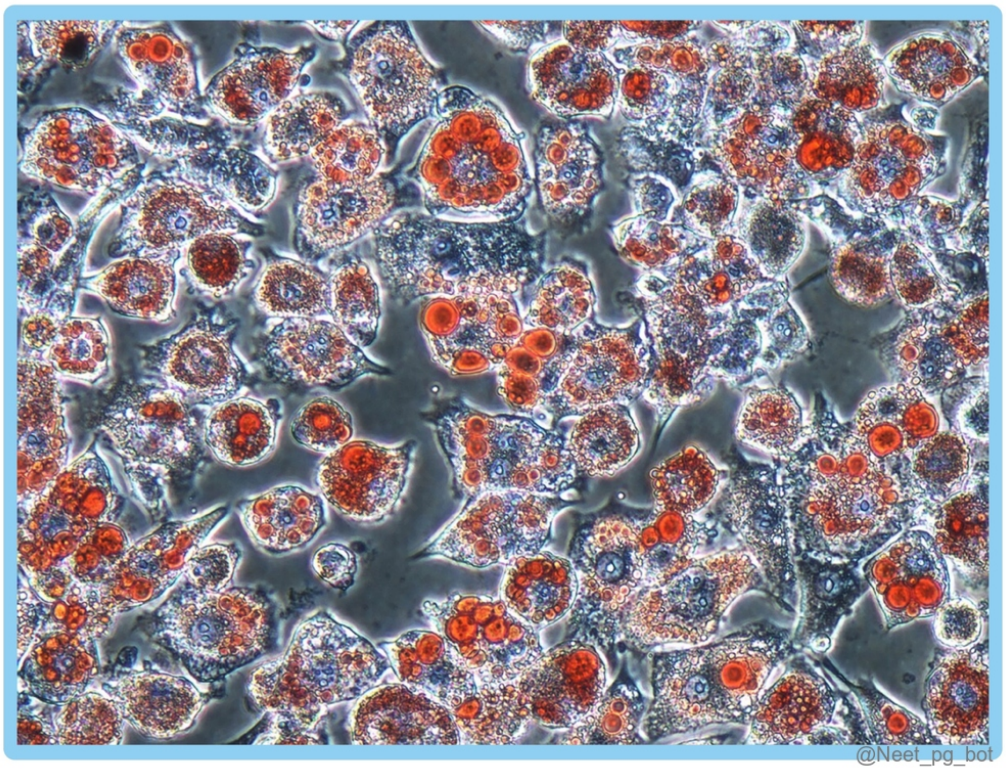

References:

Oil Red O - Wikipedia

An optimized method for Oil Red O staining with the salicylic acid ethanol solution

↑ *Back to this question in Part A*

@Neet_pg_bot

Q7: The vacutainer tube shown in the given image contains the following: (Q855434)

A. EDTA

B. Trisodium citrate

C. NAF - heparin

D. Clot activator



Correct Answer: D. Clot activator

Explanation: The vacutainer tube shown in the image contains a clot activator, which is a substance designed to accelerate the blood clotting process. It promotes quicker coagulation of the blood sample. This type of tube is typically used to collect serum samples for various laboratory tests. Colour Anti-coagulants Uses Purple/Lavender {{caption_text}} EDTA (Ca2+ chelating anticoagulant) (Option A ruled out) CBC, Peripheral Smear, ESR, HbA1c Light Blue {{caption_text}} Trisodium Citrate (Ca2+ chelating anticoagulant) (Option B ruled out) ESR, PT, aPTT Red {{caption_text}} No anti-coagulant is added. Clot activator without gel (Option D) Serum studies (Proteins, enzymes, hormones) Yellow {{caption_text}} Clot activator/Gel separator Serum studies (Proteins, enzymes, hormones) Grey {{caption_text}} Sodium Fluoride Blood Glucose Green {{caption_text}} Heparin (Option C ruled out) ABG, Osmotic fragility, flow cytometry, immunophenotyping

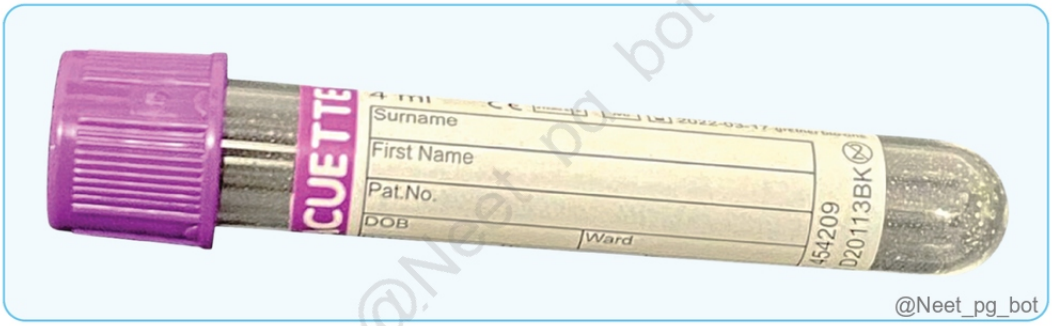


BD Vacutainer®
Buff. Na Citrate
0.109M, 3.2%
REF 363083
LOT 21241322 2013-02
@Neet_pg_bot


Surname
First Name
6 ml
@Neet_pg_bot


UETTE
5 ml
Surname
First Name
Pat.No.
2022-02-12
greiner bio-one
018
103BM


UETTE
2 ml
Surname
First Name
Pat.No.
2022-05-03
greiner bio-one
238
01368

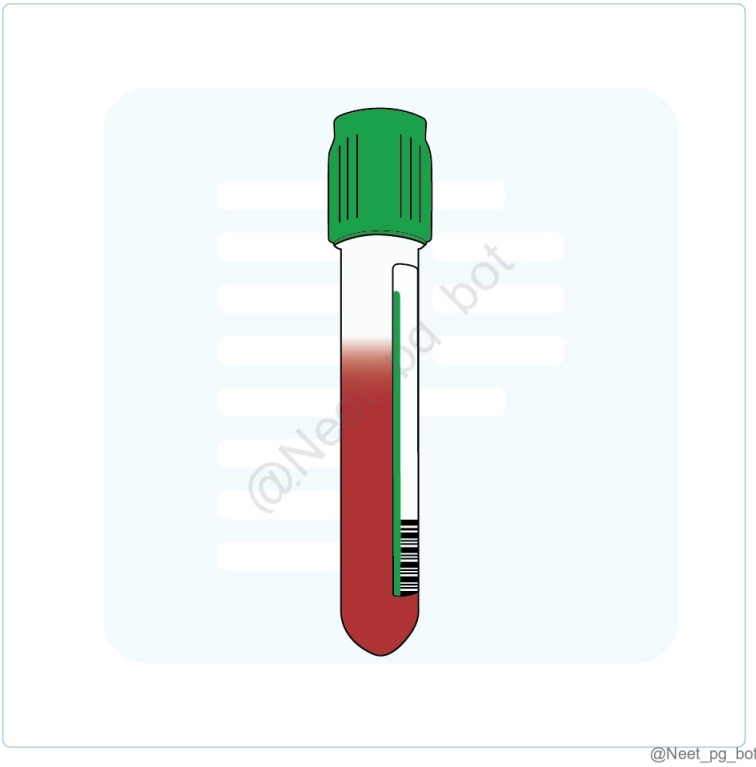

References:

Atlas of Clinical Hematology, Chapter 1, Page 4

Laboratory tube collection

↑ *Back to this question in Part A*

@Neet_pg_bot

Q8: The following image shows an instrument used to estimate haemoglobin levels. What does it measure? (Q855893)

A. Alkaline hematin

B. Acid hematin

C. Oxyhemoglobin

D. Deoxyhemoglobin



@Neet_pg_bot

Correct Answer: B. Acid hematin

Explanation: The image depicts a device known as the Sahli hemoglobinometer, which is used to estimate haemoglobin levels in blood. The hemoglobinometer works by adding a dilute acid to a small sample of blood, causing the formation of acid hematin , a derivative of haemoglobin formed when haemoglobin reacts with an acid. This acid hematin is then compared to a standard colour chart to determine the haemoglobin concentration.

References:

https://pmc.ncbi.nlm.nih.gov/articles/PMC2536237/

↑ *Back to this question in Part A*

@Neet_pg_bot

Q9: Which of the following methods is iron in tissues stained? (Q855899)

A. Masson’s trichrome

B. Prussian blue

C. PAS

D. Fite-Faraco

Correct Answer: B. Prussian blue

Explanation: Iron in tissues is stained using Prussian blue. This staining technique relies on the reaction between Fe3+ ions and ferrocyanide ions to form an insoluble blue pigment. When tissue sections are treated with a solution of potassium ferrocyanide and hydrochloric acid, any iron present in the tissue reacts with the ferrocyanide, producing the blue pigment. This stain is specific for iron and is frequently employed to detect iron deposition in conditions like hemochromatosis and hemosiderosis. Prussian blue stain Iron {{caption_text}} Masson Trichrome Differentiate Collagen & muscle fibers {{caption_text}} Fite-Faraco stain Leprosy {{caption_text}} PAS stain Glycogen {{caption_text}}

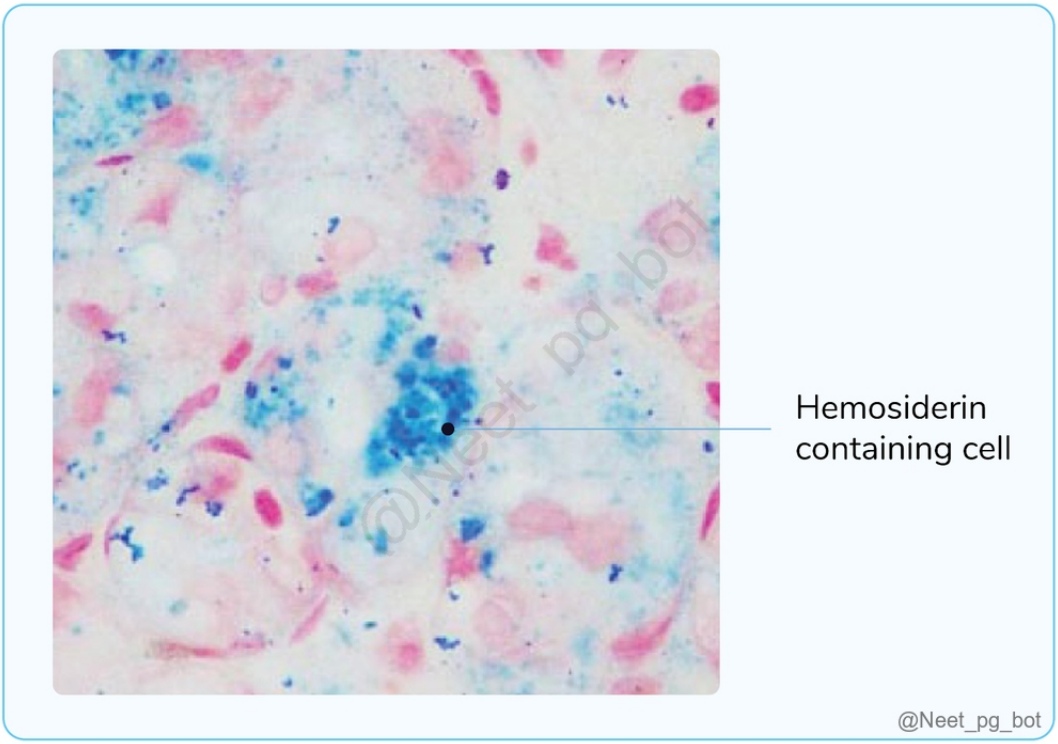

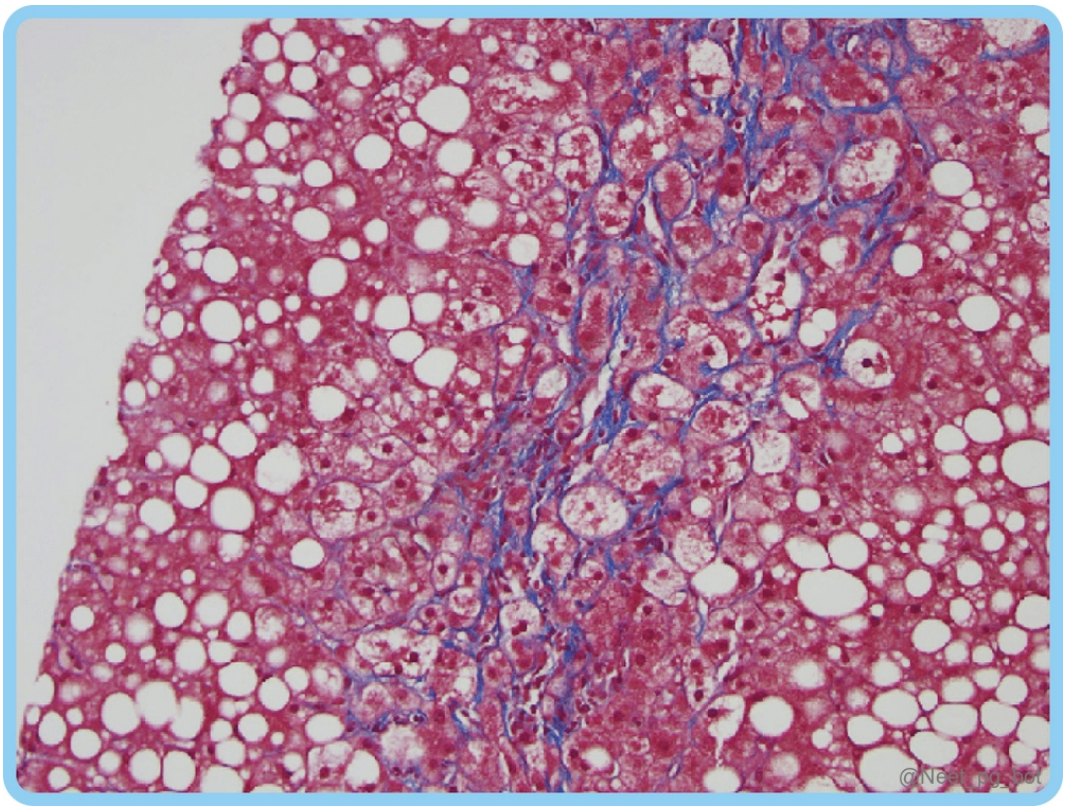
@Neet_pg_bot

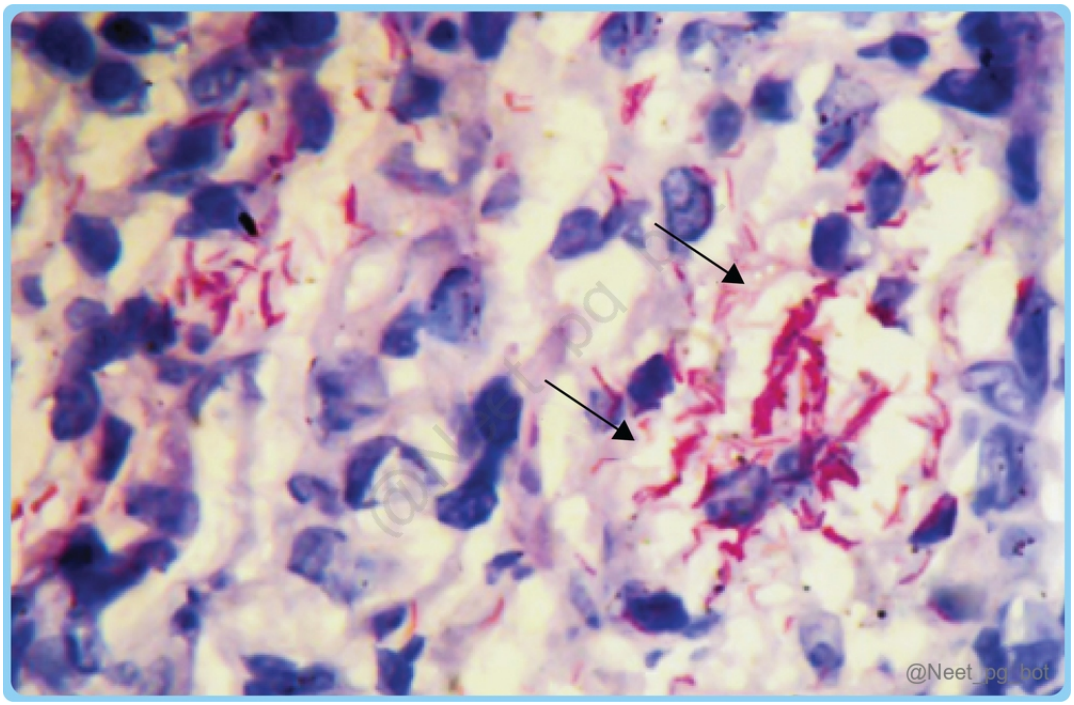
@Neet_pg_bot

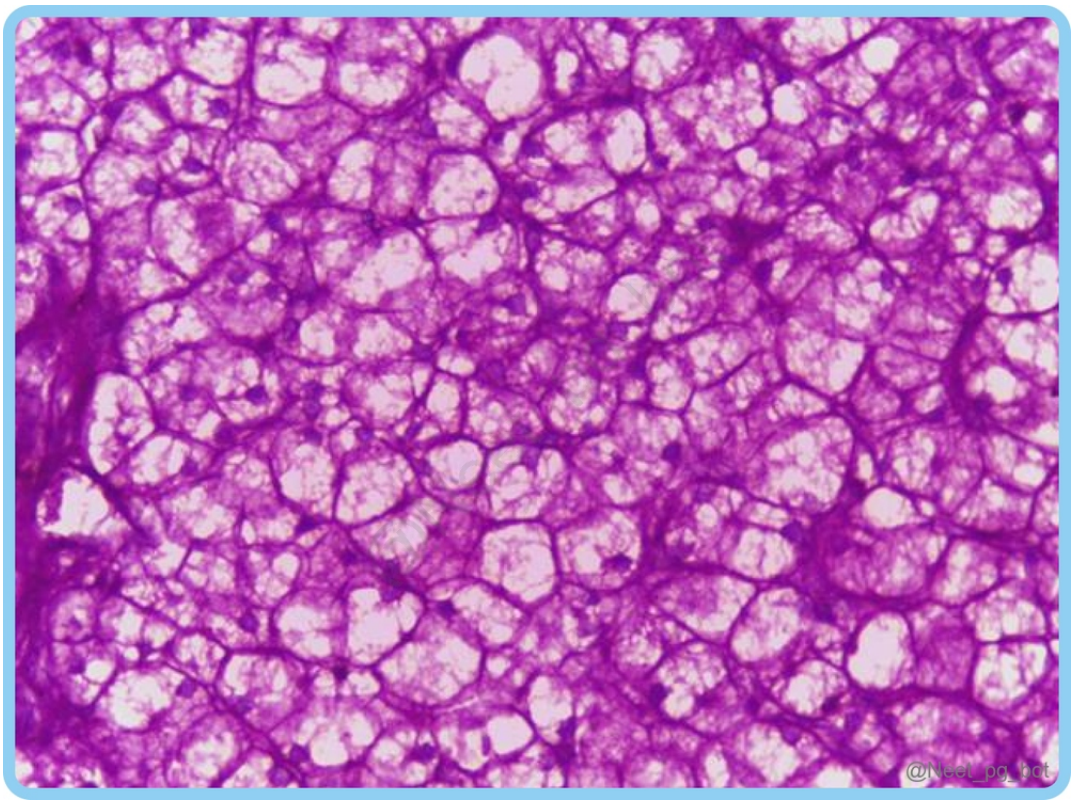

References:

Robbins & Cotran Pathologic Basis of Disease, 10th Edition, Page 259, 260, 574, 655, 768, 848

↑ *Back to this question in Part A*

@Neet_pg_bot

Q10: A woman presents with nodular lesions, 4-6 mm in size, on the inner thighs and peri-anal region. The lesions appear pale, and histopathological examination reveals multiple intracytoplasmic inclusion bodies consistent with Henderson-Patterson bodies. What is the most likely diagnosis? (Q855907)

A. Trichodysplasia spinulosa

B. Condyloma acuminata

C. Molluscum contagiosum

D. Donovanosis

Correct Answer: C. Molluscum contagiosum

Explanation: The patient's presentation of pale, nodular lesions on the inner thighs and peri-anal region, along with the presence of Henderson-Patterson bodies, is characteristic of Molluscum contagiosum . Henderson-Patterson bodies are eosinophilic inclusion bodies that are diagnostic for Molluscum contagiosum virus (MCV) infection. The virus primarily infects the skin, causing characteristic lesions that are typically described as pearl-like, dome-shaped, and umbilicated. The lesions are generally painless and self-limiting, though they can persist for months or even years. {{caption_text}} Molluscum Contagiosum: Caused by: Poxvirus (MCV-1 to MCV-4) MCV-1 is the most common. MCV-2 is often sexually transmitted. Common in: Children (2-12 years): Spread through direct contact or shared items (e.g., towels). Adults: Typically sexually transmitted, affecting genitals, lower abdomen, buttocks, and inner thighs. Incubation period: Approximately 6 weeks. Clinical Features: Pearly, dome-shaped papules with a dimpled centre. Papules are 1-5 mm in diameter. The central waxy core contains cytoplasmic viral inclusions. Common sites in children: Trunk, arms, and legs. Common sites in adults: Genitals, lower abdomen, buttocks, and inner thighs. Microscopic examination: Lesion Characteristics: Cup-like, verrucous epidermal hyperplasia. Diagnostic Structure : Molluscum body , a large (up to 35 µm), ellipsoid, homogeneous cytoplasmic inclusion. Found in the stratum granulosum and stratum corneum . Eosinophilic in the stratum granulosum. Pale blue hue in the stratum corneum. Trichodysplasia Spinulosa (Option A) is a viral infection that predominantly affects immunocompromised individuals, especially organ transplant recipients. It typically manifests as follicular papules and spiny nodules on the face, neck, and upper extremities. Histologically, it shows hyperkeratosis, follicular plugging, and hair shaft abnormalities. Condyloma acuminata (Option B) , or genital warts, is caused by the human papillomavirus (HPV) and is a sexually transmitted infection. These warts usually appear as flesh-coloured, cauliflower-like growths in the genital and perianal regions. Histologically, they are characterized by hyperkeratosis, acanthosis, and koilocytosis, where squamous cells exhibit a clear halo around the nucleus. {{caption_text}} Donovanosis (Option D), also called granuloma inguinale, is a bacterial infection caused by Klebsiella granulomatis . It presents as painless nodules or ulcers in the genital and perianal regions. Histologically, it shows granulomatous inflammation with Donovan bodies, which are large, rod-shaped, intracytoplasmic bacteria

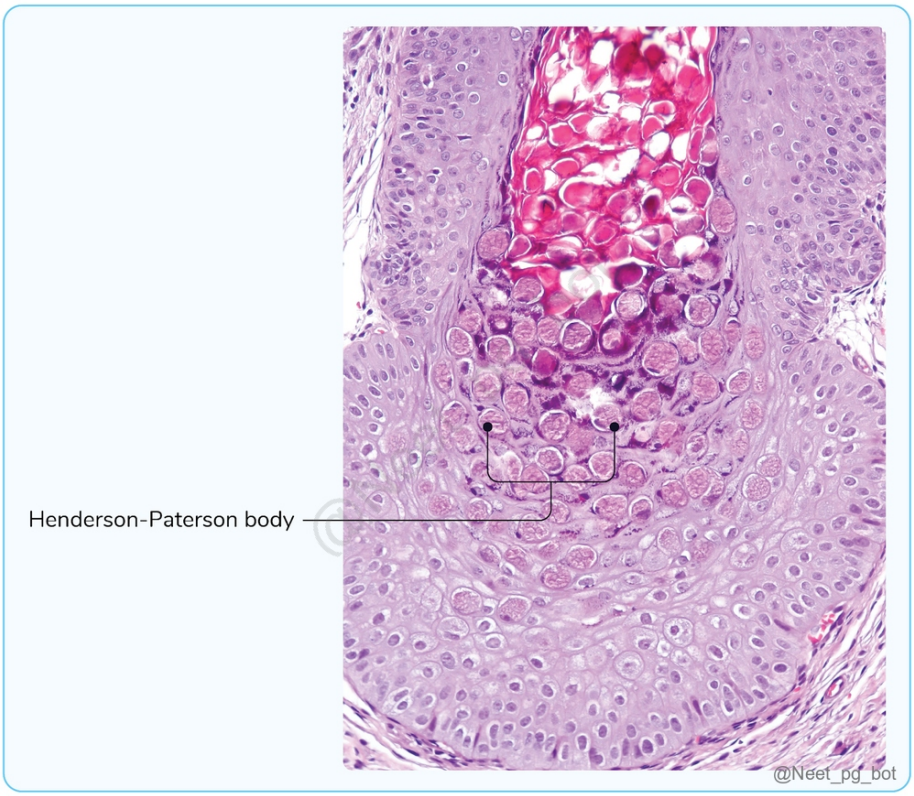

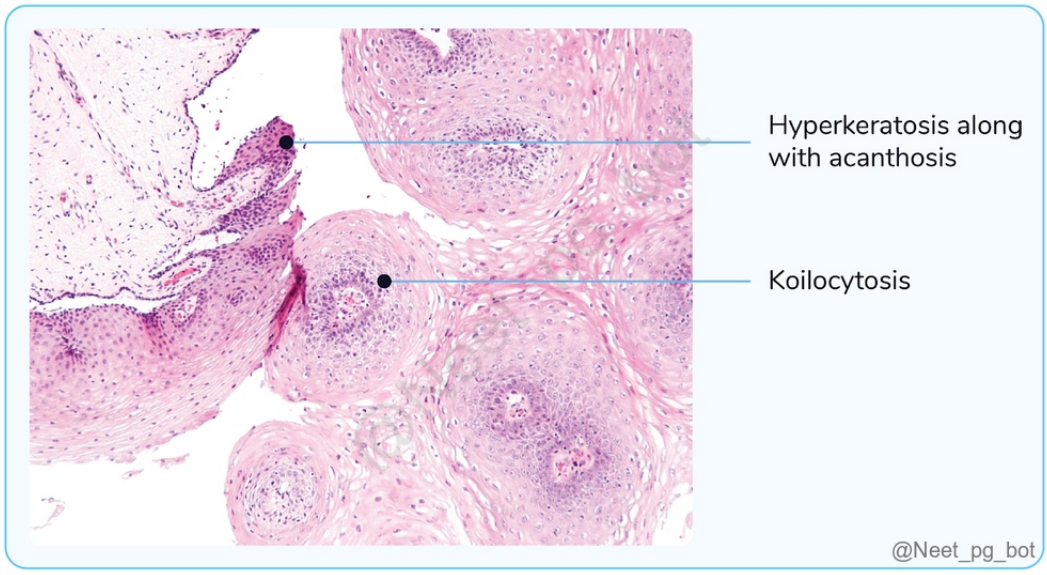

References:

Robbins & Cotran Pathologic Basis of Disease, 10th Edition, Page 987,988

↑ *Back to this question in Part A*

@Neet_pg_bot

Q11: The given inclusion bodies are characteristic of which of the following organisms? (Q858119)

A. Human papillomavirus

B. Cytomegalovirus

C. Epstein-Barr virus

D. Herpes simplex virus

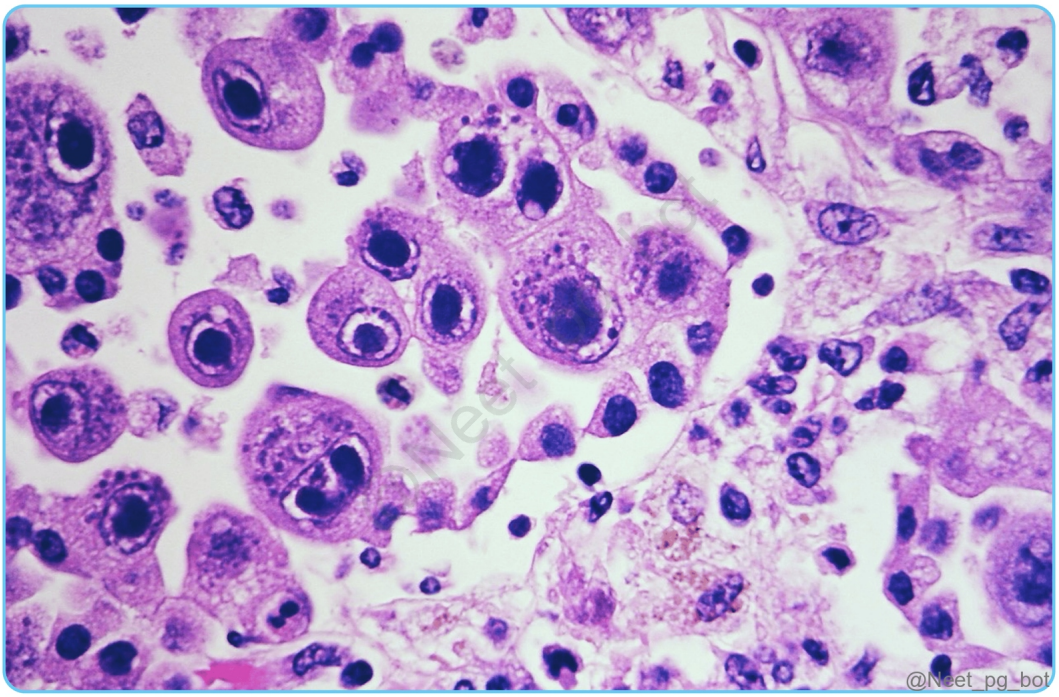

Correct Answer: B. Cytomegalovirus

Explanation: The presence of inclusion bodies, which gives the characteristic “Owl-eye appearance,” suggests Cytomegalovirus. CMV infection Modes of transmission Oral route, respiratory & body secretions (most common) Vertical transmission Sexual transmission Organ transplantation Blood transfusion Investigations Peripheral smear Owl’s eye appearance of inclusion bodies {{caption_text}} Virus isolation It is done by Human fibroblast cell line culture Shell vial culture Antigen detected PP65 Antibody detection It is done by ELISA, and the antibodies detected are CMV IgM antibodies. CMV IgG antibodies. Against PP150 and PP65. Against the PP52. PCR Used in detecting CMV DNA. Quantitative nucleic acid testing (QNAT) by PCR is the most sensitive and specific testing. Treatment Ganciclovir (drug of choice) Foscarnet (in Ganciclovir resistance) CMV immunoglobulins and Ganciclovir are given to bone marrow transplant patients. Incorrect Options: Human papillomavirus (Option A) is a sexually transmitted virus, including low-risk strains 6 & 11, causing benign genital warts, and high-risk strains 16 & 18 , linked to cervical carcinoma, vulvar intraepithelial neoplasia (VIN) and vulvar carcinoma. It is characterised by the presence of enlarged, hyperchromatic nuclei with perinuclear halos (koilocytes) in the superficial layers of the epithelium. {{caption_text}} Epstein-Barr virus (Option C) is primarily associated with infectious mononucleosis and certain lymphoproliferative disorders. It is characterised by ‘ Downey cells’, i.e. atypical lymphocytes (large, vacuolated) and Ballerina skirt appearance. {{caption_text}} Herpes simplex virus (Option D) causes vesicular lesions and is characterised by intranuclear inclusion bodies in infected cells. It is characterised by multinucleated giant cells with faceted nuclei and homogeneously stained 'ground-glass' chromatin (Tzanck cells) in the Tzanck smear and the formation of Lipschutz bodies (Cowdry type A). {{caption_text}}

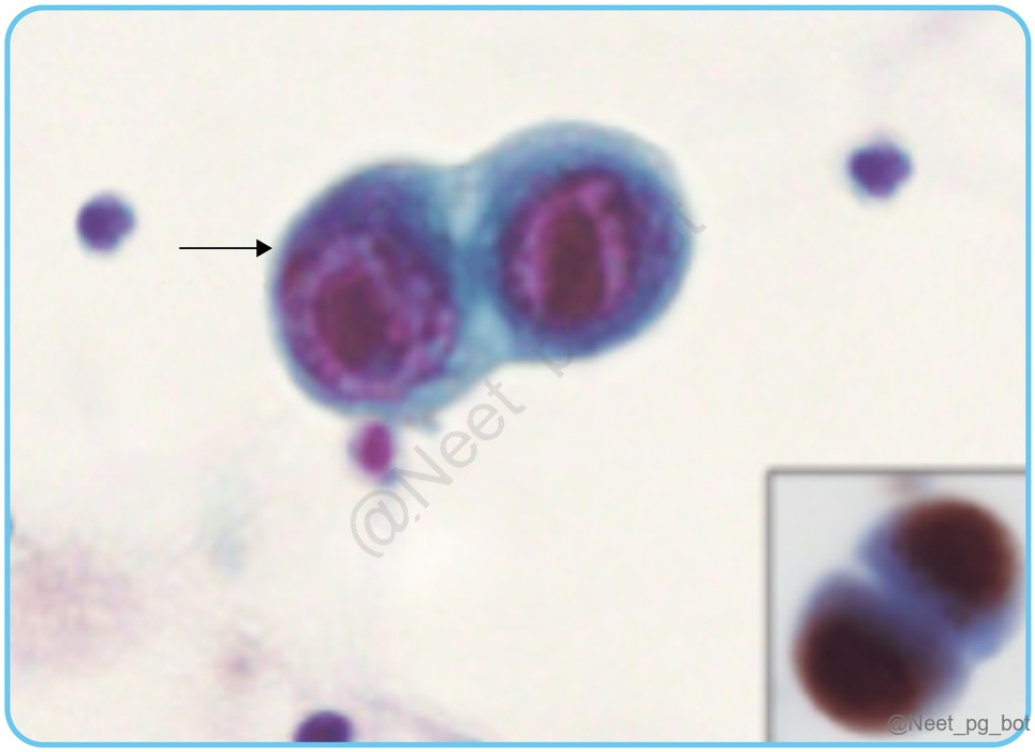

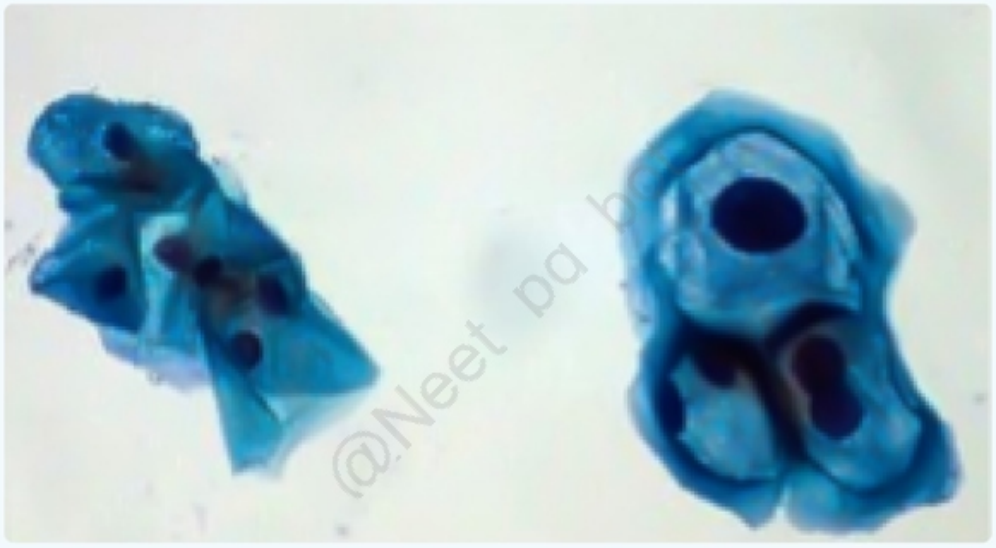

Koilocytes showing perinuclear halo on pap smear

@Neet_pg_bot

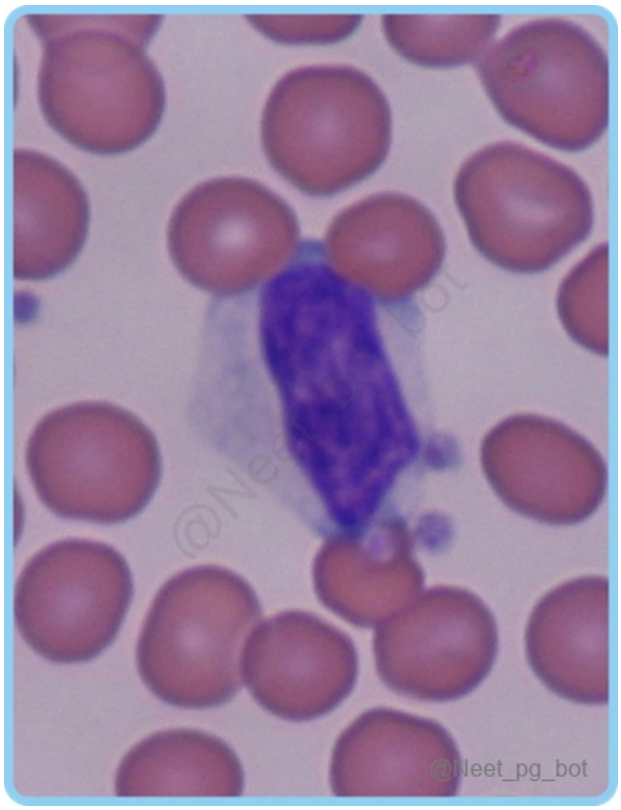

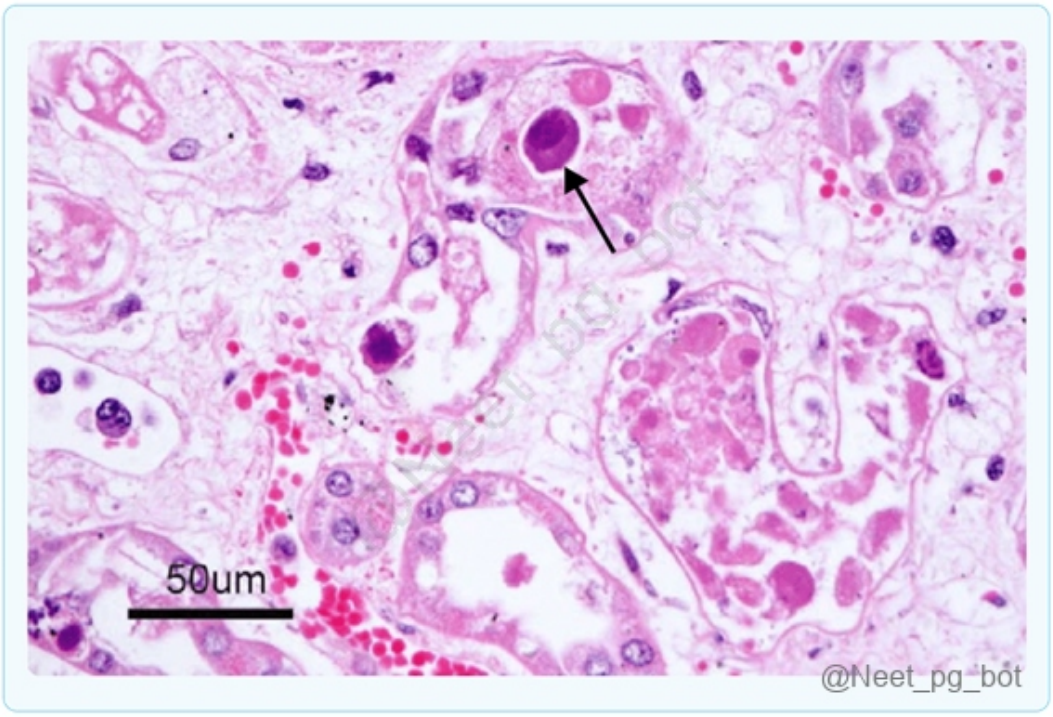

References:

Apurba S Sastry’s Essentials of Medical Microbiology, 3rd Edition, Page 795, 796, 797

↑ *Back to this question in Part A*

@Neet_pg_bot

Q12: CD markers can be detected by which of the following tests? (Q866390)

A. Cytogenetics

B. Next-generation sequencing

C. Flow cytometry

D. Karyotype

Correct Answer: C. Flow cytometry

Explanation: CD markers (Cluster of Differentiation) are surface proteins used to identify and classify immune cells, and they are typically detected using Flow Cytometry , which employs fluorescent-labeled antibodies. Principle : Detects physical and chemical characteristics of individual cells in a fluid stream using laser-based technology. Detects : CD markers (surface antigens) using fluorescent-labeled antibodies. Cell size, granularity, and fluorescence. Used in : Immunophenotyping (e.g., leukemia/lymphoma classification) Stem cell enumeration Monitoring HIV (CD4 count) Output : Dot plots or histograms showing expression of specific markers. Incorrect Options: Cytogenetics (Option A): Detects chromosomal abnormalities, not surface markers. Next-generation sequencing (NGS) (Option B): Detects gene mutations, not surface proteins. Karyotype (Option D): Analyzes chromosome structure and number, not proteins.

↑ *Back to this question in Part A*

@Neet_pg_bot

Q13: In Pap smear cytology, which of the following is the most appropriate fixative used to preserve cellular details immediately after smearing? (Q866744)

A. 50% formaldehyde

B. 95% ethanol

C. 70% ethanol

D. 10% buffered formalin

Correct Answer: B. 95% ethanol

Explanation: 95% ethanol is the fixative used in a conventional pap smear. Fixatives are chemicals that preserve biological tissues by stabilizing cellular structures and preventing decay or degradation. The goal is to maintain the

tissue in a life-like state as much as possible for microscopic examination. Fixation helps maintain the tissue's integrity by preventing autolysis (self-digestion) and putrefaction (bacterial decay). Crosslinking Fixatives: These fixatives work by forming covalent bonds between the proteins and other cellular structures, effectively "locking" them in place. This preserves the tissue’s structural integrity. Formaldehyde: Most commonly used in the form of 10% neutral-buffered formalin. (Option D) Glutaraldehyde : Often used for electron microscopy due to its ability to preserve fine cellular structures. Osmium tetroxide : Used primarily for electron microscopy, particularly for preserving lipids and membranes. Precipitating Fixatives: These work by precipitating proteins and other cellular components, which makes them less soluble and helps preserve their structure. Methanol Ethanol Additive Fixatives: They chemically bind to tissue components, such as proteins or nucleic acids, and stabilise them. They are typically more gentle and produce better preservation of ultrastructure. Formaldehyde (Option A) Glutaraldehyde Non-Additive Fixatives: Alcohol Acetone Pap smear Site The transformation zone of the cervix, where the squamous epithelium (ectocervix) and columnar epithelium (endocervix) meet. This is the most common site for cervical cancer to develop. Instruments Ayre spatula collects cells from the ectocervix Cervical broom (also called a cytobrush) from the transition zone Endocervical brush from the endocervix Procedure Conventional Pap smear : Cells are collected with a spatula or brush, smeared onto a slide, and immediately fixed with a spray fixative or by immersing in 95% ethanol with/without ether Liquid-based cytology : Cells are collected and then rinsed into a liquid fixative vial. This is considered more sensitive than the conventional Pap smear as it provides a more uniform distribution of cells.

↑ *Back to this question in Part A*

@Neet_pg_bot

• [23_Skin Pathology] 085 Skin Pathology

« Back to Folder Directory

[23_Skin Pathology] 085 Skin Pathology — Quick Jump

Q1 (p. 3221) *Q2 (p. 3222)* *Q3 (p. 3225)* *Q4 (p. 3228)* *Q5 (p. 3229)* *Q6 (p. 3231)*
Q7 (p. 3232) *Q8 (p. 3233)* *Q9 (p. 3235)* *Q10 (p. 3238)* *Q11 (p. 3239)* *Q12 (p. 3243)*
Q13 (p. 3245) *Q14 (p. 3247)*

Q1: In which following layer of the epidermis would you most likely find the melanin-producing cells of the skin? (Q845865)

A. Stratum corneum

B. Stratum spinosum

C. Stratum granulosum

D. Stratum basale

Correct Answer: D. Stratum basale

Explanation: Stratum basale is the basal layer of the epidermis, which contains the melanin-producing melanocytes. Layers of the epidermis (superficial to deep) and their components: Stratum Corneum : Keratin and dead keratinocytes. (Option A) Stratum Lucidum : Eleidin (present in areas with thick skin- palms and soles) Stratum Granulosum : Granules of Keratohyalin (Option C) Stratum Spinosum : Dendritic cells (Option B) Stratum Basale / germinativum : Contains cuboidal to columnar mitotically active stem cells; it also contains melanocytes (Option D) Mnemonic : Come Let's Get Sun Burnt

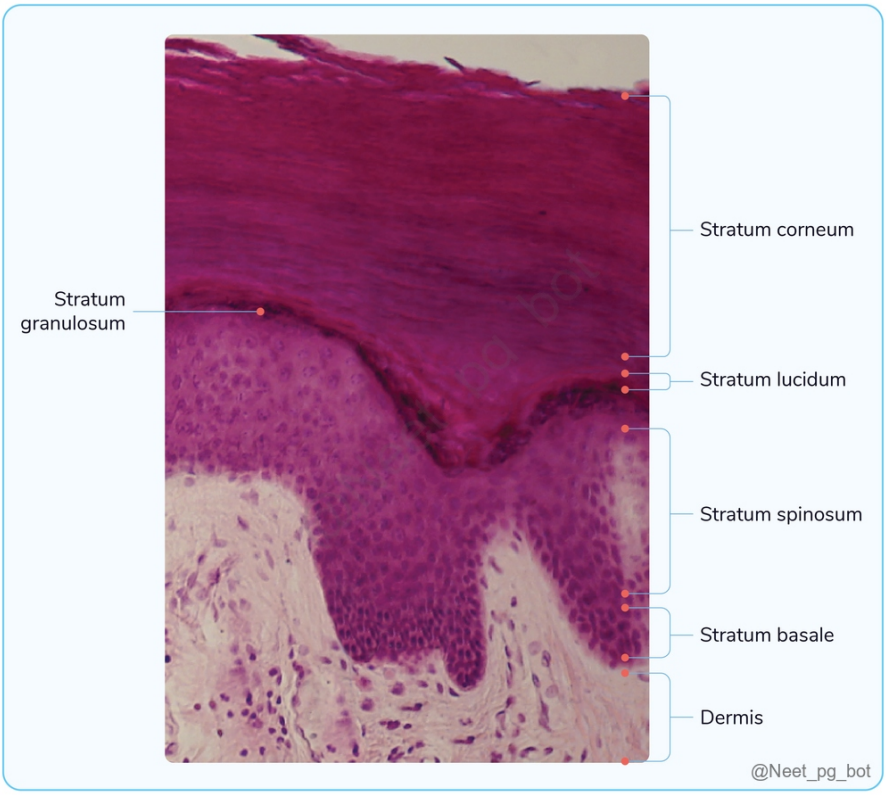

References:

Robbins and Cotran Pathologic Basis of Disease, 10th Edition, Pages 1134-1135

Rook’s textbook of Dermatology, 9th Edition, Page 2.5.2.7

https://www.ncbi.nlm.nih.gov/books/NBK470464/

↑ *Back to this question in Part A*

@Neet_pg_bot

Q2: A 35-year-old male presents with a rash on his hands and feet characterised by clusters of small, fluid-filled blisters. Histopathological examination of a skin biopsy reveals intracellular oedema of keratinocytes. Which term best describes this histological finding? (Q845866)

A. Acanthosis

B. Ballooning

C. Spongiosis

D. Parakeratosis

Correct Answer: B. Ballooning

Explanation: The clinical presentation of small, fluid-filled blisters and the biopsy finding of intracellular oedema of keratinocytes are consistent with hydropic swelling, also known as ballooning . This condition is often seen in viral infections. Acanthosis (Option A): Diffuse thickening of the epidermis. Spongiosis (Option C): Intercellular oedema of the epidermis Parakeratosis (Option D): Retention of nuclei in the stratum corneum.

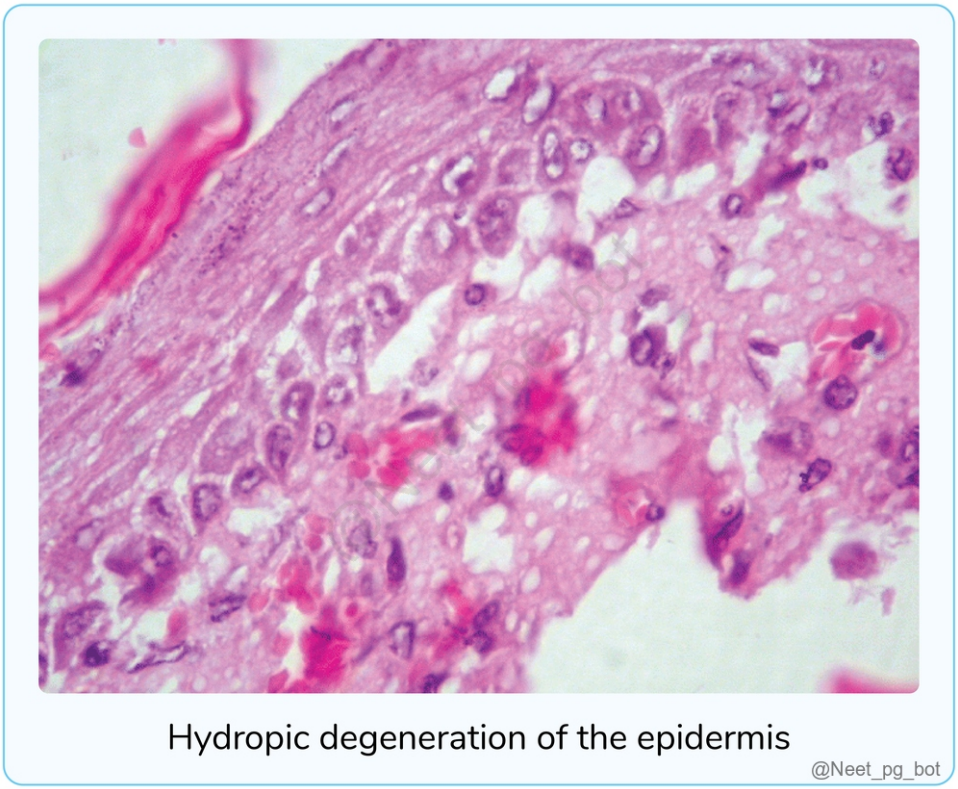



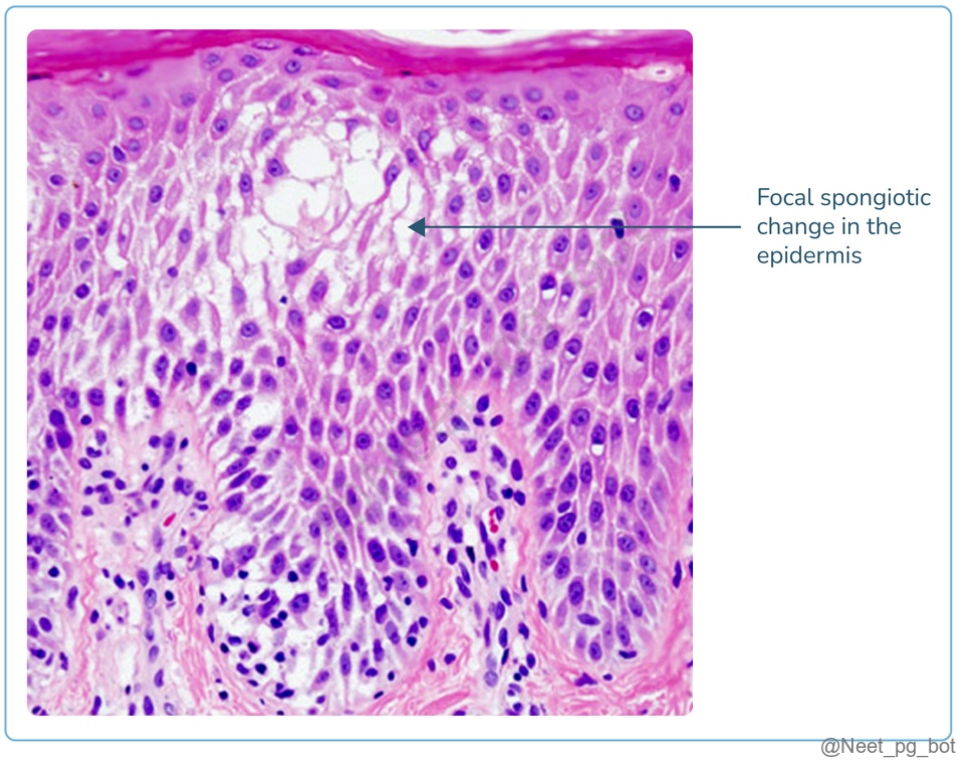

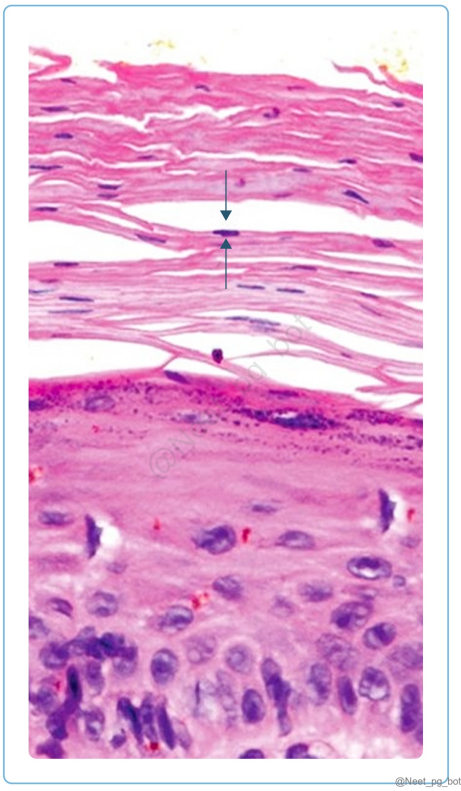

References:

Robbins and Cotran Pathologic Basis of Disease, 10th Edition, Page 1135

basicmedicalkey.com/histological-clues-in-interpreting-vulvar-inflammatory-and-autoimmune-dermatoses/

↑ *Back to this question in Part A*

@Neet_pg_bot

Q3: A 10-year-old child exhibits rough, scaly skin on the elbows, knees, and trunk, accompanied by hyperkeratotic plaques. Which skin condition is typically associated with this manifestation of excessive keratin buildup? (Q845867)

A. Freckles

B. Lentigo

C. Nevus

D. Ichthyosis

Correct Answer: D. Ichthyosis

Explanation: Ichthyosis is an inherited skin disorder causing chronic hyperkeratosis, leading to dry, scaly skin due to defective shedding and retention of abnormal scales. Freckles (Option A): Freckles (Ephelides) are small tan-brown spots from increased melanin in basal cells after sun exposure; melanocyte numbers remain normal. Lentigo (Option B): Lentigo is a benign tan-brown spot from increased melanocytes in the basal layer that doesn’t darken with sun exposure. Nevus (Mole) (Option C): Nevi are benign melanocyte tumors caused by RAS pathway mutations, appearing as small, uniform pigmented spots without excess keratin.



Ichthyosis
(fish like scales)

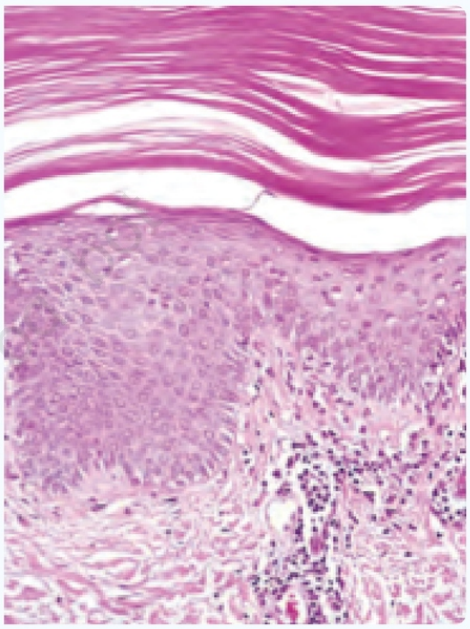

Thickened
stratum corneum

@Neet_pg_bot



@Neet_pg_bot



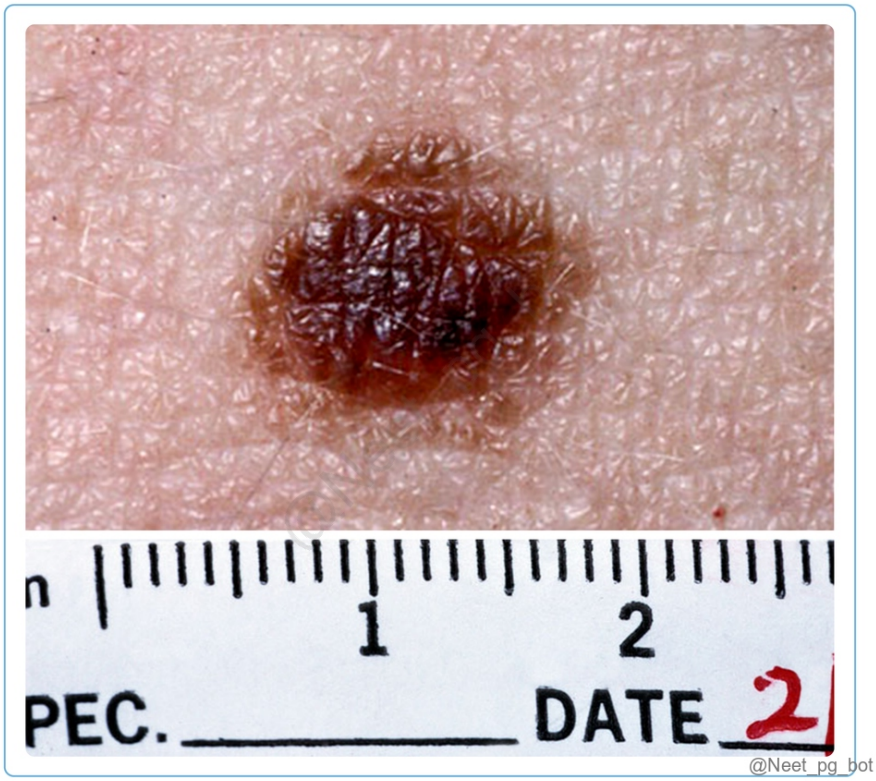

References:

Robbins and Cotran Pathologic Basis of Disease, 10th Edition, Page 1135, 1136, 1152, 1153

↑ *Back to this question in Part A*

@Neet_pg_bot

Q4: A 45-year-old woman presents with a dark, irregularly shaped mole on her back that has rapidly increased in size over the past few months. On examination, the lesion has uneven borders and varying shades of colour. Which of the following is true regarding its pathogenesis? (Q845868)

A. Associated with TERT mutations

B. Spreads radially with metastatic potential

C. Spreads vertically with no metastatic potential

D. Associated with mutations that decrease telomerase activity

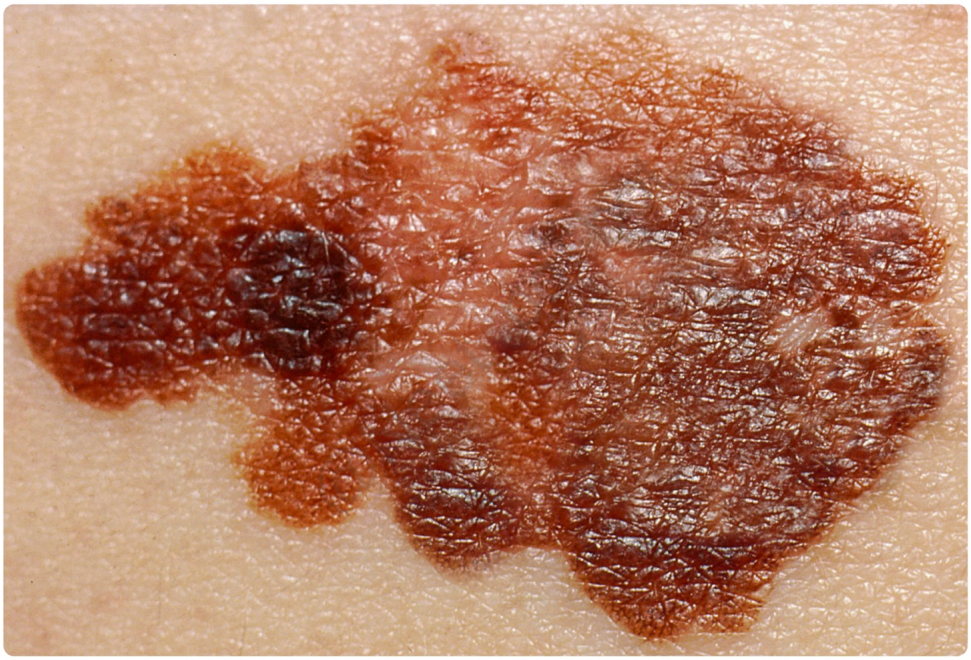

@Neet_pg_bot

Correct Answer: A. Associated with TERT mutations

■ *Listen (English)*

■ *Listen (Hindi)*

Explanation: Malignant melanoma is characterized by the clinical presentation of a rapidly changing mole with irregular borders and varying color. It is often associated with activating mutation in the TERT gene , which is

responsible for increased telomerase activity (Ruled out Option D) . An activating mutation in the TERT gene reactivates telomerase (immortality gene), preventing cell death and leading to increased cell survival. They show two patterns of growth. Radially : Superficial spread on the epidermis and dermis, lack metastatic potential. (Option B) Vertical spread into the deep dermis, characterised by the appearance of a nodule, has metastatic potential. (Option C) ABCDE criteria of Melanoma: A - Asymmetry: One half doesn't match the other half in shape. B - Border: The edges of the mole are irregular rather than smooth and defined. C - Colour: Uneven colour. It may include different shades of brown, black, or tan. D - Diameter: Growns larger (about the size of a pencil eraser). E - Evolving: The mole changes in size, shape, colour, or appearance over time. On microscopy, they have enlarged nuclei and prominent red (eosinophilic) nucleoli with melanin pigment.

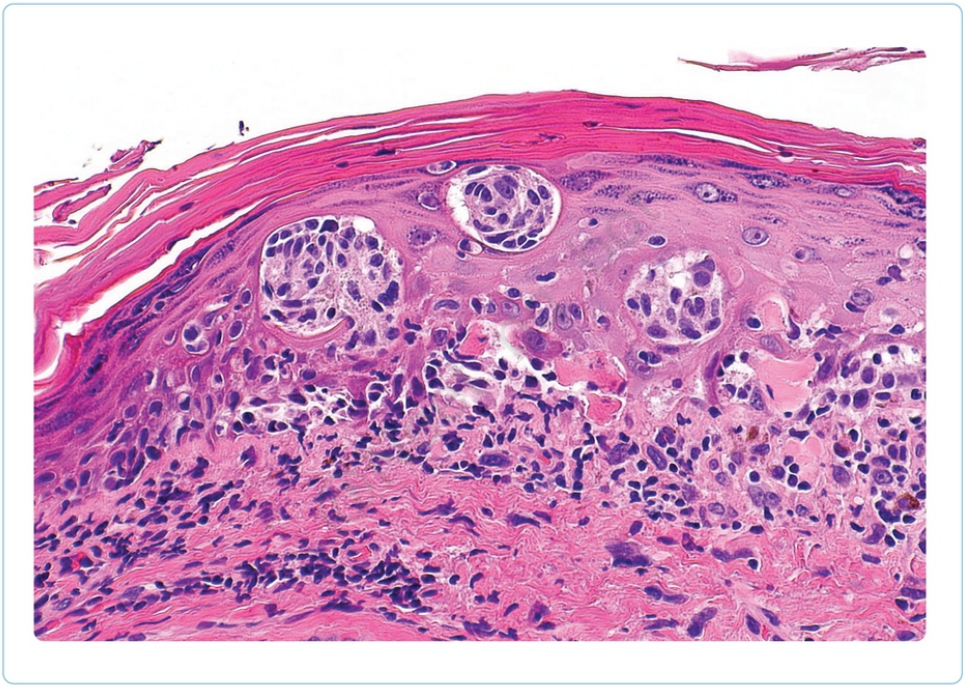

@Neet_pg_bot

References:

Robbins and Cotran Pathologic Basis of Disease, 10th Edition, Pages 1139-1142

↑ *Back to this question in Part A*

@Neet_pg_bot

Q5: A 70-year-old woman presents with a finding as shown in the image. A biopsy confirms basal cell carcinoma. Which molecular pathway is primarily involved? (Q845904)

A. Hippo pathway signaling

B. Hedgehog signaling pathway

C. WNT signaling

D. RAS/MAPK signaling



@Neet_pg_bot

Correct Answer: B. Hedgehog signaling pathway

Explanation: The hedgehog signaling pathway is associated with the pathogenesis of basal cell carcinoma, a locally aggressive cutaneous tumour. Hippo pathway signaling (Option A): It is seen in Neurofibromatosis type 2. WNT signaling pathway (Option C): WNT pathway, disrupted by APC mutations, drives familial polyps and cancers of the stomach, colon, pancreas, and melanomas. RAS/MAPK signaling (Option D): Inhibition of RAS/MAPK signaling is seen in Neurofibromatosis type 1.

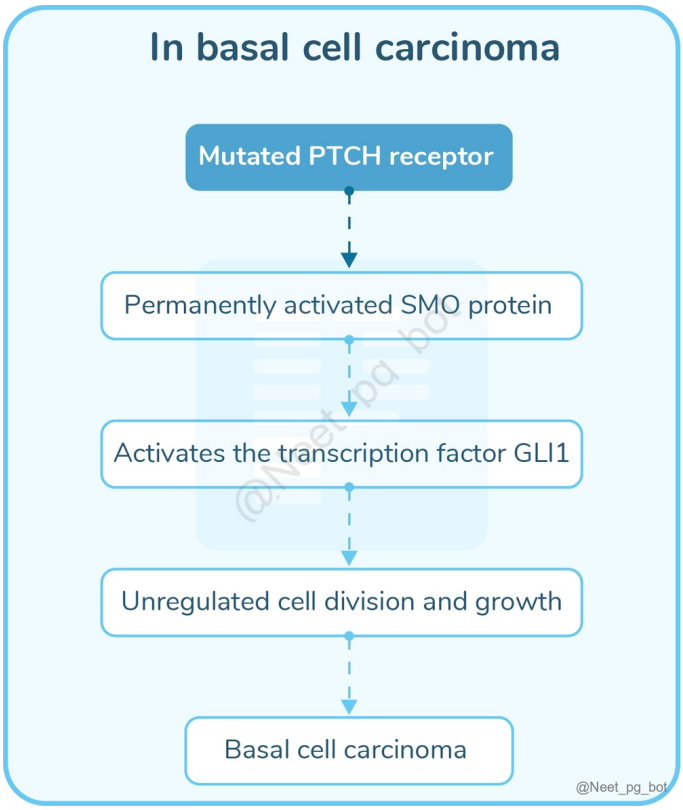

References:

Robbins and Cotran Pathologic Basis of Disease, 10th Edition, Page 292, 1147-1149 File:Basal Cell Carcinoma.jpg - Wikimedia Commons

↑ *Back to this question in Part A*

@Neet_pg_bot

Q6: A 25-year-old woman presents with multiple basal cell carcinomas (BCCs) on her face, neck, and back. She also has a history of medulloblastoma, diagnosed during childhood. On examination, she has palmar pits and macrocephaly. Which of the following is not true regarding this syndrome? (Q845906)

A. Associated with odontogenic keratocysts.

B. Associated with mutations in the PTCH gene

C. An Autosomal dominant disorder

D. Associated with loss of nucleotide excision repair mechanism

Correct Answer: D. Associated with loss of nucleotide excision repair mechanism

■ *Listen (English)*

■ *Listen (Hindi)*

Explanation: The above clinical scenario is suggestive of Gorlin syndrome which is associated with mutations in the PTCH gene , a tumor suppressor gene. (Option B) The clinical presentation is suggestive of Gorlin syndrome , an autosomal dominant disorder (Option C) characterised by the development of multiple basal cell carcinomas. It also presents with various other tumours like medulloblastomas , bilateral ovarian fibromas , odontogenic keratocysts (Option A) and pits on the palms and soles . Loss of nucleotide excision repair mechanism is associated with Xeroderma pigmentosum and these patients are at increased risk of squamous cell and basal cell skin cancers due to exposure to UV light because of an inability to repair pyrimidine dimers. (Option D)

References:

Robbins and Cotran Pathologic Basis of Disease, 10th Edition, Pages 1147, 315

↑ *Back to this question in Part A*

@Neet_pg_bot

Q7: A 72-year-old man with a history of extensive sun exposure and recent organ transplant presents with a rapidly growing, painless, reddish nodule on his left cheek over two months. Biopsy shows small, round blue cells with salt and pepper chromatin and positivity for neuroendocrine markers. What marker is typically associated with this condition? (Q845908)

A. S-100

B. CK20

C. Melan-A

D. p40

Correct Answer: B. CK20

Explanation: The given clinical scenario points towards the diagnosis of Merkel cell carcinoma, which is an aggressive neuroendocrine skin cancer marked by rapid growth, early metastasis, and high mortality. Risk factors: Immune suppression, sun exposure, and advanced age. It appears as a fast-growing, firm nodule on sun-exposed skin. CK20 with perinuclear dot staining is a key diagnostic marker. S-100 (Option A) and Melan-A (Option C) are more useful in the diagnosis of Melanoma. p40 (Option D) is a marker commonly used in diagnosing squamous cell carcinoma.

References:

Robbins and Cotran Pathologic Basis of Disease, 10th Edition, Page 1146-1147

https://www.ncbi.nlm.nih.gov/books/NBK482329/

Rook's Textbook of Dermatology, 9th Edition Page 145.1-145.3

↑ *Back to this question in Part A*

@Neet_pg_bot

Q8: An 18-year-old female has multiple itchy silvery scales on her knees and elbows. A biopsy of the lesion revealed the presence of nuclei and neutrophilic infiltration in the stratum corneum. Match the following with their appropriate answers. a. Auspitz sign 1. Nucelated stratum corneum b. Munro’s microabscess 2. Pinpoint bleed after scraping off old lesion c. Spongiform pustules of kogoj 3. Neutrophilic infiltrate in stratum corneum d. Parakeratosis 4. Neutrophilic infiltrate in stratum spinosum (Q845909)

A. a-2, b-4, c-3, d-1

B. a-2, b-3, c-4, d-1

C. a-1, b-3, c-4, d-2

D. a-2, b-4, c-3, d-1

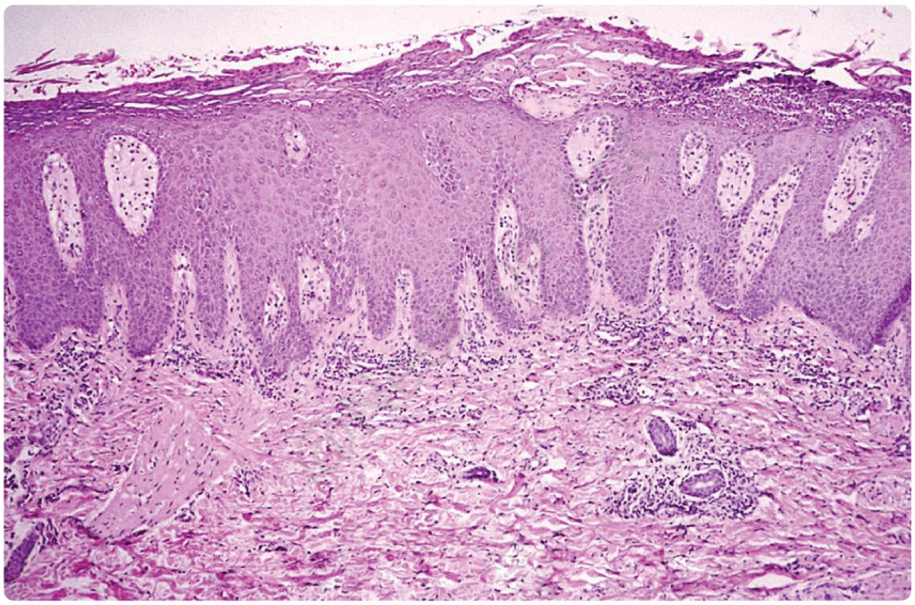

@Neet_pg_bot



@Neet_pg_bot

Correct Answer: B. a-2, b-3, c-4, d-1

Listen to Audio 1

Explanation: Psoriasis is an autoimmune chronic inflammatory dermatosis. Clinical manifestations include skin changes such as itchy, silvery scales over salmon-pink plaques, with pinpoint bleeding upon scraping (Auspitz Sign). Histopathology of psoriasis: Parakeratosis: Retention of nuclei in the stratum corneum cells. Munro's microabscess : Collection of neutrophilic infiltrates in the Stratum corneum. Spongiform pustules of Kogoj: Collection of inflammatory cells in the Stratum spinosum. Presence of evenly elongated, thin rete ridges with equally long dermal papillae.

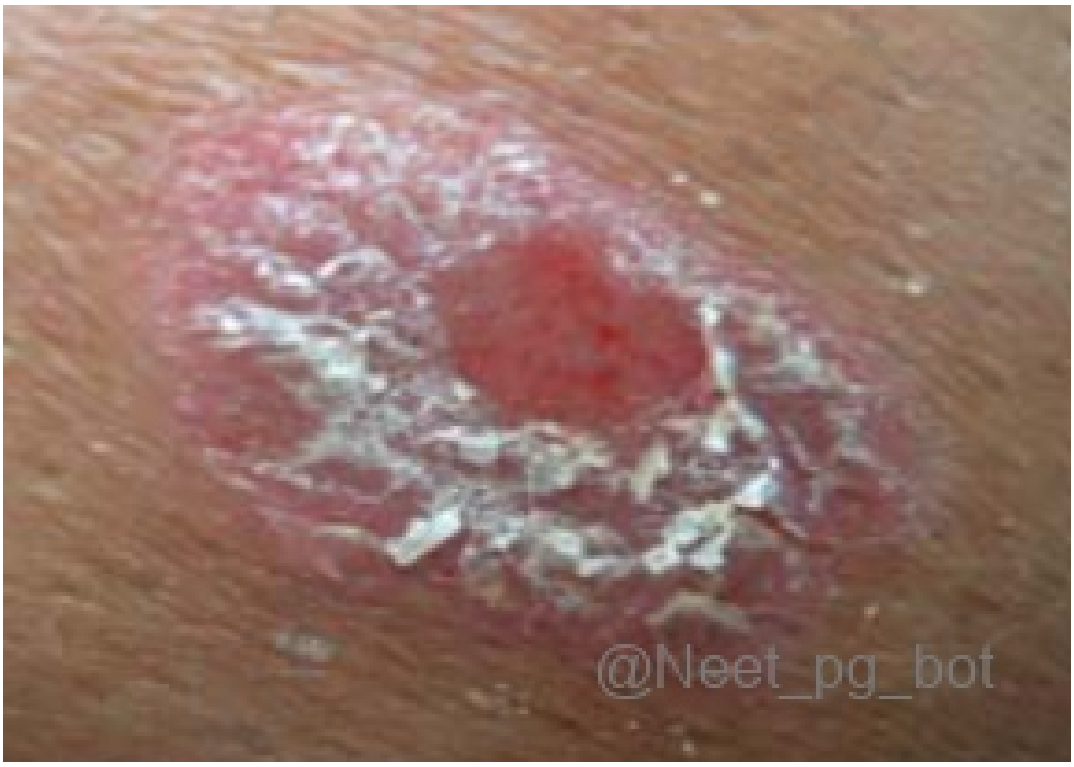

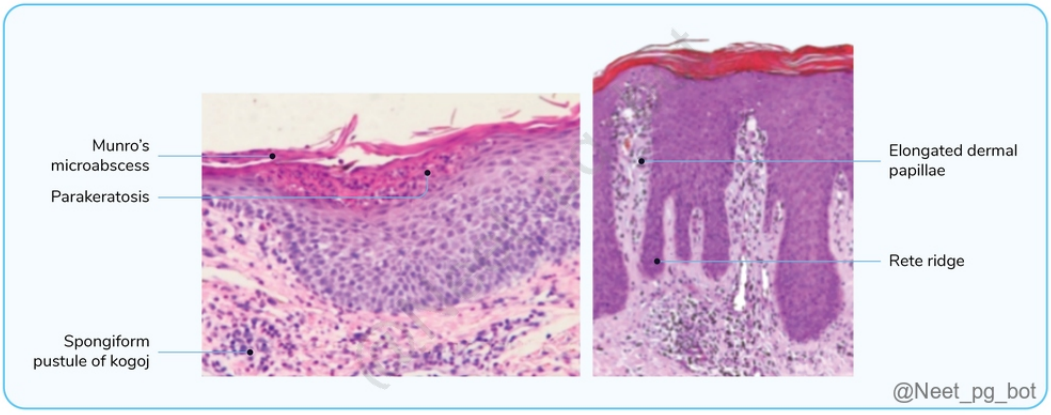

References:

Robbins and Cotran Pathologic Basis of Disease, 10th Edition, Pages 1157-1158

↑ *Back to this question in Part A*

@Neet_pg_bot

Q9: A 45-year-old female presents to the dermatology clinic with an itchy rash on her wrists and ankles. On examination, small, flat-topped, polygonal, purple papules with fine white lines on their surface are noted. Which of the following is a characteristic histological finding in this condition? (Q845911)

A. Munro microabscesses

B. Spongiform pustules

C. Sawtoothing of the dermo-epidermal junction

D. Follicular lipping



Correct Answer: C. Sawtoothing of the dermo-epidermal junction

Explanation: The clinical signs and biopsy suggest lichen planus, a skin condition with itchy, purple, flat-topped bumps that may join into plaques, featuring fine white lines called Wickham striae. Lichen planus usually appears symmetrically on wrists, elbows, and limbs, often involving the mouth. Under the microscope, there is a dense lymphocyte layer at the dermo-epidermal junction, creating a sawtooth pattern. Munro microabscesses (Option A) are neutrophil clusters in the outer skin layer, seen in psoriasis. Spongiform pustules (Option B) are neutrophil clusters in the skin’s outermost layer, typical of psoriasis . Follicular lipping (Option D) is neutrophil-rich parakeratosis at hair follicles, seen in seborrheic dermatitis .



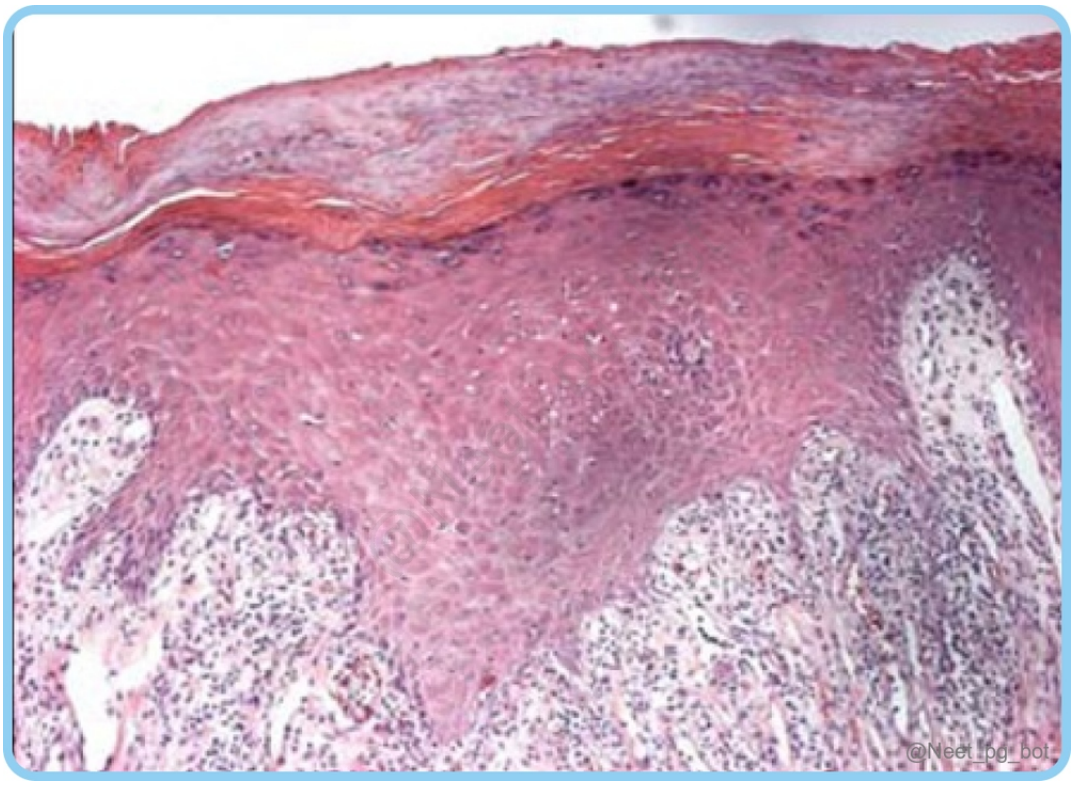

References:

Robbins and Cotran Pathologic Basis of Disease, 10th Edition, Page 1158

en.wikipedia.org/wiki/Lichen_planus

↑ *Back to this question in Part A*

Q10: A 55-year-old man presents with widespread blistering of the skin and oral mucosa. Skin biopsy reveals acantholysis and intraepidermal blister formation above the basal layer. Which of the following describes the location of the split in this bullous disorder? (Q845912)

A. Subcorneal split

B. Suprabasal split

C. Subepidermal split

D. Intraepidermal split

Correct Answer: B. Suprabasal split

Explanation: The given clinical scenario is consistent with Pemphigus vulgaris, which causes a suprabasal split above the basal layer due to autoantibodies against desmoglein, leading to loss of cell adhesion (acantholysis) and blistering. Subcorneal split (Option A) occurs just below the stratum corneum and is typical of pemphigus foliaceus. Subepidermal split (Option C) is a split in bullous pemphigoid caused by autoantibodies against basement membrane proteins, leading to blistering below the epidermis. Junctional split (Option D) occurs at the lamina lucida in the basement membrane, causing fragile skin blisters in junctional epidermolysis bullosa.

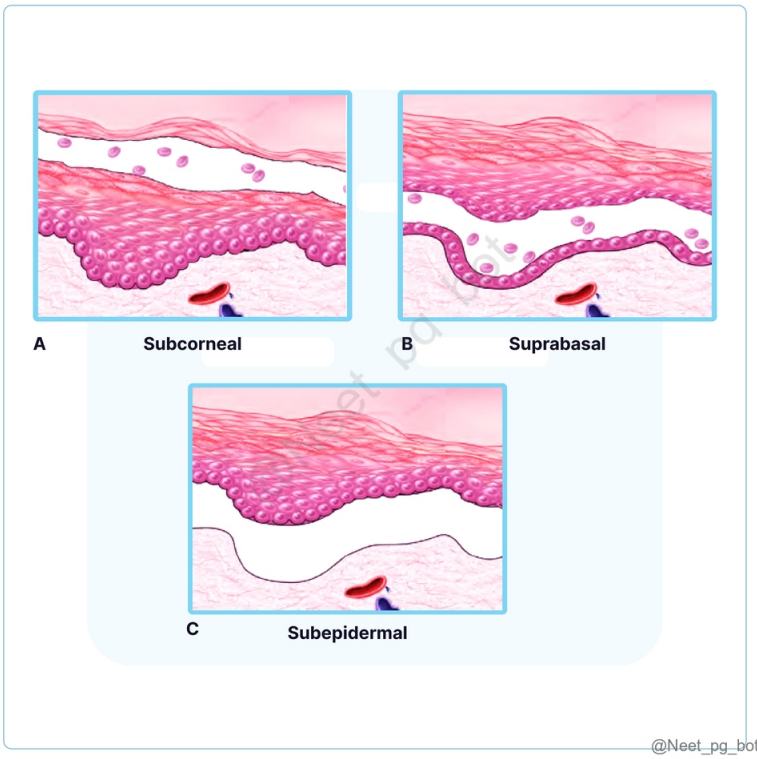

References:

Robbins and Cotran Pathologic Basis of Disease, 10th Edition, Page 1159

↑ *Back to this question in Part A*

@Neet_pg_bot

Q11: A 45-year-old woman presents with a slow-growing, painless nodule on her scalp that has recently enlarged. Examination reveals a firm, well-circumscribed nodule. Histopathology shows ductal differentiation with multiple cysts and papillary projections. Which of the following is the most likely diagnosis? (Q845913)

A. Cylindroma

B. Pilomatrixoma

C. Syringoma

D. Trichilemmoma

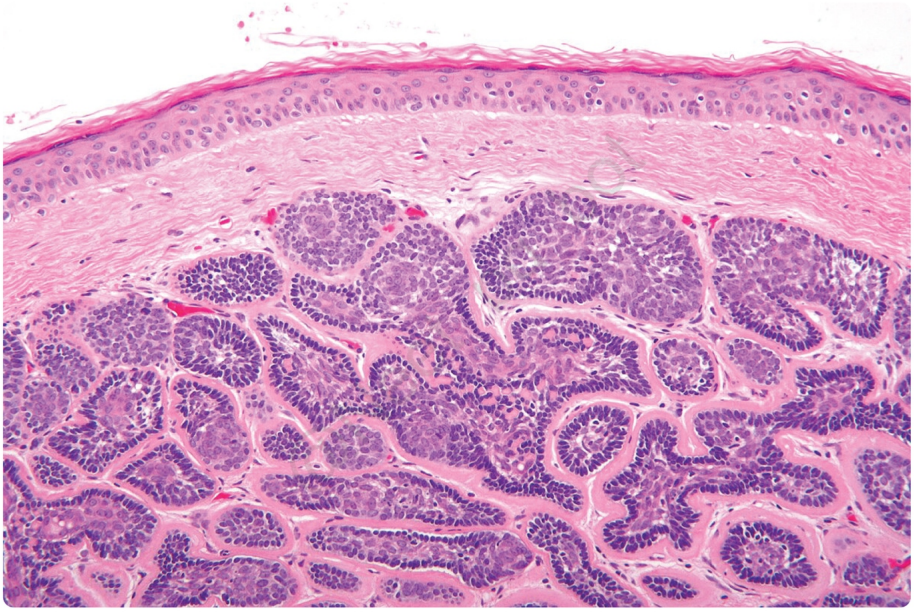

@Neet_pg_bot

Correct Answer: A. Cylindroma

■ *Listen to Audio 1*

Explanation: The clinical and histological features described in the scenario are consistent with Cylindroma , benign skin tumours that often appear on the head and neck area. They exhibit ductal differentiation and histologically present as basaloid cell islands fitting together like a " jigsaw puzzle " within a fibrous stroma. These tumours can merge over time to form larger, turban-like growths . They may be inherited in an autosomal dominant fashion due to mutations in the CYLD gene . Cylindromas are also associated with Brooke-Spiegler syndrome , characterized by the occurrence of multiple adnexal tumours, including cylindromas, trichoepitheliomas, and spiradenomas. Pilomatrixoma (Option B) are benign tumours derived from hair matrix cells. Histologically, they are characterized by ghost cells . Syringomas (Option C) are benign tumours of eccrine sweat glands. Histologically, syringomas are characterized by comma-shaped or tadpole-like projections when viewed under a microscope. Trichilemmomas (Option D) are benign tumours arising from the outer root sheath of hair follicles and are associated with Cowden syndrome . Histologically, they exhibit clear cells and peripheral palisading, resembling the outer root sheath.



@Neet_pg_bot

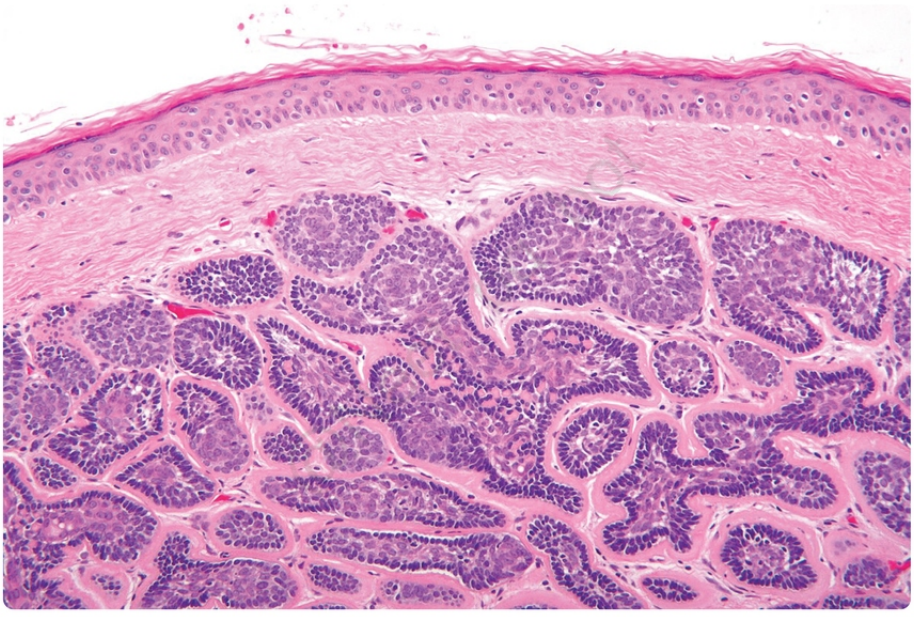

@Neet_pg_bot

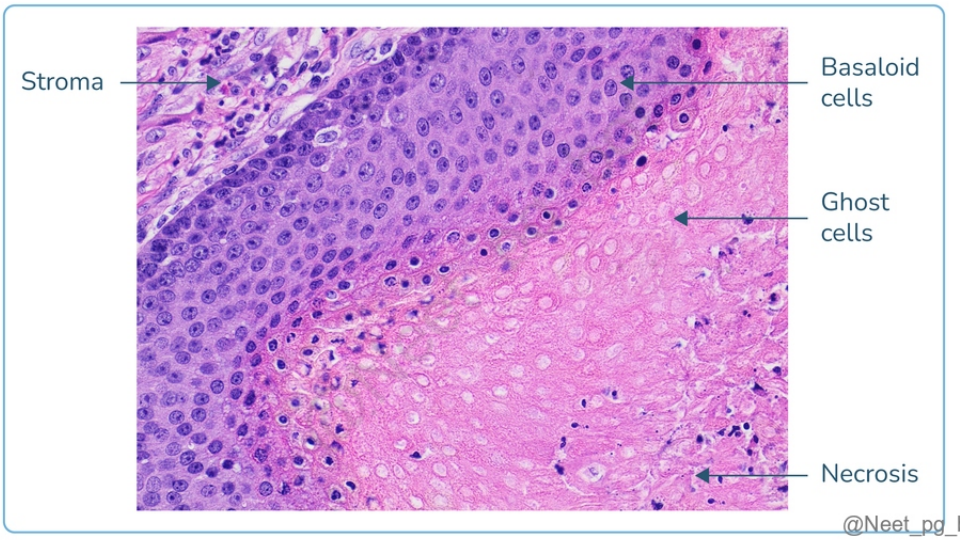

@Neet_pg_bot

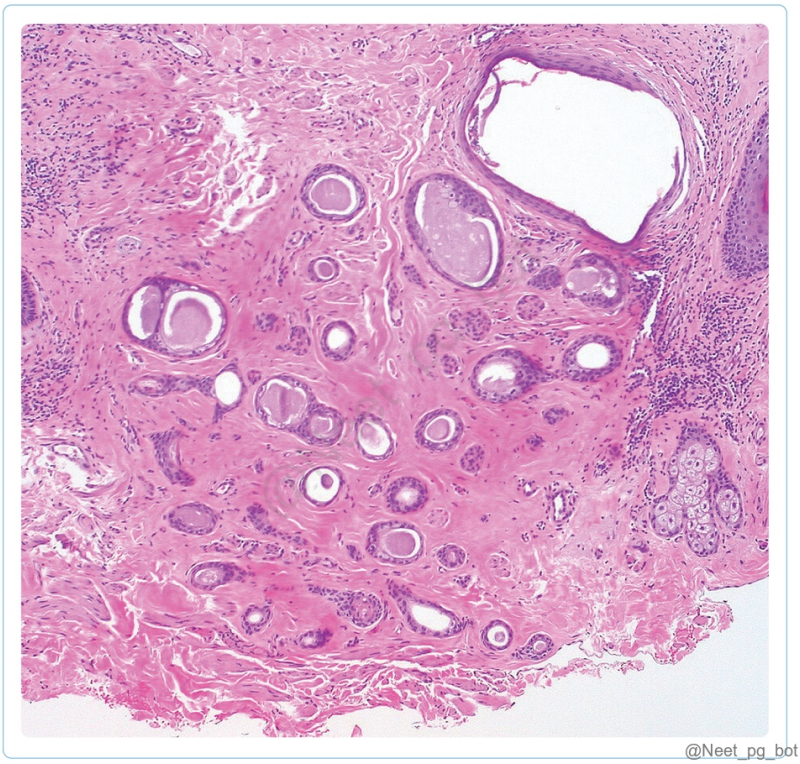
@Neet_pg_bot

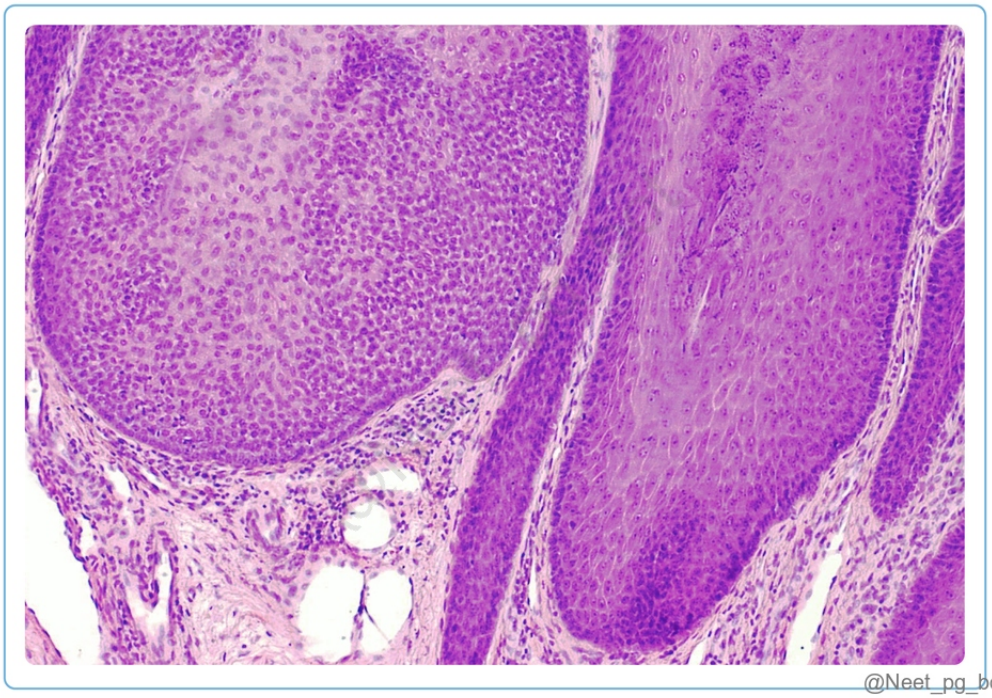

References:

Robbins and Cotran Pathologic Basis of Disease, 10th Edition, Pages 1144 - 1145

↑ *Back to this question in Part A*

@Neet_pg_bot

Q12: A 38-year-old man complains of severe itching and recurrent skin lesions on his elbows, knees, and upper back. His medical history includes occasional gastrointestinal discomfort. Examination reveals bilateral, symmetric lesions with grouped vesicles. Skin biopsy reveals small microabscesses at the tips of dermal papillae. Which of the following is associated with a disease condition? (Q845916)

A. Associated with Crohn's disease

B. IgA deposits at dermal papilla tips

C. Subendothelial blisters

D. Linear deposits in immunofluorescence

Correct Answer: B. IgA deposits at dermal papilla tips

Explanation: Based on the given scenario and biopsy findings, the likely diagnosis is Dermatitis herpetiformis, characterized by urticaria and grouped vesicles, often presents with bilateral, symmetric lesions involving the extensor surfaces Linear deposits in immunofluorescence (Option D): Direct IF in dermatitis herpetiformis shows granular deposits of IgA, not linear deposits. Associated with Crohn's disease (Option A): Dermatitis herpetiformis is primarily associated with Celiac disease . Subendothelial blisters (Option C): HPE of Dermatitis herpetiformis shows subepidermal blisters with fibrin and neutrophil microabscesses at dermal papillae tips.

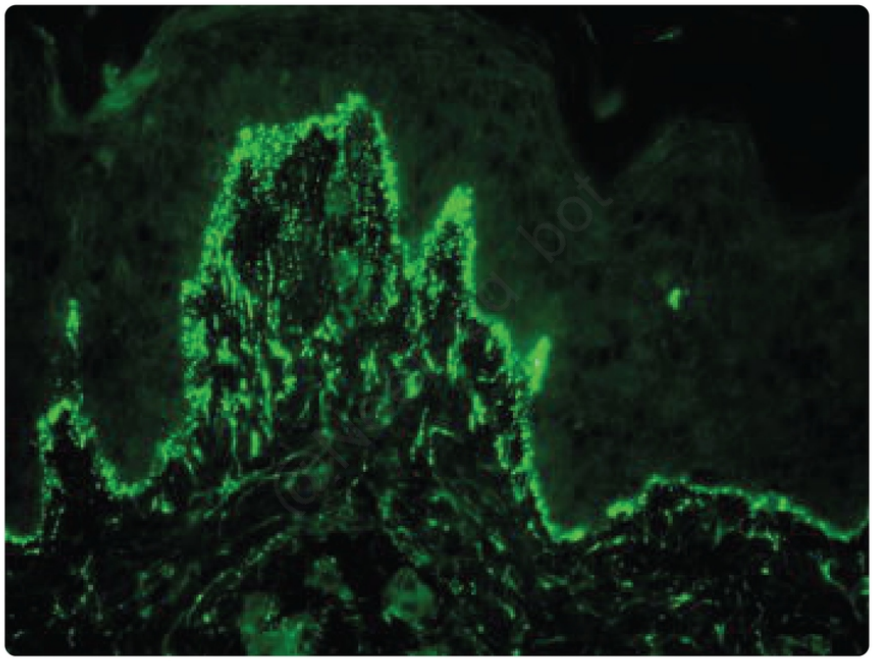

@Neet_pg_bot

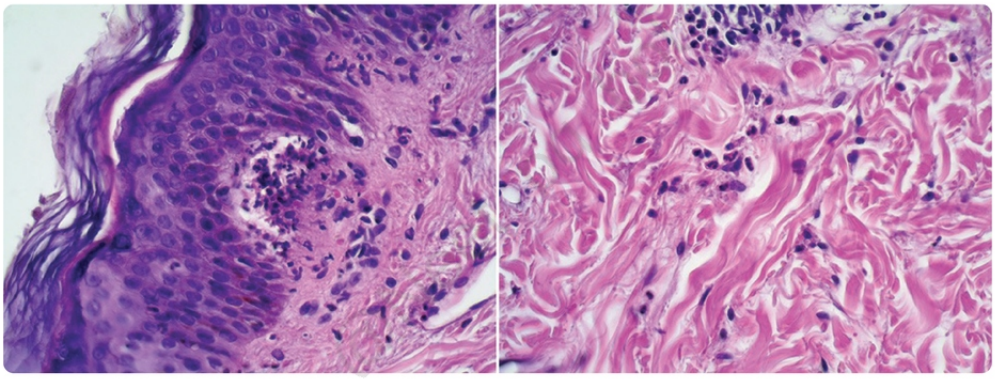

@Neet_pg_bot

References:

Robbins and Cotran Pathologic Basis of Disease, 10th Edition, Page 1163

↑ *Back to this question in Part A*

Q13: A 3-year-old child has a chronic, non-healing scalp rash, showing red-brown papules and plaques with crusting on examination. Electron microscopy reveals tennis racket-like structures in histiocytes cytoplasm, and immunohistochemical staining confirms CD1a and S100 protein presence. Which mutation is likely associated with this condition? (Q845918)

A. TP53 mutation

B. RAS mutation

C. BRAF mutation

D. MET mutation



Correct Answer: C. BRAF mutation

■ *Listen to Audio 1*

Explanation: The clinical presentation and electron microscopy findings suggest the diagnosis of Langerhans cell histiocytosis (LCH) The mutation associated with LCH is the BRAF V600E mutation . Forms of LCH : Letterer–Siwe disease → involves liver and skin . Eosinophilic granuloma → shows eosinophils and

microscopically coffee-bean nuclei . Hand–Schüller–Christian disease → Triad: B, C = Bone Calvarial defects (skull/scalp bone lesions). D = Diabetes insipidus . E = Exophthalmos . Immunohistochemistry (IHC) tests show these cells are positive for CD1a, CD207 (langerin), S100, and HLA-DR . Electron microscopy , considered the gold standard for diagnosis , reveals the characteristic tennis racket appearance of Birbeck granules. TP53 mutation (Option A): This is the "guardian of the genome" and is associated with Li-Fraumeni Syndrome and a vast array of common malignancies, but it is not a primary driver of LCH. RAS mutation (Option B): While part of the same MAPK pathway, RAS mutations are typically associated with melanomas or leukemias rather than the specific histiocytic proliferation seen here. MET mutation (Option D): This is a tyrosine kinase receptor mutation most commonly linked to Papillary Renal Cell Carcinoma (Type 1) or subsets of Non-Small Cell Lung Cancer.

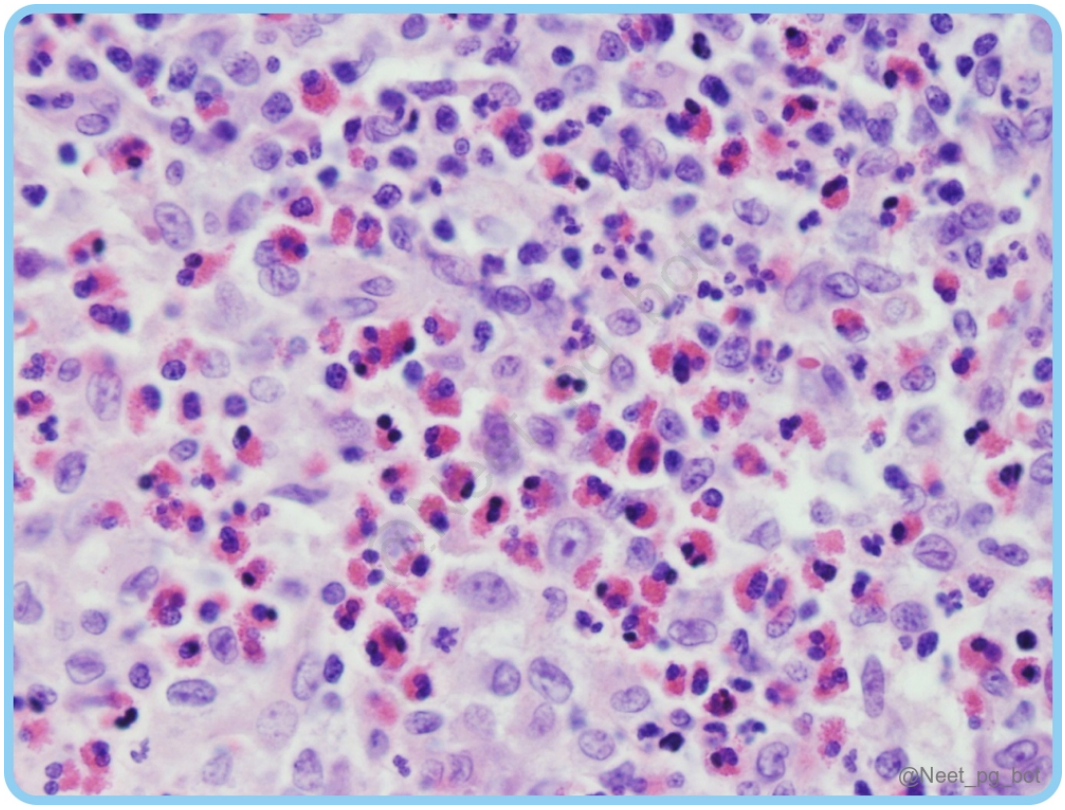

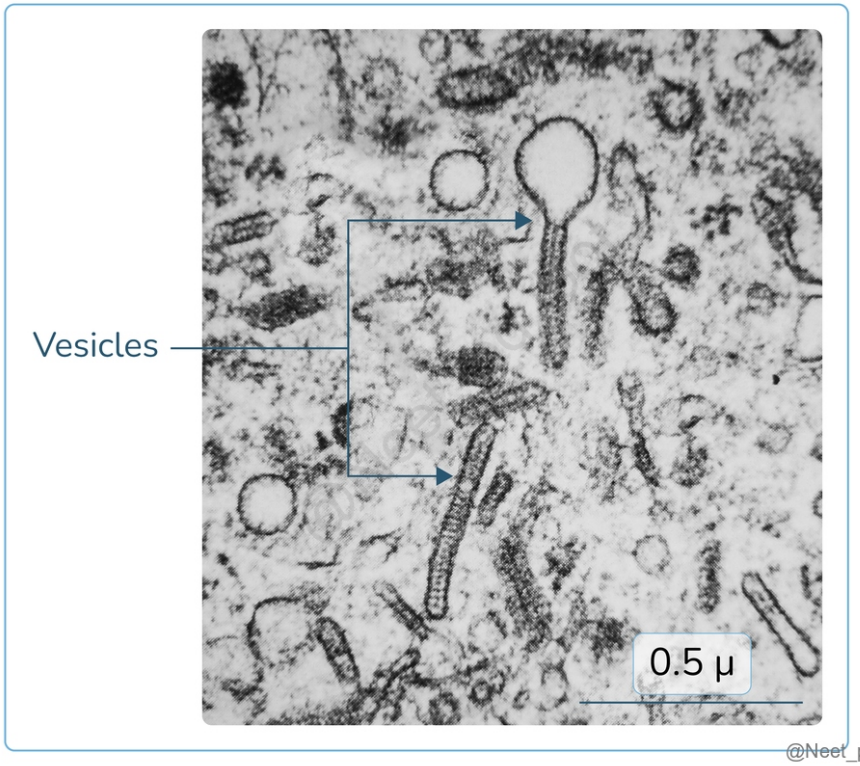

@Neet_pg_bot

References:

Robbins and Cotran Pathologic Basis of Disease, 10th Edition, Pages 627-628

www.ncbi.nlm.nih.gov/books/NBK430885/

↑ *Back to this question in Part A*

@Neet_pg_bot

Q14: A 65-year-old male presents with tense blisters on his abdomen and extremities, filled with clear fluid. The skin appears normal between the blisters, which are painful but not itchy. A skin biopsy reveals a subepidermal blister with linear IgG and complement deposition along the basement membrane on direct immunofluorescence as shown in the image. What is the most likely diagnosis? (Q845920)

A. Epidermolysis Bullosa Acquisita

B. Bullous Pemphigoid

C. Pemphigus Vulgaris

D. Dermatitis Herpetiformis

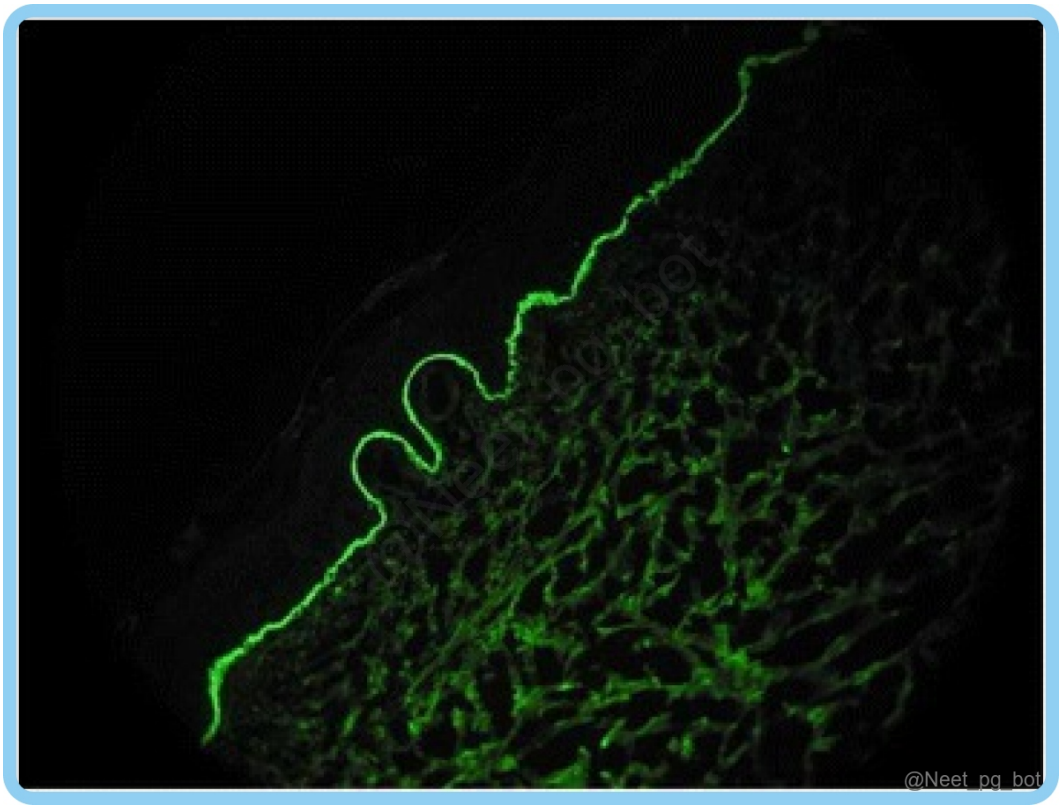

Correct Answer: B. Bullous Pemphigoid

■ *Listen to Audio 1*

Explanation: Bullous pemphigoid: Has subepidermal split Antibodies are against hemidesmosomes , and IgG is deposited linearly along the roof of the bulla . Commonly seen in: Flexor aspect of the forearm, Axilla, and Groin Under Immunofluorescence : Linear Immunofluorescence/ Ribbon candy appearance Epidermolysis Bullosa Acquisita (Option A): It also has subepidermal split but antibodies are against collagen VII , and IgG is deposited along the floor of the bulla . Epidermolysis bullosa acquisita (Option A) : Typical presentation includes trauma-induced blistering, and direct immunofluorescence would show IgG targeting type VII collagen. Direct IMF displaying linear deposition of IgG, IgA, and C3 at the basement membrane zone. Pemphigus Vulgaris (Option C) is an autoimmune blistering disorder characterized by intraepithelial blisters. Dermatitis Herpetiformis (Option D): In dermatitis herpetiformis, the deposited immunoglobulin is IgA , and it tends to deposit in the dermal papillae , forming tip lesions. It is also commonly associated with GI disorders , particularly celiac disease .

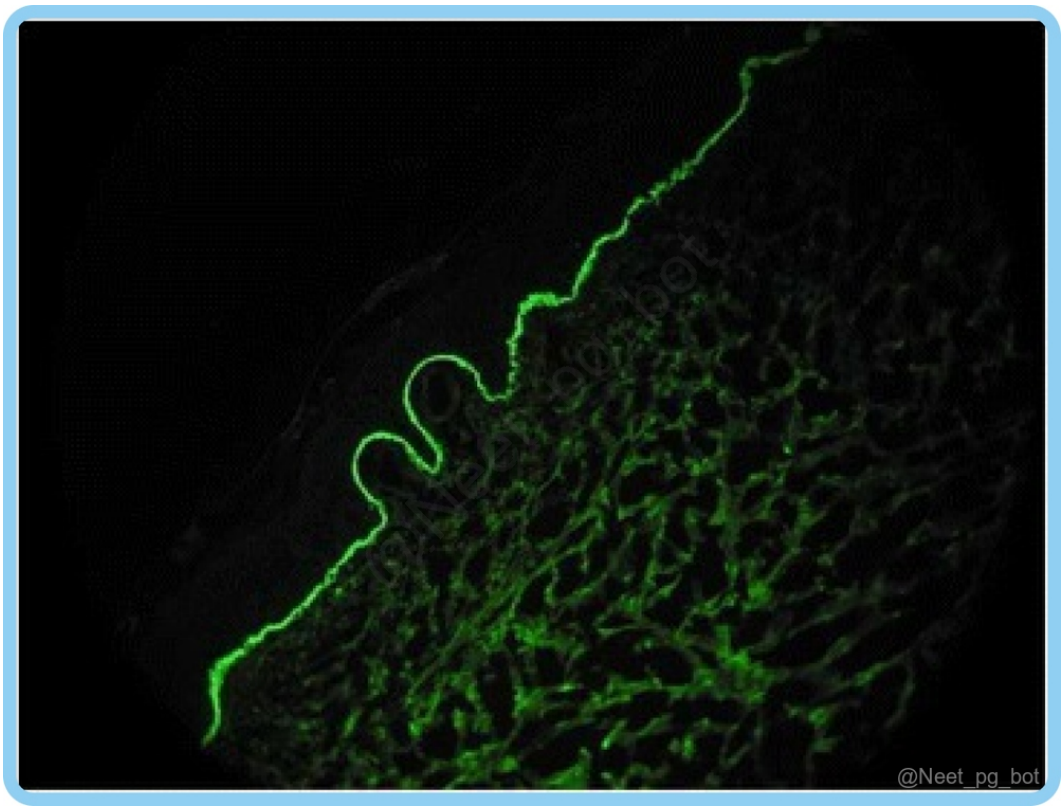

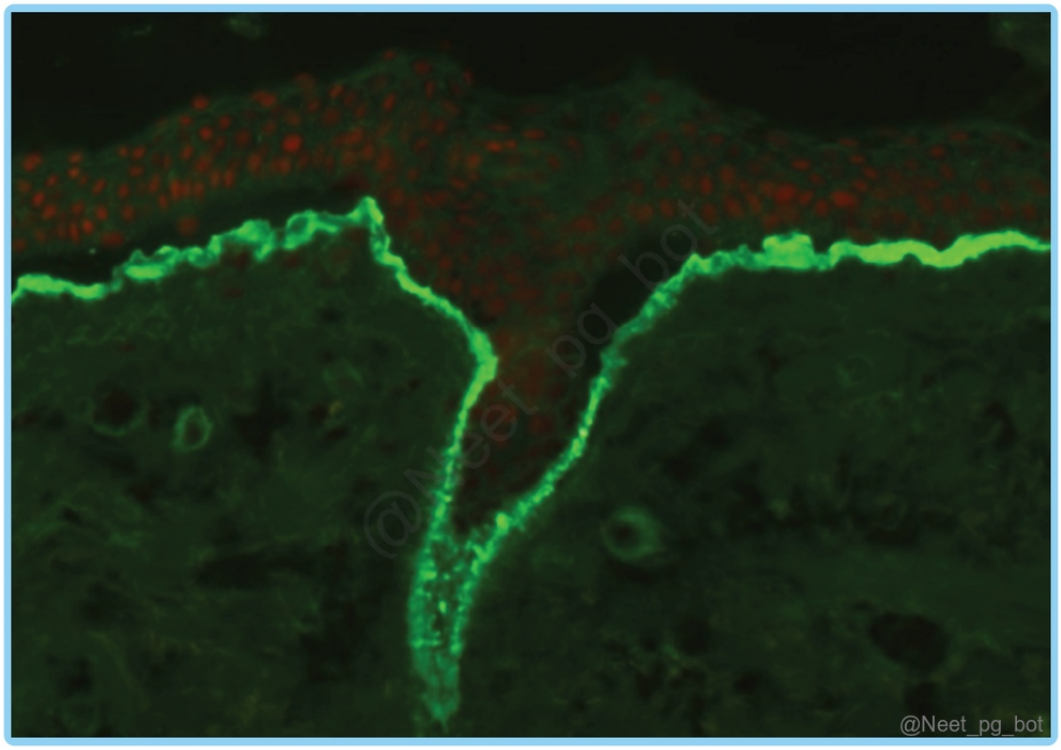

References:

Robbins and Cotran Pathologic Basis of Disease, 10th Edition, Page1162

↑ *Back to this question in Part A*

• [23_Skin Pathology] 086 Previous Year Questions

« Back to Folder Directory

[23_Skin Pathology] 086 Previous Year Questions — Quick Jump

Q1 (p. 3251) *Q2 (p. 3251)* *Q3 (p. 3252)* *Q4 (p. 3256)* *Q5 (p. 3260)* *Q6 (p. 3261)*
Q7 (p. 3264) *Q8 (p. 3270)* *Q9 (p. 3271)*

Q1: A child presents with skin eruptions upon exposure to sunlight and is diagnosed with a DNA repair defect. Which type of repair defect is most likely responsible? (Q844175)

A. Nucleotide excision repair defect

B. Base excision repair defect

C. Mismatch repair defect

D. Recombination repair defect

Correct Answer: A. Nucleotide excision repair defect

Explanation: Correct Option A - Nucleotide excision repair defect: Xeroderma pigmentosa is caused by a defect in nucleotide excision repair, leading to an inability to repair UV-induced DNA damage, which results in extreme sensitivity to sunlight and a high risk of skin cancers. Incorrect Options: Options B, C, and D do not cause xeroderma pigmentosa.

↑ *Back to this question in Part A*

@Neet_pg_bot

Q2: Identify the diagnosis based on the image provided: (Q844180)

A. Tuberculosis (TB)

B. Malakoplakia

C. Pyoderma gangrenosum

D. Squamous cell carcinoma (SCC)

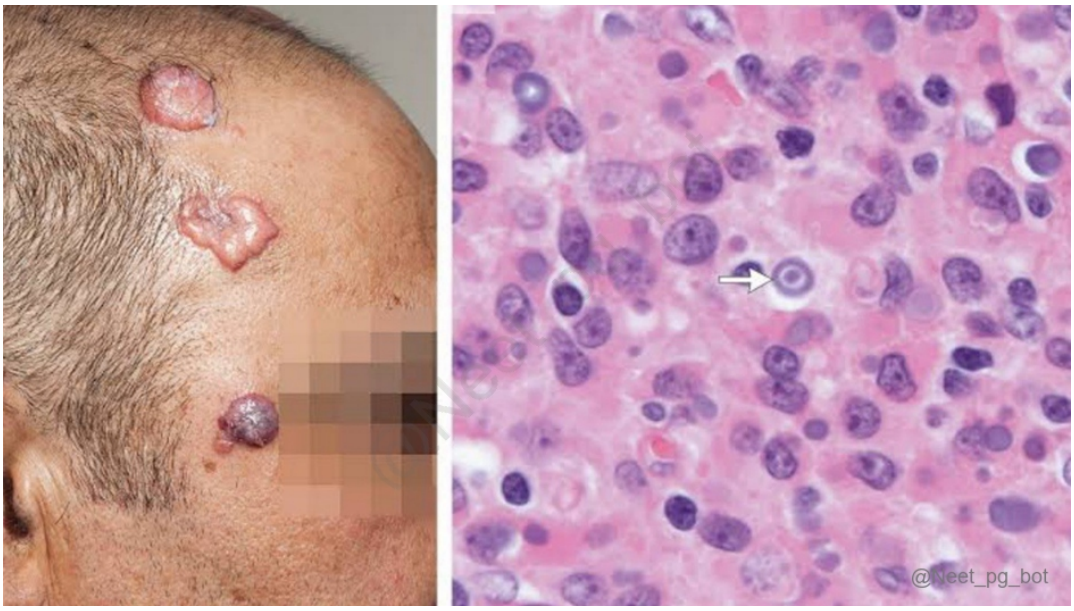

Correct Answer: B. Malakoplakia

Explanation: Correct Option B – Malakoplakia: The given microscopy image reveals Michaelis Guttman bodies, along with cutaneous malakoplakia on the scalp region. Incorrect Options: Options A, C, and D do not show Michaelis Guttman's bodies.

References:

.

↑ *Back to this question in Part A*

@Neet_pg_bot

Q3: A farmer has a lesion on the shoulder. What is the most likely diagnosis based on the histopathological image of the lesion given below? (Q860532)

A. SCC

B. BCC

C. Molluscum contagiosum

D. Verrucous carcinoma

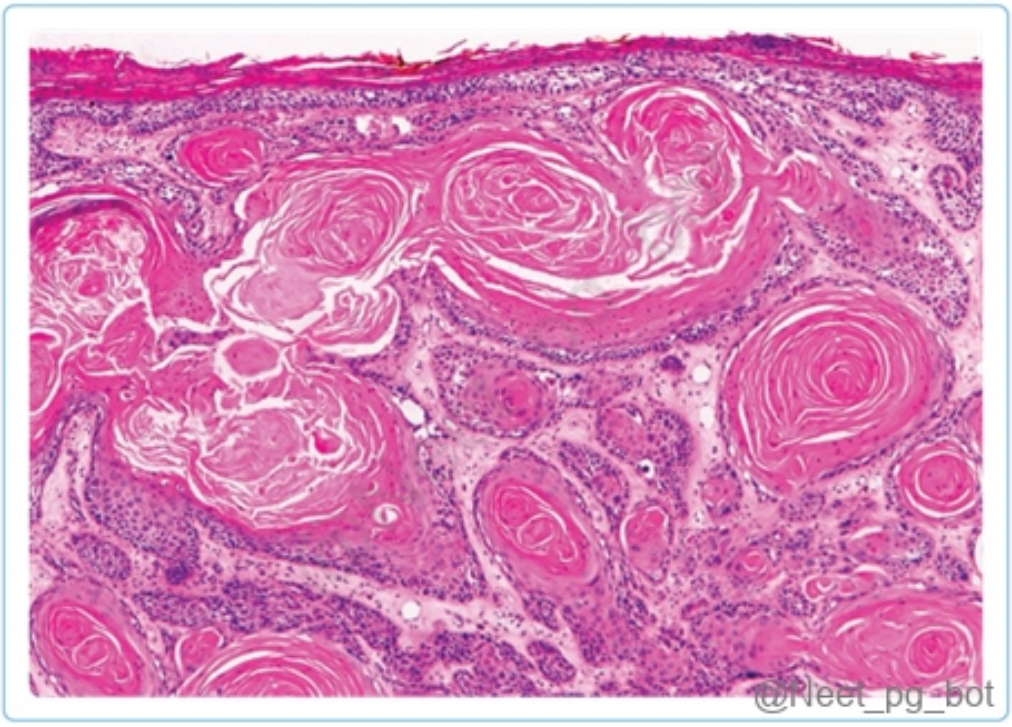

Correct Answer: A. SCC

Explanation: The histopathological image showing keratin pearls on histopathology is suggestive of Squamous Cell Carcinoma (SCC) . It is a malignant tumour originating from epidermal keratinocytes. It is the second most common skin tumour after basal cell carcinoma (BCC). SCC is notably the most common skin tumour in immunocompromised individuals . Predisposing factors include UV exposure, immunosuppression, and conditions like xeroderma pigmentosum, albinism, LP, and DLE, which can rarely progress into SCC. Clinical features: It typically exhibits a lower rate of local, regional, and distant spread compared to other skin malignancies. Associated with immunocompromised states such as HIV infection and renal transplant recipients. It presents as papules, nodules, or plaques with induration and signs of photodamage like crusting and scaling. {{caption_text}} Histopathological examination reveals characteristic keratin pearls . {{caption_text}} Treatment: Primary treatment involves wide surgical excision with margins. Advanced cases may require radiation or chemotherapy. BCC (Basal Cell Carcinoma) (Option B) is the most common type of skin cancer , originating from the basal cells in the epidermis. It is typically slow-growing, often appearing as a painless, pearly nodule with telangiectasias on sun-exposed areas like the face. Histologically, BCC is characterised by nests of basaloid cells with a palisading pattern at the periphery, fibrotic stroma, and clefting between the tumour and surrounding tissue. {{caption_text}} Molluscum contagiosum (Option C) is a viral skin infection causing small, flesh-coloured lesions with central umbilication, often in children and immunocompromised individuals. Histologically, it shows epidermal hyperplasia, ballooning keratinocytes, and Henderson-Patterson (HP) bodies in cup-shaped spaces. {{caption_text}} Verrucous carcinoma (Option D) is a rare, low-grade squamous cell carcinoma often found in areas with chronic irritation (e.g., oral cavity, genitals). It presents as a slow-growing, wart-like lesion and is associated with HPV infection. Histopathologically, it shows exophytic growth, thick keratinisation, well-differentiated squamous cells, and pushing borders with minimal atypia. {{caption_text}}


@Neet_pg_bot

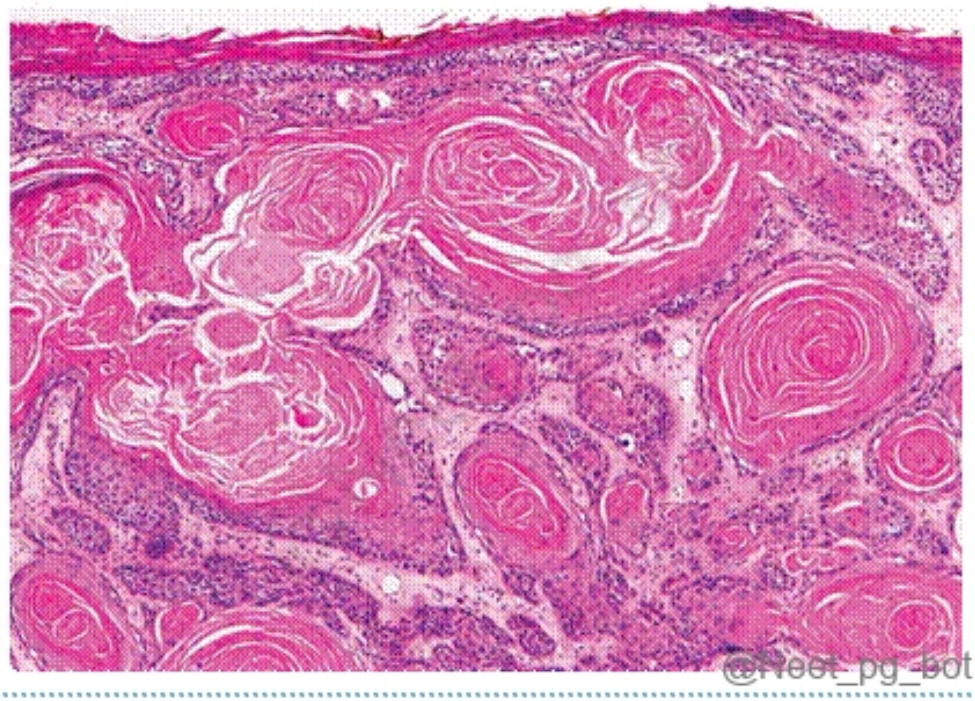
@Neet_pg_bot

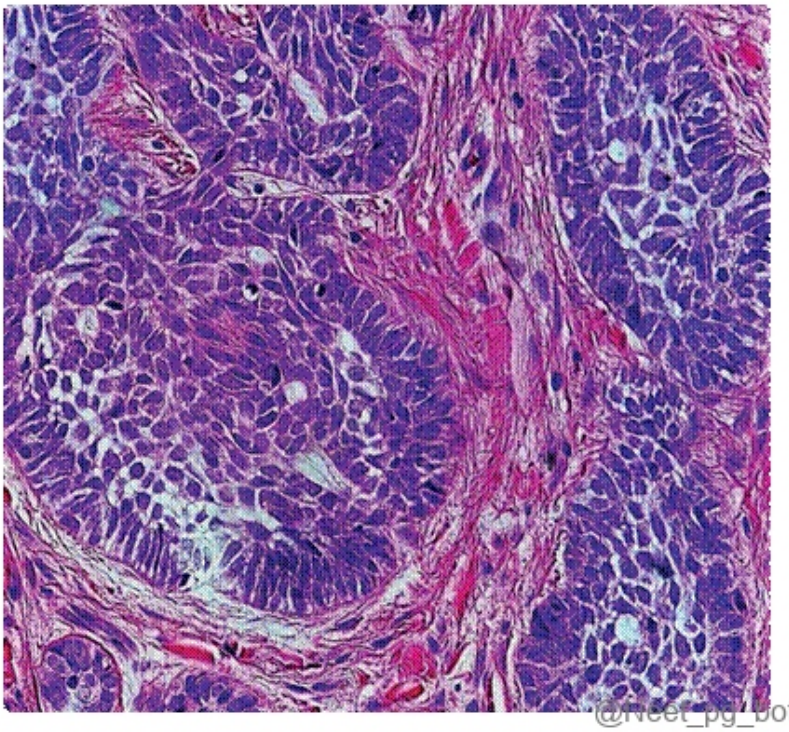
@Neet_pg_bot

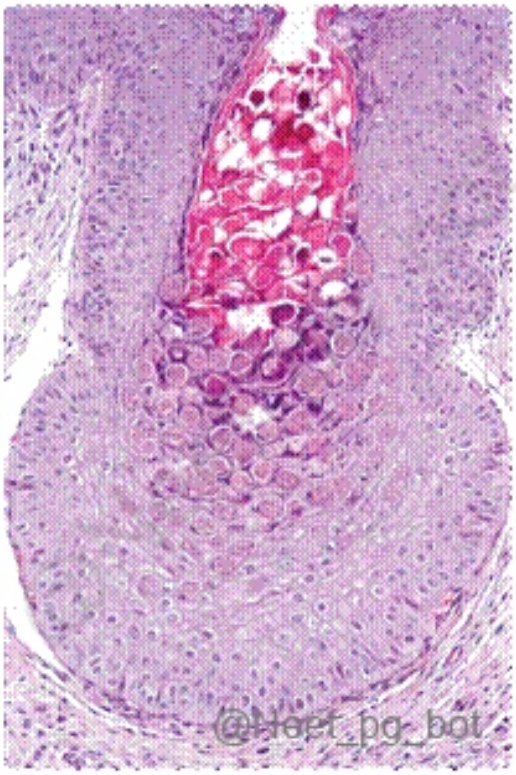
@Neet_pg_bot

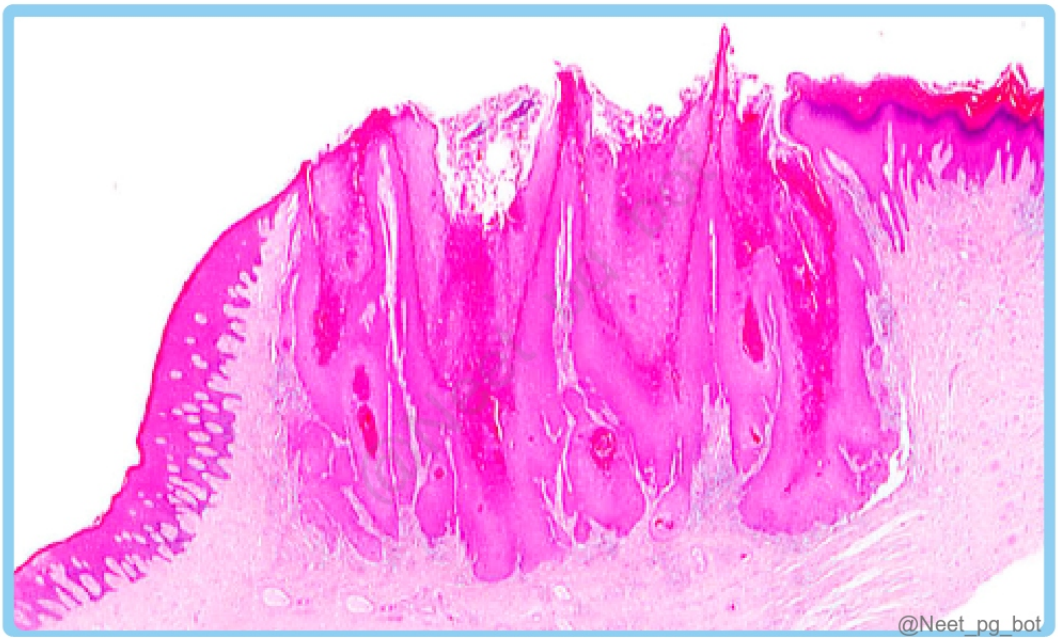

References:

Robbins and Cotran, Pathologic Basis of Diseases, 10th Edition, Page 271.

Rook’s Textbook of Dermatology, 9th Edition, Page 142.10.

↑ *Back to this question in Part A*

@Neet_pg_bot

Q4: Identify the histopathological image. (Q860535)

A. Basal cell carcinoma

B. Squamous cell carcinoma

C. Adenocarcinoma

D. Malignant melanoma

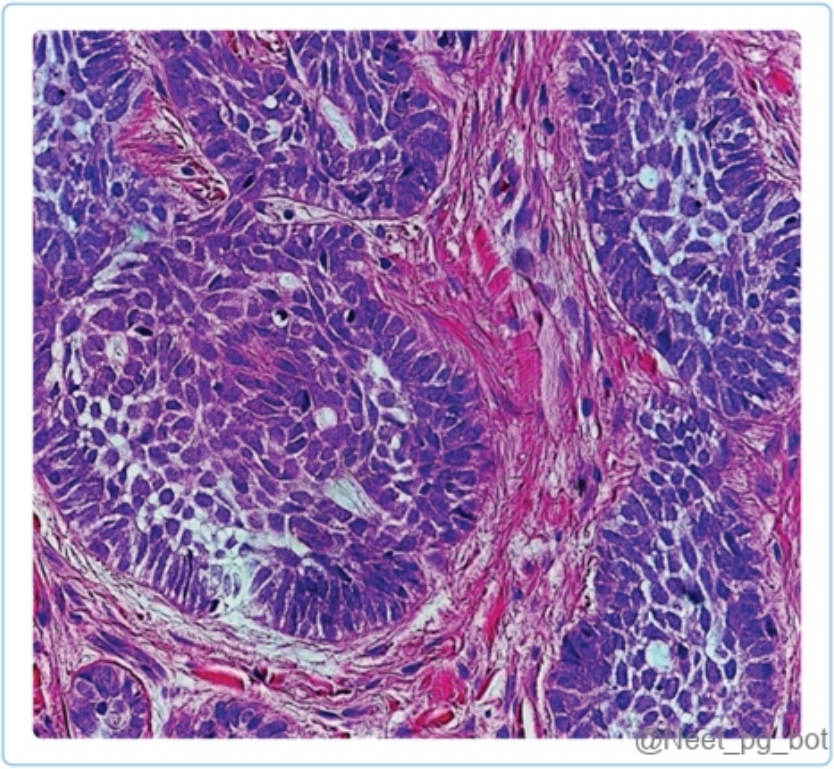

Correct Answer: A. Basal cell carcinoma

Explanation: The histopathological image of the skin biopsy reveals nests of basaloid cells with peripheral palisading and a distinctive stromal retraction artefact, characteristic of Basal Cell Carcinoma (BCC), also known as Rodent Ulcer. It is the most common type of skin cancer and is typically seen in sun-exposed areas of the skin. It is a slow-growing, locally invasive tumour, and it rarely metastasises. Origin: Arises from pluripotent cells within the basal layer of the epidermis or follicular structures. Pathogenesis: Site: Face, Around eyes, Nose Clinical Features It presents initially small, scaly plaque. They present as pearly papules containing dilated blood vessels (telangiectasias) They may ulcerate locally and invade the underlying bone or facial sinuses (rodent ulcers). Slow progressive course of peripheral extension. {{caption_text}} Histologically: The tumour cells are basophilic cells with hyperchromatic nuclei (basaloid cells) arranged in clusters with a palisading pattern . The stroma sometimes retracts from the malignant cells. {{caption_text}} Treatment Medical: Imiquimod, 5-FU,Intralesional interferon α-2b Hedgehog pathway inhibitors:(Vismodegib) Surgical: Mohs micrographic surgery, Done in recurrent BCCs. Squamous cell Carcinoma (Option B) typically exhibits keratin pearls and intercellular bridges, features not present in the image provided. Additionally, the cells are generally larger and have more abundant cytoplasm, unlike the smaller basaloid cells seen in BCC. {{caption_text}} Adenocarcinoma (Option C) arises from glandular epithelium and shows glandular structures or mucin production. {{caption_text}} Malignant Melanoma (Option D) is characterised by atypical melanocytes, which can be seen in various configurations, such as nests or single cells within the epidermis and dermis. These cells often contain melanin pigment. {{caption_text}}

In basal cell carcinoma

Mutated PTCH receptor

↓

Permanently activated SMO protein

↓

Activates the transcription factor GLI1

↓

Unregulated cell division and growth

↓

Basal cell carcinoma

@Neet_pg_bot



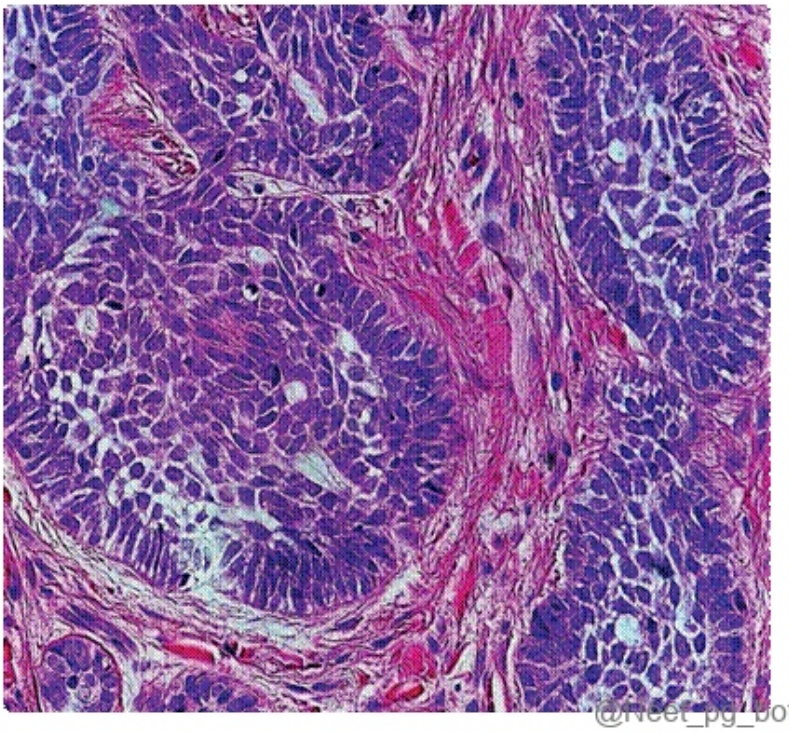
@Neet_pg_bot


@Neet_pg_bot

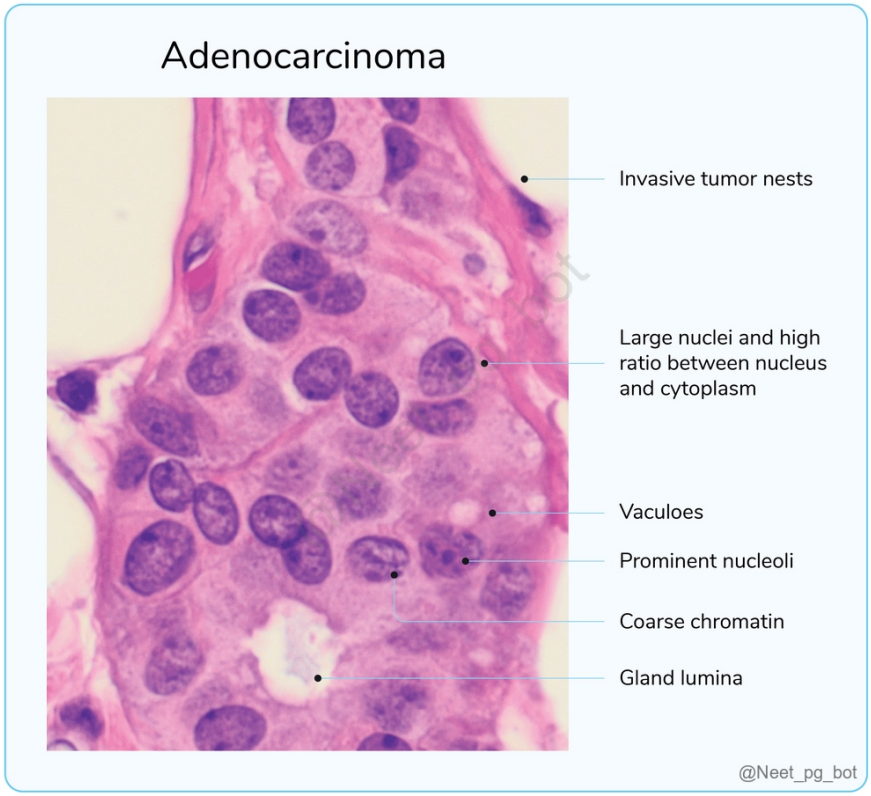

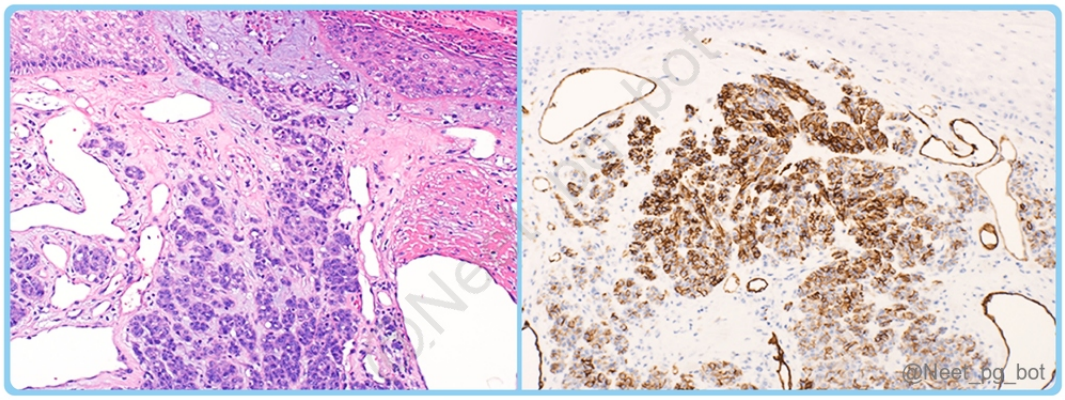

References:

Robbins and Cotran, Pathologic Basis of Diseases, 10th Edition, Page 292, 1147-1149.

Rooks Textbook of Dermatology, 9th Edition, Page 141.4-141.6.

↑ *Back to this question in Part A*

@Neet_pg_bot

Q5: An 8-year-old boy presents with progressive muscle weakness and walking difficulties. On examination, pseudohypertrophy of the calf muscles was noted. Which

of the following is true regarding this condition? (Q858113)

A. Abnormal collagen

B. Absent dystrophin

C. Expansions of CAG triplet repeats

D. Defective fibrillin

Correct Answer: B. Absent dystrophin

Explanation: The patient described is likely suffering from Duchenne muscular dystrophy (DMD) , a genetic disorder characterised by progressive muscle weakness, particularly in the lower limbs, with pseudohypertrophy of the calf muscles . This condition is caused by a mutation in the dystrophin gene , resulting in the absence or severe deficiency of dystrophin , a protein that helps anchor the muscle cell membrane. Aspect Duchenne Muscular Dystrophy (DMD) Type of Mutation Frameshift mutations lead to a disrupted reading frame Dystrophin Protein Dystrophin deficient Truncated and unstable (< 3% of normal) Clinical Severity Severe, early onset, rapid progression Inheritance Pattern X-linked recessive. Age of onset Early childhood (Before 5 years) Incorrect Options: Abnormal collagen (Option A) would be more consistent with conditions like Ehlers-Danlos syndrome or osteogenesis imperfecta , which involve defective collagen synthesis. Dystrophinopathies, like DMD, do not primarily involve collagen. Expansion of CAG triplet repeats (Option C) can cause Huntington's disease or fragile X syndrome, but DMD is caused by a mutation in the dystrophin gene , not CAG repeats. Defective fibrillin (Option D) is the cause of Marfan syndrome , which affects connective tissue and is characterized by features like tall stature, long limbs, and aortic dissection, but it is not involved in muscle degeneration like DMD.

References:

Nelson Textbook of Pediatrics, 21st Edition, Page 3283

↑ *Back to this question in Part A*

@Neet_pg_bot

Q6: A patient underwent surgery for lipoma 5 weeks ago and now presents with a scar at the incision site, which is limited to the original wound boundaries. What is the most likely diagnosis? (Q857162)

A. Keloid

B. Exuberant granulation

C. Hypertrophic scar

D. Granulation tissue

Correct Answer: C. Hypertrophic scar

Explanation: The most likely diagnosis is a hypertrophic scar, characterised by a raised scar confined to the original wound boundaries, unlike keloids that extend beyond the wound. It is marked by excess collagen, rapid growth, and the presence of myofibroblasts. Hypertrophic scars tend to regress over time and recur less frequently than keloids. {{caption_text}} Keloid: (Option A) Scar grows beyond the original wound boundaries and doesn’t regress. More common among African Americans. Develops after deep dermal injuries. {{caption_text}} Exuberant Granulation Tissue: (Option B) {{caption_text}} Excessive granulation tissue above skin level. Blocks reepithelialisation (also called "proud flesh"). Requires cauterisation or surgical excision for healing Contractures: {{caption_text}} Abnormal tightening of the wound and surrounding tissues. Common in palms, soles, and chest. Seen in severe burns, it may impair joint movement.







@Neet_pg_bot



References:

Robbins & Cotran Pathologic Basis of Disease, 10th Edition, Page 110,111

↑ *Back to this question in Part A*

@Neet_pg_bot

Q7: Identify the given condition. (Q856687)

A. Pemphigus Vulgaris

B. Leprosy

C. Mycosis fungoides

D. Visceral leishmaniasis

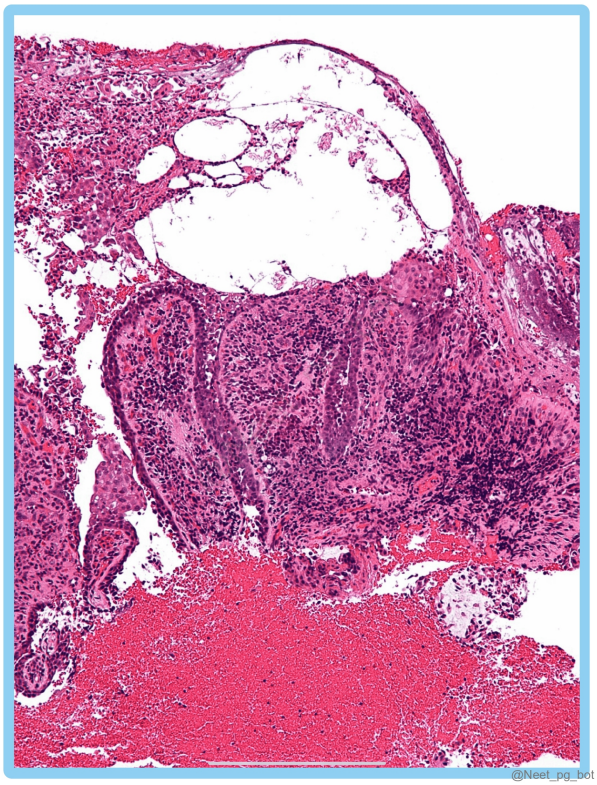

Correct Answer: A. Pemphigus Vulgaris

Explanation: The histopathological image shows Pemphigus Vulgaris (PV) , with intraepidermal cleavage and acantholysis in the suprabasal layer, along with a "row of tombstones" appearance due to the separation of basal keratinocytes at the basement membrane zone. It is the most common chronic autoimmune blistering disease caused by antibodies against desmosomal adhesion proteins. The target antigens for PV are most commonly Desmoglein 3 and sometimes Desmoglein 1. Clinical features: Flaccid blisters filled with clear fluid present on normal skin or an erythematous base. The blisters rupture, producing painful erosion. {{caption_text}} Mucosal involvement is a very important and one of the distinguishing features of PV. {{caption_text}} {{caption_text}} Histopathology: Intraepidermal cleavage with acantholysis (detached keratinocytes) primarily localized to the suprabasal region. Separation of basal keratinocytes along the basement membrane zone, resulting in an appearance that resembles a "row of tombstones". {{caption_text}} Leprosy (Option B) , also known as Hansen's disease , is a chronic infection caused by Mycobacterium leprae , affecting the skin, peripheral nerves, and mucous membranes. Tuberculous leprosy shows granulomatous lesions similar to tuberculosis, while lepromatous leprosy features lipid-laden macrophages (lepra cells) containing "globi" of acid-fast bacilli. {{caption_text}} {{caption_text}} Mycosis fungoides (Option C) is the most common type of cutaneous T-cell lymphoma. It presents with a variety of skin lesions, including patches, plaques, and tumours. Histologically, the epidermis and upper dermis are infiltrated by neoplastic T cells, which often have a cerebriform appearance due to marked infolding of the nuclear membrane. {{caption_text}} Visceral leishmaniasis (Option D) , also known as kala-azar, is a systemic parasitic infection caused by Leishmania species. It is characterized by granulomatous inflammation, phagocytosed parasites, hyperplasia of the reticuloendothelial system, necrosis with fibrosis, and hemophagocytosis, where macrophages engulf red blood cells, white blood cells, or platelets. {{caption_text}}


@Neet_pg_bot


@Neet_pg_bot


@Neet_pg_bot

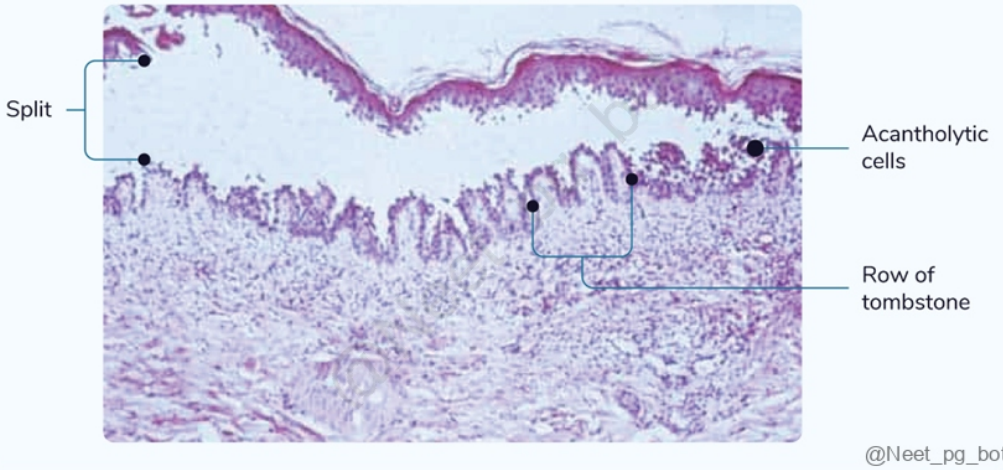
Split
Acantholytic cells
Row of tombstone
@Neet_pg_bot

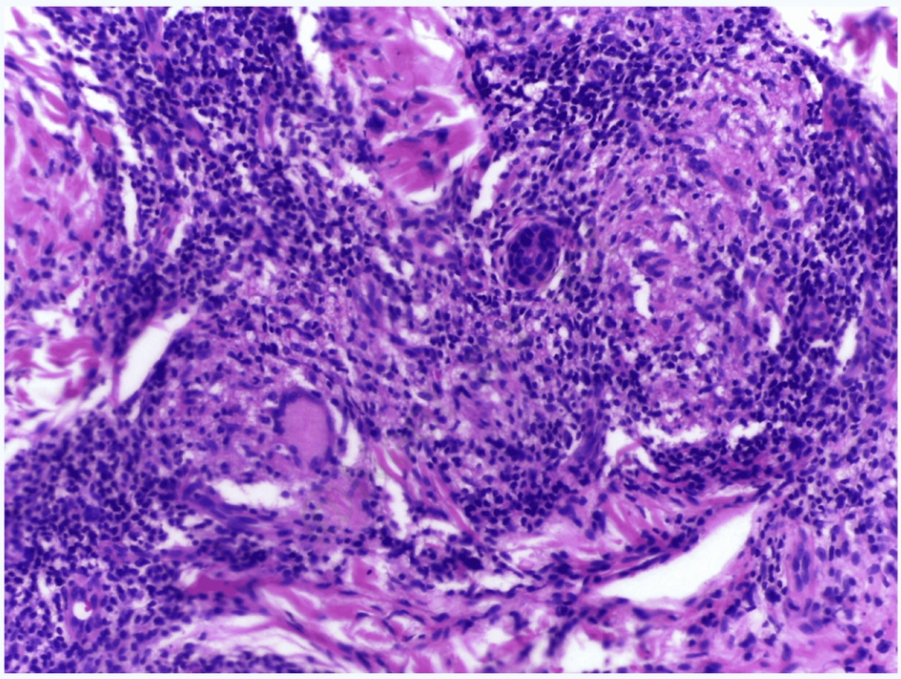

Tuberculoid Leprosy

@Neet_pg_bot

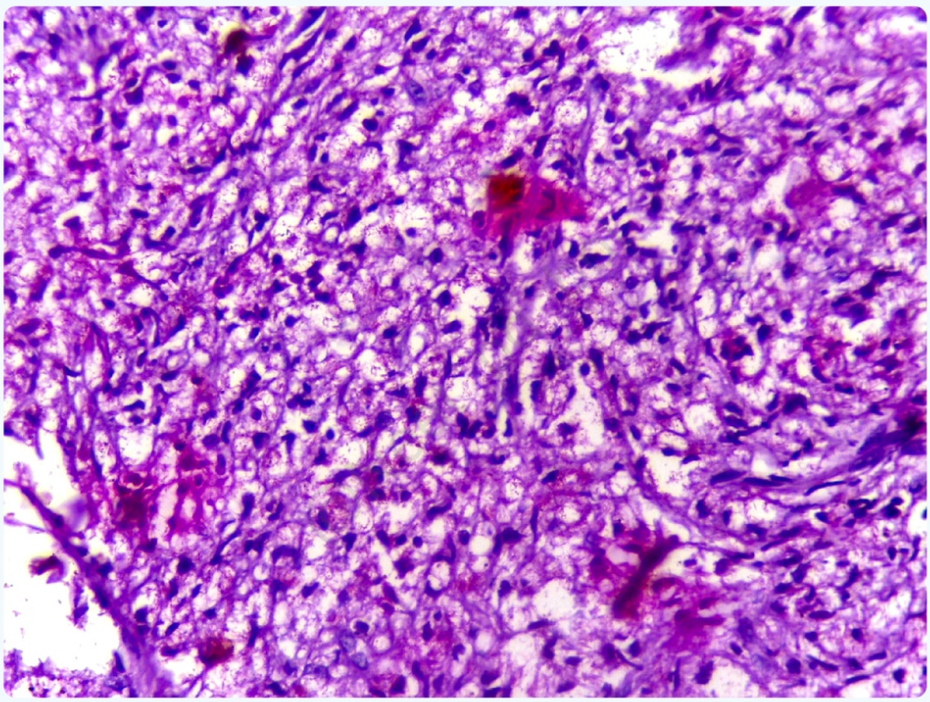

Lepromatous Leprosy

@Neet_pg_bot

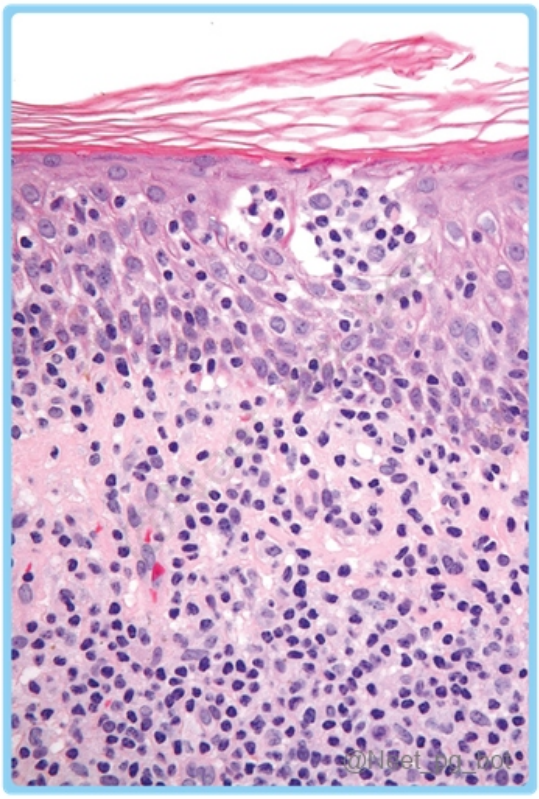

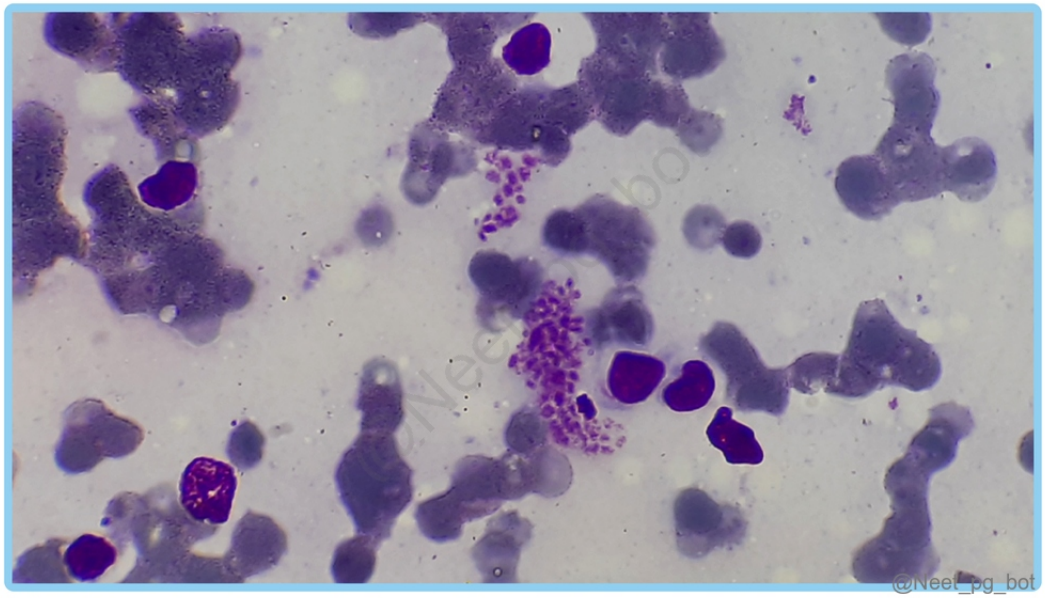

References:

Robbins and Cotran, Pathologic Basis of Disease, 10th Edition, Page 1159-1162.

Rooks Textbook of Dermatology, 9th Edition, Page, 50.1-50.4.

↑ *Back to this question in Part A*

@Neet_pg_bot

Q8: A 5-year-old child who presented with proptosis of one of the eyes was found to have a desmin-positive tumour. What is the probable diagnosis? (Q856705)

A. Ewing’s sarcoma

B. Embryonal rhabdomyosarcoma

C. Leukaemia

D. Retinoblastoma

Correct Answer: B. Embryonal rhabdomyosarcoma

Explanation: The clinical presentation of a 5-year-old child with proptosis and a desmin-positive tumour suggests embryonal rhabdomyosarcoma (RMS). Desmin is a marker for muscle differentiation, and rhabdomyosarcoma, a malignant tumour of skeletal muscle origin, is common in children and can present with proptosis if it involves the orbit. Rhabdomyosarcoma (RMS) Origin A malignant tumour arising from skeletal muscle progenitors Types Embryonal rhabdomyosarcoma. Alveolar rhabdomyosarcoma. Pleomorphic rhabdomyosarcoma. Spindle cell/sclerosing rhabdomyosarcoma Clinical features It is the most common soft tissue sarcoma in children and adolescents. It commonly presents in the extremities. Pediatric rhabdomyosarcomas mostly arise in the sinuses, head and neck, and genitourinary tract. IHC Positive Markers Desmin Myogenin MyoD1 Muscle-specific actin Gross appearance The tumours are often large, soft, and infiltrative, with areas of necrosis and haemorrhage. Microscopy Small, round to spindle-shaped cells with hyperchromatic nuclei and scant cytoplasm, sometimes with a myxoid stroma, are also seen. {{caption_text}} Ewing’s sarcoma (Option A) is a malignant tumour typically affecting bones or soft tissues, often seen in children and adolescents. It is characterized by a specific genetic translocation (t(11;22)) and is usually not associated with desmin positivity, which is more typical of rhabdomyosarcoma. Ewing's sarcoma may cause localized swelling or pain but rarely presents with proptosis unless it involves the orbit or surrounding tissues. It is composed of sheets of uniform, small, round cells with scant cytoplasm that may be clear due to abundant glycogen. Leukaemia (Option C) is a type of cancer that affects the blood and bone marrow, leading to the uncontrolled production of abnormal white blood cells. It typically doesn't present with localized tumours or proptosis. However, in cases of leukemic infiltration of the orbit, proptosis may occur, though it's relatively rare. Retinoblastoma (Option D) is a malignant eye tumour that primarily affects young children, often before the age of 5. While it can cause proptosis due to orbital involvement, it is typically not associated with a desmin-positive tumour. Retinoblastoma usually presents with a white reflex in the pupil (leukocoria) and can cause vision problems or strabismus.

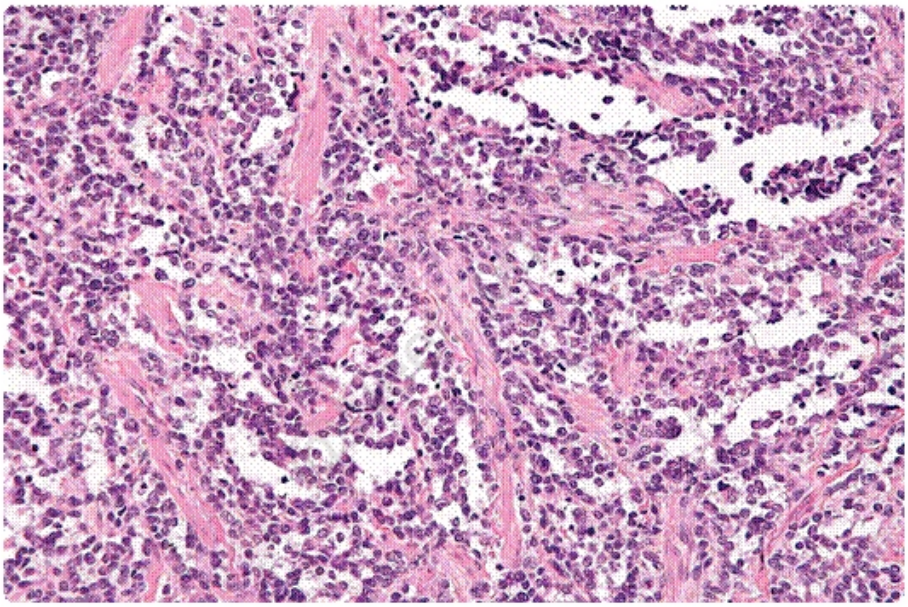

References:

Robbins and Cotran Pathologic Basis of Disease, 10th Edition, Page 1212.

↑ *Back to this question in Part A*

@Neet_pg_bot

Q9: Which connective tissue disorder is not associated with aneurysm formation? (Q840020)

A. Marfan syndrome

B. Scurvy

C. Atherosclerosis

D. Ehler-Danlos syndrome

Correct Answer: B. Scurvy

Explanation: Scurvy is caused by vitamin C deficiency , leading to defective collagen synthesis. Although it causes fragile blood vessels, petechiae, and poor wound healing, it does not typically cause aneurysm formation. The vascular issues are mainly due to impaired collagen cross-linking, not structural weakness severe enough to form aneurysms. Incorrect Options: Option A) Marfan syndrome: Causes cystic medial necrosis of the aorta →

high risk of aortic aneurysm and dissection . Option C) Atherosclerosis: Weakens the arterial media → most common cause of abdominal aortic aneurysm . Option D) Ehlers–Danlos syndrome: Defective type III collagen → predisposes to vascular aneurysms and ruptures

References:

.

↑ *Back to this question in Part A*

@Neet_pg_bot

• [24_Miscellaneous] 087 Previous Year Questions

« Back to Folder Directory

[24_Miscellaneous] 087 Previous Year Questions — Quick Jump

Q1 (p. 3273) *Q2 (p. 3276)* *Q3 (p. 3281)* *Q4 (p. 3282)* *Q5 (p. 3283)* *Q6 (p. 3283)*
Q7 (p. 3284) *Q8 (p. 3285)* *Q9 (p. 3289)* *Q10 (p. 3289)* *Q11 (p. 3290)*

Q1: For testing blood clotting/ coagulation parameters, blood is collected in which color-coded vacutainer tube? (Q866663)

A. Red

B. Green

C. Blue

D. Gray

Correct Answer: C. Blue

Explanation: The light blue Vacutainer contains sodium citrate as an anticoagulant and is specifically used for coagulation studies, such as Prothrombin Time (PT) and Activated Partial Thromboplastin Time (aPTT). The anticoagulant preserves the coagulation factors for accurate testing. Colour Anti-coagulants Uses Purple/Lavender EDTA (Ca2+ chelating anticoagulant) CBC, Peripheral Smear, ESR, HbA1c Light Blue (Option B) Citrate (Ca2+ chelating anticoagulant) ESR, PT, aPTT Red (Option A) No anti-coagulant is added Serum studies (Proteins, enzymes, hormones) Yellow Clot activator/Gel separator Serum studies (Proteins, enzymes, hormones) Grey (Option D) Sodium Fluoride Blood Glucose Green (Option B) Heparin ABG, Osmotic fragility, flow cytometry, immunophenotyping




@Neet_pg_bot


@Neet_pg_bot



@Neet_pg_bot



@Neet_pg_bot



↑ *Back to this question in Part A*

@Neet_pg_bot

Q2: Basophilic stippling of red blood cells is most characteristically seen in which of the following conditions? (Q866743)

A. Iron deficiency anaemia X

B. Lead poisoning

C. Megaloblastic anemia

D. Hereditary spherocytosis

Correct Answer: B. Lead poisoning

Explanation: Basophilic stippling is a characteristic haematological finding in lead toxicity. Acute lead poisoning It’s rare, and there may be exacerbations of chronic lead poisoning. Symptoms: Astringent or metallic taste, dry throat, thirst, burning abdominal pain, nausea, vomiting, diarrhoea, peripheral circulatory collapse, paraesthesia, depression, coma, and death. Chronic lead poisoning (also known as Plumbism or Saturnism) Clinical manifestations Description Facial pallor It is caused by vasospasm and specifically occurs circumorally , which is the earliest and most specific feature. Anemia Type: Microcytic-hypochromic . Enzymes inhibited: Ferrochelatase

ALA-dehydratase Coproporphyrinogen oxidase Blood picture: Cabot rings in RBCs Microcytic-hypochromic Sideroblasts (nucleated red cells) Anisocytosis Poikilocytosis Polycythemia Basophilic stippling or Punctate basophilia Multiple blue-coloured pinhead dots in RBCs due to the toxic action of lead on porphyrin metabolism (inhibition of enzyme 5- Pyrimidine nucleotidase) (PNN). Accumulation of ribosomes in RBC Lead line or Burtonian lines The stippled blue line observed on the gums, resulting from a subepithelial deposit of granules that develops within one week, is seen in 50-70% of cases and is more common in individuals with carious teeth (bacteria form lead sulfide). Lead osteopathy/Lead line (Bone-line) In children, calcium deposition occurs at the growth plates of bones (specifically the lower end of the femur and the upper end of the tibia), which appears as a radiopaque band and occurs over 4 weeks due to the inhibition of osteoclastic activity. Colic and constipation (Painter's Colic or Devonshire colic) Late presentation occurs in 85% of cases, typically at night, and is characterised by spasmodic pain relieved by pressure. Lead palsy Predominantly motor features include: Dry belly ache Wrist drop (Radial nerve) Foot drop (Common peroneal nerve) Encephalopathy This condition is seen in nearly all cases, is associated with tetraethyl lead exposure, primarily affects children, results in permanent brain damage in 85% of cases, and accounts for 25% of fatalities. Reproductive system Amenorrhea Dysmenorrhea Abortion Sterility derangements (both sexes) Cardiovascular system and Kidneys Hypertension (vascular constriction) Permanent arteriolar degeneration Nephritis Gout Saturnine gout (due to decreased excretion of uric acid) Others These include generalised weakness, anorexia, dyspepsia, emaciation, exhaustion, irritability, foul breath, headache, vertigo, alopecia, and dizziness. Conditions associated with Basophilic stippling: Lead poisoning Thalassemia (Beta-thalassemia) Sideroblastic anemia Arsenic poisoning Alcoholism Pyrimidine 5′-Nucleotidase deficiency Megaloblastic anemia Severe infections (e.g., malaria) Myelodysplastic syndromes Chronic inflammatory conditions Iron deficiency anaemia (Option A): microcytic hypochromic cells, but no basophilic stippling. Megaloblastic anaemia (Option C) : macrocytosis with hypersegmented neutrophils, no stippling. Hereditary spherocytosis (Option D): spherocytes, increased MCHC, but no stippling.

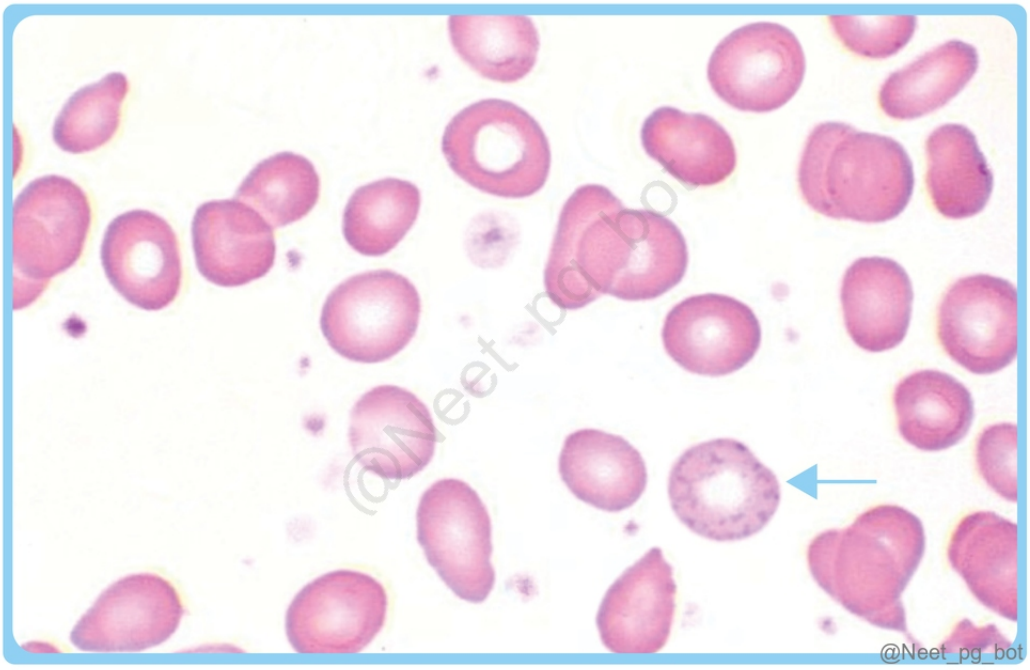



@Neet_pg_bot

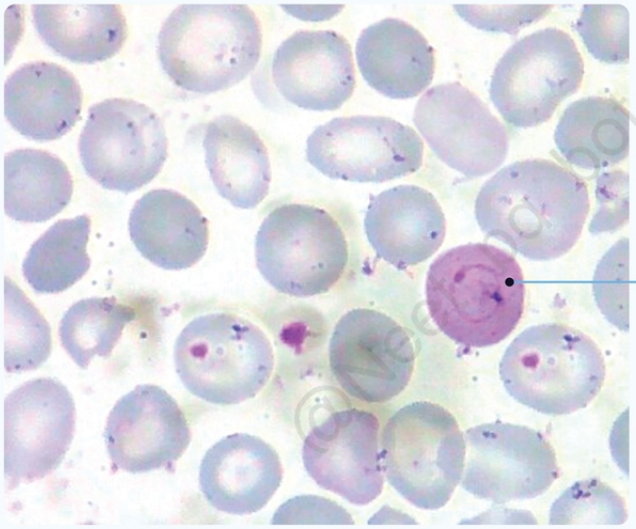

@Neet_pg_bot

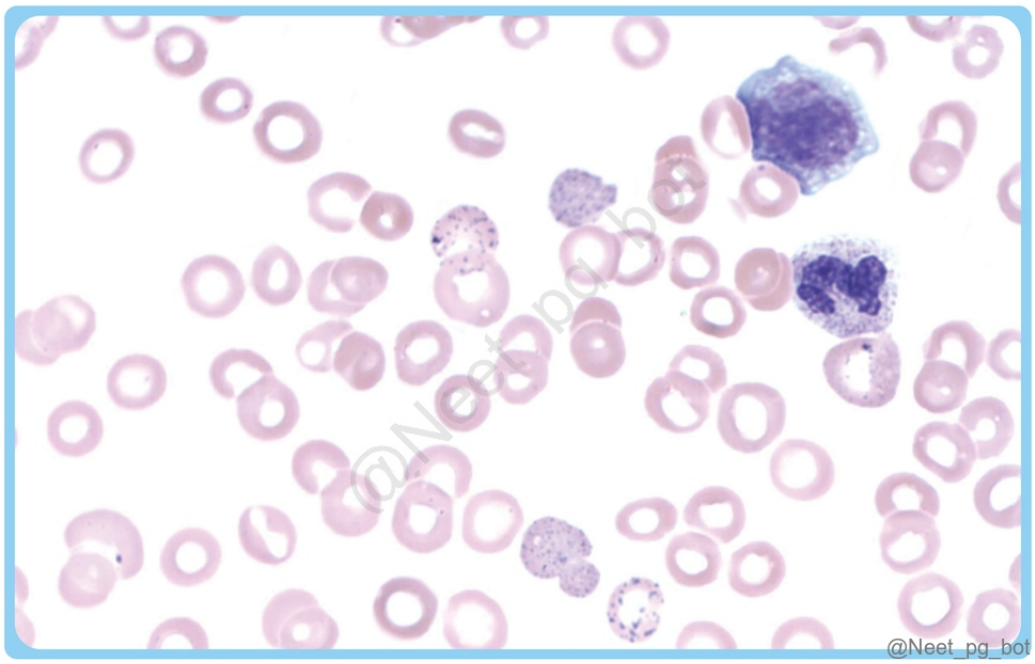
@Neet_pg_bot


@Neet_pg_bot


@Neet_pg_bot


@Neet_pg_bot
@Neet_pg_bot

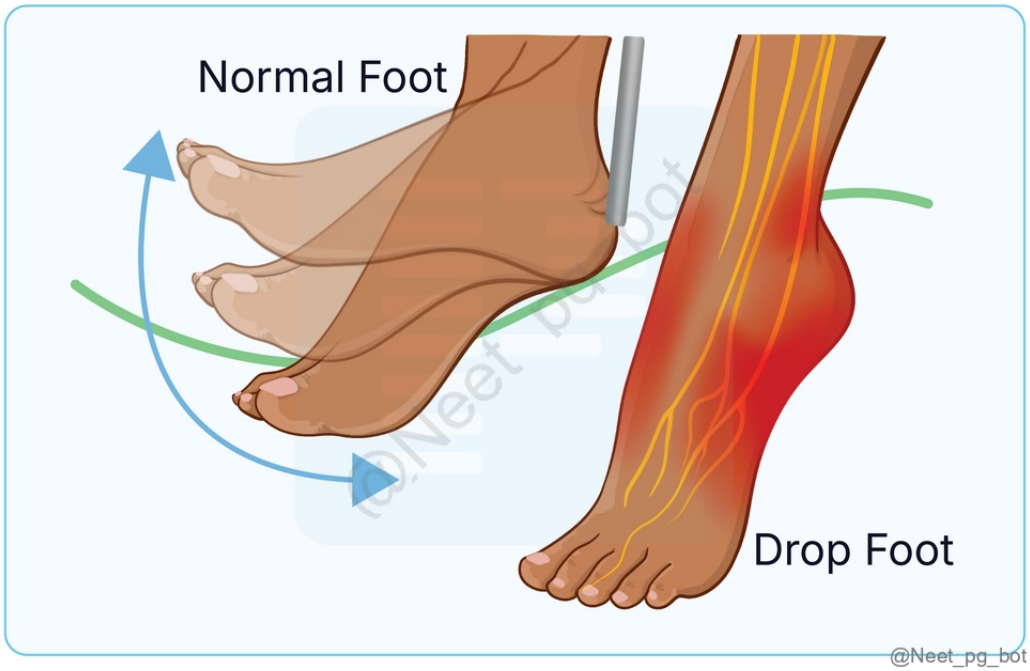

References:

.

↑ *Back to this question in Part A*

@Neet_pg_bot

Q3: A chronic smoker presents with a whitish exophytic lesion over the vocal cords, as shown in the image below. During direct laryngoscopy, the ENT surgeon applies a dye to help identify areas of dysplasia and select the most appropriate biopsy site. Which stain is being used? (Q844052)

A. Supravital stain

B. Congo red

C. Hematoxylin and eosin (H&E)

D. Oil red O



Correct Answer: A. Supravital stain

Explanation: The given image shows a laryngeal mass, for which toluidine blue is used for identification, and it is a supravital stain. Commonly used during oral and laryngeal examinations to highlight dysplastic and malignant areas, especially in smokers. It binds strongly to acidic nuclear material (DNA/RNA), which is increased in premalignant and malignant cells due to higher mitotic activity. Thus, abnormal mucosa appears dark blue, while normal mucosa remains unstained. This helps clinicians identify the most suspicious areas and choose the optimal site for biopsy. Biopsy with H&E is still the final diagnostic method, but Toluidine blue is used for identification/screening during the procedure. Incorrect Options: Option B) Congo red : Used for detecting amyloid deposits with apple-green birefringence- unrelated to laryngeal lesions. Option C) Hematoxylin and eosin (H&E): Used for histopathologic diagnosis, not for in vivo identification of dysplastic mucosa. Option D) Oil red O : Stains neutral lipids in frozen sections; not used for mucosal screening or carcinoma detection.

References:

.

↑ *Back to this question in Part A*

@Neet_pg_bot

Q4: Which among the following is the least radiosensitive cell? (Q860529)

A. Monocytes

B. Platelets

C. Lymphocytes

D. Neutrophils

Correct Answer: B. Platelets

Explanation: Among the given options, platelets are the least radiosensitive cells. Radiosensitivity refers to the susceptibility of cells or tissues to the effects of radiation. Cells with higher rates of proliferation and less differentiation tend to be more radiosensitive because they are actively dividing and thus more vulnerable to the damaging effects of radiation. Platelets are the least radiosensitive as they do not divide actively. Order of Radiosensitivity: Lymphocytes > neutrophils ~ monocytes > platelets

References:

Radiation sensitivity of human and murine peripheral blood lymphocytes, stem and progenitor cells - ScienceDirect .

↑ *Back to this question in Part A*

@Neet_pg_bot

Q5: Which of the following instruments is not used in the colorimetric method for the estimation of hemoglobin? (Q840012)

Correct Answer: Unknown

Explanation: Correct Option: D) The instrument shown in Option D is an RBC pipette, which is used for manual RBC counting in hemocytometry. It is not a part of Sahli’s hemoglobinometer kit and is not required in the colorimetric estimation of hemoglobin. Colorimetric methods rely on comparing the color intensity of acid-hematin with a standard, not on cell dilution. Incorrect Options: The images in Options A, B, and C show a comparator, hemoglobin tube, and a stirrer respectively. They are components of Sahli's hemoglobinometer set. Sahli's method of hemoglobin estimation is a colorimetric method.

References:

.

↑ *Back to this question in Part A*

@Neet_pg_bot

Q6: Which of the following is not a part of the criteria for diagnosis of Kawasaki disease? (Q840066)

A. Strawberry tongue

B. Polymorphic rash

C. Purulent conjunctivitis

D. Cervical lymphadenopathy

Correct Answer: C. Purulent conjunctivitis

Explanation: Correct Option C - Purulent conjunctivitis: The diagnostic criteria for Kawasaki disease include non-purulent conjunctivitis rather than purulent conjunctivitis. Incorrect Options: Options A, B & D: Strawberry tongue, Polymorphic rash, and Cervical lymphadenopathy are all features of Kawasaki disease.

References:

.

↑ *Back to this question in Part A*

@Neet_pg_bot

Q7: Which of the following disorders presents with repeated catalase-positive infections? (Q840071)

A. X linked hypogammaglobinemia

B. SCID

C. Chronic granulomatous disease

D. Chediak Higashi Syndrome

Correct Answer: C. Chronic granulomatous disease

Explanation: Correct Option C - Chronic granulomatous disease: Chronic Granulomatous Disease is characterized by a defect in the NADPH oxidase enzyme complex. Without a functional NADPH oxidase, the patient is susceptible to recurrent infections caused by catalase-positive organisms. Incorrect Options: Options A, B, and D are not associated with recurrent catalase-positive infections.

References:

.

↑ *Back to this question in Part A*

@Neet_pg_bot

Q8: A Diabetic patient's blood sample is kept in the given container. What will be added to the blood sample? (Q860268)

A. Na fluoride

B. EDTA

C. Na citrate

D. Heparin



Correct Answer: A. Na fluoride

Explanation: Grey top containers, used for glucose estimation, contain potassium oxalate as an anticoagulant and sodium fluoride to inhibit glycolysis by blocking enolase. Colour Anti-coagulants Uses {{caption_text}} Purple/Lavender EDTA (Ca2+ chelating anticoagulant) (Option B ruled out) CBC, Peripheral Smear, ESR, HbA1c {{caption_text}} Light Blue Trisodium Citrate (Ca2+ chelating anticoagulant) (Option C ruled out) ESR, PT, aPTT {{caption_text}} Red No anti-coagulant is added. Clot activator without gel Serum studies (Proteins, enzymes, hormones) {{caption_text}} Yellow Clot activator/Gel separator Serum studies (Proteins, enzymes,

hormones) {{caption_text}} Grey Sodium Fluoride (Option A) Blood Glucose Green Heparin (Option D ruled out) ABG, Osmotic fragility, flow cytometry, immunophenotyping

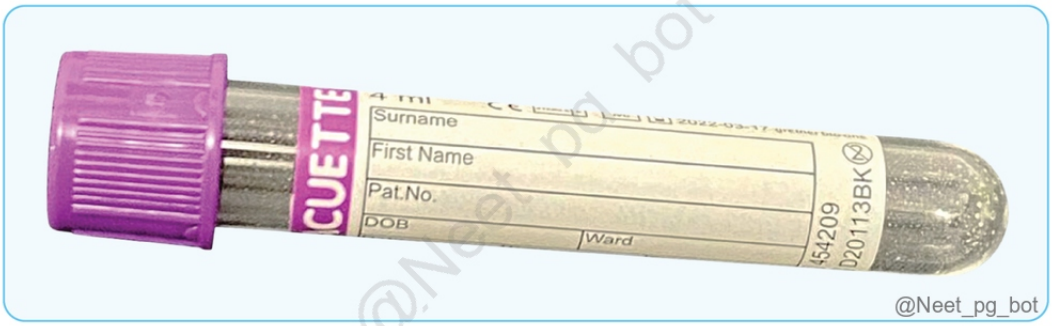




CUETTE
6 ml
Surname
First Name
Pat.No.
@Neet_pg_bot


UETTE
5 ml
Surname
First Name
Pat.No.
2022-02-12
@Neet_pg_bot



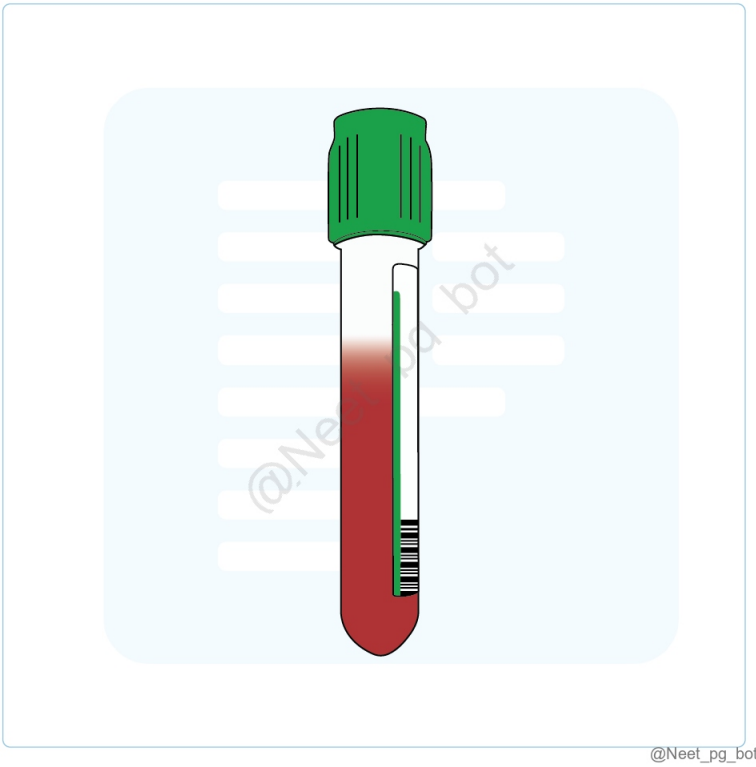

References:

Atlas of Clinical Hematology, Chapter 1, Page 4

Laboratory tube collection

↑ *Back to this question in Part A*

@Neet_pg_bot

Q9: Which amino acid is necessary for the production of nitric oxide in the blood vessels? (Q859910)

A. Citrulline

B. Arginine

C. Histidine

D. Tryptophan

Correct Answer: B. Arginine

Explanation: Nitric oxide (NO) is a vital signalling molecule involved in vasodilation and various other physiological processes. Nitric oxide synthesis in blood vessels requires the amino acid arginine , which serves as its precursor. Steps in Nitric Oxide Synthesis: Enzyme Involved : Nitric oxide synthase (NOS) converts L-arginine to nitric oxide (NO) and L-citrulline in the presence of oxygen and cofactors like NADPH and tetrahydrobiopterin (BH4). Physiological Role of NO : NO is a potent vasodilator that relaxes vascular smooth muscle cells, thus regulating blood pressure and improving blood flow. It also has roles in neurotransmission and immune response. Citrulline (Option A) is a byproduct of nitric oxide synthesis and can be recycled back into arginine via the urea cycle , but it is not directly used in NO production. Histidine (Option C) is a precursor for histamine and is involved in immune responses, but it does not play a role in NO synthesis. Tryptophan (Option D) is a precursor for serotonin and melatonin but is not involved in nitric oxide production.

References:

https://pubmed.ncbi.nlm.nih.gov/34251644/

↑ *Back to this question in Part A*

@Neet_pg_bot

Q10: Which of the following is right regarding these stains? (Q879218)

A. Perl’s Prussian blue – stains iron, color red

B. Alizarin Red S – stains calcium, color black

C. Van Gieson – stains elastin, color blue

D. Giemsa – stains mast cells, color purple

Correct Answer: D. Giemsa – stains mast cells, color purple

Explanation: The accurate target structures and associated colors for these stains are: Stain Description Perl's Prussian blue It stains iron (ferric) - Blue Used to detect hemosiderin in tissues. Alizarin Red S Stains calcium deposits orange to red Van Gieson stain It stains collagen (red) and muscle (yellow). Elastic fibers stain black/blue-black only with Verhoeff's elastic stain (Verhoeff–Van Gieson). Giemsa stain Stains mast cell granules purple (metachromatic staining). Also used for blood smears and parasite detection (egmalaria).

References:

Histology, Verhoeff Stain - StatPearls - NCBI Bookshelf Color | Definition, Perception, Types, & Facts | Britannica The Giemsa stain: its history and applications - PubMed

↑ *Back to this question in Part A*

@Neet_pg_bot

Q11: Lipid is best visualised on which technique in pathology? (Q879231)

A. Frozen section / Cryostat

B. Paraffin-embedded section

C. Immunohistochemistry

D. Electron microscopy

Correct Answer: A. Frozen section / Cryostat

Explanation: Lipids are best visualised in frozen sections (cryostat technique) because routine paraffin embedding dissolves fats during tissue processing with organic solvents like xylene and alcohol. In frozen sections, the tissue is rapidly frozen and cut without chemical processing , thereby preserving lipids for demonstration with fat stains such as: Oil Red O Sudan III / IV Sudan Black B Incorrect Options: Paraffin-embedded section (Option B): Lipids are dissolved during routine processing, so they are not visualized. Immunohistochemistry (Option C): Detects specific proteins, not lipids. Electron microscopy (Option D): Can show lipid droplets ultrastructurally but is not the standard technique for routine lipid visualization.

References:

Robbins & Cotran, Pathologic Basis of Diseases, 10th Edition, Pages 132.

↑ *Back to this question in Part A*

@Neet_pg_bot

• [25_Platelets and Blood Transfusion] 088 Previous Year Questions

« Back to Folder Directory

[25_Platelets and Blood Transfusion] 088 Previous Year Questions — Quick Jump

Q1 (p. 3292) *Q2 (p. 3292)* *Q3 (p. 3293)* *Q4 (p. 3294)* *Q5 (p. 3294)* *Q6 (p. 3295)*
Q7 (p. 3297) *Q8 (p. 3298)* *Q9 (p. 3299)*

Q1: Match the following blood products with their shelf lives. a. 1-Granulocytes A- 5 days b. 2- PRBC B- 24 hours c. 3- SDP C- 42 days d. 4- CRYO D- 1 year (Q840026)

A. 1-A, 2-C, 3D, 4-B

B. 1-B, 2-D, 3-A, 4-C

C. 1-C, 2-A, 3-B, 4-D

D. 1-B, 2-C, 3-A, 4-D

Correct Answer: D. 1-B, 2-C, 3-A, 4-D

Explanation: Correct Option D - 1-B, 2-C, 3-A, 4-D: Granulocyte concentrate : They have a very short shelf life of 24 hours. PRBC (Packed Red Blood Cells) : Packed Red Blood cells have a shelf life of 35 to 42 days, depending on the anti-coagulant used: 21 days (ACD/CPD), 35 days (CPDA) and 42 days (SAGM). SDP (Single Donor Platelets) : Single Donor Platelets have a shelf life of 5 days, CRYO (Cryoprecipitate) : Cryoprecipitate has a shelf life of 1 year. Incorrect Options: Options A, B, and C are incorrectly matched.

References:

.

↑ *Back to this question in Part A*

@Neet_pg_bot

Q2: Which of the following is used in the treatment of Hemophilia B? (Q840031)

A. Factor 9

B. Cryoprecipitate

C. Factor 8

D. Tranexamic acid

Correct Answer: A. Factor 9

Explanation: Hemophilia B is caused by Factor IX deficiency (Christmas disease). Replacement therapy with Factor IX concentrate restores the intrinsic coagulation pathway and stops bleeding. It can be given prophylactically or during bleeding episodes or surgery. Incorrect Answers: Option B) Cryoprecipitate: Rich in Factor VIII, fibrinogen, and vWF, but contains minimal Factor IX. Not effective for Hemophilia B. Option C) Factor VIII: Used in Hemophilia A (Factor VIII deficiency). Does not correct Factor IX deficiency. Option D) Tranexamic acid : Antifibrinolytic; stabilizes formed clots. Supportive only, does not replace missing Factor IX.

References:

.

↑ *Back to this question in Part A*

@Neet_pg_bot

Q3: In a trauma patient with an unknown blood group who is unstable and requires urgent blood transfusion, which type of blood should be transfused? (Q840032)

A. A positive

B. AB positive

C. O positive

D. O negative

Correct Answer: D. O negative

Explanation: O-negative red blood cells are called the universal donor for RBC transfusion. O blood group has no A or B antigens, and negative Rh (D) antigen avoids Rh sensitization in Rh-negative recipients. This is critical in trauma or emergency situations when there is no time to determine blood group. Allows rapid transfusion while minimizing risk of acute hemolytic transfusion reactions. After stabilizing the patient and determining the blood group, group-specific blood should be transfused. Incorrect Options: Option A) A positive: May cause hemolytic reaction if the patient is type B or O. Option B) AB positive: Contains A and B antigens; unsafe for most unknown recipients. Option C) O positive: Safe for Rh-positive patients, but can sensitize Rh-negative recipients.

References:

.

↑ *Back to this question in Part A*

@Neet_pg_bot

Q4: Which of the following is not seen in a delayed hemolytic transfusion reaction? (Q840056)

A. Raised LDH

B. Raised indirect bilirubin

C. No improvement in Hb despite transfusion

D. Cola-colored urine after 2 hrs

Correct Answer: D. Cola-colored urine after 2 hrs

Explanation: Correct Option D - Cola-colored urine after 2 hrs Cola-colored urine is not a typical presentation in delayed hemolytic transfusion reactions. Instead, urine color typically ranges from red to brown during hemolysis. Additionally, delayed reactions typically occur after 2-3 days or even a few weeks. Incorrect Options: Options A, B & C: Raised LDH, Raised indirect bilirubin, and No improvement in Hb despite transfusion are all features of delayed hemolytic transfusion reactions.

↑ *Back to this question in Part A*

@Neet_pg_bot

Q5: A patient presents with a tingling sensation in both legs, polyuria, and weight loss. Based on the given bone marrow aspirate findings, what is the most likely diagnosis? (Q844224)

A. Multiple myeloma with renal failure

B. SACD with vitamin B12 deficiency

C. SACD with diabetes

D. Waldenstrom's Macroglobulinemia

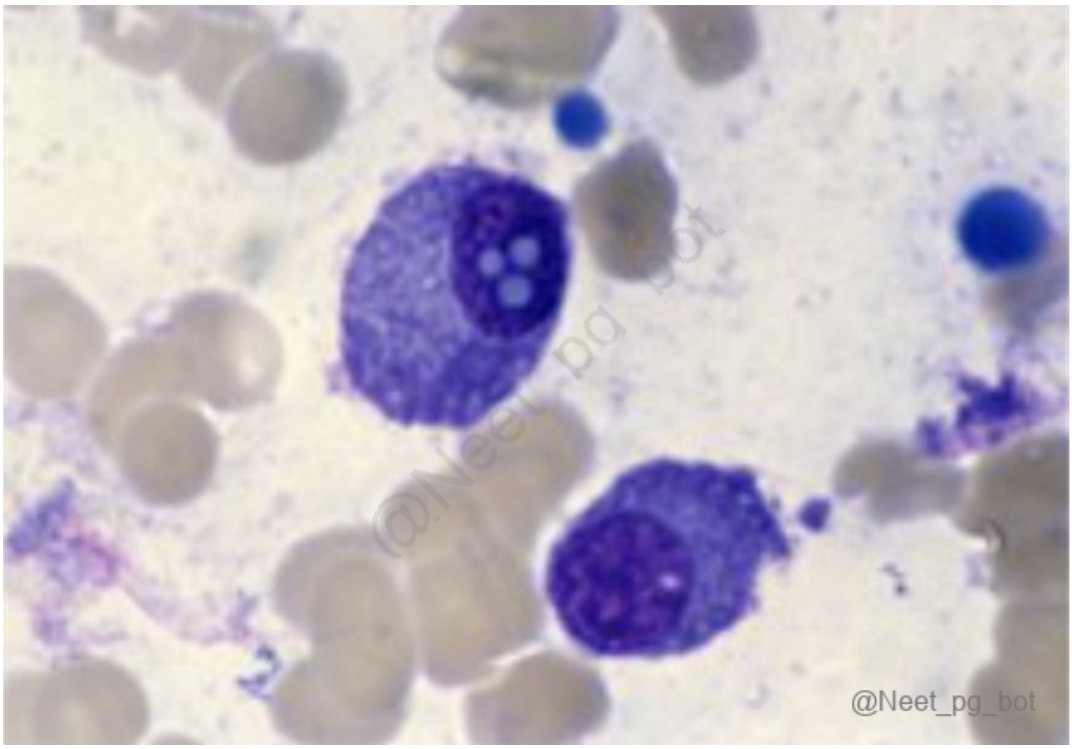

Correct Answer: A. Multiple myeloma with renal failure

Explanation: Correct Option A - Multiple myeloma with renal failure: The bone marrow aspirate shows intranuclear inclusions known as Dutcher's bodies, which are characteristic of multiple myeloma. Multiple myeloma often presents with renal failure, polyuria (due to hypercalcemia), and tingling sensations (due to amyloid deposition or hypercalcemia-related neuropathy). Incorrect Options: Options B, C, and D do not show Dutcher bodies on bone marrow biopsy.

References:

.

↑ *Back to this question in Part A*

@Neet_pg_bot

Q6: A child is brought to the emergency department with a large lesion on his forearm. As a surgery resident, you decide to excise the lesion in the emergency operation theatre. Which of the following investigations will test the entire coagulation pathway? (Q856915)

A. Activated partial thromboplastin time

B. Prothrombin time

C. Thromboelastography

D. Bleeding time

Correct Answer: C. Thromboelastography

Explanation: Thromboelastography (TEG) is a coagulation test that evaluates the entire coagulation pathway, including both the intrinsic and extrinsic pathways and fibrinolysis. It offers a comprehensive assessment of clot formation, clot strength, and clot breakdown. Thromboelastography (TEG) is a diagnostic tool used to evaluate coagulation profiles and guide management with transfusions and hemostatic therapies. Studies show that TEG can reduce blood product usage by up to 40%, decrease postoperative length of stay, and lower the risk of reoperation. TEG measures the viscoelastic properties of blood as clotting occurs. The resulting data is plotted on a graph with time on the x-axis and amplitude (clot strength) on the y-axis. Key values include: Reaction time (R): The time it takes for the clot strength to reach an amplitude of 2 mm. Kinetics (K): The time from R to when the amplitude reaches 20 mm. α-angle: The angle formed by a line from R to the point where K intersects with the 20 mm amplitude mark. Maximum amplitude (MA): The highest amplitude reached. Lysis at 30 minutes (Ly30): The per cent decrease in amplitude 30 minutes after MA (or 60 minutes in some cases). Inference: A prolonged R time may indicate coagulation factor deficiency or anticoagulation. A decreased α-angle can result from hypofibrinogenemia Low MA can be due to thrombocytopenia or platelet dysfunction. Increased Ly30 indicates hyperfibrinolysis, often seen in severe trauma or with thrombolytic therapy. Based on the TEG findings, targeted blood products can be administered to normalize coagulation. For example: Fresh frozen plasma for prolonged R time Cryoprecipitate for decreased α-angle Platelets for decreased MA Tranexamic acid or aminocaproic acid for increased Ly30 Incorrect Options: Activated Partial Thromboplastin Time (aPTT) (Option A) primarily evaluates the intrinsic pathway of the coagulation cascade. Prothrombin Time (PT) (Option B) mainly assesses the extrinsic pathway of the coagulation cascade. Bleeding Time (Option D) measures the duration for bleeding to cease following a standardized skin incision. It primarily evaluates platelet function and primary hemostasis.

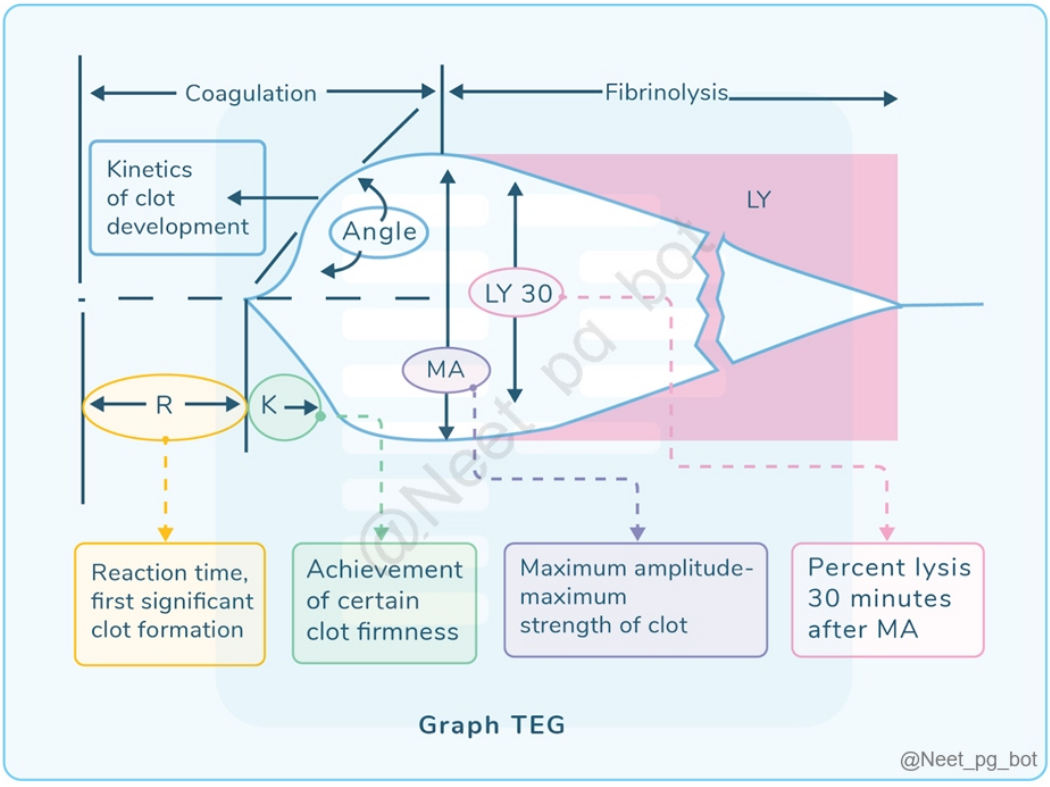

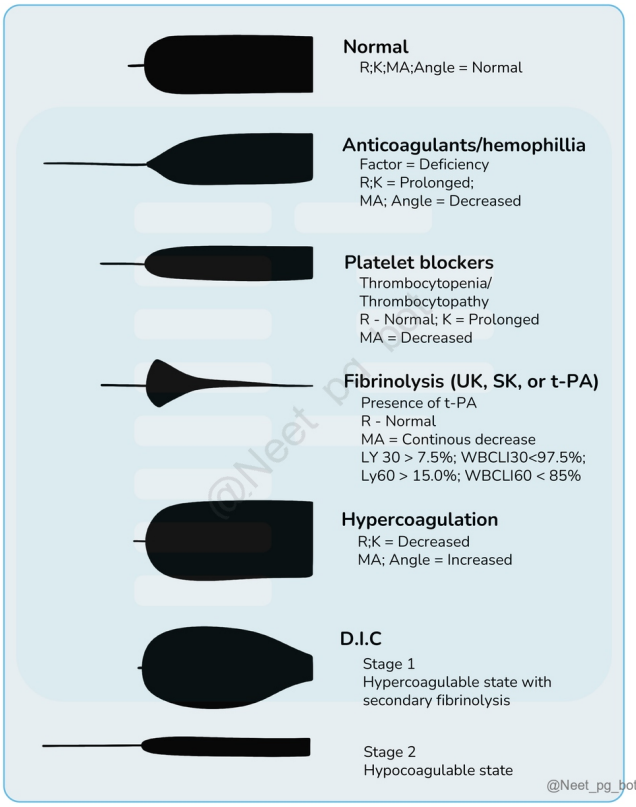

References:

Bailey & Love's Short Practice of Surgery, 27th Edition, Page 1161

https://pmc.ncbi.nlm.nih.gov/articles/PMC10117405/#:~:text=Thromboelastography%20(TEG)%20is%20a%20diagnostic,University%20of%20Heidelberg%20(1).

↑ *Back to this question in Part A*

@Neet_pg_bot

Q7: How does Total plasma exchange help in the management of TTP (Q857426)

A. TPE removes the Von Willebrand factor

B. TPE removes the Antiplatelet antibodies

C. TPE removes Anti ADAMTS13 autoantibodies and thereby increases the ADAMTS protease activity

D. TPE replenishes the coagulation factor

Correct Answer: C. TPE removes Anti ADAMTS13 autoantibodies and thereby increases the ADAMTS protease activity

Explanation: Total plasma exchange (TPE) is a key treatment for thrombotic thrombocytopenic purpura (TTP); it removes the autoantibodies against ADAMTS13. (Option B ruled out) ADAMTS13 is a protease that cleaves von Willebrand factor, preventing the formation of large, thrombogenic von Willebrand factor multimers. (Option A ruled out) This helps restore normal ADAMTS13 activity and reduces the microvascular clotting that characterizes TTP. Treatment of TTP Plasma exchange (PEX) with high-dose corticosteroid therapy. It is the mainstay of treatment in TTP. Corticosteroids operate by decreasing the activity of the reticuloendothelial system as well as decreasing autoantibody production. Both the ultra-large VWF multimers and the ADAMTS13 autoantibodies are effectively removed from circulation by plasma exchange therapy. The recommended volume of exchange is one estimated plasma volume (usually 40 mL/kg of body weight) with each treatment. The recommended dose for corticosteroids is 1 mg/kg per day of prednisolone. Rituximab An anti-CD20 monoclonal antibody was found to help treat TTP refractory to PEX. It targets B-lymphocytes and has a good response rate in refractory and relapsed TTP. Caplacizumab It has a high potential for TTP. It is a humanized monoclonal antibody fragment (a bivalent, variable-domain-only fragment) that attacks the A1 section of VWF and prevents platelet adhesion. Others Splenectomy, Vincristine, Cyclosporine and Cyclophosphamide. TPE replenishes the coagulation factor (Option D) : TPE does not replenish coagulation factors; instead, it removes harmful substances like autoantibodies against ADAMTS13 in TTP, where clotting issues stem from defective vWF cleavage, not coagulation factor deficiencies.

References:

NIH Link

↑ *Back to this question in Part A*

@Neet_pg_bot

Q8: What is the commonest cause of a hypercoagulable state? (Q857441)

A. Antithrombin III deficiency

B. Protein C deficiency

C. Factor V Leiden mutation

D. G20210A prothrombin gene mutation

Correct Answer: C. Factor V Leiden mutation

Explanation: The most common inherited cause of a hypercoagulable state (predisposing to thrombosis) is the Factor V Leiden mutation . Mutation: Factor V becomes resistant to cleavage and inactivation by protein C, disrupting the antithrombotic pathway. Inheritance: Autosomal dominant. Primary causes of Hypercoagulable states Common causes Factor V mutation (Factor V Leiden) Prothrombin mutation (G20210A) - It is comparatively less common than Factor V mutation (Option D ruled out) Elevated factor levels (VIII, IX, XI, or fibrinogen) Rare causes Antithrombin III deficiency (Option A ruled out) Protein C deficiency (Option B ruled out) Protein S deficiency Very rare causes Fibrinolysis Defects Homozygous Homocystinuria Secondary causes of Hypercoagulable states Major risk factors Myocardial infarction Atrial fibrillation Tissue injury (surgery, fracture, burn) Cancer Prosthetic cardiac valves DIC Heparin-induced thrombocytopenia Prolonged rest or immobilisation

Additional risk factors for thrombosis Cardiomyopathy Nephrotic syndrome Hyperestrogenic states (pregnancy and postpartum) Oral contraceptive use Sickle cell anemia Smoking

References:

Robbins and Cotran Pathologic Basis of Disease, 10th Edition, Pages 126, 127

↑ *Back to this question in Part A*

@Neet_pg_bot

Q9: Which of the following is the most common inherited bleeding disorder? (Q865368)

A. Von Willebrand Disease

B. Disseminated Intravascular Coagulation

C. Factor V Deficiency

D. Hemophilia

Correct Answer: A. Von Willebrand Disease

Explanation: Von Willebrand Disease (VWD) is the most common inherited bleeding disorder. Types: vWD type 1 vWD Type 2 vWD Type 3 Autosomal dominant. The most common type. Mild to moderate vWF deficiency. Quantitative defect. point substitutions prevent the vWF protein from maturing or cause it to leave the plasma quickly Autosomal dominant. Qualitative defect. Types: 2A, 2B, 2M, 2N 2A (Most common) - Decrease in binding between vWF and Gp1b/9 missense mutations cause faulty multimer formation → the most active forms of vWF, i.e. large- and intermediate-sized multimers are absent. 2B - Increase in binding between vWF and Gp1b/9 2M - VWF dependant platelet adhesion is decreased. There is impairment of VWF binding to platelets. Type 2M VWD typically has mild to moderate mucocutaneous bleeding 2N - There is marked decline in the binding affinity for factor VIII. The level of factor VIII is lower when compared to the VWF:Ag. This led to misdiagnosis as haemophilia A Autosomal recessive . Quantitative defect. produced by frameshift mutations or deletions affecting both alleles (autosomal recessive), which produce little or no vWF. Factor VIII levels are also lowered because vWF stabilizes factor VIII in the blood, and the resulting bleeding condition is severe. Disseminated Intravascular Coagulation (DIC) (Option B) is an acquired (not inherited), secondary condition due to systemic activation of the clotting cascade (e.g., in sepsis, trauma, malignancy). Factor V Deficiency (Option C) is a rare inherited bleeding disorder, also known as parahemophilia. Far less common than vWD. Hemophilia (A or B) (Option D) is an inherited X-linked recessive disorder involving Factor VIII (A) or Factor IX (B) deficiency. More common in males but still less prevalent than von Willebrand disease.

References:

Textbook of Robbin and Cotran’s Pathological Basis of Diseases, 10th Edition, Page 668.

↑ *Back to this question in Part A*