Anatomy Collection

Question Bank with Answers & Explanations

Generated on April 18, 2026

52 Topics • 1021 Questions

Need help or updates?
■ *Click here to contact the creator of this PDF*

Viewer Guide

Navigation Tips:

- Use the outline/bookmarks pane (left side in most PDF viewers) to jump between sections.
- Click links at the bottom of each question to switch between Part A (questions) and Part B (answers).
- Master Index links take you to topic parts.

Viewer Settings:

- Adobe Reader: View > Show/Hide > Navigation Panes > Bookmarks
- Chrome: Install PDF viewer extension if needed.
- Mobile: Use apps like Adobe Acrobat or Xodo for outline support.

■ *For queries & support: Message @Neet_pg_bot on Telegram*

DIRECTORY EXPLORER

Click a folder below to open it.

» **01_General Embryology**

» **02_Histology**

» **03_Neuro Anatomy**

» **04_Head and Neck**

» **05_Upper Limb**

» **06_Lower Limb**

» **07_Thorax**

» **08_Abdomen**

» **09_Pelvis and Perineum**

» **10_Systemic Embryology**

» **11_Osteology and Arthrology**

» **12_Back Region**

» 01_General Embryology

« Back to Parent Directory

Path: 01_General Embryology

• 001 Gametogenesis And Ivf	***Questions***	***Answers***
• 002 Development Period	***Questions***	***Answers***
• 003 General Embryology	***Questions***	***Answers***
• 004 Previous Year Questions	***Questions***	***Answers***

» 02_Histology

« Back to Parent Directory

Path: 02_Histology

• 005 Tissue Histology- I	***Questions***	***Answers***
• 006 Tissue Histology- Ii	***Questions***	***Answers***
• 007 Previous Year Questions	***Questions***	***Answers***

» 03_Neuro Anatomy

« Back to Parent Directory

Path: 03_Neuro Anatomy

• 008 Nervous System Development	***Questions***	***Answers***
• 009 Ventricular System White Matter And Neural Columns	***Questions***	***Answers***
• 010 Cerebrum And Associated Structures	***Questions***	***Answers***
• 011 Brainstem Cranial Nerves And Cerebellum - I	***Questions***	***Answers***
• 012 Applied Neuroanatomy Tracts Brainstem Autonomic System	***Questions***	***Answers***
• 013 Previous Year Questions	***Questions***	***Answers***

» 04_Head and Neck

« Back to Parent Directory

Path: 04_Head and Neck

• 014 Pharyngeal Arches Pouches And Clefts	***Questions***	***Answers***
• 015 Skull Bones And Cranial Cavity- Part I	***Questions***	***Answers***
• 016 Cranial Cavity- Part Ii	***Questions***	***Answers***
• 017 Cranial Nerves And Cervical Plexus	***Questions***	***Answers***
• 018 Scalenus Anterior Head And Neck Vasculature And Lymphatic Drainage	***Questions***	***Answers***
• 019 Scalp Neck Triangles And Parotid Gland	***Questions***	***Answers***
• 020 Pharynx Esophagus And Larynx - I	***Questions***	***Answers***
• 021 Anatomy Of Ear Nose And Eyeball	***Questions***	***Answers***
• 022 Previous Year Questions	***Questions***	***Answers***

» 05_Upper Limb

« Back to Parent Directory

Path: 05_Upper Limb

• 023 Upper Limb Embryology And Nerves	***Questions***	***Answers***
• 024 Muscles And Bones Of Forearm And Hand	***Questions***	***Answers***
• 025 Bones And Muscles Of Proximal Region Axilla And Scapula	***Questions***	***Answers***
• 026 Upper Limb Nerve Supply And Their Lesions	***Questions***	***Answers***
• 027 Upper Limb Arterial Supply Venous Drainage Lymphatic Drainage Hand Spaces	***Questions***	***Answers***
• 028 Previous Year Questions	***Questions***	***Answers***

» 06_Lower Limb

« Back to Parent Directory

Path: 06_Lower Limb

• 029 Muscles And Nerve Supply Of The Hip Thigh And Gluteal Region	***Questions***	***Answers***
• 030 Lower Limb Anatomy Knee And Leg	***Questions***	***Answers***
• 031 Vascular Supply Of Lower Limb	***Questions***	***Answers***
• 032 Previous Year Questions	***Questions***	***Answers***

» 07_Thorax

« Back to Parent Directory

Path: 07_Thorax

• 033 Development Of The Cardiovascular System And Fetal Circulation	***Questions***	***Answers***
• 034 Heart And Thorax Anatomy - I	***Questions***	***Answers***
• 035 Thorax Lungs Joints Respiratory Movements	***Questions***	***Answers***
• 036 Previous Year Questions	***Questions***	***Answers***

» 08_Abdomen

« Back to Parent Directory

Path: 08_Abdomen

• 037 Embryology Of Abdominal Organs	***Questions***	***Answers***
• 038 Inguinal And Femoral Anatomy And Hernia Abdominal Wall Layers Peritoneal Cavity	***Questions***	***Answers***
• 039 Abdomen Arterial Supply Venous Drainage Of Thorax And Abdomen	***Questions***	***Answers***
• 040 Anatomy Abdominal Organs	***Questions***	***Answers***
• 041 Anatomy Pancreas Kidney And Ureter	***Questions***	***Answers***
• 042 Abdominal Neurovascular Bundles	***Questions***	***Answers***
• 043 Previous Year Questions	***Questions***	***Answers***

» 09_Pelvis and Perineum

« Back to Parent Directory

Path: 09_Pelvis and Perineum

• 044 Development Of Gut Pelvis Perineum	***Questions***	***Answers***
• 045 Neurovascular Anatomy Of Pelvis Perineum Rectum And Anal Canal	***Questions***	***Answers***
• 046 Perineal Pouches And Ischiorectal Fossa Extravasation Of Urine	***Questions***	***Answers***
• 047 Prostate Male Urethra And Female Reproductive System	***Questions***	***Answers***
• 048 Previous Year Questions	***Questions***	***Answers***

» 10_Systemic Embryology

« Back to Parent Directory

Path: 10_Systemic Embryology

• 049 Previous Year Questions	***Questions***	***Answers***

» 11_Osteology and Arthrology

« Back to Parent Directory

Path: 11_Osteology and Arthrology

• 050 Previous Year Questions	***Questions***	***Answers***

» 12_Back Region

« Back to Parent Directory

Path: 12_Back Region

• 051 Back Region	***Questions***	***Answers***
• 052 Previous Year Questions	***Questions***	***Answers***

Part A — All Questions

• [01_General Embryology] 001 Gametogenesis And Ivf

« Back to Folder Directory

[01_General Embryology] 001 Gametogenesis And Ivf — Quick Jump

Q1 (p. 16) *Q2 (p. 16)* *Q3 (p. 17)* *Q4 (p. 17)* *Q5 (p. 17)* *Q6 (p. 18)*
Q7 (p. 18) *Q8 (p. 18)* *Q9 (p. 19)* *Q10 (p. 19)* *Q11 (p. 19)* *Q12 (p. 20)*
Q13 (p. 20) *Q14 (p. 21)* *Q15 (p. 21)*

Q1: Which phase of the cell cycle does DNA replication occur in? (Q848036)

A. S phase

B. G1 phase

C. G2 phase

D. M phase

See Answer in Part B → Q1

@Neet_pg_bot

Q2: Which of the following is wrongly paired? (Q848037)

A. Mitosis - no crossing over

B. Meiosis - 4 daughter cells

C. Mitosis - 1 division

D. Meiosis - daughter cells are diploid

See Answer in Part B → Q2

@Neet_pg_bot

Q3: 23 bivalents are formed in which stage of prophase 1? (Q848038)

A. Leptotene

B. Zygotene

C. Pachytene

D. Diplotene

See Answer in Part B → Q3

@Neet_pg_bot

Q4: In which of the following stages of the first meiotic division do the chromosomes get attached to the spindle fibers? (Q848039)

A. Prophase 1

B. Metaphase 1

C. Anaphase 1

D. Telophase 1

See Answer in Part B → Q4

@Neet_pg_bot

Q5: Which of the following statements on Anaphase 1 is true? (Q848040)

A. Centromere divides into 2

B. Each chromatid becomes a chromosome

C. DNA replicates

D. Each chromosome from the pair migrates to opposite poles of the spindle

See Answer in Part B → Q5

@Neet_pg_bot

Q6: Which of the following events occurs during telophase of meiosis? (Q848041)

A. Chromatids condense into chromosomes.

B. Nuclear envelope disintegrates.

C. Chromatids are pulled towards the spindle poles.

D. None of the above

See Answer in Part B → Q6

@Neet_pg_bot

Q7: Which of the following best describes the stage at which the primary oocyte is arrested during oogenesis before puberty? (Q848042)

A. Metaphase of meiosis I

B. Prophase of meiosis II

C. Anaphase of meiosis I

D. Prophase of meiosis I

See Answer in Part B → Q7

@Neet_pg_bot

Q8: Which of the following correctly describes the role of Sertoli cells during spermatogenesis? (Q848043)

A. They induce spermatogonial stem cells to initiate spermatogenesis.

B. They stimulate Leydig cells to produce testosterone.

C. They secrete androgen-binding proteins and support germ cells.

D. They transform type A spermatogonia into spermatids.

See Answer in Part B → Q8

@Neet_pg_bot

Q9: Which of the following statements is most accurate regarding the relationship between the luteinizing hormone (LH) surge and ovulation? A) The LH surge typically begins 24 hours before ovulation. B) The LH surge stimulates the release of the second polar body from the oocyte. C) The LH surge is initiated by a rise in progesterone levels from the corpus luteum. D) The peak of the LH surge occurs approximately 10-12 hours before ovulation. E) A smaller follicle size is always associated with a higher LH peak. (Q848044)

A. D only

B. Only E

C. Both D and E

D. None of the above

See Answer in Part B → Q9

@Neet_pg_bot

Q10: Which of the following is most accurate regarding in vitro fertilization (IVF) for women with bilateral tubal blockage? (Q848045)

A. IVF is ineffective for women with bilateral tubal blockage.

B. Bilateral salpingectomy is always required before IVF in cases of tubal blockage.

C. ICSI is used to fertilize the egg in all IVF cases, regardless of sperm quality.

D. Preimplantation genetic testing (PGT) is necessary for women of advanced maternal age.

See Answer in Part B → Q10

@Neet_pg_bot

Q11: What is the correct sequence of stem cell potency based on their ability to differentiate? (Q848046)

A. Pluripotent > Totipotent > Multipotent > Oligopotent > Unipotent

B. Totipotent > Pluripotent > Multipotent > Oligopotent > Unipotent

C. Totipotent > Pluripotent > Oligopotent > Multipotent > Unipotent

D. Totipotent > Pluripotent > Oligopotent > Multipotent > Unipotent

See Answer in Part B → Q11

@Neet_pg_bot

Q12: Which stage of spermatogenesis is characterised by an independent assortment of maternal and paternal chromosomes? (Q848047)

A. Spermatogonia to primary spermatocyte

B. Primary spermatocyte to secondary spermatocyte

C. Secondary spermatocyte to spermatid

D. Spermatid to spermatozoa

See Answer in Part B → Q12

@Neet_pg_bot

Q13: What is the part of the embryo that exerts morphogenetic stimulus on its adjacent part called? (Q848048)

A. Differentiator

B. Organiser

C. Stem cell

D. Inducer

See Answer in Part B → Q13

@Neet_pg_bot

Q14: During fertilisation , all of the following barriers in the ovum are penetrated by the sperm except: (Q848049)

A. Corona radiata

B. Zona pellucida

C. Oocyte cell membrane

D. Nuclear membrane

See Answer in Part B → Q14

@Neet_pg_bot

Q15: Which of the following is not an acrosomal enzymes? (Q848050)

A. Acrosin

B. Hyaluronidase

C. Acid phosphatase

D. Alkaline phosphatase

See Answer in Part B → Q15

@Neet_pg_bot

• [01_General Embryology] 002 Development Period

« Back to Folder Directory

[01_General Embryology] 002 Development Period — Quick Jump

Q1 (p. 22) *Q2 (p. 23)* *Q3 (p. 23)* *Q4 (p. 23)* *Q5 (p. 24)* *Q6 (p. 24)*
Q7 (p. 24) *Q8 (p. 25)* *Q9 (p. 27)* *Q10 (p. 27)*

Q1: Which day during Week 1 of embryonic development matches with the given image? (Q848086)

A. Day 1

B. Day 2

C. Day 4

D. Day 5

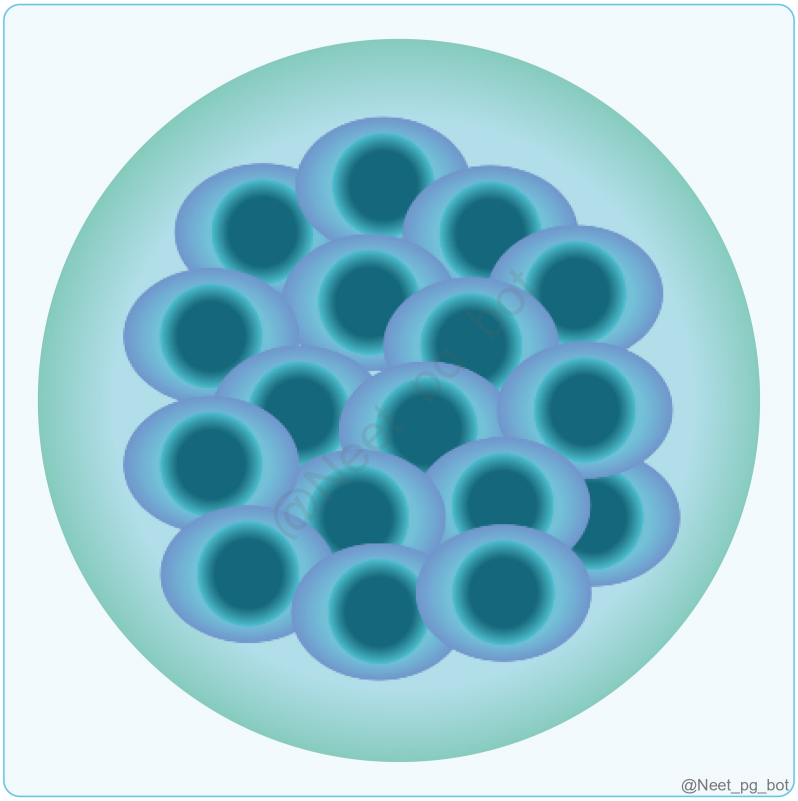

See Answer in Part B → Q1

Q2: How many cells are typically present in the morula stage? (Q848087)

A. 4-8 cells

B. 16-32 cells

C. 64-128 cells

D. 2 cells

See Answer in Part B → Q2

@Neet_pg_bot

Q3: What is the function of cortical reaction in fertilization? (Q848088)

A. Facilitate the entry of additional sperm into the oocyte.

B. Prevent polyspermy by modifying the egg's outer membrane.

C. Help the sperm to penetrate the zona pellucida.

D. Release digestive enzymes that help break down the oocyte's nucleus.

See Answer in Part B → Q3

@Neet_pg_bot

Q4: During which phase of the menstrual cycle does implantation typically occur? (Q848089)

A. Menstrual phase

B. Follicular phase

C. Ovulatory phase

D. Luteal phase

See Answer in Part B → Q4

@Neet_pg_bot

Q5: Which substance helps in the attachment of the blastocyst to the uterus? (Q848090)

A. L-selectin

B. Integrin

C. E-cadherin

D. Fibronectin

See Answer in Part B → Q5

@Neet_pg_bot

Q6: What is the most characteristic event of the 3rd week of development? (Q848091)

A. Formation of blastocyst

B. Gastrulation

C. Implantation

D. Formation of morula

See Answer in Part B → Q6

@Neet_pg_bot

Q7: What structure forms at the surface of the epiblast to initiate gastrulation? (Q848092)

A. 2

B. 3

C. 4

D. 1

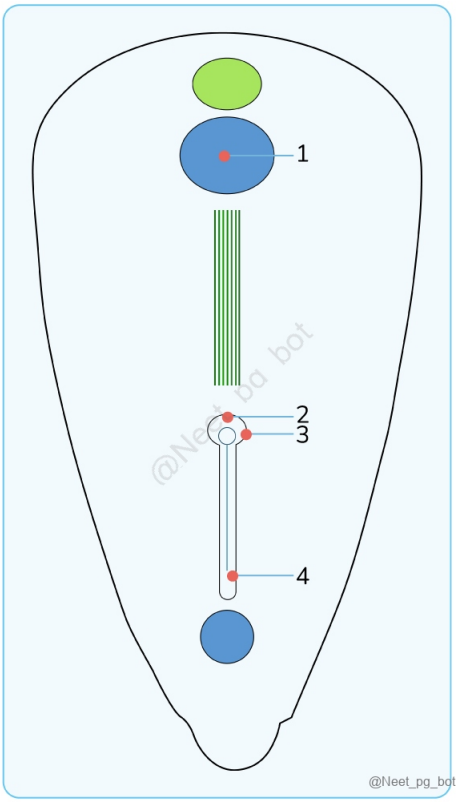

See Answer in Part B → Q7

@Neet_pg_bot

Q8: A stillborn baby was noted to have the following findings. The above pathology is derived from which among the following structure shown in the image below? (Q848093)

A. 1

B. 2

C. 3

D. 4



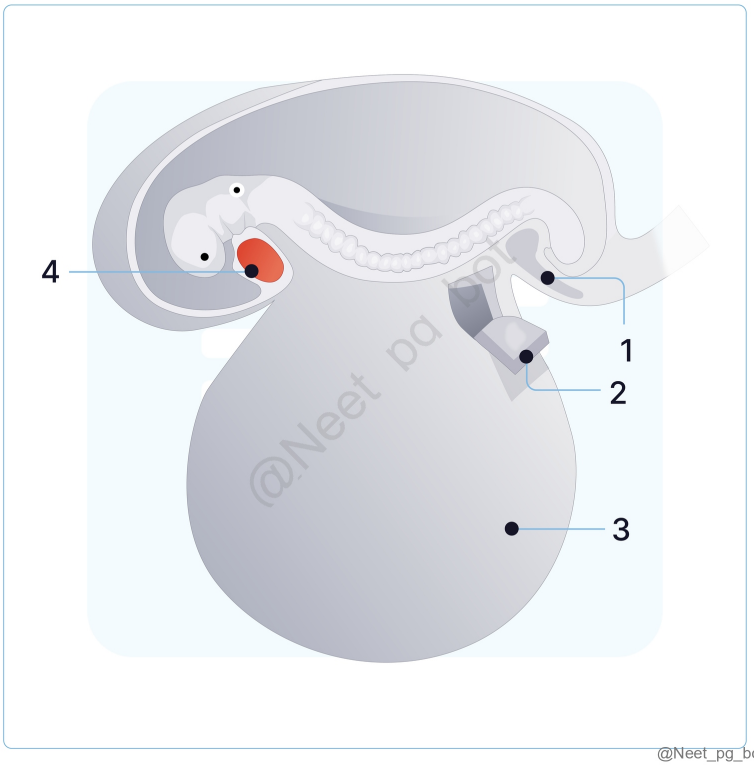

See Answer in Part B → Q8

@Neet_pg_bot

Q9: A patient with a history of 6 weeks of amenorrhea and a positive urinary pregnancy test underwent an ultrasonography, which showed the following The marked structure in the image communicates via a duct with which of the following parts of the gastrointestinal system? (Q848094)

A. Foregut

B. Midgut

C. Hindgut

D. Cloacal membrane

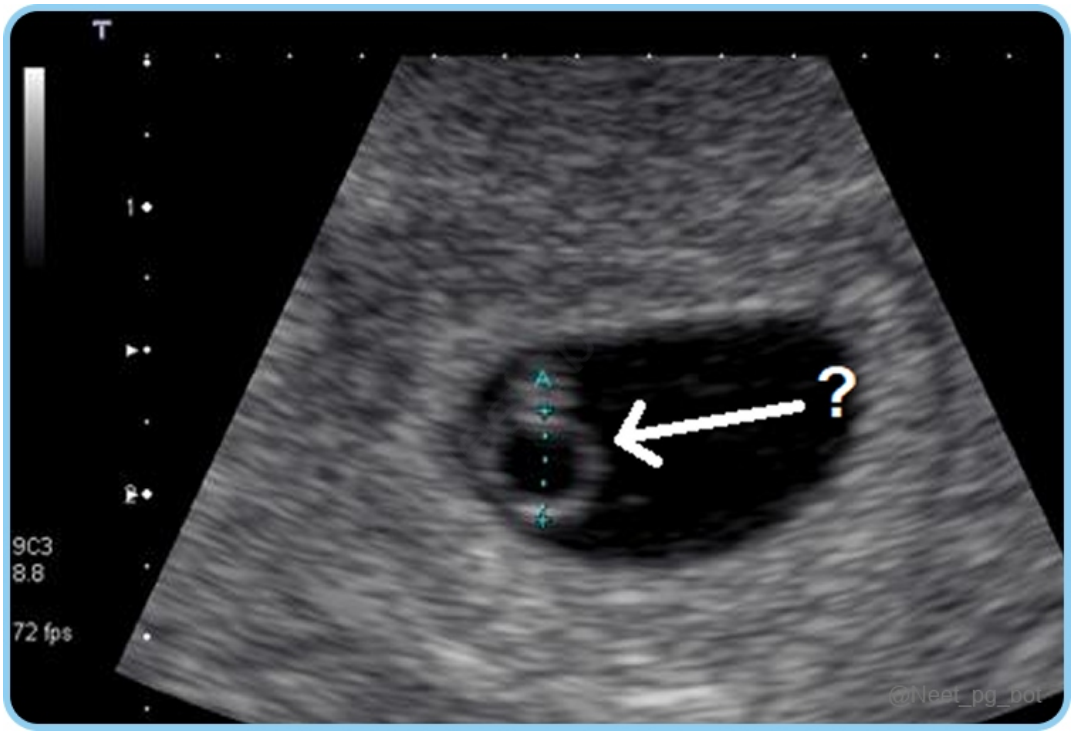

See Answer in Part B → Q9

@Neet_pg_bot

Q10: The floor of the amniotic cavity is formed by which among the following cells? (Q848095)

A. Trophoblast cells

B. Endodermal cells

C. Ectodermal cells

D. Mesodermal cells

See Answer in Part B → Q10

@Neet_pg_bot

• [01_General Embryology] 003 General Embryology

« Back to Folder Directory

[01_General Embryology] 003 General Embryology — Quick Jump

Q1 (p. 29)	*Q2 (p. 29)*	*Q3 (p. 30)*	*Q4 (p. 30)*	*Q5 (p. 31)*	*Q6 (p. 31)*
Q7 (p. 32)	*Q8 (p. 32)*	*Q9 (p. 33)*	*Q10 (p. 33)*	*Q11 (p. 33)*	*Q12 (p. 34)*
Q13 (p. 34)	*Q14 (p. 34)*	*Q15 (p. 35)*	*Q16 (p. 35)*	*Q17 (p. 36)*	*Q18 (p. 36)*
Q19 (p. 37)	*Q20 (p. 37)*	*Q21 (p. 37)*	*Q22 (p. 38)*	*Q23 (p. 38)*	*Q24 (p. 39)*
Q25 (p. 39)	*Q26 (p. 40)*	*Q27 (p. 40)*			

Q1: A 10-week-old fetus is found to have a developmental anomaly affecting the iris muscles and the posterior pituitary. Which of the following is directly involved in the formation of these structures? (Q848200)

A. Neural crest cells

B. Surface ectoderm

C. Neuroectoderm

D. Epiblast cells

See Answer in Part B → Q1

@Neet_pg_bot

Q2: A 3-week-old infant shows signs of a developmental abnormality involving the formation of tongue muscles. Which group of somites is responsible for this condition? (Q848202)

A. Cervical somites

B. Occipital somites

C. Preoccipital somites

D. Thoracic somites

See Answer in Part B → Q2

@Neet_pg_bot

Q3: If the development of the endoderm is negatively affected and fails to normally differentiate, which of the following glands would not be affected by this? (Q848206)

A. Follicular cells of thyroid

B. Parenchyma of parathyroid glands

C. Anterior pituitary

D. Pancreas

See Answer in Part B → Q3

@Neet_pg_bot

Q4: What is the structure marked “C” formed of? (Q848208)

A. Trophoblast + Somatopleuric EEM

B. Trophoblast+ Splanchnopleuric EEM

C. Ectoderm + EEM

D. Amniogenic cells + Somatopleuric EEM

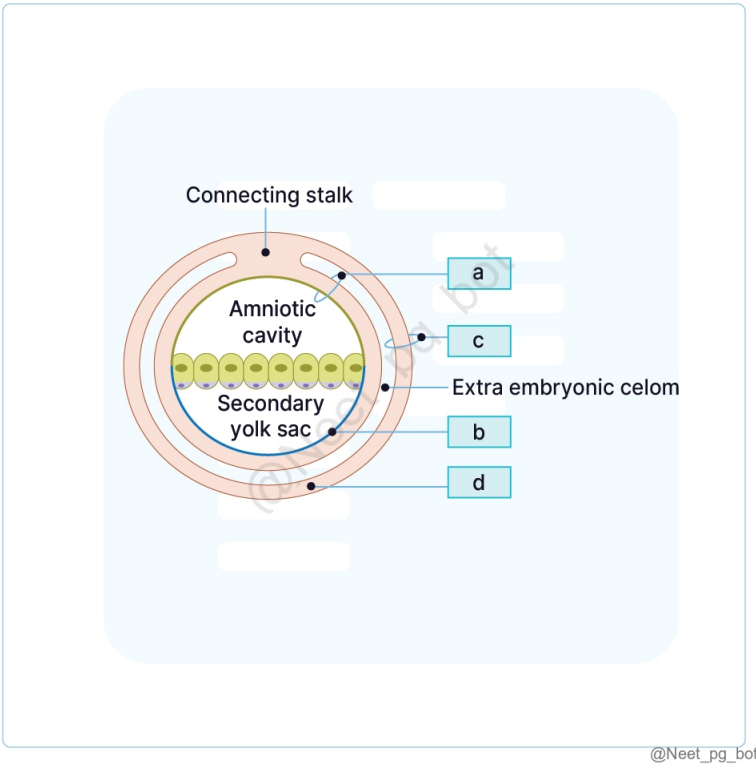

See Answer in Part B → Q4

@Neet_pg_bot

Q5: A portion of the arch of the aorta is derived from which of the following aortic arches? (Q876184)

A. Aortic arch 1

B. Aortic arch 2

C. Aortic arch 3

D. Aortic arch 4

See Answer in Part B → Q5

@Neet_pg_bot

Q6: A portion of the arch of the aorta is derived from which of the following aortic arches? (Q876004)

A. Aortic arch 1

B. Aortic arch 2

C. Aortic arch 3

D. Aortic arch 4

See Answer in Part B → Q6

@Neet_pg_bot

Q7: Which of the following statements about the lamina terminalis is incorrect? (Q848219)

A. It forms the anterior wall of the third ventricle.

B. It gives rise to the septum pellucidum.

C. The lamina terminalis is located at the caudal end of the prosencephalon.

D. The first commissural fibers to develop pass through the lamina terminalis.

See Answer in Part B → Q7

@Neet_pg_bot

Q8: The cecal bed arises from which part of the embryonic gut? (Q848218)

A. Post-arterial segment of Midgut

B. Pre-arterial segment of Midgut

C. Pre-allantoic part of Hindgut

D. Post-allantoic part of Hindgut

See Answer in Part B → Q8

@Neet_pg_bot

Q9: The stomatodeum is derived from which of the following? (Q848217)

A. Ectoderm

B. Endoderm

C. Mesoderm

D. Neural crest cells

See Answer in Part B → Q9

@Neet_pg_bot

Q10: What is the correct sequence of events in the maturation of the lungs? (Q848216)

A. Canalicular phase → Pseudoglandular phase → Alveolar phase → Saccular phase.

B. Pseudoglandular phase → Canalicular phase → Saccular phase → Alveolar phase.

C. Saccular phase → Alveolar phase → Pseudoglandular phase → Canalicular phase.

D. Alveolar phase → Canalicular phase → Saccular phase → Pseudoglandular phase.

See Answer in Part B → Q10

@Neet_pg_bot

Q11: Which of the following structures is derived from the endodermal lining of the laryngotracheal tube? (Q848215)

A. Cartilaginous framework of the trachea

B. Alveolar epithelial cells

C. Muscular components of the respiratory tract

D. Parietal pleura covering the lungs

See Answer in Part B → Q11

@Neet_pg_bot

Q12: Which of the following is the first sign of respiratory development? (Q848214)

A. Formation of primary bronchi

B. Appearance of the lung bud

C. Development of type I alveolar cells

D. Formation of the tracheoesophageal septum

See Answer in Part B → Q12

@Neet_pg_bot

Q13: Which of the following embryological structures contributes to the development of the post-renal segment of the inferior vena cava? (Q848213)

A. Right vitelline vein

B. Right subcardinal vein

C. Right supracardinal vein

D. Right posterior cardinal vein

See Answer in Part B → Q13

@Neet_pg_bot

Q14: A 25-year-old male is found to have a persistent left-sided superior vena cava (SVC) during routine imaging. What is the most likely cause of this anomaly? (Q848212)

A. Failure of right-sided SVC to develop

B. Abnormal development of the left anterior cardinal vein

C. Persistence of the left umbilical vein

D. Abnormal development of the right posterior cardinal vein

See Answer in Part B → Q14

@Neet_pg_bot

Q15: The structure “b” fuses with structure “c” during the 3rd month of pregnancy. Identify the structure “c”. (Q848211)

A. Decidua capsularis

B. Decidua basalis

C. Myometrium

D. Decidua parietalis

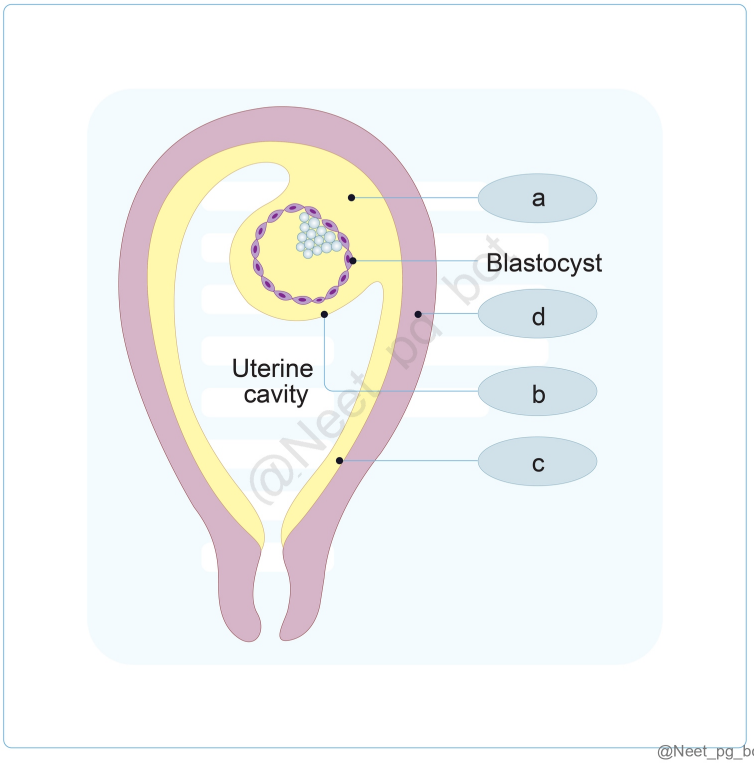

See Answer in Part B → Q15

@Neet_pg_bot

Q16: Which of the following statements is true about villi? (Q848210)

A. The secondary villi have a central core of cytotrophoblast

B. The uteroplacental circulation begins only after the formation of tertiary villi

C. The tertiary villi have a mesoderm core that carries the fetal blood

D. The primary villi have a core of extraembryonic mesoderm

See Answer in Part B → Q16

@Neet_pg_bot

Q17: A woman who is Rh-negative is pregnant with a Rh-positive baby and is advised to take anti-D immunoglobulin for safe future pregnancies. Which of the following disappears from the placental membrane, thus thinning it out later in the pregnancy? (Q848209)

A. Syncytiotrophoblast

B. Endothelium of fetal capillaries

C. The basement membrane of fetal capillaries

D. Cytotrophoblasts

See Answer in Part B → Q17

@Neet_pg_bot

Q18: During the third week of gestation, the formation of the primitive streak signifies the start of gastrulation. Which statement about the primitive streak accurately describes this process? (Q848195)

A. It forms from hypoblast cells and establishes the embryonic central axis.

B. It appears dorsally, becoming linear and marking the transition to a trilaminar disc.

C. It develops into the prechordal plate, defining the head-tail axis.

D. It originates from trophoblast cells, contributing to the amniotic cavity and yolk sac formation.

See Answer in Part B → Q18

@Neet_pg_bot

Q19: Which of the following statements about yolk sac development is correct? (Q848207)

A. Primary yolk sac is lined by cuboidal cells.

B. Secondary yolk sac is lined by flattened cells.

C. Primary yolk sac forms by the end of the first week

D. Tertiary yolk sac connects to the midgut via the vitellointestinal duct.

See Answer in Part B → Q19

@Neet_pg_bot

Q20: During embryonic development, different structures are derived from the lateral plate mesoderm. Which of the following structures are not derived from the lateral plate mesoderm? (Q848205)

A. Shoulder and hip girdle bones

B. Smooth muscle layers of the gut

C. Smooth muscle of the iris

D. Visceral and Parietal layers of body cavities

See Answer in Part B → Q20

@Neet_pg_bot

Q21: A newborn is diagnosed with congenital abnormalities of both the kidneys and reproductive organs, including hypoplasia of the kidneys and abnormal development of the gonads. Which embryological structure is most likely affected? (Q848204)

A. Paraxial mesoderm

B. Intermediate mesoderm

C. Lateral plate mesoderm

D. Extraembryonic mesoderm

See Answer in Part B → Q21

@Neet_pg_bot

Q22: An embryo is observed to have 12 pairs of somites on ultrasound. Based on this, what is the most likely developmental age of the embryo? (Q848203)

A. 21 days

B. 23 days

C. 26 days

D. 30 days

See Answer in Part B → Q22

@Neet_pg_bot

Q23: A newborn presents with scoliosis and underdeveloped axial muscles. Imaging reveals defects in the vertebral column. Which embryological structure is primarily responsible for the development of these affected tissues? (Q848201)

A. Paraxial mesoderm

B. Lateral plate mesoderm

C. Intermediate mesoderm

D. Extraembryonic mesoderm

See Answer in Part B → Q23

@Neet_pg_bot

Q24: Which of the following is a correct pairing of a structure and its corresponding embryological origin? (Q848199)

A. Sweat glands – Neural crest cells

B. Sebaceous glands – Mesoderm

C. Parotid gland – Surface ectoderm

D. Lens – Mesoderm

See Answer in Part B → Q24

@Neet_pg_bot

Q25: Which of the following components is responsible for the formation of sensory ganglia during embryonic development in the given figure? (Q848198)

A. A

B. B

C. C

D. D

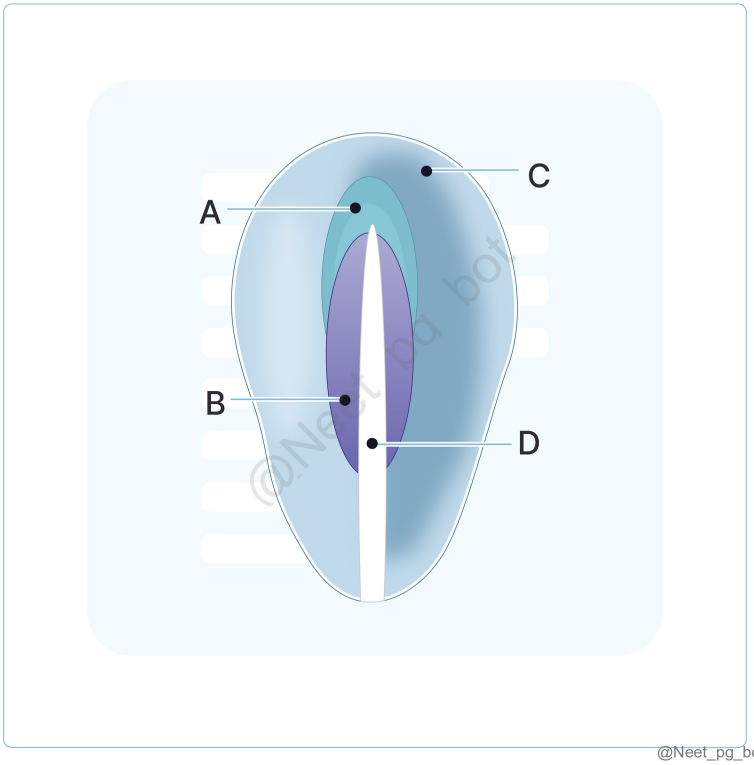

@Neet_pg_bot

See Answer in Part B → Q25

@Neet_pg_bot

Q26: Which of the following statements about the prechordal plate is incorrect? (Q848197)

A. Derived from hypoblast cells

B. Formed before primitive streak formation

C. Forms the cephalocaudal axis of the embryo

D. Gives rise to the notochord

See Answer in Part B → Q26

@Neet_pg_bot

Q27: Which of the following correctly describes the sequence of events during gastrulation in the third week of gestation? (Q848196)

A. Epiblast cells form the primitive streak, leading to the formation of the three germ layers.

B. The primitive streak forms at the cephalic end, initiating neural tube, gut, and cardiovascular development.

C. The prechordal plate forms after the notochord, and epiblast cells migrate to create the three germ layers.

D. The Endoderm forms from mesodermal cells, with ectoderm and mesoderm forming later.

See Answer in Part B → Q27

@Neet_pg_bot

• [01_General Embryology] 004 Previous Year Questions

« Back to Folder Directory

[01_General Embryology] 004 Previous Year Questions — Quick Jump

Q1 (p. 42)	*Q2 (p. 43)*	*Q3 (p. 43)*	*Q4 (p. 44)*	*Q5 (p. 44)*	*Q6 (p. 45)*
Q7 (p. 46)	*Q8 (p. 47)*	*Q9 (p. 48)*	*Q10 (p. 49)*	*Q11 (p. 49)*	*Q12 (p. 50)*
Q13 (p. 51)	*Q14 (p. 51)*	*Q15 (p. 52)*	*Q16 (p. 52)*	*Q17 (p. 53)*	*Q18 (p. 54)*
Q19 (p. 55)	*Q20 (p. 55)*	*Q21 (p. 56)*	*Q22 (p. 57)*	*Q23 (p. 57)*	*Q24 (p. 57)*
Q25 (p. 58)	*Q26 (p. 58)*	*Q27 (p. 59)*	*Q28 (p. 59)*	*Q29 (p. 60)*	*Q30 (p. 60)*
Q31 (p. 61)					

Q1: What are the derivatives of the marked cells? 1. Odontoblasts 2. Sympathetic chain 3. Melanocytes 4. Nephrogenic cord 5. Bulbus cordis 6. Conotruncal septum (Q855418)

A. 1,3,5,6

B. 2,3,4,6

C. 1,2,3,6

D. 1,2,3,4

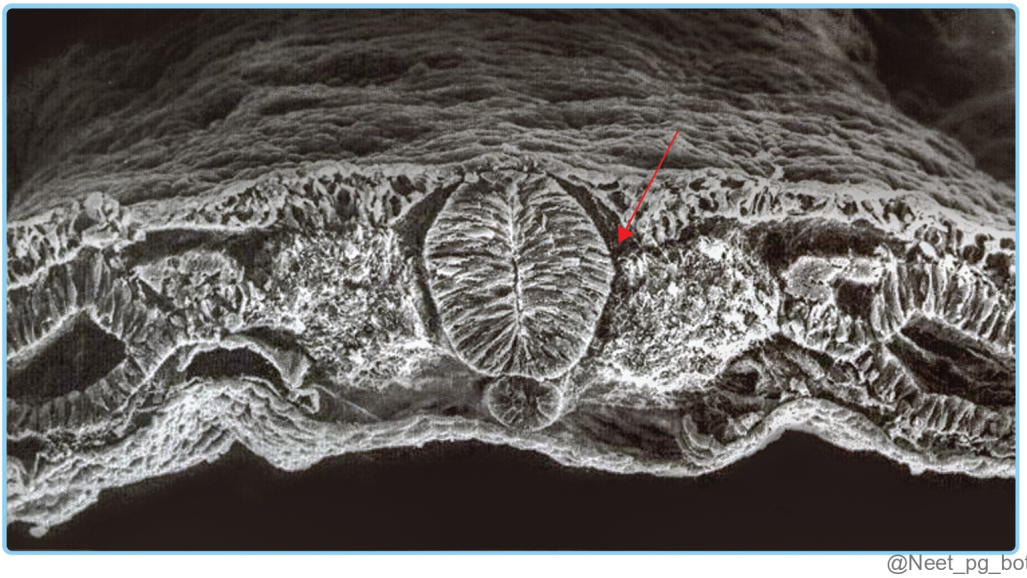

See Answer in Part B → Q1

@Neet_pg_bot

Q2: Match the following aortic arches with their derivatives: Aortic Arch Derivative 1. 1st arch a. Common carotid artery 2. 2nd arch b. Right subclavian artery (right side) 3. 3rd arch c. Maxillary artery 4. 4th arch d. Hyoid and stapedial arteries (Q879188)

A. 1–c, 2–d, 3–a, 4–b

B. 1–d, 2–c, 3–b, 4–a

C. 1–a, 2–b, 3–c, 4–d

D. 1–b, 2–a, 3–d, 4–c

See Answer in Part B → Q2

@Neet_pg_bot

Q3: The structure marked A in the image below gives rise to which of the following structures? (Q856067)

A. Gastrosplenic ligament

B. Lienorenal ligament

C. Falciform ligament

D. Gastrophrenic ligament

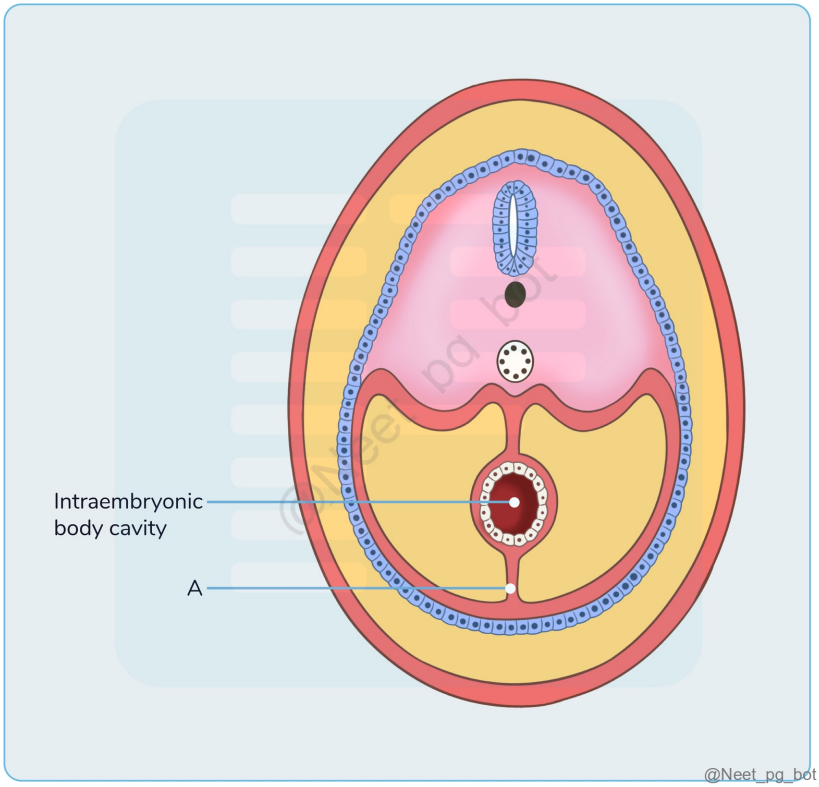

See Answer in Part B → Q3

@Neet_pg_bot

Q4: Which of the following statements regarding anatomical closure is incorrect? (Q854993)

A. Anatomical closure of foramen ovale is by 3 to 5 days

B. Anatomical closure of ductus venosus is by 2 to 3 weeks

C. Right umbilical vein is absent after birth

D. Anatomical closure of ductus arteriosus is by 2 to 3 weeks

See Answer in Part B → Q4

@Neet_pg_bot

Q5: The long left recurrent laryngeal nerve is due to the persistence of which arch artery? (Q854988)

A. 3rd arch

B. 4th arch

C. 5th arch

D. 6th arch

See Answer in Part B → Q5

@Neet_pg_bot

Q6: What structure develops from the region labeled as "A" in the model of embryological heart development? (Q856363)

A. Atria

B. Left ventricle

C. Infundibulum

D. Interventricular septum

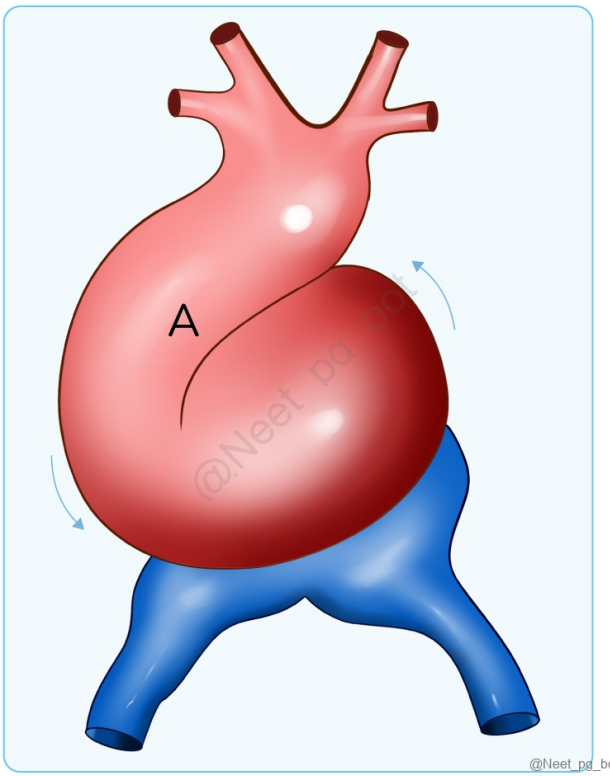

See Answer in Part B → Q6

@Neet_pg_bot

Q7: The marked structure develops from which of the following structures? (Q856670)

A. Common cardinal vein

B. Anterior cardinal vein

C. Supracardinal vein

D. Subcardinal vein

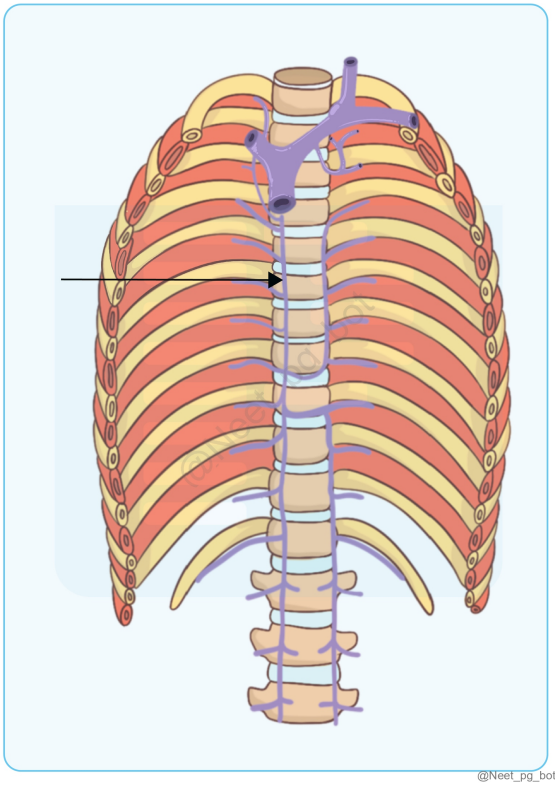

See Answer in Part B → Q7

@Neet_pg_bot

Q8: A young child with absent thymus is brought to the OPD with features of hypoparathyroidism and tetany. Which of the following marked areas in the picture is defective in this condition? (Q855837)

A. 1

B. 2

C. 3

D. 4

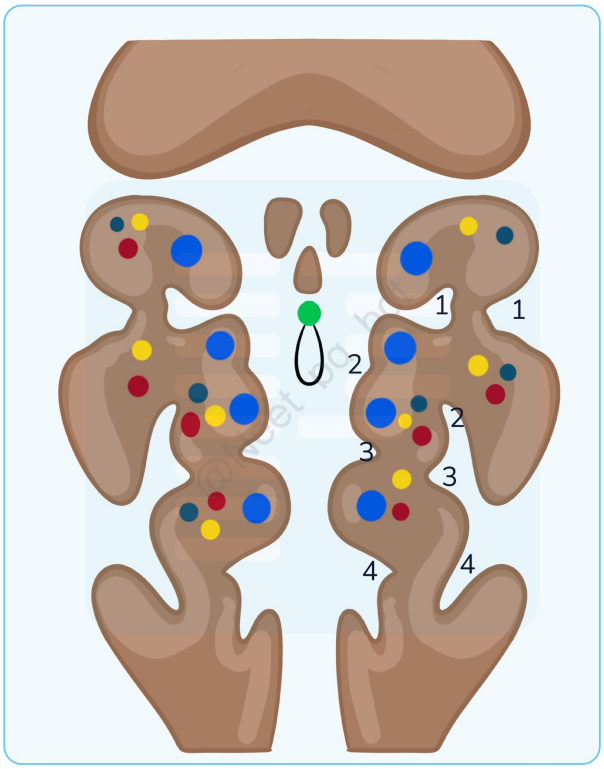

See Answer in Part B → Q8

@Neet_pg_bot

Q9: What is the embryological basis of the developmental defects shown in the image below? (Q857218)

A. Failure in closure of anterior neuropore of neural tube

B. Failure in closure of posterior neuropore of neural tube

C. Failure in closure of complete neural tube

D. Failure in closure of caudal neuropore of neural tube



See Answer in Part B → Q9

@Neet_pg_bot

Q10: A newborn presented to the NICU with respiratory distress and meconium discharge from the umbilicus. The condition occurs due to the patency of which structure? (Q857217)

A. Mesonephric duct

B. Allantois

C. Urachus

D. Vitelline Fistula

See Answer in Part B → Q10

@Neet_pg_bot

Q11: A child lacks thymus and inferior parathyroid glands. Defective development of which of the following structures is likely to be the cause? (Q855422)

A. 1

B. 2

C. 3

D. 4

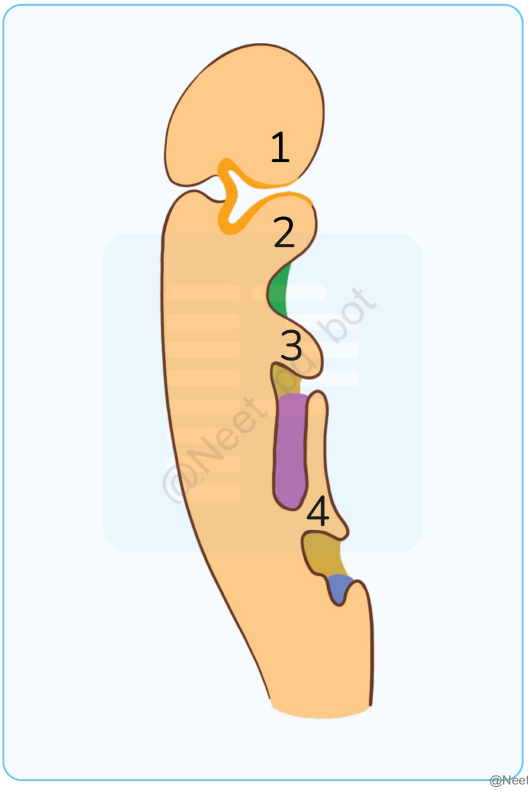

See Answer in Part B → Q11

@Neet_pg_bot

Q12: Which of the following structures develops from the structure marked? (Q855401)

A. Medial umbilical ligament

B. Median umbilical ligament

C. Meckel's diverticulum

D. Ligamentum teres

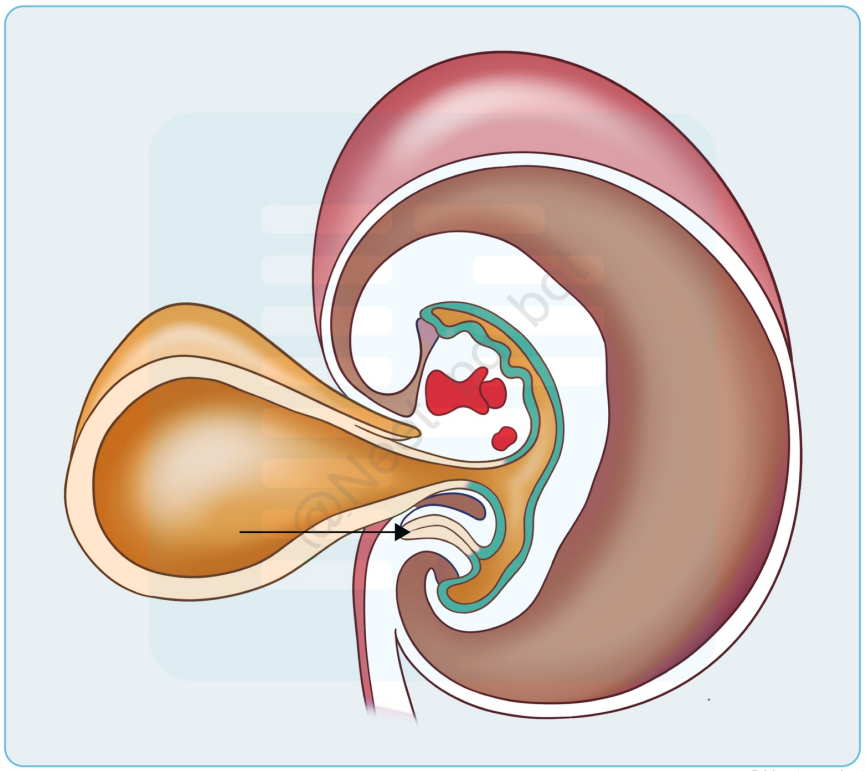

See Answer in Part B → Q12

@Neet_pg_bot

Q13: Which of the following arises from 6th pharyngeal arch? (Q859907)

A. Medial pterygoids

B. Lateral pterygoids

C. Ductus arteriosus

D. Tensor veli palatini

See Answer in Part B → Q13

@Neet_pg_bot

Q14: Which of the following develops from the dorsal mesogastrium? (Q859527)

A. Falciform ligament

B. Spleen

C. Lesser omentum

D. Liver

See Answer in Part B → Q14

@Neet_pg_bot

Q15: Meiosis occurs in: (Q858490)

A. Adrenal

B. Adult ovary

C. Prepubertal testis

D. Hypothalamus

See Answer in Part B → Q15

@Neet_pg_bot

Q16: Identify the structure marked in the diagram showing the development of ovarian follicles. (Q857584)

A. Primary follicle

B. Antral follicle

C. Primordial follicle

D. Corpus luteum

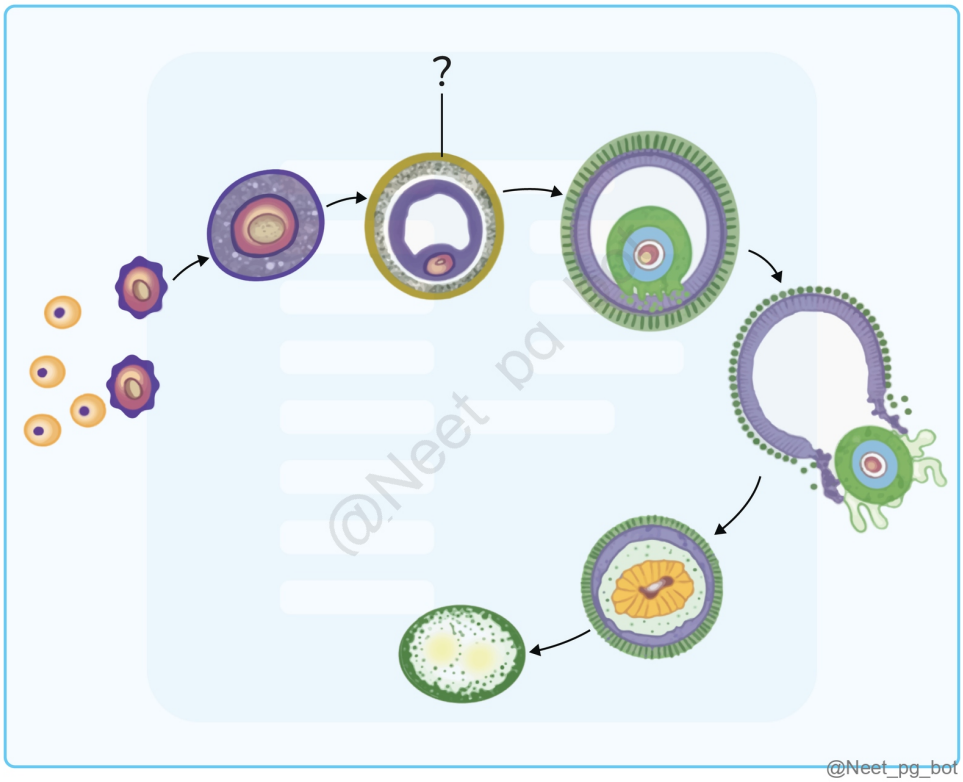

See Answer in Part B → Q16

@Neet_pg_bot

Q17: Which structure is formed by the structure indicated by the arrow? (Q866622)

A. Annulus

B. Nucleus pulposus

C. Neural tube

D. Septum transversum

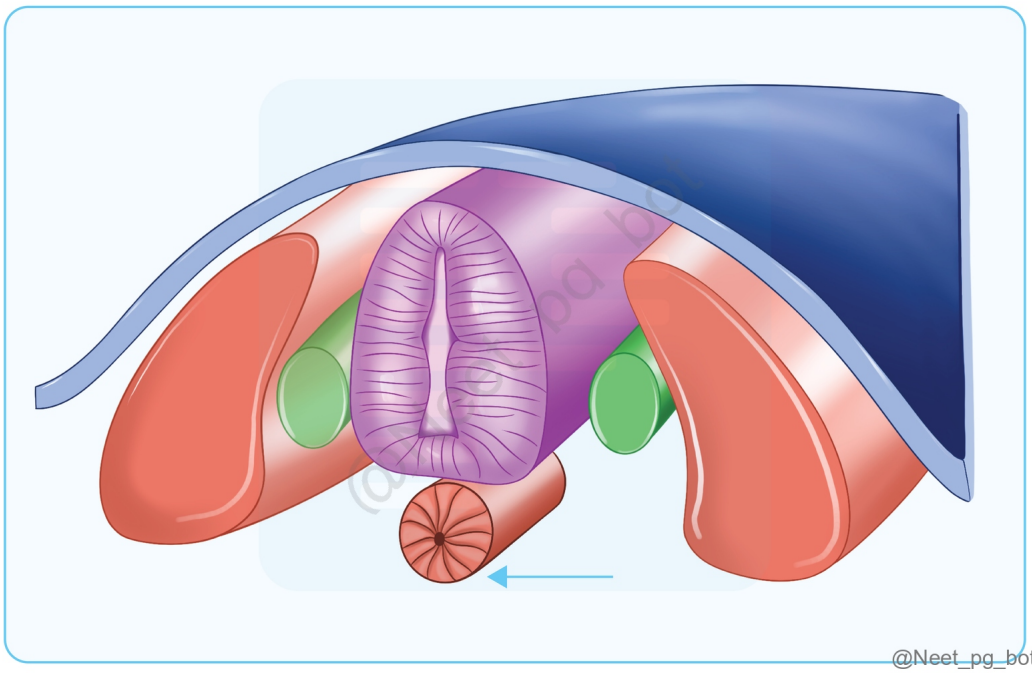

See Answer in Part B → Q17

@Neet_pg_bot

Q18: Which of the following statements is incorrect related to the given image? (Q857337)

A. Benign tumor of coccyx

B. Presence of teeth and hair

C. Result from the aberrant migration of primordial germ cell

D. Prechordal plate anomaly



See Answer in Part B → Q18

@Neet_pg_bot

Q19: On what is the SRY gene located? (Q857329)

A. Y chromosome short arm

B. Y chromosome long arm

C. X chromosome short arm

D. X chromosome long arm

See Answer in Part B → Q19

@Neet_pg_bot

Q20: Absence or mutation of SRY gene results in ? (Q857314)

A. Agenesis of testis

B. Undescended testis

C. Hydrocele testis

D. None of the above

See Answer in Part B → Q20

@Neet_pg_bot

Q21: Which of the following structures develop from the 6th pharyngeal arch artery on the left side? (Q860265)

A. Arch of Aorta

B. Ductus arteriosus

C. Carotid arteries

D. Subclavian artery

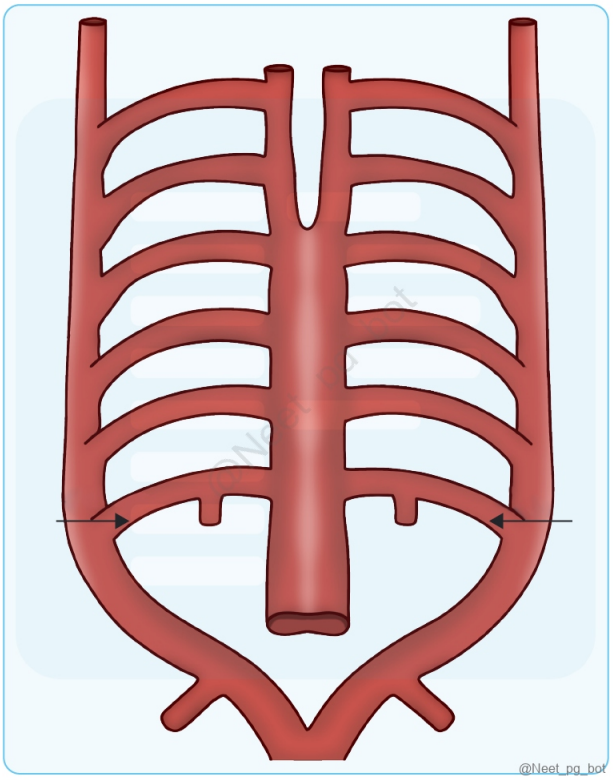

See Answer in Part B → Q21

@Neet_pg_bot

Q22: Implantation occurs on which day post fertilization? (Q844315)

A. 2

B. 5

C. 8

D. 15

See Answer in Part B → Q22

@Neet_pg_bot

Q23: Post ovulation the oocyte is: (Q844313)

A. Primary oocyte arrested in prophase- 1

B. Primary oocyte arrested in prophase- 2

C. Secondary oocyte arrested in prophase- 2

D. Secondary oocyte arrested in metaphase- 2

See Answer in Part B → Q23

@Neet_pg_bot

Q24: The covering of an omphalocele is derived from which layer? (Q844155)

A. Amnion

B. Chorion

C. Mesoderm

D. Endoderm

See Answer in Part B → Q24

@Neet_pg_bot

Q25: Which of the following prevents polyspermy? (Q844149)

A. Acrosome reaction

B. Cortical reaction

C. Zona reaction

D. Capacitation

See Answer in Part B → Q25

@Neet_pg_bot

Q26: Identify the marked structure: {{caption_text}} (Q852890)

A. Primitive streak

B. Notochord

C. Neural groove

D. Secondary neural plate

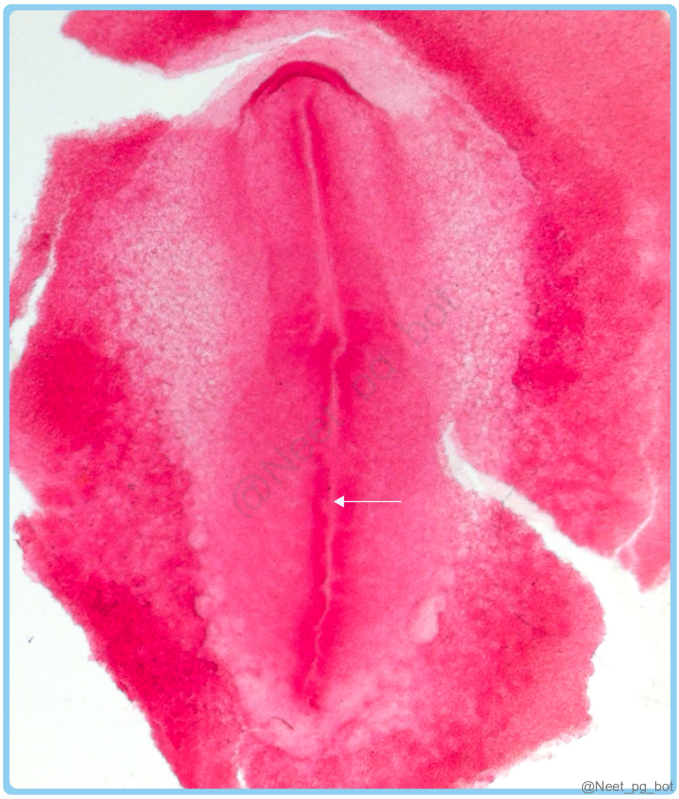

See Answer in Part B → Q26

@Neet_pg_bot

Q27: Which of the following is not a derivative of neural crest cells? (Q852887)

A. Ciliary muscles

B. Retinal pigment epithelium

C. Ciliary ganglion

D. Melanocytes

See Answer in Part B → Q27

@Neet_pg_bot

Q28: Which of the following is the 1st to be formed by the migration of the epiblast along the primitive streak? (Q852886)

A. Endoderm

B. Cardiac mesoderm

C. Epidermis

D. Neural groove

See Answer in Part B → Q28

@Neet_pg_bot

Q29: Which of the following best describes the normal vascular composition of the umbilical cord? (Q866311)

A. 1 artery and 2 veins

B. 1 vein and 1 artery

C. 2 arteries and 1 vein

D. 2 arteries and 2 vein

See Answer in Part B → Q29

@Neet_pg_bot

Q30: The image shows a congenital cardiac defect. Abnormal development of which branch of aortic arch leads to this defect? (Q866305)

A. Right 4th aortic arch

B. Left 6th aortic arch

C. Right 6th aortic arch

D. Left 4th aortic arch

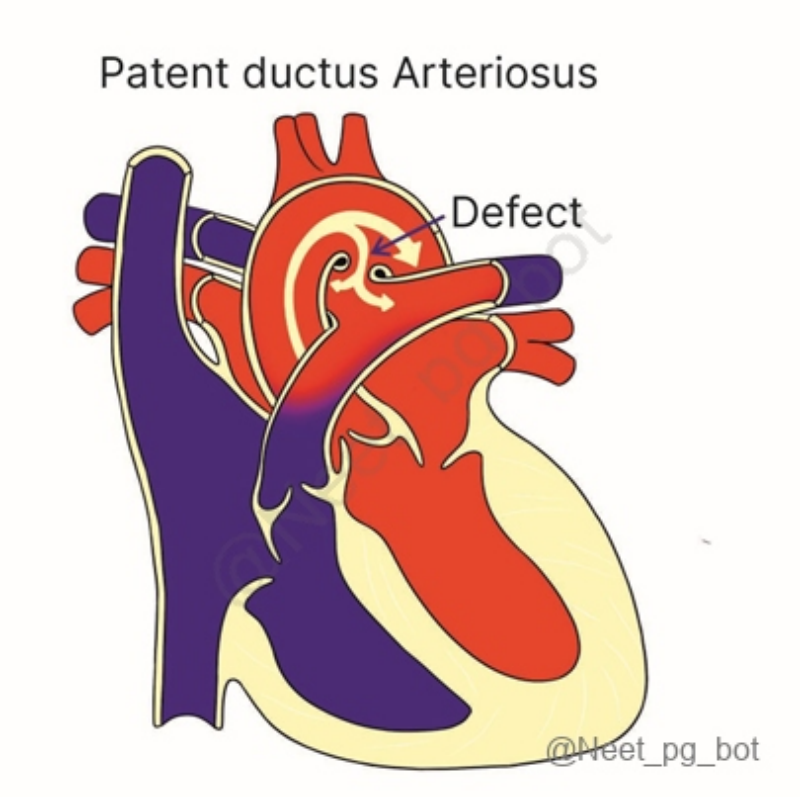

See Answer in Part B → Q30

@Neet_pg_bot

Q31: A newborn had hypoplasia of the mandibles and zygomatic bones, malformed external ears, and slanted palpebral fissures. Abnormality in the development of which of the following pharyngeal arches will most likely lead to the given condition? (Q793118)

A. Pharyngeal arch 1

B. Pharyngeal arch 2

C. Pharyngeal arch 3

D. Pharyngeal arch 4

See Answer in Part B → Q31

@Neet_pg_bot

• [02_Histology] 005 Tissue Histology- I

« Back to Folder Directory

[02_Histology] 005 Tissue Histology- I — Quick Jump

Q1 (p. 62) *Q2 (p. 62)* *Q3 (p. 63)* *Q4 (p. 63)* *Q5 (p. 64)* *Q6 (p. 64)*
Q7 (p. 65) *Q8 (p. 66)* *Q9 (p. 66)* *Q10 (p. 67)* *Q11 (p. 67)* *Q12 (p. 67)*
Q13 (p. 68) *Q14 (p. 68)* *Q15 (p. 69)* *Q16 (p. 69)* *Q17 (p. 70)* *Q18 (p. 70)*
Q19 (p. 72)

Q1: Which of the following is an apocrine gland? (Q848060)

A. Sweat gland

B. Pancreas

C. Sebaceous gland

D. None of the above

See Answer in Part B → Q1

@Neet_pg_bot

Q2: Match the following layer of skin with the cells present in it. 1. Stratum Corneum a) Melanocytes 2. Stratum Granulosum b) Keratin Squames 3. Stratum Spinosum c) Keratohyalin granules 4. Stratum Basale d) Langerhan cells (Q848076)

A. 1-c, 2-d, 3-b, 4-a

B. 1-d, 2-a, 3-b, 4-c

C. 1-a, 2-b, 3-c, 4-d

D. 1-b, 2-c, 3-d, 4-a

See Answer in Part B → Q2

@Neet_pg_bot

Q3: Which of the following statements is true about the given image? (Q848075)

A. GALT tissues are part of the Waldeyer ring.

B. Tonsils primarily produce secretory IgA to protect mucosal surfaces.

C. Tonsils are covered by stratified squamous epithelium that forms deep crypts.

D. Tonsils contain diffuse lymphoid tissue scattered in the lamina propria.

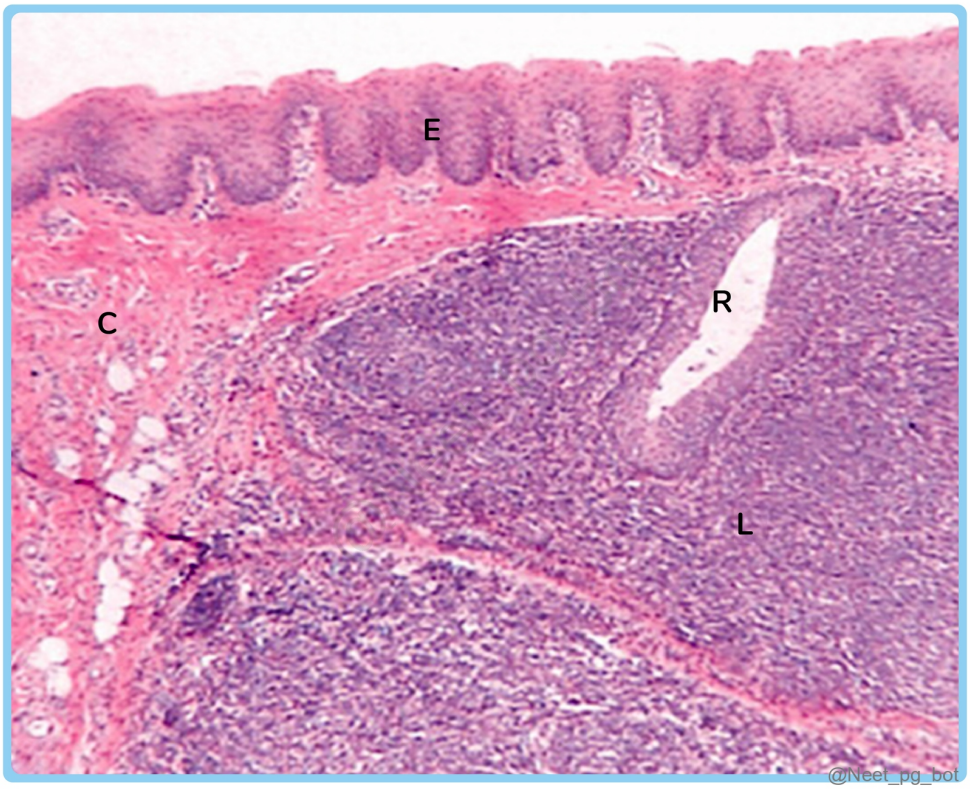

See Answer in Part B → Q3

@Neet_pg_bot

Q4: Which of the following statements about the spleen is true? (Q848073)

A. White pulp occupies most of the spleen and contains a higher number of RBCs.

B. The red pulp parenchyma is supported by reticular fibers and contains sheathed capillaries.

C. B cells form an eccentric cylindrical sheath around a central artery, known as PALS.

D. The Perilymphoid zone contains numerous sinuses and abundant reticulin meshwork.

See Answer in Part B → Q4

@Neet_pg_bot

Q5: In a histological image of the thymus, which cell type is not present in the medulla? (Q848071)

A. Thymocytes

B. Epithelial cells

C. Hassall's corpuscles

D. Dendritic cells

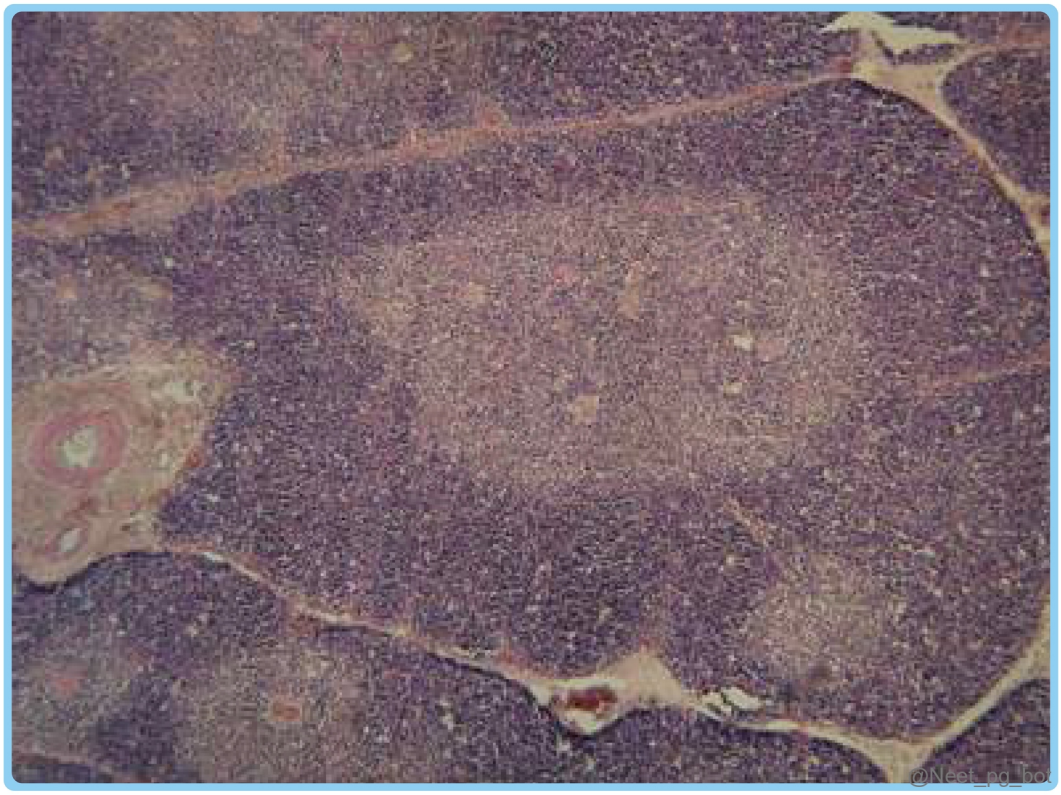

See Answer in Part B → Q5

@Neet_pg_bot

Q6: A pathologist is examining a lymph node biopsy. Which of the following correctly identifies these structures? (Q848069)

A. (1) Capsule, (2) Subcapsular sinus, (3) Germinal centers, (4) Lymphoid nodule, (5) Trabeculae

B. (1) Capsule, (2) Cortex, (3) Medulla, (4) Germinal centers, (5) Hilum

C. (1) Trabecula, (2) Capsule, (3) Medulla, (4) Germinal center, (5) Cortex

D. (1) Capsule, (2) Medulla, (3) Subcapsular sinus, (4) Germinal center, (5) Cortex



See Answer in Part B → Q6

@Neet_pg_bot

Q7: A histologist is examining three different cartilage samples. Sample A shows a homogeneous basophilic matrix with groups of chondrocytes in cell nests. Sample B contains numerous branching and anastomosing fibers forming a network. Sample C lacks perichondrium and has chondrocytes arranged in single rows or groups with numerous collagen bundles. Which of the following correctly identifies these cartilage types? (Q848067)

A. A - Elastic, B - Hyaline, C - Fibrocartilage

B. A - Hyaline, B - Elastic, C - Fibrocartilage

C. A - Fibrocartilage, B - Hyaline, C - Elastic

D. A - Hyaline, B - Fibrocartilage, C - Elastic

See Answer in Part B → Q7

@Neet_pg_bot

Q8: Match the following types of collagen with their primary location: 1. Found in cartilage (Hyaline and Elastic Cartilage) a. Type I collagen 2. Major component of basement membranes b. Type II collagen 3. Predominant in bowel and blood vessels c. Type III collagen 4. Primary collagen in bones, tendons, and dermis d. Type IV collagen (Q848066)

A. 1-d, 2-b, 3-c, 4-a

B. 1-b, 2-d, 3-a, 4-c

C. 1-b, 2-d, 3-c, 4-a

D. 1-d, 2-c, 3-b, 4-a

See Answer in Part B → Q8

@Neet_pg_bot

Q9: A histologist is examining three different tissue samples. Sample A shows loosely arranged fibers with numerous cells and abundant ground substance. Sample B exhibits densely packed, parallel collagen bundles with elongated fibroblast nuclei. Sample C contains interwoven collagen fibers without a specific orientation. Which of the following correctly matches the samples to their connective tissue types? (Q848065)

A. A - Dense irregular, B - Loose connective, C - Dense regular

B. A - Loose connective, B - Dense regular, C - Dense irregular

C. A - Dense regular, B - Dense irregular, C - Loose connective

D. A - Loose connective, B - Dense irregular, C - Dense regular

See Answer in Part B → Q9

@Neet_pg_bot

Q10: A pathologist is analyzing a biopsy sample from a patient with suspected connective tissue disorder. Upon staining, she observes fibers that appear black with silver impregnation and form a delicate network throughout the tissue. Which of the following best describes these fibers? (Q848064)

A. Type I collagen fibers

B. Elastic fibers

C. Reticular fibers

D. Smooth muscle fibers

See Answer in Part B → Q10

@Neet_pg_bot

Q11: Which of the following pairs correctly identifies the locations of Meissner's and Auerbach's plexus in the gastrointestinal tract, respectively? (Q848051)

A. Between the circular and longitudinal muscle layers; Mucosa

B. Submucosa; Between the circular and longitudinal muscle layers

C. Between the circular and longitudinal muscle layers; Muscularis propri

D. Between serosa and longitudinal muscle layer; Between the submucosa and mucosa

See Answer in Part B → Q11

@Neet_pg_bot

Q12: Which two of the following statements about serous, mucinous, and mixed glands are correct? Serous glands produce a proteinaceous, enzyme-rich watery fluid, while mucinous glands secrete mucopolysaccharides that form a thick, viscous mucus.

Cells of serous acini are triangular with centrally placed rounded nuclei, whereas cells of mucous acini are tall with flat nuclei at their bases. The pancreas is an example of a mixed gland, containing both serous and mucous secreting acini. The lumen of mucous acini is typically smaller than that of serous acini. (Q848059)

A. 1 and 2 are correct

B. 2 and 3 are correct

C. 3 and 4 are correct

D. 1 and 4 are correct

See Answer in Part B → Q12

@Neet_pg_bot

Q13: Which of the following histological features is characteristic of Barrett's esophagus? (Q848058)

A. Squamous cell hyperplasia

B. Columnar epithelium with intestinal metaplasia

C. Columnar epithelium with gastric metaplasia

D. Glandular adenomatous hyperplasia

See Answer in Part B → Q13

@Neet_pg_bot

Q14: Which of the following structures in the human body is primarily lined by stratified squamous epithelium? (Q848057)

A. Lumen of the trachea

B. Skin surface

C. Gastric lumen

D. Alveoli of lungs

See Answer in Part B → Q14

@Neet_pg_bot

Q15: Which of the following best describes transitional epithelium? (Q848056)

A. It is specialized for absorption and secretion and consists of a single layer of cuboidal cells.

B. It is found in the skin and is composed of multiple layers of flat cells that provide a protective barrier.

C. It is found in the urinary bladder and ureters, consisting of multiple layers of cells that can stretch and change shape.

D. It lines the digestive tract and is characterized by a single layer of columnar cells that facilitate nutrient absorption.

See Answer in Part B → Q15

@Neet_pg_bot

Q16: Which of the following locations contains pseudostratified ciliated columnar epithelium? (Q848055)

A. Oral cavity

B. Esophagus

C. Respiratory tract

D. Uterine cervix

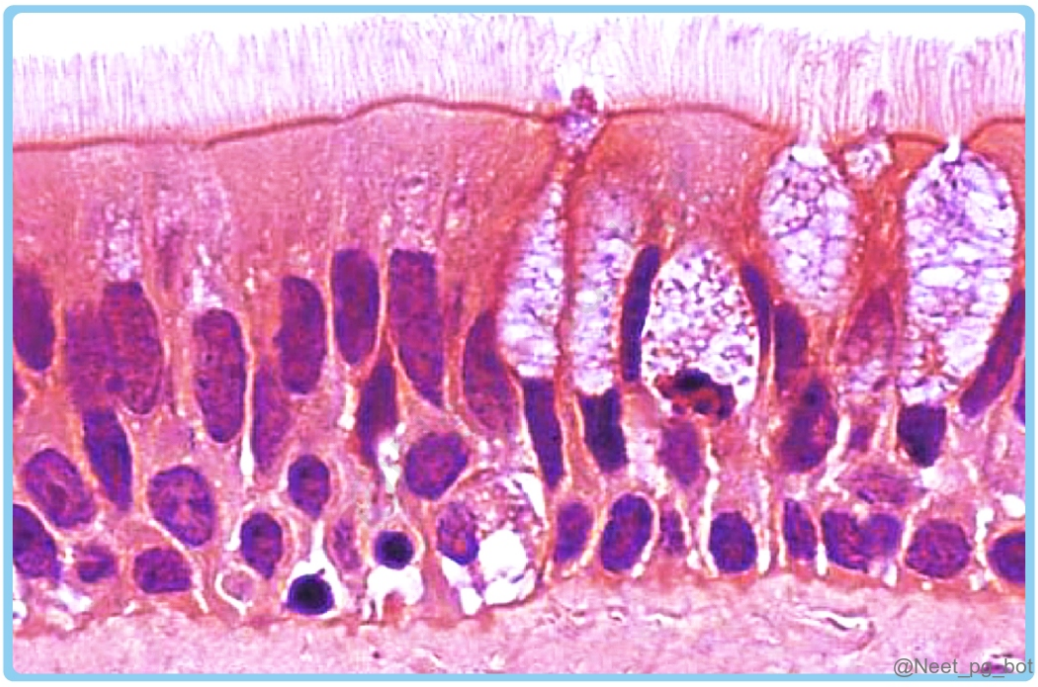

See Answer in Part B → Q16

@Neet_pg_bot

Q17: Match the following: 1. Simple squamous epithelium a) Proximal convoluted tubule 2. Simple cuboidal epithelium b) Gallbladder 3. Simple columnar epithelium c) Femoral Endothelium (Q848054)

A. 1- a, 2-b, 3-c

B. 1- c, 2-a, 3-b

C. 1- b, 2-c, 3-a

D. 1- b, 2-a, 3-c

See Answer in Part B → Q17

@Neet_pg_bot

Q18: Given below are two histological images 1 and 2, which of the following pairs accurately represents the tissues depicted? (Q848053)

A. 1- Stomach; 2- Lymph node

B. 1- Urinary Bladder; 2- Trachea

C. 1- Lymph node; 2- Stomach

D. 1-Trachea; 2- Urinary Bladder

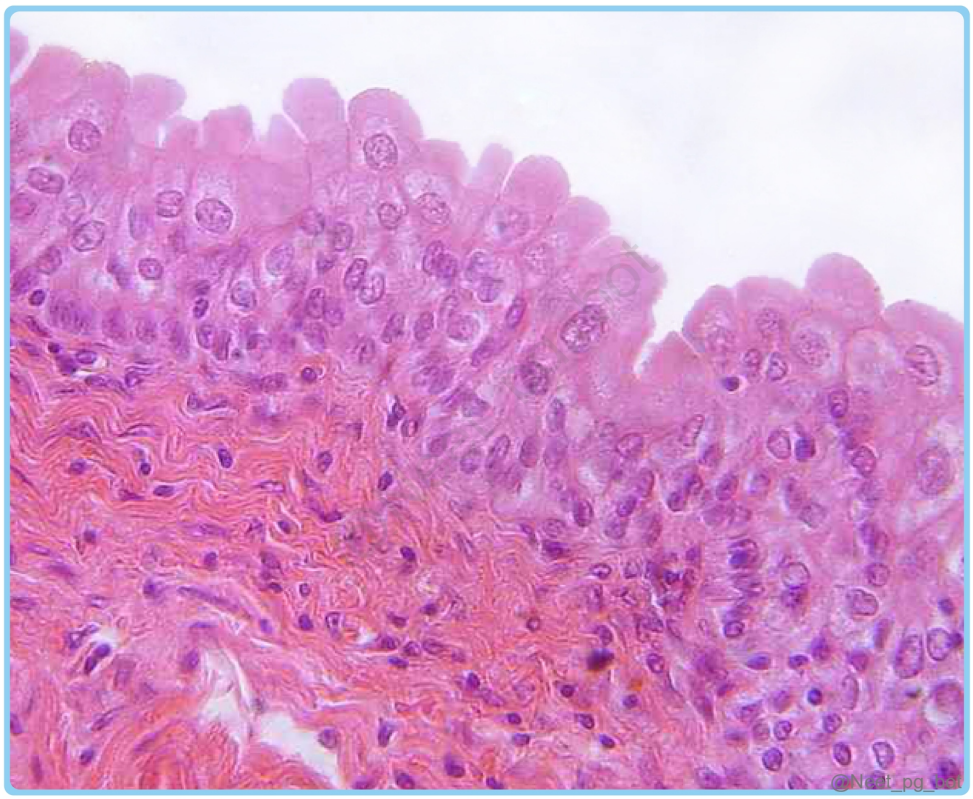

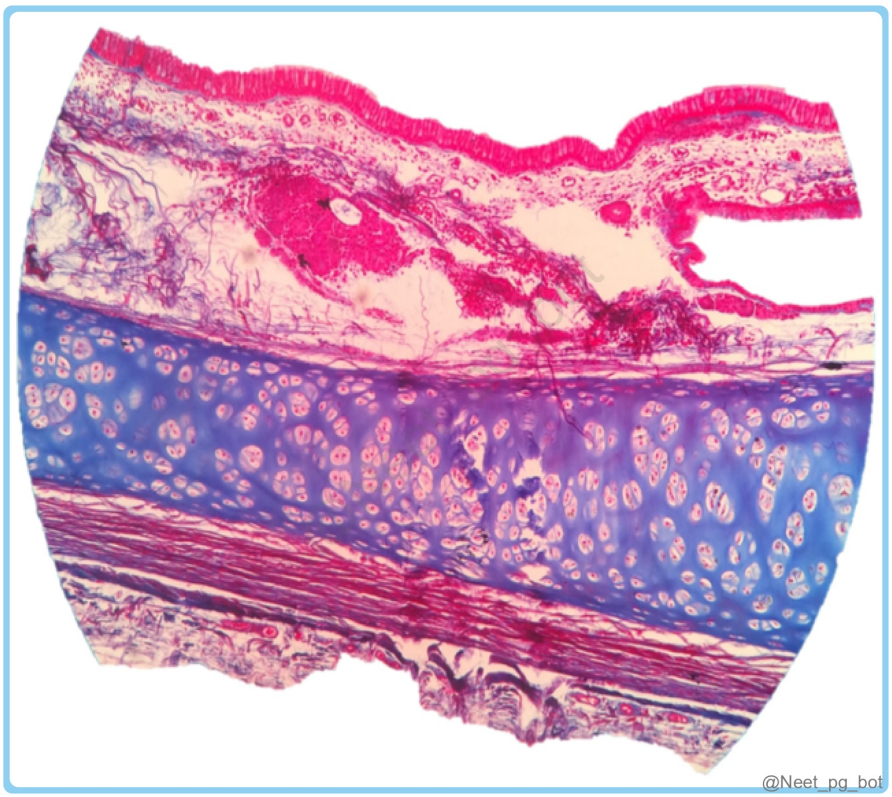

See Answer in Part B → Q18

@Neet_pg_bot

Q19: Which of the following structures is characterized by the presence of compound tubuloalveolar mucous glands in the submucosa, and a muscular layer that transitions from skeletal to smooth muscle? (Q848052)

A. Esophagus

B. Stomach

C. Small intestine

D. Both A & C are correct

See Answer in Part B → Q19

@Neet_pg_bot

• [02_Histology] 006 Tissue Histology- Ii

« Back to Folder Directory

[02_Histology] 006 Tissue Histology- Ii — Quick Jump

Q1 (p. 73) *Q2 (p. 74)* *Q3 (p. 77)* *Q4 (p. 77)* *Q5 (p. 78)* *Q6 (p. 79)*
Q7 (p. 79) *Q8 (p. 80)* *Q9 (p. 80)* *Q10 (p. 81)* *Q11 (p. 81)* *Q12 (p. 81)*
Q13 (p. 82) *Q14 (p. 82)* *Q15 (p. 83)* *Q16 (p. 83)* *Q17 (p. 84)* *Q18 (p. 84)*
Q19 (p. 85) *Q20 (p. 86)*

Q1: A 28-year-old patient with recurrent abdominal pain undergoes an endoscopic biopsy of the small intestine. The pathologist observes cells with prominent eosinophilic secretory granules located in the deeper parts of the intestinal crypts. These cells are known to produce substances that destroy bacteria. Which of the following cell types is the pathologist most likely observing as shown below? (Q848170)

A. Enterocytes

B. M cells

C. Paneth cells

D. Enterochromaffin cells

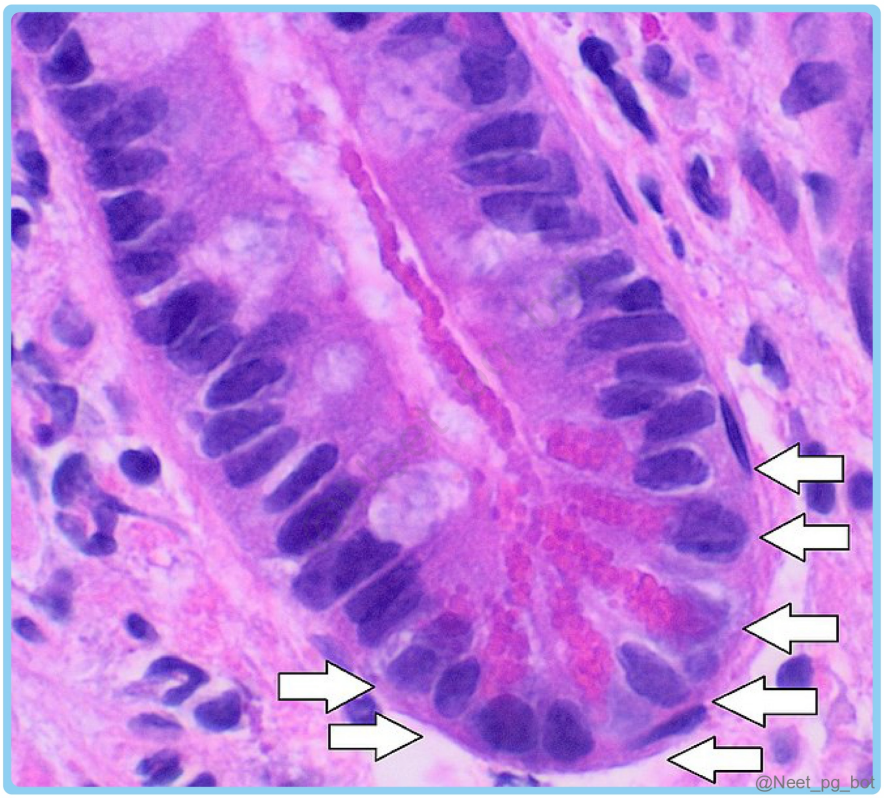

See Answer in Part B → Q1

@Neet_pg_bot

Q2: Match the following: 1. Cervix a) 2. Fallopian tube b) 3. Ovary c) 4. Uterus d) 5. Vagina e) (Q848179)

A. 1-b, 2-c, 3-e, 4-a, 5-d

B. 1-d, 2-e, 3-a, 4-c, 5-b

C. 1-c, 2-b, 3-e, 4-d, 5-a

D. 1-b, 2-e, 3-a, 4-c, 5-d

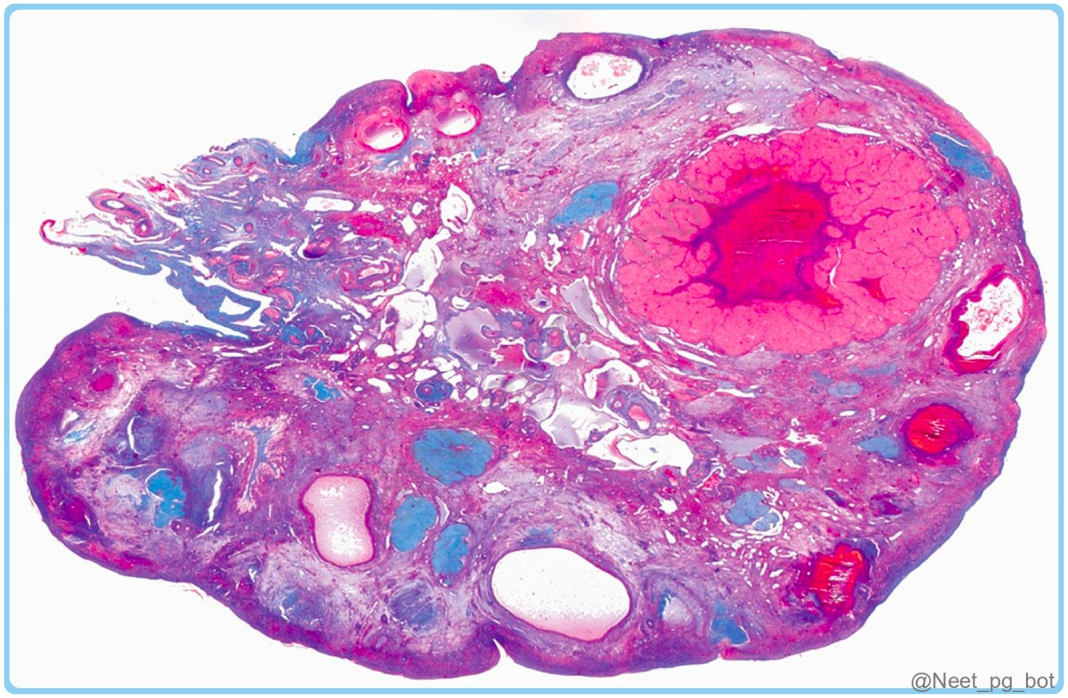
@Neet_pg_bot

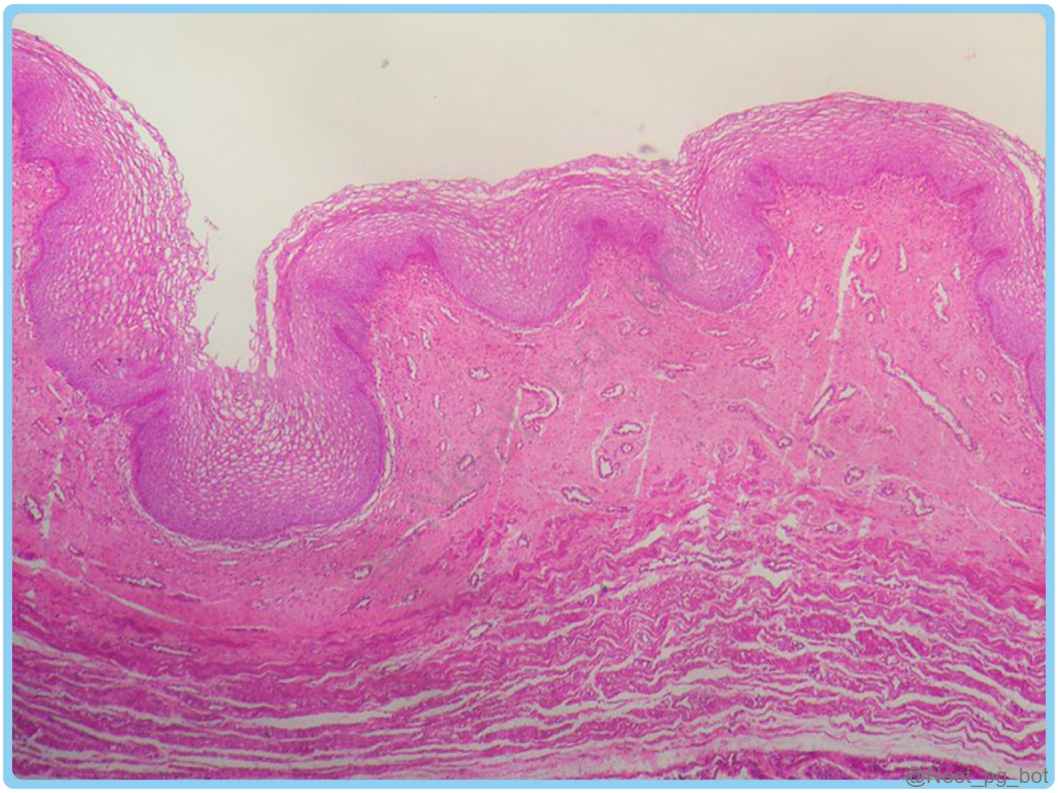
@Neet_pg_bot

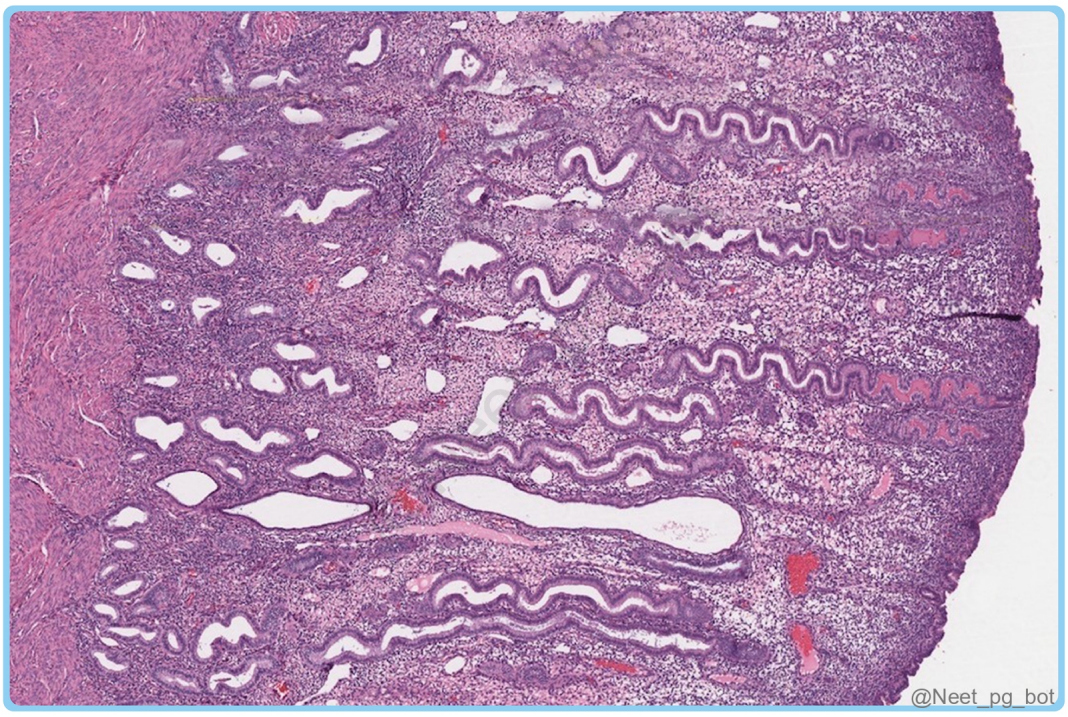
@Neet_pg_bot

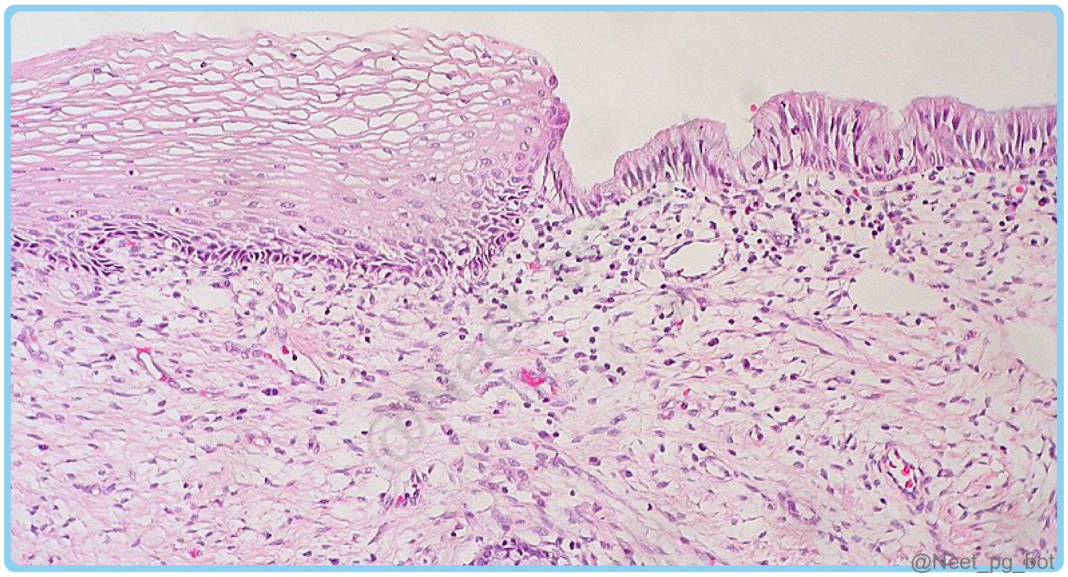
@Neet_pg_bot



See Answer in Part B → Q2

@Neet_pg_bot

Q3: Which of the following statements about the structure of sperm is true? (Q848178)

A. The head of sperm contains a central core of axoneme.

B. The principal piece of the tail contains hyaluronidase.

C. The neck of the sperm contains centrioles.

D. The tail contains the nucleus of the sperm.

See Answer in Part B → Q3

@Neet_pg_bot

Q4: Which of the following statements about the structure of the testis is false? (Q848177)

A. The testis is surrounded by the tunica vaginalis.

B. The seminiferous tubules produce sperm.

C. The ductuli efferentes carry sperm from the epididymis to the rete testis.

D. The blood-testis barrier is formed by sertoli cells.

See Answer in Part B → Q4

@Neet_pg_bot

Q5: Which of the following correctly describes the epithelial lining at the prostatic urethra shown in the histological section below? (Q848176)

A. Keratinized stratified squamous epithelium

B. Non-keratinized stratified squamous epithelium

C. Transitional epithelium

D. Stratified columnar epithelium

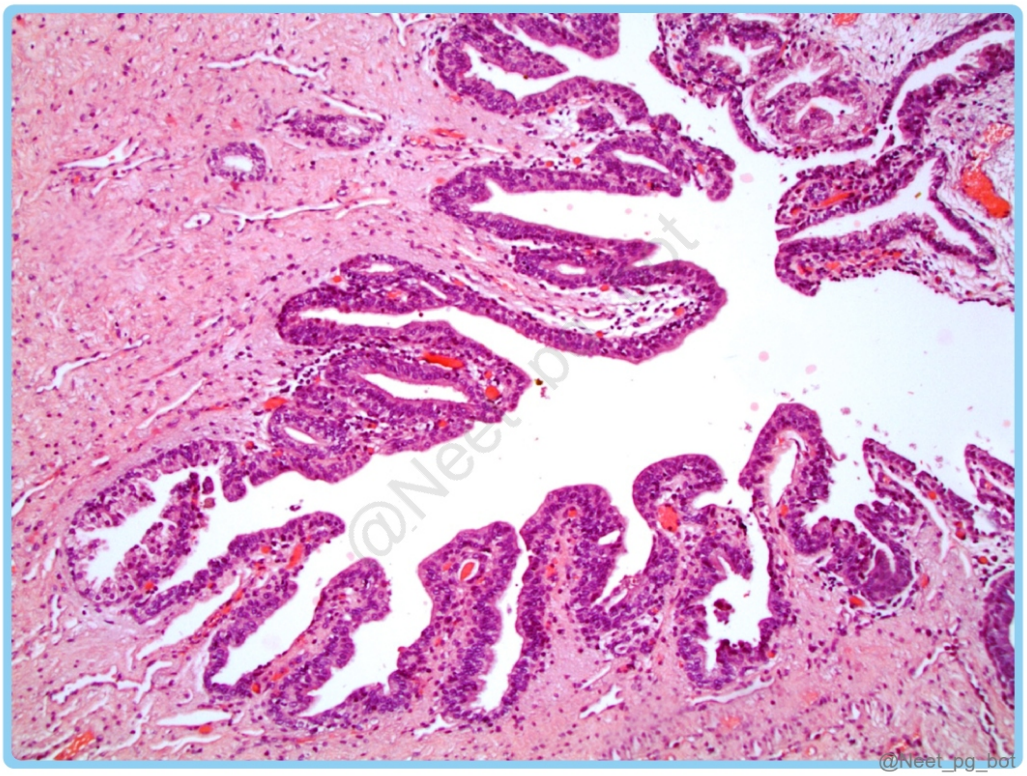

See Answer in Part B → Q5

@Neet_pg_bot

Q6: Which part of the nephron is characterized by cuboidal epithelial cells with a prominent brush border? (Q848175)

A. Renal corpuscle

B. Proximal convoluted tubule

C. Loop of Henle

D. Distal convoluted tubule

See Answer in Part B → Q6

@Neet_pg_bot

Q7: Which of the following liver units is considered the most relevant functional unit for understanding patterns of toxic liver injury? (Q848174)

A. Classic lobule

B. Portal lobule

C. Portal acinus

D. Sinusoidal unit

See Answer in Part B → Q7

@Neet_pg_bot

Q8: A 35-year-old patient with chronic hepatitis C undergoes a liver biopsy. The pathologist observes the classical hexagonal structure of liver lobules. Which of the following statements correctly regarding the blood flow and architecture within a liver lobule? (Q848173)

A. Blood flows from the central vein to the portal triad

B. The hepatic artery provides 70% of the liver's blood supply

C. Bile flows in the same direction as blood within the lobule

D. Sinusoids drain blood into the central vein

See Answer in Part B → Q8

@Neet_pg_bot

Q9: A 55-year-old patient presents with rectal bleeding. During the examination, the proctologist identifies a lesion at the junction between the columnar epithelium and the non-keratinized stratified squamous epithelium in the anal canal. At which of the following anatomical landmarks is this lesion most likely located? (Q848172)

A. White line of Hilton

B. Pectinate line

C. Internal anal sphincter

D. External anal sphincter

See Answer in Part B → Q9

@Neet_pg_bot

Q10: A pathologist is examining a biopsy sample from a patient's large intestine. The sample shows a mucosa without villi, numerous goblet cells, and an abundance of lymphoid tissue in the submucosa. The muscularis externa lacks taenia coli. Which part of the large intestine is this sample most likely from? (Q848171)

A. Cecum

B. Appendix

C. Colon

D. Rectum

See Answer in Part B → Q10

@Neet_pg_bot

Q11: Which of the following skin receptors is a rapidly adapting cell? (Q848133)

A. Merkel cell

B. Ruffini receptor

C. Free nerve endings

D. Pacinian corpuscle

See Answer in Part B → Q11

@Neet_pg_bot

Q12: A pathologist is examining biopsy samples from different parts of the small intestine. Which of the following histological features would most likely indicate that

the sample is from the ileum? (Q848153)

A. Presence of numerous tall villi

B. Abundant Brunner's glands in the submucosa

C. Numerous large Peyer's patches

D. Thick circular folds in the lumen

See Answer in Part B → Q12

@Neet_pg_bot

Q13: A 45-year-old patient undergoes an endoscopic biopsy of the stomach due to persistent dyspepsia. Histological examination of the glandular tissue reveals cells that are columnar in shape, located in the lower half of the gland, and stain blue with hematoxylin. Which of the following statements is most likely true about these cells? (Q848152)

A. They secrete hydrochloric acid and intrinsic factor

B. They produce mucus

C. They secrete pepsinogen

D. They release the hormone gastrin

See Answer in Part B → Q13

@Neet_pg_bot

Q14: Which of the following statements with respect to histology of alveoli is incorrect? (Q848151)

A. The most abundant cell type lines form 70-90% of the alveolar surface and are of simple squamous type

B. Type II alveolar epithelial cells are microvilli containing cells which secrete surfactant similar to that of Clara cells

C. In some alveolar area, basement membrane of the endothelium fuses with that of the alveolar epithelium

D. Type I alveolar epithelial cells are involved in replacing the damaged type II alveolar cells

See Answer in Part B → Q14

@Neet_pg_bot

Q15: A 45-year-old patient presents with chronic cough and shortness of breath. Bronchoscopy is performed, and a biopsy of the bronchial wall is taken. Histological examination reveals an epithelium with tall columnar cells bearing cilia on their apical surface, interspersed with goblet cells. Which part of the respiratory tract is most likely represented by this biopsy? (Q848150)

A. Trachea

B. Terminal bronchioles

C. Respiratory bronchioles

D. Alveoli

See Answer in Part B → Q15

@Neet_pg_bot

Q16: Which histological feature most accurately describes the epithelium responsible for mucociliary clearance in the upper respiratory tract? (Q848149)

A. Stratified squamous epithelium, non-keratinized

B. Pseudostratified ciliated columnar epithelium with goblet cells

C. Simple cuboidal epithelium with Clara cells

D. Simple squamous epithelium with alveolar macrophages

See Answer in Part B → Q16

@Neet_pg_bot

Q17: A 30-year-old man presents with difficulty swallowing and a mild hoarse voice. Examination reveals no significant findings, and imaging shows no abnormal masses in the oropharynx. A biopsy is taken from a structure in the oropharynx that histologically shows a mixture of stratified squamous epithelium and pseudostratified columnar epithelium. This structure also contains seromucous glands and an elastic cartilage core. Which of the following structures is most likely biopsied? (Q848137)

A. Hard palate

B. Soft palate

C. Epiglottis

D. Vocal cords

See Answer in Part B → Q17

@Neet_pg_bot

Q18: Identify the type of tissue shown in the image below: (Q848136)

A. Smooth muscle

B. Skeletal muscle

C. Cardiac muscle

D. Purkinje fibers

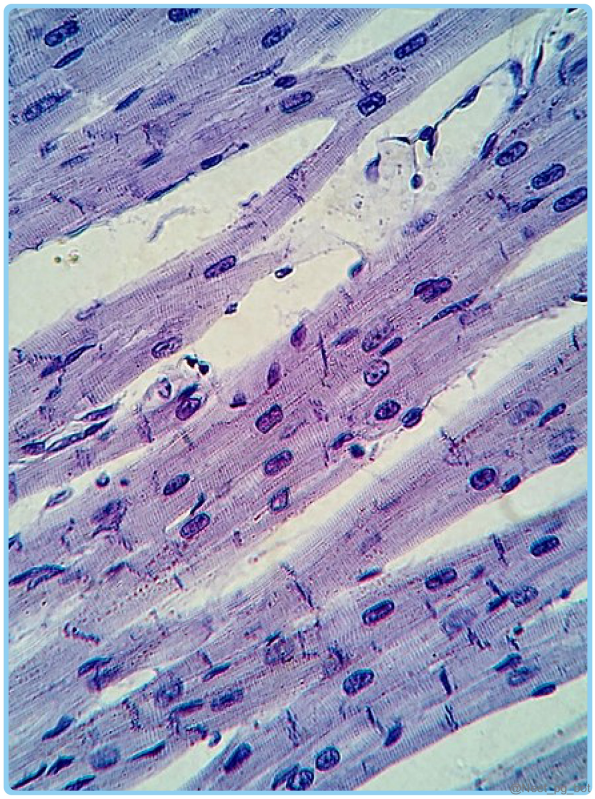

See Answer in Part B → Q18

@Neet_pg_bot

Q19: A 45-year-old woman presents with signs of progressive muscle weakness and fatigue. She is diagnosed with a rare genetic disorder affecting intercellular communication in her skeletal and cardiac muscles. Genetic testing reveals a mutation in a connexin protein. Which of the following best describes the physiological consequence of this mutation? (Q848135)

A. Impaired electrical signal propagation between cardiac myocytes

B. Disruption of epithelial barrier function

C. Reduced mechanical stability between cells

D. Abnormal attachment of muscle fibers to the extracellular matrix

See Answer in Part B → Q19

@Neet_pg_bot

Q20: In the provided image of epithelial cell junctions, identify the correct sequence of junctions from the apical to the basal surface: (Q848134)

A. A- Adherens junction, B- Tight junction, C- Desmosome, D- Hemidesmosome, E- Gap junction

B. A- Tight junction, B- Adherens junction, C- Desmosome, D- Gap junction, E- Hemidesmosome

C. A- Desmosome, B- Tight junction, C- Hemidesmosome, D- Adherens junction, E- Gap junction

D. A- Hemidesmosome, B- Gap junction, C- Adherens junction, D- Tight junction, E- Desmosome

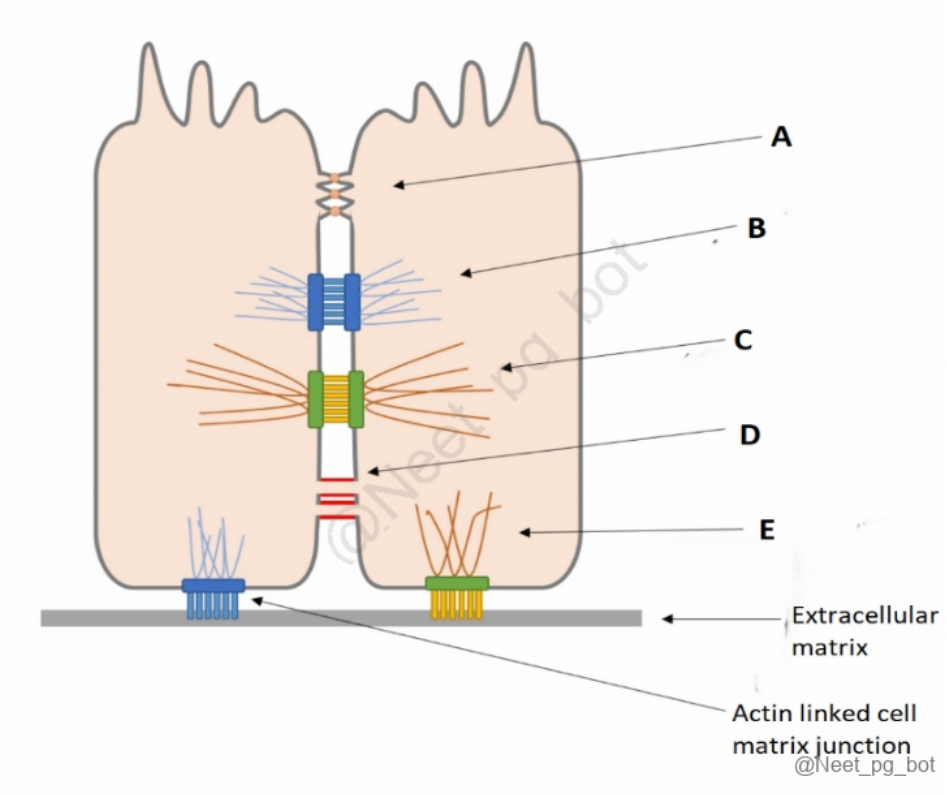

See Answer in Part B → Q20

@Neet_pg_bot

• [02_Histology] 007 Previous Year Questions

« Back to Folder Directory

[02_Histology] 007 Previous Year Questions — Quick Jump

Q1 (p. 87)	*Q2 (p. 88)*	*Q3 (p. 88)*	*Q4 (p. 89)*	*Q5 (p. 89)*	*Q6 (p. 90)*
Q7 (p. 91)	*Q8 (p. 92)*	*Q9 (p. 93)*	*Q10 (p. 94)*	*Q11 (p. 94)*	*Q12 (p. 95)*
Q13 (p. 95)	*Q14 (p. 96)*	*Q15 (p. 97)*	*Q16 (p. 98)*	*Q17 (p. 99)*	*Q18 (p. 99)*
Q19 (p. 100)	*Q20 (p. 101)*	*Q21 (p. 101)*	*Q22 (p. 102)*	*Q23 (p. 103)*	*Q24 (p. 104)*

Q1: Identify which of the following structure is a merocrine gland: (Q855430)

A. 1

B. 2

C. 3

D. 4



See Answer in Part B → Q1

@Neet_pg_bot

Q2: Which of the following does not have an endocrine component? (Q879163)

See Answer in Part B → Q2

@Neet_pg_bot

Q3: Identify the cartilage given below (Q856074)

A. Non-articular hyaline cartilage

B. Articular hyaline cartilage

C. Yellow cartilage

D. White fibrocartilage

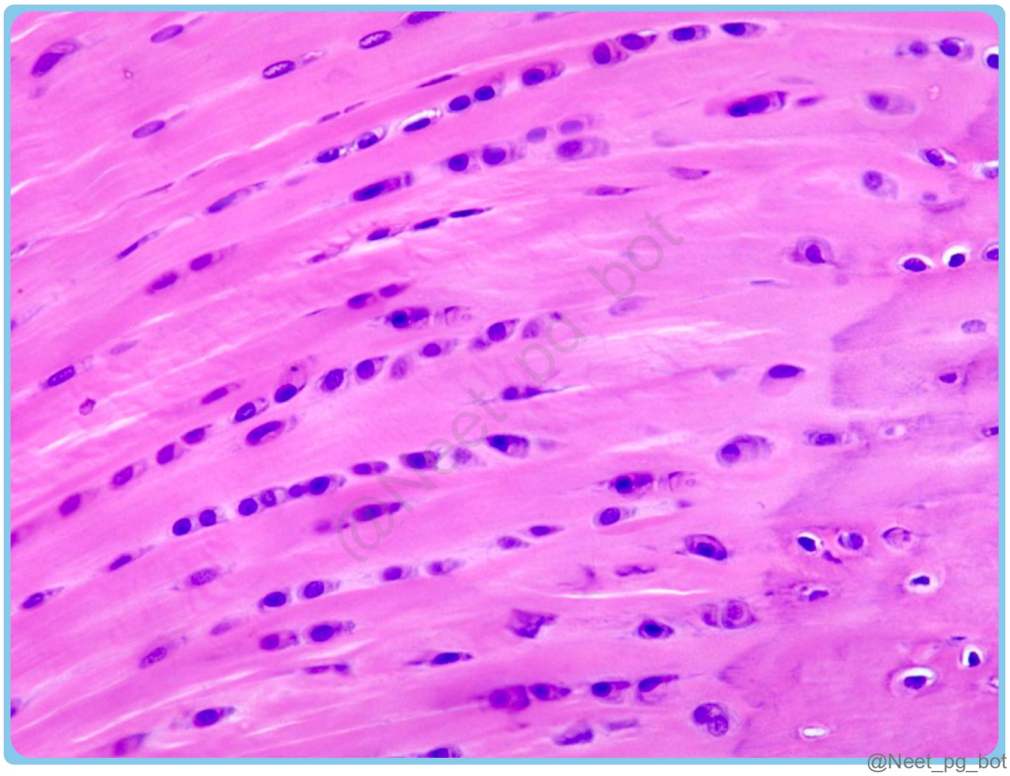

See Answer in Part B → Q3

@Neet_pg_bot

Q4: Identify the given structure. (Q856073)

A. Lymph node

B. Glomerulus

C. Spleen

D. Pancreatic islet cells

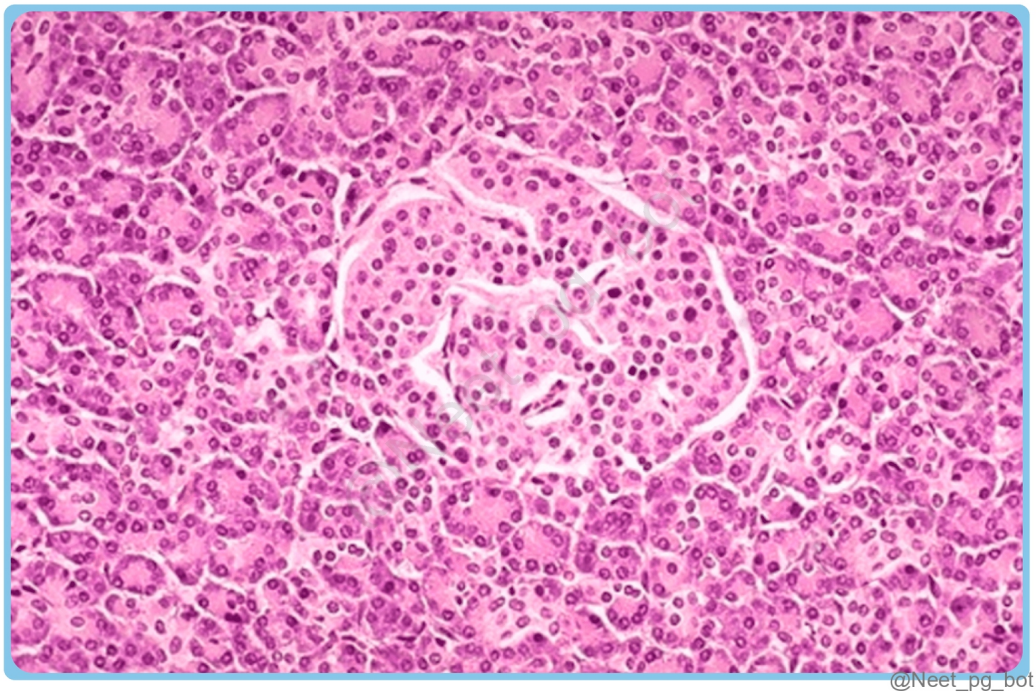

See Answer in Part B → Q4

@Neet_pg_bot

Q5: Identify the cell marked in the histological image of the cerebellum shown below: (Q858478)

A. Purkinje cells

B. Basket cells

C. Golgi cells

D. Granule cell

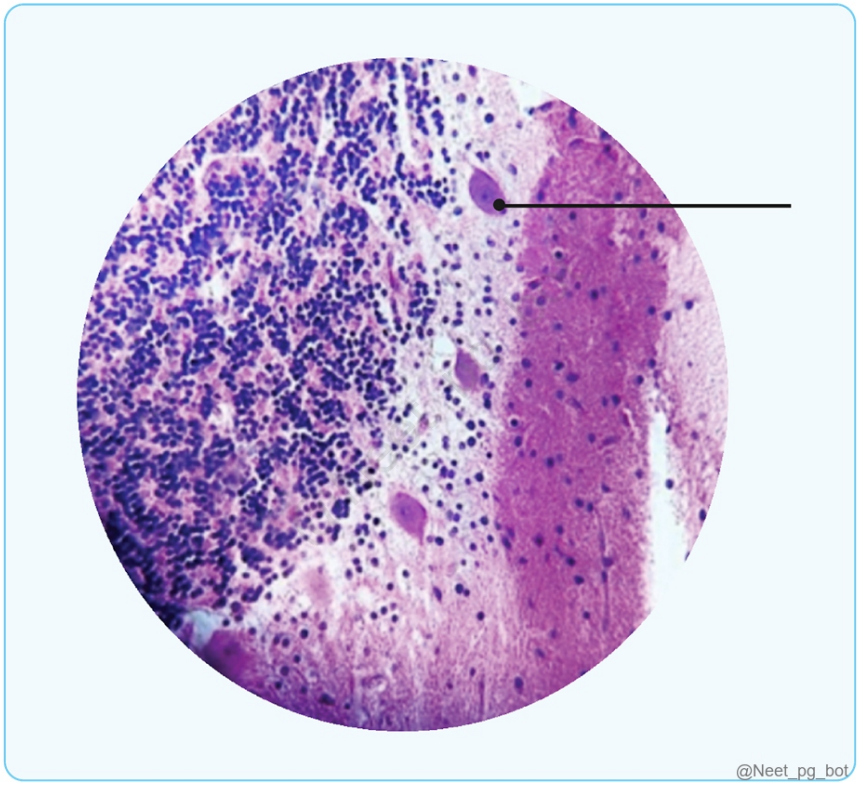

See Answer in Part B → Q5

@Neet_pg_bot

Q6: Identify the type of cartilage shown in the image below: (Q858471)

A. Hyaline cartilage

B. Elastic cartilage

C. Articular cartilage

D. Fibrocartilage

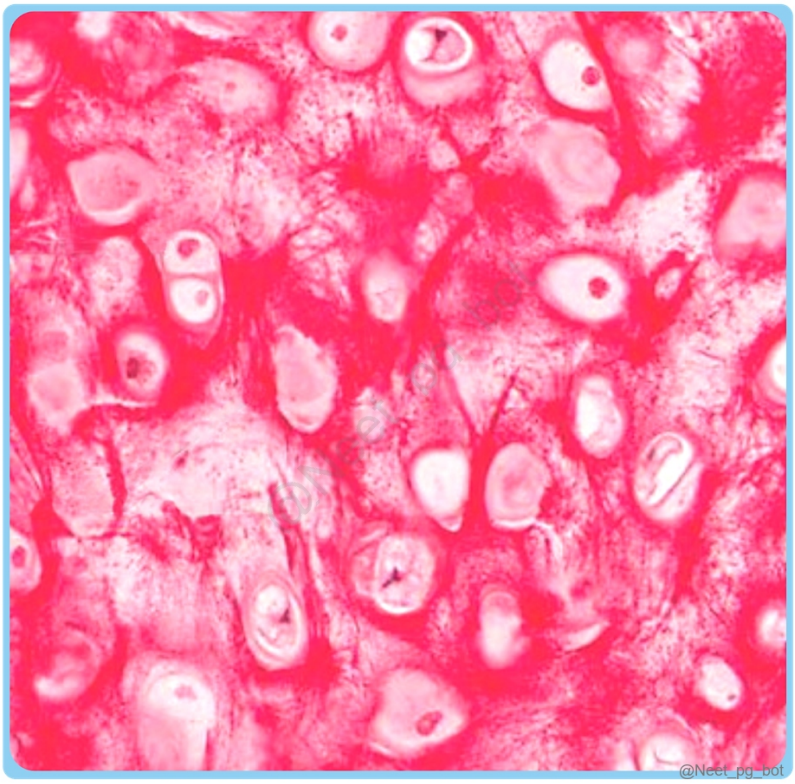

See Answer in Part B → Q6

@Neet_pg_bot

Q7: The cell marked in the below slide is inhibitory to (Q855788)

A. Deep nuclei of cerebellum

B. Vestibular nuclei

C. Inferior olivary nucleus

D. Basal ganglia

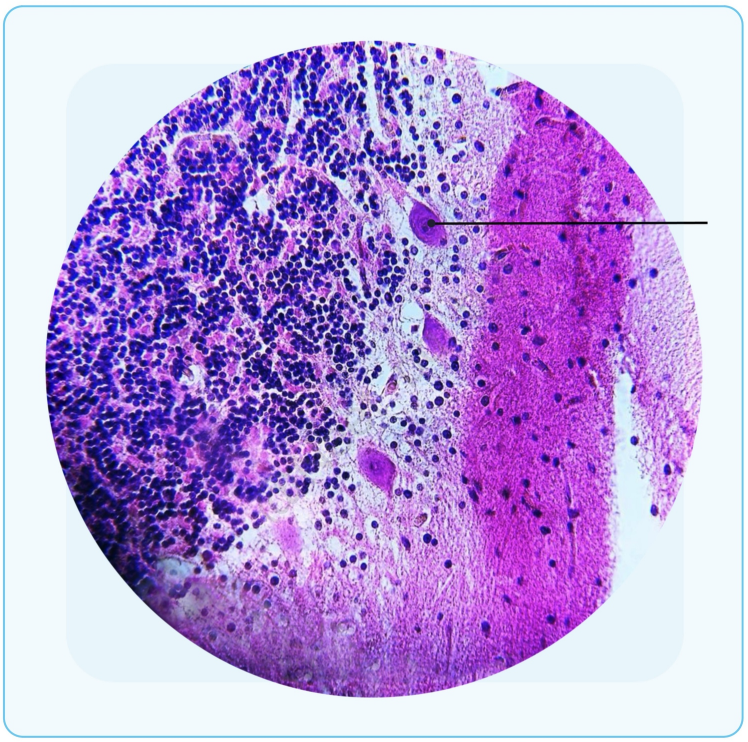

@Neet_pg_bot

See Answer in Part B → Q7

@Neet_pg_bot

Q8: Identify the incorrect match: (Q855762)

A. 1-cilia

B. 4-lamina propria

C. 2-goblet cells

D. 3-nuclei of epithelial cell

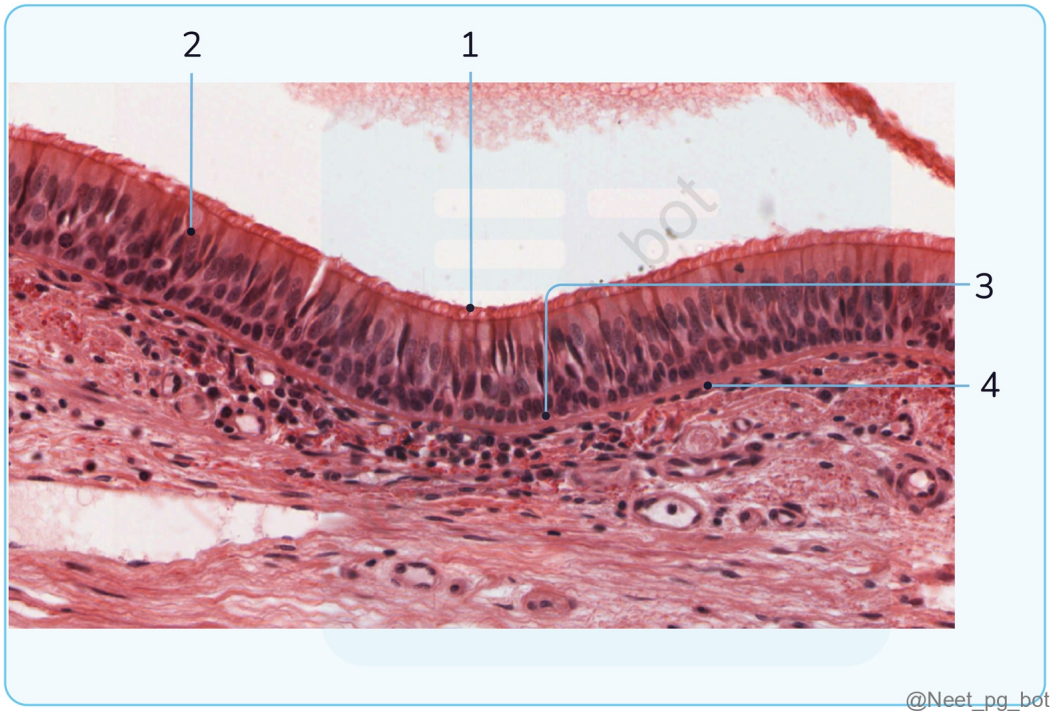

See Answer in Part B → Q8

@Neet_pg_bot

Q9: Given below is a histological section of the thyroid gland. Which of the following is secreted by the cell marked ‘X’ in the image? (Q857639)

A. Thyroxine

B. Calcitonin

C. PTH

D. SerotoninX

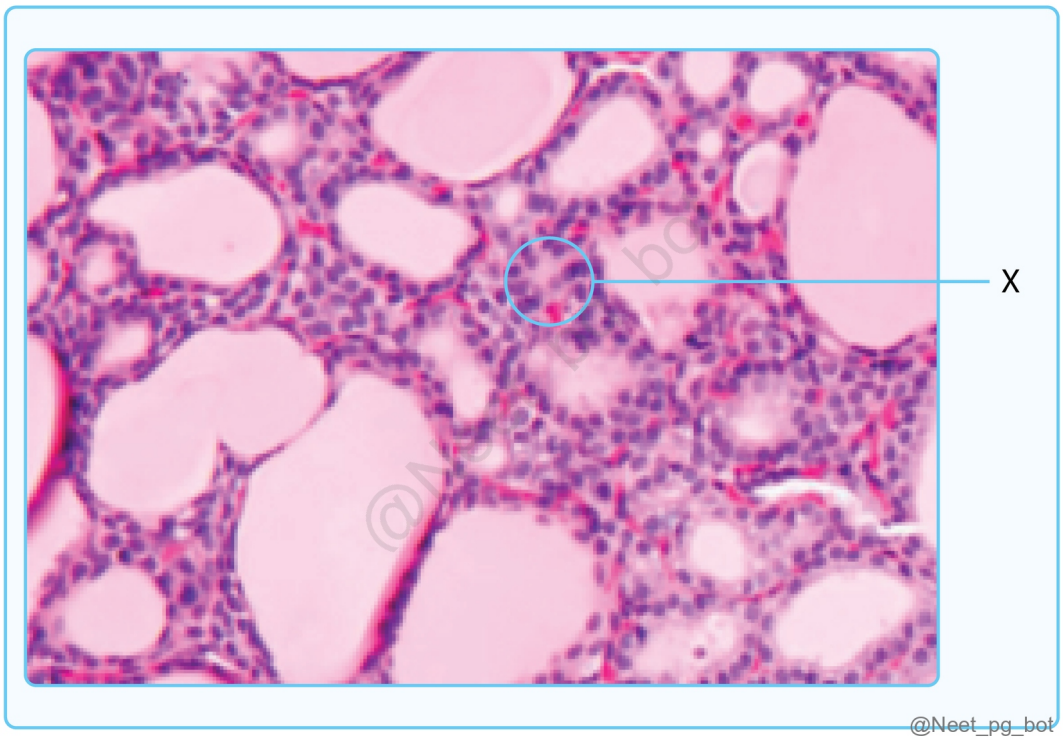

See Answer in Part B → Q9

@Neet_pg_bot

Q10: Which of the following statements regarding bones is false? (Q857230)

A. Osteocytes are the major cell type in mature bone

B. Collagen is synthesized in bone osteoblasts

C. Bone mainly contains type 2 collagen

D. Calcium phosphate is one of the major inorganic mineral

See Answer in Part B → Q10

@Neet_pg_bot

Q11: Which type of collagen is present in cartilage? (Q857215)

A. Type 1 collagen

B. Type 2 collagen

C. Type 3 collagen

D. Type 4 collagen

See Answer in Part B → Q11

@Neet_pg_bot

Q12: The inner layer of the fallopian tube is covered by: (Q857208)

A. Simple columnar epithelium

B. Pseudostratified ciliated columnar epithelium

C. Ciliated columnar epithelium

D. Cuboidal epithelium with microvilli

See Answer in Part B → Q12

@Neet_pg_bot

Q13: The area marked by the arrows in the given histopathological image can influence the surrounding cells by: (Q865311)

A. Portal Vasculature

B. Paracrine effect

C. Nerve mediated

D. Epitheliomesenchymal transition

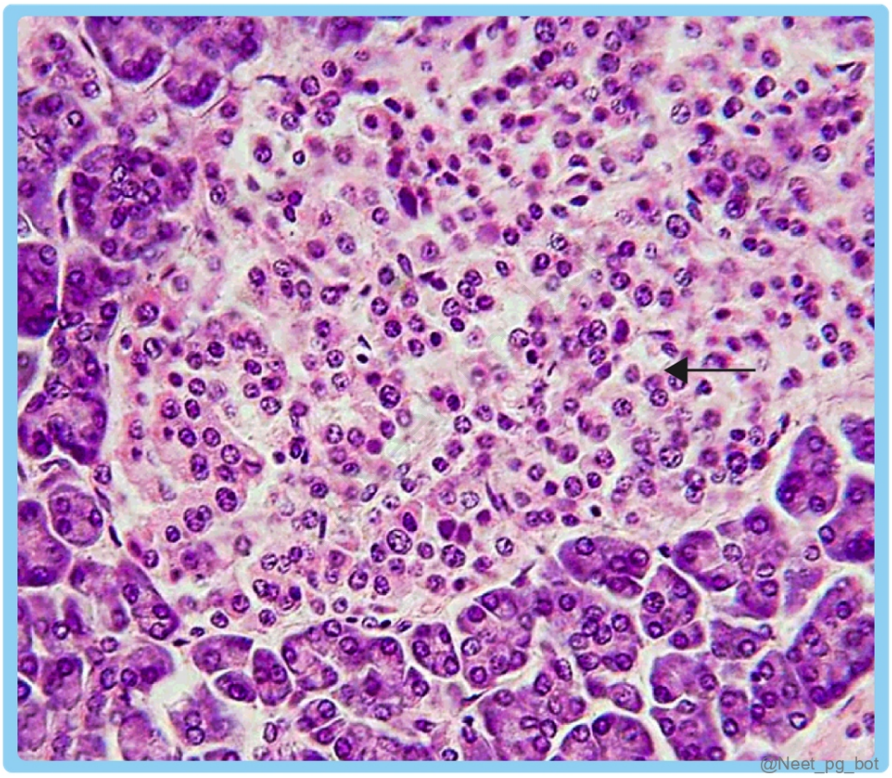

See Answer in Part B → Q13

@Neet_pg_bot

Q14: A 35-year-old patient underwent an endoscopic examination of the gastrointestinal tract due to recurrent abdominal discomfort and altered bowel habits. Identify the arrow-marked structure in the given image. (Q857953)

A. Brunner’s gland

B. Intestinal cells of kajal

C. Crypts of lieberkuhn

D. Peyer's patch

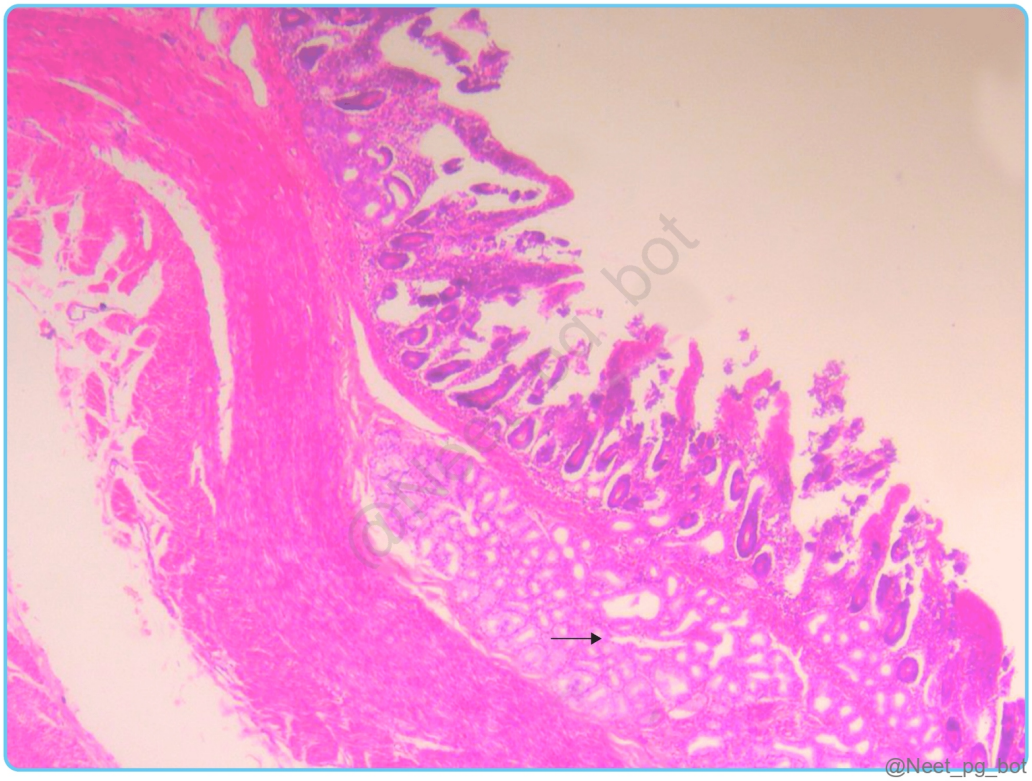

See Answer in Part B → Q14

@Neet_pg_bot

Q15: The given histology image is of? (Q855394)

A. Leydig cells of testis

B. Pancreatic islet cells

C. Hassall's corpuscles

D. Glomerulus

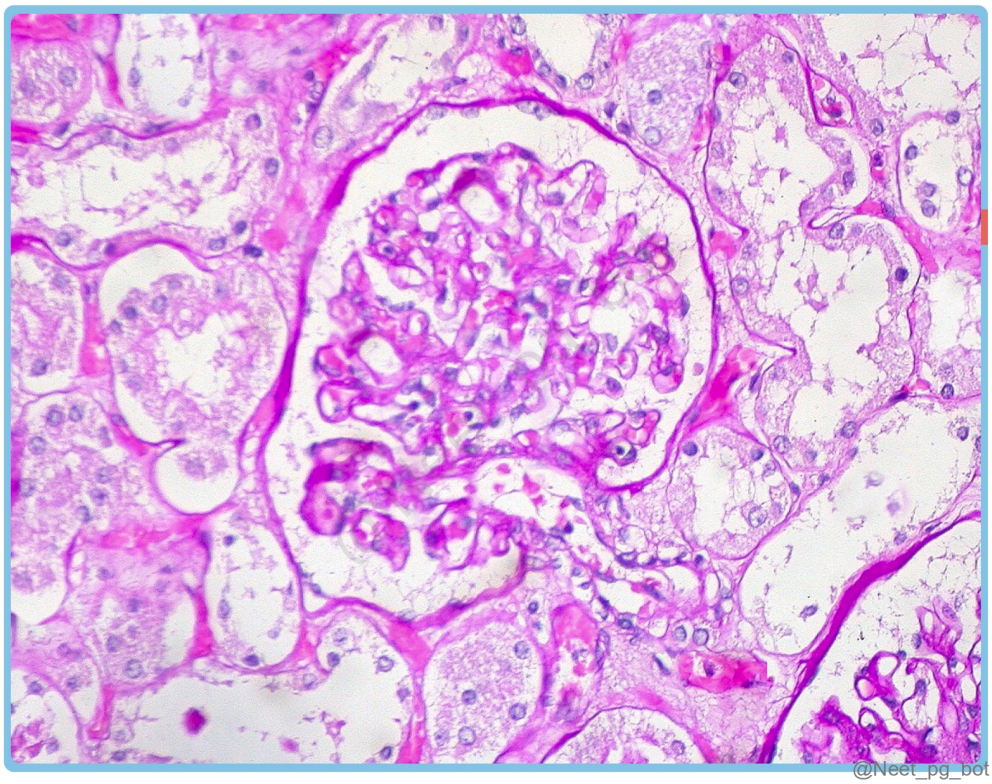

See Answer in Part B → Q15

@Neet_pg_bot

Q16: Identify the structure marked in the given image? (Q857346)

A. Respiratory bronchus

B. Terminal bronchioles

C. Alveolar sac

D. Intrapulmonary bronchus

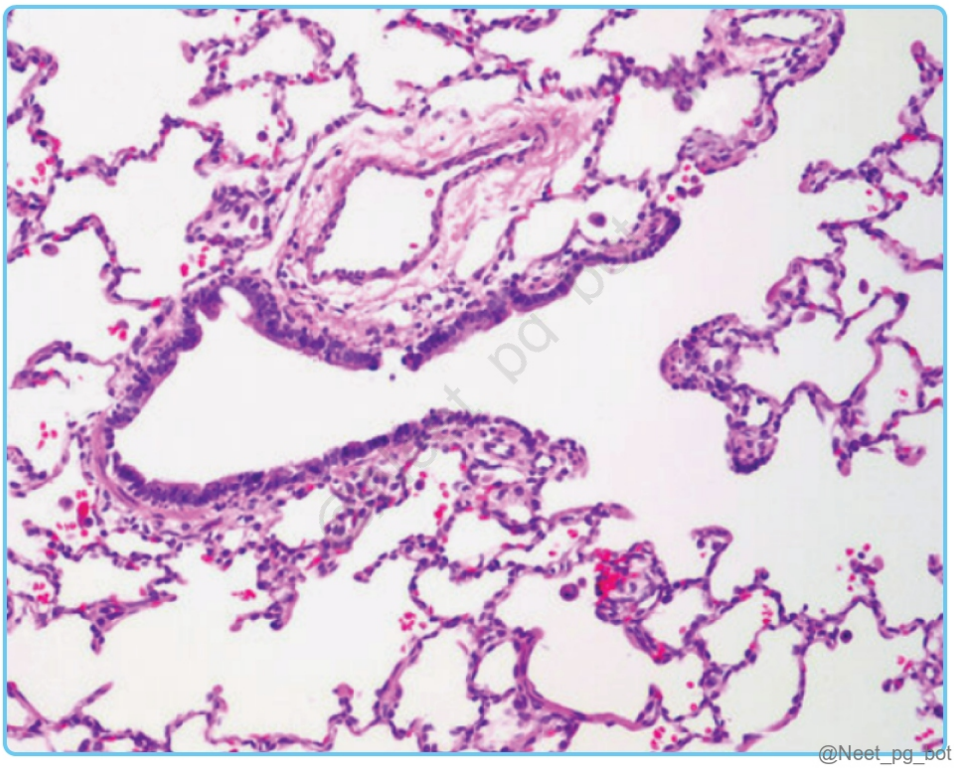

See Answer in Part B → Q16

@Neet_pg_bot

Q17: Which of the following is the lining epithelium of the trachea? (Q860289)

A. Simple squamous epithelium

B. Transitional epithelium

C. Stratified squamous epithelium

D. Pseudostratified ciliated columnar

See Answer in Part B → Q17

@Neet_pg_bot

Q18: Which hormone is produced from the layer marked in the given image? (Q860615)

A. Androgen

B. Cortisol

C. Corticosterone

D. Epinephrine

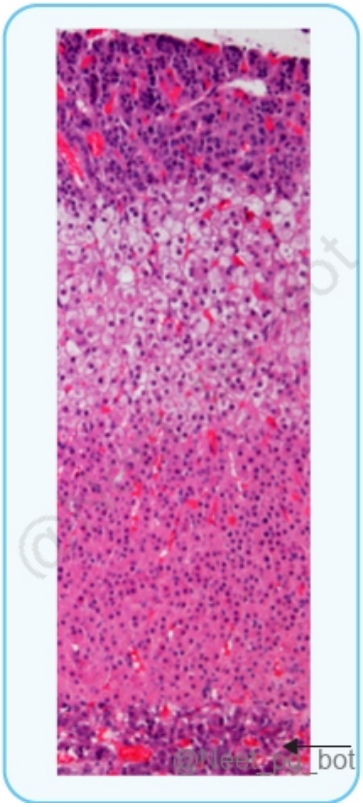

See Answer in Part B → Q18

@Neet_pg_bot

Q19: Match the receptors with their correct function: 1. Ruffini corpuscle A. Vibration 2. Merkel cells B. Sustained pressure 3. Pacinian corpuscle C. Stretching 4. Meissner's corpuscle D. Fine touch (Q844320)

A. 1C, 2B, 3A, 4D

B. 1D, 2C, 3B, 4A

C. 1B, 2A, 3D, 4C

D. 1C, 2D, 3B, 4A

See Answer in Part B → Q19

@Neet_pg_bot

Q20: Identify the markers in the given slide: (Q844183)

A. A- Eccrine sweat gland, B- Arrector pilorum, C- Sebaceous gland, D- Apocrine gland

B. A- Arrector pilorum, B- Eccrine sweat gland, C- Sebaceous gland, D- Apocrine gland

C. A- Eccrine sweat gland, B- Arrector pilorum, C- Apocrine gland, D-Sebaceous gland

D. A- Sebaceous gland, B- Apocrine gland, C- Eccrine sweat gland, D- Arrector pilorum



See Answer in Part B → Q20

@Neet_pg_bot

Q21: Identify the lymphatic structure from the histology section given below? (Q852536)

A. Tonsil

B. Lymph node

C. Spleen

D. Thymus

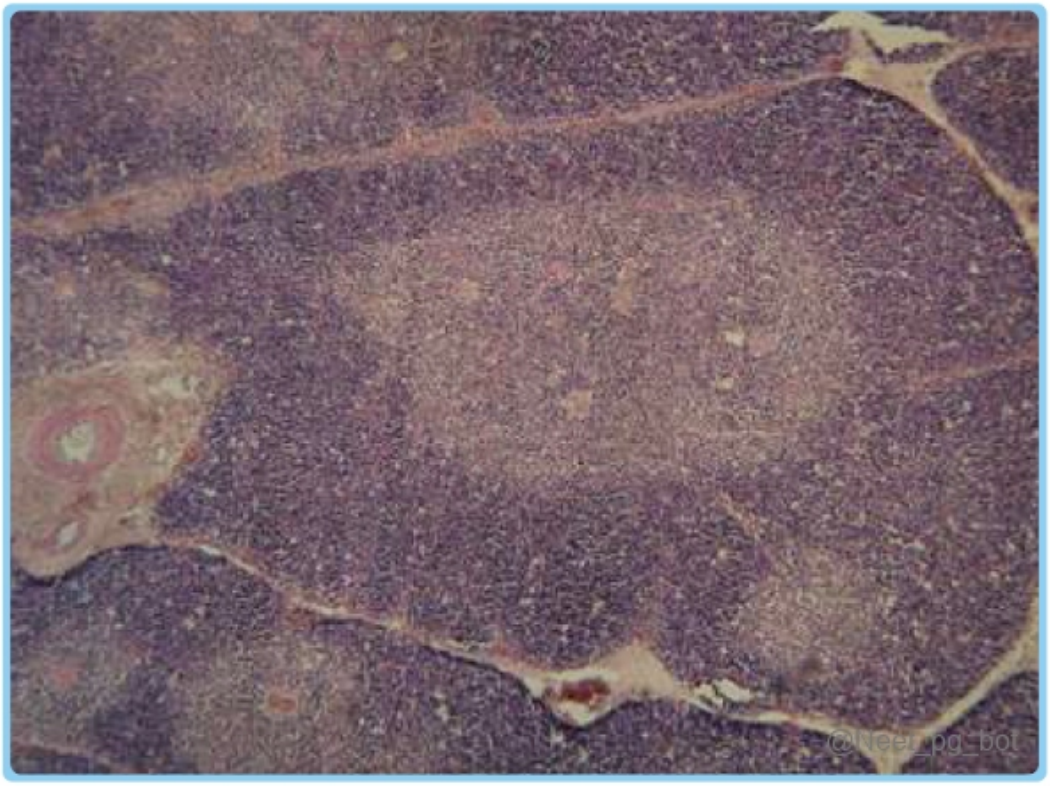

See Answer in Part B → Q21

@Neet_pg_bot

Q22: What is the type of cartilage present in the histology section given below? (Q852465)

A. Hyaline cartilage

B. Elastic cartilage

C. Articular cartilage

D. Fibrocartilage

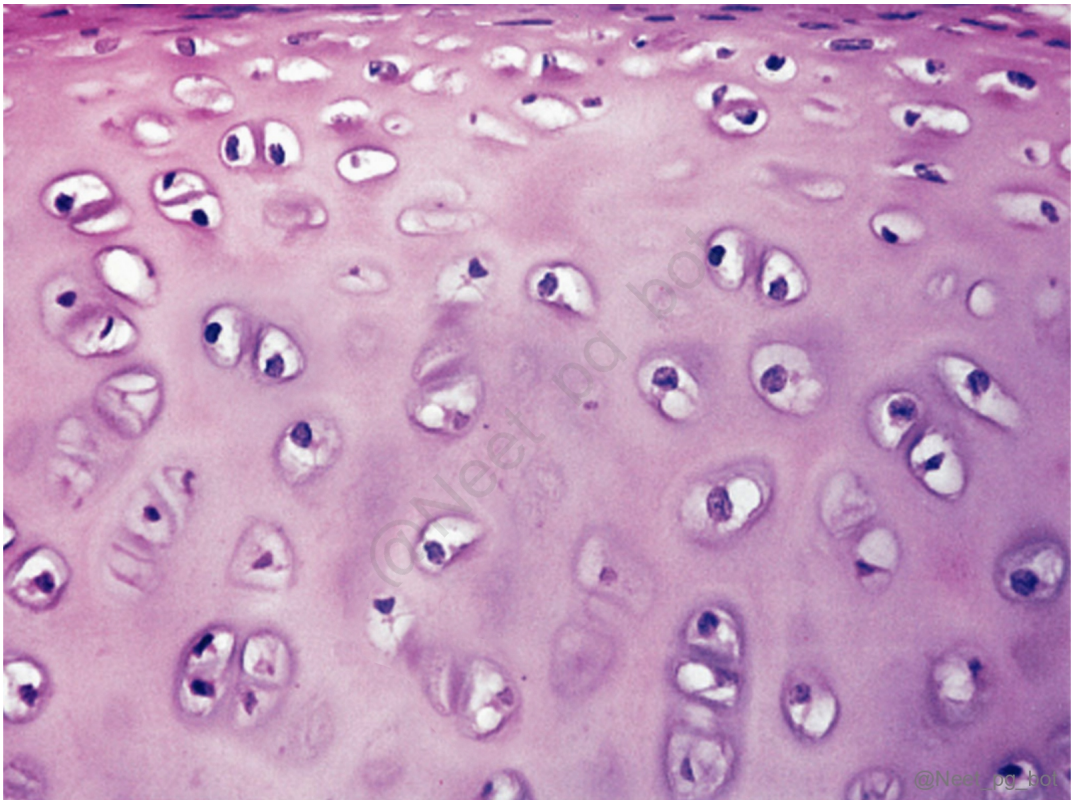

See Answer in Part B → Q22

@Neet_pg_bot

Q23: Histological section is given below. Identify the marked cell. (Q852541)

A. Stellate cell

B. Basket cell

C. Purkinje cell

D. Granular cell

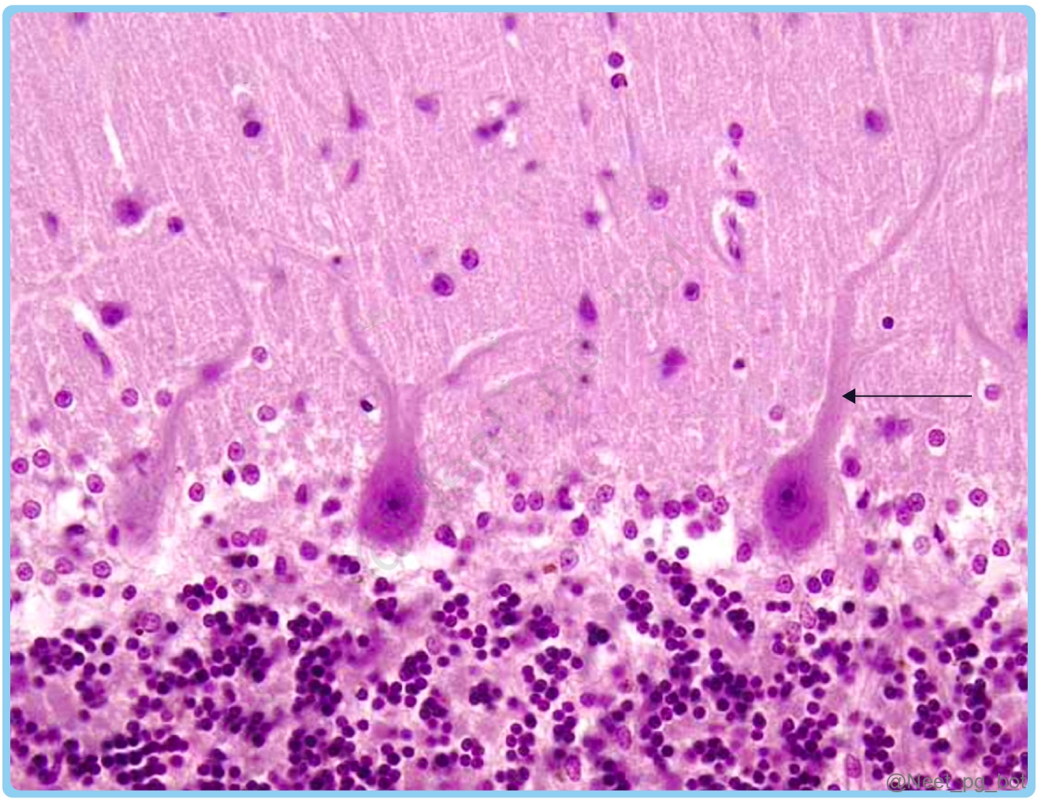

See Answer in Part B → Q23

@Neet_pg_bot

Q24: Which of the following organs does this epithelium most likely belong to? (Q866312)

A. Ureter

B. Gallbladder

C. Trachea

D. Intestine

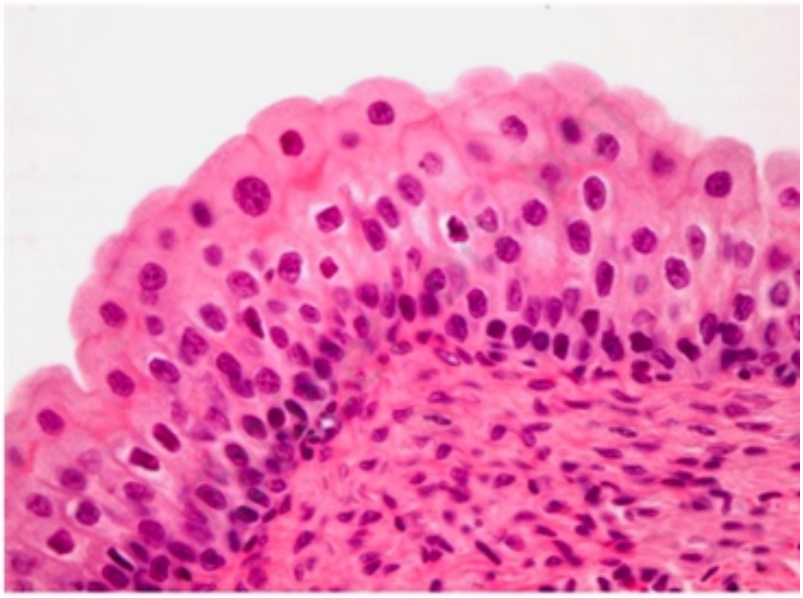

@Neet_pg_bot

See Answer in Part B → Q24

@Neet_pg_bot

• [03_Neuro Anatomy] 008 Nervous System Development

« Back to Folder Directory

[03_Neuro Anatomy] 008 Nervous System Development — Quick Jump

Q1 (p. 106) *Q2 (p. 106)* *Q3 (p. 107)* *Q4 (p. 107)* *Q5 (p. 107)* *Q6 (p. 108)*
Q7 (p. 109) *Q8 (p. 109)* *Q9 (p. 109)* *Q10 (p. 110)* *Q11 (p. 110)* *Q12 (p. 111)*

Q1: Which of the following statements is incorrect about the organization of the nervous system? (Q848437)

A. Gray matter in the CNS is called a nucleus.

B. PNS ganglia are mostly derived from the neural tube.

C. White matter in the CNS forms structures like tracts and fasciculi.

D. Axons in the CNS are covered by oligodendrocytes, and in the PNS by Schwann cells

See Answer in Part B → Q1

@Neet_pg_bot

Q2: A 30 year old patient presents with sudden vision loss in one eye and pain during eye movement. The patient has a history of recurrent neurological symptoms and Imaging studies reveal inflammation and demyelination of the optic nerve. The patient is diagnosed with multiple sclerosis (MS). Why is the optic nerve affected in MS, despite being considered a peripheral nerve? (Q848438)

A. The optic nerve is not affected by MS.

B. It is an extension of the diencephalon and is myelinated by Schwann cells, which are affected in MS.

C. It is an extension of the diencephalon and myelinated by oligodendrocytes, which are involved in MS.

D. It does not regenerate, making it more vulnerable to damage.

See Answer in Part B → Q2

@Neet_pg_bot

Q3: Which of the following options correctly identifies the true statement about the formation of the neural tube? Neural plate → Neural groove → Neural tube The anterior neuropore closes on day 28 The posterior neuropore closes around day 25 (Q848439)

A. 1 is correct

B. 2 and 3 is correct

C. 1 and 2 is correct

D. All are correct

See Answer in Part B → Q3

@Neet_pg_bot

Q4: Which of the following is not a characteristic of ectodermal placodes? (Q848440)

A. Developing into the lens vesicle

B. Forming the olfactory epithelium

C. Contributing to the development of the membranous labyrinth of the inner ear

D. Directly gives rise to neurons in the Vestibulocochlear ganglion

See Answer in Part B → Q4

@Neet_pg_bot

Q5: Which of the following structural abnormalities is most commonly associated with the given image? (Q848441)

A. Malformation of the vertebral arches

B. Incomplete development of the basichondrocranium

C. Herniation of brain tissue through the skull

D. Fusion of the cranial sutures



See Answer in Part B → Q5

@Neet_pg_bot

Q6: Which of the following is a common feature of craniorachischisis compared to rachischisis? (Q848442)

A. Craniorachischisis results from failure of caudal neural tube closure, while rachischisis affects the entire tube.

B. Craniorachischisis exposes both the brain and spinal cord; rachischisis exposes only the spinal cord.

C. Craniorachischisis is less severe than rachischisis and affects only the vertebrae.

D. Craniorachischisis involves complete neural tube closure, while rachischisis exposes both the brain and spinal cord.

See Answer in Part B → Q6

@Neet_pg_bot

Q7: Which of the following statements about spina bifida is false? (Q848443)

A. Spina bifida occulta presents with an abnormal U or V shape in the vertebrae.

B. Meningocele involves protrusion of the meninges and spinal cord through the defect.

C. Diastematomyelia is rarely associated with spina bifida and splits the spinal cord.

D. The incidence of myelomeningocele has decreased due to prenatal diagnosis and termination options.

See Answer in Part B → Q7

@Neet_pg_bot

Q8: Which of the following correctly pairs a brain region with its corresponding structure or function? (Q848449)

A. Myelencephalon: Develops into the cerebellum, involved in motor control and balance.

B. Tectum: Located in the hindbrain and responsible for auditory and visual reflexes.

C. Hypothalamus: Part of the diencephalon, regulates hunger, thirst, body temperature, and sleep-wake cycles.

D. Frontal Lobe: Primarily involved in visual processing and spatial awareness.

See Answer in Part B → Q8

@Neet_pg_bot

Q9: Which of the following statements about the treatment of aqueduct stenosis is correct? (Q848450)

A. Ventriculoperitoneal shunting permanently cures aqueduct stenosis.

B. Endoscopic third ventriculostomy involves diverting CSF to the abdominal cavity.

C. Aqueduct stenosis can be treated with medications alone in most cases.

D. Ventriculoperitoneal shunting involves diverting CSF to reduce intracranial pressure.

See Answer in Part B → Q9

@Neet_pg_bot

Q10: Which of the following statements about the cerebellar peduncles and corpora quadrigemina is correct? (Q848451)

A. Superior cerebellar peduncles carry afferent signals from the cerebellum to the medulla.

B. Middle cerebellar peduncles transmit sensory information from the spinal cord to the cerebellum.

C. Inferior cerebellar peduncles connect the cerebellum to the medulla and aid in balance and posture.

D. Superior colliculi are involved in auditory processing and relay signals to the auditory cortex.

See Answer in Part B → Q10

@Neet_pg_bot

Q11: Identify the labelled structures in the given diagram. (Q848452)

A. A- Fornix; B- Hippocampus; C- Corpus Callosum

B. A – Fornix; B – Amygdala; C – Hippocampus

C. A- Fornix; B- Corpus Callosum; C- Hippocampus

D. A – Fornix; B – Hypothalamus; C – Amygdala

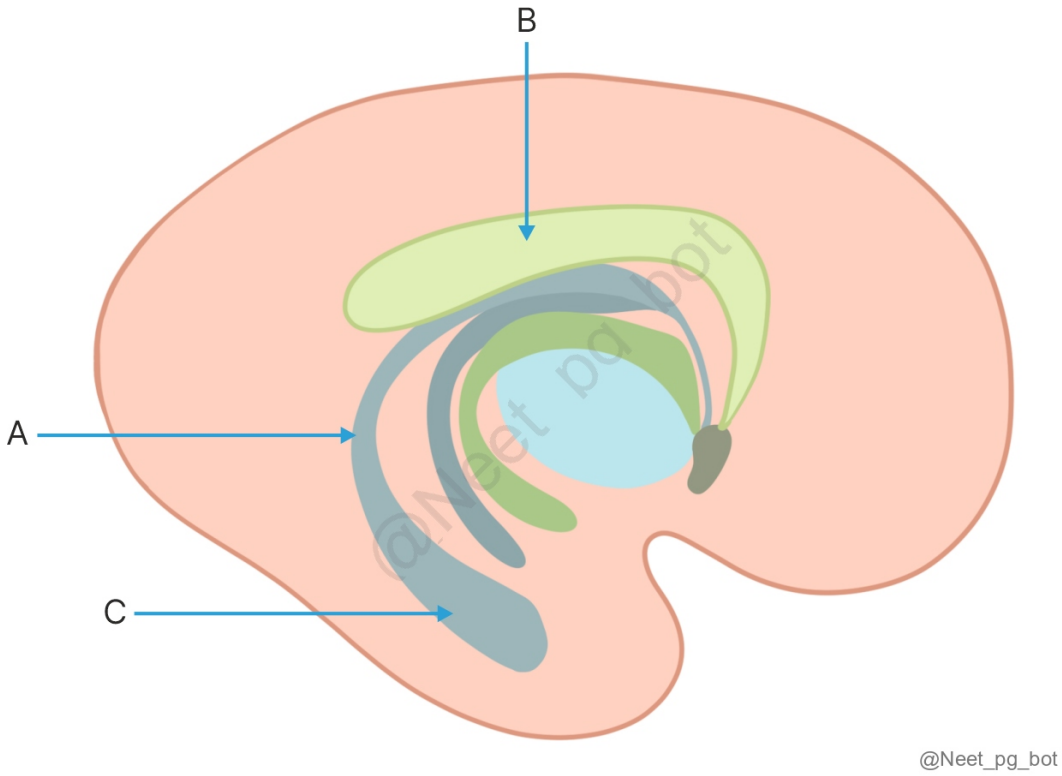

See Answer in Part B → Q11

@Neet_pg_bot

Q12: Which of the following accurately describes the pathway of the Papez circuit? (Q848458)

A. Cingulate cortex → Hippocampus → Mammillary bodies → Anterior thalamic nuclei → Fornix

B. Cingulate cortex → Mammillary bodies → Hippocampus → Fornix → Anterior thalamic nuclei

C. Hippocampus → Cingulate cortex → Anterior thalamic nuclei → Mammillary bodies → Fornix

D. Hippocampus → Fornix → Mammillary bodies → Anterior thalamic nuclei → Cingulate cortex

See Answer in Part B → Q12

@Neet_pg_bot

• [03_Neuro Anatomy] 009 Ventricular System White Matter And Neural Columns

« Back to Folder Directory

[03_Neuro Anatomy] 009 Ventricular System White Matter And Neural Columns — Quick Jump

Q1 (p. 112)	*Q2 (p. 112)*	*Q3 (p. 113)*	*Q4 (p. 113)*	*Q5 (p. 114)*	*Q6 (p. 114)*
Q7 (p. 115)	*Q8 (p. 115)*	*Q9 (p. 116)*	*Q10 (p. 116)*	*Q11 (p. 116)*	*Q12 (p. 117)*
Q13 (p. 117)	*Q14 (p. 117)*	*Q15 (p. 118)*	*Q16 (p. 118)*		

Q1: Which structure forms the lateral wall of the anterior horn of the lateral ventricle? (Q848499)

A. Corpus callosum

B. Head of the caudate nucleus

C. Thalamus

D. Hippocampus

See Answer in Part B → Q1

@Neet_pg_bot

Q2: Which cranial nerve sensory fibres transmit sensory information from the skin and mucous membranes of the face, head, and neck? (Q848509)

A. Special Somatic Afferent (SSA) fibres

B. General Visceral Afferent (GVA) fibres

C. Special Visceral Afferent (SVA) fibres

D. General Somatic Afferent (GSA) fibres

See Answer in Part B → Q2

@Neet_pg_bot

Q3: A 7-year-old girl presents with severe headaches, vomiting, and papilloedema. Imaging reveals obstructive hydrocephalus due to a tumour blocking the exit of cerebrospinal fluid from the fourth ventricle. Which of the following structures is most likely blocked? (Q848493)

A. The Foramen of Monro

B. Foramina of Luschka

C. Foramen rotundum

D. Foramen ovale

See Answer in Part B → Q3

@Neet_pg_bot

Q4: Which of the given options are correctly matched based on the image given? (Q848494)

A. 3- Lateral recess, 5- Frontal horn

B. 1- Occipital horn, 7- Third Ventricle

C. 2- Fourth Ventricle, 4- Aqueduct

D. 3- Temporal horn, 6- Aqueduct

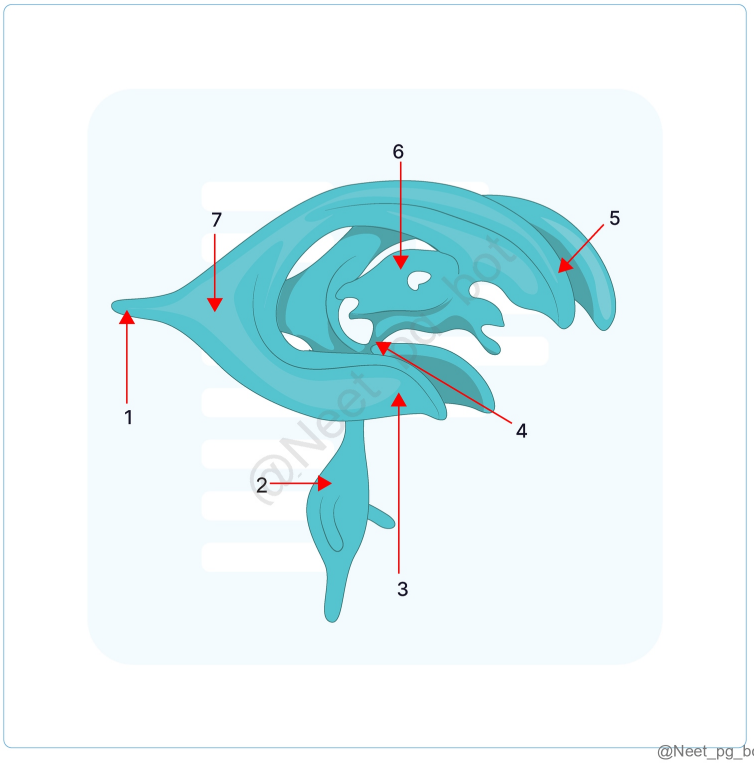

See Answer in Part B → Q4

@Neet_pg_bot

Q5: What is a primary characteristic of Benign External Hydrocephalus (BEH) in infants? (Q848495)

A. Severe neurological symptoms

B. Macrocephaly without significant symptoms

C. Necessitates immediate surgical intervention

D. Increased ventricular enlargement

See Answer in Part B → Q5

@Neet_pg_bot

Q6: Match the following wall of the 3rd ventricle with its respective component. 1. Anterior wall a) Hypothalamus 2. Posterior Wall b) Mammillary bodies 3. Lateral wall c) Lamina terminalis 4. Floor d) Pineal gland (Q848496)

A. 1-d, 2-a, 3-b, 4-c

B. 1-b, 2-a, 3-c, 4-d

C. 1-a, 2-b, 3-d, 4-c

D. 1-c, 2-d, 3-a, 4-b

See Answer in Part B → Q6

@Neet_pg_bot

Q7: Match the following boundary of the 4th ventricle with its component. 1. Lateral wall a) Superior medullary velum 2. Posterior wall b) Superior medulla 3. Rhomboid fossa c) Superior cerebellar peduncle (Q848497)

A. 1-c, 2-b, 3-a

B. 1-c, 2-a, 3-b

C. 1-b, 2-a, 3-c

D. 1-a, 2-b, 3-c

See Answer in Part B → Q7

@Neet_pg_bot

Q8: Which structure in the floor of the 4th ventricle consists of transverse white fibres derived from the arcuate nuclei? (Q848498)

A. Sulcus limitans

B. Stria medullaris

C. Locus ceruleus

D. Area postrema

See Answer in Part B → Q8

@Neet_pg_bot

Q9: Which of the following does not cross the midline? (Q848500)

A. Corpus Callosum

B. Anterior Commissure

C. Fornix

D. Arcuate Fasciculus

See Answer in Part B → Q9

@Neet_pg_bot

Q10: Which association fibre connects Wernicke's area with Broca's area (Q848502)

A. Uncinate Fasciculus

B. Inferior Longitudinal Fasciculus

C. Arcuate Fasciculus

D. Superior Longitudinal Fasciculus

See Answer in Part B → Q10

@Neet_pg_bot

Q11: Which part of the corpus callosum contains fibres that connect the right and left occipital cortices? (Q848503)

A. Rostrum

B. Genu

C. Body or Trunk

D. Splenium

See Answer in Part B → Q11

@Neet_pg_bot

Q12: Which cranial nerve motor fibres are responsible for innervating skeletal muscles that develop from somites? (Q848505)

A. General Somatic Efferent fibers

B. Special Visceral Efferent fibers

C. General Visceral Efferent fibers

D. Special Somatic Afferent fibers

See Answer in Part B → Q12

@Neet_pg_bot

Q13: Which cranial nerve sensory fibres are primarily responsible for transmitting taste sensations from the tongue to the brainstem? (Q848510)

A. Special Somatic Afferent (SSA) fibres

B. Special Visceral Afferent (SVA) fibres

C. General Somatic Afferent (GSA) fibres

D. General Visceral Afferent (GVA) fibres

See Answer in Part B → Q13

@Neet_pg_bot

Q14: What is the primary function of the alar plate in the developing neural tube? (Q848513)

A. Development of motor nuclei

B. Processing sensory information

C. Formation of autonomic motor fibres

D. Regulation of somatic motor output

See Answer in Part B → Q14

@Neet_pg_bot

Q15: Which of the following cranial nerve nuclei originates from the General Visceral Efferent (GVE) column of the basal plate? (Q848515)

A. Edinger-Westphal nucleus

B. Hypoglossal nucleus

C. Facial nucleus

D. Cochlear nucleus

See Answer in Part B → Q15

@Neet_pg_bot

Q16: A 5 year old boy came with complaints of sudden onset weakness in his lower limbs. His parents mention a history of viral illness with fever and sore throat. On examination, the boy has flaccid paralysis of his legs with muscle wasting, absent deep tendon reflexes, and no sensory deficits. Which of the following structures is primarily affected in this condition, leading to muscle paralysis and wasting? (Q848516)

A. Posterior white columns of the spinal cord

B. Anterior grey columns of the spinal cord

C. Spinothalamic tract

D. Cerebellar peduncles

See Answer in Part B → Q16

@Neet_pg_bot

• [03_Neuro Anatomy] 010 Cerebrum And Associated Structures

« Back to Folder Directory

[03_Neuro Anatomy] 010 Cerebrum And Associated Structures — Quick Jump

Q1 (p. 119)	*Q2 (p. 119)*	*Q3 (p. 120)*	*Q4 (p. 120)*	*Q5 (p. 121)*	*Q6 (p. 121)*
Q7 (p. 121)	*Q8 (p. 122)*	*Q9 (p. 122)*	*Q10 (p. 122)*	*Q11 (p. 123)*	*Q12 (p. 124)*
Q13 (p. 124)	*Q14 (p. 125)*	*Q15 (p. 125)*	*Q16 (p. 126)*	*Q17 (p. 126)*	

Q1: A 5 year old child presents with developmental delays, including difficulties in motor coordination and speech. MRI reveals a complete absence of the corpus callosum. Which of the following is not typically associated with this condition? (Q848567)

A. Intellectual disability

B. Seizures

C. Hemispatial neglect

D. Hyperactivity and impulsivity

See Answer in Part B → Q1

@Neet_pg_bot

Q2: Which of the following is part of the complete syndrome triad associated with Anterior Choroidal Artery Syndrome? (Q848555)

A. Bilateral hemiplegia

B. Contralateral hemisensory loss

C. Bitemporal hemianopia

D. Ipsilateral homonymous hemianopia

See Answer in Part B → Q2

@Neet_pg_bot

Q3: The labyrinthine artery arises from which of the following arteries? (Q848581)

A. Internal carotid artery

B. External carotid artery

C. Vertebral artery

D. Basilar artery

See Answer in Part B → Q3

@Neet_pg_bot

Q4: In the image below, which structure is labeled as the rostrum of the corpus callosum? (Q848568)

A. Structure A

B. Structure B

C. Structure C

D. Structure D



See Answer in Part B → Q4

@Neet_pg_bot

Q5: A 35 year old patient presents with rapid weight gain and persistent hunger despite adequate food intake. MRI reveals a lesion in the hypothalamus. Which of the following hypothalamic nuclei, when lesioned, is most likely to cause an uncontrolled appetite and extreme obesity? (Q848566)

A. Anterior Hypothalamic Area

B. Ventromedial nucleus

C. Lateral hypothalamus

D. Suprachiasmatic Nucleus

See Answer in Part B → Q5

@Neet_pg_bot

Q6: Which of the following is the function of the Ventral Posteromedial Nucleus within the Ventral Group Nuclei? (Q848565)

A. Influences motor activities by connecting with the premotor cortex.

B. Receives sensory information from the cerebellum and red nucleus.

C. Receives trigeminal and gustatory pathways.

D. Projects to the primary motor areas of the cerebral cortex.

See Answer in Part B → Q6

@Neet_pg_bot

Q7: Which of the following thalamic nuclei is concerned with recent memory and emotional tone? (Q848564)

A. Medial geniculate body

B. Anterior Thalamic Nuclei

C. Dorsomedial Nucleus

D. Lateral geniculate body

See Answer in Part B → Q7

@Neet_pg_bot

Q8: A 62 year old patient presents with sudden onset of right-sided weakness and facial droop. Neurological examination reveals upper motor neuron signs with weakness in both the arm and leg on the right side. MRI confirms an infarct in the middle cerebral artery (MCA) territory involving the genu of the internal capsule. Which of the following tracts passes through the genu? (Q848563)

A. Corticobulbar tract

B. Corticospinal tract

C. Spinothalamic tract

D. Medial lemniscus

See Answer in Part B → Q8

@Neet_pg_bot

Q9: Which of the following tracts passes through the genu of the internal capsule? (Q848562)

A. Corticospinal tract

B. Corticonuclear tract

C. Optic radiation

D. Auditory radiation

See Answer in Part B → Q9

@Neet_pg_bot

Q10: Which sulcus is involved in separating the frontal lobe from the parietal lobe? (Q848538)

A. Lateral Sulcus

B. Central Sulcus

C. Calcarine Sulcus

D. Parieto-occipital Sulcus

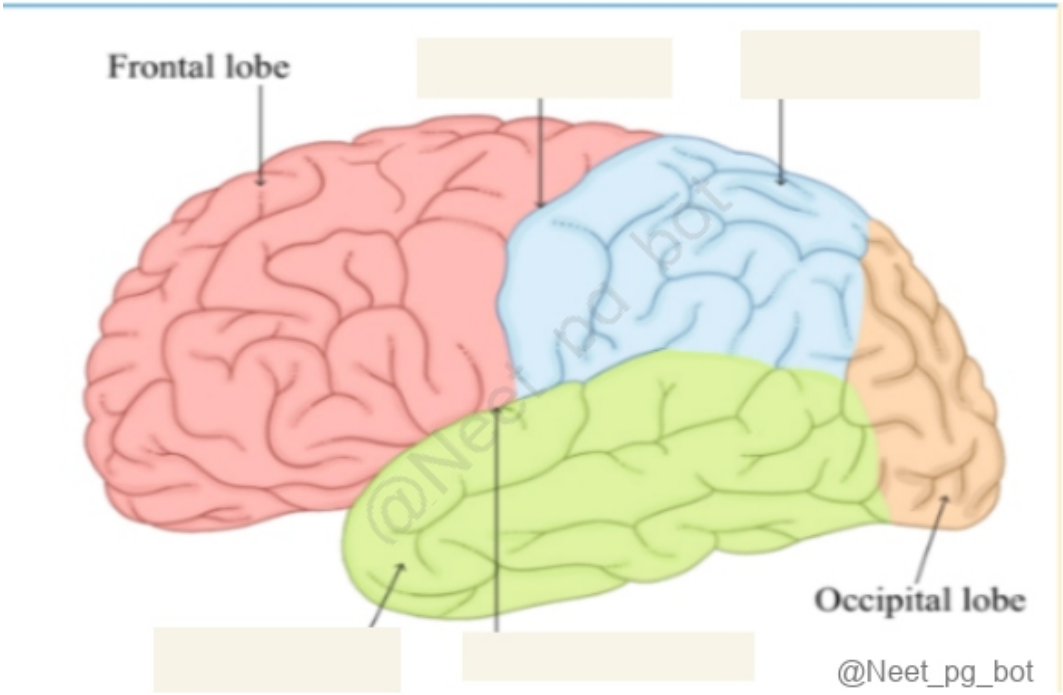

See Answer in Part B → Q10

@Neet_pg_bot

Q11: Which of the following correctly describes the anatomical relations of the internal capsule? (Q848554)

A. The anterior limb lies between the thalamus and the posterior part of the lentiform nucleus.

B. The genu is located posterior to the head of the caudate nucleus.

C. The medial boundary consists of the thalamus and the caudate nucleus.

D. The retro lentiform part is situated above the lentiform nucleus.

See Answer in Part B → Q11

@Neet_pg_bot

Q12: Match the following: (Q848553)

A. A-Putamen; B- Globus Pallidus; C- Caudate Nucleus; D- Subthalamic Nucleus; E- Substantia Nigra; F- Thalamus

B. A- Caudate Nucleus; B- Putamen; C- Thalamus; D- Globus Pallidus; E- Subthalamic Nucleus; F- Substantia Nigra

C. A- Caudate Nucleus; B- Globus Pallidus; C- Substantia Nigra; D- Globus Pallidus; E- Thalamus; F- Subthalamic Nucleus

D. A- Caudate Nucleus; B- Putamen; C- Globus Pallidus; D- Thalamus; E- Subthalamic Nucleus; F- Substantia Nigra

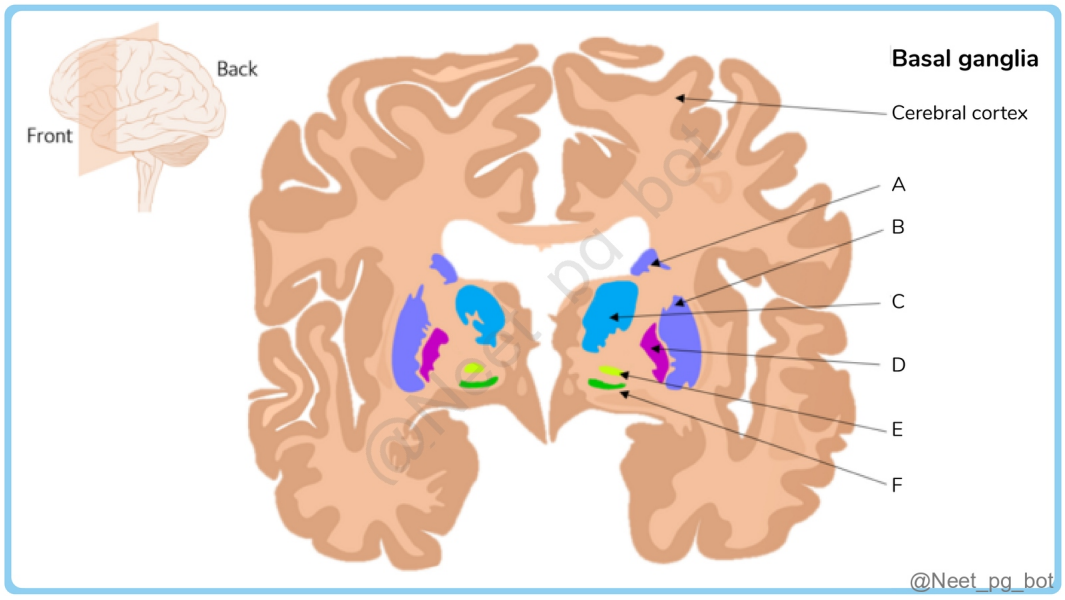

See Answer in Part B → Q12

@Neet_pg_bot

Q13: A 70 year old female presents with tremors, rigidity, and bradykinesia. Neurological examination reveals degeneration of dopaminergic neurons in a specific region of the brain. Which component of the basal ganglia is primarily affected in this

patient's condition? (Q848552)

A. Caudate Nucleus

B. Putamen

C. Substantia Nigra

D. Globus Pallidus

See Answer in Part B → Q13

@Neet_pg_bot

Q14: A 65 year old male presents with fluent but nonsensical speech and difficulty understanding spoken language. He is unaware of his language difficulties, and his reading and writing abilities are also severely impaired. Which type of aphasia is most likely present in this patient? (Q848551)

A. Global aphasia

B. Broca's aphasia

C. Wernicke's aphasia

D. Anomic aphasia

See Answer in Part B → Q14

@Neet_pg_bot

Q15: Match the Brodmann areas with their respective functions: Brodmann Area Function a) BA 1, 2, 3 1) Primary visual cortex b) BA 4 2) Primary motor cortex c) BA 17 3) Primary somatosensory cortex d) BA 44, 45 4) Language production (Broca’s area) (Q848550)

A. a-1; b-2; c-4; d-3

B. a-3; b-2; c-4; d-1

C. a-3; b-2; c-1; d-4

D. a-2; b-3; c-1; d-4

See Answer in Part B → Q15

@Neet_pg_bot

Q16: A 68 year old male presents with sudden onset weakness in his right arm and face, along with difficulty speaking. MRI reveals an ischemic stroke. Which artery is most likely involved in this patient's stroke based on his symptoms? (Q848549)

A. Anterior cerebral artery

B. Middle cerebral artery

C. Posterior cerebral artery

D. Vertebral artery

See Answer in Part B → Q16

@Neet_pg_bot

Q17: Which statement correctly describes the representation of body parts in the motor and sensory homunculi? (Q848548)

A. In the motor homunculus, finer motor control areas like arms and legs have larger cortical regions.

B. The sensory homunculus shows body parts with higher acuity, like fingertips, having smaller cortical areas.

C. Both homunculi are in the precentral gyrus and represent the same body parts.

D. The motor homunculus in the precentral gyrus has larger areas for fine motor parts like hands and face.

See Answer in Part B → Q17

@Neet_pg_bot

• [03_Neuro Anatomy] 011 Brainstem Cranial Nerves And Cerebellum - I

« Back to Folder Directory

[03_Neuro Anatomy] 011 Brainstem Cranial Nerves And Cerebellum - I — Quick Jump

Q1 (p. 127)	*Q2 (p. 127)*	*Q3 (p. 128)*	*Q4 (p. 128)*	*Q5 (p. 129)*	*Q6 (p. 129)*
Q7 (p. 130)	*Q8 (p. 130)*	*Q9 (p. 131)*	*Q10 (p. 131)*	*Q11 (p. 132)*	*Q12 (p. 132)*
Q13 (p. 132)	*Q14 (p. 133)*	*Q15 (p. 134)*	*Q16 (p. 135)*	*Q17 (p. 135)*	*Q18 (p. 135)*
Q19 (p. 136)	*Q20 (p. 136)*	*Q21 (p. 136)*	*Q22 (p. 137)*	*Q23 (p. 137)*	*Q24 (p. 137)*
Q25 (p. 138)	*Q26 (p. 138)*				

Q1: Which cerebellar zone is mainly associated with processing proprioceptive information? (Q848603)

A. Archicerebellum

B. Paleocerebellum

C. Neocerebellum

D. Vestibulocerebellum

See Answer in Part B → Q1

@Neet_pg_bot

Q2: Which pathway involves inhibitory projections originating from the cerebellar nuclei, contributing to the regulation of motor activity and coordination? (Q848619)

A. Rubrospinal tract

B. Nucleo-olivary pathway

C. Ventral spinocerebellar tract

D. Vestibulospinal tract

See Answer in Part B → Q2

@Neet_pg_bot

Q3: Which of the following statements about cerebellar circuitry is false? (Q848618)

A. Climbing fibres directly excite Purkinje cells by forming extensive synaptic connections.

B. Mossy fibres excite Purkinje cells through granule cells, creating a diffuse excitatory effect.

C. Purkinje cells send excitatory signals to deep cerebellar nuclei.

D. Stellate, basket, and Golgi cells serve as inhibitory interneurons in the cerebellar cortex.

See Answer in Part B → Q3

@Neet_pg_bot

Q4: A 62-year-old male presents to the emergency department with a sudden onset of severe vertigo, bilateral hearing loss, and tinnitus. He also exhibits facial weakness on the right side and demonstrates ataxia when attempting to walk. An MRI performed to evaluate the condition is given below. Which artery is most likely affected in this patient's condition? {{caption_text}} (Q848617)

A. Middle cerebral artery

B. Superior cerebellar artery

C. Anterior inferior cerebellar artery

D. Vertebral artery

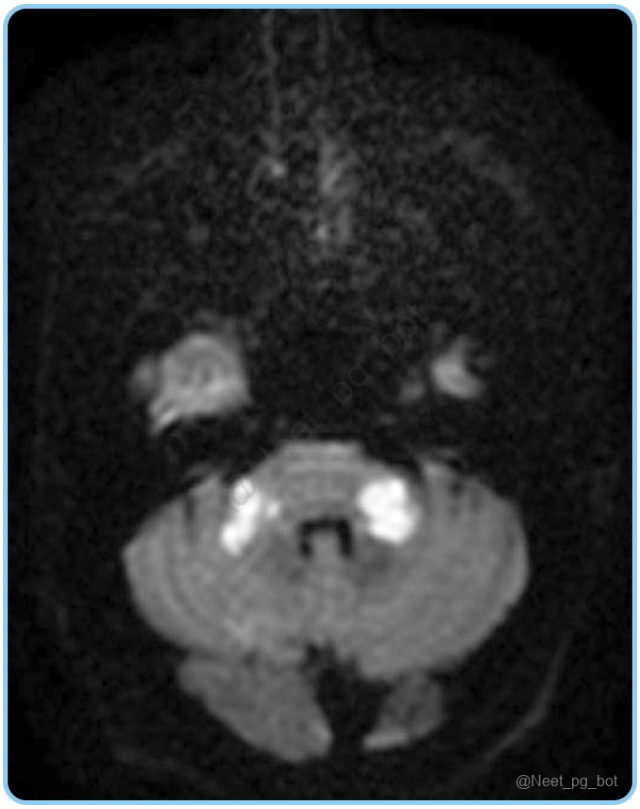

See Answer in Part B → Q4

@Neet_pg_bot

Q5: Which type of fibres enter the cerebellum via the middle cerebellar peduncle? (Q848616)

A. Olivo-cerebellar fibres

B. Cerebro-ponto-cerebellar fibres

C. Spinocerebellar fibers

D. Vestibulo-cerebellar fibres

See Answer in Part B → Q5

@Neet_pg_bot

Q6: Which of the following structures receives direct projections from the dentate nucleus? (Q848615)

A. Premotor cortex

B. Ventrolateral nucleus of the thalamus

C. The anterior nucleus of the thalamus

D. Parietal cortex

See Answer in Part B → Q6

@Neet_pg_bot

Q7: The fastigial nucleus primarily projects to which of the following structures? (Q848610)

A. Red nucleus

B. Thalamus

C. Vestibular nuclei

D. Cerebral cortex

See Answer in Part B → Q7

@Neet_pg_bot

Q8: Which of the following intrinsic neurons are correctly matched with their respective layers in the cerebellar cortex? {{caption_text}} (Q848609)

A. 1- Plexiform layers; Golgi cells

B. 2- Molecular layer; Purkinje cells

C. 2- Granular layer; Basket cells

D. 3- Granular layer; Golgi cells

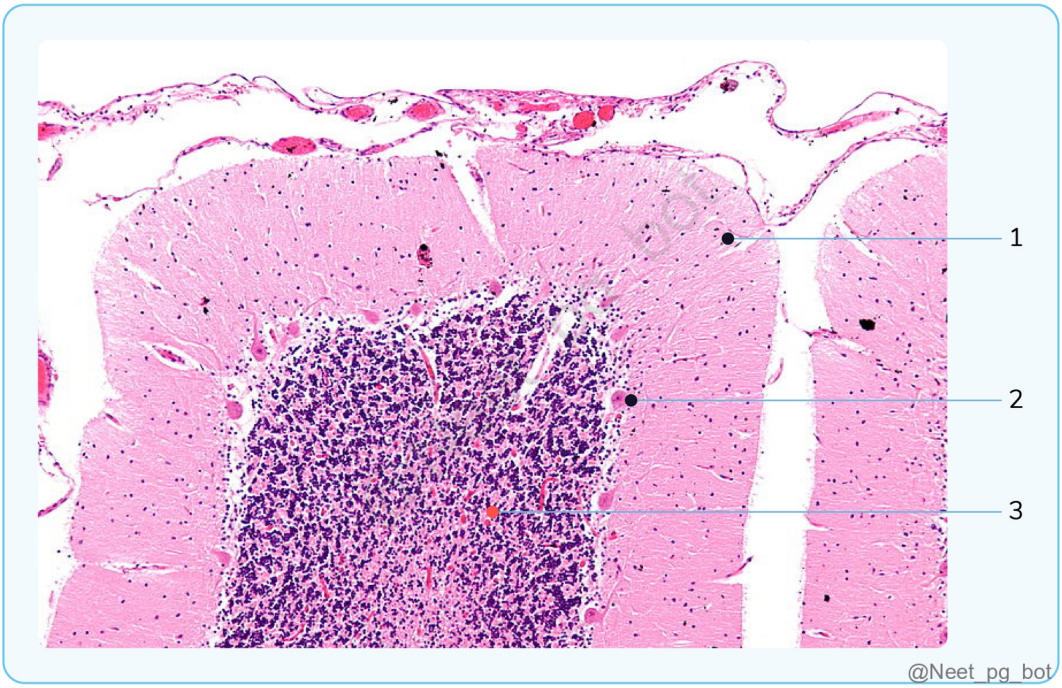

See Answer in Part B → Q8

@Neet_pg_bot

Q9: Which of the following deep cerebellar nuclei is primarily involved in the smooth execution of skilled voluntary movements? (Q848608)

A. Fastigial nucleus

B. Emboliform nucleus

C. Globose nucleus

D. Dentate nucleus

See Answer in Part B → Q9

@Neet_pg_bot

Q10: What is the significance of the second decussation of the ventral spinocerebellar tract within the cerebellum? (Q848607)

A. Enables contralateral proprioceptive processing

B. Ensures ipsilateral proprioceptive termination

C. Blocks incorrect proprioceptive signals

D. Causes all fibres to terminate bilaterally

See Answer in Part B → Q10

@Neet_pg_bot

Q11: From which anatomical structure does the dorsal spinocerebellar tract originate? (Q848606)

A. Anterior horn of the spinal cord

B. Cerebellar cortex

C. Medulla oblongata

D. Posterior thoracic nucleus (Clarke's column)

See Answer in Part B → Q11

@Neet_pg_bot

Q12: Which cerebellar peduncle is primarily composed of only afferent fibres? (Q848605)

A. Inferior cerebellar peduncle

B. Middle cerebellar peduncle

C. Superior cerebellar peduncle

D. All of the above

See Answer in Part B → Q12

@Neet_pg_bot

Q13: Which cerebellar lobe is associated with maintaining balance and controlling eye movements? (Q848604)

A. Flocculonodular Lobe

B. The anterior lobe

C. The posterior lobe

D. Neocerebellum

See Answer in Part B → Q13

@Neet_pg_bot

Q14: Identify the correct option. (Q848477)

A. 6- Trigeminal nerve; 7- Trochlear nerve

B. 5- Abducens nerve; 3- Vagus nerve

C. 1- Hypoglossal nerve; 2- Facial nerve

D. 4- Vestibulocochlear nerve; 8- Optic Nerve

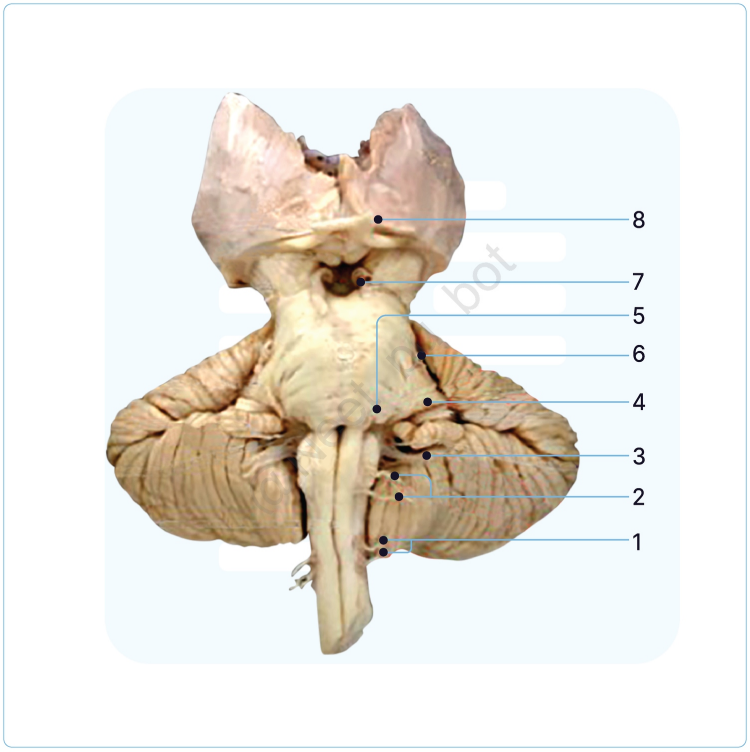

@Neet_pg_bot

See Answer in Part B → Q14

@Neet_pg_bot

Q15: Match the following neural columns with their corresponding cranial nerve nuclei. 1. General Somatic Efferent (GSE) A) Nucleus ambiguus 2. Special Visceral Afferent (SVA) B) Edinger-Westphal nucleus 3. General Visceral Efferent (GVE) C) Oculomotor nucleus 4. Special Visceral Efferent (SVE) D) Nucleus of the solitary tract (Q848590)

A. 1-A, 2-B, C-3, 4-D

B. 1-D, 2-C, 3-B, 4-A

C. 1-C, 2-D, 3-B, 4-A

D. 1-B, 2-A, 3-D, 4-C

See Answer in Part B → Q15

@Neet_pg_bot

Q16: Which of the following correctly arranges the brainstem nuclei from medial to lateral in the brainstem? (Q848518)

A. Oculomotor nucleus → Trochlear nucleus → Edinger Westphal nucleus

B. Hypoglossal nucleus → Dorsal motor nucleus of the vagus → Nucleus tractus solitarius

C. Motor nuclei of Trigeminal → Motor nuclei of Facial → Abducent nucleus

D. Nucleus ambiguus → Hypoglossal nucleus → Nucleus tractus solitarius

See Answer in Part B → Q16

@Neet_pg_bot

Q17: Which nuclei belong to the Special Somatic Afferent (SSA) column? (Q848517)

A. Cochlear and vestibular nuclei

B. Sensory nucleus of the trigeminal nerve

C. Hypoglossal and abducens nuclei

D. Nucleus ambiguus and facial nucleus

See Answer in Part B → Q17

@Neet_pg_bot

Q18: Which artery is most commonly occluded, leading to medial medullary syndrome and lateral pontine syndrome, respectively? (Q848514)

A. Anterior cerebral artery, PICA

B. Posterior cerebral artery, Basilar artery

C. Anterior spinal artery, AICA

D. Vertebral artery, superior cerebellar artery

See Answer in Part B → Q18

@Neet_pg_bot

Q19: Which arteries supply the posterior region of the superior medulla and pons respectively? (Q848512)

A. Posterior Inferior Cerebellar Artery and Anterior Inferior Cerebellar Artery

B. Basilar Artery and Vertebral Artery

C. Anterior Spinal Artery and Posterior Spinal Artery

D. Superior Cerebellar Artery and Anterior Inferior Cerebellar Artery

See Answer in Part B → Q19

@Neet_pg_bot

Q20: Which artery supplies the posterior region of the midbrain? (Q848511)

A. Basilar Artery

B. Posterior Choroidal Arteries

C. Posterior Cerebral Artery

D. Superior Cerebellar Artery

See Answer in Part B → Q20

@Neet_pg_bot

Q21: The baroreceptor reflex that helps regulate blood pressure involves general visceral afferent (GVA) fibres from which of the following receptors and pathways? (Q848508)

A. Carotid body via the glossopharyngeal nerve

B. Aortic bodies via the vagus nerve

C. Carotid sinus via the vagus nerve

D. Pulmonary arteries via the glossopharyngeal nerve

See Answer in Part B → Q21

@Neet_pg_bot

Q22: The nucleus of the solitary tract receives _____ sensations from the carotid body and carotid sinus primarily through _____ nerve. (Q848507)

A. General Somatic Efferent; Vagus nerve

B. Special Visceral Afferent; Facial nerve

C. General Visceral Afferent; Glossopharyngeal nerve

D. Special Somatic Efferent; Trigeminal nerve

See Answer in Part B → Q22

@Neet_pg_bot

Q23: Which of the following statements about the jaw jerk reflex is false? (Q848506)

A. It is a spinal reflex initiated by tapping the jaw.

B. It involves the mesencephalic trigeminal nucleus as an integration centre.

C. The efferent pathway includes the mandibular nerve.

D. It is a monosynaptic reflex involving a single synapse.

See Answer in Part B → Q23

@Neet_pg_bot

Q24: Which of the following nuclei of the trigeminal nerve is primarily responsible for proprioceptive sensations from the muscles of mastication? (Q848504)

A. Main Sensory Nucleus

B. Spinal Nucleus

C. Mesencephalic Nucleus

D. Motor Nucleus

See Answer in Part B → Q24

@Neet_pg_bot

Q25: Which of the following statements regarding damage to the midline brainstem nuclei is false? (Q848481)

A. Damage to the oculomotor nucleus can result in the eye looking laterally and ptosis.

B. Injury to the trochlear nucleus leads to difficulty in upward gaze and may cause a compensatory head tilt to the same side.

C. Damage to the abducens nucleus results in medial strabismus, causing the affected eye to turn inward.

D. Lesion of the hypoglossal nucleus leads to weakness and atrophy of the tongue on the affected side.

See Answer in Part B → Q25

@Neet_pg_bot

Q26: A 65 y/o patient presents with sudden dizziness, difficulty swallowing, ipsilateral loss of temperature sensation on the face, contralateral loss of pain and temperature sensation in the trunk, ipsilateral ataxia, and giddiness. Which anatomical structure is responsible for the ipsilateral loss of temperature sensation on the face of this patient? (Q848478)

A. Spinothalamic tract

B. Spinal nucleus and tract of the trigeminal nerve

C. Inferior cerebellar peduncle

D. Vestibular nuclei

See Answer in Part B → Q26

• [03_Neuro Anatomy] 012 Applied Neuroanatomy Tracts Brainstem Autonomic System

« Back to Folder Directory

[03_Neuro Anatomy] 012 Applied Neuroanatomy Tracts Brainstem Autonomic System — Quick Jump

Q1 (p. 140)	*Q2 (p. 140)*	*Q3 (p. 141)*	*Q4 (p. 141)*	*Q5 (p. 141)*	*Q6 (p. 142)*
Q7 (p. 142)	*Q8 (p. 142)*	*Q9 (p. 143)*	*Q10 (p. 144)*	*Q11 (p. 144)*	*Q12 (p. 144)*
Q13 (p. 145)	*Q14 (p. 145)*	*Q15 (p. 146)*	*Q16 (p. 146)*	*Q17 (p. 147)*	*Q18 (p. 147)*
Q19 (p. 148)	*Q20 (p. 148)*	*Q21 (p. 149)*	*Q22 (p. 149)*	*Q23 (p. 150)*	*Q24 (p. 150)*
Q25 (p. 151)					

Q1: Which of the following statements is incorrect regarding Weber syndrome? (Q848613)

A. Lesion is in the oculomotor nerve fascicles and corticospinal fibers

B. Hemiplegia is present on the opposite side of the lesion

C. There is a lateral squint on the same side of the lesion

D. None of the above

See Answer in Part B → Q1

@Neet_pg_bot

Q2: Which of the following statements is incorrect? (Q848573)

A. The PNS relays impulses in neurons away from the viscera.

B. The sympathetic nervous system has thoracolumbar outflow.

C. Erection is controlled by the parasympathetic nervous system.

D. Tearing is regulated by the parasympathetic nervous system.

See Answer in Part B → Q2

@Neet_pg_bot

Q3: Where does the hypothalamospinal tract terminate before synapsing with the second-order neurons? (Q848576)

A. Superior cervical ganglion

B. Inferior cervical ganglion

C. Intermediolateral cell column of the spinal cord

D. Posterior horn of the spinal cord

See Answer in Part B → Q3

@Neet_pg_bot

Q4: All of the following are branches of the internal carotid artery except? (Q848580)

A. Ophthalmic artery

B. Anterior choroidal artery

C. Posterior communicating artery

D. Anterior inferior cerebellar artery

See Answer in Part B → Q4

@Neet_pg_bot

Q5: A transverse section of the medulla oblongata at the level of the motor (pyramidal) decussation reveals modifications to the typical spinal cord structure. Which of the following changes is observed at this level? (Q848596)

A. Formation of the medial lemniscus from second-order axons

B. Crossing of corticospinal fibres from the anterior funiculi

C. Presence of the vestibular nuclei near the fourth ventricle

D. Appearance of the inferior olivary complex lateral to the pyramid

See Answer in Part B → Q5

@Neet_pg_bot

Q6: Which of the following is the correct match of brainstem components with the respective cranial nerve nuclei that originate from them? Column A Column B a. Midbrain 1. Trigeminal nerve b. Pons 2. Oculomotor nerve c. Medulla oblongata 3. Glossopharyngeal nerve d. Pontomedullary junction 4. Facial nerve (Q848592)

A. a-2, b-1, c-3, d-4

B. a-1, b-2, c-4, d-3

C. a-3, b-4, c-1, d-2

D. a-4, b-3, c-2, d-1

See Answer in Part B → Q6

@Neet_pg_bot

Q7: Which of the following findings is not a clinical manifestation of Wallenberg syndrome? (Q848614)

A. Contralateral ataxia

B. Horner's syndrome

C. Ipsilateral facial pain and temperature loss

D. Contralateral body pain and temperature loss

See Answer in Part B → Q7

@Neet_pg_bot

Q8: Which of the following nerve palsy would suggest a lesion affecting the structures within the interpeduncular fossa? (Q848612)

A. Glossopharyngeal nerve

B. Vagus nerve

C. Oculomotor nerve

D. Hypoglossal nerve

See Answer in Part B → Q8

@Neet_pg_bot

Q9: Which among the following options is correctly matched for the alphabet labeled in the below image? (Q848611)

A. A- Pyramid

B. B- Trochlear nerve

C. C- Basilar sulcus

D. D- Olive

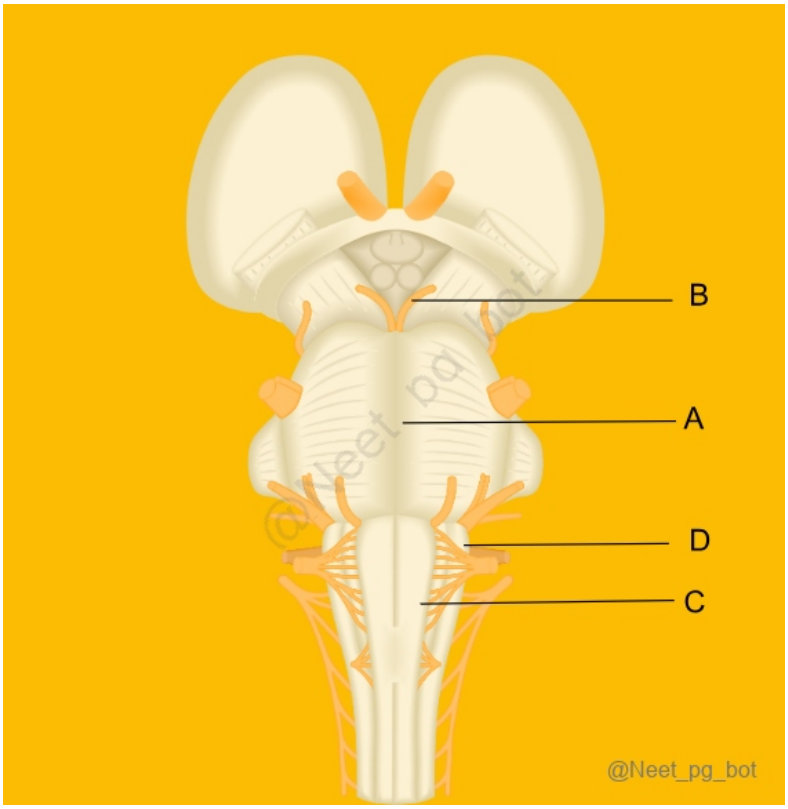

See Answer in Part B → Q9

@Neet_pg_bot

Q10: A 45-year-old patient presents with a severe infection of the face. Which of the following venous structures could allow the infection to spread to the cavernous sinus? (Q848600)

A. Superior petrosal sinus

B. Inferior ophthalmic vein

C. Inferior petrosal sinus

D. Basilar plexus of veins

See Answer in Part B → Q10

@Neet_pg_bot

Q11: A 45-year-old patient presents with symptoms of headache and visual disturbances. Imaging studies reveal a large clot in the superior sagittal sinus. Which of the following statements about the superior sagittal sinus is correct? (Q848599)

A. It drains directly into the internal jugular vein.

B. It runs along the midline, attached to the falx cerebri, and drains into the confluence of sinuses.

C. It is located in the falx cerebelli and connects with the occipital sinus.

D. It receives blood from the diploic veins within the cranial bones.

See Answer in Part B → Q11

@Neet_pg_bot

Q12: A 56-year-old patient presents with difficulty speaking, swallowing, and hoarseness of voice. On examination, there is noticeable wasting of one side of the tongue and weakness in the sternocleidomastoid and trapezius muscles. The patient

also exhibits contralateral hemiplegia and contralateral loss of sensation. Which of the following lesions is most likely responsible for these symptoms? (Q848598)

A. Multiple sclerosis

B. Meningioma of the cerebellum

C. Medullary infarct

D. Vestibular schwannoma

See Answer in Part B → Q12

@Neet_pg_bot

Q13: Which of the following accurately describes the corticonuclear tract? (Q848597)

A. It terminates exclusively in the spinal cord with an ipsilateral projection.

B. It descends through the internal capsule and pons, terminating on cranial nerve nuclei with a contralateral projection.

C. It controls involuntary movements of the head and neck muscles.

D. The term "corticobulbar" is more accurate than "corticonuclear" for describing its function.

See Answer in Part B → Q13

@Neet_pg_bot

Q14: At the level of the facial colliculus, the fibres of which cranial nerves form a loop around the abducens nucleus, creating the colliculus? (Q848595)

A. Glossopharyngeal nerve

B. Trigeminal nerve

C. Facial nerve

D. Hypoglossal nerve

See Answer in Part B → Q14

@Neet_pg_bot

Q15: Which of the following conditions is associated with lesions at the level marked in the midbrain? (Q848594)

A. Weber’s syndrome

B. Benedikt’s syndrome

C. Parinaud’s syndrome

D. All of the above

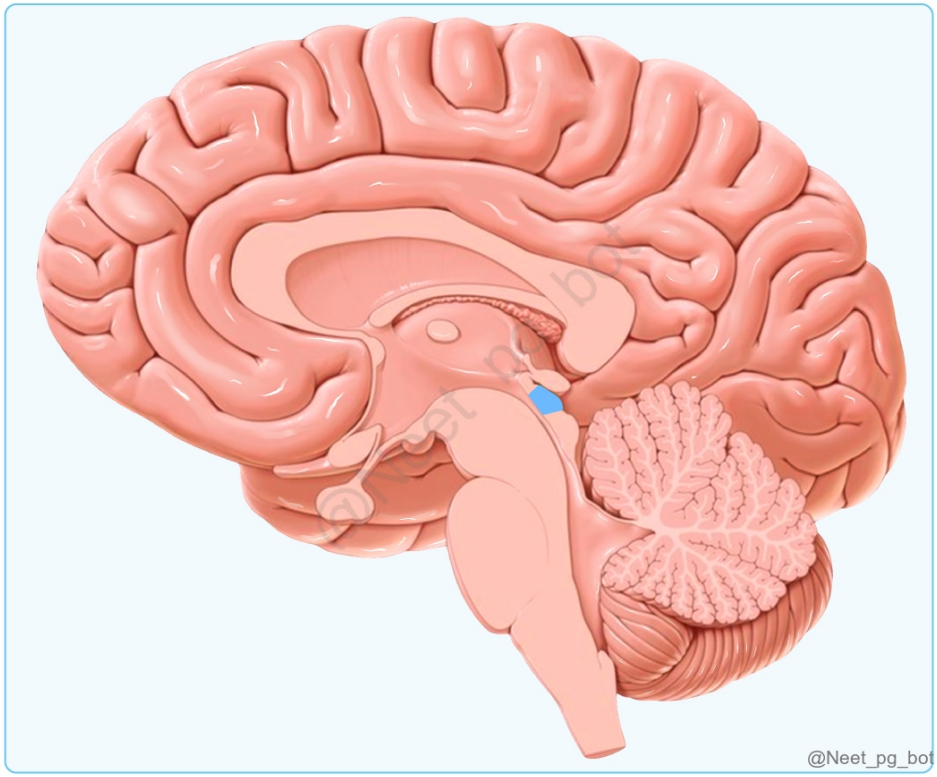

See Answer in Part B → Q15

@Neet_pg_bot

Q16: Which of the following statements is not correct regarding lemniscus? (Q848593)

A. It is a collection of axons running in the spinal cord

B. The lateral lemniscus is a part of the auditory pathway

C. Spinal leminiscus is affected in wallenberg syndrome

D. Spinal lemniscus carries pain and temperature sensation

See Answer in Part B → Q16

@Neet_pg_bot

Q17: A 55-year-old man diagnosed with B12 deficiency presents with difficulty maintaining balance. On examination, he shows a loss of vibration and fine touch sensation in his lower limbs, while pain and temperature sensations are intact. Which of the following pathways is most likely affected in this patient? (Q848569)

A. Lateral Spinothalamic Tract

B. Ventral Spinothalamic Tract

C. Tract of Goll

D. Corticospinal Tract

See Answer in Part B → Q17

@Neet_pg_bot

Q18: Which of the following arteries is primarily responsible for supplying the sublenticular part of the internal capsule, which carries auditory fibres? (Q848579)

A. Recurrent branch of anterior cerebral artery

B. Direct branches from the internal carotid

C. Branch of anterior choroidal

D. Branch of posterior communicating

See Answer in Part B → Q18

@Neet_pg_bot

Q19: A 62-year-old presents with sudden-onset left-sided weakness, primarily affecting the arm and face. On examination, he has difficulty with speech, displaying both expressive and receptive aphasia. He also shows left-sided facial drooping and an inability to move his left upper limb effectively. Sensation is relatively intact in his lower limb. Which artery is most likely affected? (Q848578)

A. Anterior cerebral artery (ACA)

B. Posterior cerebral artery (PCA)

C. Middle cerebral artery (MCA)

D. Basilar artery

See Answer in Part B → Q19

@Neet_pg_bot

Q20: Identify the artery highlighted in blue in the following image. (Q848577)

A. Anterior communicating artery

B. Posterior communicating artery

C. Anterior cerebral artery

D. Middle cerebral artery

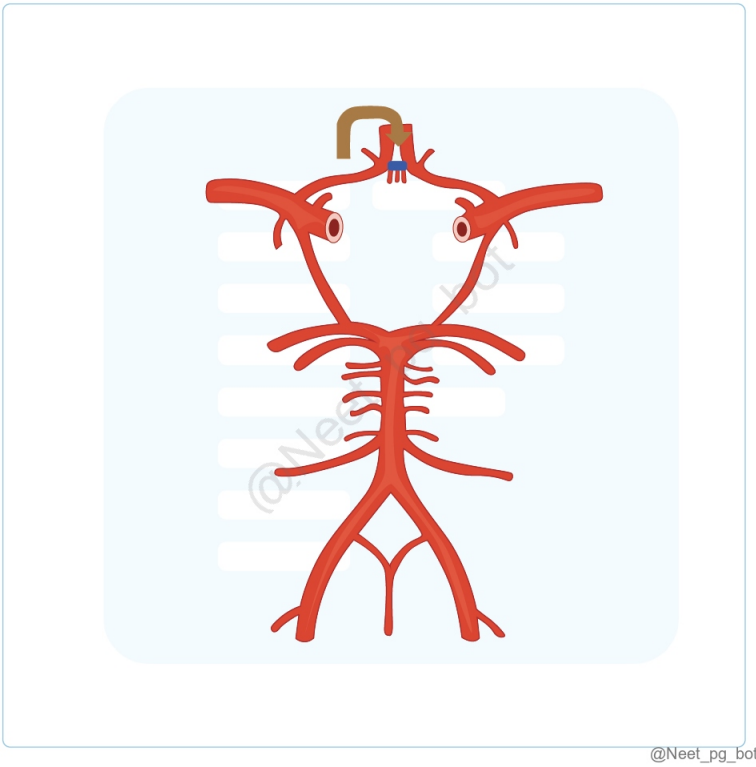

See Answer in Part B → Q20

@Neet_pg_bot

Q21: A 45-year-old patient presents with Horner's syndrome, but notably, the patient does not exhibit anhidrosis. Based on the absence of anhidrosis, which of the following is the most likely location of the lesion? (Q848575)

A. First-order neuron (central)

B. Second-order neuron (peripheral)

C. Third-order neuron (postganglionic)

D. Superior cervical ganglion

See Answer in Part B → Q21

@Neet_pg_bot

Q22: Which of the following statements about prevertebral/paravertebral ganglia is/are true? Prevertebral ganglia are also known as collateral ganglia. Prevertebral ganglia are a part of the parasympathetic nervous system. Paravertebral ganglia supply the abdominal viscera. The celiac ganglion is a paravertebral ganglion. (Q848574)

A. I only

B. I and III only

C. II, III and IV only

D. All the above

See Answer in Part B → Q22

@Neet_pg_bot

Q23: Which of the following statements is incorrect? (Q848572)

A. Preganglionic fibers in both the sympathetic and parasympathetic systems are myelinated.

B. Postganglionic fibers in both the sympathetic and parasympathetic systems are unmyelinated

C. Most sweat glands are sympathetic and adrenergic.

D. Acetylcholine is a neurotransmitter found in sympathetic ganglia.

See Answer in Part B → Q23

@Neet_pg_bot

Q24: A 64-year-old woman presents with progressive weakness in her left leg. On examination, you observe that her left leg has decreased muscle tone, and shows significant muscle atrophy. Given these findings, which of the following additional signs is likely to be present? (Q848571)

A. Exaggerated Deep Tendon Reflexes

B. Positive Babinski Sign

C. Muscle Spasticity

D. Fasciculations

See Answer in Part B → Q24

@Neet_pg_bot

Q25: A 35-year-old patient presents following a fall from a ladder. The patient exhibits specific neurological symptoms: loss of pain and temperature sensation in the left leg, difficulty identifying the position of the right leg with eyes closed, and complete loss of sensation at the T12 level of the trunk on the right. Which of the following statements is false for this condition? (Q848570)

A. Loss of proprioception in the right leg occurs due right dorsal column.

B. Loss of pain in the left leg occurs due to the left spinothalamic tract.

C. Damage to the ventral nerve roots at the T12 level results in motor loss.

D. Spastic paralysis of the right leg

See Answer in Part B → Q25

@Neet_pg_bot

• [03_Neuro Anatomy] 013 Previous Year Questions

« Back to Folder Directory

[03_Neuro Anatomy] 013 Previous Year Questions — Quick Jump

Q1 (p. 152)	*Q2 (p. 152)*	*Q3 (p. 153)*	*Q4 (p. 153)*	*Q5 (p. 154)*	*Q6 (p. 154)*
Q7 (p. 155)	*Q8 (p. 155)*	*Q9 (p. 156)*	*Q10 (p. 157)*	*Q11 (p. 158)*	*Q12 (p. 159)*
Q13 (p. 159)	*Q14 (p. 160)*	*Q15 (p. 161)*	*Q16 (p. 162)*	*Q17 (p. 162)*	*Q18 (p. 163)*
Q19 (p. 163)	*Q20 (p. 164)*	*Q21 (p. 164)*	*Q22 (p. 165)*	*Q23 (p. 165)*	*Q24 (p. 166)*
Q25 (p. 167)	*Q26 (p. 168)*	*Q27 (p. 168)*	*Q28 (p. 169)*	*Q29 (p. 170)*	*Q30 (p. 171)*
Q31 (p. 172)	*Q32 (p. 173)*	*Q33 (p. 173)*	*Q34 (p. 174)*	*Q35 (p. 174)*	*Q36 (p. 175)*
Q37 (p. 175)	*Q38 (p. 176)*	*Q39 (p. 176)*	*Q40 (p. 177)*	*Q41 (p. 177)*	*Q42 (p. 178)*
Q43 (p. 179)	*Q44 (p. 180)*	*Q45 (p. 180)*	*Q46 (p. 181)*	*Q47 (p. 182)*	*Q48 (p. 182)*
Q49 (p. 183)					

Q1: The type of fibers present in the fornix are: (Q856949)

A. Projection and commissural fibers

B. Association and projection fibers

C. Commissural and association fibers

D. Association fibers

See Answer in Part B → Q1

@Neet_pg_bot

Q2: Which of the following options are included in the limbic system? 1. Amygdala 2. Hippocampus 3. Thalamus (Q855039)

A. 1,2

B. 1,3

C. 2,3

D. 1,2,3

See Answer in Part B → Q2

@Neet_pg_bot

Q3: Identify the cranial nerve that arises from the marked part. (Q855041)

A. Oculomotor nerve

B. Glossopharyngeal nerve

C. Abducens nerve

D. Facial nerve

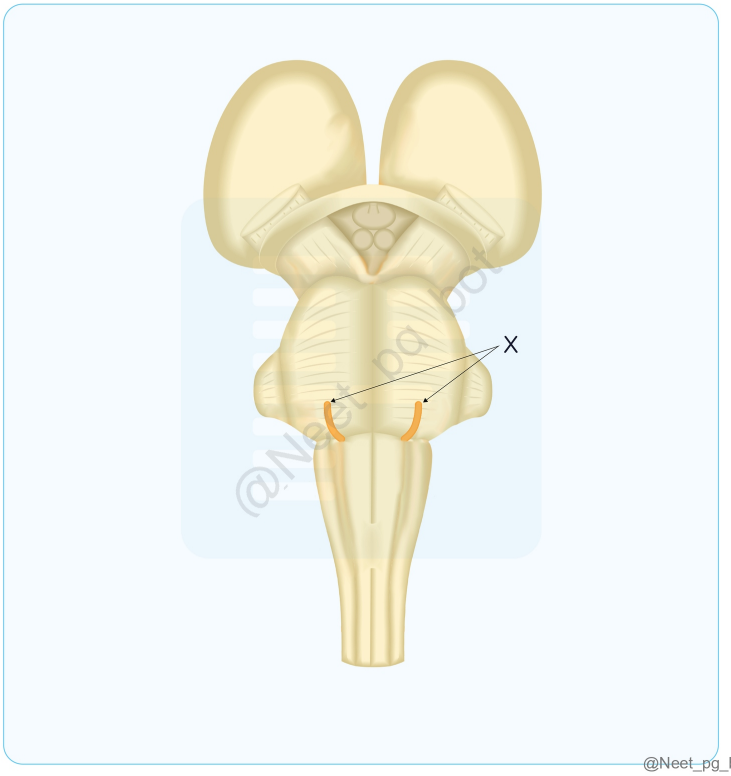

See Answer in Part B → Q3

@Neet_pg_bot

Q4: Arrange in sequence the structures involved in the direct pathway of the basal ganglia:- 1. Striatum 2. Globus pallidus 3. Substantia nigra 4. Thalamus 5. Cortex (Q855038)

A. 1,2,3,4,5

B. 5,4,2,31

C. 5,1,2,3,4

D. 1,3,4,2,5

See Answer in Part B → Q4

@Neet_pg_bot

Q5: Neostriatum consists of? (Q857229)

A. Caudate nucleus and globus pallidus

B. Globus pallidus and putamen

C. Globus pallidus and lentiform nucleus

D. Caudate nucleus and putamen

See Answer in Part B → Q5

@Neet_pg_bot

Q6: A 55-year-old man is accompanied by his wife to the Neurology OPD. His wife expressed concern about her husband's condition and they were directed to this facility by a local doctor. According to the doctor's note, the patient is unable to repeat spoken words but can comprehend them and respond appropriately by nodding. The patient also experiences difficulty in naming people and writing. The doctor referred the patient to a specialized facility for a CT brain scan. As the intern on duty, you would inform the Chief Medical Officer (CMO) that this condition could be indicative of a brain lesion in which specific area? (Q857234)

A. Arcuate fasciculus

B. Anterior commissure

C. Corpus callosum

D. Fornix

See Answer in Part B → Q6

@Neet_pg_bot

Q7: At what level does the spinal cord end in infants? (Q857622)

A. L1

B. L2

C. L3

D. L4

See Answer in Part B → Q7

@Neet_pg_bot

Q8: In this image of basal ganglia, all of the following are correctly labeled except? (Q857646)

A. 1-Caudate nucleus

B. 2-Globus pallidus

C. 3-Putamen

D. 4-Internal capsule

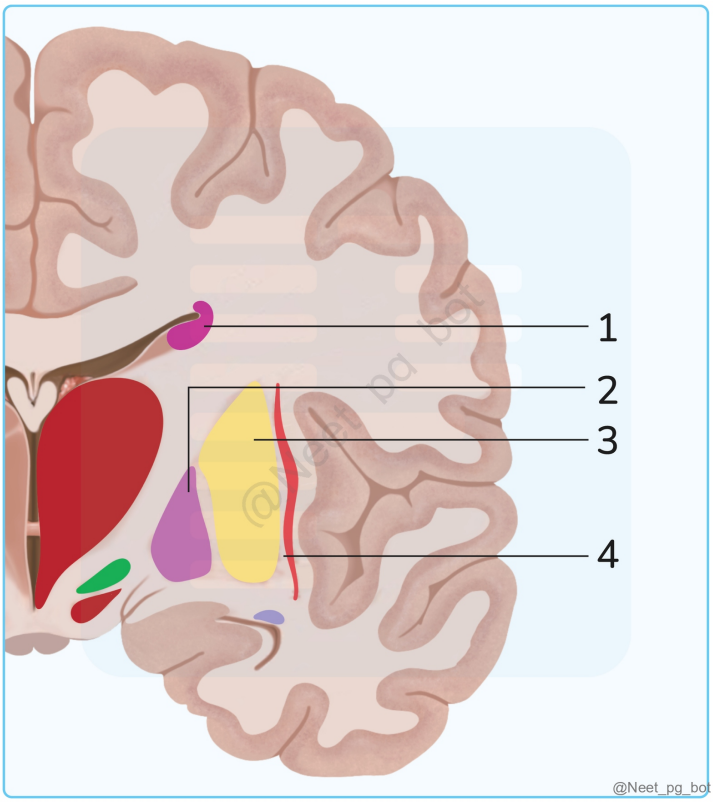

See Answer in Part B → Q8

@Neet_pg_bot

Q9: Fibers from the marked structure end in which of the following areas of the thalamus? (Q855816)

A. Posterior nucleus

B. Reticular nucleus

C. Anterior nucleus

D. Ventral lateral nucleus

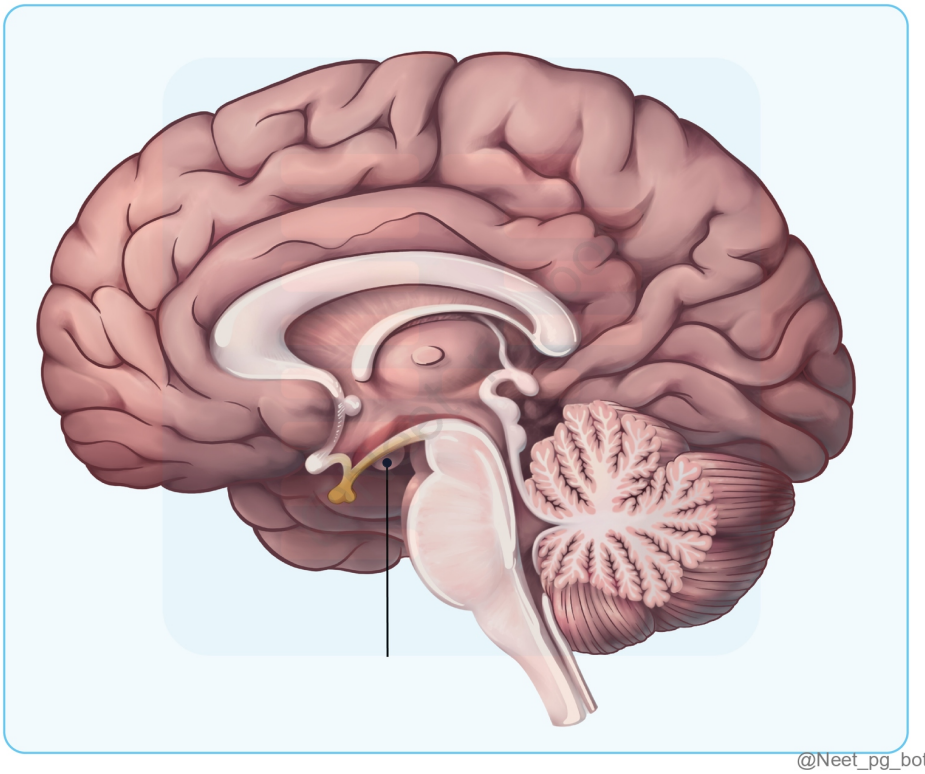

See Answer in Part B → Q9

@Neet_pg_bot

Q10: At which level does the nerve supply for the marked structure arise? (Q855851)

A. Red nucleus

B. Sub thalamic nuclei

C. Decussation of pyramidal tract

D. Olivary nucleus

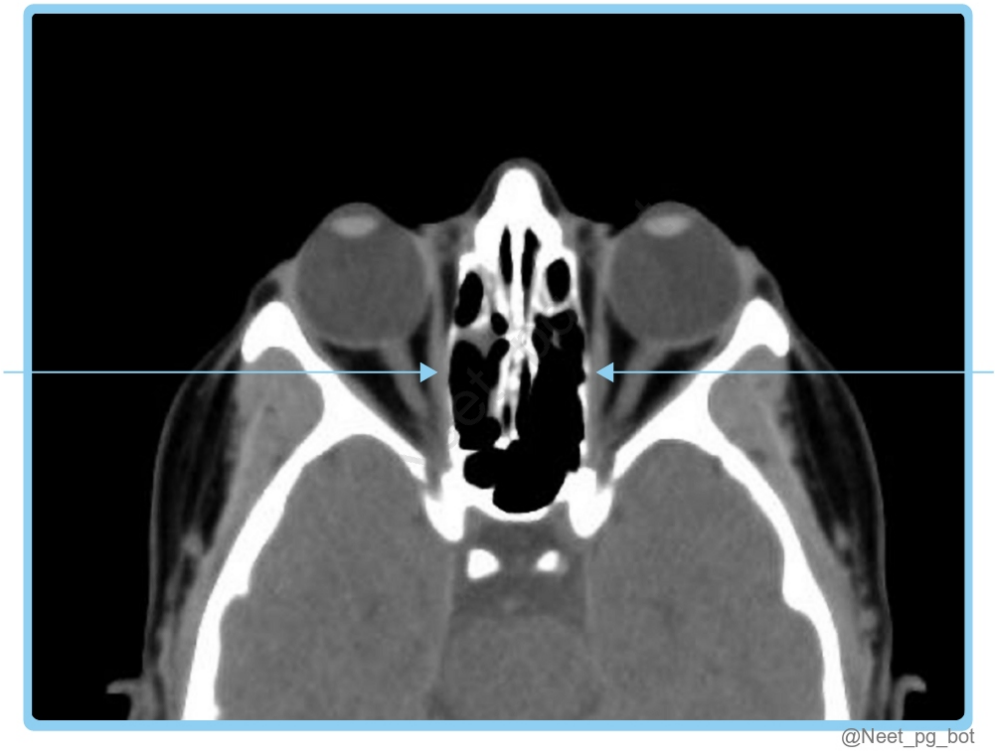

See Answer in Part B → Q10

@Neet_pg_bot

Q11: A 6-month-old boy was brought to the casualty with seizures. The pediatrician tries to do CSF sampling. What are the structures punctured by the pediatrician while piercing through the marked structure? (Q856633)

A. Scalp, dura mater, arachnoid mater

B. Scalp, epicranium, dura mater

C. Scalp synchondral membrane, dura mater, arachnoid mater

D. Pericranium, dura mater, endocranium

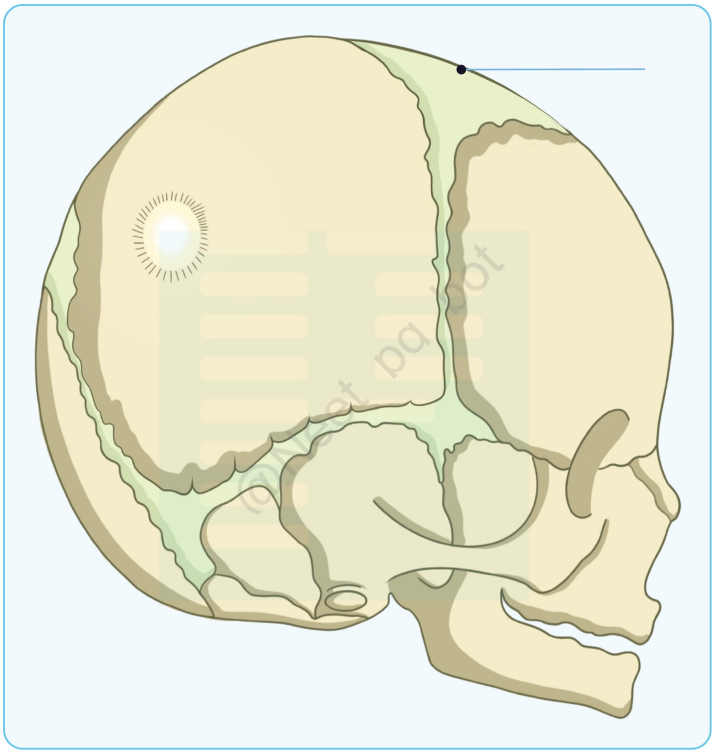

See Answer in Part B → Q11

@Neet_pg_bot

Q12: A woman with right-sided loss of sensations of both the upper and lower limb complains of shooting pain from her fingers to the right shoulder and a burning sensation when touching cold water. Motor functions are normal. Which of the following structures is likely to be involved? (Q856682)

A. Dorsal Horn

B. Thalamus

C. Ventral Horn

D. Dorsal Root Ganglion

See Answer in Part B → Q12

@Neet_pg_bot

Q13: A patient presented with vision loss. On radiological investigation, an aneurysm causing damage to the optic chiasma was noted. Which of the following arteries is most likely to be the artery that is causing the damage? (Q856181)

A. Anterior communicating artery

B. Anterior choroidal artery

C. Middle cerebral artery

D. Anterior cerebral artery

See Answer in Part B → Q13

@Neet_pg_bot

Q14: Identify the nerves passing through the marked structure? {{caption_text}} (Q852994)

A. CN I, CN II, CN III, CN IV

B. CN III, CN IV, CN V 1 , CN VI

C. CN IV, CN V 1 , CN VI, CN VII

D. CN VI, CN VII, CN VIII, CN IX



See Answer in Part B → Q14

@Neet_pg_bot

Q15: The neurotransmitter secreted by the area marked in the given image is? (Q856963)

A. Acetylcholine

B. Dopamine

C. Glutamine

D. Noradrenaline



See Answer in Part B → Q15

@Neet_pg_bot

Q16: The medial lemniscus is a continuation of which of the following structures? (Q856346)

A. Spinothalamic tract

B. Spinocerebellar tract

C. Spinotectal tract

D. Fasciculus gracilis

See Answer in Part B → Q16

@Neet_pg_bot

Q17: Decussation of the superior cerebellar peduncle occurs at which level? (Q856352)

A. Pons

B. Midbrain

C. Diencephalon

D. Medulla

See Answer in Part B → Q17

@Neet_pg_bot

Q18: Where is the probable location of the lesion in a patient who has presented with weakness and loss of pain and temperature sensation on the right side of the face along with loss of pain and temperature sensation on the left leg? (Q854985)

A. Medial medulla

B. Lateral pons

C. Medial pons

D. Lateral medulla

See Answer in Part B → Q18

@Neet_pg_bot

Q19: A patient presented with clinical features of ataxia and incoordination. This is due to thrombosis of which artery? (Q858495)

A. Posterior cerebral artery (PCA)

B. Middle cerebral artery (MCA)

C. Internal carotid artery (ICA)

D. Superior cerebellar artery (SCA)

See Answer in Part B → Q19

@Neet_pg_bot

Q20: Which of the following is not used for the identification of the facial nerve trunk? (Q858498)

A. Retrograde dissection from distal branch

B. Tragal pointer

C. Inferior belly of omohyoid muscle

D. Posterior belly of digastric

See Answer in Part B → Q20

@Neet_pg_bot

Q21: An exhausted man was brought to the casualty with minimal response. He had a progressive history of weakness in his body for 2 days with facial droop, and slurring speech. Which vessel is likely to be thrombosed? (Q859911)

A. Posterior cerebral artery

B. Anterior cerebral artery

C. Middle cerebral artery

D. Posterior inferior cerebellar artery

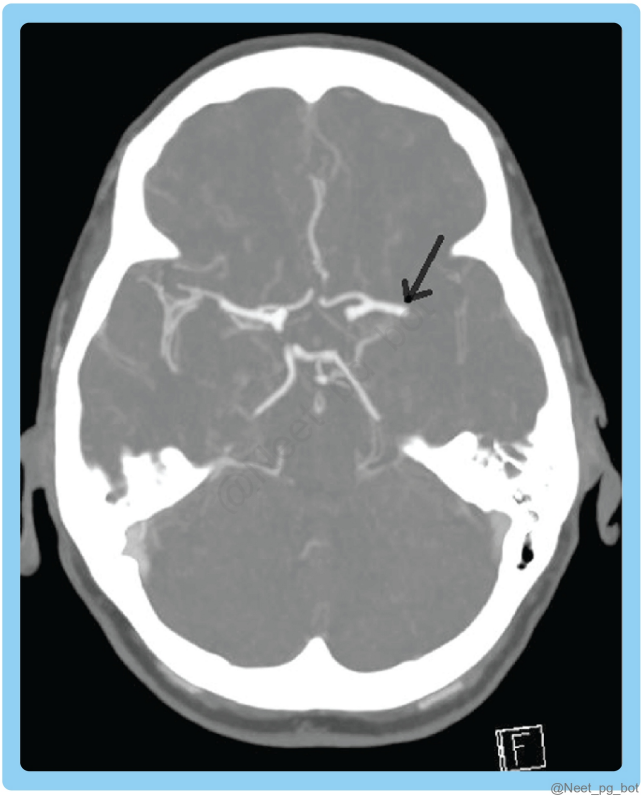

See Answer in Part B → Q21

@Neet_pg_bot

Q22: Identify the structure marked in the below image. (Q859925)

A. Caudate nucleus

B. Insula

C. Lentiform nucleus

D. Third ventricle

See Answer in Part B → Q22

@Neet_pg_bot

Q23: Which of the following structures is separated by the marked structure (“X”) in the diagram? (Q879149)

A. Lateral ventricle

B. Third ventricle

C. Fourth ventricle

D. Cisterna magna

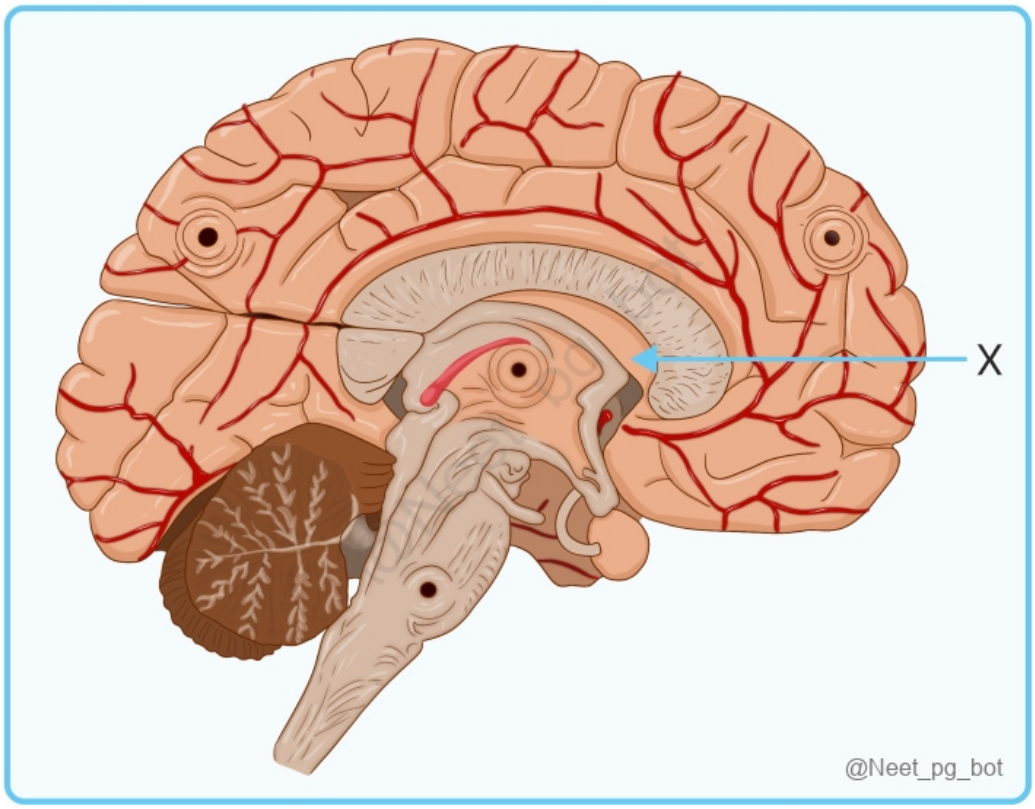

See Answer in Part B → Q23

@Neet_pg_bot

Q24: In the given image the marked structure articulates with which of the following bones? (Q879152)

A. Occipital bone

B. Axis

C. Sphenoid bone

D. Temporal bone

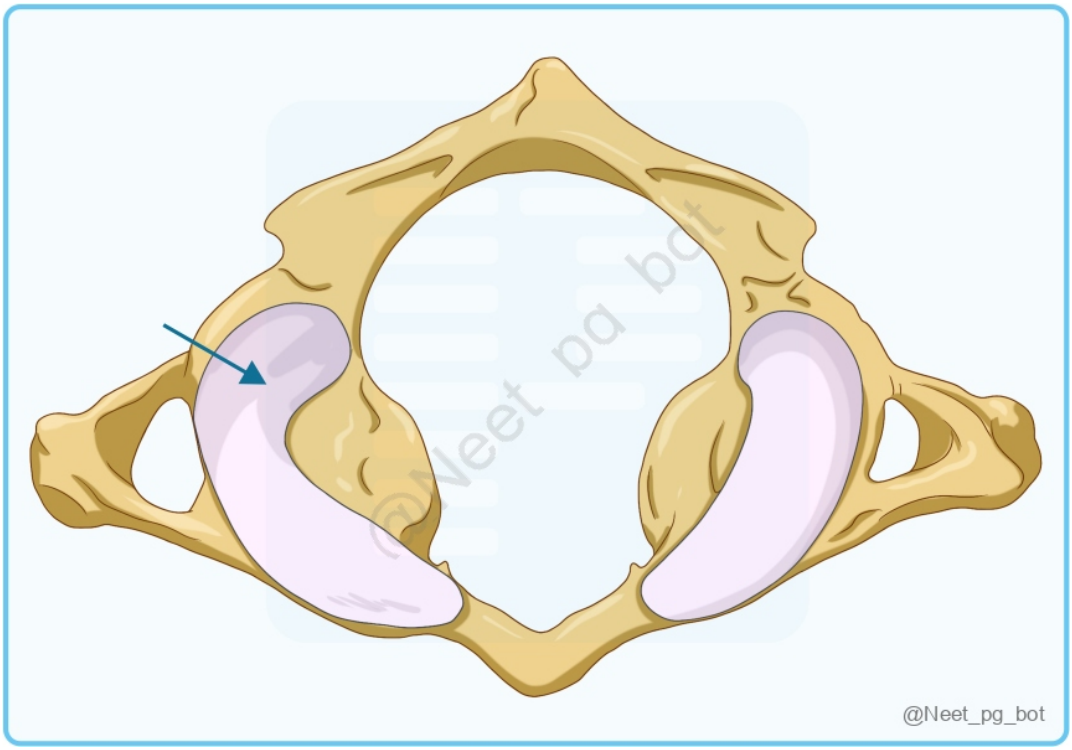

See Answer in Part B → Q24

@Neet_pg_bot

Q25: Match the following regions marked with their respective structures? (Q879157)

A. Inferior colliculus

B. Superior cerebellar peduncle

C. Middle cerebellar peduncle

D. Inferior cerebellar peduncle

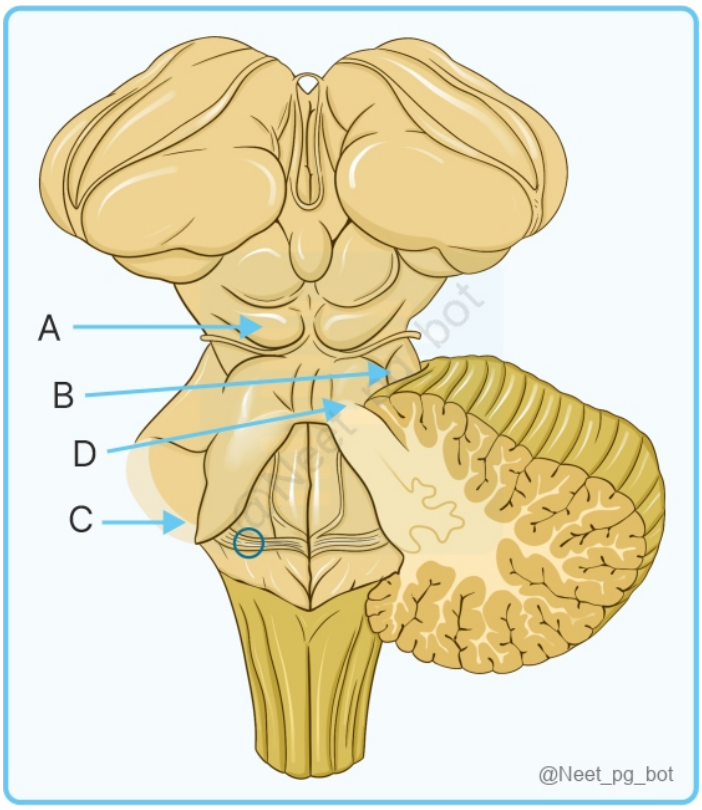

See Answer in Part B → Q25

@Neet_pg_bot

Q26: While administering epidural anesthesia, which structure is not punctured before injecting the drug? (Q860626)

A. Supraspinous ligament

B. Interspinous ligament

C. Ligamentum flavum

D. Arachnoid mater

See Answer in Part B → Q26

@Neet_pg_bot

Q27: During a neck dissection, a nerve was identified and marked that is most likely the vagus nerve (CN X). Which of the following is NOT a functional component of the vagus nerve? (Q866306)

A. General visceral afferent

B. General somatic efferent

C. General visceral efferent

D. General somatic afferent

See Answer in Part B → Q27

@Neet_pg_bot

Q28: Identify the defect in the given image: (Q852509)

A. Open neural tube defect

B. Meningomyelocele

C. Occult Spina bifida

D. Encephalocele



See Answer in Part B → Q28

@Neet_pg_bot

Q29: The nerve passing through the red arrow marked region has been lesioned. Which of the following will be the clinical presentation? (Q844152)

A. Loss of sensation in the mucosa of nasopharynx

B. Loss of sensation in maxillary area of face

C. Loss of sensation in jaw area

D. Loss of sensation in scalp and nose

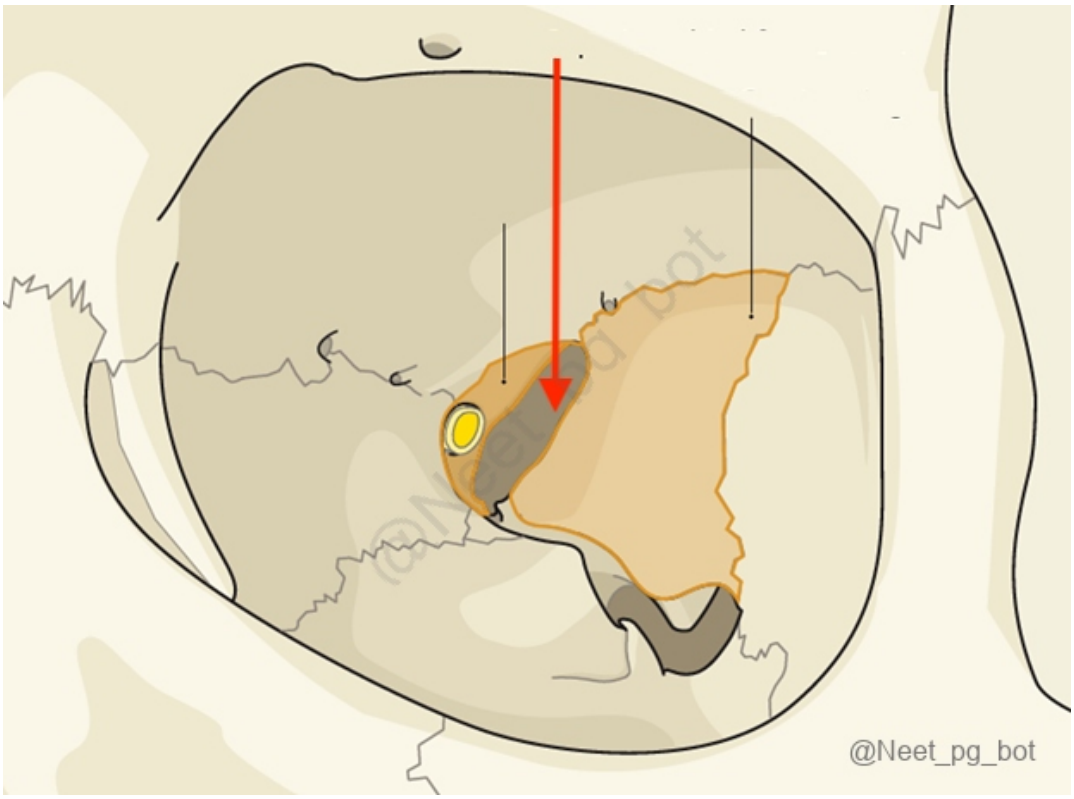

See Answer in Part B → Q29

@Neet_pg_bot

Q30: A 35 year old female presented with lesion shown below. This would result in which kind of field abnormality? (Q844165)

A. Homonymous hemianopia

B. Bitemporal hemianopia

C. Complete blindness

D. Single vision field loss

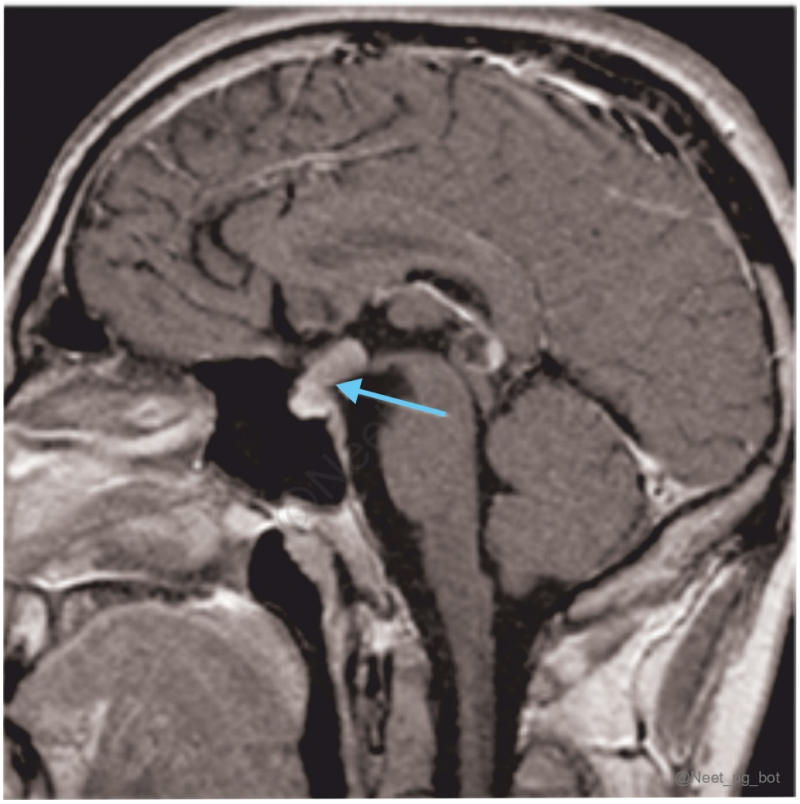

See Answer in Part B → Q30

@Neet_pg_bot

Q31: Identify the arrow marked nerve: (Q844201)

A. Medial pectoral nerve

B. Lateral pectoral nerve

C. Long thoracic nerve

D. Thoracodorsal nerve

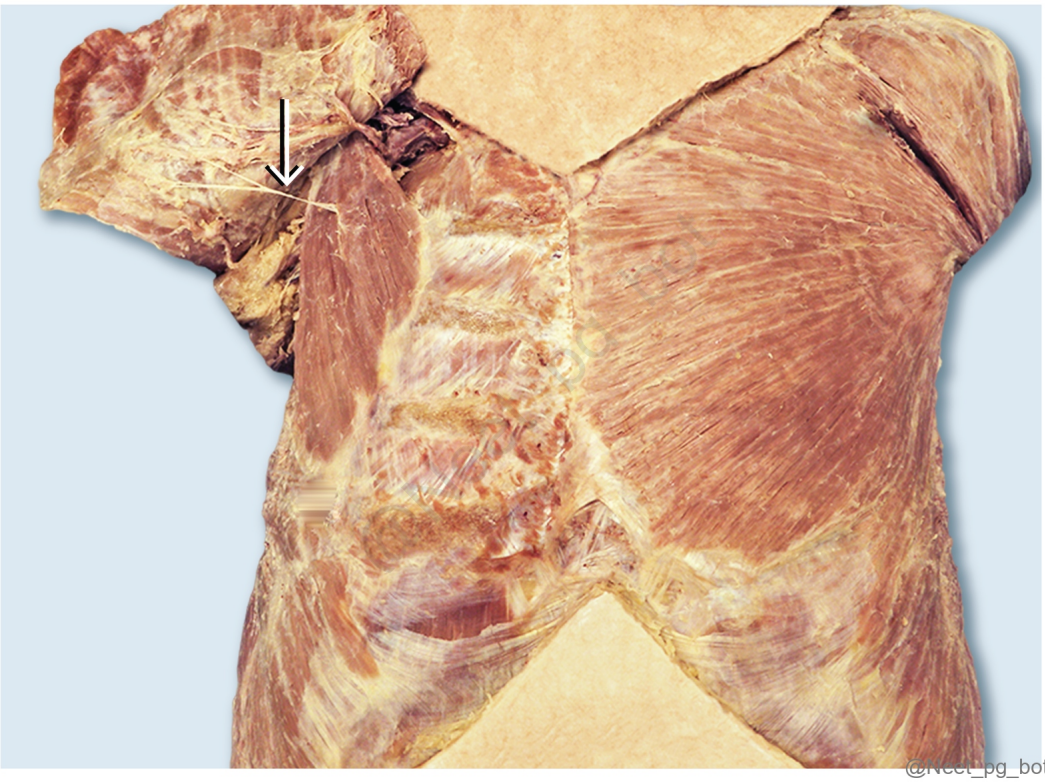

See Answer in Part B → Q31

@Neet_pg_bot

Q32: Ptosis in horner's syndrome is due to paralysis of which muscle? (Q844194)

A. Superior tarsal muscle

B. Orbitalis

C. Orbicularis oculi

D. Sphincter pupillae

See Answer in Part B → Q32

@Neet_pg_bot

Q33: What are the effects of a lesion in Brodmann area 22? (Q844210)

A. Expressive aphasia

B. Receptive aphasia

C. Poor repetition of language

D. Poor naming

See Answer in Part B → Q33

@Neet_pg_bot

Q34: A patient with loss of sensation on the lateral 3 1 / 2 (palmar aspect) hand and thenar atrophy. Which nerve is involved? (Q844239)

A. Median

B. Ulnar

C. Radial

D. Anterior interosseous nerve

See Answer in Part B → Q34

@Neet_pg_bot

Q35: An elderly woman reports difficulty in buttoning her shirt and increased clumsiness during daily activities. On examination, she is unable to make an 'O' shape by opposing her thumb and index finger. Which of the following muscles is most likely involved? (Q844243)

A. Opponens pollicis

B. Abductor pollicis brevis

C. Flexor pollicis brevis

D. Palmar interossei

See Answer in Part B → Q35

@Neet_pg_bot

Q36: An absent gag reflex can result from injury to which cranial nerve? (Q844318)

A. 9 and 10

B. 10 and 7

C. 7 and 5

D. 5 and 9

See Answer in Part B → Q36

@Neet_pg_bot

Q37: Identify the marked structure: (Q860613)

A. Internal capsule

B. Body of fornix

C. Globus pallidus

D. Lateral ventricle

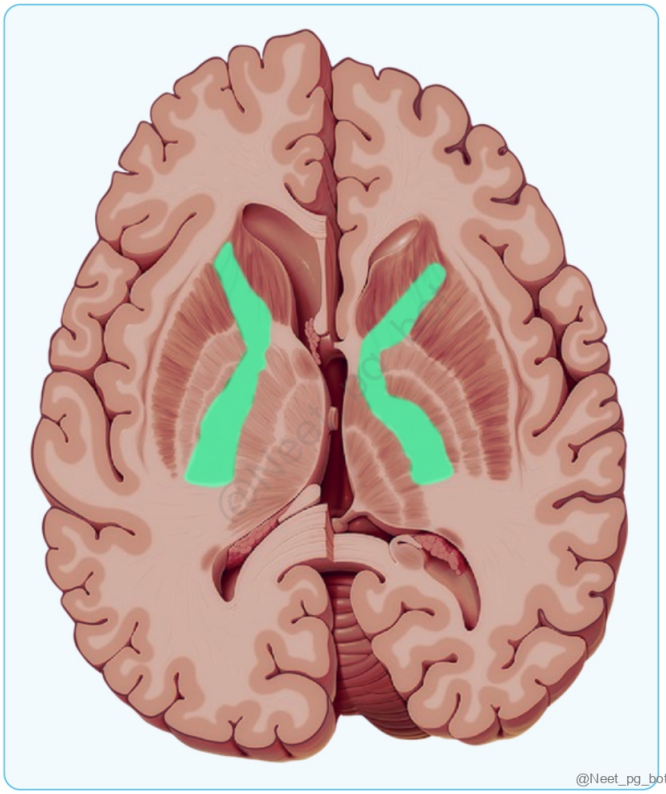

See Answer in Part B → Q37

@Neet_pg_bot

Q38: Which structure is not present in the floor of the inferior horn of the lateral ventricle? (Q839923)

A. Hippocampus

B. Tail of the caudate nucleus

C. Fimbriae

D. Collateral eminence

See Answer in Part B → Q38

@Neet_pg_bot

Q39: Which artery is involved in Lateral medullary syndrome? (Q857312)

A. Posterior inferior cerebellar artery

B. Anterior inferior cerebellar artery

C. Superior cerebellar artery

D. Inferior cerebellar artery

See Answer in Part B → Q39

@Neet_pg_bot

Q40: Match the following: A) Glossopharyngeal nerve 1) Shrugging of shoulder B) Spinal accessory nerve 2) Touch sensation from the posterior one-third of the tongue C) Facial nerve 3) Chewing D) Mandibular nerve 4) Taste from the anterior two-thirds of the tongue (Q857316)

A. A-2, B-1, C-4, D-3

B. A-2, B-3, C-4, D-1

C. A-4, B-1, C-2, D-3

D. A-3, B-1, C-4, D-2

See Answer in Part B → Q40

@Neet_pg_bot

Q41: The marked structure relays efferents to which nucleus of the thalamus? [(Q857333)

A. Anterior nucleus of thalamus

B. Lateral nucleus of thalamus

C. Ventro-postero-lateral nucleus of thalamus

D. Posterior nucleus of thalamus

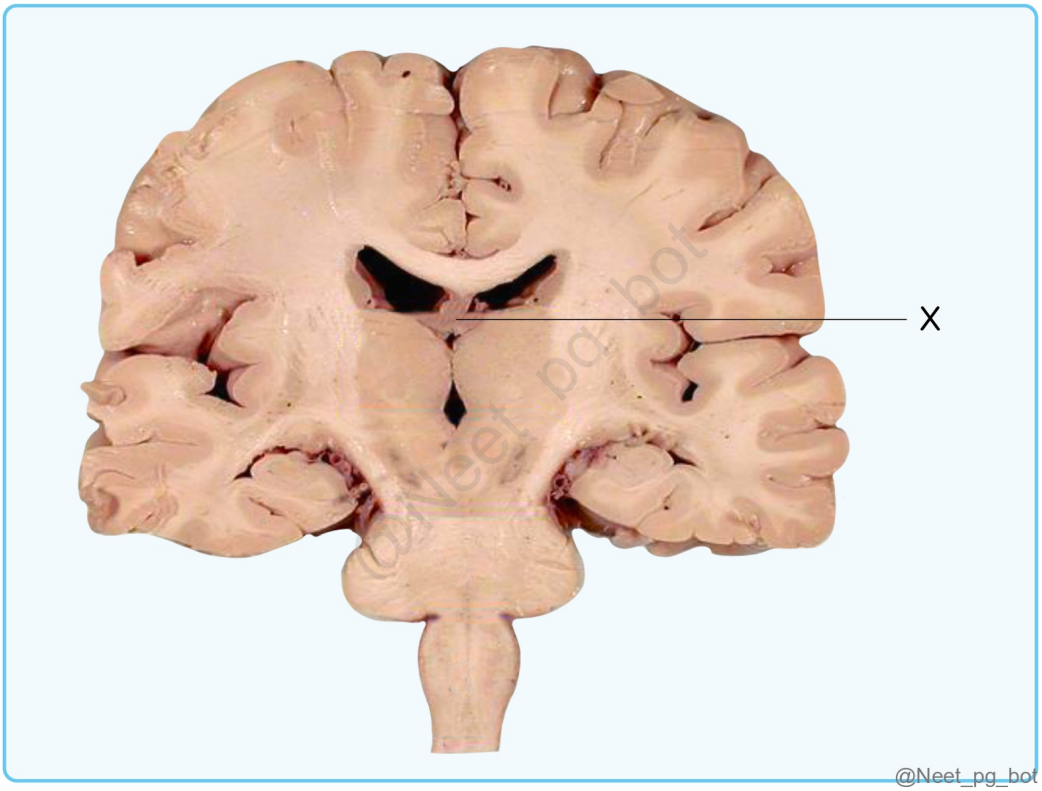

See Answer in Part B → Q41

@Neet_pg_bot

Q42: Which of the following structures is derived from the marked point in the given image? (Q857335)

A. Ribs

B. Kidneys

C. Dorsal root ganglion

D. Parietal pleura

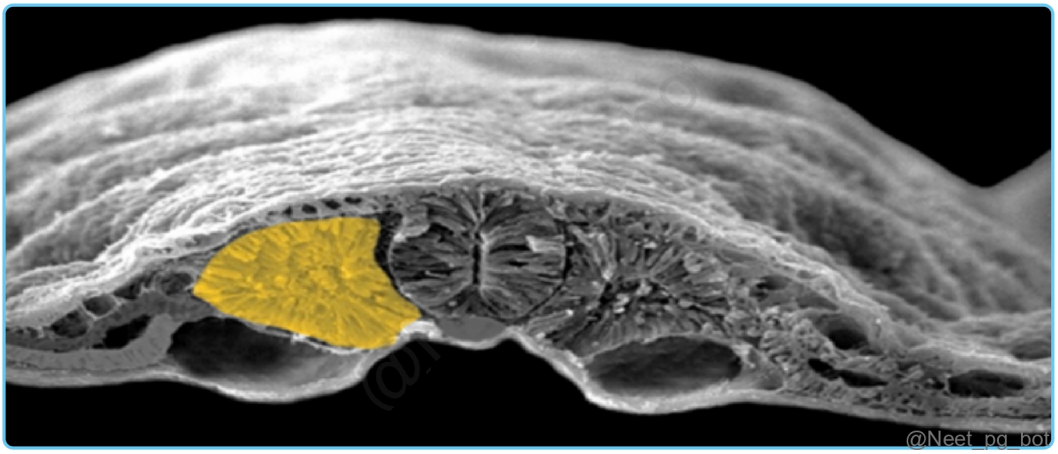

See Answer in Part B → Q42

@Neet_pg_bot

Q43: What is the blood supply of the marked area in the given image? (Q857347)

A. Posterior inferior cerebellar artery

B. Anterior inferior cerebellar artery

C. Superior cerebellar artery

D. Posterior cerebral artery



See Answer in Part B → Q43

@Neet_pg_bot

Q44: Arrange the neural columns in medial-to-lateral order in the floor of fourth ventricle 1. Special somatic afferent 2. Special visceral afferent 3. General somatic afferent 4. General somatic afferent (Q854785)

A. GVA, SVA, GSA, SSA

B. VA, GSA, GVA, SSA

C. SSA, GSA, SVE, GVA

D. GSA, SSA, SVA, GSA

See Answer in Part B → Q44

@Neet_pg_bot

Q45: The patient presented with ipsilateral loss of pain and temperature sensation in the face, Horner's syndrome, and Contralateral loss of pain and temperature sensation in the body. Which artery is involved in the syndrome based on clinical features? (Q854799)

A. Posterior inferior cerebellar artery

B. Superior cerebellar artery

C. Basilar artery

D. Anterior inferior cerebellar artery

See Answer in Part B → Q45

@Neet_pg_bot

Q46: What is the vertebral level shown by the arrow in the image? (Q857934)

A. L2-L3

B. L4-L5

C. L5-S1

D. L3-L4

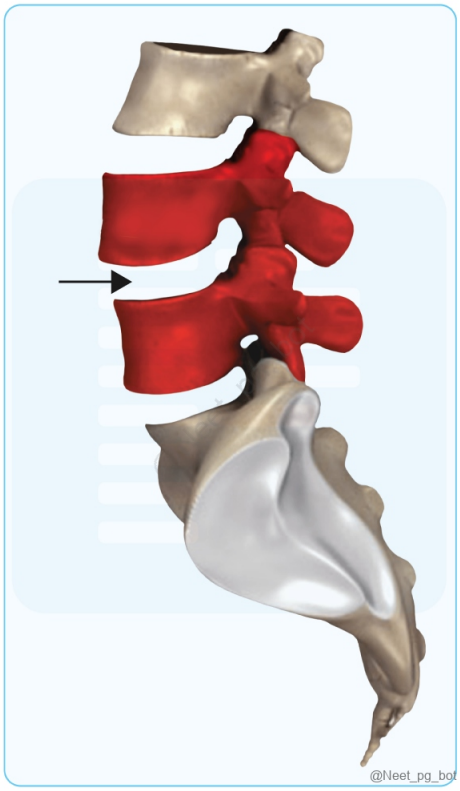

See Answer in Part B → Q46

@Neet_pg_bot

Q47: A 32-year-old patient presents with a swelling below the ear and complains of pain in the lobule of the ear. The patient also reports difficulty in completely closing the left eye and experiences trouble while eating food. What nerve is most likely to be damaged in this case? (Q857937)

A. Greater Auricular nerve

B. Auriculotemporal nerve

C. Facial nerve

D. Vagus nerve

See Answer in Part B → Q47

@Neet_pg_bot

Q48: A woman presented with sudden onset of dysphagia, dysarthria, and gait ataxia. MRI revealed an acute infarct in the right dorsolateral medulla. What is the likely diagnosis? (Q793142)

A. Dejerine’s anterior bulbar syndrome

B. Wallenberg syndrome

C. Babinski-Nageotte syndrome

D. Weber syndrome

See Answer in Part B → Q48

@Neet_pg_bot

Q49: Please identify the structure indicated in the image below. (Q793128)

A. Midbrain

B. Pons

C. Medulla oblongata

D. Spinal cord

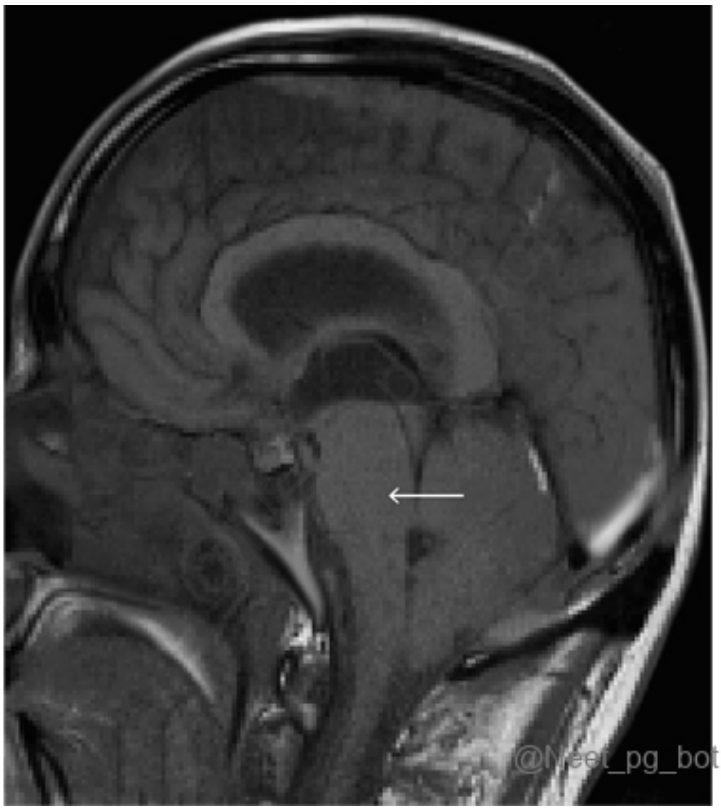

See Answer in Part B → Q49

@Neet_pg_bot

• [04_Head and Neck] 014 Pharyngeal Arches Pouches And Clefts

« Back to Folder Directory

[04_Head and Neck] 014 Pharyngeal Arches Pouches And Clefts — Quick Jump

Q1 (p. 185) *Q2 (p. 185)* *Q3 (p. 186)* *Q4 (p. 186)* *Q5 (p. 186)* *Q6 (p. 187)*
Q7 (p. 187) *Q8 (p. 187)* *Q9 (p. 188)* *Q10 (p. 188)* *Q11 (p. 189)* *Q12 (p. 189)*
Q13 (p. 189)

Q1: Which among the following are Skeletal derivatives of 3rd pharyngeal arch? Greater cornu of hyoid Stylohyoid ligament Lesser cornu of hyoid Upper half of body of hyoid Lower half of body of hyoid (Q848484)

A. All the above

B. Only 1

C. 5 and 4

D. 1 and 5

See Answer in Part B → Q1

@Neet_pg_bot

Q2: Arrange the events in the development of the thyroid gland in the correct sequence: Fusion with caudal pharyngeal complex Formation of pharyngeal arches Thyroglossal duct formation Tuberculum impar is formed (Q848488)

A. 2, 4, 3, 1

B. 1, 2, 3, 4

C. 4, 3, 2, 1

D. 3, 1, 2, 4

See Answer in Part B → Q2

@Neet_pg_bot

Q3: Which of the following statements on double aortic arch is false? (Q848490)

A. Dyspnea and dysphagia are symptoms

B. Compression of esophagus and trachea

C. Right dorsal aorta is persisted

D. Right aortic arch passes in front of the trachea and esophagus

See Answer in Part B → Q3

@Neet_pg_bot

Q4: Which pharyngeal arch primarily contributes to the development of the anterior two-thirds of the tongue? (Q848491)

A. First pharyngeal arch

B. Second pharyngeal arch

C. Third pharyngeal arch

D. Fourth pharyngeal arch

See Answer in Part B → Q4

@Neet_pg_bot

Q5: A patient with a malignant lesion involving the posterior one-third of the tongue is being evaluated for regional lymph node metastasis. Which lymph nodes are most commonly involved in the lymphatic drainage of this region? (Q882294)

A. Deep cervical lymphnodes

B. Submental lymphnodes

C. Submandibular lymphnodes

D. Periauricular lymphnodes

See Answer in Part B → Q5

@Neet_pg_bot

Q6: A 4-year-old child presents with recurrent infections and signs of hypocalcemia. Investigation shows low levels of parathyroid hormone. The physician suspects an embryological defect. Which among the following could be a possible reason? (Q848480)

A. Defect in the development of 1st pharyngeal pouch

B. Defect in the development of 2nd pharyngeal pouch

C. Defect in the development of 3rd pharyngeal pouch

D. Defect in the development of 5th pharyngeal pouch

See Answer in Part B → Q6

@Neet_pg_bot

Q7: Which of the following muscles of the first pharyngeal arch are migratory? Mylohyoid Masseter Temporalis Tensor tympani Tensor palati (Q848482)

A. All the above

B. Only 5

C. All except 5 and 4

D. All except 4

See Answer in Part B → Q7

@Neet_pg_bot

Q8: Which among the following are formed from Reichert's cartilage? Stapes Styloid process Stylohyoid ligament Lesser cornu of hyoid Upper half of body of hyoid (Q848483)

A. All the above

B. Only 5

C. All except 5 and 4

D. All except 4

See Answer in Part B → Q8

@Neet_pg_bot

Q9: Match the following pharyngeal arch to its corresponding nerve and artery derivatives. (Multiple options are correct) Arch Nerve of arch Artery of arch 1) Fourth a) Superior laryngeal nerve (Vagus) i) Arch of aorta ii) Subclavian artery 2) Sixth b) Recurrent laryngeal nerve (vagus) iii) Ductus arteriosus iv) Pulmonary artery (Q848485)

A. 1 - a - i and iii

B. 2 - b - iii and iv

C. 1 - a - i and ii

D. 2 - a - i and iii

See Answer in Part B → Q9

@Neet_pg_bot

Q10: Match the pharyngeal arches to the nerves arising from it. Pharyngeal arch Nerve a. First 1. Facial nerve b. Second 2. Glossopharyngeal nerve c. Third 3. Chorda tympani d. Sixth 4. Recurrent laryngeal nerve (Q848486)

A. a-3, b-1, c-2, d-4

B. a-1, b-2, c-3, d-4

C. a-4, b-3, c-2, d-1

D. a-2, b-1, c-3, d-4

See Answer in Part B → Q10

@Neet_pg_bot

Q11: Which of the following is the correct pairing of the pharyngeal pouch with its derivative? (Q848487)

A. 1st pharyngeal pouch-Thymus

B. 2nd pharyngeal pouch-Tonsillar fossa

C. 3rd pharyngeal pouch-Auditory tube

D. 4th pharyngeal pouch-Palatine tonsil

See Answer in Part B → Q11

@Neet_pg_bot

Q12: Match the pharyngeal arch with the artery developing from it Pharyngeal arch Artery a. First 1. Hyoid artery b. Second 2. Maxillary artery c. Third 3. Arch of aorta d. Fourth 4. Internal carotid artery (Q848489)

A. a-2, b-1, c-4, d-3

B. a-1, b-2, c-3, d-4

C. a-4, b-3, c-2, d-1

D. a-3, b-2, c-1, d-4

See Answer in Part B → Q12

@Neet_pg_bot

Q13: Which of the following nerves provides general sensation to the area of the tongue marked in blue? (Q848492)

A. Glossopharyngeal nerve

B. Facial nerve

C. Lingual nerve

D. Hypoglossal nerve

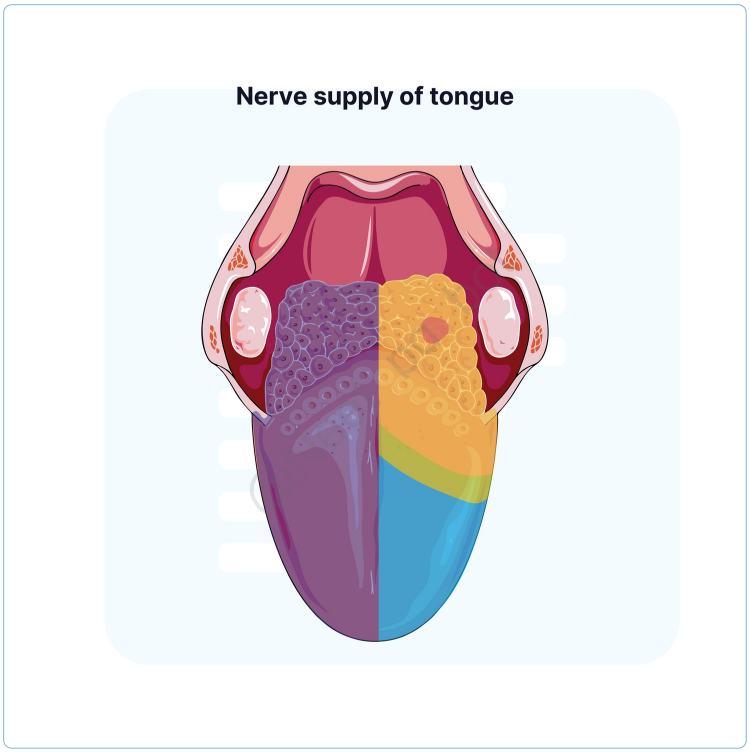

See Answer in Part B → Q13

@Neet_pg_bot

• [04_Head and Neck] 015 Skull Bones And Cranial Cavity- Part I

« Back to Folder Directory

[04_Head and Neck] 015 Skull Bones And Cranial Cavity- Part I — Quick Jump

Q1 (p. 191)	*Q2 (p. 192)*	*Q3 (p. 192)*	*Q4 (p. 192)*	*Q5 (p. 193)*	*Q6 (p. 193)*
Q7 (p. 194)	*Q8 (p. 195)*	*Q9 (p. 196)*	*Q10 (p. 196)*	*Q11 (p. 196)*	*Q12 (p. 197)*

Q1: Which of the following cranial nerves that pass through foramina or canals located entirely within the given bone? (Q876243)

A. Optic (CN II), Oculomotor (CN III), Trochlear (CN IV), Abducens (CN VI), Trigeminal divisions V1 and V2

B. Olfactory (CN I), Optic (CN II), Facial (CN VII), Vestibulocochlear (CN VIII)

C. Trigeminal (CN V), Glossopharyngeal (CN IX), Vagus (CN X), Accessory (CN XI)

D. Hypoglossal (CN XII), Accessory (CN XI), Vagus (CN X), Glossopharyngeal (CN IX)

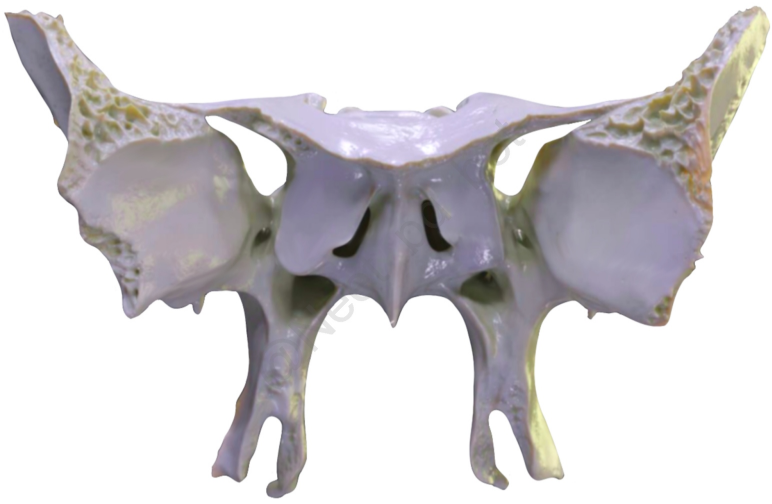

@Neet_pg_bot

See Answer in Part B → Q1

@Neet_pg_bot

Q2: The base of the skull is primarily formed by which type of ossification? (Q848582)

A. Intramembranous ossification

B. Endochondral ossification

C. Partly intramembranous and partly endochondral

D. Perichondral ossification

See Answer in Part B → Q2

@Neet_pg_bot

Q3: Which bones form the weakest point of the skull? (Q848583)

A. Frontal, parietal, temporal and sphenoid bones

B. Frontal, occipital, and temporal bones

C. Sphenoid and ethmoid bones

D. Occipital, temporal, and parietal bones

See Answer in Part B → Q3

@Neet_pg_bot

Q4: Which among the following are pneumatic bones? (Q848584)

A. 1,2,3,6,7

B. 1,2,3,5,7

C. 1,2,4,6

D. 1,3,5,6,7

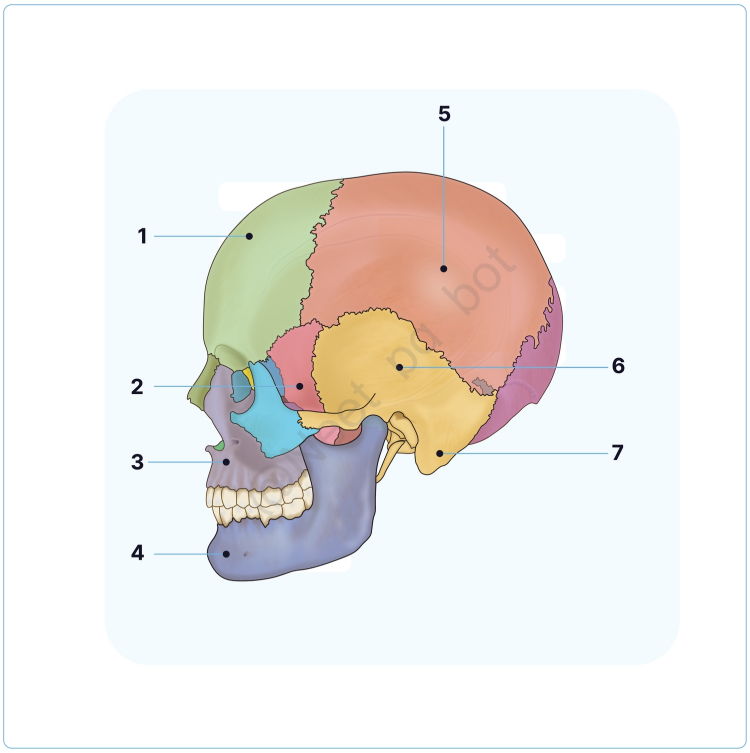

@Neet_pg_bot

See Answer in Part B → Q4

@Neet_pg_bot

Q5: All among the following would be of adult size at birth except (Q848585)

A. Mastoid process

B. Mastoid antrum

C. Tympanic membrane

D. Semicircular canal

See Answer in Part B → Q5

@Neet_pg_bot

Q6: A patient following a road traffic accident presented to the ED in a confused state. Ecchymosis around the eyes was noted, and CT showed the following. Which of the

following does not contribute to the floor of the affected structure? (Q848586)

A. Cribriform plate

B. Lesser wing of sphenoid

C. Orbital plate of the frontal bone

D. Greater wing of sphenoid

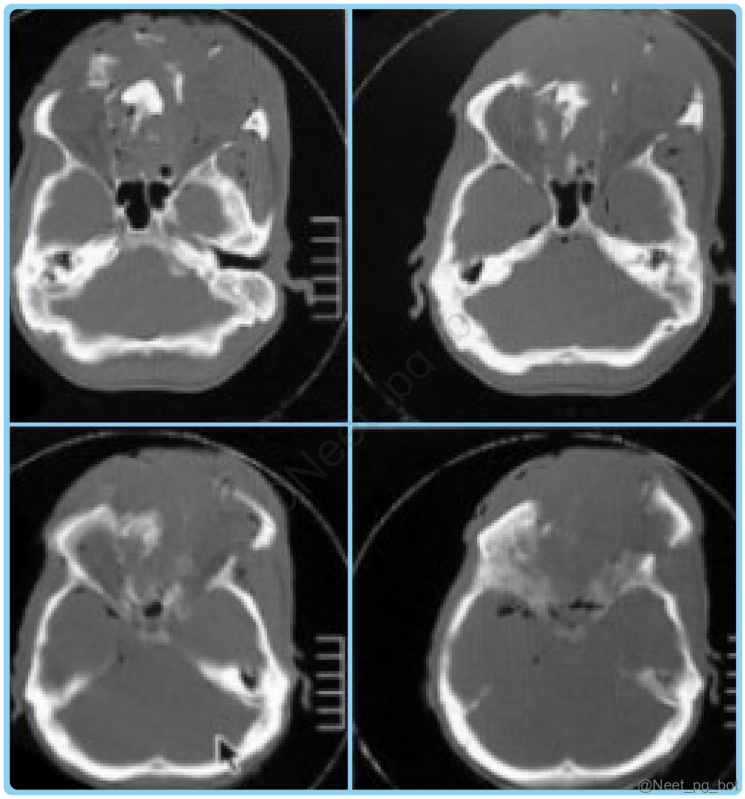

See Answer in Part B → Q6

@Neet_pg_bot

Q7: Following an RTA, a structure passing through the marked foramen was injured. Which of the following defects is likely to be seen in this patient? (Q848587)

A. Loss of corneal reflex

B. Loss of jaw jerk

C. Inability to abduct eye

D. Loss of sensation over cheek



See Answer in Part B → Q7

@Neet_pg_bot

Q8: A young female with history of recurrent attacks of pain over medial canthus of eye and cheek presents with chills, rigor, diplopia on lateral gaze and restriction of eye movements. She was diagnosed with PCOS and is on OCPs for the same since 6 months. On examination, edema over eyelids and exophthalmos were noted. Choose the correct combination regarding communication of the most likely structure affected in this patient. (Q848588)

A. Transverse sinus through Inferior petrosal sinus

B. Internal jugular vein through emissary veins

C. Pterygoid plexus through superior petrosal sinus

D. Facial vein through superior ophthalmic vein

See Answer in Part B → Q8

@Neet_pg_bot

Q9: Which of the following nerves pass through the internal acoustic meatus? (Q848589)

A. Hypoglossal and vagus

B. Glossopharyngeal and accessory

C. Hypoglossal and facial

D. Facial and vestibulocochlear

See Answer in Part B → Q9

@Neet_pg_bot

Q10: Which of the following is not a structure passing through the superior orbital fissure? (Q848591)

A. Trochlear nerve

B. Nasociliary nerve

C. Abducens nerve

D. Facial nerve

See Answer in Part B → Q10

@Neet_pg_bot

Q11: Which of the following structure does not pass through the common tendinous ring of Zinn? (Q848601)

A. Nasociliary nerve

B. Abducens nerve

C. Oculomotor nerve

D. Inferior ophthalmic vein

See Answer in Part B → Q11

@Neet_pg_bot

Q12: Match the walls of the orbit with the bones forming it Wall Bone a. Roof 1. Greater wing of sphenoid b. Lateral wall 2. Orbital surface of maxilla c. Floor 3. Orbital plate of frontal d. Medial wall 4. Lacrimal (Q848602)

A. a-1, b-2, c-3, d-4

B. a-4, b-3, c-2, d-1

C. a-3, b-1, c-2, d-4

D. a-2, b-1, c-3, d-4

See Answer in Part B → Q12

@Neet_pg_bot

• [04_Head and Neck] 016 Cranial Cavity- Part Ii

« Back to Folder Directory

[04_Head and Neck] 016 Cranial Cavity- Part Ii — Quick Jump

Q1 (p. 198)	*Q2 (p. 201)*	*Q3 (p. 201)*	*Q4 (p. 201)*	*Q5 (p. 202)*	*Q6 (p. 203)*
Q7 (p. 204)	*Q8 (p. 205)*	*Q9 (p. 206)*	*Q10 (p. 206)*	*Q11 (p. 207)*	*Q12 (p. 207)*
Q13 (p. 208)	*Q14 (p. 208)*	*Q15 (p. 208)*	*Q16 (p. 209)*		

Q1: Match each type of haemorrhage with its corresponding source of bleeding and Location. Which of the following combinations is correct? Type of Hemorrhage Source of Bleeding Location a. Epidural Hemorrhage 1. Middle meningeal artery i. b. Subdural Hemorrhage 2. Bridging veins ii. c. Subarachnoid Hemorrhage 3. Cerebral arteries iii. d. Intracerebral Hemorrhage 4. Ruptured cerebral aneurysm iv. (Q848724)

A. a-2-i

B. b-1-iv

C. c-4-iii

D. d-3-ii


@Neet_pg_bot

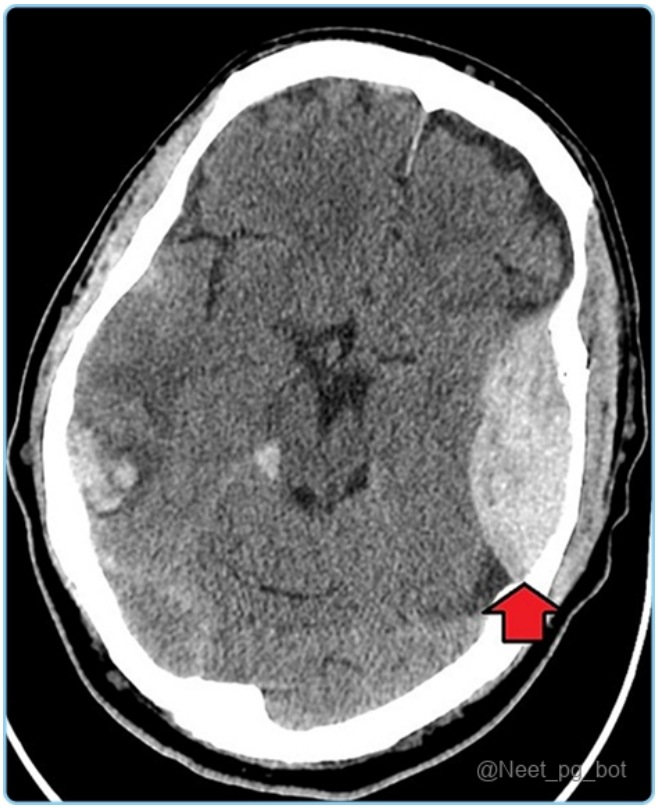
@Neet_pg_bot



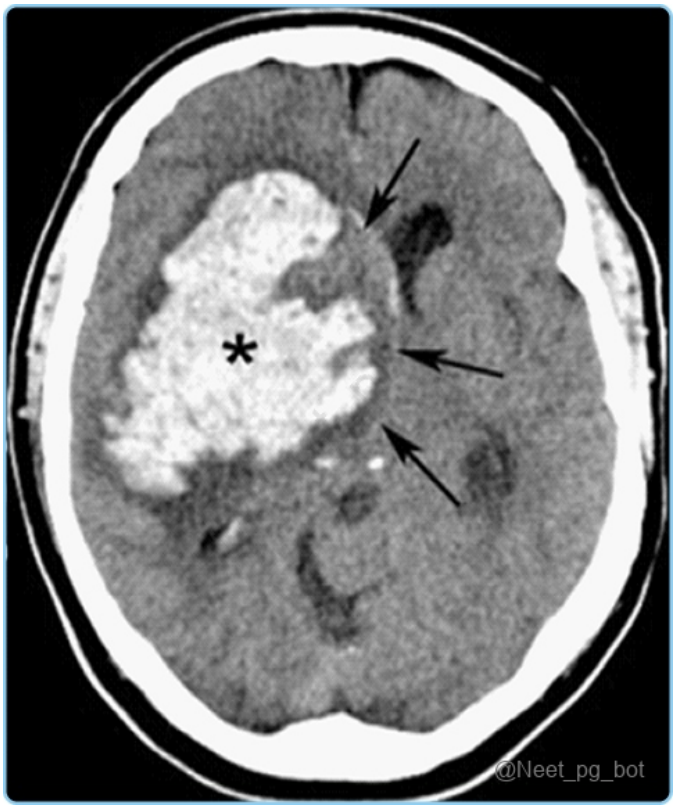

See Answer in Part B → Q1

@Neet_pg_bot

Q2: A 45-year-old man presents to the emergency department after a motor vehicle accident with severe head trauma. His GCS is 5. On examination, there is a loss of sensation below the level of the neck and flaccid paralysis of all four limbs. Which of the following structures pass through the same cranial foramen as the structure involved in this patient? (Q848726)

A. Hypoglossal nerve

B. Internal Carotid Artery

C. Spinal root of accessory nerve

D. Middle meningeal artery

See Answer in Part B → Q2

@Neet_pg_bot

Q3: A 30-year-old female presents with severe headaches and neurological deficits. Imaging reveals thrombosis of the inferior sagittal sinus. Which sinus does the inferior sagittal sinus primarily drain into? (Q848733)

A. Confluence of Sinuses

B. Transverse sinus

C. Straight sinus

D. Sigmoid sinus

See Answer in Part B → Q3

@Neet_pg_bot

Q4: A 34 y/o male presents to the emergency department following a road traffic accident. He complains of difficulty in chewing and numbness over the lower jaw. Upon examination, he has weakness in the muscles of mastication. Which of the following structures do not course along with the nerve implicated in the patient's

symptoms through the same cranial foramen? (Q848719)

A. Lesser Petrosal nerve

B. Mandibular nerve

C. Accessory meningeal artery

D. Vidian’s nerve

See Answer in Part B → Q4

@Neet_pg_bot

Q5: A 30-year-old man presents with numbness in his upper lip and cheek, along with difficulty sensing temperature changes, following a dental procedure. Through which of the following marked structures does the affected nerve pass? (Q848720)

A. A

B. B

C. C

D. D

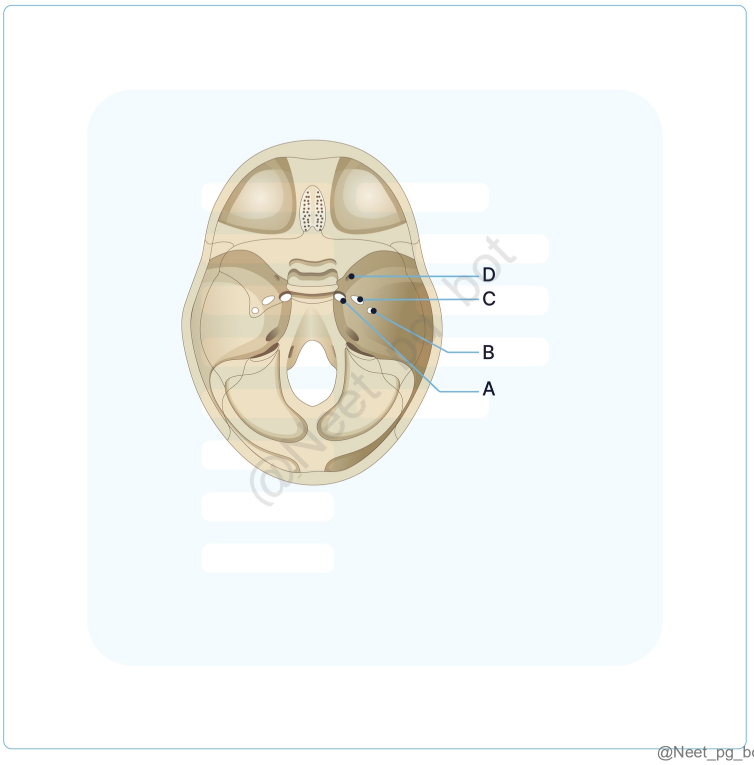

@Neet_pg_bot

See Answer in Part B → Q5

@Neet_pg_bot

Q6: Which of the following contributes to the formation of the marked structure? (Q848721)

A. Lesser wing of the sphenoid

B. Maxilla

C. Zygomatic bone

D. Greater wing of the sphenoid

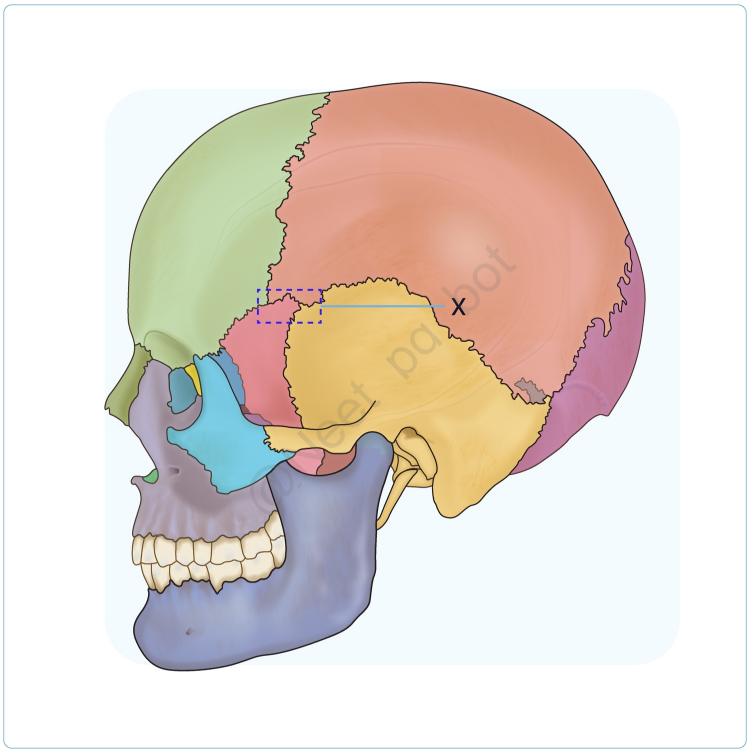

@Neet_pg_bot

See Answer in Part B → Q6

@Neet_pg_bot

Q7: A 25 y/o male presents to the emergency department after a road traffic accident. He was initially unconscious but regained full consciousness shortly afterward, reporting only a mild headache. On examination, the patient starts to experience drowsiness, and eventually loses consciousness again. A CT scan was performed, what is the most likely source of her bleeding? (Q848722)

A. Emissary veins

B. Rupture of berry aneurysm

C. Diploic veins

D. Middle meningeal artery

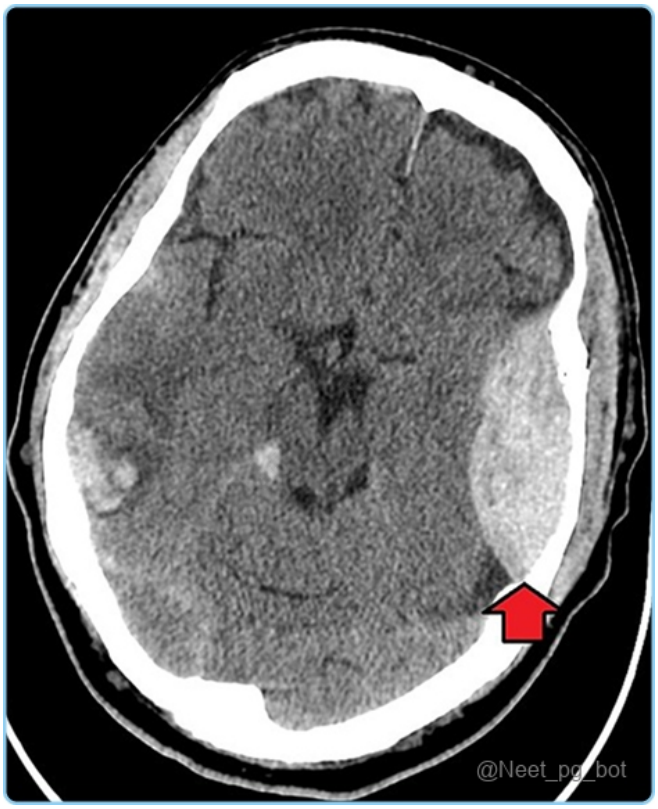

See Answer in Part B → Q7

@Neet_pg_bot

Q8: A 50-year-old man with a history of poorly controlled hypertension presents with sudden severe headache, blurred vision, slurred speech, and right-sided weakness. A CT scan shows an acute haemorrhage in the basal ganglia. What is the most likely cause? (Q848723)

A. Berry aneurysm

B. Mycotic aneurysm

C. Ruptured arteriovenous malformation

D. Charcot–Bouchard aneurysm



See Answer in Part B → Q8

@Neet_pg_bot

Q9: Which of the following combinations of structures passing through the posterior cranial fossa is incorrectly matched with their corresponding openings? (Q848725)

A. Spinal cord, vertebral arteries – Foramen Magnum

B. Glossopharyngeal nerve, vagus nerve – Jugular Foramen

C. Facial nerve, vestibulocochlear nerve – Internal acoustic meatus

D. Hypoglossal nerve, emissary vein – Hypoglossal Canal

See Answer in Part B → Q9

@Neet_pg_bot

Q10: Which of the following statements about the course of the spinal accessory nerve is TRUE? (Q848727)

A. Passes through the internal acoustic meatus before innervating the trapezius muscle.

B. Exits the skull via the jugular foramen alongside the vagus nerve.

C. Passes through the foramen rotundum with the maxillary nerve.

D. Originates from the dorsal horn of C1 to C5/6 spinal cord segments.

See Answer in Part B → Q10

@Neet_pg_bot

Q11: A 45-year-old patient undergoes surgery for a suspected brain mass. During the operation, the surgeon identifies a dural fold extending between the cerebellum and the occipital lobes, creating a partition in the cranial cavity. Which dural fold is being described? (Q848728)

A. Falx cerebri

B. Falx cerebelli

C. Diaphragma sellae

D. Tentorium cerebelli

See Answer in Part B → Q11

@Neet_pg_bot

Q12: Which of the following sinuses is NOT located between the meningeal and endosteal layers of the dura mater? (Q848729)

A. Superior sagittal sinus

B. Transverse sinus

C. Inferior sagittal sinus

D. Sigmoid sinus

See Answer in Part B → Q12

@Neet_pg_bot

Q13: A 40-year-old female presents with double vision and drooping eyelids. An MRI reveals involvement of the cavernous sinus, prompting the neurologist to evaluate the cranial nerves associated with this structure. Which of the following nerves is not a content of the cavernous sinus? (Q848730)

A. Ophthalmic nerve

B. Maxillary nerve

C. Mandibular nerve

D. Abducens nerve

See Answer in Part B → Q13

@Neet_pg_bot

Q14: A 35-year-old patient presents with symptoms of cavernous sinus thrombosis, including severe headache, visual disturbances, and facial swelling. Which of the following is not a tributary of the cavernous sinus? (Q848731)

A. Superior ophthalmic vein

B. Inferior ophthalmic vein

C. Deep facial vein

D. Sphenoparietal sinus

See Answer in Part B → Q14

@Neet_pg_bot

Q15: A 60-year-old patient is evaluated for chronic headaches and altered mental status. A CT scan reveals potential thrombosis in an unpaired dural sinus. Which of

the following sinus is unpaired? (Q848732)

A. Superior sagittal sinus

B. Sigmoid sinus

C. Inferior petrosal sinus

D. Transverse sinus

See Answer in Part B → Q15

@Neet_pg_bot

Q16: A 5-year-old child is brought to the pediatric clinic with symptoms of hydrocephalus and developmental delays. An MRI reveals a malformation of a vein associated with increased intracranial pressure. Which of the following veins primarily contributes to its formation? (Q848734)

A. Internal cerebral veins

B. Basal veins

C. Superior sagittal sinus

D. Veins from the cerebellum

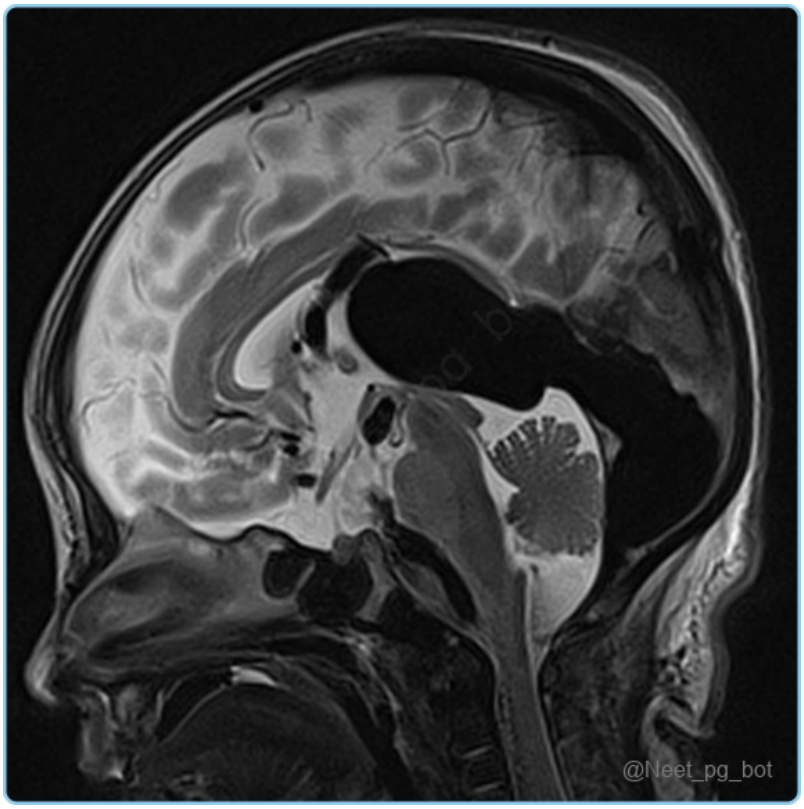

See Answer in Part B → Q16

@Neet_pg_bot

• [04_Head and Neck] 017 Cranial Nerves And Cervical Plexus

« Back to Folder Directory

[04_Head and Neck] 017 Cranial Nerves And Cervical Plexus — Quick Jump

Q1 (p. 211)	*Q2 (p. 211)*	*Q3 (p. 212)*	*Q4 (p. 212)*	*Q5 (p. 212)*	*Q6 (p. 213)*
Q7 (p. 213)	*Q8 (p. 214)*	*Q9 (p. 214)*	*Q10 (p. 214)*	*Q11 (p. 215)*	*Q12 (p. 216)*
Q13 (p. 217)	*Q14 (p. 217)*	*Q15 (p. 218)*	*Q16 (p. 219)*	*Q17 (p. 219)*	*Q18 (p. 220)*
Q19 (p. 220)	*Q20 (p. 221)*	*Q21 (p. 221)*	*Q22 (p. 222)*	*Q23 (p. 222)*	*Q24 (p. 223)*
Q25 (p. 223)	*Q26 (p. 224)*	*Q27 (p. 224)*	*Q28 (p. 225)*		

Q1: A 38-year-old female with down-out and intorsion of the eye presents with worsening night vision, occasional headaches, and mild dizziness. Examination shows ptosis and a larger, non-reactive left pupil. Which of the following structures is the parasympathetic component of the affected nerve? (Q848465)

A. Edinger-Westphal nucleus

B. Oculomotor nucleus

C. Superior colliculus

D. Red nucleus

See Answer in Part B → Q1

@Neet_pg_bot

Q2: A 32-year-old male presents with difficulty chewing and numbness on the right side of his jaw following a recent sports injury. Examination reveals weakened jaw clenching on the right and decreased sensation over the anterior cheek, but intact sensation in the lower lip. Which of the following nerves might be affected? (Q848447)

A. Facial nerve

B. Anterior division of mandibular nerve

C. Posterior division of mandibular nerve

D. Maxillary nerve

See Answer in Part B → Q2

@Neet_pg_bot

Q3: A 55-year-old patient presents with difficulty swallowing and a hoarse voice after recent neck surgery. What structure does the vagus nerve primarily run between as it descends in the neck? (Q848463)

A. Internal carotid artery and external jugular vein

B. Internal jugular vein and common carotid artery

C. Subclavian artery and internal thoracic artery

D. External carotid artery and internal jugular vein

See Answer in Part B → Q3

@Neet_pg_bot

Q4: A 60-year-old woman presents with unilateral facial pain and sensory loss on the left side of her face. Examination reveals that she cannot feel light touch, pain, or temperature on the left side, but her corneal reflex remains intact. Which of the following is the most likely explanation for her symptoms? (Q848454)

A. Lesion of right mesencephalic nucleus

B. Lesion of left mesencephalic nucleus

C. Lesion of right spinal trigeminal nucleus

D. Lesion of left spinal trigeminal nucleus

See Answer in Part B → Q4

@Neet_pg_bot

Q5: Which of the following cranial nerves does not receive motor fibers from the nucleus ambiguus? (Q848473)

A. Glossopharyngeal nerve (IX)

B. Vagus nerve (X)

C. Accessory nerve (XI)

D. Trigeminal nerve (V)

See Answer in Part B → Q5

@Neet_pg_bot

Q6: Which of the following statements correctly distinguishes the role of the hypoglossal nerve from the olfactory nerve? (Q848471)

A. The hypoglossal nerve supplies the muscles of the tongue, while the olfactory nerve mediates smell via the thalamus.

B. The hypoglossal nerve is involved in motor control of the tongue, while the olfactory nerve mediates smell without synapsing in the thalamus.

C. The hypoglossal nerve supplies the tongue and is part of the olfactory pathway.

D. Both the hypoglossal and olfactory nerves are involved in taste and smell.

See Answer in Part B → Q6

@Neet_pg_bot

Q7: A 62-year-old patient presents with hoarseness and difficulty swallowing. Physical examination reveals a diminished gag reflex and weakened pharyngeal elevation during swallowing. Which of the following structures is not innervated by the affected nerve? (Q848460)

A. Carotid body

B. Stylopharyngeus muscle

C. Parotid gland

D. Palatopharyngeus

See Answer in Part B → Q7

@Neet_pg_bot

Q8: Which of the following cranial nerves is not involved in the Special Visceral Afferent (SVA) pathway? (Q848472)

A. Facial nerve (VII)

B. Glossopharyngeal nerve (IX)

C. Vagus nerve (X)

D. Trochlear nerve (IV)

See Answer in Part B → Q8

@Neet_pg_bot

Q9: A 29-year-old male presents with a head tilt and double vision that worsens when looking down, especially while reading or using his phone. Examination shows a significant limitation in the left eye's downward movement, extorsion of the eyeball, and a noticeable right head tilt. At what site does the decussation of the affected nerve occur? (Q848467)

A. Crus cerebri

B. Superior colliculus

C. Superior medullary velum

D. Substantia nigra

See Answer in Part B → Q9

@Neet_pg_bot

Q10: Below is an image of a transverse section of the lower pons, specifically at the level of the facial colliculus. Please identify the structures marked as "X" and "Y." (Q848468)

A. Abducens nucleus and Facial nucleus

B. Facial nucleus and Abducens nucleus

C. Trigeminal nucleus and Vestibular nucleus

D. Vestibular nucleus and Trigeminal nucleus

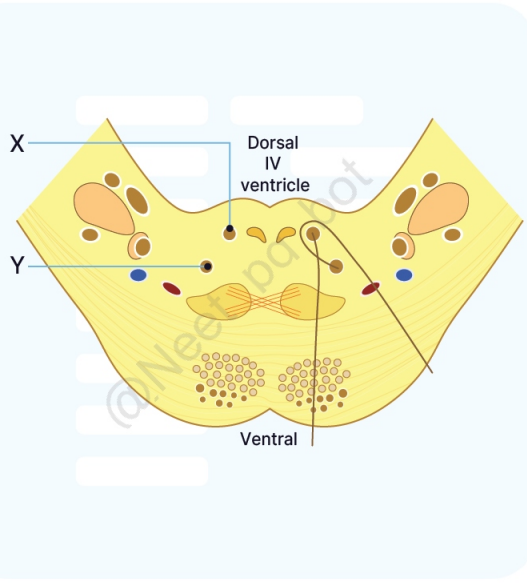

@Neet_pg_bot

See Answer in Part B → Q10

@Neet_pg_bot

Q11: A 54-year-old male presents with double vision and difficulty moving his left eye outward. Examination reveals the left eye is deviated medially with limited abduction. Which muscle is involved in this condition? (Q848469)

A. Right medial rectus palsy

B. Left medial rectus palsy

C. Right lateral rectus palsy

D. Left lateral rectus palsy

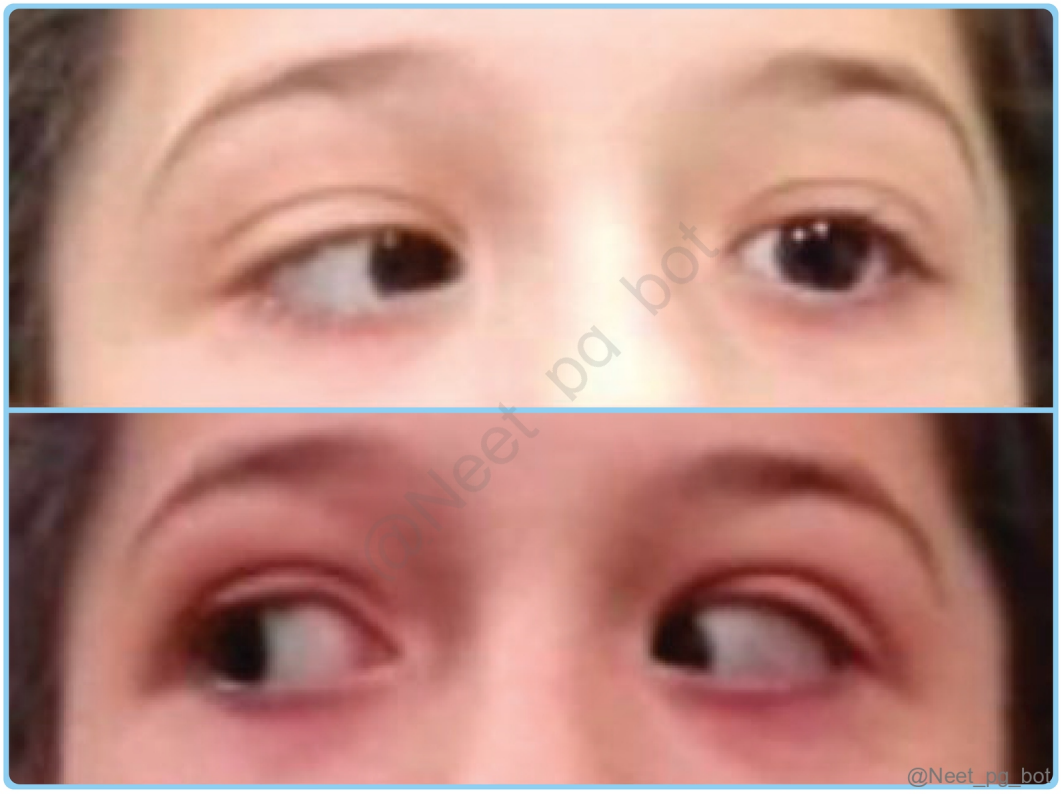

See Answer in Part B → Q11

@Neet_pg_bot

Q12: Which of the following correctly describes the arrangement of cranial nerve nuclei from ventral to dorsal in the brainstem? (Q848470)

A. General Visceral Efferent (GVE), General Visceral Afferent (GVA), Special Visceral Afferent (SVA), Special Somatic Afferent (SSA).

B. General Somatic Afferent (GSA), Special Somatic Afferent (SSA), General Visceral Efferent (GVE), General Somatic Efferent (GSE).

C. General Somatic Efferent (GSE), Special Visceral Efferent (SVE), General Visceral Efferent (GVE), General Somatic Afferent (GSA).

D. Special Visceral Afferent (SVA), Special Somatic Afferent (SSA), General Somatic Efferent (GSE), General Visceral Afferent (GVA).

See Answer in Part B → Q12

@Neet_pg_bot

Q13: A 50-year-old patient experiences numbness in the area around the neck following a cervical block performed for neck surgery. Which of the following is not a branch of the cervical plexus? (Q848464)

A. Greater Auricular Nerve

B. Transverse Cutaneous Nerve of the Neck

C. Supraclavicular Nerve

D. Phrenic Nerve

See Answer in Part B → Q13

@Neet_pg_bot

Q14: Identify the structure marked with the arrow and select which nerve root arises from it. (Q848474)

A. Abducens nerve

B. Glossopharyngeal nerve

C. Hypoglossal nerve

D. Vagus nerve

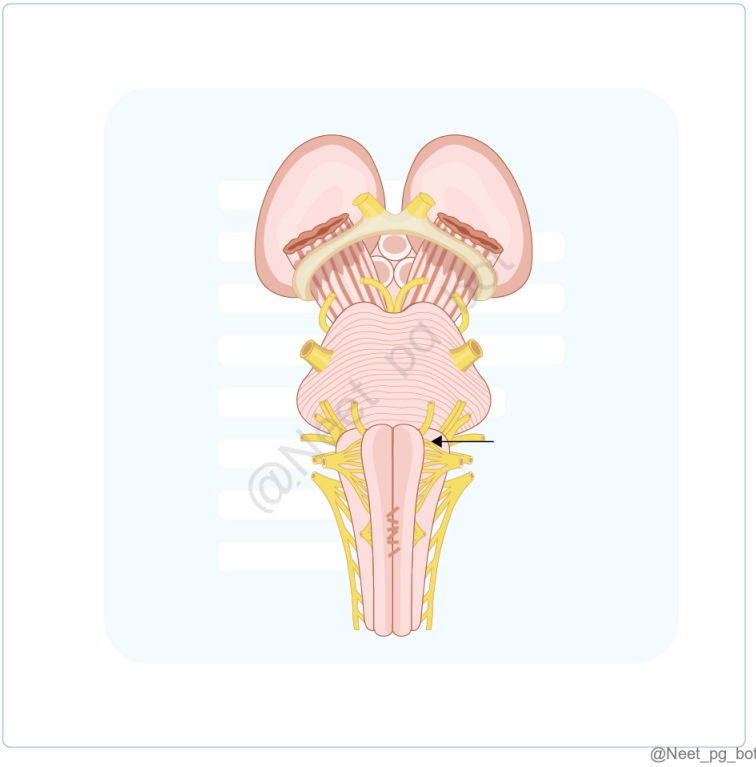

See Answer in Part B → Q14

@Neet_pg_bot

Q15: A 60-year-old female presents with drooping of her left eyelid, double vision, and a dilated, fixed left pupil. She also reports difficulty focusing on close objects and some mild forward projection of her left eye. Neurological examination reveals that the left eye is turned downward and outward. A CT scan shows no evidence of mass lesions or hemorrhage.Which of the following is most likely responsible for the patient's symptoms? (Q848475)

A. Complete Oculomotor Nerve Palsy

B. Trochlear Nerve Palsy

C. Abducens Nerve Palsy

D. Supranuclear Lesion

See Answer in Part B → Q15

@Neet_pg_bot

Q16: A 45-year-old patient presents with facial asymmetry and difficulty smiling. Upon examination, the physician suspects a lesion affecting the facial nerve. Where does the facial nerve divide into its five terminal branches within the parotid gland? (Q848476)

A. At the stylomastoid foramen

B. Behind the neck of the mandible

C. Near the spine of the sphenoid

D. Within the middle ear

See Answer in Part B → Q16

@Neet_pg_bot

Q17: The anesthetic agent used for providing the nerve block in the diagram below will not affect which nerve? (Q876192)

A. Inferior alveolar nerve

B. Buccal nerve

C. Lingual nerve

D. Mental nerve

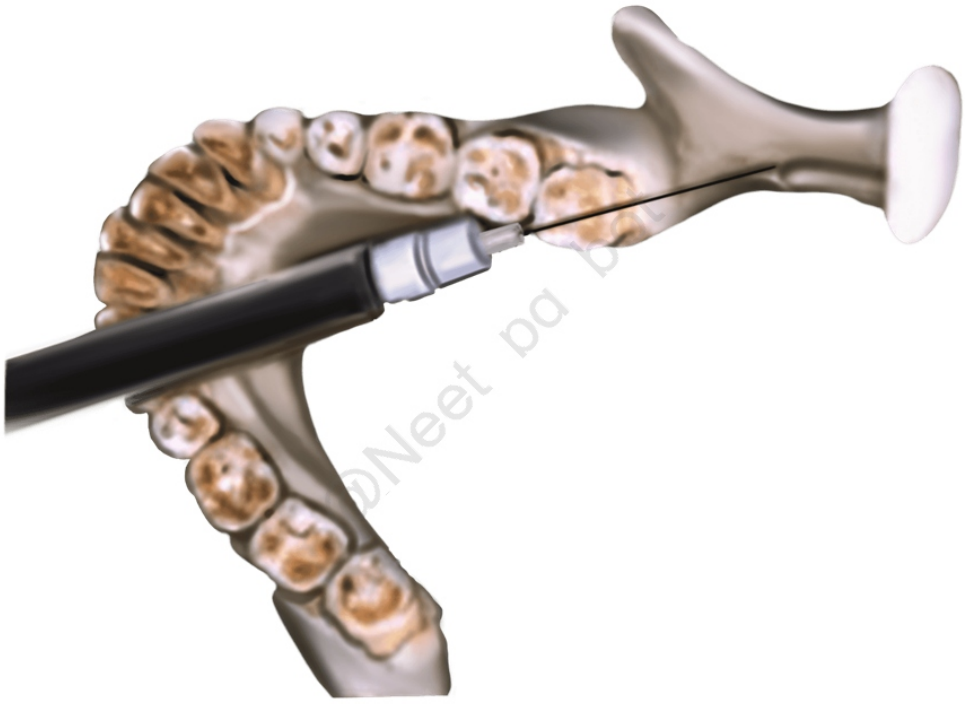

See Answer in Part B → Q17

@Neet_pg_bot

Q18: A 62-year-old male with diabetes arrives at the emergency department with sudden right-sided weakness and trouble speaking. His examination shows left-sided ptosis, the left eye in a "down and out" position, and right-sided paralysis of the lower face. What is the most likely diagnosis? (Q848466)

A. Horner’s syndrome

B. Benedikt’s syndrome

C. Parinaud’s syndrome

D. Weber’s syndrome

See Answer in Part B → Q18

@Neet_pg_bot

Q19: A 35-year-old female presents with sharp, shooting pain and numbness in her forehead, upper eyelid, upper face, upper lip, and part of her cheek after a recent car accident. She has a diminished corneal reflex on the right side. Which divisions of the trigeminal nerve are affected? (Q848444)

A. V1, V2

B. V2, V3

C. V1, V3

D. V1, V2, V3

See Answer in Part B → Q19

@Neet_pg_bot

Q20: A 60-year-old patient presents with difficulty swallowing and changes in voice quality. Upon examination, the physician suspects a neurological issue affecting the muscles of the larynx and pharynx. Which nucleus is responsible for the motor innervation of these muscles? (Q848462)

A. Dorsal nucleus of the vagus

B. Nucleus ambiguus

C. Nucleus tractus solitarius

D. Spinal nucleus

See Answer in Part B → Q20

@Neet_pg_bot

Q21: A 65-year-old patient experiences redness and sweating in the right cheek while eating. Which of the following components is directly involved in the aberrant nerve regeneration causing these symptoms? (Q848461)

A. Jacobson’s nerve

B. Auriculotemporal preganglionic fibers

C. Auriculotemporal postganglionic fibers

D. Sympathetic postganglionic fibers

See Answer in Part B → Q21

@Neet_pg_bot

Q22: A 45-year-old male presents to the clinic with complaints of difficulty swallowing and loss of taste sensation from the posterior third of his tongue. On examination, there is a loss of the gag reflex on the right side. Further tests reveal decreased salivary secretion from the parotid gland. Given the clinical findings, which of the following structures is most likely affected in this patient? (Q848457)

A. Otic ganglion

B. Submandibular ganglion

C. Ciliary ganglion

D. Pterygopalatine ganglion

See Answer in Part B → Q22

@Neet_pg_bot

Q23: A 45-year-old patient presents with difficulty in smiling and closing eyelids on the right side. The patient does not have any history of recent trauma or infections. The image below shows the patient's face. Sensory function, including taste on the anterior two-thirds of the tongue and sensation to light touch, appears intact. Which nerve column is primarily responsible for this condition? (Q848456)

A. General Somatic Efferent (GSE)

B. General Visceral Efferent (GVE)

C. Special Visceral Efferent (SVE)

D. General Somatic Afferent (GSA)



See Answer in Part B → Q23

@Neet_pg_bot

Q24: A 50-year-old woman presents with excessive tearing while eating, which started a few months ago. Upon further questioning, she recalls having facial nerve palsy about a year ago, which has since improved. Based on this presentation, at what level of the facial nerve pathway did the injury most likely occur? (Q848455)

A. At the level of the geniculate ganglion

B. At the level of the chorda tympani

C. At the stylomastoid foramen

D. At the level of the greater petrosal nerve

See Answer in Part B → Q24

@Neet_pg_bot

Q25: A 35-year-old male presents with difficulty chewing and pain near his temporomandibular joint (TMJ) after sustaining blunt trauma to the side of his face. Upon examination, there is tenderness over the ramus of the mandible. Which muscle is most likely affected? (Q848453)

A. Temporalis

B. Masseter

C. Lateral Pterygoid

D. Medial Pterygoid

See Answer in Part B → Q25

@Neet_pg_bot

Q26: A 34-year-old male presents with difficulty opening his mouth following a jaw injury. Which of the following muscles is primarily responsible for opening the mouth? (Q848448)

A. Masseter

B. Temporalis

C. Medial pterygoid

D. Lateral pterygoid

See Answer in Part B → Q26

@Neet_pg_bot

Q27: A 48-year-old female with diabetes presents with severe, sharp right-sided facial pain triggered by light touch, along with numbness and tingling. Examination shows hyperesthesia and decreased sensation on the right side. Which of the following structures is most likely involved in this condition? (Q848446)

A. Spinal nucleus

B. Motor nucleus

C. Mesencephalic nucleus

D. Principal sensory nucleus

See Answer in Part B → Q27

@Neet_pg_bot

Q28: A 55-year-old woman presents with sudden numbness, tingling, heaviness, dull pain, and heightened sensitivity on the right side of her face. Examination shows reduced sensation in the right maxillary and mandibular areas, with intact motor function and no other deficits. From which location does the affected cranial nerve emerge? (Q848445)

A. Midbrain

B. Cerebrum

C. Pons

D. Medulla oblongata

See Answer in Part B → Q28

@Neet_pg_bot

• [04_Head and Neck] 018 Scalenus Anterior Head And Neck Vasculature And Lymphatic Drainage

« Back to Folder Directory

[04_Head and Neck] 018 Scalenus Anterior Head And Neck Vasculature And Lymphatic Drainage — Quick Jump

Q1 (p. 226)	*Q2 (p. 226)*	*Q3 (p. 227)*	*Q4 (p. 227)*	*Q5 (p. 227)*	*Q6 (p. 228)*
Q7 (p. 229)	*Q8 (p. 229)*	*Q9 (p. 229)*	*Q10 (p. 230)*	*Q11 (p. 230)*	*Q12 (p. 231)*
Q13 (p. 231)	*Q14 (p. 232)*	*Q15 (p. 232)*	*Q16 (p. 233)*	*Q17 (p. 234)*	

Q1: A 45-year-old male presents with a progressively enlarging mass in his neck. He has a history of heavy smoking and reports recent difficulty swallowing. A biopsy confirms squamous cell carcinoma of the base of the tongue. Which of the following lymph nodes is most likely to be involved in the initial spread of cancer from this region? (Q848747)

A. Jugulodigastric node

B. Supraclavicular node

C. Pretracheal node

D. Paratracheal node

See Answer in Part B → Q1

@Neet_pg_bot

Q2: A 65-year-old patient presents with a neck mass and difficulty swallowing. On imaging, the mass is located in the area bordered by the internal jugular vein, scalenus anterior muscle, and longus colli muscle. Which lymph node group is most likely located in this area? (Q848746)

A. Level I (Submental and Submandibular nodes)

B. Level II (Upper Jugular nodes)

C. Level III (Middle Jugular nodes)

D. Level IV (Lower Jugular nodes)

See Answer in Part B → Q2

@Neet_pg_bot

Q3: During surgery, the surgeon notices an additional thyroid vein, known as the Kocher's vein, which drains into the internal jugular vein. The surgeon carefully ligates this additional vein to avoid any postoperative complications. What is the most likely origin of this additional vein? (Q848744)

A. Between the middle and inferior thyroid veins

B. Between the superior and inferior thyroid veins

C. Middle of the thyroid lobe

D. Thyroid isthmus

See Answer in Part B → Q3

@Neet_pg_bot

Q4: During a thyroidectomy, the surgeon identifies an artery supplying the lower part of the thyroid isthmus, originating from the arch of the aorta. What is the name of this artery? (Q848743)

A. Accessory thyroid artery

B. Middle thyroid artery

C. Inferior thyroid artery

D. Thyroidea ima artery

See Answer in Part B → Q4

@Neet_pg_bot

Q5: A patient presents with the following symptoms: when sticking out the tongue, it deviates towards the left side, and there is noticeable atrophy on the left side of the tongue. Based on the image, which of the following is the most likely diagnosis? (Q848751)

A. Hypoglossal nerve injury (left side)

B. Hypoglossal nerve injury (right side)

C. Right vagus nerve

D. Left vagus nerve



See Answer in Part B → Q5

@Neet_pg_bot

Q6: Which of the following statements about the nerve supply of the four types of papillae on the tongue is incorrect? (Q848750)

A. Filiform papillae are primarily innervated by the lingual nerve (branch of the mandibular nerve) for general sensation.

B. Fungiform papillae are innervated by the chorda tympani (branch of the facial nerve) for taste sensation.

C. Circumvallate papillae are innervated by the glossopharyngeal nerve for both taste and general sensation.

D. Foliate papillae are innervated by the vagus nerve for taste sensation.

See Answer in Part B → Q6

@Neet_pg_bot

Q7: Which lymph nodes are primarily involved in the drainage of lymphatic vessels from the dorsal region of the tongue? (Q848749)

A. Submental nodes

B. Submandibular nodes

C. Jugulodigastric nodes

D. Subclavicular nodes

See Answer in Part B → Q7

@Neet_pg_bot

Q8: Which lymphoid tissue is not a part of Waldeyer’s ring? (Q848748)

A. Palatine tonsils

B. Nasopharyngeal tonsil (adenoid)

C. Submandibular lymph nodes

D. Lingual tonsils

See Answer in Part B → Q8

@Neet_pg_bot

Q9: A surgeon is performing a neck dissection and encounters the internal jugular vein. Which of the following structures does not directly drain into the internal jugular vein? (Q848745)

A. Facial vein

B. Lingual vein

C. Maxillary vein

D. Superior thyroid vein

See Answer in Part B → Q9

@Neet_pg_bot

Q10: A 6-month-old infant is evaluated after a complicated delivery in which upward traction was applied to the arm. The parents report that the infant's left hand has fingers curled and cannot extend them. On examination, the left eyelid droops, and the pupil is smaller. What is the most likely diagnosis? (Q848735)

A. Erb's Palsy

B. Klumpke's Palsy

C. Radial Nerve Palsy

D. Ulnar Nerve Injury

See Answer in Part B → Q10

@Neet_pg_bot

Q11: A 65-year-old male presents with complaints of dizziness, syncope, and numbness in his left arm during physical activity. On examination, his left radial pulse is weak, and the blood pressure in the left arm is significantly lower than in the right arm. What is the most likely pathophysiological mechanism behind this patient's symptoms? (Q848742)

A. Retrograde blood flow in the left vertebral artery due to subclavian artery stenosis

B. Reduced blood flow in the left subclavian artery due to thoracic aortic dissection

C. Retrograde blood flow in the left internal carotid artery due to basilar artery stenosis

D. Retrograde blood flow in the right vertebral artery due to subclavian artery stenosis

See Answer in Part B → Q11

@Neet_pg_bot

Q12: Which of the following arteries does not supply the upper part of the tonsil? (Q848741)

A. Ascending pharyngeal artery

B. Ascending palatine artery

C. Descending palatine artery

D. Greater palatine artery

See Answer in Part B → Q12

@Neet_pg_bot

Q13: A 12 y/o boy presents with nasal bleeding, after nose-picking. On examination, the bleeding site is located in the anterior nasal septum, and the diagnosis of epistaxis from Kiesselbach's plexus is made. Which of the following arteries is LEAST likely to contribute to the bleeding from this plexus? (Q848740)

A. Anterior ethmoid artery

B. Posterior ethmoid artery

C. Superior labial artery

D. Sphenopalatine artery

See Answer in Part B → Q13

@Neet_pg_bot

Q14: Which statement about the maxillary artery is false? (Q848739)

A. It arises behind the neck of the mandible.

B. The middle meningeal artery passes through the foramen ovale.

C. The posterior superior alveolar artery supplies upper molar teeth.

D. The sphenopalatine artery is the artery of epistaxis.

See Answer in Part B → Q14

@Neet_pg_bot

Q15: Identify the marked branch of the External carotid artery? (Q848738)

A. Lingual Artery

B. Facial Artery

C. Maxillary Artery

D. Superior Thyroid Artery

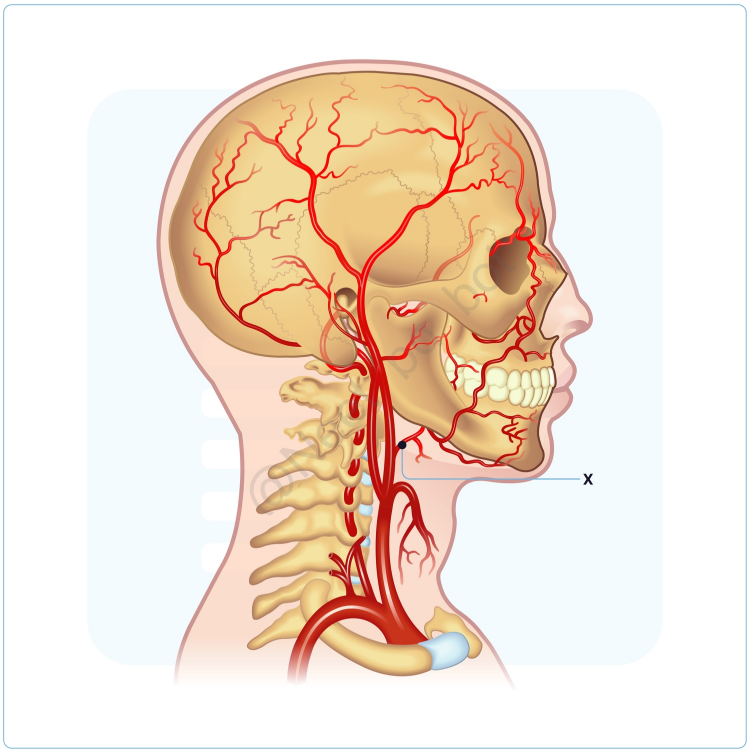

@Neet_pg_bot

See Answer in Part B → Q15

@Neet_pg_bot

Q16: Which of the following is not the branch of the marked artery? (Q848737)

A. Thyrocervical Trunk

B. Costocervical trunk

C. Dorsal scapular artery

D. Axillary artery

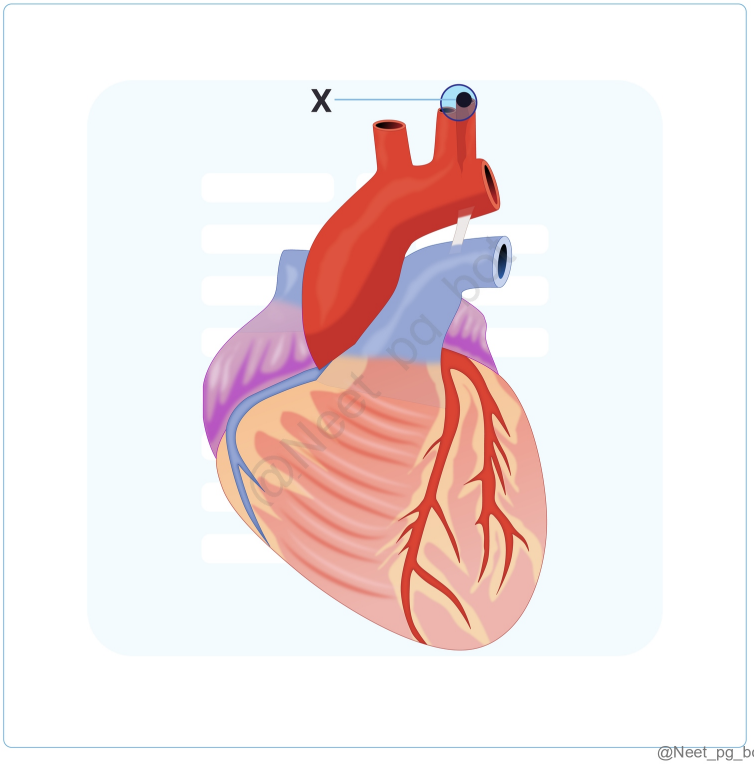

@Neet_pg_bot

See Answer in Part B → Q16

@Neet_pg_bot

Q17: Which of the following statements about the scalenus anterior muscle is incorrect? (Q848736)

A. The phrenic nerve lies anteriorly to the muscle.

B. The thoracic duct arches laterally on the right side.

C. The brachial plexus is posterior to the muscle.

D. The lateral part of the carotid sheath contains the internal jugular vein.

See Answer in Part B → Q17

@Neet_pg_bot

• [04_Head and Neck] 019 Scalp Neck Triangles And Parotid Gland

« Back to Folder Directory

[04_Head and Neck] 019 Scalp Neck Triangles And Parotid Gland — Quick Jump

Q1 (p. 235) *Q2 (p. 235)* *Q3 (p. 235)* *Q4 (p. 236)* *Q5 (p. 237)* *Q6 (p. 238)*
Q7 (p. 238) *Q8 (p. 239)* *Q9 (p. 240)* *Q10 (p. 241)* *Q11 (p. 241)* *Q12 (p. 242)*
Q13 (p. 242) *Q14 (p. 243)* *Q15 (p. 243)*

Q1: Which of the following structures is enclosed by the prevertebral fascia in the neck? (Q848761)

A. Trapezius muscle

B. Internal carotid artery

C. Cervical sympathetic trunk

D. Thyroid gland

See Answer in Part B → Q1

@Neet_pg_bot

Q2: Which of these form the scalp proper? (Q848752)

A. Skin of the scalp

B. Skin and superficial fascia of the scalp

C. Skin, superficial fascia, and deep fascia of the scalp

D. Skin, superficial fascia, deep fascia, and loose areolar tissue of the scalp

See Answer in Part B → Q2

@Neet_pg_bot

Q3: All of the following are the contents of the occipital triangle of the neck except? (Q848753)

A. Transverse cervical artery

B. Occipital artery

C. Spinal accessory nerve

D. External jugular vein

See Answer in Part B → Q3

@Neet_pg_bot

Q4: Choose the appropriate set of correct statement(s) regarding the triangle shown in the image below (red-shaded region) 1) bounded posteroinferiorly by posterior belly of digastric 2) Floor of the triangle is formed by hyoglossus anteriorly 3) Submental artery runs through anterior part of triangle 4) Carotid artery runs through posterior part of triangle (Q848754)

A. only 1

B. only 2

C. 1,3,4

D. 2,3,4

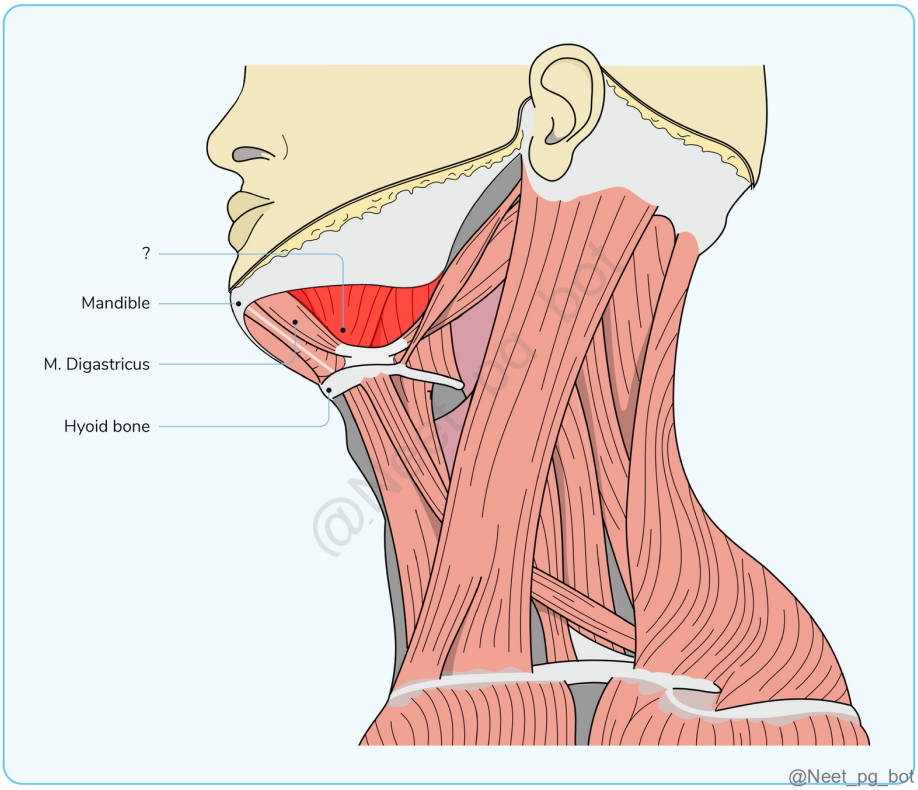

See Answer in Part B → Q4

@Neet_pg_bot

Q5: You notice the following examination being done in ED, all of the following are boundaries of the space containing the palpated structure except (Q848755)

A. Anterior belly of digastric

B. Stylohyoid

C. Superior belly of omohyoid

D. Anterior border of sternocleidomastoid



See Answer in Part B → Q5

@Neet_pg_bot

Q6: During thyroid surgery, the surgeon retracts the muscles forming the floor of the muscular triangle of neck to access the thyroid gland. Which of the following muscles does he not retract? (Q848756)

A. Sternothyroid

B. Sternohyoid

C. Geniohyoid

D. Thyrohyoid

See Answer in Part B → Q6

@Neet_pg_bot

Q7: Image below shows a method of brachial plexus block. Identify the correct set of approaches and the corresponding space in the neck. (Q848757)

A. Interscalene approach - muscular triangle

B. Interscalene approach - posterior triangle

C. Supraclavicular approach - muscular triangle

D. Supraclavicular approach - posterior triangle

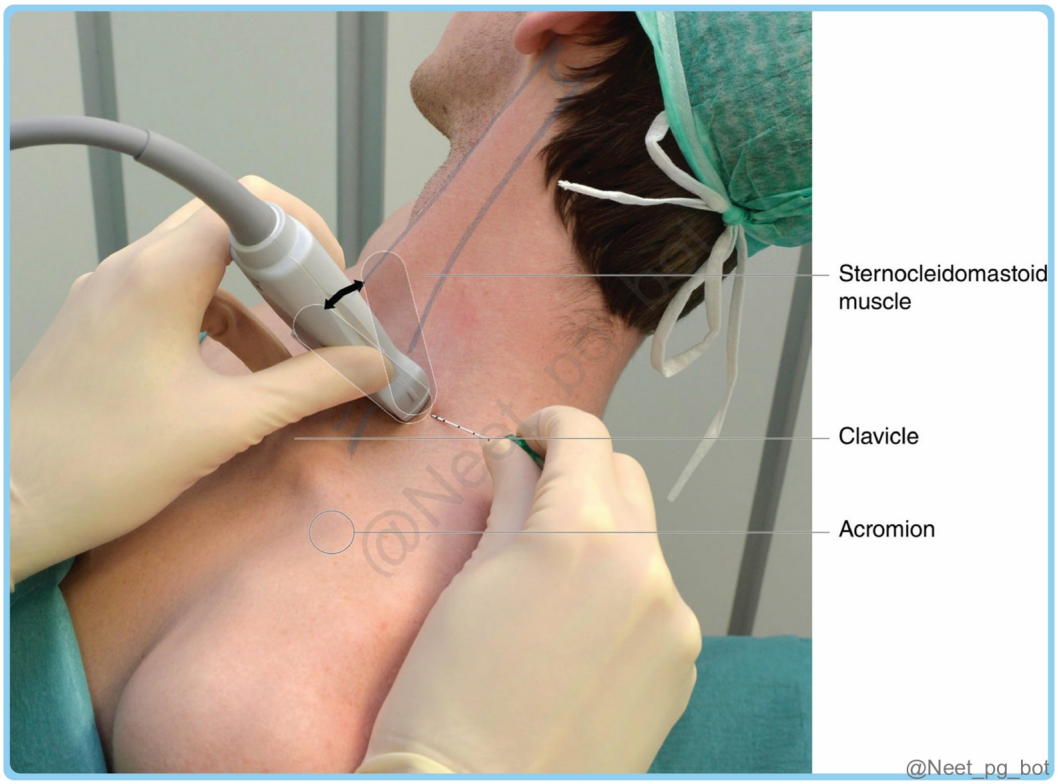

See Answer in Part B → Q7

@Neet_pg_bot

Q8: You notice the following procedure being done in OT. Choose the appropriate set of incorrect statement(s) regarding the same. 1) Congenital long QT syndrome is an indication in children 2) Can be done to manage Hyperhidrosis and Raynaud's phenomenon 3) Local anaesthetic is injected superior to longus colli muscle 4) Relatively unsafe procedure 5) Contralateral Horner syndrome is verification for correct placement of block (Q848758)

A. 1,5

B. only 5

C. 2,3

D. 3,5

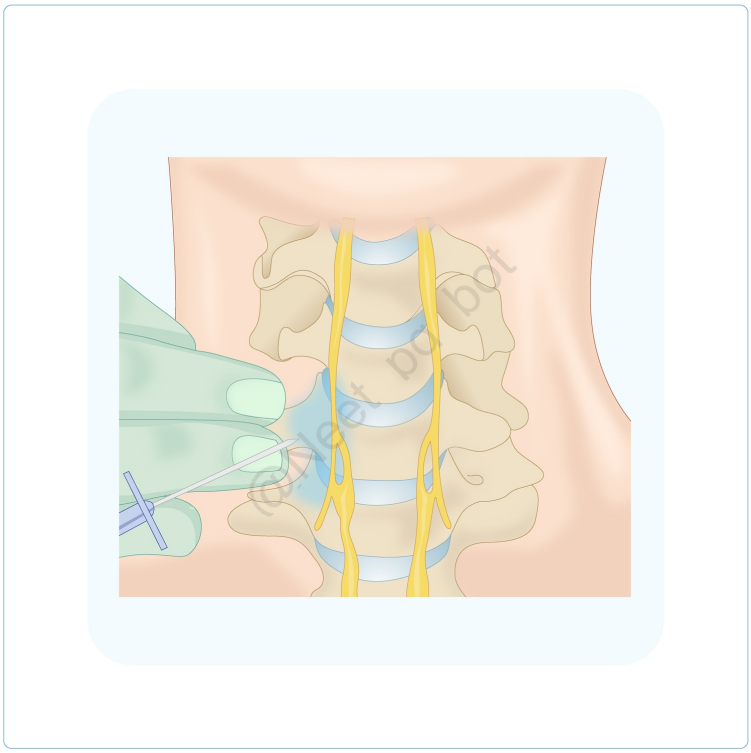

See Answer in Part B → Q8

@Neet_pg_bot

Q9: Patient presented with a painful swelling as shown below. Senior doctor says the pain is due to the underlying fascia. All of the following structures are enclosed by the layer forming this fascia except (Q848759)

A. Levator scapulae

B. Trapezius

C. Submandibular gland

D. External jugular vein



See Answer in Part B → Q9

@Neet_pg_bot

Q10: Which of the following is NOT a function of the pretracheal fascia? (Q848760)

A. Enclosing the thyroid gland

B. Enclosing the trachea and esophagus

C. Surrounding the carotid sheath

D. Limiting the spread of infection in the anterior neck

See Answer in Part B → Q10

@Neet_pg_bot

Q11: A 45-year-old man presents to the emergency department with severe neck pain, difficulty swallowing, and fever. A CT scan reveals a deep neck infection that has spread into the mediastinum. Which anatomical space is most likely involved in this patient's condition? (Q848762)

A. Parapharyngeal space

B. Carotid space

C. Danger Space

D. Prevertebral space

See Answer in Part B → Q11

@Neet_pg_bot

Q12: Which of the following structures is not the content of carotid sheath? (Q848763)

A. Common carotid artery

B. Internal jugular vein

C. Vagus nerve

D. External jugular vein

See Answer in Part B → Q12

@Neet_pg_bot

Q13: Which of the following statements about parotid gland is true? (Q848764)

A. The parotid duct passes through the masseter muscle

B. The parotid gland is innervated by the facial nerve (CN VII)

C. The parotid gland is located anterior to the sternocleidomastoid muscle

D. The parotid gland primarily secretes mucous saliva

See Answer in Part B → Q13

@Neet_pg_bot

Q14: A 60-year-old man is scheduled for a parotidectomy due to a tumor in the parotid gland. The surgeon reviews the anatomical relationships to avoid damage to surrounding structures. Which of the following structures is located superiorly to the parotid gland? (Q848765)

A. Styloglossus

B. Masseter muscle

C. Zygomatic arch

D. External carotid artery

See Answer in Part B → Q14

@Neet_pg_bot

Q15: Which of the following statements about the structures within the parotid gland are accurate? The external carotid artery enters the parotid gland through the posteromedial surface. The maxillary artery exits through the posterior surface of the gland. The superficial temporal artery branches into the transverse facial artery and emerges from the anterior part of the superior surface. The superficial temporal vein and maxillary vein unite to form the retromandibular vein, which divides into anterior and posterior divisions near the apex of the gland. The facial nerve enters the parotid gland and passes behind the retromandibular vein. (Q848766)

A. Only 1,3 and 4

B. Only 1 and 3

C. All except 2

D. All the above

See Answer in Part B → Q15

@Neet_pg_bot

• [04_Head and Neck] 020 Pharynx Esophagus And Larynx - I

« Back to Folder Directory

[04_Head and Neck] 020 Pharynx Esophagus And Larynx - I — Quick Jump

Q1 (p. 244)	*Q2 (p. 244)*	*Q3 (p. 245)*	*Q4 (p. 245)*	*Q5 (p. 245)*	*Q6 (p. 246)*
Q7 (p. 247)	*Q8 (p. 247)*	*Q9 (p. 248)*	*Q10 (p. 249)*	*Q11 (p. 249)*	*Q12 (p. 250)*
Q13 (p. 250)	*Q14 (p. 251)*	*Q15 (p. 251)*	*Q16 (p. 252)*	*Q17 (p. 253)*	*Q18 (p. 254)*
Q19 (p. 254)	*Q20 (p. 254)*	*Q21 (p. 255)*	*Q22 (p. 255)*		

Q1: Which of the following correctly describes the histology of the esophagus? (Q848626)

A. The upper third consists of smooth muscle, and the lower third is composed of striated muscle.

B. The adventitia is made up of dense connective tissue with blood vessels and nerves.

C. The middle third contains a mix of striated and smooth muscle fibers.

D. The entire esophagus is lined with keratinized stratified squamous epithelium.

See Answer in Part B → Q1

@Neet_pg_bot

Q2: Which among the following is the correct pairing of the part of the larynx to the structure from which it is derived? (Q848631)

A. Epiglottis-4th pharyngeal arch

B. Cricoid cartilage-5th pharyngeal arch

C. Intrinsic muscles-7th pharyngeal arch

D. Cricothyroid muscle-5th pharyngeal arch

See Answer in Part B → Q2

@Neet_pg_bot

Q3: Which of the following structures of the larynx have seromucous glands? False vocal cord True vocal cord Ventricle Saccule (Q848632)

A. 1 and 4

B. 1 and 2

C. 2 and 4

D. 2 and 3

See Answer in Part B → Q3

@Neet_pg_bot

Q4: A 58-year-old male patient presents with difficulty swallowing (dysphagia) and nasal regurgitation of food. He also reports that his speech has become nasal and less clear. On examination, you notice that his soft palate does not elevate properly during swallowing, and there is an abnormal ridge in the nasopharynx. Which of the following is the most likely cause of this patient's symptoms? (Q848642)

A. Paralysis of the superior pharyngeal constrictor muscle

B. Damage to the glossopharyngeal nerve (Cranial Nerve IX)

C. Weakness of the levator veli palatini muscle

D. Dysfunction of the palatopharyngeus muscle

See Answer in Part B → Q4

@Neet_pg_bot

Q5: Mark the false statement about the structure being palpated here (Q848641)

A. Blood supply is by superior thyroid artery

B. Extends from C6-T6 in standing position

C. Lined by pseudostratified ciliated columnar epithelium

D. Left recurrent laryngeal nerve lies posterior to it

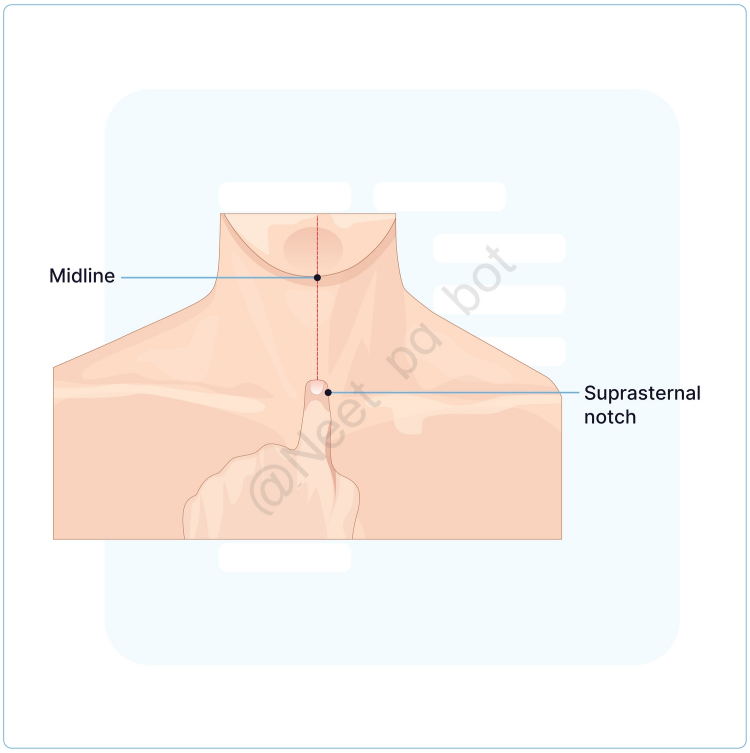

See Answer in Part B → Q5

@Neet_pg_bot

Q6: Patient who had suspected lung pathology was advised to undergo CT chest. While analysing the CT images, what vertebral level could this image likely correspond to? (Q848640)

A. T2

B. T3

C. T4

D. T5



See Answer in Part B → Q6

@Neet_pg_bot

Q7: All of the following are true about structures related to the extent of larynx except (Q848639)

A. Extent of larynx in adult female is C3-C6

B. Bifurcation of common carotid occurs at superior border of thyroid cartilage

C. Cricoid is the lowermost cartilage of larynx

D. Extent of larynx in children is C1-C4

See Answer in Part B → Q7

@Neet_pg_bot

Q8: Choose the appropriate set of incorrect statement(s) about the course of the marked nerve in image 1) Left sided nerve loops around arch of aorta 2) Travels anterior to the lung hilum 3) Originates from the lateral aspect of medulla 4) Runs within the carotid sheath with IJV laterally and ICA medially 5) Right nerve has a longer course than the Left. (Q848638)

A. 1,2,3

B. 1,5

C. 2,4,5

D. 2,5

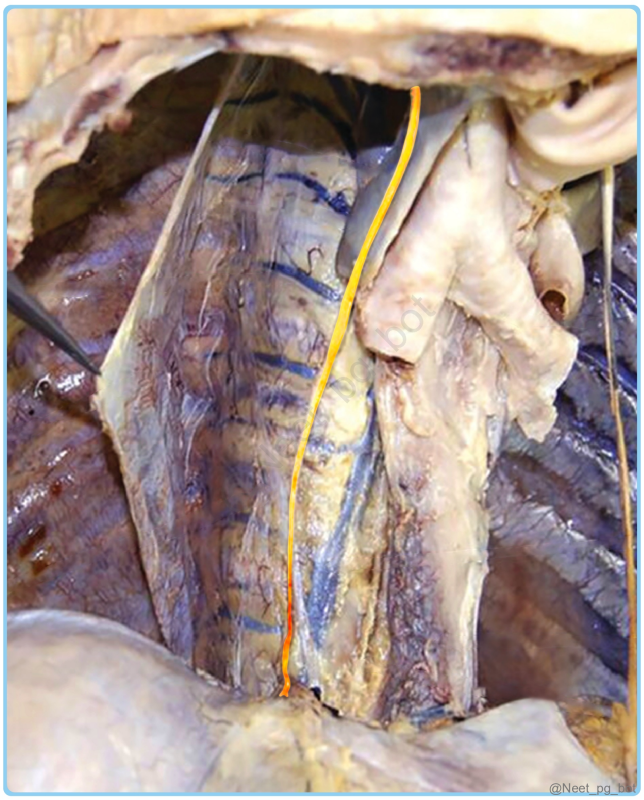

See Answer in Part B → Q8

@Neet_pg_bot

Q9: Arterial supply of larynx is by (Q848637)

A. Superior laryngeal artery- branch of superior thyroid artery & inferior laryngeal artery- branch of inferior thyroid artery

B. Both superior and inferior laryngeal artery - branch of inferior thyroid artery

C. Both superior and inferior laryngeal artery - branch of superior thyroid artery

D. Superior laryngeal artery- branch of subclavian artery & inferior laryngeal artery- branch of inferior thyroid artery

See Answer in Part B → Q9

@Neet_pg_bot

Q10: What is the structure marked as X in the laryngoscopy diagram given below? (Q848636)

A. Corniculate cartilage

B. Thyroid cartilage

C. Cricoid cartilage

D. Arytenoid cartilage

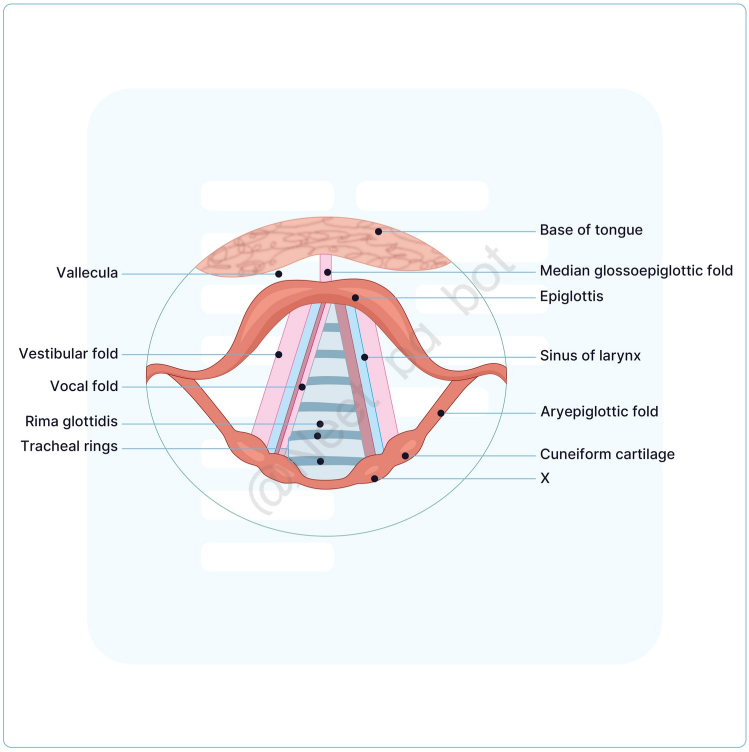

@Neet_pg_bot

See Answer in Part B → Q10

@Neet_pg_bot

Q11: Match the intrinsic muscles of the vocal cord with its function Function Muscle a. Abduct the vocal cords 1. Aryepiglottic b. Tense the vocal cords 2. Posterior

cricoarytenoid c. Close the inlet of the larynx 3. Cricothyroid d. Open inlet of larynx 4. Thyroepiglotticus (Q848635)

A. a2,b3,c1,d4

B. a1,b2,c3,d4

C. a4,b3,c2,d1

D. a3,b1,c2,d4

See Answer in Part B → Q11

@Neet_pg_bot

Q12: Which of the following cartilages of the larynx is paired? (Q848634)

A. Thyroid cartilage

B. Cricoid cartilage

C. Epiglottis

D. Arytenoid

See Answer in Part B → Q12

@Neet_pg_bot

Q13: From the sagittal section of the larynx given below, identify the part marked as X. (Q848633)

A. Thyroid cartilage

B. Cricoid cartilage

C. Arytenoid cartilage

D. Cuneiform cartilage

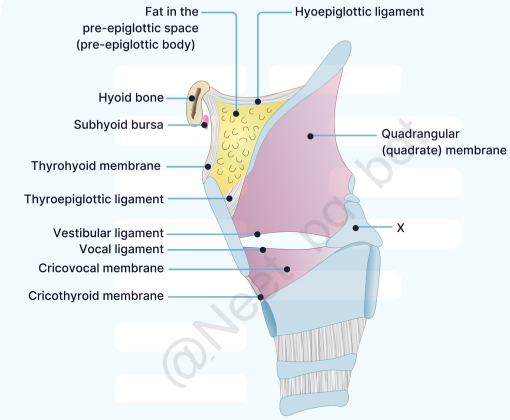

@Neet_pg_bot

See Answer in Part B → Q13

@Neet_pg_bot

Q14: Arrange the structures of the pharynx in the correct sequential order from innermost to outermost. (Q848621)

A. Mucosa, Submucosa, Buccopharyngeal fascia, Pharyngobasilar fascia, Muscular coat

B. Mucosa, Submucosa, Muscular coat, Buccopharyngeal fascia, Pharyngobasilar fascia

C. Mucosa, Submucosa, Pharyngobasilar fascia, Muscular coat, Buccopharyngeal fascia

D. Mucosa, Submucosa, Buccopharyngeal fascia, Muscular coat, Pharyngobasilar fascia

See Answer in Part B → Q14

@Neet_pg_bot

Q15: A 55-year-old male presents with difficulty swallowing (dysphagia) and is scheduled for an oesophagoscopy. During the procedure, the gastroenterologist must navigate the natural constrictions of the esophagus. At approximately 27.5 cm from the patient's incisor teeth, which anatomical structure is causing the narrowing? (Q848630)

A. Cricopharyngeus muscle

B. Aortic arch

C. Left main bronchus

D. Diaphragmatic hiatus

See Answer in Part B → Q15

@Neet_pg_bot

Q16: A 45 year old male presents with difficulty swallowing and occasional regurgitation of undigested food. A barium swallow study is shown below. Esophageal manometry reveals impaired relaxation of the lower esophageal sphincter (LES). What is the most likely underlying cause of this condition? (Q848629)

A. Loss of parasympathetic innervation from the recurrent laryngeal nerves

B. Hyperactivity of the sympathetic nerves from the upper thoracic ganglia

C. Degeneration of the esophageal plexus affecting peristalsis

D. Overactivity of the middle cervical ganglion fibres



See Answer in Part B → Q16

@Neet_pg_bot

Q17: A 48 year old male with a long-standing history of alcohol-related liver cirrhosis presents to the ER department with hematemesis. On examination, icterus is seen and the abdomen is distended. An upper gastrointestinal endoscopy confirms the presence of bleeding oesophageal varices at the lower end of the oesophagus. Which of the following vessels is primarily responsible for creating the portosystemic anastomoses that lead to the development of these varices? (Q848628)

A. Inferior phrenic veins

B. Left gastric vein

C. Brachiocephalic vein

D. Internal thoracic vein

See Answer in Part B → Q17

@Neet_pg_bot

Q18: Which of the following statements is true regarding the course of the esophagus in thorax and abdomen. The esophagus begins at the lower border of the cricoid cartilage. The esophagus enters the abdomen at the level of the T10 vertebra. The esophagus ends at the cardiac end of the stomach at T11 vertebra. The thoracic esophagus passes through the anterior mediastinum. (Q848627)

A. Only 1 and 2

B. All except 1

C. All except 4

D. All the above

See Answer in Part B → Q18

@Neet_pg_bot

Q19: A 8 year old child presents to the pediatric clinic with recurrent ear infections and complaints of ear pain, especially after upper respiratory infections. What is the most likely reason for this child's increased susceptibility to ear infections? (Q848625)

A. The Eustachian tube's shorter length allows for quicker drainage of secretions from the middle ear.

B. The more horizontal orientation of the Eustachian tube in children impairs proper ventilation and drainage of the middle ear.

C. The Eustachian tube opens more frequently during normal activities in children, causing increased exposure to environmental allergens.

D. The Eustachian tube is typically narrow in children, which facilitates the entry of pathogens from the nasopharynx.

See Answer in Part B → Q19

@Neet_pg_bot

Q20: A 32 year old male involved in smuggling accidentally swallowed a foreign object, which became lodged in his piriform fossa. After its removal, he reports

numbness and loss of sensation in his throat. Which nerve is most likely damaged during the procedure? (Q848624)

A. Recurrent laryngeal nerve

B. External laryngeal nerve

C. Internal laryngeal nerve

D. Glossopharyngeal nerve

See Answer in Part B → Q20

@Neet_pg_bot

Q21: Match the spaces between the constrictor muscles with the structures that pass through them: Spaces Structures 1) Sinus of Morgagni A) Internal laryngeal nerve, superior laryngeal vessels 2) Space between superior and middle constrictors B) Recurrent laryngeal nerve, inferior laryngeal vessels 3) Space between middle and inferior constrictors C) Stylopharyngeus muscle, glossopharyngeal nerve 4) Space below the inferior constrictor D) Auditory tube, levator veli palatini muscle, ascending palatine artery, palatine branch of ascending pharyngeal artery (Q848623)

A. 1-D; 2-C; 3-A; 4-B

B. 1-B; 2-C; 3-A; 4-D

C. 1-C; 2-D; 3-A; 4-B

D. 1-D; 2-A; 3-C; 4-B

See Answer in Part B → Q21

@Neet_pg_bot

Q22: Which of the following nerves supplies motor fibres to all pharyngeal muscles except the stylopharyngeus? (Q848622)

A. Glossopharyngeal nerve

B. Hypoglossal nerve

C. Vagus nerve

D. Superior cervical sympathetic ganglion

See Answer in Part B → Q22

@Neet_pg_bot

• [04_Head and Neck] 021 Anatomy Of Ear Nose And Eyeball

« Back to Folder Directory

[04_Head and Neck] 021 Anatomy Of Ear Nose And Eyeball — Quick Jump

Q1 (p. 257) *Q2 (p. 257)* *Q3 (p. 258)* *Q4 (p. 258)* *Q5 (p. 259)* *Q6 (p. 260)*
Q7 (p. 261) *Q8 (p. 261)* *Q9 (p. 262)* *Q10 (p. 263)* *Q11 (p. 264)*

Q1: A 5-year-old child presents with conductive hearing loss. Imaging reveals a congenital anomaly involving the stapes footplate. Which embryological structure is primarily responsible for the development of the stapes footplate? (Q848643)

A. First pharyngeal arch

B. Second pharyngeal arch

C. Otic placode

D. Otic capsule

See Answer in Part B → Q1

@Neet_pg_bot

Q2: Which of the following nerves is primarily responsible for the sensory innervation of the structure marked? (Q848644)

A. Great auricular nerve

B. Auriculotemporal nerve

C. Lesser occipital nerve

D. Auricular branch of the vagus nerve

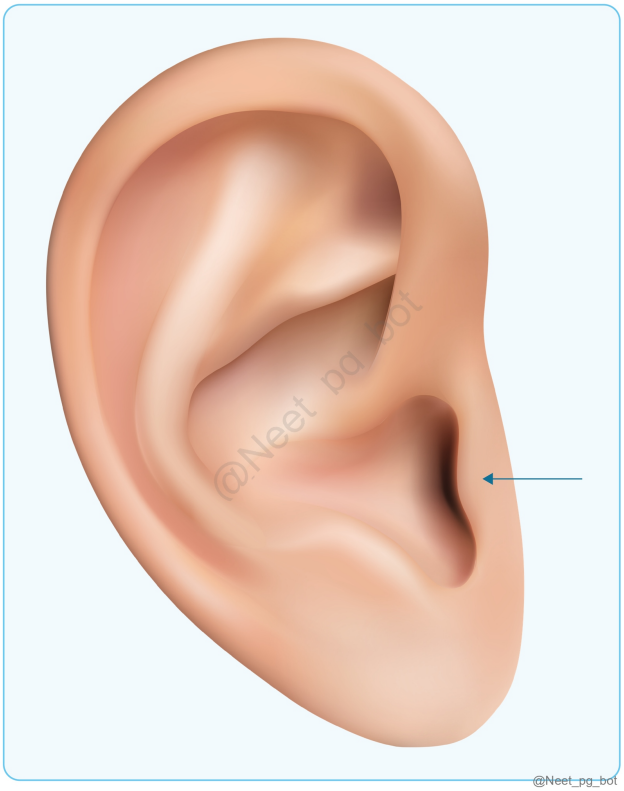

See Answer in Part B → Q2

@Neet_pg_bot

Q3: Match the following structures with their respective locations in the middle ear A. Tympanic Plexus 1. Epitympanum B. Head of malleus 2. Lateral wall C. Stapedius muscle 3. Promontory of cochlea D. Tympanic membrane 4. Mesotympanum (Q848645)

A. A-2, B-3, C-4, D-1

B. A-3, B-4, C-1, D-2

C. A-4, B-1, C-2, D-3

D. A-3, B-1, C-4, D-2

See Answer in Part B → Q3

@Neet_pg_bot

Q4: A 60-year-old patient presents with dizziness and balance issues. The physician suspects a problem in the vestibular system. Which of the following structures is primarily responsible for detecting horizontal linear acceleration and head position relative to gravity? (Q848646)

A. Saccule

B. Utricle

C. Semicircular canals

D. Organ of Corti

See Answer in Part B → Q4

@Neet_pg_bot

Q5: Match the following labelled parts of the nasal septum: 1 a. Septal Cartilage 2 b. Vomer 3 c. Palatine crest 4 d. Perpendicular Plate of Ethmoid (Q848647)

A. 1-d, 2-a, 3-b, 4-c

B. 1-a, 2-c, 3-d, 4-b

C. 1-b, 2-d, 3-a, 4-c

D. 1-c, 2-b, 3-d, 4-a

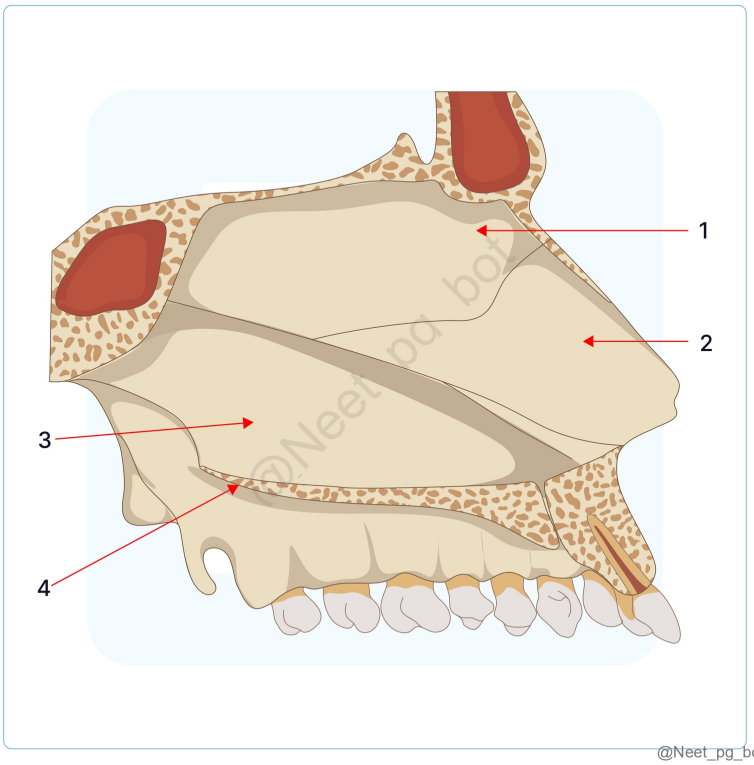

See Answer in Part B → Q5

@Neet_pg_bot

Q6: A 32-year-old female presents to the ENT clinic with persistent nasal congestion, facial pain, and reduced sense of smell. After minimal relief from medications, a nasal endoscopy is planned. Which of the following openings is not present in the structure labelled "X" in the image below? (Q848648)

A. Frontal air sinus

B. Maxillary air sinus

C. Anterior ethmoidal air sinuses

D. Posterior ethmoidal air sinuses



See Answer in Part B → Q6

@Neet_pg_bot

Q7: A 5-month-old child is experiencing excessive tearing in both eyes. The doctor recommends that the parents perform a massage along the nasolacrimal duct (NLD). How should the parents be instructed to carry out this procedure? (Q848649)

A. Downward, backward and lateral

B. Upward, backward and medial

C. Downward, backward and medial

D. Upward, backward and lateral

See Answer in Part B → Q7

@Neet_pg_bot

Q8: During retinoscopy, the ophthalmologist inquired of the intern about the development of the eyeball. Could you identify what will develop from the structure labeled "X" in the diagram below? (Q848650)

A. Optic nerve

B. Lens

C. Light-sensitive neural layer

D. Retinal pigment epithelium



See Answer in Part B → Q8

@Neet_pg_bot

Q9: All of the following structures pass through the area labeled "A" in the image except? (Q848651)

A. Zygomatic nerve

B. Infraorbital nerve

C. Pterygopalatine ganglion branches

D. Lacrimal nerve



See Answer in Part B → Q9

@Neet_pg_bot

Q10: A 50-year-old male presents with difficulty lifting his right eye, describing it as "stuck" when looking upward, along with double vision. Examination reveals a significant limitation in the upward gaze of the right eye. What is the action of the structure labelled "A" in the image below? (Q848652)

A. Elevation

B. Adduction

C. Intorsion

D. All of the above

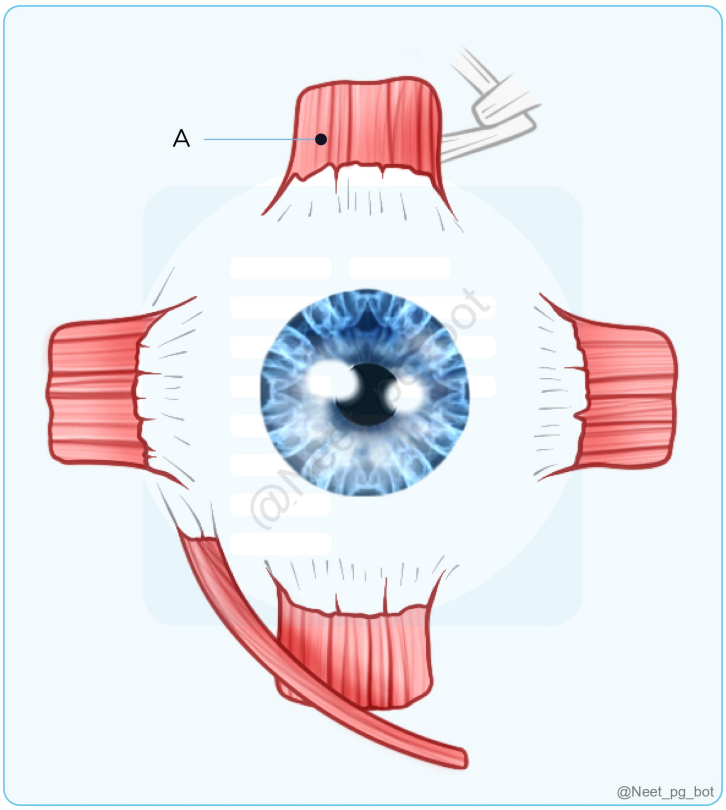

See Answer in Part B → Q10

@Neet_pg_bot

Q11: Which of the following arteries is not typically injured during mandibular fracture repair? (Q848653)

A. Inferior alveolar artery

B. Lingual artery

C. Facial artery

D. Maxillary artery

See Answer in Part B → Q11

@Neet_pg_bot

• [04_Head and Neck] 022 Previous Year Questions

« Back to Folder Directory

[04_Head and Neck] 022 Previous Year Questions — Quick Jump

Q1 (p. 265)	*Q2 (p. 266)*	*Q3 (p. 266)*	*Q4 (p. 267)*	*Q5 (p. 268)*	*Q6 (p. 269)*
Q7 (p. 269)	*Q8 (p. 270)*	*Q9 (p. 270)*	*Q10 (p. 270)*	*Q11 (p. 271)*	*Q12 (p. 272)*
Q13 (p. 273)	*Q14 (p. 274)*	*Q15 (p. 275)*	*Q16 (p. 275)*	*Q17 (p. 276)*	*Q18 (p. 276)*
Q19 (p. 276)	*Q20 (p. 277)*	*Q21 (p. 277)*	*Q22 (p. 277)*	*Q23 (p. 278)*	*Q24 (p. 279)*
Q25 (p. 279)	*Q26 (p. 280)*	*Q27 (p. 281)*	*Q28 (p. 282)*	*Q29 (p. 282)*	*Q30 (p. 283)*
Q31 (p. 284)	*Q32 (p. 284)*	*Q33 (p. 285)*	*Q34 (p. 286)*	*Q35 (p. 286)*	*Q36 (p. 287)*
Q37 (p. 288)	*Q38 (p. 289)*	*Q39 (p. 289)*	*Q40 (p. 290)*	*Q41 (p. 291)*	*Q42 (p. 291)*
Q43 (p. 291)	*Q44 (p. 292)*	*Q45 (p. 293)*	*Q46 (p. 293)*	*Q47 (p. 294)*	*Q48 (p. 295)*
Q49 (p. 296)	*Q50 (p. 297)*	*Q51 (p. 297)*	*Q52 (p. 298)*	*Q53 (p. 299)*	*Q54 (p. 299)*
Q55 (p. 299)	*Q56 (p. 300)*	*Q57 (p. 300)*	*Q58 (p. 301)*	*Q59 (p. 301)*	*Q60 (p. 301)*
Q61 (p. 302)	*Q62 (p. 302)*	*Q63 (p. 302)*	*Q64 (p. 303)*	*Q65 (p. 304)*	*Q66 (p. 305)*
Q67 (p. 305)	*Q68 (p. 306)*	*Q69 (p. 306)*	*Q70 (p. 307)*	*Q71 (p. 307)*	*Q72 (p. 308)*
Q73 (p. 308)	*Q74 (p. 309)*				

Q1: What is the structure marked in the image below? (Q857223)

A. Genioglossus

B. Hyoglossus

C. Styloglossus

D. Palatoglossus

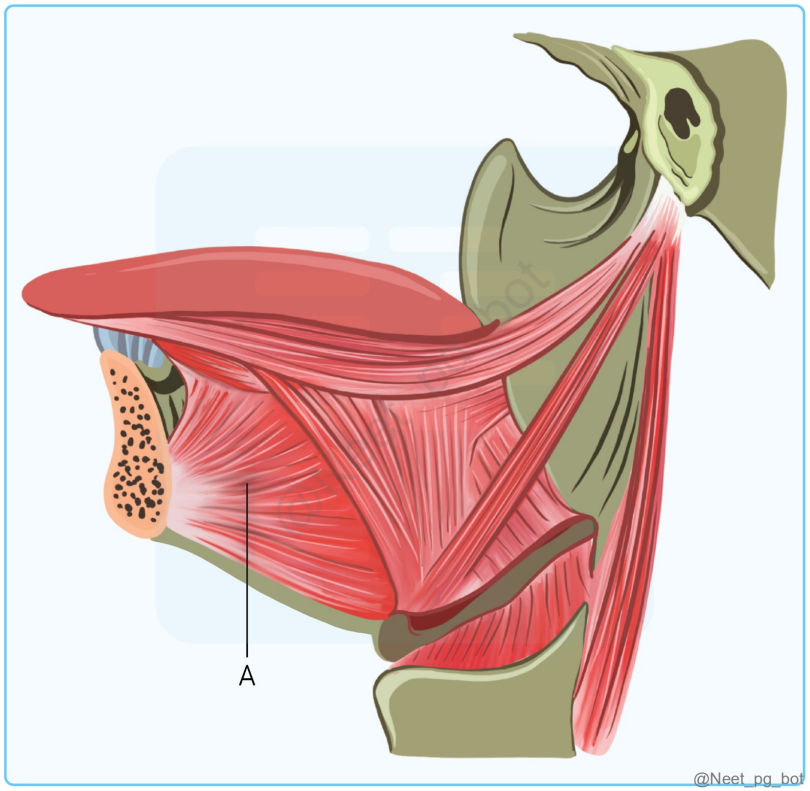

See Answer in Part B → Q1

@Neet_pg_bot

Q2: Inferior thyroid artery supplies which of the following structures? 1. Thyroid 2. Parathyroid 3. Esophagus 4. Thymus (Q856669)

A. 1, 2, 3 and 4

B. 1, 2 and 3

C. 1 and 2 only

D. 1, 2 and 4 only

See Answer in Part B → Q2

@Neet_pg_bot

Q3: The third part of the vertebral artery is related to which of the following? (Q856635)

A. 4

B. 3

C. 2

D. 1

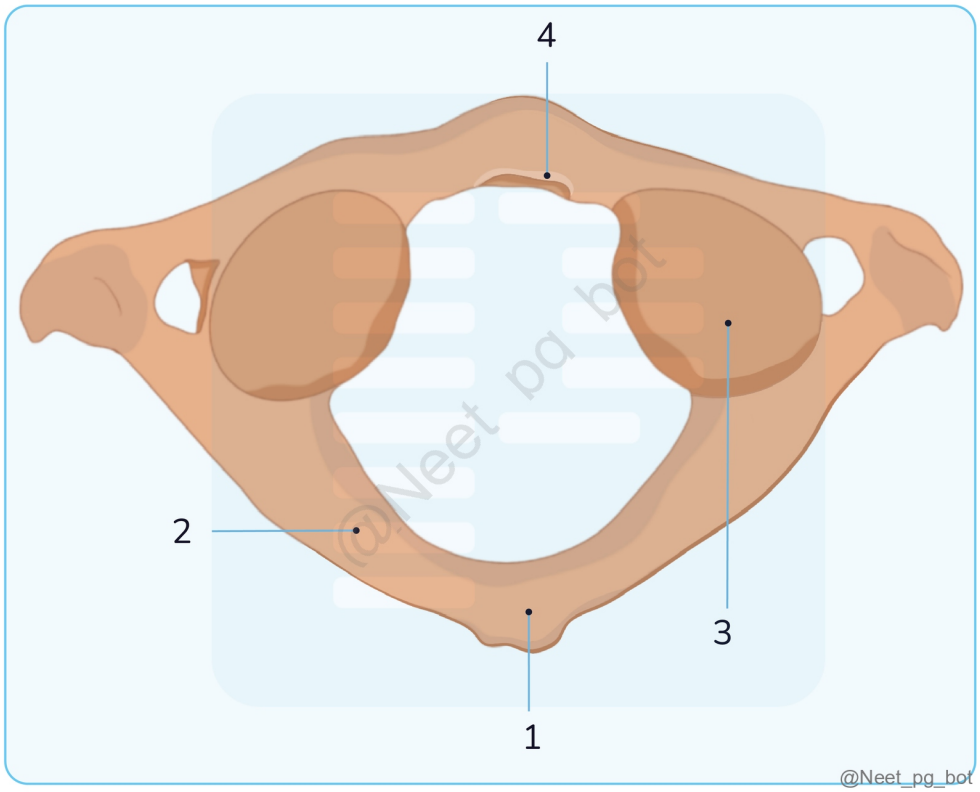

See Answer in Part B → Q3

@Neet_pg_bot

Q4: Identify the cranial nerve passing through the given structure? (Q856634)

A. III

B. V

C. IV

D. VI

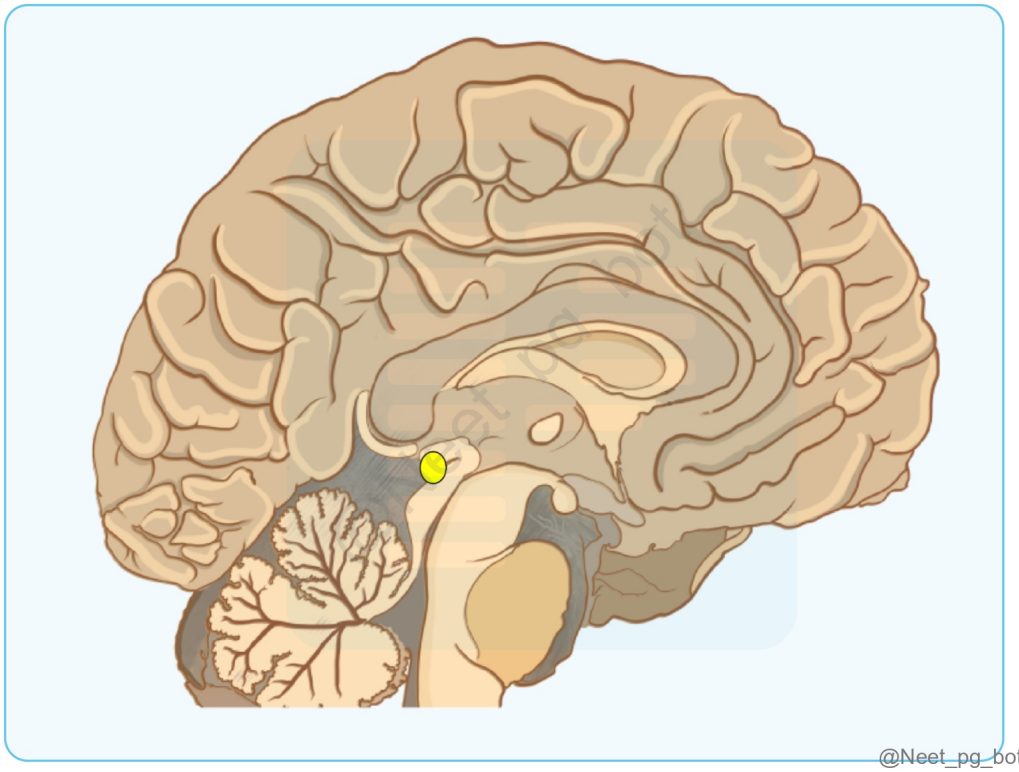

See Answer in Part B → Q4

@Neet_pg_bot

Q5: A 12-year-old presented with fever and difficulty swallowing. He had swelling in the marked region and was advised to undergo surgery. Post-surgery the gauze continued to soak with blood. Which of the following vessels must have been injured? (Q858149)

A. Tonsillar branch of facial artery

B. Ascending pharyngeal artery

C. Paratonsillar vein

D. Retromandibular vein

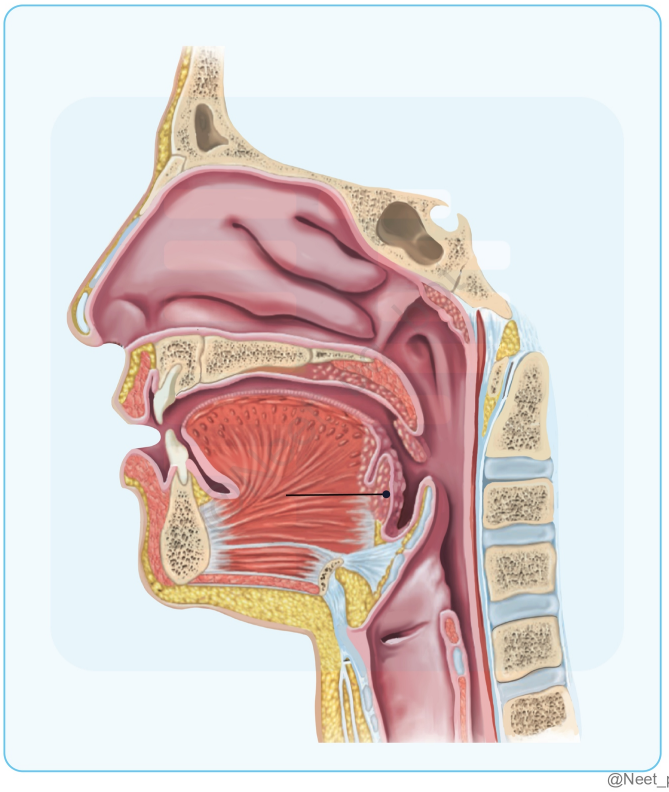

See Answer in Part B → Q5

@Neet_pg_bot

Q6: Which of the following muscles is an abductor of the vocal cord? (Q857636)

A. Lateral cricoarytenoid

B. Posterior cricoarytenoid

C. Thyroarytenoid

D. Vocalis

See Answer in Part B → Q6

@Neet_pg_bot

Q7: All of the following are paired cartilages except? (Q857617)

A. Arytenoid

B. Thyroid

C. Cuneiform

D. Corniculate

See Answer in Part B → Q7

@Neet_pg_bot

Q8: Which of the following cartilage do not calcify with age? (Q857580)

A. Thyroid

B. Arytenoid

C. Epiglottis

D. Cricoid

See Answer in Part B → Q8

@Neet_pg_bot

Q9: Killian’s dehiscence is seen between? (Q857232)

A. Palatopharyngeus and cricopharyngeus

B. Thyropharyngeus and palatopharyngeus

C. Cricopharyngeus and thyropharyngeus

D. Palatopharyngeus and salpingopharyngeus

See Answer in Part B → Q9

@Neet_pg_bot

Q10: A patient after a road traffic accident presents to the emergency room with difficulty in swallowing and slurred speech. Investigations reveal fractures in the

occipitotemporal region. Which of the following areas should be tested in order to find the nerve which is involved? (Q856672)

A. 1

B. 2

C. 3

D. 4

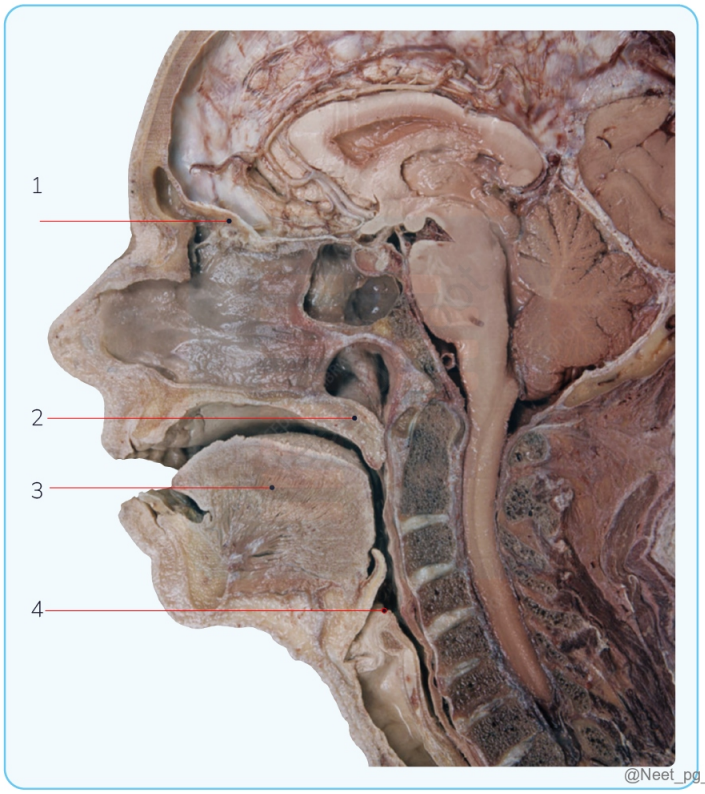

See Answer in Part B → Q10

@Neet_pg_bot

Q11: The image below shows the cross-section of the trachea. Identify the structure marked. (Q857212)

A. Trachealis muscle

B. Tracheal cartilage

C. Esophageal submucosal gland

D. Perichondrium

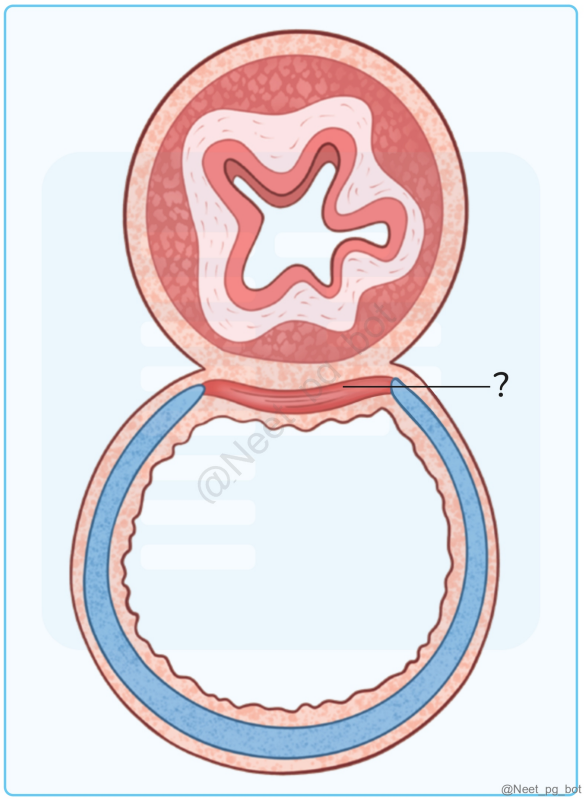

See Answer in Part B → Q11

@Neet_pg_bot

Q12: Identify the structure C. (Q857207)

A. Epiglottis

B. Hyoid bone

C. Thyroid cartilage

D. Cricoid cartilage

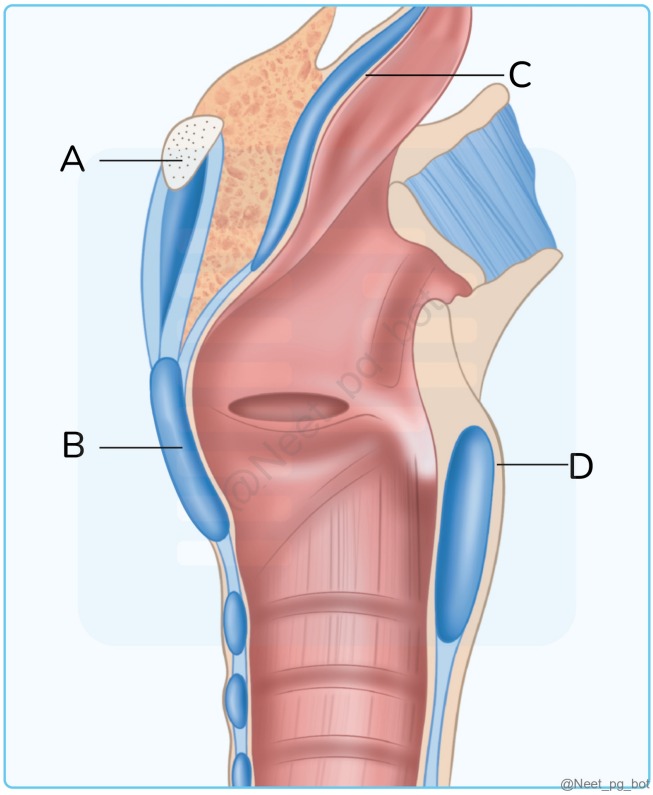

See Answer in Part B → Q12

@Neet_pg_bot

Q13: The bleeding shown in the image is usually due to which of the following vessels? (Q855450)

A. Bridging veins

B. Middle meningeal artery

C. Lenticulostriate artery

D. Vertebral artery

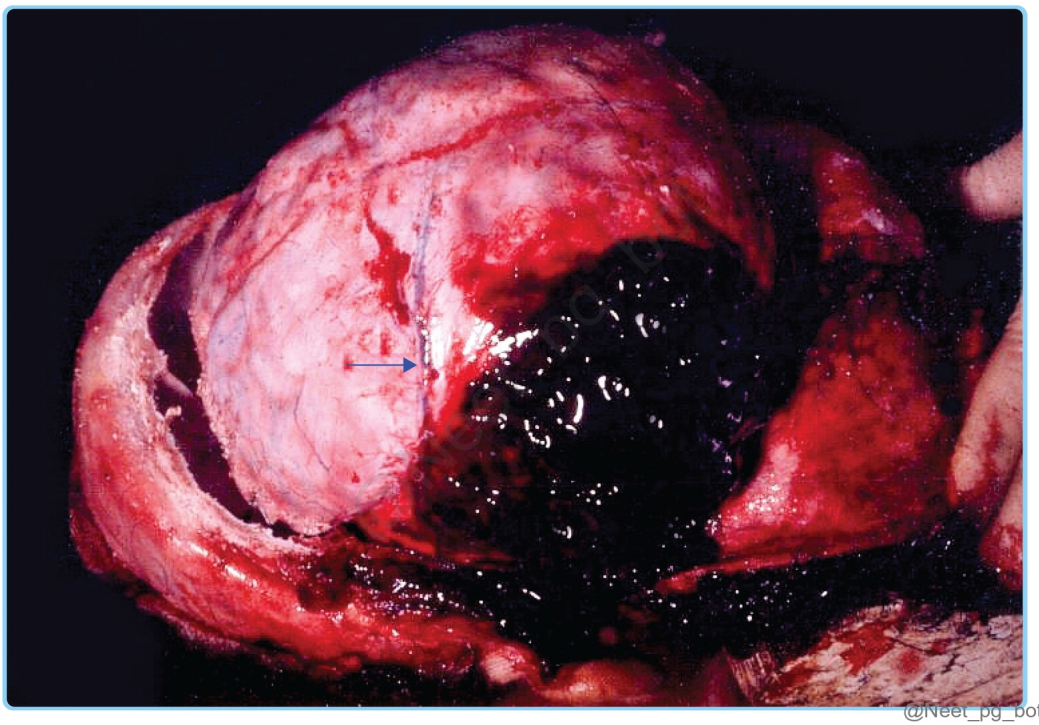

See Answer in Part B → Q13

@Neet_pg_bot

Q14: Identify the incorrect statement regarding the marked structure (Q855443)

A. It is the thinnest and weakest part of the skull

B. The region overlies the anterior division of the middle meningeal artery

C. It provides a surgical landmark for accessing the middle cerebral artery

D. This area corresponds to the location of the posterior fontanelle in the fetal skull.

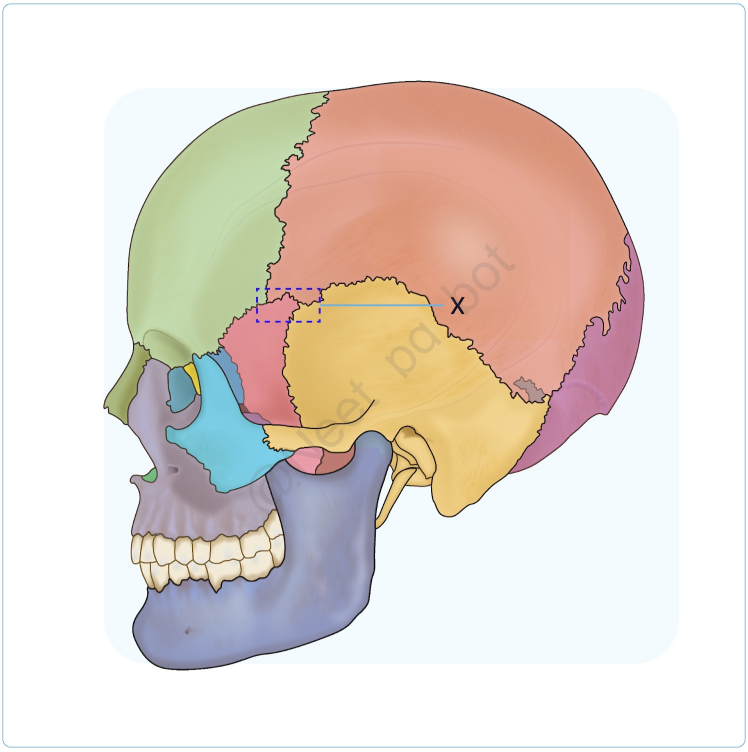

@Neet_pg_bot

See Answer in Part B → Q14

@Neet_pg_bot

Q15: Which among the following is not a branch of the facial artery? (Q855428)

A. Lateral nasalartery

B. Mentalartery

C. Superior labialartery

D. Inferior labialartery

See Answer in Part B → Q15

@Neet_pg_bot

Q16: Which of the following muscles is involved in smiling and grimacing? (Q855426)

A. Lateral rectus

B. Superior oblique

C. Risorius

D. Levator palpebrae superioris

See Answer in Part B → Q16

@Neet_pg_bot

Q17: How might a fracture of the jugular canal manifest itself? (Q855414)

A. Loss of taste sensation in anterior 2/3rd of tongue

B. Loss of taste sensation in posterior 1/3rd of tongue

C. Loss of general sensation in anterior 2/3rd of tongue

D. Loss of motor function in anterior 2/3rd of tongue

See Answer in Part B → Q17

@Neet_pg_bot

Q18: Which foramen in the skull is created by the union of three bones? (Q855037)

A. Foramen lacerum

B. Foramen magnum

C. Foramen rotundum

D. Foramen jugulare

See Answer in Part B → Q18

@Neet_pg_bot

Q19: All of the following are the contents of the carotid sheath except? (Q856357)

A. Sympathetic chain

B. Carotid artery

C. Internal jugular vein

D. 10 th cranial nerve

See Answer in Part B → Q19

@Neet_pg_bot

Q20: A woman has difficulty opening her mouth, but no problem closing it. Which of the following is true about the muscle affected in the condition described: The muscle attaches close to the temporomandibular joint The muscle depresses the mandible It attached to the medial pterygoid plate The muscle is supplied by the mandibular nerve (Q879182)

A. 1,2,3,4

B. 1,2,4

C. 1,3,4

D. 2,3,4

See Answer in Part B → Q20

@Neet_pg_bot

Q21: Which of the following bones contains a cranial nerve related directly to the CNS? (Q879160)

See Answer in Part B → Q21

@Neet_pg_bot

Q22: Among the following foramina, the nerve supply to the muscles of mastication passes through which one? ■■■■■■■ (Q879155)

A. A

B. B

C. C

D. D

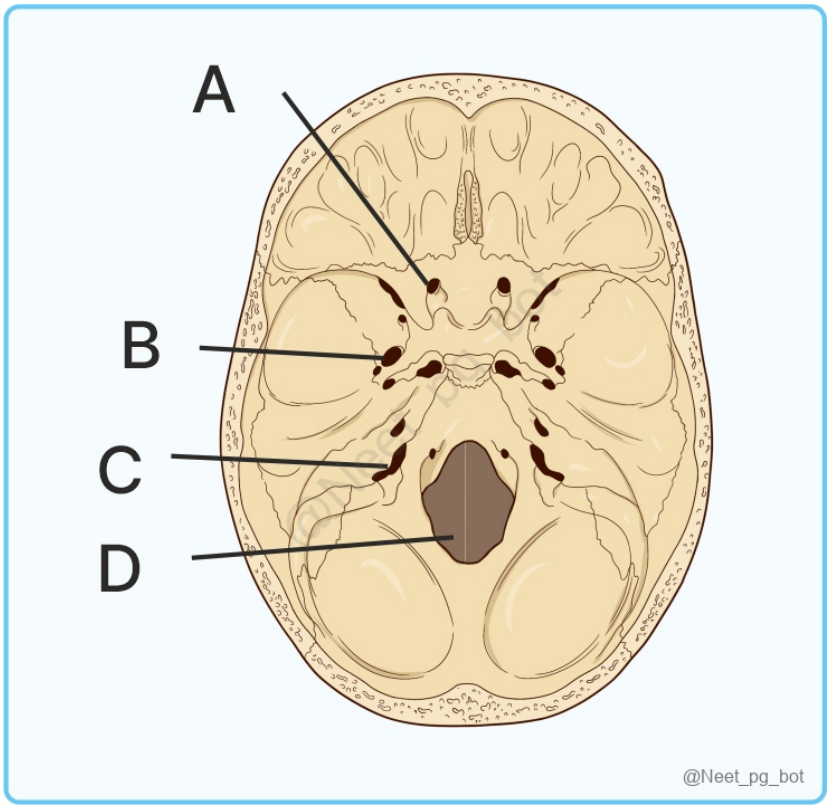

See Answer in Part B → Q22

@Neet_pg_bot

Q23: A patient presents with a unilateral throbbing headache, photophobia, and excessive lacrimation. He also complains of hemifacial pain on the clenching of teeth. On examination, pupillary reaction, light reflex, and accommodation reflex are normal. Which of the following marked nerves is involved in the above scenario? (Q856077)

A. 1

B. 2

C. 3

D. 4

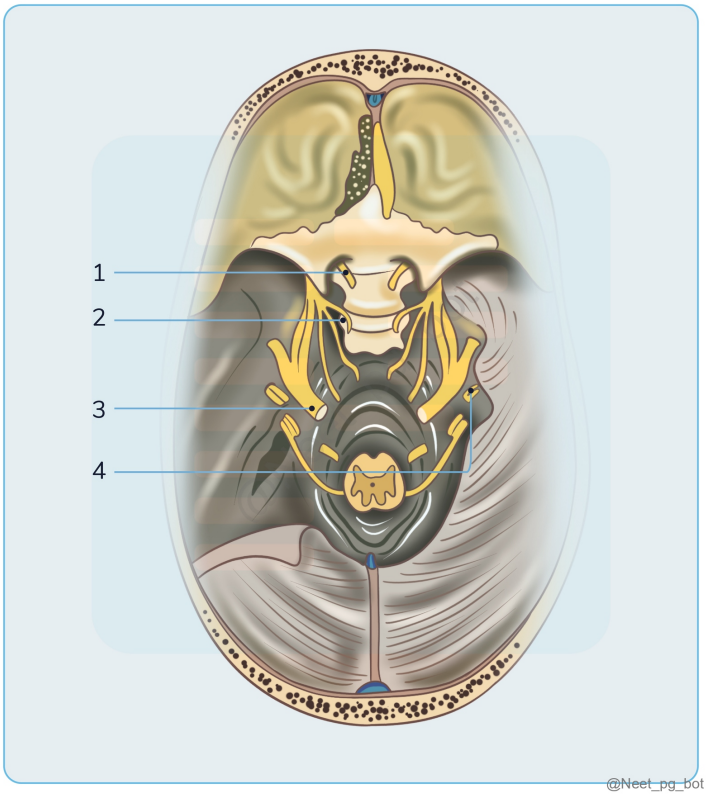

See Answer in Part B → Q23

@Neet_pg_bot

Q24: Which structure anchors the thyroid gland to the larynx, restricting its upward movement during swelling? (Q854991)

A. Pretracheal fascia

B. Sternothyroid

C. Thyrohyoid membrane

D. Ligament of Berry

See Answer in Part B → Q24

@Neet_pg_bot

Q25: The muscle marked by the arrow in the image below is innervated by the : (Q854980)

A. Dorsal scapular nerve

B. Suprascapular nerve

C. From the dorsal rami of C1

D. Subscapular nerve

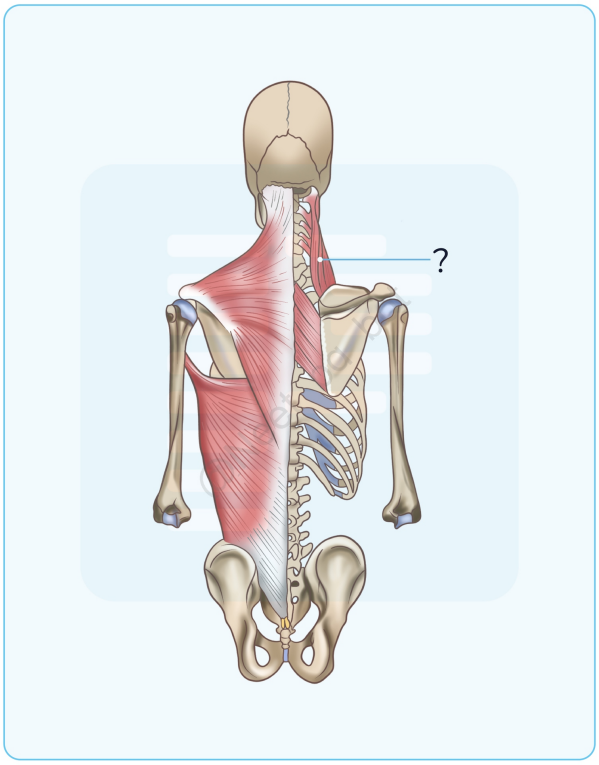

See Answer in Part B → Q25

@Neet_pg_bot

Q26: All of the following nerves are involved in the movement of the eyeball except: (Q856396)

A. Optic nerve

B. Oculomotor nerve

C. Trochlear nerve

D. Abducens nerve

See Answer in Part B → Q26

@Neet_pg_bot

Q27: Which of the following arteries passes in close proximity to the area marked by the arrow in the given image? (Q856369)

A. Internal carotid artery

B. Middle meningeal artery

C. Anterior cerebral artery

D. Deep temporal artery

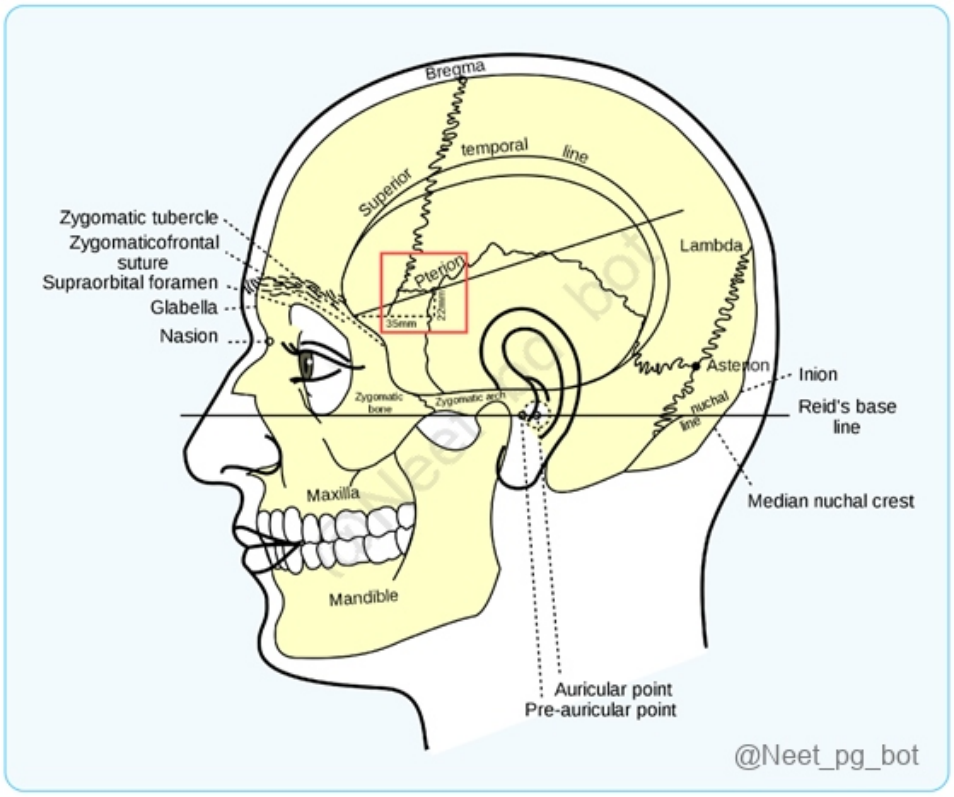

See Answer in Part B → Q27

@Neet_pg_bot

Q28: Which is the narrowest part of the adult laryngeal airway? (Q866626)

A. Supraglottic region

B. Glottis

C. Subglottic region

D. Trachea

See Answer in Part B → Q28

@Neet_pg_bot

Q29: Which of the following bony structures is present behind the marked area? (Q856987)

A. Post clivus

B. Lesser wing of sphenoid

C. Sella turcica

D. Carotid canal

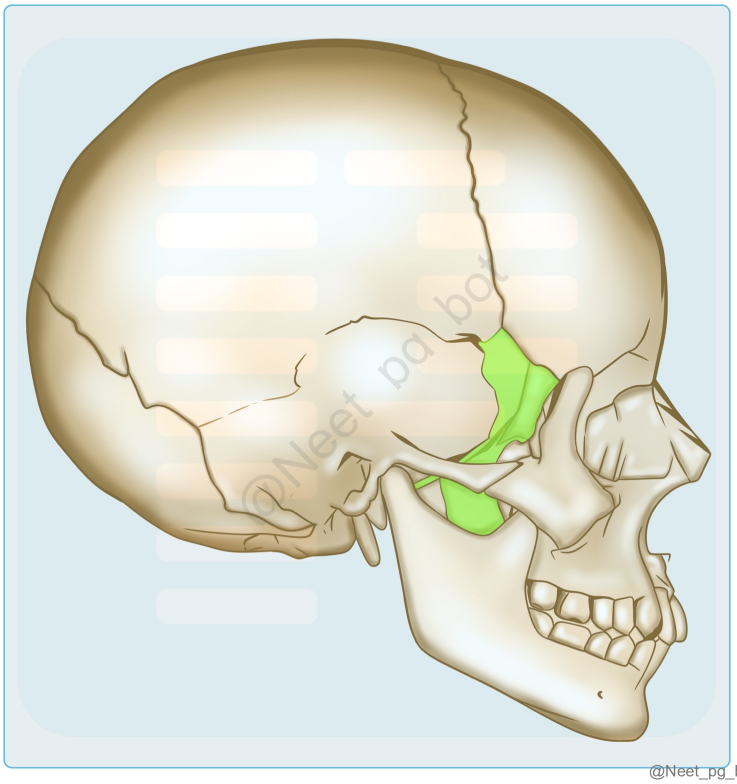

See Answer in Part B → Q29

@Neet_pg_bot

Q30: Which of the following marked structures does not form part of the laryngeal skeleton? (Q856979)

A. A

B. B

C. C

D. D

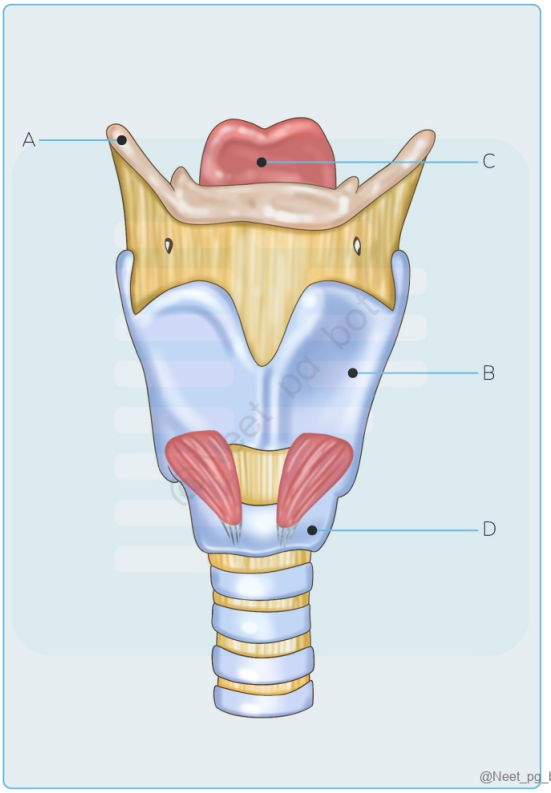

See Answer in Part B → Q30

@Neet_pg_bot

Q31: A patient is unable to abduct his arm. Which of the following root values is likely to be affected (Q856959)

A. C4

B. C5

C. C6

D. C7

See Answer in Part B → Q31

@Neet_pg_bot

Q32: The pre-tracheal layer of deep cervical fascia encloses all of the following except: (Q856951)

A. Oesophagus

B. Sternocleidomastoid

C. Sternohyoid

D. Thyroid gland

See Answer in Part B → Q32

@Neet_pg_bot

Q33: During the clinical examination of the nervous system, which of the following nerves can be tested by touching the highlighted structure? (Q856186)

A. IX

B. X

C. XI

D. XII

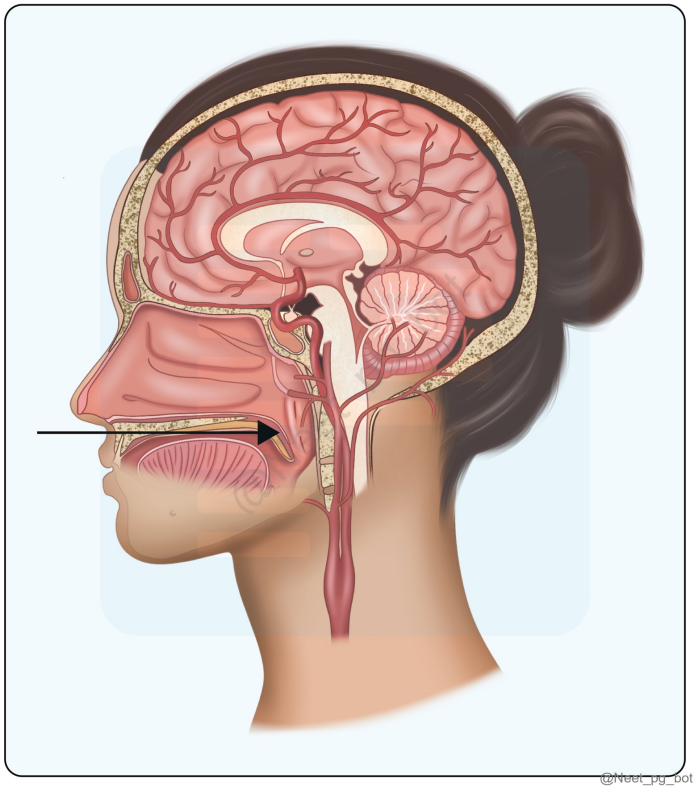

See Answer in Part B → Q33

@Neet_pg_bot

Q34: A patient presented with jaw swelling and weight loss. Suspecting a malignancy, the submandibular gland was resected. Which is the most likely nerve to be damaged during submandibular gland resection? (Q856185)

A. Nerve to mylohyoid

B. Inferior alveolar nerve

C. Lingual nerve

D. Hypoglossal nerve

See Answer in Part B → Q34

@Neet_pg_bot

Q35: Identify the papillae from the given histological section? (Q856183)

A. Fungiform

B. Circumvallate

C. Filiform

D. Foliate

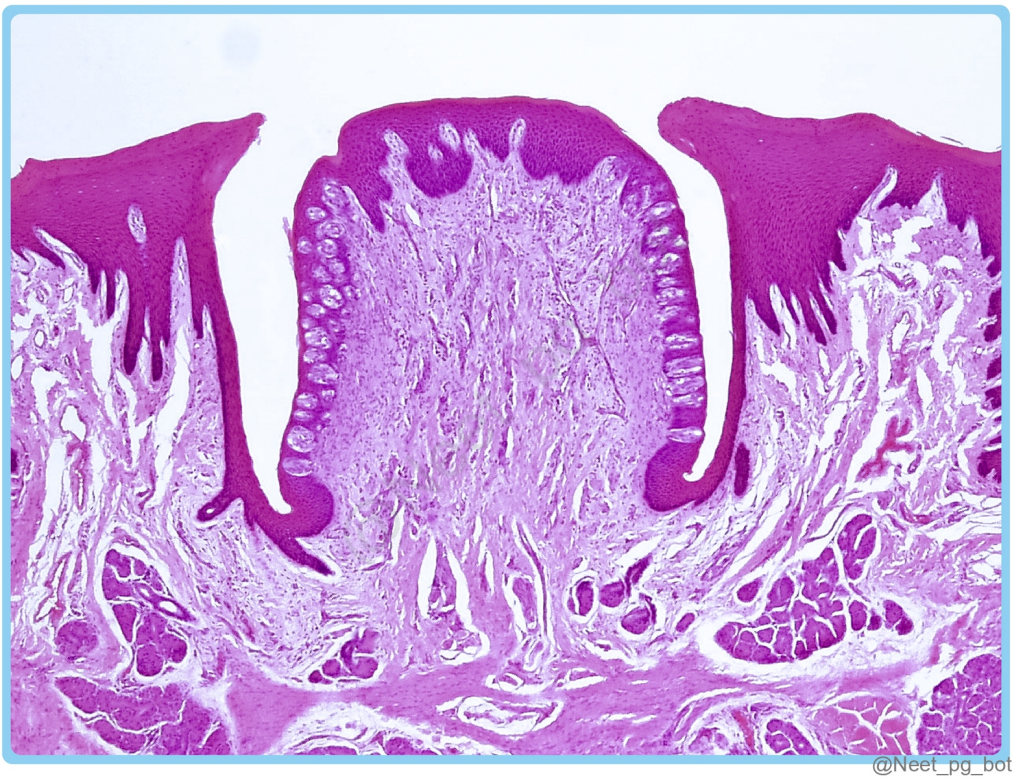

See Answer in Part B → Q35

@Neet_pg_bot

Q36: Through which of the following marked sites does COVID 19 spread to the brain? (Q856674)

A. D

B. C

C. B

D. A

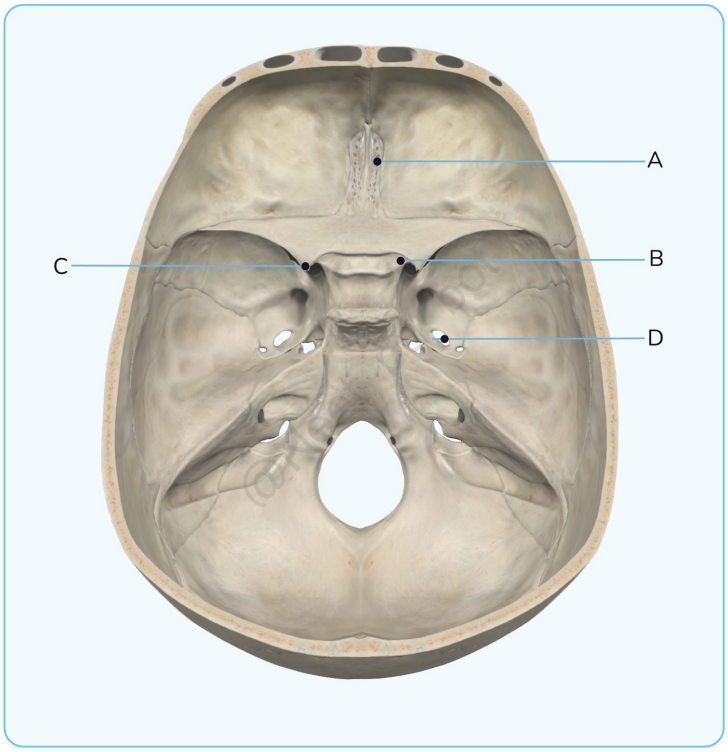

@Neet_pg_bot

See Answer in Part B → Q36

@Neet_pg_bot

Q37: What is the correct nerve supply to the muscles labelled as A and B? (Q866307)

A. A - Nerve to mylohyoid, B- Facial nerve

B. A - Facial nerve, B- Spinal accessory nerve

C. A- Facial nerve, B- Mandibular nerve

D. A - Spinal accessory nerve, B- Mandibular nerve

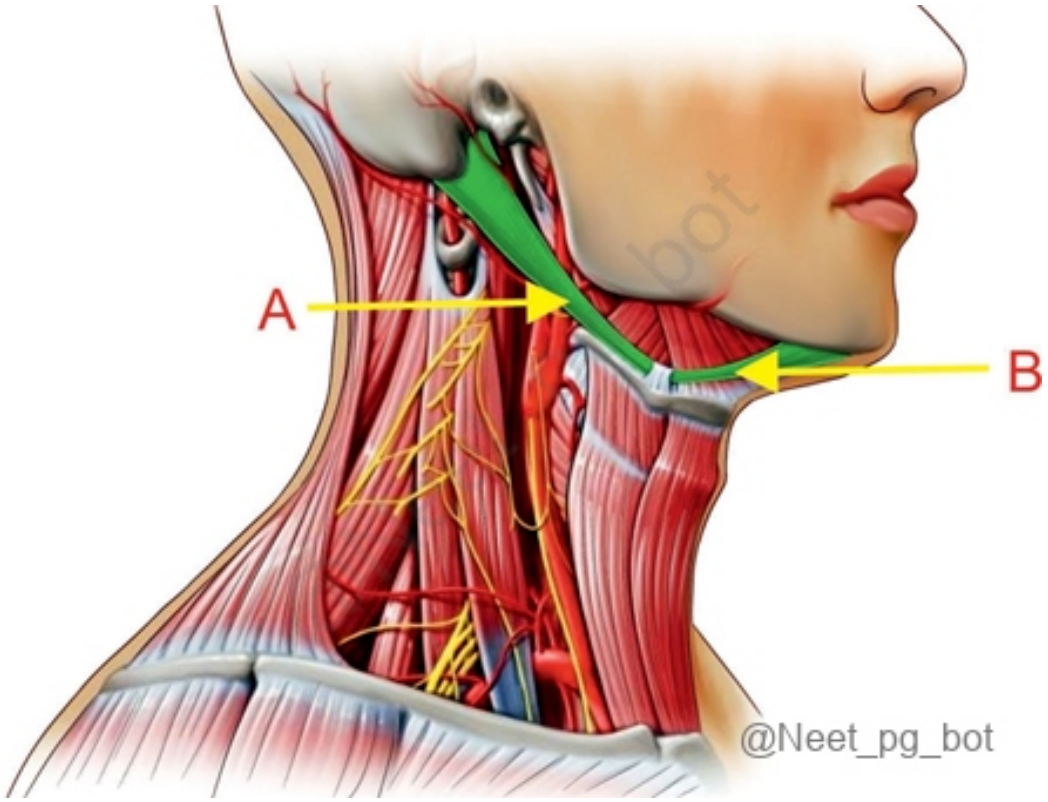

See Answer in Part B → Q37

@Neet_pg_bot

Q38: Which muscle movements are related to the Abducens nerve? (Q860606)

A. Lateral rectus

B. Medial rectus

C. Superior oblique

D. Inferior oblique

See Answer in Part B → Q38

@Neet_pg_bot

Q39: A singer presents with singing at high pitch. On examination, bowing of the vocal cord is seen on the right side. Which of the following muscles has been compromised? (Q844197)

A. Posterior cricoarytenoid

B. Lateral cricoarytenoid

C. Cricothyroid

D. Thyroarytenoid

See Answer in Part B → Q39

@Neet_pg_bot

Q40: A patient presents with the palsy of the face as shown. Which of the following is most likely involved? (Q852520)

A. 7th nerve palsy

B. 3rd nerve palsy

C. Erb’s palsy

D. Orbicularis oculi palsy



See Answer in Part B → Q40

@Neet_pg_bot

Q41: A 28-year-old man presents with sudden onset inability to close his right eye and drooping of the right side of his mouth. On examination, he is unable to raise his right eyebrow, cannot puff his right cheek, and shows complete paralysis of all muscles of facial expression on the right side. Forehead involvement is clearly noted. No neurological deficits are present on the left side.Which of the following is the most likely diagnosis? (Q852515)

A. Infranuclear facial palsy on right side

B. Supranuclear facial palsy on left side

C. Infranuclear facialpalsy on left side

D. Supranuclear facial palsyon right side

See Answer in Part B → Q41

@Neet_pg_bot

Q42: Which of the following is the afferent limb of the corneal reflex? (Q852452)

A. Optic nerve

B. Facial nerve

C. Trigeminal nerve

D. Trochlear nerve

See Answer in Part B → Q42

@Neet_pg_bot

Q43: Identify the structure marked in the image given below. (Q852505)

A. Buccopharyngeal fascia

B. Capsule

C. Superior constrictor muscle

D. Pharyngobasilar fascia

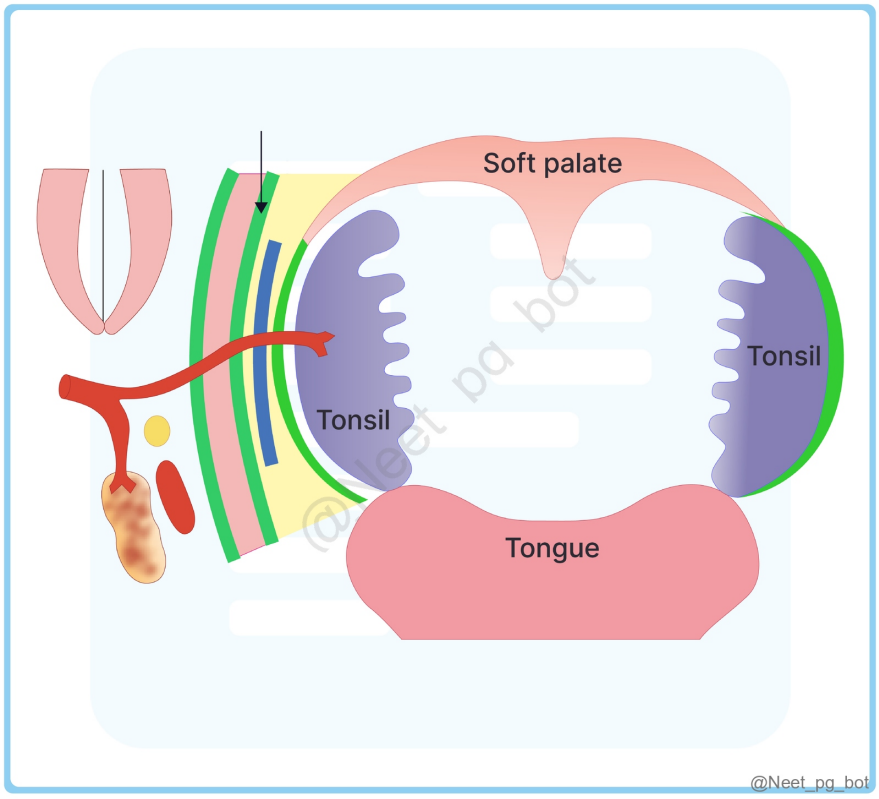

See Answer in Part B → Q43

@Neet_pg_bot

Q44: A 60-year-old male recovering from facial nerve palsy complains of food getting stuck between the cheek and teeth while eating. What is the muscle affected in this case? (Q852995)

A. Buccinator

B. Levator labii superioris

C. Zygomaticus major

D. Orbicularis oris

See Answer in Part B → Q44

@Neet_pg_bot

Q45: The posterior end of the marked structure is present at the level of which of the following? {{caption_text}} (Q852993)

A. Eustachian tube

B. Sphenopalatine foramen

C. Odontoid process

D. Sphenoidal sinus

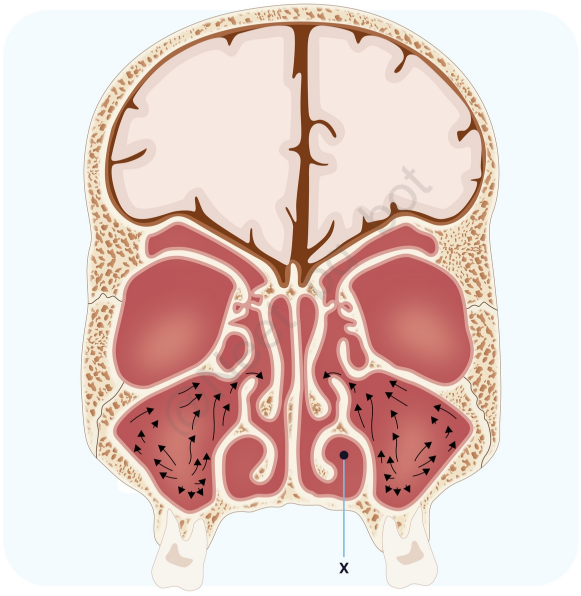

@Neet_pg_bot

See Answer in Part B → Q45

@Neet_pg_bot

Q46: Identify the marked structure {{caption_text}} (Q852991)

A. Superficial temporal artery

B. Posterior auricular artery

C. Middle meningeal artery

D. Occipital artery



See Answer in Part B → Q46

@Neet_pg_bot

Q47: Which artery passes in close proximity to the area of the skull shown in the image? (Q860616)

A. Anterior cerebral artery

B. Internal carotid artery

C. Middle meningeal artery

D. Deep temporal artery

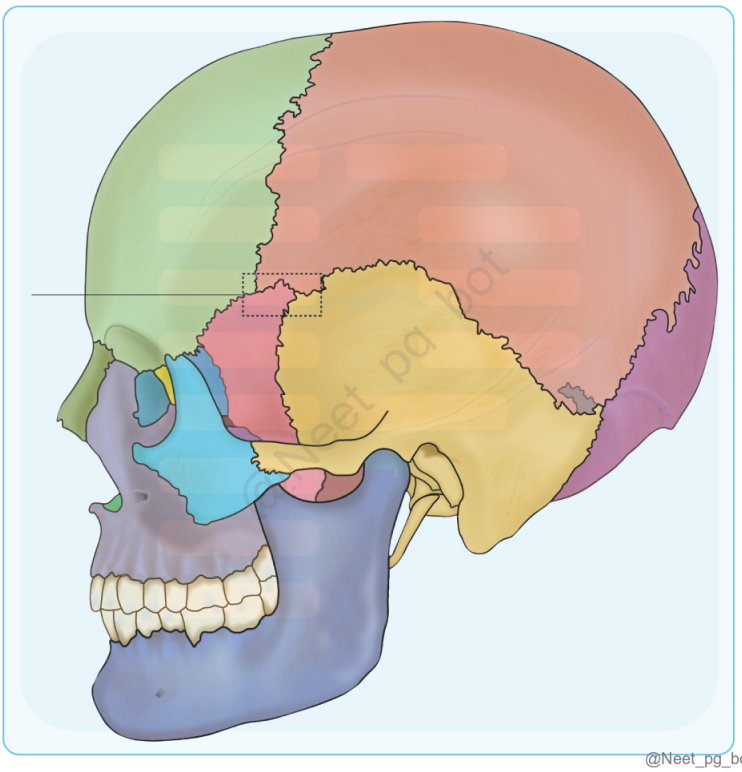

See Answer in Part B → Q47

@Neet_pg_bot

Q48: The image below highlights the jugular foramen. Which of the following does NOT pass through this foramen? (Q866301)

A. Hypoglossal nerve

B. Accessory nerve

C. Glossopharyngeal nerve

D. Vagus nerve



See Answer in Part B → Q48

@Neet_pg_bot

Q49: Dura when inflamed under the part marked by the arrow gets referred pain at the following site: (Q865318)

A. Back of the head/neck

B. Vertex

C. Ear

D. Shoulder

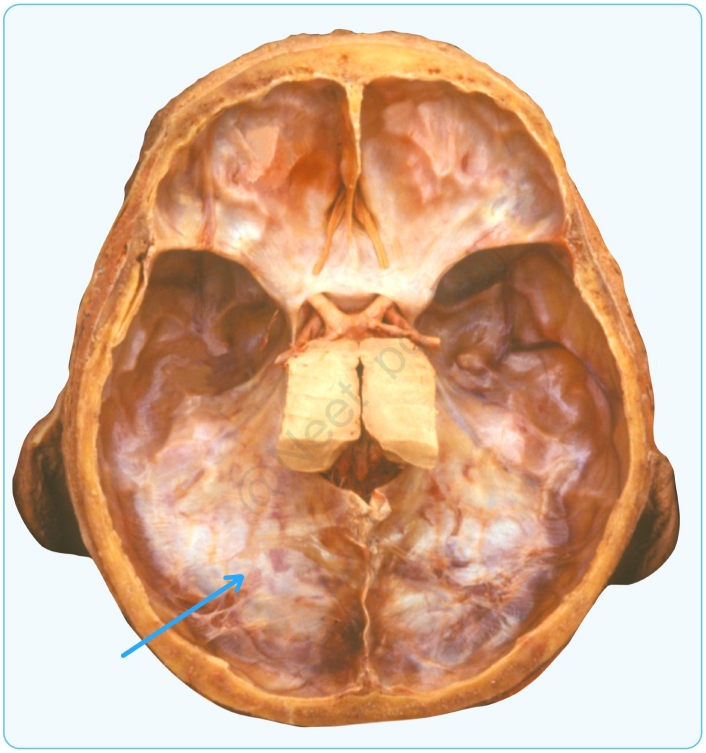

See Answer in Part B → Q49

@Neet_pg_bot

Q50: Which one of the following cranial nerves is not involved in olfaction ? (Q865306)

A. Hypoglossal nerve

B. Vagus nerve

C. Glossopharyngeal nerve

D. Trigeminal nerve

See Answer in Part B → Q50

@Neet_pg_bot

Q51: What is the primary action of the muscle originating from this structure? (Q865276)

A. Protracts and depresses the mandible

B. Elevates and protrudes the mandible

C. Elevates and retracted the mandible

D. Elevates the mandible

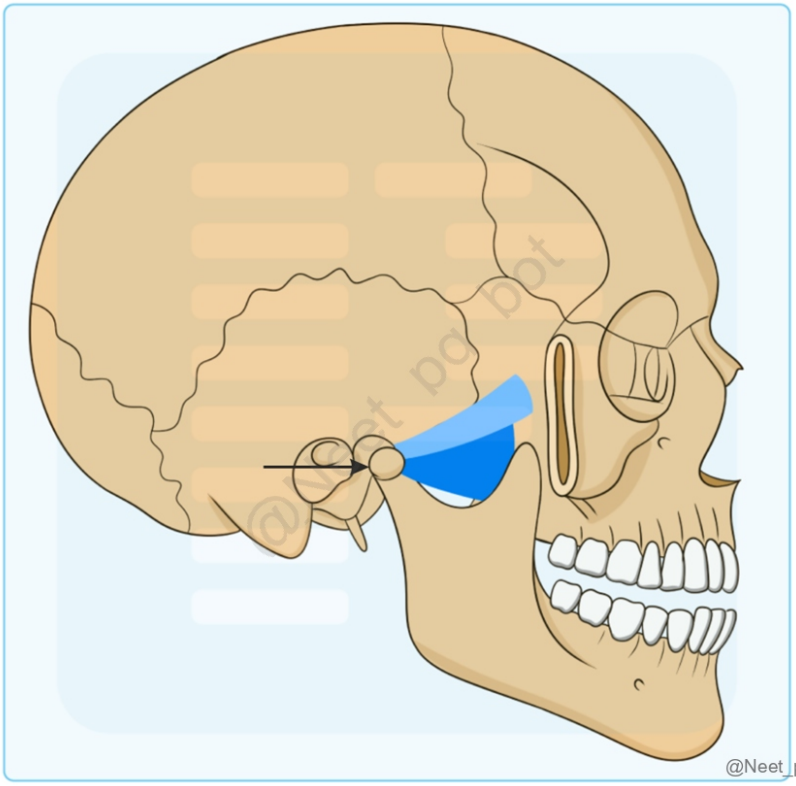

See Answer in Part B → Q51

@Neet_pg_bot

Q52: After the parotidectomy operation, a patient presents with excessive sweating and redness over the parotid region. What is the diagnosis? (Q866642)

A. Frey’s Syndrome

B. Horner’s syndrome

C. Bell’s Palsy

D. Glossopharyngeal neuralgia

See Answer in Part B → Q52

@Neet_pg_bot

Q53: A patient presented to OPD with ophthalmoplegia and ptosis. Diagnosis of superior orbital fissure syndrome was confirmed after examination. Which nerves are compressed in this case ? (Q866637)

A. III, IV, V1, VI

B. III, IV, V1, V2

C. II, III, IV, VI

D. II, III, IV, V1

See Answer in Part B → Q53

@Neet_pg_bot

Q54: The upper part of the uncinate process commonly attaches to? (Q866630)

A. Middle turbinate

B. Superior turbinate

C. Inferior turbinate

D. Bulla ethmoidalis

See Answer in Part B → Q54

@Neet_pg_bot

Q55: A 30-year-old man came with choking episodes after ingestion of fish bone while eating. The fishbone got impacted at the level of T4 in the esophagus. Which is the most likely site of obstruction? (Q866618)

A. Left bronchus

B. Arch of aorta

C. Cricopharyngeus

D. Diaphragm

See Answer in Part B → Q55

@Neet_pg_bot

Q56: Which X-ray view is best for visualizing the frontal sinuses? (Q839894)

A. Lateral view

B. Waters view

C. Caldwell view

D. Towne view

See Answer in Part B → Q56

@Neet_pg_bot

Q57: A 42-year-old man presented with swelling due to a collection of blood around the eyes after sustaining a head injury. Which structural attachment is the cause of this condition? (Q857936)

A. Aponeurosis attachment

B. Periosteum

C. Cellulitis

D. None of the above

See Answer in Part B → Q57

@Neet_pg_bot

Q58: A 42-year-old female who had the extraction of her 3rd molar tooth reported loss of sensation in the anterior 2/3rd of the tongue and floor of the mouth. Which nerve is most likely to be damaged? (Q857927)

A. Lingual Nerve

B. Glossopharyngeal Nerve

C. Spinal Accessory Nerve

D. Chorda Tympani Nerve

See Answer in Part B → Q58

@Neet_pg_bot

Q59: A 27-year-old male was climbing the stair, suddenly he fell & an iron nail hit on his neck. After the injury, the patient is having a hard time shrugging his shoulders and he is having difficulty turning his head. This might be due to an injury to? (Q857917)

A. Spinal accessory Nerve

B. Deltoid Muscle

C. Sternocleidomastoid Muscle

D. Long thoracic Nerve

See Answer in Part B → Q59

@Neet_pg_bot

Q60: A patient presents with swelling under the left ear lobule and complains of pain. Which of the following structures is the likely cause of the pain? (Q855406)

A. Facial nerve

B. Greater auricular nerve

C. Auriculotemporal nerve

D. Investing layer of deep cervical fascia

See Answer in Part B → Q60

@Neet_pg_bot

Q61: A student had his jaw locked while yawning. Which of the following muscles attached to the articular disc of the temporomandibular joint is under spasmodic contraction? (Q855390)

A. Lateral pterygoid

B. Temporalis

C. Medial pterygoid

D. Masseter

See Answer in Part B → Q61

@Neet_pg_bot

Q62: The correct sequence of the auditory pathway? (Q854586)

A. Cochlea → Spiral Ganglion → Cochlear Nerve → Superior Olivary Nucleus

B. Spiral Ganglion → Cochlea → Cochlear Nerve → Superior Olivary Nucleus

C. Spiral Ganglion → Cochlear Nerve → Cochlea → Superior Olivary Nucleus

D. Cochlea → Spiral Ganglion → Cochlear Nerve → Inferior Olivary Nucleus

See Answer in Part B → Q62

@Neet_pg_bot

Q63: Name the type of joint marked in the following image (Q854532)

A. Ball and socket joint

B. Saddle joint

C. Pivot joint

D. Gliding joint

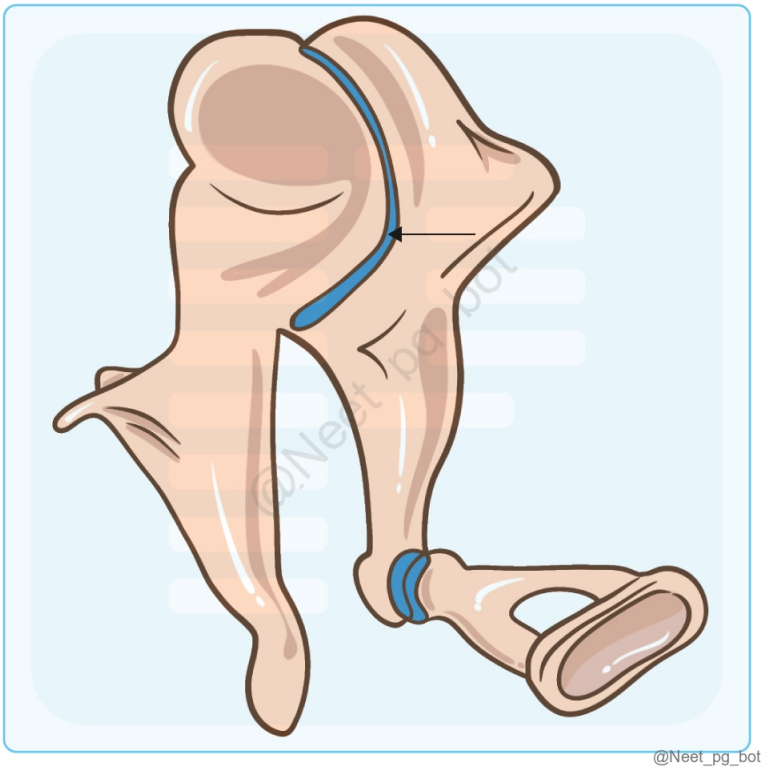

See Answer in Part B → Q63

@Neet_pg_bot

Q64: Which of the following sulcus will be injured in a patient with trauma to the pointed area 'X'? (Q857344)

A. Central sulcus

B. Stem of lateral sulcus

C. Inferior frontal sulcus

D. Intraparietal sulcus

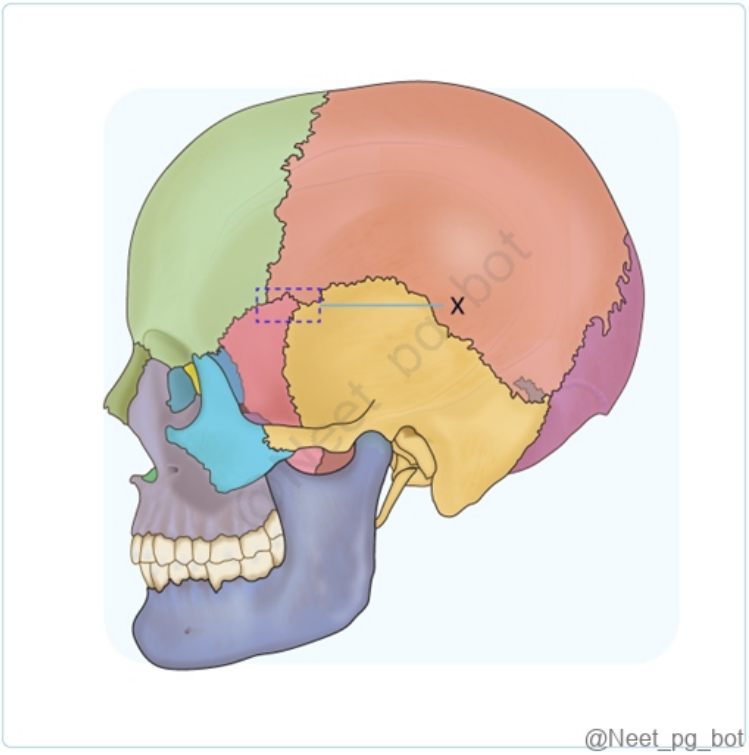

See Answer in Part B → Q64

@Neet_pg_bot

Q65: Which ganglia is located in the marked area? (Q860277)

A. Otic ganglia

B. Ciliary ganglia

C. Pterygopalatine ganglia

D. Submandibular ganglia



See Answer in Part B → Q65

@Neet_pg_bot

Q66: Which of the following steps in thyroid surgery is least likely to result in hoarseness of voice? (Q839918)

A. Ligation of superior thyroid artery

B. Division of strap muscles

C. Removal of tubercle of Zuckerkandi

D. Dissection of Beahr's triangle

See Answer in Part B → Q66

@Neet_pg_bot

Q67: A 32-year-old patient presents with a swelling below the ear and complains of pain in the lobule of the ear. The patient also reports difficulty in completely closing the left eye and experiences trouble while eating food. What nerve is most likely to be damaged in this case? (Q820349)

A. Greater Auricular nerve

B. Auriculotemporal nerve

C. Facial nerve

D. Vagus nerve

See Answer in Part B → Q67

@Neet_pg_bot

Q68: A 42-year-old man presented with swelling due to a collection of blood around the eyes after sustaining a head injury. Which structural attachment is the cause of this condition? (Q820346)

A. Aponeurosis attachment

B. Periosteum

C. Cellulitis

D. None of the above

See Answer in Part B → Q68

@Neet_pg_bot

Q69: A 42-year-old female who had the extraction of her 3rd molar tooth reported loss of sensation in the anterior 2/3rd of the tongue and floor of the mouth. Which nerve is most likely to be damaged? (Q820322)

A. Lingual Nerve

B. Glossopharyngeal Nerve

C. Spinal Accessory Nerve

D. Chorda Tympani Nerve

See Answer in Part B → Q69

@Neet_pg_bot

Q70: A 27-year-old male was climbing the stair, suddenly he fell & an iron nail hit on his neck. After the injury, the patient is having a hard time shrugging his shoulders and he is having difficulty turning his head. This might be due to an injury to? (Q820314)

A. Spinal accessory Nerve

B. Deltoid Muscle

C. Sternocleidomastoid Muscle

D. Long thoracic Nerve

See Answer in Part B → Q70

@Neet_pg_bot

Q71: Infer the extent of the thyroid gland from the given image. (Q793138)

A. B to D

B. A to C

C. A to D

D. C to D

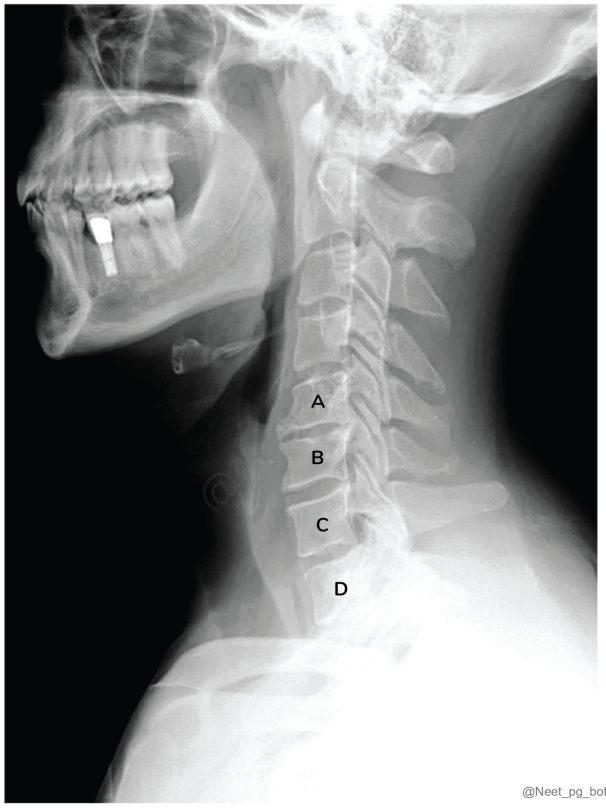

See Answer in Part B → Q71

@Neet_pg_bot

Q72: A patient underwent a left submandibular gland excision during which the hypoglossal nerve was injured. Which of the following deficits would be seen in this case? (Q793129)

A. Deviated tongue to the contralateral side

B. Deviated tongue to the same side

C. Inability to protrude tongue

D. Loss of taste in posterior 1/3rd of the tongue

See Answer in Part B → Q72

@Neet_pg_bot

Q73: Name the dural venous arrow marked in the radiograph. (Q793166)

A. Straight sinus

B. Superior sagittal sinus

C. Inferior sagittal sinus

D. Confluence of sinuses



See Answer in Part B → Q73

@Neet_pg_bot

Q74: Which of the following dural venous sinuses receives the great cerebral vein of Galen as its tributary? (Q793147)

A. A

B. B

C. C

D. D

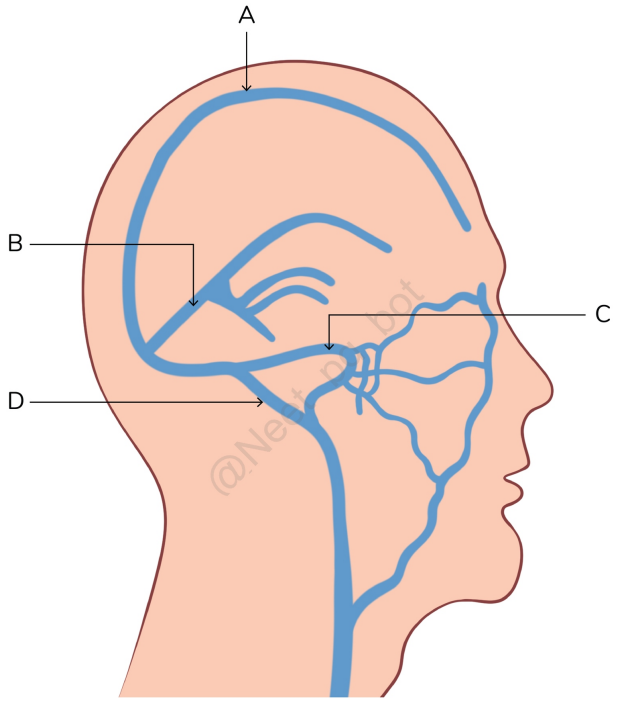

See Answer in Part B → Q74

@Neet_pg_bot

• [05_Upper Limb] 023 Upper Limb Embryology And Nerves

« Back to Folder Directory

[05_Upper Limb] 023 Upper Limb Embryology And Nerves — Quick Jump

Q1 (p. 311) *Q2 (p. 311)* *Q3 (p. 312)* *Q4 (p. 312)* *Q5 (p. 312)* *Q6 (p. 313)*
Q7 (p. 313) *Q8 (p. 314)* *Q9 (p. 314)* *Q10 (p. 315)* *Q11 (p. 315)* *Q12 (p. 315)*
Q13 (p. 316)

Q1: A 35-year-old man presents with numbness and tingling in the lateral aspect of his forearm and thumb after a fall. Upon examination, the physician notes that the sensation is decreased in a specific area corresponding to a dermatome. Which of the following dermatomes is likely affected in this patient? (Q848387)

A. C5

B. C6

C. C7

D. C8

See Answer in Part B → Q1

@Neet_pg_bot

Q2: A newborn is delivered with a shoulder dystocia complication. On examination, the infant has paralysis of the arm with the shoulder adducted, the elbow extended, and the forearm pronated. This injury most likely involves which of the following structures? (Q848389)

A. Lower trunk of the brachial plexus

B. Radial nerve

C. Upper trunk of the brachial plexus

D. Median nerve

See Answer in Part B → Q2

@Neet_pg_bot

Q3: A newborn presents with weakness in the right arm after a difficult vaginal delivery. The arm is limp and hangs by the side, with the forearm pronated and the hand facing inward in a "waiter's tip" position. The infant has difficulty with shoulder abduction and elbow flexion. Which of the following nerve roots are most likely involved in this condition? (Q848392)

A. C5 and C6

B. C7 and C8

C. C8 and T1

D. C3 and C4

See Answer in Part B → Q3

@Neet_pg_bot

Q4: A newborn presents with weakness in the hand following a difficult delivery. Examination reveals a claw hand deformity characterized by hyperextension at the metacarpophalangeal joints and flexion at the interphalangeal joints. Sensory loss is noted along the ulnar aspect of the forearm and hand. Which of the following is the most likely nerve root involved in this condition? (Q848393)

A. C5

B. C7

C. C8

D. T1

See Answer in Part B → Q4

@Neet_pg_bot

Q5: Which of the following gives rise to the bones and connective tissues of the limb? (Q848384)

A. Intermediate mesoderm

B. The parietal (somatic) layer of lateral plate mesoderm

C. Paraxial mesoderm

D. Neural crest cells

See Answer in Part B → Q5

@Neet_pg_bot

Q6: A 35-year-old man presents with numbness and tingling along the lateral aspect of his forearm and thumb following a fall on his outstretched arm. Which dermatome is most likely involved? (Q848385)

A. C5

B. C6

C. C7

D. C8

See Answer in Part B → Q6

@Neet_pg_bot

Q7: A 40-year-old male presents with difficulty extending his elbow after a recent injury. On examination, you notice weakness in elbow extension and diminished triceps reflex. Sensory examination is normal. Which myotome is most likely affected? (Q848386)

A. C5

B. C6

C. C7

D. C8

See Answer in Part B → Q7

@Neet_pg_bot

Q8: A 25-year-old male presents with weakness in the upper limb following a fall on his shoulder. Physical examination reveals impaired movement in the extensor muscles of the arm. Injury to which part of the brachial plexus is most likely responsible for this patient's symptoms? (Q848388)

A. Upper trunk, anterior division

B. Middle trunk, anterior division

C. Middle trunk, posterior division

D. Lower trunk, anterior division

See Answer in Part B → Q8

@Neet_pg_bot

Q9: A 25-year-old male is brought to the emergency department after a high-speed motorcycle accident. He complains of severe pain and weakness in his right arm. On examination, there is loss of sensation in the right shoulder and upper arm with weakness in shoulder abduction and elbow flexion. Which of the following is the most likely type of brachial plexus lesion in this patient? (Q848390)

A. Intradural rupture

B. Compression injury

C. Closed traction injury

D. Iatrogenic injury

See Answer in Part B → Q9

@Neet_pg_bot

Q10: A 35-year-old male presents with weakness in elbow flexion and loss of sensation over the lateral aspect of his forearm. Which of the following nerves is most likely involved in this patient's condition? (Q848391)

A. Axillary nerve

B. Musculocutaneous nerve

C. Radial nerve

D. Ulnar nerve

See Answer in Part B → Q10

@Neet_pg_bot

Q11: Which of the following statements is true regarding the variations in the prefixed and postfixed brachial plexus? (Q848394)

A. Prefixed brachial plexus is characterized by contributions from C5 to T2

B. T2 spinal nerve replaces the usual T1 contribution in postfixed brachial plexus

C. Prefixed brachial plexus has an increased contribution from C4 and decreased from T1

D. Postfixed brachial plexus is associated with an increased contribution from C3 and C4

See Answer in Part B → Q11

@Neet_pg_bot

Q12: Which part of the brachial plexus does not give off any branches? (Q848405)

A. Roots

B. Trunks

C. Divisions

D. Cords

See Answer in Part B → Q12

@Neet_pg_bot

Q13: Which of the following statements regarding the anterior and posterior axial lines is correct? (Q848409)

A. Axial lines form as a result of limb rotational and elongation processes during embryogenesis

B. Axial lines divide dermatomes that are adjacent in the spinal nerve sequence

C. Overlapping of nerve supply can overlap across axial lines

D. Overlapping of Ventral and dorsal axial lines can occur

See Answer in Part B → Q13

@Neet_pg_bot

• [05_Upper Limb] 024 Muscles And Bones Of Forearm And Hand

« Back to Folder Directory

[05_Upper Limb] 024 Muscles And Bones Of Forearm And Hand — Quick Jump

Q1 (p. 317)	*Q2 (p. 317)*	*Q3 (p. 317)*	*Q4 (p. 318)*	*Q5 (p. 319)*	*Q6 (p. 319)*
Q7 (p. 320)	*Q8 (p. 321)*	*Q9 (p. 321)*	*Q10 (p. 322)*	*Q11 (p. 322)*	*Q12 (p. 323)*
Q13 (p. 323)	*Q14 (p. 324)*	*Q15 (p. 325)*	*Q16 (p. 326)*	*Q17 (p. 326)*	*Q18 (p. 327)*

Q1: Which of the following is NOT a content of the cubital fossa? (Q848417)

A. Brachial artery

B. Median nerve

C. Ulnar nerve

D. Radial nerve

See Answer in Part B → Q1

@Neet_pg_bot

Q2: Which of the following is a unique feature of the clavicle compared to other bones in the body? (Q848432)

A. It ossifies from both membranous and cartilaginous origins.

B. It articulates directly with the scapula without an intervening joint cavity.

C. It is the only bone in the body that does not have a medullary cavity.

D. It is entirely covered by the periosteum, unlike other bones.

See Answer in Part B → Q2

@Neet_pg_bot

Q3: Which of the following is not a content in the 4th compartment of extensor retinaculum? (Q848424)

A. Extensor digitorum

B. Extensor indicis

C. Posterior interosseous nerve

D. Extensor pollicis brevis

See Answer in Part B → Q3

@Neet_pg_bot

Q4: After a fall from a height with undue arm abduction, the patient presented as shown. Mark the wrong statement about this condition. (Q848422)

A. C7, C8 & T1 are affected

B. Complete clawing of hand is seen

C. Associated horner syndrome can be seen

D. Due to injury to lower trunk of brachial plexus



See Answer in Part B → Q4

@Neet_pg_bot

Q5: Which of the following statements about the carrying angle of the elbow is correct? (Q848436)

A. The carrying angle is formed by the angle between the humerus and the ulna when the elbow is flexed.

B. The carrying angle disappears during full flexion and pronation of the forearm.

C. The carrying angle is greater in males, usually more than 15°.

D. The carrying angle increases as the arm moves from full flexion to extension.

See Answer in Part B → Q5

@Neet_pg_bot

Q6: Which of the following structures can be palpated in the infraclavicular fossa ? (Q848435)

A. Subclavian vein

B. Biceps tendon

C. Coracoid process

D. Thoracoacromial artery

See Answer in Part B → Q6

@Neet_pg_bot

Q7: Identify the correctly marked attachments of the Upper end of the Humerus. (Q848434)

A. A- Supraspinatus; B- Infraspinatus; D- Pectoralis major

B. A- Teres minor; B- Infraspinatus; D- Subscapularis

C. C- Pectoralis major; D- Supraspinatus; E- Subscapularis

D. B- Infraspinatus; C- Pectoralis major; D- Supraspinatus

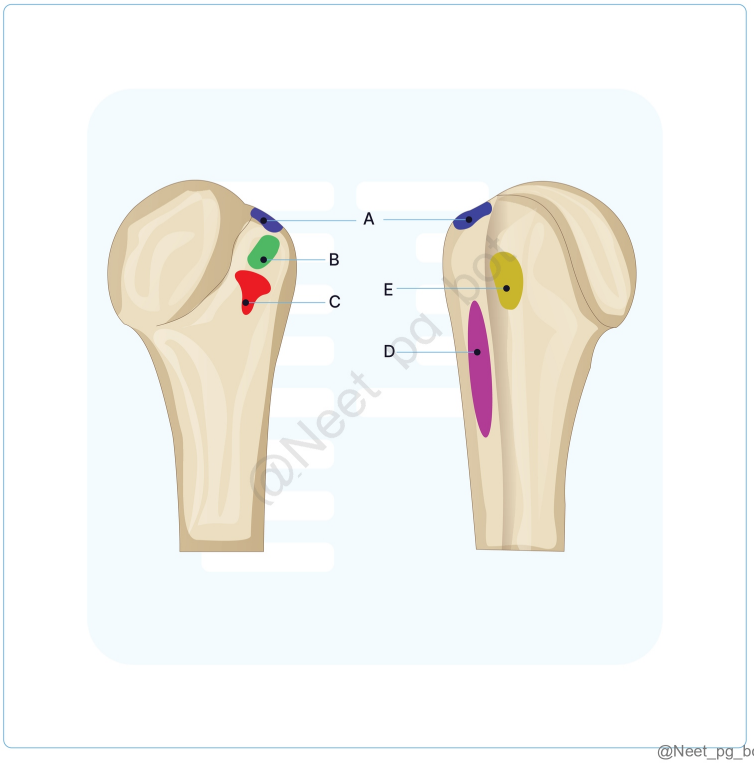

See Answer in Part B → Q7

@Neet_pg_bot

Q8: Which of the following correctly describes the attachments on the coracoid process? (Q848433)

A. The short head of biceps brachii and coracobrachialis insert onto its medial border.

B. The conoid ligament attaches to the tip of the coracoid process.

C. The pectoralis minor muscle inserts onto the medial border of the upper surface.

D. The coracoacromial ligament attaches to the superior ridge of the coracoid process.

See Answer in Part B → Q8

@Neet_pg_bot

Q9: Which of the following bones is not directly involved in the radiocarpal (wrist) joint? (Q848431)

A. Scaphoid

B. Lunate

C. Pisiform

D. Triquetrum

See Answer in Part B → Q9

@Neet_pg_bot

Q10: The muscles in the posterior aspect of the forearm are given below. Which among these is involved in the extension of the elbow joint? (Q848423)

A. Anconeus

B. Brachioradialis

C. Supinator

D. Extensor digitorum

See Answer in Part B → Q10

@Neet_pg_bot

Q11: A 28-year-old woman falls off her bicycle and lands on her outstretched hand. She presents with pain and swelling over the lateral aspect of her wrist. On examination, there is tenderness in the anatomical snuff box. Which underlying bone is most likely fractured? (Q848413)

A. Trapezium

B. Scaphoid

C. Lunate

D. Capitate

See Answer in Part B → Q11

@Neet_pg_bot

Q12: Choose the correct statement regarding the muscle being tested in the given image. (Q848421)

A. Unipennate muscle

B. Muscles of 1st and 2nd digits are supplied by median nerve and 3rd & 4th digit muscles are supplied by ulnar nerve

C. Causes flexion of interphalangeal and extension of metacarpophalangeal joints

D. Absent in thumb

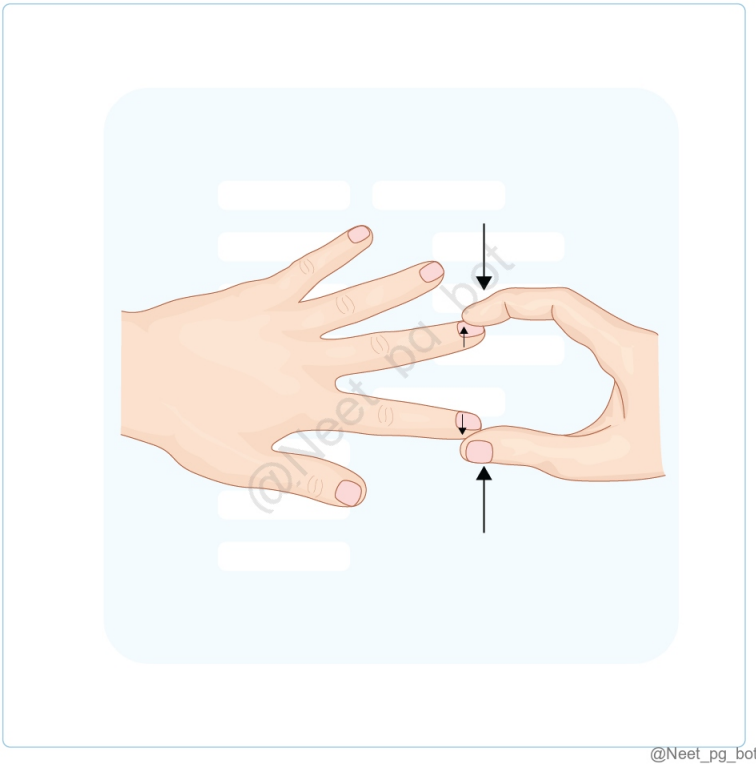

See Answer in Part B → Q12

@Neet_pg_bot

Q13: Given below is an image showing insertion of a muscle (marked in red) on the palmar aspect of the hand. Identify the correct pair of muscles and its corresponding nerve supply. (Q848420)

A. Opponens digiti minimi - radial nerve

B. Opponens digiti minimi - ulnar nerve

C. Abductor digiti minimi - median nerve

D. Abductor digiti minimi - ulnar nerve



See Answer in Part B → Q13

@Neet_pg_bot

Q14: Patient following RTA was brought to ED, where he was told that his ulnar nerve is injured. Which of the following muscles would be affected in this patient? (Q848419)

A. 4

B. 3

C. 2

D. 1

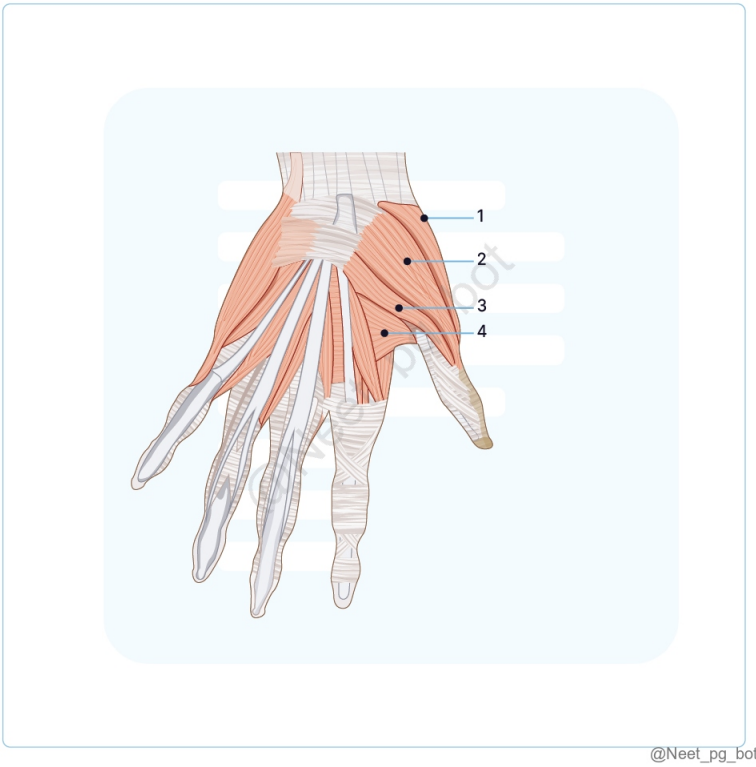

See Answer in Part B → Q14

@Neet_pg_bot

Q15: All are true about the shown muscle except. (Q848418)

A. Supplied by musculocutaneous nerve

B. Causes flexion of arm at shoulder joint

C. Paralyzed in Erb’s palsy

D. Attached to medial coracoid process

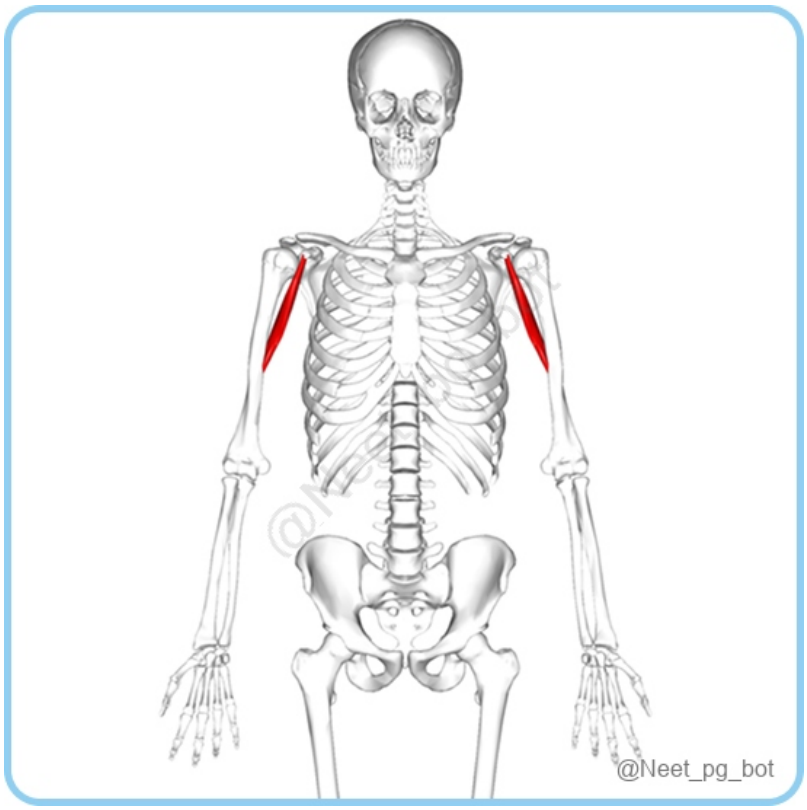

See Answer in Part B → Q15

@Neet_pg_bot

Q16: In which sequence do the following carpal bones typically ossify: capitate, pisiform, scaphoid? (Q848416)

A. Capitate → Scaphoid → Pisiform

B. Pisiform → Capitate → Scaphoid

C. Scaphoid → Capitate → Pisiform

D. Capitate → Pisiform → Scaphoid

See Answer in Part B → Q16

@Neet_pg_bot

Q17: Which of the following muscles is responsible for flexing the distal interphalangeal joints of the fingers? (Q848415)

A. Flexor digitorum superficialis

B. Flexor digitorum profundus

C. Pronator quadratus

D. Flexor pollicis longus

See Answer in Part B → Q17

@Neet_pg_bot

Q18: A 35-year-old carpenter presents with pain and weakness in his right forearm after repetitive hammering. On examination, you note tenderness over the medial epicondyle and weakness in wrist flexion. There is no sensory loss. Based on these findings, which muscle is not likely involved? (Q848414)

A. Flexor pollicis longus

B. Flexor carpi ulnaris

C. Flexor carpi radialis

D. Palmaris longus

See Answer in Part B → Q18

@Neet_pg_bot

• [05_Upper Limb] 025 Bones And Muscles Of Proximal Region Axilla And Scapula

« Back to Folder Directory

[05_Upper Limb] 025 Bones And Muscles Of Proximal Region Axilla And Scapula — Quick Jump

Q1 (p. 328) *Q2 (p. 328)* *Q3 (p. 329)* *Q4 (p. 329)* *Q5 (p. 329)* *Q6 (p. 330)*
Q7 (p. 331) *Q8 (p. 331)* *Q9 (p. 332)* *Q10 (p. 332)* *Q11 (p. 333)* *Q12 (p. 333)*
Q13 (p. 334)

Q1: A surgeon is performing an axillary dissection for breast cancer and must be cautious not to damage structures piercing the clavipectoral fascia. Which of the following statements about these structures is TRUE? (Q848330)

A. The cephalic vein pierces the clavipectoral fascia and runs through the deltopectoral groove before draining into the axillary vein.

B. The thoracoacromial artery pierces the clavipectoral fascia and divides into pectoral, deltoid, axillary, and clavicular branches.

C. Lateral pectoral nerve passes through the clavipectoral fascia and innervates the pectoralis minor muscle after piercing the pectoralis major.

D. Lymphatic vessels draining the lateral breast region pierce the clavipectoral fascia and drain into the central axillary lymph nodes.

See Answer in Part B → Q1

@Neet_pg_bot

Q2: Which of the following statements is TRUE regarding the rotator cuff muscles? (Q848337)

A. The rotator cuff includes the Supraspinatus, Infraspinatus, Subscapularis, and Teres major, which collectively aid in shoulder abduction and external rotation.

B. The Subscapularis is the only rotator cuff muscle involved in internal rotation of the humerus.

C. The Infraspinatus and Teres minor are responsible for medial rotation of the shoulder joint.

D. The rotator cuff muscles are primarily located in the anterior aspect of the shoulder joint

See Answer in Part B → Q2

@Neet_pg_bot

Q3: Which of the following is the correct pairing of shoulder movement and the muscle involved? (Q848327)

A. Adduction-pectoralis major

B. Adduction-serratus anterior

C. Abduction-teres major

D. Adduction-supraspinatus

See Answer in Part B → Q3

@Neet_pg_bot

Q4: Match the wall of the axilla with the structure forming it: Wall Structure forming a. Anterior wall 1. Serratus anterior b. Posterior wall 2. Bicipital groove c. Medial wall 3. Clavipectoral fascia d. Lateral wall 4. Subscapularis (Q848328)

A. a1,b2,c3,d4

B. a4,b3,c2,d1

C. a3,b4,c1,d2

D. a2,b3,c4,d1

See Answer in Part B → Q4

@Neet_pg_bot

Q5: Which of the following fasciae is the axillary sheath derived from? (Q848329)

A. Deep cervical fascia

B. Clavipectoral fascia

C. Superficial cervical fascia

D. Axillary fascia

See Answer in Part B → Q5

@Neet_pg_bot

Q6: A 35-year-old construction worker falls from a ladder and lands on his outstretched hand, resulting in a clavicular fracture as shown in the X- Ray given below. Which ligament plays a crucial role in stabilizing the medial end of the clavicle to the first rib, preventing excessive elevation of the clavicle? (Q848331)

A. Coracoclavicular ligament

B. Costoclavicular ligament

C. Sternoclavicular ligament

D. Interclavicular ligament

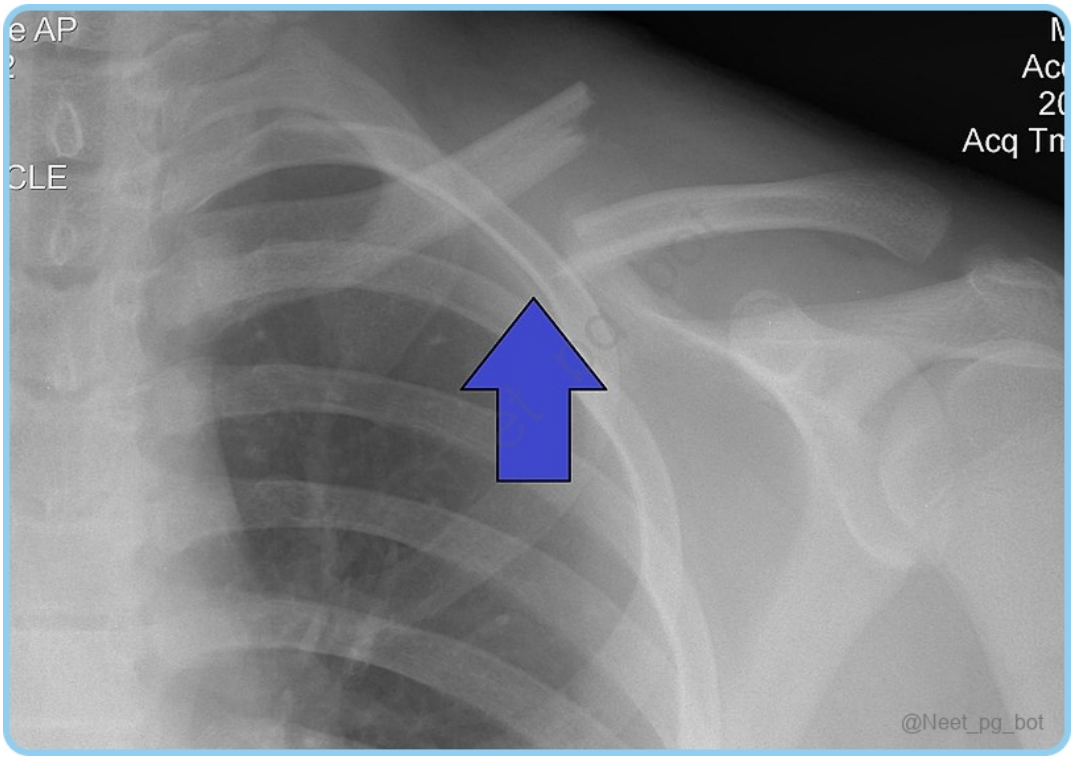

See Answer in Part B → Q6

@Neet_pg_bot

Q7: A 45-year-old painter presents with shoulder pain and weakness, particularly when raising his arm. He reports difficulty lifting objects overhead. On physical examination, there is tenderness over the shoulder and weakness in initiating arm abduction. Which rotator cuff muscle is most likely injured? (Q848332)

A. Infraspinatus

B. Teres Minor

C. Supraspinatus

D. Subscapularis

See Answer in Part B → Q7

@Neet_pg_bot

Q8: A 55 year old man, a former construction worker, presents with shoulder pain and limited range of motion. His examination finding is shown below in the image and there is tenderness over the lateral aspect of his ribcage. Which muscle is most likely compromised in function, and what nerve injury could be contributing to his condition? (Q848333)

A. Pectoralis Major; Medial pectoral nerve injury

B. Pectoralis Minor; Lateral pectoral nerve injury

C. Subclavius; Nerve to subclavius injury

D. Serratus Anterior; Long thoracic nerve injury



See Answer in Part B → Q8

@Neet_pg_bot

Q9: A 35-year-old swimmer presents with weakness during arm extension and difficulty pulling objects toward himself. He also reports pain during forceful expiration, such as coughing or sneezing. Which muscle is most likely involved, and what is its nerve supply? (Q848334)

A. Trapezius; Spinal accessory nerve

B. Latissimus Dorsi; Thoracodorsal nerve

C. Rhomboid Minor; Dorsal scapular nerve

D. Levator Scapulae; Dorsal scapular nerve

See Answer in Part B → Q9

@Neet_pg_bot

Q10: A 60-year-old female patient presents to the ED with a tension pneumothorax. The physician decides to perform a chest drain insertion to relieve the pressure. As the physician prepares for the procedure, they review the anatomical landmarks to ensure they insert the drain safely. Which muscle defines the posterior boundary of the Triangle of Safety, ensuring that the physician avoids vital structures during the chest drain insertion? (Q848335)

A. Pectoralis major

B. Latissimus dorsi

C. Serratus anterior

D. Trapezius

See Answer in Part B → Q10

@Neet_pg_bot

Q11: Which muscle forms the medial border of the Triangle of Auscultation? (Q848336)

A. Latissimus dorsi

B. Trapezius

C. Rhomboid major

D. Deltoid

See Answer in Part B → Q11

@Neet_pg_bot

Q12: Which of the following nerves is responsible for winging of scapula? (Q848338)

A. Dorsal scapular nerve

B. Spinal accesory nerve

C. Long thoracic nerve

D. Suprascapular nerve

See Answer in Part B → Q12

@Neet_pg_bot

Q13: Which of the following statements is TRUE regarding the muscles involved in abduction of shoulder? (Q848339)

A. Supraspinatous is involved in initiation of abduction.

B. Deltoid is responsible for 0-15 degree abduction.

C. Supraspinatous is responsible for 15-90 degree abduction.

D. Infraspinatous is responsible for 0-15 degree abduction.

See Answer in Part B → Q13

@Neet_pg_bot

• [05_Upper Limb] 026 Upper Limb Nerve Supply And Their Lesions

« Back to Folder Directory

[05_Upper Limb] 026 Upper Limb Nerve Supply And Their Lesions — Quick Jump

Q1 (p. 335)	*Q2 (p. 335)*	*Q3 (p. 336)*	*Q4 (p. 336)*	*Q5 (p. 336)*	*Q6 (p. 337)*
Q7 (p. 338)	*Q8 (p. 338)*	*Q9 (p. 339)*	*Q10 (p. 340)*	*Q11 (p. 341)*	*Q12 (p. 341)*
Q13 (p. 342)	*Q14 (p. 343)*	*Q15 (p. 343)*	*Q16 (p. 344)*	*Q17 (p. 344)*	

Q1: A patient with a humeral fracture presents with difficulty extending the elbow and wrist. Which of the following nerves is most likely affected? (Q848534)

A. Radial nerve

B. Median nerve

C. Ulnar nerve

D. Axillary nerve

See Answer in Part B → Q1

@Neet_pg_bot

Q2: A 35-year-old office worker presents with numbness and tingling in her thumb, index, and middle fingers. The physician taps over the ventral aspect of the wrist, reproducing her symptoms. Which test is the physician likely performing? (Q848529)

A. Tinel's sign

B. Phalen's test

C. Finkelstein's test

D. Froment's test

See Answer in Part B → Q2

@Neet_pg_bot

Q3: A 30-year-old man presents with a laceration to his right wrist after a slash injury. On examination, there is weakness of thumb opposition and numbness over the thenar eminence. Which structure is most likely to be injured? (Q848537)

A. Flexor carpi radialis

B. Radial nerve

C. Ulnar nerve

D. Median nerve

See Answer in Part B → Q3

@Neet_pg_bot

Q4: A 30-year-old man sustains an elbow dislocation with a medial epicondyle fracture. He now presents with difficulty flexing the fourth and fifth fingers and an inability to adduct the thumb. Which nerve is most likely injured? (Q848520)

A. Axillary nerve

B. Radial nerve

C. Median nerve

D. Ulnar nerve

See Answer in Part B → Q4

@Neet_pg_bot

Q5: A patient with a history of recurrent shoulder dislocations presents with a deformity as shown below. On physical examination, the patient is unable to fully protract the scapula when pushing against a wall. Which nerve is most likely involved? (Q848536)

A. Long thoracic nerve

B. Dorsal scapular nerve

C. Suprascapular nerve

D. Accessory nerve



See Answer in Part B → Q5

@Neet_pg_bot

Q6: Which of the following is the root value of the nerve that provides sensory innervation in the area marked (X)? (Q848535)

A. T2

B. T1, T2

C. C5

D. C5, C6

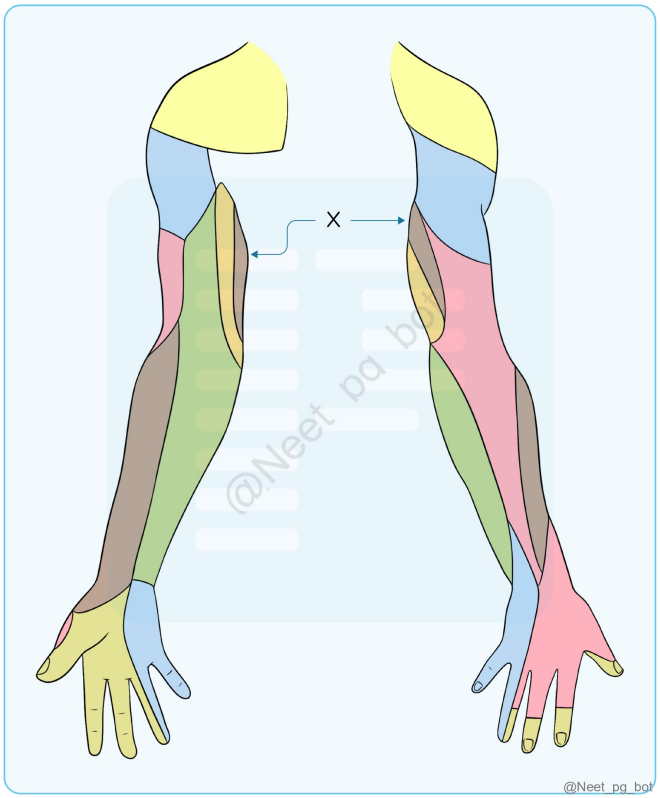

See Answer in Part B → Q6

@Neet_pg_bot

Q7: A 25-year-old male sustains a traumatic shoulder dislocation after a motor vehicle accident. On examination, the patient is unable to abduct his arm beyond 15 degrees and experiences numbness over the lateral shoulder. Which of the following nerve injury is the most likely cause of his symptoms? (Q848533)

A. Suprascapular nerve

B. Axillary nerve

C. Subscapular nerve

D. Long Thoracic nerve

See Answer in Part B → Q7

@Neet_pg_bot

Q8: A 35-year-old man presents with inability to extend his wrist and fingers. O/E, he exhibits a wrist drop and demonstrates weakness in elbow extension & loss of sensation over the posterior arm and the lateral aspect of the dorsum of the hand. Based on these findings, at which level is the radial nerve likely injured? (Q848532)

A. At the axilla

B. At the spiral groove

C. Lateral epicondyle of the humerus

D. Posterior interosseous nerve at the forearm

See Answer in Part B → Q8

@Neet_pg_bot

Q9: A patient is asked to hold a piece of paper between their thumb and index finger. When the examiner attempts to pull the paper away, the patient tries to hold the paper as shown in the image. Based on this observation, which muscle is likely affected? (Q848531)

A. Flexor pollicis brevis

B. Abductor pollicis brevis

C. Adductor pollicis

D. Opponens pollicis



See Answer in Part B → Q9

@Neet_pg_bot

Q10: A 45-year-old musician presents with a noticeable deformity affecting his ring and little fingers as shown in the image. Which muscle is primarily responsible for this deformity? (Q848530)

A. Flexor digitorum superficialis

B. Flexor digitorum profundus

C. Lumbricals

D. Dorsal interossei



See Answer in Part B → Q10

@Neet_pg_bot

Q11: A 45-year-old carpenter reports tingling and weakness in his ring and little fingers. Examination reveals hypothenar atrophy and a positive Froment's sign. Which structure is likely compressed? (Q848528)

A. Cubital tunnel

B. Guyon’s canal

C. Carpal tunnel

D. Palmar aponeurosis

See Answer in Part B → Q11

@Neet_pg_bot

Q12: A 35-year-old patient struggles to make a fist. When attempting to flex, the index and middle fingers remain straight, while the ring and little fingers flex normally. What is the most likely diagnosis? (Q848527)

A. Ulnar nerve injury

B. Median nerve injury at the wrist

C. Median nerve injury at the elbow

D. Radial nerve injury

See Answer in Part B → Q12

@Neet_pg_bot

Q13: Identify the X correctly from the below image of cubital fossa. (Q848526)

A. Brachial artery

B. Cephalic vein

C. Musculocutaneous nerve

D. Branchial cutaneous nerve



See Answer in Part B → Q13

@Neet_pg_bot

Q14: Which of the following correctly pairs a cutaneous nerve with its corresponding area of supply? (Q848524)

A. X-Median nerve

B. Z-Radial nerve

C. Y-Median nerve

D. X-Ulnar nerve

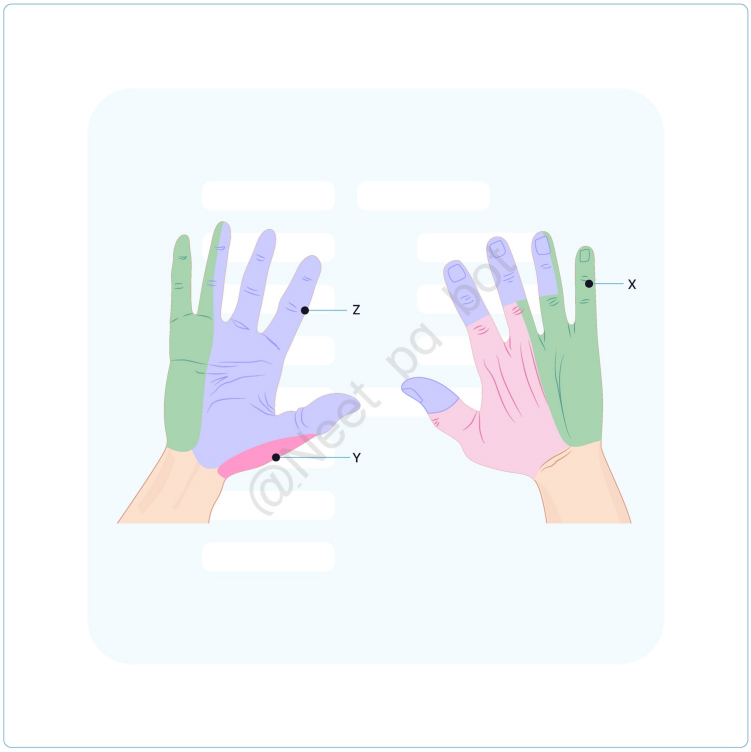

@Neet_pg_bot

See Answer in Part B → Q14

@Neet_pg_bot

Q15: A patient has a forearm laceration that results in an inability to flex the distal phalanges of the index and middle fingers. The affected muscle has dual nerve supply. Identify the muscle injured. (Q848523)

A. Flexor digitorum superficialis

B. Flexor pollicis longus

C. Palmaris longus

D. Flexor digitorum profundus

See Answer in Part B → Q15

@Neet_pg_bot

Q16: A 46-year-old woman presents with difficulty in thumb abduction and weak opposition. She gives a history of repetitive wrist movements. Which anterior rami nerve roots are likely involved in this condition? (Q848522)

A. C5 - C7

B. C5, C6

C. C8, T1

D. C5 - T1

See Answer in Part B → Q16

@Neet_pg_bot

Q17: Which of the following nerves innervates the muscle indicated below? (Q848521)

A. Ulnar nerve

B. Posterior interosseous nerve

C. Superficial branch of radial nerve

D. Anterior interosseous nerve

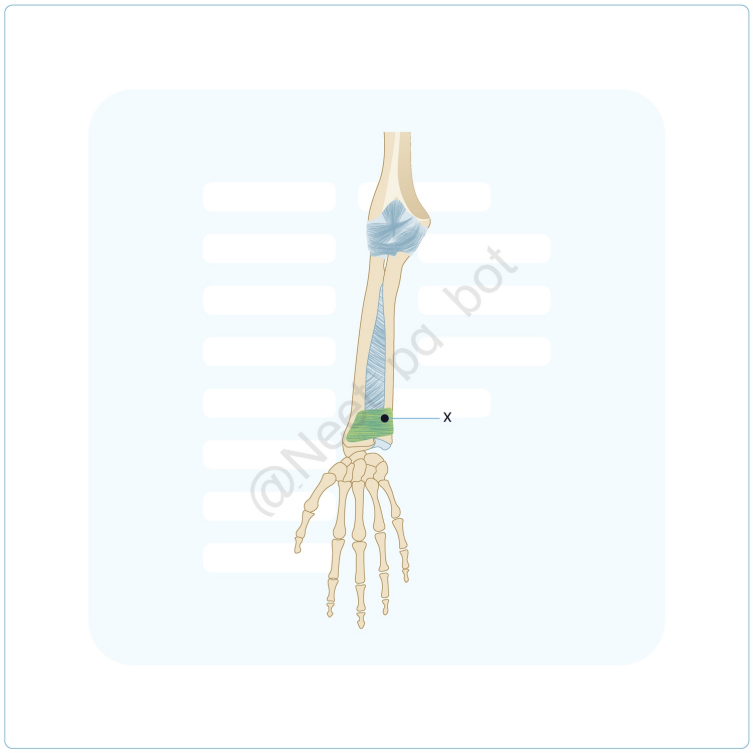

@Neet_pg_bot

See Answer in Part B → Q17

@Neet_pg_bot

• [05_Upper Limb] 027 Upper Limb Arterial Supply Venous Drainage Lymphatic Drainage Hand Spaces

« Back to Folder Directory

[05_Upper Limb] 027 Upper Limb Arterial Supply Venous Drainage Lymphatic Drainage Hand Spaces — Quick Jump

Q1 (p. 346) *Q2 (p. 346)* *Q3 (p. 347)* *Q4 (p. 347)* *Q5 (p. 348)* *Q6 (p. 348)*
Q7 (p. 349) *Q8 (p. 349)* *Q9 (p. 350)* *Q10 (p. 350)* *Q11 (p. 351)* *Q12 (p. 351)*
Q13 (p. 352) *Q14 (p. 352)* *Q15 (p. 353)*

Q1: A 35-year-old woman presents after a motor vehicle accident with a clavicle fracture. During surgery, the surgeon carefully avoids damaging nearby blood vessels, including those from the thyrocervical trunk. Which artery is not a branch of the thyrocervical trunk and is less likely to be encountered during this procedure? (Q848539)

A. Inferior Thyroid Artery

B. Suprascapular Artery

C. Superficial Cervical Artery

D. Dorsal Scapular Artery

See Answer in Part B → Q1

@Neet_pg_bot

Q2: A 40-year-old man undergoes surgery for a tumour in the axilla. During the procedure, the surgeon identifies the second part of the axillary artery and its branches. Which of the following arteries arises from this segment of the axillary artery and must be carefully preserved during the dissection? (Q848540)

A. Superior thoracic artery

B. Thoraco-acromial artery

C. Subscapular artery

D. Anterior circumflex humeral artery

See Answer in Part B → Q2

@Neet_pg_bot

Q3: The following image illustrates the blood supply to the mammary gland. Identify the artery labelled "A." (Q848541)

A. Lateral Thoracic Artery

B. Internal Thoracic Artery

C. Anterior Intercostal Arteries

D. Subscapular Artery

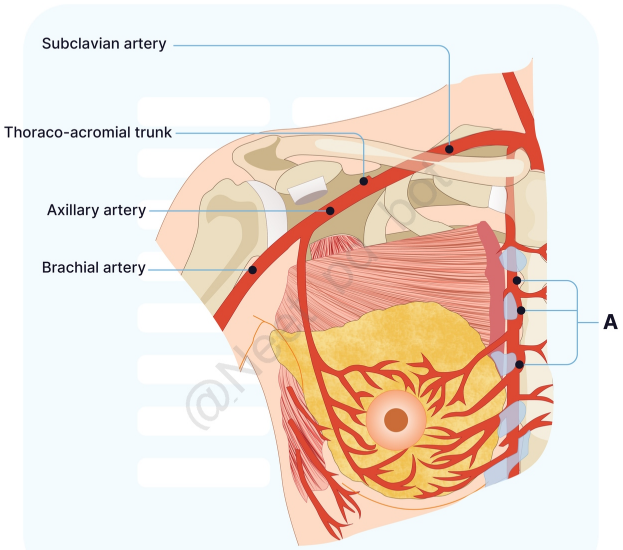

@Neet_pg_bot

See Answer in Part B → Q3

@Neet_pg_bot

Q4: A 35-year-old patient presents with a shoulder injury following a fall. During a physical examination, the physician palpates the brachial artery to assess the blood supply to the arm. At which anatomical landmark does this artery begin as a continuation of the axillary artery? (Q848542)

A. Lower border of the teres minor

B. Upper border of the teres major

C. Lower border of the teres major

D. Upper border of the teres minor

See Answer in Part B → Q4

@Neet_pg_bot

Q5: A 55-year-old male presents with intermittent pain and numbness in his right hand, especially after gripping. The physician suspects vascular insufficiency. Which test is the physician likely to perform to assess the blood supply to the hand? (Q848543)

A. Allen's test

B. Phalen's test

C. Tinel's sign

D. Capillary refill test

See Answer in Part B → Q5

@Neet_pg_bot

Q6: A 72-year-old male with a history of atherosclerosis and hypertension presents with sudden severe pain, numbness, and weakness in his left arm. Examination shows difficulty gripping and sensory loss in the hand. Which anastomosis is most critical for collateral blood flow to the left upper limb in this condition? (Q848544)

A. Suprascapular artery and dorsal scapular artery

B. Subscapular artery and circumflex scapular artery

C. Superior thoracic artery and acromiothoracic artery

D. Suprascapular artery and circumflex scapular artery

See Answer in Part B → Q6

@Neet_pg_bot

Q7: A patient with stage 5 chronic kidney disease is preparing for hemodialysis. During the examination, tenderness is noted in the right arm, and a prominent vein is visible. The doctor asks the intern to identify the vein, hinting that it pierces the clavipectoral fascia. What vein is being referenced? (Q848545)

A. Basilic vein

B. Brachial vein

C. Cephalic vein

D. Median cubital vein

See Answer in Part B → Q7

@Neet_pg_bot

Q8: A 45-year-old female presents to the clinic following her mammogram results, revealing a palpable mass in her left breast and mild discomfort. Examination shows enlarged lymph nodes in the left axilla. Which of the following is the terminal group of axillary lymph nodes? (Q848546)

A. Central

B. Pectoral

C. Apical

D. Supraclavicular

See Answer in Part B → Q8

@Neet_pg_bot

Q9: A 32-year-old male presents to the emergency department with swelling and pain in his right hand, particularly around the base of the thumb, after puncturing it with a nail. Examination shows tenderness, swelling, and limited thumb movement. An infection is diagnosed. Which statement about this space is incorrect? (Q848547)

A. It has a triangular shape

B. Infection can spread through the radial bursa

C. Associated short muscles of thumb anteriorly

D. Anterior wall is formed by the 2nd, 3rd, and 4th lumbricals

See Answer in Part B → Q9

@Neet_pg_bot

Q10: A teenager presents with severe pain and swelling in the tip of her right index finger after slamming it into a door. Examination reveals significant swelling, erythema, tenderness, increased sensitivity, and difficulty moving the finger. An infection of the structure marked 'X' is diagnosed. What is most likely? (Q848556)

A. Herpetic Whitlow

B. Felon

C. Paronychia

D. Tendon Sheath Infection

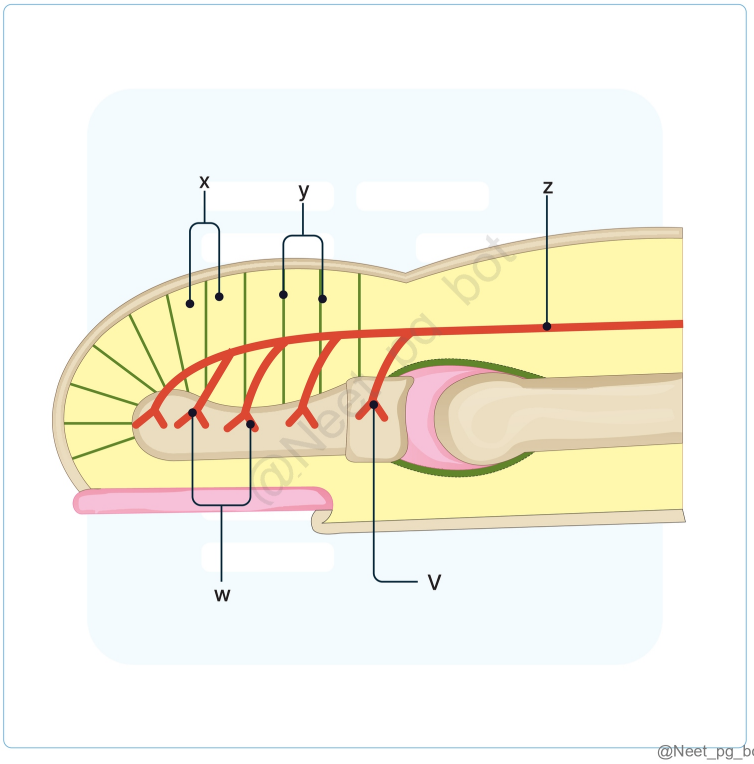

@Neet_pg_bot

See Answer in Part B → Q10

@Neet_pg_bot

Q11: A 45-year-old patient is undergoing surgery on the forearm. During the procedure, the surgeon ligates the brachial artery near the elbow. Which anastomotic site helps maintain blood flow to the forearm? (Q848557)

A. In front of the lateral epicondyle

B. Behind the lateral epicondyle

C. In front of the medial epicondyle

D. Behind the medial epicondyle

See Answer in Part B → Q11

@Neet_pg_bot

Q12: A patient sustains a deep laceration to the palm, resulting in significant bleeding. The surgeon identifies damage to an arterial structure located superficial to the flexor tendons and supplying the medial 3½ digits. Which arterial structure is most likely injured? (Q848558)

A. Superficial palmar arch

B. Deep palmar arch

C. Radial artery

D. Ulnar artery

See Answer in Part B → Q12

@Neet_pg_bot

Q13: A 28-year-old patient presents with weakness in thumb flexion and loss of forearm pronation after a deep laceration to the anterior forearm. Imaging reveals disruption of an artery accompanying the anterior interosseous nerve. Which artery is most likely damaged? (Q848559)

A. Radial artery

B. Common interosseous artery

C. Anterior interosseous artery

D. Posterior interosseous artery

See Answer in Part B → Q13

@Neet_pg_bot

Q14: Which of the following statements regarding the median cubital vein is incorrect? (Q848560)

A. It connects the cephalic vein to the basilic vein.

B. It runs obliquely downward and laterally across the forearm.

C. It is superficial to the bicipital aponeurosis, which separates it from the brachial artery.

D. It is the primary choice for venipuncture and catheterization due to its stability.

See Answer in Part B → Q14

@Neet_pg_bot

Q15: A 35-year-old woman with breast cancer presents with enlarged lymph nodes in her axilla. Biopsy reveals metastatic spread. Which group of axillary lymph nodes is most likely the initial site of cancer drainage? (Q848561)

A. Anterior (Pectoral) nodes

B. Posterior (Scapular) nodes

C. Lateral nodes

D. Apical (Infraclavicular) nodes

See Answer in Part B → Q15

@Neet_pg_bot

• [05_Upper Limb] 028 Previous Year Questions

« Back to Folder Directory

[05_Upper Limb] 028 Previous Year Questions — Quick Jump

Q1 (p. 354)	*Q2 (p. 355)*	*Q3 (p. 355)*	*Q4 (p. 356)*	*Q5 (p. 357)*	*Q6 (p. 358)*
Q7 (p. 358)	*Q8 (p. 359)*	*Q9 (p. 360)*	*Q10 (p. 360)*	*Q11 (p. 361)*	*Q12 (p. 362)*
Q13 (p. 362)	*Q14 (p. 363)*	*Q15 (p. 363)*	*Q16 (p. 364)*	*Q17 (p. 365)*	*Q18 (p. 366)*
Q19 (p. 367)	*Q20 (p. 367)*	*Q21 (p. 368)*	*Q22 (p. 369)*	*Q23 (p. 370)*	*Q24 (p. 371)*
Q25 (p. 371)	*Q26 (p. 372)*	*Q27 (p. 373)*	*Q28 (p. 374)*	*Q29 (p. 374)*	*Q30 (p. 374)*
Q31 (p. 375)	*Q32 (p. 375)*	*Q33 (p. 376)*	*Q34 (p. 376)*	*Q35 (p. 377)*	*Q36 (p. 378)*
Q37 (p. 378)	*Q38 (p. 379)*	*Q39 (p. 380)*	*Q40 (p. 380)*	*Q41 (p. 381)*	*Q42 (p. 382)*
Q43 (p. 382)	*Q44 (p. 383)*	*Q45 (p. 384)*	*Q46 (p. 384)*	*Q47 (p. 385)*	

Q1: A 16-year-old boy came to the emergency room with the following X-ray. On examination, he had a sensory loss in the lateral arm and sensory loss in the posterior aspect of the forearm. Which of the following is true about his condition? (Q859909)

A. Fracture-dislocation of the elbow

B. Surgical neck humerus fracture with axillary nerve injury

C. Spine fracture with foot drop

D. Humerus shaft fracture with radial nerve palsy



See Answer in Part B → Q1

@Neet_pg_bot

Q2: Biceps brachii functions as which type of muscle for lifting the forearm ? (Q857635)

A. Synergistic

B. Fixator

C. Antagonist

D. Primary mover

See Answer in Part B → Q2

@Neet_pg_bot

Q3: A 25 year old male presented with symptoms of inability to flex the distal interphalangeal joint of the 4 th and 5 th digits. He was also not able to hold a piece of paper between his fingers. What is the likely site of injury? (Q855844)

A. A

B. B

C. C

D. D

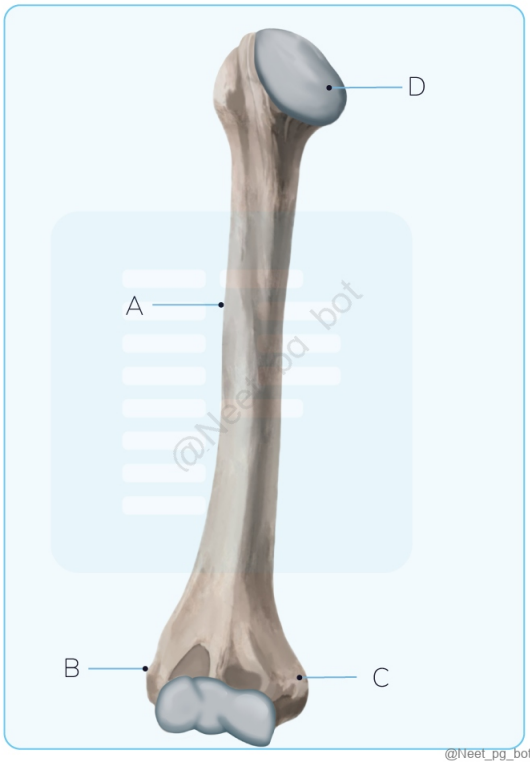

See Answer in Part B → Q3

@Neet_pg_bot

Q4: A patient who has taken the first COVID vaccine comes for the second dose. An astute nurse noticed that the shoulder was flabby, flat, and was asymmetrical. There was an associated loss of contour of the shoulder joint. Injury to which of the structures might have resulted and was avoidable? (Q856679)

A. Rotator cuff

B. Posterior circumflex artery

C. Lateral cutaneous nerve of arm

D. Axillary nerve

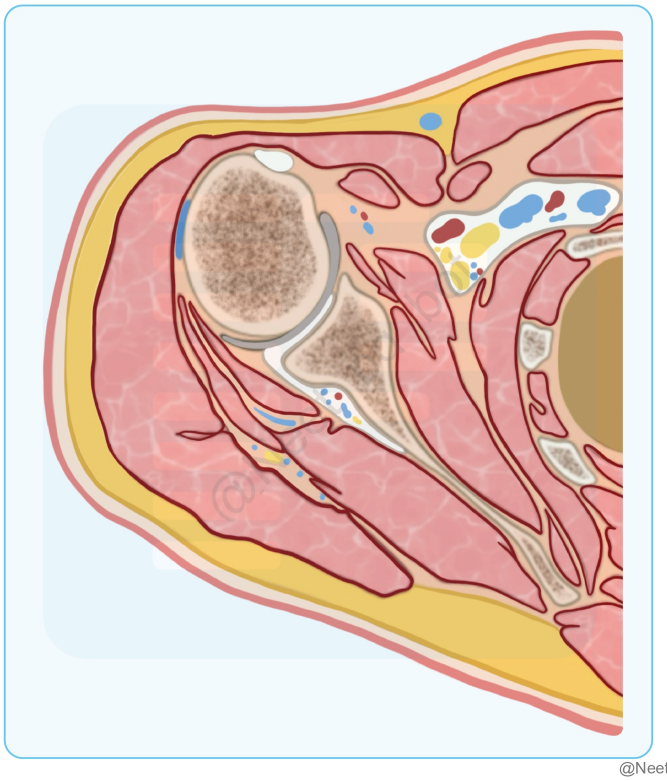

See Answer in Part B → Q4

@Neet_pg_bot

Q5: A 7-year-old boy was brought to the hospital with multiple fractures of the humerus secondary to a fall from height. On examination, there is difficulty in flexion of the elbow and supination of the forearm and associated loss of sensation over the lateral aspect of the forearm. Which is the nerve most likely to be injured? (Q856184)

A. Median nerve

B. Radial nerve

C. Musculocutaneous nerve

D. Ulnar nerve

See Answer in Part B → Q5

@Neet_pg_bot

Q6: Identify the muscle shown in the image below. (Q856374)

A. Abductor pollicis longus

B. Palmar interossei

C. Opponens pollicis

D. Flexor pollicis brevis

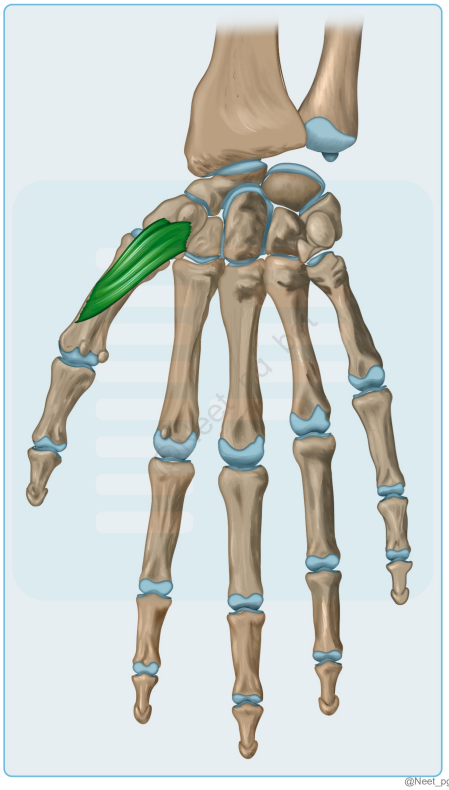

See Answer in Part B → Q6

@Neet_pg_bot

Q7: A 30-year-old female patient is presenting with wrist pain on the lateral side. On examination the following test was positive. Tendon sheaths of which two muscles have been involved? (Q854978)

A. Abductor pollicis longus and extensor pollicis brevis

B. Abductor pollicis longus and extensor pollicis longus

C. Abductor pollicis brevis and extensor pollicis brevis

D. Abductor pollicis brevis and extensor pollicis longus

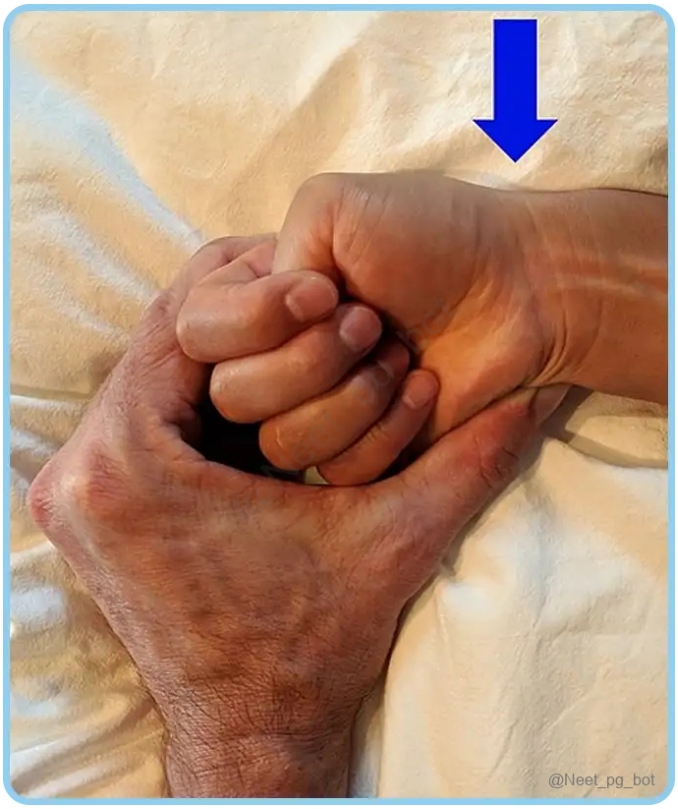

See Answer in Part B → Q7

@Neet_pg_bot

Q8: A patient presented with the extension of MCP joint and flexion of IP joints. Which muscle is affected? (Q854990)

A. Extensor digitorum

B. Interossei and lumbricals

C. Abductor pollicis longus

D. Abductor pollicis brevis

See Answer in Part B → Q8

@Neet_pg_bot

Q9: Identify the sign in the image given below: (Q858481)

A. Popeye sign

B. Hill-Sachs sign

C. Griesinger sign

D. Rising sun sign

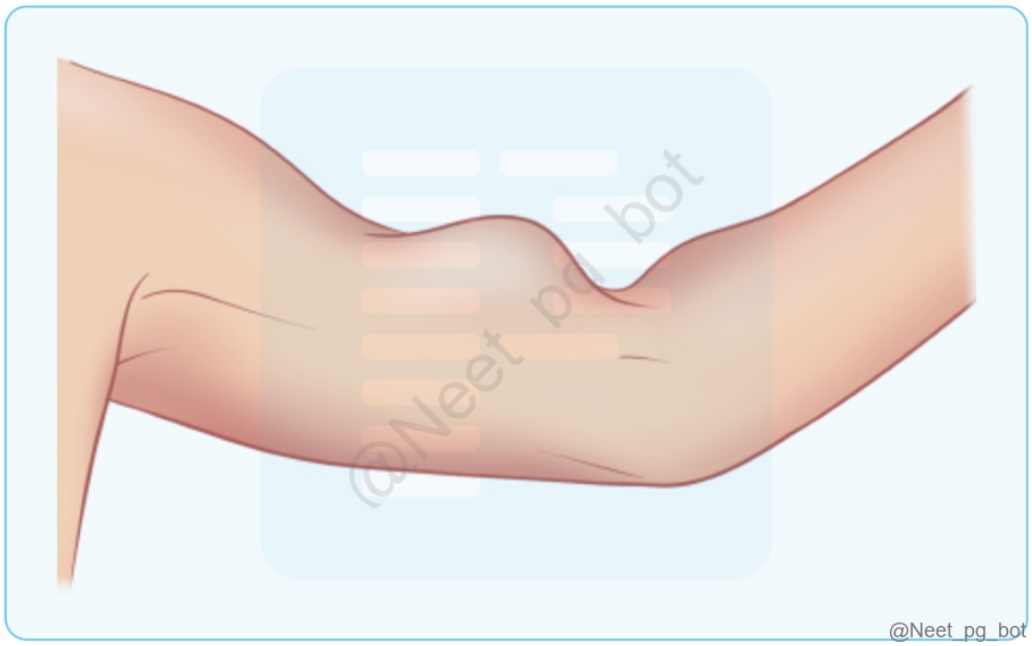

See Answer in Part B → Q9

@Neet_pg_bot

Q10: Which of the following forms the lateral boundary of the anatomical snuff box? (Q858486)

A. Extensor pollicis brevis and abductor pollicis longus

B. Extensor pollicis longus and abductor pollicis brevis

C. Extensor pollicis longus and extensor pollicis brevis

D. Abductor pollicis longus and abductor pollicis brevis

See Answer in Part B → Q10

@Neet_pg_bot

Q11: The image showed a normal elbow. What is the structure marked in the image called? (Q859519)

A. Capitulum

B. Trochlea

C. Olecranon

D. Head of radius

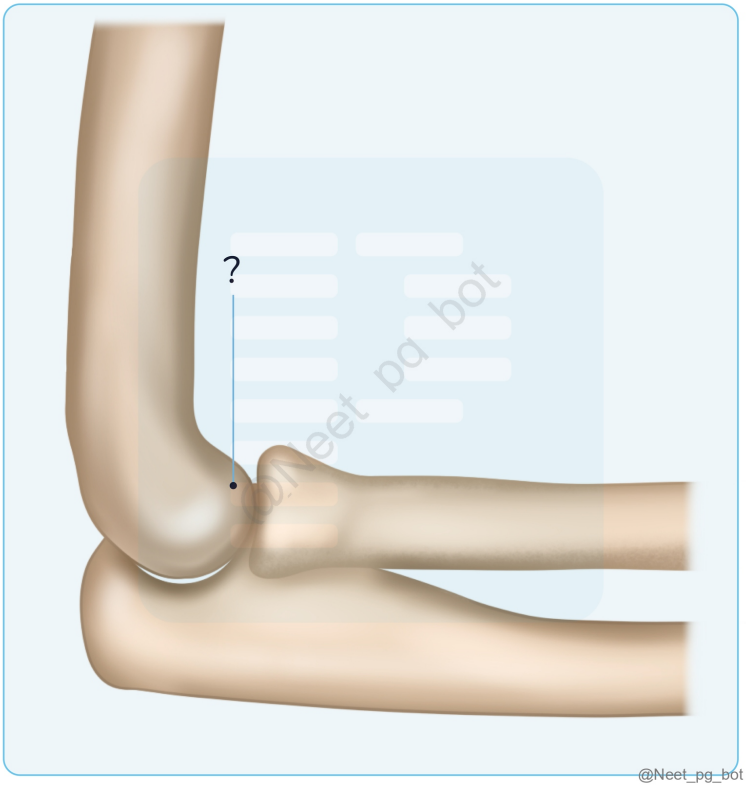

See Answer in Part B → Q11

@Neet_pg_bot

Q12: Based on the clinical image below, what is the most probable nerve to be injured? (Q859526)

A. Thoracodorsal nerve

B. Axillary nerve

C. Intercostal nerve

D. Long thoracic nerve



See Answer in Part B → Q12

@Neet_pg_bot

Q13: A patient presented with a history of chop injury to the right hand is undergoing surgical repairs . It is observed that the patient is unable to completely fold the right ring finger, while making the fist , which structure injury results in this? (Q857228)

A. Median nerve

B. Flexor retinaculum

C. Flexor digitorum profundus

D. Flexor pollicis longus

See Answer in Part B → Q13

@Neet_pg_bot

Q14: A 34-year-old male patient presents to the OPD complaining of pain in the medial part of the elbow for the past 4-6 weeks. He states that the pain worsens while lifting weights in the gym. On examination, there is tenderness over the medial epicondyle, and reverse Cozen's test is positive. Which of the following nerves is most likely to be injured in this patient? (Q859916)

A. Median nerve

B. Ulnar nerve

C. Radial nerve

D. Axillary nerve

See Answer in Part B → Q14

@Neet_pg_bot

Q15: Identify the tendon marked in the image (Q859920)

A. Flexor carpi radialis

B. Flexor carpi ulnaris

C. Palmaris longus

D. Median nerve

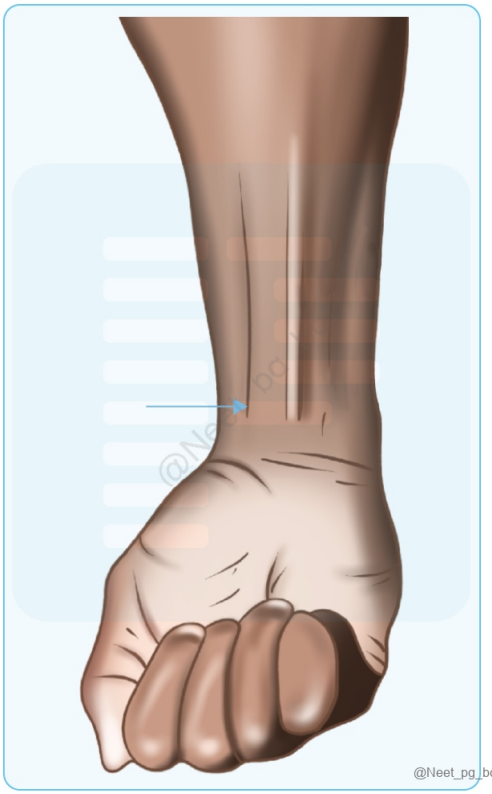

See Answer in Part B → Q15

@Neet_pg_bot

Q16: A man who was on crutches now presents with tingling and paraesthesia on the medial side of the arm, forearm, and hand. Which structure is most likely to be affected? (Q859924)

A. A

B. B

C. C

D. D

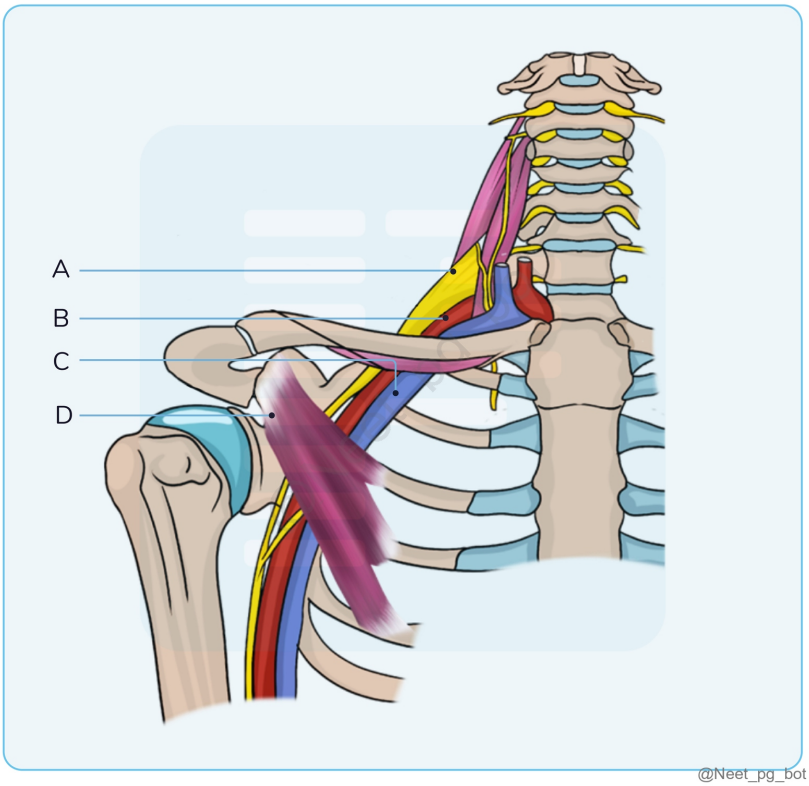

See Answer in Part B → Q16

@Neet_pg_bot

Q17: The marked structure serves as a surface landmark for which anatomical structure? (Q852990)

A. Pineal gland

B. Wernicke's area

C. Stem of lateral sulcus

D. Internal carotid artery siphon

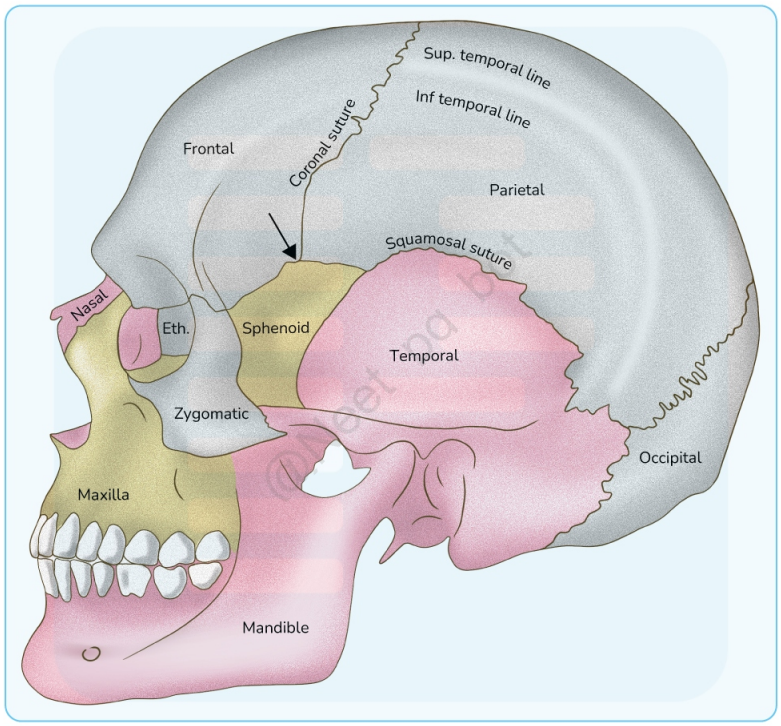

@Neet_pg_bot

See Answer in Part B → Q17

@Neet_pg_bot

Q18: The bone shown in the image is not associated with which of the following types of joints? (Q839878)

A. Syndesmosis

B. Symphysis

C. Plane synovial joint

D. Synchondrosis



See Answer in Part B → Q18

@Neet_pg_bot

Q19: Which of the following is the type of joint between epiphysis and diaphysis of a long bone? (Q860263)

A. Symphysis

B. Synchondrosis

C. Synostosis

D. Syndesmosis

See Answer in Part B → Q19

@Neet_pg_bot

Q20: Which part of this bone is palpable in the infraclavicular fossa? (Q855779)

A. 1

B. 2

C. 3

D. 4



See Answer in Part B → Q20

@Neet_pg_bot

Q21: What type of joint is seen in the labeled structure? (Q859517)

A. Syndesmosis

B. Primary cartilaginous joints

C. Fibrous joint

D. Secondary cartilaginous joint

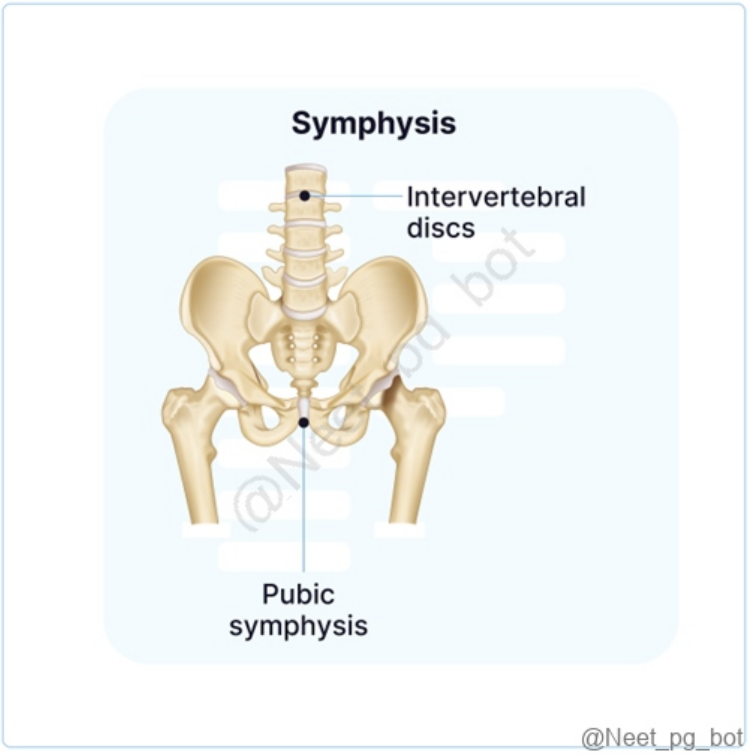

See Answer in Part B → Q21

@Neet_pg_bot

Q22: In the labeled structure, what kind of joint is present? (Q859522)

A. Sutures

B. Primary cartilaginous joints

C. Fibrous joint

D. Secondary cartilaginous joint

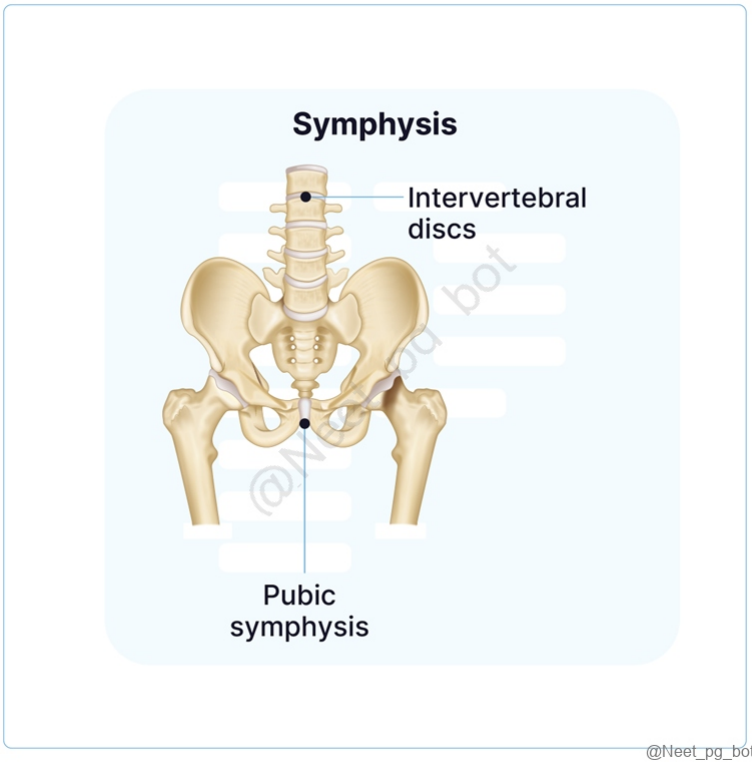

See Answer in Part B → Q22

@Neet_pg_bot

Q23: The given finding is associated with? (Q857932)

A. Trisomy 13

B. Trisomy 21

C. Klinefelter’s

D. Trisomy 18



See Answer in Part B → Q23

@Neet_pg_bot

Q24: The middle radioulnar joint is an example of a: (Q856401)

A. Plane synovial

B. Primary cartilaginous

C. Secondary cartilaginous

D. Fibrous joint

See Answer in Part B → Q24

@Neet_pg_bot

Q25: A patient is referred to a higher center with the diagnosis of fracture. On examination, the forearm pulses were not palpable. An upper arm X-ray was done, which is given below. Which artery is most likely to be injured in this condition?

(Q857902)

A. Radial artery

B. Ulnar artery

C. Brachial artery

D. Anterior interosseous artery



See Answer in Part B → Q25

@Neet_pg_bot

Q26: A diabetic worker sustains a stab injury to the central region of his palm. After 3 days, he develops swelling, severe pain, and inability to extend his middle and ring fingers. Pus accumulation is suspected in one of the palmar spaces. Which of the following spaces is most likely involved? (Q866624)

A. A

B. B

C. C

D. D

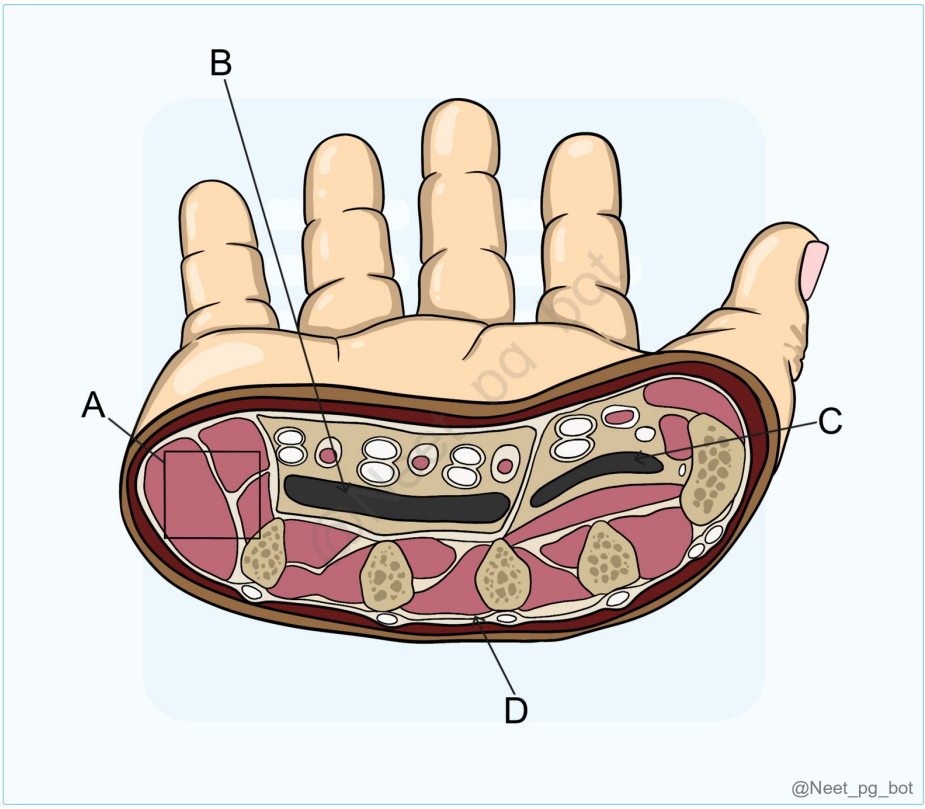

See Answer in Part B → Q26

@Neet_pg_bot

Q27: All of the following muscles are supplied by the deep branch of the ulnar nerve, except? (Q865346)

A. 4 th lumbrical

B. Dorsal interossei

C. Abductor digiti minimi

D. Flexor carpi ulnaris

See Answer in Part B → Q27

@Neet_pg_bot

Q28: During hyperextension, the long head of triceps gets detached from which site? (Q866310)

A. Infraglenoid tubercle

B. Supraglenoid tubercle

C. Shaft of humerus

D. Olecranon process

See Answer in Part B → Q28

@Neet_pg_bot

Q29: Injury to the posterior interosseous nerve leads to? (Q852996)

A. Loss of extension of digits

B. Loss of extension of wrist

C. Loss of supination

D. Wrist drop

See Answer in Part B → Q29

@Neet_pg_bot

Q30: A 45-year-old woman presented with tingling sensation of lateral 3 digits with loss of sensation of base of thumb on the dorsal aspect of the hand. Which is the nerve involved? (Q852448)

A. Radial nerve

B. Ulnar nerve

C. Median nerve

D. AIN

See Answer in Part B → Q30

@Neet_pg_bot

Q31: In the given image, the tendon marked by the arrow is? (Q860621)

A. Flexor carpi radialis

B. Flexor carpi ulnaris

C. Flexor digitorum superficialis

D. Palmaris longus

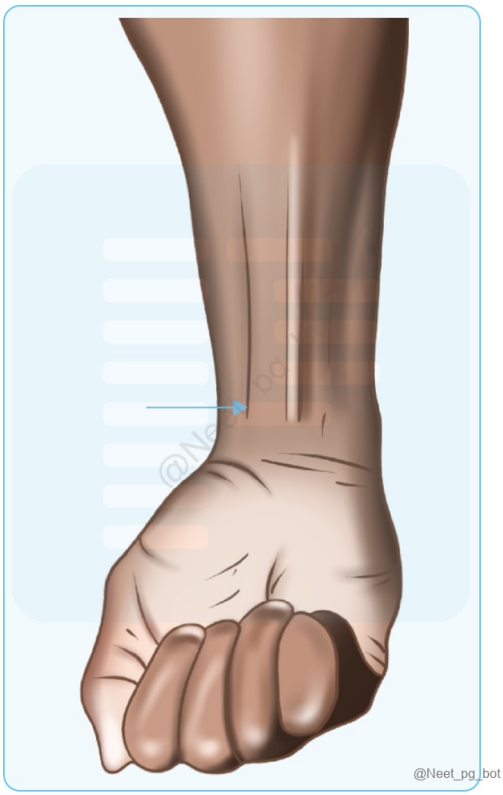

See Answer in Part B → Q31

@Neet_pg_bot

Q32: A road traffic accident patient has presented to you with features of a nerve injury involving right upper limb. On examination, the patient is able to carry out flexion at metacarpo-phalangeal joint and extension at interphalangeal joint. The

most likely nerve involved is? (Q860283)

A. Median nerve

B. Anterior interosseous nerve

C. Ulnar nerve

D. Radial nerve

See Answer in Part B → Q32

@Neet_pg_bot

Q33: A patient presents with abnormal sensations in the little finger and part of the ring finger with weakness of the hand. Also, there is a loss of coordination in the fingers. What is the nerve injured in the given scenario? (Q857315)

A. Ulnar nerve

B. Radial nerve

C. Median nerve

D. Axillary nerve

See Answer in Part B → Q33

@Neet_pg_bot

Q34: A man fell on his shoulder with his head pushed in the opposite direction. He presented with the following deformity. Which nerve root values are most likely affected? (Q866621)

A. C5 and C6

B. C6 and C7

C. C7 and C8

D. C8 and T1



See Answer in Part B → Q34

@Neet_pg_bot

Q35: A 22-year-old male patient after an injury presented with a deformity as shown in the image. Which nerve will be damaged in the given condition? (Q857913)

A. Ulnar Nerve

B. Radial Nerve

C. Median Nerve

D. Musculocutaneous Nerve



See Answer in Part B → Q35

@Neet_pg_bot

Q36: Which bone is most likely to be fractured in an injury to the anatomical snuff box? (Q857930)

A. Scaphoid

B. Lunar

C. Cuboid

D. Trapezius

See Answer in Part B → Q36

@Neet_pg_bot

Q37: Injury of the lower brachial plexus leads to Klumpke’s paralysis. What is the characteristic clinical finding seen in this lesion? (Q855411)

A. Policeman tip hand

B. Wrist drop

C. Claw hand

D. Horner’s syndrome

See Answer in Part B → Q37

@Neet_pg_bot

Q38: What is the nerve supply of the structure marked in the image? (Q855438)

A. Radial nerve

B. Median nerve

C. Ulnar nerve

D. Musculocutaneous nerve

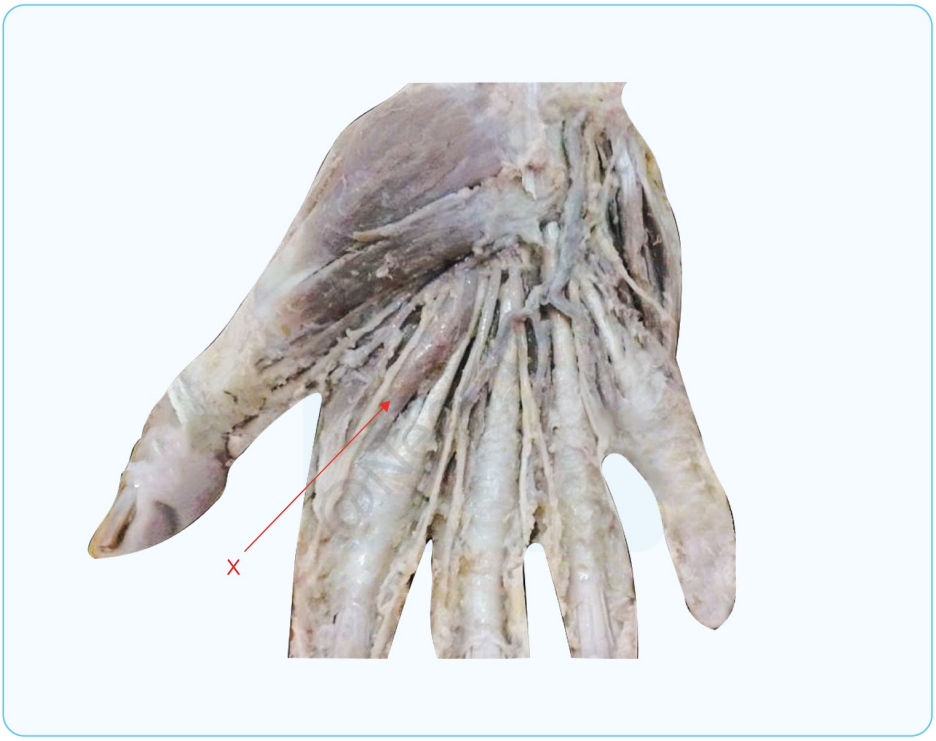

@Neet_pg_bot

See Answer in Part B → Q38

@Neet_pg_bot

Q39: Which nerve is affected in a 50-year-old male who has a positive Trendelenburg test on the right side? (Q855024)

A. Right inferior gluteal nerve

B. Right superior gluteal nerve

C. Left superior gluteal nerve

D. Left inferior gluteal nerve

See Answer in Part B → Q39

@Neet_pg_bot

Q40: A patient with leprosy presented with the deformity as shown below. Which nerve injury causes the given condition? (Q857225)

A. Ulnar nerve

B. Radial nerve

C. Median nerve

D. Posterior interosseous nerve



See Answer in Part B → Q40

@Neet_pg_bot

Q41: The given finding is associated with ? (Q820329)

A. Trisomy 13

B. Trisomy 21

C. Klinefelter’s

D. Trisomy 18

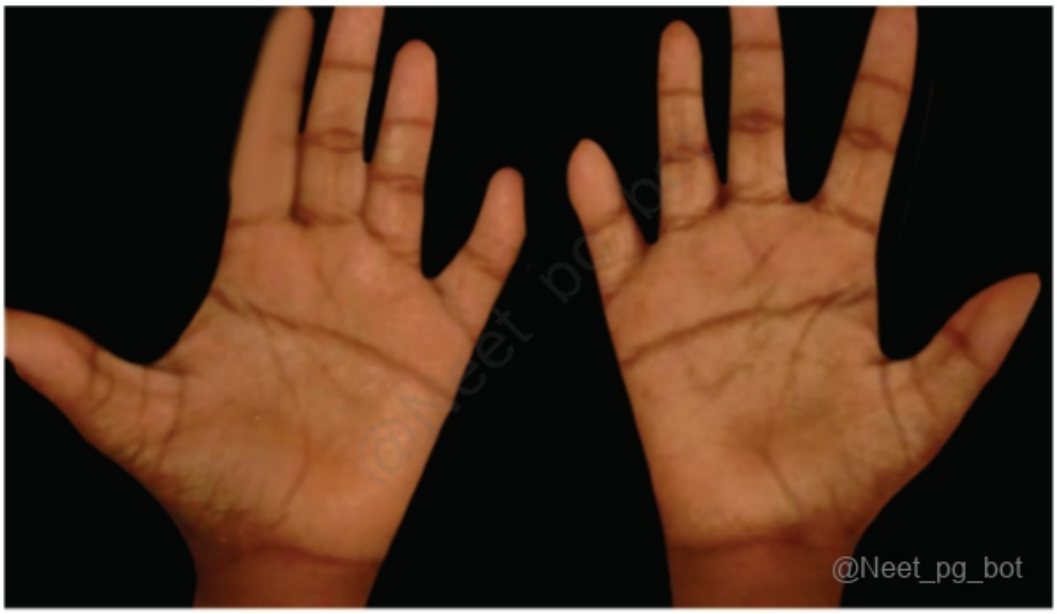

See Answer in Part B → Q41

@Neet_pg_bot

Q42: Which bone is most likely to be fractured in an injury to the anatomical snuff box? (Q820325)

A. Scaphoid

B. Lunar

C. Cuboid

D. Trapezius

See Answer in Part B → Q42

@Neet_pg_bot

Q43: A 22-year-old male patient after an injury presented with a deformity as shown in the image. Which nerve will be damaged in the given condition? (Q820304)

A. Ulnar Nerve

B. Radial Nerve

C. Median Nerve

D. Musculocutaneous Nerve



See Answer in Part B → Q43

@Neet_pg_bot

Q44: What is the function of the muscle indicated in the provided image? (Q793130)

A. Retraction of scapula

B. Protraction of scapula

C. Abduction of shoulder joint

D. Adduction of shoulder joint

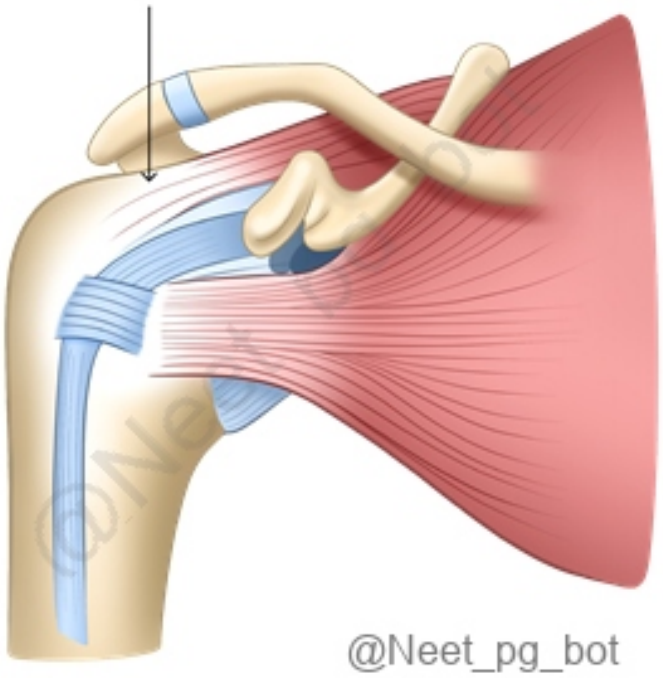

See Answer in Part B → Q44

@Neet_pg_bot

Q45: Which among the following aids in supination and pronation of the forearm? (Q793134)

A. Pivot joint

B. Saddle joint

C. Ellipsoid joint

D. Ball and socket joint

See Answer in Part B → Q45

@Neet_pg_bot

Q46: Identify the anatomical structure marked in the given image. (Q793151)

A. Abductor pollicis brevis

B. Extensor pollicis brevis

C. Abductor pollicis longus

D. Extensor pollicis longus

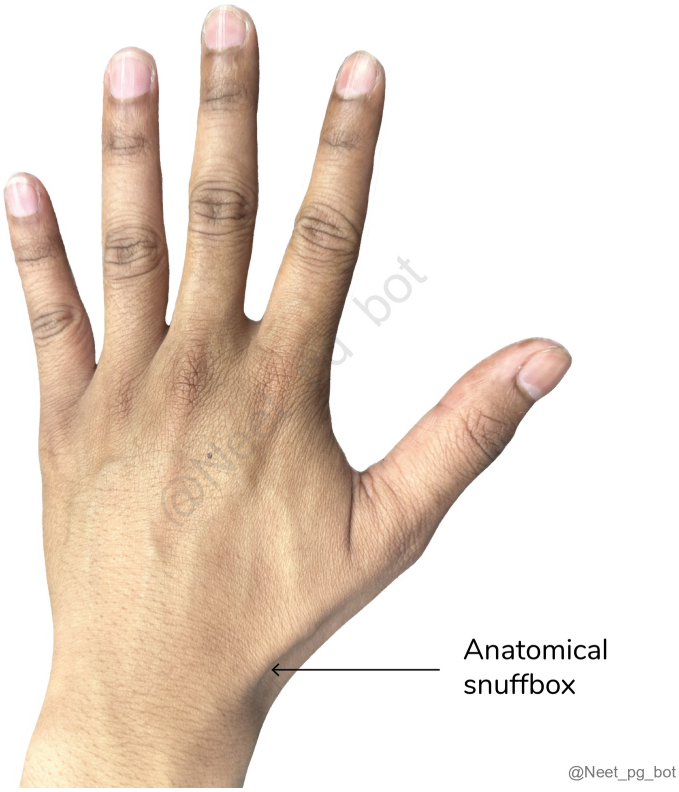

See Answer in Part B → Q46

@Neet_pg_bot

Q47: Identify the type of joint shown in the given image. (Q793154)

A. Symphysis

B. Syndesmosis

C. Synchondrosis

D. Synostosis

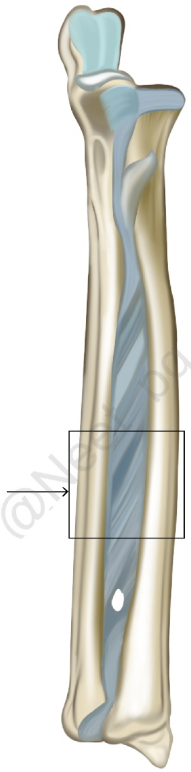

See Answer in Part B → Q47

@Neet_pg_bot

• [06_Lower Limb] 029 Muscles And Nerve Supply Of The Hip Thigh And Gluteal Region

« Back to Folder Directory

[06_Lower Limb] 029 Muscles And Nerve Supply Of The Hip Thigh And Gluteal Region — Quick Jump

Q1 (p. 387)	*Q2 (p. 388)*	*Q3 (p. 388)*	*Q4 (p. 389)*	*Q5 (p. 390)*	*Q6 (p. 390)*
Q7 (p. 391)	*Q8 (p. 391)*	*Q9 (p. 391)*	*Q10 (p. 392)*	*Q11 (p. 392)*	*Q12 (p. 393)*
Q13 (p. 393)	*Q14 (p. 393)*	*Q15 (p. 394)*	*Q16 (p. 394)*	*Q17 (p. 395)*	*Q18 (p. 395)*
Q19 (p. 396)	*Q20 (p. 396)*	*Q21 (p. 397)*	*Q22 (p. 397)*	*Q23 (p. 398)*	*Q24 (p. 399)*
Q25 (p. 399)					

Q1: Which of the following structures does not pass through the marked structure? (Q876248)

A. Piriformis muscle

B. Sciatic nerve

C. Tendon of obturator externus

D. Superior gluteal nerve and vessels

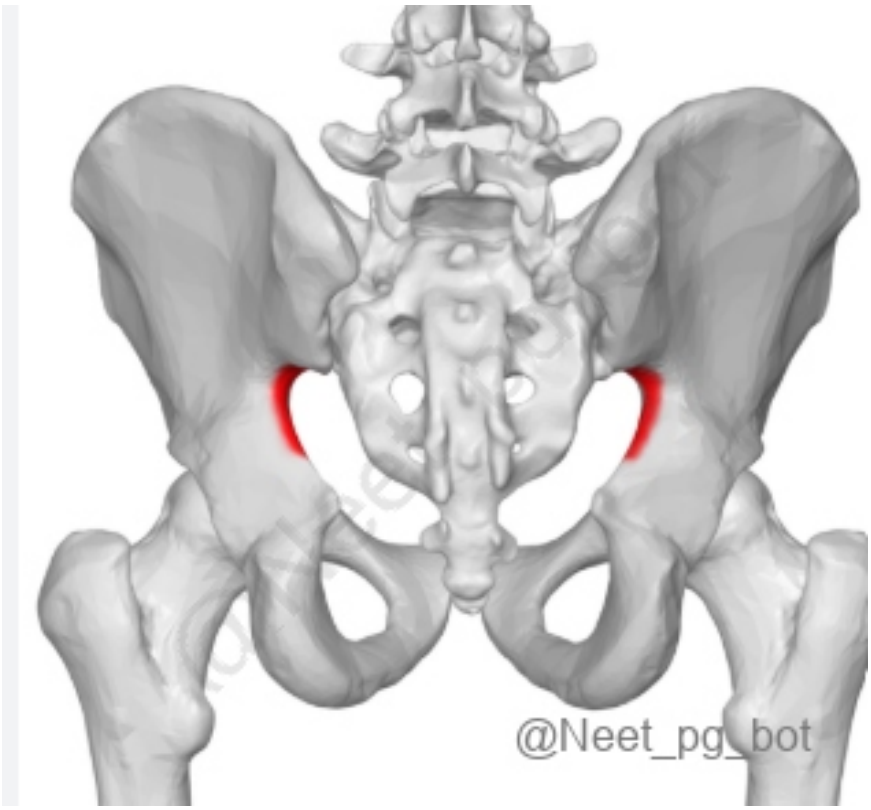

See Answer in Part B → Q1

@Neet_pg_bot

Q2: Which of the following bones forms the posterior pillar of the medial longitudinal arch? (Q848243)

A. Talus

B. Navicular

C. Calcaneum

D. Metatarsals

See Answer in Part B → Q2

@Neet_pg_bot

Q3: A 35-year-old male presents with a foot drop and weakness in the dorsiflexion of the great toe. He mentions a recent history of a herniated lumbar disc. There is decreased sensation over the dorsum of the foot and the first web space between the great toe and the second toe. Which dermatome and root value are most likely involved? (Q848223)

A. L5

B. S1

C. L4

D. L1

See Answer in Part B → Q3

@Neet_pg_bot

Q4: Identify X. (Q848242)

A. Linea semilunaris

B. Linea alba

C. Spino-umbilical line

D. Addison’s plane

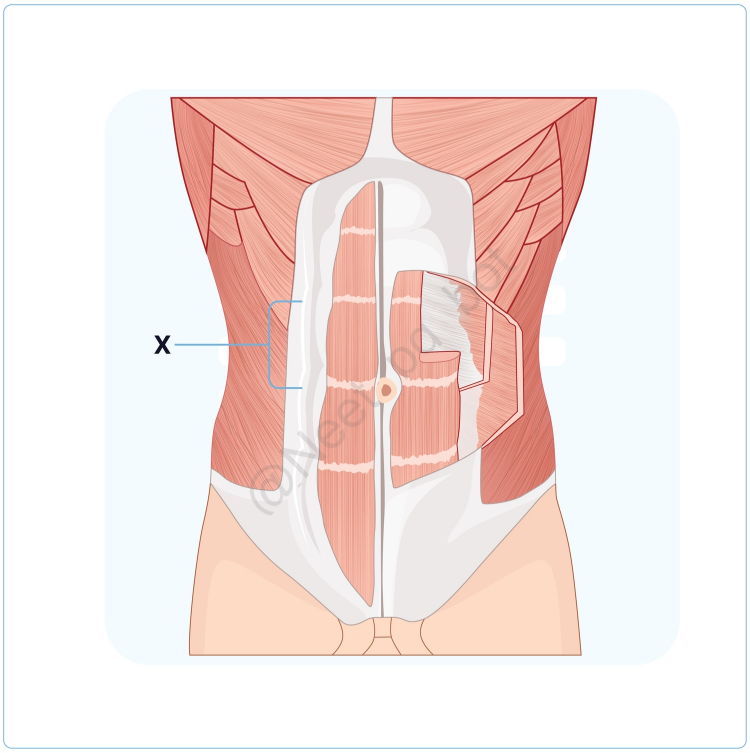

@Neet_pg_bot

See Answer in Part B → Q4

@Neet_pg_bot

Q5: Identify the muscle/muscle head that is not included in the hamstring group of muscles. (Q848227)

See Answer in Part B → Q5

@Neet_pg_bot

Q6: Which of the following muscles is/are supplied by the Nerve to the obturator internus? (Q848239)

A. Gamellus inferior and obturator internus

B. Gamellus superior and obturator internus

C. Quadratus femoris and obturator internus

D. Obturator internus only

See Answer in Part B → Q6

@Neet_pg_bot

Q7: A 35-year-old athlete presents with difficulty climbing stairs and rising from a seated position. Upon examination, there is weakness in hip extension. Which muscle is most likely affected, and what is the nerve supply? (Q848231)

A. Psoas major; Anterior rami of L1, L2, L3

B. Gluteus maximus; Inferior gluteal nerve

C. Gluteus maximus; Superior gluteal nerve

D. Sartorius; Femoral nerve

See Answer in Part B → Q7

@Neet_pg_bot

Q8: Which among the following structures do not pass through both the greater and lesser sciatic foramen? (Q848236)

A. Pudendal nerve

B. Internal pudendal artery

C. Nerve to obturator internus

D. Posterior cutaneous nerve of thigh

See Answer in Part B → Q8

@Neet_pg_bot

Q9: In a clinical setting, a physician suspects a weakness in the gluteus maximus muscle. Which of the following functions would not be affected by this? (Q848233)

A. Extension of flexed thigh

B. Raising trunk after stooping

C. Lateral rotation and abduction of the thigh

D. Stabilization of pelvis during quiet standing

See Answer in Part B → Q9

@Neet_pg_bot

Q10: A 30-year-old runner complains of difficulty flexing his knee after long-distance running. He reports that once his knee locks in an extended position, it takes effort to initiate flexion again. On examination, you notice that the patient struggles to begin flexion from full extension. Which muscle is likely impaired? (Q848232)

A. Quadriceps femoris

B. Popliteus

C. Biceps femoris

D. Vastus medialis

See Answer in Part B → Q10

@Neet_pg_bot

Q11: The iliotibial tract provides attachment to which of the following muscles? (Q848241)

A. Gluteus medius

B. Tensor fasciae latae

C. Gluteus maximus

D. Both B and C

See Answer in Part B → Q11

@Neet_pg_bot

Q12: Which of the following does not participate in the cruciate anastomosis? (Q848240)

A. Inferior gluteal artery

B. Medial circumflex femoral artery

C. Lateral circumflex femoral artery

D. Deep femoral artery

See Answer in Part B → Q12

@Neet_pg_bot

Q13: The femoral nerve splits into anterior and posterior divisions, which are separated by which of the following structures? (Q848238)

A. Femoral vein

B. Lateral circumflex femoral artery

C. Inguinal ligament

D. Obturator artery

See Answer in Part B → Q13

@Neet_pg_bot

Q14: Which two nerves provide the dual innervation of the pectineus muscle? (Q848237)

A. Obturator Nerve and Femoral Nerve

B. Sciatic Nerve and Tibial Nerve

C. Medial Pectoral Nerve and Lateral Pectoral Nerve

D. Musculocutaneous Nerve and Radial Nerve

See Answer in Part B → Q14

@Neet_pg_bot

Q15: Which of the following regarding the marked structure is true? (Q848235)

A. Nerve to obturator internus passes above it

B. Innervated by L5, S1 nerve roots

C. Pudendal nerve passes below it

D. It is a medial rotator of the hip joint

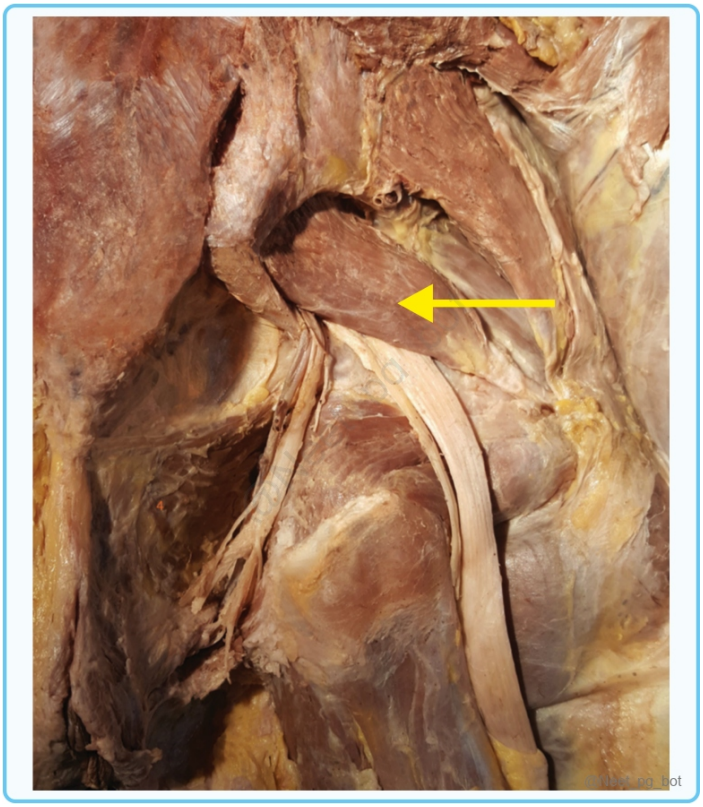

See Answer in Part B → Q15

@Neet_pg_bot

Q16: A 30-year-old male is being examined for abnormal gait. His Trendelenberg sign is positive. What is false about testing for the Trendelenburg sign? (Q848234)

A. The side of the hip that droops down is the unaffected side

B. The gluteus medius and minimus muscles are affected

C. The patients have a characteristic lurching gait

D. The uncompensated Trendelenburg sign is elicited with a walking patient

See Answer in Part B → Q16

@Neet_pg_bot

Q17: A patient reports pain and decreased sensation along the posterolateral aspect of the lower leg, extending onto the lateral side of the foot, following an ankle sprain. Which nerve is most likely injured? (Q848220)

A. Sural nerve

B. Saphenous nerve

C. Superficial peroneal nerve

D. Lateral femoral cutaneous nerve

See Answer in Part B → Q17

@Neet_pg_bot

Q18: A 40-year-old man is involved in a car accident and sustains a fracture to the ischial tuberosity. He now presents with weakness in knee flexion and hip extension, with intact sensation. Which muscle group and nerve are likely involved? (Q848230)

A. Quadriceps; femoral nerve

B. Hamstrings; sciatic nerve

C. Adductors; obturator nerve

D. Gluteal muscles; superior gluteal nerve

See Answer in Part B → Q18

@Neet_pg_bot

Q19: Identify the marked structures in the given image: (Q848229)

A. a) Semitendinosus, b) Biceps femoris, c) Popliteal artery, d) Tibial nerve

B. a) Semitendinosus, b) Biceps femoris, c) Tibial nerve, d) Popliteal artery

C. a) Biceps femoris, b) Semitendinosus, c) Popliteal artery, d) Tibial nerve

D. a) Biceps femoris, b) Semitendinosus, c) Tibial nerve, d) Popliteal artery

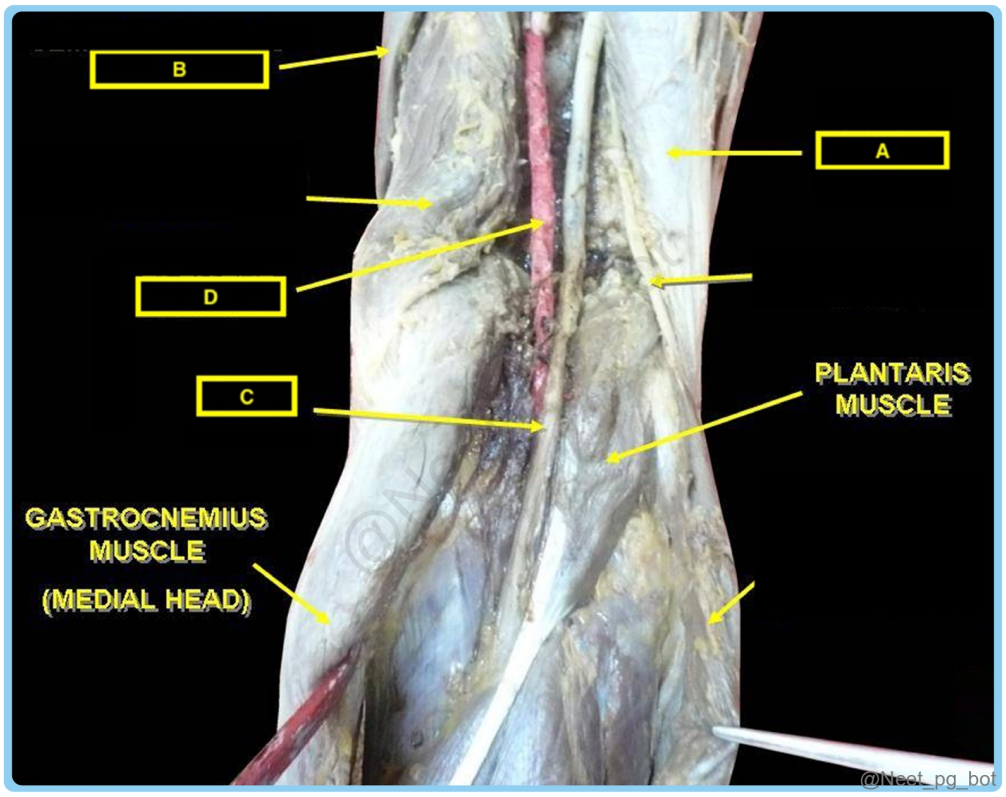

See Answer in Part B → Q19

@Neet_pg_bot

Q20: Which of the following sets of muscles is referred to as "guy rope" muscles that stabilise the bony pelvis on the femur? (Q848228)

A. Semitendinosus, Semimembranosus, Gracilis

B. Sartorius, Gracilis, Semitendinosus

C. Semimembranosus, Sartorius, Adductor magnus

D. Semimembranosus, Gracilis, Sartorius

See Answer in Part B → Q20

@Neet_pg_bot

Q21: A 25-year-old male presents with difficulty in adducting his thigh after sustaining an injury during a soccer match. Upon examination, weakness in adduction and medial rotation of the thigh is noted. Which of the following muscles is primarily responsible for these actions, and what is its nerve supply? (Q848226)

A. Pectineus; Femoral nerve

B. Gracilis; Femoral nerve

C. Adductor longus; Obturator nerve (posterior division)

D. Adductor part of adductor magnus; Obturator nerve (posterior division)

See Answer in Part B → Q21

@Neet_pg_bot

Q22: Which of the following is not the action of the marked structure? (Q848225)

A. Flexion of knee

B. Flexion of thigh

C. Extension of knee

D. Flexion of leg



See Answer in Part B → Q22

@Neet_pg_bot

Q23: A 50-year-old male presents with leg pain and weakness after a heavy deadlift. He reports heaviness in his feet, difficulty standing on his toes, and performing calf raises. Neurological examination reveals weakness in plantar flexion, inability to flex his toes and diminished ankle reflexes. Which spinal cord segments are primarily involved in this patient's symptoms? (Q848224)

A. L4, L5

B. S1, S2

C. L2, L3

D. L3, L4

See Answer in Part B → Q23

@Neet_pg_bot

Q24: A 45-year-old patient presents with a foot drop following a recent knee injury. Which of the following nerves, part of the sacral plexus, is most likely injured, leading to the inability to dorsiflex the foot? (Q848222)

A. Posterior Femoral Cutaneous Nerve

B. Tibial nerve

C. Common peroneal nerve

D. Pudendal nerve

See Answer in Part B → Q24

@Neet_pg_bot

Q25: A 45-year-old man presents to the clinic with complaints of tingling and numbness in the outer aspect of his right thigh. He reports that the symptoms worsen when he sits for prolonged periods and improves when he stands or walks. Upon examination, there is a sensory deficit in the lateral thigh region. Which nerve root value is primarily involved in this condition? (Q848221)

A. L1 and L2

B. L2 and L3

C. L2, L3 and L4

D. L4 and L5

See Answer in Part B → Q25

@Neet_pg_bot

• [06_Lower Limb] 030 Lower Limb Anatomy Knee And Leg

« Back to Folder Directory

[06_Lower Limb] 030 Lower Limb Anatomy Knee And Leg — Quick Jump

Q1 (p. 400)	*Q2 (p. 400)*	*Q3 (p. 401)*	*Q4 (p. 401)*	*Q5 (p. 401)*	*Q6 (p. 402)*
Q7 (p. 402)	*Q8 (p. 403)*	*Q9 (p. 403)*	*Q10 (p. 404)*	*Q11 (p. 404)*	*Q12 (p. 404)*
Q13 (p. 405)	*Q14 (p. 405)*	*Q15 (p. 406)*	*Q16 (p. 406)*	*Q17 (p. 406)*	*Q18 (p. 407)*
Q19 (p. 407)	*Q20 (p. 407)*				

Q1: A 28 y/o football player experiences sudden pain on the inside of his left knee after getting tackled while running with the ball. He reports feeling a pop and is unable to continue playing. O/E, there is swelling, tenderness along the medial joint line, and pain when attempting to flex the knee. Which of the following injuries is most likely? (Q848265)

A. Lateral collateral ligament (LCL) sprain

B. Anterior cruciate ligament (ACL) tear

C. Medial meniscus tear

D. Posterior cruciate ligament (PCL) tear

See Answer in Part B → Q1

@Neet_pg_bot

Q2: Which of the following statements regarding sustentaculum tali is correct: It is a shelf like projection, projecting from posterior surface of calcaneus. Superior surface of sustentaculum tali bears a facet for talus. Inferior surface of sustentaculum tali bears a groove for the tendon of flexor hallucis longus (Q848279)

A. Only 2

B. 1, 2, 3

C. 2 and 3

D. Only 3

See Answer in Part B → Q2

@Neet_pg_bot

Q3: Which statement best describes the relationship of the tibial nerve in the popliteal fossa? (Q848277)

A. It is the most medial structure crossing to the lateral side of the fossa.

B. It is deep to the popliteal artery and vein.

C. It lies lateral to the popliteal vessels crossing to the medial side.

D. It does not enter the popliteal fossa.

See Answer in Part B → Q3

@Neet_pg_bot

Q4: A 35 y/o man is hiking on uneven terrain. As he steps on a rock with his right foot, his foot tilts inward, his medial arch elevates, and his foot becomes more rigid. This movement is best described as: (Q848275)

A. Pronation

B. Supination

C. Eversion

D. Dorsiflexion

See Answer in Part B → Q4

@Neet_pg_bot

Q5: A 30 y/o athlete reports sudden pain in the back of his left leg and an inability to push off the ground while sprinting. Examination reveals a significant weakness in plantar flexion. Which muscle is primarily responsible for the action of plantarflexion

in this patient? (Q848271)

A. Tibialis Anterior

B. Gastrocnemius

C. Fibularis tertius

D. Fibularis Longus

See Answer in Part B → Q5

@Neet_pg_bot

Q6: A 40 y/o woman presents with ankle instability and pain on the lateral side after rolling her ankle while walking on uneven ground. Examination reveals weakness in foot eversion and tenderness over the base of the fifth metatarsal. Which muscle is primarily responsible for foot eversion in this patient? (Q848273)

A. Tibialis Anterior

B. Fibularis Longus

C. Fibularis Brevis

D. Gastrocnemius

See Answer in Part B → Q6

@Neet_pg_bot

Q7: A 25-year-old runner presents with pain along the front part of his right leg and difficulty in lifting the foot upwards after increasing his training intensity. O/E, he shows weakness in extending the big toe and foot drop. Which muscle is most likely affected in this patient, leading to his symptoms? (Q848272)

A. Tibialis Anterior

B. Extensor Hallucis Longus

C. Extensor Digitorum Longus

D. Fibularis Tertius

See Answer in Part B → Q7

@Neet_pg_bot

Q8: Which of the following is the correct statement regarding the ligaments of the hip joint. The fibrous capsule is made up of outer fibres which are longitudinal and inner circular fibres which are called zona orbicularis. Ligamentum teres femoris transmits the arteries to the head of femur. IIiofemoral ligament is inverted Y shaped ligament. The acetabular labrum helps in holding the femur in position. (Q848281)

A. 1,2,3,4

B. 1 and 4

C. Only 1

D. None of the above

See Answer in Part B → Q8

@Neet_pg_bot

Q9: A 35-year-old woman presents with pain and swelling in the prepatellar region of her left knee, which developed gradually over the past few weeks. She works as a housemaid and spends long hours kneeling on hard surfaces while cleaning floors. On physical examination, the knee is swollen, and there is tenderness over the anterior part of the knee. The swelling is soft and fluctuant, and there is no redness or heat over the area. What is the most likely diagnosis? (Q848280)

A. Prepatellar bursitis

B. Baker’s cyst

C. Osteoarthritis of the knee

D. Clergyman’s knee

See Answer in Part B → Q9

@Neet_pg_bot

Q10: Which dermatome supplies the middle of the back of the thigh and leg? (Q848278)

A. S1

B. S2

C. L4

D. L5

See Answer in Part B → Q10

@Neet_pg_bot

Q11: A 50 y/o man undergoes a total hip replacement. Postoperatively, he develops difficulty walking and reports numbness along the posterior thigh, lateral leg, and sole of the foot. O/E, he has weakness in extending the hip and flexing the knee. The injured nerve originates from which of the following spinal roots? (Q848276)

A. L2–L4

B. L4–S3

C. L5–S1

D. S1–S5

See Answer in Part B → Q11

@Neet_pg_bot

Q12: A 55 y/o man presents with difficulty walking and reports pain along the medial aspect of his foot. Physical examination reveals weakness in inversion and signs of flatfoot. Which muscle is primarily responsible for the inversion of the foot in this patient? (Q848274)

A. Gastrocnemius

B. Soleus

C. Tibialis Posterior

D. Flexor Digitorum Longus

See Answer in Part B → Q12

@Neet_pg_bot

Q13: Where does the popliteus muscle originate, and what is its nerve supply? (Q848262)

A. Medial condyle of femur; Femoral nerve

B. Lateral condyle of femur; Tibial nerve

C. Tibial tuberosity; Sciatic nerve

D. Fibular head; Peroneal nerve

See Answer in Part B → Q13

@Neet_pg_bot

Q14: A 30-year-old runner comes in with weakness when trying to lift his foot and numbness on the outside of his right leg after hurting his knee. Examination reveals weakness in dorsiflexion and tenderness over the lateral aspect of the popliteal fossa. Which of the following structures is most likely compressed in the popliteal fossa, leading to the patient's symptoms? (Q848270)

A. Popliteal artery

B. Tibial nerve

C. Common peroneal nerve

D. Popliteal vein

See Answer in Part B → Q14

@Neet_pg_bot

Q15: Which of the following correctly matches a boundary of the popliteal fossa with its associated structure? (Q848269)

A. Superolaterally - Semimembranosus and semitendinosus

B. Inferomedially - Medial head of the gastrocnemius

C. Roof of the popliteal fossa - Biceps femoris

D. Inferolaterally - Popliteal surface of the femur

See Answer in Part B → Q15

@Neet_pg_bot

Q16: Which of the following accurately describes the boundaries of the adductor canal? (Q848268)

A. Anteriorly bounded by the sartorius muscle, laterally by the rectus femoris.

B. Posteromedially bounded by adductor longus and adductor magnus.

C. Roofed by the iliotibial band and bounded posteriorly by the adductor brevis.

D. Medially bounded by the gluteus maximus and anteriorly by the vastus lateralis.

See Answer in Part B → Q16

@Neet_pg_bot

Q17: Which of the following muscles forms the lateral part of the floor of the femoral triangle? (Q848267)

A. Pectineus

B. Iliacus

C. Adductor longus

D. Sartorius

See Answer in Part B → Q17

@Neet_pg_bot

Q18: A 28 y/o male presents with knee pain and instability after a football injury. The Lachmann Test is performed to assess for an ACL tear. At what degree of knee flexion is the Lachmann Test typically performed? (Q848266)

A. 0 degrees

B. 15-20 degrees

C. 60-70 degrees

D. 80-90 degrees

See Answer in Part B → Q18

@Neet_pg_bot

Q19: A 25 y/o male presents to the emergency after a sports injury involving a sudden pivot on his left knee. An MRI reveals a tear in the anterior cruciate ligament (ACL). Which statement regarding the knee ligaments is true? (Q848264)

A. ACL is an extracapsular ligament.

B. Lateral collateral ligament attaches to the patella.

C. The medial meniscus is wider anteriorly.

D. PCL prevents anterior displacement of the femur.

See Answer in Part B → Q19

@Neet_pg_bot

Q20: Which muscles are involved in the locking and unlocking of the knee joint? (Q848263)

A. Hamstring muscles for both locking and unlocking

B. Quadriceps femoris for locking and popliteus for unlocking

C. Popliteus for both locking and unlocking

D. Soleus for unlocking and hamstring for locking

See Answer in Part B → Q20

@Neet_pg_bot

• [06_Lower Limb] 031 Vascular Supply Of Lower Limb

« Back to Folder Directory

[06_Lower Limb] 031 Vascular Supply Of Lower Limb — Quick Jump

Q1 (p. 409) *Q2 (p. 410)* *Q3 (p. 410)* *Q4 (p. 410)* *Q5 (p. 411)* *Q6 (p. 411)*
Q7 (p. 412) *Q8 (p. 412)* *Q9 (p. 412)* *Q10 (p. 413)* *Q11 (p. 413)* *Q12 (p. 414)*
Q13 (p. 414) *Q14 (p. 415)* *Q15 (p. 415)*

Q1: Which of the following is incorrect about the highlighted area? (Q848292)

A. It consists of a superficial part and a deep part.

B. Prone to injuries in eversion.

C. Excessive tensile forces cause avulsion fracture.

D. It's crossed by tibialis posterior and flexor digitorum longus.

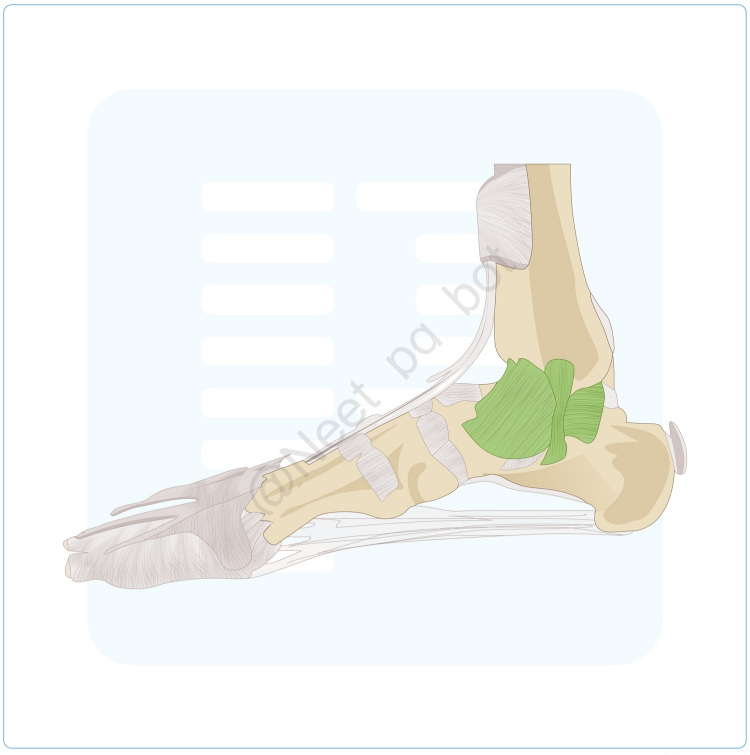

See Answer in Part B → Q1

@Neet_pg_bot

Q2: A 42-year-old woman complains of difficulty adducting her toes. Which of the following muscles is primarily responsible for adducting the lateral three toes? (Q848294)

A. Adductor halucis

B. Dorsal interossei

C. Plantar interossei

D. Adductor digitorum brevis

See Answer in Part B → Q2

@Neet_pg_bot

Q3: A 30-year-old athlete complains of difficulty in flexion at the metatarsophalangeal joint and extension at the interphalangeal joint of the second toe. Which of the following statements is correct? (Q848295)

A. First lumbrical is affected and is supplied by the lateral plantar nerve.

B. First lumbrical is affected and is supplied by the medial plantar nerve.

C. Second lumbrical is affected and is supplied by the lateral plantar nerve.

D. Second lumbrical is affected and is supplied by the medial plantar nerve.

See Answer in Part B → Q3

@Neet_pg_bot

Q4: A 55-year-old man presents with complaints of claudication and cramping pain in his left lower limb while walking short distances, which is relieved by rest. On further examination, his left dorsalis pedis pulse is diminished, and he has cool skin on the affected leg. Doppler ultrasound reveals significant atherosclerosis at the bifurcation of the common iliac artery. Which of the following arteries, if most affected by this condition, is likely responsible for the reduced blood flow to his lower limb?

(Q848296)

A. Internal iliac artery

B. Inferior epigastric artery

C. External iliac artery

D. Internal pudendal artery

See Answer in Part B → Q4

@Neet_pg_bot

Q5: During surgery for a femoral shaft fracture, the surgeon notes damage to the vastus lateralis muscle. Which artery is primarily responsible for supplying the vastus lateralis? (Q848298)

A. Ascending branch of femoral circumflex artery

B. Ascending branch of medial femoral circumflex artery

C. Descending branch of lateral femoral circumflex artery

D. Transverse branch if medial femoral circumflex artery

See Answer in Part B → Q5

@Neet_pg_bot

Q6: A patient is experiencing discomfort in the lower limb due to venous insufficiency. Which of the following mechanisms aid in the venous return of blood from the lower limb to the heart? (Q848299)

A. Deep fascia limits muscle expansion

B. Contraction of calf muscles leads to compression of superficial veins

C. Increased intrathoracic pressure

D. Vasodilation of superficial veins

See Answer in Part B → Q6

@Neet_pg_bot

Q7: A 30-year-old female presents to the emergency department with a swollen right leg and pain following a long-haul flight. Doppler ultrasound confirms a deep vein thrombosis (DVT) in the right calf. Which statement about the anatomy of the deep veins of the lower limb is correct? (Q848300)

A. The anterior tibial vein runs alongside the fibular artery.

B. The medial and lateral plantar veins contribute to the formation of the popliteal vein.

C. Perforating veins carry blood from deep veins to superficial veins.

D. The fibular veins drain directly into the femoral vein.

See Answer in Part B → Q7

@Neet_pg_bot

Q8: A 35-year-old female presents with symptoms of heaviness and visible varicose veins primarily affecting her left leg. Duplex ultrasonography reveals dilation of the great saphenous vein (GSV) with incompetent valves. She is scheduled for vein stripping surgery. Which of the following statements regarding the anatomical features of the GSV compared to the small saphenous vein (SSV) is correct? (Q848301)

A. The GSV has fewer valves than the SSV, making it less prone to varicosities

B. The GSV originates from the lateral end of the dorsal venous arch of the foot

C. The GSV is a continuation of the medial marginal vein.

D. The GSV pierces the deep fascia to drain into the popliteal vein.

See Answer in Part B → Q8

@Neet_pg_bot

Q9: A 45-year-old female presents with burning pain and tingling in the plantar aspect of her foot. She reports that the symptoms worsen with prolonged standing and improve with rest. You tap over the region just behind the medial malleolus, and the patient experiences tingling and numbness radiating into the sole of her foot. The underlying cause of her symptoms is likely related to? (Q848288)

A. Inadequate Blood Supply

B. Compressive Neuropathy

C. Morton’s neuroma

D. Arthritis

See Answer in Part B → Q9

@Neet_pg_bot

Q10: A 45-year-old woman presents with difficulty wearing shoes and discomfort in her toes. She reports pain in the forefoot and has noticed that the tips of her toes frequently press into the ground while walking. On physical examination, the toes are bent at the middle and distal joints, with hyperextension at the base. The deformity worsens when wearing tight shoes. What is the most likely diagnosis based on the description of the deformity?. (Q848289)

A. Claw toe

B. Hammer toe

C. Mallet toe

D. Bunion toe

See Answer in Part B → Q10

@Neet_pg_bot

Q11: A 32-year-old man presents to the emergency department after a fall from a height. He complains of severe pain in the heel and inability to bear weight on his foot. On physical examination, there is swelling and tenderness at the heel. Which bone is

most likely affected?. (Q848290)

A. Calcaneus

B. Talus

C. Navicular

D. Cuboid

See Answer in Part B → Q11

@Neet_pg_bot

Q12: A 35-year-old male marathon runner presents with complaints of foot pain after long-distance runs. On examination, the foot shows a well-formed arch, and palpation reveals tenderness along the medial aspect of the foot. An X-ray confirms a normal medial longitudinal arch structure. Which of the following statements incorrectly describes the function or anatomy of the medial longitudinal arch in this patient? (Q848291)

A. Provides better shock absorption.

B. The bony keystone is Talus

C. Has limited mobility

D. Main joint is Talocalcaneonavicular joint

See Answer in Part B → Q12

@Neet_pg_bot

Q13: A 35-year-old patient presents with difficulty in flexing the lateral four toes. On examination, it is noted that the action of the flexor digitorum longus tendon is intact. Which of the following muscles, in the second layer of the sole, assists the flexor digitorum longus during this action? (Q848293)

A. Abductor hallucis

B. Flexor digitorum brevis

C. Quadratus plantae

D. Lumbricals

See Answer in Part B → Q13

@Neet_pg_bot

Q14: A 35-year-old male presents with a deep laceration on the posterior aspect of his knee after a road traffic accident. On surgical exploration, the popliteal artery is injured. Which of the following is not a direct branch of the popliteal artery? (Q848297)

A. Superior medial genicular artery

B. Posterior tibial artery

C. Anterior tibial artery

D. Fibular artery

See Answer in Part B → Q14

@Neet_pg_bot

Q15: During a surgical procedure involving the reconstruction of the lower limb, the surgeon plans to use a perforator flap. Which of the following statements about perforating arteries is correct? (Q848302)

A. Perforating arteries are exclusively found in the thigh region.

B. Musculocutaneous perforators run along intermuscular septa before supplying the skin.

C. Perforating arteries can originate from major source arteries or adjacent vessels and are essential for flap surgery.

D. Septocutaneous perforators only supply the periosteum of bones.

See Answer in Part B → Q15

@Neet_pg_bot

• [06_Lower Limb] 032 Previous Year Questions

« Back to Folder Directory

[06_Lower Limb] 032 Previous Year Questions — Quick Jump

Q1 (p. 417)	*Q2 (p. 417)*	*Q3 (p. 418)*	*Q4 (p. 419)*	*Q5 (p. 419)*	*Q6 (p. 420)*
Q7 (p. 420)	*Q8 (p. 421)*	*Q9 (p. 422)*	*Q10 (p. 423)*	*Q11 (p. 424)*	*Q12 (p. 425)*
Q13 (p. 425)	*Q14 (p. 426)*	*Q15 (p. 427)*	*Q16 (p. 427)*	*Q17 (p. 428)*	*Q18 (p. 428)*
Q19 (p. 429)	*Q20 (p. 429)*	*Q21 (p. 430)*	*Q22 (p. 431)*	*Q23 (p. 431)*	*Q24 (p. 432)*
Q25 (p. 433)	*Q26 (p. 433)*	*Q27 (p. 434)*	*Q28 (p. 434)*	*Q29 (p. 435)*	*Q30 (p. 435)*
Q31 (p. 436)	*Q32 (p. 437)*	*Q33 (p. 437)*	*Q34 (p. 438)*	*Q35 (p. 439)*	*Q36 (p. 439)*

Q1: Which of the following branches of the anterior division of the internal iliac artery? 1. Superior gluteal artery 2. Inferior gluteal artery 3. Superior vesical artery 4. Middle rectal artery 5. Inferior vesical artery 6. Vaginal artery (Q855754)

A. 1,2,3,5

B. 2,3,4,6

C. 2,3,4,5,6

D. 1,4,5,6

See Answer in Part B → Q1

@Neet_pg_bot

Q2: A 34-year-old female, who works as a maid complained of knee pain and swelling. Which of the following area gets damaged in Housemaid’s knee? (Q857918)

A. A

B. B

C. C

D. D

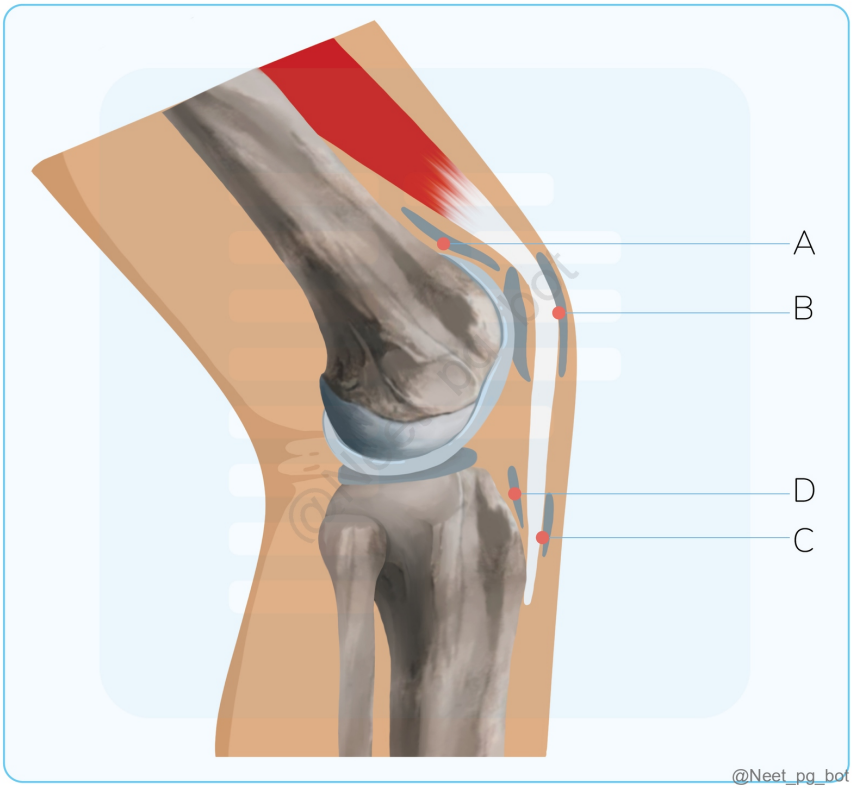

See Answer in Part B → Q2

@Neet_pg_bot

Q3: Which of the following arteries is palpated in the image shown below? (Q793152)

A. Anterior tibial artery

B. Posterior tibial artery

C. Dorsalis pedis artery

D. Popliteal artery



See Answer in Part B → Q3

@Neet_pg_bot

Q4: Which of the following structures is not supplied by the superior gluteal nerve? (Q855034)

A. Gluteus medius

B. Gluteus minimus

C. Piriformis

D. Tensor fasciae latae

See Answer in Part B → Q4

@Neet_pg_bot

Q5: What is the ligament that links the medial cuneiform bone to the base of the second metatarsal bone? (Q855036)

A. Chopart

B. Spring

C. Lisfranc

D. Deltoid

See Answer in Part B → Q5

@Neet_pg_bot

Q6: Identify the tarsal bone labeled in the image below. (Q857553)

A. Calcaneus

B. Cuboid

C. Navicular

D. Talus



See Answer in Part B → Q6

@Neet_pg_bot

Q7: The prevention of lateral dislocation of the patella during knee flexion is by- (Q857555)

A. Vastus medialis

B. Patellar ligament

C. Gracilis

D. Rectus femoris

See Answer in Part B → Q7

@Neet_pg_bot

Q8: The dermatome of the area marked in the given below image is- (Q857565)

A. L4

B. L5

C. S1

D. S2

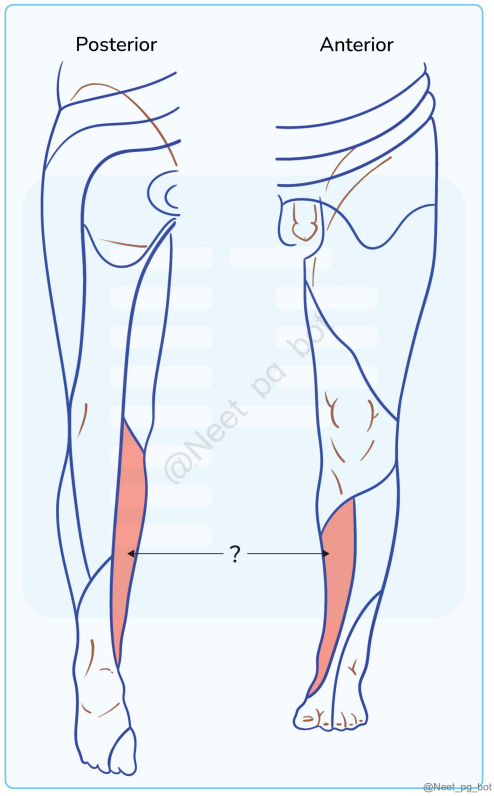

See Answer in Part B → Q8

@Neet_pg_bot

Q9: Which artery is being palpated in the image shown below? (Q857569)

A. Anterior tibial artery

B. Posterior tibial artery

C. Dorsalis pedis artery

D. Popliteal artery

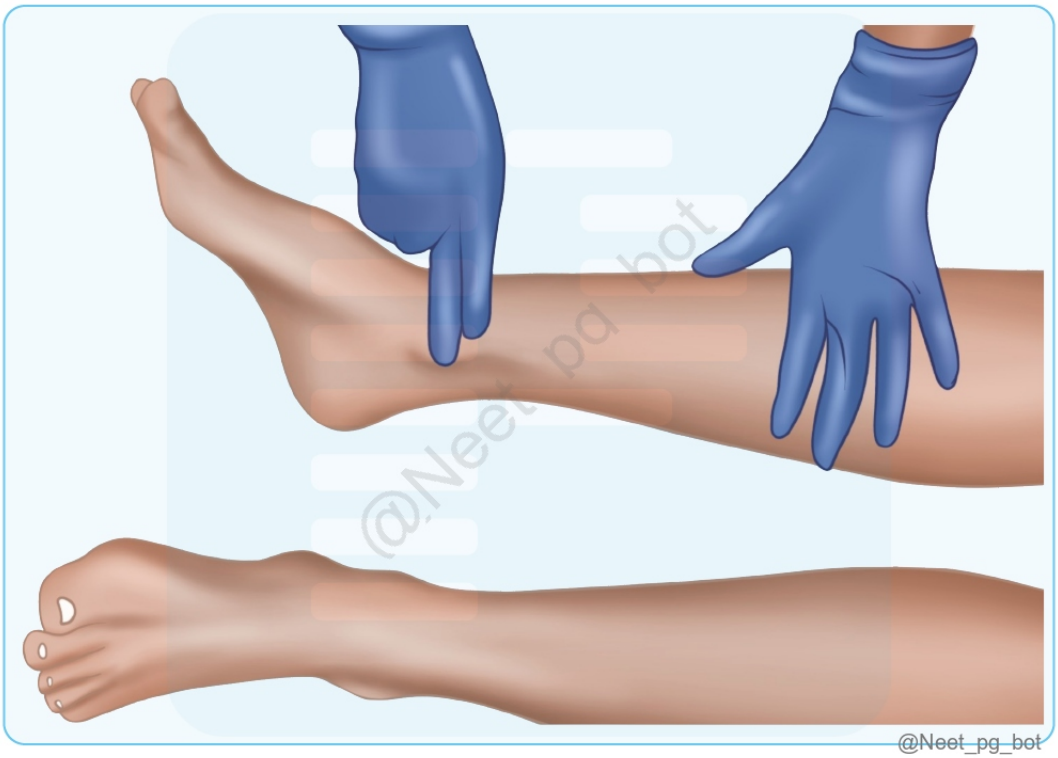

See Answer in Part B → Q9

@Neet_pg_bot

Q10: Injury at which of the following marked sites causes failure of dorsiflexion? (Q855307)

A. 3

B. 2

C. 1

D. 4

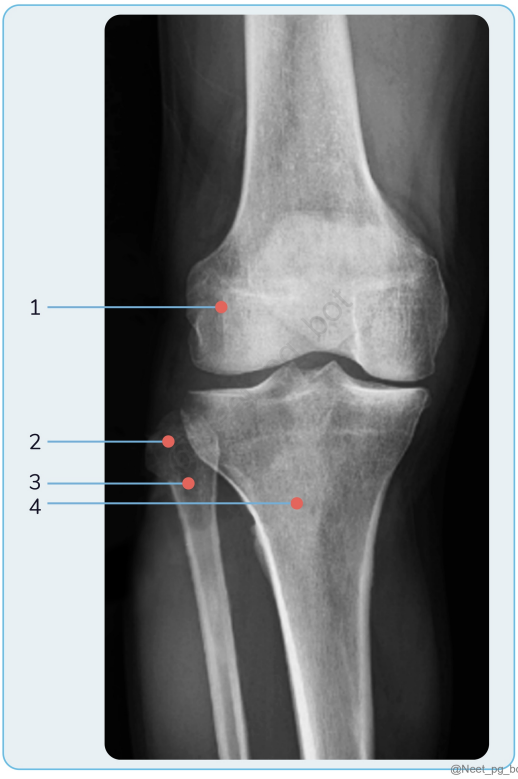

See Answer in Part B → Q10

@Neet_pg_bot

Q11: A boy with a history of a fall from a tree presents with a lurching gait and dragging of his feet. Which of the following structures are involved? (Q856616)

A. 1

B. 2

C. 3

D. 4



See Answer in Part B → Q11

@Neet_pg_bot

Q12: Which nerve is most likely to be affected in a patient who underwent a coronary bypass graft with the great saphenous vein and is now experiencing paresthesia and sensory loss over the inner side of the leg and foot? (Q856180)

A. Superficial peroneal nerve

B. Saphenous nerve

C. Femoral nerve

D. Sural nerve

See Answer in Part B → Q12

@Neet_pg_bot

Q13: A muscle is attached to the area marked in the given Image. What is the action of this muscle on the hip joint? (Q856367)

A. Flexion and medial rotation

B. Adduction and lateral rotation

C. Abduction and medial rotation

D. Extension and lateral rotation



See Answer in Part B → Q13

@Neet_pg_bot

Q14: The artery that is palpated between the medial malleolus and the calcaneal tendon is? (Q859515)

A. Anterior tibial artery

B. Posterior tibial artery

C. Dorsalis pedis artery

D. Popliteal artery

See Answer in Part B → Q14

@Neet_pg_bot

Q15: A patient has lost sensation over the dorsum of the foot and medial four toes. There is the associated difficulty of eversion of the foot. Which nerve injury is likely to be the reason for this? (Q859516)

A. Deep peroneal nerve

B. Superficial peroneal nerve

C. Common peroneal nerve

D. Posterior tibial nerve

See Answer in Part B → Q15

@Neet_pg_bot

Q16: Identify the labelled tarsal bone in the image below. (Q859520)

A. Calcaneus

B. Cuboid

C. Navicular

D. Talus



See Answer in Part B → Q16

@Neet_pg_bot

Q17: A patient underwent surgery for the varicose vein. He now complains of sensory loss over the medial aspect of the leg and foot. Which of the following nerves is most likely to be injured? (Q856063)

A. Sural nerve

B. Superficial peroneal nerve

C. Deep peroneal nerve

D. Saphenous nerve

See Answer in Part B → Q17

@Neet_pg_bot

Q18: Which of the following provides attachment to the muscle responsible for extension at the hip and the knee? (Q878935)

A. 1

B. 2

C. 3

D. 4

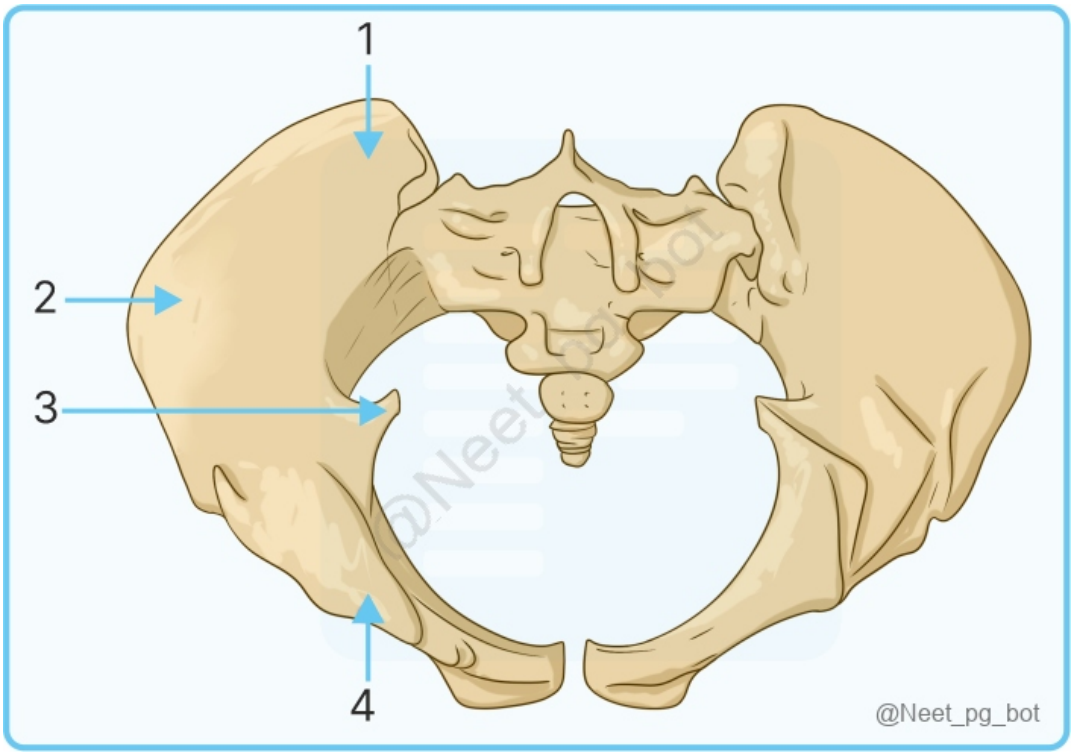

See Answer in Part B → Q18

@Neet_pg_bot

Q19: A patient diagnosed with sciatica had tender hamstrings. Which of the following supplies a hybrid muscle, which is spared in this patient? (Q844232)

A. Femoral nerve

B. Common peroneal nerve

C. Obturator nerve

D. Tibial nerve

See Answer in Part B → Q19

@Neet_pg_bot

Q20: In the given image which vein is mainly affected? (Q866633)

A. Great saphenous vein

B. Short saphenous vein

C. Femoral vein

D. Perforator veins



See Answer in Part B → Q20

@Neet_pg_bot

Q21: The artery that is palpated between the medial malleolus and the calcaneal tendon is? (Q866640)

A. Anterior tibial artery

B. Posterior tibial artery

C. Dorsalis pedis artery

D. Popliteal artery

See Answer in Part B → Q21

@Neet_pg_bot

Q22: Which of the following muscles is/are supplied by the superficial fibular (peroneal) nerve? (Q865266)

A. Peroneus longus &Peroneus brevis

B. Extensor digitorum longus

C. Tibialis anterior

D. None of the above

See Answer in Part B → Q22

@Neet_pg_bot

Q23: What is the primary action of this muscle attached to the area marked? (Q865282)

A. Abduction of the thigh

B. Flexion of the knee

C. Extension of the knee

D. Internal rotation of the thigh

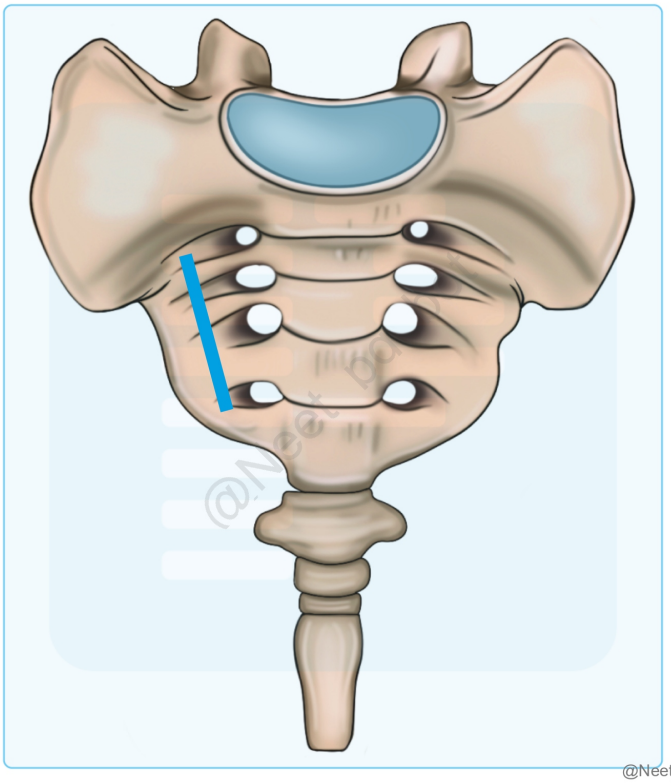

See Answer in Part B → Q23

@Neet_pg_bot

Q24: A patient presents with meralgia paraesthetica. Based on the diagram, identify the nerve involved in this condition. (Q866308)

A. A

B. B

C. C

D. D

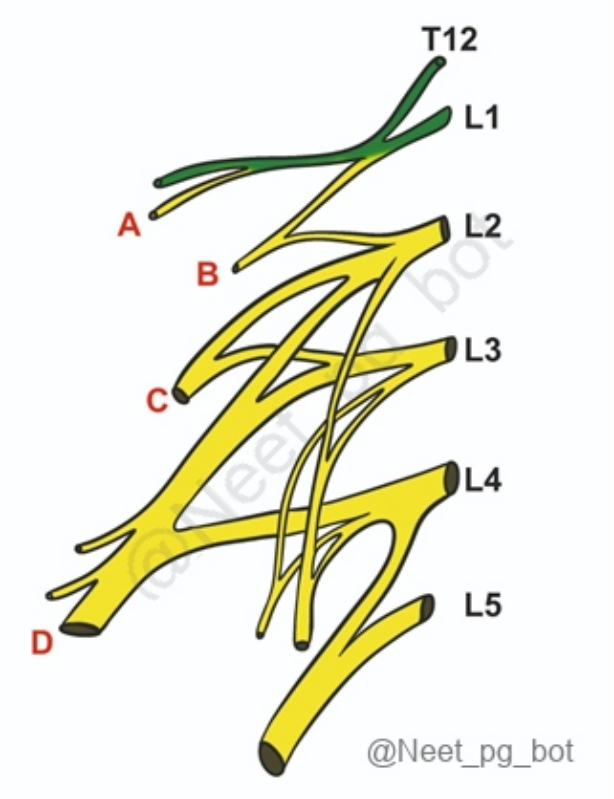

See Answer in Part B → Q24

@Neet_pg_bot

Q25: A patients presents with ankle pain and swelling after a forceful eversion injury. Based on the mechanism of injury, which ligament is most likely to be damaged? (Q866309)

A. Anterior talofibular ligament

B. Calcaneofibular ligament

C. Deltoid ligament

D. Posterior talofibular ligament

See Answer in Part B → Q25

@Neet_pg_bot

Q26: Behind the medial malleolus and in front of Achilles which artery is present? (Q844160)

A. Posterior tibial artery

B. Peroneal artery

C. Anterior tibial artery

D. Dorsalis pedis artery

See Answer in Part B → Q26

@Neet_pg_bot

Q27: Patient presenting with pain in back of thigh and leg after lifting heavy weights. Which segment is involved? (Q844229)

A. L4

B. L5

C. S1

D. S2

See Answer in Part B → Q27

@Neet_pg_bot

Q28: A man sustained trauma on the lateral side of his right knee. Two days later, he complains of difficulty in walking, as his toes keep dragging on the ground. He also notices numbness over the upper lateral aspect of the leg and dorsum of the foot. Which nerve is most likely injured? (Q866627)

A. Tibial nerve

B. Common peroneal nerve

C. Deep peroneal nerve

D. Femoral nerve

See Answer in Part B → Q28

@Neet_pg_bot

Q29: The muscle attached to the marked bony structure is? (Q860617)

A. Ilio-psoas

B. Gluteus maximus

C. Gluteus medius

D. Sartorius



See Answer in Part B → Q29

@Neet_pg_bot

Q30: Muscle inserted on lesser trochanter? (Q860625)

A. Psoas major muscle

B. Psoas minor

C. Obturator internus

D. Piriformis

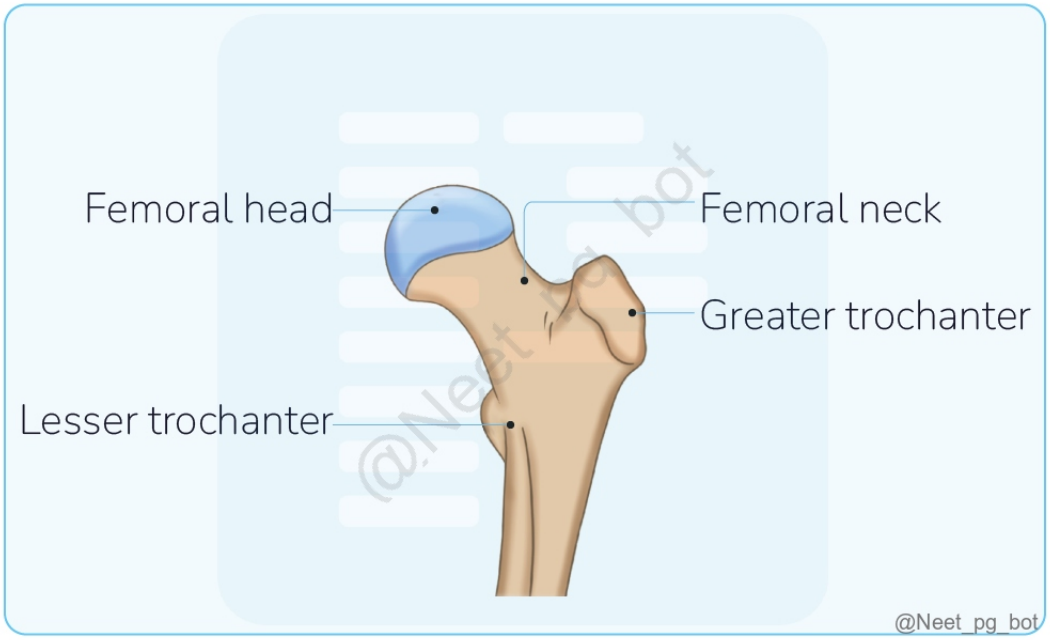

See Answer in Part B → Q30

@Neet_pg_bot

Q31: Identify the muscle that is defective in the given image. (Q860261)

A. Gluteus medius and Gluteus minimus

B. Gluteus maximus

C. Piriformis

D. Obturator internus

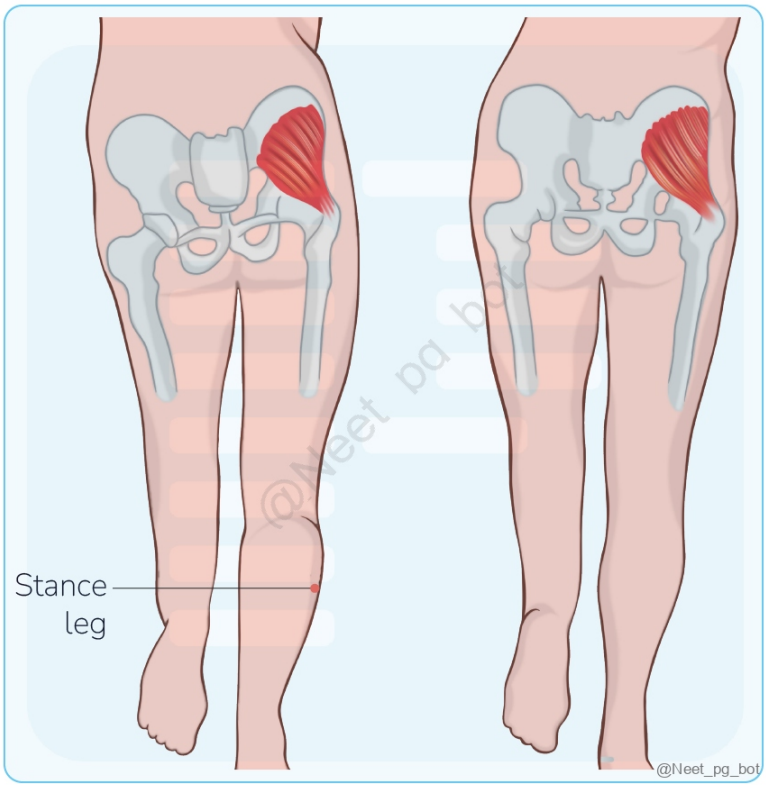

See Answer in Part B → Q31

@Neet_pg_bot

Q32: A surgical procedure is performed on the great saphenous vein, around 2.5 cm anterior to the medial malleolus. Which of the following structures is most likely to be injured? (Q860269)

A. Saphenous nerve

B. Sural nerve

C. Deep peroneal nerve

D. Tibial nerve

See Answer in Part B → Q32

@Neet_pg_bot

Q33: In the given image, the physician is trying to palpate which of the following arteries? (Q860275)

A. Anterior tibial artery

B. Posterior tibial artery

C. Dorsalis pedis artery

D. Lateral plantar artery



See Answer in Part B → Q33

@Neet_pg_bot

Q34: A 34-year-old female, who works as a maid complained of knee pain and swelling. Which of the following area gets damaged in Housemaid's knee? (Q820318)

A. A

B. B

C. C

D. D

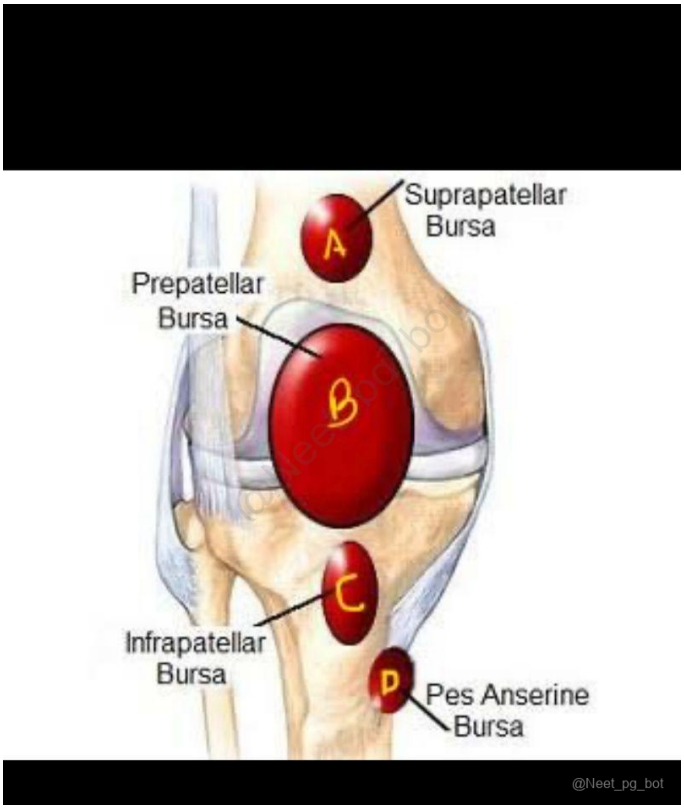

See Answer in Part B → Q34

@Neet_pg_bot

Q35: Which nerve supplies the Gluteus maximus? (Q854569)

A. Femoral nerve

B. Inferior gluteal nerve

C. Obturator nerve

D. Superior gluteal nerve

See Answer in Part B → Q35

@Neet_pg_bot

Q36: Lateral plantar nerve supplies which of the following muscles? (Q854581)

A. Flexor digitorum brevis, Abductor hallucis, Flexor hallucis brevis

B. Flexor digitorum brevis, Abductor hallucis, Extensor digitorum brevis

C. Flexor digiti minimi brevis, Extensor digitorum brevis, Abductor digiti minimi

D. Flexor digiti minimi brevis, Abductor digiti minimi, Adductor hallucis

See Answer in Part B → Q36

@Neet_pg_bot

• [07_Thorax] 033 Development Of The Cardiovascular System And Fetal Circulation

« Back to Folder Directory

[07_Thorax] 033 Development Of The Cardiovascular System And Fetal Circulation — Quick Jump

Q1 (p. 441)	*Q2 (p. 441)*	*Q3 (p. 442)*	*Q4 (p. 442)*	*Q5 (p. 442)*	*Q6 (p. 443)*
Q7 (p. 443)	*Q8 (p. 444)*	*Q9 (p. 444)*	*Q10 (p. 445)*	*Q11 (p. 445)*	*Q12 (p. 445)*

Q1: Which of the following statements about the embryonic development of the heart is incorrect? (Q848244)

A. Heart tube is derived from the splanchnopleuric mesoderm.

B. Truncus arteriosus forms the ascending aorta and pulmonary trunk.

C. Bulbus cordis is located at the caudal end of the developing heart tube.

D. Disappearance of the dorsal mesocardium creates the transverse sinus.

See Answer in Part B → Q1

@Neet_pg_bot

Q2: A newborn baby is found to have bluish discoloration of lips, tongue, and nails with poor feeding and signs of congestive heart failure. She is diagnosed with patent truncus arteriosus. What developmental error leads to this condition? (Q848245)

A. Overriding aorta and pulmonary stenosis

B. Switching of the aorta and pulmonary artery position.

C. Incomplete closure of interventricular septum

D. Complete absence of the spiral septum

See Answer in Part B → Q2

@Neet_pg_bot

Q3: An infant's echocardiogram reveals an enlarged coronary sinus. This finding most likely results from an abnormality in which embryological structure? (Q848246)

A. Right horn of the sinus venosus

B. Left horn of the sinus venosus

C. Right common cardinal vein

D. Right vitelline vein

See Answer in Part B → Q3

@Neet_pg_bot

Q4: Which of the following statements about cardiac jelly is incorrect? (Q848247)

A. Provide structural support during early heart development

B. Facilitates end-systolic occlusion, improving pumping efficiency

C. Store elastic energy during systole for the refilling phase of the heart.

D. Cellular matrix secreted by the endocardium in the developing heart.

See Answer in Part B → Q4

@Neet_pg_bot

Q5: In the image depicting fetal heart development, which structures are labelled as A and B, respectively? (Q848248)

A. A: Ostium primum, B: Ostium secundum

B. A: Foramen ovale, B: Ostium primum

C. A: Septum primum, B: Septum secundum

D. A: Septum secundum, B: Septum primum

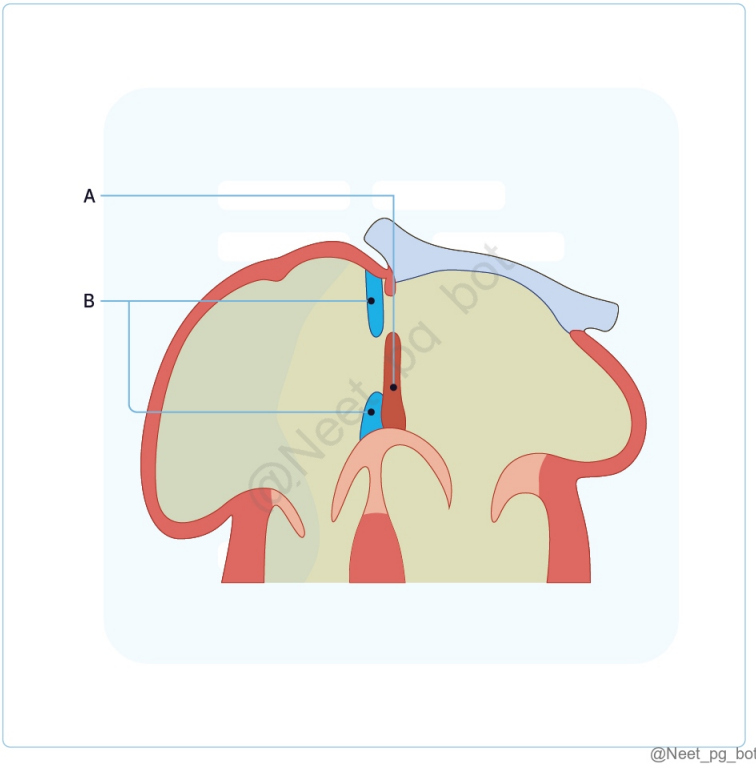

See Answer in Part B → Q5

@Neet_pg_bot

Q6: A 5-year-old patient is diagnosed with an atrial septal defect (ASD) characterized by a large opening between the left and right atria. Which embryological defect is most commonly associated with this significant type of ASD? (Q848249)

A. Ostium primum defect

B. Ostium secundum defect

C. Sinus venosus defect

D. Coronary Sinus Defect

See Answer in Part B → Q6

@Neet_pg_bot

Q7: During an echocardiogram, a raised ridge is observed around a depression on the interatrial septum. Which structure is most likely involved? (Q848250)

A. Septum primum

B. Septum secundum

C. Fossa ovalis

D. Limbus fossa ovalis

See Answer in Part B → Q7

@Neet_pg_bot

Q8: During the spiraling process of the septum, what anatomical change occurs in relation to the pulmonary trunk and aorta? (Q848251)

A. The pulmonary trunk moves posteriorly.

B. The aorta moves to the right side of the body.

C. The pulmonary trunk crosses anteriorly and to the left of the aorta.

D. There is no change in the position of either vessel.

See Answer in Part B → Q8

@Neet_pg_bot

Q9: A newborn presents with significant cyanosis and a single large vessel exiting the heart on imaging studies. The echocardiogram shows a defect in the interventricular septum.What embryological failure led to this condition? (Q848254)

A. Failure of the atrioventricular septum to form.

B. Failure of the conotruncal ridges to form.

C. Failure of the aorticopulmonary septum to spiral.

D. Anterior displacement of the septum.

See Answer in Part B → Q9

@Neet_pg_bot

Q10: Which of the following statements about the development of the interventricular septum is incorrect? (Q848255)

A. Muscular part grows from the floor of the bulboventricular cavity

B. Bulbar part forms from the fusion of two bulbar ridges.

C. Posterior part of the membranous septum separates the right ventricle from the left atrium.

D. Interventricular foramen forms above the muscular septum.

See Answer in Part B → Q10

@Neet_pg_bot

Q11: In fetal circulation, which structure allows oxygenated blood to bypass the lungs and directly enter the systemic circulation, ensuring oxygen delivery to the fetal brain and upper body? (Q848256)

A. Ductus venosus

B. Ductus arteriosus

C. Foramen ovale

D. Umbilical vein

See Answer in Part B → Q11

@Neet_pg_bot

Q12: A 3-day-old neonate presents with cyanosis, rapid breathing, and a machinery-like murmur on auscultation. Echocardiography reveals a left-to-right shunt at the level of the great vessels. Which of the following fetal circulatory changes is most likely responsible for this presentation? (Q848257)

A. Persistent foramen ovale

B. Patent ductus arteriosus

C. Closure of ductus venosus

D. Malrotation of the great arteries

See Answer in Part B → Q12

@Neet_pg_bot

• [07_Thorax] 034 Heart And Thorax Anatomy - I

« Back to Folder Directory

[07_Thorax] 034 Heart And Thorax Anatomy - I — Quick Jump

Q1 (p. 447)	*Q2 (p. 448)*	*Q3 (p. 448)*	*Q4 (p. 448)*	*Q5 (p. 449)*	*Q6 (p. 450)*
Q7 (p. 450)	*Q8 (p. 451)*	*Q9 (p. 452)*	*Q10 (p. 452)*	*Q11 (p. 453)*	*Q12 (p. 453)*
Q13 (p. 453)	*Q14 (p. 454)*	*Q15 (p. 454)*	*Q16 (p. 455)*	*Q17 (p. 456)*	*Q18 (p. 456)*
Q19 (p. 456)	*Q20 (p. 457)*	*Q21 (p. 457)*	*Q22 (p. 457)*	*Q23 (p. 458)*	*Q24 (p. 458)*
Q25 (p. 459)	*Q26 (p. 459)*	*Q27 (p. 460)*	*Q28 (p. 460)*	*Q29 (p. 461)*	*Q30 (p. 461)*

Q1: In the given CT slice, A and B respectively represent? {{caption_text}} (Q848347)

A. Main bronchus, Ascending Aorta

B. Main bronchus, Descending Aorta

C. Ascending Aorta, Descending Aorta

D. Descending Aorta, Ascending Aorta

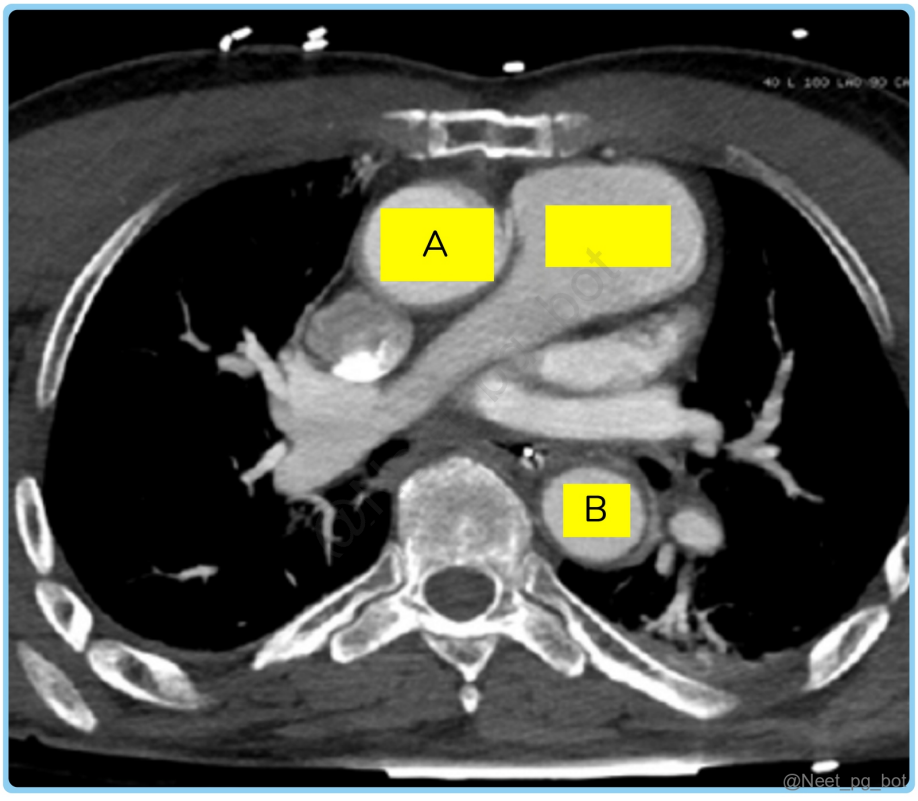

See Answer in Part B → Q1

@Neet_pg_bot

Q2: The pleural cupola is located: (Q848361)

A. Above the diaphragm, covering the lower lung

B. Over the apex of the lung, reaching 2 to 3 cm above the clavicle

C. Near the midline of the chest at the level of the heart

D. At the base of the lungs, covered by the suprapleural membrane

See Answer in Part B → Q2

@Neet_pg_bot

Q3: Where is pain from the mediastinal pleura typically referred? (Q848360)

A. In the lower abdomen

B. Over the ipsilateral shoulder

C. In the lumbar region

D. In the lower back near the kidneys

See Answer in Part B → Q3

@Neet_pg_bot

Q4: Which of the following statements is correct regarding the cardiac plexuses? (Q848359)

A. The superficial cardiac plexus is located behind the arch of the aorta, in front of the bifurcation of the trachea.

B. The deep cardiac plexus receives cardiac branches from the vagus and recurrent laryngeal nerves, except the inferior cervical cardiac branch of the left vagus nerve.

C. The superficial cardiac plexus distributes to the left coronary artery and right anterior pulmonary plexus.

D. The deep cardiac plexus is formed only by the superior cervical cardiac branch of the left sympathetic chain.

See Answer in Part B → Q4

@Neet_pg_bot

Q5: An axial CT scan of the thorax shows a slice where the aortic arch is visible, along with the trachea bifurcating into the main bronchi. At which anatomical level is this axial section most likely taken? {{caption_text}} (Q848358)

A. T1-T2

B. T4-T5

C. T5-T6

D. T7-T8

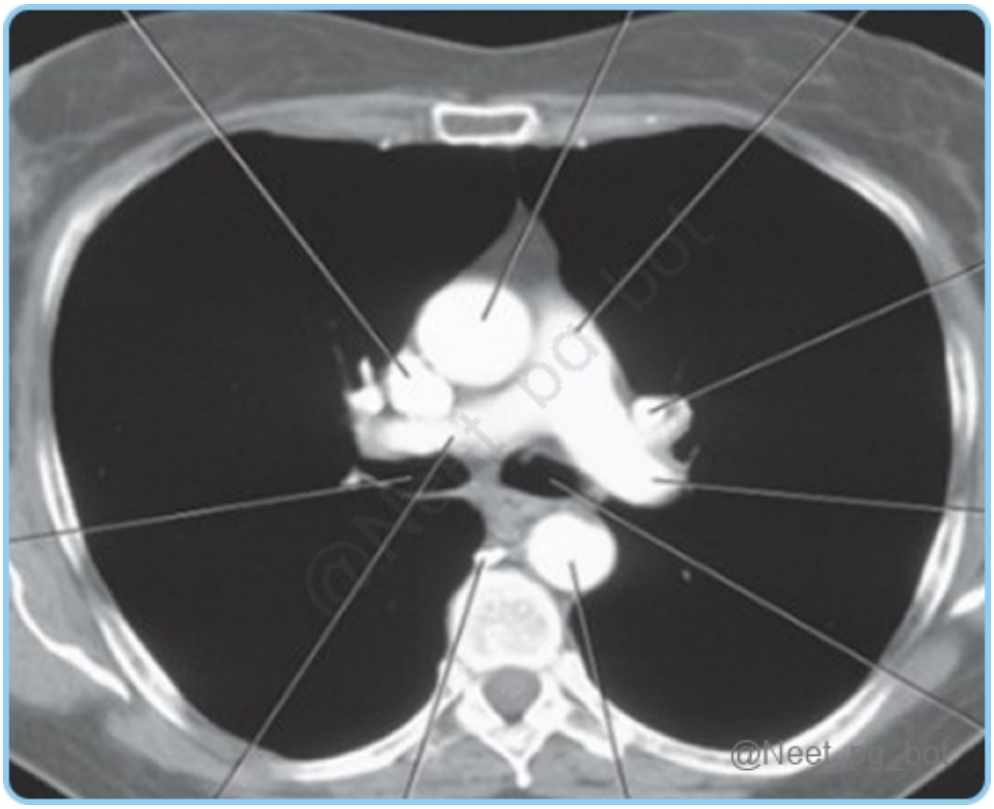

See Answer in Part B → Q5

@Neet_pg_bot

Q6: Which of the following structures is commonly associated with a notable impression on the left lung? (Q848357)

A. Aorta

B. Superior vena cava

C. Oesophagus

D. Azygos vein

See Answer in Part B → Q6

@Neet_pg_bot

Q7: A 60-year-old patient presents with a history of progressive shortness of breath and swelling in the neck. Imaging reveals distended chest wall veins and a mediastinal mass with known metastasis. Which of the following is the most likely cause of these findings? {{caption_text}} (Q848356)

A. Right heart failure

B. Superior vena cava (SVC) obstruction

C. Pulmonary embolism

D. Thoracic aortic aneurysm



See Answer in Part B → Q7

@Neet_pg_bot

Q8: A 56-year-old male patient with a history of gastric carcinoma now presents with sharp or pleuritic pain that worsens with deep breaths or coughing. Pleural effusion is suspected and a pleural tap was done which showed the fluid shown in the image. Based on the knowledge of the course of thoracic duct, where does the thoracic duct drain lymph? {{caption_text}} (Q848355)

A. Into the right brachiocephalic vein

B. Into the junction of the left subclavian vein and left internal jugular vein

C. Directly into the inferior vena cava

D. Into the right lymphatic duct



See Answer in Part B → Q8

@Neet_pg_bot

Q9: Which part of the body is not drained by the right lymphatic duct? (Q848354)

A. Right side of the head and neck

B. Right upper limb

C. Right side of the thorax

D. Right abdomen

See Answer in Part B → Q9

@Neet_pg_bot

Q10: Which of the following statements is true regarding the azygos and hemiazygos veins? (Q848353)

A. The azygos vein drains directly into the inferior vena cava.

B. The inferior hemiazygos vein drains into the superior vena cava.

C. The superior hemiazygos vein drains into the azygos vein.

D. In an obstruction of the SVC, the superior hemiazygos vein acts as the primary collateral pathway.

See Answer in Part B → Q10

@Neet_pg_bot

Q11: Which of the following statements about the phrenic nerve is false? (Q848352)

A. The phrenic nerve contains both motor and sensory fibers.

B. Efferent fibers of the phrenic nerve supply the diaphragm muscle.

C. Afferent fibers transmit sensory information from the liver capsule.

D. Paralysis of the phrenic nerve can result from pressure from malignant tumors in the mediastinum.

See Answer in Part B → Q11

@Neet_pg_bot

Q12: Which of the following statements accurately describes a difference between the right and left phrenic nerves? (Q848351)

A. The left phrenic nerve is shorter than the right

B. The right phrenic nerve passes anterior to the aortic arch

C. The left phrenic nerve passes through the caval foramen of the diaphragm

D. The right phrenic nerve has a more vertical course in the thorax

See Answer in Part B → Q12

@Neet_pg_bot

Q13: Regarding intercostal nerve blocks, which of the following statements is incorrect? (Q848350)

A. The intercostal neurovascular bundle is arranged inferior to superior as vein, artery, nerve

B. The lateral cutaneous branch of the intercostal nerve arises anterior to the midaxillary line

C. The innermost intercostal muscle separates the intercostal nerve from the pleura

D. The angle of the rib, approximately 6 to 8 cm from the midline, is used as a landmark for needle insertion

See Answer in Part B → Q13

@Neet_pg_bot

Q14: During a pleural tap procedure, which of the following structures is encountered immediately before reaching the parietal pleura? (Q848349)

A. Internal intercostal muscle

B. Endothoracic fascia

C. Serratus anterior muscle

D. Innermost intercostal muscle

See Answer in Part B → Q14

@Neet_pg_bot

Q15: A 65-year-old man with a history of congestive heart failure presents with increasing dyspnea. Chest X-ray is given below. The physician decides to perform a thoracentesis. Which of the following anatomical landmarks is most important to be identified, to prevent damage to important structures at its level? {{caption_text}} (Q848348)

A. Midclavicular line

B. Anterior axillary line

C. Midscapular line

D. Inferior border of the rib

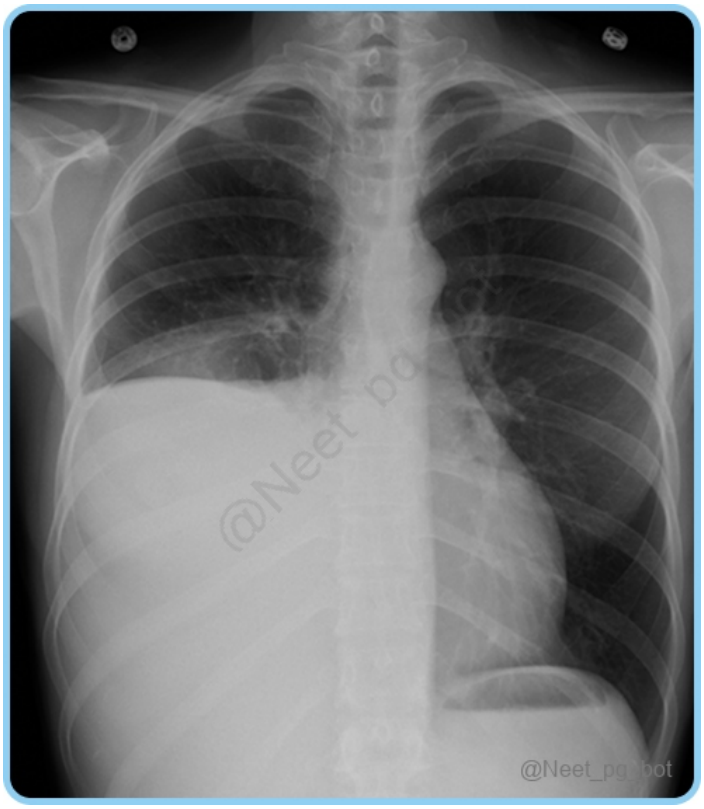

See Answer in Part B → Q15

@Neet_pg_bot

Q16: Which of the following structures does not make up the anterior surface (sternocostal) of the heart? (Q848260)

A. Left atrium

B. Right ventricle

C. Left ventricle

D. Left auricle

See Answer in Part B → Q16

@Neet_pg_bot

Q17: A 65-year-old male presents with shortness of breath and chest pain. On examination, he has a prominent sternal angle. A CT scan reveals an enlarged mediastinal lymph node at the level of the tracheal bifurcation. Which of the following anatomical structures is most likely to be found at the same level as the bifurcation of the trachea? (Q848346)

A. Left atrium of the heart

B. Junction of the azygos vein and superior vena cava

C. Origin of the thoracic duct

D. Superior border of the aortic arch

See Answer in Part B → Q17

@Neet_pg_bot

Q18: All the following are contents of the posterior mediastinum except: (Q848345)

A. Descending thoracic aorta

B. Esophagus

C. Azygos and hemiazygos veins

D. Pulmonary trunk

See Answer in Part B → Q18

@Neet_pg_bot

Q19: A 55-year-old man presents with exertional chest pain radiating to his left arm. Coronary angiography reveals a significant blockage in the right coronary artery (RCA). Which of the following regions of the heart is most likely at risk of ischemia? (Q848344)

A. Anterior two-thirds of the interventricular septum

B. Lateral wall of the left ventricle

C. Posterior one-third of the interventricular septum

D. Apex of the heart

See Answer in Part B → Q19

@Neet_pg_bot

Q20: A 50-year-old male presents with inferior wall MI. Angiography shows occlusion in the artery supplying the SA node. Which of the following arteries is most likely affected? (Q848343)

A. Right coronary artery

B. Left coronary artery

C. Circumflex artery

D. Posterior interventricular artery

See Answer in Part B → Q20

@Neet_pg_bot

Q21: A transverse section through the heart at the level of the ventricles reveals several anatomical structures. Which of the following structures is most likely to be observed in this section? (Q848342)

A. Left atrial appendage

B. Papillary muscles

C. Aortic arch

D. Superior vena cava

See Answer in Part B → Q21

@Neet_pg_bot

Q22: A 45-year-old male patient is undergoing coronary angiography for chest pain evaluation. The angiogram reveals a dominant left coronary system, with the left coronary artery supplying the majority of the heart's posterior structures. Based on this finding, which of the following statements about cardiac dominance is most accurate? (Q848341)

A. In a left-dominant coronary system, RCA gives off the posterior descending artery (PDA) and the PDA supplies the right atrium.

B. In a right-dominant coronary system, the LCA gives off the PDA and the PDA supplies the left atrium.

C. In a left-dominant coronary system, the PDA is supplied by the left anterior descending artery, which arises from the left circumflex artery.

D. In a right-dominant coronary system, the RCA supplies the PDA, which in turn supplies the majority of the interventricular septum.

See Answer in Part B → Q22

@Neet_pg_bot

Q23: Match the following coronary arteries with the areas of the heart they predominantly supply: Coronary Arteries Supplied Areas 1) Right conus artery a) Anterior 2/3 of interventricular septum 2) Left anterior descending artery (LAD) b) Infundibulum of right ventricle 3) Left circumflex artery (LCX) c) Posterior interventricular septum 4) Posterior descending artery (PDA) d) Lateral wall of the left ventricle e) Apex of the heart (Q848340)

A. 1- c, 2- a, 3- d, 4- b

B. 1- b, 2- e, 3 - a, 4- d

C. 1- b, 2- a, 3- d, 4- c

D. 1-d, 2- e, 3- b, 4- a

See Answer in Part B → Q23

@Neet_pg_bot

Q24: A 45-year-old man is undergoing evaluation for palpitations. ECG reveals a supraventricular tachycardia with HR of 190/min. An echocardiogram reveals hypertrophy of the right ventricle and enlargement of the right ventricular outflow tract. Which structure separates the inflow and outflow tracts in the right ventricle? (Q848287)

A. Crista terminalis

B. Supraventricular crest

C. Moderator band

D. Interventricular septum

See Answer in Part B → Q24

@Neet_pg_bot

Q25: A 36-year-old woman presents with sudden-onset palpitations and lightheadedness. Her ECG shows a regular narrow complex tachycardia at 170 bpm. Vagal maneuvers temporarily relieve her symptoms. Atrioventricular Nodal Reentrant Tachycardia (AVNRT) is suspected. The reentrant circuit in AVNRT is most likely located in which anatomical region? (Q848286)

A. Crista terminalis

B. His bundle

C. Koch’s triangle

D. Right atrial appendage

See Answer in Part B → Q25

@Neet_pg_bot

Q26: A 45-year-old patient presents with recurrent episodes of supraventricular tachycardia. The electrophysiologist plans to perform catheter ablation. Which of the following structures is most likely to be found at the apex of Koch's triangle? (Q848285)

A. Sinoatrial node

B. Atrioventricular node

C. Bundle of His

D. Right bundle branch

See Answer in Part B → Q26

@Neet_pg_bot

Q27: A 32-year-old man undergoes a coronary angiography after presenting with chest pain. The cardiologist is explaining the venous drainage of the heart as observed in the angiographic images. Which of the following structures is primarily visible on the posterior view of the heart? (Q848284)

A. Great cardiac vein

B. Small cardiac vein

C. Coronary sinus

D. Anterior cardiac veins

See Answer in Part B → Q27

@Neet_pg_bot

Q28: Which of the following veins does not drain into the coronary sinus but rather drains directly into the right atrium? (Q848283)

A. Great Cardiac Vein

B. Middle Cardiac Vein

C. Anterior Cardiac Veins

D. Small Cardiac Vein

See Answer in Part B → Q28

@Neet_pg_bot

Q29: In a chest X-ray given below, the inferior border of the heart is primarily contributed by which structure? {{caption_text}} (Q848282)

A. Right Atrium

B. Superior Vena Cava

C. Left Ventricle

D. Right Ventricle

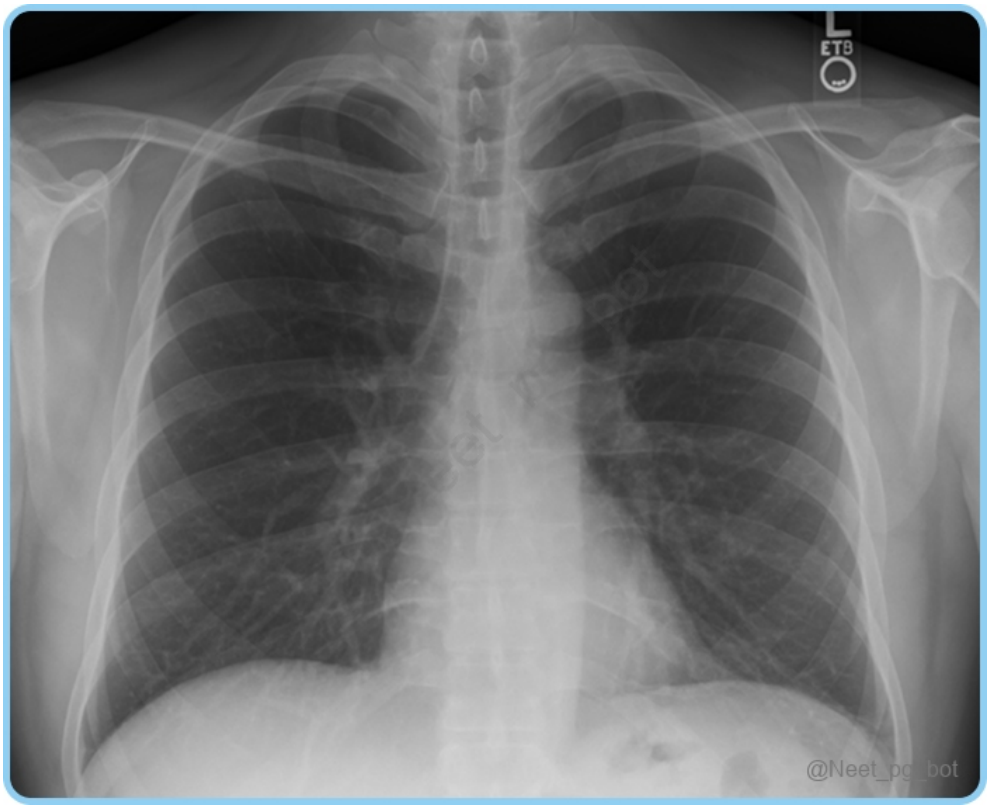

See Answer in Part B → Q29

@Neet_pg_bot

Q30: Which sulcus contains major coronary arteries? (Q848261)

A. Sulcus of Waterston

B. Atrioventricular Sulcus

C. Anterior Interventricular Sulcus

D. Inferior Interventricular Sulcus

See Answer in Part B → Q30

@Neet_pg_bot

• [07_Thorax] 035 Thorax Lungs Joints Respiratory Movements

« Back to Folder Directory

[07_Thorax] 035 Thorax Lungs Joints Respiratory Movements — Quick Jump

Q1 (p. 463)	*Q2 (p. 463)*	*Q3 (p. 463)*	*Q4 (p. 464)*	*Q5 (p. 464)*	*Q6 (p. 465)*
Q7 (p. 466)	*Q8 (p. 466)*	*Q9 (p. 466)*	*Q10 (p. 467)*	*Q11 (p. 467)*	*Q12 (p. 468)*
Q13 (p. 468)	*Q14 (p. 469)*	*Q15 (p. 469)*	*Q16 (p. 470)*	*Q17 (p. 470)*	*Q18 (p. 470)*
Q19 (p. 471)	*Q20 (p. 471)*				

Q1: The costal cartilages of which ribs attach directly to the sternum? (Q848374)

A. 1–7

B. 8-12

C. 11 and 12

D. 8-10

See Answer in Part B → Q1

@Neet_pg_bot

Q2: Ductus venosus is an embryologic shunt that connects which of the following structures? (Q882121)

A. Pulmonary trunk and descending aorta

B. Right atrium and left atrium

C. Umbilical vein and IVC

D. Pulmonary trunk and ascending aorta

See Answer in Part B → Q2

@Neet_pg_bot

Q3: A 36-year-old male presents with sharp, stabbing pain in the right upper abdomen for 2 weeks. The pain is aggravated by deep breathing and movement, especially when bending or twisting. There is tenderness over the right costal margin, but no signs of gastrointestinal distress, fever, or abdominal distension. His medical history is unremarkable. What is the most likely diagnosis? (Q848382)

A. Acute cholecystitis

B. Subcostal neuralgia

C. Appendicitis

D. Peptic ulcer disease

See Answer in Part B → Q3

@Neet_pg_bot

Q4: A 48-year-old woman presents to the clinic complaining of a burning, aching sensation on the inner side of her left upper arm. She mentions that about two weeks ago she underwent mastectomy with axillary clearance. She describes the pain as localized along the inner part of the upper arm, extending from the axilla (armpit) to the medial elbow. The pain seems to worsen when she raises her arm. On physical examination, there is tenderness over the left axillary region and the medial upper arm, but no signs of swelling or lymphadenopathy. Based on the patient's history of breast surgery and the clinical presentation, which of the following is the most likely diagnosis? (Q848381)

A. Radial nerve injury

B. Cervical radiculopathy (C7)

C. Intercostobrachial nerve injury

D. Thoracic outlet syndrome

See Answer in Part B → Q4

@Neet_pg_bot

Q5: Identify the structure marked as X in the image. {{caption_text}} (Q848380)

A. Subclavian vein

B. Subclavian artery

C. Median nerve

D. Ulnar nerve



See Answer in Part B → Q5

@Neet_pg_bot

Q6: Which of the following structures is the mediastinal surface of the right lung not related to? (Q848379)

A. Right atrium

B. Azygos vein

C. Thoracic aorta

D. Esophagus

See Answer in Part B → Q6

@Neet_pg_bot

Q7: In a healthy individual at rest, which of the following is a primary muscle involved in expiration? (Q848378)

A. Diaphragm

B. External intercostal muscles

C. Scalene muscles

D. None of the above

See Answer in Part B → Q7

@Neet_pg_bot

Q8: Which of the following muscles plays the primary role in quiet inspiration? (Q848377)

A. Anterior abdominal wall muscles

B. External intercostal muscles

C. Scalene muscles

D. Sternocleidomastoid muscle

See Answer in Part B → Q8

@Neet_pg_bot

Q9: Which rib movements are responsible for increasing the anteroposterior diameter of the thoracic cavity during inspiration? (Q848376)

A. Pump-handle movement of ribs 1-6

B. Bucket-handle movement of ribs 7-10

C. Bucket-handle movement of ribs 1-6

D. Pump-handle movement of ribs 7-10

See Answer in Part B → Q9

@Neet_pg_bot

Q10: The 2nd to 7th sternocostal joints are categorized as which type of joint? (Q848375)

A. Synovial

B. Symphysis

C. Synarthrosis

D. Synchondrosis

See Answer in Part B → Q10

@Neet_pg_bot

Q11: Identify the correct labels. (Q848362)

A. A. Left main bronchus, B. Descending aorta, C. T5 vertebrae, D.Esophagus, H.Ascending aorta

B. A. Left main bronchus, B. Ascending aorta, C. T5 vertebrae, D. Esophagus, H. Descending aorta

C. A. Right main bronchus, B. Descending aorta, C. T5 vertebrae, D. Ascending aorta, H. Pulmonary artery

D. A. Right main bronchus, B. Descending aorta, C. T5 vertebrae, D. Esophagus, H. Ascending aorta

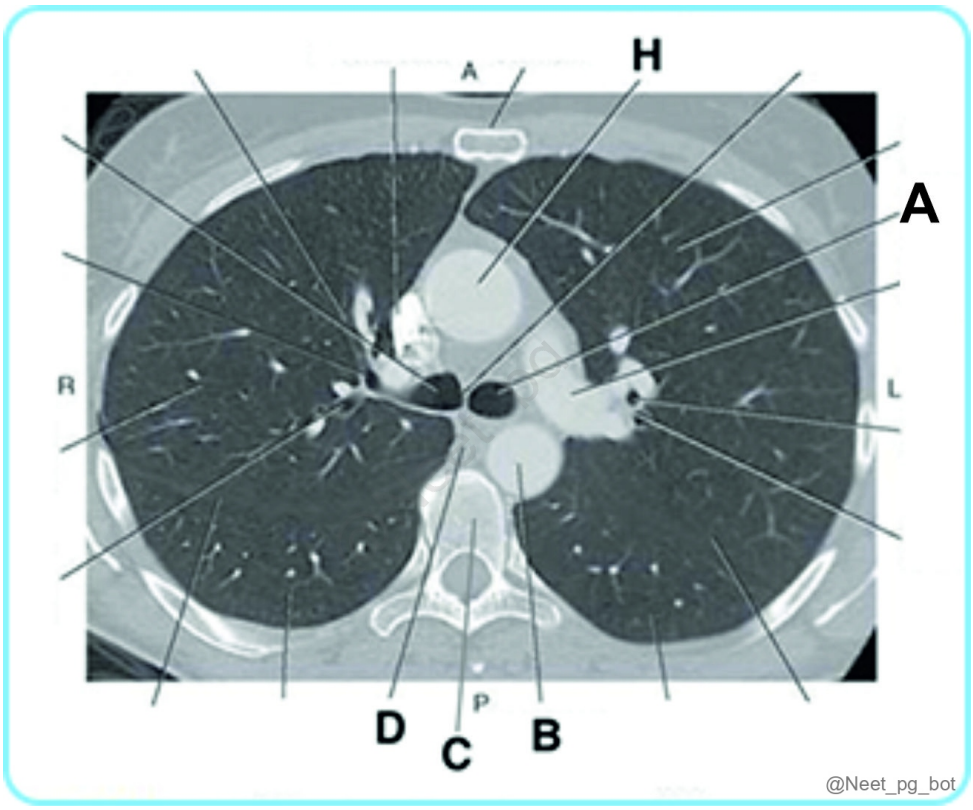

See Answer in Part B → Q11

@Neet_pg_bot

Q12: At the midaxillary line, the inferior border of the right lung typically corresponds to which rib level? (Q848373)

A. 4th

B. 6th

C. 8th

D. 10th

See Answer in Part B → Q12

@Neet_pg_bot

Q13: The pleura extends inferiorly to which rib at the midclavicular line in a normal adult? (Q848372)

A. 6th rib

B. 8th rib

C. 10th rib

D. 12th rib

See Answer in Part B → Q13

@Neet_pg_bot

Q14: A 40-year-old patient with known dextrocardia comes for a routine checkup. Where would you expect to hear the loudest apex beat on physical examination? (Q848371)

A. Left 4th intercostal space

B. Right 5th intercostal space

C. Midline of the sternum

D. Right 3rd intercostal space

See Answer in Part B → Q14

@Neet_pg_bot

Q15: During bronchoscopy, the carina is an important landmark that separates the openings of the right and left main bronchi. Which of the following statements about the tracheal bifurcation is true? (Q848370)

A. The left main bronchus is shorter and more vertical than the right

B. The right main bronchus is wider and more horizontal than the left

C. The left main bronchus is longer and more horizontal than the right

D. The right main bronchus is narrower and more vertical than the left

See Answer in Part B → Q15

@Neet_pg_bot

Q16: Which segment of the left lung is located in the inferior lobe? (Q848369)

A. S5: Inferior Lingular

B. S3: Anterior

C. S10: Posterior Basal

D. S2: Posterior

See Answer in Part B → Q16

@Neet_pg_bot

Q17: A 65-year-old male patient is admitted to the hospital after undergoing elective surgery. Post-anesthesia, he is found to be unconscious and placed in a supine position for monitoring. The healthcare team is concerned about the risk of aspiration due to his current state. Which location is most likely to collect aspirated material in this patient? (Q848368)

A. Anterior Basal BPS of the right lower lobe

B. Posterior BPS of the right upper lobe

C. Apical Basal BPS of the right lower lobe

D. Lateral BPS of the right middle lobe

See Answer in Part B → Q17

@Neet_pg_bot

Q18: A 60-year-old female undergoes right lower lobe resection for a tumor. Which statement about bronchopulmonary segments is true? (Q848367)

A. Each segment shares a bronchus with adjacent segments.

B. Segments are supplied by segmental arteries and share venous drainage.

C. Each segment has independent arterial and venous supplies.

D. The shape is pyramidal with the base at the hilum.

See Answer in Part B → Q18

@Neet_pg_bot

Q19: Which of the following statements correctly describes a difference between the right and left lungs? (Q848366)

A. The left lung is longer and narrower than the right lung.

B. The right lung has a cardiac notch.

C. The right lung has only one fissure and two lobes.

D. The left lung is larger and heavier than the right lung.

See Answer in Part B → Q19

@Neet_pg_bot

Q20: A 55-year-old male patient presents with a persistent cough and shortness of breath. A chest X-ray shows a mass in the right lung. The attending physician is reviewing the anatomical structures relevant to potential surgical intervention. Which of the following statements about the anatomy of the right and left lungs is correct? (Q848363)

A. The right superior pulmonary vein is located posteriorly to the bronchus.

B. The eparterial bronchus in the right lung is found above the pulmonary artery.

C. The most superior structure of the left lung hilum is the Pulmonary vein.

D. The bronchus on the left side is shorter in length compared to the right bronchus.

See Answer in Part B → Q20

• [07_Thorax] 036 Previous Year Questions

« Back to Folder Directory

[07_Thorax] 036 Previous Year Questions — Quick Jump

Q1 (p. 473)	*Q2 (p. 474)*	*Q3 (p. 474)*	*Q4 (p. 475)*	*Q5 (p. 476)*	*Q6 (p. 477)*
Q7 (p. 478)	*Q8 (p. 478)*	*Q9 (p. 479)*	*Q10 (p. 479)*	*Q11 (p. 480)*	*Q12 (p. 481)*
Q13 (p. 482)	*Q14 (p. 483)*	*Q15 (p. 484)*	*Q16 (p. 485)*	*Q17 (p. 485)*	*Q18 (p. 486)*
Q19 (p. 487)	*Q20 (p. 487)*	*Q21 (p. 488)*	*Q22 (p. 489)*	*Q23 (p. 490)*	*Q24 (p. 491)*
Q25 (p. 492)	*Q26 (p. 492)*				

Q1: Identify the labeling correctly: (Q844206)

A. A- Superior vena cava, B- Ascending aorta, C- Pulmonary trunk, D- Descending aorta

B. A- Ascending aorta, B- Descending aorta, C- Pulmonary trunk, D- Superior vena cava

C. A- Ascending aorta, B- Superior vena cava, C- Descending aorta, D- Pulmonary trunk,

D. A- Ascending aorta, B- Superior Vena Cava, C- Pulmonary trunk, D- Descending aorta

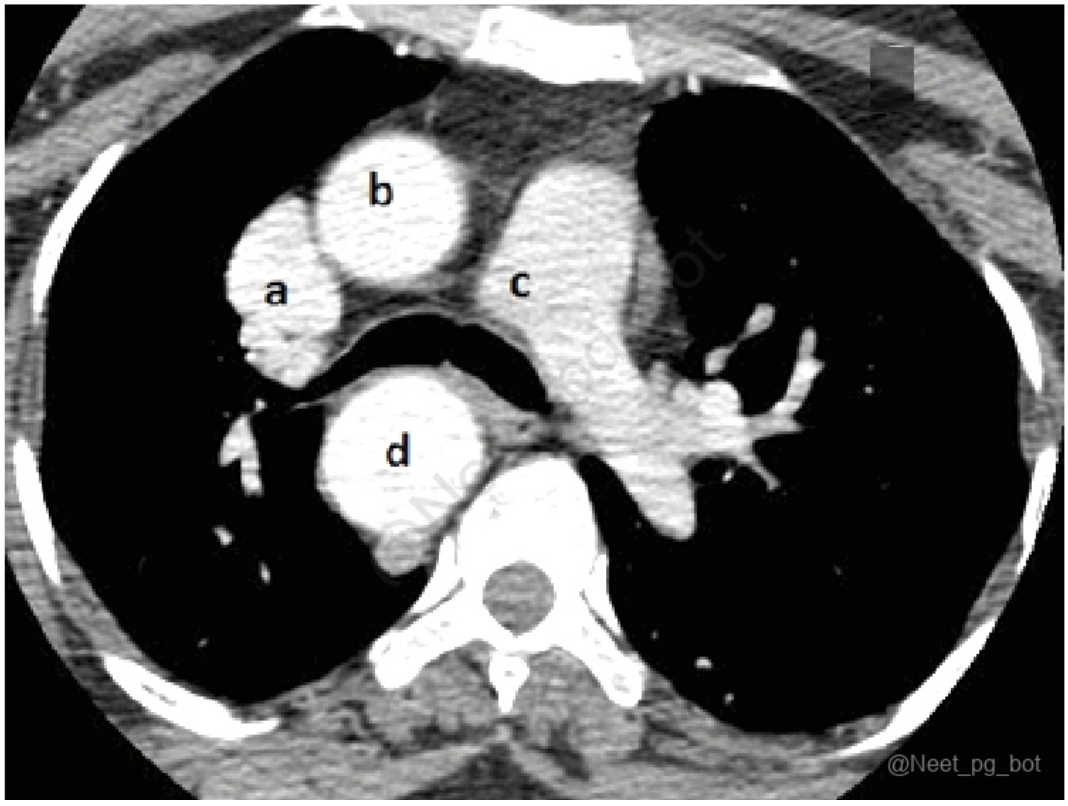

See Answer in Part B → Q1

@Neet_pg_bot

Q2: The subcostal line corresponds to which vertebrae level? (Q860619)

A. T12

B. L1

C. L2

D. L3

See Answer in Part B → Q2

@Neet_pg_bot

Q3: The structure marked in the image drains into: (Q859919)

A. Junction of superior vena cava and left brachiocephalic veins

B. Thoracic Duct

C. Directly into the coronary sinus

D. Azygos vein

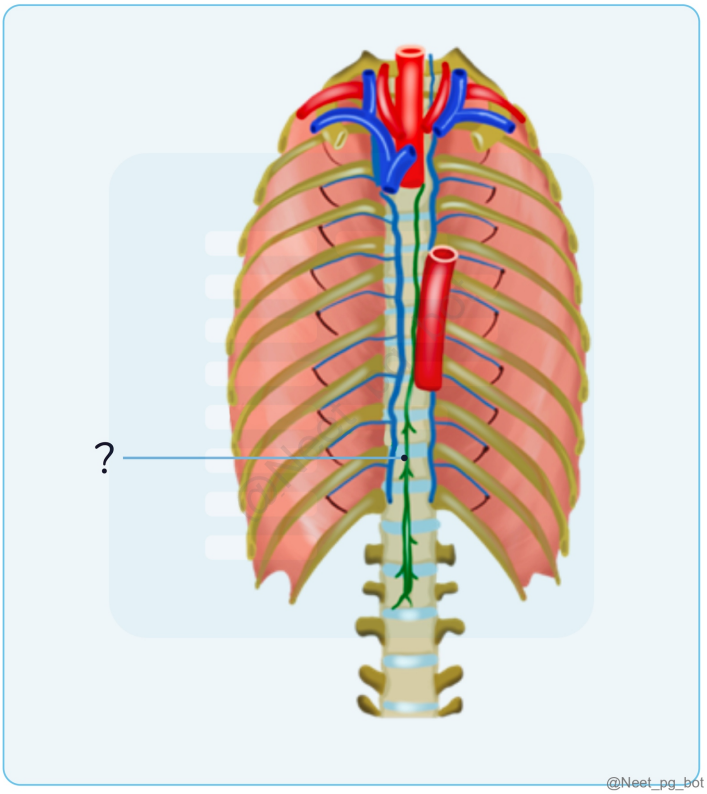

See Answer in Part B → Q3

@Neet_pg_bot

Q4: A patient developed the following deformity, after overhead (weight-lifting) exercises. Which of the following muscles is involved? (Q859904)

A. Trapezius

B. Serratus anterior

C. Lattisimus dorsi

D. Supraspinatus



See Answer in Part B → Q4

@Neet_pg_bot

Q5: The type of joint marked in the image below is: (Q858475)

A. Syndesmosis

B. Synarthrosis

C. Synchondrosis

D. Synovial

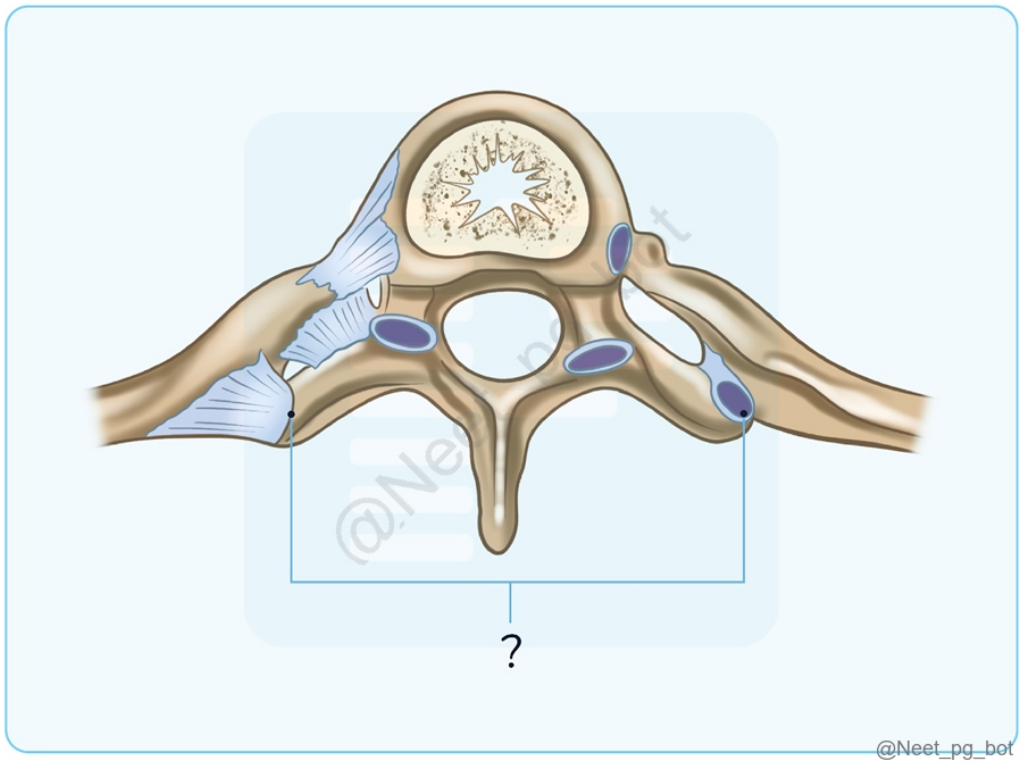

See Answer in Part B → Q5

@Neet_pg_bot

Q6: Identify the level of the cross-section shown in the image below:- (Q856403)

A. T1-T2

B. T2-T3

C. T3-T4

D. T4-T5

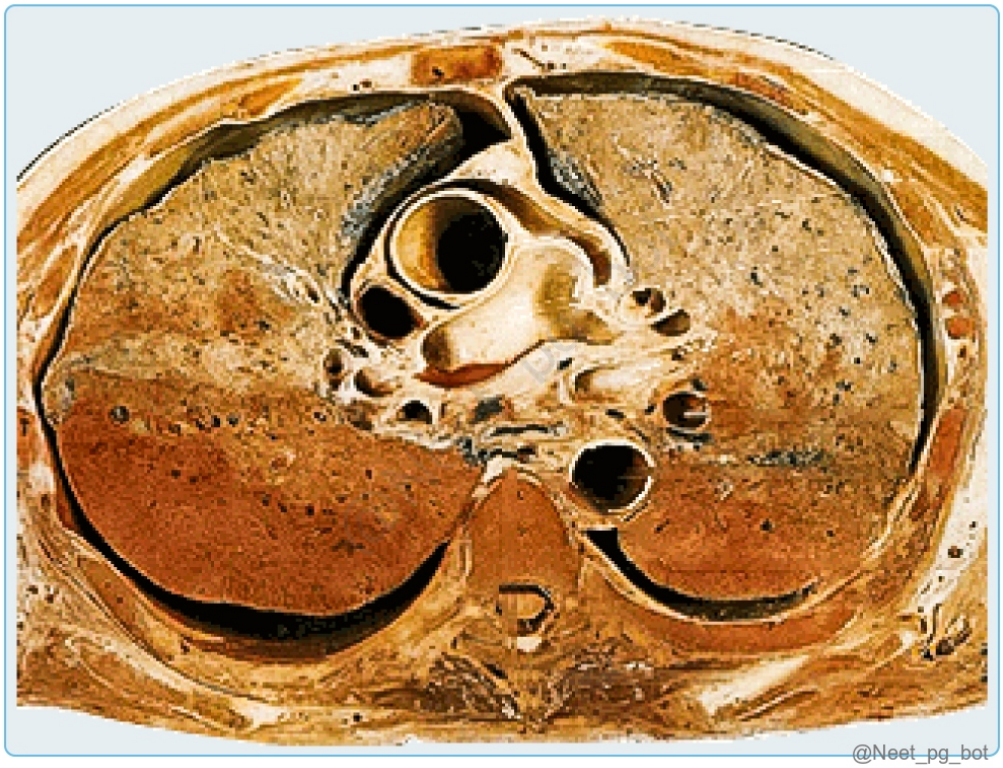

See Answer in Part B → Q6

@Neet_pg_bot

Q7: Which of the following muscles is not involved in the overhead abduction of the arm? (Q856383)

A. Serratus anterior

B. Deltoid

C. Trapezius

D. Pectoralis major

See Answer in Part B → Q7

@Neet_pg_bot

Q8: A patient presented with paradoxical respiration. Which of the following nerves is most likely to be affected? (Q856967)

A. Right Vagus Nerve

B. Left Vagus Nerve

C. Recurrent Laryngeal Nerve

D. Phrenic Nerve

See Answer in Part B → Q8

@Neet_pg_bot

Q9: Reticular fibers are not present in which of the following structures? (Q856954)

A. Thymus

B. Lymph node

C. Bone marrow

D. Spleen

See Answer in Part B → Q9

@Neet_pg_bot

Q10: What is the most common complication of the central line insertion below the marked bone? (Q855756)

A. Arterial puncture

B. Thrombophlebitis

C. Empyema

D. Chylothorax

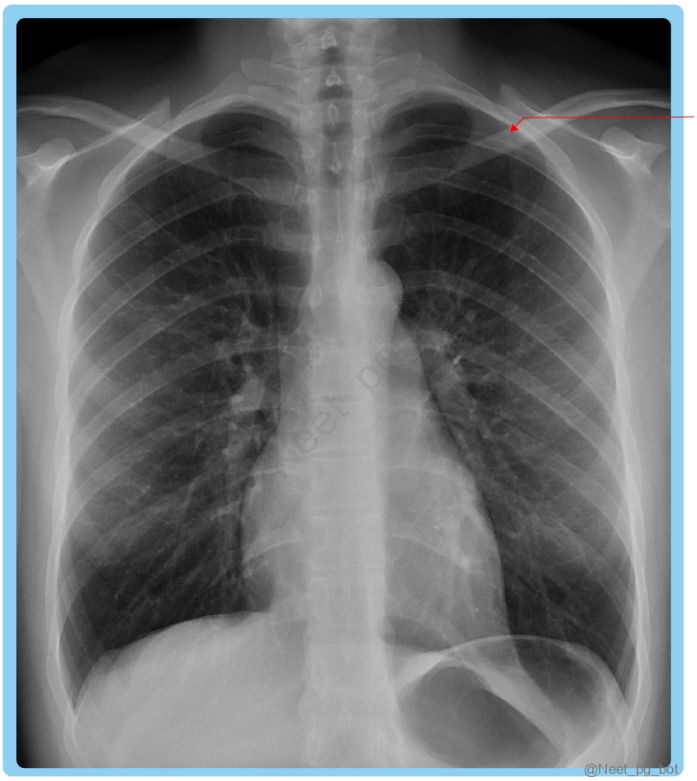

See Answer in Part B → Q10

@Neet_pg_bot

Q11: Identify the arrow-marked chamber. (Q857560)

A. Right atrium

B. Left atrium

C. Right ventricle

D. Left ventricle



See Answer in Part B → Q11

@Neet_pg_bot

Q12: Which of the following is wrongly labeled here? (Q857226)

A. A- Superior thoracic artery

B. B- Thoracoacromial artery

C. C- Subscapular artery

D. D- Posterior circumflex artery

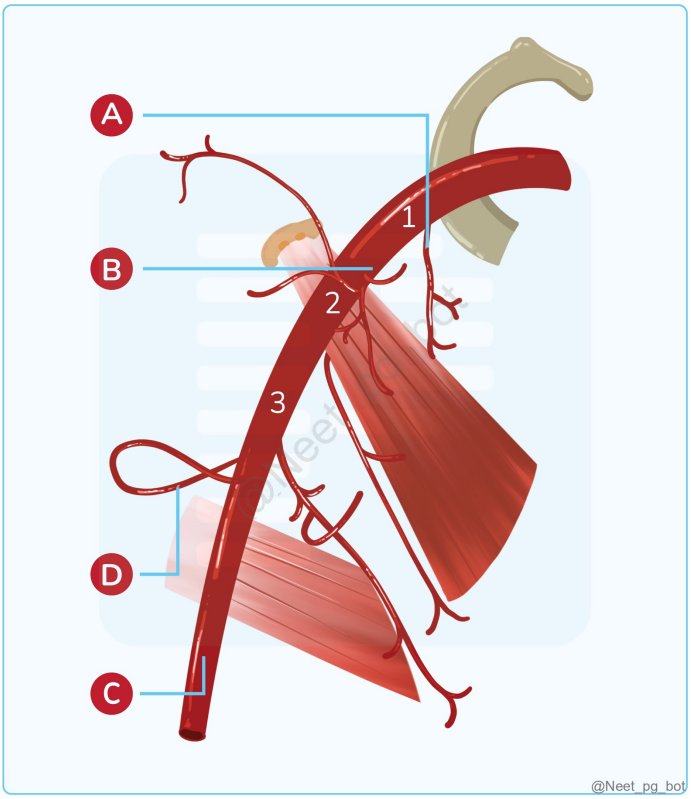

See Answer in Part B → Q12

@Neet_pg_bot

Q13: Match the auscultatory areas of the heart from the image given below. (Q857213)

A. 1-aortic, 2-pulmonary, 3-mitral, 4-tricuspid

B. 1-aortic, 2-pulmonary, 3- tricuspid, 4-mitral

C. 1-mitral, 2-pulmonary, 3- tricuspid, 4-aortic

D. 1-aortic,2-tricuspid, 3- pulmonary, 4-mitral

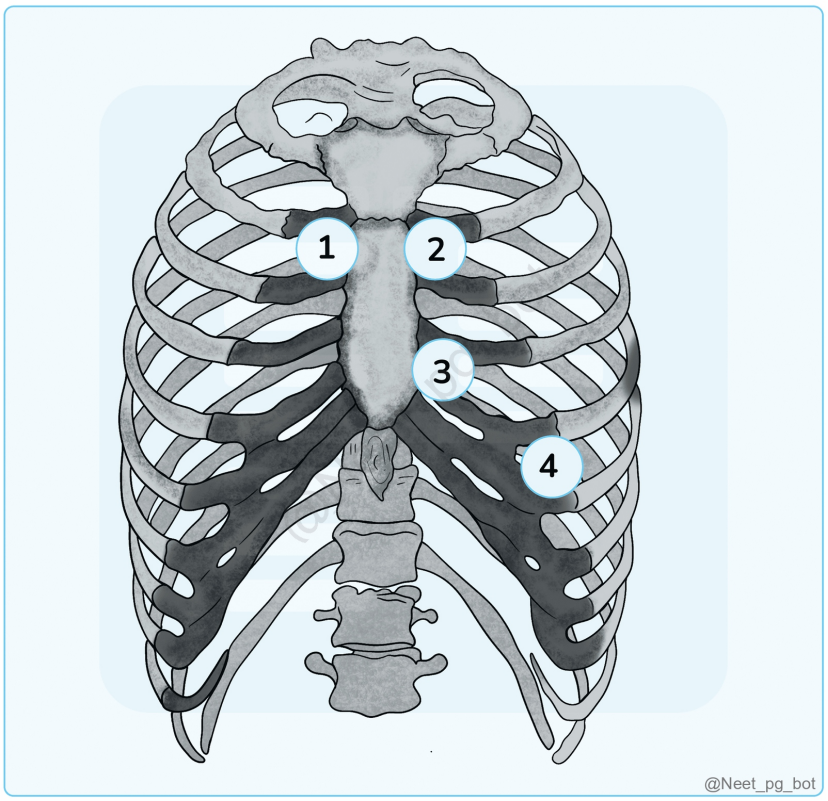

See Answer in Part B → Q13

@Neet_pg_bot

Q14: A defect in which of the following pharyngeal arch artery causes the defect shown in the image? (Q855396)

A. Right 4th arch artery

B. Left 4th arch artery

C. Right 6th arch artery

D. Left 6th arch artery

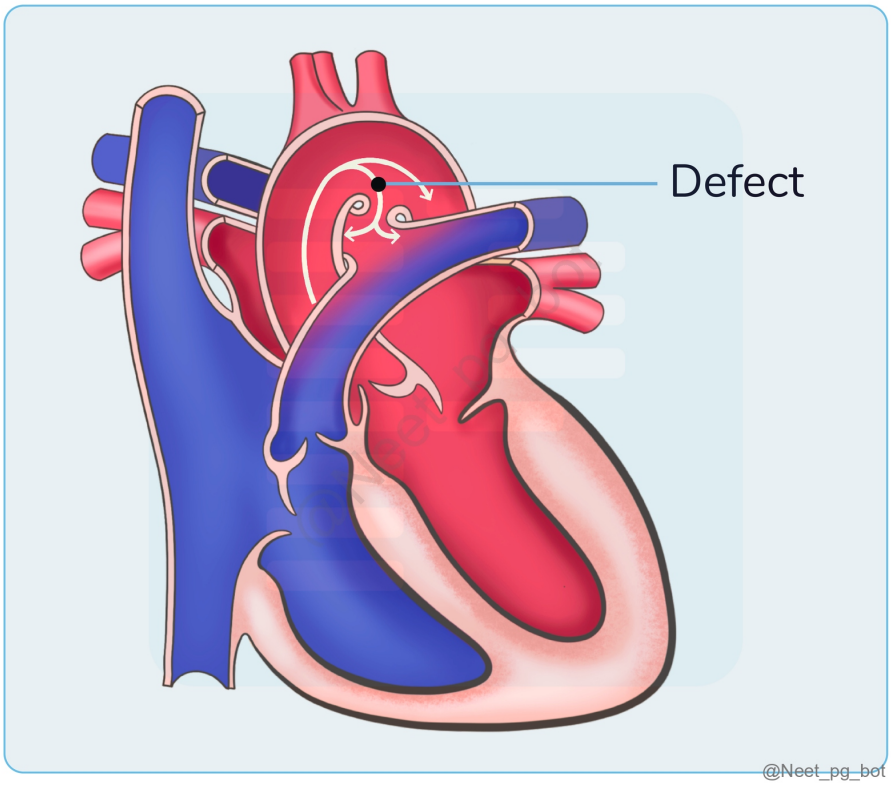

See Answer in Part B → Q14

@Neet_pg_bot

Q15: Identify the structure marked in the given image (Q854583)

A. Bronchus

B. Arch of aorta

C. Brachiocephalic trunk

D. Pulmonary trunk

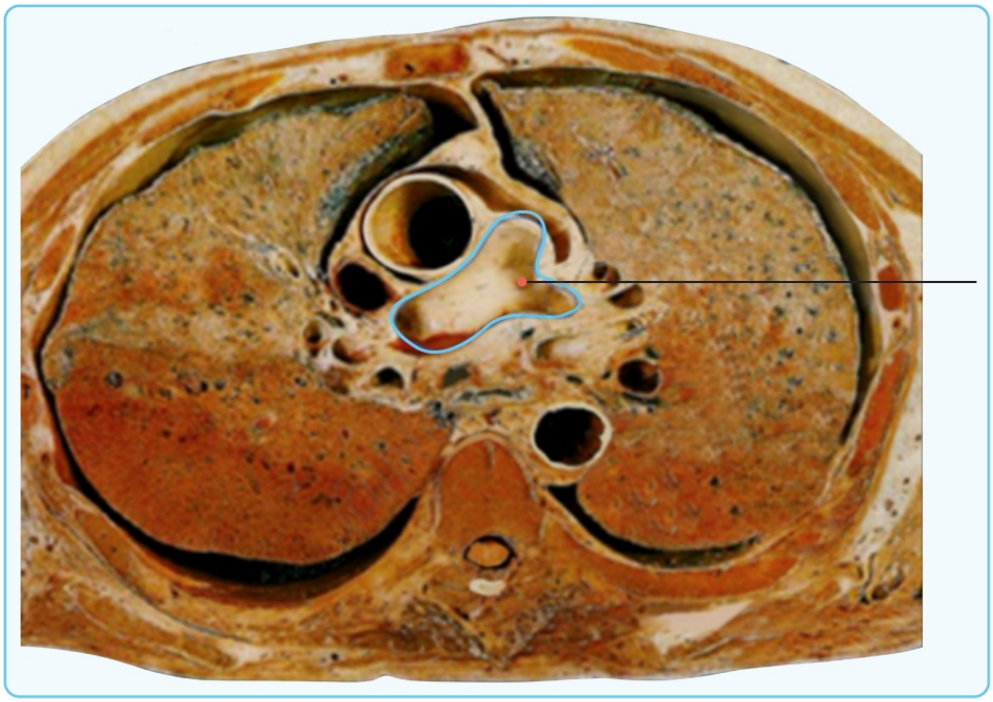

@Neet_pg_bot

See Answer in Part B → Q15

@Neet_pg_bot

Q16: During the surgical procedure for Patent Ductus Arteriosus, the structure that is in close relation to it can be damaged. Which of the following can be the structure? (Q860291)

A. Left recurrent laryngeal nerve

B. Right recurrent laryngeal nerve

C. Thoracic duct

D. Hemiazygos vein

See Answer in Part B → Q16

@Neet_pg_bot

Q17: Which structure is located approximately 23 cm from the central incisor? (Q860286)

A. Cricopharynx

B. Arch of Aorta

C. Left principal bronchus

D. Diaphragm

See Answer in Part B → Q17

@Neet_pg_bot

Q18: Identify the vascular structure marked in the given radiology image? (Q839934)

A. Aberrant right subclavian artery

B. Aberrant left subclavian artery

C. Ascending aorta

D. Main pulmonary artery



See Answer in Part B → Q18

@Neet_pg_bot

Q19: Which of the following statements is true regarding the anatomy of the breast? (Q839893)

A. The superior medial quadrant has more tissue

B. There are 10 lobules present

C. The axillary tail of Spence crosses the anterior axillary fold

D. The nipple is located at the level of the fourth intercostal space in most women

See Answer in Part B → Q19

@Neet_pg_bot

Q20: Identify the marked structure? (Q839890)

A. Anterior end of rib

B. Posterior end of rib

C. Right pulmonary artery

D. Costal cartilage



See Answer in Part B → Q20

@Neet_pg_bot

Q21: Identify the artery that supplies the anatomical region of the heart shown in the provided image. (Q839884)

A. Anterior interventricular artery

B. left circumflex artery

C. Left marginal artery

D. Right coronary artery (RCA)



@Neet_pg_bot

See Answer in Part B → Q21

@Neet_pg_bot

Q22: At which vertebral level is the anatomical cross-section shown in the image provided? (Q839871)

A. T10

B. T12

C. T11

D. T9

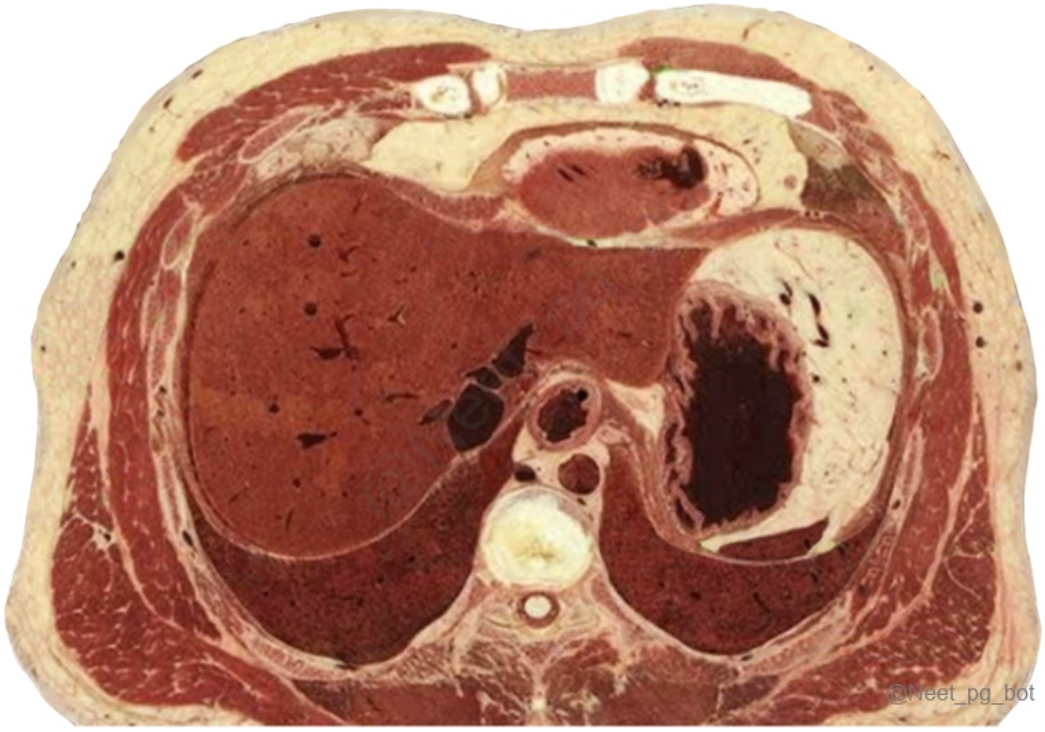

See Answer in Part B → Q22

@Neet_pg_bot

Q23: Identify the arrow-marked chamber? (Q860624)

A. Right atrium

B. Left atrium

C. Right ventricle

D. Left ventricle



See Answer in Part B → Q23

@Neet_pg_bot

Q24: Identify the part of the respiratory tract based on the image given below. (Q865297)

A. Bronchus

B. Respiratory bronchiole

C. Terminal bronchiole

D. Alveolar duct

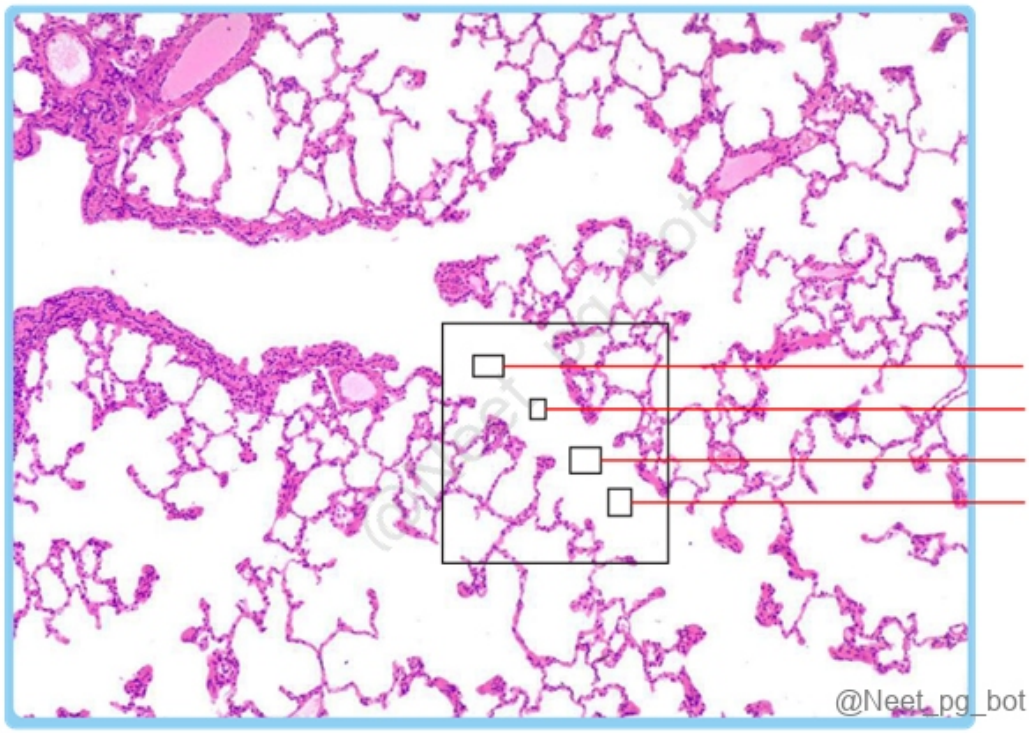

See Answer in Part B → Q24

@Neet_pg_bot

Q25: After a fall from a height with his hand outstretched, a man is brought to the emergency department. An X-ray reveals a fracture in the clavicle. Which specific region of the clavicle is the most likely to be fractured? (Q793159)

A. Junction of medial 2/3rd and lateral 1/3rd

B. Junction of medial 1/3rd and lateral 2/3rd

C. Junction of middle 1/3rd and medial 1/3rd

D. Middle of the clavicle

See Answer in Part B → Q25

@Neet_pg_bot

Q26: The image shows the cross-section of the abdominal cavity. Identify the structure marked ‘A.’ (Q793144)

A. Descending aorta

B. Superior vena cava

C. Inferior vena cava

D. Ascending aorta

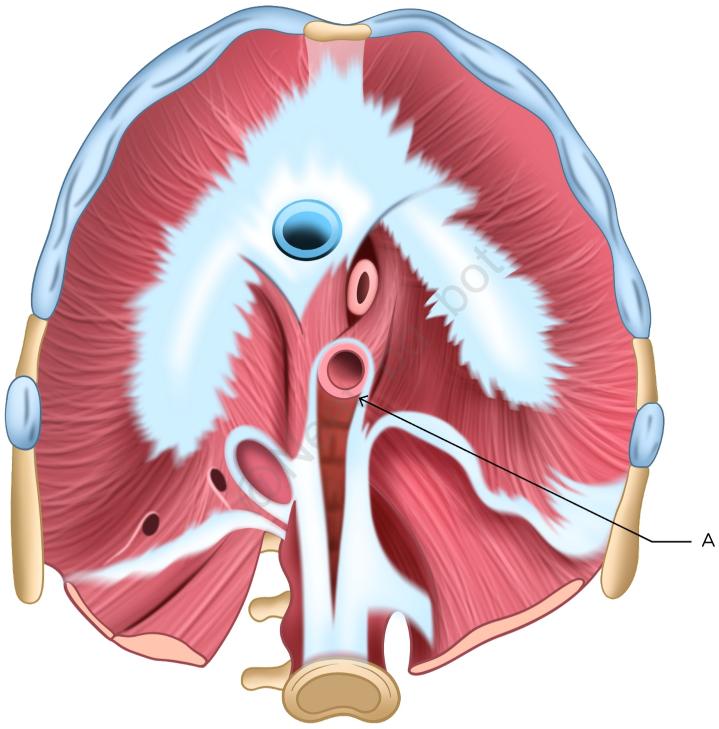

See Answer in Part B → Q26

@Neet_pg_bot

• [08_Abdomen] 037 Embryology Of Abdominal Organs

« Back to Folder Directory

[08_Abdomen] 037 Embryology Of Abdominal Organs — Quick Jump

Q1 (p. 494)	*Q2 (p. 494)*	*Q3 (p. 495)*	*Q4 (p. 496)*	*Q5 (p. 496)*	*Q6 (p. 496)*
Q7 (p. 497)	*Q8 (p. 497)*	*Q9 (p. 497)*	*Q10 (p. 498)*	*Q11 (p. 498)*	*Q12 (p. 499)*
Q13 (p. 500)	*Q14 (p. 500)*	*Q15 (p. 500)*	*Q16 (p. 501)*	*Q17 (p. 501)*	*Q18 (p. 501)*
Q19 (p. 502)	*Q20 (p. 503)*	*Q21 (p. 504)*	*Q22 (p. 505)*	*Q23 (p. 505)*	*Q24 (p. 506)*

Q1: A newborn presents with bilious vomiting and abdominal distension. An abdominal X-ray shows signs of bowel obstruction. Intraoperatively, the surgeon finds multiple fibrous bands with the cecum on the left side and the small intestine on the right side. What is the most likely underlying anomaly? (Q848815)

A. Nonrotation of the midgut

B. Reversed rotation of the midgut

C. Incomplete midgut rotation

D. Midgut volvulus with normal rotation

See Answer in Part B → Q1

@Neet_pg_bot

Q2: A newborn presents with bilious vomiting shortly after birth. X-ray abdomen is taken and is shown below. Further evaluation reveals pancreatic tissue encircling and compressing the second part of the duodenum. Which embryological structure is primarily responsible for this congenital abnormality? (Q848811)

A. Dorsal pancreatic bud

B. Ventral pancreatic bud

C. Hepatic diverticulum

D. Vitelline duct

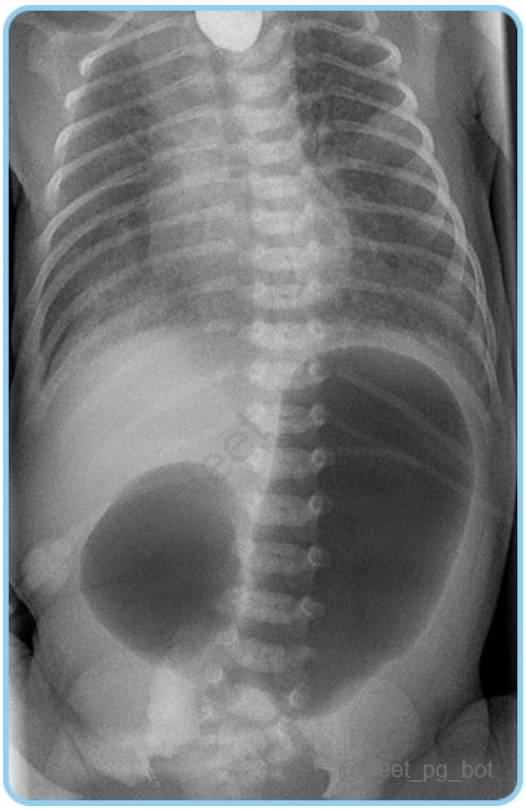

See Answer in Part B → Q2

@Neet_pg_bot

Q3: Which of the following statements is correct regarding the peritoneal folds of abdomen? (Q848822)

A. The greater omentum attaches to the lesser curvature of the stomach and the duodenum, providing a barrier to infections in the peritoneal cavity.

B. The lesser omentum connects the greater curvature of the stomach to the diaphragm and provides support to the liver

C. The greater omentum forms a fold between the liver and the diaphragm, providing structural support to the stomach.

D. The greater omentum is often used as a free flap in reconstructive surgeries based on gastro-omental vessels in gastrointestinal perforations.

See Answer in Part B → Q3

@Neet_pg_bot

Q4: Match the following with their corresponding dermatomal distribution: 1. Thumb 1) L3 2. Umblicus 2) L5 3. Knee 3) C6 4. Dorsum of foot 4) T10 (Q848821)

A. A-1, B-2, C-3, D-4

B. A-2, B-3, C-4, D-1

C. A-3, B-4, C-1, D-2

D. A-4, B-1, C-2, D-3

See Answer in Part B → Q4

@Neet_pg_bot

Q5: A 35-year-old male is involved in a high-speed motor vehicle accident and presents to the trauma unit with severe abdominal pain and hypotension. On examination, he has contusion on the left side of his abdomen. FAST reveals free fluid in the abdomen. CT scan shows a retroperitoneal hematoma and signs of injury to a retroperitoneal organ. Which of the following organs is most likely to be injured in this case? (Q848820)

A. Stomach

B. Small intestine

C. Left kidney

D. D) Spleen

See Answer in Part B → Q5

@Neet_pg_bot

Q6: Which of the following planes carries the origin of the hepatic portal vein and the termination of the spinal cord? (Q848819)

A. Subcostal plane

B. Supracristal plane

C. Intertubercular plane

D. Transpyloric plane

See Answer in Part B → Q6

@Neet_pg_bot

Q7: A triangular area formed in the bladder is called the trigone. Which of the following is the origin of the epithelium of the trigone? (Q848818)

A. Cranial vesicourethral canal

B. Mesonephric duct

C. Splanchnic mesoderm

D. Allantois

See Answer in Part B → Q7

@Neet_pg_bot

Q8: A newborn baby was found to have hydronephrosis. Which of the following would be the cause of this? (Q848817)

A. Obstruction by the umbilical arteries

B. Crossed ectopia

C. Malrotation of kidneys

D. Aberrant renal arteries

See Answer in Part B → Q8

@Neet_pg_bot

Q9: A newborn presents with a congenital urinary tract anomaly. During evaluation, the physician explains the stages of kidney development and associated structures. Which of the following statements is true regarding the formation of the definitive kidney in mammals? (Q848816)

A. Pronephros is the functional kidney in humans and contributes to the urinary system.

B. Mesonephros develops in the cervical region and contains excretory tubules.

C. Metanephros arises from the metanephric blastema and the ureteric bud.

D. Lateral plate mesoderm forms the foundation of the urinary and genital systems.

See Answer in Part B → Q9

@Neet_pg_bot

Q10: A newborn presents with bilious vomiting and abdominal distension. Imaging reveals malrotation of the midgut. The pediatric surgeon explains that during normal embryological development, the midgut should rotate around a specific arterial axis to reach its anatomical position. How many degrees does the midgut rotate, and what is the axis of this rotation? (Q848814)

A. 180 degrees, Inferior Mesenteric Artery

B. 270 degrees, Superior Mesenteric Artery

C. 90 degrees, Inferior Mesenteric Artery

D. 360 degrees, Superior Mesenteric Artery

See Answer in Part B → Q10

@Neet_pg_bot

Q11: A 26-year-old woman with a history of recurrent abortion undergoes an ultrasound at 8 weeks of gestation and is found to have an abnormality in the fetus as shown below (arrow). The doctor reassures her that this condition typically resolves on its own. When should she schedule a follow-up ultrasound to monitor the resolution of the abnormality? (Q848813)

A. 12 weeks

B. 14 weeks

C. 16 weeks

D. 18 weeks

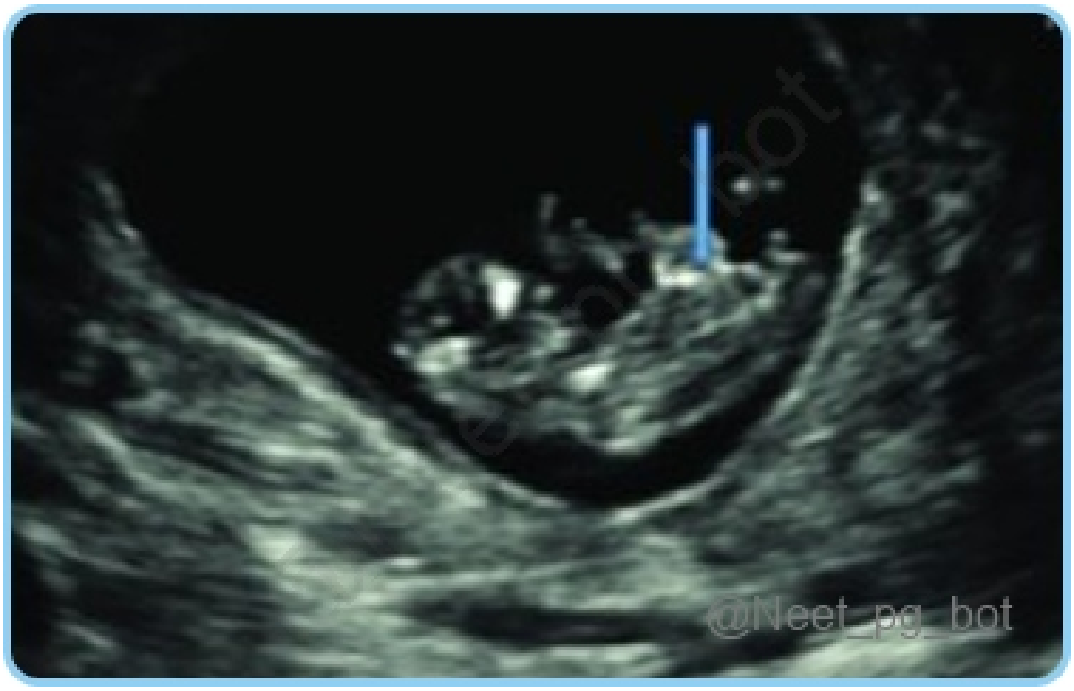

See Answer in Part B → Q11

@Neet_pg_bot

Q12: Which of the following statements about the ligament of Treitz is not true? (Q848812)

A. It connects the duodenojejunal flexure to the right crus of the diaphragm.

B. It contains striated muscle fibers in its upper part.

C. It primarily serves as a conduit for blood supply to the small intestine.

D. It acts as a landmark in the diagnosis of intestinal malrotation.

See Answer in Part B → Q12

@Neet_pg_bot

Q13: A healthcare provider is discussing the anatomy of the umbilical cord with a medical student. How many arteries and veins are typically present in a normal umbilical cord? (Q848767)

A. 1 artery and 1 vein

B. 2 arteries and 1 vein

C. 2 arteries and 2 veins

D. 1 artery and 2 veins

See Answer in Part B → Q13

@Neet_pg_bot

Q14: Which of the following statements about the development of the liver and gallbladder is correct? (Q848810)

A. Liver develops from the mesodermal hepatic bud.

B. Cystic duct forms from the pars hepatica of the hepatic bud.

C. Bile duct initially opens on the dorsal aspect of the developing duodenum.

D. Vitelline and umbilical veins contribute to the formation of hepatic sinusoids.

See Answer in Part B → Q14

@Neet_pg_bot

Q15: A research study is conducted to understand the embryological development of gastrointestinal (GI) structures in an embryo. Which of the following statements about the normal embryological development of the GI tract is incorrect? (Q848809)

A. Esophagus develops entirely from the foregut.

B. Stomach initially forms as a fusiform dilation of the foregut.

C. Duodenum forms a C-shaped loop during stomach rotation.

D. Midgut-derived parts of the duodenum are supplied by the celiac artery

See Answer in Part B → Q15

@Neet_pg_bot

Q16: Which of the following statements about the development of mesentery is correct? (Q848808)

A. Dorsal mesentery is derived from the septum transversum.

B. Ventral mesentery gives rise to the greater omentum.

C. Dorsal mesentery extends from the lower esophagus to the rectum.

D. Ventral mesentery is continuous with the dorsal mesentery.

See Answer in Part B → Q16

@Neet_pg_bot

Q17: A patient on examination and radiological imaging was found to have an absent gallbladder. Which gut tube structure is associated with this defect, and what is the primitive artery that supplies it? (Q848775)

A. Midgut, superior mesenteric artery

B. Foregut, celiac trunk

C. Midgut, celiac trunk

D. Hindgut, inferior mesenteric artery

See Answer in Part B → Q17

@Neet_pg_bot

Q18: A 2-day-old infant is brought to the emergency department with severe respiratory distress. The physical examination reveals scaphoid abdomen, decreased

breath sounds on the left side, and a chest X-ray shows a mediastinal shift to the right. Which type of hernia is most likely responsible for this presentation? (Q848774)

A. Morgagni hernia

B. Bochdalek hernia

C. Hiatal hernia

D. Umbilical hernia

See Answer in Part B → Q18

@Neet_pg_bot

Q19: What structures are transmitted through the marked opening of the diaphragm in the given image? (Q848773)

A. Oesophagus and gastric nerves

B. Aorta and thoracic duct

C. Inferior vena cava and right phrenic nerve

D. Inferior vena cava and left phrenic nerve



@Neet_pg_bot

See Answer in Part B → Q19

@Neet_pg_bot

Q20: All of the following are the derivatives of the structure labeled A in the image below, except: (Q848772)

A. Falciform ligament

B. Coronary ligament

C. Ligamentum teres

D. Lesser omentum

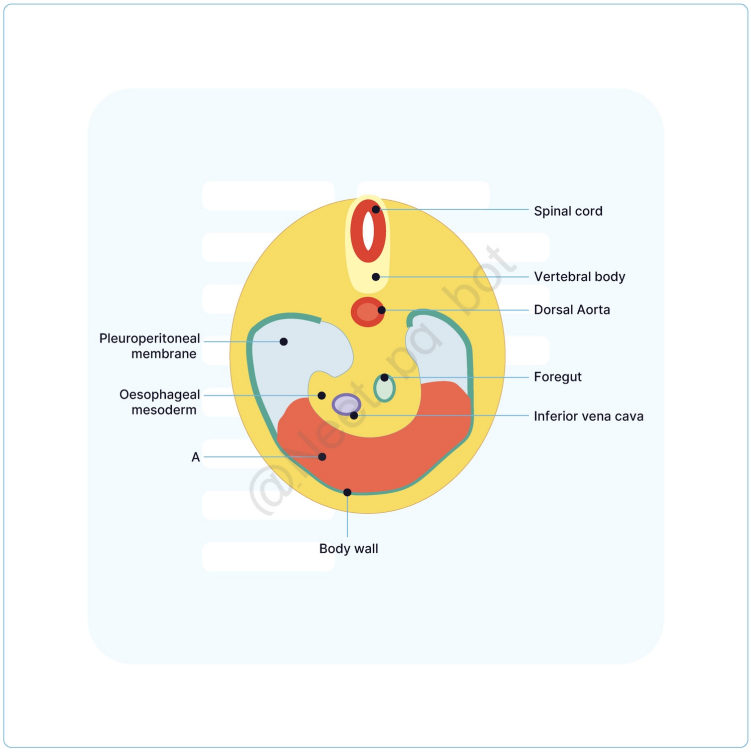

@Neet_pg_bot

See Answer in Part B → Q20

@Neet_pg_bot

Q21: Which of the following structures contributes to the formation of the marked part of the diaphragm (inferior view)? (Q848771)

A. Septum transversum

B. Pleuro-peritoneal membrane

C. Dorsal mesentery of esophagus

D. Mesoderm of body wall

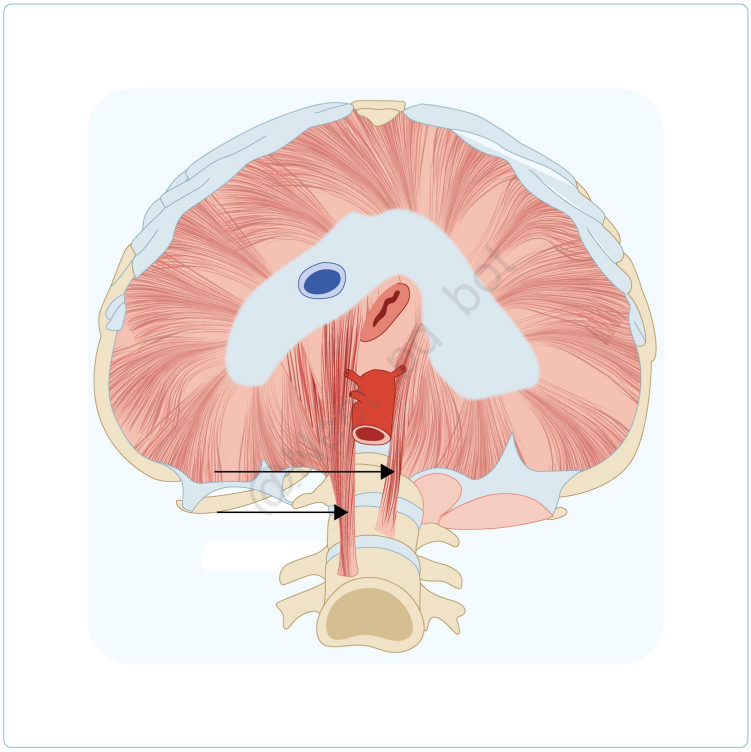

See Answer in Part B → Q21

@Neet_pg_bot

Q22: Which of the following is true about gastroschisis as opposed to an omphalocele? (Q848770)

A. Has a covering of amnion around the herniated bowels

B. Is associated with chromosomal anomalies and cardiac anomalies

C. Due to the failure of the gut tube back to return into the abdomen

D. The herniated bowel loops are damaged due to amniotic fluid

See Answer in Part B → Q22

@Neet_pg_bot

Q23: A neonate presents with dribbling of urine from the umbilicus. Which of the following statements is true regarding the affected structure? (Q848769)

A. Persistence of a small area of allantois

B. The lumen of the upper part of the urachus persists

C. Forms a cystic dilation due to secretions from the lining

D. Persistence of intraembryonic part of allantois

See Answer in Part B → Q23

@Neet_pg_bot

Q24: A newborn is scheduled for surgery after presenting with fecal discharge from the umbilicus. An intraoperative image is shown below. What is the most likely diagnosis? (Q848768)

A. Meckel’s diverticulum

B. Vitelline fistula

C. Vitelline sinus

D. Vitelline cyst



See Answer in Part B → Q24

@Neet_pg_bot

• [08_Abdomen] 038 Inguinal And Femoral Anatomy And Hernia Abdominal Wall Layers Peritoneal Cavity

« Back to Folder Directory

[08_Abdomen] 038 Inguinal And Femoral Anatomy And Hernia Abdominal Wall Layers Peritoneal Cavity — Quick Jump

Q1 (p. 508) *Q2 (p. 508)* *Q3 (p. 509)* *Q4 (p. 509)* *Q5 (p. 509)* *Q6 (p. 510)*
Q7 (p. 510) *Q8 (p. 510)* *Q9 (p. 511)* *Q10 (p. 511)* *Q11 (p. 512)* *Q12 (p. 513)*
Q13 (p. 513) *Q14 (p. 513)*

Q1: A 6-month-old boy is brought to the clinic by his parents due to a mass noticed in his right groin. An ultrasound confirms that it is an undescended testis, located just at the superficial inguinal ring Based on the normal developmental timeline of testicular descent, at which intrauterine period should the testis have normally reached the deep inguinal ring? (Q848777)

A. 8th week of gestation

B. 3rd month of gestation

C. 5th month of gestation

D. 7th month of gestation

See Answer in Part B → Q1

@Neet_pg_bot

Q2: Which of the following statements is FALSE regarding the peritoneal cavity? (Q848804)

A. The abdominal cavity is divided into supracolic and infracolic compartments.

B. The supracolic compartment is further divided into subphrenic spaces.

C. The infracolic compartment is divided into right and left parts by the falciform ligament.

D. The right paracolic gutter lies along the lateral side of the ascending colon.

See Answer in Part B → Q2

@Neet_pg_bot

Q3: A 14-year-old girl presents with a mass in the right groin that is suspected to be an ovary. Imaging confirms that her ovary has been drawn into the inguinal canal. Which structure is most likely responsible for the abnormal descent of the ovary into the inguinal canal? (Q848778)

A. Round ligament of the uterus

B. Suspensory ligament of the ovary

C. Broad ligament of the uterus

D. Uterosacral ligament

See Answer in Part B → Q3

@Neet_pg_bot

Q4: Which of the following structures is NOT found in the spermatic cord? (Q848779)

A. Vas deferens

B. Testicular artery

C. Epididymis

D. Pampiniform plexus

See Answer in Part B → Q4

@Neet_pg_bot

Q5: What is the correct order of the layers of the anterior abdominal wall from superficial to deep? (Q848780)

A. Skin → Scarpa fascia → Internal oblique → External oblique → Transversalis fascia → Transversus abdominis → Peritoneum

B. Skin → Transversalis fascia → Internal oblique → External oblique → Transversus abdominis → Scarpa fascia → Peritoneum

C. Skin → Scarpa fascia → External oblique → Internal oblique → Transversus abdominis → Transversalis fascia → Peritoneum

D. Skin → External oblique → Scarpa fascia → Internal oblique → Transversus abdominis → Transversalis fascia → Peritoneum

See Answer in Part B → Q5

@Neet_pg_bot

Q6: At which level does the rectus sheath become entirely anterior to the rectus abdominis muscle due to absence of the posterior sheath? (Q848781)

A. At the level of the xiphoid process

B. At the level of umbilicus

C. Below the arcuate line

D. None of the above

See Answer in Part B → Q6

@Neet_pg_bot

Q7: Which of the following statements about the inguinal canal is false? (Q848782)

A. The posterior wall of the inguinal canal is formed by the transversalis fascia.

B. The inguinal canal contains the ilioinguinal nerve.

C. The aponeurosis of the external oblique muscle forms the roof of the inguinal canal.

D. In males, the inguinal canal contains the spermatic cord.

See Answer in Part B → Q7

@Neet_pg_bot

Q8: A 45-year-old male presents with a swelling in the right inguinal region that increases in size on coughing or standing. Upon examination, a diagnosis of indirect inguinal hernia is made, and surgical repair is planned. While preparing for the surgery, the anatomical relations of the inguinal canal are reviewed. Which of the following correctly describes the anatomical relations of the inguinal canal? (Q848783)

A. The posterior wall of the inguinal canal is formed by the transversalis fascia.

B. The inguinal canal contains the inferior epigastric vessels.

C. The deep inguinal ring is located medial to the inferior epigastric vessels.

D. D) The floor of the inguinal canal is formed by the conjoint tendon

See Answer in Part B → Q8

@Neet_pg_bot

Q9: Which of the following statements about the femoral triangle is FALSE? (Q848784)

A. The medial boundary of the femoral triangle is formed by the adductor longus muscle.

B. The lateral boundary of the femoral triangle is formed by the iliacus and psoas major muscles

C. The femoral nerve is one of the contents of the femoral triangle.

D. The anterior boundary of the femoral ring is the inguinal ligament.

See Answer in Part B → Q9

@Neet_pg_bot

Q10: Which of the marked structures is formed directly by the rotation of the stomach and duodenum? (Q848802)

A. both a and b

B. both b and c

C. b only

D. d only

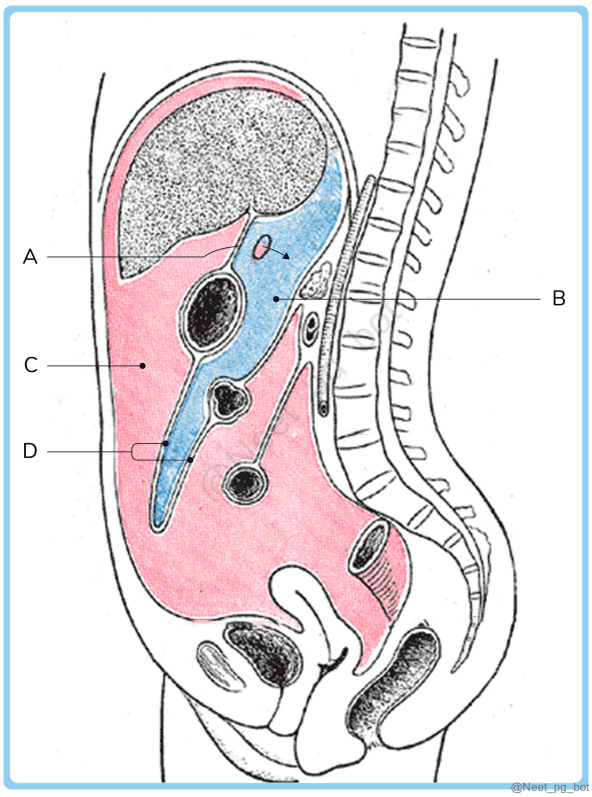

See Answer in Part B → Q10

@Neet_pg_bot

Q11: A 50-year-old male undergoes an emergency laparotomy for severe upper abdominal bleeding after blunt abdominal trauma. During the procedure, the surgeon performs the Pringle maneuver by clamping the hepatoduodenal ligament to control hemorrhage. The clamp is applied to temporarily occlude the portal triad and assess the source of bleeding. Which structure forms the superior boundary of the anatomical space where the Pringle maneuver is performed? (Q848803)

A. Inferior vena cava

B. Caudate lobe of the liver

C. First part of the duodenum

D. Proper hepatic artery

See Answer in Part B → Q11

@Neet_pg_bot

Q12: A 35-year-old female presents with lower abdominal pain, high fever, and an elevated heart rate. She appears pale and diaphoretic on examination, with hypotension and a leukocytosis noted on laboratory tests. Imaging reveals a pelvic abscess. The surgeon suspects that pus has spread from an upper abdominal source. Which of the following sequences represents the correct flow of pus between important peritoneal spaces, leading to a pelvic abscess? (Q848805)

A. Rectouterine pouch → Hepatorenal pouch → Paracolic gutter → Lesser sac → Pelvic abscess

B. Lesser sac → Foramen of Winslow → Greater sac → Hepatorenal pouch → Paracolic gutter → Rectouterine pouch → Pelvic abscess

C. Greater sac → Foramen of Winslow → Hepatorenal pouch → Paracolic gutter → Lesser sac → Pelvic abscess

D. Hepatorenal pouch → Paracolic gutter → Lesser sac → Foramen of Winslow → Pelvic abscess

See Answer in Part B → Q12

@Neet_pg_bot

Q13: Which muscle is primarily involved in a midline abdominal incision? (Q848806)

A. Rectus Abdominis

B. External Oblique

C. Internal Oblique

D. Transverse Abdominis

See Answer in Part B → Q13

@Neet_pg_bot

Q14: Which of the following statements about the conjoint tendon is false ? (Q848807)

A. The conjoint tendon is formed by the fusion of the internal oblique and transversus abdominis muscles.

B. The conjoint tendon contributes to the posterior wall of the inguinal canal.

C. The conjoint tendon is located in the anterior wall of the inguinal canal.

D. A weakness in the conjoint tendon can lead to a direct inguinal hernia.

See Answer in Part B → Q14

@Neet_pg_bot

• [08_Abdomen] 039 Abdomen Arterial Supply Venous Drainage Of Thorax And Abdomen

« Back to Folder Directory

[08_Abdomen] 039 Abdomen Arterial Supply Venous Drainage Of Thorax And Abdomen — Quick Jump

Q1 (p. 515)	*Q2 (p. 515)*	*Q3 (p. 516)*	*Q4 (p. 516)*	*Q5 (p. 517)*	*Q6 (p. 517)*
Q7 (p. 518)	*Q8 (p. 519)*	*Q9 (p. 519)*	*Q10 (p. 519)*	*Q11 (p. 520)*	*Q12 (p. 521)*
Q13 (p. 521)	*Q14 (p. 522)*	*Q15 (p. 522)*	*Q16 (p. 523)*	*Q17 (p. 523)*	

Q1: Which of the following is NOT a common collateral pathway for venous return in cases of IVC obstruction? (Q848708)

A. Vertebral venous plexus

B. Internal thoracic veins

C. Superficial veins of the anterior abdominal wall

D. Pulmonary veins

See Answer in Part B → Q1

@Neet_pg_bot

Q2: How many Houston's valves are typically present in the human rectum? (Q848718)

A. 3

B. 4

C. 5

D. 6

See Answer in Part B → Q2

@Neet_pg_bot

Q3: Which of the following is not involved in the formation of the Marginal Artery of Drummond? (Q848717)

A. Ileocolic artery

B. Right colic artery

C. Left colic artery

D. Inferior epigastric artery

See Answer in Part B → Q3

@Neet_pg_bot

Q4: Examine the image below showing a cross-section of the small intestine. Which part of the small intestine does this section belong to? (Q848716)

A. Duodenum

B. Jejunum

C. Ileum

D. Cecum



See Answer in Part B → Q4

@Neet_pg_bot

Q5: Where is the paraduodenal recess located, and which structure is found in its fold? (Q848714)

A. To the right of the duodenum, contains the superior mesenteric artery.

B. To the left of the fourth part of the duodenum, contains the inferior mesenteric vein.

C. To the left of the fourth part of the duodenum, contains the superior mesenteric vein.

D. In front of the pancreas, contains the splenic vein.

See Answer in Part B → Q5

@Neet_pg_bot

Q6: Which of the following statements accurately describes the anatomical extent of the attached border of the following structure? (Q848713)

A. Duodenojejunal flexure to the ileocecal junction

B. Pylorus of the stomach to the transverse colon

C. Duodenojejunal flexure to the right iliac fossa

D. Stomach to the appendix



See Answer in Part B → Q6

@Neet_pg_bot

Q7: A 55-year-old man with a history of chronic liver disease presents with increasing abdominal swelling, difficulty swallowing, and hematemesis. On examination, he has a distended abdomen, and upon palpation, his spleen is enlarged. Which anatomical feature is primarily responsible for his hematemesis? (Q848712)

A. Paraumbilical to epigastric vein connections

B. Left gastric to esophageal vein connections

C. Superior to middle rectal vein connections

D. Splenic to inferior mesenteric vein connections

See Answer in Part B → Q7

@Neet_pg_bot

Q8: In cases of a strangulated internal hernia into the lesser sac through the epiploic foramen, the surgical approach is often made through the greater omentum as the epiploic foramen cannot be safely widened. Which of the following structures around the epiploic foramen restricts its enlargement during surgery? (Q848710)

A. Hepatic artery, bile duct, portal vein

B. Celiac trunk and splenic artery

C. Portal vein, duodenum, hepatic vein

D. Superior mesenteric artery, cystic duct, portal vein

See Answer in Part B → Q8

@Neet_pg_bot

Q9: Which of the following anatomical relationships is incorrect regarding portal venous circulation? (Q848709)

A. The portal vein is formed posterior to the neck of the pancreas

B. The splenic vein joins the superior mesenteric vein to form the portal vein

C. The portal vein ends at the porta hepatis

D. The portal vein is located posterior to the Inferior vena cava

See Answer in Part B → Q9

@Neet_pg_bot

Q10: A 55-year-old male presents with abdominal pain and constipation. A CT scan reveals a lesion affecting the distal third of the transverse colon and the descending

colon. Which of the following arteries is most likely involved in the blood supply to this region? (Q848700)

A. Celiac trunk

B. Superior mesenteric artery

C. Inferior mesenteric artery

D. Common hepatic artery

See Answer in Part B → Q10

@Neet_pg_bot

Q11: During abdominal surgery, the surgeon encounters a paired venous structure running vertically along the posterior abdominal wall continuing into the thoracic cavity, just lateral to the vertebral column as shown in the image below. What is this structure most likely? (Q848707)

A. Inferior vena cava

B. Hemiazygos vein

C. Ascending lumbar vein

D. Renal vein

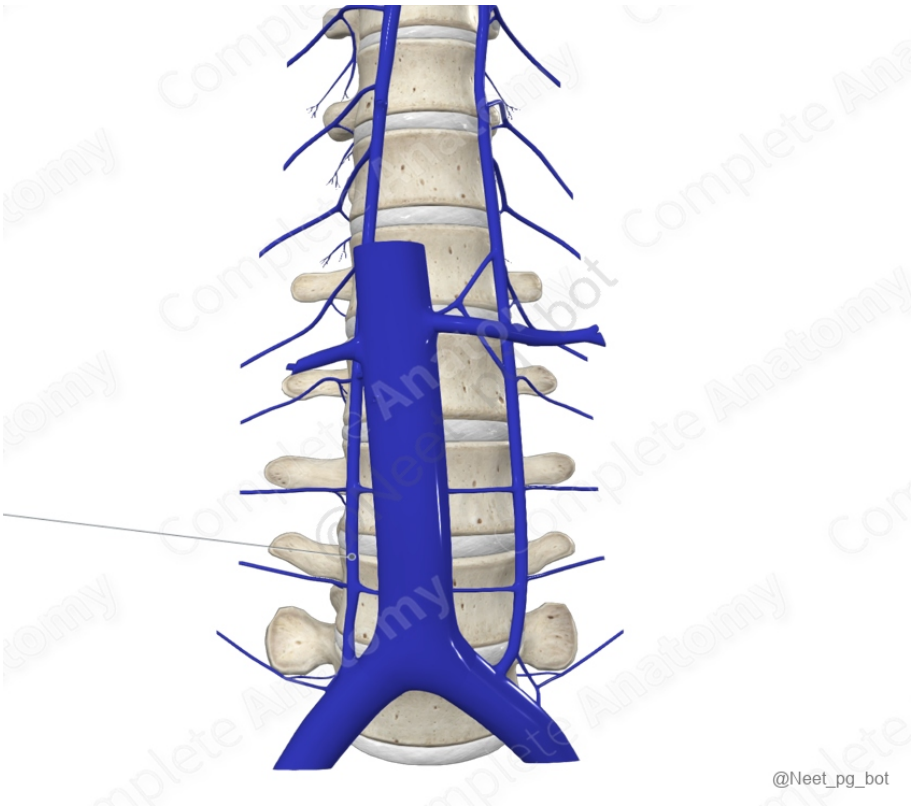

See Answer in Part B → Q11

@Neet_pg_bot

Q12: A surgeon must be careful with the inferior vena cava and its associated vessels during laparoscopic nephrectomy. Which of the following is true about IVC? (Q848706)

A. Left gonadal vein drains directly into IVC

B. Common iliac veins join to form the inferior vena cava at L3 vertebra level

C. Three large hepatic veins drain the liver into inferior vena cava

D. Right and left 5th lumbar veins drain into IVC

See Answer in Part B → Q12

@Neet_pg_bot

Q13: Which of the following is/are NOT a branch of the anterior division of the internal iliac artery? Superior vesical Obturator Middle rectal Iliolumbar Inferior gluteal (Q848705)

A. 1, 2, and 5

B. 2, 4, and 5

C. Only 4

D. 1, and 2

See Answer in Part B → Q13

@Neet_pg_bot

Q14: A medical student is reviewing the anatomy of the inferior mesenteric artery (IMA) and its branches. Which of the following statements about the IMA is false? (Q848704)

A. The IMA arises from the abdominal aorta at the level of the third lumbar vertebra (L3).

B. The IMA supplies the proximal segments of the small intestine.

C. The IMA gives rise to the superior rectal artery, which supplies the rectum.

D. IMA provides collateral circulation if SMA is stenosed

See Answer in Part B → Q14

@Neet_pg_bot

Q15: A 50-year-old male presents with chronic postprandial abdominal pain and weight loss. Imaging reveals compression of the third part of the duodenum between the superior mesenteric artery and the aorta. Which of the following best explains the patient's condition? (Q848703)

A. Superior Mesenteric Artery Syndrome

B. Inferior Mesenteric Artery Syndrome

C. Mesenteric Arterial Thrombosis

D. Aortic Aneurysm

See Answer in Part B → Q15

@Neet_pg_bot

Q16: A surgical procedure is planned to remove a tumor from the head of the pancreas. Which of the following arterial arcades is primarily responsible for supplying the posterior aspect of the head of the pancreas? (Q848702)

A. Anterior pancreaticoduodenal arcade

B. Posterior pancreaticoduodenal arcade

C. Kirk's arcade

D. Communicating artery

See Answer in Part B → Q16

@Neet_pg_bot

Q17: A 45-year-old patient presents with chronic upper abdominal pain and is diagnosed with compression of the celiac trunk by the median arcuate ligament. Which of the following arteries is not a direct branch of the celiac trunk? (Q848701)

A. Left gastric artery

B. Splenic artery

C. Common hepatic artery

D. Inferior mesenteric artery

See Answer in Part B → Q17

@Neet_pg_bot

• [08_Abdomen] 040 Anatomy Abdominal Organs

« Back to Folder Directory

[08_Abdomen] 040 Anatomy Abdominal Organs — Quick Jump

Q1 (p. 524) *Q2 (p. 524)* *Q3 (p. 525)* *Q4 (p. 525)* *Q5 (p. 525)* *Q6 (p. 526)*
Q7 (p. 526) *Q8 (p. 527)* *Q9 (p. 527)* *Q10 (p. 527)* *Q11 (p. 528)* *Q12 (p. 528)*

Q1: A 35-year-old man presents with abdominal pain and ascites. Imaging reveals obstruction of hepatic venous outflow consistent with Budd-Chiari syndrome. Which of the following statements best explains the preservation of the caudate lobe in this condition? (Q848788)

A. The caudate lobe has a separate arterial supply that protects it from hepatic venous obstruction.

B. The caudate lobe drains directly into the inferior vena cava via emissary veins, bypassing the obstructed hepatic veins.

C. The caudate lobe is less affected by portal hypertension due to its anatomical position.

D. The caudate lobe undergoes necrosis less frequently than other liver segments in Budd-Chiari syndrome.

See Answer in Part B → Q1

@Neet_pg_bot

Q2: During a surgical procedure involving the stomach, the surgeon needs to ensure adequate blood supply. Which artery should the surgeon be most concerned about when addressing the lesser curvature of the stomach? (Q848789)

A. Left gastroepiploic artery

B. Right gastric artery

C. Short gastric arteries

D. Right gastroepiploic artery

See Answer in Part B → Q2

@Neet_pg_bot

Q3: During a cholecystectomy, a surgeon encounters a variation in the biliary anatomy where the cystic duct is unusually short and close to the hepatic duct. Which of the following structures must the surgeon identify to avoid injury and ensure proper bile drainage? (Q848793)

A. Common bile duct

B. Sphincter of Oddi

C. Right hepatic duct

D. Pancreatic duct

See Answer in Part B → Q3

@Neet_pg_bot

Q4: Which of the following structures is not a component of the sphincter of Oddi? (Q848798)

A. Sphincter of the bile duct

B. Sphincter of the pancreatic duct

C. Sphincter of the ampulla

D. Sphincter of Rosenmuller

See Answer in Part B → Q4

@Neet_pg_bot

Q5: A 45-year-old patient is scheduled for a liver imaging study. The radiologist explains that dividing the liver into physiological lobes is important for understanding liver anatomy and function. Which of the following is primarily responsible for dividing the liver into physiological lobes? (Q848785)

A. Falciform ligament

B. Cantlie's line

C. Ligamentum teres

D. Porta hepatis

See Answer in Part B → Q5

@Neet_pg_bot

Q6: Match the following Sectors of the liver with their respective segments. 1. Right Posterior Sector a) Segments IV 2. Right Anterior Sector b) Segments III 3. Left Medial Sector c) Segment VII 4. Left Lateral Sector d) Segments V (Q848786)

A. 1-a, 2-d, 3-c, 4-b

B. 1-a, 2-d, 3-b, 4-c

C. 1-d, 2-c, 3-b, 4-a

D. 1-c, 2-d, 3-a, 4-b

See Answer in Part B → Q6

@Neet_pg_bot

Q7: A patient is undergoing imaging for liver evaluation. The radiologist describes a segment located posterior to the right hepatic vein and in the superior part of the right posterior sector. Which segment of the liver is being described? (Q848787)

A. Segment V

B. Segment III

C. Segment VII

D. Segment II

See Answer in Part B → Q7

@Neet_pg_bot

Q8: A 45 y/o man presents with symptoms of gastric dysmotility and increased acid secretion. Which structures are primarily involved in the parasympathetic innervation of the stomach? (Q848790)

A. Greater splanchnic nerves and coeliac plexus

B. Vagus nerves and their branches

C. T6 to T10 spinal segments

D. Lumbar sympathetic ganglia

See Answer in Part B → Q8

@Neet_pg_bot

Q9: Which of the following structures is not part of the stomach bed? (Q848791)

A. Left kidney

B. Pancreas

C. Diaphragm

D. Right kidney

See Answer in Part B → Q9

@Neet_pg_bot

Q10: A 60 y/o woman presents with abdominal pain localized to the upper right quadrant. Imaging reveals a mass adjacent to the uncinate process of the pancreas. Which part of the duodenum is most likely in direct relation to this mass? (Q848792)

A. First (superior) part

B. Second (descending) part

C. Third (horizontal) part

D. Fourth (ascending) part

See Answer in Part B → Q10

@Neet_pg_bot

Q11: Which of the following is a characteristic feature of the ileum compared to the jejunum? (Q848800)

A. Thicker and more vascular wall

B. Fewer Peyer’s patches

C. More numerous straight arteries

D. Larger and more prominent circular folds

See Answer in Part B → Q11

@Neet_pg_bot

Q12: A 45 y/o male patient presents with abdominal pain and distension. A CT scan reveals multiple appendices epiploicae, particularly prominent in the sigmoid colon. Which of the following statements regarding the anatomy of the large intestine is false? (Q848801)

A. The caecum is typically 8-10 cm long and is a common site for appendices epiploicae.

B. The sigmoid colon, which is S-shaped, leads directly into the rectum.

C. The total length of the large intestine in adults ranges from 1 to 1.5 meters.

D. Appendices epiploicae are more common in the distal colon.

See Answer in Part B → Q12

@Neet_pg_bot

• [08_Abdomen] 041 Anatomy Pancreas Kidney And Ureter

« Back to Folder Directory

[08_Abdomen] 041 Anatomy Pancreas Kidney And Ureter — Quick Jump

Q1 (p. 529) *Q2 (p. 529)* *Q3 (p. 529)* *Q4 (p. 530)* *Q5 (p. 530)* *Q6 (p. 531)*
Q7 (p. 531) *Q8 (p. 531)* *Q9 (p. 532)* *Q10 (p. 532)*

Q1: What structure crosses the ureter anteriorly on both sides during its abdominal course? (Q848669)

A. Inferior mesenteric artery

B. Gonadal vessels

C. Genitofemoral nerve

D. Duodenum

See Answer in Part B → Q1

@Neet_pg_bot

Q2: Which vessels primarily supply the middle part of the ureter? (Q848671)

A. Renal artery

B. Vesical vessels

C. Aorta

D. Uterine vessels

See Answer in Part B → Q2

@Neet_pg_bot

Q3: A 9 y/o child presents with abdominal pain and hematuria. Imaging reveals that the left renal vein is compressed between the abdominal aorta and the superior

mesenteric artery. What is a key anatomical feature contributing to this condition? (Q848664)

A. The left renal vein passes behind the abdominal aorta.

B. The pancreas lies directly posterior to the superior mesenteric artery.

C. The left renal vein travels behind the pancreas before crossing the aorta.

D. The pancreas is situated inferior to the left renal vein.

See Answer in Part B → Q3

@Neet_pg_bot

Q4: Which vein receives drainage from both the left gonadal and left adrenal veins? (Q848665)

A. Inferior vena cava

B. Right renal vein

C. Left renal vein

D. Right adrenal vein

See Answer in Part B → Q4

@Neet_pg_bot

Q5: Which of the following layers immediately surrounds the kidney and adheres closely to its surface? (Q848666)

A. Pararenal fat

B. Fibrous capsule

C. Renal fascia

D. Perirenal fat

See Answer in Part B → Q5

@Neet_pg_bot

Q6: Which structure is in direct contact with the upper pole of the right kidney? (Q848667)

A. Right lobe of the liver

B. Duodenum

C. Right suprarenal gland

D. Right colic flexure

See Answer in Part B → Q6

@Neet_pg_bot

Q7: Which rib is related to the posterior surface of the left kidney but not the right kidney? (Q848668)

A. 7th rib

B. 8th rib

C. 12th rib

D. 11th rib

See Answer in Part B → Q7

@Neet_pg_bot

Q8: Which of the following is not a typical site of ureteric constriction? (Q848670)

A. Junction with the renal pelvis

B. Crossing by ductus deferens

C. At the pelvic outlet

D. Opening at the trigone

See Answer in Part B → Q8

@Neet_pg_bot

Q9: Which part of the pancreas is covered by the peritoneum? (Q848672)

A. Head of the pancreas

B. Body of the pancreas

C. Tail of the pancreas

D. Entire pancreas

See Answer in Part B → Q9

@Neet_pg_bot

Q10: A 45-year-old male presents with complaints of a progressively enlarged abdomen and discomfort on the left side. Imaging studies reveal splenomegaly. Which structure is primarily responsible for preventing the downward displacement of the spleen in this case? (Q848673)

A. Phrenicocolic Ligament

B. Gastrosplenic Ligament

C. Splenorenal Ligament

D. Diaphragm

See Answer in Part B → Q10

@Neet_pg_bot

• [08_Abdomen] 042 Abdominal Neurovascular Bundles

« Back to Folder Directory

[08_Abdomen] 042 Abdominal Neurovascular Bundles — Quick Jump

Q1 (p. 533) *Q2 (p. 533)* *Q3 (p. 534)* *Q4 (p. 534)* *Q5 (p. 534)* *Q6 (p. 535)*
Q7 (p. 535) *Q8 (p. 536)*

Q1: Which of the following statements about the autonomic innervation of the gastrointestinal tract is correct? (Q848676)

A. The vagus nerve provides parasympathetic innervation to the entire length of the gut.

B. The pelvic splanchnic nerves supply sympathetic innervation to the hindgut.

C. The greater splanchnic nerves provide sympathetic innervation primarily to the midgut.

D. The parasympathetic supply to the hindgut originates from the sacral spinal cord.

See Answer in Part B → Q1

@Neet_pg_bot

Q2: A 45-year-old male presents with severe epigastric pain radiating to the back. He reports that the pain worsens after eating and is associated with nausea. On examination, there is epigastric tenderness, but no rebound or guarding. The patient's past medical history is significant for chronic pancreatitis. You suspect autonomic involvement in his pain pattern. Which of the following nerves is most likely involved in transmitting the visceral pain signals from the pancreas? (Q848679)

A. Greater splanchnic nerve

B. Lesser splanchnic nerve

C. Pelvic splanchnic nerve

D. Vagus nerve

See Answer in Part B → Q2

@Neet_pg_bot

Q3: A 45-year-old man presents with dull, poorly localized abdominal pain that began 12 hours ago. Over time, the pain becomes sharper and more localized in the right lower quadrant. The patient also reports nausea and loss of appetite. On physical examination, tenderness is noted at McBurney's point. Which of the following best explains the initial presentation of the patient's pain? (Q848680)

A. Irritation of the peritoneum

B. Stimulation of visceral afferent fibers accompanying sympathetic nerves

C. Direct irritation of somatic nerves in the abdominal wall

D. Referred pain via the phrenic nerve (C3-C5)

See Answer in Part B → Q3

@Neet_pg_bot

Q4: At which vertebral level does the abdominal aorta typically bifurcate into the common iliac arteries? (Q848674)

A. T12

B. L2

C. L4

D. L5

See Answer in Part B → Q4

@Neet_pg_bot

Q5: A 45-year-old patient presents with severe abdominal pain and bloody diarrhea. CT angiography reveals thrombosis of a major vein draining the distal transverse colon, descending colon, and sigmoid colon. Which of the following veins is most likely to be affected in this patient's condition? (Q848675)

A. Hepatic portal vein

B. Superior mesenteric vein

C. Inferior mesenteric vein

D. Celiac vein

See Answer in Part B → Q5

@Neet_pg_bot

Q6: Which of the following statements about the innervation and vascular supply of the uterus and vagina is correct? (Q848677)

A. The parasympathetic supply to the entire uterus and vagina comes from the pelvic splanchnic nerves (S2-S4)

B. The uterine artery is a branch of the external iliac artery

C. The vaginal venous plexus drains primarily into the internal pudendal vein

D. The superior part of the vagina receives its arterial supply from the vaginal artery, while the inferior part is supplied by branches of the internal pudendal artery

See Answer in Part B → Q6

@Neet_pg_bot

Q7: Which of the following statements about pre-aortic and para-aortic lymph nodes is correct? (Q848678)

A. Pre-aortic nodes primarily drain lymph from the lower limbs

B. Para-aortic nodes are located posterior to the abdominal aorta

C. Coeliac nodes are a subset of pre-aortic nodes

D. Lateral aortic nodes drain lymph from the stomach and pancreas

See Answer in Part B → Q7

@Neet_pg_bot

Q8: A 36-year-old male presents with pain in his right lower quadrant. Imaging reveals no abnormalities in the appendix, yet the patient experiences referred pain that radiates to the periumbilical region. Which of the following best explains this phenomenon? (Q848681)

A. Convergence of somatic and visceral afferent fibers in the dorsal horn of the spinal cord

B. Specific nerve injury affecting the parietal peritoneum

C. Direct stimulation of visceral pain fibers in the appendix

D. Local irritation of the somatic sensory nerves in the abdominal wall

See Answer in Part B → Q8

@Neet_pg_bot

• [08_Abdomen] 043 Previous Year Questions

« Back to Folder Directory

[08_Abdomen] 043 Previous Year Questions — Quick Jump

Q1 (p. 537)	*Q2 (p. 537)*	*Q3 (p. 538)*	*Q4 (p. 538)*	*Q5 (p. 538)*	*Q6 (p. 539)*
Q7 (p. 539)	*Q8 (p. 539)*	*Q9 (p. 540)*	*Q10 (p. 541)*	*Q11 (p. 541)*	*Q12 (p. 541)*
Q13 (p. 542)	*Q14 (p. 542)*	*Q15 (p. 543)*	*Q16 (p. 544)*	*Q17 (p. 545)*	*Q18 (p. 546)*
Q19 (p. 546)	*Q20 (p. 547)*	*Q21 (p. 547)*	*Q22 (p. 547)*	*Q23 (p. 548)*	*Q24 (p. 548)*
Q25 (p. 549)	*Q26 (p. 549)*	*Q27 (p. 550)*	*Q28 (p. 550)*	*Q29 (p. 551)*	*Q30 (p. 552)*

Q1: A patient with a medical history of liver cirrhosis now presents with abdominal pain, jaundice, and portal hypertension. Anastomosis between which of the following veins will be seen? (Q855402)

A. Left colic vein and middle colic veins

B. Esophageal veins and left gastric veins

C. Superior and phrenic veins

D. Sigmoid and superior rectal veins

See Answer in Part B → Q1

@Neet_pg_bot

Q2: Deep inguinal ring is a defect in (Q859524)

A. External oblique aponeurosis

B. Internal oblique aponeurosis

C. Fascia transversalis

D. Rectus sheath

See Answer in Part B → Q2

@Neet_pg_bot

Q3: A tumor of the uncinate process of the pancreas affects which of the following vessels? (Q854984)

A. Superior mesenteric artery

B. Portal vein

C. Common hepatic artery

D. Inferior mesenteric artery

See Answer in Part B → Q3

@Neet_pg_bot

Q4: Ligation of common hepatic artery will impair blood supply in: (Q854913)

A. Right gastric and right gastroepiploic artery

B. Right gastric and left gastric artery

C. Right gastroepiploic and short gastric vessels

D. Right gastric and short gastric vessels

See Answer in Part B → Q4

@Neet_pg_bot

Q5: The patient exhibited an enlarged lymph node in the inguinal area. The primary cause that is most probable is (Q854911)

A. Testicular cancer

B. Anal cancer

C. Sigmoid colon cancer

D. Prostate cancer

See Answer in Part B → Q5

@Neet_pg_bot

Q6: Which of the following features differentiated the exocrine pancreas from the parotid gland? (Q856946)

A. Basal lamina lining the serous acini

B. Absence of striated duct

C. Presence of serous acini with acidophilic tip

D. Presence of apical acinar villi

See Answer in Part B → Q6

@Neet_pg_bot

Q7: Where are the Ito cells in the liver located? (Q856943)

A. Space of disse

B. Space of moll

C. Sinusoids

D. Bile canaliculi

See Answer in Part B → Q7

@Neet_pg_bot

Q8: A 34-year-old man presented with a fever and massive splenomegaly. The spleen was 15 cm on palpation and directed obliquely when measured from the right iliac fossa. Which of the following structures prevent the vertical and downward descent of the spleen? (Q856182)

A. Lienorenal ligament

B. Gastrosplenic ligament

C. Phrenicocolic ligament

D. Lienophrenic ligament

See Answer in Part B → Q8

@Neet_pg_bot

Q9: The para-sagittal section of the abdomen is given below. What is the superior border of the marked structure? (Q855828)

A. Caudate lobe of liver

B. Duodenum

C. Lesser omentum

D. Inferior vena cava

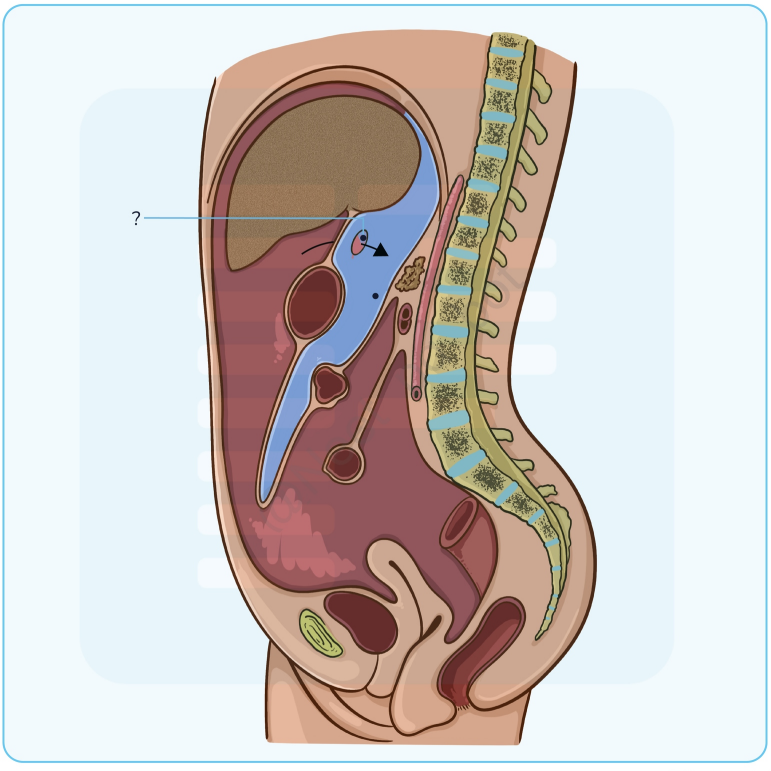

@Neet_pg_bot

See Answer in Part B → Q9

@Neet_pg_bot

Q10: Which anatomical plane contains the neurovascular structures supplying the abdominal wall, located below the rectus abdominis muscle and above the transversalis fascia? (Q857643)

A. Between the internal oblique and external oblique

B. Deep to transversus abdominis

C. Between the internal oblique and rectus abdominis

D. Between the internal oblique and transversus abdominis

See Answer in Part B → Q10

@Neet_pg_bot

Q11: What is the term used to describe the vertical plane that separates the body into anterior and posterior sections? (Q857568)

A. Coronal plane

B. Transverse plane

C. Axial plane

D. Median plane

See Answer in Part B → Q11

@Neet_pg_bot

Q12: Which of the following statements is false about thoracolumbar fascia? (Q857210)

A. They contain nociceptive nerve endings

B. In the lumbar region, it is in 4 layers

C. In the thoracic region, it is attached medially to the vertebrae

D. The anterior, posterior and middle join to form the aponeurotic origin of transversus abdominis

See Answer in Part B → Q12

@Neet_pg_bot

Q13: To what level of vertebrae does the marked structure correspond? (Q857910)

A. At the junction of L1 & L2

B. At the junction of L2 & L3

C. At the junction of T12 & L1

D. At the junction of L3 & L4



See Answer in Part B → Q13

@Neet_pg_bot

Q14: Which of the following is not a boundary of the hepatocystic triangle ? (Q865261)

A. Cystic duct

B. Common hepatic duct

C. Cystic artery

D. Inferior border of liver

See Answer in Part B → Q14

@Neet_pg_bot

Q15: A defect in which of the following forms the structure marked below? (Q855296)

A. Internal oblique B) External oblique C) Parietal peritoneum D) Fascia transversalis

B. External oblique

C. Parietal peritoneum

D. Fascia transversalis

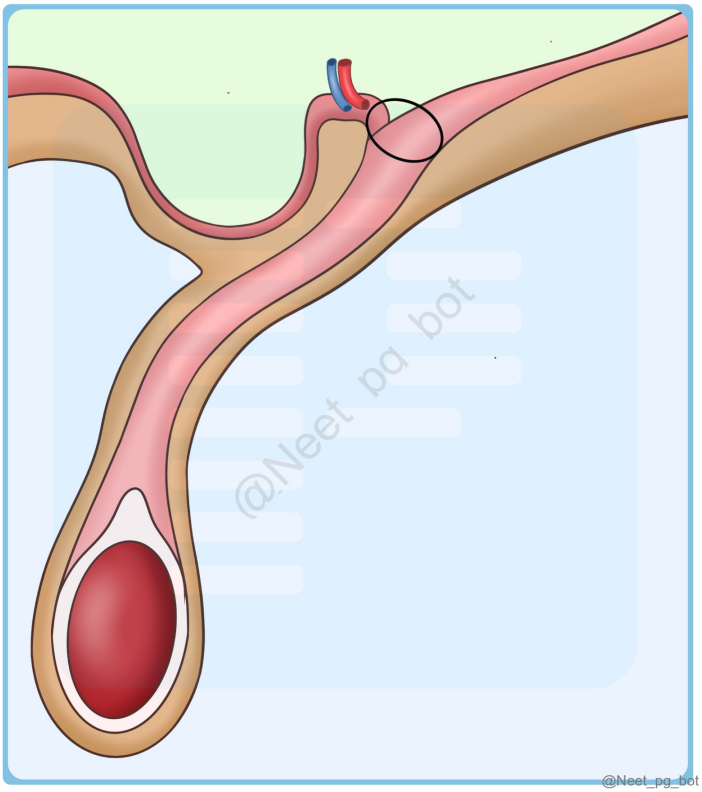

See Answer in Part B → Q15

@Neet_pg_bot

Q16: Please identify the position of the appendix in the image provided . (Q854796)

A. A-Retrocecal; B-Preileal, C- Postileal, D-Pelvic; E- Subcecal

B. A- Retrocecal; B- Postileal; C Preileal; D-Pelvic: E-Paracecal

C. A- Retrocecal; B- Postileal; C- Preileal; D - Subcecal; E - Pelvic

D. A- Retrocecal; B- Postileal; C- Preileal; D-Pelvic; E- Subcecal

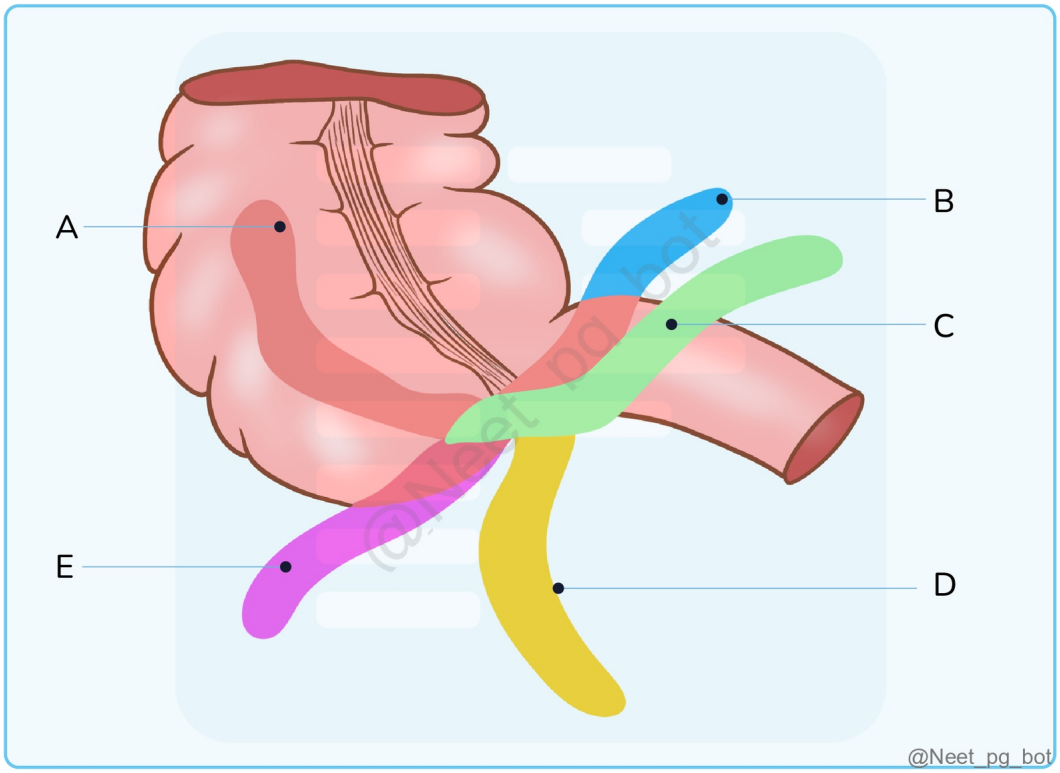

See Answer in Part B → Q16

@Neet_pg_bot

Q17: During the examination of a patient with a hernia, a surgeon forcefully pushes the hernial sac back into the abdominal cavity without directly pushing back the contents first. What type of hernia has occurred as a result of this, which is depicted in the image below? (Q854794)

A. Strangulated hernia

B. Reduction en masse

C. Sliding hernia

D. Maydl's hernia

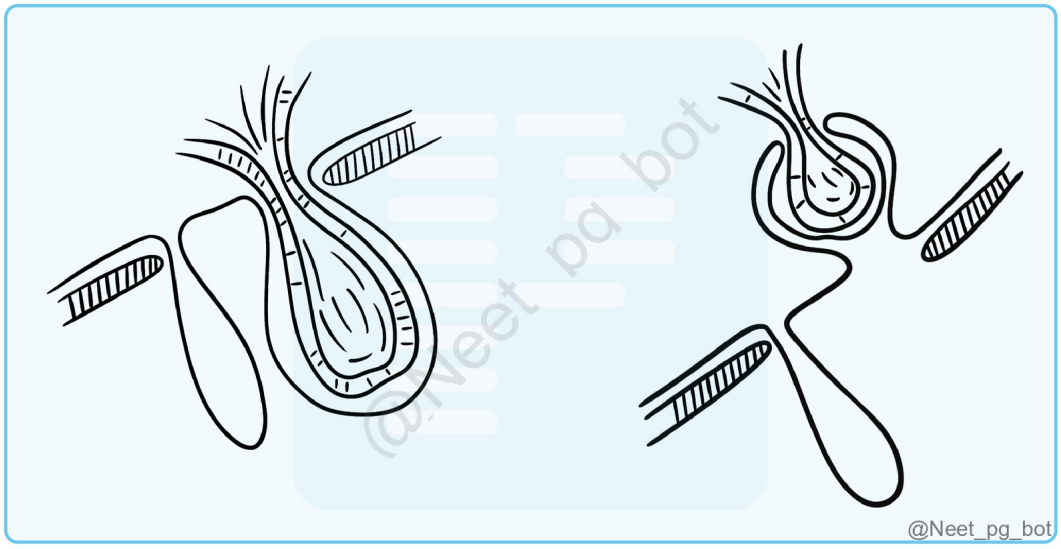

See Answer in Part B → Q17

@Neet_pg_bot

Q18: All are anterior to the third part of the duodenum except? (Q854777)

A. Superior mesenteric artery

B. Root of mesentery

C. Jejunum

D. Fundus of gallbladder

See Answer in Part B → Q18

@Neet_pg_bot

Q19: Which of the following drains into the IVC? (Q854578)

A. Left gonadal vein

B. Left adrenal vein

C. Left renal vein

D. Right ascending lumbar

See Answer in Part B → Q19

@Neet_pg_bot

Q20: Which statement is incorrect regarding the Adrenal gland? (Q854577)

A. Yellow-colored structures

B. The left adrenal gland is present below the spleen

C. The right adrenal gland is crescent in shape

D. It is located retroperitoneally

See Answer in Part B → Q20

@Neet_pg_bot

Q21: The fibers of the internal oblique and transversus abdominis contribute to which wall of the inguinal canal? (Q854573)

A. Anterior

B. Posterior

C. Roof

D. Floor

See Answer in Part B → Q21

@Neet_pg_bot

Q22: Identify the marked structure: (Q860255)

A. Splenogastric ligament

B. Lienorenal ligament

C. Greater omentum

D. Lesser omentum

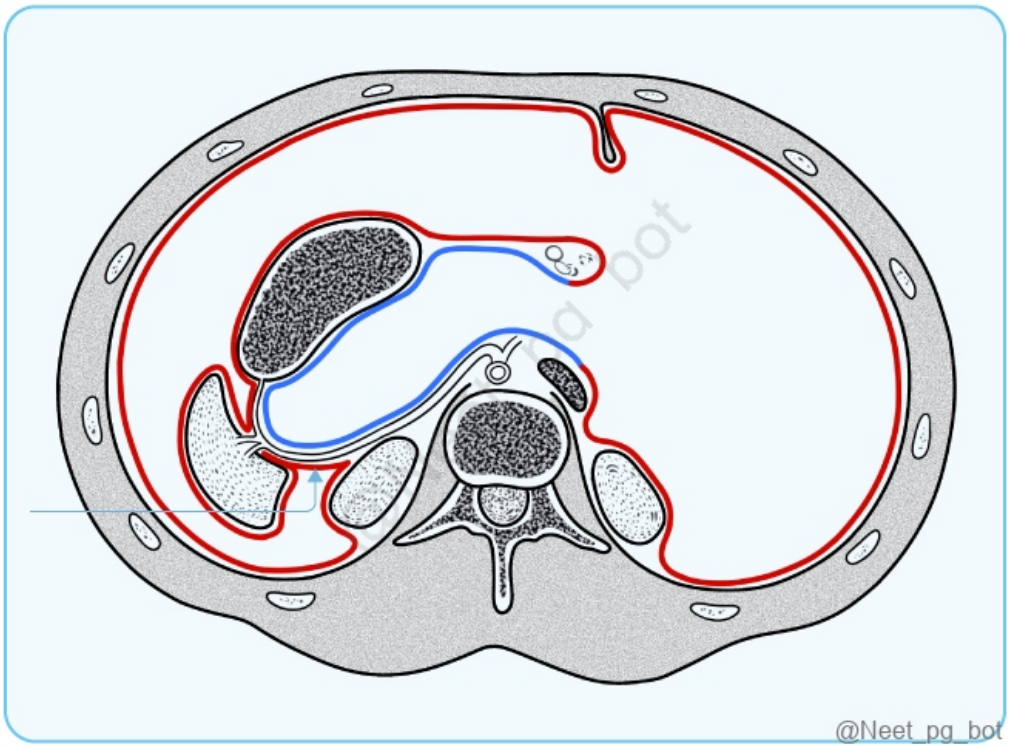

See Answer in Part B → Q22

@Neet_pg_bot

Q23: What is the most common type of hernia in females? (Q839895)

A. Obturator hernia

B. Direct inguinal hernia

C. Indirect inguinal hernia

D. Femoral hernia

See Answer in Part B → Q23

@Neet_pg_bot

Q24: A patient presents with fecal discharge from the umbilicus. What's the most likely diagnosis? (Q844322)

A. Urachal fistula

B. Ileal diverticulum

C. Omphalocele

D. Gastroschisis

See Answer in Part B → Q24

@Neet_pg_bot

Q25: Most common site of Congenital diaphragmatic hernia is? (Q844237)

A. Central tendon

B. Posterolateral

C. Crural

D. Anterolateral

See Answer in Part B → Q25

@Neet_pg_bot

Q26: A 15-year-old boy underwent splenectomy for immune thrombocytopenic purpura. During the procedure, the surgeon noticed bleeding while separating the spleen from the stomach. Which vessel is most likely implicated in this bleeding? (Q852997)

A. Left gastric vessels

B. Short gastric vessels

C. Gastroepiploic vessels

D. Splenic vessels

See Answer in Part B → Q26

@Neet_pg_bot

Q27: A surgeon by mistake injures one structure posterio to epiploic foramen. Which of the following structure is most likely involved? (Q866325)

A. Abdominal aorta

B. Hepatic artery

C. Inferior vena cava

D. Portal vein

See Answer in Part B → Q27

@Neet_pg_bot

Q28: What is the vertebral level of the abdominal plane labelled 2? (Q793131)

A. Lower border of L1

B. Upper border of L1

C. Upper border of L3

D. Lower border of L4

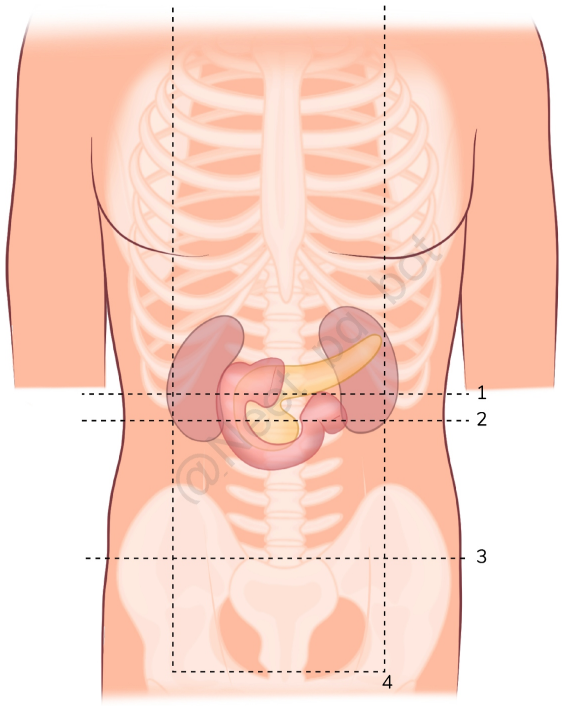

@Neet_pg_bot

See Answer in Part B → Q28

@Neet_pg_bot

Q29: To what level of vertebrae does the given structure correspond? (Q793160)

A. At the junction of L1 & L2

B. At the junction of L2 & L3

C. At the junction of T12 & L1

D. At the junction of L3 & L4

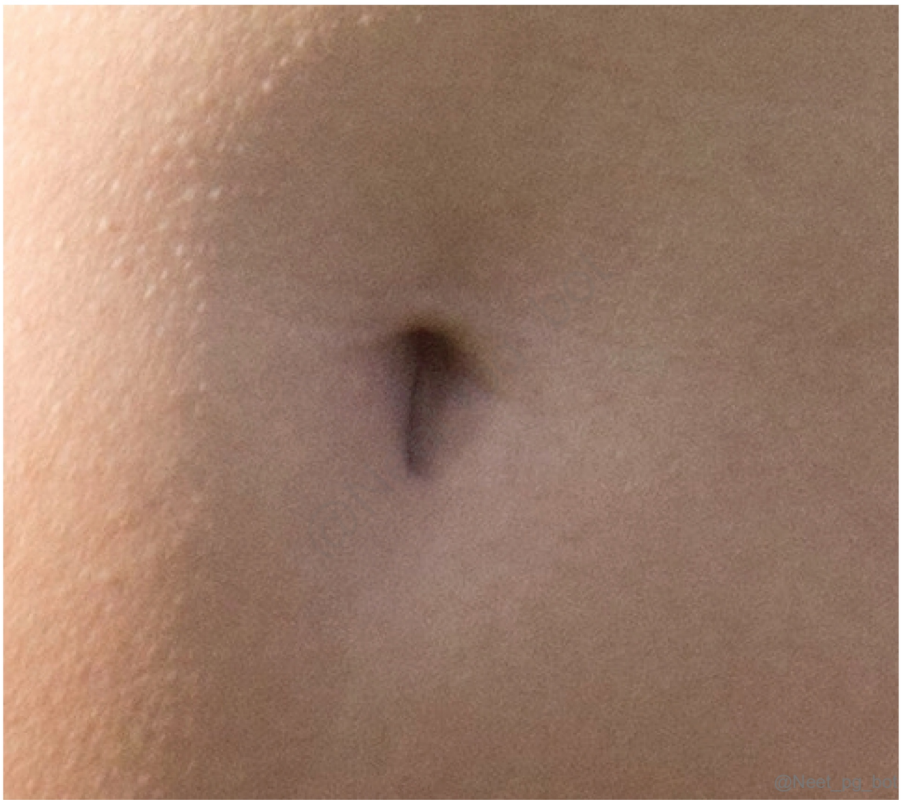

See Answer in Part B → Q29

@Neet_pg_bot

Q30: A 35-year-old patient underwent an endoscopic examination of the gastrointestinal tract due to recurrent abdominal discomfort and altered bowel habits. Identify the a rrow-marked structure in the given image . (Q820692)

A. Bruner gland

B. Intestinal cells of kajal

C. Crypts of lieberkuhn

D. Peyer's patch

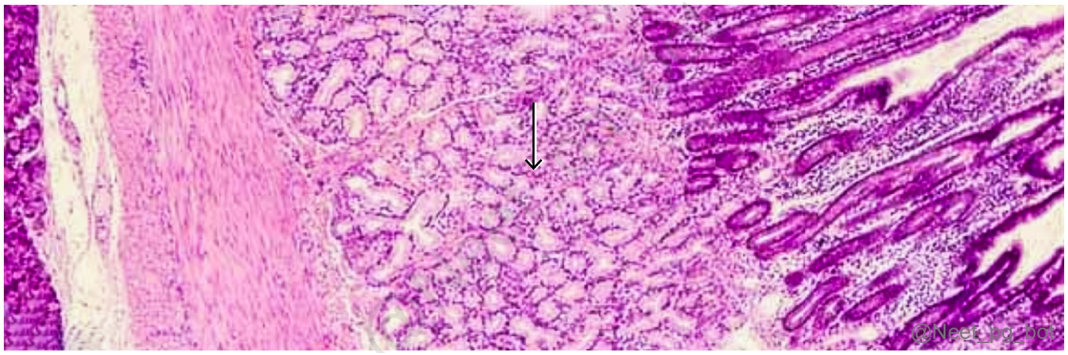

See Answer in Part B → Q30

@Neet_pg_bot

• [09_Pelvis and Perineum] 044 Development Of Gut Pelvis Perineum

« Back to Folder Directory

[09_Pelvis and Perineum] 044 Development Of Gut Pelvis Perineum — Quick Jump

Q1 (p. 554) *Q2 (p. 554)* *Q3 (p. 555)* *Q4 (p. 555)* *Q5 (p. 555)* *Q6 (p. 556)*
Q7 (p. 556) *Q8 (p. 557)* *Q9 (p. 557)* *Q10 (p. 558)*

Q1: A 35-year-old female presents with persistent flank pain. An abdominal ultrasound reveals that the lower poles of both kidneys are fused. What is the most likely developmental cause of this condition? (Q848304)

A. Abnormal migration of the metanephros derivative

B. Failure of the ureteric bud to differentiate

C. Complete degeneration of the pronephros

D. Improper development of the urogenital sinus

See Answer in Part B → Q1

@Neet_pg_bot

Q2: A 17-year-old girl with primary amenorrhea is diagnosed with Mullerian agenesis. Which all structures are likely to be affected? (Q848308)

A. Fallopian tubes, uterus, and upper 1/3rd of the vagina

B. Uterus, epoophoron, and lower 2/3rd of the vagina

C. Fallopian tube, trigone of bladder, and clitoris

D. Ovaries, clitoris, and labia majora

See Answer in Part B → Q2

@Neet_pg_bot

Q3: A 26-year-old female patient presents to the emergency department in active labour. The obstetrician is concerned about the size of the pelvic outlet and its implications for the delivery of the baby. Which of the following structures is NOT considered a boundary of the pelvic outlet? (Q848310)

A. Lower border of the pubic symphysis

B. Ischial tuberosities

C. Tip of the coccyx

D. Sacral promontory

See Answer in Part B → Q3

@Neet_pg_bot

Q4: A 35 yr old male with injury to the perineum, presented with blood collection in the perineal area extending to the mid-thigh. Which of the following correctly describes the location and characteristics of the perineal space involved in this patient? (Q848311)

A. Obturator fascia and inferior pelvic diaphragm fascia meet to form its apex

B. Located below the perineal membrane, open anteriorly, and continuous with spaces in the scrotum and penis

C. It contains the urethral sphincter within the wall of the urethra

D. Wedge-shaped spaces located below the pelvic diaphragm on either side of the anal canal

See Answer in Part B → Q4

@Neet_pg_bot

Q5: In a newborn presenting with ambiguous genitalia at birth, USG reveals the presence of a uterus. The karyotype was found to be XY. What is the most common cause? (Q848303)

A. Excessive production of DHT.

B. Mutation in the SRY gene.

C. Inadequate expression of WNT4.

D. Increased levels of estrogen.

See Answer in Part B → Q5

@Neet_pg_bot

Q6: A 16-year-old adolescent girl developed secondary sexual characteristics at 12 but has never menstruated. Ultrasound indicates no uterus. Karyotyping and hormone assays are normal. Which structure is most likely NOT affected in this patient? (Q848305)

A. Ovaries

B. Fallopian Tubes

C. Upper part of the Vagina

D. Cervix

See Answer in Part B → Q6

@Neet_pg_bot

Q7: An 8-year-old male child presents with a history of recurrent urinary tract infections. Imaging studies reveal a significant dilation of the ureters and an abnormal configuration of the bladder trigone. The patient is diagnosed with vesicoureteral reflux (VUR). Urologists suspect that the anomaly is linked to the embryological development of the trigone of the bladder. Which of the following statements about the trigone of the urinary bladder is FALSE? (Q848306)

A. The trigone is formed from the mesonephric duct.

B. The trigone is composed of endodermal tissue.

C. The proximal part of the mesonephric duct is the Wolffian duct. Mucosal rugosities are absent in trigone region.

D. The trigone is formed on the posterior wall of the bladder.

See Answer in Part B → Q7

@Neet_pg_bot

Q8: A one-day-old newborn is admitted to the neonatal intensive care unit (NICU) due to severe respiratory distress. Prenatal ultrasounds had revealed bilateral renal agenesis and severe oligohydramnios. The neonatologist explains that this malformation occurred early in gestation. Which of the following developmental processes is most likely responsible for the bilateral renal agenesis seen in this newborn? (Q848307)

A. Failure of the ureteric bud formation and induce the metanephric mesenchyme.

B. Failure of the pronephros development

C. Failure of the mesonephric duct to fuse with the urogenital sinus

D. Failure of the mesonephric duct to differentiate into kidney

See Answer in Part B → Q8

@Neet_pg_bot

Q9: Which of the following pairs correctly matches the embryonic structure with its corresponding differentiated structure in males and females during the development of external genitalia? (Q848309)

A. Genital tubercle → Clitoris (Female), Glans penis (Male)

B. Genital fold → Labia majora (Female), Penoscrotal raphe (Male)

C. Genital swelling → Labia majora (Female), Glans penis (Male)

D. Genital fold → Labia minora (Female), Scrotum (Male)

See Answer in Part B → Q9

@Neet_pg_bot

Q10: During a pelvic exam, a gynaecologist is teaching the medical students about the structures of the vestibule of the vagina. Which of the following structures is NOT located within the vestibule? (Q848312)

A. External urethral orifice

B. Vaginal orifice

C. Clitoral glans

D. Openings of the Bartholin glands

See Answer in Part B → Q10

@Neet_pg_bot

• [09_Pelvis and Perineum] 045 Neurovascular Anatomy Of Pelvis Perineum Rectum And Anal Canal

« Back to Folder Directory

[09_Pelvis and Perineum] 045 Neurovascular Anatomy Of Pelvis Perineum Rectum And Anal Canal — Quick Jump

Q1 (p. 559) *Q2 (p. 559)* *Q3 (p. 560)* *Q4 (p. 560)* *Q5 (p. 561)* *Q6 (p. 561)*
Q7 (p. 561) *Q8 (p. 562)* *Q9 (p. 563)* *Q10 (p. 563)* *Q11 (p. 564)* *Q12 (p. 564)*
Q13 (p. 564) *Q14 (p. 565)*

Q1: A 58-year-old male patient presents with difficulty in urination and reports a sensation of incomplete bladder emptying. Upon examination, the neurologist suspects an issue with autonomic innervation to the urinary bladder. What are the root values for the sympathetic and parasympathetic innervation of the urinary bladder? (Q848316)

A. Sympathetic: S1-S2; Parasympathetic: T10-L2

B. Sympathetic: T12-L1; Parasympathetic: S3-S5

C. Sympathetic: L1-L3; Parasympathetic: S1-S3

D. Sympathetic: T10-L2; Parasympathetic: S2-S4

See Answer in Part B → Q1

@Neet_pg_bot

Q2: A 45-year-old female presents with sharp pain and swelling in her right buttock and thigh after falling on her side, leading to difficulty sitting and walking. Examination shows swelling, tenderness, and bruising over the right buttock, with no deformity, dislocation, or neurological deficits, indicating a possible hematoma. What is the origin of the affected artery? (Q848318)

A. Anterior division of the internal iliac artery

B. Posterior division of the internal iliac artery

C. Anterior division of the obturator artery

D. Posterior division of the obturator artery

See Answer in Part B → Q2

@Neet_pg_bot

Q3: A 55-year-old male presents with rectal bleeding and changes in bowel habits. The physician evaluates the rectal anatomy to determine the best surgical approach. Which part of the rectum is covered by peritoneum only on the anterior aspect? (Q848320)

A. Upper 1/3rd

B. Middle 1/3rd

C. Lower 1/3rd

D. Whole of the rectum

See Answer in Part B → Q3

@Neet_pg_bot

Q4: A 58-year-old woman presents with faecal incontinence, particularly during activities that increase intra-abdominal pressure, such as coughing or lifting heavy objects. MRI reveals atrophy in a muscle responsible for maintaining the anorectal angle. What's the likely muscle involved in this? (Q848323)

A. External anal sphincter

B. Conjoint longitudinal muscle

C. Puborectalis

D. Internal anal sphincter

See Answer in Part B → Q4

@Neet_pg_bot

Q5: A 46-year-old female reports intermittent rectal bleeding and a feeling of fullness during bowel movements. She has a history of constipation and obesity. Examination reveals internal haemorrhoids. Which of the following options correctly describes their characteristics concerning location and nerve supply? Presence of a visible thrombus in the anal region Ability to manually reduce the mass. Located below the dentate line, covered by anoderm. Innervated by pelvic splanchnic nerves; generally painless. (Q848325)

A. 1,2,3

B. 2,3

C. 1,2

D. 2,4

See Answer in Part B → Q5

@Neet_pg_bot

Q6: A 33-year-old woman in labour is experiencing discomfort and perianal pain and is scheduled to receive a pudendal nerve block. Which anatomical landmarks should the clinician identify to locate the pudendal nerve accurately? (Q848313)

A. Lesser sciatic notch

B. Pubic symphysis

C. Greater sciatic notch

D. Ischial spine

See Answer in Part B → Q6

@Neet_pg_bot

Q7: Which of the following accurately describes the X, Y, and Z listed below? (Q848314)

A. Posterior rami of S1, S2, S3

B. Anterior rami of S1, S2, S3

C. Posterior rami of S2, S3, S4

D. Anterior rami of S2, S3, S4

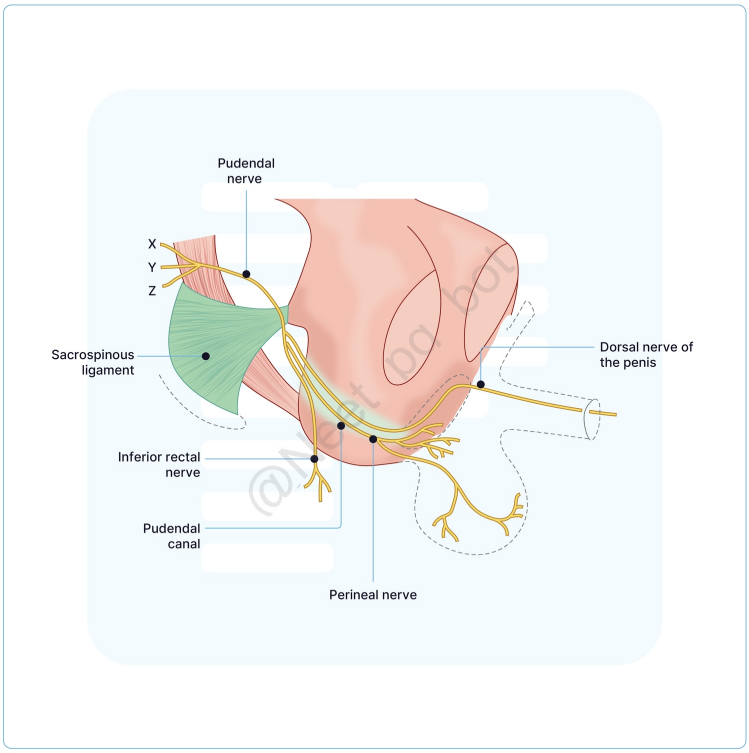

@Neet_pg_bot

See Answer in Part B → Q7

@Neet_pg_bot

Q8: A 45-year-old woman presents with chronic perineal pain and numbness following a difficult vaginal delivery. The clinician suspects entrapment of the nerve supplying sensation to the perineum. Through which foramina does this nerve exit and re-enter the pelvis? (Q848315)

A. Greater sciatic foramen → Obturator foramen

B. Lesser sciatic foramen → Greater sciatic foramen

C. Obturator foramen → Lesser sciatic foramen

D. Greater sciatic foramen → Lesser sciatic foramen

See Answer in Part B → Q8

@Neet_pg_bot

Q9: A 62-year-old female presents with persistent pelvic pain and urinary incontinence. Imaging reveals a mass in the pelvic region compressing nearby vascular structures. During the surgical workup, the surgeon reviews the arterial supply of the pelvis. Which of the following is not a branch of the internal iliac artery? (Q848317)

A. Lateral sacral artery

B. Uterine artery

C. Internal pudendal artery

D. Deep circumflex iliac artery

See Answer in Part B → Q9

@Neet_pg_bot

Q10: A 65-year-old male presents with urinary retention and pelvic discomfort. A digital rectal examination reveals an enlarged prostate gland. During surgery to relieve the obstruction, the urologist must take care to avoid damaging the structures that separate the prostate from the rectum. Which of the following structures separates the prostate gland from the rectum? (Q848319)

A. Waldeyer’s fascia

B. Scarpa’s fascia

C. Denonvilliers’ fascia

D. Camper’s fascia

See Answer in Part B → Q10

@Neet_pg_bot

Q11: A 55-year-old male with intermittent abdominal pain, changes in bowel habits, and occasional rectal bleeding is scheduled for a sigmoidoscopy. The cannula is inserted in the left lateral position to avoid injuring the rectal folds that are present against the concavities of the rectum. Which of the following statements regarding these folds is inaccurate? (Q848321)

A. First fold is situated near the rectosigmoid junction.

B. These folds are permanent.

C. Third fold is located at the upper end of the ampulla.

D. They are flattened in a distended rectum.

See Answer in Part B → Q11

@Neet_pg_bot

Q12: A 50-year-old man presents with perianal pain and bleeding during bowel movements. The region affected is supplied by a vessel that arises from the internal iliac system and supplies the lower anal canal. Which of the following arteries is the direct source of this vessel? (Q848322)

A. Inferior mesenteric artery

B. Internal pudendal artery

C. Obturator artery

D. Superior gluteal artery

See Answer in Part B → Q12

@Neet_pg_bot

Q13: A 50-year-old male presents with painful anal swelling and bleeding. External haemorrhoids are diagnosed, and the physician explains the pain is due to somatic innervation below a specific anatomical landmark in the anal canal. Which of the following separates the areas of somatic and visceral nerve supply in the anal canal?

(Q848324)

A. White line of Hilton

B. Anorectal junction

C. Iliopectineal line

D. Pectinate line

See Answer in Part B → Q13

@Neet_pg_bot

Q14: A 73-year-old male presents with rectal pain, and there is concern for rectal metastasis, given his history of prostate cancer. Which lymph nodes are most likely involved in the lymphatic drainage of the region marked 'X' in the image? (Q848326)

A. Para-aortic lymph nodes

B. Inferior mesenteric lymph nodes

C. Superficial inguinal lymph nodes

D. Internal iliac lymph nodes

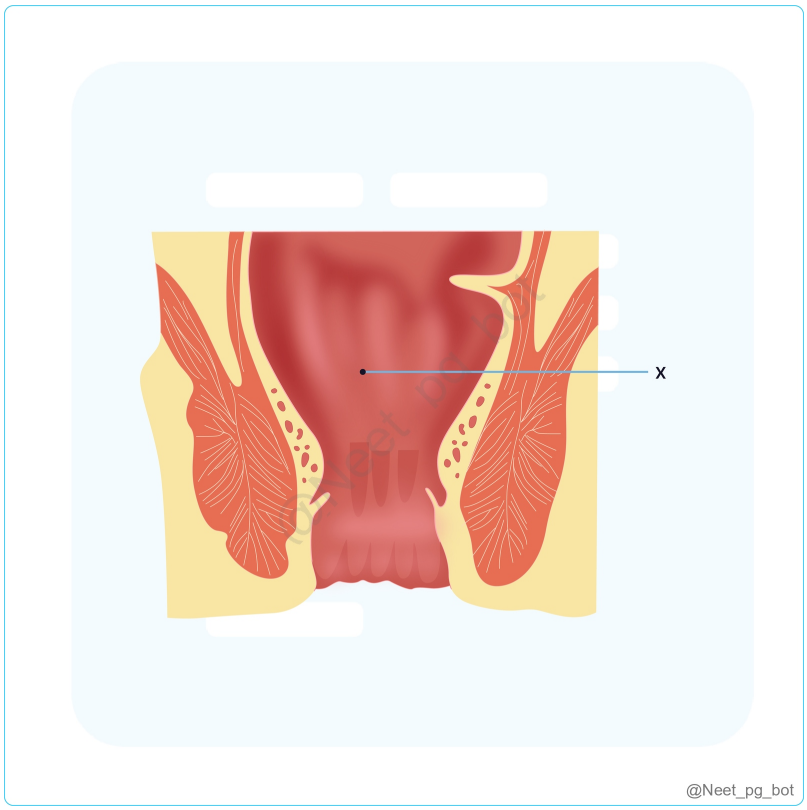

See Answer in Part B → Q14

@Neet_pg_bot

• [09_Pelvis and Perineum] 046 Perineal Pouches And Ischiorectal Fossa Extravasation Of Urine

« Back to Folder Directory

[09_Pelvis and Perineum] 046 Perineal Pouches And Ischiorectal Fossa Extravasation Of Urine — Quick Jump

Q1 (p. 567) *Q2 (p. 567)* *Q3 (p. 567)* *Q4 (p. 568)* *Q5 (p. 568)* *Q6 (p. 569)*
Q7 (p. 569) *Q8 (p. 570)*

Q1: Which of the following best describes the boundaries of the ischiorectal fossa? (Q848398)

A. Medially by the obturator internus, laterally by the levator ani.

B. Medially by the external anal sphincter, laterally by the ischial tuberosity.

C. Medially by the coccyx, laterally by the sacrotuberous ligament.

D. Medially by the pubic symphysis, laterally by the ischial spine.

See Answer in Part B → Q1

@Neet_pg_bot

Q2: Which of the following structures encloses all three masses of erectile tissue but does not extend into the glans penis? (Q848400)

A. Superficial fascia

B. Tunica albuginea

C. Bulbospongiosus muscle

D. Buck’s fascia

See Answer in Part B → Q2

@Neet_pg_bot

Q3: A 32-year-old man presents to the ER after falling onto a sharp object while riding a bicycle. He complains of difficulty urinating and swelling around his genital area. Examination reveals urine extravasation into the scrotum and anterior abdominal wall. What is the most likely site of urethral injury in this patient? (Q848401)

A. Membranous urethra

B. Prostatic urethra

C. Bulb of the penis

D. Can be any of the above

See Answer in Part B → Q3

@Neet_pg_bot

Q4: Which of the following muscles is NOT found in the superficial perineal pouch? (Q848395)

A. Bulbospongiosus

B. Ischiocavernosus

C. Superficial transverse perineal muscle

D. External urethral sphincter

See Answer in Part B → Q4

@Neet_pg_bot

Q5: A 40-year-old woman presents with stress urinary incontinence following childbirth. She reports leakage of urine during physical activity. Physical examination reveals no signs of infection or injury, but pelvic floor weakness is noted. The pelvic ultrasound shows damage to the muscles of the urogenital diaphragm. Which of the following muscles is most likely involved in this patient's condition? (Q848396)

A. Ischiocavernosus

B. Superficial transverse perineal muscle

C. External urethral sphincter

D. Bulbospongiosus

See Answer in Part B → Q5

@Neet_pg_bot

Q6: A 45-year-old woman is undergoing a gynecological procedure in the lithotomy position. The surgeon is identifying the bony landmarks for access to the pelvic organs. During the examination, the surgeon palpates a bony structure near the midline at the anterior aspect of the perineum. Which of the following bony landmarks is the surgeon most likely palpating? (Q848397)

A. Ischial tuberosity

B. Sacrum

C. Pubic symphysis

D. Pubic tubercle

See Answer in Part B → Q6

@Neet_pg_bot

Q7: Which of the following muscles is composed of the pelvic diaphragm? (Q848399)

A. Puborectalis, pubococcygeus

B. Obturator internus, piriformis

C. Levator ani, ischiococcygeus

D. Ischiocavernosus, bulbospongiosus

See Answer in Part B → Q7

@Neet_pg_bot

Q8: A 40-year-old male presents to the emergency department after a motor vehicle accident. He has an inability to urinate and perineal pain. Physical examination reveals a high-riding prostate on digital rectal examination, and imaging confirms extravasation of urine around the bladder and prostate. What is the most likely site of urethral injury? (Q848402)

A. Membranous urethra

B. Penile urethra

C. Bulb of the penis

D. Can be any of the above

See Answer in Part B → Q8

@Neet_pg_bot

• [09_Pelvis and Perineum] 047 Prostate Male Urethra And Female Reproductive System

« Back to Folder Directory

[09_Pelvis and Perineum] 047 Prostate Male Urethra And Female Reproductive System — Quick Jump

Q1 (p. 571) *Q2 (p. 571)* *Q3 (p. 572)* *Q4 (p. 572)* *Q5 (p. 572)* *Q6 (p. 573)*
Q7 (p. 573) *Q8 (p. 573)* *Q9 (p. 574)* *Q10 (p. 574)* *Q11 (p. 575)* *Q12 (p. 576)*

Q1: A 35 year old male presents with perineal pain and swelling after a traumatic injury during a sporting event. On examination, there is significant bruising over the scrotum and penis. Imaging confirms fluid collection in the superficial perineal space. Which of the following structures is most likely affected by the injury? (Q848403)

A. Sphincter urethrae muscle

B. Bulb of the penis

C. Dorsal nerve of the penis

D. Prostate gland

See Answer in Part B → Q1

@Neet_pg_bot

Q2: From the muscles given below, choose the muscles forming the pelvic diaphragm. Levator ani Coccygeus Bulbospongiosus Ischiocavernosus Superficial transverse perineal muscle Deep transverse perineal muscle (Q848404)

A. 1 and 2

B. 2 and 6

C. 3 and 4

D. 2 and 5

See Answer in Part B → Q2

@Neet_pg_bot

Q3: Choose the wrong pairing of fibers of pubococcygeus with its name. (Q848408)

A. Anterior fibers-levator prostatae

B. Anterior fibers-sphincter urethrovaginalis

C. Middle fibers-puborectalis

D. Posterior fibers-puborectalis

See Answer in Part B → Q3

@Neet_pg_bot

Q4: Which of the following lobes of the prostate is responsible for producing uvula vesicae? (Q848410)

A. Anterior lobe

B. Posterior lobe

C. Median lobe

D. Lateral lobe

See Answer in Part B → Q4

@Neet_pg_bot

Q5: A 72-year-old man visits the clinic for evaluation of urinary symptoms, including nocturia, increased urgency, and a sensation of incomplete bladder emptying. During the examination, a digital rectal exam reveals a smooth, enlarged prostate without any palpable nodules. The patient's PSA level is slightly elevated at 5.5 ng/mL. In which zone of the prostate does this condition primarily occur? (Q848411)

A. Peripheral zone

B. Central zone

C. Transitional zone

D. Anterior fibromuscular stroma

See Answer in Part B → Q5

@Neet_pg_bot

Q6: A 65-year-old male presents to the clinic with complaints of frequent urination, especially at night, and difficulty initiating urination. He reports that he feels an urge to urinate but often has to wait before the stream begins. During the digital rectal exam, the physician notes a smooth, enlarged prostate. Patient has a medical history of diabetes and hyperlipidemia. What is the most likely diagnosis? (Q848412)

A. Prostate cancer

B. Prostatitis

C. Benign prostatic hyperplasia (BPH)

D. Urinary tract infection (UTI)

See Answer in Part B → Q6

@Neet_pg_bot

Q7: Which of the following statements about the prostatic urethra is true? (Q848425)

A. It is primarily lined by stratified squamous epithelium.

B. It is the shortest segment of the male urethra.

C. It connects the bladder to the membranous urethra and receives the ejaculatory ducts.

D. It is solely responsible for the passage of urine, with no role in the reproductive system.

See Answer in Part B → Q7

@Neet_pg_bot

Q8: Which of the following correctly lists the segments of the male urethra in the order they occur from the bladder to the external urethral orifice? (Q848426)

A. Prostatic urethra → Membranous urethra → Spongy urethra

B. Spongy urethra → Membranous urethra → Prostatic urethra

C. Membranous urethra → Spongy urethra → Prostatic urethra

D. Prostatic urethra → Spongy urethra → Membranous urethra

See Answer in Part B → Q8

@Neet_pg_bot

Q9: Gynaecologist is planning to do uterine artery ligation. She must be careful while performing it due to the risk of injuring which structure? (Q848427)

A. Ureter, as it lies anterior to uterine artery

B. Ureter, as it lies posterior to uterine artery

C. Bladder, as it lies superior to uterine artery

D. Urethra, as it lies inferior to uterine artery

See Answer in Part B → Q9

@Neet_pg_bot

Q10: Match the branches of uterine arteries with their names based on the image given: 1 a) Basal artery 2 b) Spiral artery 3 c) Arcuate artery 4 d) Radial artery (Q848428)

A. 1-c, 2-a, 3-d, 4-b

B. 1-a, 2-b, 3-c, 4-d

C. 1-a, 2-d, 3-c, 4-b

D. 1-c, 2-d, 3-a, 4-b

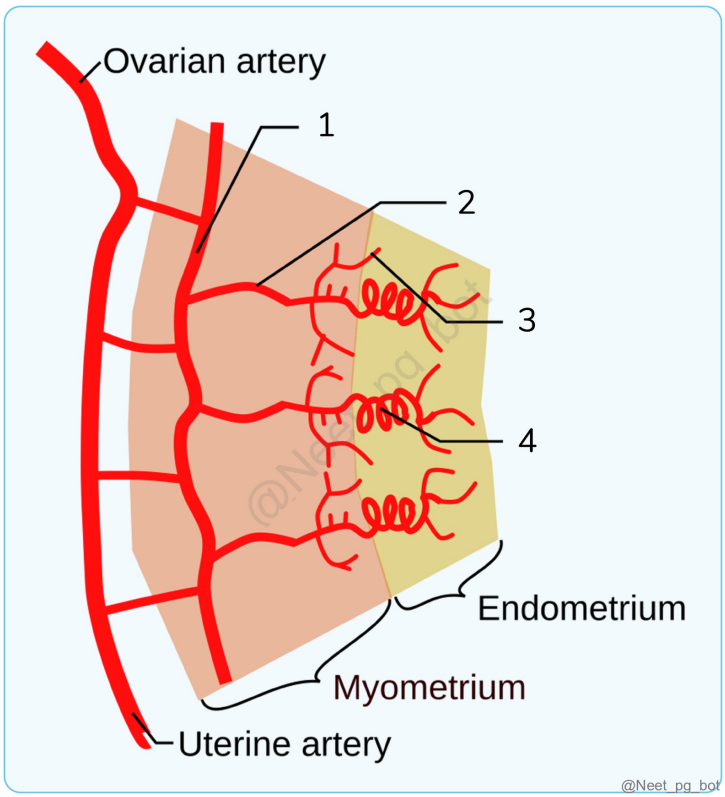

See Answer in Part B → Q10

@Neet_pg_bot

Q11: A 30 year old female presented with post coital bleeding. Hysterectomy with lymph node dissection was done. Gross specimen of the uterus is shown below. Which of the following nodes group is least likely to be positive for malignancy? (Q848429)

A. Superficial inguinal

B. Internal iliac

C. Obturator

D. Sacral



See Answer in Part B → Q11

@Neet_pg_bot

Q12: Angle shown in the image below in a non-gravid uterus is maintained by? (Q848430)

A. Round ligament

B. Uterosacral ligament

C. Both (A) and (B)

D. Pubocervical ligament

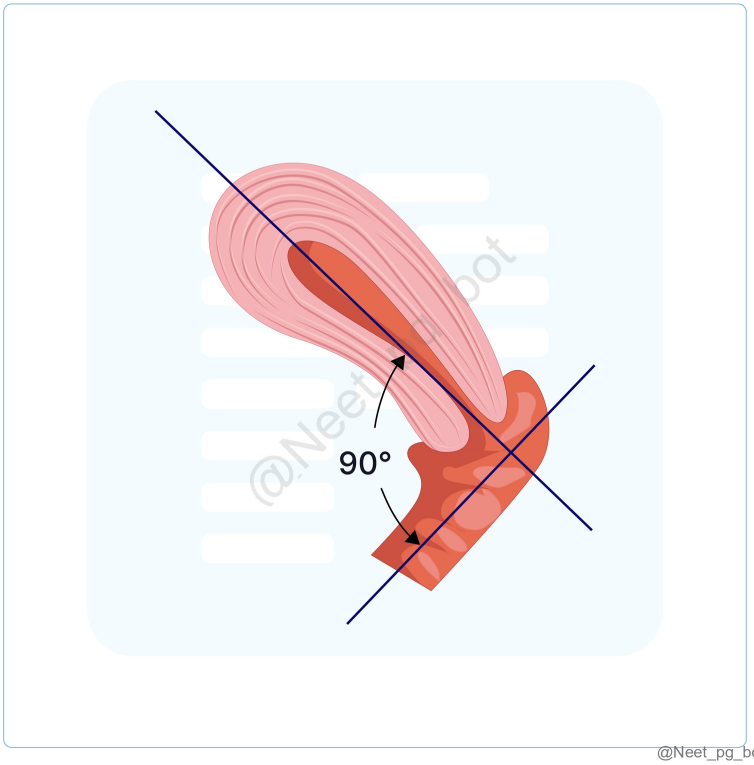

@Neet_pg_bot

See Answer in Part B → Q12

@Neet_pg_bot

• [09_Pelvis and Perineum] 048 Previous Year Questions

« Back to Folder Directory

[09_Pelvis and Perineum] 048 Previous Year Questions — Quick Jump

Q1 (p. 578)	*Q2 (p. 578)*	*Q3 (p. 579)*	*Q4 (p. 580)*	*Q5 (p. 581)*	*Q6 (p. 582)*
Q7 (p. 583)	*Q8 (p. 584)*	*Q9 (p. 584)*	*Q10 (p. 585)*	*Q11 (p. 585)*	*Q12 (p. 586)*
Q13 (p. 586)	*Q14 (p. 587)*	*Q15 (p. 587)*	*Q16 (p. 588)*	*Q17 (p. 588)*	*Q18 (p. 589)*
Q19 (p. 590)	*Q20 (p. 590)*				

Q1: Which muscles are responsible for constituting the pelvic diaphragm? A. Iliococcygeus B. Pubococcygeus C. Obturator internus D. Deep transverse perinei (Q855033)

A. A and B

B. A, B, C and D

C. A, B and D

D. A and D

See Answer in Part B → Q1

@Neet_pg_bot

Q2: In the given image which of the following structures is not associated with the marked area? (Q879187)

A. Pudendal nerve

B. Internal pudendal vessel

C. Tendon of obturator externus

D. Ischiococcygeus

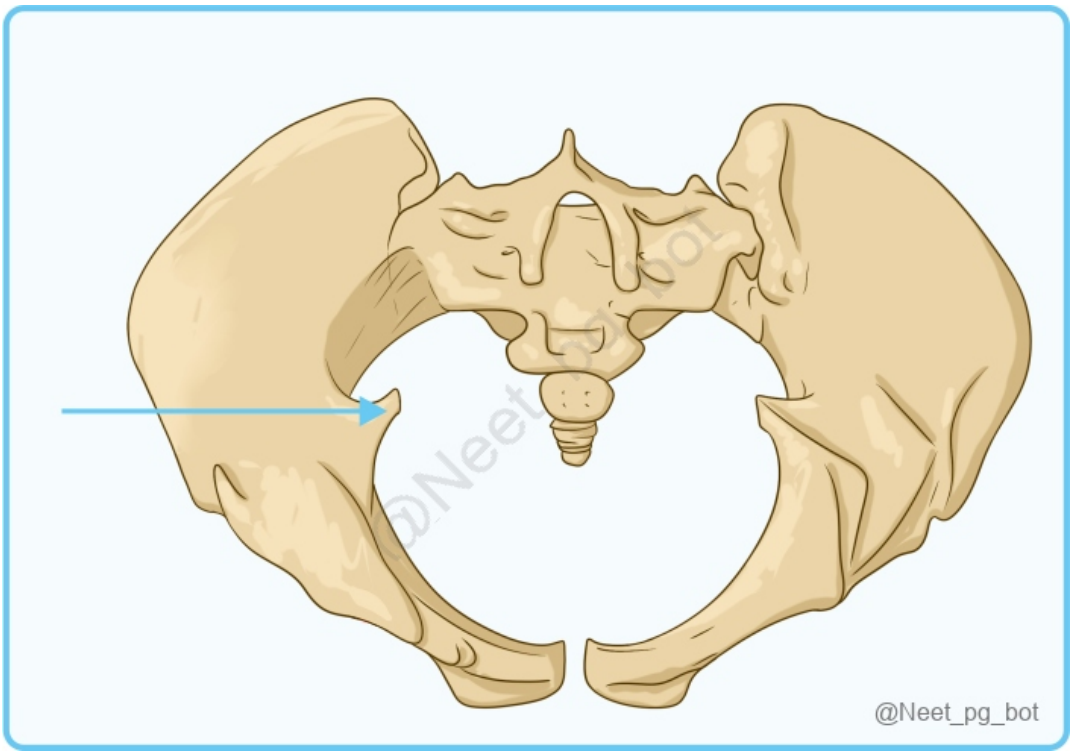

See Answer in Part B → Q2

@Neet_pg_bot

Q3: The below image is of a femur bone. Which muscles are attached to "A"? (Q859518)

A. Gluteus maximus

B. Iliopsoas

C. Quadriceps femoris

D. Adductor magnus

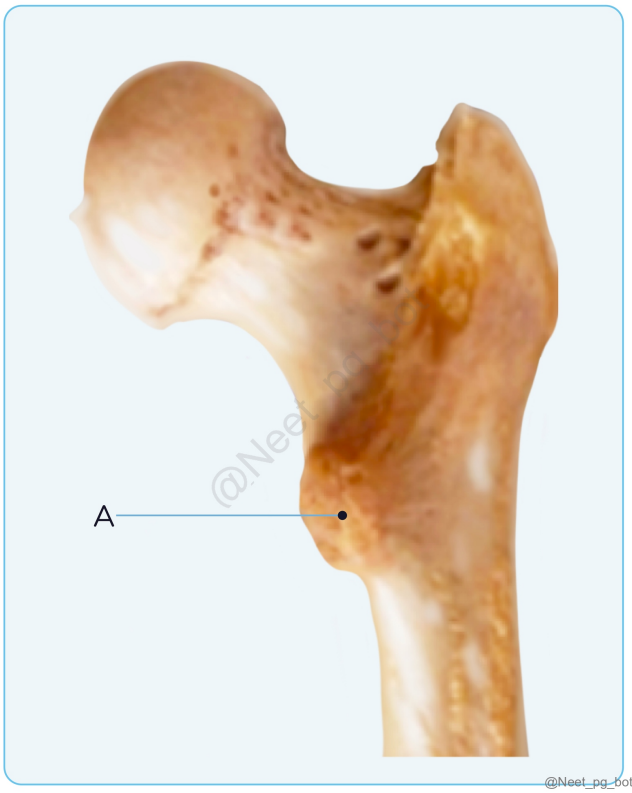

See Answer in Part B → Q3

@Neet_pg_bot

Q4: Identify the foramen marked in the image below:- (Q856378)

A. Foramen rotundum

B. Foramen ovale

C. Vidian canal

D. Foramen spoinosum



See Answer in Part B → Q4

@Neet_pg_bot

Q5: What is the action of the muscle shown in the image below at the hip joint? (Q856991)

A. Abduction and external rotation

B. Extension, adduction, and lateral rotation

C. Flexion and abduction

D. Flexion and external rotation

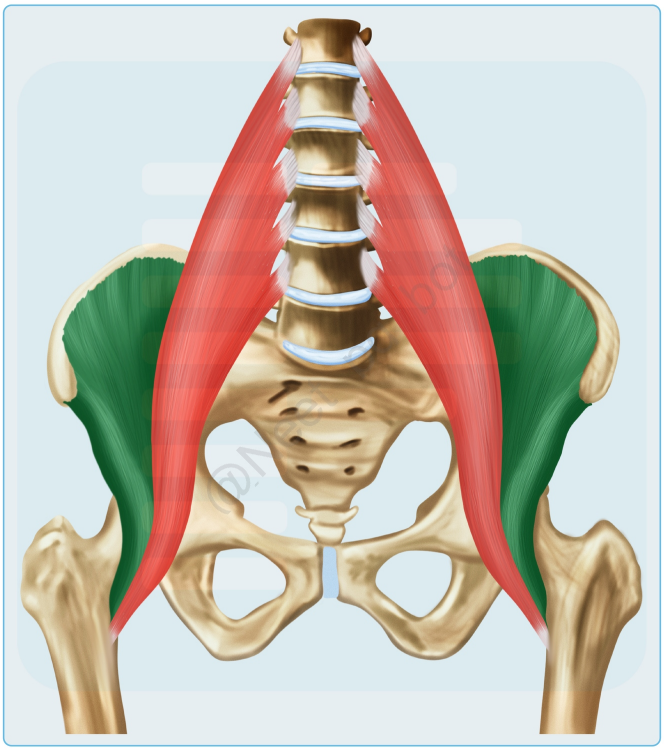

See Answer in Part B → Q5

@Neet_pg_bot

Q6: The structures marked in the image below are found in the epithelial lining of all of the following sites, except: (Q856956)

A. Oviduct

B. Epididymis

C. Bronchi

D. Ependyma

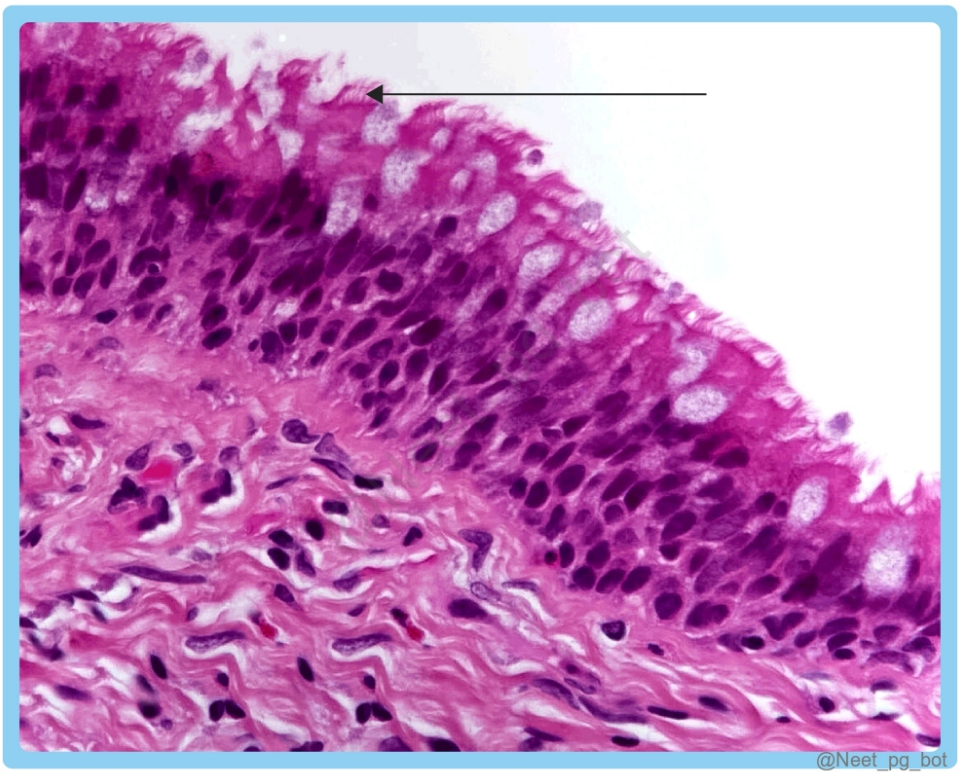

See Answer in Part B → Q6

@Neet_pg_bot

Q7: Identify the pelvic diaphragm in the given picture. (Q856615)

A. 1

B. 2

C. 3

D. 4

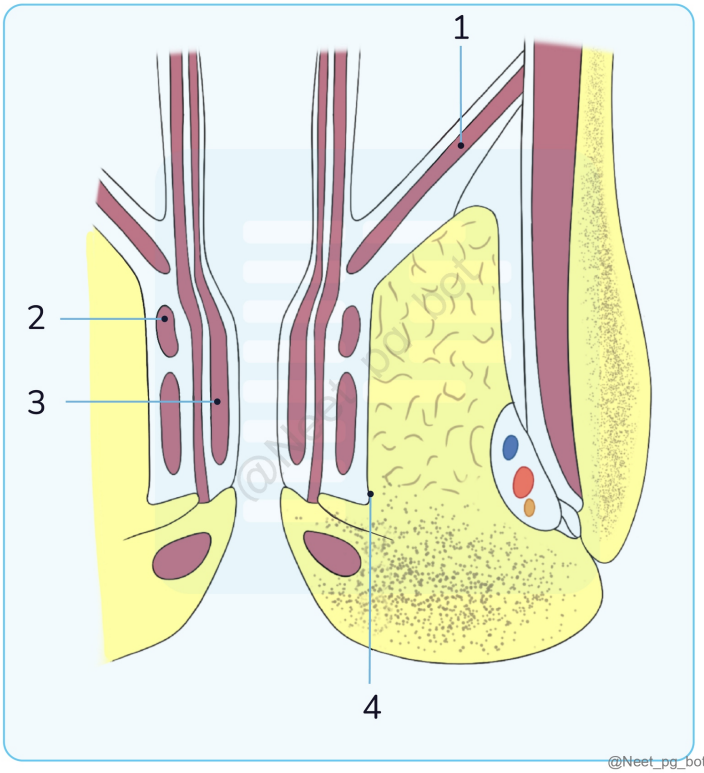

See Answer in Part B → Q7

@Neet_pg_bot

Q8: In the scenario of a man who fell into a manhole and sustained perineal injury, leading to difficulty in urination and presence of blood at the urethral tip, a diagnosis of bulbar urethral injury was determined. In this particular case, where would the urine accumulation be the least expected? (Q857583)

A. Perineum

B. Anterior abdominal wall

C. The medial portion of thigh

D. Root of scrotum

See Answer in Part B → Q8

@Neet_pg_bot

Q9: A woman delivered a healthy baby and to control her postpartum hemorrhage an artery was ligated. Then later she developed pain under her gluteus muscle. Which was the artery ligated ? (Q857577)

A. Uterine artery

B. Superior gluteal artery

C. Inferior gluteal artery

D. Internal iliac artery

See Answer in Part B → Q9

@Neet_pg_bot

Q10: The rupture of the penile urethra does not cause extravasation of blood into which of the following spaces? (Q855035)

A. Superficial perineal pouch

B. Anterior abdominal wall

C. Ischiorectal fossa

D. Skin around the scrotum

See Answer in Part B → Q10

@Neet_pg_bot

Q11: Match the following (Q865302)

A. A- prostate, B- ureter, C- vas deferens , D- seminal vesicle

B. A- vas deferens, B- ureter, C- prostate , D- seminal vesicle

C. A- ureter, B-prostate, C- vas deferens , D- seminal vesicle

D. A- vas deferens, B- ureter, C-prostate , D- seminal vesicle

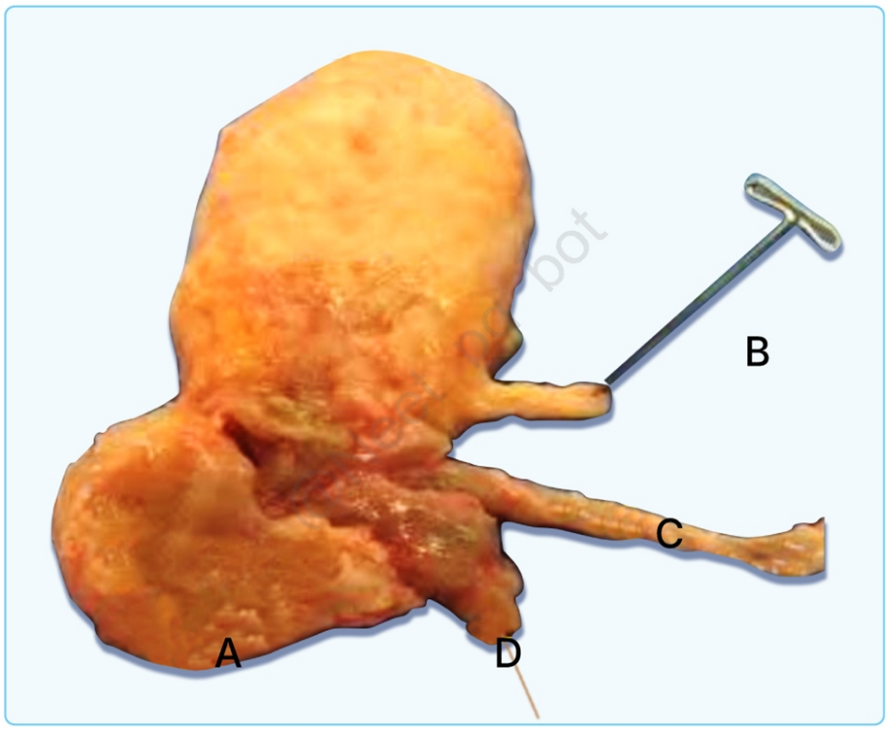

@Neet_pg_bot

See Answer in Part B → Q11

@Neet_pg_bot

Q12: What is the volume of the prostate in healthy adult males? (Q855006)

A. 20cc

B. 50cc

C. 75cc

D. 100cc

See Answer in Part B → Q12

@Neet_pg_bot

Q13: A person who had a road traffic accident presented to ER with injury to bulbar urethra. What can be the location of collection of the urine due to this injury?

(Q857915)

A. Inguinal pouch

B. Peritoneal cavity

C. Ischiorectal fossa

D. Anterior abdominal wall

See Answer in Part B → Q13

@Neet_pg_bot

Q14: A 55-year-old woman presents to the clinic complaining of blood in her stools. Physical exam reveals firm, enlarged inguinal lymph nodes. A contrast CT scan is performed and a possibly cancerous mass is visualized in the lower part of the gastrointestinal tract. In which location is the mass most likely located? (Q854571)

A. Anal canal inferior to the pectinate line

B. Distal rectum

C. Sigmoid colon

D. Proximal rectum

See Answer in Part B → Q14

@Neet_pg_bot

Q15: What is the vertebral level shown by the blue line in the image? (Q820335)

A. L2-L3

B. L4-L5

C. L5-S1

D. L3-L4

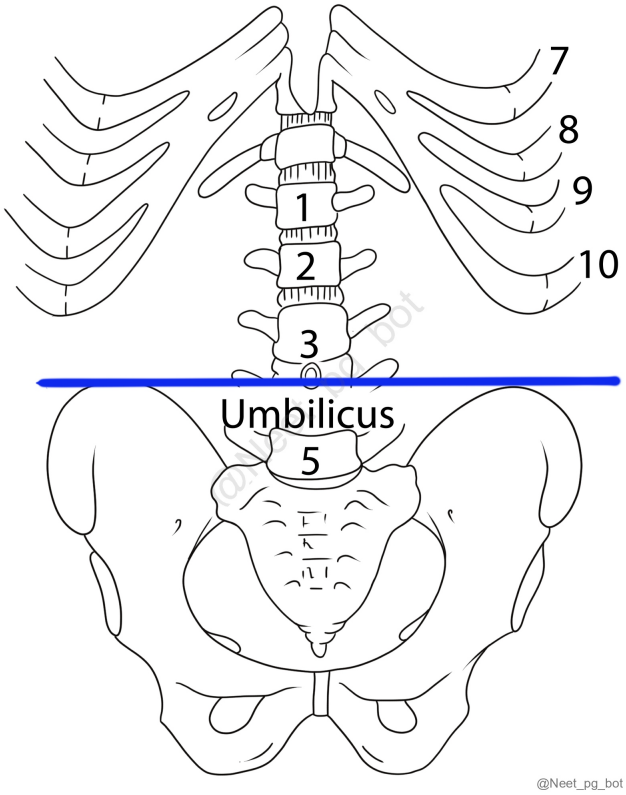

See Answer in Part B → Q15

@Neet_pg_bot

Q16: A person who had a road traffic accident presented to ER with injury to bulbar urethra. What can be the location of collection of the urine due to this injury? (Q820309)

A. Inguinal pouch

B. Peritoneal cavity

C. Ischiorectal fossa

D. Anterior abdominal wall

See Answer in Part B → Q16

@Neet_pg_bot

Q17: The ischial spine corresponds to which level? (Q839931)

A. S3-S5

B. Tip of the coccyx

C. L4

D. S2

See Answer in Part B → Q17

@Neet_pg_bot

Q18: Identify the marked area in the image given. (Q852526)

A. Morrison's pouch

B. Vesicouterine pouch

C. Pouch of Douglas

D. Ischioanal Fossa

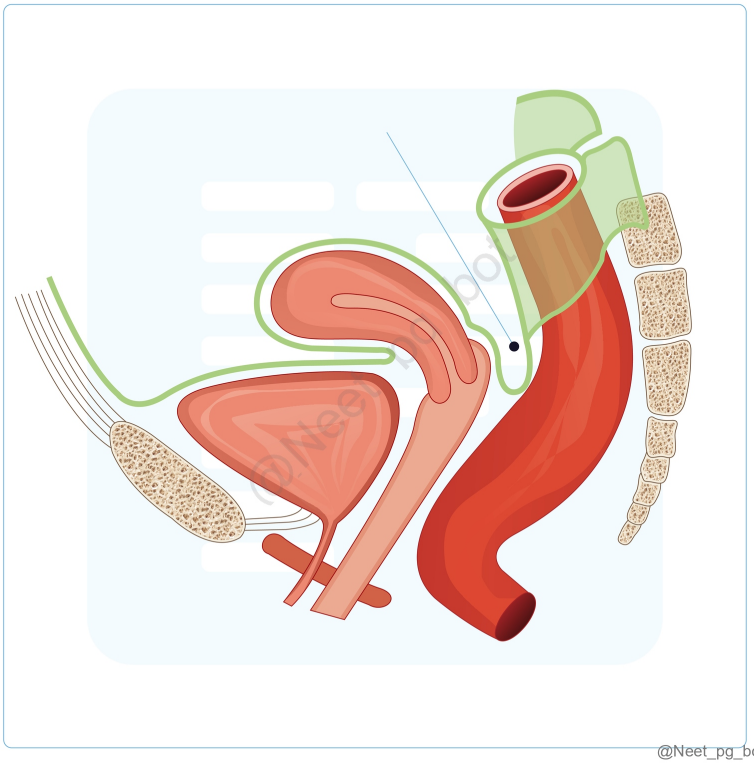

@Neet_pg_bot

See Answer in Part B → Q18

@Neet_pg_bot

Q19: During walking, the hip bone on the side of the suspended leg is raised by the action of which muscle present in the supporting leg? (Q852998)

A. Gluteus medius

B. Gluteus maximus

C. Obturator internus

D. Quadratus femoris

See Answer in Part B → Q19

@Neet_pg_bot

Q20: A patient presents with carcinoma near anal opening. Which of the following lymph node is most likely involved first? (Q866313)

A. Superficial inguinal lymph node

B. Deep inguinal lymph node

C. Paraaortic lymph node

D. Internal iliac lymph node

See Answer in Part B → Q20

@Neet_pg_bot

• [10_Systemic Embryology] 049 Previous Year Questions

« Back to Folder Directory

[10_Systemic Embryology] 049 Previous Year Questions — Quick Jump

Q1 (p. 591) *Q2 (p. 591)* *Q3 (p. 591)* *Q4 (p. 592)* *Q5 (p. 593)* *Q6 (p. 594)*
Q7 (p. 595) *Q8 (p. 596)* *Q9 (p. 597)* *Q10 (p. 597)*

Q1: The long left recurrent laryngeal nerve is due to the persistence of which arch artery? (Q854988)

A. 3rd arch

B. 4th arch

C. 5th arch

D. 6th arch

See Answer in Part B → Q1

@Neet_pg_bot

Q2: Which of the following statements regarding anatomical closure is incorrect? (Q854993)

A. Anatomical closure of foramen ovale is by 3 to 5 days

B. Anatomical closure of ductus venosus is by 2 to 3 weeks

C. Right umbilical vein is absent after birth

D. Anatomical closure of ductus arteriosus is by 2 to 3 weeks

See Answer in Part B → Q2

@Neet_pg_bot

Q3: Which of the following structures develops from the structure marked? (Q855401)

A. Medial umbilical ligament

B. Median umbilical ligament

C. Meckel's diverticulum

D. Ligamentum teres

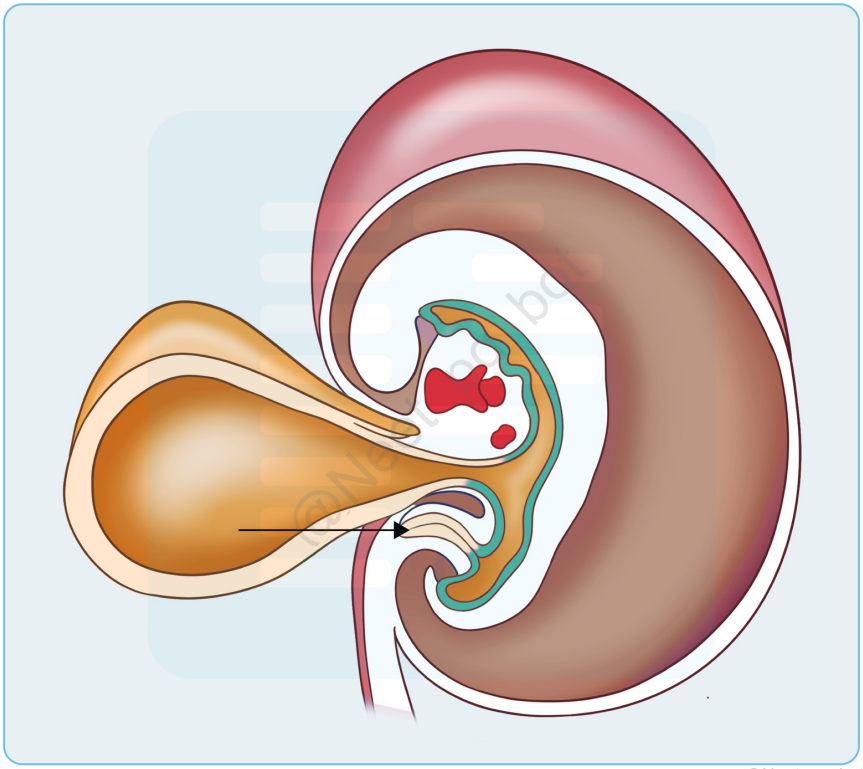

See Answer in Part B → Q3

@Neet_pg_bot

Q4: A child lacks thymus and inferior parathyroid glands. Defective development of which of the following structures is likely to be the cause? (Q855422)

A. 1

B. 2

C. 3

D. 4

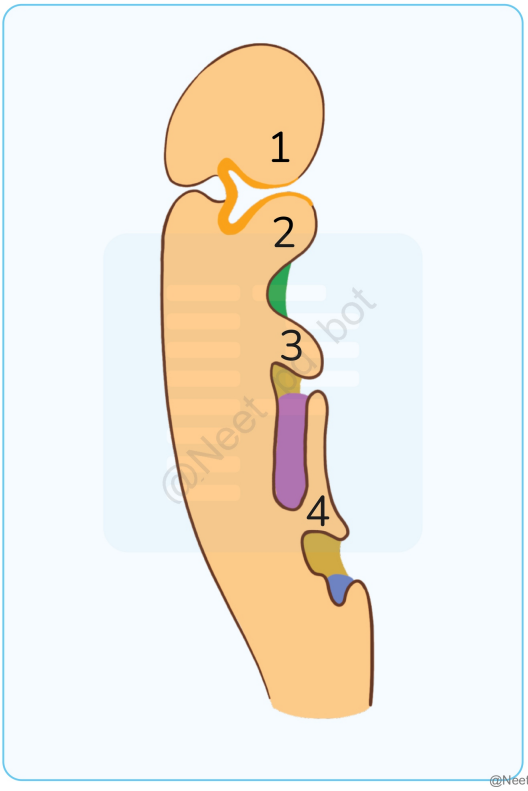

See Answer in Part B → Q4

@Neet_pg_bot

Q5: A young child with absent thymus is brought to the OPD with features of hypoparathyroidism and tetany. Which of the following marked areas in the picture is defective in this condition? (Q855837)

A. 1

B. 2

C. 3

D. 4

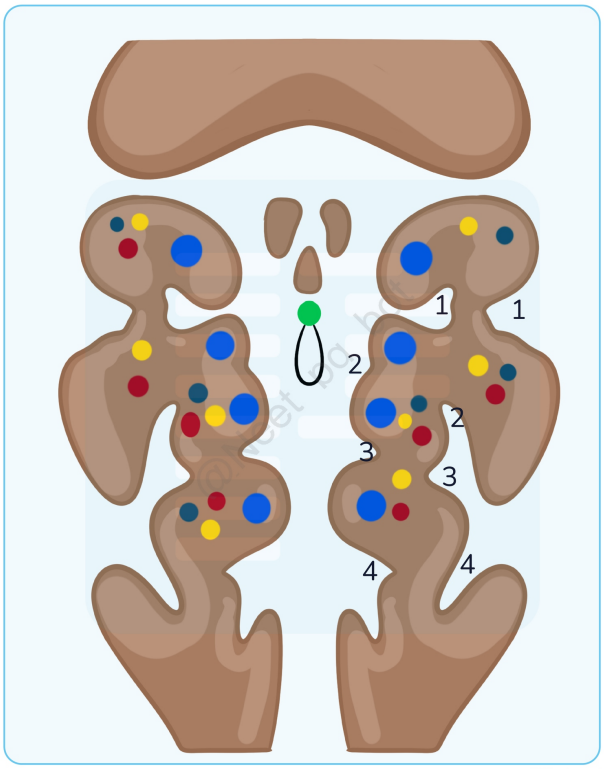

See Answer in Part B → Q5

@Neet_pg_bot

Q6: The structure marked A in the image below gives rise to which of the following structures? (Q856067)

A. Gastrosplenic ligament

B. Lienorenal ligament

C. Falciform ligament

D. Gastrophrenic ligament

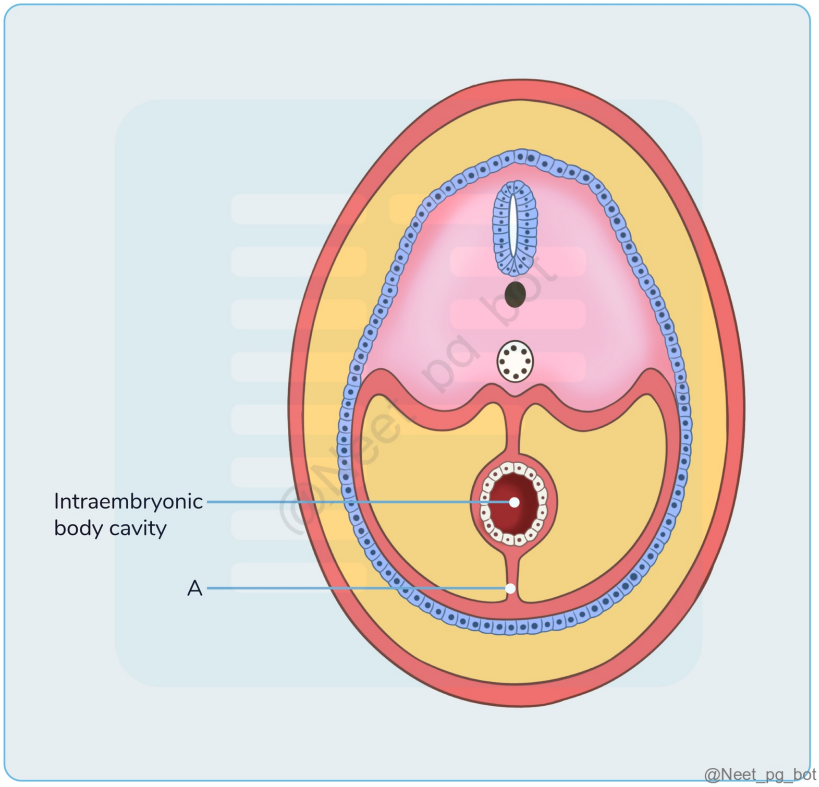

See Answer in Part B → Q6

@Neet_pg_bot

Q7: What structure develops from the region labeled as "A" in the model of embryological heart development? (Q856363)

A. Atria

B. Left ventricle

C. Infundibulum

D. Interventricular septum

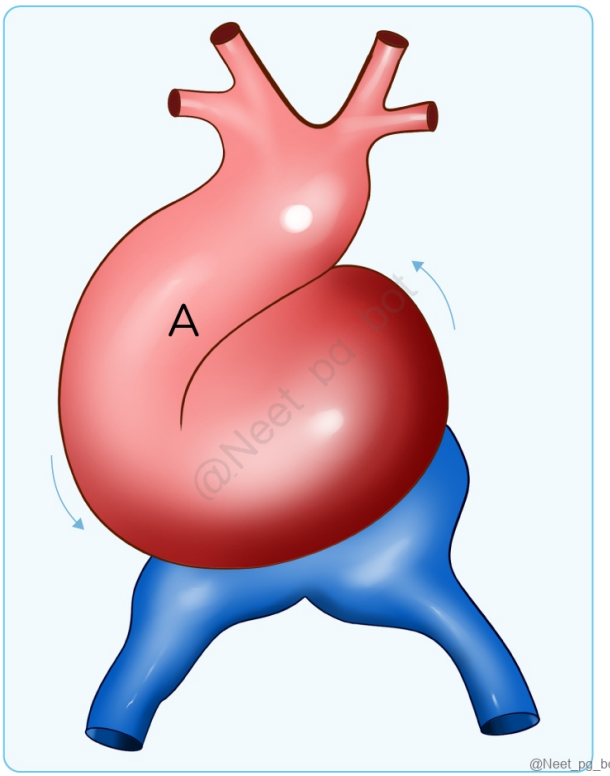

See Answer in Part B → Q7

@Neet_pg_bot

Q8: The marked structure develops from which of the following structures? (Q856670)

A. Common cardinal vein

B. Anterior cardinal vein

C. Supracardinal vein

D. Subcardinal vein

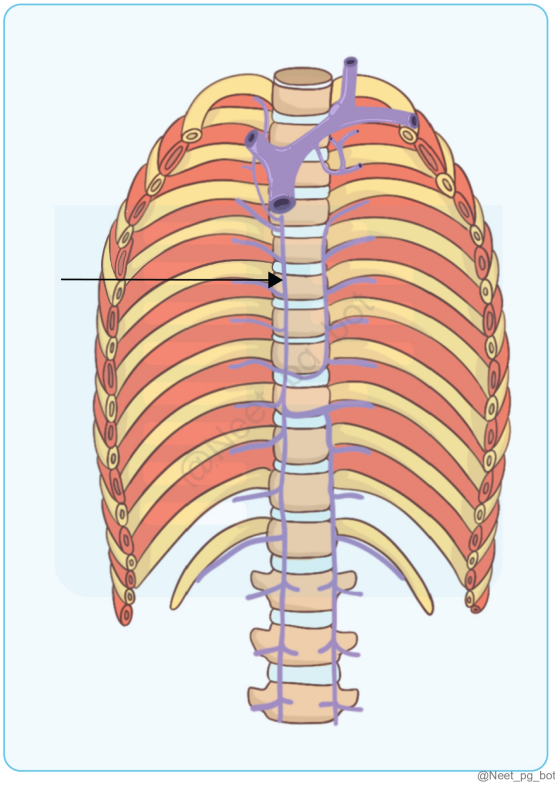

See Answer in Part B → Q8

@Neet_pg_bot

Q9: A newborn presented to the NICU with respiratory distress and meconium discharge from the umbilicus. The condition occurs due to the patency of which structure? (Q857217)

A. Mesonephric duct

B. Allantois

C. Urachus

D. Vitelline Fistula

See Answer in Part B → Q9

@Neet_pg_bot

Q10: What is the embryological basis of the developmental defects shown in the image below? (Q857218)

A. Failure in closure of anterior neuropore of neural tube

B. Failure in closure of posterior neuropore of neural tube

C. Failure in closure of complete neural tube

D. Failure in closure of caudal neuropore of neural tube



See Answer in Part B → Q10

@Neet_pg_bot

• [11_Osteology and Arthrology] 050 Previous Year Questions

« Back to Folder Directory

[11_Osteology and Arthrology] 050 Previous Year Questions — Quick Jump

Q1 (p. 599) *Q2 (p. 600)* *Q3 (p. 600)* *Q4 (p. 601)* *Q5 (p. 602)* *Q6 (p. 603)*

Q1: The bone shown in the image is not associated with which of the following types of joints? (Q839878)

A. Syndesmosis

B. Symphysis

C. Plane synovial joint

D. Synchondrosis



See Answer in Part B → Q1

Q2: The marked structure serves as a surface landmark for which anatomical structure? (Q852990)

A. Pineal gland

B. Wernicke's area

C. Stem of lateral sulcus

D. Internal carotid artery siphon

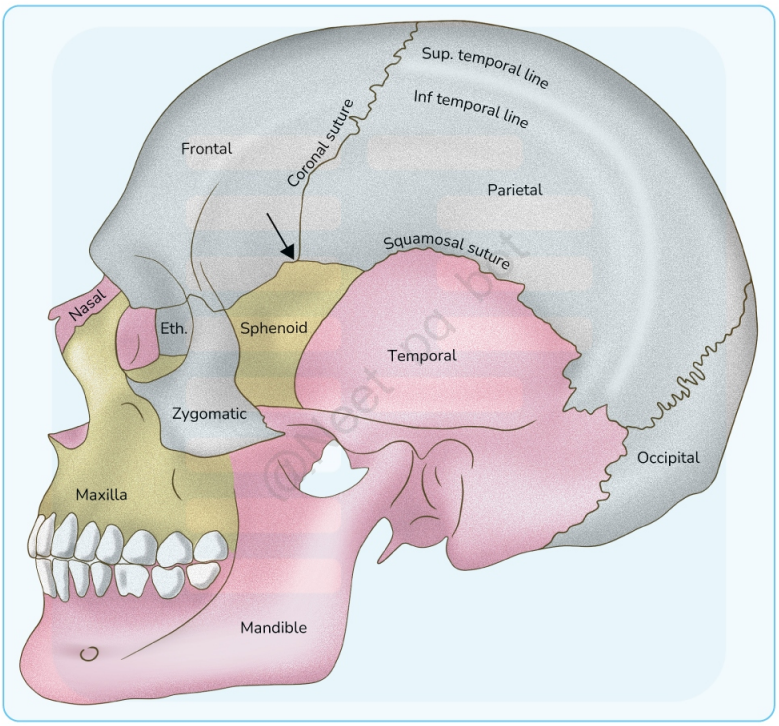

See Answer in Part B → Q2

@Neet_pg_bot

Q3: Which part of this bone is palpable in the infraclavicular fossa? (Q855779)

A. 1

B. 2

C. 3

D. 4



See Answer in Part B → Q3

@Neet_pg_bot

Q4: What type of joint is seen in the labeled structure? (Q859517)

A. Syndesmosis

B. Primary cartilaginous joints

C. Fibrous joint

D. Secondary cartilaginous joint

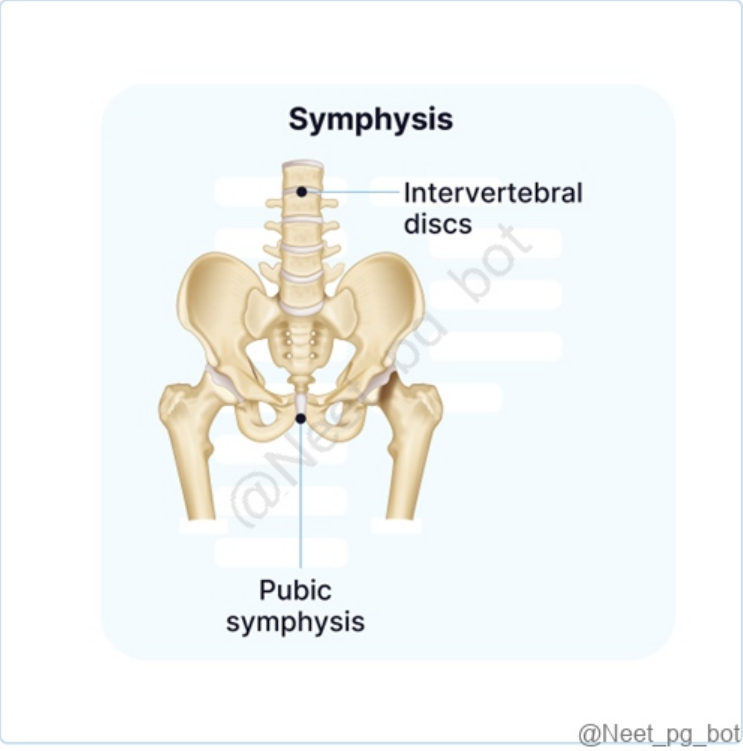

See Answer in Part B → Q4

@Neet_pg_bot

Q5: In the labeled structure, what kind of joint is present? (Q859522)

A. Sutures

B. Primary cartilaginous joints

C. Fibrous joint

D. Secondary cartilaginous joint

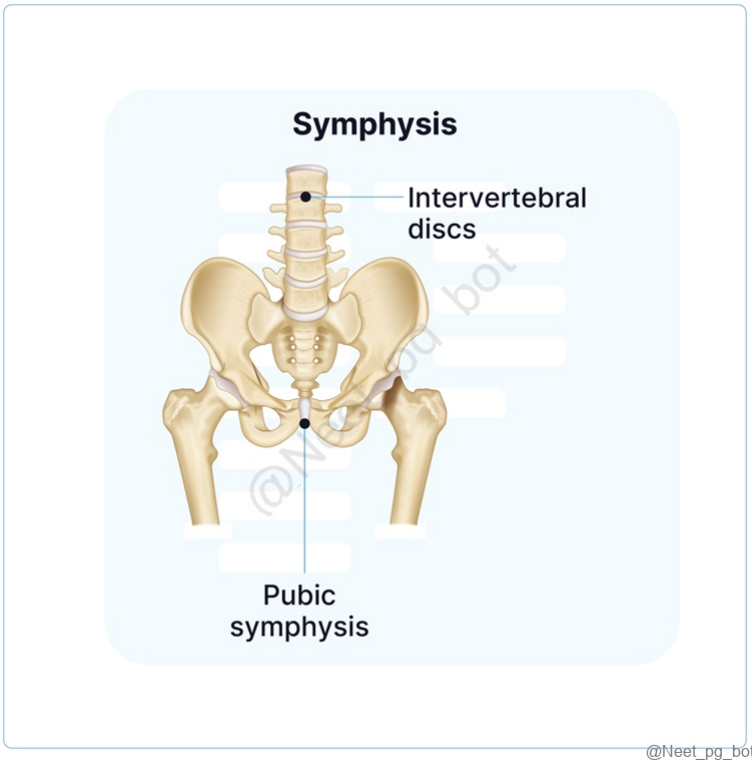

See Answer in Part B → Q5

@Neet_pg_bot

Q6: Which of the following is the type of joint between epiphysis and diaphysis of a long bone? (Q860263)

A. Symphysis

B. Synchondrosis

C. Synostosis

D. Syndesmosis

See Answer in Part B → Q6

@Neet_pg_bot

• [12_Back Region] 051 Back Region

« Back to Folder Directory

[12_Back Region] 051 Back Region — Quick Jump

Q1 (p. 604)	*Q2 (p. 604)*	*Q3 (p. 605)*	*Q4 (p. 605)*	*Q5 (p. 606)*	*Q6 (p. 606)*
Q7 (p. 607)	*Q8 (p. 608)*	*Q9 (p. 608)*	*Q10 (p. 608)*	*Q11 (p. 609)*	*Q12 (p. 609)*
Q13 (p. 610)	*Q14 (p. 610)*	*Q15 (p. 611)*	*Q16 (p. 612)*	*Q17 (p. 613)*	

Q1: Which of the following muscles contributes to forming both Petit’s triangle and the triangle of auscultation? (Q848696)

A. Latissimus dorsi

B. Internal oblique

C. Rhomboid major

D. Trapezius

See Answer in Part B → Q1

@Neet_pg_bot

Q2: All of the following statements about the atlantooccipital joint is/are true except: 1. Allows for flexion and extension of the head 2. It is a synovial condyloid joint 3. Primarily responsible for lateral bending of the head 4. Formed by the articulation between the occipital condyles and the superior articular facets of the atlas 5. It facilitates rotational movement of the head (Q848694)

A. 1, 2, and 4

B. 2 and 3

C. 3 and 5

D. 3, 4, and 5

See Answer in Part B → Q2

@Neet_pg_bot

Q3: A 5-month-old infant with suspected meningitis is scheduled for a lumbar puncture. Which of the following statements about lumbar puncture in infants is incorrect? (Q848688)

A. Procedure is typically done at the L3-L4 intervertebral space.

B. Procedure is preferably performed under ultrasound guidance.

C. Supracristal plane corresponds to the L4-L5 vertebral level.

D. Depth to the subarachnoid space is approximately 1.4 cm in neonates.

See Answer in Part B → Q3

@Neet_pg_bot

Q4: {{caption_text}} Based on the image, which of the following structures is primarily responsible for facilitating the described movement of the head? (Q848693)

A. Dens (Odontoid process) of C2

B. Transverse ligament of C1

C. Atlanto-occipital joint

D. Superior Articular Facet of C1

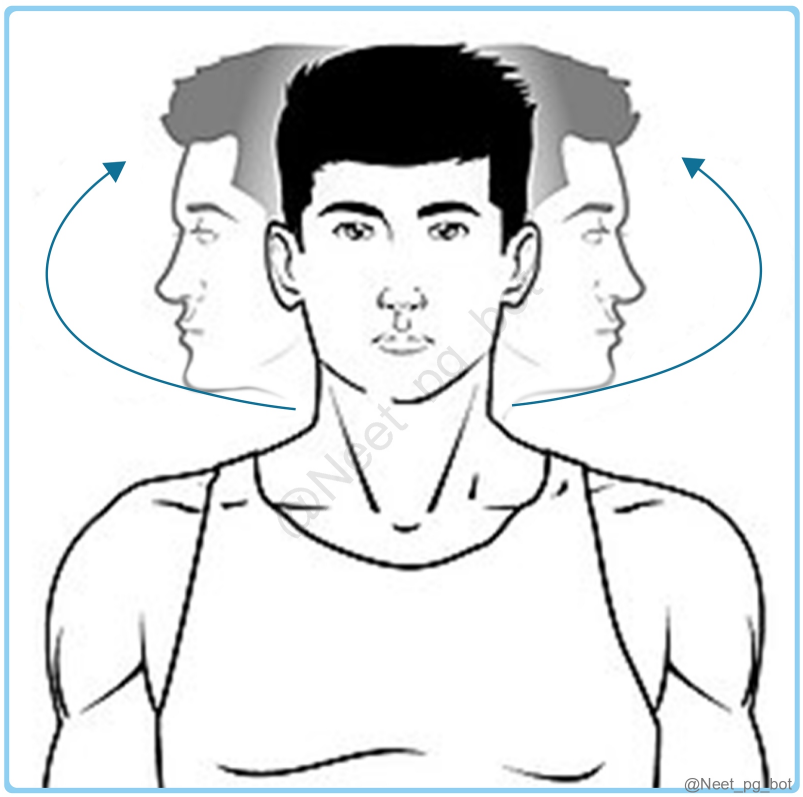

See Answer in Part B → Q4

@Neet_pg_bot

Q5: Assertion (A): There are 8 cervical spinal nerves despite there being only 7 cervical vertebrae. Reason (R): The first cervical nerve exits above the first cervical vertebra, and the remaining nerves exit below their corresponding vertebrae. (Q848690)

A. Both Assertion and Reason are correct, and the Reason is the correct explanation for the Assertion

B. Both Assertion and Reason are correct, but the Reason is not the correct explanation for the Assertion

C. The Assertion is correct, but the Reason is incorrect

D. The Assertion is incorrect, but the Reason is correct

See Answer in Part B → Q5

@Neet_pg_bot

Q6: An anatomy professor presents an image of the back region and asks to identify the nerve innervation of muscle marked in green? (Q848698)

A. Dorsal scapular nerve

B. Suprascapular nerve

C. From the dorsal rami of C1

D. Subscapular nerve



See Answer in Part B → Q6

@Neet_pg_bot

Q7: By the end of fetal development, at which vertebral level does the spinal cord terminate? (Q848682)

A. Lower border of L1

B. Lower border of L2

C. Upper border of L3

D. Lower border of L3

See Answer in Part B → Q7

@Neet_pg_bot

Q8: A 54-year-old female is a known case of rheumatoid arthritis, underwent MRI which showed tectorial membrane thickening. This structure is derived from which of the following ligaments? (Q848697)

A. Anterior atlanto occipital membrane

B. Posterior atlanto occipital membrane

C. Anterior longitudinal ligament

D. Posterior longitudinal ligament

See Answer in Part B → Q8

@Neet_pg_bot

Q9: Match the right options. a Spine of scapula i T2 b Highest point of iliac crest ii T3 c Superior angle of scapula iii T7 d Inferior angle of scapula iv L4 (Q848695)

A. a-i, b-iii, c-ii, d-iv

B. a-ii, b-i, c-iv, d-iii

C. a-iv, b-ii, c-iii, d-i

D. a-ii, b-iv, c-i, d-iii

See Answer in Part B → Q9

@Neet_pg_bot

Q10: Which of the following is true about cauda equina? (Q848692)

A. It is comprised of the terminal end of the spinal cord

B. Ends at L1-L2 vertebra in adults

C. Surrounded by CSF in the subarachnoid space

D. The filum terminale begins from the apex of cauda equina

See Answer in Part B → Q10

@Neet_pg_bot

Q11: A 42-year-old male presents with complaints of lower back pain radiating down his left leg, associated with numbness over the top of his foot and difficulty in dorsiflexing his big toe. On examination, he has weakness in the extension of the great toe and decreased sensation along the dorsum of the foot. Reflexes are normal. Based on the symptoms, which vertebral level is most likely affected? (Q848691)

A. L3-L4

B. L4-L5

C. L5-S1

D. T12-L1

See Answer in Part B → Q11

@Neet_pg_bot

Q12: A 2-year-old child is brought in for a routine check-up. The parents have noticed a pronounced lumbar curvature since the child began walking. Which of the following best describes this lumbar curvature? (Q848689)

A. Primary curvature

B. Secondary curvature

C. Compensatory curve from sacral kyphosis

D. Curvature related to increased abdominal weight

See Answer in Part B → Q12

@Neet_pg_bot

Q13: A patient has restricted spinal rotation and lateral flexion. Which vertebral structure primarily functions as a lever for these movements? (Q848687)

A. Spinous process

B. Superior articular process

C. Inferior articular process

D. Transverse process

See Answer in Part B → Q13

@Neet_pg_bot

Q14: An anatomy professor presents an image of a vertebra in class and asks the students to identify its type. Which type of vertebra is depicted in the image? {{caption_text}} (Q848686)

A. Cervical vertebrae

B. Thoracic vertebrae

C. Lumbar vertebrae

D. Sacral vertebrae

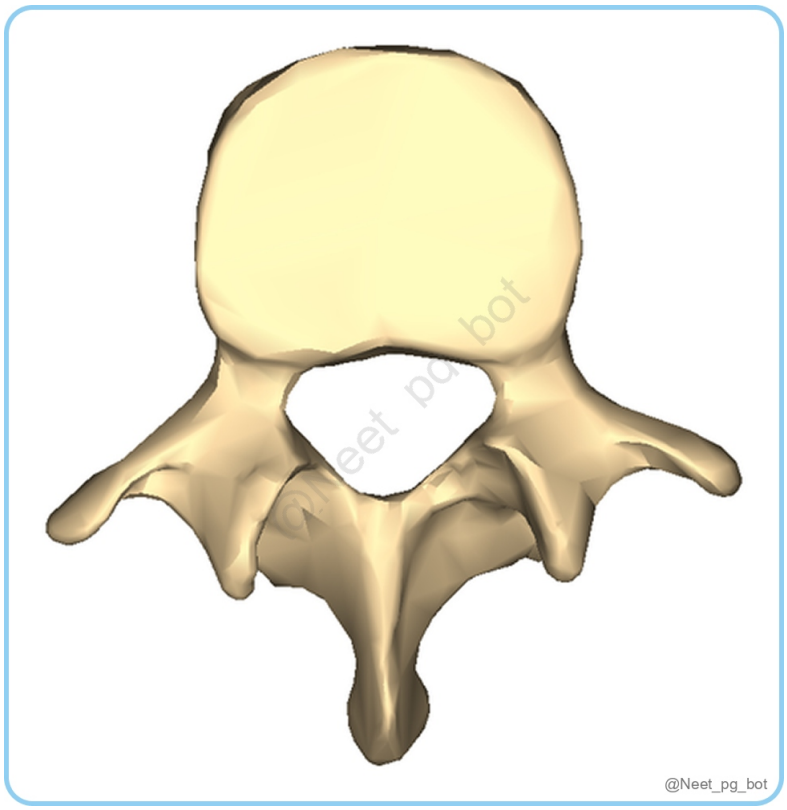

See Answer in Part B → Q14

@Neet_pg_bot

Q15: A 35-year-old patient undergoes spinal surgery. Postoperatively, he develops a cerebrospinal fluid leak. Which space is most likely compromised? (Q848685)

A. A

B. B

C. C

D. D

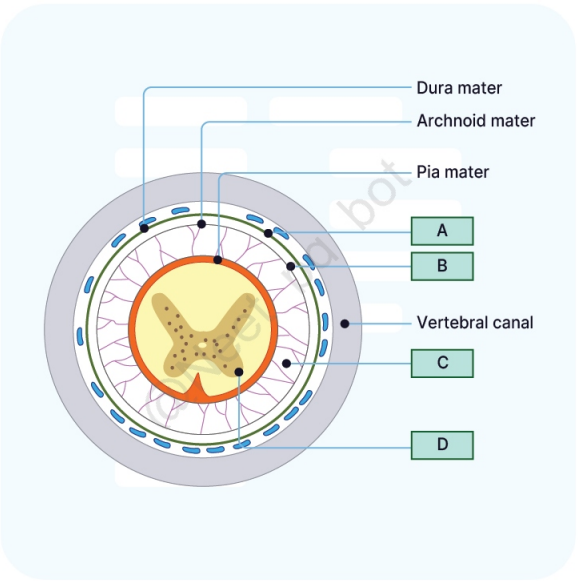

@Neet_pg_bot

See Answer in Part B → Q15

@Neet_pg_bot

Q16: A patient undergoes a procedure affecting a delicate, thread-like structure extending from the conus medullaris to the coccyx as marked in the figure. Which of the following statements regarding this structure is correct? {{caption_text}} (Q848684)

A. It is composed mainly of dura mater and contains no nerve fibers

B. Distal part of it is called the coccygeal ligament.

C. It does not extend beyond the sacral hiatus

D. It measures about 50 cm in length



See Answer in Part B → Q16

@Neet_pg_bot

Q17: Which of the following spinal segments is located between the cervical enlargement of the spinal cord? (Q848683)

A. T9 to L1

B. C5 to T1

C. L2 to S3

D. C3 to T1

See Answer in Part B → Q17

@Neet_pg_bot

• [12_Back Region] 052 Previous Year Questions

« Back to Folder Directory

[12_Back Region] 052 Previous Year Questions — Quick Jump

Q1 (p. 614) *Q2 (p. 615)* *Q3 (p. 615)*

Q1: Which of the following nerves supplies the muscle that is involved in the moment given below? (Q860271)

A. Spinal accessory nerve

B. Long thoracic nerve

C. Spinal branch of axillary nerve

D. Radial nerve



See Answer in Part B → Q1

@Neet_pg_bot

Q2: What is the action of the muscle shown in the image below? (Q857327)

A. Retracts the scapula

B. Adduction of the shoulder

C. Extension of the shoulder

D. Medial rotation of the shoulder

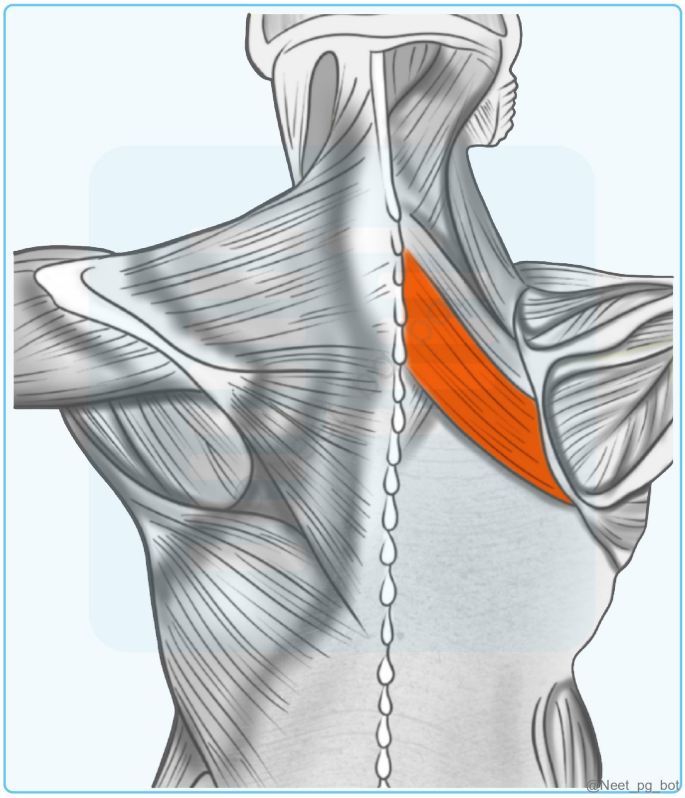

See Answer in Part B → Q2

@Neet_pg_bot

Q3: Match the following: Muscle Action a. Pectoralis major 1. Extension at shoulder b. Supraspinatus 2. Flexion at shoulder c. Infraspinatus 3. Lateral rotation of shoulder d. Latissimus dorsi 4. Abduction at shoulder (Q857330)

A. a-4, b-3, c-2, d-1

B. a-4, b-2, c-3, d-1

C. a-2, b-4, c-1, d-3

D. a-2, b-4, c-3, d-1

See Answer in Part B → Q3

@Neet_pg_bot

Part B — All Answers & Explanations

• [01_General Embryology] 001 Gametogenesis And Ivf

« Back to Folder Directory

[01_General Embryology] 001 Gametogenesis And Ivf — Quick Jump

Q1 (p. 617) *Q2 (p. 618)* *Q3 (p. 619)* *Q4 (p. 623)* *Q5 (p. 624)* *Q6 (p. 625)*
Q7 (p. 626) *Q8 (p. 627)* *Q9 (p. 628)* *Q10 (p. 629)* *Q11 (p. 630)* *Q12 (p. 631)*
Q13 (p. 633) *Q14 (p. 633)* *Q15 (p. 634)*

Q1: Which phase of the cell cycle does DNA replication occur in? (Q848036)

A. S phase

B. G1 phase

C. G2 phase

D. M phase

Correct Answer: A. S phase

■ *Listen (English)*

■ *Listen (Hindi)*

Explanation: DNA replication occurs in S phase The cell cycle is divided into two basic parts: Mitosis (M phase) and interphase. Interphase: The phase of cell growth Includes G1, S, and G2 phases In S phase (synthesis) - DNA replication occurs

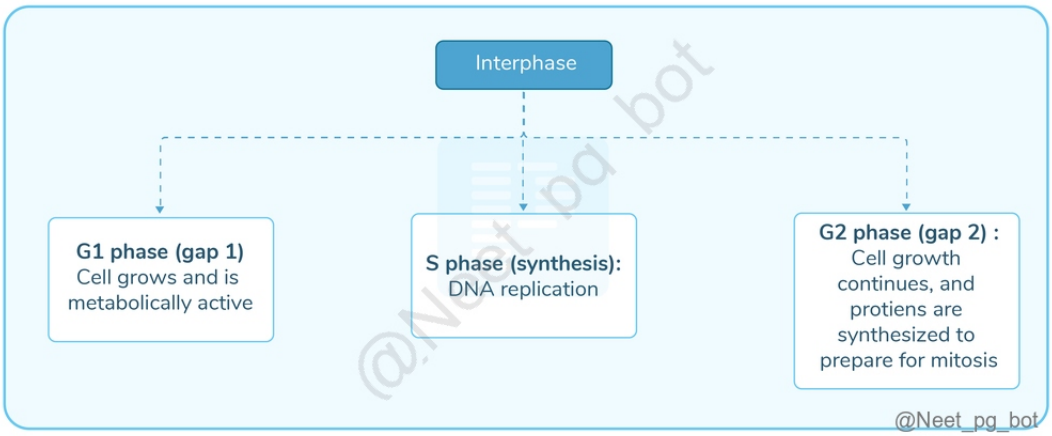

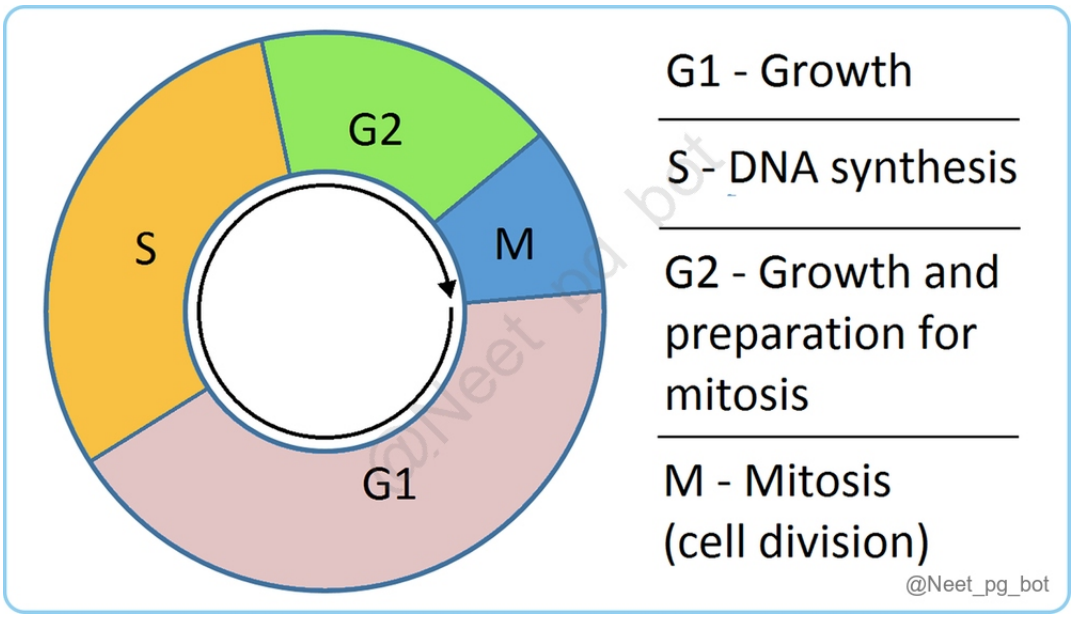

References:

https://www.ncbi.nlm.nih.gov/books/NBK9876/

↑ *Back to this question in Part A*

@Neet_pg_bot

Q2: Which of the following is wrongly paired? (Q848037)

A. Mitosis - no crossing over

B. Meiosis - 4 daughter cells

C. Mitosis - 1 division

D. Meiosis - daughter cells are diploid

Correct Answer: D. Meiosis - daughter cells are diploid

■ *Listen (English)*

■ *Listen (Hindi)*

Explanation: In meiosis, the daughter cells are haploid, not diploid. Mitosis Meiosis Purpose Growth, repair, and replacement of cells Production of gametes Number of Divisions One (Option C) Two successive divisions (first and second meiotic division) Resulting Daughter Cells Two daughter cells, genetically identical to the parent cell Four daughter cells, genetically diverse and haploid (Option B) Chromosome Number Maintains diploid number (46 chromosomes) Reduces chromosome number from diploid (46) to haploid (23) (Option D) Crossing Over Does not occur (Option A) Occurs during prophase I (pachytene), leading to genetic variation

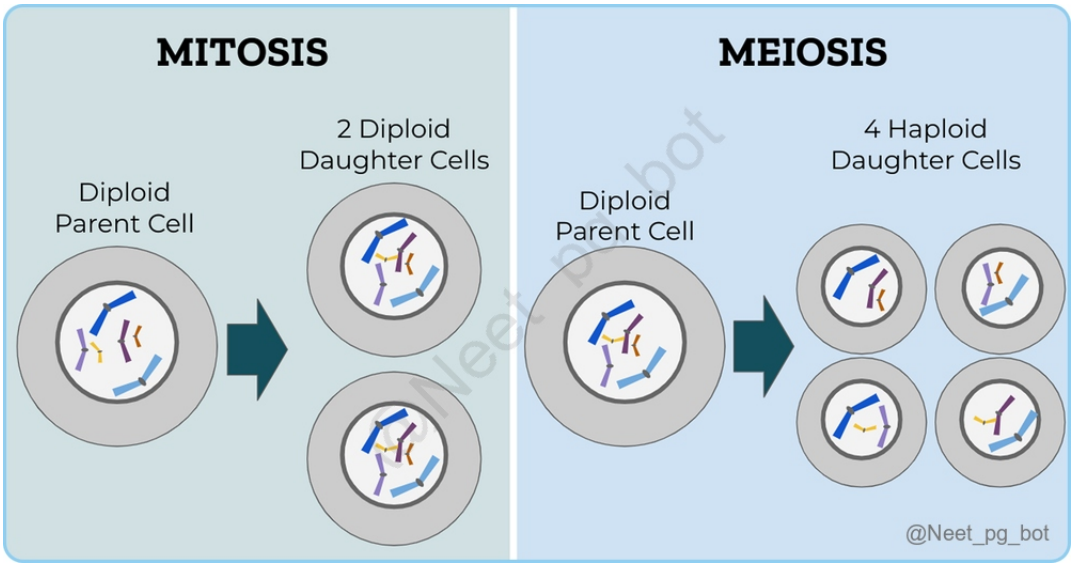

References:

Inderbir Singh's Human Embryology, 11th Edition, Page 18-21

↑ *Back to this question in Part A*

@Neet_pg_bot

Q3: 23 bivalents are formed in which stage of prophase 1? (Q848038)

A. Leptotene

B. Zygotene

C. Pachytene

D. Diplotene

Correct Answer: B. Zygotene

- *Listen (English)*
- *Listen (Hindi)*

Explanation: Prophase 1 is the first stage of the first meiotic division Prophase 1 is subdivided into stages as given below: Leptotene (Option A): Chromosomes become visible Zygotene: 46 chromosomes form 23 pairs = 23 bivalents Pachytene (Option C): The two chromatids of each chromosome become distinct. Thus, a bivalent consists of four chromatids - tetrad (Crossing over occurs where the two central chromatids coil and cross at several points called chiasmata). Diplotene (Option D): The two chromosomes of the bivalent begin to separate. Chromatids involved in crossing over break at the chiasmata, and the "loose" pieces attach to the opposite chromatid. Diakinesis: Final stage of prophase 1 Chromosomes continue to condense, and the nuclear envelope breaks down. Homologous chromosomes are still attached at the chiasmata, which begin to move towards the ends of the chromosomes (terminalization). Spindle fibers start to form in preparation for metaphase I.

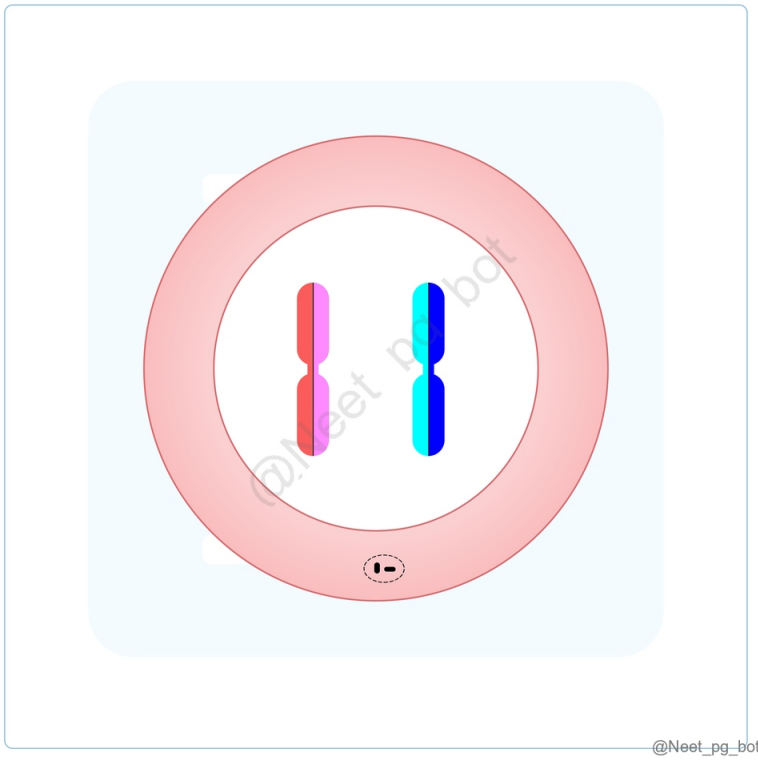

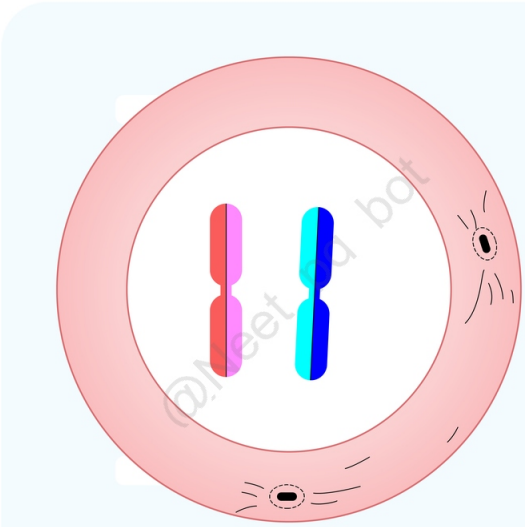

@Neet_pg_bot

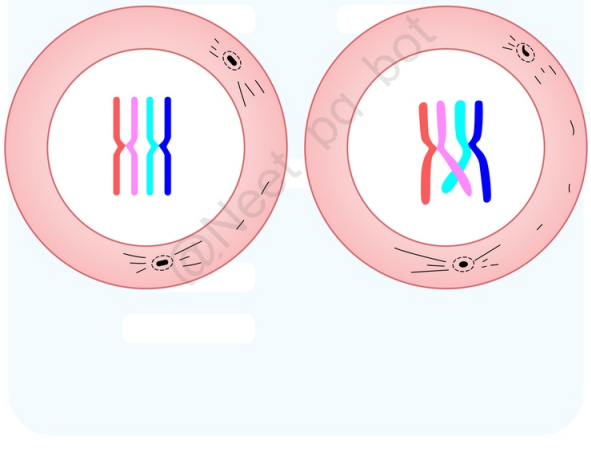

@Neet_pg_bot

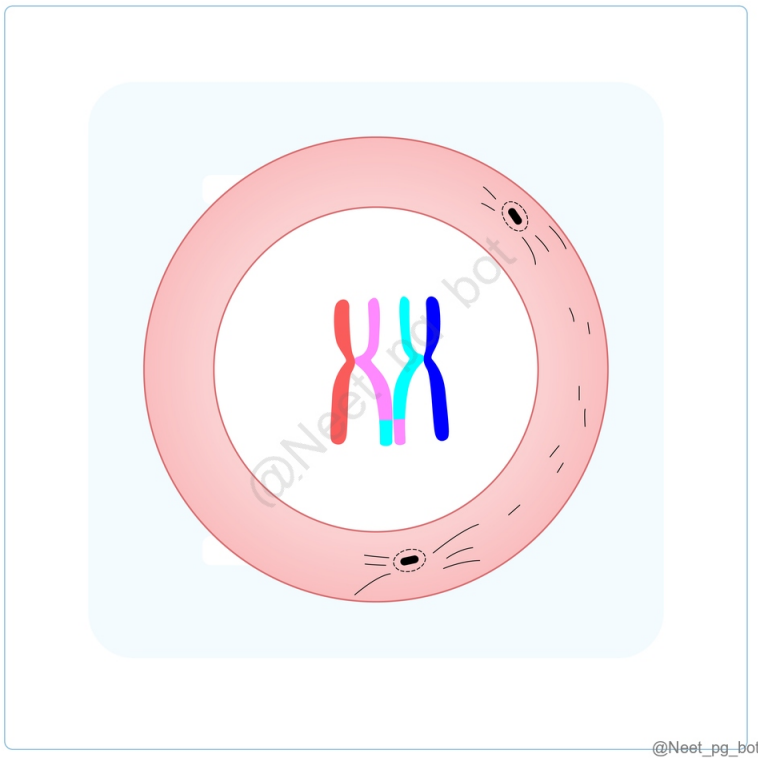

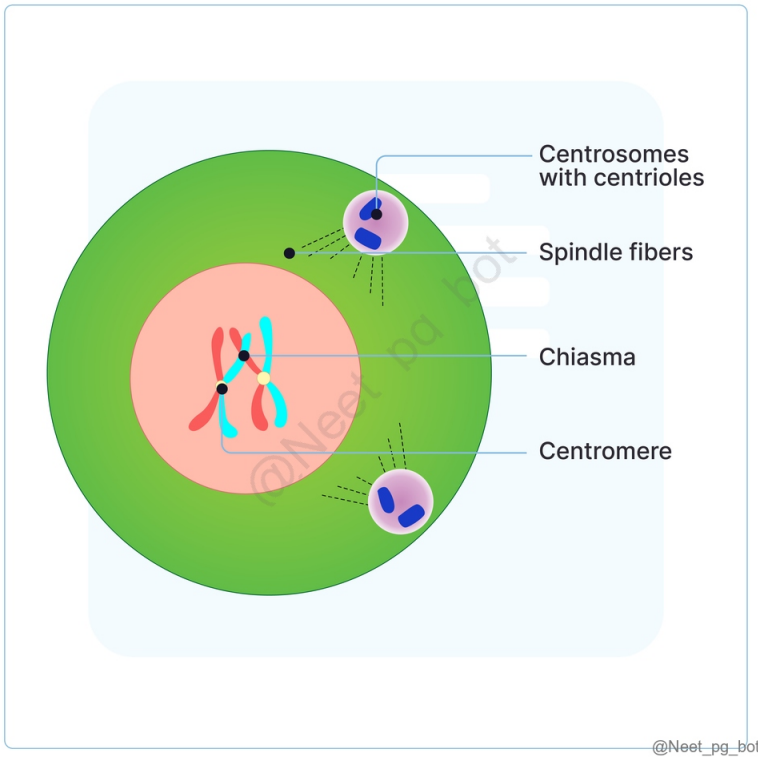

References:

Inderbir Singh’s Human Embryology, 11th Edition, Page 19-20

↑ *Back to this question in Part A*

@Neet_pg_bot

Q4: In which of the following stages of the first meiotic division do the chromosomes get attached to the spindle fibers? (Q848039)

A. Prophase 1

B. Metaphase 1

C. Anaphase 1

D. Telophase 1

Correct Answer: B. Metaphase 1

■ *Listen (English)*

■ *Listen (Hindi)*

Explanation: Metaphase 1: The second stage of first meiotic division. Chromosomes get arranged as a metaphase plate in the equator of the cells - midway between the 2 centrioles → Chromosome’s centromeres get attached to microtubules of the spindle via kinetochores. Kinetochore fibers pull the chromosomes toward the poles, creating tension through the cohesin complex. The tension indicates that the sister chromatids have achieved proper biorientation. The cell monitors the attachment of microtubules to chromosomes and possibly the tension generated by the microtubules.

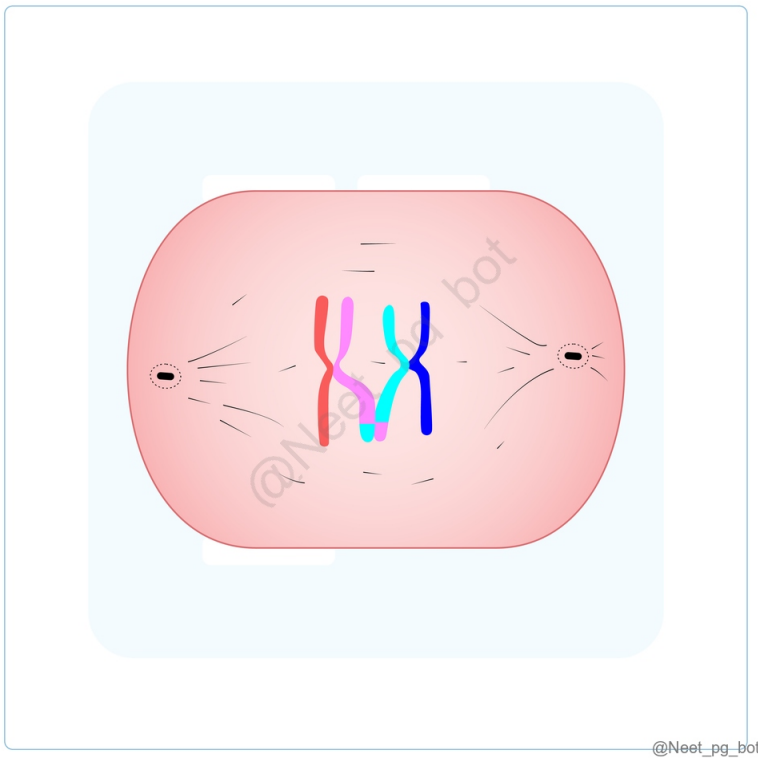

References:

Inderbir Singh's Human Embryology, 11th Edition, Page 20

https://www.sciencedirect.com/topics/medicine-and-dentistry/metaphase#definition

↑ *Back to this question in Part A*

@Neet_pg_bot

Q5: Which of the following statements on Anaphase 1 is true? (Q848040)

A. Centromere divides into 2

B. Each chromatid becomes a chromosome

C. DNA replicates

D. Each chromosome from the pair migrates to opposite poles of the spindle

Correct Answer: D. Each chromosome from the pair migrates to opposite poles of the spindle

■ *Listen (English)*

■ *Listen (Hindi)*

Explanation: Anaphase 1: The third stage of first meiotic division. Each chromosome from the pair migrates to opposite poles of the spindle. No division of centromere.

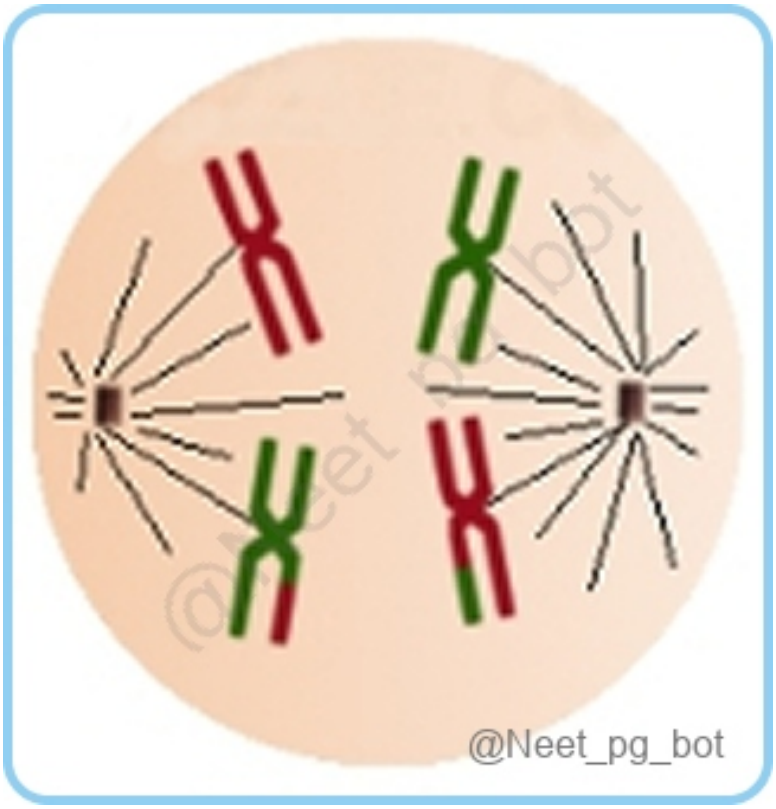

References:

Inderbir Singh's Human Embryology, 11th Edition, Page 20

↑ *Back to this question in Part A*

@Neet_pg_bot

Q6: Which of the following events occurs during telophase of meiosis? (Q848041)

A. Chromatids condense into chromosomes.

B. Nuclear envelope disintegrates.

C. Chromatids are pulled towards the spindle poles.

D. None of the above

Correct Answer: D. None of the above

■ *Listen (English)*

■ *Listen (Hindi)*

Explanation: In telophase, chromosomes unwind and return to a less condensed chromatin state. Telophase is the concluding stage of both mitosis and meiosis, following the movement of chromatids to the spindle poles. It is essential for ensuring that each daughter cell inherits an identical chromosome set, preserving genetic continuity in cell divisions. Key events in this phase include: Chromosome Relaxation : The chromatids start to unwind and revert to chromatin, becoming less distinct under a microscope. Nuclear Envelope Reassembly: A new nuclear membrane forms around each set of separated chromatids, resulting in two distinct nuclei. Spindle Breakdown: The spindle fibers, responsible for chromosome movement, are disassembled. Cytokinesis Begins: While telophase focuses on nuclear changes, it often coincides with cytokinesis, where the cytoplasm splits, producing two daughter cells. Chromatids condense into chromosomes (Option A) : This event occurs in prophase , not telophase. During prophase, chromatin condenses to form visible chromosomes. Nuclear envelope disintegrates (Option B) : This event happens in prophase , where the nuclear membrane breaks down to allow spindle fibers access to the chromosomes. In telophase, the nuclear envelope re-forms. Chromatids are pulled towards the spindle poles (Option C) : This occurs in anaphase when the chromatids are separated and moved to opposite ends of the cell by the spindle fibers.

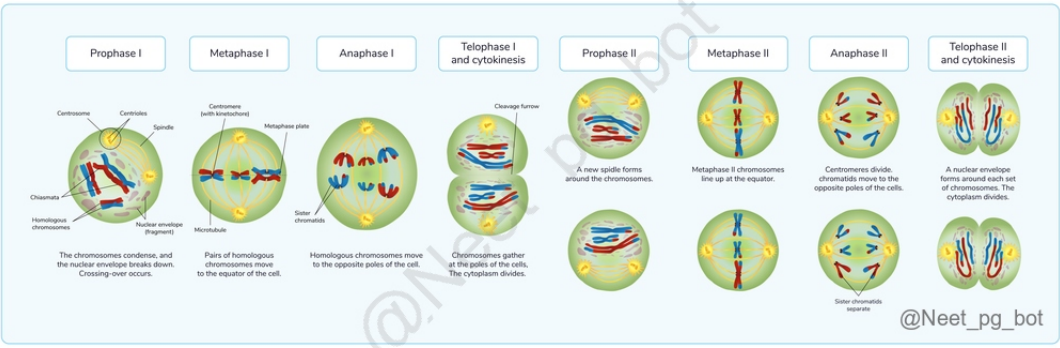

References:

https://www.sciencedirect.com/topics/medicine-and-dentistry/telophase

↑ *Back to this question in Part A*

@Neet_pg_bot

Q7: Which of the following best describes the stage at which the primary oocyte is arrested during oogenesis before puberty? (Q848042)

A. Metaphase of meiosis I

B. Prophase of meiosis II

C. Anaphase of meiosis I

D. Prophase of meiosis I

Correct Answer: D. Prophase of meiosis I

■ *Listen (English)*

■ *Listen (Hindi)*

Explanation: The primary oocyte arrests in Prophase of meiosis I during fetal development and remains in this stage until puberty. PGCs → Oogonia (mitotic divisions) → Primary Oocytes (arrest in prophase I) → Primordial Follicles

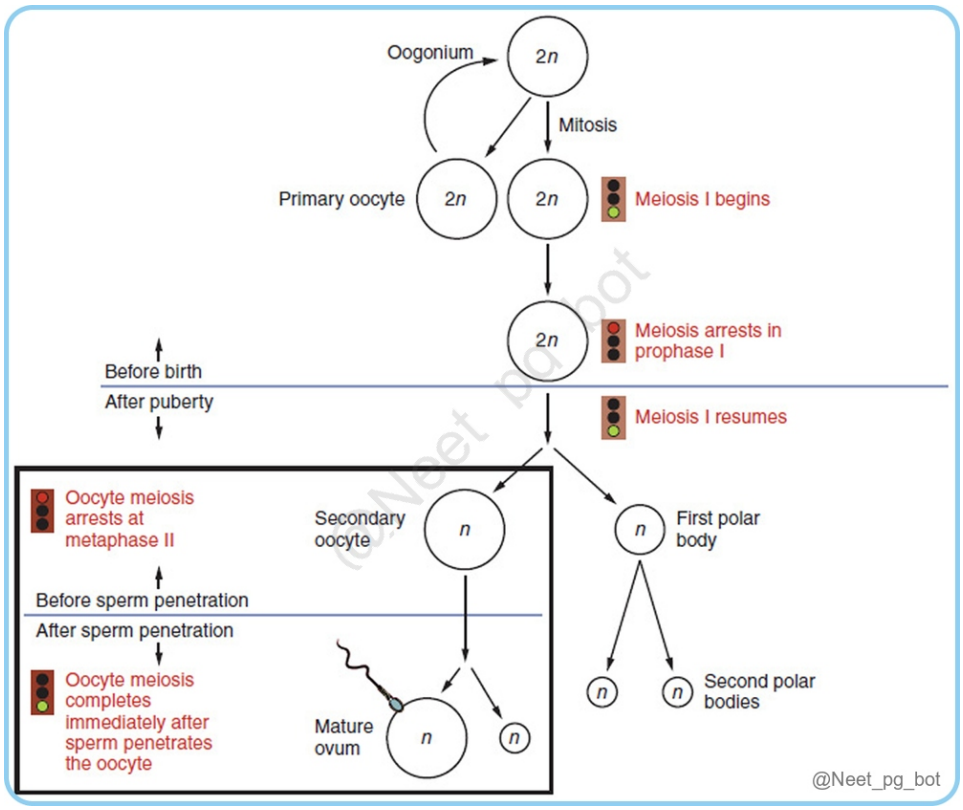

References:

Langman's Medical Embryology, 14th Edition, Page 25-29

↑ *Back to this question in Part A*

@Neet_pg_bot

Q8: Which of the following correctly describes the role of Sertoli cells during spermatogenesis? (Q848043)

A. They induce spermatogonial stem cells to initiate spermatogenesis.

B. They stimulate Leydig cells to produce testosterone.

C. They secrete androgen-binding proteins and support germ cells.

D. They transform type A spermatogonia into spermatids.

Correct Answer: C. They secrete androgen-binding proteins and support germ cells.

■ *Listen (English)*

■ *Listen (Hindi)*

Explanation: Sertoli cells play a crucial role in spermatogenesis by secreting androgen-binding proteins that support, protect, and nourish the developing germ cells. Key roles of Sertoli cells: Structural and nutritional support for spermatogenic cells. Secretion of ABP (under FSH influence) → concentrates testosterone. Phagocytosis of residual cytoplasm during spermiogenesis. Secretion of inhibin → negative feedback on FSH. Formation of blood-testis barrier via tight junctions. Induction of spermatogenesis is hormonally regulated by FSH and testosterone , not directly by Sertoli cells. (Option A) Sertoli cells do not stimulate Leydig cells; rather, LH acts directly on Leydig cells. (Option B) Type A spermatogonia transform into spermatids through multiple stages; Sertoli cells only support this process, not directly convert them. (Option D)

References:

Langman’s Medical Embryology, 14th Edition, Page 29- 31

↑ *Back to this question in Part A*

@Neet_pg_bot

Q9: Which of the following statements is most accurate regarding the relationship between the luteinizing hormone (LH) surge and ovulation? A) The LH surge typically begins 24 hours before ovulation. B) The LH surge stimulates the release of the second polar body from the oocyte. C) The LH surge is initiated by a rise in progesterone levels from the corpus luteum. D) The peak of the LH surge occurs approximately 10-12 hours before ovulation. E) A smaller follicle size is always associated with a higher LH peak. (Q848044)

A. D only

B. Only E

C. Both D and E

D. None of the above

Correct Answer: A. D only

■ *Listen (English)*

■ *Listen (Hindi)*

Explanation: The luteinizing hormone (LH) surge plays a crucial role in the menstrual cycle, preceding ovulation. The LH surge is essential for triggering ovulation, with its peak closely preceding the release of the egg. The surge is triggered by a significant rise in estradiol , produced by the dominant follicle, typically larger than 15mm on ultrasound. (Statement C) While the LH surge happens about 36 hours before ovulation, the LH surge peaks 10-12 hours before ovulation , making it a useful marker for timing ovulation (Statement A) It stimulates luteinization of granulosa cells , promotes progesterone production, and prompts the oocyte to resume meiosis, leading to the release of the first polar body. (Statement B) Surges with multiple peaks are linked to smaller follicle sizes before rupture and lower LH levels on the day of ovulation. (Statement E)

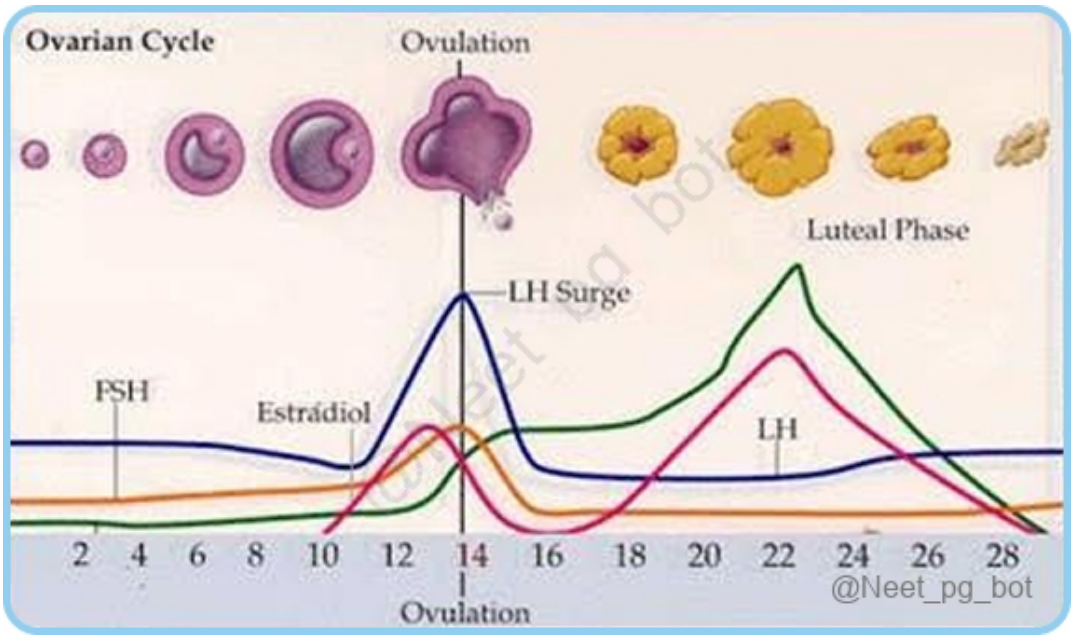

References:

https://www.ncbi.nlm.nih.gov/books/NBK279054/

https://www.sciencedirect.com/science/article/pii/S0015028212021358

↑ *Back to this question in Part A*

@Neet_pg_bot

Q10: Which of the following is most accurate regarding in vitro fertilization (IVF) for women with bilateral tubal blockage? (Q848045)

A. IVF is ineffective for women with bilateral tubal blockage.

B. Bilateral salpingectomy is always required before IVF in cases of tubal blockage.

C. ICSI is used to fertilize the egg in all IVF cases, regardless of sperm quality.

D. Preimplantation genetic testing (PGT) is necessary for women of advanced maternal age.

Correct Answer: D. Preimplantation genetic testing (PGT) is necessary for women of advanced maternal age.

■ *Listen (English)*

■ *Listen (Hindi)*

Explanation: IVF provides a solution for women with bilateral tubal blockage, a condition in which both fallopian tubes are blocked, preventing natural conception. Mechanism : IVF bypasses the fallopian tubes by directly retrieving eggs from the ovaries, fertilizing them in a lab, and transferring the embryos into the uterus. Surgical Considerations : Women with severe tubal damage may undergo bilateral salpingectomy (removal of both fallopian tubes) to improve IVF success rates by avoiding complications from dysfunctional tubes. Success Rates: IVF success in cases of bilateral tubal blockage depends on factors like age, overall reproductive health, and egg/embryo quality. Despite these variables, IVF remains a highly effective treatment. The main steps of IVF include: Controlled Ovarian Hyperstimulation : Most often done using injectable gonadotropins. Fertilization: Retrieved eggs are placed in a special medium, and normal sperm is added for insemination. If sperm abnormalities are present, intracytoplasmic sperm injection (ICSI) is used, where a single sperm is injected directly into the egg's cytoplasm. Embryo Assessment: After fertilization, embryos are assessed and graded. Transfer usually occurs on Day 3 or Day 5. Preimplantation Genetic Testing (PGT): It’s a procedure used to detect genetic mutations, chromosomal translocations, or aneuploidy (abnormal number of chromosomes). It’s especially useful in cases of advanced maternal age , recurrent IVF failures, recurrent pregnancy loss, or unexplained infertility. (Option D) IVF is ineffective for women with bilateral tubal blockage (Option A): IVF was specifically designed to bypass the fallopian tubes . In cases of bilateral tubal blockage, eggs are retrieved directly from the ovaries and fertilized in a laboratory setting. Because the embryos are then transferred directly into the uterus, the patency of the tubes is irrelevant, making IVF a highly effective solution for this condition. Bilateral salpingectomy is always required before IVF (Option B): Bilateral salpingectomy is not a universal requirement for IVF. While it is a surgical consideration for women with severe tubal damage or hydrosalpinx (fluid-filled tubes) to prevent toxic interference with the embryo and improve success rates, it is not "always" necessary. For simple blockages without fluid accumulation, the tubes are often left intact. ICSI is used in all IVF cases, regardless of sperm quality (Option C): ICSI (Intracytoplasmic Sperm Injection) is an auxiliary technique reserved for specific indications (like severe oligospermia, asthenospermia, teratospermia, previous fertilization failure, etc.), not a default for all cases. In standard IVF, eggs are placed in a medium and fertilized naturally by the addition of normal sperm. ICSI, which involves injecting a single sperm directly into the egg's cytoplasm, is strictly indicated only when sperm abnormalities are present.

References:

https://www.ncbi.nlm.nih.gov/books/NBK556033/

↑ *Back to this question in Part A*

@Neet_pg_bot

Q11: What is the correct sequence of stem cell potency based on their ability to differentiate? (Q848046)

A. Pluripotent > Totipotent > Multipotent > Oligopotent > Unipotent

B. Totipotent > Pluripotent > Multipotent > Oligopotent > Unipotent

C. Totipotent > Pluripotent > Oligopotent > Multipotent > Unipotent

D. Totipotent > Pluripotent > Oligopotent > Multipotent > Unipotent

Correct Answer: B. Totipotent > Pluripotent > Multipotent > Oligopotent > Unipotent

■ *Listen (English)*

■ *Listen (Hindi)*

Explanation: The correct order of arrangement of stem cells based on their potency to differentiate into different cells from (highest to lowest) is Totipotent > Pluripotent > Multipotent > Oligopotent > Unipotent

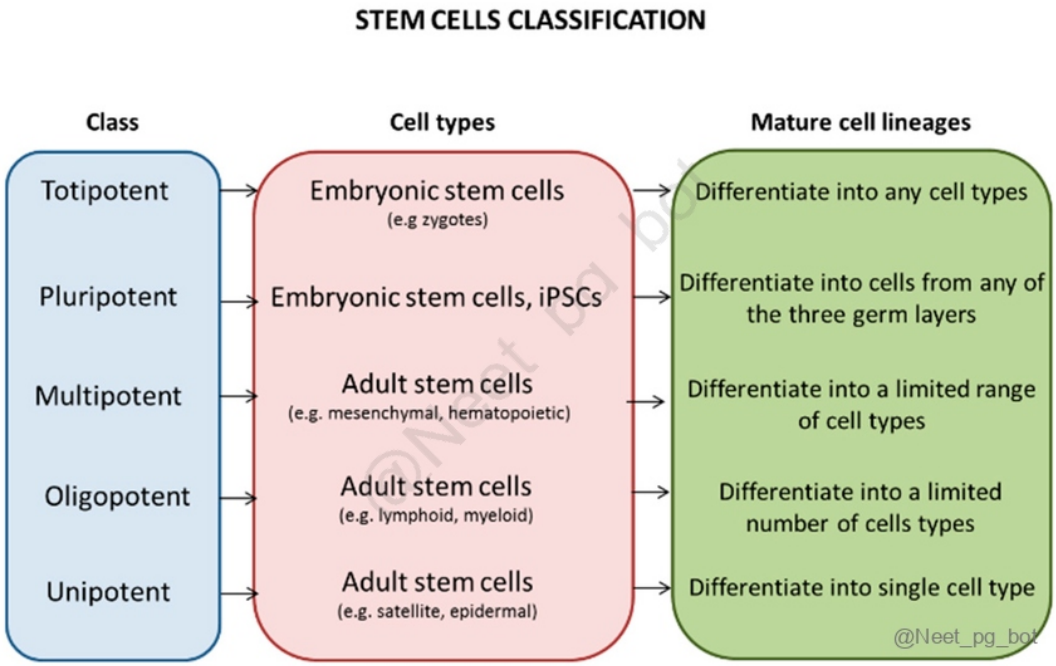

References:

Inderbir Singh's Human Embryology, 11th Edition, Page 5

↑ *Back to this question in Part A*

@Neet_pg_bot

Q12: Which stage of spermatogenesis is characterised by an independent assortment of maternal and paternal chromosomes? (Q848047)

A. Spermatogonia to primary spermatocyte

B. Primary spermatocyte to secondary spermatocyte

C. Secondary spermatocyte to spermatid

D. Spermatid to spermatozoa

Correct Answer: B. Primary spermatocyte to secondary spermatocyte

■ *Listen (English)*

■ *Listen (Hindi)*

Explanation: Independent assortment is the random distribution of chromosomes It occurs at Meiosis 1 where there is division from primary spermatocyte to secondary spermatocyte. It states that genes located on different chromosomes are inherited independently of each other. In other words, the allele a parent passes on for one trait does not affect the allele passed on for another trait. During Metaphase I of meiosis, the homologous chromosomes line up in pairs at the cell's equator. The orientation of each chromosome pair is random, meaning the maternal or paternal chromosome can go into either of the two daughter cells. This random alignment is the basis of independent assortment . Independent assortment is a key factor in genetic variation. This prevents all chromosomes from the same source ending up in the same gamete.

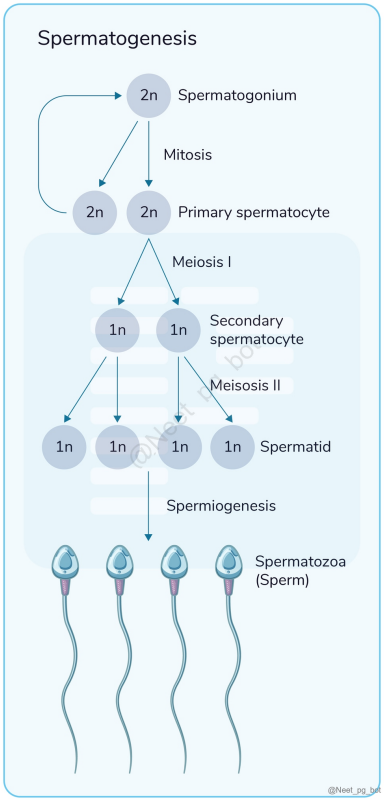

References:

Inderbir Singh's Human Embryology, 11th Edition, Page 21,28

↑ *Back to this question in Part A*

@Neet_pg_bot

Q13: What is the part of the embryo that exerts morphogenetic stimulus on its adjacent part called? (Q848048)

A. Differentiator

B. Organiser

C. Stem cell

D. Inducer

Correct Answer: B. Organiser

Explanation: Any part of the embryo that exerts a morphogenetic stimulus on adjacent part is known as the organiser. In morphogenetic development, organizers can be classified into different levels depending on their roles in inducing specific developmental patterns in the embryo. First level is the organiser that induces the development of new tissues. This newly developed tissue can then induce another tissue to become secondary organisers. Therefore, there is a sequence or chain of organiser called primary , secondary and tertiary organisers.

References:

Inderbir Singh’s Human Embryology, 11th Edition, Page 5

↑ *Back to this question in Part A*

@Neet_pg_bot

Q14: During fertilisation , all of the following barriers in the ovum are penetrated by the sperm except: (Q848049)

A. Corona radiata

B. Zona pellucida

C. Oocyte cell membrane

D. Nuclear membrane

Correct Answer: D. Nuclear membrane

■ *Listen (English)*

■ *Listen (Hindi)*

Explanation: The sperm does not penetrate the nuclear membrane of oocyte Sperm must overcome three barriers to fertilize an egg: Corona Radiata (Option A ruled out) Zona Pellucida (Option B ruled out) Oocyte cell membrane (Option C ruled out) After the fusion of sperm and oocyte cell membranes , the nucleus of ovum is converted to the female pronucleus. The nucleus of sperm become male pronucleus.

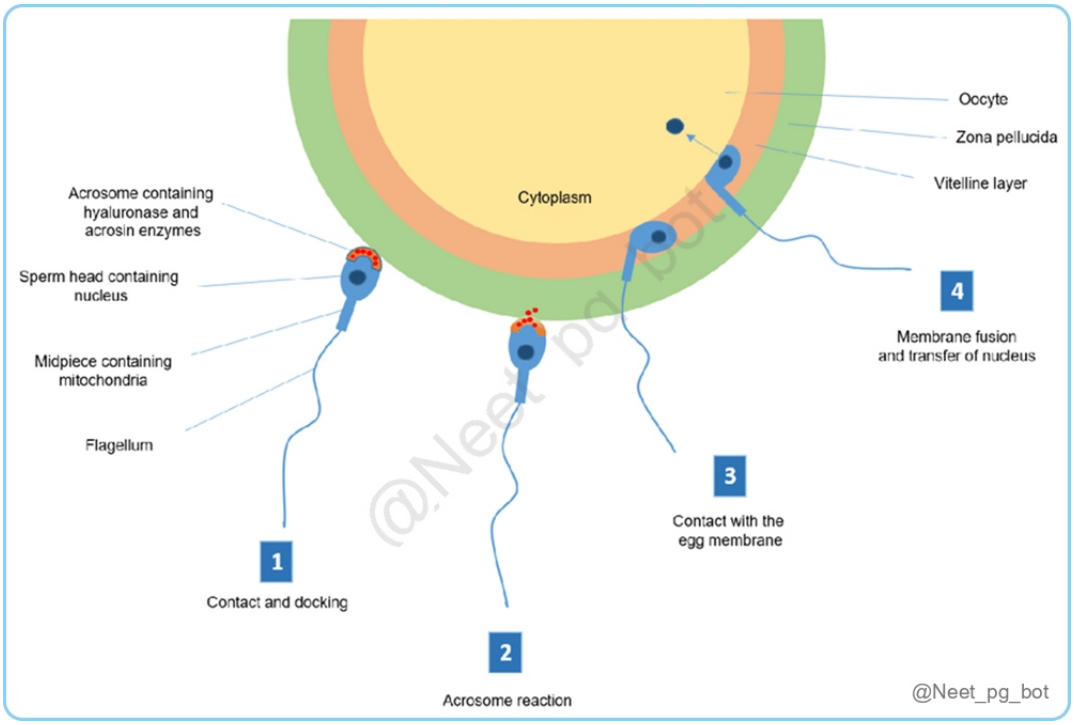

References:

Langman's Medical Embryology, 14th Edition, Page 35

↑ *Back to this question in Part A*

@Neet_pg_bot

Q15: Which of the following is not an acrosomal enzymes? (Q848050)

A. Acrosin

B. Hyaluronidase

C. Acid phosphatase

D. Alkaline phosphatase

Correct Answer: D. Alkaline phosphatase

■ *Listen (English)*

■ *Listen (Hindi)*

Explanation: Alkaline phosphatase is not an acrosomal enzyme. The three main acrosomal enzymes are: acrosin , hyaluronidase and acid phosphatase. The sperm binds to the zona pellucida through the glycoprotein ligands ZP3 and ZP2(zona proteins). The binding causes the release of the acrosomal enzymes that allow the sperm to penetrate the zona pellucida. This is called an acrosomal reaction.

References:

Inderbir Singh's Human Embryology, 11th Edition, Page 49, 50

↑ *Back to this question in Part A*

@Neet_pg_bot

• [01_General Embryology] 002 Development Period

« Back to Folder Directory

[01_General Embryology] 002 Development Period — Quick Jump

Q1 (p. 636) *Q2 (p. 637)* *Q3 (p. 638)* *Q4 (p. 640)* *Q5 (p. 641)* *Q6 (p. 642)*
Q7 (p. 644) *Q8 (p. 645)* *Q9 (p. 648)* *Q10 (p. 651)*

Q1: Which day during Week 1 of embryonic development matches with the given image? (Q848086)

A. Day 1

B. Day 2

C. Day 4

D. Day 5

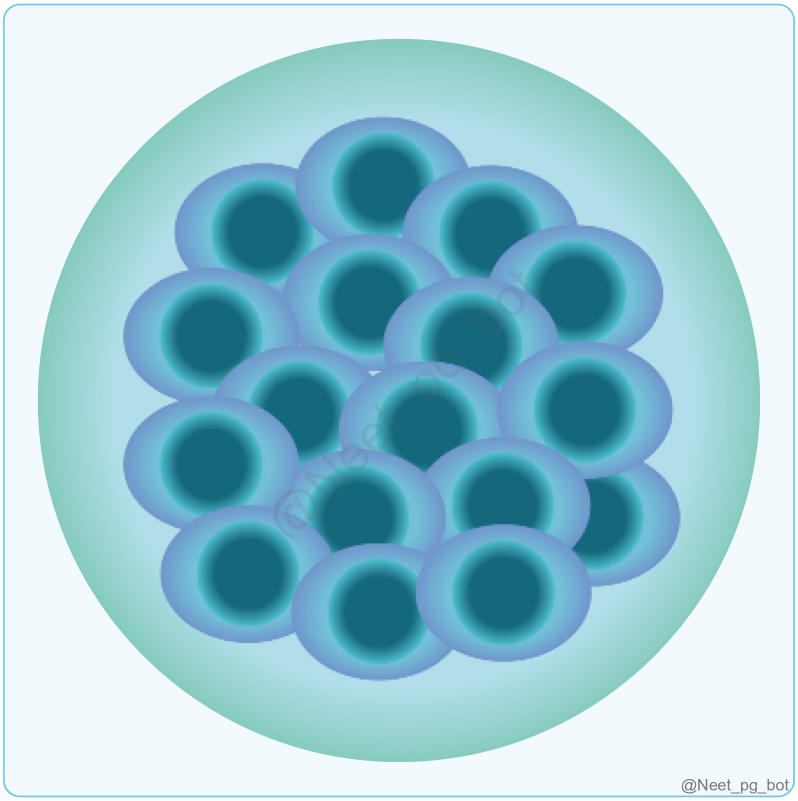

Correct Answer: C. Day 4

■ *Listen (English)*

■ *Listen (Hindi)*

Explanation: Day Event Day 0 Fertilization: The sperm fertilizes the egg in the fallopian tube, forming a zygote (single diploid cell) Day 1 Two cell stage Day 2 Four cell stage Day 3 Twelve cell stage Day 4 Morula Formation: The zygote becomes a solid ball of 16-32 cells. Day 5 Blastocyst Formation: The morula continues to divide and develops a fluid-filled cavity (blastocoel), which consists of the outer trophoblast (future placenta) and the inner cell mass (future embryo). Day 6 & 7 Implantation begins: Blastocyst attaches to the endometrial lining of the uterus and trophoblast begins to invade the uterine wall to start implantation.

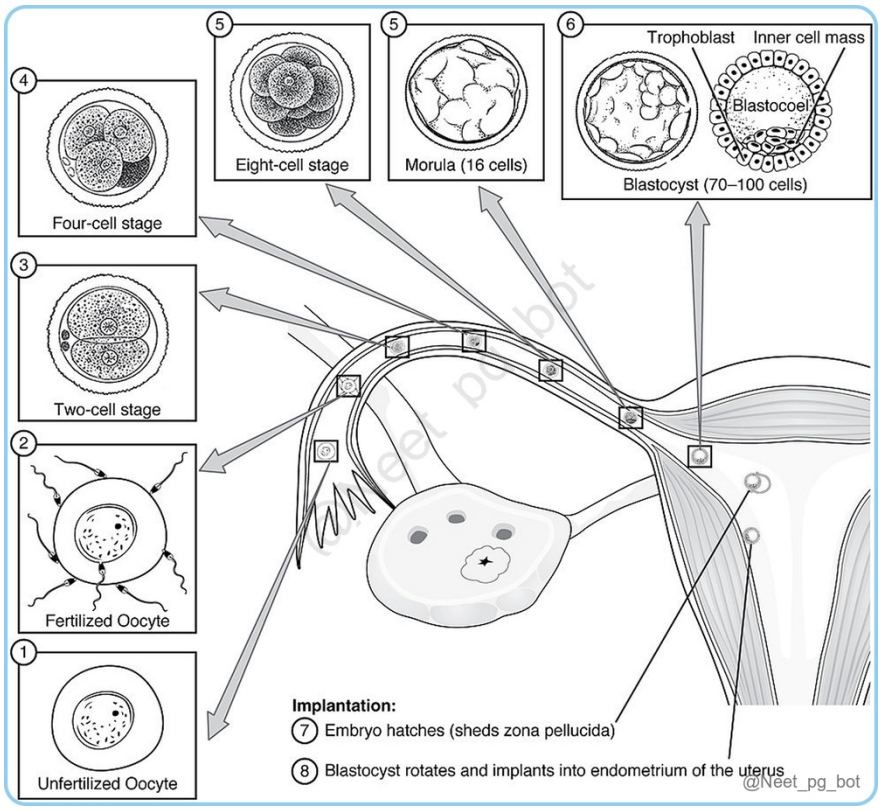

References:

Langman’s Medical Embryology, 14th Edition, Pages 42, 43, 48

First week of development

↑ *Back to this question in Part A*

@Neet_pg_bot

Q2: How many cells are typically present in the morula stage? (Q848087)

A. 4-8 cells

B. 16-32 cells

C. 64-128 cells

D. 2 cells

Correct Answer: B. 16-32 cells

■ *Listen (English)*

■ *Listen (Hindi)*

Explanation: Morula The morula forms around day 3–4 after fertilization as the zygote undergoes rapid cleavage divisions . Contains about 16–32 blastomeres tightly packed into a solid mass resembling a mulberry . Despite increasing cell number, the overall size remains constant (no growth between divisions). Inner cell mass → forms the embryo proper. Outer cell mass → forms trophoblast and contributes to the blastocyst formation.

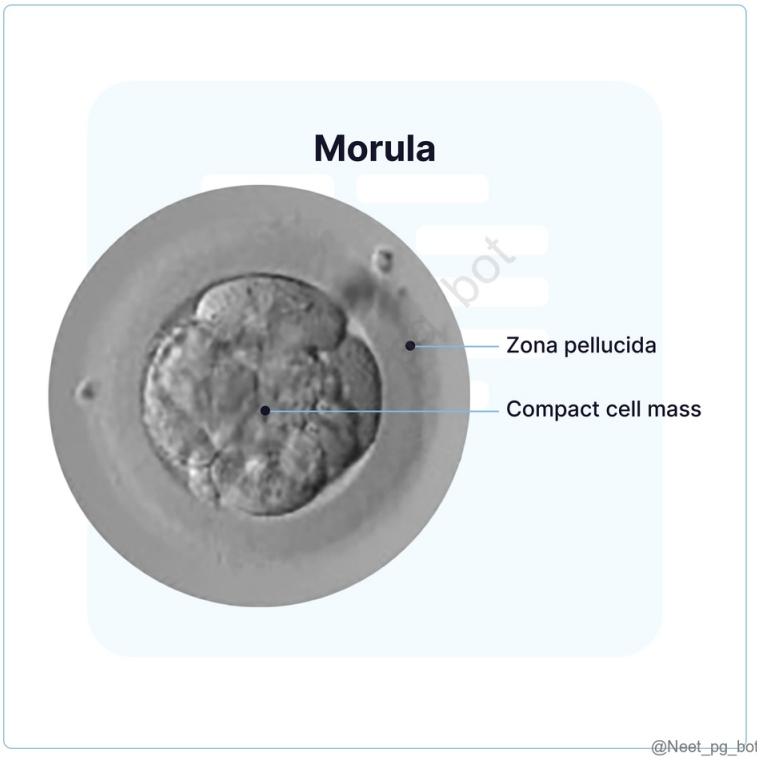

References:

Langman’s Medical Embryology, 14th Edition, Page 49

Morula

↑ *Back to this question in Part A*

@Neet_pg_bot

Q3: What is the function of cortical reaction in fertilization? (Q848088)

A. Facilitate the entry of additional sperm into the oocyte.

B. Prevent polyspermy by modifying the egg's outer membrane.

C. Help the sperm to penetrate the zona pellucida.

D. Release digestive enzymes that help break down the oocyte's nucleus.

Correct Answer: B. Prevent polyspermy by modifying the egg's outer membrane.

- *Listen (English)*
- *Listen (Hindi)*

Explanation: Process Mechanism Purpose Cortical Reaction The fusion of the sperm with the egg membrane triggers the release of cortical granules (vesicles) into the perivitelline space. The contents of these granules alter the zona pellucida and egg membrane, preventing additional sperm from binding and penetrating. Prevents polyspermy (entry of more than one sperm), ensuring viable embryo development. Facilitate the entry of additional sperm into the oocyte (Option A): This is exactly what the cortical reaction prevents . Multiple sperm entering would lead to polyspermy , which is fatal to the embryo. Help the sperm to penetrate the zona pellucida (Option C): This is the role of the acrosome reaction , not the cortical reaction. The sperm's acrosome releases enzymes to penetrate the zona pellucida before fertilization . Release digestive enzymes that help break down the oocyte's nucleus (Option D): This is not a function of the cortical reaction . Also, the oocyte's nucleus is not broken down ; it fuses with the sperm nucleus to form a zygote.

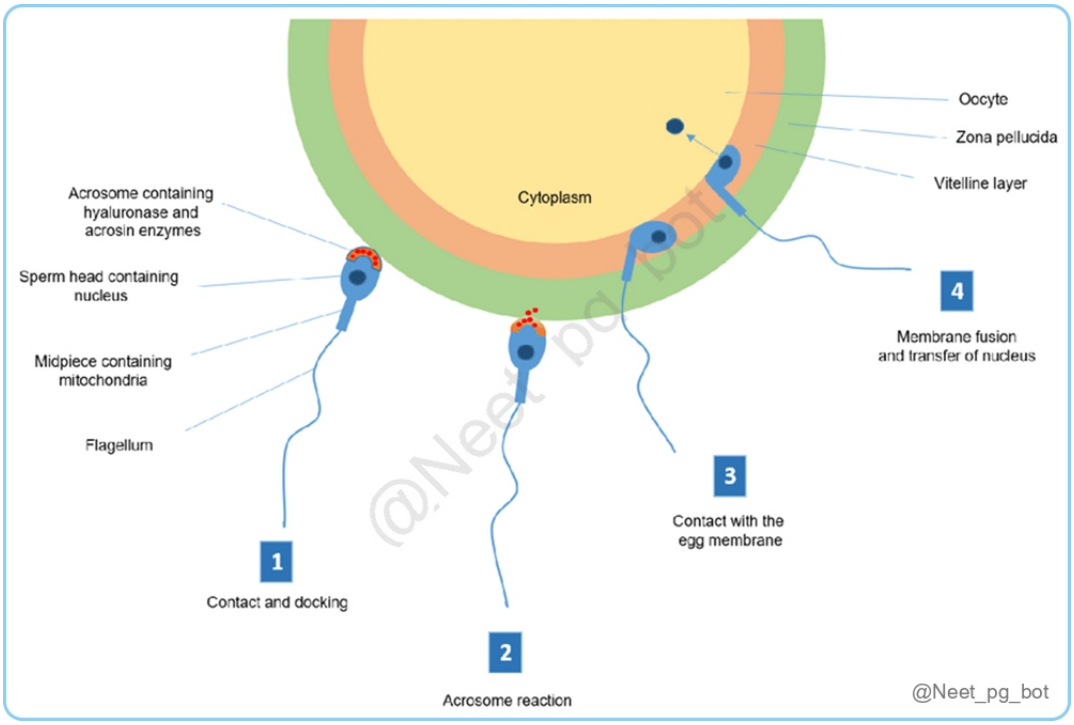

References:

Langman’s Medical Embryology, 14th Edition, Page 39, 40

Cortical reaction

↑ *Back to this question in Part A*

@Neet_pg_bot

Q4: During which phase of the menstrual cycle does implantation typically occur? (Q848089)

A. Menstrual phase

B. Follicular phase

C. Ovulatory phase

D. Luteal phase

Correct Answer: D. Luteal phase

Explanation: Implantation occurs during the luteal phase , when the endometrium is thick, vascular, and receptive under the influence of progesterone from the corpus luteum . Timing: ~6–10 days after ovulation (≈ day 20–24 of the cycle). Blastocyst stage: Fertilized ovum reaches the uterus and forms a blastocyst with an inner cell mass and trophoblast . Trophoblast: Attaches to and invades the endometrium using enzymes to establish maternal–fetal contact. Hormonal support: Implantation triggers hCG release , maintaining the corpus luteum and preventing menstruation.

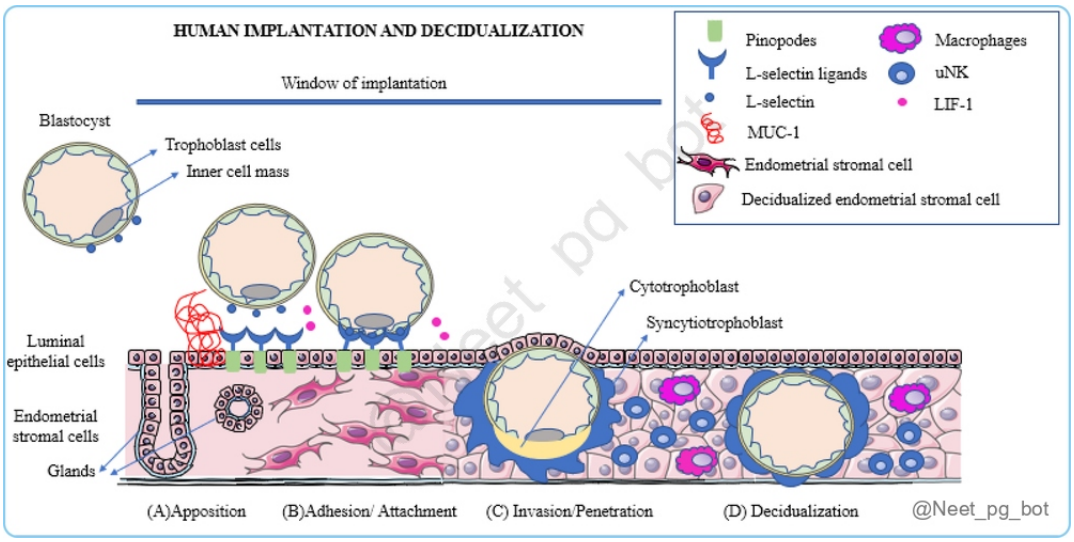

References:

Langman’s Medical Embryology, 14th Edition, Page 46, 47, 48

Implantation

↑ *Back to this question in Part A*

@Neet_pg_bot

Q5: Which substance helps in the attachment of the blastocyst to the uterus? (Q848090)

A. L-selectin

B. Integrin

C. E-cadherin

D. Fibronectin

Correct Answer: A. L-selectin

■ *Listen (English)*

■ *Listen (Hindi)*

Explanation: L-Selectin on trophoblast cells and its carbohydrate receptors on the uterine epithelium mediate the initial attachment of the blastocyst to the uterus. Blastocyst: ~ day 5 post-fertilization Inner cell mass (embryoblast): Forms embryo and extraembryonic tissues. Outer cell mass (trophoblast): Forms part of the placenta and aids implantation. Blastocoel: Fluid-filled cavity that helps expansion and implantation. Integrin (Option B): Involved in firm adhesion and invasion after initial attachment, not the first contact. E-cadherin (Option C): Mediates cell-to-cell adhesion within the embryo. Fibronectin (Option D): Involved in trophoblastic migration, not in initial attachment.

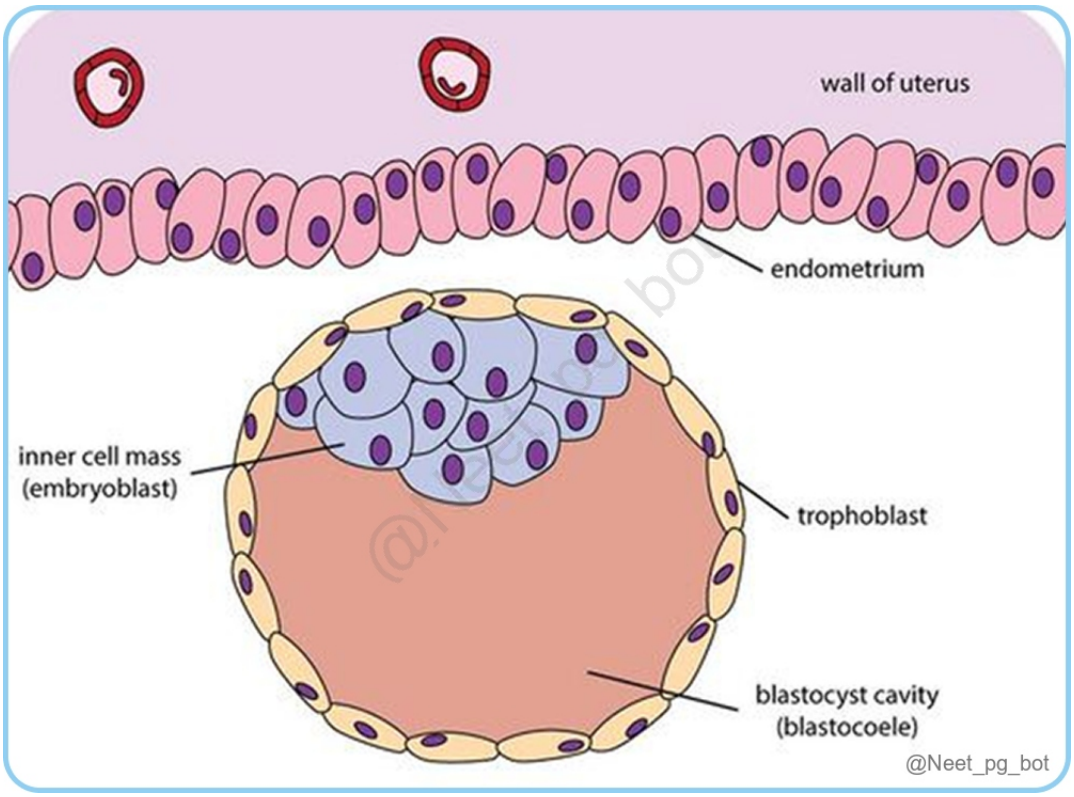

References:

Langman's Medical Embryology, 14th Edition, Page 43, 44

↑ *Back to this question in Part A*

@Neet_pg_bot

Q6: What is the most characteristic event of the 3rd week of development? (Q848091)

A. Formation of blastocyst

B. Gastrulation

C. Implantation

D. Formation of morula

Correct Answer: B. Gastrulation

■ *Listen (English)*

■ *Listen (Hindi)*

Explanation: Gastrulation: The most characteristic event occurring during the third week of gestation. Gastrulation forms the three germ layers —ectoderm, mesoderm, and endoderm—from the epiblast of the blastula. It begins with the primitive streak (day 15–16), whose cephalic end forms the primitive node and pit . Epiblast cells migrate inward (invagination) through the streak under control of FGF8 , which regulates BRACHYURY (T) for mesoderm formation. Invaginating cells replace hypoblast → endoderm , others form mesoderm , and remaining epiblast forms ectoderm —thus generating all germ layers. Formation of blastocyst (Option A): The blastocyst forms around the 5th day, much earlier than the 3rd week. Implantation (Option C): Happens around the end of the first week or beginning of the second week. Formation of morula (Option D): The morula is formed on day 3 or 4 after fertilization, before the blastocyst stage, so it's much earlier than the 3rd week. Timeline of Embryonic Development (Weeks 1–4): Week (Fertilization age) Gestational Age CRL (mm) Major events Week 1 3 weeks 0.1-0.2 Fertilization: Occurs in the ampulla. Morula: Formed on Day 3 or 4. Blastocyst: Forms by Day 5. Implantation: Begins at the end of Week 1. Week 2 4 weeks 0.1-0.2 Implantation Completion: Finished by the beginning of Week 2. Bilaminar Disc: Formation of Epiblast and Hypoblast layers. Week 3 5 weeks 1-2 Gastrulation: Formation of the three germ layers (Ectoderm, Mesoderm, Endoderm) from the epiblast. Primitive Streak: Appears on Day 15–16. Invagination: Controlled by FGF8 ; replaces hypoblast with endoderm. Week 4 6 weeks 2-5 Organogenesis: Neural tube closure and heart begins to beat. Folding: Embryo undergoes lateral and cephalocaudal folding.

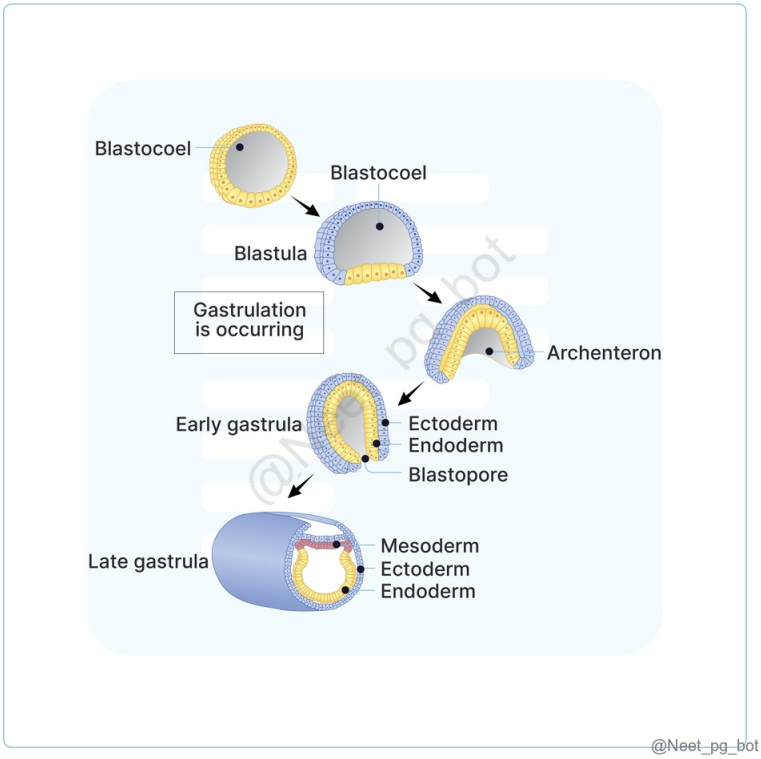

References:

Langman's Medical Embryology, 14th Edition, Pages 59, 94

↑ *Back to this question in Part A*

@Neet_pg_bot

Q7: What structure forms at the surface of the epiblast to initiate gastrulation? (Q848092)

A. 2

B. 3

C. 4

D. 1

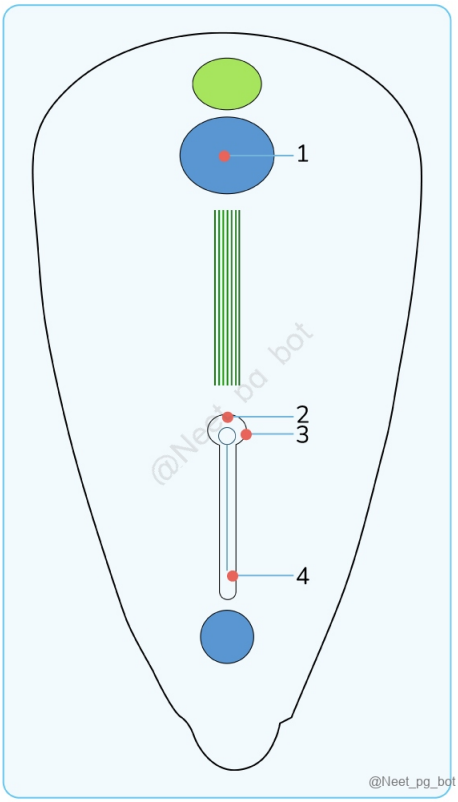

Correct Answer: C. 4

Explanation: Primitive streak/groove (structure-4) forms at the surface of epiblast to initiate gastrulation. Markings in image: 1 - Prechordal plate 2 - Primitive pit 3 - Primitive node 4 - Primitive streak/ groove

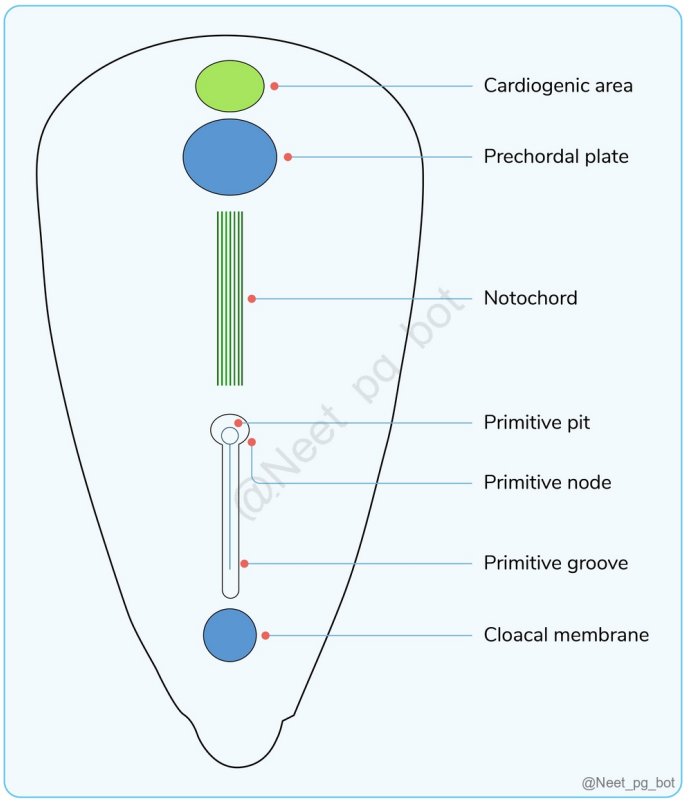

References:

Langman's Medical Embryology, 14th Edition, Page 59, 60

↑ *Back to this question in Part A*

@Neet_pg_bot

Q8: A stillborn baby was noted to have the following findings. The above pathology is derived from which among the following structure shown in the image below? (Q848093)

A. 1

B. 2

C. 3

D. 4



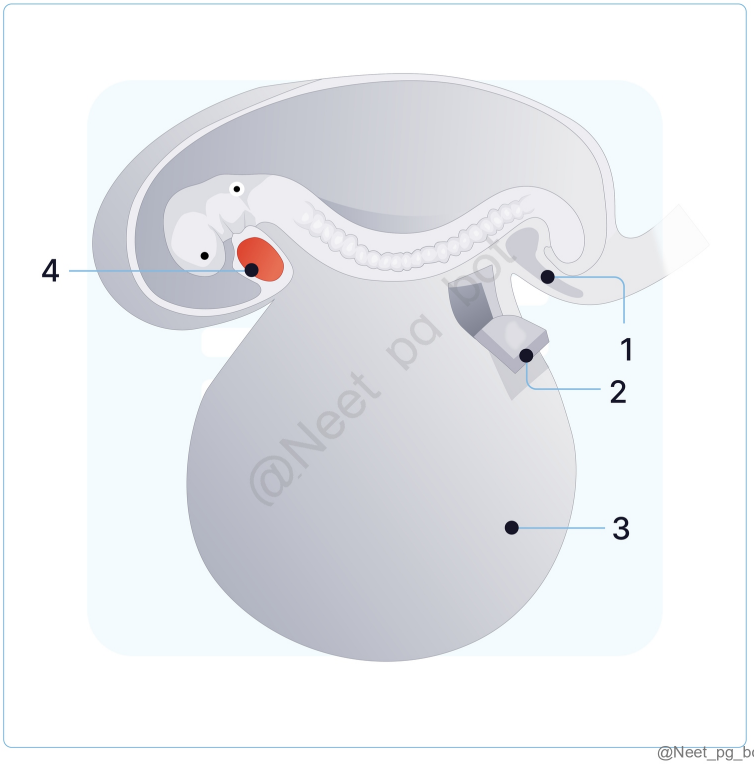

Correct Answer: B. 2

■ *Listen (English)*

■ *Listen (Hindi)*

Explanation: The pathology shown is Oropharyngeal teratoma , arises from Primordial germ cells that fail to migrate to the gonadal ridge and Primordial germ cells (PGC) in the image corresponds to “2”. Markings in the image are: 1 - Allantois 2 - Primordial Germ cells (Option B) 3 - Yolk sac 4 - Heart



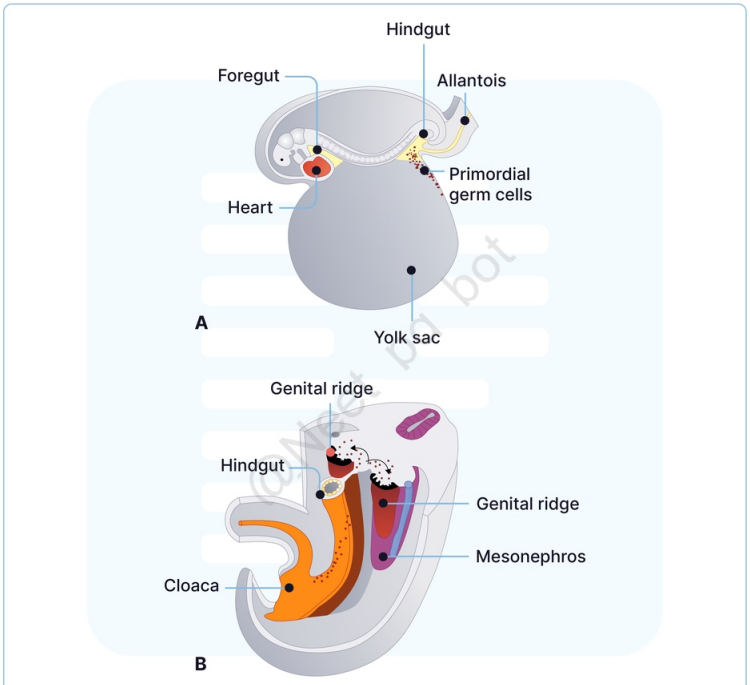

A. A 3-week embryo showing the primordial germ cells in the wall of the yolk sac close to the attachment of the allantois. **B.** Migrational path of the primordial germ cells along the wall of the hindgut and the dorsal mesentery into the genital ridge.

@Neet_pg_bot

References:

Langman's Medical Embryology, 14th Edition, Page 14, 268

↑ *Back to this question in Part A*

@Neet_pg_bot

Q9: A patient with a history of 6 weeks of amenorrhea and a positive urinary pregnancy test underwent an ultrasonography, which showed the following The marked structure in the image communicates via a duct with which of the following parts of the gastrointestinal system? (Q848094)

A. Foregut

B. Midgut

C. Hindgut

D. Cloacal membrane

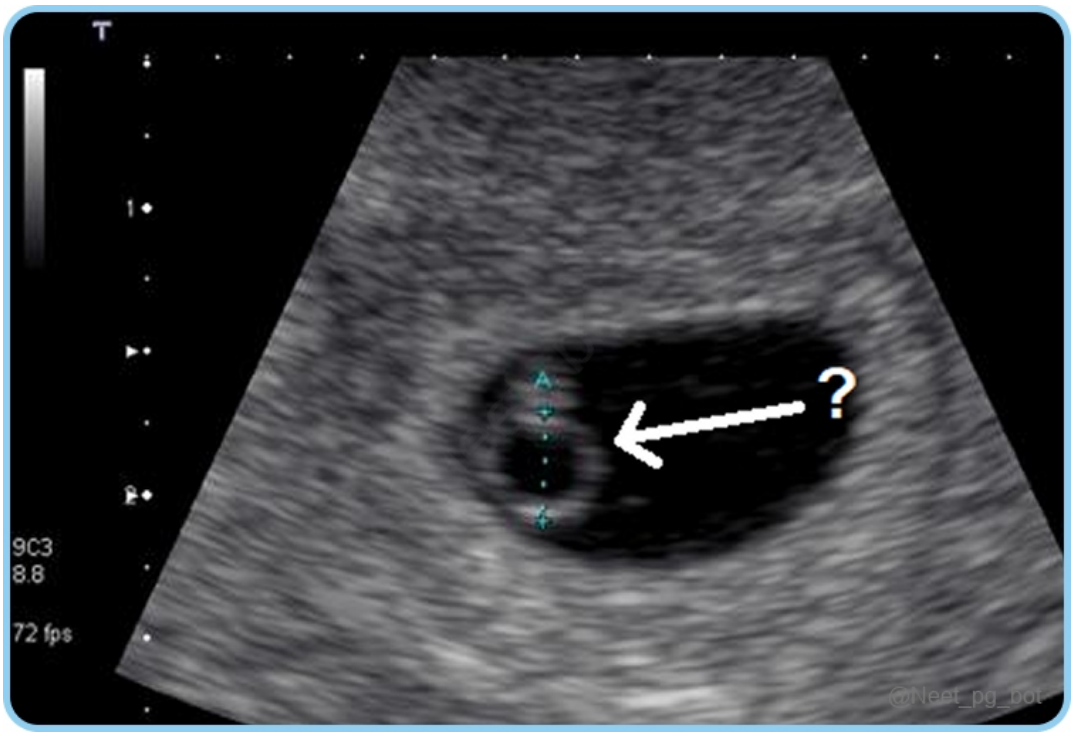

Correct Answer: B. Midgut

- *Listen (English)*
- *Listen (Hindi)*

Explanation: The marked structure in the image is the Yolk sac. The Midgut of the embryo communicates with the yolk sac via a stalk called the Vitelline duct. Yolk sac: Description A small membranous structure outside the embryo. The yolk sac connects to the developing embryo at midgut via the vitelline duct. (Option B) The primitive yolk sac is lined by Hypoblast cells, which is derived from Endoderm (forms the first lining). Functions Primitive hematopoiesis Germ cell production. Nutritive role (before blood vessels form) Foregut (Option A): The foregut is initially bounded by the oropharyngeal membrane, which separates the stomodeum (primitive oral cavity) from the pharynx. The membrane ruptures in the 4th week, establishing an open connection between the oral cavity and primitive gut. Hindgut (Option C) and Cloacal membrane (Option D): The hindgut terminates at the cloacal membrane , which separates the upper anal canal (endodermal) from the lower proctodeum (ectodermal) . The membrane breaks down in the 7th week to create the anal opening. Cephalocaudal growth and lateral folding incorporate part of the allantois into the embryo, forming the cloaca.

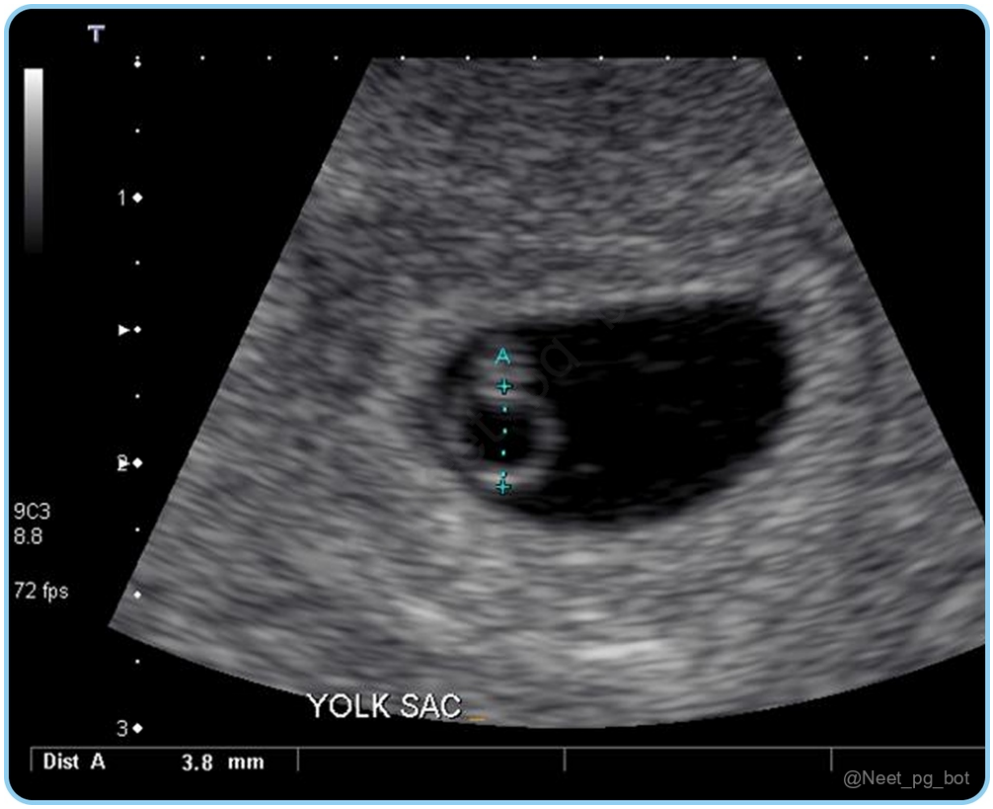

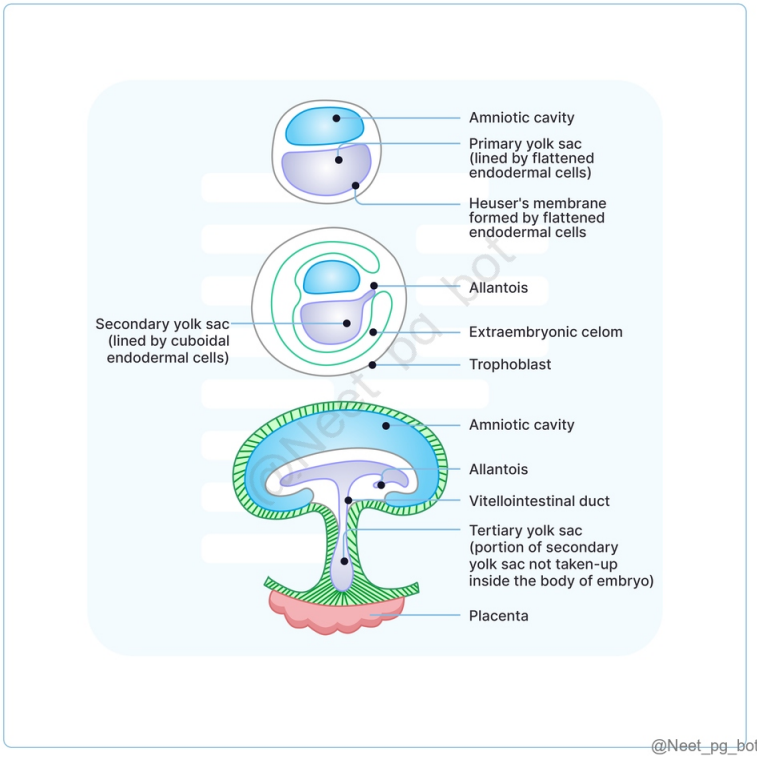

References:

Langman’s Medical Embryology, 14th Edition, Page 51-54, 87-89

https://www.ncbi.nlm.nih.gov/books/NBK555965/

↑ *Back to this question in Part A*

@Neet_pg_bot

Q10: The floor of the amniotic cavity is formed by which among the following cells? (Q848095)

A. Trophoblast cells

B. Endodermal cells

C. Ectodermal cells

D. Mesodermal cells

Correct Answer: C. Ectodermal cells

■ *Listen (English)*

■ *Listen (Hindi)*

Explanation: Amnion: It is the fetal membrane that covers the embryo and forms the amniotic sac that is filled with amniotic fluid. It appears in the 2nd week of development. Formation and expansion of amniotic cavity: The amniotic cavity is lined by extension of cells of ectoderm from the inner cell mass and amniogenic cells. The roof, lateral wall and its floor is formed by ectodermal cells. (Option C)

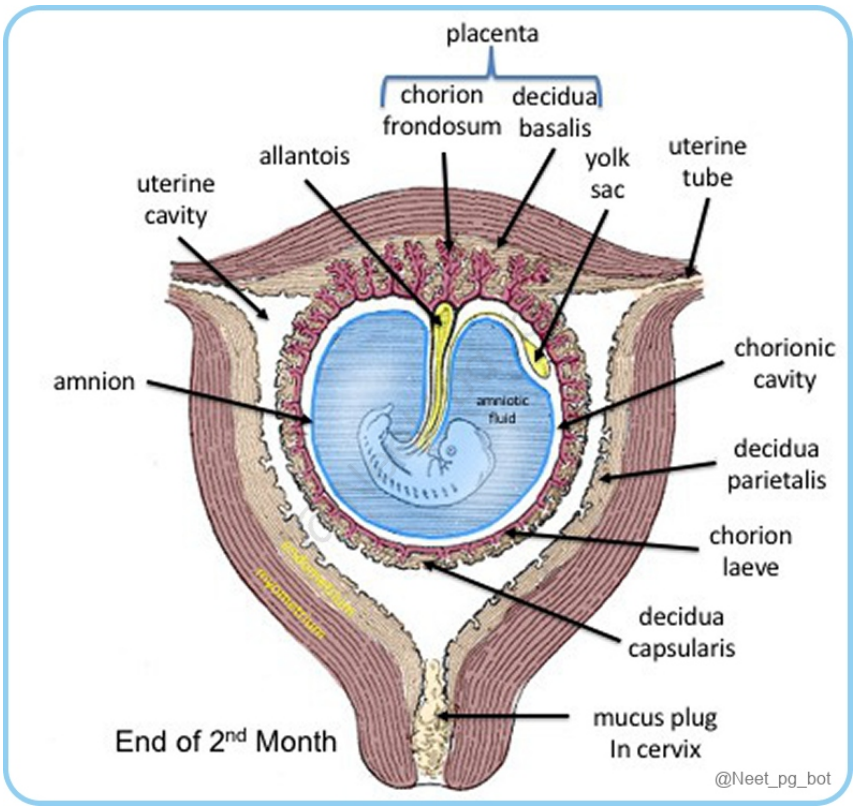

References:

Inderbir Singh's Human Embryology, 11th Edition, Page 90

↑ *Back to this question in Part A*

@Neet_pg_bot

• [01_General Embryology] 003 General Embryology

« Back to Folder Directory

[01_General Embryology] 003 General Embryology — Quick Jump

Q1 (p. 653)	*Q2 (p. 654)*	*Q3 (p. 655)*	*Q4 (p. 656)*	*Q5 (p. 659)*	*Q6 (p. 660)*
Q7 (p. 661)	*Q8 (p. 661)*	*Q9 (p. 662)*	*Q10 (p. 663)*	*Q11 (p. 664)*	*Q12 (p. 665)*
Q13 (p. 665)	*Q14 (p. 667)*	*Q15 (p. 668)*	*Q16 (p. 671)*	*Q17 (p. 674)*	*Q18 (p. 675)*
Q19 (p. 676)	*Q20 (p. 678)*	*Q21 (p. 679)*	*Q22 (p. 682)*	*Q23 (p. 682)*	*Q24 (p. 685)*
Q25 (p. 685)	*Q26 (p. 687)*	*Q27 (p. 688)*			

Q1: A 10-week-old fetus is found to have a developmental anomaly affecting the iris muscles and the posterior pituitary. Which of the following is directly involved in the formation of these structures? (Q848200)

A. Neural crest cells

B. Surface ectoderm

C. Neuroectoderm

D. Epiblast cells

Correct Answer: C. Neuroectoderm

■ *Listen (English)*

■ *Listen (Hindi)*

Explanation: Neural plate ectoderm derivatives include various structures of the central nervous system and associated tissues, specifically: Iris muscles (Dilator pupillae and sphincter pupillae) are derived from the neuroectoderm. Neurohypophysis (posterior pituitary) is also derived from the neuroectoderm, specifically from an extension of the diencephalon. Retina, optic nerve, ciliaris Membranous labyrinth Neural crest cells (Option A) originate from the edge of the neural tube and contribute to various peripheral structures, including parts of the PNS and some facial bones . Surface ectoderm (Option B) primarily forms the outer skin layers, sweat glands, sebaceous glands, and other structures . Epiblast cells (Option D) are early embryonic cells that give rise to the three germ layers .

References:

Inderbir Singh's Human Embryology, 11th Edition, Page 314, 321, 329

https://embryology.med.unsw.edu.au/embryology/index.php?title=Ectoderm

↑ *Back to this question in Part A*

Q2: A 3-week-old infant shows signs of a developmental abnormality involving the formation of tongue muscles. Which group of somites is responsible for this condition? (Q848202)

A. Cervical somites

B. Occipital somites

C. Preoccipital somites

D. Thoracic somites

Correct Answer: B. Occipital somites

■ *Listen (English)*

■ *Listen (Hindi)*

Explanation: Occipital somites contribute to the formation of the muscles of the tongue. Somites: Paraxial mesoderm becomes segmented to form 42-44 pairs of somites develop on either side of the neural tube and notochord. Appear between the 20th and 30th day, marking the 4th week as the somite period. Somite Structure: Sclerotome: Ventromedial part; forms vertebral column and ribs. Dermatome: Lateral part; forms dermis of skin and subcutaneous tissue. Myotome: Intermediate part; forms striated muscle. Somites Number of Pairs Skeletal Elements Musculature Preoccipital (Option C) 3 Base of skull Extraocular muscles of eyeball Occipital (Option B) 4 - 5 Tongue musculature except palatoglossus Cervical (Option A) 8 Vertebra Striated muscles of trunk, diaphragm, limbs Thoracic (Option D) 12 Vertebra and ribs Lumbar 5 Vertebra Sacral 5 Coccygeal 8 - 10

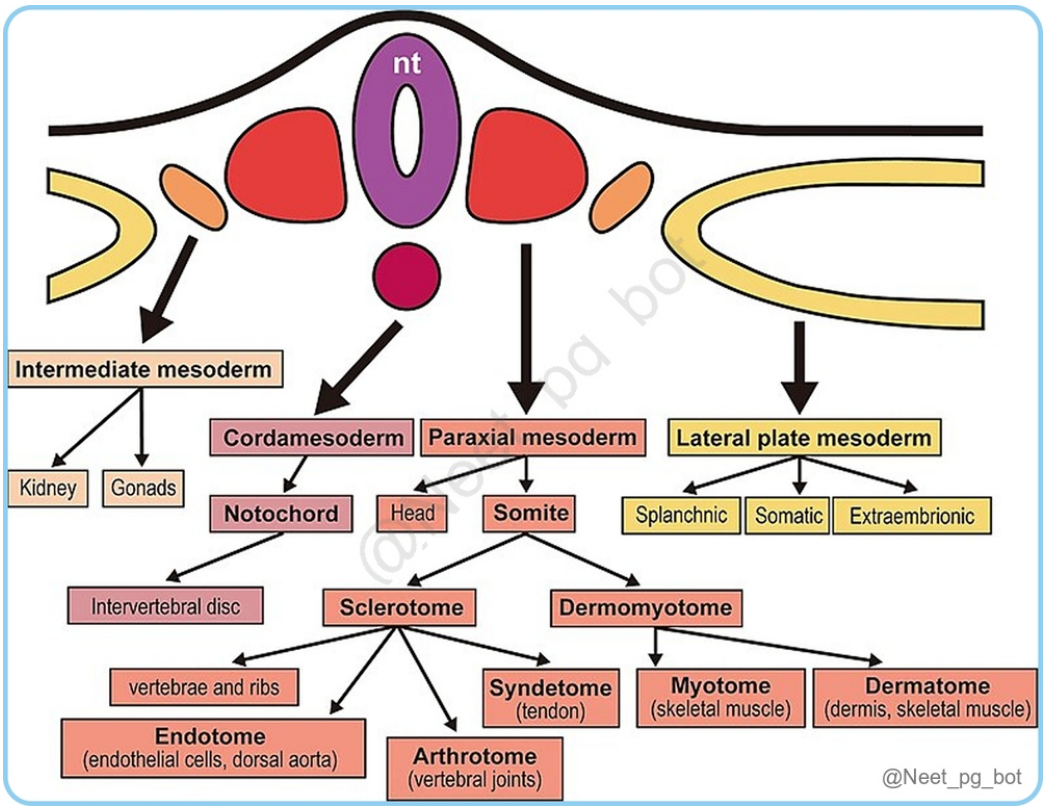

References:

Inderbir Singh's Human Embryology, 11th Edition, Page 138,139

↑ *Back to this question in Part A*

@Neet_pg_bot

Q3: If the development of the endoderm is negatively affected and fails to normally differentiate, which of the following glands would not be affected by this? (Q848206)

A. Follicular cells of thyroid

B. Parenchyma of parathyroid glands

C. Anterior pituitary

D. Pancreas

Correct Answer: C. Anterior pituitary

■ *Listen (English)*

■ *Listen (Hindi)*

Explanation: The pituitary gland develops from the ectoderm, and hence, an improper differentiation of the endoderm would not affect it. Glands developed from ectoderm and endoderm: Ectoderm Endoderm Neural ectoderm: Posterior pituitary Connective tissue of thymus Connective tissue of thyroid and parathyroids Adrenal medulla Connective tissue of lacrimal, nasal, labial, palatine, oral, and salivary glands Thymus glands (parenchyma) Parathyroid glands (parenchyma) (Option B) Liver Pancreas (Option D) Follicular cells of thyroid (Option A) C cells of thyroid Prostate Urethral glands Surface ectoderm: Rathke's pouch gives rise to the anterior pituitary (Option C) Sweat glands and sebaceous glands Parotid, sublingual, submandibular salivary glands Mammary glands Lacrimal glands

References:

Gray's Anatomy, The Anatomical Basis of Clinical Practice, 42nd Edition, Page 204

↑ *Back to this question in Part A*

@Neet_pg_bot

Q4: What is the structure marked "C" formed of? (Q848208)

A. Trophoblast + Somatopleuric EEM

B. Trophoblast+ Splanchnopleuric EEM

C. Ectoderm + EEM

D. Amniogenic cells + Somatopleuric EEM

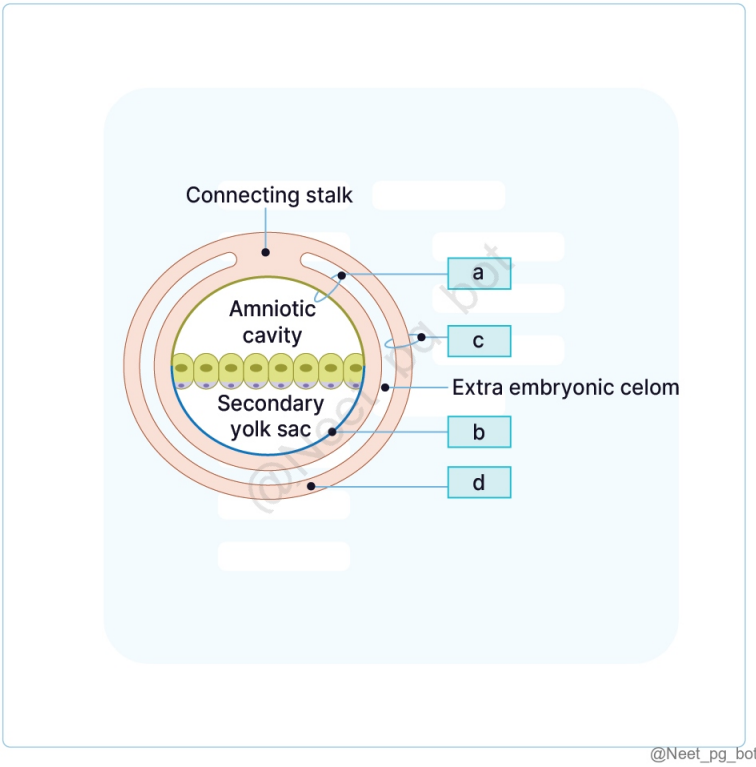

@Neet_pg_bot

Correct Answer: A. Trophoblast + Somatopleuric EEM

■ *Listen (English)*

■ *Listen (Hindi)*

Explanation: The structure marked “C” is c horion , which is formed by the parietal (or somatopleuric) extraembryonic mesoderm and the trophoblast.

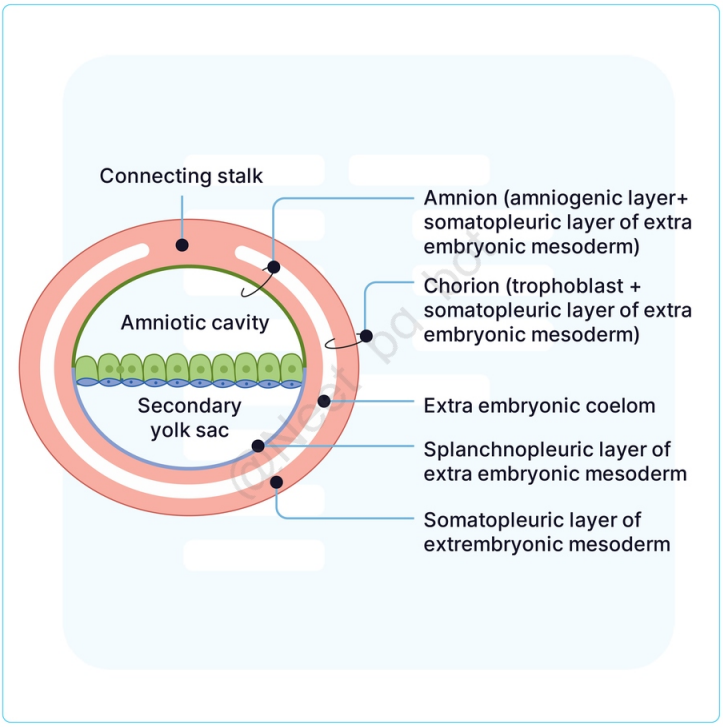

@Neet_pg_bot

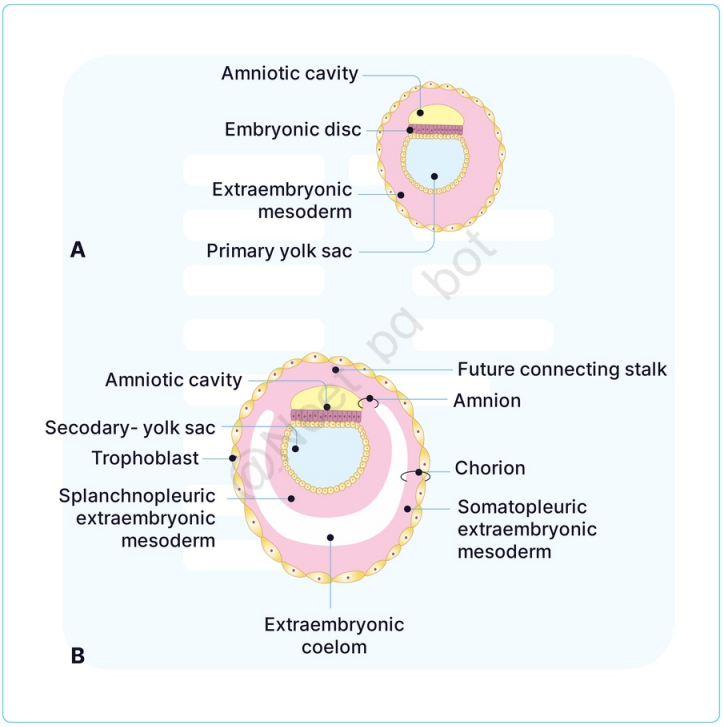

@Neet_pg_bot

References:

Langman’s Medical Embryology, 14th Edition, Page 52

Inderbir Singh’s Human Embryology, 11th Edition, Page 55, 56

https://pubmed.ncbi.nlm.nih.gov/8322818/

↑ *Back to this question in Part A*

@Neet_pg_bot

Q5: A portion of the arch of the aorta is derived from which of the following aortic arches? (Q876184)

A. Aortic arch 1

B. Aortic arch 2

C. Aortic arch 3

D. Aortic arch 4

Correct Answer: D. Aortic arch 4

Explanation: Option D: Aortic arch 4 Aortic arch 4 develops into the following structures: Right subclavian artery (a portion of) Arch of the aorta (a portion of) Option A: Aortic arch 1 It develops into a portion of the maxillary artery Option B: Aortic arch 2 It develops into a portion of the stapedial artery. Option C: Aortic arch 3 Arch 3 develops into the following structures: Right and left common carotid arteries (a portion of) Right and left internal carotid arteries

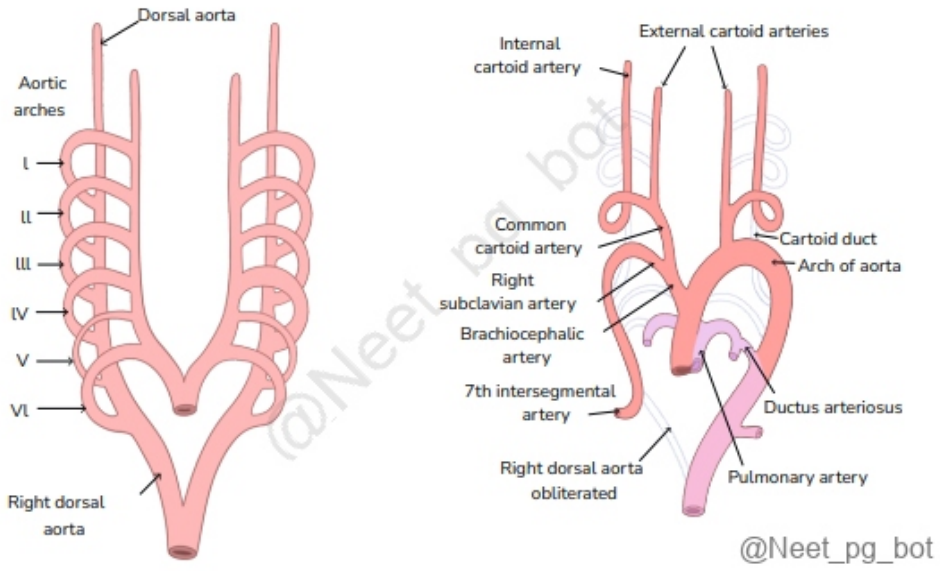

References:

Page number 278 Gray's anatomy Ed. 42e

↑ *Back to this question in Part A*

@Neet_pg_bot

Q6: A portion of the arch of the aorta is derived from which of the following aortic arches? (Q876004)

A. Aortic arch 1

B. Aortic arch 2

C. Aortic arch 3

D. Aortic arch 4

Correct Answer: D. Aortic arch 4

Explanation: Option D: Aortic arch 4 Aortic arch 4 develops into the following structures: Right subclavian artery (a portion of) Arch of the aorta (a portion of) Option A: Aortic arch 1 It develops into a portion of the maxillary artery Option B: Aortic arch 2 It develops into a portion of the stapedial artery. Option C: Aortic arch 3 Arch 3 develops into the following structures: Right and left common carotid arteries (a portion of) Right and left internal carotid arteries

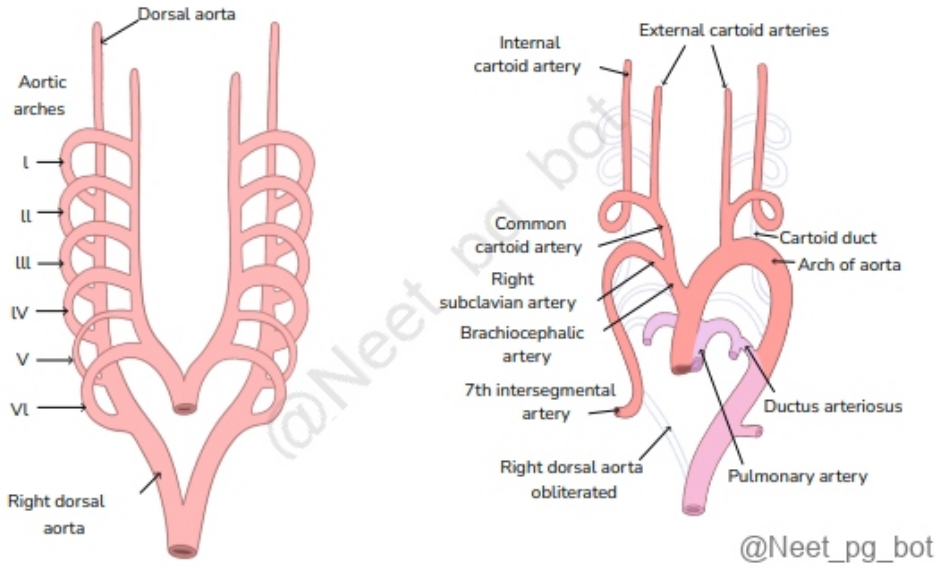

References:

Page number 278 Gray's anatomy Ed. 42e

↑ *Back to this question in Part A*

@Neet_pg_bot

Q7: Which of the following statements about the lamina terminalis is incorrect? (Q848219)

A. It forms the anterior wall of the third ventricle.

B. It gives rise to the septum pellucidum.

C. The lamina terminalis is located at the caudal end of the prosencephalon.

D. The first commissural fibers to develop pass through the lamina terminalis.

Correct Answer: C. The lamina terminalis is located at the caudal end of the prosencephalon.

■ *Listen (English)*

■ *Listen (Hindi)*

Explanation: The lamina terminalis is the part of the neural tube wall that closes the cranial end of the prosencephalon . (Option C) It lies in the anterior wall of the third ventricle after the appearance of the telencephalic vesicles. (Option A) The lamina terminalis forms the commissural plate , which allows neural fibers to pass between hemispheres. Commissural fibers : Anterior commissure (first to develop). (Option D) Hippocampal commissure/fornix (second). Corpus callosum (largest, forms later and extends backward, roofing over the diencephalon). The septum pellucidum persists from the portion of the lamina terminalis between the corpus callosum and fornix. (Option B) Other commissures include the optic chiasma, habenular commissure, and posterior commissure.

References:

Inderbir Singh’s Human Embryology, 11th Edition, Page 307

↑ *Back to this question in Part A*

@Neet_pg_bot

Q8: The cecal bed arises from which part of the embryonic gut? (Q848218)

A. Post-arterial segment of Midgut

B. Pre-arterial segment of Midgut

C. Pre-allantoic part of Hindgut

D. Post-allantoic part of Hindgut

Correct Answer: A. Post-arterial segment of Midgut

■ *Listen (English)*

■ *Listen (Hindi)*

Explanation: The postarterial segment of the midgut loop gives off a cecal bud. The cecum and appendix are formed by enlargement of this bud. Derivatives of Midgut: Prearterial segment (Option B): Duodenum: Descending (second) part distal to the major papilla; horizontal (third) and ascending (fourth) parts Jejunum Ileum except the terminal part. Postarterial segment: Terminal ileum Cecum and appendix Ascending colon Right two-thirds of the transverse colon.

References:

Inderbir Singh's Human Embryology, 11th Edition, Page 175

↑ *Back to this question in Part A*

@Neet_pg_bot

Q9: The stomatodeum is derived from which of the following? (Q848217)

A. Ectoderm

B. Endoderm

C. Mesoderm

D. Neural crest cells

Correct Answer: A. Ectoderm

■ *Listen (English)*

■ *Listen (Hindi)*

Explanation: The stomatodeum (future mouth) is a depression bounded cranially by a bulging produced by the brain, and caudally by a bulging produced by the pericardial cavity. It is derived from the ectoderm . It forms the oral epithelium , including the lips, teeth, and part of the palate. Endoderm (Option B) contributes to the internal lining of the gastrointestinal tract but is not responsible for the stomatodeum. Mesoderm (Option C) contributes to structures such as muscles and connective tissues but not to the stomatodeum directly. Neural Crest Cells (Option D) contribute to structures like the face and skull but do not form the stomatodeum.

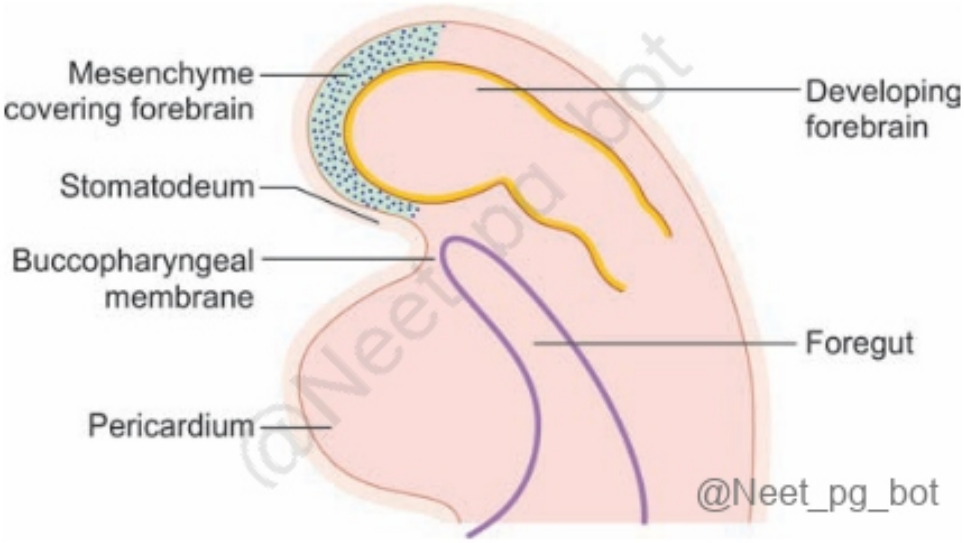

References:

Inderbir Singh's Human Embryology, 11th Edition, Page 152

↑ *Back to this question in Part A*

@Neet_pg_bot

Q10: What is the correct sequence of events in the maturation of the lungs? (Q848216)

A. Canalicular phase → Pseudoglandular phase → Alveolar phase → Saccular phase.

B. Pseudoglandular phase → Canalicular phase → Saccular phase → Alveolar phase.

C. Saccular phase → Alveolar phase → Pseudoglandular phase → Canalicular phase.

D. Alveolar phase → Canalicular phase → Saccular phase → Pseudoglandular phase.

Correct Answer: B. Pseudoglandular phase → Canalicular phase → Saccular phase → Alveolar phase.

■ *Listen (English)*

■ *Listen (Hindi)*

Explanation: The development of the lungs follows a well-defined sequence: Pseudoglandular phase (5–16 weeks): Formation of terminal bronchioles. Canalicular phase (16–26 weeks): Formation of respiratory bronchioles and capillary networks. Saccular phase (26–36 weeks): Formation of primitive alveoli and and capillaries establish close contact. Alveolar phase (36 weeks–postnatal): Formation of mature alveoli and blood-air barrier.

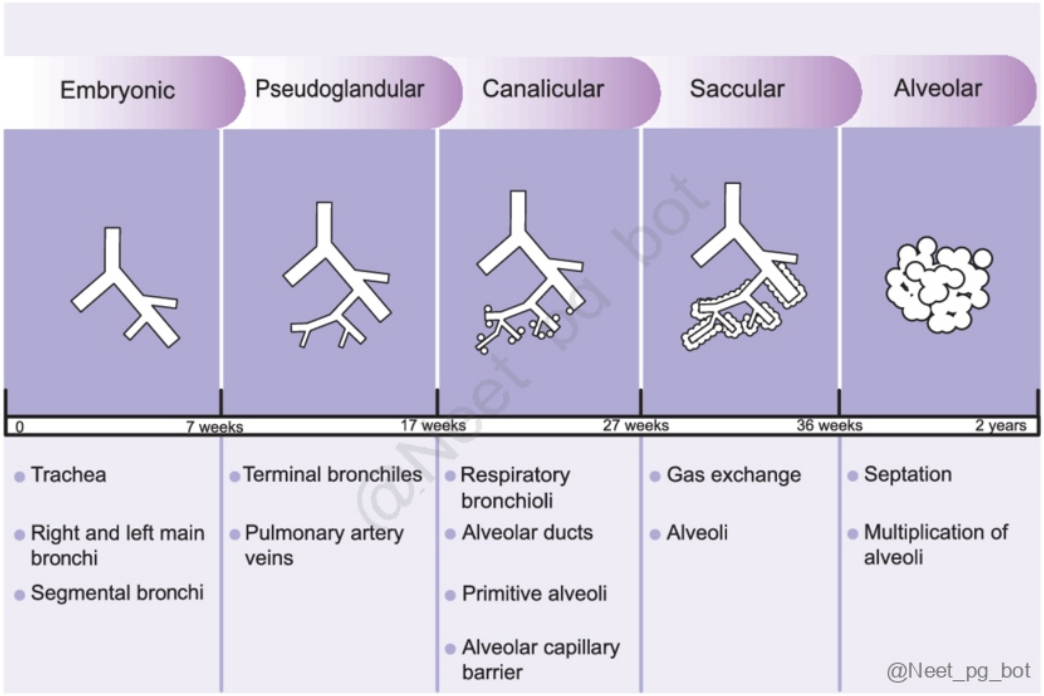

References:

Langman's Medical Embryology, 14th Edition, Page 227,228

↑ *Back to this question in Part A*

@Neet_pg_bot

Q11: Which of the following structures is derived from the endodermal lining of the laryngotracheal tube? (Q848215)

A. Cartilaginous framework of the trachea

B. Alveolar epithelial cells

C. Muscular components of the respiratory tract

D. Parietal pleura covering the lungs

Correct Answer: B. Alveolar epithelial cells

■ *Listen (English)*

■ *Listen (Hindi)*

Explanation: The alveolar epithelial cells (Type I and Type II) are derived from the endoderm of the laryngotracheal tube. Derivatives of the Laryngotracheal Tube: The laryngotracheal tube develops from the

foregut and gives rise to critical structures in the respiratory system. Endodermal Derivatives : Endoderm : Forms the lining of the larynx , trachea , bronchi , and alveoli , including the Type I and Type II alveolar cells . Mesodermal Derivatives : Splanchnic Mesoderm : Forms the cartilage (Option A) , smooth muscle (Option C) , and visceral pleura of the respiratory tract. Somatic Mesoderm : Forms the parietal pleura (Option D) lining the thoracic cavity.

References:

Langman’s Medical Embryology, 14th Edition, Page 223

↑ *Back to this question in Part A*

@Neet_pg_bot

Q12: Which of the following is the first sign of respiratory development? (Q848214)

A. Formation of primary bronchi

B. Appearance of the lung bud

C. Development of type I alveolar cells

D. Formation of the tracheoesophageal septum

Correct Answer: B. Appearance of the lung bud

■ *Listen (English)*

■ *Listen (Hindi)*

Explanation: The first sign of respiratory development is the appearance of the lung bud (also called the respiratory diverticulum) It appears as an outgrowth from the ventral wall of the foregut around the 4th week of embryonic development. Development depends on retinoic acid (RA) produced by adjacent mesoderm, which upregulates the transcription factor TBX4 . This marks the initiation of lung formation and the beginning of the respiratory system's development. Formation of primary bronchi (Option A) occurs later in development, around the 5th week . Development of type I alveolar cells (Option C) : Type I alveolar cells, which are involved in the formation of the blood-air barrier, begin to form later during the canalicular phase (16–26 weeks). Formation of the tracheoesophageal septum (Option D) occurs shortly after the appearance of the lung bud and serves to separate the respiratory tract from the esophagus. This process occurs during the 4th to 5th week .

References:

Langman’s Medical Embryology, 14th Edition, Page 223

↑ *Back to this question in Part A*

@Neet_pg_bot

Q13: Which of the following embryological structures contributes to the development of the post-renal segment of the inferior vena cava? (Q848213)

A. Right vitelline vein

B. Right subcardinal vein

C. Right supracardinal vein

D. Right posterior cardinal vein

Correct Answer: C. Right supracardinal vein

■ *Listen (English)*

■ *Listen (Hindi)*

Explanation: The Post-renal (Infra-renal) segment of the Inferior vena cava (IVC) develops primarily from the right supracardinal vein. Formation of IVC: The beginning of the IVC is called the Posterior cardinal vein. (Option D) Posterior cardinal vein contributes to Sacro cardinal vein. Kidneys drain into the inferior vena cava with the help of renal veins. Right supracardinal vein contributes the Post-renal (infra-renal) segment of the IVC. Right subcardinal vein contributes the Renal and Pre-renal (suprarenal) segment of IVC. (Option B) Terminal portion of the IVC is contributed by the right sided vitelline veins. The right sided vitelline veins will contribute to the right Hepatiocardiac channel. (Option A) All this happen in the right side whereas Left sided veins will disappear. There is Anastomosis between: Supracardinal and Subcardinal vein Subcardinal and hepatocardiac channel

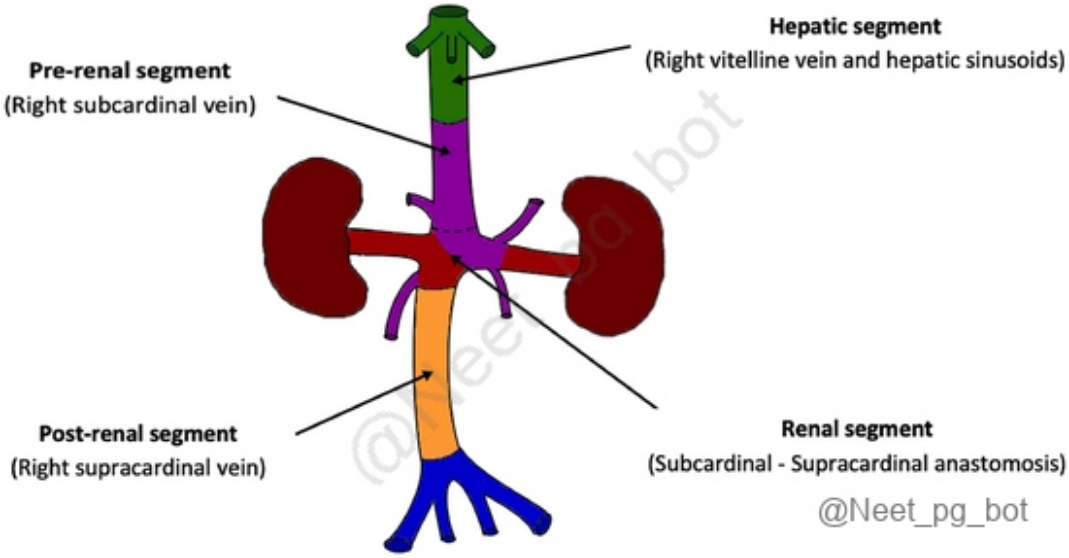

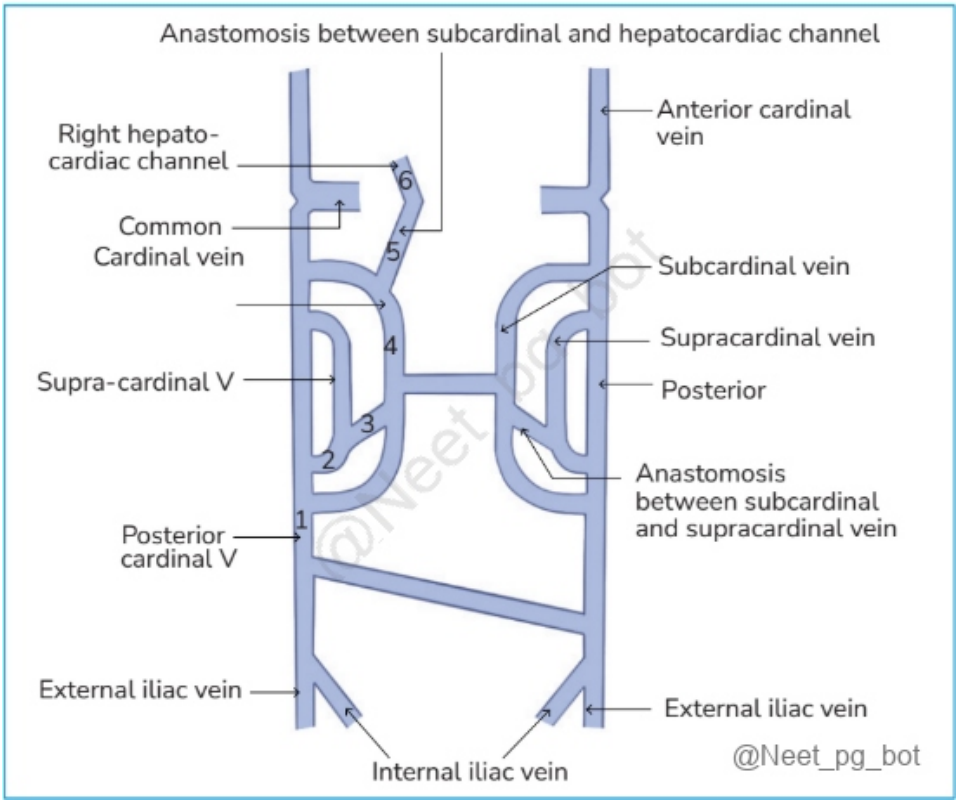

References:

Inderbir Singh's Human Embryology, 11th Edition, Page 256

↑ *Back to this question in Part A*

@Neet_pg_bot

Q14: A 25-year-old male is found to have a persistent left-sided superior vena cava (SVC) during routine imaging. What is the most likely cause of this anomaly? (Q848212)

A. Failure of right-sided SVC to develop

B. Abnormal development of the left anterior cardinal vein

C. Persistence of the left umbilical vein

D. Abnormal development of the right posterior cardinal vein

Correct Answer: B. Abnormal development of the left anterior cardinal vein

■ *Listen (English)*

■ *Listen (Hindi)*

Explanation: A persistent left-sided SVC arises from the left anterior cardinal vein , which typically regresses during fetal development. Normal Development : The right anterior cardinal vein forms the right SVC . The left anterior cardinal vein regresses, with its remnant forming the left brachiocephalic vein , which connects the left and right venous systems. Persistent Left-Sided SVC : Occurs due to the failure of the left anterior cardinal vein to regress . This results in the formation of a left-sided SVC , which drains into the right atrium through the coronary sinus . The right SVC typically develops normally. Double SVC : If the left brachiocephalic vein fails to form , the left anterior cardinal vein persists as a separate venous channel. In this condition: The right anterior cardinal vein forms the right SVC . The left anterior cardinal vein persists as the left SVC . A . Left superior vena cava draining into the right atrium by way of the coronary sinus B . Double superior vena cava. The communicating [brachiocephalic] vein between the two anterior cardinals has failed to develop

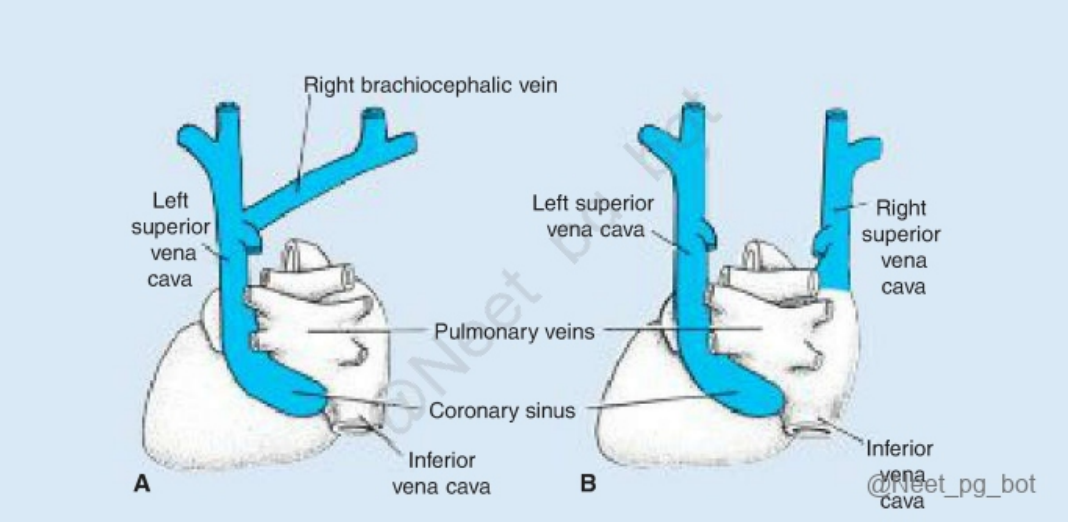

References:

Langman’s Medical Embryology, 14th Edition, Page 215, 216

↑ *Back to this question in Part A*

@Neet_pg_bot

Q15: The structure “b” fuses with structure “c” during the 3rd month of pregnancy. Identify the structure “c”. (Q848211)

A. Decidua capsularis

B. Decidua basalis

C. Myometrium

D. Decidua parietalis

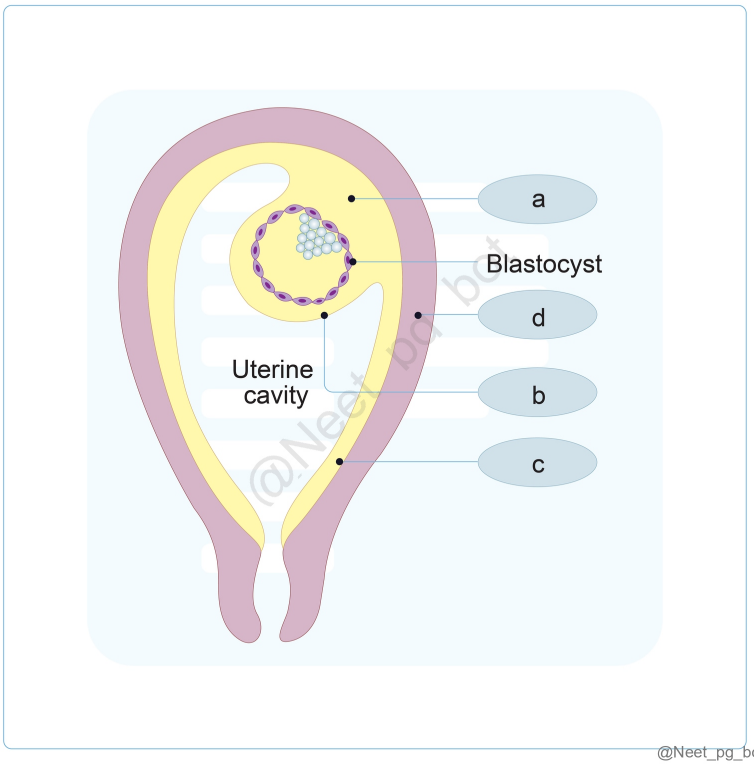

Correct Answer: D. Decidua parietalis

- *Listen (English)*
- *Listen (Hindi)*

Explanation: The structure “c” is decidua parietalis that fuses with the growing decidua capsularis around the embryo. Three types of decidua: Decidua basalis/Serotina (Option B ruled out) Decidua capsularis/Reflexa (Option A ruled out) Decidua parietalis/Vera This forms the maternal component of the placenta The maternal spiral arteries grow and dilate to form sinusoids with blood Firmly attached to the chorion Separates the embryo from the uterine cavity Covers the embryo like a capsule Lines the rest of the uterine cavity Myometrium (Option C) : is labelled as structure "d" in the image

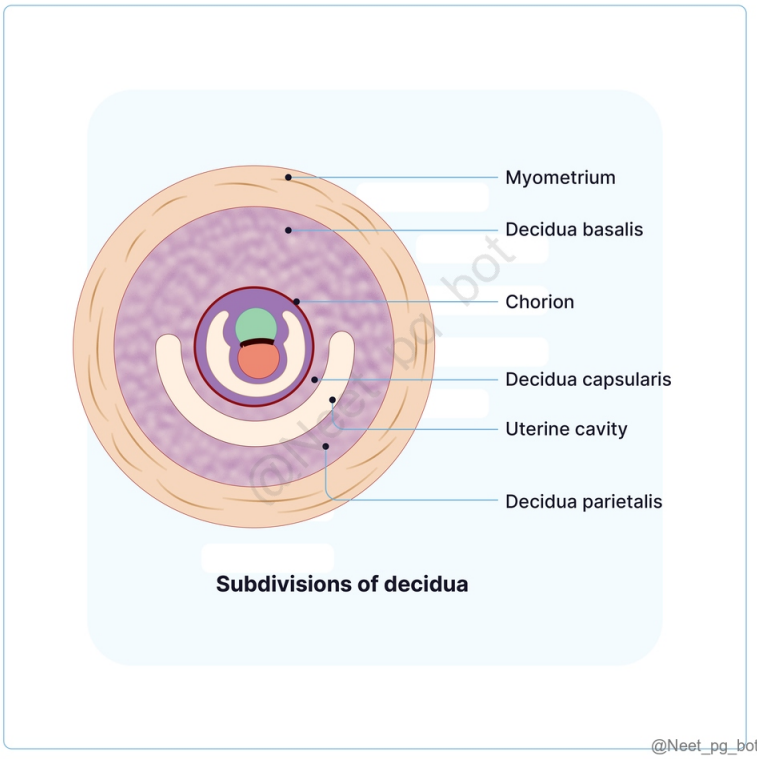

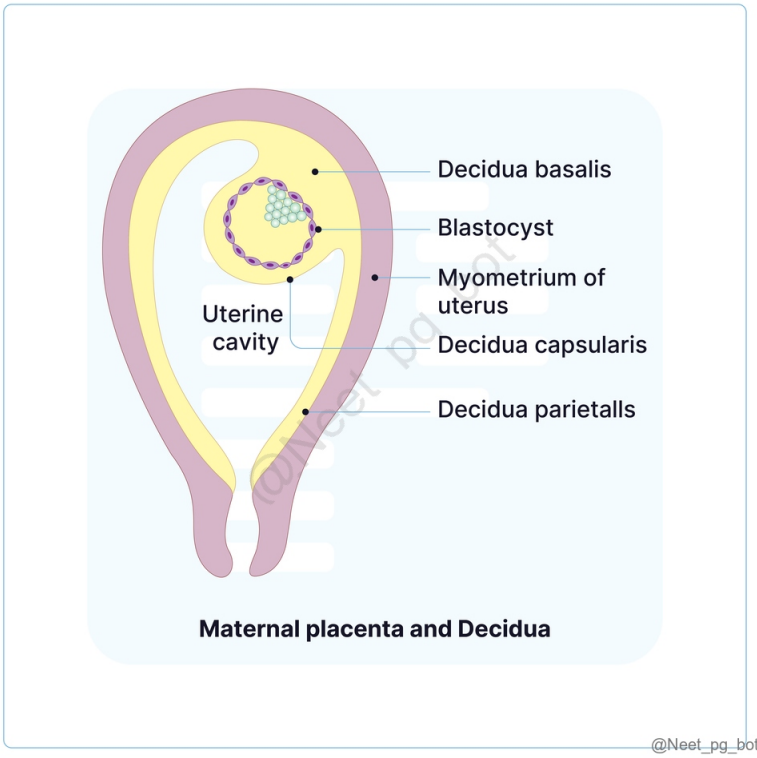

References:

Inderbir Singh’s Human Embryology, 11th Edition, Page 78

↑ *Back to this question in Part A*

@Neet_pg_bot

Q16: Which of the following statements is true about villi? (Q848210)

A. The secondary villi have a central core of cytotrophoblast

B. The uteroplacental circulation begins only after the formation of tertiary villi

C. The tertiary villi have a mesoderm core that carries the fetal blood

D. The primary villi have a core of extraembryonic mesoderm

Correct Answer: C. The tertiary villi have a mesoderm core that carries the fetal blood

■ *Listen (English)*

■ *Listen (Hindi)*

Explanation: The tertiary villi are formed with the extraembryonic mesoderm core filled with fetal blood, which establishes the fetoplacental circulation. Stages of villi formation: Primary villi: Core of cytotrophoblast covered by syncytiotrophoblast. (Option D) Secondary villi: Core of extraembryonic mesoderm covered by cytotrophoblast and syncytiotrophoblast. (Option A) Tertiary villi: Mesodermal core contains fetal capillaries , allowing maternal–fetal exchange. Erosion of maternal endometrium: The endometrium of the maternal uterus is eroded by the growing syncytiotrophoblasts, which leads to the opening of some blood vessels and the leaking of blood into the lacunar space (uteroplacental circulation). (Option B) Uteroplacental circulation begins earlier , with erosion of maternal vessels during lacunar stage. (Option B)

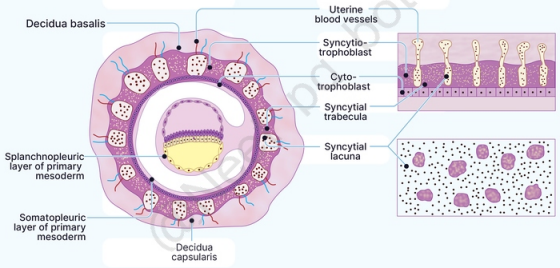

@Neet_pg_bot

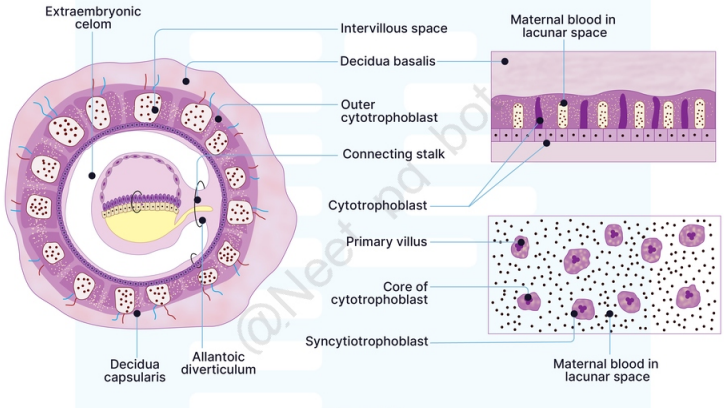

Primary villi

@Neet_pg_bot

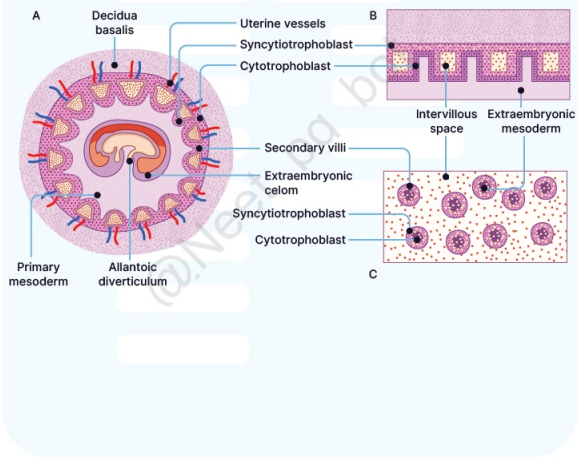

@Neet_pg_bot

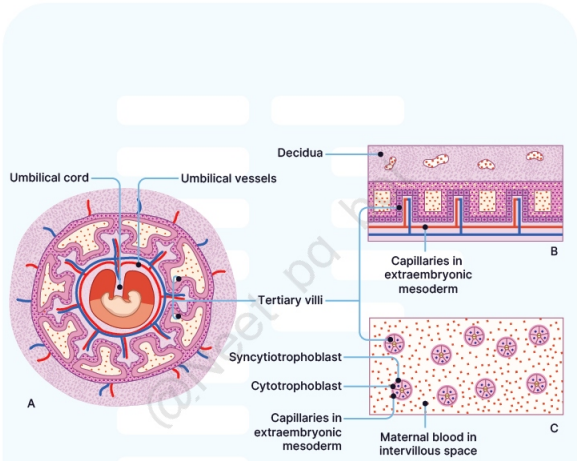

@Neet_pg_bot

References:

Inderbir Singh’s Human Embryology, 11th Edition, Page 81, 82, 83

↑ *Back to this question in Part A*

@Neet_pg_bot

Q17: A woman who is Rh-negative is pregnant with a Rh-positive baby and is advised to take anti-D immunoglobulin for safe future pregnancies. Which of the following disappears from the placental membrane, thus thinning it out later in the pregnancy? (Q848209)

A. Syncytiotrophoblast

B. Endothelium of fetal capillaries

C. The basement membrane of fetal capillaries

D. Cytotrophoblasts

Correct Answer: D. Cytotrophoblasts

■ *Listen (English)*

■ *Listen (Hindi)*

Explanation: The placental membrane or barrier separates the maternal and fetal blood in the intrauterine period but thins out towards the end of pregnancy for many reasons, one of which is the disappearance of the cytotrophoblast. Placental Membrane: This separates the fetal blood in the villi from the maternal blood in the intervillous space running side by side but opposite in direction. The following are the structures that form the placental membrane early in pregnancy : Endothelium of maternal blood vessels and its basement membrane Syncytiotrophoblast Cytotrophoblast Extraembryonic mesoderm (EEM) Endothelium of fetal blood vessels and its basement membrane Structures that form the placental membrane l ater in pregnancy: Endothelium of fetal capillaries and their basement membrane (Option B & C) Syncytiotrophoblast (Option A) The placental membrane thins later in pregnancy due to : Disappearance of cytotrophoblast Thinning of syncytiotrophoblast Edematous stroma Peripheral migration of fetal blood vessels

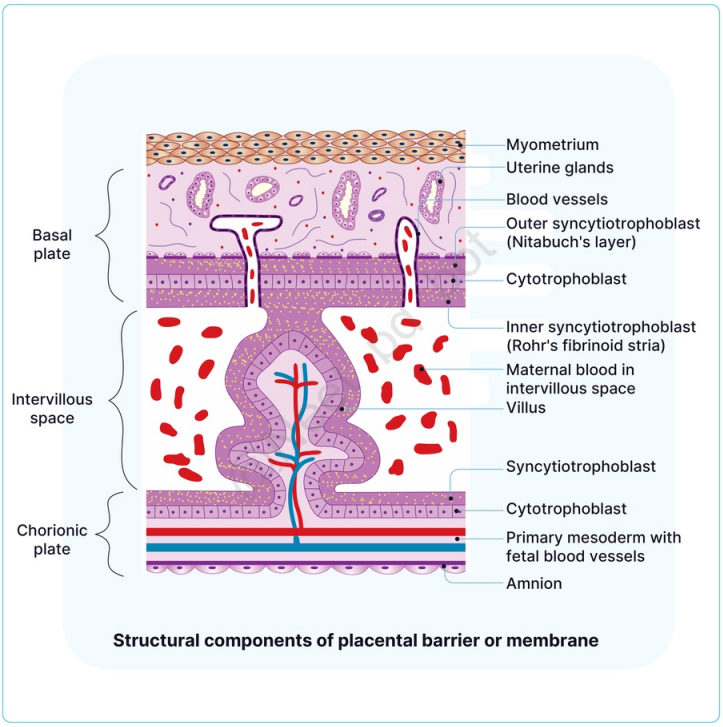

@Neet_pg_bot

References:

Inderbir Singh's Human Embryology, 11th Edition, Page 84, 85, 86

↑ *Back to this question in Part A*

@Neet_pg_bot

Q18: During the third week of gestation, the formation of the primitive streak signifies the start of gastrulation. Which statement about the primitive streak accurately describes this process? (Q848195)

A. It forms from hypoblast cells and establishes the embryonic central axis.

B. It appears dorsally, becoming linear and marking the transition to a trilaminar disc.

C. It develops into the prechordal plate, defining the head-tail axis.

D. It originates from trophoblast cells, contributing to the amniotic cavity and yolk sac formation.

Correct Answer: B. It appears dorsally, becoming linear and marking the transition to a trilaminar disc.

■ *Listen (English)*

■ *Listen (Hindi)*

Explanation: The primitive streak is a key structure that forms on the dorsal aspect of the embryonic disc and becomes a linear structure as the disc elongates. This marks the beginning of gastrulation and the transition from a bilaminar to a trilaminar disc , establishing the embryonic axis . The primitive streak is an early, temporary structure that emerges in the blastula during the initial stages of embryonic development. Around the 15th day of development, following the formation of the prechordal plate, epiblast cells along the central axis near the tail end of the embryo start to proliferate, creating an elevation that protrudes into the amniotic cavity known as the primitive streak . (Option A, B and D) Its cranial end forms the primitive node. A groove called a primitive groove appears in the primitive streak, which continues with a small depression, a primitive pit , in the primitive node.

References:

Inderbir Singh’s Human Embryology, 11th Edition, Page 56

Langman Medical Embryology, 14th Edition, Page 59

↑ *Back to this question in Part A*

@Neet_pg_bot

Q19: Which of the following statements about yolk sac development is correct? (Q848207)

A. Primary yolk sac is lined by cuboidal cells.

B. Secondary yolk sac is lined by flattened cells.

C. Primary yolk sac forms by the end of the first week

D. Tertiary yolk sac connects to the midgut via the vitellointestinal duct.

Correct Answer: D. Tertiary yolk sac connects to the midgut via the vitellointestinal duct.

■ *Listen (English)*

■ *Listen (Hindi)*

Explanation: Tertiary yolk sac communicates with the midgut via the vitellointestinal duct. Development of Yolk Sac: 3 stages of development: Primary yolk sac: Blastocyst cavity (blastocele) becomes the primary yolk sac when it is lined by Heuser’s membrane (flattened cells from endoderm of embryoblast). (Option A) Heuser's membrane attaches to the undersurface of the embryonic disc. Formed by the end of the second week. (Option C) Secondary yolk sac: With the formation of extraembryonic coelom, the primary yolk sac becomes smaller and is termed as secondary yolk sac. Cells lining the yolk sac become cuboidal. (Option B) ■■■■ Tertiary (definitive) yolk sac: Remnant of the secondary yolk sac. As the embryo folds, most of the yolk sac is incorporated into the embryo to form the primitive gut. Remaining portion not absorbed into the embryo is termed as tertiary/definitive yolk sac. It communicates with the midgut via the vitellointestinal duct. (Option D)

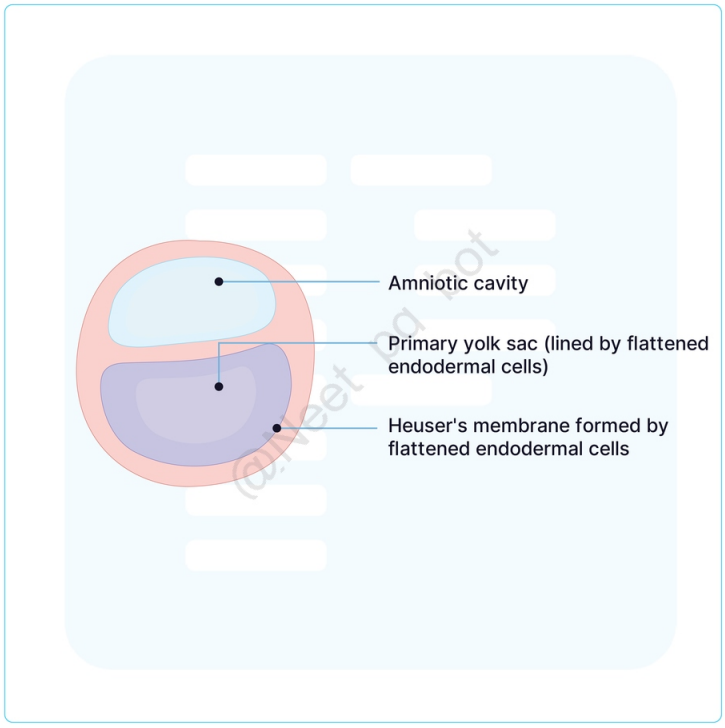

@Neet_pg_bot

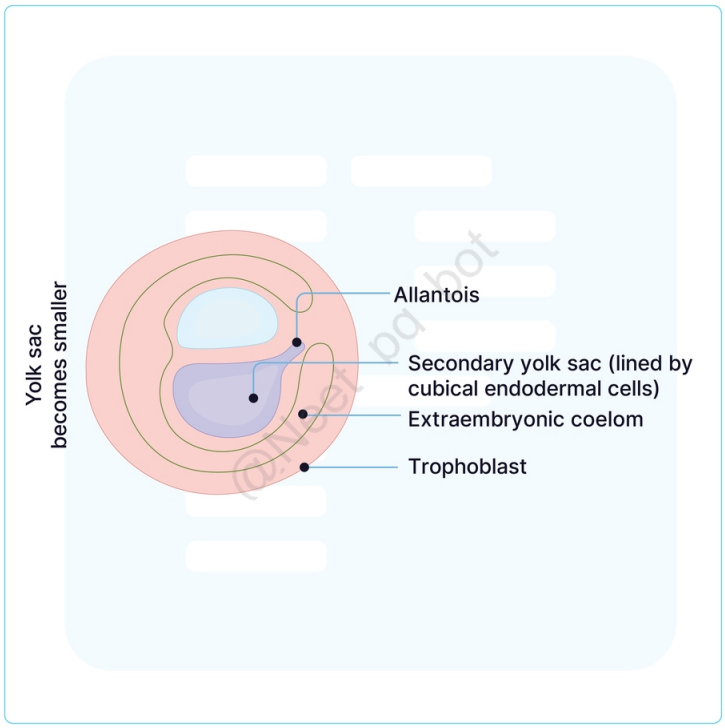

@Neet_pg_bot

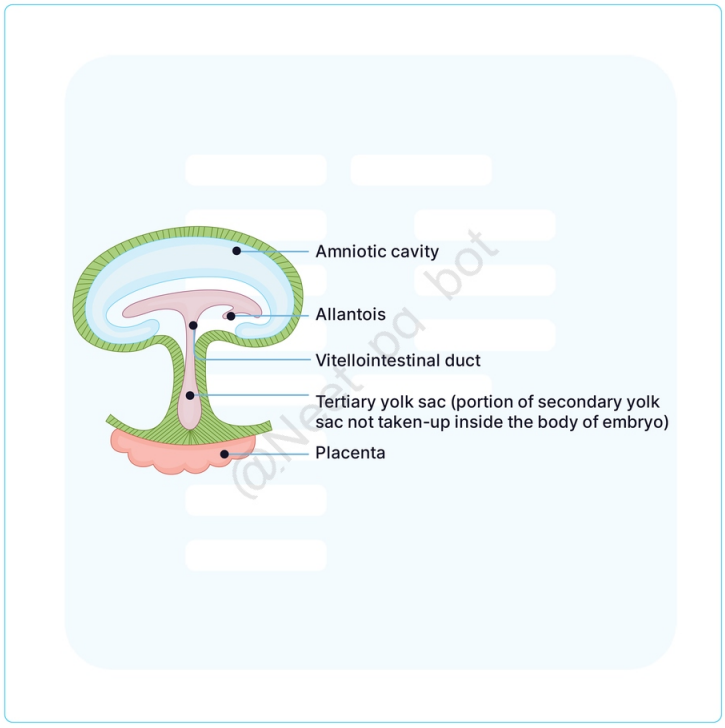

@Neet_pg_bot

References:

Vishram Singh Textbook of Clinical Embryology, 2nd Edition, Page 65

↑ *Back to this question in Part A*

@Neet_pg_bot

Q20: During embryonic development, different structures are derived from the lateral plate mesoderm. Which of the following structures are not derived from the lateral plate mesoderm? (Q848205)

A. Shoulder and hip girdle bones

B. Smooth muscle layers of the gut

C. Smooth muscle of the iris

D. Visceral and Parietal layers of body cavities

Correct Answer: C. Smooth muscle of the iris

■ *Listen (English)*

■ *Listen (Hindi)*

Explanation: Smooth muscle of the iris (sphincter and dilator pupillae) is derived from mesenchymal cells originating from the ectoderm , not the lateral plate mesoderm. Lateral Plate Mesoderm Somatopleuric (Parietal) Layer Splanchnopleuric (Visceral) Layer In contact with the ectoderm. In contact with the endoderm. Forms the dermis of the skin in the body wall and limbs. Contributes to bones and connective tissues of the limbs and sternum. Sclerotome and muscle precursor cells that migrate into the parietal layer of lateral plate mesoderm form the costal cartilages , l imb muscles , and most of the body wall muscles. (Option D) Gives rise to shoulder and hip girdle bones. (Option A) Forms a parietal layer around peritoneal, pleural, and pericardial cavities. Forms connective tissue and smooth muscle layers of the gut , cardiac muscle, and the circulatory system. (Option B) Form a visceral layer around peritoneal, pleural, and pericardial cavities.

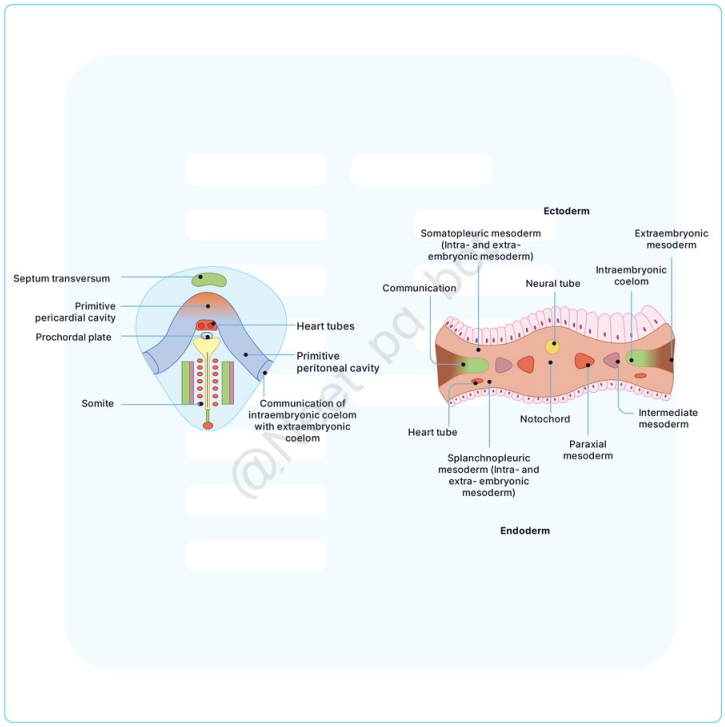

@Neet_pg_bot

References:

Inderbir Singh’s Human Embryology, 11th Edition, Pages 67,138, 201

Langman’s Medical Embryology, 14th Edition, Pages 84-85

https://www.ncbi.nlm.nih.gov/books/NBK537140/

↑ *Back to this question in Part A*

@Neet_pg_bot

Q21: A newborn is diagnosed with congenital abnormalities of both the kidneys and reproductive organs, including hypoplasia of the kidneys and abnormal development of the gonads. Which embryological structure is most likely affected? (Q848204)

A. Paraxial mesoderm

B. Intermediate mesoderm

C. Lateral plate mesoderm

D. Extraembryonic mesoderm

Correct Answer: B. Intermediate mesoderm

- *Listen (English)*
- *Listen (Hindi)*

Explanation: Intermediate mesoderm is crucial for the development of the nephrogenic cord (which forms the urinary system) and the genital ridge (which forms the genital system). Abnormalities in this structure can result in both renal and gonadal defects. Paraxial mesoderm (Option A) forms somites that give rise to the axial skeleton, skeletal muscles, and dermis of the skin. It does not primarily contribute to kidney or gonadal development. Lateral plate mesoderm (Option C) contributes to the connective tissue of the body wall, limbs, and the visceral layers of the gut and circulatory system but does not directly form the kidneys or gonads. Extraembryonic mesoderm (Option D) supports embryonic development by forming structures like the yolk sac, allantois, and chorionic villi, which are essential for placental and early embryonic support but do not directly form the kidneys or reproductive organs.

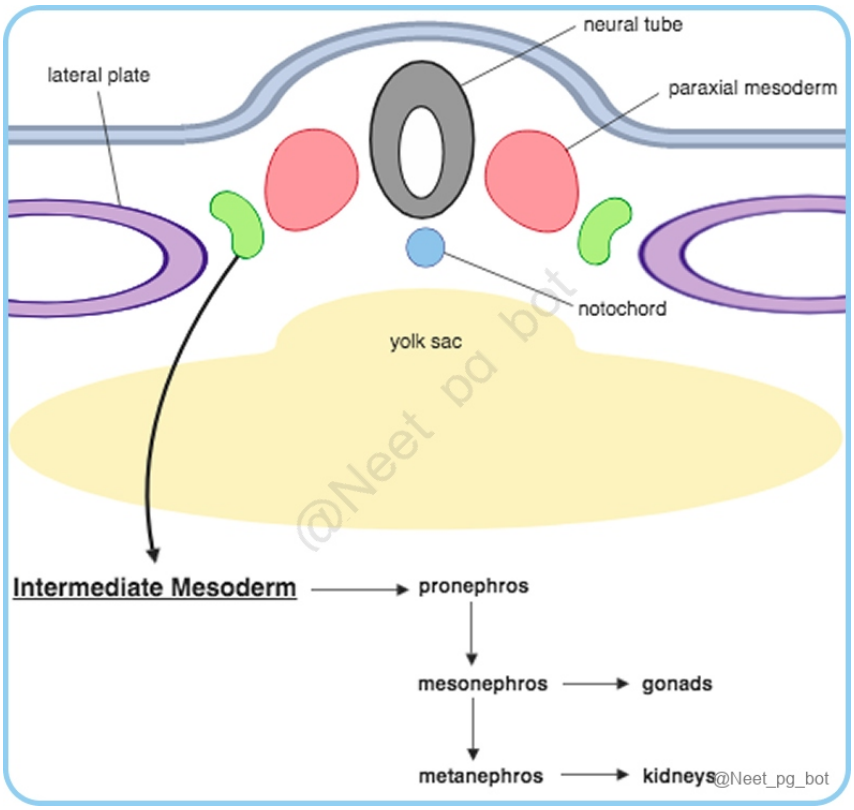

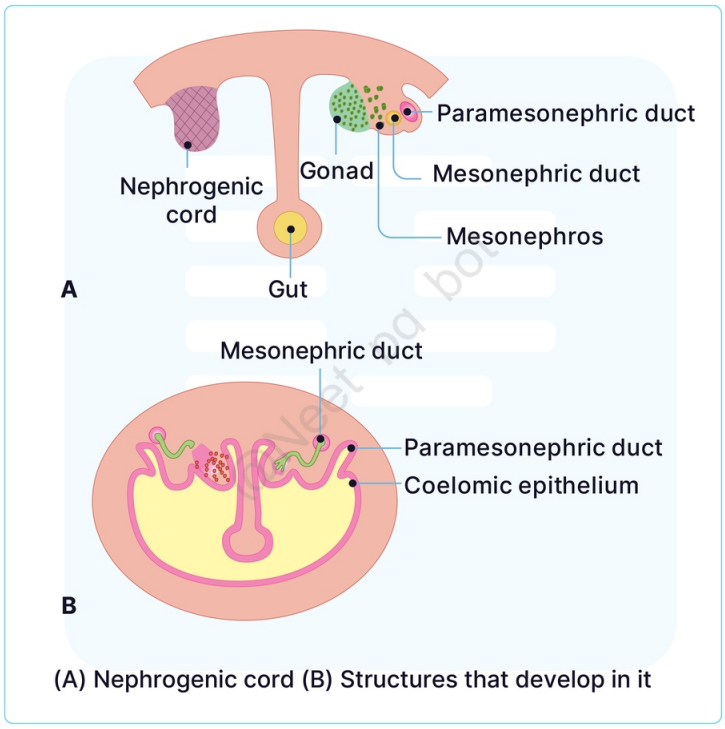

References:

Inderbir Singh's Human Embryology, 11th Edition, Pages 264-265

↑ *Back to this question in Part A*

@Neet_pg_bot

Q22: An embryo is observed to have 12 pairs of somites on ultrasound. Based on this, what is the most likely developmental age of the embryo? (Q848203)

A. 21 days

B. 23 days

C. 26 days

D. 30 days

Correct Answer: B. 23 days

■ *Listen (English)*

■ *Listen (Hindi)*

Explanation: Somites begin forming around day 20 , and new somites form at a rate of approximately three pairs per day. By 23 days, an embryo typically has about 12 pairs of somites, making this the most likely developmental age. Number of Somites Correlated to Approximate Age in Days Approximate Age (days) Number of Somites 20 1 - 4 21 (Option A) 4 - 7 22 7 - 10 23 (Option B) 10 - 13 24 13 - 17 25 17 - 20 26 (Option C) 20 - 23 27 23 - 26 28 26 - 29 30 (Option D) 34 - 35

References:

Langman’s Medical Embryology, 14th Edition, Page 80, 82

↑ *Back to this question in Part A*

@Neet_pg_bot

Q23: A newborn presents with scoliosis and underdeveloped axial muscles. Imaging reveals defects in the vertebral column. Which embryological structure is primarily responsible for the development of these affected tissues? (Q848201)

A. Paraxial mesoderm

B. Lateral plate mesoderm

C. Intermediate mesoderm

D. Extraembryonic mesoderm

Correct Answer: A. Paraxial mesoderm

■ *Listen (English)*

■ *Listen (Hindi)*

Explanation: Paraxial mesoderm gives rise to somites , which further differentiate into the sclerotome (forming the vertebral column), myotome (forming skeletal muscles), and dermatome (forming dermis). Defects in this structure can result in abnormalities in the axial skeleton (such as scoliosis) and skeletal muscles. 1. Paraxial Mesoderm (Option A) 2. Lateral Plate Mesoderm (Option B) 3. Intermediate Mesoderm (Option C) Located on either side of the notochord and becomes thick. It forms a thinner layer located laterally. A longitudinal strip found between the paraxial and lateral plate mesoderm. It forms: Somitomeres: Form mesoderm and muscles of the head and jaw. Somites: Form midline axial skeleton, skeletal muscles and dermis of back. It forms: Somatopleuric (parietal) layer: Forms connective tissue of the body wall and limbs, such as appendicular skeleton bones , muscles and dermis of periphery. Splanchnopleuric (visceral) layers: Forms connective tissue and smooth muscle layers of the gut, cardiac muscle and the circulatory system. It forms: Urinary and genital systems. Extraembryonic Mesoderm/ Primary Mesoderm (Option D): Arises from the cells of the trophoblast. Crucial in supporting embryonic development by forming tissues such as the yolk sac, allantois, and chorionic villi.

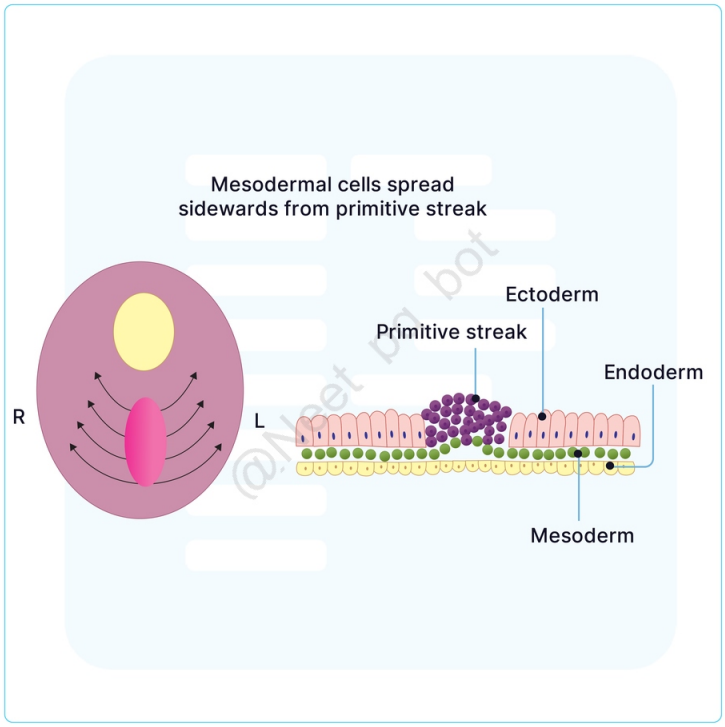

@Neet_pg_bot

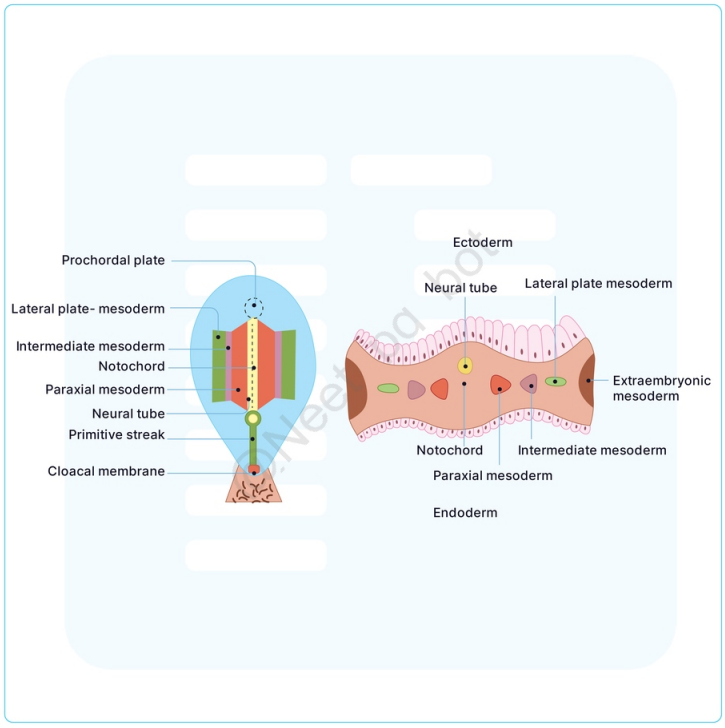

@Neet_pg_bot

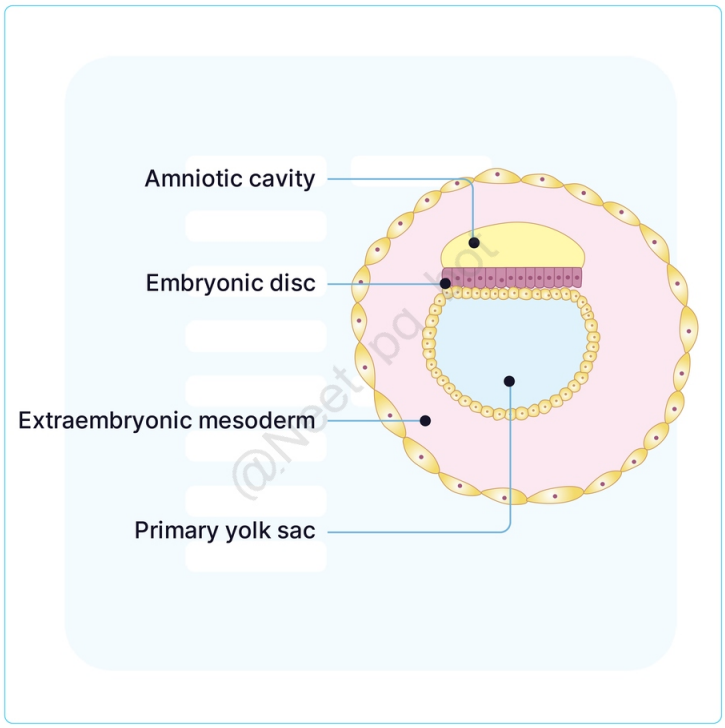

@Neet_pg_bot

References:

Inderbir Singh’s Human Embryology, 11th Edition, Pages 55-57, 65, 67

https://www.ncbi.nlm.nih.gov/books/NBK546679/#

https://www.ncbi.nlm.nih.gov/pmc/articles/PMC10380231/#:

↑ *Back to this question in Part A*

@Neet_pg_bot

Q24: Which of the following is a correct pairing of a structure and its corresponding embryological origin? (Q848199)

A. Sweat glands – Neural crest cells

B. Sebaceous glands – Mesoderm

C. Parotid gland – Surface ectoderm

D. Lens – Mesoderm

Correct Answer: C. Parotid gland – Surface ectoderm

■ *Listen (English)*

■ *Listen (Hindi)*

Explanation: The surface ectoderm gives rise to the Parotid gland. Derivatives of Surface Ectoderm: Structures Derivatives Epithelium & Glands Skin epithelium Sweat glands (Option A) Sebaceous glands (Option B) Myoepithelioctyes of skin Eyes Conjunctiva Surface epithelium of cornea Lens (Option D) Salivary Glands Parotid gland (Option C) Opening Structures Oral opening Stomodeum Proctodeum Rathke pouch (Anterior pituitary)

References:

Inderbir Singh’s Human Embryology, 11th Edition, Page 99, 314

↑ *Back to this question in Part A*

@Neet_pg_bot

Q25: Which of the following components is responsible for the formation of sensory ganglia during embryonic development in the given figure? (Q848198)

A. A

B. B

C. C

D. D

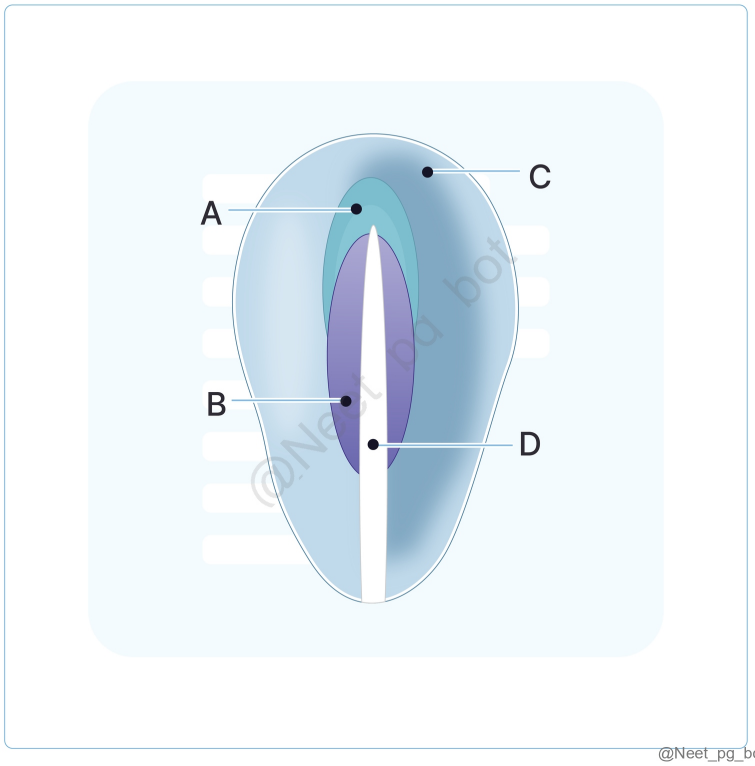

Correct Answer: B. B

- *Listen (English)*
- *Listen (Hindi)*

Explanation: Neural crest cells are responsible for forming sensory ganglia , among other structures, during embryonic development. In the above image, B denotes the neural crest cell. Components of Ectoderm: Neural Plate (Option D) : Forms above the notochord and paraxial mesoderm; Develops into the central nervous system. Neural Crest cells: Present dorsal to the neural tube at the edges of the neural plate. Cells move throughout the embryo and contribute to various structures such as Dorsal root ganglia, autonomic ganglia, adrenal medulla, skin melanocytes, craniofacial skeleton, teeth odontoblasts etc. Surface Ectoderm (Option C) : Forms the epidermis, hair, glands, and other structures. Placodal Ectoderm (Option A) : Specialized ectodermal patches contributing to sensory structures (e.g., Otic, nasal, and lens placodes) and endocrine structures.

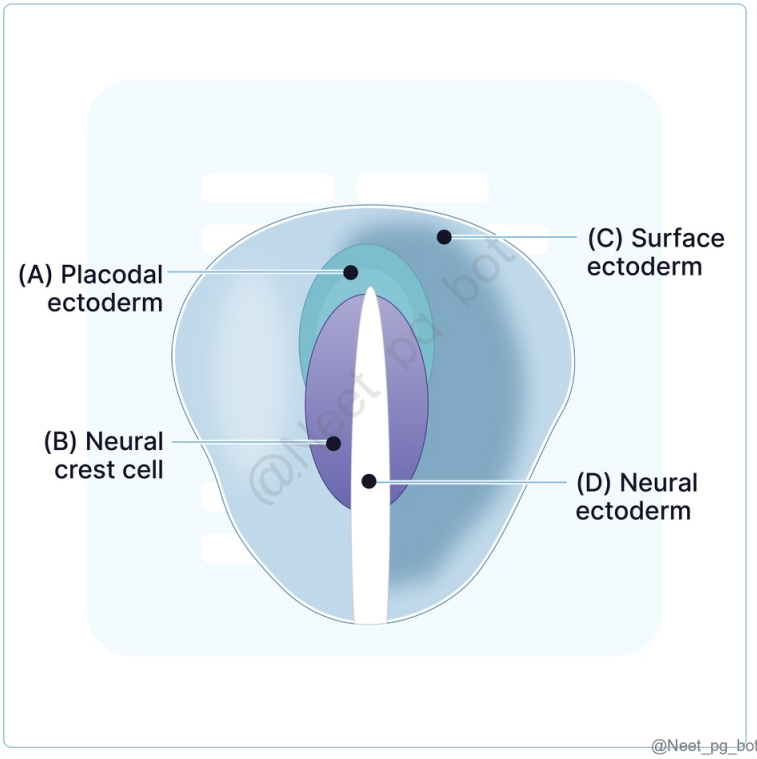

References:

Inderbir Singh’s Human Embryology, 11th Edition, Page 99

https://embryology.med.unsw.edu.au/embryology/inde cx.php?title=Ectoderm

↑ *Back to this question in Part A*

@Neet_pg_bot

Q26: Which of the following statements about the prechordal plate is incorrect? (Q848197)

A. Derived from hypoblast cells

B. Formed before primitive streak formation

C. Forms the cephalocaudal axis of the embryo

D. Gives rise to the notochord

Correct Answer: D. Gives rise to the notochord

Explanation: The prechordal plate itself does not give rise to the notochord but is located anterior to it and contributes to head and forebrain development. The prechordal plate is derived from hypoblast cells initially and forms before primitive streak formation. (Option A and B) It is important in establishing the cephalocaudal axis of the embryo. (Option C) However, the notochord arises from the notochordal process, which is distinct and posterior to the prechordal plate.

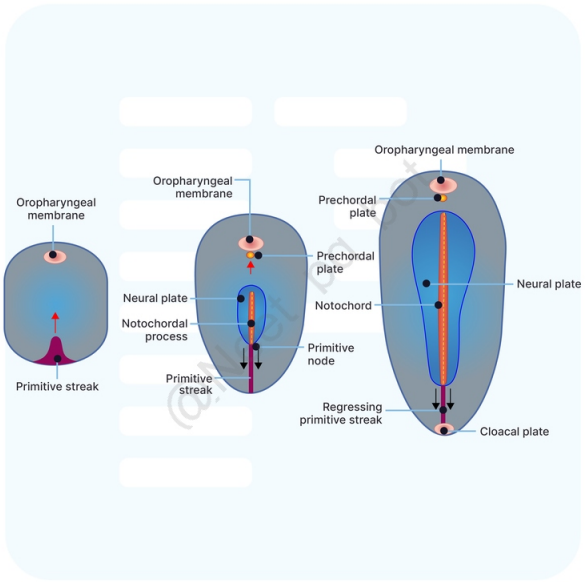

@Neet_pg_bot

References:

Inderbir Singh's Human Embryology, 11th Edition, Page 59

↑ *Back to this question in Part A*

@Neet_pg_bot

Q27: Which of the following correctly describes the sequence of events during gastrulation in the third week of gestation? (Q848196)

A. Epiblast cells form the primitive streak, leading to the formation of the three germ layers.

B. The primitive streak forms at the cephalic end, initiating neural tube, gut, and cardiovascular development.

C. The prechordal plate forms after the notochord, and epiblast cells migrate to create the three germ layers.

D. The Endoderm forms from mesodermal cells, with ectoderm and mesoderm forming later.

Correct Answer: A. Epiblast cells form the primitive streak, leading to the formation of the three germ layers.

- *Listen (English)*
- *Listen (Hindi)*

Explanation: During gastrulation, epiblast cells migrate to form the primitive streak. This migration leads to the differentiation of epiblast cells into the three germ layers: endoderm, mesoderm, and ectoderm. Start of Process Formation of the primitive streak on the surface of the epiblast. Primitive Streak Initially indistinct, it becomes a narrow groove with bulging regions by days 15-16. Primitive Node Located at the cephalic end of the streak, a slightly raised area surrounding a small pit. Cell Migration Epiblast cells migrate toward the primitive streak and undergo invagination. Invagination Cells transform into flask-shaped forms, detach from the epiblast, and move beneath it. Regulation Fibroblast growth factor 8 (FGF8) regulates cell movement and mesoderm formation. FGF8 decreases E-cadherin levels, which helps in migration Cell Spread Invaginated cells replace the hypoblast and spread laterally and cranially. Contact with Extraembryonic Mesoderm Cells establish contact with the extraembryonic mesoderm covering the yolk sac and amnion. Prechordal Plate Forms between the notochord tip and the oropharyngeal membrane. Important for forebrain induction. Oropharyngeal Membrane Composed of tightly joined ectoderm and endoderm cells. Will become the future oral cavity opening. Formation of Germ Layers Endoderm : Displaces the hypoblast. Mesoderm : Forms between the epiblast and endoderm. Ectoderm : Develops from the Remains of the epiblast. Outcome The epiblast gives rise to all embryonic tissues and organs through the process of gastrulation.

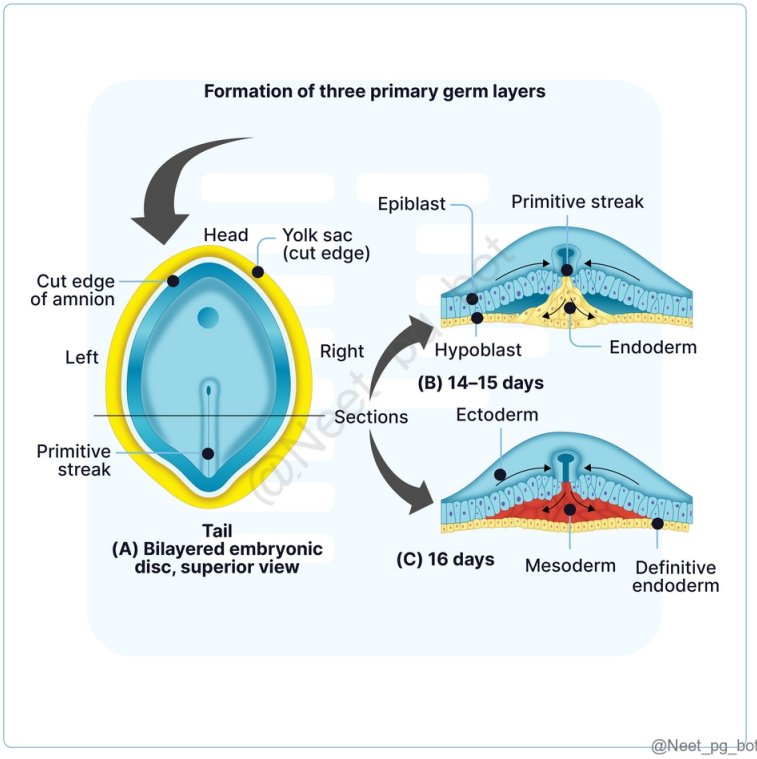

References:

Langman Medical Embryology, 14th Edition, Page 59, 60

↑ *Back to this question in Part A*

@Neet_pg_bot

• [01_General Embryology] 004 Previous Year Questions

« Back to Folder Directory

[01_General Embryology] 004 Previous Year Questions — Quick Jump

Q1 (p. 691)	*Q2 (p. 692)*	*Q3 (p. 693)*	*Q4 (p. 695)*	*Q5 (p. 700)*	*Q6 (p. 701)*
Q7 (p. 705)	*Q8 (p. 706)*	*Q9 (p. 708)*	*Q10 (p. 709)*	*Q11 (p. 710)*	*Q12 (p. 712)*
Q13 (p. 714)	*Q14 (p. 715)*	*Q15 (p. 717)*	*Q16 (p. 719)*	*Q17 (p. 720)*	*Q18 (p. 722)*
Q19 (p. 725)	*Q20 (p. 725)*	*Q21 (p. 726)*	*Q22 (p. 728)*	*Q23 (p. 729)*	*Q24 (p. 730)*
Q25 (p. 730)	*Q26 (p. 731)*	*Q27 (p. 733)*	*Q28 (p. 734)*	*Q29 (p. 735)*	*Q30 (p. 736)*
Q31 (p. 737)					

Q1: What are the derivatives of the marked cells? 1. Odontoblasts 2. Sympathetic chain 3. Melanocytes 4. Nephrogenic cord 5. Bulbus cordis 6. Conotruncal septum (Q855418)

A. 1,3,5,6

B. 2,3,4,6

C. 1,2,3,6

D. 1,2,3,4

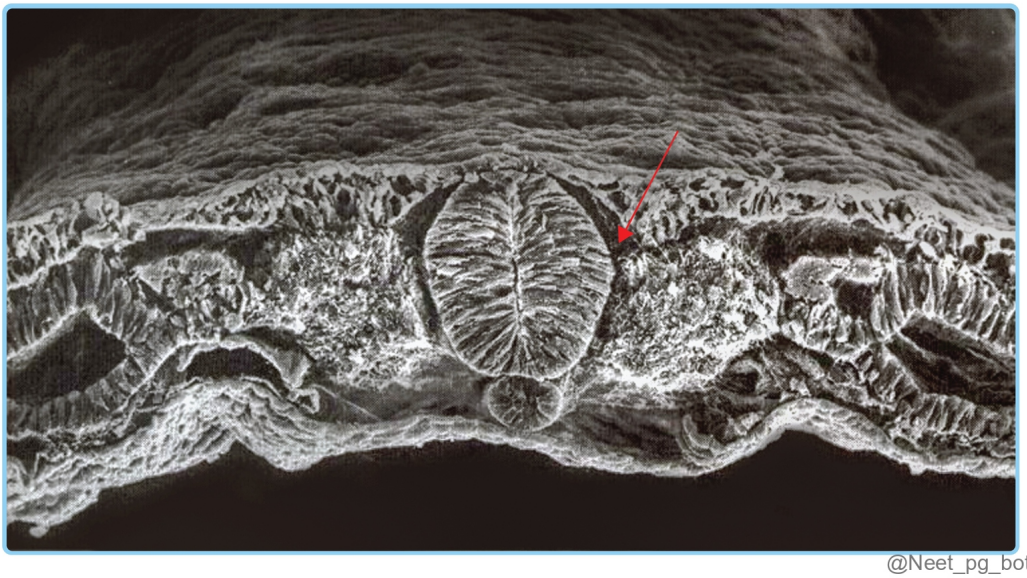

Correct Answer: C. 1,2,3,6

Explanation: Neural crest cells (NCC) are a group of cells that arise from the ectoderm during early development and give rise to a wide variety of structures in the body. The derivatives of neural crest cells include: Odontoblasts: Neural crest cells contribute to the development of odontoblasts , which are responsible for the formation of dentin in teeth. Sympathetic chain: Neural crest cells give rise to the sympathetic ganglia and the sympathetic chain , which is part of the autonomic nervous system. Melanocytes: Neural crest cells also give rise to melanocytes , which are the pigment-producing cells in the skin. Conotruncal septum: Neural crest cells contribute to the formation of the conotruncal septum , which is important in the proper separation of the pulmonary trunk and aorta during heart development. Nephrogenic cord (4): The nephrogenic cord is derived from the mesoderm , not the neural crest cells. It forms the precursors to the kidneys . Bulbus cordis (5): The bulbus cordis is part of the heart and is derived from the mesoderm . It contributes to the formation of the right ventricle and the outflow tract of the heart.

References:

Grey’s Anatomy, 42nd Edition, Page 236

↑ *Back to this question in Part A*

@Neet_pg_bot

Q2: Match the following aortic arches with their derivatives: Aortic Arch Derivative 1. 1st arch a. Common carotid artery 2. 2nd arch b. Right subclavian artery (right side) 3. 3rd arch c. Maxillary artery 4. 4th arch d. Hyoid and stapedial arteries (Q879188)

A. 1–c, 2–d, 3–a, 4–b

B. 1–d, 2–c, 3–b, 4–a

C. 1–a, 2–b, 3–c, 4–d

D. 1–b, 2–a, 3–d, 4–c

Correct Answer: A. 1–c, 2–d, 3–a, 4–b

Explanation: Aortic Arch Derivatives First Maxillary artery Second Hyoid artery, Stapedial artery Third Common carotid artery, Internal carotid artery Fourth Arch of aorta (left side), Subclavian artery (right side) Sixth Ductus arteriosus (left side), Pulmonary artery (right side)

References:

Inderbir Singh’s Human Embryology, 11th Edition, Page 130

↑ *Back to this question in Part A*

@Neet_pg_bot

Q3: The structure marked A in the image below gives rise to which of the following structures? (Q856067)

A. Gastrosplenic ligament

B. Lienorenal ligament

C. Falciform ligament

D. Gastrophrenic ligament

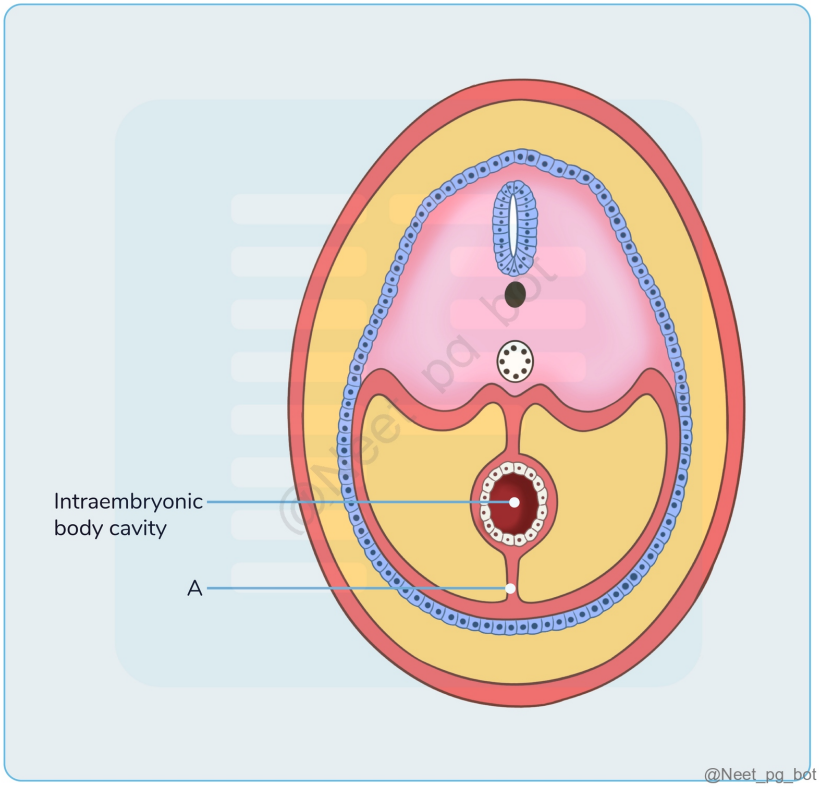

Correct Answer: C. Falciform ligament

Explanation: The structure marked A in the image is the Ventral mesentery, which gives rise to the falciform ligament. This broad, lean, mesentery-like structure connects the liver to the anterior abdominal wall and separates the right and left lobes of the liver. Omenta : Sources Structure From To Contains Dorsal mesentery Greater omentum Greater curvature of stomach (and spleen) Transverse colon right and left gastroepiploic vessels and fat Gastrosplenic ligament Stomach Spleen Short gastric artery, Left gastroepiploic artery Gastrophrenic ligament Stomach Diaphragm Left inferior phrenic artery Gastrocolic ligament Stomach Transverse colon Right gastroepiploic artery Splenorenal ligament Spleen Kidney Splenic artery, Tail of pancreas Ventral mesentery Lesser omentum Lesser curvature of the stomach (and duodenum) Liver The right free margin-hepatic artery, portal vein, and bile duct,lymph nodes and the lymph vessels,hepatic plexus of nerve,all enclosed in perivascular fibrous sheath. Along the lesser curvature of the stomach-left and right gastric artery,the gastric group of lymph

nodes and lymphatics, branches from the gastric nerve. Hepatogastric ligament Stomach Liver Right and left gastric artery Hepatoduodenal ligament Duodenum Liver Hepatic artery proper, hepatic portal vein, bile duct, autonomic nerves {{caption_text}} Horizontal disposition of the peritoneum in the upper part of the abdomen {{caption_text}} Horizontal disposition of the peritoneum in the lower part of the abdomen Mesenteries Sources Structure From To Contains Dorsal mesentery Mesentery proper Small intestine (jejunum and ileum) Posterior abdominal wall Superior mesenteric artery, accompanying veins, autonomic nerve plexuses, lymphatics, 100–200 lymph nodes and connective tissue with fat Transverse mesocolon Transverse colon Posterior abdominal wall Middle colic Sigmoid mesocolon Sigmoid colon Pelvic wall Sigmoid arteries and superior rectal artery Mesoappendix Mesentery of ileum Appendix Appendicular artery Other ligaments and folds Sources Structure From To Contains Ventral mesentery Falciform ligament Liver Thoracic diaphragm, anterior abdominal wall Round ligament of liver, paraumbilical vein Left umbilical vein Round ligament of liver Liver Umbilicus Ventral mesentery Coronary ligament Liver Thoracic diaphragm Ductus venosus Ligamentum venosum Liver Liver Phrenicocolic ligament Left colic flexure Thoracic diaphragm Ventral mesentery Left triangular ligament, right triangular ligament Liver Umbilical folds Urinary bladder Ileocecal fold Ileum Cecum Broad ligament of the uterus Uterus Pelvic wall Mesovarium, mesosalpinx, mesometrium Round ligament of uterus Uterus Inguinal canal Suspensory ligament of the ovary Ovary Pelvic wall Ovarian artery

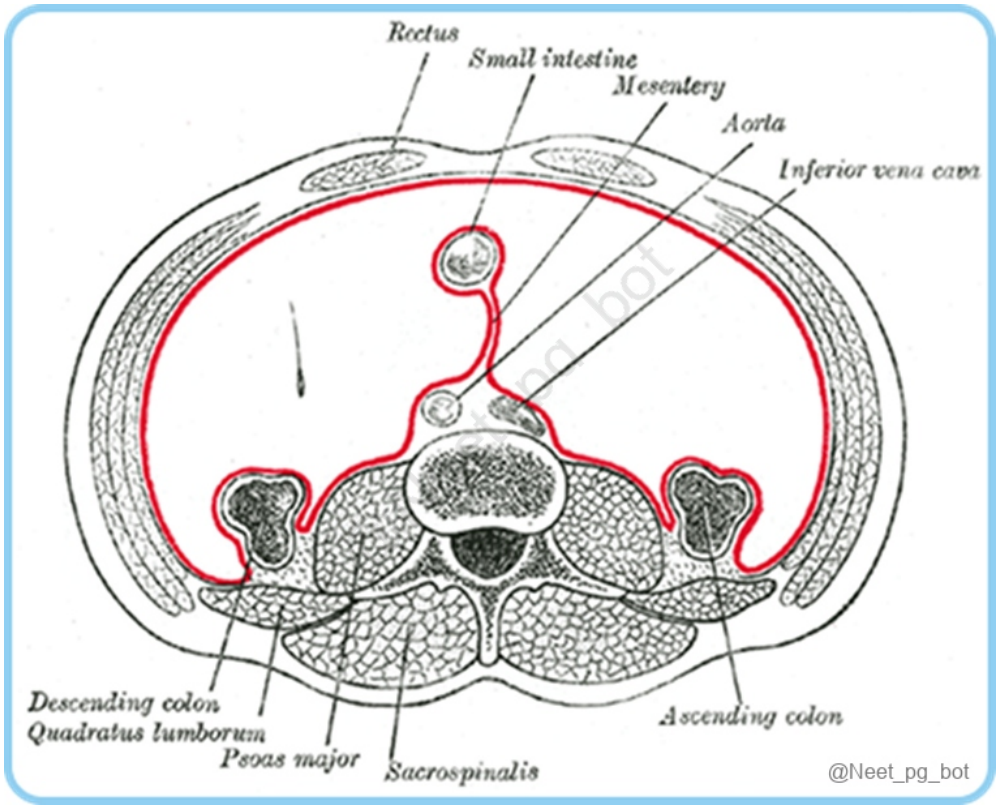

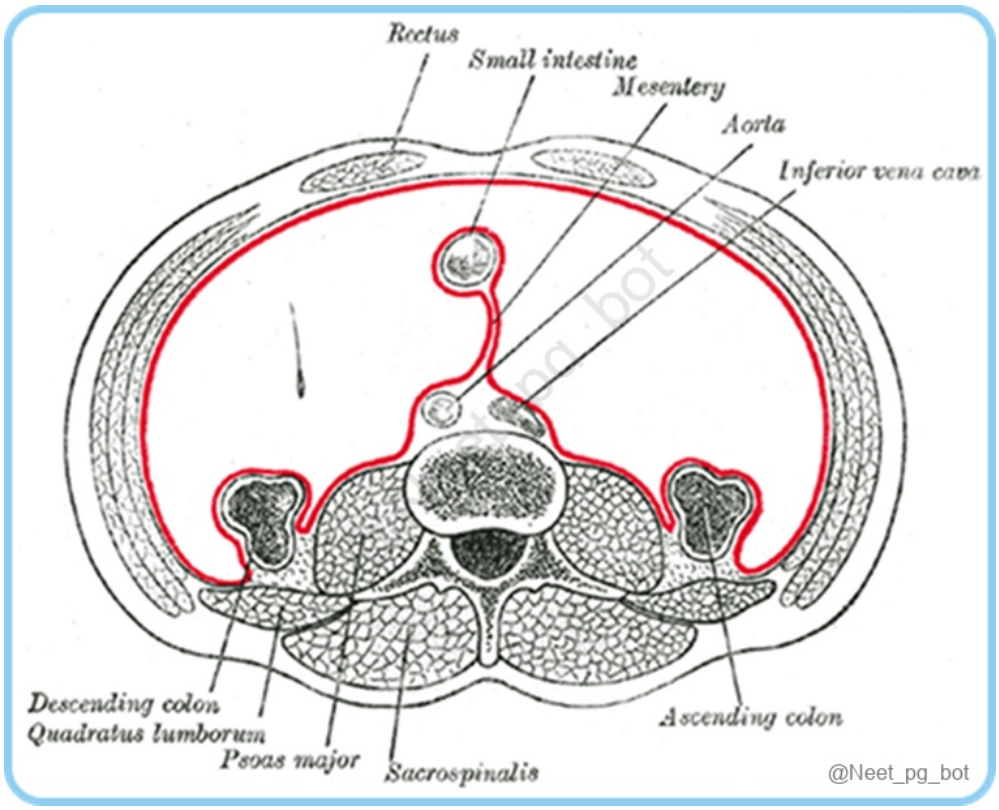

References:

Gray’s anatomy, 42nd edition, Page 1151-1157

https://en.wikipedia.org/wiki/Peritoneum#:~:text=Peritoneal%20folds%20are%20omentums%2C%20mesenteries,red%20in%20the%20diagrams%20above.

https://www.ncbi.nlm.nih.gov/books/NBK534788/#:~:text=The%20peritoneum%20is%20comprised%20of,%2C%20transverse%2C%20and%20sigmoid%20colon

↑ *Back to this question in Part A*

@Neet_pg_bot

Q4: Which of the following statements regarding anatomical closure is incorrect? (Q854993)

A. Anatomical closure of foramen ovale is by 3 to 5 days

B. Anatomical closure of ductus venosus is by 2 to 3 weeks

C. Right umbilical vein is absent after birth

D. Anatomical closure of ductus arteriosus is by 2 to 3 weeks

Correct Answer: A. Anatomical closure of foramen ovale is by 3 to 5 days

Explanation: Foramen ovale does not anatomically close within 3 to 5 days . Functional closure occurs soon after birth due to increased left atrial pressure , but anatomical closure (fusion of the septum primum and septum secundum) takes months to years . In some individuals, it may persist as a patent foramen ovale (PFO) . Anatomical closure of ductus venosus is by 2 to 3 weeks (option B): The ductus venosus shunts oxygenated blood from the umbilical vein to the inferior vena cava in fetal circulation. After birth, it functionally closes within hours and anatomically closes in 2 to 3 weeks , forming the ligamentum venosum . Formation of the Interatrial Septum: Septum Primum Formed as a sickle-shaped fold from the roof and dorsal wall of the primitive atrium due to pressure from the bulbus cordis. Grows downward toward the atrioventricular (AV) canal and septum intermedium, fusing with the latter. Ostium Primum Before the septum primum reaches and fuses with the septum intermedium, a gap (foramen primum) allows blood flow between the right and left atria. Ostium Secundum Upper part of the septum primum breaks down, creating a new gap (foramen secundum) before the foramen primum closes. The septum primum now has a free upper edge. Septum Secundum Grows down from the roof of the atrial chamber, to the right of the septum primum, overlapping the free upper edge of the septum primum as it grows. Foramen Ovale Formation Overlapping septa create the foramen ovale, allowing blood to flow from right to left atrium during fetal life, preventing left-to-right flow. Patent throughout fetal life. Obliteration of Foramen Ovale Post-birth, the left atrium receives oxygenated blood from the lungs, increasing pressure in this chamber greater than the right atrium, causing fusion of the septum primum and septum secundum, closing the foramen ovale. Annulus ovalis (adults) corresponds to the lower free edge of the septum secundum, while the fossa ovalis represents the septum primum. Right umbilical vein is absent after birth (option C): The right umbilical vein degenerates during fetal life , leaving only the left umbilical vein to carry blood from the placenta. After birth, the left umbilical vein also closes , forming the ligamentum teres (round ligament of the liver) . Anatomical closure of ductus arteriosus is by 2 to 3 weeks (option D): The ductus arteriosus functionally closes within 24 to 48 hours due to oxygenation and prostaglandin metabolism. Anatomical closure occurs by 2 to 3 weeks , forming the ligamentum arteriosum .

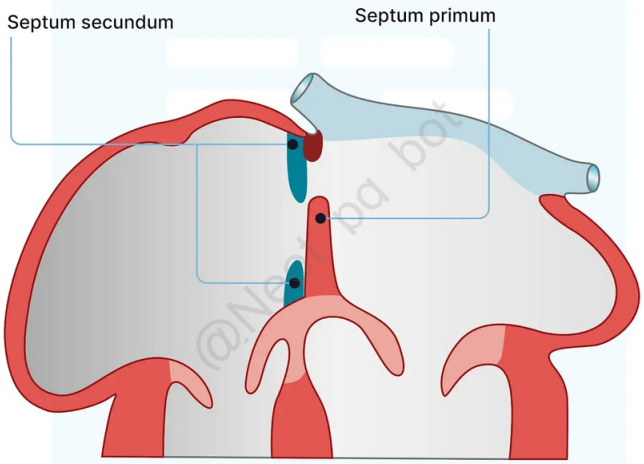

@Neet_pg_bot

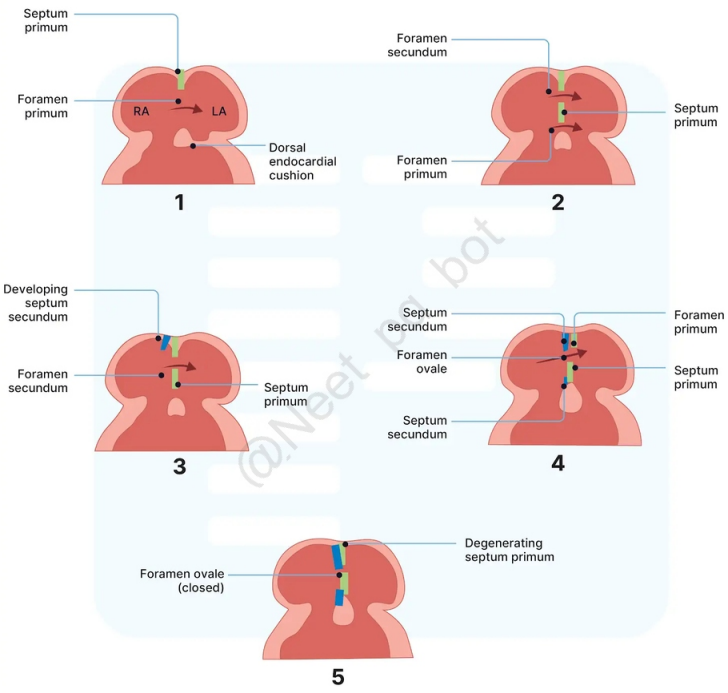

@Neet_pg_bot

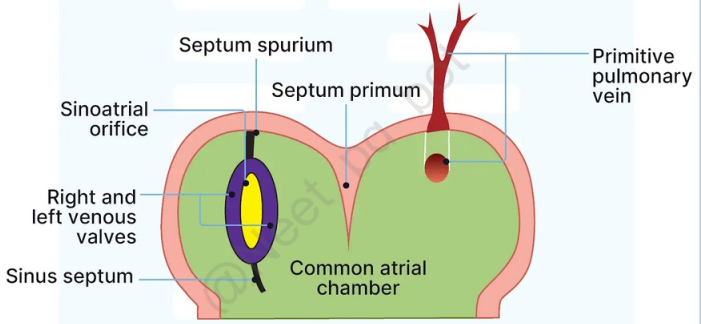

Septum primum appears

@Neet_pg_bot

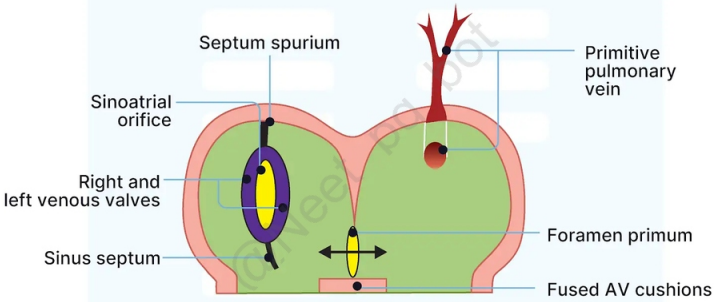

Septum primum grows towards fused AV cushions. The gap between them is foramen primum

@Neet_pg_bot

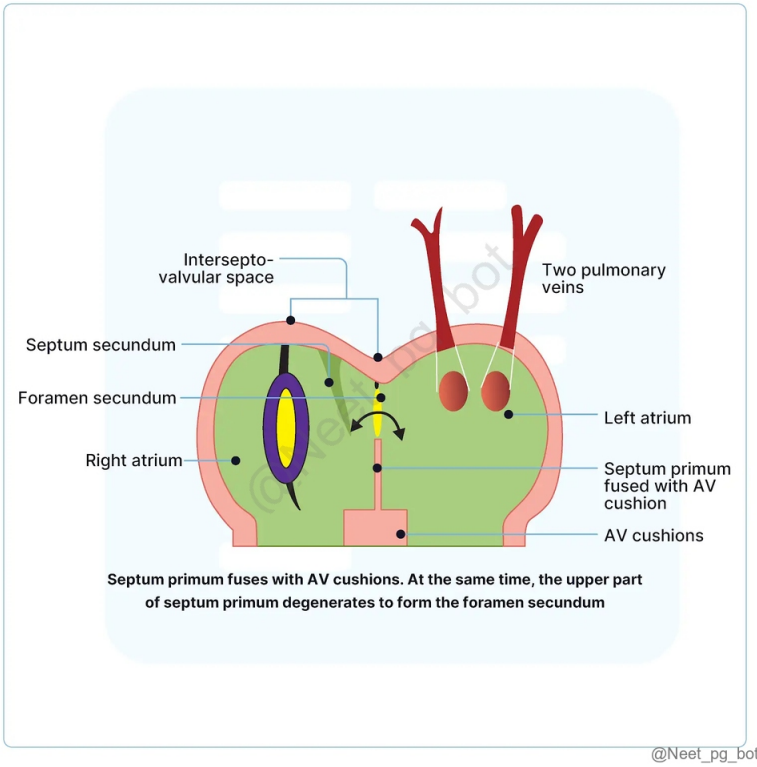

Septum primum fuses with AV cushions. At the same time, the upper part of septum primum degenerates to form the foramen secundum

@Neet_pg_bot

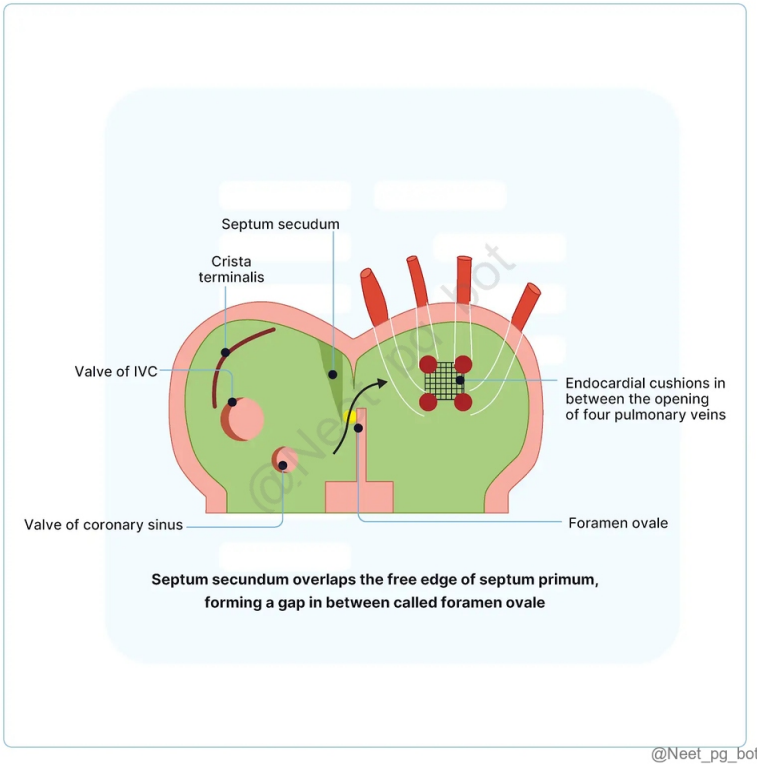

Septum secundum overlaps the free edge of septum primum, forming a gap in between called foramen ovale

@Neet_pg_bot

References:

Inderbir Singh’s Human Embryology, 11th Edition, Page 233, 234, 235

↑ *Back to this question in Part A*

@Neet_pg_bot

Q5: The long left recurrent laryngeal nerve is due to the persistence of which arch artery? (Q854988)

A. 3rd arch

B. 4th arch

C. 5th arch

D. 6th arch

Correct Answer: D. 6th arch

Explanation: During embryonic development, the sixth arch contributes to the formation of the pulmonary arteries and the ductus arteriosus, and the recurrent laryngeal nerve loops around the aortic arch on the left side, giving it its characteristic long course. Recurrent laryngeal nerve anatomy : The right recurrent laryngeal nerve branches from the vagus at the level of the subclavian artery, looping around it before ascending between the trachea and esophagus. The left recurrent laryngeal nerve arises at the arch of the aorta, loops around it, and ascends along the tracheoesophageal groove, giving it a longer course compared to the right nerve, making it more prone to injury. Superior laryngeal nerve : Origin - from the inferior ganglion of the vagus nerve; courses behind the internal carotid artery; divides into external and internal branches at the level of the greater cornua of the hyoid bone. The external branch innervates the cricothyroid muscle. The internal branch provides sensory innervation to the larynx and hypopharynx after piercing through the thyrohyoid membrane. 3rd arch (Option A): This is incorrect because the 3rd arch gives rise to the common carotid artery and part of the internal carotid artery , but not the structures associated with the recurrent laryngeal nerve. 4th arch (Option B): This is incorrect for the left recurrent laryngeal nerve, as the right recurrent laryngeal nerve loops around the right subclavian artery , which is derived from the 4th arch . The left recurrent nerve loops around the aortic arch, which is from the sixth arch. 5th arch (Option C): This is incorrect because the 5th arch is rudimentary and does not contribute to the development of significant vascular structures or nerves.

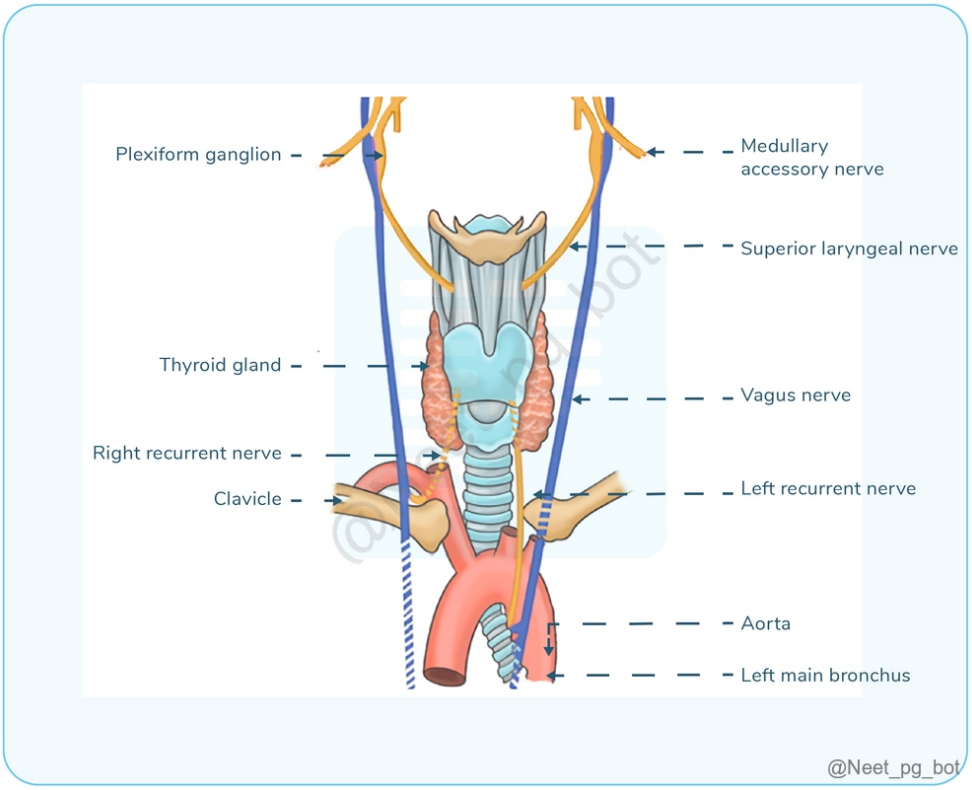

References:

Dhingra's Diseases Of Ear, Nose And Throat, & Head and Neck Surgery, 8th edition, Page 347

↑ *Back to this question in Part A*

@Neet_pg_bot

Q6: What structure develops from the region labeled as "A" in the model of embryological heart development? (Q856363)

A. Atria

B. Left ventricle

C. Infundibulum

D. Interventricular septum

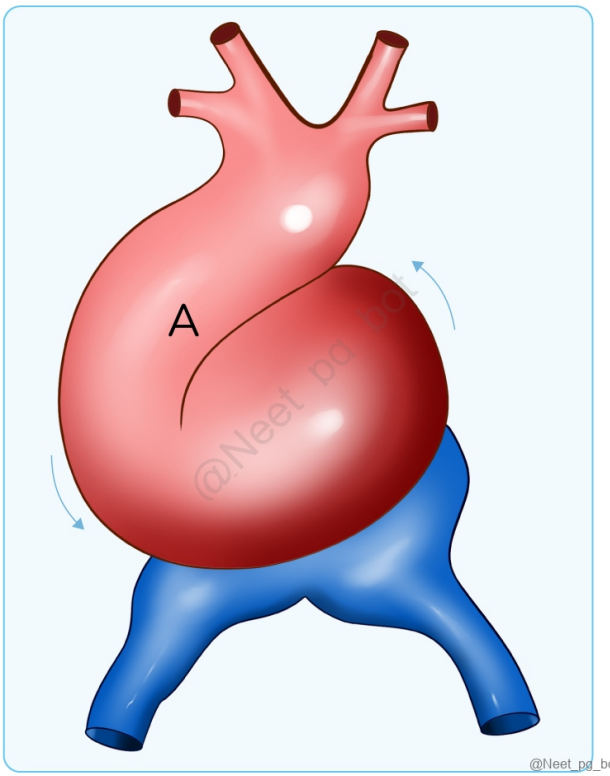

Correct Answer: C. Infundibulum

Explanation: In the embryological development of the heart, the area marked as "A" corresponds to the outflow tract of the developing heart. This outflow tract gives rise to several structures, including the infundibulum. The infundibulum is a conical structure located at the outflow of the right ventricle. It connects the right ventricle to the pulmonary artery and directs blood flow from the heart to the lungs. Formation of Heart Tubes: The endothelial heart tube is derived from the splanchnopleuric mesoderm, located near the pericardial cavity. Initially, the heart appears as right and left endothelial heart tubes. These tubes fuse to form a single heart tube. The heart tube has 5 dilatations, which are: Truncus arteriosus Bulbus cordis Primitive ventricle Primitive atrium Sinus venosus Sinus venosus is located at the caudal (venous) end of the primitive heart tube. It consists of a body with two prolongations known as the right and left horns. Right horn: Forms smooth part of the right atrium (sinus venarum). Left horn: Forms coronary sinus. Each horn receives blood from three veins: Vitelline vein Umbilical vein Common cardinal vein Bulbus cordis is the cranial most part of the developing heart tube. Forms outflow (smooth) parts of the right ventricle (conus arteriosus) and left ventricle (aortic vestibule). Primitive ventricle: Forms inflow (rough) parts of both ventricles. Primitive atrium: Forms trabeculated part of the right and left atrium. Truncus arteriosus: Forms ascending aorta and pulmonary trunk. Formation of Transverse Pericardial Sinus: Heart Tube Folding: Brings the arterial and venous ends closer together. Disappearance of the dorsal mesocardium creates the transverse sinus of the pericardium. Parietal and visceral layers of the serous pericardium become continuous at the arterial and venous ends of the heart. Pericardium forms two tubes: One enclosing the aorta and pulmonary trunk. Other enclosing the SVC, IVC, and four pulmonary veins. Two tubes are separated by the transverse sinus of the pericardium. Atria (Option A): The atria develop from the primitive heart tube, specifically from the regions known as the primitive atrium and sinus venosus. Left ventricle (Option B): The left ventricle develops from the primitive heart tube and forms the main pumping chamber of the heart that sends oxygenated blood to the systemic circulation. I nterventricular septum (Option D): The interventricular septum develops from the fusion of several components during heart development.

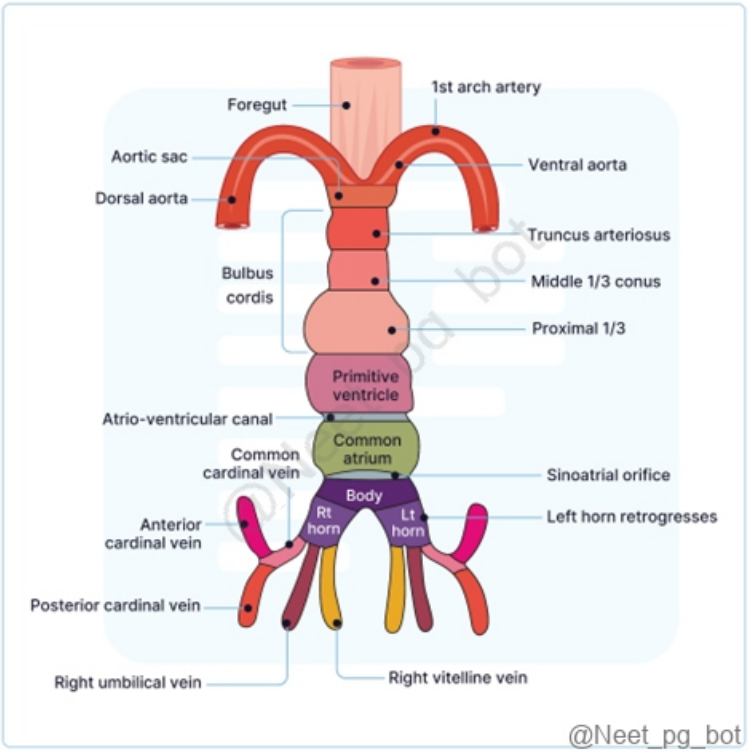

@Neet_pg_bot

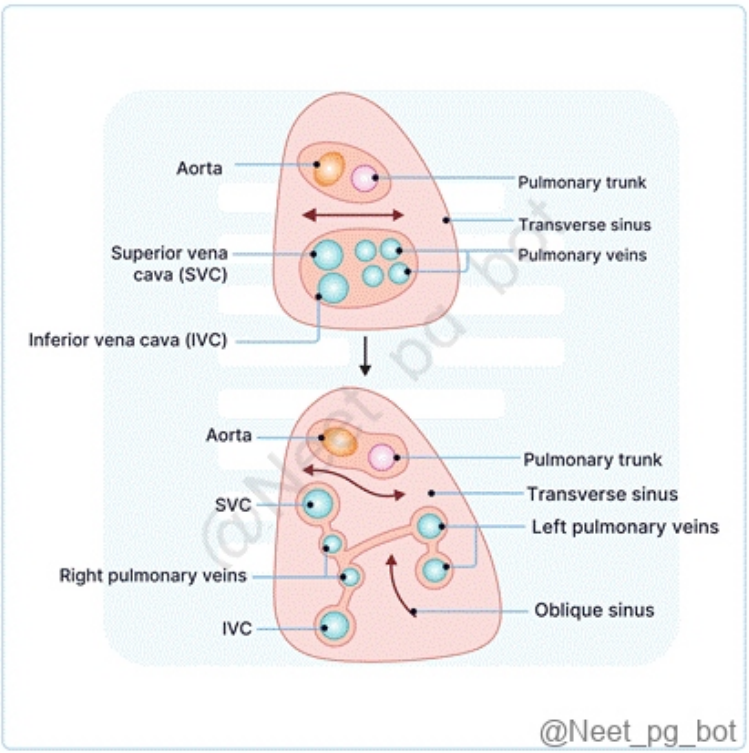

@Neet_pg_bot

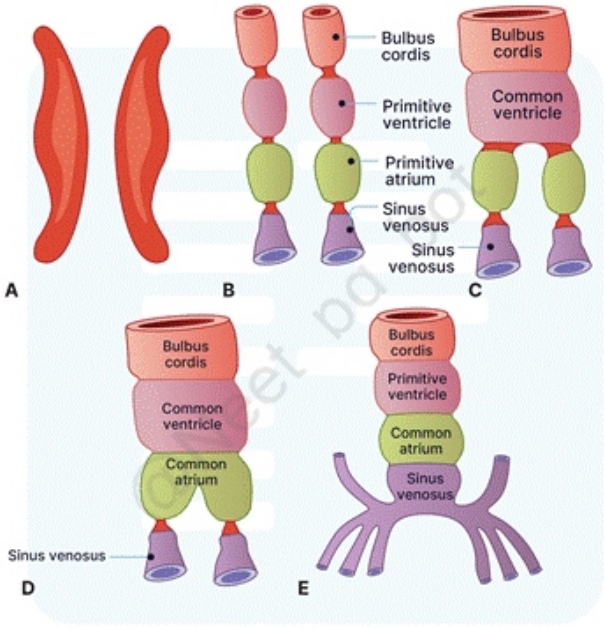

(A) Right and left heart tubes; (B to E) Progressive fusion of tubes from cranial to caudal end. Fusion of sinus venosus is partial

@Neet_pg_bot

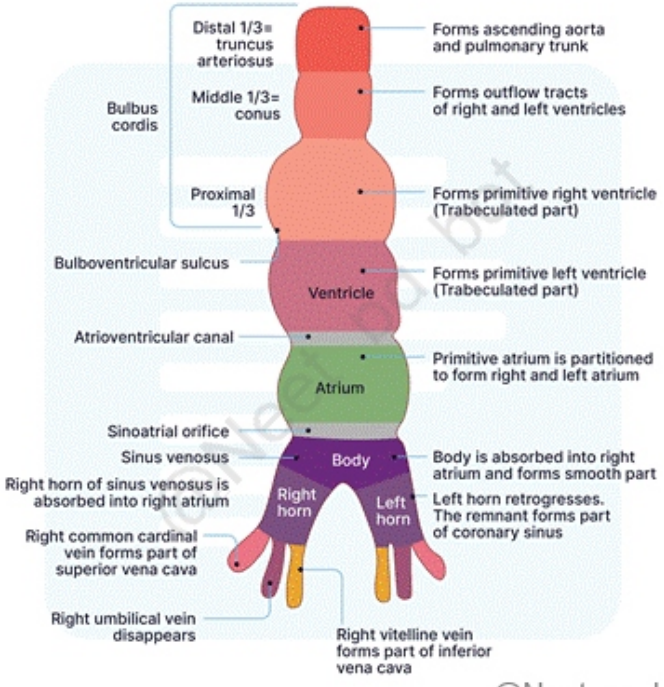

@Neet_pg_bot

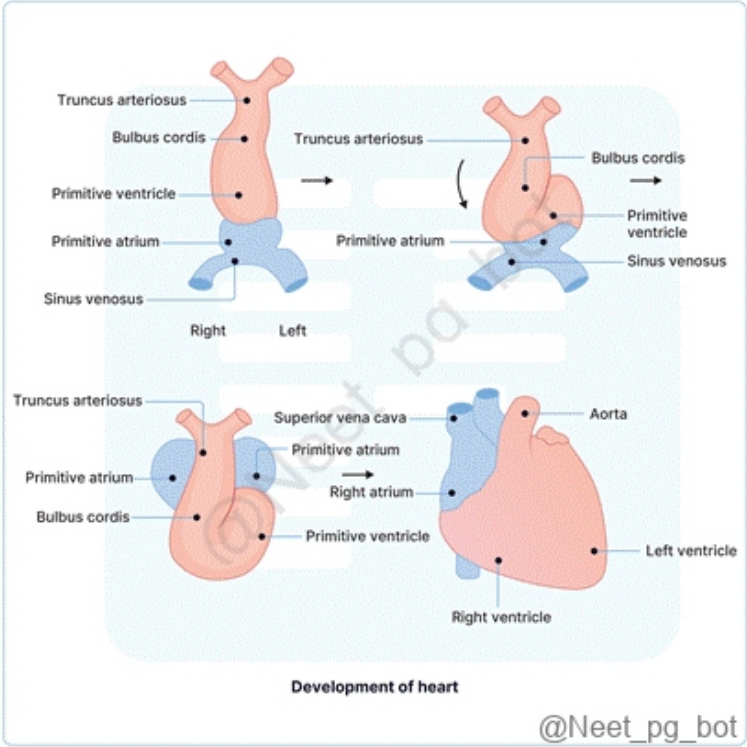

References:

BD Chaurasia's Human Anatomy, 8th Edtion, Page no: 123

↑ *Back to this question in Part A*

@Neet_pg_bot

Q7: The marked structure develops from which of the following structures? (Q856670)

A. Common cardinal vein

B. Anterior cardinal vein

C. Supracardinal vein

D. Subcardinal vein

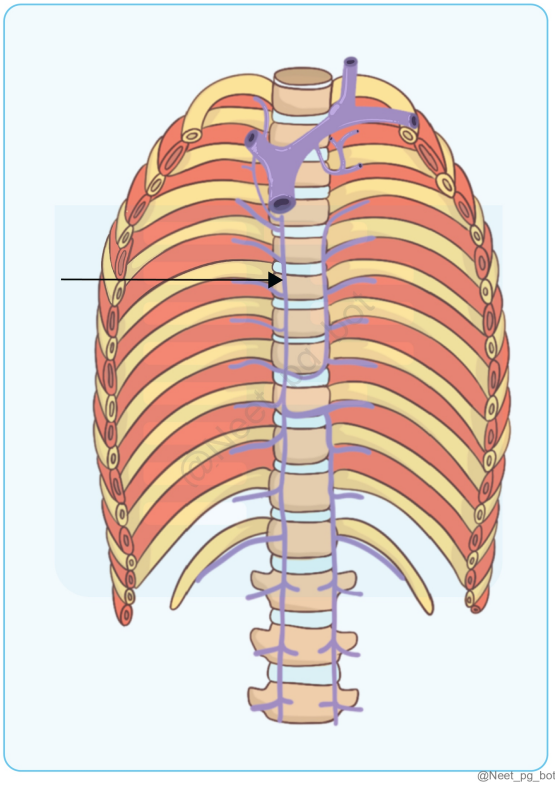

Correct Answer: C. Supracardinal vein

Explanation: The marked structure is the azygos vein , which develops primarily from the right supracardinal vein during embryogenesis. The supracardinal veins appear in the embryo as part of the venous system and contribute to the formation of azygos and hemiazygos veins . The right supracardinal vein persists to form the azygos vein , which drains blood from the posterior thoracic wall. The left supracardinal vein contributes to the hemiazygos vein , which drains into the azygos system. Thus, the correct answer is Option C (Supracardinal vein). Venous System Development Embryonic Vein Adult Derivative Common cardinal vein Contributes to superior vena cava (SVC) Anterior cardinal vein Forms jugular veins and part of SVC Supracardinal vein Azygos and hemiazygos veins Subcardinal vein Renal veins, gonadal veins, and part of IVC Common cardinal vein (Option A): Incorrect – Contributes to the formation of the superior vena cava (SVC) but not the azygos vein. Anterior cardinal vein (Option B): Incorrect – Develops into internal jugular veins and part of the SVC , not the azygos system. Subcardinal vein (Option D): Incorrect – Primarily forms renal veins and parts of the inferior vena cava (IVC) , not the azygos vein.

References:

Langman’s Medical Embryology, Edition 14, Page 214

BD Chaurasia’s Human Anatomy, Edition 6, Volume 1, Page 249

↑ *Back to this question in Part A*

@Neet_pg_bot

Q8: A young child with absent thymus is brought to the OPD with features of hypoparathyroidism and tetany. Which of the following marked areas in the picture is defective in this condition? (Q855837)

A. 1

B. 2

C. 3

D. 4

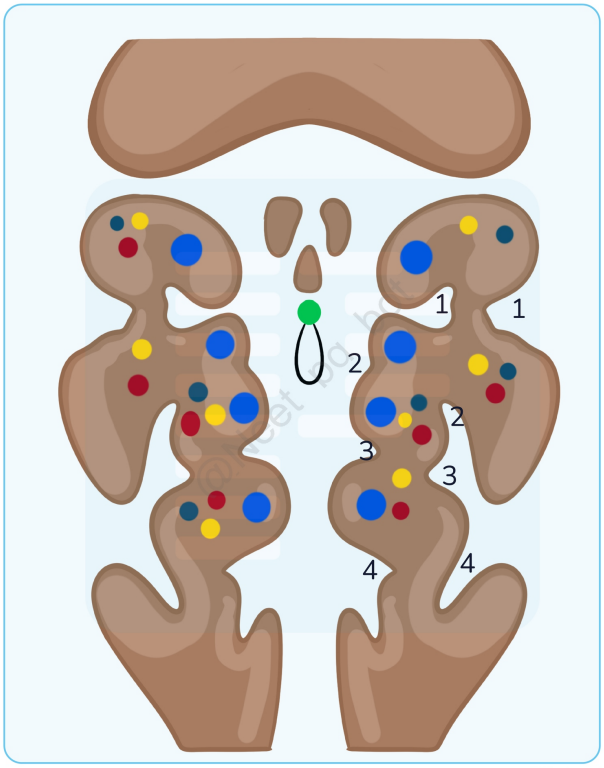

Correct Answer: C. 3

Explanation: The given image represents the development of pharyngeal pouches . The condition described is DiGeorge syndrome , which is caused by defective development of the 3rd and 4th pharyngeal pouches , leading to: Absence of thymus → Immunodeficiency (T-cell deficiency) Hypoparathyroidism → Hypocalcemia and tetany The 3rd pharyngeal pouch (marked as 3) gives rise to: Thymus Inferior parathyroid glands The 4th pharyngeal pouch gives rise to: Superior parathyroid glands Ultimobranchial body (C-cells of thyroid) Since DiGeorge syndrome mainly affects the 3rd pouch , the correct answer is Option C (3) . Pharyngeal Pouch Derivatives Pharyngeal Pouch Derivatives 1st Pouch Eustachian tube (Auditory tube) Middle ear cavity Mastoid air cells 2nd Pouch Palatine tonsil (epithelial crypts) Tonsillar fossa 3rd Pouch Inferior parathyroid glands Thymus 4th Pouch Superior parathyroid glands Ultimobranchial body (forms C-cells of the thyroid) DiGeorge Syndrome: Cause: Deletion of 22q11.2, leading to defective neural crest migration CATCH-22 Cardiac defects (Tetralogy of Fallot, truncus arteriosus) Abnormal face Thymic aplasia (T-cell immunodeficiency) Cleft palate Hypocalcemia (due to

parathyroid agenesis) 22q11.2 deletion 1- (Option A): Incorrect , as the 1st pouch develops into the Eustachian tube and middle ear cavity , unrelated to the thymus or parathyroid. 2- (Option B): Incorrect , as the 2nd pouch forms the palatine tonsils , not affected in DiGeorge syndrome. 4-(Option D): Incorrect , as while the 4th pouch forms the superior parathyroid glands, the major defect in DiGeorge syndrome is due to failure of 3rd pouch development.

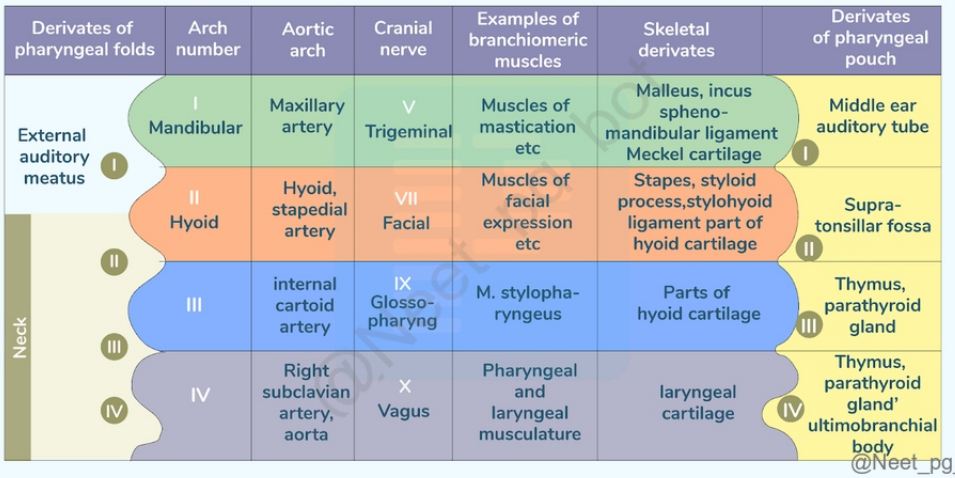

References:

Gray's Anatomy: The Anatomical Basis of Clinical Practice, 41st Edition - Page no: e37, e38, 619

Langman's Medical Embryology, 14th Edition - Page no: 211, 284, 285, 286, 296, 297

↑ *Back to this question in Part A*

@Neet_pg_bot

Q9: What is the embryological basis of the developmental defects shown in the image below? (Q857218)

A. Failure in closure of anterior neuropore of neural tube

B. Failure in closure of posterior neuropore of neural tube

C. Failure in closure of complete neural tube

D. Failure in closure of caudal neuropore of neural tube



Correct Answer: A. Failure in closure of anterior neuropore of neural tube

Explanation: The left image shows anencephaly , a severe neural tube defect (NTD) caused by failure of the anterior neuropore to close during embryogenesis (by day 25 of gestation). This leads to absence of the brain, skull, and scalp , with exposed brain tissue. The right image suggests difficulty in feeding, which is often associated with cranial NTDs . Neural Tube Defects (NTDs) and Neuropore Closure Defects Neuropore Failure of Closure Leads to Clinical Features Anterior Neuropore Anencephaly Absence of brain, skull, and scalp; open cranial vault; polyhydramnios (due to absent swallowing reflex) Posterior Neuropore Spina bifida (Occulta, Meningocele, Myelomeningocele) Defects in vertebral arch, meninges, or spinal cord; may present with tuft of hair, sac-like protrusion, or neurological deficits Complete Neural Tube Craniorachischisis Entire brain and spinal cord remain open, leading to lethal defects Caudal Neuropore Spina bifida occulta Mildest form of spina bifida, often asymptomatic, with a tuft of hair over the lumbar region Failure in closure of posterior neuropore (Option B): Incorrect because it causes spina bifida , affecting the spinal cord and vertebral column, not the brain. Failure in closure of the complete neural tube (Option C): Incorrect because it results in craniorachischisis , a lethal defect where both the brain and spinal cord remain open . Failure in closure of caudal neuropore (Option D): Incorrect because it leads to spina bifida occulta , a mild defect limited to the lower spine , not affecting brain development.

References:

Gray’s Anatomy, Ed 42, Pg 233

↑ *Back to this question in Part A*

@Neet_pg_bot

Q10: A newborn presented to the NICU with respiratory distress and meconium discharge from the umbilicus. The condition occurs due to the patency of which structure? (Q857217)

A. Mesonephric duct

B. Allantois

C. Urachus

D. Vitelline Fistula

Correct Answer: D. Vitelline Fistula

Explanation: A vitelline fistula occurs due to the failure of the vitelline duct (omphalomesenteric duct) to obliterate , leading to meconium discharge from the umbilicus . It connects the midgut to the yolk sac during fetal development, and its persistence results in fecal or intestinal content drainage from the umbilicus . Embryological Remnants of Umbilical Structures Structure Embryological Origin Failure of Obliteration Leads to Clinical Presentation Vitelline Duct Connects midgut to yolk sac Vitelline fistula Meconium discharge from the umbilicus Urachus Remnant of allantois (connects bladder to umbilicus) Patent urachus Urine discharge from umbilicus Allantois Contributes to bladder development Urachal cyst, urachal sinus Cystic swelling or umbilical urine leakage Mesonephric Duct Wolffian duct (forms male reproductive structures) No relation to umbilical anomalies Affects male genital development Mesonephric duct (Option A): Incorrect because it forms the male reproductive system (vas deferens, epididymis, seminal vesicles) and does not contribute to umbilical structures. Allantois (Option B): Incorrect because it contributes to bladder development , and its failure results in urachal anomalies (urine leakage, not meconium discharge). Urachus (Option C): Incorrect because a patent urachus leads to urinary discharge from the umbilicus , not meconium .

References:

https://pmc.ncbi.nlm.nih.gov/articles/PMC4601947/

https://pubmed.ncbi.nlm.nih.gov/29709845/

↑ *Back to this question in Part A*

@Neet_pg_bot

Q11: A child lacks thymus and inferior parathyroid glands. Defective development of which of the following structures is likely to be the cause? (Q855422)

A. 1

B. 2

C. 3

D. 4

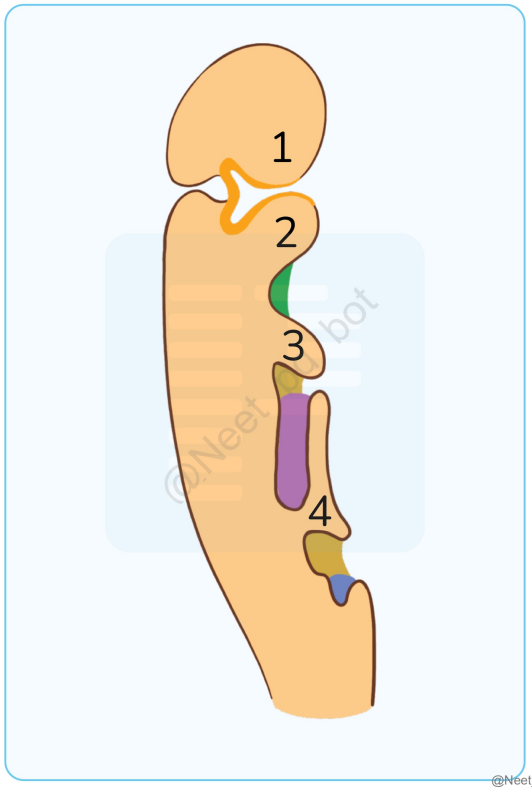

Correct Answer: C. 3

Explanation: The thymus and inferior parathyroid glands are both derived from the third pharyngeal pouch . Thymus : Forms from the endoderm of the third pharyngeal pouch , and is responsible for the development of T lymphocytes . Inferior parathyroid glands : Also arise from the third pharyngeal pouch , and are responsible for calcium homeostasis through parathyroid hormone (PTH) secretion. If there is a defect in the development of the third pharyngeal pouch , both the thymus and inferior parathyroid glands would fail to develop, leading to conditions such as DiGeorge syndrome , which is characterized by thymic hypoplasia and hypoparathyroidism . Pharyngeal arches, clefts and pouches Pharyngeal arches Pharyngeal arches are key structures in head and neck development, appearing in the fourth and fifth weeks as mesenchymal tissue bars. They resemble gills but do not function as such in humans. Pharyngeal arches are divided by pharyngeal clefts on the outside and pharyngeal pouches on the inside. Pharyngeal pouches develop as outpocketings from the lateral walls of the pharynx and do not connect to the exterior, playing crucial roles in organ development. Each arch incorporates neural crest cells essential for forming facial skeleton components, while mesoderm differentiates into facial and neck musculature. Each arch has its own cranial nerve and artery. Pharyngeal Pouches Four Pairs (fifth is rudimentary) First Pouch : Forms the middle ear cavity and Eustachian tube, contributing to the tympanic membrane. Second Pouch : Develops into palatine tonsils; remnants persist as the tonsillar fossa. Third Pouch: Dorsal wing becomes the inferior parathyroid gland; ventral wing forms the thymus, migrating to the thorax. Fourth Pouch : Dorsal region forms the superior parathyroid gland; ventral region becomes the ultimobranchial body, integrating into the thyroid. Pharyngeal Clefts Five-week-old Embryo: Four clefts are present. First Cleft: Does not form the external auditory meatus (EAM); instead, the EAM arises from surface ectoderm invagination. It eventually disappears due to overgrowth by the second arch. Second, Third, and Fourth Clefts: Overgrown by the second arch, they lose exterior contact and may temporarily form the cervical sinus, which ultimately disappears. First pharyngeal pouch (Option A) is incorrect because it gives rise to the auditory tube and middle ear cavity , not the thymus or parathyroid glands. Second pharyngeal pouch (Option B) is incorrect because it forms the palatine tonsils , not the

thymus or parathyroid glands. Fourth pharyngeal pouch (Option D) is incorrect because it gives rise to the superior parathyroid glands and parts of the ultimobranchial body , not the thymus or inferior parathyroid glands.

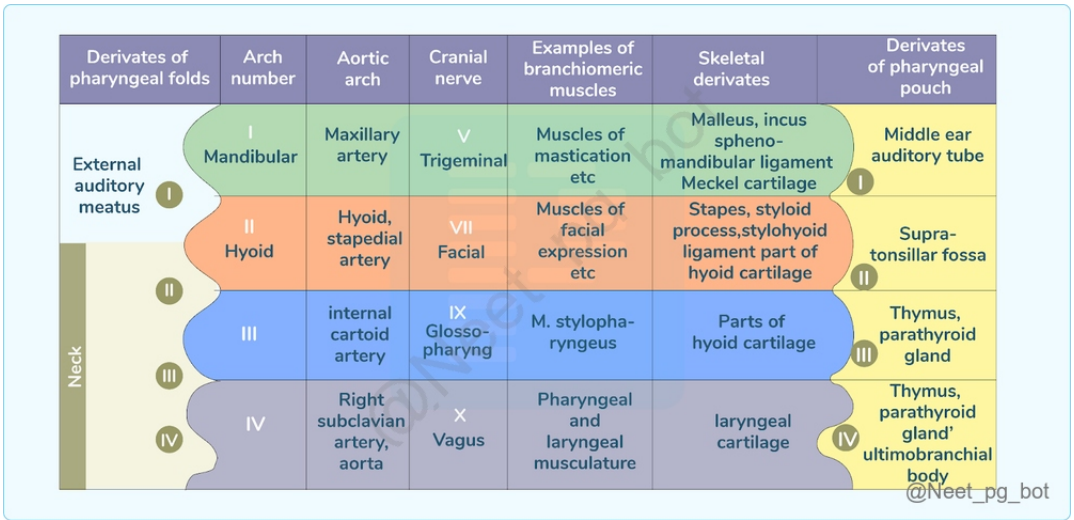

References:

Langman’s Medical Embryology, 14th edition, Page 285, 286, 290, 291, 292

↑ *Back to this question in Part A*

@Neet_pg_bot

Q12: Which of the following structures develops from the structure marked? (Q855401)

A. Medial umbilical ligament

B. Median umbilical ligament

C. Meckel's diverticulum

D. Ligamentum teres

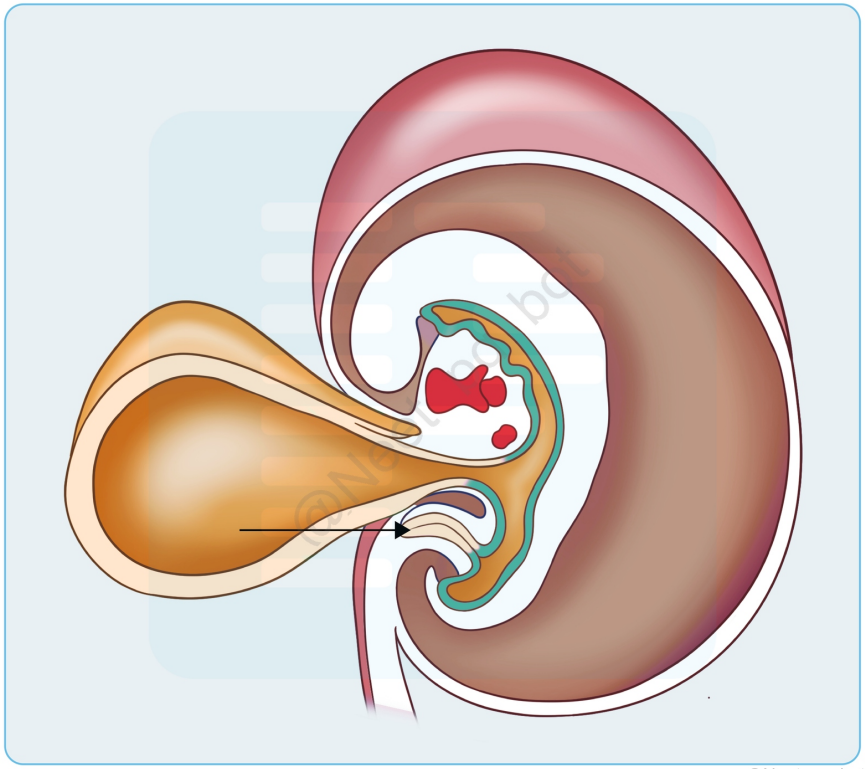

Correct Answer: B. Median umbilical ligament

Explanation: The marked structure is the allantois, a hindgut diverticulum. It forms the urachus during fetal development, connecting the bladder apex to the umbilicus, which later degenerates into the median umbilical ligament. This ligament runs along the midline of abdominal wall. {{caption_text}} Fetal Structure Postnatal derivative Notes Ductus arteriosus Ligamentum arteriosum Near the left recurrent laryngeal nerve Ductus venosus Ligamentum venosum - Foramen ovale Fossa ovalis - Allantois → urachus Median umbilical ligament Urachus is part of allantois between bladder and umbilicus Umbilical arteries Medial umbilical ligaments (Option A) - Umbilical vein Ligamentum teres hepatis (round ligament) (Option D) Contained in falciform ligament Meckel's diverticulum (Option C): This arises from the vitelline duct, not the urachus.

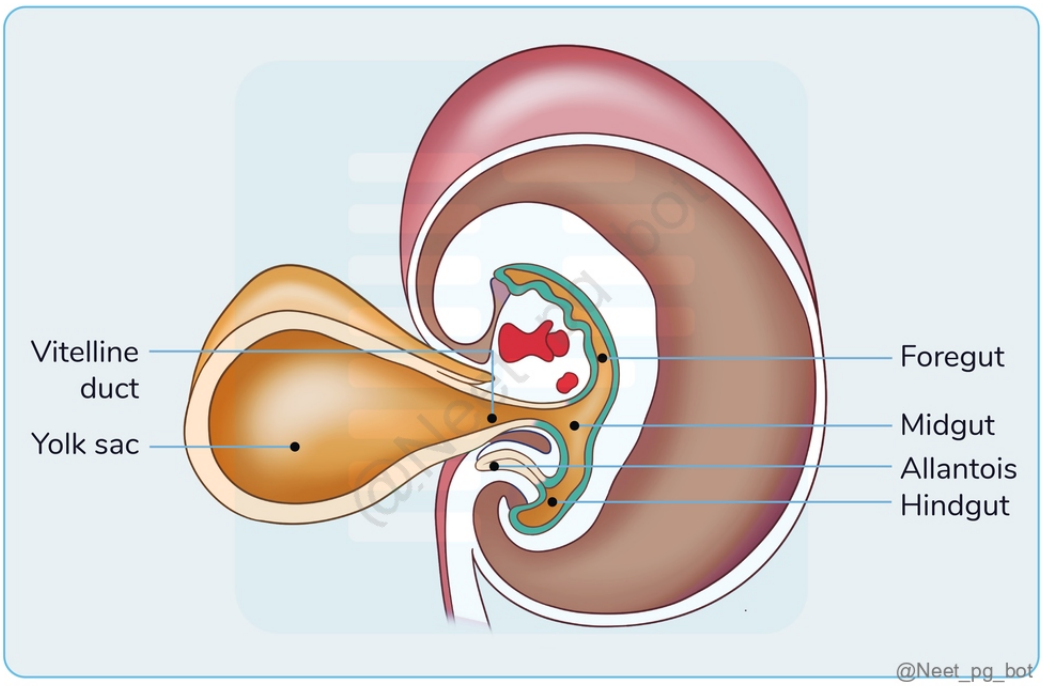

References:

https://pmc.ncbi.nlm.nih.gov/articles/PMC5838699/#:~:text

↑ *Back to this question in Part A*

@Neet_pg_bot

Q13: Which of the following arises from 6th pharyngeal arch? (Q859907)

A. Medial pterygoids

B. Lateral pterygoids

C. Ductus arteriosus

D. Tensor veli palatini

Correct Answer: C. Ductus arteriosus

Explanation: The ductus arteriosus arises from the sixth pharyngeal arch The ductus arteriosus is a fetal blood vessel that connects the pulmonary trunk to the descending aorta, allowing a portion of oxygenated blood to bypass the developing fetal lungs. This shunt helps direct oxygenated blood towards the systemic circulation while the lungs are not yet fully functional in the prenatal period. Arch Nerve of arch Artery of arch Skeletal derivatives Muscles of arch (Options A, B, and D) First Maxillary (Sensory) and mandibular (Motor and sensory) branches of trigeminal nerve Maxillary artery Meckel's cartilage Malleus Incus Anterior ligament of malleus

Sphenomandibular ligament Mandible Maxilla Zygomatic Palatine Temporal (part) Masseter Temporalis Medial pterygoid Lateral pterygoids Mylohyoid Anterior belly of digastric Tensor tympani, and Tensor palati All are migratory except T. tympani Second Facial nerve Hyoid artery Stapedial artery The cartilage of the second arch (Reichert's) forms the Following: Stapes Styloid process Stylohyoid ligament Lesser cornu of hyoid Upper half of body of hyoid Stapedius Stylohyoid Posterior belly of digastric Epicranius Orbicularis oculi Orbicularis oris Zygomaticus Buccinator Nasal muscles Platysma Levator labii superioris, levator labii inferioris Levator anguli oris Auricular muscles All are migratory except stapedius, stylohyoid Third Glossopharyngeal nerve Common carotid artery Internal carotid artery Greater cornu of hyoid Lower half of body of hyoid Stylopharyngeus Fourth Superior laryngeal branch of vagus nerve Arch of aorta (left side) Subclavian artery (right side) Thyroid Cricoid Corniculate Cuneiform Arytenoid Thyrohyoid ligament Epiglottis—from mesodermal core of hypobranchial eminence Larynx–Cricothyroid Muscles of pharynx Intrinsic muscles of soft palate except tensor palati Sixth Recurrent laryngeal branch of vagus nerve Ductus arteriosus (left side) Pulmonary artery (right side) All intrinsic muscles of larynx except cricothyroid

References:

Inderbir Singh's Human Embryology 11th edition, page 129, 130

↑ *Back to this question in Part A*

@Neet_pg_bot

Q14: Which of the following develops from the dorsal mesogastrium? (Q859527)

A. Falciform ligament

B. Spleen

C. Lesser omentum

D. Liver

Correct Answer: B. Spleen

Explanation: The spleen develops from the dorsal mesogastrium. During embryonic development, the spleen forms from mesenchymal cells within the mesoderm, specifically in the dorsal mesogastrium. Structures Developed from Ventral Mesogastrium Structures Developed from Dorsal Mesogastrium Falciform ligament (Option A ruled out) Lesser omentum (Option C ruled out) Liver ■■■■■■■(Option D ruled out) Spleen (Option B) Pancreas Greater omentum (from dorsal mesentery continuation) {{caption_text}} {{caption_text}}

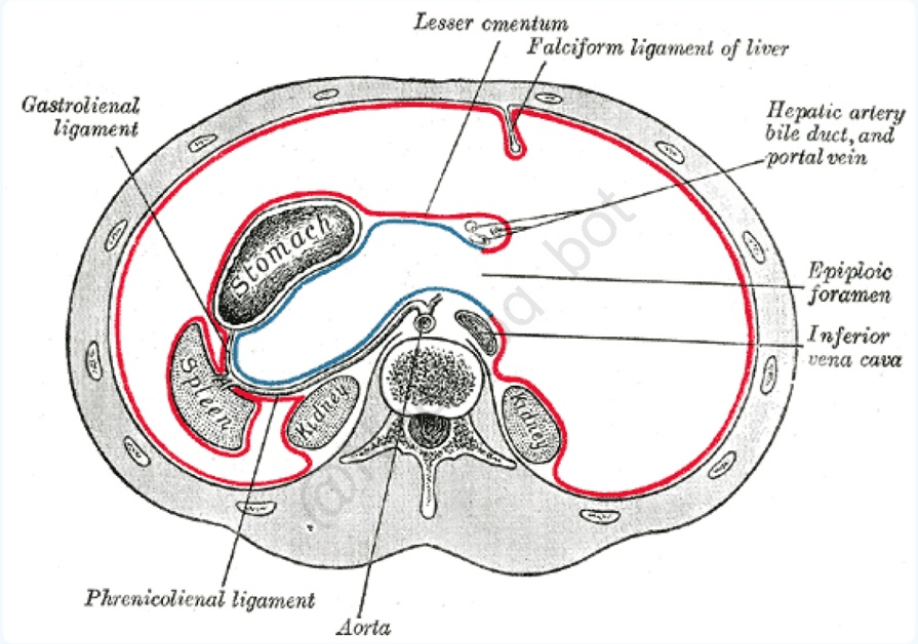

Horizontal disposition of the peritoneum in the upper part of the abdomen

@Neet_pg_bot

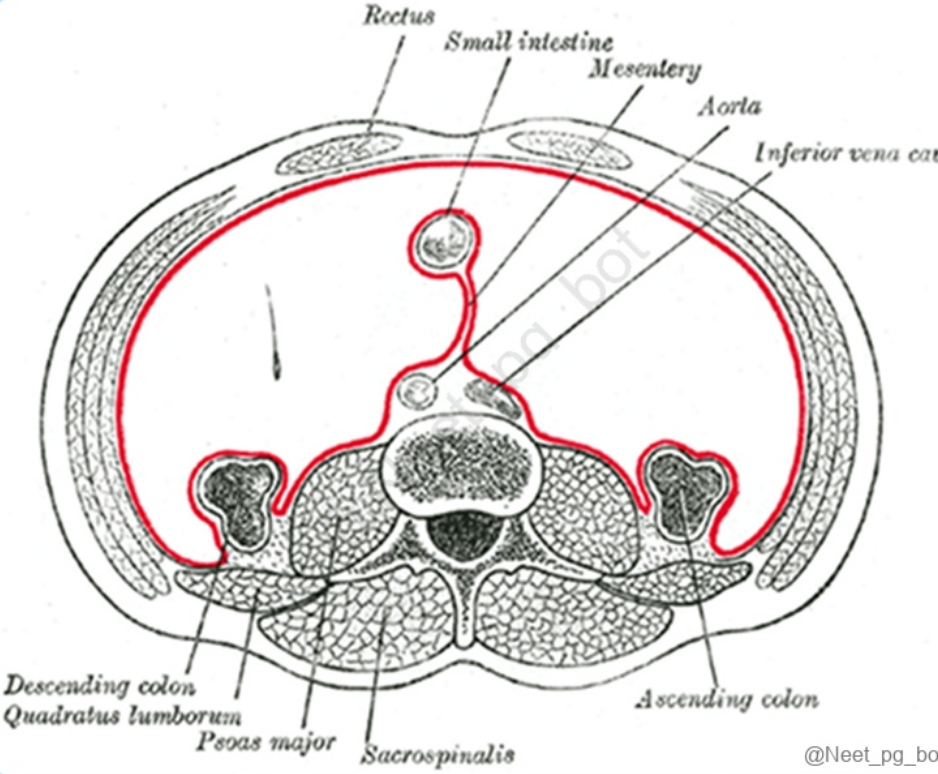

@Neet_pg_bot

References:

Gray's anatomy, 42nd edition, Page 1151-1157

https://en.wikipedia.org/wiki/Peritoneum#:~:text=Peritoneal%20folds%20are%20omentums%2C%20mesenteries,red%20in%20the%20diagrams%20above.

https://www.ncbi.nlm.nih.gov/books/NBK534788/#:~:text=The%20peritoneum%20is%20comprised%20of,%2C%20transverse%2C%20and%20sigmoid%20colon.

↑ *Back to this question in Part A*

@Neet_pg_bot

Q15: Meiosis occurs in: (Q858490)

A. Adrenal

B. Adult ovary

C. Prepubertal testis

D. Hypothalamus

Correct Answer: B. Adult ovary

Explanation: Meiosis occurs in the adult ovary as part of oogenesis. In females, during fetal development, primary oocytes are arrested in prophase I of meiosis. These oocytes remain in this arrested state until puberty, when they resume meiosis. Meiosis continues during ovulation, leading to the formation of a secondary oocyte, which is arrested in metaphase II until fertilization. {{caption_text}} Incorrect Options: Adrenal (option A): This is incorrect because meiosis does not occur in the adrenal glands. The adrenal glands are involved in hormone production, not gametogenesis. Prepubertal testis (option C): This is incorrect because meiosis in males begins at puberty, not before. In the prepubertal testis, germ cells undergo mitosis, not meiosis. Hypothalamus (option D): This is incorrect because the hypothalamus is part of the brain that regulates various physiological processes, including hormone release. It does not participate in meiosis.

Before Birth:

Oogonia peak at 7 million → Degeneration → Remaining oocytes enter prophase I

At Birth:

Oocyte maturation inhibitor (OMI) causes arrest in prophase I (diplotene stage)

Puberty:

- Pool of growing follicles established → 15-20 follicles mature monthly
- Formation of antral (vesicular) follicles with fluid-filled spaces → Primary Follicle

Follicular Development:

- Follicular cells → Cuboidal (granulosa cells) → Secrete zona pellucida
- Theca folliculi forms → Theca interna and externa layers around the granulosa cells
- Antrum enlarges, forming Graafian Follicle (25mm)

Ovulation:

- LH surge induces completion of meiosis I
- Formation of the secondary oocyte and polar body
- Secondary oocyte arrests in metaphase II

Fertilisation

- Yes: Meiosis II is completed
- No: Oocyte degenerates 24 hours post-ovulation

@Neet_pg_bot

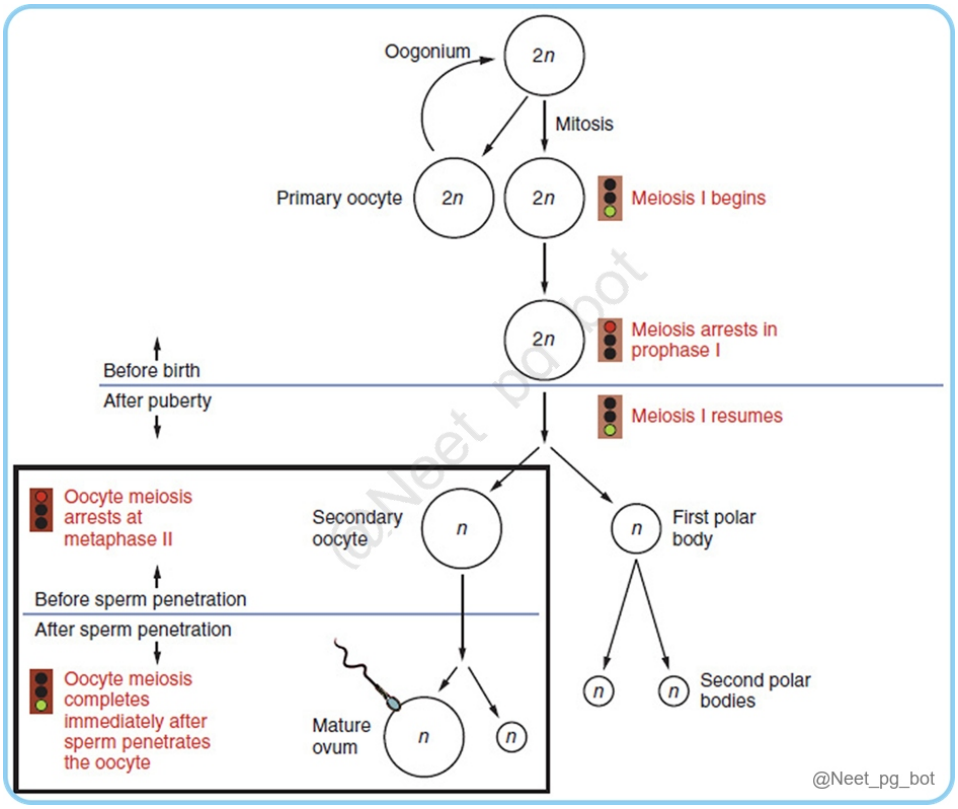

References:

Langman's Medical Embryology, 14th Edition, Page 25-29

↑ *Back to this question in Part A*

@Neet_pg_bot

Q16: Identify the structure marked in the diagram showing the development of ovarian follicles. (Q857584)

A. Primary follicle

B. Antral follicle

C. Primordial follicle

D. Corpus luteum

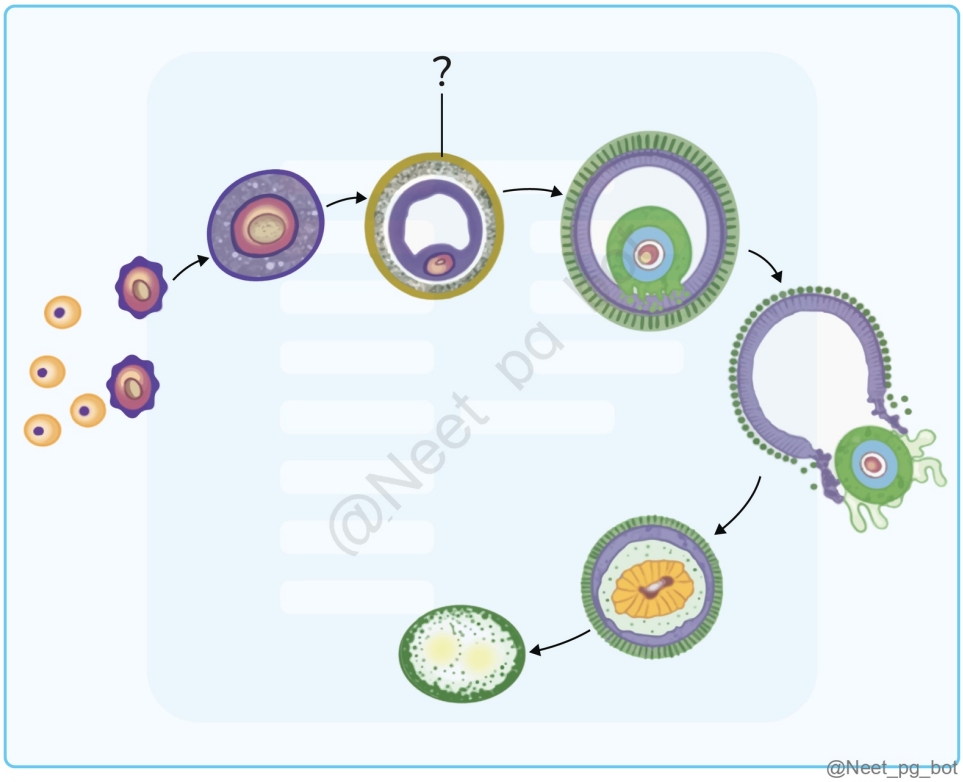

Correct Answer: B. Antral follicle

Explanation: Antral follicles are characterized by the presence of a fluid-filled cavity (antrum) surrounding the oocyte. These follicles have multiple layers of granulosa cells , a well-developed theca interna and theca externa , and contribute to hormone production . The presence of the antrum differentiates them from primary follicles , which lack this cavity. Development of Ovarian Follicles Stage Characteristics Primordial follicle Oocytes surrounded by a single layer of flattened granulosa cells . Dormant until puberty. Primary follicle Granulosa cells become cuboidal , zona pellucida begins forming around the oocyte. No antrum. Secondary follicle Multiple layers

of granulosa cells and theca cells form. Early follicular development but no antrum yet. Antral follicle Fluid-filled antrum appears , granulosa and theca cells differentiate. Prepares for ovulation. Graafian follicle Fully matured, large antrum , ready for ovulation. Corpus luteum Formed after ovulation, secretes progesterone to support pregnancy. If there is no fertilization, it degenerates. Incorrect Options: Primary follicle (Option A): Incorrect because primary follicles lack an antrum and have a single or multilayered granulosa cell arrangement. Primordial follicle (Option C): Incorrect because primordial follicles are the earliest stage, with a single layer of flattened granulosa cells and no antrum. Corpus luteum (Option D): Incorrect because the corpus luteum is a post-ovulatory structure that does not resemble a developing follicle and lacks an antrum.

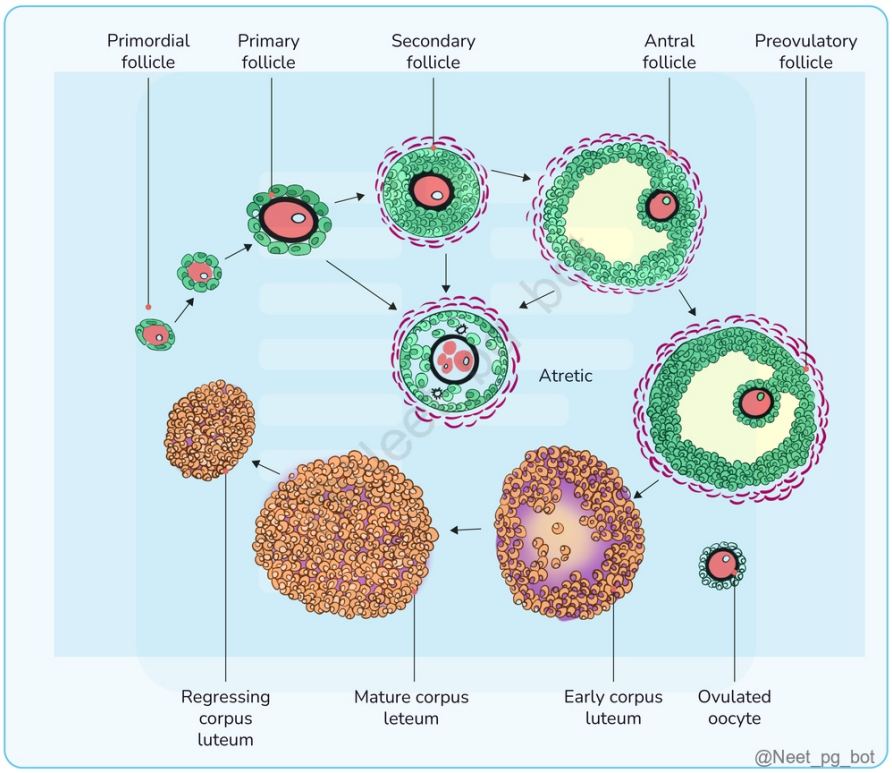

References:

Williams Gynecology, 4th Edition, Page 436,437.

Shaw’s Textbook of Gynaecology, 17th Edition, Page 225

↑ *Back to this question in Part A*

@Neet_pg_bot

Q17: Which structure is formed by the structure indicated by the arrow? (Q866622)

A. Annulus

B. Nucleus pulposus

C. Neural tube

D. Septum transversum

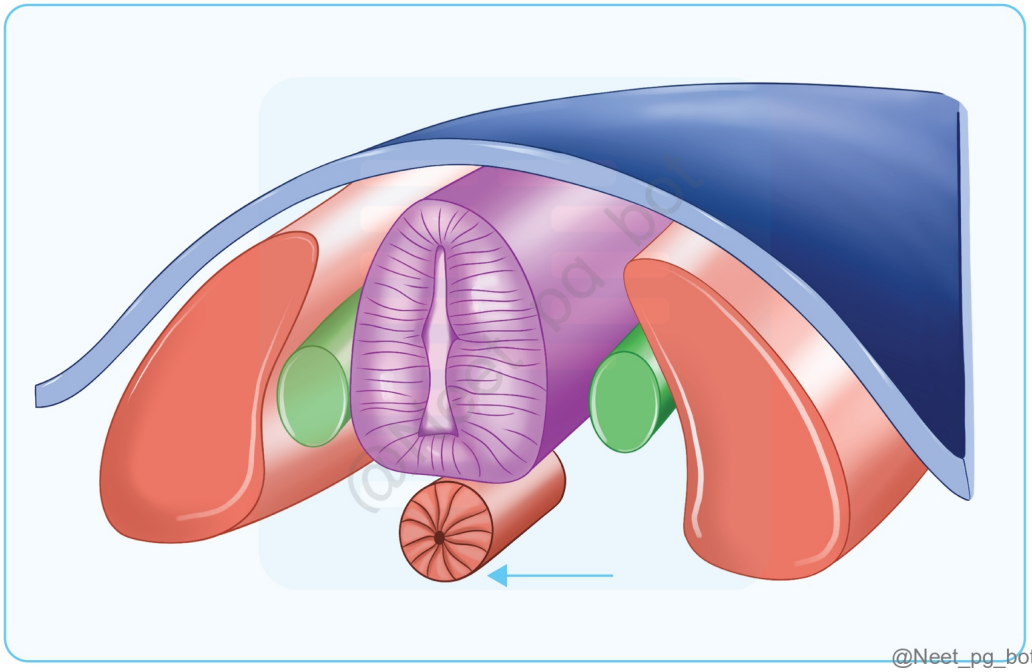

Correct Answer: B. Nucleus pulposus

Explanation: The arrow points to the Notochord , an embryonic midline structure that acts as the primitive axial skeleton, induces neural tube formation, and later forms the nucleus pulposus of the intervertebral disc in adults. Nucleus pulposus: The core of the intervertebral disc, derived from the embryonic notochord, and functions to absorb spinal compression and provide flexibility. Notochord Formation: Formation of the primitive streak Migration of mesodermal cells through the primitive node Formation of the notochordal process Formation of the notochordal plate Detachment of the notochordal plate Rolling into the definitive notochord Incorrect Options: Annulus (Option A) refers to the annulus fibrosus, the outer fibrous ring of the intervertebral disc, which does not originate from the notochord, but from mesoderm (sclerotome). Neural tube (Option C) forms from the ectoderm, induced by signals from the notochord, but it is not formed by the notochord itself. Septum transversum (Option D) contributes to the diaphragm and develops from mesoderm, unrelated to the notochord.

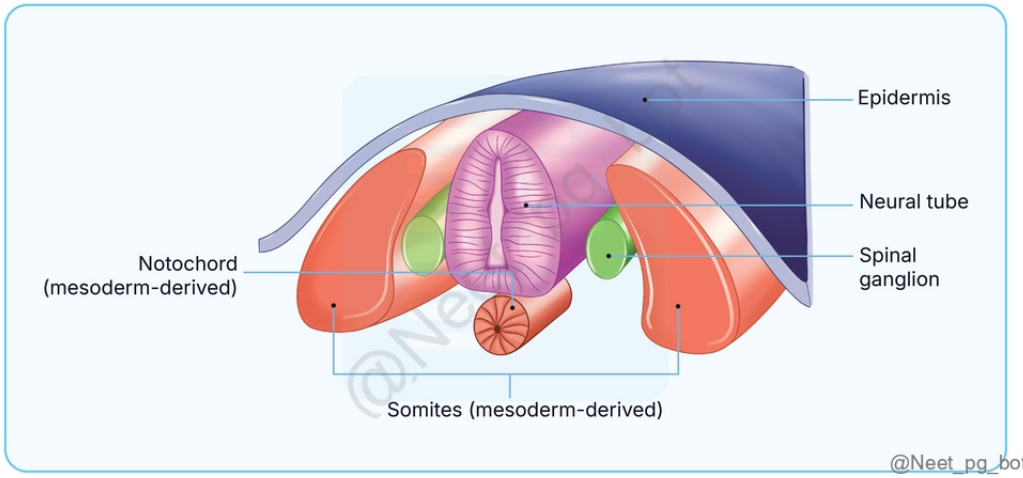

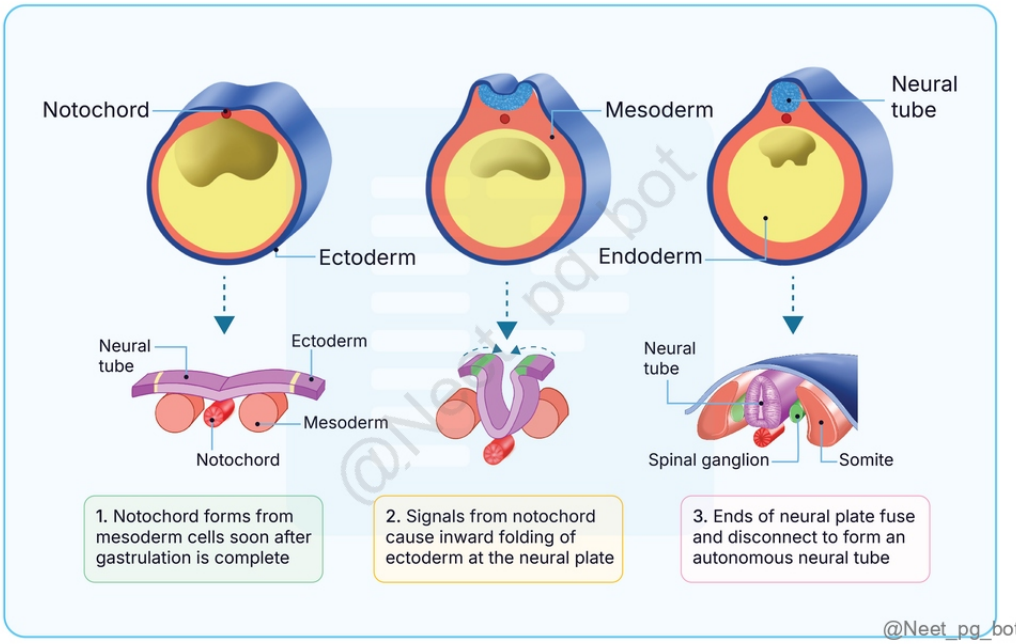

References:

.

↑ *Back to this question in Part A*

@Neet_pg_bot

Q18: Which of the following statements is incorrect related to the given image? (Q857337)

A. Benign tumor of coccyx

B. Presence of teeth and hair

C. Result from the aberrant migration of primordial germ cell

D. Prechordal plate anomaly



Correct Answer: D. Prechordal plate anomaly

Explanation: Sacrococcygeal teratomas are tumors that originate from primordial germ cells and are typically found at the base of the spine. They are associated with the remnants of the primitive streak rather than the prechordal plate. {{caption_text}} {{caption_text}} Teratomas mostly occur during the neonatal period and most of them are benign Most common site- Sacrococcygeal region Females > males The risk of malignancy increases with age It is thought to be derivative of the primitive streak Clinical features: External presacral mass with minimal intrapelvic presacral component Symptoms include weakness, paralysis, and bladder or bowel dysfunction Currarino Triad: Anorectal malformations + sacrococcygeal osseous defect + presacral mass Diagnosis: Clinical diagnosis CT/MRI is done to detect intra-abdominal and intra-pelvic components. Treatment: Complete surgical excision of the tumor should be done To avoid local recurrence - resection of the coccyx is done Benign tumor of coccyx (Option A): Sacrococcygeal teratoma is a tumor that arises at the base of the spine, often from remnants of primitive tissue, and it can exhibit both benign(mostly) and malignant (few) characteristics. Presence of teeth and hair (Option B): Teratomas can have any of the 3 germ layers (Endoderm, ectoderm or mesoderm) because primordial germ cells themselves are pluripotent cells. Result from the aberrant migration of primordial germ cell (Option C): Abrupt migration of primordial germ cells may cause oropharyngeal teratoma and sacrococcygeal teratoma.





References:

SRB’s Manual Of Surgery (6th edition) page 987

↑ *Back to this question in Part A*

@Neet_pg_bot

Q19: On what is the SRY gene located? (Q857329)

A. Y chromosome short arm

B. Y chromosome long arm

C. X chromosome short arm

D. X chromosome long arm

Correct Answer: A. Y chromosome short arm

Explanation: The SRY gene (Sex-determining Region Y) is located on the short arm (p arm) of the Y chromosome, specifically at Yp11.2. It plays a critical role in initiating male sex determination by triggering the development of testes. Sex differentiation Male Development: SRY Gene: Located on the Y chromosome ; initiates the development of testes. Activates downstream genes like SOX9 and SF1 , which are essential for Sertoli and Leydig cell differentiation. Testosterone Effects: Testosterone, secreted by Leydig cells, stimulates the mesonephric (Wolffian) ducts to form male reproductive structures (e.g., epididymis, vas deferens, and seminal vesicles, and ejaculatory duct). Dihydrotestosterone (DHT): Promotes the development of external genitalia (penis and scrotum). Müllerian Inhibiting Substance (MIS): Known as Anti-Müllerian Hormone (AMH) Secreted by Sertoli cells; causes the regression of the paramesonephric (Müllerian) ducts , preventing the development of female reproductive structures. Female Development: Absence of SRY Gene: Without the SRY gene, the gonads develop into ovaries . Paramesonephric (Müllerian) Ducts: Develop into the fallopian tubes, uterus, and upper 1/3rd of the vagina . External Genitalia: Develop in the absence of testosterone, forming the clitoris, labia minora, and labia majora .

References:

Langman’s medical embryology 14e,pg,283

Embryology, Sexual Development - StatPearls - NCBI Bookshelf (nih.gov)

↑ *Back to this question in Part A*

@Neet_pg_bot

Q20: Absence or mutation of SRY gene results in ? (Q857314)

A. Agenesis of testis

B. Undescended testis

C. Hydrocele testis

D. None of the above

Correct Answer: A. Agenesis of testis

Explanation: The SRY gene (Sex-determining Region Y gene) is located on the Y chromosome and plays a crucial role in the development of male sex characteristics. If the SRY gene is absent or mutated, it can lead to a failure in the development of testes, resulting in agenesis of testis. Sex differentiation Male Development: SRY Gene: Located on the Y chromosome ; initiates the development of testes. Activates downstream genes like SOX9 and SF1 , which are essential for Sertoli and Leydig cell differentiation. Testosterone Effects: Testosterone, secreted by Leydig cells, stimulates the mesonephric (Wolffian) ducts to form male reproductive structures (e.g., epididymis, vas deferens, and seminal vesicles, and ejaculatory duct). Dihydrotestosterone (DHT): Promotes the development of external genitalia (penis and scrotum). Müllerian Inhibiting Substance (MIS): Known as Anti-Müllerian Hormone (AMH) Secreted by Sertoli cells; causes the regression of the paramesonephric (Müllerian) ducts , preventing the development of female reproductive structures. Female Development: Absence of SRY Gene: Without the SRY gene, the gonads develop into ovaries . Paramesonephric (Müllerian) Ducts: Develop into the fallopian tubes, uterus, and upper 1/3rd of the vagina . External Genitalia: Develop in the absence of testosterone, forming the clitoris, labia minora, and labia majora . Undescended testis (Option B): Undescended testis (cryptorchidism) is usually due to issues with testicular descent, not a lack of the SRY gene. Hydrocele testis (Option C): Hydrocele is a condition where there is fluid accumulation around the testis, which is unrelated to the SRY gene. None of the above (Option D): This is incorrect because the absence or mutation of the SRY gene does lead to agenesis of testis, as mentioned above.

References:

Langman’s medical embryology 14e,pg,283

Embryology, Sexual Development - StatPearls - NCBI Bookshelf (nih.gov)

↑ *Back to this question in Part A*

@Neet_pg_bot

Q21: Which of the following structures develop from the 6th pharyngeal arch artery on the left side? (Q860265)

A. Arch of Aorta

B. Ductus arteriosus

C. Carotid arteries

D. Subclavian artery

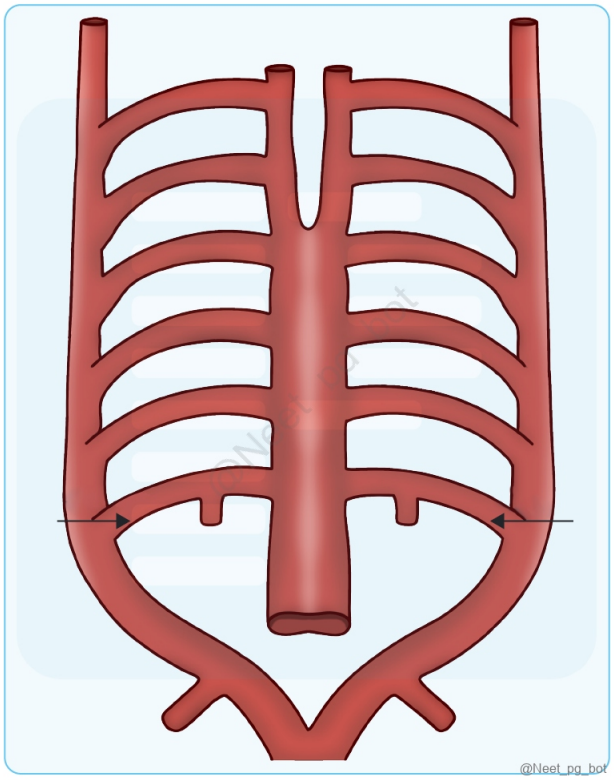

Correct Answer: B. Ductus arteriosus

Explanation: The 6th pharyngeal arch artery gives rise to different structures on the right and left sides: Left 6th arch → Ductus arteriosus + proximal part of left pulmonary artery Right 6th arch → Proximal part of right pulmonary artery (Right distal portion disappears) Therefore, only the ductus arteriosus comes from the left 6th arch. Incorrect Options : Option A) Arch of Aorta – Develops mainly from left 4th arch , not 6th. Option C) Carotid arteries – Develop from 3rd arch . Option D) Subclavian artery – Right from right 4th arch ; left subclavian from 7th intersegmental artery .

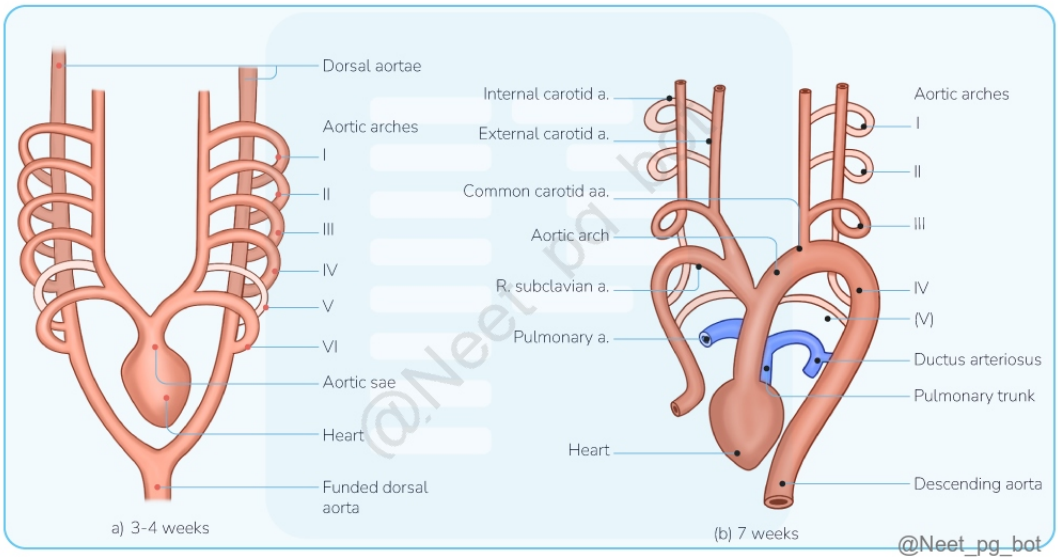

References:

Inderbir Singh’s Human Embryology 11th edition, page 130

↑ *Back to this question in Part A*

@Neet_pg_bot

Q22: Implantation occurs on which day post fertilization? (Q844315)

A. 2

B. 5

C. 8

D. 15

Correct Answer: C. 8

Explanation: Implantation begins around Day 6–7 after fertilization and is usually completed by Day 10–12. Fertilisation to Implantation: Stage Day (Post-Fertilization) Key Event Fertilization Day 0 Sperm fertilizes oocyte in ampulla of fallopian tube Zygote Formation Day 1 Single-cell zygote undergoes cleavage Morula Formation Day 3-4 16-cell stage compacted into a solid ball Blastocyst Formation Day 5 Fluid-filled cavity forms; blastocyst reaches the uterus Implantation Begins Day 6-7 Blastocyst attaches to the endometrium Trophoblast Invasion Day 6-8 Syncytiotrophoblast formation, hCG secretion begins Complete Implantation Day 10-12 Blastocyst is fully embedded in the endometrial lining

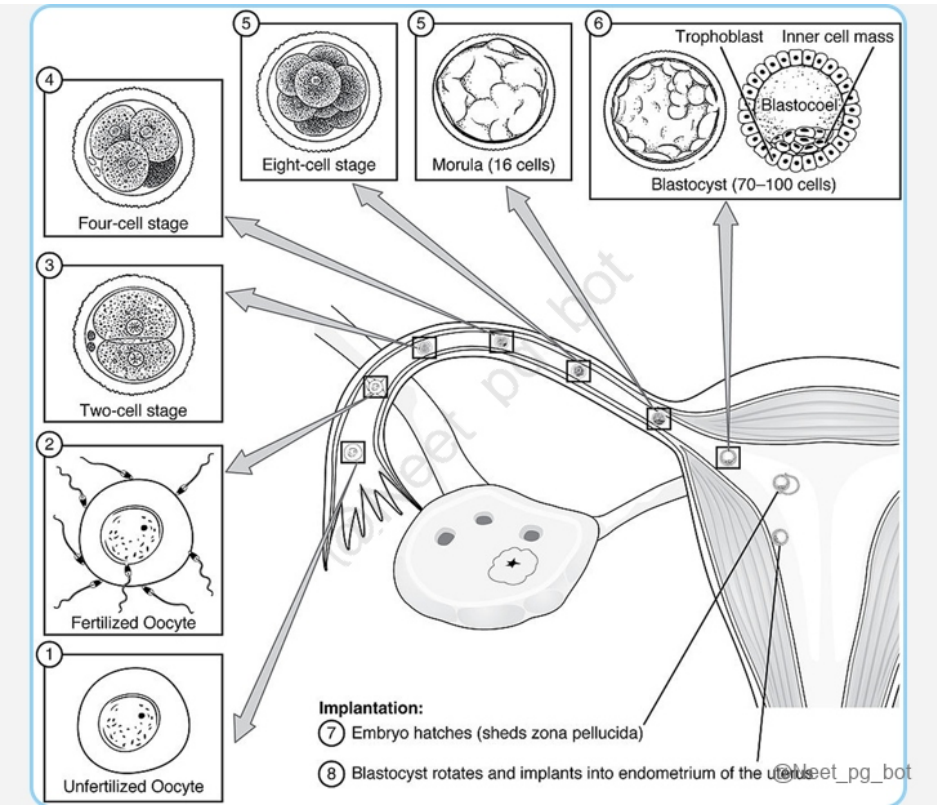

References:

First week of development

Langman's Medical Embryology 14th edition, page 42,43 & 48

↑ *Back to this question in Part A*

@Neet_pg_bot

Q23: Post ovulation the oocyte is: (Q844313)

A. Primary oocyte arrested in prophase- 1

B. Primary oocyte arrested in prophase- 2

C. Secondary oocyte arrested in prophase- 2

D. Secondary oocyte arrested in metaphase- 2

Correct Answer: D. Secondary oocyte arrested in metaphase- 2

Explanation: Correct Option D - Secondary oocyte arrested in metaphase-2: After ovulation, the oocyte is a secondary oocyte that is arrested in metaphase of the second meiotic division. It completes the second meiotic

division only if fertilization occurs. If fertilization does not take place, the oocyte will degenerate. Incorrect Options: Option A - Primary oocyte arrested in prophase-1: The primary oocyte is arrested in prophase of the first meiotic division. This arrest occurs before ovulation. During ovulation, the oocyte has already completed the first meiotic division to become a secondary oocyte. Option B - Primary oocyte arrested in prophase-2: The primary oocyte is not arrested in prophase-2; it is arrested in prophase-1. Prophase-2 arrest does not occur until after the first meiotic division is completed. Option C - Secondary oocyte arrested in prophase-2: The secondary oocyte is arrested in metaphase-2, not prophase-2. Prophase-2 arrest is not a correct description for the secondary oocyte's state after ovulation.

↑ *Back to this question in Part A*

@Neet_pg_bot

Q24: The covering of an omphalocele is derived from which layer? (Q844155)

A. Amnion

B. Chorion

C. Mesoderm

D. Endoderm

Correct Answer: A. Amnion

Explanation: Correct Option A - Amnion: Amnion : The covering of an omphalocele is derived from the amnion. An omphalocele is a congenital defect where abdominal organs herniate through the umbilical ring into the base of the umbilical cord, and these herniated organs are covered by a membrane composed of amnion on the outside and peritoneum on the inside. Incorrect Options: Option B - Chorion : The chorion is another fetal membrane, but it does not contribute to the covering of an omphalocele. Option C - Mesoderm : The mesoderm is a germ layer involved in the formation of various tissues and organs but not in the direct covering of an omphalocele. Option D - Endoderm : The endoderm forms the lining of the gastrointestinal tract and other internal structures but does not contribute to the covering of an omphalocele.

↑ *Back to this question in Part A*

@Neet_pg_bot

Q25: Which of the following prevents polyspermy? (Q844149)

A. Acrosome reaction

B. Cortical reaction

C. Zona reaction

D. Capacitation

Correct Answer: C. Zona reaction

Explanation: Zona reaction Penetration of the zona pellucida is facilitated by the release of hyaluronidase from the acrosomal cap. More than one sperm may penetrate the zona pellucida. ■ Out of the many sperm, one touches the oolemma. Soon after sperm fusion, penetration by other sperm is prevented by the zona reaction (hardening) and the oolemma block. This is due to the release of cortical granules by exocytosis from the oocyte. Incorrect Options: Option A - Acrosome reaction: Incorrect: The acrosome reaction is the process by which the sperm releases enzymes to penetrate the zona pellucida of the oocyte. It is crucial for sperm to access the egg but does not prevent polyspermy. Option B - Cortical reaction: Incorrect: Triggers changes leading to zona reaction, but is indirectly responsible. Option D - Capacitation: Incorrect: Capacitation is a physiological process that sperm undergo to gain the ability to fertilize an egg. It involves changes to the sperm's membrane and is necessary for fertilization but does not prevent polyspermy.

↑ *Back to this question in Part A*

@Neet_pg_bot

Q26: Identify the marked structure: {{caption_text}} (Q852890)

A. Primitive streak

B. Notochord

C. Neural groove

D. Secondary neural plate

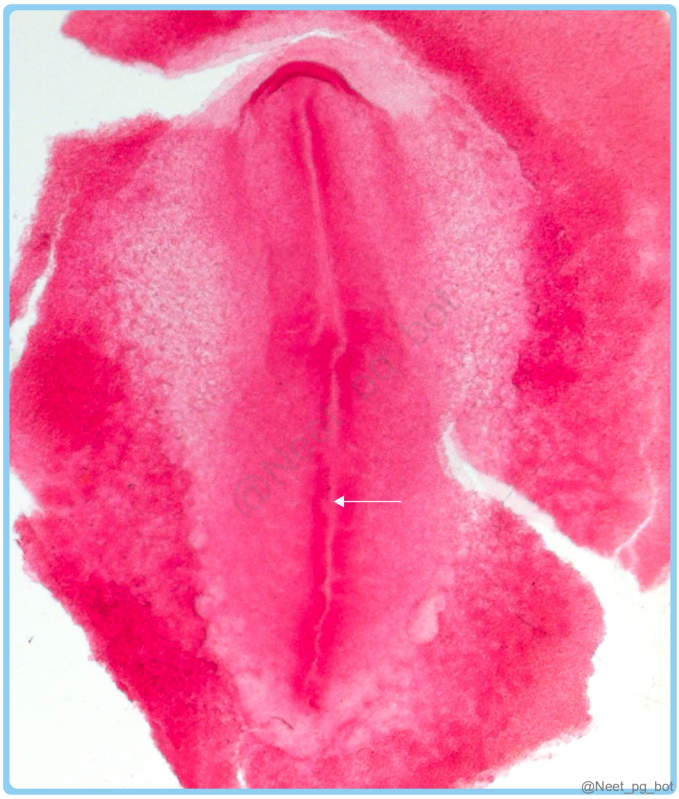

Correct Answer: A. Primitive streak

Explanation: The primitive streak is the first structure to form during gastrulation , appearing as a linear midline thickening in the epiblast . It acts as the site of cell migration , leading to the formation of the three germ layers (ectoderm, mesoderm, and endoderm). Primitive Streak and Its Role in Gastrulation Stage Description Formation Appears on day 15 of development as a linear thickening in the epiblast of the bilaminar disc. Function Acts as a site for epiblast cell migration , which forms the mesoderm and endoderm. Regression By the end of the 4th week , the primitive streak regresses, leaving behind the notochord and mesoderm. Clinical Significance If it fails to regress , it may lead to sacrococcygeal teratoma (tumor with all three germ layers). {{caption_text}} Notochord (Option B): Incorrect because the notochord forms after the primitive streak from mesodermal cells. Neural Groove (Option C): Incorrect because the neural groove forms later during neurulation , as the neural plate invaginates. Secondary Neural Plate (Option D): Incorrect because it is involved in secondary neurulation (formation of the caudal neural tube), not in early gastrulation.

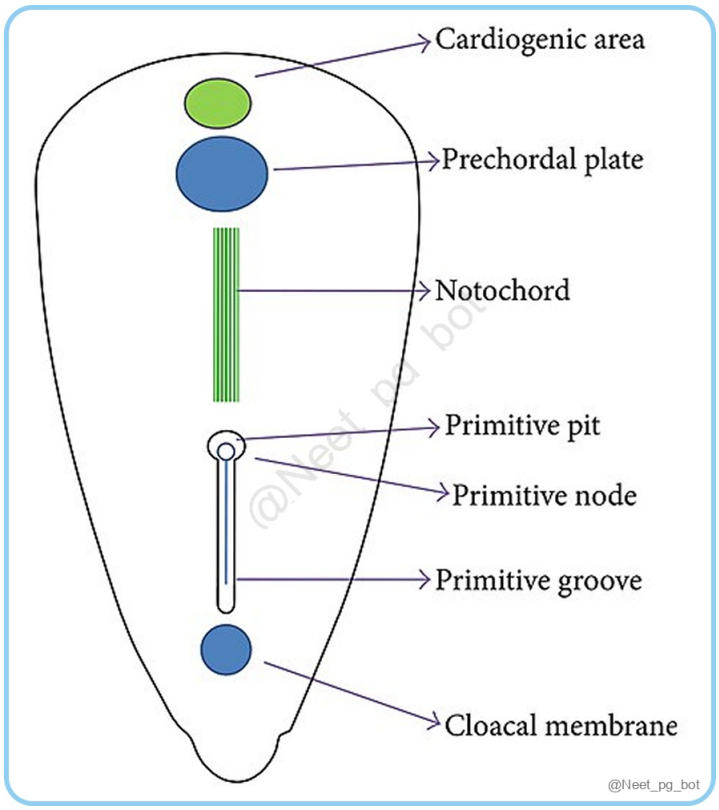

References:

Inderbir Singh's Human Embryology, 11th edition, Page 56

Langman Medical Embryology, 14th edition, Page 59

↑ *Back to this question in Part A*

@Neet_pg_bot

Q27: Which of the following is not a derivative of neural crest cells? (Q852887)

A. Ciliary muscles

B. Retinal pigment epithelium

C. Ciliary ganglion

D. Melanocytes

Correct Answer: B. Retinal pigment epithelium

Explanation: Neural crest cells (NCCs) give rise to a wide variety of structures, including components of the peripheral nervous system, connective tissue, and pigment cells . The retinal pigment epithelium (RPE) , however,

arises from the neural ectoderm , not from neural crest cells. The RPE is derived from the outer layer of the optic cup , which forms from the neural tube. Derivatives of Neural Crest Cells Structure Neural Crest Origin Ciliary muscles Derived from neural crest Ciliary ganglion Derived from neural crest Melanocytes Derived from neural crest Retinal pigment epithelium (RPE) Derived from neural ectoderm Ciliary muscles (Option A): incorrect because they arise from neural crest cells , forming part of the intraocular muscles. Ciliary ganglion (Option C): incorrect because it is a parasympathetic ganglion derived from neural crest cells. Melanocytes (Option D): incorrect because melanocytes originate from neural crest cells , contributing to pigmentation in various tissues.

References:

Grey's Anatomy, 42nd edition. Page 236

↑ *Back to this question in Part A*

@Neet_pg_bot

Q28: Which of the following is the 1st to be formed by the migration of the epiblast along the primitive streak? (Q852886)

A. Endoderm

B. Cardiac mesoderm

C. Epidermis

D. Neural groove

Correct Answer: A. Endoderm

Explanation: During gastrulation , epiblast cells migrate through the primitive streak to form the three germ layers. The first cells to migrate displace the hypoblast and form the endoderm . Subsequent migration leads to mesoderm formation, while non-migrating epiblast cells remain as ectoderm. Gastrulation and Germ Layer Formation Stage Description Primitive Streak Formation Forms along the midline of the epiblast, marking the site of cell migration. Endoderm Formation The first wave of migrating epiblast cells replaces the hypoblast to form the definitive endoderm , which later gives rise to the gut and associated organs. Mesoderm Formation Subsequent migration of epiblast cells forms the mesoderm, which differentiates into structures like the cardiac mesoderm and notochord. Ectoderm Formation Epiblast cells that do not migrate remain as ectoderm, which later forms the epidermis and neural structures. {{caption_text}} Cardiac mesoderm (Option B): Incorrect because it arises from the mesoderm, which forms after the endoderm. Epidermis (Option C): Incorrect as it originates from ectoderm, which forms last. Neural groove (Option D): Incorrect since it arises from the ectoderm later during neurulation, after gastrulation.

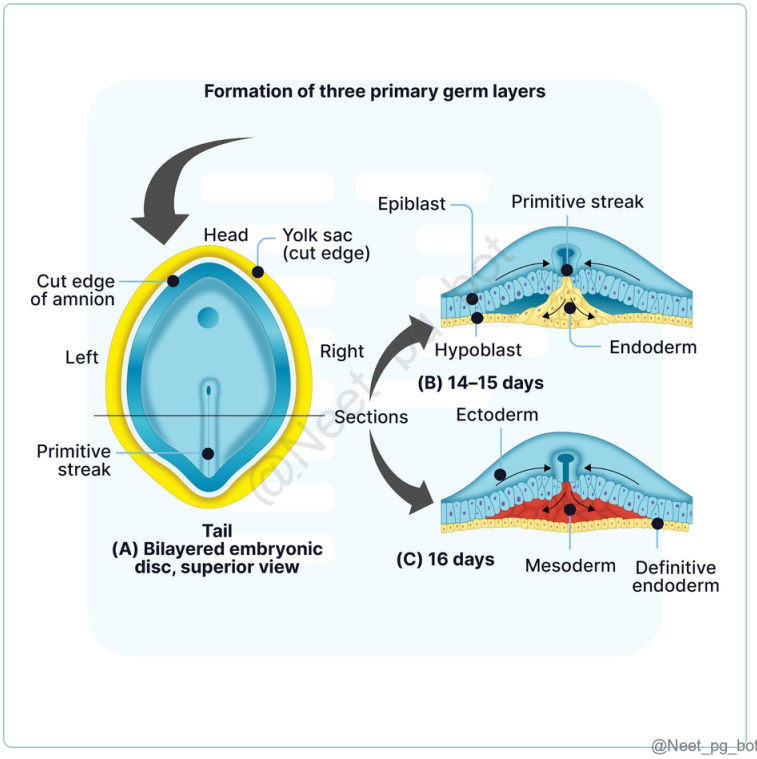

References:

Langman Medical Embryology, 14th edition, Pages 59, 60

↑ *Back to this question in Part A*

@Neet_pg_bot

Q29: Which of the following best describes the normal vascular composition of the umbilical cord? (Q866311)

A. 1 artery and 2 veins

B. 1 vein and 1 artery

C. 2 arteries and 1 vein

D. 2 arteries and 2 vein

Correct Answer: C. 2 arteries and 1 vein

Explanation: The umbilical cord contains two arteries that carry deoxygenated blood from the fetus to the placenta, and one vein that carries oxygenated blood from the placenta back to the fetus. Incorrect Options: Option A - 1

artery and 2 veins: This is incorrect because the umbilical cord normally has two arteries and only one vein, not the other way around. Option B - 1 vein and 1 artery: This represents an abnormal or incomplete vascular arrangement, often linked to congenital anomalies. Option D - 2 arteries and 2 veins: The umbilical cord typically contains only one vein, so having two veins is not normal.

↑ *Back to this question in Part A*

@Neet_pg_bot

Q30: The image shows a congenital cardiac defect. Abnormal development of which branch of aortic arch leads to this defect? (Q866305)

A. Right 4th aortic arch

B. Left 6th aortic arch

C. Right 6th aortic arch

D. Left 4th aortic arch

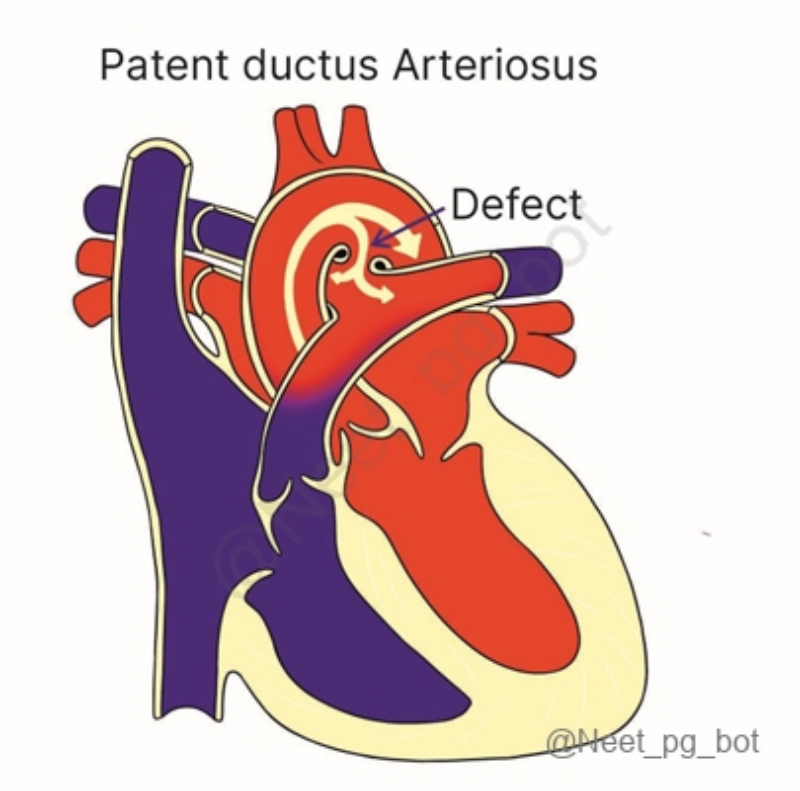

Correct Answer: B. Left 6th aortic arch

Explanation: The image illustrates Patent Ductus Arteriosus (PDA) , a congenital heart defect that occurs when the ductus arteriosus—originating from the left 6th aortic arch—fails to close after birth. It creates a left-to-right shunt

→ Ooxygenated blood from the aorta flow into the pulmonary artery → Excessive pulmonary blood flow This results in respiratory distress, cyanosis, and a machinery-like murmur, often worsening despite oxygen administration. Pharyngeal Arch Artery of Arch First Maxillary artery Second Hyoid artery Stapedial artery Third Common carotid artery Internal carotid artery Fourth Arch of aorta (left side) (Option D ruled out) Subclavian artery (right side) (Option A ruled out) Sixth Ductus arteriosus (left side) (Option B) Pulmonary artery (right side) (Option C ruled out)

↑ *Back to this question in Part A*

@Neet_pg_bot

Q31: A newborn had hypoplasia of the mandibles and zygomatic bones, malformed external ears, and slanted palpebral fissures. Abnormality in the development of which of the following pharyngeal arches will most likely lead to the given condition? (Q793118)

A. Pharyngeal arch 1

B. Pharyngeal arch 2

C. Pharyngeal arch 3

D. Pharyngeal arch 4

Correct Answer: A. Pharyngeal arch 1

Explanation: Correct Option A - Pharyngeal arch 1 The first pharyngeal arch, also known as the mandibular arch, is a crucial structure in embryonic development, forming part of the head and neck region. It gives rise to various structures that are essential for the formation of the face and neck. Defects in the development of this arch can result in a condition called mandibulofacial dysostosis or Treacher-Collins syndrome, which is characterized by the same features described in the scenario. Incorrect Options: Option B - Pharyngeal arch 2: . Abnormal development of this arch can result in abnormalities of the ear and hearing, but not the features described in the scenario. Option C - Pharyngeal arch 3: Abnormal development of this arch can result in problems with swallowing and speech, but not the features described in the scenario. Option D - Pharyngeal arch 4: Abnormal development of these arches can cause problems with speech and breathing, but not the features described in the scenario.

References:

.

↑ *Back to this question in Part A*

@Neet_pg_bot

• [02_Histology] 005 Tissue Histology- I

« Back to Folder Directory

[02_Histology] 005 Tissue Histology- I — Quick Jump

Q1 (p. 738) *Q2 (p. 739)* *Q3 (p. 740)* *Q4 (p. 742)* *Q5 (p. 743)* *Q6 (p. 746)*
Q7 (p. 747) *Q8 (p. 749)* *Q9 (p. 750)* *Q10 (p. 752)* *Q11 (p. 755)* *Q12 (p. 756)*
Q13 (p. 758) *Q14 (p. 760)* *Q15 (p. 761)* *Q16 (p. 762)* *Q17 (p. 765)* *Q18 (p. 768)*
Q19 (p. 772)

Q1: Which of the following is an apocrine gland? (Q848060)

A. Sweat gland

B. Pancreas

C. Sebaceous gland

D. None of the above

Correct Answer: A. Sweat gland

■ *Listen (English)*

■ *Listen (Hindi)*

Explanation: The sweat gland is a type of apocrine gland. They are found in the axilla, perigenital area, and as ceruminous glands in the ear. Apocrine Glands Merocrine Glands (Option B) Holocrine Glands (Option C) The secretions are released along with the apical part of the cell membrane. Blebs are formed. Mammary gland: Modified sweat gland. E.g: Breast, Sweat gland Also called eccrine glands. The secretion is released by exocytosis without losing a part of the secretory cell Secretions are released without the loss of the cell membrane. E.g: Salivary glands, Pancreas The whole cell membrane is lost. Becomes the sebum. Entire cell organelles break down and become secretions. Peripheral cells are intact. E.g: Sebaceous gland

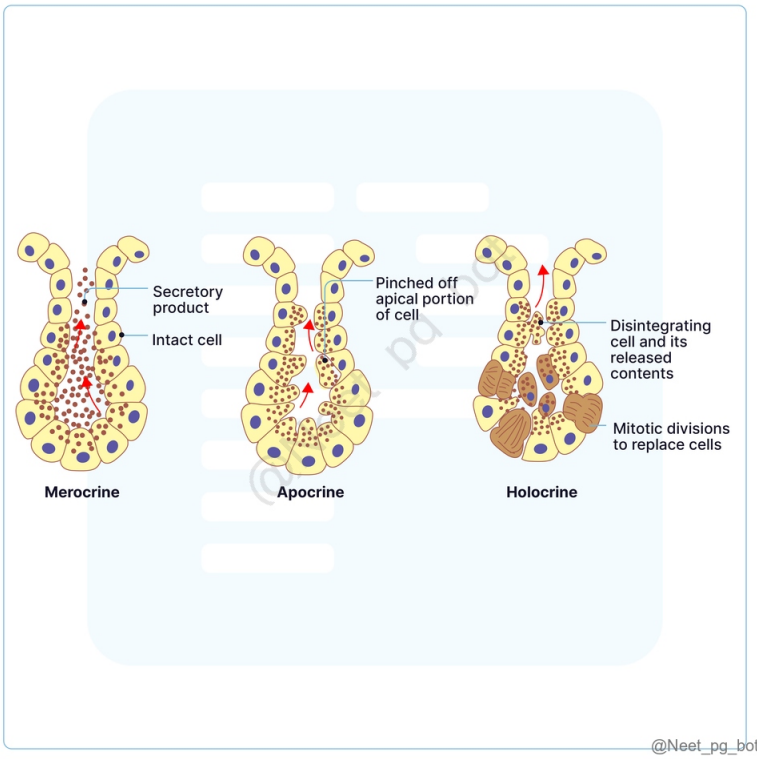

References:

Inderbir Singh's Textbook of Anatomy, 9th Edition, Page 108.

↑ *Back to this question in Part A*

@Neet_pg_bot

Q2: Match the following layer of skin with the cells present in it. 1. Stratum Corneum a) Melanocytes 2. Stratum Granulosum b) Keratin Squames 3. Stratum Spinosum c) Keratohyalin granules 4. Stratum Basale d) Langerhan cells (Q848076)

A. 1-c, 2-d, 3-b, 4-a

B. 1-d, 2-a, 3-b, 4-c

C. 1-a, 2-b, 3-c, 4-d

D. 1-b, 2-c, 3-d, 4-a

Correct Answer: D. 1-b, 2-c, 3-d, 4-a

■ *Listen (English)*

■ *Listen (Hindi)*

Explanation: There are 5 layers of skin epithelium (epidermis). The cells present in these layers are: Stratum Corneum: Keratin Squames: Flattened, water-repellent cells composed of keratin. Stratum Lucidum: Only seen in thick skin like palm and sole. Stratum Granulosum: Keratinocytes: Contain keratohyaline granules for keratin production. Stratum Spinosum: Prickle cell layer Keratinocytes: Multilayered cells with desmosomes; involved in keratin synthesis. Langerhan cells: Act as antigen presenting cells. Stratum Basale: Basal Keratinocytes: Cuboidal cells that proliferate and replenish upper layers. Melanocytes: Produce melanin. Merkel Cells: Touch receptors. Dermis: Fibroblasts: Produce collagen and elastin. Sensory Nerve Endings: Detect stimuli.

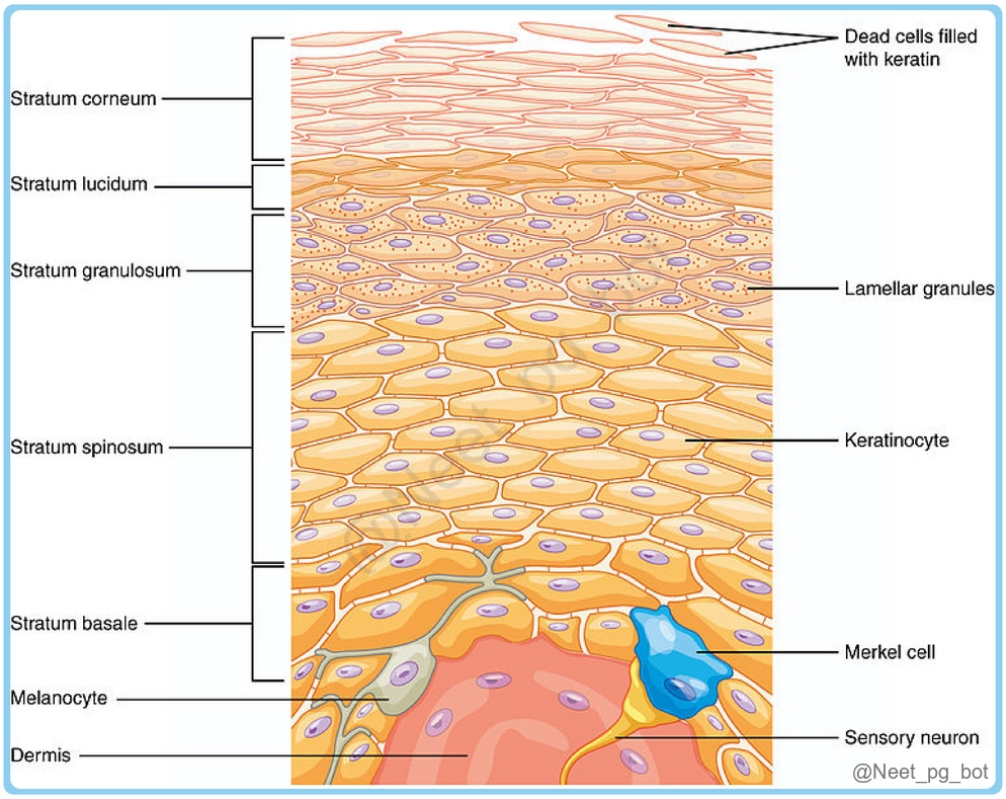

References:

Wheater Functional Histology. 6th Edition, Page 160-163.

↑ *Back to this question in Part A*

@Neet_pg_bot

Q3: Which of the following statements is true about the given image? (Q848075)

A. GALT tissues are part of the Waldeyer ring.

B. Tonsils primarily produce secretory IgA to protect mucosal surfaces.

C. Tonsils are covered by stratified squamous epithelium that forms deep crypts.

D. Tonsils contain diffuse lymphoid tissue scattered in the lamina propria.

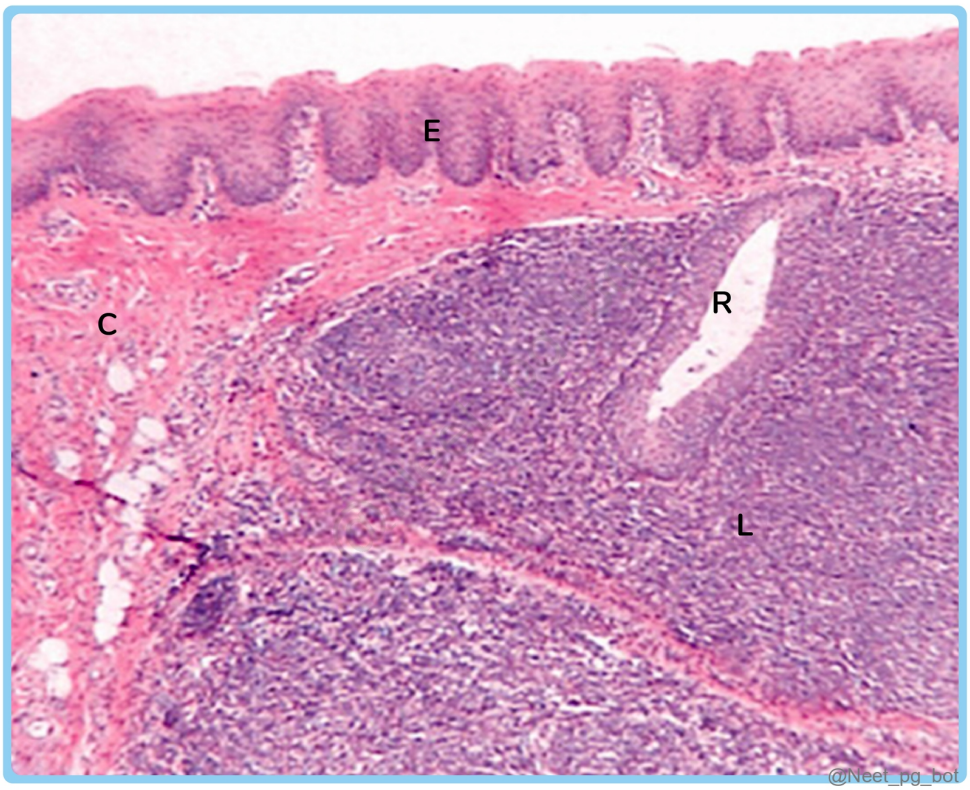

Correct Answer: C. Tonsils are covered by stratified squamous epithelium that forms deep crypts.

■ *Listen (English)*

■ *Listen (Hindi)*

Explanation: The Tonsils are covered by stratified squamous epithelium that forms crypts, a key feature of tonsils. Mucosa Associated Lymphoid Tissue (MALT) Tonsils Includes diffuse lymphoid cells and organized aggregates (e.g., tonsils, Peyer's patches). (Option D) Parts: GALT: Found in the gastrointestinal tract (e.g., Peyer's patches). (Option A) BALT: Present in the bronchial tree. Waldeyer Ring: Lymphoid tissue in the oropharynx. Antibody Production: IgA: MALT produces IgA, which is the main antibody in mucosal areas, protects mucosal surfaces. (Option B) IgG & IgM: Present in lamina propria. IgE: Involved in allergic reactions. The palatine tonsils are part of Waldeyer's ring, along with the lingual, pharyngeal, and tubal tonsils. They are covered by stratified squamous epithelium , which forms deep tonsillar crypts. (Option C) Beneath the tonsil is a collagenous hemicapsule separating it from muscle.

References:

Wheater Functional Histology, 6th Edition, Page 216.

Inderbir Singh Histology, 9th Edition, Page 254-257.

↑ *Back to this question in Part A*

@Neet_pg_bot

Q4: Which of the following statements about the spleen is true? (Q848073)

A. White pulp occupies most of the spleen and contains a higher number of RBCs.

B. The red pulp parenchyma is supported by reticular fibers and contains sheathed capillaries.

C. B cells form an eccentric cylindrical sheath around a central artery, known as PALS.

D. The Perilymphoid zone contains numerous sinuses and abundant reticulin meshwork.

Correct Answer: B. The red pulp parenchyma is supported by reticular fibers and contains sheathed capillaries.

■ *Listen (English)*

■ *Listen (Hindi)*

Explanation: Red pulp is supported by reticular fibers, and it contains capillaries that terminate as sheathed capillaries. Spleen Red pulp occupies most of the area. The red pulp parenchyma is made up of loose tissue supported by reticular fibers, interspersed with capillaries, which end as sheathed capillaries. (Option B) The perilymphoid (Perifollicular) zone of red pulp, surrounding the white pulp, lacks sinuses, has a sparse reticulin meshwork, and contains red and white blood cells in proportions similar to those in blood. (Option D) White pulp constitutes 5% - 20% of the total spleen mass. (Option A) White pulp contains both T and B cells. T cells form an eccentric cylindrical sheath around a central artery, mainly containing T helper cells, like PALS. (Option C) B cells form follicles at the edge of the PALS, often showing germinal centers in younger individuals.

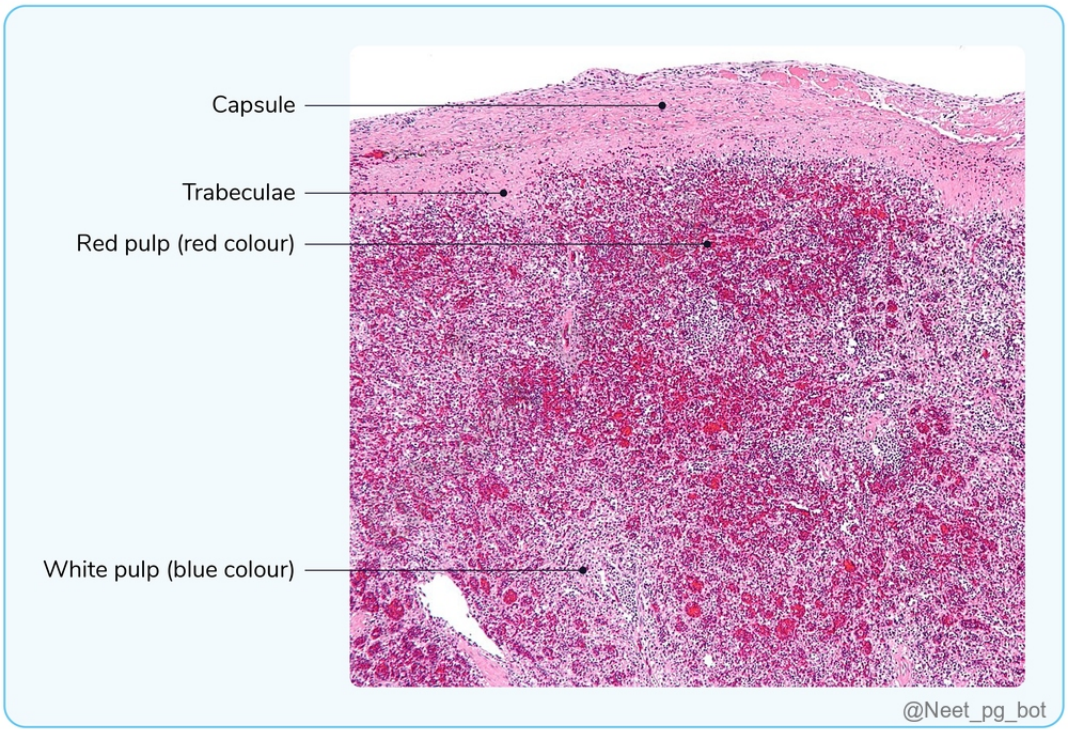

References:

Wheater Functional Histology, 6th Edition, Page 217-223.

↑ *Back to this question in Part A*

@Neet_pg_bot

Q5: In a histological image of the thymus, which cell type is not present in the medulla? (Q848071)

A. Thymocytes

B. Epithelial cells

C. Hassall's corpuscles

D. Dendritic cells

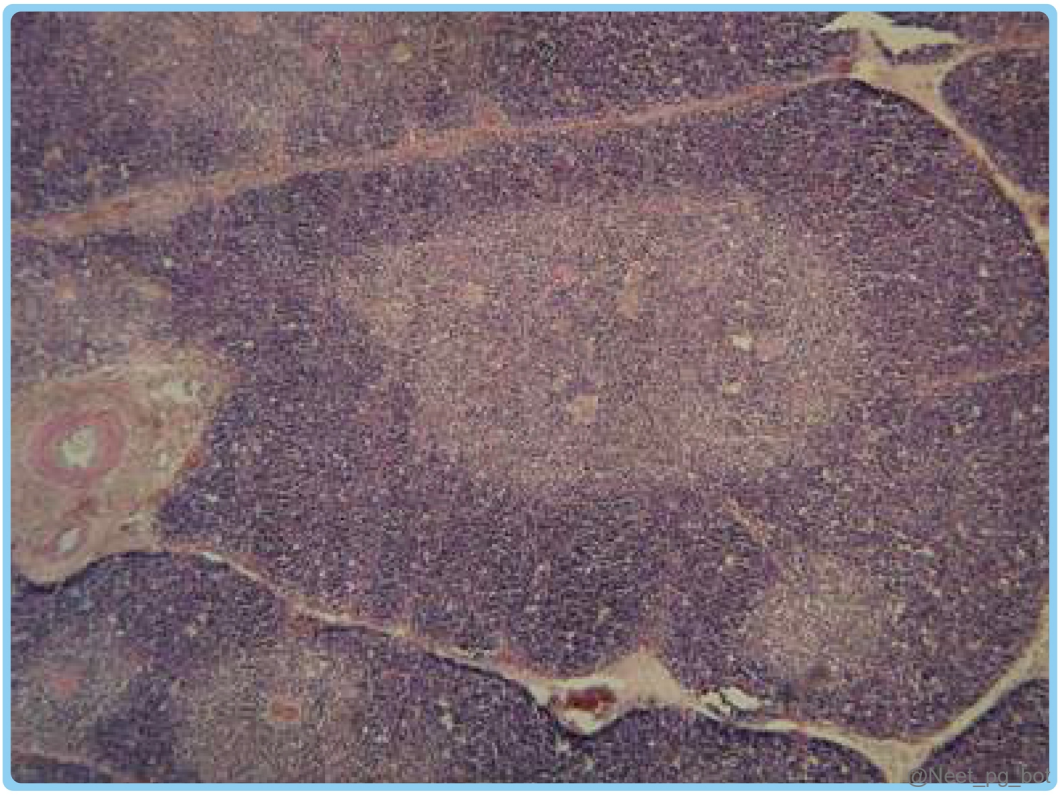

Correct Answer: A. Thymocytes

■ *Listen (English)*

■ *Listen (Hindi)*

Explanation: Thymocytes are primarily located in the cortex of the thymus and are not present in the medulla. Parts of the Thymus: Cortex : The outer, more densely packed region of the thymus. Filled with immature T cells (thymocytes) , undergoing differentiation and maturation as they move towards the medulla. The cortex contains thymic nurse cells that support the maturing thymocytes. T cells express surface markers (like TCR, CD3, CD4, and CD8) during maturation. Macrophages are present to phagocytose apoptotic T cells, which fail to mature properly. Medulla : The inner, less densely populated region. Dominated by epithelial cells with pale-staining nuclei and large cytoplasm. (Option B) Contains Hassall's corpuscles , concentric structures made of keratinized epithelial cells, involved in T cell regulation. (Option C) Dendritic cells and macrophages in the medulla present self-antigens to maturing T cells, ensuring the elimination of self-reactive cells to prevent autoimmunity. (Option D)

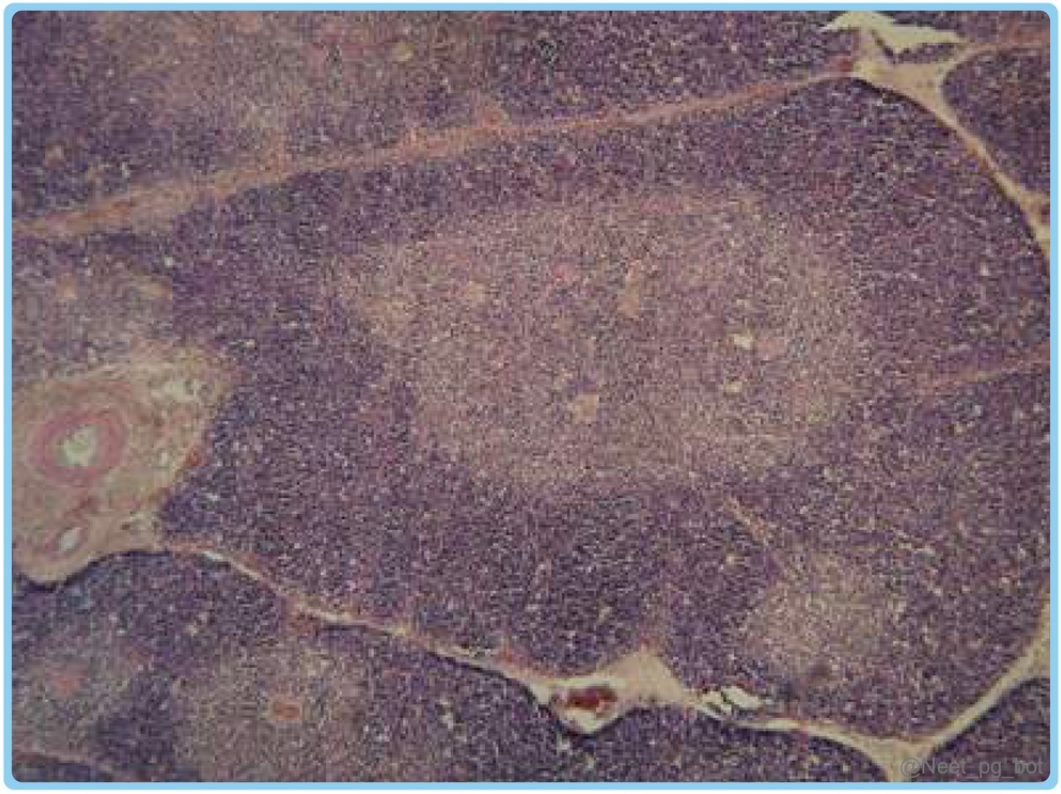

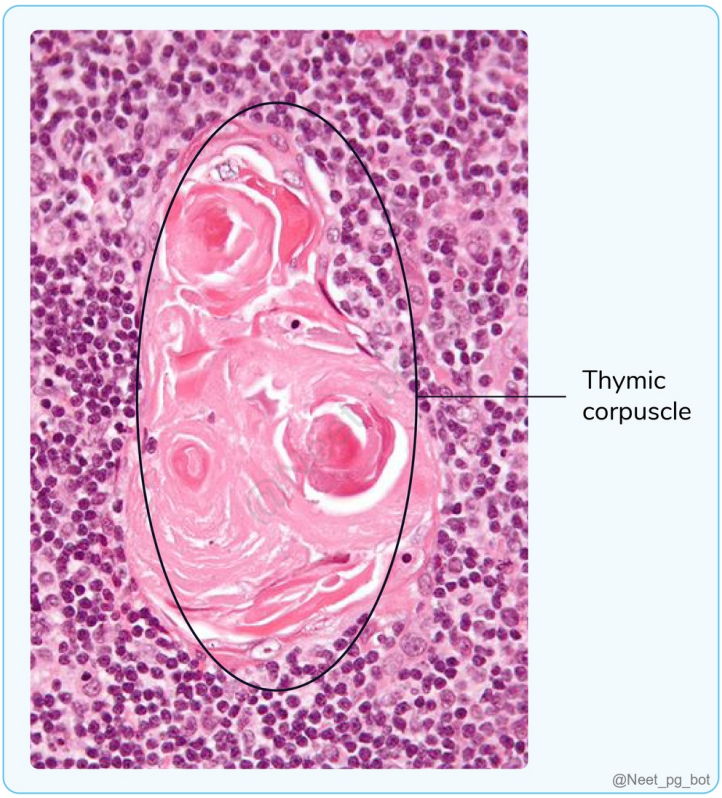

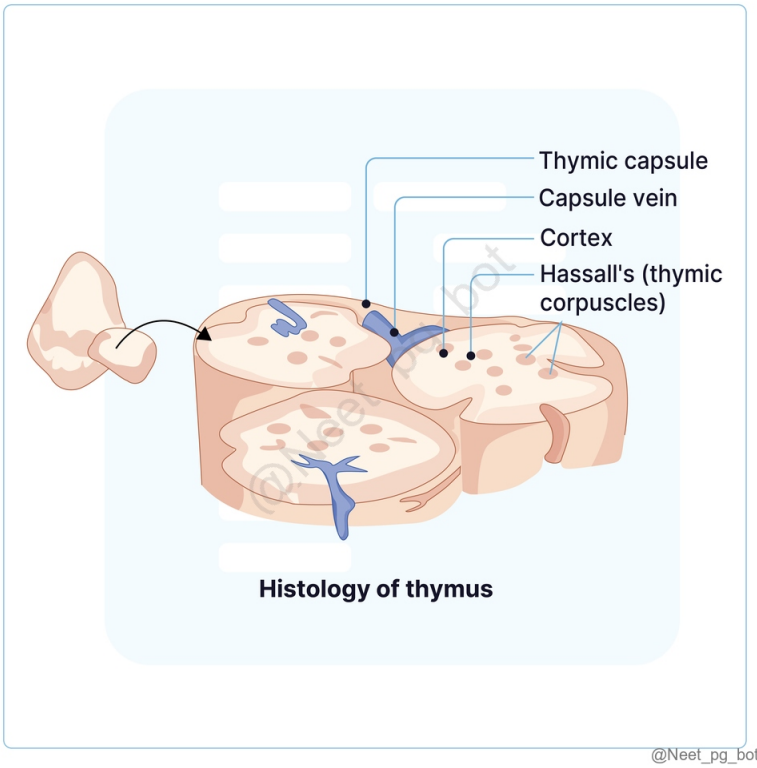

References:

Wheater Functional Histology, 6th Edition, Page 204- 206.

Inderbir Singh Histology, 9th Edition, Page 249- 254.

↑ *Back to this question in Part A*

@Neet_pg_bot

Q6: A pathologist is examining a lymph node biopsy. Which of the following correctly identifies these structures? (Q848069)

A. (1) Capsule, (2) Subcapsular sinus, (3) Germinal centers, (4) Lymphoid nodule, (5) Trabeculae

B. (1) Capsule, (2) Cortex, (3) Medulla, (4) Germinal centers, (5) Hilum

C. (1) Trabecula, (2) Capsule, (3) Medulla, (4) Germinal center, (5) Cortex

D. (1) Capsule, (2) Medulla, (3) Subcapsular sinus, (4) Germinal center, (5) Cortex



Correct Answer: A. (1) Capsule, (2) Subcapsular sinus, (3) Germinal centers, (4) Lymphoid nodule, (5) Trabeculae

Explanation: Parts of the Lymph Node Structure Description Function Capsule (1) Dense connective tissue covering the lymph node. Provides protection and structural support. Subcapsular sinus (2) Space just beneath the capsule that receives afferent lymph. First site of lymph filtration. Cortex Outer region beneath capsule containing lymphoid follicles. Site of B-cell activation and proliferation (superficial cortex) and T-cell activity (paracortex). Lymphoid nodule (follicle) (4) Rounded lymphocyte aggregation within the cortex. Houses B-lymphocytes; may contain a germinal center when active. Germinal centers (3) Pale-staining central area of an active follicle. Site of B-cell proliferation, maturation, and selection during immune response. Medulla Inner region with medullary cords and sinuses. Contains plasma cells and macrophages; site of antibody secretion and lymph filtration. Hilum

Concave area where vessels enter and efferent lymph exits. Provides vascular and lymphatic connections. Trabeculae (5) Inward extensions of the capsule made of connective tissue. Provide internal support and act as conduits for blood vessels and sinuses.

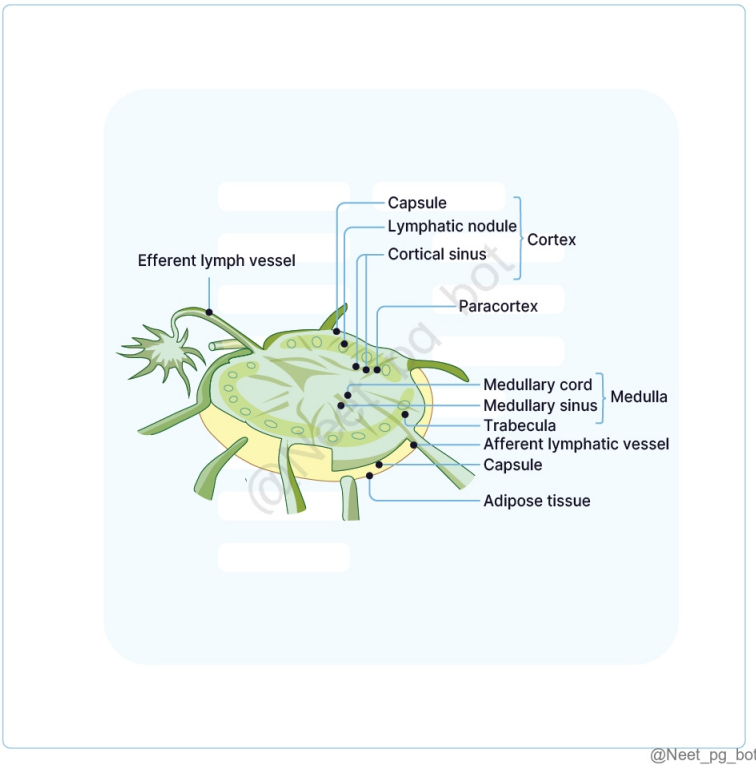

References:

Inderbir Singh Textbook of Human Histology, 9th Edition, Page 239-243.

↑ *Back to this question in Part A*

@Neet_pg_bot

Q7: A histologist is examining three different cartilage samples. Sample A shows a homogeneous basophilic matrix with groups of chondrocytes in cell nests. Sample B contains numerous branching and anastomosing fibers forming a network. Sample C lacks perichondrium and has chondrocytes arranged in single rows or groups with numerous collagen bundles. Which of the following correctly identifies these cartilage types? (Q848067)

A. A - Elastic, B - Hyaline, C - Fibrocartilage

B. A - Hyaline, B - Elastic, C - Fibrocartilage

C. A - Fibrocartilage, B - Hyaline, C - Elastic

D. A - Hyaline, B - Fibrocartilage, C - Elastic

Correct Answer: B. A - Hyaline, B - Elastic, C - Fibrocartilage

- *Listen (English)*
- *Listen (Hindi)*

Explanation: Types of Cartilage Characteristic Hyaline Cartilage (Most Common) Elastic Cartilage Fibrocartilage Matrix appearance Homogeneous, basophilic Contains elastic fiber network Numerous collagen bundles Chondrocyte arrangement Groups (cell nests/isogenous groups) Similar to hyaline Single rows or isogenous groups Perichondrium Present (except in articular cartilage) Present Absent Main fiber type Type II collagen Elastic fibers Type I (primarily) and Type II collagen Main functions Structural support, forms articular surfaces Provides flexibility and resilience Resists compression and shearing, shock absorption Examples Costal cartilage, tracheal rings, articular cartilage Auricle, epiglottis, auditory tube Intervertebral discs, menisci

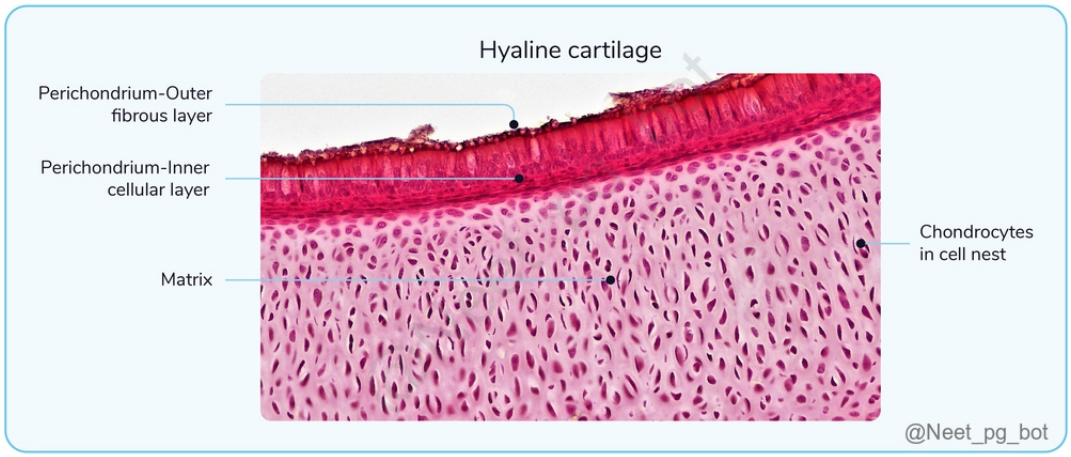

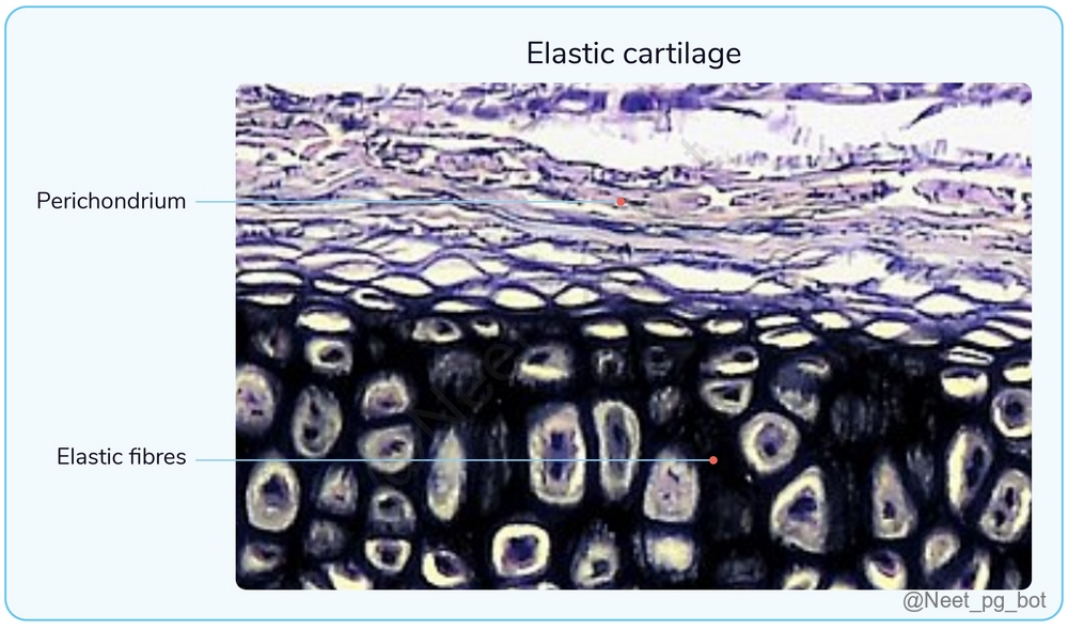

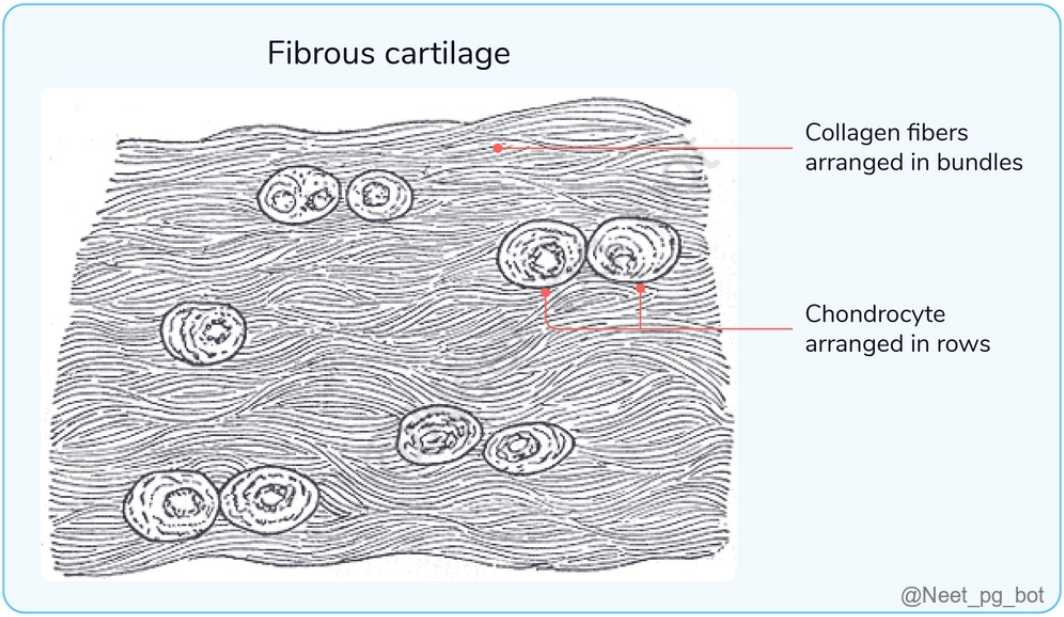

References:

Inderbir Singh Textbook of Human Histology, 9th Edition, Page 158-166.

↑ *Back to this question in Part A*

@Neet_pg_bot

Q8: Match the following types of collagen with their primary location: 1. Found in cartilage (Hyaline and Elastic Cartilage) a. Type I collagen 2. Major component of basement membranes b. Type II collagen 3. Predominant in bowel and blood vessels c. Type III collagen 4. Primary collagen in bones, tendons, and dermis d. Type IV collagen (Q848066)

A. 1-d, 2-b, 3-c, 4-a

B. 1-b, 2-d, 3-a, 4-c

C. 1-b, 2-d, 3-c, 4-a

D. 1-d, 2-c, 3-b, 4-a

Correct Answer: C. 1-b, 2-d, 3-c, 4-a

■ *Listen (English)*

■ *Listen (Hindi)*

Explanation: Types of Collagen Types of Collagen Locations Type I Skin, tendon, sclera, bone, fascia, dermis Type II Vitreous humor of eye, intervertebral disc, cartilage (Hyaline and Elastic Cartilage) Type III Skin, blood vessels, bowel Type IV Basement membrane

References:

Inderbir Singh Textbook of Human Histology, 9th Edition, Page 154 Pubmed

↑ *Back to this question in Part A*

@Neet_pg_bot

Q9: A histologist is examining three different tissue samples. Sample A shows loosely arranged fibers with numerous cells and abundant ground substance. Sample B exhibits densely packed, parallel collagen bundles with elongated fibroblast nuclei. Sample C contains interwoven collagen fibers without a specific orientation. Which of the following correctly matches the samples to their connective tissue types? (Q848065)

A. A - Dense irregular, B - Loose connective, C - Dense regular

B. A - Loose connective, B - Dense regular, C - Dense irregular

C. A - Dense regular, B - Dense irregular, C - Loose connective

D. A - Loose connective, B - Dense irregular, C - Dense regular

Correct Answer: B. A - Loose connective, B - Dense regular, C - Dense irregular

■ *Listen (English)*

■ *Listen (Hindi)*

Explanation: Types of Connective Tissue Characteristic Loose Connective Tissue Dense Regular Connective Tissue Dense Irregular Connective Tissue Fiber arrangement Loosely arranged Densely packed, parallel arrangement Densely packed, interwoven without specific orientation Cell content Numerous fibroblasts and macrophages Few cells, mainly fibroblasts Few cells (fibroblasts) Ground substance Abundant Less in amount Less in amount Main function Bind different tissues together, allow tissue movement Provide strength and resistance to tensile forces Provide strength in multiple directions Examples Endomysium, subperiosteal tissue, lamina propria of GIT, hypodermis, mesentery Tendons, ligaments, deep fascia, aponeuroses, central tendon of diaphragm, dura mater Dermis, CT sheath of muscle and nerves, capsules of glands, sclera, periosteum Dense Regular Connective Tissue

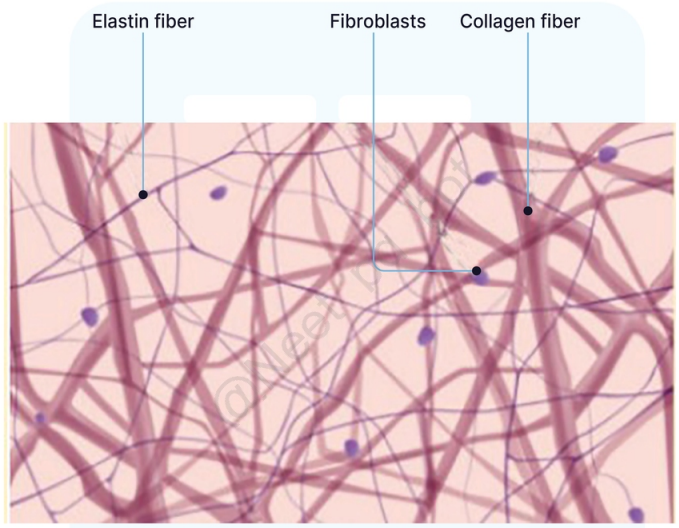

Loose connective tissue

@Neet_pg_bot

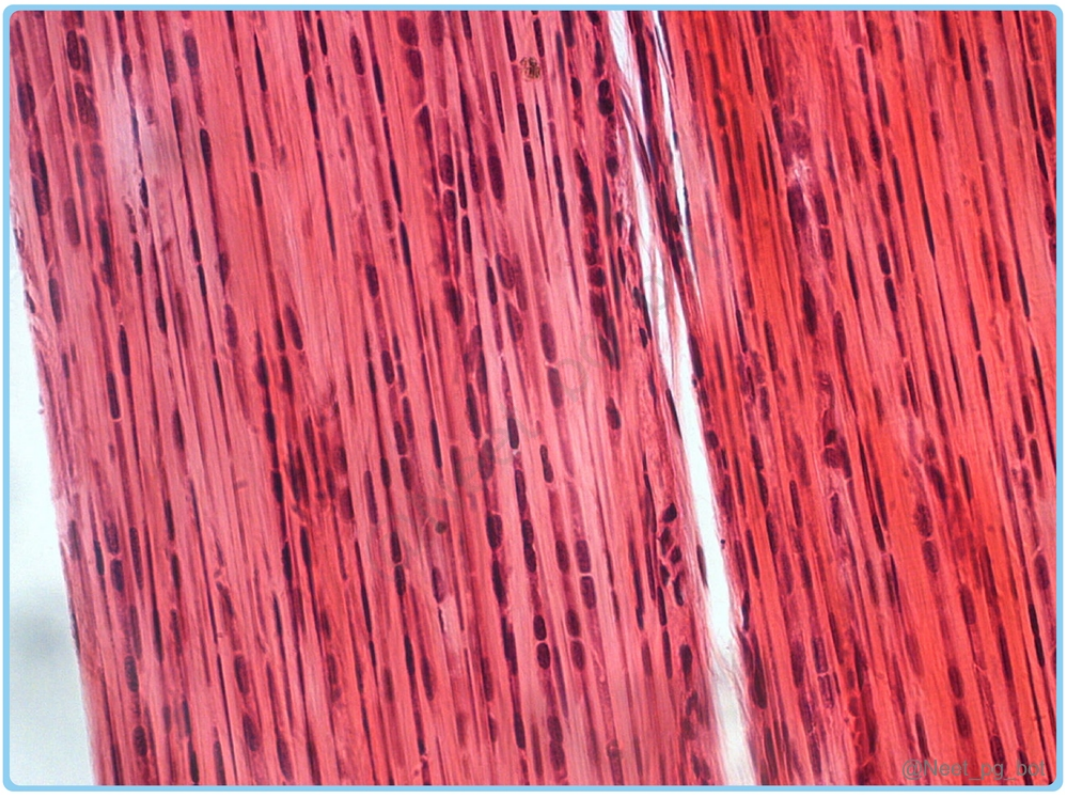
@Neet_pg_bot

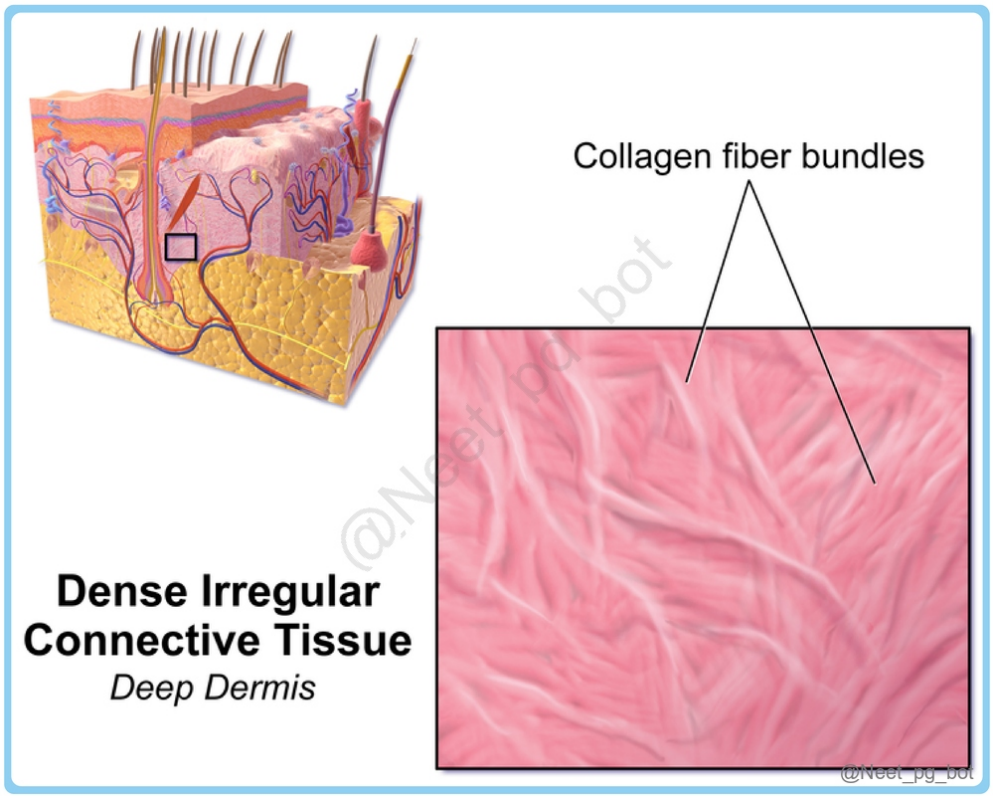

References:

Inderbir Singh Textbook of Human Histology, 9th Edition, Page 142, 143.

↑ *Back to this question in Part A*

@Neet_pg_bot

Q10: A pathologist is analyzing a biopsy sample from a patient with suspected connective tissue disorder. Upon staining, she observes fibers that appear black with silver impregnation and form a delicate network throughout the tissue. Which of the following best describes these fibers? (Q848064)

A. Type I collagen fibers

B. Elastic fibers

C. Reticular fibers

D. Smooth muscle fibers

Correct Answer: C. Reticular fibers

■ *Listen (English)*

■ *Listen (Hindi)*

Explanation: Reticular fibers stain black with silver impregnation , which is a unique feature among connective tissue fibers. Also, reticular fibers anastomose and form networks. Type of Connective Tissue Fibers Characteristic Collagen Fibers (Option A) Reticular Fibers (Option C) Elastic Fibers (Option B) Appearance under light microscope Wavy bundles White on naked eye Fine & anastomose to form network Thin, branching fibers Single Staining characteristics Pink with H&E Blue with Masson's trichrome Red with Van Gieson Brown with Silver impregnation (Option A) Black with silver impregnation (specific) PAS positive Not visible with H&E Black with Verhoeff's stain Purple with orcein stain Functions Tensile strength Structural support in lymphoid organs Component of basement membrane Elasticity and resilience Locations Widespread (e.g., dermis, tendons, ligaments) Lymphoid organs, liver, kidney, bone marrow Blood vessels, skin, lungs, elastic cartilage Smooth muscle fibers (Option D) are not relevant in this context, as they are not connective tissue fibers and do not have the characteristics described.



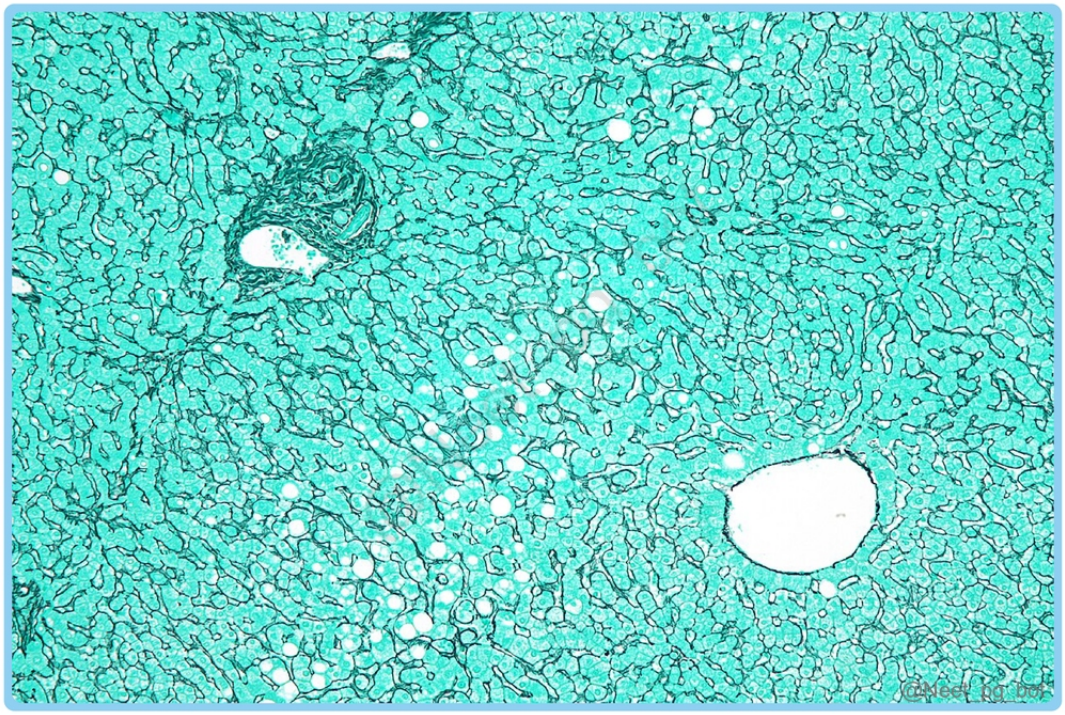

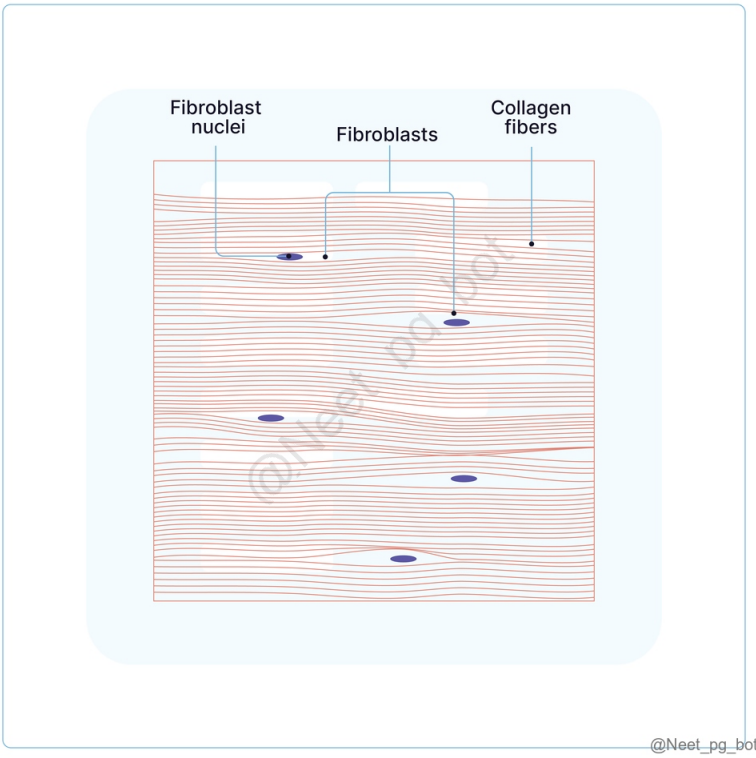

References:

Inderbir Singh Textbook of Human Histology, 9th Edition, Page 135 to 140. Wheater Functional Histology, 6th Edition, Page 67, 68.

↑ *Back to this question in Part A*

@Neet_pg_bot

Q11: Which of the following pairs correctly identifies the locations of Meissner's and Auerbach's plexus in the gastrointestinal tract, respectively? (Q848051)

A. Between the circular and longitudinal muscle layers; Mucosa

B. Submucosa; Between the circular and longitudinal muscle layers

C. Between the circular and longitudinal muscle layers; Muscularis propri

D. Between serosa and longitudinal muscle layer; Between the submucosa and mucosa

Correct Answer: B. Submucosa; Between the circular and longitudinal muscle layers

■ *Listen (English)*

■ *Listen (Hindi)*

Explanation: Meissner's plexus (submucosal plexus) is located in the submucosa, while Auerbach's plexus (myenteric plexus) is located between the circular and longitudinal muscle layers of the muscularis propria. The enteric nervous system controls gut function with the Meissner (submucosal) plexus and Auerbach (myenteric) plexus. Meissner's Plexus (Submucosal Plexus): Located in the submucosa. Contains parasympathetic ganglion cells and postganglionic sympathetic fibres. Regulates mucosal glands and the smooth muscle of the muscularis mucosae. Auerbach's Plexus (Myenteric Plexus): Found between the circular and longitudinal muscle layers of the muscularis propria. Contains larger clusters of parasympathetic ganglion cells. Primarily controls smooth muscle contractions for peristalsis. Fig. Auerbach plexus between two sets of muscles

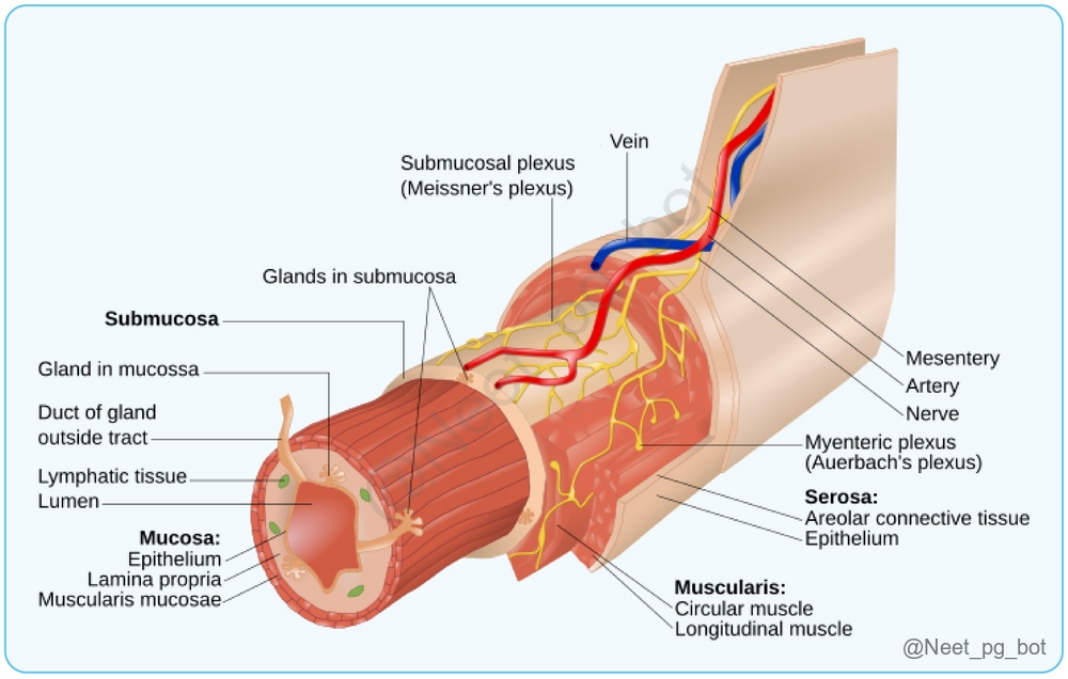

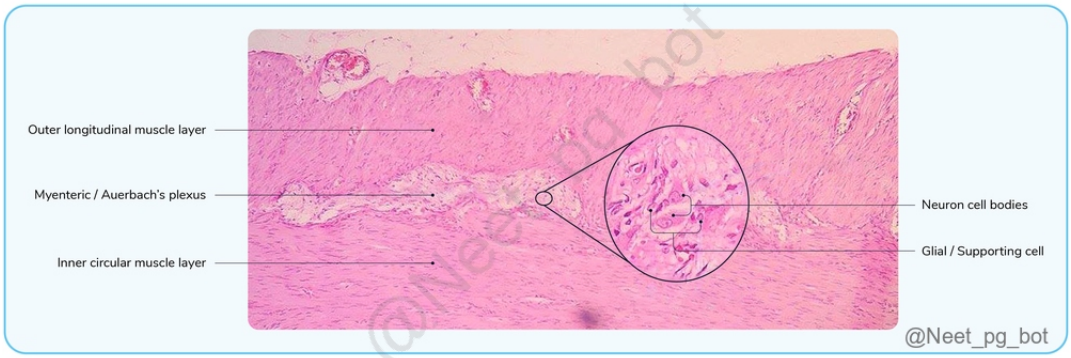

References:

Wheater Functional Histology, 6th Edition, Page 252.

↑ *Back to this question in Part A*

@Neet_pg_bot

Q12: Which two of the following statements about serous, mucinous, and mixed glands are correct? Serous glands produce a proteinaceous, enzyme-rich watery fluid, while mucinous glands secrete mucopolysaccharides that form a thick, viscous mucus. Cells of serous acini are triangular with centrally placed rounded nuclei, whereas cells of mucous acini are tall with flat nuclei at their bases. The pancreas is an example of a mixed gland, containing both serous and mucous secreting acini. The lumen of mucous

acini is typically smaller than that of serous acini. (Q848059)

A. 1 and 2 are correct

B. 2 and 3 are correct

C. 3 and 4 are correct

D. 1 and 4 are correct

Correct Answer: A. 1 and 2 are correct

- *Listen (English)*
- *Listen (Hindi)*

Explanation: Serous gland Mucous gland Mixed gland The secretions of serous glands are proteinaceous in nature. Cells secrete an enzyme-rich watery fluid. (Statement 1) Cells of serous acini are triangular with a rounded nucleus. Their nuclei are centrally placed. (Statement 2) E.g. pancreas. (Statement 3) In mucous glands, the secretion contains mucopolysaccharides . Cells secrete mucus which is a thick, viscous, and jelly-like protective lubricant known as mucin. (Statement 1) Cells of mucous acini are tall with flat nuclei at their bases. (Statement 2) The lumen of these acini is larger than the serous acini (Statement 4) E. g. goblet cells, and minor salivary glands of the tongue and palate. The gland contains acini that secrete both mucus and serous secretions E.g. submandibular and sublingual glands. Fig: Histology of serous and mucinous glands Fig: Histology of mixed glands

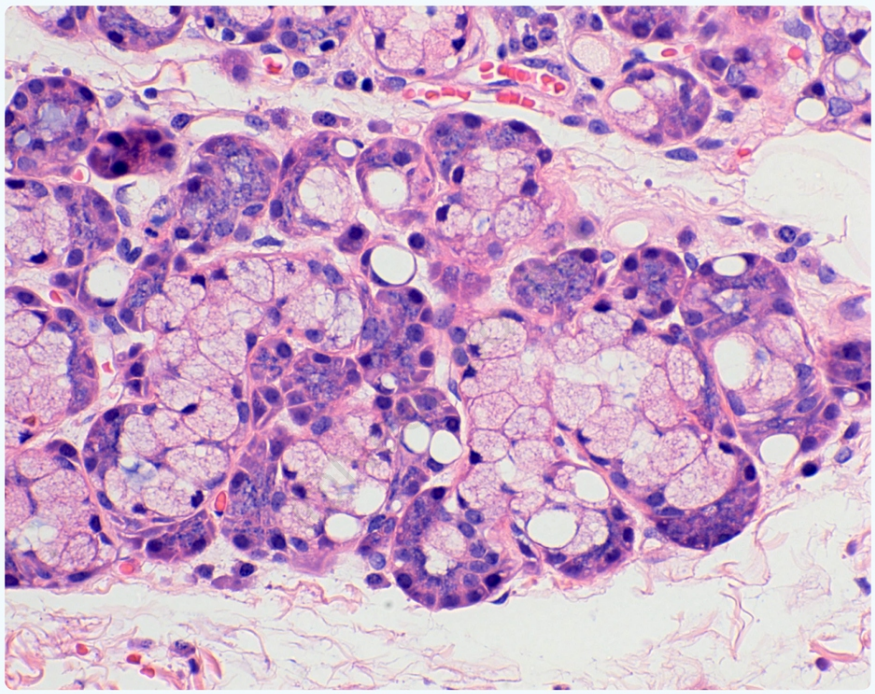

Mucous acini with crescent shaped caps (demilunes) of serous cells.

@Neet_pg_bot

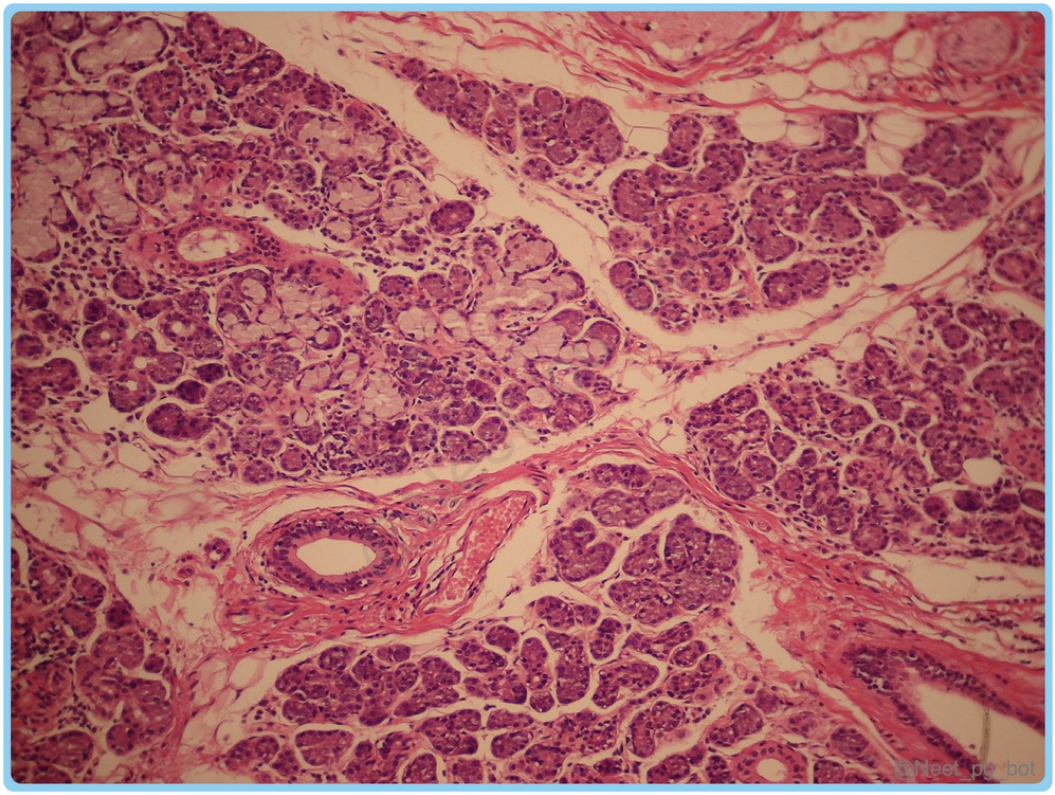

References:

Inderbir Singh's Textbook of Anatomy, 9th Edition, Page109-110.

↑ *Back to this question in Part A*

@Neet_pg_bot

Q13: Which of the following histological features is characteristic of Barrett's esophagus? (Q848058)

A. Squamous cell hyperplasia

B. Columnar epithelium with intestinal metaplasia

C. Columnar epithelium with gastric metaplasia

D. Glandular adenomatous hyperplasia

Correct Answer: B. Columnar epithelium with intestinal metaplasia

■ *Listen (English)*

■ *Listen (Hindi)*

Explanation: Barrett's esophagus occurs when chronic reflux esophagitis causes the stratified squamous epithelium of the lower esophagus to be replaced by columnar epithelium . Intestinal metaplasia is present, with columnar epithelium containing goblet cells at the lower esophagus. The Z-line (where squamous transitions to columnar epithelium) is normally at the gastroesophageal junction but may shift up to 5 cm proximally , increasing the risk of esophageal cancer . Fig: Histology picture of Barrett’s esophagus Squamous cell hyperplasia (Option A): This is typically not a feature of Barrett's esophagus; rather, it refers to an increase in the number of squamous cells, which occurs in response to irritation. Columnar epithelium with gastric metaplasia (Option C): Barrett’s esophagus specifically involves intestinal metaplasia, not gastric metaplasia. Intestinal metaplasia is defined by the presence of goblet cells. Glandular adenomatous hyperplasia (Option D): While Barrett's esophagus can predispose to dysplasia and adenocarcinoma, the primary change is intestinal metaplasia, not hyperplasia of glandular structures.

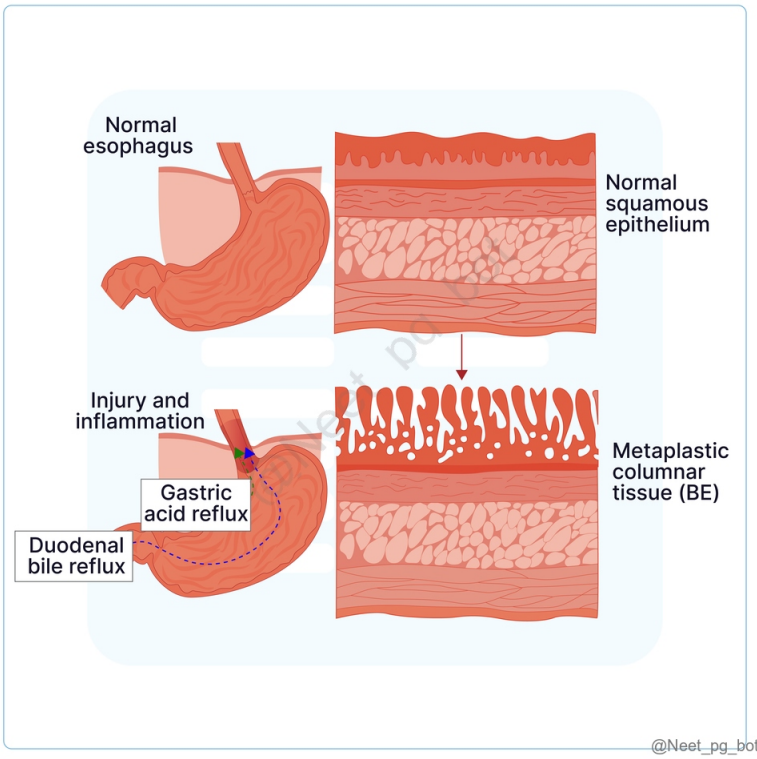

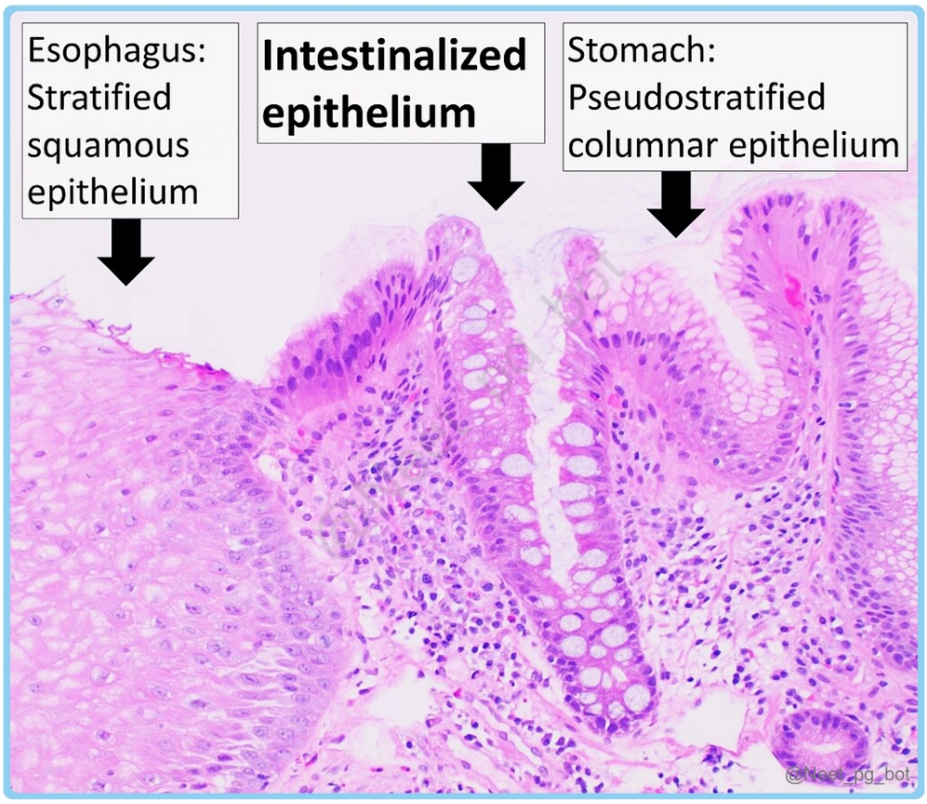

References:

Inderbir Singh's Textbook of Anatomy, 9th Edition, Page 451.

↑ *Back to this question in Part A*

@Neet_pg_bot

Q14: Which of the following structures in the human body is primarily lined by stratified squamous epithelium? (Q848057)

A. Lumen of the trachea

B. Skin surface

C. Gastric lumen

D. Alveoli of lungs

Correct Answer: B. Skin surface

■ *Listen (English)*

■ *Listen (Hindi)*

Explanation: The outer layer of the skin (epidermis) is composed of keratinized stratified squamous epithelium, providing a barrier against environmental damage. It is characterized by multiple layers of cells, providing protection against abrasion, pathogens, and chemical exposure. It is particularly well-suited for areas subject to friction and wear. There are seven openings that are divided into two categories which are lined by stratified squamous epithelium: Four on the face: Nasal cavity Oral cavity Eye Ear Three on the perineum: Urethra Vagina Anal canal Lumen of the trachea (Option A): Lined by ciliated pseudostratified columnar epithelium, which helps trap and move particles. Gastric lumen (Option C): Lined by simple columnar epithelium, which is specialized for secretion and absorption in the stomach. Alveoli in the lungs (Option D) Lined by simple squamous epithelium, allowing for efficient gas exchange.

References:

https://www.ncbi.nlm.nih.gov/pmc/articles/PMC4283209/

Wheater Functional Histology, 6th Edition, Page 85, 86.

↑ *Back to this question in Part A*

@Neet_pg_bot

Q15: Which of the following best describes transitional epithelium? (Q848056)

A. It is specialized for absorption and secretion and consists of a single layer of cuboidal cells.

B. It is found in the skin and is composed of multiple layers of flat cells that provide a protective barrier.

C. It is found in the urinary bladder and ureters, consisting of multiple layers of cells that can stretch and change shape.

D. It lines the digestive tract and is characterized by a single layer of columnar cells that facilitate nutrient absorption.

Correct Answer: C. It is found in the urinary bladder and ureters, consisting of multiple layers of cells that can stretch and change shape.

■ *Listen (English)*

■ *Listen (Hindi)*

Explanation: Transitional epithelium is found in the renal pelvis and calyces, the ureter, the urinary bladder, and prostatic urethra. Because of this distribution, it is also called urothelium. This is a multilayered epithelium with four to six thick cells that can contract and expand as needed (stretchable epithelium). The epithelium most specialized for absorption and secretion would be simple columnar epithelium, which lines organs involved in these processes, such as the intestines and glands. (Option A) Transitional epithelium is not found in the skin; the skin is lined by stratified squamous epithelium (Option B). The digestive tract is lined by different types of epithelium depending on the region. (Option D)

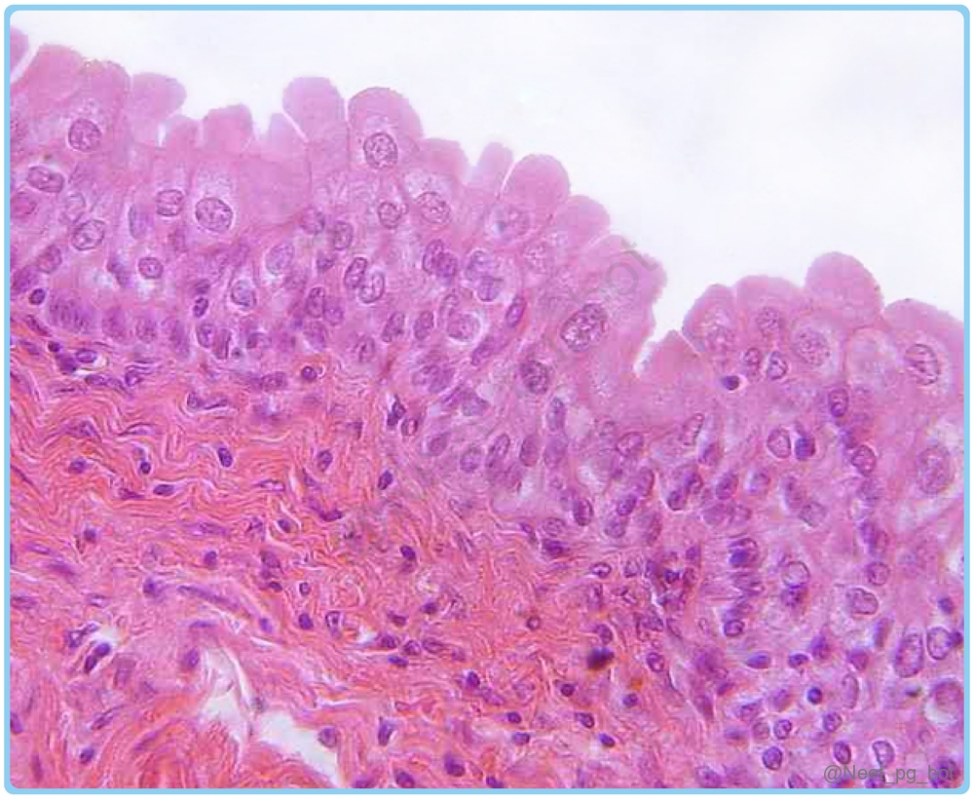

References:

Inderbir Singh's Textbook of Anatomy, 9th Edition, Page 97

↑ *Back to this question in Part A*

@Neet_pg_bot

Q16: Which of the following locations contains pseudostratified ciliated columnar epithelium? (Q848055)

A. Oral cavity

B. Esophagus

C. Respiratory tract

D. Uterine cervix

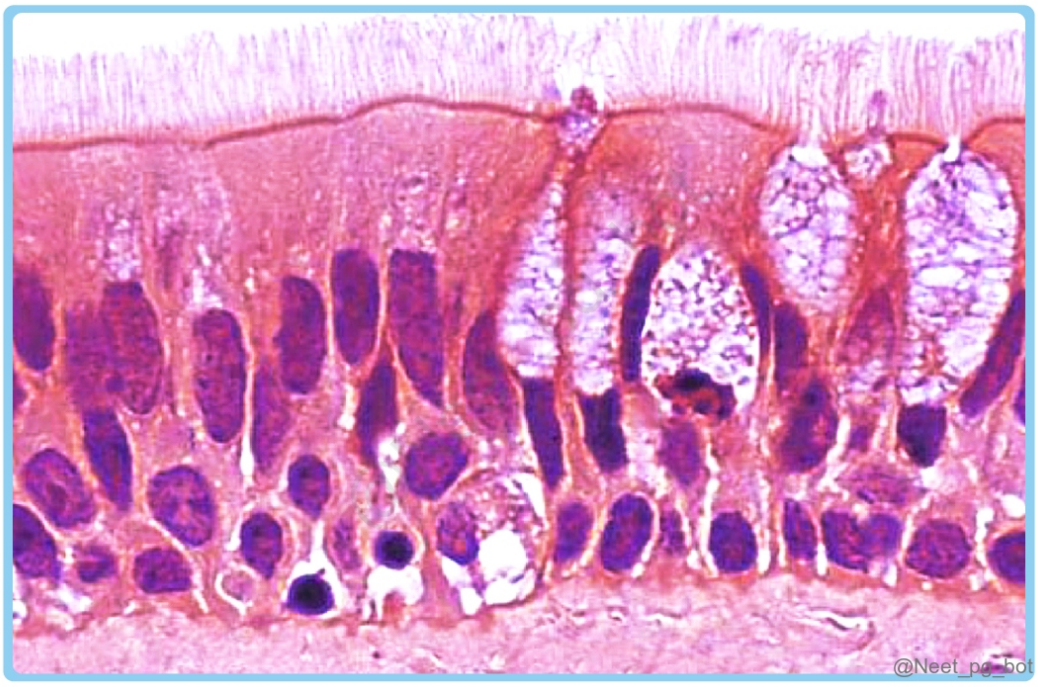

Correct Answer: C. Respiratory tract

- *Listen (English)*
- *Listen (Hindi)*

Explanation: The respiratory tract, including the trachea and bronchi, is lined by pseudostratified ciliated columnar epithelium, which helps move mucus. Stratified squamous epithelium Pseudostratified ciliated columnar epithelium Multiple layers of cells undergo maturation from a cuboidal basal layer to a flattened surface layer. Cilia are never present on true stratified epithelia. True simple epithelium. Cilia is present to move the mucus Lines the oral cavity, pharynx, esophagus, anal canal, uterine cervix and vagina. (Options A, B, & D ruled out) Respiratory epithelium in the respiratory tract. (Option C)

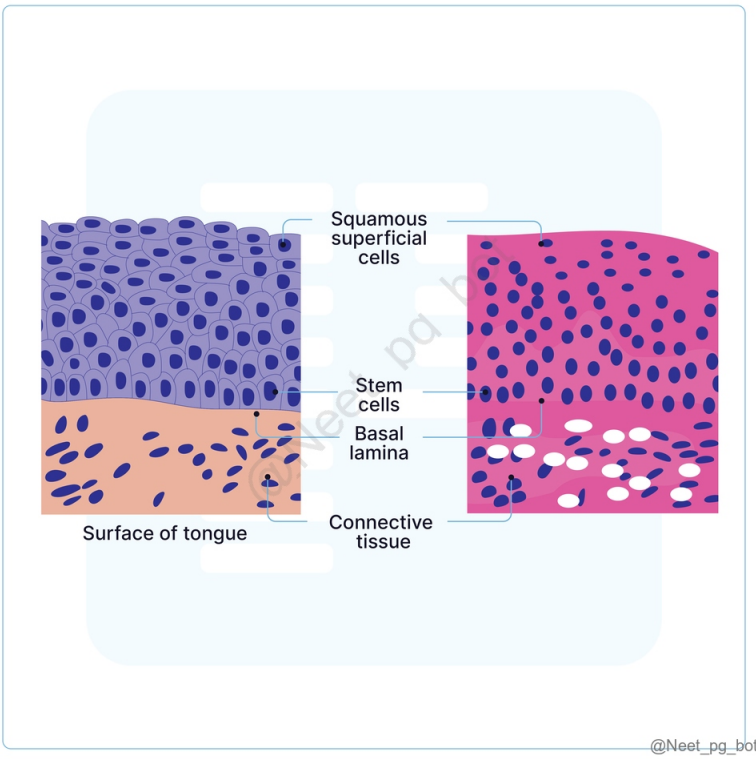

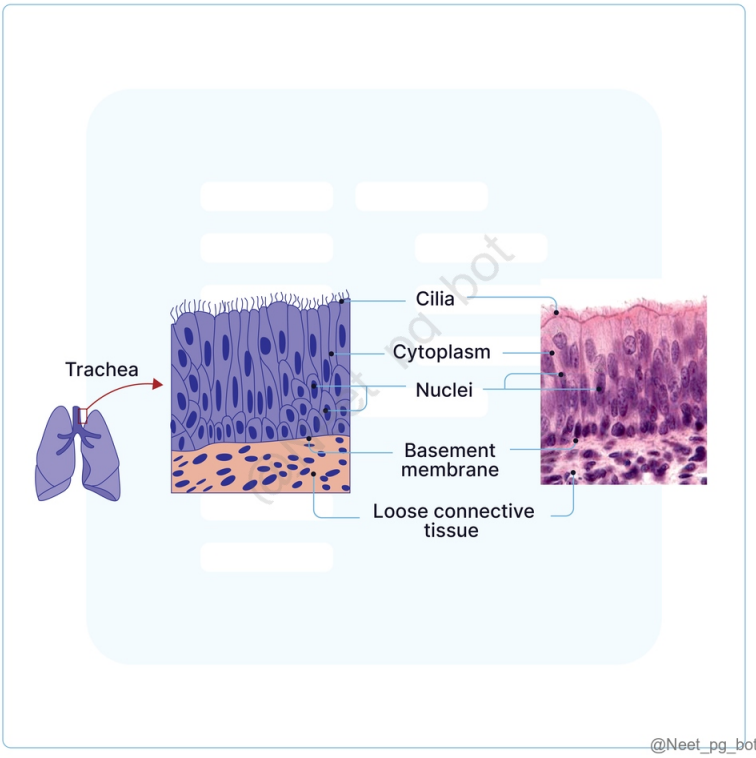

References:

Wheater Functional Histology, 6th Edition, Pages 85-86.

↑ *Back to this question in Part A*

@Neet_pg_bot

Q17: Match the following: 1. Simple squamous epithelium a) Proximal convoluted tubule 2. Simple cuboidal epithelium b) Gallbladder 3. Simple columnar epithelium c) Femoral Endothelium (Q848054)

A. 1- a, 2-b, 3-c

B. 1- c, 2-a, 3-b

C. 1- b, 2-c, 3-a

D. 1- b, 2-a, 3-c

Correct Answer: B. 1- c, 2-a, 3-b

■ *Listen (English)*

■ *Listen (Hindi)*

Explanation: Simple epithelia consist of a single layer of cells and are primarily found at interfaces where selective diffusion, absorption, and secretion occur. They are of three types. Types of Simple epithelium Description Simple squamous epithelium Pavemented epithelium Flattened, irregularly shaped cells forming a continuous surface. Lining surfaces of gas and fluid exchange Lining pleural, pericardial, and peritoneal cavities to enable fluid exchange and reduce friction. Peritoneum (mesothelium) Vascular endothelium Simple cuboidal epithelium The cells are polygonal and nucleus is round located in the center of the cell. Usually lines small ducts and tubules that have excretory, secretory or absorptive functions Collecting tubules of the kidney Small excretory ducts of the salivary glands and pancreas. Microvilli- PCT of kidney Simple columnar epithelium Tall columnar cells with the nuclei being located in the middle of the cells. Non-ciliated cells have secretory function whereas ciliated cells help in transport. Non-ciliated- Gallbladder lining. Microvilli- Small intestine Surface cilia- Fallopian tube Pseudostratification- Respiratory tract Goblet cells- Small and large bowel Stereocilia- Vas deferens

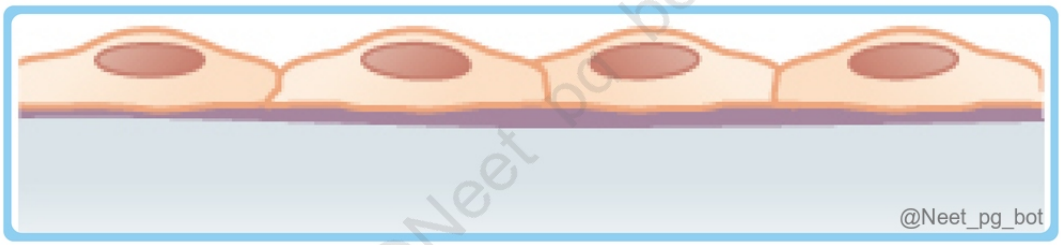

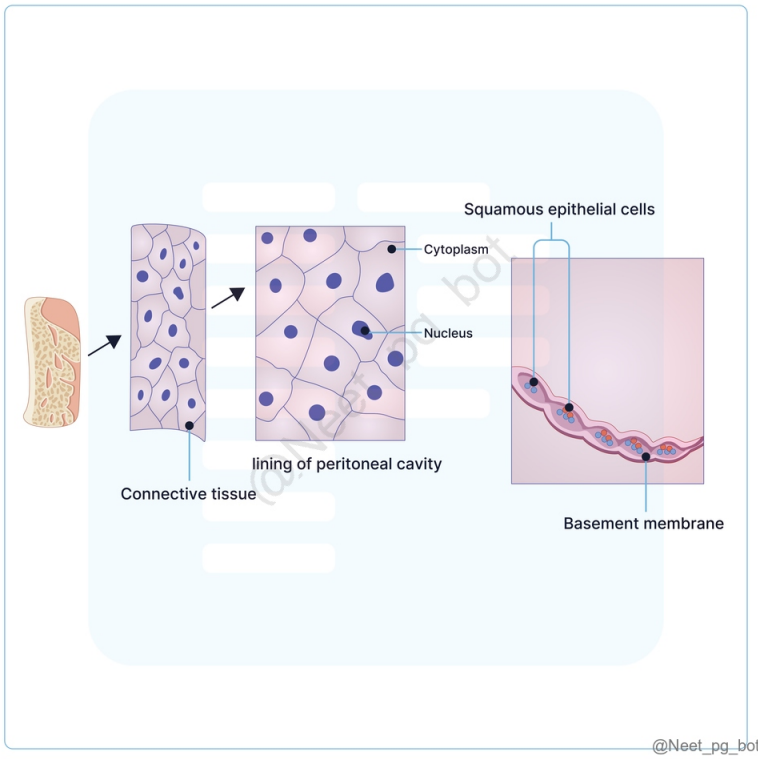
Squamous epithelial cells
Cytoplasm
Nucleus
lining of peritoneal cavity
Connective tissue
Basement membrane
@Neet_pg_bot

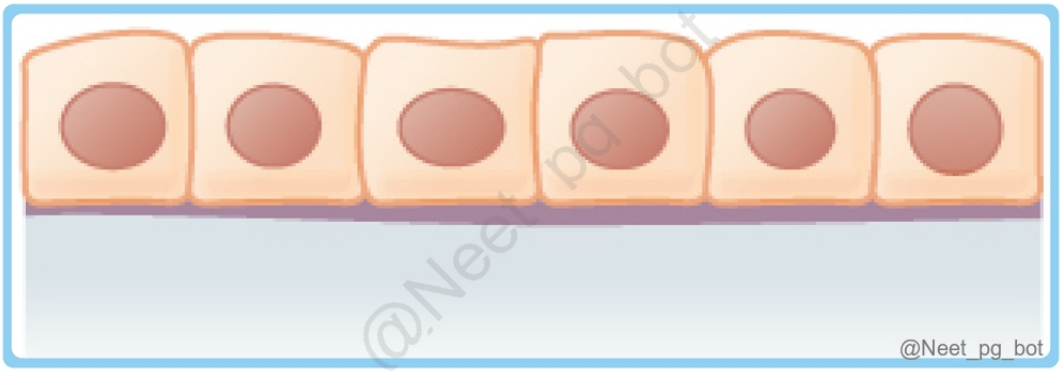
@Neet_pg_bot

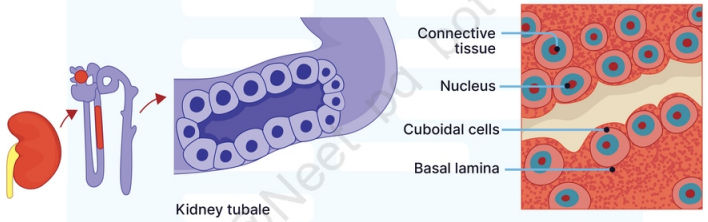

@Neet_pg_bot

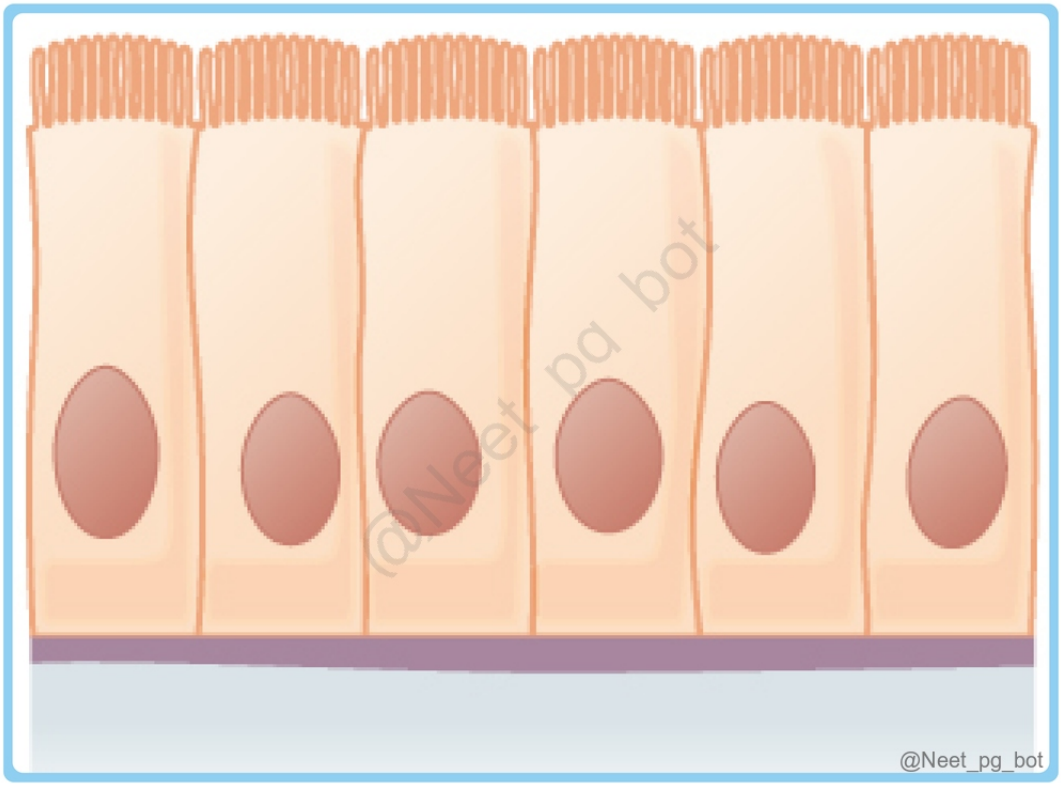

@Neet_pg_bot

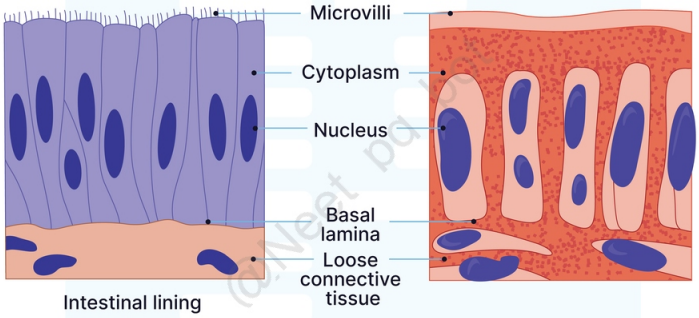

@Neet_pg_bot

References:

Wheater's Functional Histology, 6th Edition, Page 82-85.

↑ *Back to this question in Part A*

@Neet_pg_bot

Q18: Given below are two histological images 1 and 2, which of the following pairs accurately represents the tissues depicted? (Q848053)

A. 1- Stomach; 2- Lymph node

B. 1- Urinary Bladder; 2- Trachea

C. 1- Lymph node; 2- Stomach

D. 1-Trachea; 2- Urinary Bladder

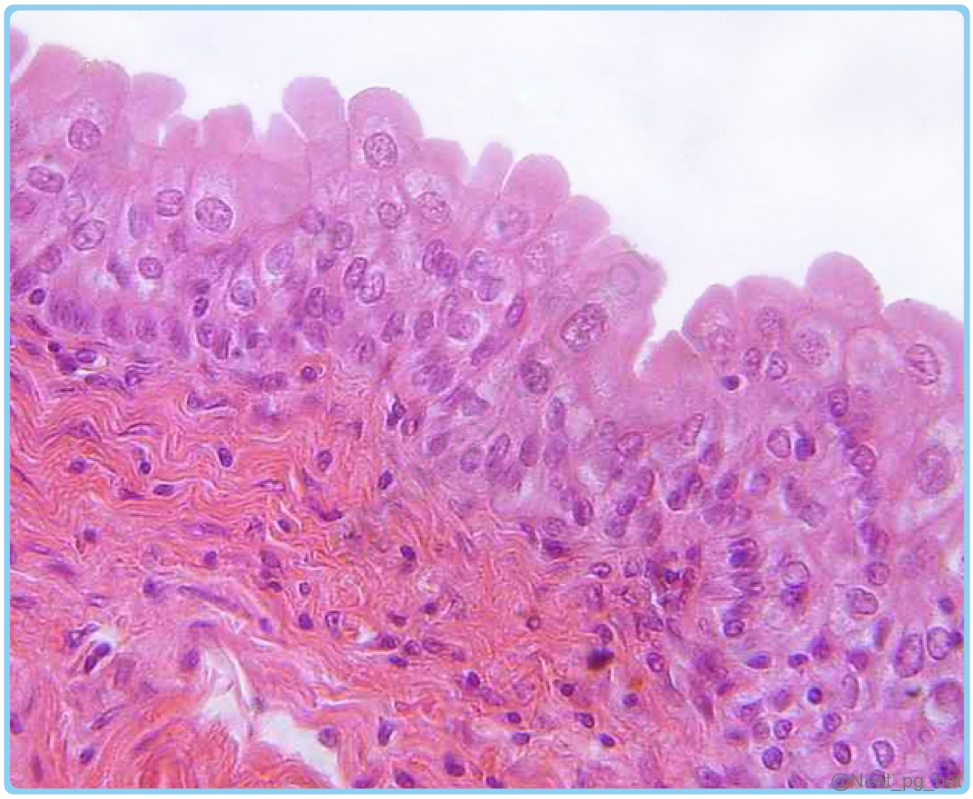

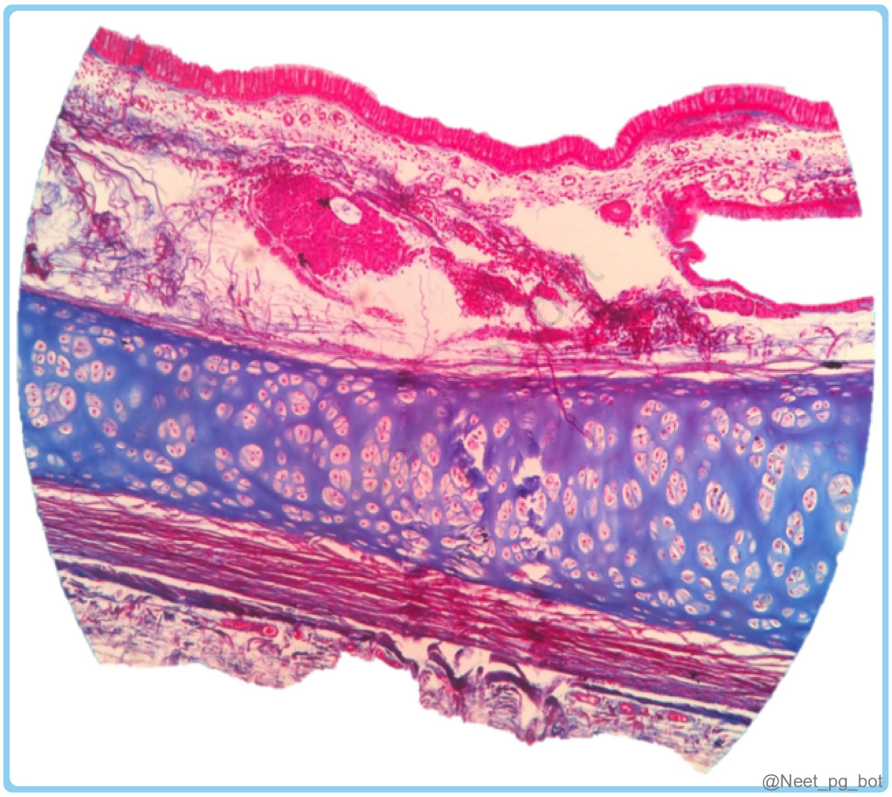

Correct Answer: B. 1- Urinary Bladder; 2- Trachea

■ *Listen (English)*

■ *Listen (Hindi)*

Explanation: Trachea Urinary Bladder Epithelium: Pseudostratified ciliated columnar epithelium with goblet, serous, and basal (neuroendocrine/stem) cells. Upper trachea: More goblet and basal cells. Lower trachea: More ciliated cells. Lamina propria: Loose, highly vascular connective tissue, becoming denser with fibroelastic fibers deeper down. Submucosa: Contains seromucinous glands (fewer distally); serous cells stain dark , mucous cells pale on H&E. Cartilage: Hyaline rings support wall; submucosa blends with perichondrium or fibroelastic tissue between rings. Epithelium: Transitional epithelium (urothelium) forming folds when relaxed. Muscle Layers: Three smooth muscle layers — inner longitudinal, middle circular, outer longitudinal — together forming the detrusor muscle , which contracts during micturition. Muscularis mucosa: Often incomplete or absent , separating lamina propria from submucosa. Adventitia: Outer layer with blood vessels, veins, and lymphatics . Stomach (Option A & C): The stomach is lined by simple columnar epithelium with gastric pits and glands, including surface mucous cells, mucous neck cells, parietal cells, and chief cells. It would not typically show the features of the urinary bladder or trachea Fig. Histology of stomach Lymph node (Option A & C): A lymph node features a capsule, cortex with lymphatic follicles, and a medulla with medullary cords and sinuses. It does not match the typical histological features of the trachea or urinary bladder. Fig. Histology of lymph node

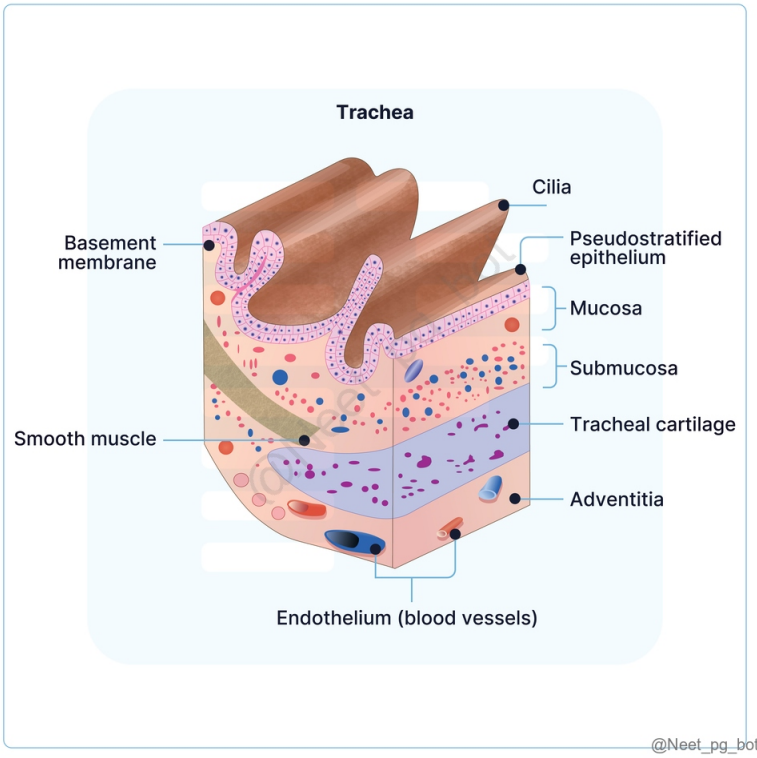

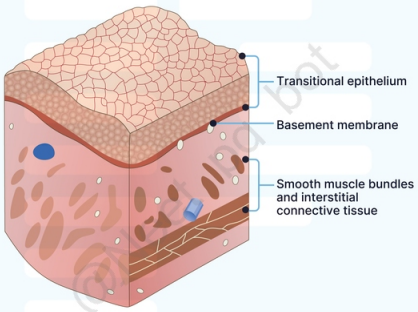

@Neet_pg_bot

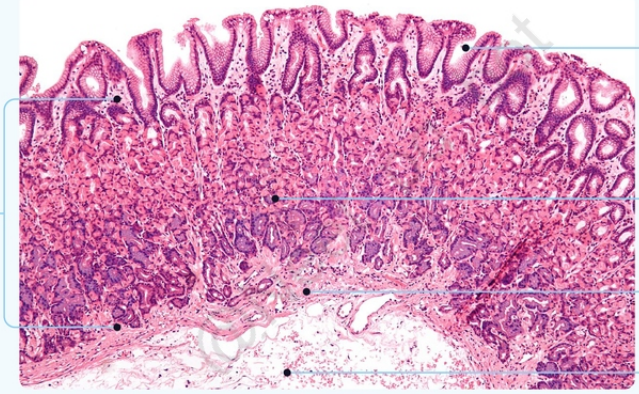

@Neet_pg_bot

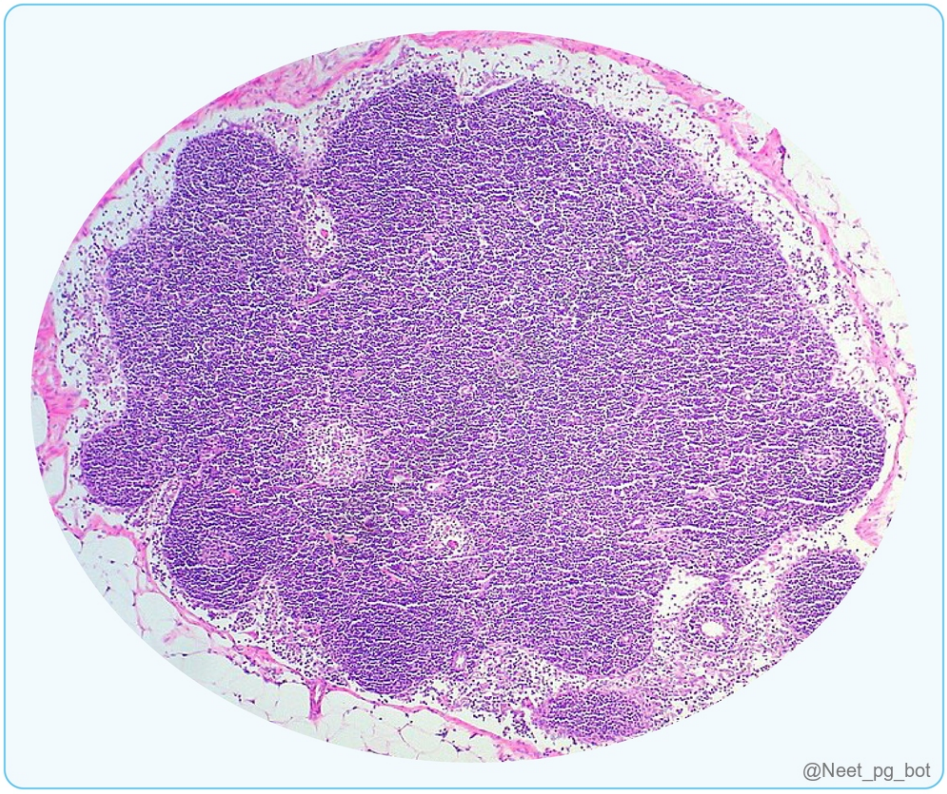

References:

Wheater's Functional Histology, 6th Edition, Page 228, 315.

↑ *Back to this question in Part A*

@Neet_pg_bot

Q19: Which of the following structures is characterized by the presence of compound tubuloalveolar mucous glands in the submucosa, and a muscular layer that transitions from skeletal to smooth muscle? (Q848052)

A. Esophagus

B. Stomach

C. Small intestine

D. Both A & C are correct

Correct Answer: A. Esophagus

■ *Listen (English)*

■ *Listen (Hindi)*

Explanation: The esophagus is lined with nonkeratinized stratified squamous epithelium and contains mucous glands (esophageal glands proper) in its submucosa for lubrication. Its muscular layer transitions from skeletal muscle (upper third) to smooth muscle (lower third), characteristic of the process of swallowing. Structure Description Esophagus Epithelium: Nonkeratinized stratified squamous. Submucosa: Contains mucous (tubuloalveolar) glands for lubrication. Muscularis externa: Upper third – Skeletal muscle (voluntary). Middle third – Mixed. Lower third – Smooth muscle (involuntary). Adventitia (no serosa except near stomach). Stomach (Option B ruled out) Simple columnar epithelium, gastric glands in mucosa, no skeletal muscle. Small Intestine (Option C & D ruled out) Has villi, crypts, Peyer's patches; no skeletal muscle or submucosal mucous glands.

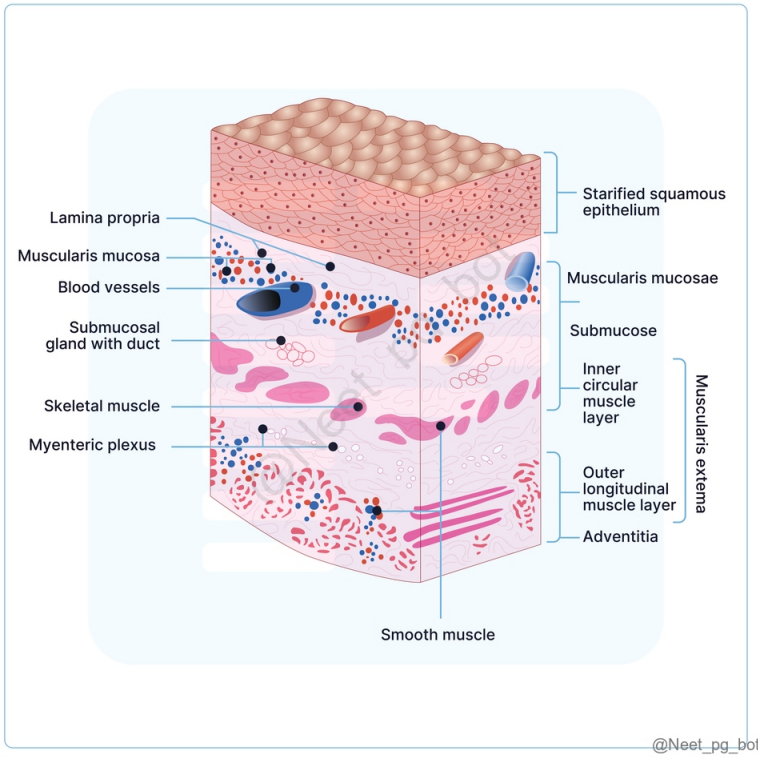

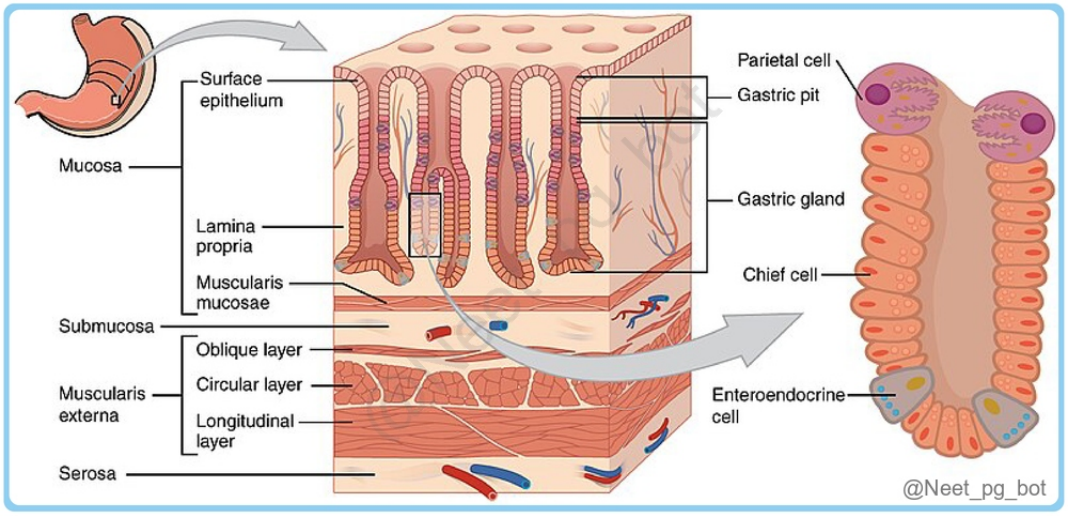

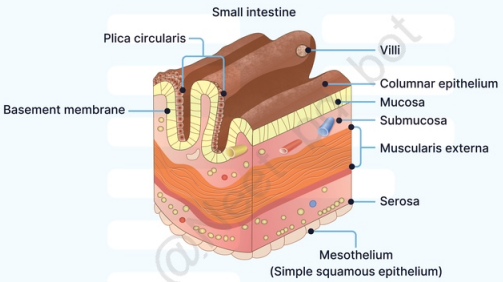

@Neet_pg_bot

References:

Wheater’s Functional Histology, 6th Edition, Page 255- 260, 264, 265.

Inderbir Singh Textbook of Human Histology, 9th Edition, Page 418, 419.

↑ *Back to this question in Part A*

@Neet_pg_bot

• [02_Histology] 006 Tissue Histology- Ii

« Back to Folder Directory

[02_Histology] 006 Tissue Histology- Ii — Quick Jump

Q1 (p. 775) *Q2 (p. 777)* *Q3 (p. 783)* *Q4 (p. 784)* *Q5 (p. 785)* *Q6 (p. 786)*
Q7 (p. 787) *Q8 (p. 788)* *Q9 (p. 789)* *Q10 (p. 791)* *Q11 (p. 792)* *Q12 (p. 793)*
Q13 (p. 796) *Q14 (p. 798)* *Q15 (p. 799)* *Q16 (p. 800)* *Q17 (p. 802)* *Q18 (p. 804)*
Q19 (p. 806) *Q20 (p. 807)*

Q1: A 28-year-old patient with recurrent abdominal pain undergoes an endoscopic biopsy of the small intestine. The pathologist observes cells with prominent eosinophilic secretory granules located in the deeper parts of the intestinal crypts. These cells are known to produce substances that destroy bacteria. Which of the following cell types is the pathologist most likely observing as shown below? (Q848170)

A. Enterocytes

B. M cells

C. Paneth cells

D. Enterochromaffin cells

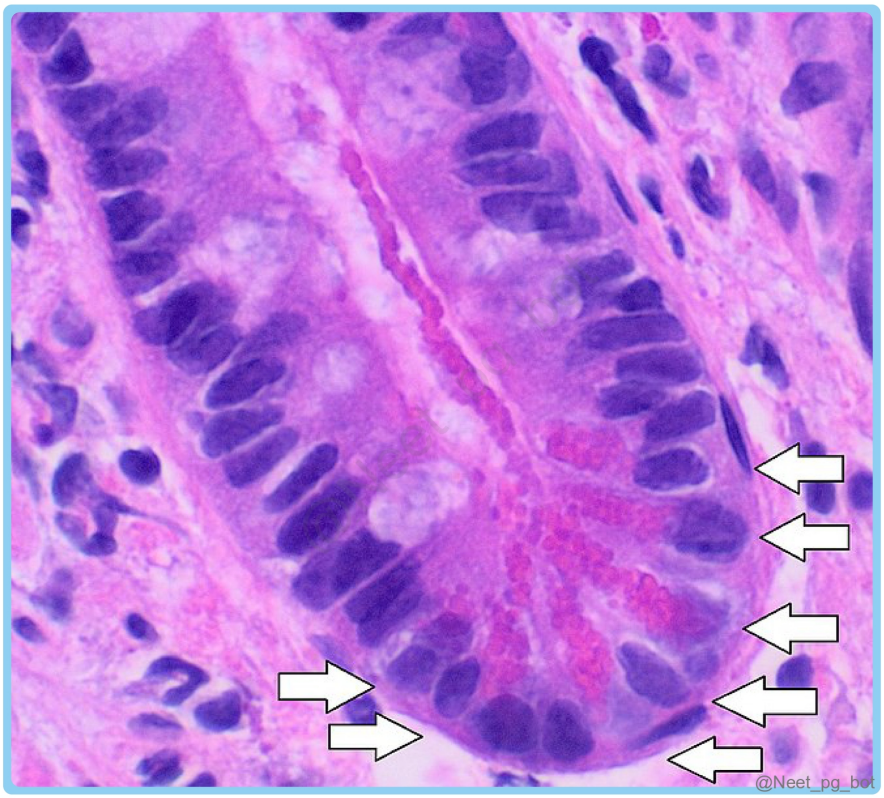

Correct Answer: C. Paneth cells

- *Listen (English)*
- *Listen (Hindi)*

Explanation: The cells located in the deeper parts of the intestinal crypts having prominent eosinophilic secretory granules are Paneth cells , which produce lysozyme that destroys bacteria and other microorganisms in the small intestine. Cell Type Location Function Characteristics Absorptive Columnar Cells (Enterocytes) (Option A) Luminal surface (villi) Absorption of amino acids, carbohydrates, and lipids Oval nucleus in lower part Striated border (microvilli) Junctional complexes and desmosomes Paneth Cells (Zymogen Cells) Deeper parts of intestinal crypts Produce lysozyme (destroys bacteria) May produce other enzymes Prominent eosinophilic secretory granules Considerable Golgi apparatus Rough endoplasmic reticulum Endocrine Cells (Argentaffin/Enterochromaffin Cells) (Option D) Epithelial lining, most numerous near lower ends of crypts Secrete endocrine substances Membrane-bound vesicles with neuroactive substances Granules stain with silver salts M Cells (Option B) Overlying Peyer's patches Engulf and transport microbes to basolateral surface Stimulate gut-associated lymphoid tissue (GALT) Antigen-presenting function Microfolds instead of microvilli

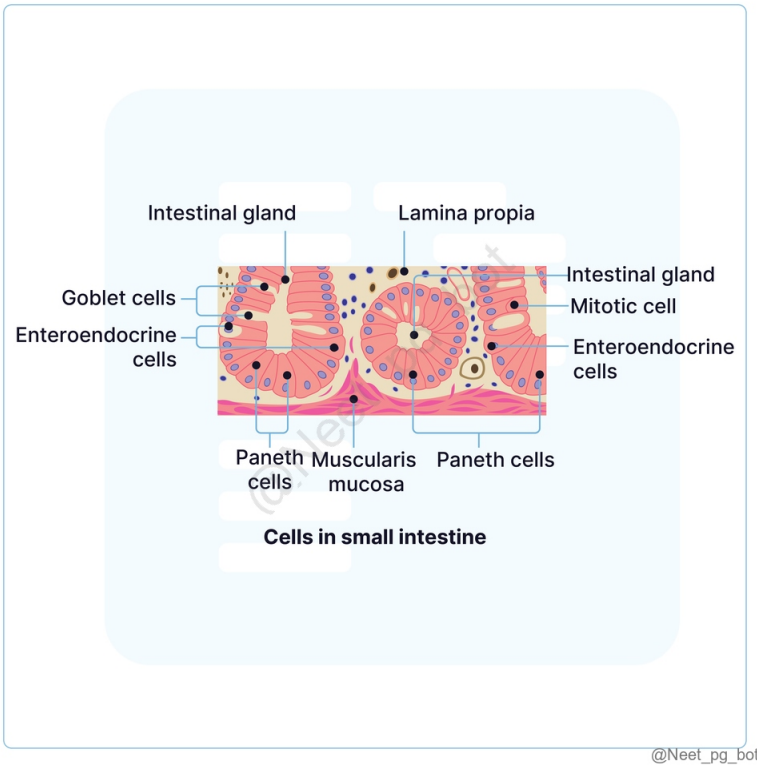

References:

Inderbir Singh Textbook of Human Histology, 9th Edition, Page 438- 442.

↑ *Back to this question in Part A*

@Neet_pg_bot

Q2: Match the following: 1. Cervix a) 2. Fallopian tube b) 3. Ovary c) 4. Uterus d) 5. Vagina e) (Q848179)

A. 1-b, 2-c, 3-e, 4-a, 5-d

B. 1-d, 2-e, 3-a, 4-c, 5-b

C. 1-c, 2-b, 3-e, 4-d, 5-a

D. 1-b, 2-e, 3-a, 4-c, 5-d

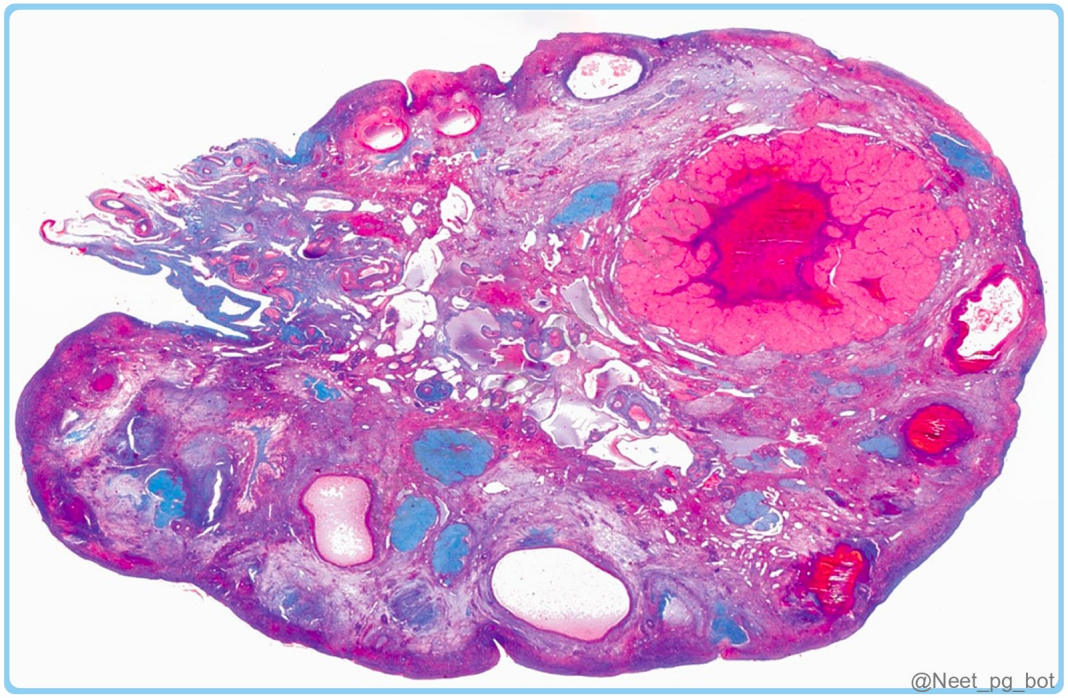
@Neet_pg_bot

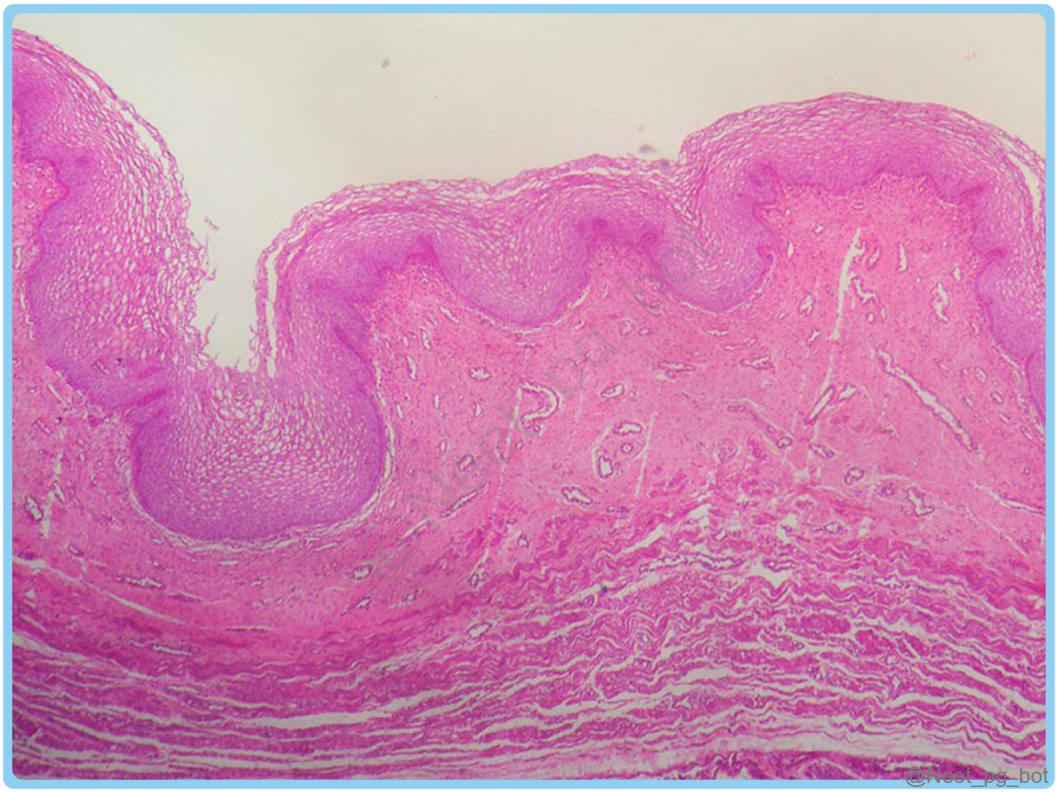
@Neet_pg_bot

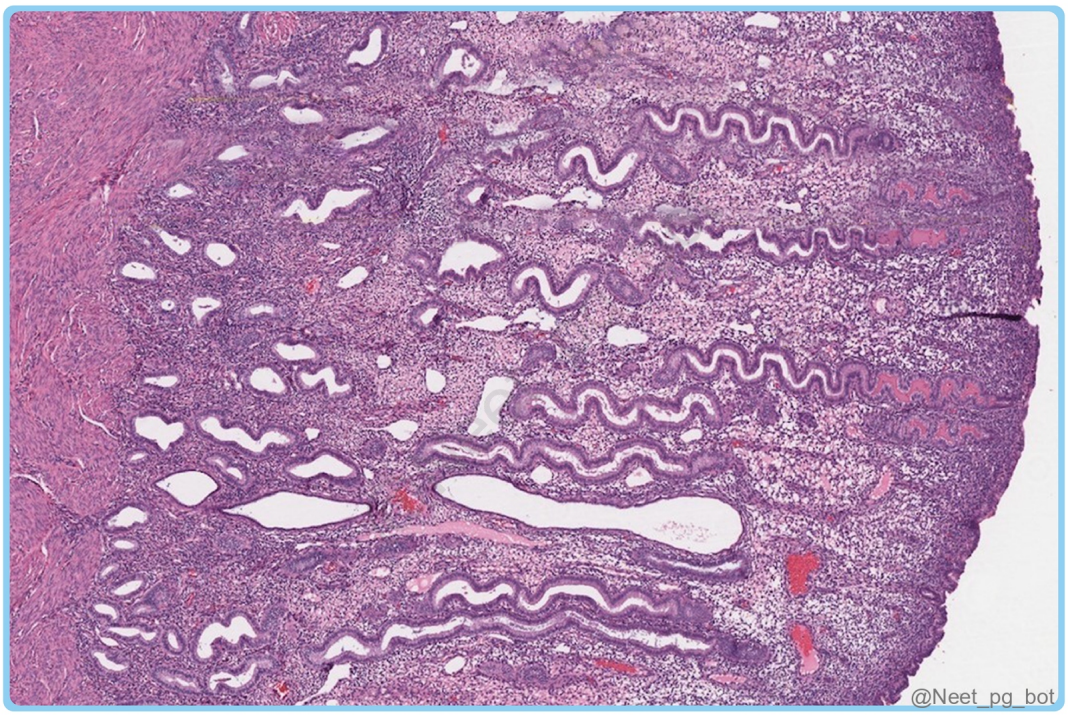
@Neet_pg_bot

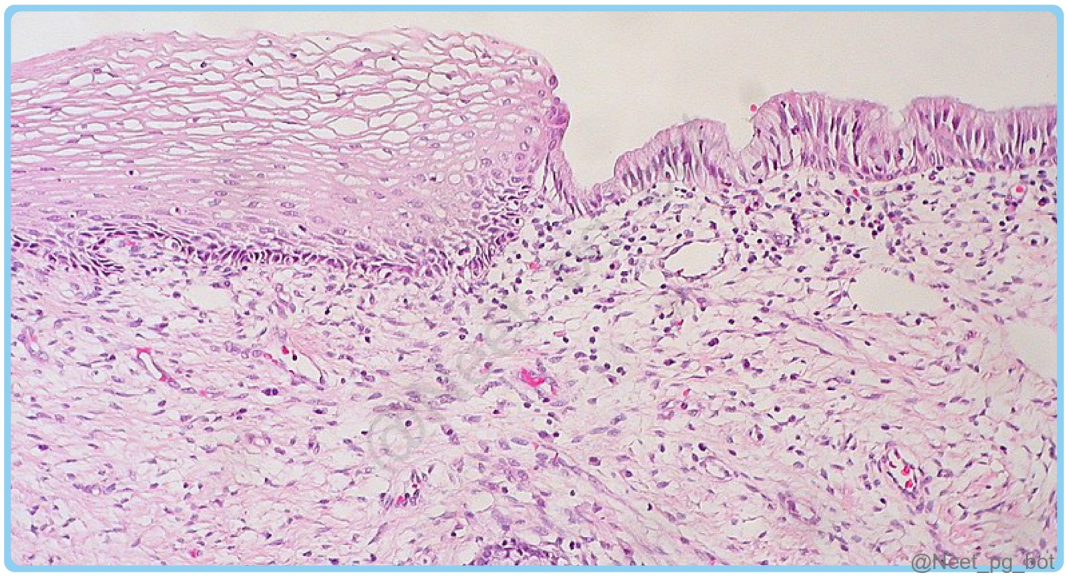
@Neet_pg_bot



Correct Answer: B. 1-d, 2-e, 3-a, 4-c, 5-b

■ *Listen (English)*

■ *Listen (Hindi)*

Explanation: Structures of the Female Reproductive Tract Ovary The ovary's cortex contains numerous follicles at different developmental stages, along with postovulatory structures like corpora lutea and degenerated follicles . The superficial cortex is fibrous, known as the tunica albuginea, and is covered by germinal epithelium, a continuation of the peritoneum. Fallopian Tube Mucosal lining with branching longitudinal folds , especially prominent in the ampulla, the usual site of fertilization. The wall consists of an inner circular and outer longitudinal smooth muscle layer, while the serosa, continuous with the broad ligament, has a mesothelial surface. The epithelium is composed of ciliated, non-ciliated secretory , and intercalated cells. Uterus The endometrium has three distinct layers: the stratum basalis (deepest, stable layer), the stratum spongiosum (intermediate, spongy appearance), and the stratum compactum (superficial, compact layer). The stratum functionalis , comprising the compact and spongy layers, undergoes significant changes and is shed during menstruation. Cervix The cervix consists of the endocervical canal lined by tall columnar mucus-secreting cells and the ectocervix lined by thic k stratified squamous epithelium , adapted to different environments. The squamocolumnar junction between the ectocervix and endocervical epithelium is located at the external os and marks an abrupt transition. Vagina The vaginal wall consists of a mucosal layer lined by stratified squamous epithelium , a sm ooth muscle layer , and an outer adventitial layer. The lamina propria is rich in elastin and small veins but lacks glands.

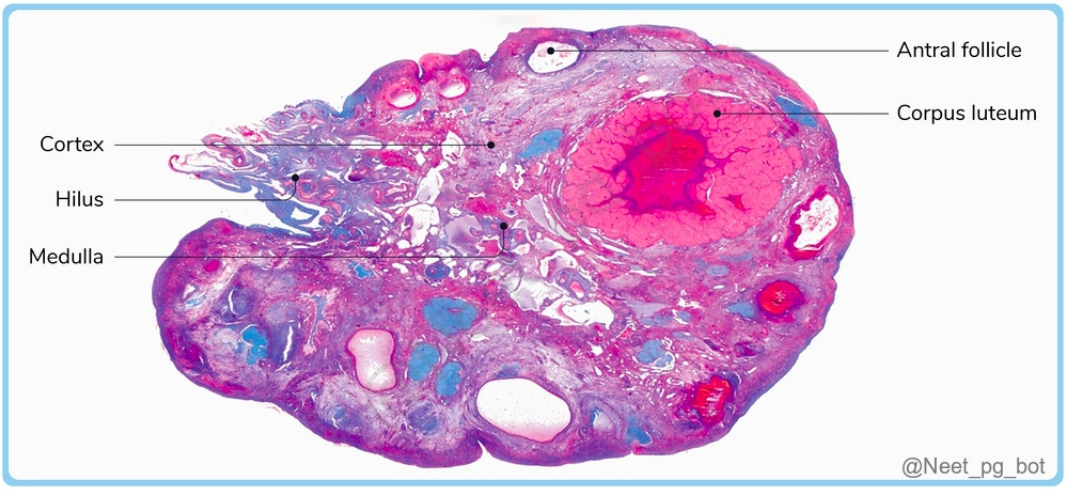
Antral follicle
Corpus luteum
Cortex
Hilus
Medulla
@Neet_pg_bot

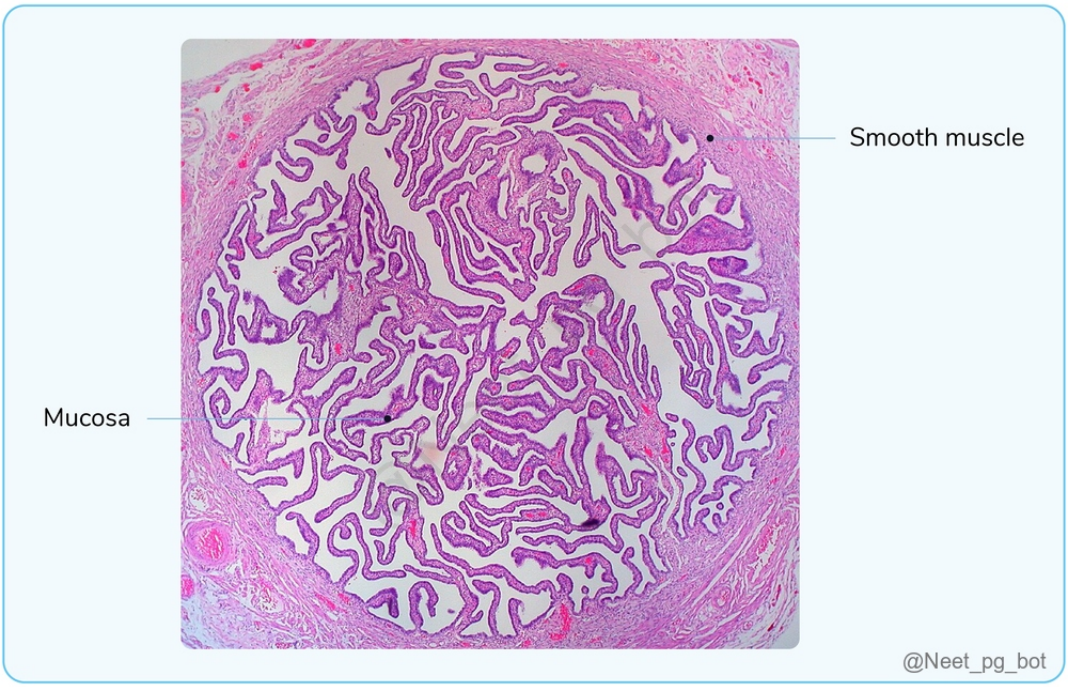
Smooth muscle
Mucosa
@Neet_pg_bot

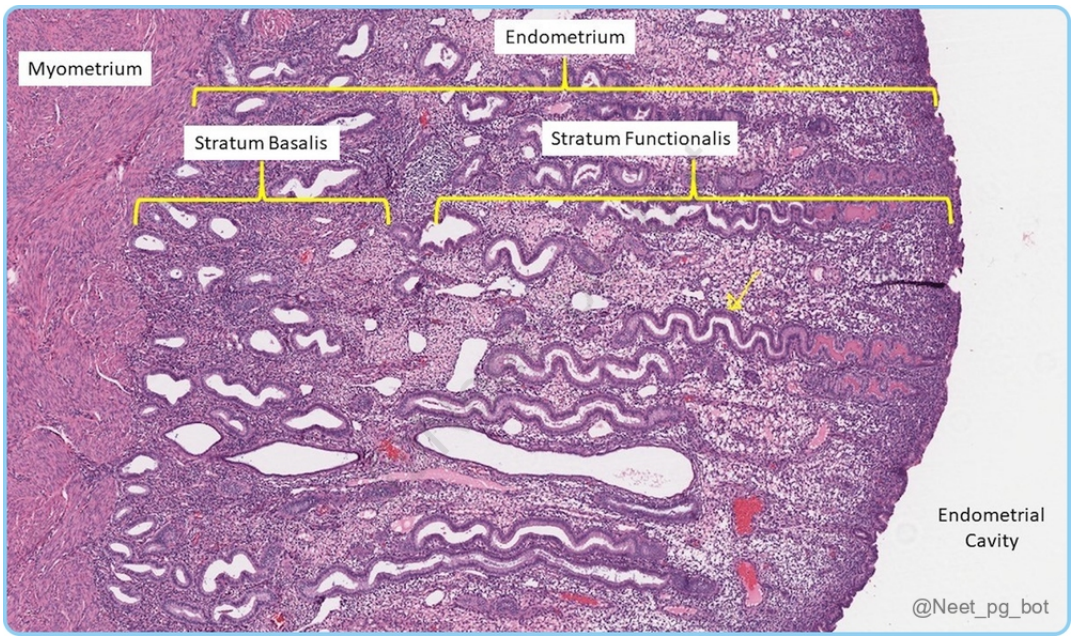
Myometrium
Endometrium
Stratum Basalis
Stratum Functionalis
Endometrial Cavity
@Neet_pg_bot

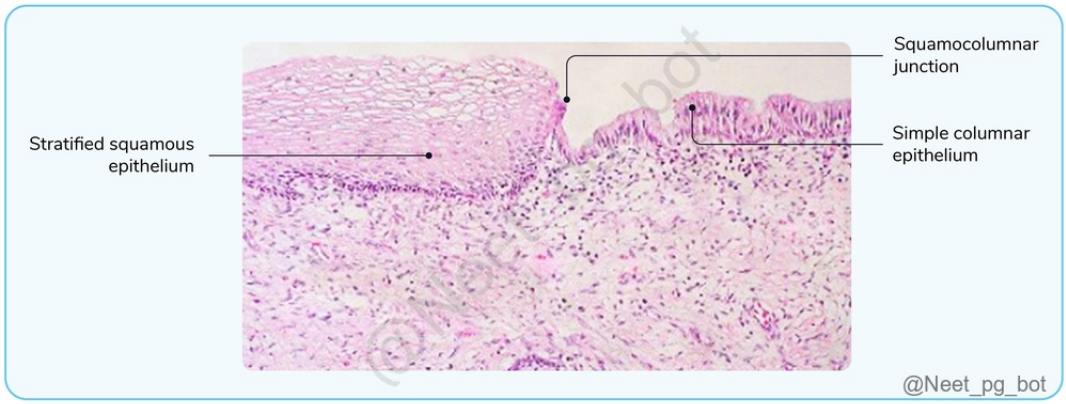
Squamocolumnar junction
Stratified squamous epithelium
Simple columnar epithelium
@Neet_pg_bot

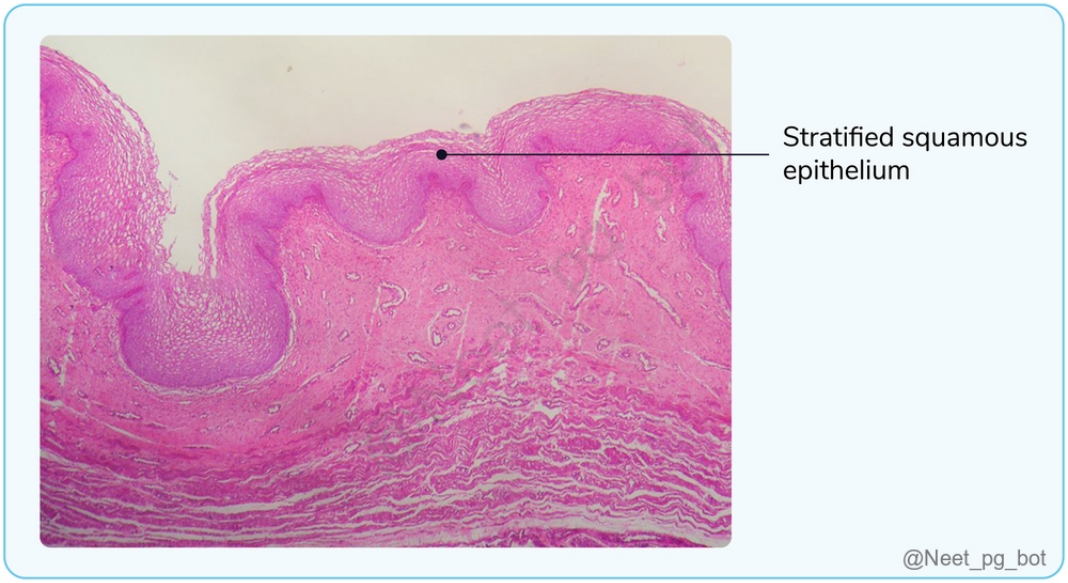
Stratified squamous epithelium
@Neet_pg_bot

References:

Wheater’s Functional Histology, 6th Edition, Page 352, 360, 361, 368, 369.

↑ *Back to this question in Part A*

@Neet_pg_bot

Q3: Which of the following statements about the structure of sperm is true? (Q848178)

A. The head of sperm contains a central core of axoneme.

B. The principal piece of the tail contains hyaluronidase.

C. The neck of the sperm contains centrioles.

D. The tail contains the nucleus of the sperm.

Correct Answer: C. The neck of the sperm contains centrioles.

■ *Listen (English)*

■ *Listen (Hindi)*

Explanation: The neck of the sperm contains centrioles, which play a crucial role in cell division and in forming the axoneme of the flagellum. Structure of Sperm Head Nucleus: Contains very condensed chromatin with areas of dispersed chromatin known as nuclear vacuoles. (Option D) Acrosomal Cap: Surrounds the anterior two-thirds of the nucleus; a membrane-bound vesicle containing glycoproteins and hydrolytic enzymes (e.g., hyaluronidase) that assist in fertilization by dissolving the zona pellucida. (Option B) Neck This is a short segment linking the head to the tail. Contain remnants of centrioles , one of which forms the axoneme of the flagellum. Often retains some cytoplasmic material in this region. Tail Middle Piece: Contains the flagellar axoneme surrounded by nine outer dense fibres and tightly packed elongated mitochondria arranged in a helix for energy. Principal Piece: Constitutes most of the tail's length; has a central core with axoneme and coarse fibres, surrounded by fibrous ribs arranged circularly. Features dorsal and ventral columns for potential propulsion during movement. (Option A) End Piece: Short tapering portion containing only the axoneme.

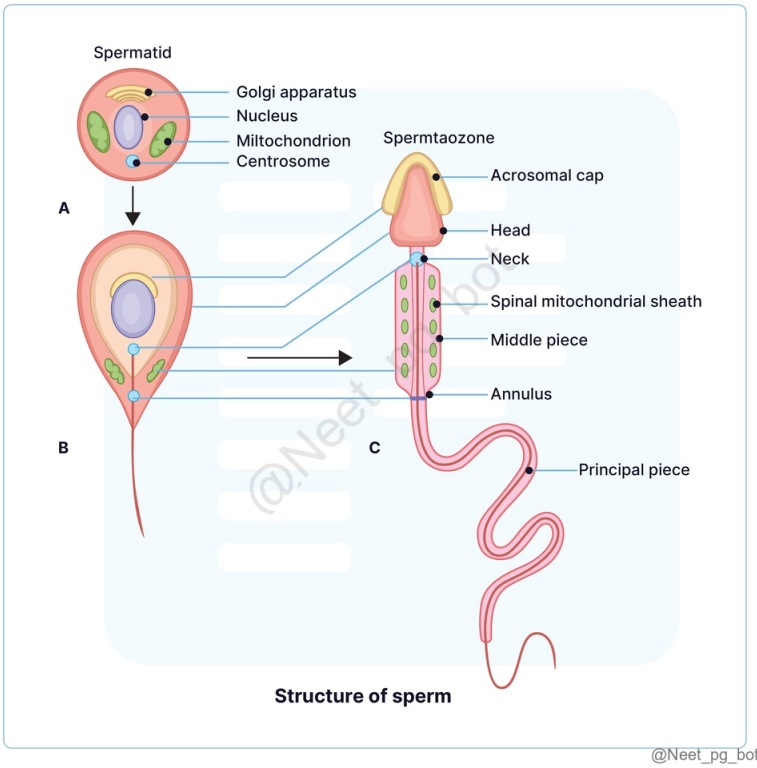

References:

Wheater's Functional Histology, 6th Edition, Page 342.

↑ *Back to this question in Part A*

@Neet_pg_bot

Q4: Which of the following statements about the structure of the testis is false? (Q848177)

A. The testis is surrounded by the tunica vaginalis.

B. The seminiferous tubules produce sperm.

C. The ductuli efferentes carry sperm from the epididymis to the rete testis.

D. The blood-testis barrier is formed by sertoli cells.

Correct Answer: C. The ductuli efferentes carry sperm from the epididymis to the rete testis.

■ *Listen (English)*

■ *Listen (Hindi)*

Explanation: The ductuli efferentes carry sperm from the rete testis to the epididymis , not the other way around. Tunica Vaginalis: Testis is surrounded by a double layer of mesothelium (visceral and parietal layers), enclosing a potential space filled with serous fluid for lubrication. (Option A) Tunica Albuginea: Capsule of the testis, forms incomplete collagenous septa dividing the testis into ~250 lobules. Seminiferous Tubules: 1-4 convoluted tubes in each lobule, responsible for sperm production. (Option B) Rete Testis: Convergence point for seminiferous tubules. The blood-testis barrier is formed by sertoli cells, which are connected by junctional complexes, including extensive tight junctions located towards the basal layer of the spermatogenic epithelium. (Option D)

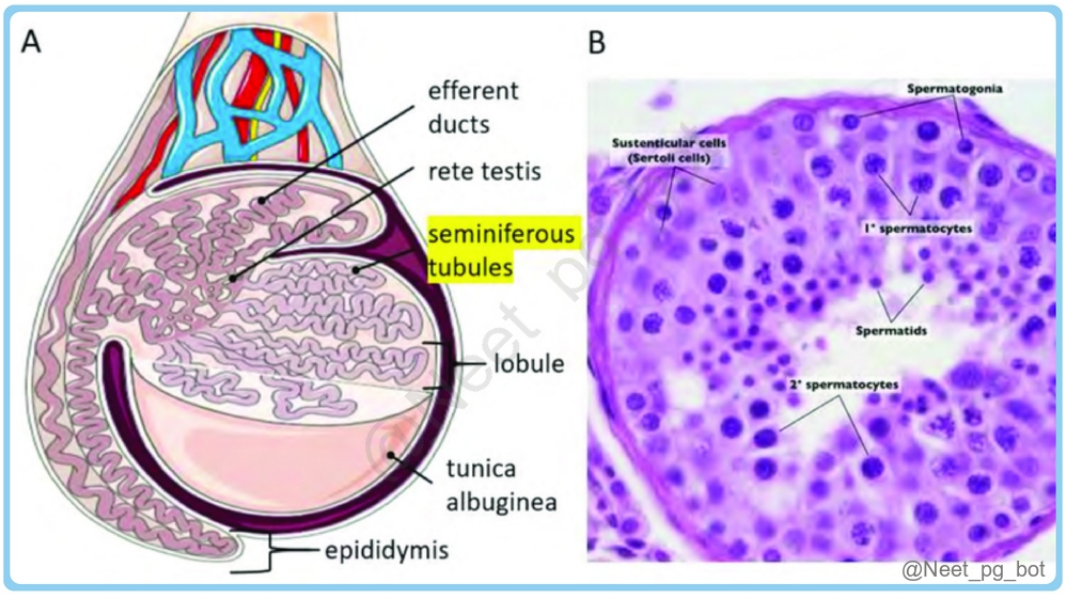

References:

Wheater's Functional Histology, 6th Edition, Page 338, 343.

↑ *Back to this question in Part A*

@Neet_pg_bot

Q5: Which of the following correctly describes the epithelial lining at the prostatic urethra shown in the histological section below? (Q848176)

A. Keratinized stratified squamous epithelium

B. Non-keratinized stratified squamous epithelium

C. Transitional epithelium

D. Stratified columnar epithelium

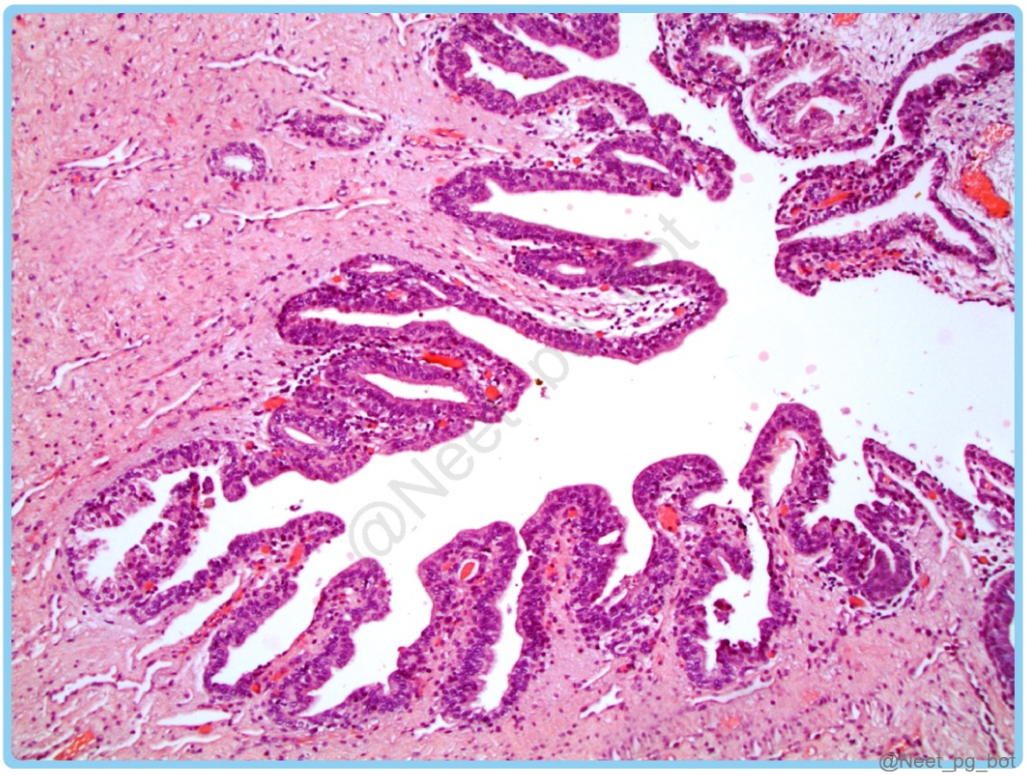

Correct Answer: C. Transitional epithelium

■ *Listen (English)*

■ *Listen (Hindi)*

Explanation: The prostatic urethra is the portion of the male urethra that passes through the prostate gland. It is lined by transitional epithelium , also known as urothelium, which is continuous with the lining of the bladder. Epithelial Lining of the Male Urethra Segment of Urethra Epithelial Lining Prostatic urethra Transitional epithelium (urothelium) Membranous urethra Stratified (Option D) or pseudostratified columnar Penile (spongy) urethra Stratified columnar (Option D) → non-keratinized squamous (distally) Fossa navicularis (tip) Non-keratinized stratified squamous (Option B) Keratinized stratified squamous epithelium (Option A): Found at the external urethral meatus, not in the prostatic urethra.

References:

Inderbir Singh Textbook of Human Histology, 9th Edition, Pages 509, 514.

↑ *Back to this question in Part A*

@Neet_pg_bot

Q6: Which part of the nephron is characterized by cuboidal epithelial cells with a prominent brush border? (Q848175)

A. Renal corpuscle

B. Proximal convoluted tubule

C. Loop of Henle

D. Distal convoluted tubule

Correct Answer: B. Proximal convoluted tubule

■ *Listen (English)*

■ *Listen (Hindi)*

Explanation: The PCT is characterized by cuboidal epithelial cells with a prominent brush border and is responsible for reabsorbing about 65-80% of the filtered solutes and water. Part of Nephron Epithelial Lining Key Feature Main Function Renal Corpuscle (Option D) Podocytes and simple squamous Contains glomerulus Blood filtration Proximal Convoluted Tubule Cuboidal with brush border Prominent brush border Major solute and water reabsorption Loop of Henle (Option C) Simple squamous (descending) to cuboidal (ascending) U-shaped structure Urine concentration Distal Convoluted Tubule (Option D) Cuboidal without brush border Basal striations Electrolyte balance Collecting Duct Cuboidal (principal and intercalated cells) Responsive to ADH Final urine concentration

References:

Inderbir Singh Textbook of Human Histology, 9th Edition, Page 494, 498, 499.

↑ *Back to this question in Part A*

@Neet_pg_bot

Q7: Which of the following liver units is considered the most relevant functional unit for understanding patterns of toxic liver injury? (Q848174)

A. Classic lobule

B. Portal lobule

C. Portal acinus

D. Sinusoidal unit

Correct Answer: C. Portal acinus

■ *Listen (English)*

■ *Listen (Hindi)*

Explanation: The parenchyma of liver is divided into 3 type of units: Classic Lobule (Option A): Hexagonal shape with central vein and portal triads at corners Represents the basic structural unit of the liver Portal Lobule: (Option

B) Triangular shape with portal triad at center and central veins at corners Emphasizes bile drainage Portal Acinus: Diamond-shaped unit between two portal triads Divided into three zones based on oxygen and nutrient supply: Zone 1 (periportal): Most oxygenated, more affected by toxins, least susceptible to ischaemia Zone 2 (midlobular): Intermediate oxygenation, Intermediate affected by toxins, Intermediate susceptible to ischaemia Zone 3 (centrilobular): Farthest from blood supply, least susceptible to toxicity, more susceptible to ischaemia Sinusoidal unit (Option D) is not a type of recognized liver unit.

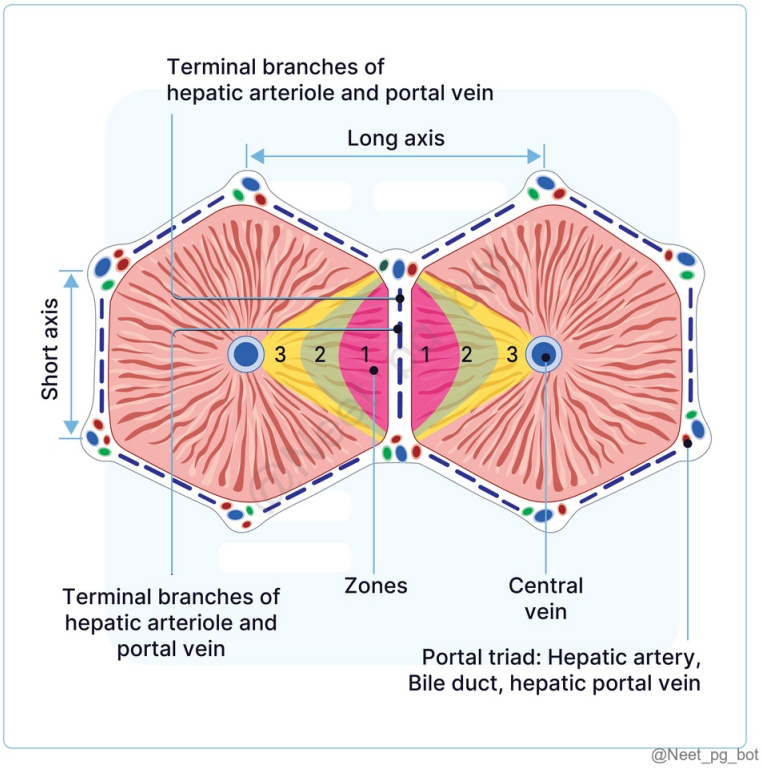

References:

Inderbir Singh Textbook of Human Histology, 9th Edition, Page 459, 460, 461, 463.

↑ *Back to this question in Part A*

@Neet_pg_bot

Q8: A 35-year-old patient with chronic hepatitis C undergoes a liver biopsy. The pathologist observes the classical hexagonal structure of liver lobules. Which of the following statements correctly regarding the blood flow and architecture within a liver lobule? (Q848173)

A. Blood flows from the central vein to the portal triad

B. The hepatic artery provides 70% of the liver's blood supply

C. Bile flows in the same direction as blood within the lobule

D. Sinusoids drain blood into the central vein

Correct Answer: D. Sinusoids drain blood into the central vein

■ *Listen (English)*

■ *Listen (Hindi)*

Explanation: Blood flow in the liver is in the direction as given below: Hepatic artery/Portal vein → Hepatic Sinusoids → Central vein → Hepatic vein→ Inferior vena cava → Heart Blood flows from the portal triad towards the central vein. (Option A) The portal vein provides about 70% of the blood supply (Option B) , while the hepatic artery provides the remaining 30%. Bile flows in the opposite direction to blood (Option C) , moving from hepatocytes towards the bile ducts in the portal triad.

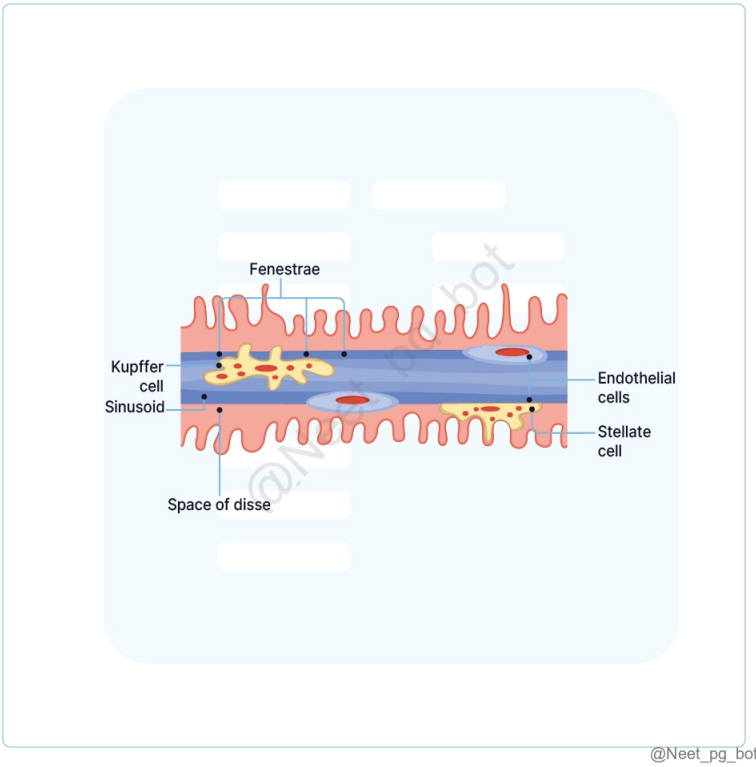

References:

Inderbir Singh Textbook of Human Histology, 9th Edition, Page 458, 459, 460.

↑ *Back to this question in Part A*

@Neet_pg_bot

Q9: A 55-year-old patient presents with rectal bleeding. During the examination, the proctologist identifies a lesion at the junction between the columnar epithelium and the non-keratinized stratified squamous epithelium in the anal canal. At which of the following anatomical landmarks is this lesion most likely located? (Q848172)

A. White line of Hilton

B. Pectinate line

C. Internal anal sphincter

D. External anal sphincter

Correct Answer: B. Pectinate line

■ *Listen (English)*

■ *Listen (Hindi)*

Explanation: The lesion described is most likely located at the pectinate line (also known as the dentate line). This is the junction between the columnar epithelium of the upper anal canal and the non-keratinized stratified squamous epithelium of the middle anal canal (pecten). Region Length Epithelium Features Pectinate (dentate) line - Transition zone Junction between columnar and non-keratinized stratified squamous epithelium Formed by anal valves (lower ends of anal columns) White line of Hilton (Option A) - Transition zone Lower limit of the pecten Junction between non-keratinized and keratinized epithelium Internal anal sphincter (Option C) - - Formed by smooth muscles present in muscularis externa External anal sphincter (Option D) - - Formed by skeletal muscles present in muscularis externa

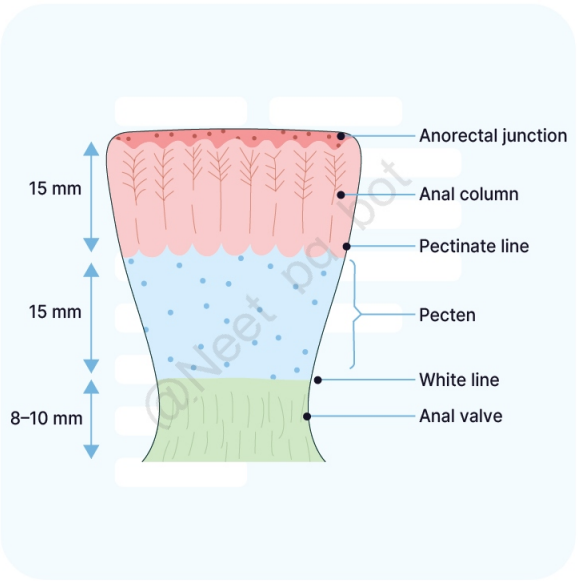

@Neet_pg_bot

References:

Inderbir Singh Textbook of Human Histology, 9th Edition, Page 449, 450, 451.

↑ *Back to this question in Part A*

@Neet_pg_bot

Q10: A pathologist is examining a biopsy sample from a patient's large intestine. The sample shows a mucosa without villi, numerous goblet cells, and an abundance of lymphoid tissue in the submucosa. The muscularis externa lacks taenia coli. Which part of the large intestine is this sample most likely from? (Q848171)

A. Cecum

B. Appendix

C. Colon

D. Rectum

Correct Answer: B. Appendix

■ *Listen (English)*

■ *Listen (Hindi)*

Explanation: The biopsy sample with features of mucosa without villi, numerous goblet cells, absence of taenia coli and an abundance of lymphoid tissue in the submucosa is most likely from the appendix. Features Cecum (Option A) Appendix Colon (Option C) Rectum (Option D) Villi Absent Absent Absent Absent Goblet cells Numerous Numerous Numerous Numerous Taenia coli Present Absent Present Absent Epithelium Simple columnar Simple columnar Simple columnar Simple columnar Distinctive features Widest part of large intestine Abundant lymphoid tissue Sacculations, appendices epiploicae Temporary and permanent folds

References:

Inderbir Singh Textbook of Human Histology, 9th Edition, Page 443- 449.

↑ *Back to this question in Part A*

@Neet_pg_bot

Q11: Which of the following skin receptors is a rapidly adapting cell? (Q848133)

A. Merkel cell

B. Ruffini receptor

C. Free nerve endings

D. Pacinian corpuscle

Correct Answer: D. Pacinian corpuscle

■ *Listen (English)*

■ *Listen (Hindi)*

Explanation: Pacinian corpuscle is a rapidly adapting mechanoreceptor that detects vibration and deep pressure. Rapidly adapting cells Slowly adapting cells Meissner corpuscle Pacinian corpuscle (Option D) Merkel cell (Option A) Ruffini receptor (Option B) Free nerve endings (Option C)

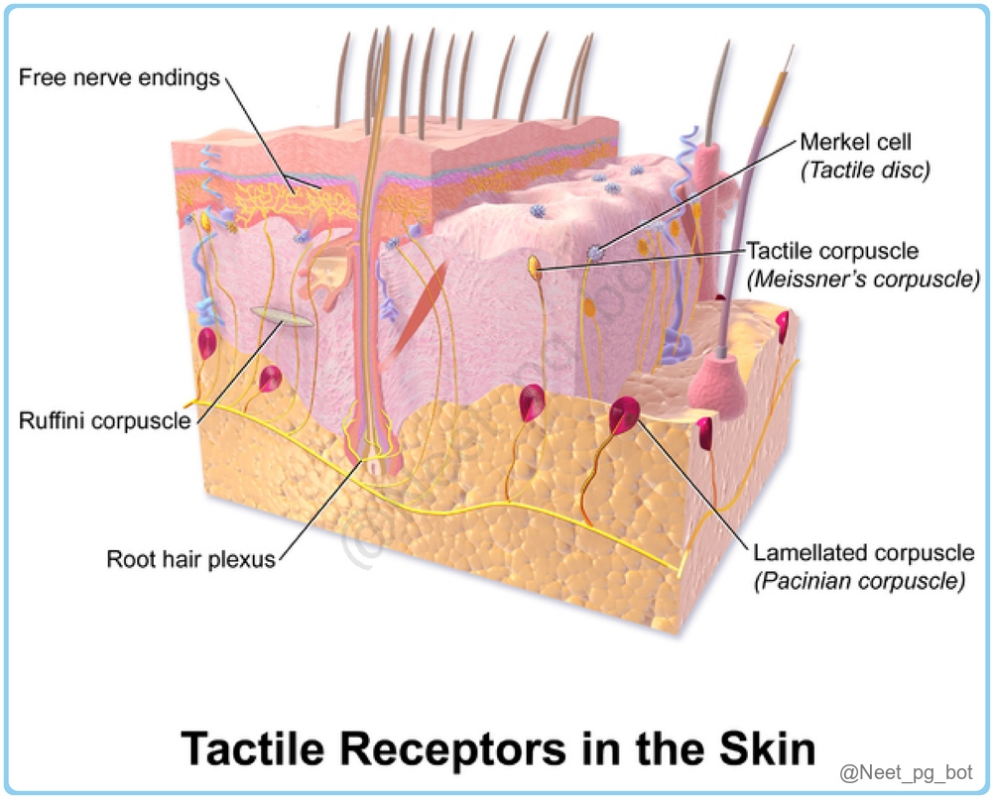

References:

Wheater's Functional Histology, 6th Edition, Page 168. The Major Classes of Somatic Sensory Receptors

↑ *Back to this question in Part A*

@Neet_pg_bot

Q12: A pathologist is examining biopsy samples from different parts of the small intestine. Which of the following histological features would most likely indicate that the sample is from the ileum? (Q848153)

A. Presence of numerous tall villi

B. Abundant Brunner's glands in the submucosa

C. Numerous large Peyer's patches

D. Thick circular folds in the lumen

Correct Answer: C. Numerous large Peyer's patches

■ *Listen (English)*

■ *Listen (Hindi)*

Explanation: Numerous large Peyer's patches are a characteristic feature of the ileum . The table below discusses various histological features of small intestine: Feature Duodenum Jejunum Ileum Lumen and Wall Wider lumen, thicker wall Wider lumen, thicker wall Narrow lumen, thinner wall Circular Folds Large, thick circular folds (Option D) Large, thick circular folds (Option D) Small, few circular folds Villi Numerous broad villi with goblet cells Numerous tall villi with goblet cells (Option A) Few, short and slender villi with goblet cells Brunner's Glands Present in submucosa (Option B) Absent Absent Peyer's Patches Absent Very few, only in distal part Numerous, extending into mucosa (Option C) Histology image

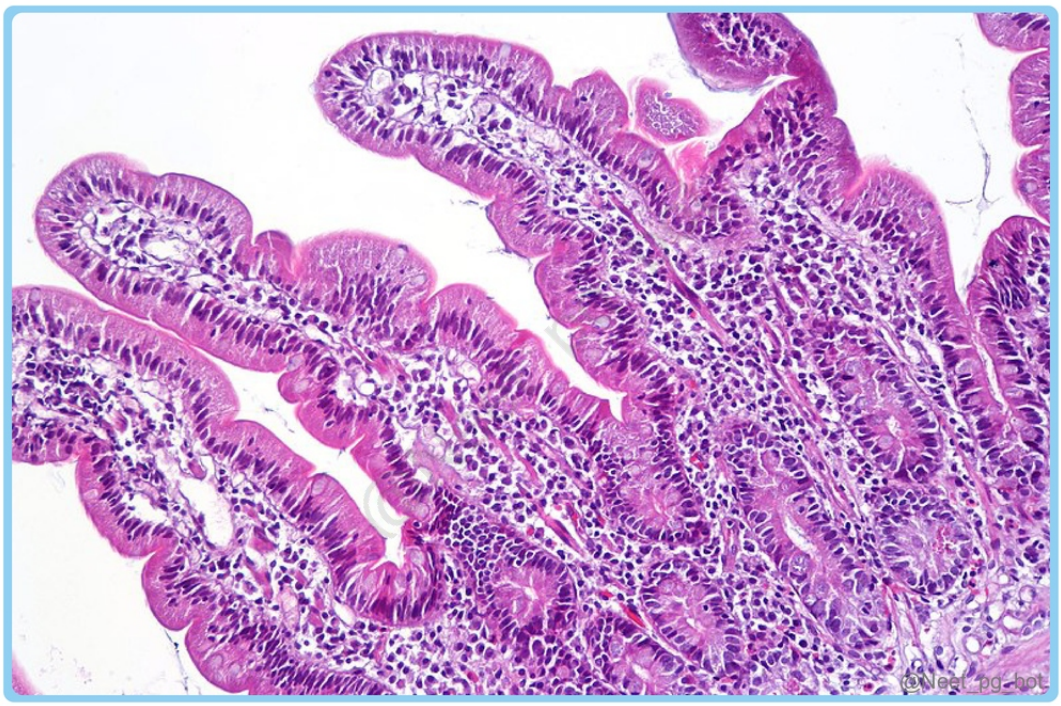



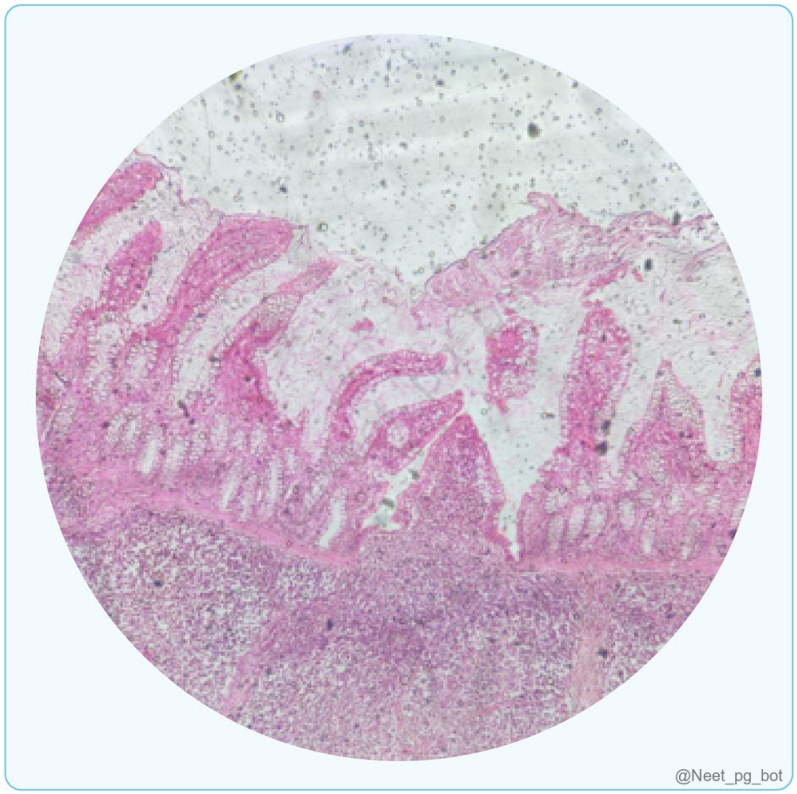

References:

Inderbir Singh Textbook of Human Histology, 9th Edition, Page 430-437.

↑ *Back to this question in Part A*

@Neet_pg_bot

Q13: A 45-year-old patient undergoes an endoscopic biopsy of the stomach due to persistent dyspepsia. Histological examination of the glandular tissue reveals cells that are columnar in shape, located in the lower half of the gland, and stain blue with hematoxylin. Which of the following statements is most likely true about these cells? (Q848152)

A. They secrete hydrochloric acid and intrinsic factor

B. They produce mucus

C. They secrete pepsinogen

D. They release the hormone gastrin

Correct Answer: C. They secrete pepsinogen

■ *Listen (English)*

■ *Listen (Hindi)*

Explanation: The histological features describe chief cells of the gastric glands. Chief cell/peptic cell/ zymogen cells stain blue with hematoxylin due to basophilic cytoplasm, are columnar in shape and located in the basal (lower) part of the gastric pit. They secrete pepsinogen and gastric lipase Cell Type Function Chief cells (Peptic cells) Secrete pepsinogen (precursor of pepsin) Parietal cells (Oxyntic cells) Secrete hydrochloric acid Produce intrinsic factor (Option A) Mucous neck cells Secrete mucus (Option B) G cells Secrete gastrin hormone (Option D)

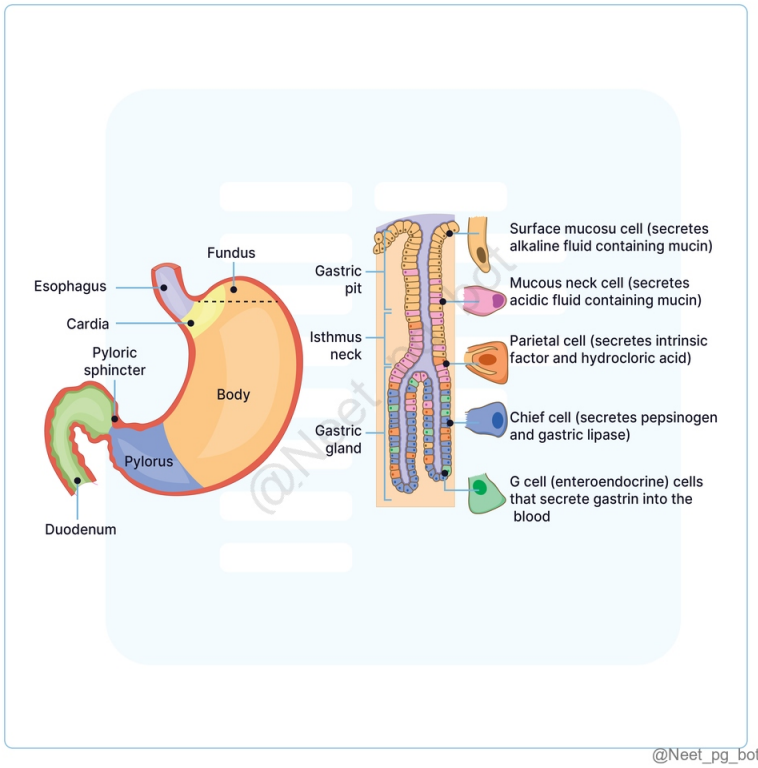

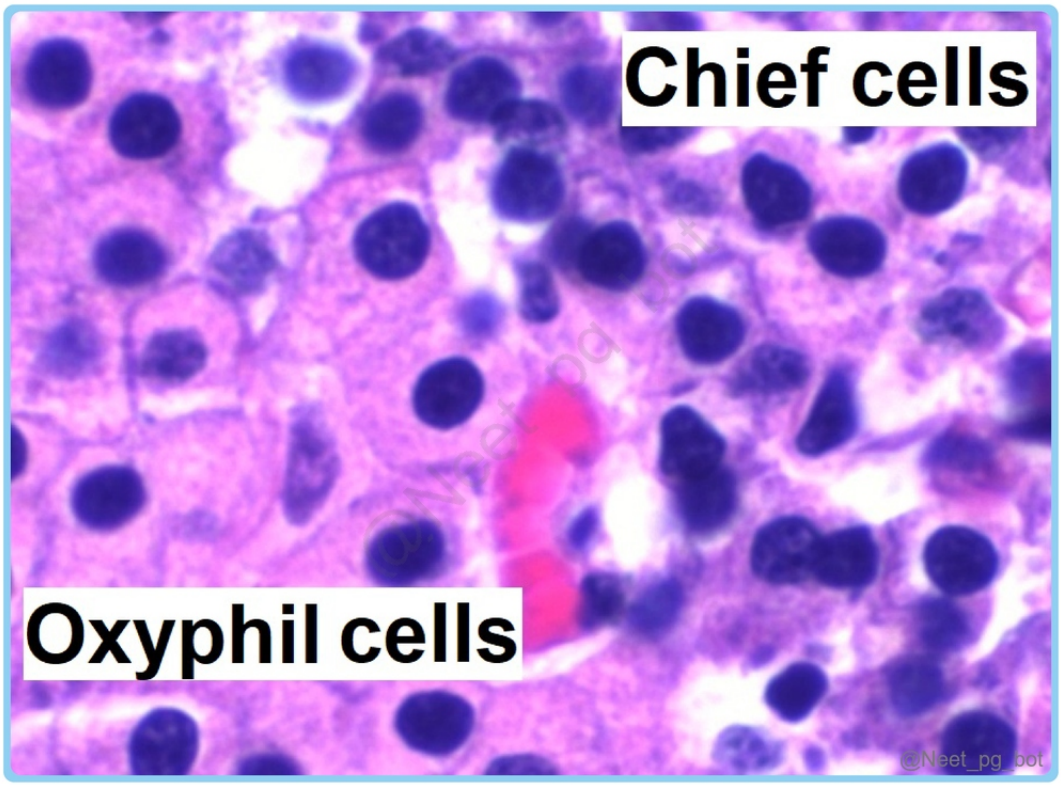

References:

Inderbir Singh Textbook of Human Histology, 9th Edition, Page 423, 426, 427, 428, 429.

↑ *Back to this question in Part A*

@Neet_pg_bot

Q14: Which of the following statements with respect to histology of alveoli is incorrect? (Q848151)

A. The most abundant cell type lines form 70-90% of the alveolar surface and are of simple squamous type

B. Type II alveolar epithelial cells are microvilli containing cells which secrete surfactant similar to that of Clara cells

C. In some alveolar area, basement membrane of the endothelium fuses with that of the alveolar epithelium

D. Type I alveolar epithelial cells are involved in replacing the damaged type II alveolar cells

Correct Answer: D. Type I alveolar epithelial cells are involved in replacing the damaged type II alveolar cells

■ *Listen (English)*

■ *Listen (Hindi)*

Explanation: T ype II alveolar epithelial cells are involved in replacing the damaged type I alveolar cells , not vice versa. Type I Alveolar Epithelial Cells Simple squamous cells, cover 90% of alveolar surface (Option A) Main site of gas exchange Type II Alveolar Epithelial Cells Rounded secretory cells with microvilli Secrete pulmonary surfactant, can replace Type I cells (Option B) Capillary basement membrane can fuse with alveolar basement membrane at certain places (Option C)

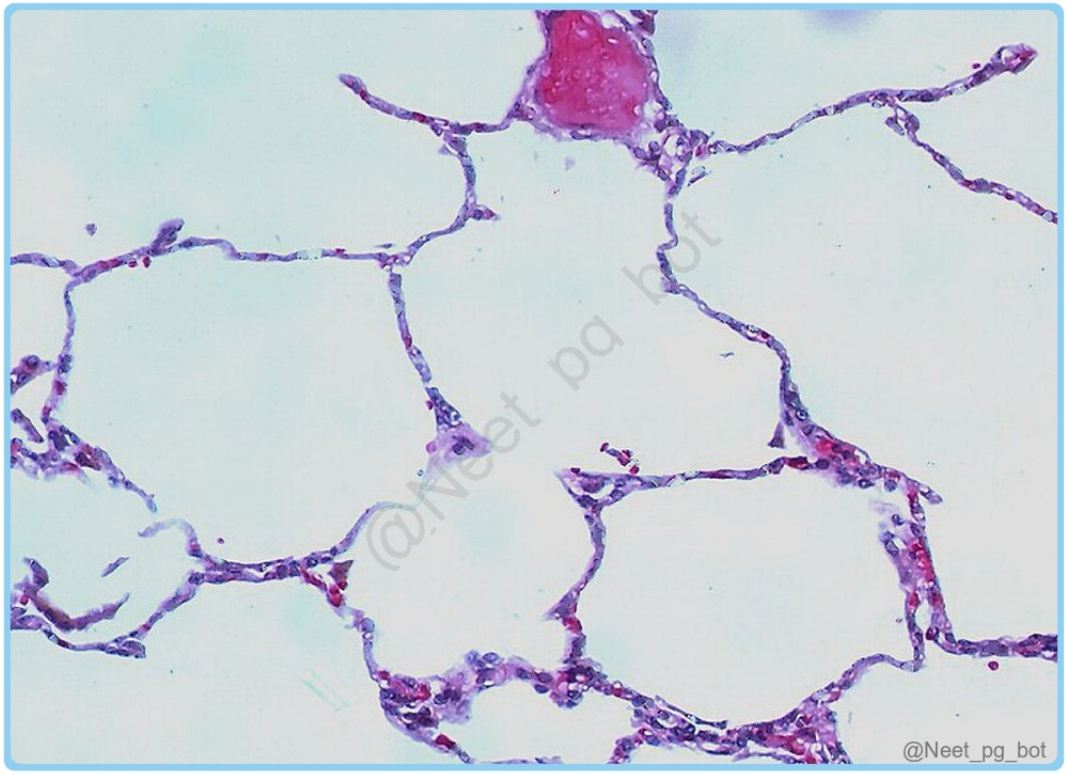

References:

Inderbir Singh Textbook of Human Histology, 9th Edition, Pages 382, 385-386.

↑ *Back to this question in Part A*

@Neet_pg_bot

Q15: A 45-year-old patient presents with chronic cough and shortness of breath. Bronchoscopy is performed, and a biopsy of the bronchial wall is taken. Histological examination reveals an epithelium with tall columnar cells bearing cilia on their apical surface, interspersed with goblet cells. Which part of the respiratory tract is most likely represented by this biopsy? (Q848150)

A. Trachea

B. Terminal bronchioles

C. Respiratory bronchioles

D. Alveoli

Correct Answer: A. Trachea

■ *Listen (English)*

■ *Listen (Hindi)*

Explanation: The epithelium described in the question- tall columnar cells with cilia and interspersed goblet cells- is characteristic of the trachea and principal bronchi. Epithelium in Respiratory Tract Location Type of Epithelium Description Trachea and Main Bronchi Pseudostratified ciliated columnar Tall columnar cells with cilia, goblet cells present Terminal Bronchioles (Option B) Simple ciliated columnar/cuboidal Single layer of cuboidal cells, some ciliated cells, no goblet cells, Clara cells Respiratory Bronchioles (Option C) Simple ciliated cuboidal to simple squamous Single layer of ciliated cuboidal cells or single layer of simple squamous, no goblet cells, Clara cells Alveoli (Option D) Simple squamous Thin, flat cells for efficient gas exchange Respiratory System Histology (Cross-Sections):

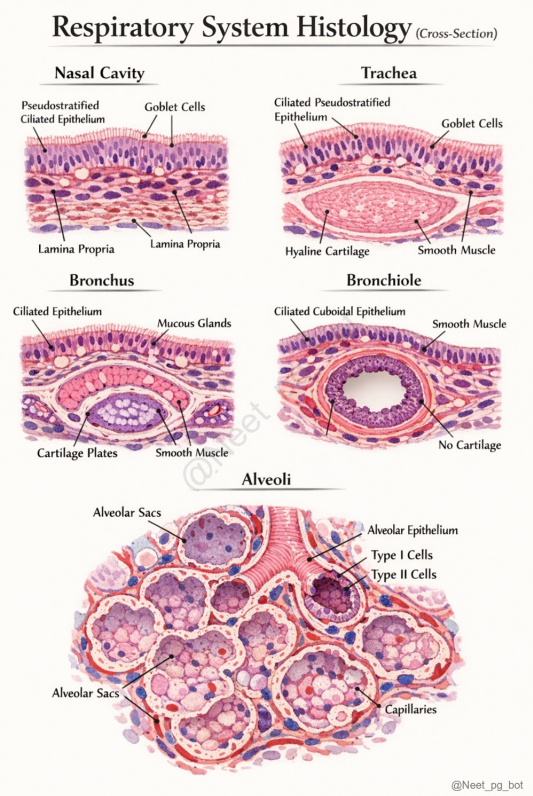

References:

Wheater’s Functional Histology, 6th Edition, Pages 236-232.

↑ *Back to this question in Part A*

@Neet_pg_bot

Q16: Which histological feature most accurately describes the epithelium responsible for mucociliary clearance in the upper respiratory tract? (Q848149)

A. Stratified squamous epithelium, non-keratinized

B. Pseudostratified ciliated columnar epithelium with goblet cells

C. Simple cuboidal epithelium with Clara cells

D. Simple squamous epithelium with alveolar macrophages

Correct Answer: B. Pseudostratified ciliated columnar epithelium with goblet cells

■ *Listen (English)*

■ *Listen (Hindi)*

Explanation: The epithelium responsible for mucociliary clearance in the upper respiratory tract is the respiratory epithelium. The respiratory epithelium is predominantly composed of pseudostratified ciliated columnar epithelium with numerous goblet cells in the trachea and larger bronchi, which is essential for mucociliary clearance. Stratified squamous epithelium, non-keratinized (Option A): Found in areas subjected to mechanical stress, like the oropharynx, but lacks the cilia and goblet cells needed for mucociliary clearance. Simple cuboidal epithelium with Clara cells (Option C): Found in terminal bronchioles, where Clara cells secrete surfactant-like substances, but this epithelium is not responsible for the primary mucociliary clearance in the larger airways. Simple squamous epithelium with alveolar macrophages (Option D): Found in the alveoli, this epithelium is thin to facilitate gas exchange, while alveolar macrophages perform phagocytosis of debris. It does not participate in mucociliary clearance.

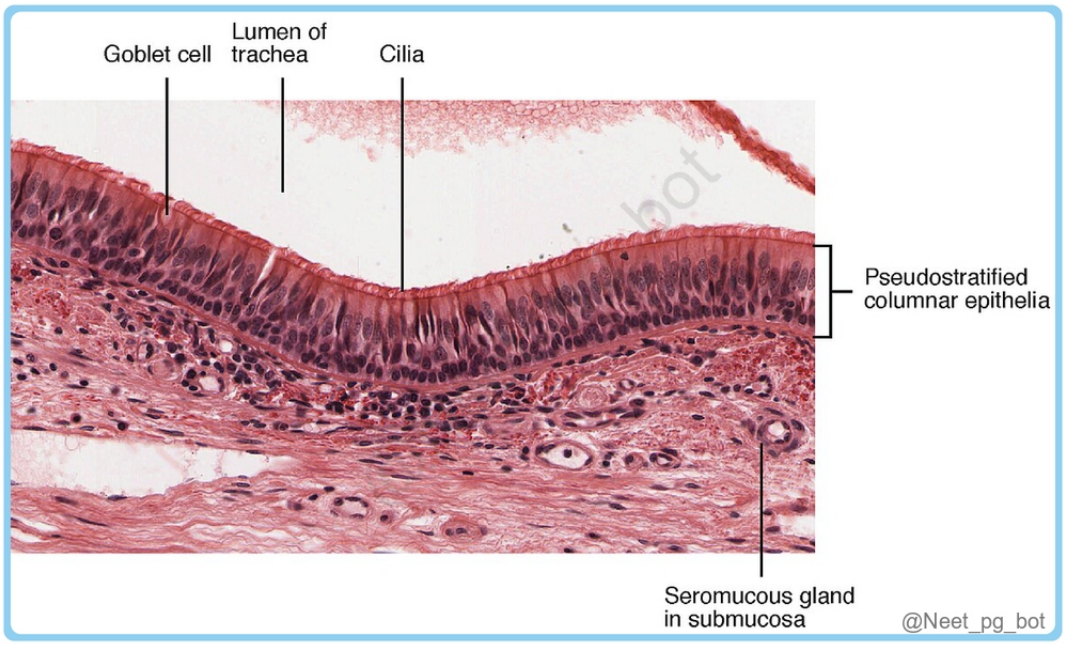

References:

Inderbir Singh Textbook of Human Histology, 9th Edition, Pages 371-373.

↑ *Back to this question in Part A*

@Neet_pg_bot

Q17: A 30-year-old man presents with difficulty swallowing and a mild hoarse voice. Examination reveals no significant findings, and imaging shows no abnormal masses in the oropharynx. A biopsy is taken from a structure in the oropharynx that histologically shows a mixture of stratified squamous epithelium and pseudostratified columnar epithelium. This structure also contains seromucous glands and an elastic cartilage core. Which of the following structures is most likely biopsied? (Q848137)

A. Hard palate

B. Soft palate

C. Epiglottis

D. Vocal cords

Correct Answer: C. Epiglottis

■ *Listen (English)*

■ *Listen (Hindi)*

Explanation: The structure biopsied in this scenario is the epiglottis. Histology of the Epiglottis: The epiglottis is a leaf-shaped structure that serves as a flap during swallowing, closing the laryngeal inlet to prevent food from entering the airway. Its upper surface is covered by stratified squamous epithelium (in the area exposed to mechanical wear from food), while the lower surface (facing the airway) has pseudostratified ciliated columnar epithelium (respiratory epithelium). The core of the epiglottis contains elastic cartilage , which provides flexibility and support. There are seromucous glands present, especially in the lamina propria, which help keep the surface moist. Epiglottis Histology of the Palate: The hard palate is lined by keratinized stratified squamous epithelium on its oral side, with a bony core. It lacks elastic cartilage and respiratory epithelium. (Option A) The soft palate has a surface of non-keratinized stratified squamous epithelium on the oral side, and pseudostratified columnar ciliated epithelium on the nasal side. Unlike the epiglottis, the core of the soft palate consists of skeletal muscle rather than cartilage. (Option B) Palate Vocal cords (Option D) : The true vocal cords are lined by stratified squamous epithelium , but they lack pseudostratified columnar epithelium and elastic cartilage. Instead, they have a ligamentous core (vocal ligament) and skeletal muscle (vocalis muscle).

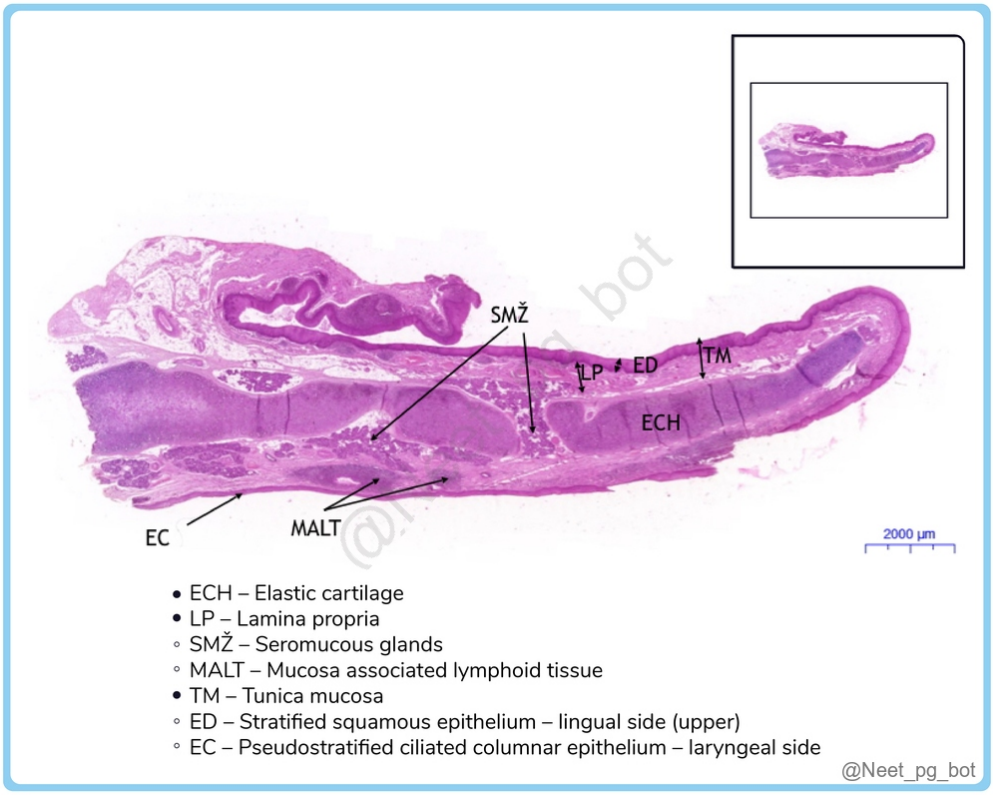

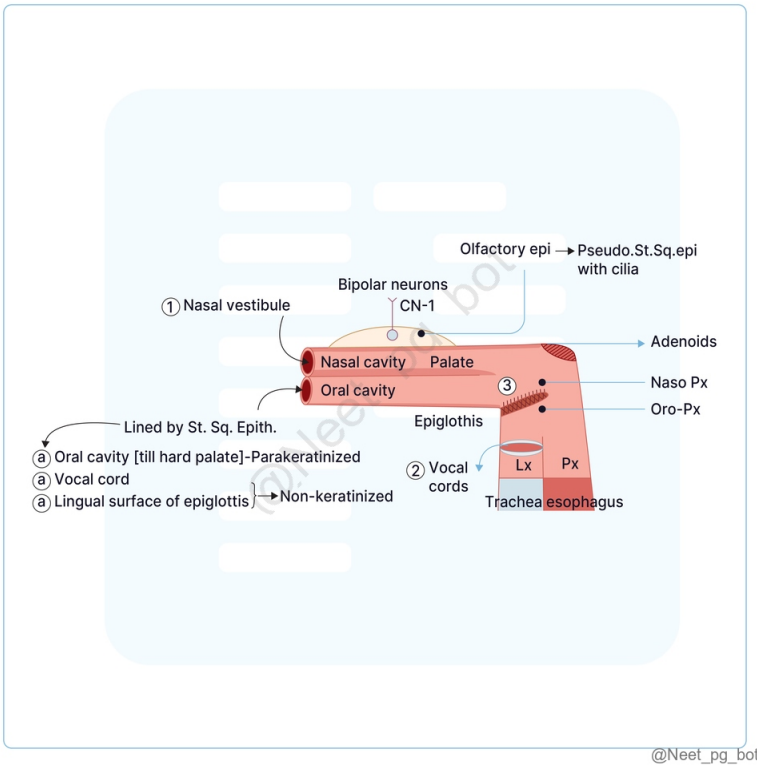

References:

Inderbir Singh's Textbook of Human Histology, 9th Edition, Page 370, 373, 374.

↑ *Back to this question in Part A*

@Neet_pg_bot

Q18: Identify the type of tissue shown in the image below: (Q848136)

A. Smooth muscle

B. Skeletal muscle

C. Cardiac muscle

D. Purkinje fibers

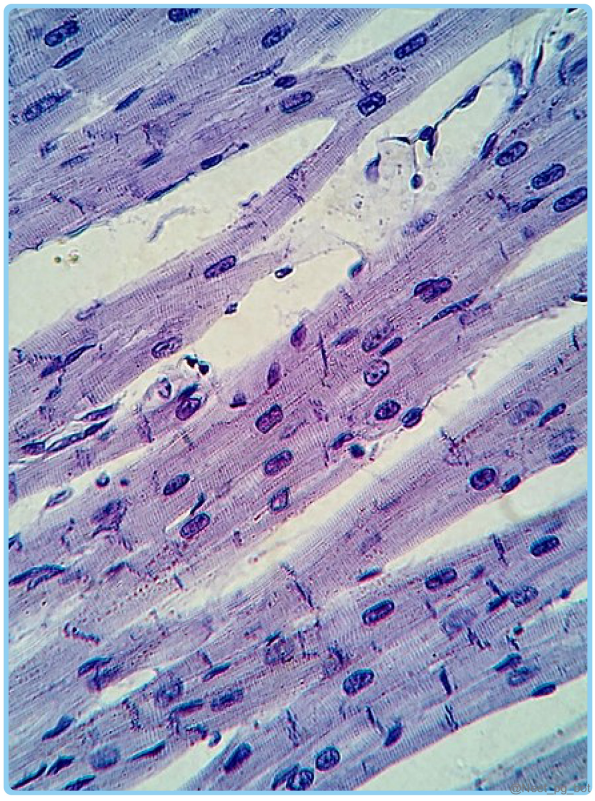

Correct Answer: C. Cardiac muscle

■ *Listen (English)*

■ *Listen (Hindi)*

Explanation: The image shows a tissue section with the following key histological features: Branched and striated fibers Centrally located nuclei Intercalated discs (seen as dark transverse lines) One or two nuclei per cell These features are characteristic of cardiac muscle tissue . Skeletal Muscle Cardiac Muscle Smooth Muscle Longitudinal Section : Fibers are long, parallel, and non-branching . Characteristic transverse striations are visible. Multiple flat nuclei located at the periphery . Fibers are separated by connective tissue (Epimysium, perimysium, endomysium).

Composed of individual cells with centrally placed nuclei . Displays transverse striations. Clear perinuclear halo around the nucleus. Cells are separated by intercalated discs (transverse lines). Fibers exhibit branching. Blood vessels are present. Loose connective tissue is seen above and below muscle layers. Longitudinal Section : Fibers are spindle-shaped with tapering ends . Centrally located elongated nucleus . No visible striations. Purkinje fibers (Option D): Purkinje fibers are a specialized type of cardiac conducting fiber , larger , pale-staining , and often lack prominent striations . They are not the dominant feature in this section.

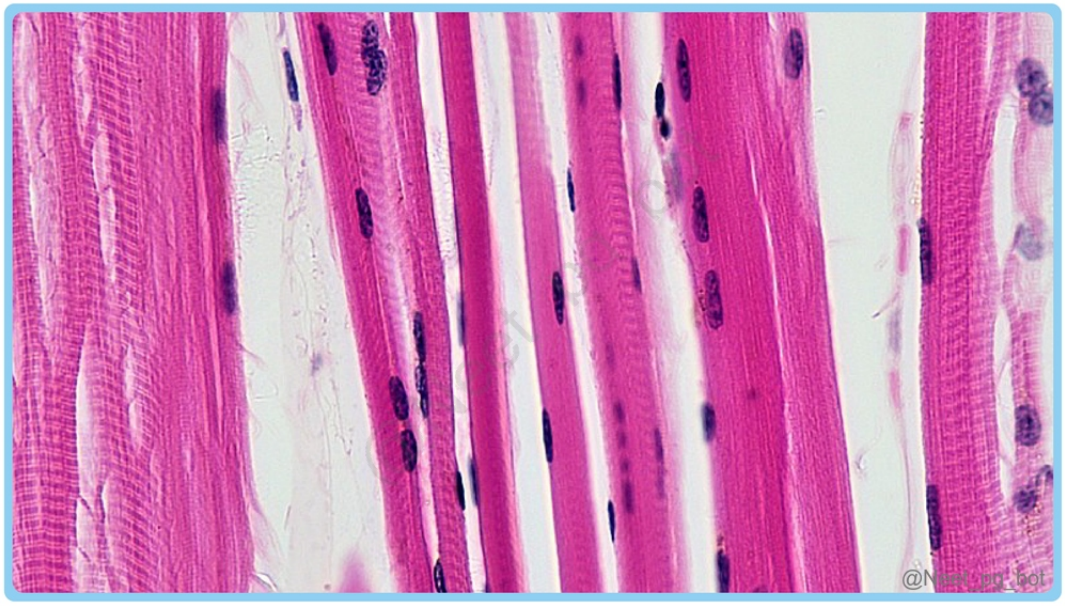

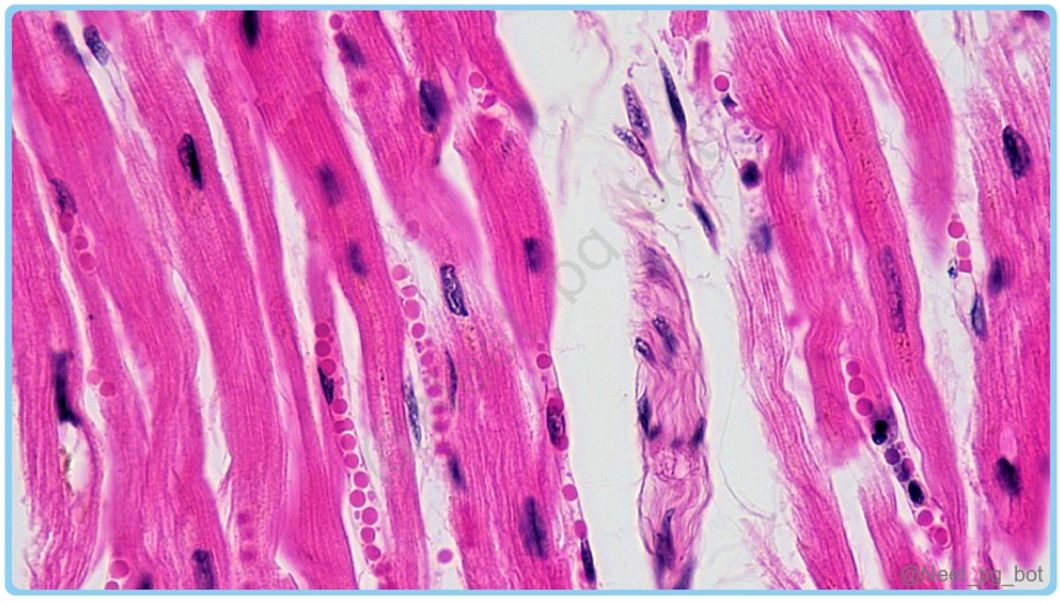

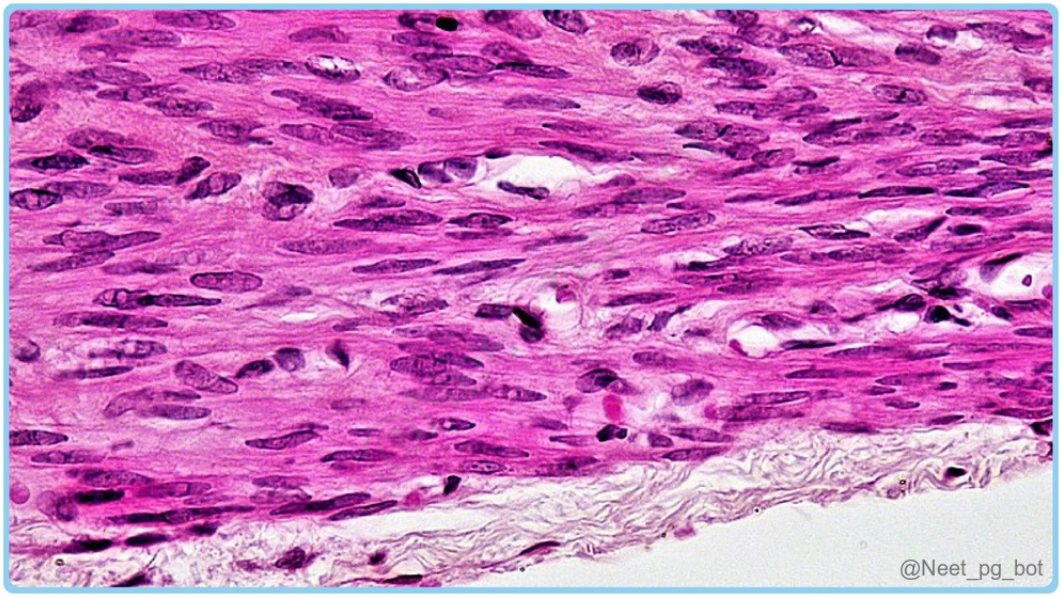

References:

Inderbir Singh's Textbook of Human Histology, 9th Edition, Page 208, 210, 222, 228, 229.

↑ *Back to this question in Part A*

@Neet_pg_bot

Q19: A 45-year-old woman presents with signs of progressive muscle weakness and fatigue. She is diagnosed with a rare genetic disorder affecting intercellular communication in her skeletal and cardiac muscles. Genetic testing reveals a mutation in a connexin protein. Which of the following best describes the physiological consequence of this mutation? (Q848135)

A. Impaired electrical signal propagation between cardiac myocytes

B. Disruption of epithelial barrier function

C. Reduced mechanical stability between cells

D. Abnormal attachment of muscle fibers to the extracellular matrix

Correct Answer: A. Impaired electrical signal propagation between cardiac myocytes

Explanation: Gap junctions, also called macula communicans, are specialized cell structures that facilitate direct communication between adjacent cells. Features of gap junctions: Connexons : Each channel is made of six connexin proteins that align between two cells to create a passage for substances like sodium, potassium, calcium, and small molecules. Electrical Communication : In tissues like cardiac and nerve cells, gap junctions enable rapid

transmission of electrical impulses for synchronized function. Regulation : The channels can close in response to changes in pH or calcium levels, controlling the communication between cells. Disruption of epithelial barrier function (Option B) : This is characteristic of defects in tight junctions (zonula occludens), which prevent paracellular leakage between epithelial cells. Tight junctions are unrelated to connexin proteins. Reduced mechanical stability between cells (Option C) : This describes the role of desmosomes , which provide structural integrity by linking intermediate filaments between cells. Desmosomes are crucial for mechanical stress resistance but have no role in direct cell communication. Abnormal attachment of muscle fibers to the extracellular matrix (Option D) : This refers to hemidesmosomes or integrins , which anchor cells to the basement membrane or extracellular matrix. These structures are involved in cell adhesion rather than communication through gap junctions.

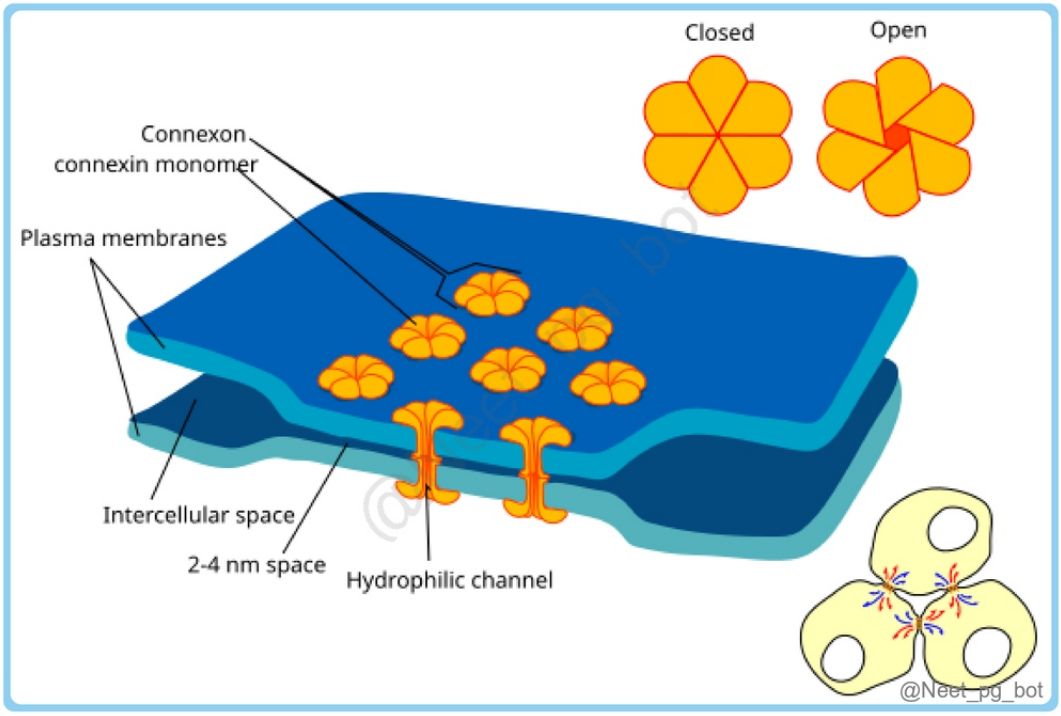

References:

Victor P. Eroschenko, Atlas of Histology with Functional Correlations,13th Edition, Page 88.

IB Singh Histology, 9th Edition, Chapter 2, Cellular Junctions, Communicating (Gap) Junction.

↑ *Back to this question in Part A*

@Neet_pg_bot

Q20: In the provided image of epithelial cell junctions, identify the correct sequence of junctions from the apical to the basal surface: (Q848134)

A. A- Adherens junction, B- Tight junction, C- Desmosome, D- Hemidesmosome, E- Gap junction

B. A- Tight junction, B- Adherens junction, C- Desmosome, D- Gap junction, E- Hemidesmosome

C. A- Desmosome, B- Tight junction, C- Hemidesmosome, D- Adherens junction, E- Gap junction

D. A- Hemidesmosome, B- Gap junction, C- Adherens junction, D- Tight junction, E- Desmosome

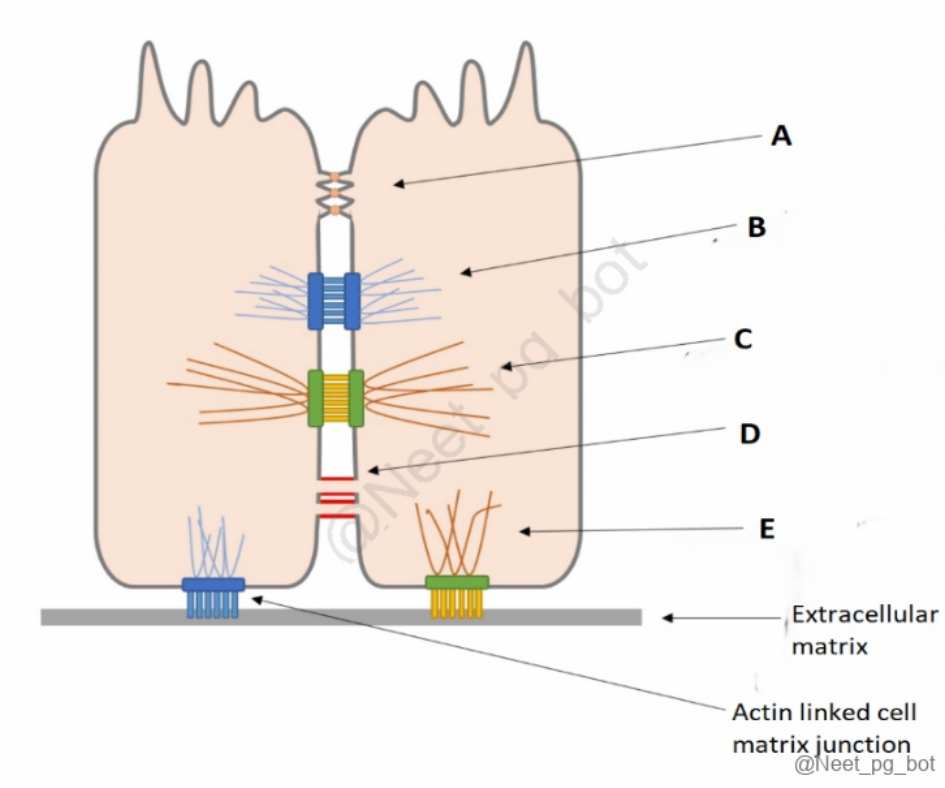

Correct Answer: B. A- Tight junction, B- Adherens junction, C- Desmosome, D- Gap junction, E- Hemidesmosome

■ *Listen (English)*

■ *Listen (Hindi)*

Explanation: The sequence of junctions from apical to basal is: Tight junctions (Zonula occludens) Adherens junctions (Zonula adherens) Desmosomes (Macula adherens) Gap junctions Hemidesmosomes

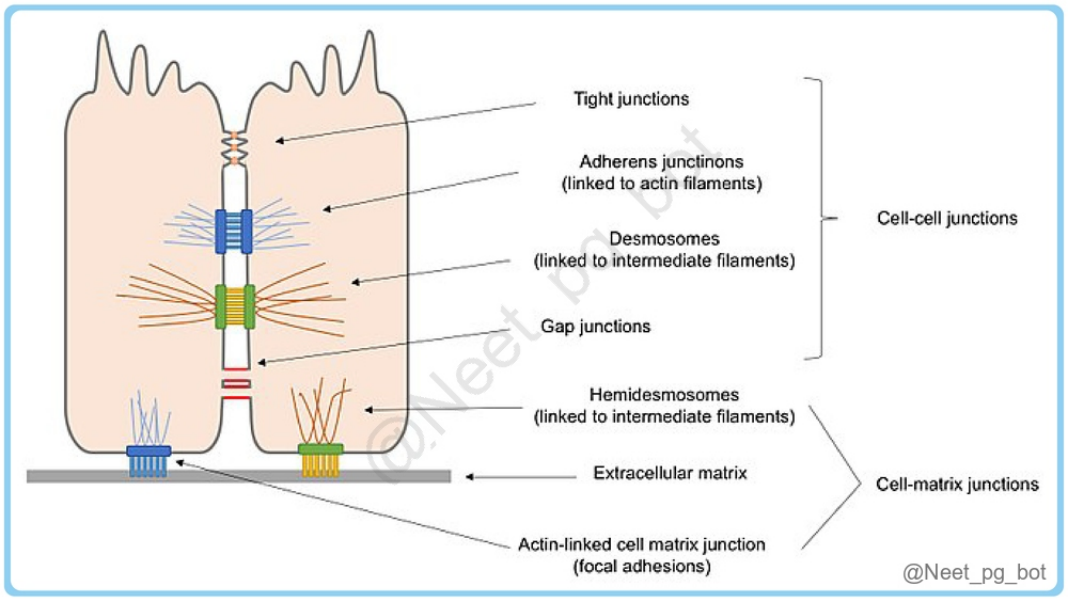

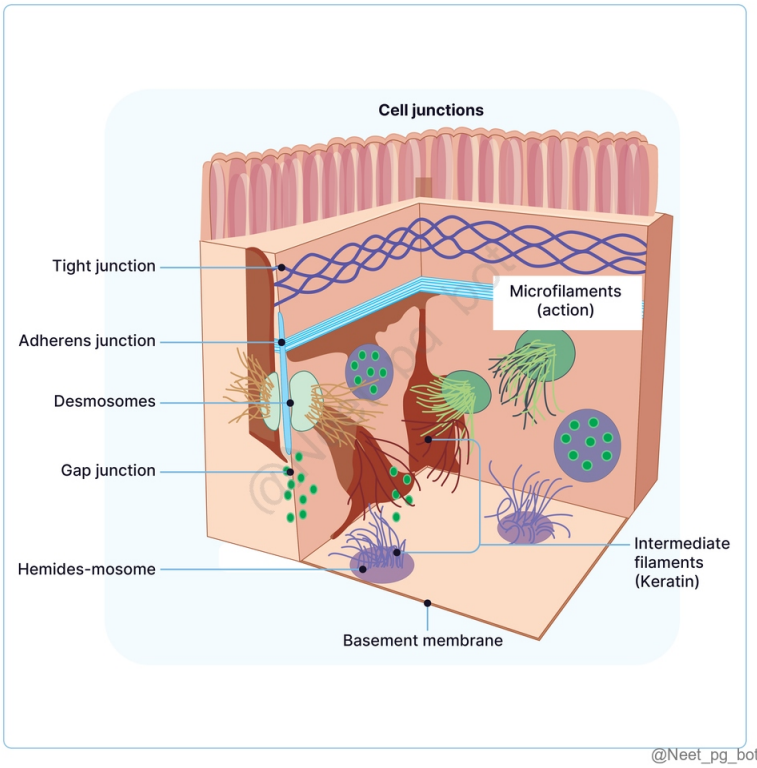

References:

Victor P. Eroschenko, Atlas of Histology with Functional Correlations,13th Edition, Page 86-88.

↑ *Back to this question in Part A*

@Neet_pg_bot

• [02_Histology] 007 Previous Year Questions

« Back to Folder Directory

[02_Histology] 007 Previous Year Questions — Quick Jump

Q1 (p. 810)	*Q2 (p. 811)*	*Q3 (p. 812)*	*Q4 (p. 815)*	*Q5 (p. 817)*	*Q6 (p. 820)*
Q7 (p. 822)	*Q8 (p. 824)*	*Q9 (p. 827)*	*Q10 (p. 828)*	*Q11 (p. 829)*	*Q12 (p. 830)*
Q13 (p. 830)	*Q14 (p. 832)*	*Q15 (p. 834)*	*Q16 (p. 838)*	*Q17 (p. 840)*	*Q18 (p. 841)*
Q19 (p. 842)	*Q20 (p. 843)*	*Q21 (p. 844)*	*Q22 (p. 848)*	*Q23 (p. 853)*	*Q24 (p. 855)*

Q1: Identify which of the following structure is a merocrine gland: (Q855430)

A. 1

B. 2

C. 3

D. 4



Correct Answer: B. 2

Explanation: Merocrine glands, also referred to as eccrine glands, release their secretions through the cell membrane via exocytosis, without any loss of cellular material. These glands are the most common type of sweat gland, particularly abundant on the palms, soles, and forehead. They are crucial for thermoregulation, as they secrete sweat that evaporates from the skin, helping to cool the body and maintain temperature balance. 1- Hair shaft; 2- Merocrine glands ; 3- Sebaceous gland; 4- Inner root sheath Feature Merocrine Glands Apocrine Glands Holocrine Glands Other Name Eccrine glands Modified sweat glands (e.g., mammary glands) - Cell Membrane Integrity Membrane is intact Secretions covered by cell membrane Entire cell membrane is lost Secretions Released without loss of cell membrane Released along with apical part of cell membrane Whole cell is lost; becomes sebum Mechanism of Secretion Exocytosis Blebs are formed; secretion is part of the cell membrane Breakdown of entire cell, organelles become secretions Examples Salivary glands Mammary gland (modified sweat gland) Sebaceous glands Function Thermoregulation (e.g., sweat) Involved in secretion of milk (in modified sweat glands) Lubrication of skin (sebum secretion)

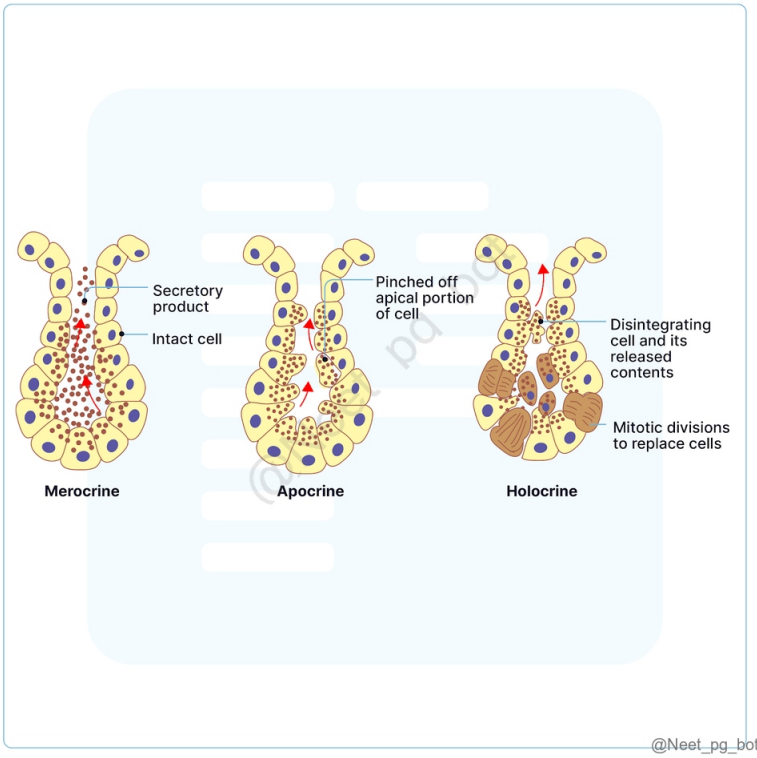

References:

Fitzpatrick’s Dermatology, 9th edition, Page 104

↑ *Back to this question in Part A*

@Neet_pg_bot

Q2: Which of the following does not have an endocrine component? (Q879163)

Correct Answer: Unknown

Explanation: The uterus does not produce hormones , it only responds to hormones (estrogen, progesterone, oxytocin). Organ Endocrine component Comments Testis (1) Leydig cells → testosterone Both endocrine (Leydig) and exocrine (sperm production) Uterus (2) None It is hormonally responsive , not hormone-producing. No endocrine tissue. Ovary (3) Follicular & luteal cells → estrogen & progesterone Mixed endocrine & exocrine (ova release) Pancreas (4) Islets of Langerhans → insulin, glucagon, somatostatin Mixed endocrine & exocrine

References:

Junqueira’s Basic Histology, 15th Edition, Pages 428, 440, 469, 471.

↑ *Back to this question in Part A*

@Neet_pg_bot

Q3: Identify the cartilage given below (Q856074)

A. Non-articular hyaline cartilage

B. Articular hyaline cartilage

C. Yellow cartilage

D. White fibrocartilage

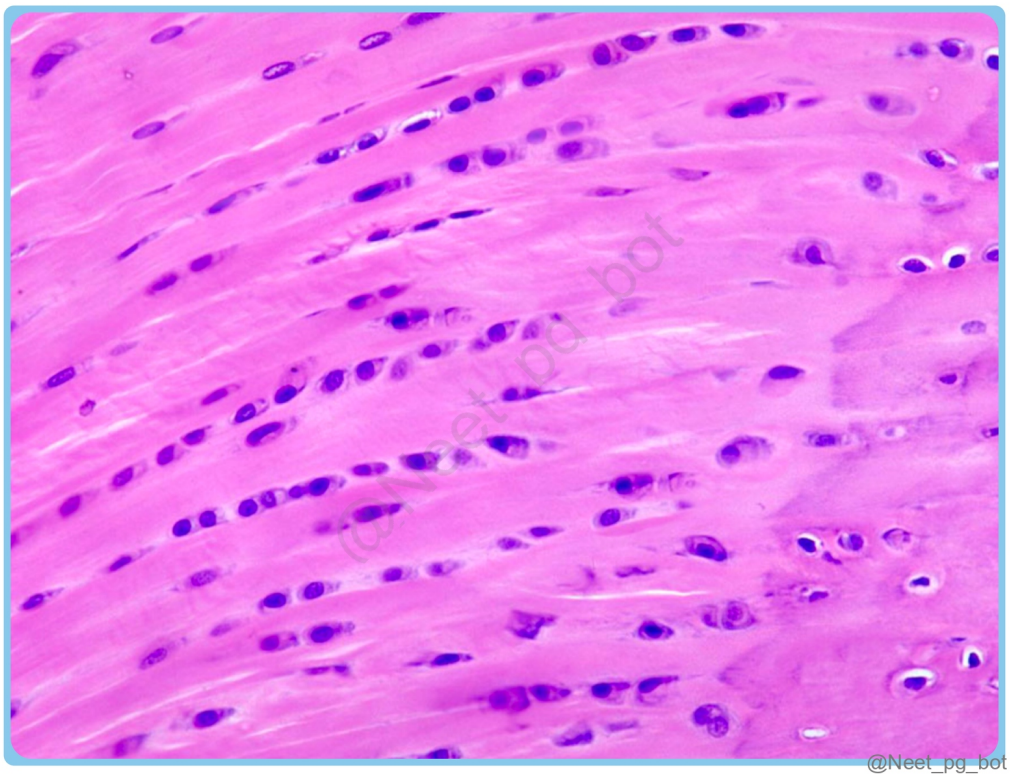

Correct Answer: D. White fibrocartilage

Explanation: It is a cartilage with collagen fibers arranged in parallel bundles, giving it its characteristic strength and unbending nature. White fibrocartilage is found in zones of the body where strength and support are required, such as the intervertebral discs, pubic symphysis, and menisci of the knee. Types of Cartilage Characteristic Hyaline Cartilage (Most Common) (Options A, B) Elastic Cartilage (Yellow cartilage) (Option C) Fibrocartilage Matrix appearance Homogeneous, basophilic Contains elastic fiber network Numerous collagen bundles Chondrocyte arrangement Groups (cell nests/isogenous groups) Similar to hyaline Single rows or isogenous groups Perichondrium Present (except in articular cartilage) Present Absent Main fibre type Type II collagen Elastic fibers Type I (primarily) and Type II collagen Main functions Structural support forms articular surfaces Provides flexibility and resilience Resists compression and shearing, shock absorption Examples Costal cartilage, tracheal rings, articular cartilage Auricle, epiglottis, auditory tube Intervertebral discs, menisci {{caption_text}} {{caption_text}} {{caption_text}}

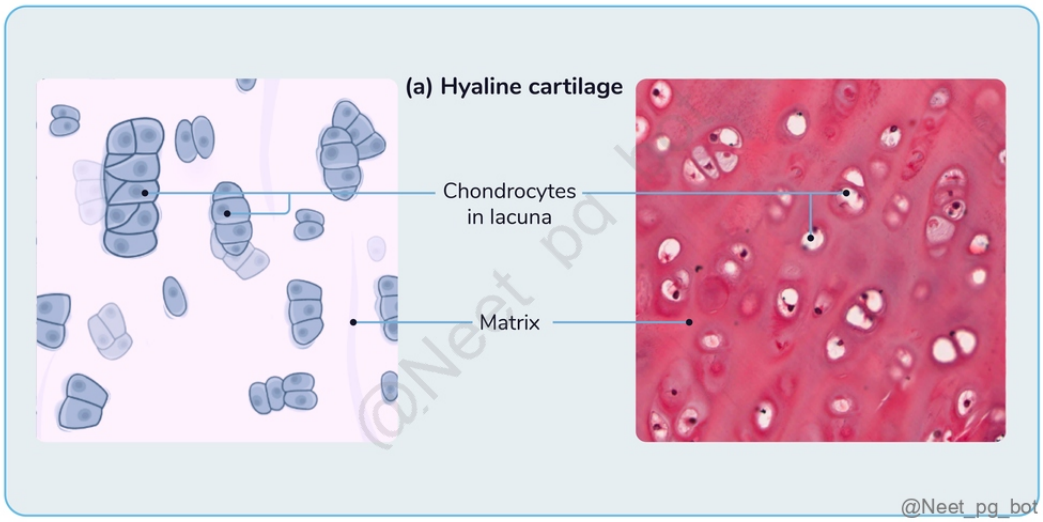
(a) Hyaline cartilage
Chondrocytes in lacuna
Matrix
@Neet_pg_bot

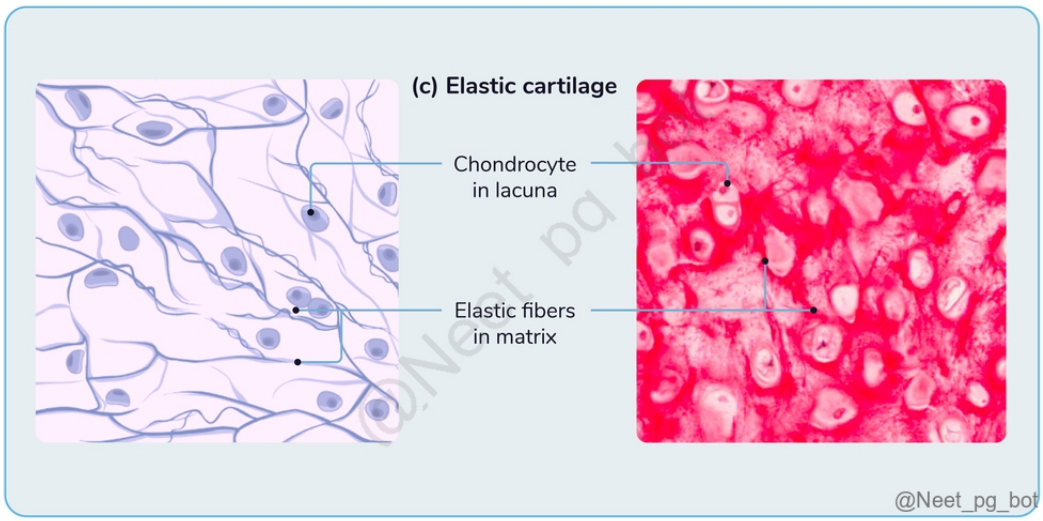
(c) Elastic cartilage
Chondrocyte in lacuna
Elastic fibers in matrix
@Neet_pg_bot

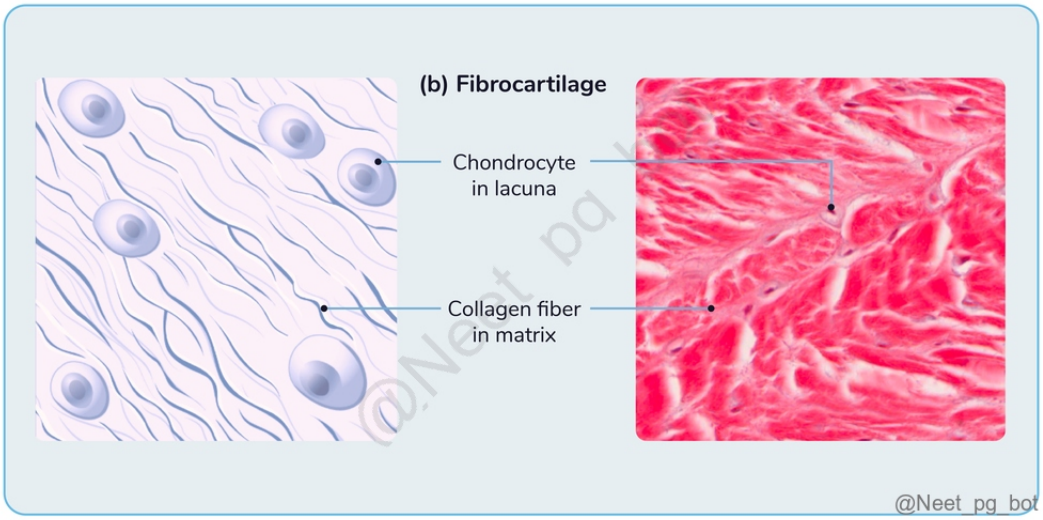
(b) Fibrocartilage
Chondrocyte in lacuna
Collagen fiber in matrix
@Neet_pg_bot

References:

Inderbir Singh Histology 9th Edition Pg. 158-166

↑ *Back to this question in Part A*

@Neet_pg_bot

Q4: Identify the given structure. (Q856073)

A. Lymph node

B. Glomerulus

C. Spleen

D. Pancreatic islet cells

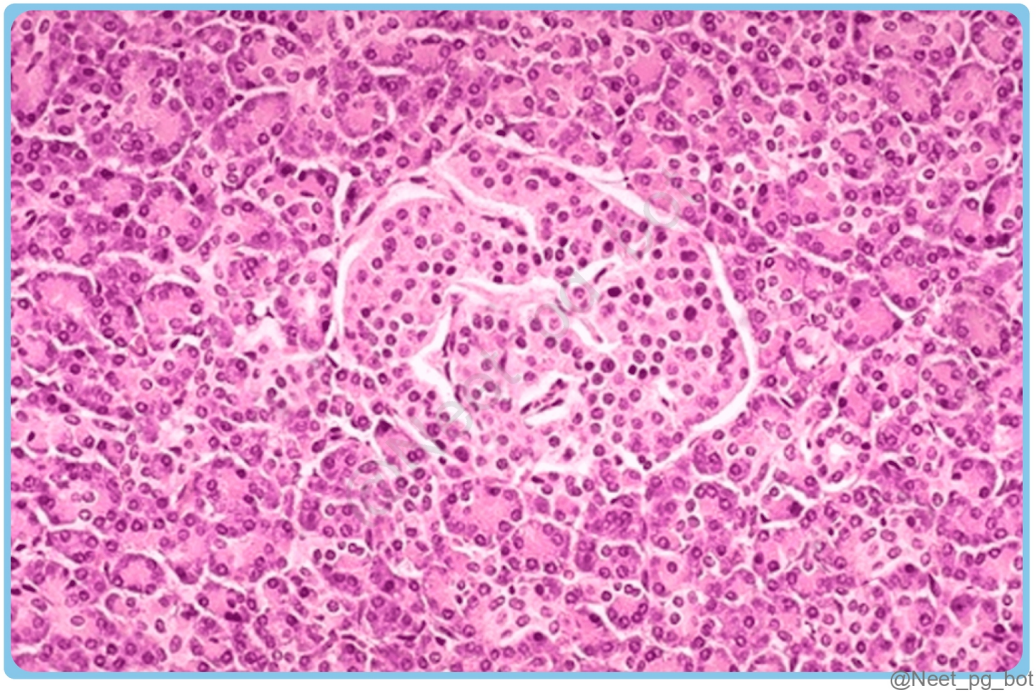

Correct Answer: D. Pancreatic islet cells

Explanation: Pancreatic islet cells are clusters of endocrine cells within the pancreas that secrete hormones such as insulin and glucagon. Pancreatic islet cells are also known as islets of Langerhans. Each islet comprises a few distinctive sorts of cells, including alpha, beta, delta, and PP cells that work together to direct blood glucose levels. The islet cells are organized in a round or unpredictably molded cluster and are encompassed by a thin layer of connective tissue. {{caption_text}} Lymph node (Option A): {{caption_text}} Glomerulus (Option B): {{caption_text}} Spleen (Option C): {{caption_text}}

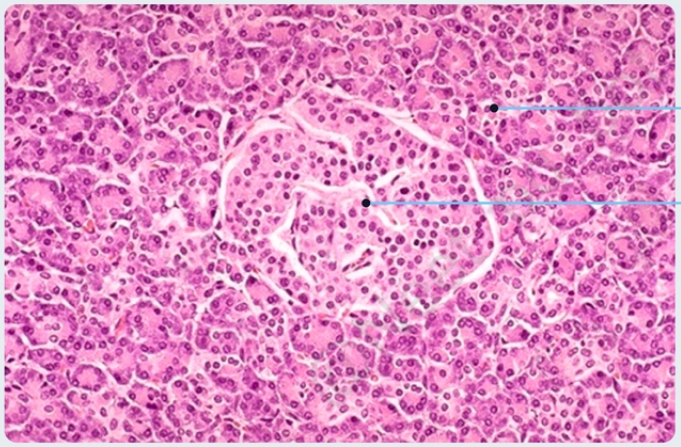

@Neet_pg_bot

Lymph Node

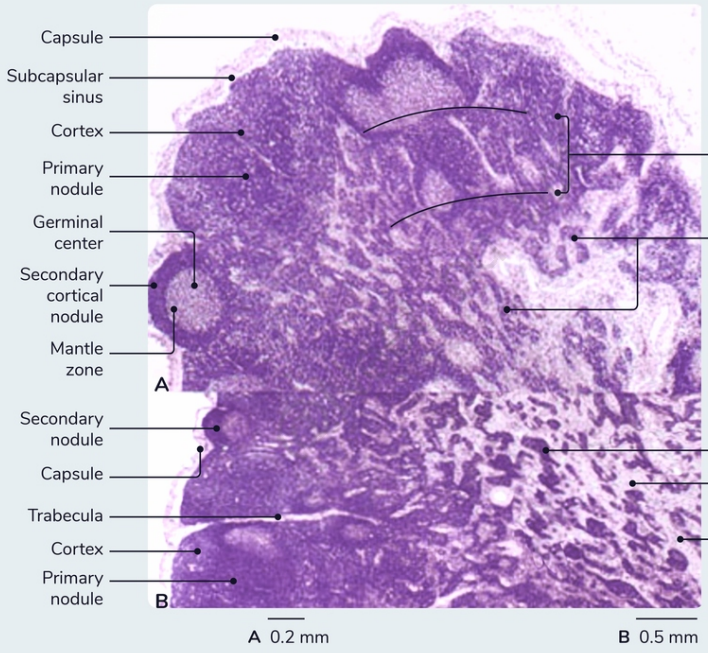

@Neet_pg_bot

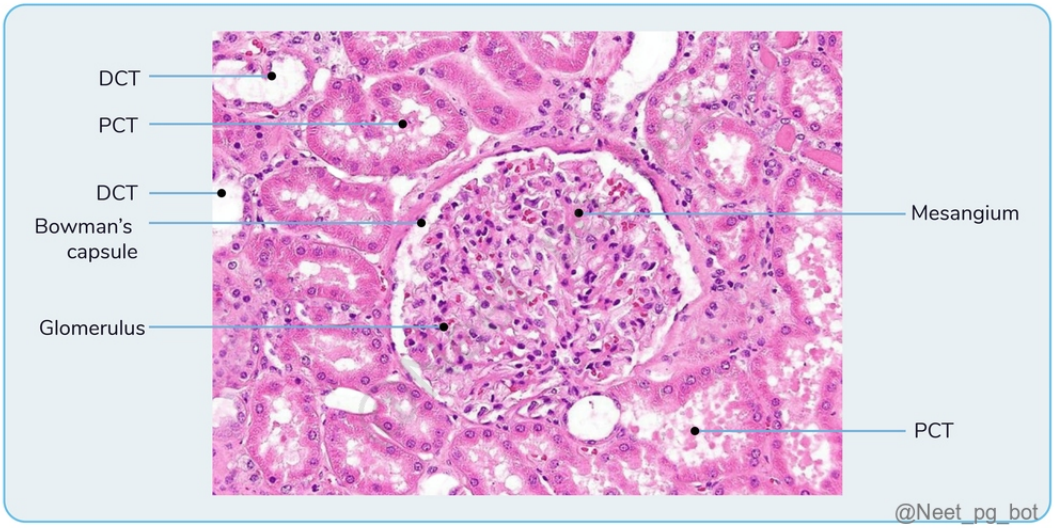

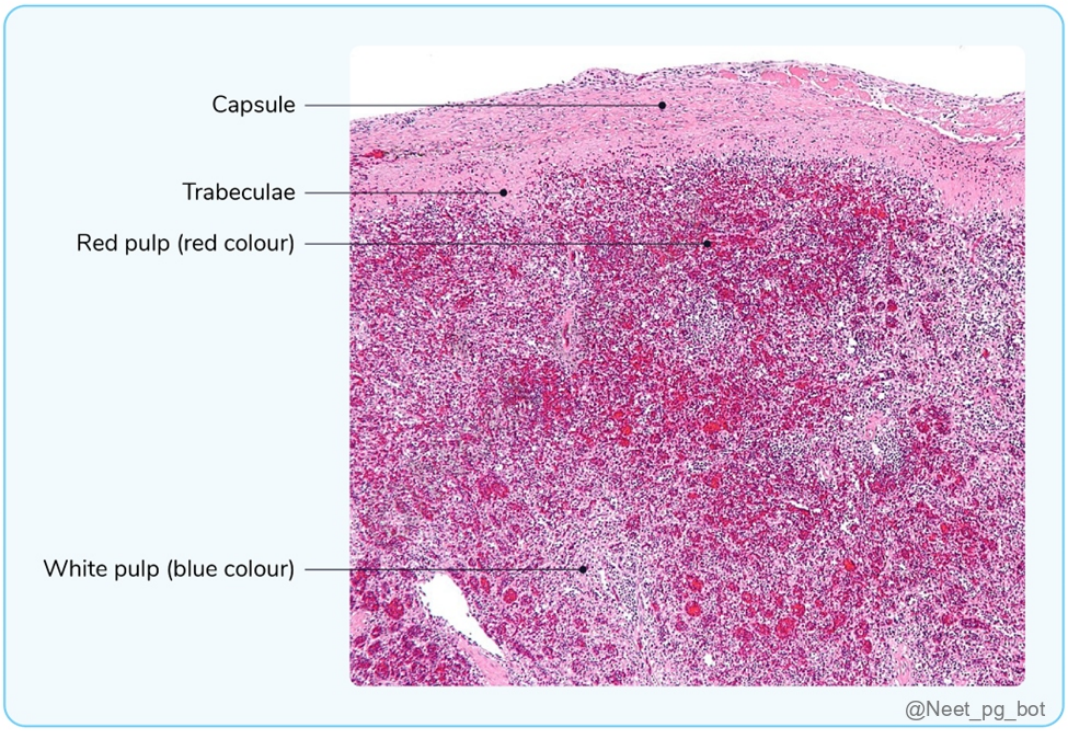

References:

https://pmc.ncbi.nlm.nih.gov/articles/PMC7565096/

↑ *Back to this question in Part A*

@Neet_pg_bot

Q5: Identify the cell marked in the histological image of the cerebellum shown below: (Q858478)

A. Purkinje cells

B. Basket cells

C. Golgi cells

D. Granule cell

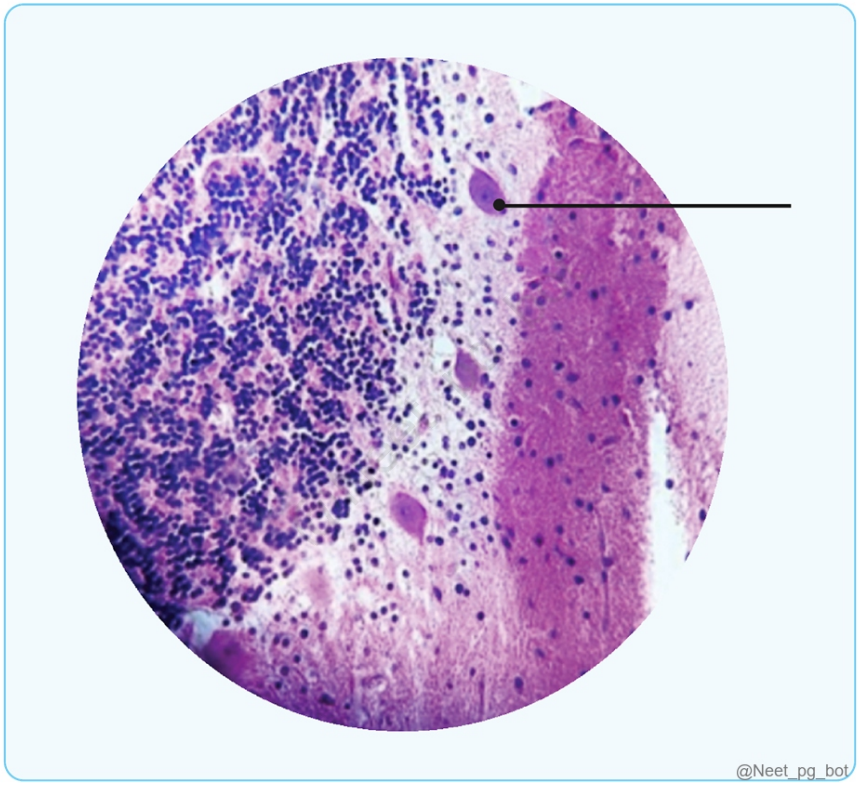

Correct Answer: A. Purkinje cells

Explanation: Purkinje cells are large, flask-shaped neurons located in the Purkinje layer of the cerebellar cortex . They have extensive dendritic trees that branch into the molecular layer and receive synaptic inputs from parallel fibers (granule cells) . These cells serve as the primary output neurons of the cerebellar cortex, sending inhibitory signals (GABAergic) to the deep cerebellar nuclei . The cerebellar cortex consists of the following three distinct layers: Layers of the cerebellar cortex Molecular (plexiform) layer Purkinje cell layer Granular layer It primarily contains numerous dendritic branches from Purkinje cells, with relatively few widely spaced nerve cells. It consists of a single row of large flask-shaped cells, the Purkinje cells . The inner granular layer is made up of many closely packed small granule cells , along with a few larger Golgi cells. These nerve cells are of two types: (a) Basket cells (b) Stellate cells. The axons of Purkinje cells are the only output from the cerebellar cortex and have an inhibitory effect on the intracerebellar nuclei. Golgi cells are inhibitory while the granular cells are excitatory. Among the five types of intrinsic neurons (Basket cells, Stellate cells, Purkinje cells, Granule cells and Golgi cells)- All are inhibitory except granule cells. {{caption_text}} {{caption_text}} Incorrect Options: Basket cells

(option B): Small inhibitory interneurons in the molecular layer of the cerebellum. Form synapses on the cell bodies of Purkinje cells , but are not flask-shaped. Golgi cells (option C): Inhibitory interneurons found in the granule layer . Provide feedback inhibition to granule cells but do not have the distinctive flask shape of Purkinje cells. Granule cells (option D): The smallest and most numerous neurons in the cerebellum, found in the granule cell layer . They excite Purkinje cells via parallel fibers but are not flask-shaped.

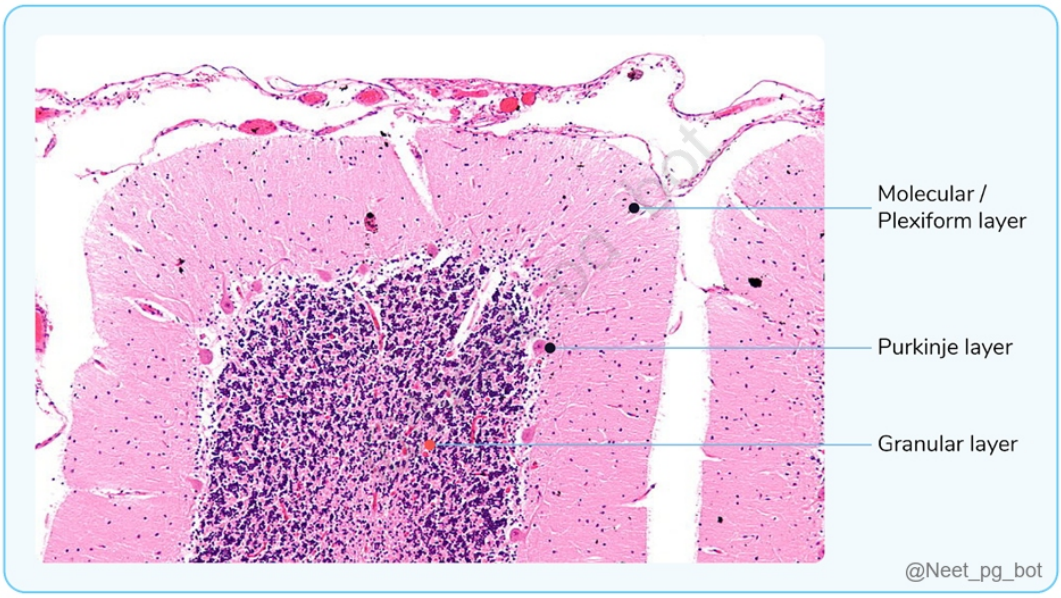

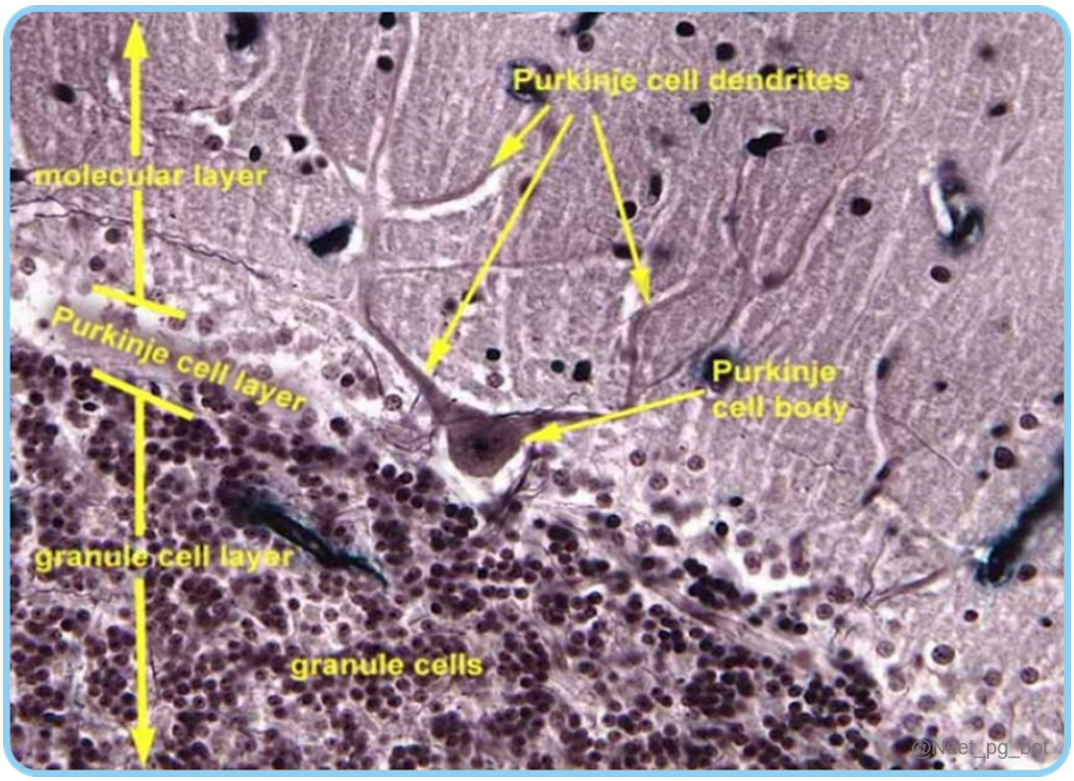

References:

Gray’s Anatomy, 42nd Edition, Pg.469,471

Textbook of Anatomy Vishram Singh, 2nd Edition, Volume 3, Pg.377

↑ *Back to this question in Part A*

@Neet_pg_bot

Q6: Identify the type of cartilage shown in the image below: (Q858471)

A. Hyaline cartilage

B. Elastic cartilage

C. Articular cartilage

D. Fibrocartilage

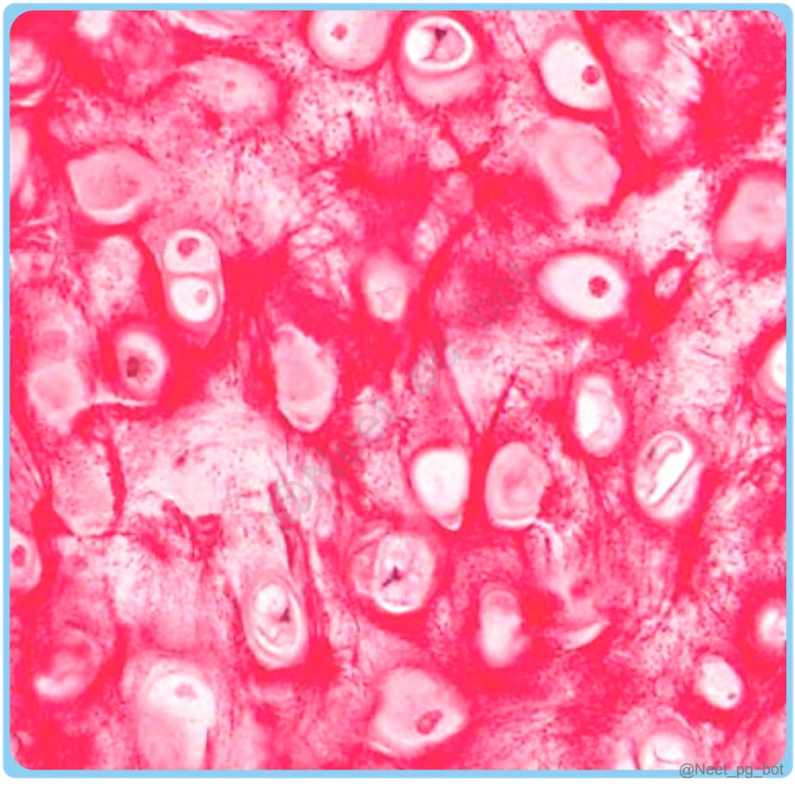

Correct Answer: B. Elastic cartilage

Explanation: The histological image shows numerous branching elastic fibers , which are characteristic of elastic cartilage . Elastic cartilage contains elastic fibers in the extracellular matrix , providing flexibility and resilience . It is found in structures requiring both strength and elasticity , such as: Auricle of the ear Epiglottis Eustachian tube Types of Cartilage Characteristic Hyaline Cartilage (Most Common) Elastic Cartilage Fibrocartilage Matrix appearance Homogeneous, basophilic Contains elastic fiber network Numerous collagen bundles Chondrocyte arrangement Groups (cell nests/isogenous groups) Similar to hyaline Single rows or isogenous groups

Perichondrium Present (except in articular cartilage) Present Absent Main fiber type Type II collagen Elastic fibers Type I (primarily) and Type II collagen Main functions Structural support, forms articular surfaces Provides flexibility and resilience Resists compression and shearing, shock absorption Examples Costal cartilage, tracheal rings, articular cartilage Auricle, epiglottis, auditory tube Intervertebral discs, menisci {{caption_text}} {{caption_text}} {{caption_text}} Incorrect Options: Hyaline cartilage (option A): Lacks elastic fibers and appears as a glassy, homogenous matrix . Found in articular surfaces, costal cartilages, trachea, and nasal septum . Articular cartilage (option C): A specialized type of hyaline cartilage covering joint surfaces . It lacks elastic fibers and has a smooth, glassy appearance . Fibrocartilage (option D): Contains dense collagen fibers but lacks elastic fibers . Found in intervertebral discs, pubic symphysis, and menisci .

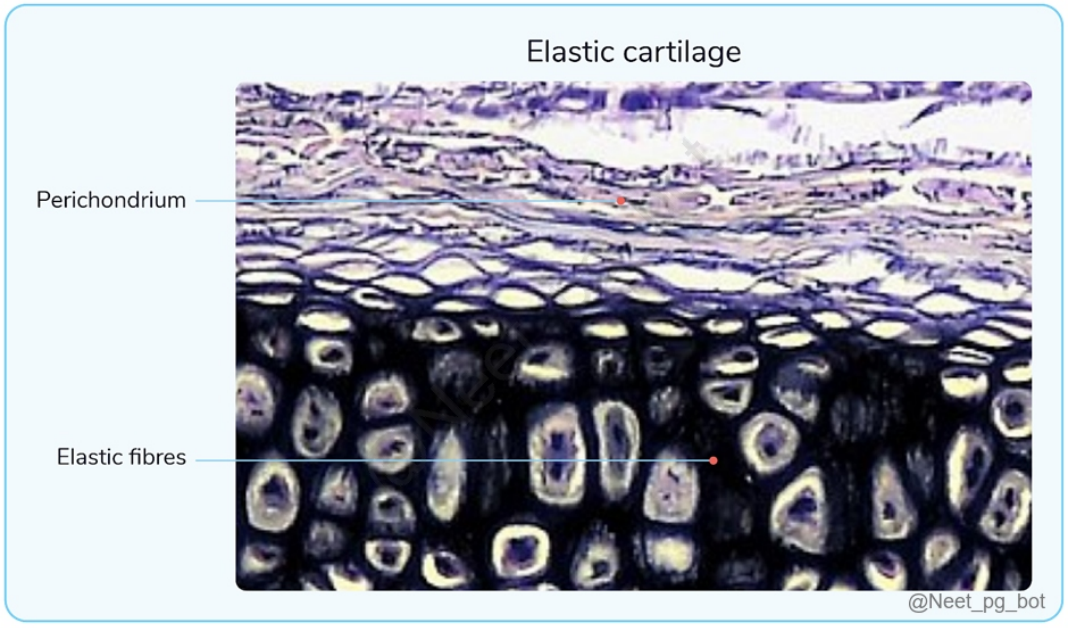

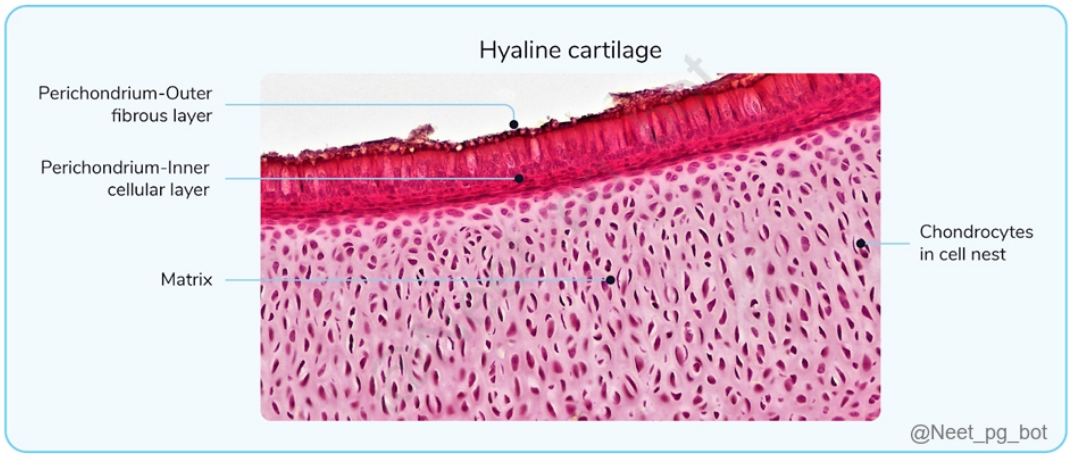

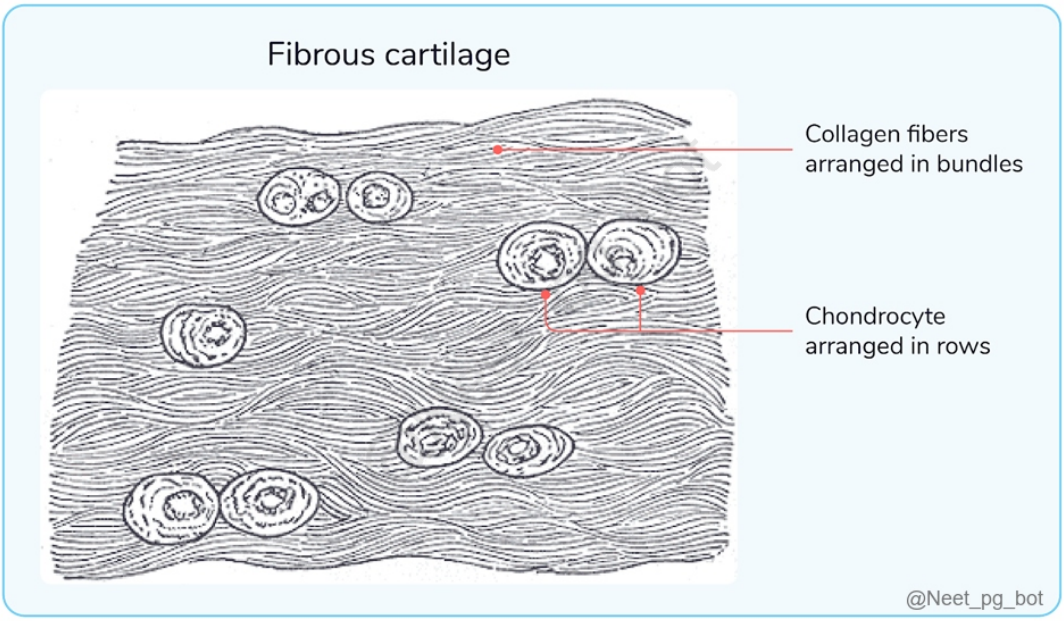

References:

Inderbir Singh Histology 9th Edition, Page 158-166

↑ *Back to this question in Part A*

@Neet_pg_bot

Q7: The cell marked in the below slide is inhibitory to (Q855788)

A. Deep nuclei of cerebellum

B. Vestibular nuclei

C. Inferior olivary nucleus

D. Basal ganglia

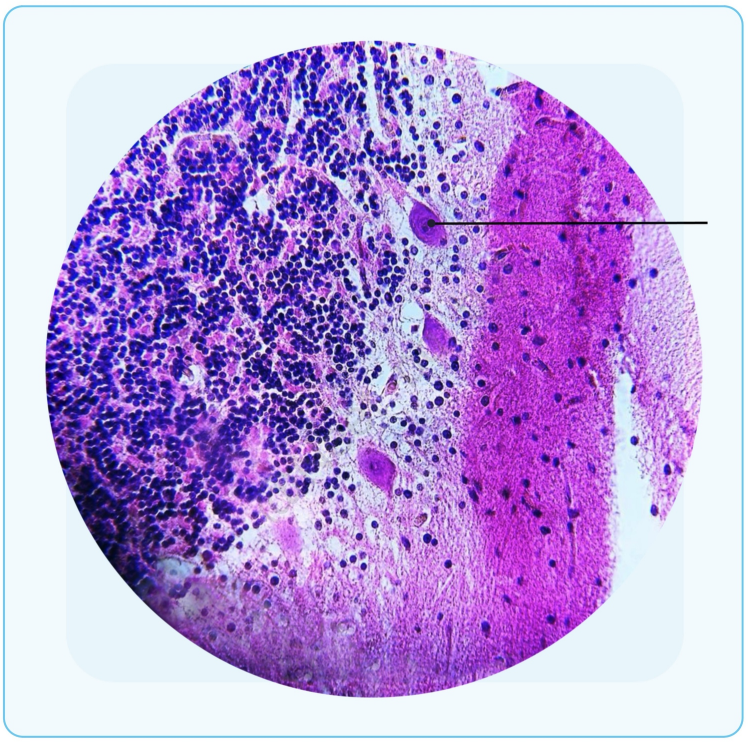

@Neet_pg_bot

Correct Answer: A. Deep nuclei of cerebellum

Explanation: The marked cell is a Purkinje cell , identified by its large cell body and prominent nucleus in the cerebellar cortex. Purkinje cells are inhibitory and use GABA as their neurotransmitter. Their primary function is to inhibit the deep nuclei of the cerebellum , which are responsible for motor coordination and fine-tuning of movements. Purkinje Cells and Their Inhibitory Role Feature Details Location Cerebellar cortex (between molecular & granular layers) Neurotransmitter GABA (gamma-aminobutyric acid) Function Inhibitory regulation of deep cerebellar nuclei Target Deep nuclei of cerebellum Significance Helps coordinate fine motor control by regulating output from deep cerebellar nuclei Vestibular nuclei (Option B): Incorrect , as Purkinje cells do send some projections here but do not primarily inhibit them. Inferior olivary nucleus (Option C): Incorrect , as it provides excitatory input to Purkinje cells, but is not their target. Basal ganglia (Option D): Incorrect , as Purkinje cells have no direct connection to the basal ganglia.

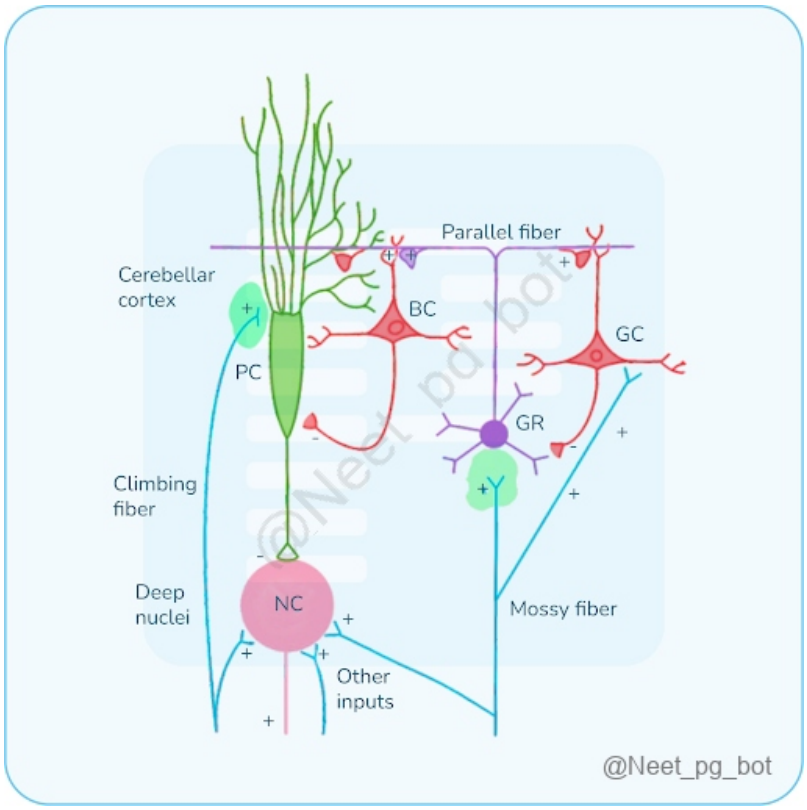

References:

Gray's Anatomy: The Anatomical Basis of Clinical Practice, 41st Edition - Page no: 333 - 335

Inderbir Singh’s Textbook of Human Histology, 8th Edition - Page no: 121-122

Robbins Basic Pathology, 10e - Page no: 1266, 1256

https://www.ncbi.nlm.nih.gov/books/NBK560638/

↑ *Back to this question in Part A*

@Neet_pg_bot

Q8: Identify the incorrect match: (Q855762)

A. 1-cilia

B. 4-lamina propria

C. 2-goblet cells

D. 3-nuclei of epithelial cell

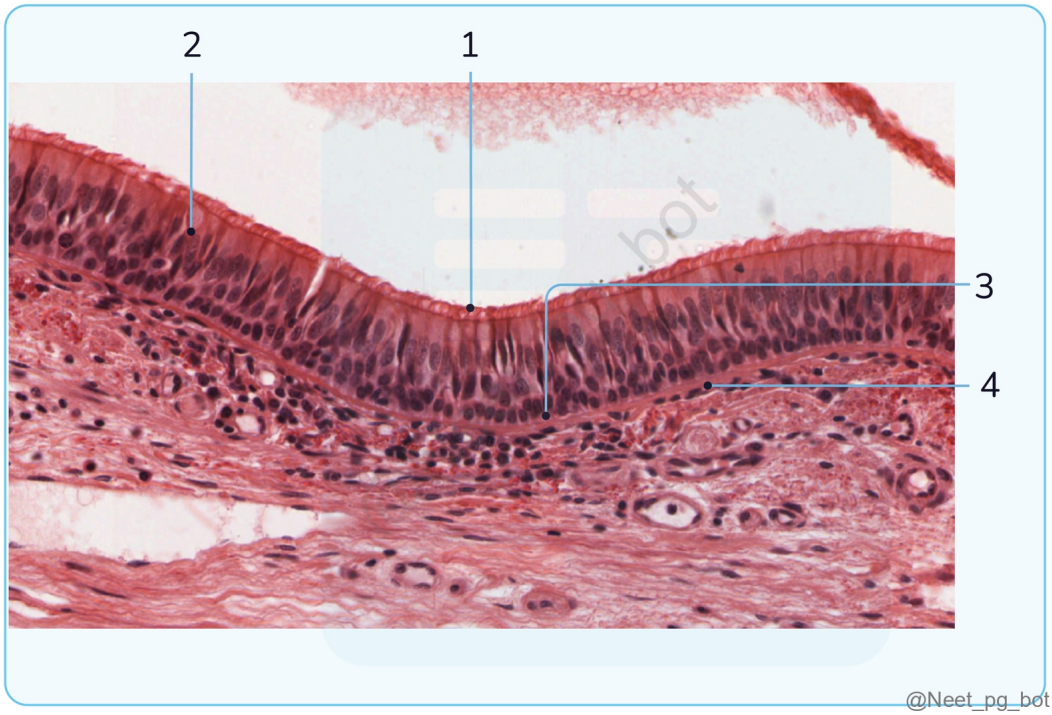

Correct Answer: B. 4-lamina propria

Explanation: 1 (Cilia) – These are hair-like projections on the apical surface of columnar epithelial cells, helping in mucus clearance via coordinated movement. Correct 2 (Goblet cells) – These are unicellular mucus-secreting glands dispersed within the pseudostratified columnar epithelium, aiding in airway moisture and protection. Correct 3 (Nuclei of epithelial cells) – The nuclei are at varying levels , creating a pseudostratified appearance. Correct 4 (Incorrectly matched as Lamina Propria) – This label belongs to the epithelial layer , whereas the lamina propria is the connective tissue layer beneath the basement membrane. Incorrect Pseudostratified Ciliated Columnar Epithelium (Respiratory Epithelium) Feature Description Location Found in the trachea, bronchi, and nasal cavity . Cell Types Ciliated columnar cells , goblet cells , basal cells , and brush cells . Function Mucociliary clearance – Cilia move mucus upward, trapping and removing debris. Lamina Propria A loose connective tissue layer beneath the epithelium, not part of the epithelial layer . Pathological Relevance Loss of cilia function leads to chronic respiratory infections (e.g., in Kartagener syndrome). Incorrect Options: 1- Cilia (Option A): Correct , as cilia are present on the epithelial surface. 2- Goblet cells (Option C): Correct , as goblet cells are present within the pseudostratified epithelium. 3- Nuclei of epithelial cells (Option D): Correct , as these belong to pseudostratified columnar epithelium.

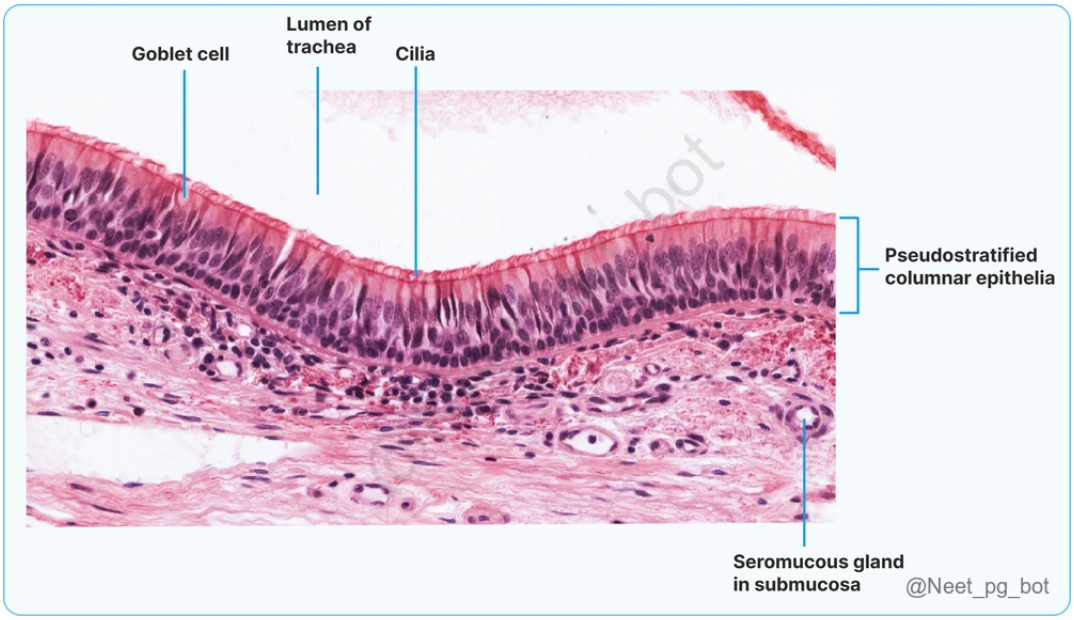
Goblet cell
Lumen of trachea
Cilia
Pseudostratified columnar epithelia
Seromucous gland in submucosa
@Neet_pg_bot

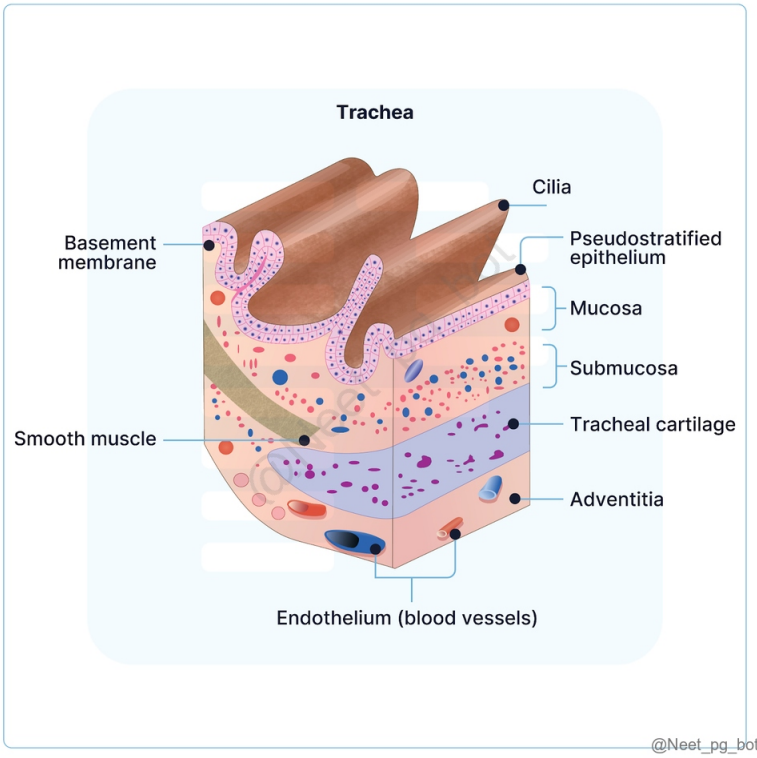
Trachea
Cilia
Basement membrane
Pseudostratified epithelium
Mucosa
Submucosa
Smooth muscle
Tracheal cartilage
Adventitia
Endothelium (blood vessels)
@Neet_pg_bot

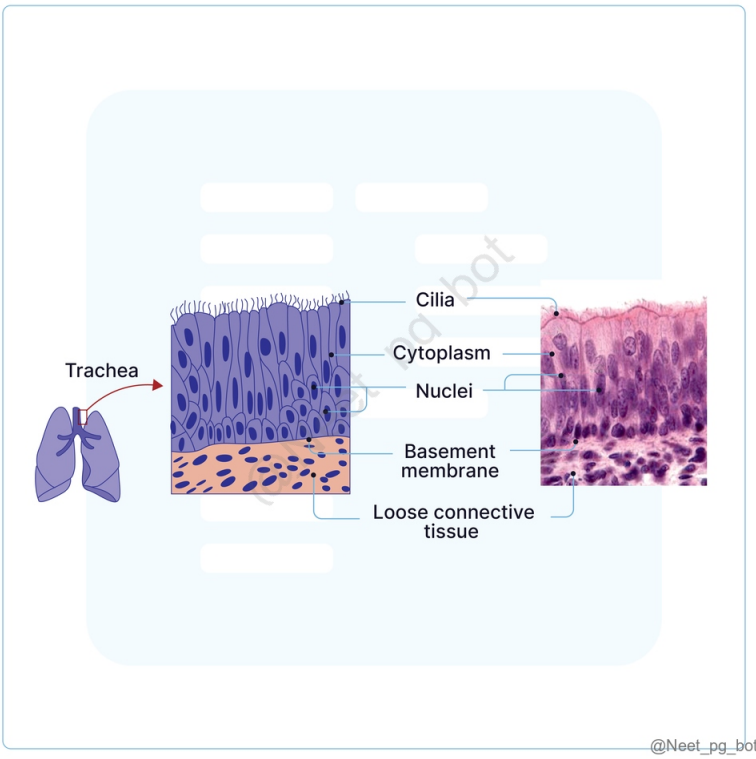

References:

Inderbir Singh's Textbook of Human Histology, 8th Edition - Colour atlas A4, 29

Junqueira's Basic Histology: Text and Atlas, 14th Edition - Page 84 and 85

↑ *Back to this question in Part A*

@Neet_pg_bot

Q9: Given below is a histological section of the thyroid gland. Which of the following is secreted by the cell marked 'X' in the image? (Q857639)

A. Thyroxine

B. Calcitonin

C. PTH

D. SerotoninX

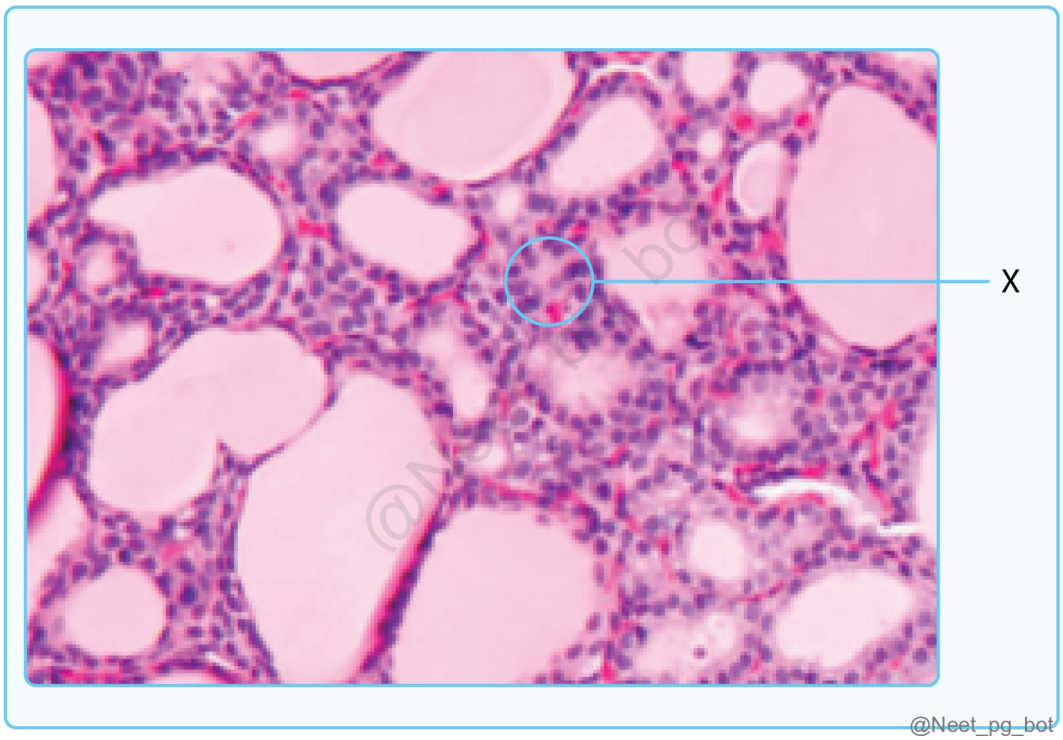

Correct Answer: B. Calcitonin

Explanation: The marked structure in the image is a parafollicular (C) cell of the thyroid gland. These cells secrete calcitonin , a hormone involved in calcium homeostasis by reducing blood calcium levels. Thyroid Gland Histology Cell Type Location Hormone Secreted Function Follicular cells Line the thyroid follicles Thyroxine (T3, T4) Regulates metabolism. Parafollicular (C) cells Between follicles Calcitonin Lowers blood calcium by inhibiting osteoclasts. Thyroxine (Option A): Incorrect because thyroxine (T3/T4) is secreted by follicular cells , not parafollicular cells. PTH (Option C): Incorrect because parathyroid hormone (PTH) is secreted by the parathyroid gland , not the thyroid. Serotonin (Option D): Incorrect because serotonin is a neurotransmitter mainly found in the CNS and enterochromaffin cells , not the thyroid.

References:

13e Victor P. Eroschenko - Atlas of Histology with Functional Correlations Pg 771.

↑ *Back to this question in Part A*

@Neet_pg_bot

Q10: Which of the following statements regarding bones is false? (Q857230)

A. Osteocytes are the major cell type in mature bone

B. Collagen is synthesized in bone osteoblasts

C. Bone mainly contains type 2 collagen

D. Calcium phosphate is one of the major inorganic mineral

Correct Answer: C. Bone mainly contains type 2 collagen

Explanation: Bone primarily contains Type I collagen , not Type II. Type I collagen provides structural support and tensile strength to bones. Type II collagen is mainly found in cartilage , not bone. Bone Composition and Structure Component Function Cells Osteoblasts (bone formation), Osteocytes (maintenance), Osteoclasts (resorption) Collagen Type Type I collagen is the primary structural protein in bone Inorganic Component Hydroxyapatite (Calcium phosphate) provides bone rigidity Bone Matrix Composed of organic (collagen and proteins) and inorganic (minerals) components Osteocytes are the major cell type in mature bone (Option A): Correct because osteocytes are the most abundant bone cells, maintaining bone matrix. Collagen is synthesized in bone by osteoblasts (Option B): Correct because osteoblasts produce Type I collagen, a key component of bone matrix. Calcium phosphate is one of the major inorganic minerals (Option D): Correct as hydroxyapatite (a form of calcium phosphate) is the main inorganic component of bone.

References:

Gray’s Anatomy, 42nd Edition, Pg.90,91,92,99,105

Fibrocartilage

↑ *Back to this question in Part A*

@Neet_pg_bot

Q11: Which type of collagen is present in cartilage? (Q857215)

A. Type 1 collagen

B. Type 2 collagen

C. Type 3 collagen

D. Type 4 collagen

Correct Answer: B. Type 2 collagen

Explanation: Cartilage is primarily composed of Type 2 collagen , which provides tensile strength and elasticity while resisting compressive forces. It is the main structural protein in hyaline and elastic cartilage . Types of Collagen and Their Locations Collagen Type Location Function Type I Bone, skin, tendons, ligaments, cornea Provides tensile strength Type II Cartilage (hyaline, elastic, fibrocartilage), vitreous humor Provides resistance to pressure Type III Reticular fibers (skin, blood vessels, fetal tissue) Provides structural support Type IV Basement membrane Forms structural network in BM Type 1 collagen (Option A): Incorrect because it is found in bone, tendons, and skin , not cartilage. Type 3 collagen (Option C): Incorrect because it is found in reticular fibers of blood vessels and skin , not cartilage. Type 4 collagen (Option D): Incorrect because it is a non-fibrillar collagen

found in basement membranes , not cartilage.

References:

Gray’s Anatomy, 42nd Edition, Pg.90,91,92,99,105

Fibrocartilage

↑ *Back to this question in Part A*

@Neet_pg_bot

Q12: The inner layer of the fallopian tube is covered by: (Q857208)

A. Simple columnar epithelium

B. Pseudostratified ciliated columnar epithelium

C. Ciliated columnar epithelium

D. Cuboidal epithelium with microvilli

Correct Answer: C. Ciliated columnar epithelium

Explanation: The inner lining of the fallopian tube (also called the mucosa) is composed of ciliated columnar epithelium , which helps in the transport of the ovum toward the uterus through rhythmic ciliary movements. Histology of the Fallopian Tube Layer Structure Function Mucosa Ciliated columnar epithelium with secretory (peg) cells Helps in ovum transport and secretion of nutrients Muscularis Inner circular and outer longitudinal smooth muscle layers Peristalsis aids in ovum movement Serosa Outer peritoneal covering Provides structural integrity Simple columnar epithelium (Option A) : Incorrect because while the fallopian tube has columnar cells, they are primarily ciliated , aiding ovum movement. Pseudostratified ciliated columnar epithelium (Option B) : Incorrect because this type is typically found in the respiratory tract, not the fallopian tube. Cuboidal epithelium with microvilli (Option D) : Incorrect because cuboidal epithelium with microvilli is characteristic of renal tubules , not the fallopian tube.

References:

https://pmc.ncbi.nlm.nih.gov/articles/PMC7565394/

↑ *Back to this question in Part A*

@Neet_pg_bot

Q13: The area marked by the arrows in the given histopathological image can influence the surrounding cells by: (Q865311)

A. Portal Vasculature

B. Paracrine effect

C. Nerve mediated

D. Epitheliomesenchymal transition

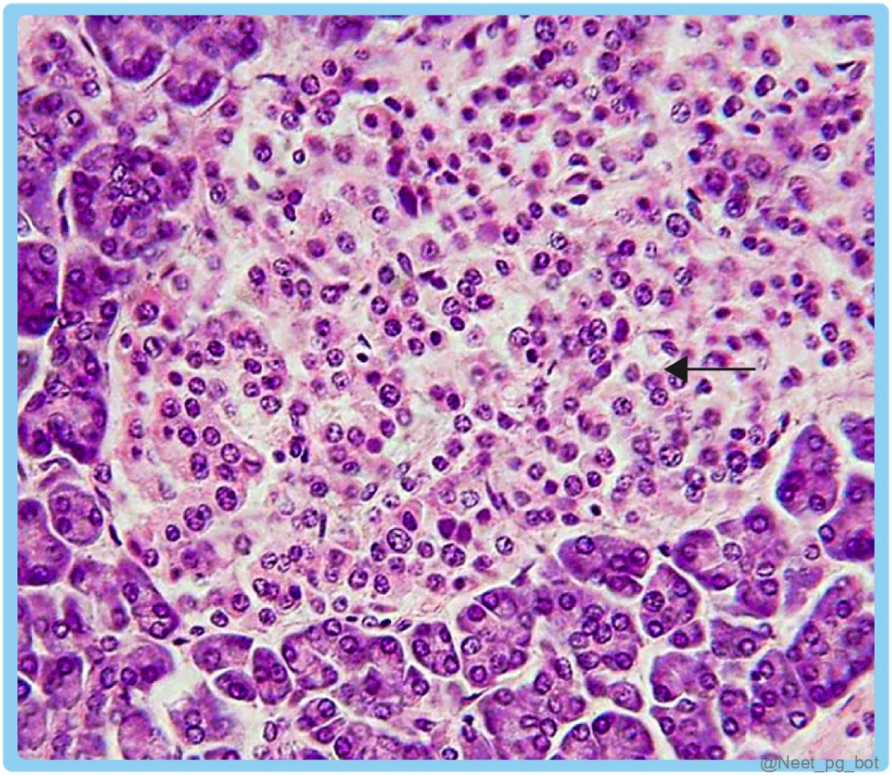

Correct Answer: B. Paracrine effect

Explanation: The area marked in the image is the Islet of Langerhans, located in the pancreas. These hormones can act locally to influence nearby cells within the islet before reaching systemic circulation — this is known as a paracrine effect . Paracrine Mechanism in the Islets: Cell Type Hormone Secreted Paracrine Effect On β cells Insulin Inhibits α cells (↓ glucagon) α cells Glucagon Stimulates β cells (↑ insulin) δ cells Somatostatin Inhibits both α and β cells Portal Vasculature (Option A) - Not involved in direct local cell-to-cell signaling. Nerve mediated (Option C) - Islet regulation is mostly hormonal, not neural. Epitheliomesenchymal transition (Option D) - An epithelial-mesenchymal transition (EMT) is a biologic process that allows a polarized epithelial cell, which normally interacts with basement membrane via its basal surface, to undergo multiple biochemical changes that enable it to assume a mesenchymal cell phenotype, which includes enhanced migratory capacity, invasiveness, elevated resistance to apoptosis, and greatly increased production of ECM components.

References:

Guyton and Hall Textbook of Medical Physiology, 14th Edition, Pages 915, 973
https://pmc.ncbi.nlm.nih.gov/articles/PMC2689101/

↑ *Back to this question in Part A*

@Neet_pg_bot

Q14: A 35-year-old patient underwent an endoscopic examination of the gastrointestinal tract due to recurrent abdominal discomfort and altered bowel habits. Identify the arrow-marked structure in the given image. (Q857953)

A. Brunner’s gland

B. Intestinal cells of kajal

C. Crypts of lieberkuhn

D. Peyer's patch

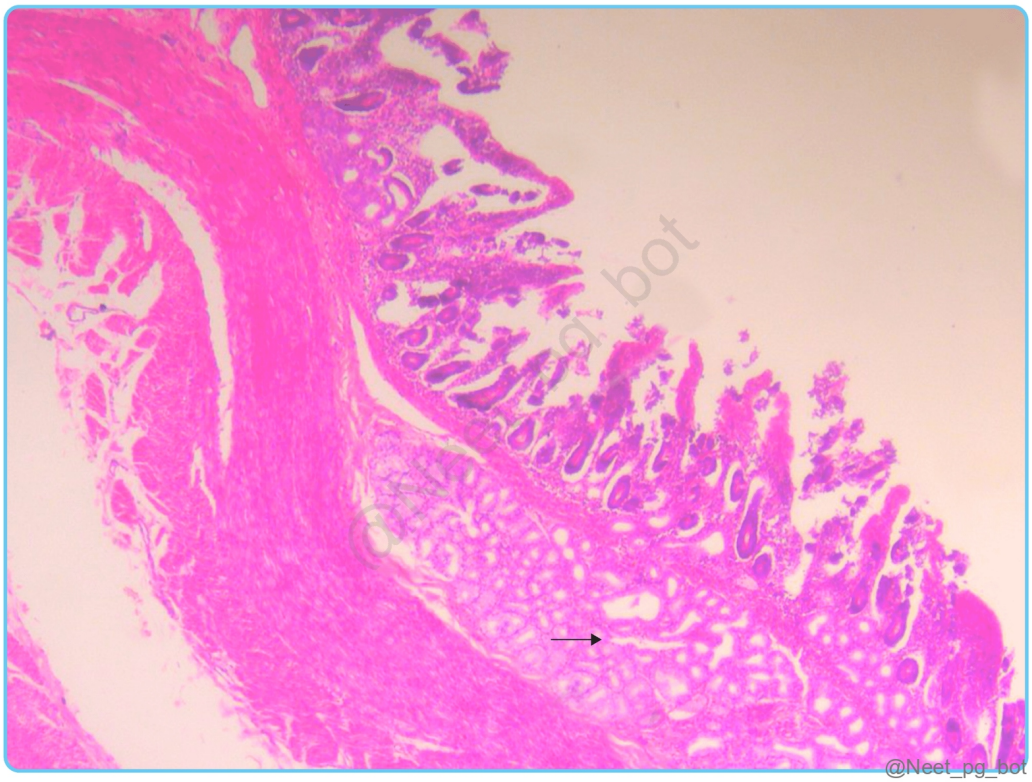

Correct Answer: A. Brunner’s gland

Explanation: The given histology slide is of duodenum. Identification points: Wall made up of four layers. Mucosa – presence of numerous broad villi lined by simple columnar epithelium with microvilli and goblet cells. Presence of crypts of lieberkuhn Presence of submucous Brunner’s gland. The marked structure by the arrow is of Brunner's gland. Histology: Feature Duodenum Jejunum Ileum Villi Present Present Present Brunner's Glands Present Absent Absent Peyer's Patches Absent Absent Present Intestinal Cells of Kajal (Option B): Incorrect term (likely a

misinterpretation of interstitial cells of Cajal, which regulate gut motility). Crypts of Lieberkühn (Option C): Present in the duodenum but are located in the mucosa , whereas Brunner’s glands are in the submucosa . Peyer’s Patch (Option D): Found in the ileum , not the duodenum.

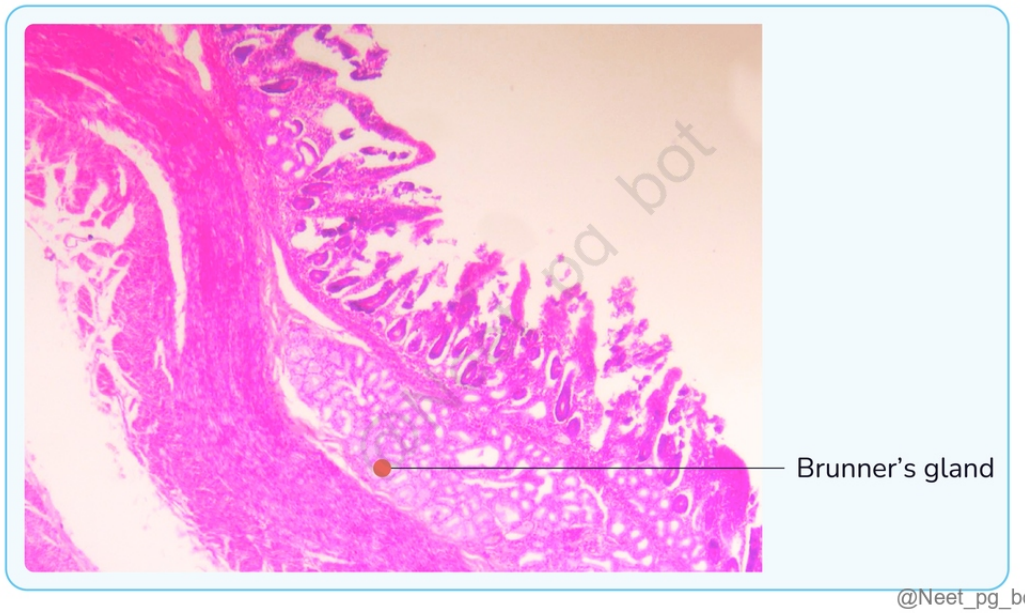

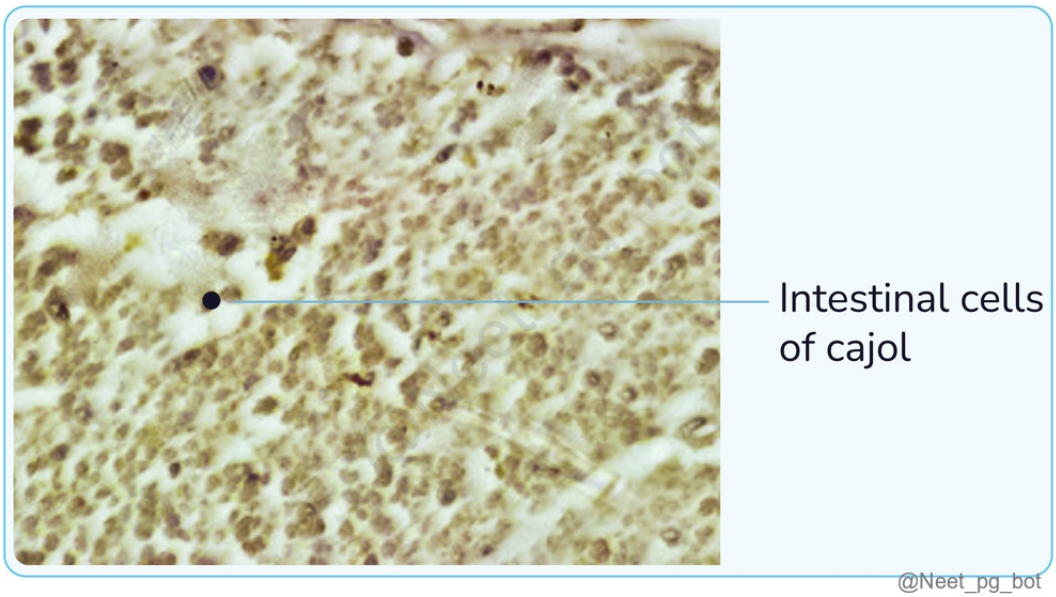

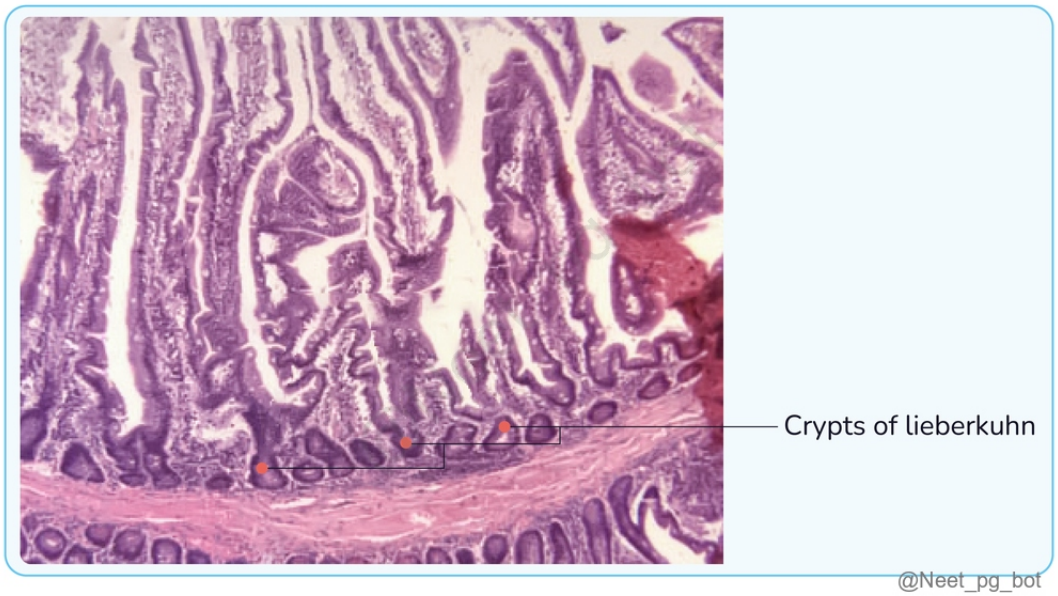



References:

BD Chaurasia's Human Anatomy, 8th Edtion, Page no: 765

↑ *Back to this question in Part A*

@Neet_pg_bot

Q15: The given histology image is of? (Q855394)

A. Leydig cells of testis

B. Pancreatic islet cells

C. Hassall's corpuscles

D. Glomerulus

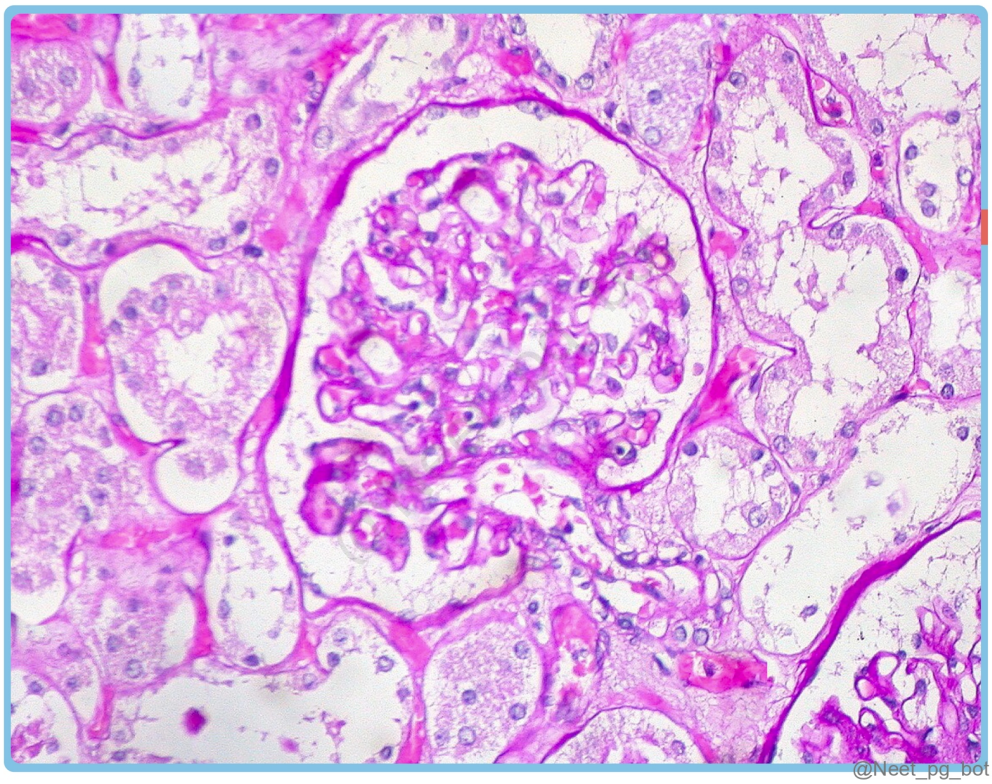

Correct Answer: D. Glomerulus

Explanation: The structure of the histological image given is of the kidney showing a glomerulus by proximal convoluted tubules (PCT), and distal convoluted tubules (DCT). {{caption_text}} Leydig cells of the testis (Option A): Leydig cells are found between the seminiferous tubules in the interstitial tissue of the testis. They are larger than the neighboring cells and have a distinct morphology. Their cytoplasm is often eosinophilic. The cells typically have a single, large, central nucleus. {{caption_text}} Pancreatic islet cells (Option B): Islet cells have a large, round nucleus and a lightly-stained cytoplasm. Islet cells are typically arranged in groups, with different cell types clustered together. {{caption_text}} Hassall's corpuscles (Option C): These structures are located in the medulla of the thymus gland. They are composed of reticular epithelial cells arranged in a concentric fashion with central degenerating eosinophilic matter. The cells in each layer are tightly packed, forming a flattened, disc-like shape. The blue dots are lymphocytes with large nucleus (basophilic). {{caption_text}}

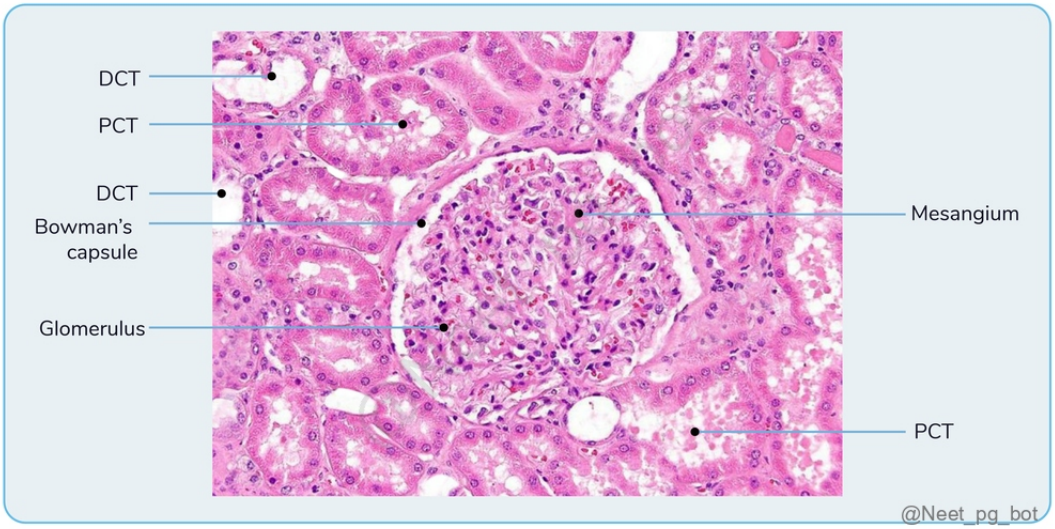
DCT
PCT
DCT
Bowman's capsule
Glomerulus
Mesangium
PCT
@Neet_pg_bot

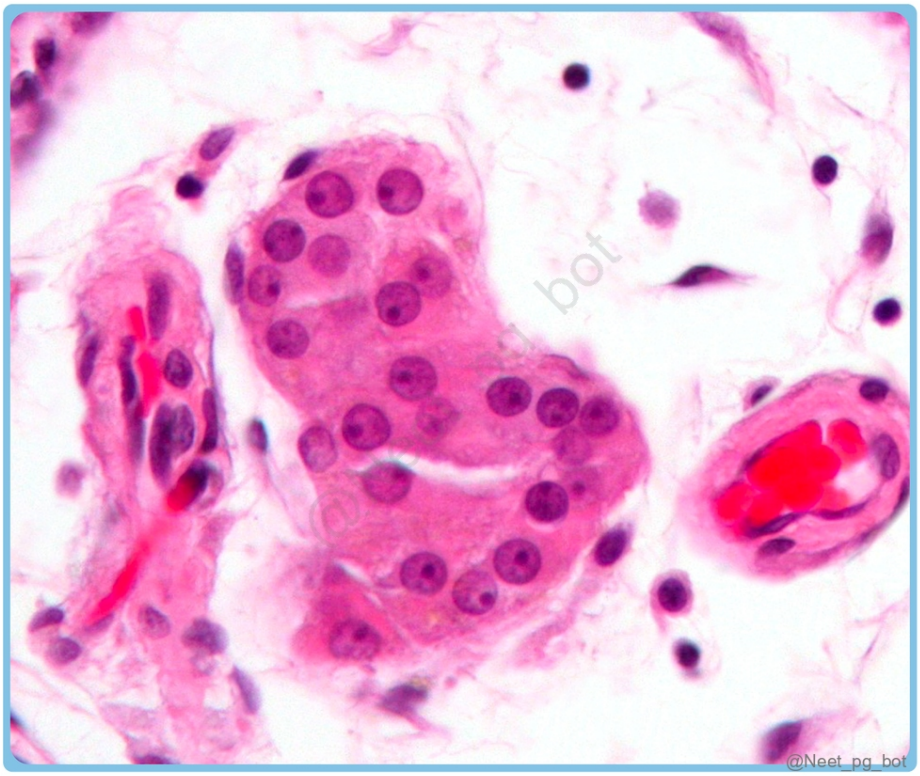
@Neet_pg_bot

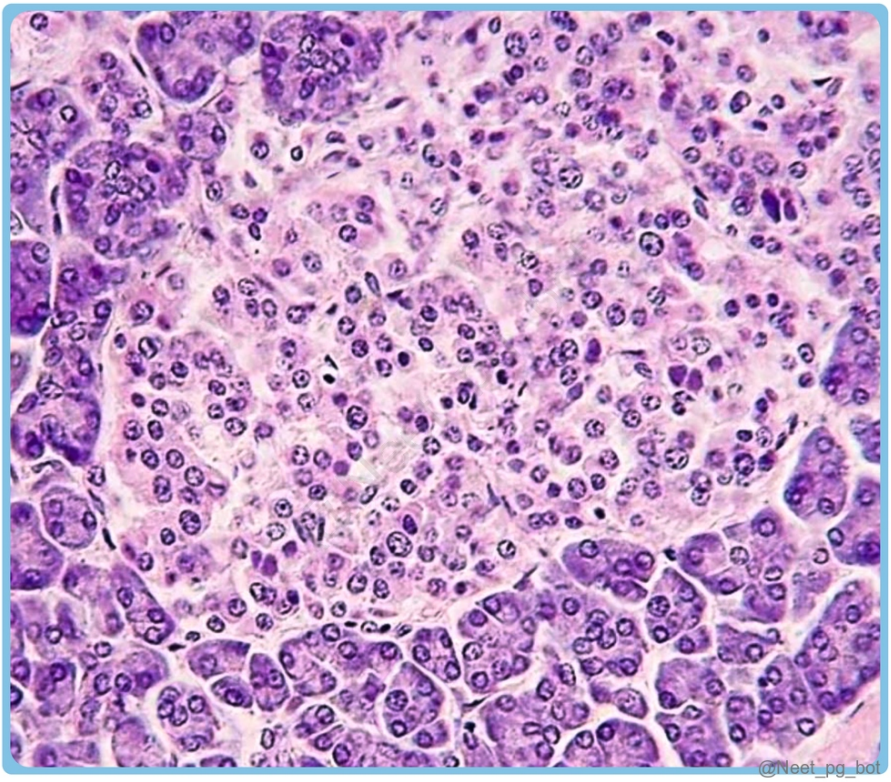

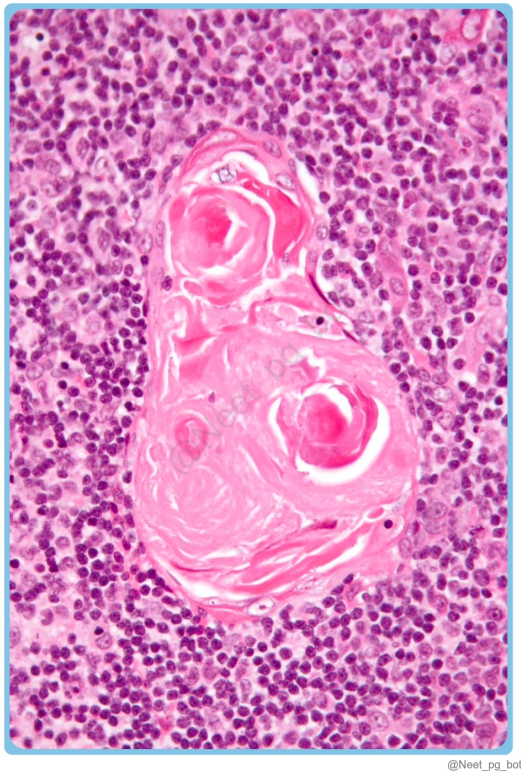

References:

https://www.ncbi.nlm.nih.gov/books/NBK554411/

↑ *Back to this question in Part A*

@Neet_pg_bot

Q16: Identify the structure marked in the given image? (Q857346)

A. Respiratory bronchus

B. Terminal bronchioles

C. Alveolar sac

D. Intrapulmonary bronchus

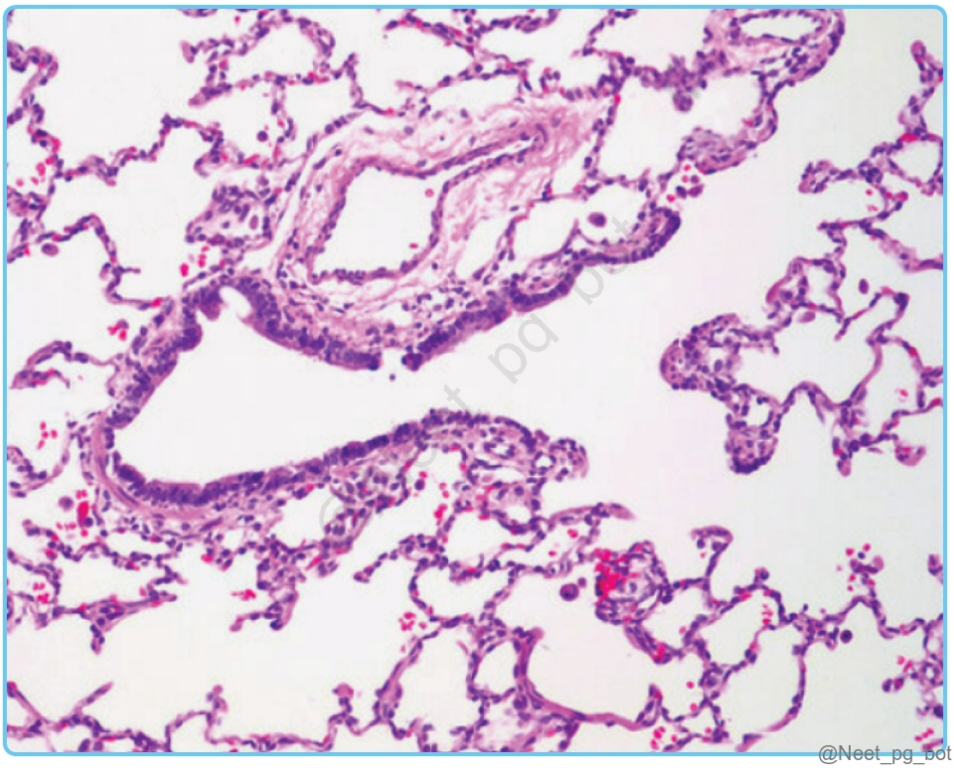

Correct Answer: B. Terminal bronchioles

Explanation: Terminal bronchioles differ from larger bronchi as they are devoid of cartilage in their walls. The ciliated cells are still present in terminal bronchioles, but their abundance is reduced. Additionally, terminal bronchioles exhibit alveolar outgrowths, marking the transition to structures involved in gas exchange. Respiratory bronchus (Option A): Respiratory bronchioles have alveoli budding directly from their walls. This is a distinctive feature that indicates their role in gas exchange. Epithelium may become more cuboidal, eventually transitioning to simple squamous epithelium in the alveoli. Similar to terminal bronchioles, respiratory bronchioles lack cartilage in their walls. Alveolar sac (Option C): Alveolar sacs are composed of clusters of alveoli, which are small, balloon-like structures. Alveolar walls are extremely thin to facilitate efficient gas exchange.

Intrapulmonary bronchus (Option D): Intrapulmonary bronchi have smooth muscle in their walls, which helps regulate airflow. Goblet cells, found in the epithelium of intrapulmonary bronchi, secrete mucus to aid in capturing particles and facilitating their expulsion from the respiratory tract. Cartilage found in the intrapulmonary bronchus helps maintain the shape of the bronchi, preserving the integrity of the airway structure.

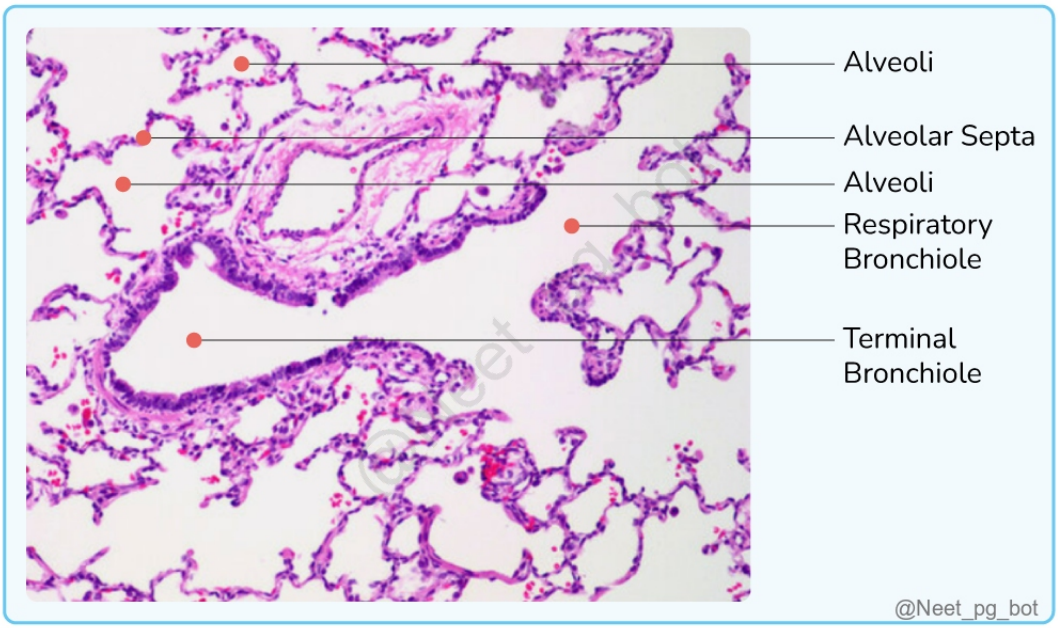

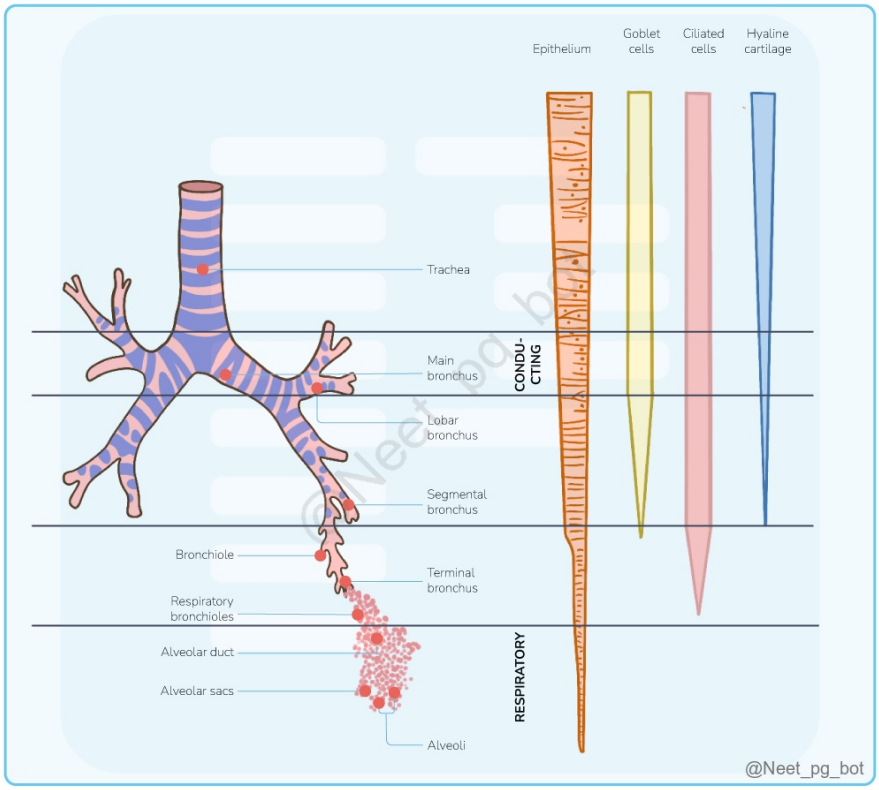

References:

https://www.ncbi.nlm.nih.gov/books/NBK534789/

↑ *Back to this question in Part A*

@Neet_pg_bot

Q17: Which of the following is the lining epithelium of the trachea? (Q860289)

A. Simple squamous epithelium

B. Transitional epithelium

C. Stratified squamous epithelium

D. Pseudostratified ciliated columnar

Correct Answer: D. Pseudostratified ciliated columnar

Explanation: The trachea is lined by pseudostratified ciliated columnar epithelium with goblet cells . This specialized epithelium plays a key role in: Mucociliary clearance : The cilia help move mucus and trapped particles upward toward the pharynx. Protection : Goblet cells secrete mucus that traps dust, bacteria, and other particles. Respiratory Epithelium: Features of the various parts of the respiratory passages: Simple squamous epithelium (Option A): Found in alveoli, allowing gas exchange, not in the trachea. Transitional epithelium (Option B): Found in the urinary system (bladder, ureters, renal pelvis), not in the trachea. Stratified squamous epithelium (Option C): Found in the oropharynx, laryngopharynx, and vocal cords, but not in the normal trachea (except in chronic irritation like smoking, where metaplasia can occur).

Division	Support	Glands	Epithelium	Ciliated cells	Goblet cells	Special features
Trachea, primary bronchi	C shaped hyaline cartilage rings	Mucous and seromucous gland	Pseudostratified ciliated columnar	Yes	Yes	Trachealis muscle, elastic lamina, two mucous cell types, short cells, diffuse endocrine cells
Intra-pulmonary bronchi	Plates of hyaline cartilage	Seromucous	Pseudostratified ciliated columnar	Yes	Yes	Two helically oriented ribbons of smooth muscle
Primary bronchioles	Smooth muscle	None	Simple ciliated columnar to simple cuboidal	Yes	Only in large ones	Clara cells
Terminal bronchioles	Smooth muscle	None	Simple cuboidal	Some	None	Clara cells
Respiratory bronchioles	Some smooth muscle	None	Simple cuboidal	Some	None	Occasional alveoli and clara cells
Alveolar ducts	Smooth muscle at alveolar openings, some reticular fibers	None	Simple squamous	None	None	Linear structure formed by adjacent alveoli type 1 and type 2 pneumocytes, alveolar macrophages
Alveoli	Reticular fibers, elastic fibers at alveolar openings	None	Simple squamous	None	None	Type 1 and type 2 pneumocytes, alveolar marcophages

@Neet_pg_bot

References:

https://www.ncbi.nlm.nih.gov/books/NBK556044/#

↑ *Back to this question in Part A*

@Neet_pg_bot

Q18: Which hormone is produced from the layer marked in the given image? (Q860615)

A. Androgen

B. Cortisol

C. Corticosterone

D. Epinephrine

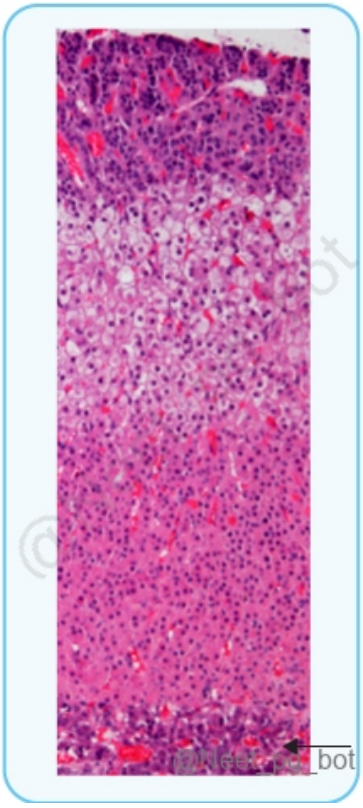

Correct Answer: D. Epinephrine

Explanation: The marked area is the adrenal medulla, which is responsible for producing catecholamines like norepinephrine and epinephrine. Layers of Adrenal Gland Adrenal Cortex Zones of the cortex Hormones produced Main function Morphology of Zone Zona Glomerulosa Mineralocorticoid Aldosterone(main) Deoxycorticosterone

Maintenance of sodium balance Small clumps of cells Zona fasciculata Glucocorticoids Cortisol Corticosterone Maintenance of sugars Columnar cells that form long cords Zona reticularis Sex steroids Dehydroepiandrosterone Androstenedione Maintenance of sexual functioning Network of intercalated cells Adrenal medulla: Medulla Catecholamines: Norepinephrine Epinephrine Small amounts of dopamine Carbohydrate and fat metabolisms Fight or flight responses Specialized sympathetic ganglion Clumps and strands of chromaffin cells (Options A, B, and C)

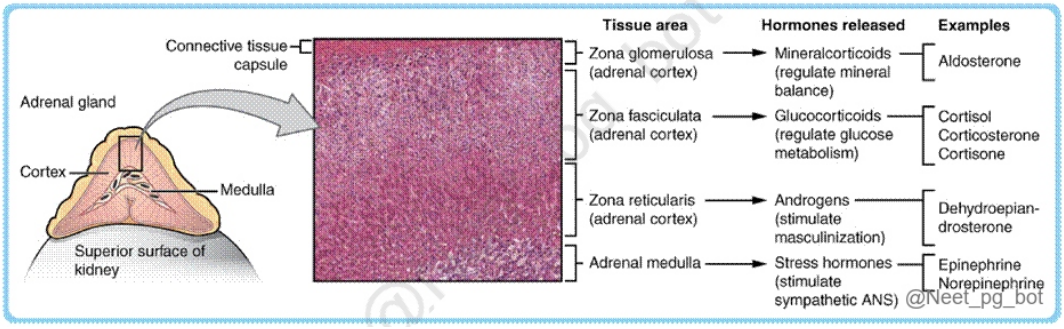

References:

Ganong's Review of Medical Physiology, 26th Edition, pg 329-333

G. K Pal 1st edition pg 507

↑ *Back to this question in Part A*

@Neet_pg_bot

Q19: Match the receptors with their correct function: 1. Ruffini corpuscle A. Vibration 2. Merkel cells B. Sustained pressure 3. Pacinian corpuscle C. Stretching 4. Meissner’s corpuscle D. Fine touch (Q844320)

A. 1C, 2B, 3A, 4D

B. 1D, 2C, 3B, 4A

C. 1B, 2A, 3D, 4C

D. 1C, 2D, 3B, 4A

Correct Answer: A. 1C, 2B, 3A, 4D

Explanation: Correct Option A - 1C, 2B, 3A, 4D: Ruffini corpuscle (1C) : These are mechanoreceptors that respond to the stretching of the skin, which is crucial for the perception of the direction and amount of stretch. Merkel cells (2B) : These are slowly adapting receptors that are sensitive to sustained pressure and texture, providing fine details about objects touching the skin. Pacinian corpuscle (3A) : These are rapidly adapting receptors that detect vibration and deep pressure, essential for sensing rapid changes in the environment.

Meissner’s corpuscle (4D) : These receptors are sensitive to fine touch and low-frequency vibration, allowing the detection of textures and slight pressure changes. Incorrect Options: Options B, C and D are marked incorrect.

↑ *Back to this question in Part A*

@Neet_pg_bot

Q20: Identify the markers in the given slide: (Q844183)

A. A- Eccrine sweat gland, B- Arrector pilorum, C- Sebaceous gland, D- Apocrine gland

B. A- Arrector pilorum, B- Eccrine sweat gland, C- Sebaceous gland, D- Apocrine gland

C. A- Eccrine sweat gland, B- Arrector pilorum, C- Apocrine gland, D-Sebaceous gland

D. A- Sebaceous gland, B- Apocrine gland, C- Eccrine sweat gland, D- Arrector pilorum



Correct Answer: A. A- Eccrine sweat gland, B- Arrector pilorum, C- Sebaceous gland, D- Apocrine gland

Explanation: Correct Option A - A- Eccrine sweat gland, B- Arrector pilorum, C- Sebaceous gland, D- Apocrine gland: A - Eccrine Sweat Gland: Eccrine sweat glands are responsible for thermoregulation and are found throughout the body, primarily in the palms, soles, and forehead. They are characterized by their tubular structure and are often found deep in the dermis. B - Arrector Pilorum: These are small muscles attached to hair follicles.

When they contract, they cause the hair to stand up, commonly known as piloerection. They are typically found alongside hair follicles. C - Sebaceous Gland: Sebaceous glands are responsible for producing sebum, an oily substance that lubricates the skin and hair. They are usually associated with hair follicles and appear as small clusters of cells in the dermis. D - Apocrine Gland: Apocrine sweat glands are primarily found in the axillary and genital regions. They secrete a thicker, milky fluid into hair follicles and are involved in scent production. These glands are larger than eccrine glands and have a more complex structure. Incorrect Options: Options B, C, and D: These options are incorrectly matched.

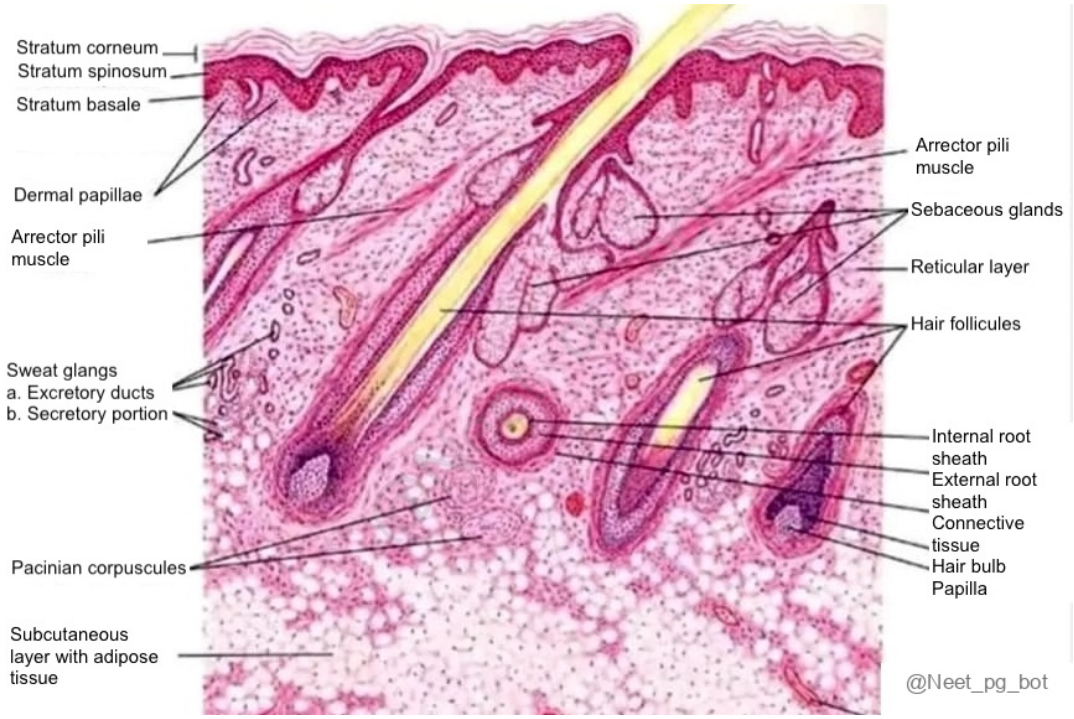

References:

.

↑ *Back to this question in Part A*

@Neet_pg_bot

Q21: Identify the lymphatic structure from the histology section given below? (Q852536)

A. Tonsil

B. Lymph node

C. Spleen

D. Thymus

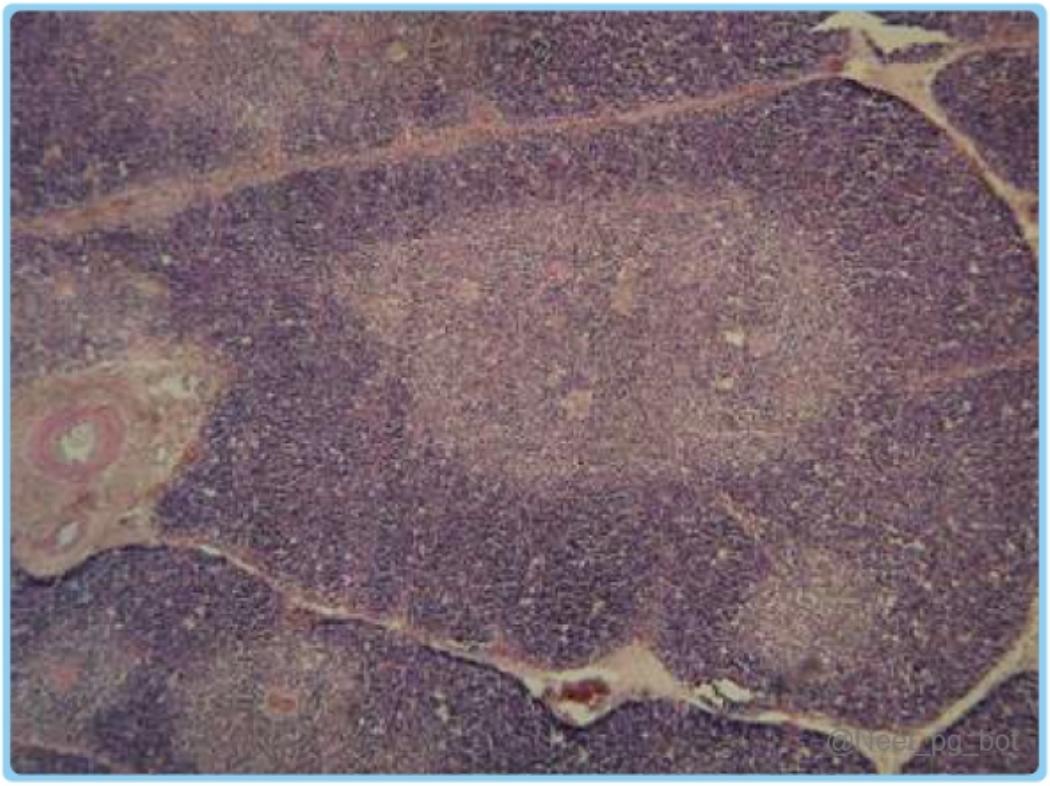

Correct Answer: D. Thymus

Explanation: The image shows a distinct lobulated structure with a darker outer cortex and a lighter inner medulla. This is characteristic of the thymus. Parts of the Thymus: Cortex : The outer, more densely packed region of the thymus. Filled with immature T cells (thymocytes) , undergoing differentiation and maturation as they move towards the medulla. The cortex contains thymic nurse cells that support the maturing thymocytes. T cells express surface markers (like TCR, CD3, CD4, and CD8) during maturation. Macrophages are present to phagocytose apoptotic T cells, which fail to mature properly. Medulla : The inner, less densely populated region. Dominated by epithelial cells with pale-staining nuclei and large cytoplasm. Contains Hassall's corpuscles , concentric structures made of keratinized epithelial cells, involved in T cell regulation. Dendritic cells and macrophages in the medulla present self-antigens to maturing T cells, ensuring the elimination of self-reactive cells to prevent autoimmunity. Histology of the Thymus: Epithelial Framework : Throughout the thymus, epithelial cells provide a structural scaffold for lymphocyte development and produce hormones like thymopoietin, which regulate T cell maturation and proliferation. It is divided into lobules by connective tissue septa. A protective blood-thymus barrier prevents antigens from entering, safeguarding T cell maturation. With age, the thymus undergoes involution , where lymphoid tissue is replaced by fat, but it continues to produce mature T cells. Tonsil (Option A): Tonsils contain lymphoid follicles with germinal centers. The histology of tonsils features these follicles, unlike the thymus. Lymph node (Option B): Lymph nodes also have lymphoid follicles but have a more defined capsule, cortex, paracortex, and medulla. Spleen (Option C): The spleen has a characteristic red pulp (containing blood) and white pulp (containing lymphocytes)

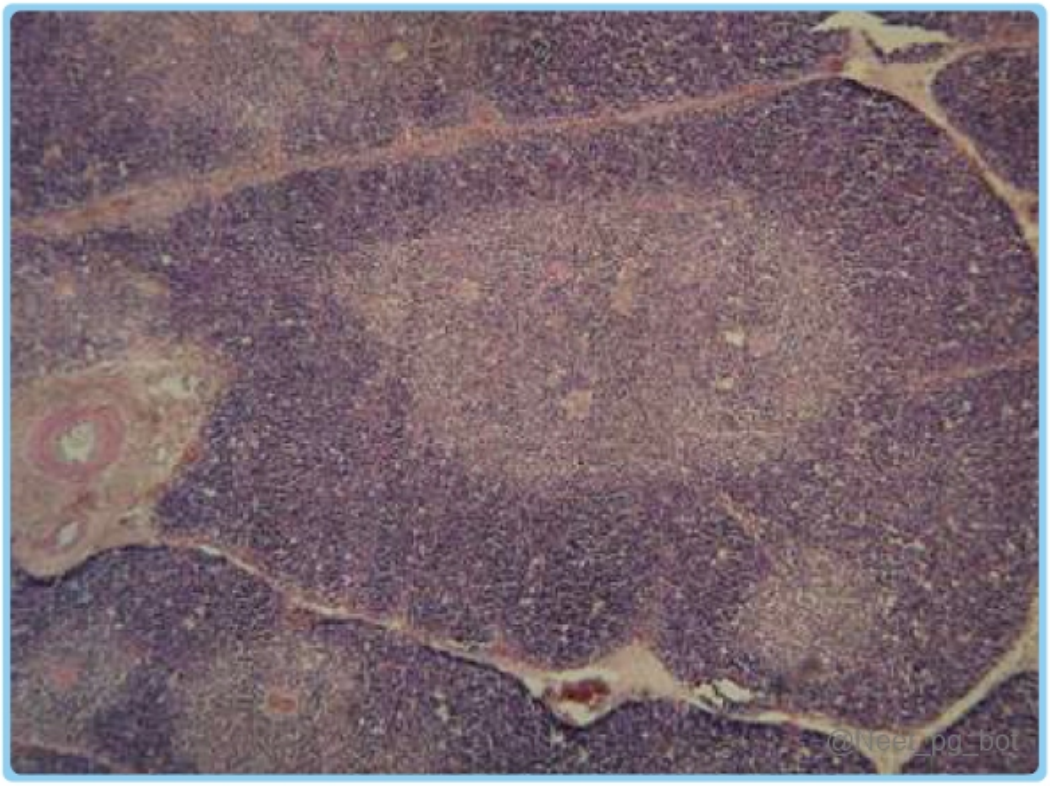
@Neet_pg_bot



@Neet_pg_bot

Fig. Histology of Thymus

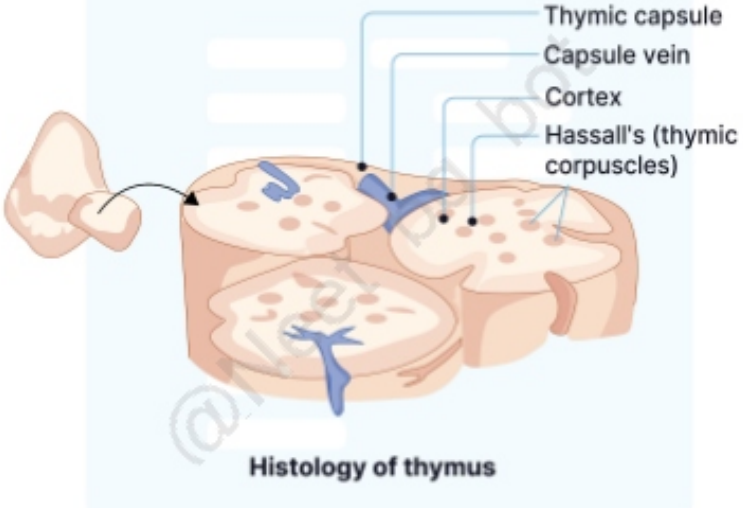

Histology of thymus

@Neet_pg_bot

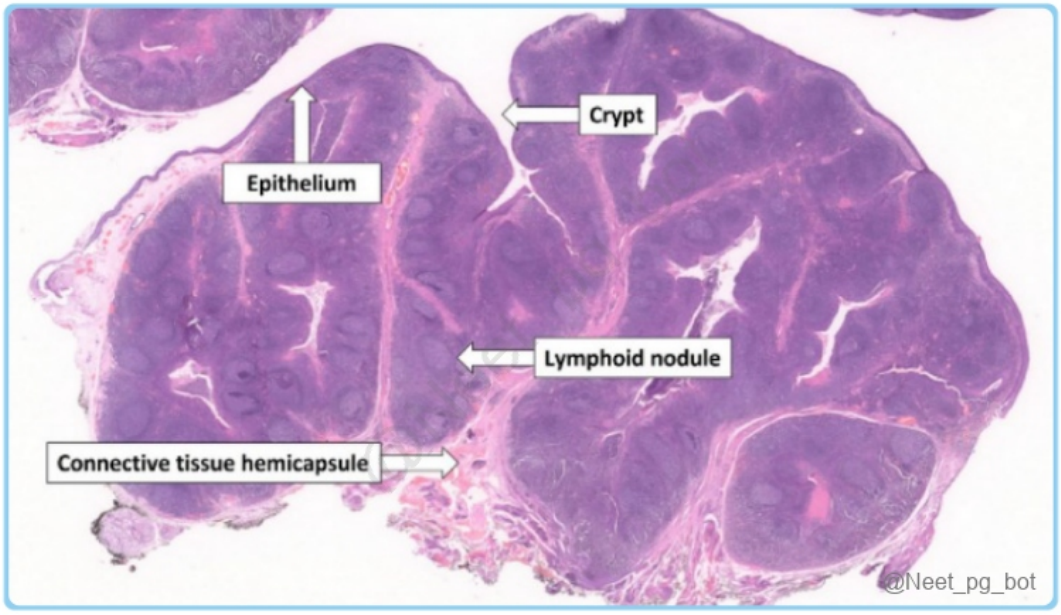



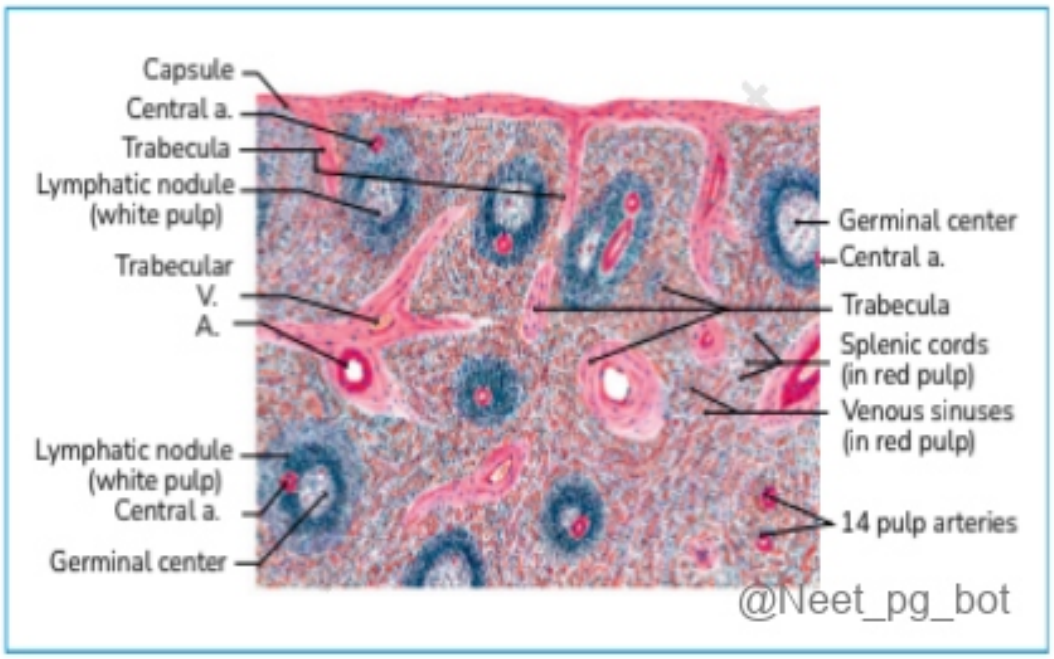

References:

Wheater Functional Histology, 6th Edition, Page: 204- 206. Inderbir Singh Histology, 9th Edition. Page: 249- 254.

↑ *Back to this question in Part A*

@Neet_pg_bot

Q22: What is the type of cartilage present in the histology section given below? (Q852465)

A. Hyaline cartilage

B. Elastic cartilage

C. Articular cartilage

D. Fibrocartilage

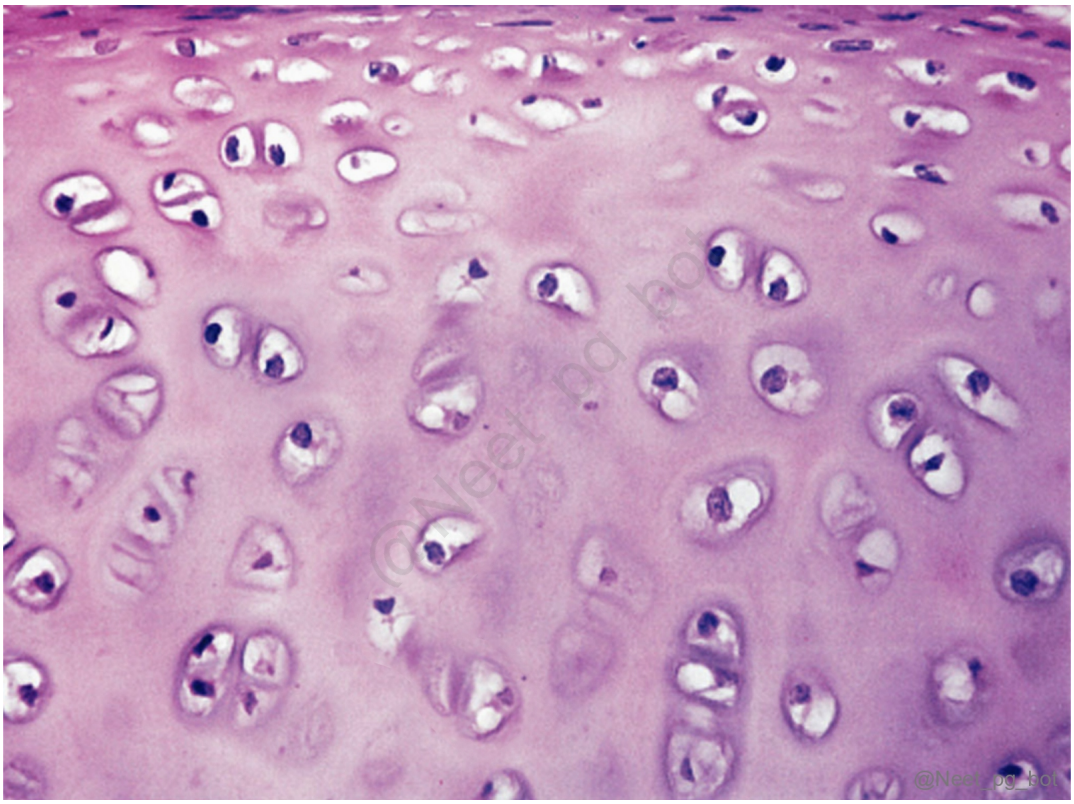

Correct Answer: A. Hyaline cartilage

Explanation: The image shows a glassy, bluish-white matrix with chondrocytes in lacunae Hyaline cartilage is the most common type. It has a glassy, translucent matrix due to the fine collagen fibrils. Chondrocytes (cartilage cells) are scattered throughout the matrix, often appearing in small groups (isogenous groups) within lacunae (spaces). Types of Cartilage Characteristic Hyaline Cartilage (Most Common) Elastic Cartilage (Yellow cartilage) (Option B) Fibrocartilage (Option D) Matrix appearance Homogeneous, basophilic Contains elastic fiber network Numerous collagen bundles Chondrocyte arrangement Groups (cell nests/isogenous groups) Similar to hyaline Single rows or isogenous groups Perichondrium Present (except in articular cartilage) Present Absent Main fiber type Type II collagen Elastic fibers Type I (primarily) and Type II collagen Main functions Structural support, forms articular surfaces Provides flexibility and resilience Resists compression and shearing, shock absorption Examples Costal cartilage, tracheal rings, articular cartilage Auricle, epiglottis, auditory tube Intervertebral discs, menisci Articular cartilage (Option C): Articular cartilage is a specific type of hyaline cartilage covering the bones' surfaces in synovial joints. While it is a form of hyaline cartilage, the term "articular" refers to its location rather than a different type of cartilage.

Hyaline cartilage



@Neet_pg_bot

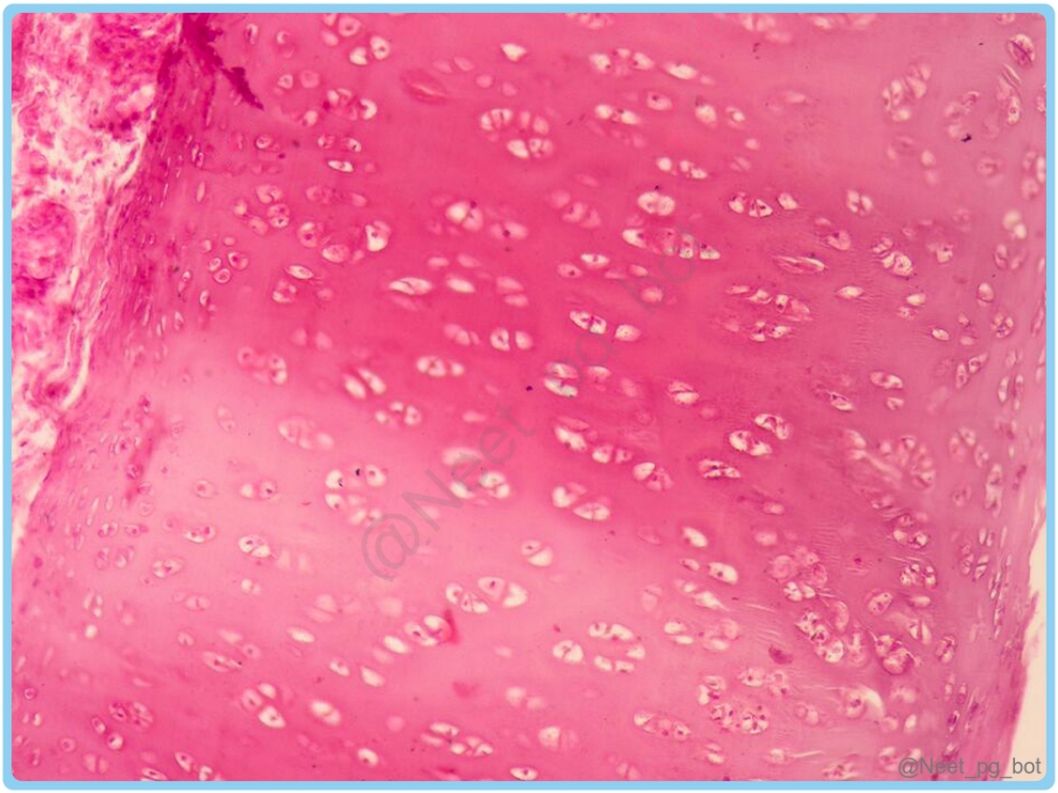

@Neet_pg_bot

Elastic cartilage

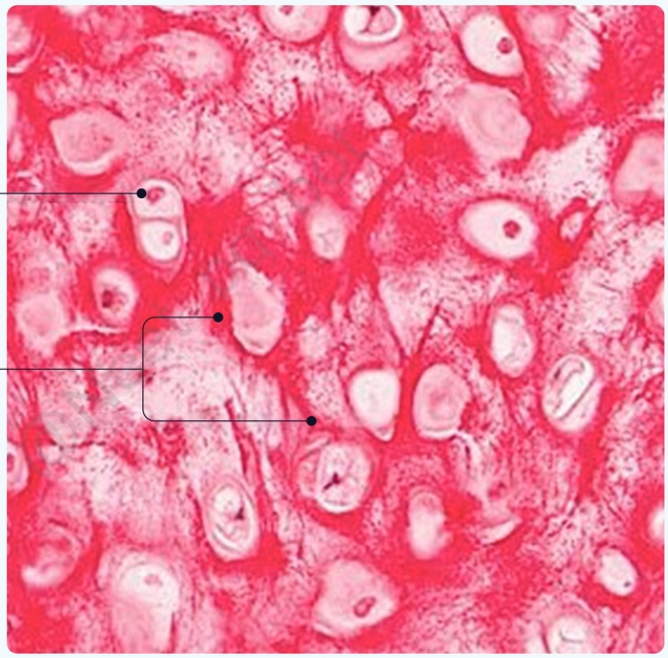

@Neet_pg_bot

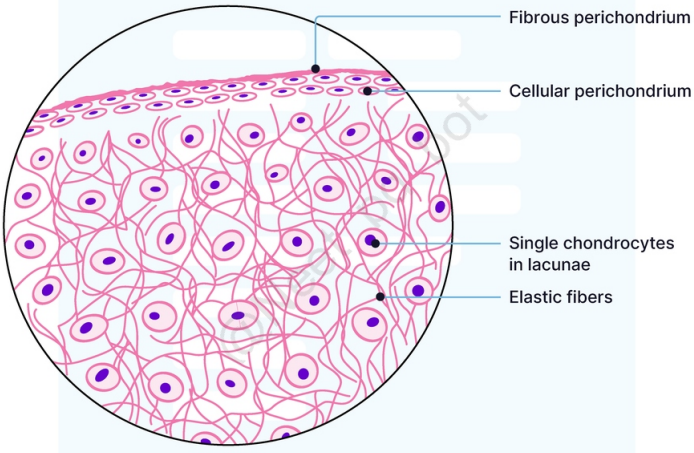

@Neet_pg_bot

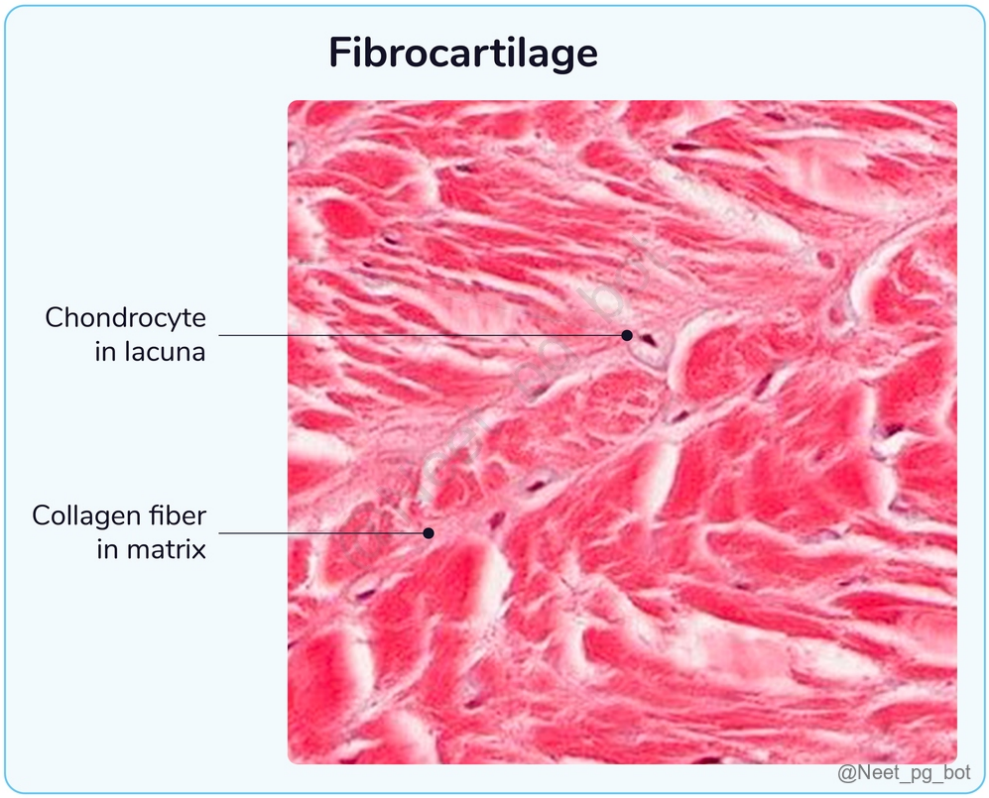



References:

Inderbir Singh Histology, 9th Edition, Page: 158-166

↑ *Back to this question in Part A*

@Neet_pg_bot

Q23: Histological section is given below. Identify the marked cell. (Q852541)

A. Stellate cell

B. Basket cell

C. Purkinje cell

D. Granular cell

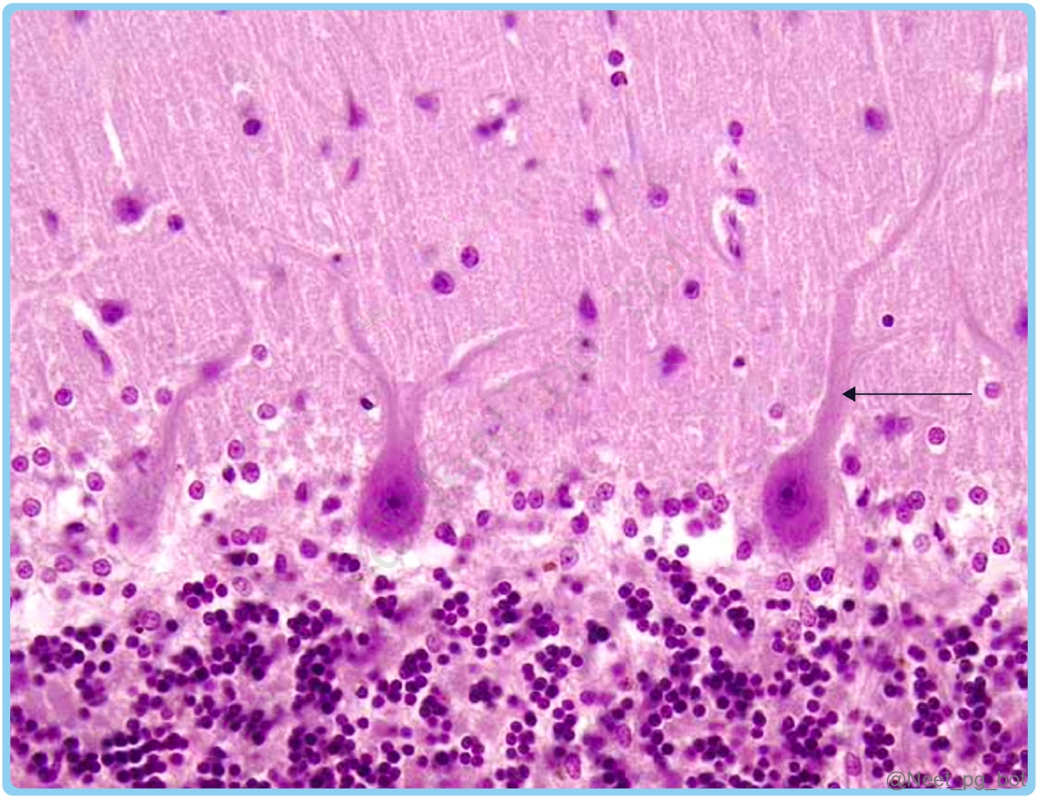

Correct Answer: C. Purkinje cell

Explanation: The marked area in the image is a Purkinje cell. The cerebellar cortex consists of the following three distinct layers: Layers of the cerebellar cortex Molecular (plexiform) layer (Options A, B) Purkinje cell layer Granular layer (Option D) It primarily contains numerous dendritic branches from Purkinje cells, with relatively few widely spaced nerve cells. It consists of a single row of large flask-shaped cells, the Purkinje cells . The inner granular layer is made up of many closely packed small granule cells , along with a few larger Golgi cells. These nerve cells are of two types: (a) Basket cells (b) Stellate cells. The axons of Purkinje cells are the only output from the cerebellar cortex and have an inhibitory effect on the intracerebellar nuclei. Golgi cells are inhibitory while the granular cells are excitatory. Among the five types of intrinsic neurons (Basket cells, Stellate cells, Purkinje cells,

Granule cells and Golgi cells)- All are inhibitory except granule cells.

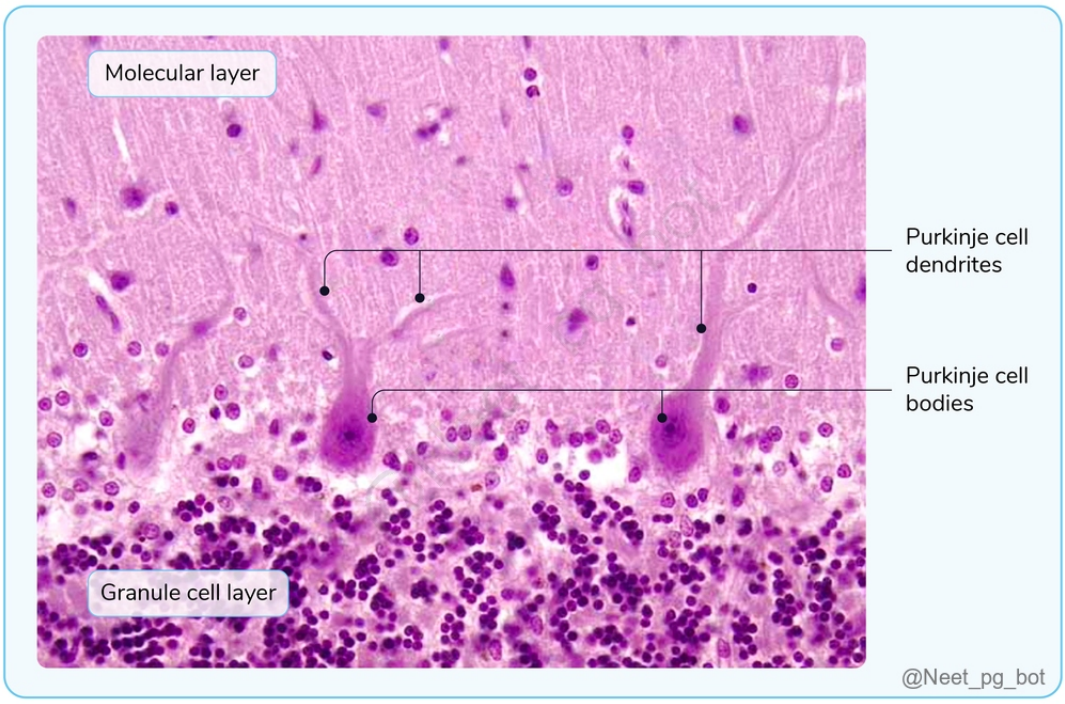

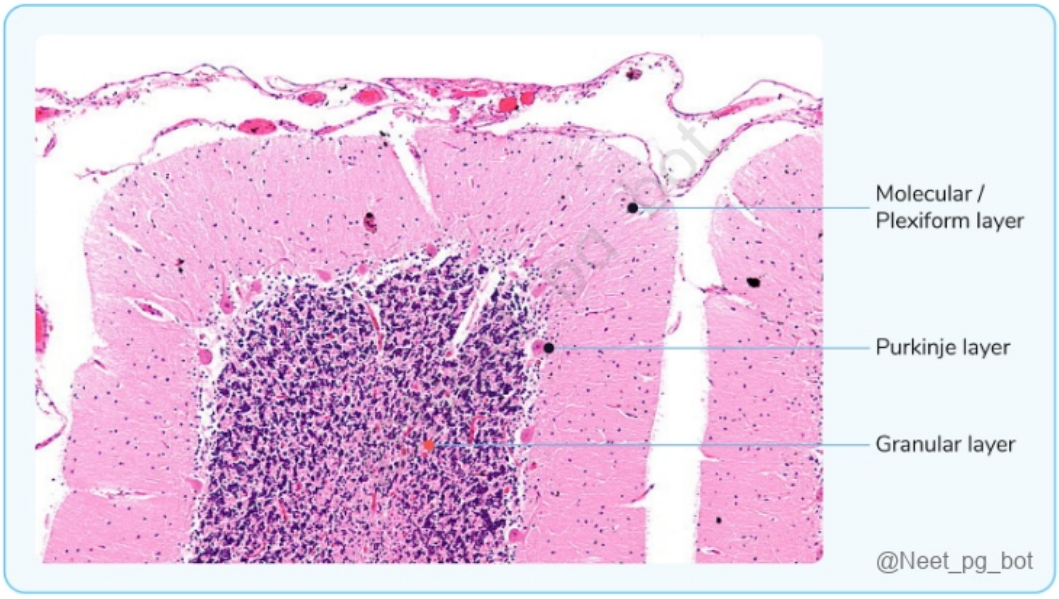

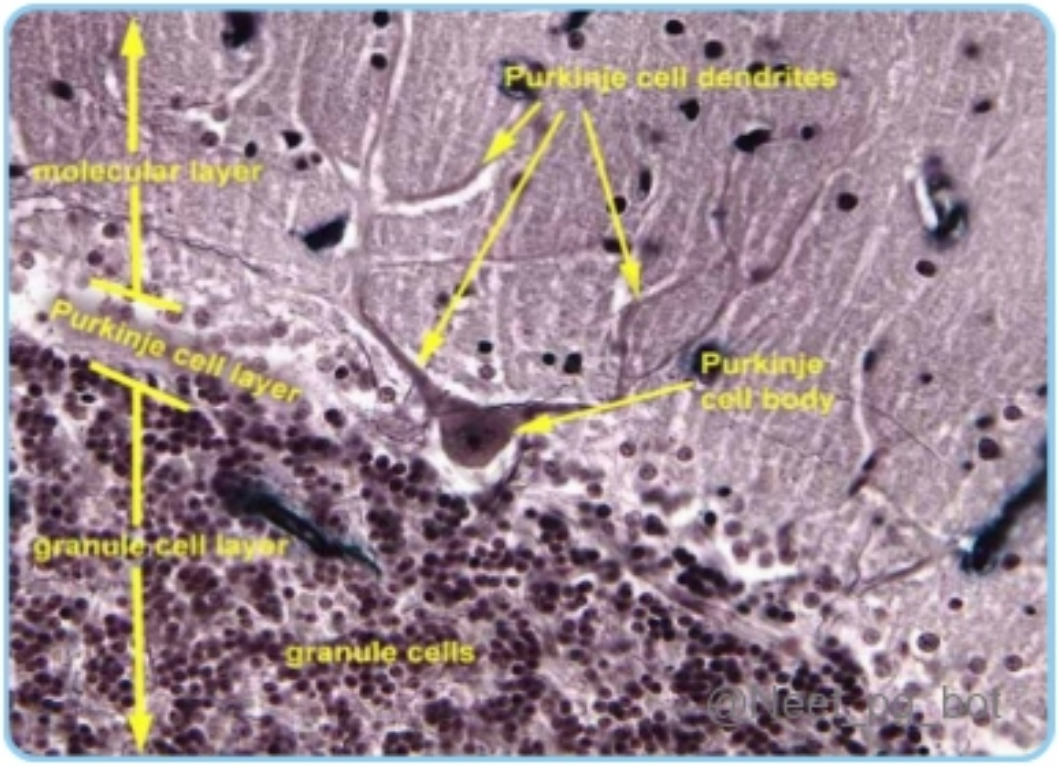

References:

Gray's Anatomy, 42nd Edition, Page: 469, 471. Textbook of Anatomy, Vishram Singh, Volume 3, 2nd Edition, Page: 377.

↑ *Back to this question in Part A*

@Neet_pg_bot

Q24: Which of the following organs does this epithelium most likely belong to? (Q866312)

A. Ureter

B. Gallbladder

C. Trachea

D. Intestine

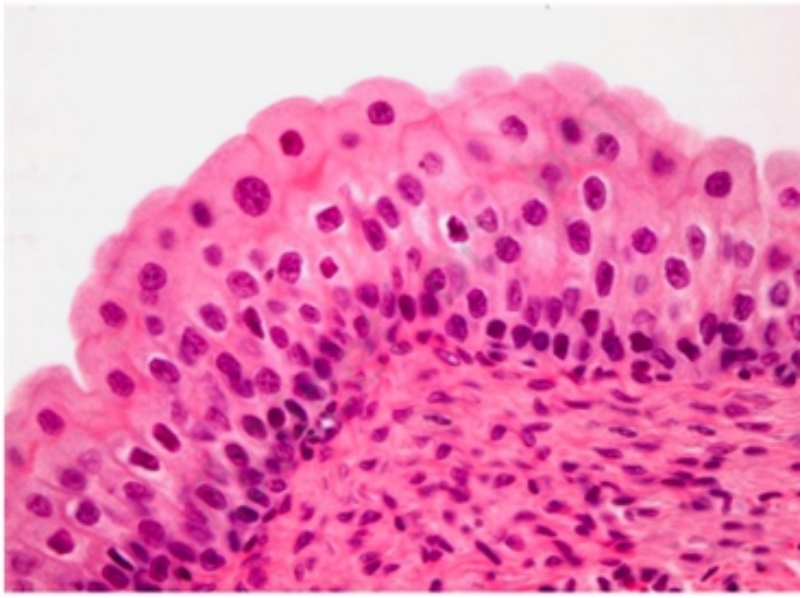

@Neet_pg_bot

Correct Answer: A. Ureter

Explanation: The image shows Urothelium, or Transitional Epithelium , a specialized tissue found exclusively in the urinary tract—specifically, the ureter, among the given options. A multilayered epithelium with four to six thick cells that can contract and expand as needed (stretchable epithelium). It is found in the renal pelvis and calyces, the ureter, the urinary bladder, and prostatic urethra. Features: Cells towards the lumen are very large and called umbrella-shaped cells (typical for transitional epithelium). Each cell is attached to the basement membrane by a cytoplasmic extension. The basement membrane is straight. Transitional between stratified squamous and stratified columnar epithelia. Cells at the surface are not squamous. Deepest cells are columnar or cuboidal. Middle layers are made up of polyhedral or pear-shaped cells. Superficial cell layer (lines the lumen): Only fully differentiated layer of the epithelium → Provides an impenetrable barrier between the lumen and the bloodstream. Incorrect Options: Option B: Gallbladder is lined by simple columnar epithelium with microvilli. Option C: Trachea is lined by pseudostratified ciliated columnar epithelium with goblet cells. Option D: Intestine is lined by simple columnar epithelium with goblet cells.

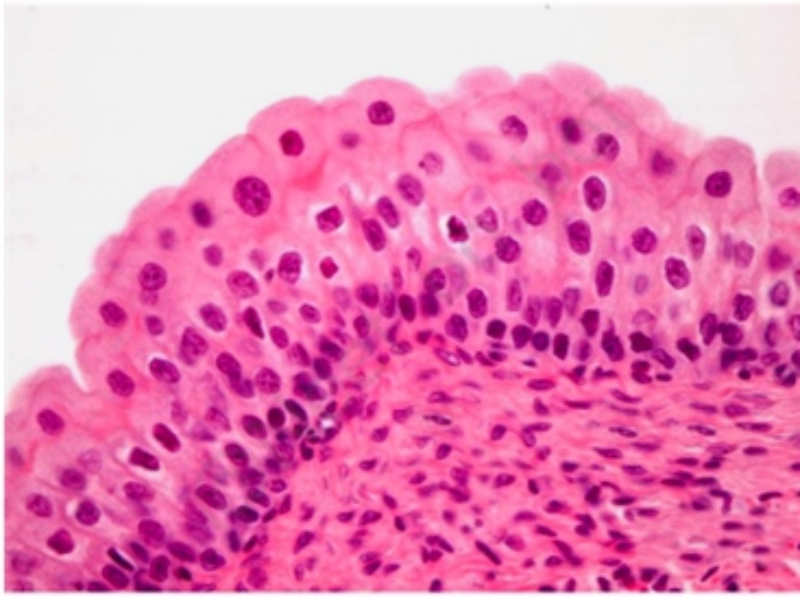

@Neet_pg_bot



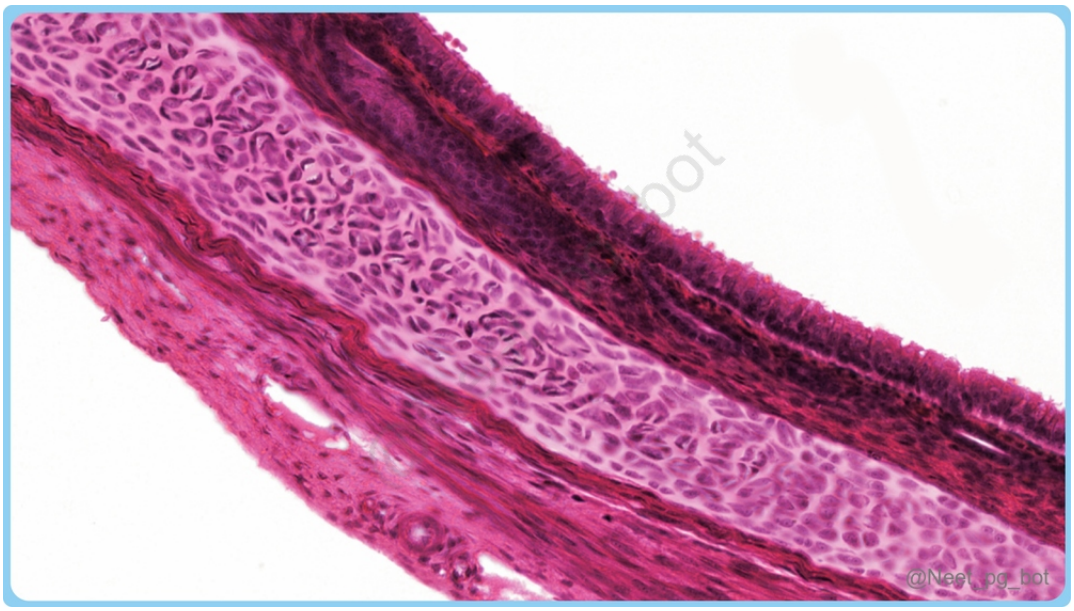

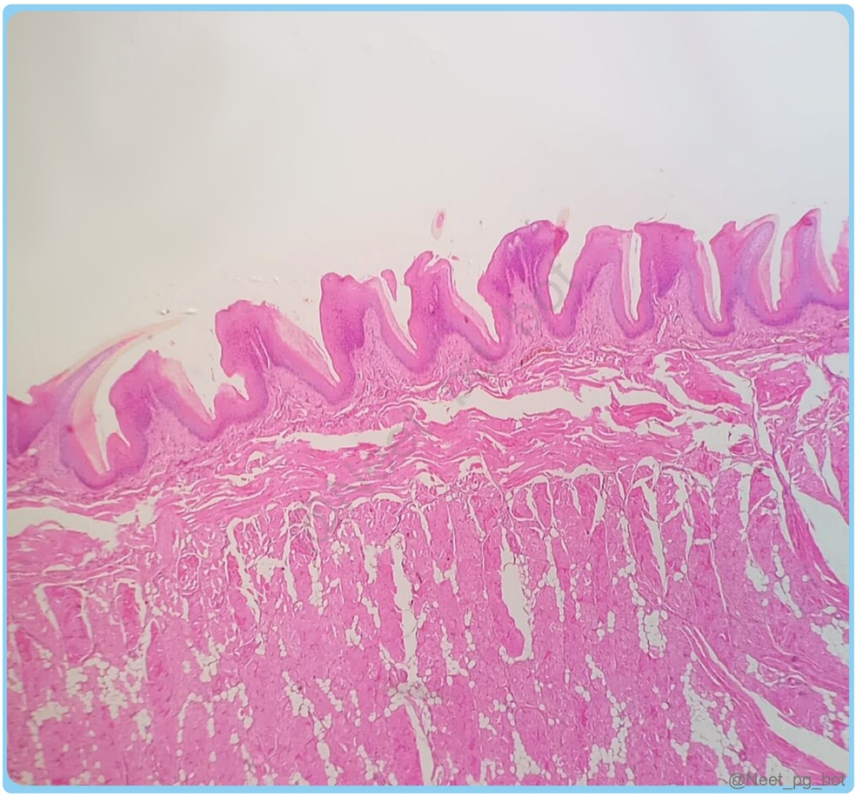

References:

.

↑ *Back to this question in Part A*

@Neet_pg_bot

• [03_Neuro Anatomy] 008 Nervous System Development

« Back to Folder Directory

[03_Neuro Anatomy] 008 Nervous System Development — Quick Jump

Q1 (p. 859) *Q2 (p. 860)* *Q3 (p. 862)* *Q4 (p. 864)* *Q5 (p. 864)* *Q6 (p. 866)*
Q7 (p. 868) *Q8 (p. 869)* *Q9 (p. 871)* *Q10 (p. 871)* *Q11 (p. 872)* *Q12 (p. 874)*

Q1: Which of the following statements is incorrect about the organization of the nervous system? (Q848437)

A. Gray matter in the CNS is called a nucleus.

B. PNS ganglia are mostly derived from the neural tube.

C. White matter in the CNS forms structures like tracts and fasciculi.

D. Axons in the CNS are covered by oligodendrocytes, and in the PNS by Schwann cells

Correct Answer: B. PNS ganglia are mostly derived from the neural tube.

■ *Listen (English)*

■ *Listen (Hindi)*

Explanation: PNS ganglia are derived from neural crest cells, not the neural tube. The neural tube gives rise to the CNS. Grey matter in the CNS consists of nerve cell bodies, called nuclei. (Option A) CNS white matter consists of myelinated axons and these axons form structures like tracts and fasciculi. (Option C) Oligodendrocytes cover CNS axons, while PNS axons are covered by Schwann cells. (Option D)

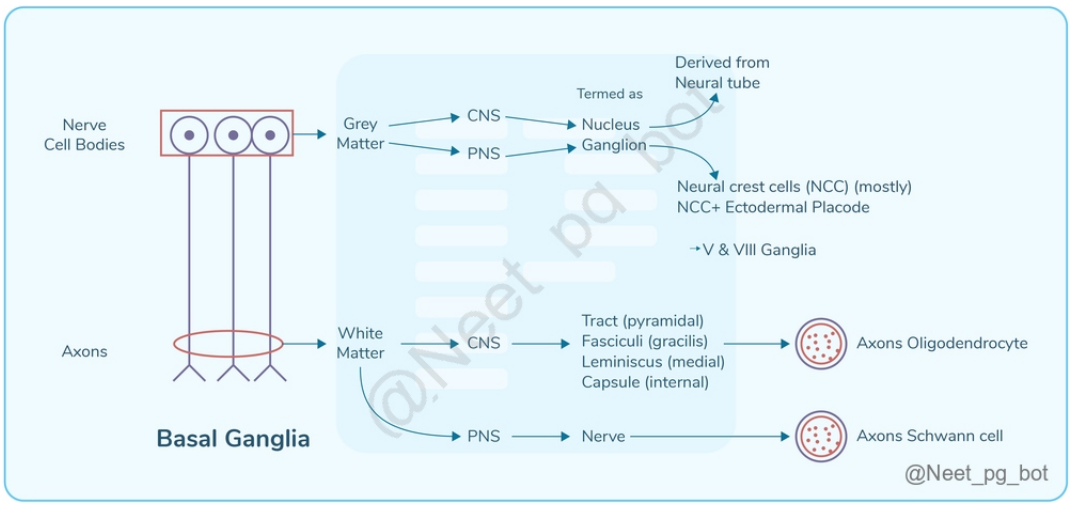

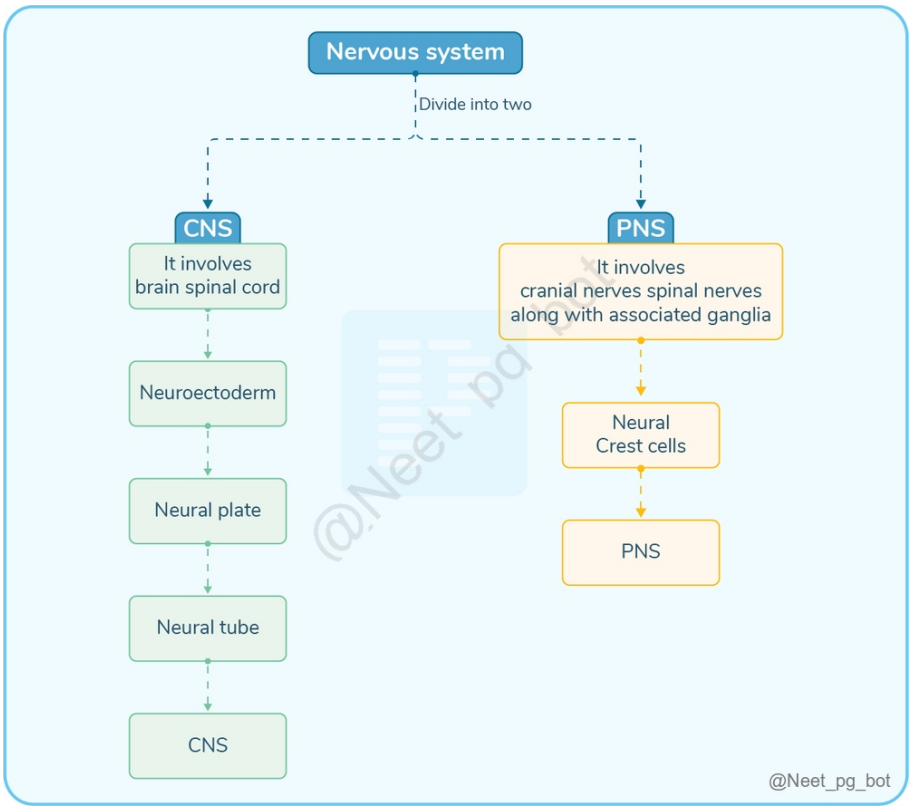

References:

Langman Medical Embryology 14th Edition. Pages 315, 349, 350

Grey's Anatomy 42nd Edition. Pages 239, 240

Grey and White Matter - Physiopedia

↑ *Back to this question in Part A*

@Neet_pg_bot

Q2: A 30 year old patient presents with sudden vision loss in one eye and pain during eye movement. The patient has a history of recurrent neurological symptoms and Imaging studies reveal inflammation and demyelination of the optic nerve. The patient is diagnosed with multiple sclerosis (MS). Why is the optic nerve affected in MS, despite being considered a peripheral nerve? (Q848438)

A. The optic nerve is not affected by MS.

B. It is an extension of the diencephalon and is myelinated by Schwann cells, which are affected in MS.

C. It is an extension of the diencephalon and myelinated by oligodendrocytes, which are involved in MS.

D. It does not regenerate, making it more vulnerable to damage.

Correct Answer: C. It is an extension of the diencephalon and myelinated by oligodendrocytes, which are involved in MS.

Listen (English)

Listen (Hindi)

Explanation: The optic nerve is part of the CNS because it develops as an extension of the diencephalon during embryological development. Unlike peripheral nerves, it is myelinated by oligodendrocytes, not Schwann cells. Multiple sclerosis (MS) is a demyelinating disease that affects oligodendrocytes , which are responsible for the myelination of CNS axons. Since the optic nerve is part of the CNS, it is susceptible to the demyelinating process in MS. Optic neuritis , which involves inflammation and demyelination of the optic nerve, is a common presenting symptom in MS, leading to vision loss and pain in eye movement . (Option A) Optic Nerve: Ganglion cell neurons in the retina collect visual information and transmit it towards the CNS via the optic nerve. Thus although being a peripheral nerve, the optic nerve is myelinated by oligodendrocytes- since it is a part of the CNS. (Option B) The optic nerve does not regenerate, making it more vulnerable to damage (Option D): The issue in MS is CNS demyelination, not the regeneration capacity.

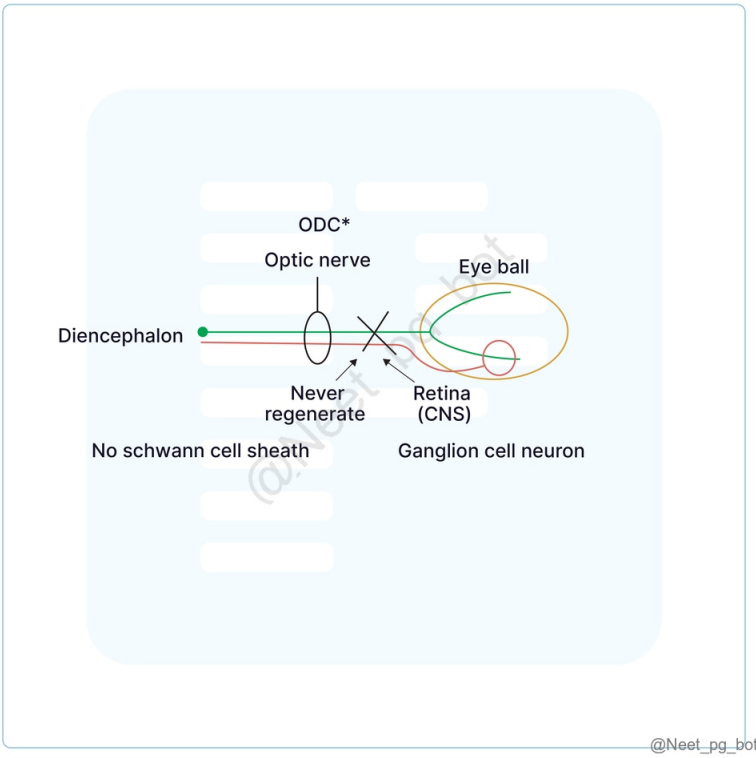

References:

Grey's Anatomy, 42nd Edition, Pages 264-266

www.ncbi.nlm.nih.gov/pmc/articles/PMC5398757/

↑ *Back to this question in Part A*

@Neet_pg_bot

Q3: Which of the following options correctly identifies the true statement about the formation of the neural tube? Neural plate → Neural groove → Neural tube The anterior neuropore closes on day 28 The posterior neuropore closes around day 25 (Q848439)

A. 1 is correct

B. 2 and 3 is correct

C. 1 and 2 is correct

D. All are correct

Correct Answer: A. 1 is correct

■ *Listen (English)*

■ *Listen (Hindi)*

Explanation: Neural plate → Neural groove → Neural tube describes the sequence of neural tube formation. {{caption_text}} The Rostral/ Anterior neuropore (top end) closes on day 25 when around 20 somites (segments) are present. (Statement 2) The Caudal/ Posterior neuropore (bottom end) closes around the level of the future second sacral vertebra on day 28 . (Statement 3)

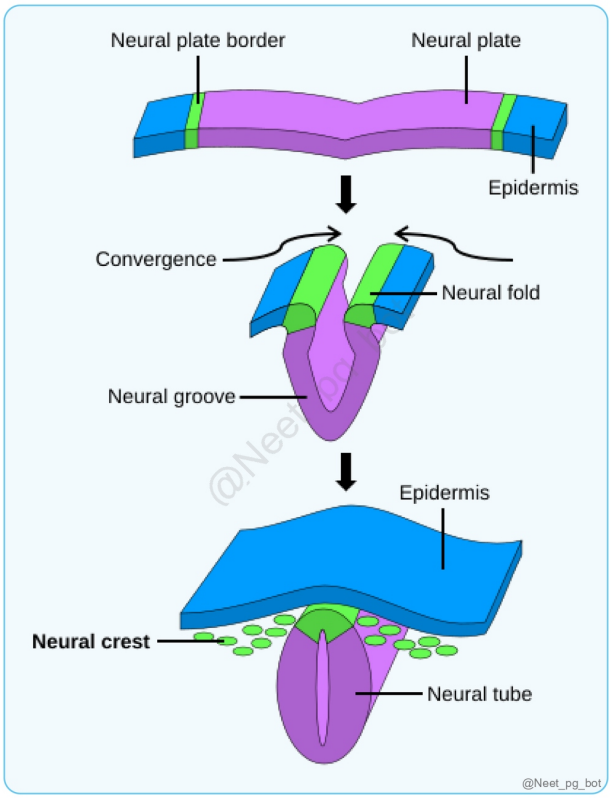

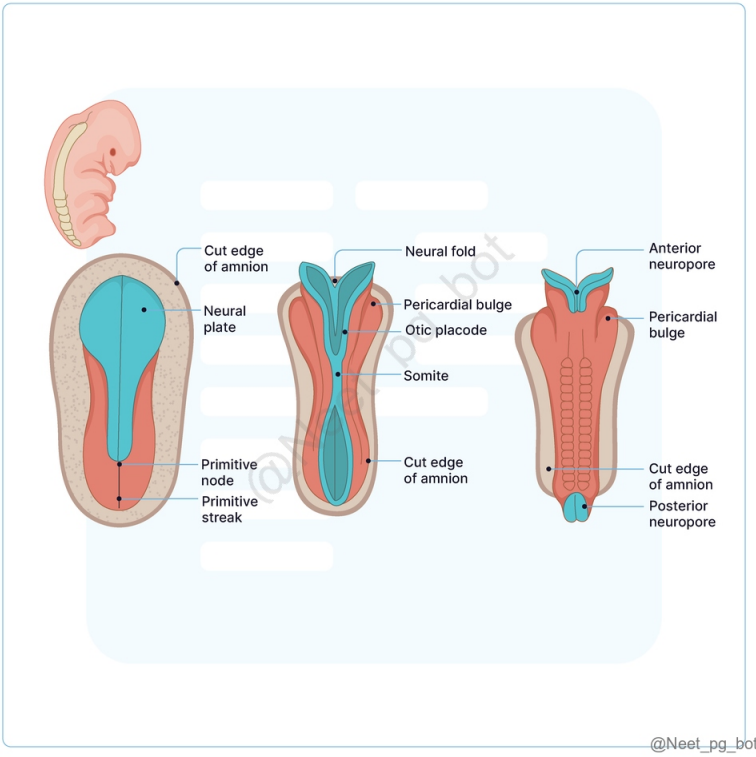

References:

Grey's Anatomy, 42nd Edition. Pages 233, 234

www.ncbi.nlm.nih.gov/books/NBK557414/#

↑ *Back to this question in Part A*

@Neet_pg_bot

Q4: Which of the following is not a characteristic of ectodermal placodes? (Q848440)

A. Developing into the lens vesicle

B. Forming the olfactory epithelium

C. Contributing to the development of the membranous labyrinth of the inner ear

D. Directly gives rise to neurons in the Vestibulocochlear ganglion

Correct Answer: D. Directly gives rise to neurons in the Vestibulocochlear ganglion

■ *Listen (English)*

■ *Listen (Hindi)*

Explanation: Otic Placodes are specific types of ectodermal placodes that form the inner ear structures. They invaginate to become otic vesicles, which eventually develop into the membranous labyrinth of the inner ear, including the cochlea (for hearing) and the vestibular apparatus (for balance). Vestibulocochlear Ganglion: This is a cluster of nerve cell bodies located near the inner ear. It contains sensory neurons that are responsible for hearing and balance. While the otic placodes contribute to the development of the inner ear structures, the neurons of the vestibulocochlear ganglion do not arise directly from the ectodermal placodes. Instead, the otic placodes form the otic vesicles, and neurons for the vestibulocochlear ganglion develop from the cells that bud off from these vesicles. Ectodermal Placodes: Neural crest cells migrate before neural tube closure, while neuroepithelial cells become part of the surface ectoderm, forming placodes. Placodes thicken after receiving an inductive signal, generating migratory neuronal cells for cranial sensory ganglia or forming a vesicle. Ectodermal placodes can either form nervous tissue (neurogenic) or non-neurogenic tissues like the lens vesicle. (Option A) Olfactory Placode (Option B): Develops into nasal cavity epithelium. Otic Placodes (Option C): Develop into the inner ear (membranous labyrinth) structures.

References:

Grey’s Anatomy, 42nd Edition, Page 236

↑ *Back to this question in Part A*

@Neet_pg_bot

Q5: Which of the following structural abnormalities is most commonly associated with the given image? (Q848441)

A. Malformation of the vertebral arches

B. Incomplete development of the basichondrocranium

C. Herniation of brain tissue through the skull

D. Fusion of the cranial sutures



Correct Answer: B. Incomplete development of the basichondrocranium

■ *Listen (English)*

■ *Listen (Hindi)*

Explanation: Anencephaly is associated with severe abnormalities in the base of the skull (basichondrocranium), affecting its shape, position, and ossification. Anencephaly: Neurulation failure : Anencephaly occurs when the neural tube fuses in the spinal cord (Caudal neuropore) but fails to fuse in the brain region (Cranial neuropore), leading to missing parts of the brain and skull. The cranial and caudal neuropores close around day 25 and 28 of development respectively in a normally developing fetus. {{caption_text}} Malformation of the vertebral arches (Option A) : This is characteristic of spina bifida, not anencephaly. Herniation of brain tissue through the skull (Option C) : This describes encephalocele, a different neural tube defect, not anencephaly. Fusion of the cranial sutures (Option D) : This refers to craniosynostosis, which is not related to anencephaly.



References:

Gray's Anatomy, 42nd Edition, Page 233

↑ *Back to this question in Part A*

@Neet_pg_bot

Q6: Which of the following is a common feature of craniorachischisis compared to rachischisis? (Q848442)

A. Craniorachischisis results from failure of caudal neural tube closure, while rachischisis affects the entire tube.

B. Craniorachischisis exposes both the brain and spinal cord; rachischisis exposes only the spinal cord.

C. Craniorachischisis is less severe than rachischisis and affects only the vertebrae.

D. Craniorachischisis involves complete neural tube closure, while rachischisis exposes both the brain and spinal cord.

Correct Answer: B. Craniorachischisis exposes both the brain and spinal cord; rachischisis exposes only the spinal cord.

■ *Listen (English)*

■ *Listen (Hindi)*

Explanation: This option correctly identifies the extent of exposure associated with each condition, with craniorachischisis being more severe and involving both structures. Rachischisis and Craniorachischisis: Condition Rachischisis Craniorachischisis Description A type of spina bifida where a portion of the spinal cord remains open. The most severe form of neural tube defect- involving exposure of both the brain and spinal cord. Neural Tube Involvement Occurs due to the failure of fusion of the caudal portion of the neural tube. (Option A) Occurs due to the failure of fusion of both the cranial as well as the caudal portions of the neural tube (Option D) Severity Severe, but localised to the spinal cord Most severe (Option C) Exposure Spinal cord neural tissue is exposed Both the brain and spinal cord are exposed. Diagram

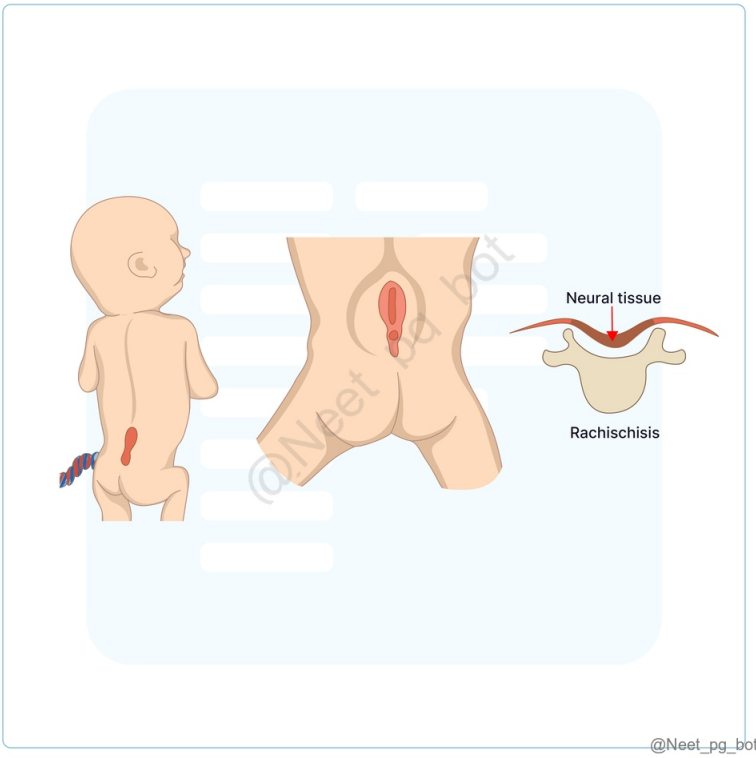

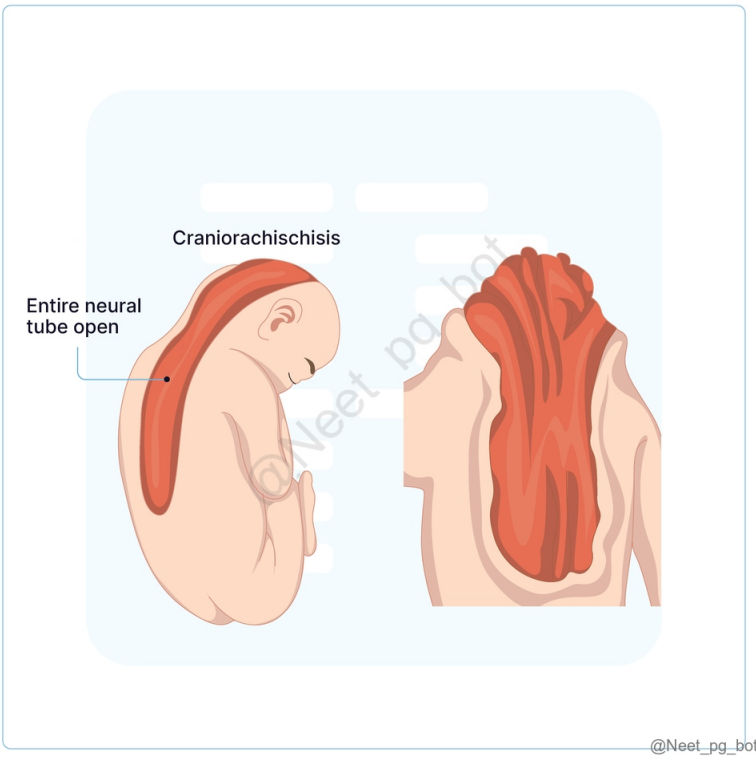

References:

Gray's Anatomy, 42nd Edition, Pages 233, 300

↑ *Back to this question in Part A*

@Neet_pg_bot

Q7: Which of the following statements about spina bifida is false? (Q848443)

A. Spina bifida occulta presents with an abnormal U or V shape in the vertebrae.

B. Meningocele involves protrusion of the meninges and spinal cord through the defect.

C. Diastematomyelia is rarely associated with spina bifida and splits the spinal cord.

D. The incidence of myelomeningocele has decreased due to prenatal diagnosis and termination options.

Correct Answer: B. Meningocele involves protrusion of the meninges and spinal cord through the defect.

■ *Listen (English)*

■ *Listen (Hindi)*

Explanation: Meningocele involves only the protrusion of the meninges , not the spinal cord. When the spinal cord is also involved, the condition is called myelomeningocele . Spina bifida is a birth defect where the neural tube fails to close properly, affecting the caudal portion of the spinal neural tube. Prenatal Diagnosis: Detection : Spina bifida can be identified through ultrasound imaging during pregnancy. Spina Bifida Occulta Indicator : The posterior ossification centres of the vertebrae may display an abnormal U or V shape. (Option A) Incidence : The prevalence of severe types, such as myelomeningocele, has decreased due to improved prenatal diagnosis and options for termination. (Option D) Diastematomyelia (Option C): An extremely rare condition where the spinal cord is split into two columns by a bony or cartilaginous spur, often associated with tethered cord.

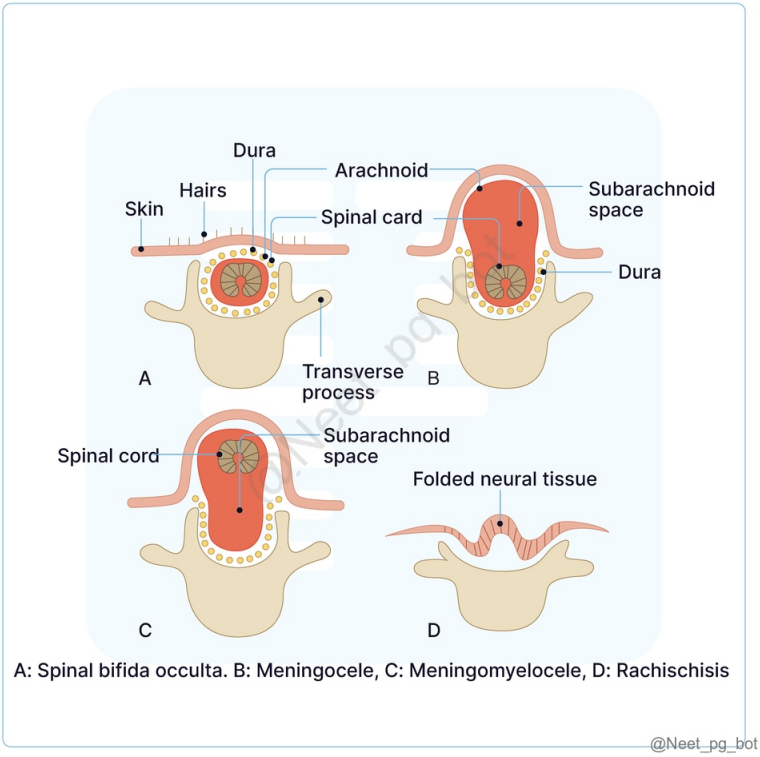

A: Spinal bifida occulta. B: Meningocele, C: Meningomyelocele, D: Rachischisis

@Neet_pg_bot

References:

Gray's Anatomy, 42nd Edition, Pages 246, 300

↑ *Back to this question in Part A*

@Neet_pg_bot

Q8: Which of the following correctly pairs a brain region with its corresponding structure or function? (Q848449)

A. Myelencephalon: Develops into the cerebellum, involved in motor control and balance.

B. Tectum: Located in the hindbrain and responsible for auditory and visual reflexes.

C. Hypothalamus: Part of the diencephalon, regulates hunger, thirst, body temperature, and sleep-wake cycles.

D. Frontal Lobe: Primarily involved in visual processing and spatial awareness.

Correct Answer: C. Hypothalamus: Part of the diencephalon, regulates hunger, thirst, body temperature, and sleep-wake cycles.

- *Listen (English)*
- *Listen (Hindi)*

Explanation: Parts of the Brain: Brain Region Components Functions/Derivatives Prosencephalon (Forebrain) Diencephalon Relay centre for sensory information, regulates endocrine system, autonomic functions Thalamus Relays sensory information to the cerebral cortex. Hypothalamus Regulates hunger, thirst, temperature, sleep-wake cycles, endocrine system Epithalamus The pineal gland (melatonin production) Subthalamus Involved in motor control Telencephalon Forms cerebral hemispheres, median part in front of the interventricular foramen and lateral ventricle Cerebral Cortex Higher cognitive functions (language, memory, reasoning, movement) Frontal Lobe (Option D) Planning, decision-making, problem-solving, voluntary movement Parietal Lobe Sensory information, spatial awareness, navigation Temporal Lobe Auditory processing, language comprehension Occipital Lobe Visual processing Lateral Ventricles Fluid-filled cavities for cerebrospinal fluid circulation Mesencephalon (Midbrain) Cerebral Peduncles Connects cerebrum to the brainstem Tectum (Option B) Made of superior and inferior colliculi. Tegmentum Contains nuclei of 5,6,7,8 nerves. Rhombencephalon (Hindbrain) Myelencephalon (Option A) Develops into the medulla oblongata (breathing, heart rate) Metencephalon Forms the pons (signal relay) and cerebellum (motor control, balance)

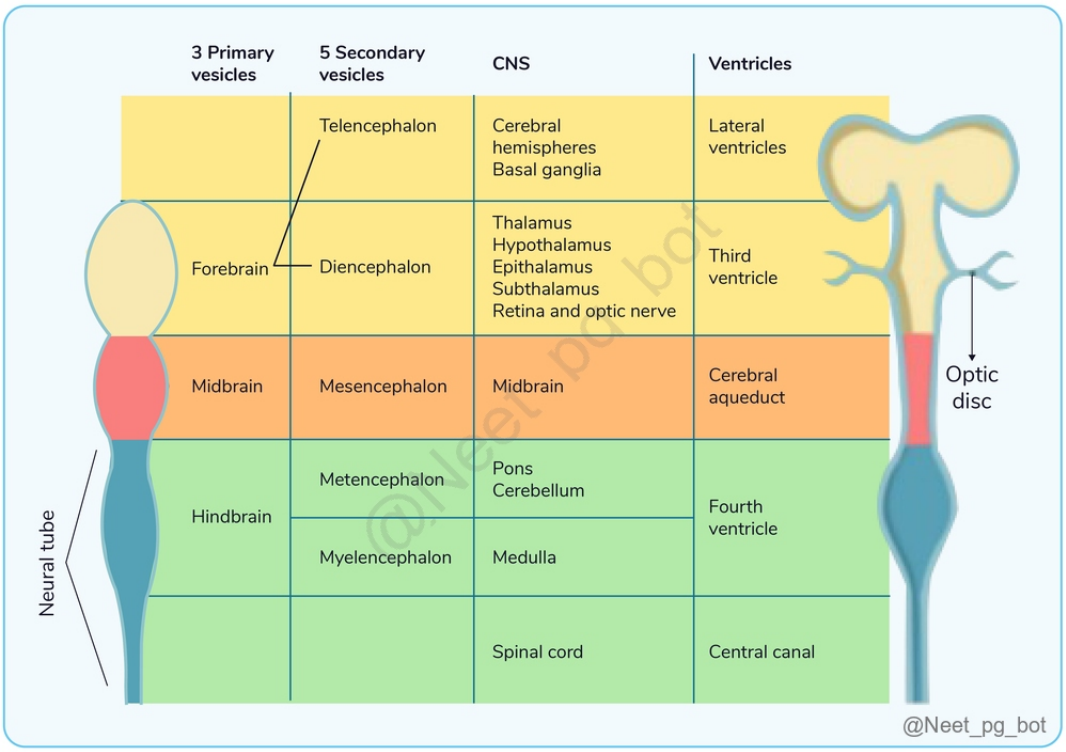

References:

Gray’s Anatomy, 42nd Edition, Pages 247-252

B.D. Chaurasia’s Human Anatomy, 8th Edition, Volume 4, Pages 9, 18, 108, 110, 143, 153, 155

↑ *Back to this question in Part A*

@Neet_pg_bot

Q9: Which of the following statements about the treatment of aqueduct stenosis is correct? (Q848450)

A. Ventriculoperitoneal shunting permanently cures aqueduct stenosis.

B. Endoscopic third ventriculostomy involves diverting CSF to the abdominal cavity.

C. Aqueduct stenosis can be treated with medications alone in most cases.

D. Ventriculoperitoneal shunting involves diverting CSF to reduce intracranial pressure.

Correct Answer: D. Ventriculoperitoneal shunting involves diverting CSF to reduce intracranial pressure.

■ *Listen (English)*

■ *Listen (Hindi)*

Explanation: Ventriculoperitoneal shunting diverts CSF to relieve pressure caused by hydrocephalus. Aqueduct Stenosis: Category Details Causes Congenital: Developmental anomalies Acquired: Tumours, infections, trauma Symptoms Headache, nausea, vomiting (Due to CSF accumulation) Cognitive impairments due to increased intracranial pressure. Treatment Ventriculoperitoneal shunting : Diverts excess CSF (Option A) Endoscopic third ventriculostomy : Bypasses obstruction (high relapse rate) (Option B) Aqueduct stenosis can be treated with medications alone in most cases (Option C): It usually requires surgical intervention, as medications alone are not sufficient.

References:

Gray’s Anatomy, 42nd Edition, Page 409

Aqueduct StenosisPages 523, 525

Third Ventriculostomy

Ventriculoperitoneal Shunt

↑ *Back to this question in Part A*

@Neet_pg_bot

Q10: Which of the following statements about the cerebellar peduncles and corpora quadrigemina is correct? (Q848451)

A. Superior cerebellar peduncles carry afferent signals from the cerebellum to the medulla.

B. Middle cerebellar peduncles transmit sensory information from the spinal cord to the cerebellum.

C. Inferior cerebellar peduncles connect the cerebellum to the medulla and aid in balance and posture.

D. Superior colliculi are involved in auditory processing and relay signals to the auditory cortex.

Correct Answer: C. Inferior cerebellar peduncles connect the cerebellum to the medulla and aid in balance and posture.

■ *Listen (English)*

■ *Listen (Hindi)*

Explanation: The inferior cerebellar peduncles carry both afferent and efferent fibres, connecting the cerebellum to the medulla oblongata and playing a role in balance and posture control. Cerebellar Peduncles Peduncle Function Components Role Superior Cerebellar Peduncles Carry efferent (outgoing) signals from the cerebellum to the midbrain. (Option A) Connects the cerebellum to the midbrain. It contains axons from the Dentate, Emboliform and the Globose nuclei of the cerebellum. Movement planning and coordination. Middle Cerebellar Peduncles The main route for afferent (incoming) signals to the cerebellum. Connects cerebellum to the pons. (Option B) Provides information about planned movements. Inferior Cerebellar Peduncles (Option C) Carry both afferent and efferent fibres. Connects cerebellum to the medulla oblongata. It contains axons from the fastigial nucleus of the cerebellum. Receives sensory information for balance and posture, and sends signals to vestibular nuclei and reticular formation. Corpora Quadrigemina (Tectum) Colliculi Function Components Role Superior Colliculi Involved in visual processing and eye movement control. (Option D) Receives input from optic nerves and visual processing areas. Coordinates head and eye movements in response to visual stimuli. Inferior Colliculi Plays a role in auditory processing. [musIC- Inferior Colliculus] Receives input from auditory pathways. Projects to the medial geniculate nucleus of the thalamus for auditory signal relay.

References:

Gray’s Anatomy, 42nd Edition, Page 467

B.D. Chaurasia’s Human Anatomy, 8th Edition, Volume 4, Pages 110, 111, 121, 122, 151

Textbook of Anatomy Vishram Singh, 2nd Edition, Volume 3, Page 356

↑ *Back to this question in Part A*

@Neet_pg_bot

Q11: Identify the labelled structures in the given diagram. (Q848452)

A. A- Fornix; B- Hippocampus; C- Corpus Callosum

B. A – Fornix; B – Amygdala; C – Hippocampus

C. A- Fornix; B- Corpus Callosum; C- Hippocampus

D. A – Fornix; B – Hypothalamus; C – Amygdala

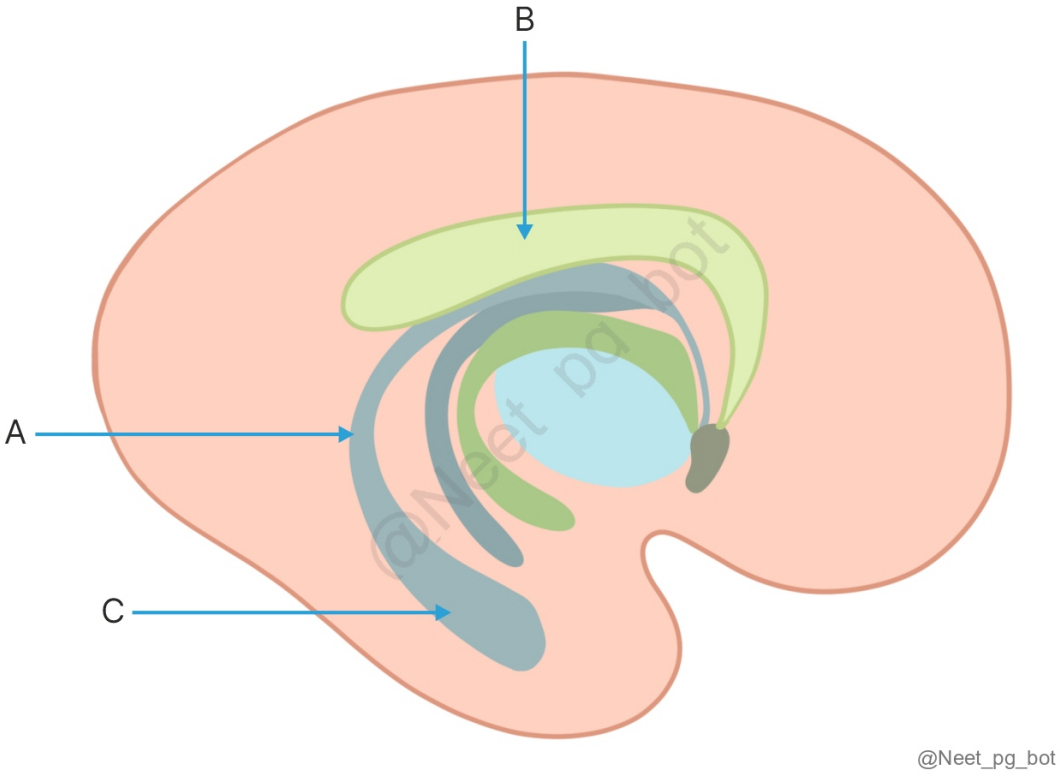

Correct Answer: C. A- Fornix; B- Corpus Callosum; C- Hippocampus

■ *Listen (English)*

■ *Listen (Hindi)*

Explanation: The diagram above shows the thalamus and the structures surrounding it. Structure Description Thalamus Grey matter mass; sensory and motor roles Fornix A c-shaped fibre bundle; connects the hippocampal formations of the two sides. The main efferent tract of the hippocampus. Corpus Callosum The largest commissure of the brain; links the cerebra hemispheres. Caudate Nucleus The comma-shaped nucleus of the basal ganglia Choroid Plexus Produces CSF; vascular network. Hippocampus Seahorse-shaped (Curved and elongated); stores long-term memory and is a part of the limbic system.

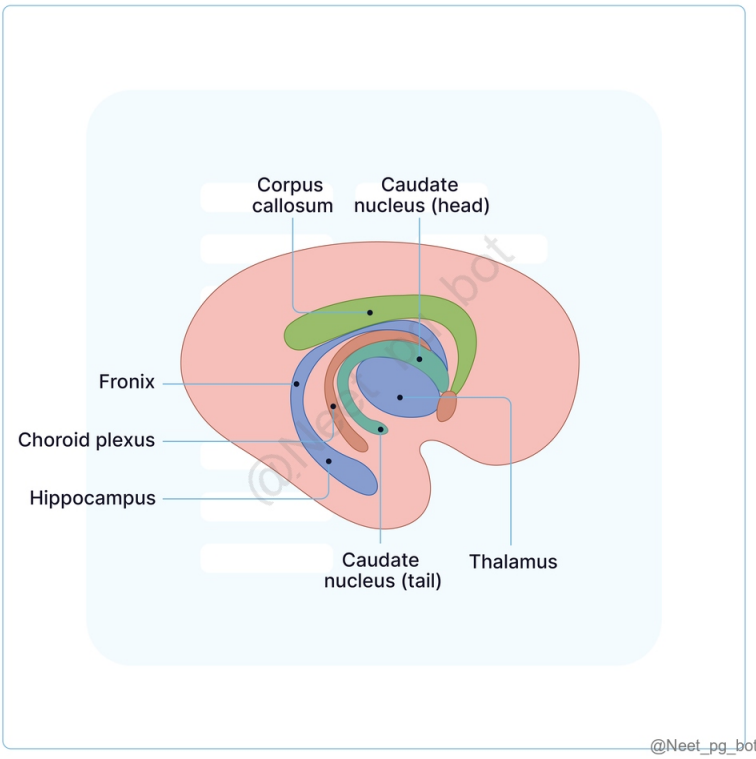

References:

Gray's Anatomy, 42nd Edition, Pages 389, 504

B.D. Chaurasia's Human Anatomy, 8th Edition, Volume 4, Pages 31, 147, 149, 156, 160

Textbook of Anatomy Vishram Singh, 2nd Edition, Volume 3, Page 403

↑ *Back to this question in Part A*

@Neet_pg_bot

Q12: Which of the following accurately describes the pathway of the Papez circuit? (Q848458)

A. Cingulate cortex → Hippocampus → Mammillary bodies → Anterior thalamic nuclei → Fornix

B. Cingulate cortex → Mammillary bodies → Hippocampus → Fornix → Anterior thalamic nuclei

C. Hippocampus → Cingulate cortex → Anterior thalamic nuclei → Mammillary bodies → Fornix

D. Hippocampus → Fornix → Mammillary bodies → Anterior thalamic nuclei → Cingulate cortex

Correct Answer: D. Hippocampus → Fornix → Mammillary bodies → Anterior thalamic nuclei → Cingulate cortex

■ *Listen (English)*

■ *Listen (Hindi)*

Explanation: The Papez circuit starts in the hippocampus, travels through the fornix to the mammillary bodies, then to the anterior thalamic nuclei, and finally projects back to the cingulate cortex.

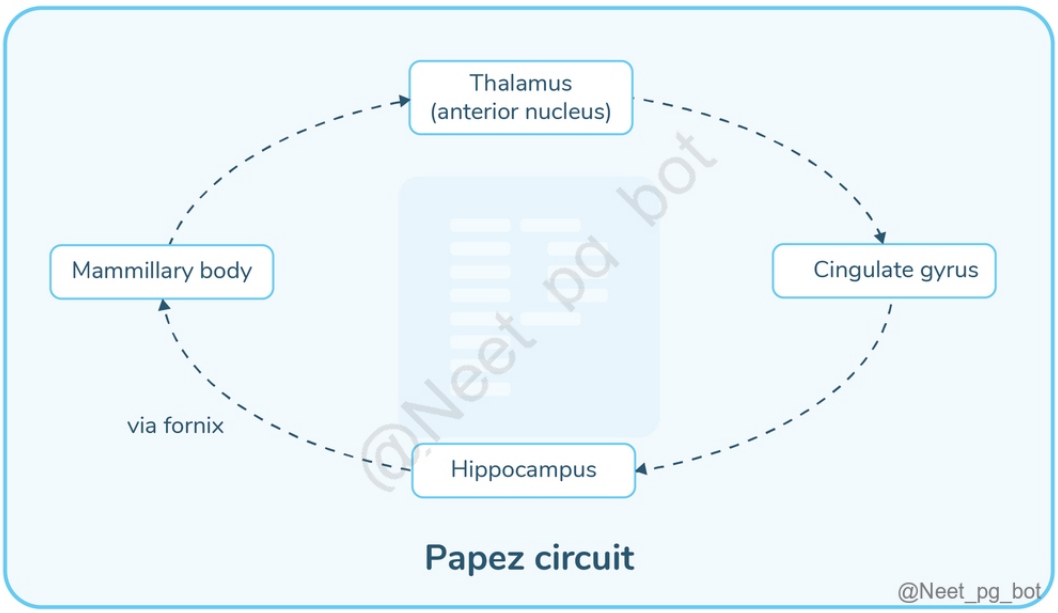

References:

Gray's Anatomy, 42nd Edition, Page 521

B.D. Chaurasia's Human Anatomy, 8th Edition, Volume 4, Page 176

Papez Circuit

↑ *Back to this question in Part A*

@Neet_pg_bot

• [03_Neuro Anatomy] 009 Ventricular System White Matter And Neural Columns

« Back to Folder Directory

[03_Neuro Anatomy] 009 Ventricular System White Matter And Neural Columns — Quick Jump

Q1 (p. 876)	*Q2 (p. 877)*	*Q3 (p. 878)*	*Q4 (p. 879)*	*Q5 (p. 881)*	*Q6 (p. 882)*
Q7 (p. 883)	*Q8 (p. 885)*	*Q9 (p. 886)*	*Q10 (p. 887)*	*Q11 (p. 888)*	*Q12 (p. 890)*
Q13 (p. 891)	*Q14 (p. 892)*	*Q15 (p. 893)*	*Q16 (p. 895)*		

Q1: Which structure forms the lateral wall of the anterior horn of the lateral ventricle? (Q848499)

A. Corpus callosum

B. Head of the caudate nucleus

C. Thalamus

D. Hippocampus

Correct Answer: B. Head of the caudate nucleus

■ *Listen (English)*

■ *Listen (Hindi)*

Explanation: The head of the caudate nucleus forms the lateral wall of the anterior horn of the lateral ventricle. Wall Structure forming it Roof Corpus callosum (body) (Option A ruled out) Floor Rostrum of the corpus callosum and the head of the caudate nucleus Medial wall Septum pellucidum Lateral wall Head of the caudate nucleus Thalamus (Option C): The thalamus forms the walls of the third ventricle and does not form part of the lateral wall of the anterior horn of the lateral ventricle. Hippocampus (Option D): The hippocampus is located in the inferior (temporal) horn of the lateral ventricle and does not form the lateral wall of the anterior horn.

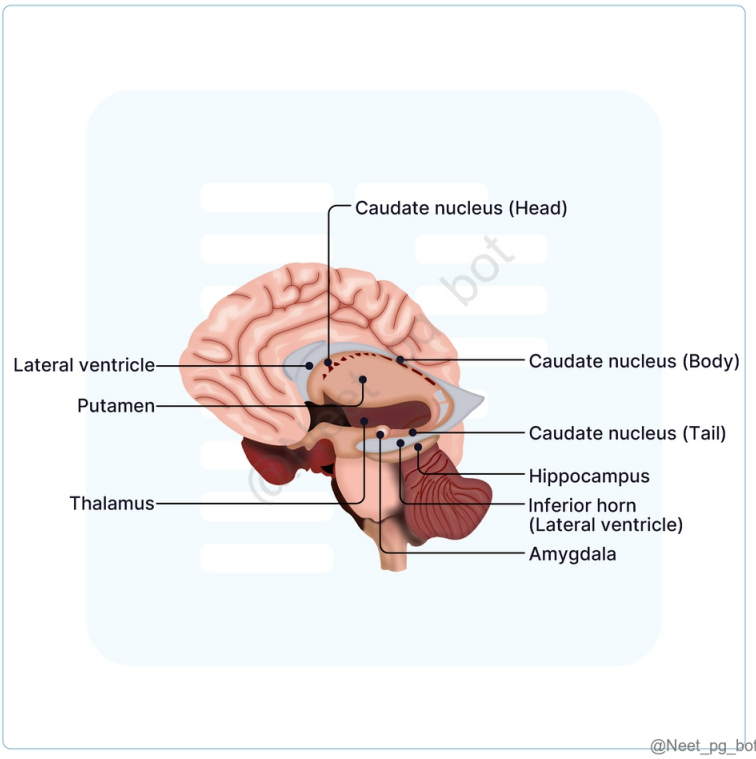

References:

Snell’s Clinical Anatomy, 10th Edition, Pages 439,440

Vishram Singh Textbook of Anatomy, 2nd Edition, Volume 3, Page 397

↑ *Back to this question in Part A*

@Neet_pg_bot

Q2: Which cranial nerve sensory fibres transmit sensory information from the skin and mucous membranes of the face, head, and neck? (Q848509)

A. Special Somatic Afferent (SSA) fibres

B. General Visceral Afferent (GVA) fibres

C. Special Visceral Afferent (SVA) fibres

D. General Somatic Afferent (GSA) fibres

Correct Answer: D. General Somatic Afferent (GSA) fibres

■ *Listen (English)*

■ *Listen (Hindi)*

Explanation: General Somatic Afferent (GSA) fibres carry sensory input like pain, temperature, touch, and proprioception from the skin, mucous membranes, and other somatic regions of the face, head, and neck. In the cranial region, these sensations are primarily carried by: Trigeminal nerve (CN V) – chief sensory nerve of the face Facial nerve (CN VII) – small area of the external ear Glossopharyngeal nerve (CN IX) – posterior 1/3 rd of the tongue, pharynx Vagus nerve (CN X) – part of the external auditory meatus, pharynx, and larynx These fibres terminate in the trigeminal sensory nuclear complex (main sensory nucleus, spinal nucleus, and mesencephalic nucleus). Thus, GSA fibres are responsible for general somatic sensations from the face and related mucous membranes. Special Somatic Afferent (SSA) fibres (Option A): SSA fibres carry sensory impulses from organs derived from somatic ectoderm and are concerned with special senses , namely: Vision – via Optic nerve (CN II) Hearing and balance – via Vestibulocochlear nerve (CN VIII) They do not transmit general sensations like pain, touch, or temperature from skin or mucosa. General Visceral Afferent (GVA) fibres (Option B): GVA fibres carry sensory information from viscera , including: Carotid body and sinus Pharynx Thoracic and abdominal organs They are mainly carried by: Glossopharyngeal nerve (CN IX) Vagus nerve (CN X) These fibres transmit visceral sensations (e.g., chemoreception, baroreception), not general somatic sensations from skin and mucous membranes. Special Visceral Afferent (SVA) fibres (Option C): SVA fibres are concerned with special visceral senses , namely: Taste – via Facial nerve (CN VII) , Glossopharyngeal nerve (CN IX) , and Vagus nerve (CN X) Smell – via Olfactory nerve (CN I) They are related to branchial arch derivatives and do not carry general sensory modalities such as pain, touch, or temperature.

References:

Gray’s Anatomy, 42nd Edition, Pages 391, 442

Textbook of Anatomy Vishram Singh, 2nd Edition, Volume 3, Page 333

↑ *Back to this question in Part A*

@Neet_pg_bot

Q3: A 7-year-old girl presents with severe headaches, vomiting, and papilloedema. Imaging reveals obstructive hydrocephalus due to a tumour blocking the exit of cerebrospinal fluid from the fourth ventricle. Which of the following structures is most likely blocked? (Q848493)

A. The Foramen of Monro

B. Foramina of Luschka

C. Foramen rotundum

D. Foramen ovale

Correct Answer: B. Foramina of Luschka

■ *Listen (English)*

■ *Listen (Hindi)*

Explanation: Cerebrospinal fluid (CSF) leaves the fourth ventricle through: Foramina of Luschka (lateral apertures)→ Drain CSF from the fourth ventricle into the cerebellopontine angle cistern of the subarachnoid space. Foramen of Magendie (median aperture)→ Drains CSF into the cisterna magna. Obstruction of either results in non-communicating hydrocephalus. The Foramen of Monro (Option A): Connects the lateral ventricles to the third ventricle, not the fourth ventricle. Foramen rotundum (Option C): Transmits the maxillary nerve (V2) and is unrelated to CSF flow or the ventricular system. Foramen ovale (Option D): It transmits the mandibular nerve (V3) and is not involved in CSF drainage from the fourth ventricle.

References:

B.D. Chaurasia's Human Anatomy, 8th Edition, Volume 4, Page 131

↑ *Back to this question in Part A*

@Neet_pg_bot

Q4: Which of the given options are correctly matched based on the image given? (Q848494)

A. 3- Lateral recess, 5- Frontal horn

B. 1- Occipital horn, 7- Third Ventricle

C. 2- Fourth Ventricle, 4- Aqueduct

D. 3- Temporal horn, 6- Aqueduct

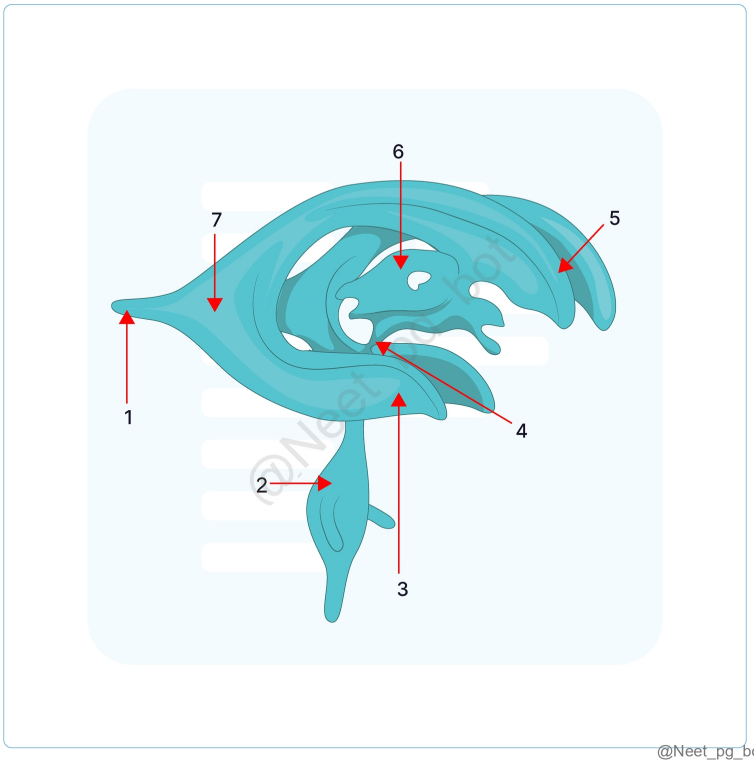

Correct Answer: C. 2- Fourth Ventricle, 4- Aqueduct

- *Listen (English)*
- *Listen (Hindi)*

Explanation: The given image shows the ventricular system of the brain Lateral ventricle horns: Anterior horn (5) - extends into the frontal lobe Posterior horn (1) - extends into the occipital lobe Inferior horn (3) - extends into the temporal lobe The third ventricle (6) is a narrow space located between the two thalami. It connects to the lateral ventricles to the fourth ventricle (2) in the back through the cerebral aqueduct of Sylvius (4) Atrium (7)

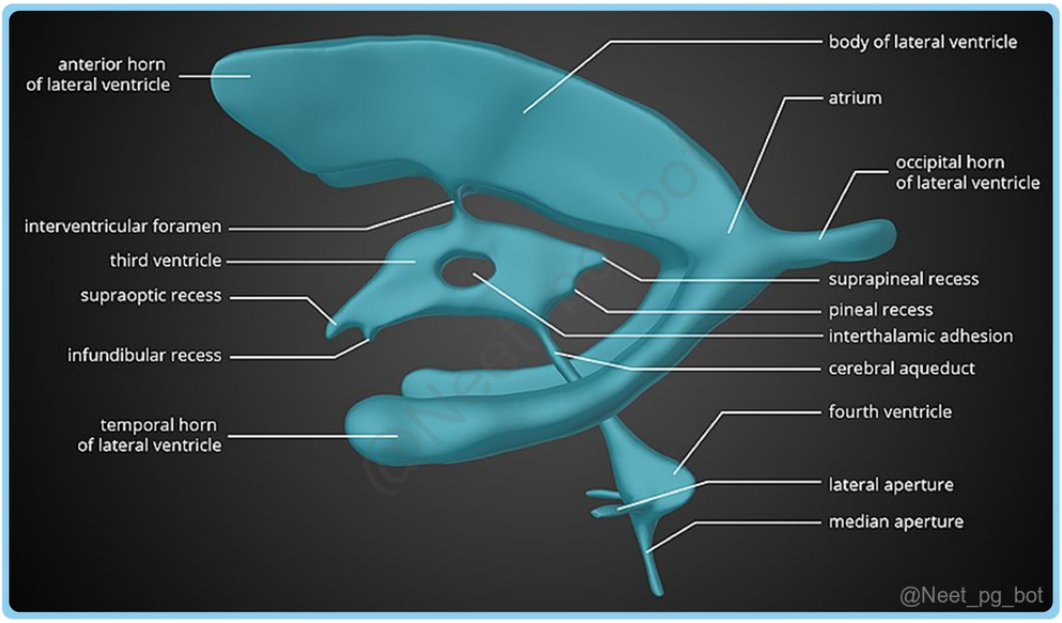

References:

Snells Clinical Neuroanatomy, 8th Edition, Pages 436, 440, 443

↑ *Back to this question in Part A*

@Neet_pg_bot

Q5: What is a primary characteristic of Benign External Hydrocephalus (BEH) in infants? (Q848495)

A. Severe neurological symptoms

B. Macrocephaly without significant symptoms

C. Necessitates immediate surgical intervention

D. Increased ventricular enlargement

Correct Answer: B. Macrocephaly without significant symptoms

■ *Listen (English)*

■ *Listen (Hindi)*

Explanation: Benign External Hydrocephalus in infants is defined by an increase in head size (macrocephaly) without accompanying significant neurological symptoms. It is often self-limiting and can be monitored. Severe neurological symptoms (Option A): BEH is characterized by macrocephaly without significant neurological symptoms. Infants with BEH typically do not exhibit major cognitive or physical impairments. Necessitates

immediate surgical intervention (Option C): BEH generally does not require immediate surgical intervention. Most cases are mild and self-resolving; surgery is only considered if there are complications or increased intracranial pressure. Increased ventricular enlargement (Option D): In BEH, there is an increase in the subarachnoid space volume with minimal or no enlargement of the ventricles. This distinguishes it from other types of hydrocephalus where ventricular enlargement is more prominent.

References:

www.ncbi.nlm.nih.gov/pmc/articles/PMC3171652/

www.ncbi.nlm.nih.gov/pmc/articles/PMC4202856/

link.springer.com/article/10.1007/s00381-018-4007-3

↑ *Back to this question in Part A*

@Neet_pg_bot

Q6: Match the following wall of the 3rd ventricle with its respective component. 1. Anterior wall a) Hypothalamus 2. Posterior Wall b) Mammillary bodies 3. Lateral wall c) Lamina terminalis 4. Floor d) Pineal gland (Q848496)

A. 1-d, 2-a, 3-b, 4-c

B. 1-b, 2-a, 3-c, 4-d

C. 1-a, 2-b, 3-d, 4-c

D. 1-c, 2-d, 3-a, 4-b

Correct Answer: D. 1-c, 2-d, 3-a, 4-b

■ *Listen (English)*

■ *Listen (Hindi)*

Explanation: The Third ventricle is a cavity located in the diencephalon. It is a narrow, midline space positioned between the two thalami and part of the hypothalamus. It connects to the lateral ventricle via the interventricular foramen (of Monro) anteriorly, and posteriorly, it connects to the fourth ventricle through the cerebral aqueduct (of Sylvius). It has an anterior wall, posterior wall, roof, floor and two lateral walls.

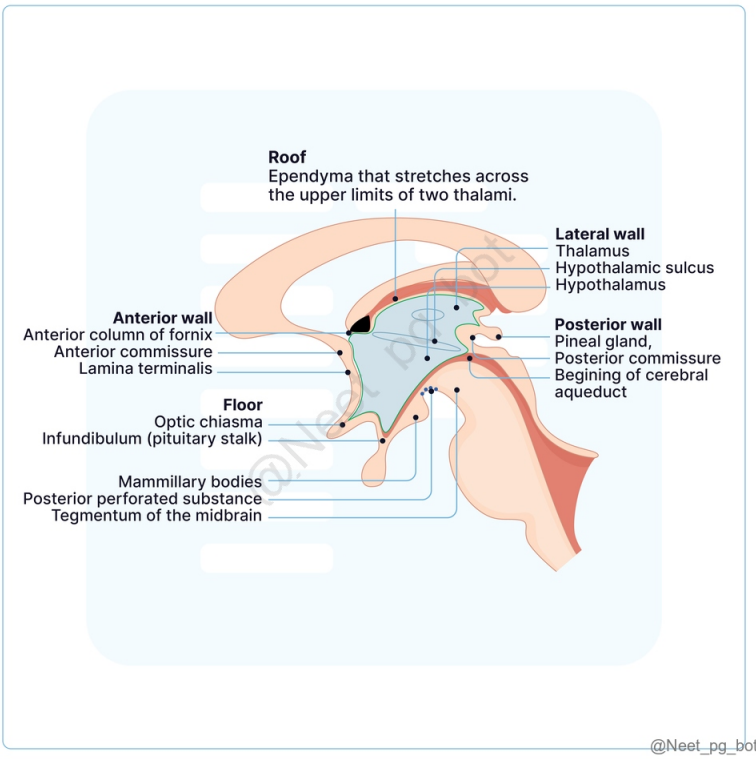

References:

Snells Clinical Neuroanatomy, 8th Edition, Pages 254, 255

Gray's Anatomy, 42nd Edition, Page 251

Vishram Singh Anatomy of Head, Neck, Brain, Volume 3, Pages386, 387

↑ *Back to this question in Part A*

@Neet_pg_bot

Q7: Match the following boundary of the 4th ventricle with its component. 1. Lateral wall a) Superior medullary velum 2. Posterior wall b) Superior medulla 3. Rhomboid fossa c) Superior cerebellar peduncle (Q848497)

A. 1-c, 2-b, 3-a

B. 1-c, 2-a, 3-b

C. 1-b, 2-a, 3-c

D. 1-a, 2-b, 3-c

Correct Answer: B. 1-c, 2-a, 3-b

■ *Listen (English)*

■ *Listen (Hindi)*

Explanation: Boundaries of 4th Ventricle Description Lateral Wall Inferolaterally- Inferior cerebellar peduncle, and gracile and cuneate tubercles Superolaterally- Superior cerebellar peduncle Roof (Posterior Wall) Superior Part : Medial borders of the two superior cerebellar peduncles. Superior medullary velum (a sheet of white matter). Inferior Part : Inferior medullary velum (ventricular ependyma and pia mater) Median aperture (foramen of Magendie) in the midline. Lateral Recesses : Extend laterally around the medulla. Open anteriorly as the foramina of Luschka (lateral openings of the fourth ventricle). Rhomboid Fossa (Floor) The posterior surface of the pons The upper part of the medulla

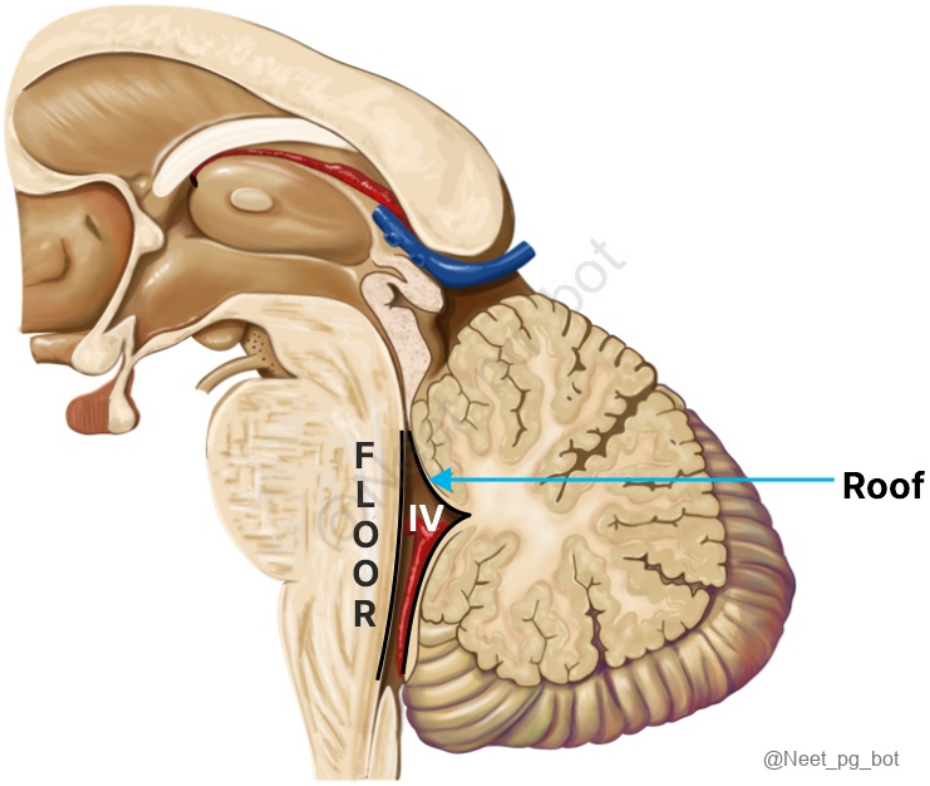

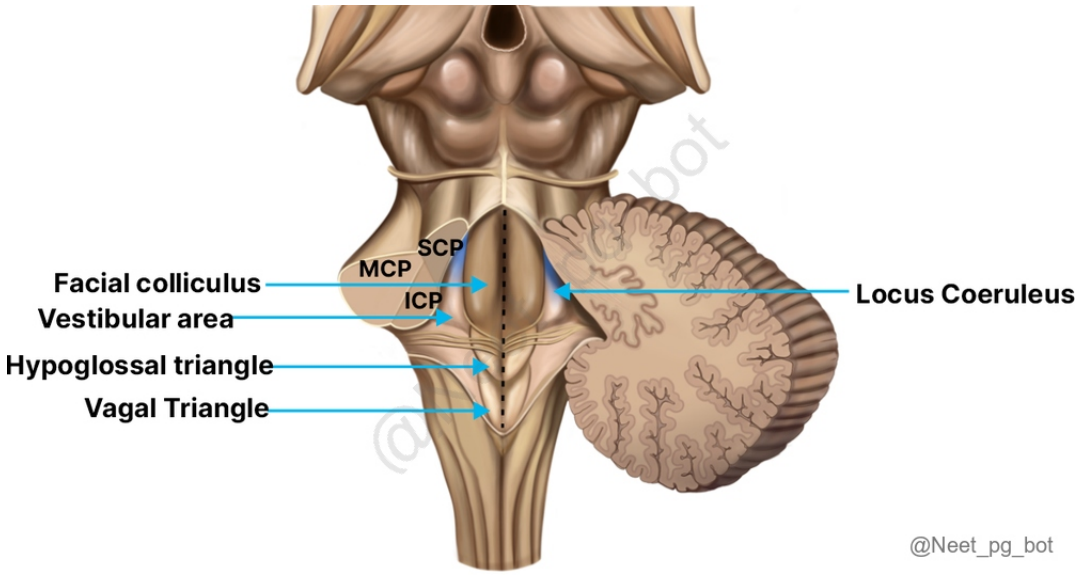

References:

Snells Clinical Neuroanatomy, 8th Edition, Pages 443-446

Vishram Singh. Anatomy of Head, Neck, Brain, Volume 3, Pages 378, 379

↑ *Back to this question in Part A*

@Neet_pg_bot

Q8: Which structure in the floor of the 4th ventricle consists of transverse white fibres derived from the arcuate nuclei? (Q848498)

A. Sulcus limitans

B. Stria medullaris

C. Locus ceruleus

D. Area postrema

Correct Answer: B. Stria medullaris

■ *Listen (English)*

■ *Listen (Hindi)*

Explanation: The stria medullaris consists of transverse white fibres originating from the arcuate nuclei, which cross the floor of the 4th ventricle to enter the inferior cerebellar peduncle. Structures and relation with the 4th Ventricle Divided into right and left halves by the median sulcus, from the aqueduct to the central canal. Stria Medullaris: White fibres from arcuate nuclei cross the floor → enter inferior cerebellar peduncle. Medial

Eminence: Elevation beside median sulcus, bounded laterally by sulcus limitans (Option A). Vestibular Area: Lateral to sulcus limitans; overlies vestibular nuclei. Superior Fovea & Locus Ceruleus: At upper sulcus limitans; superior fovea = triangular depression, locus ceruleus = bluish-grey area with pigmented cells (Option C). Facial Colliculus: Oval swelling on pontine floor from facial fibres looping over abducent nucleus. Hypoglossal Triangle: Overlies hypoglossal nucleus. Vagal Triangle: Overlies vagus, glossopharyngeal & accessory nuclei. Area Postrema: Small area between vagal triangle and gracile tubercle (Option D). Obex: Fold at lower ventricle formed by meeting of two teniae. Central Canal: Opens into 4th ventricle, continues through medulla & spinal cord; lined by ependymal cells, lacks choroid plexus.

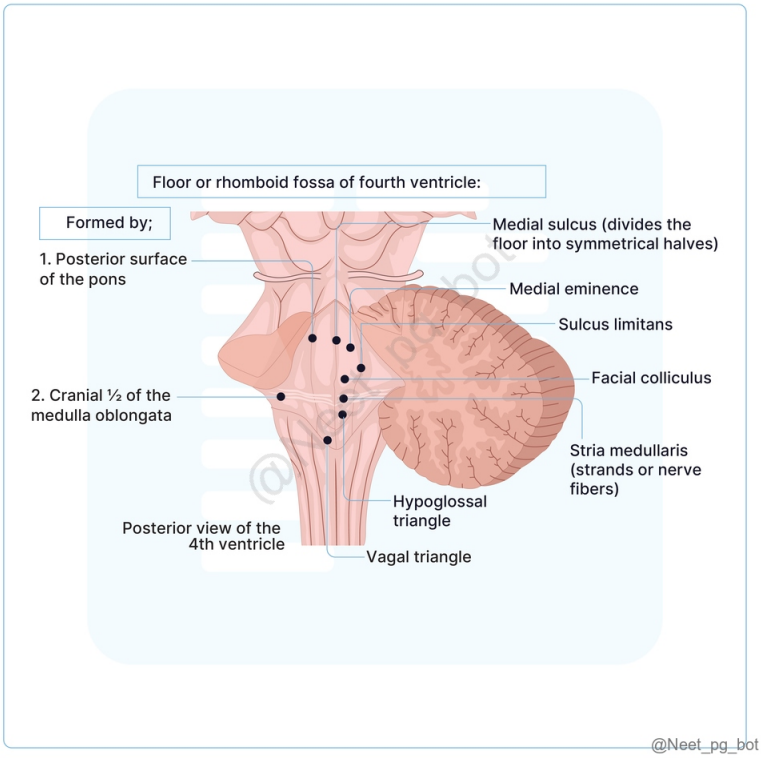

References:

Snells Clinical Neuroanatomy, 8th Edition, Pages 445-447

Vishram Singh Anatomy of Head, Neck, Brain, Volume 3, Pages379, 380

↑ *Back to this question in Part A*

@Neet_pg_bot

Q9: Which of the following does not cross the midline? (Q848500)

A. Corpus Callosum

B. Anterior Commissure

C. Fornix

D. Arcuate Fasciculus

Correct Answer: D. Arcuate Fasciculus

■ *Listen (English)*

■ *Listen (Hindi)*

Explanation: The white matter of the cerebral hemispheres is divided into association, commissural, and projection fibres . Commissural fibres connect the two cerebral hemispheres and therefore cross the midline (Option A ruled out) Corpus callosum: The largest commissural tract connecting both hemispheres Anterior commissure: Connects the temporal lobes and olfactory areas across the midline (Option A ruled out) Fornix: Fibres from the hippocampus form the hippocampal commissure (commissure of fornix) , allowing communication between the two hippocampi (Option C ruled out) Association fibres connect cortical areas within the same hemisphere and do not cross the midline The arcuate fasciculus connects Broca’s area with Wernicke’s area in the same hemisphere

References:

Snells Clinical Neuroanatomy, 8th Edition, Pages 262, 263, 264

Gray’s Anatomy, 42nd Edition, Pages 534, 537

Vishram Singh Anatomy of Head, Neck, Brain, Volume 3, Pages 394, 395

↑ *Back to this question in Part A*

@Neet_pg_bot

Q10: Which association fibre connects Wernicke's area with Broca's area (Q848502)

A. Uncinate Fasciculus

B. Inferior Longitudinal Fasciculus

C. Arcuate Fasciculus

D. Superior Longitudinal Fasciculus

Correct Answer: C. Arcuate Fasciculus

■ *Listen (English)*

■ *Listen (Hindi)*

Explanation: The Arcuate Fasciculus connects Wernicke's area, located in the superior temporal gyrus and responsible for language comprehension, with Broca's area, found in the inferior frontal gyrus and involved in language production. Association Tracts Association tracts connect different areas within the same hemisphere, with short U-fibers linking nearby gyri and long fibres connecting gyri across different lobes. Short fibres are

closer to the surface, near the cortex, while longer fibres run deeper within the white matter, allowing for fast communication and sensory processing. Examples of association tracts are: Arcuate fasciculus Uncinate fasciculus (Option A ruled out) Inferior and Superior longitudinal fasciculus (Option B & D ruled out) It is seen on the left side of the cerebrum. In 95% of people, the language area is on the left dominant hemisphere. Wernicke's sensory speech area in the temporal lobe is connected with Broca's motor speech area in the inferior frontal gyrus by arcuate fasciculus. It does not cross the midline. Connecting the temporal lobe with the frontal lobe. It does not cross the midline. Superior longitudinal fasciculus : Connects the anterior part of the frontal lobe to the occipital and temporal lobes. Inferior longitudinal fasciculus : Connects the occipital lobe to the temporal lobe. They do not cross the midline.

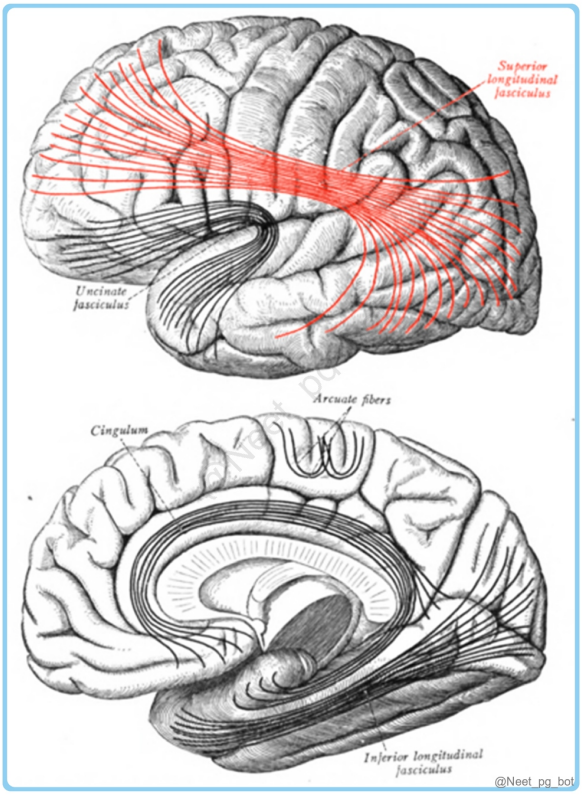

References:

Snells Clinical Neuroanatomy, 8th Edition, Pages 264

Gray’s Anatomy, 42nd Edition, Pages 534, 535, 536

↑ *Back to this question in Part A*

@Neet_pg_bot

Q11: Which part of the corpus callosum contains fibres that connect the right and left occipital cortices? (Q848503)

A. Rostrum

B. Genu

C. Body or Trunk

D. Splenium

Correct Answer: D. Splenium

■ *Listen (English)*

■ *Listen (Hindi)*

Explanation: The splenium is part of the corpus callosum where fibers connect the right occipital cortex with the left occipital cortex. Corpus callosum is the largest commissure of the brain and connects the two cerebral hemispheres. Corpus callosum Parts Rostrum (anterior) : Axons here connect the orbitofrontal cortex on the right and left side. (Option A ruled out) Genu: Most anterior portion of the corpus callosum; forms the anterior wall of the frontal horn of the lateral ventricle and contains fibres that connect the prefrontal cortex. (Option B ruled out) Body (central part): It connects motor and premotor areas in the frontal and parietal lobes (Option C ruled out) Splenium (posterior): Axons connect the right occipital cortex with the left occipital cortex. Corpus Callosum Fibers: Frontal Forceps (Forceps Minor): Connects the frontal lobes across hemispheres Fibers pass through the genu of the corpus callosum Occipital Forceps (Forceps Major): Connects the occipital visual cortices across hemispheres Fibers pass through the splenium of the corpus callosum Tapetum Fibers: Fibres from splenium and isthmus that arc forward along the lateral wall of the inferior horn of the lateral ventricle.

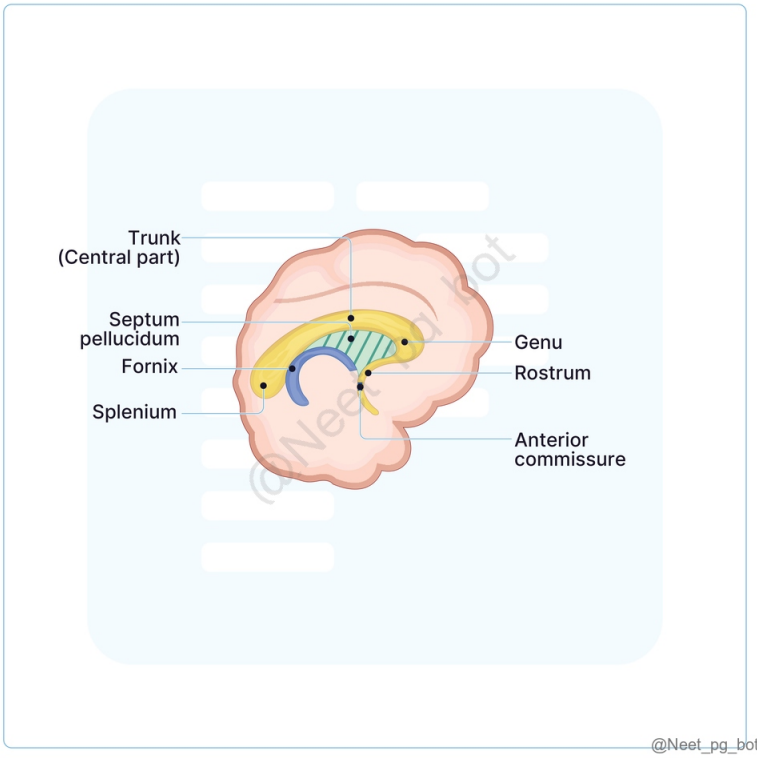

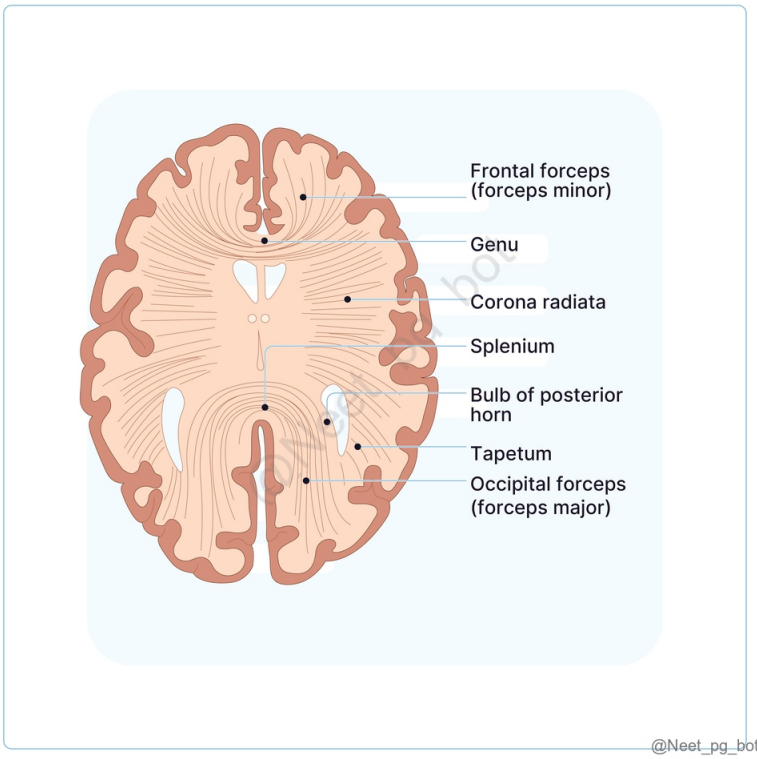

References:

Snells Clinical Neuroanatomy, 8th Edition, Page 262

Gray's Anatomy, 42nd Edition, Page 537

Vishram Singh Anatomy of Head, Neck, Brain, Volume 3, Pages 394, 395

↑ *Back to this question in Part A*

@Neet_pg_bot

Q12: Which cranial nerve motor fibres are responsible for innervating skeletal muscles that develop from somites? (Q848505)

A. General Somatic Efferent fibers

B. Special Visceral Efferent fibers

C. General Visceral Efferent fibers

D. Special Somatic Afferent fibers

Correct Answer: A. General Somatic Efferent fibers

■ *Listen (English)*

■ *Listen (Hindi)*

Explanation: Motor Neural Columns GSE (General Somatic Efferent) (Option A) GVE (General Visceral Efferent) (Option C ruled out) SVE (Special Visceral Efferent) (Option B ruled out) Innervation Motor innervation to skeletal muscles that develop from somites. Autonomic (involuntary) innervation to smooth muscles and glands. Innervate muscles that are derived from pharyngeal arches, not somites. Function Voluntary movements such as eye and tongue movements. Functions such as pupil constriction, salivation, digestion, and heart rate regulation. Functions like facial expression, mastication, and swallowing. Nerves Oculomotor (III) Trochlear (IV) Abducens (VI) Hypoglossal (XII) Oculomotor (III) Facial (VII) Glossopharyngeal (IX) Vagus (X) Facial (VII) Trigeminal (V) Accessory spinal nerve (XI) Neural Columns Special Somatic Afferent (SSA) fibres (Option D): SSA fibres are not motor but sensory, transmitting sensory information related to vision and hearing. These fibres are involved in processing external stimuli rather than controlling motor functions.

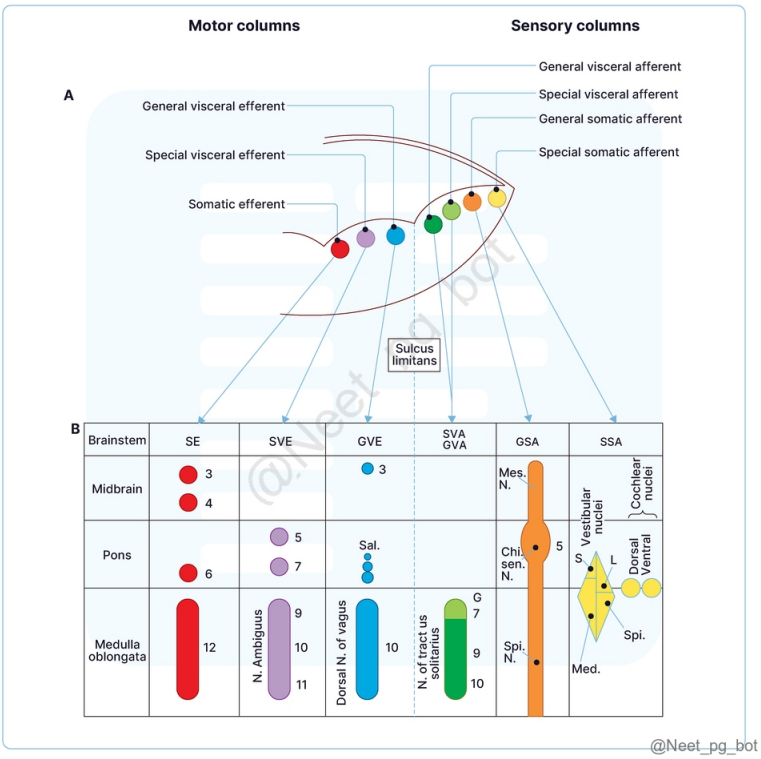

References:

Gray’s Anatomy, 42nd Edition, Pages 391, 442

Textbook of Anatomy Vishram Singh, 2nd Edition, Volume 3, Page 333

↑ *Back to this question in Part A*

@Neet_pg_bot

Q13: Which cranial nerve sensory fibres are primarily responsible for transmitting taste sensations from the tongue to the brainstem? (Q848510)

A. Special Somatic Afferent (SSA) fibres

B. Special Visceral Afferent (SVA) fibres

C. General Somatic Afferent (GSA) fibres

D. General Visceral Afferent (GVA) fibres

Correct Answer: B. Special Visceral Afferent (SVA) fibres

■ *Listen (English)*

■ *Listen (Hindi)*

Explanation: Special Sensory Column Special Visceral Afferent (SVA) fibres (Option B) Special Somatic Afferent (SSA) fibres (Option A ruled out) SVA fibres are sensory fibres responsible for transmitting taste sensations from the tongue to the brainstem. These fibres terminate in the nucleus solitarius in the medulla Cranial nerves - Facial (VII), Glossopharyngeal (IX). SSA fibres are responsible for transmitting sensory information related to the special senses of smell, vision, hearing, and balance. The optic nerve (II), olfactory nerve (I), and vestibulocochlear nerve (VIII) are part of SSA. General Somatic Afferent (GSA) fibres (Option C): GSA fibres carry general sensory information such as touch, pain, and temperature from the skin and mucous membranes of the head and neck. They do not transmit special senses like taste. General Visceral Afferent (GVA) fibres (Option D): GVA fibres convey sensory information from internal organs (viscera) such as distension, pressure, and pain. They are not involved in transmitting taste or other special sensory modalities.

References:

Gray’s Anatomy, 42nd Edition, Pages 391, 442

Textbook of Anatomy Vishram Singh, 2nd Edition, Volume 3, Page 341

↑ *Back to this question in Part A*

@Neet_pg_bot

Q14: What is the primary function of the alar plate in the developing neural tube? (Q848513)

A. Development of motor nuclei

B. Processing sensory information

C. Formation of autonomic motor fibres

D. Regulation of somatic motor output

Correct Answer: B. Processing sensory information

■ *Listen (English)*

■ *Listen (Hindi)*

Explanation: The alar plate is involved in developing sensory nuclei, which process sensory information such as pain, touch, and proprioception, as well as special sensory modalities like taste, hearing, and vision. They give rise to Special Somatic Afferent (SSA) fibres Special Visceral Afferent (SVA) fibres General Somatic Afferent (GSA) fibres General Visceral Afferent (GVA) fibres Development of motor nuclei (Option A): The development of motor nuclei is linked to the basal plate, not the alar plate, which primarily focuses on sensory processing. Formation of autonomic motor fibres (Option C): Autonomic motor fibres originate from the basal plate and are part of the general visceral efferent (GVE) system, not the alar plate. Regulation of somatic motor output (Option D): Somatic motor output is regulated by motor neurons that arise from the basal plate, not the alar plate.

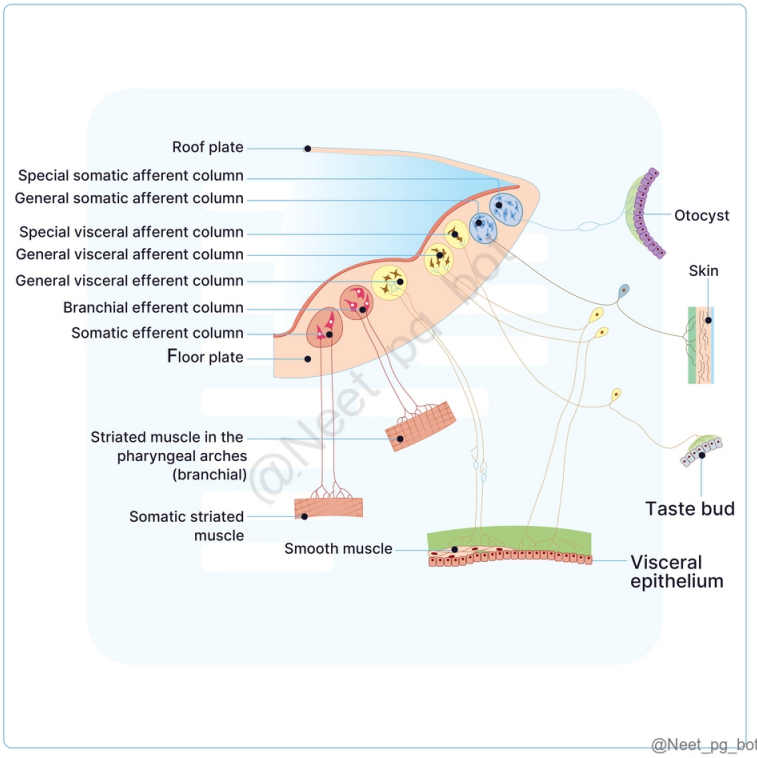

References:

Gray’s Anatomy, 42nd Edition, Pages 247, 442

Textbook of Anatomy Vishram Singh, 2nd Edition, Volume 3, Page 371

↑ *Back to this question in Part A*

@Neet_pg_bot

Q15: Which of the following cranial nerve nuclei originates from the General Visceral Efferent (GVE) column of the basal plate? (Q848515)

A. Edinger-Westphal nucleus

B. Hypoglossal nucleus

C. Facial nucleus

D. Cochlear nucleus

Correct Answer: A. Edinger-Westphal nucleus

- *Listen (English)*
- *Listen (Hindi)*

Explanation: The Edinger-Westphal nucleus is part of the GVE column via the Oculomotor (III) nerve , responsible for functions like pupil constriction and accommodation. Along with the Edinger-Westphal nucleus, The GVE column also involves the Salivatory nuclei (for saliva secretion) and the vagal nucleus (controls the heart, lungs, and digestive system) The basal plate of the neural tube has motor function and gives rise to General Somatic Efferent (GSE) fibres Special Visceral Efferent (SVE) fibres General Visceral Efferent (GVE) fibres Hypoglossal nucleus (Option B): The hypoglossal nucleus belongs to the General Somatic Efferent (GSE) column and controls voluntary movements of the tongue. Facial nucleus (Option C): The facial nucleus is part of the Special Visceral Efferent (SVE) column and controls facial muscles, not autonomic functions. The cochlear nucleus (Option D): The cochlear nucleus is involved in sensory functions related to hearing and originates from the Special Somatic Afferent (SSA) column, not the GVE column.

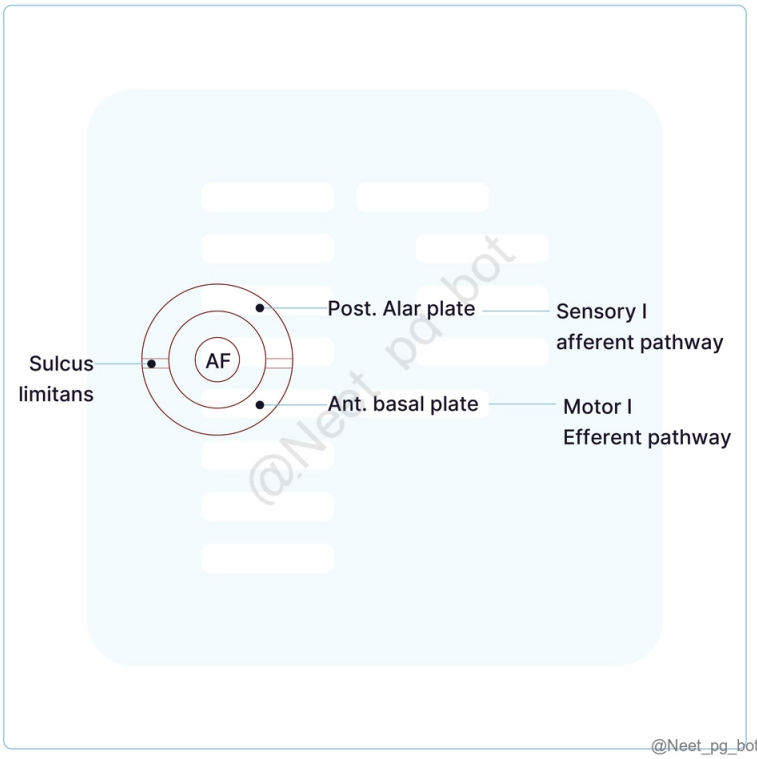

References:

Gray's Anatomy, 42nd Edition, Pages 391, 442

Textbook of Anatomy Vishram Singh, 2nd Edition, Volume 3, Page 372

↑ *Back to this question in Part A*

@Neet_pg_bot

Q16: A 5 year old boy came with complaints of sudden onset weakness in his lower limbs. His parents mention a history of viral illness with fever and sore throat. On examination, the boy has flaccid paralysis of his legs with muscle wasting, absent deep tendon reflexes, and no sensory deficits. Which of the following structures is primarily affected in this condition, leading to muscle paralysis and wasting? (Q848516)

A. Posterior white columns of the spinal cord

B. Anterior grey columns of the spinal cord

C. Spinothalamic tract

D. Cerebellar peduncles

Correct Answer: B. Anterior grey columns of the spinal cord

■ *Listen (English)*

■ *Listen (Hindi)*

Explanation: The clinical scenario of this child points to a diagnosis of poliomyelitis due to the history of acute flaccid paralysis following fever and lower motor neuron involvement. Poliomyelitis primarily affects the anterior grey columns, leading to lower motor neuron damage, causing muscle paralysis and wasting. Poliomyelitis : Viral infection of anterior grey columns of the spinal cord and cranial nerve motor nuclei. Causes muscle paralysis and wasting, often affecting lower limbs more. Severe cases can impair respiration and affect facial, pharyngeal, laryngeal, and tongue muscles. It is a lower motor neuron palsy. Posterior white columns of the spinal cord (Option A): These columns are responsible for sensory functions, not motor control. Spinothalamic tract (Option C): This tract transmits sensory information related to pain and temperature, not motor function. Cerebellar peduncles (Option D): These are involved in coordinating movement, not directly causing paralysis associated with poliomyelitis.

References:

Snells Clinical Neuroanatomy, 8th Edition, Page 171

↑ *Back to this question in Part A*

@Neet_pg_bot

• [03_Neuro Anatomy] 010 Cerebrum And Associated Structures

« Back to Folder Directory

[03_Neuro Anatomy] 010 Cerebrum And Associated Structures — Quick Jump

Q1 (p. 897)	*Q2 (p. 898)*	*Q3 (p. 899)*	*Q4 (p. 900)*	*Q5 (p. 902)*	*Q6 (p. 903)*
Q7 (p. 904)	*Q8 (p. 906)*	*Q9 (p. 907)*	*Q10 (p. 908)*	*Q11 (p. 910)*	*Q12 (p. 911)*
Q13 (p. 913)	*Q14 (p. 914)*	*Q15 (p. 915)*	*Q16 (p. 916)*	*Q17 (p. 917)*	

Q1: A 5 year old child presents with developmental delays, including difficulties in motor coordination and speech. MRI reveals a complete absence of the corpus callosum. Which of the following is not typically associated with this condition? (Q848567)

A. Intellectual disability

B. Seizures

C. Hemispatial neglect

D. Hyperactivity and impulsivity

Correct Answer: C. Hemispatial neglect

■ *Listen (English)*

■ *Listen (Hindi)*

Explanation: Hemispatial neglect is not typically associated with agenesis of the corpus callosum. Hemispatial neglect is often seen in patients with damage to one hemisphere , particularly the right hemisphere, leading to inattention to the opposite side of space (usually the left). In agenesis, both hemispheres may function independently, so hemispatial neglect is not a hallmark of this condition. Agenesis of the corpus callosum is a rare congenital condition in which the corpus callosum , the structure connecting the two cerebral hemispheres, fails to develop properly or is absent. Clinical Features: Developmental delays (Option A) : Intellectual disability, motor delays, and speech impairments. Seizures (Option B) : Common due to lack of communication between brain hemispheres. Motor problems : Coordination issues, ataxia. Behavioral issues (Option D) : Hyperactivity, impulsivity, and autistic-like behaviors. Cognitive challenges : Attention deficits and difficulty with higher cognitive functions.



References:

https://pubmed.ncbi.nlm.nih.gov/

https://authors.library.caltech.edu/56045/2/NRN_final.pdf

↑ *Back to this question in Part A*

@Neet_pg_bot

Q2: Which of the following is part of the complete syndrome triad associated with Anterior Choroidal Artery Syndrome? (Q848555)

A. Bilateral hemiplegia

B. Contralateral hemisensory loss

C. Bitemporal hemianopia

D. Ipsilateral homonymous hemianopia

Correct Answer: B. Contralateral hemisensory loss

■ *Listen (English)*

■ *Listen (Hindi)*

Explanation: Anterior choroidal artery syndrome is associated with contralateral hemisensory loss. Anterior Choroidal Artery Syndrome: Cause : Infarction in the anterior choroidal artery territory Structure Supplied Result of Infarction Posterior limb of the internal capsule Contralateral hemiplegia Thalamocortical sensory fibers Contralateral hemisensory loss Optic tract / lateral geniculate body / optic radiation Contralateral homonymous hemianopia Complete syndrome triad : Contralateral hemiplegia - Weakness or paralysis on one side of the body opposite to the brain injury (Option A ruled out) Contralateral hemisensory loss - Loss of sensation on one side of the body opposite to the brain injury Contralateral homonymous hemianopia - Loss of the same visual field (either right or left) in both eyes, opposite to the side of brain damage. (Options C and D ruled out)

References:

www.ncbi.nlm.nih.gov/pmc/articles/PMC5835707/#

radiopaedia.org/articles/anterior-choroidal-artery-syndrome

↑ *Back to this question in Part A*

@Neet_pg_bot

Q3: The labyrinthine artery arises from which of the following arteries? (Q848581)

A. Internal carotid artery

B. External carotid artery

C. Vertebral artery

D. Basilar artery

Correct Answer: D. Basilar artery

■ *Listen (English)*

■ *Listen (Hindi)*

Explanation: Labyrinthine artery is a long, slender branch that typically originates from either the basilar artery or the anterior-inferior cerebellar artery . It travels alongside the vestibulocochlear nerve and passes through the internal auditory meatus to supply blood to the inner ear. It is an end artery.

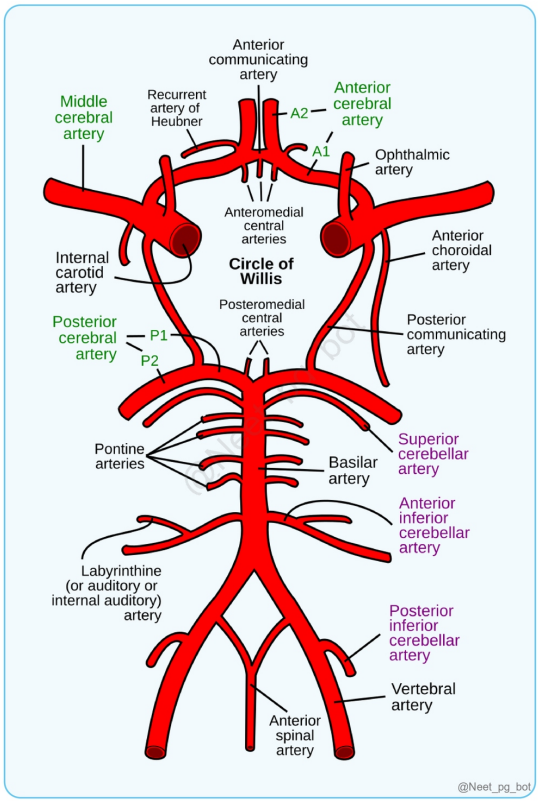

References:

Textbook of Anatomy, Head, Neck and Brain, Vishram Singh, Volume III, 2nd Edition, Page 406

↑ *Back to this question in Part A*

@Neet_pg_bot

Q4: In the image below, which structure is labeled as the rostrum of the corpus callosum? (Q848568)

A. Structure A

B. Structure B

C. Structure C

D. Structure D



Correct Answer: D. Structure D

- *Listen (English)*
- *Listen (Hindi)*

Explanation: The corpus callosum is the largest commissure of the brain. It is divided from before backwards into the following four parts: Genu: This is the thick, curved front part of the corpus callosum, located about 4 cm behind the front of the brain. (Structure C) Rostrum: The genu extends downward and backward as a thin extension called the rostrum, which connects to the lamina terminalis.(Structure D) Body: It is the central part of the corpus callosum, situated between the front (genu) and back (splenium) parts.(Structure B) Splenium: The splenium is the large, back part of the corpus callosum, located about 6 cm in front of the occipital region. (Structure A)

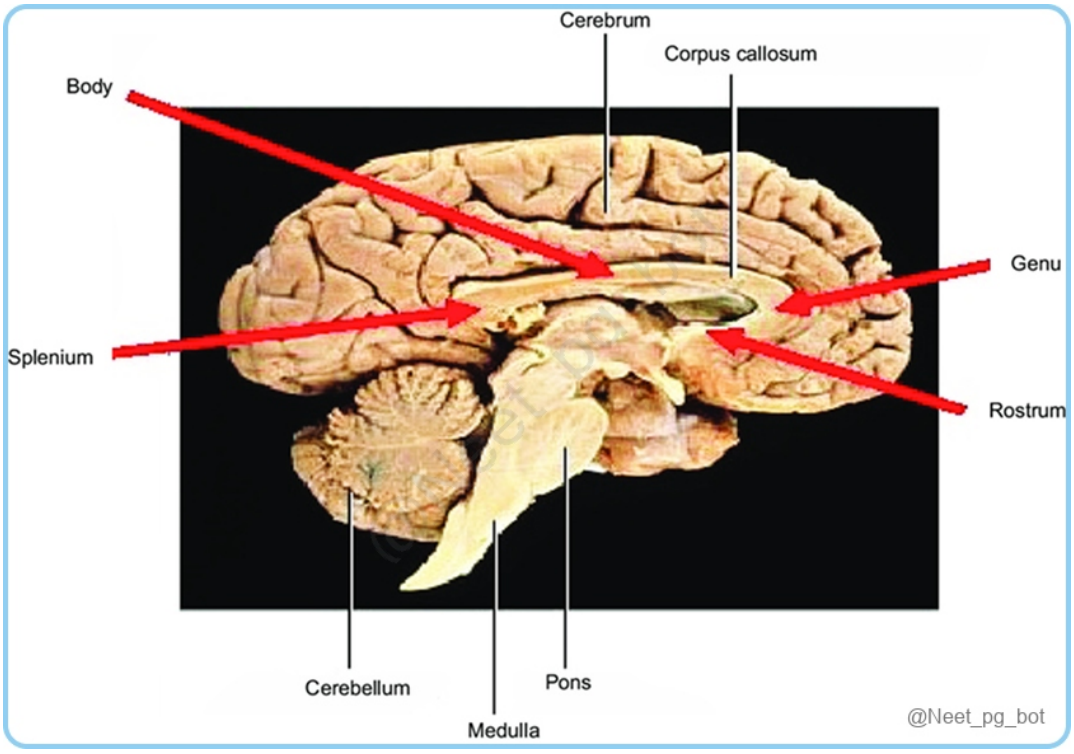

References:

Textbook of Anatomy, Head, Neck and Brain, Vishram Singh, Volume III, 2nd Edition, Pages 394, 395

↑ *Back to this question in Part A*

@Neet_pg_bot

Q5: A 35 year old patient presents with rapid weight gain and persistent hunger despite adequate food intake. MRI reveals a lesion in the hypothalamus. Which of the following hypothalamic nuclei, when lesioned, is most likely to cause an uncontrolled appetite and extreme obesity? (Q848566)

A. Anterior Hypothalamic Area

B. Ventromedial nucleus

C. Lateral hypothalamus

D. Suprachiasmatic Nucleus

Correct Answer: B. Ventromedial nucleus

■ *Listen (English)*

■ *Listen (Hindi)*

Explanation: Lesions in the ventromedial nucleus of the hypothalamus are known to lead to uncontrolled appetite and extreme obesity, as this area is critical for satiety and regulating food intake. Hypothalamic Nuclei and Effects of Lesions Area/Nuclei Function Lesion Anterior Hypothalamic Area & Preoptic Area (Option A) Influences parasympathetic responses (e.g., lowers blood pressure, slows heart rate, heat regulation) Can disrupt thermoregulation and lead to hyperthermia. Lateral Hypothalamus (Option C) Acts as the hunger & thirst centre; stimulates food intake. Leads to anorexia and significant weight loss. Medial Hypothalamus- Ventromedial nucleus Acts as the satiety centre ; inhibits eating. Causes uncontrolled appetite and extreme obesity. Suprachiasmatic Nucleus (Option D) Regulates circadian rhythms and biological clocks. Can disrupt sleep-wake cycles and lead to insomnia.

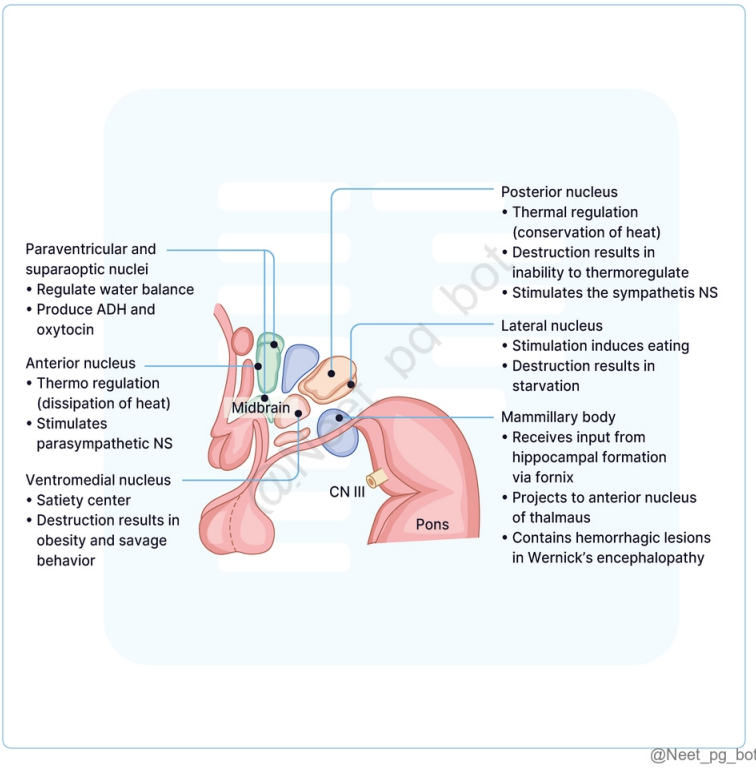

@Neet_pg_bot

References:

Snell's Clinical Neuroanatomy, 8th Edition, Pages 381, 382

↑ *Back to this question in Part A*

@Neet_pg_bot

Q6: Which of the following is the function of the Ventral Posteromedial Nucleus within the Ventral Group Nuclei? (Q848565)

A. Influences motor activities by connecting with the premotor cortex.

B. Receives sensory information from the cerebellum and red nucleus.

C. Receives trigeminal and gustatory pathways.

D. Projects to the primary motor areas of the cerebral cortex.

Correct Answer: C. Receives trigeminal and gustatory pathways.

■ *Listen (English)*

■ *Listen (Hindi)*

Explanation: The Ventral Posteromedial Nucleus receives trigeminal and gustatory pathways which are responsible for processing sensory information from the face. Ventral Group Nuclei Ventral Anterior Nucleus: Connects to the reticular formation, substantia nigra, corpus striatum, and premotor cortex Influences motor cortex activities. (Option A) Ventral Lateral Nucleus: Similar connections to the ventral anterior nucleus. Receives input from the cerebellum and red nucleus (Option B) Projects to motor and premotor areas. (Option D) Ventral Posterior Nucleus: Ventral Posterolateral Nucleus: Receives sensory tracts; projects to primary somatic sensory areas in the postcentral gyrus (BA 1, 2, 3) Ventral Posteromedial Nucleus: Receives trigeminal and gustatory pathways.

References:

Snell's Clinical Neuroanatomy, 8th Edition, Page 366

↑ *Back to this question in Part A*

@Neet_pg_bot

Q7: Which of the following thalamic nuclei is concerned with recent memory and emotional tone? (Q848564)

A. Medial geniculate body

B. Anterior Thalamic Nuclei

C. Dorsomedial Nucleus

D. Lateral geniculate body

Correct Answer: B. Anterior Thalamic Nuclei

■ *Listen (English)*

■ *Listen (Hindi)*

Explanation: Anterior Thalamic Nuclei are directly connected to the limbic system and play a crucial role in emotional tone and mechanisms of recent memory. Thalamic Nuclei: Medial Geniculate Body (Option A): Processes auditory information; projects to the auditory cortex. Medial Thalamic Nuclei (Option C): Responsible

for integrating sensory (somatic, visceral, olfactory) information with emotional and subjective states. Lateral Geniculate Body (Option D) : Processes visual input; projects to the visual cortex.

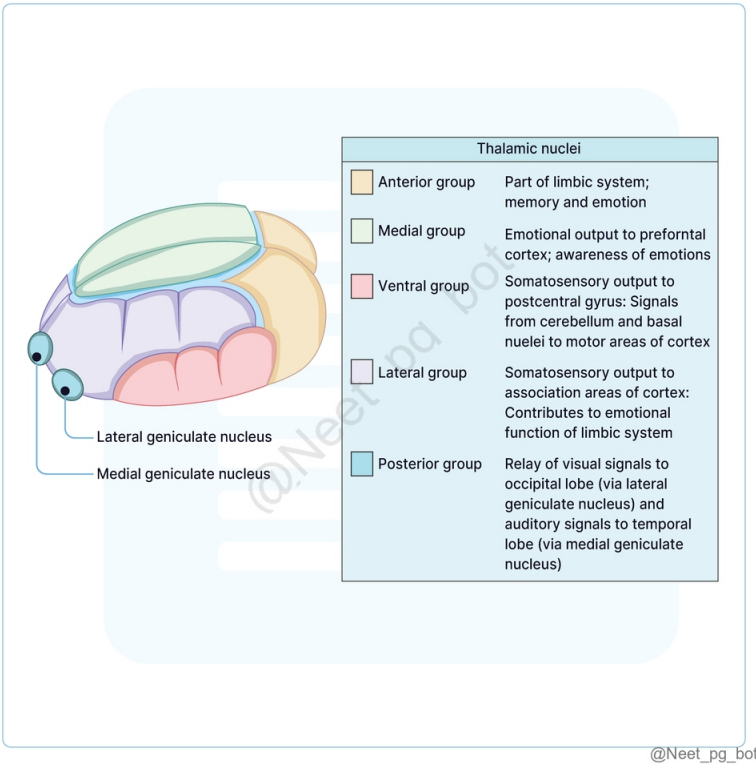

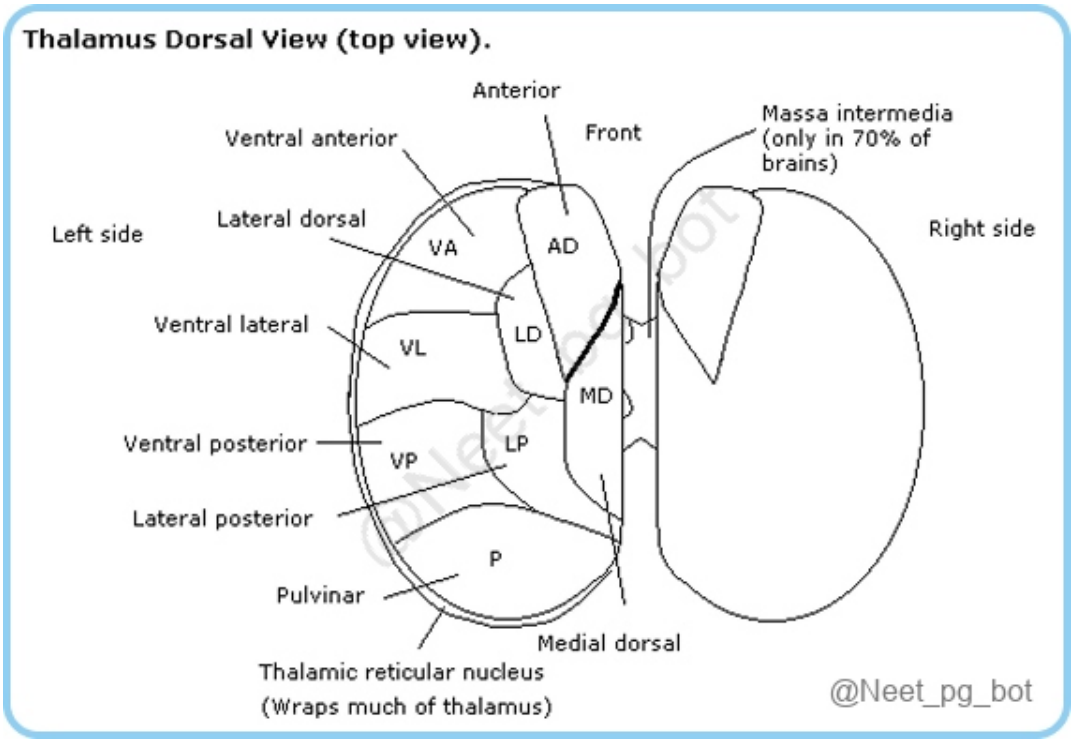

References:

Snell’s Clinical Neuroanatomy, 8th Edition, Pages 365, 366

↑ *Back to this question in Part A*

@Neet_pg_bot

Q8: A 62 year old patient presents with sudden onset of right-sided weakness and facial droop. Neurological examination reveals upper motor neuron signs with weakness in both the arm and leg on the right side. MRI confirms an infarct in the middle cerebral artery (MCA) territory involving the genu of the internal capsule. Which of the following tracts passes through the genu? (Q848563)

A. Corticobulbar tract

B. Corticospinal tract

C. Spinothalamic tract

D. Medial lemniscus

Correct Answer: A. Corticobulbar tract

■ *Listen (English)*

■ *Listen (Hindi)*

Explanation: The genu of the internal capsule contains the corticobulbar tract (corticonuclear tract), which is responsible for motor control of the cranial nerves, especially facial movements. Damage here can result in facial weakness, as seen in the patient. Blood Supply of the Internal Capsule: Middle Cerebral Artery (MCA) Parts of the anterior limb Genu Posterior limb Corticobulbar tract (genu) : Facial muscle weakness and motor deficits in cranial nerves Corticospinal tract (posterior limb) : Contralateral limb weakness or paralysis (Option B) Spinothalamic tract (Option C) : This tract is responsible for transmitting pain and temperature sensations from the body to the brain. It does not pass through the genu of the internal capsule. Medial lemniscus (Option D) : This tract carries proprioception and vibration sense from the body to the brain, passing through the brainstem, not the genu of the internal capsule.

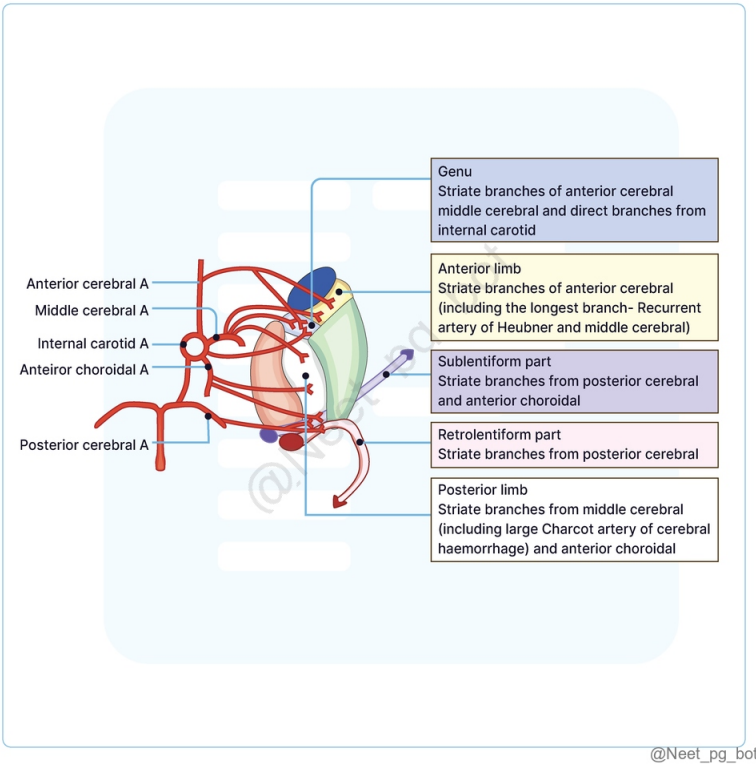

@Neet_pg_bot

References:

Gray’s Anatomy, 42nd Edition, Page 538

Blood Supply of the Internal Capsule

↑ *Back to this question in Part A*

@Neet_pg_bot

Q9: Which of the following tracts passes through the genu of the internal capsule? (Q848562)

A. Corticospinal tract

B. Corticonuclear tract

C. Optic radiation

D. Auditory radiation

Correct Answer: B. Corticonuclear tract

■ *Listen (English)*

■ *Listen (Hindi)*

Explanation: The corticonuclear tract, which contains motor fibres to cranial nerve motor nuclei, specifically passes through the genu of the internal capsule. Tracts Passing Through Internal Capsule: Genu : Corticonuclear tract Posterior Limb : Corticospinal tract (Option A) . Corticopontine fibres Fibres for the upper limb (anteriorly) and trunk/lower limbs (posteriorly). Superior Thalamic Peduncle Other Tracts Passing Through the Internal Capsule: Anterior limb Retrolentiform part Sublentiform part Frontopontine fibres (Arnold's bundle) Corticorubral fibres Parietopontine, occipitopontine, and occipitotectal fibres Optic radiation (Option C) Temporopontine fibres Auditory radiation (Option D) Thalamic fibres to the temporal cortex and amygdala.

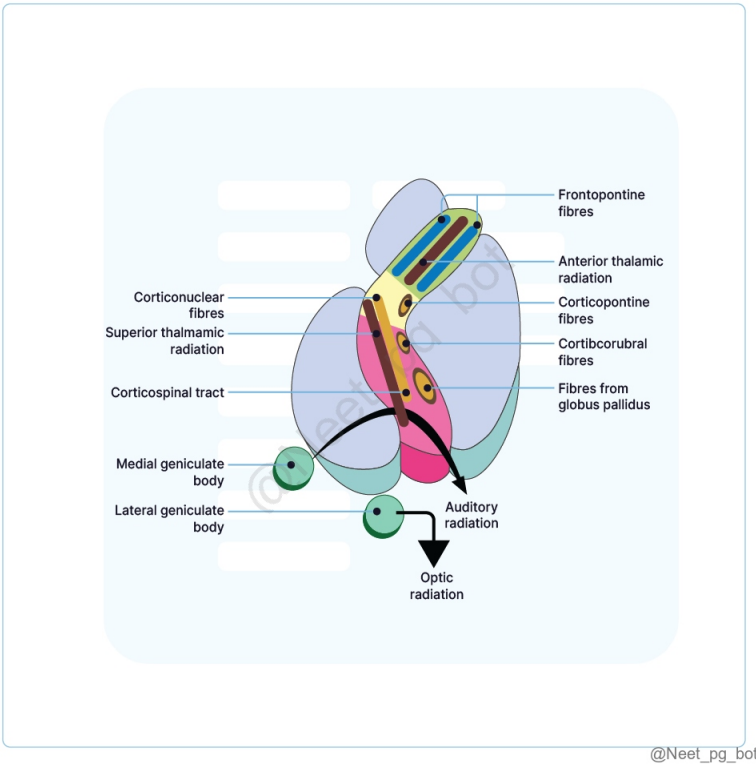

@Neet_pg_bot

References:

Gray’s Anatomy, 42nd Edition, Page 538

↑ *Back to this question in Part A*

@Neet_pg_bot

Q10: Which sulcus is involved in separating the frontal lobe from the parietal lobe? (Q848538)

A. Lateral Sulcus

B. Central Sulcus

C. Calcarine Sulcus

D. Parieto-occipital Sulcus

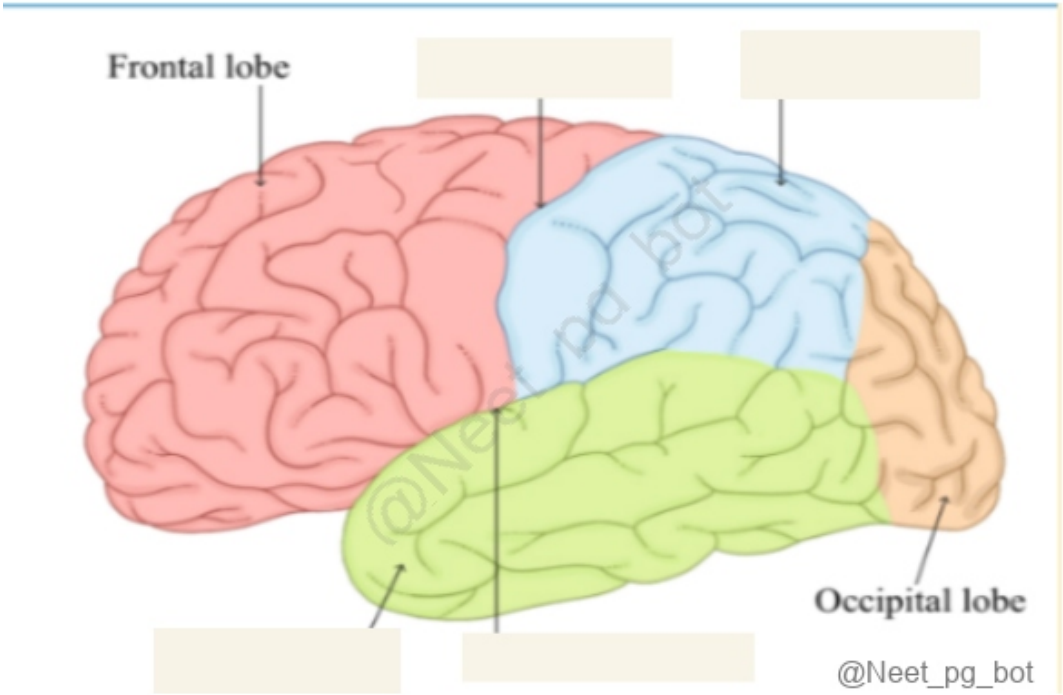

Correct Answer: B. Central Sulcus

■ *Listen (English)*

■ *Listen (Hindi)*

Explanation: The central sulcus separates the frontal lobe from the parietal lobe . It runs roughly from the top of the brain down towards the lateral sulcus. Sulci of the Cerebrum Lateral Sulcus : Seen laterally; separates the temporal lobe from the frontal and parietal lobes. (Option A) Central Sulcus : Runs Antero-inferiorly; separates the frontal lobe from the parietal lobe; visible laterally and medially. Calcarine Sulcus : Visible medially; located in the occipital lobe, associated with the visual cortex. (Option C) Parieto-occipital Sulcus : Seen medially; separates the parietal and occipital lobes. (Option D)

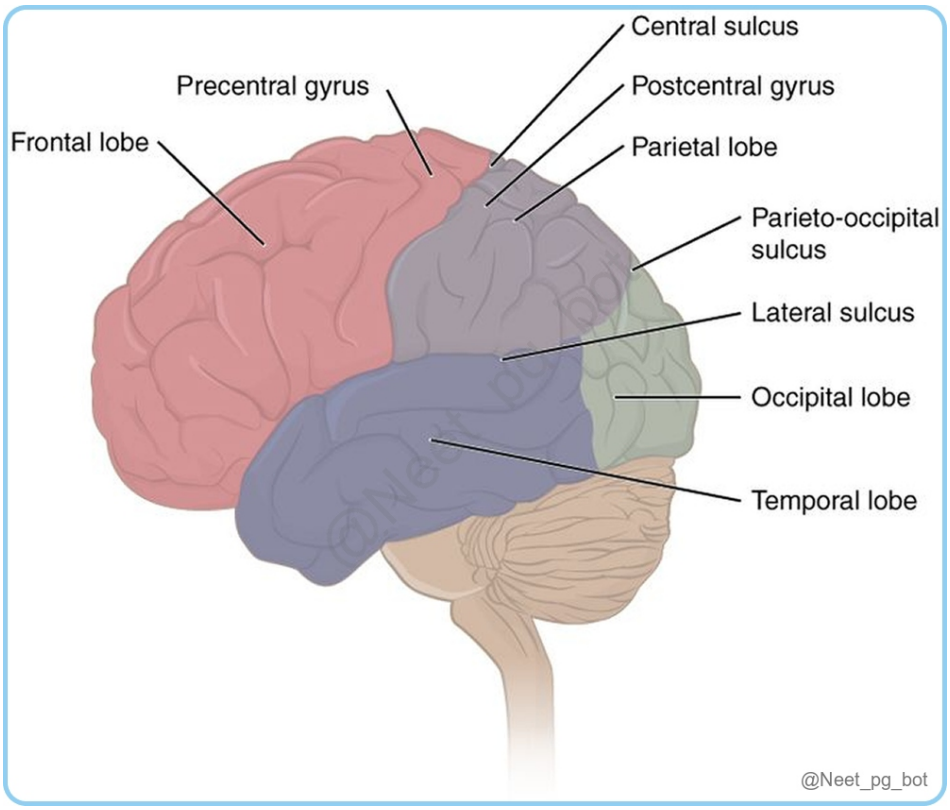

References:

Gray's Anatomy, 42nd Edition, Pages 395, 396

Vishram Singh Anatomy of Head, Neck, Brain, Volume 3, Pages 389-391

↑ *Back to this question in Part A*

@Neet_pg_bot

Q11: Which of the following correctly describes the anatomical relations of the internal capsule? (Q848554)

A. The anterior limb lies between the thalamus and the posterior part of the lentiform nucleus.

B. The genu is located posterior to the head of the caudate nucleus.

C. The medial boundary consists of the thalamus and the caudate nucleus.

D. The retro lentiform part is situated above the lentiform nucleus.

Correct Answer: C. The medial boundary consists of the thalamus and the caudate nucleus.

■ *Listen (English)*

■ *Listen (Hindi)*

Explanation: The internal capsule is positioned medially next to both the thalamus and the caudate nucleus Relations of Internal Capsule Medially : Thalamus and caudate nucleus Laterally : Lentiform nucleus Anterior limb : Between the head of the caudate nucleus and the anterior part of the lentiform nucleus (Option A) Posterior limb : Between the thalamus and the posterior part of the lentiform nucleus. Genu : Bend between the anterior and posterior limbs, concave laterally (Option B) Retrolentiform part : Behind the lentiform nucleus (Option D) Sublentiform part : Below the lentiform nucleus.

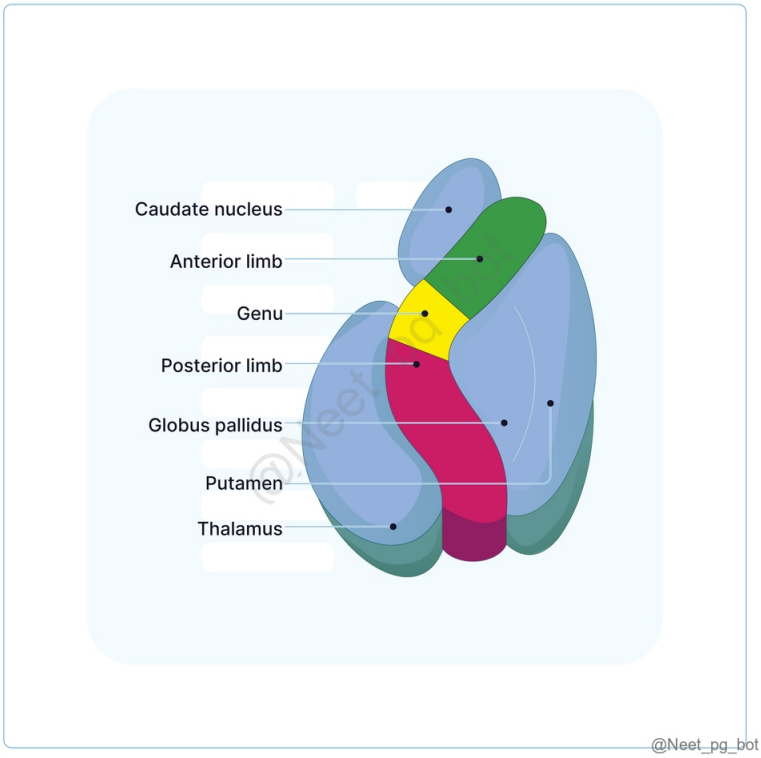

References:

Gray's Anatomy, 42nd Edition, Pages 537, 538

Vishram Singh, Anatomy of Head, Neck, Brain, Volume 3, Pages 395, 396

↑ *Back to this question in Part A*

@Neet_pg_bot

Q12: Match the following: (Q848553)

A. A-Putamen; B- Globus Pallidus; C- Caudate Nucleus; D- Subthalamic Nucleus; E- Substantia Nigra; F- Thalamus

B. A- Caudate Nucleus; B- Putamen; C- Thalamus; D- Globus Pallidus; E- Subthalamic Nucleus; F- Substantia Nigra

C. A- Caudate Nucleus; B- Globus Pallidus; C- Substantia Nigra; D- Globus Pallidus; E- Thalamus; F- Subthalamic Nucleus

D. A- Caudate Nucleus; B- Putamen; C- Globus Pallidus; D- Thalamus; E- Subthalamic Nucleus; F- Substantia Nigra

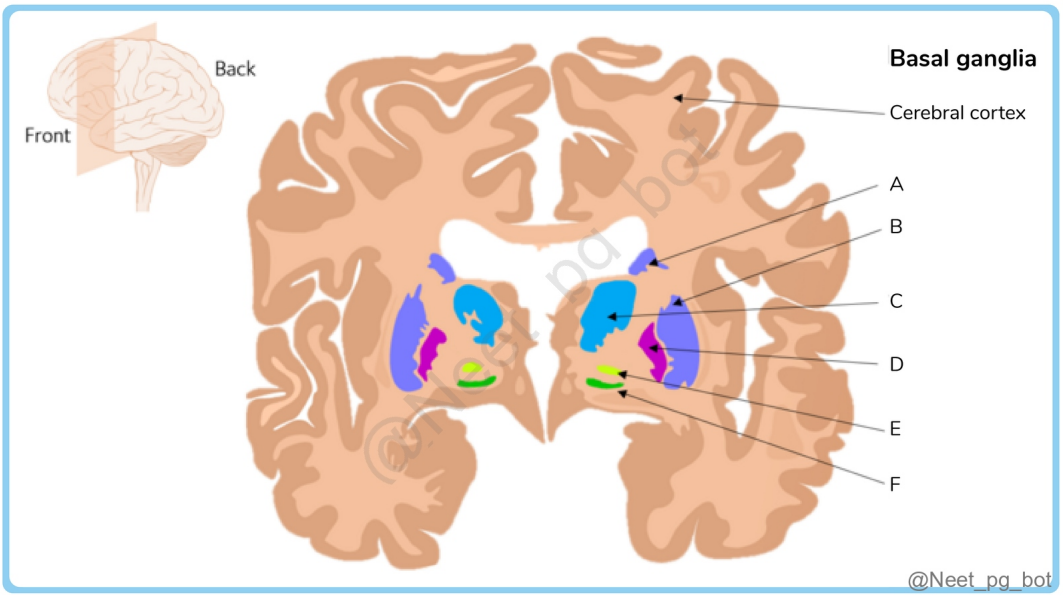

Correct Answer: B. A- Caudate Nucleus; B- Putamen; C- Thalamus; D- Globus Pallidus; E- Subthalamic Nucleus; F- Substantia Nigra

■ *Listen (English)*

■ *Listen (Hindi)*

Explanation: The basal ganglia work together to control movement by balancing excitatory and inhibitory signals. They help to initiate, plan, and execute movements, as well as to suppress unwanted movements. Dysfunctions in the basal ganglia can lead to various movement disorders, such as Parkinson's disease, Huntington's disease, and Tourette syndrome.

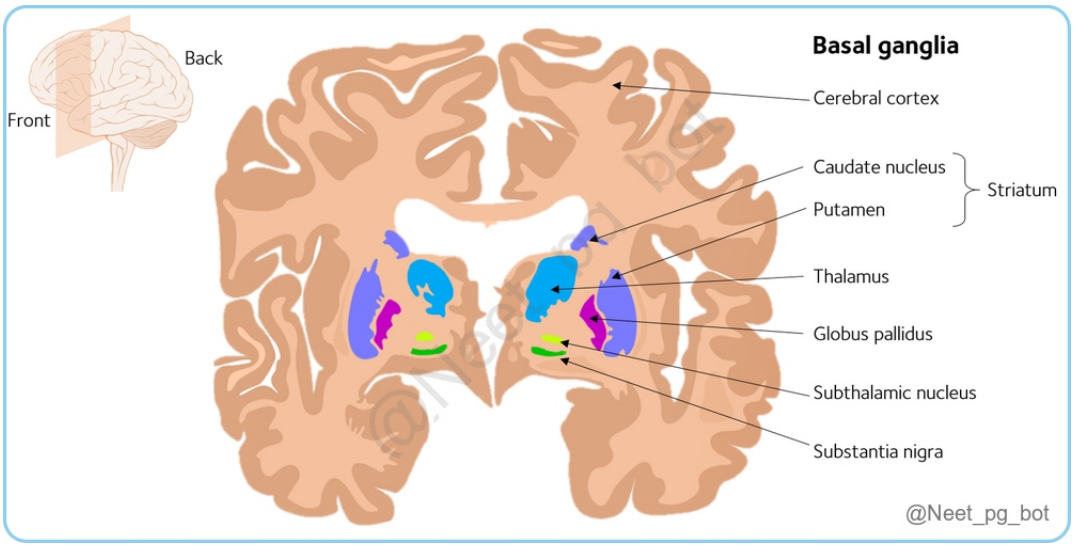

References:

upload.wikimedia.org/wikipedia/commons/f/f3/The_structures_of_the_basal_ganglia.png

↑ *Back to this question in Part A*

@Neet_pg_bot

Q13: A 70 year old female presents with tremors, rigidity, and bradykinesia. Neurological examination reveals degeneration of dopaminergic neurons in a specific region of the brain. Which component of the basal ganglia is primarily affected in this patient's condition? (Q848552)

A. Caudate Nucleus

B. Putamen

C. Substantia Nigra

D. Globus Pallidus

Correct Answer: C. Substantia Nigra

■ *Listen (English)*

■ *Listen (Hindi)*

Explanation: Substantia Nigra produces dopamine, and its degeneration is primarily associated with Parkinson's disease, leading to the classic symptoms of tremors, rigidity, and bradykinesia. Component Location Role/Function Caudate Nucleus (Option A) Near the thalamus and internal capsule C-shaped structure; contributes to lateral ventricle floor; forms the striatum with the putamen; receives cortical input. Putamen (Option B) Basal

forebrain, close to claustrum Part of the corpus striatum; receives input from various cortical areas and is involved in motor control. Globus Pallidus (Option D) Basal ganglia; divided into internal and external segments The primary output nucleus; is involved in movement control pathways (direct and indirect). Substantia Nigra Midbrain; divided into pars compacta and pars reticulata Produces dopamine (crucial for smooth, coordinated movements); degeneration of neurons in pars compacta is implicated in Parkinson's disease .

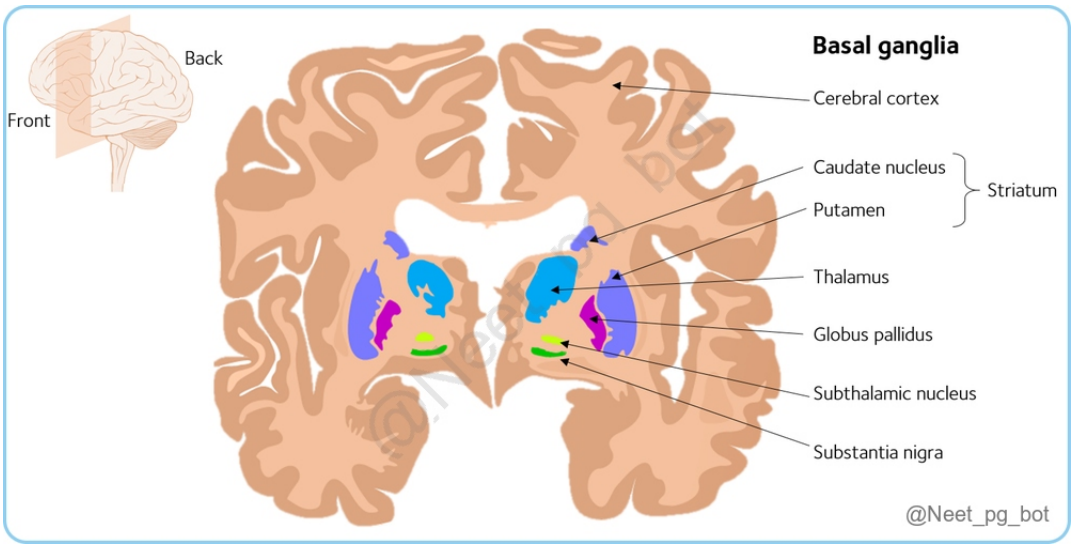

References:

Gray's Anatomy, 42nd Edition, Pages 501-509

↑ *Back to this question in Part A*

@Neet_pg_bot

Q14: A 65 year old male presents with fluent but nonsensical speech and difficulty understanding spoken language. He is unaware of his language difficulties, and his reading and writing abilities are also severely impaired. Which type of aphasia is most likely present in this patient? (Q848551)

A. Global aphasia

B. Broca's aphasia

C. Wernicke's aphasia

D. Anomic aphasia

Correct Answer: C. Wernicke's aphasia

■ *Listen (English)*

■ *Listen (Hindi)*

Explanation: Wernicke's aphasia: Fluent speech but impaired comprehension, often with nonsensical language. Reading and writing are typically affected. The patient may be unaware of their deficits, which fits this case. Types of Aphasia: Type Description Characteristics Global Aphasia (Option A) Most severe form; few recognizable words, little/no comprehension Common after stroke; may improve if brain damage is limited Broca's Aphasia (Option B) Non-fluent aphasia Severely reduced speech output; can't speak fluently; short utterances (≤ 4 words) Good comprehension, poor writing; speech is laborious Wernicke's Aphasia (Option C) Fluent aphasia Impaired comprehension; fluent but nonsensical speech Speech filled with jargon; severe reading/writing issues Anomic Aphasia (Option D) Difficulty finding correct nouns/verbs. Fluent speech, speech filled with vague words; good comprehension/reading.

References:

aphasia.org/what-is-aphasia/

www.ncbi.nlm.nih.gov/books/NBK537006/#

↑ *Back to this question in Part A*

@Neet_pg_bot

Q15: Match the Brodmann areas with their respective functions: Brodmann Area Function a) BA 1, 2, 3 1) Primary visual cortex b) BA 4 2) Primary motor cortex c) BA 17 3) Primary somatosensory cortex d) BA 44, 45 4) Language production (Broca’s area) (Q848550)

A. a-1; b-2; c-4; d-3

B. a-3; b-2; c-4; d-1

C. a-3; b-2; c-1; d-4

D. a-2; b-3; c-1; d-4

Correct Answer: C. a-3; b-2; c-1; d-4

■ *Listen (English)*

■ *Listen (Hindi)*

Explanation: Brodmann’s numbers Function Location BA 1, 2, 3 Primary Somatosensory Cortex Processes tactile information from the body. Postcentral gyrus. BA 4 Primary Motor Cortex Controls voluntary movements via corticospinal and cortico-nuclear tracts. Precentral gyrus. BA 17 Primary Visual Cortex (V1) Processes visual information from the lateral geniculate nucleus. Occipital lobe (calcarine sulcus, cuneus, and lingual gyrus). BA 44 and 45 Broca’s area Speech production. BA 44 (Opercular part): Syntactic processing (grammar). BA 45 (Triangular part): Semantic processing (meaning). Left BA 44 is typically larger, reflecting language dominance. Inferior frontal gyrus of the frontal lobe.



References:

Gray's Anatomy, 42nd Edition, Pages 528, 530

B.D. Chaurasia's Human Anatomy, 8th Edition, Volume 4, Page 143

↑ *Back to this question in Part A*

@Neet_pg_bot

Q16: A 68 year old male presents with sudden onset weakness in his right arm and face, along with difficulty speaking. MRI reveals an ischemic stroke. Which artery is most likely involved in this patient's stroke based on his symptoms? (Q848549)

A. Anterior cerebral artery

B. Middle cerebral artery

C. Posterior cerebral artery

D. Vertebral artery

Correct Answer: B. Middle cerebral artery

■ *Listen (English)*

■ *Listen (Hindi)*

Explanation: The middle cerebral artery supplies the lateral surface of the brain, including areas responsible for motor control of the arm, face, and language centres (Broca's and Wernicke's areas), which align with the patient's symptoms. Blood Supply to the Cerebrum: The anterior cerebral artery (Option A) primarily supplies the medial portions of the frontal lobes, affecting leg motor control, not the arm or face. It might also present with urinary incontinence, mutism, apathy, or euphoria. The posterior cerebral artery (Option C) supplies the occipital lobe and inferior temporal lobe, which are more associated with visual processing, not motor control or speech. The vertebral artery (Option D) supplies the brainstem and cerebellum, which would cause different symptoms like coordination issues, brainstem stroke syndromes, or vertigo.

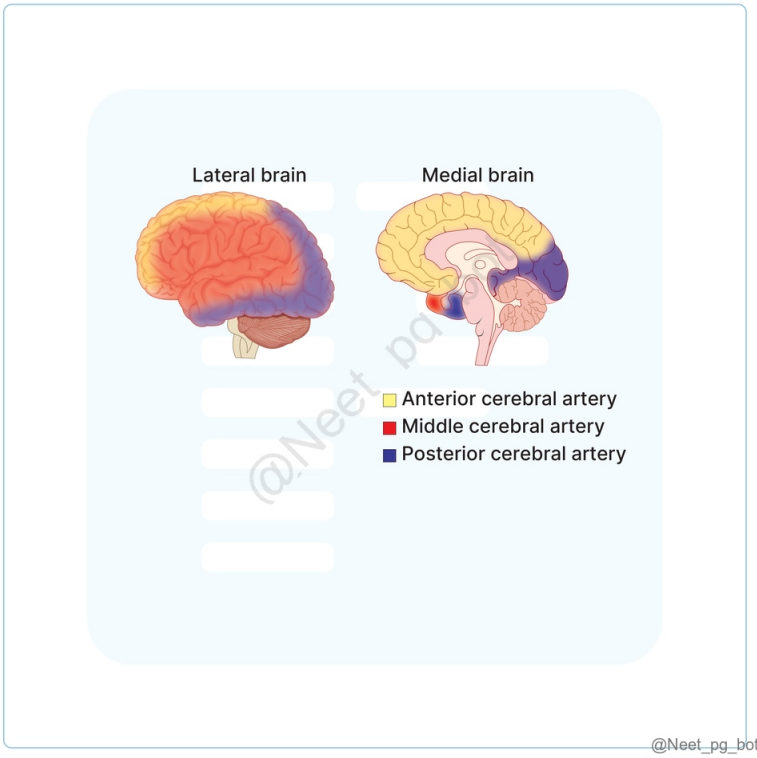

References:

Gray’s Anatomy, 42nd Edition, Pages 420, 421

↑ *Back to this question in Part A*

@Neet_pg_bot

Q17: Which statement correctly describes the representation of body parts in the motor and sensory homunculi? (Q848548)

A. In the motor homunculus, finer motor control areas like arms and legs have larger cortical regions.

B. The sensory homunculus shows body parts with higher acuity, like fingertips, having smaller cortical areas.

C. Both homunculi are in the precentral gyrus and represent the same body parts.

D. The motor homunculus in the precentral gyrus has larger areas for fine motor parts like hands and face.

Correct Answer: D. The motor homunculus in the precentral gyrus has larger areas for fine motor parts like hands and face.

- *Listen (English)*
- *Listen (Hindi)*

Explanation: Homunculus maps body parts onto the cerebral cortex, illustrating how different areas of the brain correspond to specific body regions based on motor and sensory functions. Areas with more intricate sensory or motor functions occupy more space in the brain. Motor Homunculus: Location : Precentral gyrus, frontal lobe It is a map (‘motor homunculus’) of the opposite body half, where, The face is represented most laterally and inferiorly, The hand is represented in the central region Leg and foot are represented on the medial surface of the hemisphere Hands and faces occupy a larger area than arms and legs in the motor homunculus. (Option A) Sensory Homunculus: Location : Postcentral gyrus, parietal lobe. (Option C) Function : Represents sensory perception, mapping body parts based on sensitivity to touch, pain, and temperature. Body parts with higher sensory acuity, like lips and fingertips, occupy larger areas. (Option B)

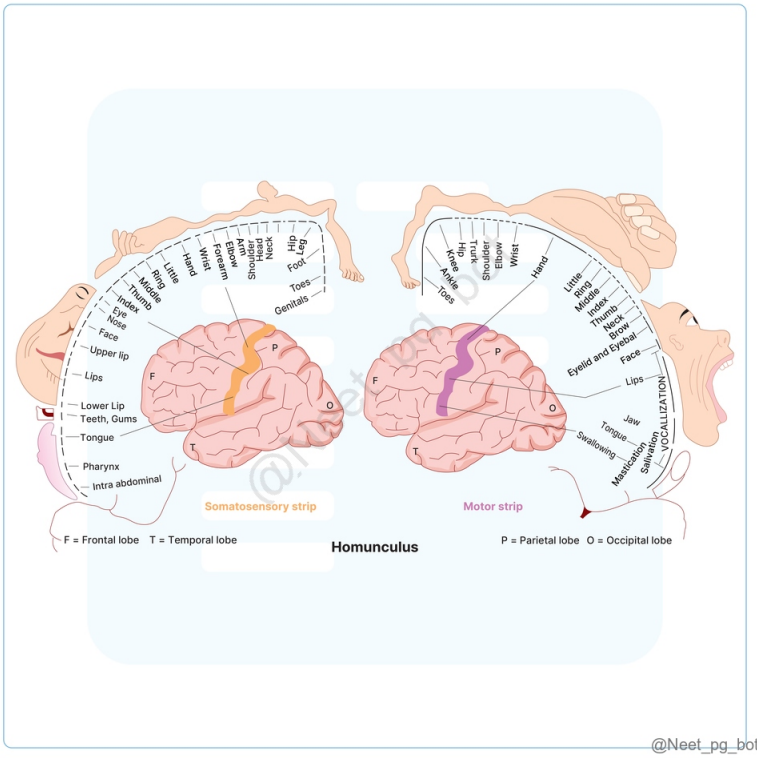

References:

Gray’s Anatomy, 42nd Edition, Page 527

Homunculus

↑ *Back to this question in Part A*

@Neet_pg_bot

• [03_Neuro Anatomy] 011 Brainstem Cranial Nerves And Cerebellum - I

« Back to Folder Directory

[03_Neuro Anatomy] 011 Brainstem Cranial Nerves And Cerebellum - I — Quick Jump

Q1 (p. 920)	*Q2 (p. 921)*	*Q3 (p. 922)*	*Q4 (p. 924)*	*Q5 (p. 926)*	*Q6 (p. 927)*
Q7 (p. 928)	*Q8 (p. 930)*	*Q9 (p. 933)*	*Q10 (p. 934)*	*Q11 (p. 935)*	*Q12 (p. 936)*
Q13 (p. 937)	*Q14 (p. 939)*	*Q15 (p. 942)*	*Q16 (p. 942)*	*Q17 (p. 944)*	*Q18 (p. 946)*
Q19 (p. 947)	*Q20 (p. 949)*	*Q21 (p. 950)*	*Q22 (p. 952)*	*Q23 (p. 953)*	*Q24 (p. 954)*
Q25 (p. 957)	*Q26 (p. 958)*				

Q1: Which cerebellar zone is mainly associated with processing proprioceptive information? (Q848603)

A. Archicerebellum

B. Paleocerebellum

C. Neocerebellum

D. Vestibulocerebellum

Correct Answer: B. Paleocerebellum

■ *Listen (English)*

■ *Listen (Hindi)*

Explanation: The paleocerebellum is responsible for processing proprioceptive information obtained from the spinal cord. It plays a vital role in coordinating limb movements and maintaining body posture through feedback from muscle and joint receptors. Comprises the anterior lobe (excluding the lingula) and parts of the posterior lobe, particularly the pyramid and uvula of the inferior vermis. Archicerebellum (Option A): This zone is primarily linked to the vestibular system, which focuses on balance and posture rather than proprioceptive input from the body. The nodules (lobule X) and lingula (lobule I) are part of the archicerebellum. Neocerebellum (Option C): Its function is integrating sensory information from the cerebral cortex for higher-level motor planning. Mainly consists of the posterior lobe, particularly the large cerebellar hemispheres, excluding the pyramid and uvula. Vestibulocerebellum (Option D): This term refers to the archicerebellum, which is more focused on balance and eye movement rather than proprioception

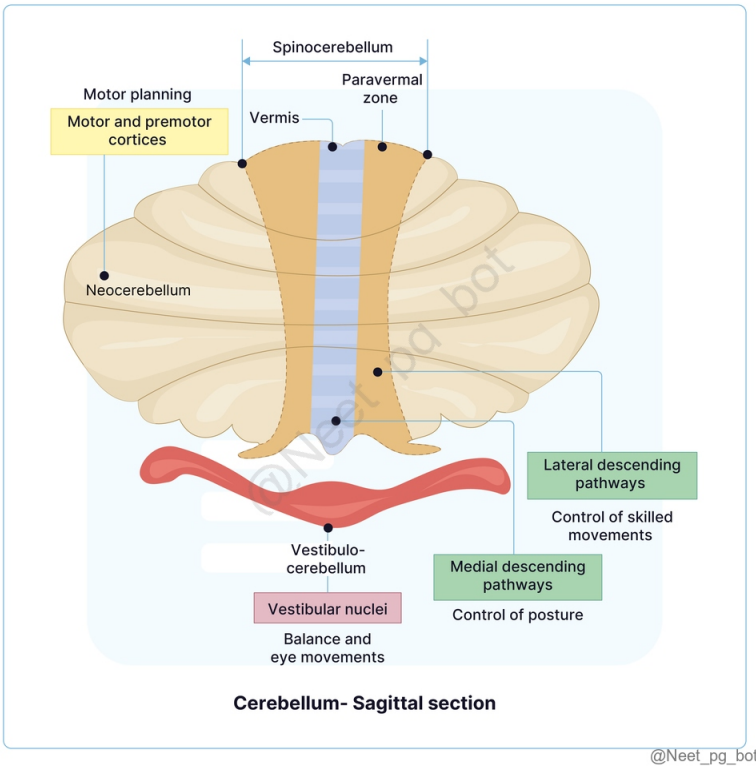

References:

Gray's Anatomy, 42nd Edition, Page 465

Netter Atlas of Human Anatomy, 8th Edition, Plate 141,198

Vishram Singh Anatomy of head, neck and brain, Volume 3, 2nd Edition, Page 376

↑ *Back to this question in Part A*

@Neet_pg_bot

Q2: Which pathway involves inhibitory projections originating from the cerebellar nuclei, contributing to the regulation of motor activity and coordination? (Q848619)

A. Rubrospinal tract

B. Nucleo-olivary pathway

C. Ventral spinocerebellar tract

D. Vestibulospinal tract

Correct Answer: B. Nucleo-olivary pathway

■ *Listen (English)*

■ *Listen (Hindi)*

Explanation: The nucleo-olivary pathway sends inhibitory projections from the cerebellar nuclei , particularly regulating motor activity and coordination. This pathway helps in adjusting cerebellar output to maintain smooth, coordinated movement. Cerebellar Output Excitatory Cerebellar nuclei to Brainstem nuclei (via Glutamate) Inhibitory Purkinjee cells to the Cerebellum (via GABA) Cerebellar Nuclei to Inferior Olive: Nucleo-Olivary Pathway (via GABA) Rubrospinal tract (Option A): The rubrospinal tract transmits signals from the red nucleus to the spinal cord, primarily assisting in controlling limb movements. While influenced by cerebellar output, it does not carry inhibitory projections from the cerebellar nuclei. Ventral spinocerebellar tract (Option C): This tract transmits proprioceptive signals to the cerebellum, mainly providing feedback from spinal interneurons. However, it does not carry inhibitory projections from the cerebellar nuclei. Vestibulospinal tract (Option D): This pathway sends excitatory signals from the vestibular nuclei to the spinal cord, helping in balance and posture control. It is not related to the cerebellar inhibitory pathways.

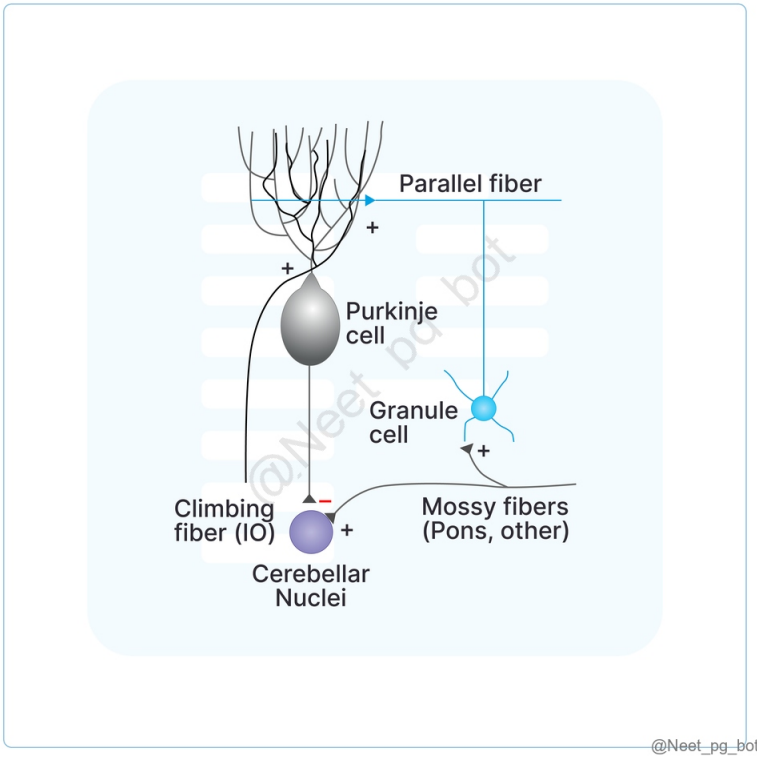

References:

Gray’s Anatomy, 42nd Edition, Pages 468, 476, 478

Vishram Singh Anatomy of Head, Neck and Brain, Volume 3, 2nd Edition, Page 309, 311, 312

↑ *Back to this question in Part A*

@Neet_pg_bot

Q3: Which of the following statements about cerebellar circuitry is false? (Q848618)

A. Climbing fibres directly excite Purkinje cells by forming extensive synaptic connections.

B. Mossy fibres excite Purkinje cells through granule cells, creating a diffuse excitatory effect.

C. Purkinje cells send excitatory signals to deep cerebellar nuclei.

D. Stellate, basket, and Golgi cells serve as inhibitory interneurons in the cerebellar cortex.

Correct Answer: C. Purkinje cells send excitatory signals to deep cerebellar nuclei.

■ *Listen (English)*

■ *Listen (Hindi)*

Explanation: Purkinje cells send inhibitory signals, not excitatory, to deep cerebellar nuclei. The cerebellar cortex contains five types of intrinsic neurons: Purkinje cells, granule cells, stellate cells, basket cells, and Golgi cells. All are inhibitory except for granule cells, making this unique arrangement of inhibitory neurons exclusive to the cerebellum in the central nervous system Cerebellum Circuit The cerebellar circuitry operates with a balance between excitatory and inhibitory inputs. Climbing fibres (from olivocerebellar tracts) excite Purkinje cells by forming extensive synapses with their dendrites. One climbing fibre connects with multiple Purkinje cells. (Option A ruled out) Mossy fibres (from other cerebellar tracts) excite thousands of Purkinje cells indirectly via granule cells , creating a more diffuse excitatory effect. (Option B ruled out) The stellate, basket and Golgi cells serve as inhibitory interneurons within the cerebellar cortex, controlling the spread and intensity of excitation in Purkinje cells. (Option D ruled out) This inhibition refines and modulates the excitatory input from both the climbing and mossy fibres, ensuring precise motor coordination. Purkinje cells send inhibitory signals to deep cerebellar nuclei (Output centres), which integrate both excitatory inputs from climbing and mossy fibres and inhibitory input from Purkinje cells.

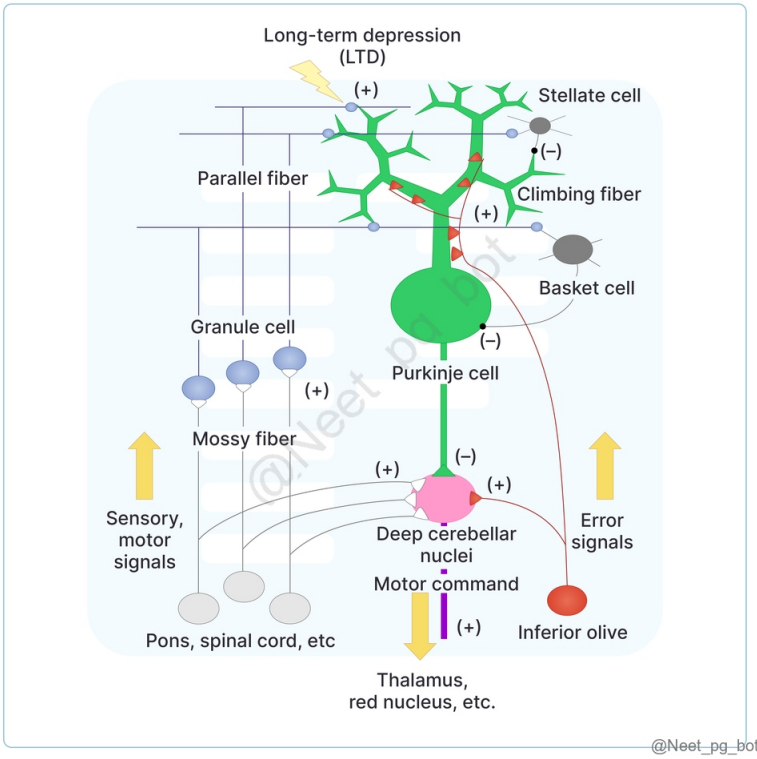

References:

Snells Neuroanatomy, 8th Edition, Pages 234, 235

Grays Anatomy, 42nd Edition, Pages 473-475

Vishram Singh Anatomy of head, neck and brain, Volume 3, 2nd Edition, Page 377

↑ *Back to this question in Part A*

@Neet_pg_bot

Q4: A 62-year-old male presents to the emergency department with a sudden onset of severe vertigo, bilateral hearing loss, and tinnitus. He also exhibits facial weakness on the right side and demonstrates ataxia when attempting to walk. An MRI performed to evaluate the condition is given below. Which artery is most likely affected in this patient's condition? {{caption_text}} (Q848617)

A. Middle cerebral artery

B. Superior cerebellar artery

C. Anterior inferior cerebellar artery

D. Vertebral artery

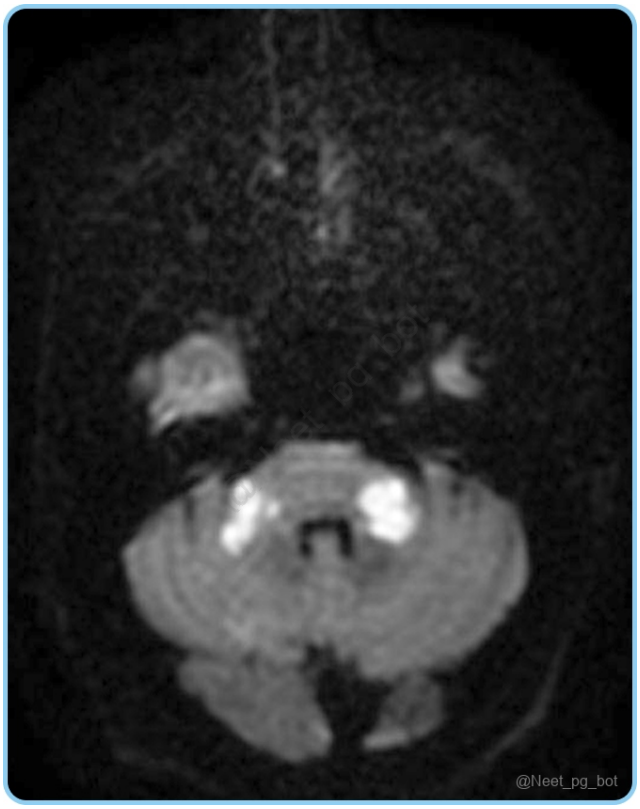

Correct Answer: C. Anterior inferior cerebellar artery

- *Listen (English)*
- *Listen (Hindi)*

Explanation: The symptoms—severe vertigo, bilateral hearing loss, tinnitus, and facial weakness—are indicative of an AICA stroke. The MRI image shows a B/L infarct in the anterior cerebellum, which further confirms the involvement of AICA. The AICA arises from the caudal third of the basilar artery and supplies the inner ear, lateral pons, and the anterior inferior cerebellum. {{caption_text}} Diffusion-weighted MRI shows B/L infarct in the anterior cerebellum The anterior inferior cerebellar artery (AICA) generally arises from the caudal third of the basilar artery and supplies the following areas: Inner ear Lateral pons Middle cerebellar peduncle Anterior inferior cerebellum (including the flocculus) Middle cerebral artery (Option A): Supplies the lateral surface of the cerebral hemispheres, not typically associated with vertigo or hearing loss. Superior cerebellar artery (Option B): Supplies the superior part of the cerebellum and may cause ataxia, but not the specific vestibular symptoms seen in this case. Vertebral artery (Option D): Supplies the posterior circulation, including parts of the brainstem, but does not directly cause the combination of symptoms presented here.

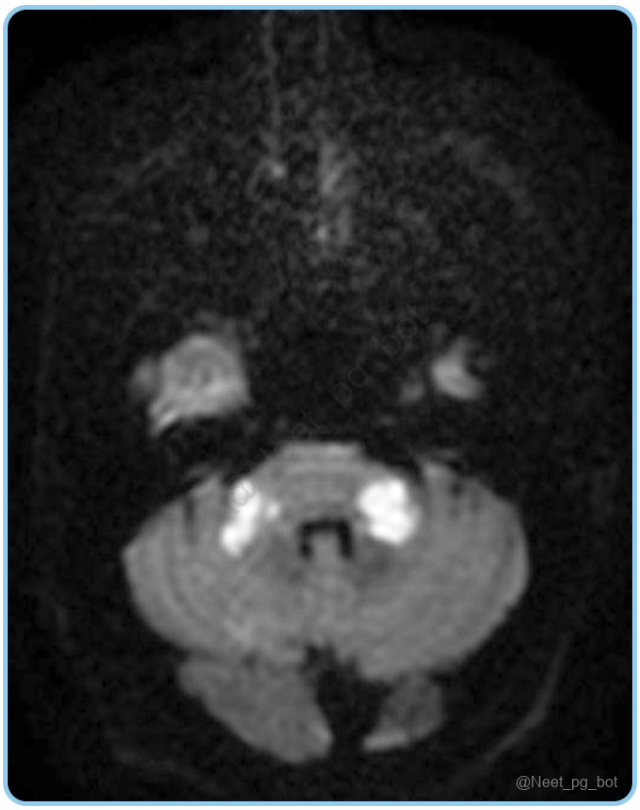

References:

radiopaedia.org/articles/anterior-inferior-cerebellar-artery-aica-infarct-1

www.ahajournals.org/doi/10.1161/STROKEAHA.109.564682

↑ *Back to this question in Part A*

@Neet_pg_bot

Q5: Which type of fibres enter the cerebellum via the middle cerebellar peduncle? (Q848616)

A. Olivo-cerebellar fibres

B. Cerebro-ponto-cerebellar fibres

C. Spinocerebellar fibers

D. Vestibulo-cerebellar fibres

Correct Answer: B. Cerebro-ponto-cerebellar fibres

■ *Listen (English)*

■ *Listen (Hindi)*

Explanation: Cerebro-ponto-cerebellar fibres, a part of mossy fibres, originate from the cerebral cortex, synapse in the pons, and then project to the cerebellum via the middle cerebellar peduncle , playing a key role in coordinating movement and processing sensory information. They have excitatory terminals on granule cells , which excite Purkinje cells. Climbing fibres, on the other hand, enter via the inferior cerebellar peduncle and target Purkinje cells directly. Afferent fibres Tract Enter Cerebellum Via Target and Function Climbing fibres Olivo-cerebellar (Option A ruled out) Inferior cerebellar peduncle (decussates) Excitatory terminals on Purkinje cells (glutamate) Mossy fibres Cerebro-ponto- cerebellar (Option B) Middle cerebellar peduncle (decussates) Excitatory terminals on granule cells (glutamate), which are excitatory to Purkinje cells Spinocerebellar (Option C ruled out) Inferior cerebellar peduncle Superior cerebellar peduncle Vestibulo-cerebellar (Option D ruled out) Inferior cerebellar peduncle

References:

Snell’s Clinical Neuroanatomy, 8th Edition, Pages 234- 237

↑ *Back to this question in Part A*

@Neet_pg_bot

Q6: Which of the following structures receives direct projections from the dentate nucleus? (Q848615)

A. Premotor cortex

B. Ventrolateral nucleus of the thalamus

C. The anterior nucleus of the thalamus

D. Parietal cortex

Correct Answer: B. Ventrolateral nucleus of the thalamus

■ *Listen (English)*

■ *Listen (Hindi)*

Explanation: The ventrolateral nucleus of the thalamus is the primary structure receiving direct projections from the dentate nucleus via the superior cerebellar peduncle. This pathway is crucial for motor control and coordination. Premotor cortex (Option A): The premotor cortex is involved in planning and organising movements but does not receive direct projections from the dentate nucleus. Information reaches the premotor cortex indirectly through the thalamus. The anterior nucleus of the thalamus (Option C): The anterior nucleus of the thalamus primarily relays information related to limbic functions and is not a target for direct projections from the dentate nucleus. Parietal cortex (Option D): The parietal cortex is involved in sensory processing and higher cognitive functions. While it receives input from the thalamus, it does not receive direct projections from the dentate nucleus.

References:

Gray’s Anatomy, 42nd Edition, Pages 468, 484

Vishram Singh Anatomy of Head, Neck and Brain, Volume 3, 2nd Edition, Pages 354, 369, 378, 392

↑ *Back to this question in Part A*

@Neet_pg_bot

Q7: The fastigial nucleus primarily projects to which of the following structures? (Q848610)

A. Red nucleus

B. Thalamus

C. Vestibular nuclei

D. Cerebral cortex

Correct Answer: C. Vestibular nuclei

■ *Listen (English)*

■ *Listen (Hindi)*

Explanation: The vestibular nuclei receive major projections from the fastigial nucleus , playing a key role in maintaining balance, regulating posture, and coordinating head and eye movements via the vestibulospinal tracts. {{caption_text}} Connections of Cerebellum Part of cerebellum Cerebellar Nuclei Centre Neocerebellum Dentate Red Nucleus and Thalamus (Option B ruled out) Paleocerebellum Globose and Emobliform Red Nucleus (Option A ruled out) Archicerebellum Fastigial Vestibular Nuclei (Option C) Cerebral cortex (Option D): The cerebral cortex is influenced indirectly by cerebellar nuclei, especially via the thalamus. However, the fastigial nucleus does not send direct projections to the cortex.

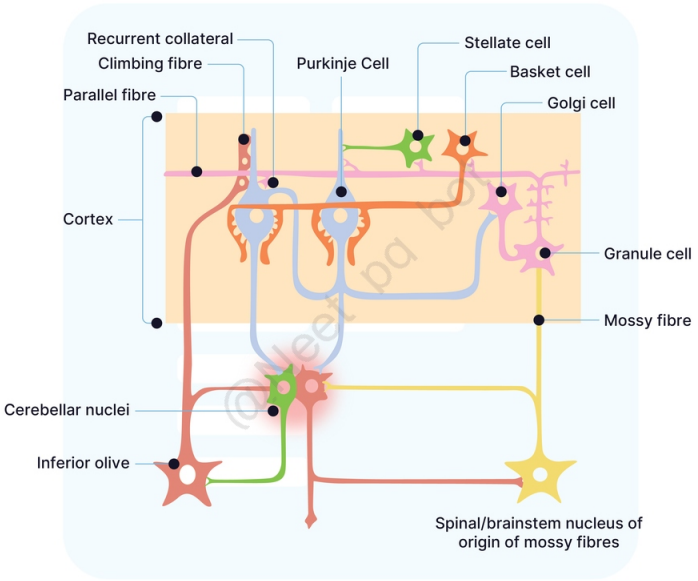

@Neet_pg_bot

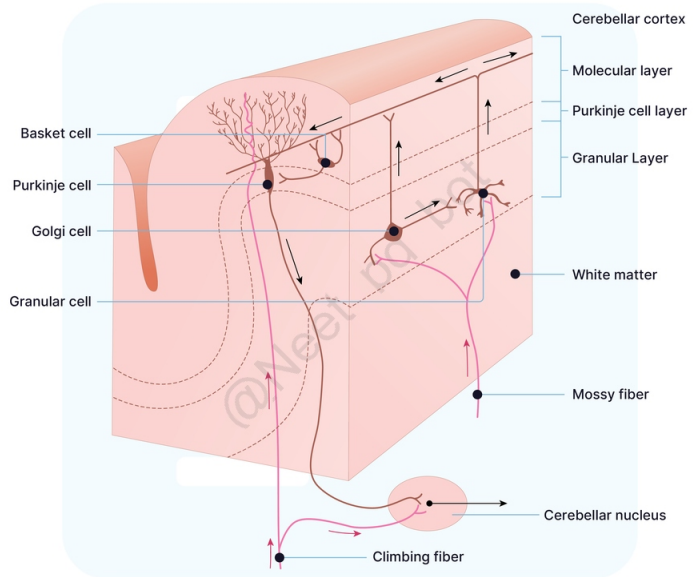

@Neet_pg_bot

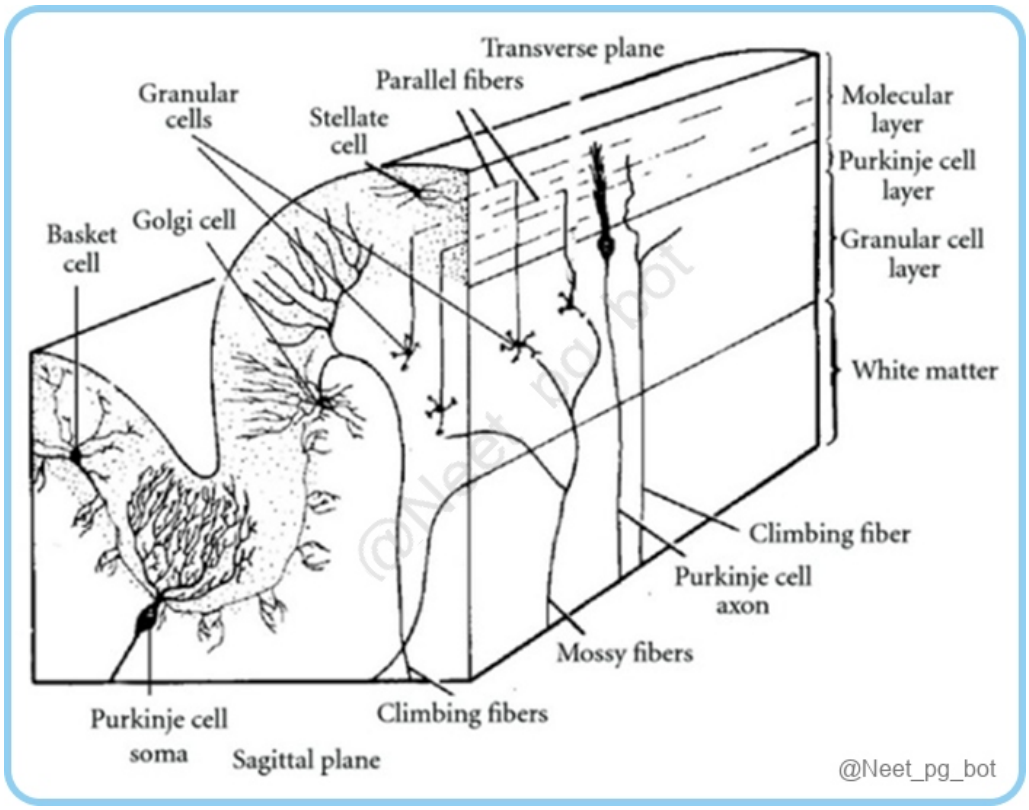

References:

Gray's Anatomy, 42nd Edition, Pages 481, 483, 484.e1

Vishram Singh Anatomy of head, neck and brain, Volume 3, 2nd Edition, Page 377

↑ *Back to this question in Part A*

@Neet_pg_bot

Q8: Which of the following intrinsic neurons are correctly matched with their respective layers in the cerebellar cortex? {{caption_text}} (Q848609)

A. 1- Plexiform layers; Golgi cells

B. 2- Molecular layer; Purkinje cells

C. 2- Granular layer; Basket cells

D. 3- Granular layer; Golgi cells

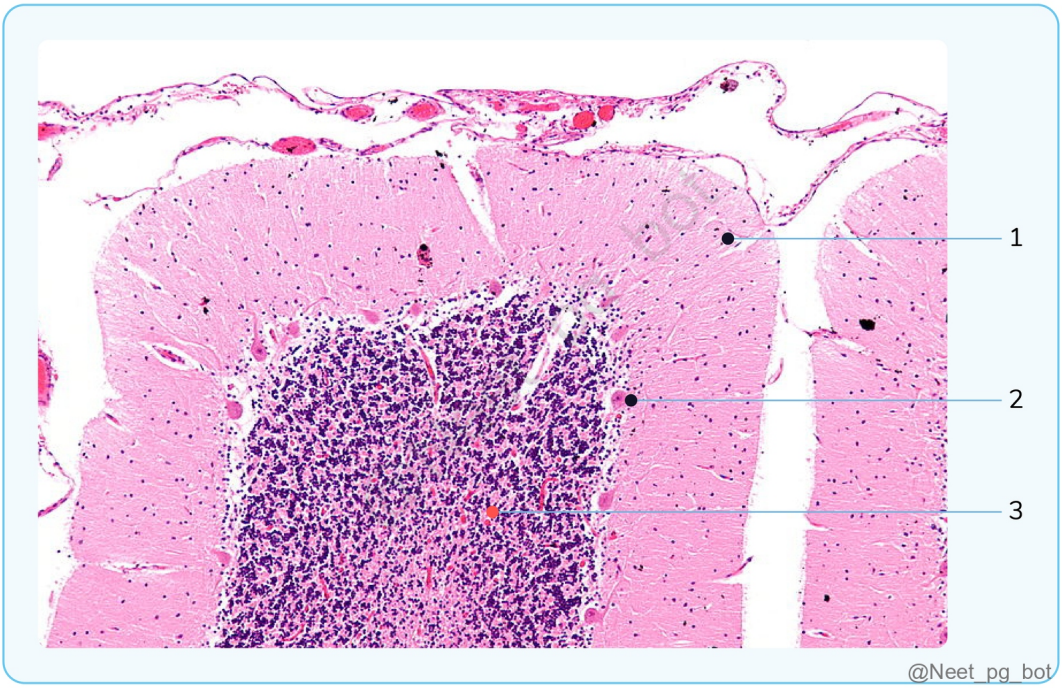

Correct Answer: D. 3- Granular layer; Golgi cells

■ *Listen (English)*

■ *Listen (Hindi)*

Explanation: Golgi cells are found in the granular layer of the cerebellar cortex. They are inhibitory interneurons that play a role in modulating the activity of granule cells. The cerebellar cortex consists of the following three distinct layers: Layers of the cerebellar cortex Molecular (plexiform) layer (Option C ruled out) Purkinje cell layer (Option B ruled out) Granular layer (Option A ruled out) It primarily contains numerous dendritic branches from Purkinje cells, with relatively few widely spaced nerve cells. It consists of a single row of large flask-shaped cells, the Purkinje cells . The inner granular layer is made up of many closely packed small granule cells , along with a few larger Golgi cells. These nerve cells are of two types: (a) Basket cells (b) Stellate cells. The axons of Purkinje cells are the only output from the cerebellar cortex and have an inhibitory effect on the intracerebellar nuclei. Golgi cells are inhibitory while the granular cells are excitatory. Among the five types of intrinsic neurons (Basket cells, Stellate cells, Purkinje cells, Granule cells and Golgi cells)- All are inhibitory except granule cells. {{caption_text}} {{caption_text}}

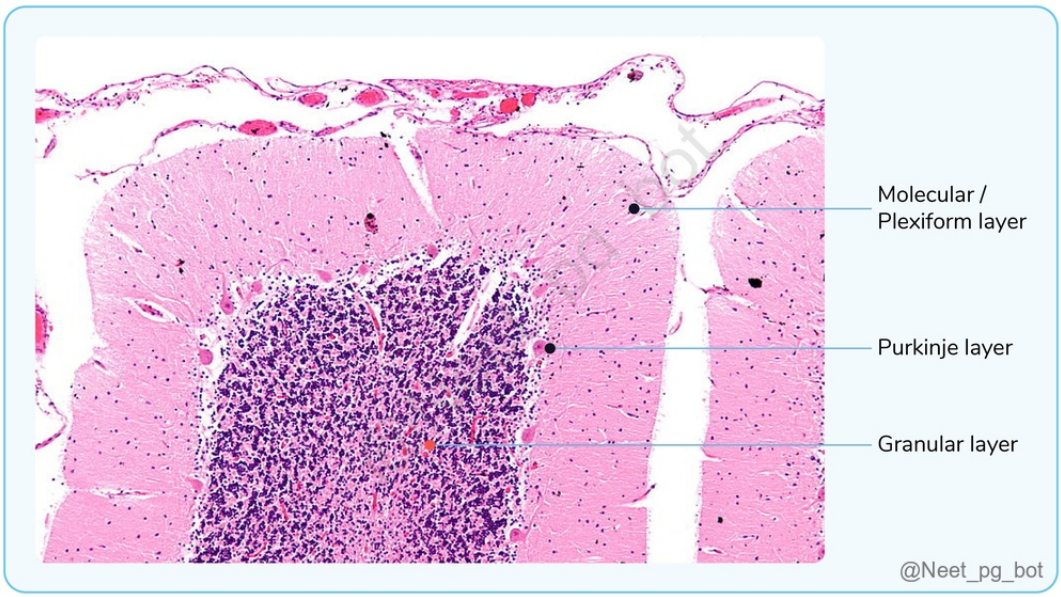

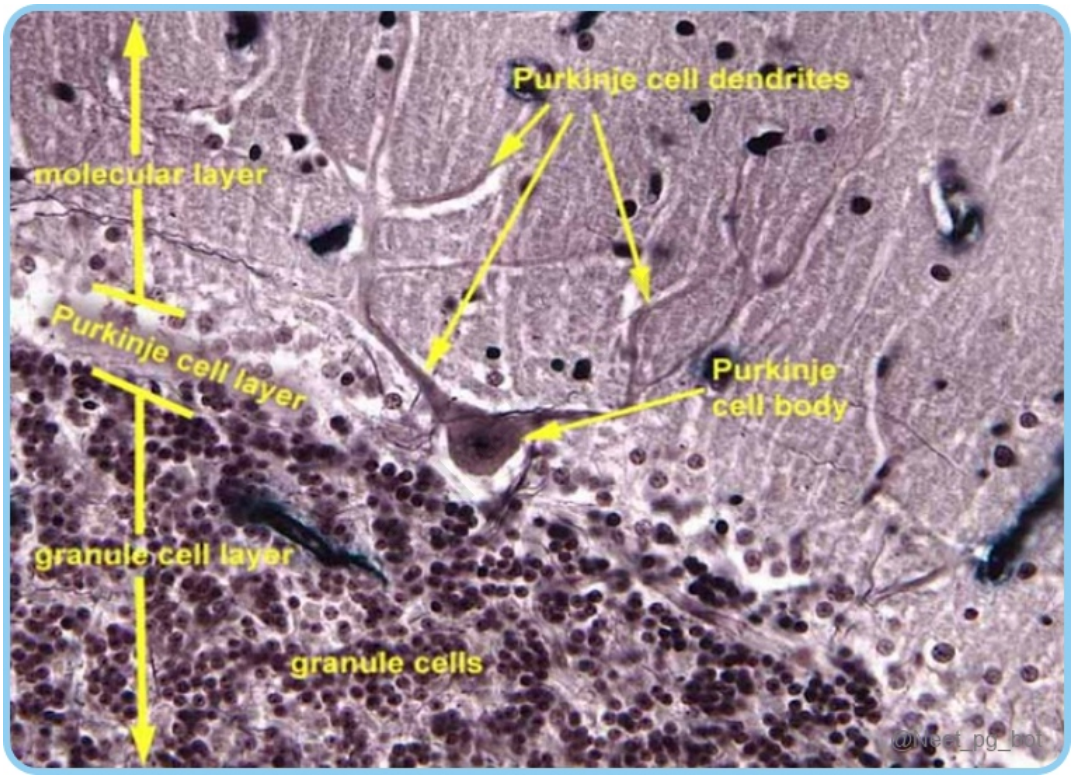

References:

Gray’s Anatomy, 42nd Edition, Pages 469, 471

Vishram Singh Anatomy of head, neck and brain, Volume 3, 2nd Edition, Page 377

↑ *Back to this question in Part A*

@Neet_pg_bot

Q9: Which of the following deep cerebellar nuclei is primarily involved in the smooth execution of skilled voluntary movements? (Q848608)

A. Fastigial nucleus

B. Emboliform nucleus

C. Globose nucleus

D. Dentate nucleus

Correct Answer: D. Dentate nucleus

■ *Listen (English)*

■ *Listen (Hindi)*

Explanation: The deep cerebellar nuclei are clusters of grey matter situated within the white matter of the cerebellum. These nuclei are critical hubs for processing and relaying information related to motor control and coordination. Deep Cerebellar nuclei Dentate Nucleus (Option D) Emboliform Nucleus Globose Nucleus Fastigial Nucleus Largest and most lateral. Receives input from the neocerebellum. Involved in coordinating skilled, voluntary movements, especially of the limbs. Efferent fibres exit through the superior cerebellar peduncle . Oval-shaped, medial to the dentate nucleus. The emboliform nucleus combined with the globose nucleus is called Nucleus Interposus. Receives input from the paleocerebellum. Plays a role in general motor coordination. (Option B ruled out) Rounded, positioned between the emboliform and fastigial nuclei. Also part of the paleocerebellum. Works together with the emboliform nucleus for motor control. (Option C ruled out) Most medial, near the midline. Receives input from the archicerebellum , specifically the flocculonodular lobe. Important for balance, posture, and coordinating head and eye movements. (Option A ruled out)

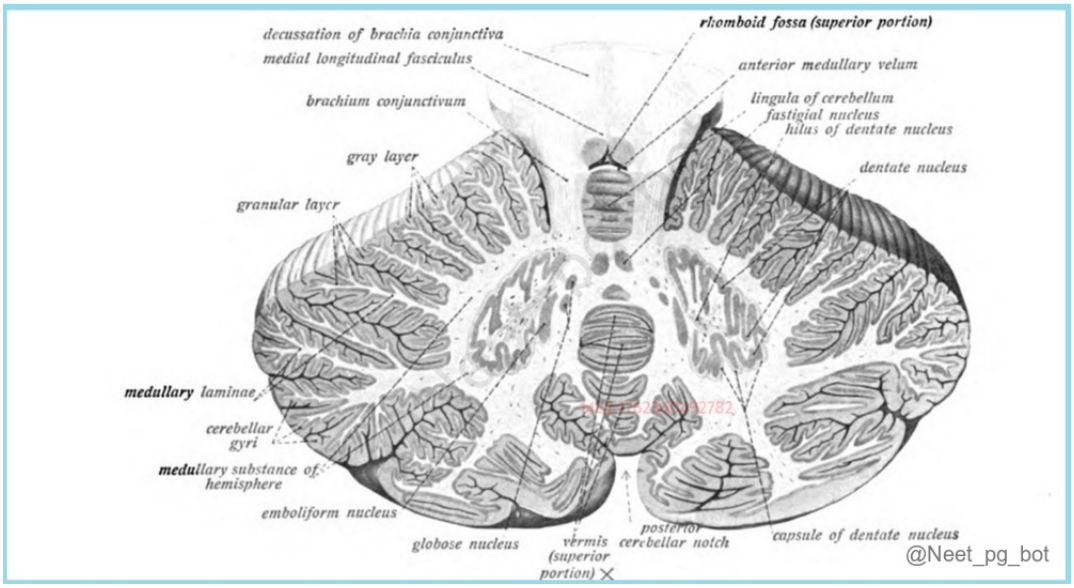

References:

Gray’s Anatomy, 42nd Edition, Pages 465, 468, 481, 483, 484

Netter Atlas of Human Anatomy, 8th Edition, Plate 142, Page 199

Vishram Singh Anatomy of head, neck and brain, Volume 3, 2nd Edition, Page 376, 377, 378

↑ *Back to this question in Part A*

@Neet_pg_bot

Q10: What is the significance of the second decussation of the ventral spinocerebellar tract within the cerebellum? (Q848607)

A. Enables contralateral proprioceptive processing

B. Ensures ipsilateral proprioceptive termination

C. Blocks incorrect proprioceptive signals

D. Causes all fibres to terminate bilaterally

Correct Answer: B. Ensures ipsilateral proprioceptive termination

■ *Listen (English)*

■ *Listen (Hindi)*

Explanation: The second crossing within the cerebellum ensures that the proprioceptive signals from one side of the body ultimately terminate on the same side of the cerebellum , aiding in precise coordination of movement. Ventral Spinocerebellar Tract Pathway Begins in the lumbar and sacral spinal cord (intermediate grey matter and dorsal horn base). ↓ Fibers cross the midline in the spinal cord via the ventral white commissure. ↓ The tract ascends through the spinal cord and brainstem, running near the spinothalamic tract. ↓ Enters the cerebellum through the superior cerebellar peduncle at the level of the midbrain. ↓ Fibres recross within the cerebellum’s white matter. ↓ The majority of fibres end in the anterior cerebellar vermis, with a smaller portion terminating bilaterally. Enables contralateral proprioceptive processing (Option A): The second decussation does not lead to contralateral processing but instead causes the proprioceptive signals to be processed on the same side (ipsilateral) as their origin. Blocks incorrect proprioceptive signals (Option C): The second decussation does not prevent signal transmission but ensures that signals from the body are processed correctly by the cerebellum after crossing back to the original side. Causes all fibres to terminate bilaterally (Option D): Only about 15% of fibres may terminate bilaterally, the main role of the second decussation is not to cause bilateral termination but to direct most fibres to terminate ipsilaterally.

References:

Gray’s Anatomy, 42nd Edition, Pages 431, 448

↑ *Back to this question in Part A*

@Neet_pg_bot

Q11: From which anatomical structure does the dorsal spinocerebellar tract originate? (Q848606)

A. Anterior horn of the spinal cord

B. Cerebellar cortex

C. Medulla oblongata

D. Posterior thoracic nucleus (Clarke's column)

Correct Answer: D. Posterior thoracic nucleus (Clarke's column)

■ *Listen (English)*

■ *Listen (Hindi)*

Explanation: The dorsal spinocerebellar tract originates from neurons located in the Posterior thoracic nucleus (Clarke's column) nucleus, situated in the thoracic and upper lumbar regions of the spinal cord. It enters the cerebellum through the inferior cerebellar peduncle and terminates in the ipsilateral cerebellar cortex. These neurons process input from proprioceptive receptors, such as muscle spindles and Golgi tendon organs. It carries unconscious proprioception. {{caption_text}} Tracts of the spinal cord Anterior horn of the spinal cord (Option A): This region mainly contains motor neurons responsible for transmitting signals to skeletal muscles. It does not give rise to the dorsal spinocerebellar tract, which is primarily involved in sensory processing. Cerebellar cortex (Option B): This area is the termination for the dorsal spinocerebellar tract fibres, where proprioceptive information is integrated for coordination and balance, rather than being the site of origin for the tract itself. Medulla oblongata (Option C): This structure is part of the brainstem and plays a role in autonomic functions and motor control. However, it does not serve as the origin point for the dorsal spinocerebellar tract.

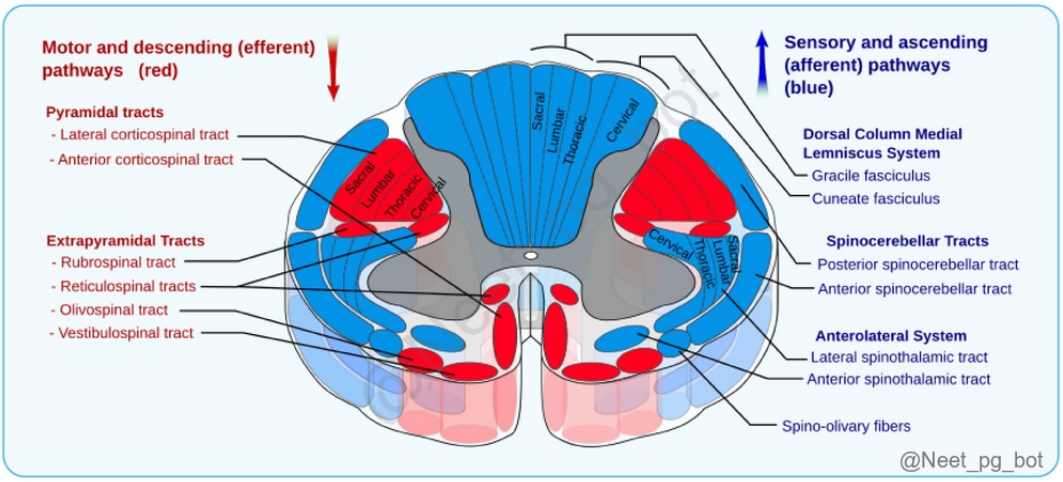

References:

Gray’s Anatomy, 42nd Edition, Pages 431, 445, 477

Netter Atlas of Human Anatomy, 8th Edition, Plate 40, Page 305

Vishram Singh Anatomy of head, neck and brain, Volume 3, 2nd Edition, Page 306, 310, 311, 356

↑ *Back to this question in Part A*

@Neet_pg_bot

Q12: Which cerebellar peduncle is primarily composed of only afferent fibres? (Q848605)

A. Inferior cerebellar peduncle

B. Middle cerebellar peduncle

C. Superior cerebellar peduncle

D. All of the above

Correct Answer: B. Middle cerebellar peduncle

■ *Listen (English)*

■ *Listen (Hindi)*

Explanation: The middle cerebellar peduncle is composed exclusively of afferent fibres originating from the contralateral pontine nuclei. It plays a crucial role in relaying information from various areas of the cerebral cortex to the cerebellum, facilitating the coordination of movement and motor planning. Cerebellar Peduncles Afferent Efferent Superior cerebellar peduncle Ventral Spinocerebellar Tract All efferent fibres from dentate, emboliform, fastigial and globose nuclei (Option C ruled out) Middle cerebellar peduncle Pontocerebellar Mossy Fibre Pathway No efferent fibres (Option B) Inferior cerebellar peduncle Dorsal Spinocerebellar Tract Olivocerebellar Tract Reticulocerebellar Tract Few efferents from the cerebellum to the medulla oblongata, mainly to vestibular nuclei and reticular formation. (Option A ruled out) All of the above (Option D): Incorrect, as the only peduncle that consists solely of afferent fibres is the middle cerebellar peduncle. The others include both afferent and efferent fibres.



@Neet_pg_bot

References:

Gray’s Anatomy, 42nd Edition, Page 445, 467, 468

Netter Atlas of Human Anatomy, 8th Edition, Page 141, 198

Vishram Singh Anatomy of head, neck and brain, Volume 3, 2nd Edition, Page 378

↑ *Back to this question in Part A*

@Neet_pg_bot

Q13: Which cerebellar lobe is associated with maintaining balance and controlling eye movements? (Q848604)

A. Flocculonodular Lobe

B. The anterior lobe

C. The posterior lobe

D. Neocerebellum

Correct Answer: A. Flocculonodular Lobe

■ *Listen (English)*

■ *Listen (Hindi)*

Explanation: The Flocculonodular Lobe, also known as the vestibulocerebellum, has direct and strong connections to the vestibular system, which governs balance, posture, and eye movements. The flocculonodular lobe helps coordinate head, neck, and eye movements based on vestibular input, which is crucial for maintaining equilibrium. Cerebellum The anterior lobe (Option B): Found on the superior surface of the cerebellum, this lobe plays a key role in motor coordination, through its connections to the spinocerebellar tracts that transmit sensory information from the spinal cord. The posterior lobe (Option C) is involved in motor planning and higher cognitive functions. Its connections with association areas of the cerebral cortex, such as the prefrontal and parietal regions, allow it to contribute to the coordination of complex movements rather than balance. Neocerebellum (Option D): Referring primarily to the posterior lobe, the neocerebellum is involved in regulating complex movements and processing higher cognitive functions.

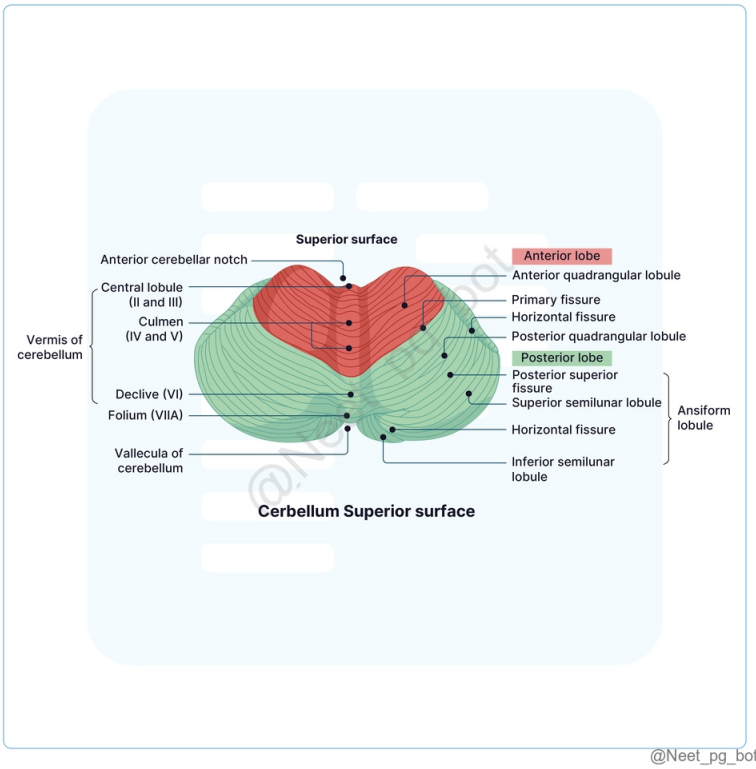

@Neet_pg_bot

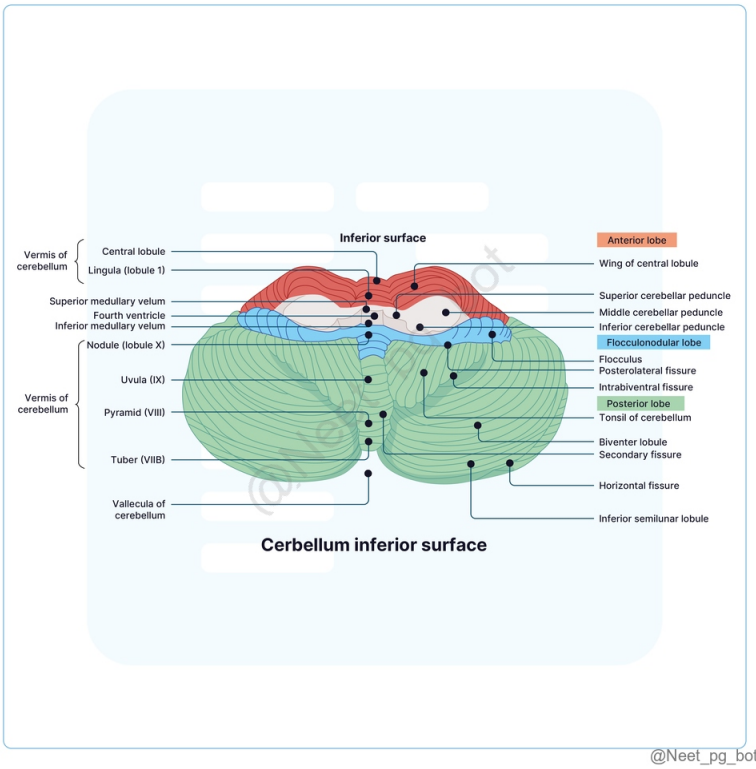

@Neet_pg_bot

References:

Gray’s Anatomy, 42nd Edition, Page 477, 485, 486

Netter Atlas of Human Anatomy, 8th Edition, Page 142, 199

Vishram Singh Anatomy of head, neck and brain, Volume 3, 2nd Edition, Page 376

↑ *Back to this question in Part A*

@Neet_pg_bot

Q14: Identify the correct option. (Q848477)

A. 6- Trigeminal nerve; 7- Trochlear nerve

B. 5- Abducens nerve; 3- Vagus nerve

C. 1- Hypoglossal nerve; 2- Facial nerve

D. 4- Vestibulocochlear nerve; 8- Optic Nerve

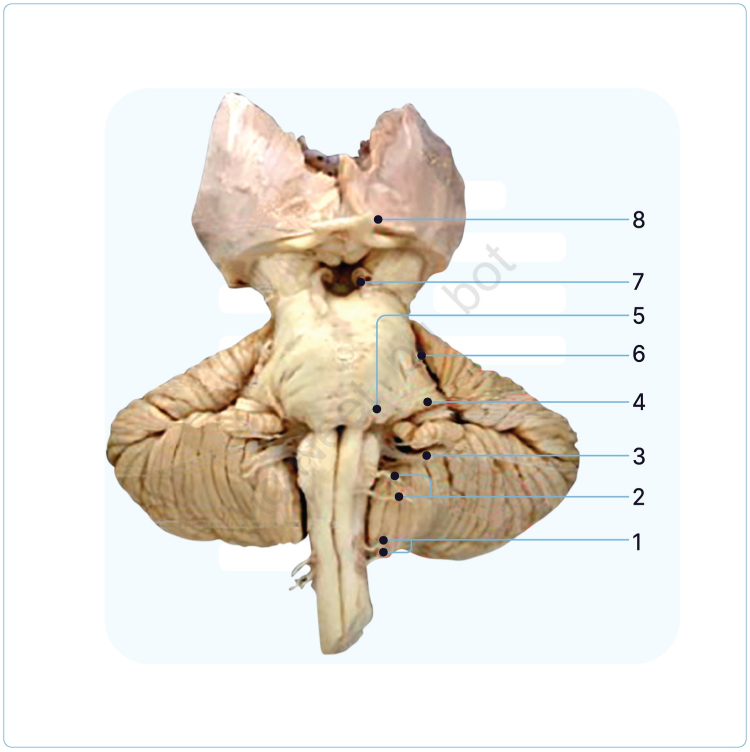

@Neet_pg_bot

Correct Answer: B. 5- Abducens nerve; 3- Vagus nerve

■ *Listen (English)*

■ *Listen (Hindi)*

Explanation: Attachment of the nerves to the brain: 1, 2 - Forebrain 3- Arises from ventral midbrain 4- Dorsal midbrain (cannot see its origin in the Anterior view of the brainstem) 5- Lateral pons 6, 7, 8- Ponto medullary junction (from medial to lateral respectively) 9, 10, 11- Lateral to olives (from superior to inferior respectively) 12- Between pyramid and olives {{caption_text}} {{caption_text}}

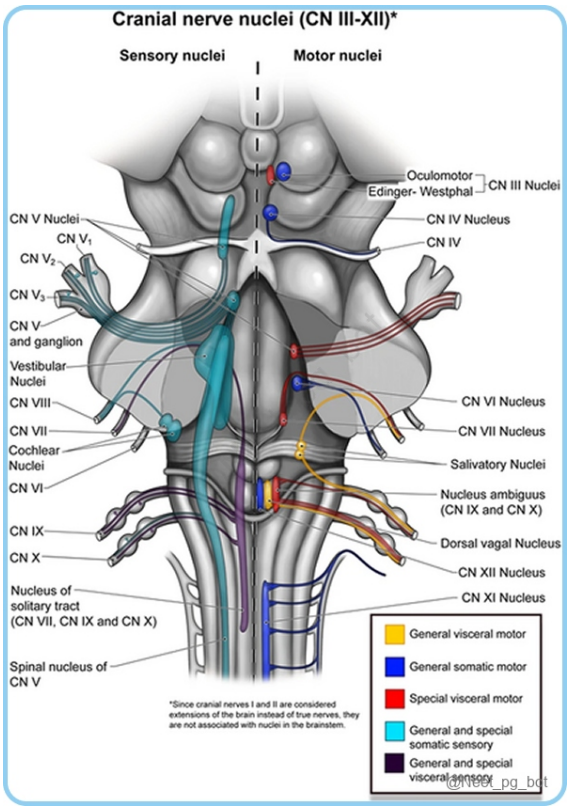

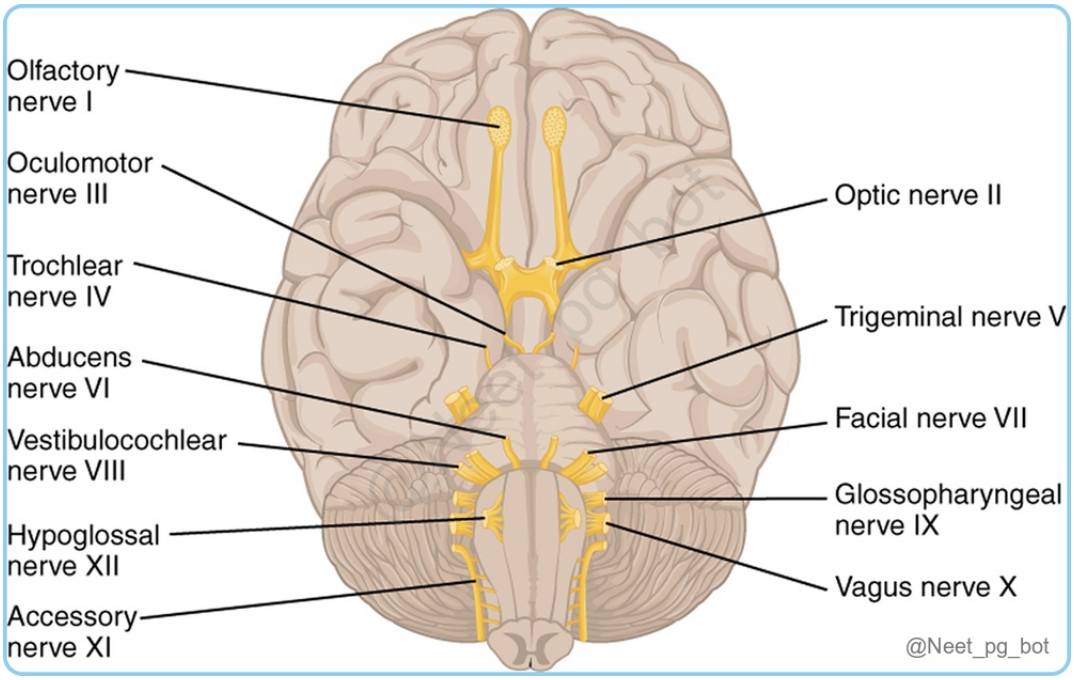

References:

Snell’s Clinical Neuroanatomy, 8th Edition, Pages 196, 197

BD Chaurasia Neuroanatomy, Volume 4, 8th Edition, Pages 56, 57

↑ *Back to this question in Part A*

@Neet_pg_bot

Q15: Match the following neural columns with their corresponding cranial nerve nuclei. 1. General Somatic Efferent (GSE) A) Nucleus ambiguus 2. Special Visceral Afferent (SVA) B) Edinger-Westphal nucleus 3. General Visceral Efferent (GVE) C) Oculomotor nucleus 4. Special Visceral Efferent (SVE) D) Nucleus of the solitary tract (Q848590)

A. 1-A, 2-B, C-3, 4-D

B. 1-D, 2-C, 3-B, 4-A

C. 1-C, 2-D, 3-B, 4-A

D. 1-B, 2-A, 3-D, 4-C

Correct Answer: C. 1-C, 2-D, 3-B, 4-A

■ *Listen (English)*

■ *Listen (Hindi)*

Explanation: 1. General Somatic Efferent (GSE) The GSE column controls muscles derived from somites, specifically the striated muscles. C) Oculomotor nucleus In the brainstem, it is represented by nuclei like the oculomotor nucleus , which innervates the extraocular muscles, facilitating eye movement. 2. Special Visceral Afferent (SVA) The SVA column is responsible for processing special sensory information related to taste. D) Nucleus of the solitary tract In the brainstem, the nucleus of the solitary tract receives taste signals from the tongue, transmitted by cranial nerves like the facial and glossopharyngeal nerves. 3. General Visceral Efferent (GVE) The GVE column regulates autonomic functions, particularly parasympathetic innervation. B) Edinger-Westphal nucleus The Edinger-Westphal nucleus in the midbrain is part of this system, controlling pupil constriction and lens accommodation. 4. Special Visceral Efferent (SVE) The SVE column innervates muscles derived from the branchial arches, responsible for functions like swallowing and speech. A) Nucleus ambiguus The nucleus ambiguus provides motor innervation to muscles involved in these actions, via cranial nerves like the vagus and glossopharyngeal nerves.

References:

Gray’s Anatomy, 42nd Edition, Page 391

Vishram Singh Anatomy of Head, Neck and brain, Volume 3, 2nd Edition, Page 372

↑ *Back to this question in Part A*

@Neet_pg_bot

Q16: Which of the following correctly arranges the brainstem nuclei from medial to lateral in the brainstem? (Q848518)

A. Oculomotor nucleus → Trochlear nucleus → Edinger Westphal nucleus

B. Hypoglossal nucleus → Dorsal motor nucleus of the vagus → Nucleus tractus solitarius

C. Motor nuclei of Trigeminal → Motor nuclei of Facial → Abducent nucleus

D. Nucleus ambiguus → Hypoglossal nucleus → Nucleus tractus solitarius

Correct Answer: B. Hypoglossal nucleus → Dorsal motor nucleus of the vagus → Nucleus tractus solitarius

■ *Listen (English)*

■ *Listen (Hindi)*

Explanation: {{caption_text}} Oculomotor nucleus → Trochlear nucleus → Edinger Westphal nucleus (Option A): Edinger Westphal lies dorsal to the oculomotor nucleus and not lateral. Motor nuclei of Trigeminal → Motor nuclei of Facial → Abducent nucleus (Option C): The motor nucleus of the facial nerve lies ventrolateral to the abducent nucleus. Nucleus ambiguus → Hypoglossal nucleus → Nucleus tractus solitarius (Option D): Hypoglossal nuclei are medial to Nucleus Ambiguus.

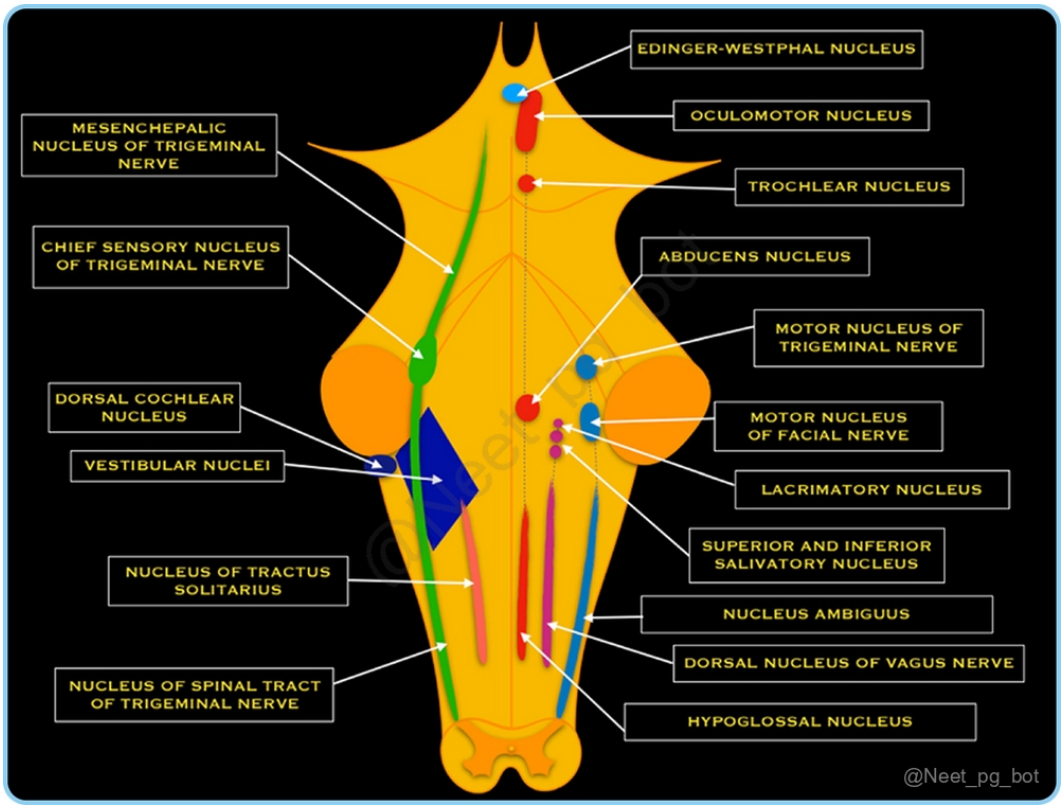

References:

Gray’s Anatomy, 42nd Edition, Pages 444, 453, 458

Snell’s Clinical Neuroanatomy, 8th Edition, Page 203

doctorlib.info/anatomy/textbook-clinical-neuroanatomy/9.html.

↑ *Back to this question in Part A*

@Neet_pg_bot

Q17: Which nuclei belong to the Special Somatic Afferent (SSA) column? (Q848517)

A. Cochlear and vestibular nuclei

B. Sensory nucleus of the trigeminal nerve

C. Hypoglossal and abducens nuclei

D. Nucleus ambiguus and facial nucleus

Correct Answer: A. Cochlear and vestibular nuclei

■ *Listen (English)*

■ *Listen (Hindi)*

Explanation: Cochlear and vestibular nuclei are part of the SSA column, carrying special senses of hearing and balance. Neural column Nuclei and Cranial Nerves GSE (General Somatic Efferent) (Option C ruled out) SVE (Special Visceral Efferent) (Option D ruled out) GVE (General Visceral Efferent) GVA/SVA (General/Special Visceral Afferent) GSA (General Somatic Afferent) (Option B ruled out) SSA (Special Somatic Afferent) (Option A) Oculomotor nucleus (III) Trochlear nucleus (IV) Abducent nucleus (VI) Hypoglossal nucleus (XII) Motor nucleus of Trigeminal Nerve (V) Motor nucleus of the facial nerve (VII) Nucleus ambiguus (IX, X, XI) Edinger Westphal nucleus (III) Superior salivatory nucleus (VII) Inferior salivatory nucleus (IX) Dorsal nucleus of Vagus (X) Nucleus Tractus Solitarius (GVA - IX, X) (SVA - VII, IX) Sensory nuclei of Trigeminal Nerve (V, IX, X) Vestibular nuclei (VIII) Cochlear nuclei (VIII) The lateral geniculate nucleus of the thalamus (II). Olfactory bulb (I) Mnemonic: Rule of 12: Any nucleus that is inclusive of 12 is medial. It includes nuclei III, IV, VI and XII. The rest are lateral. Rule of M: 3 primary medial tracts of the Brainstem. Includes Motor Tract (Corticospinal Tract), Medial Lemniscus and Medial Longitudinal Fasciculus. Rule of S: Lateral or “side” tracts. Includes Spinothalamic tract, Sympathetic tract and spinocerebellar tracts. B- Branchial Motor, CST-Corticospinal, STT- Spinothalamic, ML- Medial Lemniscus, Sm- Somatic motor, Sp-Special sensory, Ss- Somatic sensory Section through medulla showing arrangement of cranial nerve nuclei

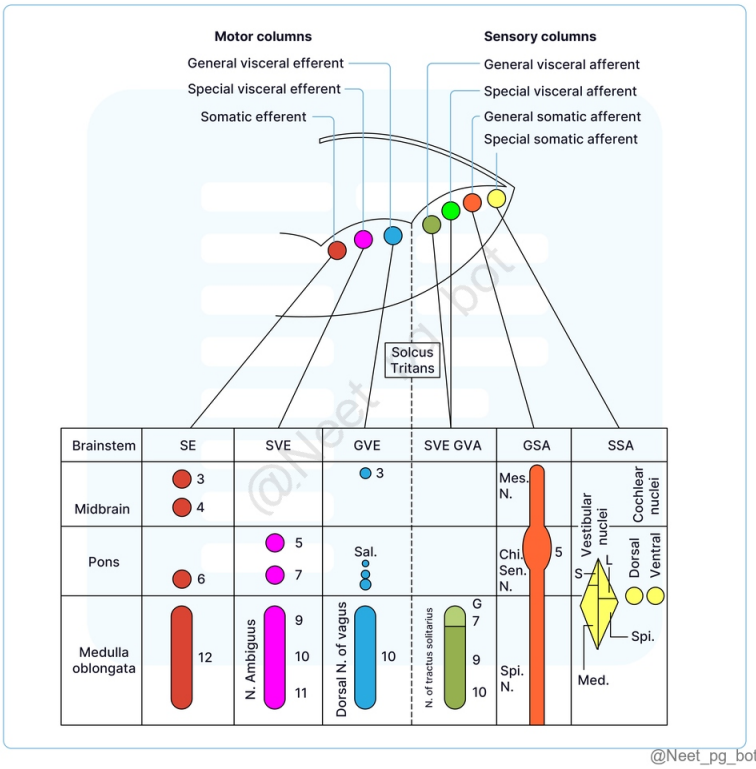

@Neet_pg_bot

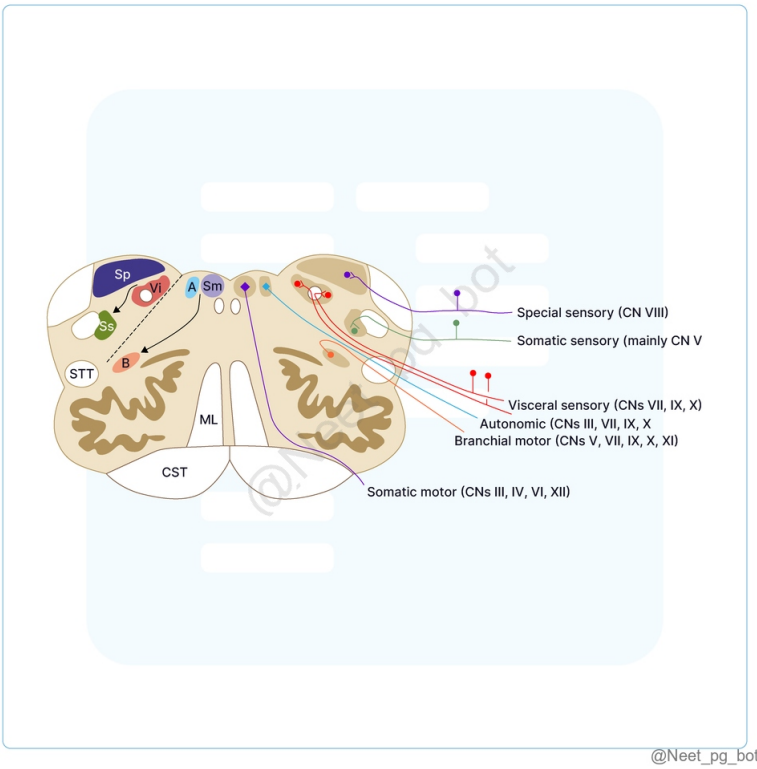

@Neet_pg_bot

References:

Gray’s Anatomy, 42nd Edition, Pages 391, 444

Vishram Singh Anatomy of head, neck and brain, Volume 3, 2nd Edition, Page 372

clinicalgate.com/brainstem/

www.icesi.edu.co/blogs/neuroanatomia/files/2018/09/Learning-Brainstem-Anatomy-A-Mnemonic-Device.pdf Page 965

↑ *Back to this question in Part A*

@Neet_pg_bot

Q18: Which artery is most commonly occluded, leading to medial medullary syndrome and lateral pontine syndrome, respectively? (Q848514)

A. Anterior cerebral artery, PICA

B. Posterior cerebral artery, Basilar artery

C. Anterior spinal artery, AICA

D. Vertebral artery, superior cerebellar artery

Correct Answer: C. Anterior spinal artery, AICA

■ *Listen (English)*

■ *Listen (Hindi)*

Explanation: Anterior Spinal Artery: Its occlusion leads to medial medullary syndrome, resulting in contralateral hemiplegia, loss of vibration and position sense, and tongue paralysis on the same side. AICA (Anterior Inferior Cerebellar Artery): Occlusion leads to lateral pontine syndrome, causing symptoms like facial paralysis, vertigo, nystagmus, and ataxia. Medial Medullary Syndrome (Dejerine Syndrome) Cause: Occlusion of the anterior spinal artery Features: Contralateral Hemiplegia: Due to damage to the medullary pyramid. Loss of Vibration and Position Sense: Resulting from damage to the medial lemniscus. Tongue Paralysis (Same Side): Caused by injury to the hypoglossal (XII) cranial nerve. Lateral Inferior Pontine Syndrome Cause: Occlusion of the anterior inferior cerebellar artery (AICA) On Side of Lesion: Nystagmus, Vertigo, Nausea, Vomiting, Oscillopsia: Due to vestibular nerve/nucleus involvement. Facial Paralysis Impaired Conjugate Gaze: Involvement of the center for lateral gaze. Deafness and Tinnitus: Related to the auditory nerve or cochlear nucleus. Ataxia: Affecting the middle cerebellar peduncle and cerebellar hemisphere. Impaired Sensation Over Face: Due to involvement of the descending tract and nucleus of the fifth nerve. On Side Opposite Lesion: Impaired Pain and Thermal Sensation: Involving the spinothalamic tract over one-half of the body, which may include the face. Anterior cerebral artery, PICA (Option A): Anterior Cerebral Artery: Occlusion affects the medial frontal and parietal lobes, causing contralateral leg weakness and sensory loss, but does not cause the medial medullary syndrome. PICA: Occlusion leads to lateral medullary syndrome (Wallenberg syndrome), not lateral pontine syndrome. Posterior cerebral artery, Basilar artery (Option B): Posterior Cerebral Artery: Occlusion affects the occipital lobe, causing visual field deficits and sensory disturbances, but not medial medullary syndrome. Basilar Artery: Occlusion leads to various brainstem syndromes, but is not specifically linked to lateral pontine syndrome. Vertebral artery, Superior cerebellar artery (Option D): Vertebral Artery: Occlusion affects posterior circulation, causing various syndromes,

but not medial medullary syndrome. Superior Cerebellar Artery: Occlusion primarily impacts the cerebellum and brainstem, but does not cause lateral pontine syndrome. {{caption_text}}

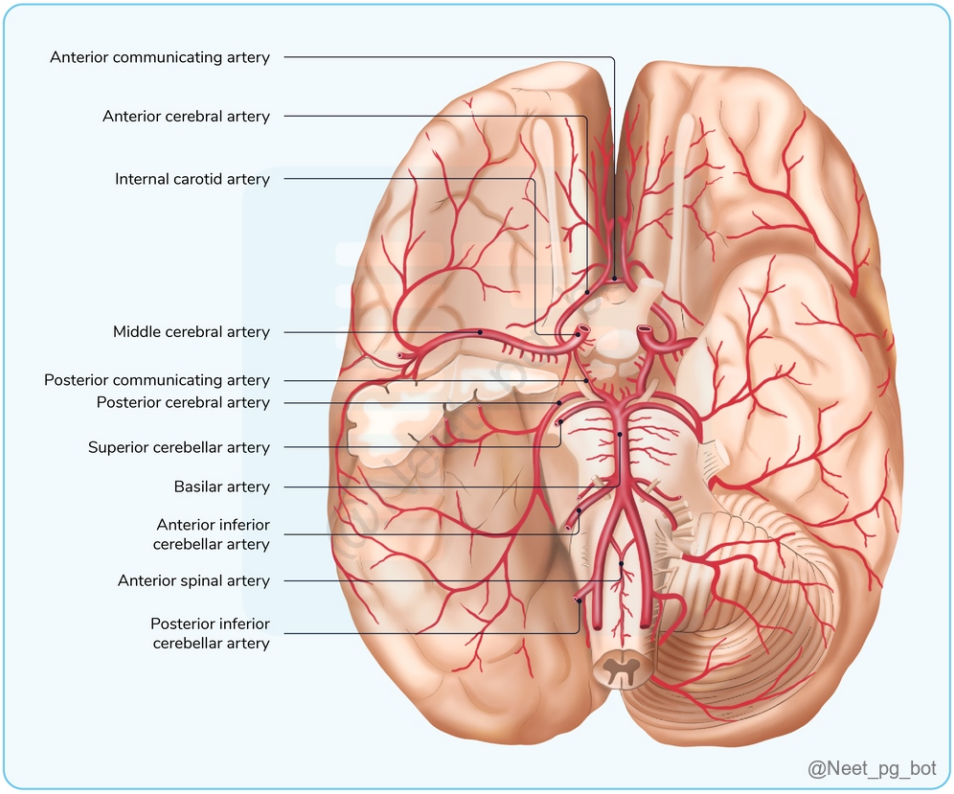

References:

BD Chaurasia Neuroanatomy, Volume 4, 8th Edition, Page 106

Harrisons Internal Medicine, 21st Edition, Page 3330

↑ *Back to this question in Part A*

@Neet_pg_bot

Q19: Which arteries supply the posterior region of the superior medulla and pons respectively? (Q848512)

A. Posterior Inferior Cerebellar Artery and Anterior Inferior Cerebellar Artery

B. Basilar Artery and Vertebral Artery

C. Anterior Spinal Artery and Posterior Spinal Artery

D. Superior Cerebellar Artery and Anterior Inferior Cerebellar Artery

Correct Answer: A. Posterior Inferior Cerebellar Artery and Anterior Inferior Cerebellar Artery

■ *Listen (English)*

■ *Listen (Hindi)*

Explanation: Blood supply of Medulla Oblongata: Caudally Anterior-Medial Supply: Anterior Spinal Artery (Option C ruled out) Posterior-Lateral Supply: Posterior Spinal Artery Superiorly Lateral Supply: Vertebral Artery (Option B ruled out) Anterior Supply: Basilar Artery branches Posterior Supply: Posterior Inferior Cerebellar Artery (PICA) Blood supply of Pons: Main Supply: Pontine branches of the Basilar Artery Posterior-Lateral Supply: Branches of the Superior Cerebellar Artery (Option D ruled out) and the Anterior Inferior Cerebellar Artery (AICA)

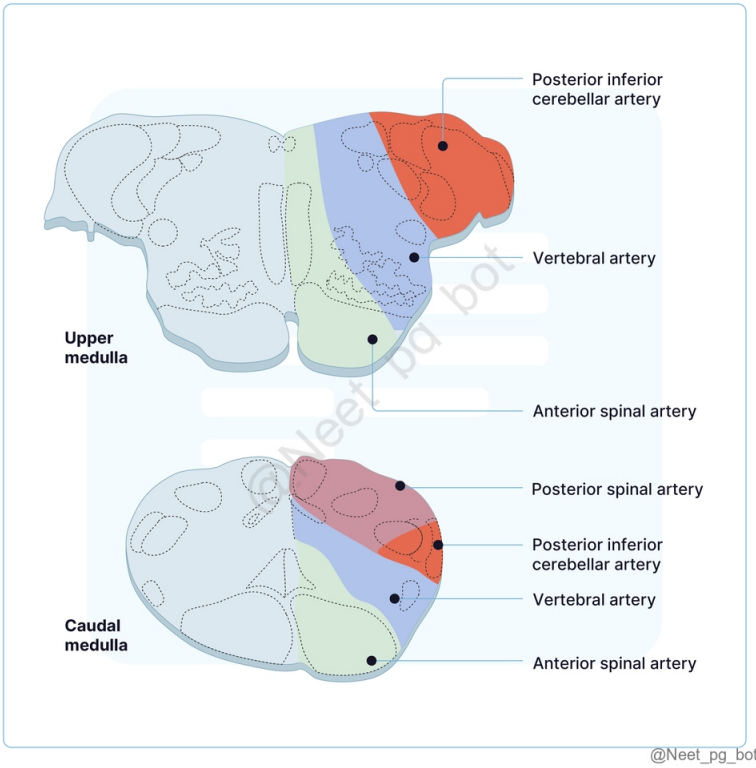

@Neet_pg_bot

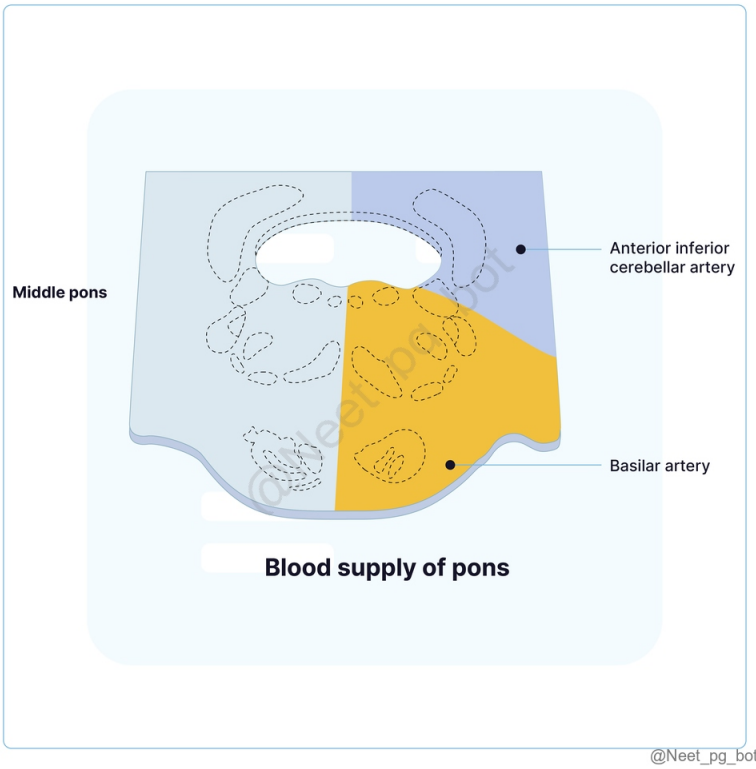

References:

www.ncbi.nlm.nih.gov/books/NBK544297/

↑ *Back to this question in Part A*

@Neet_pg_bot

Q20: Which artery supplies the posterior region of the midbrain? (Q848511)

A. Basilar Artery

B. Posterior Choroidal Arteries

C. Posterior Cerebral Artery

D. Superior Cerebellar Artery

Correct Answer: D. Superior Cerebellar Artery

■ *Listen (English)*

■ *Listen (Hindi)*

Explanation: Superior Cerebellar Artery provides significant blood supply to the posterior region of the midbrain Midbrain Blood Supply: Anterior-Medial Supply: branches of the Basilar artery (Option A ruled out) Anterior-Lateral Supply: branches of the Posterior Choroidal arteries and Quadrigeminal artery from the Posterior Cerebral Artery (Option B & C ruled out) Posterior Supply: Quadrigeminal Artery and Superior Cerebellar Artery



References:

www.ncbi.nlm.nih.gov/books/NBK544297/

teachmeanatomy.info/neuroanatomy/brainstem/midbrain/

↑ *Back to this question in Part A*

@Neet_pg_bot

Q21: The baroreceptor reflex that helps regulate blood pressure involves general visceral afferent (GVA) fibres from which of the following receptors and pathways? (Q848508)

A. Carotid body via the glossopharyngeal nerve

B. Aortic bodies via the vagus nerve

C. Carotid sinus via the vagus nerve

D. Pulmonary arteries via the glossopharyngeal nerve

Correct Answer: B. Aortic bodies via the vagus nerve

- *Listen (English)*
- *Listen (Hindi)*

Explanation: The aortic bodies detect changes in blood pressure and relay sensory input through GVA fibres of the vagus nerve, contributing to the baroreceptor reflex. Baroreceptor Reflex: Baroreceptors in the aortic arch and carotid sinus monitor blood pressure changes. GVA fibres from the aortic arch transmit signals via the vagus nerve (X), and from the carotid sinus via the glossopharyngeal nerve (IX). The brainstem's nucleus tractus solitarius (NTS) receives signals from GVA fibres. GVE fibres originating from the vagus nerve (X) from the dorsal motor nucleus mediate parasympathetic responses. They adjust heart rate by influencing the sinoatrial (SA) node, AV node, myocardium and other cardiac structures, helping to lower blood pressure when necessary. Carotid body via the glossopharyngeal nerve (Option A): Carotid body detects gases, not pressure; the glossopharyngeal nerve (CN IX) relates to baroreceptors in the carotid sinus. Carotid sinus via the vagus nerve (Option C): While the carotid sinus does detect blood pressure changes, it transmits signals via the glossopharyngeal nerve (IX), not the vagus nerve. Pulmonary arteries via the glossopharyngeal nerve (Option D): Pulmonary arteries have baroreceptors, but they are transmitted via the vagus nerve (CN X), not the glossopharyngeal nerve (CN IX), which mainly serves the carotid body and sinus.

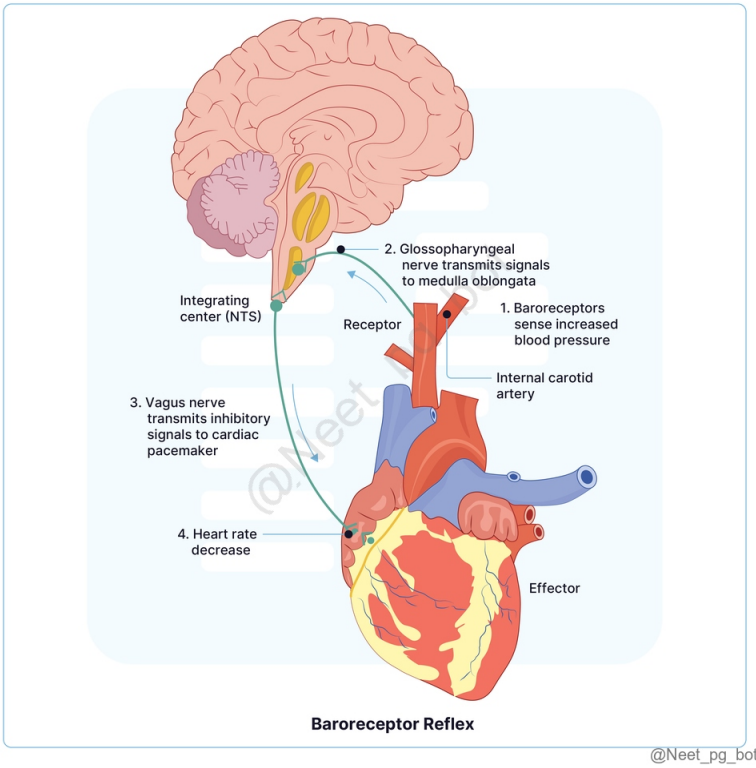

References:

Gray’s Anatomy, 42nd Edition, Page 52,394,1464

Vishram Singh Anatomy of head, neck and brain, Volume 3, 2nd Edition, Page 346

↑ *Back to this question in Part A*

@Neet_pg_bot

Q22: The nucleus of the solitary tract receives _____ sensations from the carotid body and carotid sinus primarily through _____ nerve. (Q848507)

A. General Somatic Efferent; Vagus nerve

B. Special Visceral Afferent; Facial nerve

C. General Visceral Afferent; Glossopharyngeal nerve

D. Special Somatic Efferent; Trigeminal nerve

Correct Answer: C. General Visceral Afferent; Glossopharyngeal nerve

■ *Listen (English)*

■ *Listen (Hindi)*

Explanation: The nucleus of the solitary tract receives general visceral afferent sensations from the carotid body and carotid sinus primarily through the glossopharyngeal nerve (IX). The glossopharyngeal nerve (cranial nerve IX) carries sensory information from the carotid body (chemoreceptor) and carotid sinus (baroreceptor) to the nucleus of the solitary tract, which is involved in regulating blood pressure and respiratory responses. Nucleus of Tractus Solitarius It is a composite nucleus located in the medulla. Its functions are: General Visceral Afferent (Lower Part): Receives visceral sensations. Glossopharyngeal nerve (IX): From tonsil, pharynx, posterior tongue, carotid body, and carotid sinus. Vagus nerve (X): From the pharynx, larynx, trachea, oesophagus, and thoracic/abdominal viscera. (Option A ruled out) Special Visceral Afferent (Upper Part): Receives taste sensations. Facial nerve (VII): Anterior two-thirds of tongue and palate (except circumvallate papillae). (Option B ruled out) The glossopharyngeal nerve (IX): Posterior one-third of the tongue, including circumvallate papillae. Vagus nerve (X): Posterior tongue and epiglottis. Special somatic efferent; Trigeminal nerve (Option D): Special somatic efferent fibers are related to the motor innervation of certain muscles, while the trigeminal nerve (CN V) primarily carries sensory information (touch, pain) from the face and does not innervate the carotid body or sinus.

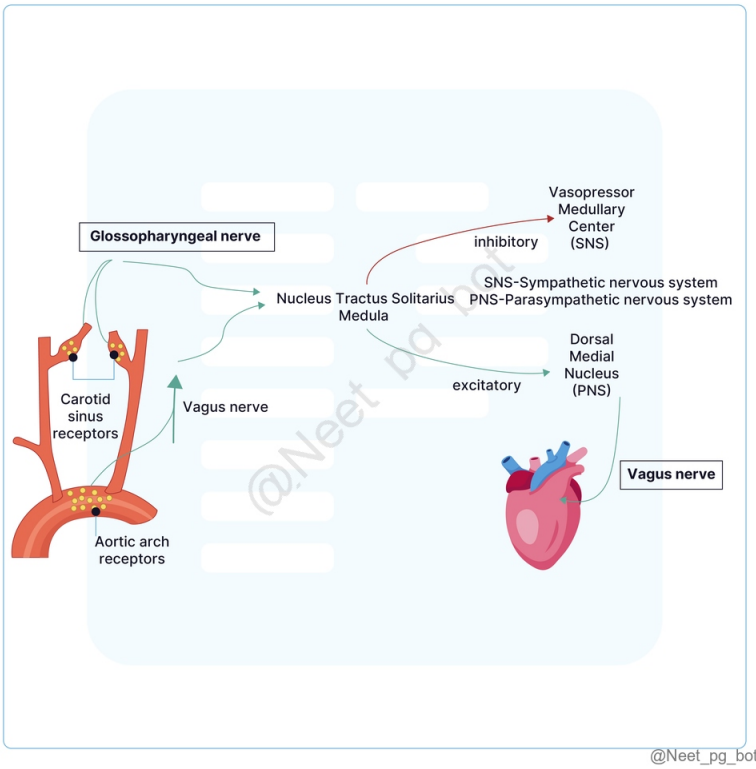

@Neet_pg_bot

References:

BD Chaurasia Neuroanatomy, Volume 4, 8th Edition, Pages 59-61

Gray's Anatomy, 42nd edition, Page 449

↑ *Back to this question in Part A*

@Neet_pg_bot

Q23: Which of the following statements about the jaw jerk reflex is false? (Q848506)

A. It is a spinal reflex initiated by tapping the jaw.

B. It involves the mesencephalic trigeminal nucleus as an integration centre.

C. The efferent pathway includes the mandibular nerve.

D. It is a monosynaptic reflex involving a single synapse.

Correct Answer: A. It is a spinal reflex initiated by tapping the jaw.

■ *Listen (English)*

■ *Listen (Hindi)*

Explanation: The jaw jerk reflex is a deep tendon reflex with supraspinal involvement which is initiated by tapping the jaw. Masseter reflex or Jaw jerk reflex It is a deep tendon reflex. The reflex is initiated by tapping the midline of the mandible, which rapidly stretches the jaw-closing muscles (masseter, temporalis, medial pterygoid). The stretch activates muscle spindle afferents, which are sensory receptors in the muscles. Afferent pathway: Muscle spindle afferents → Mandibular division of the trigeminal nerve. Integration centre (Relay): Mesencephalic trigeminal nucleus. (Option B ruled out) Efferent pathway: Motor nucleus of the trigeminal nerve → Mandibular nerve. (Option C ruled out) This results in the contraction of these jaw-closing muscles and finally closure of the jaw. The jaw jerk reflex is the only significant supraspinal monosynaptic reflex due to its relay in the mesencephalic trigeminal nucleus. (Option D ruled out) The jaw jerk reflex can be tested in neurological examinations to assess the integrity of the trigeminal nerve and the brainstem pathways.

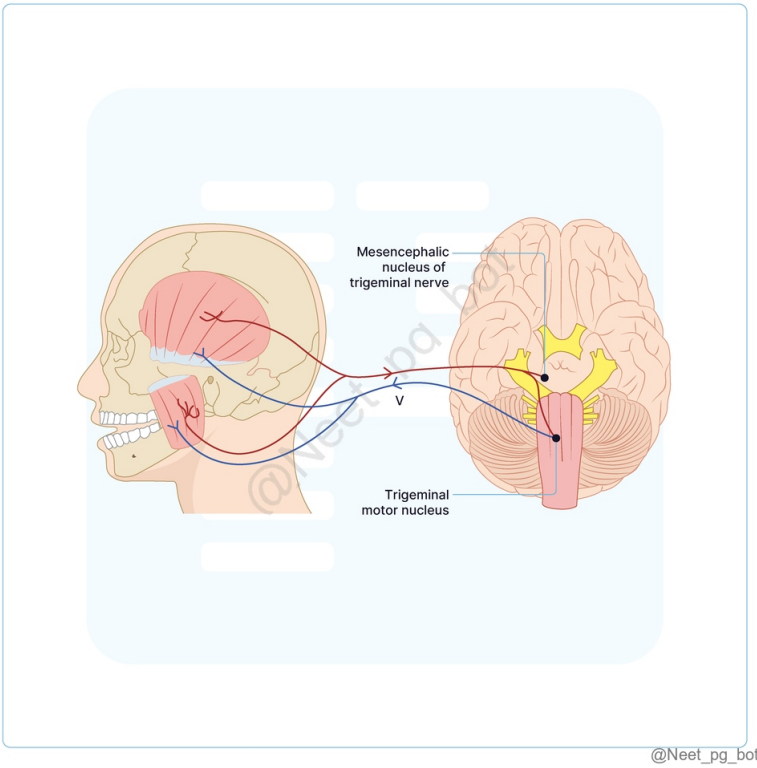

References:

Gray's Anatomy, 42nd Edition, Pages 454, 455, 456, 1464

↑ *Back to this question in Part A*

@Neet_pg_bot

Q24: Which of the following nuclei of the trigeminal nerve is primarily responsible for proprioceptive sensations from the muscles of mastication? (Q848504)

A. Main Sensory Nucleus

B. Spinal Nucleus

C. Mesencephalic Nucleus

D. Motor Nucleus

Correct Answer: C. Mesencephalic Nucleus

- *Listen (English)*
- *Listen (Hindi)*

Explanation: Mesencephalic Nucleus is located around the cerebral aqueduct and carries proprioceptive impulses from the muscles of mastication, facial, and extraocular muscles. The trigeminal nerve has four nuclei as follows: Main Sensory Nucleus Located in the posterior part of the pons, lateral to the motor nucleus. Continuous below with the spinal nucleus. Spinal Nucleus Extends from the pons to the second cervical segment of the spinal cord. Receives sensations of pain and temperature. (Option B ruled out) Mesencephalic Nucleus Located in the lateral part of the grey matter around the cerebral aqueduct. Receives proprioceptive impulses from muscles of mastication, facial, and extraocular muscles. Motor Nucleus Located in the pons, medial to the main sensory nucleus. Controls muscles of mastication, tensor tympani, tensor veli palatini, mylohyoid, and anterior belly of digastric. (Option D ruled out) Sensory component of Trigeminal Nuclei The motor component of Trigeminal Nuclei Carries pain, temperature, touch, pressure, and proprioception from the face. Main sensory nucleus - touch and pressure. (Option A ruled out) Spinal nucleus - pain and temperature. It extends till C2 of the spinal cord. Mesencephalic nucleus - proprioception. The motor nucleus receives inputs from both cerebral hemispheres, the reticular formation, and the red nucleus and forms a reflex arc with the mesencephalic nucleus. Supplies muscles of mastication- Temporalis Masseter Lateral pterygoid Medial pterygoid Other muscles like Tensor tympani Tensor veli palatini Mylohyoid Anterior belly of digastric

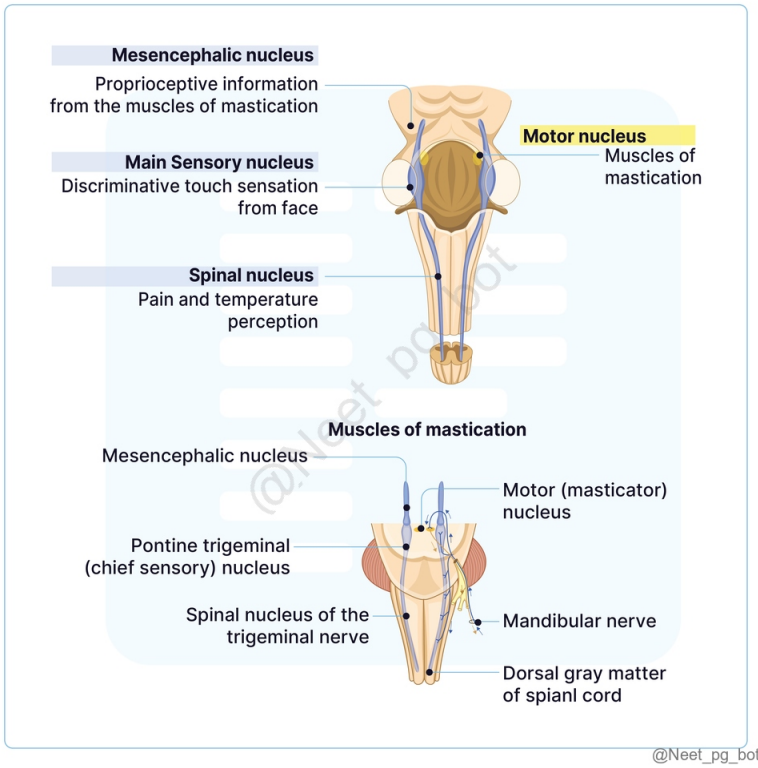

@Neet_pg_bot

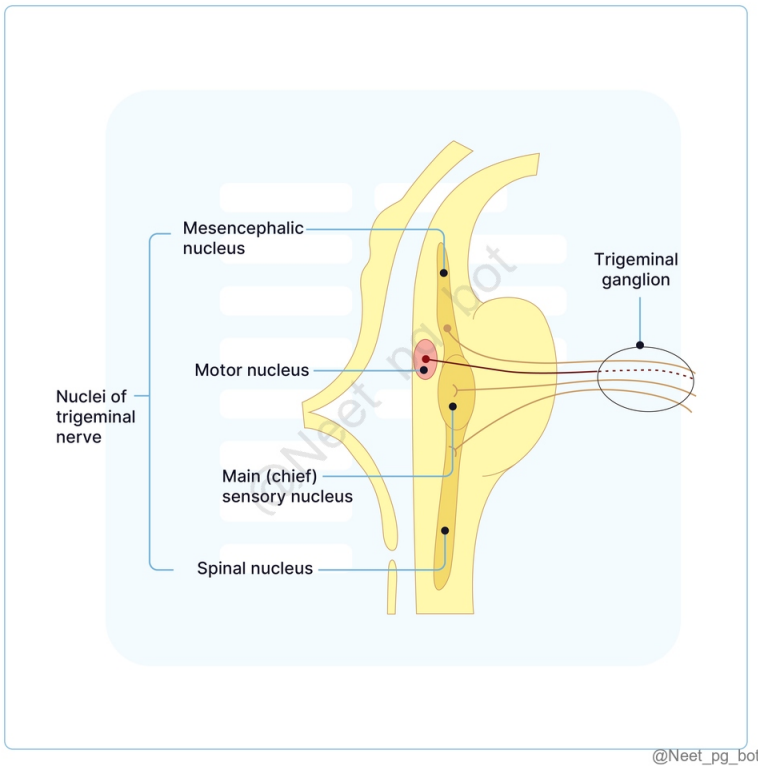

@Neet_pg_bot

References:

Snell’s Clinical Neuroanatomy, 8th Edition, Pages 332- 335

BD Chaurasia Neuroanatomy, Volume 4, 8th Edition, Pages 74, 75

↑ *Back to this question in Part A*

@Neet_pg_bot

Q25: Which of the following statements regarding damage to the midline brainstem nuclei is false? (Q848481)

A. Damage to the oculomotor nucleus can result in the eye looking laterally and ptosis.

B. Injury to the trochlear nucleus leads to difficulty in upward gaze and may cause a compensatory head tilt to the same side.

C. Damage to the abducens nucleus results in medial strabismus, causing the affected eye to turn inward.

D. Lesion of the hypoglossal nucleus leads to weakness and atrophy of the tongue on the affected side.

Correct Answer: B. Injury to the trochlear nucleus leads to difficulty in upward gaze and may cause a compensatory head tilt to the same side.

■ *Listen (English)*

■ *Listen (Hindi)*

Explanation: Damage to the trochlear nucleus causes difficulty in downward and lateral gaze, often resulting in a compensatory head tilt to the opposite side. Lesions to Medial Brainstem Nuclei- Together form the somatic motor column (GSE) Oculomotor Nucleus (CN III) : (Option A ruled out) The eye cannot move upward, downward, or inward. At rest, the eye is in a down-and-out position. The patient experiences double vision (diplopia). The upper eyelid droops (ptosis) from paralysis of the levator palpebrae superioris. The pupil is widely dilated and nonreactive to light due to paralysis of the sphincter pupillae and unopposed sympathetic dilator activity. Accommodation is impaired. Trochlear Nucleus (CN IV) : Difficulty in downward and lateral gaze. Patients may exhibit a compensatory head tilt to the opposite side to manage diplopia (double vision). Abducens Nucleus (CN VI) : Medial strabismus (the affected eye cannot abduct), leading to horizontal diplopia. The affected eye is often turned inward. Diplopia is also seen. (Option C ruled out) Hypoglossal Nucleus (CN XII) : Weakness of the tongue on the side of the lesion, causing atrophy and fasciculations. On protrusion, the tongue may deviate toward the affected side. (Option D ruled out)

References:

Snell’s Clinical Neuroanatomy, 8th Edition, Pages 350, 351, 353

Gray’s Anatomy, 42nd Edition, Page 453

↑ *Back to this question in Part A*

@Neet_pg_bot

Q26: A 65 y/o patient presents with sudden dizziness, difficulty swallowing, ipsilateral loss of temperature sensation on the face, contralateral loss of pain and temperature sensation in the trunk, ipsilateral ataxia, and giddiness. Which anatomical structure is responsible for the ipsilateral loss of temperature sensation on the face of this patient? (Q848478)

A. Spinothalamic tract

B. Spinal nucleus and tract of the trigeminal nerve

C. Inferior cerebellar peduncle

D. Vestibular nuclei

Correct Answer: B. Spinal nucleus and tract of the trigeminal nerve

■ *Listen (English)*

■ *Listen (Hindi)*

Explanation: The patient is diagnosed with Wallenberg Syndrome due to the presence of ipsilateral loss of temperature sensation on the face, contralateral loss of pain and temperature sensation in the trunk, difficulty swallowing, ipsilateral ataxia, and giddiness. The spinal nucleus and tract of the trigeminal nerve are responsible for the ipsilateral loss of pain and temperature sensation over the face, which is a hallmark feature of Wallenberg Syndrome. Wallenberg Syndrome (Lateral Medullary Syndrome) Due to stroke or infarction in the lateral part of the medulla oblongata. Mainly due to occlusion of the posterior inferior cerebellar artery (PICA), a branch of the vertebral artery. Sometimes the vertebral artery directly supplies the lateral brainstem. Affects the dorsolateral aspect of the medulla and the inferior surface of the cerebellum. Anatomical structure affected and features: Spinothalamic tract: Contralateral loss of pain and temperature sensation of the trunk. (Option A ruled out) Spinal nucleus and tract of the trigeminal nerve: Ipsilateral loss of pain and temperature sensation of the face. Nucleus ambiguus: Ipsilateral paralysis of muscles of the palate, pharynx, and larynx. Inferior cerebellar peduncle and cerebellum: Ipsilateral ataxia. (Option C ruled out) Vestibular nuclei: Giddiness. (Option D ruled out)

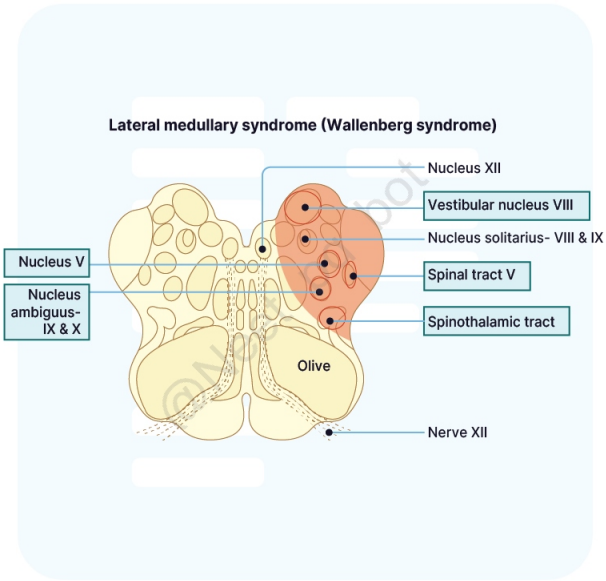

@Neet_pg_bot

References:

Vishram Singh Anatomy of head, neck and brain, Volume 3, 2nd Edition, Page 366

↑ *Back to this question in Part A*

@Neet_pg_bot

• [03_Neuro Anatomy] 012 Applied Neuroanatomy Tracts Brainstem Autonomic System

« Back to Folder Directory

[03_Neuro Anatomy] 012 Applied Neuroanatomy Tracts Brainstem Autonomic System — Quick Jump

Q1 (p. 960)	*Q2 (p. 961)*	*Q3 (p. 962)*	*Q4 (p. 963)*	*Q5 (p. 964)*	*Q6 (p. 966)*
Q7 (p. 966)	*Q8 (p. 967)*	*Q9 (p. 969)*	*Q10 (p. 970)*	*Q11 (p. 973)*	*Q12 (p. 975)*
Q13 (p. 975)	*Q14 (p. 976)*	*Q15 (p. 977)*	*Q16 (p. 979)*	*Q17 (p. 980)*	*Q18 (p. 982)*
Q19 (p. 983)	*Q20 (p. 984)*	*Q21 (p. 986)*	*Q22 (p. 988)*	*Q23 (p. 989)*	*Q24 (p. 990)*
Q25 (p. 991)					

Q1: Which of the following statements is incorrect regarding Weber syndrome? (Q848613)

A. Lesion is in the oculomotor nerve fascicles and corticospinal fibers

B. Hemiplegia is present on the opposite side of the lesion

C. There is a lateral squint on the same side of the lesion

D. None of the above

Correct Answer: D. None of the above

■ *Listen (English)*

■ *Listen (Hindi)*

Explanation: Lesion is in the oculomotor nerve fascicles and corticospinal fiber s (Option A) : Weber syndrome involves a midbrain lesion affecting the corticospinal tract and the oculomotor nerve fascicles. Hemiplegia is present on the opposite side of the lesion (Option B) : Corticospinal fibers before decussation are damaged, causing contralateral hemiplegia. There is a lateral squint on the same side of the lesion (Option C) : Oculomotor nerve palsy causes the eye to deviate laterally on the ipsilateral side. Weber Syndrome:

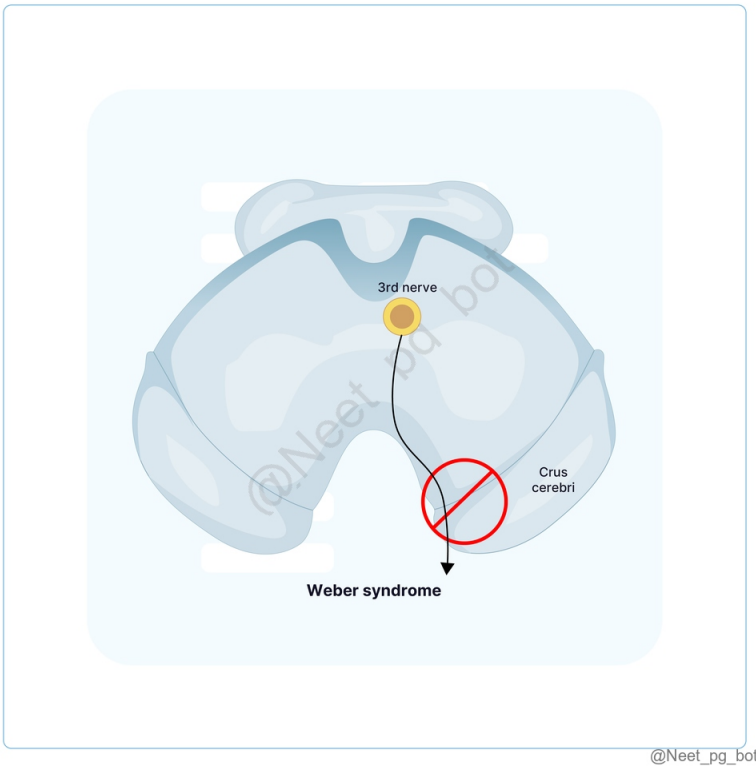

References:

BD Chaurasia Neuroanatomy, Volume 4, 8th Edition, Page 113, 114.

↑ *Back to this question in Part A*

@Neet_pg_bot

Q2: Which of the following statements is incorrect? (Q848573)

A. The PNS relays impulses in neurons away from the viscera.

B. The sympathetic nervous system has thoracolumbar outflow.

C. Erection is controlled by the parasympathetic nervous system.

D. Tearing is regulated by the parasympathetic nervous system.

Correct Answer: A. The PNS relays impulses in neurons away from the viscera.

■ *Listen (English)*

■ *Listen (Hindi)*

Explanation: The statement is incorrect because in the parasympathetic nervous system (PNS), the ganglia (relay stations) are located near or within the wall of the target viscera, not away from them. The parasympathetic system is characterized by: Long preganglionic fibres Short postganglionic fibres Ganglia situated in or near the effector organ Thus, impulses are relayed close to the viscera, not away from them. Feature Parasympathetic Nervous System Sympathetic Nervous System Outflow Craniosacral outflow Sympathetic fibres arise from T1–L2 spinal segments , hence termed thoracolumbar outflow (Option B ruled out) Sexual functions Erection is mediated by parasympathetic fibres from S2–S4 (pelvic splanchnic nerves) Point (Erection) → Parasympathetic Shoot (Ejaculation) → Sympathetic (Option C ruled out) Ejaculation, orgasm Lacrimal glands Lacrimation is mediated via parasympathetic fibres from: Facial nerve Greater petrosal nerve Pterygopalatine ganglion (Option D ruled out) -

References:

BD Chaurasia Neuroanatomy, Volume 4, 8th Edition, Page 212

↑ *Back to this question in Part A*

@Neet_pg_bot

Q3: Where does the hypothalamospinal tract terminate before synapsing with the second-order neurons? (Q848576)

A. Superior cervical ganglion

B. Inferior cervical ganglion

C. Intermediolateral cell column of the spinal cord

D. Posterior horn of the spinal cord

Correct Answer: C. Intermediolateral cell column of the spinal cord

■ *Listen (English)*

■ *Listen (Hindi)*

Explanation: The hypothalamospinal tract terminates in the intermediolateral cell column (IML) of the spinal cord, where it synapses with the second-order sympathetic neurons.

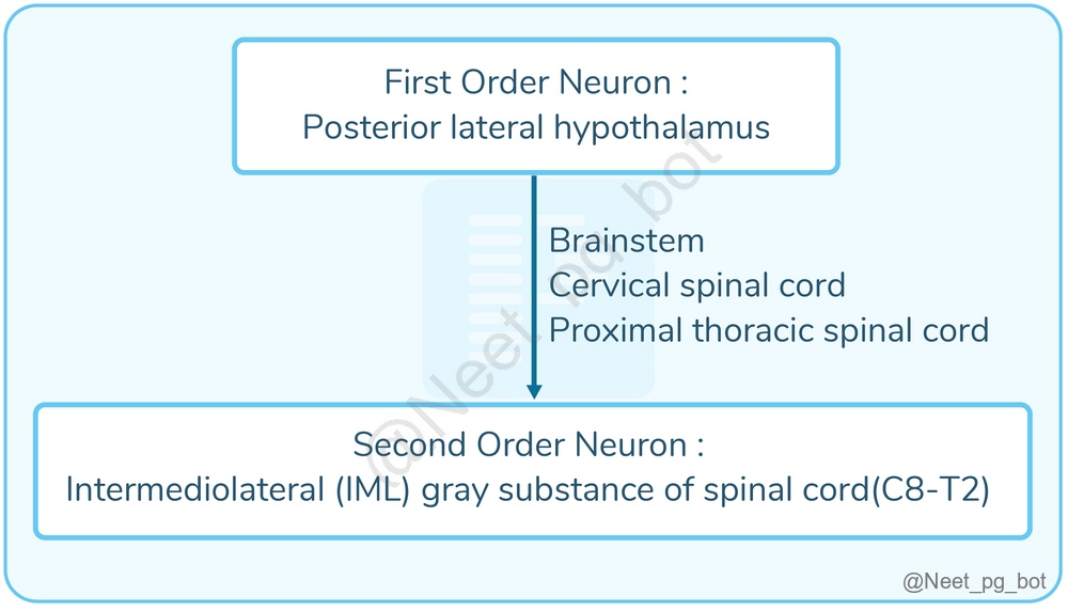

References:

Gray's Anatomy, The Anatomical Basis of Clinical Practice, 41st Edition, Page 304.

↑ *Back to this question in Part A*

@Neet_pg_bot

Q4: All of the following are branches of the internal carotid artery except? (Q848580)

A. Ophthalmic artery

B. Anterior choroidal artery

C. Posterior communicating artery

D. Anterior inferior cerebellar artery

Correct Answer: D. Anterior inferior cerebellar artery

■ *Listen (English)*

■ *Listen (Hindi)*

Explanation: Anterior inferior cerebellar artery is a branch of the basilar artery. The internal carotid artery is divided into three parts based on its course. Petrous part Branches are caroticotympanic artery and pterygoid artery Cavernous part Branches are meningohypophyseal trunk and the inferolateral trunk Intracranial part Branches of the intracranial part of internal carotid artery: Branches Areas supplied Ophthalmic artery (Option A ruled out) Contents of orbit Posterior communicating artery (Option C ruled out) Crus cerebri, optic tract, hypophysis and hypothalamus Anterior choroidal artery (Option B ruled out) Crus cerebri and choroid plexus of inferior horn of

lateral ventricle Anterior cerebral artery Deep branches supply part of the internal capsule and the basal nuclei. Cortical branches supply the medial surface of the hemisphere. Middle cerebral artery Deep or perforating branches supply the anterior limb of the internal capsule and part of the basal nuclei. Cortical branches supply temporal, frontal and parietal lobe.

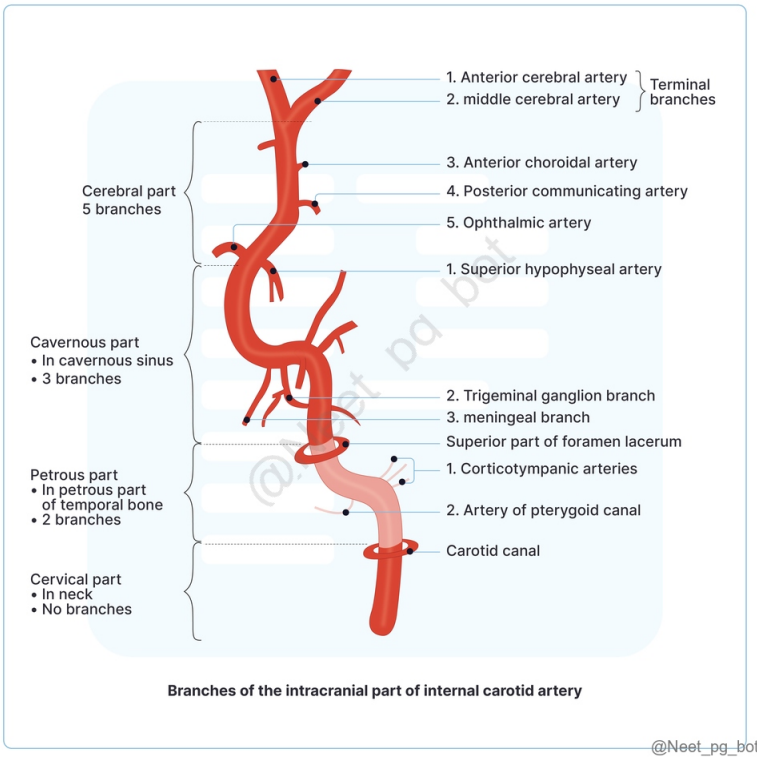

References:

Gray's Anatomy The Anatomical Basis of Clinical Practice, 42nd Edition, Pages 415-418

BD Chaurasia Neuroanatomy, Volume 4, 8th Edition, Pages 189, 190.

↑ *Back to this question in Part A*

@Neet_pg_bot

Q5: A transverse section of the medulla oblongata at the level of the motor (pyramidal) decussation reveals modifications to the typical spinal cord structure. Which of the following changes is observed at this level? (Q848596)

A. Formation of the medial lemniscus from second-order axons

B. Crossing of corticospinal fibres from the anterior funiculi

C. Presence of the vestibular nuclei near the fourth ventricle

D. Appearance of the inferior olivary complex lateral to the pyramid

Correct Answer: B. Crossing of corticospinal fibres from the anterior funiculi

■ *Listen (English)*

■ *Listen (Hindi)*

Explanation: At the level of the motor (pyramidal) decussation in the medulla, the corticospinal fibres cross from the anterior funiculi to the contralateral side , forming the lateral corticospinal tract —a defining feature of this level. The pyramids appear smaller due to this crossing. Internal Organization of the Medulla Oblongata Level Key Features Motor Decussation Level Corticospinal fibers crossing, ventral grey column divides, nucleus gracilis, spinocerebellar tracts. Sensory Decussation Level Nuclei gracilis and cuneatus, internal arcuate fibers forming the medial lemniscus, inferior olivary complex, spinocerebellar tracts, trigeminal nerve tracts. Caudal End of Fourth Ventricle Increased grey matter, cranial nerve nuclei (IX, X, XI, VIII), olivary complex, restiform body carrying afferent fibers. Formation of medial lemniscus (Option A): Occurs higher up at the sensory decussation where internal arcuate fibres cross. Vestibular nuclei near the 4th ventricle (Option C): Seen at the open medulla level, not at motor decussation. Inferior olivary complex (Option D): Appears lateral to the pyramid at a higher medullary level (sensory decussation level).

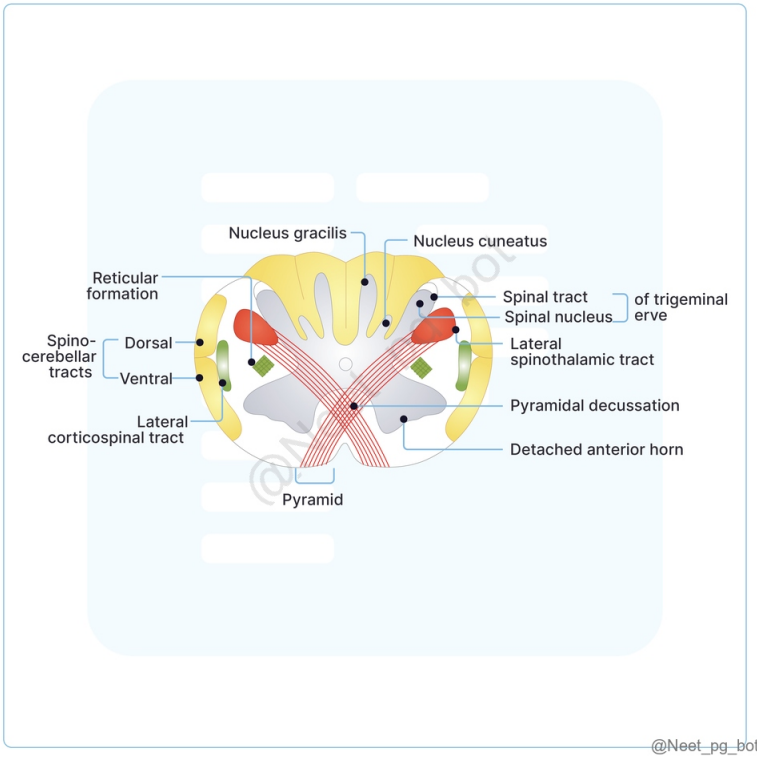

References:

Gray’s Anatomy The Anatomical Basis of Clinical Practice, 42nd Edition, Pages 443 - 444

↑ *Back to this question in Part A*

@Neet_pg_bot

Q6: Which of the following is the correct match of brainstem components with the respective cranial nerve nuclei that originate from them? Column A Column B a. Midbrain 1. Trigeminal nerve b. Pons 2. Oculomotor nerve c. Medulla oblongata 3. Glossopharyngeal nerve d. Pontomedullary junction 4. Facial nerve (Q848592)

A. a-2, b-1, c-3, d-4

B. a-1, b-2, c-4, d-3

C. a-3, b-4, c-1, d-2

D. a-4, b-3, c-2, d-1

Correct Answer: A. a-2, b-1, c-3, d-4

■ *Listen (English)*

■ *Listen (Hindi)*

Explanation: Components of brainstem Cranial nerves nuclei Midbrain Oculomotor (III) and trochlear (IV) Pons Trigeminal (V) Medulla oblongata Glossopharyngeal (IX), vagus (X), cranial accessory (XIcr) and hypoglossal (XII) Pontomedullary junction Abducens (VI), facial (VII) and vestibulocochlear (VIII)

References:

Gray’s Anatomy, The Anatomical Basis of Clinical Practice, 42nd Edition, Page 442

↑ *Back to this question in Part A*

@Neet_pg_bot

Q7: Which of the following findings is not a clinical manifestation of Wallenberg syndrome? (Q848614)

A. Contralateral ataxia

B. Horner's syndrome

C. Ipsilateral facial pain and temperature loss

D. Contralateral body pain and temperature loss

Correct Answer: A. Contralateral ataxia

■ *Listen (English)*

■ *Listen (Hindi)*

Explanation: Ipsilateral ataxia is seen in Wallenburg sybdrome due to damage to inferior cerebellar peduncle, spino cerebellar tracts, and part of cerebellum. Clinical manifestation of Wallenburg syndrome: Anatomical location Presenting clinical feature Nucleus ambiguous gives fibers to IX, X, and XI cranial nerves Ipsilateral paralysis of muscles of the soft palate, pharynx, and larynx Spinal nucleus and spinal tract of the trigeminal nerve Ipsilateral facial pain and temperature loss (Option C ruled out) Lateral spinothalamic tract Contralateral body pain and temperature loss (Option D ruled out) Vestibular nuclei Vertigo Inferior cerebellar peduncle, spino cerebellar tracts, and part of cerebellum Ipsilateral ataxia (Option A) Sympathetic fibres descend from the hypothalamus to cells in the lateral horn of spinal cord Horner's syndrome (Option B ruled out) , comprising ptosis, enophthalmos, miosis, and anhydrosis

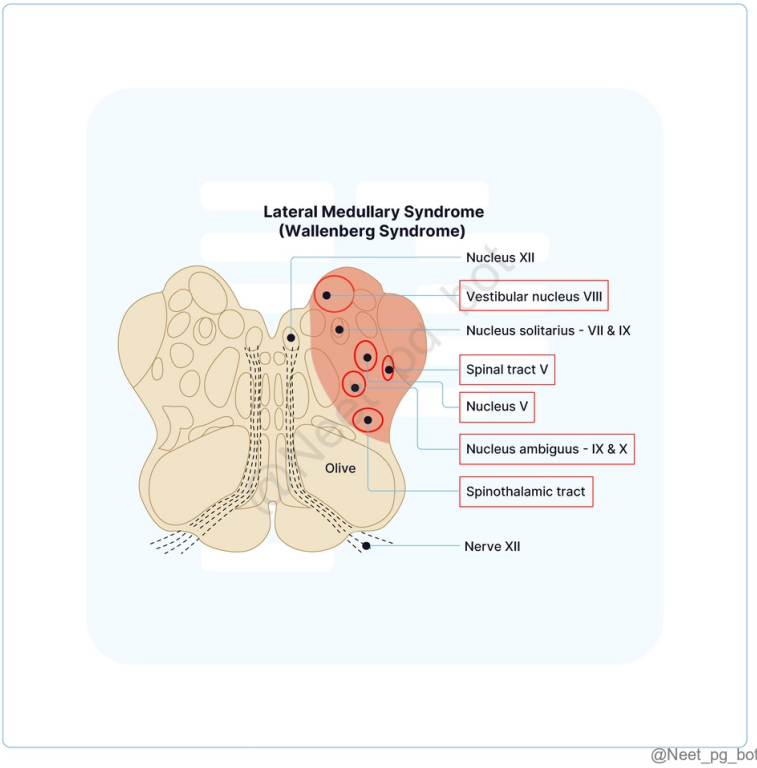

References:

BD Chaurasia Neuroanatomy, Volume 4, 8th Edition, Pages 106, 107

↑ *Back to this question in Part A*

@Neet_pg_bot

Q8: Which of the following nerve palsy would suggest a lesion affecting the structures within the interpeduncular fossa? (Q848612)

A. Glossopharyngeal nerve

B. Vagus nerve

C. Oculomotor nerve

D. Hypoglossal nerve

Correct Answer: C. Oculomotor nerve

■ *Listen (English)*

■ *Listen (Hindi)*

Explanation: A lesion affecting the interpeduncular fossa could damage the oculomotor nerve (CN III), which emerges from this region, leading to diplopia and ptosis. Contents Interpeduncular fossa: Oculomotor nerve (Option C) Circle of Willis Bifurcation of the basilar artery Peduncular segments of the posterior cerebral artery (PCA) and superior cerebellar artery, (SCA) Medial and lateral posterior choroidal arteries Basal vein of Rosenthal Glossopharyngeal nerve (Option A): and vagus nerve (Option B): The rootlets of the cranial nerves IX (Glossopharyngeal) and X (vagus) emerge through the posterolateral fissure, behind the olive. Hypoglossal nerve (Option D): The rootlets of the hypoglossal nerve emerge from the anterolateral sulcus between the pyramid and the olive.

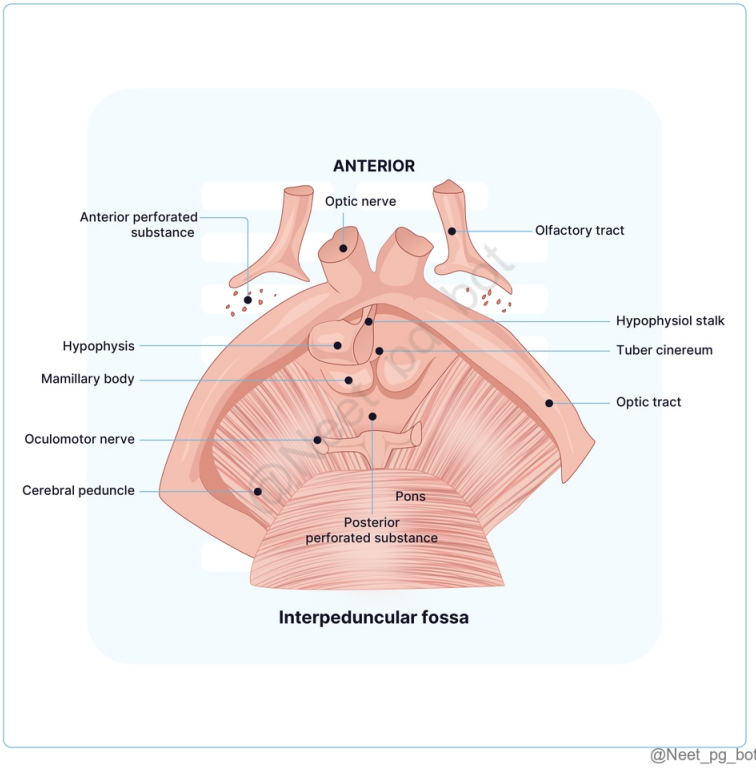

@Neet_pg_bot

References:

Gray’s Anatomy The Anatomical Basis of Clinical Practice, 42nd Edition, Pages 456

BD Chaurasia Neuroanatomy, Volume 4, 8th Edition, Pages 187, 190, 100

Interpeduncular Fossa - an overview | ScienceDirect Topics

↑ *Back to this question in Part A*

@Neet_pg_bot

Q9: Which among the following options is correctly matched for the alphabet labeled in the below image? (Q848611)

A. A- Pyramid

B. B- Trochlear nerve

C. C- Basilar sulcus

D. D- Olive

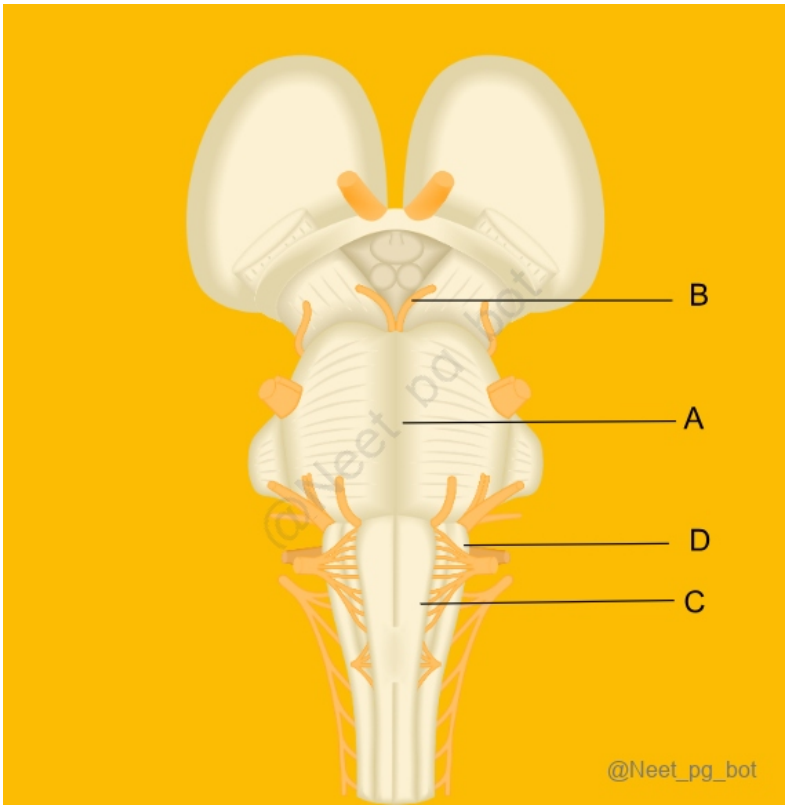

Correct Answer: D. D- Olive

■ *Listen (English)*

■ *Listen (Hindi)*

Explanation: Image in the question represents the ventral surface of the brainstem. Alphabet D labelled in the image is olive, a pair of prominent oval structures on either side of the medullary pyramids in the medulla. Ventral surface (Frontal view) of the brainstem: Alphabet C is Pyramid Alphabet A is the basilar sulcus of pons Alphabet B is occulomotor nerve

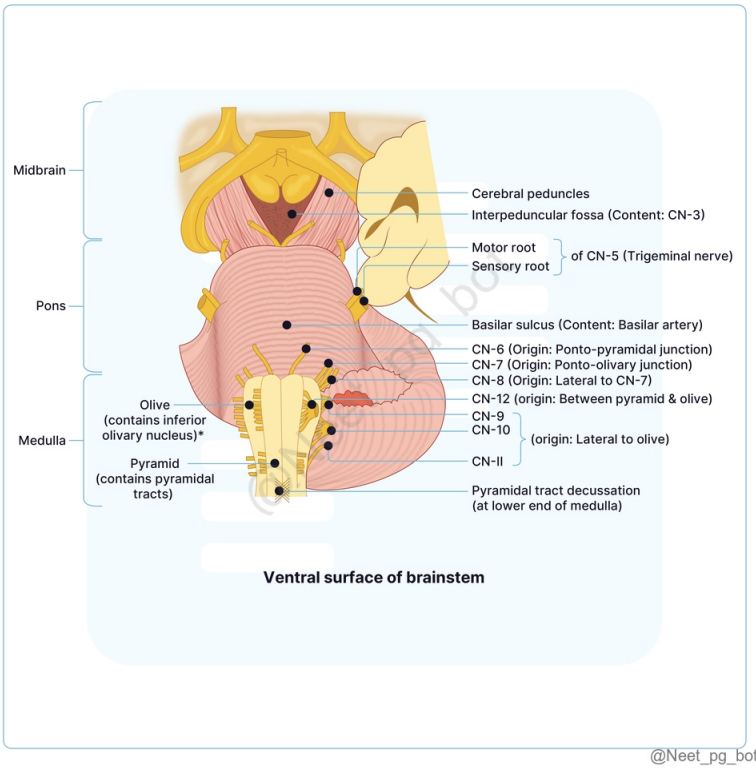

References:

BD Chaurasia Neuroanatomy, Volume 4, 8th Edition, Pages 100, 101, 102, 107, 111

↑ *Back to this question in Part A*

@Neet_pg_bot

Q10: A 45-year-old patient presents with a severe infection of the face. Which of the following venous structures could allow the infection to spread to the cavernous sinus? (Q848600)

A. Superior petrosal sinus

B. Inferior ophthalmic vein

C. Inferior petrosal sinus

D. Basilar plexus of veins

Correct Answer: B. Inferior ophthalmic vein

Listen to Audio 1

Explanation: The inferior ophthalmic vein connects the facial veins to the cavernous sinus, making it a route for the spread of infections from the face. Cavernous sinus: It is two large venous spaces situated in the middle cranial fossa, on either side of the body of the sphenoid bone. Important structures related to Cavernous Sinus: Tributaries or Incoming Channels From the orbit: Superior ophthalmic vein Inferior ophthalmic vein- connects facial vein to cavernous sinus (Option B) Central vein of the retina- drains either into the superior ophthalmic vein or directly into the cavernous sinus. From the brain: Superficial middle cerebral vein Inferior cerebral veins from the temporal lobe From the meninges Sphenoparietal sinus Frontal trunk of the middle meningeal- drains into the pterygoid plexus or the sphenoparietal or cavernous sinus Draining Channels or Communications Into the transverse sinus through the superior petrosal sinus. (Option A ruled out) Into the internal jugular vein through the inferior petrosal sinus. (Option C ruled out) Into the pterygoid plexus of veins through the emissary veins. Into the facial vein through the superior ophthalmic vein. The right and left cavernous sinuses communicate with each other through the anterior and posterior intercavernous sinuses and the basilar plexus of veins. (Option D ruled out) Note: All these communications are valveless, and blood flows in both directions.

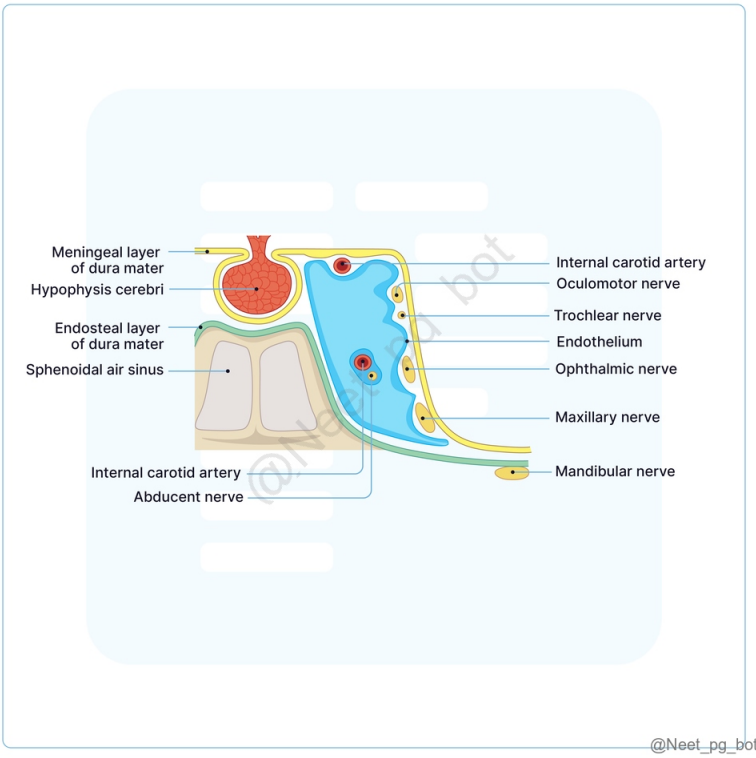

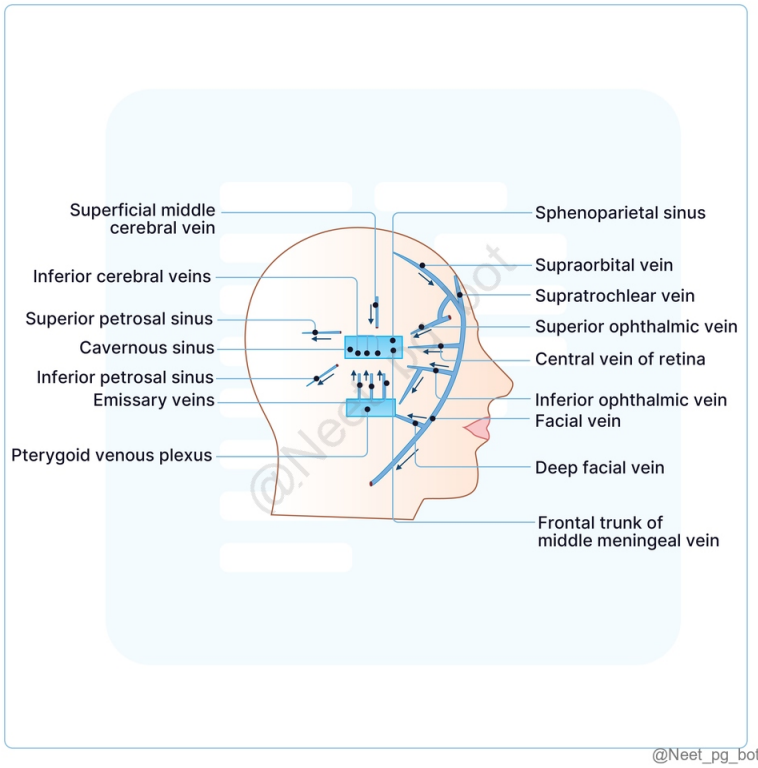

@Neet_pg_bot

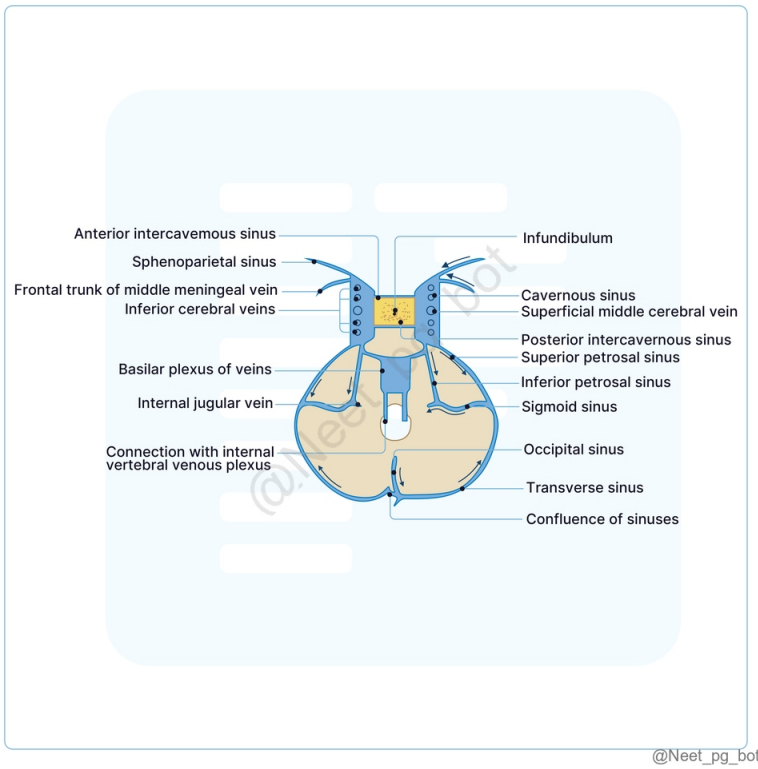

@Neet_pg_bot

References:

Gray’s Anatomy The Anatomical Basis of Clinical Practice, 42nd Edition, Page 1464.e101

BD Chaurasia Neuroanatomy, Volume 4, 8th Edition, Pages 76, 216-18

↑ *Back to this question in Part A*

@Neet_pg_bot

Q11: A 45-year-old patient presents with symptoms of headache and visual disturbances. Imaging studies reveal a large clot in the superior sagittal sinus. Which of the following statements about the superior sagittal sinus is correct? (Q848599)

A. It drains directly into the internal jugular vein.

B. It runs along the midline, attached to the falx cerebri, and drains into the confluence of sinuses.

C. It is located in the falx cerebelli and connects with the occipital sinus.

D. It receives blood from the diploic veins within the cranial bones.

Correct Answer: B. It runs along the midline, attached to the falx cerebri, and drains into the confluence of sinuses.

■ *Listen (English)*

■ *Listen (Hindi)*

Explanation: The superior sagittal sinus runs along the midline, is attached to the falx cerebri, and typically drains into the confluence of sinuses. {{caption_text}} Sinus Location Drainage Superior sagittal sinus (Option B) Along midline, attached to falx cerebri (Option C ruled out) Confluence of sinuses, usually right side (Option A ruled out) Tributaries: Cerebral veins: Drain brain parenchyma. Diploic veins: Within cranial bones. (Option D ruled out - The superior sagittal sinus does not receive blood from diploic veins; these veins are tributaries to other sinuses.) Meningeal veins: Drain dura mater. Emissary veins: Connect intracranial and extracranial veins.

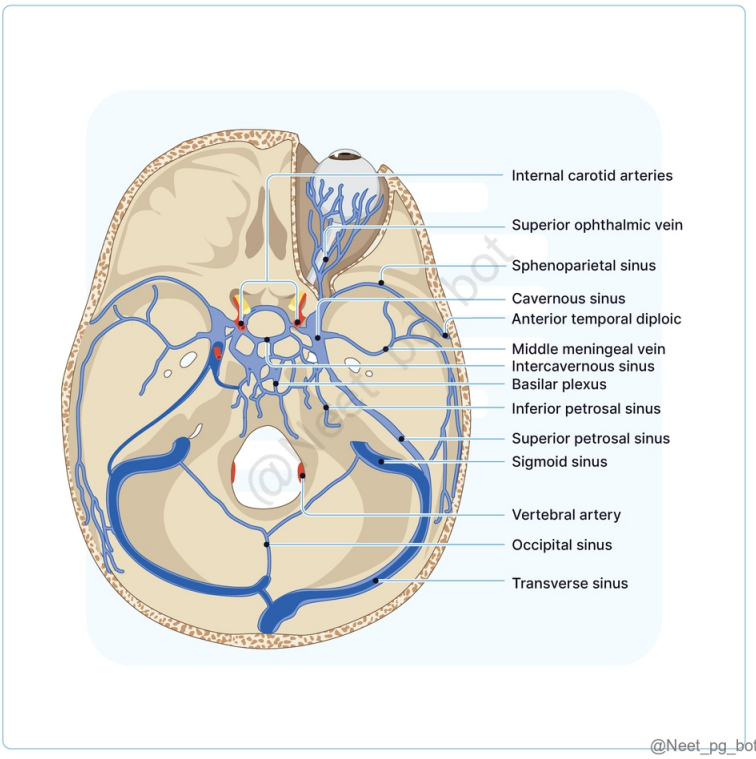

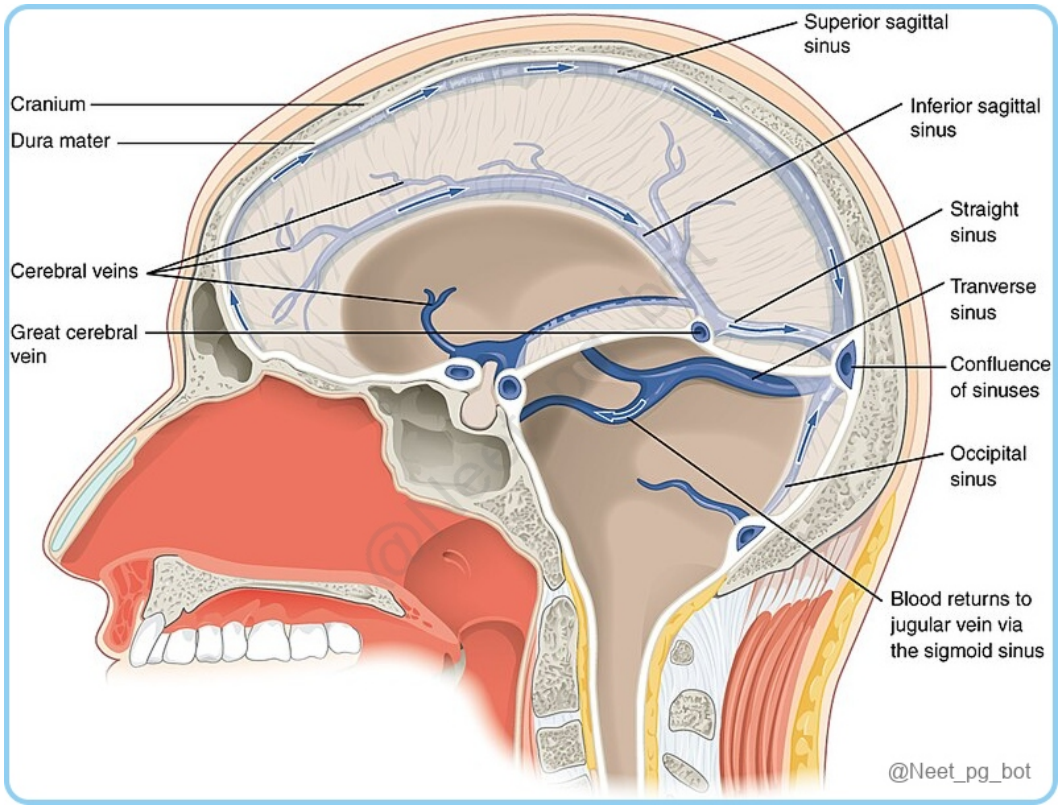

References:

Gray’s Anatomy The Anatomical Basis of Clinical Practice, 42nd Edition, Pages 399 - 404.

↑ *Back to this question in Part A*

@Neet_pg_bot

Q12: A 56-year-old patient presents with difficulty speaking, swallowing, and hoarseness of voice. On examination, there is noticeable wasting of one side of the tongue and weakness in the sternocleidomastoid and trapezius muscles. The patient also exhibits contralateral hemiplegia and contralateral loss of sensation. Which of the following lesions is most likely responsible for these symptoms? (Q848598)

A. Multiple sclerosis

B. Meningioma of the cerebellum

C. Medullary infarct

D. Vestibular schwannoma

Correct Answer: C. Medullary infarct

■ *Listen (English)*

■ *Listen (Hindi)*

Explanation: Medullary infarct is the most likely cause as it affects the medulla oblongata, leading to symptoms like bulbar palsy (difficulty speaking and swallowing), tongue wasting, muscle weakness, contralateral hemiplegia , and loss of sensation. These are consistent with the involvement of both ascending and descending tracts through the medulla. Multiple sclerosis (Option A) primarily causes demyelination and could present with various neurological symptoms but is less likely to produce isolated medullary symptoms with the specific combination of deficits described. Meningioma of the cerebellum (Option B) would more likely cause cerebellar symptoms rather than a specific combination of bulbar palsy and contralateral deficits. Vestibular schwannoma (Option D) typically presents with hearing loss and balance issues rather than the described bulbar symptoms and contralateral deficits.

References:

Gray’s Anatomy The Anatomical Basis of Clinical Practice, 42nd Edition, Pages 462, 438.

↑ *Back to this question in Part A*

@Neet_pg_bot

Q13: Which of the following accurately describes the corticonuclear tract? (Q848597)

A. It terminates exclusively in the spinal cord with an ipsilateral projection.

B. It descends through the internal capsule and pons, terminating on cranial nerve nuclei with a contralateral projection.

C. It controls involuntary movements of the head and neck muscles.

D. The term "corticobulbar" is more accurate than "corticonuclear" for describing its function.

Correct Answer: B. It descends through the internal capsule and pons, terminating on cranial nerve nuclei with a contralateral projection.

■ *Listen (English)*

■ *Listen (Hindi)*

Explanation: The corticonuclear tract fibres descend from the cerebral cortex through the internal capsule and pons. They then terminate on cranial nerve nuclei in the brainstem. The fibres exhibit a contralateral projection pattern, meaning they cross the midline of the brainstem to innervate the nuclei on the opposite side of the brainstem. Feature Details Origin Motor cortex (precentral gyrus) Course Internal capsule → Crus cerebri (midbrain) → Pons (broken into fascicles) Termination Cranial nerve motor nuclei in the brainstem (III–XII, except I & II) (Option A) Projection Mostly contralateral , some bilateral (e.g., facial, trigeminal, hypoglossal nuclei) Function Voluntary control of facial expression, mastication, swallowing, speech, and tongue movement (Option C) “ C orticonuclear ” is the preferred term, as it includes all cranial motor nuclei , not just those in the medulla (“bulb”) (Option D)

References:

Gray’s Anatomy, The Anatomical Basis of Clinical Practice, 42nd Edition, Pages 444, 445, 389, 390

↑ *Back to this question in Part A*

@Neet_pg_bot

Q14: At the level of the facial colliculus, the fibres of which cranial nerves form a loop around the abducens nucleus, creating the colliculus? (Q848595)

A. Glossopharyngeal nerve

B. Trigeminal nerve

C. Facial nerve

D. Hypoglossal nerve

Correct Answer: C. Facial nerve

■ *Listen (English)*

■ *Listen (Hindi)*

Explanation: The fibres of the facial nerve curve dorsally around the abducens nucleus, forming the facial colliculus. Structures in the Pons Section Level Key Structures Facial colliculus (lower pons) Fourth ventricle above stria medullaris Facial nerve fibres form the facial colliculus Dorsal aspect (lower pons) Medial longitudinal fasciculus Abducens and facial nerve nuclei Inferior cerebellar peduncle Ventral aspect (lower pons) Medial lemniscus Trapezoid body and nuclei Pontine nuclei and pontocerebellar fibres Trigeminal nerve nuclei (mid pons) Superior cerebellar peduncle Motor and sensory nuclei of the trigeminal nerve Mesencephalic tract Ventral aspect (mid pons) Lemniscal arch (medial and lateral lemnisci) Trapezoid body fibres and nuclei Glossopharyngeal nerve (Option A) : This nerve is not involved at the level of the facial colliculus. Trigeminal nerve (Option B) : The trigeminal nerve nuclei are located higher in the mid-pons, not at the level of the facial colliculus. Hypoglossal nerve (Option D) : This nerve is located in the medulla, not the pons, and does not contribute to the formation of the facial colliculus.

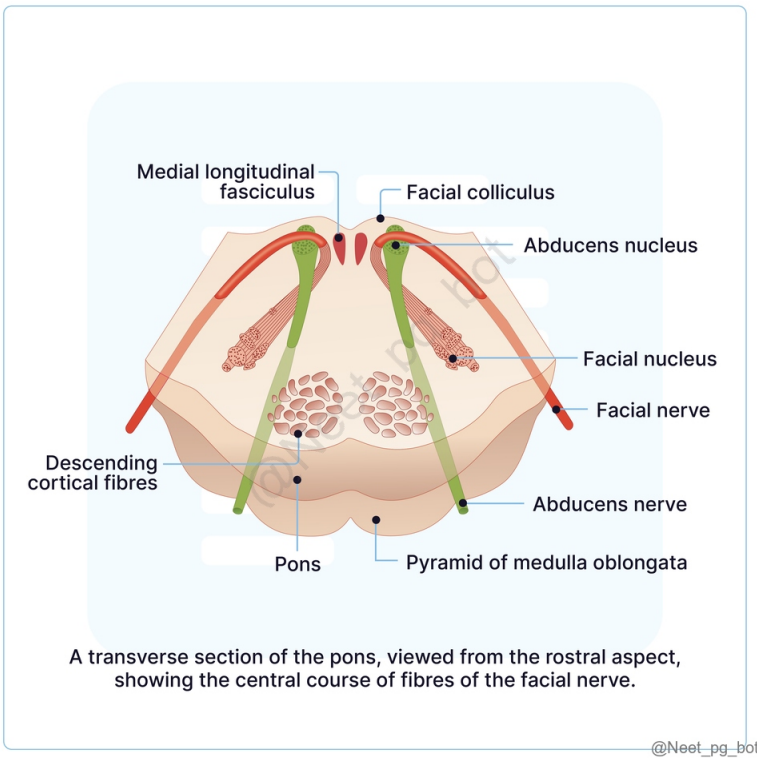

A transverse section of the pons, viewed from the rostral aspect, showing the central course of fibres of the facial nerve.

@Neet_pg_bot

References:

Gray’s Anatomy, The Anatomical Basis of Clinical Practice, 42nd Edition, Pages 450 - 452

↑ *Back to this question in Part A*

@Neet_pg_bot

Q15: Which of the following conditions is associated with lesions at the level marked in the midbrain? (Q848594)

A. Weber’s syndrome

B. Benedikt’s syndrome

C. Parinaud’s syndrome

D. All of the above

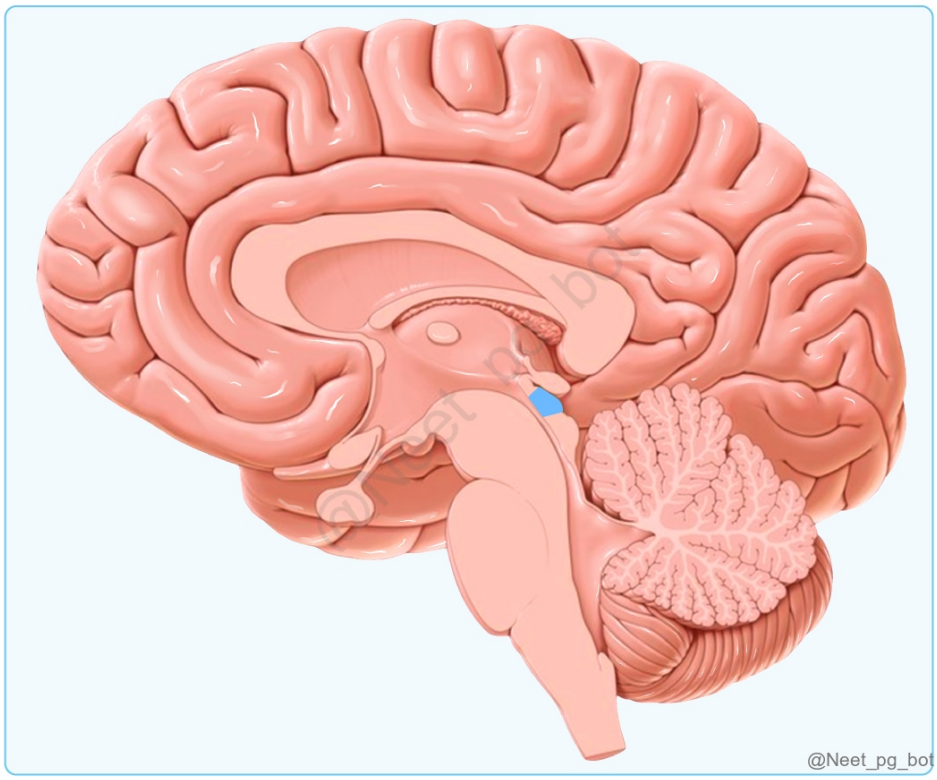

Correct Answer: D. All of the above

■ *Listen (English)*

■ *Listen (Hindi)*

Explanation: The superior colliculus is marked in the above image and all the given syndromes are associated with lesions at this level. Transverse section at level of the superior colliculus in midbrain Syndromes associated with lesions at the level of superior colliculus: Weber’s syndrome: Involves III nerve nucleus and corticospinal fibres. Features: Hemiplegia on the opposite side due to the involvement of corticospinal fibres. Pupil points downwards and laterally due to paralysis of the III nerve. Benedikt’s syndrome: Most of the tegmentum of the midbrain is damaged. Involves medial lemniscus, red nucleus, superior cerebellar peduncle, and fibres of III nerve. Features: Medial lemniscus- Loss of proprioception. III nerve- Pupil points downwards and laterally. Red nucleus and superior cerebellar peduncle- Tremors and twitching of the opposite side. Parinaud’s syndrome : Lesion of superior colliculi. Features: Weakness of upward gaze and vertical nystagmus due to damage to the superior colliculus.

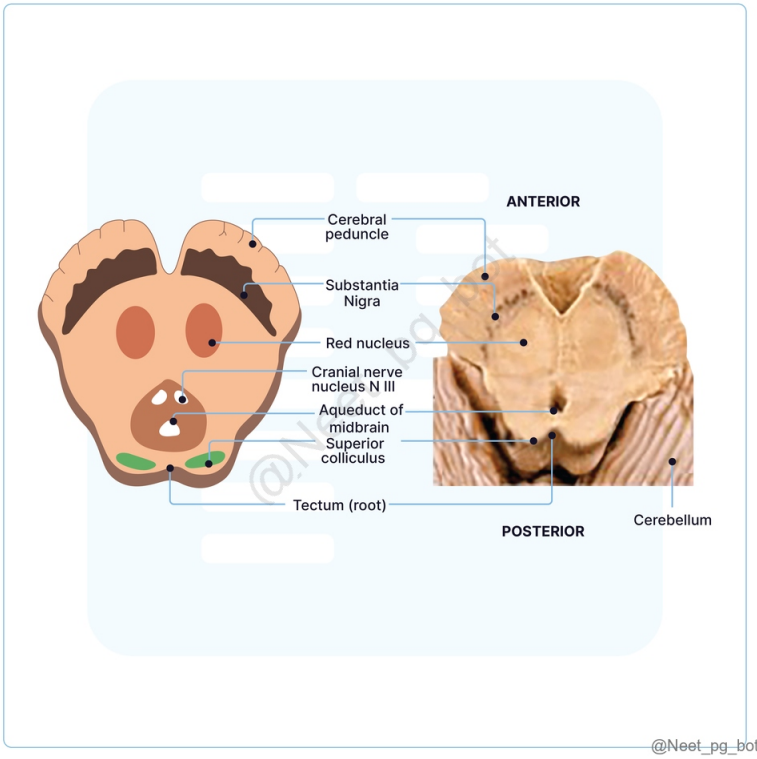

References:

Gray's Anatomy, The Anatomical Basis of Clinical Practice, 42nd Edition, Page 456

BD Chaurasia Neuroanatomy, Volume 4, 8th Edition, Pages 112-114

↑ *Back to this question in Part A*

@Neet_pg_bot

Q16: Which of the following statements is not correct regarding lemniscus? (Q848593)

A. It is a collection of axons running in the spinal cord

B. The lateral lemniscus is a part of the auditory pathway

C. Spinal leminiscus is affected in wallenberg syndrome

D. Spinal lemniscus carries pain and temperature sensation

Correct Answer: A. It is a collection of axons running in the spinal cord

■ *Listen (English)*

■ *Listen (Hindi)*

Explanation: Lemniscus Collection of axons running in the brainstem (Option A) Four types (MTSL) : Medial lemniscus Lateral lemniscus Spinal lemniscus Trigeminal lemniscus Continuation of dorsal column (nucleus gracilis and cuneatus) Sensations it carries are Pressure, Vibration, Tactile discrimination, Stereognosis, Conscious proprioception Formed by fibres arising in nuclei lying in close relation to the trapezoid body (superior olivary nucleus and nucleus of trapezoid body). It carries auditory information from the cochlear nuclei. (Option B ruled out) Carries pain and temperature. (Option D ruled out) Lateral medullary ischemia - Wallenberg syndrome (Option C ruled out) Contains fibres arising in the spinal nucleus of the trigeminal nerve and traveling to the thalamus. Extends into the midbrain, medulla, and the spinal cord

References:

BD Chaurasia Neuroanatomy, Volume 4, 8th Edition, Page 103, 106, 108, 109.

Neuroanatomy, Brainstem - StatPearls - NCBI Bookshelf (nih.gov)

↑ *Back to this question in Part A*

@Neet_pg_bot

Q17: A 55-year-old man diagnosed with B12 deficiency presents with difficulty maintaining balance. On examination, he shows a loss of vibration and fine touch sensation in his lower limbs, while pain and temperature sensations are intact. Which of the following pathways is most likely affected in this patient? (Q848569)

A. Lateral Spinothalamic Tract

B. Ventral Spinothalamic Tract

C. Tract of Goll

D. Corticospinal Tract

Correct Answer: C. Tract of Goll

■ *Listen (English)*

■ *Listen (Hindi)*

Explanation: Tract of Goll (Gracile fasciculus) is a part of the dorsal column-medial lemniscus pathway, responsible for transmitting fine touch, vibration, and proprioception from the lower limbs. B12 deficiency can lead to subacute combined degeneration, affecting this pathway and causing the sensory deficits seen in the patient. Spinothalamic Tract (Spinal Lemniscus System): Category Details Types (Options A & B ruled out) Lateral Spinothalamic Tract: Carries pain and temperature sensations Ventral Spinothalamic Tract: Carries crude touch and pressure sensations Pyramidal Tract (Corticospinal Tract) (Option D ruled out): Involved in voluntary motor control .

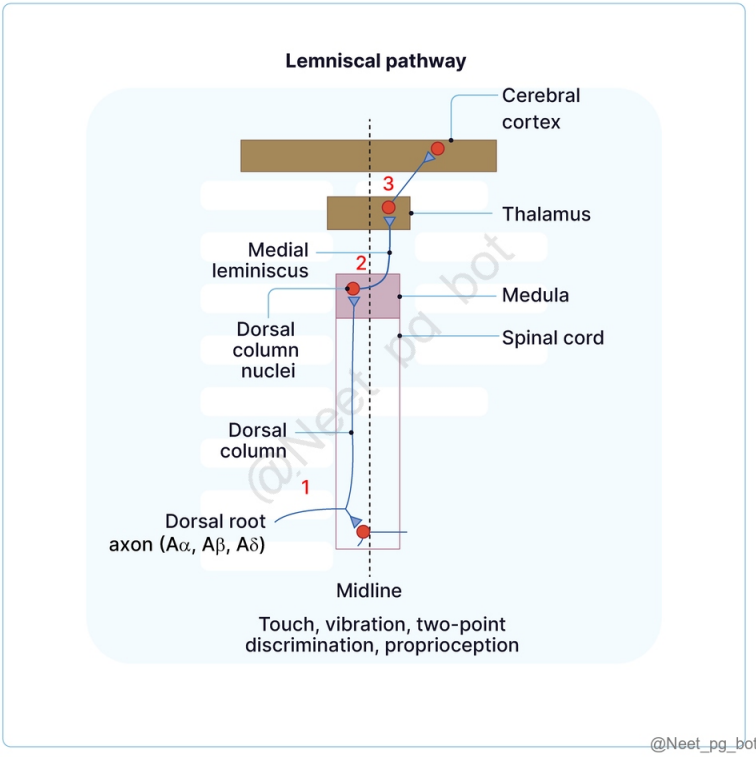

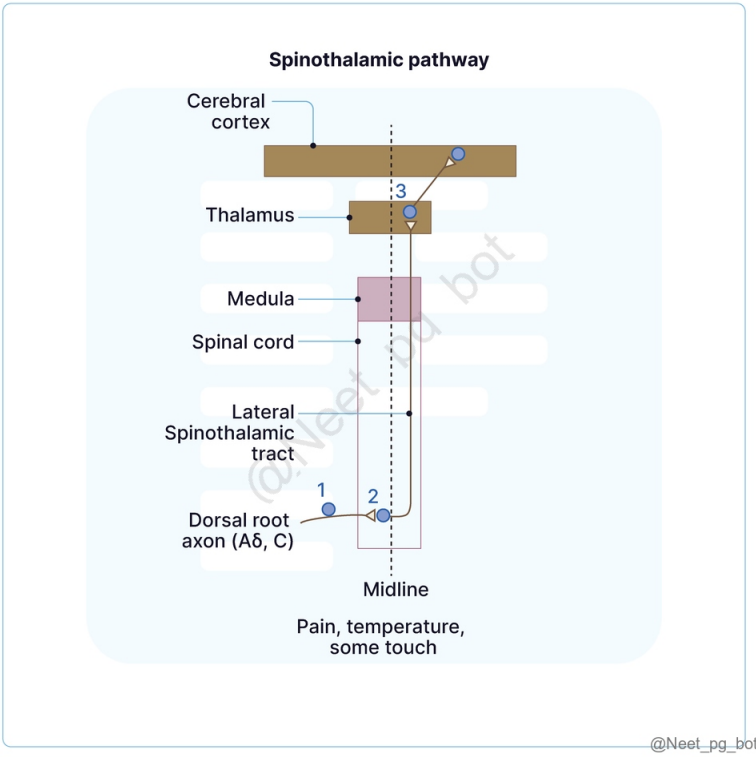

References:

BD Chaurasia Neuroanatomy, Volume 4, 8th Edition, Pages 41-47

Vishram Singh Anatomy of head, Neck and Brain, Volume 3, 2nd Edition, Pages 308-312

↑ *Back to this question in Part A*

@Neet_pg_bot

Q18: Which of the following arteries is primarily responsible for supplying the sublenticular part of the internal capsule, which carries auditory fibres? (Q848579)

A. Recurrent branch of anterior cerebral artery

B. Direct branches from the internal carotid

C. Branch of anterior choroidal

D. Branch of posterior communicating

Correct Answer: C. Branch of anterior choroidal

■ *Listen (English)*

■ *Listen (Hindi)*

Explanation: Sublenticular part of the internal capsule is supplied by the branch of anterior choroidal artery and the branch of the posterior cerebral artery. It carries ascending auditory fibres from temporal lobe to thalamus. Vascular supply of internal capsule Recurrent branch of anterior cerebral artery (Option A): Supplies anterior limb of the internal capsule. Direct branches from the internal carotid (Option B): Supplies genu of the internal capsule. Branch of posterior communicating (Option D): Supplies genu and part of the posterior limb of the internal capsule.

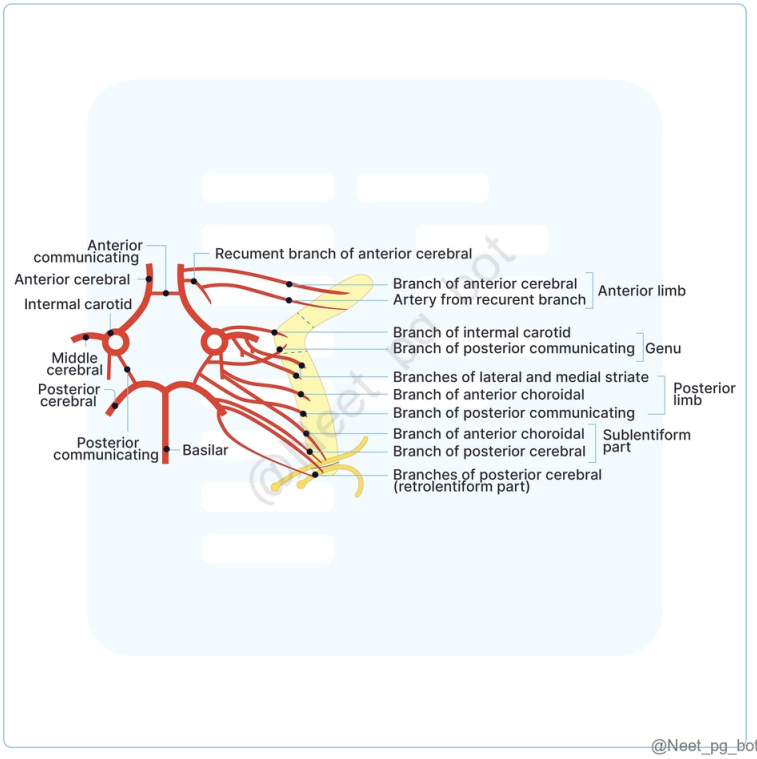

References:

Gray's Anatomy The Anatomical Basis of Clinical Practice, 42nd Edition, Page 420

BD Chaurasia Neuroanatomy, Volume 4, 8th Edition, Pages 163,164.

↑ *Back to this question in Part A*

@Neet_pg_bot

Q19: A 62-year-old presents with sudden-onset left-sided weakness, primarily affecting the arm and face. On examination, he has difficulty with speech, displaying both expressive and receptive aphasia. He also shows left-sided facial drooping and an inability to move his left upper limb effectively. Sensation is relatively intact in his lower limb. Which artery is most likely affected? (Q848578)

A. Anterior cerebral artery (ACA)

B. Posterior cerebral artery (PCA)

C. Middle cerebral artery (MCA)

D. Basilar artery

Correct Answer: C. Middle cerebral artery (MCA)

■ *Listen (English)*

■ *Listen (Hindi)*

Explanation: The MCA supplies the lateral aspects of the cerebral hemispheres, including the motor and sensory cortices controlling the face, upper limb, and speech areas (in the dominant hemisphere). The patient's symptoms of weakness in the face and arm, combined with aphasia, strongly suggest an MCA stroke , as this artery is responsible for these regions. Artery Affected Areas Involved Clinical Manifestations Anterior Cerebral Artery (ACA) (Option A) Medial surface of the frontal and parietal lobes, corpus callosum Contralateral weakness and sensory loss (lower limb > upper limb) Urinary incontinence, Personality changes (frontal lobe involvement), Transcortical motor aphasia (dominant hemisphere) Middle Cerebral Artery (MCA) (Option C) Lateral surface of the frontal, temporal, and parietal lobes, basal ganglia, internal capsule Contralateral weakness and sensory loss (face and upper limb > lower limb) Aphasia (dominant hemisphere), Hemineglect (non-dominant hemisphere), Homonymous hemianopia Gaze preference towards the side of the lesion Posterior Cerebral Artery (PCA) (Option B) Occipital lobe, inferior part of temporal lobe, thalamus Contralateral homonymous hemianopia , Visual agnosia , Thalamic pain syndrome, Cortical blindness (if bilateral), Memory deficits (if temporal lobe is involved)

References:

Harrison’s principles of internal medicine, 20th Edition, Page 420.

↑ *Back to this question in Part A*

@Neet_pg_bot

Q20: Identify the artery highlighted in blue in the following image. (Q848577)

A. Anterior communicating artery

B. Posterior communicating artery

C. Anterior cerebral artery

D. Middle cerebral artery

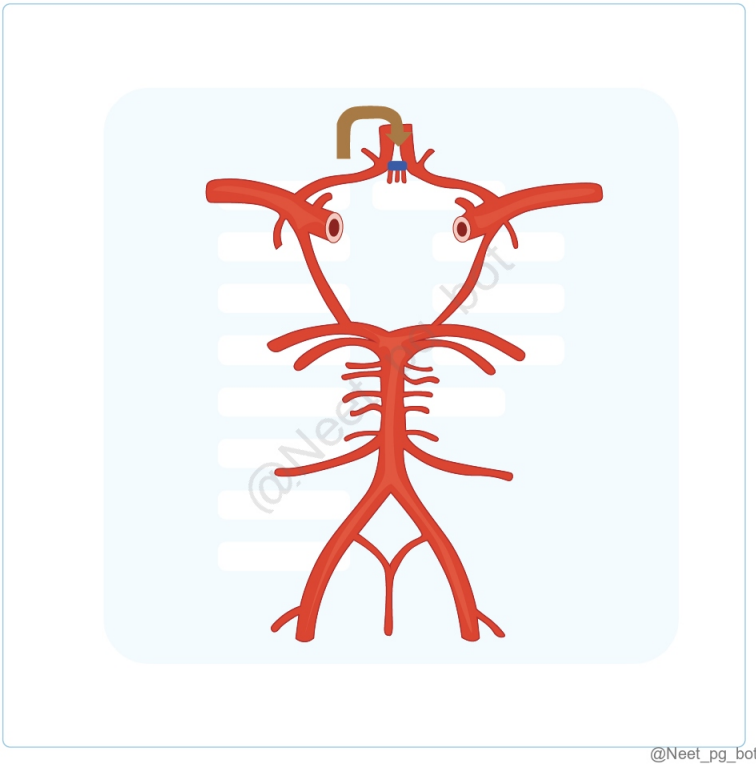

Correct Answer: A. Anterior communicating artery

- *Listen (English)*
- *Listen (Hindi)*

Explanation: The anterior communicating artery connects the two anterior cerebral arteries and forms part of the Circle of Willis. This artery plays a critical role in allowing collateral blood flow between the left and right sides of the cerebral circulation. {{caption_text}}

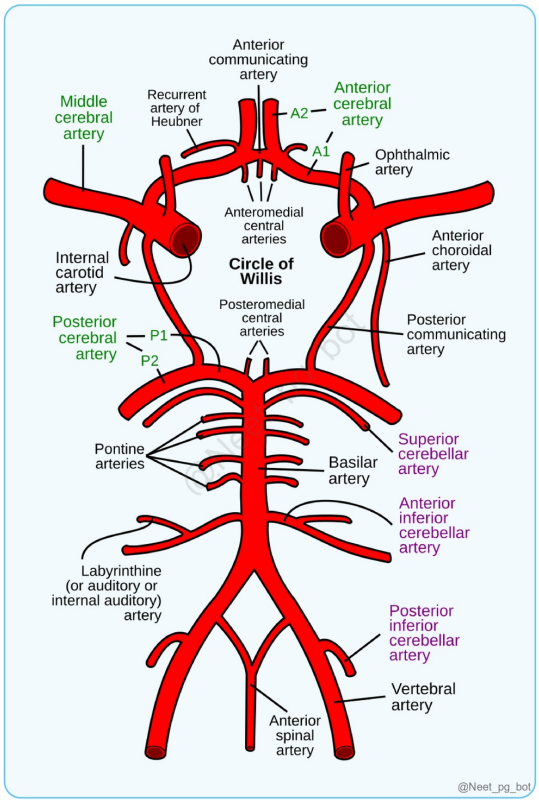

References:

Gray's Anatomy, The Anatomical Basis of Clinical Practice, 41st Edition, Pages 281 - 284.

↑ *Back to this question in Part A*

@Neet_pg_bot

Q21: A 45-year-old patient presents with Horner's syndrome, but notably, the patient does not exhibit anhidrosis. Based on the absence of anhidrosis, which of the following is the most likely location of the lesion? (Q848575)

A. First-order neuron (central)

B. Second-order neuron (peripheral)

C. Third-order neuron (postganglionic)

D. Superior cervical ganglion

Correct Answer: C. Third-order neuron (postganglionic)

■ *Listen (English)*

■ *Listen (Hindi)*

Explanation: The absence of anhidrosis in Horner's syndrome suggests that the lesion is likely located in the postganglionic (third-order neuron) segment of the oculosympathetic pathway. The sweat glands are primarily innervated by sympathetic fibers that branch off earlier. Hence, in third-order Horner's syndrome, if the disruption occurs after these fibers have already branched off, sweating pathways are unaffected, and anhidrosis does not occur. In contrast, anhidrosis is always present in first-order or second-order Horner's syndrome.

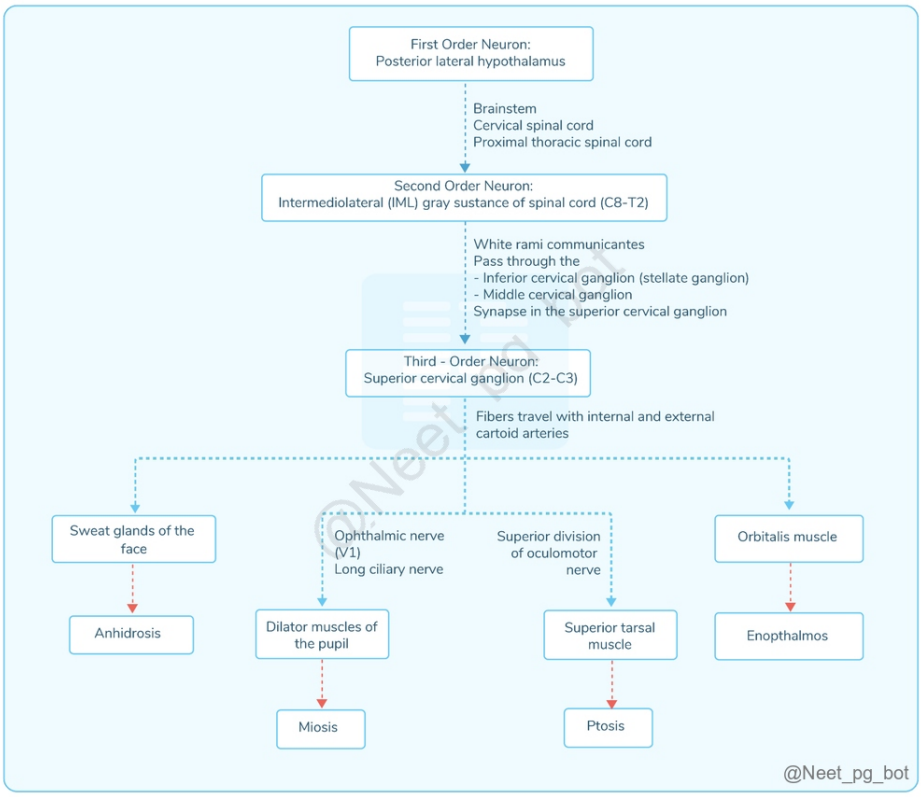

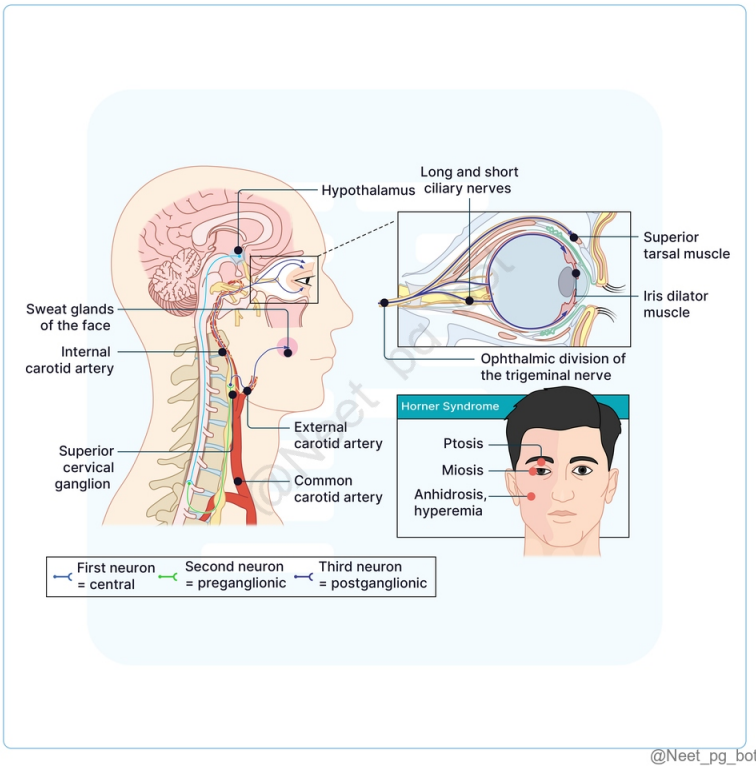

@Neet_pg_bot

References:

Gray’s Anatomy, The Anatomical Basis of Clinical Practice, 41st Edition, Pages469, 670, 681, 772, 786, 981.

Horner's syndrome/ Research gate

↑ *Back to this question in Part A*

@Neet_pg_bot

Q22: Which of the following statements about prevertebral/paravertebral ganglia is/are true? Prevertebral ganglia are also known as collateral ganglia. Prevertebral ganglia are a part of the parasympathetic nervous system. Paravertebral ganglia supply the abdominal viscera. The celiac ganglion is a paravertebral ganglion. (Q848574)

A. I only

B. I and III only

C. II, III and IV only

D. All the above

Correct Answer: A. I only

■ *Listen (English)*

■ *Listen (Hindi)*

Explanation: Prevertebral ganglia are also known as collateral ganglia. Prevertebral ganglia and paravertebral ganglia both are part of the sympathetic nervous system , not the parasympathetic nervous system. Paravertebral ganglia (sympathetic trunk ganglia) primarily supply the body wall and limbs, while prevertebral ganglia (e.g., celiac ganglion) supply the abdominal viscera . The celiac ganglion is a prevertebral (collateral) ganglion , not a paravertebral ganglion.

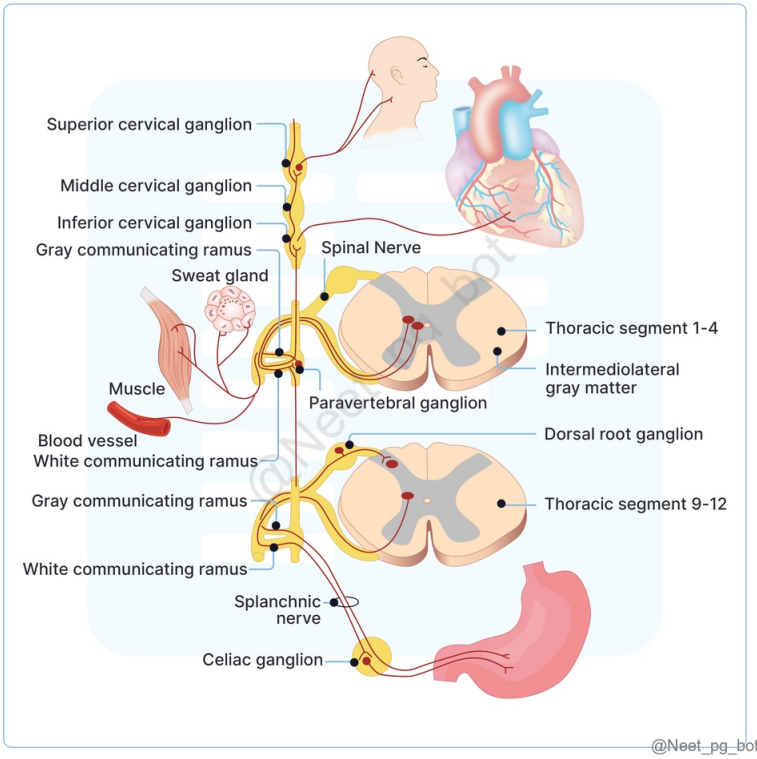

References:

BD Chaurasia Neuroanatomy, Volume 4, 8th Edition, Pages 205 - 208.

↑ *Back to this question in Part A*

@Neet_pg_bot

Q23: Which of the following statements is incorrect? (Q848572)

A. Preganglionic fibers in both the sympathetic and parasympathetic systems are myelinated.

B. Postganglionic fibers in both the sympathetic and parasympathetic systems are unmyelinated

C. Most sweat glands are sympathetic and adrenergic.

D. Acetylcholine is a neurotransmitter found in sympathetic ganglia.

Correct Answer: C. Most sweat glands are sympathetic and adrenergic.

■ *Listen (English)*

■ *Listen (Hindi)*

Explanation: Most sweat glands (eccrine) are sympathetic and cholinergic, not adrenergic. Only a few sweat glands (apocrine) are sympathetic and adrenergic. Neurotransmitters and Efferent Innervation: Autonomic Efferent Innervation - GVE Preganglionic Fibers: Myelinated (both in sympathetic and parasympathetic systems) (Option A ruled out) Postganglionic Fibers: Unmyelinated (both in sympathetic and parasympathetic systems) (Option B ruled out) Neurotransmitters: Acetylcholine: Found in parasympathetic and sympathetic ganglia (Option D ruled out) Effector Organ Responses: Parasympathetic: Cholinergic (acetylcholine) Sympathetic: Adrenergic (epinephrine and norepinephrine) (rare) Sweat Glands: Most sweat glands (eccrine) are sympathetic and cholinergic Few sweat glands (apocrine) are sympathetic and adrenergic

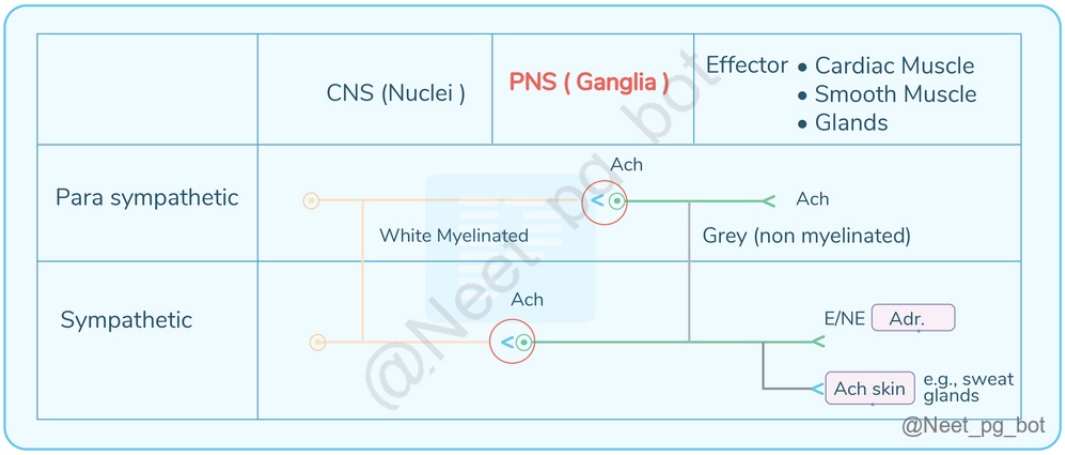

References:

BD Chaurasia Neuroanatomy, Volume 4, 8th Edition, Page 207 - 212

↑ *Back to this question in Part A*

@Neet_pg_bot

Q24: A 64-year-old woman presents with progressive weakness in her left leg. On examination, you observe that her left leg has decreased muscle tone, and shows significant muscle atrophy. Given these findings, which of the following additional signs is likely to be present? (Q848571)

A. Exaggerated Deep Tendon Reflexes

B. Positive Babinski Sign

C. Muscle Spasticity

D. Fasciculations

Correct Answer: D. Fasciculations

■ *Listen (English)*

■ *Listen (Hindi)*

Explanation: The patient’s findings of decreased muscle tone, muscle atrophy, and flaccid paralysis are indicative of Lower Motor Neuron (LMN) involvement. Fasciculations, which are involuntary muscle twitches, are a common additional sign in LMN lesions due to denervation of the muscle fibers. Feature LMN Paralysis UMN Paralysis Muscle Tone Decreased Increased Type of Paralysis Flaccid Spastic (Option C ruled out) Muscle Atrophy Occurs later No atrophy Reaction of Degeneration Seen Not seen Tendon Reflexes Absent Exaggerated (Option A ruled out) Side of Affected Body Ipsilateral Contralateral Babinski Sign Negative Positive (Option B ruled out) Fasciculation Present Absent

References:

BD Chaurasia Neuroanatomy, Volume 4, 8th Edition, Page 51

↑ *Back to this question in Part A*

@Neet_pg_bot

Q25: A 35-year-old patient presents following a fall from a ladder. The patient exhibits specific neurological symptoms: loss of pain and temperature sensation in the left leg, difficulty identifying the position of the right leg with eyes closed, and complete loss of sensation at the T12 level of the trunk on the right. Which of the following statements is false for this condition? (Q848570)

A. Loss of proprioception in the right leg occurs due right dorsal column.

B. Loss of pain in the left leg occurs due to the left spinothalamic tract.

C. Damage to the ventral nerve roots at the T12 level results in motor loss.

D. Spastic paralysis of the right leg

Correct Answer: B. Loss of pain in the left leg occurs due to the left spinothalamic tract.

■ *Listen (English)*

■ *Listen (Hindi)*

Explanation: The patient's presentation is consistent with Brown-Séquard Syndrome, resulting from a hemisection of the spinal cord. In Brown-Séquard syndrome, pain, and temperature sensations are lost on the opposite side of the body from the lesion due to the crossing of the spinothalamic tract fibers. Therefore, loss of pain in the left leg would be due to damage to the right spinothalamic tract, not the left. Brown-Sequard syndrome Below the Level of Lesion: Ipsilateral Upper Motor Neuron Paralysis: Due to damage to the pyramidal tract (corticospinal tract) (Option D ruled out) . Ipsilateral Loss of Conscious Proprioceptive Sensations: Caused by damage to the posterior white column (Option A ruled out) . Contralateral Loss of Pain and Temperature Sensations: Due to damage to the lateral spinothalamic tract and anterior spinothalamic tract. At the Level of Lesion: (Option C ruled out) Ipsilateral Lower Motor Neuron Paralysis: Resulting from damage to the ventral nerve roots. Ipsilateral Anesthesia Over the Skin of the Segment: Due to injury to the dorsal nerve roots. Above the Level of Lesion: Ipsilateral Hyperesthesia: Resulting from irritation of the dorsal nerve roots.

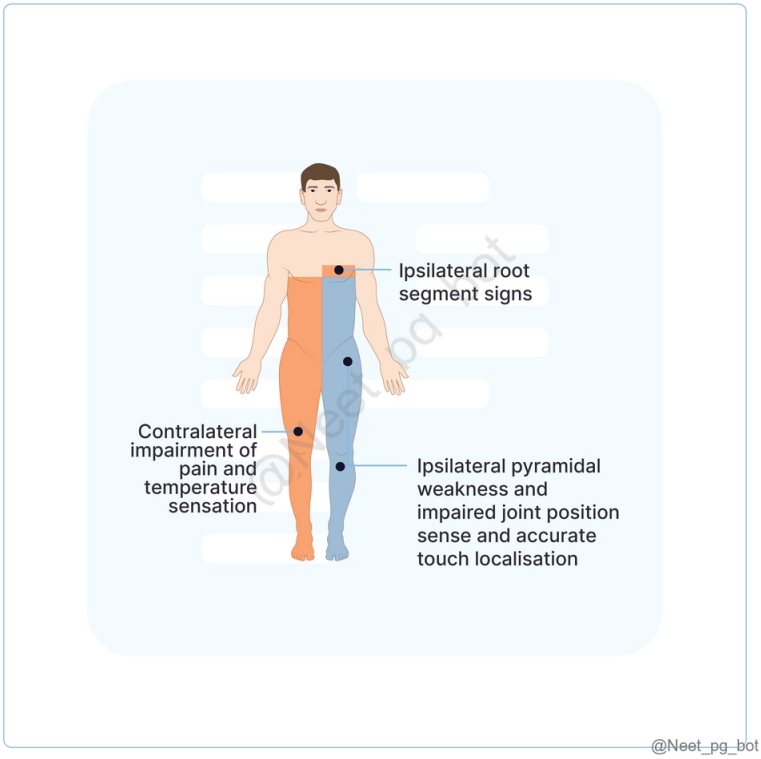

References:

BD Chaurasia Neuroanatomy, Volume 4, 8th Edition, Pages 51

↑ *Back to this question in Part A*

@Neet_pg_bot

• [03_Neuro Anatomy] 013 Previous Year Questions

« Back to Folder Directory

[03_Neuro Anatomy] 013 Previous Year Questions — Quick Jump

Q1 (p. 993)	*Q2 (p. 994)*	*Q3 (p. 994)*	*Q4 (p. 997)*	*Q5 (p. 998)*	*Q6 (p. 999)*
Q7 (p. 1000)	*Q8 (p. 1001)*	*Q9 (p. 1002)*	*Q10 (p. 1004)*	*Q11 (p. 1006)*	*Q12 (p. 1007)*
Q13 (p. 1008)	*Q14 (p. 1009)*	*Q15 (p. 1011)*	*Q16 (p. 1012)*	*Q17 (p. 1014)*	*Q18 (p. 1014)*
Q19 (p. 1016)	*Q20 (p. 1017)*	*Q21 (p. 1019)*	*Q22 (p. 1020)*	*Q23 (p. 1022)*	*Q24 (p. 1023)*
Q25 (p. 1027)	*Q26 (p. 1028)*	*Q27 (p. 1030)*	*Q28 (p. 1030)*	*Q29 (p. 1033)*	*Q30 (p. 1034)*
Q31 (p. 1035)	*Q32 (p. 1037)*	*Q33 (p. 1037)*	*Q34 (p. 1038)*	*Q35 (p. 1039)*	*Q36 (p. 1040)*
Q37 (p. 1041)	*Q38 (p. 1043)*	*Q39 (p. 1044)*	*Q40 (p. 1046)*	*Q41 (p. 1047)*	*Q42 (p. 1048)*
Q43 (p. 1051)	*Q44 (p. 1052)*	*Q45 (p. 1054)*	*Q46 (p. 1056)*	*Q47 (p. 1057)*	*Q48 (p. 1060)*
Q49 (p. 1061)					

Q1: The type of fibers present in the fornix are: (Q856949)

A. Projection and commissural fibers

B. Association and projection fibers

C. Commissural and association fibers

D. Association fibers

Correct Answer: A. Projection and commissural fibers

Explanation: Fornix is made up of projection fibers and commissural fibers. Projection fibers: The fornix is the chief efferent pathway of the hippocampus. It carries fibers from: Hippocampus → mammillary bodies Hippocampus → hypothalamus / septal area / anterior thalamic nuclei These are classic projection fibers connecting cortex (hippocampus) to subcortical structures. Commissural fibers: Some fibers of the fornix cross the midline via the hippocampal commissure. These are described as: Pre-commissural fibers Post-commissural fibers Hence, the fornix does contain commissural fibers . Options B, C and D include “Association fibres”. Association fibers connect cortical areas within the same hemisphere eg. Cingulum, uncinate fasciculus. The fornix does not connect hippocampus to other cortical areas . It connects hippocampus to subcortical nuclei , not to another cortical region.

References:

https://pmc.ncbi.nlm.nih.gov/articles/PMC7231447/

↑ *Back to this question in Part A*

@Neet_pg_bot

Q2: Which of the following options are included in the limbic system? 1. Amygdala 2. Hippocampus 3. Thalamus (Q855039)

A. 1,2

B. 1,3

C. 2,3

D. 1,2,3

Correct Answer: D. 1,2,3

Explanation: The limbic system is a collection of brain structures involved in emotion, memory, and motivation . The key components of the limbic system include: Amygdala → Plays a crucial role in emotion processing , particularly fear and aggression . Hippocampus → Essential for learning and memory , particularly long-term memory formation . Other Major Components of the Limbic System: Hypothalamus → Regulates autonomic functions and emotional responses . Cingulate gyrus → Involved in emotion formation and processing . Mammillary bodies → Associated with memory processing . Thalamus → It is important for sensory relay. Certain nuclei within the thalamus, especially the anterior and dorsomedial nuclei, are considered limbic system components.

References:

G.K. Pal Comprehensive Textbook of Physiology, 1st Edition, Pages 1127, 1129-1131

↑ *Back to this question in Part A*

@Neet_pg_bot

Q3: Identify the cranial nerve that arises from the marked part. (Q855041)

A. Oculomotor nerve

B. Glossopharyngeal nerve

C. Abducens nerve

D. Facial nerve

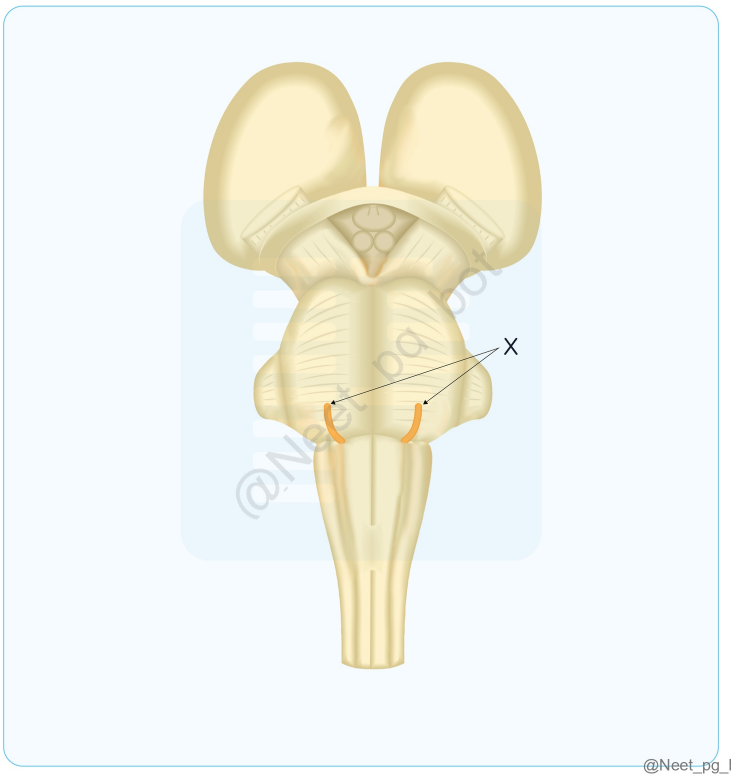

Correct Answer: C. Abducens nerve

Explanation: The abducens nerve (CN VI) arises from the pontomedullary junction , specifically from the ventral surface of the brainstem , near the midline . It travels forward to innervate the lateral rectus muscle , which controls abduction of the eye (lateral movement). Attachment of the nerves to the brain: 1, 2 - Forebrain 3- Arises from ventral midbrain 4- Dorsal midbrain (cannot see its origin in the Anterior view of the brainstem) 5- Lateral pons 6, 7, 8- Ponto medullary junction (from medial to lateral respectively) 9, 10, 11- Lateral to olives (from superior to inferior respectively) 12- Between pyramid and olives {{caption_text}} {{caption_text}} Oculomotor nerve (option A): The oculomotor nerve (CN III) arises from the midbrain (interpeduncular fossa) , not the pontomedullary junction . Glossopharyngeal nerve (option B): The glossopharyngeal nerve (CN IX) emerges from the medulla , specifically the postolivary sulcus , above the vagus nerve , not from the pontomedullary junction . Facial nerve (option D): The facial nerve (CN VII) also arises from the pontomedullary junction , but it is located laterally , near the cerebellopontine angle . The abducens nerve is more medial , while the facial nerve is lateral to it.

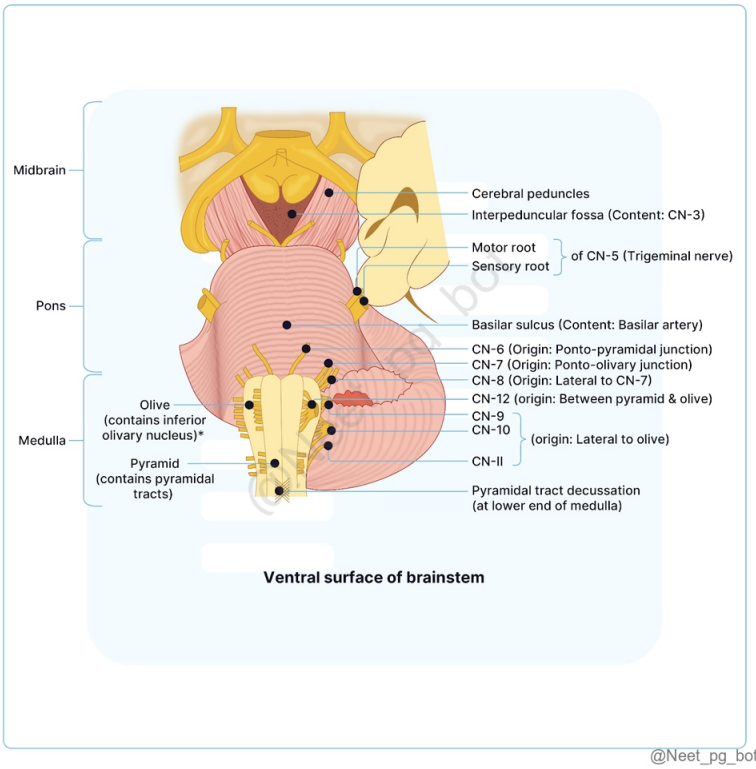

@Neet_pg_bot

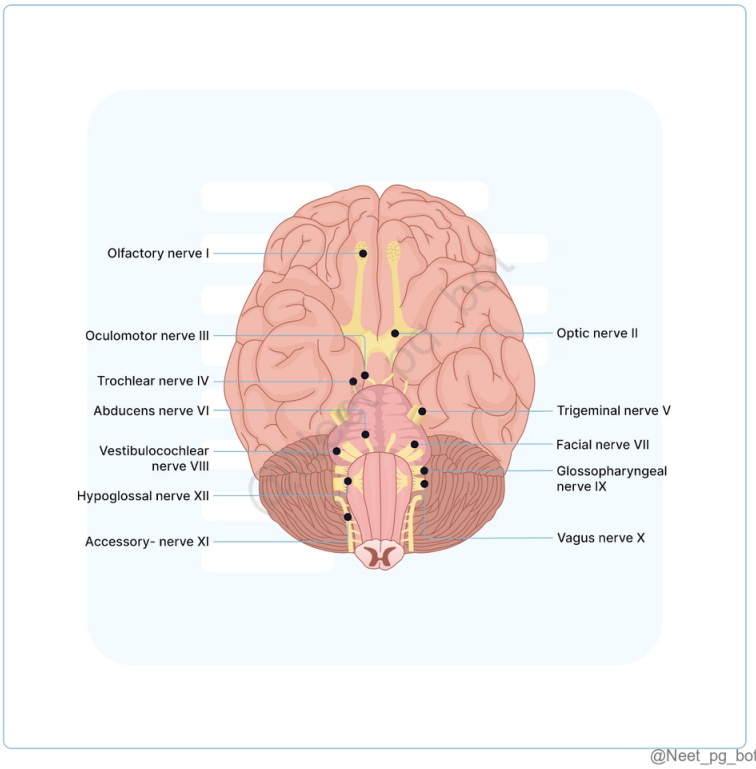

@Neet_pg_bot

References:

Snell’s Clinical Neuroanatomy, 8th edition, Page 196, 197

BD Chaurasia Neuroanatomy, Volume 4, Page 56, 57

↑ *Back to this question in Part A*

@Neet_pg_bot

Q4: Arrange in sequence the structures involved in the direct pathway of the basal ganglia:- 1. Striatum 2. Globus pallidus 3. Substantia nigra 4. Thalamus 5. Cortex (Q855038)

A. 1,2,3,4,5

B. 5,4,2,31

C. 5,1,2,3,4

D. 1,3,4,2,5

Correct Answer: C. 5,1,2,3,4

Explanation: Cortex (5) → Initiates movement and sends excitatory signals to the striatum. Striatum (1) (Caudate + Putamen) → Receives input from the cortex and modulates basal ganglia output. Globus pallidus (2) (Internal and External segments) → Affects the output to the thalamus. Substantia nigra (3) (Pars compacta and Pars reticulata) → Modulates the activity of the striatum and globus pallidus. Thalamus (4) → Relays processed signals back to the cortex for movement execution. Direct Pathway: Promotes movement by reducing inhibitory output from the GPi to the thalamus. Mechanism: The striatum inhibits the GPi, leading to less inhibition of the thalamus and increased motor activity. Indirect Pathway: Inhibits movement by increasing inhibitory output from the GPe to the thalamus. Mechanism: The striatum inhibits the GPe, resulting in less inhibition of the STN, which then excites the GPi. This increased activity of the GPi leads to more inhibition of the thalamus and decreased motor activity. {{caption_text}} Direct Pathway Indirect Pathway Function Facilitates motor activity Suppresses motor activity Input Excitatory input from the cerebral cortex Excitatory input from the cerebral cortex Target Striatum (caudate nucleus and putamen) Striatum (caudate nucleus and putamen) Striatum Output Inhibits internal segment of globus pallidus (GPi) Inhibits external segment of globus pallidus (GPe) GPi/SNr Effect Reduced inhibition of thalamus Increased inhibition of thalamus Thalamus Effect Increased thalamic activation Decreased thalamic activation Motor Cortex Effect Enhanced motor activity Reduced motor activity Subthalamic Nucleus (STN) Not directly involved Activated by reduced inhibition from GPe

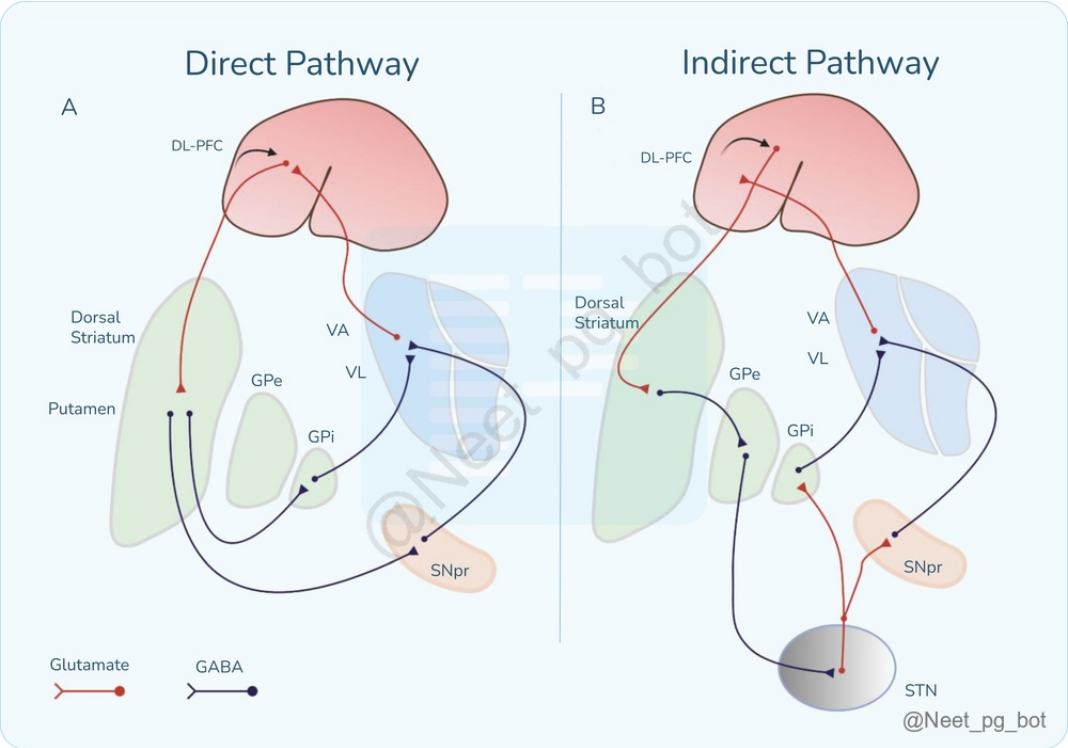

References:

Berne and Levy Physiology, 8th Edition, Ch 9 - Motor control by the basal ganglia.

↑ *Back to this question in Part A*

@Neet_pg_bot

Q5: Neostriatum consists of? (Q857229)

A. Caudate nucleus and globus pallidus

B. Globus pallidus and putamen

C. Globus pallidus and lentiform nucleus

D. Caudate nucleus and putamen

Correct Answer: D. Caudate nucleus and putamen

Explanation: The neostriatum (or striatum) consists of the caudate nucleus and putamen . These structures are functionally and anatomically linked as part of the basal ganglia , playing a crucial role in motor control and cognitive functions. Components of the Basal Ganglia Component Includes Function Striatum (Neostriatum) Caudate nucleus + Putamen Main input center of the basal ganglia, receives input from the cortex Lentiform nucleus Putamen + Globus pallidus Part of the extrapyramidal motor system, regulates movement Globus pallidus

Internal (medial) and External (lateral) segments Main output structure, modulates thalamocortical circuits Subthalamic nucleus Located in the diencephalon Plays a role in modulating basal ganglia output Substantia nigra Located in the midbrain Produces dopamine; degeneration leads to Parkinson’s disease Caudate nucleus and globus pallidus (Option A): Incorrect because globus pallidus is not part of the neostriatum. Globus pallidus and putamen (Option B): Incorrect because globus pallidus belongs to the paleostriatum , not neostriatum. Globus pallidus and lentiform nucleus (Option C): Incorrect because lentiform nucleus includes putamen and globus pallidus , but the neostriatum consists only of caudate and putamen .

References:

Gray’s Anatomy, 42nd Edition, Page 537,538

Vishram Singh, Anatomy of Head, Neck, Brain, Volume 3, Page 395,396

↑ *Back to this question in Part A*

@Neet_pg_bot

Q6: A 55-year-old man is accompanied by his wife to the Neurology OPD. His wife expressed concern about her husband's condition and they were directed to this facility by a local doctor. According to the doctor's note, the patient is unable to repeat spoken words but can comprehend them and respond appropriately by nodding. The patient also experiences difficulty in naming people and writing. The doctor referred the patient to a specialized facility for a CT brain scan. As the intern on duty, you would inform the Chief Medical Officer (CMO) that this condition could be indicative of a brain lesion in which specific area? (Q857234)

A. Arcuate fasciculus

B. Anterior commissure

C. Corpus callosum

D. Fornix

Correct Answer: A. Arcuate fasciculus

Explanation: Difficulty in repeating spoken words, trouble with naming and writing, yet intact comprehension of spoken language, suggests Conduction Aphasia. It's caused by a disconnection between language centers in the brain, possibly affecting the Arcuate Fasciculus. This white matter tract links Broca's area (speech production) with Wernicke's area (language comprehension). Damage here can lead to symptoms like those described in conduction aphasia, where patients struggle to repeat words or phrases accurately despite understanding them. Aphasia Type Area Affected Features Broca's Aphasia Left frontal lobe (Broca's area) Non-fluent speech, difficulty forming sentences, good comprehension, and poor writing/speech output. Wernicke's Aphasia Left temporal lobe (Wernicke's area) Fluent speech with normal grammar, but speech is nonsensical or meaningless,

poor comprehension. Conduction Aphasia Arcuate fasciculus (connecting Broca's and Wernicke's areas) Difficulty repeating words or phrases, fluent speech with errors, good comprehension. Global Aphasia Widespread damage to left hemisphere (Broca's, Wernicke's, and arcuate fasciculus) Severe communication deficits: non-fluent speech, poor comprehension, and inability to repeat. Incorrect Options: Anterior commissure (Option B): The anterior commissure is involved in the connection between the two cerebral hemispheres but is not typically associated with the specific language symptoms described. Corpus callosum (Option C): Damage to the corpus callosum can result in a variety of symptoms but is not specifically associated with the language deficits described. Fornix (Option D): The fornix is a white matter structure involved in memory processes but is not typically associated with the language symptoms described.

References:

BD Chaurasia’s Human Anatomy, 8th Edtion, Page no: 765

↑ *Back to this question in Part A*

@Neet_pg_bot

Q7: At what level does the spinal cord end in infants? (Q857622)

A. L1

B. L2

C. L3

D. L4

Correct Answer: C. L3

Explanation: At birth, the spinal cord extends down to L3 , but as the child grows, the vertebral column elongates more than the spinal cord, and by adulthood, it typically ends at L1-L2 . Spinal Cord Termination in Different Ages Age Group Spinal Cord Termination Level Clinical Relevance Fetus (24 weeks) Extends to S1 Early spinal development stage Newborn (Infants) Ends at L3 Important for lumbar puncture site selection Adults Ends at L1-L2 Safe lumbar puncture site is L3-L4 or L4-L5 L1 (Option A): Incorrect because in infants , the spinal cord does not end as high as L1; this is the adult level. L2 (Option B): Incorrect because the spinal cord in newborns extends lower, typically to L3. L4 (Option D): Incorrect because while the spinal cord is lower in fetuses, in infants, it usually stops at L3 , not L4.

References:

https://www.ncbi.nlm.nih.gov/pmc/articles/PMC9671389/#

↑ *Back to this question in Part A*

@Neet_pg_bot

Q8: In this image of basal ganglia, all of the following are correctly labeled except? (Q857646)

A. 1-Caudate nucleus

B. 2-Globus pallidus

C. 3-Putamen

D. 4-Internal capsule

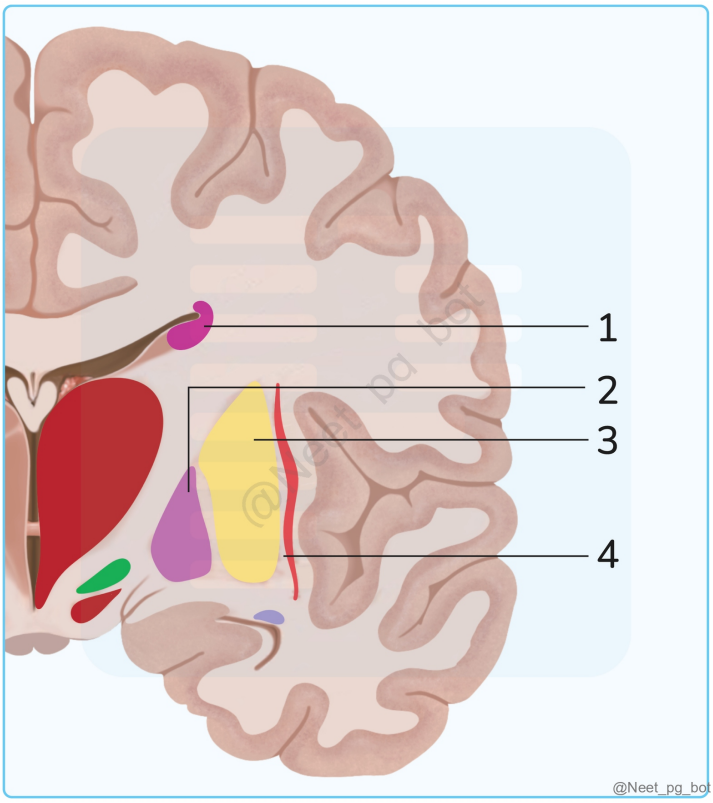

Correct Answer: D. 4-Internal capsule

Explanation: The internal capsule is a white matter tract separating the caudate nucleus from the putamen and globus pallidus , whereas the structure labeled as 4 in the image corresponds to the Claustrum . Basal Ganglia Anatomy Structure Function Location Caudate nucleus Motor processes, learning, associative functions Lateral to lateral ventricle, near thalamus Putamen Regulates movements, influences learning Part of the striatum, lateral to globus pallidus Globus pallidus Inhibitory control of movements Medial to putamen, part of lentiform nucleus Internal capsule Contains motor and sensory pathways Between caudate nucleus and lentiform nucleus Thalamus Sensory relay station Medial to basal ganglia, near third ventricle {{caption_text}} 1 - Caudate nucleus (Option A) : Forms part of the striatum, involved in motor control. 2 - Globus pallidus (Option B) : Part of the lentiform nucleus, modulates motor activity. 3 - Putamen (Option C) : Works with the caudate to regulate movements.

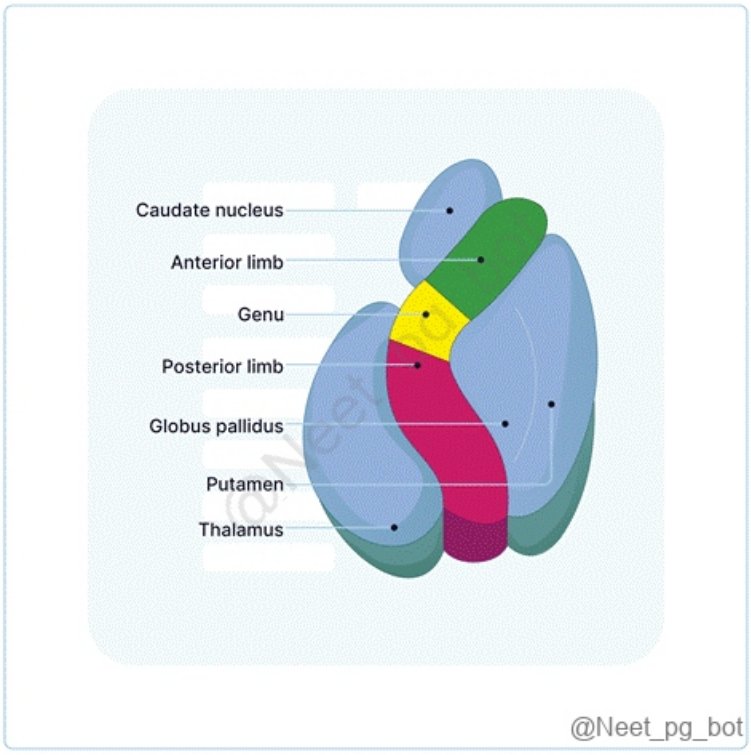

References:

Gray's Anatomy, 42nd Edition, Page 537,538

Vishram Singh, Anatomy of Head, Neck, Brain, Volume 3, Page 395,396

↑ *Back to this question in Part A*

@Neet_pg_bot

Q9: Fibers from the marked structure end in which of the following areas of the thalamus? (Q855816)

A. Posterior nucleus

B. Reticular nucleus

C. Anterior nucleus

D. Ventral lateral nucleus

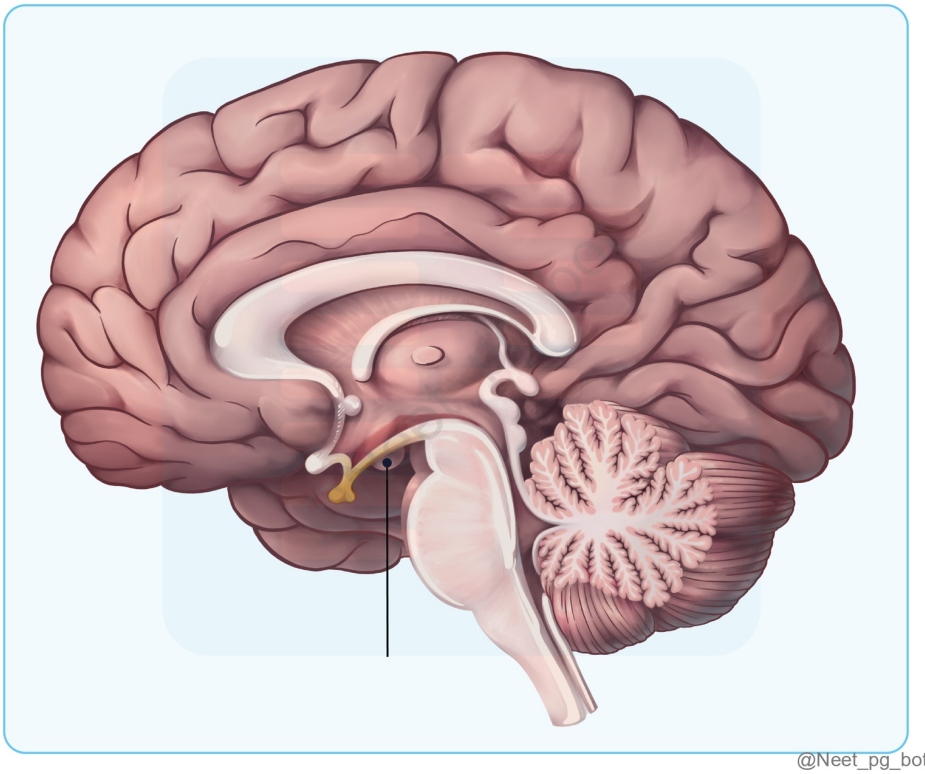

Correct Answer: C. Anterior nucleus

Explanation: The marked structure is the mammillary body , which is part of the Papez circuit , responsible for memory processing. The mammillothalamic tract carries fibers from the mammillary bodies to the anterior nucleus of the thalamus . The anterior nucleus further relays this information to the cingulate gyrus, playing a crucial role in learning and memory. Mammillary Bodies and Their Connections Feature Details Structure Mammillary bodies (part of the hypothalamus) Pathway Mammillothalamic tract Target in Thalamus Anterior nucleus of the thalamus Function Memory processing, part of the Papez circuit Clinical Significance Damage leads to memory deficits (e.g., Wernicke-Korsakoff syndrome) Posterior nucleus (Option A): Incorrect , as it is involved in pain perception and thermoregulation, not in the Papez circuit. Reticular nucleus (Option B): Incorrect , as it regulates thalamocortical activity but does not receive direct input from the mammillary bodies. Ventral lateral nucleus (Option D): Incorrect , as it is involved in motor relay from the cerebellum and basal ganglia, not memory processing.

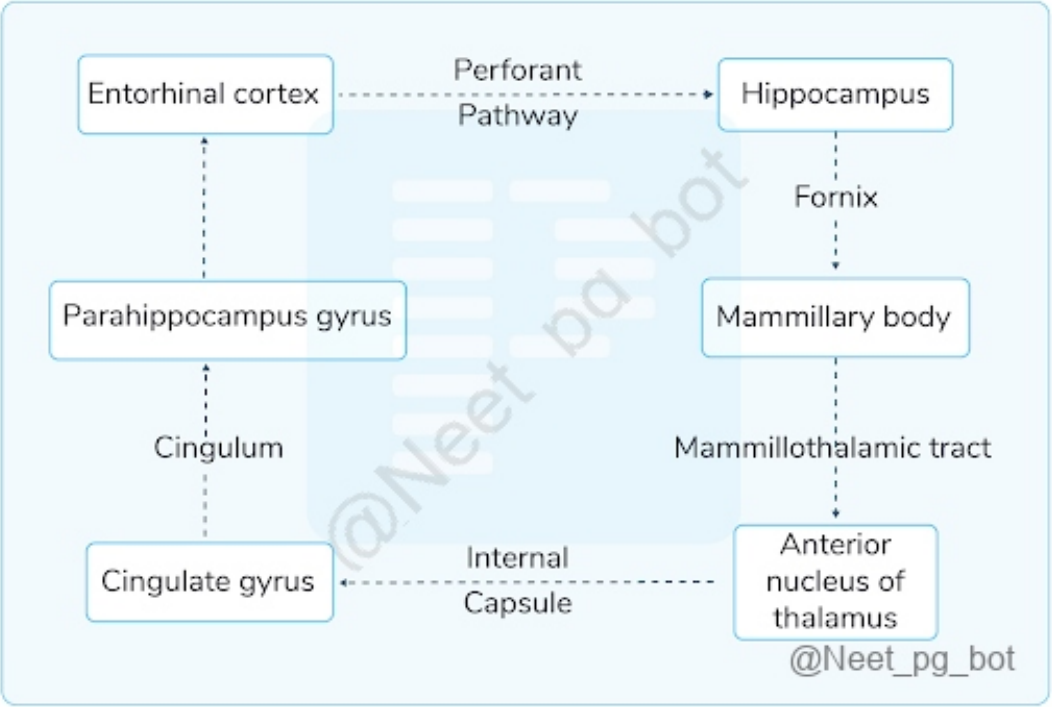

References:

Gray's Anatomy: The Anatomical Basis of Clinical Practice, 41st Edition - Page no: 351, 356

↑ *Back to this question in Part A*

@Neet_pg_bot

Q10: At which level does the nerve supply for the marked structure arise? (Q855851)

A. Red nucleus

B. Sub thalamic nuclei

C. Decussation of pyramidal tract

D. Olivary nucleus

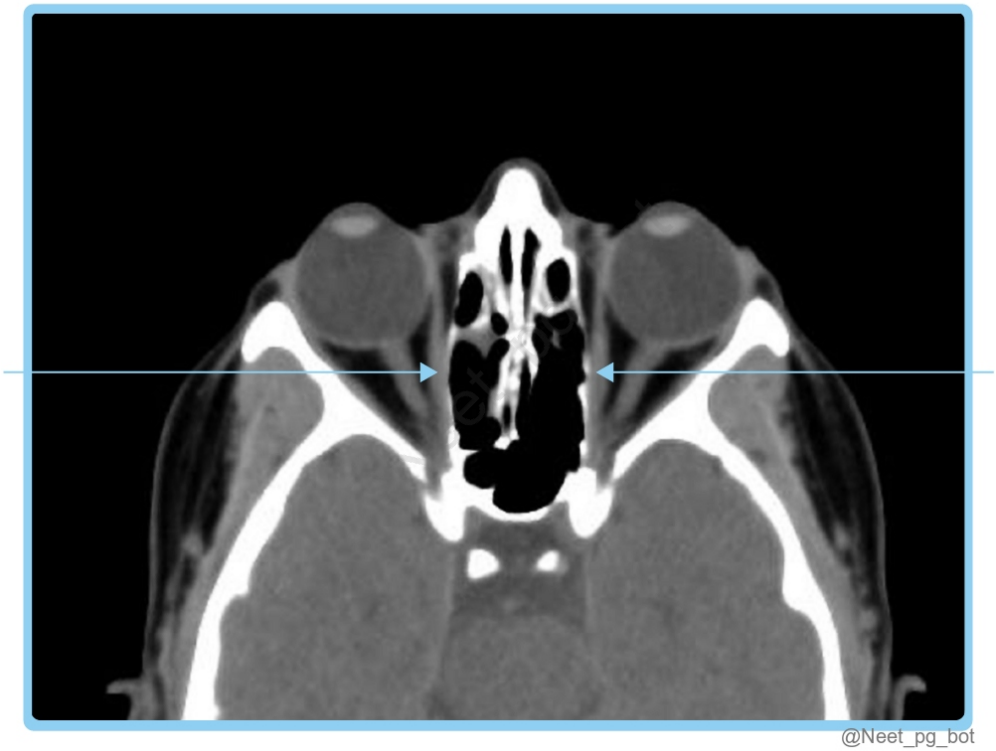

Correct Answer: A. Red nucleus

Explanation: The image is a coronal CT scan of the orbit , highlighting the extraocular muscles , specifically the medial rectus muscles (marked structures) . The medial rectus is supplied by the oculomotor nerve (CN III) , which originates from the oculomotor nucleus in the midbrain . The oculomotor nucleus receives input from the Red Nucleus, which is involved in coordinating eye movements and muscle tone through the rubro-oculomotor connections. The Red Nucleus is an important structure in the midbrain tegmentum , involved in motor coordination , particularly in controlling extraocular muscles via the rubro-oculomotor pathway . It plays a role in conjugate gaze and eye movement control , making it relevant to the medial rectus function . Oculomotor Nerve and Its Control Structure Function Oculomotor Nucleus (Midbrain) Origin of CN III, controls most extraocular muscles Red Nucleus (Midbrain) Regulates motor coordination and eye movements via rubro-oculomotor pathways Edinger-Westphal Nucleus Provides parasympathetic fibers for pupil constriction and accommodation Medial Rectus Muscle Controlled by CN III, responsible for adduction of the eye Blood Supply Supplied by paramedian branches of the basilar artery and PCA Clinical Correlation Oculomotor nerve palsy causes ptosis, mydriasis, and eye deviation ("down and out") Subthalamic Nucleus (Option B): Incorrect because it is primarily involved in indirect basal ganglia pathways and has no direct role in extraocular muscle control . Decussation of Pyramidal Tract (Option C): Incorrect because it primarily relates to corticospinal tract fibers , which control voluntary movements of the limbs, not the eyes . Olivary Nucleus (Option D): Incorrect because it is part of the olivocerebellar system , which is responsible for motor learning and coordination , rather than direct eye movement control.

References:

Gray's Anatomy: The Anatomical Basis of Clinical Practice, 41st Edition - Page no: 232, 323, 324, 325, 666, 671

BD Chaurasia Human Anatomy - Volume 3 - Page no: 398

↑ *Back to this question in Part A*

@Neet_pg_bot

Q11: A 6-month-old boy was brought to the casualty with seizures. The pediatrician tries to do CSF sampling. What are the structures punctured by the pediatrician while piercing through the marked structure? (Q856633)

A. Scalp, dura mater, arachnoid mater

B. Scalp, epicranium, dura mater

C. Scalp synchondral membrane, dura mater, arachnoid mater

D. Pericranium, dura mater, endocranium

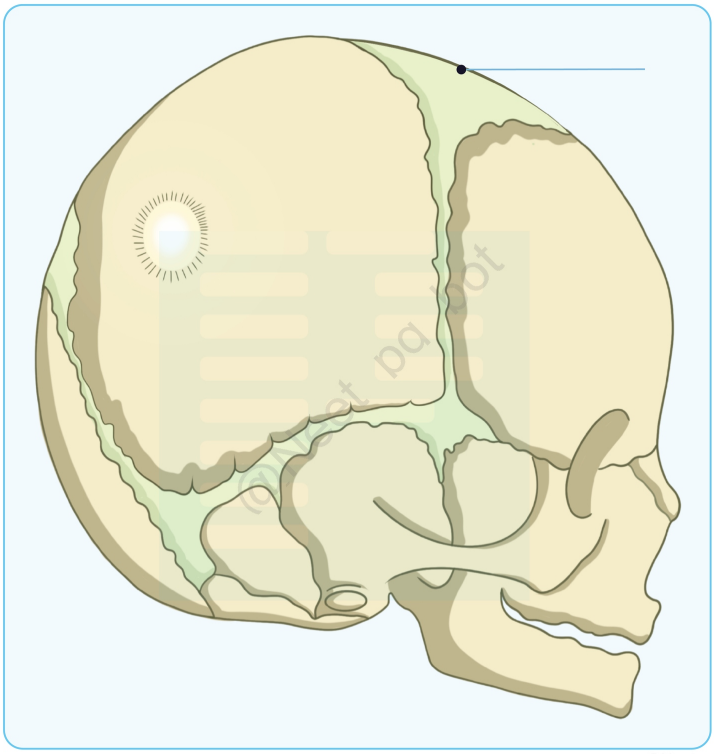

@Neet_pg_bot

Correct Answer: A. Scalp, dura mater, arachnoid mater

Explanation: The anterior fontanelle is the largest fontanelle in an infant and remains open until around 18 months . It provides an accessible site for cranial ultrasound and CSF sampling in neonates. During CSF sampling via the anterior fontanelle , the needle pierces : Scalp (including skin and subcutaneous tissue) Dura mater (outermost meningeal layer) Arachnoid mater (middle meningeal layer) The pia mater is not pierced as it remains intact while CSF is drawn from the subarachnoid space . Anterior Fontanelle and CSF Sampling Feature Details Location

Intersection of frontal and parietal bones Closure 12-18 months Clinical Uses CSF sampling in neonates Cranial ultrasound to assess hydrocephalus or hemorrhage Structures Pierced Scalp → Dura mater → Arachnoid mater → CSF space Why Not Endocranium? The endocranium is part of the bone , which is not yet ossified at the fontanelle. Scalp, epicranium, dura mater (Option B): incorrect because the epicranium is a broad term for the scalp layers, but arachnoid mater is missing , which is an essential layer pierced in CSF sampling. Scalp, synchondral membrane, dura mater, arachnoid mater (Option C): incorrect because there is no synchondral membrane at the fontanelle; it is composed of fibrous tissue , not cartilage. Pericranium, dura mater, endocranium (Option D): incorrect because endocranium is the inner table of the skull, which is not yet ossified at the fontanelle. The arachnoid mater is also missing in this option.

References:

Gray's Anatomy: The Anatomical Basis of Clinical Practice, 41st Edition - Page no: 440, 441, 475

↑ *Back to this question in Part A*

@Neet_pg_bot

Q12: A woman with right-sided loss of sensations of both the upper and lower limb complains of shooting pain from her fingers to the right shoulder and a burning sensation when touching cold water. Motor functions are normal. Which of the following structures is likely to be involved? (Q856682)

A. Dorsal Horn

B. Thalamus

C. Ventral Horn

D. Dorsal Root Ganglion

Correct Answer: B. Thalamus

Explanation: The shooting pain from fingers to shoulder and burning sensation when touching cold water (allodynia) suggests neuropathic pain, which is characteristic of central sensitization seen in thalamic lesions. The thalamus is the major relay station for sensory information (including pain and temperature) to the cerebral cortex. The lateral spinothalamic tract carries pain and temperature sensations to the VPL nucleus of the thalamus . Lesions in the ventral posterolateral (VPL) nucleus of the thalamus can produce contralateral sensory loss and neuropathic pain syndrome (thalamic pain syndrome). Dorsal Horn (Option A) - Incorrect: It processes sensory information but does not transmit pain and temperature to higher centers. Lesion here would cause segmental sensory loss, not widespread involvement. Ventral Horn (Option C) - Incorrect: Contains lower motor neurons, so a lesion here would cause motor weakness or paralysis, which is absent in this case. Dorsal Root Ganglion (Option D) - Incorrect: Damage would result in dermatomal sensory loss, not the widespread sensory deficit seen in this patient.

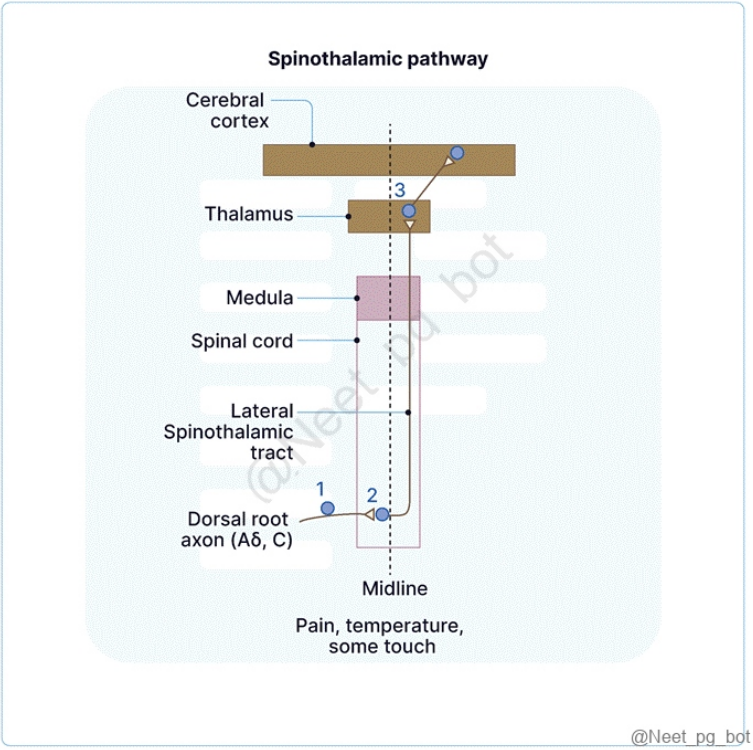

References:

BD chaurasia Neuroanatomy ,8e,pg,41 to 47

Vishram Head, Neck and Brain, 2e, pg,308 to 312

↑ *Back to this question in Part A*

@Neet_pg_bot

Q13: A patient presented with vision loss. On radiological investigation, an aneurysm causing damage to the optic chiasma was noted. Which of the following arteries is most likely to be the artery that is causing the damage? (Q856181)

A. Anterior communicating artery

B. Anterior choroidal artery

C. Middle cerebral artery

D. Anterior cerebral artery

Correct Answer: A. Anterior communicating artery

Explanation: Answer A - Anterior communicating artery The optic chiasma is located just above the anterior communicating artery (AComA) in the suprasellar cistern . Aneurysms of the AComA are the most common intracranial aneurysms and can compress the optic chiasma , leading to bitemporal hemianopia (loss of peripheral vision in both eyes). These aneurysms often present with vision loss, headaches, and possibly subarachnoid hemorrhage if they rupture. Anterior choroidal artery (option B): This artery arises from the internal carotid artery and supplies parts of the optic tract, lateral geniculate body, and posterior limb of the internal capsule . Aneurysms here are rare and typically cause contralateral motor deficits rather than optic chiasma compression. Middle cerebral artery (option C): The MCA does not course near the optic chiasma . MCA aneurysms more commonly affect the lateral convexity of the brain , leading to contralateral hemiparesis, aphasia (dominant hemisphere), or neglect (non-dominant hemisphere). Anterior cerebral artery (option D): The ACA courses superior to the optic chiasma , but aneurysms at this location usually do not cause direct compression. ACA infarcts more commonly lead to leg weakness (contralateral) due to involvement of the paracentral lobule .

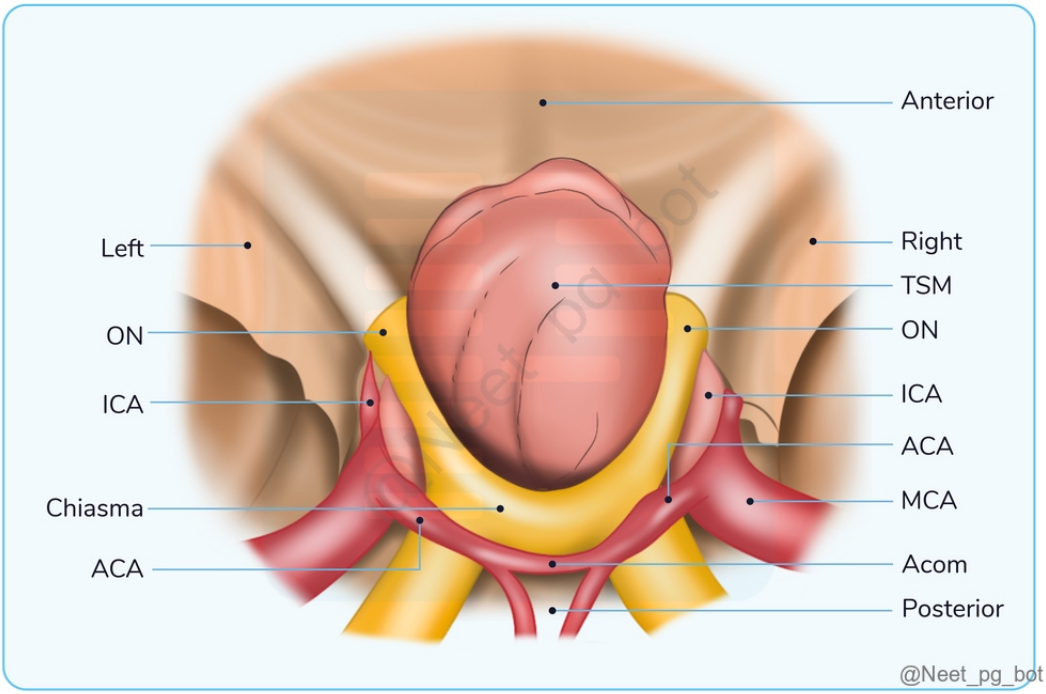

References:

Anterior Communicating Artery Aneurysm Related to Visual Symptoms - PMC

↑ *Back to this question in Part A*

@Neet_pg_bot

Q14: Identify the nerves passing through the marked structure? {{caption_text}} (Q852994)

A. CN I, CN II, CN III, CN IV

B. CN III, CN IV, CN V 1 , CN VI

C. CN IV, CN V 1 , CN VI, CN VII

D. CN VI, CN VII, CN VIII, CN IX



Correct Answer: B. CN III, CN IV, CN V 1 , CN VI

Explanation: The marked structure is the superior orbital fissure. The nerves that pass through the superior orbital fissure are: Oculomotor nerve (CN III) ■■ Divides into superior and inferior divisions before entering the orbit. Supplies most of the extraocular muscles. Trochlear nerve (CN IV) Supplies the superior oblique muscle . Ophthalmic division of the trigeminal nerve (CN V 1): Divides into three branches: ■■■■■■■■■■■■■■■Lacrimal nerve Frontal nerve Nasociliary nerve Abducens nerve (CN VI): ■■■■■■■■■■■■■■■■■■ Supplies the lateral rectus muscle . These nerves connect the middle cranial fossa to the orbit and function in extraocular muscle movement and sensory innervation of orbital and forehead structures.

References:

Grey's Anatomy, 42nd Edition, Pages 458, 781

BD Chaurasia’s Human Anatomy, 8th Edition, Pages 69, 70, 240, 241

Vishram Singh Textbook of Anatomy, 2nd Edition, Pages 335, 336

↑ *Back to this question in Part A*

@Neet_pg_bot

Q15: The neurotransmitter secreted by the area marked in the given image is? (Q856963)

A. Acetylcholine

B. Dopamine

C. Glutamine

D. Noradrenaline



Correct Answer: B. Dopamine

Explanation: The marked area corresponds to the substantia nigra, located in the midbrain. It's pivotal for producing and releasing dopamine, a neurotransmitter crucial for motor control, reward and motivation, and emotional regulation. Dopaminergic neurons in the substantia nigra release dopamine into areas like the basal ganglia, vital for voluntary movements and motor coordination. Internal Structure of the Midbrain The midbrain consists of the posterior part (tectum) and the large anterior part (cerebral peduncle). The cerebral peduncle is divided into three regions: tegmentum , substantia nigra , and crus cerebri . Substantia nigra and crus cerebri remain consistent throughout sections. Crus Cerebri: The medial two-thirds of the crus cerebri contains corticonuclear and corticospinal fibers . The medial one-third of the crus contains frontopontine fibers . The lateral one-third of the crus contains temporopontine , parietopontine , and occipitopontine fibers . Substantia Nigra: A

pigmented band of gray matter situated between the tegmentum and the crus cerebri. It is a large motor nucleus that spans the length of the midbrain. The substantia nigra is divided into pars compacta and pars reticularis . It contains melanin (a precursor to dopamine) and iron . The substantia nigra synthesizes dopamine , which is transmitted via axons to the corpus striatum . Acetylcholine (Option A): Acetylcholine influences muscle contraction, memory, and learning, but it's not primarily secreted by the substantia nigra. Glutamine (Option C): Glutamine is an amino acid that serves as a building block for proteins in the body. It is not a neurotransmitter involved in the substantia nigra's function. Noradrenaline (Option D): Noradrenaline, crucial for the "fight-or-flight" response and attention, is primarily produced in the locus coeruleus, not the substantia nigra.



References:

BD Chaurasia’s Human Anatomy, 8th Edtion, Page no: 546

↑ *Back to this question in Part A*

@Neet_pg_bot

Q16: The medial lemniscus is a continuation of which of the following structures? (Q856346)

A. Spinothalamic tract

B. Spinocerebellar tract

C. Spinotectal tract

D. Fasciculus gracilis

Correct Answer: D. Fasciculus gracilis

Explanation: The medial lemniscus is a continuation of the fasciculus gracilis and fasciculus cuneatus, which are part of the dorsal column-medial lemniscus pathway. This pathway carries sensory information related to fine touch, vibration, and proprioception from the lower body (fasciculus gracilis) and upper body (fasciculus cuneatus) to the brain. The fasciculus gracilis and fasciculus cuneatus are composed of ascending sensory fibers that originate from the dorsal root ganglia in the spinal cord. Dorsal Column (Posterior Column-Medial Lemniscus Pathway): Category Details Components Fasciculus Gracilis: Carries sensory information from the lower limbs (Option C) Fasciculus Cuneatus: Carries sensory information from the upper limbs Sensations Pressure Tactile discrimination Vibration Conscious Proprioception Stereognosis Neuronal Pathway 1st Order Neuron: Located in the dorsal root ganglion 2nd Order Neuron: Located in the medulla oblongata 3rd Order Neuron: Located in the thalamus Spinothalamic tract (Option A): The spinothalamic tract is a separate pathway that carries pain, temperature, and crude touch sensations from the body to the thalamus. Spinocerebellar tract (Option B): The spinocerebellar tracts are involved in carrying proprioceptive information from the spinal cord to the cerebellum, which helps in coordinating and fine-tuning motor movements. Spinotectal tract (Option C): The spinotectal tract is involved in conveying sensory information related to pain and temperature from the body to the superior colliculus in the midbrain, which plays a role in orienting visual and auditory responses to stimuli.

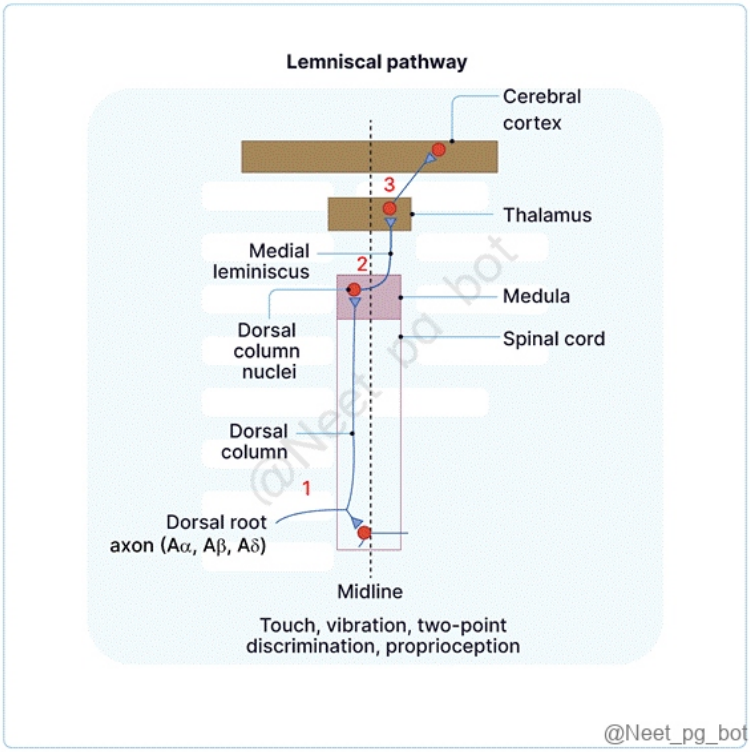

References:

BD Chaurasia’s Human Anatomy, 8th Edtion, Page 133

↑ *Back to this question in Part A*

@Neet_pg_bot

Q17: Decussation of the superior cerebellar peduncle occurs at which level? (Q856352)

A. Pons

B. Midbrain

C. Diencephalon

D. Medulla

Correct Answer: B. Midbrain

Explanation: The superior cerebellar peduncle, also known as the brachium conjunctivum, is one of the three major fiber tracts that connect the cerebellum with the rest of the brain. It is located on the dorsal aspect of the brainstem. The decussation of the superior cerebellar peduncle refers to the crossing over of its fibers from one side of the brainstem to the other. This decussation occurs at the level of the midbrain, specifically in the region called the upper midbrain tegmentum. Cerebellar Peduncle: It connects the cerebellum to the brainstem. Superior cerebellar peduncle connects the cerebellum to the midbrain. Middle cerebellar peduncle connects the cerebellum to the pons. Inferior cerebellar peduncle connects the cerebellum to the medulla. Pons (Option A): While the pons is involved in the transmission of various neural signals, the decussation of the superior cerebellar peduncle does not occur at this level. Diencephalon (Option C): The diencephalon, housing the thalamus and hypothalamus, lies above the midbrain. The superior cerebellar peduncle's decussation doesn't happen within the diencephalon. Medulla (Option D): While the medulla is involved in various vital functions, including cardiovascular and respiratory control, the decussation of the superior cerebellar peduncle does not occur at the level of the medulla.

References:

BD Chaurasia’s Human Anatomy, 8th Edition, Page 765

↑ *Back to this question in Part A*

@Neet_pg_bot

Q18: Where is the probable location of the lesion in a patient who has presented with weakness and loss of pain and temperature sensation on the right side of the face along with loss of pain and temperature sensation on the left leg? (Q854985)

A. Medial medulla

B. Lateral pons

C. Medial pons

D. Lateral medulla

Correct Answer: D. Lateral medulla

Explanation: The clinical features described— weakness and loss of pain and temperature sensation on the right side of the face , along with loss of pain and temperature sensation on the left leg —are indicative of a lateral medullary syndrome , also known as Wallenberg syndrome . In this condition, there is damage to the lateral part of the medulla . This syndrome typically involves the spinothalamic tract (for pain and temperature sensation), the descending trigeminal tract (for facial sensation), and other structures like the nucleus ambiguus (which affects the motor function of the larynx and pharynx). Wallenberg Syndrome (Lateral Medullary Syndrome) Due to stroke or infarction in the lateral part of the medulla oblongata. Mainly due to occlusion of the posterior inferior cerebellar artery (PICA), a branch of the vertebral artery. Sometimes the vertebral artery directly supplies the lateral brainstem. Affects the dorsolateral aspect of the medulla and the inferior surface of the cerebellum. Anatomical structure affected and features: Spinothalamic tract: Contralateral loss of pain and temperature sensation of the trunk. Spinal nucleus and tract of the trigeminal nerve: Ipsilateral loss of pain and temperature sensation of the face. Nucleus ambiguus: Ipsilateral paralysis of muscles of the palate, pharynx, and larynx. Inferior cerebellar peduncle and cerebellum: Ipsilateral ataxia. Vestibular nuclei: Giddiness. Medial medulla (option A): Lesions here typically affect the medial lemniscus (responsible for touch and proprioception) and corticospinal tract (which affects motor function). This would cause contralateral weakness and loss of touch/proprioception , but not facial pain/temperature loss . Lateral pons (option B): Lesions in the lateral pons often affect the spinothalamic tract and trigeminal nerve (similar to the lateral medulla), but this would typically involve contralateral body symptoms, not the contralateral leg . The face could have sensory loss on the same side , but the involvement of the left leg would point more toward the medulla . Medial pons (option C): A lesion here would primarily affect structures like the corticospinal tract , abducens nucleus , and the medial lemniscus , leading to contralateral motor deficits and sensory loss of the body. Facial pain/temperature loss would not occur with a medial pontine lesion.

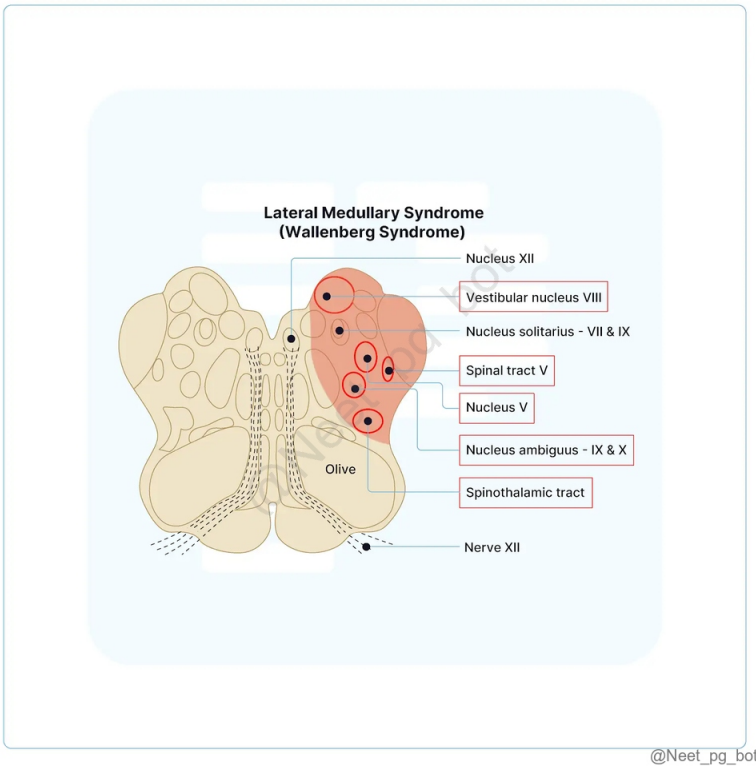

References:

Vishram Singh Anatomy of Head, Neck and brain, Volume 3, Page 366

↑ *Back to this question in Part A*

@Neet_pg_bot

Q19: A patient presented with clinical features of ataxia and incoordination. This is due to thrombosis of which artery? (Q858495)

A. Posterior cerebral artery (PCA)

B. Middle cerebral artery (MCA)

C. Internal carotid artery (ICA)

D. Superior cerebellar artery (SCA)

Correct Answer: D. Superior cerebellar artery (SCA)

Explanation: The SCA supplies the superior part of the cerebellum and parts of the midbrain. Thrombosis of this artery leads to cerebellar ataxia , incoordination, dysmetria, and sometimes vertigo due to cerebellar dysfunction.

The symptoms primarily affect balance, limb coordination, and gait stability. Midbrain Blood Supply: Anterior-Medial Supply: branches of the Basilar artery Anterior-Lateral Supply: branches of the Posterior Choroidal arteries and Quadrigeminal artery from the Posterior Cerebral Artery Posterior Supply: Quadrigeminal Artery and Superior Cerebellar Artery Incorrect Options: Posterior cerebral artery (PCA) (option A): Incorrect because PCA infarcts primarily affect the occipital lobe , leading to visual deficits (e.g., homonymous hemianopia) rather than ataxia. Middle cerebral artery (MCA) (option B): Incorrect because MCA occlusion leads to contralateral motor and sensory deficits (especially in the face and upper limb) and aphasia (if the dominant hemisphere is involved), but not significant ataxia. Internal carotid artery (ICA) (option C): Incorrect because ICA occlusion affects multiple territories, mainly causing hemiparesis, hemisensory loss, and aphasia rather than isolated cerebellar ataxia.



References:

Neuroanatomy, Brainstem - StatPearls - NCBI Bookshelf

The Midbrain - Colliculi - Peduncles - TeachMeAnatomy

↑ *Back to this question in Part A*

@Neet_pg_bot

Q20: Which of the following is not used for the identification of the facial nerve trunk? (Q858498)

A. Retrograde dissection from distal branch

B. Tragal pointer

C. Inferior belly of omohyoid muscle

D. Posterior belly of digastric

Correct Answer: C. Inferior belly of omohyoid muscle

Explanation: The inferior belly of omohyoid muscle is not used for identifying the facial nerve trunk because it is located in the lower neck and does not have any anatomical relation to the facial nerve . The facial nerve exits the stylomastoid foramen and is identified in the parotid region , where it divides into its branches. Origin: The facial nerve arises from the pons, a part of the brainstem, at the pontomedullary junction. Pathway: After its origin, the facial nerve enters the internal acoustic meatus along with the vestibulocochlear nerve (CN VIII). It then travels through the facial canal within the temporal bone. Key Structures Along Its Course Geniculate Ganglion: Located within the facial canal, this is a sensory ganglion where the nerve fibers for taste (from the anterior two-thirds of the tongue) and some general sensory fibers synapse. Branches within the Facial Canal: Greater Petrosal Nerve: Arises from the geniculate ganglion, carrying parasympathetic fibers to the lacrimal gland and nasal mucosa. Chorda Tympani: This branch arises after the geniculate ganglion and carries taste fibers from the anterior two-thirds of the tongue and parasympathetic fibers to the submandibular and sublingual salivary glands. Exit from the Skull Stylomastoid Foramen: The facial nerve exits the skull here, located between the styloid and mastoid processes of the temporal bone. Extracranial part of facial nerve: Entry into Parotid Gland The main trunk enters on the posteromedial surface of the parotid gland. Division of Nerve Divides within the gland, behind and superficial to the retromandibular vein and external carotid artery (ECA). Temporofacial vs. Cervicofacial Trunks Temporofacial trunk: Contains more axons but fewer fascicles. Cervicofacial trunk: Contains more fascicles but fewer axons. Formation of Parotid Plexus The trunks branch further to form the parotid plexus (pes anserinus) from which the terminal branches arise. Terminal Branches Temporal, zygomatic, buccal, marginal mandibular, and cervical. Incorrect Options: Retrograde dissection from distal branch (option A): In cases where the main trunk is difficult to locate, tracing a distal branch backward helps in identifying the facial nerve trunk . Tragal pointer (option B): The tragal pointer (cartilaginous structure of the external auditory canal) is an important surgical landmark, located about 1 cm anterior and inferior to the stylomastoid foramen , where the facial nerve trunk emerges . Posterior belly of digastric (option D): The posterior belly of the digastric muscle is another key landmark. The facial nerve trunk is located just superior to this muscle at its attachment to the mastoid process.

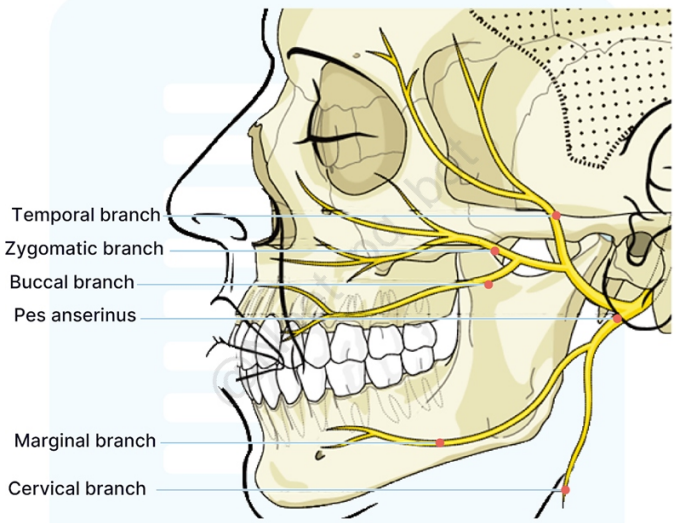

References:

Scott Brown's Otorhinolaryngology, Vol 2, 8th Edition, Page 1387

↑ *Back to this question in Part A*

@Neet_pg_bot

Q21: An exhausted man was brought to the casualty with minimal response. He had a progressive history of weakness in his body for 2 days with facial droop, and slurring speech. Which vessel is likely to be thrombosed? (Q859911)

A. Posterior cerebral artery

B. Anterior cerebral artery

C. Middle cerebral artery

D. Posterior inferior cerebellar artery

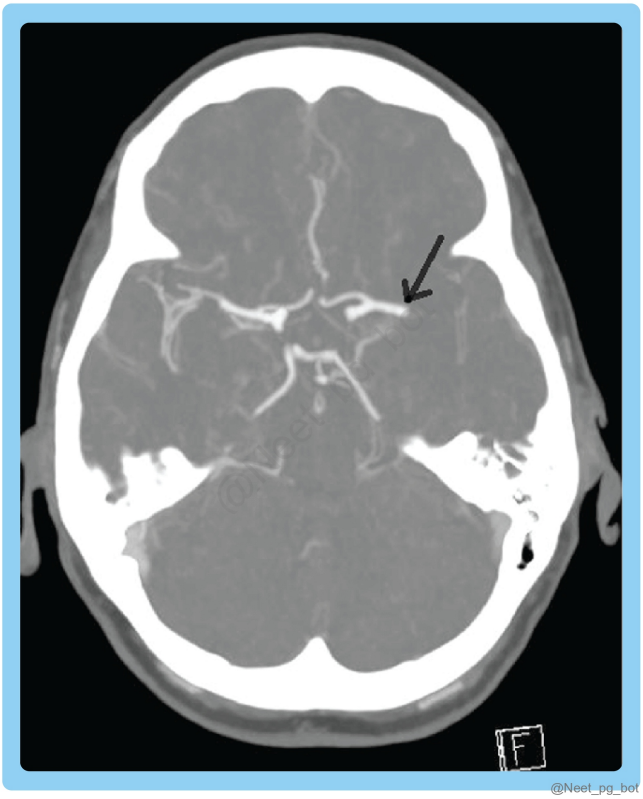

Correct Answer: C. Middle cerebral artery

Explanation: MCA stroke best explains the symptoms (facial droop, weakness, slurred speech), making option C the correct choice. Blood supply to the major cortical areas: Artery Supplies Occlusion: Affected Areas and Deficits Anterior cerebral artery (Option B) Medial aspect of hemisphere - Paracentral lobule: Contralateral somatosensory loss in the lower extremity and perineum, contralateral weakness and hyperreflexia in the lower extremity, urinary incontinence Middle cerebral artery Lateral surface Frontal lobe: Contralateral facial weakness and weakness in upper limb, conjugate deviation of the eye to the affected side, Broca aphasia Temporal lobe: Deafness, Wernicke aphasia, auditory hallucinations Parietal lobe: Gerstmann syndrome (dominant hemisphere lesion), hemi neglect syndrome (nondominant hemisphere) Posterior cerebral artery (Option A) Occipital lobe, inferior aspect of temporal lobe, splenium of corpus callosum Occipital lobe: Contralateral homonymous hemianopia with macular sparing Temporal lobe: Incapacity to create and store new memory Posterior inferior cerebellar artery (PICA) thrombosis (Option D): Causes lateral medullary syndrome (Wallenberg syndrome) with dizziness, ataxia, dysphagia, and Horner's syndrome

References:

Gray’s Anatomy, 42nd Edition, Page 420, 421

↑ *Back to this question in Part A*

@Neet_pg_bot

Q22: Identify the structure marked in the below image. (Q859925)

A. Caudate nucleus

B. Insula

C. Lentiform nucleus

D. Third ventricle

Correct Answer: C. Lentiform nucleus

Explanation: The structure marked in the image is the Lentiform nucleus. This structure is a part of the basal ganglia and consists of two components: the putamen and the globus pallidus. It plays a key role in motor control and coordination. {{caption_text}} (Options A, C) (Option D) Caudate nucleus (Option A): is a subcortical paired "C "shaped structure which lies deep inside the brain near thalamus Insula (Option B): is a small region of the cerebral cortex located deeply in the cerebral cortex. It is a large fissure that separates the frontal and parietal lobes from the temporal lobe. Third ventricle (Option D): is a funnel-shaped structure that lies in the center of the brain. It is sandwiched between the right and left thalamus

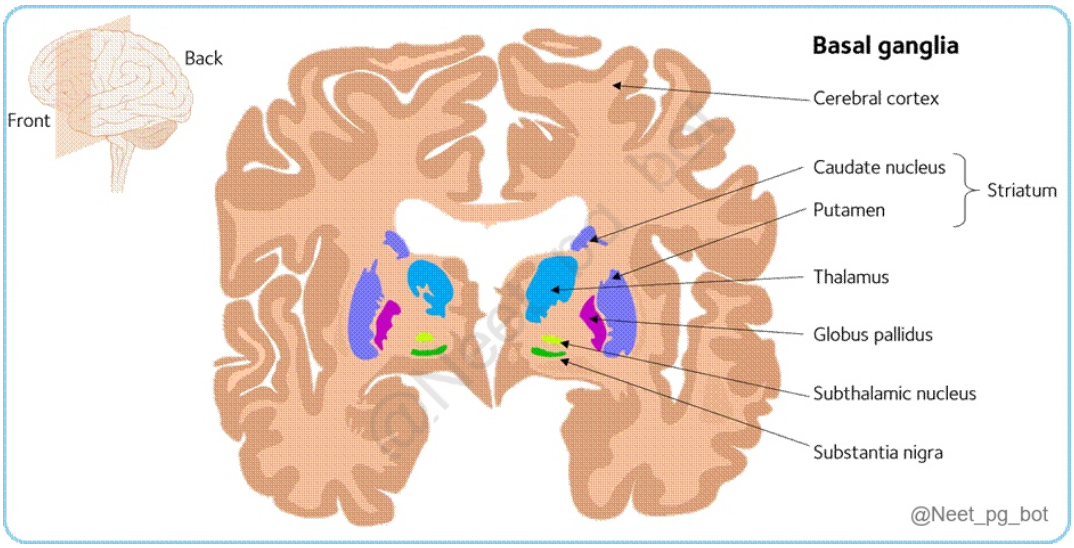

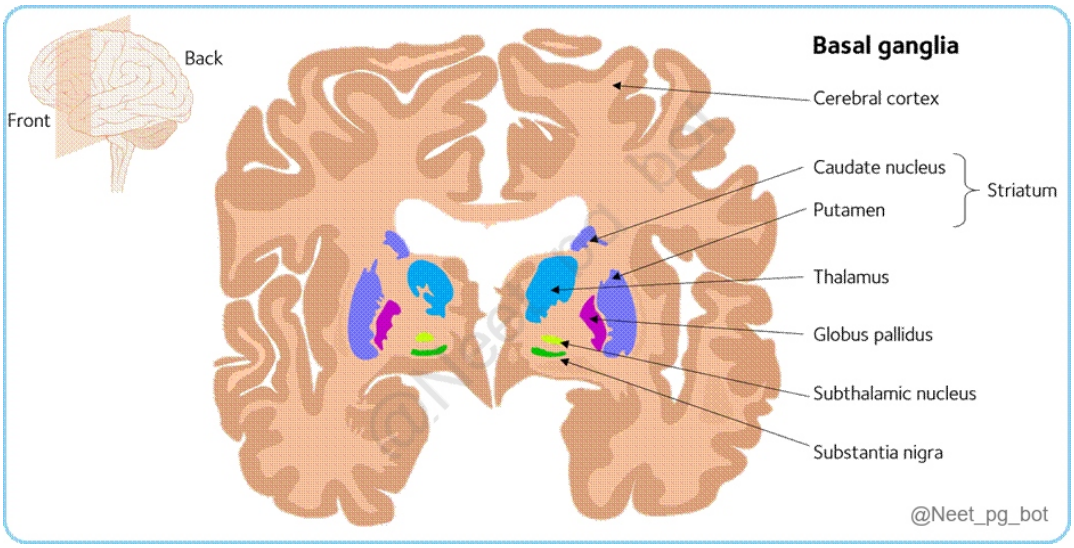

References:

https://www.ncbi.nlm.nih.gov/books/NBK537141/

↑ *Back to this question in Part A*

@Neet_pg_bot

Q23: Which of the following structures is separated by the marked structure (“X”) in the diagram? (Q879149)

A. Lateral ventricle

B. Third ventricle

C. Fourth ventricle

D. Cisterna magna

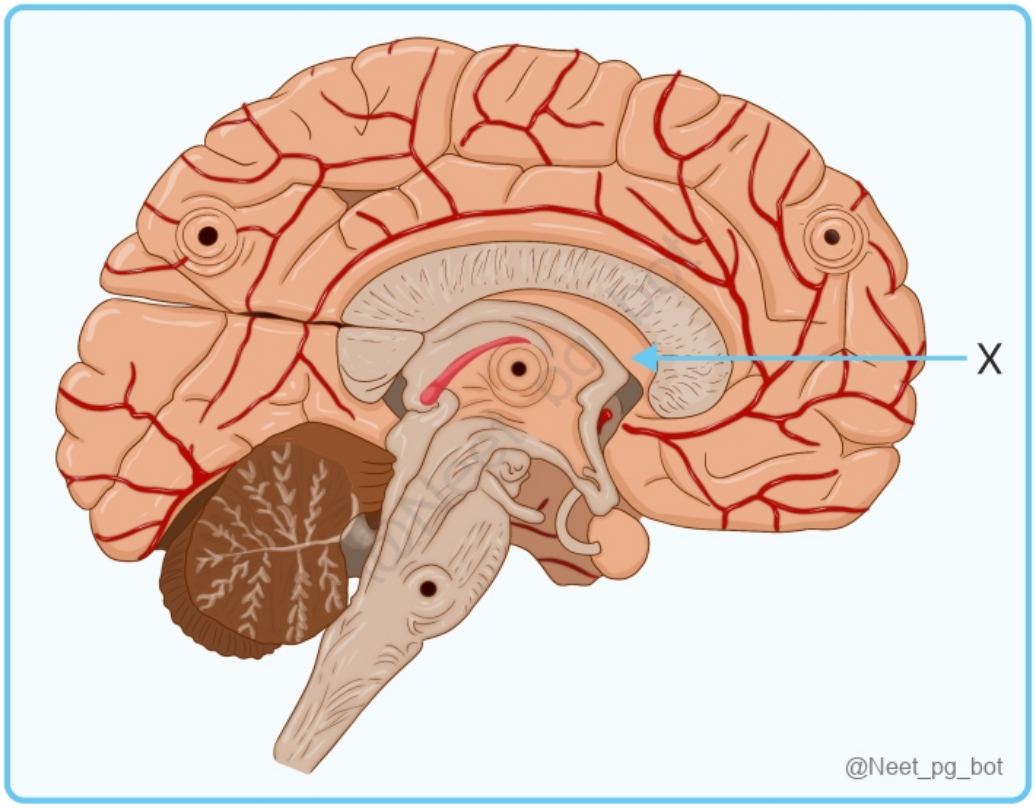

Correct Answer: A. Lateral ventricle

Explanation: The marked structure is the septum pellucidum , a thin, membranous partition that separates the anterior horns of the right and left lateral ventricles . It extends superiorly to the corpus callosum and inferiorly to

the fornix . Incorrect Options: Third ventricle (Option B): The septum pellucidum does not separate the third ventricle; it lies lateral to it. Fourth ventricle (Option C): The fourth ventricle is located in the brainstem and is not related to the septum pellucidum. Cisterna magna (Option D): The cisterna magna is a subarachnoid space below the cerebellum, unrelated to the septum pellucidum.

References:

BD Chaurasia's Human Anatomy, Volume 4, 3rd Edition, Page 215.

↑ *Back to this question in Part A*

@Neet_pg_bot

Q24: In the given image the marked structure articulates with which of the following bones? (Q879152)

A. Occipital bone

B. Axis

C. Sphenoid bone

D. Temporal bone

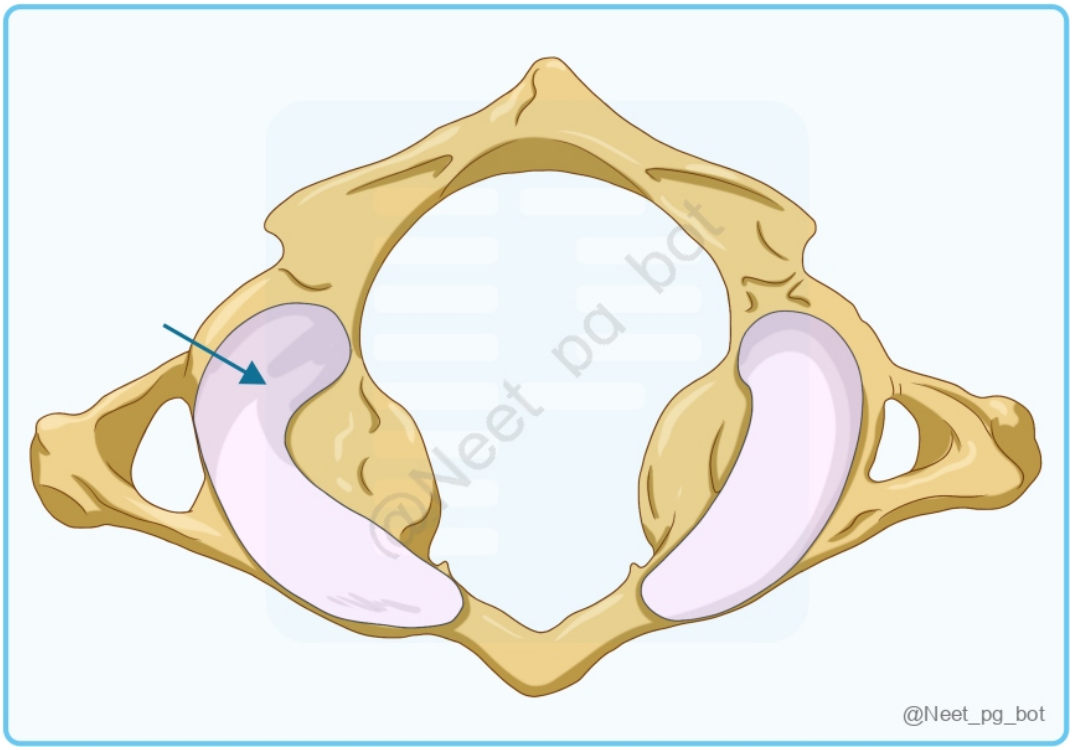

Correct Answer: A. Occipital bone

Explanation: The marked structure in the given image is the superior articular facet of the atlas, which articulates with the occipital bone. C1 Vertebra (Atlas) C2 Vertebra (Axis) ■ ■■ ■ ■ Body Lacks a traditional vertebral body. Consists of an anterior and posterior arch. Prominent body with a unique projection called the odontoid process (dens). Odontoid process: Bony projection that fits into the atlas ring, allowing for rotational movement of the head and neck. Spine Lacks spine The spine is massive with a bifid tip Superior Articular Facets Articulate with the occipital condyles of the skull (atlantooccipital joint) Articulate with the inferior facets of the atlas (atlantoaxial joint) ; oriented to permit head rotation. Inferior Articular Facets Articulates with C2 (atlantoaxial joint) Articulates with C3 Transverse process Long transverse process. Has anterior and posterior tubercles for ligament and muscle attachments. Small transverse processes. Lacks anterior tubercle. Transverse Foramen Contains a transverse foramen for the passage of the vertebral artery Role and Movement Supports the skull; allows nodding movements (flexion and extension) of the head. Yes movement ■ ■ Crucial for head rotation, the dens serves as the central pivot point. No movement ■ Special Note Distinct for lacking a vertebral body and spinous process. Provides stability and acts as the primary pivot for head rotation.

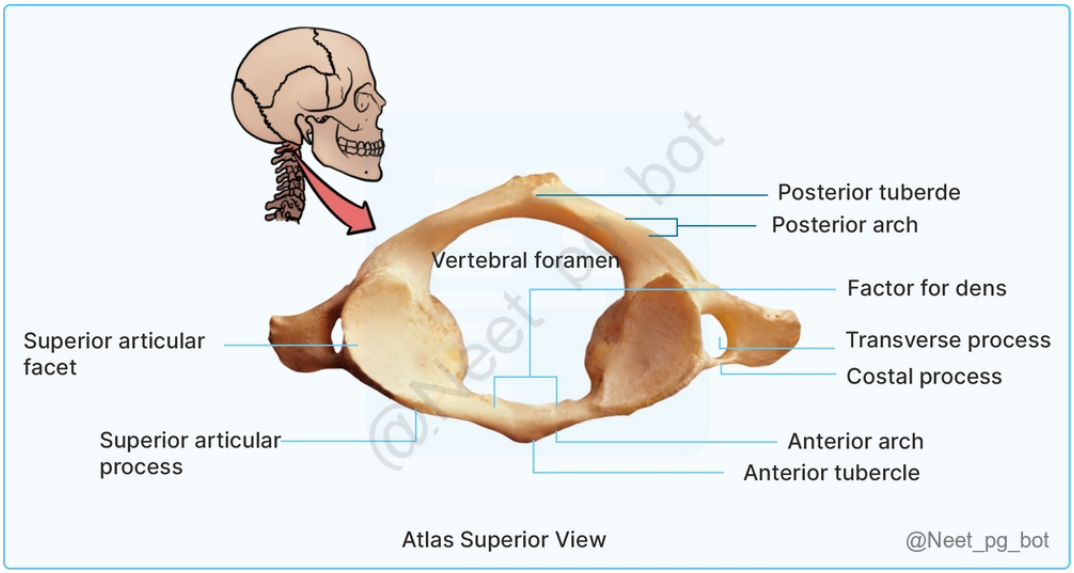



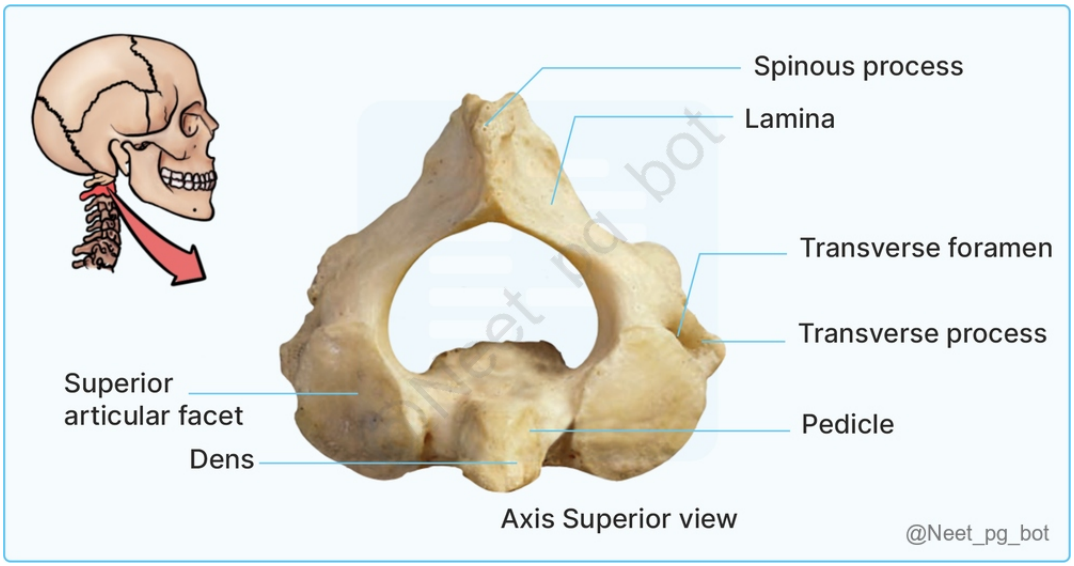
Spinous process
Lamina
Transverse foramen
Transverse process
Pedicle
Superior articular facet
Dens
Axis Superior view
@Neet_pg_bot

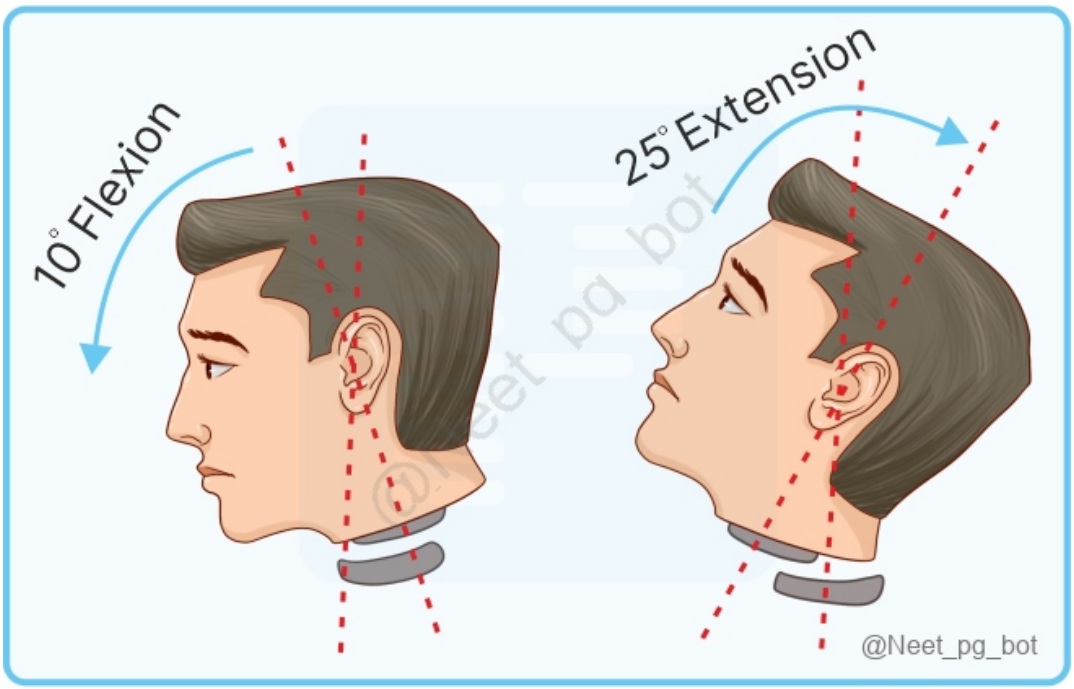



References:

Gray’s Anatomy, 42nd Edition, Page 826-828

BD Chaurasia's Human Anatomy, (Volume 3,4) 8th Edition, Page 53-55

↑ *Back to this question in Part A*

Q25: Match the following regions marked with their respective structures? (Q879157)

A. Inferior colliculus

B. Superior cerebellar peduncle

C. Middle cerebellar peduncle

D. Inferior cerebellar peduncle

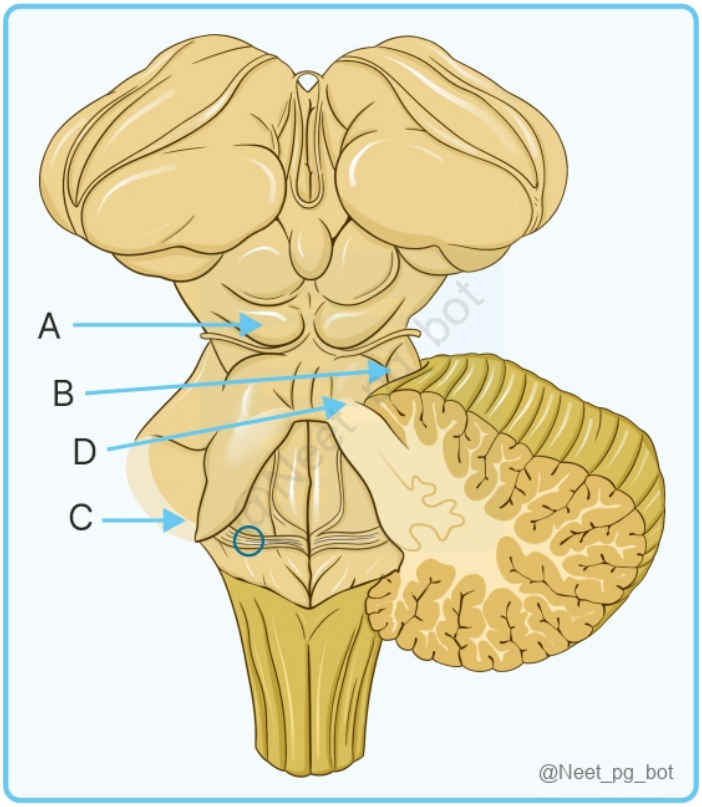

Correct Answer: A. Inferior colliculus

Explanation: ■ The structure marked as A is the Inferior colliculus B - Middle cerebellar peduncle C - Inferior cerebellar peduncle D - Superior cerebellar peduncle Cerebellar Peduncles Afferent Efferent Superior cerebellar peduncle Ventral Spinocerebellar Tract All efferent fibres from dentate, emboliform, fastigial and globose nuclei Middle cerebellar peduncle Pontocerebellar Mossy Fibre Pathway No efferent fibres Inferior cerebellar peduncle Dorsal Spinocerebellar Tract Olivocerebellar Tract Reticulocerebellar Tract Few efferents from the cerebellum to the medulla oblongata, mainly to vestibular nuclei and reticular formation.



@Neet_pg_bot

References:

Gray’s Anatomy, 42nd Edition, Page 445,467,468

Netter Atlas of Human Anatomy, 8th Edition, Plate 141, Page198

Vishram Singh, Textbook of Anatomy, 2nd Edition, Volume 3, Page 378

↑ *Back to this question in Part A*

@Neet_pg_bot

Q26: While administering epidural anesthesia, which structure is not punctured before injecting the drug? (Q860626)

A. Supraspinous ligament

B. Interspinous ligament

C. Ligamentum flavum

D. Arachnoid mater

Correct Answer: D. Arachnoid mater

Explanation: The arachnoid mater is not punctured while administering epidural anesthesia. The arachnoid mater extends up to the S2 vertebrae. The arachnoid and the dura matter are punctured while performing lumbar puncture. Structures pierced to reach epidural space:

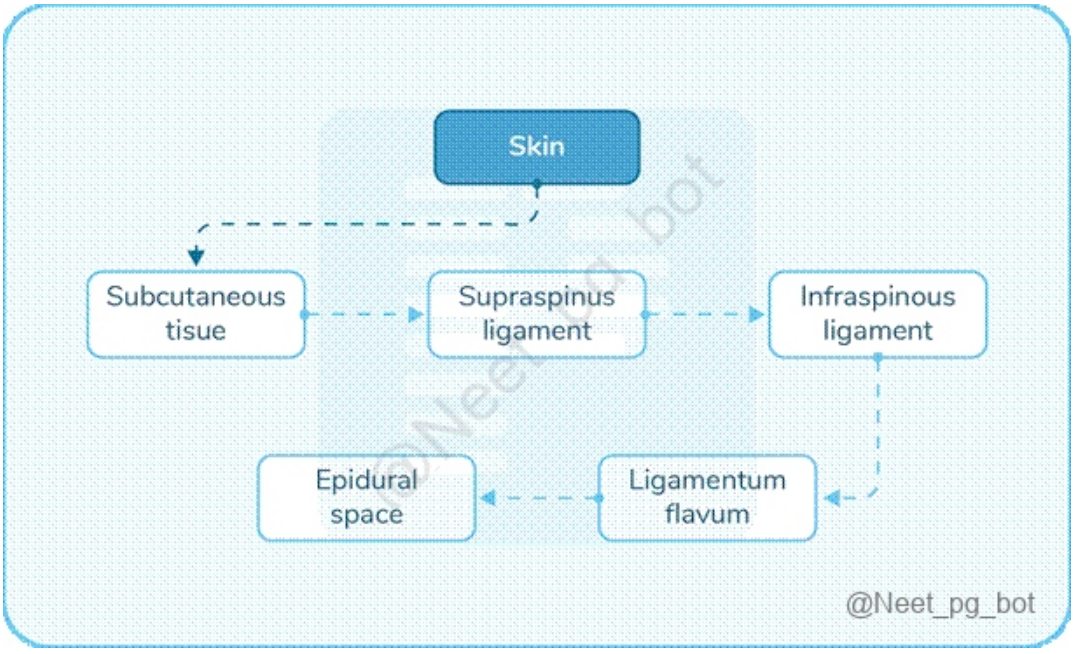

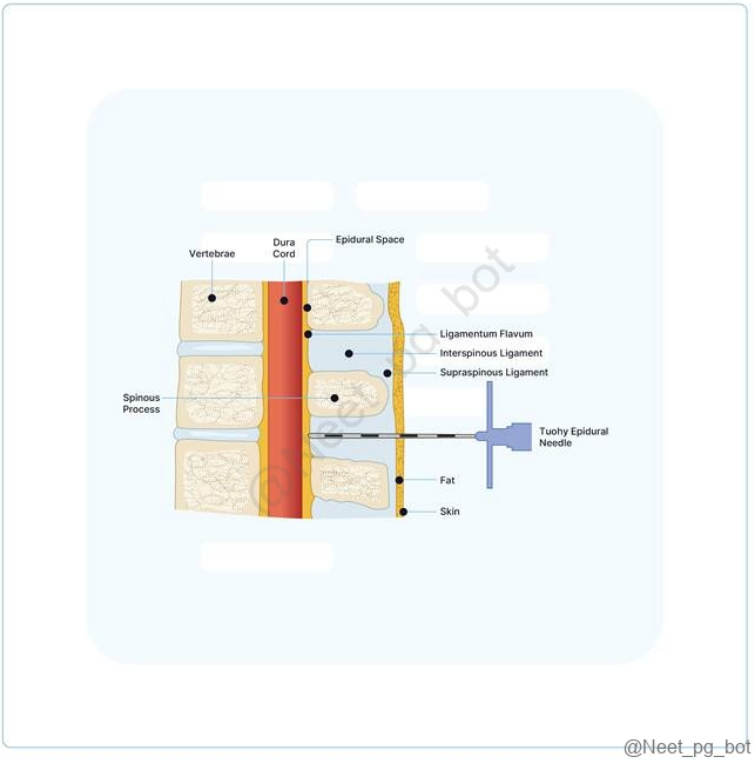

References:

Miller’s Anesthesia, 9th Edition, Pages 1435, 1436

Morgan and Mikhail's Clinical Anesthesiology, 7th Edition, Pages 1836, 1837

↑ *Back to this question in Part A*

@Neet_pg_bot

Q27: During a neck dissection, a nerve was identified and marked that is most likely the vagus nerve (CN X). Which of the following is NOT a functional component of the vagus nerve? (Q866306)

A. General visceral afferent

B. General somatic efferent

C. General visceral efferent

D. General somatic afferent

Correct Answer: B. General somatic efferent

Explanation: The vagus nerve does not contain a functional component classified as GSE (General Somatic Efferent). Neural column Nuclei and Cranial Nerves GSE (General Somatic Efferent) SVE (Special Visceral Efferent) GVE (General Visceral Efferent) GVA/SVA (General/Special Visceral Afferent) GSA (General Somatic Afferent) SSA (Special Somatic Afferent) Oculomotor nucleus (III) Trochlear nucleus (IV) Abducent nucleus (VI) Hypoglossal nucleus (XII) Motor nucleus of Trigeminal Nerve (V) Motor nucleus of the facial nerve (VII) Nucleus ambiguus (IX, X, XI) Edinger Westphal nucleus (III) Superior salivatory nucleus (VII) Inferior salivatory nucleus (IX) Dorsal nucleus of Vagus (X) (Option C ruled out) Nucleus Tractus Solitarius (GVA - IX, X) (SVA - VII, IX) (Option A ruled out) Sensory nuclei of Trigeminal Nerve (shared by cranial nerves V, IX, X (Option D ruled out) Vestibular nuclei (VIII) Cochlear nuclei (VIII) The lateral geniculate nucleus of the thalamus (II). Olfactory bulb (I)

References:

.

↑ *Back to this question in Part A*

@Neet_pg_bot

Q28: Identify the defect in the given image: (Q852509)

A. Open neural tube defect

B. Meningomyelocele

C. Occult Spina bifida

D. Encephalocele



Correct Answer: D. Encephalocele

Explanation: The given image depicts an occipital cranial defect with a sac containing brain tissue herniated through a skull defect, which defines an encephalocele . Open neural tube defect (Option A): Broad term; while encephaloceles are neural tube defects, the specific diagnosis is encephalocele, not a generic category Meningomyelocele (Option B) : This is a spinal defect in the lumbosacral region with herniation of spinal cord, meninges, and CSF through vertebral arches, not cranial/occipital like the image. Occult Spina Bifida (Option C): Incorrect because occult spina bifida is a closed defect where the vertebral arch fails to fuse, but the skin remains intact, often presenting with subtle external markers like a tuft of hair or dimple.

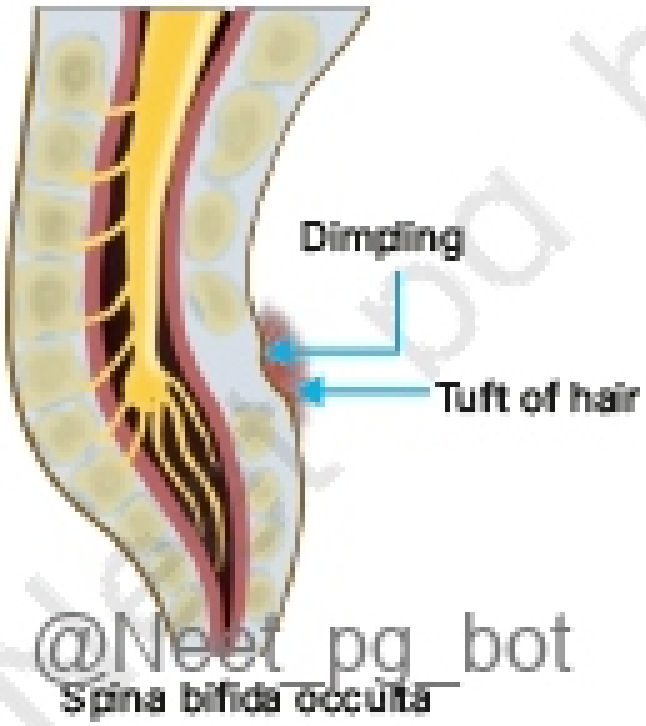

@Neet_pg_bot


@Neet_pg_bot

References:

Ghai Essential of Paediatrics, 10th Edition, Page 575

↑ *Back to this question in Part A*

@Neet_pg_bot

Q29: The nerve passing through the red arrow marked region has been lesioned. Which of the following will be the clinical presentation? (Q844152)

A. Loss of sensation in the mucosa of nasopharynx

B. Loss of sensation in maxillary area of face

C. Loss of sensation in jaw area

D. Loss of sensation in scalp and nose

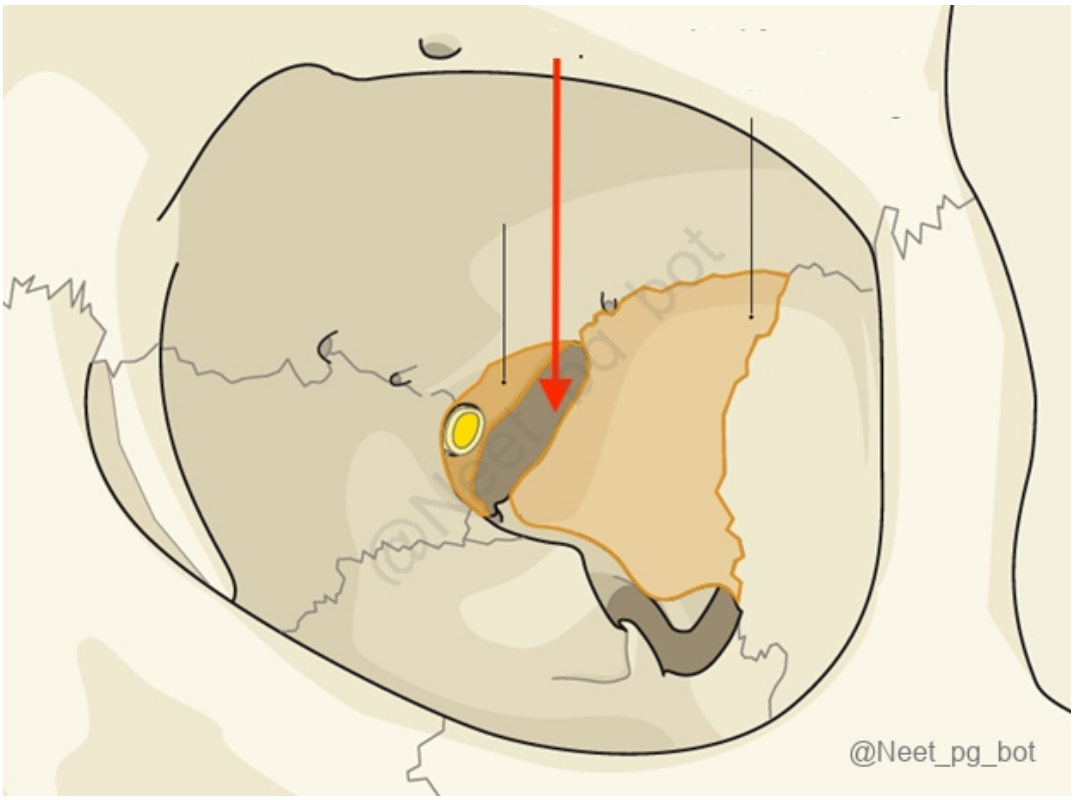

Correct Answer: D. Loss of sensation in scalp and nose

Explanation: Correct Option D - Loss of sensation in scalp and nose: The superior orbital fissure is a crucial anatomical opening in the skull through which several important nerves pass. These include the oculomotor nerve (CN III), trochlear nerve (CN IV), abducens nerve (CN VI), and the ophthalmic division (V1) of the trigeminal nerve (CN V). The ophthalmic division (V1) of the trigeminal nerve provides sensory innervation to the scalp, forehead, upper eyelid, nose, and the mucosa of the frontal sinuses. If the nerve passing through the superior orbital fissure is lesioned, the patient would experience loss of sensation in the scalp and nose due to the

impairment of the ophthalmic nerve (V1). Incorrect Options: Option A - Loss of sensation in the mucosa of nasopharynx: Incorrect: This sensation is typically provided by branches of the maxillary nerve (V2) and glossopharyngeal nerve (CN IX), not by the ophthalmic nerve (V1), which passes through the superior orbital fissure. Option B - Loss of sensation in maxillary area of face: Incorrect: The maxillary division (V2) of the trigeminal nerve provides sensation to the maxillary region, but it exits the skull through the foramen rotundum, not the superior orbital fissure. Option C - Loss of sensation in jaw area: Incorrect: The mandibular division (V3) of the trigeminal nerve provides sensation to the jaw, but it exits through the foramen ovale, not the superior orbital fissure.

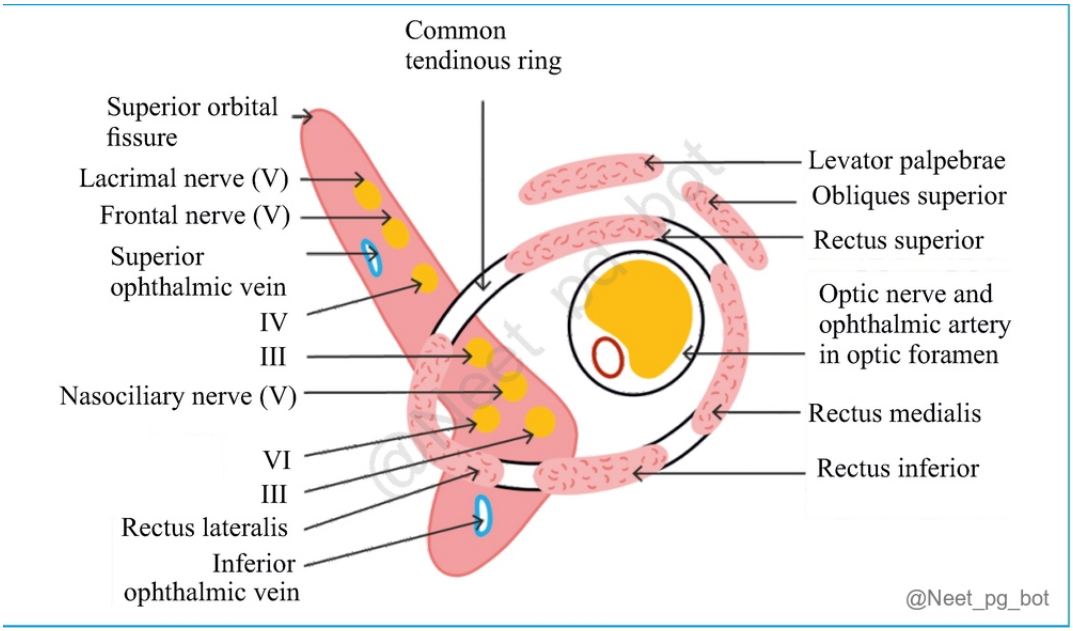

References:

Parson's Diseases of the Eye, 23rd Edition, Page 1130

↑ *Back to this question in Part A*

@Neet_pg_bot

Q30: A 35 year old female presented with lesion shown below. This would result in which kind of field abnormality? (Q844165)

A. Homonymous hemianopia

B. Bitemporal hemianopia

C. Complete blindness

D. Single vision field loss

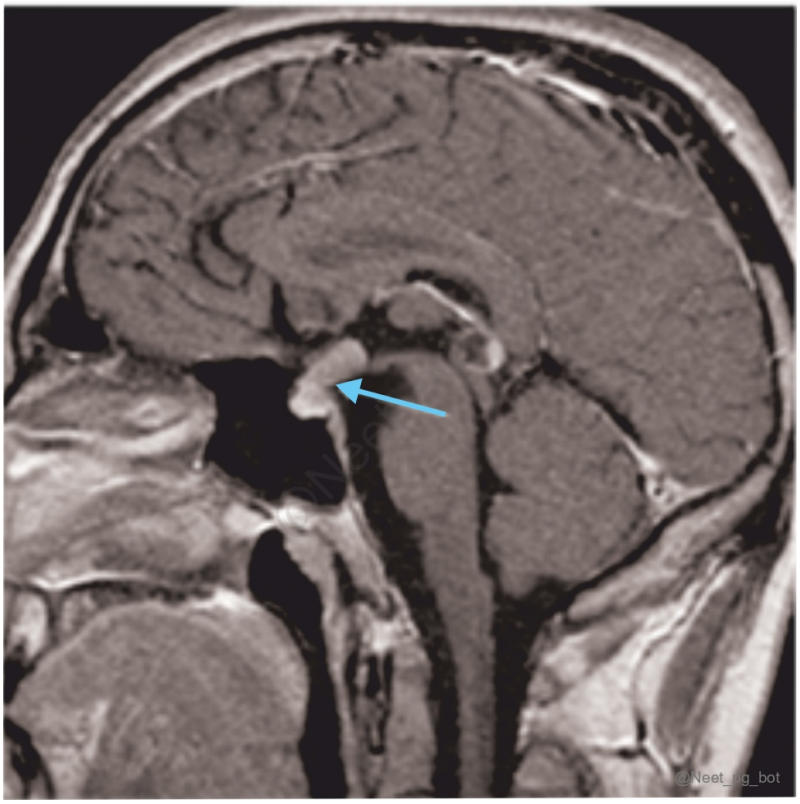

Correct Answer: B. Bitemporal hemianopia

Explanation: Craniopharyngiomas are often located near the pituitary gland and the optic chiasm. A tumor in this area can compress the optic chiasm, which affects the crossing fibers of the optic nerves from the nasal (medial) fields of vision. This results in loss of vision in the temporal (lateral) fields of both eyes, known as bitemporal hemianopia. Homonymous hemianopia (Option A) : This type of vision loss occurs when there is damage to the optic tract or the visual cortex, leading to loss of vision in the same field of both eyes (either left or right). This is not typically associated with craniopharyngiomas. Complete blindness(Option C) : Complete blindness would occur with damage to both the optic nerves or the visual pathways at a more extensive level, not just from a craniopharyngioma affecting the optic chiasm. Single vision field loss (Option D) : This would imply a unilateral field loss, which is not characteristic of craniopharyngiomas. They usually affect the visual fields in a bitemporal manner due to their location affecting the optic chiasm.

References:

Gray's Anatomy, 42nd Edition, Page 538

↑ *Back to this question in Part A*

@Neet_pg_bot

Q31: Identify the arrow marked nerve: (Q844201)

A. Medial pectoral nerve

B. Lateral pectoral nerve

C. Long thoracic nerve

D. Thoracodorsal nerve

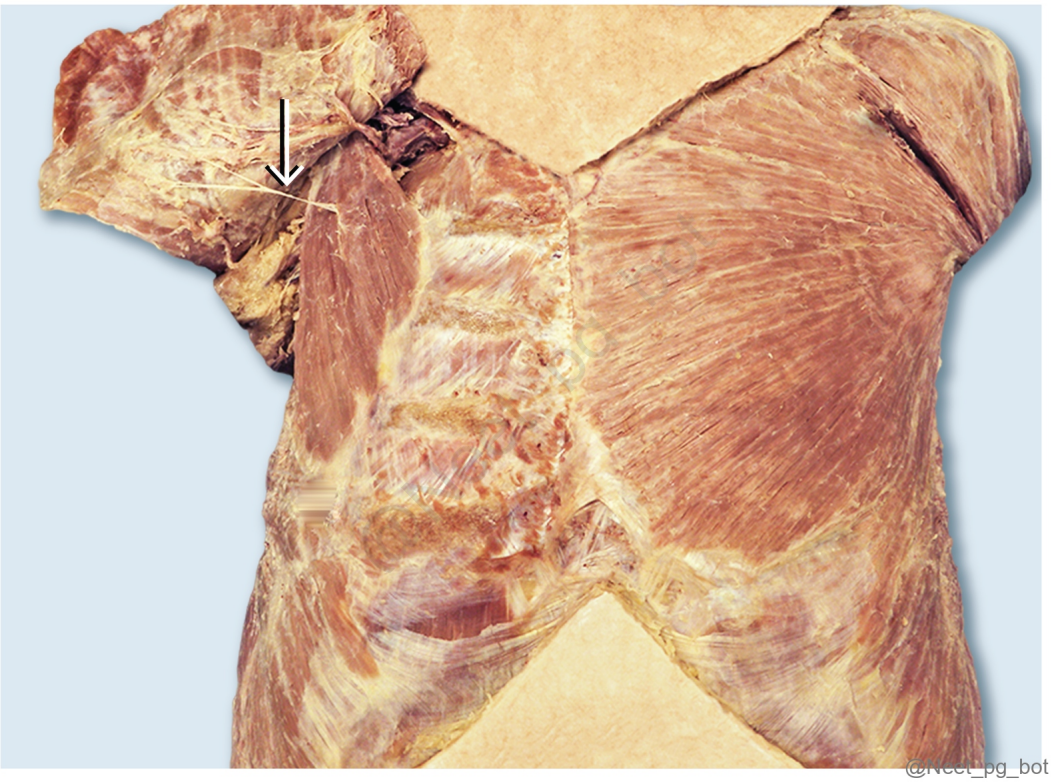

Correct Answer: A. Medial pectoral nerve

Explanation: Correct Option A - Medial pectoral nerve: The medial pectoral nerve arises from the medial cord of the brachial plexus and innervates the pectoralis minor and part of the pectoralis major muscles. The nerve typically pierces the pectoralis minor before reaching the pectoralis major. In an anatomical image or dissection, the medial pectoral nerve can be identified as the nerve that passes through or near the pectoralis minor and then continues to supply the pectoralis major. Incorrect Options: Option B - Lateral Pectoral Nerve: The lateral pectoral nerve arises from the lateral cord of the brachial plexus and primarily innervates the pectoralis major muscle. Unlike the medial pectoral nerve, it does not pierce the pectoralis minor but rather passes above it. The lateral pectoral nerve is generally found more laterally and superiorly than the medial pectoral nerve. Option C - Long Thoracic Nerve: The long thoracic nerve innervates the serratus anterior muscle. It runs down the side of the thorax and can be seen on the surface of the serratus anterior. It is not associated with the pectoral muscles and is positioned more posteriorly and laterally compared to the pectoral nerves. Option D - Thoracodorsal Nerve: The thoracodorsal nerve arises from the posterior cord of the brachial plexus and innervates the latissimus dorsi muscle. It is found on the posterior side of the thorax and is not involved with the pectoral muscles, making it distinct from the medial pectoral nerve.

References:

.

↑ *Back to this question in Part A*

@Neet_pg_bot

Q32: Ptosis in horner’s syndrome is due to paralysis of which muscle? (Q844194)

A. Superior tarsal muscle

B. Orbitalis

C. Orbicularis oculi

D. Sphincter pupillae

Correct Answer: A. Superior tarsal muscle

Explanation: This muscle is a smooth muscle that assists the levator palpebrae superioris in raising the upper eyelid. In Horner's syndrome, there is a disruption of the sympathetic innervation, leading to paralysis of the superior tarsal muscle. This results in a mild ptosis (drooping of the upper eyelid). Orbitalis (Option B): The orbitalis muscle (also known as Müller's muscle) is not directly involved in eyelid movement but is instead associated with the structure of the orbit. It is not the cause of ptosis in Horner's syndrome. Orbicularis Oculi (Option C): The orbicularis oculi muscle is responsible for closing the eyelids and is innervated by the facial nerve (cranial nerve VII). It is not affected in Horner's syndrome and is not responsible for ptosis. Sphincter Pupillae (Option D): The sphincter pupillae muscle is responsible for constricting the pupil and is innervated by the parasympathetic nervous system. It is not involved in eyelid movement and is not the cause of ptosis in Horner's syndrome.

References:

Gray’s Anatomy, The Anatomical Basis of Clinical Practice, 42nd Edition, Page 456

↑ *Back to this question in Part A*

@Neet_pg_bot

Q33: What are the effects of a lesion in Brodmann area 22? (Q844210)

A. Expressive aphasia

B. Receptive aphasia

C. Poor repetition of language

D. Poor naming

Correct Answer: B. Receptive aphasia

Explanation: Brodmann area 22 corresponds to Wernicke's area , located in the superior temporal gyrus of the dominant hemisphere (usually left). A lesion in this area causes Wernicke's aphasia , also known as receptive aphasia , characterized by impaired comprehension and fluent but meaningless speech (word salad). Comparison of Different Types of Aphasias Feature Broca's Aphasia (Expressive) Wernicke's Aphasia (Receptive) Conduction Aphasia Global Aphasia Anomic Aphasia Brodmann Area 44, 45 (Broca's area) 22 (Wernicke's area) Arcuate fasciculus Large perisylvian lesion Various, including temporal & parietal lobes Fluency Non-fluent , effortful speech Fluent , but meaningless (word salad) Fluent , but with word-finding pauses Non-fluent , severely reduced speech Fluent , but with word-finding difficulty Comprehension Intact Impaired Intact Impaired Intact Repetition Impaired Impaired Severely impaired (hallmark) Impaired Intact Naming Ability Impaired Impaired Impaired Severely impaired Severely impaired (hallmark) Common Causes Stroke in MCA territory affecting frontal lobe Stroke in MCA territory affecting temporal lobe Damage to arcuate fasciculus (stroke, trauma) Large MCA infarct affecting Broca's & Wernicke's areas Focal temporal/parietal lesions (tumors, stroke) Expressive aphasia (Option A): Incorrect because expressive aphasia (Broca's aphasia) results from a lesion in Brodmann area 44 & 45 (Broca's area) , causing non-fluent speech with intact comprehension . Poor repetition of language (Option C): Incorrect because this is characteristic of conduction aphasia , which occurs due to damage in the arcuate fasciculus , disrupting communication between Wernicke's and Broca's areas. Poor naming (Option D): Incorrect because while naming impairment can occur, it is not specific to Wernicke's aphasia ; anomic aphasia primarily affects naming ability.

References:

Snells Clinical Neuroanatomy, 8th Edition. Page 264

Gray's Anatomy, 42nd Edition. Pages 534, 535, 536

aphasia.org/what-is-aphasia/

www.ncbi.nlm.nih.gov/books/NBK537006/

↑ *Back to this question in Part A*

@Neet_pg_bot

Q34: A patient with loss of sensation on the lateral 3 1 / 2 (palmar aspect) hand and thenar atrophy. Which nerve is involved? (Q844239)

A. Median

B. Ulnar

C. Radial

D. Anterior interosseous nerve

Correct Answer: A. Median

Explanation: Lateral 3½ fingers (thumb, index, middle, and lateral half of ring finger) on the palmar side are supplied sensory-wise by the median nerve . Thenar atrophy suggests motor loss to thenar muscles, which are innervated by the recurrent branch of the median nerve . These two features together are classic for median nerve injury , typically at the wrist (e.g., carpal tunnel syndrome) or more proximally. Nerves of the hand : Nerve Motor Dysfunction Sensory Dysfunction Common Deformity/Condition Median Nerve Weakness of thenar muscles (thumb opposition), flexor muscles of forearm Loss of sensation in lateral 3.5 fingers (thumb, index, middle, half of the ring finger) Ape hand (thenar atrophy), Carpal tunnel syndrome Ulnar Nerve (Option B ruled out) Weakness of intrinsic hand muscles (especially interossei), hypothenar muscles Loss of sensation in medial 1.5 fingers (little and half of the ring finger) Claw hand , Hypothenar atrophy , Cubital tunnel syndrome Radial Nerve (Option C ruled out) Inability to extend wrist and fingers (wrist drop) Loss of sensation over the dorsum of the hand Wrist drop , Saturday night palsy , Radial tunnel syndrome Anterior Interosseous Nerve (AIN) (Option D ruled out) Inability to flex thumb and index finger (loss of flexion of distal phalanges) No sensory loss (pure motor neuropathy) Inability to make "OK" sign (difficulty flexing thumb and index finger) Long Thoracic Nerve Weakness of serratus anterior muscle, affecting scapular movement No sensory loss Winged scapula (scapula protrudes from the back) .

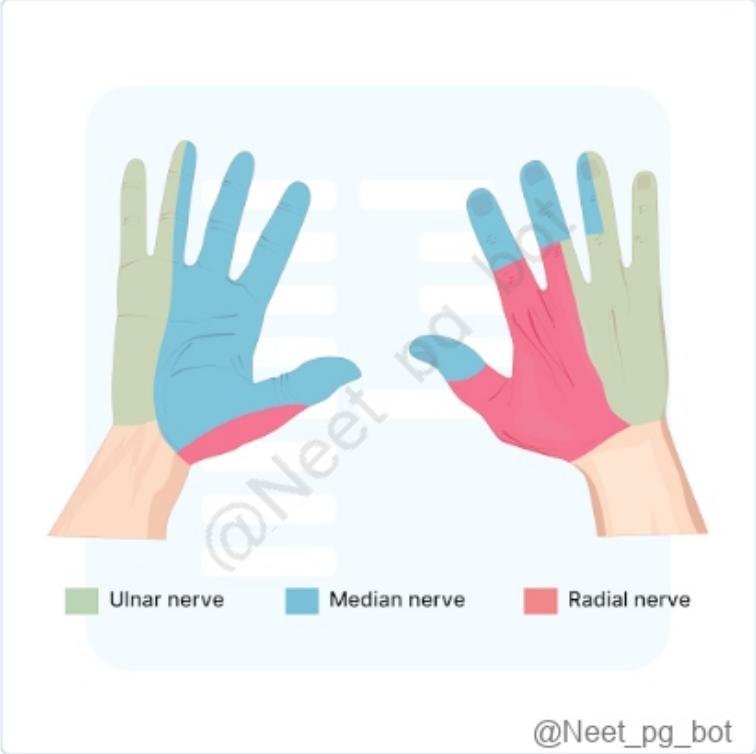

References:

B. D. Chaurasia’s Human Anatomy, Volume 1, 8th Edition, Page 139

↑ *Back to this question in Part A*

@Neet_pg_bot

Q35: An elderly woman reports difficulty in buttoning her shirt and increased clumsiness during daily activities. On examination, she is unable to make an 'O' shape by opposing her thumb and index finger. Which of the following muscles is most likely involved? (Q844243)

A. Opponens pollicis

B. Abductor pollicis brevis

C. Flexor pollicis brevis

D. Palmar interossei

Correct Answer: A. Opponens pollicis

Explanation: The patient’s inability to make an 'O' shape with the thumb and index finger (tip-to-tip pinch) is a classical sign of anterior interosseous nerve (AIN) syndrome , which is a pure motor branch of the median nerve . The AIN innervates deep forearm muscles , specifically: Flexor pollicis longus Lateral half of flexor digitorum profundus Pronator quadratus Considering the options, Opponens pollicis is responsible for opposition of the thumb, a key component of precision grip, and making an “O” shape. Median nerve is innervated (most appropriate) Abductor Pollicis Brevis (Option B): Incorrect. This muscle abducts the thumb (moves it away from the palm). While important for overall thumb function, its primary role isn't making the 'O' shape. Flexor pollicis brevis (Option C): Incorrect. It has dual innervation (superficial head by median, deep head by ulnar). Not purely median. Palmar interossei (Option D): Incorrect. These are ulnar nerve -innervated muscles, unrelated to thumb-index pinch or median nerve pathology.

References:

Gray's Anatomy: The Anatomical Basis of Clinical Practice, 42nd Edition, Page No: 980

↑ *Back to this question in Part A*

@Neet_pg_bot

Q36: An absent gag reflex can result from injury to which cranial nerve? (Q844318)

A. 9 and 10

B. 10 and 7

C. 7 and 5

D. 5 and 9

Correct Answer: A. 9 and 10

Explanation: Correct Option A - 9 and 10 Cranial Nerves IX (Glossopharyngeal) and X (Vagus): The gag reflex involves both sensory and motor components. The sensory component of the gag reflex is mediated by the glossopharyngeal nerve (cranial nerve IX), which detects the stimulus at the back of the throat. The motor component is controlled by the vagus nerve (cranial nerve X), which causes the muscles in the throat to contract. Injury to either of these nerves can result in an absent gag reflex. Incorrect Options: Option B - 10 and 7: While cranial nerve X (vagus) is involved in the gag reflex, cranial nerve VII (facial nerve) is not. The facial nerve primarily controls muscles of facial expression, not the gag reflex. Option C - 7 and 5: Incorrect: Cranial nerve V (trigeminal) provides sensation to the face and motor control for mastication, and cranial nerve VII controls facial expression. Neither of these nerves is involved in the gag reflex. Option D - 5 and 9: While cranial nerve IX (glossopharyngeal) is involved in the gag reflex, cranial nerve V (trigeminal) is not. The trigeminal nerve is responsible for facial sensation and chewing.

↑ *Back to this question in Part A*

@Neet_pg_bot

Q37: Identify the marked structure: (Q860613)

A. Internal capsule

B. Body of fornix

C. Globus pallidus

D. Lateral ventricle

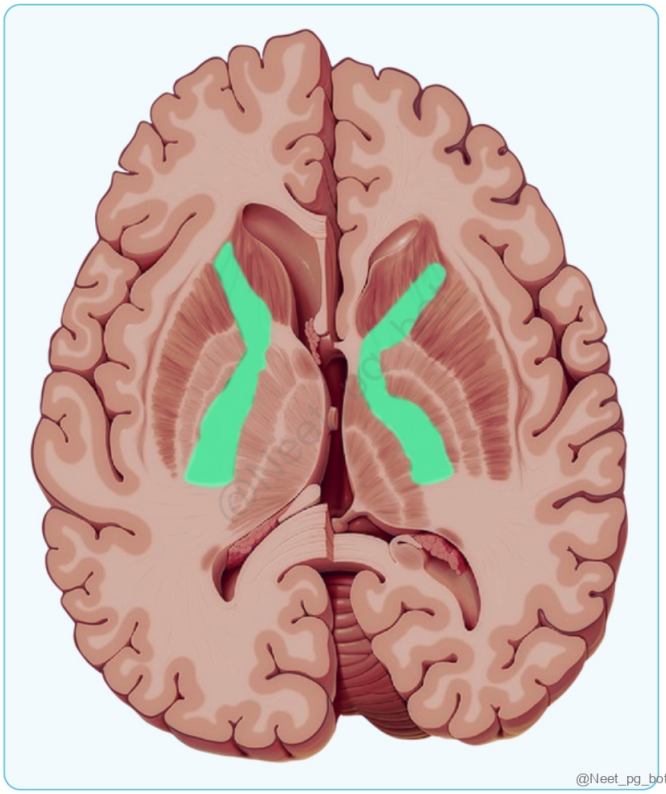

Correct Answer: A. Internal capsule

Explanation: Internal Capsule The internal capsule is a compact bundle of projection fibres that connects the cerebral cortex with subcortical centres such as the thalamus, brainstem, and spinal cord. It contains both afferent (sensory) fibres from the thalamus to the cortex and efferent (motor) fibres from the cortex to the cerebral peduncle and midbrain. INTERNAL CAPSULE: V-shaped projection fiber—angled laterally, present between thalamus and caudate nucleus medially and lentiform nucleus laterally. Parts of Internal Capsule: Anterior limb : Between caudate nucleus medially and lentiform nucleus laterally. Posterior limb : Between thalamus medially and lentiform nucleus laterally. Genu : Between anterior and posterior limb . Sublentiform : Present below the lentiform . Retrolentiform : Present behind lentiform . Lesion of Internal Capsule Occurs due to hemorrhage , leading to spastic paralysis (due to involvement of pyramidal and extrapyramidal fibers for the upper limb, trunk, and lower limb) and loss of sensations in the opposite half of the body. Most commonly involved artery – Charcot’s artery of cerebral hemorrhage (striate branches from middle cerebral artery). Lesions in the sublentiform and retrolentiform parts of the internal capsule lead to visual loss and auditory defects . (Option B, C, and D ruled out)

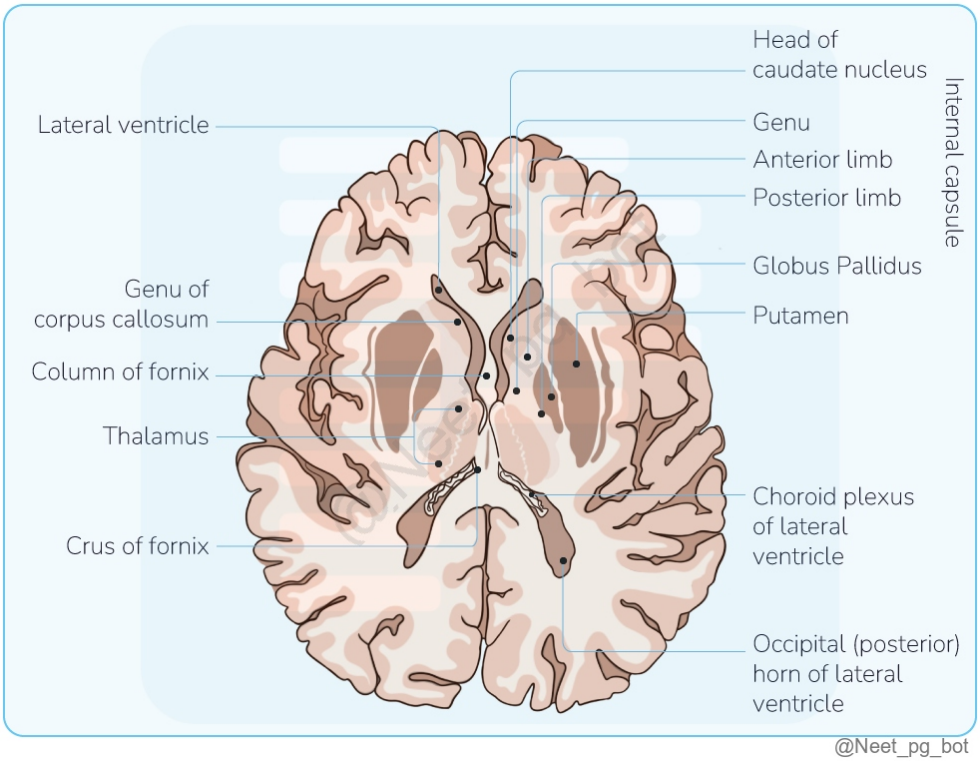

References:

Gray's Anatomy, 42nd Edition, Page 538

↑ *Back to this question in Part A*

@Neet_pg_bot

Q38: Which structure is not present in the floor of the inferior horn of the lateral ventricle? (Q839923)

A. Hippocampus

B. Tail of the caudate nucleus

C. Fimbriae

D. Collateral eminence

Correct Answer: B. Tail of the caudate nucleus

Explanation: The tail of the caudate nucleus is not present in the floor of the inferior horn of the lateral ventricle. The caudate nucleus is part of the basal ganglia and its tail arches around and terminates in the roof of the inferior

horn of the lateral ventricle. Hippocampus (Option A): The hippocampus is present in the floor of the inferior horn of the lateral ventricle. It is a key structure involved in memory and spatial navigation. Fimbriae (Option C): The fimbriae of the hippocampus are present in the floor of the inferior horn of the lateral ventricle. They are bundles of axons that emerge from the hippocampus and converge to form the fornix. Collateral eminence (Option D): The collateral eminence is a ridge on the floor of the inferior horn of the lateral ventricle caused by the underlying collateral sulcus. It is indeed present in the floor of the inferior horn.

References:

Grey's Anatomy, 42nd Edition, Pages 456-458

↑ *Back to this question in Part A*

@Neet_pg_bot

Q39: Which artery is involved in Lateral medullary syndrome? (Q857312)

A. Posterior inferior cerebellar artery

B. Anterior inferior cerebellar artery

C. Superior cerebellar artery

D. Inferior cerebellar artery

Correct Answer: A. Posterior inferior cerebellar artery

Explanation: The occlusion of the posterior inferior cerebellar artery causes lateral medullary syndrome also called the Wallenberg syndrome. Wallenberg syndrome: Also known as Lateral medullary syndrome Pathology: Blockage of the posterior inferior cerebellar artery. It supplies areas behind the inferior olivary nucleus. Damage to the lateral segment of the medulla posterior to the inferior olivary nucleus. Clinical manifestation: Anatomical location Presenting clinical feature Nucleus ambiguous gives fibers to IX, X, and XI cranial nerves Ipsilateral paralysis of muscles of the soft palate, pharynx, and larynx Spinal nucleus and spinal tract of the trigeminal nerve Ipsilateral facial pain and temperature loss Lateral spinothalamic tract Contralateral body pain and temperature loss Vestibular nuclei Vertigo Inferior cerebellar peduncle, spino cerebellar tracts, and part of cerebellum Ipsilateral ataxia Sympathetic fibres descend from the hypothalamus to cells in the lateral horn of spinal cord Horner’s syndrome, comprising ptosis, enophthalmos, miosis, and anhydrosis

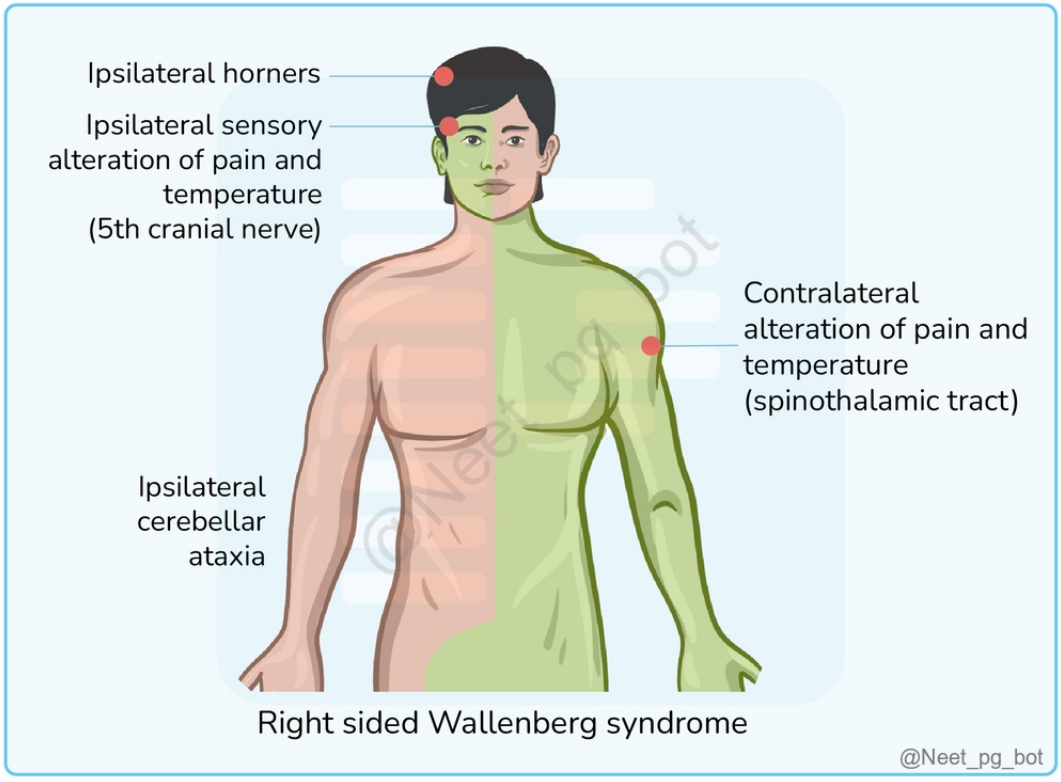
Ipsilateral horners
Ipsilateral sensory alteration of pain and temperature (5th cranial nerve)
Contralateral alteration of pain and temperature (spinothalamic tract)
Ipsilateral cerebellar ataxia
Right sided Wallenberg syndrome
@Neet_pg_bot

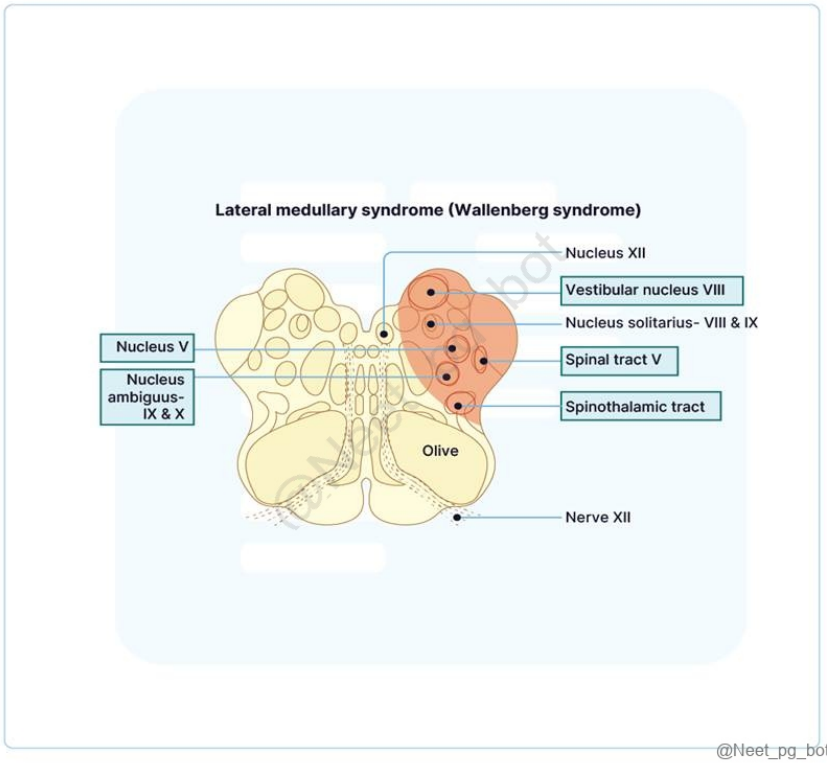
Lateral medullary syndrome (Wallenberg syndrome)
Nucleus XII
Vestibular nucleus VIII
Nucleus solitarius- VIII & IX
Nucleus V
Spinal tract V
Nucleus ambiguus- IX & X
Spinothalamic tract
Olive
Nerve XII
@Neet_pg_bot

References:

BD Chaurasia’s Human Anatomy, Regional and Applied Dissection and Clinical, Volume 4, Brain-Neuroanatomy, 8th Edition, Pages 106, 107

Image: https://www.researchgate.net/figure/Lateral-medullary-syndrome-affected-structures_fig1_364960089

↑ *Back to this question in Part A*

@Neet_pg_bot

Q40: Match the following: A) Glossopharyngeal nerve 1) Shrugging of shoulder B) Spinal accessory nerve 2) Touch sensation from the posterior one-third of the tongue C) Facial nerve 3) Chewing D) Mandibular nerve 4) Taste from the anterior two-thirds of the tongue (Q857316)

A. A-2, B-1, C-4, D-3

B. A-2, B-3, C-4, D-1

C. A-4, B-1, C-2, D-3

D. A-3, B-1, C-4, D-2

Correct Answer: A. A-2, B-1, C-4, D-3

Explanation: Correct Option is: A-2, B-1, C-4, D-3 A) Glossopharyngeal nerve 2) Touch sensation from the posterior one-third of the tongue B) Spinal accessory nerve 1) Shrugging of shoulder C) Facial nerve 4) Taste from the anterior two third of the tongue D) Mandibular nerve 3) Chewing Cranial nerves: Nerve CN Function Type Olfactory I Smell (only CN without thalamic relay to cortex) Sensory Optic II Sight Sensory Oculomotor III Eye movement (SR, IR, MR, IO), pupillary constriction (sphincter pupillae), accommodation (ciliary muscle), eyelid opening (levator palpebrae) Motor Trochlear IV Eye movement (SO) Motor Trigeminal V Mastication, facial sensation (ophthalmic, maxillary, mandibular divisions), somatosensation from anterior 2/3 of tongue, dampening loud noises (tensor tympani) Both Abducens VI Eye movement (LR) Motor Facial VII Facial movement, eye closing (orbicularis oculi), auditory volume modulation (stapedius), taste from anterior 2/3 of tongue (chorda tympani), lacrimation, salivation (submandibular and sublingual glands) Both Vestibulocochlear VIII Hearing, balance Sensory Glossopharyngeal IX Taste and sensation from posterior 1/3 of tongue, swallowing, salivation (parotid gland), monitoring carotid body and sinus chemo- and baroreceptors, elevation of pharynx/larynx (stylopharyngeus) Both Vagus X Taste from supraglottic region, swallowing, soft palate elevation, midline uvula, talking, cough reflex, parasympathetics to thoracoabdominal viscera, monitoring aortic arch chemo- and baroreceptors Both Accessory XI Head turning, shoulder shrugging (SCM, trapezius) Motor Hypoglossal XII Tongue movement Motor

References:

https://www.ncbi.nlm.nih.gov/books/NBK470353/

↑ *Back to this question in Part A*

Q41: The marked structure relays efferents to which nucleus of the thalamus? [(Q857333)

A. Anterior nucleus of thalamus

B. Lateral nucleus of thalamus

C. Ventro-postero-lateral nucleus of thalamus

D. Posterior nucleus of thalamus

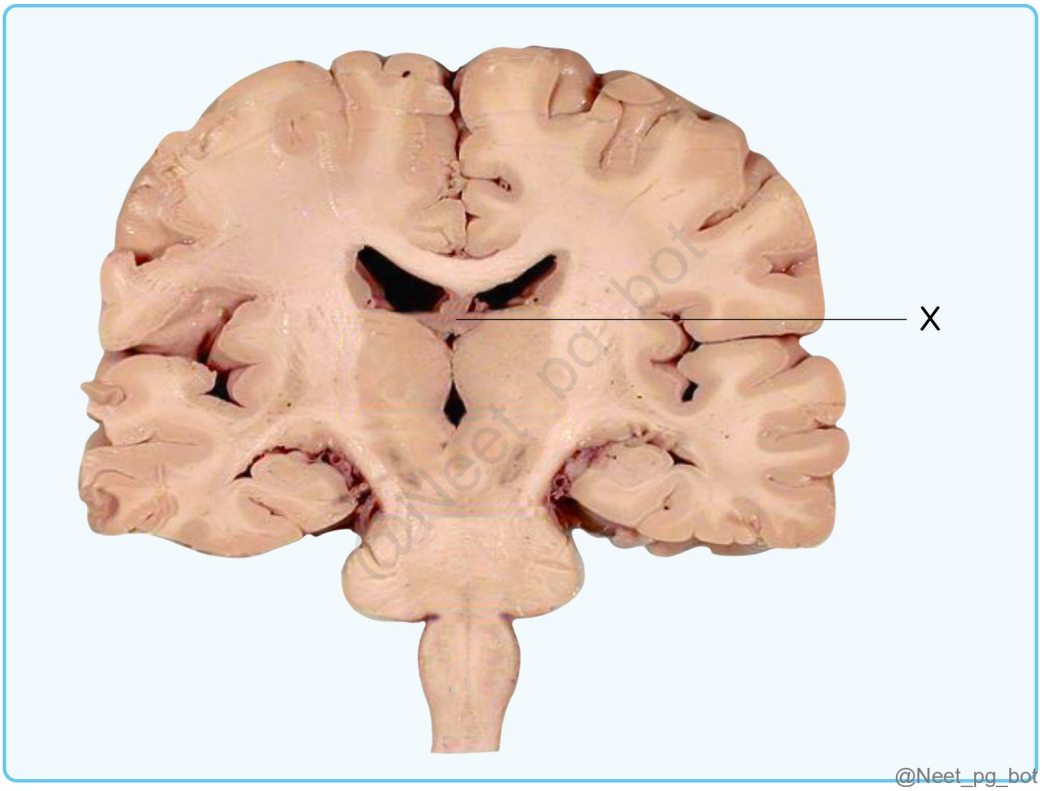

Correct Answer: A. Anterior nucleus of thalamus

Explanation: The marked structure is the fornix. Fornix is the major efferent tract of the hippocampus. The fornix sends efferents to the mammillary bodies, and the mammillothalamic tract connects the mammillary bodies to the anterior nucleus of the thalamus. This pathway is part of the Papez circuit, involved in memory and emotional processing. Thalamic Nuclei and their Connection: Anterior nucleus Receives input from hypothalamic mammillary nuclei via mammillothalamic tract. Receives input from the hippocampus via fornix. Projects fibers to the cingulate gyrus. Dorsomedial nucleus Part of the limbic system. Lesion results in memory loss (Wernicke–Korsakoff syndrome). Intralaminar nuclei Receives input from the reticular formation. Projects fibers to the neocortex. Sends fibers to other thalamic nuclei (unlike other thalamic nuclei, which project to different

cortical areas). Dorsal tier nucleus Lateral dorsal nucleus : Posterior extension of the anterior nucleus. Pulvinar : Largest thalamic nucleus. Receives input from the lateral and medial geniculate bodies. Integrates visual and auditory input. Ventral tier nucleus Ventral anterior nucleus : Receives input from globus pallidus and substantia nigra. Projects fibers to the motor cortex. Ventral posterior nucleus : Contains three subnuclei: Ventral posterolateral (VPL) : Receives input from spinothalamic tracts and medial lemniscus. Ventral posteromedial (VPM) : Receives input from trigeminothalamic tracts. Ventral posterior inferior (VPI) : Receives input from vestibular nuclei. Lateral nucleus of thalamus (Option B): The lateral nucleus functions as the hunger center, promoting eating when stimulated, while its destruction leads to starvation. Ventro-postero-lateral nucleus of thalamus (Option C): The ventro-postero-lateral nucleus of the thalamus processes sensations like pain, vibration, proprioception, and light touch from the spinothalamic tract and dorsal column pathways. Posterior nucleus of the thalamus (Option D): The posterior nucleus aids in thermoregulation by promoting heat conservation. It triggers the sympathetic nervous system, causing peripheral vasoconstriction to retain heat.

References:

www.ncbi.nlm.nih.gov/books/NBK549908/#

↑ *Back to this question in Part A*

@Neet_pg_bot

Q42: Which of the following structures is derived from the marked point in the given image? (Q857335)

A. Ribs

B. Kidneys

C. Dorsal root ganglion

D. Parietal pleura

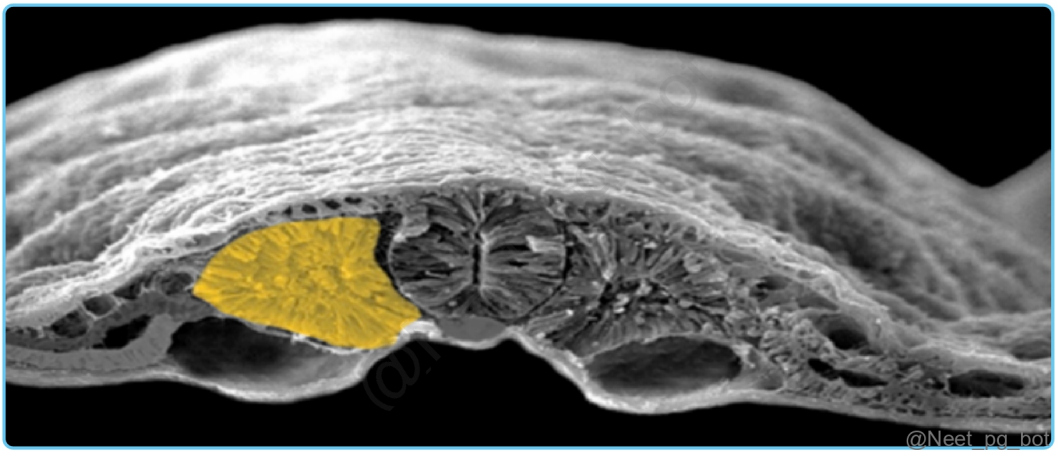

Correct Answer: A. Ribs

Explanation: Structures derived from the paraxial mesoderm include the somites. Somites are bilaterally paired blocks of mesoderm that form on either side of the neural tube during early embryonic development. The somites give rise to various structures in the embryo, including the axial skeleton (such as vertebrae), skeletal muscles, and the dermis of the skin. Intraembryonic Mesoderm/ Secondary Mesoderm: Formed by the proliferation of cells from the primitive streak. Separates the ectoderm and endoderm except in specific regions that remain bilaminar throughout life: Prochordal plate (future oral cavity) Cloacal membrane (future anal and urogenital openings) Midline caudal to the prochordal plate Formation of intraembryonic mesoderm. (B) is a section along axis in (A) Subdivisions: 1. Paraxial Mesoderm 2. Lateral Plate Mesoderm 3. Intermediate Mesoderm Located on either side of the notochord and becomes thick. It forms a thinner layer located laterally. A longitudinal strip found between the paraxial and lateral plate mesoderm. It forms: Somitomeres: Form mesoderm and muscles of the head and jaw. Somites: Form midline axial skeleton, skeletal muscles and dermis of back. It forms: Somatopleuric (parietal) layer: Forms connective tissue of the body wall and limbs, such as appendicular skeleton bones , muscles and dermis of periphery. Splanchnopleuric (visceral) layers: Forms connective tissue and smooth muscle layers of the gut, cardiac muscle and the circulatory system. It forms: Urinary and genital systems. Somites: Paraxial mesoderm becomes segmented to form 42-44 pairs of somites develop on either side of the neural tube and notochord. Appear between the 20th and 30th day, marking the 4th week as the somite period. Somite Structure: Sclerotome: Ventromedial part; forms vertebral column and ribs. Dermatome: Lateral part; forms dermis of skin and subcutaneous tissue. Myotome: Intermediate part; forms striated muscle. {{caption_text}} Kidneys (Option B): Kidneys are the derivatives of the intermediate mesoderm. Dorsal root ganglion (Option C): Dorsal root ganglia are derived from the neural crest cells. Parietal pleura (Option D): The pericardial, pleural, and peritoneal cavities, housing vital organs, originate from the lateral plate mesoderm during embryonic development.

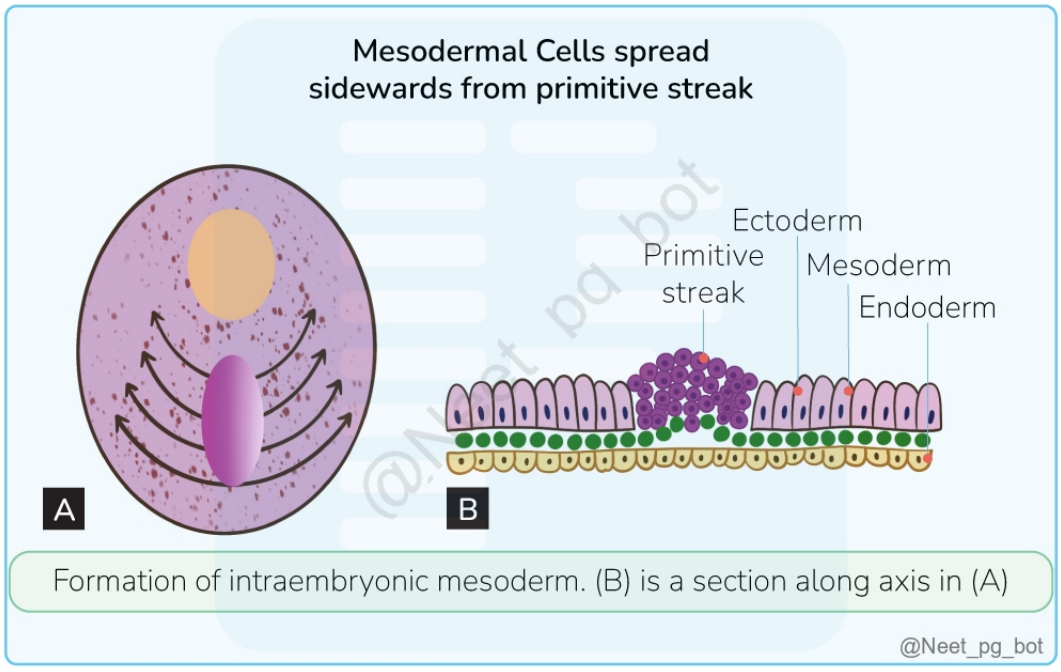

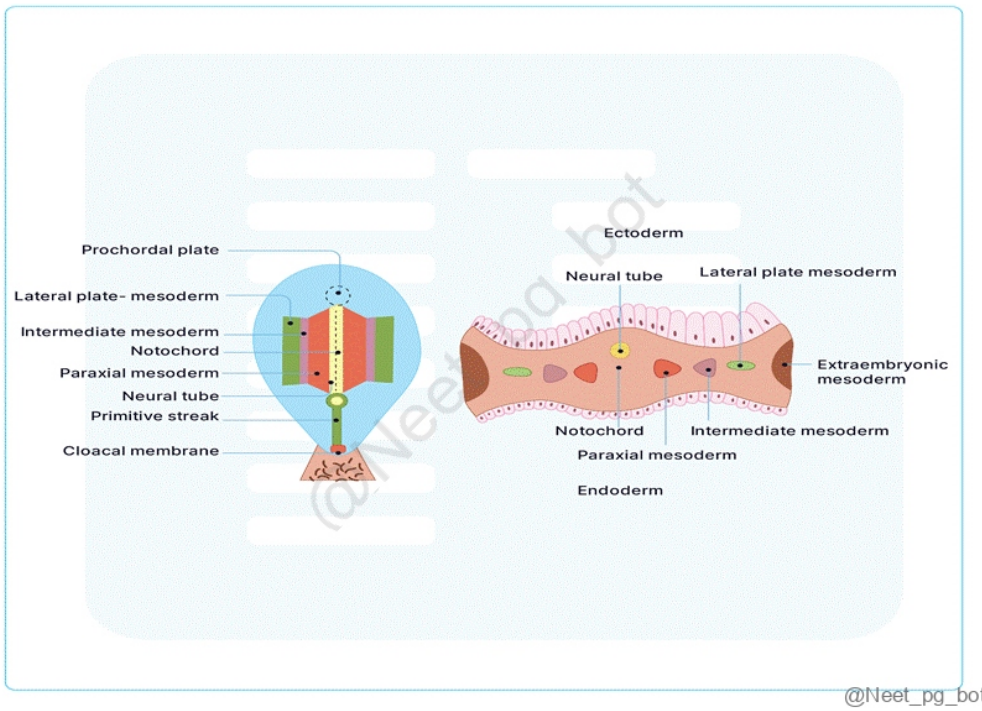

@Neet_pg_bot

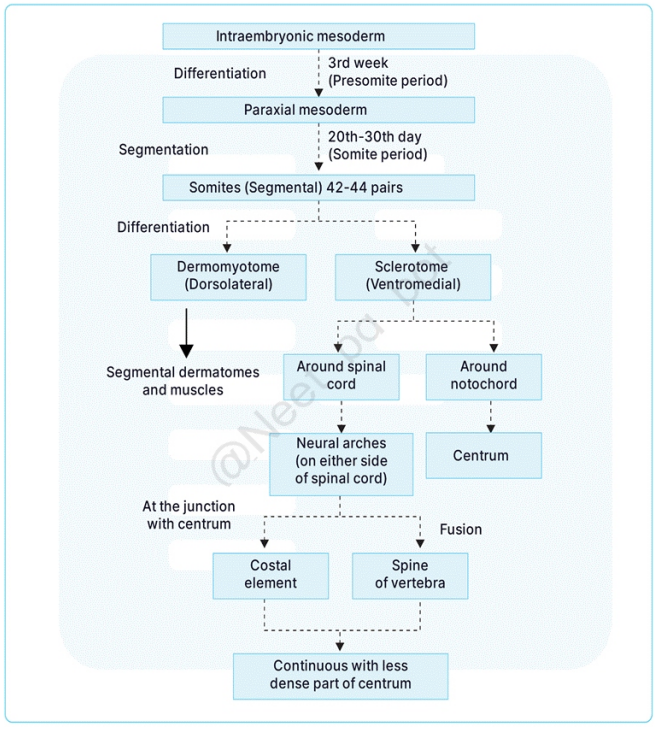

@Neet_pg_bot

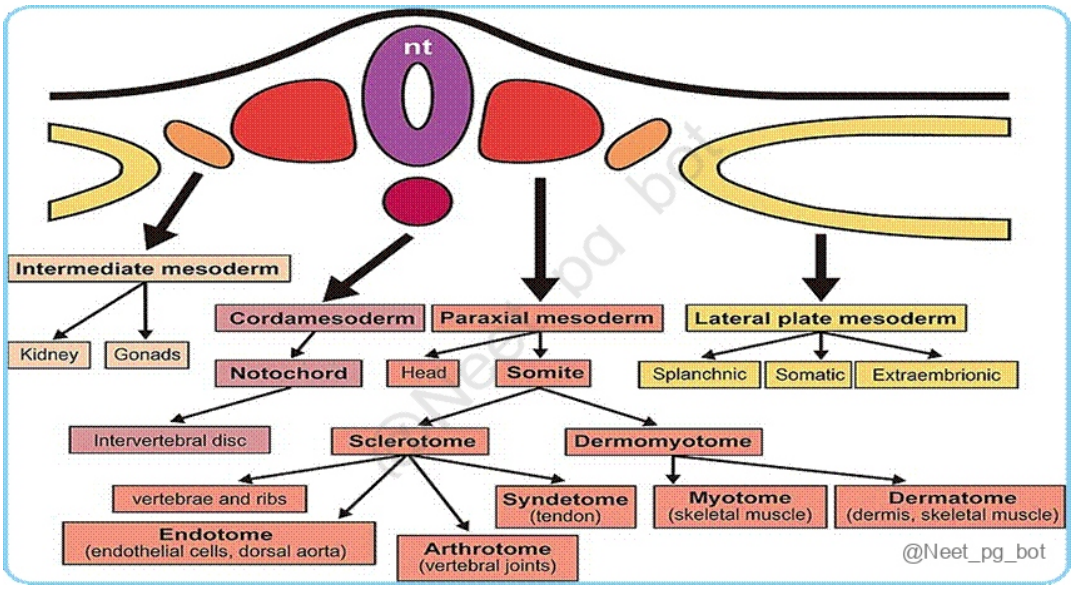

References:

Inderbir Singh's Human Embryology, 11th Edition, Page no: 55,56,57,65,67

https://www.ncbi.nlm.nih.gov/books/NBK546679/#

https://www.ncbi.nlm.nih.gov/pmc/articles/PMC10380231/#:

↑ *Back to this question in Part A*

@Neet_pg_bot

Q43: What is the blood supply of the marked area in the given image? (Q857347)

A. Posterior inferior cerebellar artery

B. Anterior inferior cerebellar artery

C. Superior cerebellar artery

D. Posterior cerebral artery



Correct Answer: A. Posterior inferior cerebellar artery

Explanation: The highlighted structure is the inferior cerebellar peduncle, a white matter bundle linking the medulla oblongata to the cerebellum. It is mainly supplied by the Posterior Inferior Cerebellar Artery (PICA), a branch of the vertebral artery. Blood supply of various parts of brain: Structure Blood Supply Medulla Anterior spinal artery Posterior spinal artery Posterior inferior cerebellar artery Medullary branch from basilar artery Pons Anterior inferior cerebellar artery Pontine branch from basilar artery Superior cerebellar artery Midbrain Posterior cerebral artery Superior cerebellar artery Thalamus Posterior communicating artery Posterior cerebral artery Cerebellum Posterior inferior cerebellar artery Anterior inferior cerebellar artery Superior cerebellar artery Anterior inferior cerebellar artery (Option B): The anterior inferior cerebral artery (AICA) a branch of the basilar artery, supplies blood to the anteroinferior cerebellum, middle cerebellar peduncle, and inferolateral pons. Superior cerebellar artery (Option C): Superior cerebellar artery (SCA) supplies the superior surface of the cerebellum, superior and middle cerebellar peduncles, and the lower midbrain. Posterior Cerebral Artery (Option D): The Posterior Cerebral Artery (PCA) provides blood supply to the occipital cortex, inferior and medial temporal cortices, thalamus, and rostral midbrain.

References:

https://pmc.ncbi.nlm.nih.gov/articles/PMC7646108/#:~:text

↑ *Back to this question in Part A*

@Neet_pg_bot

Q44: Arrange the neural columns in medial-to-lateral order in the floor of fourth ventricle 1. Special somatic afferent 2. Special visceral afferent 3. General somatic afferent 4. General somatic afferent (Q854785)

A. GVA, SVA, GSA, SSA

B. VA, GSA, GVA, SSA

C. SSA, GSA, SVE, GVA

D. GSA, SSA, SVA, GSA

Correct Answer: A. GVA, SVA, GSA, SSA

Explanation: The neural columns are arranged in the alar lamina of the developing spinal cord in the following order: Medial to lateral: GVE → SVE → SE → GVA →SVA → GSA → SSA Functional Columns and Nuclei of Cranial Nerve: Sulcus limitans divides the mantle zone of brain stem and spinal cord into anterior motor efferent basal plate and posterior sensory afferent alar plate. Afferents and efferents from brainstem:

Efferent	Afferent
General somatic efferent Supply somatic origin striated muscles. **Occipital somites** form tongue muscles Supplied by XII nerve **Pre occipital somites** -form extraocular muscles **Supplied by III, IV and VI nerve.** So, nucleus of **III, IV, VI and XII** in this column.	**General somatic afferent** Carry general sensation • Chief sensory nucleus in pons, • Spinal nucleus in medulla and • Mesencephalic nucleus of trigeminal nerve in mid brain
Special visceral efferent To supply Pharyngeal arch muscles **Motor nucleus of V, VII & nucleus ambigus (IX, X, XI)** **Nucleus ambigus**-fibers from IX, X and XI mingle	Special somatic afferent. **Somatic origin and Carry special sensation** I, II and VIII **(vestibular and cochlear nuclei)**
General visceral efferent-(parasympathetic) Supply the **glands and smooth muscles** • Superior salivatory nucleus • Lacrimatory nucleus (caudal part of superior salivatory nucleus) • Inferior salivatory nucleus • Dorsal nucleus of vagus • Edinger westpaul nucleus **(Cranial nerve with parasympathetic function III, VII, IX, X)**	General visceral afferent - **Nucleus tractus solitarius** Carry general sensation from viscera (heart, lung, GIT)
	Special visceral afferent - **Nucleus tractus solitarius** Carry special sensation taste from tongue Nucleus of solitary tract (VII, IX and X)

@Neet_pg_bot

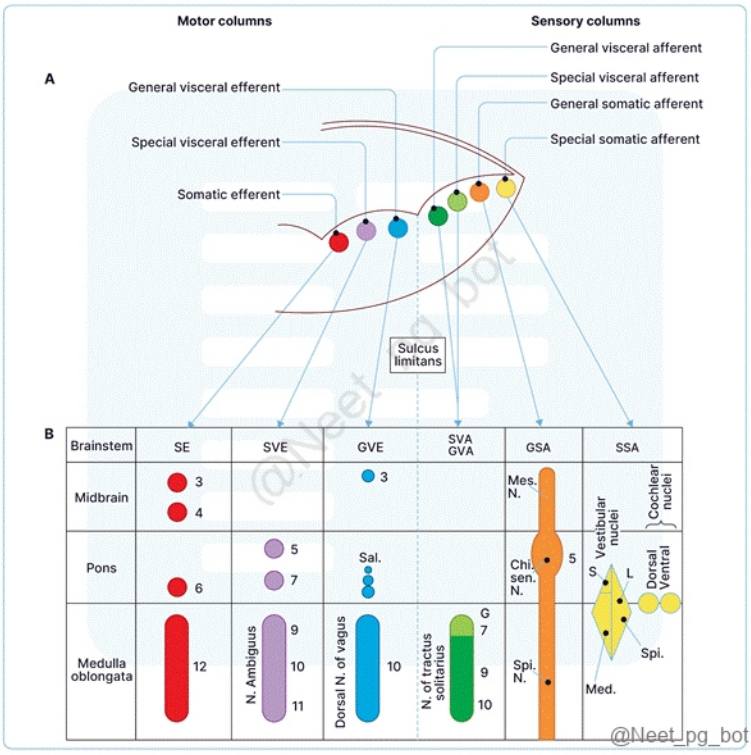

References:

https://www.ncbi.nlm.nih.gov/books/NBK470353/

↑ *Back to this question in Part A*

@Neet_pg_bot

Q45: The patient presented with ipsilateral loss of pain and temperature sensation in the face, Horner's syndrome, and Contralateral loss of pain and temperature sensation in the body. Which artery is involved in the syndrome based on clinical features? (Q854799)

A. Posterior inferior cerebellar artery

B. Superior cerebellar artery

C. Basilar artery

D. Anterior inferior cerebellar artery

Correct Answer: A. Posterior inferior cerebellar artery

Explanation: The patient's presentation with ipsilateral loss of pain and temperature sensation in the face, Horner's syndrome, and contralateral loss of pain and temperature sensation in the body is suggestive lateral medullary syndrome also called the Wallenberg syndrome. The occlusion of the posterior inferior cerebellar artery causes lateral medullary syndrome also called the Wallenberg syndrome. Wallenberg syndrome: Also known as Lateral medullary syndrome Pathology: Blockage of the posterior inferior cerebellar artery. It supplies areas behind the inferior olivary nucleus. Damage to the lateral segment of the medulla posterior to the inferior olivary nucleus. Clinical manifestation: Anatomical location Presenting clinical feature Nucleus ambiguous gives fibers to IX, X, and XI cranial nerves Ipsilateral paralysis of muscles of the soft palate, pharynx, and larynx Spinal nucleus and spinal tract of the trigeminal nerve Ipsilateral facial pain and temperature loss Lateral spinothalamic tract Contralateral body pain and temperature loss Vestibular nuclei Vertigo Inferior cerebellar peduncle, spino cerebellar tracts, and part of cerebellum Ipsilateral ataxia Sympathetic fibres descend from the hypothalamus to cells in the lateral horn of spinal cord Horner’s syndrome, comprising ptosis, enophthalmos, miosis, and anhydrosis Superior cerebellar artery (Option B) : The superior cerebellar artery primarily supplies the superior portion of the cerebellum and parts of the midbrain. While it can lead to symptoms like ataxia or vertigo, it doesn’t typically cause the specific signs described (ipsilateral loss of pain and temperature sensation in the face, Horner's syndrome, and contralateral loss of pain and temperature in the body). Basilar artery (Option C): NA blockage in the basilar artery can lead to locked-in syndrome or other pontine deficits Anterior inferior cerebellar artery (AICA) (Option D) : AICA strokes can cause symptoms like vertigo, ataxia, and facial weakness.

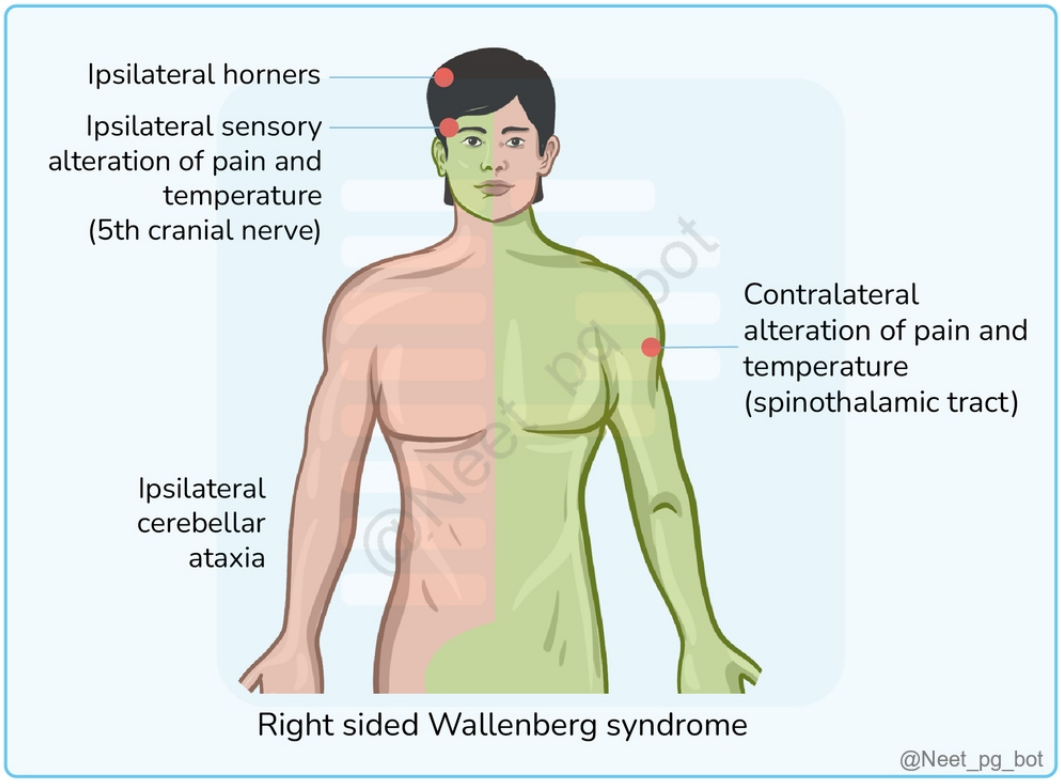

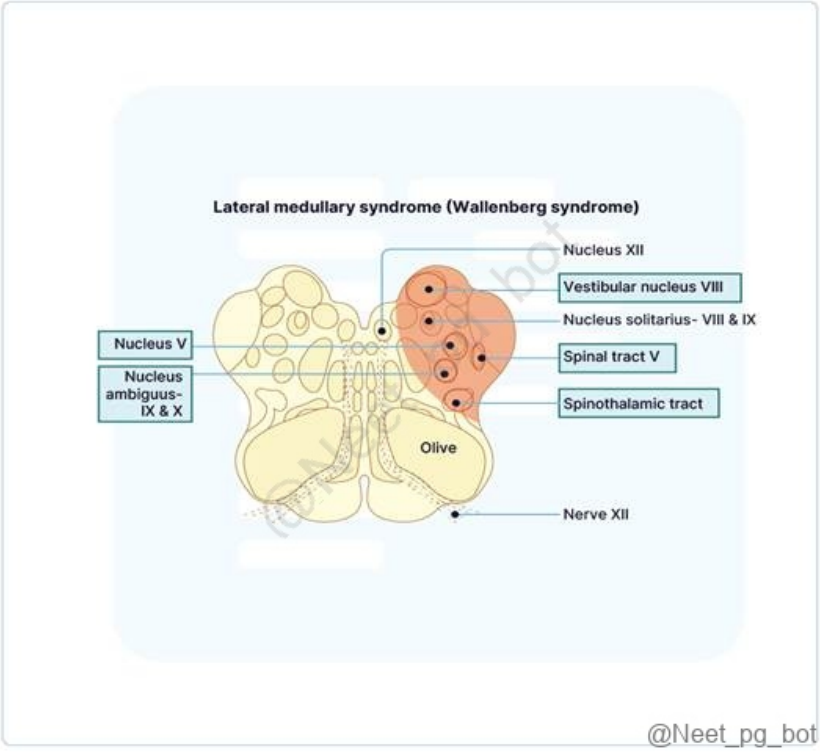

References:

BD Chaurasia's Human Anatomy Regional and Applied Dissection and Clinical, Volume 4, Brain-Neuroanatomy, 8th Edition, Pages 106, 107

Image: www.researchgate.net/figure/Lateral-medullary-syndrome-affected-structures_fig1_364960089

↑ *Back to this question in Part A*

@Neet_pg_bot

Q46: What is the vertebral level shown by the arrow in the image? (Q857934)

A. L2-L3

B. L4-L5

C. L5-S1

D. L3-L4

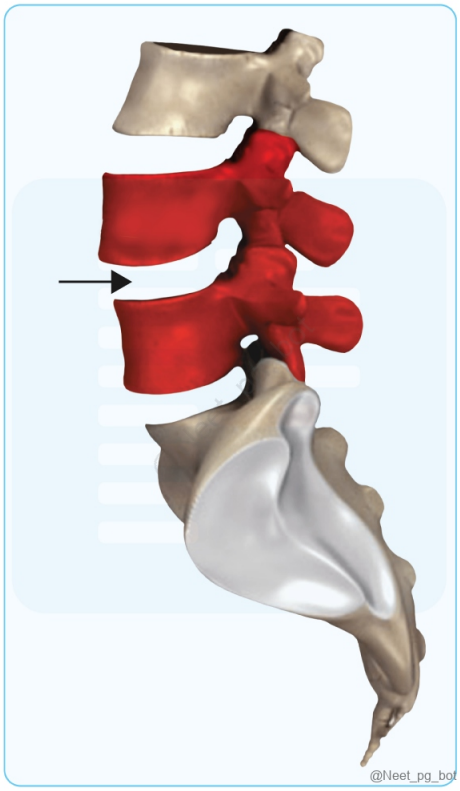

Correct Answer: B. L4-L5

Explanation: The arrow indicates the L4–L5 intervertebral disc space, located between the fourth lumbar vertebra (L4) and the fifth lumbar vertebra (L5). This level is clinically significant as it is a high-mobility segment and the most common site for lumbar disc herniation, often affecting the L5 nerve root. The position of the marker in the image clearly corresponds to this anatomical level. Incorrect Options: Option A) L2–L3 : Incorrect because the L2–L3 disc space lies higher in the lumbar column. The arrow in the image indicates a lower lumbar level, consistent with L4–L5 , not the upper lumbar segment. Option C) L5–S1 : Incorrect as L5–S1 is located below the L4–L5 level , at the lumbosacral junction. The marker in the image is placed above the sacrum, aligning with L4–L5 , not the L5–S1 interspace. Option D) L3–L4 : Incorrect because L3–L4 lies one level above the indicated site. The arrow is directed lower, specifically at the L4–L5 disc level, making L3–L4 inconsistent with the image.

References:

BD Chaurasia’s Human Anatomy, 8th Edtion, Page no: 156

↑ *Back to this question in Part A*

@Neet_pg_bot

Q47: A 32-year-old patient presents with a swelling below the ear and complains of pain in the lobule of the ear. The patient also reports difficulty in completely closing the left eye and experiences trouble while eating food. What nerve is most likely to be

damaged in this case? (Q857937)

A. Greater Auricular nerve

B. Auriculotemporal nerve

C. Facial nerve

D. Vagus nerve

Correct Answer: C. Facial nerve

Explanation: The facial nerve (cranial nerve VII) controls facial expressions, including eye closure and smiling. Damage to it can cause weakness or paralysis in these muscles. Additionally, it regulates muscles for eating and swallowing, which aligns with the patient's eating difficulties. External Ear consists of two main parts: Pinna (Auricle) External Auditory Meatus Aspects Auricle (Pinna) External Auditory Meatus Composition Elastic cartilage, except lobule (fibrofatty tissue) Cartilaginous part (Outer 1/3) with hair and ceruminous glands Bony part (Inner 2/3), with thin skin continuous with the tympanic membrane, lacks hair and glands. Parts Concha (Depression leading to the external meatus) Helix (Prominent rim with anterior and posterior limbs) Antihelix (Parallel ridge to the helix) Tragus & Antitragus (Separated by inter-tragic notch) Cymba Conchae (Above crus of helix) Lobule (Soft, fleshy part below antitragus) Nerve Supply Lateral Surface Lower third: Great auricular nerve (C2, C3) Upper two-thirds: Auriculotemporal nerve (CN V3) Concha: Auricular branch of vagus (CN X) (Alderman’s Nerve) Medial Surface Lower third: Great auricular nerve Upper two-thirds: Lesser occipital nerve (C2) Roof & Anterior Wall: Auriculotemporal nerve (CN V3) Floor & Posterior Wall: Auricular branch of vagus (CN X) Clinical Relevance McEwen’s triangle (Cymba Conchae) It is a surgical landmark on the temporal bone to locate the mastoid antrum. Furuncles (cartilaginous part) susceptible to infections {{caption_text}} Greater Auricular nerve (Option A): Damage to this nerve might result in altered sensation around the ear, but it wouldn't explain the symptoms mentioned in the case. Auriculotemporal nerve (Option B): provides sensation to the external ear and part of the scalp. However, it doesn't control facial movement, eye closure, or eating functions. Vagus nerve (Option D): While damage to the vagus nerve might cause some difficulties in swallowing and speech, it would not explain the specific symptoms of facial muscle weakness, inability to close the eye, or earlobe pain described in the case.

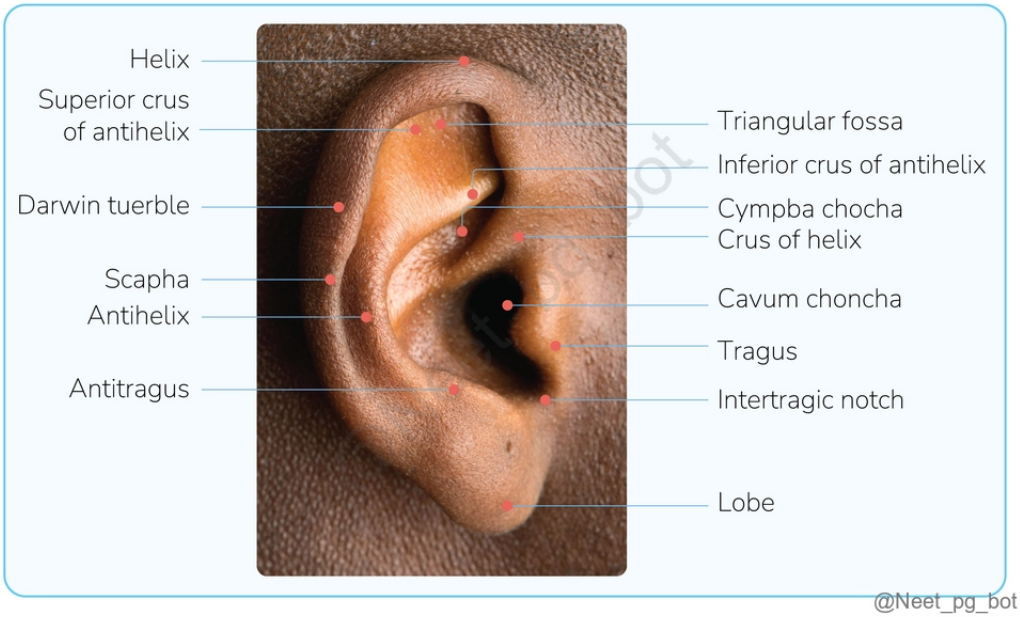

@Neet_pg_bot

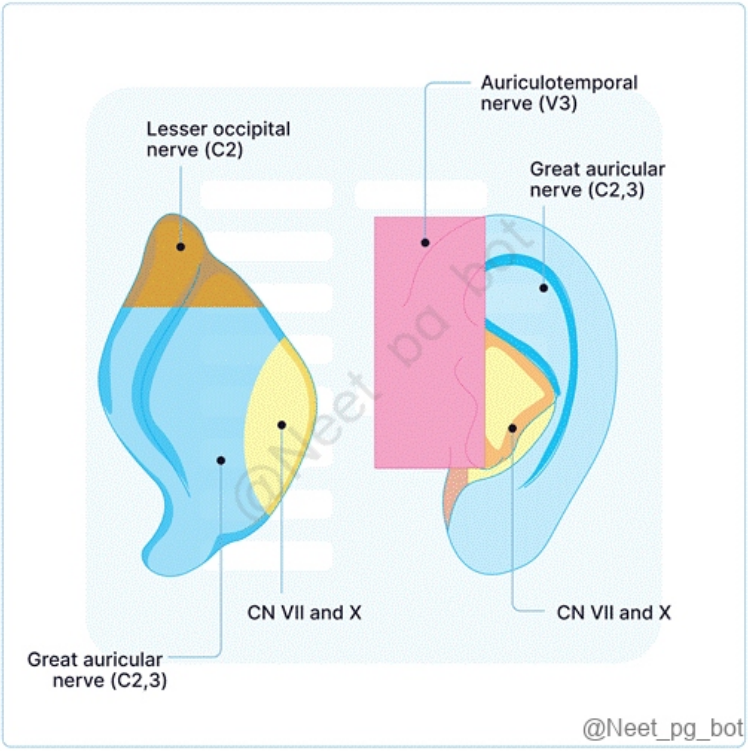

@Neet_pg_bot

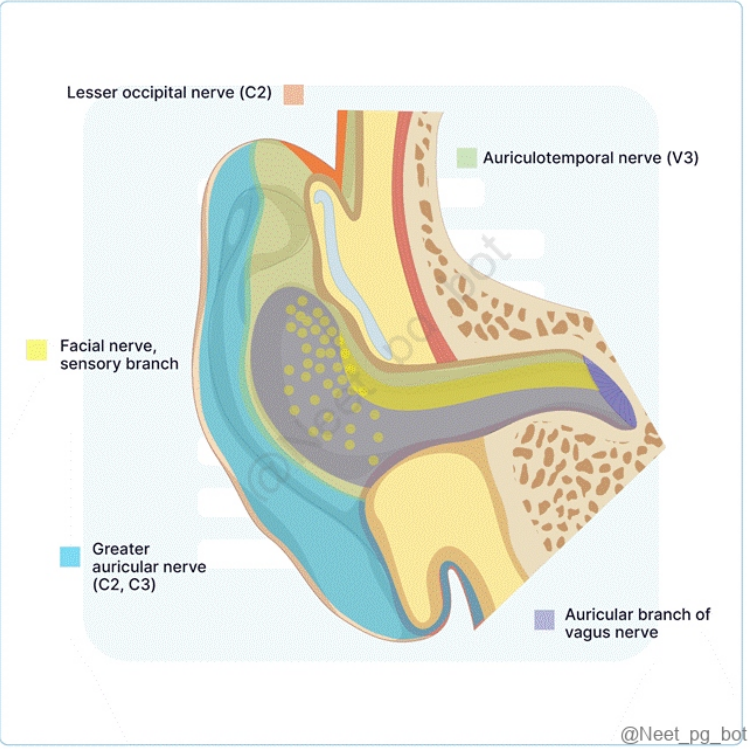

References:

BD Chaurasia's Human Anatomy, 8th Edtion, Page no: 145

↑ *Back to this question in Part A*

@Neet_pg_bot

Q48: A woman presented with sudden onset of dysphagia, dysarthria, and gait ataxia. MRI revealed an acute infarct in the right dorsolateral medulla. What is the likely diagnosis? (Q793142)

A. Dejerine's anterior bulbar syndrome

B. Wallenberg syndrome

C. Babinski-Nageotte syndrome

D. Weber syndrome

Correct Answer: B. Wallenberg syndrome

Explanation: Correct Option B - Wallenberg syndrome: Wallenberg syndrome, AKA Lateral medullary syndrome, is caused by occlusion of the PICA (most common) or vertebral artery . Key clinical features (classic triad): Dysphagia, dysarthria, hoarseness → nucleus ambiguus involvement (CN IX, X) Gait ataxia, limb ataxia → inferior cerebellar peduncle Vertigo, nystagmus → vestibular nuclei Loss of pain & temperature Ipsilateral face (spinal trigeminal nucleus) Contralateral body (spinothalamic tract) Ipsilateral Horner's syndrome → descending sympathetic fibers Loss of taste may occur (solitary nucleus) Incorrect Options: Option A - Dejerine's anterior bulbar syndrome: Rare condition from damage to lower part of brainstem. Symptoms: Paralysis of muscles for chewing, swallowing, and speaking. Different from Wallenberg syndrome, which involves dorsolateral medulla specifically. Option C - Babinski-Nageotte syndrome: Babinski-Nageotte syndrome is a term that is not commonly used in medical literature. It may refer to a combination of symptoms involving weakness or paralysis of the arm and leg on one side of the body, along with abnormal reflexes. However, this is not a well-defined syndrome Option D - Weber syndrome: Results from midbrain damage, leading to weakness or paralysis on one side of the body. Other symptoms: Abnormal eye movements.

References:

Prepladder Notes

↑ *Back to this question in Part A*

@Neet_pg_bot

Q49: Please identify the structure indicated in the image below. (Q793128)

A. Midbrain

B. Pons

C. Medulla oblongata

D. Spinal cord

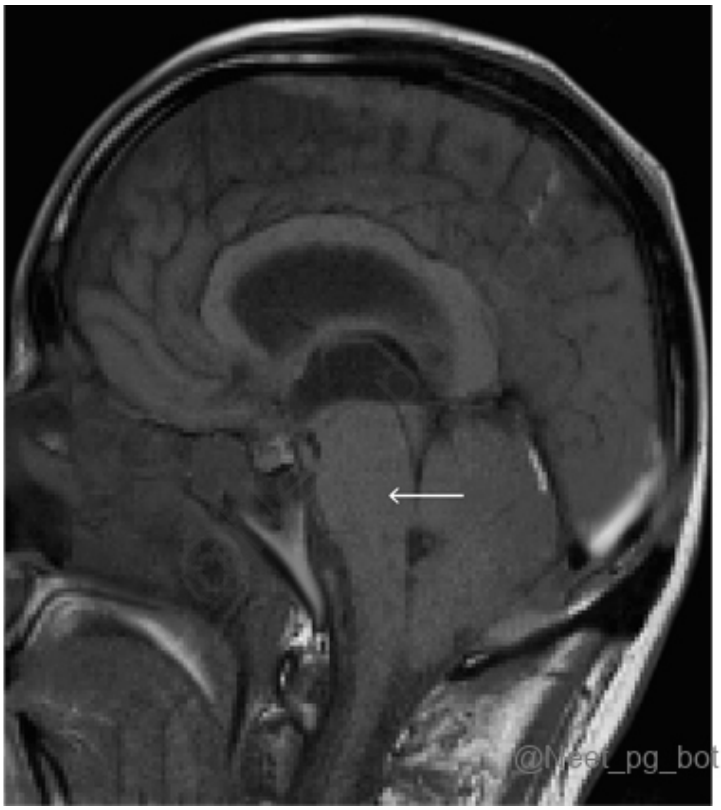

Correct Answer: B. Pons

Explanation: Correct Option B - Pons: The marked structure in the image is the pons. It is visible on an MRI or CT scan as a larger bulge in the brainstem. In a sagittal section, the pons may appear as a larger, oval-shaped structure located below the midbrain and above the medulla oblongata. Incorrect Options: Option A - Midbrain: In a sagittal section, the midbrain may appear as a small round structure located above the pons and below the thalamus. It is located anterior to the fourth ventricle and has a distinctive "butterfly" shape on axial views. Option C - Medulla oblongata: The medulla oblongata is visible on an MRI or CT scan as a tapering structure that connects the brainstem to the spinal cord. In a sagittal section, the medulla oblongata may appear as a smaller, pointed structure located below the pons. The medulla oblongata appears as a tapering structure that connects the brainstem to the spinal cord and is located at the bottom of the brainstem. Option D - Spinal cord: The spinal cord is located within the spinal canal, which is formed by the vertebrae of the spine. In a sagittal section, the spinal cord may appear as a central canal surrounded by white matter and gray matter.

References:

PrepLadder Notes

↑ *Back to this question in Part A*

@Neet_pg_bot

• [04_Head and Neck] 014 Pharyngeal Arches Pouches And Clefts

« Back to Folder Directory

[04_Head and Neck] 014 Pharyngeal Arches Pouches And Clefts — Quick Jump

Q1 (p. 1063) *Q2 (p. 1063)* *Q3 (p. 1065)* *Q4 (p. 1066)* *Q5 (p. 1067)* *Q6 (p. 1068)*
Q7 (p. 1069) *Q8 (p. 1070)* *Q9 (p. 1070)* *Q10 (p. 1071)* *Q11 (p. 1072)* *Q12 (p. 1072)*
Q13 (p. 1073)

Q1: Which among the following are Skeletal derivatives of 3rd pharyngeal arch? Greater cornu of hyoid Stylohyoid ligament Lesser cornu of hyoid Upper half of body of hyoid Lower half of body of hyoid (Q848484)

A. All the above

B. Only 1

C. 5 and 4

D. 1 and 5

Correct Answer: D. 1 and 5

■ *Listen (English)*

■ *Listen (Hindi)*

Explanation: Arch Nerve of the arch Artery of the arch Skeletal derivatives Muscles of the arch Third Glossopharyngeal nerve Common carotid artery Internal carotid artery Greater cornu of the hyoid Lower half of the body of the hyoid Stylopharyngeus The stylohyoid ligament (2) , the lesser cornu (3) , and the upper half of the body of the hyoid (4) are derived from the second arch.

References:

Inderbir Singh’s Human Embryology, 11th Edition, Pages 129, 130

↑ *Back to this question in Part A*

@Neet_pg_bot

Q2: Arrange the events in the development of the thyroid gland in the correct sequence: Fusion with caudal pharyngeal complex Formation of pharyngeal arches Thyroglossal duct formation Tuberculum impar is formed (Q848488)

A. 2, 4, 3, 1

B. 1, 2, 3, 4

C. 4, 3, 2, 1

D. 3, 1, 2, 4

Correct Answer: A. 2, 4, 3, 1

■ *Listen (English)*

■ *Listen (Hindi)*

Explanation: Development of thyroid gland : After the formation of pharyngeal arches → Tuberculum impar (midline swelling in the floor of the pharynx) → Behind the tuberculum impar the epithelium thickens and forms a diverticulum: Thyroglossal duct → Grows downwards and bifurcates → Proliferation of cells at the ends forms two lobes → Developing thyroid gland fuses with the caudal pharyngeal complex

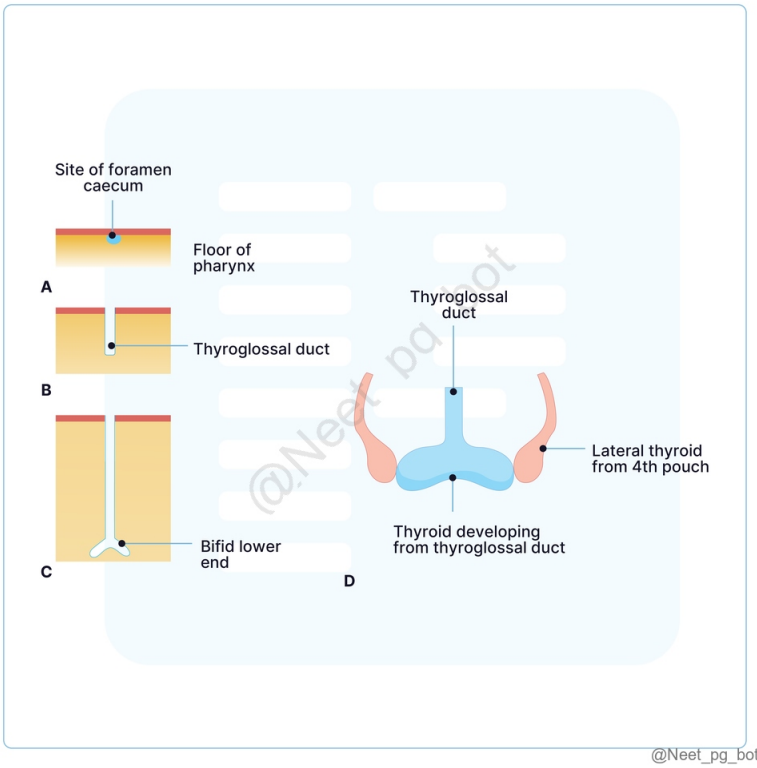

References:

Inderbir Singh's Human Embryology, 11th Edition, Page 133.

↑ *Back to this question in Part A*

@Neet_pg_bot

Q3: Which of the following statements on double aortic arch is false? (Q848490)

A. Dyspnea and dysphagia are symptoms

B. Compression of esophagus and trachea

C. Right dorsal aorta is persisted

D. Right aortic arch passes in front of the trachea and esophagus

Correct Answer: D. Right aortic arch passes in front of the trachea and esophagus

■ *Listen (English)*

■ *Listen (Hindi)*

Explanation: In a double aortic arch, the right aortic arch passes behind the trachea and esophagus, not in front of it. Double aortic arch: A developmental anomaly in which a vascular ring surrounds the trachea and esophagus. The dorsal aorta is a midline artery dorsal to the gut In normal development, the right dorsal aorta between the origin of the 7th cervical intersegmental artery and its fusion with the left dorsal aorta disappears. In this case, the right dorsal aorta persisted. (Option C) The right aortic arch passes behind the trachea and esophagus. (Option D) The left aortic arch passes in front of the trachea and esophagus, forming a vascular ring. The vascular ring compresses the trachea and esophagus (Option B), leading to dyspnea and dysphagia (Option A)

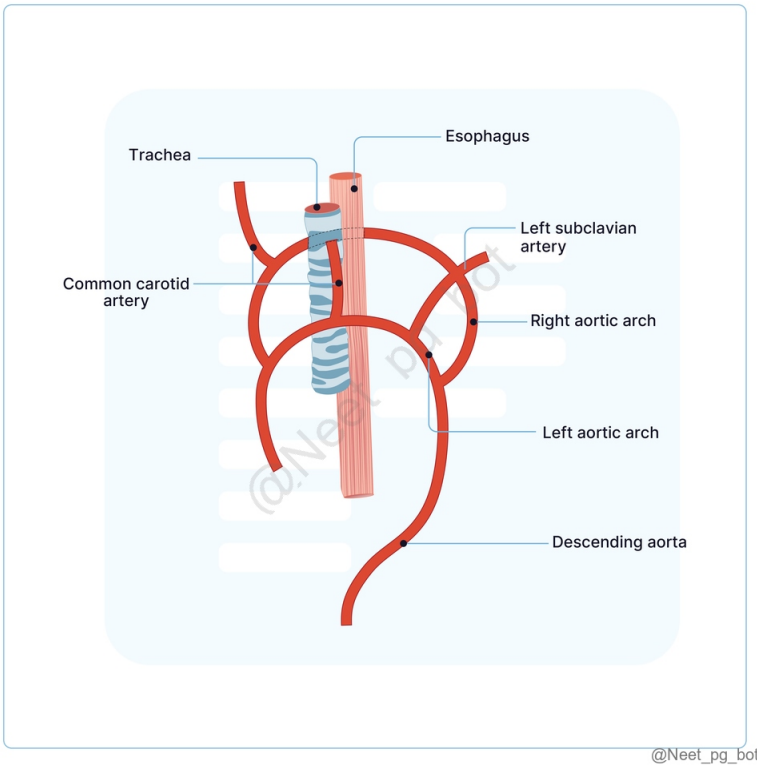

References:

Inderbir Singh’s Human Embryology, 11th Edition, Pages 173, 243-246, 262

↑ *Back to this question in Part A*

@Neet_pg_bot

Q4: Which pharyngeal arch primarily contributes to the development of the anterior two-thirds of the tongue? (Q848491)

A. First pharyngeal arch

B. Second pharyngeal arch

C. Third pharyngeal arch

D. Fourth pharyngeal arch

Correct Answer: A. First pharyngeal arch

■ *Listen (English)*

■ *Listen (Hindi)*

Explanation: The first pharyngeal arch forms the anterior two-thirds of the tongue via the lateral lingual swellings and tuberculum impar. Second pharyngeal arch (Option B): Contributes transiently and later gets overgrown by first and third arches. Third pharyngeal arch (Option C): Forms the posterior one-third of the tongue. Fourth pharyngeal arch (Option D): Contributes to the epiglottic region , not the anterior tongue.

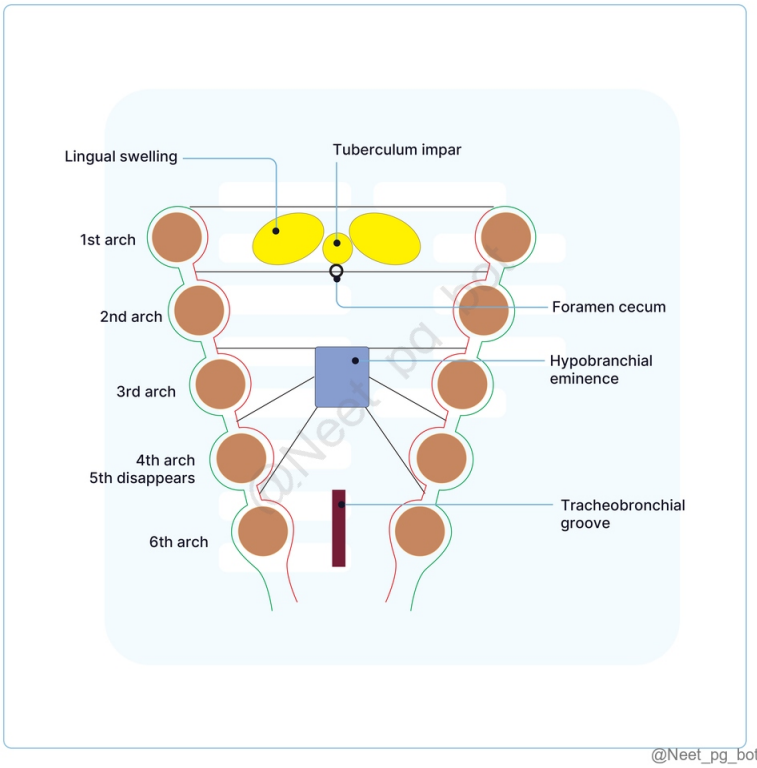

References:

https://www.ncbi.nlm.nih.gov/books/NBK547697/

↑ *Back to this question in Part A*

@Neet_pg_bot

Q5: A patient with a malignant lesion involving the posterior one-third of the tongue is being evaluated for regional lymph node metastasis. Which lymph nodes are most commonly involved in the lymphatic drainage of this region? (Q882294)

A. Deep cervical lymphnodes

B. Submental lymphnodes

C. Submandibular lymphnodes

D. Periauricular lymphnodes

Correct Answer: A. Deep cervical lymphnodes

Explanation: The posterior one-third of the tongue is embryologically and anatomically part of the oropharynx. Its lymphatic drainage is bilateral and occurs predominantly to the upper deep cervical lymph nodes, especially the jugulodigastric nodes. Hence, these nodes are the most commonly involved in malignancies arising from this region. Submental lymph nodes (Option B): Drain the tip of the tongue and anterior floor of mouth; not involved in posterior tongue lesions. Submandibular lymph nodes (Option C): Drain the anterior two-thirds of the tongue (lateral part); posterior third does not primarily drain here. Periauricular lymph nodes (Option D): Drain superficial structures of the scalp, eyelids, and external ear; unrelated to tongue drainage.

References:

Grey's Anatomy, 42nd Edition, Pages 450-451

↑ *Back to this question in Part A*

@Neet_pg_bot

Q6: A 4-year-old child presents with recurrent infections and signs of hypocalcemia. Investigation shows low levels of parathyroid hormone. The physician suspects an embryological defect. Which among the following could be a possible reason? (Q848480)

A. Defect in the development of 1st pharyngeal pouch

B. Defect in the development of 2nd pharyngeal pouch

C. Defect in the development of 3rd pharyngeal pouch

D. Defect in the development of 5th pharyngeal pouch

Correct Answer: C. Defect in the development of 3rd pharyngeal pouch

■ *Listen (English)*

■ *Listen (Hindi)*

Explanation: Here the scenario is suggestive of defect in thymus development (recurrent infections) and defect in development of parathyroid gland (signs of hypocalcemia and low levels of parathyroid hormone). The 3rd pharyngeal pouch is responsible for the development of thymus and inferior parathyroid gland while the 4th pharyngeal pouch is responsible for the development of superior parathyroid gland. Hence, there could be a defect in only the 3rd pharyngeal pouch or defect could be in both 3rd and 4th pharyngeal pouches.

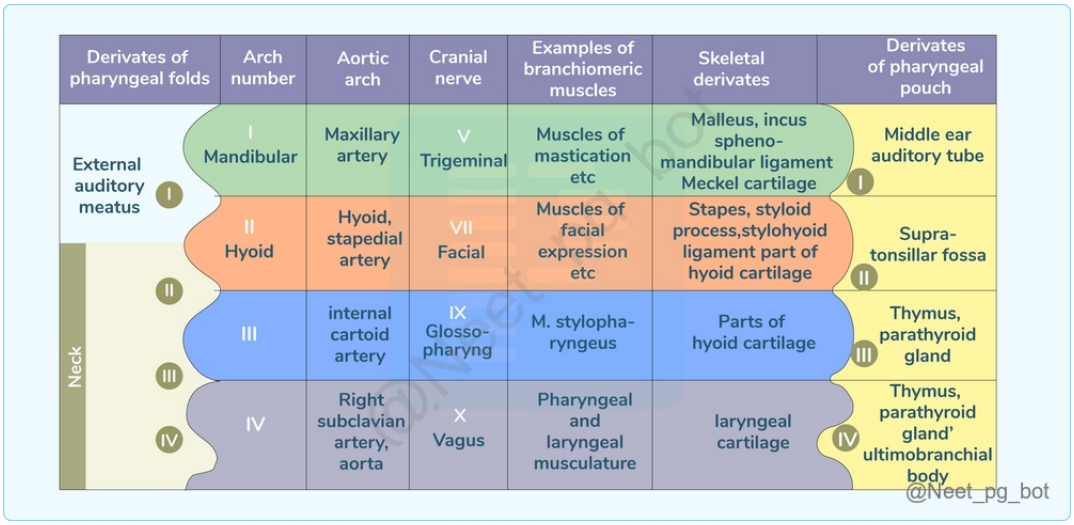

References:

Langman's Medical Embryology, 14th Edition, Page 285, 286, 290, 291, 292.

↑ *Back to this question in Part A*

@Neet_pg_bot

Q7: Which of the following muscles of the first pharyngeal arch are migratory? Mylohyoid Masseter Temporalis Tensor tympani Tensor palati (Q848482)

A. All the above

B. Only 5

C. All except 5 and 4

D. All except 4

Correct Answer: D. All except 4

■ *Listen (English)*

■ *Listen (Hindi)*

Explanation: All first pharyngeal arch muscles except the tensor tympani are migratory; tensor tympani remains localized in the middle ear region. Muscles of First Arch: Masseter Temporalis Medial pterygoid Lateral pterygoids Mylohyoid Anterior belly of digastric Tensor tympani, and Tensor palati All are migratory except T. tympani (Option D)

References:

Inderbir Singh's Human Embryology, 11th Edition, Pages 129, 130

↑ *Back to this question in Part A*

@Neet_pg_bot

Q8: Which among the following are formed from Reichert's cartilage? Stapes Styloid process Stylohyoid ligament Lesser cornu of hyoid Upper half of body of hyoid (Q848483)

A. All the above

B. Only 5

C. All except 5 and 4

D. All except 4

Correct Answer: A. All the above

■ *Listen (English)*

■ *Listen (Hindi)*

Explanation: The cartilage of the second arch (Reichert's) forms the following: Stapes Styloid process Stylohyoid ligament Lesser cornu of hyoid Upper half of body of hyoid

References:

Inderbir Singh's Human Embryology, 11th Edition, Page 129, 130

↑ *Back to this question in Part A*

@Neet_pg_bot

Q9: Match the following pharyngeal arch to its corresponding nerve and artery derivatives. (Multiple options are correct) Arch Nerve of arch Artery of arch 1) Fourth a) Superior laryngeal nerve (Vagus) i) Arch of aorta ii) Subclavian artery 2) Sixth b) Recurrent laryngeal nerve (vagus) iii) Ductus arteriosus iv) Pulmonary artery (Q848485)

A. 1 - a - i and iii

B. 2 - b - iii and iv

C. 1 - a - i and ii

D. 2 - a - i and iii

Correct Answer: B. 2 - b - iii and iv

■ *Listen (English)*

■ *Listen (Hindi)*

Explanation: Arch Nerve of arch Artery of arch Skeletal derivatives Muscles of arch Fourth Superior laryngeal branch of vagus nerve Arch of aorta (left side) Subclavian artery (right side) Thyroid Cricoid Corniculate Cuneiform Arytenoid Thyrohyoid ligament Epiglottis: From mesodermal core of hypobranchial eminence Larynx: Cricothyroid Muscles of pharynx Intrinsic muscles of soft palate except tensor palati Sixth Recurrent laryngeal branch of vagus nerve Ductus arteriosus (left side) Pulmonary artery (right side) All intrinsic muscles of larynx except cricothyroid Note: High-pitch phonation is controlled by the cricothyroid muscle, which develops from the 4th pharyngeal arch and is innervated by the external branch of the superior laryngeal nerve.

References:

Inderbir Singh's Human Embryology, 11th Edition, Pages 129, 130

↑ *Back to this question in Part A*

@Neet_pg_bot

Q10: Match the pharyngeal arches to the nerves arising from it. Pharyngeal arch Nerve a. First 1. Facial nerve b. Second 2. Glossopharyngeal nerve c. Third 3. Chorda tympani d. Sixth 4. Recurrent laryngeal nerve (Q848486)

A. a-3, b-1, c-2, d-4

B. a-1, b-2, c-3, d-4

C. a-4, b-3, c-2, d-1

D. a-2, b-1, c-3, d-4

Correct Answer: A. a-3, b-1, c-2, d-4

■ *Listen (English)*

■ *Listen (Hindi)*

Explanation: Pharyngeal Arch Pretrematic Nerve Post-trematic Nerve First Chorda tympani (branch of facial nerve, CN VII) Maxillary (sensory) and mandibular (motor & sensory) branches of trigeminal nerve (CN V) Second Possible: Tympanic branch of glossopharyngeal nerve (CN IX) Facial nerve (CN VII) Third Possible: Auricular branch of vagus nerve (CN X) Glossopharyngeal nerve (CN IX) Fourth – Superior laryngeal branch of vagus nerve (CN X) Sixth – Recurrent laryngeal branch of vagus nerve (CN X)

References:

Inderbir Singh’s Human Embryology, 11th Edition, Pages 129, 130

↑ *Back to this question in Part A*

@Neet_pg_bot

Q11: Which of the following is the correct pairing of the pharyngeal pouch with its derivative? (Q848487)

A. 1st pharyngeal pouch-Thymus

B. 2nd pharyngeal pouch-Tonsillar fossa

C. 3rd pharyngeal pouch-Auditory tube

D. 4th pharyngeal pouch-Palatine tonsil

Correct Answer: B. 2nd pharyngeal pouch-Tonsillar fossa

■ *Listen (English)*

■ *Listen (Hindi)*

Explanation: Pharyngeal Pouch Derivatives 1st Pharyngeal Pouch Tympanic cavity Auditory tube Inner surface of the eardrum 2nd Pharyngeal Pouch Palatine tonsil Tonsillar fossa 3rd Pharyngeal Pouch Thymus Inferior parathyroid glands 4th Pharyngeal Pouch Superior parathyroid glands Thyroid gland

References:

Inderbir Singh’s Human Embryology, 11th Edition, Pages 131, 132

↑ *Back to this question in Part A*

@Neet_pg_bot

Q12: Match the pharyngeal arch with the artery developing from it Pharyngeal arch Artery a. First 1. Hyoid artery b. Second 2. Maxillary artery c. Third 3. Arch of aorta d. Fourth 4. Internal carotid artery (Q848489)

A. a-2, b-1, c-4, d-3

B. a-1, b-2, c-3, d-4

C. a-4, b-3, c-2, d-1

D. a-3, b-2, c-1, d-4

Correct Answer: A. a-2, b-1, c-4, d-3

■ *Listen (English)*

■ *Listen (Hindi)*

Explanation: Pharyngeal Arch Artery of Arch First Maxillary artery Second Hyoid artery, Stapedial artery Third Common carotid artery, Internal carotid artery Fourth Arch of aorta (left side), Subclavian artery (right side) Sixth Ductus arteriosus (left side), Pulmonary artery (right side)

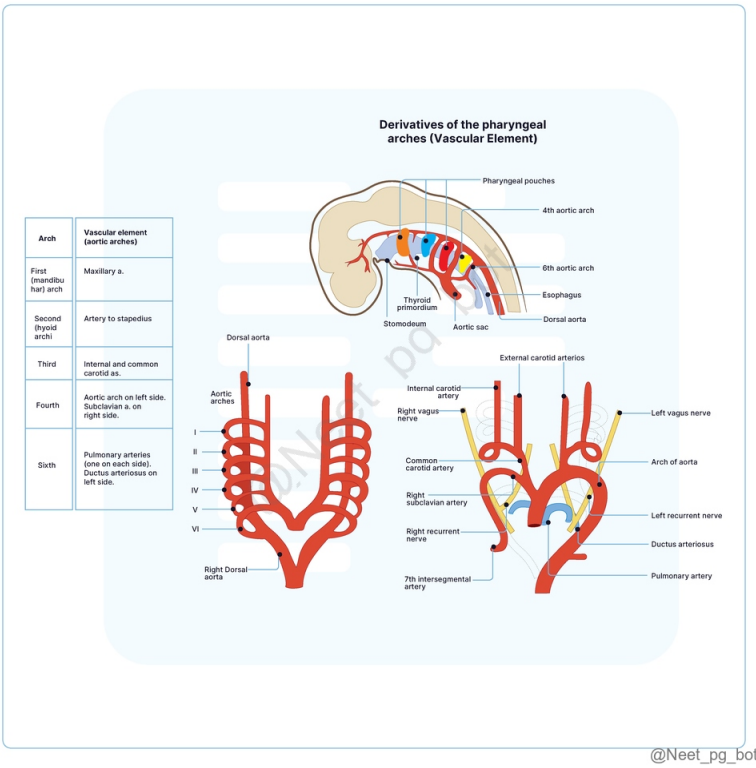

@Neet_pg_bot

References:

Inderbir Singh’s Human Embryology, 11th Edition, Page 130

↑ *Back to this question in Part A*

@Neet_pg_bot

Q13: Which of the following nerves provides general sensation to the area of the tongue marked in blue? (Q848492)

A. Glossopharyngeal nerve

B. Facial nerve

C. Lingual nerve

D. Hypoglossal nerve

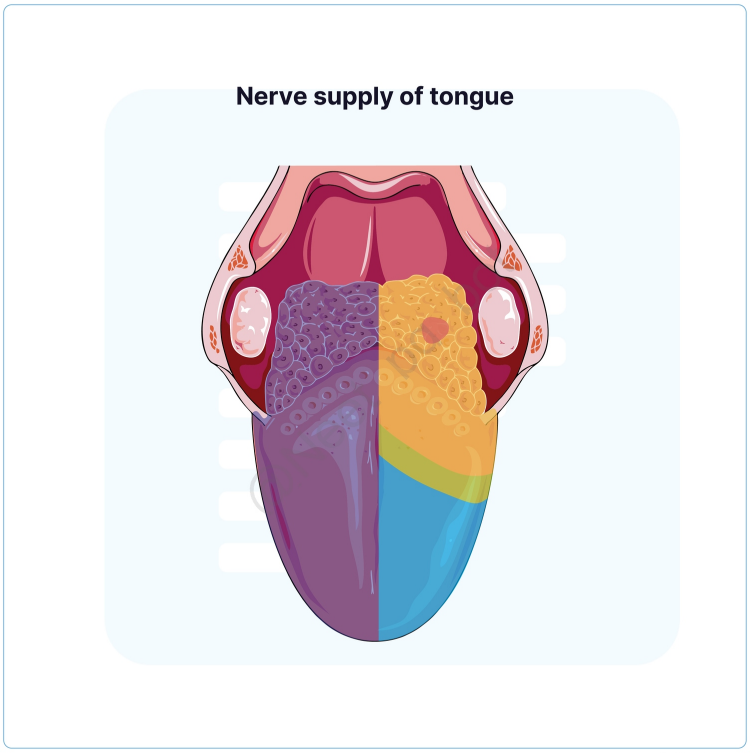

Correct Answer: C. Lingual nerve

■ *Listen (English)*

■ *Listen (Hindi)*

Explanation: The lingual nerve (branch of mandibular division of trigeminal, CN V■) supplies general sensation to the anterior two-thirds of the tongue (area usually shown in blue). Glossopharyngeal nerve (IX) (Option A): General and taste sensation to posterior one-third . Facial nerve (VII) (Option B): Taste only (via chorda tympani) to anterior two-thirds, not general sensation. Hypoglossal nerve (XII) (Option D): Motor supply to tongue muscles, not sensory.

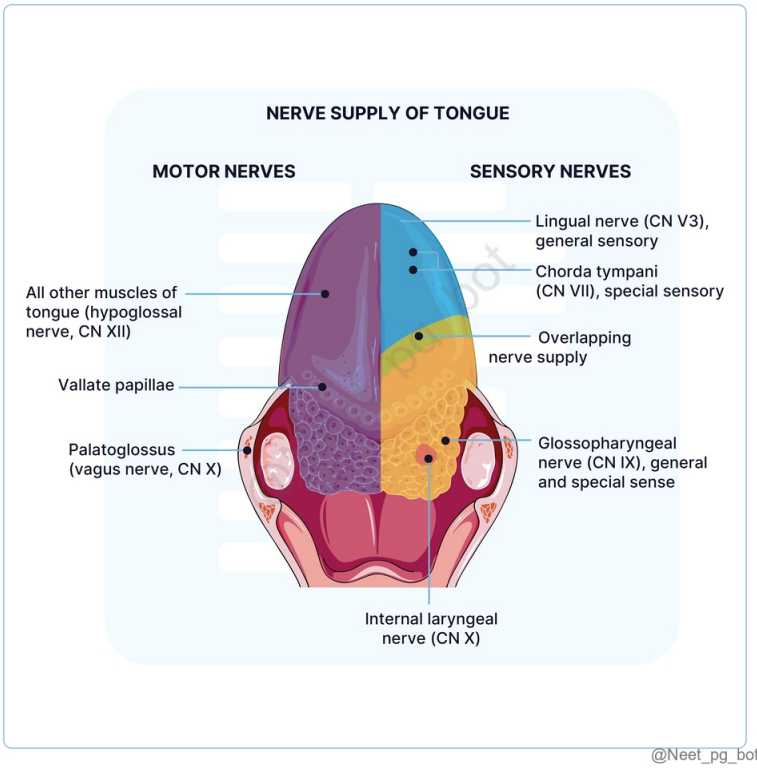

@Neet_pg_bot

References:

https://www.ncbi.nlm.nih.gov/books/NBK507782/

↑ *Back to this question in Part A*

@Neet_pg_bot

• [04_Head and Neck] 015 Skull Bones And Cranial Cavity- Part I

« Back to Folder Directory

[04_Head and Neck] 015 Skull Bones And Cranial Cavity- Part I — Quick Jump

Q1 (p. 1076) *Q2 (p. 1077)* *Q3 (p. 1077)* *Q4 (p. 1079)* *Q5 (p. 1080)* *Q6 (p. 1081)*
Q7 (p. 1083) *Q8 (p. 1084)* *Q9 (p. 1085)* *Q10 (p. 1086)* *Q11 (p. 1088)* *Q12 (p. 1089)*

Q1: Which of the following cranial nerves that pass through foramina or canals located entirely within the given bone? (Q876243)

A. Optic (CN II), Oculomotor (CN III), Trochlear (CN IV), Abducens (CN VI), Trigeminal divisions V1 and V2

B. Olfactory (CN I), Optic (CN II), Facial (CN VII), Vestibulocochlear (CN VIII)

C. Trigeminal (CN V), Glossopharyngeal (CN IX), Vagus (CN X), Accessory (CN XI)

D. Hypoglossal (CN XII), Accessory (CN XI), Vagus (CN X), Glossopharyngeal (CN IX)

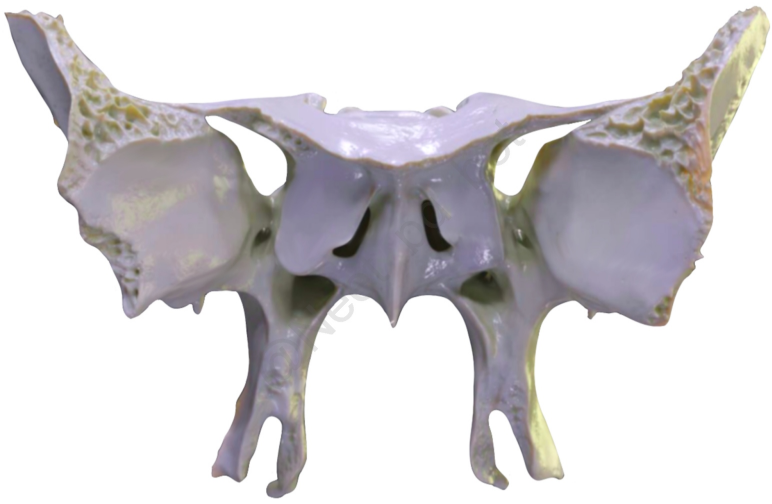

@Neet_pg_bot

Correct Answer: A. Optic (CN II), Oculomotor (CN III), Trochlear (CN IV), Abducens (CN VI), Trigeminal divisions V1 and V2

Explanation: Correct Option A - Optic (CN II), Oculomotor (CN III), Trochlear (CN IV), Abducens (CN VI), Trigeminal divisions V1 and V2: The given image is of sphenoid bone is a complex, butterfly-shaped bone at the base of the skull that contains several important openings for structures, including numerous cranial nerves. The relevant openings and the nerves that pass through them are: Optic Canal: Transmits the Optic nerve (CN II) and the ophthalmic artery. Superior Orbital Fissure: Transmits the Oculomotor nerve (CN III) , the Trochlear nerve (CN IV) , the Abducens nerve (CN VI) , and the first division of the trigeminal nerve (V1 Ophthalmic). Foramen Rotundum: Transmits the second division of the trigeminal nerve (V2 Maxillary). Foramen Ovale: Transmits the third division of the trigeminal nerve (V3 Mandibular). Incorrect Options: Option B includes nerves (CN I, VII, VIII) that pass through the ethmoid and temporal bones, not solely the sphenoid. Options C and D list nerves that primarily exit through the jugular foramen (between the temporal and occipital bones) and the hypoglossal canal (occipital bone).

↑ *Back to this question in Part A*

@Neet_pg_bot

Q2: The base of the skull is primarily formed by which type of ossification? (Q848582)

A. Intramembranous ossification

B. Endochondral ossification

C. Partly intramembranous and partly endochondral

D. Perichondral ossification

Correct Answer: B. Endochondral ossification

■ *Listen (English)*

■ *Listen (Hindi)*

Explanation: The base of the skull (chondrocranium) develops from cartilage that later ossifies by endochondral ossification. Intramembranous ossification (Option A): Forms flat bones of the skull vault. Partly intramembranous and partly endochondral (Option C): Describes the entire skull, not specifically the base. Perichondral ossification (Option D): Refers to bone formation around cartilage, not primary skull base ossification.

References:

https://www.ncbi.nlm.nih.gov/books/NBK10056/

↑ *Back to this question in Part A*

@Neet_pg_bot

Q3: Which bones form the weakest point of the skull? (Q848583)

A. Frontal, parietal, temporal and sphenoid bones

B. Frontal, occipital, and temporal bones

C. Sphenoid and ethmoid bones

D. Occipital, temporal, and parietal bones

Correct Answer: A. Frontal, parietal, temporal and sphenoid bones

■ *Listen (English)*

■ *Listen (Hindi)*

Explanation: Pterion, the junction where the frontal, parietal, temporal, and sphenoid bones meet is deemed the skull's weakest part. Frontal, occipital, and temporal bones (Option B): These bones do not meet at a single point. The occipital bone is located posteriorly, far from the frontal bone. No known anatomical weak spot or danger zone is formed by this combination. Sphenoid and ethmoid bones (Option C): These bones are part of the anterior cranial base, not the lateral skull. While fragile, this area (e.g., cribriform plate) is internally vulnerable, not the weakest external impact point. Injury here might cause CSF rhinorrhea, but it's not the most fracture-prone site on impact. Occipital, temporal, and parietal bones (Option D): These meet at the asterion, which is stronger than the pterion. The bones here are thicker and less prone to fracture from minor trauma.

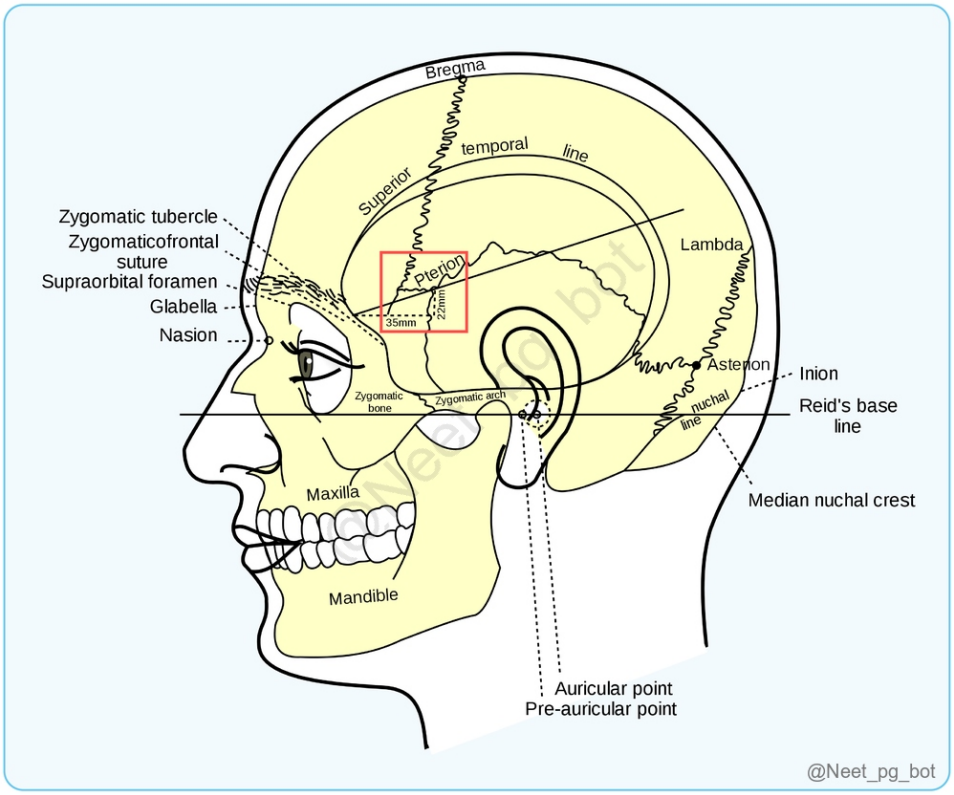

References:

https://www.ncbi.nlm.nih.gov/books/NBK526011/

↑ *Back to this question in Part A*

@Neet_pg_bot

Q4: Which among the following are pneumatic bones? (Q848584)

A. 1,2,3,6,7

B. 1,2,3,5,7

C. 1,2,4,6

D. 1,3,5,6,7

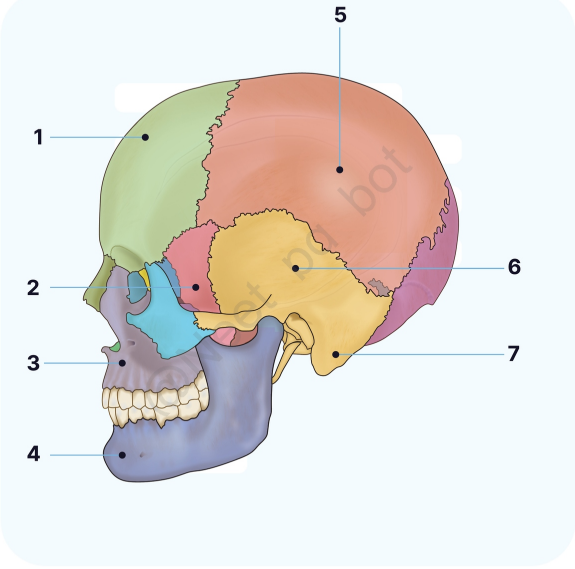

@Neet_pg_bot

Correct Answer: A. 1,2,3,6,7

■ *Listen (English)*

■ *Listen (Hindi)*

Explanation: Pneumatic bones: Frontal (1): Contains sinuses Sphenoid (2): Contains sinuses Maxilla (3): Contains sinuses Temporal (6): Contains ear cavity Mastoid (7): Contains mastoid air cells

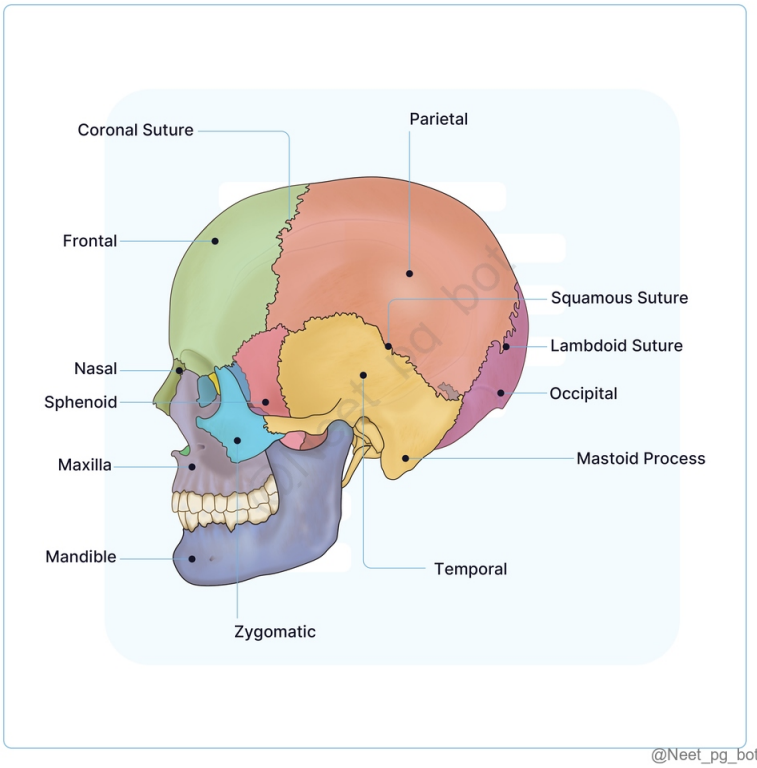

References:

BD Chaurasia's Human Anatomy, 8th Edition, Volume 3, Page 5.

↑ *Back to this question in Part A*

@Neet_pg_bot

Q5: All among the following would be of adult size at birth except (Q848585)

A. Mastoid process

B. Mastoid antrum

C. Tympanic membrane

D. Semicircular canal

Correct Answer: A. Mastoid process

■ *Listen (English)*

■ *Listen (Hindi)*

Explanation: The mastoid process is absent at birth and develops by 2 years of age, while the mastoid air cells are formed by 6 years of age. In contrast, the mastoid or tympanic antrum is of adult size at birth . Structures at Adult Size (at Birth) Structures NOT at Adult Size (at Birth) Tympanic membrane (Option C) Tegmen tympani Tympanic cavity External ear (auricle/pinna, external auditory canal) Ear ossicles (malleus, incus, stapes) Mastoid process (forms by ~2 years; shorter process increases risk to stylomastoid foramen during ear surgery) (Option A) Mastoid (tympanic) antrum (Option B) Mastoid air cells (develop by ~6 years) Internal ear (vestibule, cochlea, semicircular canals) (Option D) Eustachian (auditory) tube

References:

BD Chaurasia's Human Anatomy, 8th Edition, Volume 3, Page 30, 31, 268, 318.

↑ *Back to this question in Part A*

@Neet_pg_bot

Q6: A patient following a road traffic accident presented to the ED in a confused state. Ecchymosis around the eyes was noted, and CT showed the following. Which of the following does not contribute to the floor of the affected structure? (Q848586)

A. Cribriform plate

B. Lesser wing of sphenoid

C. Orbital plate of the frontal bone

D. Greater wing of sphenoid

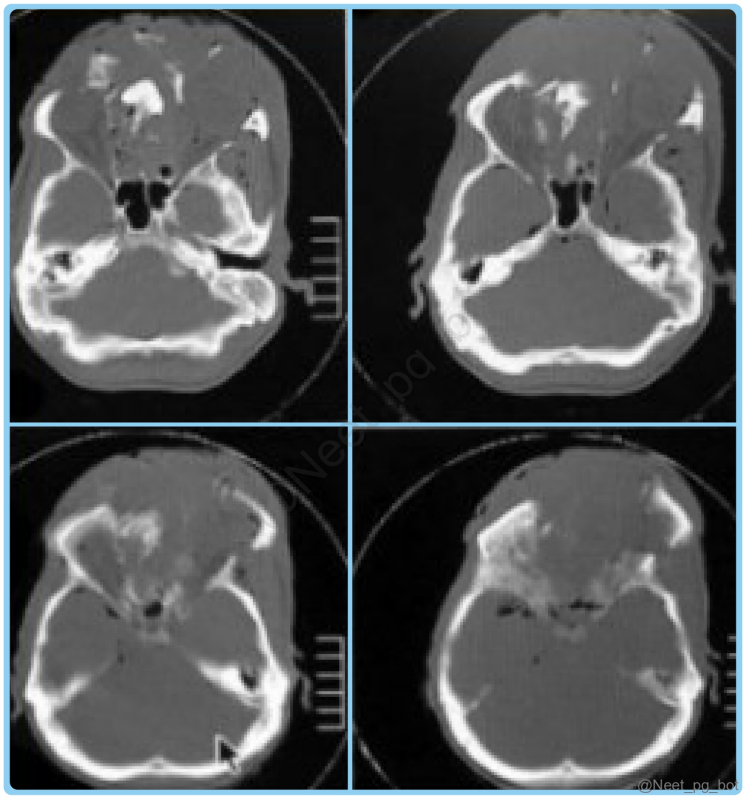

Correct Answer: D. Greater wing of sphenoid

- *Listen (English)*
- *Listen (Hindi)*

Explanation: Given clinical scenario and radiological images are suggestive of Anterior cranial fossa fracture. The greater wing of the sphenoid bone does not contribute to the floor of Anterior cranial fossa. Floor of Anterior cranial fossa (ACF): Cribriform plate of the ethmoid bone (anterior) (Option A) Superior surface of the anterior part of the body of the sphenoid or Jugum sphenoidale (posterior) Lesser wing of sphenoid (posterior) (Option B) Orbital plate of frontal (on either side) (Option C)

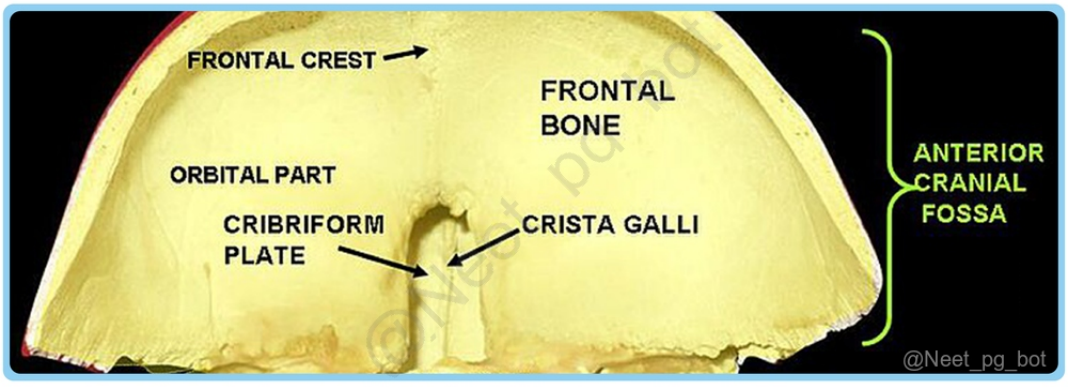

References:

BD Chaurasia's Human Anatomy, 8th Edition, Volume 3, Page 45,46.

↑ *Back to this question in Part A*

@Neet_pg_bot

Q7: Following an RTA, a structure passing through the marked foramen was injured. Which of the following defects is likely to be seen in this patient? (Q848587)

A. Loss of corneal reflex

B. Loss of jaw jerk

C. Inability to abduct eye

D. Loss of sensation over cheek



Correct Answer: D. Loss of sensation over cheek

■ *Listen (English)*

■ *Listen (Hindi)*

Explanation: The image shows the Sphenoid bone with the lesser wing, and the opening marked is the foramen rotundum . The maxillary division of the Trigeminal nerve (V2) and the emissary vein pass through the foramen rotundum, and hence, loss of sensations of the cheek would be the defect seen in this patient. Loss of corneal reflex (Option A): Seen with injury to the Ophthalmic division of the trigeminal (V2) , which passes through the superior

orbital fissure . Loss of jaw jerk (Option B): Seen with injury to the Mandibular division of the trigeminal (V3) , which passes through the foramen ovale . Inability to abduct the eye (Option C): Abduction of the eye is done by the lateral rectus, supplied by the Abducens Nerve (VI), which passes through the superior orbital fissure .

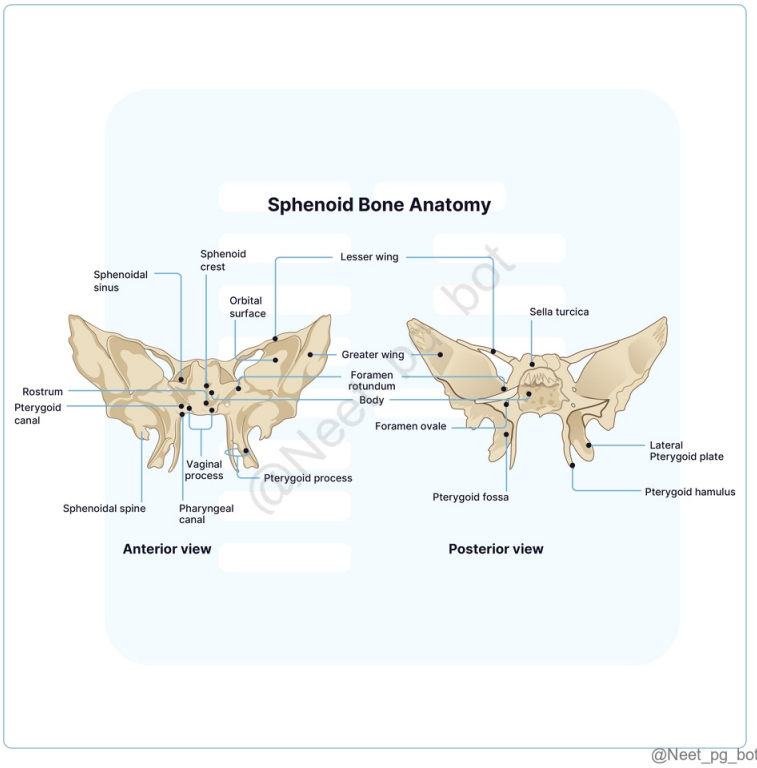

References:

BD Chaurasia's Human Anatomy, 8th Edition, Volume 3, Pages 45,46

↑ *Back to this question in Part A*

@Neet_pg_bot

Q8: A young female with history of recurrent attacks of pain over medial canthus of eye and cheek presents with chills, rigor, diplopia on lateral gaze and restriction of eye movements. She was diagnosed with PCOS and is on OCPs for the same since 6 months. On examination, edema over eyelids and exophthalmos were noted. Choose the correct combination regarding communication of the most likely structure affected in this patient. (Q848588)

A. Transverse sinus through Inferior petrosal sinus

B. Internal jugular vein through emissary veins

C. Pterygoid plexus through superior petrosal sinus

D. Facial vein through superior ophthalmic vein

Correct Answer: D. Facial vein through superior ophthalmic vein

■ *Listen (English)*

■ *Listen (Hindi)*

Explanation: Given clinical scenario of restriction of eye movements (III, IV nerve involvement) pain over medial canthus (V1) , pain over cheek (V2), diplopia of lateral gaze (VI) with exophthalmos and eyelid edema (venous congestion symptoms) and no history of blindness is suggestive of Cavernous sinus syndrome. Infection from the medial canthus of the eye can spread via the facial vein → angular vein → superior ophthalmic vein → cavernous sinus, leading to cavernous sinus thrombosis. Transverse sinus through inferior petrosal sinus (Option A): Drains from cavernous to sigmoid sinus, not facial region. Internal jugular vein through emissary veins (Option B): Not the primary route of spread from facial infections. Pterygoid plexus through superior petrosal sinus (Option C): No direct communication; pterygoid plexus connects via inferior ophthalmic vein.

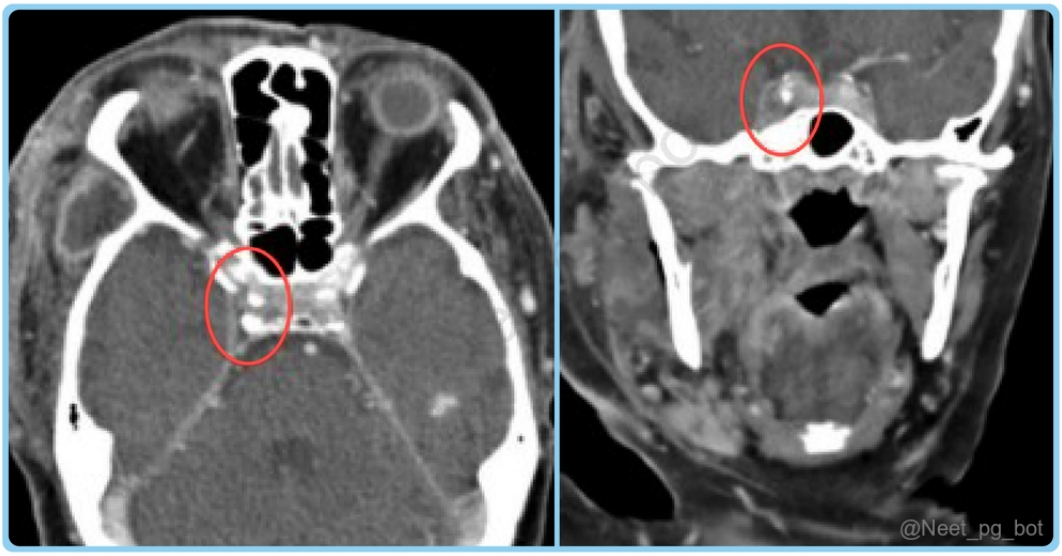

References:

BD Chaurasia's Human Anatomy, 8th Edition, Volume 3, Page 216-218

↑ *Back to this question in Part A*

@Neet_pg_bot

Q9: Which of the following nerves pass through the internal acoustic meatus? (Q848589)

A. Hypoglossal and vagus

B. Glossopharyngeal and accessory

C. Hypoglossal and facial

D. Facial and vestibulocochlear

Correct Answer: D. Facial and vestibulocochlear

■ *Listen (English)*

■ *Listen (Hindi)*

Explanation: Internal acoustic meatus is seen on the floor of the posterior cranial fossa and it transmits facial and vestibulocochlear nerves Hypoglossal and vagus (Option A): Exit via the hypoglossal canal and jugular foramen, respectively. Glossopharyngeal and accessory (Option B): Both pass through the jugular foramen. Hypoglossal and facial (Option C): Hypoglossal uses the hypoglossal canal; facial uses the internal acoustic meatus.

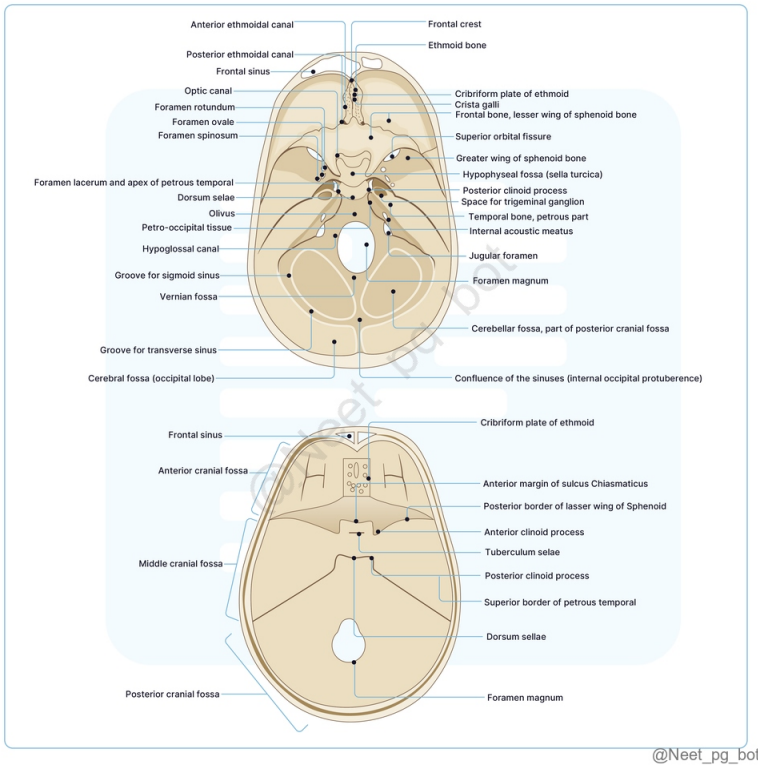

@Neet_pg_bot

References:

BD Chaurasia’s Human Anatomy, 8th Edition, Volume 3, Pages 25-26

↑ *Back to this question in Part A*

@Neet_pg_bot

Q10: Which of the following is not a structure passing through the superior orbital fissure? (Q848591)

A. Trochlear nerve

B. Nasociliary nerve

C. Abducens nerve

D. Facial nerve

Correct Answer: D. Facial nerve

- *Listen (English)*
- *Listen (Hindi)*

Explanation: Facial nerve does not pass through the superior orbital fissure. Superior orbital fissure: triangular gap through which the middle cranial fossa connects with the orbit. Trochlear nerve (Option A): Passes through the superior orbital fissure. Nasociliary nerve (Option B): A branch of ophthalmic nerve passing through the superior orbital fissure. Abducens nerve (Option C): Passes through the superior orbital fissure to supply the lateral rectus muscle. Foramen Location Contents Optic canal Middle cranial fossa CN II, Ophthalmic artery Superior orbital fissure Between greater & lesser wing of sphenoid CN III, IV, V1, VI, Superior ophthalmic vein Foramen rotundum Sphenoid CN V2 Foramen ovale Sphenoid CN V3, Lesser petrosal nerve, Accessory meningeal artery Foramen spinosum Sphenoid Middle meningeal artery, Meningeal branch of V3 Foramen lacerum Between sphenoid & temporal Filled with cartilage (no major nerve passes through it directly) Jugular foramen Posterior cranial fossa CN IX, X, XI, Internal jugular vein Hypoglossal canal Occipital bone CN XII Foramen magnum Base of skull Medulla, Vertebral arteries, Spinal root of XI Stylomastoid foramen Temporal bone Exit of Facial nerve Cribriform plate Anterior cranial fossa Olfactory nerve filaments

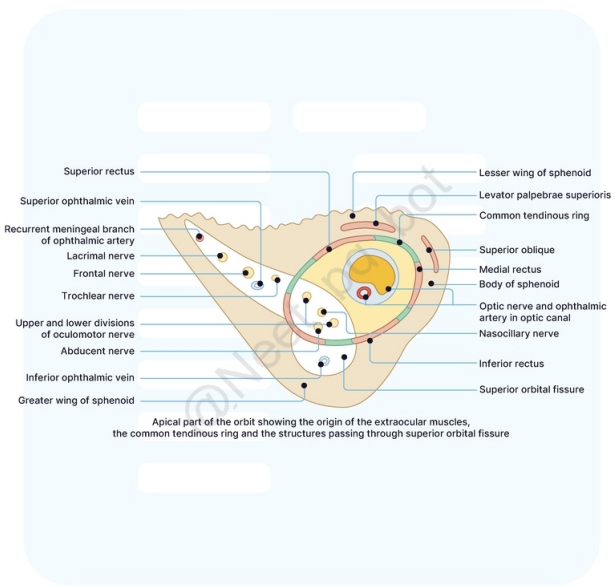

@Neet_pg_bot

References:

BD Chaurasia's Human Anatomy, 8th Edition, Volume 3, Pages 46, 58

↑ *Back to this question in Part A*

@Neet_pg_bot

Q11: Which of the following structure does not pass through the common tendinous ring of Zinn? (Q848601)

A. Nasociliary nerve

B. Abducens nerve

C. Oculomotor nerve

D. Inferior ophthalmic vein

Correct Answer: D. Inferior ophthalmic vein

■ *Listen (English)*

■ *Listen (Hindi)*

Explanation: The inferior ophthalmic vein passes below the common tendinous ring of Zinn, not through it. Structures passing through common tendinous ring of Zinn: Superior division of oculomotor nerve (CN III) (Option C) Inferior division of oculomotor nerve (Option C) Nasociliary nerve (Option A) Abducens nerve (CN VI) (Option B) Sympathetic root of ciliary ganglion Contents of the optic canal (optic nerve and ophthalmic artery)

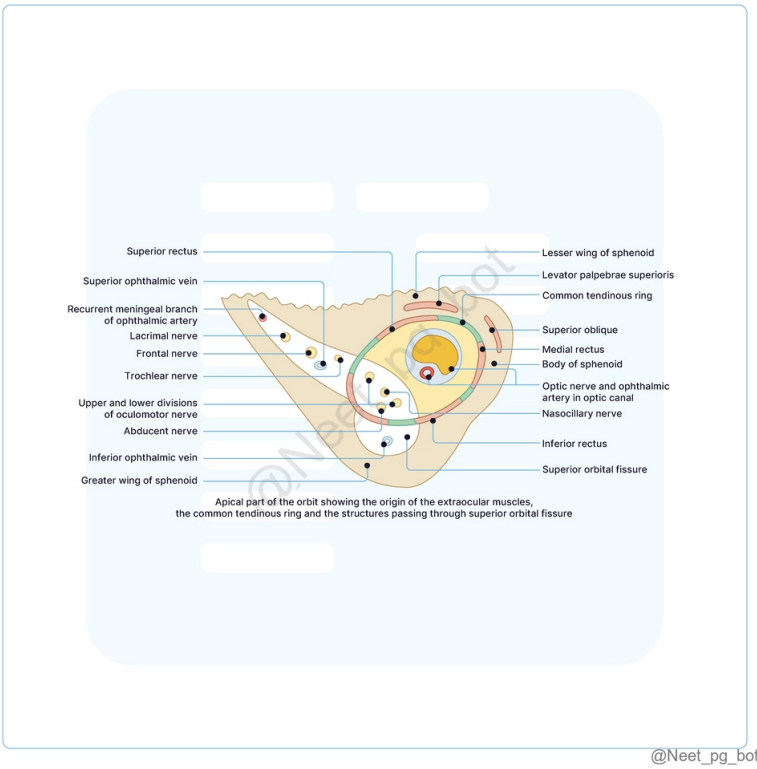

@Neet_pg_bot

References:

Vishram Singh’s Textbook of Anatomy, 2nd Edition, Volume 3, Pages 285, 319

↑ *Back to this question in Part A*

@Neet_pg_bot

Q12: Match the walls of the orbit with the bones forming it Wall Bone a. Roof 1. Greater wing of sphenoid b. Lateral wall 2. Orbital surface of maxilla c. Floor 3. Orbital plate of frontal d. Medial wall 4. Lacrimal (Q848602)

A. a-1, b-2, c-3, d-4

B. a-4, b-3, c-2, d-1

C. a-3, b-1, c-2, d-4

D. a-2, b-1, c-3, d-4

Correct Answer: C. a-3, b-1, c-2, d-4

■ *Listen (English)*

■ *Listen (Hindi)*

Explanation: Orbital Wall Structures Forming the Wall Roof Orbital plate of the frontal bone (main part) Lesser wing of the sphenoid (posterior part) Lateral Wall Greater wing of the sphenoid bone (posterior part) Orbital surface of the frontal process of the zygomatic bone (anterior part) Floor Orbital surface of the maxilla (main part) Lower part of the orbital surface of the zygomatic bone (anterolaterally) Orbital process of the palatine bone (posterior angle) Medial Wall From before backward: Frontal process of the maxilla Lacrimal bone Orbital plate of the ethmoid bone Body of the sphenoid bone

References:

BD Chaurasia’s Human Anatomy, 8th Edition, Volume 3, Page 28, 29

↑ *Back to this question in Part A*

@Neet_pg_bot

• [04_Head and Neck] 016 Cranial Cavity- Part Ii

« Back to Folder Directory

[04_Head and Neck] 016 Cranial Cavity- Part Ii — Quick Jump

Q1 (p. 1091) *Q2 (p. 1096)* *Q3 (p. 1097)* *Q4 (p. 1099)* *Q5 (p. 1100)* *Q6 (p. 1102)*
Q7 (p. 1104) *Q8 (p. 1108)* *Q9 (p. 1109)* *Q10 (p. 1110)* *Q11 (p. 1111)* *Q12 (p. 1112)*
Q13 (p. 1114) *Q14 (p. 1115)* *Q15 (p. 1116)* *Q16 (p. 1118)*

Q1: Match each type of haemorrhage with its corresponding source of bleeding and Location. Which of the following combinations is correct? Type of Hemorrhage Source of Bleeding Location a. Epidural Hemorrhage 1. Middle meningeal artery i. b. Subdural Hemorrhage 2. Bridging veins ii. c. Subarachnoid Hemorrhage 3. Cerebral arteries iii. d. Intracerebral Hemorrhage 4. Ruptured cerebral aneurysm iv. (Q848724)

A. a-2-i

B. b-1-iv

C. c-4-iii

D. d-3-ii


@Neet_pg_bot

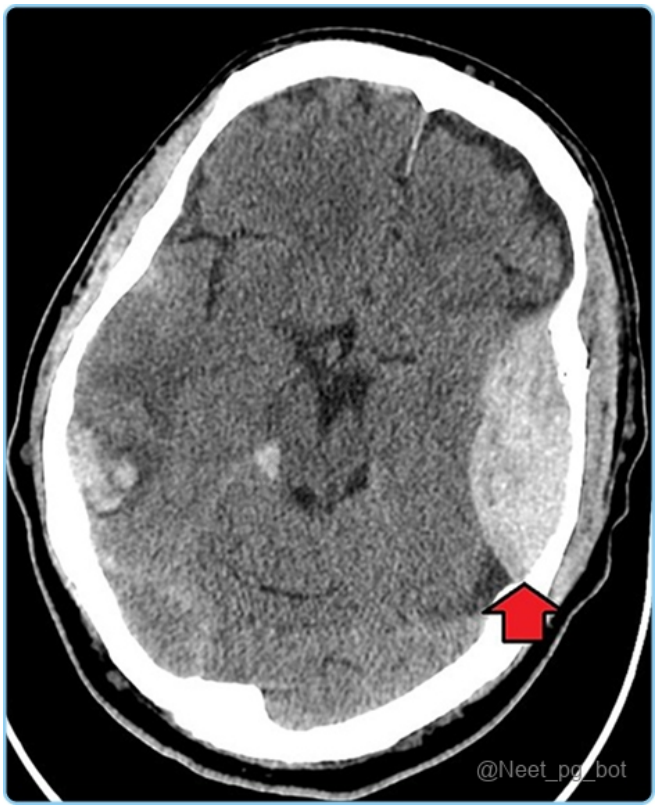
@Neet_pg_bot



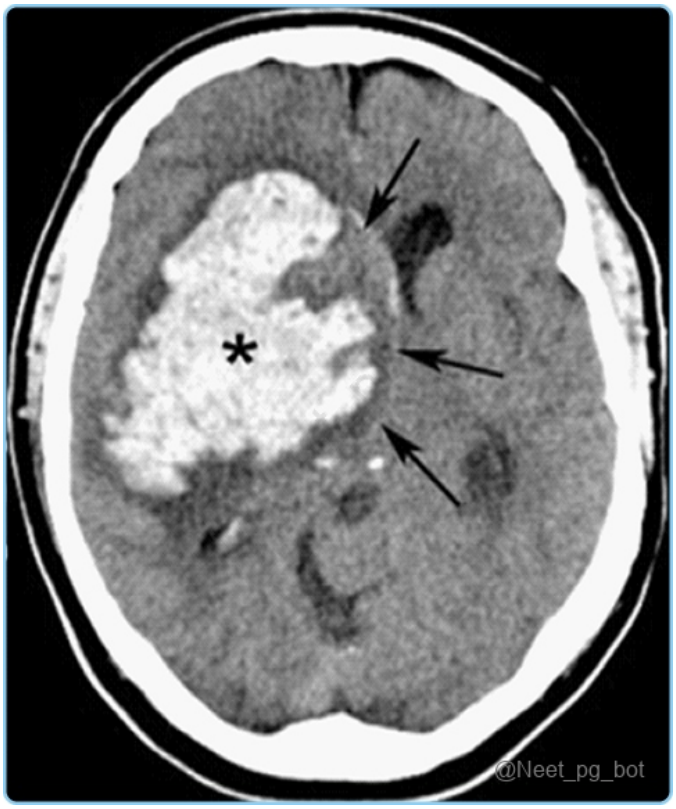

Correct Answer: C. c-4-iii

■ *Listen (English)*

■ *Listen (Hindi)*

Explanation: Subarachnoid haemorrhage often results from a ruptured cerebral aneurysm (e.g., a berry aneurysm). It can also occur due to head trauma or arteriovenous malformations (AVMs). Bleeding occurs in the subarachnoid space, which lies between the arachnoid and pia mater. Type of Hemorrhage Source of Bleeding Location of Blood Collection Epidural Hemorrhage Middle meningeal artery Between the skull bone and endosteal layer of the dura mater. Subdural Hemorrhage Bridging veins (venous bleed) Between dura mater and arachnoid mater. Subarachnoid Hemorrhage Rupture of small arteries (e.g., aneurysms) Subarachnoid space at the base of the brain (cisterns) Intracerebral Hemorrhage Rupture of arteries within brain parenchyma Brain tissue (parenchyma) itself, often in basal ganglia or cortex

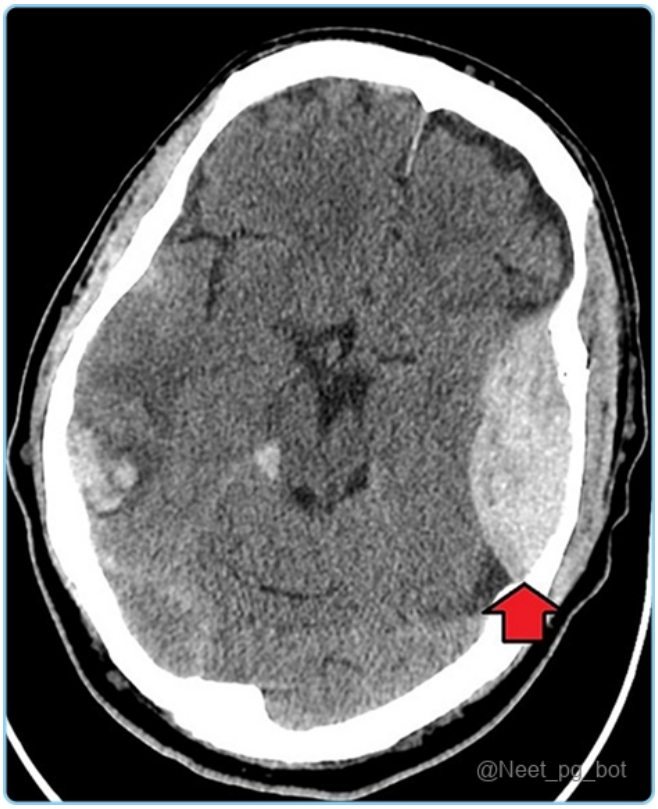


@Neet_pg_bot


@Neet_pg_bot

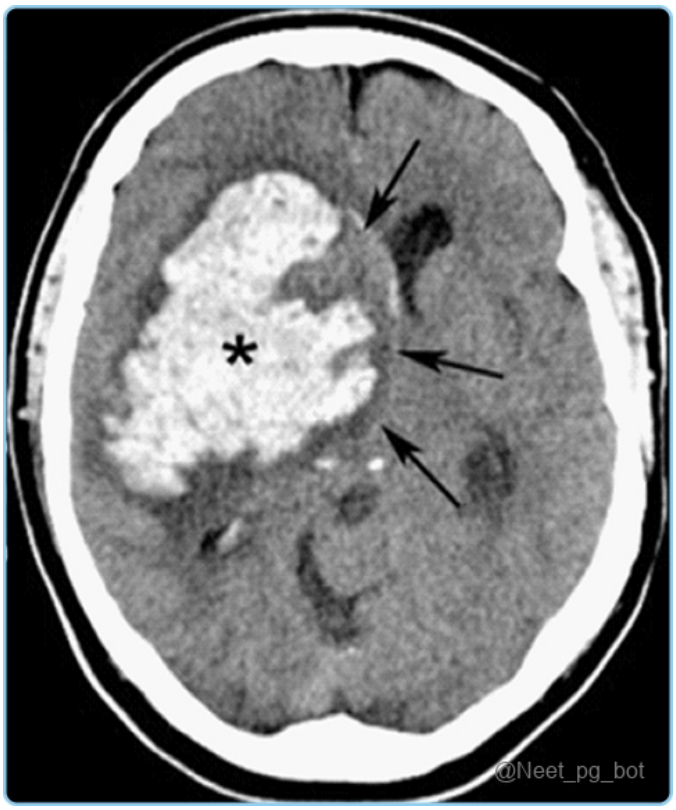

References:

B. D. Chaurasia's Human Anatomy, Volume-3,4, Edition 8, Page 216,218

↑ *Back to this question in Part A*

@Neet_pg_bot

Q2: A 45-year-old man presents to the emergency department after a motor vehicle accident with severe head trauma. His GCS is 5. On examination, there is a loss of sensation below the level of the neck and flaccid paralysis of all four limbs. Which of the following structures pass through the same cranial foramen as the structure involved in this patient? (Q848726)

A. Hypoglossal nerve

B. Internal Carotid Artery

C. Spinal root of accessory nerve

D. Middle meningeal artery

Correct Answer: C. Spinal root of accessory nerve

■ *Listen (English)*

■ *Listen (Hindi)*

Explanation: The structure involved in this patient is the spinal cord, which is the continuation of the medulla oblongata, which passes through the foramen magnum , the largest foramen in the skull, located in the occipital bone. It allows for the passage of several critical structures, including: Medulla Oblongata exits the skull through the foramen magnum and continues as the spinal cord. Spinal roots of the spinal accessory nerve . Meninges, which surround the brain and spinal cord. Vertebral arteries and veins . Hypoglossal nerve (Option A) passes through the Hypoglossal canal . Internal Carotid Artery (Option B) enters the skull through the carotid canal. Middle meningeal artery (Option D) passes through the Foramen Spinosum.

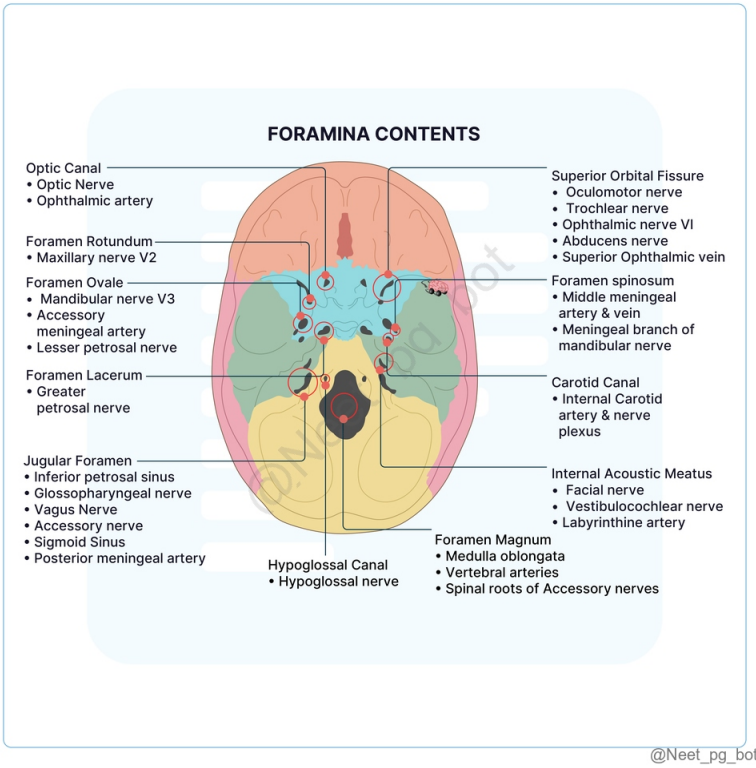

@Neet_pg_bot

References:

Grey's anatomy textbook, 42 Edition, Page-564.

↑ *Back to this question in Part A*

@Neet_pg_bot

Q3: A 30-year-old female presents with severe headaches and neurological deficits. Imaging reveals thrombosis of the inferior sagittal sinus. Which sinus does the inferior sagittal sinus primarily drain into? (Q848733)

A. Confluence of Sinuses

B. Transverse sinus

C. Straight sinus

D. Sigmoid sinus

Correct Answer: C. Straight sinus

■ *Listen (English)*

■ *Listen (Hindi)*

Explanation: The inferior sagittal sinus drains into the straight sinus , where it joins with the great cerebral vein to continue venous drainage from deep brain structures. Confluence of sinuses (Option A): Receives blood from the superior sagittal and straight sinuses, not directly from the inferior sagittal sinus. Transverse sinus (Option B): Drains the confluence of sinuses, not the inferior sagittal sinus. Sigmoid sinus (Option D): Continuation of the transverse sinus leading to the internal jugular vein, not directly connected to the inferior sagittal sinus.

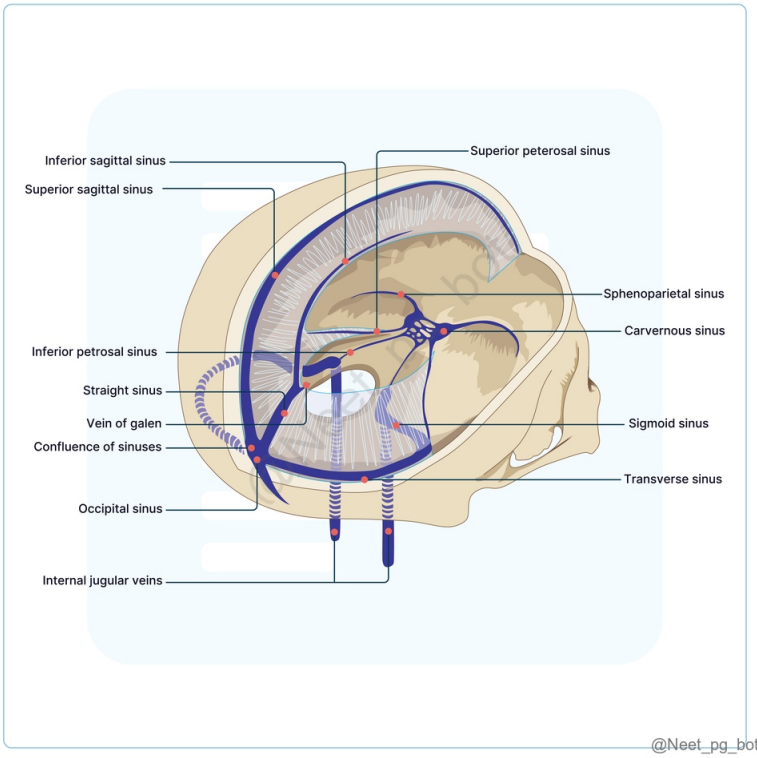

References:

Vishram Singh, Textbook of Anatomy, 2nd Edition, Page 328, 329, 330

↑ *Back to this question in Part A*

@Neet_pg_bot

Q4: A 34 y/o male presents to the emergency department following a road traffic accident. He complains of difficulty in chewing and numbness over the lower jaw. Upon examination, he has weakness in the muscles of mastication. Which of the following structures do not course along with the nerve implicated in the patient's symptoms through the same cranial foramen? (Q848719)

A. Lesser Petrosal nerve

B. Mandibular nerve

C. Accessory meningeal artery

D. Vidian’s nerve

Correct Answer: D. Vidian’s nerve

■ *Listen (English)*

■ *Listen (Hindi)*

Explanation: The patient's symptoms indicate mandibular nerve (V3) involvement, as it innervates the muscles of mastication and provides sensory function to the lower face. This nerve exits through the foramen ovale . The Vidian nerve , formed by the union of the greater petrosal nerve and the deep petrosal nerve , passes through the anterior wall of the foramen lacerum. Structures that traverse foramen ovale (Mnemonic: MALE) M andibular nerve (Option B). A ccessory meningeal artery (Option C). L esser petrosal nerve (Option A). E missary vein Occasionally, the Anterior trunk of the middle meningeal vein At times, there is a canaliculus innominatus situated between the foramen ovale and the foramen spinosum.

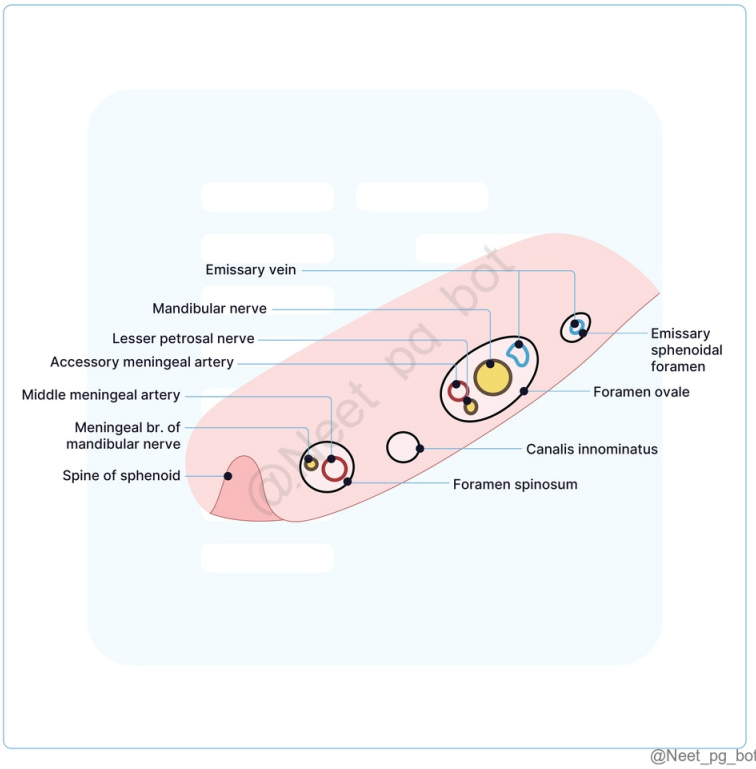

References:

B. D. Chaurasia's Human Anatomy, Volume 3, 8th Edition, Page 19

↑ *Back to this question in Part A*

@Neet_pg_bot

Q5: A 30-year-old man presents with numbness in his upper lip and cheek, along with difficulty sensing temperature changes, following a dental procedure. Through which of the following marked structures does the affected nerve pass? (Q848720)

A. A

B. B

C. C

D. D

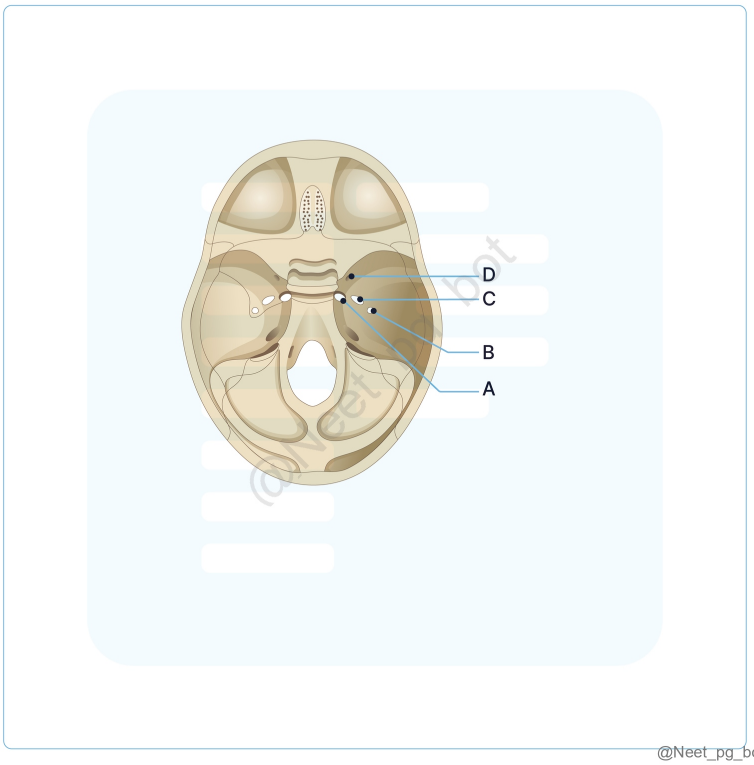

Correct Answer: D. D

■ *Listen (English)*

■ *Listen (Hindi)*

Explanation: The nerve affected in the given scenario is the Maxillary nerve , which passes through the foramen rotundum in the middle cranial fossa. Foramen of Middle Cranial Fossa Structures Passing Through Foramen Rotundum Maxillary nerve (CN V■) Foramen Ovale (Option C) M andibular nerve A ccessory meningeal artery L esser petrosal nerve E missary vein Occasionally, the Anterior trunk of the middle meningeal vein Foramen Spinosum (Option B) M iddle meningeal artery and vein, E missary vein N ervus spinosus (Meningeal branch of mandibular nerve) Foramen Lacerum (Option A) Foramen lacerum contributed by 3 bones-temporal, occipital and sphenoid The internal carotid artery and nerve plexus traverse its superior end; The nerve to the pterygoid canal passes through its anterior wall. The meningeal branch of the ascending pharyngeal artery and an emissary vein pass through it .

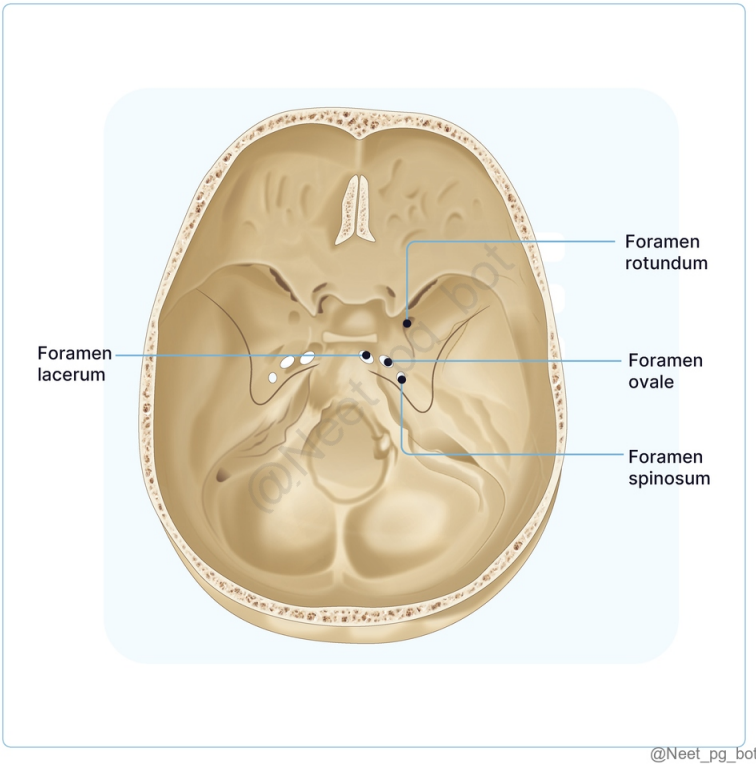

References:

B. D. Chaurasia's Human Anatomy, Volume 3 & 4, 8th Edition, Pages 58, 280

↑ *Back to this question in Part A*

@Neet_pg_bot

Q6: Which of the following contributes to the formation of the marked structure? (Q848721)

A. Lesser wing of the sphenoid

B. Maxilla

C. Zygomatic bone

D. Greater wing of the sphenoid

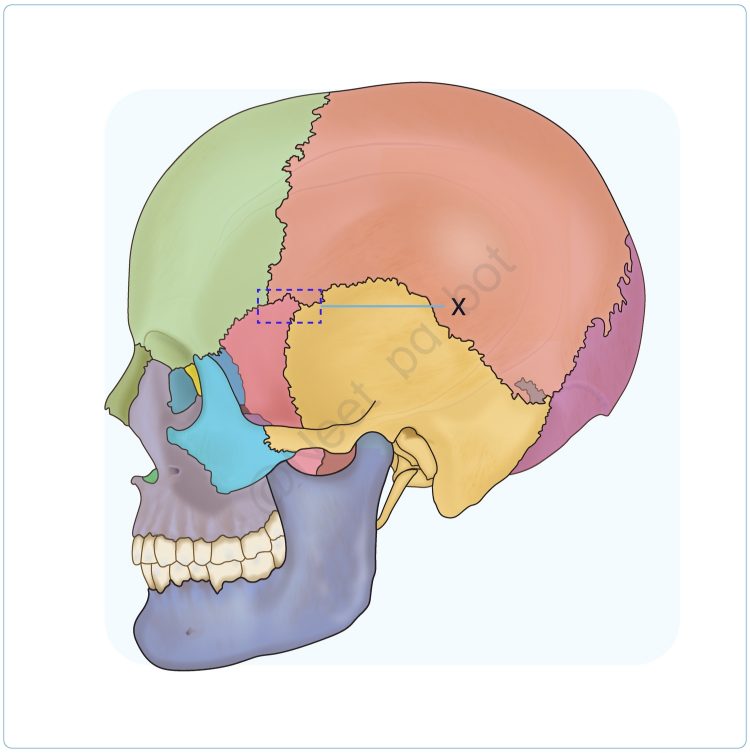

Correct Answer: D. Greater wing of the sphenoid

- *Listen (English)*
- *Listen (Hindi)*

Explanation: The marked area is Pterion , located at the anterolateral fontanelle and is formed by the union of Frontal bone Parietal bone Squamous temporal bones & Greater wing of the sphenoid. Lesser wing of sphenoid (Option A) helps separate the anterior and middle cranial fossae and serves as an attachment point for various muscles and ligaments. Maxilla (Option B) is a paired facial bone that forms the upper jaw and holds the upper teeth. Zygomatic bone (Option C) also known as the cheekbone, provides support for the muscles involved in facial expressions and chewing.

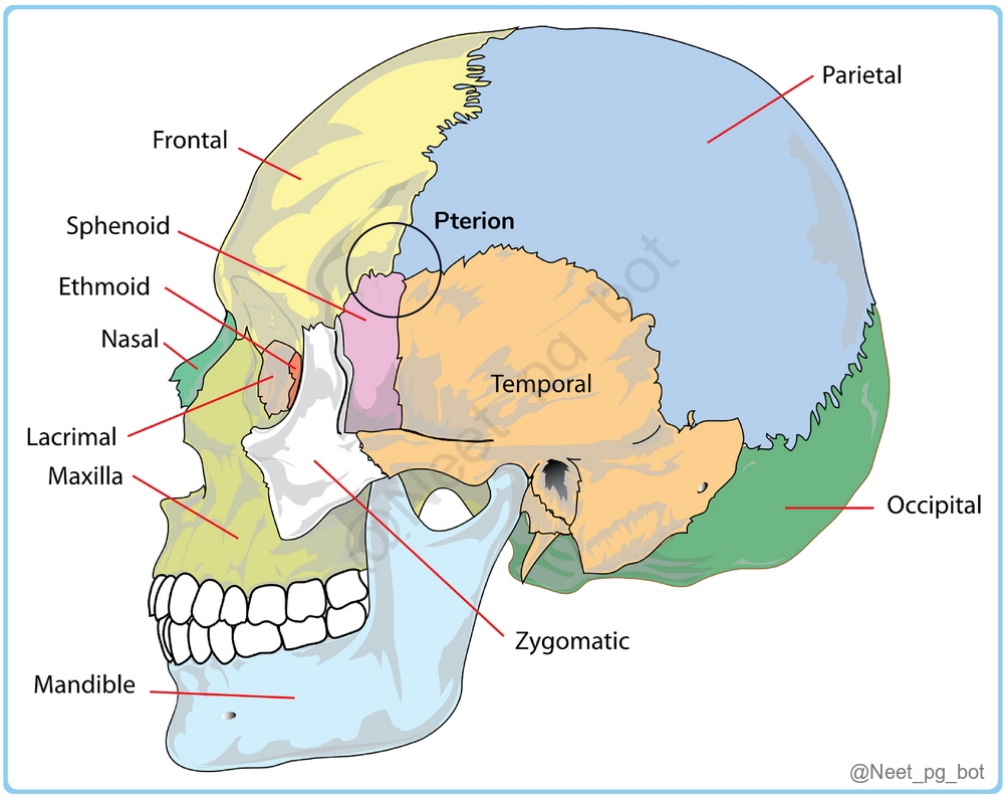

References:

Grey's Anatomy textbook, 42nd Edition, Page 290

B. D. Chaurasia’s Human Anatomy, Volume 3 & 4, 8th Edition, Pages 130, 339

↑ *Back to this question in Part A*

@Neet_pg_bot

Q7: A 25 y/o male presents to the emergency department after a road traffic accident. He was initially unconscious but regained full consciousness shortly afterward, reporting only a mild headache. On examination, the patient starts to experience drowsiness, and eventually loses consciousness again. A CT scan was performed, what is the most likely source of her bleeding? (Q848722)

A. Emissary veins

B. Rupture of berry aneurysm

C. Diploic veins

D. Middle meningeal artery

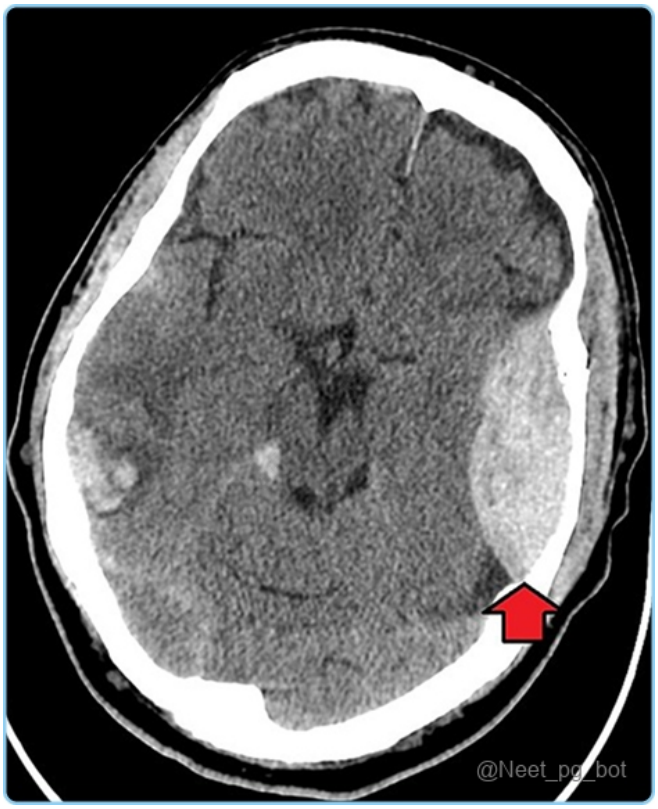

Correct Answer: D. Middle meningeal artery

- *Listen (English)*
- *Listen (Hindi)*

Explanation: Findings of CT with biconvex hyperdense shadow indicate Epidural Hematoma and the most likely source for this bleeding is the Middle Meningeal artery (MMA) (Commonly Anterior division at level of pterion) This is a surgical emergency. Lucid interval: Brief consciousness after injury, followed by rapid deterioration due to expanding hematoma. Emissary veins (Option A) serve as a venous link between intracranial and extracranial spaces, which can contribute to subdural haemorrhage. Rupture of a berry aneurysm (Option B) causes subarachnoid haemorrhage (SAH), with the most likely cause being persistent hypertension . Diploic veins (Option C) begin within the two tables of the skull, with four veins on each side, and can contribute to subdural or extradural haemorrhage.

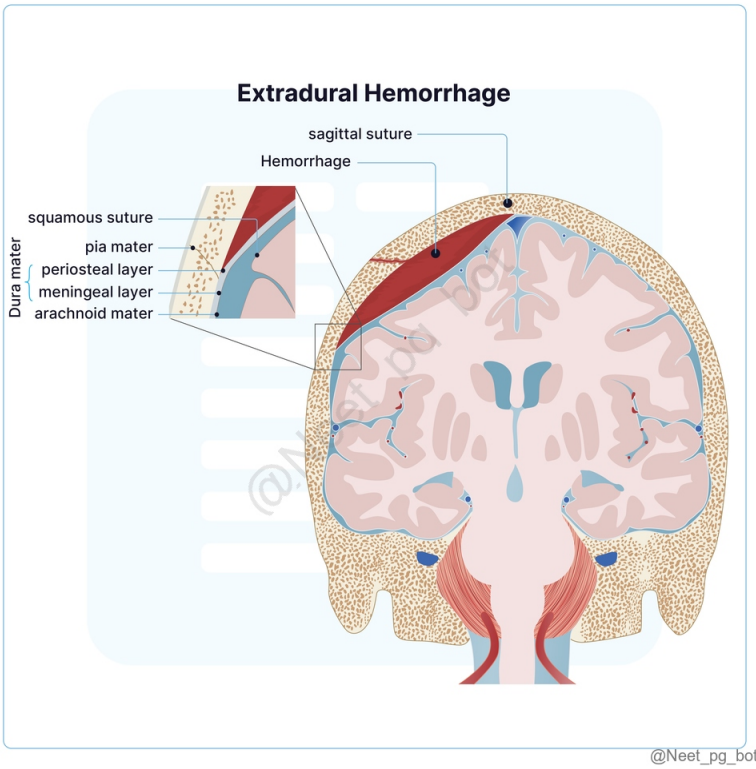
Extradural Hemorrhage
sagittal suture
Hemorrhage
squamous suture
pia mater
periosteal layer
meningeal layer
arachnoid mater
Dura mater
@Neet_pg_bot


@Neet_pg_bot



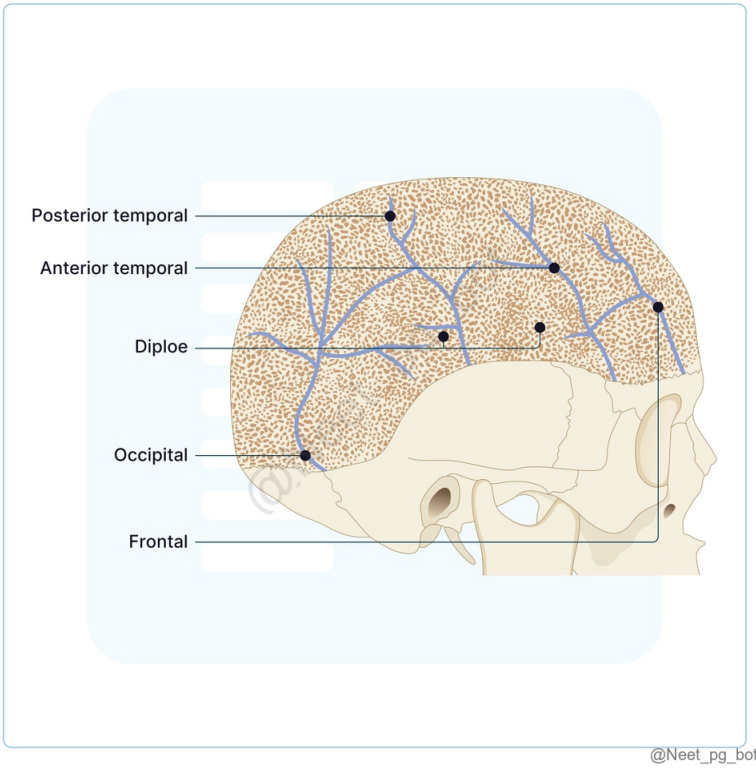

References:

B. D. Chaurasia’s Human Anatomy, Volume 3 & 4 Edition 8, Pages 216, 32, 225, 226

↑ *Back to this question in Part A*

@Neet_pg_bot

Q8: A 50-year-old man with a history of poorly controlled hypertension presents with sudden severe headache, blurred vision, slurred speech, and right-sided weakness. A CT scan shows an acute haemorrhage in the basal ganglia. What is the most likely cause? (Q848723)

A. Berry aneurysm

B. Mycotic aneurysm

C. Ruptured arteriovenous malformation

D. Charcot–Bouchard aneurysm



Correct Answer: D. Charcot–Bouchard aneurysm

■ *Listen (English)*

■ *Listen (Hindi)*

Explanation: Charcot–Bouchard aneurysms are small microaneurysms that develop in the penetrating arteries, particularly in regions such as the basal ganglia, thalamus, pons, and cerebellum. They are strongly associated with chronic hypertension and are a common cause of intracerebral haemorrhage, often resulting from the rupture of deep-seated arteries in the brain tissue. The lenticulostriate branches (LSA) of the middle cerebral artery are commonly affected, leading to: Sudden onset headache Contralateral hemiplegia or hemianesthesia Aphasia Visual disturbances Vomiting Berry aneurysms (Option A): are larger aneurysms located at the bifurcations of major cerebral arteries. Rupture of these aneurysms can lead to subarachnoid haemorrhage, often associated with hypertension, causing bleeding between the arachnoid and pia mater. Presents as an extremely severe headache, often described as the worst headache of one's life. Mycotic aneurysm (Option B): is caused by infection, often associated with endocarditis or other systemic infections, leading to weakened vessel walls and aneurysm formation. It presents with fever, localised pain, inflammation, and headaches. Rupture arteriovenous malformation (Option C) may cause intracerebral hemorrhage but is less strongly associated with chronic hypertension and typically affects younger individuals.

References:

Vishram Singh Textbook of Anatomy, 2nd Edition, Page 409

https://www.ncbi.nlm.nih.gov/books/NBK553103/

↑ *Back to this question in Part A*

@Neet_pg_bot

Q9: Which of the following combinations of structures passing through the posterior cranial fossa is incorrectly matched with their corresponding openings? (Q848725)

A. Spinal cord, vertebral arteries – Foramen Magnum

B. Glossopharyngeal nerve, vagus nerve – Jugular Foramen

C. Facial nerve, vestibulocochlear nerve – Internal acoustic meatus

D. Hypoglossal nerve, emissary vein – Hypoglossal Canal

Correct Answer: A. Spinal cord, vertebral arteries – Foramen Magnum

■ *Listen (English)*

■ *Listen (Hindi)*

Explanation: The medulla passes through the Foramen Magnum and then continues as the spinal cord Structures passing through the posterior cranial fossa Foramen Magnum Medulla oblongata Meninges (dura, arachnoid, pia mater) Vertebral arteries and veins Spinal accessory nerve (spinal root ascends) Spinal arteries Jugular Foramen Glossopharyngeal nerve (CN IX) Vagus nerve (CN X) Spinal accessory nerve (cranial & spinal roots, CN XI) Internal jugular vein (formation) Sigmoid sinus Internal Acoustic Meatus Facial nerve (CN VII) Vestibulocochlear nerve (CN VIII) Nervus intermedius Labyrinthine arteries and veins Hypoglossal Canal Hypoglossal nerve (CN XII) Meningeal branch of ascending pharyngeal artery Emissary vein from basilar plexus

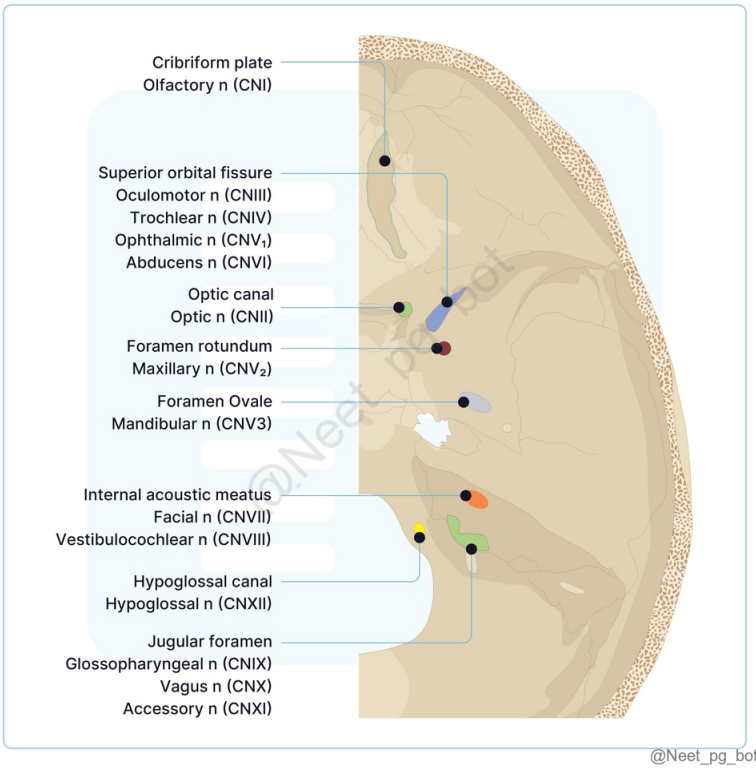

References:

Grey's Anatomy textbook, 42 Edition, Page - 567,568

↑ *Back to this question in Part A*

@Neet_pg_bot

Q10: Which of the following statements about the course of the spinal accessory nerve is TRUE? (Q848727)

A. Passes through the internal acoustic meatus before innervating the trapezius muscle.

B. Exits the skull via the jugular foramen alongside the vagus nerve.

C. Passes through the foramen rotundum with the maxillary nerve.

D. Originates from the dorsal horn of C1 to C5/6 spinal cord segments.

Correct Answer: B. Exits the skull via the jugular foramen alongside the vagus nerve.

■ *Listen (English)*

■ *Listen (Hindi)*

Explanation: The spinal accessory nerve (CN XI) exits the skull through the jugular foramen with the vagus (CN X) and glossopharyngeal (CN IX) nerves to supply the sternocleidomastoid and trapezius muscles. Passes through the internal acoustic meatus (Option A): This is for facial and vestibulocochlear nerves, not CN XI. Passes through the foramen rotundum (Option C): This transmits the maxillary nerve (V2). Originates from the dorsal horn (Option D): It arises from the ventral horn of C1–C5/6 spinal cord segments.

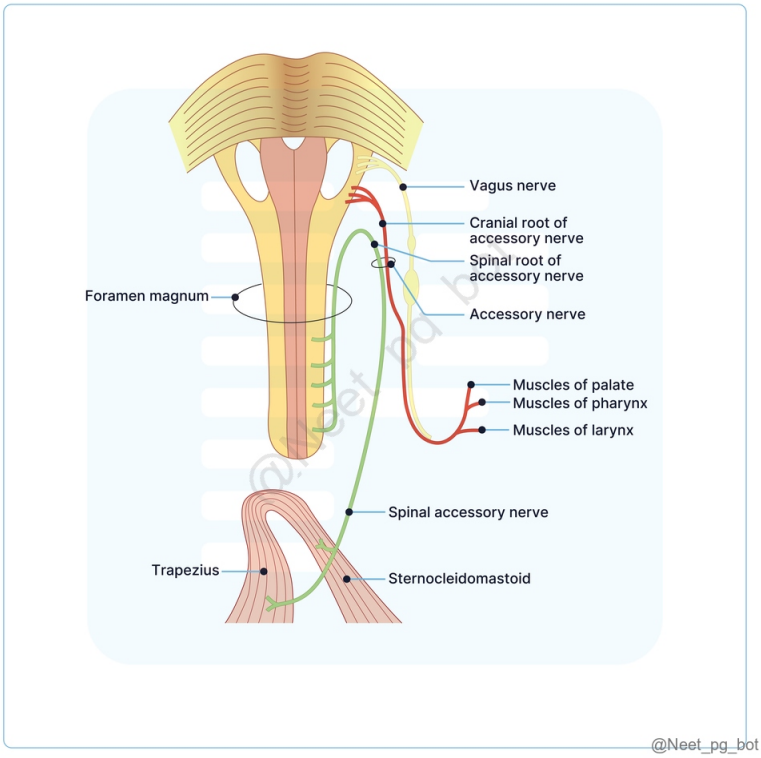

References:

Grey's Anatomy Textbook, 42nd Edition, Page 1464

↑ *Back to this question in Part A*

@Neet_pg_bot

Q11: A 45-year-old patient undergoes surgery for a suspected brain mass. During the operation, the surgeon identifies a dural fold extending between the cerebellum and the occipital lobes, creating a partition in the cranial cavity. Which dural fold is being described? (Q848728)

A. Falx cerebri

B. Falx cerebelli

C. Diaphragma sellae

D. Tentorium cerebelli

Correct Answer: D. Tentorium cerebelli

■ *Listen (English)*

■ *Listen (Hindi)*

Explanation: The tentorium cerebelli is a horizontal structure that separates the cerebellum from the occipital lobes. It extends across the posterior cranial fossa, attaching to the clinoid processes of the sphenoid bone and the inner surface of the occipital bone, thereby creating a partition between these regions. Falx cerebri (Option A) separates the left and right cerebral hemispheres and contains the superior sagittal sinus along its upper margin. Falx cerebelli (Option B) separates the cerebellar hemispheres and contains the occipital sinus within its posterior margin. Diaphragma sellae (Option C) forms a roof over the pituitary gland, containing an opening through which the infundibulum passes.

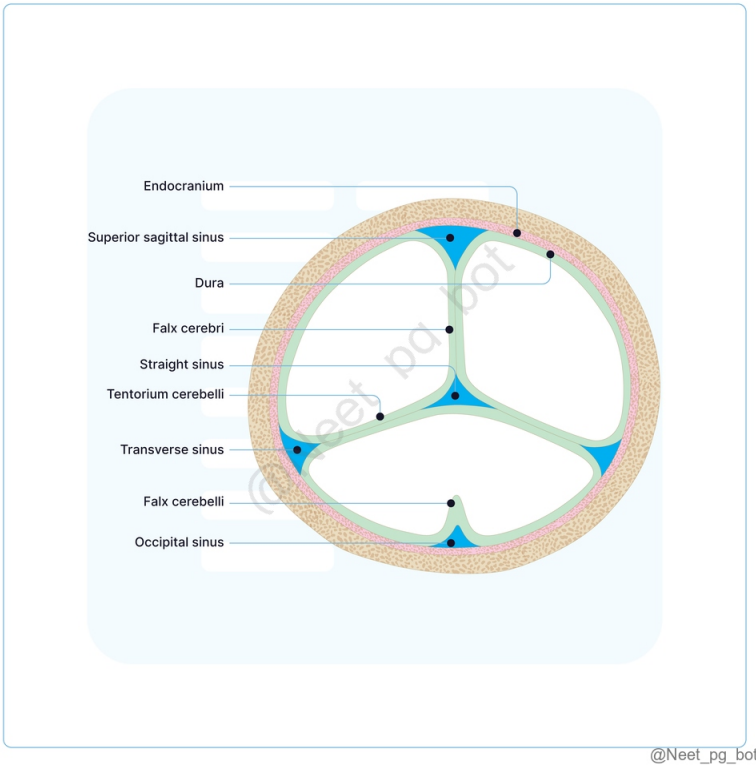

References:

Grey's Anatomy textbook, 42 Edition, Page 398

↑ *Back to this question in Part A*

@Neet_pg_bot

Q12: Which of the following sinuses is NOT located between the meningeal and endosteal layers of the dura mater? (Q848729)

A. Superior sagittal sinus

B. Transverse sinus

C. Inferior sagittal sinus

D. Sigmoid sinus

Correct Answer: C. Inferior sagittal sinus

■ *Listen (English)*

■ *Listen (Hindi)*

Explanation: The inferior sagittal sinus lies within the lower free margin of the falx cerebri , between two layers of the meningeal dura only , not between the meningeal and endosteal layers. Superior sagittal sinus (Option A): Lies between the meningeal and endosteal layers. Transverse sinus (Option B): Located between the two dural layers in the tentorium cerebelli. Sigmoid sinus (Option D): Also situated between the meningeal and endosteal layers of the dura.

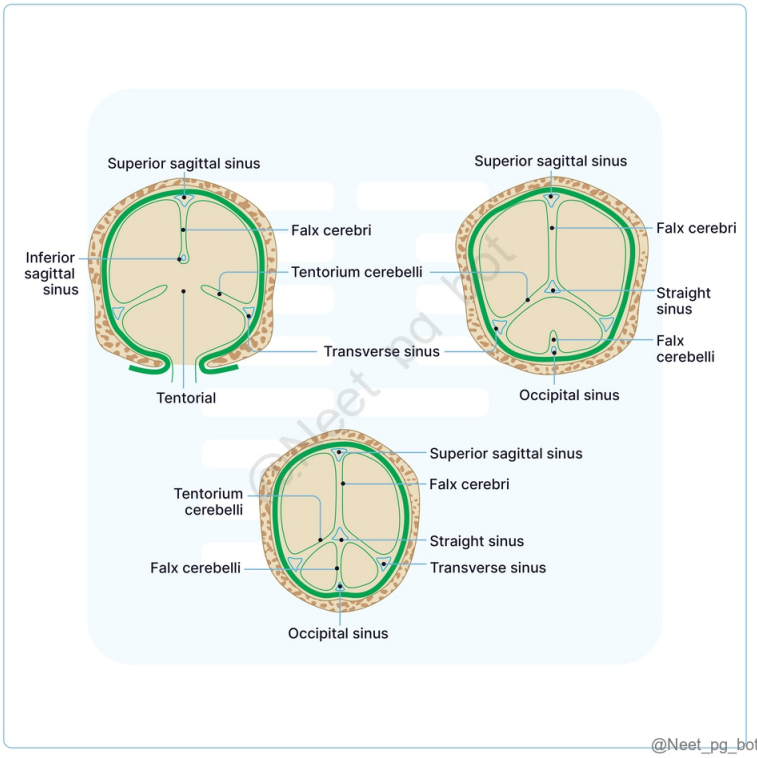

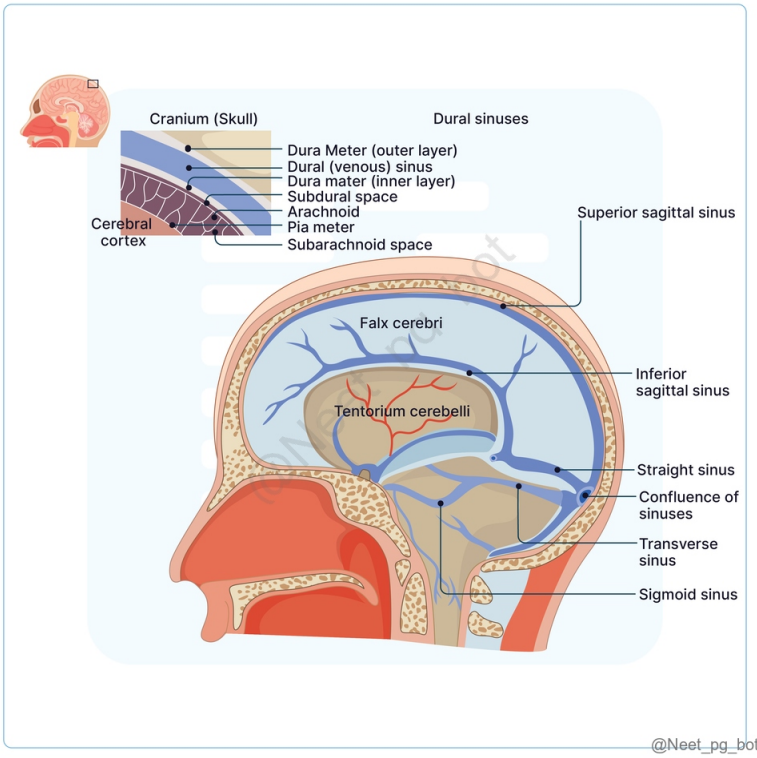

References:

Vishram Singh, Textbook of Anatomy, 2nd Edition, Page 325

↑ *Back to this question in Part A*

@Neet_pg_bot

Q13: A 40-year-old female presents with double vision and drooping eyelids. An MRI reveals involvement of the cavernous sinus, prompting the neurologist to evaluate the cranial nerves associated with this structure. Which of the following nerves is not a content of the cavernous sinus? (Q848730)

A. Ophthalmic nerve

B. Maxillary nerve

C. Mandibular nerve

D. Abducens nerve

Correct Answer: C. Mandibular nerve

■ *Listen (English)*

■ *Listen (Hindi)*

Explanation: The cavernous sinus contains the oculomotor nerve, trochlear nerve, ophthalmic nerve, maxillary nerve (according to the latest updates), and abducens nerve. The mandibular nerve does not pass through the cavernous sinus; it exits the skull via the foramen ovale. Ophthalmic nerve (Option A): Lies in the lateral wall of the cavernous sinus. Maxillary nerve (Option B): Also runs in the lateral wall of the cavernous sinus. Abducens nerve (Option D): Passes through the sinus proper, close to the internal carotid artery.

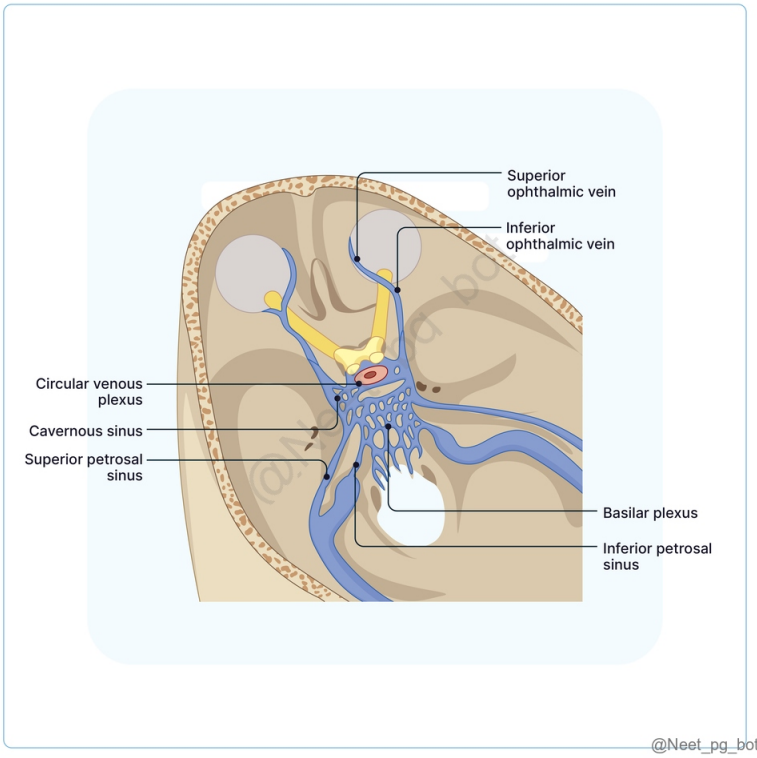

References:

Vishram Singh, Textbook of Anatomy, 2nd Edition, Page 326,327

↑ *Back to this question in Part A*

@Neet_pg_bot

Q14: A 35-year-old patient presents with symptoms of cavernous sinus thrombosis, including severe headache, visual disturbances, and facial swelling. Which of the following is not a tributary of the cavernous sinus? (Q848731)

A. Superior ophthalmic vein

B. Inferior ophthalmic vein

C. Deep facial vein

D. Sphenoparietal sinus

Correct Answer: C. Deep facial vein

■ *Listen (English)*

■ *Listen (Hindi)*

Explanation: The deep facial vein typically drains the face and communicates with the internal jugular vein rather than entering the cavernous sinus. Superior ophthalmic vein (Option A): Drains directly into the cavernous sinus. Inferior ophthalmic vein (Option B): Drains partly into the cavernous sinus and partly into the pterygoid plexus. Sphenoparietal sinus (Option D): Drains into the anterior part of the cavernous sinus.

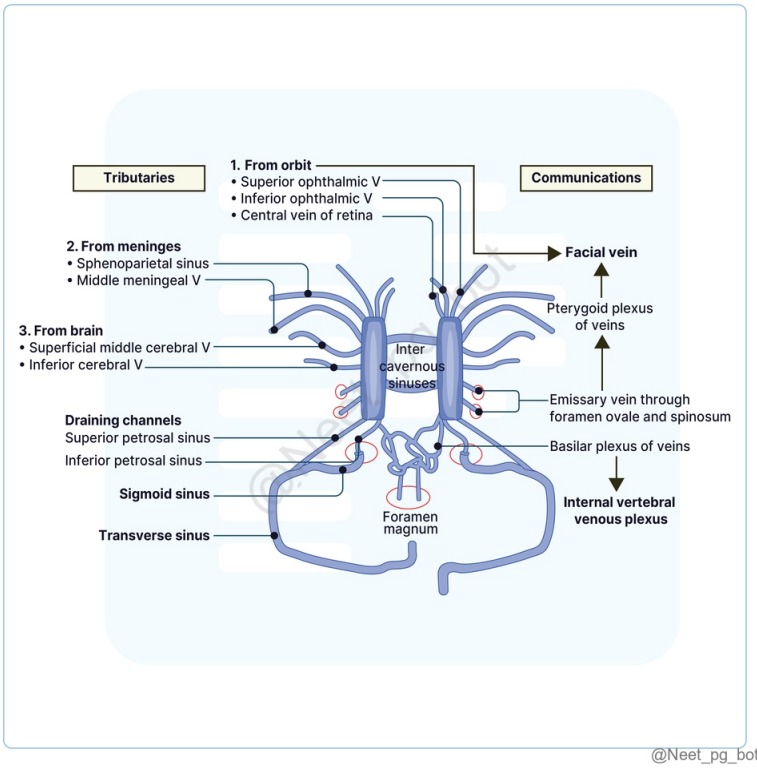

@Neet_pg_bot

References:

Vishram Singh, Textbook of Anatomy, 2nd Edition, Page 327

↑ *Back to this question in Part A*

@Neet_pg_bot

Q15: A 60-year-old patient is evaluated for chronic headaches and altered mental status. A CT scan reveals potential thrombosis in an unpaired dural sinus. Which of the following sinus is unpaired? (Q848732)

A. Superior sagittal sinus

B. Sigmoid sinus

C. Inferior petrosal sinus

D. Transverse sinus

Correct Answer: A. Superior sagittal sinus

Listen (English)

Listen (Hindi)

Explanation: The superior sagittal sinus is a midline, unpaired dural venous sinus that runs along the upper border of the falx cerebri and drains into the confluence of sinuses. Sigmoid sinus (Option B): Paired structure on each side of the brain. Inferior petrosal sinus (Option C): Paired sinus draining the cavernous sinus into the internal jugular vein. Transverse sinus (Option D): Also paired, running along the attached margin of the tentorium cerebelli.

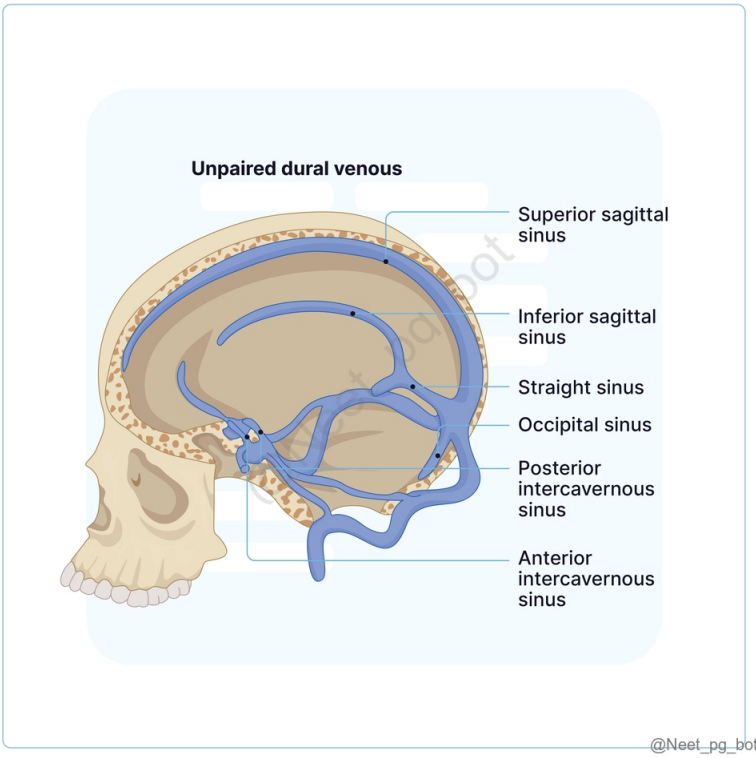

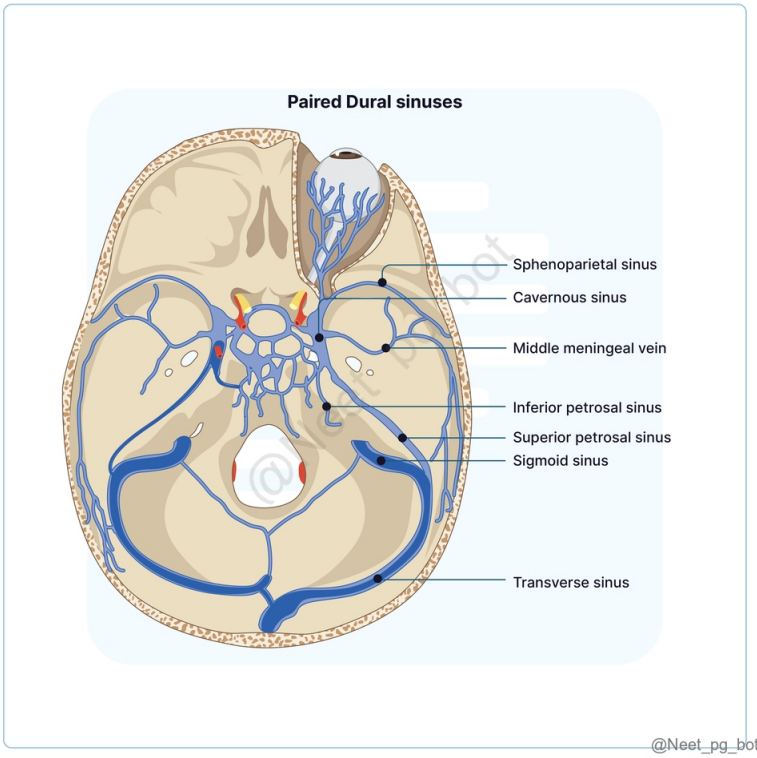

References:

Vishram Singh's Textbook of Anatomy, 2nd Edition, Page 325

↑ *Back to this question in Part A*

@Neet_pg_bot

Q16: A 5-year-old child is brought to the pediatric clinic with symptoms of hydrocephalus and developmental delays. An MRI reveals a malformation of a vein associated with increased intracranial pressure. Which of the following veins primarily contributes to its formation? (Q848734)

A. Internal cerebral veins

B. Basal veins

C. Superior sagittal sinus

D. Veins from the cerebellum

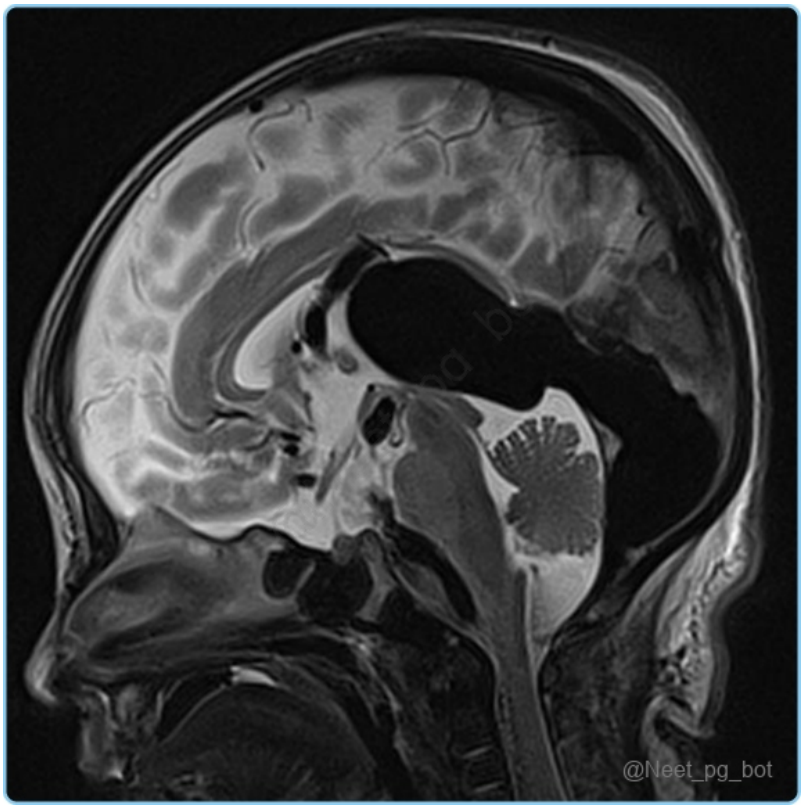

Correct Answer: A. Internal cerebral veins

- *Listen (English)*
- *Listen (Hindi)*

Explanation: The scenario with the given image findings indicates a Vein of Galen malformation , which involves the abnormal dilation of the vein formed by the union of the internal cerebral veins. In malformations, abnormal connections and dilations can occur, leading to significant clinical symptoms and complications such as hydrocephalus, developmental delays, seizures, congestive heart failure, headaches, neurological deficits. Basal veins (Option B): Drain into the great cerebral vein but do not form it. Superior sagittal sinus (Option C): Drains cortical veins, not involved in formation of the great cerebral vein. Veins from the cerebellum (Option D): Drain into the straight or transverse sinuses, not the great cerebral vein.

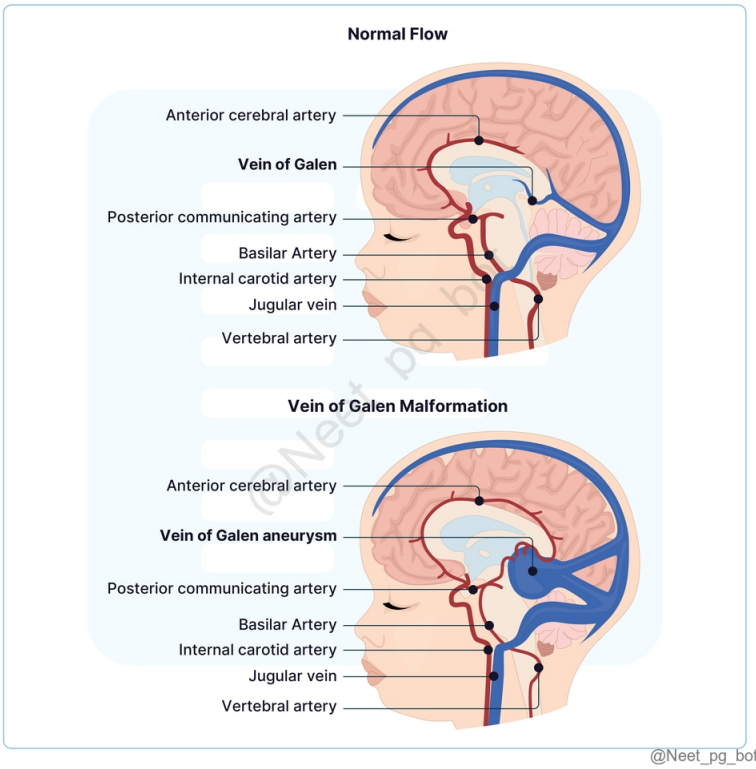

@Neet_pg_bot

References:

Vishram Singh, Textbook of Anatomy, 2nd Edition, Page 410

↑ *Back to this question in Part A*

@Neet_pg_bot

• [04_Head and Neck] 017 Cranial Nerves And Cervical Plexus

« Back to Folder Directory

[04_Head and Neck] 017 Cranial Nerves And Cervical Plexus — Quick Jump

Q1 (p. 1121)	*Q2 (p. 1122)*	*Q3 (p. 1125)*	*Q4 (p. 1126)*	*Q5 (p. 1128)*	*Q6 (p. 1129)*
Q7 (p. 1130)	*Q8 (p. 1132)*	*Q9 (p. 1133)*	*Q10 (p. 1134)*	*Q11 (p. 1136)*	*Q12 (p. 1138)*
Q13 (p. 1139)	*Q14 (p. 1142)*	*Q15 (p. 1143)*	*Q16 (p. 1145)*	*Q17 (p. 1147)*	*Q18 (p. 1148)*
Q19 (p. 1150)	*Q20 (p. 1152)*	*Q21 (p. 1153)*	*Q22 (p. 1154)*	*Q23 (p. 1157)*	*Q24 (p. 1158)*
Q25 (p. 1160)	*Q26 (p. 1161)*	*Q27 (p. 1165)*	*Q28 (p. 1167)*		

Q1: A 38-year-old female with down-out and intorsion of the eye presents with worsening night vision, occasional headaches, and mild dizziness. Examination shows ptosis and a larger, non-reactive left pupil. Which of the following structures is the parasympathetic component of the affected nerve? (Q848465)

A. Edinger-Westphal nucleus

B. Oculomotor nucleus

C. Superior colliculus

D. Red nucleus

Correct Answer: A. Edinger-Westphal nucleus

■ *Listen (English)*

■ *Listen (Hindi)*

Explanation: The given scenario suggests the lesion of the parasympathetic component of the oculomotor nerve, which is the Edinger-Westphal nucleus. Oculomotor nerve (cranial nerve III) Type Motor Origin Midbrain (Oculomotor sulcus on the medial aspect of the cerebral peduncle). Components Oculomotor nucleus (somatic component) (Option B): General somatic efferent (GSE) fibres emerge from this site and supply - Superior division : Levator palpebrae superioris Superior rectus Inferior division : Medial rectus Inferior rectus Inferior oblique Edinger-Westphal nucleus (parasympathetic component) (Option A): General visceral efferent (GVE) fibres arise from this site and supply: Sphincter pupillae Ciliaris

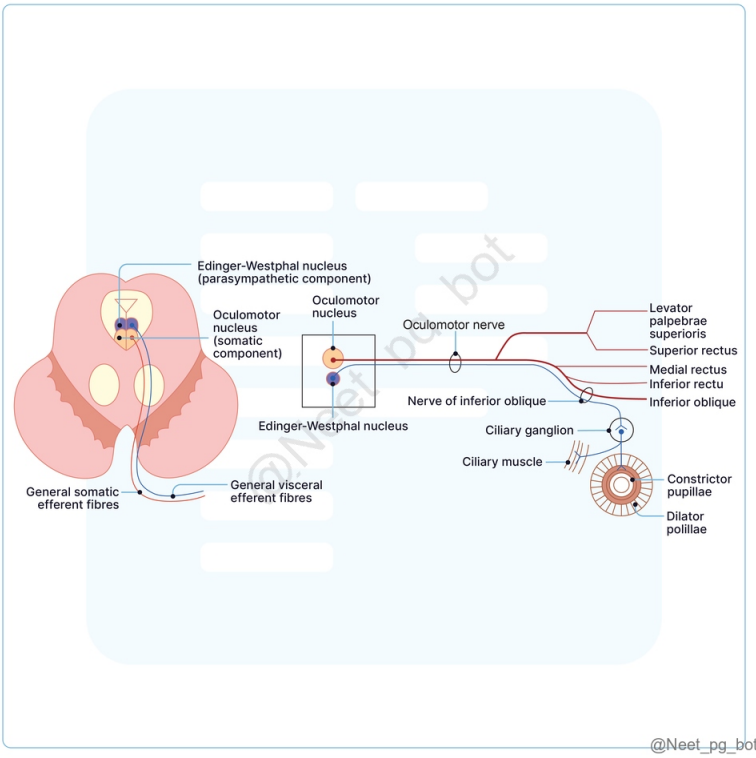

References:

Gray’s Anatomy, 42nd Edition, Pages 458, 781

BD Chaurasia’s Human Anatomy, 8th Edition, Pages 69, 70, 240, 241

Vishram Singh's Textbook of Anatomy, 2nd Edition, Pages 335, 336

https://www.ncbi.nlm.nih.gov/books/NBK526112/

↑ *Back to this question in Part A*

@Neet_pg_bot

Q2: A 32-year-old male presents with difficulty chewing and numbness on the right side of his jaw following a recent sports injury. Examination reveals weakened jaw clenching on the right and decreased sensation over the anterior cheek, but intact sensation in the lower lip. Which of the following nerves might be affected? (Q848447)

A. Facial nerve

B. Anterior division of mandibular nerve

C. Posterior division of mandibular nerve

D. Maxillary nerve

Correct Answer: B. Anterior division of mandibular nerve

■ *Listen (English)*

■ *Listen (Hindi)*

Explanation: The presented scenario indicates a lesion of the anterior division of the Mandibular nerve , characterized by symptoms such as weakness of the jaw and reduced sensation in the anterior cheek, while sensation in the lower lip remains intact. Mandibular Nerve: It is the largest, mixed branch of the trigeminal nerve (nerve of the first branchial arch). Course: Branches of the Main trunk: Branches of the Anterior division:

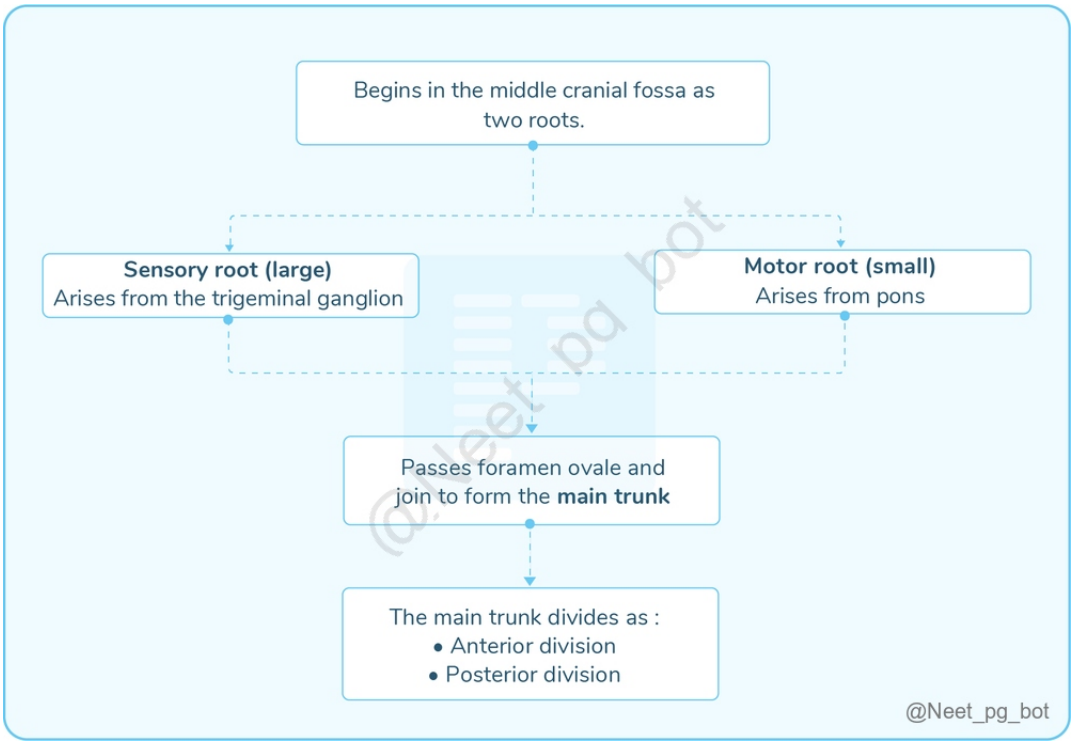

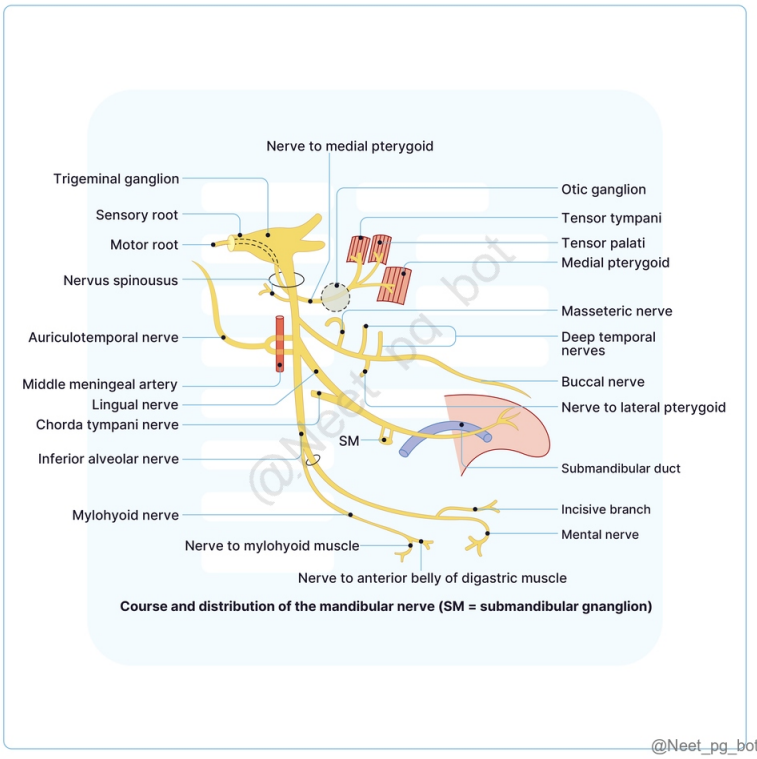

Course and distribution of the mandibular nerve (SM = submandibular gnanglion)

@Neet_pg_bot

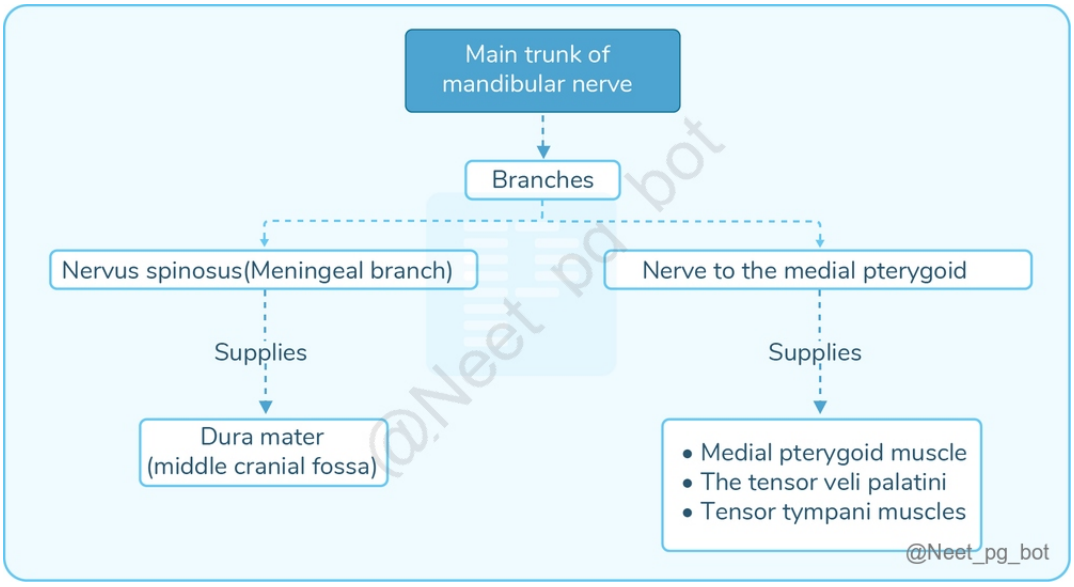

@Neet_pg_bot

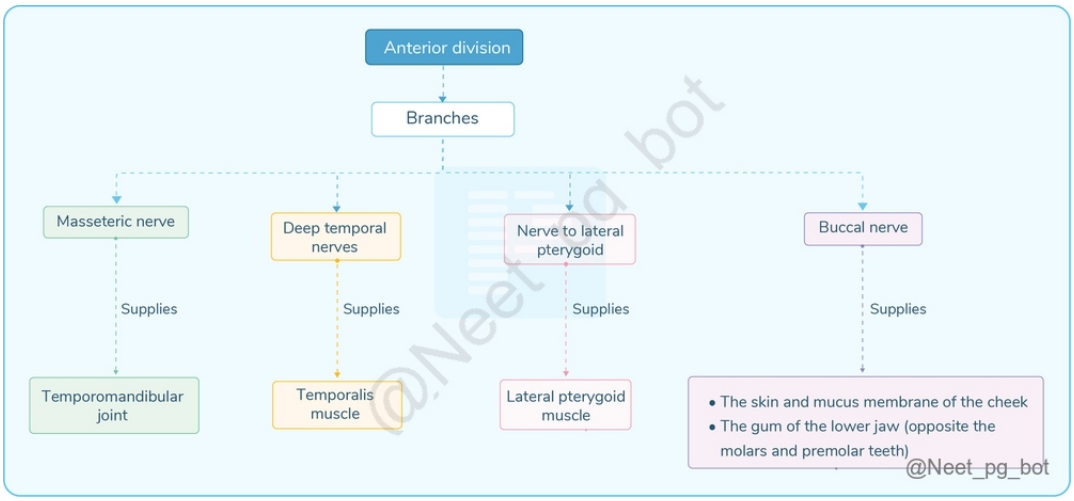

References:

Gray's Anatomy, 42nd Edition, Page 632, 645.

BD Chaurasia’s Human Anatomy, 8th Edition, Page 134-137.

Vishram Singh's Textbook of Anatomy, 2nd Edition, Page 139-141.

↑ *Back to this question in Part A*

@Neet_pg_bot

Q3: A 55-year-old patient presents with difficulty swallowing and a hoarse voice after recent neck surgery. What structure does the vagus nerve primarily run between as it descends in the neck? (Q848463)

A. Internal carotid artery and external jugular vein

B. Internal jugular vein and common carotid artery

C. Subclavian artery and internal thoracic artery

D. External carotid artery and internal jugular vein

Correct Answer: B. Internal jugular vein and common carotid artery

■ *Listen (English)*

■ *Listen (Hindi)*

Explanation: The vagus nerve descends within the carotid sheath, positioned between the internal jugular vein (laterally) and the common carotid artery (medially). Injury or irritation to the vagus nerve can lead to symptoms like difficulty swallowing (dysphagia) and hoarseness due to its innervation of the laryngeal muscles and pharynx.

Internal carotid artery and external jugular vein (Option A): The external jugular vein is superficial and not part of the carotid sheath. Subclavian artery and internal thoracic artery (Option C): The recurrent laryngeal nerve loops around the subclavian artery on the right, but the vagus nerve itself is higher up in the carotid sheath. External carotid artery and internal jugular vein (Option D): The external carotid artery is anterior and branches out above the carotid bifurcation, not forming a sheath with the vagus.

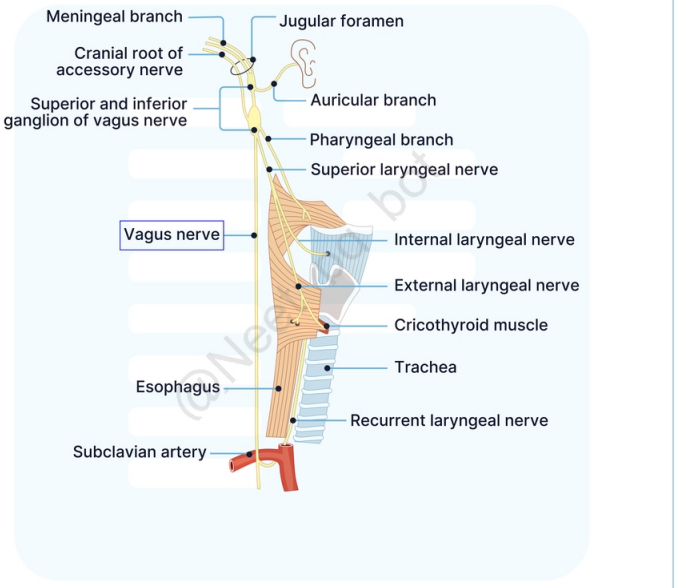

References:

BD Chaurasia’s Human Anatomy, 8th Edition, Page 90

Vishram Singh's Textbook of Anatomy, 2nd Edition, Page 347, 348

↑ *Back to this question in Part A*

@Neet_pg_bot

Q4: A 60-year-old woman presents with unilateral facial pain and sensory loss on the left side of her face. Examination reveals that she cannot feel light touch, pain, or temperature on the left side, but her corneal reflex remains intact. Which of the following is the most likely explanation for her symptoms? (Q848454)

A. Lesion of right mesencephalic nucleus

B. Lesion of left mesencephalic nucleus

C. Lesion of right spinal trigeminal nucleus

D. Lesion of left spinal trigeminal nucleus

Correct Answer: D. Lesion of left spinal trigeminal nucleus

■ *Listen (English)*

■ *Listen (Hindi)*

Explanation: Unilateral facial pain and sensory loss with an intact corneal reflex indicate a lesion in the spinal trigeminal nucleus . This nucleus carries pain and temperature sensations from the ipsilateral face . The corneal reflex (V1–VII) remains intact, confirming that only the spinal trigeminal nucleus is affected. Nuclei of the trigeminal nerve: Nucleus Location Function Mesencephalic Nucleus Midbrain Proprioception (position sense) of muscles of mastication and jaw. A lesion here would affect the jaw-jerk reflex. Main Sensory Nucleus Pons Mediates tactile (light touch) and pressure sensations from the face. Spinal Trigeminal Nucleus Extends from the pons to the spinal cord. Handles pain and temperature sensations from the face. Motor Nucleus Pons Controls muscles involved in chewing (mastication).

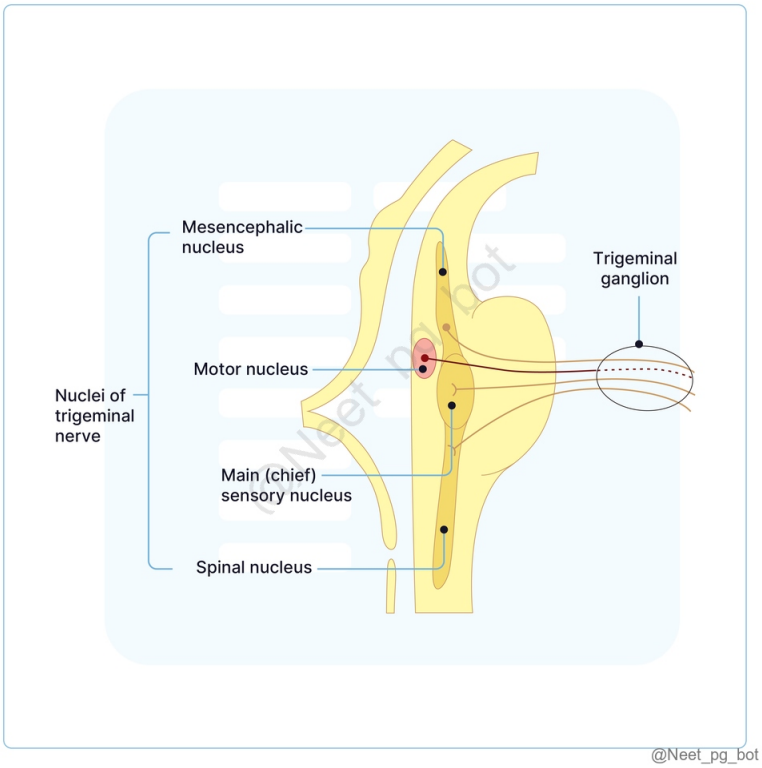

References:

Gray's Anatomy, 42nd Edition, Page 449, 450

↑ *Back to this question in Part A*

@Neet_pg_bot

Q5: Which of the following cranial nerves does not receive motor fibers from the nucleus ambiguus? (Q848473)

A. Glossopharyngeal nerve (IX)

B. Vagus nerve (X)

C. Accessory nerve (XI)

D. Trigeminal nerve (V)

Correct Answer: D. Trigeminal nerve (V)

■ *Listen (English)*

■ *Listen (Hindi)*

Explanation: The trigeminal nerve does not receive fibers from the nucleus ambiguus; it is primarily sensory and motor for muscles of mastication, supplied by the trigeminal motor nucleus, not the nucleus ambiguus. Nucleus Ambiguus Location and Function: The nucleus ambiguus is a motor nucleus. It provides fibres to cranial nerves IX (Glossopharyngeal) , X (Vagus) , and the cranial root of XI (Accessory) nerve. (Option A, B, and C ruled out) Cranial Part: Supplies muscles of the palate, pharynx, and larynx via cranial nerves IX, X, and XI. Caudal Part: Sends fibres to the spinal root of the accessory nerve (XI) , supporting motor function. Innervation Source: Receives inputs from ipsilateral and contralateral motor cortices , ensuring coordinated motor control.

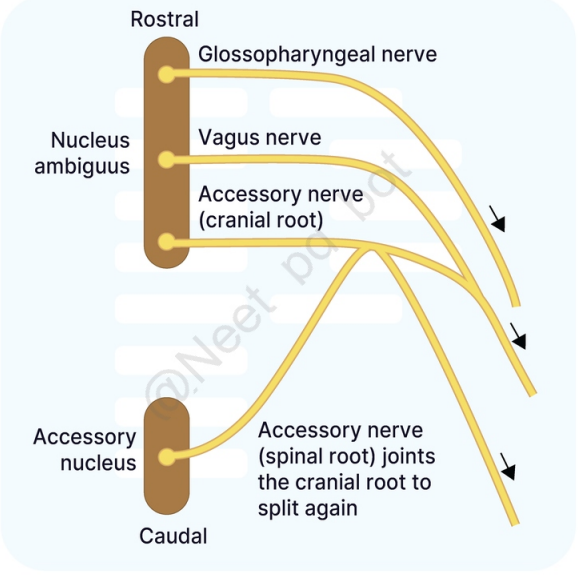

@Neet_pg_bot

References:

Grey's Anatomy, 42nd Edition, Pages 1464

BD Chaurasia’s Human Anatomy, 8th Edition, Pages 56, 61

↑ *Back to this question in Part A*

@Neet_pg_bot

Q6: Which of the following statements correctly distinguishes the role of the hypoglossal nerve from the olfactory nerve? (Q848471)

A. The hypoglossal nerve supplies the muscles of the tongue, while the olfactory nerve mediates smell via the thalamus.

B. The hypoglossal nerve is involved in motor control of the tongue, while the olfactory nerve mediates smell without synapsing in the thalamus.

C. The hypoglossal nerve supplies the tongue and is part of the olfactory pathway.

D. Both the hypoglossal and olfactory nerves are involved in taste and smell.

Correct Answer: B. The hypoglossal nerve is involved in motor control of the tongue, while the olfactory nerve mediates smell without synapsing in the thalamus.

■ *Listen (English)*

■ *Listen (Hindi)*

Explanation: The hypoglossal nerve controls tongue movements, and the olfactory nerve processes smell without thalamic involvement. Hypoglossal Nerve and Olfactory Pathway Hypoglossal Nerve (Cranial Nerve XII): Supplies the muscles of the tongue . Belongs to the general somatic efferent column . Not involved in the olfactory pathway. (Option C and D ruled out) Olfactory Pathway (Cranial Nerve I): Belongs to the special visceral afferent column. Receptors and First Neuron: Bipolar olfactory cells in the nasal mucosa serve as receptors and first neurons. Second Neuron: Mitral and tufted cells in the olfactory bulb form the olfactory tract and reach the primary olfactory areas (e.g., periamygdaloid and prepiriform areas). Third Neuron: Located in the primary olfactory cortex, including the anterior perforated substance. Fourth Neuron: Fibres project to the secondary olfactory cortex in the entorhinal area and tertiary cortex in the orbitofrontal region. Pathway bypasses the thalamus and is solely sensory, unrelated to the hypoglossal nerve. (Option A ruled out)

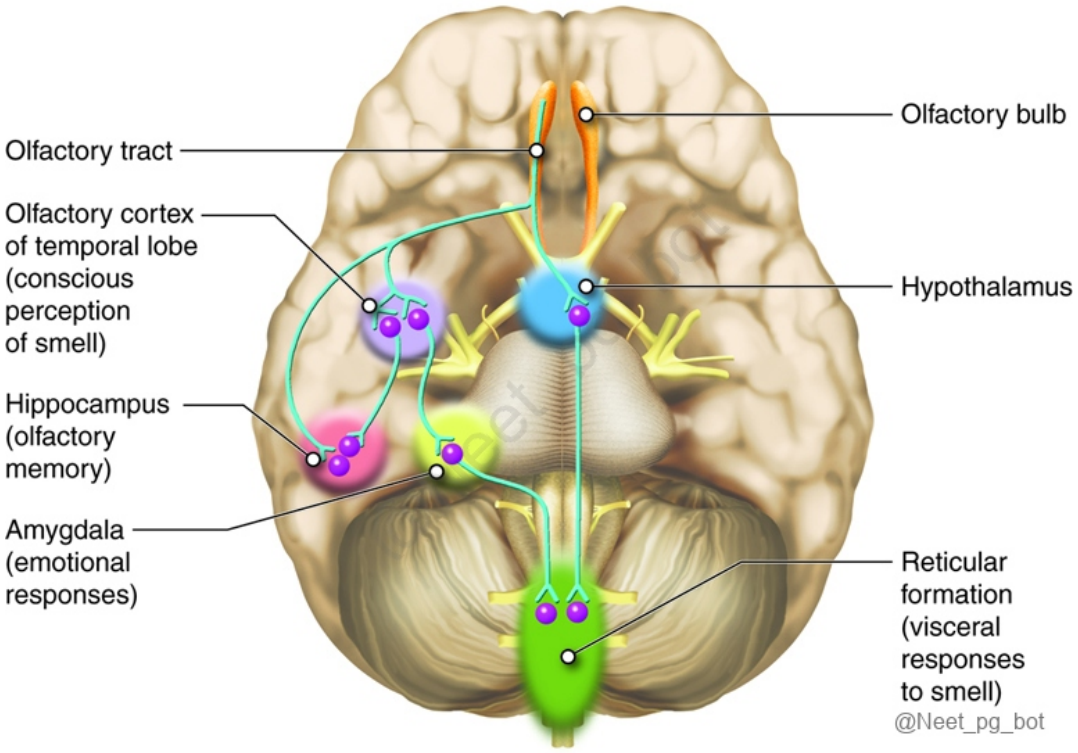

References:

Grey's Anatomy, 42nd Edition, Page 1464-e26

BD Chaurasia’s Human Anatomy, 8th Edition, Pages 63, 94

↑ *Back to this question in Part A*

@Neet_pg_bot

Q7: A 62-year-old patient presents with hoarseness and difficulty swallowing. Physical examination reveals a diminished gag reflex and weakened pharyngeal elevation during swallowing. Which of the following structures is not innervated by the affected nerve? (Q848460)

A. Carotid body

B. Stylopharyngeus muscle

C. Parotid gland

D. Palatopharyngeus

Correct Answer: D. Palatopharyngeus

- *Listen (English)*
- *Listen (Hindi)*

Explanation: The affected nerve in the given scenario is Glossopharyngeal nerve (Cranial nerve IX). The Palatopharyngeus muscle is innervated by branches of the pharyngeal plexus from the vagus nerve CN (X). Glossopharyngeal Nerve: (Cranial Nerve IX) Mixed nerve , primarily responsible for sensory functions. Branches and their functions: Tympanic Branch (Jacobson's Nerve): Enters the middle ear and forms the tympanic plexus , which gives: Lesser petrosal nerve : Carries preganglionic parasympathetic fibers to the otic ganglion , supplying the parotid gland (Option C) Twigs to the tympanic cavity , auditory tube , and mastoid air cells . Carotid Nerve (Herring's Nerve) : Supplies Carotid sinus and Carotid body (Option A) Pharyngeal Branch: Forms pharyngeal plexus on the middle constrictor muscle. Branch to Stylopharyngeus : Only motor branch, innervating Stylopharyngeus muscle (Option B) Tonsillar Branches : Sensory innervation to the mucous membrane of the tonsils, fauces, and palate. Lingual Branches : Provide taste and general sensory innervation to the posterior one-third of the tongue and vallate papillae .

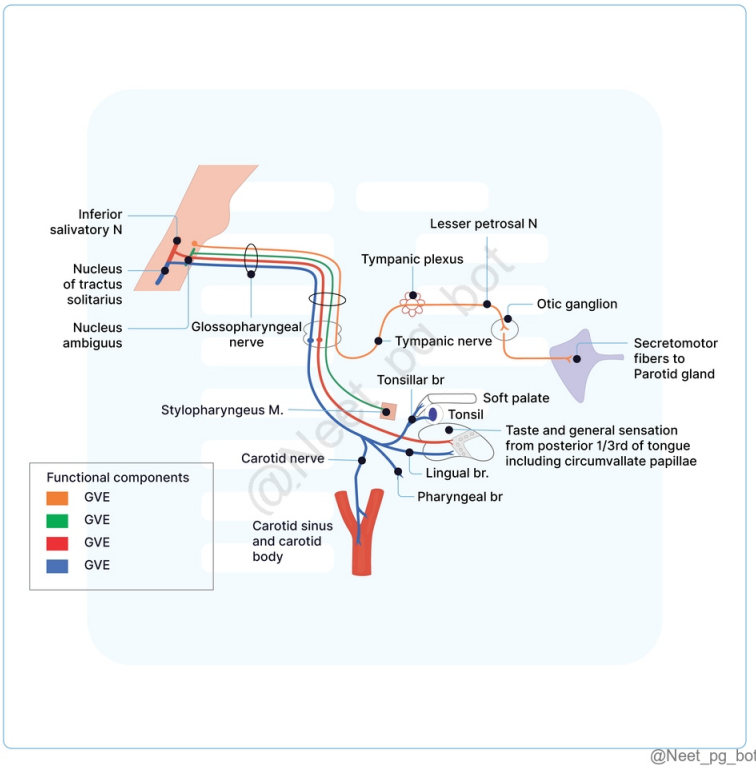

References:

Vishram Singh's Textbook of Anatomy, 2nd Edition, Page 344, 345, 346

↑ *Back to this question in Part A*

@Neet_pg_bot

Q8: Which of the following cranial nerves is not involved in the Special Visceral Afferent (SVA) pathway? (Q848472)

A. Facial nerve (VII)

B. Glossopharyngeal nerve (IX)

C. Vagus nerve (X)

D. Trochlear nerve (IV)

Correct Answer: D. Trochlear nerve (IV)

■ *Listen (English)*

■ *Listen (Hindi)*

Explanation: The trochlear nerve is a General Somatic Efferent (GSE) nerve responsible for motor control of the superior oblique muscle and does not participate in the SVA pathway. Trochlear Nerve and Special Visceral Afferent (SVA) Column Trochlear Nerve (Cranial Nerve IV): Special Visceral Afferent (SVA): Located in the midbrain at the level of the inferior colliculus . Belongs to the General Somatic Efferent (GSE) column. Responsible for the movement of the superior oblique muscle of the eye. Not involved in the Special Visceral Afferent (SVA) column, as it lacks any sensory function for taste or olfaction. Mediates taste and olfaction via the nucleus of the tractus solitarius . Involves cranial nerves VII (Facial), IX (Glossopharyngeal), and X (Vagus) . (Option A, B, C ruled out) The trochlear nerve does not contribute to these sensory pathways.

References:

Grey's Anatomy, 42nd Edition, Pages 391, 1464

BD Chaurasia’s Human Anatomy, 8th Edition, Page 59

↑ *Back to this question in Part A*

@Neet_pg_bot

Q9: A 29-year-old male presents with a head tilt and double vision that worsens when looking down, especially while reading or using his phone. Examination shows a significant limitation in the left eye's downward movement, extorsion of the eyeball, and a noticeable right head tilt. At what site does the decussation of the affected nerve occur? (Q848467)

A. Crus cerebri

B. Superior colliculus

C. Superior medullary velum

D. Substantia nigra

Correct Answer: C. Superior medullary velum

■ *Listen (English)*

■ *Listen (Hindi)*

Explanation: The presented scenario is indicative of a trochlear nerve lesion , characterized by diplopia and a head tilt to the opposite side. Trochlear nerve (cranial nerve IV) Type Motor Origin Dorsal aspect of the midbrain at the level of inferior colliculus Special features The only cranial nerve which emerges on the dorsal aspect of the brain. The most slender nerve of all the cranial nerves. The smallest cranial nerve. Only cranial nerve whose nuclear fibres decussate before emerging on the surface of the brain. Nucleus receives only ipsilateral corticonuclear fibres. Phylogenetically, it is the nerve of the 3rd eye. Nuclei Trochlear nucleus is situated in the ventromedial part of the central grey matter in the midbrain at the level of the inferior colliculus. Supply Superior oblique muscle of the eyeball. Clinical aspect Trochlear nerve lesions/injury causes paralysis of the superior oblique muscle,

presenting clinically as: Extorsion of the eyeball and weakness of downward gaze (difficulty while going downstairs or reading the newspaper) Diplopia (double vision) occurs when the patient looks laterally and glances downward (there is a compensatory head tilt to the opposite side).

References:

Gray’s Anatomy, 42nd Edition, Page 782.

BD Chaurasia’s Human Anatomy, 8th Edition, Page 71-73, 241.

Vishram Singh’s Textbook of Anatomy, 2nd Edition, Page 336, 337.

↑ *Back to this question in Part A*

@Neet_pg_bot

Q10: Below is an image of a transverse section of the lower pons, specifically at the level of the facial colliculus. Please identify the structures marked as "X" and "Y." (Q848468)

A. Abducens nucleus and Facial nucleus

B. Facial nucleus and Abducens nucleus

C. Trigeminal nucleus and Vestibular nucleus

D. Vestibular nucleus and Trigeminal nucleus

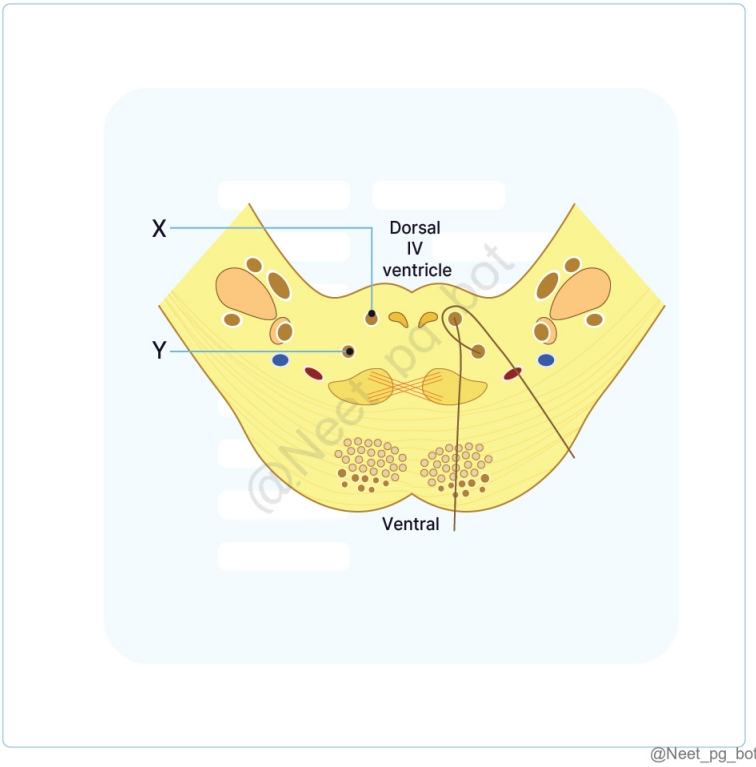

Correct Answer: A. Abducens nucleus and Facial nucleus

- *Listen (English)*
- *Listen (Hindi)*

Explanation: The abducens nucleus (X) is located medially and is responsible for innervating the lateral rectus muscle, which controls lateral eye movement. The facial nucleus (Y) is positioned more laterally and ventrally. It is responsible for the motor function of the muscles of facial expression. The fibres of the facial nerve loop around the abducens nucleus before exiting the brainstem, which forms the facial colliculus.

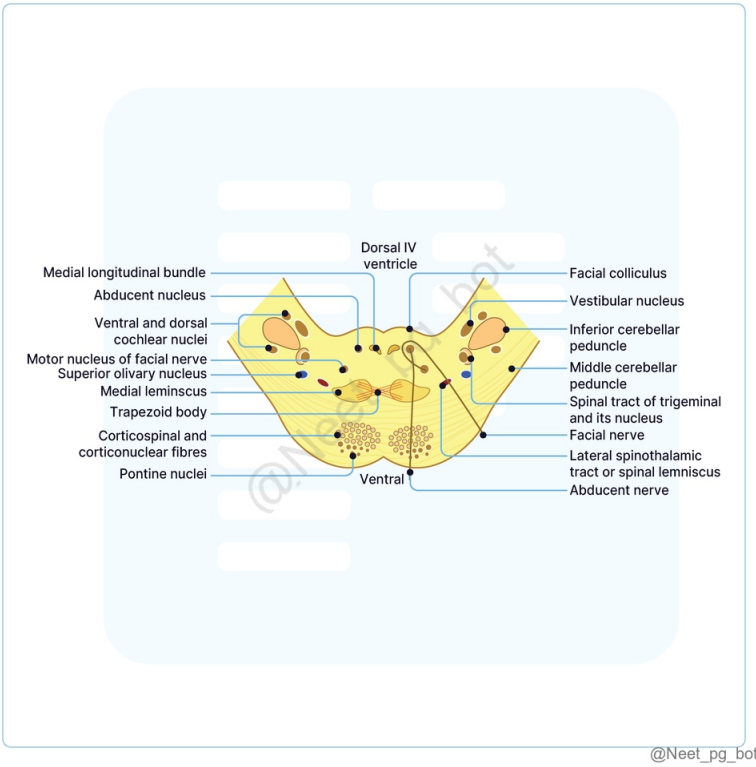

@Neet_pg_bot

References:

Gray’s Anatomy, 42nd Edition, Page 453, 782.

BD Chaurasia’s Human Anatomy, 8th Edition, Page 108

Vishram Singh’s Textbook of Anatomy, 2nd Edition, Page 337, 338.

https://www.researchgate.net/publication/10853629_False_localising_signs

↑ *Back to this question in Part A*

@Neet_pg_bot

Q11: A 54-year-old male presents with double vision and difficulty moving his left eye outward. Examination reveals the left eye is deviated medially with limited abduction. Which muscle is involved in this condition? (Q848469)

A. Right medial rectus palsy

B. Left medial rectus palsy

C. Right lateral rectus palsy

D. Left lateral rectus palsy

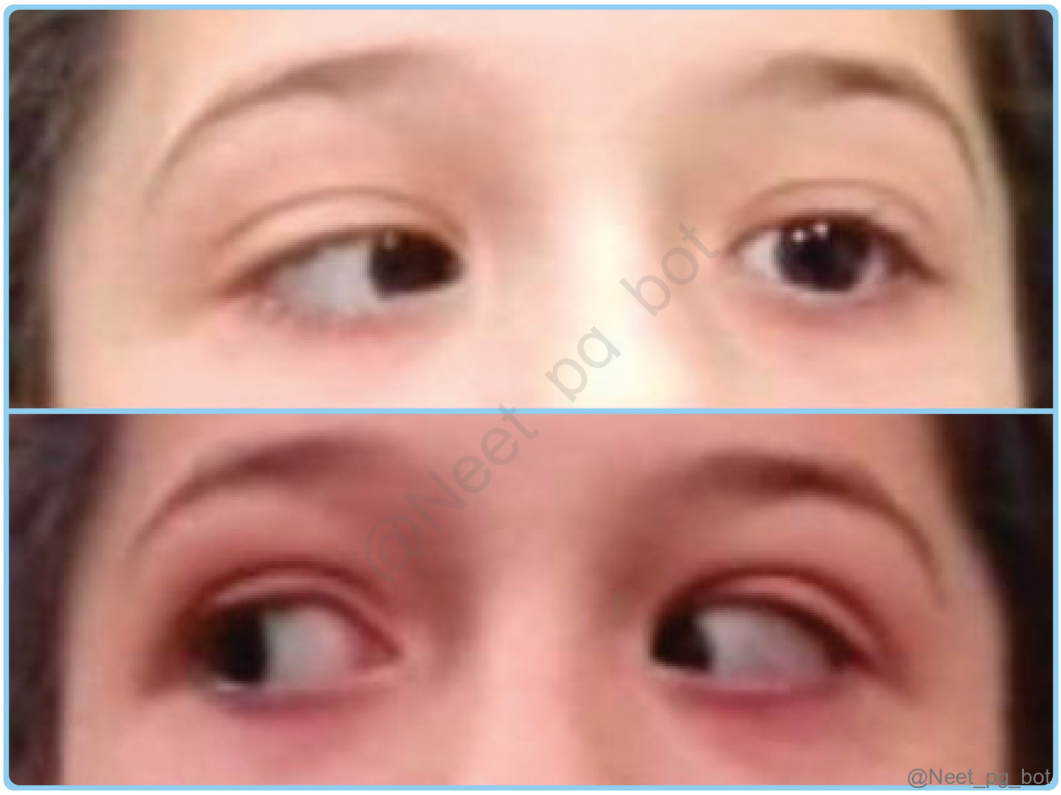

Correct Answer: D. Left lateral rectus palsy

- *Listen (English)*
- *Listen (Hindi)*

Explanation: The scenario suggests damage to the left abducens nerve, which leads to left lateral rectus palsy and an ipsilateral medial squint , while the right side remains unaffected. Abducens Nerve (cranial nerve VI) Type Motor Origin Pons (lower border, opposite the pyramid of the medulla). Functional component General somatic efferent fibres : Arise from the abducent nucleu s in the pons and supply the lateral rectus muscle of the eyeball. General somatic afferent fibres carry proprioceptive sensations from the lateral rectus and terminate in the mesencephalic nucleus of the trigeminal nerve. Supply The lateral rectus muscle of the eyeball Clinical aspect Lesion or injury (elevated intracranial pressure) of the abducens nerve results in paralysis of the lateral rectus muscle, leading to: Inability to abduct the eye Diplopia (double vision) Convergent squint (due to the unopposed action of medial rectus) (Option B) Right medial rectus palsy (Option A) impairs right eye adduction only, without affecting the left eye's position or causing its medial deviation . Left medial rectus palsy (Option B) causes impaired adduction with lateral deviation of the left eye, leading to inability to look medially , not laterally. Right lateral rectus palsy (Option C) impairs abduction of the right eye , not the left, and does not cause medial deviation of the left eye — inconsistent with the case.

References:

Gray's Anatomy, 42nd Edition, Page 782

BD Chaurasia's Human Anatomy, 8th Edition, Page 73, 74

Vishram Singh’s Textbook of Anatomy, 2nd Edition, Page 337, 338

↑ *Back to this question in Part A*

@Neet_pg_bot

Q12: Which of the following correctly describes the arrangement of cranial nerve nuclei from ventral to dorsal in the brainstem? (Q848470)

A. General Visceral Efferent (GVE), General Visceral Afferent (GVA), Special Visceral Afferent (SVA), Special Somatic Afferent (SSA).

B. General Somatic Afferent (GSA), Special Somatic Afferent (SSA), General Visceral Efferent (GVE), General Somatic Efferent (GSE).

C. General Somatic Efferent (GSE), Special Visceral Efferent (SVE), General Visceral Efferent (GVE), General Somatic Afferent (GSA).

D. Special Visceral Afferent (SVA), Special Somatic Afferent (SSA), General Somatic Efferent (GSE), General Visceral Afferent (GVA).

Correct Answer: A. General Visceral Efferent (GVE), General Visceral Afferent (GVA), Special Visceral Afferent (SVA), Special Somatic Afferent (SSA).

■ *Listen (English)*

■ *Listen (Hindi)*

Explanation: Functional Columns of Cranial Nerve Nuclei (Ventral to Dorsal Arrangement) Motor Columns (Basal Lamina, Medial Position): General Somatic Efferent (GSE): Supplies muscles derived from somites (e.g., eye and tongue muscles). Special Visceral Efferent (SVE): Supplies branchial apparatus-derived muscles (e.g., facial and pharyngeal muscles). General Visceral Efferent (GVE): Autonomic motor supply to viscera, vessels, and glands. Sensory Columns (Alar Lamina, Lateral Position): General Visceral Afferent (GVA): Sensory input from viscera. Special Visceral Afferent (SVA): Sensory input from taste and olfaction (branchial apparatus-related). General Somatic Afferent (GSA): Sensory input from skin and somatic structures. Special Somatic Afferent (SSA): Sensory input for special senses (e.g., vision, hearing, balance). The nuclei are organized into longitudinal columns in the brainstem. Motor nuclei are positioned medially , derived from the basal lamina . Sensory nuclei are positioned laterally , derived from the alar lamina . Pontine flexure influences the horizontal stretching of the neural tube, affecting this arrangement.

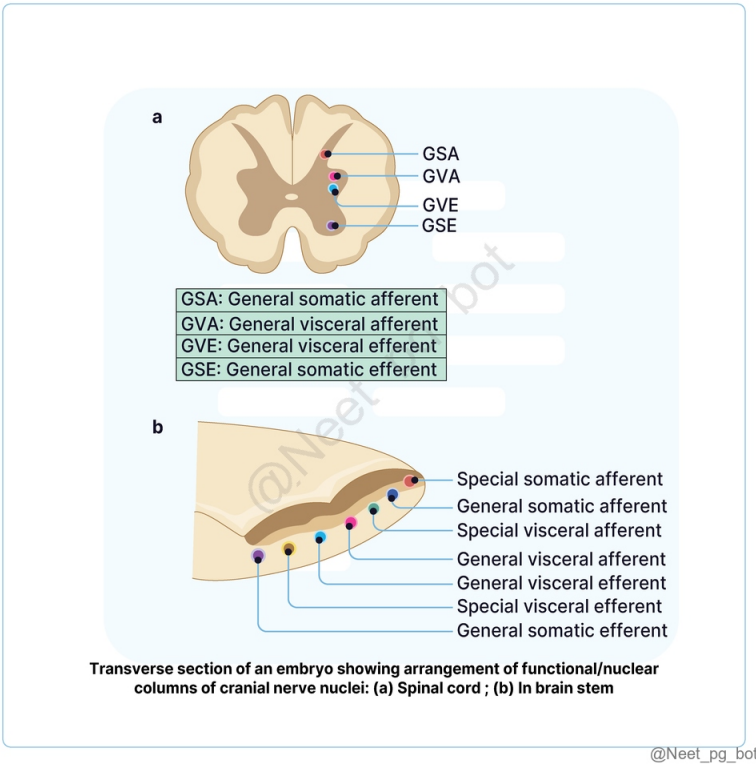

Transverse section of an embryo showing arrangement of functional/nuclear columns of cranial nerve nuclei: (a) Spinal cord ; (b) In brain stem

@Neet_pg_bot

References:

Grey's Anatomy, 42nd Edition, Page 242, 243

BD Chaurasia’s Human Anatomy, 8th edition, Volume 3, Page 56, 57

↑ *Back to this question in Part A*

@Neet_pg_bot

Q13: A 50-year-old patient experiences numbness in the area around the neck following a cervical block performed for neck surgery. Which of the following is not a branch of the cervical plexus? (Q848464)

A. Greater Auricular Nerve

B. Transverse Cutaneous Nerve of the Neck

C. Supraclavicular Nerve

D. Phrenic Nerve

Correct Answer: D. Phrenic Nerve

■ *Listen (English)*

■ *Listen (Hindi)*

Explanation: The Phrenic nerve arises primarily from the cervical spinal roots C3, C4, and C5 & its primary function is to provide motor innervation to the diaphragm, essential for breathing. Cervical Plexus: Formed by the ventral rami of the upper four cervical nerves (C1-C4) The Four roots interconnect to form three loops. Position and Relations: Posteriorly : It is related to muscles arising from the posterior tubercles of the transverse processes, including the levator scapulae and scalenus medius. Anteriorly : It is associated with the prevertebral fascia, the internal jugular vein, and the sternocleidomastoid muscle. Branches: Superficial (Cutaneous) Branches: Lesser Occipital (C2) Great Auricular (C2, C3) Transverse Cutaneous Nerve of the Neck (C2, C3) Supraclavicular Nerves (C3, C4) Deep Branches : Communicating Branches : A branch from C1 joins the hypoglossal nerve, supplying the thyrohyoid and geniohyoid muscles directly & superior belly of the omohyoid via ansa cervicalis. Branches from C2 and C3 supply the sternocleidomastoid, while branches from C3 and C4 s upply the trapezius, communicating with the accessory nerve.

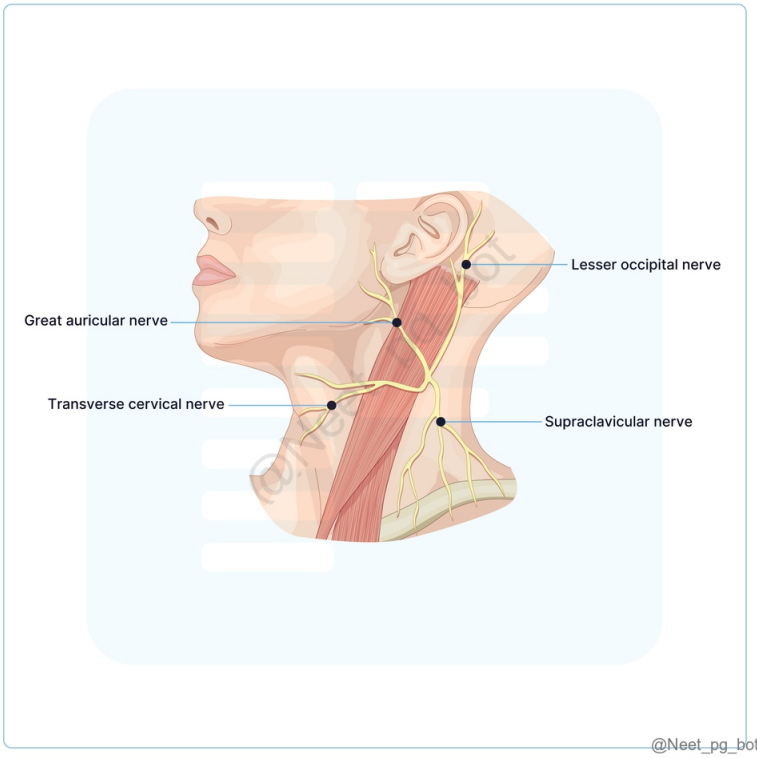

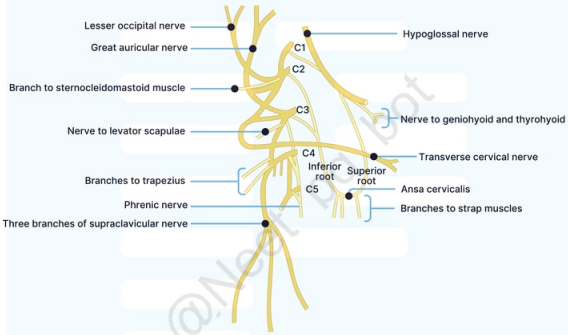

@Neet_pg_bot

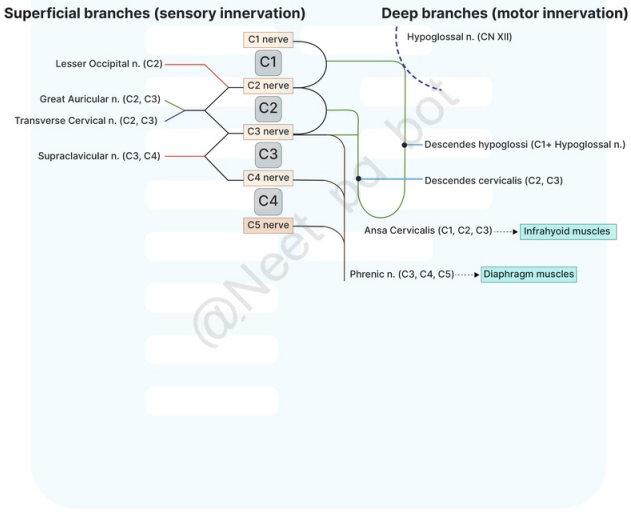

@Neet_pg_bot

References:

BD Chaurasia’s Human Anatomy, 8th Edition, Page 190, 191, 192

↑ *Back to this question in Part A*

@Neet_pg_bot

Q14: Identify the structure marked with the arrow and select which nerve root arises from it. (Q848474)

A. Abducens nerve

B. Glossopharyngeal nerve

C. Hypoglossal nerve

D. Vagus nerve

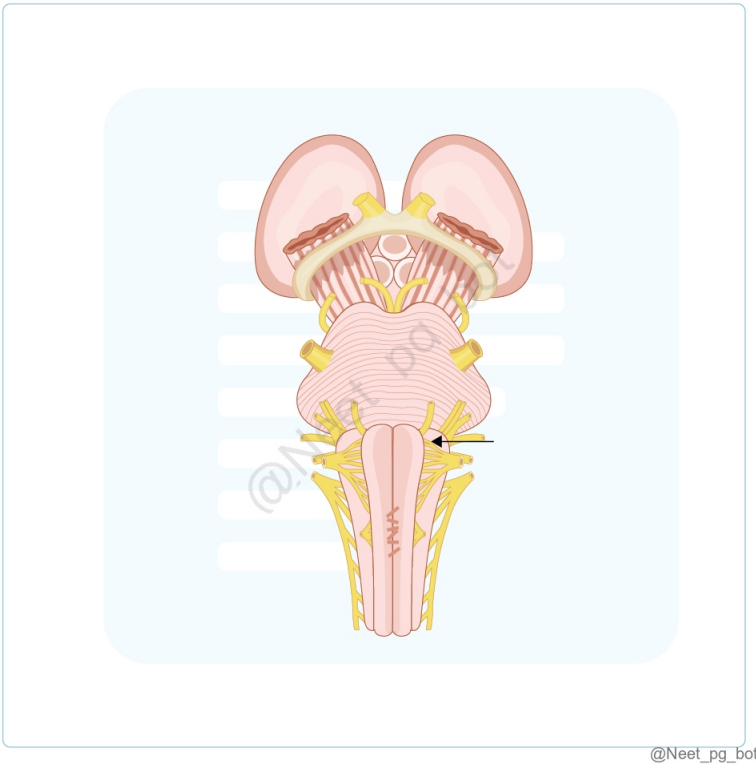

Correct Answer: C. Hypoglossal nerve

■ *Listen (English)*

■ *Listen (Hindi)*

Explanation: The olive, marked by the arrow, is located near the preolivary sulcus where the hypoglossal nerve rootlets emerge. Olive (Inferior Olivary Nucleus) Location and Structure: The olive is an oval elevation in the medulla , formed by the inferior olivary nucleus . Appears like a crumpled purse due to its grey matter. Located in the upper lateral region of the medulla. The principal olivary nucleus is C-shaped with a medial hilum . The medial

and dorsal accessory olivary nuclei are near the olive. Function: Receives inputs from the cortex, red nucleus, PAG, and spinal cord. Sends contralateral (mainly) olivocerebellar fibres forming climbing fibres that branch to deep cerebellar nuclei and the molecular layer. Anatomy: Bounded by the pre-olivary (hypoglossal rootlets) and retro-olivary (glossopharyngeal, vagus, accessory rootlets) sulci. Vestibular fibres emerge below the inferior cerebellar peduncle. Olivocerebellar fibres cross to the contralateral restiform body . Abducens nerve (Option A) : The abducens nerve arises from the pons, not the medulla. Glossopharyngeal nerve (Option A): The glossopharyngeal nerve rootlets emerge from the retro-olivary sulcus but not from the olive itself. Vagus nerve (Option D) :The vagus nerve rootlets also emerge from the retro-olivary sulcus, not from the olive directly.

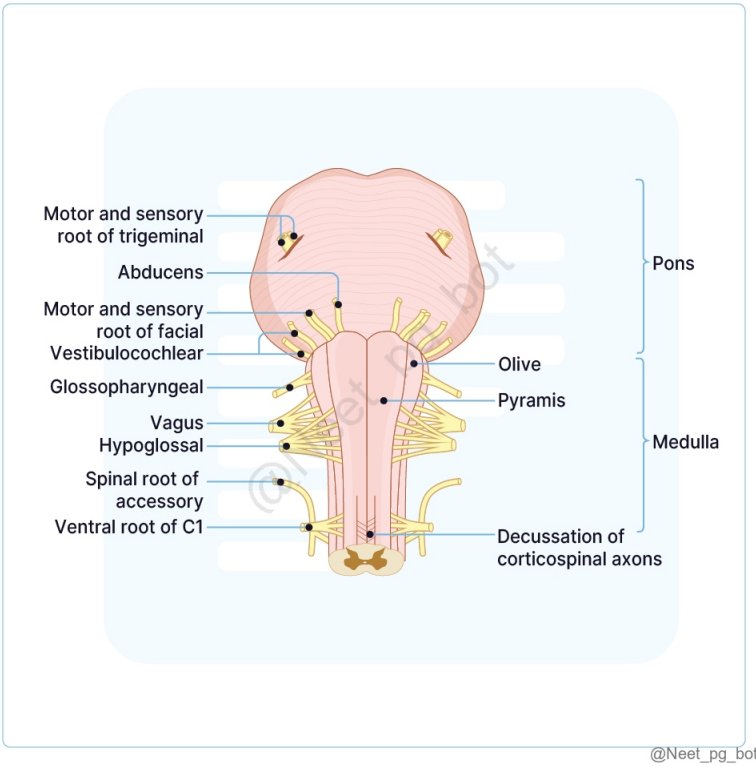

References:

Grey's Anatomy, 42nd Edition, Page 444, 474

BD Chaurasia’s Human Anatomy, 8th Edition, Page 94, 100

↑ *Back to this question in Part A*

@Neet_pg_bot

Q15: A 60-year-old female presents with drooping of her left eyelid, double vision, and a dilated, fixed left pupil. She also reports difficulty focusing on close objects and some mild forward projection of her left eye. Neurological examination reveals that the left eye is turned downward and outward. A CT scan shows no evidence of mass lesions or

hemorrhage.Which of the following is most likely responsible for the patient's symptoms? (Q848475)

A. Complete Oculomotor Nerve Palsy

B. Trochlear Nerve Palsy

C. Abducens Nerve Palsy

D. Supranuclear Lesion

Correct Answer: A. Complete Oculomotor Nerve Palsy

■ *Listen (English)*

■ *Listen (Hindi)*

Explanation: The patient's symptoms, including ptosis (drooping eyelid), diplopia (double vision), dilated pupil with absent light reflex, lateral squint (due to unopposed action of lateral rectus and superior oblique muscles), and difficulty focusing on near objects (loss of accommodation), are classic signs of oculomotor nerve palsy. The absence of mass lesions or hemorrhage in the CT scan makes this diagnosis more likely than other options. Oculomotor Nerve Palsy Features: Ptosis: Paralysis of the levator palpebrae superioris Lateral squint: Unopposed lateral rectus and superior oblique Dilated pupil & loss of light reflex: Parasympathetic fibre paralysis Loss of accommodation: Ciliary muscle paralysis Slight proptosis & diplopia due to eye misalignment Causes: Weber’s syndrome: Midbrain lesion → ipsilateral CN III palsy + contralateral hemiplegia Supranuclear lesion: Impaired conjugate eye movement Compression (e.g., extradural hematoma): Parasympathetic fibres affected first → early pupil dilation Aneurysm (posterior cerebral/superior cerebellar artery): May compress CN III between vessels

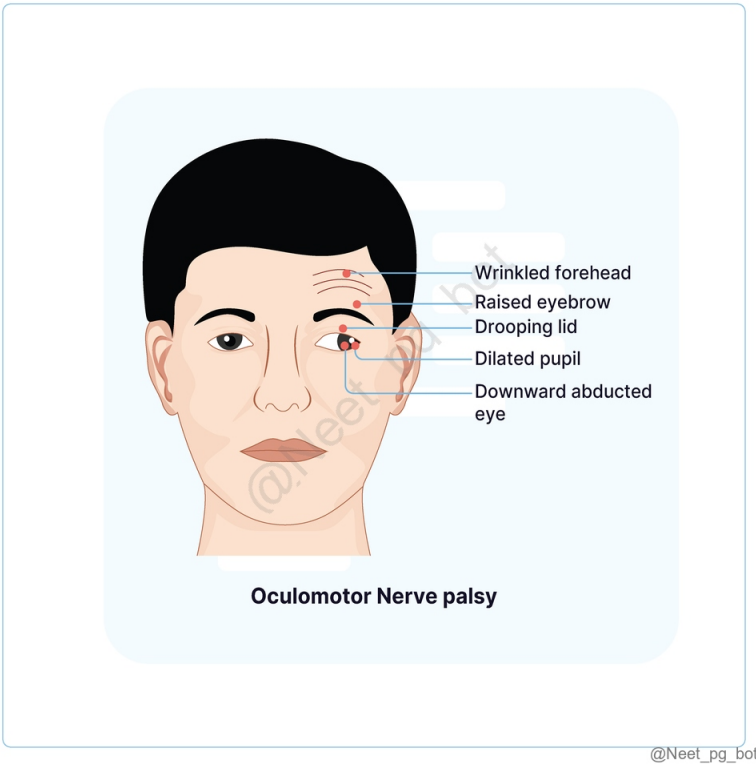

References:

BD Chaurasia’s Human Anatomy, 8th Edition, Page 71

Grey's Anatomy, 42nd Edition, Page 1464

↑ *Back to this question in Part A*

@Neet_pg_bot

Q16: A 45-year-old patient presents with facial asymmetry and difficulty smiling. Upon examination, the physician suspects a lesion affecting the facial nerve. Where does the facial nerve divide into its five terminal branches within the parotid gland? (Q848476)

A. At the stylomastoid foramen

B. Behind the neck of the mandible

C. Near the spine of the sphenoid

D. Within the middle ear

Correct Answer: B. Behind the neck of the mandible

■ *Listen (English)*

■ *Listen (Hindi)*

Explanation: The facial nerve divides into its five terminal branches (temporal, zygomatic, buccal, marginal mandibular, and cervical) behind the neck of the mandible, within the parotid gland. Anatomical Landmark for Identification of the Facial Nerve Trunk Location of Exit: The facial nerve exits the skull through the stylomastoid foramen . (Option A ruled out) Proximity to Structures: Crosses the lateral side of the base of the styloid process . Enters the posteromedial surface of the parotid gland . In Relation to Parotid Gland: Within the parotid gland, it runs forward and crosses: The retromandibular vein . The external carotid artery . Division Point: Behind the neck of the mandible, the trunk divides into its five terminal branches : temporal, zygomatic, buccal, marginal mandibular, and cervical. Nearby Landmarks: The stylomastoid foramen serves as a key entry/exit point for surgical or clinical identification. The nerve lies near the spine of the sphenoid after exiting the middle ear through the petrotympanic fissure. (Option C ruled out) Within the middle ear (Option D): The facial nerve passes through the middle ear but does not divide there. It exits the middle ear through the petrotympanic fissure before running toward the stylomastoid foramen and ultimately dividing behind the mandible.

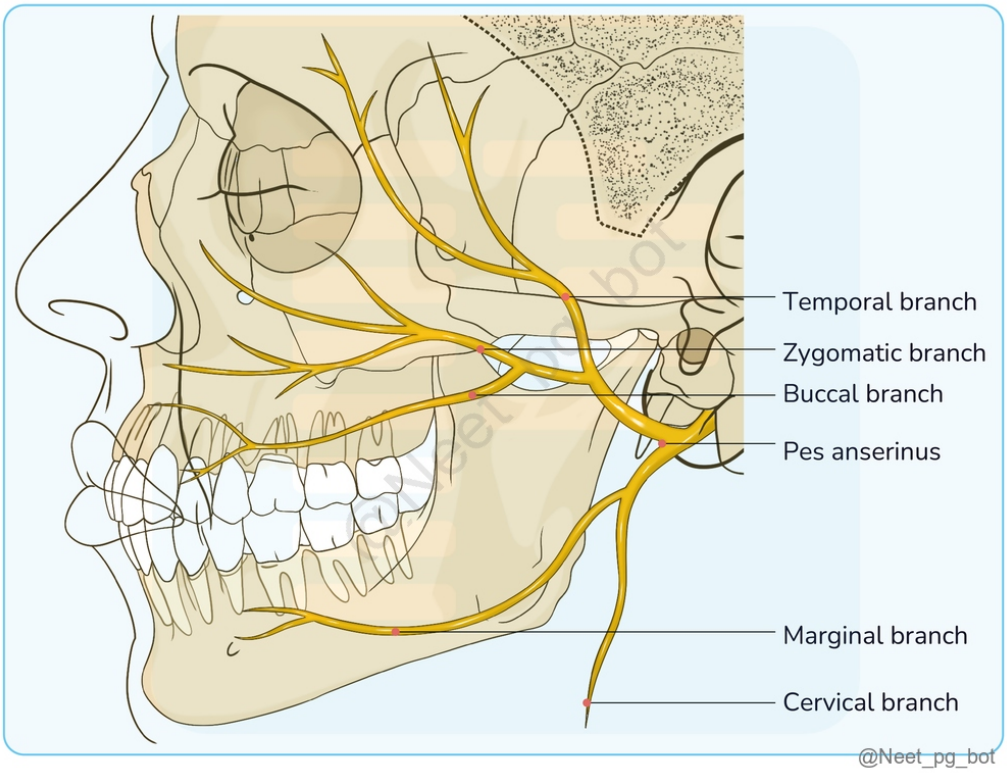

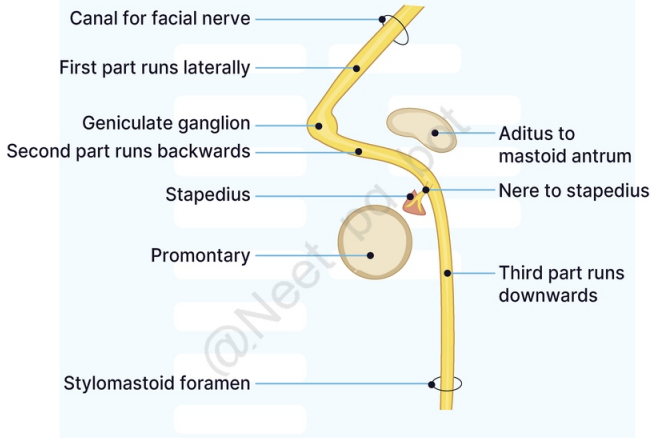

@Neet_pg_bot

References:

Grey's Anatomy 42nd edition, Pages 1464-e17-19

BD Chaurasia’s Human Anatomy, 8th edition, Pages 78,79

↑ *Back to this question in Part A*

@Neet_pg_bot

Q17: The anesthetic agent used for providing the nerve block in the diagram below will not affect which nerve? (Q876192)

A. Inferior alveolar nerve

B. Buccal nerve

C. Lingual nerve

D. Mental nerve

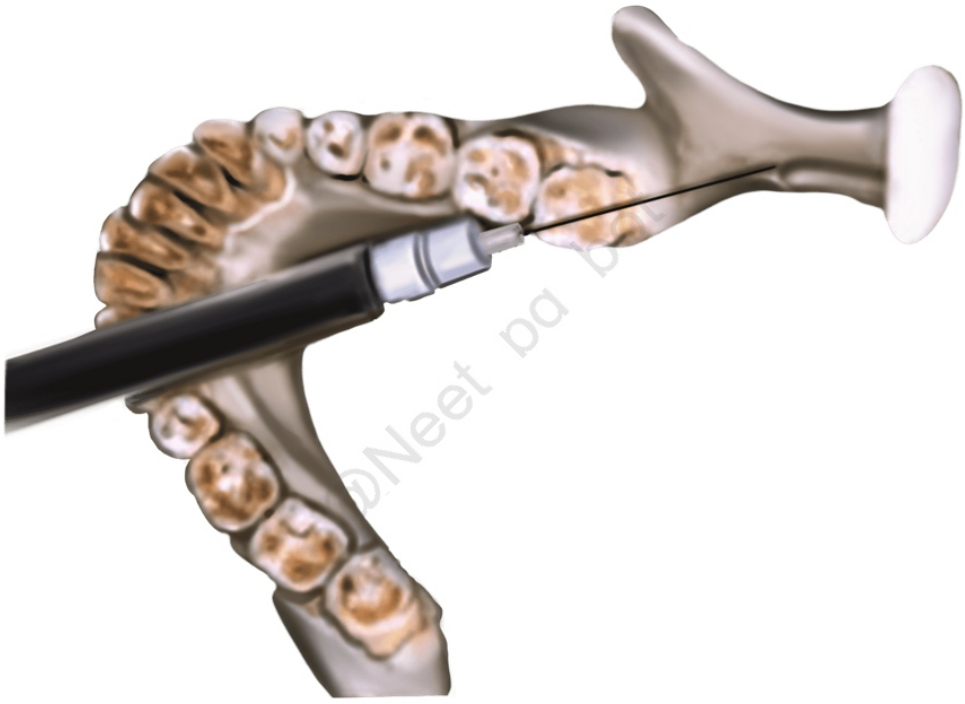

@Neet_pg_bot

Correct Answer: B. Buccal nerve

Explanation: Correct Option B - Buccal nerve: Anaesthesia at this location is not going to block buccal nerve. It is the site for inferior alveolar nerve block and is most commonly used for dental procedures, which results in loss of signaling from it and its branches. Incorrect Options: Option A - Inferior alveolar nerve: The block shown in the diagram is of the inferior alveolar nerve. It can be blocked near the mandibular foramen before dental procedures Option C - Lingual nerve: The lingual nerve is involved in the inferior alveolar nerve block. Option D - Mental nerve: The mental nerve is a branch of the inferior alveolar nerve and is also blocked by it.

References:

Page No. 3672 (Kindle edition); Gray's Anatomy (42nd Edition)

↑ *Back to this question in Part A*

@Neet_pg_bot

Q18: A 62-year-old male with diabetes arrives at the emergency department with sudden right-sided weakness and trouble speaking. His examination shows left-sided ptosis, the left eye in a "down and out" position, and right-sided paralysis of the lower face. What is the most likely diagnosis? (Q848466)

A. Horner’s syndrome

B. Benedikt’s syndrome

C. Parinaud’s syndrome

D. Weber’s syndrome

Correct Answer: D. Weber’s syndrome

■ *Listen (English)*

■ *Listen (Hindi)*

Explanation: The presented case is diagnosed as Weber's Syndrome , which is characterized by right-sided hemiparesis, ight-sided paralysis of the lower face, left-sided ptosis and a "down and out" position of the left eye. This syndrome impacts the oculomotor nerve (cranial nerve III) nucleus and corticospinal fibers , leading to the l oss of the medial lemniscus, red nucleus, superior cerebellar peduncle, and oculomotor nerve fibers. Characteristic features: Ipsilateral squint (pupil points downwards and laterally) due to injury to the oculomotor nerve. Contralateral hemiplegia due to involvement of corticospinal tract. Involvement of the rostral interstitial nucleus of the medial longitudinal fasciculus (riMLF) in the midbrain causes Weber syndrome with vertical gaze palsy. Syndrome Level Structure Involved Artery Clinical Features Midbrain Syndromes Weber syndrome Midbrain (base) CN III + corticospinal tract PCA Ipsilateral oculomotor palsy + contralateral hemiplegia Benedikt syndrome Midbrain (tegmentum) CN III + red nucleus PCA Ipsilateral CN III palsy + contralateral tremor/ataxia Claude syndrome Midbrain CN III + red nucleus + superior cerebellar peduncle PCA CN III palsy + contralateral ataxia Pontine Syndromes Millard-Gubler syndrome Ventral pons CN VI, VII + corticospinal tract Basilar Ipsilateral facial palsy + contralateral hemiplegia Foville syndrome Dorsal pons CN VI nucleus + PPRF Basilar Ipsilateral gaze palsy + facial palsy Lateral pontine syndrome Lateral pons CN VII, VIII, spinal trigeminal nucleus AICA Facial paralysis, loss of lacrimation, vertigo Medullary Syndromes Medial medullary syndrome Medial medulla CN XII, pyramids, medial lemniscus ASA Ipsilateral tongue deviation + contralateral hemiplegia + loss of proprioception Lateral medullary syndrome Lateral medulla Nucleus ambiguus, spinothalamic tract PICA Dysphagia, hoarseness, contralateral body pain loss

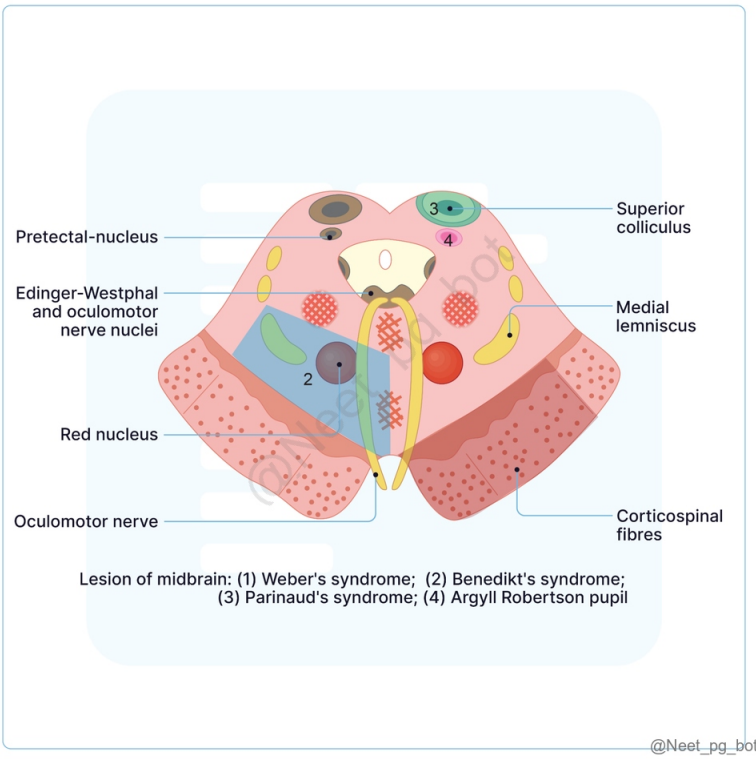

References:

BD Chaurasia’s Human Anatomy, 8th Edition, Page 113, 114

Vishram Singh’s Textbook of Anatomy, 2nd Edition, Page 371

↑ *Back to this question in Part A*

@Neet_pg_bot

Q19: A 35-year-old female presents with sharp, shooting pain and numbness in her forehead, upper eyelid, upper face, upper lip, and part of her cheek after a recent car accident. She has a diminished corneal reflex on the right side. Which divisions of the trigeminal nerve are affected? (Q848444)

A. V1, V2

B. V2, V3

C. V1, V3

D. V1, V2, V3

Correct Answer: A. V1, V2

■ *Listen (English)*

■ *Listen (Hindi)*

Explanation: The scenario with sharp, shooting pain in the forehead, upper lip, and cheek, along with a loss of the corneal reflex, indicates that the V1 and V2 divisions of the trigeminal nerve are likely affected. Trigeminal nerve (5th cranial nerve): Has three divisions Ophthalmic division (V1) Maxillary division (V2) Mandibular division (V3) Type Sensory Sensory Mixed Branches Frontal Supratrochlear Supraorbital Nasociliary Branch to the ciliary ganglion 2–3 long ciliary nerves Posterior ethmoidal Infratrochlear Anterior ethmoidal Lacrimal: Branch to the upper eyelid and secretomotor fibres to the lacrimal gland. Infraorbital Zygomaticofacial Zygomaticotemporal Mental Buccal Auriculo-temporal Supply Forehead Upper eyelids Root of nose Tip of nose Frontal air sinus Scalp Lower eyelids Lateral sides of the nose Upper lip Cheek (upper part) Anterior part of the temporal region Lower lip Chin Lower teeth Lower part of the cheek Lateral side (Upper 2/3rd) of auricle, temporal region

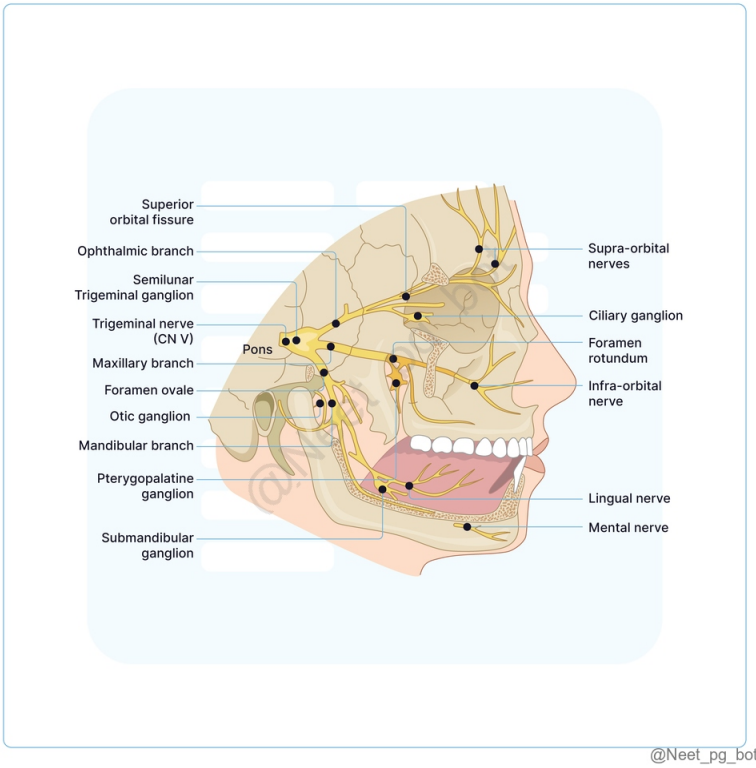

References:

Gray's Anatomy 42nd Edition, Page 1464, e13-15.

BD Chaurasia’s Human Anatomy, 8th Edition, Page 241-244.

Vishram Singh's Textbook of Anatomy, 2nd Edition, Page 58, 59.

↑ *Back to this question in Part A*

@Neet_pg_bot

Q20: A 60-year-old patient presents with difficulty swallowing and changes in voice quality. Upon examination, the physician suspects a neurological issue affecting the muscles of the larynx and pharynx. Which nucleus is responsible for the motor innervation of these muscles? (Q848462)

A. Dorsal nucleus of the vagus

B. Nucleus ambiguus

C. Nucleus tractus solitarius

D. Spinal nucleus

Correct Answer: B. Nucleus ambiguus

■ *Listen (English)*

■ *Listen (Hindi)*

Explanation: The nucleus ambiguus is the primary nucleus that provides motor innervation to the muscles of the larynx and pharynx via the vagus nerve. Vagus Nerve (Cranial Nerve X) This mixed nerve is primarily motor in function and the longest of the cranial nerves. Carry most of the parasympathetic output from the cranial region, including fibers from the cranial part of the accessory nerve. Functional Components and Nuclei: Functional Column Function Nucleus Special Visceral Efferent Supply muscles of the palate, pharynx, and larynx Nucleus Ambiguus General Visceral Efferent Parasympathetic innervation to the heart, bronchial tree, and GIT Dorsal Nucleus of the Vagus (Option A) Special Visceral Afferent Taste sensations from the posterior part of the tongue and epiglottis Nucleus Tractus Solitarius (Option C) General Visceral Afferent Convey sensations from the mucous membranes of the pharynx, larynx, trachea, esophagus, and thoracic/abdominal viscera Nucleus Tractus Solitarius & Dorsal Nucleus of Vagus General Somatic Afferent Carry sensations from the skin of the Auricle Spinal Nucleus of Trigeminal Nerve (Option D)

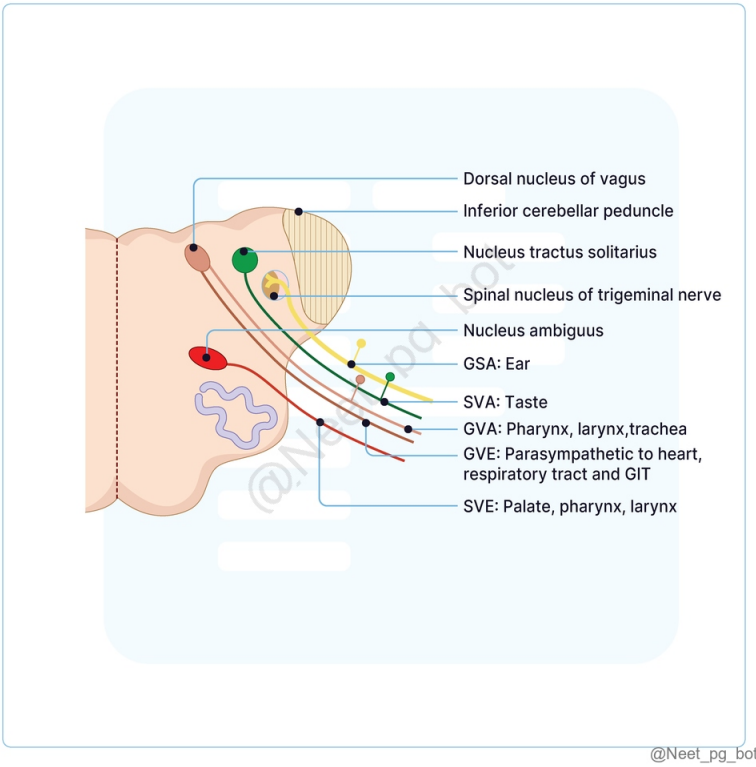

@Neet_pg_bot

References:

Vishram Singh's Textbook of Anatomy, 2nd Edition, Page 346, 347, 348

↑ *Back to this question in Part A*

@Neet_pg_bot

Q21: A 65-year-old patient experiences redness and sweating in the right cheek while eating. Which of the following components is directly involved in the aberrant nerve regeneration causing these symptoms? (Q848461)

A. Jacobson’s nerve

B. Auriculotemporal preganglionic fibers

C. Auriculotemporal postganglionic fibers

D. Sympathetic postganglionic fibers

Correct Answer: C. Auriculotemporal postganglionic fibers

■ *Listen (English)*

■ *Listen (Hindi)*

Explanation: The scenario indicates Frey's syndrome , which results from the aberrant regeneration of auriculotemporal postganglionic fibres following parotid surgery. When these nerves are severed, the regenerating secretomotor fibres can aberrantly grow into the endoneural sheaths of fibres that supply cutaneous receptors for pain, touch, and temperature, as well as sympathetic fibres that innervate sweat glands and blood vessels. As a result, a stimulus meant for salivation can trigger: Gustatory Sweating : When eating, the affected cheek (parotid region) may become red, hot, and painful, accompanied by beads of perspiration. Cutaneous Hyperesthesia : While shaving, the area in front of the ear may exhibit heightened sensitivity.

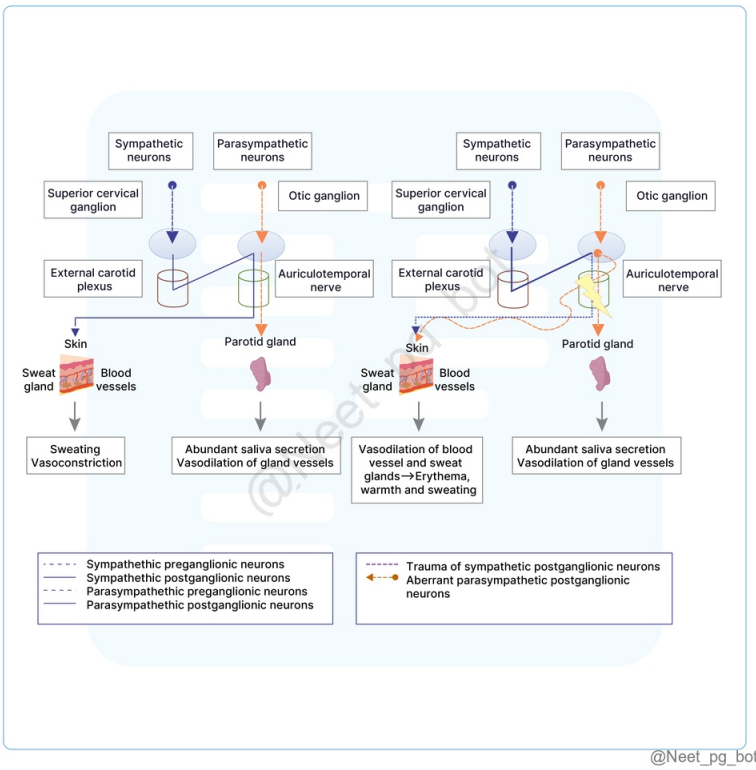

References:

Vishram Singh's Textbook of Anatomy, 2nd Edition, Page 116

↑ *Back to this question in Part A*

@Neet_pg_bot

Q22: A 45-year-old male presents to the clinic with complaints of difficulty swallowing and loss of taste sensation from the posterior third of his tongue. On examination, there is a loss of the gag reflex on the right side. Further tests reveal decreased salivary secretion from the parotid gland. Given the clinical findings, which of the following structures is most likely affected in this patient? (Q848457)

A. Otic ganglion

B. Submandibular ganglion

C. Ciliary ganglion

D. Pterygopalatine ganglion

Correct Answer: A. Otic ganglion

■ *Listen (English)*

■ *Listen (Hindi)*

Explanation: The patient's symptoms suggest a lesion of the glossopharyngeal nerve (cranial nerve IX) , which provides sensory innervation to the posterior third of the tongue and contributes to the gag reflex. The submandibular ganglion (Option B) is part of the parasympathetic nervous system and is associated with the facial nerve (cranial nerve VII) Ciliary ganglion (Option C) is a parasympathetic ganglion associated with the oculomotor nerve (cranial nerve III). Pterygopalatine ganglion (Option D) is also part of the parasympathetic nervous system but is associated with the facial nerve (cranial nerve VII)

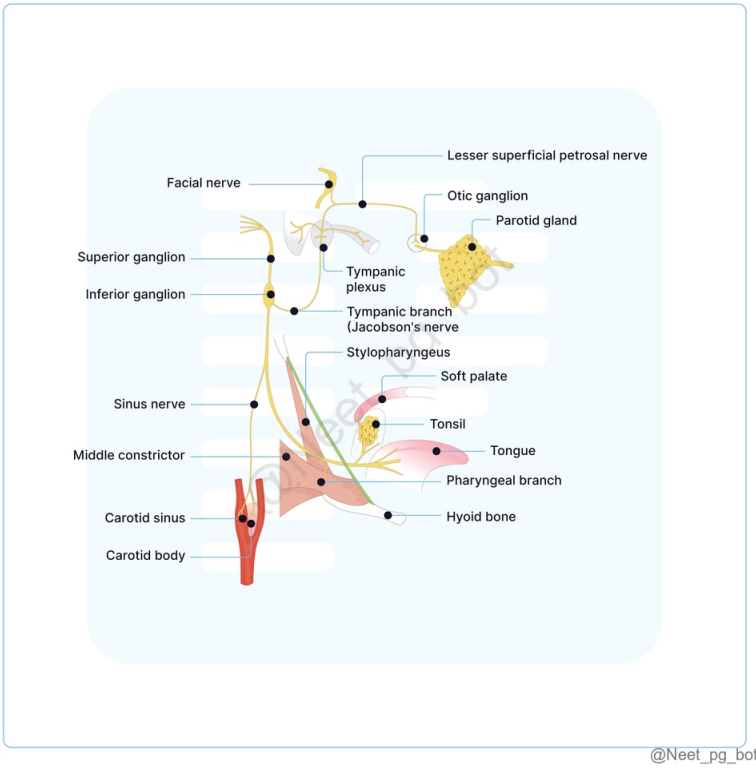

@Neet_pg_bot

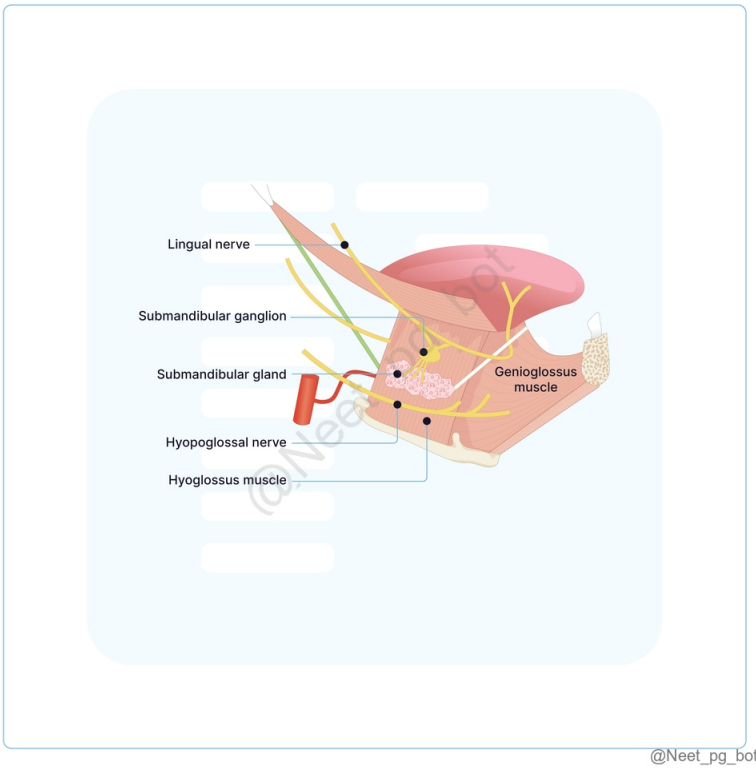

@Neet_pg_bot

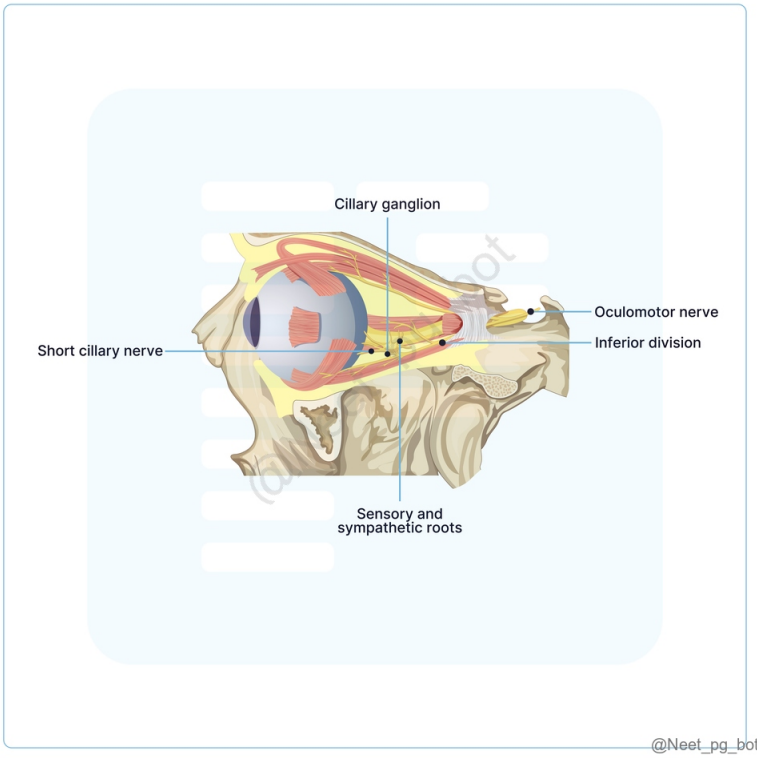

@Neet_pg_bot

References:

Gray's Anatomy, 42nd Edition, Page 1464-e20, 1464-e21.

↑ *Back to this question in Part A*

@Neet_pg_bot

Q23: A 45-year-old patient presents with difficulty in smiling and closing eyelids on the right side. The patient does not have any history of recent trauma or infections. The image below shows the patient's face. Sensory function, including taste on the anterior two-thirds of the tongue and sensation to light touch, appears intact. Which nerve column is primarily responsible for this condition? (Q848456)

A. General Somatic Efferent (GSE)

B. General Visceral Efferent (GVE)

C. Special Visceral Efferent (SVE)

D. General Somatic Afferent (GSA)



Correct Answer: C. Special Visceral Efferent (SVE)

■ *Listen (English)*

■ *Listen (Hindi)*

Explanation: The patient’s image reveals weakness of the facial muscles on one side of the face. Based on the clinical presentation and the image Special Visceral Efferent (SVE) is most likely to be affected. The muscles of facial expression, originating from the second branchial arch , are innervated by the facial nerve, with the SVE component arising from the facial nucleus in the brainstem. The special visceral efferent (SVE) column innervates muscles derived from the branchial arches. Nerve Column Nucleus Origin Function Special Visceral Afferent Nucleus Solitarius Carries taste sensations from the anterior two-thirds of the tongue via the chorda tympani branch of the facial nerve. General Visceral Efferent Superior salivatory nucleus Parasympathetic innervation to glands (lacrimal, submandibular, sublingual). Special Visceral Efferent Facial nucleus in the pons Innervates muscles derived from branchial (pharyngeal) arches. General Somatic Afferent Geniculate ganglion Carries sensory information from the skin (e.g., touch, pain). The General Somatic Efferent (GSE) (Option A) is responsible for innervating skeletal muscles derived from somites, including extraocular muscles and tongue muscles. It is not relevant to the facial nerve.

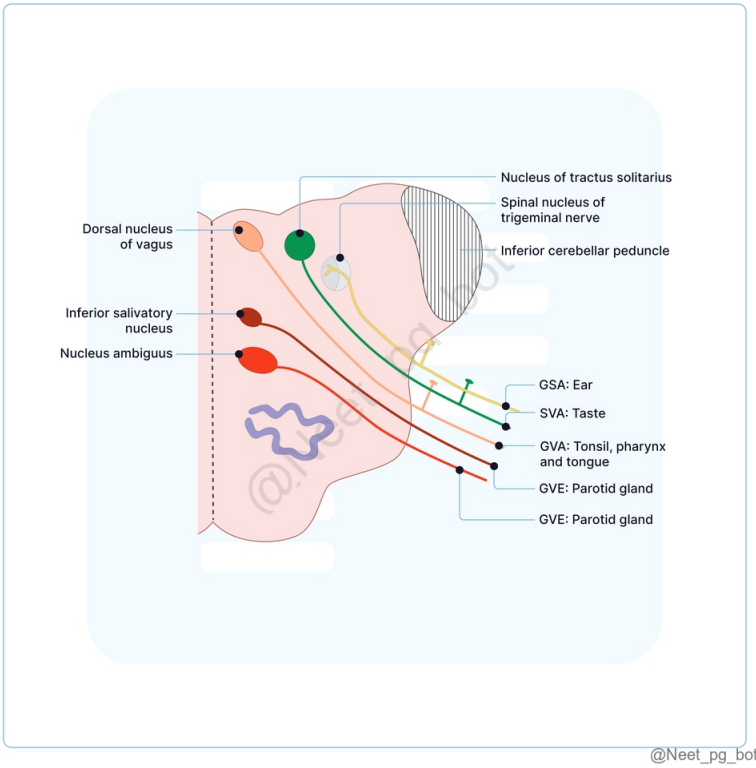

References:

Grey's Anatomy, 42nd Edition, Page 1464

↑ *Back to this question in Part A*

@Neet_pg_bot

Q24: A 50-year-old woman presents with excessive tearing while eating, which started a few months ago. Upon further questioning, she recalls having facial nerve palsy

about a year ago, which has since improved. Based on this presentation, at what level of the facial nerve pathway did the injury most likely occur? (Q848455)

A. At the level of the geniculate ganglion

B. At the level of the chorda tympani

C. At the stylomastoid foramen

D. At the level of the greater petrosal nerve

Correct Answer: A. At the level of the geniculate ganglion

■ *Listen (English)*

■ *Listen (Hindi)*

Explanation: The clinical presentation suggests Bogorad syndrome , also known as Crocodile tears syndrome , occurring due to the misdirection of parasympathetic fibres that regenerate after facial nerve injury. These fibres, which originally control salivation, are misdirected to the lacrimal gland, leading to involuntary tear production during eating. The injury that leads to this phenomenon typically occurs around the geniculate ganglion , where the parasympathetic fibers for both salivation and lacrimation are present. Damage here can lead to a mix of motor and sensory dysfunction, including taste disturbances and autonomic dysfunction.

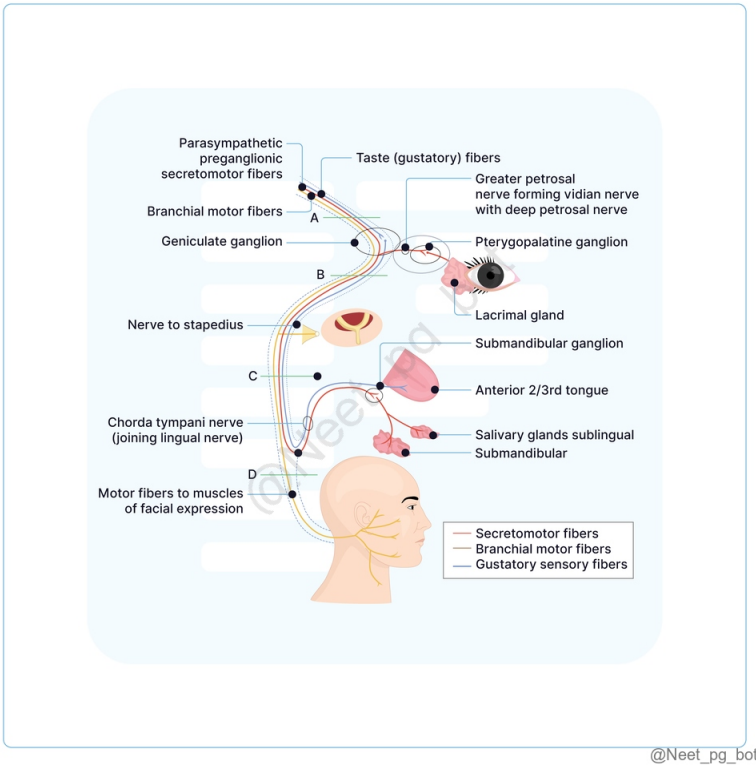

@Neet_pg_bot

References:

Gray's Anatomy, 42nd Edition, Page 632, 633, 1464e17,18,19

Diseases of Ear, Nose, Throat - PL Dhingra, 8th Edition, Page 117

↑ *Back to this question in Part A*

@Neet_pg_bot

Q25: A 35-year-old male presents with difficulty chewing and pain near his temporomandibular joint (TMJ) after sustaining blunt trauma to the side of his face. Upon examination, there is tenderness over the ramus of the mandible. Which muscle is most likely affected? (Q848453)

A. Temporalis

B. Masseter

C. Lateral Pterygoid

D. Medial Pterygoid

Correct Answer: B. Masseter

■ *Listen (English)*

■ *Listen (Hindi)*

Explanation: Masseter covers the ramus of the mandible, making it most likely to be affected by trauma to the side of the face, as described in the scenario. Its primary action is elevating the mandible , which is essential for biting and chewing. Muscles of mandible Muscle Location Action Nerve Supply Masseter Covers the ramus of the mandible Elevates the mandible for biting and chewing Mandibular branch of the trigeminal nerve (CN V3) Temporalis Attached to the coronoid process Elevates and retracts the mandible Lateral Pterygoid Located in the infratemporal fossa Protracts and depresses the mandible and moves it laterally. Medial Pterygoid It runs parallel to the masseter on the inner side of the ramus of mandible. Elevates and assists in protrusion of the mandible

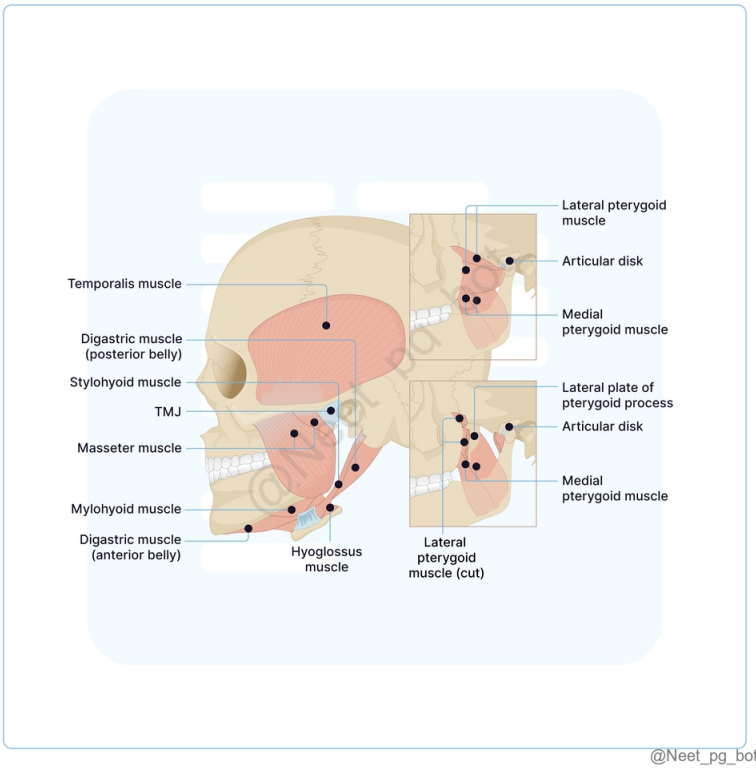

@Neet_pg_bot

References:

Grey's Anatomy, 42nd Edition, Page 667, 669, 676, 677, 678.

↑ *Back to this question in Part A*

@Neet_pg_bot

Q26: A 34-year-old male presents with difficulty opening his mouth following a jaw injury. Which of the following muscles is primarily responsible for opening the mouth? (Q848448)

A. Masseter

B. Temporalis

C. Medial pterygoid

D. Lateral pterygoid

Correct Answer: D. Lateral pterygoid

■ *Listen (English)*

■ *Listen (Hindi)*

Explanation: The scenario describes trauma to the muscles responsible for depressing the jaw and opening the mouth, particularly the lateral pterygoid muscle. Muscles of mastication They are responsible for moving the mandible at the temporomandibular joints during the process of chewing. They are divided into: Principal muscles Accessory muscles Temporalis Masseter Lateral pterygoid Medial pterygoid Digastric Buccinator Mylohyoid Geniohyoid. Principal muscles of mastication Nerve supply Action Masseter (Option A) Masseteric nerve (Anterior division of mandibular nerve) Elevates the mandible (close the mouth). Protrusion Temporalis (Option B) Deep temporal nerves (Anterior division of mandibular nerve) Elevates mandible (close the mouth) Side-to-side (grinding) movement Retraction of mandible Lateral pterygoid (Option D) A branch from the anterior division of the mandibular nerve Depresses mandible (open the mouth) Protrusion Turns chin to the opposite side (right lateral pterygoid turns chin to left) Medial pterygoid (Option C) Nerve to medial pterygoid (main trunk of the mandibular nerve) Elevates the mandible (close the mouth) Protrusion Grinding movement

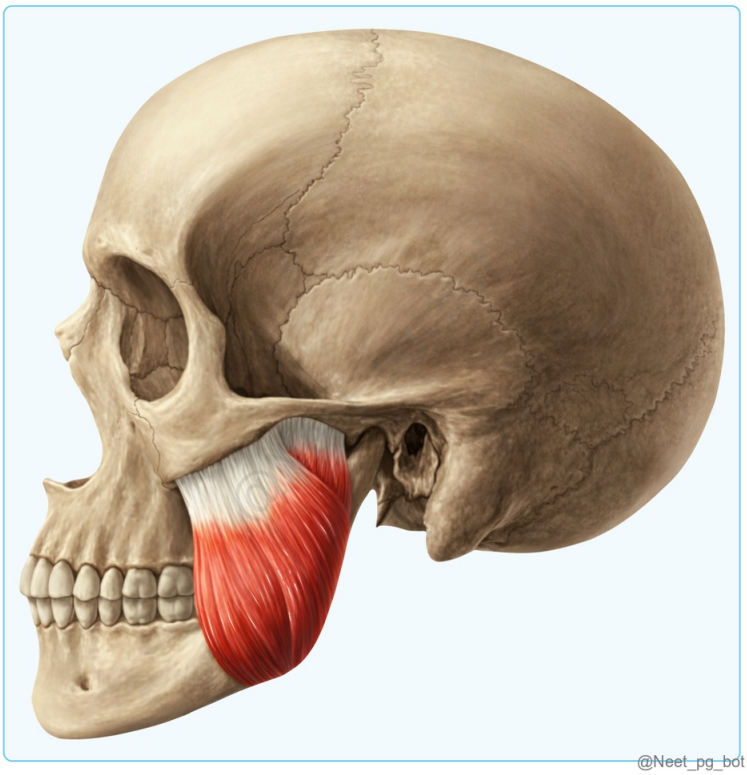



@Neet_pg_bot

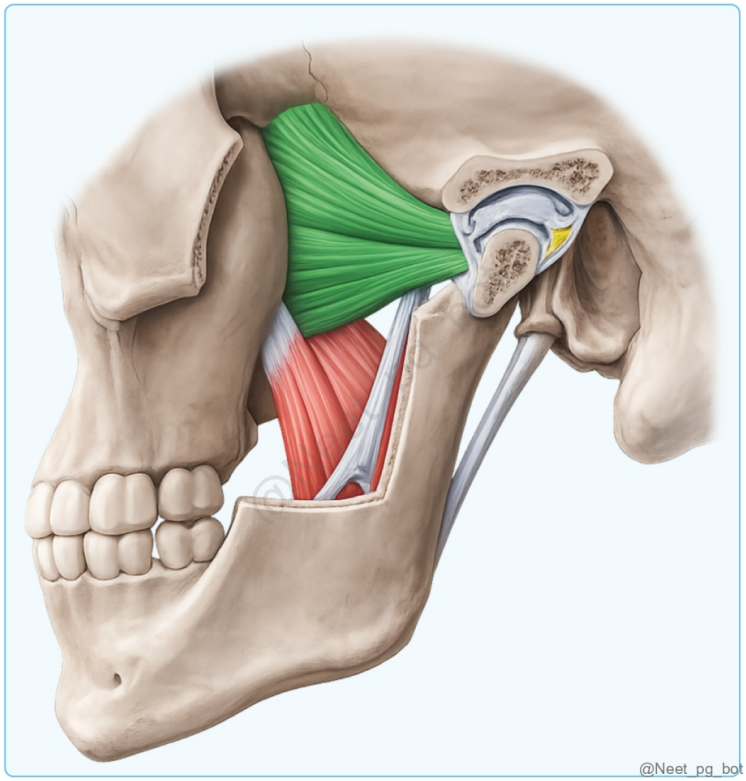

@Neet_pg_bot

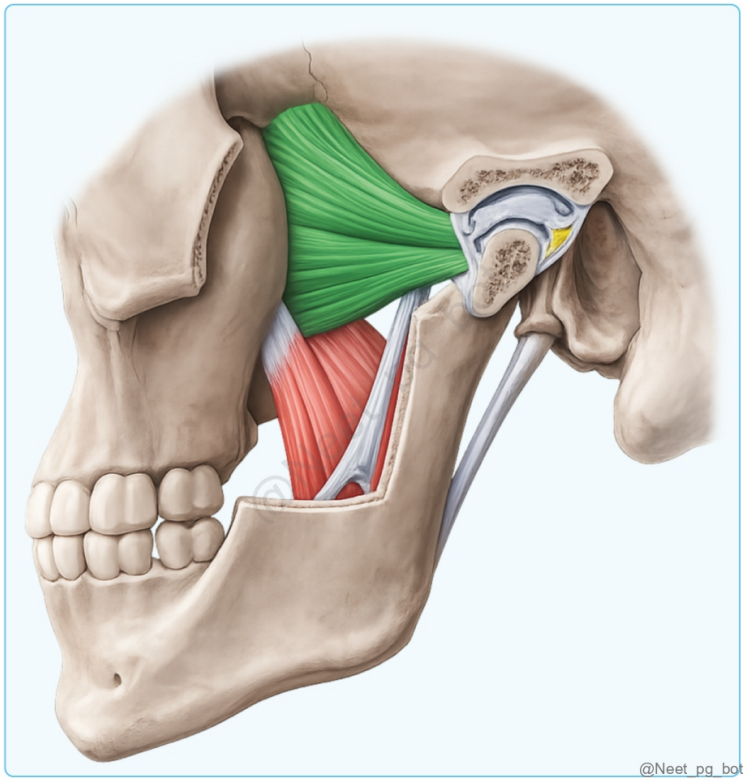
@Neet_pg_bot

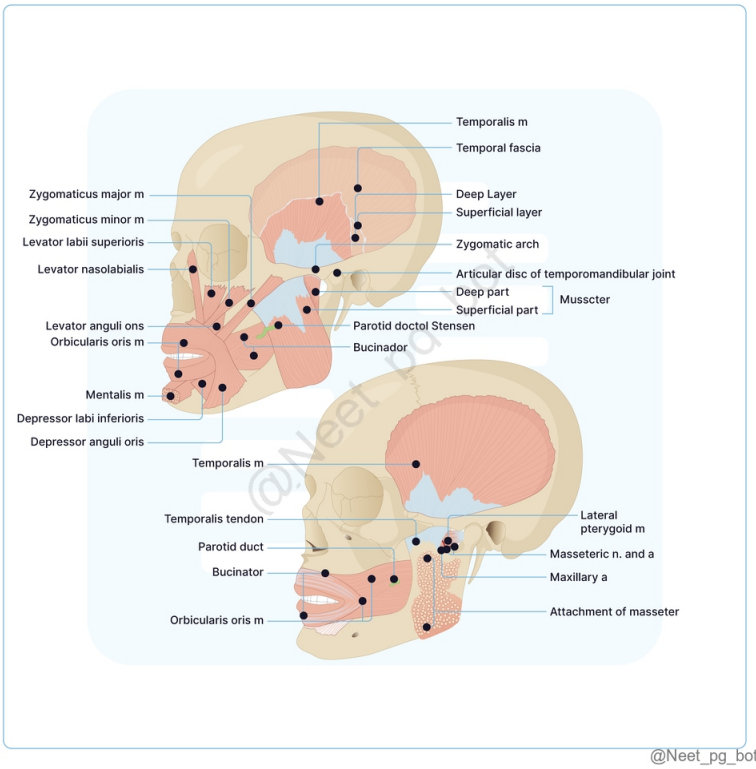
Temporalis m
Temporal fascia
Zygomaticus major m
Zygomaticus minor m
Levator labii superioris
Levator nasolabialis
Deep Layer
Superficial layer
Zygomatic arch
Articular disc of temporomandibular joint
Deep part
Superficial part
Musscter
Levator anguli ons
Orbicularis oris m
Parotid doctol Stensen
Bucinador
Mentalis m
Depressor labi inferioris
Depressor anguli oris
Temporalis m
Temporalis tendon
Parotid duct
Bucinator
Orbicularis oris m
Lateral pterygoid m
Masseteric n. and a
Maxillary a
Attachment of masseter
@Neet_pg_bot

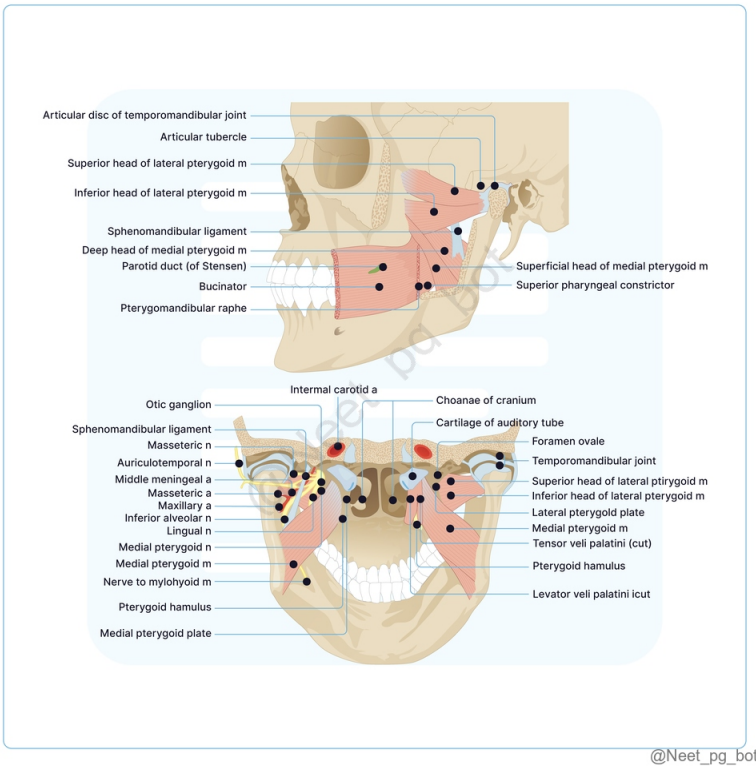

@Neet_pg_bot

References:

Gray's Anatomy 42nd Edition, Pages 676, 677, 678

BD Chaurasia’s Human Anatomy, 8th Edition, Pages 124-127

Vishram Singh's Textbook of Anatomy, 2nd Edition, Pages 148-150

Netter Atlas of Human Anatomy: Classic Regional Approach, Pages 72, 73

↑ *Back to this question in Part A*

@Neet_pg_bot

Q27: A 48-year-old female with diabetes presents with severe, sharp right-sided facial pain triggered by light touch, along with numbness and tingling. Examination shows hyperesthesia and decreased sensation on the right side. Which of the following structures is most likely involved in this condition? (Q848446)

A. Spinal nucleus

B. Motor nucleus

C. Mesencephalic nucleus

D. Principal sensory nucleus

Correct Answer: A. Spinal nucleus

■ *Listen (English)*

■ *Listen (Hindi)*

Explanation: The given scenario suggests a lesion of the spinal nucleus of the trigeminal nerve. The trigeminal nerve is associated with four nuclei (1 motor and three sensory). Nuclear columns of Trigeminal nerve (Extends throughout the brainstem) General somatic afferent column : Has three nuclei Spinal nucleus of Vth nerve (Option A) Principal sensory nucleus of Vth nerve (Option D) Mesencephalic nucleus (Option C) Fibers conveying pain and temperature sensations from the majority of the facial area synapse at this location. Fibers transmitting touch and pressure sensations synapse in this nucleus This nucleus extends into the midbrain and receives proprioceptive impulses from the muscles of mastication, the temporomandibular joint, and the teeth. Special visceral efferent column: Motor nucleus of the Vth nerve (Option B) These fibres supply the muscles derived from the first pharyngeal arch, namely the muscles of mastication, the mylohyoid, the anterior belly of the digastric, the tensor palatini and the tensor tympani.

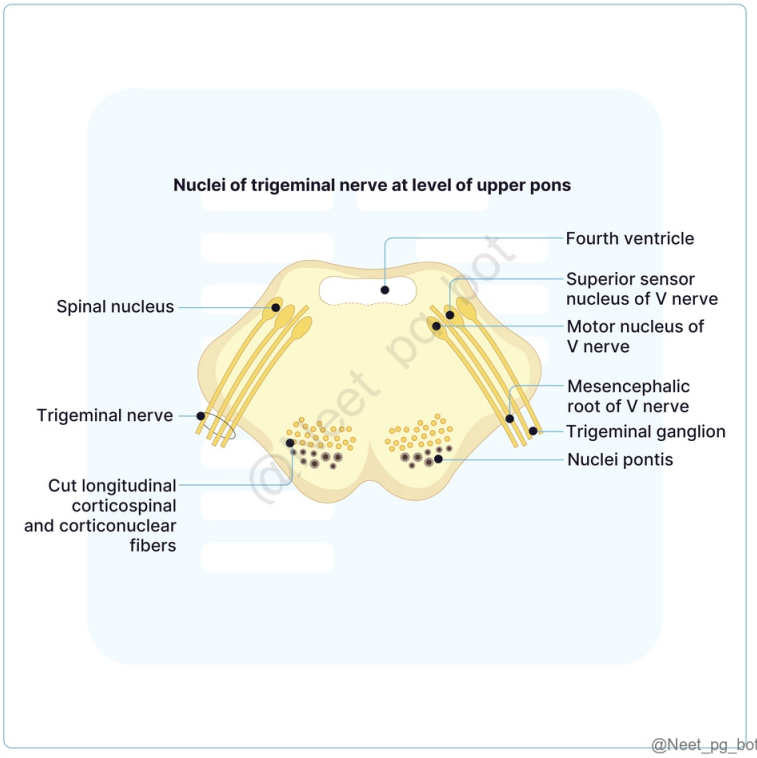

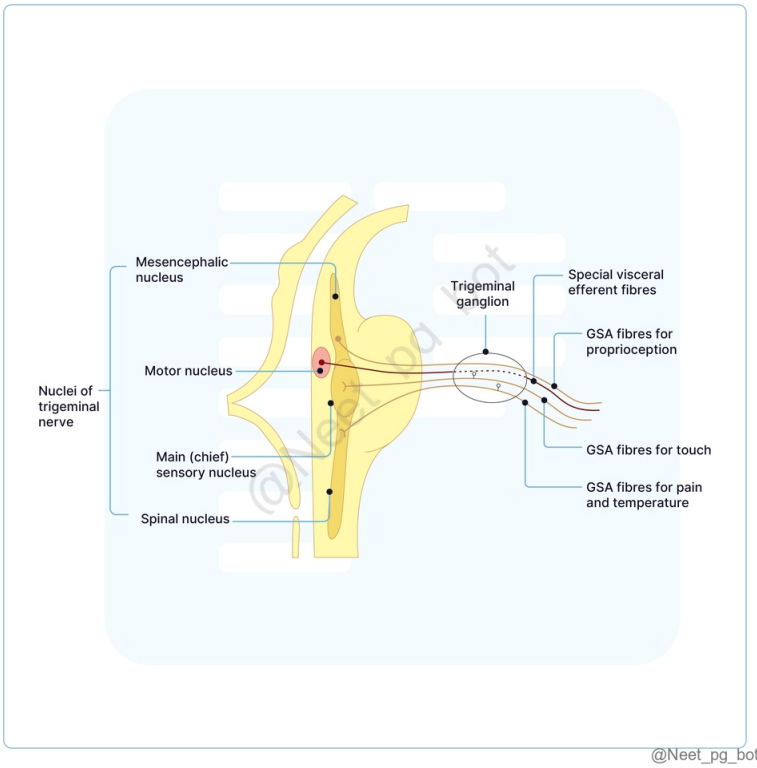

References:

Gray's Anatomy, 42nd Edition, Page 453-455.

BD Chaurasia’s Human Anatomy, 8th Edition, Page 73-76.

Vishram Singh's Textbook of Anatomy, 2nd Edition, Page 338-340.

↑ *Back to this question in Part A*

@Neet_pg_bot

Q28: A 55-year-old woman presents with sudden numbness, tingling, heaviness, dull pain, and heightened sensitivity on the right side of her face. Examination shows reduced sensation in the right maxillary and mandibular areas, with intact motor function and no other deficits. From which location does the affected cranial nerve emerge? (Q848445)

A. Midbrain

B. Cerebrum

C. Pons

D. Medulla oblongata

Correct Answer: C. Pons

■ *Listen (English)*

■ *Listen (Hindi)*

Explanation: The presented scenario suggests a lesion at the sensory root of the trigeminal nerve, which originates from the pons. Trigeminal nerve (Cranial nerve V) The largest and thickest mixed nerve, containing both sensory and motor components. It is associated with four nuclei (1 motor and 3 sensory) and three primary divisions as: Ophthalmic division Maxillary division Mandibular division Course: Midbrain (Option A) is the origin of cranial nerves III (oculomotor nerve) and IV (trochlear). Cerebrum (Option B) is the origin of cranial nerves I (Olfactory nerve) and II (optic nerve). Medulla oblongata (Option D) is the origin of cranial nerves IX (glossopharyngeal nerve), X (vagus nerve), XI (accessory nerve) , and XII (hypoglossal nerve).

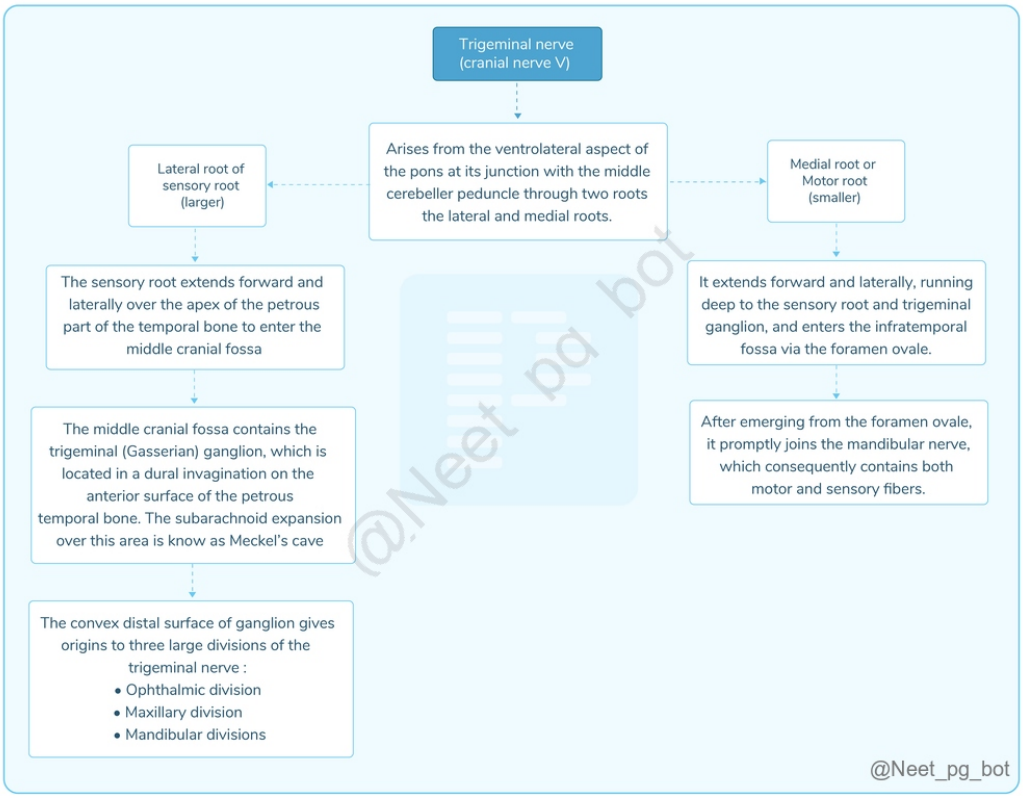

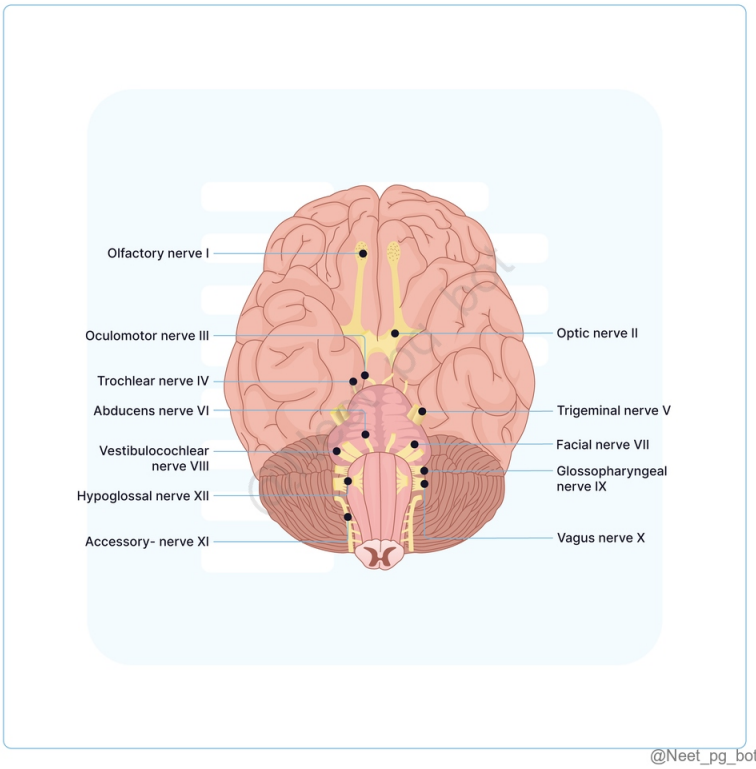

@Neet_pg_bot

References:

Gray's Anatomy, 42nd Edition, Page 630, 631, 632

BD Chaurasia’s Human Anatomy, 8th Edition, Pages 74-77

Vishram Singh's Textbook of Anatomy, 2nd Edition, Pages 338, 339, 340

↑ *Back to this question in Part A*

@Neet_pg_bot

• [04_Head and Neck] 018 Scalenus Anterior Head And Neck Vasculature And Lymphatic Drainage

« Back to Folder Directory

[04_Head and Neck] 018 Scalenus Anterior Head And Neck Vasculature And Lymphatic Drainage — Quick Jump

Q1 (p. 1170)	*Q2 (p. 1171)*	*Q3 (p. 1172)*	*Q4 (p. 1173)*	*Q5 (p. 1175)*	*Q6 (p. 1176)*
Q7 (p. 1177)	*Q8 (p. 1178)*	*Q9 (p. 1179)*	*Q10 (p. 1181)*	*Q11 (p. 1182)*	*Q12 (p. 1184)*
Q13 (p. 1186)	*Q14 (p. 1187)*	*Q15 (p. 1188)*	*Q16 (p. 1190)*	*Q17 (p. 1192)*	

Q1: A 45-year-old male presents with a progressively enlarging mass in his neck. He has a history of heavy smoking and reports recent difficulty swallowing. A biopsy confirms squamous cell carcinoma of the base of the tongue. Which of the following lymph nodes is most likely to be involved in the initial spread of cancer from this region? (Q848747)

A. Jugulodigastric node

B. Supraclavicular node

C. Pretracheal node

D. Paratracheal node

Correct Answer: A. Jugulodigastric node

■ *Listen (English)*

■ *Listen (Hindi)*

Explanation: The base of the tongue drains primarily into the jugulodigastric node , which is part of the deep cervical lymphatic chain. Deep Lymphatics of Head & Neck Deep cervical nodes: Final drainage points; along carotid sheath; superior & inferior groups. Drainage paths: Superficial → external jugular vein Deep → internal jugular vein Specific drainage: Tongue: Jugulodigastric & jugulo-omohyoid (Option A) Thyroid: Pretracheal, paratracheal, deep cervical (OptionC, D) Infratemporal fossa: Superior deep cervical Clinical: Infections spread via retropharyngeal/parapharyngeal spaces to the mediastinum. Deep cervical nodes key for cancer staging. Supraclavicular (Option B): Metastasis from lung & upper GI cancers.

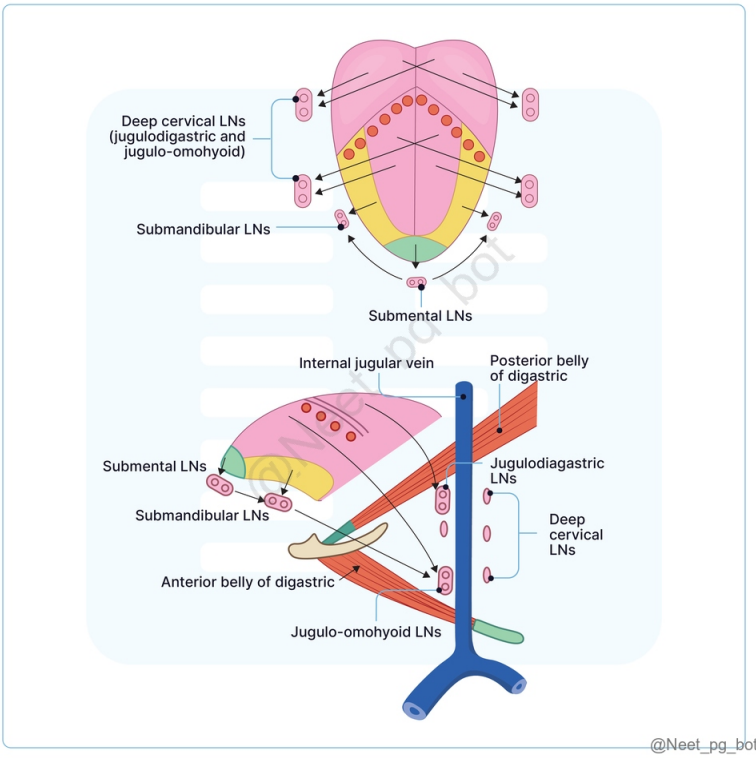

References:

Gray's Anatomy, 41st Edition, Pages 548, 556, 579, 593, 594, 602, 630, 644, 680, 729

↑ *Back to this question in Part A*

@Neet_pg_bot

Q2: A 65-year-old patient presents with a neck mass and difficulty swallowing. On imaging, the mass is located in the area bordered by the internal jugular vein, scalenus anterior muscle, and longus colli muscle. Which lymph node group is most likely located in this area? (Q848746)

A. Level I (Submental and Submandibular nodes)

B. Level II (Upper Jugular nodes)

C. Level III (Middle Jugular nodes)

D. Level IV (Lower Jugular nodes)

Correct Answer: D. Level IV (Lower Jugular nodes)

■ *Listen (English)*

■ *Listen (Hindi)*

Explanation: Chassaignac’s triangle (bounded by the internal jugular vein, scalenus anterior, and longus colli) contains Level IV lower jugular nodes . Level I: submental/submandibular nodes. Level II: upper jugular (skull base to hyoid). Level III: middle jugular (hyoid to cricoid). Takeaway: Chassaignac’s triangle → Level IV nodes (important in head & neck cancers).

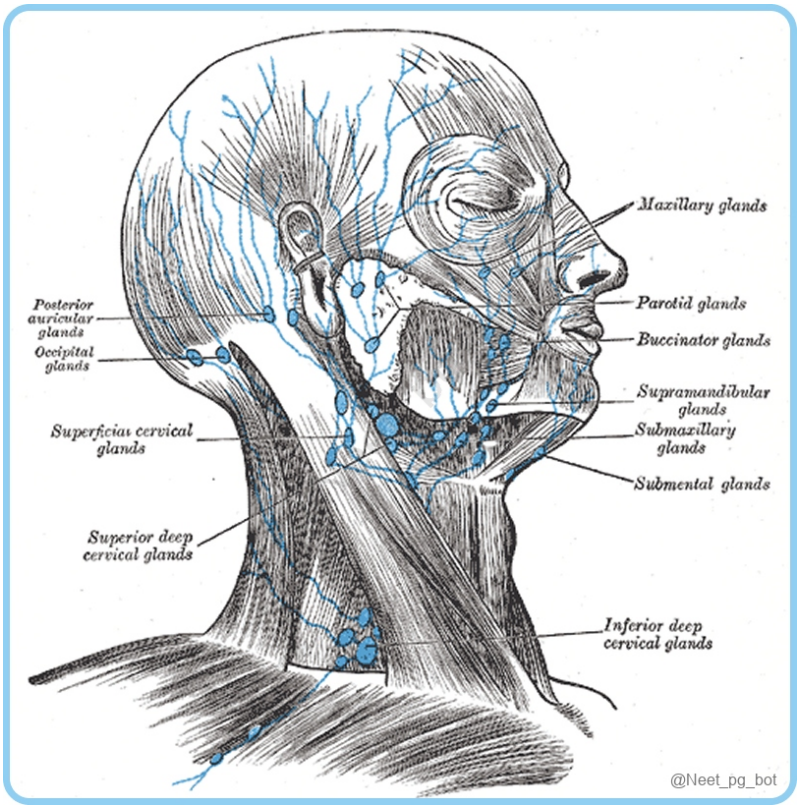

References:

Gray’s Anatomy, 41st Edition, Page 548, 593, 594, 595, 630.

↑ *Back to this question in Part A*

@Neet_pg_bot

Q3: During surgery, the surgeon notices an additional thyroid vein, known as the Kocher’s vein, which drains into the internal jugular vein. The surgeon carefully ligates this additional vein to avoid any postoperative complications. What is the most likely origin of this additional vein? (Q848744)

A. Between the middle and inferior thyroid veins

B. Between the superior and inferior thyroid veins

C. Middle of the thyroid lobe

D. Thyroid isthmus

Correct Answer: A. Between the middle and inferior thyroid veins

■ *Listen (English)*

■ *Listen (Hindi)*

Explanation: The Kocher’s vein originates between the middle and inferior thyroid veins. Venous drainage of the Thyroid Gland: Vein Origin Drainage Superior Thyroid Vein The upper pole of the thyroid Internal jugular vein Middle Thyroid Vein Middle of the thyroid lobe Internal jugular vein Inferior Thyroid Vein The lower border of the isthmus Plexus in front of trachea → Left brachiocephalic vein Kocher's Vein (Fourth Thyroid Vein) Between middle and inferior veins (Option A) Internal jugular vein

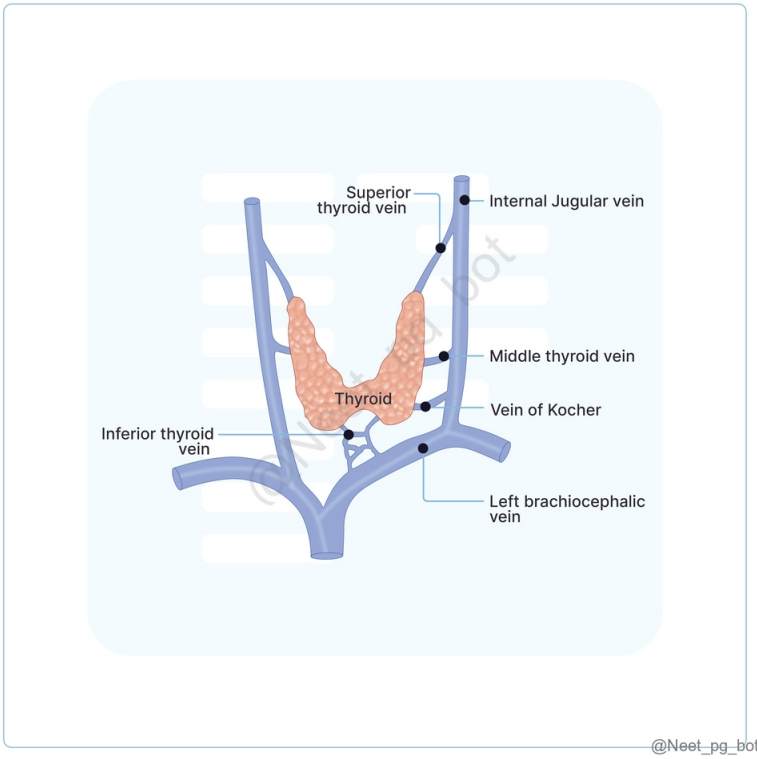

References:

BD Chaurasia’s Human Anatomy, 8th Edition, Volume 3, Page 157.

↑ *Back to this question in Part A*

@Neet_pg_bot

Q4: During a thyroidectomy, the surgeon identifies an artery supplying the lower part of the thyroid isthmus, originating from the arch of the aorta. What is the name of this artery? (Q848743)

A. Accessory thyroid artery

B. Middle thyroid artery

C. Inferior thyroid artery

D. Thyroidea ima artery

Correct Answer: D. Thyroidea ima artery

■ *Listen (English)*

■ *Listen (Hindi)*

Explanation: Rarely (in about 3% of cases), the thyroid gland receives additional blood supply from the thyroidea ima artery, which can originate from the brachiocephalic trunk or the arch of the aorta and enters the lower part of the isthmus. Accessory thyroid arteries (Option A) arising from tracheal and esophageal arteries also supply the thyroid. The Middle thyroid artery (Option B) does not exist. The inferior thyroid artery (Option C) does not arise from the arch of aorta.

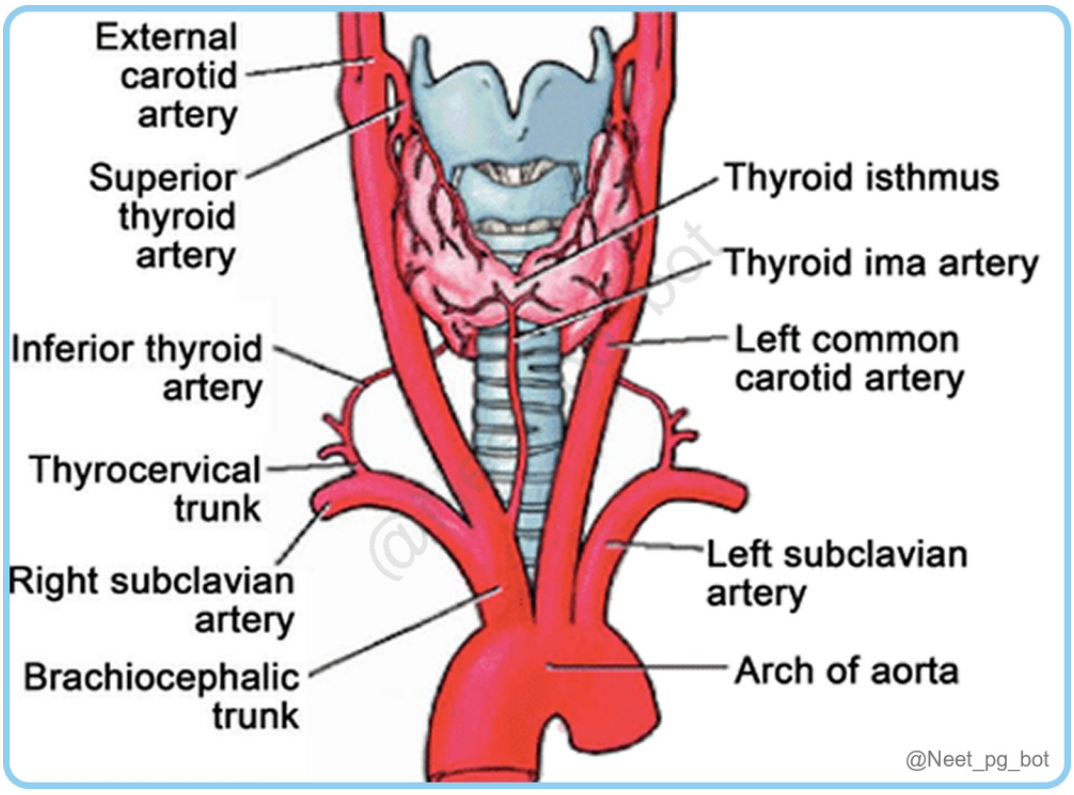

References:

BD Chaurasia's Human Anatomy, 8th Edition, Volume 3, Page 157

↑ *Back to this question in Part A*

@Neet_pg_bot

Q5: A patient presents with the following symptoms: when sticking out the tongue, it deviates towards the left side, and there is noticeable atrophy on the left side of the tongue. Based on the image, which of the following is the most likely diagnosis? (Q848751)

A. Hypoglossal nerve injury (left side)

B. Hypoglossal nerve injury (right side)

C. Right vagus nerve

D. Left vagus nerve



Correct Answer: A. Hypoglossal nerve injury (left side)

■ *Listen (English)*

■ *Listen (Hindi)*

Explanation: Injury to the hypoglossal nerve (CN XII) leads to tongue weakness or paralysis on the affected side. The tongue will deviate toward the side of the injury when protruded. In this case, the leftward deviation of the tongue and atrophy on the left side of the tongue suggest a left-sided hypoglossal nerve injury.

References:

https://www.ncbi.nlm.nih.gov/books/NBK532869/

↑ *Back to this question in Part A*

@Neet_pg_bot

Q6: Which of the following statements about the nerve supply of the four types of papillae on the tongue is incorrect? (Q848750)

A. Filiform papillae are primarily innervated by the lingual nerve (branch of the mandibular nerve) for general sensation.

B. Fungiform papillae are innervated by the chorda tympani (branch of the facial nerve) for taste sensation.

C. Circumvallate papillae are innervated by the glossopharyngeal nerve for both taste and general sensation.

D. Foliate papillae are innervated by the vagus nerve for taste sensation.

Correct Answer: D. Foliate papillae are innervated by the vagus nerve for taste sensation.

■ *Listen (English)*

■ *Listen (Hindi)*

Explanation: The foliate papillae are actually innervated by the glossopharyngeal nerve (for taste sensation), not the vagus nerve. The vagus nerve is involved in other sensory functions, but it does not innervate the taste buds of the foliate papillae. Papillae and Nerve Supply (Concise): Filiform (FL): Lingual nerve – general sensation. Fungiform (FG): Chorda tympani (taste, CN VII); Lingual nerve (sensation). Circumvallate (CV): Glossopharyngeal nerve (taste & sensation). Foliate: Glossopharyngeal nerve (taste); Lingual nerve (sensation). Anterior 2/3 Chorda tympani Lingual nerve (V3) Posterior 1/3 Glossopharyngeal (IX) Glossopharyngeal (IX) Epiglottis Vagus (X) Vagus (X)

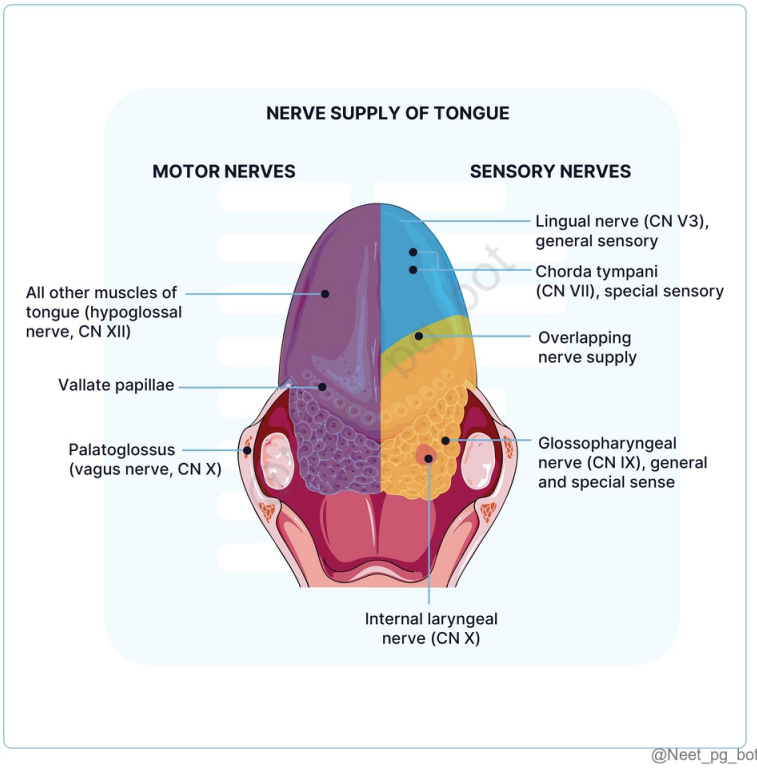

References:

BD Chaurasia's Human Anatomy, 8th Edition, Volume 3, Page 303

Wheater's Functional Histology, 6th Edition, Page 246-47

↑ *Back to this question in Part A*

@Neet_pg_bot

Q7: Which lymph nodes are primarily involved in the drainage of lymphatic vessels from the dorsal region of the tongue? (Q848749)

A. Submental nodes

B. Submandibular nodes

C. Jugulodigastric nodes

D. Subclavicular nodes

Correct Answer: C. Jugulodigastric nodes

■ *Listen (English)*

■ *Listen (Hindi)*

Explanation: Dorsal lymphatic vessels of the tongue typically drain into the jugulodigastric nodes. Lymphatic Drainage of the Tongue Region Drainage Pathways Nodes Involved Marginal Submental Route. Jugulodigastric and Jugulo-omohyoid Route Submandibular Route Posterior Marginal Submental (Option A) Jugulodigastric Jugulo-omohyoid Submandibular (Option B) Central Ascending Route Submandibular Route Deep cervical nodes (Jugulodigastric, Jugulo-omohyoid) Dorsal Posteroinferior Course Convergence with Marginal Direct Jugulo-omohyoid Drainage Jugulodigastric (Option C) Jugulo-omohyoid Subclavicular nodes (Option D) : These nodes are not directly involved in the drainage from the tongue. They are more related to the drainage from the upper limb and part of the thorax.

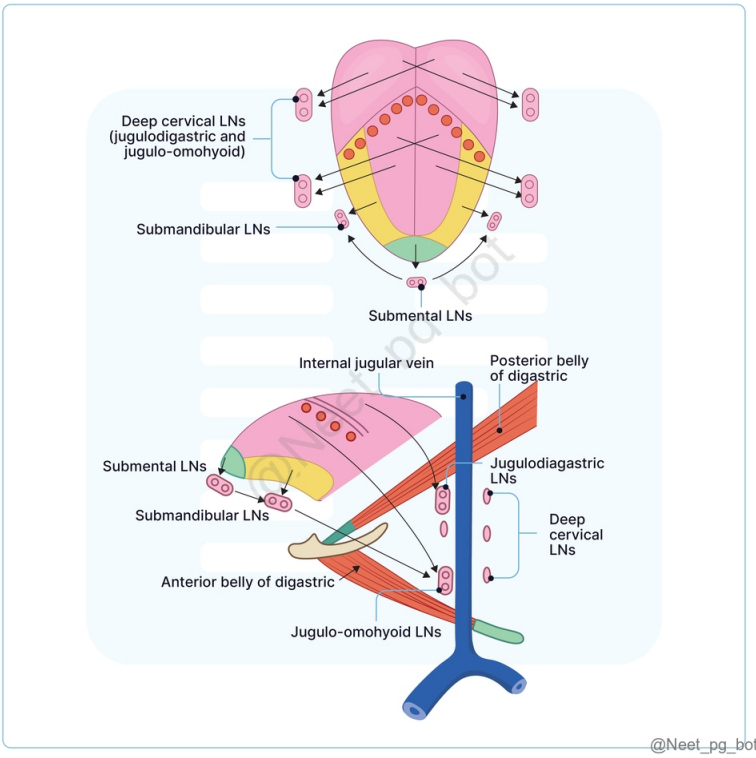

References:

Gray’s Anatomy, 41st Edition, Page 644

↑ *Back to this question in Part A*

@Neet_pg_bot

Q8: Which lymphoid tissue is not a part of Waldeyer’s ring? (Q848748)

A. Palatine tonsils

B. Nasopharyngeal tonsil (adenoid)

C. Submandibular lymph nodes

D. Lingual tonsils

Correct Answer: C. Submandibular lymph nodes

■ *Listen (English)*

■ *Listen (Hindi)*

Explanation: Submandibular lymph nodes are part of the superficial lymphatic ring, not Waldeyer’s ring. Waldeyer's Ring: Definition : Inner, deep ring of lymphatic tissue in the head and neck Composed of mucosa-associated lymphoid tissue (MALT) Location : Situated in the nasopharynx and oropharynx Guards the entrance to respiratory and digestive tracts Components : (Options A, B & D) Major Components: Palatine tonsils, Nasopharyngeal tonsil (adenoid), Lingual tonsil Less Prominent Components: Tubal tonsils, Lateral pharyngeal bands

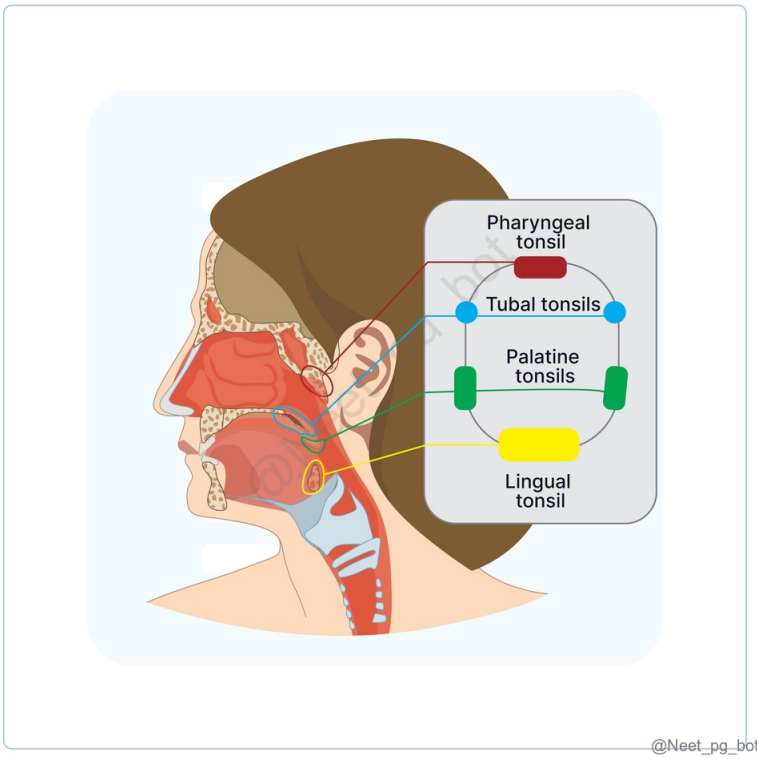

References:

Gray’s Anatomy, 41st Edition, Pages 548, 704, 707.

https://pubmed.ncbi.nlm.nih.gov/11082757/

↑ *Back to this question in Part A*

@Neet_pg_bot

Q9: A surgeon is performing a neck dissection and encounters the internal jugular vein. Which of the following structures does not directly drain into the internal jugular vein? (Q848745)

A. Facial vein

B. Lingual vein

C. Maxillary vein

D. Superior thyroid vein

Correct Answer: C. Maxillary vein

■ *Listen (English)*

■ *Listen (Hindi)*

Explanation: The internal jugular vein (IJV) receives direct tributaries from several veins of the face and neck, including: Facial vein Lingual vein Superior and middle thyroid veins However, the maxillary vein does not drain directly into the IJV. Instead, it joins the superficial temporal vein to form the retromandibular vein , which subsequently drains into the external jugular vein (and partly into the facial vein in some cases).

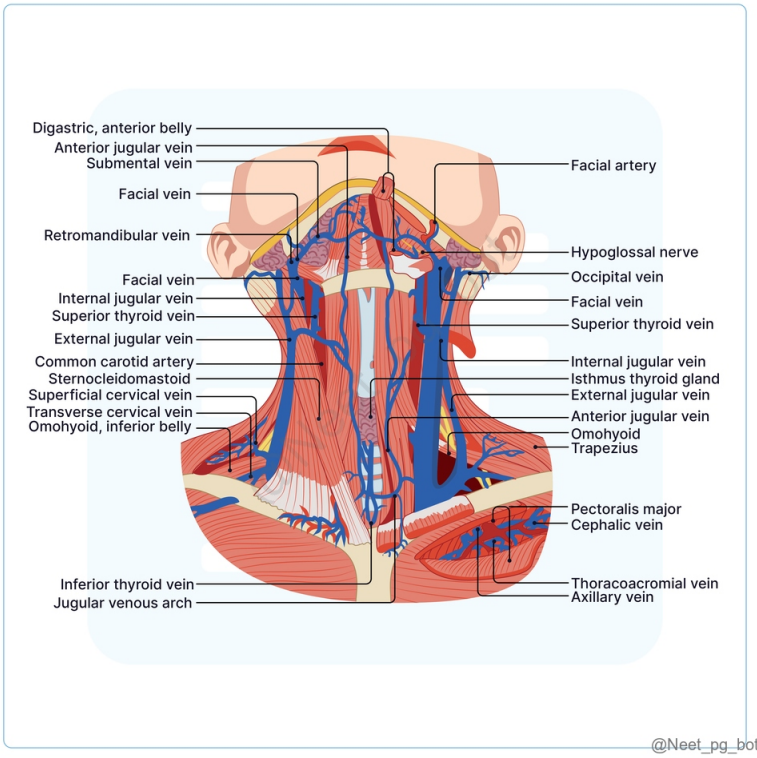

References:

Gray’s Anatomy, 41st Edition, Pages 590- 593

↑ *Back to this question in Part A*

@Neet_pg_bot

Q10: A 6-month-old infant is evaluated after a complicated delivery in which upward traction was applied to the arm. The parents report that the infant's left hand has fingers curled and cannot extend them. On examination, the left eyelid droops, and the pupil is smaller. What is the most likely diagnosis? (Q848735)

A. Erb's Palsy

B. Klumpke's Palsy

C. Radial Nerve Palsy

D. Ulnar Nerve Injury

Correct Answer: B. Klumpke's Palsy

■ *Listen (English)*

■ *Listen (Hindi)*

Explanation: Upward traction on the arm during delivery → injury to lower brachial plexus (C8–T1 roots) . Clinical features: Claw hand: Paralysis of intrinsic hand muscles → flexed fingers, inability to extend. Ptosis & miosis: Due to involvement of T1 sympathetic fibres → Horner's syndrome . Therefore, a Combination of claw hand + Horner's syndrome → Klumpke's palsy Erb's palsy (Option A) Involves C5–C6 (upper trunk) Mechanism: Downward traction on the head/neck Produces "waiter's tip" posture (arm adducted, medially rotated) Radial nerve palsy (Option C) Causes wrist drop due to loss of the extensors Sensory loss over the dorsum of hand Does not cause intrinsic hand paralysis → no true claw hand Ulnar nerve injury (Option D) Can produce clawing of 4th & 5th digits only Does notinvolve sympathetic fibers , so no ptosis or miosis Also injury mechanism is usually trauma at elbow/wrist, not birth traction.



References:

BD Chaurasia’s Human Anatomy, 8th Edition, Volume 1, Page 63

↑ *Back to this question in Part A*

@Neet_pg_bot

Q11: A 65-year-old male presents with complaints of dizziness, syncope, and numbness in his left arm during physical activity. On examination, his left radial pulse is weak, and the blood pressure in the left arm is significantly lower than in the right arm. What is the most likely pathophysiological mechanism behind this patient's symptoms? (Q848742)

A. Retrograde blood flow in the left vertebral artery due to subclavian artery stenosis

B. Reduced blood flow in the left subclavian artery due to thoracic aortic dissection

C. Retrograde blood flow in the left internal carotid artery due to basilar artery stenosis

D. Retrograde blood flow in the right vertebral artery due to subclavian artery stenosis

Correct Answer: A. Retrograde blood flow in the left vertebral artery due to subclavian artery stenosis

■ *Listen (English)*

■ *Listen (Hindi)*

Explanation: The clinical scenario described above is suggestive of subclavian steal syndrome. Obstruction to the subclavian artery proximal to the origin of the vertebral artery may lead to retrograde blood flow in the left vertebral artery. Subclavian steal Syndrome: Pathophysiology:

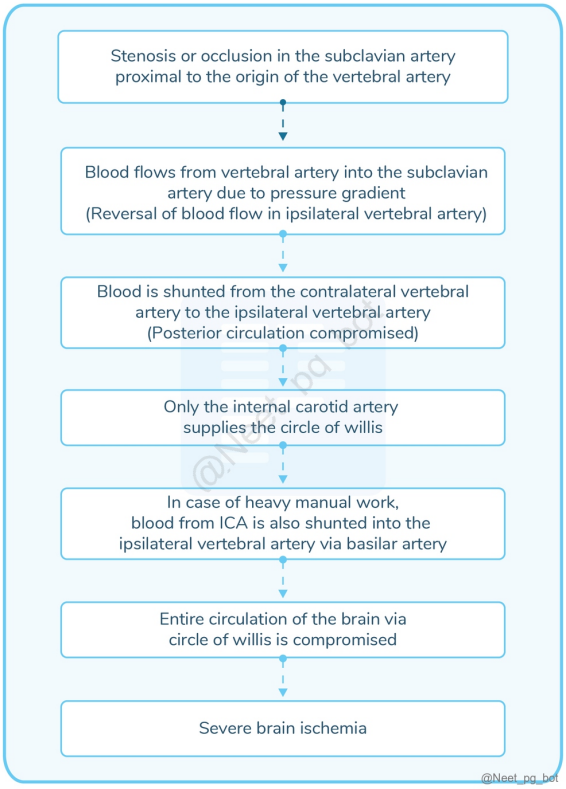

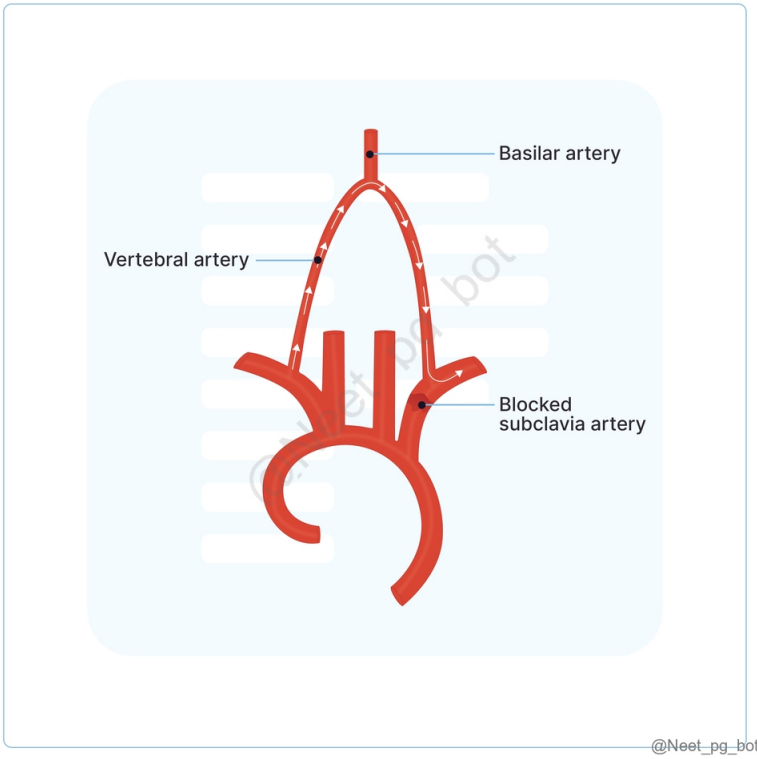

References:

BD Chaurasia's Human Anatomy, 8th Edition, Volume 3, Page 165

↑ *Back to this question in Part A*

@Neet_pg_bot

Q12: Which of the following arteries does not supply the upper part of the tonsil? (Q848741)

A. Ascending pharyngeal artery

B. Ascending palatine artery

C. Descending palatine artery

D. Greater palatine artery

Correct Answer: B. Ascending palatine artery

■ *Listen (English)*

■ *Listen (Hindi)*

Explanation: The upper part of the tonsil is supplied by the ascending pharyngeal, descending palatine, and the greater and lesser palatine arteries. Ascending palatine artery does not contribute to the blood supply of the upper part of the tonsil, instead, it predominantly supplies the lower part. Blood Supply of the Tonsil:

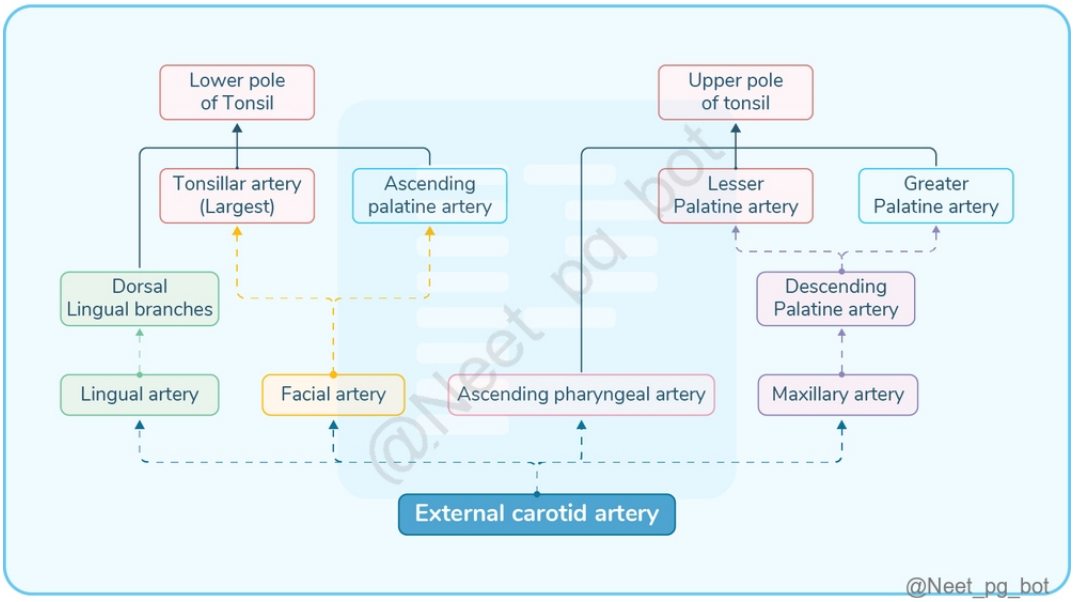

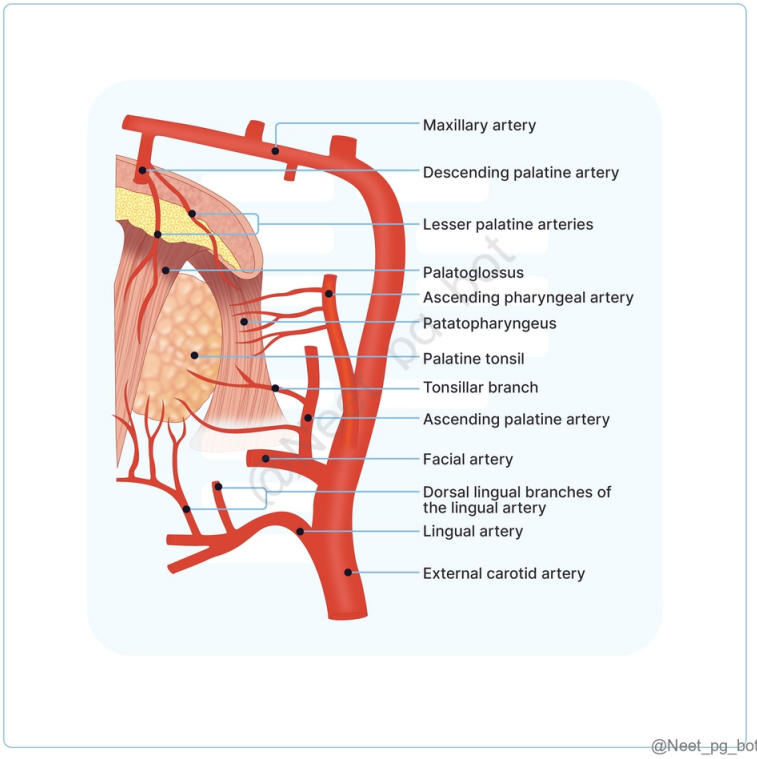

References:

Gray’s Anatomy, 41st Edition, Page 577.

↑ *Back to this question in Part A*

@Neet_pg_bot

Q13: A 12 y/o boy presents with nasal bleeding, after nose-picking. On examination, the bleeding site is located in the anterior nasal septum, and the diagnosis of epistaxis from Kiesselbach's plexus is made. Which of the following arteries is LEAST likely to contribute to the bleeding from this plexus? (Q848740)

A. Anterior ethmoid artery

B. Posterior ethmoid artery

C. Superior labial artery

D. Sphenopalatine artery

Correct Answer: B. Posterior ethmoid artery

■ *Listen (English)*

■ *Listen (Hindi)*

Explanation: Kiesselbach's plexus (Little's area) is the most common site of epistaxis due to its rich vascular supply. Arteries that contribute to this plexus include: Anterior ethmoid artery Septal branches of the superior labial artery and greater palatine artery Sphenopalatine artery The posterior ethmoid artery (Option B) supplies the posterosuperior nasal septum and does not contribute to the vascular supply of Kiesselbach’s plexus.

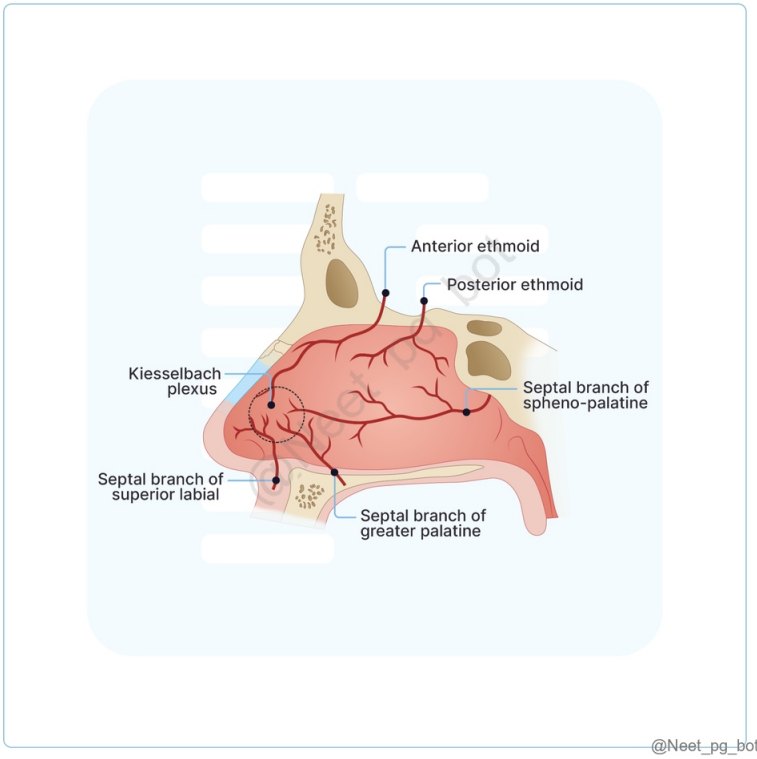

References:

Gray's Anatomy, 41st Edition, Page 563

Scott-Brown's Otorhinolaryngology Head & Neck Surgery, 8th Edition, Volume 1, Section 3, Page987

↑ *Back to this question in Part A*

@Neet_pg_bot

Q14: Which statement about the maxillary artery is false? (Q848739)

A. It arises behind the neck of the mandible.

B. The middle meningeal artery passes through the foramen ovale.

C. The posterior superior alveolar artery supplies upper molar teeth.

D. The sphenopalatine artery is the artery of epistaxis.

Correct Answer: B. The middle meningeal artery passes through the foramen ovale.

■ *Listen (English)*

■ *Listen (Hindi)*

Explanation: The middle meningeal artery transmits through the foramen spinosum, not the foramen ovale. Contents of the Foramen Ovale: (Mnemonic: MALE) Mandibular nerve (V3) Accessory meningeal artery Lesser petrosal nerve Emissary veins Maxillary Artery Definition: A larger terminal branch of the external carotid artery, arises behind the neck of the mandible (Option A) . It has 3 parts Third Part Posterior Superior Alveolar (Option C) Distribution: Upper molar and premolar teeth and gums Infraorbital Greater Palatine Distribution: Soft palate, tonsil, palatine glands, mucosa of upper gums Pharyngeal Artery of Pterygoid Canal Sphenopalatine Distribution: Lateral and medial walls of nose, various sinuses. Clinical Significance: Known as the artery of epistaxis (Option D) .

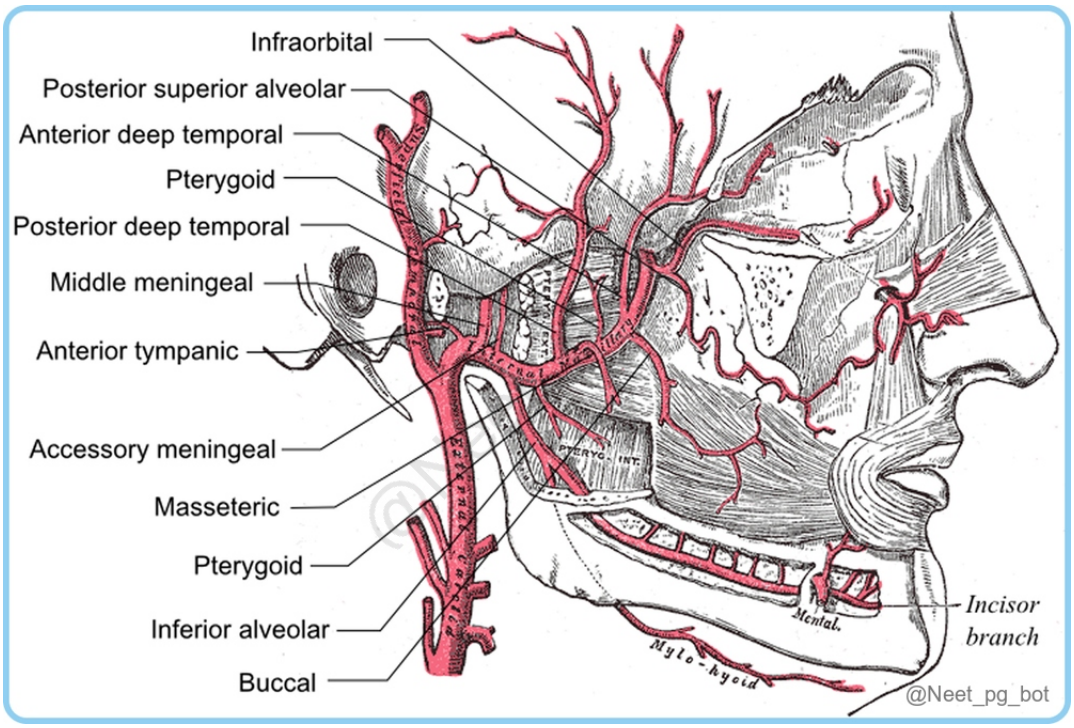

References:

BD Chaurasia's Human Anatomy, 8th Edition, Volume 4, Pages 127-128

↑ *Back to this question in Part A*

@Neet_pg_bot

Q15: Identify the marked branch of the External carotid artery? (Q848738)

A. Lingual Artery

B. Facial Artery

C. Maxillary Artery

D. Superior Thyroid Artery

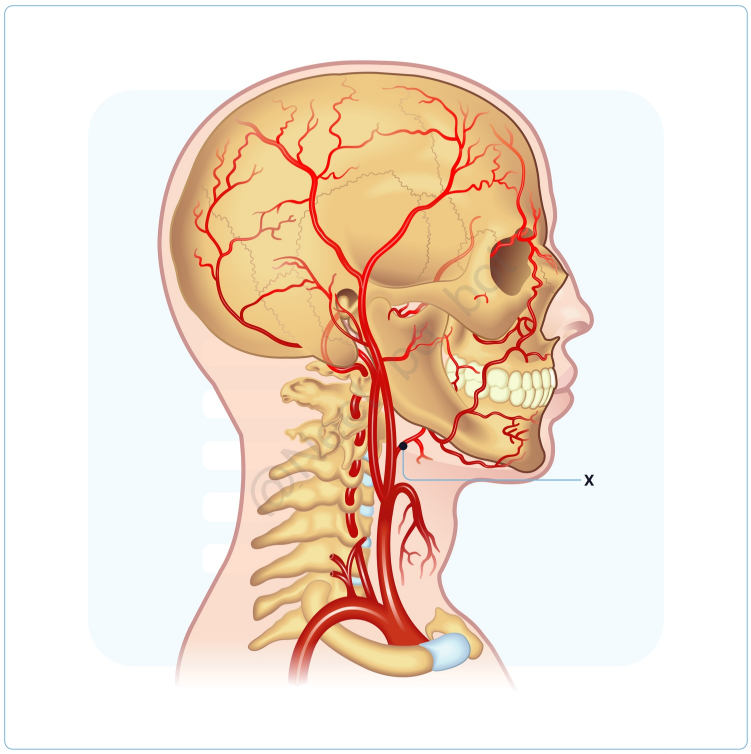

@Neet_pg_bot

Correct Answer: A. Lingual Artery

- *Listen (English)*
- *Listen (Hindi)*

Explanation: Lingual artery: A major branch of the external carotid artery. Supplies the tongue and the oral floor. Arises anteromedially from the external carotid artery. Located at the tip of the greater horn of the hyoid bone, between the superior thyroid artery and the facial artery. External Carotid Artery Group Branches Notes Anterior branches Superior thyroid artery Lingual artery Facial artery Supply thyroid, tongue, and face Posterior branches Occipital artery Posterior auricular artery Supply scalp & auricle Medial branch Ascending pharyngeal artery Smallest branch; supplies pharynx, meninges Terminal branches Maxillary artery Superficial temporal artery End branches in the parotid gland

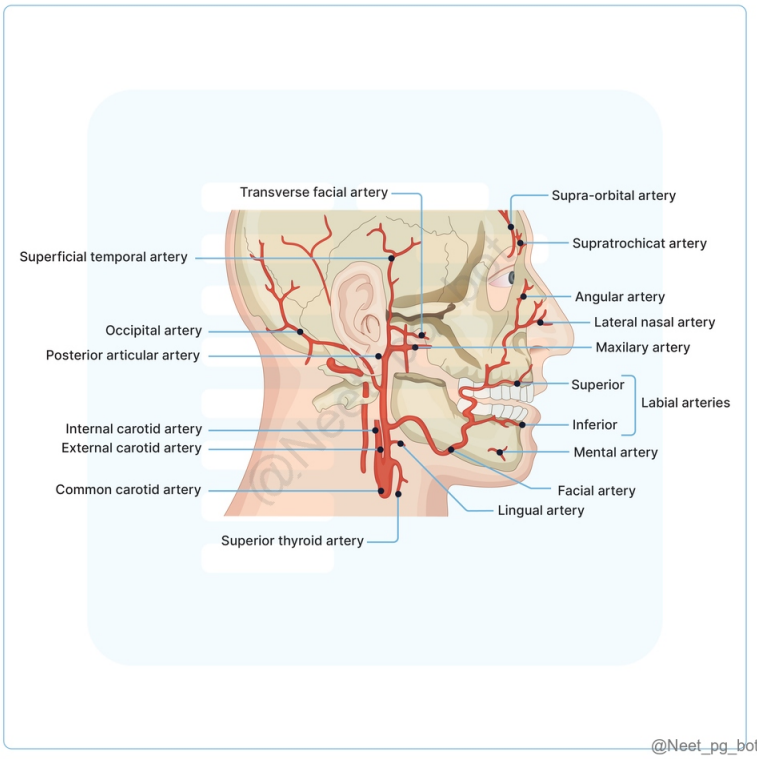

References:

BD Chaurasia's Human Anatomy, 8th Edition, Volume 4, Pages 109, 110

https://www.ncbi.nlm.nih.gov/books/NBK554513/

↑ *Back to this question in Part A*

@Neet_pg_bot

Q16: Which of the following is not the branch of the marked artery? (Q848737)

A. Thyrocervical Trunk

B. Costocervical trunk

C. Dorsal scapular artery

D. Axillary artery

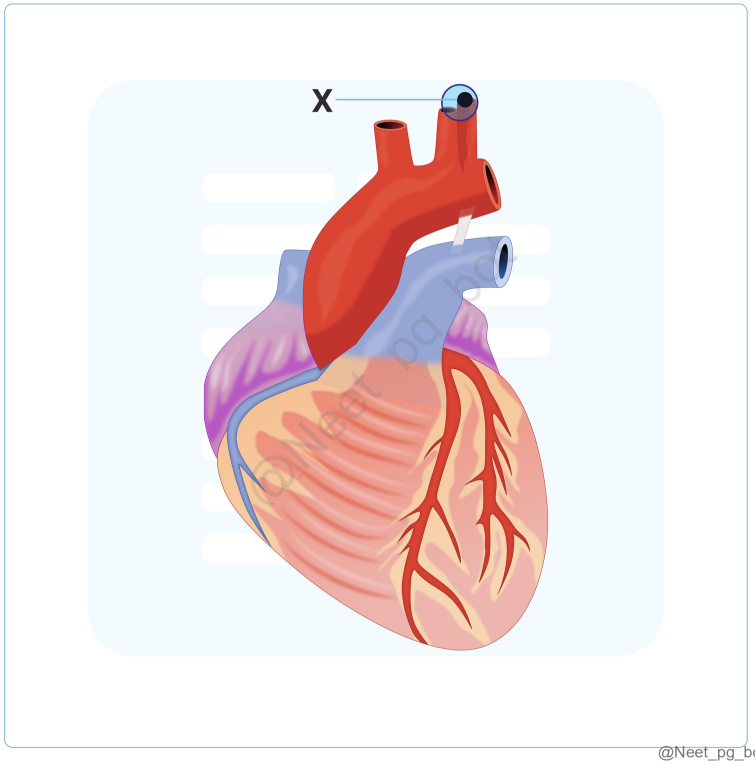

Correct Answer: D. Axillary artery

- *Listen (English)*
- *Listen (Hindi)*

Explanation: The highlighted structure in the provided image indicates the subclavian artery. The axillary artery is not a branch of the Subclavian Artery rather, it is a continuation of the subclavian artery beyond the outer border of the first rib Subclavian Artery The subclavian artery is divided into three parts by the scalenus anterior muscle , and its branches can be remembered as: 1 st Part (before scalenus anterior) 2 nd Part (behind scalenus anterior) 3 rd Part (beyond scalenus anterior) VIT mnemonic V → Vertebral artery I → Internal thoracic artery T → Thyrocervical trunk Costocervical trunk Dorsal scapular artery (may arise directly or from the transverse cervical artery) Embryological Origin of the Subclavian Artery Right Subclavian Right 4 th aortic arch (proximal part) Right dorsal aorta Right 7 th intersegmental artery (distal part) Left Subclavian Left 7 th intersegmental artery

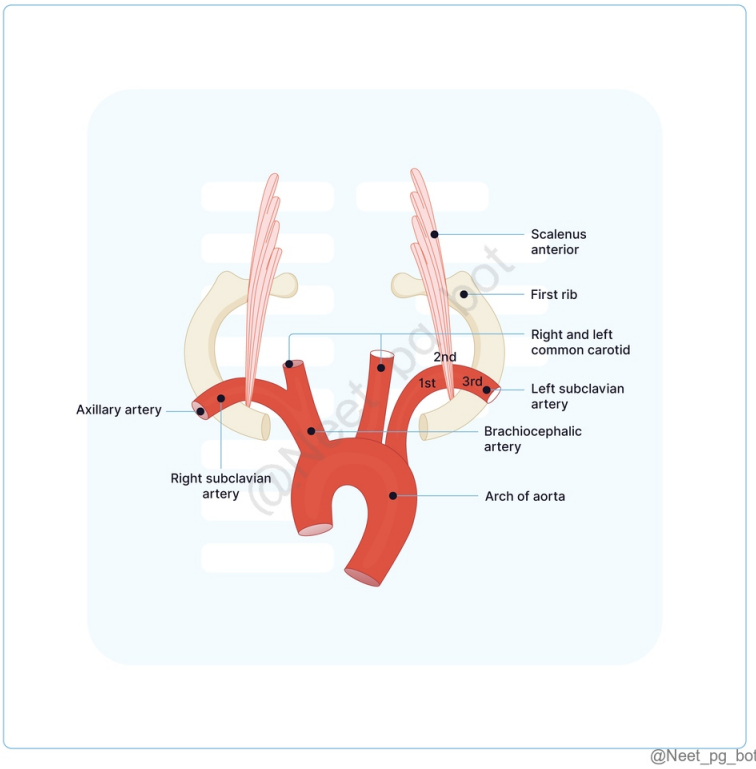

@Neet_pg_bot

References:

BD Chaurasia's Human Anatomy, 8th Edition, Volume 4, Pages 162-165

↑ *Back to this question in Part A*

@Neet_pg_bot

Q17: Which of the following statements about the scalenus anterior muscle is incorrect? (Q848736)

A. The phrenic nerve lies anteriorly to the muscle.

B. The thoracic duct arches laterally on the right side.

C. The brachial plexus is posterior to the muscle.

D. The lateral part of the carotid sheath contains the internal jugular vein.

Correct Answer: B. The thoracic duct arches laterally on the right side.

■ *Listen (English)*

■ *Listen (Hindi)*

Explanation: The thoracic duct typically arches laterally on the left side at the level of the seventh cervical transverse process. Phrenic nerve lies anterior to the muscle (Option A) – Correct The phrenic nerve arises from C3, C4, C5 and descends on the anterior surface of the scalenus anterior muscle in the neck. Thoracic duct arches laterally on the right side(Option B) – Incorrect The thoracic duct arches laterally on the left side , behind the carotid sheath, before draining into the left venous angle (junction of left internal jugular and subclavian veins). On the right side , the right lymphatic duct drains, not the thoracic duct. Brachial plexus is posterior to the muscle (Option C)– Correct The brachial plexus emerges between the scalenus anterior and scalenus medius muscles , hence it lies posterior to scalenus anterior . Lateral part of carotid sheath contains internal jugular vein (Option D)– Correct Within the carotid sheath : Medially → Common carotid artery Laterally → Internal jugular vein Posteriorly and superficially → Vagus nerve

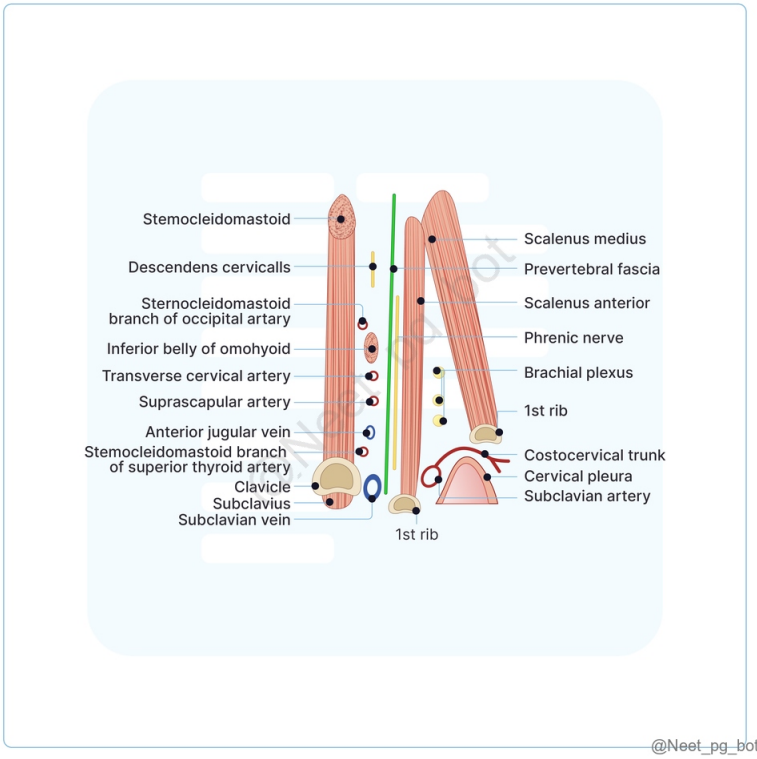

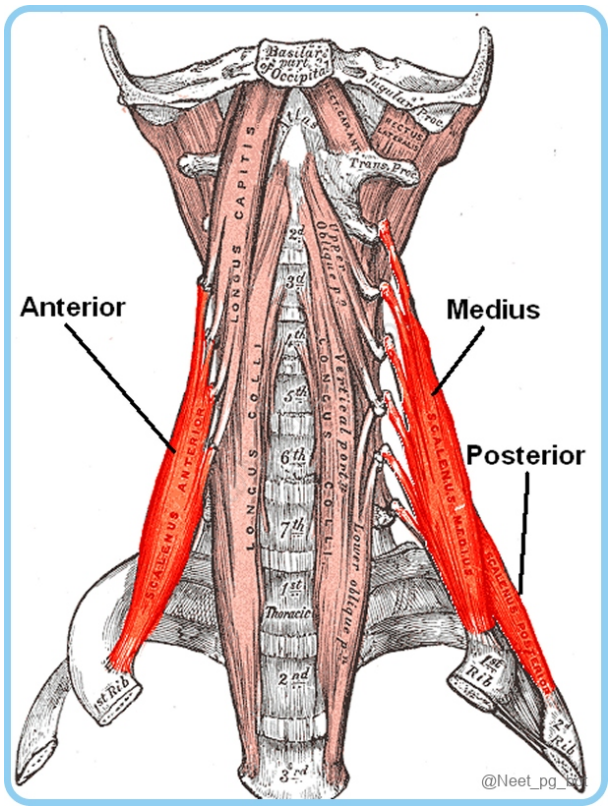

References:

BD Chaurasia's Human Anatomy, 8th Edition, Volume 4, Page 188-190.

↑ *Back to this question in Part A*

@Neet_pg_bot

• [04_Head and Neck] 019 Scalp Neck Triangles And Parotid Gland

« Back to Folder Directory

[04_Head and Neck] 019 Scalp Neck Triangles And Parotid Gland — Quick Jump

Q1 (p. 1195) *Q2 (p. 1197)* *Q3 (p. 1198)* *Q4 (p. 1199)* *Q5 (p. 1202)* *Q6 (p. 1205)*
Q7 (p. 1206) *Q8 (p. 1210)* *Q9 (p. 1211)* *Q10 (p. 1213)* *Q11 (p. 1215)* *Q12 (p. 1216)*
Q13 (p. 1217) *Q14 (p. 1219)* *Q15 (p. 1221)*

Q1: Which of the following structures is enclosed by the prevertebral fascia in the neck? (Q848761)

A. Trapezius muscle

B. Internal carotid artery

C. Cervical sympathetic trunk

D. Thyroid gland

Correct Answer: C. Cervical sympathetic trunk

■ *Listen (English)*

■ *Listen (Hindi)*

Explanation: Cervical sympathetic trunk is enclosed by the prevertebral fascia, which surrounds the vertebral column and associated structures. Prevertebral fascia/Lamina prevertebralis: Coronal extension from the internal aspect of the deep cervical fascia that runs anterior to the prevertebral muscles is called the Preethi layer of deep cervical fascia. Trapezius muscle (Option A): Enclosed by the investing layer of the deep cervical fascia, not the prevertebral fascia. Internal carotid artery (Option B): Contained within the carotid sheath, not the prevertebral fascia. Thyroid gland (Option D): Enclosed by the pretracheal fascia, not the prevertebral fascia.

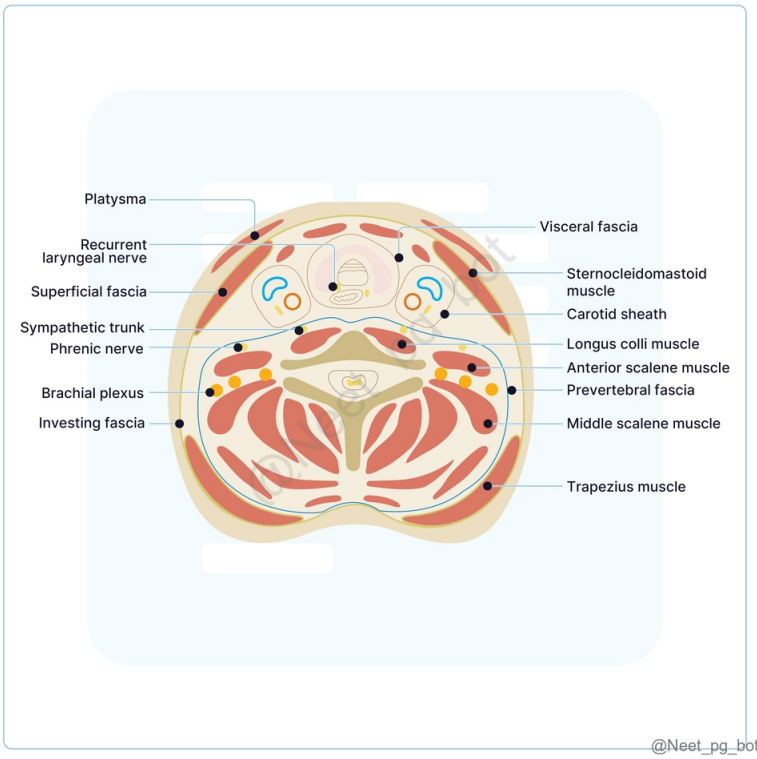

@Neet_pg_bot

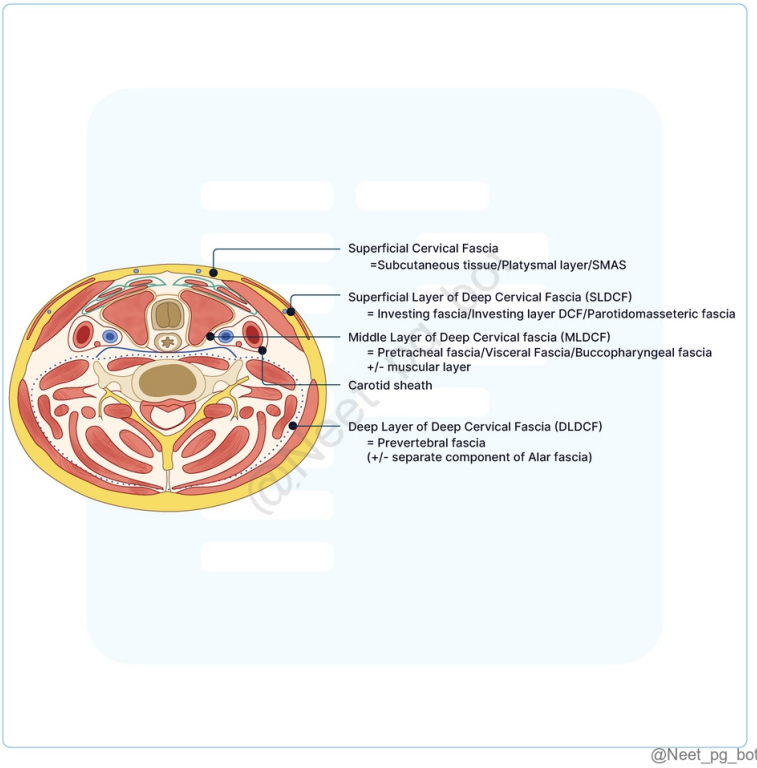

@Neet_pg_bot

References:

Inderbir Singh's Textbook of Anatomy, 6th Edition, Volume 3, Page 123.

↑ *Back to this question in Part A*

@Neet_pg_bot

Q2: Which of these form the scalp proper? (Q848752)

A. Skin of the scalp

B. Skin and superficial fascia of the scalp

C. Skin, superficial fascia, and deep fascia of the scalp

D. Skin, superficial fascia, deep fascia, and loose areolar tissue of the scalp

Correct Answer: C. Skin, superficial fascia, and deep fascia of the scalp

■ *Listen (English)*

■ *Listen (Hindi)*

Explanation: The first three layers of the scalp - surgical layers of the scalp = scalp proper The scalp is made up of five layers: Skin: Hairy and has numerous sweat glands and sebaceous glands Superficial fascia (Connective tissue): Provides a medium for vessels and nerves to pass to the skin Deep fascia in the form of the epicranial aponeurosis or galea aponeurotica with the occipitofrontalis muscle Loose areolar tissue: Provides passage for emissary veins connecting extracranial veins to intracranial venous sinuses Pericranium

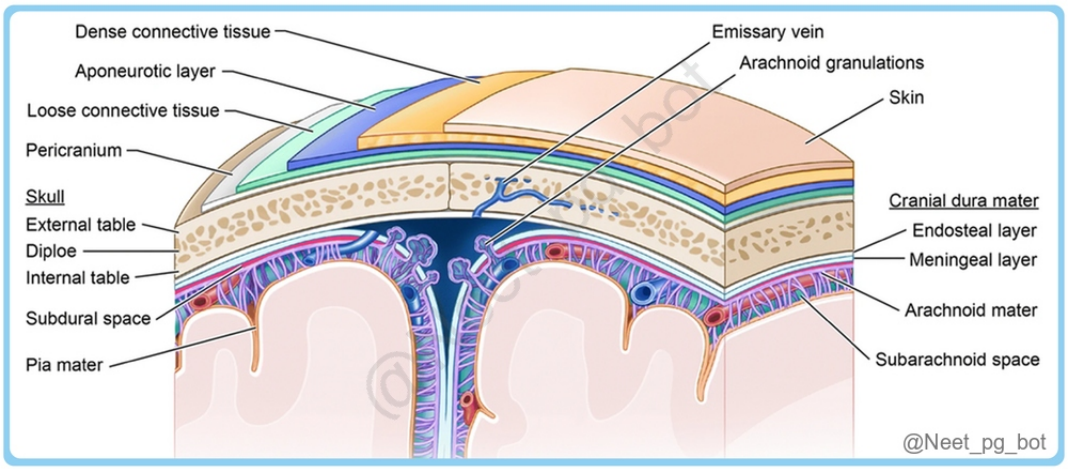

References:

BD Chaurasia’s Human Anatomy, 8th Edition, Volume 3, Page 63-64.

↑ *Back to this question in Part A*

@Neet_pg_bot

Q3: All of the following are the contents of the occipital triangle of the neck except? (Q848753)

A. Transverse cervical artery

B. Occipital artery

C. Spinal accessory nerve

D. External jugular vein

Correct Answer: D. External jugular vein

■ *Listen (English)*

■ *Listen (Hindi)*

Explanation: The external jugular vein is a part of the subclavian triangle , not the occipital triangle. The posterior triangle is a space on the side of the neck behind the sternocleidomastoid muscle. Boundaries Anterior: Posterior border of sternocleidomastoid Posterior: Anterior border of trapezius Base: Middle one-third of clavicle Division (by the inferior belly of omohyoid) Occipital part -larger upper part Supraclavicular part or Subclavian part-smaller lower part

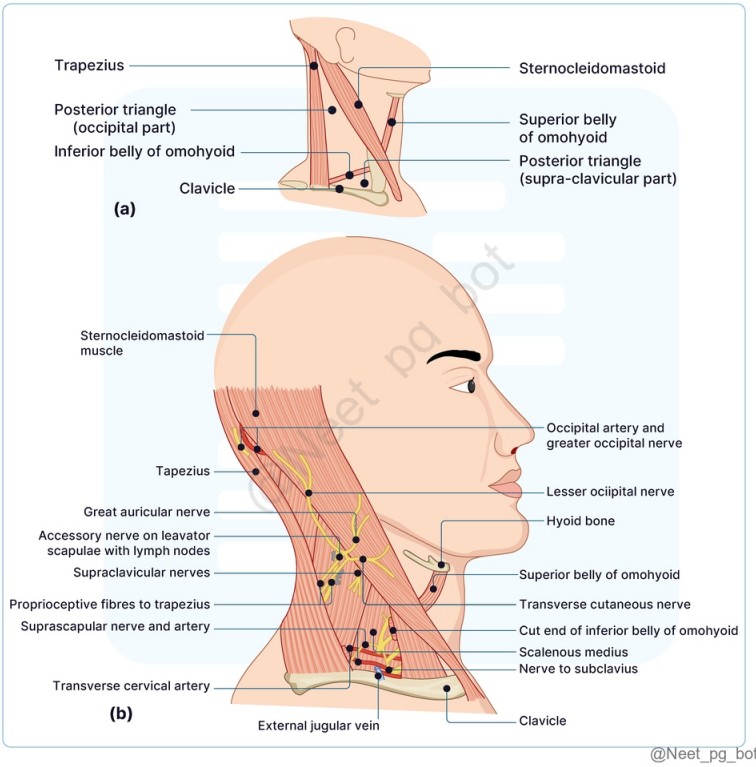

References:

BD Chaurasia’s Human Anatomy, 8th Edition, Volume 3, Pages 93-95.

↑ *Back to this question in Part A*

@Neet_pg_bot

Q4: Choose the appropriate set of correct statement(s) regarding the triangle shown in the image below (red-shaded region) 1) bounded posteroinferiorly by posterior belly of digastric 2) Floor of the triangle is formed by hyoglossus anteriorly 3) Submental artery runs through anterior part of triangle 4) Carotid artery runs through posterior part of triangle (Q848754)

A. only 1

B. only 2

C. 1,3,4

D. 2,3,4

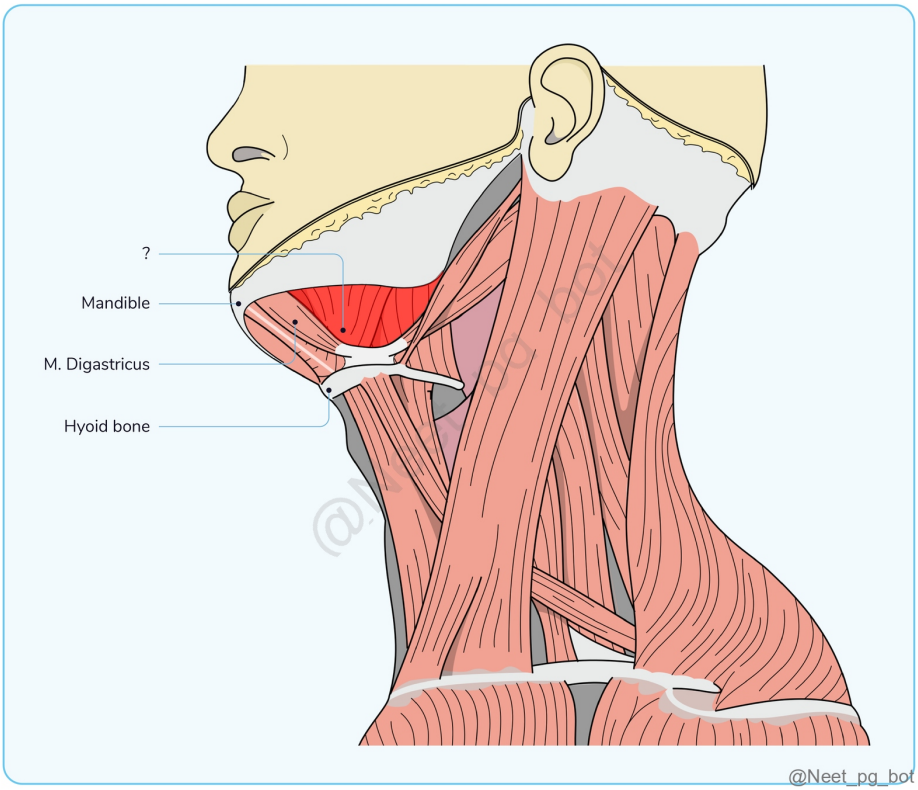

Correct Answer: C. 1,3,4

■ *Listen (English)*

■ *Listen (Hindi)*

Explanation: The yellow shaded region is the submandibular/digastric triangle Floor of the triangle is formed by mylohyoid anteriorly and hyoglossus posteriorly; other statements are correct. Digastric triangle: Description: Also known as submandibular triangle Enclosed between two bellies of digastric muscle Attachments: Anteroinferiorly Anterior belly of the digastric muscle Posteroinferiorly Posterior belly of the digastric muscle (Statement 1) and stylohyoid muscle Base Base of the mandible, with an imaginary line from the mandible angle to the mastoid process Apex Intermediate tendon of the digastric muscle Floor: Anteriorly Mylohyoid (Statement 2) Posteriorly Hyoglossus Roof: Investing layer of deep cervical fascia: Encloses submandibular lymph nodes Superficial fascia: Platysma, cervical branch of facial nerve, ascending branch of transverse cervical nerve Contents: Anterior part Submandibular salivary gland Submandibular lymph nodes Hypoglossal nerve Facial vein (superficial to gland) Facial artery (deep to gland) Submental artery (Statement 3) Mylohyoid nerve and vessels Posterior part External carotid artery (Statement 4) Carotid sheath and contents: Internal carotid artery, internal jugular vein, vagus nerve Structures passing between the external and internal carotid arteries: Styloglossus, stylopharyngeus, glossopharyngeal nerve , styloid process

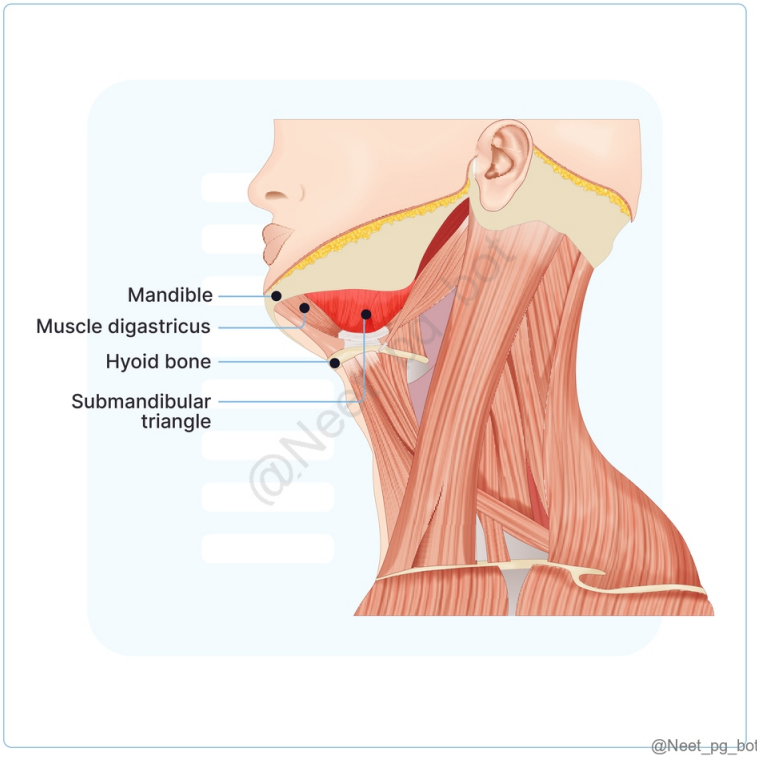

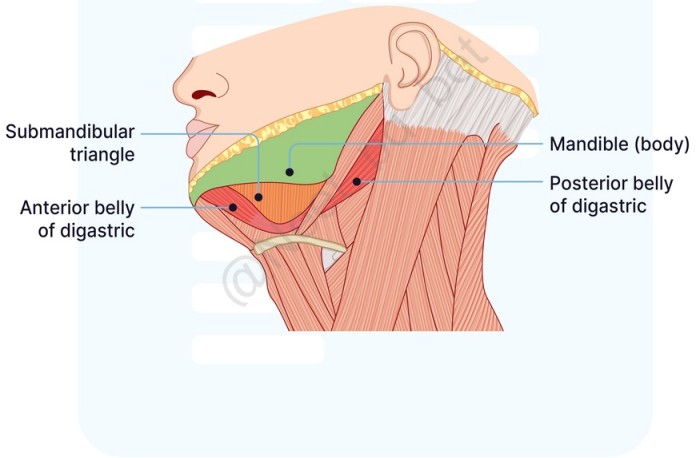

@Neet_pg_bot

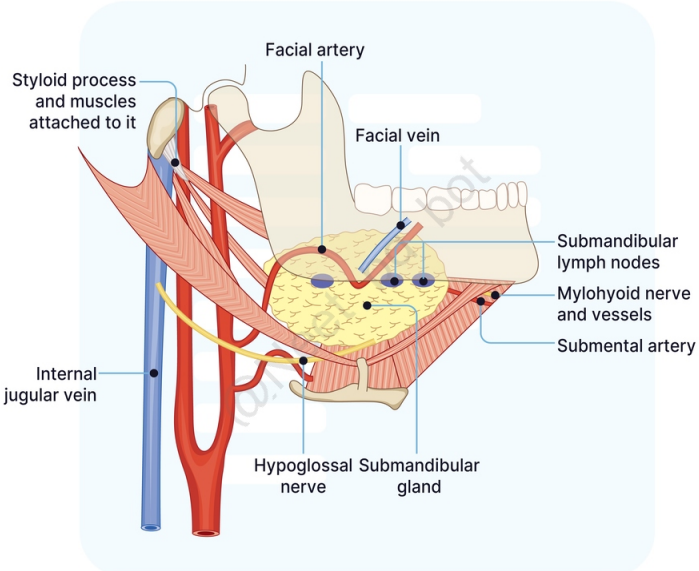

@Neet_pg_bot

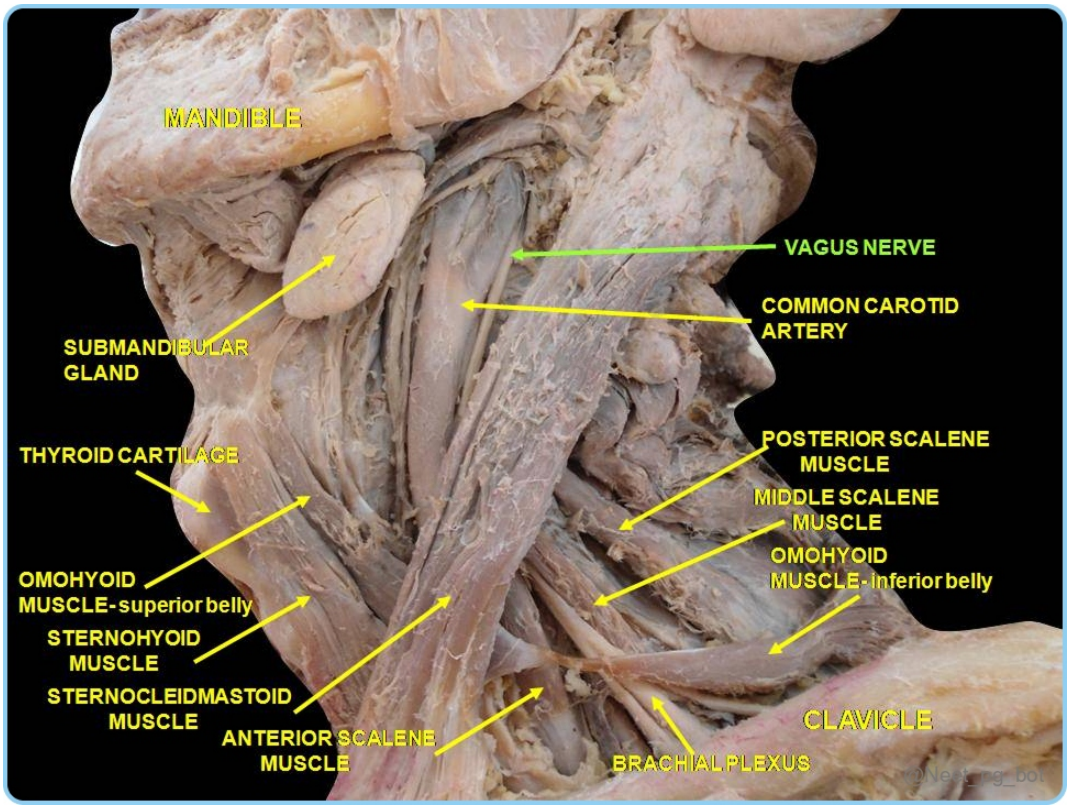

References:

BD Chaurasia's Human Anatomy, 8th Edition, Volume 3, Page 103-105.

↑ *Back to this question in Part A*

@Neet_pg_bot

Q5: You notice the following examination being done in ED, all of the following are boundaries of the space containing the palpated structure except (Q848755)

A. Anterior belly of digastric

B. Stylohyoid

C. Superior belly of omohyoid

D. Anterior border of sternocleidomastoid



Correct Answer: A. Anterior belly of digastric

- *Listen (English)*
- *Listen (Hindi)*

Explanation: Carotid artery pulsation is being palpated here, which is present in the carotid triangle . Carotid triangle: Boundaries Anterosuperior: Posterior belly of digastric (vs Option A) ; Stylohyoid (Option B) Anteroinferior : Superior belly of omohyoid (Option C) Posterior: Anterior border of sternocleidomastoid (Option D)

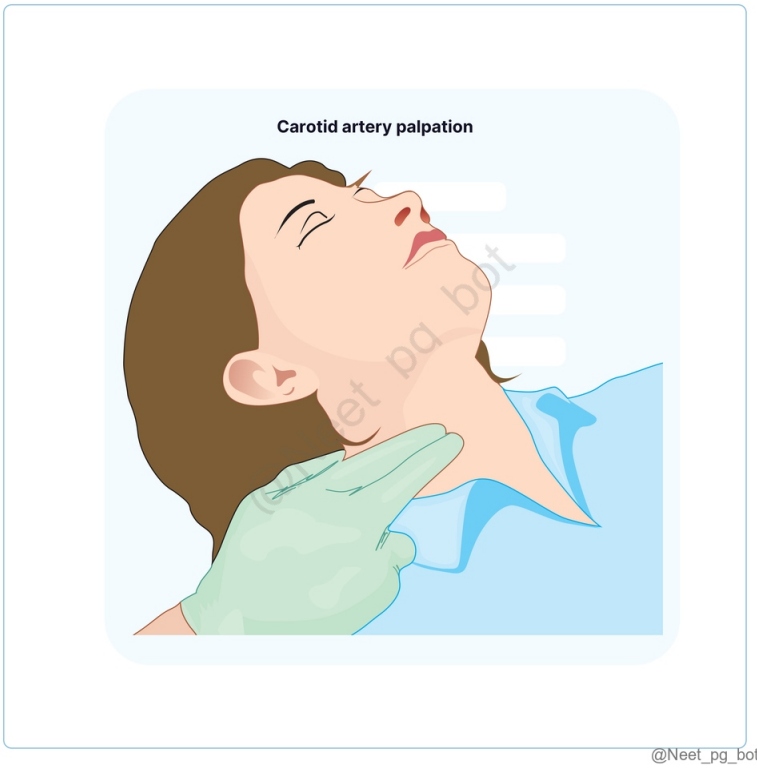

@Neet_pg_bot

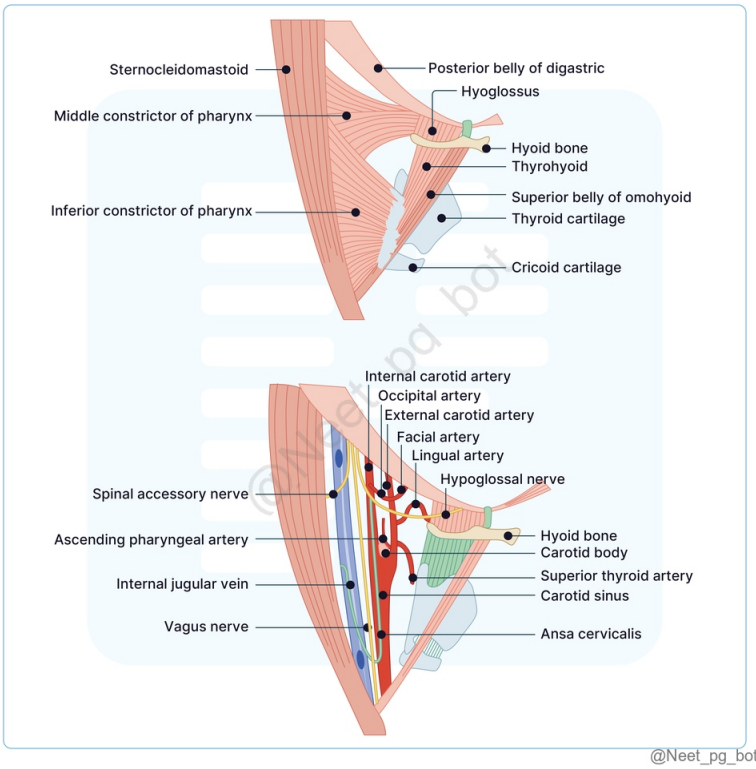

@Neet_pg_bot

References:

BD Chaurasia’s Human Anatomy, 8th Edition, Volume 3, Page 105-107.

↑ *Back to this question in Part A*

@Neet_pg_bot

Q6: During thyroid surgery, the surgeon retracts the muscles forming the floor of the muscular triangle of neck to access the thyroid gland. Which of the following muscles does he not retract? (Q848756)

A. Sternothyroid

B. Sternohyoid

C. Geniohyoid

D. Thyrohyoid

Correct Answer: C. Geniohyoid

■ *Listen (English)*

■ *Listen (Hindi)*

Explanation: Geniohyoid does not contribute to the floor of the muscular triangle of the neck. Muscular triangle: Location In the anterior region of the neck Boundaries Anterior: Midline of the neck (from hyoid bone to suprasternal notch) Anterosuperior: Superior belly of the omohyoid muscle Posteroinferior: Anterior border of the sternocleidomastoid muscle Floor Sternothyroid, sternohyoid, and thyrohyoid muscles Roof Investing layer: Deep cervical fascia Superficial fascia: Contains the anterior jugular vein and lymph nodes Contents Infrahyoid muscles: Sternohyoid & Omohyoid (superficial) and Sternothyroid & Thyrohyoid (deep) (Option C) Deeper structures: Thyroid gland, trachea, and esophagus

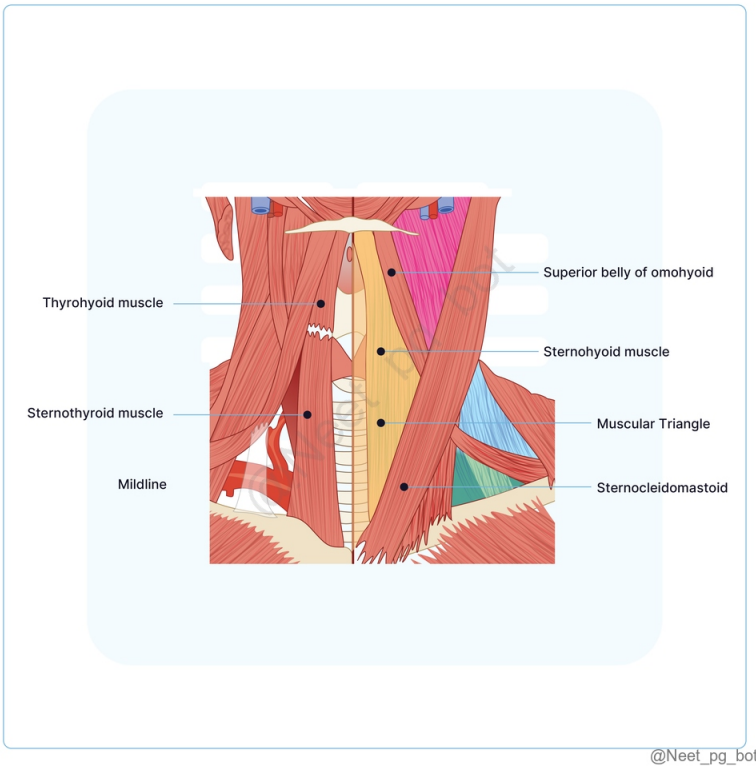

@Neet_pg_bot

References:

BD Chaurasia's Human Anatomy, 8th Edition, Volume 3, Page 107

↑ *Back to this question in Part A*

@Neet_pg_bot

Q7: Image below shows a method of brachial plexus block. Identify the correct set of approaches and the corresponding space in the neck. (Q848757)

A. Interscalene approach - muscular triangle

B. Interscalene approach - posterior triangle

C. Supraclavicular approach - muscular triangle

D. Supraclavicular approach - posterior triangle

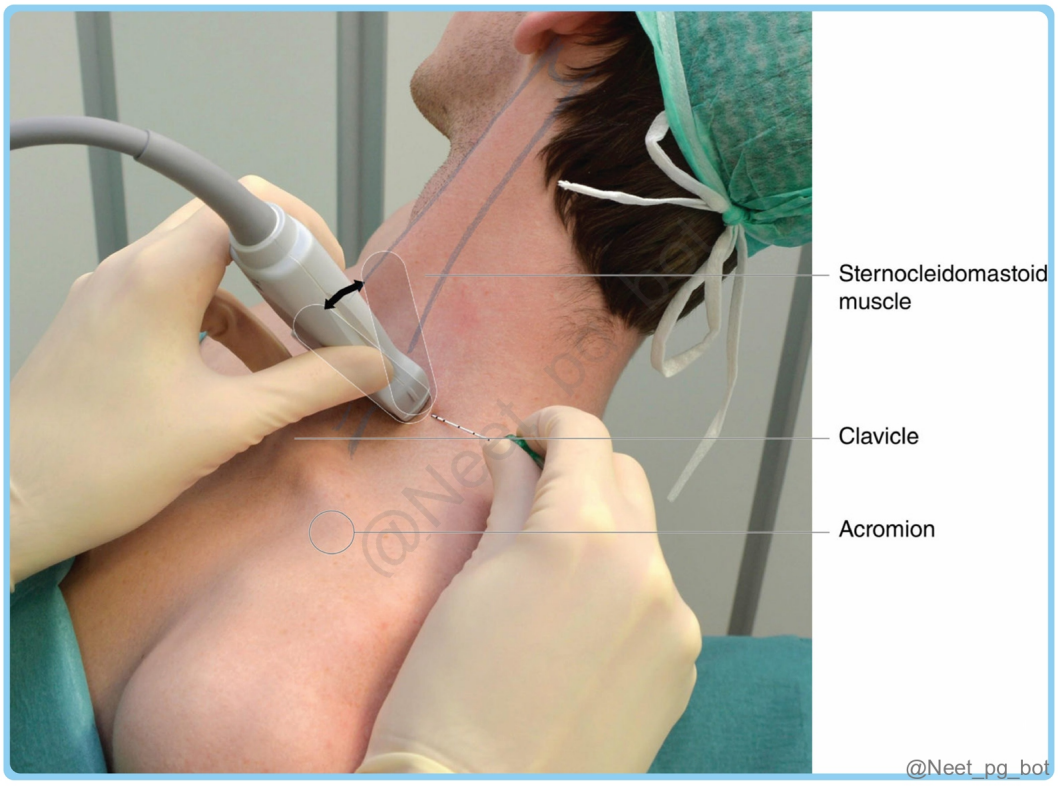

Correct Answer: B. Interscalene approach - posterior triangle

- *Listen (English)*
- *Listen (Hindi)*

Explanation: Procedure shown is the interscalene approach for brachial plexus block which is done via the space present between scalene muscles, known as Scalenus triangle or Subclavian triangle , which is a part of the posterior triangle of neck . Blocks in posterior triangle: Brachial plexus block: Approaches Interscalene approach: Difficult to perform Landmark: Transverse process of C6 vertebra Relatively less safe Indication Emergency and elective surgery of the upper extremity

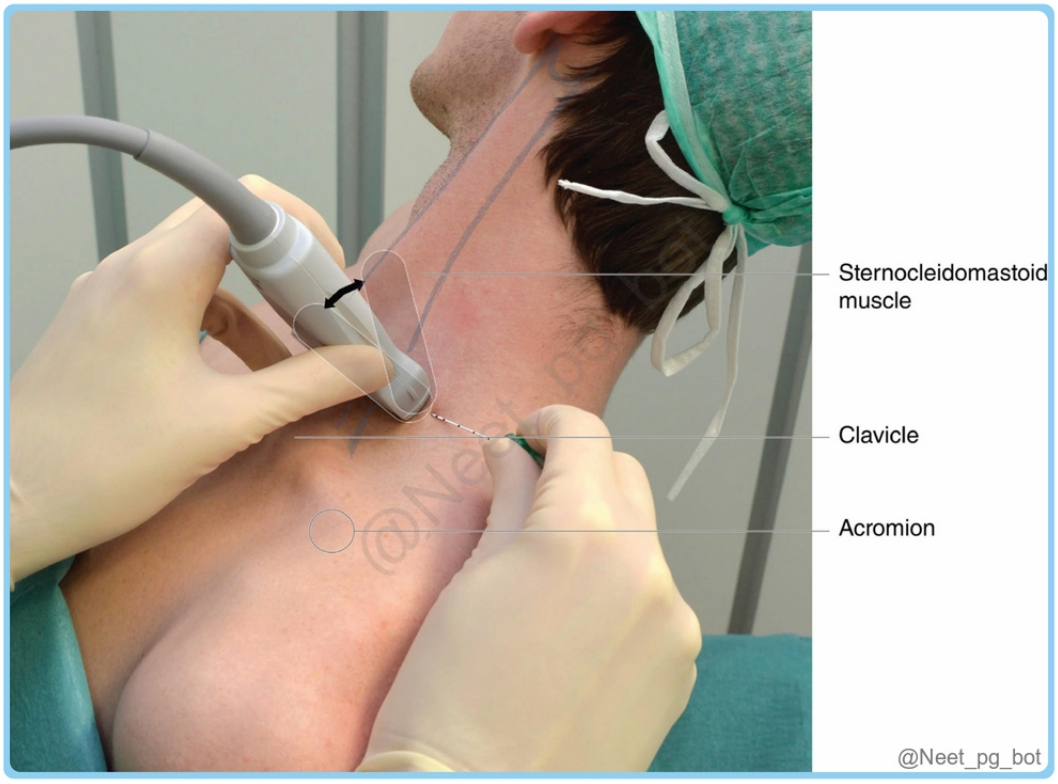

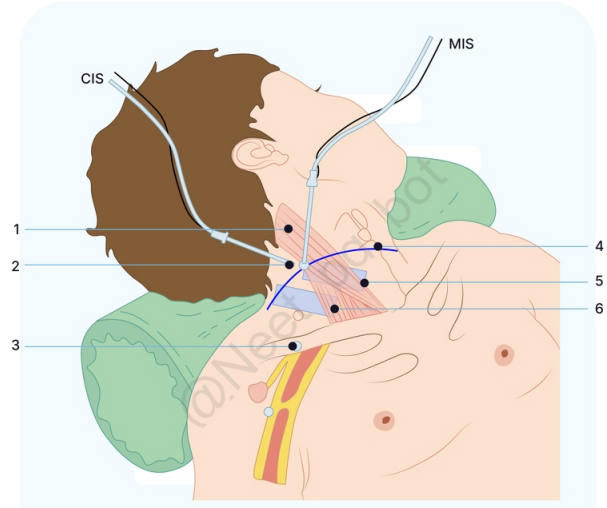

Interscalene approach to the brachial plexus
1.sternocleidomastoid muscle; 2.Skin projection of the Chassaignac tubercle; 3.midpoint of the clavicle ; 4.cricoid cartilage 5.probe positioning (Classic approach); 6.probe positioning (Borgeat approach); CIS- Classic interscalene approach, MIS- Modified interscalene approach

@Neet_pg_bot

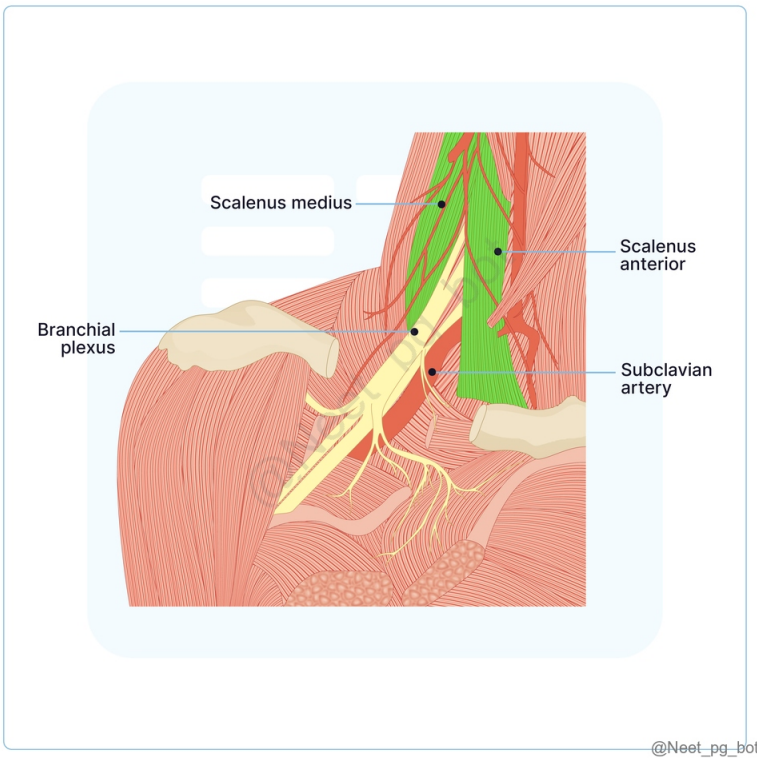

@Neet_pg_bot

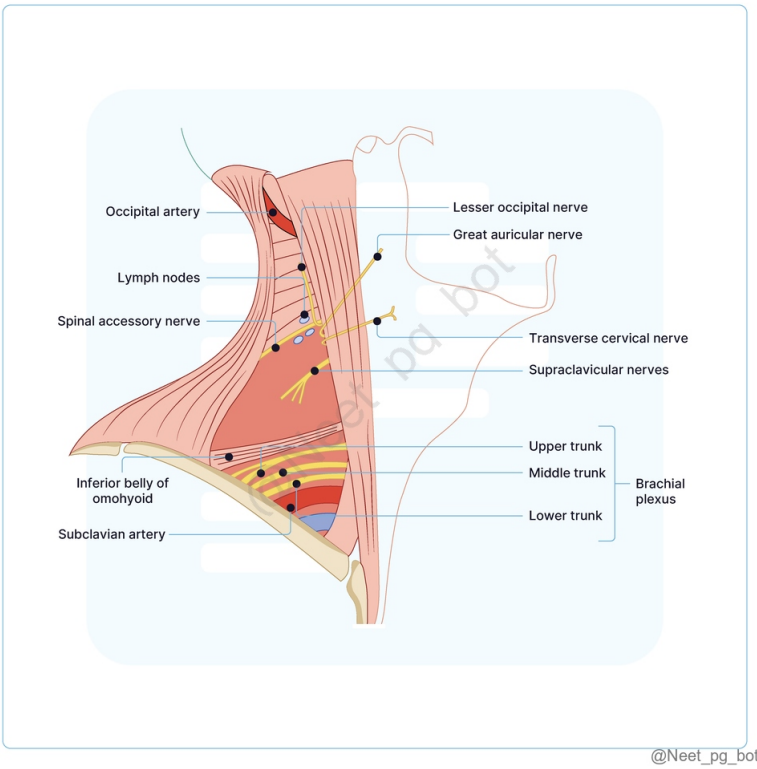

@Neet_pg_bot

References:

1. Miller’s Anesthesia, 9th Edition, Page 2392-2396, 2414. 2. BD Chaurasia’s Human Anatomy, 8th Edition, Volume 3, Page 94-97. 3. Vishram Singh’s Textbook of Anatomy, 2nd Edition, Volume 3, Page 84.

↑ *Back to this question in Part A*

@Neet_pg_bot

Q8: You notice the following procedure being done in OT. Choose the appropriate set of incorrect statement(s) regarding the same. 1) Congenital long QT syndrome is an indication in children 2) Can be done to manage Hyperhidrosis and Raynaud’s phenomenon 3) Local anaesthetic is injected superior to longus colli muscle 4) Relatively unsafe procedure 5) Contralateral Horner syndrome is verification for correct placement of block (Q848758)

A. 1,5

B. only 5

C. 2,3

D. 3,5

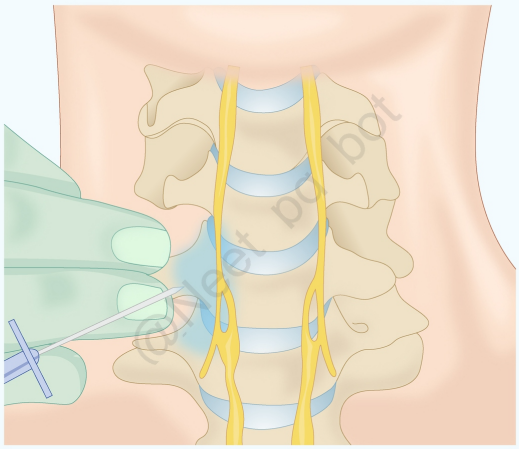

@Neet_pg_bot

Correct Answer: B. only 5

■ *Listen (English)*

■ *Listen (Hindi)*

Explanation: Procedure shown in the image is stellate ganglion block . Ipsilateral horner syndrome is a verification for correct placement of block (not contralateral) (Statement 5) . Other statements are correct. Stellate ganglion block is considered an unsafe procedure due to its high risk of injuries to surrounding structures. (Statement 4) Stellate ganglion block: Indications Children: Congenital long QT syndrome , pain syndromes (eg. herpes zoster ophthalmicus) (Statement 1) Adults: Hyperhidrosis, Raynaud's phenomenon (Statement 2) Procedure Local anesthetic is injected superior to longus colli muscle . (Statement 3) Cervicothoracic (stellate) sympathetic block is identified via USG-guided probe and block given. Verification Ipsilateral Horner syndrome is seen after correct placement of block (vs Statement 5) Complications Injury to vital vascular structures in proximity (carotid artery, internal jugular vein) Neural puncture (recurrent laryngeal nerve, vagus nerve) Injury to thyroid gland/esophagus/trachea Pneumothorax

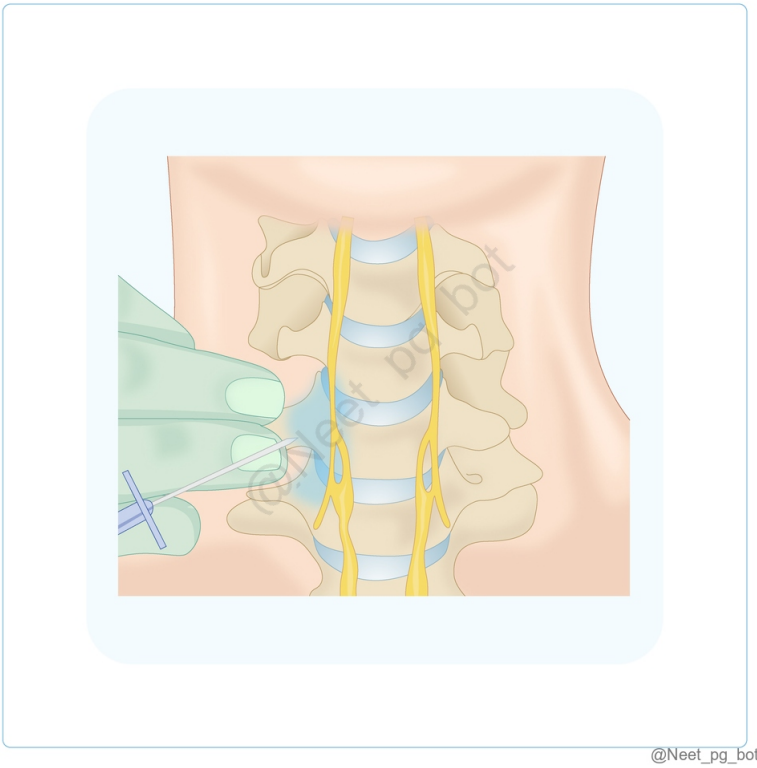

References:

Miller's Anesthesia, 9th Edition, Page 2416

https://www.ncbi.nlm.nih.gov/books/NBK507798/

↑ *Back to this question in Part A*

@Neet_pg_bot

Q9: Patient presented with a painful swelling as shown below. Senior doctor says the pain is due to the underlying fascia. All of the following structures are enclosed by the layer forming this fascia except (Q848759)

A. Levator scapulae

B. Trapezius

C. Submandibular gland

D. External jugular vein



Correct Answer: A. Levator scapulae

■ *Listen (English)*

■ *Listen (Hindi)*

Explanation: The given clinical scenario is suggestive of parotid gland swelling. Pain is due to the underlying parotid fascia formed by the investing layer of deep cervical fascia. Levator scapulae is not enclosed by the investing layer. Parotid fascia: Investing layer splits into two. Superficial layer: Thick and dense, attached to zygomatic arch Deep layer: Thin and attached to styloid process Investing layer of deep cervical fascia: Enclosed Structures Muscles: Trapezius (Option B) , Sternocleidomastoid Salivary glands: Parotid , Submandibular gland (Option C) Spaces: Suprasternal space of Burns: Sternal heads of bilateral sternocleidomastoid; Jugular venous arch; Interclavicular ligament Supraclavicular space: External jugular vein (Option D) ; Supraclavicular nerves

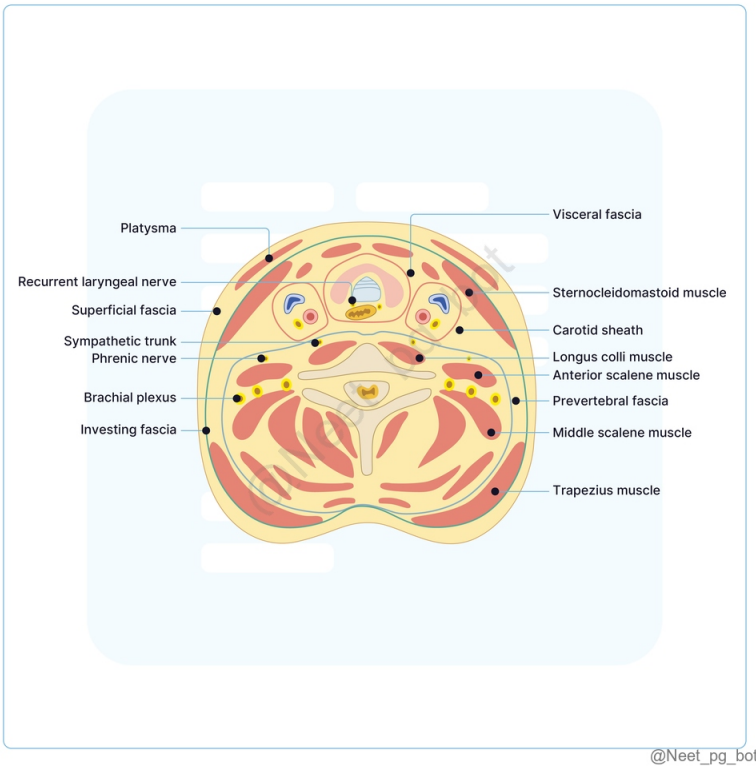

@Neet_pg_bot

References:

BD Chaurasia's Human Anatomy, 8th Edition, Volume 3, Page 86-88.

↑ *Back to this question in Part A*

@Neet_pg_bot

Q10: Which of the following is NOT a function of the pretracheal fascia? (Q848760)

A. Enclosing the thyroid gland

B. Enclosing the trachea and esophagus

C. Surrounding the carotid sheath

D. Limiting the spread of infection in the anterior neck

Correct Answer: C. Surrounding the carotid sheath

■ *Listen (English)*

■ *Listen (Hindi)*

Explanation: Pretracheal fascia does not surround the carotid sheath. Pretracheal fascia/Middle cervical fascia/Porter’s fascia: Thin layer of deep fascia limited to anterior part of the neck and is a coronal extension from internal surface of the investing layer, that encloses the thyroid gland and stretches in front of trachea. It can be divided into two layers: Muscular Layer: Encloses the infrahyoid muscles (strap muscles) such as the sternohyoid, sternothyroid, and omohyoid. Visceral Layer: Encloses the thyroid gland, trachea and esophagus. Attachments: Superiorly : Attached to the hyoid bone. Inferiorly : Extends to the upper thorax and blends with the fibrous pericardium. Laterally : Blends with the carotid sheath, though it does not enclose the structures within the sheath. Functions : Support : Provides structural support for the thyroid gland, trachea, and esophagus. (Option A & B) Infection Control : Helps limit the spread of infections within the neck, particularly in the anterior compartment. (Option D) Facilitates Movement: Allows for movement of the thyroid gland and trachea during swallowing and breathing.

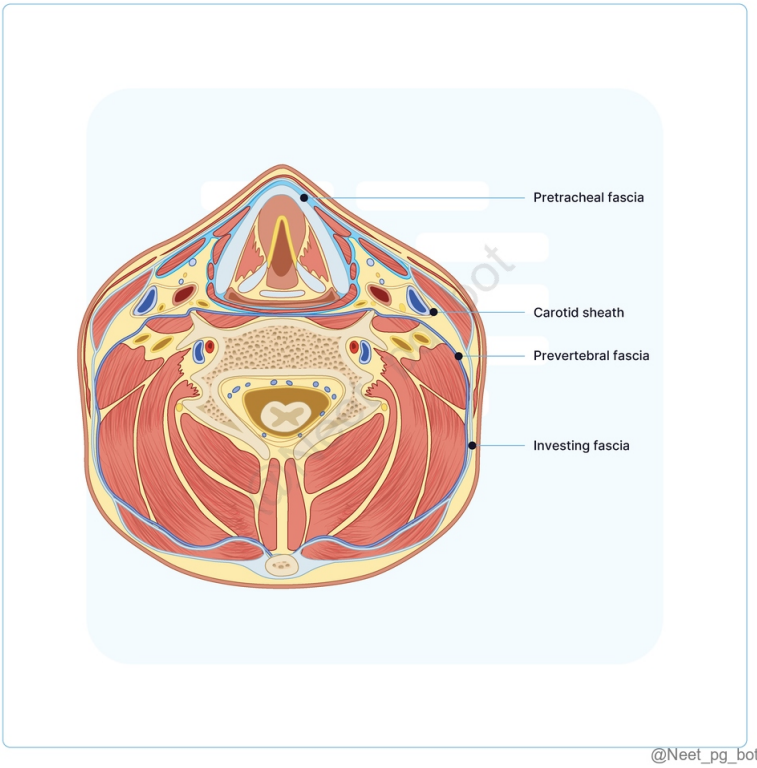

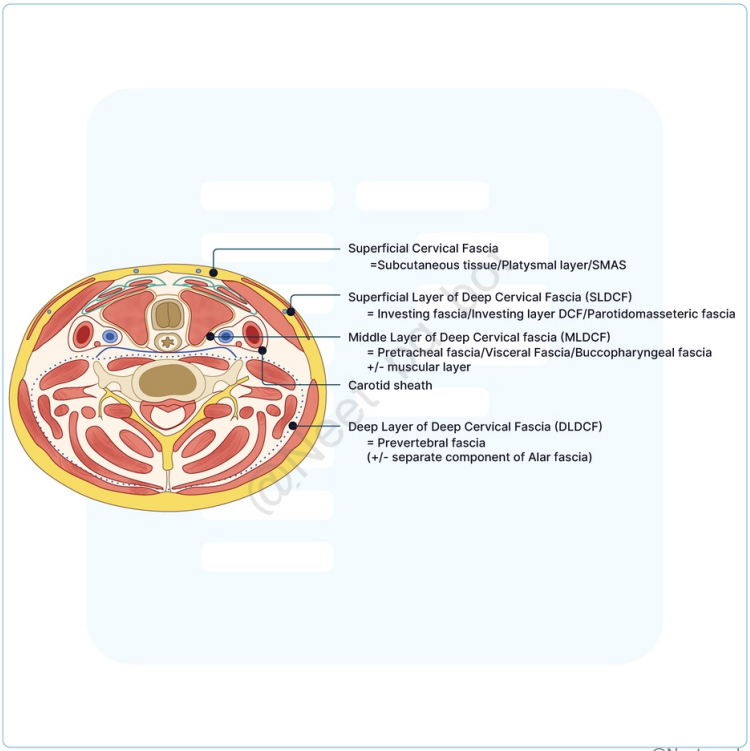

@Neet_pg_bot

References:

Inderbir Singh's Textbook of Anatomy, 6th Edition, Volume 3, Page 122, 123, 239.

↑ *Back to this question in Part A*

@Neet_pg_bot

Q11: A 45-year-old man presents to the emergency department with severe neck pain, difficulty swallowing, and fever. A CT scan reveals a deep neck infection that has spread into the mediastinum. Which anatomical space is most likely involved in this patient's condition? (Q848762)

A. Parapharyngeal space

B. Carotid space

C. Danger Space

D. Prevertebral space

Correct Answer: C. Danger Space

■ *Listen (English)*

■ *Listen (Hindi)*

Explanation: Danger space extends from the base of the skull down to the posterior mediastinum. It is present between the alar and prevertebral fascia. Infections in this space can easily spread to the mediastinum, leading to mediastinitis (compresses the trachea and esophagus, causing dyspnea and dysphagia). Parapharyngeal space (Option A): While this space is adjacent to the pharynx and can be a site of infection, it does not communicate directly with the mediastinum. Carotid space (Option B): This space contains the carotid artery, internal jugular vein, and vagus nerve but is not typically involved in spreading infections to the mediastinum. Prevertebral space (Option D): Infections here can affect the vertebrae or muscles but are less likely to spread to the mediastinum compared to the retropharyngeal space.

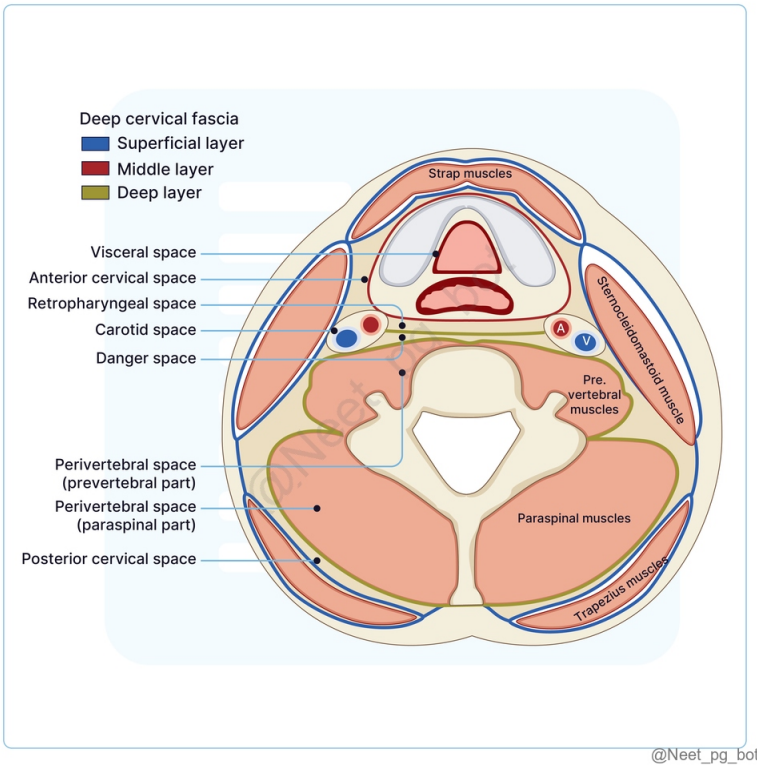

References:

Inderbir Singh's Textbook of Anatomy, 6th Edition, Volume 3, Page 122, 123.

↑ *Back to this question in Part A*

@Neet_pg_bot

Q12: Which of the following structures is not the content of carotid sheath? (Q848763)

A. Common carotid artery

B. Internal jugular vein

C. Vagus nerve

D. External jugular vein

Correct Answer: D. External jugular vein

■ *Listen (English)*

■ *Listen (Hindi)*

Explanation: Carotid Sheath: Condensation of the connective tissue around the great vessels of the neck, forming a tubular sheet of fascia. Contents Common carotid artery Internal carotid artery Internal jugular vein Vagus nerve. Anatomical Details The carotid sheath extends from the upper border of the thyroid cartilage down to the bifurcation of the carotid arteries. The internal jugular vein is lateral to the carotid artery; the vagus nerve is located between and posterior to the vessels. Anteriorly The carotid sheath is covered by the pretracheal fascia. Posteriorly The carotid sheath is bordered by the prevertebral fascia.

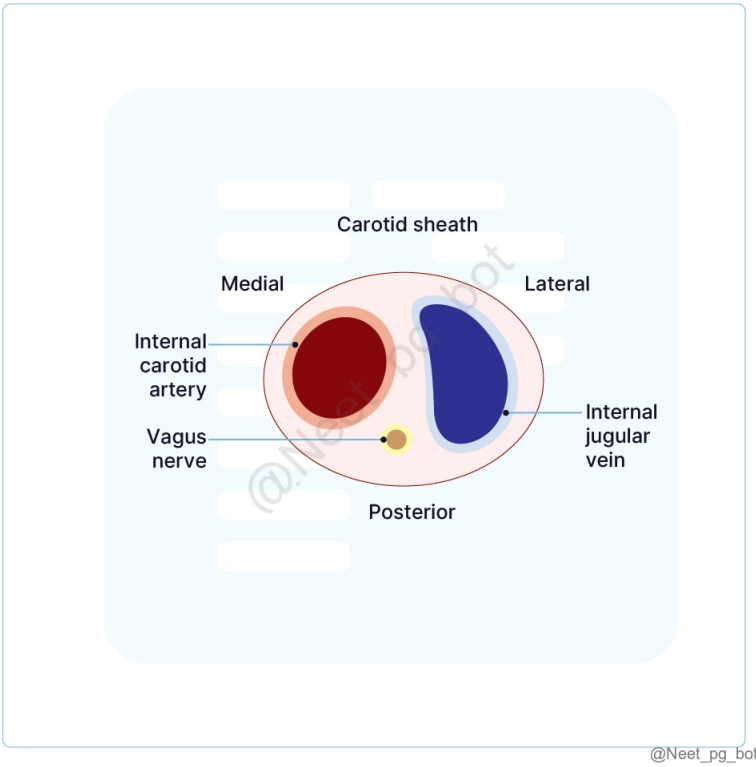

References:

Inderbir Singh's Textbook of Anatomy, 6th Edition, Volume 3, Page 123.

↑ *Back to this question in Part A*

@Neet_pg_bot

Q13: Which of the following statements about parotid gland is true? (Q848764)

A. The parotid duct passes through the masseter muscle

B. The parotid gland is innervated by the facial nerve (CN VII)

C. The parotid gland is located anterior to the sternocleidomastoid muscle

D. The parotid gland primarily secretes mucous saliva

Correct Answer: A. The parotid duct passes through the masseter muscle

■ *Listen (English)*

■ *Listen (Hindi)*

Explanation: Parotid gland : Largest salivary gland is located on each side of the face anterior to the ears and is made up of two lobes, a superficial lobe, and a deep lobe. Located in the retromandibular fossa. The superficial lobe lies lateral to the facial nerve and overlies the lateral surface of the masseter muscle. The deep lobe lies medial to the facial nerve and is situated between the mastoid process of the temporal bone and the mandibular ramus. A fascial capsule called the parotid sheath surrounds the parotid gland. The duct of the parotid gland, also termed the Stensen duct , runs over the masseter muscle and exits into the oral cavity at the level of the upper second molar. The parotid gland is supplied by the external carotid artery and its branches and drained by the external jugular vein.

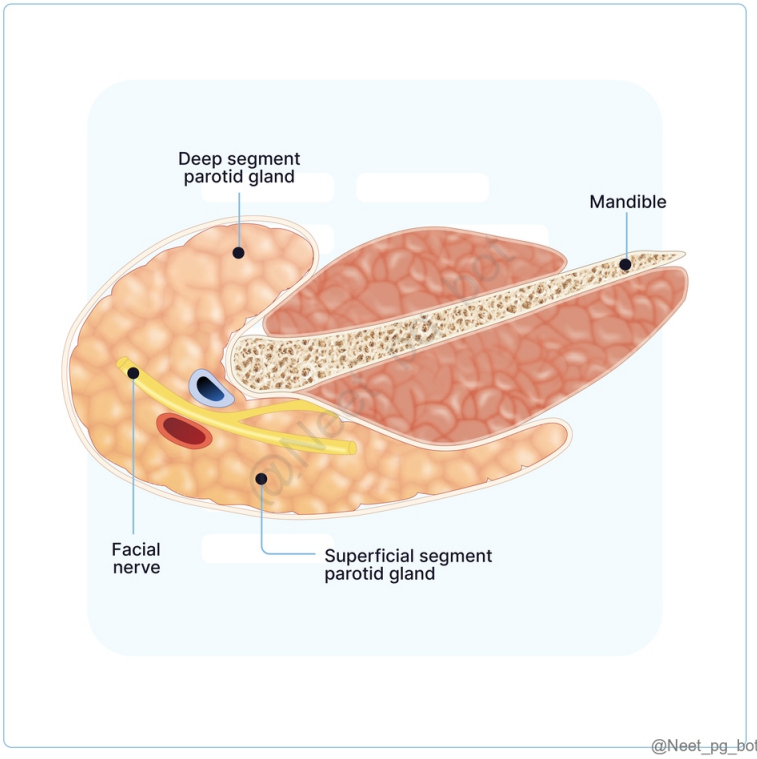

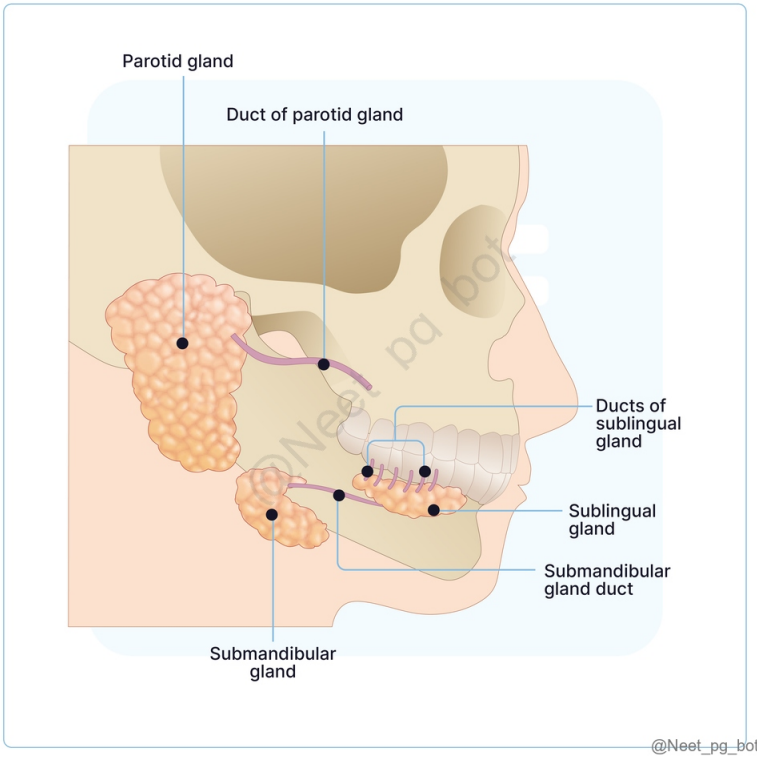

References:

https://www.ncbi.nlm.nih.gov/books/NBK542251/

https://www.ncbi.nlm.nih.gov/books/NBK534225/

↑ *Back to this question in Part A*

@Neet_pg_bot

Q14: A 60-year-old man is scheduled for a parotidectomy due to a tumor in the parotid gland. The surgeon reviews the anatomical relationships to avoid damage to surrounding structures. Which of the following structures is located superiorly to the parotid gland? (Q848765)

A. Styloglossus

B. Masseter muscle

C. Zygomatic arch

D. External carotid artery

Correct Answer: C. Zygomatic arch

■ *Listen (English)*

■ *Listen (Hindi)*

Explanation: Zygomatic arch is located superiorly to the parotid gland. Relations to parotid gland Anteriorly Masseter muscle Buccal fat pad Posteriorly External ear Mastoid process Sternocleidomastoid muscle Medially Styloid process and associated muscles (styloglossus, stylohyoid, digastric) Carotid artery and internal jugular vein Cranial nerves IX (glossopharyngeal), X (vagus), and XI (accessory) Mandibles ramus Laterally Skin and superficial fascia Inferiorly Angle of the mandible Submandibular gland Superiorly Zygomatic arch

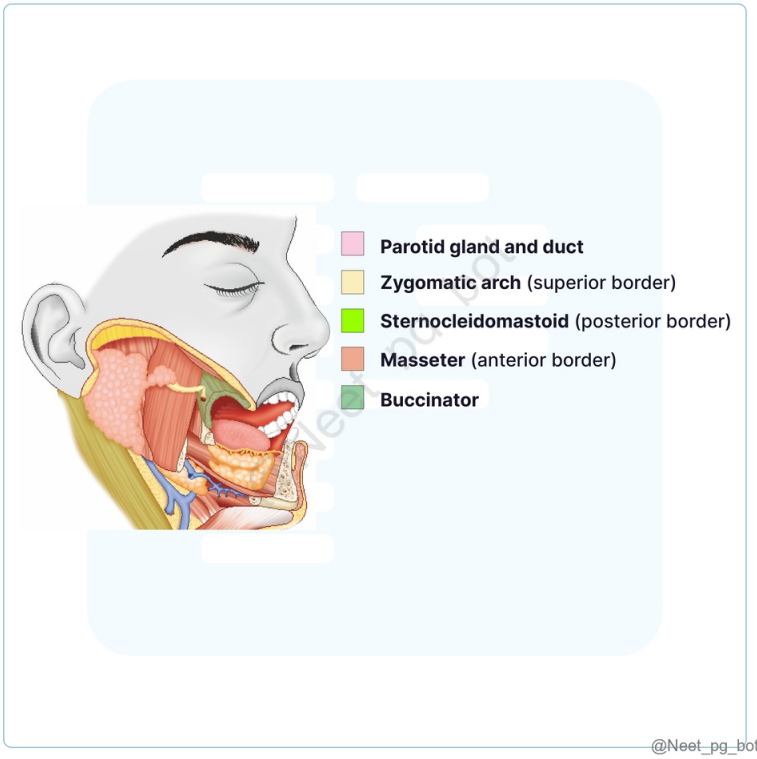

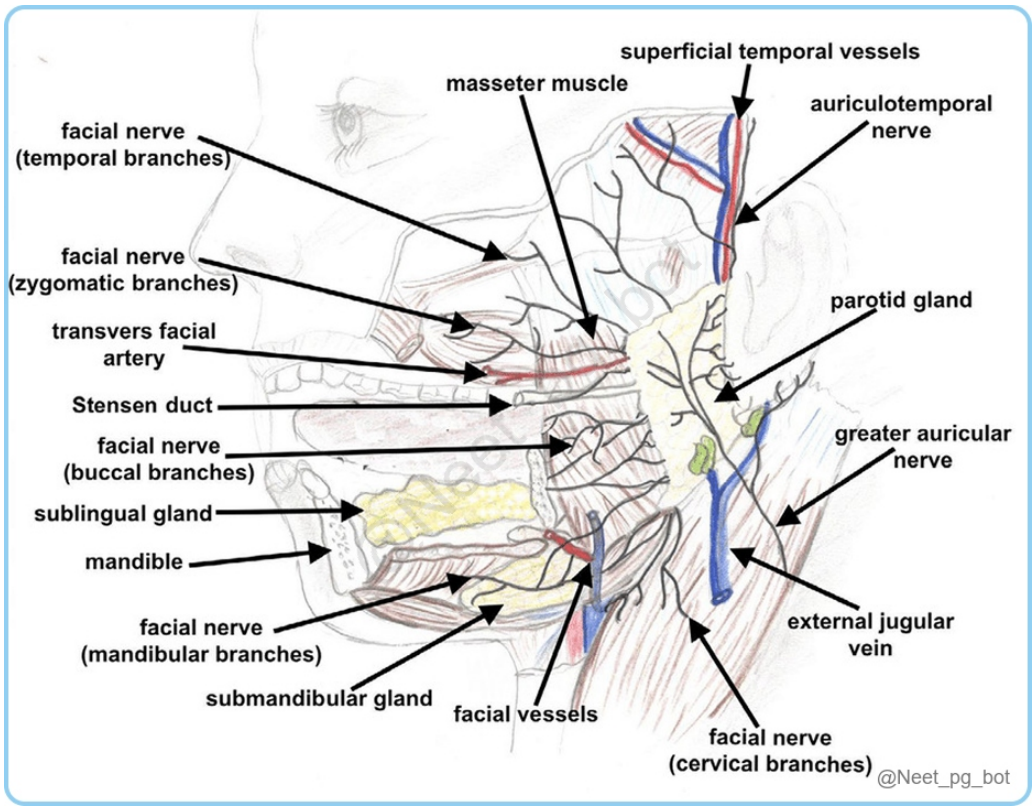

References:

https://www.ncbi.nlm.nih.gov/books/NBK534225/

↑ *Back to this question in Part A*

@Neet_pg_bot

Q15: Which of the following statements about the structures within the parotid gland are accurate? The external carotid artery enters the parotid gland through the posteromedial surface. The maxillary artery exits through the posterior surface of the gland. The superficial temporal artery branches into the transverse facial artery and emerges from the anterior part of the superior surface. The superficial temporal vein and maxillary vein unite to form the retromandibular vein, which divides into anterior and posterior divisions near the apex of the gland. The facial nerve enters the parotid gland and passes behind the retromandibular vein. (Q848766)

A. Only 1,3 and 4

B. Only 1 and 3

C. All except 2

D. All the above

Correct Answer: A. Only 1,3 and 4

■ *Listen (English)*

■ *Listen (Hindi)*

Explanation: The maxillary artery exits through the anteromedial surface, not the posterior surface. The facial nerve enters the parotid gland at the posteromedial surface, passing in front of the retromandibular vein, not behind it. Structures Within the Parotid Gland Arteries External Carotid Artery: Enters through the posteromedial surface. Maxillary Artery: Exits through the anteromedial surface. Superficial Temporal Artery : Branches into the transverse facial artery and emerges from the anterior part of the superior surface. Veins Superficial Temporal Vein and Maxillary Vein unite to form the Retromandibular Vein , which divides into anterior and posterior divisions near the apex of the gland. Facial Nerve Exits the skull through the Stylomastoid Foramen, enters the parotid gland at the posteromedial surface , passing in front of the retromandibular vein and external carotid artery. Divides into Temporofacial and Cervicofacial branches near the neck of the mandible, further branching into five terminal branches: Temporal, Zygomatic, Buccal, Marginal Mandibular, and Cervical, exiting along the anterior border and apex of the gland. Lymphatics Parotid Duct/ Stensen's Duct

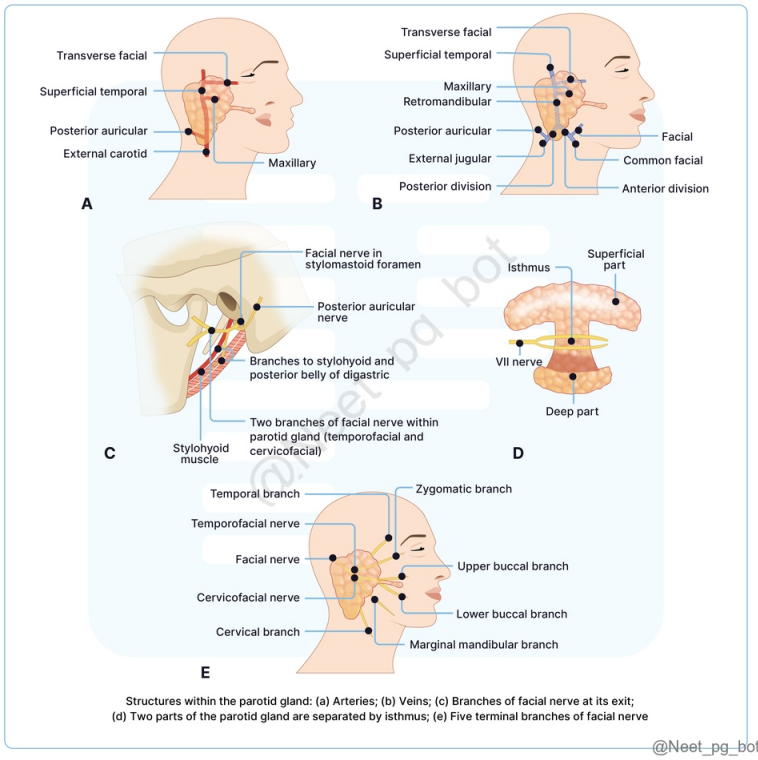

References:

BD Chaurasia’s Human Anatomy, 8th Edition, Volume 3, Page 117, 118.

↑ *Back to this question in Part A*

• [04_Head and Neck] 020 Pharynx Esophagus And Larynx - I

« Back to Folder Directory

[04_Head and Neck] 020 Pharynx Esophagus And Larynx - I — Quick Jump

Q1 (p. 1224)	*Q2 (p. 1225)*	*Q3 (p. 1226)*	*Q4 (p. 1226)*	*Q5 (p. 1227)*	*Q6 (p. 1230)*
Q7 (p. 1231)	*Q8 (p. 1232)*	*Q9 (p. 1235)*	*Q10 (p. 1236)*	*Q11 (p. 1238)*	*Q12 (p. 1239)*
Q13 (p. 1241)	*Q14 (p. 1242)*	*Q15 (p. 1244)*	*Q16 (p. 1245)*	*Q17 (p. 1246)*	*Q18 (p. 1247)*
Q19 (p. 1248)	*Q20 (p. 1249)*	*Q21 (p. 1250)*	*Q22 (p. 1251)*		

Q1: Which of the following correctly describes the histology of the esophagus? (Q848626)

A. The upper third consists of smooth muscle, and the lower third is composed of striated muscle.

B. The adventitia is made up of dense connective tissue with blood vessels and nerves.

C. The middle third contains a mix of striated and smooth muscle fibers.

D. The entire esophagus is lined with keratinized stratified squamous epithelium.

Correct Answer: C. The middle third contains a mix of striated and smooth muscle fibers.

■ *Listen (English)*

■ *Listen (Hindi)*

Explanation: The middle portion of the esophagus has both striated and smooth muscle fibers. Histology of the Oesophagus When empty, the mucous membrane forms longitudinal folds. The lining is non-keratinized stratified squamous epithelium, providing protection. (Option D ruled out) Lamina propria: Contains papillae extending into the epithelium. Muscularis mucosae: More distinct as it progresses down the esophagus. Submucosa: Contains mucus-secreting oesophageal glands with rounded or oval acini. The muscularis externa consists of: (Option A ruled out) Striated muscle in the upper third A combination of striated and smooth muscle in the middle third (Option C) Smooth muscle in the lower third Adventitia : Composed of loose connective tissue containing capillaries and nerves. (Option B ruled out) The esophagus lacks a serosa, unlike many other organs in the digestive tract.

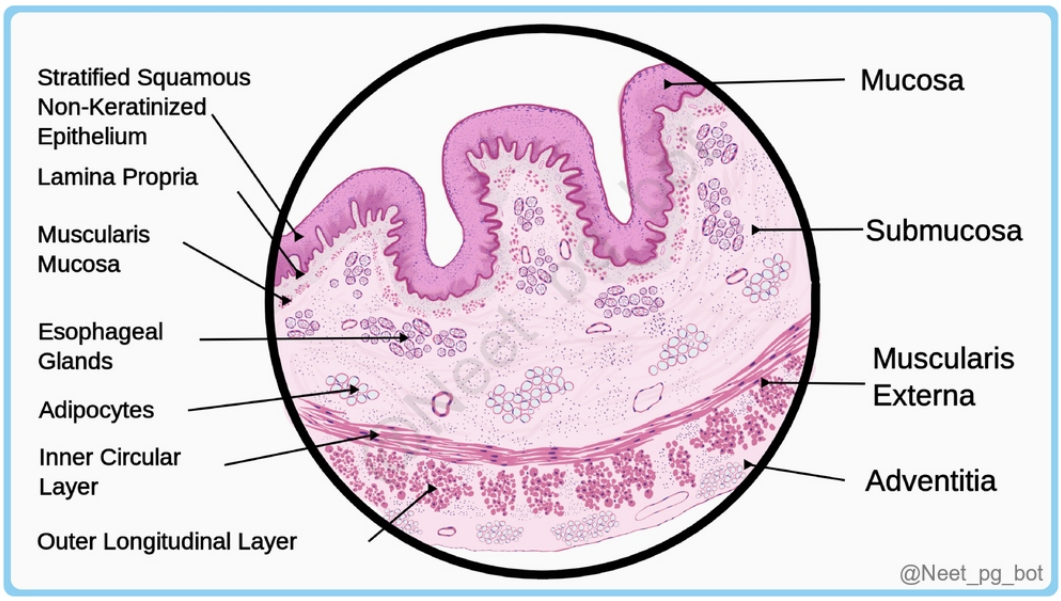

References:

BD Chaurasia's Human Anatomy, 8th Edition, Volume 1, Pages 325-326

↑ *Back to this question in Part A*

@Neet_pg_bot

Q2: Which among the following is the correct pairing of the part of the larynx to the structure from which it is derived? (Q848631)

A. Epiglottis-4th pharyngeal arch

B. Cricoid cartilage-5th pharyngeal arch

C. Intrinsic muscles-7th pharyngeal arch

D. Cricothyroid muscle-5th pharyngeal arch

Correct Answer: A. Epiglottis-4th pharyngeal arch

■ *Listen (English)*

■ *Listen (Hindi)*

Explanation: Development of larynx: Component Derivation/Description Lining Epithelium Derived from endoderm Cartilages Epiglottis , thyroid, cuneiform cartilages: Derived from 4th pharyngeal arch Cricoid, arytenoid, corniculate cartilages: Derived from 6th pharyngeal arch Muscles Derived from branchial mesoderm All intrinsic muscles: Develops from the 6th pharyngeal arch Supplied by recurrent laryngeal nerve Cricothyroid muscle: Develops from the 4th pharyngeal arch Supplied by external laryngeal branch of superior laryngeal nerve

References:

Inderbir Singh’s Human Embryology, 11th Edition, Page 215-217

↑ *Back to this question in Part A*

@Neet_pg_bot

Q3: Which of the following structures of the larynx have seromucous glands? False vocal cord True vocal cord Ventricle Saccule (Q848632)

A. 1 and 4

B. 1 and 2

C. 2 and 4

D. 2 and 3

Correct Answer: A. 1 and 4

■ *Listen (English)*

■ *Listen (Hindi)*

Explanation: False vocal cord and saccule have seromucous glands Histology of larynx: Structure Histological Features False Vocal Cord Columnar ciliated respiratory-type epithelium with seromucous glands True Vocal Cord Stratified squamous epithelium Ventricle Respiratory-type columnar epithelium Saccule Respiratory-type columnar epithelium with seromucous glands

References:

Wheater’s Functional Histology, 6th Edition, Page 227.

↑ *Back to this question in Part A*

@Neet_pg_bot

Q4: A 58-year-old male patient presents with difficulty swallowing (dysphagia) and nasal regurgitation of food. He also reports that his speech has become nasal and less clear. On examination, you notice that his soft palate does not elevate properly during swallowing, and there is an abnormal ridge in the nasopharynx. Which of the following is the most likely cause of this patient's symptoms? (Q848642)

A. Paralysis of the superior pharyngeal constrictor muscle

B. Damage to the glossopharyngeal nerve (Cranial Nerve IX)

C. Weakness of the levator veli palatini muscle

D. Dysfunction of the palatopharyngeus muscle

Correct Answer: C. Weakness of the levator veli palatini muscle

■ *Listen (English)*

■ *Listen (Hindi)*

Explanation: This muscle is the primary elevator of the soft palate. Weakness or paralysis of the levator veli palatini would directly lead to the soft palate not elevating properly, resulting in failure to seal off the nasopharynx during swallowing (nasal regurgitation) and speech (nasal speech). This matches all the key symptoms perfectly.

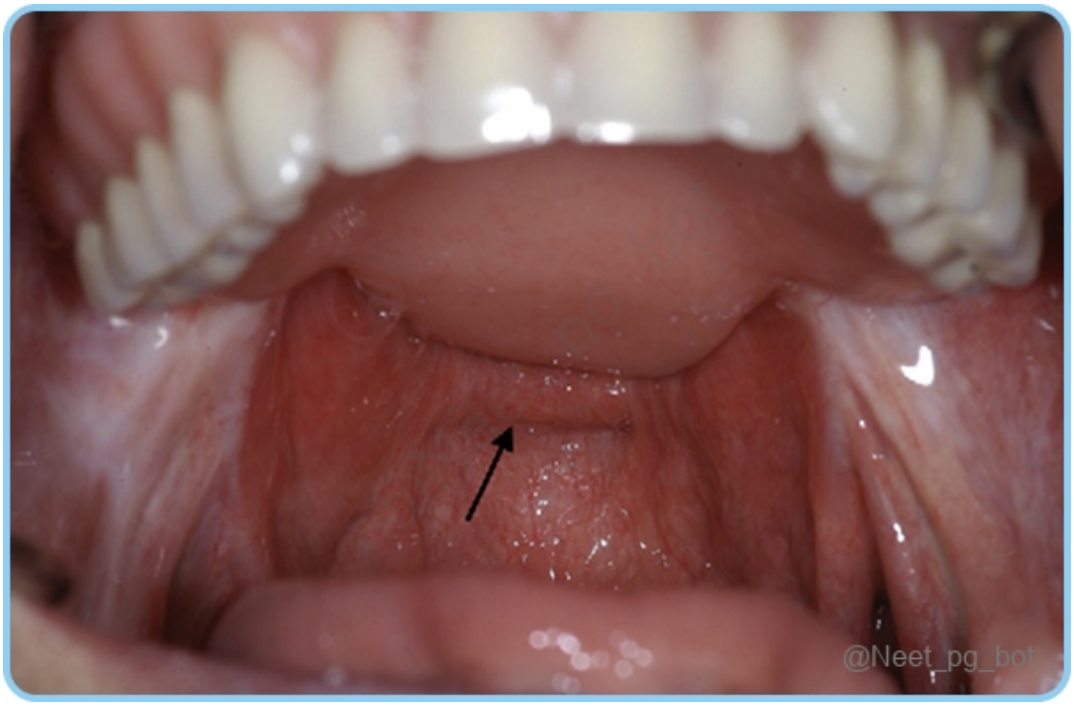

References:

BD Chaurasia's Human Anatomy, Volume 3, Page 263-266

↑ *Back to this question in Part A*

@Neet_pg_bot

Q5: Mark the false statement about the structure being palpated here (Q848641)

A. Blood supply is by superior thyroid artery

B. Extends from C6-T6 in standing position

C. Lined by pseudostratified ciliated columnar epithelium

D. Left recurrent laryngeal nerve lies posterior to it

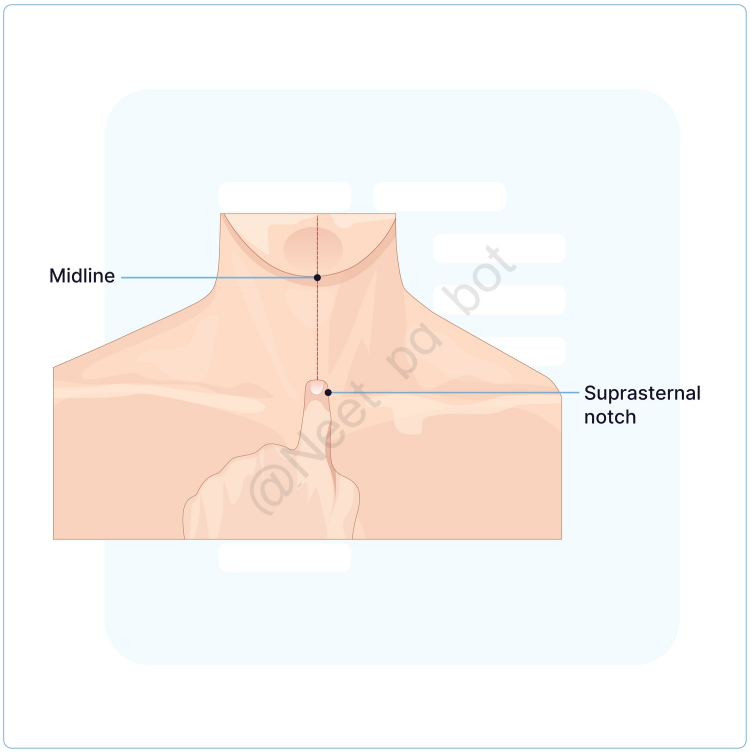

Correct Answer: A. Blood supply is by superior thyroid artery

- *Listen (English)*
- *Listen (Hindi)*

Explanation: Superior thyroid artery (Option A): False. The superior thyroid artery primarily supplies the larynx and thyroid gland , not the trachea . The trachea is mainly supplied by the inferior thyroid artery (branch of thyrocervical trunk) and bronchial arteries . Trachea: Structure The trachea is a flexible fibrocartilaginous tube forming the start of the lower respiratory tract, supported by 16–20 C-shaped hyaline cartilage rings . Location Extends from the lower border of the cricoid cartilage (C6 vertebra) to the lower border of the T4 vertebra. The upper half lies in the neck (cervical part) Lower half in the superior mediastinum (thoracic part). Variations Cadaver (supine): C6 to T4 Living (standing): C6 to T6 (Option B ruled out) Newborns: C6 to T3 Relations Anterior: Arch of aorta Brachiocephalic trunk Left brachiocephalic vein Superior vena cava Posterior: Esophagus Left recurrent laryngeal nerve (Option D ruled out) Vertebral column Right: Azygous vein Left: Arch of aorta, Left subclavian vein, Left phrenic nerve On either sides: Lung and pleura, vagus nerve Histology Mucosa is lined by pseudostratified ciliated columnar epithelium with goblet cells (Option C ruled out) Blood supply Arterial supply: Inferior thyroid artery (Option A) Venous drainage: Left brachiocephalic vein

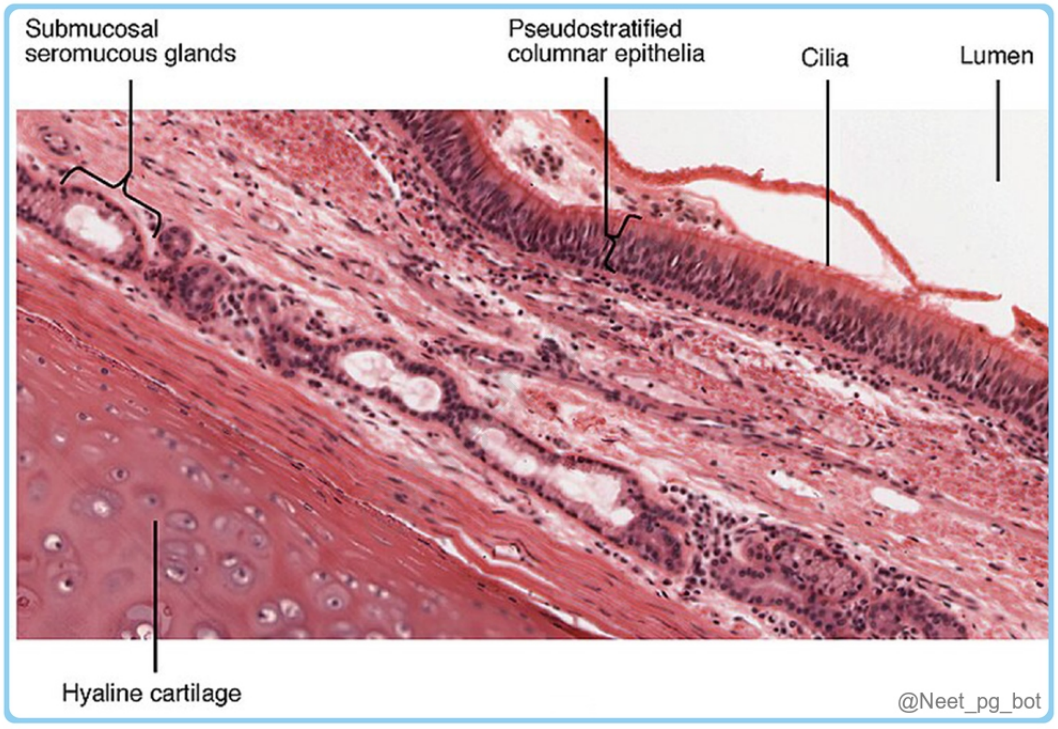

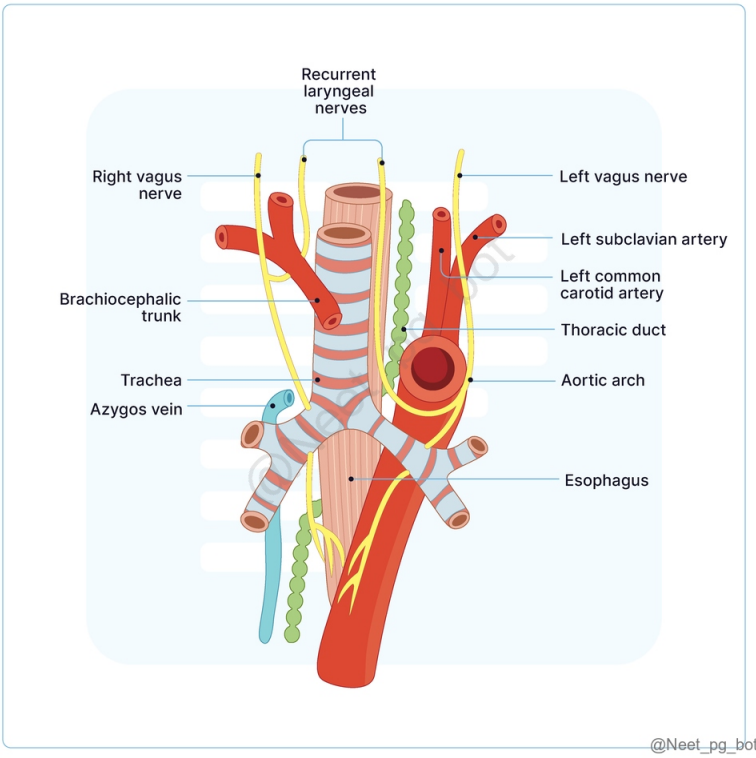

References:

Vishram Singh's Textbook of Anatomy, 2nd Edition, Volume 3, Page 292-294.

↑ *Back to this question in Part A*

Q6: Patient who had suspected lung pathology was advised to undergo CT chest. While analysing the CT images, what vertebral level could this image likely correspond to? (Q848640)

A. T2

B. T3

C. T4

D. T5



Correct Answer: C. T4

■ *Listen (English)*

■ *Listen (Hindi)*

Explanation: CT image given in question shows arch of aorta, which corresponds to T4 vertebral level. Vertebral levels and structures: Structure Vertebral level Cricoid cartilage End of larynx & pharynx Beginning of esophagus & trachea C6 Tracheal bifurcation Sternal angle (Angle of Louis) Arch of aorta Azygous vein drains into SVC T4 (Option C) Openings of diaphragm: IVC opening T8 Esophageal hiatus T10 Aortic hiatus T12

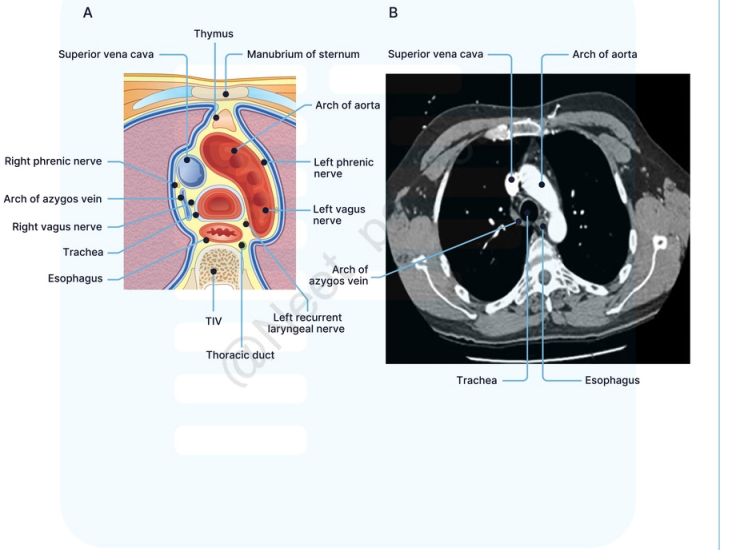

@Neet_pg_bot

References:

Vishram Singh textbook of Anatomy, 2nd Edition, Volume 1, Pages 211, 287, 296, 305

Vishram Singh textbook of Anatomy 2nd Edition, Volume 3, Pages 87,177

https://radiopaedia.org/articles/vertebral-levels-anatomical-landmarks

↑ *Back to this question in Part A*

@Neet_pg_bot

Q7: All of the following are true about structures related to the extent of larynx except (Q848639)

A. Extent of larynx in adult female is C3-C6

B. Bifurcation of common carotid occurs at superior border of thyroid cartilage

C. Cricoid is the lowermost cartilage of larynx

D. Extent of larynx in children is C1-C4

Correct Answer: A. Extent of larynx in adult female is C3-C6

■ *Listen (English)*

■ *Listen (Hindi)*

Explanation: Extent of larynx in adult female is higher up , at the level of C1-C4 and that of adult male is C3-C6. Extent of larynx: Adult male C3-C6 Adult female C1-C4 (Option A) Children C1-C4 (Option D) Structures related to the level of the larynx: Bifurcation of common carotid: At the superior border of thyroid cartilage (Option B) , carotid sinus present at the same level. Cricoid cartilage: The lowermost cartilage of the larynx (Option C) , at the lower border of the C6 vertebra. The larynx and pharynx end at the same level, at the lower border of the C6 vertebra. Branches of vagi: Recurrent and superior laryngeal nerve.

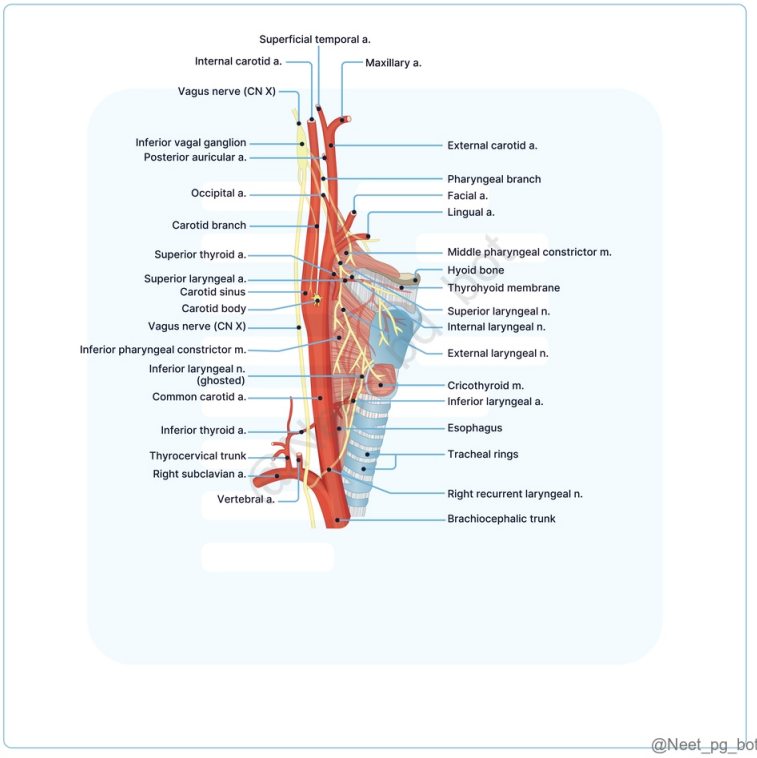

References:

BD Chaurasia’s Human Anatomy, 8th Edition, Volume 3, Page 286.

https://medicaltechservices.com/lessons/head-and-neck/pharynx-larynx-neck/

↑ *Back to this question in Part A*

@Neet_pg_bot

Q8: Choose the appropriate set of incorrect statement(s) about the course of the marked nerve in image 1) Left sided nerve loops around arch of aorta 2) Travels anterior to the lung hilum 3) Originates from the lateral aspect of medulla 4) Runs within the carotid sheath with IJV laterally and ICA medially 5) Right nerve has a

longer course than the Left. (Q848638)

A. 1,2,3

B. 1,5

C. 2,4,5

D. 2,5

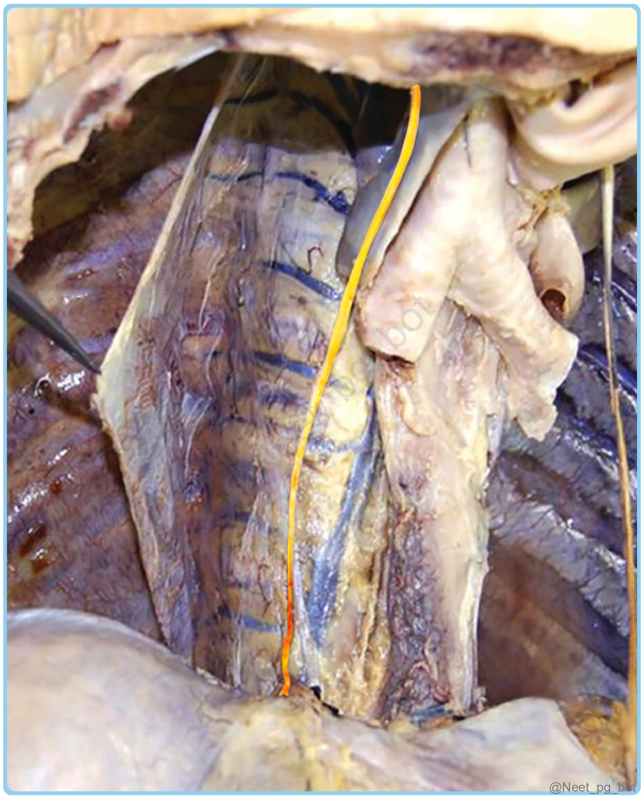

Correct Answer: D. 2,5

Explanation: The nerve in the cadaveric image is the Vagus (X) . Vagus travels posterior to lung hilum (not anterior), and the Right vagus has a shorter course than the Left . Vagus nerve course: Origin and course Exits from the lateral aspect of the medulla (Statement 3) , posterior to the pontomedullary junction, and leaves the skull through the jugular foramen. Runs within the carotid sheath with IJV laterally and ICA medially (Statement 4) The right vagus has a shorter course than the Left (Statement 5) Branches Superior Laryngeal Nerve: Emerges in the neck and supplies the larynx, divides further into Internal laryngeal nerve: Responsible for cough reflex External laryngeal nerve: Supplies the Cricothyroid muscle Recurrent Laryngeal Nerves: Ascend from the brachiocephalic artery on the right and aortic arch on the left Supplies all muscles of the larynx except the cricothyroid

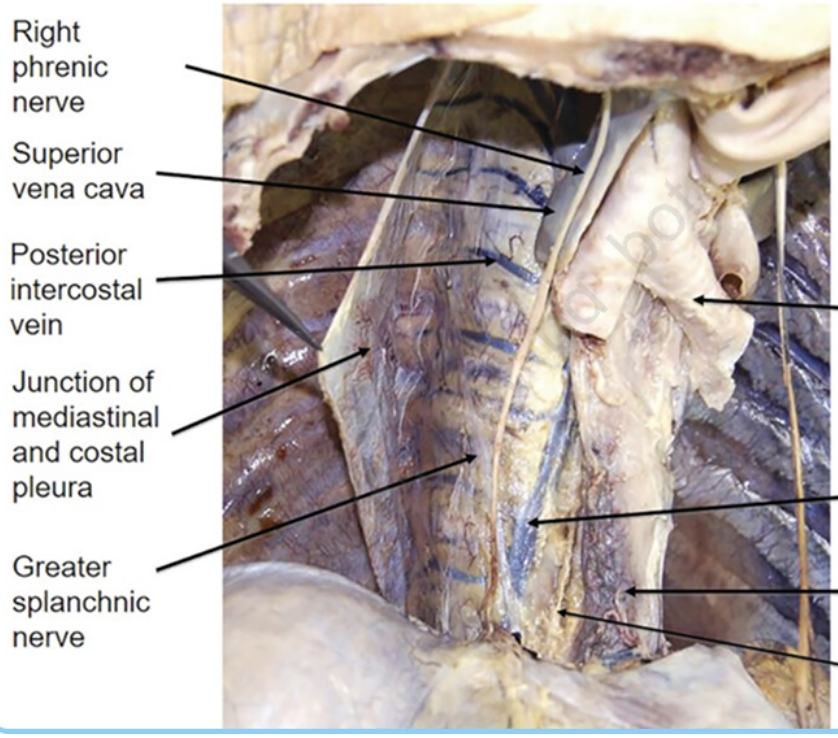

@Neet_pg_bot

Left vagus	Right vagus
Crosses the anterior surface of the left subclavian artery and **aortic arch** (Statement 1)	Crosses the anterior surface of the right subclavian artery
Passes lateral to the ligamentum arteriosum and posterior to the pulmonary trunk	Moves posteriorly near the brachiocephalic artery and reaches the right side of the trachea
Travels behind the left primary bronchus and **posterior to lung hilum** (Statement 2)	Travels behind the right primary bronchus and **posterior to lung hilum**
Contributes to the anterior esophageal plexus	Contributes to the posterior esophageal plexus
Descends through the esophageal hiatus to the abdomen	Descends through the esophageal hiatus to the abdomen

@Neet_pg_bot

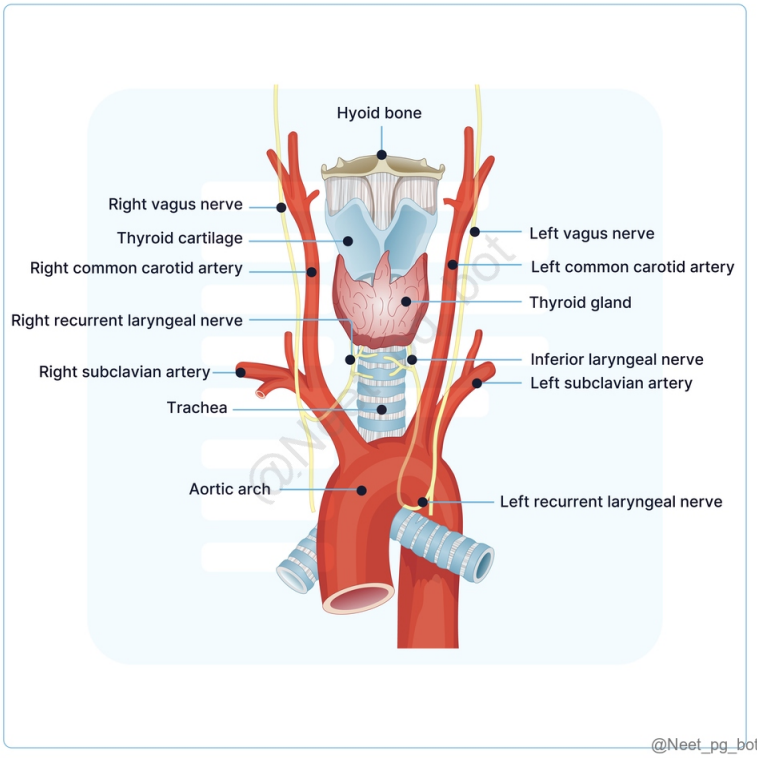

References:

https://www.elsevier.com/resources/anatomy/nervous-system/peripheral-nervous-system/vagus-nerve/22197

Vishram Singh's Textbook of Anatomy, 2nd Edition, Volume 3, Page 346-348.

↑ *Back to this question in Part A*

@Neet_pg_bot

Q9: Arterial supply of larynx is by (Q848637)

A. Superior laryngeal artery- branch of superior thyroid artery & inferior laryngeal artery- branch of inferior thyroid artery

B. Both superior and inferior laryngeal artery - branch of inferior thyroid artery

C. Both superior and inferior laryngeal artery - branch of superior thyroid artery

D. Superior laryngeal artery- branch of subclavian artery & inferior laryngeal artery- branch of inferior thyroid artery

Correct Answer: A. Superior laryngeal artery- branch of superior thyroid artery & inferior laryngeal artery- branch of inferior thyroid artery

■ *Listen (English)*

■ *Listen (Hindi)*

Explanation: The arterial supply of the larynx is mainly provided by the Superior and inferior laryngeal arteries, which are branches of the superior and inferior thyroid arteries, respectively. Arterial supply: Artery Branch of Superior laryngeal artery Superior thyroid artery (branch of External carotid) Inferior laryngeal artery Inferior thyroid artery (branch of Thyrocervical trunk) Cricothyroid artery (occasionally) Superior thyroid artery (branch of External carotid) Rima glottidis: Has dual blood supply (from both superior and inferior laryngeal)

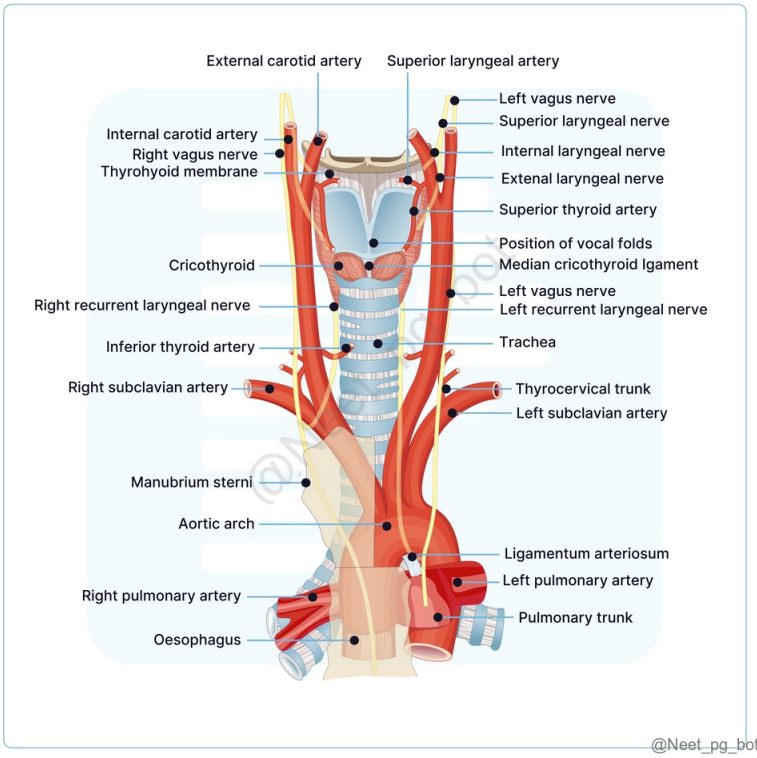

References:

Gray’s Anatomy, 42nd Edition, Page 729, 730

↑ *Back to this question in Part A*

@Neet_pg_bot

Q10: What is the structure marked as X in the laryngoscopy diagram given below? (Q848636)

A. Corniculate cartilage

B. Thyroid cartilage

C. Cricoid cartilage

D. Arytenoid cartilage

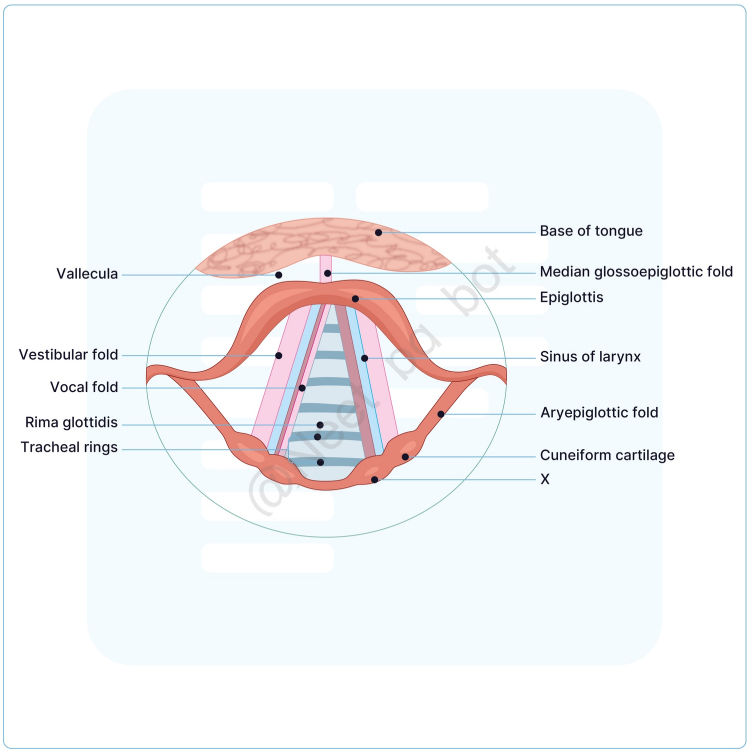

Correct Answer: A. Corniculate cartilage

■ *Listen (English)*

■ *Listen (Hindi)*

Explanation: Structures visible in laryngoscopy: Epiglottis:Appears as a leaf-shaped structure at the upper part of the laryngeal inlet. Vocal cords (vocal folds): True vocal cords: Visible as two pearly white, horizontally oriented bands. False vocal cords (vestibular folds): Located superior to the true vocal cords, these are less prominent and do not move during sound production. Aryepiglottic folds:Folds of tissue that run from the sides of the epiglottis to the arytenoids. These are seen framing the laryngeal inlet.

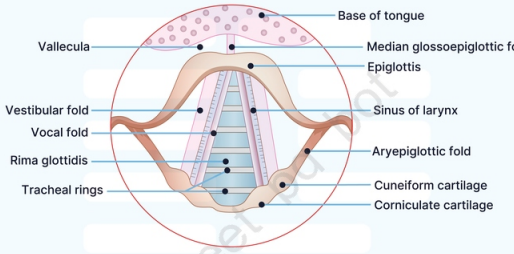

@Neet_pg_bot

References:

Vishram Singh's Textbook of Anatomy, 2nd Edition, Volume 3, Page 229

↑ *Back to this question in Part A*

@Neet_pg_bot

Q11: Match the intrinsic muscles of the vocal cord with its function Function Muscle a. Abduct the vocal cords 1. Aryepiglottic b. Tense the vocal cords 2. Posterior cricoarytenoid c. Close the inlet of the larynx 3. Cricothyroid d. Open inlet of larynx 4. Thyroepiglotticus (Q848635)

A. a2,b3,c1,d4

B. a1,b2,c3,d4

C. a4,b3,c2,d1

D. a3,b1,c2,d4

Correct Answer: A. a2,b3,c1,d4

■ *Listen (English)*

■ *Listen (Hindi)*

Explanation: Intrinsic muscles of the larynx: Function Muscles Abduct the vocal cords Posterior cricoarytenoids (safety muscle of larynx) Adduct the vocal cords Lateral cricoarytenoids Transverse arytenoid Cricothyroids (tuning fork of larynx) Thyroarytenoids Tense the vocal cords Cricothyroids Relax the vocal cords Thyroarytenoids Vocalis Close the inlet of the larynx Oblique arytenoids Aryepiglottic Open the inlet of the larynx Thyroepiglotticus

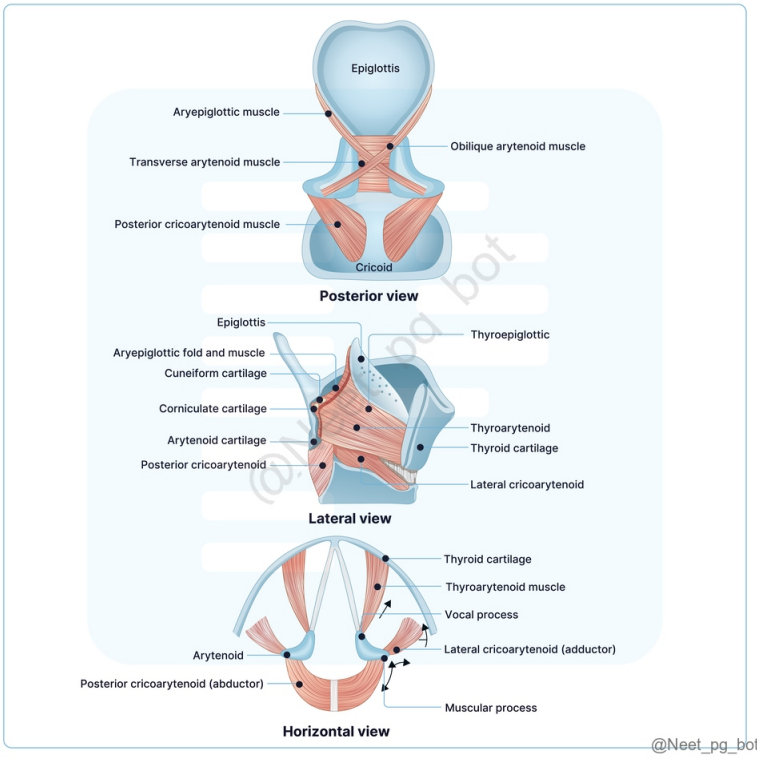

References:

BD Chaurasia’s Human Anatomy, 8th Edition, Volume 3, Pages 292, 293

↑ *Back to this question in Part A*

@Neet_pg_bot

Q12: Which of the following cartilages of the larynx is paired? (Q848634)

A. Thyroid cartilage

B. Cricoid cartilage

C. Epiglottis

D. Arytenoid

Correct Answer: D. Arytenoid

- *Listen (English)*
- *Listen (Hindi)*

Explanation: Cartilages of larynx-9 in total: Unpaired cartilages Thyroid (Hyaline cartilage) Cricoid (Hyaline cartilage) Epiglottis (Elastic cartilage) Paired cartilages: Arytenoid (Hyaline cartilage) Corniculate (Elastic cartilage) Cuneiform (Elastic cartilage)

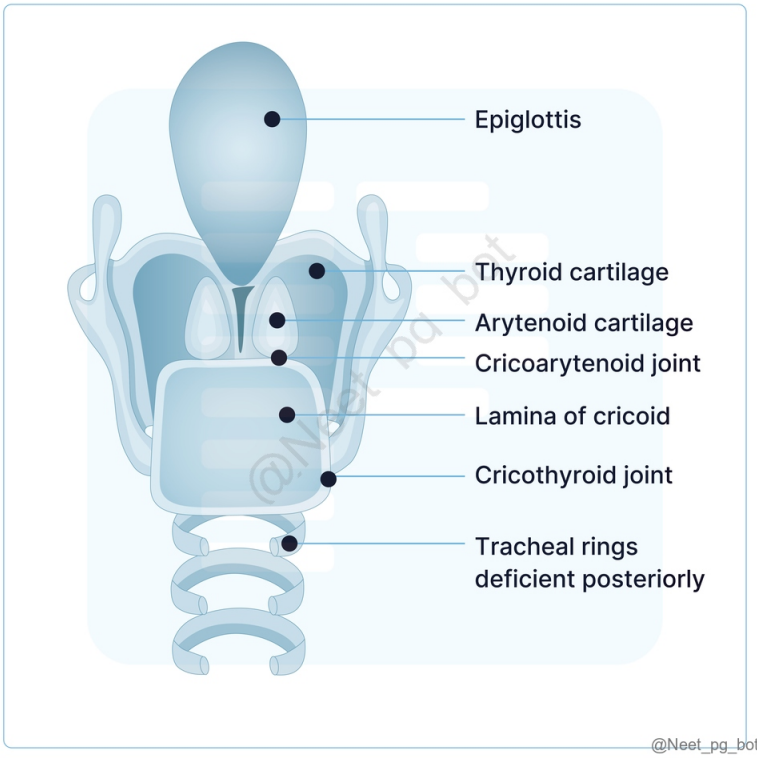

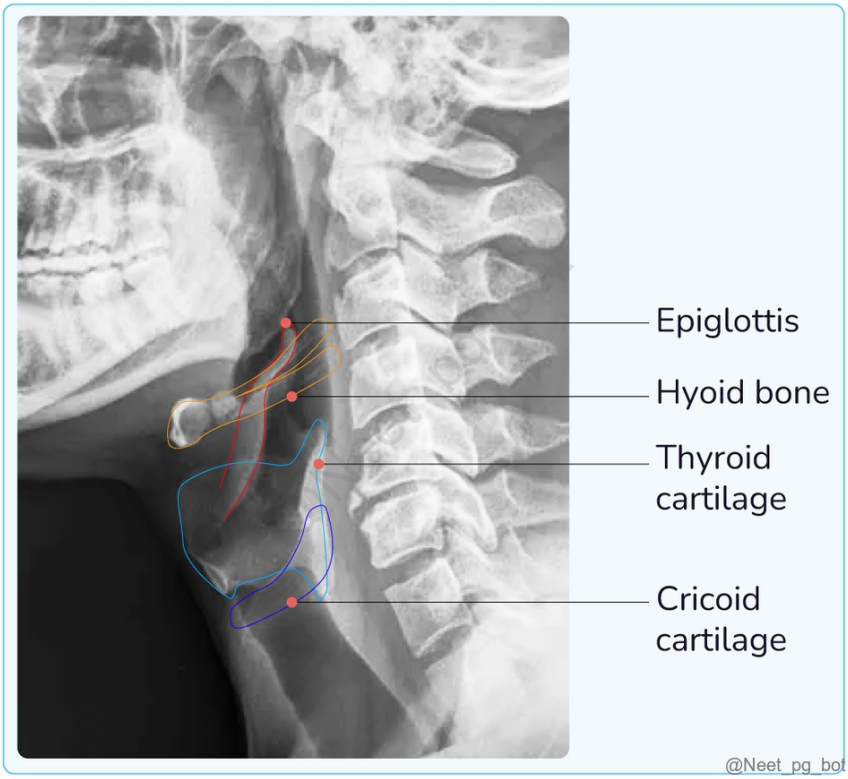

References:

BD Chaurasia's Human Anatomy, 8th Edition, Volume 3, Page 287

www.ncbi.nlm.nih.gov/books/NBK553185/#

↑ *Back to this question in Part A*

@Neet_pg_bot

Q13: From the sagittal section of the larynx given below, identify the part marked as X. (Q848633)

A. Thyroid cartilage

B. Cricoid cartilage

C. Arytenoid cartilage

D. Cuneiform cartilage

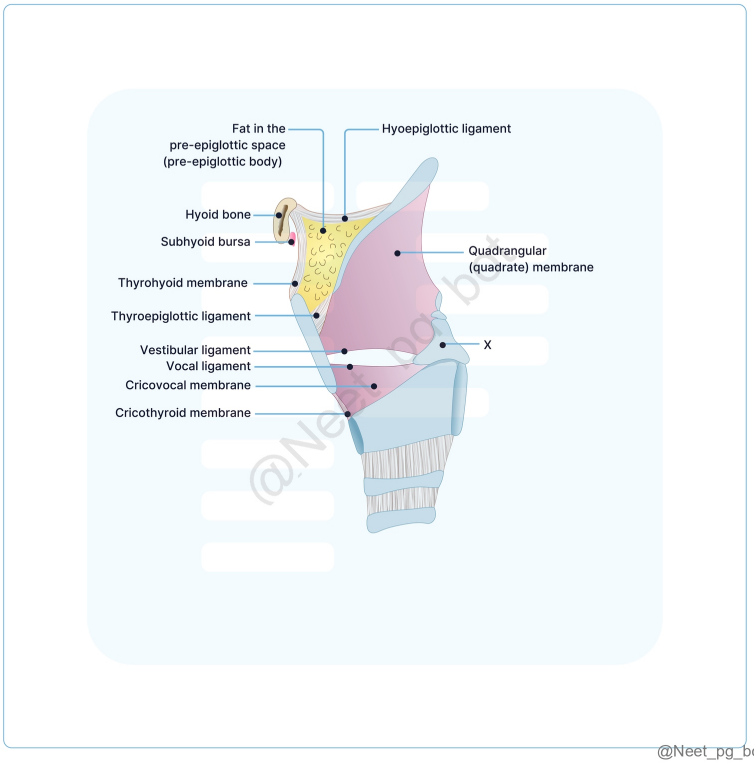

Correct Answer: C. Arytenoid cartilage

■ *Listen (English)*

■ *Listen (Hindi)*

Explanation: Epiglottis: Leaf-shaped cartilage located at the superior aspect of the larynx Thyroid cartilage: The largest cartilage of the larynx, visible as a large shield-like structure with its anterior prominence forming the Adam's apple. Cricoid cartilage: A ring-shaped cartilage below the thyroid cartilage, marking the lower limit of the larynx. Arytenoid cartilages: Pair of cartilages located on top of the posterior part of the cricoid cartilage Thyrohyoid membrane: Connects the thyroid cartilage to the hyoid bone. Cricothyroid membrane: Connects the cricoid and thyroid cartilages, seen between them.

References:

Vishram Singh’s Textbook of Anatomy, 2nd Edition, Volume 3, Page 222

↑ *Back to this question in Part A*

@Neet_pg_bot

Q14: Arrange the structures of the pharynx in the correct sequential order from innermost to outermost. (Q848621)

A. Mucosa, Submucosa, Buccopharyngeal fascia, Pharyngobasilar fascia, Muscular coat

B. Mucosa, Submucosa, Muscular coat, Buccopharyngeal fascia, Pharyngobasilar fascia

C. Mucosa, Submucosa, Pharyngobasilar fascia, Muscular coat, Buccopharyngeal fascia

D. Mucosa, Submucosa, Buccopharyngeal fascia, Muscular coat, Pharyngobasilar fascia

Correct Answer: C. Mucosa, Submucosa, Pharyngobasilar fascia, Muscular coat, Buccopharyngeal fascia

■ *Listen (English)*

■ *Listen (Hindi)*

Explanation: Structures of the pharynx in the correct sequential order from innermost to outermost is Mucosa, Submucosa, Pharyngobasilar fascia, Muscular coat and Buccopharyngeal fascia Layer Description Clinical Significance Mucosa Innermost lining (nasopharynx = ciliated columnar; oro-/laryngopharynx = stratified squamous) Site of pharyngitis , tonsillitis, and primary carcinoma Submucosa Connective tissue layer containing glands & vessels Infection can spread here; edema causes dysphagia Pharyngobasilar fascia Thick fibrous layer replacing circular muscle superiorly Provides structural support; defect may lead to pharyngeal diverticulum (Zenker's) Muscular coat Circular (constrictors) + longitudinal muscles Dysfunction → dysphagia; weakness at Killian's dehiscence → diverticulum Buccopharyngeal fascia Outermost fascial layer; continuous with pretracheal fascia Infection spreads to retropharyngeal space → mediastinum (danger space)

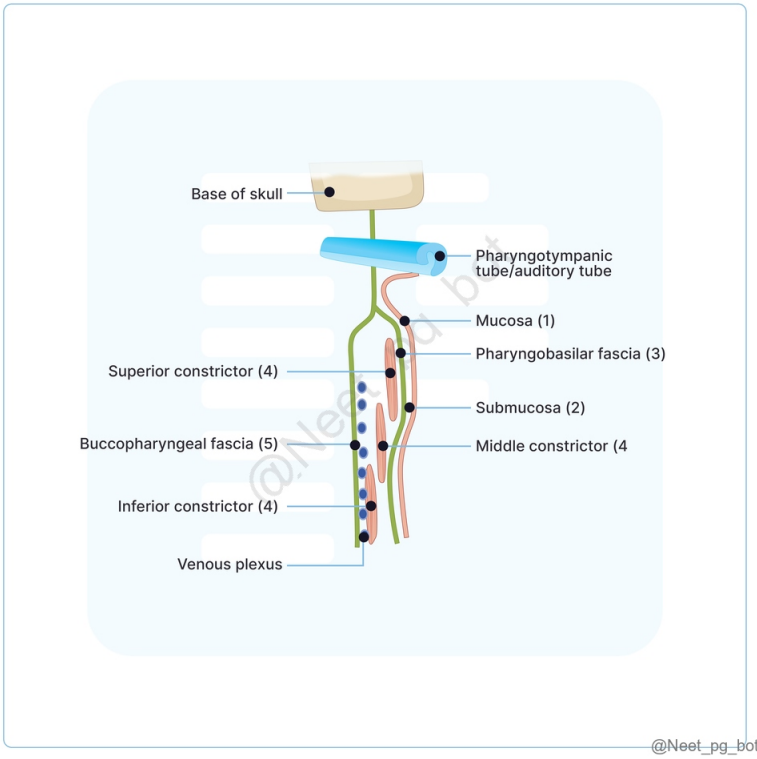

References:

BD Chaurasia's Human Anatomy, 8th Edition, Volume 3, Pages 257-259

Vishram Singh’s Textbook of Anatomy, 2nd Edition, Volume 3, Pages 200, 201, 202

↑ *Back to this question in Part A*

@Neet_pg_bot

Q15: A 55-year-old male presents with difficulty swallowing (dysphagia) and is scheduled for an oesophagoscopy. During the procedure, the gastroenterologist must navigate the natural constrictions of the esophagus. At approximately 27.5 cm from the patient's incisor teeth, which anatomical structure is causing the narrowing? (Q848630)

A. Cricopharyngeus muscle

B. Aortic arch

C. Left main bronchus

D. Diaphragmatic hiatus

Correct Answer: C. Left main bronchus

■ *Listen (English)*

■ *Listen (Hindi)*

Explanation: Understanding the constrictions of esophagus is crucial for procedures like oesophagoscopy, which involves using a flexible camera to inspect the esophagus. Awareness of these narrow points ensures the safe passage of the esophagoscope. Constrictions occur at four main points: Cricopharyngeus Muscle (6 inches from incisors): This first constriction is at the upper esophageal sphincter where the esophagus begins. It is caused by the cricopharyngeus muscle, which plays a role in swallowing. (Option A) Aortic Arch (9 inches from incisors) : The second narrowing occurs where the esophagus is crossed by the arch of the aorta. The pressure from the aorta causes this indentation. (Option B) Left Main Bronchus (11 inches from incisors): Third constriction is where the left bronchus crosses over the esophagus, leading to a narrowing. (Option C) Diaphragmatic Hiatus (15 inches from incisors): The final narrowing happens where the esophagus passes through the diaphragm at the esophageal hiatus. (Option D)

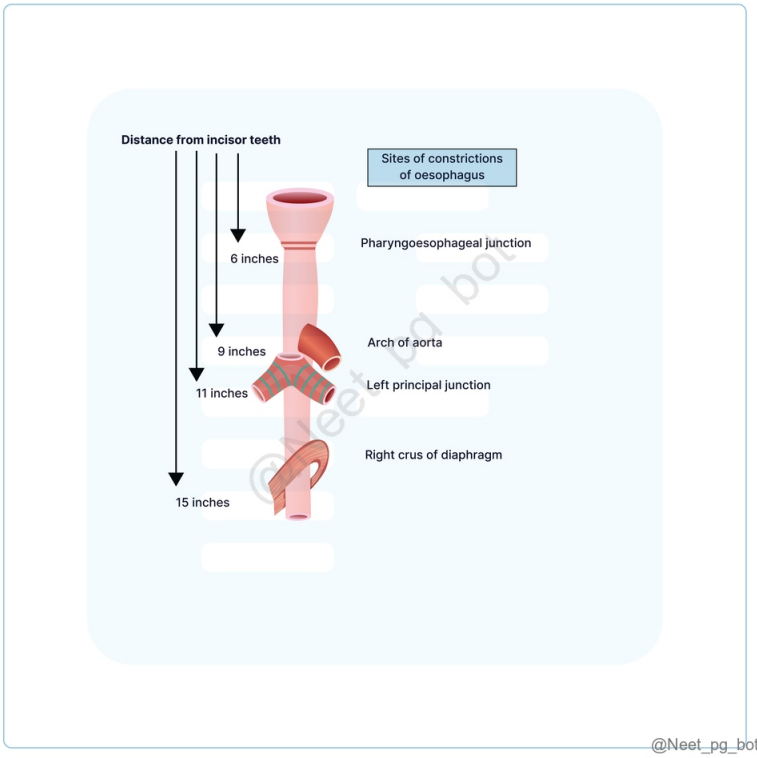

References:

BD Chaurasia's Human Anatomy, 8th Edition, Volume 1, Page 324

↑ *Back to this question in Part A*

@Neet_pg_bot

Q16: A 45 year old male presents with difficulty swallowing and occasional regurgitation of undigested food. A barium swallow study is shown below. Esophageal manometry reveals impaired relaxation of the lower esophageal sphincter (LES). What is the most likely underlying cause of this condition? (Q848629)

A. Loss of parasympathetic innervation from the recurrent laryngeal nerves

B. Hyperactivity of the sympathetic nerves from the upper thoracic ganglia

C. Degeneration of the esophageal plexus affecting peristalsis

D. Overactivity of the middle cervical ganglion fibres



Correct Answer: C. Degeneration of the esophageal plexus affecting peristalsis

■ *Listen (English)*

■ *Listen (Hindi)*

Explanation: Achalasia cardia, with a "bird-beak" appearance in barium swallow study at the gastroesophageal junction is often associated with the degeneration of the esophageal plexus, leading to impaired peristalsis and failure of LES relaxation. Achalasia Cardia Definition Failure of LES relaxation + loss of esophageal peristalsis Primary Pathology Degeneration of Auerbach (myenteric) plexus LES Tone Increased resting tone Esophageal Body Aperistalsis Most Common Age 25–60 years (Can occur in children) Symptoms Dysphagia (solids + liquids), regurgitation, weight loss Chest Pain Retrosternal (May mimic angina) Complication Aspiration pneumonia Barium Swallow “Bird-beak” appearance Manometry (Gold Standard) ↑ LES pressure + incomplete relaxation (Definitive test) Endoscopy Dilated esophagus, rule out cancer X-ray Finding Megaesophagus Secondary Cause Chagas disease (Trypanosoma cruzi) Cancer Risk ↑ Risk of SCC of esophagus Definitive Treatment Heller’s myotomy Non-surgical Tx Pneumatic dilatation Medical Tx Nitrates, CCB (temporary) Botulinum toxin Relaxes LES (Elderly patients)

References:

B.D. Chaurasia’s Human Anatomy, 8th Edition, Volume 1, Page 325, 326

↑ *Back to this question in Part A*

@Neet_pg_bot

Q17: A 48 year old male with a long-standing history of alcohol-related liver cirrhosis presents to the ER department with hematemesis. On examination, icterus is seen and the abdomen is distended. An upper gastrointestinal endoscopy confirms the presence of bleeding oesophageal varices at the lower end of the oesophagus. Which of the following vessels is primarily responsible for creating the portosystemic anastomoses that lead to the development of these varices? (Q848628)

A. Inferior phrenic veins

B. Left gastric vein

C. Brachiocephalic vein

D. Internal thoracic vein

Correct Answer: B. Left gastric vein

■ *Listen (English)*

■ *Listen (Hindi)*

Explanation: The lower esophagus is drained by the left gastric vein , which connects to the portal vein. In portal hypertension , blood flow through the left gastric vein becomes congested. The increased pressure causes dilation of submucosal veins in the lower esophagus. These dilated veins (varices) are fragile and prone to rupture, leading to massive hematemesis (vomiting blood). Acute Management involves band ligation & octreotide. Definitive management: TIPS procedure Portal Hypertension Normal Portal Pressure 5–10 mmHg Portal Hypertension >12 mmHg Causes Liver cirrhosis Portal vein thrombosis Cirrhosis (most common) Budd–Chiari syndrome Major Complications Varices Ascites Splenomegaly Hepatic encephalopathy

References:

BD Chaurasia’s Human Anatomy, 8th Edition, Volume 1, Pages 324-325

↑ *Back to this question in Part A*

@Neet_pg_bot

Q18: Which of the following statements is true regarding the course of the esophagus in thorax and abdomen. The esophagus begins at the lower border of the cricoid cartilage. The esophagus enters the abdomen at the level of the T10 vertebra. The esophagus ends at the cardiac end of the stomach at T11 vertebra. The thoracic esophagus passes through the anterior mediastinum. (Q848627)

A. Only 1 and 2

B. All except 1

C. All except 4

D. All the above

Correct Answer: C. All except 4

■ *Listen (English)*

■ *Listen (Hindi)*

Explanation: Esophagus passes through the superior and posterior mediastinum in the thorax. Course of esophagus Origin Begins at the lower border of the cricoid cartilage, connecting to the lower end of the pharynx. (Option C) Course in the Neck Travels downward in front of the vertebral column. Thoracic Course Passes through the superior and posterior mediastinum in the thorax. Diaphragmatic Passage Passes through the esophageal hiatus at the level of T10 vertebra, slightly left of the midline. Abdominal Course Becomes the abdominal esophagus, approximately 1.25 cm long, moves downward and left. Lies in front of the left crus of the diaphragm and inferior surface of the left lobe of the liver. Termination Ends at the cardiac end of the stomach at T11 vertebra, about 2.5 cm to the left of the midline. Clinical Significance Esophageal Hiatus: Transmits gastric nerves and esophageal vessels. Esophageal veins form portosystemic anastomoses; portal hypertension may cause varices and haematemesis.

References:

BD Chaurasia’s Human Anatomy, 8th Edition, Volume 1, Page 325-326

BD Chaurasia’s Human Anatomy, 8th Edition, Volume 2, Page 291-292

↑ *Back to this question in Part A*

@Neet_pg_bot

Q19: A 8 year old child presents to the pediatric clinic with recurrent ear infections and complaints of ear pain, especially after upper respiratory infections. What is the most likely reason for this child's increased susceptibility to ear infections? (Q848625)

A. The Eustachian tube's shorter length allows for quicker drainage of secretions from the middle ear.

B. The more horizontal orientation of the Eustachian tube in children impairs proper ventilation and drainage of the middle ear.

C. The Eustachian tube opens more frequently during normal activities in children, causing increased exposure to environmental allergens.

D. The Eustachian tube is typically narrow in children, which facilitates the entry of pathogens from the nasopharynx.

Correct Answer: B. The more horizontal orientation of the Eustachian tube in children impairs proper ventilation and drainage of the middle ear.

■ *Listen (English)*

■ *Listen (Hindi)*

Explanation: In children, infections often spread from the throat to the middle ear through the Eustachian tube. This occurs more commonly because the Eustachian tube in children is shorter, wider, and more horizontally oriented, which impairs proper ventilation and drainage of the middle ear. Eustachian Tube Total Length ~36 mm (Adults) ~18–20 mm (Children) Parts 1/3 lateral bony 2/3 medial cartilaginous Orientation Adults: 45° angle Children: More horizontal (~10°) Opens Into Nasopharynx (at torus tubarius) Lateral Relation Middle ear cavity Medial Relation Nasopharynx Blood Supply Ascending pharyngeal & middle meningeal branches Nerve Supply Glossopharyngeal nerve (IX) Function Ventilation, pressure equalization, drainage

References:

BD Chaurasia's Human Anatomy, 8th Edition, Volume 3, Page 266-268

↑ *Back to this question in Part A*

@Neet_pg_bot

Q20: A 32 year old male involved in smuggling accidentally swallowed a foreign object, which became lodged in his piriform fossa. After its removal, he reports numbness and loss of sensation in his throat. Which nerve is most likely damaged during the procedure? (Q848624)

A. Recurrent laryngeal nerve

B. External laryngeal nerve

C. Internal laryngeal nerve

D. Glossopharyngeal nerve

Correct Answer: C. Internal laryngeal nerve

■ *Listen (English)*

■ *Listen (Hindi)*

Explanation: The internal laryngeal nerve is responsible for sensory innervation to the supraglottic region of the larynx, and damage during foreign body removal from the piriform fossa can cause anesthesia in this area. The piriform fossa is a small depression found on each side of the laryngopharynx. It is positioned on both sides of the laryngeal inlet. The boundaries of the piriform fossa include: Medial boundary: Aryepiglottic fold Lateral boundary: Thyroid cartilage and thyrohyoid membrane The internal laryngeal nerve runs just beneath the mucosa of the piriform fossa. Damage to the internal laryngeal nerve, such as during the removal of foreign bodies from the fossa, can result in loss of sensation (anesthesia) in the supraglottic region of the larynx.

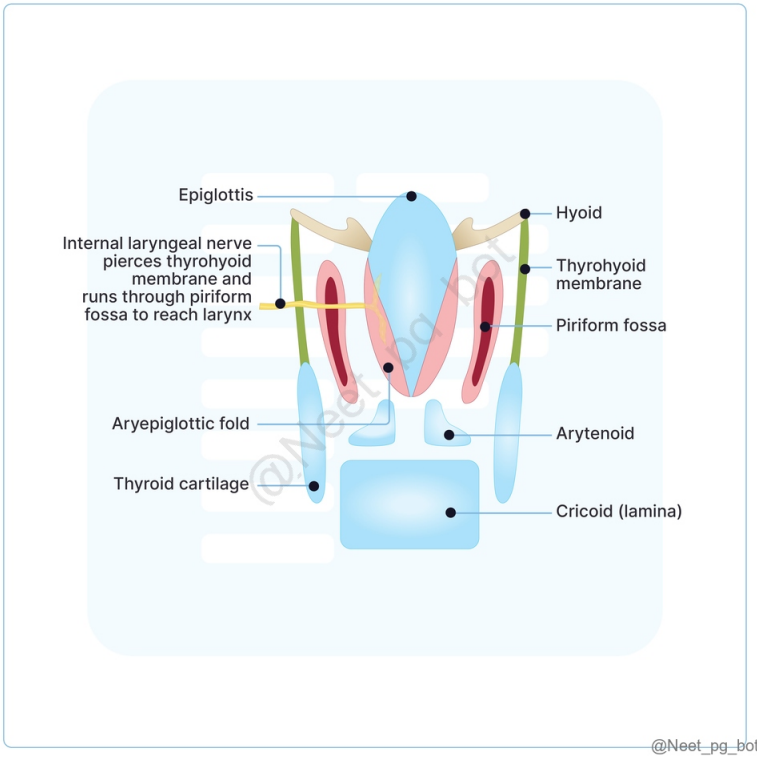

References:

BD Chaurasia's Human Anatomy, 8th Edition, Volume 3, Page 262

↑ *Back to this question in Part A*

@Neet_pg_bot

Q21: Match the spaces between the constrictor muscles with the structures that pass through them: Spaces Structures 1) Sinus of Morgagni A) Internal laryngeal nerve, superior laryngeal vessels 2) Space between superior and middle constrictors B) Recurrent laryngeal nerve, inferior laryngeal vessels 3) Space between middle and inferior constrictors C) Stylopharyngeus muscle, glossopharyngeal nerve 4) Space below the inferior constrictor D) Auditory tube, levator veli palatini muscle, ascending palatine artery, palatine branch of ascending pharyngeal artery (Q848623)

A. 1-D; 2-C; 3-A; 4-B

B. 1-B; 2-C; 3-A; 4-D

C. 1-C; 2-D; 3-A; 4-B

D. 1-D; 2-A; 3-C; 4-B

Correct Answer: A. 1-D; 2-C; 3-A; 4-B

■ *Listen (English)*

■ *Listen (Hindi)*

Explanation: Constrictors muscles and the spaces between them Spaces Between the Constrictor Muscles (Option A) The overlapping nature of these muscles forms spaces through which nerves and blood vessels pass: Gaps Between Pharyngeal Constrictors: Sinus of Morgagni: Auditory tube, levator veli palatini, ascending palatine a., palatine branch of ascending pharyngeal a. Between Superior & Middle: Stylopharyngeus, glossopharyngeal n. Between Middle & Inferior: Internal laryngeal n., superior laryngeal vessels. Below Inferior: Recurrent laryngeal n., inferior laryngeal vessels. Killian's Dehiscence Killian’s Dehiscence: Located below the vocal folds and above the cricopharyngeal sphincter — a weak area in the inferior constrictor (thyropharyngeus) prone to pharyngeal diverticulum formation.

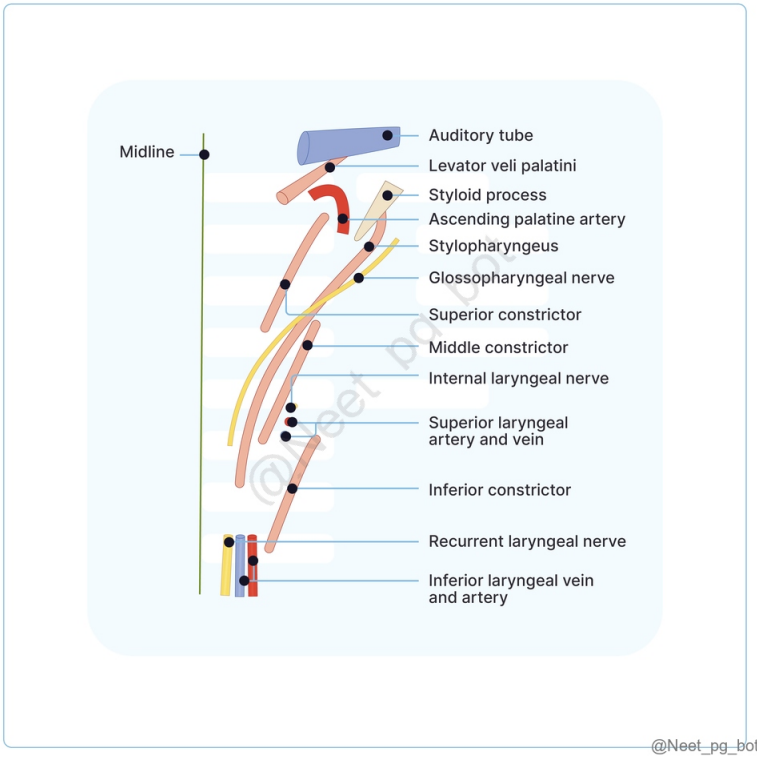

References:

BD Chaurasia’s Human Anatomy, 8th Edition, Volume 3, Page 263-265

↑ *Back to this question in Part A*

@Neet_pg_bot

Q22: Which of the following nerves supplies motor fibres to all pharyngeal muscles except the stylopharyngeus? (Q848622)

A. Glossopharyngeal nerve

B. Hypoglossal nerve

C. Vagus nerve

D. Superior cervical sympathetic ganglion

Correct Answer: C. Vagus nerve

■ *Listen (English)*

■ *Listen (Hindi)*

Explanation: The vagus nerve supplies motor fibres to all pharyngeal muscles except the stylopharyngeus, which is innervated by the glossopharyngeal nerve. Muscles of pharynx and nerve supply Muscles of the Pharynx Pharyngeal muscles have two layers: Outer circular (constrictors): Superior, middle, and inferior (thyropharyngeus & cricopharyngeus). Inner longitudinal: Stylopharyngeus (styloid → pharynx), Palatopharyngeus (palate → pharynx), and Salpingopharyngeus (auditory tube → pharynx). Nerve Supply The pharynx is innervated by the pharyngeal plexus (located on the middle constrictor), which includes: Vagus nerve: Carries fibers from the cranial accessory nerve. Glossopharyngeal nerve Superior cervical sympathetic ganglion Motor fibers: Supplied by the cranial accessory nerve via vagus nerve branches (except the stylopharyngeus, supplied by the glossopharyngeal nerve). (Option C) Sensory fibers: Mostly from the glossopharyngeal nerve, partly from the vagus nerve. Parasympathetic secretomotor fibers: From the lesser palatine branches of the pterygopalatine ganglion.

References:

BD Chaurasia’s Human Anatomy, 8th Edition, Volume 3, Page 263-266

↑ *Back to this question in Part A*

@Neet_pg_bot

• [04_Head and Neck] 021 Anatomy Of Ear Nose And Eyeball

« Back to Folder Directory

[04_Head and Neck] 021 Anatomy Of Ear Nose And Eyeball — Quick Jump

Q1 (p. 1253) *Q2 (p. 1254)* *Q3 (p. 1257)* *Q4 (p. 1258)* *Q5 (p. 1260)* *Q6 (p. 1262)*
Q7 (p. 1265) *Q8 (p. 1266)* *Q9 (p. 1269)* *Q10 (p. 1271)* *Q11 (p. 1273)*

Q1: A 5-year-old child presents with conductive hearing loss. Imaging reveals a congenital anomaly involving the stapes footplate. Which embryological structure is primarily responsible for the development of the stapes footplate? (Q848643)

A. First pharyngeal arch

B. Second pharyngeal arch

C. Otic placode

D. Otic capsule

Correct Answer: D. Otic capsule

■ *Listen (English)*

■ *Listen (Hindi)*

Explanation: The stapes footplate develops from the otic capsule, a cartilaginous structure that surrounds the inner ear during development and later ossifies to form the bony labyrinth. This capsule provides structural support and protection to the inner ear, which originates from the otic placode. (Option C) Middle Ear: Includes the Eustachian tube, Tympanic cavity, Attic, Antrum, and Mastoid air cells, which develop from the endoderm of the tubotympanic recess Ossicles: Malleus and incus from the first arch (Option A) Stapes from the second arch (Option B) The Footplate of Stapes and annular ligament originates from the Otic capsule .

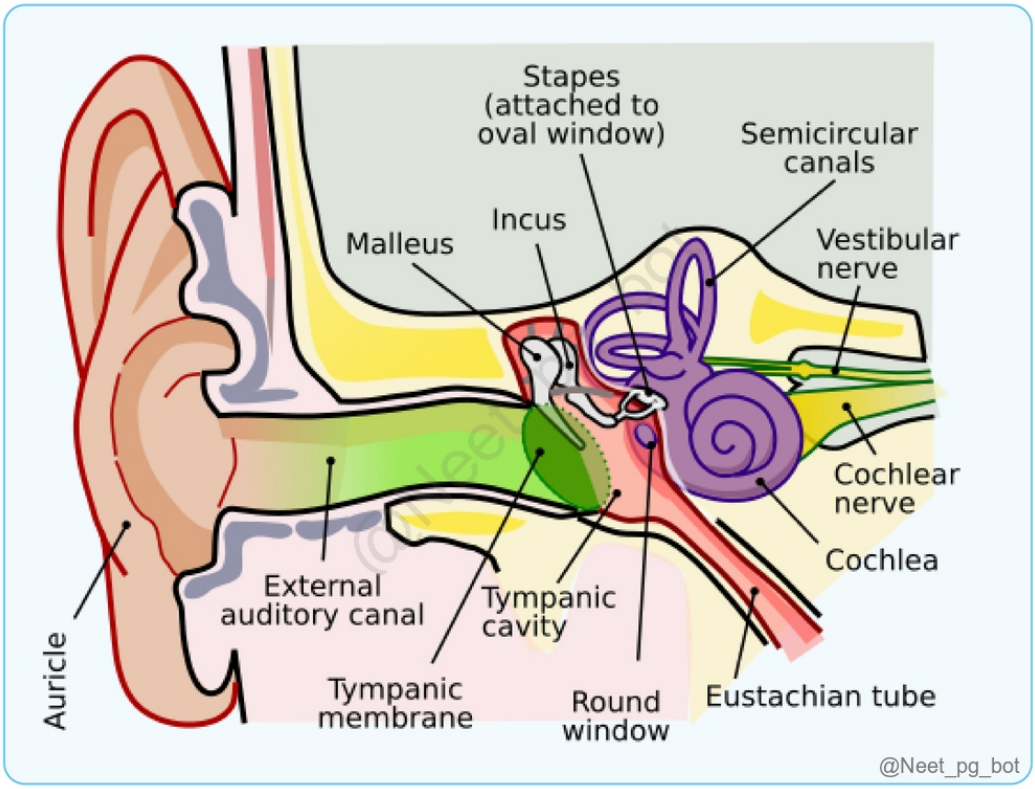

References:

Grey's Anatomy, 42nd Edition, Pages 270, 272

Diseases of Ear, Nose, and Throat, PL Dhingra, 8th Edition, Pages 14, 15

↑ *Back to this question in Part A*

@Neet_pg_bot

Q2: Which of the following nerves is primarily responsible for the sensory innervation of the structure marked? (Q848644)

A. Great auricular nerve

B. Auriculotemporal nerve

C. Lesser occipital nerve

D. Auricular branch of the vagus nerve

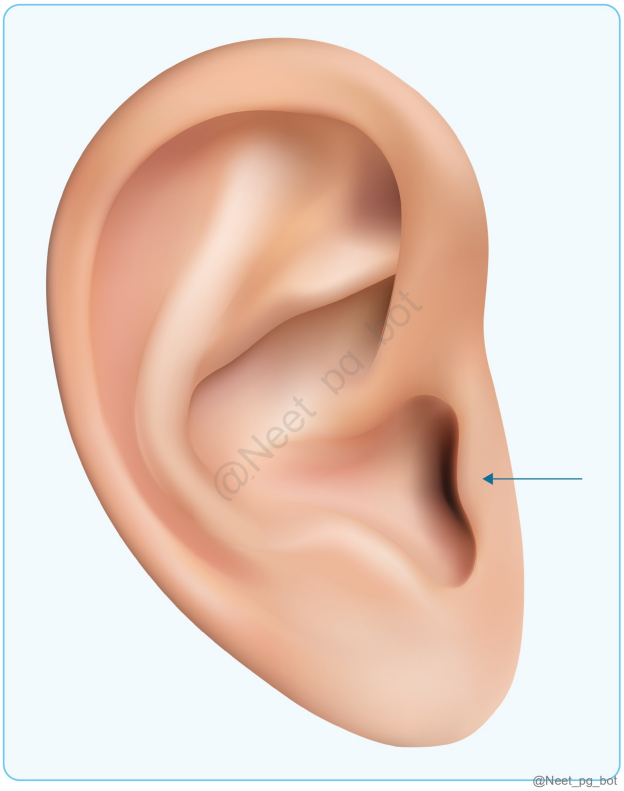

Correct Answer: B. Auriculotemporal nerve

- *Listen (English)*
- *Listen (Hindi)*

Explanation: The marked structure in the image is Tragus , which is supplied by the Auriculotemporal Nerve , a branch of the mandibular division of the trigeminal nerve (CN V). External Ear consists of two main parts: Pinna (Auricle) External Auditory Meatus Aspects Auricle (Pinna) External Auditory Meatus Composition Elastic cartilage, except lobule (fibrofatty tissue) Cartilaginous part (Outer 1/3) with hair and ceruminous glands Bony part (Inner 2/3), with thin skin continuous with the tympanic membrane, lacks hair and glands. Parts Concha (Depression leading to the external meatus) Helix (Prominent rim with anterior and posterior limbs) Antihelix (Parallel ridge to the helix) Tragus & Antitragus (Separated by inter-tragic notch) Cymba Conchae (Above crus of helix) Lobule (Soft, fleshy part below antitragus) Nerve Supply Lateral Surface Lower third: Great auricular nerve (C2, C3) Upper two-thirds: Auriculotemporal nerve (CN V3) Concha: Auricular branch of vagus (CN X) (Alderman's Nerve) Medial Surface Lower third: Great auricular nerve Upper two-thirds: Lesser occipital nerve (C2) Roof & Anterior Wall: Auriculotemporal nerve (CN V3) Floor & Posterior Wall: Auricular branch of vagus (CN X) Clinical Relevance McEwen's triangle (Cymba Conchae) It is a surgical landmark on the temporal bone to locate the mastoid antrum. Furuncles (cartilaginous part) susceptible to infections

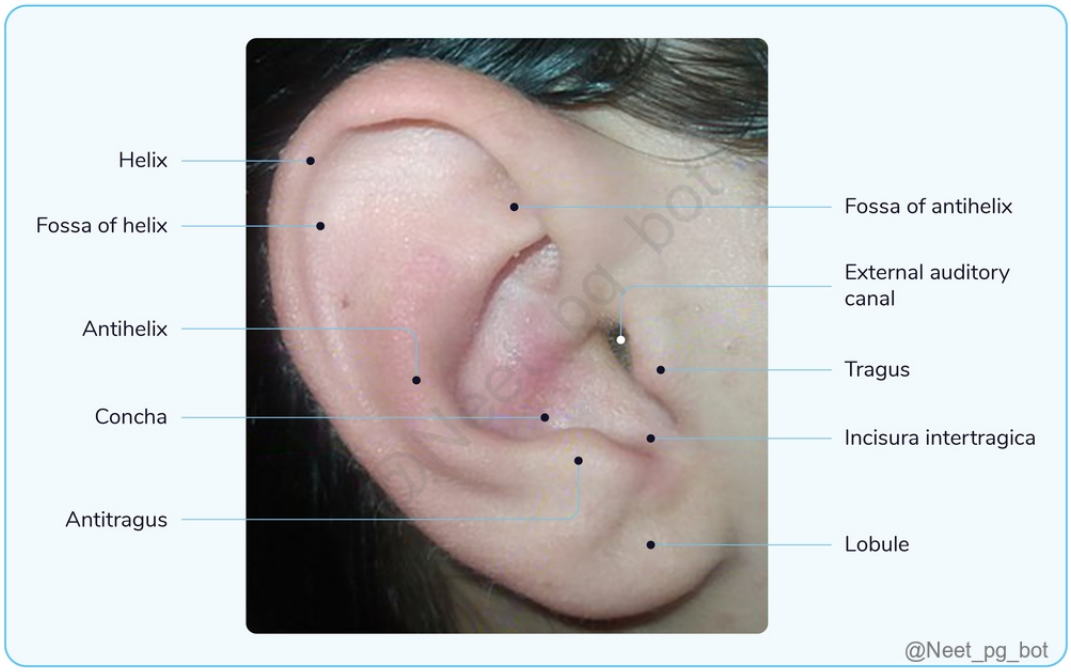
Helix
Fossa of helix
Antihelix
Concha
Antitragus
Fossa of antihelix
External auditory canal
Tragus
Incisura intertragica
Lobule
@Neet_pg_bot

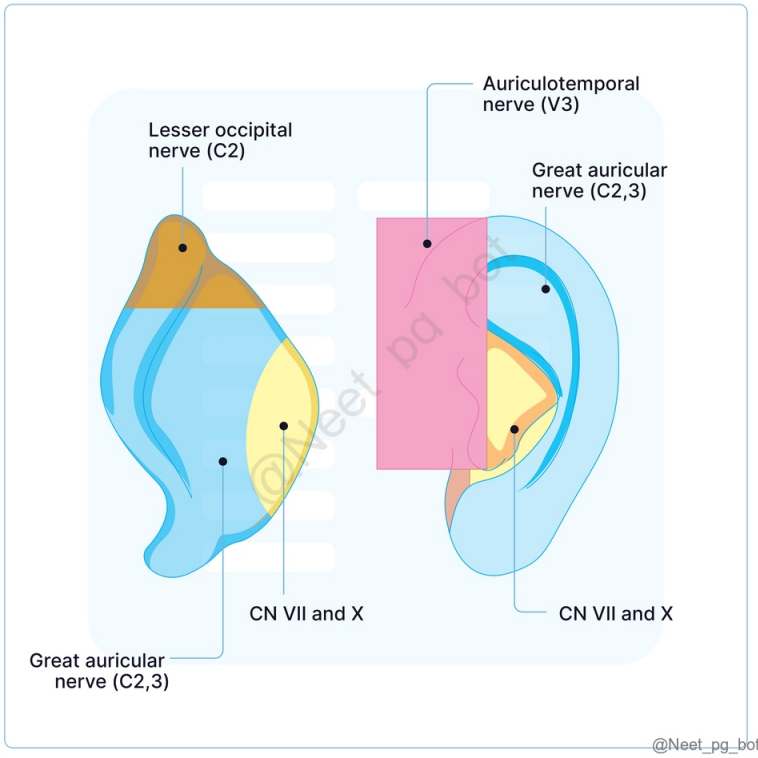
Lesser occipital nerve (C2)
Auriculotemporal nerve (V3)
Great auricular nerve (C2,3)
CN VII and X
Great auricular nerve (C2,3)
CN VII and X
@Neet_pg_bot

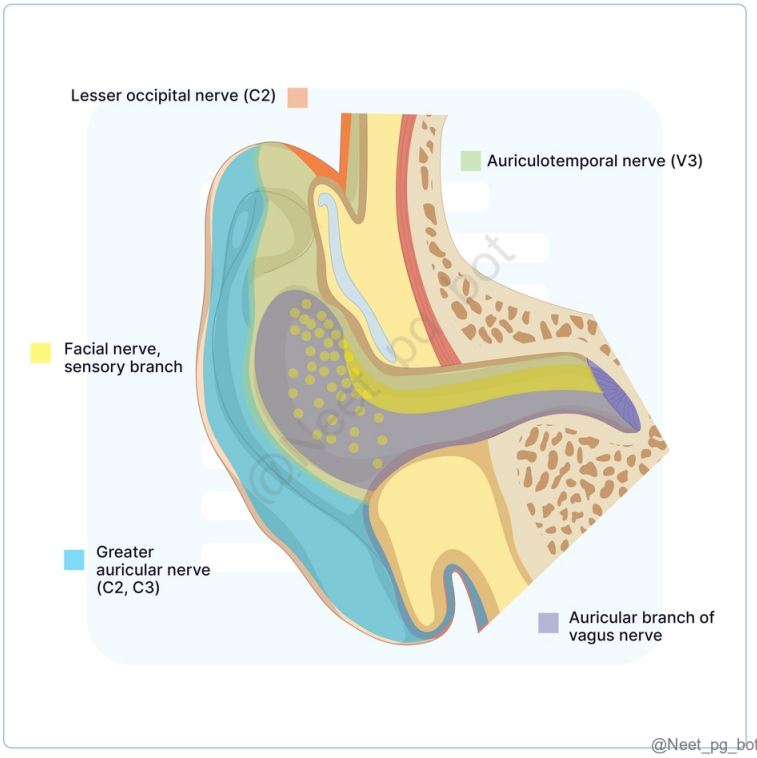

References:

Vishram Singh's Textbook of Anatomy, 2nd Edition, Page 267, 268.

↑ *Back to this question in Part A*

@Neet_pg_bot

Q3: Match the following structures with their respective locations in the middle ear A. Tympanic Plexus 1. Epitympanum B. Head of malleus 2. Lateral wall C. Stapedius muscle 3. Promontory of cochlea D. Tympanic membrane 4. Mesotympanum (Q848645)

A. A-2, B-3, C-4, D-1

B. A-3, B-4, C-1, D-2

C. A-4, B-1, C-2, D-3

D. A-3, B-1, C-4, D-2

Correct Answer: D. A-3, B-1, C-4, D-2

■ *Listen (English)*

■ *Listen (Hindi)*

Explanation: Middle Ear (Tympanic cavity or Tympanum) A narrow air-filled space located in the petrous part of the temporal bone, situated between the external ear and the internal ear. Subdivisions: Epitympanum (Attic): Located above the tympanic membrane, it contains the head of the malleus and the body and short process of the incus. Mesotympanum: Opposite the tympanic membrane; contains the handle of the malleus, long process of the incus, and stapes. It is the narrowest part. Hypotympanum: Located below the tympanic membrane. Boundaries: Boundaries of Middle ear cavity Roof (Tegmental Wall) Formed by the Tegmen tympani , separating the middle ear from the middle cranial fossa. Floor (Jugular Wall) A thin bony plate that separates the middle ear from the Internal Jugular Vein. Tympanic canaliculus for the tympanic branch of the glossopharyngeal nerve. Anterior Wall (Carotid Wall) Separates the Middle ear from the Internal Carotid Artery Posterior Wall (Mastoid Wall) Aditus ad antrum : Opening to the mastoid antrum. Fossa incudis : Lodges the short process of the incus. Pyramid: Contains the stapedius muscle. Posterior canaliculus for the chorda tympani nerve. Lateral Wall (Membranous Wall) The tympanic membrane , with contributions from the squamous temporal bone. Medial Wall (Labyrinthine Wall) Separates the Tympanic cavity from the internal ear

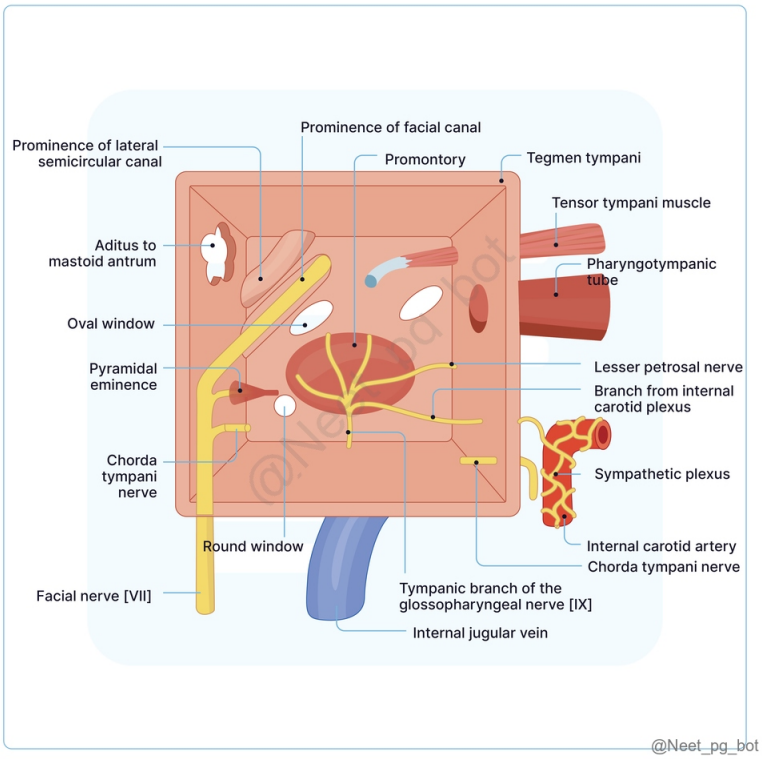

References:

BD Chaurasia’s Human Anatomy, 8th Edition, Volume 3, Page 315, 316.

↑ *Back to this question in Part A*

@Neet_pg_bot

Q4: A 60-year-old patient presents with dizziness and balance issues. The physician suspects a problem in the vestibular system. Which of the following structures is primarily responsible for detecting horizontal linear acceleration and head position relative to gravity? (Q848646)

A. Saccule

B. Utricle

C. Semicircular canals

D. Organ of Corti

Correct Answer: B. Utricle

- *Listen (English)*
- *Listen (Hindi)*

Explanation: The Utricle is a part of the vestibular system that detects horizontal linear acceleration and head position in relation to gravity, whereas the Saccule is responsible for vertical linear acceleration. The semicircular canals detect rotational movements. The Organ of Corti contains hair cells that convert sound vibrations into neural signals and are responsible for hearing.

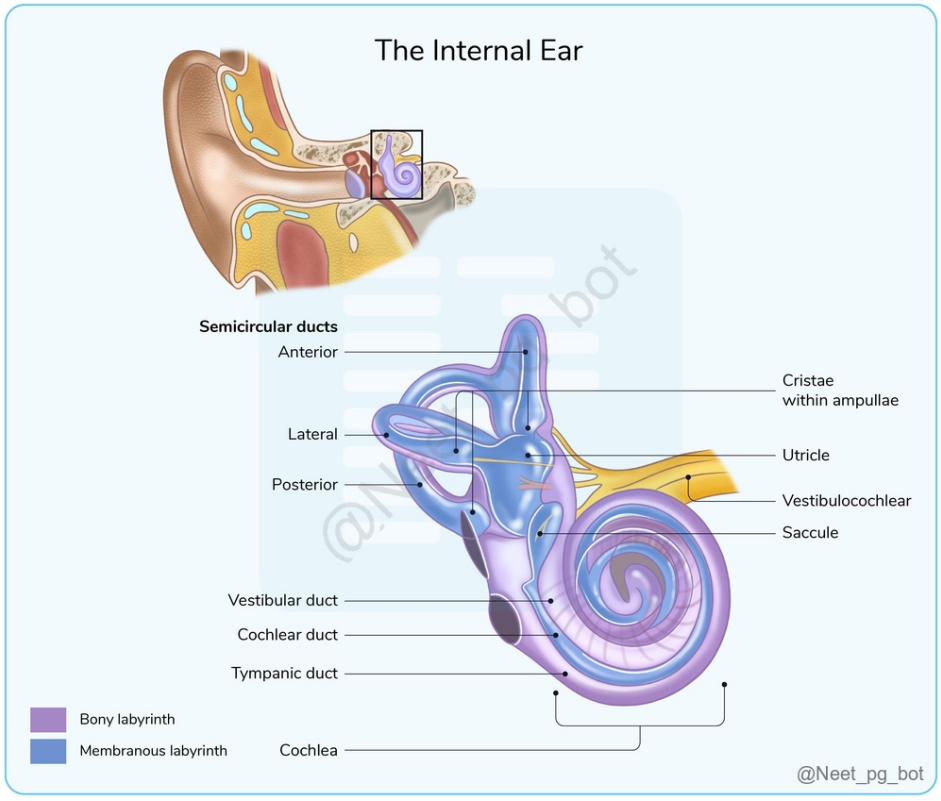

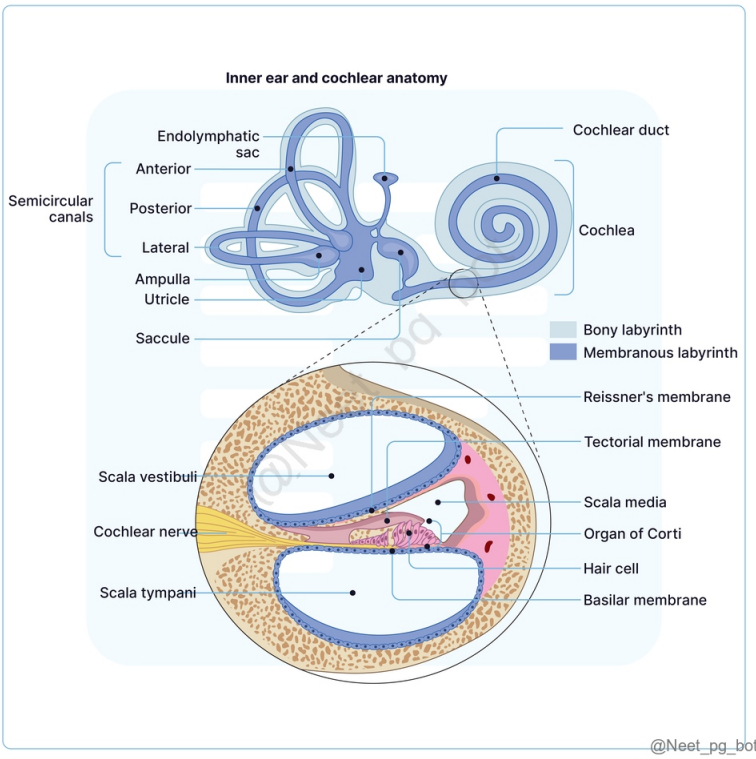

References:

Vishram Singh’s Textbook of Anatomy, 2nd Edition, Volume 3, Page 276, 278, 279.

Diseases of Ear, Nose, and Throat, PL Dhingra, 8th Edition, Page 13.

↑ *Back to this question in Part A*

@Neet_pg_bot

Q5: Match the following labelled parts of the nasal septum: 1 a. Septal Cartilage 2 b. Vomer 3 c. Palatine crest 4 d. Perpendicular Plate of Ethmoid (Q848647)

A. 1-d, 2-a, 3-b, 4-c

B. 1-a, 2-c, 3-d, 4-b

C. 1-b, 2-d, 3-a, 4-c

D. 1-c, 2-b, 3-d, 4-a

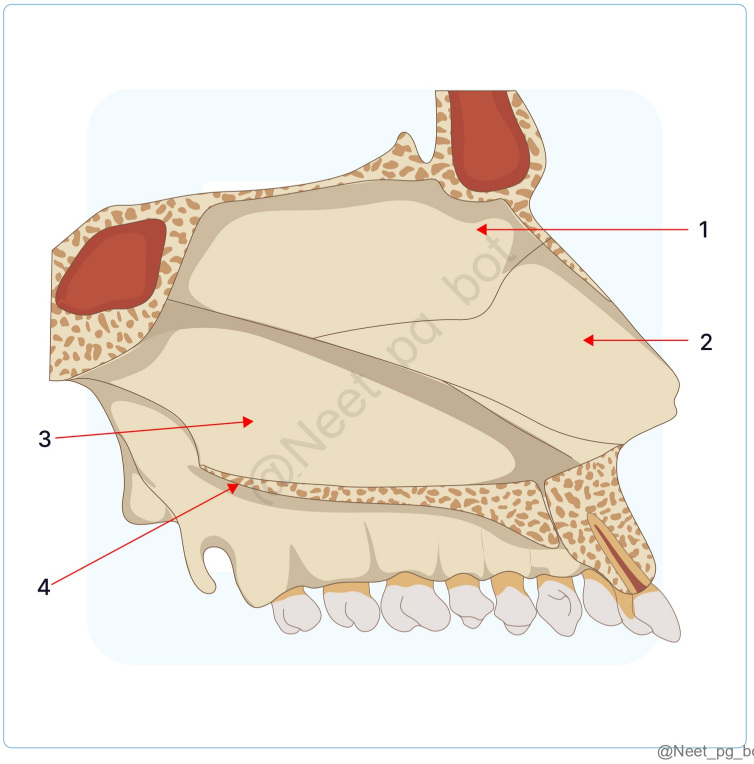

Correct Answer: A. 1-d, 2-a, 3-b, 4-c

- *Listen (English)*
- *Listen (Hindi)*

Explanation: The nasal septum is a median osseocartilaginous partition that divides the two nasal cavities. It typically deviates slightly to one side, most often to the right. Structure of the Nasal Septum: Bony Components Cartilaginous Components Perpendicular Plate of Ethmoid : Forms the posterosuperior part of the septum. Vomer : Makes up the posteroinferior part. Nasal spine of the frontal bone. Crest formed by nasal bones. Sphenoidal crest. Nasal crest from the fusion of the palatine processes of the maxillae and horizontal plates of the palatine bones. Septal Cartilage : Constitutes the major anterior part of the septum , fitting into the angle between the vomer and the perpendicular plate of the ethmoid. Septal Processes of Alar Cartilages : The medial crura of the two major alar cartilages unite at the midline, forming the columella (or columellar septum). Below the columella, a small portion of the septum comprises a double layer of skin without bony or cartilaginous support, known as the membranous septum .

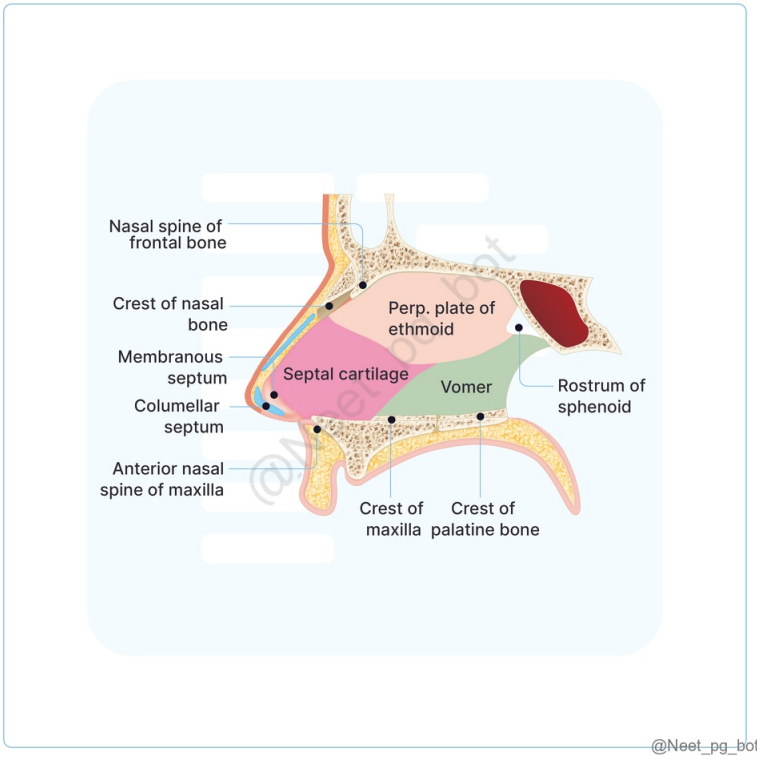

References:

Vishram Singh's Textbook of Anatomy, 2nd Edition, Page 253

↑ *Back to this question in Part A*

@Neet_pg_bot

Q6: A 32-year-old female presents to the ENT clinic with persistent nasal congestion, facial pain, and reduced sense of smell. After minimal relief from medications, a nasal endoscopy is planned. Which of the following openings is not present in the structure labelled "X" in the image below? (Q848648)

A. Frontal air sinus

B. Maxillary air sinus

C. Anterior ethmoidal air sinuses

D. Posterior ethmoidal air sinuses

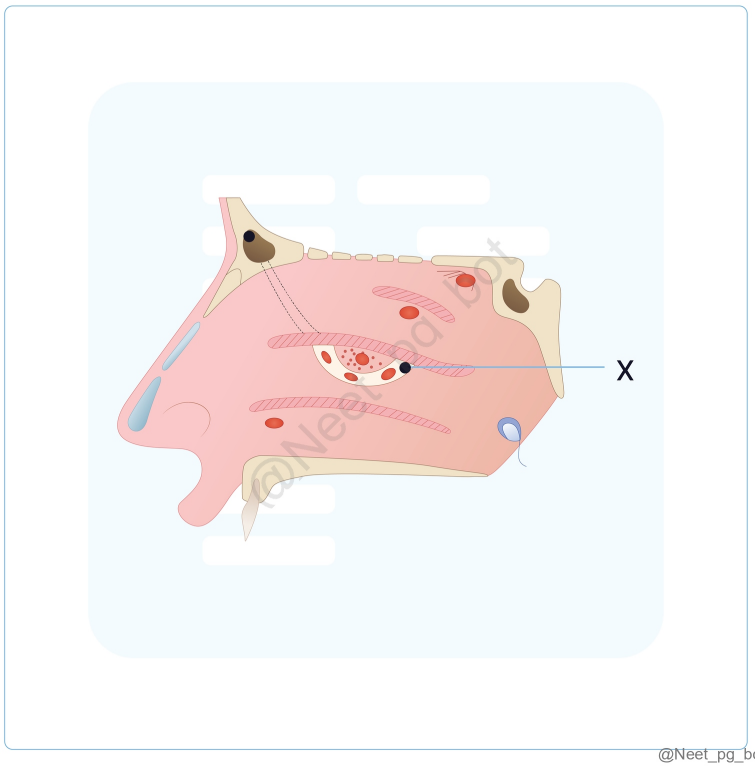

Correct Answer: D. Posterior ethmoidal air sinuses

- *Listen (English)*
- *Listen (Hindi)*

Explanation: The provided image depicts the lateral wall of the nose , with the structure labelled as the hiatus semilunaris, which contains three openings: The maxillary sinus, the frontal sinus, and the anterior ethmoidal air cells. Lateral wall of the nose: The conchae, or turbinates, are curved bony structures extending downward and medially. They are classified into superior, middle, and inferior nasal conchae. Below these conchae lies over the recesses referred to as meatuses. The atrium is a shallow depression located just in front of the middle meatus and above the nasal vestibule. It is bordered superiorly by a slight mucous membrane ridge known as the agger nasi , which extends from the upper end of the middle concha. Site Location Openings Sphenoethmoidal recess Triangular depression located above and behind the superior concha Sphenoidal air sinus Superior meatus Lies below the superior concha (Smallest) . Posterior ethmoidal air sinuses (Option D) Middle meatus Lies underneath the middle concha. Has the following parts: Ethmoidal bulla /bulla ethmoidalis (round elevation produced by the underlying middle ethmoidal sinuses). Hiatus semilunaris (semicircular sulcus below the bulla ethmoidalis). Infundibulum (passage at the anterior end of middle meatus). Bulla ethmoidalis: Middle ethmoidal air sinuses Hiatus semilunaris: Frontal air sinus (Option A) Anterior ethmoidal air sinuses (Option C) Maxillary air sinus (Option B) Inferior meatus Lies underneath the inferior nasal concha (Largest). Nasolacrimal duct (in the anterior part of inferior meatus) Hasner’s valve guards the opening of the nasolacrimal duct.

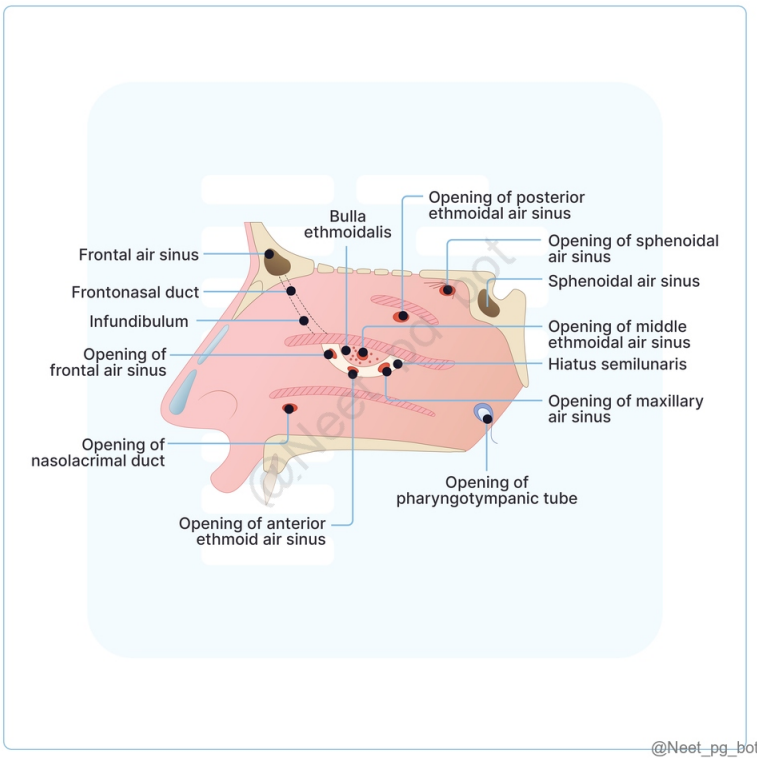

@Neet_pg_bot

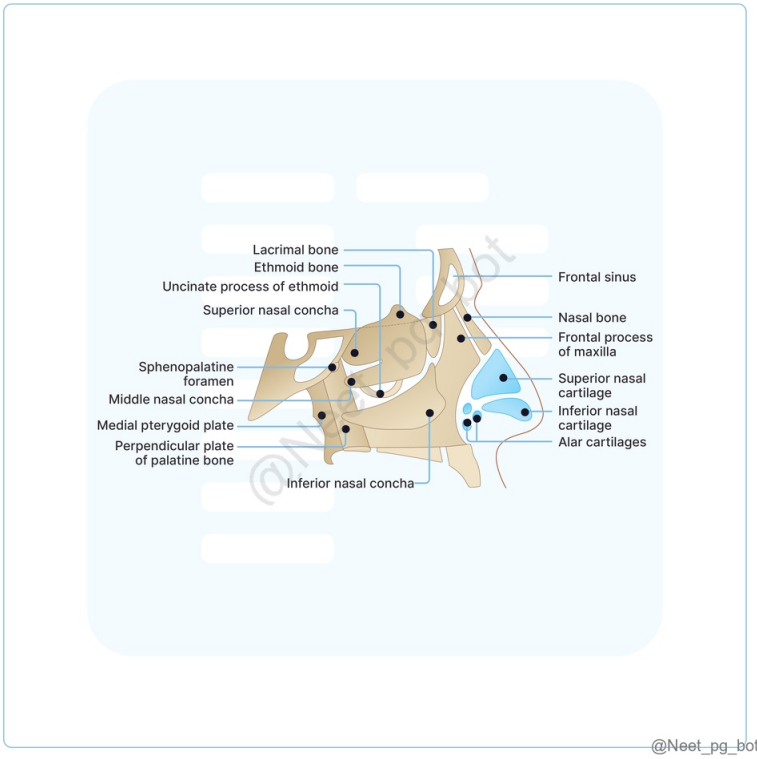

@Neet_pg_bot

References:

Grey's Anatomy, 42nd Edition, Page 690, 691, 692.

BD Chaurasia’s Human Anatomy, 8th Edition, Volume 3, Page 274-277.

Vishram Singh’s Textbook of Anatomy, 2nd Edition, Volume 3, Page 254, 255, 256.

↑ *Back to this question in Part A*

@Neet_pg_bot

Q7: A 5-month-old child is experiencing excessive tearing in both eyes. The doctor recommends that the parents perform a massage along the nasolacrimal duct (NLD). How should the parents be instructed to carry out this procedure? (Q848649)

A. Downward, backward and lateral

B. Upward, backward and medial

C. Downward, backward and medial

D. Upward, backward and lateral

Correct Answer: A. Downward, backward and lateral

■ *Listen (English)*

■ *Listen (Hindi)*

Explanation: The scenario describes a condition known as Epiphora in the bilateral eye, characterized by excessive tearing. The canal involved in this condition is the Nasolacrimal Duct , which runs downward, backwards, and laterally. Lacrimal glands produce tears and are located in the eye, draining into the nose through a membranous passage known as the nasolacrimal duct. Massage in the direction of NLD encourages drainage and can assist in relieving blockages. Nasolacrimal duct Length 18 mm Extent It extends from the lacrimal sac and opens anteriorly into the inferior meatus of the nose. Orientation Runs downwards, backwards and laterally (Option A) Valve Hasner’s valve: An incomplete mucous fold at the lower end of the duct, preventing air from entering the duct and blowing into the eye when one blows their nose to clear nasal secretions. Clinical aspect Epiphora: Excessive secretion of the lacrimal fluid overflowing on the cheeks. It may occur due to: Hyperlacrimation: Excessive secretion of tears (intake of spicy food or emotional outbreak) Obstruction in lacrimal passages (lacrimal punctum, lacrimal canaliculi, lacrimal sac and nasolacrimal duct) Ectropion (eversion of lower eyelid). Patency evaluation Jones dye test 1 & 2 are procedures to assess the patency of the nasolacrimal duct and identify problems related to tear drainage.

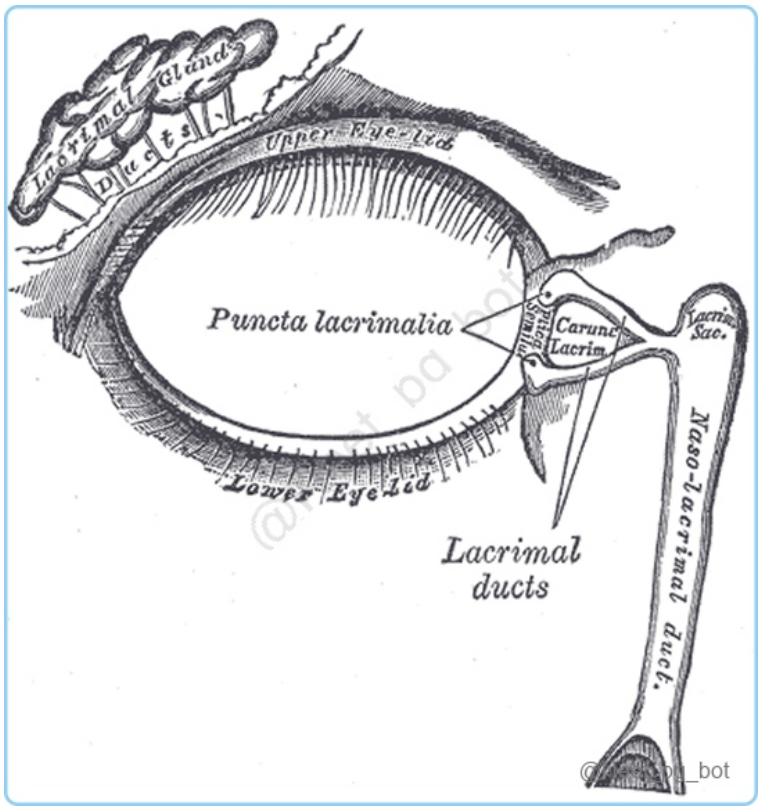

References:

Grey's Anatomy, 42nd Edition, Page 786, 789.

BD Chaurasia’s Human Anatomy, 8th Edition, Volume 3, Page 80, 81.

Vishram Singh’s Textbook of Anatomy, 2nd Edition, Volume 3, Page 66.

↑ *Back to this question in Part A*

@Neet_pg_bot

Q8: During retinoscopy, the ophthalmologist inquired of the intern about the development of the eyeball. Could you identify what will develop from the structure labeled "X" in the diagram below? (Q848650)

A. Optic nerve

B. Lens

C. Light-sensitive neural layer

D. Retinal pigment epithelium



@Neet_pg_bot

Correct Answer: C. Light-sensitive neural layer

- *Listen (English)*
- *Listen (Hindi)*

Explanation: The marked structure in the above image represents the inner layer of the optic cup , which develops into the light-sensitive neural layer of the retina. Development of Retina The retina develops from the optic vesicle. Retinal detachment: In retinal detachment there is separation of two layers of the retina (i.e., pigment and neural layers). Optic nerve (Option A) is derived from optic stalk. The center of the optic cup form the optic disc where the neural retina connects with the optic stalk, transforming it into the optic nerve. Lens (Option B) develops from the lens vesicle. The posterior cells of the vesicle form transparent primary lens fibers whereas the cells in the equatorial region produce secondary lens fibers. Retinal pigment epithelium (Option D) is developed from the outer layer of the optic cup.

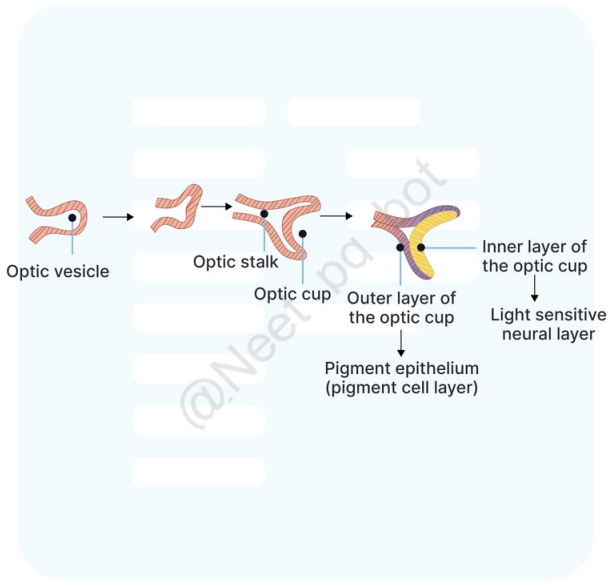

@Neet_pg_bot

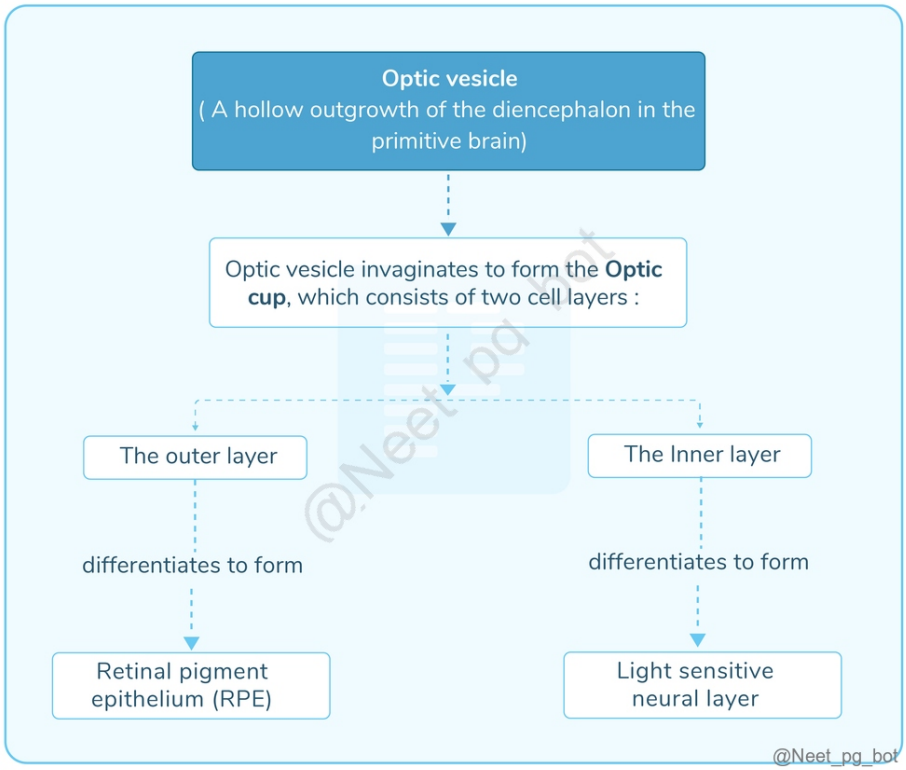

@Neet_pg_bot

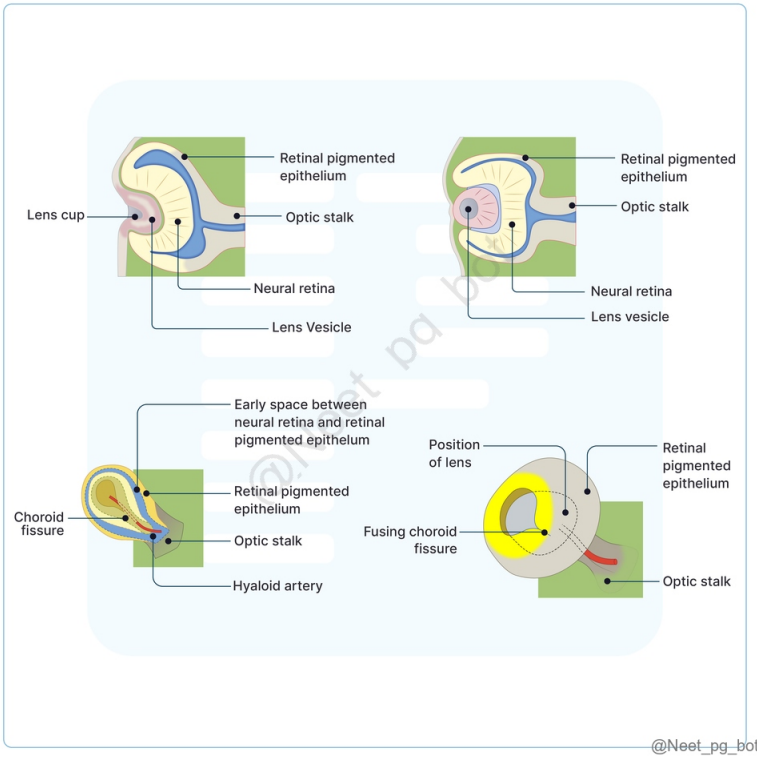

References:

Gray's Anatomy, 42nd Edition, Page 265.

BD Chaurasia’s Human Anatomy, 8th Edition, Volume 3, Page 335.

Vishram Singh’s Textbook of Anatomy, 2nd Edition, Volume 3, Page 297, 298.

↑ *Back to this question in Part A*

@Neet_pg_bot

Q9: All of the following structures pass through the area labeled "A" in the image except? (Q848651)

A. Zygomatic nerve

B. Infraorbital nerve

C. Pterygopalatine ganglion branches

D. Lacrimal nerve



Correct Answer: D. Lacrimal nerve

- *Listen (English)*
- *Listen (Hindi)*

Explanation: The image provided depicts the orbit. The ‘A’ marked structure is the inferior orbital fissure , which transmits the zygomatic nerve, infraorbital nerve, and pterygopalatine ganglion branches . However, the lacrimal nerve is transmitted from the superior oblique fissure.



@Neet_pg_bot

References:

Gray's Anatomy, 42nd Edition, Page 615

BD Chaurasia’s Human Anatomy, 8th Edition, Volume 3, Pages 28, 29, 30

Vishram Singh’s Textbook of Anatomy, 2nd Edition, Volume 3, Pages 282-285

↑ *Back to this question in Part A*

@Neet_pg_bot

Q10: A 50-year-old male presents with difficulty lifting his right eye, describing it as "stuck" when looking upward, along with double vision. Examination reveals a significant limitation in the upward gaze of the right eye. What is the action of the structure labelled "A" in the image below? (Q848652)

A. Elevation

B. Adduction

C. Intorsion

D. All of the above

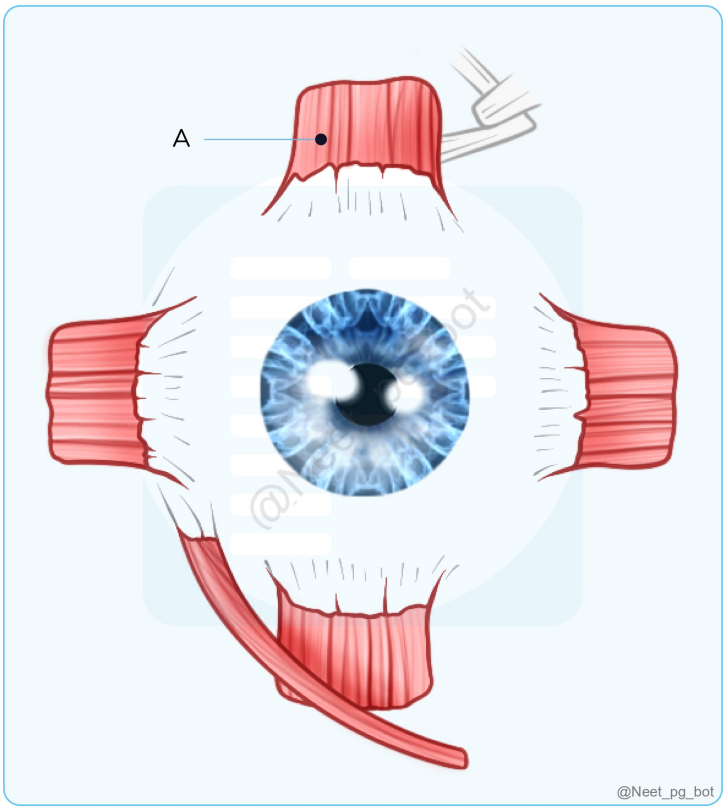

Correct Answer: D. All of the above

- *Listen (English)*
- *Listen (Hindi)*

Explanation: The structure marked in the given image is the Superior rectus muscle , which, in the primary position, performs elevation, adduction, and intorsion. Extraocular muscles Actions of muscles on the eyeball (Mnemonic): SIN- S uperior rectus/ S uperior oblique assist i IN torsion RAD- R ectus muscles help in AD duction Superior rectus (SR) (Option D) Medial rectus (MR) Inferior rectus (IR) Lateral rectus (LR) Superior oblique (SO) Inferior oblique (IO) Elevation Adduction Intorsion Adduction Depression Adduction Extorsion Abduction Depression Abduction Intorsion Elevation Abduction Extorsion

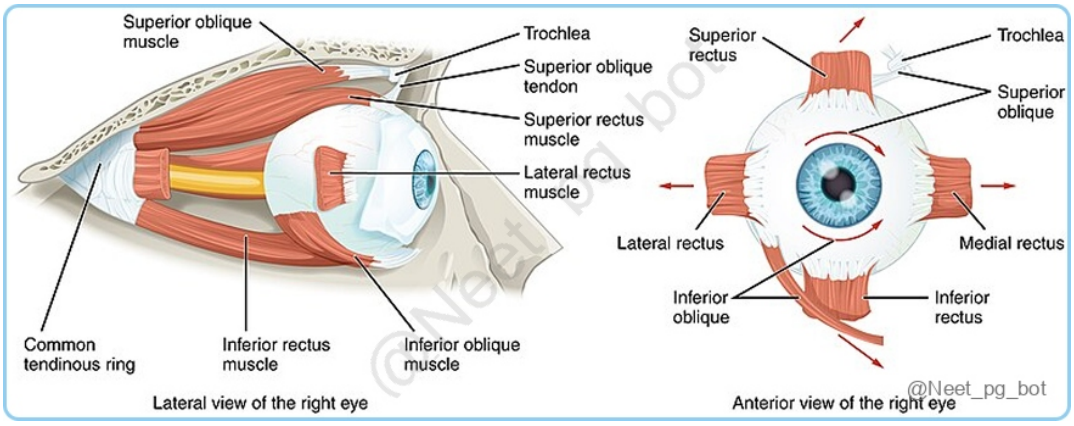

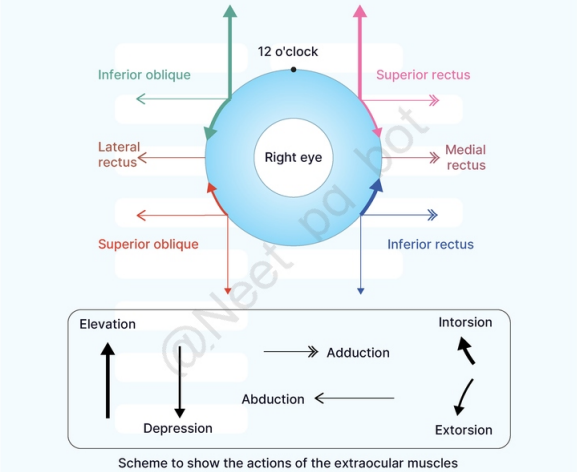

@Neet_pg_bot

References:

Gray's Anatomy, 42nd Edition, Page 773-777.

BD Chaurasia’s Human Anatomy, 8th edition, Volume 3, Page 232-237.

Vishram Singh’s Textbook of Anatomy, 2nd Edition, Volume 3, Page 285-288.

↑ *Back to this question in Part A*

@Neet_pg_bot

Q11: Which of the following arteries is not typically injured during mandibular fracture repair? (Q848653)

A. Inferior alveolar artery

B. Lingual artery

C. Facial artery

D. Maxillary artery

Correct Answer: C. Facial artery

■ *Listen (English)*

■ *Listen (Hindi)*

Explanation: Facial artery: The facial artery supplies blood to the face, but it is typically not directly involved in mandibular fractures. It is less likely to be injured in mandibular fracture repair, as it is located more superficially and does not directly supply the mandible. Mandibular fractures often involve injury to the arteries that supply the mandible and its surrounding structures Inferior alveolar artery (Option A): This artery, which is a branch of the maxillary artery, is commonly injured during mandibular fractures, especially in fractures of the body or angle of the mandible. Lingual artery (Option B): The lingual artery, which supplies the tongue and floor of the mouth, can also be injured in fractures of the mandibular body or ramus. It is often at risk during fractures near the midline or in the region of the tongue. Maxillary artery (Option D): This major artery supplies blood to the mandible through its branches, such as the inferior alveolar artery. It is closely related to the mandible, as it originates behind the neck and passes between the ramus and the sphenomandibular ligament.

References:

Gray's Atlas of Anatomy, 3rd Edition, Pages 988, 1013, 1218, 1219

Gray’s Anatomy, 42nd Edition, Pages 405, 585, 586

↑ *Back to this question in Part A*

@Neet_pg_bot

• [04_Head and Neck] 022 Previous Year Questions

« Back to Folder Directory

[04_Head and Neck] 022 Previous Year Questions — Quick Jump

Q1 (p. 1275)	*Q2 (p. 1276)*	*Q3 (p. 1278)*	*Q4 (p. 1279)*	*Q5 (p. 1280)*	*Q6 (p. 1282)*
Q7 (p. 1283)	*Q8 (p. 1284)*	*Q9 (p. 1285)*	*Q10 (p. 1286)*	*Q11 (p. 1287)*	*Q12 (p. 1289)*
Q13 (p. 1290)	*Q14 (p. 1293)*	*Q15 (p. 1294)*	*Q16 (p. 1295)*	*Q17 (p. 1295)*	*Q18 (p. 1296)*
Q19 (p. 1297)	*Q20 (p. 1299)*	*Q21 (p. 1300)*	*Q22 (p. 1302)*	*Q23 (p. 1304)*	*Q24 (p. 1309)*
Q25 (p. 1311)	*Q26 (p. 1313)*	*Q27 (p. 1314)*	*Q28 (p. 1316)*	*Q29 (p. 1317)*	*Q30 (p. 1318)*
Q31 (p. 1320)	*Q32 (p. 1321)*	*Q33 (p. 1323)*	*Q34 (p. 1324)*	*Q35 (p. 1325)*	*Q36 (p. 1329)*
Q37 (p. 1330)	*Q38 (p. 1331)*	*Q39 (p. 1333)*	*Q40 (p. 1334)*	*Q41 (p. 1336)*	*Q42 (p. 1336)*
Q43 (p. 1337)	*Q44 (p. 1339)*	*Q45 (p. 1341)*	*Q46 (p. 1342)*	*Q47 (p. 1343)*	*Q48 (p. 1345)*
Q49 (p. 1346)	*Q50 (p. 1347)*	*Q51 (p. 1348)*	*Q52 (p. 1349)*	*Q53 (p. 1350)*	*Q54 (p. 1351)*
Q55 (p. 1352)	*Q56 (p. 1353)*	*Q57 (p. 1355)*	*Q58 (p. 1356)*	*Q59 (p. 1357)*	*Q60 (p. 1358)*
Q61 (p. 1360)	*Q62 (p. 1361)*	*Q63 (p. 1363)*	*Q64 (p. 1364)*	*Q65 (p. 1367)*	*Q66 (p. 1368)*
Q67 (p. 1369)	*Q68 (p. 1369)*	*Q69 (p. 1370)*	*Q70 (p. 1371)*	*Q71 (p. 1371)*	*Q72 (p. 1372)*
Q73 (p. 1374)	*Q74 (p. 1375)*				

Q1: What is the structure marked in the image below? (Q857223)

A. Genioglossus

B. Hyoglossus

C. Styloglossus

D. Palatoglossus

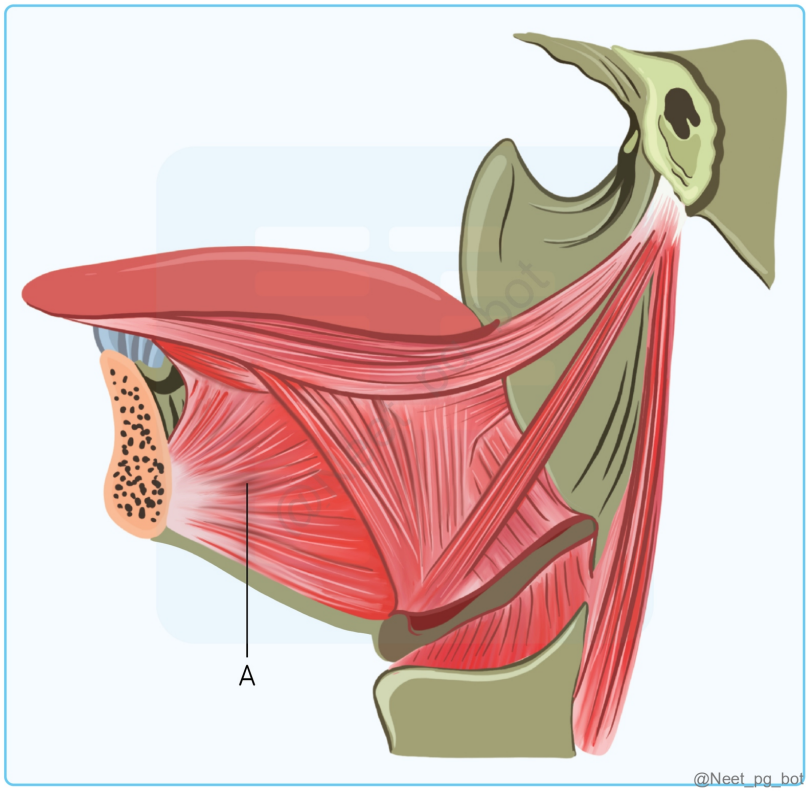

Correct Answer: A. Genioglossus

Explanation: The Genioglossus muscle is fan-shaped and extends from the mandible to the tongue . The direction of fibers in the image indicates a broad origin from the mandible and insertion into the tongue . Function: It protrudes the tongue (helps in sticking out the tongue). Extrinsic Muscles of the Tongue Muscle Origin Insertion Function Innervation Genioglossus Genial tubercle of mandible Entire tongue Protrudes tongue Hypoglossal nerve (CN XII) Hyoglossus Hyoid bone Side of the tongue Depresses and retracts tongue Hypoglossal nerve (CN XII) Styloglossus Styloid process of temporal bone Side of tongue Retracts and elevates tongue Hypoglossal nerve (CN XII) Palatoglossus Soft palate Side of tongue Elevates posterior tongue Vagus nerve (CN X) Hyoglossus (Option B): Incorrect because it arises from the hyoid bone and functions in tongue depression . Styloglossus (Option C): Incorrect because it originates from the styloid process and functions in tongue retraction . Palatoglossus (Option D): Incorrect because it arises from the soft palate and functions in elevating the tongue .

References:

https://pubmed.ncbi.nlm.nih.gov/11113811/

↑ *Back to this question in Part A*

@Neet_pg_bot

Q2: Inferior thyroid artery supplies which of the following structures? 1. Thyroid 2. Parathyroid 3. Esophagus 4. Thymus (Q856669)

A. 1, 2, 3 and 4

B. 1, 2 and 3

C. 1 and 2 only

D. 1, 2 and 4 only

Correct Answer: A. 1, 2, 3 and 4

Explanation: The inferior thyroid artery , a branch of the thyrocervical trunk (from the subclavian artery) , supplies multiple structures in the neck and thorax: Thyroid gland (Primary blood supply to the posterior-inferior part). Parathyroid glands (Main arterial supply). Esophagus (Via esophageal branches). Thymus (Via small branches extending into the upper thorax). Since all four structures receive blood from the inferior thyroid artery, the correct answer is Option A (1, 2, 3, and 4). Inferior Thyroid Artery Feature Details Origin Thyrocervical trunk (branch of subclavian artery) Course Ascends posterior to the carotid sheath , loops medially toward the thyroid Branches Ascending cervical artery (supplies prevertebral muscles) Esophageal branches (to upper esophagus) Tracheal branches (to trachea) Inferior laryngeal artery (to larynx via recurrent laryngeal nerve) Supplies Thyroid gland (posterior part) Parathyroid glands Esophagus Thymus 1, 2, and 3 (Option B): Incorrect – Excludes thymus , which receives supply from the inferior thyroid artery. 1 and 2 only (Option C): Incorrect – Excludes esophagus and thymus , both of which receive supply from the inferior thyroid artery. 1, 2, and 4 only (Option D): Incorrect – Excludes esophagus , which is supplied by esophageal branches of the inferior thyroid artery .

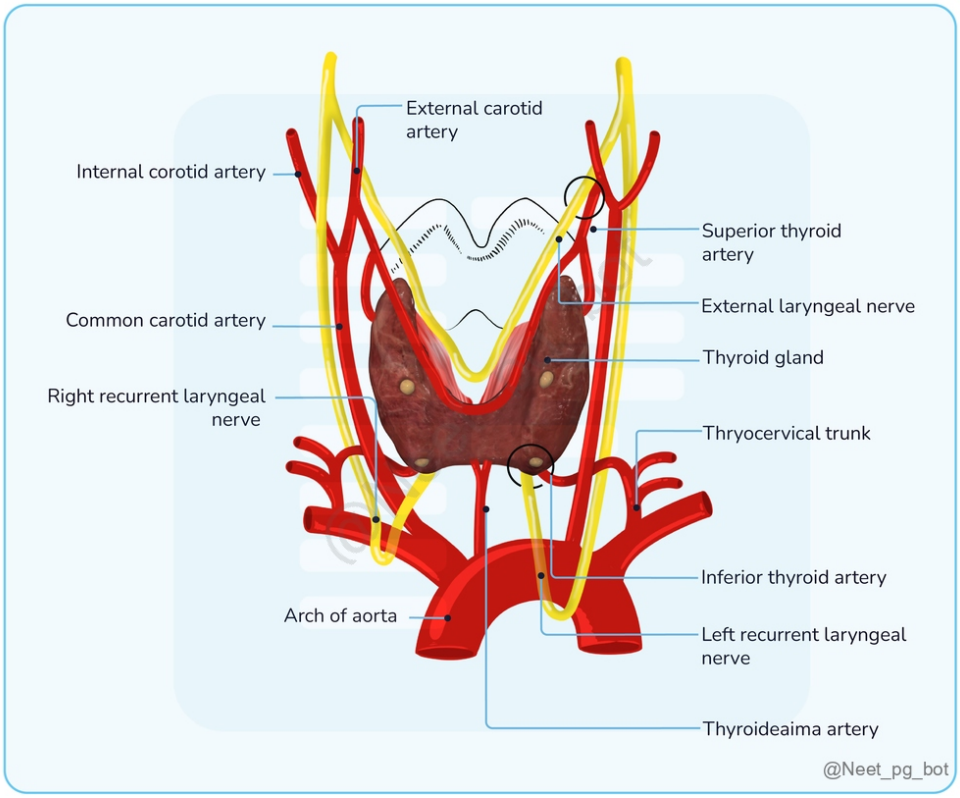

References:

Gray's Anatomy: The Anatomical Basis of Clinical Practice, 42nd Edition - Page no: 601-603, 1055

↑ *Back to this question in Part A*

@Neet_pg_bot

Q3: The third part of the vertebral artery is related to which of the following? (Q856635)

A. 4

B. 3

C. 2

D. 1

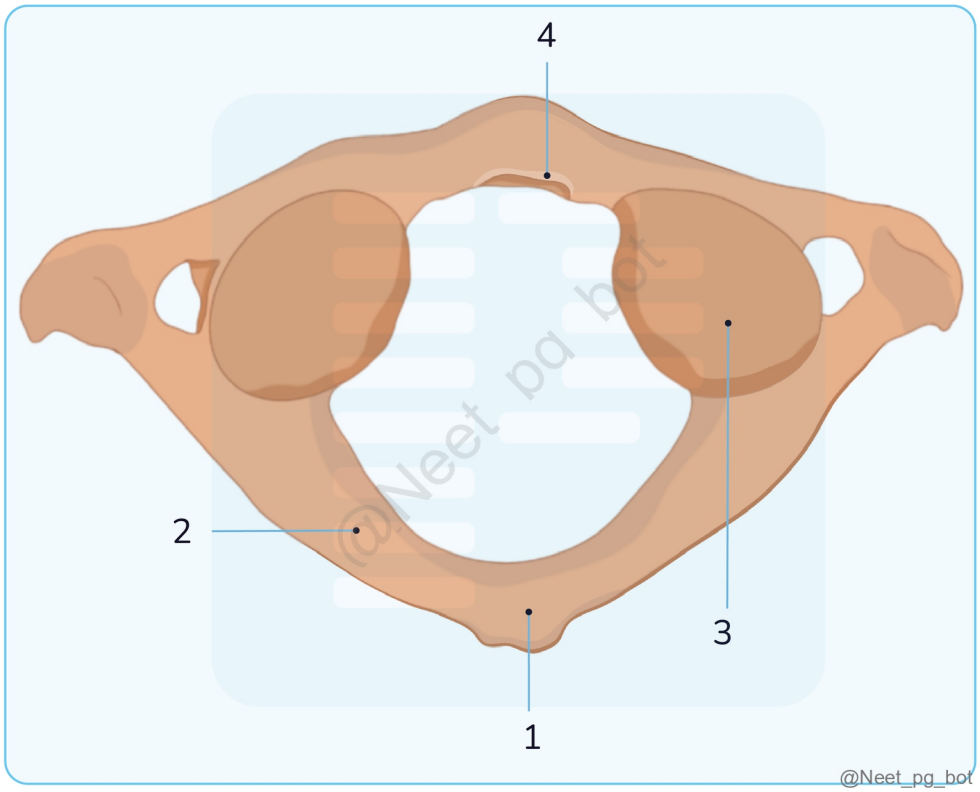

Correct Answer: C. 2

Explanation: The third part of the vertebral artery (V3 segment) runs posterior to the lateral mass of the atlas (C1) and passes through the vertebral groove before turning medially to enter the foramen magnum . Label 2 in the image represents the posterior arch of the atlas , which is where the vertebral artery runs before entering the cranial cavity. Hence, the correct answer is Option C (2) . Vertebral Artery Course & Relations Vertebral Artery Segment Course & Relations V1 (Pre-foraminal) Arises from subclavian artery , enters C6 transverse foramen . V2 (Foraminal) Ascends through transverse foramina (C6 to C1) . V3 (Extracranial/Suboccipital) Exits C1 transverse

foramen , curves over posterior arch (Label 2) , turns medially before piercing dura. V4 (Intracranial) Enters the skull via foramen magnum , joins contralateral vertebral artery to form basilar artery . 4 (Option A): Incorrect – Represents the anterior arch of atlas , which is unrelated to the vertebral artery. 3 (Option B): Incorrect – Identified as the superior articular facet , which articulates with the occipital condyles but is not related to the vertebral artery. 1 (Option D): Incorrect – Corresponds to the posterior tubercle.

References:

Gray's Anatomy: The Anatomical Basis of Clinical Practice, 41st Edition - Page no: 456-458, 722

↑ *Back to this question in Part A*

@Neet_pg_bot

Q4: Identify the cranial nerve passing through the given structure? (Q856634)

A. III

B. V

C. IV

D. VI

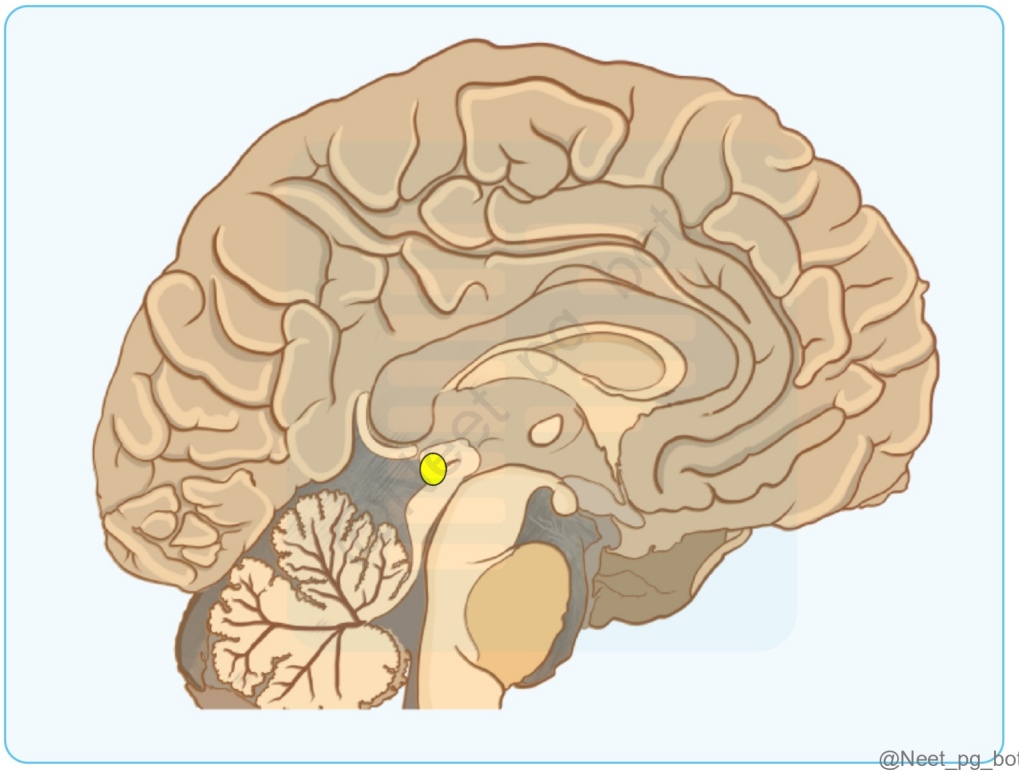

@Neet_pg_bot

Correct Answer: C. IV

Explanation: The marked structure is the dorsal aspect of the brainstem , specifically the region of the midbrain , near the inferior colliculus . Cranial Nerve IV (Trochlear Nerve) is the only cranial nerve that emerges from the dorsal aspect of the brainstem. The trochlear nerve decussates (crosses) before exiting , meaning a lesion in one trochlear nucleus affects the contralateral superior oblique muscle. Function: It innervates the superior oblique muscle , aiding in intorsion and depression of the eye in adduction . Trochlear Nerve (CN IV) and its Unique Features Feature Details Origin Dorsal midbrain , just below the inferior colliculus Exit Point Only cranial nerve to exit dorsally Decussation Crosses completely before exiting, affecting the contralateral superior oblique muscle Function Eye movement (intorsion & depression in adduction) Lesion Effect Vertical diplopia (trouble looking down, especially while reading or descending stairs) Cranial Nerve III (Option A): Incorrect because CN III emerges from the ventral midbrain (interpeduncular fossa), not the dorsal brainstem. Cranial Nerve V (Option B): Incorrect because CN V emerges from the pons , not the dorsal aspect of the brainstem. Cranial Nerve VI (Option D): Incorrect because CN VI emerges from the pontomedullary junction (ventral side) , not dorsally.

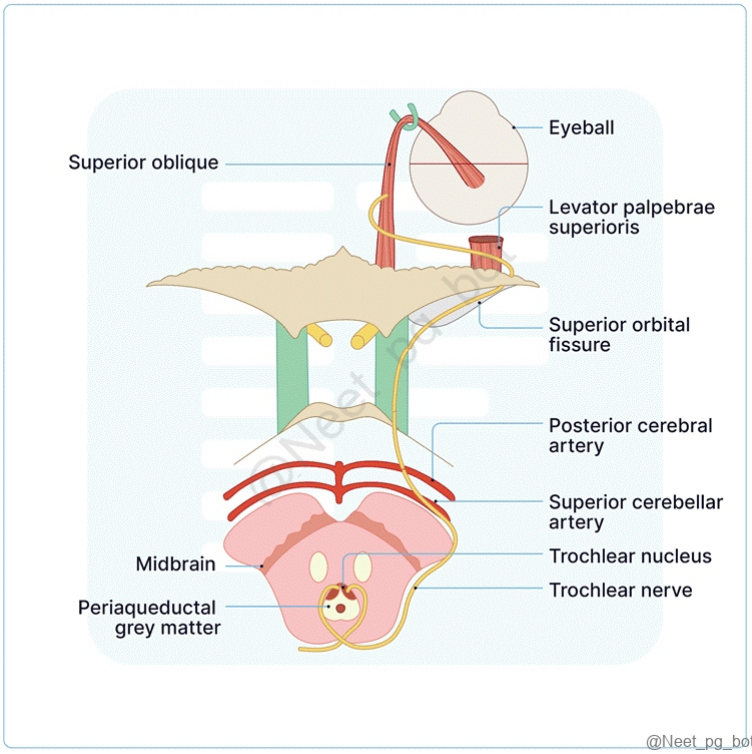

References:

Gray's Anatomy: The Anatomical Basis of Clinical Practice, 41st Edition - Page no: 678, 671

https://www.ncbi.nlm.nih.gov/books/NBK537244/

↑ *Back to this question in Part A*

@Neet_pg_bot

Q5: A 12-year-old presented with fever and difficulty swallowing. He had swelling in the marked region and was advised to undergo surgery. Post-surgery the gauze continued to soak with blood. Which of the following vessels must have been injured? (Q858149)

A. Tonsillar branch of facial artery

B. Ascending pharyngeal artery

C. Paratonsillar vein

D. Retromandibular vein

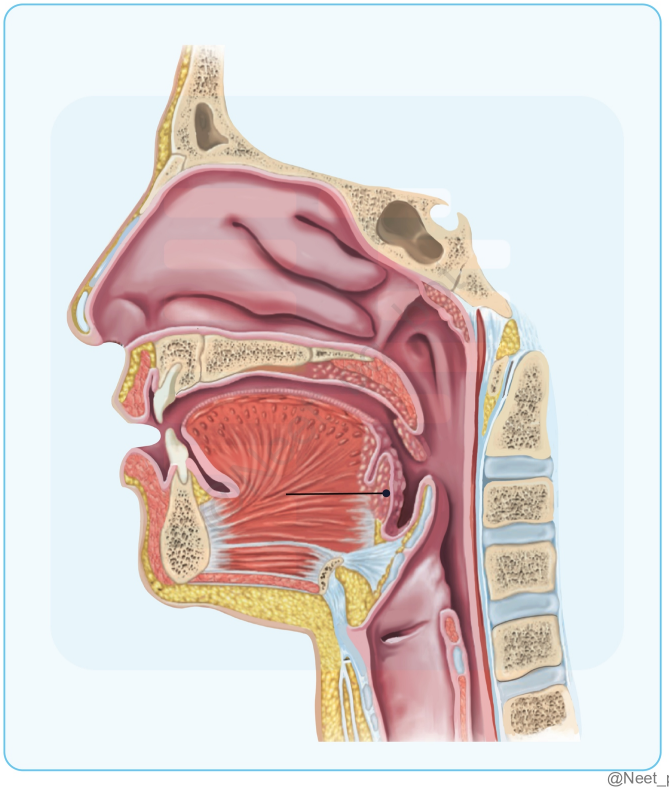

Correct Answer: C. Paratonsillar vein

Explanation: The paratonsillar vein is a major venous drainage pathway of the palatine tonsils and is vulnerable to injury during tonsillectomy . Profuse post-tonsillectomy hemorrhage , especially after surgery, commonly results from the rupture of this vein, leading to continuous bleeding. Vascular Supply of the Tonsils Vessel Type Clinical Relevance Tonsillar branch of the facial artery Arterial Major arterial supply to the tonsils Ascending pharyngeal artery Arterial Secondary supply to the pharynx & tonsils Paratonsillar vein Venous Major drainage vein, commonly injured in tonsillectomy Retromandibular vein Venous Drains the face, not directly involved in tonsillar bleeding Tonsillar branch of the facial artery (Option A): Incorrect because while it supplies the tonsil, arterial bleeding is less common post-tonsillectomy compared to venous bleeding. Ascending pharyngeal artery (Option B): Incorrect because it primarily supplies the pharynx but is not the major source of post-tonsillectomy

hemorrhage. Retromandibular vein (Option D): Incorrect because it drains the face and has no direct relation to the tonsils.

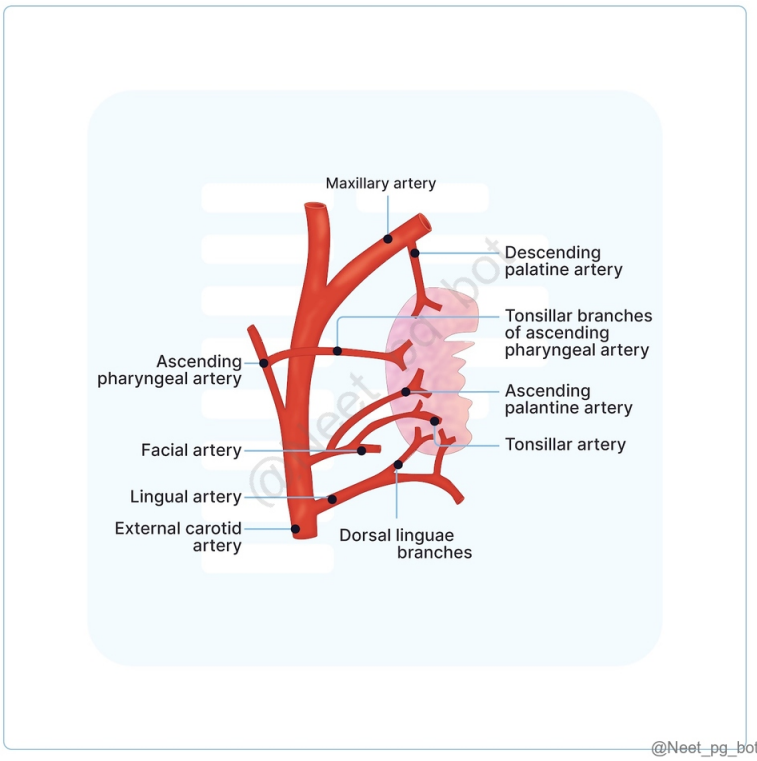

References:

Gray's Anatomy: The Anatomical Basis of Clinical Practice, 41st Edition - Page no 576, 577.

Diseases of Ear, Nose, Throat - PL Dhingra, 7th edition, Pg 291, 292, 489

↑ *Back to this question in Part A*

@Neet_pg_bot

Q6: Which of the following muscles is an abductor of the vocal cord? (Q857636)

A. Lateral cricoarytenoid

B. Posterior cricoarytenoid

C. Thyroarytenoid

D. Vocalis

Correct Answer: B. Posterior cricoarytenoid

Explanation: The posterior cricoarytenoid muscle is the only abductor of the vocal cords. It pulls the arytenoid cartilages laterally , opening the glottis and allowing air passage during respiration. Muscles of the Larynx Muscle Action Function Posterior cricoarytenoid Abducts vocal cords Only abductor, opens airway during inspiration. Lateral cricoarytenoid Adducts vocal cords Closes glottis for phonation. Thyroarytenoid Relaxes vocal cords Lowers pitch of voice. Vocalis Tenses vocal cords Fine control of voice modulation. Lateral cricoarytenoid (Option A): Incorrect because it adducts the vocal cords, closing the glottis. Thyroarytenoid (Option C): Incorrect because it relaxes the vocal cords, reducing tension. Vocalis (Option D): Incorrect because it tenses the vocal cords, adjusting voice pitch.

References:

Dhingra's Diseases Of Ear, Nose And Throat, & Head and Neck Surgery, 8th edition, Pages.331,332,335

Scott-Brown’s Otorhinolaryngology Head and Neck Surgery , 8th Edition, 3rd Volume, Page 886

↑ *Back to this question in Part A*

@Neet_pg_bot

Q7: All of the following are paired cartilages except? (Q857617)

A. Arytenoid

B. Thyroid

C. Cuneiform

D. Corniculate

Correct Answer: B. Thyroid

Explanation: The thyroid cartilage is an unpaired cartilage of the larynx, forming the Adam’s apple . It is the largest laryngeal cartilage and consists of two laminae fused in the midline. Type Cartilage Paired/Unpaired Function Unpaired Thyroid (Option B) Unpaired Forms the laryngeal prominence (Adam’s apple), provides structural support. Cricoid Unpaired Complete ring, supports larynx, attachment site for muscles. Epiglottis Unpaired Leaf-shaped, prevents food from entering the trachea. Paired Arytenoid (Option A ruled out) Paired Controls vocal cord movement. Corniculate (Option D ruled out) Paired Sits on top of arytenoids, helps with voice modulation. Cuneiform (Option C ruled out) Paired Provides structural support to the laryngeal inlet.
{{caption_text}}

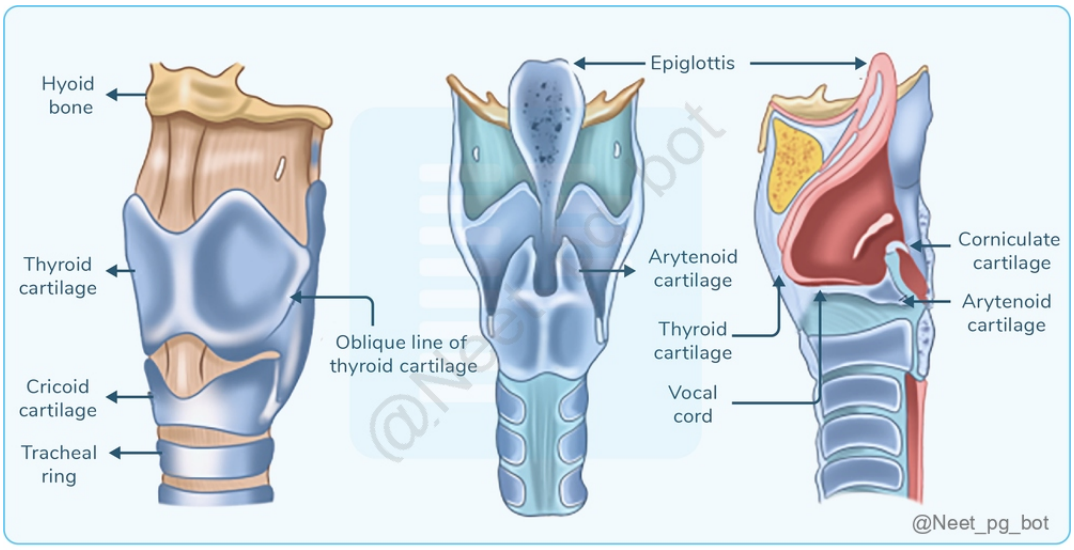

References:

Dhingra's Diseases Of Ear, Nose And Throat, & Head and Neck Surgery, 8th edition, Pages.331,332,335

Scott-Brown’s Otorhinolaryngology Head and Neck Surgery , 8th Edition, 3rd Volume, Page 886

↑ *Back to this question in Part A*

@Neet_pg_bot

Q8: Which of the following cartilage do not calcify with age? (Q857580)

A. Thyroid

B. Arytenoid

C. Epiglottis

D. Cricoid

Correct Answer: C. Epiglottis

Explanation: The epiglottis is composed of elastic cartilage , which does not undergo calcification with age. In contrast, cartilages made of hyaline cartilage - such as the thyroid, cricoid, and parts of the arytenoid cartilage - tend to calcify and ossify over time. Laryngeal Cartilages and Aging Changes Cartilage Type Function Calcification with Age Thyroid Hyaline Protects vocal cords, supports larynx Yes, calcifies and ossifies Cricoid Hyaline Provides structural support to the airway Yes, calcifies and ossifies Arytenoid Hyaline (except vocal process, which has elastic cartilage) Controls vocal cord movement Yes, except vocal process Epiglottis Elastic Prevents food from entering airway No, remains flexible Thyroid cartilage (Option A): incorrect because it is composed of hyaline cartilage , which calcifies and ossifies with age. Arytenoid cartilage (Option B): incorrect because it has both hyaline and elastic components . The hyaline part calcifies , but the elastic part (vocal process)

does not . Cricoid cartilage (Option D): incorrect because it is made of hyaline cartilage , which undergoes calcification over time.

References:

Dhingra's Diseases Of Ear, Nose And Throat, & Head and Neck Surgery, 8th edition, Page 331

Scott-Brown’s Otorhinolaryngology Head and Neck Surgery , 8th Edition, 3rd Volume, Pages 886, 887.

Logan Turner’s Diseases Of Nose, Throat And Ear Head and Neck Surgery, 11th edition. Page 150

↑ *Back to this question in Part A*

@Neet_pg_bot

Q9: Killian’s dehiscence is seen between? (Q857232)

A. Palatopharyngeus and cricopharyngeus

B. Thyropharyngeus and palatopharyngeus

C. Cricopharyngeus and thyropharyngeus

D. Palatopharyngeus and salpingopharyngeus

Correct Answer: C. Cricopharyngeus and thyropharyngeus

Explanation: Killian’s dehiscence is a potential weak area in the posterior pharyngeal wall, located between the cricopharyngeus (inferior part of the inferior pharyngeal constrictor) and thyropharyngeus (superior part of the inferior pharyngeal constrictor) . This site is prone to the formation of Zenker’s diverticulum , a pharyngeal pouch due to increased pressure during swallowing. Pharyngeal Muscles and Weak Areas Pharyngeal Muscle Function Clinical Relevance Thyropharyngeus (Superior part of Inferior Constrictor) Constricts pharynx Forms upper boundary of Killian's dehiscence Cricopharyngeus (Inferior part of Inferior Constrictor) Acts as upper esophageal sphincter Forms lower boundary of Killian's dehiscence Killian’s Dehiscence Weak area between these muscles Site of Zenker’s diverticulum Palatopharyngeus and Cricopharyngeus (Option A): Incorrect because palatopharyngeus is a longitudinal muscle of the pharynx, unrelated to Killian’s dehiscence. Thyropharyngeus and Palatopharyngeus (Option B): Incorrect because palatopharyngeus is not involved in this weak area. Palatopharyngeus and Salpingopharyngeus (Option D): Incorrect as these muscles are involved in pharyngeal elevation, not the formation of Killian’s dehiscence.

References:

BD Chaurasia’s Human Anatomy, Volume 3, 8th Edition, Pages 263-266

↑ *Back to this question in Part A*

@Neet_pg_bot

Q10: A patient after a road traffic accident presents to the emergency room with difficulty in swallowing and slurred speech. Investigations reveal fractures in the occipitotemporal region. Which of the following areas should be tested in order to find the nerve which is involved? (Q856672)

A. 1

B. 2

C. 3

D. 4

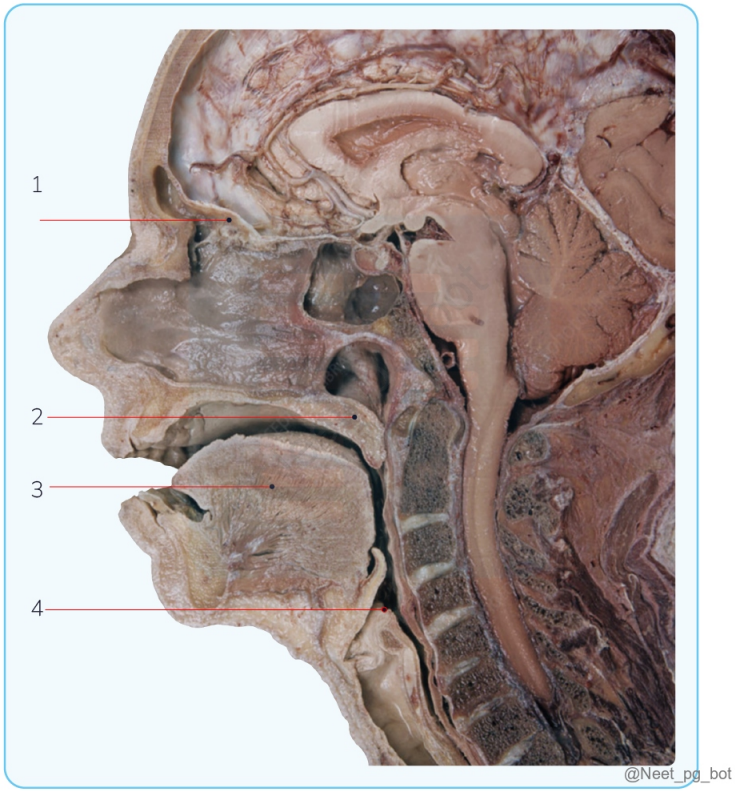

Correct Answer: B. 2

Explanation: The patient presents with dysphagia (difficulty swallowing) and dysarthria (slurred speech) after a road traffic accident with fractures in the occipitotemporal region . These symptoms suggest injury to the vagus nerve (CN X), which controls motor function of the larynx and pharynx . Option B (2) is correct because this area corresponds to the oropharynx, where CN IX (Glossopharyngeal) and CN X (Vagus) can be tested . Injury to the jugular foramen (through which CN IX, X, and XI pass) can lead to loss of gag reflex, hoarseness, and swallowing difficulty . Cranial Nerve Involvement in Dysphagia & Dysarthria Cranial Nerve Function Clinical Signs of Injury Glossopharyngeal (IX) Sensory to oropharynx, motor to stylopharyngeus Loss of gag reflex, impaired swallowing Vagus (X) Motor to larynx, pharynx, soft palate Hoarseness, dysphagia, absent gag reflex Hypoglossal (XII)

Motor to tongue muscles Tongue deviation to lesion side, slurred speech Testing the oropharynx (Option 2) helps assess Glossopharyngeal and Vagus nerve function since both are responsible for swallowing and speech. 1 (Option A) – Incorrect: The cribriform plate is associated with CN I (Olfactory nerve), involved in smell, not speech or swallowing. 3 (Option C) – Incorrect: The tongue is controlled mainly by CN XII (Hypoglossal), which affects tongue movements but not swallowing reflex. 4 (Option D) – Incorrect: The larynx is controlled by CN X, but primary motor function testing for swallowing is done at the oropharynx (Option 2).

References:

Snell's Clinical Neuroanatomy, 8th Edition - Pg 194

Macleod's Clinical Examination, 13th Edition - Pg 132

Harrison's Principles of Internal Medicine, 20th Edition - Pg 3028

↑ *Back to this question in Part A*

@Neet_pg_bot

Q11: The image below shows the cross-section of the trachea. Identify the structure marked. (Q857212)

A. Trachealis muscle

B. Tracheal cartilage

C. Esophageal submucosal gland

D. Perichondrium

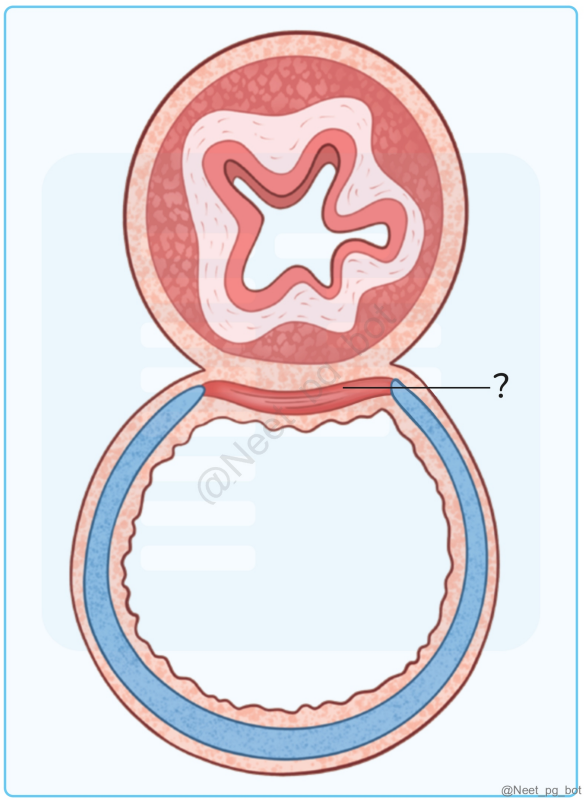

Correct Answer: A. Trachealis muscle

Explanation: The marked structure is located posteriorly in the trachea, bridging the open ends of the C-shaped tracheal cartilage rings . This is the trachealis muscle , a smooth muscle that allows flexibility during swallowing and coughing. Tracheal Structure Structure Location Function Tracheal cartilage C-shaped hyaline cartilage rings Keeps the airway open Trachealis muscle Posterior, between cartilage ends Regulates tracheal diameter, aids in forceful expiration Esophageal submucosal gland In the esophagus (posterior to trachea) Produces mucus for lubrication Perichondrium Surrounds cartilage Provides nutrition and support Tracheal cartilage (Option B): Incorrect because the marked structure is soft muscle, whereas cartilage forms the rigid anterior C-shaped rings . Esophageal submucosal gland (Option C): Incorrect because the structure is within the trachea , not the esophagus . Perichondrium (Option D): Incorrect because the perichondrium is the fibrous layer covering the tracheal cartilage , not the posterior muscle.

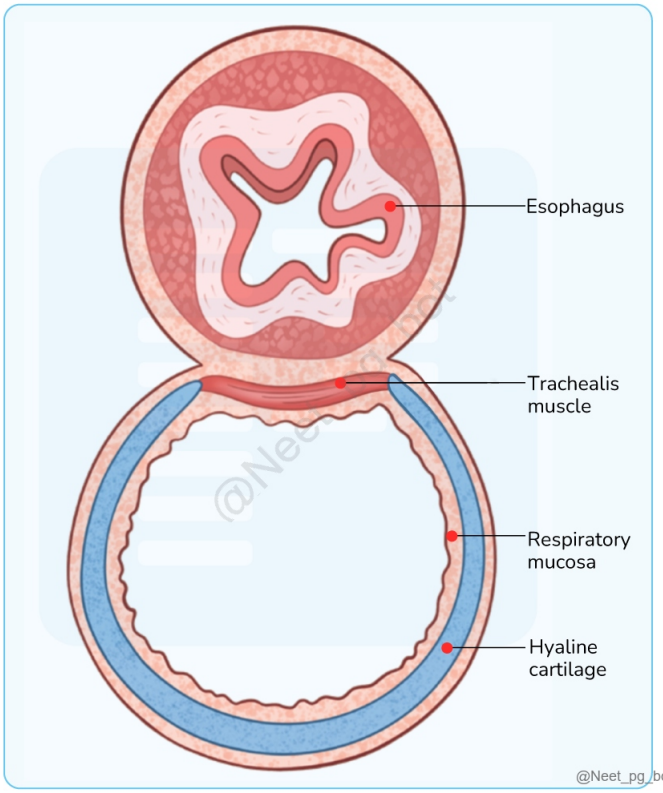

References:

https://pubmed.ncbi.nlm.nih.gov/439039/

↑ *Back to this question in Part A*

@Neet_pg_bot

Q12: Identify the structure C. (Q857207)

A. Epiglottis

B. Hyoid bone

C. Thyroid cartilage

D. Cricoid cartilage

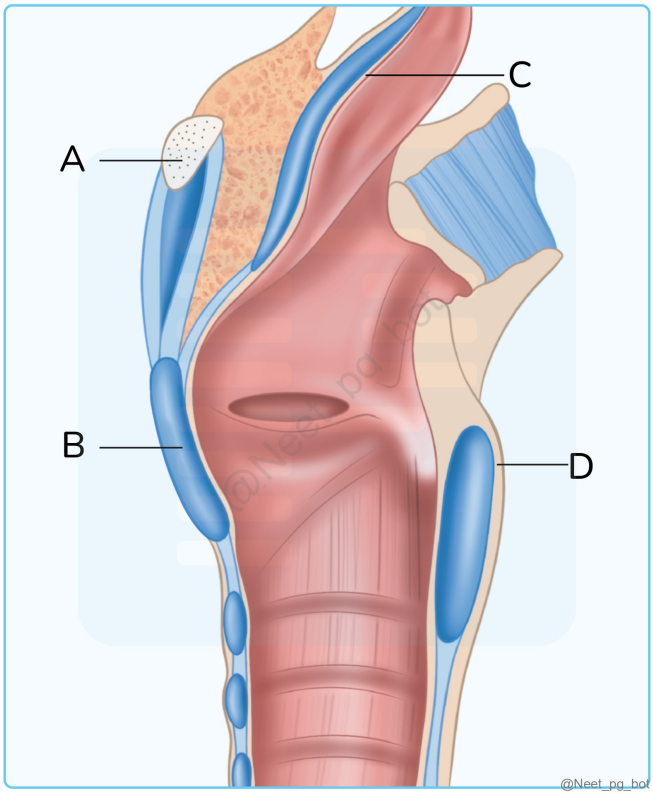

Correct Answer: A. Epiglottis

Explanation: Structure C in the image represents the epiglottis , a leaf-shaped elastic cartilage that functions as a flap to prevent food and liquid from entering the trachea during swallowing. Laryngeal Cartilages Cartilage Description Function Epiglottis Leaf-shaped, elastic cartilage Prevents aspiration by covering the glottis during swallowing Thyroid cartilage Largest, shield-shaped cartilage Provides structure and protects the vocal cords Cricoid cartilage Ring-shaped, below thyroid cartilage Maintains airway patency, attachment for muscles Arytenoid cartilage Paired, pyramid-shaped Controls vocal cord movement Thyroid cartilage (Option C) : Incorrect because the thyroid cartilage is larger and shield-shaped, forming the laryngeal prominence (Adam's apple). Hyoid bone (Option B) : Incorrect because the hyoid bone is a U-shaped structure located above the larynx, providing muscle attachment. Cricoid cartilage (Option D) : Incorrect because the cricoid cartilage is a complete ring below the thyroid cartilage, forming the inferior part of the larynx.

References:

Dhingra's Diseases Of Ear, Nose And Throat, & Head and Neck Surgery, 8th edition, Pages.331,332,335

Scott-Brown's Otorhinolaryngology Head and Neck Surgery , 8th Edition, 3rd Volume, Page 886

↑ *Back to this question in Part A*

@Neet_pg_bot

Q13: The bleeding shown in the image is usually due to which of the following vessels? (Q855450)

A. Bridging veins

B. Middle meningeal artery

C. Lenticulostriate artery

D. Vertebral artery

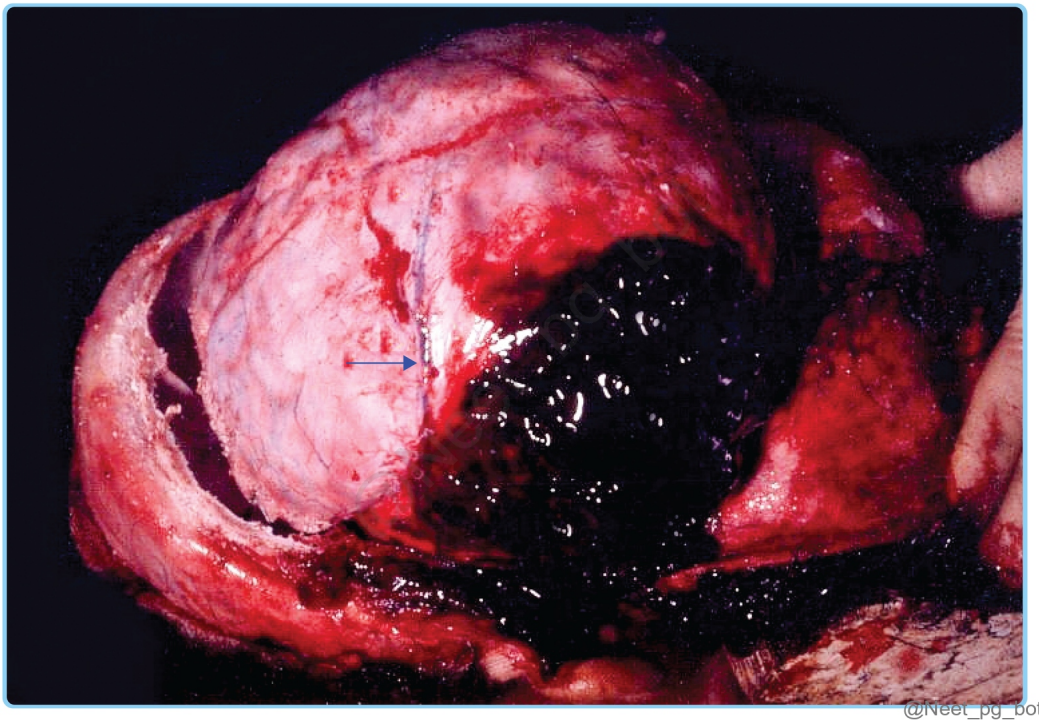

Correct Answer: B. Middle meningeal artery

Explanation: The most common cause of an epidural hematoma is the rupture of the middle meningeal artery , which is located beneath the pterion (a vulnerable area on the skull). This rupture typically occurs due to a blunt force trauma to the skull, leading to blood accumulation between the skull and dura mater . This results in the characteristic biconvex (lens-shaped) hematoma seen on imaging. Aspects Extradural Subdural Location Between the skull bone and endosteal layer of dura mater Between dura mater and arachnoid mater Source Middle meningeal artery Bridging veins Suture line Does not cross the suture line Crosses the suture line Classic manifestation Lucid interval and delayed paralysis that begins in the face and progresses to the lower body The progress of paralysis is haphazard. Appearance on CT ‘Biconvex’ shaped hemorrhage {{caption_text}} ‘ Crescent’ shaped hemorrhage {{caption_text}} Bridging veins (option A) are responsible for subdural hematomas , not epidural hematomas . These veins, which connect the brain's surface to the dural sinuses, can rupture due to acceleration-deceleration injuries , leading to bleeding between the dura mater and arachnoid mater . Lenticulostriate artery (option C): The lenticulostriate arteries supply the basal ganglia , and their rupture causes intracerebral hemorrhages , not epidural hematomas . Vertebral artery (option D): The vertebral artery supplies the

posterior brain and is associated with subarachnoid hemorrhages or brainstem ischemia , but it is not involved in epidural hematomas .





References:

B. D. Chaurasia’s Human Anatomy, Volume 3 & 4, 8th Edition, Page 216, 32, 225, 226

↑ *Back to this question in Part A*

@Neet_pg_bot

Q14: Identify the incorrect statement regarding the marked structure (Q855443)

A. It is the thinnest and weakest part of the skull

B. The region overlies the anterior division of the middle meningeal artery

C. It provides a surgical landmark for accessing the middle cerebral artery

D. This area corresponds to the location of the posterior fontanelle in the fetal skull.

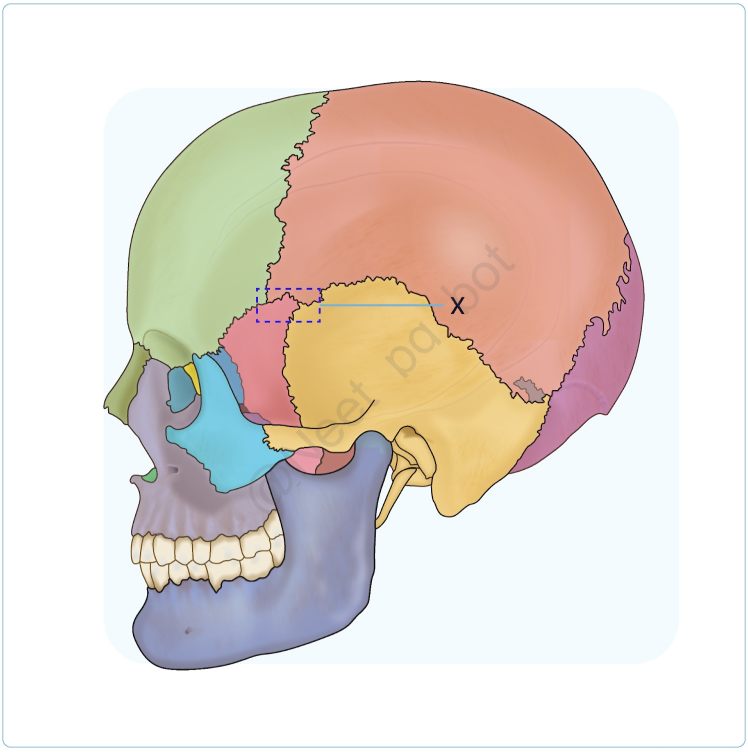

@Neet_pg_bot

Correct Answer: D. This area corresponds to the location of the posterior fontanelle in the fetal skull.

Explanation: The image shown is the pterion , the junction of the frontal, parietal, sphenoid (greater wing), and squamous temporal bones on the lateral aspect of the skull. This region corresponds to the anterolateral (sphenoidal) fontanelle in the fetal skull, not the posterior fontanelle . At birth, this area is filled with a membrane, which typically closes by around 2 months of age , though it can sometimes be delayed until 6 months. It is the

thinnest (weakest) part of the skull and lies over the anterior division of the middle meningeal artery. (Option A, B ruled out) The anterior branch of the middle meningeal artery runs beneath the Pterion and Stem of lateral sulcus . Injury to this area can result in extradural or epidural haemorrhage . The pterion is a frequent location for trephination (creating an opening in the skull) during surgical procedures (surface landmark to reach the sylvian fissure and MCA). (Option C ruled out) {{caption_text}}

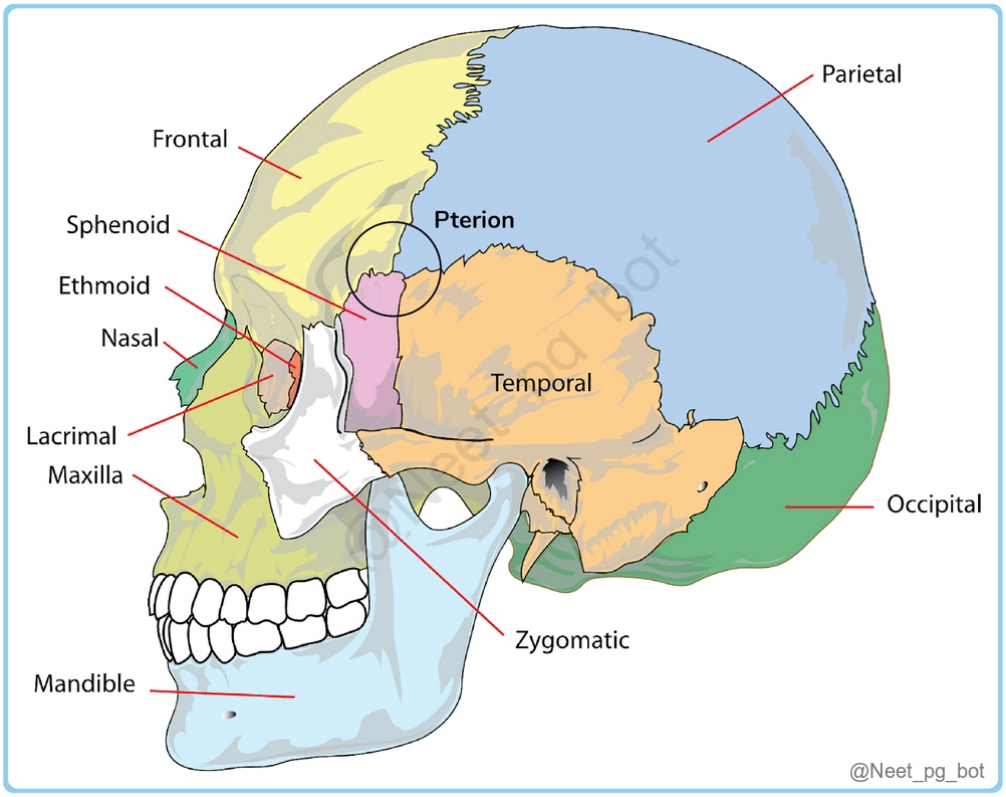

References:

Grey's Anatomy Textbook, 42 Edition, Page 290 B. D. Chaurasia’s Human Anatomy, Volume 3,4, 8th Edition, Page 130, 339

↑ *Back to this question in Part A*

@Neet_pg_bot

Q15: Which among the following is not a branch of the facial artery? (Q855428)

A. Lateral nasalartery

B. Mentalartery

C. Superior labialartery

D. Inferior labialartery

Correct Answer: B. Mentalartery

Explanation: The mental artery is a branch of the inferior alveolar artery, which is a branch of the maxillary artery, not the facial artery. Therefore, it is not a branch of the facial artery. Lateral nasal (Option A): The lateral nasal artery is a branch of the facial artery, supplying the lateral part of the nose. Superior labial (Option C): The superior labial artery is a branch of the facial artery, and it supplies the upper lip and part of the nasal septum. Inferior labial (Option D): The inferior labial artery is also a branch of the facial artery, supplying the lower lip.

References:

Gray's Atlas of Anatomy, 3rd Edition, Pages 988, 1013, 1218, 1219 Gray’s Anatomy, 42nd Edition, Pages 405, 585, 586

↑ *Back to this question in Part A*

@Neet_pg_bot

Q16: Which of the following muscles is involved in smiling and grimacing? (Q855426)

A. Lateral rectus

B. Superior oblique

C. Risorius

D. Levator palpebrae superioris

Correct Answer: C. Risorius

Explanation: The risorius muscle is responsible for smiling and grimacing . It is a facial muscle that pulls the corners of the mouth laterally, helping create expressions like a smile or a grimace. Lateral rectus (Option A) : The lateral rectus is an extraocular muscle responsible for lateral movement of the eye, not involved in facial expressions like smiling or grimacing. Superior oblique (Option B) : The superior oblique is another extraocular muscle that controls eye movement , specifically enabling downward and outward gaze . It has no role in facial expressions. Levator palpebrae superioris (Option D) : The levator palpebrae superioris muscle is responsible for raising the upper eyelid , not involved in smiling or grimacing.

References:

Dhingra Diseases of Ear, Nose and Throat and Head and Neck Surgery, 8th edition, Page 111, 112

↑ *Back to this question in Part A*

@Neet_pg_bot

Q17: How might a fracture of the jugular canal manifest itself? (Q855414)

A. Loss of taste sensation in anterior 2/3rd of tongue

B. Loss of taste sensation in posterior 1/3rd of tongue

C. Loss of general sensation in anterior 2/3rd of tongue

D. Loss of motor function in anterior 2/3rd of tongue

Correct Answer: B. Loss of taste sensation in posterior 1/3rd of tongue

Explanation: The jugular canal contains the glossopharyngeal nerve (CN IX) , which provides taste sensation to the posterior 1/3rd of the tongue . A fracture of the jugular canal can damage the glossopharyngeal nerve , leading to a loss of taste sensation in the posterior 1/3rd of the tongue . Additionally, glossopharyngeal nerve injury may also lead to other symptoms like loss of sensation in the pharynx and impaired swallowing . Loss of taste sensation in anterior 2/3rd of tongue (option A): The anterior 2/3rd of the tongue is innervated by the chorda tympani branch of the facial nerve (CN VII) , not the glossopharyngeal nerve. Loss of general sensation in anterior 2/3rd of tongue (option C): General sensation (touch, pain, temperature) in the anterior 2/3rd of the tongue is carried by the lingual nerve , a branch of the mandibular division of CN V , not by the glossopharyngeal nerve. Loss of motor function in anterior 2/3rd of tongue (option D): Motor function to the tongue is provided by the hypoglossal nerve (CN XII) , not the glossopharyngeal nerve. Therefore, a jugular canal fracture would not affect motor function of the tongue.

↑ *Back to this question in Part A*

@Neet_pg_bot

Q18: Which foramen in the skull is created by the union of three bones? (Q855037)

A. Foramen lacerum

B. Foramen magnum

C. Foramen rotundum

D. Foramen jugulare

Correct Answer: A. Foramen lacerum

Explanation: The foramen lacerum is formed by the union of three bones : Sphenoid bone (anteriorly) Temporal bone (petrous part) (laterally) Occipital bone (posteriorly) It is located at the base of the skull and is filled with fibrocartilage in vivo, meaning no major structures pass through it directly. The internal carotid artery passes over the foramen lacerum but does not pass through it. Foramen of Middle Cranial Fossa Structures Passing through Foramen Rotundum Maxillary Nerve Foramen Ovale M andibular nerve A ccessory meningeal artery L esser petrosal nerve E missary vein Occasionally, the Anterior trunk of the middle meningeal vein Foramen Spinosum M iddle meningeal artery and vein, E missary vein N ervus spinosus(Meningeal branch of mandibular nerve)

Foramen Lacerum A triangular opening at the base of the skull, but in living individuals, it is filled with cartilage, and no major structures pass through it. Foramen lacerum contributed by 3 bones-temporal, occipital and sphenoid The internal carotid artery and nerve plexus traverse its superior end; The nerve to the pterygoid canal passes through its anterior wall. The meningeal branch of the ascending pharyngeal artery and an emissary vein pass through it . {{caption_text}} Foramen magnum (option B): It is entirely within the occipital bone and does not involve three bones. It allows passage of the medulla oblongata, vertebral arteries, and spinal accessory nerve (CN XI) . Foramen rotundum (option C): This is part of the sphenoid bone only. It transmits the maxillary nerve (V2) of the trigeminal nerve. Foramen jugulare (option D): Formed by the temporal and occipital bones , but not three bones. It allows passage of the internal jugular vein, glossopharyngeal nerve (CN IX), vagus nerve (CN X), and accessory nerve (CN XI) .

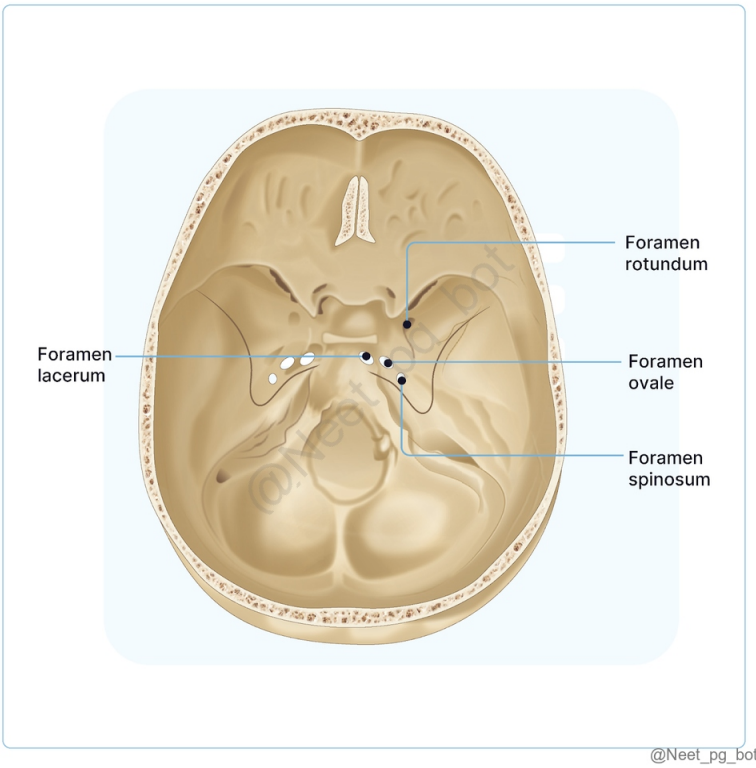

References:

B. D. Chaurasia’s Human Anatomy, Volume 3&4, 8th Edition, Page 58, 280

↑ *Back to this question in Part A*

@Neet_pg_bot

Q19: All of the following are the contents of the carotid sheath except? (Q856357)

A. Sympathetic chain

B. Carotid artery

C. Internal jugular vein

D. 10 th cranial nerve

Correct Answer: A. Sympathetic chain

Explanation: The carotid sheath is a fibrous connective tissue structure located in the neck. It contains several important structures, including the carotid artery, internal jugular vein, and 10th cranial nerve (vagus nerve). Sympathetic chain: The sympathetic chain, also known as the sympathetic trunk or sympathetic ganglia, is not a content of the carotid sheath. The sympathetic chain runs alongside the vertebral column and is responsible for carrying sympathetic nerve fibers. Carotid Sheath: Condensation of the connective tissue around the great vessels of the neck, forming a tubular sheet of fascia. Contents Common carotid artery Internal carotid artery Internal jugular vein Vagus nerve Anatomical Details The carotid sheath extends from the upper border of the thyroid cartilage down to the bifurcation of the carotid arteries. The internal jugular vein is lateral to the carotid artery; the vagus nerve is located between and posterior to the vessels. Anteriorly The carotid sheath is covered by the pretracheal fascia. Posteriorly The carotid sheath is bordered by the prevertebral fascia. Carotid artery (Option B): The carotid artery, specifically the common carotid artery, is a major blood vessel that supplies blood to the head and neck. It is a content of the carotid sheath. Internal jugular vein (Option C): The internal jugular vein, running parallel to the carotid artery, drains blood from the brain, face, and neck, and is contained within the carotid sheath. 10th cranial nerve (vagus nerve) (Option D): The vagus nerve, or the 10th cranial nerve, innervates numerous thoracic and abdominal organs. In the neck, it travels within the carotid sheath.

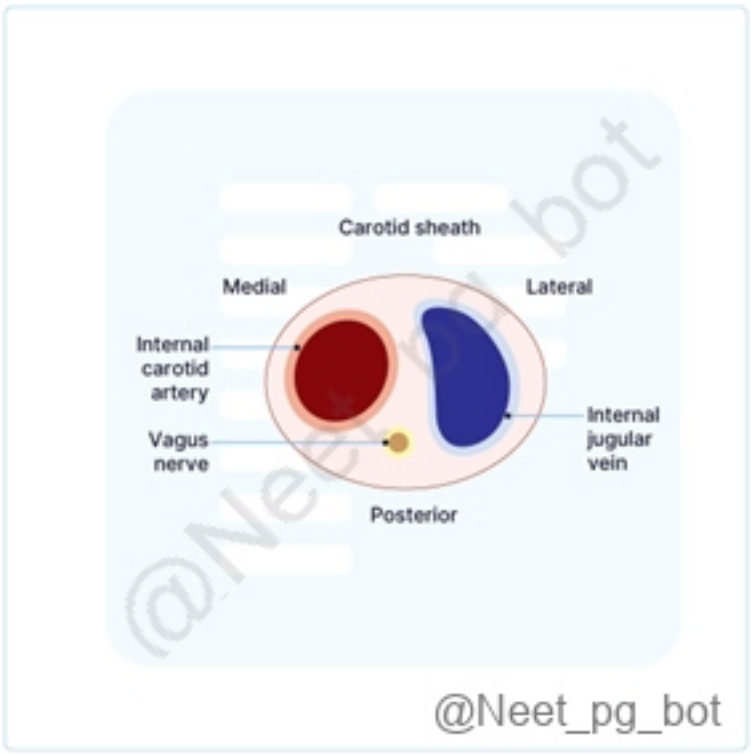

References:

BD Chaurasia’s Human Anatomy, 8th Edtion, Page no: 654

↑ *Back to this question in Part A*

@Neet_pg_bot

Q20: A woman has difficulty opening her mouth, but no problem closing it. Which of the following is true about the muscle affected in the condition described: The muscle attaches close to the temporomandibular joint The muscle depresses the mandible It attached to the medial pterygoid plate The muscle is supplied by the mandibular nerve (Q879182)

A. 1,2,3,4

B. 1,2,4

C. 1,3,4

D. 2,3,4

Correct Answer: B. 1,2,4

Explanation: Difficulty opening the mouth indicates dysfunction of the lateral pterygoid muscle , the only muscle of mastication that depresses (opens) the mandible. Statement 1: True — The lateral pterygoid inserts into the neck of the mandible and the TMJ articular disc , i.e., close to the temporomandibular joint. Statement 2: True — It depresses (opens) the mandible. Statement 4: True — It is supplied by the mandibular nerve (V3) via the lateral pterygoid branch. Statement 3: False — It arises from the lateral surface of the lateral pterygoid plate , not the medial pterygoid plate. Muscles of Mastication: Muscle Origin Insertion Main Action Masseter Zygomatic arch Lateral surface of ramus and angle of mandible Elevates (closes) the mandible Temporalis Temporal fossa Coronoid process of mandible Elevates and retracts mandible Medial Pterygoid Medial surface of lateral pterygoid plate Medial surface of ramus and angle of mandible Elevates and assists in side-to-side (grinding) movement Lateral Pterygoid Lateral surface of lateral pterygoid plate & greater wing of sphenoid Neck of mandible and articular disc of TMJ Opens mouth, protrudes mandible, side-to-side movement

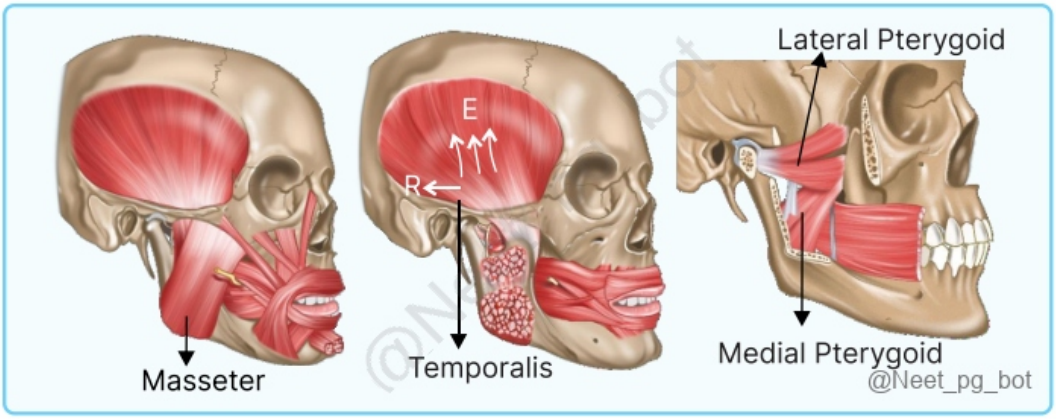

References:

BD Chaurasia’s Human Anatomy, 8th Edition, Volume 3, Page 125

↑ *Back to this question in Part A*

@Neet_pg_bot

Q21: Which of the following bones contains a cranial nerve related directly to the CNS? (Q879160)

Correct Answer: Unknown

Explanation: The olfactory nerve (CN I) is unique because its fibers are direct extensions of the forebrain (CNS) . These fibers pass through the cribriform plate of the ethmoid bone to synapse in the olfactory bulb , which is itself a CNS structure. Incorrect Options: Temporal Bone (Option A): It transmits CN VII & VIII via internal acoustic meatus, which are peripheral cranial nerves, not direct CNS extensions. Zygomatic bone (Option B): It transmits the zygomaticofacial nerve (branch of V2), which is a purely peripheral nerve. Maxilla (Option C): It transmits the infraorbital nerve (V2), which is a peripheral sensory nerve.

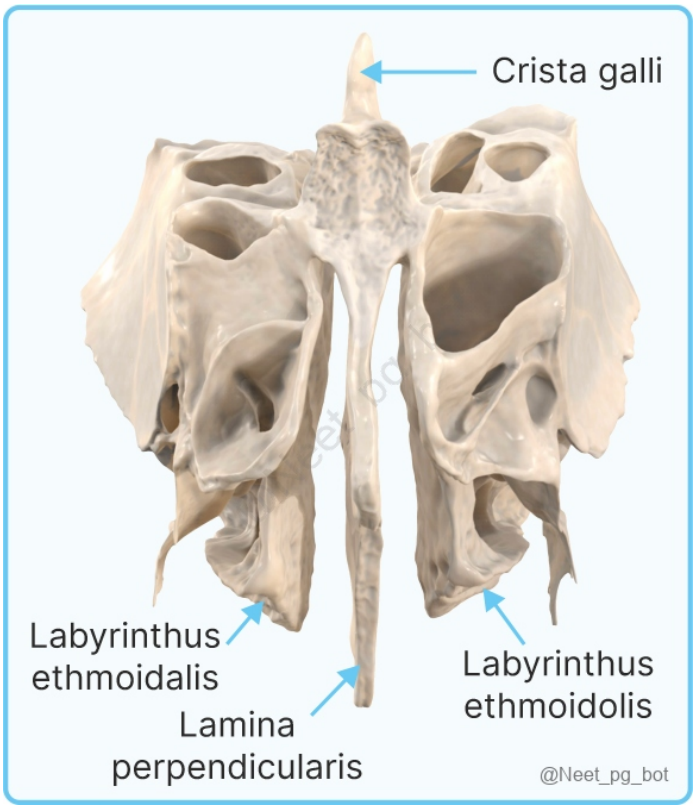

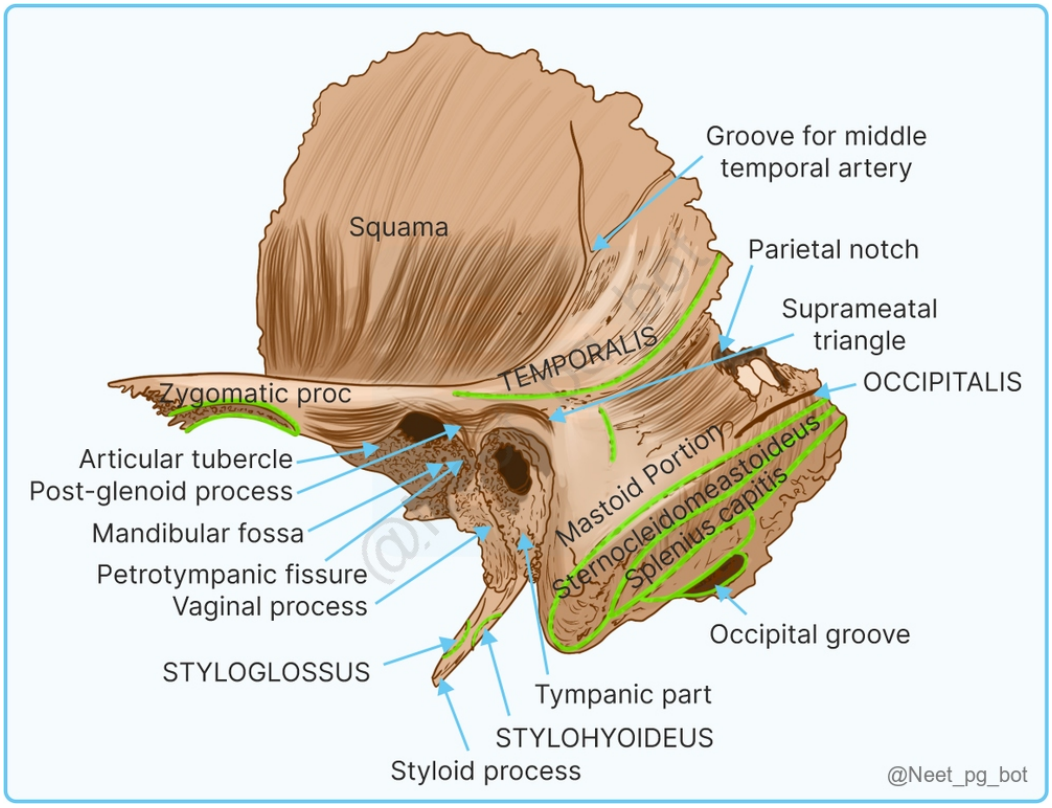
Groove for middle temporal artery
Squama
Parietal notch
Suprameatal triangle
TEMPORALIS
OCCIPITALIS
Zygomatic proc
Articular tubercle
Post-glenoid process
Mandibular fossa
Petrotympanic fissure
Vaginal process
Mastoid Portion
Sternocleidomeastoideus
Splenius capitis
Occipital groove
STYLOGLOSSUS
Tympanic part
STYLOHYOIDEUS
Styloid process
@Neet_pg_bot

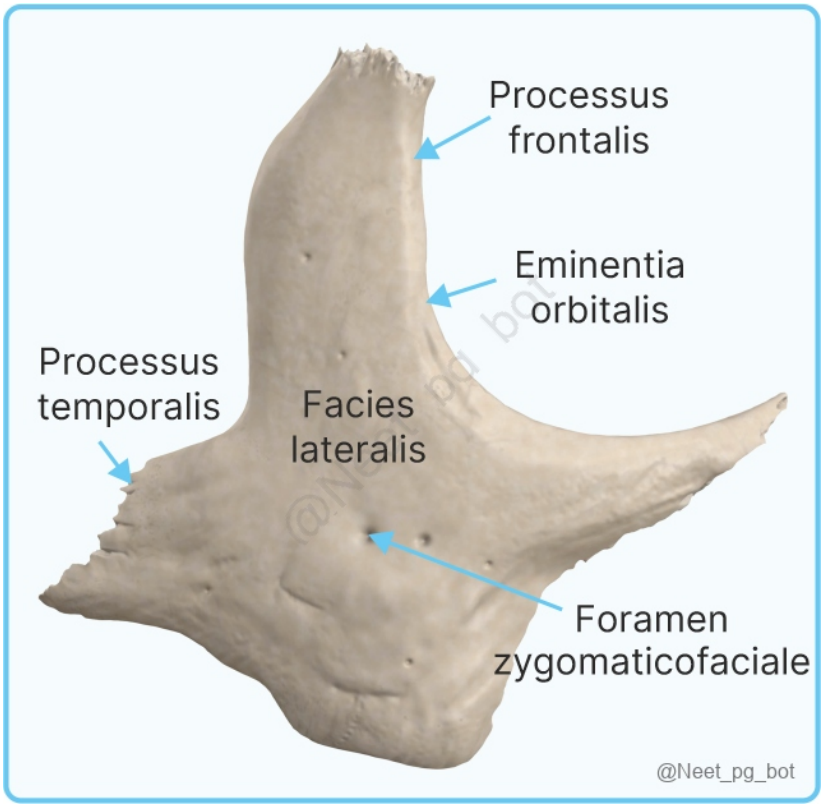
Processus frontalis
Eminentia orbitalis
Processus temporalis
Facies lateralis
Foramen zygomaticofaciale
@Neet_pg_bot

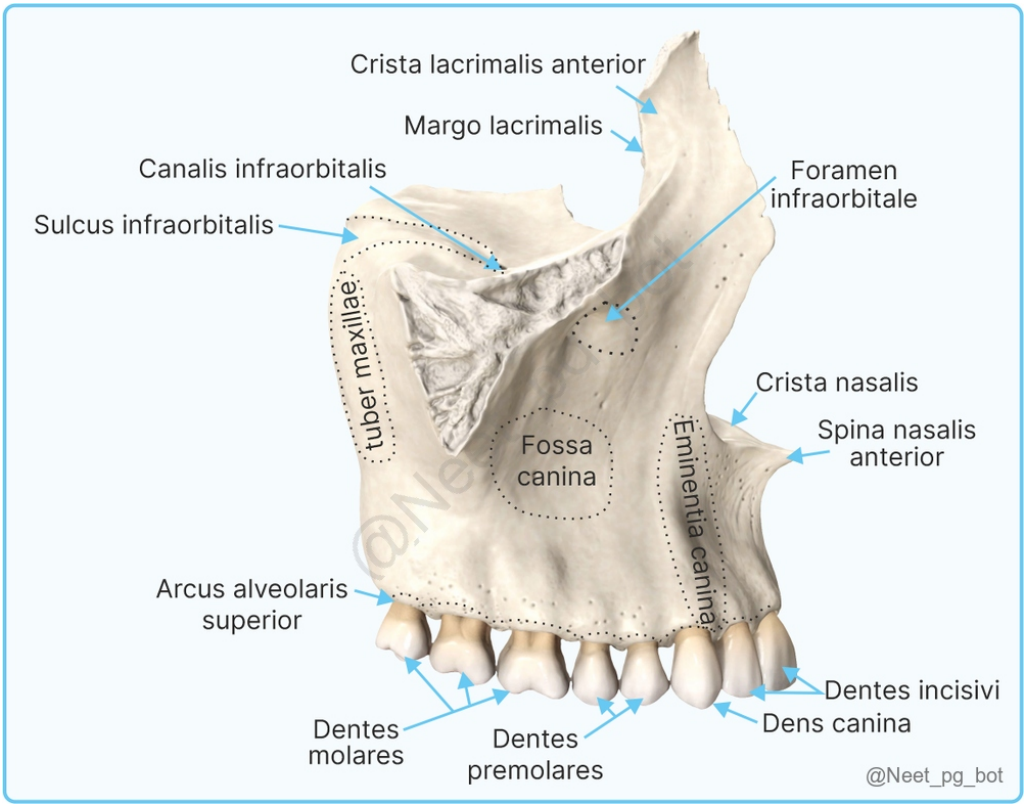

References:

Grey's Anatomy for Students, Edition, Pages 612, 615.

↑ *Back to this question in Part A*

@Neet_pg_bot

Q22: Among the following foramina, the nerve supply to the muscles of mastication passes through which one? ■■■■■■■ (Q879155)

A. A

B. B

C. C

D. D

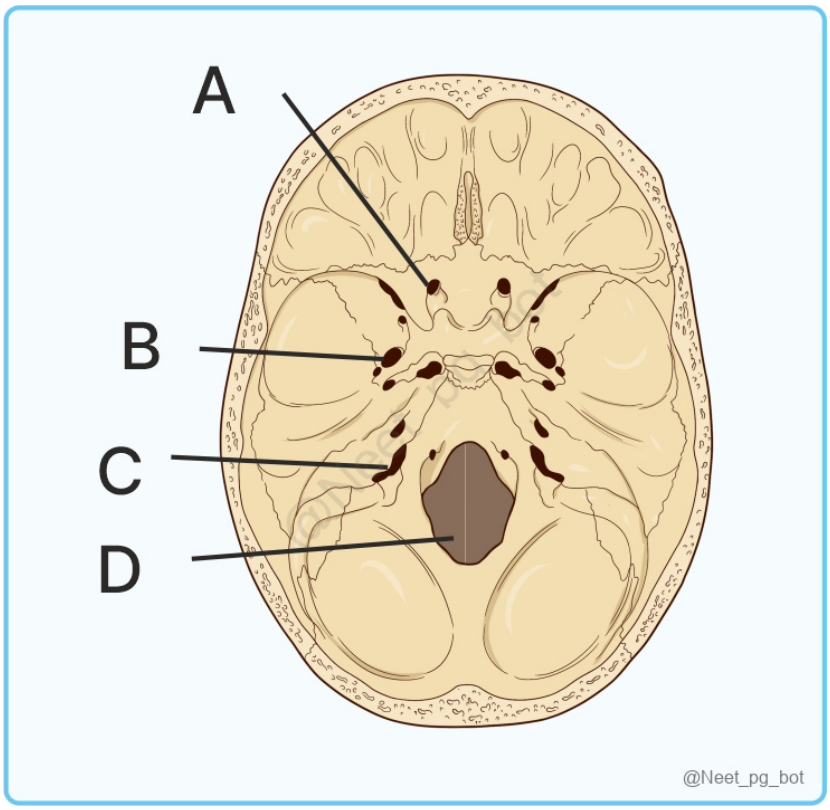

Correct Answer: B. B

Explanation: The mandibular nerve (V3) passes through the foramen ovale . It supplies the muscles of mastication (masseter, temporalis, medial & lateral pterygoids). Foramen of Middle Cranial Fossa Structures Passing through Foramen Rotundum Maxillary Nerve Foramen Ovale M andibular nerve A ccessory meningeal artery L esser petrosal nerve E missary vein Occasionally, the Anterior trunk of the middle meningeal vein Foramen Spinosum M iddle meningeal artery and vein, E missary vein N ervus spinosus(Meningeal branch of mandibular nerve) Foramen Lacerum A triangular opening at the base of the skull, but in living individuals, it is filled with cartilage, and no major structures pass through it. Foramen lacerum contributed by 3 bones-temporal, occipital and sphenoid The internal carotid artery and nerve plexus traverse its superior end; The nerve to the pterygoid canal passes through its anterior wall. The meningeal branch of the ascending pharyngeal artery and an emissary vein pass through it .

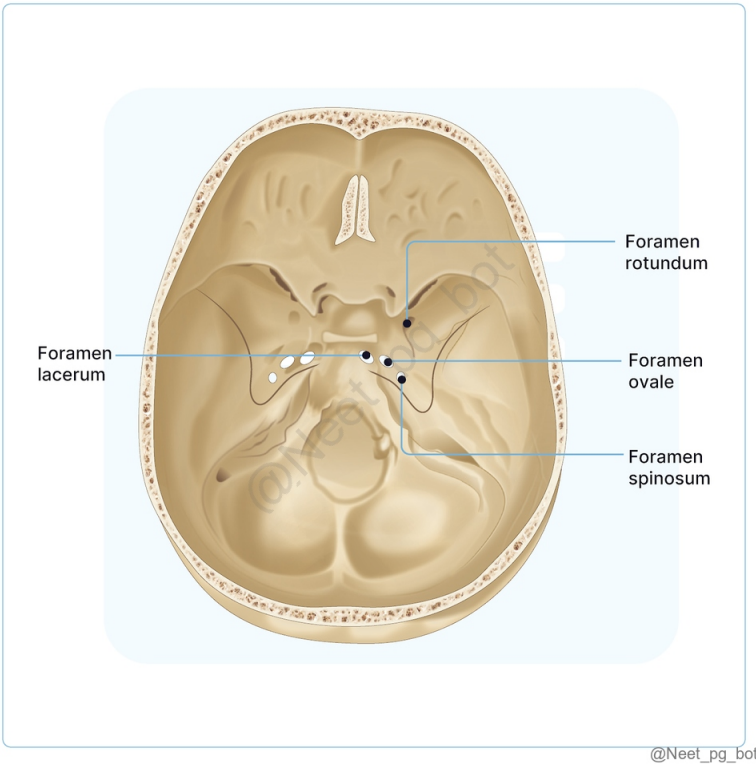

References:

B. D. Chaurasia's Human Anatomy, Volume 3,4, 8th Edition, Page 58,280

↑ *Back to this question in Part A*

@Neet_pg_bot

Q23: A patient presents with a unilateral throbbing headache, photophobia, and excessive lacrimation. He also complains of hemifacial pain on the clenching of teeth. On examination, pupillary reaction, light reflex, and accommodation reflex are normal. Which of the following marked nerves is involved in the above scenario? (Q856077)

A. 1

B. 2

C. 3

D. 4

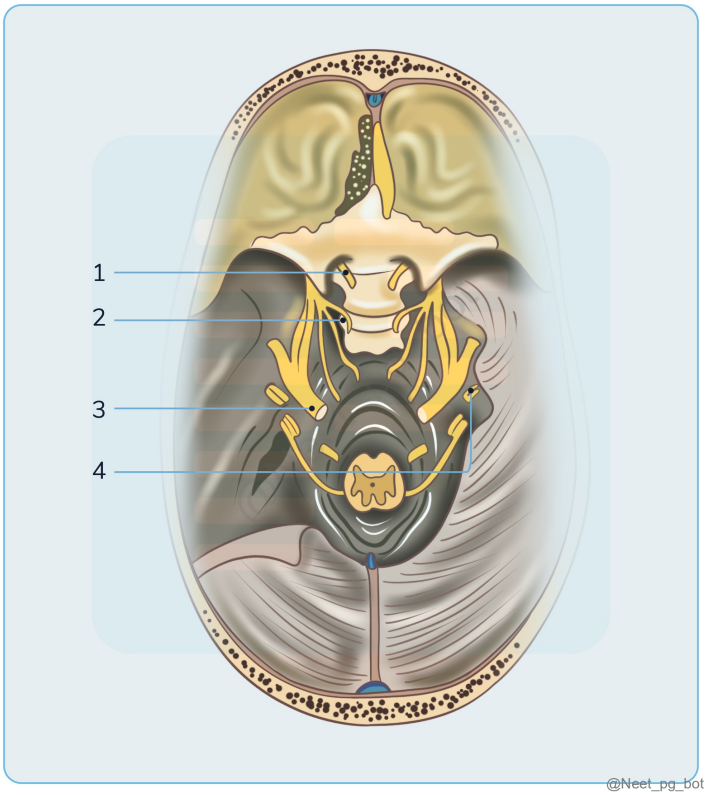

Correct Answer: C. 3

Explanation: 3 is the right choice since the effects depicted involve the Trigeminal nerve ophthalmic division (V1), which supplies sensation to the forehead, scalp, and eye. Other labelled areas: 1- Optic nerve; 2- Occulomotor nerve; 4- Vestibulocochlear nerve Trigeminal nerve (5th cranial nerve): Has three divisions Ophthalmic division (V1) Maxillary division (V2) Mandibular division (V3) Type Sensory Sensory Mixed Course Branches Frontal Supratrochlear Supraorbital Nasociliary Branch to the ciliary ganglion 2–3 long ciliary nerves Posterior ethmoidal Infratrochlear Anterior ethmoidal Lacrimal: Branch to the upper eyelid and secretomotor fibres to the lacrimal gland. Infraorbital Zygomaticofacial Zygomaticotemporal Mental Buccal Auriculo-temporal Supply Forehead Upper eyelids Root of nose Tip of nose Frontal air sinus Scalp Lower eyelids Lateral sides of the nose Upper lip Cheek (upper part) Anterior part of the temporal region Lower lip Chin Lower teeth Lower part of the cheek Lateral side (Upper 2/3rd) of auricle, temporal region (Options A, B, and D)

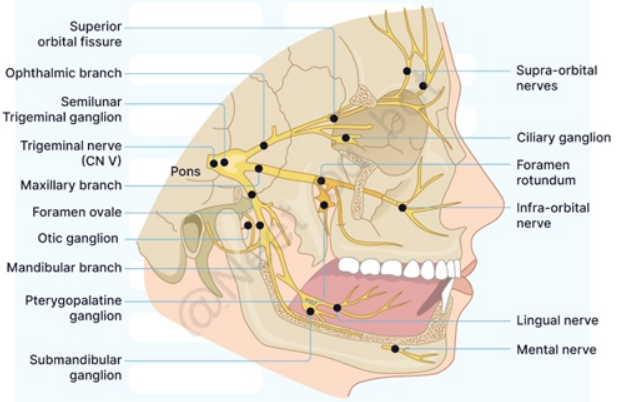

@Neet_pg_bot

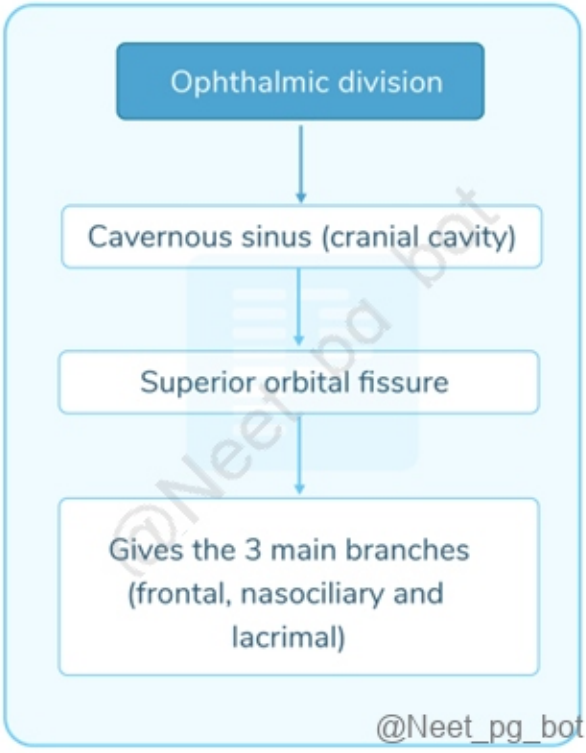

@Neet_pg_bot

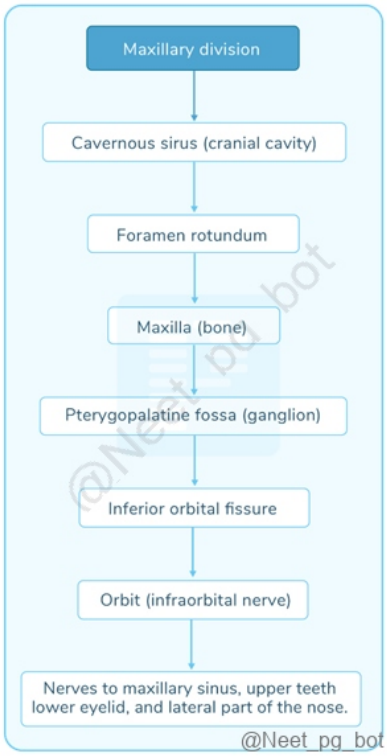
Maxillary division
Cavernous sirus (cranial cavity)
Foramen rotundum
Maxilla (bone)
Pterygopalatine fossa (ganglion)
Inferior orbital fissure
Orbit (infraorbital nerve)
Nerves to maxillary sinus, upper teeth lower eyelid, and lateral part of the nose.
@Neet_pg_bot

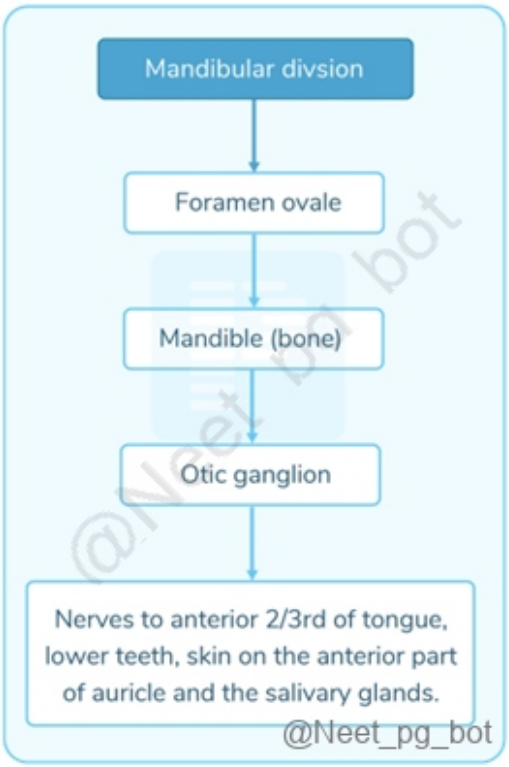
Mandibular divsion
Foramen ovale
Mandible (bone)
Otic ganglion
Nerves to anterior 2/3rd of tongue, lower teeth, skin on the anterior part of auricle and the salivary glands.
@Neet_pg_bot

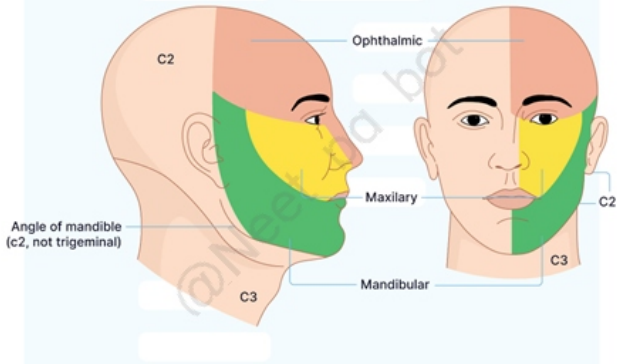

@Neet_pg_bot

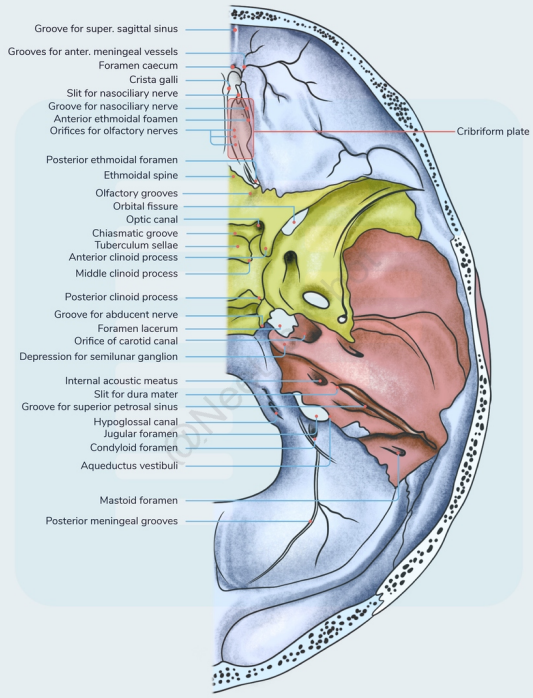

@Neet_pg_bot

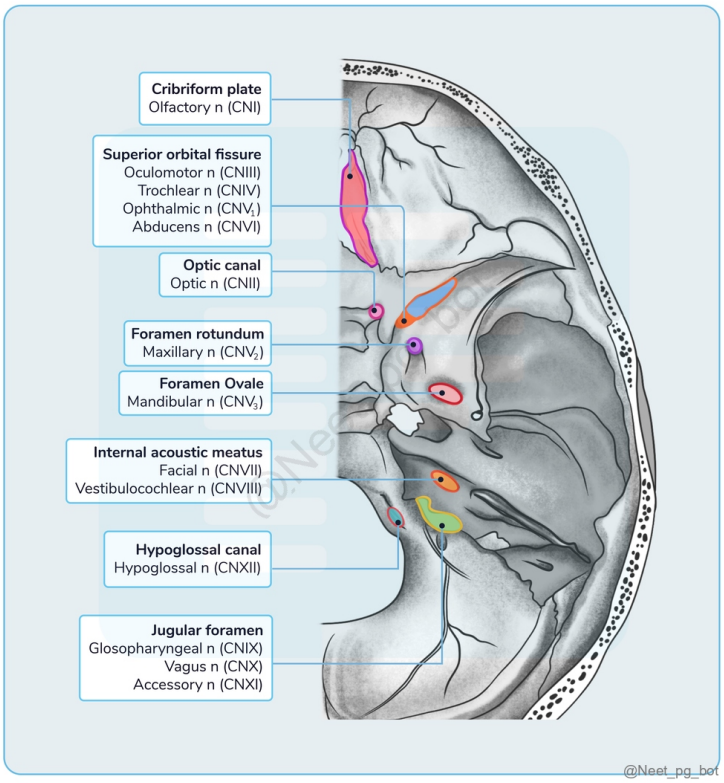

References:

Grey's Anatomy 42nd edition, pg 1464, e13-15.

BD Chaurasia’s Human Anatomy, 8th edition, pg 241-244.

Vishram Singh Textbook of Anatomy, 2nd edition, pg 58, 59.

↑ *Back to this question in Part A*

@Neet_pg_bot

Q24: Which structure anchors the thyroid gland to the larynx, restricting its upward movement during swelling? (Q854991)

A. Pretracheal fascia

B. Sternothyroid

C. Thyrohyoid membrane

D. Ligament of Berry

Correct Answer: D. Ligament of Berry

Explanation: The structure that anchors the thyroid gland to the larynx and restricts its upward movement during swelling is the Ligament of Berry (also known as the posterior suspensory ligament) . This ligament is a thickening of the pretracheal fascia that attaches the posteromedial aspect of the thyroid gland to the cricoid cartilage and first and second tracheal rings. Because of this firm attachment, the thyroid gland is tethered to the larynx, limiting excessive upward movement, especially noticeable during thyroid swelling or enlargement. The pretracheal fascia encloses the thyroid gland and allows it to move with the trachea during swallowing. Berry's ligament also strengthens this connection, making thyroid movement during swallowing a useful clinical sign to distinguish thyroid swellings (which move) from other neck masses (which remain static). (Option A ruled out) Sternothyroid muscle (Option B): A depressor of the larynx; not involved in fixing the thyroid gland. Thyrohyoid membrane (Option C): Connects thyroid cartilage to the hyoid bone; unrelated to thyroid gland attachment.

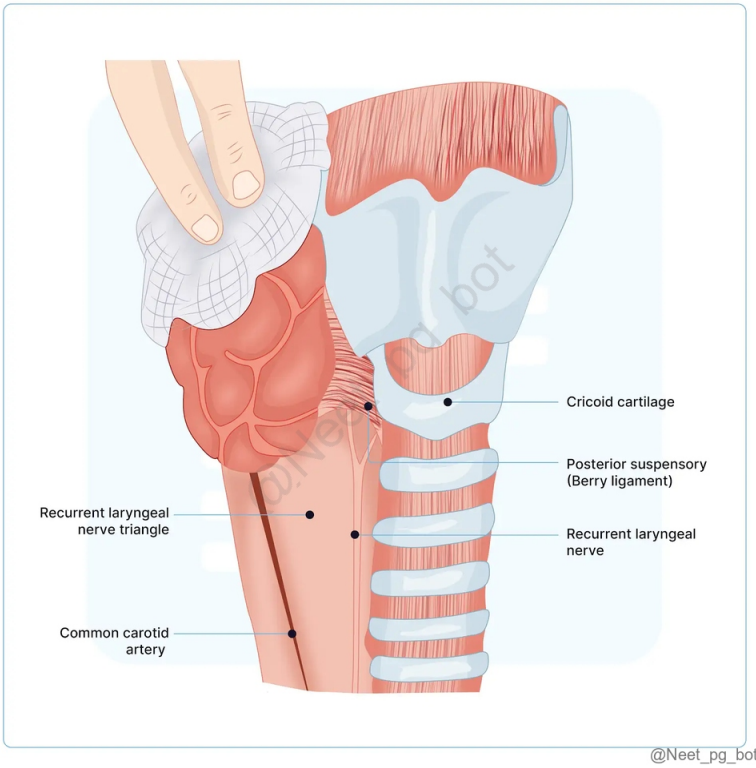

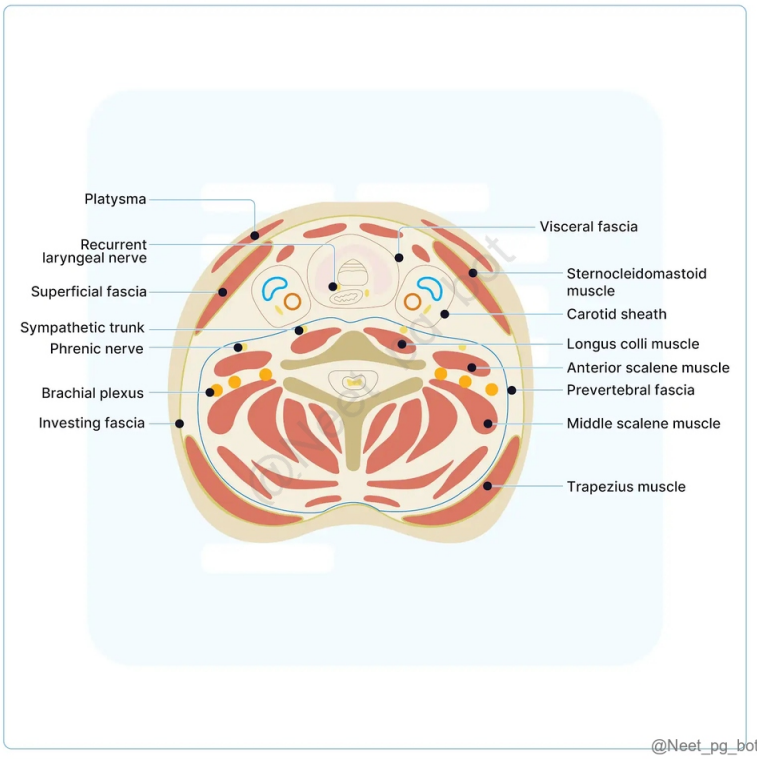

References:

Bailey & Love's Short Practice of Surgery, 28th Edition, Page 785,786

↑ *Back to this question in Part A*

@Neet_pg_bot

Q25: The muscle marked by the arrow in the image below is innervated by the : (Q854980)

A. Dorsal scapular nerve

B. Suprascapular nerve

C. From the dorsal rami of C1

D. Subscapular nerve

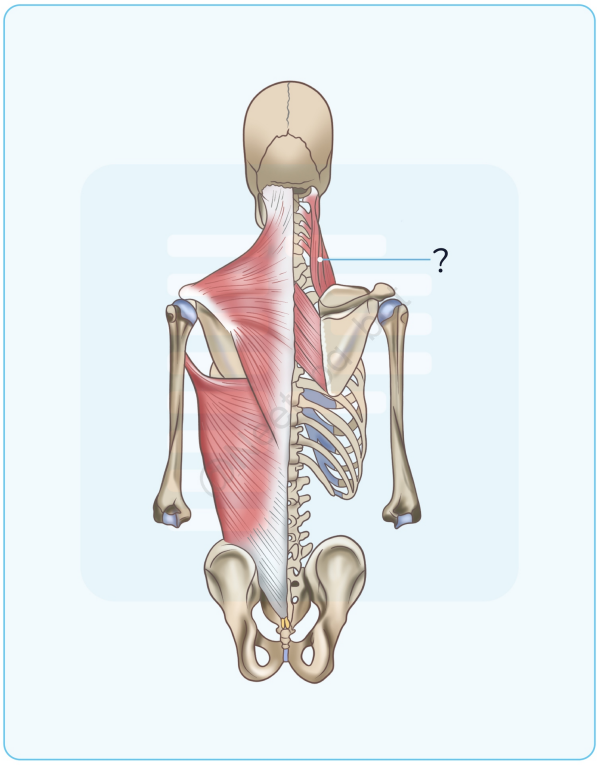

Correct Answer: A. Dorsal scapular nerve

Explanation: The levator scapulae muscle is primarily innervated by the dorsal scapular nerve (C5) , with additional contributions from C3 and C4 spinal nerves . The dorsal scapular nerve arises from the C5 root of the brachial plexus and also supplies the rhomboid major and minor muscles . Function: Elevates the scapula and assists in downward rotation. Part of brachial plexus Branches Roots Dorsal scapular nerve - C5 Long thoracic nerve - C5 to C7 Trunks Suprascapular nerve - C5 , C6 Nerve to subclavius - C5 , C6 Division None Cords Lateral pectoral nerve (Lateral cord: C5 - C7) Upper subscapular nerve (Posterior cord: C5, C6) Thoracodorsal nerve (Posterior cord: C6 - C8) Lower subscapular nerve (Posterior cord: C5 , C6) Medial pectoral nerve (Medial cord: C8 , T1) Medial cutaneous nerve of arm (Medial cord: C8 , T1) Medial cutaneous nerve of forearm (Medial cord: C8 , T1) Terminal branches Musculocutaneous nerve (Lateral cord, C5-C7) Axillary nerve (Posterior cord, C5, C6) Radial nerve (Posterior cord, C5-T1) Median nerve (Lateral and Medial cords, C5-T1) Ulnar nerve (Medial cord, C8, T1) {{caption_text}} Suprascapular nerve (option B): Innervates supraspinatus and infraspinatus , not the levator scapulae . Arises from the upper trunk (C5-C6) of the brachial plexus . From the dorsal rami of C1 (option C): C1 dorsal ramus contributes to the suboccipital nerve , which innervates suboccipital muscles , not the levator scapulae . Subscapular nerve (option D): The upper and lower subscapular nerves (from C5-C6) supply the subscapularis and teres major , not the levator scapulae .

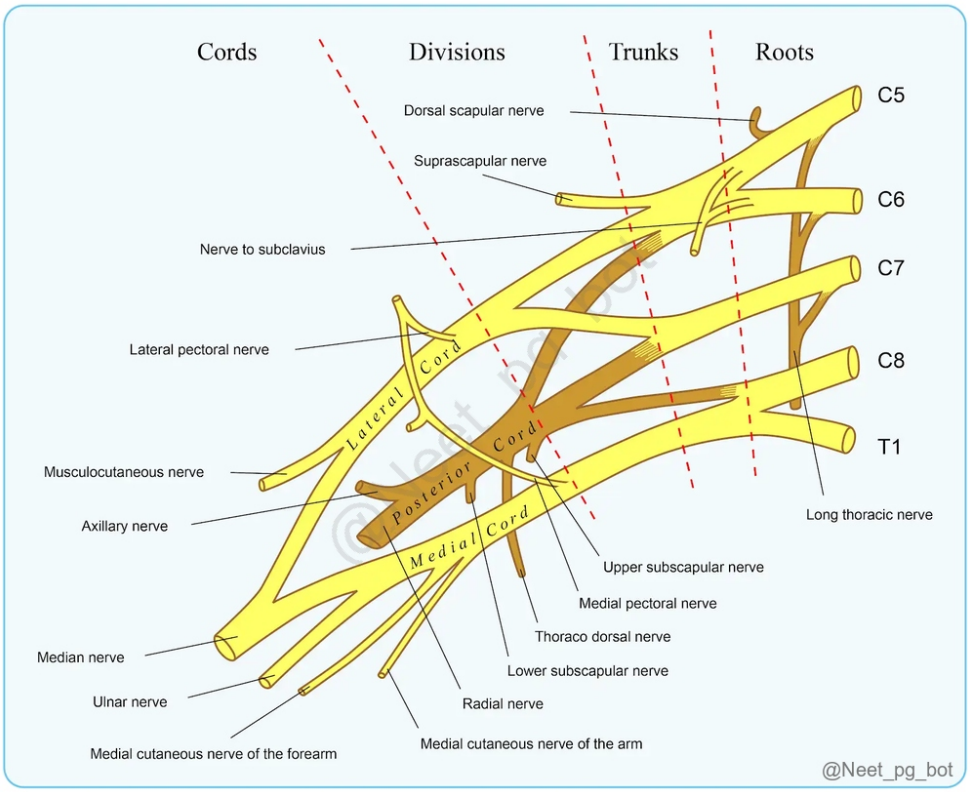

References:

Gray's Anatomy The Anatomical Basis of Clinical Practice, 42nd Edition, Page 876, 878, 879

↑ *Back to this question in Part A*

@Neet_pg_bot

Q26: All of the following nerves are involved in the movement of the eyeball except: (Q856396)

A. Optic nerve

B. Oculomotor nerve

C. Trochlear nerve

D. Abducens nerve

Correct Answer: A. Optic nerve

Explanation: The optic nerve is a pure sensory nerve. Its function is vision, carrying visual information from the retina to the brain. It has no motor fibers and therefore does NOT innervate any extraocular muscles. Since eyeball

movement requires motor innervation, the optic nerve plays no role in moving the eye. Hence, the optic nerve is NOT involved in the movement of the eyeball. Incorrect Options: Option B) Oculomotor Nerve : Controls most extraocular muscles (SR, IR, MR, IO). Essential for up, down, and inward eye movements. Option C) Trochlear Nerve : Innervates the superior oblique muscle. Important for downward and inward movement of the eyeball. Option D) Abducens Nerve : Supplies the lateral rectus muscle. Responsible for abduction (outward movement) of the eye.

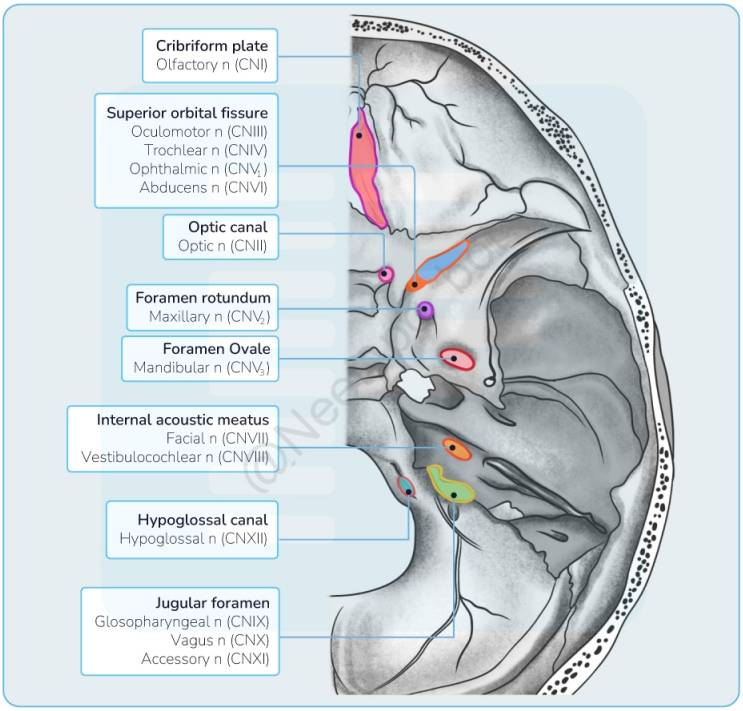

@Neet_pg_bot

References:

BD Chaurasia's Human Anatomy, 8th Edtion, Page no: 345

↑ *Back to this question in Part A*

@Neet_pg_bot

Q27: Which of the following arteries passes in close proximity to the area marked by the arrow in the given image? (Q856369)

A. Internal carotid artery

B. Middle meningeal artery

C. Anterior cerebral artery

D. Deep temporal artery

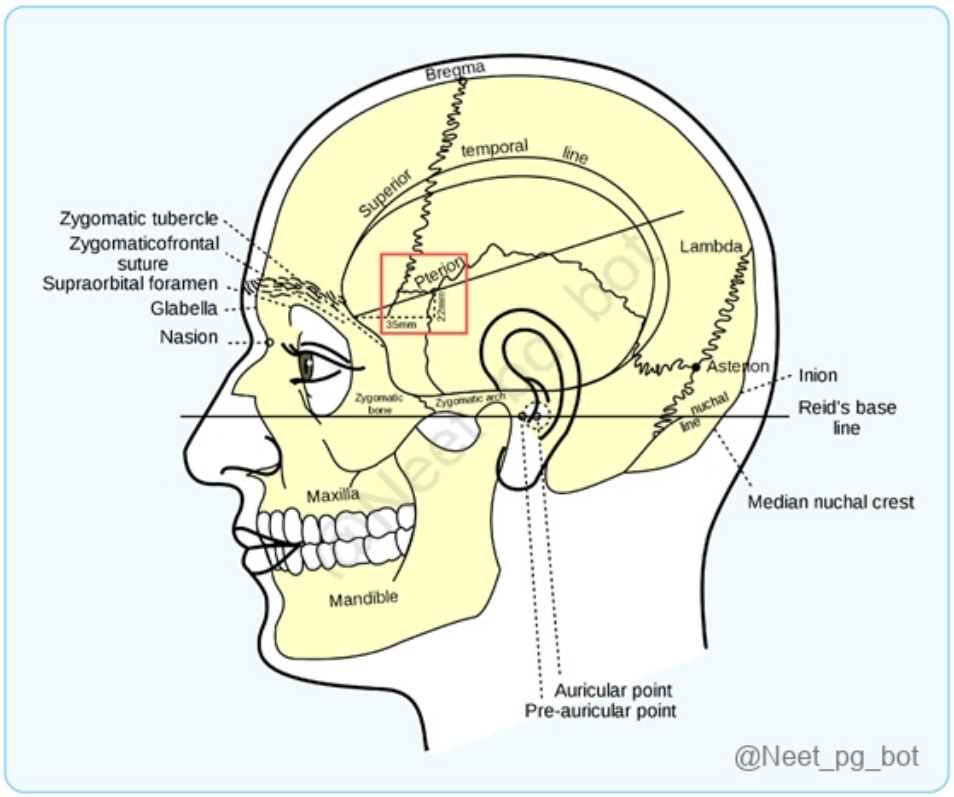

Correct Answer: B. Middle meningeal artery

Explanation: The area marked by the arrow corresponds to the pterion, where several skull bones meet. The middle meningeal artery, a branch of the maxillary artery, runs nearby. It supplies blood to the meninges surrounding the brain and spinal cord, passing through the pterion and branching out to supply surrounding structures. Pterion: Located at the anterolateral fontanelle and is formed by the union of Frontal bone Parietal bone Squamous temporal bones & Greater wing of the sphenoid. At birth, this area is filled with a membrane, which typically closes by around 2 months of age , though it can sometimes be delayed until 6 months. The anterior branch of the middle meningeal artery runs beneath the Pterion and Stem of lateral sulcus . Injury to this area can result in extradural or epidural haemorrhage . The pterion is a frequent location for trephination (creating an opening in the skull) during surgical procedures. Internal carotid artery (Option A): The internal carotid artery is crucial for brain blood supply but doesn't closely pass by the pterion. Anterior cerebral artery (Option C): The anterior cerebral artery, a branch of the internal carotid artery, provides blood to the frontal lobes and medial brain regions, but it doesn't closely approach the pterion. Deep temporal artery (Option D): The deep temporal arteries, stemming from the maxillary artery, nourish the temporal head region. Although they are nearby, they don't directly approach the pterion.

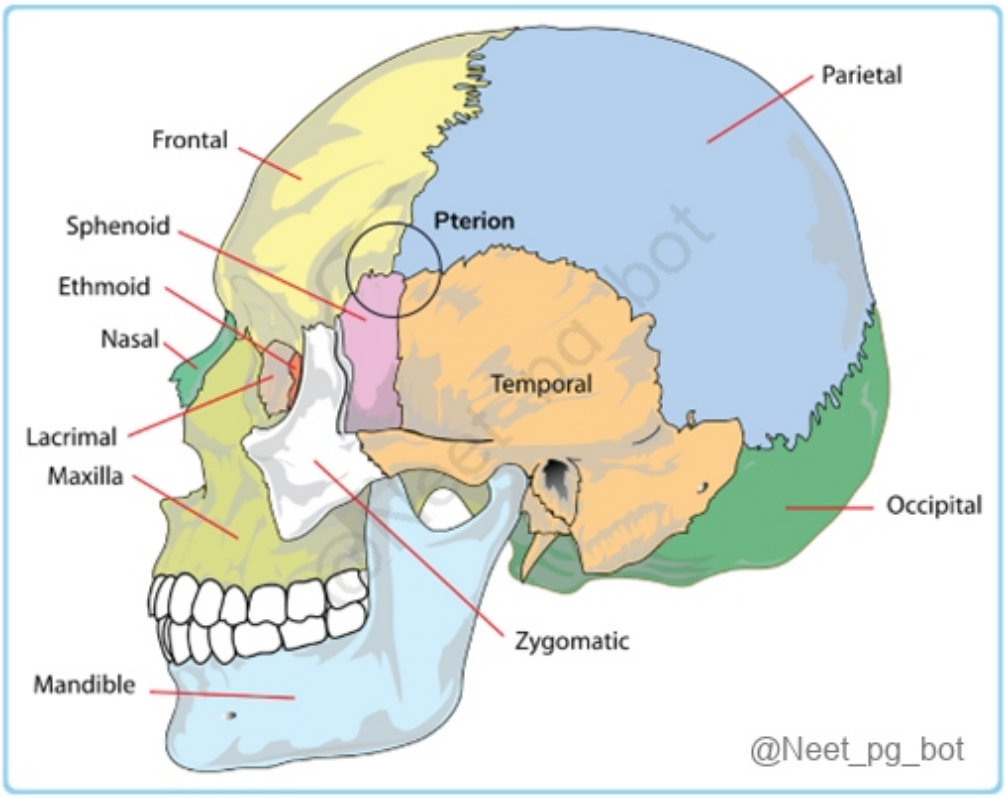

References:

BD Chaurasia's Human Anatomy, 8th Edtion, Page no: 234

↑ *Back to this question in Part A*

@Neet_pg_bot

Q28: Which is the narrowest part of the adult laryngeal airway? (Q866626)

A. Supraglottic region

B. Glottis

C. Subglottic region

D. Trachea

Correct Answer: B. Glottis

Explanation: In adults, the glottis- specifically the rima glottidis, the space between the true vocal cords - is the narrowest part of the laryngeal airway and plays a key role in controlling airflow and voice production. Infant Larynx Adult Larynx Position Superiorly placed (C1-C4) 3rd -6th cervical vertebrae (C3-C6) Epiglottis Omega-shaped, floppy Leaf like Narrowest area Subglottis Glottis (Option B) Submucosal tissue More abundant

Less abundant Incorrect Options: Supraglottic region (Option A) includes the structures above the vocal cords (like the epiglottis and false vocal cords), and it is wider than the glottis. Subglottic region (Option C) is located below the vocal cords; it's wider than the glottis in adults but is the narrowest part in children. Trachea (Option D) is significantly wider than the glottis.

↑ *Back to this question in Part A*

@Neet_pg_bot

Q29: Which of the following bony structures is present behind the marked area? (Q856987)

A. Post clivus

B. Lesser wing of sphenoid

C. Sella turcica

D. Carotid canal

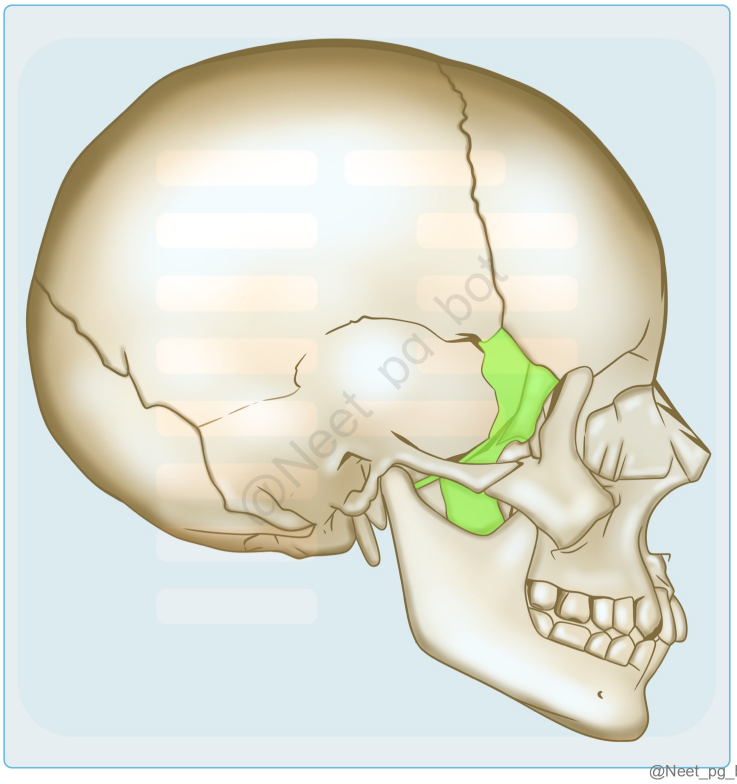

Correct Answer: B. Lesser wing of sphenoid

Explanation: The lesser wing of the sphenoid bone is one of the two pairs of wings that extend from the body of the sphenoid bone. It is located at the anterior portion of the sphenoid bone and contributes to the formation of the

middle cranial fossa. Post clivus (Option A): The term "post clivus" is not a specific anatomical structure. The clivus refers to a sloping surface on the occipital bone that forms the posterior part of the cranial base. Sella turcica (Option C): The sella turcica, a bony depression found on the superior surface of the sphenoid bone, houses the pituitary gland. Carotid canal (Option D): The carotid canal, a bony canal situated in the petrous portion of the temporal bone, permits the passage of the internal carotid artery.

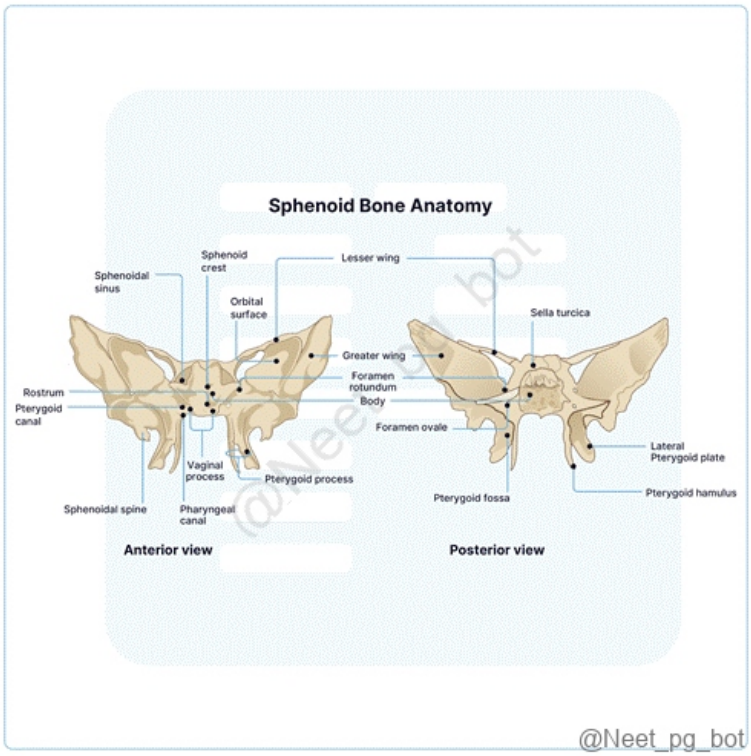

References:

BD Chaurasia’s Human Anatomy, 8th Edition, Page no: 543

↑ *Back to this question in Part A*

@Neet_pg_bot

Q30: Which of the following marked structures does not form part of the laryngeal skeleton? (Q856979)

A. A

B. B

C. C

D. D

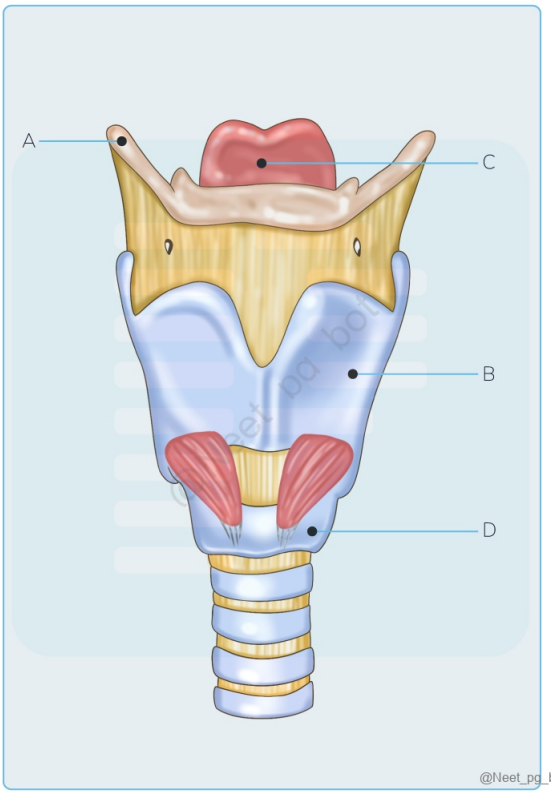

Correct Answer: A. A

Explanation: The hyoid bone is not considered part of the laryngeal skeleton. Instead, it is a U-shaped bone located in the neck region above the larynx. The hyoid bone serves as a point of attachment for various muscles involved in swallowing and speech production. It does not directly contribute to the structure or support of the larynx itself. Larynx- Anatomy The larynx is in front of the hypopharynx, roughly opposite the third to sixth cervical vertebrae. It moves up and down and back and forth during swallowing and speaking. It can also be moved from side to side, which creates a grating feeling known as laryngeal crepitus. In adults, the larynx extends down to the lower border of the C6 vertebra. Type of Cartilage Paired Cartilage Unpaired Cartilage Hyaline Cartilage (Calcifies with age) Arytenoid Thyroid, Cricoid Elastic Cartilage Corniculate, Cuneiform Epiglottis B (Option B): The thyroid cartilage, a key component of the larynx, forms the prominent Adam's apple and helps protect the vocal cords. C (Option C): The epiglottis, a leaf-shaped cartilage above the larynx, aids in swallowing by covering the glottis and preventing food from entering the airway. D (Option D): The cricoid cartilage, situated beneath the thyroid cartilage, forms the larynx's base, offering support and stability.

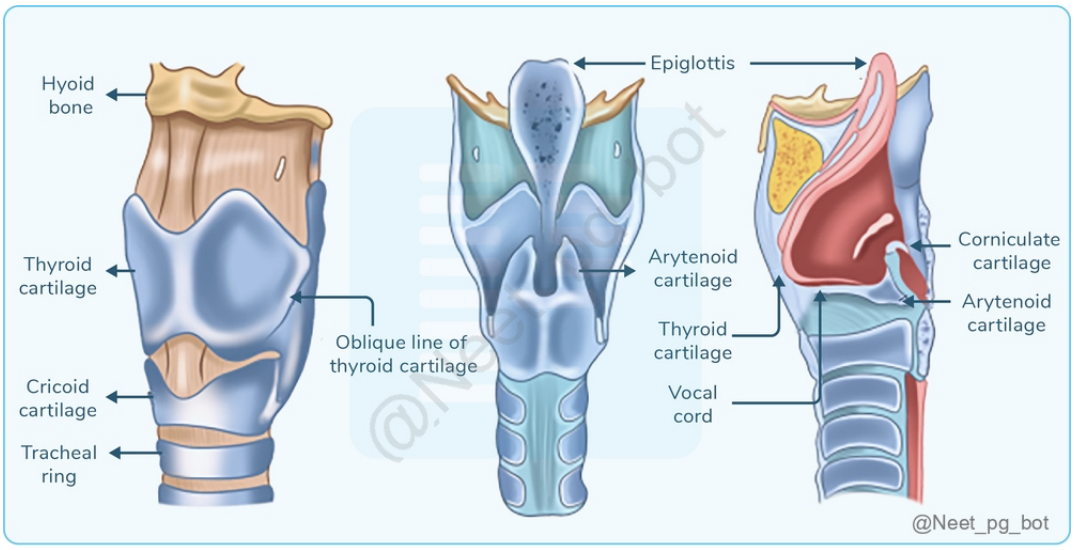

References:

BD Chaurasia’s Human Anatomy, 8th Edtion, Page 234

↑ *Back to this question in Part A*

@Neet_pg_bot

Q31: A patient is unable to abduct his arm. Which of the following root values is likely to be affected (Q856959)

A. C4

B. C5

C. C6

D. C7

Correct Answer: B. C5

Explanation: Arm abduction is mainly controlled by muscles innervated by the axillary nerve from the brachial plexus's posterior cord. It supplies the deltoid muscle, crucial for this action. The axillary nerve is formed from contributions of the C5 and C6 nerve roots, which give rise to its posterior division in the upper trunk of the brachial plexus. Damage at the C5 level can weaken or paralyze the deltoid muscle, affecting arm abduction. {{caption_text}} C4 (Option A): C4 nerve root mainly provides sensation to the upper shoulder, not directly controlling arm abduction. Damage to it wouldn't typically impair arm abduction. C6 (Option C): C6 nerve root primarily controls elbow flexion and wrist extension. While it aids in initiating arm abduction, isolated damage to C6 wouldn't fully prevent arm abduction. C7 (Option D): Damage to the C7 nerve root mainly affects elbow and wrist movements, not shoulder motion. It wouldn't usually cause an isolated inability to abduct the arm.

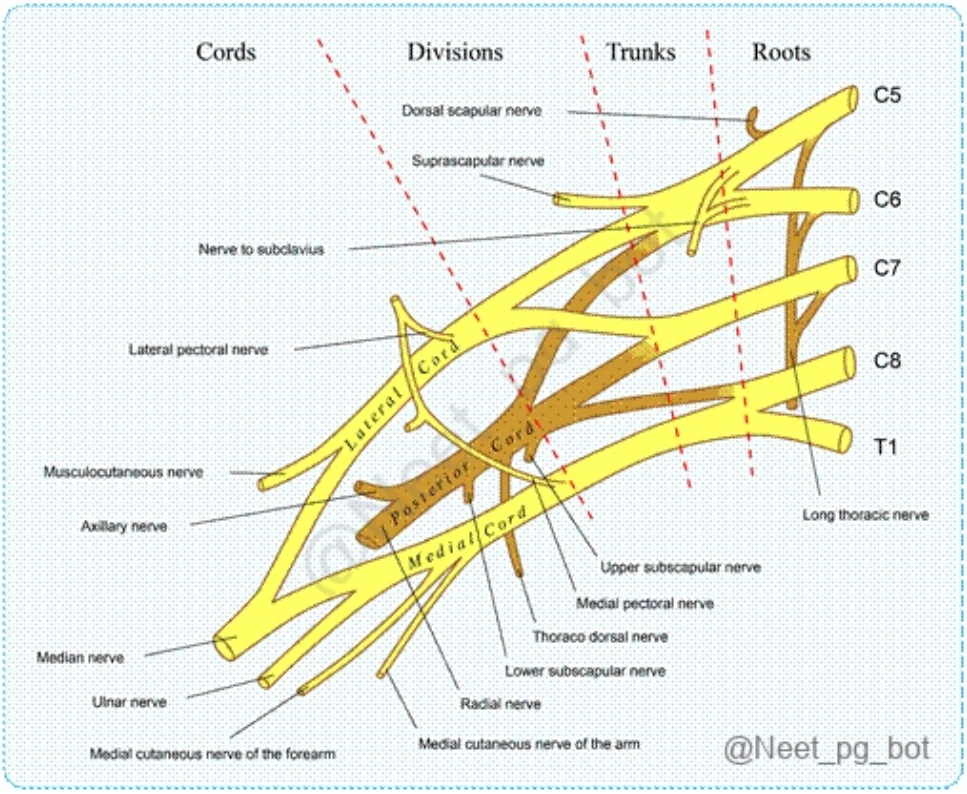

References:

BD Chaurasia's Human Anatomy, 8th Edtion, Page no: 135

↑ *Back to this question in Part A*

@Neet_pg_bot

Q32: The pre-tracheal layer of deep cervical fascia encloses all of the following except: (Q856951)

A. Oesophagus

B. Sternocleidomastoid

C. Sternohyoid

D. Thyroid gland

Correct Answer: B. Sternocleidomastoid

Explanation: The deep cervical fascia is a connective tissue that partitions the neck and supports its structures. The pretracheal layer of the deep cervical fascia surrounds the trachea, esophagus, and thyroid gland in the front of the

neck. However, it doesn't cover the sternocleidomastoid muscle, a major neck muscle that sits above it. Oesophagus (Option A): The pretracheal layer of the deep cervical fascia envelops the esophagus, providing a protective covering as it traverses the neck. Sternohyoid (Option C) : The pretracheal layer of the deep cervical fascia envelops the sternohyoid muscle, situated beneath the sternocleidomastoid muscle in the front of the neck.. Thyroid gland (Option D) : The pretracheal layer of the deep cervical fascia encloses the thyroid gland. It forms a sheath around the gland, providing support and protection.

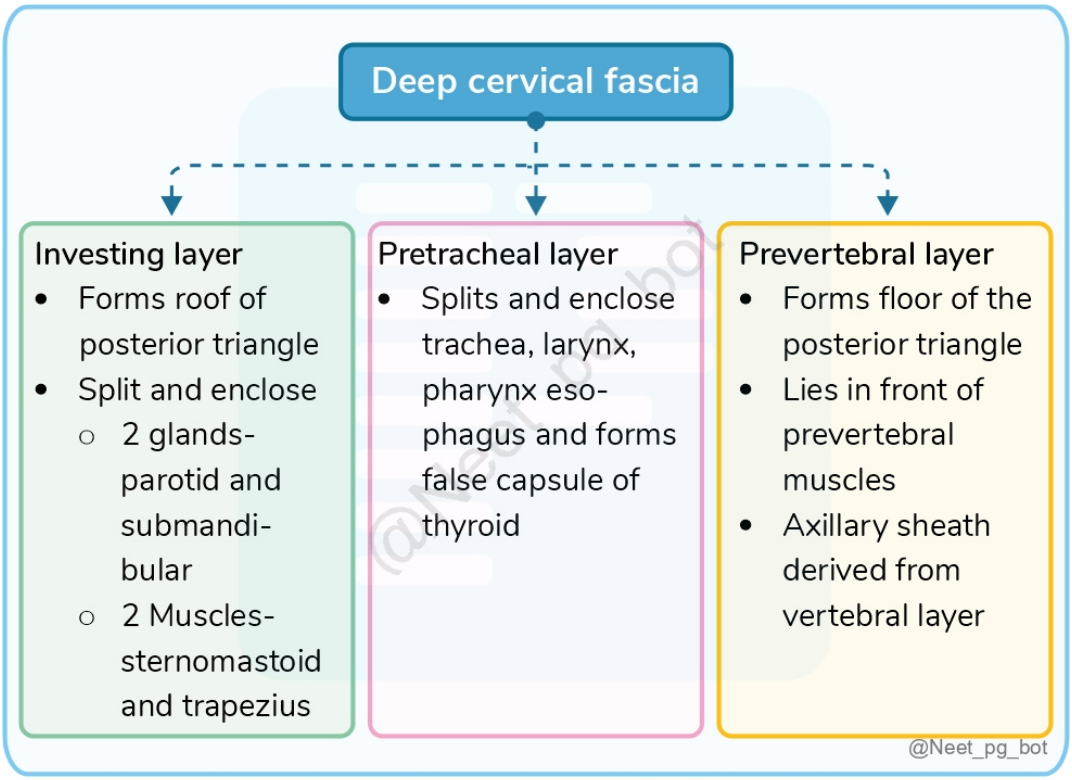

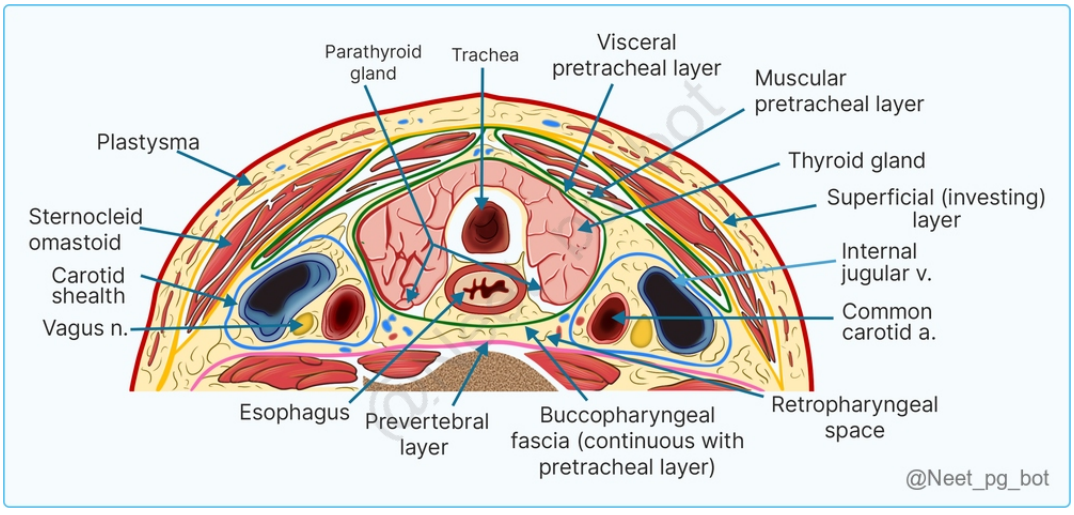

References:

.

↑ *Back to this question in Part A*

Q33: During the clinical examination of the nervous system, which of the following nerves can be tested by touching the highlighted structure? (Q856186)

A. IX

B. X

C. XI

D. XII

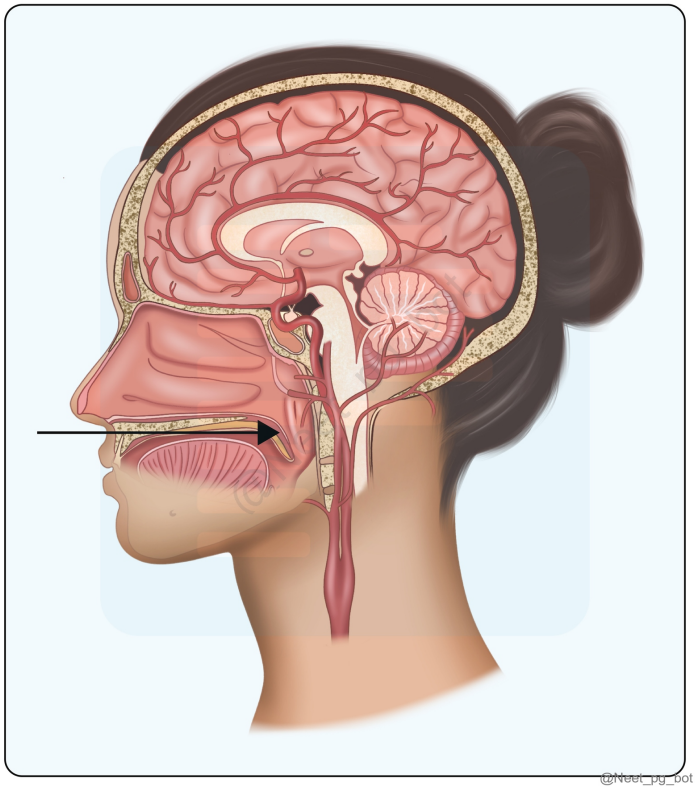

Correct Answer: A. IX

Explanation: ontrols motor innervation of the soft palate and pharynx but does not carry sensory input from the uvula . If damaged, it causes uvula deviation to the opposite side , but it is not responsible for sensation . Accessory nerve (Option XI): Innervates the sternocleidomastoid and trapezius muscles . Has no role in sensation or movement of the uvula . Hypoglossal nerve (Option XII): Controls tongue muscles , affecting tongue movement. Does not contribute to the gag reflex or uvula sensation.

References:

Cranial Nerves IX and X: The Glossopharyngeal and Vagus Nerves - Clinical Methods - NCBI Bookshelf

Neuroanatomy, Cranial Nerve 9 (Glossopharyngeal) - StatPearls - NCBI Bookshelf

↑ *Back to this question in Part A*

@Neet_pg_bot

Q34: A patient presented with jaw swelling and weight loss. Suspecting a malignancy, the submandibular gland was resected. Which is the most likely nerve to be damaged during submandibular gland resection? (Q856185)

A. Nerve to mylohyoid

B. Inferior alveolar nerve

C. Lingual nerve

D. Hypoglossal nerve

Correct Answer: C. Lingual nerve

Explanation: - Lingual nerve The lingual nerve , a branch of the mandibular division (V3) of the trigeminal nerve , runs very close to the submandibular gland and is at high risk of injury during gland resection. Functions affected if damaged: Loss of general sensation from the anterior two-thirds of the tongue . Loss of taste from the anterior two-thirds of the tongue (as it carries fibres from the chorda tympani nerve , a branch of the facial nerve). Possible decreased salivation (as chorda tympani also carries parasympathetic fibres to the submandibular and sublingual glands). The lingual nerve originates from the posterior division of the mandibular nerve (V3) in the infratemporal fossa. It then descends and moves forward, initially positioned medially to the lateral pterygoid muscle and deep to the ramus of the mandible. As it enters the floor of the mouth, it lies superficial to the hyoglossus muscle and deep to the submandibular duct. The nerve loops under the duct, passing from lateral to medial, before ascending to supply sensory innervation to the anterior two-thirds of the tongue. This intricate course places the lingual nerve close to the submandibular gland, making it particularly susceptible to injury during surgical procedures in this area. Nerve to mylohyoid (option A): A branch of the inferior alveolar nerve (V3) , it supplies the mylohyoid muscle and anterior belly of the digastric muscle . Damage would affect floor of mouth muscle function , but not tongue sensation or taste . Inferior alveolar nerve (option B): This nerve runs inside the mandibular canal and supplies sensation to the lower teeth, chin, and lower lip . It is not closely related to the submandibular gland . Hypoglossal nerve (option D): Supplies motor function to all intrinsic and extrinsic muscles of the tongue (except palatoglossus) . Injury would cause tongue deviation towards the affected side, but not sensory or taste loss .

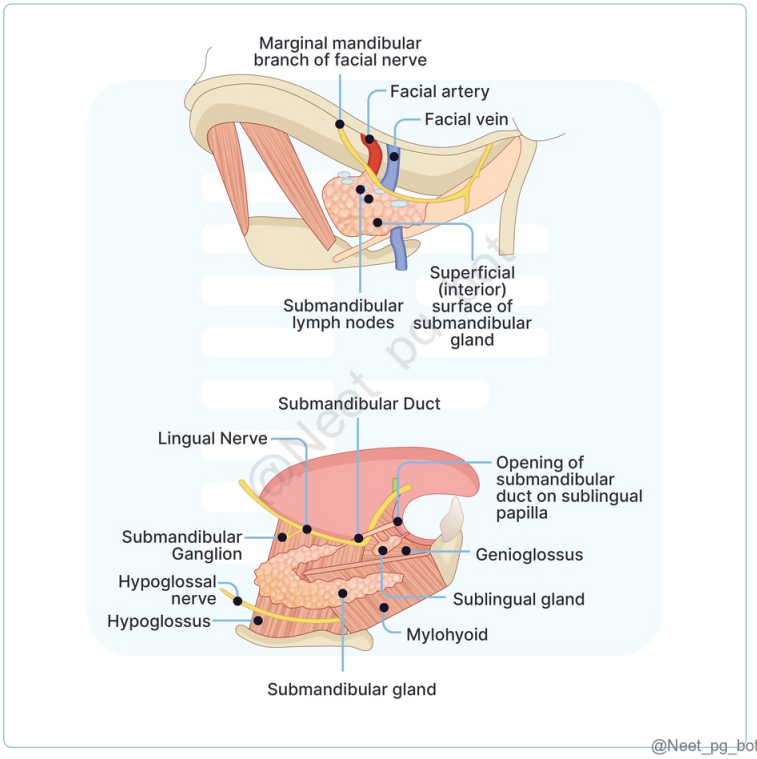

References:

Sabiston Textbook of Surgery (21st edition) page 780

Bailey and Love's Short Practice of Surgery (28th Edition) page 833, 849

SRB's Manual of Surgery (6th Edition) page 394, 398

Anatomy, Head and Neck, Lingual Nerve - StatPearls - NCBI Bookshelf.

↑ *Back to this question in Part A*

@Neet_pg_bot

Q35: Identify the papillae from the given histological section? (Q856183)

A. Fungiform

B. Circumvallate

C. Filiform

D. Foliate

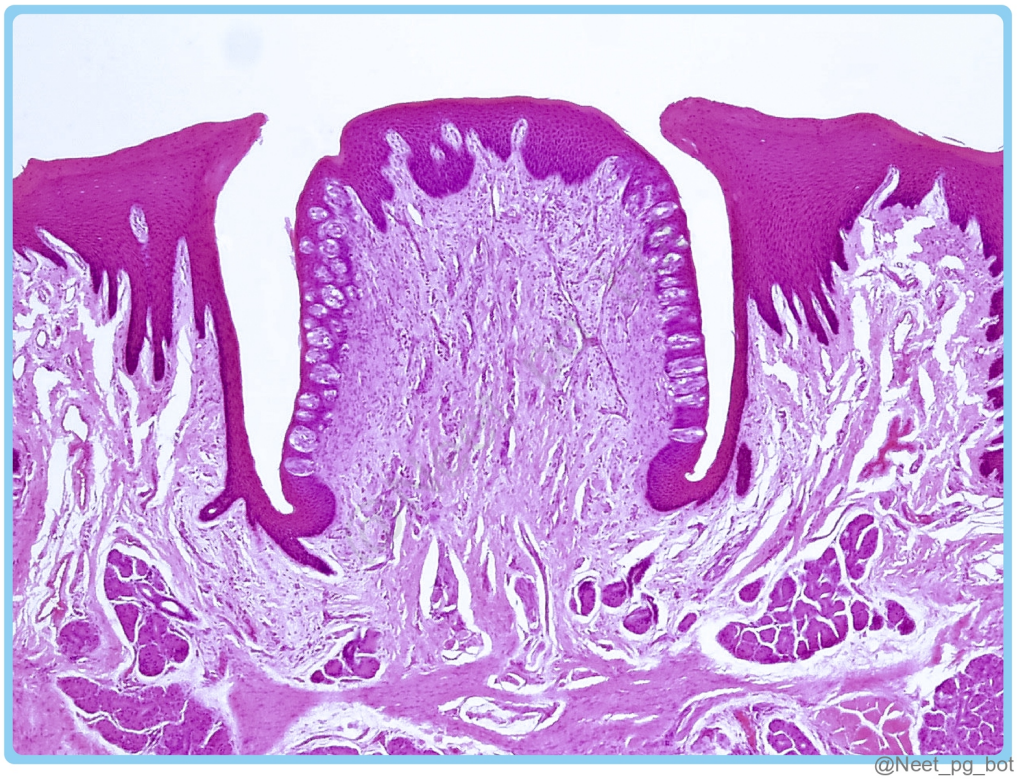

Correct Answer: B. Circumvallate

Explanation: Circumvallate papillae are large, dome-shaped papillae located at the posterior part of the tongue, arranged in a V-shape anterior to the sulcus terminalis. They have deep surrounding trenches (moats) lined by taste buds, which help in taste perception. Von Ebner's glands, which secrete serous fluid to cleanse taste buds, are located at the base of the trenches. Fungiform papillae (option A): Mushroom-shaped papillae are scattered on the anterior tongue, mainly on the tip and sides. Contain taste buds on their apical surface but lack surrounding trenches. Filiform papillae (option C): Most numerous, thin, and conical papillae covering most of the tongue's dorsal surface. They do not contain taste buds; instead, they aid in mechanical functions, such as food manipulation. Foliate papillae (option D): Located on the lateral margins of the tongue as vertical folds. Contain numerous taste buds but are less developed in human s.

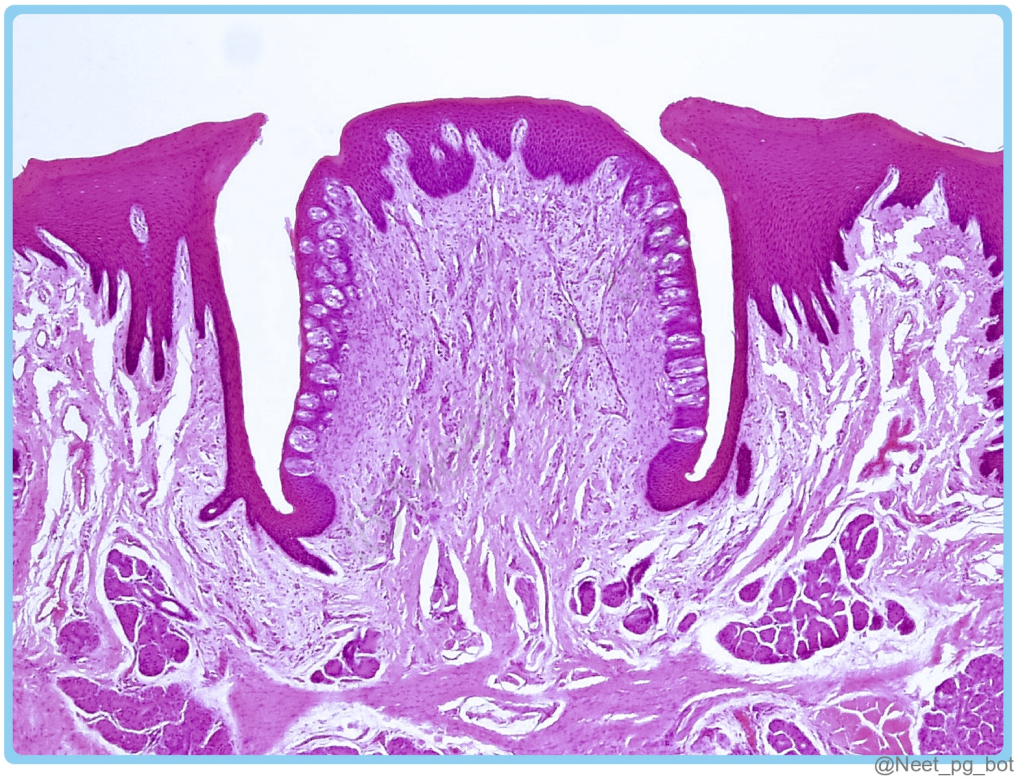

@Neet_pg_bot

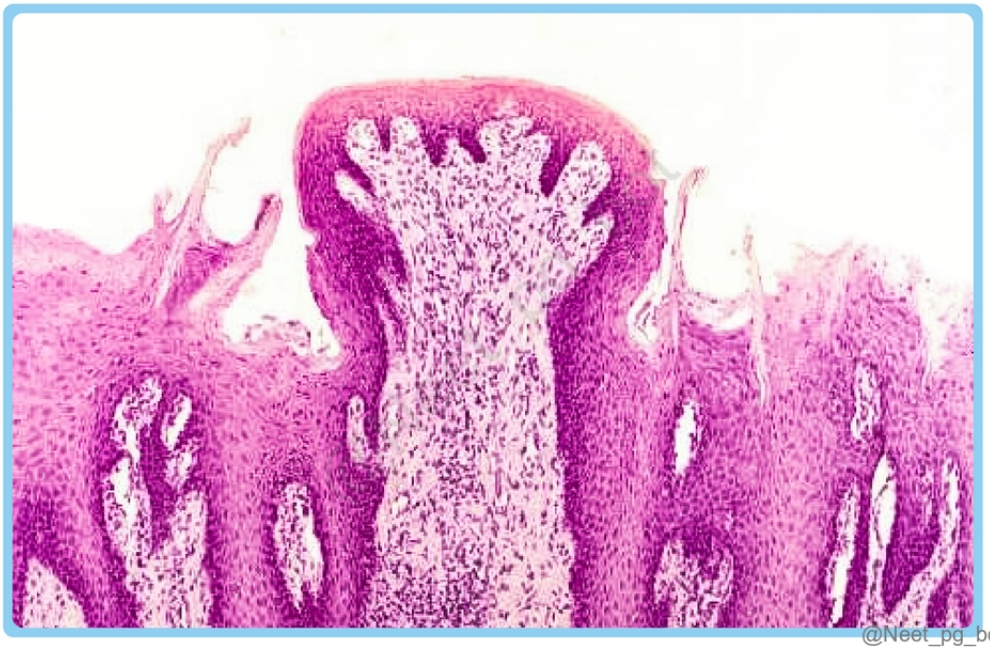

@Neet_pg_bot

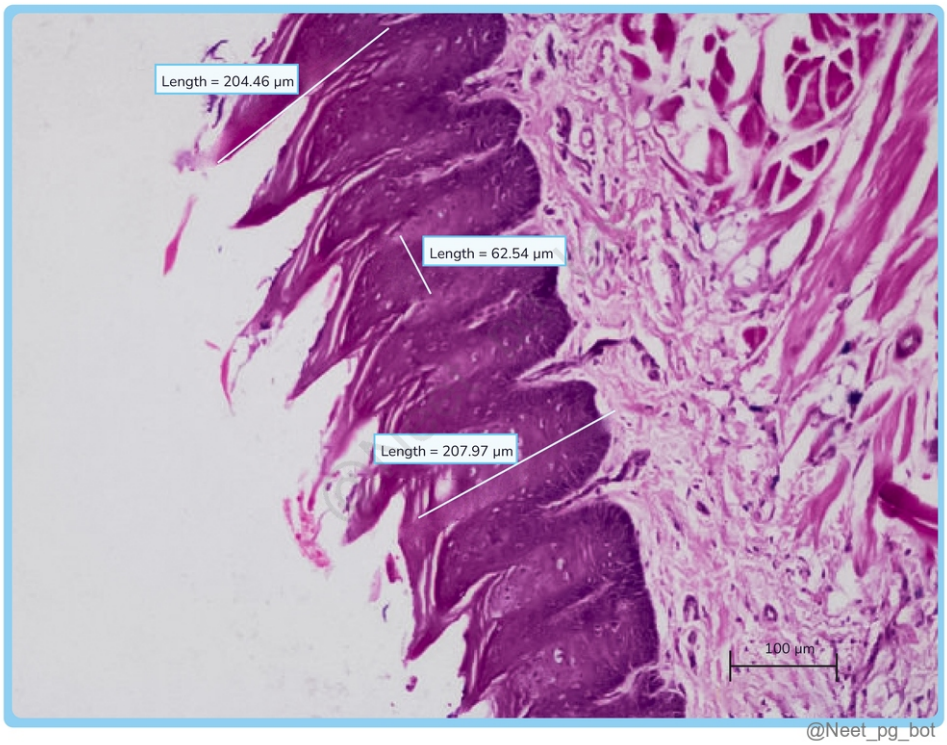

@Neet_pg_bot


@Neet_pg_bot

References:

Anatomy, Head and Neck, Tongue Taste Buds - StatPearls - NCBI Bookshelf

↑ *Back to this question in Part A*

@Neet_pg_bot

Q36: Through which of the following marked sites does COVID 19 spread to the brain? (Q856674)

A. D

B. C

C. B

D. A

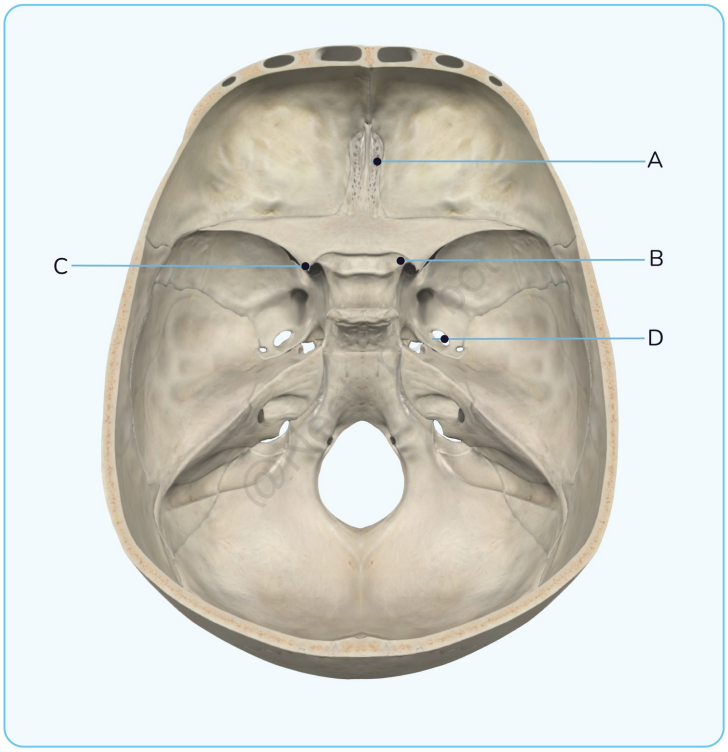

@Neet_pg_bot

Correct Answer: D. A

Explanation: COVID-19 can spread to the brain through the cribriform plate of the ethmoid bone (marked as A in the image). The olfactory nerve (CN I) passes through this region, providing a direct route for SARS-CoV-2 to reach the brain . This explains why anosmia (loss of smell) is one of the early neurological symptoms in COVID-19 patients. The virus can travel along the olfactory nerve fibers to the olfactory bulb , leading to further neurological symptoms. COVID-19 Neuroinvasion Route Mechanism Clinical Implications Olfactory Route Virus enters via nasal mucosa, travels through cribriform plate to the olfactory bulb Anosmia, encephalopathy

Hematogenous Route Viral entry through blood-brain barrier via infected endothelial cells Stroke, brain inflammation Lymphatic Route Virus spreads via lymphatics from the nasopharynx Meningitis-like symptoms D- Foramen Ovale (Option A) – Incorrect: Transmits mandibular nerve (V3) and does not provide a route for viral spread. C- Clinoid Process (Option B) – Incorrect: Bony projection of the sphenoid bone, not associated with olfactory transmission. B- Optic Canal (Option C) – Incorrect: Located near the optic canal , which is not the primary route for SARS-CoV-2 entry.

References:

Gray's Anatomy: The Anatomical Basis of Clinical Practice, 41st Edition - Page no: 430-432

https://pubmed.ncbi.nlm.nih.gov/32422545/

↑ *Back to this question in Part A*

@Neet_pg_bot

Q37: What is the correct nerve supply to the muscles labelled as A and B? (Q866307)

A. A - Nerve to mylohyoid, B- Facial nerve

B. A - Facial nerve, B- Spinal accessory nerve

C. A- Facial nerve, B- Mandibular nerve

D. A - Spinal accessory nerve, B- Mandibular nerve

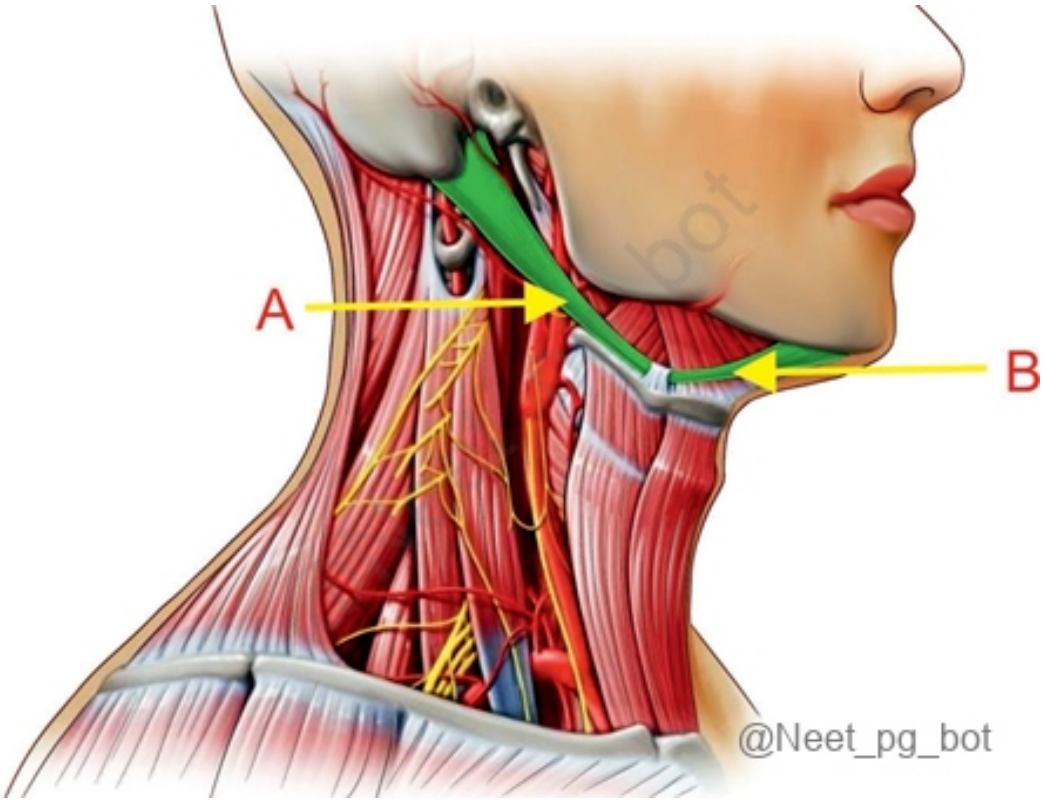

Correct Answer: C. A- Facial nerve, B- Mandibular nerve

Explanation: The labeled structures receive their nerve supply as follows: A (Posterior belly of digastric): Facial nerve B (Anterior belly of digastric): Mandibular nerve Incorrect Options: Option A - A - Nerve to mylohyoid, B- Facial nerve: This incorrectly swaps the nerves; the posterior belly is innervated by the facial nerve, not the nerve to mylohyoid. Option B - A - Facial nerve, B- Spinal accessory nerve: The spinal accessory nerve does not supply the anterior belly of digastric but innervates the sternocleidomastoid and trapezius muscles. Option D - A - Spinal accessory nerve, B- Mandibular nerve: The posterior belly is not supplied by the spinal accessory nerve but by the facial nerve.

↑ *Back to this question in Part A*

@Neet_pg_bot

Q38: Which muscle movements are related to the Abducens nerve? (Q860606)

A. Lateral rectus

B. Medial rectus

C. Superior oblique

D. Inferior oblique

Correct Answer: A. Lateral rectus

Explanation: The lateral rectus muscle is supplied by the Abducens nerve. Extraocular muscles Voluntary muscles Involuntary muscles Four recti muscles Superior rectus Inferior rectus Medial rectus Lateral rectus Two oblique muscles Superior oblique Inferior oblique Levator palpebrae superioris (1) Superior tarsal or Muller's muscle Inferior tarsal Orbitalis. Origin, insertion, and nerve supply of extraocular muscles: Origin Insertion Nerve supply (SO4, LR6) Recti Common annular tendon or tendinous ring of Zinn. (all recti have the same origin) Sclera little posterior to the limbus (corneoscleral junction) The average distance from Limbus is: Superior: 7.7 mm Inferior: 6.5 mm Medial: 5.5 mm Lateral: 6.9 mm Lateral rectus: Abducens nerve Rest all other recti: Oculomotor nerve (Option B) Superior oblique The undersurface of the lesser wing of the sphenoid Into the sclera behind the equator in the posterior superior quadrant of the eyeball. Trochlear nerve (Option C) Inferior oblique The orbital surface of the maxilla Into the sclera behind the equator in the posterior superior quadrant of the eyeball, a little below the superior oblique. Oculomotor nerve (Option D) Levator palpebrae superioris Orbital surface of the lesser wing of the sphenoid bone. Superior lamella: Anterior surface of the superior tarsus and skin of the upper eyelid. Inferior lamella: Upper margin of the superior tarsus and the superior conjunctival fornix. Actions of muscles on the eyeball: Mnemonic SIN- S uperior rectus/ S uperior oblique assist in IN torsion RAD- R ectus muscles help in AD duction Superior rectus (SR) Medial rectus (MR) Inferior rectus (IR) Lateral rectus (LR) Superior oblique (SO) Inferior oblique (IO) Elevation Adduction Intorsion Adduction Depression Adduction Extorsion Abduction Depression Abduction Intorsion Elevation Abduction Extorsion

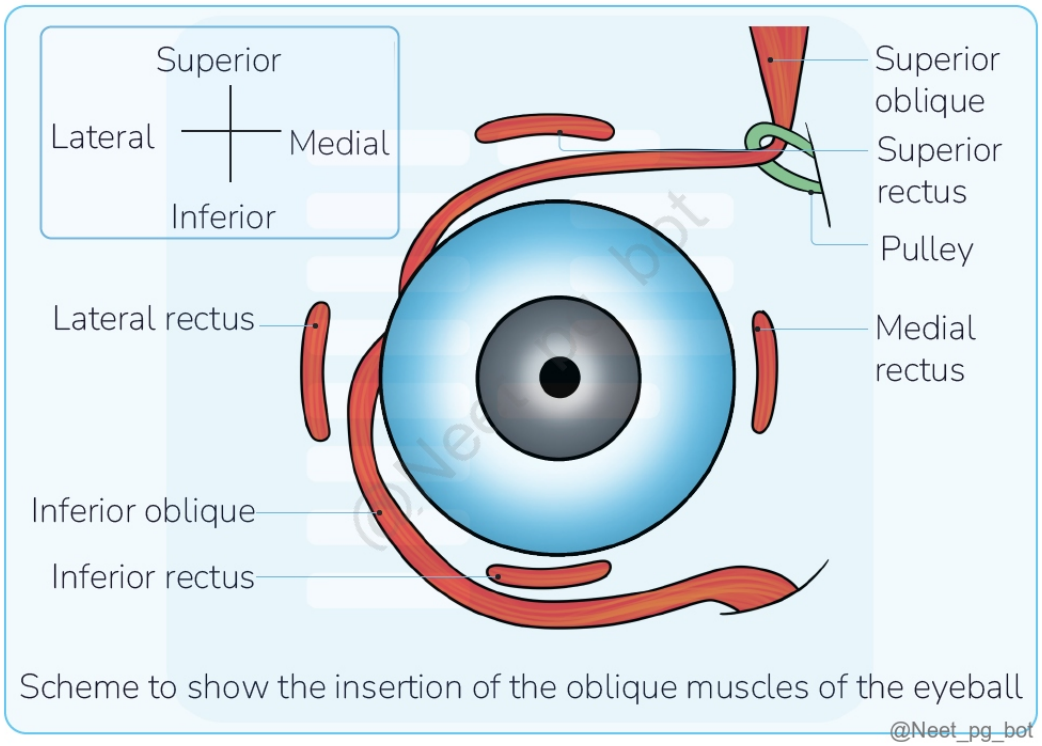

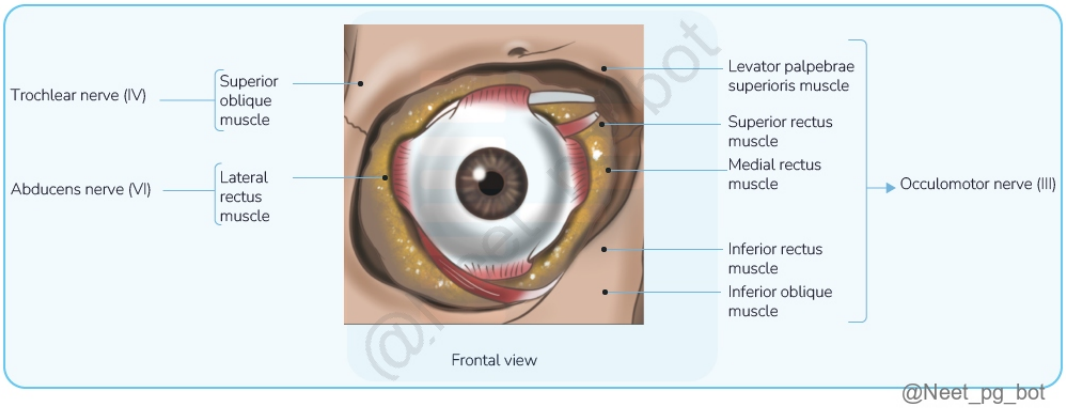

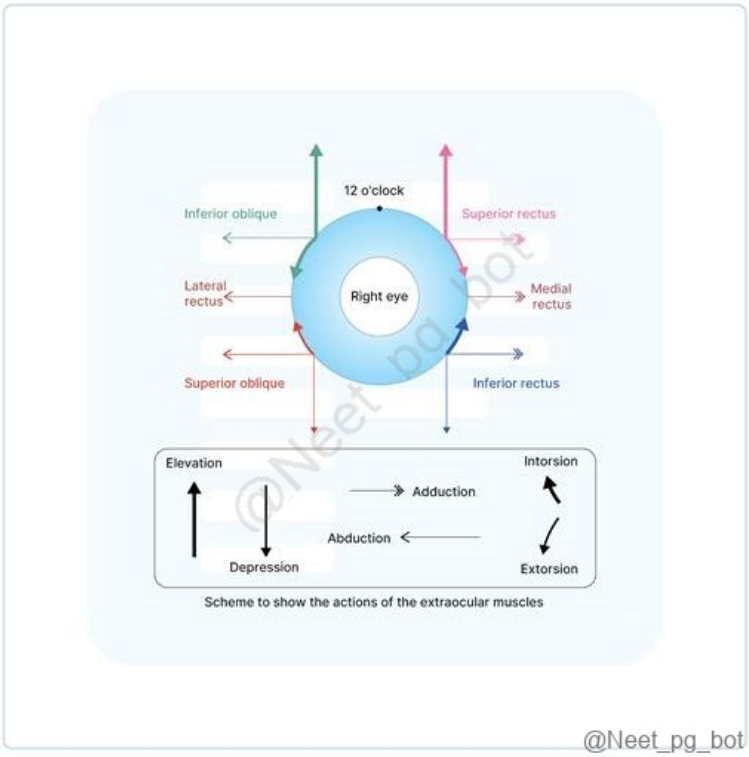

References:

Grey's Anatomy 42nd edition, pg 773-777.

BD Chaurasia’s Human Anatomy, 8th edition, pg 232-237.

Vishram Singh Textbook of Anatomy, 2nd edition, pg 285-288.

↑ *Back to this question in Part A*

@Neet_pg_bot

Q39: A singer presents with singing at high pitch. On examination, bowing of the vocal cord is seen on the right side. Which of the following muscles has been compromised? (Q844197)

A. Posterior cricoarytenoid

B. Lateral cricoarytenoid

C. Cricothyroid

D. Thyroarytenoid

Correct Answer: C. Cricothyroid

Explanation: Correct Option C - Cricothyroid: The cricothyroid muscle is responsible for tensing and elongating the vocal cords, which is crucial for producing high-pitched sounds. When the cricothyroid muscle is compromised, it can lead to an inability to tense the vocal cords properly, resulting in bowing or a lack of tension, particularly during high-pitched singing. This bowing may be observed on laryngoscopy as a gap between the vocal cords, contributing to a weak or breathy voice. Incorrect Options: Option A - Posterior cricoarytenoid: The posterior cricoarytenoid muscle is responsible for abducting (opening) the vocal cords. If this muscle were compromised, the vocal cords would remain in a partially closed position, leading to difficulty breathing rather than issues with pitch. Option B - Lateral cricoarytenoid: The lateral cricoarytenoid muscle adducts (closes) the vocal cords. Its impairment would affect the closure of the vocal cords, leading to issues with sound production, but not specifically related to pitch. Option D - Thyroarytenoid: The thyroarytenoid muscle helps to shorten and relax the vocal cords, lowering the pitch. While it plays a role in vocal cord tension, it is more involved in lower pitches and overall voice modulation rather than the high-pitch tension that the cricothyroid muscle manages.

↑ *Back to this question in Part A*

@Neet_pg_bot

Q40: A patient presents with the palsy of the face as shown. Which of the following is most likely involved? (Q852520)

A. 7th nerve palsy

B. 3rd nerve palsy

C. Erb’s palsy

D. Orbicularis oculi palsy



Correct Answer: A. 7th nerve palsy

Explanation: The image presents a clinical case of facial palsy. The child's facial asymmetry, particularly the drooping of one side of the face, suggests a lower motor neuron (LMN) facial nerve (CN VII) palsy, commonly known as Bell’s palsy. Bell’s palsy: Description Most common cause of facial palsy Characterized by idiopathic, LMN facial paralysis of acute onset Most commonly the Labyrinthine segment of facial nerve is involved. Males and females are equally affected. Aetiology Idiopathic: Most common cause Viral Infection: HSV >> Herpes zoster Vascular Ischemia Hereditary: Positive family history in 6-8% Autoimmune Risk Factors More common in diabetics (due to angiopathy) and pregnant women (due to fluid retention). Clinical Features Sudden onset of facial paralysis with inability to close the eye (Bell's phenomenon), asymmetry of the face, epiphora, drooping mouth, and dribbling of saliva. Associated symptoms may include ear pain, noise intolerance (stapedial paralysis), or loss of taste (chorda tympani involvement). Diagnosis Diagnosis is made by excluding other causes of peripheral facial paralysis. Treatment General: Reassurance, pain relief, eye protection and physiotherapy Medical: Prednisolone 60 mg per day for 5 days then reduced by 10 mg per day (for a total treatment time of 10 days) and 50 mg per day (in two divided doses) for 10 days, Acyclovir (Adult doses) Surgical: Nerve decompression Prognosis 85%-90% of patients fully recover Incomplete resolution are mainly seen in recurrent/late recovery cases 3rd N. Palsy (Option B): Affects the oculomotor nerve (CN III), causing ptosis, ophthalmoplegia, and pupil involvement, not facial asymmetry. Erb’s Palsy (Option C): A brachial plexus injury affecting arm movement, not facial muscles. Orbicularis Oculi Palsy (Option D): Would only affect eyelid closure, not the entire face.

References:

Diseases of Ear, Nose, and Throat & Head and Neck Surgery, PL Dhingra, 8th edition, Page: 108, 112-114. Scott Brown's Otorhinolaryngology, Volume 2, 8th edition, Page: 1400.

↑ *Back to this question in Part A*

@Neet_pg_bot

Q41: A 28-year-old man presents with sudden onset inability to close his right eye and drooping of the right side of his mouth. On examination, he is unable to raise his right eyebrow, cannot puff his right cheek, and shows complete paralysis of all muscles of facial expression on the right side. Forehead involvement is clearly noted. No neurological deficits are present on the left side.Which of the following is the most likely diagnosis? (Q852515)

A. Infranuclear facial palsy on right side

B. Supranuclear facial palsy on left side

C. Infranuclear facialpalsy on left side

D. Supranuclear facial palsyon right side

Correct Answer: A. Infranuclear facial palsy on right side

Explanation: Infranuclear (LMN) palsy causes complete paralysis of all muscles of facial expression on the same side , including forehead muscles . The patient shows right-sided total facial paralysis with forehead involvement , consistent with a right LMN lesion (e.g., Bell's palsy). Facial nerve palsy: Feature Upper Motor Neuron Lesion (Supranuclear) Lower Motor Neuron Lesion (Infranuclear) Lesion Location Motor cortex, connection from motor cortex to facial nucleus in pons Facial nucleus, anywhere along CN VII Affected Side Contralateral Ipsilateral Muscles Involved Lower muscles of facial expression Upper and lower muscles of facial expression Forehead Involved? Spared, due to bilateral UMN innervation Affected Other Symptoms Variable; depends on size of lesion Incomplete eye closure (dry eyes, corneal ulceration), hyperacusis, loss of taste sensation to anterior tongue

References:

.

↑ *Back to this question in Part A*

@Neet_pg_bot

Q42: Which of the following is the afferent limb of the corneal reflex? (Q852452)

A. Optic nerve

B. Facial nerve

C. Trigeminal nerve

D. Trochlear nerve

Correct Answer: C. Trigeminal nerve

Explanation: The corneal reflex (blink reflex) involves two components: Afferent limb (sensory input): The ophthalmic division (V1) of the trigeminal nerve (CN V) detects touch or irritation on the cornea and sends sensory signals to the brainstem. Efferent limb (motor response): The facial nerve (CN VII) activates the orbicularis oculi muscle, causing eyelid closure. Reflex Afferent Nerve Efferent Nerve Accommodation II (Optic nerve) III (Oculomotor nerve) Corneal V■ (Ophthalmic, nasociliary branch) Bilateral VII (Facial nerve, temporal branch - orbicularis oculi) Cough X (Vagus nerve) X (Vagus nerve, also phrenic and spinal nerves) Gag IX (Glossopharyngeal nerve) X (Vagus nerve) Jaw Jerk V■ (Mandibular branch, sensory from masseter) V■ (Mandibular branch, motor to masseter) Lacrimation V■ (Ophthalmic branch) (loss of reflex does not preclude emotional tears) VII (Facial nerve) Pupillary II (Optic nerve) III (Oculomotor nerve) Optic nerve (Option A): Involved in the pupillary light reflex, not the corneal reflex. Facial nerve (Option B): Acts as the efferent limb, responsible for blinking, not the afferent limb. Trochlear nerve (Option D): Innervates the superior oblique muscle, which controls eye movement but has no role in the corneal reflex.

References:

https://www.ncbi.nlm.nih.gov/books/NBK534247/

↑ *Back to this question in Part A*

@Neet_pg_bot

Q43: Identify the structure marked in the image given below. (Q852505)

A. Buccopharyngeal fascia

B. Capsule

C. Superior constrictor muscle

D. Pharyngobasilar fascia

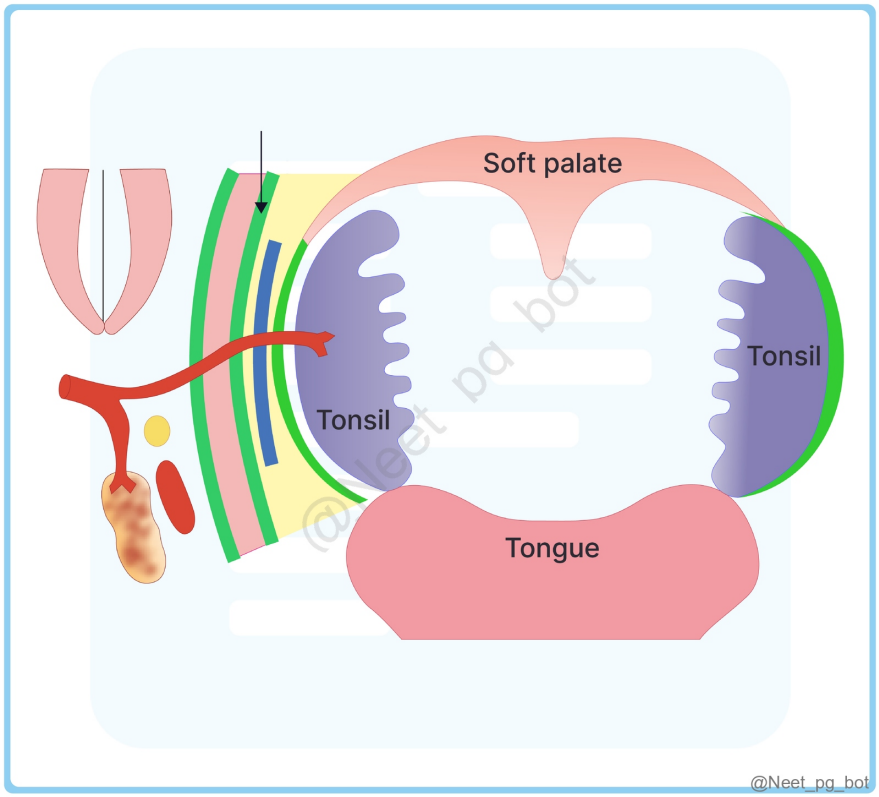

Correct Answer: D. Pharyngobasilar fascia

Explanation: The arrow in the image points to the pharyngobasilar fascia. Structures forming the Tonsillar bed Muscles forming the tonsillar bed Superior Constrictor Muscle Styloglossus Muscle Structures close to the tonsillar bed (outside the superior constrictor muscle) Facial Artery (Tonsillar Branch): Major blood supply to the tonsils, at risk for haemorrhage during surgery. Paratonsillar Vein: Venous drainage of the tonsil, risk of bleeding during tonsillectomy. Submandibular Salivary Gland Posterior Belly of Digastric Muscle Medial Pterygoid Muscle Mandible Glossopharyngeal Nerve: Provides sensory innervation to the tonsils.

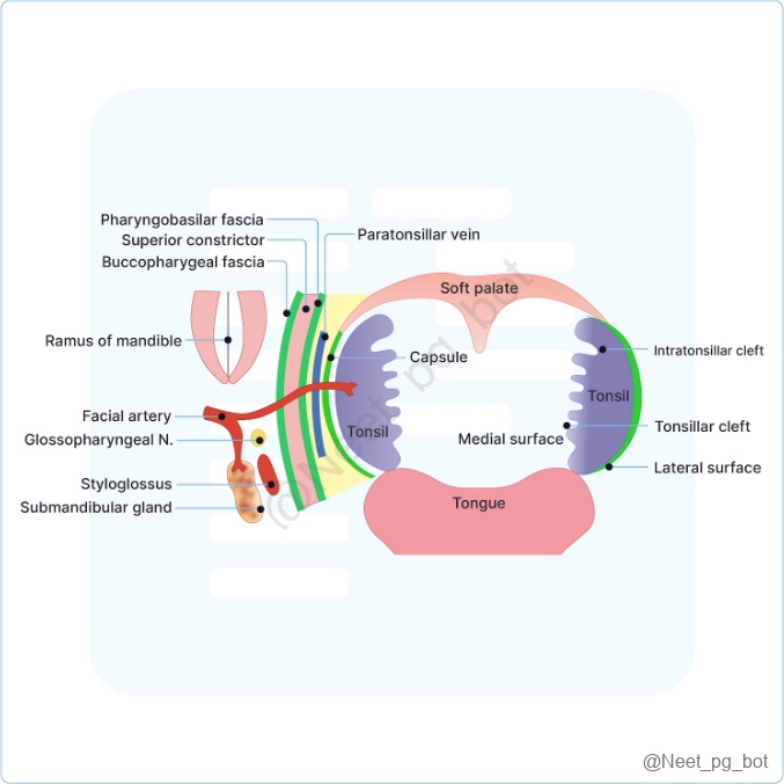

References:

Diseases of Ear, Nose, Throat, PL Dhingra, 8th Edition, Page 303, 304

↑ *Back to this question in Part A*

@Neet_pg_bot

Q44: A 60-year-old male recovering from facial nerve palsy complains of food getting stuck between the cheek and teeth while eating. What is the muscle affected in this case? (Q852995)

A. Buccinator

B. Levator labii superioris

C. Zygomaticus major

D. Orbicularis oris

Correct Answer: A. Buccinator

Explanation: The buccinator muscle is responsible for compressing the cheek against the teeth , preventing food from accumulating in the vestibule of the mouth . It is innervated by the facial nerve (CN VII) and is often affected in facial nerve palsy . Damage to this muscle leads to difficulty in controlling food while chewing , causing food to get stuck between the cheek and teeth . The buccinator also helps in blowing air out (whistling) and articulation of speech sounds . Buccinator Muscle and Its Function Feature Description Location Forms the muscular layer of the cheek Origin Alveolar processes of maxilla and mandible, pterygomandibular raphe Insertion Blends with fibers of orbicularis oris Innervation Facial nerve (CN VII) Function Compresses cheek against teeth, aids in chewing and speech Clinical Relevance Dysfunction leads to food trapping in the vestibule, difficulty in blowing air {{caption_text}} Levator labii superioris (Option B): Incorrect because this muscle elevates the upper lip , contributing to facial expressions but not affecting food trapping. Zygomaticus major (Option C): Incorrect because it is a smiling muscle , pulling the angle of the mouth superiorly and laterally, unrelated to chewing. Orbicularis oris (Option D): Incorrect because it closes and puckers the lips , playing a role in speech and whistling, but not in preventing food accumulation in the cheek.

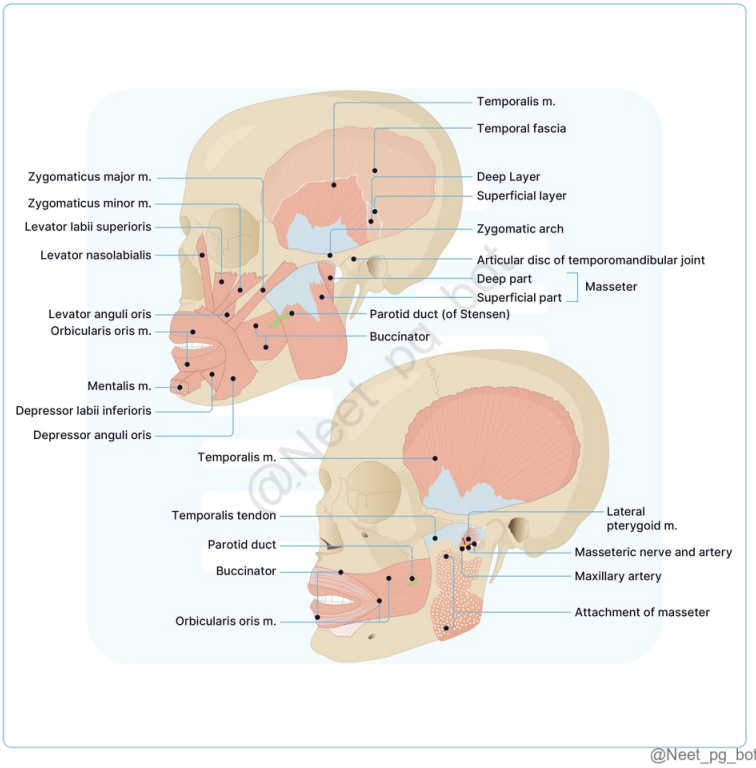

References:

Grey's Anatomy 42nd edition, Pages 676, 677, 678.

BD Chaurasia’s Human Anatomy, 8th edition, Pages 124-127.

Vishram Singh Textbook of Anatomy, 2nd edition, Pages 148-150.

Netter Atlas of Human Anatomy: Classic Regional Approach, Pages 72, 73

↑ *Back to this question in Part A*

@Neet_pg_bot

Q45: The posterior end of the marked structure is present at the level of which of the following? {{caption_text}} (Q852993)

A. Eustachian tube

B. Sphenopalatine foramen

C. Odontoid process

D. Sphenoidal sinus

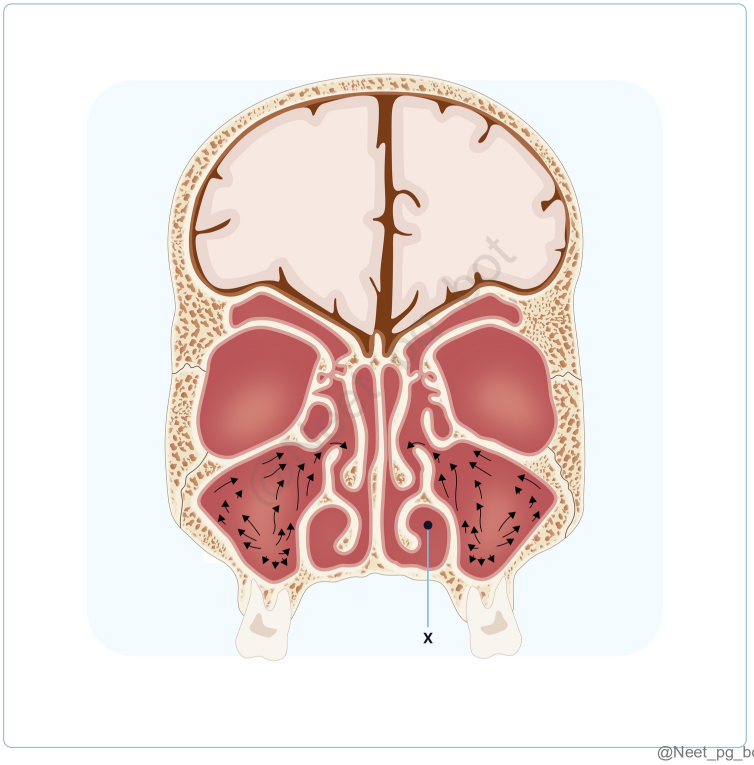

Correct Answer: A. Eustachian tube

Explanation: The structure in question is likely the inferior turbinate or the nasal cavity . The posterior end of the inferior nasal meatus , where the inferior turbinate terminates, is near the opening of the Eustachian tube in the nasopharynx. The Eustachian tube connects the middle ear to the nasopharynx, allowing pressure equalization. It is located at the level of the posterior end of the inferior turbinate , around the level of the soft palate . Eustachian Tube and Its Anatomical Relations Feature Description Location Connects middle ear to nasopharynx Opening Level Posterior to the inferior nasal meatus Function Equalizes middle ear pressure with the external environment Relations Posterior to the inferior turbinate, anterior to the torus tubarius Clinical Relevance Dysfunction can lead to otitis media and barotrauma Sphenopalatine foramen (Option B): Incorrect because it is located in the posterior part of the nasal cavity , transmitting the sphenopalatine artery and nerves , not related to the posterior end of the

marked structure. Odontoid process (Option C): Incorrect because the odontoid process (dens) is a part of the axis (C2 vertebra) , far from the nasal cavity. Sphenoidal sinus (Option D): Incorrect because the sphenoidal sinus is located superiorly in the nasal cavity, draining into the sphenoethmoidal recess , not at the level of the posterior end of the marked structure.

References:

PL Dhingra- Diseases of the ear, nose and throat, 8th edition, Page 67, 68, 69

↑ *Back to this question in Part A*

@Neet_pg_bot

Q46: Identify the marked structure {{caption_text}} (Q852991)

A. Superficial temporal artery

B. Posterior auricular artery

C. Middle meningeal artery

D. Occipital artery



Correct Answer: A. Superficial temporal artery

Explanation: The superficial temporal artery (STA) is a terminal branch of the external carotid artery . It runs superficially over the zygomatic arch , making it a visible and palpable landmark on the lateral aspect of the head. It supplies the scalp, temporalis muscle, and part of the face . It is commonly involved in temporal arteritis (Giant Cell Arteritis), where biopsy of this artery helps in diagnosis. Superficial Temporal Artery and Its Significance Feature Description Origin Terminal branch of the external carotid artery Course Runs over the zygomatic arch towards the scalp Branches Frontal and parietal branches Supplies Scalp, temporalis muscle, face Clinical Relevance Temporal arteritis, used in microvascular surgery {{caption_text}} Posterior auricular artery (Option B): Incorrect because it arises from the external carotid artery and runs behind the ear , supplying the auricle and scalp, not over the temporal region. Middle meningeal artery (Option C): Incorrect because it is a branch of the maxillary artery and enters the skull through the foramen spinosum , supplying the dura mater, not the scalp. Occipital artery (Option D): Incorrect because it arises from the external carotid artery and supplies the posterior scalp and occipital region , not the lateral temporal region.

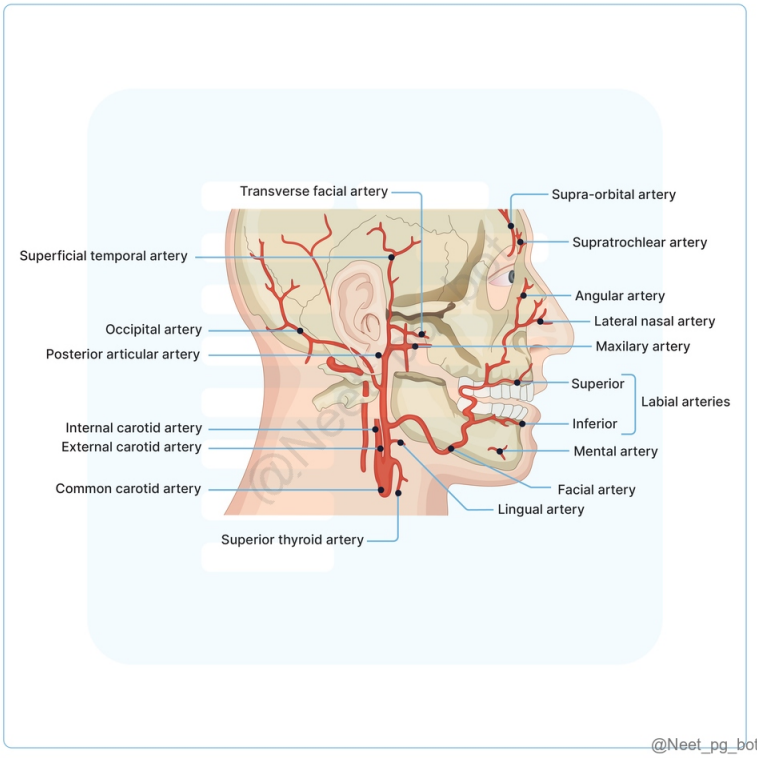

References:

BD Chaurasia’s Human Anatomy Regional and Applied Dissection and Clinical, Volume 4 Brain-Neuroanatomy, 8th Edition, Pages 109, 110.

https://www.ncbi.nlm.nih.gov/books/NBK554513/

↑ *Back to this question in Part A*

@Neet_pg_bot

Q47: Which artery passes in close proximity to the area of the skull shown in the image? (Q860616)

A. Anterior cerebral artery

B. Internal carotid artery

C. Middle meningeal artery

D. Deep temporal artery

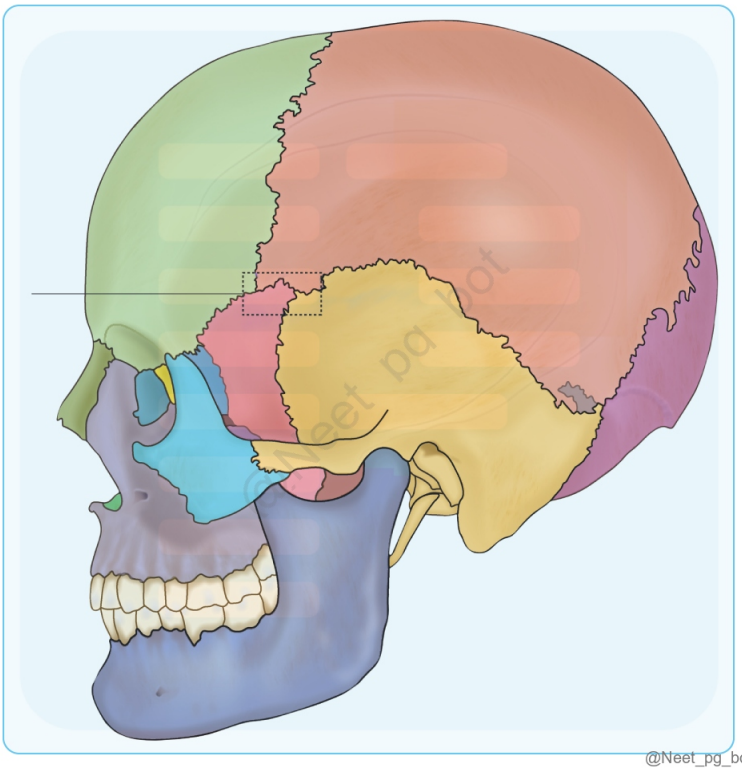

Correct Answer: C. Middle meningeal artery

Explanation: The middle meningeal artery is a branch of the maxillary artery, itself a branch of the external carotid artery. It passes through the foramen spinosum, located near the pterion. The pterion is the H-shaped formation of sutures on the side of the calvarium representing the junction of four skull bones sphenoid, temporal, frontal, and parietal. Traumatic fractures in this area can result in rupture of the middle meningeal artery, leading to epidural hematoma, a potentially life-threatening condition. Pterion : Located at the anterolateral fontanelle and is formed by the union of: Frontal bone Parietal bone Squamous temporal bones & Greater wing of the sphenoid. At birth, this area is filled with a membrane, which typically closes by around 2 months of age , though it can sometimes be delayed until 6 months. The anterior branch of the middle meningeal artery runs beneath the Pterion and Stem of lateral sulcus . Injury to this area can result in extradural or epidural haemorrhage . The pterion is a frequent location for trephination (creating an opening in the skull) during surgical procedures.

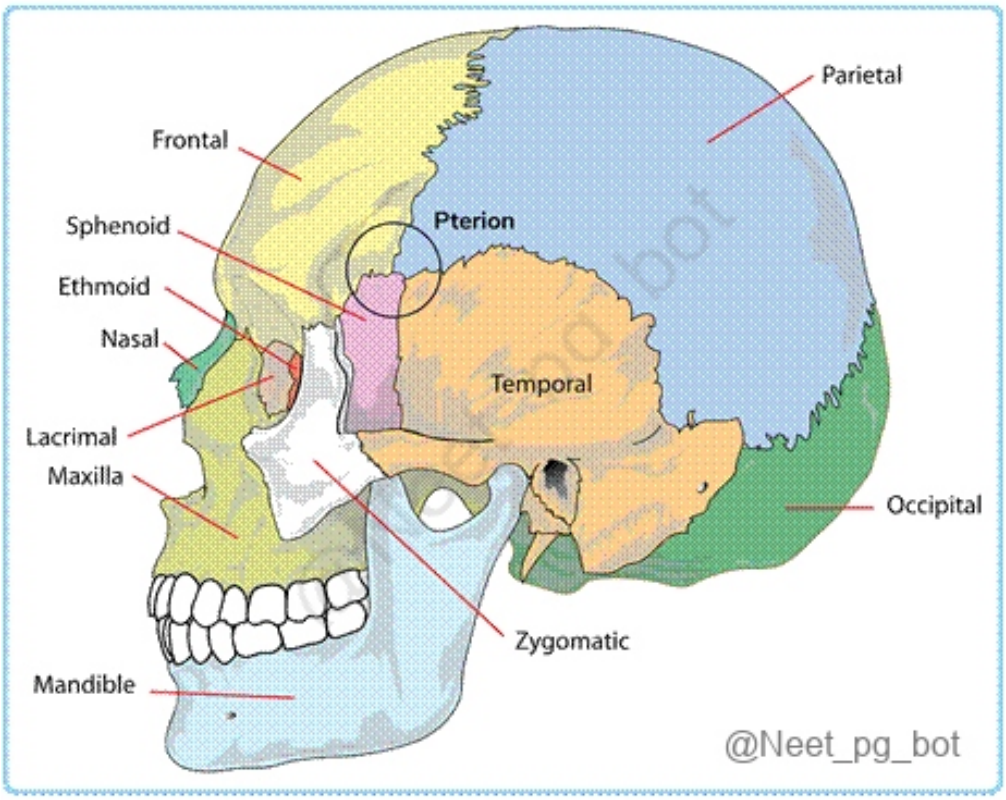

References:

Grey's Anatomy textbook 42 Ed pg 290

B. D. Chaurasia’s Human Anatomy, VOL-3,4, Edition 8, pg 130, 339.

↑ *Back to this question in Part A*

@Neet_pg_bot

Q48: The image below highlights the jugular foramen. Which of the following does NOT pass through this foramen? (Q866301)

A. Hypoglossal nerve

B. Accessory nerve

C. Glossopharyngeal nerve

D. Vagus nerve



Correct Answer: A. Hypoglossal nerve

Explanation: The jugular foramen, located at the base of the skull, transmits several cranial nerves and venous structures; however, the hypoglossal nerve (CN XII) does not pass through it, as it exits the skull via the hypoglossal canal situated medial and anterior to the foramen. Structures passing through the posterior cranial fossa Opening Structures Foramen Magnum Medulla oblongata Meninges (dura, arachnoid, pia mater) Vertebral arteries and veins Spinal accessory nerve (Spinal root ascends) Spinal arteries Jugular Foramen Glossopharyngeal nerve (Option C ruled out) Vagus nerve (Option D ruled out) Spinal accessory nerve (Cranial and Spinal root) (Option B ruled out) Internal jugular vein (exits skull here) Sigmoid sinus Internal Acoustic Meatus Facial nerve Vestibulocochlear nerve Nervus intermedius Labyrinthine arteries and veins Hypoglossal Canal Hypoglossal nerve (Option A) The meningeal branch of the ascending pharyngeal artery Emissary vein from the basilar plexus

↑ *Back to this question in Part A*

@Neet_pg_bot

Q49: Dura when inflamed under the part marked by the arrow gets referred pain at the following site: (Q865318)

A. Back of the head/neck

B. Vertex

C. Ear

D. Shoulder

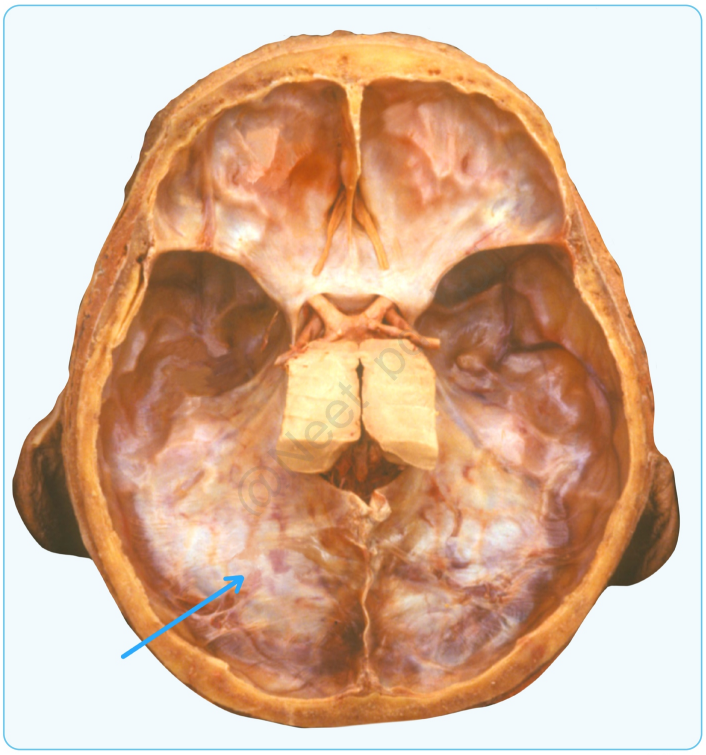

Correct Answer: A. Back of the head/neck

Explanation: The arrow likely points to the posterior cranial fossa, specifically the tentorium cerebelli (a dural fold), as this area is clinically significant for referred pain. The dura mater in the posterior cranial fossa (innervated by the meningeal branches of the upper cervical nerves, particularly C1-C3) refers pain to the occipital region (back of the head) and neck. This is because the sensory innervation of the dura in this region shares spinal cord segments (C1-C3) with cutaneous nerves supplying the occiput and neck, leading to referred pain in these areas. Referred pain sites: Vertex (Option B) - Pain from supratentorial dura (innervated by the trigeminal nerve, V1-V3). Ear (Option C) Middle cranial fossa dura (trigeminal or glossopharyngeal innervation). Shoulder (Option D) Lower cervical dura (C4-C5), not typical for posterior fossa.

References:

Snell’s Clinical Neuroanatomy, 8th Edition, pages 486-487.

↑ *Back to this question in Part A*

@Neet_pg_bot

Q50: Which one of the following cranial nerves is not involved in olfaction ? (Q865306)

A. Hypoglossal nerve

B. Vagus nerve

C. Glossopharyngeal nerve

D. Trigeminal nerve

Correct Answer: A. Hypoglossal nerve

Explanation: Hypoglossal nerve is a purely a motor nerve supplying muscles of the tongue and has no sensory or olfactory role. It innervates all the tongue muscles (intrinsic and extrinsic) except for the palatoglossus, which receives motor innervation from the vagal nerve (CN X). The muscular/lingual branch is a general somatic efferent (GSE) which controls most tongue actions, including protruding, retracting, depressing the tongue, and changing the tongue's shape. Olfaction (sense of smell) is primarily carried by Cranial Nerve I (Olfactory Nerve). However, cranial nerves V (Trigeminal) (Option D) , VII (Facial) , IX (Glossopharyngeal) (Option C) , and X (Vagus) (Option B) are involved in detecting irritating or pungent odors , contributing to reflex responses like sneezing or coughing.

References:

Snell's Clinical Neuroanatomy, 8th Edition, Pages 323 - 347.

↑ *Back to this question in Part A*

@Neet_pg_bot

Q51: What is the primary action of the muscle originating from this structure? (Q865276)

A. Protracts and depresses the mandible

B. Elevates and protrudes the mandible

C. Elevates and retracted the mandible

D. Elevates the mandible

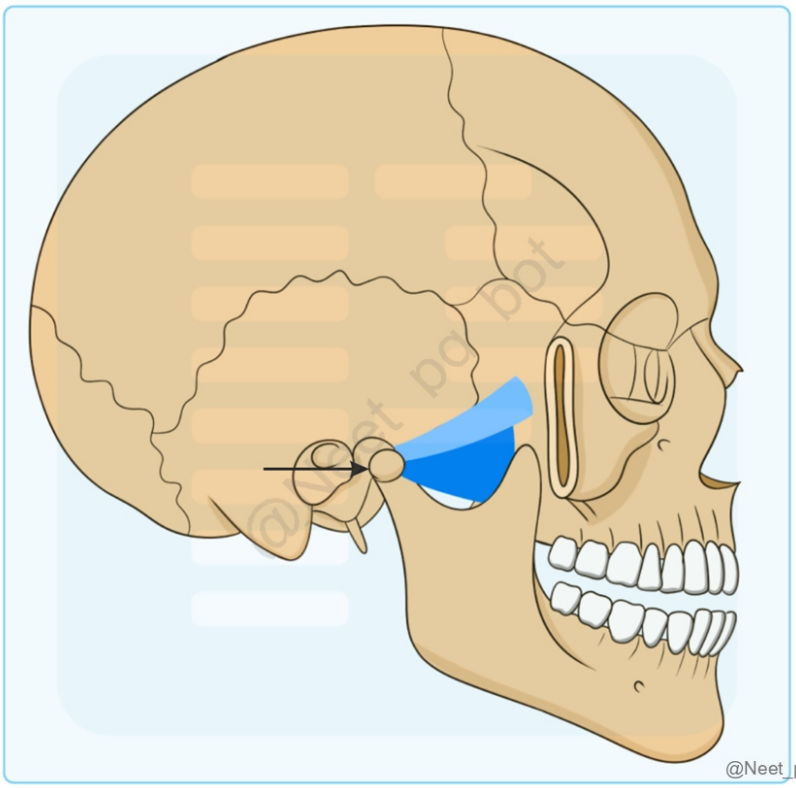

Correct Answer: A. Protracts and depresses the mandible

Explanation: The lateral pterygoid muscle plays a unique and crucial role among the muscles of mastication because it is the only one that primarily participates in depressing (Option A) the mandible (opening the mouth).

References:

Inderbir Singh textbook of anatomy, Head and Neck, 6th edition, Page 71

↑ *Back to this question in Part A*

@Neet_pg_bot

Q52: After the parotidectomy operation, a patient presents with excessive sweating and redness over the parotid region. What is the diagnosis? (Q866642)

A. Frey's Syndrome

B. Horner's syndrome

C. Bell's Palsy

D. Glossopharyngeal neuralgia

Correct Answer: A. Frey's Syndrome

Explanation: Frey's syndrome (also called gustatory sweating) occurs when a patient sweats and flushes over the parotid (preauricular) region during eating or thinking about food. Mechanism after parotidectomy: During surgery, the auriculotemporal nerve (a branch of the mandibular nerve, CN V3) is often injured. This nerve carries parasympathetic secretomotor fibres to the parotid gland and sympathetic fibres to sweat glands. After nerve injury, aberrant regeneration occurs: Parasympathetic fibres (originally meant for salivary secretion) regrow and mistakenly connect to sweat glands of the overlying skin. When eating stimulates salivation, these sweat glands are also activated, causing redness and sweating in that region. Incorrect Options: Horner's syndrome (Option B): Triad: Ptosis, miosis, anhidrosis (loss of sweating) on the same side of the face due to sympathetic pathway lesion. Here, sweating is increased, not decreased, and there's no mention of eye signs. Bell's palsy (Option C): Lower motor neuron facial nerve palsy: unilateral facial muscle weakness, inability to close the eye, drooping mouth. No sweating/redness triggered by eating. Glossopharyngeal neuralgia (Option D): Severe paroxysmal pain in the throat, tonsillar fossa, and ear due to CN IX irritation. Pain, not sweating, is the main feature.

↑ *Back to this question in Part A*

@Neet_pg_bot

Q53: A patient presented to OPD with ophthalmoplegia and ptosis. Diagnosis of superior orbital fissure syndrome was confirmed after examination. Which nerves are compressed in this case ? (Q866637)

A. III, IV, V1, VI

B. III, IV, V1, V2

C. II, III, IV, VI

D. II, III, IV, V1

Correct Answer: A. III, IV, V1, VI

Explanation: Superior orbital fissure syndrome compresses cranial nerves III, IV, V1, and VI, causing ophthalmoplegia and ptosis due to impaired eye movement and sensory loss around the eye. Superior orbital fissure: Triangular gap through which the middle cranial fossa connects with the orbit Part Structures Passing Through Lateral Part Lacrimal nerve (branch of ophthalmic nerve) Frontal nerve (branch of ophthalmic nerve) Trochlear nerve (CN IV) Superior ophthalmic vein Meningeal branch of lacrimal artery Anastomotic branch of middle meningeal artery (anastomoses with recurrent branch of lacrimal artery) Middle Part Upper division of oculomotor nerve (CN III) Lower division of oculomotor nerve (CN III) Nasociliary nerve Abducens nerve (CN VI) Medial Part Inferior ophthalmic vein Sympathetic nerve from plexus around internal carotid artery V2 (maxillary nerve) and II (optic nerve) (Option B, C, D) do not pass through the superior orbital fissure: V2 passes through the foramen rotundum. II passes through the optic canal.

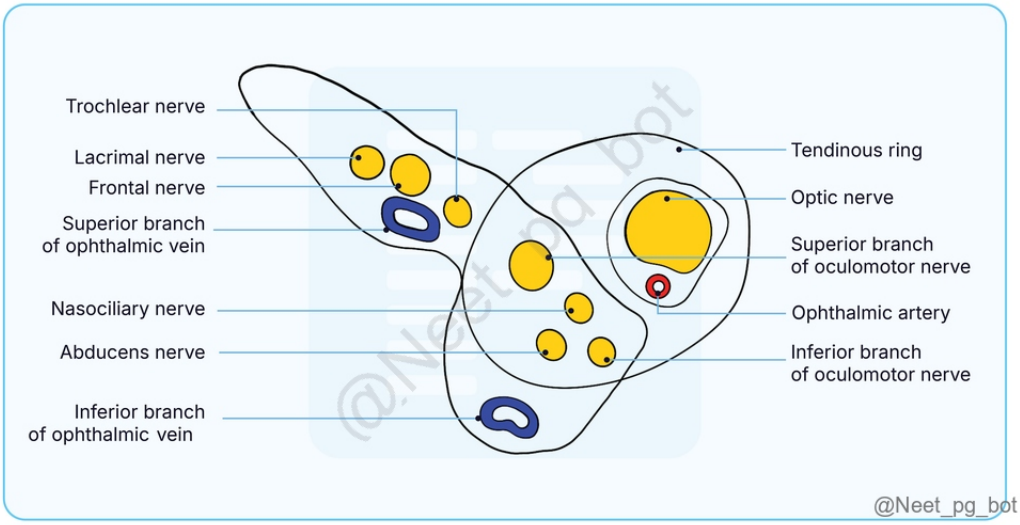

References:

.

↑ *Back to this question in Part A*

@Neet_pg_bot

Q54: The upper part of the uncinate process commonly attaches to? (Q866630)

A. Middle turbinate

B. Superior turbinate

C. Inferior turbinate

D. Bulla ethmoidalis

Correct Answer: A. Middle turbinate

Explanation: The uncinate process is a thin, curved bony structure of the ethmoid bone that extends superiorly and typically attaches to the middle nasal concha (middle turbinate), helping to form part of the lateral nasal wall and the drainage pathway of the frontal sinus. Components of the Middle Meatus of the Nose: Uncinate Process: Hook-like structure running from anterosuperior to posteroinferior. Forms a gap with the bulla ethmoidalis called the hiatus semilunaris inferior . Divides the lower middle meatus into anterior and posterior fontanelles (membranous areas). Infundibulum: Bounded medially by the uncinate process and laterally by the lamina papyracea . Contains the natural ostium of the maxillary sinus in its lower part. Bulla Ethmoidalis: Ethmoidal cell located behind the uncinate process, forming the posterior boundary of the hiatus semilunaris. May be pneumatized or a solid prominence. Hiatus Semilunaris: Inferior : The gap between the uncinate process and bulla. Superior : The cleft between the bulla and skull base. Ostiomeatal Unit (Complex): Key area where the ostia of the

frontal, ethmoidal, and maxillary sinuses drain into the middle meatus. Common drainage pathway for the anterior group of sinuses . Incorrect Options: Superior turbinate (Option B): The uncinate process does not attach here; it is located lower than the superior turbinate. Inferior turbinate (Option C): This is a separate bone and much lower in the nasal cavity, so the uncinate process doesn't attach to it. Bulla ethmoidalis (Option D): This is a separate ethmoid air cell located posterior to the uncinate process, not an attachment site.

↑ *Back to this question in Part A*

@Neet_pg_bot

Q55: A 30-year-old man came with choking episodes after ingestion of fish bone while eating. The fishbone got impacted at the level of T4 in the esophagus. Which is the most likely site of obstruction? (Q866618)

A. Left bronchus

B. Arch of aorta

C. Cricopharyngeus

D. Diaphragm

Correct Answer: B. Arch of aorta

Explanation: The fishbone is impacted at the T4 level, where the aortic arch crosses the esophagus and creates a normal anatomical narrowing, making it the most likely site of obstruction. Oesophageal Constrictions: Constrictions occur at four main points: Point of constriction Distance from Incisors Description Vertebral level Cricopharyngeus Muscle (Option C ruled out) 6 inches This first constriction is at the upper esophageal sphincter where the esophagus begins. It is caused by the cricopharyngeus muscle, which plays a role in swallowing. C6 Aortic Arch (Option B) 9 inches The second narrowing occurs where the arch of the aorta crosses the esophagus. The pressure from the aorta causes this indentation. T4 Left Main Bronchus (Option A ruled out) 11 inches Third constriction is where the left bronchus crosses over the esophagus, leading to a narrowing. T6 Diaphragmatic Hiatus (Option D ruled out) 15 inches The final narrowing happens where the esophagus passes through the diaphragm at the esophageal hiatus. T10

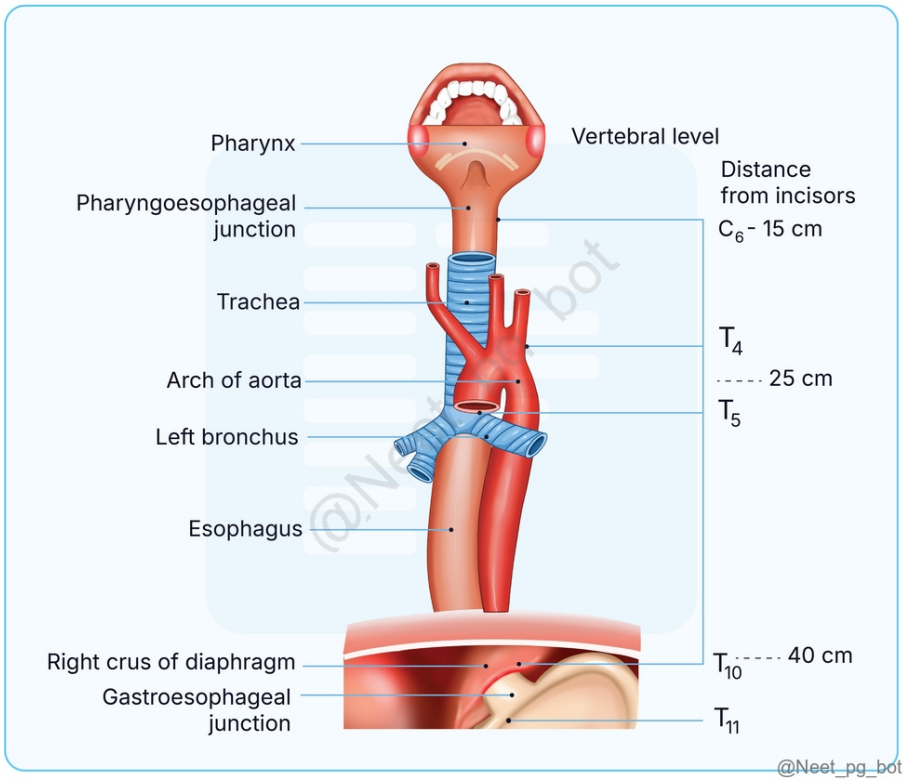

References:

.

↑ *Back to this question in Part A*

@Neet_pg_bot

Q56: Which X-ray view is best for visualizing the frontal sinuses? (Q839894)

A. Lateral view

B. Waters view

C. Caldwell view

D. Towne view

Correct Answer: C. Caldwell view

Explanation: Correct Option C - Caldwell view: The Caldwell view (also known as the occipitofrontal view) is specifically designed to provide a clear image of the frontal sinuses. This view angles the X-ray beam to project the frontal sinuses without superimposition from other facial structures, making it ideal for assessing the frontal sinuses. Incorrect Options: Option A - Lateral view: The lateral view is not ideal for visualizing the frontal sinuses.

It is typically used to view the sphenoid sinus, the nasopharynx, and to assess any anteroposterior displacement of structures in the skull. Option B - Waters view: The Waters view (also known as the occipitomental view) is best for visualizing the maxillary sinuses. It is used to see the orbits and the maxillary sinuses with minimal superimposition of the petrous ridges. Option D - Towne view: The Towne view is primarily used for visualizing the occipital bone, the posterior cranial fossa, and for assessing the foramen magnum. It is not optimal for visualizing the frontal sinuses.

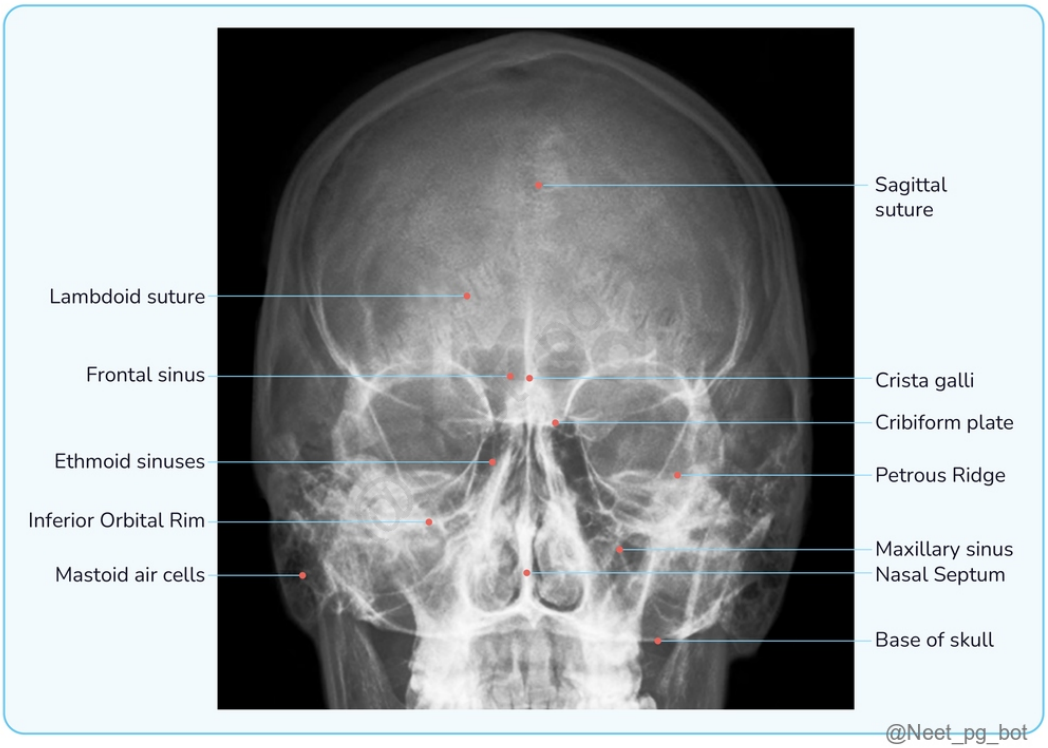

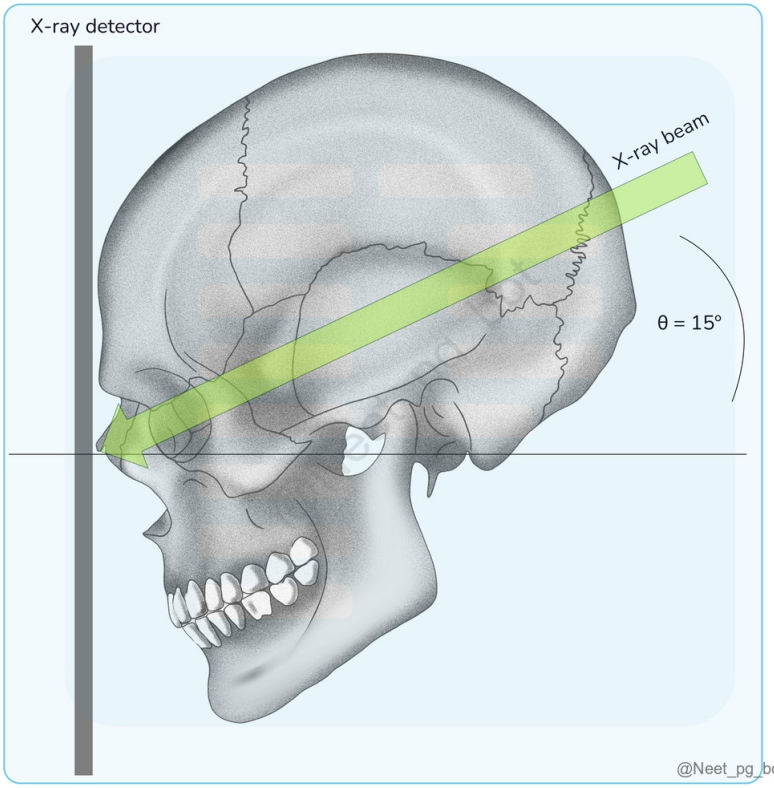

References:

.

↑ *Back to this question in Part A*

@Neet_pg_bot

Q57: A 42-year-old man presented with swelling due to a collection of blood around the eyes after sustaining a head injury. Which structural attachment is the cause of this condition? (Q857936)

A. Aponeurosis attachment

B. Periosteum

C. Cellulitis

D. None of the above

Correct Answer: A. Aponeurosis attachment

Explanation: When a person sustains a head injury, especially around the eyes, blood can collect in the surrounding tissues due to ruptured blood vessels. The blood can accumulate in the subcutaneous space, causing swelling. The structural attachment that can contribute to this condition is the aponeurosis attachment. The scalp is made up of five layers: Skin -hairy and has numerous sweat glands and sebaceous glands Superficial fascia (Connective tissue) -provides a medium for vessels and nerves to pass to the skin Deep fascia in the form of the epicranial aponeurosis or galea aponeurotica with the occipitofrontalis muscle Loose areolar tissue-provides passage for emissary veins connecting extracranial veins to intracranial venous sinuses Pericranium {{caption_text}} Periosteum (Option B): The periosteum is a tough connective tissue layer on bone surfaces. It aids in bone health but isn't directly linked to swelling around the eyes from head injuries. Cellulitis (Option C): Cellulitis, a bacterial skin infection, doesn't typically lead to blood collection and swelling post-head injury. None of the above (Option D): The correct answer is A. Aponeurosis attachment, as explained above. Therefore, the option "None of the above" is not the correct answer in this context

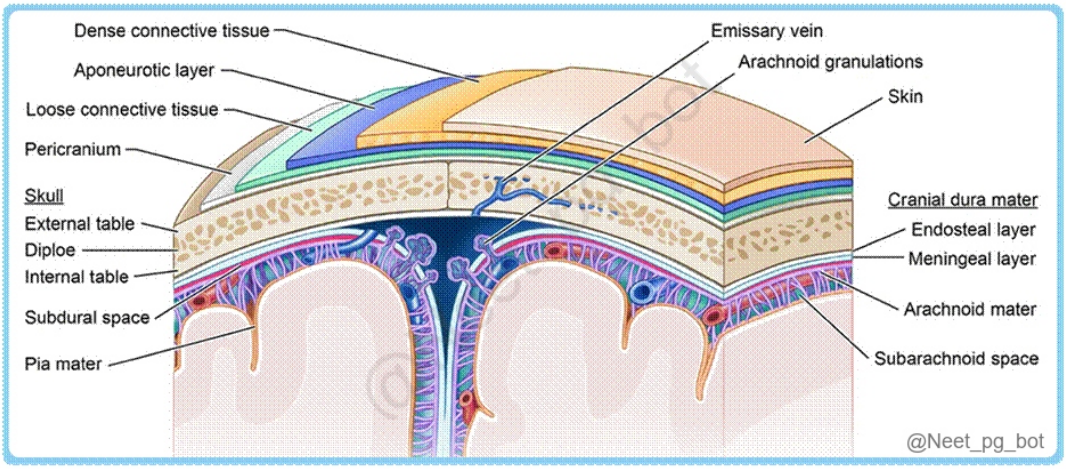

References:

BD Chaurasia’s Human Anatomy, 8th Edtion, Page no: 765

↑ *Back to this question in Part A*

@Neet_pg_bot

Q58: A 42-year-old female who had the extraction of her 3rd molar tooth reported loss of sensation in the anterior 2/3rd of the tongue and floor of the mouth. Which nerve is most likely to be damaged? (Q857927)

A. Lingual Nerve

B. Glossopharyngeal Nerve

C. Spinal Accessory Nerve

D. Chorda Tympani Nerve

Correct Answer: A. Lingual Nerve

Explanation: The lingual nerve is a branch of the mandibular division of the trigeminal nerve (V3). It provides sensory innervation to the anterior 2/3rd of the tongue and the floor of the mouth. Damage to the lingual nerve during the extraction of the 3rd molar tooth (also known as a wisdom tooth) can result in loss of sensation in these areas. Sensory supply of tongue Anterior two-thirds of tongue-derived from 1st arch Posterior one-third of tongue-from 3rd arch From the epiglottis-from 4th arch General sensory Lingual nerve Glossopharyngeal nerve Internal laryngeal branch of superior laryngeal nerve (vagus) Special sensory Except circumvallate papillae by chorda tympani (facial nerve) Including circumvallate papillae by glossopharyngeal nerve Internal laryngeal branch of superior laryngeal nerve (vagus) Glossopharyngeal Nerve (Option B): The glossopharyngeal nerve (IX) conveys taste sensation from the posterior 1/3rd of the tongue, not the anterior 2/3rd or floor of the mouth. Spinal Accessory Nerve (Option C): The spinal accessory nerve (XI) mainly controls head and shoulder movements. It's unrelated to tongue or mouth floor sensation. Chorda Tympani Nerve (Option D): The chorda tympani nerve conveys taste sensations from the front two-thirds of the tongue and regulates salivary glands. Not connected to mouth floor sensation. Damage usually from middle ear surgery, not molar extraction.

References:

BD Chaurasia’s Human Anatomy, 8th Edtion, Page no: 167

↑ *Back to this question in Part A*

@Neet_pg_bot

Q59: A 27-year-old male was climbing the stair, suddenly he fell & an iron nail hit on his neck. After the injury, the patient is having a hard time shrugging his shoulders and he is having difficulty turning his head. This might be due to an injury to? (Q857917)

A. Spinal accessory Nerve

B. Deltoid Muscle

C. Sternocleidomastoid Muscle

D. Long thoracic Nerve

Correct Answer: A. Spinal accessory Nerve

Explanation: The spinal accessory nerve (CN XI) is responsible for innervating the trapezius and sternocleidomastoid muscles. In this scenario, the patient's difficulty in shrugging his shoulders and turning his head suggests an issue with the spinal accessory nerve, which controls these muscles. The injury caused by the nail hitting his neck could have damaged or impinged the spinal accessory nerve, leading to these symptoms. Spinal accessory nerve (CN XI): Supplies: Sternomastoid muscle and Trapezius muscle Enter the cranial cavity by foramen magnum and exit by jugular foramen. Spinal accessory nerve is a content of the occipital triangle If

damaged it will lead to difficulty in shrugging the shoulder (trapezius muscle affected) Deltoid Muscle (Option B): The symptoms described are not directly related to the function of the deltoid muscle, which is responsible for shoulder abduction. Sternocleidomastoid Muscle (Option C): Sternocleidomastoid muscle is involved in head and neck movements such as rotation and tilting, it is not responsible for shoulder shrugging. Long Thoracic Nerve (Option D): Damage to the long thoracic nerve can lead to scapular "winging," where the scapula protrudes outward from the back due to weakened serratus anterior muscle.

References:

BD Chaurasia's Human Anatomy, 8th Edtion, Page no: 876

↑ *Back to this question in Part A*

@Neet_pg_bot

Q60: A patient presents with swelling under the left ear lobule and complains of pain. Which of the following structures is the likely cause of the pain? (Q855406)

A. Facial nerve

B. Greater auricular nerve

C. Auriculotemporal nerve

D. Investing layer of deep cervical fascia

Correct Answer: B. Greater auricular nerve

Explanation: The greater auricular nerve, originating from the cervical plexus, innervates the skin around the ear, angle of the mandible, and parotid region. It runs superficially along the neck and over the sternocleidomastoid muscle, making it prone to injury or irritation, leading to pain and swelling. Pain and swelling under the left ear lobule could indicate involvement of this nerve, possibly due to inflammation or compression. External Ear consists of two main parts: Pinna (Auricle) External Auditory Meatus Aspects Auricle (Pinna) External Auditory Meatus Composition Elastic cartilage, except lobule (fibrofatty tissue) Cartilaginous part (Outer 1/3) with hair and ceruminous glands Bony part (Inner 2/3), with thin skin continuous with the tympanic membrane, lacks hair and glands. Parts Concha (Depression leading to the external meatus) Helix (Prominent rim with anterior and posterior limbs) Antihelix (Parallel ridge to the helix) Tragus & Antitragus (Separated by inter-tragic notch) Cymba Conchae (Above crus of helix) Lobule (Soft, fleshy part below antitragus) Nerve Supply Lateral Surface Lower third: Great auricular nerve (C2, C3) Upper two-thirds: Auriculotemporal nerve (CN V3) Concha: Auricular branch of vagus (CN X) (Alderman's Nerve) Medial Surface Lower third: Great auricular nerve Upper two-thirds: Lesser occipital nerve (C2) Roof & Anterior Wall: Auriculotemporal nerve (CN V3) Floor & Posterior Wall: Auricular branch of vagus (CN X) Clinical Relevance McEwen's triangle (Cymba Conchae) It is a surgical landmark on the temporal bone to locate the mastoid antrum. Furuncles (cartilaginous part) susceptible to infections {{caption_text}} {{caption_text}} {{caption_text}}

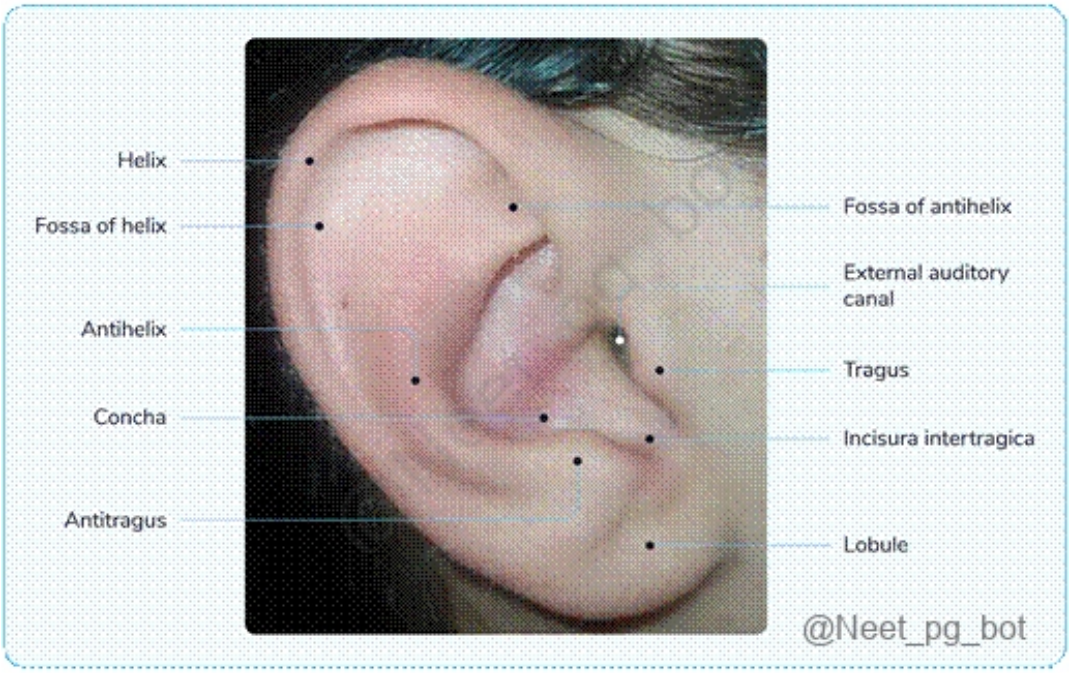
Helix
Fossa of helix
Antihelix
Concha
Antitragus
Fossa of antihelix
External auditory canal
Tragus
Incisura intertragica
Lobule
@Neet_pg_bot

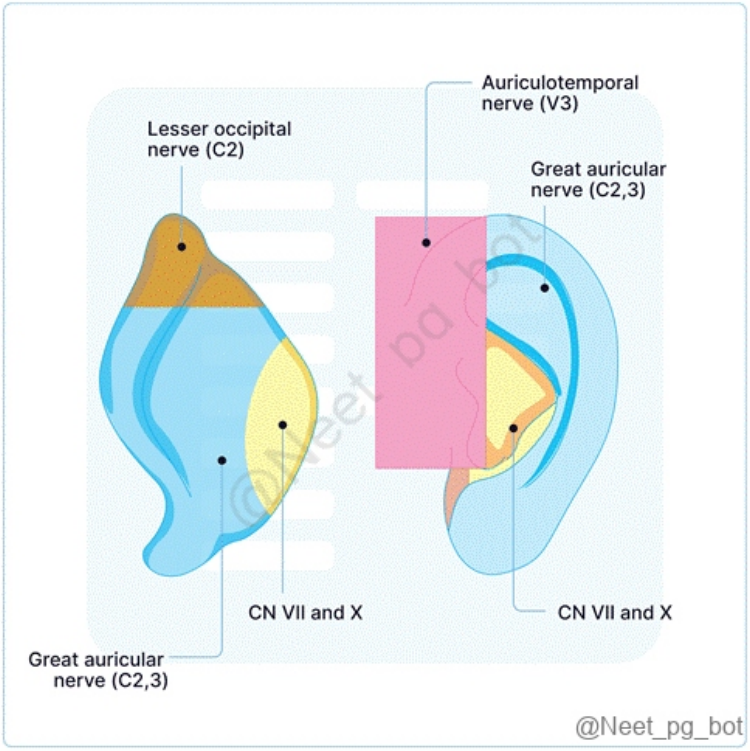
Auriculotemporal nerve (V3)
Lesser occipital nerve (C2)
Great auricular nerve (C2,3)
CN VII and X
CN VII and X
Great auricular nerve (C2,3)
@Neet_pg_bot

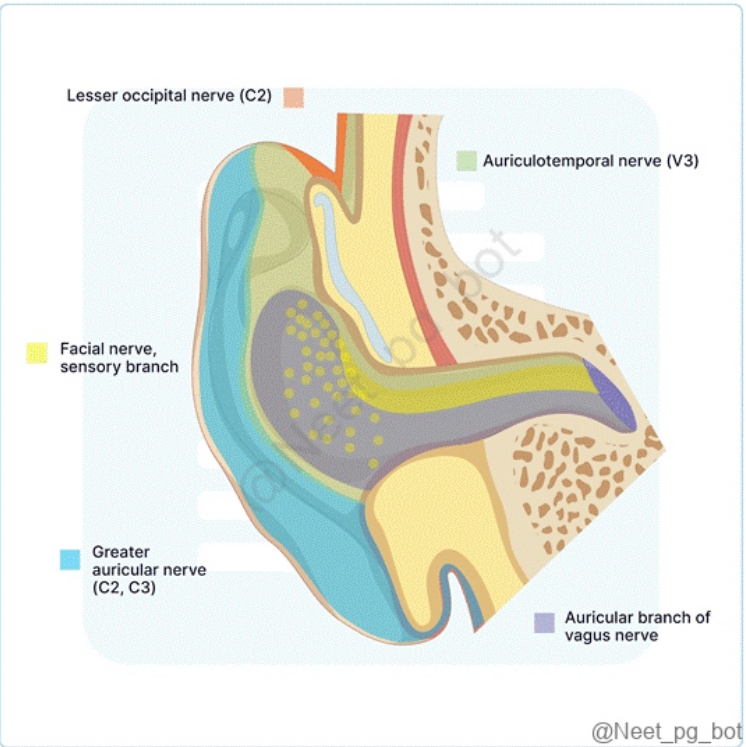

References:

Vishram Singh Textbook of Anatomy, 2nd Edition, Pg - 267,268

↑ *Back to this question in Part A*

@Neet_pg_bot

Q61: A student had his jaw locked while yawning. Which of the following muscles attached to the articular disc of the temporomandibular joint is under spasmodic contraction? (Q855390)

A. Lateral pterygoid

B. Temporalis

C. Medial pterygoid

D. Masseter

Correct Answer: A. Lateral pterygoid

Explanation: The lateral pterygoid muscle is the only muscle attached to the articular disc of the temporomandibular joint (TMJ). It plays a key role in the movement of the TMJ, particularly in opening the mouth and moving the jaw forward (protraction). Lateral pterygoid: Attachment: The superior head of the lateral pterygoid inserts into the articular disc and the joint capsule, while the inferior head attaches to the neck of the mandible. Function: It helps in: Depressing the mandible (opening the mouth). Protrusion and lateral movements of the jaw. Spasmodic contraction: During excessive yawning, prolonged contraction of the lateral pterygoid can pull the articular disc and the mandible forward, potentially leading to jaw locking due to dislocation of the TMJ. Temporalis (Option B): This muscle primarily elevates and retracts the mandible; it has no attachment to the articular disc. Medial pterygoid (Option C): Assists in elevation and side-to-side movements of the mandible but is not connected to the articular disc. Masseter (Option D): A strong elevator of the mandible; also has no attachment to the articular disc.

References:

https://www.ncbi.nlm.nih.gov/books/NBK541027/

↑ *Back to this question in Part A*

@Neet_pg_bot

Q62: The correct sequence of the auditory pathway? (Q854586)

A. Cochlea → Spiral Ganglion → Cochlear Nerve → Superior Olivary Nucleus

B. Spiral Ganglion → Cochlea → Cochlear Nerve → Superior Olivary Nucleus

C. Spiral Ganglion → Cochlear Nerve → Cochlea → Superior Olivary Nucleus

D. Cochlea → Spiral Ganglion → Cochlear Nerve → Inferior Olivary Nucleus

Correct Answer: A. Cochlea → Spiral Ganglion → Cochlear Nerve → Superior Olivary Nucleus

Explanation: The correct sequence of the auditory pathway is: Cochlea → Spiral Ganglion → Cochlear Nerve → Superior Olivary Nucleus Auditory pathway: Cochlea Cochlear Nerve Cochlear Nucleus (in the brainstem) Superior Olivary Complex Lateral Lemniscus Inferior Colliculus (in the midbrain) Medial Geniculate Nucleus (in the thalamus) Primary Auditory Cortex: Finally, the signals are sent to the primary auditory cortex in the temporal lobe (Heschl’s gyrus) , where sound perception, including the identification of pitch, rhythm and speech occurs.

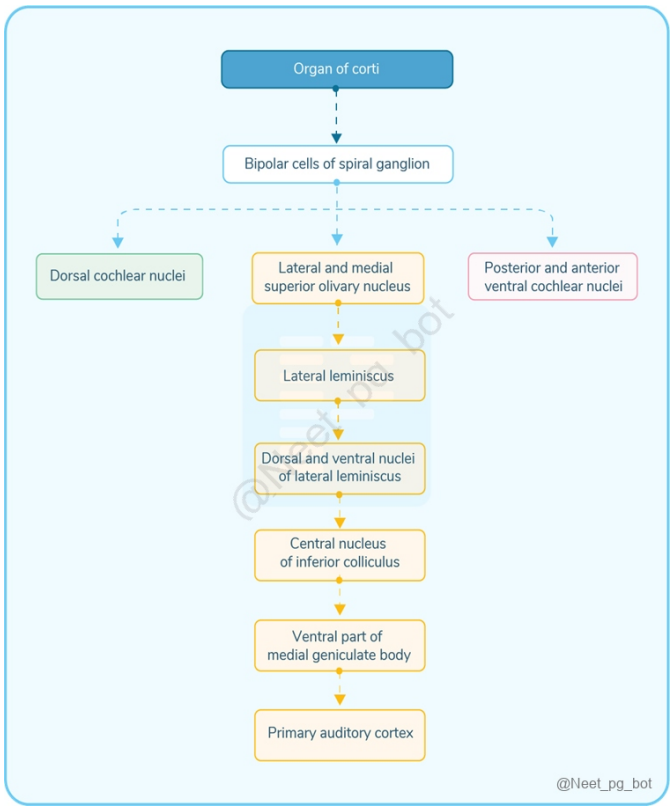

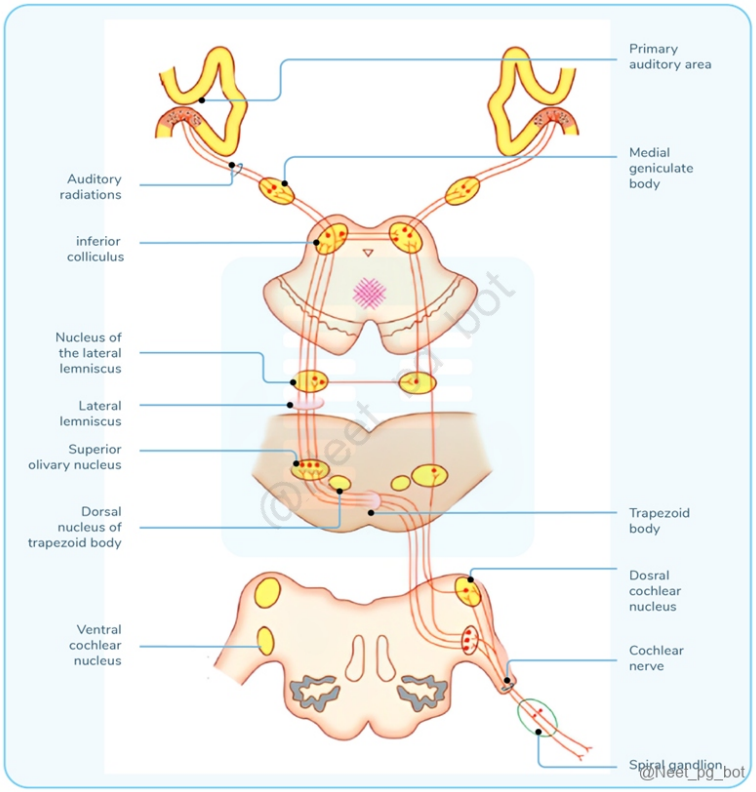

References:

GK Pal textbook of medical physiology pg-1208,1208

↑ *Back to this question in Part A*

@Neet_pg_bot

Q63: Name the type of joint marked in the following image (Q854532)

A. Ball and socket joint

B. Saddle joint

C. Pivot joint

D. Gliding joint

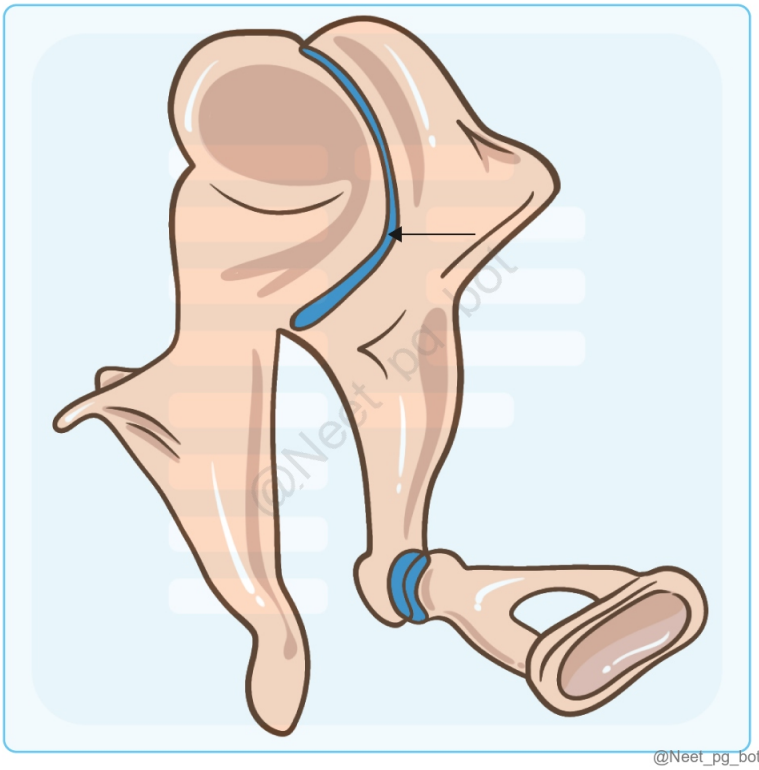

Correct Answer: B. Saddle joint

Explanation: Articulating surfaces between the malleus and incus (incudomalleolar joint) are saddle-shaped i.e. one surface is convex while the other is concave. Saddle synovial joint: Examples include Joint between malleus and incus. Sternoclavicular joint. 1st carpometacarpal joint. Calcaneocuboid joint. Type of joint Examples Hinge Joint Elbow joint, Knee joint, Interphalangeal joints Pivot Joint Superior radioulnar joint, C1 and C2 joint (Option C) Ball-and-Socket Joint Shoulder (glenohumeral) joint, Hip joint, Incus, and stapes joint (Option A) Saddle Joint Sternoclavicular joint, Carpometacarpal joint of the thumb, Joint between the malleus and the incus. Ellipsoid (Condyloid) Joint Radiocarpal (wrist) joint, atlantooccipital joint, Metacarpophalangeal joints Gliding Joint (Option D): Examples: Lateral end of clavicle and acromion process(acromioclavicular joint). Gliding joints (also

known as plane joints) have flat surfaces that glide or slide past each other. They allow for limited movement in various directions, such as sliding or twisting.

References:

Grey's Anatomy 42nd Edition, Page 105

Snell's Clinical Anatomy by Regions, 10th Edition, Page15

Types of Synovial Joints | Biology for Majors II

Types of joints

↑ *Back to this question in Part A*

@Neet_pg_bot

Q64: Which of the following sulcus will be injured in a patient with trauma to the pointed area 'X'? (Q857344)

A. Central sulcus

B. Stem of lateral sulcus

C. Inferior frontal sulcus

D. Intraparietal sulcus

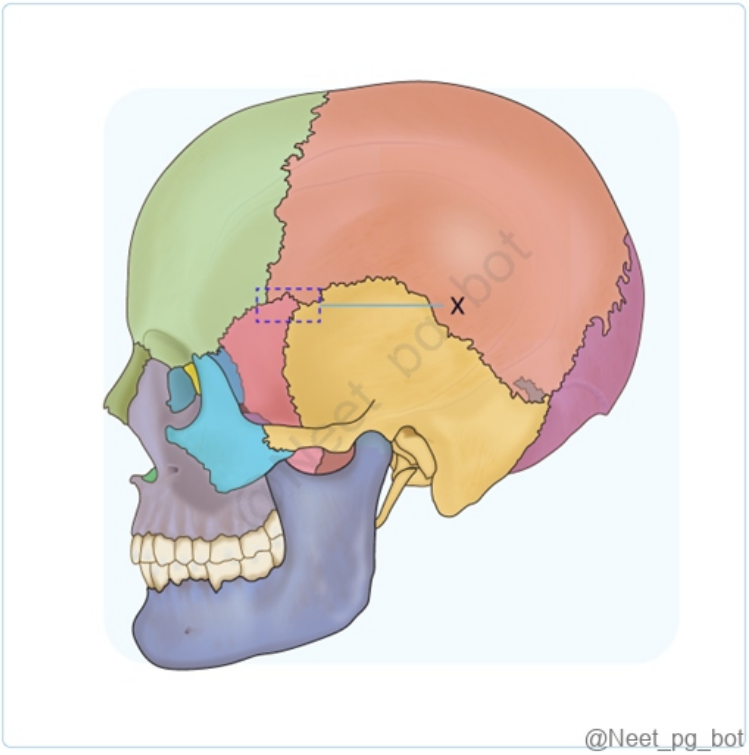

Correct Answer: B. Stem of lateral sulcus

Explanation: The marked part in the above image is the Pterion. The Pterion is a crucial anatomical landmark where several skull bones converge, forming an H-shaped sutural junction. It's particularly vulnerable due to the thinness of the bones in this region. The lateral sulcus, or Sylvian sulcus, divides the temporal lobe below from the parietal lobe above. The middle cerebral artery (MCA), a branch of the internal carotid artery (ICA), runs within it, supplying the lateral cerebrum. Pterion : Located at the anterolateral fontanelle and is formed by the union of: Frontal bone Parietal bone Squamous temporal bones & Greater wing of the sphenoid. {{caption_text}} At birth, this area is filled with a membrane, which typically closes by around 2 months of age , though it can sometimes be delayed until 6 months. The anterior branch of the middle meningeal artery runs beneath the Pterion and Stem of lateral sulcus. Injury to this area can result in extradural or epidural haemorrhage . The pterion is a frequent location for trephination (creating an opening in the skull) during surgical procedures.

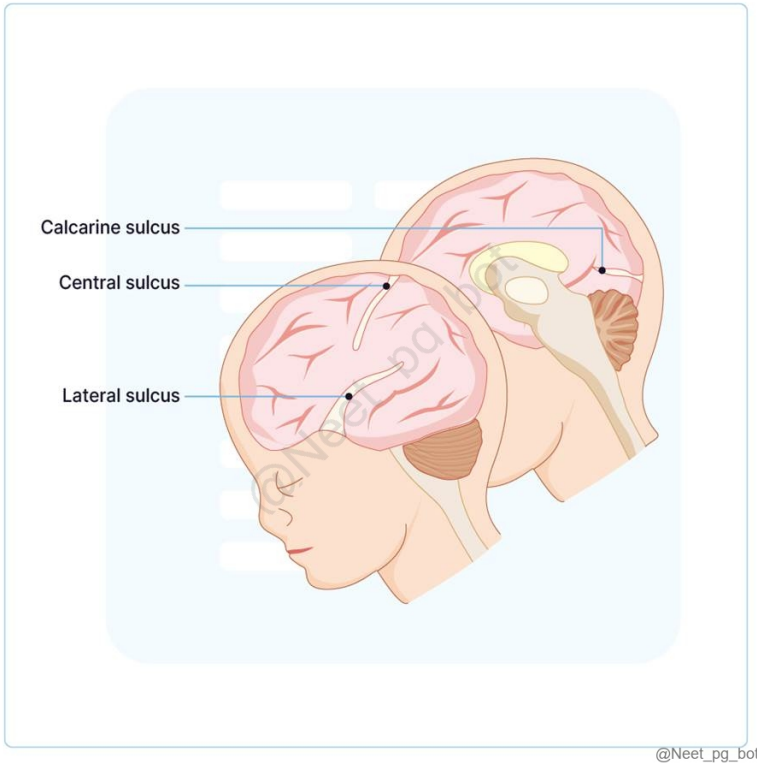

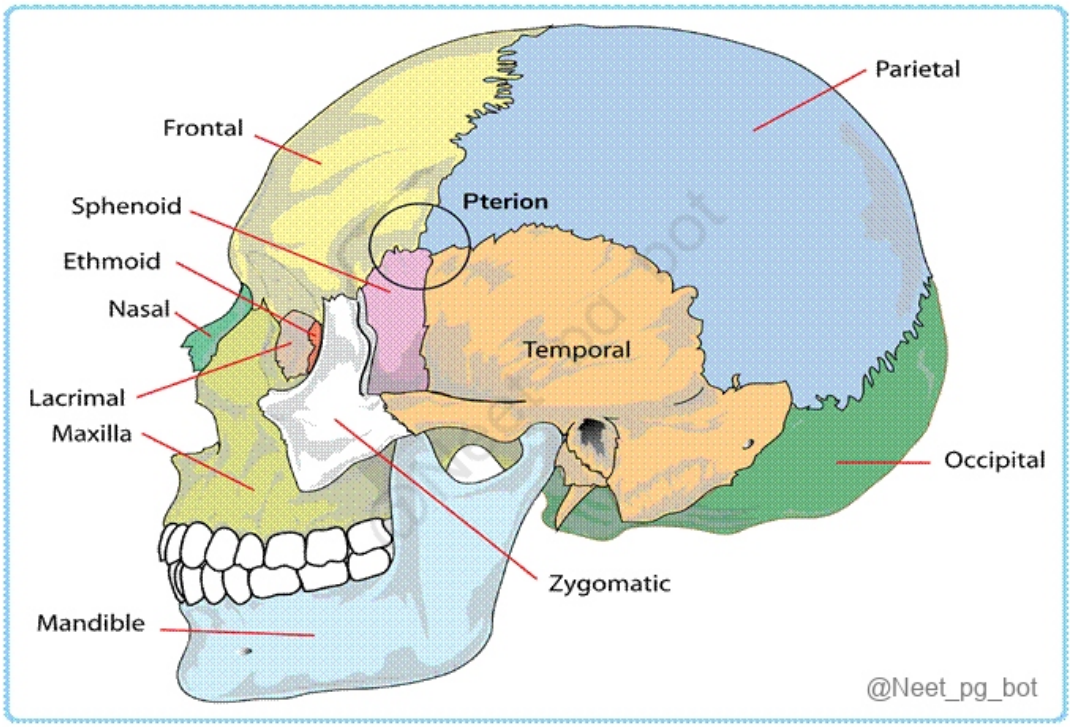

References:

Grey's Anatomy textbook 42 Ed pg 290

B. D. Chaurasia’s Human Anatomy, VOL-3,4, Edition 8, pg 130, 339.

↑ *Back to this question in Part A*

@Neet_pg_bot

Q65: Which ganglia is located in the marked area? (Q860277)

A. Otic ganglia

B. Ciliary ganglia

C. Pterygopalatine ganglia

D. Submandibular ganglia



Correct Answer: A. Otic ganglia

Explanation: The area marked in the image is the Infratemporal fossa. The otic ganglion lies just below the foramen ovale in the infratemporal fossa , medial to the mandibular nerve (V3). Various parasympathetic ganglia: Ciliary ganglion (Option B): Located in the orbit, associated with the oculomotor nerve (CN III), and controls pupil constriction & lens accommodation. Pterygopalatine ganglion (Option C): Is located in the pterygopalatine fossa, which is deeper and more posterior–medial, between the pterygoid process and the posterior wall of the maxilla, not in the region indicated in the picture. Submandibular ganglion (Option D): Located near the submandibular gland, associated with the facial nerve (CN VII) and controls salivatio n.

Name of the ganglia	Topographically related	Functionally related	Supplies
Otic	Mandibular nerve	Glossopharyneal nerve	Parotid gland
Pterygopalatine ganglion	Maxillary nerve	Facial nerve (Greater petrosal nerve)	Lacrimal gland, Nasal, palatine and pharyngeal glands
Submandibular ganglion	Mandibular nerve (Lingual nerve)	Facial (chorda tympanic nerve)	Submandibular and sublingual gland
Ciliary ganglion	Opthalmic division of trigeminal (nasociliary nerve)	Oculomotor nerve	Ciliaris and Sphincter pupillae through parasympathetic root and dilator papillae through sympathetic root

@Neet_pg_bot

References:

https://www.ncbi.nlm.nih.gov/books/NBK545308/

↑ *Back to this question in Part A*

@Neet_pg_bot

Q66: Which of the following steps in thyroid surgery is least likely to result in hoarseness of voice? (Q839918)

A. Ligation of superior thyroid artery

B. Division of strap muscles

C. Removal of tubercle of Zuckerkandi

D. Dissection of Beahr's triangle

Correct Answer: A. Ligation of superior thyroid artery

Explanation: Correct Option A - Ligation of superior thyroid artery: Ligation of the superior thyroid artery is a step in thyroid surgery that generally poses a lower risk of causing hoarseness of voice. This is because the superior laryngeal nerve, which can be affected during this procedure, primarily affects the cricothyroid muscle responsible for pitch modulation rather than causing hoarseness directly. Therefore, this step is least likely to cause hoarseness compared to other steps that have a direct impact on the recurrent laryngeal nerve. Incorrect Options: Option B - Division of strap muscles: Dividing the strap muscles (sternothyroid and sternohyoid) is a common procedure, but while it is generally safe, it is not related to the risk of voice changes directly associated with nerve damage. However, compared to ligating the superior thyroid artery, it is more likely to be involved in complex dissection areas where nerves might be at risk. Option C - Removal of tubercle of Zuckerkandl: This procedure is closely associated with the recurrent laryngeal nerve. The tubercle of Zuckerkandl is an anatomical landmark near the recurrent laryngeal nerve, and its removal carries a significant risk of nerve injury, which can result in hoarseness of voice. Option D - Dissection of Beahrs triangle: Beahrs triangle is an area near the recurrent laryngeal nerve. Dissecting this region can also pose a risk to the nerve, leading to a higher likelihood of hoarseness of voice if the nerve is damaged.

↑ *Back to this question in Part A*

@Neet_pg_bot

Q67: A 32-year-old patient presents with a swelling below the ear and complains of pain in the lobule of the ear. The patient also reports difficulty in completely closing the left eye and experiences trouble while eating food. What nerve is most likely to be damaged in this case? (Q820349)

A. Greater Auricular nerve

B. Auriculotemporal nerve

C. Facial nerve

D. Vagus nerve

Correct Answer: C. Facial nerve

Explanation: Correct Option C - Facial nerve The facial nerve (cranial nerve VII) controls facial expressions, including eye closure and smiling. Damage to it can cause weakness or paralysis in these muscles. Additionally, it regulates muscles for eating and swallowing, which aligns with the patient's eating difficulties.. Incorrect Options: Option A - Greater Auricular nerve: Damage to this nerve might result in altered sensation around the ear, but it wouldn't explain the symptoms mentioned in the case. Option B - Auriculotemporal nerve: The auriculotemporal nerve provides sensation to the external ear and part of the scalp. However, it doesn't control facial movement, eye closure, or eating functions. Option D - Vagus nerve: While damage to the vagus nerve might cause some difficulties in swallowing and speech, it would not explain the specific symptoms of facial muscle weakness, inability to close the eye, or earlobe pain described in the case.

References:

.

↑ *Back to this question in Part A*

@Neet_pg_bot

Q68: A 42-year-old man presented with swelling due to a collection of blood around the eyes after sustaining a head injury. Which structural attachment is the cause of this condition? (Q820346)

A. Aponeurosis attachment

B. Periosteum

C. Cellulitis

D. None of the above

Correct Answer: A. Aponeurosis attachment

Explanation: Correct Option A - Aponeurosis attachment: When a person sustains a head injury, especially around the eyes, blood can collect in the surrounding tissues due to ruptured blood vessels. The blood can accumulate in the subcutaneous space, causing swelling. The structural attachment that can contribute to this condition is the aponeurosis attachment. Incorrect Options: Option B - Periosteum: The periosteum is a tough connective tissue layer on bone surfaces. It aids in bone health but isn't directly linked to swelling around the eyes from head injuries. Option C - Cellulitis: Cellulitis, a bacterial skin infection, doesn't typically lead to blood collection and swelling post-head injury. Option D - None of the above: The correct answer is A. Aponeurosis attachment, as explained above. Therefore, the option "None of the above" is not the correct answer in this context.

References:

.

↑ *Back to this question in Part A*

@Neet_pg_bot

Q69: A 42-year-old female who had the extraction of her 3rd molar tooth reported loss of sensation in the anterior 2/3rd of the tongue and floor of the mouth. Which nerve is most likely to be damaged? (Q820322)

A. Lingual Nerve

B. Glossopharyngeal Nerve

C. Spinal Accessory Nerve

D. Chorda Tympani Nerve

Correct Answer: A. Lingual Nerve

Explanation: Correct Option A - Lingual Nerve: The lingual nerve is a branch of the mandibular division of the trigeminal nerve (V3). It provides sensory innervation to the anterior 2/3rd of the tongue and the floor of the mouth. Damage to the lingual nerve during the extraction of the 3rd molar tooth (also known as a wisdom tooth) can result in loss of sensation in these areas. Incorrect Options: Option B - Glossopharyngeal Nerve: The glossopharyngeal nerve (IX) conveys taste sensation from the posterior 1/3rd of the tongue, not the anterior 2/3rd or floor of the mouth. Option C - Spinal Accessory Nerve: The spinal accessory nerve (XI) mainly controls head and shoulder movements. It's unrelated to tongue or mouth floor sensation. Option D - Chorda Tympani Nerve: The chorda tympani nerve conveys taste sensations from the front two-thirds of the tongue and regulates salivary glands. Not connected to mouth floor sensation. Damage usually from middle ear surgery, not molar extraction.

References:

.

↑ *Back to this question in Part A*

@Neet_pg_bot

Q70: A 27-year-old male was climbing the stair, suddenly he fell & an iron nail hit on his neck. After the injury, the patient is having a hard time shrugging his shoulders and he is having difficulty turning his head. This might be due to an injury to? (Q820314)

A. Spinal accessory Nerve

B. Deltoid Muscle

C. Sternocleidomastoid Muscle

D. Long thoracic Nerve

Correct Answer: A. Spinal accessory Nerve

Explanation: Correct Option A - Spinal accessory Nerve : The spinal accessory nerve (CN XI) is responsible for innervating the trapezius and sternocleidomastoid muscles. In this scenario, the patient's difficulty in shrugging his shoulders and turning his head suggests an issue with the spinal accessory nerve, which controls these muscles. The injury caused by the nail hitting his neck could have damaged or impinged the spinal accessory nerve, leading to these symptoms. Incorrect Options: Option B - Deltoid Muscle: The symptoms described are not directly related to the function of the deltoid muscle, which is responsible for shoulder abduction. Option C - Sternocleidomastoid Muscle: Sternocleidomastoid muscle is involved in head and neck movements such as rotation and tilting, it is not responsible for shoulder shrugging. Option D - Long Thoracic Nerve: Damage to the long thoracic nerve can lead to scapular "winging," where the scapula protrudes outward from the back due to weakened serratus anterior muscle.

References:

.

↑ *Back to this question in Part A*

@Neet_pg_bot

Q71: Infer the extent of the thyroid gland from the given image. (Q793138)

A. B to D

B. A to C

C. A to D

D. C to D

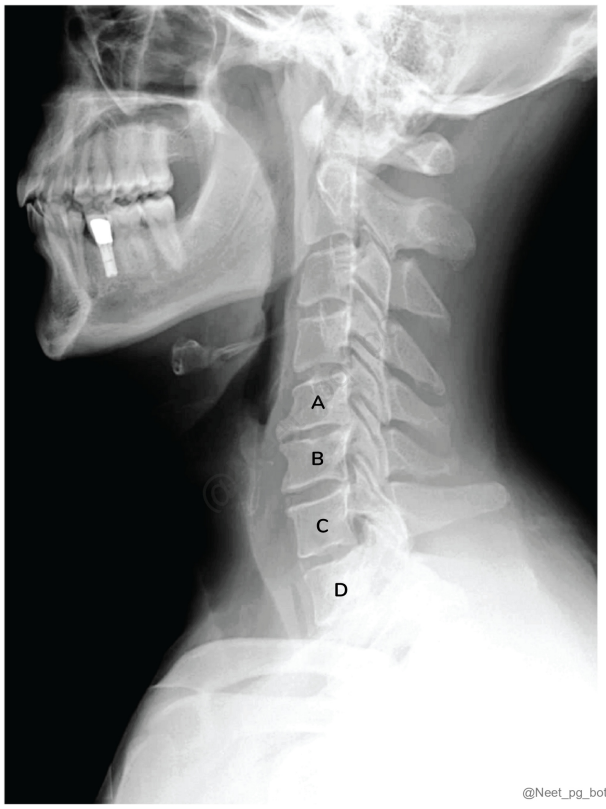

Correct Answer: C. A to D

Explanation: Correct Option C - A to D A- C5 B- C6 C- C7 D- T1 The thyroid gland is situated in the front of the neck, below the larynx, between the C5 and T1 vertebrae. Incorrect Options: Option A - B to D: The structures that extend from C6 to T1 vertebrae include the posterior cervical muscles, including the semispinalis cervicis, splenius cervicis, and longissimus cervicis muscles.. Option B - A to C: The structures that extend from C5 to C7 vertebrae include the anterior scalene, middle scalene, and posterior scalene muscles, which form the scalene triangle. Option D - C to D: The structures that extend from C7 to T1 vertebrae include the first rib, which is located between these two vertebrae.

References:

.

↑ *Back to this question in Part A*

@Neet_pg_bot

Q72: A patient underwent a left submandibular gland excision during which the hypoglossal nerve was injured. Which of the following deficits would be seen in this case? (Q793129)

A. Deviated tongue to the contralateral side

B. Deviated tongue to the same side

C. Inability to protrude tongue

D. Loss of taste in posterior 1/3rd of the tongue

Correct Answer: B. Deviated tongue to the same side

Explanation: Correct Option B - Deviated tongue to the same side The hypoglossal nerve innervates tongue muscles, including intrinsic and extrinsic muscles. Injury during submandibular gland excision can lead to weakness or paralysis on the same side, causing the tongue to deviate towards that side when protruded. This happens because the hypoglossal nerve supplies most tongue muscles on the same side, leading to an imbalance in muscle function. The deviation may be subtle or quite noticeable, depending on the severity of the injury. Incorrect Options: Option A - Deviated tongue to the contralateral side: Injury to the hypoglossal nerve during submandibular gland excision leads to ipsilateral tongue deviation when protruded, not contralateral. Option C - Inability to protrude tongue: While injury to the hypoglossal nerve may cause weakness or paralysis of the tongue muscles, it would not necessarily result in an inability to protrude the tongue.. Option D - Loss of taste in posterior 1/3rd of the tongue: . The hypoglossal nerve is not involved in taste sensation. The posterior 1/3rd of the tongue is innervated by the glossopharyngeal nerve (CN IX).

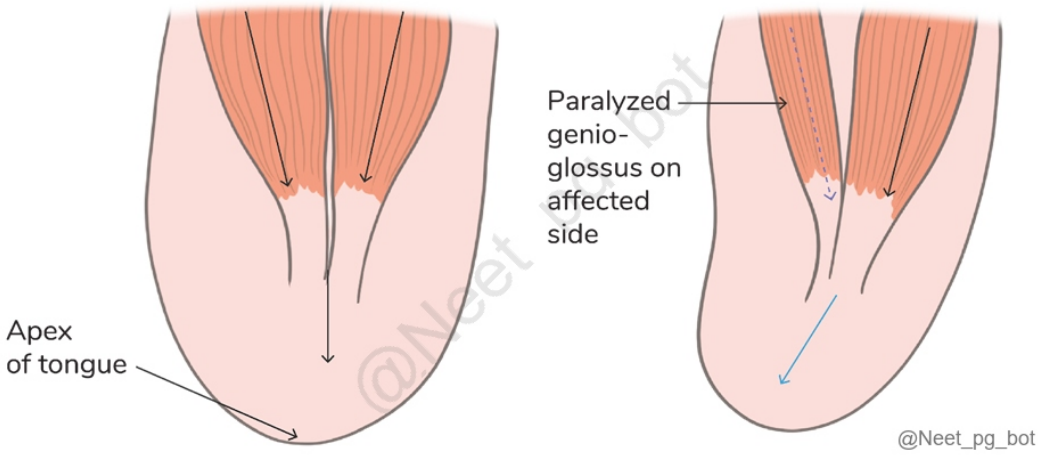

References:

.

↑ *Back to this question in Part A*

@Neet_pg_bot

Q73: Name the dural venous arrow marked in the radiograph. (Q793166)

A. Straight sinus

B. Superior sagittal sinus

C. Inferior sagittal sinus

D. Confluence of sinuses



Correct Answer: A. Straight sinus

Explanation: Correct Option A - Straight sinus The marked structure is a straight sinus. The straight sinus is a small midline structure that runs from the junction of the falx cerebri and tentorium cerebelli to the confluence of sinuses. It can be seen in imaging studies such as MRI or CT scans. It appears as a thin curvilinear opacity on the midline of the skull radiograph, just posterior to the frontal bone and anterior to the occipital bone. Incorrect Options: Option B - Superior sagittal sinus: The superior sagittal sinus is a prominent midline structure running from the frontal to the occipital regions atop the brain, often visible on MRI or CT scans. Option C - Inferior sagittal sinus: The inferior sagittal sinus, a small midline structure, extends along the underside of the brain from the frontal to the occipital regions, visible on MRI or CT scans. Option D - Confluence of sinuses: The confluence of sinuses is where the superior sagittal, straight, and occipital sinuses meet, a significant neuroanatomical landmark identifiable on MRI or CT scans.

References:

.

↑ *Back to this question in Part A*

@Neet_pg_bot

Q74: Which of the following dural venous sinuses receives the great cerebral vein of Galen as its tributary? (Q793147)

A. A

B. B

C. C

D. D

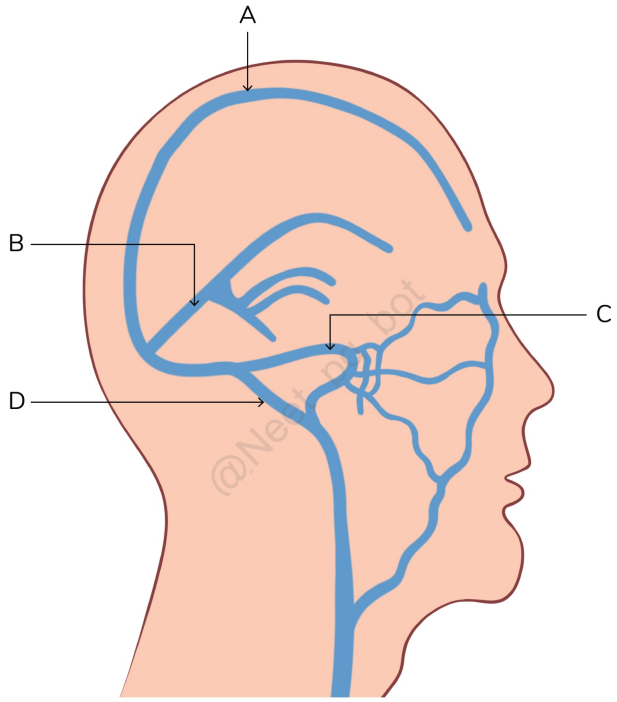

@Neet_pg_bot

Correct Answer: B. B

Explanation: Correct Option B - B The straight sinus, positioned at the junction of the falx cerebri and the tentorium cerebelli, receives tributaries like the great cerebral vein of Galen, formed by the union of the two internal cerebral veins. Other tributaries include the inferior sagittal sinus and the occipital sinus. Blood from the straight sinus ultimately drains into the confluence of sinuses, where the superior sagittal sinus, straight sinus, and occipital sinus converge. Incorrect Options: Option A - A: The superior sagittal sinus drains the blood from the

front and top of the brain and empties into the confluence of sinuses, where it meets the straight sinus and other sinuses. Option C - C:The transverse sinuses, running horizontally at the back of the skull, receive blood from various sinuses including the superior sagittal sinus and inferior sagittal sinus. They then descend to form the sigmoid sinuses. . Option D - D: The sigmoid sinuses receive blood from the transverse sinuses, petrosal sinuses, and nearby veins, draining into the jugular veins that return blood to the heart.

References:

.

↑ *Back to this question in Part A*

@Neet_pg_bot

• [05_Upper Limb] 023 Upper Limb Embryology And Nerves

« Back to Folder Directory

[05_Upper Limb] 023 Upper Limb Embryology And Nerves — Quick Jump

Q1 (p. 1377) *Q2 (p. 1379)* *Q3 (p. 1380)* *Q4 (p. 1382)* *Q5 (p. 1383)* *Q6 (p. 1384)*
Q7 (p. 1385) *Q8 (p. 1387)* *Q9 (p. 1388)* *Q10 (p. 1389)* *Q11 (p. 1390)* *Q12 (p. 1392)*
Q13 (p. 1393)

Q1: A 35-year-old man presents with numbness and tingling in the lateral aspect of his forearm and thumb after a fall. Upon examination, the physician notes that the sensation is decreased in a specific area corresponding to a dermatome. Which of the following dermatomes is likely affected in this patient? (Q848387)

A. C5

B. C6

C. C7

D. C8

Correct Answer: B. C6

■ *Listen (English)*

■ *Listen (Hindi)*

Explanation: C6 covers the lateral aspect of the forearm and the thumb(1st digit). The patient's symptoms of numbness and tingling in this area suggest involvement of the C6 nerve root. C5 (Option A) dermatome is primarily responsible for sensation over the shoulder and the upper lateral arm , not the forearm or thumb. C7 (Option C) dermatome covers the index finger (2nd digit) to ring finger (4th digit) and the posterior aspect of the forearm , which does not match the patient’s symptoms. C8 (Option D) dermatome includes the medial aspect of the forearm and the little finger (5th digit) , which is also not consistent with the presented symptoms.

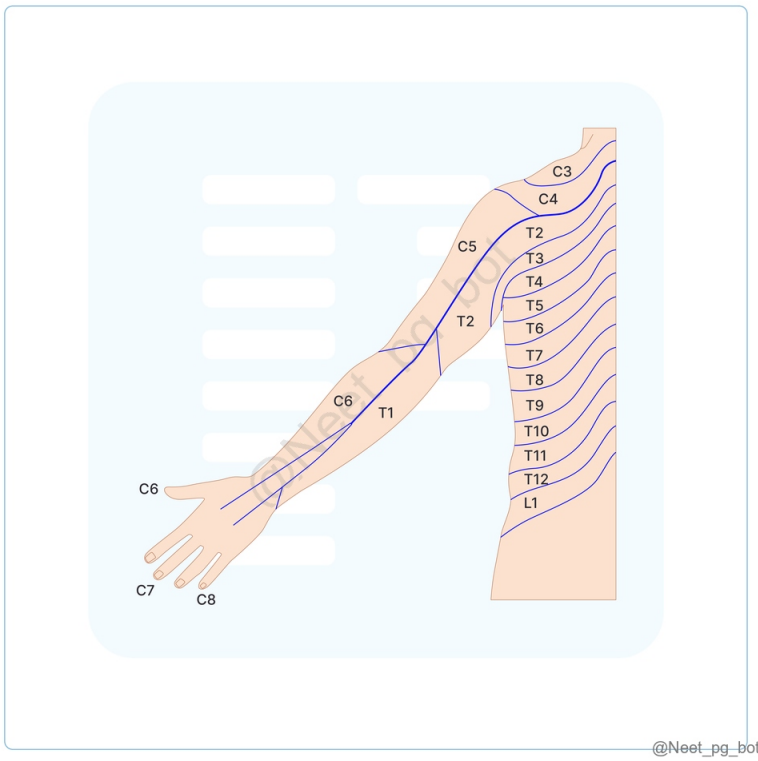

@Neet_pg_bot

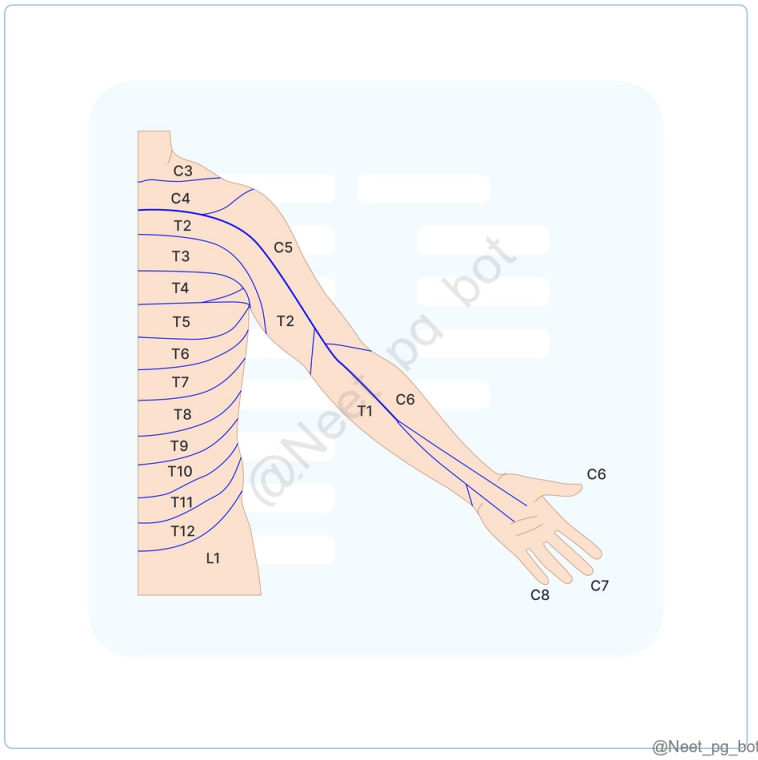

@Neet_pg_bot

References:

Gray’s Anatomy, The Anatomical Basis of Clinical Practice, 41st Edition, Page 881

↑ *Back to this question in Part A*

@Neet_pg_bot

Q2: A newborn is delivered with a shoulder dystocia complication. On examination, the infant has paralysis of the arm with the shoulder adducted, the elbow extended, and the forearm pronated. This injury most likely involves which of the following structures? (Q848389)

A. Lower trunk of the brachial plexus

B. Radial nerve

C. Upper trunk of the brachial plexus

D. Median nerve

Correct Answer: C. Upper trunk of the brachial plexus

■ *Listen (English)*

■ *Listen (Hindi)*

Explanation: The described presentation is consistent with Erb’s palsy , a result of injury to the upper trunk (C5-C6) of the brachial plexus, which occurs at Erb’s point . This injury commonly happens in cases of shoulder dystocia during birth and leads to the "waiter's tip" posture. Clinical Significance of Erb's Point: Feature Description Anatomical Role Upper trunk divides into anterior and posterior divisions Clinical Importance Injuries to this area can cause Erb's palsy with specific motor/sensory deficits Erb's Palsy Results from damage to the upper trunk , leading to weakness in the upper limb, waiter-tip posture . Lower trunk of the brachial plexus (Option A) : Injury to the lower trunk would cause Klumpke’s palsy , affecting the hand muscles, not the arm posture described here. Radial nerve (Option B) injury typically causes wrist drop , not the characteristic arm posture described in Erb’s palsy. Median nerve (Option D) injury leads to weakness in forearm flexion and the thenar muscles , not the upper limb weakness seen in this case.

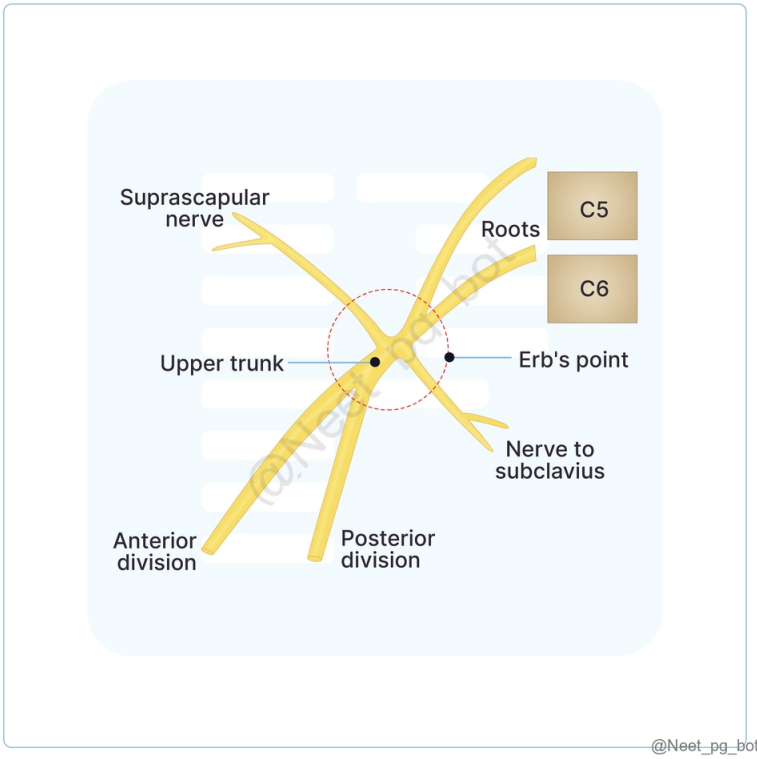

References:

BD Chaurasia's Human Anatomy Volume 1, 8th Edition, Page 62

↑ *Back to this question in Part A*

@Neet_pg_bot

Q3: A newborn presents with weakness in the right arm after a difficult vaginal delivery. The arm is limp and hangs by the side, with the forearm pronated and the hand facing inward in a "waiter's tip" position. The infant has difficulty with shoulder abduction and elbow flexion. Which of the following nerve roots are most likely involved in this condition? (Q848392)

A. C5 and C6

B. C7 and C8

C. C8 and T1

D. C3 and C4

Correct Answer: A. C5 and C6

- *Listen (English)*
- *Listen (Hindi)*

Explanation: C5 and C6 involvement is typical in Erb's palsy , causing weakness in muscles responsible for shoulder abduction , external rotation , elbow flexion , and forearm supination . Erb's Palsy : Erb-Duchenne palsy results from damage to the upper trunk of the brachial plexus (C5 and C6 nerve roots). Mechanism of Injury: Occurs due to traction or stretching of the neck during childbirth (shoulder dystocia) or traumatic separation of the head and shoulder. Clinical Presentation: Muscle Weakness/ Paralysis: Shoulder Abduction: Affected (supraspinatus, deltoid) External Rotation: Affected (infraspinatus, teres minor) Elbow Flexion: Affected (biceps brachii, brachialis) Forearm Supination: Affected (biceps brachii) Arm Position: Limp arm by the side, forearm pronated, hand inward (" waiter’s tip " position). Sensory Deficits Numbness or tingling along the lateral arm , forearm , and hand , corresponding to C5 and C6 dermatomes. C7 and C8 (Option B) : Injuries here would affect the triceps and finger extension , not the typical presentation seen in Erb's palsy. C8 and T1 (Option C) : Damage here leads to Klumpke’s palsy , affecting hand muscles and causing a "claw hand" deformity. C3 and C4 (Option D) nerve roots contribute to the phrenic nerve and control the diaphragm, not the arm.

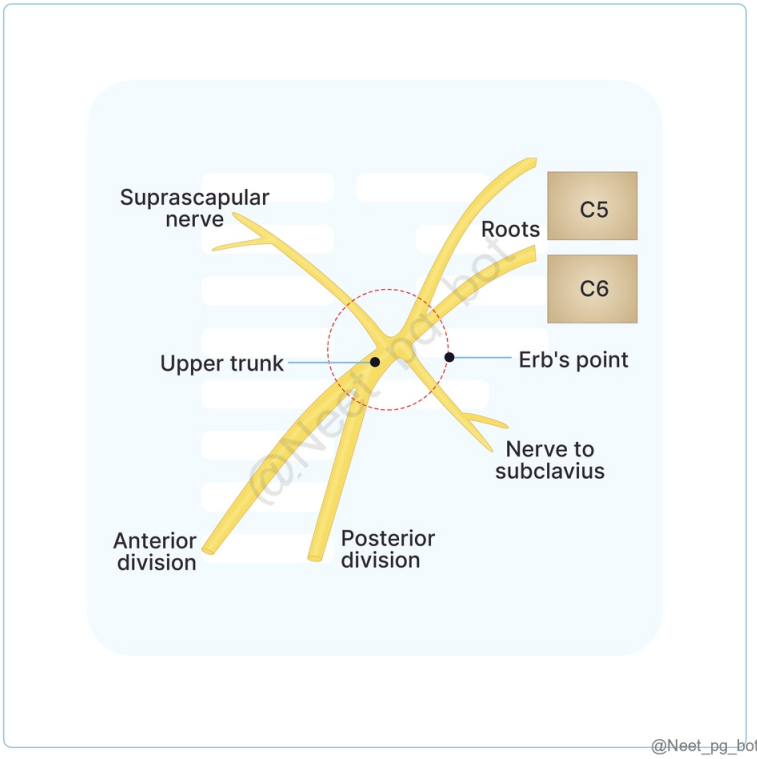

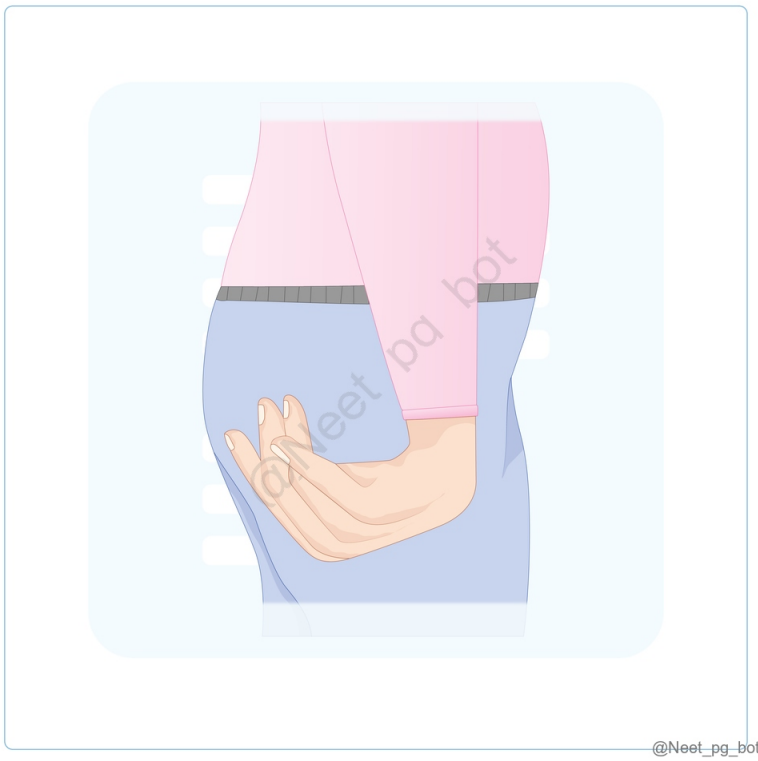

References:

BD Chaurasia’s Human Anatomy Volume1, 8th Edition, Page 62

↑ *Back to this question in Part A*

@Neet_pg_bot

Q4: A newborn presents with weakness in the hand following a difficult delivery. Examination reveals a claw hand deformity characterized by hyperextension at the metacarpophalangeal joints and flexion at the interphalangeal joints. Sensory loss is noted along the ulnar aspect of the forearm and hand. Which of the following is the most likely nerve root involved in this condition? (Q848393)

A. C5

B. C7

C. C8

D. T1

Correct Answer: D. T1

■ *Listen (English)*

■ *Listen (Hindi)*

Explanation: The given findings are associated with Klumpke’s paralysis. T1 is the main nerve root involved in Klumpke's paralysis, leading to the characteristic claw hand deformity and sensory loss along the ulnar border of the forearm and hand. Klumpke’s Paralysis : Aspect Details Site of Injury Lower trunk of the brachial plexus Cause of Injury Undue arm abduction (e.g., clutching after a fall) Birth injury Nerve Roots Involved Primarily T1, partially C8 C5 (Option A) is involved in upper trunk injuries, not Klumpke’s paralysis. C7 (Option B) does not play a primary role in the claw hand deformity associated with Klumpke’s paralysis. C8 (Option C) : While C8 is involved, the predominant nerve root affected in Klumpke’s paralysis is T1.



References:

BD Chaurasia’s Human Anatomy Volume 1, 8th Edition, Page 63

↑ *Back to this question in Part A*

@Neet_pg_bot

Q5: Which of the following gives rise to the bones and connective tissues of the limb? (Q848384)

A. Intermediate mesoderm

B. The parietal (somatic) layer of lateral plate mesoderm

C. Paraxial mesoderm

D. Neural crest cells

Correct Answer: B. The parietal (somatic) layer of lateral plate mesoderm

■ *Listen (English)*

■ *Listen (Hindi)*

Explanation: The parietal (somatic) layer of the lateral plate mesoderm forms the mesenchymal core of the limb bud, which will differentiate into the bones and connective tissues of the upper limb. Development of the Upper Limb: The upper limb bud appears around the end of the 4th week of development. These buds form as outpocketings from the lateral body wall. The Mesenchymal Core of the limb buds is derived from the parietal layer of lateral plate mesoderm, which later gives rise to bones and connective tissues. The limb bud is covered by a layer of ectoderm, which thickens at the distal end to form the apical ectodermal ridge (AER). Period of Gestation Event 4th Week Appearance of the upper limb bud 6th Week Formation of the hand plate and initiation of chondrification. 7th Week Limb rotation and further cartilage development. 12th Week Primary ossification centers in long bones. Intermediate mesoderm (Option A) forms structures like the urogenital system. Paraxial mesoderm (Option C) forms somites, which give rise to skeletal muscles and parts of the vertebrae. Neural crest cells (Option D) contribute to the peripheral nervous system, but not to the bones and connective tissues of the limbs.

References:

Langman's Medical Embryology, 14th Edition, Page 167

↑ *Back to this question in Part A*

@Neet_pg_bot

Q6: A 35-year-old man presents with numbness and tingling along the lateral aspect of his forearm and thumb following a fall on his outstretched arm. Which dermatome is most likely involved? (Q848385)

A. C5

B. C6

C. C7

D. C8

Correct Answer: B. C6

■ *Listen (English)*

■ *Listen (Hindi)*

Explanation: The C6 dermatome covers the lateral aspect of the forearm, the thumb, and part of the index finger . Numbness or tingling in this area, suggests involvement of the C6 dermatome. Dermatomes of the Upper Limb: Spinal Nerve Root Dermatome (Sensory Area) C5 (Option A ruled out) Lateral upper arm, over the deltoid C6 (Option B) Lateral forearm and thumb(1st digit) C7 (Option C ruled out) Index finger (2nd digit) to Ring finger (4th digit) C8 (Option D ruled out) Medial forearm, little finger (5th digit) T1 Medial arm and elbow

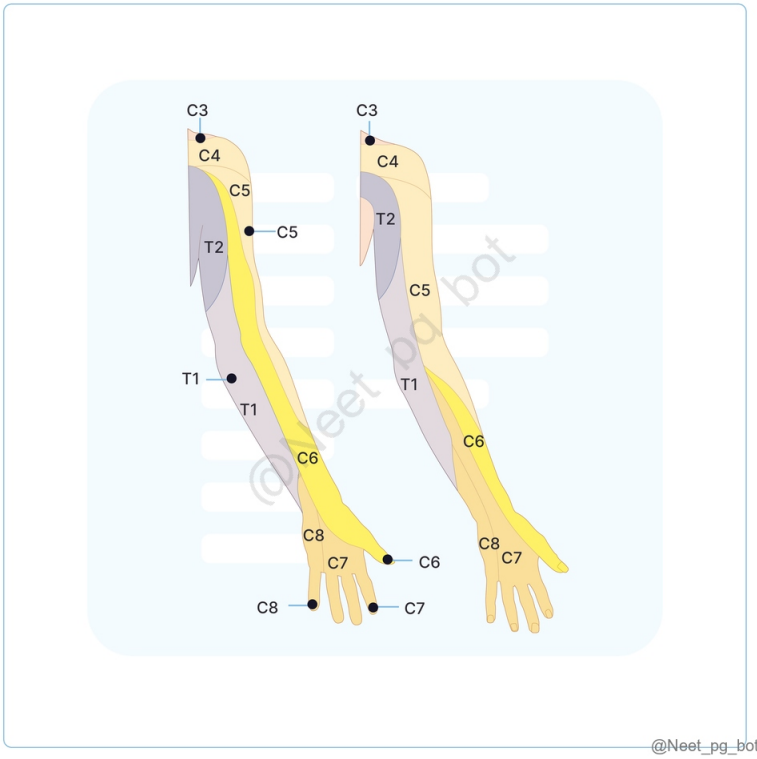

References:

Gray’s Anatomy for Students, 4th Edition, Page 685

BD Chaurasia’s Human Anatomy, Volume-1, 8th Edition, Page 87

↑ *Back to this question in Part A*

@Neet_pg_bot

Q7: A 40-year-old male presents with difficulty extending his elbow after a recent injury. On examination, you notice weakness in elbow extension and diminished triceps reflex. Sensory examination is normal. Which myotome is most likely affected? (Q848386)

A. C5

B. C6

C. C7

D. C8

Correct Answer: C. C7

- *Listen (English)*
- *Listen (Hindi)*

Explanation: The C7 myotome innervates the triceps muscle , which is responsible for elbow extension. Myotomes of the Upper Limb: Spinal Nerve Root Myotome (Motor Function) C5 (Option A ruled out) Shoulder abduction (deltoid), elbow flexion (biceps) C6 (Option B ruled out) Elbow flexion, wrist extension (biceps, wrist extensors) C7 (Option C) Elbow extension (triceps), wrist flexion (wrist flexors) C8 (Option D ruled out) Finger flexion, thumb extension (finger flexors, intrinsic hand muscles) T1 Finger abduction and adduction (intrinsic hand muscles, interossei)

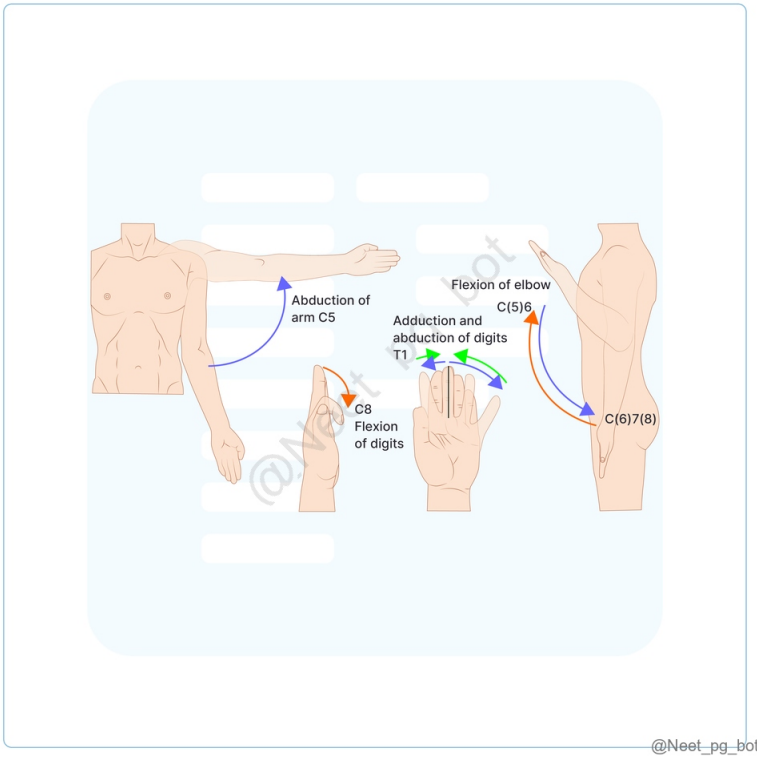

References:

Gray’s Anatomy, The Anatomical Basis of Clinical Practice, 42nd Edition, Page 881

Gray’s Anatomy for Students, 4th Edition, Page 685

↑ *Back to this question in Part A*

@Neet_pg_bot

Q8: A 25-year-old male presents with weakness in the upper limb following a fall on his shoulder. Physical examination reveals impaired movement in the extensor muscles of the arm. Injury to which part of the brachial plexus is most likely responsible for this patient's symptoms? (Q848388)

A. Upper trunk, anterior division

B. Middle trunk, anterior division

C. Middle trunk, posterior division

D. Lower trunk, anterior division

Correct Answer: C. Middle trunk, posterior division

■ *Listen (English)*

■ *Listen (Hindi)*

Explanation: The posterior divisions of the brachial plexus innervate the extensor muscles of the upper limb . The middle trunk is a direct continuation of the C7 ventral ramus and its posterior division supplies the extensor muscles. Brachial Plexus Trunks: Formation: Five ventral rami (C5–T1) form three trunks. Upper Trunk : Formed by C5 and C6. Middle Trunk : Continuation of C7. Lower Trunk : Formed by C8 and T1, crossing over the first rib. Location: Trunks emerge between anterior and middle scalene muscles. Positioned anteriorly to each other, with the subclavian artery running anteromedially. Divisions: Each trunk divides into: Posterior Divisions : Innervate extensor muscles. Anterior Divisions : Innervate flexor muscles. Clinical Relevance: Trunks, especially the upper trunk, can be palpated in the supraclavicular fossa. Important for procedures like nerve blocks. Brachial Plexus Trunk Formation and Divisions: Trunk Formation Divisions Upper Trunk Union of C5 and C6 rami Anterior: Flexor muscles (Option A ruled out) Posterior: Extensor muscles Middle Trunk Continuation of C7 Anterior: Flexor muscles (Option B ruled out) Posterior: Extensor muscles (Option C) Lower Trunk Union of C8 and T1 rami Anterior: Flexor muscles (Option A ruled out) Passing over first rib Posterior: Extensor muscles

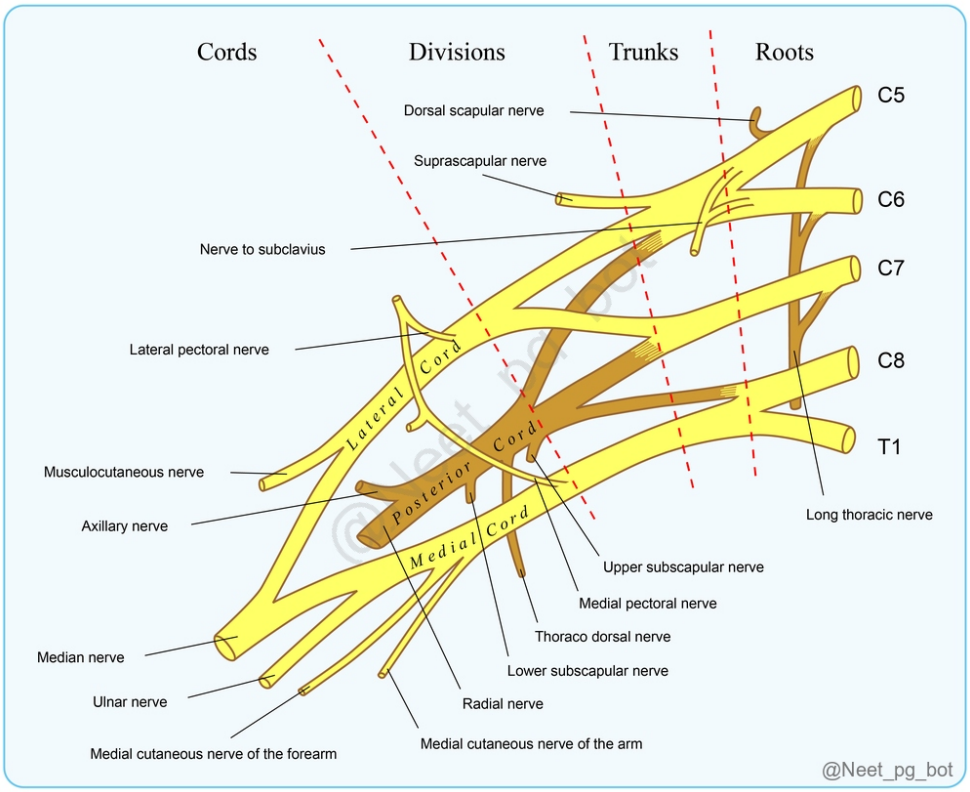

References:

Gray's Anatomy, The Anatomical Basis of Clinical Practice, 41st Edition, Page 876-878

↑ *Back to this question in Part A*

@Neet_pg_bot

Q9: A 25-year-old male is brought to the emergency department after a high-speed motorcycle accident. He complains of severe pain and weakness in his right arm. On examination, there is loss of sensation in the right shoulder and upper arm with weakness in shoulder abduction and elbow flexion. Which of the following is the most likely type of brachial plexus lesion in this patient? (Q848390)

A. Intradural rupture

B. Compression injury

C. Closed traction injury

D. Iatrogenic injury

Correct Answer: C. Closed traction injury

■ *Listen (English)*

■ *Listen (Hindi)*

Explanation: Closed traction injury commonly occurs due to violent forces, such as those experienced in high-speed accidents, which stretch or tear the nerves of the brachial plexus. The symptoms of pain, weakness, and sensory loss in this patient are consistent with this type of lesion. Brachial Plexus Lesions: Damage or dysfunction in the brachial plexus, a nerve network from the spinal cord controlling shoulder, arm, and hand functions. Causes of Brachial Plexus Lesions include: Trauma, birth trauma, tumors, radiation therapy Types of Lesions: Type Description Closed Traction Lesions (Option C) Result from forces that stretch or tear nerves, often in high-impact incidents like accidents. Intradural Ruptures/Avulsions (Option A ruled out) Nerve roots torn from the spinal cord; harder to treat than other injuries. Compression Injuries (Option B ruled out) Caused by pressure on the brachial plexus, including: Thoracic Outlet Syndrome (TOS): Compression between the clavicle and first rib. Hematoma: Internal bleeding compressing the plexus. Anomalous Muscles/Structures : Extra anatomical features causing compression. Iatrogenic Injury : Damage during medical procedures. (Option D ruled out) Symptoms: Symptom Description Sensory Changes Numbness, tingling, pain, or burning in the shoulder, arm, or hand. Motor Weakness Difficulty moving the shoulder, arm, or hand, with specific weakness patterns aiding localization. Autonomic Dysfunction Changes in sweating, skin temperature, or blood flow in the affected limb. Diagnosis: Physical Exam: Assessing sensation, muscle strength, and reflexes. Imaging Studies: X-rays, CT scans, or MRI to identify fractures, dislocations, or tumors. Electrodiagnostic Tests: Nerve conduction studies (NCS) and electromyography (EMG) to assess nerve function and damage extent.

References:

Gray’s Anatomy, The Anatomical Basis of Clinical Practice, 41st Edition, Page 882.e11

↑ *Back to this question in Part A*

@Neet_pg_bot

Q10: A 35-year-old male presents with weakness in elbow flexion and loss of sensation over the lateral aspect of his forearm. Which of the following nerves is most likely involved in this patient’s condition? (Q848391)

A. Axillary nerve

B. Musculocutaneous nerve

C. Radial nerve

D. Ulnar nerve

Correct Answer: B. Musculocutaneous nerve

■ *Listen (English)*

■ *Listen (Hindi)*

Explanation: The musculocutaneous nerve innervates the biceps brachii and brachialis muscles , responsible for elbow flexion. It also provides sensory innervation to the lateral aspect of the forearm. Cord Nerve Motor Innervation Sensory Innervation Lateral Cord Musculocutaneous (C5, C6, C7) (Option B) Biceps brachii, brachialis, coracobrachialis Lateral forearm Lateral Root of Median (C5, C6, C7) Contributes to median nerve (primarily hand muscles) Contributes to sensory innervation of the hand Posterior Cord Axillary (C5, C6) (Option A ruled out) Deltoid, teres minor Lateral shoulder Radial (C5, C6, C7, C8, T1) (Option C ruled out) Triceps, brachioradialis, wrist and finger extensors, supinator Posterior arm, forearm, dorsolateral hand Upper Subscapular (C5, C6) Subscapularis None Thoracodorsal (C6, C7, C8) Latissimus dorsi None Lower Subscapular (C5, C6) Subscapularis, teres major None Medial Cord Ulnar (C8, T1) (Option D ruled out) Flexor carpi ulnaris, flexor digitorum profundus (medial half), most intrinsic hand muscles Medial hand, little finger, medial half of ring finger Median (C5, C6, C7, C8, T1) Pronators, wrist/finger flexors (except those supplied by ulnar), thenar muscles Palmar hand (thumb, index, middle, lateral half of ring finger) Medial Pectoral (C8, T1) Pectoralis major, pectoralis minor None Medial Cutaneous Nerve of Arm (C8, T1) None Medial arm Medial Cutaneous Nerve of Forearm (C8, T1) None Medial forearm

References:

Gray’s Anatomy, The Anatomical Basis of Clinical Practice, 41st Edition, Page 878-882

↑ *Back to this question in Part A*

@Neet_pg_bot

Q11: Which of the following statements is true regarding the variations in the prefixed and postfixed brachial plexus? (Q848394)

A. Prefixed brachial plexus is characterized by contributions from C5 to T2

B. T2 spinal nerve replaces the usual T1 contribution in postfixed brachial plexus

C. Prefixed brachial plexus has an increased contribution from C4 and decreased from T1

D. Postfixed brachial plexus is associated with an increased contribution from C3 and C4

Correct Answer: C. Prefixed brachial plexus has an increased contribution from C4 and decreased from T1

■ *Listen (English)*

■ *Listen (Hindi)*

Explanation: A prefixed brachial plexus has an increased contribution from C4 and decreased from T1, while a postfixed brachial plexus involves contributions from C6-T2, with diminished input from C5 and increased input from T2. The variations are significant in clinical practice as they can affect the innervation patterns of the upper limb and may impact nerve injury presentations. Prefixed Postfixed Nerve root C4-C8 C6-T2 Shift Upward shift Downward shift C4 contribution Increased Nil or minimal C5 contribution Normal Reduced T1 contribution

Reduced or nil Normal along with added T2 Risk No risk of compression High risk of compression (Thoracic outlet syndrome) Prefixed brachial plexus is characterized by contributions from C5 to T2 (Option A): It is incorrect as in a prefixed brachial plexus, the contribution shifts upward , involving C4-C8 , not C5 to T2. There is minimal or no input from T1 in a prefixed plexus. T2 spinal nerve replaces the usual T1 contribution in postfixed brachial plexus (Option B): It is incorrect as in a postfixed brachial plexus, the contribution extends downward and typically includes C6-T2 , but T2 does not replace T1. Instead, T1 remains part of the plexus, and T2 provides an additional contribution. ■■■■■■■Postfixed brachial plexus is associated with an increased contribution from C3 and C4 (Option D): It is incorrect as a postfixed brachial plexus involves a downward shift , resulting in contributions from C6-T2 . There is no involvement of C3 and C4, which are part of the cervical plexus, not the brachial plexus.

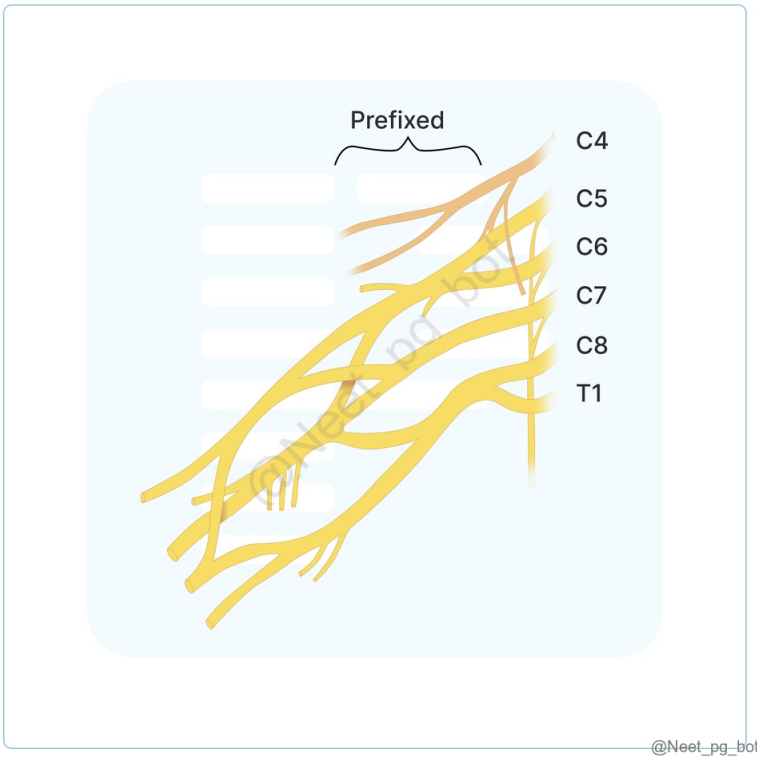

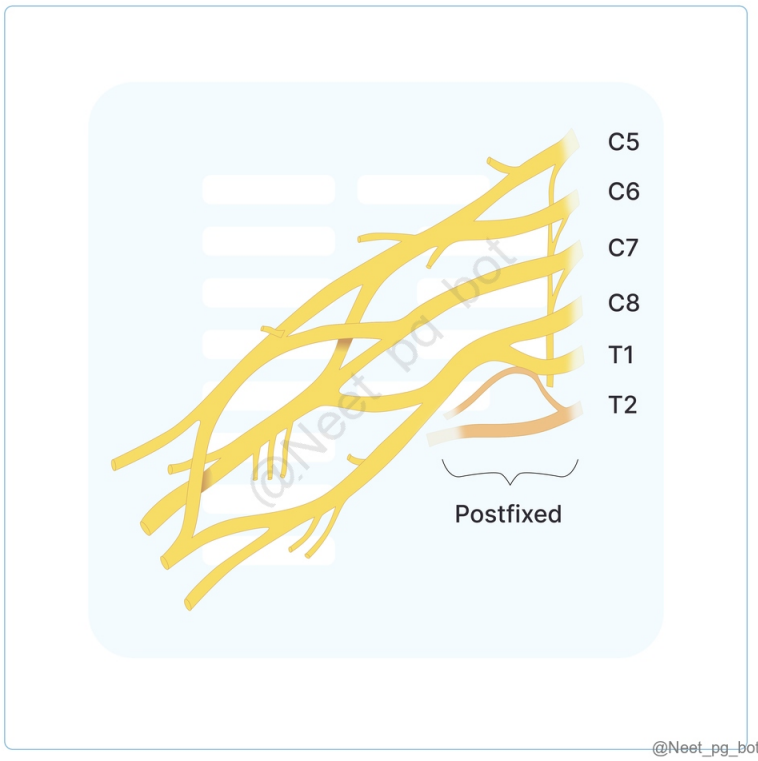

References:

BD Chaurasia’s Human Anatomy, Volume 1, 8th Edition, Pages 59-60

A Prefixed Four-Trunk Brachial Plexus with Anomalous Anatomy of All Subsequent Divisions, Cords, and Terminal Branches

↑ *Back to this question in Part A*

@Neet_pg_bot

Q12: Which part of the brachial plexus does not give off any branches? (Q848405)

A. Roots

B. Trunks

C. Divisions

D. Cords

Correct Answer: C. Divisions

■ *Listen (English)*

■ *Listen (Hindi)*

Explanation: The divisions of the brachial plexus (anterior and posterior) act as a passage for nerve fibers to reorganize and form cords but they themselves do not give rise to any branches. Part of brachial plexus Branches Roots Dorsal scapular nerve - C5 Long thoracic nerve - C5 to C7 Trunks Suprascapular nerve - C5 , C6 Nerve to subclavius - C5 , C6 Division None Cords Lateral pectoral nerve (Lateral cord: C5 - C7) Upper subscapular nerve (Posterior cord: C5, C6) Thoracodorsal nerve (Posterior cord: C6 - C8) Lower subscapular nerve (Posterior cord: C5 , C6) Medial pectoral nerve (Medial cord: C8 , T1) Medial cutaneous nerve of arm (Medial cord: C8 , T1) Medial cutaneous nerve of forearm (Medial cord: C8 , T1) Terminal branches Musculocutaneous nerve (Lateral cord, C5-C7) Axillary nerve (Posterior cord, C5, C6) Radial nerve (Posterior cord, C5-T1) Median nerve (Lateral and Medial cords, C5-T1) Ulnar nerve (Medial cord, C8, T1)

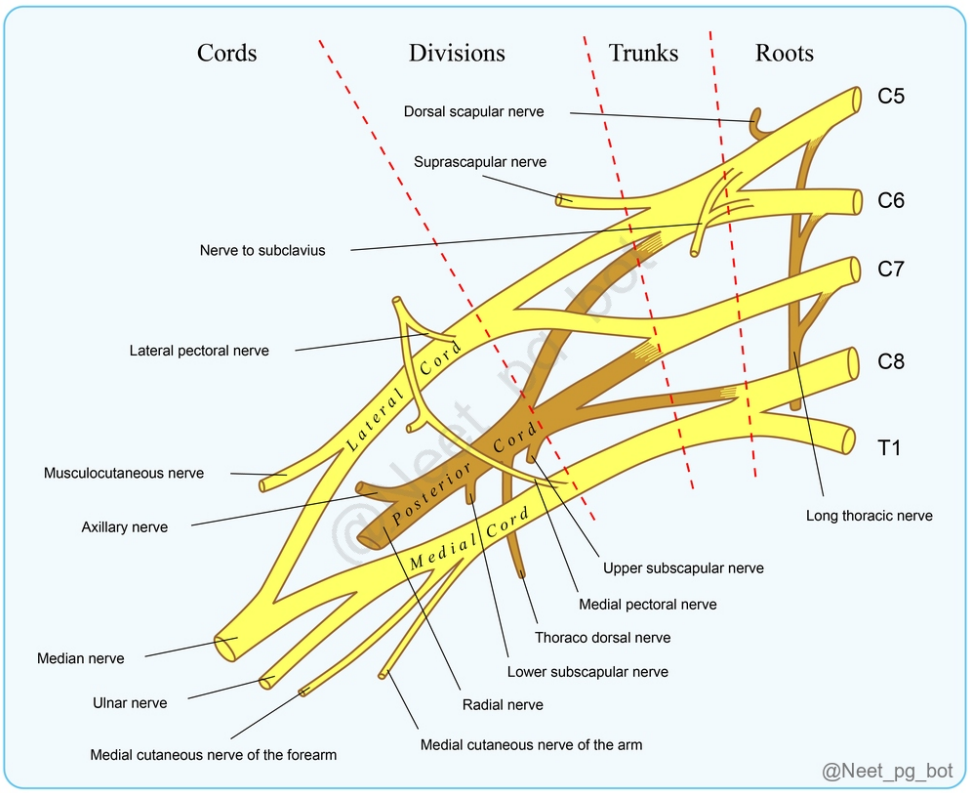

References:

Gray's Anatomy, The Anatomical Basis of Clinical Practice, 42nd Edition, Page 876, 878-879

↑ *Back to this question in Part A*

@Neet_pg_bot

Q13: Which of the following statements regarding the anterior and posterior axial lines is correct? (Q848409)

A. Axial lines form as a result of limb rotational and elongation processes during embryogenesis

B. Axial lines divide dermatomes that are adjacent in the spinal nerve sequence

C. Overlapping of nerve supply can overlap across axial lines

D. Overlapping of Ventral and dorsal axial lines can occur

Correct Answer: A. Axial lines form as a result of limb rotational and elongation processes during embryogenesis

■ *Listen (English)*

■ *Listen (Hindi)*

Explanation: Axial lines are the dividing lines between dermatomes that are not adjacent in the spinal nerve sequence, which are formed as a result of limb rotational and elongation processes during embryogenesis. Axial lines Axial lines are the dividing lines between dermatomes that are not adjacent in the spinal nerve sequence. Types Ventral Axial Line (on the anterior surface of the limb). Dorsal Axial Line (on the posterior surface of the limb). Formation During embryological development, the limbs undergo lateral rotation (upper limb) or medial rotation (lower limb). This rotation creates a spiral arrangement of dermatomes and shifts certain dermatomes distally. Axial lines form as a result of these rotational and elongation processes. Significance Axial lines are important for understanding nerve injuries and mapping sensory deficits. Across these lines, there is no overlap between dermatomes, so sensory loss in these areas can help pinpoint the exact nerve or spinal segment involved. Axial lines divide dermatomes that are adjacent in the spinal nerve sequence (Option B): Axial lines do not divide adjacent dermatomes. Instead, they divide dermatomes from non-adjacent spinal nerve roots . Adjacent dermatomes (e.g., C5 and C6) overlap significantly, and no axial line exists between them. For example, the ventral axial line separates C5, C6 from C8, T1, and T2, which are non-adjacent segments. Overlapping of nerve supply can overlap across axial lines (Option C): One of the defining features of axial lines is that there is no overlap of dermatomes across them. While overlapping of adjacent dermatomes is common elsewhere (e.g., C5 overlaps with C6), this does not happen across axial lines. Overlapping of ventral and dorsal axial lines can occur (Option D): The ventral and dorsal axial lines are distinct anatomical landmarks and do not overlap. They are located on opposite surfaces of the limb: The ventral axial line is on the anterior (palmar) surface of the limb. The dorsal axial line is on the posterior (dorsal) surface of the limb.

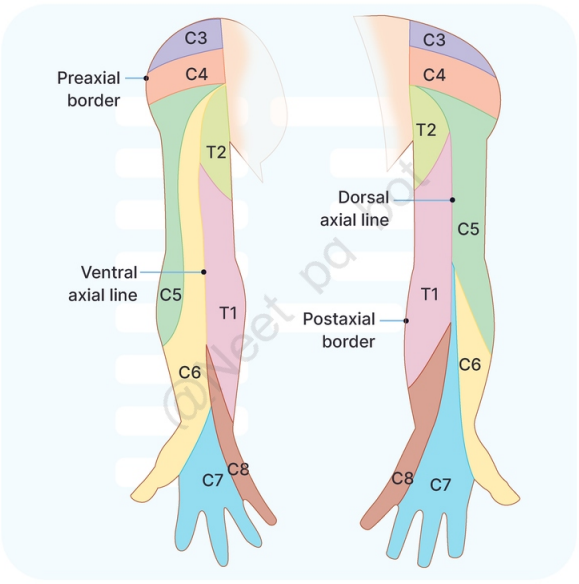

@Neet_pg_bot

References:

BD Chaurasia's Human Anatomy, Volume 1, 8th Edition, Page 86, 87

↑ *Back to this question in Part A*

@Neet_pg_bot

• [05_Upper Limb] 024 Muscles And Bones Of Forearm And Hand

« Back to Folder Directory

[05_Upper Limb] 024 Muscles And Bones Of Forearm And Hand — Quick Jump

Q1 (p. 1396)	*Q2 (p. 1397)*	*Q3 (p. 1397)*	*Q4 (p. 1398)*	*Q5 (p. 1401)*	*Q6 (p. 1402)*
Q7 (p. 1403)	*Q8 (p. 1405)*	*Q9 (p. 1407)*	*Q10 (p. 1408)*	*Q11 (p. 1409)*	*Q12 (p. 1411)*
Q13 (p. 1413)	*Q14 (p. 1416)*	*Q15 (p. 1417)*	*Q16 (p. 1420)*	*Q17 (p. 1421)*	*Q18 (p. 1422)*

Q1: Which of the following is NOT a content of the cubital fossa? (Q848417)

A. Brachial artery

B. Median nerve

C. Ulnar nerve

D. Radial nerve

Correct Answer: C. Ulnar nerve

■ *Listen (English)*

■ *Listen (Hindi)*

Explanation: Ulnar nerve is not a content of the cubital fossa; instead, it passes behind the medial epicondyle. Contents of cubital fossa from medial to lateral: (Mnemonic: MBBS) Median nerve Brachial artery Biceps brachii tendon Superficial branch of radial nerve

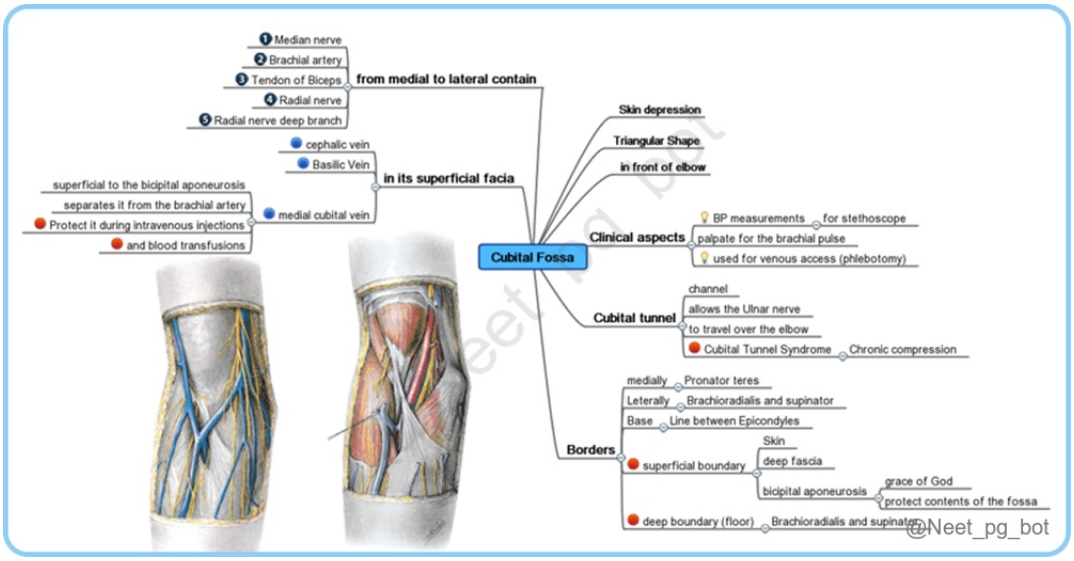

References:

Inderbir Singh's Textbook of Anatomy, Volume-1, 6th Edition, Page 170, 171

↑ *Back to this question in Part A*

@Neet_pg_bot

Q2: Which of the following is a unique feature of the clavicle compared to other bones in the body? (Q848432)

A. It ossifies from both membranous and cartilaginous origins.

B. It articulates directly with the scapula without an intervening joint cavity.

C. It is the only bone in the body that does not have a medullary cavity.

D. It is entirely covered by the periosteum, unlike other bones.

Correct Answer: A. It ossifies from both membranous and cartilaginous origins.

■ *Listen (English)*

■ *Listen (Hindi)*

Explanation: The clavicle is unique among bones in the human body due to its dual ossification process: Intramembranous Ossification : The medial and lateral parts of the clavicle develop through intramembranous ossification. This process is typical for flat bones like the skull. Endochondral Ossification : The sternal end of the clavicle ossifies through endochondral ossification, which involves a cartilage template being replaced by bone. This process is more common for long bones like the femur and humerus. The clavicle articulates with the scapula at the acromioclavicular joint , which does have a joint cavity. (Option B) While it is true that the clavicle lacks a medullary cavity, it is not the only bone with this feature (Flat bones like the sternum and skull bones). (Option C) All bones in the body are covered by periosteum except at articular surfaces. This characteristic is not unique to the clavicle. (Option D)

References:

BD Chaurasia’s Human Anatomy, Volume 1, 8th Edition, Page 6

↑ *Back to this question in Part A*

@Neet_pg_bot

Q3: Which of the following is not a content in the 4th compartment of extensor retinaculum? (Q848424)

A. Extensor digitorum

B. Extensor indicis

C. Posterior interosseous nerve

D. Extensor pollicis brevis

Correct Answer: D. Extensor pollicis brevis

■ *Listen (English)*

■ *Listen (Hindi)*

Explanation: Extensor pollicis brevis is in the 1st compartment of the extensor retinaculum. Extensor Retinaculum: Thickened deep fascia on the back of the wrist. It is divided into 6 compartments. Compartment of Extensor Retinaculum Structure(s) I Abductor pollicis longus Extensor pollicis brevis II Extensor carpi radialis longus Extensor carpi radialis brevis III Extensor pollicis longus IV Extensor digitorum Extensor indicis Posterior interosseous nerve Anterior interosseous artery V Extensor digiti minimi VI Extensor carpi ulnaris

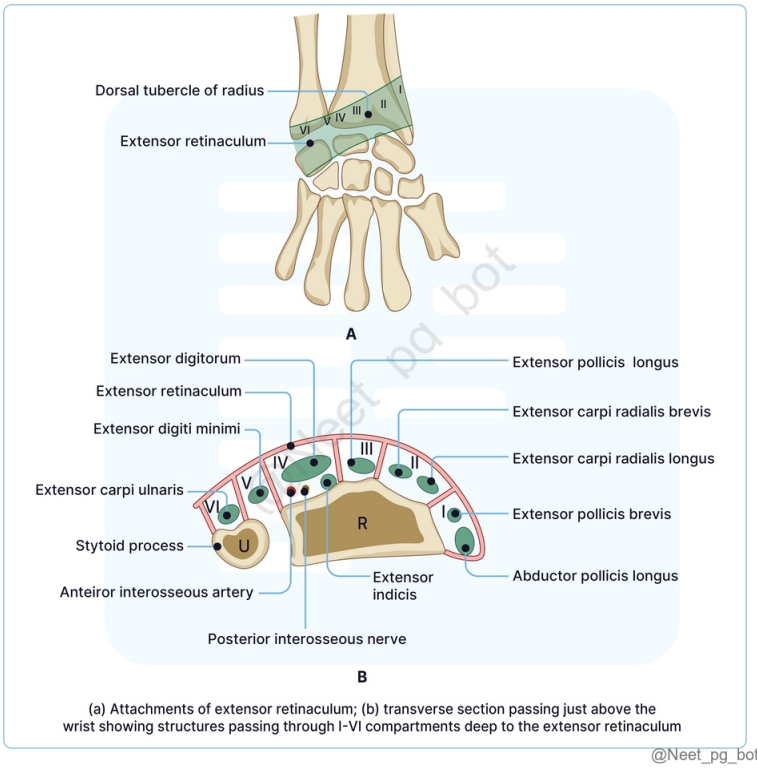

(a) Attachments of extensor retinaculum; (b) transverse section passing just above the wrist showing structures passing through I-VI compartments deep to the extensor retinaculum

@Neet_pg_bot

References:

BD Chaurasia's Human Anatomy, Volume 1, 8th Edition, Page 145-146

↑ *Back to this question in Part A*

@Neet_pg_bot

Q4: After a fall from a height with undue arm abduction, the patient presented as shown. Mark the wrong statement about this condition. (Q848422)

A. C7, C8 & T1 are affected

B. Complete clawing of hand is seen

C. Associated horner syndrome can be seen

D. Due to injury to lower trunk of brachial plexus



Correct Answer: A. C7, C8 & T1 are affected

- *Listen (English)*
- *Listen (Hindi)*

Explanation: Given clinical scenario is suggestive of Klumpke's paralysis secondary to fall with abduction of arm causing injury to C8 and T1 nerve roots resulting in complete clawing of hand . Erb's Paralysis & Klumpke's Paralysis: Feature Erb's Paralysis Klumpke's Paralysis Site of Injury Upper trunk of the brachial plexus (Erb's point) Lower trunk of the brachial plexus (Option D) Causes of Injury Undue separation of head from the shoulder Birth injury/difficult childbirth During anesthesia Undue abduction of the arm Birth injury Nerve Roots Involved Mainly C5, partly C6 Mainly T1, partly C8 (Option A) Muscles Paralyzed Biceps brachii Deltoid Brachialis Brachioradialis Partly supraspinatus, infraspinatus, supinator Intrinsic muscles of the hand (T1) Ulnar flexors of the wrist and fingers (C8) Deformity and Position Arm: Hangs by the side, adducted and medially rotated Forearm: Extended and pronated (Waiter's tip position) Also known as Policeman tip deformity Complete clawing

of hand due to hyperextension at the metacarpophalangeal joints and flexion at the interphalangeal joints. (Option B) Additional Features Sensory loss over lower deltoid. Bird winging effect of scapula. Horner’s syndrome (Option C) if T1 is injured.

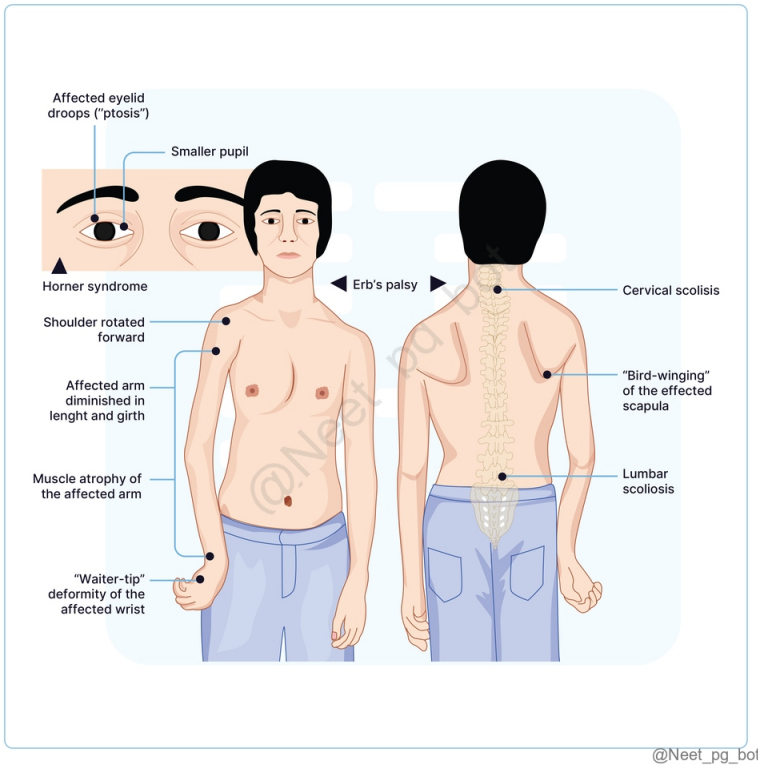

@Neet_pg_bot



@Neet_pg_bot

References:

Vishram Singh Textbook of Anatomy, Volume-1, 2nd Edition, Page 62,63

↑ *Back to this question in Part A*

@Neet_pg_bot

Q5: Which of the following statements about the carrying angle of the elbow is correct? (Q848436)

A. The carrying angle is formed by the angle between the humerus and the ulna when the elbow is flexed.

B. The carrying angle disappears during full flexion and pronation of the forearm.

C. The carrying angle is greater in males, usually more than 15°.

D. The carrying angle increases as the arm moves from full flexion to extension.

Correct Answer: B. The carrying angle disappears during full flexion and pronation of the forearm.

■ *Listen (English)*

■ *Listen (Hindi)*

Explanation: The carrying angle of the elbow is the angle formed between the humerus and the forearm when the arm is fully extended. This angle, typically 13° , is due to the medially and downwardly directed transverse axis of the elbow joint. The factors that contribute to this angle include: Medial flange of the trochlea being 6 mm deeper than the lateral flange. Oblique placement of the superior articular surface of the coronoid process of the ulna. The carrying angle disappears during full flexion and pronation of the forearm, with the forearm aligning with the arm in the mid-prone position. This allows better precision in hand control. The angle is typically 10°–15° in males and greater than 15° in females Cubitus valgus is characterized by an increased carrying angle, causing the forearm to deviate outward , while cubitus varus involves a decreased carrying angle, causing the forearm to angle inward.

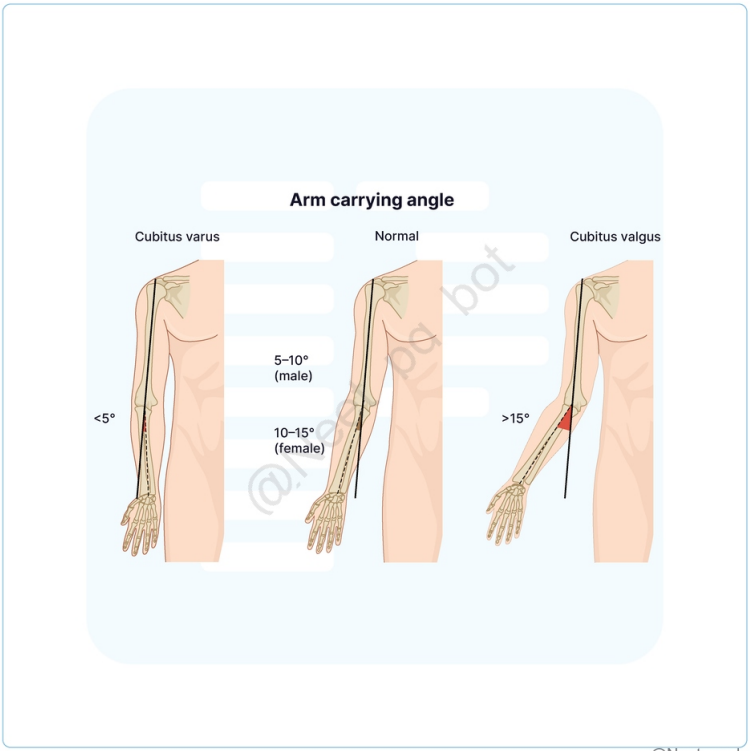

@Neet_pg_bot

References:

BD Chaurasia’s Human Anatomy, Volume 1, 8th Edition, Page 166

↑ *Back to this question in Part A*

@Neet_pg_bot

Q6: Which of the following structures can be palpated in the infraclavicular fossa ? (Q848435)

A. Subclavian vein

B. Biceps tendon

C. Coracoid process

D. Thoracoacromial artery

Correct Answer: C. Coracoid process

■ *Listen (English)*

■ *Listen (Hindi)*

Explanation: The infraclavicular fossa , also known as the deltopectoral triangle , is a triangular depression located below the junction of the lateral and middle thirds of the clavicle. It is defined by the following boundaries: Medially : The pectoralis major muscle. Laterally : The anterior fibers of the deltoid muscle. Superiorly : The clavicle . The tip of the coracoid process of the scapula lies approximately 2–3 cm below the clavicle and is overlapped by the anterior fibers of the deltoid. It can be felt during deep palpation just lateral to the infraclavicular fossa , which helps in locating important structures like the brachial plexus and subclavian artery in clinical assessments. This area is clinically significant for procedures such as brachial plexus block and the assessment of vascular structures like the subclavian artery .

References:

BD Chaurasia’s Human Anatomy, Volume 1, 8th Edition, Page 37

↑ *Back to this question in Part A*

@Neet_pg_bot

Q7: Identify the correctly marked attachments of the Upper end of the Humerus. (Q848434)

A. A- Supraspinatus; B- Infraspinatus; D- Pectoralis major

B. A- Teres minor; B- Infraspinatus; D- Subscapularis

C. C- Pectoralis major; D- Supraspinatus; E- Subscapularis

D. B- Infraspinatus; C- Pectoralis major; D- Supraspinatus

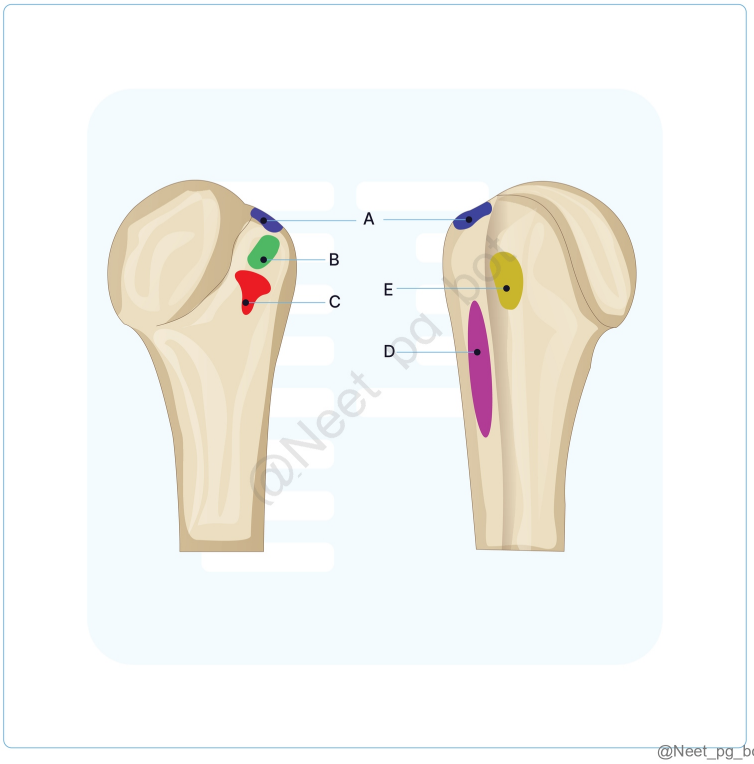

Correct Answer: A. A- Supraspinatus; B- Infraspinatus; D- Pectoralis major

- *Listen (English)*
- *Listen (Hindi)*

Explanation: Upper end of Humerus: Greater Tubercle: The most lateral part of the upper end, with three flattened facets: Upper facet: Attachment for supraspinatus. Middle facet: Attachment for infraspinatus. Lower facet: Attachment for teres minor. Mnemonic : "SIT" Lesser Tubercle: A small elevation on the front of the upper end, just above the surgical neck, providing attachment for the subscapularis muscle . Intertubercular Sulcus (Bicipital Groove): A groove between the tubercles that contains: Long head of biceps (enclosed in a synovial sheath). Ascending branch of anterior circumflex humeral artery. It provides attachment to three muscles: Pectoralis major (lateral lip) . Teres major (medial lip). Latissimus dorsi (floor). Mnemonic : "Lady between 2 Majors" (Latissimus dorsi between Pectoralis major and Teres major).

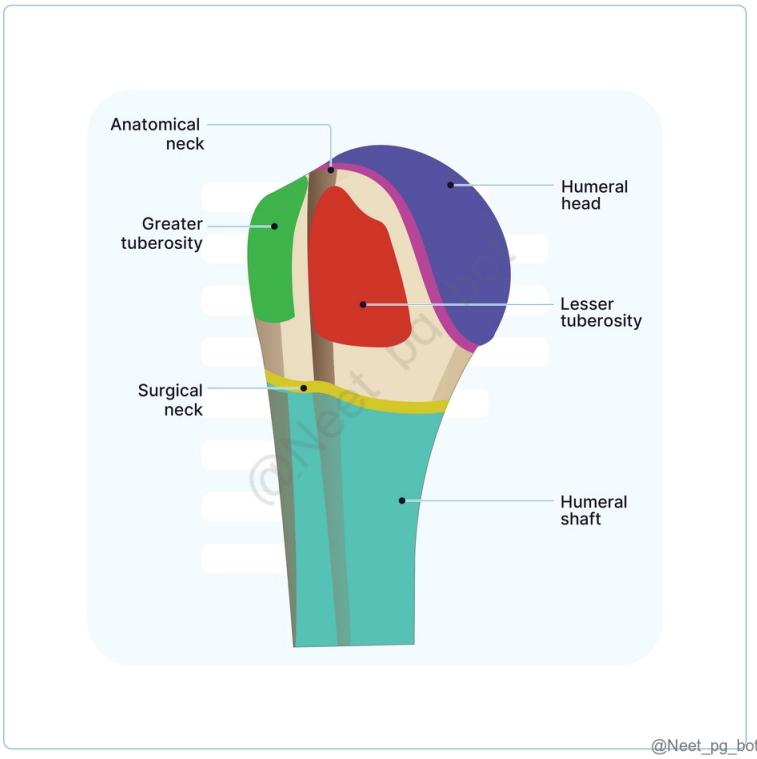

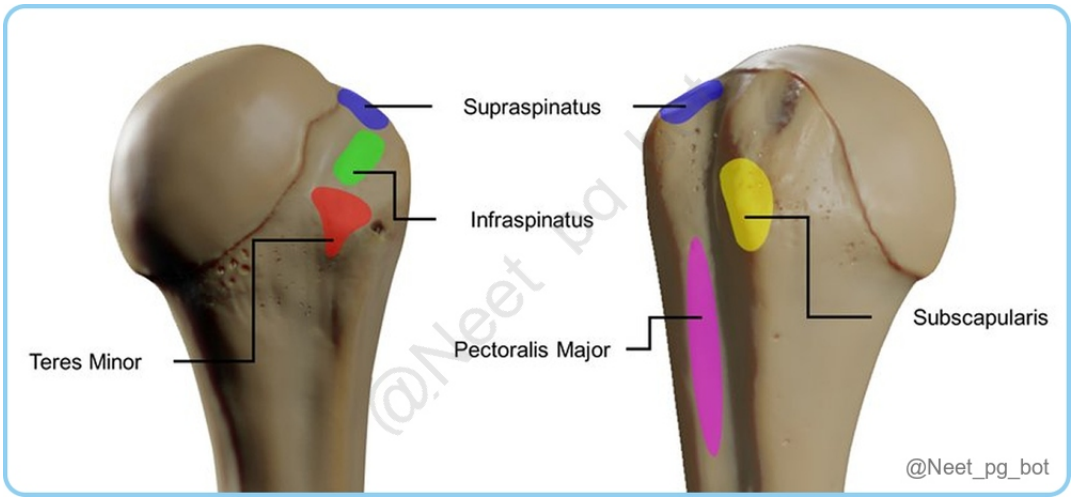

References:

Vishram Singh Textbook of Anatomy, Volume-1, 2nd Edition, Page 19-21

↑ *Back to this question in Part A*

@Neet_pg_bot

Q8: Which of the following correctly describes the attachments on the coracoid process? (Q848433)

A. The short head of biceps brachii and coracobrachialis insert onto its medial border.

B. The conoid ligament attaches to the tip of the coracoid process.

C. The pectoralis minor muscle inserts onto the medial border of the upper surface.

D. The coracoacromial ligament attaches to the superior ridge of the coracoid process.

Correct Answer: C. The pectoralis minor muscle inserts onto the medial border of the upper surface.

■ *Listen (English)*

■ *Listen (Hindi)*

Explanation: Coracoid Process Attachments: Muscle Attachments : Short head of biceps brachii and coracobrachialis arise from the tip via a common tendon. (Option A) Pectoralis minor inserts on the medial border of the upper surface . Ligament Attachments : Coracoacromial ligament attaches to the lateral border . (Option D) Conoid ligament (part of coracoclavicular) attaches to the knuckle . (Option B) Trapezoid ligament (part of coracoclavicular) attaches to the ridge on the superior aspect. Coracohumeral ligament attaches at the root , near the glenoid cavity.

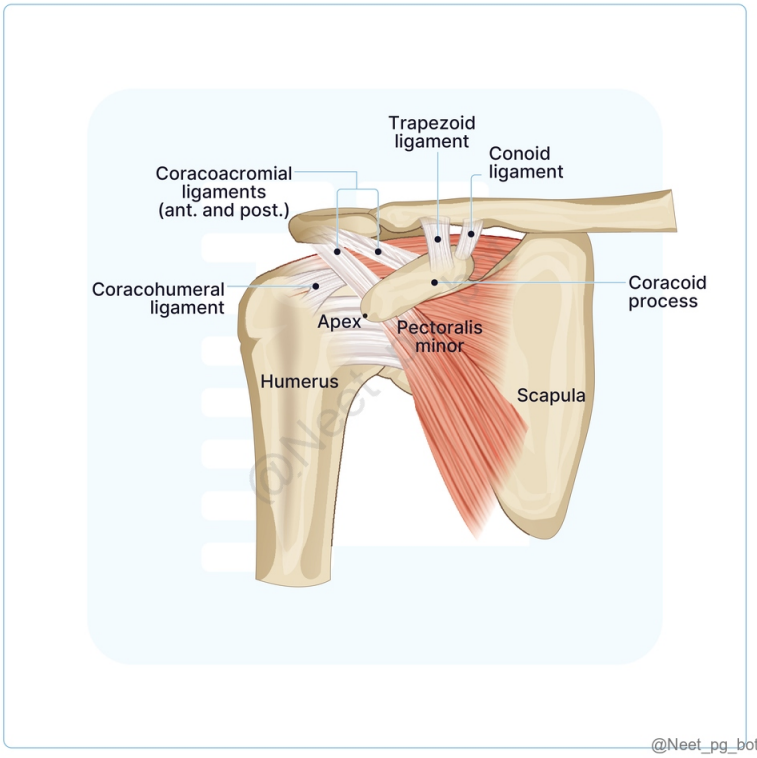

References:

Vishram Singh Textbook of Anatomy, Volume-1, 2nd Edition, Page 18

↑ *Back to this question in Part A*

@Neet_pg_bot

Q9: Which of the following bones is not directly involved in the radiocarpal (wrist) joint? (Q848431)

A. Scaphoid

B. Lunate

C. Pisiform

D. Triquetrum

Correct Answer: C. Pisiform

■ *Listen (English)*

■ *Listen (Hindi)*

Explanation: Pisiform is a sesamoid bone located in the proximal row of the carpal bones but does not participate directly in the radiocarpal articulation. Wrist joint Synovial ellipsoidal (condyloid) joint allowing flexion, extension, abduction, adduction, and circumduction. Articulating Bones The wrist joint involves the distal end of the radius and the proximal row of carpal bones (scaphoid, lunate, and triquetrum). The ulna is not directly involved in the wrist joint but is adjacent to it, separated by an articular disc (the triangular fibrocartilage). Carpal Bones Involved Scaphoid, lunate, and triquetrum are directly involved in the articulation with the radius. The pisiform is not involved in the wrist joint. Clinical Relevance Common conditions affecting the wrist joint include wrist fractures (especially of the scaphoid and radius), carpal tunnel syndrome, and arthritis.

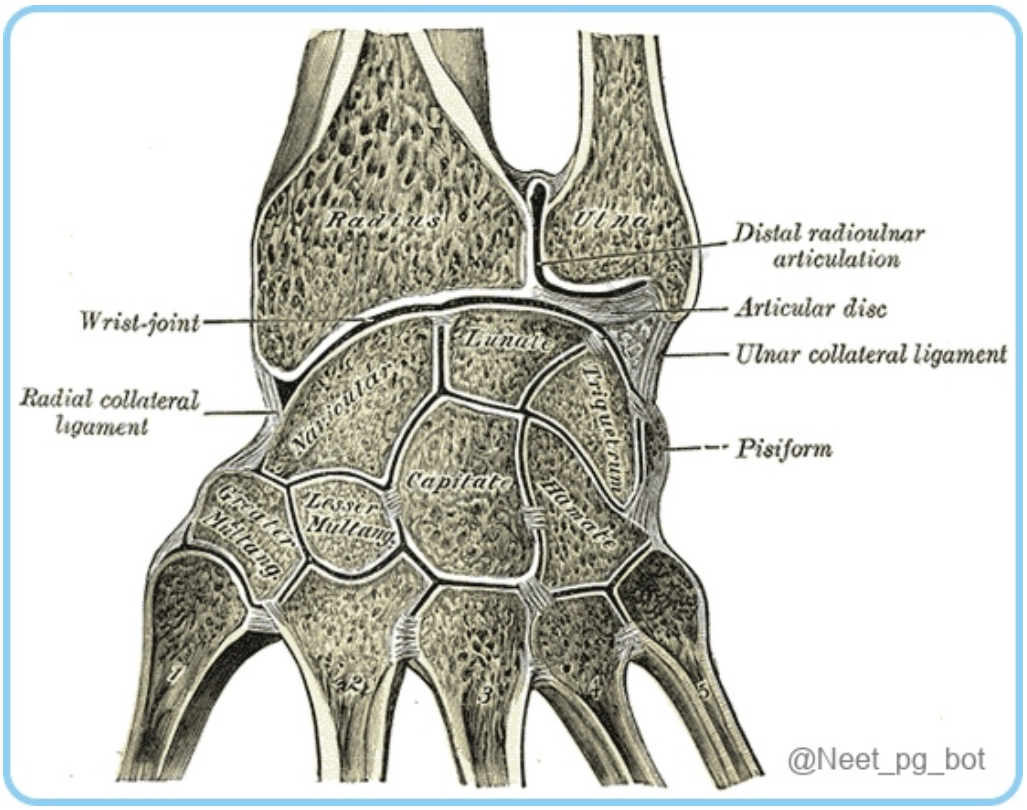

References:

www.ncbi.nlm.nih.gov/books/NBK534779/

↑ *Back to this question in Part A*

@Neet_pg_bot

Q10: The muscles in the posterior aspect of the forearm are given below. Which among these is involved in the extension of the elbow joint? (Q848423)

A. Anconeus

B. Brachioradialis

C. Supinator

D. Extensor digitorum

Correct Answer: A. Anconeus

■ *Listen (English)*

■ *Listen (Hindi)*

Explanation: Muscles Origin Insertion Nerve Supply Actions Anconeus (Option A) Lateral epicondyle of humerus Lateral surface of olecranon process of ulna Radial nerve Extends elbow joint Brachioradialis (Option B) Upper two-thirds of lateral supracondylar ridge of humerus Base of styloid process of radius Radial nerve Flexes forearm at elbow ; rotates forearm to midprone position Extensor digitorum (Option D) Lateral epicondyle of humerus Bases of middle phalanges of the 2nd–5th digits Deep branch of radial nerve Extends fingers of hand Supinator (Option C) Lateral epicondyle of humerus, annular ligament of superior radioulnar joint, supinator crest of ulna Neck and upper third of radius Deep branch of radial nerve Supinates forearm when elbow is extended

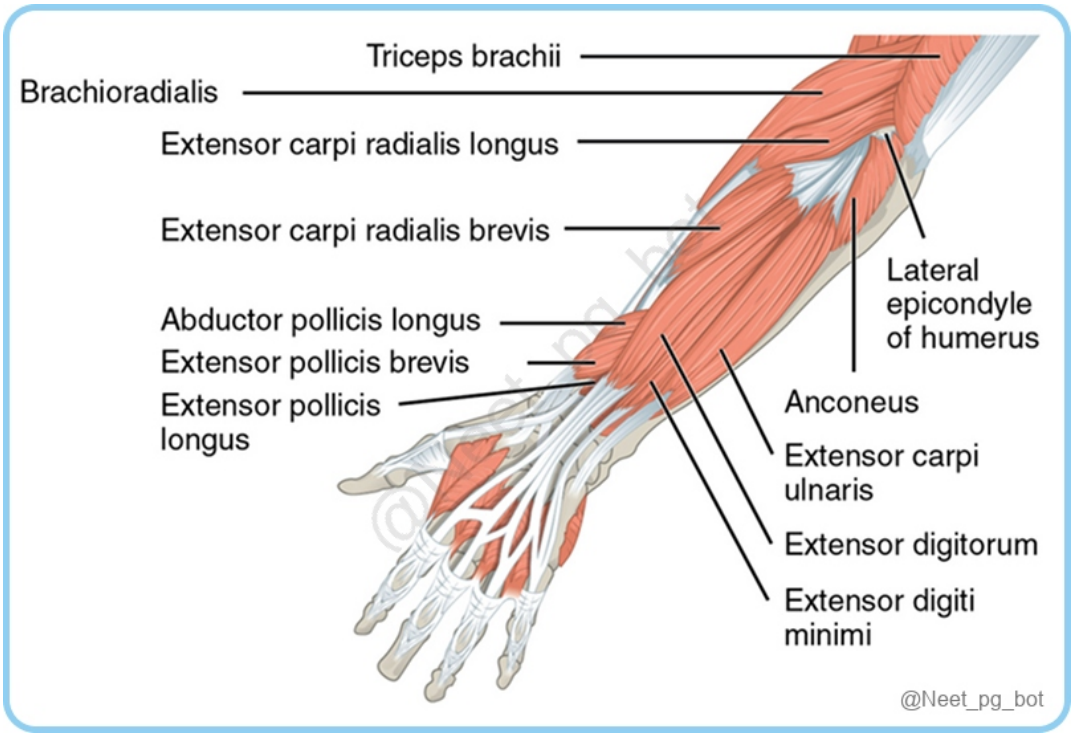

References:

BD Chaurasia's Human Anatomy, Volume 1, 8th Edition, Page 147-148

↑ *Back to this question in Part A*

@Neet_pg_bot

Q11: A 28-year-old woman falls off her bicycle and lands on her outstretched hand. She presents with pain and swelling over the lateral aspect of her wrist. On examination, there is tenderness in the anatomical snuff box. Which underlying bone is most likely fractured? (Q848413)

A. Trapezium

B. Scaphoid

C. Lunate

D. Capitate

Correct Answer: B. Scaphoid

■ *Listen (English)*

■ *Listen (Hindi)*

Explanation: Tenderness in the anatomical snuff box following a fall on an outstretched hand strongly suggests a scaphoid fracture , as the scaphoid bone lies in the floor of the anatomical snuff box. Anatomical snuff box/Radial fossa: Triangular hollow visible on the lateral aspect of the wrist when the thumb is fully extended. Boundaries: Anterolateral: Extensor pollicis brevis, Abductor pollicis longus Posteromedial: Extensor pollicis longus Roof: Dorsal cutaneous branch of radial nerve: Found in the skin and subcutaneous tissue of anatomical snuff box. Cephalic vein: Arises from dorsal venous network of hand and crosses anatomical snuff box to travel to the anterolateral aspect of forearm. Contents: Radial Artery: Crosses the floor of the anatomical snuff box Clinical Significance: Tenderness in the anatomical snuff box following a fall on an outstretched hand suggests a scaphoid fracture , which is clinically important due to its retrograde blood supply and risk of avascular necrosis of the proximal fragment. It is also a key site for palpating the radial artery and may show sensory symptoms if the superficial radial nerve is injured.

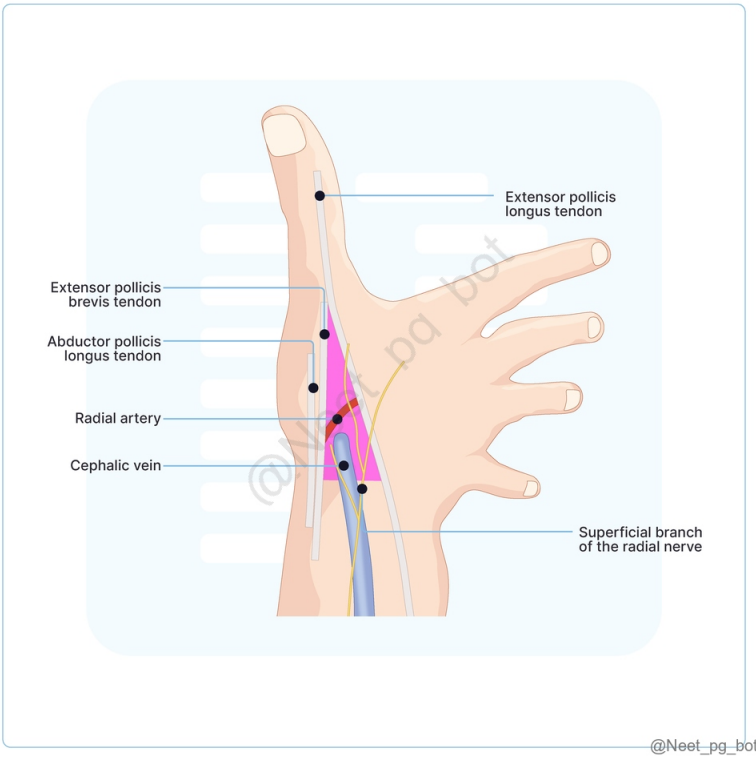

References:

Inderbir Singh's Textbook of Anatomy, Volume-1, 6th Edition, Page 197

↑ *Back to this question in Part A*

Q12: Choose the correct statement regarding the muscle being tested in the given image. (Q848421)

A. Unipennate muscle

B. Muscles of 1st and 2nd digits are supplied by median nerve and 3rd & 4th digit muscles are supplied by ulnar nerve

C. Causes flexion of interphalangeal and extension of metacarpophalangeal joints

D. Absent in thumb

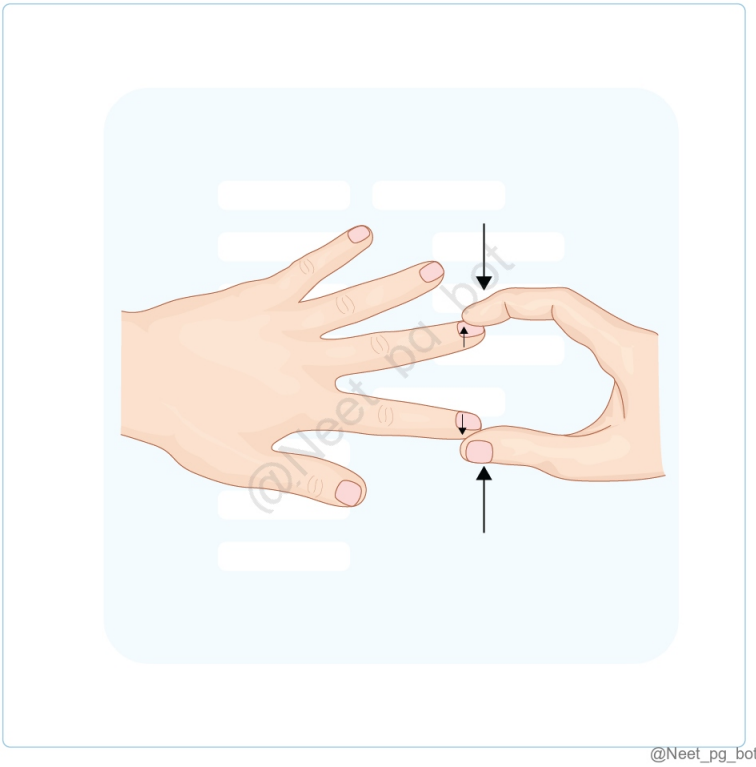

Correct Answer: D. Absent in thumb

■ *Listen (English)*

■ *Listen (Hindi)*

Explanation: Test shown in the image is done to test Dorsal interossei , where the patient is asked to abduct the fingers against resistance. Dorsal interossei are bipennate muscles , supplied by deep branch of the ulnar nerve. Palmar Interossei Dorsal Interossei Arrangement Unipennate (Option A) Bipennate Action Adduction of fingers (PAd) Abduction of fingers (DAb) Nerve supply Deep branch of ulnar nerve Absent in Middle finger Thumb and

little finger (Option D) Number of muscles 4 in no. 4 in no. (middle finger has 2) Clinical test Card test (adduction of digits) Egawa test (abduction of digits)

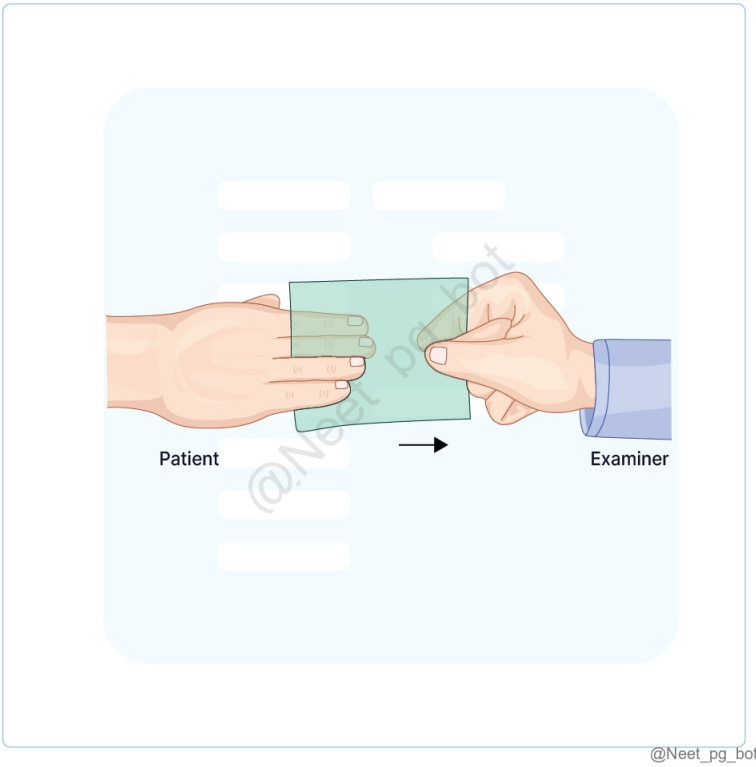

@Neet_pg_bot

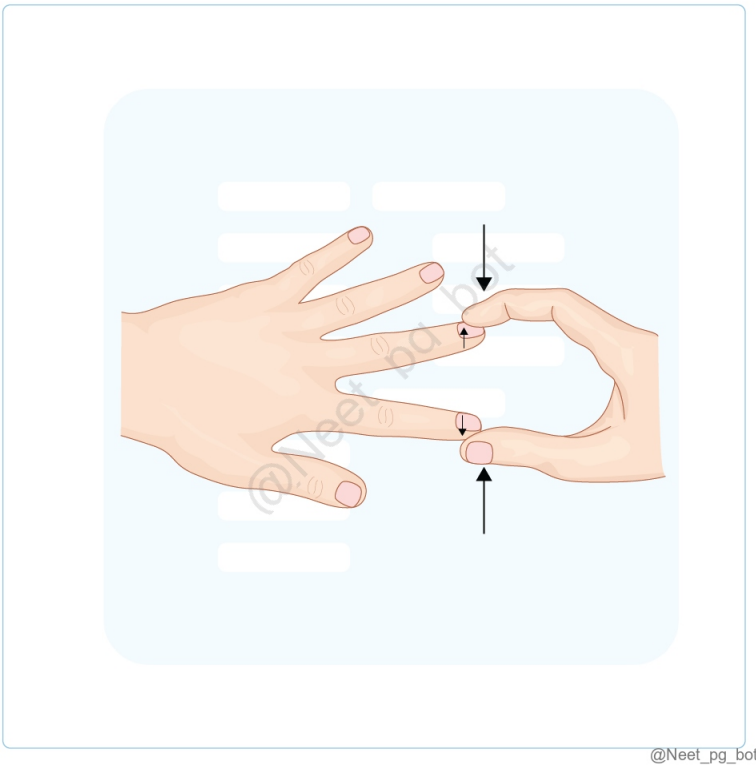

@Neet_pg_bot

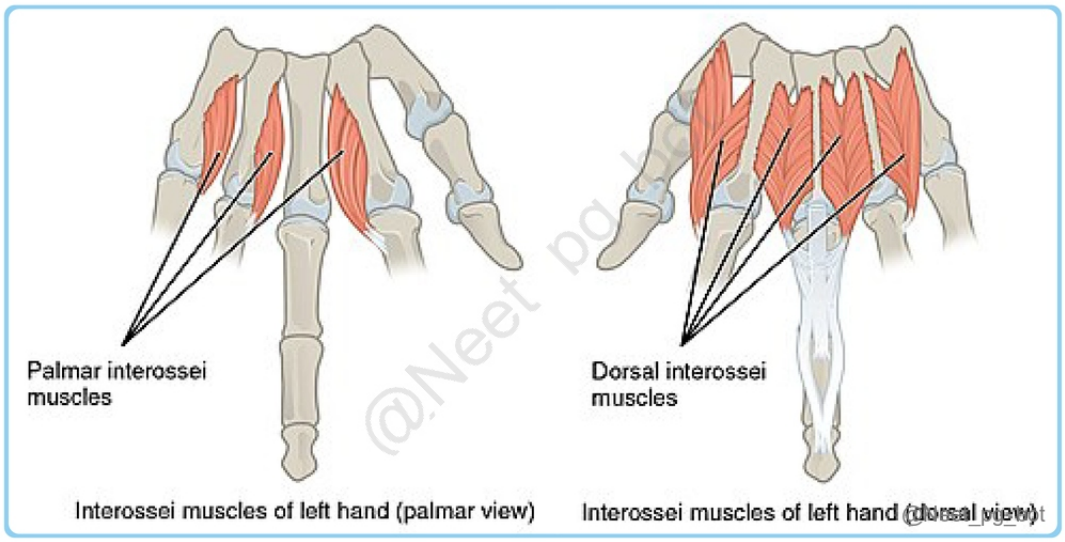

References:

BD Chaurasia's Human Anatomy, Volume-1, 8th Edition, Page 130,131

↑ *Back to this question in Part A*

@Neet_pg_bot

Q13: Given below is an image showing insertion of a muscle (marked in red) on the palmar aspect of the hand. Identify the correct pair of muscles and its corresponding nerve supply. (Q848420)

A. Opponens digiti minimi - radial nerve

B. Opponens digiti minimi - ulnar nerve

C. Abductor digiti minimi - median nerve

D. Abductor digiti minimi - ulnar nerve



Correct Answer: B. Opponens digiti minimi - ulnar nerve

- *Listen (English)*
- *Listen (Hindi)*

Explanation: The muscle shown in the image above is Opponens digiti minimi , present in the hypothenar compartment. All the hypothenar muscles are innervated by the deep branch of the Ulnar nerve. Opponens digiti minimi: Origin: Flexor retinaculum Insertion: Medial border of the fifth metacarpal bone Nerve supply: Deep branch of the ulnar nerve Action: Pulls the 5th metacarpal forward Opponens digiti minimi – Radial nerve (Option A) : The muscle identified is opponens digiti minimi, but the radial nerve does not supply intrinsic hand muscles (except extensor muscles in forearm). All hypothenar muscles are supplied by the deep branch of the ulnar nerve, not the radial nerve. Abductor digiti minimi – Median nerve (Option C): The abductor digiti minimi is a hypothenar muscle, and the median nerve does not supply hypothenar muscles. Median nerve mainly supplies thenar muscles (LOAF muscles: Lateral two lumbricals, Opponens pollicis, Abductor pollicis brevis, Flexor pollicis brevis – superficial head). Abductor digiti minimi – Ulnar nerve (Option D) : The muscle identified in the image is not the abductor digiti minimi. The muscle shown inserts into the medial border of the 5th metacarpal, which is characteristic of opponens digiti minimi, whereas abductor digiti minimi inserts into the base of the proximal phalanx of the 5th digit.

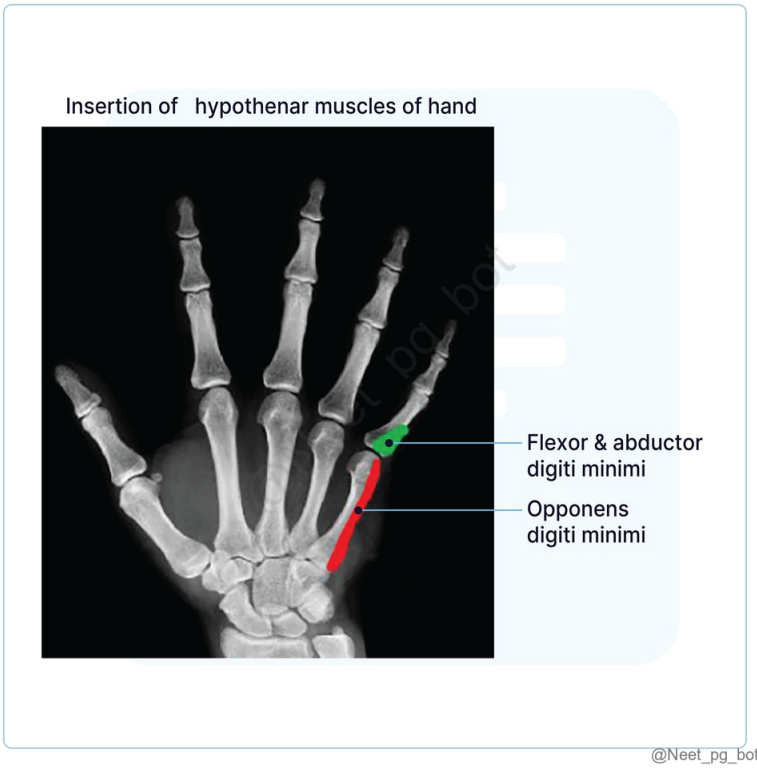

@Neet_pg_bot

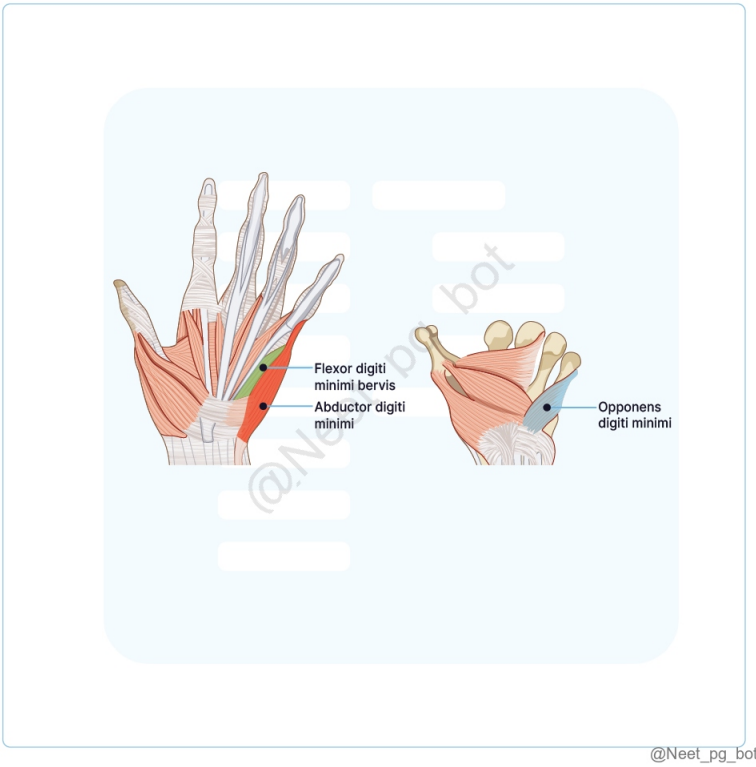

@Neet_pg_bot

References:

BD Chaurasia’s Human Anatomy, Volume-1, 8th Edition, Page 130, 131

↑ *Back to this question in Part A*

@Neet_pg_bot

Q14: Patient following RTA was brought to ED, where he was told that his ulnar nerve is injured. Which of the following muscles would be affected in this patient? (Q848419)

A. 4

B. 3

C. 2

D. 1

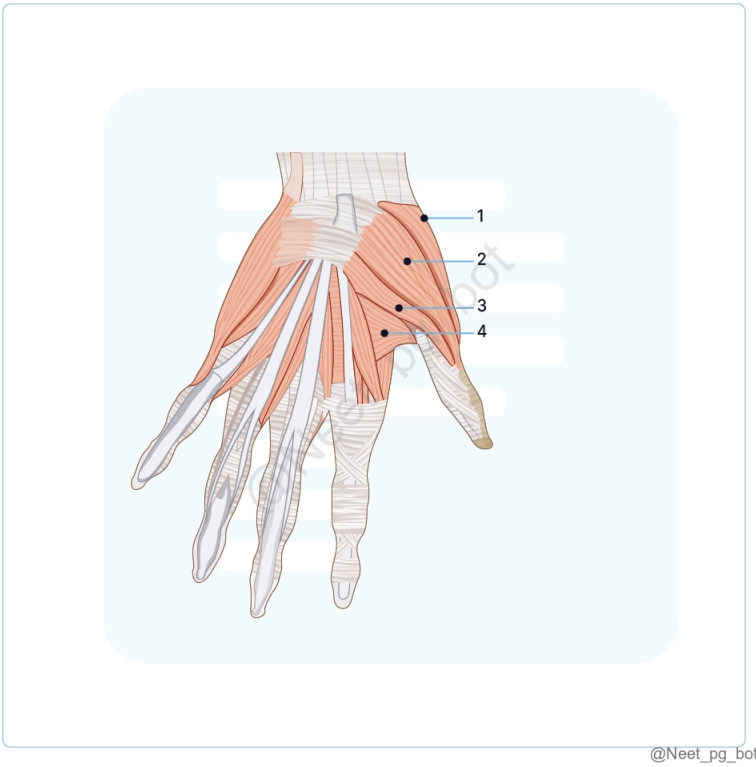

Correct Answer: A. 4

■ *Listen (English)*

■ *Listen (Hindi)*

Explanation: Image shows the thenar muscles of the hand . Only thenar muscle of the hand supplied by the ulnar nerve is Adductor pollicis (Option A) , which would be affected in this scenario. Rest of the muscles of thenar

eminence are supplied by the median nerve. Muscles of Thenar Eminence: Muscle Nerve supply Action Abductor pollicis brevis (Option C) Median nerve Abduction of thumb Flexor pollicis brevis (Option B) Median nerve Flexion of metacarpo-phalangeal joint of thumb Opponens pollicis (Option D) Median nerve Opposition of thumb towards fingers Adductor pollicis (Option A) Ulnar nerve Adduction of thumb

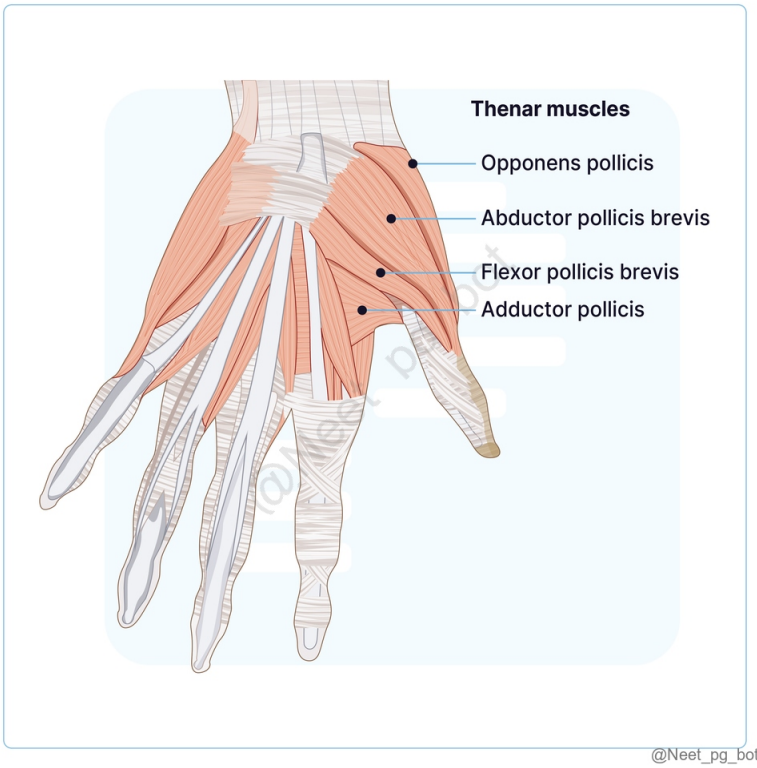

References:

BD Chaurasia's Human Anatomy, Volume-1, 8th Edition, Page 127,130,131

↑ *Back to this question in Part A*

@Neet_pg_bot

Q15: All are true about the shown muscle except. (Q848418)

A. Supplied by musculocutaneous nerve

B. Causes flexion of arm at shoulder joint

C. Paralyzed in Erb's palsy

D. Attached to medial coracoid process

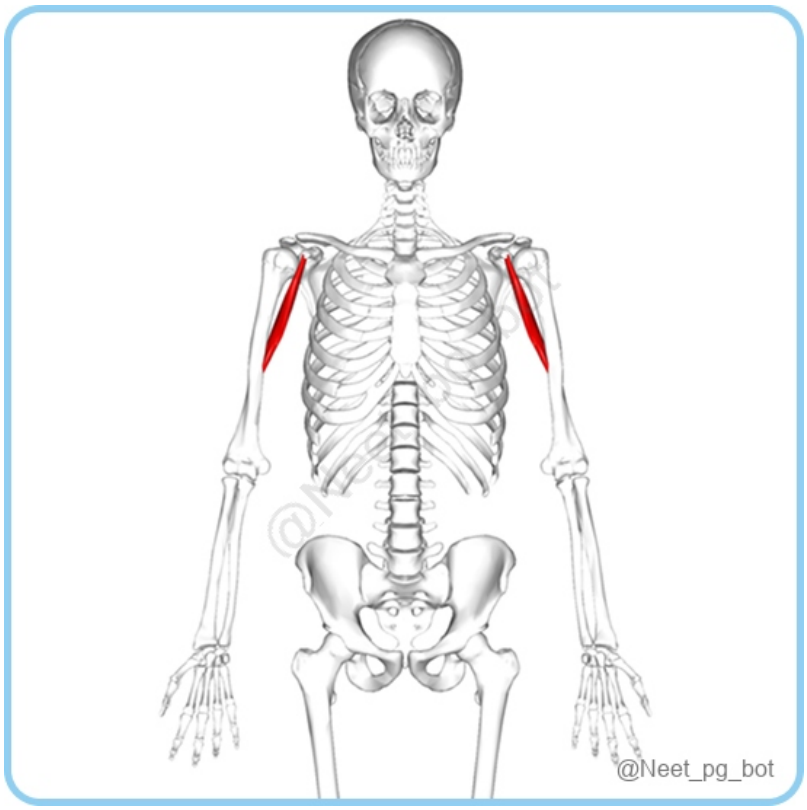

Correct Answer: C. Paralyzed in Erb’s palsy

- *Listen (English)*
- *Listen (Hindi)*

Explanation: Shown muscle is Coracobrachialis , which may not be paralyzed in Erb’s palsy as all other options are correct. Fig: Coracobrachialis muscle Coracobrachialis: Origin: Medial coracoid process Insertion: Medial aspect of middle humerus Nerve supply: Musculocutaneous nerve (C5-C7) Action: Flexion (+adduction) of arm at shoulder joint May not be paralyzed in Erb’s palsy, as in case of Erb’s palsy: C5,C6 are compromised but C7 remains unaffected and hence Coracobrachialis is not paralyzed . (Option C)

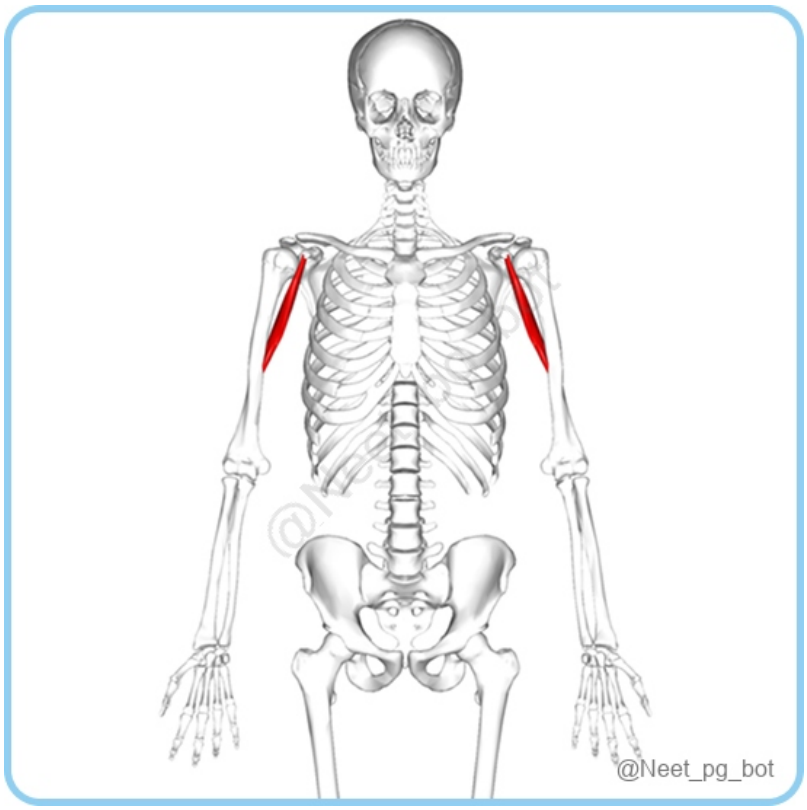

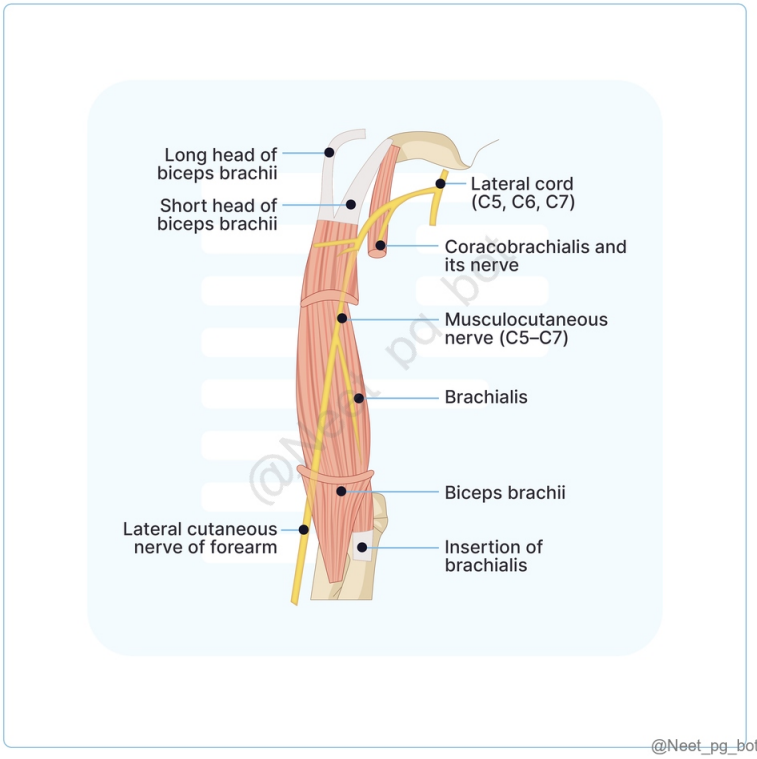

References:

BD Chaurasia's Human Anatomy, Volume-1, 8th Edition, Page 95,96

↑ *Back to this question in Part A*

@Neet_pg_bot

Q16: In which sequence do the following carpal bones typically ossify: capitate, pisiform, scaphoid? (Q848416)

A. Capitate → Scaphoid → Pisiform

B. Pisiform → Capitate → Scaphoid

C. Scaphoid → Capitate → Pisiform

D. Capitate → Pisiform → Scaphoid

Correct Answer: A. Capitate → Scaphoid → Pisiform

■ *Listen (English)*

■ *Listen (Hindi)*

Explanation: Carpal bones are 8 short bones arranged in 2 rows, each with 4 bones in the region of the wrist. From lateral to medial, bones of the proximal row are the scaphoid, lunate, triquetral, and pisiform, and those of the distal row are the trapezium, trapezoid, capitate, and hamate. Carpal Bones Ossification Age Capitate (First one to ossify) 1-3 Months Hamate 2-4 Months Triquetrum During 3rd year of life Lunate During 4th year of life Scaphoid During 5th year of life Trapezium During 6th year of life Trapezoid During 6-7th year of life Pisiform (Last one to ossify) During 9-12th year of life

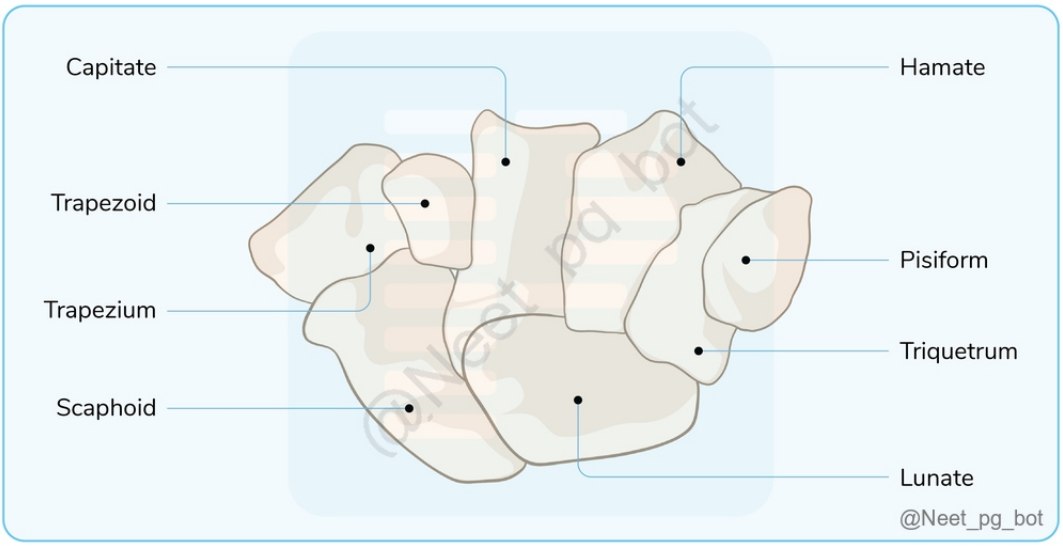

References:

Carpal bones

↑ *Back to this question in Part A*

@Neet_pg_bot

Q17: Which of the following muscles is responsible for flexing the distal interphalangeal joints of the fingers? (Q848415)

A. Flexor digitorum superficialis

B. Flexor digitorum profundus

C. Pronator quadratus

D. Flexor pollicis longus

Correct Answer: B. Flexor digitorum profundus

■ *Listen (English)*

■ *Listen (Hindi)*

Explanation: The flexor digitorum profundus (FDP) is responsible for flexing the distal interphalangeal (DIP) joints of the 2nd to 5th fingers. Flexor digitorum profundus: Origin Proximal three-quarters of the anterior and medial surfaces of the ulna and the interosseous membrane. Insertion Bases of the distal phalanges of the 2nd to 5th digits. Action Flexes the distal interphalangeal (DIP) joints of the 2nd to 5th fingers and flexion of wrist. Nerve Supply Medial part by ulnar nerve and lateral part by median nerve (C8, T1)

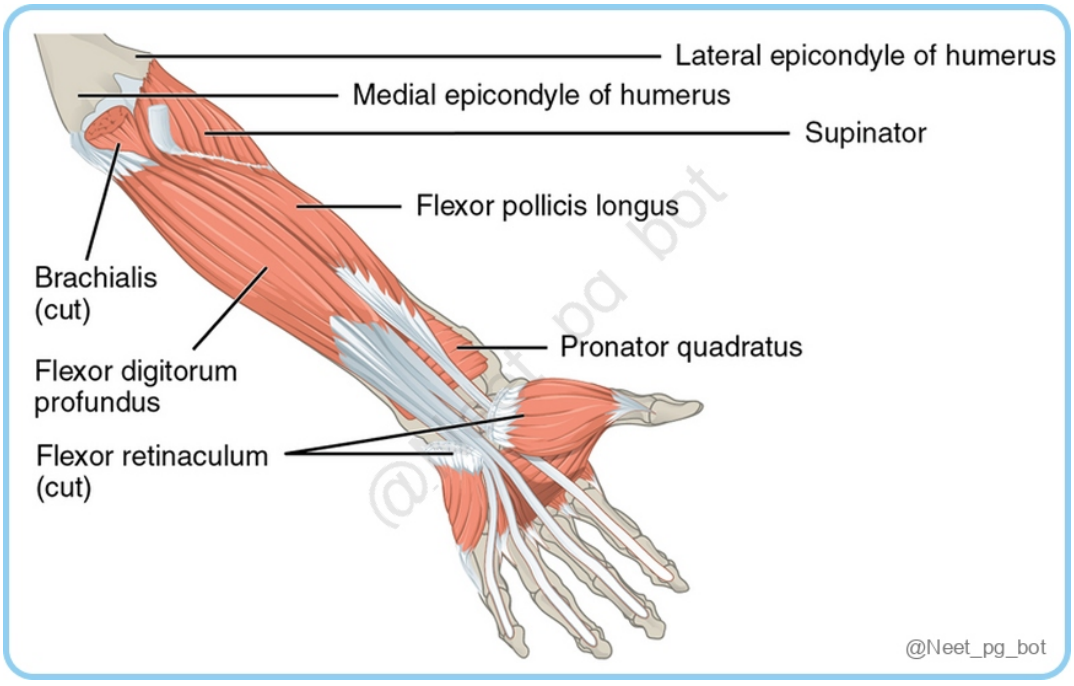

References:

Inderbir Singh's Textbook of Anatomy, Volume-1, 6th Edition, Page 176,177,179,180

↑ *Back to this question in Part A*

@Neet_pg_bot

Q18: A 35-year-old carpenter presents with pain and weakness in his right forearm after repetitive hammering. On examination, you note tenderness over the medial epicondyle and weakness in wrist flexion. There is no sensory loss. Based on these findings, which muscle is not likely involved? (Q848414)

A. Flexor pollicis longus

B. Flexor carpi ulnaris

C. Flexor carpi radialis

D. Palmaris longus

Correct Answer: A. Flexor pollicis longus

■ *Listen (English)*

■ *Listen (Hindi)*

Explanation: Flexor pollicis longus is a deep muscle of the anterior compartment of forearm which helps in flexion of distal phalanges of the thumb and no action in flexion of wrist. The muscles of the anterior compartment of forearm are the flexor-pronator muscles and arranged in 3 layers: Superficial layer: Pronator teres Flexor carpi radialis Flexor carpi ulnaris Palmaris longus Intermediate layer: Flexor digitorum superficialis Deep layer: Flexor digitorum profundus Flexor pollicis longus Pronator quadratus

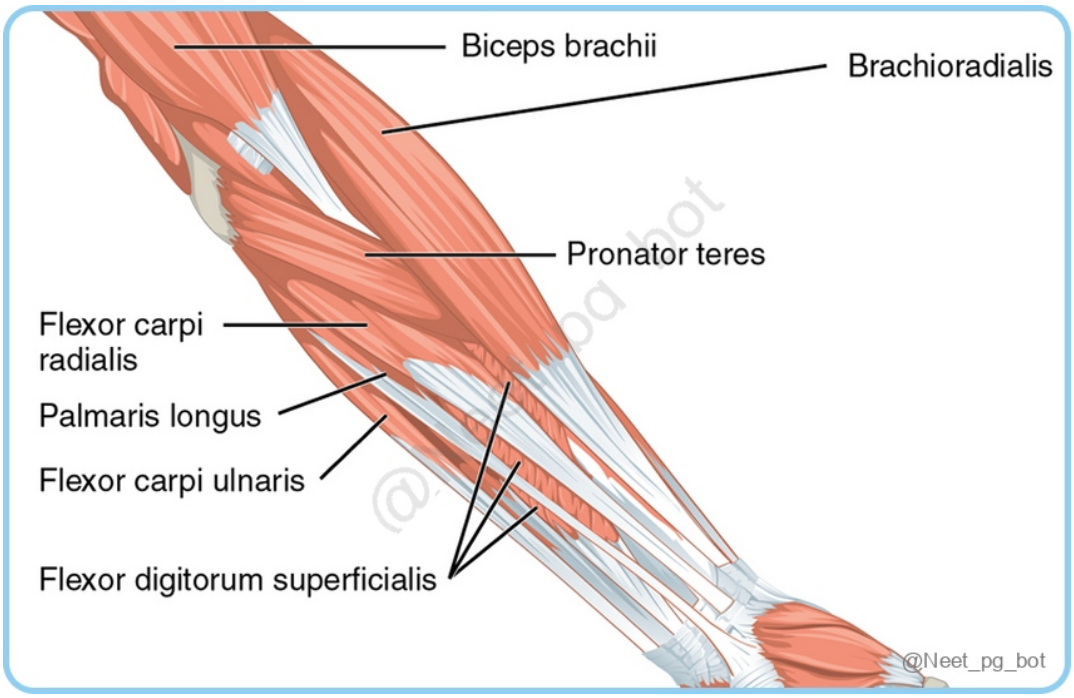

References:

Inderbir Singh's Textbook of Anatomy, Volume-1, 6th Edition, Page 176,177,178

↑ *Back to this question in Part A*

@Neet_pg_bot

• [05_Upper Limb] 025 Bones And Muscles Of Proximal Region Axilla And Scapula

« Back to Folder Directory

[05_Upper Limb] 025 Bones And Muscles Of Proximal Region Axilla And Scapula — Quick Jump

Q1 (p. 1424) *Q2 (p. 1425)* *Q3 (p. 1426)* *Q4 (p. 1427)* *Q5 (p. 1428)* *Q6 (p. 1429)*
Q7 (p. 1431) *Q8 (p. 1433)* *Q9 (p. 1434)* *Q10 (p. 1436)* *Q11 (p. 1437)* *Q12 (p. 1438)*
Q13 (p. 1439)

Q1: A surgeon is performing an axillary dissection for breast cancer and must be cautious not to damage structures piercing the clavipectoral fascia. Which of the following statements about these structures is TRUE? (Q848330)

A. The cephalic vein pierces the clavipectoral fascia and runs through the deltopectoral groove before draining into the axillary vein.

B. The thoracoacromial artery pierces the clavipectoral fascia and divides into pectoral, deltoid, axillary, and clavicular branches.

C. Lateral pectoral nerve passes through the clavipectoral fascia and innervates the pectoralis minor muscle after piercing the pectoralis major.

D. Lymphatic vessels draining the lateral breast region pierce the clavipectoral fascia and drain into the central axillary lymph nodes.

Correct Answer: A. The cephalic vein pierces the clavipectoral fascia and runs through the deltopectoral groove before draining into the axillary vein.

■ *Listen (English)*

■ *Listen (Hindi)*

Explanation: The cephalic vein courses in the deltopectoral groove , then pierces the clavipectoral fascia to drain into the axillary vein . It is a reliable landmark during axillary dissections and must be preserved or ligated with care. Feature Details Cephalic vein (Option A) Arises from the dorsal venous network of the hand Runs in the deltopectoral groove with the deltoid branch of the thoracoacromial artery Pierces the clavipectoral fascia to drain into the axillary vein Thoracoacromial artery (Option B) Branch of the second part of the axillary artery Pierces clavipectoral fascia Gives off pectoral, deltoid, clavicular, acromial branches (no 'axillary' branch) Lateral pectoral nerve (Option C) Arises from lateral cord of the brachial plexus Pierces clavipectoral fascia near the thoracoacromial artery Passes medial to the pectoralis minor Innervates the pectoralis major only Lymphatics (Option D) Drain the lateral breast and pectoral region Pierce the clavipectoral fascia to reach the apical axillary lymph nodes , not the central nodes Suspensory ligament of the axilla Inferior extension of the clavipectoral fascia Anchors the axillary fascia to maintain the axillary fossa concavity

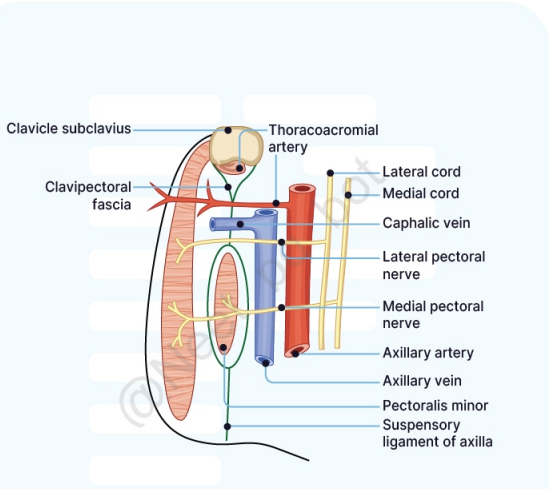

@Neet_pg_bot

References:

BD Chaurasia's Human Anatomy, Volume 1, 8th Edition, Page 47

↑ *Back to this question in Part A*

@Neet_pg_bot

Q2: Which of the following statements is TRUE regarding the rotator cuff muscles? (Q848337)

A. The rotator cuff includes the Supraspinatus, Infraspinatus, Subscapularis, and Teres major, which collectively aid in shoulder abduction and external rotation.

B. The Subscapularis is the only rotator cuff muscle involved in internal rotation of the humerus.

C. The Infraspinatus and Teres minor are responsible for medial rotation of the shoulder joint.

D. The rotator cuff muscles are primarily located in the anterior aspect of the shoulder joint

Correct Answer: B. The Subscapularis is the only rotator cuff muscle involved in internal rotation of the humerus.

■ *Listen (English)*

■ *Listen (Hindi)*

Explanation: Rotator Cuff Muscles: Muscle (Tendon) Action Nerve Supply Supraspinatus Initiates abduction of the shoulder Suprascapular nerve(C5,C6) Infraspinatus External(lateral)rotation of the shoulder Suprascapular nerve(C5,C6) Teres minor External(lateral) rotation of the shoulder Axillary nerve (C5,C6) Subscapularis Internal (medial) rotation of the shoulder Upper and lower subscapular nerves (C5,C6,C7) The rotator cuff is composed of the Supraspinatus, Infraspinatus, Subscapularis, and Teres minor, not Teres major (Option A). The Infraspinatus and Teres minor are involved in external (lateral) rotation, not medial rotation. (Option C) The rotator cuff muscles are located primarily around the shoulder joint, with some being posterior (e.g., Infraspinatus, Teres minor) and one anterior (Subscapularis) (Option D).

References:

BD Chaurasia's Human Anatomy, Volume 1, 8th Edition, Page 78

↑ *Back to this question in Part A*

@Neet_pg_bot

Q3: Which of the following is the correct pairing of shoulder movement and the muscle involved? (Q848327)

A. Adduction-pectoralis major

B. Adduction-serratus anterior

C. Abduction-teres major

D. Adduction-supraspinatus

Correct Answer: A. Adduction-pectoralis major

■ *Listen (English)*

■ *Listen (Hindi)*

Explanation: Movement of the shoulder joint Muscle(s) Involved Other movements Adduction Pectoralis major (Option A) Teres major (Option C) Latissimus dorsi Coracobrachialis Short head of biceps brachii Long head of triceps brachii Medial rotation of scapula Abduction Supraspinatus (0-15) (Option D) Deltoid (15-90) Serratus anterior (90°–180°) (Option B) Upper and lower fibers of trapezius (90°–180°) Humerus elevation Clavicle axial rotation AC joint movement Lateral rotation of scapula

References:

BD Chaurasia's Human Anatomy, Volume 1, 8th Edition, Page 162

↑ *Back to this question in Part A*

@Neet_pg_bot

Q4: Match the wall of the axilla with the structure forming it: Wall Structure forming a. Anterior wall 1. Serratus anterior b. Posterior wall 2. Bicipital groove c. Medial wall 3. Clavipectoral fascia d. Lateral wall 4. Subscapularis (Q848328)

A. a1,b2,c3,d4

B. a4,b3,c2,d1

C. a3,b4,c1,d2

D. a2,b3,c4,d1

Correct Answer: C. a3,b4,c1,d2

Listen (English)

Listen (Hindi)

Explanation: Wall of axilla Contributing structure Anterior Wall Pectoralis major Clavipectoral fascia Pectoralis minor Posterior Wall Subscapularis Teres major Latissimus dorsi Medial Wall Upper four ribs with intercostal muscles Upper part of serratus anterior Lateral Wall Bicipital groove of humerus Coracobrachialis Short head of biceps brachii

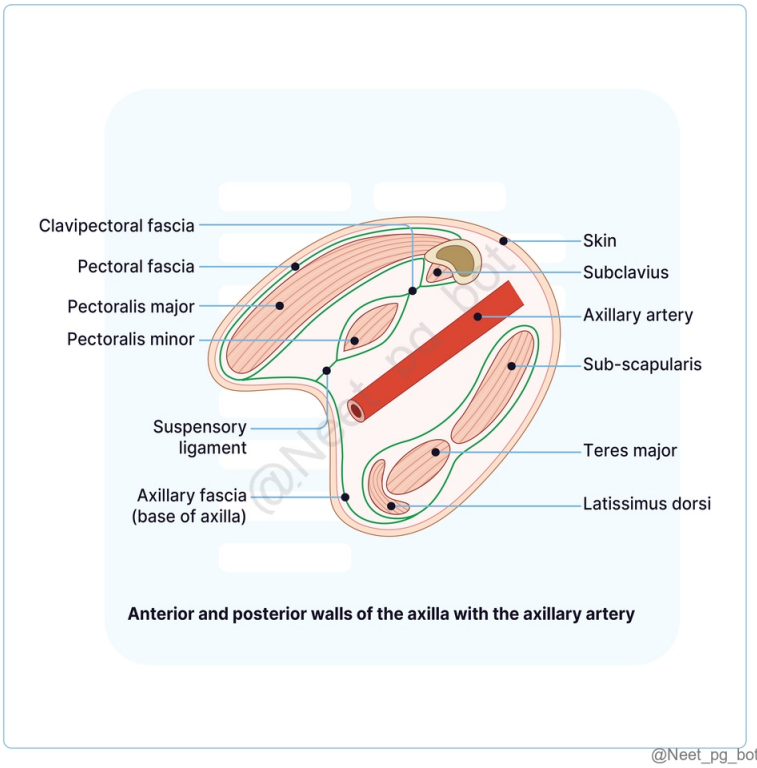

References:

BD Chaurasia’s Human Anatomy, Volume 1, 8th Edition, Page 52-53

↑ *Back to this question in Part A*

@Neet_pg_bot

Q5: Which of the following fasciae is the axillary sheath derived from? (Q848329)

A. Deep cervical fascia

B. Clavipectoral fascia

C. Superficial cervical fascia

D. Axillary fascia

Correct Answer: A. Deep cervical fascia

■ *Listen (English)*

■ *Listen (Hindi)*

Explanation: The axillary sheath is derived from the prevertebral layer of deep cervical fascia. Apex/Cervicoaxillary Canal: Directed upwards and medially towards the root of the neck Axillary artery, axillary vein, and brachial plexus enter the axilla through this canal Axillary vessels and cords of the brachial plexus are in the axillary sheath which is derived from the prevertebral layer of deep cervical fascia Boundaries of Cervicoaxillary Canal: Anteriorly Posterior surface of the clavicle Posteriorly Superior border of the scapula and medial aspect of the coracoid process Medially Outer border of the first rib Contents of the Axilla: Axillary artery and its branches Axillary vein and its tributaries Infraclavicular part of the brachial plexus Five groups of axillary lymph nodes and the associated lymphatics The long thoracic and intercostobrachial nerves Axillary fat and areolar tissue in which the other contents are embedded

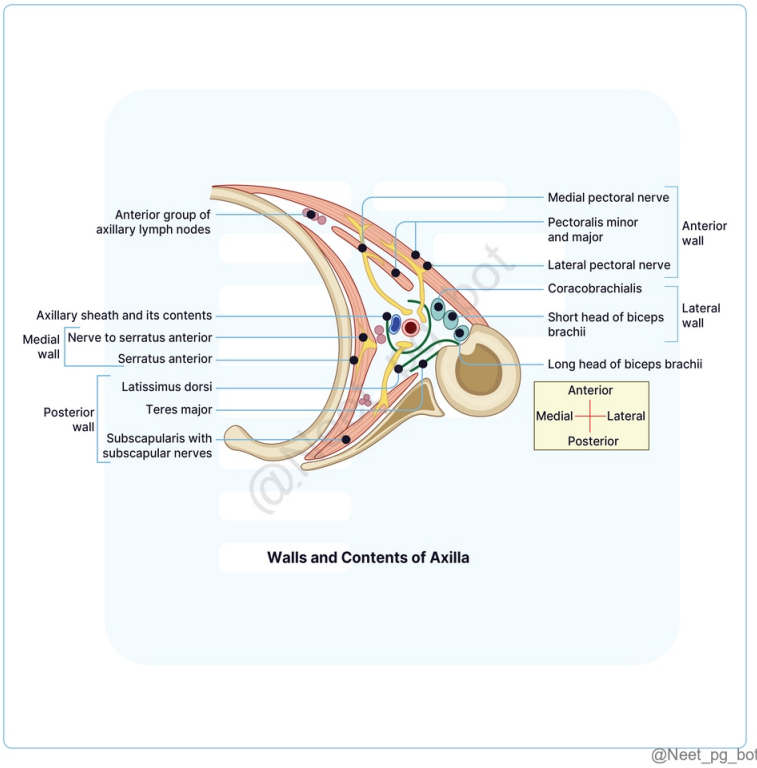

@Neet_pg_bot

References:

BD Chaurasia's Human Anatomy, Volume 1, 8th Edition, Page 51-53

↑ *Back to this question in Part A*

@Neet_pg_bot

Q6: A 35-year-old construction worker falls from a ladder and lands on his outstretched hand, resulting in a clavicular fracture as shown in the X- Ray given below. Which ligament plays a crucial role in stabilizing the medial end of the clavicle to the first rib, preventing excessive elevation of the clavicle? (Q848331)

A. Coracoclavicular ligament

B. Costoclavicular ligament

C. Sternoclavicular ligament

D. Interclavicular ligament

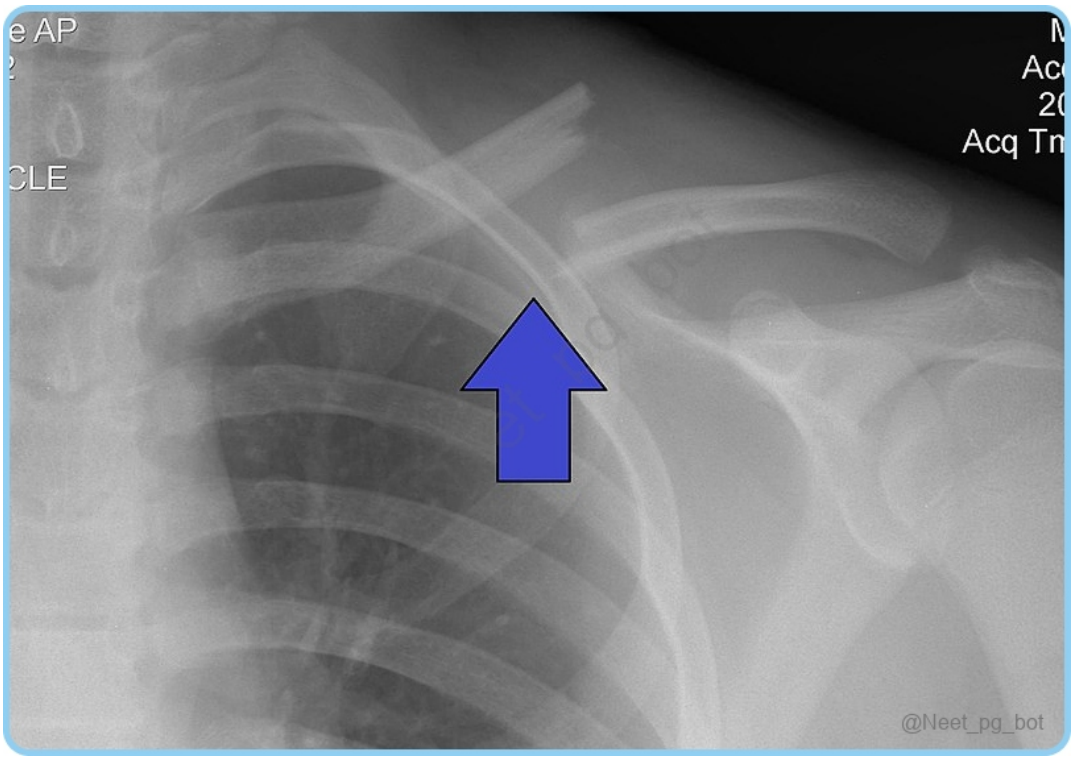

Correct Answer: B. Costoclavicular ligament

- *Listen (English)*
- *Listen (Hindi)*

Explanation: Costoclavicular ligament anchors the medial end of the clavicle to the first rib and acts as a strong stabilizer that limits excessive elevation of the clavicle . It is critical in maintaining clavicular positioning , particularly during weight-bearing activities involving the upper limb. The clavicle is often fractured by an indirect fall on an outstretched hand . The most common fracture site is at the junction of its two curvatures, the weakest point . The lateral fragment is displaced downward due to the weight of the limb, as the trapezius muscle cannot fully support it. Location on Clavicle Attachment Lateral End (Acromial end) Joint capsule of the acromioclavicular joint Medial End (Sternal end) Fibrous capsule of sternoclavicular joint (all around) Articular disc (posterosuperiorly) Interclavicular ligament (superiorly) Lateral One-Third of Shaft Anterior border: Origin of deltoid muscle Posterior border: Insertion of trapezius muscle Conoid tubercle and trapezoid ridge: Attachment to the conoid and trapezoid parts of coracoclavicular ligament Medial Two-Thirds of Shaft Anterior surface: Origin of pectoralis major Rough superior surface: Origin of clavicular head of sternocleidomastoid Oval impression (inferior surface, medial end) : Attachment of costoclavicular ligament Subclavian groove: Insertion of subclavius muscle , margins give attachment to clavipectoral fascia Posterior surface (near medial end) : Origin of sternohyoid muscle Coracoclavicular ligament (Option A) primarily stabilizes the lateral end of the clavicle by connecting it to the coracoid process of the scapula, providing support for the acromioclavicular joint . Weight transmission from upper limb to axial skeleton. Sternoclavicular ligament (Option C) : While this ligament supports the sternoclavicular joint and maintains joint integrity , it is not the primary structure responsible for limiting clavicular elevation. The costoclavicular ligament plays a more crucial role in this function. Interclavicular ligament (Option D) connects the medial ends of the clavicles and provides stability across the jugular notch of the sternum. Its primary function is to prevent excessive depression of the clavicle , not elevation.

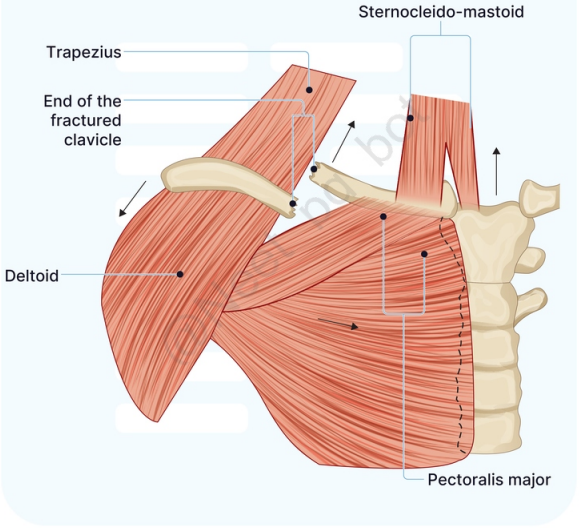

@Neet_pg_bot

References:

BD Chaurasia's Human Anatomy, Volume 1, 8th Edition, Page 7,8

↑ *Back to this question in Part A*

@Neet_pg_bot

Q7: A 45-year-old painter presents with shoulder pain and weakness, particularly when raising his arm. He reports difficulty lifting objects overhead. On physical examination, there is tenderness over the shoulder and weakness in initiating arm abduction. Which rotator cuff muscle is most likely injured? (Q848332)

A. Infraspinatus

B. Teres Minor

C. Supraspinatus

D. Subscapularis

Correct Answer: C. Supraspinatus

■ *Listen (English)*

■ *Listen (Hindi)*

Explanation: Supraspinatus is responsible for initiating arm abduction , commonly injured in overhead activities like painting. Rotator Cuff Muscles Muscles and muscle action The rotator cuff consists of four muscles: Supraspinatus: Located above the scapular spine, it aids in arm abduction and is the most commonly injured rotator cuff muscle. (Option C) Infraspinatus: Below the scapular spine, it helps with lateral arm rotation and shoulder stabilization. (Option A ruled out) Teres Minor: Works with the infraspinatus in lateral rotation and stabilizing the shoulder. (Option B ruled out) Subscapularis: On the front of the scapula, it is responsible for medial arm rotation and is the only rotator cuff muscle that doesn't attach to the greater tubercle of the humerus and forgotten tendon. (Option D ruled out) Musculotendinous Cuff: The tendons of these muscles form the rotator cuff , which supports and stabilizes the shoulder joint during movement. Functions Stabilize the shoulder. Rotate the arm (medially and laterally). Assist with arm abduction. Control arm movement, especially overhead. Clinical Relevance Rotator cuff tears: Resulting in pain, weakness, and limited movement. Subacromial bursitis: Inflammation causing shoulder pain and stiffness. Axillary nerve injury: Can weaken shoulder abduction by affecting the deltoid muscle. Muscle (Tendon) Action Nerve supply Supraspinatus Initiates abduction of the shoulder Suprascapular nerve(C5,C6) Infraspinatus External and lateral rotation of the shoulder Suprascapular nerve(C5,C6) Teres minor External and lateral rotation of the shoulder Axillary nerve (C5,C6) Subscapularis Internal and medial rotation of the shoulder Upper and lower subscapular nerves (C5,C6,C7)

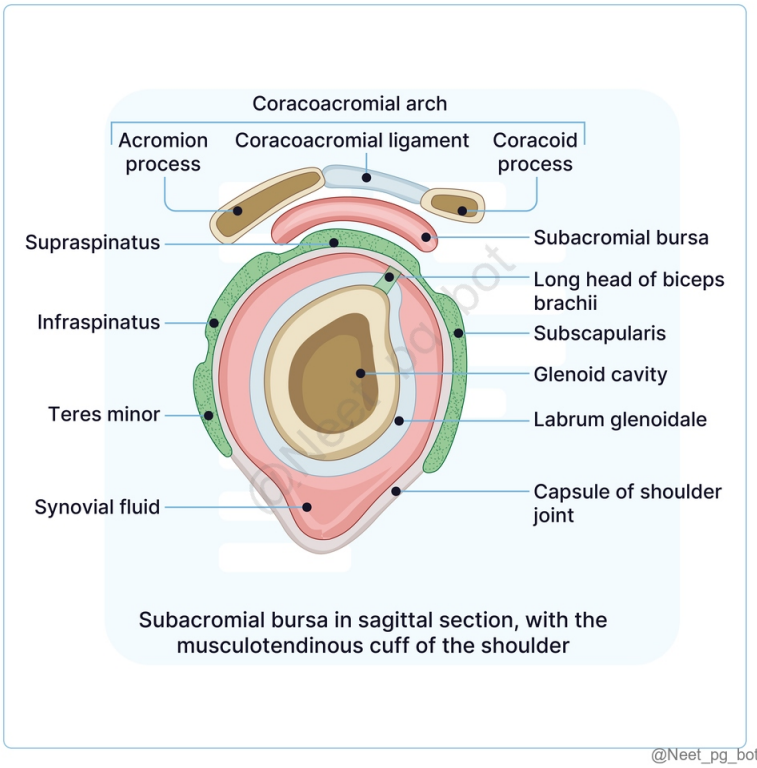

References:

BD Chaurasia's Human Anatomy, Volume 1, 8th Edition, Page 78

↑ *Back to this question in Part A*

@Neet_pg_bot

Q8: A 55 year old man, a former construction worker, presents with shoulder pain and limited range of motion. His examination finding is shown below in the image and there is tenderness over the lateral aspect of his ribcage. Which muscle is most likely compromised in function, and what nerve injury could be contributing to his condition? (Q848333)

A. Pectoralis Major; Medial pectoral nerve injury

B. Pectoralis Minor; Lateral pectoral nerve injury

C. Subclavius; Nerve to subclavius injury

D. Serratus Anterior; Long thoracic nerve injury



Correct Answer: D. Serratus Anterior; Long thoracic nerve injury

■ *Listen (English)*

■ *Listen (Hindi)*

Explanation: Serratus Anterior is essential for stabilizing the scapula and upward rotation. Serratus anterior is supplied by the long thoracic nerve (C5–C7) . Function: protraction + upward rotation of scapula → necessary for abduction >90°. Winging indicates weakness due to long thoracic nerve injury , common in repetitive overhead activities. Pectoralis Major, Pectoralis Minor, and Subclavius (Options A, B, C) do not cause scapular winging

Pectoralis Major: Functions in adduction and internal rotation of the arm. Pectoralis Minor: Depresses and protracts the scapula. Subclavius: ■■■■■■■ Anchors and depresses the clavicle, but has minimal action on scapula positioning.

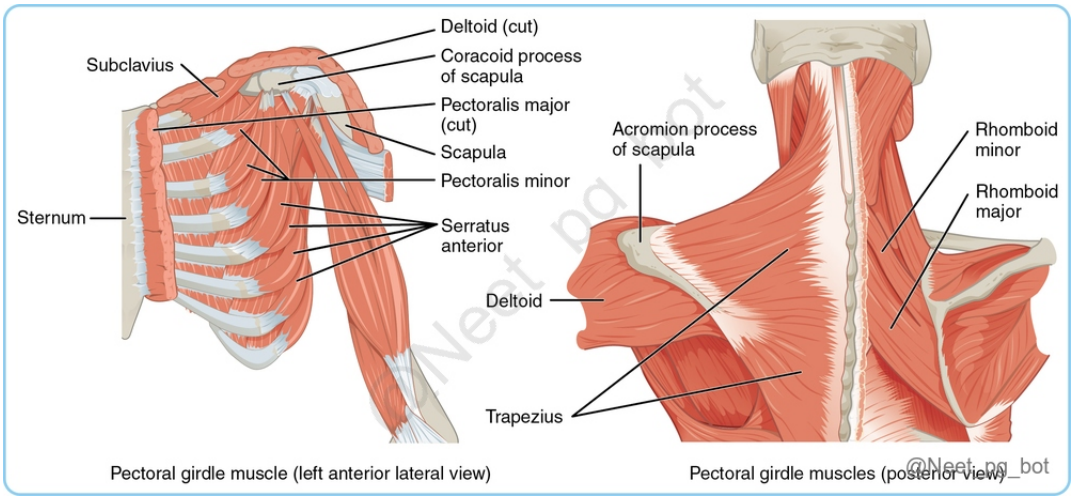

References:

BD Chaurasia's Human Anatomy, Volume 1, 8th Edition, Page 45, 46, 48, 49

https://www.ncbi.nlm.nih.gov/books/NBK541005/#

↑ *Back to this question in Part A*

@Neet_pg_bot

Q9: A 35-year-old swimmer presents with weakness during arm extension and difficulty pulling objects toward himself. He also reports pain during forceful expiration, such as coughing or sneezing. Which muscle is most likely involved, and what is its nerve supply? (Q848334)

A. Trapezius; Spinal accessory nerve

B. Latissimus Dorsi; Thoracodorsal nerve

C. Rhomboid Minor; Dorsal scapular nerve

D. Levator Scapulae; Dorsal scapular nerve

Correct Answer: B. Latissimus Dorsi; Thoracodorsal nerve

■ *Listen (English)*

■ *Listen (Hindi)*

Explanation: Latissimus Dorsi is involved in arm extension, adduction, medial rotation and forceful expiration (such as coughing or sneezing); innervated by the thoracodorsal nerve. Muscles of the posterior Axioappendicular Region Muscle Origin Insertion Nerve Supply Actions Trapezius (Option A ruled out) Medial one-third of the superior nuchal line of the skull External occipital protuberance Ligamentum nuchae Spinous processes of C7 to T12 vertebrae Corresponding supraspinous ligaments Upper fibers: Posterior border of the lateral one-third of the clavicle Middle fibers: Medial margin of the acromion and upper lip of the spine of the scapula Lower fibers: Apex of a triangular area at the medial end of the spine of the scapula (intervening bursa) Spinal accessory nerve (CN XI) Proprioceptive fibers from C3 and C4. Upper fibers: Elevate the scapula (shoulder shrugging), extend the neck (bilaterally) Middle fibers: Retract the scapula Lower fibers: Rotate the scapula upward, aiding arm abduction beyond 90 degrees Trapezius with rhomboids: Retract scapula and tilt glenoid inferiorly. Trapezius with serratus anterior: Overhead abduction and tilt glenoid superiorly. All fibers together: Stabilize the scapula during arm movements Latissimus Dorsi (Option B) Posterior one-third of the outer lip of the iliac crest Posterior layer of lumbar fascia (connecting to lumbar and sacral spines) Spinous processes of T7 to T12 Lower four ribs Inferior angle of the scapula Fibers twist to insert into the floor of the intertubercular sulcus of the humerus, wrapping around the lower border of the teres major. Thoracodorsal nerve (C6, C7, C8). Extends, adducts, and medially rotates the arm (e.g., swimming, climbing) Assists in forceful expiration (e.g., coughing, sneezing) Levator Scapulae (Option D ruled out) Transverse processes of C1 to C4 vertebrae Superior angle and upper part of the medial border of the scapula Dorsal scapular nerve (C5) and branches from C3 and C4 Elevates and stabilizes the scapula during arm movements. Rhomboid Minor (Option C ruled out) Lower part of ligamentum nuchae and spinous processes of C7 and T1 Medial border of the scapula at the base of the triangular area at the root of the spine. Dorsal scapular nerve (C5) Retracts and stabilizes the scapula. Rhomboid Major Spinous processes of T2 to T5 and supraspinous ligaments Medial border of the scapula, below the root of the spine Dorsal scapular nerve (C5) Retracts and stabilizes the scapula.

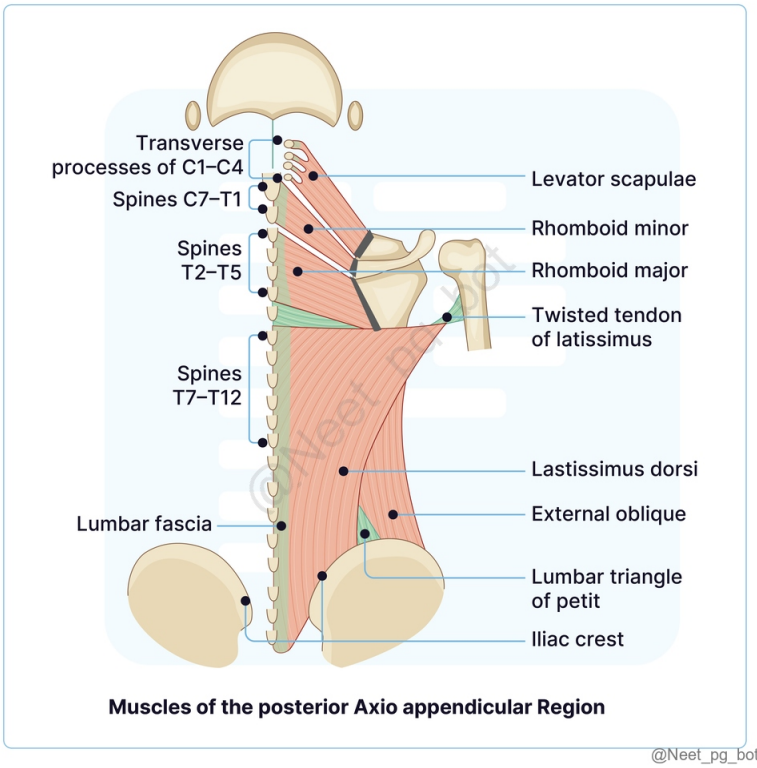

References:

BD Chaurasia’s Human Anatomy, Volume-1, 8th Edition, Page 69

https://www.ncbi.nlm.nih.gov/books/NBK537216/

↑ *Back to this question in Part A*

@Neet_pg_bot

Q10: A 60-year-old female patient presents to the ED with a tension pneumothorax. The physician decides to perform a chest drain insertion to relieve the pressure. As the physician prepares for the procedure, they review the anatomical landmarks to ensure they insert the drain safely. Which muscle defines the posterior boundary of the Triangle of Safety, ensuring that the physician avoids vital structures during the chest drain insertion? (Q848335)

A. Pectoralis major

B. Latissimus dorsi

C. Serratus anterior

D. Trapezius

Correct Answer: B. Latissimus dorsi

■ *Listen (English)*

■ *Listen (Hindi)*

Explanation: The lateral border of the latissimus dorsi muscle forms the posterior boundary of the Triangle of Safety for ICD insertion. Triangle of Safety for Intercostal Chest Drain (ICD) insertion: Anatomical area on the lateral chest wall where it is considered safest to insert a chest drain. Boundaries of the triangle: Anteriorly Lateral border of the pectoralis major muscle. Posteriorly Lateral border of the latissimus dorsi muscle. Inferiorly A horizontal line at the level of the 5th intercostal space (usually aligned with the nipple in males). Superiorly Base of the axilla(armpit). This area minimizes the risk of injury to vital structures such as nerves, blood vessels, and the lung itself. The drain is typically inserted in the 4th or 5th intercostal space along the mid-axillary line.

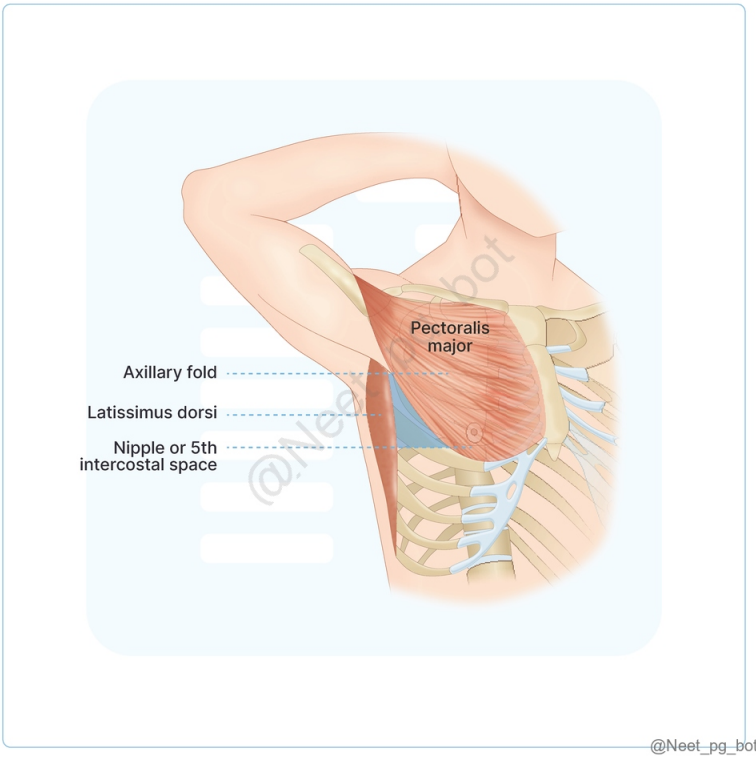

References:

radiopaedia.org/articles/triangle-of-safety#

↑ *Back to this question in Part A*

@Neet_pg_bot

Q11: Which muscle forms the medial border of the Triangle of Auscultation? (Q848336)

A. Latissimus dorsi

B. Trapezius

C. Rhomboid major

D. Deltoid

Correct Answer: B. Trapezius

■ *Listen (English)*

■ *Listen (Hindi)*

Explanation: The medial border of the Triangle of Auscultation is formed by the lateral edge of the trapezius muscle. Triangle of Auscultation: Anatomical Location: Located on the posterior thorax, specifically on the back, just below the scapula. Boundaries : Medial Border Lateral border of the trapezius muscle. Lateral Border Medial border of the scapula. Inferior Border Superior border of the latissimus dorsi muscle. Anterior or floor Rhomboid major, 6th and 7th ribs. Clinical Significance: This area is important for auscultating lung sounds because it is relatively free from muscle and bone interference. It allows for clearer sounds of breath , particularly in patients with respiratory issues. Positioning : To enhance the visibility and accessibility of the triangle, patients are often instructed to lean forward and cross their arms, which brings the scapulae apart and exposes this area.

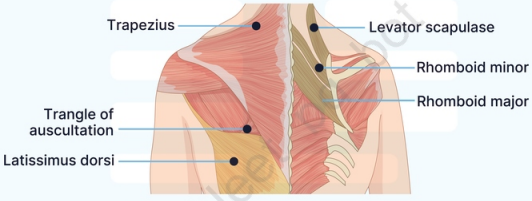

@Neet_pg_bot

References:

www.ncbi.nlm.nih.gov/books/NBK539834/#

↑ *Back to this question in Part A*

@Neet_pg_bot

Q12: Which of the following nerves is responsible for winging of scapula? (Q848338)

A. Dorsal scapular nerve

B. Spinal accesory nerve

C. Long thoracic nerve

D. Suprascapular nerve

Correct Answer: C. Long thoracic nerve

■ *Listen (English)*

■ *Listen (Hindi)*

Explanation: Winging of the scapula occurs due to paralysis or weakness of the serratus anterior muscle , which is innervated by the long thoracic nerve. The serratus anterior muscle normally holds the scapula against the thoracic wall. Damage to the long thoracic nerve results in a characteristic “winged” appearance of the scapula, especially when the patient pushes against a wall. Dorsal scapular nerve (Option A): Innervates the rhomboid major and minor and levator scapulae, which retract and elevate the scapula. Injury to this nerve does not cause winging of the scapula. Spinal accessory nerve (Option B): Innervates the trapezius muscle, which elevates and rotates the scapula. Damage leads to shoulder drooping and difficulty elevating the arm but does not cause scapular winging. Suprascapular nerve (Option D): Innervates the supraspinatus and infraspinatus muscles, which assist in shoulder abduction and external rotation. Injury affects shoulder movement, not scapular positioning.



References:

BD Chaurasia’s Human Anatomy, Volume 1, 8th Edition, Page 45,46,48,49

↑ *Back to this question in Part A*

@Neet_pg_bot

Q13: Which of the following statements is TRUE regarding the muscles involved in abduction of shoulder? (Q848339)

A. Supraspinatous is involved in initiation of abduction.

B. Deltoid is responsible for 0-15 degree abduction.

C. Supraspinatous is responsible for 15-90 degree abduction.

D. Infraspinatous is responsible for 0-15 degree abduction.

Correct Answer: A. Supraspinatous is involved in initiation of abduction.

■ *Listen (English)*

■ *Listen (Hindi)*

Explanation: Muscles Involved in Shoulder Abduction: Shoulder abduction Supraspinatus (0-15) Deltoid (15-90) Serratus anterior (90°-180°) Upper and lower fibers of trapezius (90°-180°) Infraspinatus is not involved in abduction but rather in external rotation of the arm (Option D) The supraspinatus only initiates abduction (0-15°). The deltoid is the primary muscle responsible for abduction from 15-90° (Option B and C).

References:

BD Chaurasia’s Human Anatomy, Volume 1, 8th Edition, Page 162

↑ *Back to this question in Part A*

@Neet_pg_bot

• [05_Upper Limb] 026 Upper Limb Nerve Supply And Their Lesions

« Back to Folder Directory

[05_Upper Limb] 026 Upper Limb Nerve Supply And Their Lesions — Quick Jump

Q1 (p. 1441)	*Q2 (p. 1442)*	*Q3 (p. 1443)*	*Q4 (p. 1444)*	*Q5 (p. 1445)*	*Q6 (p. 1446)*
Q7 (p. 1448)	*Q8 (p. 1450)*	*Q9 (p. 1451)*	*Q10 (p. 1453)*	*Q11 (p. 1455)*	*Q12 (p. 1456)*
Q13 (p. 1459)	*Q14 (p. 1461)*	*Q15 (p. 1462)*	*Q16 (p. 1464)*	*Q17 (p. 1465)*	

Q1: A patient with a humeral fracture presents with difficulty extending the elbow and wrist. Which of the following nerves is most likely affected? (Q848534)

A. Radial nerve

B. Median nerve

C. Ulnar nerve

D. Axillary nerve

Correct Answer: A. Radial nerve

■ *Listen (English)*

■ *Listen (Hindi)*

Explanation: Radial nerve innervates the extensor muscles of the upper limb , including the triceps brachii (for elbow extension) and the extensor muscles of the forearm (for wrist extension). It passes through the spiral groove of the humerus and is therefore at risk in humeral shaft fractures. Damage to the radial nerve leads to wrist drop (inability to extend the wrist) and loss of elbow extension. Nerves Related to Humerus Nerve Location Relative to Humerus Axillary Nerve (Option D) Around the surgical neck of the humerus. Musculocutaneous Nerve It originates from the lateral cord of the brachial plexus, pierces coracobrachialis, travels between biceps and coracobrachialis. Radial Nerve (Option A) Passes through the spiral groove of the humerus, posterior to the brachial artery, anterior to the long head of triceps. Median Nerve (Option B) Passes anterior to the humerus, but does not innervate upper arm muscles. Ulnar Nerve (Option C) Travels down the medial side of the brachium, behind the medial epicondyle of the humerus.

References:

B. D. Chaurasia’s Human Anatomy, Volume-1, 8th Edition, Page 39, 77, 96, 99

↑ *Back to this question in Part A*

@Neet_pg_bot

Q2: A 35-year-old office worker presents with numbness and tingling in her thumb, index, and middle fingers. The physician taps over the ventral aspect of the wrist, reproducing her symptoms. Which test is the physician likely performing? (Q848529)

A. Tinel's sign

B. Phalen's test

C. Finkelstein's test

D. Froment's test

Correct Answer: A. Tinel's sign

■ *Listen (English)*

■ *Listen (Hindi)*

Explanation: The patient experiences numbness and tingling specifically in her thumb, index, and middle fingers which are classic indicators of median nerve compression , often associated with carpal tunnel syndrome (CTS). Tinel's sign involves tapping or pressing over the median nerve at the wrist, which can reproduce symptoms of carpal tunnel syndrome , such as numbness and tingling in the fingers. Phalen’s Test (Option B): Phalen’s test involves maximal wrist flexion for 60 seconds to reproduce median nerve symptoms, not tapping over the wrist. The question specifically describes tapping over the ventral wrist , which corresponds to Tinel’s sign. Finkelstein’s Test (Option C): Finkelstein’s test is used to diagnose De Quervain’s tenosynovitis , not carpal tunnel syndrome. It involves flexing the thumb into the palm, making a fist, and ulnar deviating the wrist, producing pain over the radial styloid. Froment’s Test (Option D) : Froment’s test assesses ulnar nerve palsy (adductor pollicis weakness). The patient holds a paper between fingers, and compensatory thumb flexion indicates ulnar nerve injury, not median nerve compression.

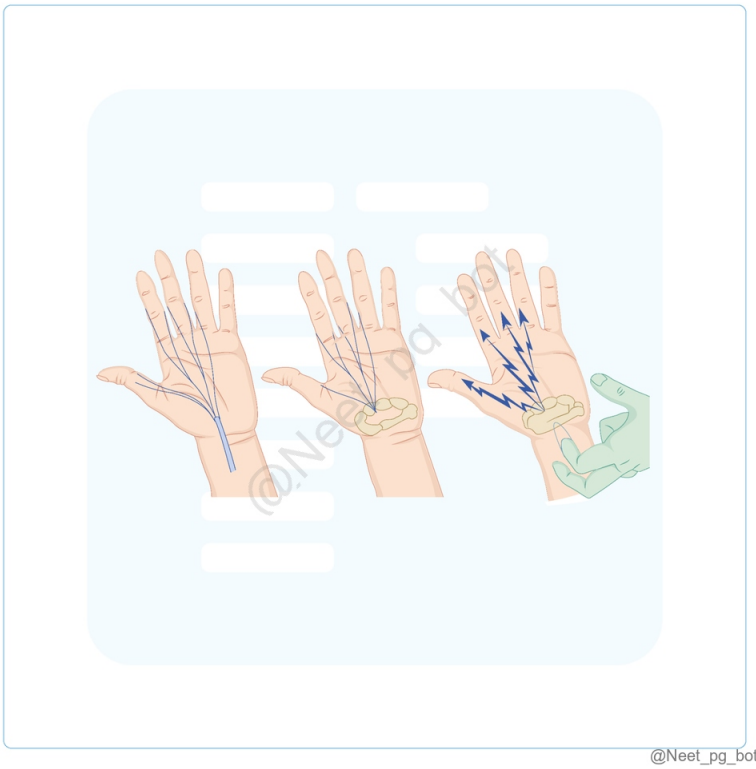

References:

Vishram Singh Textbook of Anatomy, Volume-1, 2nd Edition, Pages 177,178

↑ *Back to this question in Part A*

@Neet_pg_bot

Q3: A 30-year-old man presents with a laceration to his right wrist after a slash injury. On examination, there is weakness of thumb opposition and numbness over the thenar eminence. Which structure is most likely to be injured? (Q848537)

A. Flexor carpi radialis

B. Radial nerve

C. Ulnar nerve

D. Median nerve

Correct Answer: D. Median nerve

■ *Listen (English)*

■ *Listen (Hindi)*

Explanation: The median nerve passes through the carpal tunnel and is most commonly affected in the slash injuries that cut across the palmar side. Wrist slash injuries commonly occur due to suicide cuts at wrist and can lead to: Loss of sensation in the thenar eminence Loss of sensation in the lateral 3 1 / 2 digits on palmar side Motor loss of LOAF muscles Atrophy of thenar eminence Ape thumb deformity Flexor Carpi Radialis (Option A): Injury to flexor carpi radialis (FCR) would primarily cause weak wrist flexion and reduced radial deviation , not loss of thumb opposition. There would be no sensory loss over the thenar eminence , as FCR is a muscle and does not provide cutaneous innervation. Radial Nerve (Option B): Radial nerve injury typically presents with: Wrist drop (loss of wrist extension) Weak finger extension Sensory loss over the dorsum of hand (first web space) The radial nerve does not supply thenar muscles , so thumb opposition would remain intact. Ulnar Nerve (Option C): Ulnar nerve injury presents with: Clawing of the medial two digits Weak interossei (loss of finger abduction/adduction) Sensory loss over the medial 1½ digits (little finger and half of the ring finger) It does not affect thumb opposition primarily , which is mediated by the median nerve.

References:

pmc.ncbi.nlm.nih.gov/articles/PMC6571333/

↑ *Back to this question in Part A*

@Neet_pg_bot

Q4: A 30-year-old man sustains an elbow dislocation with a medial epicondyle fracture. He now presents with difficulty flexing the fourth and fifth fingers and an inability to adduct the thumb. Which nerve is most likely injured? (Q848520)

A. Axillary nerve

B. Radial nerve

C. Median nerve

D. Ulnar nerve

Correct Answer: D. Ulnar nerve

■ *Listen (English)*

■ *Listen (Hindi)*

Explanation: Ulnar nerve (C7, C8 & T1) originates from the medial cord of the brachial plexus, running along the medial side of the brachial artery in the arm. It passes posterior to the medial epicondyle of the humerus and enters the forearm between the two heads of the flexor carpi ulnaris , travelling between it and the flexor digitorum profundus. At the wrist, the nerve passes through Guyon’s canal into the hand, where it divides into superficial and deep branches , providing motor and sensory innervation to the hand. Damage to the ulnar nerve leads to: Difficulty in flexing the fourth and fifth fingers due to paralysis of the flexor digitorum profundus (medial part) and the lumbricals (3rd and 4th). Inability to adduct the thumb, as the adductor pollicis is also innervated by the

ulnar nerve. Ulnar Nerve Supply:

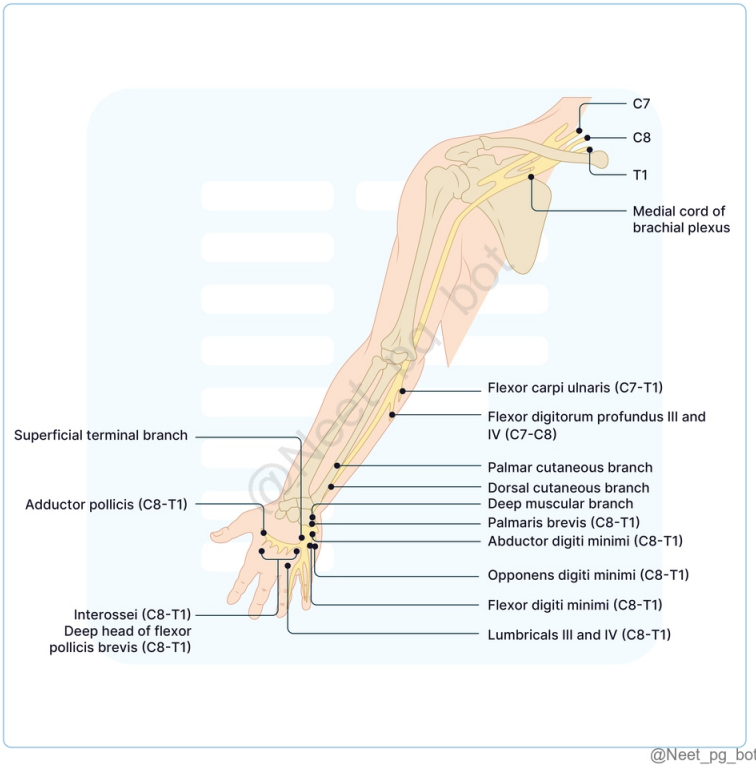

References:

B. D. Chaurasia's Human Anatomy, Volume-1, 8th Edition, Page 123,116,131,79

↑ *Back to this question in Part A*

@Neet_pg_bot

Q5: A patient with a history of recurrent shoulder dislocations presents with a deformity as shown below. On physical examination, the patient is unable to fully protract the scapula when pushing against a wall. Which nerve is most likely involved? (Q848536)

A. Long thoracic nerve

B. Dorsal scapular nerve

C. Suprascapular nerve

D. Accessory nerve



Correct Answer: A. Long thoracic nerve

■ *Listen (English)*

■ *Listen (Hindi)*

Explanation: Winging of the scapula and inability to protract the scapula are signs of long thoracic nerve injury , which innervates the serratus anterior muscle and its paralysis causes these symptoms. It also causes difficulty to hit the opponent with that hand in boxing and inability to make stores in swimming, hence it's also called Boxer’s or Swimmer’s palsy. Etiology : Long thoracic nerve injury is common in Trauma Surgeries (mastectomy) Repetitive overhead movements (like swimming) Recurrent shoulder dislocations Dorsal Scapular Nerve (Option B) s upplies rhomboids (major & minor) . Injury results in difficulty retracting the scapula and mild lateral displacement. It produces subtle lateral winging, not prominent medial winging on wall-push test. The scapula cannot be pulled medially toward vertebral column. Suprascapular Nerve (Option C) s upplies supraspinatus & infraspinatus. Injury results in weak initiation of abduction (0–15°) and weak external rotation. It does not cause scapular winging, as it does not stabilize the scapula. Accessory Nerve (Option D) s upplies trapezius . Injury results in l ateral winging of the scapula , shoulder droop, and difficulty shrugging the shoulder. It is seen after posterior triangle neck surgery . Patient has difficulty abducting arm above 90° due to impaired upward rotation.

References:

B. D. Chaurasia’s Human Anatomy, Volume-1, 8th Edition, Pages 69, 74, 201

↑ *Back to this question in Part A*

@Neet_pg_bot

Q6: Which of the following is the root value of the nerve that provides sensory innervation in the area marked (X)? (Q848535)

A. T2

B. T1, T2

C. C5

D. C5, C6

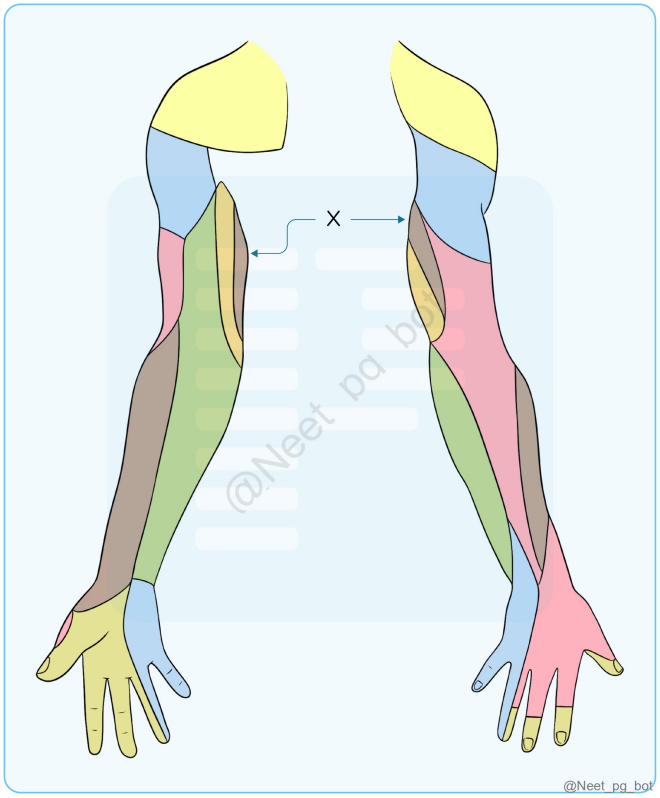

Correct Answer: A. T2

■ *Listen (English)*

■ *Listen (Hindi)*

Explanation: Sensory Supply of Arm Region Nerve Derivative of Root values Upper medial part Intercostobrachial 2nd intercostal T2 Lower medial part Medial cutaneous nerve of arm Medial cord of brachial plexus T1, T2 Upper lateral part Upper lateral cutaneous nerve of arm Axillary nerve C5, C6 Lower lateral part Lower lateral cutaneous nerve of arm Radial nerve C5, C6 Posterior region Posterior cutaneous nerve of arm Radial nerve C5

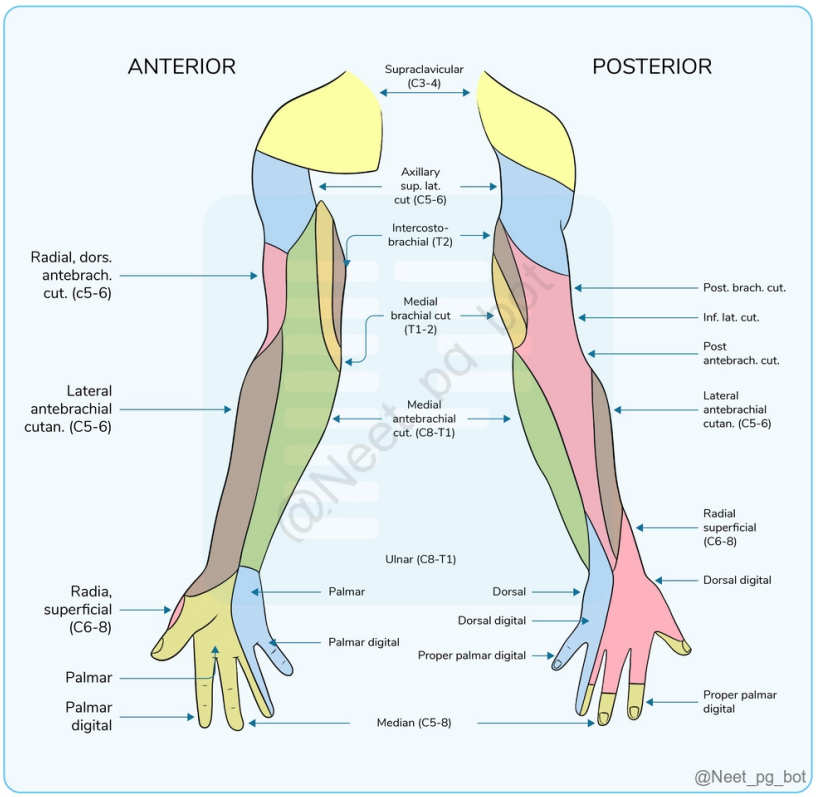

References:

B. D. Chaurasia's Human Anatomy, Volume-1, 8th Edition, Page 84

↑ *Back to this question in Part A*

@Neet_pg_bot

Q7: A 25-year-old male sustains a traumatic shoulder dislocation after a motor vehicle accident. On examination, the patient is unable to abduct his arm beyond 15 degrees and experiences numbness over the lateral shoulder. Which of the following nerve injury is the most likely cause of his symptoms? (Q848533)

A. Suprascapular nerve

B. Axillary nerve

C. Subscapular nerve

D. Long Thoracic nerve

Correct Answer: B. Axillary nerve

■ *Listen (English)*

■ *Listen (Hindi)*

Explanation: The most likely cause of this patient's symptoms is an axillary nerve injury , given the nerve's close proximity to the shoulder joint and the typical presentation of shoulder abduction weakness along with numbness over the lateral shoulder after a traumatic dislocation. The axillary nerve provides motor innervation to the deltoid and teres minor muscles , and sensory innervation to the area over the lower part of the deltoid muscle . Common Causes of Axillary Nerve Injury: Intramuscular injections : It should be given in the middle of the deltoid muscle to avoid axillary nerve injury. Fracture of surgical neck of humerus. Inferior dislocation of humerus. Symptoms: Inability to abduct shoulder joint (Deltoid paralysis). Loss of sensation in lower half of the deltoid (regimental-badge area). Loss of the rounded contour of the shoulder due to Deltoid muscle atrophy. Prominence of the greater tubercle of the humerus (due to muscle wasting).

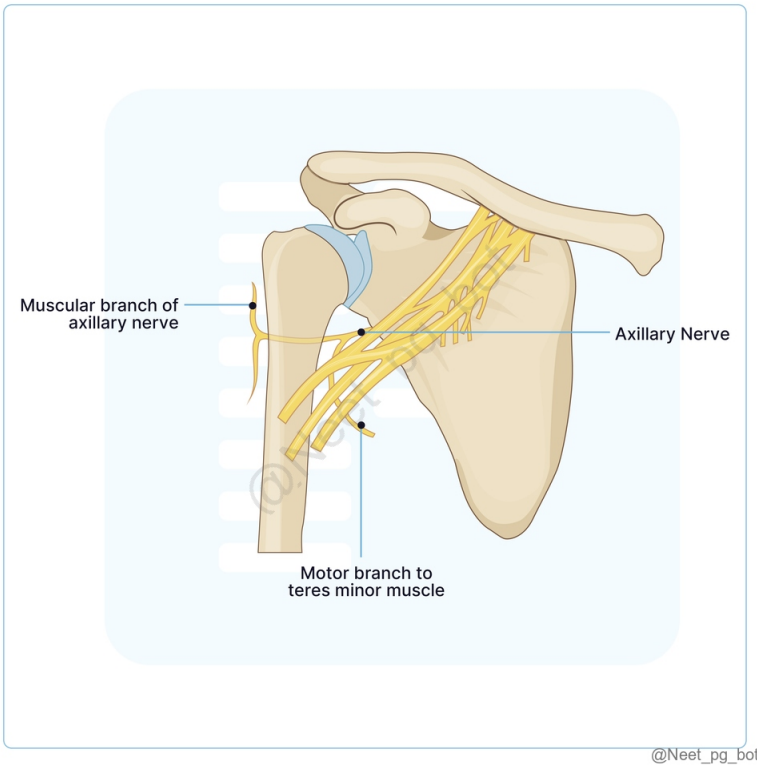

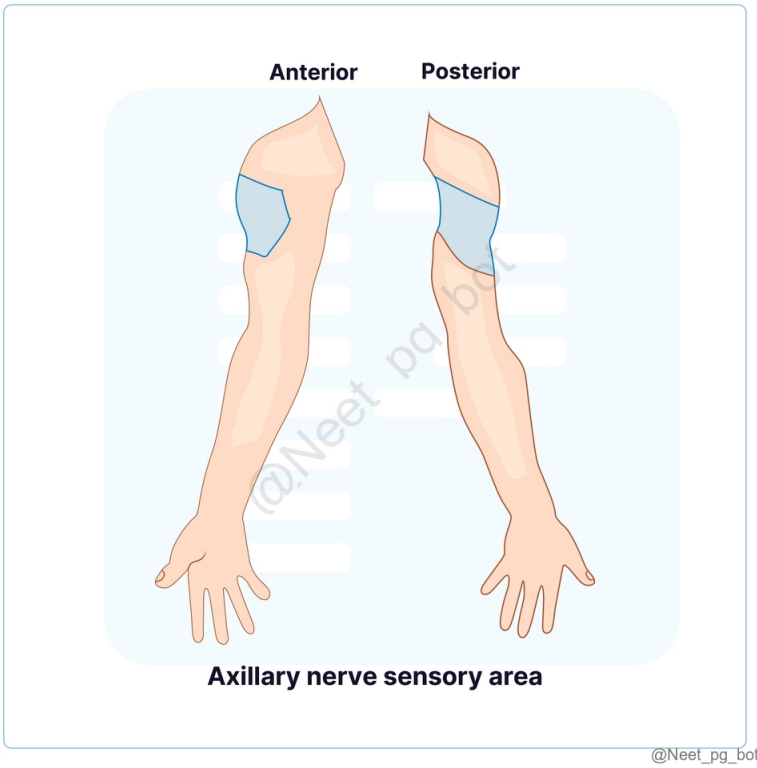

References:

B. D. Chaurasia's Human Anatomy, Volume-1, 8th Edition, Page 77

↑ *Back to this question in Part A*

@Neet_pg_bot

Q8: A 35-year-old man presents with inability to extend his wrist and fingers. O/E, he exhibits a wrist drop and demonstrates weakness in elbow extension & loss of sensation over the posterior arm and the lateral aspect of the dorsum of the hand. Based on these findings, at which level is the radial nerve likely injured? (Q848532)

A. At the axilla

B. At the spiral groove

C. Lateral epicondyle of the humerus

D. Posterior interosseous nerve at the forearm

Correct Answer: B. At the spiral groove

■ *Listen (English)*

■ *Listen (Hindi)*

Explanation: The patient presents with: Wrist drop → paralysis of wrist extensors Weakness in elbow extension → partial triceps involvement Sensory loss over posterior arm and lateral dorsum of hand These findings localize the lesion to the spiral groove of the humerus, where: The long head of triceps is spared → elbow extension is weak but not absent Wrist and finger extensors are affected → wrist drop Sensory loss involves posterior forearm and dorsum of hand

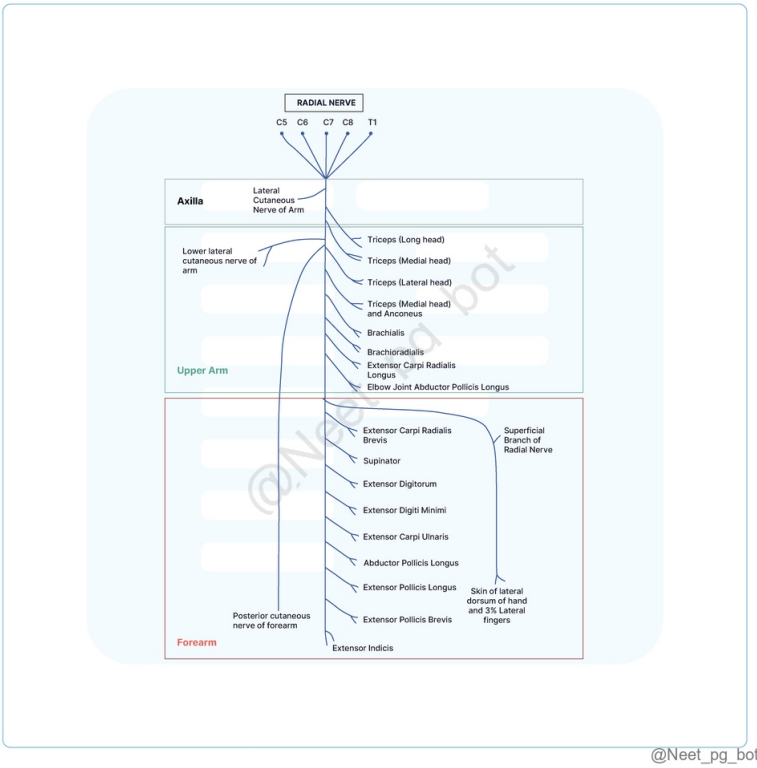

@Neet_pg_bot

References:

Vishram Singh Textbook of Anatomy, Volume-1, 2nd Edition, Page 174, 175

↑ *Back to this question in Part A*

@Neet_pg_bot

Q9: A patient is asked to hold a piece of paper between their thumb and index finger. When the examiner attempts to pull the paper away, the patient tries to hold the paper as shown in the image. Based on this observation, which muscle is likely affected? (Q848531)

A. Flexor pollicis brevis

B. Abductor pollicis brevis

C. Adductor pollicis

D. Opponens pollicis



Correct Answer: C. Adductor pollicis

■ *Listen (English)*

■ *Listen (Hindi)*

Explanation: In this scenario, the patient flexes the distal phalanx of the thumb to grip the paper when the examiner attempts to pull it away, indicating weakness in the adductor pollicis muscle, which is innervated by the ulnar nerve , thereby confirming a positive Froment's test. Froment’s test: Tests Adductor pollicis supplied by Ulnar nerve. The patient is asked to hold a piece of paper (or a card) between the thumb and index finger of the affected hand & card is pulled out. Positive Result: If the patient flexes the distal phalanx of the thumb while attempting to hold the paper, it indicates weakness of the adductor pollicis muscle due to ulnar nerve dysfunction. This flexion occurs due to flexor pollicis longus innervated by the median nerve. Clinical Tests for Limb Nerve Injuries: Test Name Nerve Tested Method Positive Sign Card Test Ulnar (Palmar Interossei) Place card between index/middle fingers; resist abduction Cannot hold card (finger spreading weak)■ Book Test / Froment's Sign Ulnar (Adductor Pollicis) Hold paper/book between thumb-IP & index; resist pull Thumb IP flexion (FPL compensation, median)■ Pen Test / Pivlal Test Median (Anterior Interosseous) Touch pen tip with index/thumb tip (OK sign) Cannot oppose tips (flat pinch)■ Egawa/Igawa Test Ulnar (Dorsal Interossei) Spread fingers; place pencil between MF/ring finger; resist adduction Pencil slips out■ Wartenberg's Sign Ulnar Palms together, fingers extended 5th finger abduction (unopposed EDM) OK Sign Median (LOAF muscles) Form circle with thumb/index Flat "pancake" pinch Rock/Paper/Scissors Median/Radial/Ulnar Fist (median flexors), wrist ext (radial), finger

spread (ulnar) Weak corresponding gesture Pen-to-Palm Test Median Fist; touch pen above palm with fingers Cannot flex DIPJ index/middle (lumbricals)

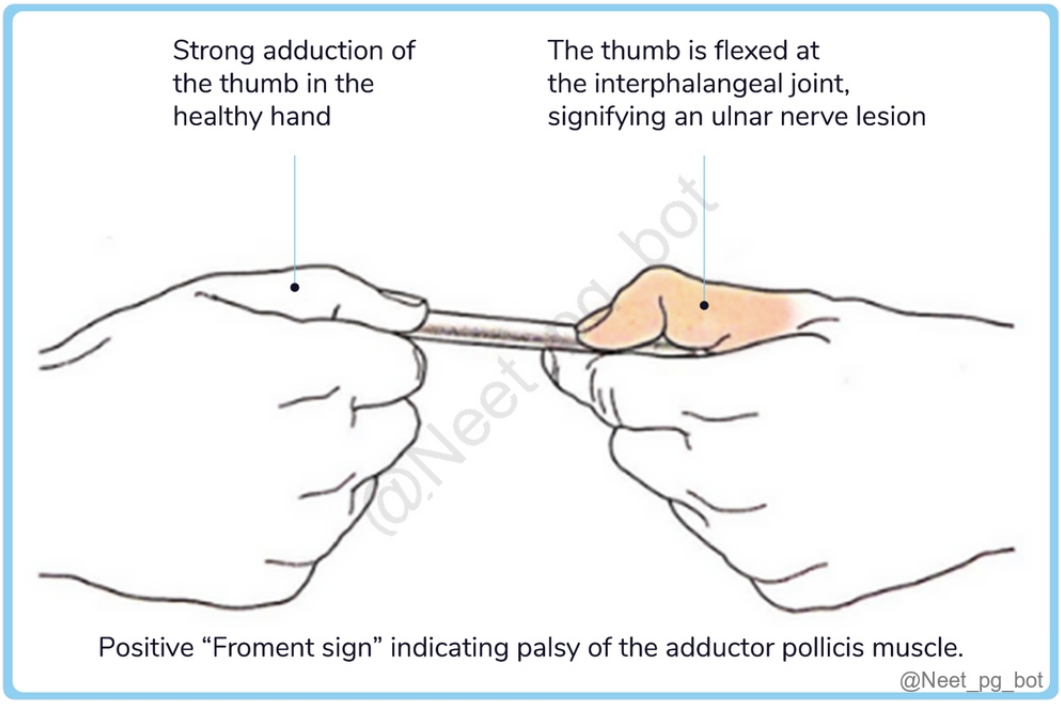

References:

Vishram Singh Textbook of Anatomy, Volume-1, 2nd Edition, Page 181

↑ *Back to this question in Part A*

@Neet_pg_bot

Q10: A 45-year-old musician presents with a noticeable deformity affecting his ring and little fingers as shown in the image. Which muscle is primarily responsible for this deformity? (Q848530)

A. Flexor digitorum superficialis

B. Flexor digitorum profundus

C. Lumbricals

D. Dorsal interossei



Correct Answer: C. Lumbricals

■ *Listen (English)*

■ *Listen (Hindi)*

Explanation: The given image depicts the Ulnar claw hand due to the paralysis of the ulnar lumbricals. Lumbricals normally flex the metacarpophalangeal (MCP) joints and extend at the interphalangeal (IP) joints. Impairment of the function of lumbricals due to ulnar injury creates the characteristic appearance of claw hand in the ring and little finger. Aspect Ulnar Claw Hand Median Claw Hand (Hand of Benediction) Affected Fingers Ring (4th) and little (5th) primarily Index (2nd) and middle (3rd) primarily Nerve Involved Distal ulnar nerve lesion Proximal median nerve lesion Deformity Severity More pronounced (intact FDP to 4-5 flexes DIP) Less severe (FDP to 2-3 median-innervated) Presentation with an open palm and at rest 4th + 5th MCPJs hyperextended 4th + 5th Interphalangeal joints flexed Normal Presentation when making a fist Normal 2nd + 3rd MCPJs hyperextended 2nd + 3rd Interphalangeal joints neutral Key Feature "Partial claw"; common in musicians/cubital tunnel "Index/middle claw"; often with ape thumb Mechanism Loss of lumbricals → unopposed FDP flexes the IP joints Paralyzed FDS/FDP (lateral) → inability to flex index/middle fingers Additional signs Wasting of hypothenar eminence and dorsal interossei Wasting of thenar eminence Flexor digitorum superficialis (Option A): Function : Flexes proximal interphalangeal (PIP) joints. If paralyzed : Patient can flex PIP with other fingers held extended (FDS specifically paralyzed, median nerve). Condition/Deformity : Swan neck deformity (FDS weak in rheumatoid arthritis, PIP hyperextends while DIP flexes). Flexor digitorum profundus (Option B): Function : Flexes distal interphalangeal (DIP) joints. If paralyzed (ulnar part) : Patient cannot flex DIP of 4th/5th fingers with others held extended (FDP specifically paralyzed). Condition/Deformity : Jersey finger (DIP extension lag from tendon rupture/avulsion).■ Dorsal interossei (Option D): Function : Abducts fingers (DAB: dorsal ABduct). If paralyzed : In ulnar nerve palsy, patient cannot abduct little finger against ring finger. Test : Positive Card test (palmar interossei weakness causes little finger to remain abducted).

References:

Vishram Singh Textbook of Anatomy, Volume-1, 2nd Edition, Pages 178,180

https://www.researchgate.net/figure/Distinguishing-hand-of-benediction-and-ulnar-claw_tbl1_380423164

↑ *Back to this question in Part A*

Q11: A 45-year-old carpenter reports tingling and weakness in his ring and little fingers. Examination reveals hypothenar atrophy and a positive Froment's sign. Which structure is likely compressed? (Q848528)

A. Cubital tunnel

B. Guyon’s canal

C. Carpal tunnel

D. Palmar aponeurosis

Correct Answer: B. Guyon’s canal

■ *Listen (English)*

■ *Listen (Hindi)*

Explanation: The given clinical scenario of tingling in the ring and little fingers, weakness of intrinsic hand muscles, atrophy of the hypothenar eminence, and a positive Froment's sign are characteristic of Ulnar nerve compression in Guyon’s canal. Guyon’s Canal (Ulnar Tunnel Syndrome): Compression of the ulnar nerve within Guyon’s canal at the wrist. Clinical Features: Claw-Hand Deformity: Ring and little fingers exhibit pronounced ulnar claw hand when compared to injury of the ulnar nerve at the elbow (ulnar paradox) due to preserved function of the FDP, resulting in marked flexion of DIP joints. Atrophy of the Hypothenar Eminence Loss of Finger Abduction and Adduction Positive Froment’s Sign: Unable to hold the book between thumb and index indicates weakness in the adductor pollicis . DIP Of thumb compensates for adductor pollicis weakness and thumb flexion occurs.

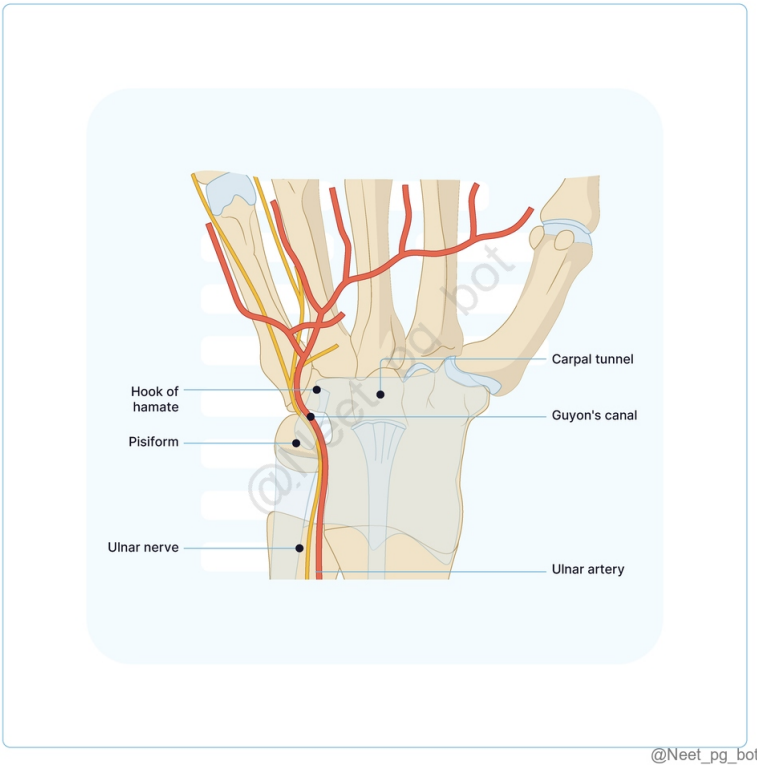

@Neet_pg_bot

References:

Vishram Singh Textbook of Anatomy, Volume-1, 2nd Edition, Page 139,150,180

↑ *Back to this question in Part A*

@Neet_pg_bot

Q12: A 35-year-old patient struggles to make a fist. When attempting to flex, the index and middle fingers remain straight, while the ring and little fingers flex normally. What is the most likely diagnosis? (Q848527)

A. Ulnar nerve injury

B. Median nerve injury at the wrist

C. Median nerve injury at the elbow

D. Radial nerve injury

Correct Answer: C. Median nerve injury at the elbow

■ *Listen (English)*

■ *Listen (Hindi)*

Explanation: The given symptoms, including the inability to flex the index and middle fingers, suggest a median nerve injury at the elbow , resulting in the "benediction deformity." Median Nerve (C5 - T1): Median Nerve Injuries: At the Elbow Lower Injury (Carpal Tunnel Syndrome) Causes: Supracondylar fractures, tight tourniquets/entrapment by the pronator teres Causes: Compression due to tenosynovitis and fractures. Symptoms: Loss of forearm pronation & weak wrist flexion. Benediction deformity (index and middle fingers remain straight when attempting to make a fist) (Pointing index finger) D/t involvement of FDS & FDP Ape-thumb deformity (flattened thenar eminence, thumb adducted). Sensory loss in the lateral palm and lateral 3½ digits. Weak "OK sign" d/t involvement of FDP & FPL Symptoms: Burning pain/tingling in Lateral 3½ Digits, especially at night. No sensory loss over the thenar eminence Ape thumb deformity Thenar muscle wasting Can make a fist (Pointing index finger not present)

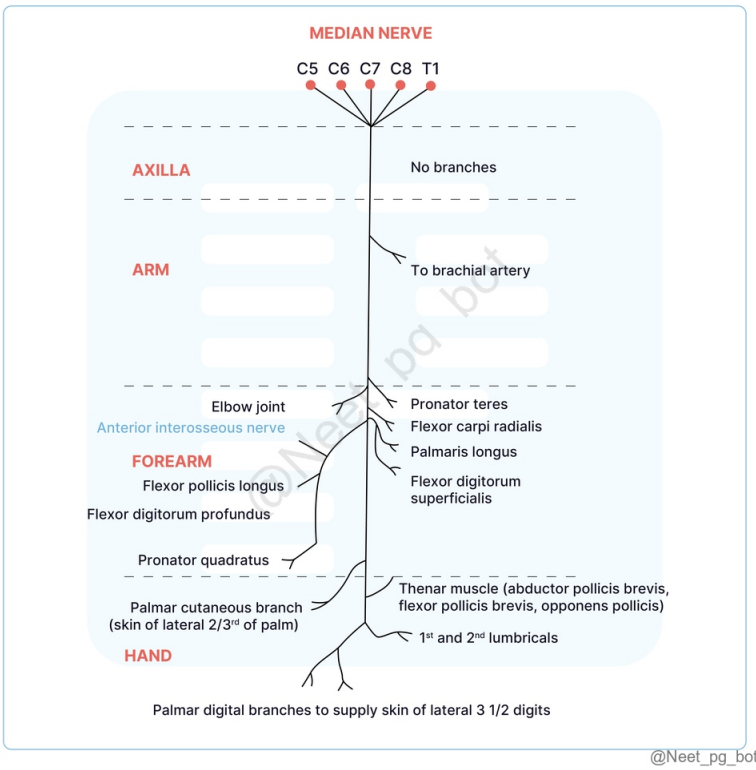

@Neet_pg_bot





References:

Vishram Singh Textbook of Anatomy, Volume-1, 2nd Edition, Page 177,178

↑ *Back to this question in Part A*

@Neet_pg_bot

Q13: Identify the X correctly from the below image of cubital fossa. (Q848526)

A. Brachial artery

B. Cephalic vein

C. Musculocutaneous nerve

D. Branchial cutaneous nerve



Correct Answer: B. Cephalic vein

■ *Listen (English)*

■ *Listen (Hindi)*

Explanation: The structure marked above is Cephalic vein. Cubital fossa is a triangular space anterior to the elbow. Bordered laterally by the brachioradialis and medially by the pronator teres , with its base formed by the anterior surfaces of the humeral epicondyles. Structure Present in the Cubital Fossa Contents from Medial to Lateral: (Mnemonic: MBBS) M edian nerve B rachial artery division to ulnar and radial artery B iceps brachii tendon S uperficial branch of radial nerve

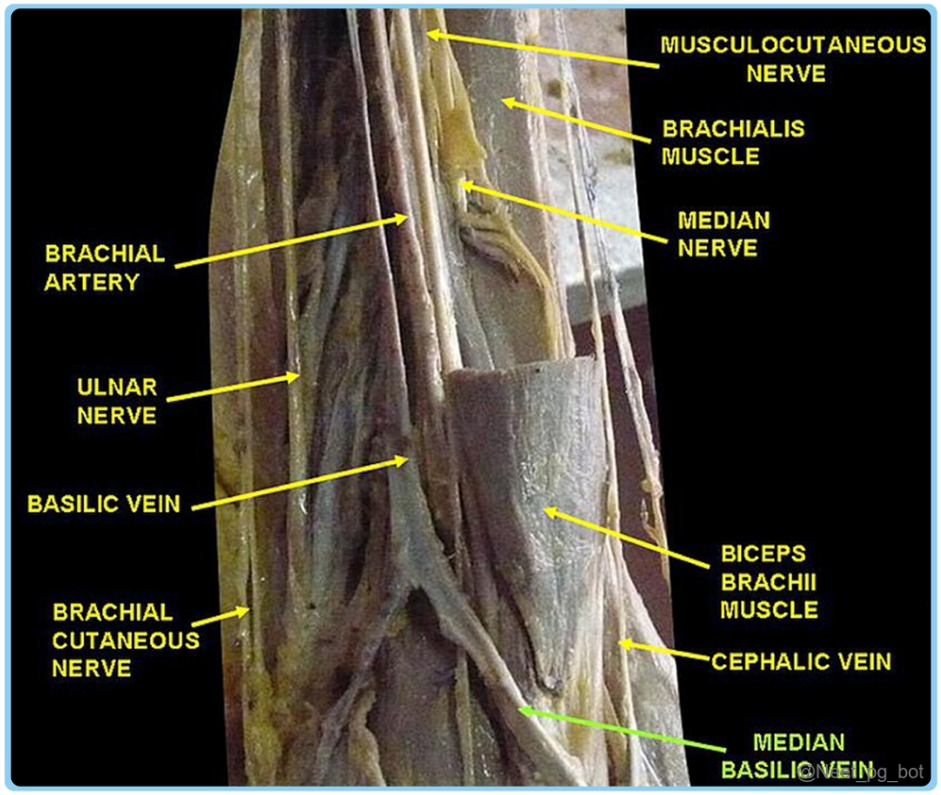

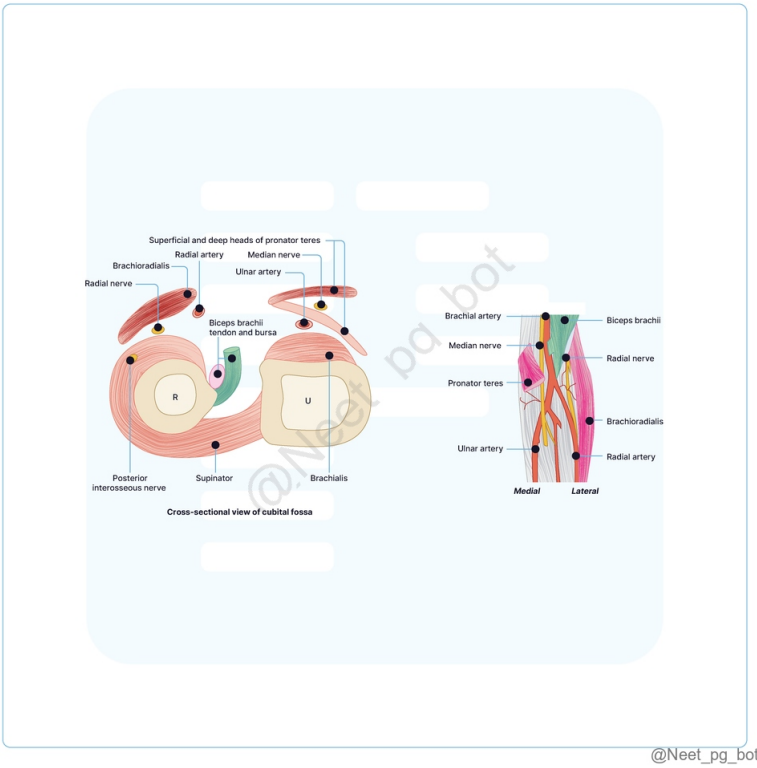

References:

B. D. Chaurasia’s Human Anatomy, Volume-1, 8th Edition, Page 104,105

↑ *Back to this question in Part A*

@Neet_pg_bot

Q14: Which of the following correctly pairs a cutaneous nerve with its corresponding area of supply? (Q848524)

A. X-Median nerve

B. Z-Radial nerve

C. Y-Median nerve

D. X-Ulnar nerve

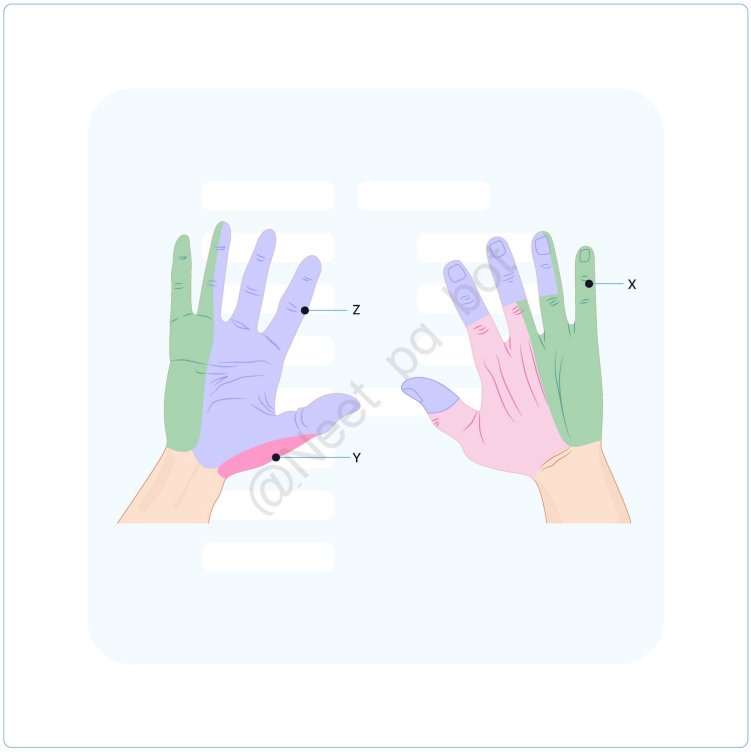

@Neet_pg_bot

Correct Answer: D. X-Ulnar nerve

■ *Listen (English)*

■ *Listen (Hindi)*

Explanation: Cutaneous Nerve Supply of hand: Nerve Cutaneous Supply Ulnar Nerve The palmar and dorsal aspects of the medial 1½ digits and adjacent palm. Medial side of the dorsum of the hand. Median Nerve Lateral 3 ½ digits on the anterior side and 3 ½ nail beds on the posterior side, along with the thenar eminence and the skin over the palm. Radial Nerve Lateral & dorsum of the hand, 3 1⁄2 fingers, excluding the nail beds on the back of the

hand Tip of index finger - Median nerve Tip of 5th finger - Ulnar nerve 1st web space - Radial nerve



References:

B. D. Chaurasia's Human Anatomy, Volume-1, 8th Edition, Page 139

↑ *Back to this question in Part A*

@Neet_pg_bot

Q15: A patient has a forearm laceration that results in an inability to flex the distal phalanges of the index and middle fingers. The affected muscle has dual nerve supply. Identify the muscle injured. (Q848523)

A. Flexor digitorum superficialis

B. Flexor pollicis longus

C. Palmaris longus

D. Flexor digitorum profundus

Correct Answer: D. Flexor digitorum profundus

■ *Listen (English)*

■ *Listen (Hindi)*

Explanation: Flexor digitorum profundus is responsible for flexing the distal phalanges of the fingers . This muscle has dual nerve supply: Median nerve: Innervates the lateral half , corresponding to the index and middle fingers. Ulnar nerve: Innervates the medial half , corresponding to the ring and little fingers. Flexor digitorum profundus is a deep muscle of the hand responsible for flexing the distal phalanges following the action of the flexor digitorum superficialis (Option A) , which flexes the middle phalanges and is the main muscle for gripping. Fig: Flexor digitorum profundus Fig: Flexor digitorum profundus

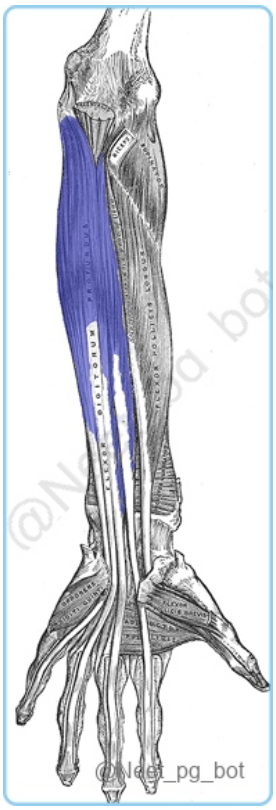



References:

B. D. Chaurasia's Human Anatomy, Volume-1, 8th Edition, Page 119,139

↑ *Back to this question in Part A*

@Neet_pg_bot

Q16: A 46-year-old woman presents with difficulty in thumb abduction and weak opposition. She gives a history of repetitive wrist movements. Which anterior rami nerve roots are likely involved in this condition? (Q848522)

A. C5 - C7

B. C5, C6

C. C8, T1

D. C5 - T1

Correct Answer: D. C5 - T1

■ *Listen (English)*

■ *Listen (Hindi)*

Explanation: Median nerve , which innervates the muscles responsible for thumb abduction and opposition , is formed from the anterior rami of spinal nerves C5 to T1, derived from the brachial plexus. It primarily supplies the anterior forearm muscles and the thenar eminence of the hand, which includes: Muscles of the Thenar eminence: Abductor Pollicis Brevis: Responsible for thumb abduction. Flexor Pollicis Brevis: Assists in thumb flexion. Opponens Pollicis: Enables opposition of the thumb. Lumbricals (Lateral 2): Responsible for flexion at the metacarpophalangeal (MCP) joints and extension at the interphalangeal (IP) joints of the 2nd and 3rd digits Sensory supply: Lateral 3½ digits in the palmar aspect & tip of same digits on the dorsum.

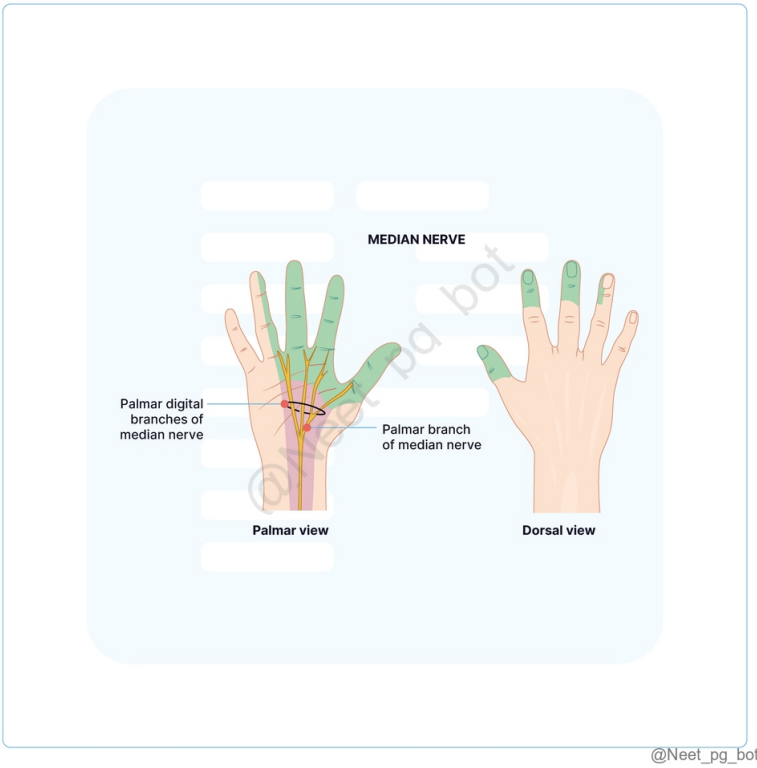

@Neet_pg_bot

References:

B. D. Chaurasia's Human Anatomy, Volume-1, 8th Edition, Page 113,161,162

↑ *Back to this question in Part A*

@Neet_pg_bot

Q17: Which of the following nerves innervates the muscle indicated below? (Q848521)

A. Ulnar nerve

B. Posterior interosseous nerve

C. Superficial branch of radial nerve

D. Anterior interosseous nerve

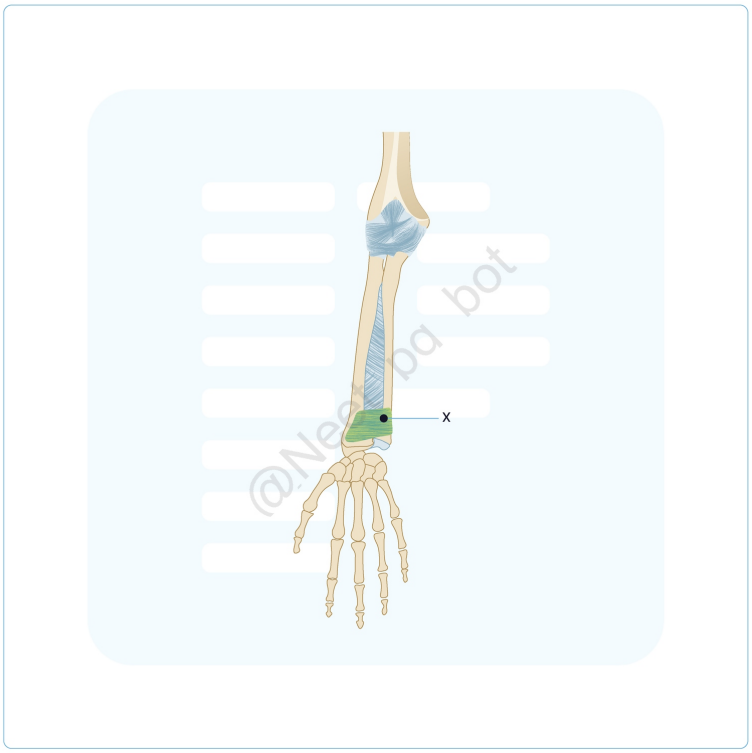

Correct Answer: D. Anterior interosseous nerve

■ *Listen (English)*

■ *Listen (Hindi)*

Explanation: The muscle marked ‘X’ is the Pronator quadratus , one of the deep muscles of the forearm and is supplied by the Anterior interosseous nerve, a branch of the Median nerve . Median nerve: Begins in the axilla, at the level of the lower border of the teres major muscle, from the medial and lateral cords of the brachial plexus. It descends through the arm without branching, travelling alongside the brachial artery. It passes through the cubital fossa, enters the forearm between the heads of the pronator teres , and runs deep to the flexor digitorum superficialis. In the hand, it enters through the carpal tunnel , supplying the thenar muscles (except adductor pollicis) and 1st and 2nd lumbricals . Motor Branches of the Median Nerve: Median Nerve (C5 to■■ T1- root value) supply of forearm Muscle Action Superficial muscles (Supplied by Median Nerve itself) Pronator teres Pronation of the forearm. Flexor carpi radialis Palmaris longus Flexion of the wrist. Flexor digitorum superficialis Flexion of the proximal interphalangeal (PIP) joints of the fingers. Deep muscles (supplied by Anterior interosseous nerve) Flexor digitorum profundus (lateral half) Flexion of the distal interphalangeal (DIP) joints of the index and middle fingers. Flexor pollicis longus Flexion of the thumb. Pronator quadratus Pronation of the forearm.

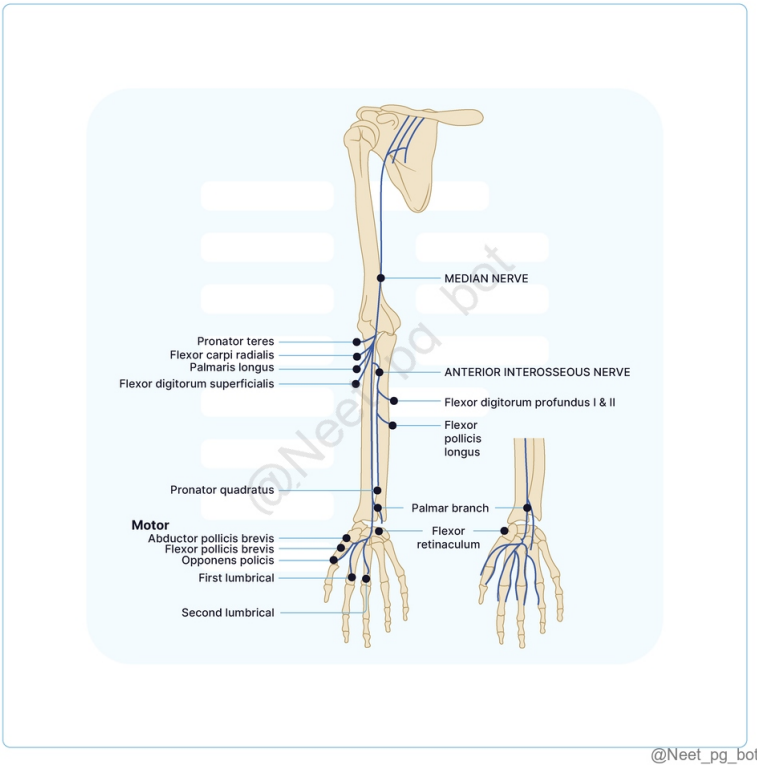

@Neet_pg_bot

References:

B. D. Chaurasia's Human Anatomy, Volume-1, 8th Edition, Page 116

↑ *Back to this question in Part A*

@Neet_pg_bot

• [05_Upper Limb] 027 Upper Limb Arterial Supply Venous Drainage Lymphatic Drainage Hand Spaces

« Back to Folder Directory

[05_Upper Limb] 027 Upper Limb Arterial Supply Venous Drainage Lymphatic Drainage Hand Spaces — Quick Jump

Q1 (p. 1468) *Q2 (p. 1469)* *Q3 (p. 1471)* *Q4 (p. 1472)* *Q5 (p. 1474)* *Q6 (p. 1478)*
Q7 (p. 1479) *Q8 (p. 1481)* *Q9 (p. 1482)* *Q10 (p. 1484)* *Q11 (p. 1485)* *Q12 (p. 1487)*
Q13 (p. 1489) *Q14 (p. 1489)* *Q15 (p. 1491)*

Q1: A 35-year-old woman presents after a motor vehicle accident with a clavicle fracture. During surgery, the surgeon carefully avoids damaging nearby blood vessels, including those from the thyrocervical trunk. Which artery is not a branch of the thyrocervical trunk and is less likely to be encountered during this procedure? (Q848539)

A. Inferior Thyroid Artery

B. Suprascapular Artery

C. Superficial Cervical Artery

D. Dorsal Scapular Artery

Correct Answer: D. Dorsal Scapular Artery

■ *Listen (English)*

■ *Listen (Hindi)*

Explanation: Dorsal Scapular Artery arises from the third part of the subclavian artery or may originate from the transverse cervical artery , but it is not a branch of the thyrocervical trunk. Thyrocervical trunk , a branch of the subclavian artery, typically gives rise to three main branches: Inferior thyroid artery Suprascapular artery Transverse cervical artery (also called superficial cervical artery) Subclavian artery : Right Subclavian Artery: From the brachiocephalic trunk (posterior or superior to the right sternoclavicular joint). Left Subclavian Artery: Directly from the arch of the aorta (after the brachiocephalic trunk and left common carotid artery).

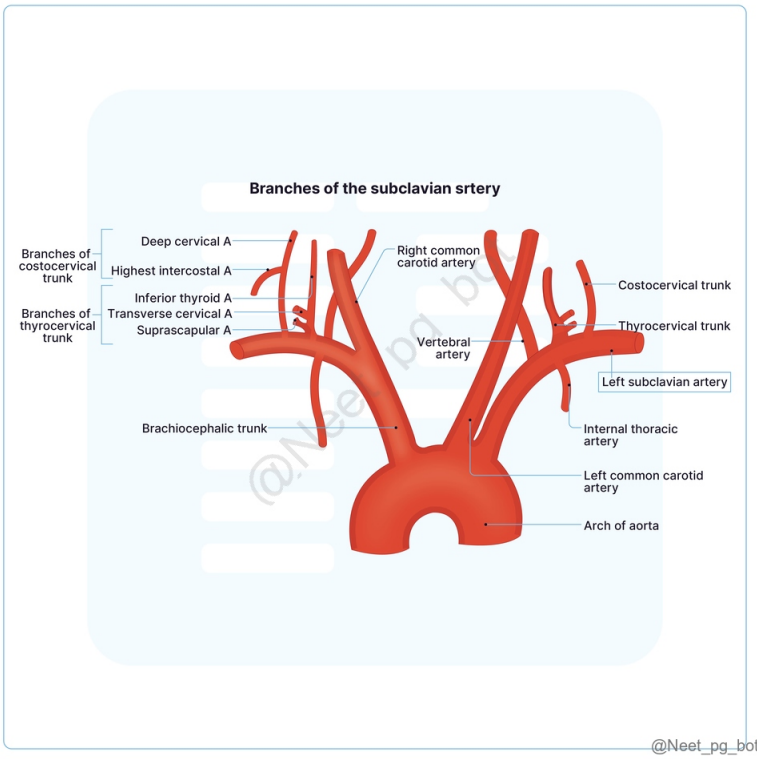

References:

Grey's Anatomy, 42nd Edition, Page 1464.e83,84

↑ *Back to this question in Part A*

@Neet_pg_bot

Q2: A 40-year-old man undergoes surgery for a tumour in the axilla. During the procedure, the surgeon identifies the second part of the axillary artery and its branches. Which of the following arteries arises from this segment of the axillary artery and must be carefully preserved during the dissection? (Q848540)

A. Superior thoracic artery

B. Thoraco-acromial artery

C. Subscapular artery

D. Anterior circumflex humeral artery

Correct Answer: B. Thoraco-acromial artery

■ *Listen (English)*

■ *Listen (Hindi)*

Explanation: Axillary artery is divided into three parts based on its position relative to the pectoralis minor muscle : First is medial, the second is behind, and the third is lateral to the muscle. Thoracoacromial artery arises from the second part of the axillary artery, which is located posterior to the pectoralis minor muscle. Superior thoracic artery arises from the first part , while the subscapular and anterior circumflex humeral arteries arise from the third part.

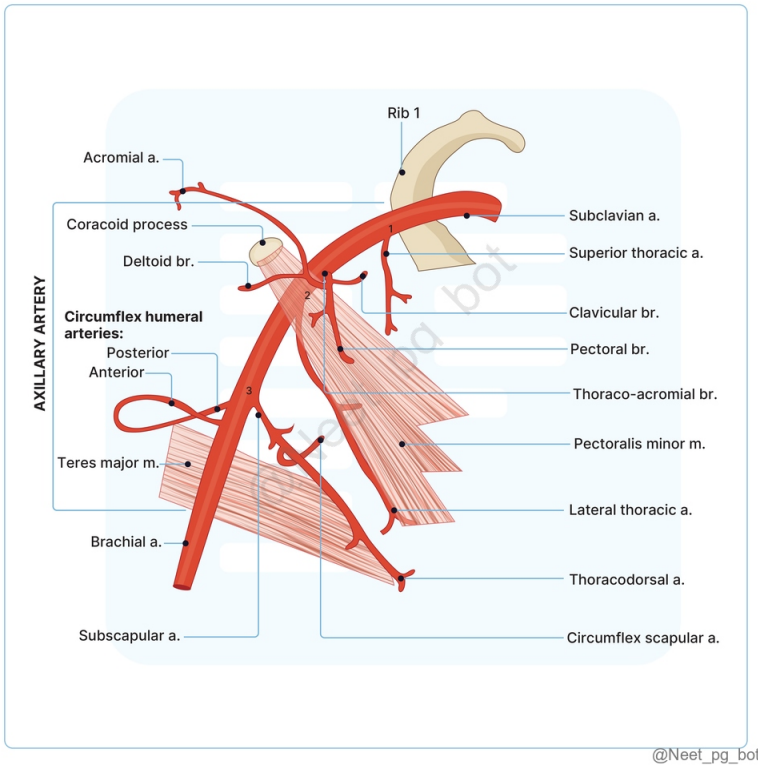

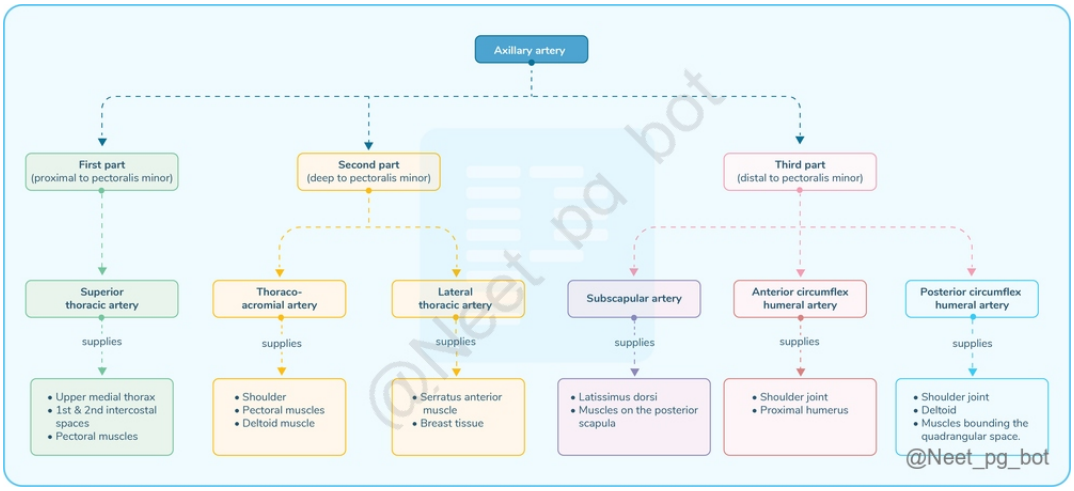

References:

Grey's Anatomy, 42nd Edition, Page 1464.e87,88

↑ *Back to this question in Part A*

@Neet_pg_bot

Q3: The following image illustrates the blood supply to the mammary gland. Identify the artery labelled "A." (Q848541)

A. Lateral Thoracic Artery

B. Internal Thoracic Artery

C. Anterior Intercostal Arteries

D. Subscapular Artery

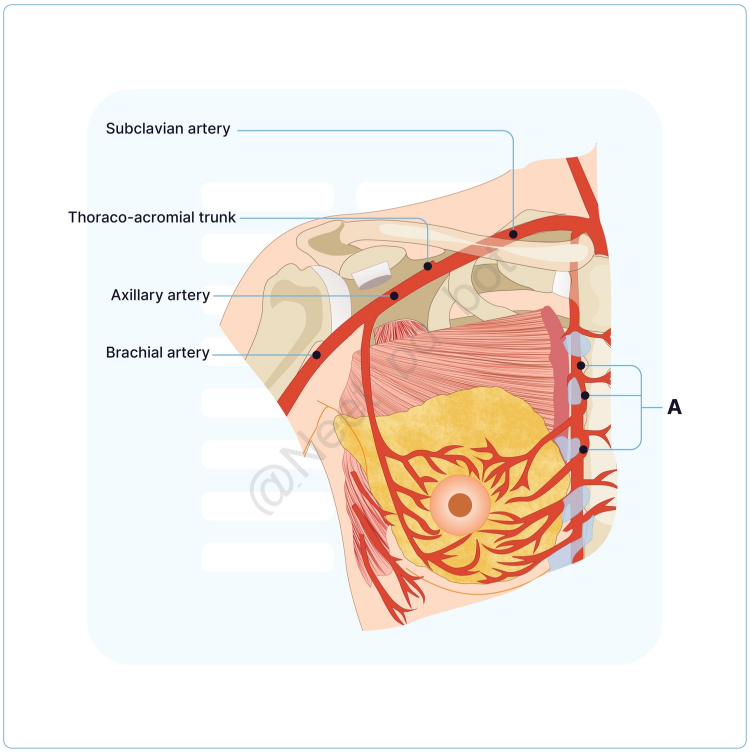

@Neet_pg_bot

Correct Answer: B. Internal Thoracic Artery

- *Listen (English)*
- *Listen (Hindi)*

Explanation: The artery labeled "A" in the image is the Internal Thoracic Artery . Internal thoracic artery supplies the anteromedial part of the breast through its medial mammary branches. Blood supply of the Mammary gland Source of Blood Supply Arteries Description Internal Thoracic Artery (Option B) Medial Mammary Branches Originates from the subclavian artery and supplies the anteromedial part of the breast. Axillary Artery Lateral

Thoracic Artery (Option A) It gives off lateral mammary branches to supply the lateral aspect of the breast. Subscapular Artery (Option D) Contributes to the blood supply to lateral and posterior aspects of the breast Anterior Intercostal Arteries (Option C) 2nd to 4th Intercostal Arteries Enlarges during lactation; Supplies superior regions of the breast

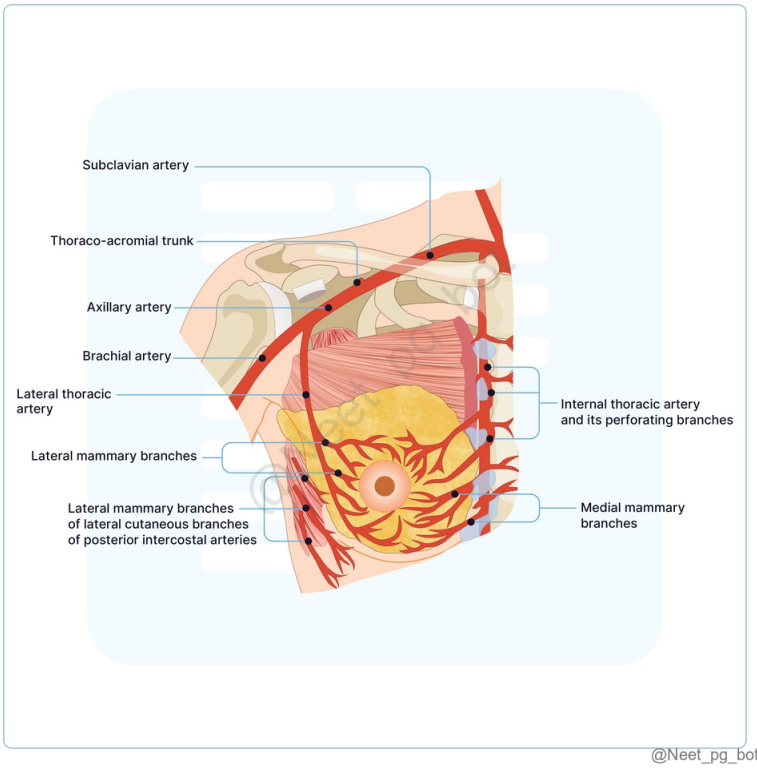

References:

Grey's Anatomy, 42nd Edition, Page 1014,1015

↑ *Back to this question in Part A*

@Neet_pg_bot

Q4: A 35-year-old patient presents with a shoulder injury following a fall. During a physical examination, the physician palpates the brachial artery to assess the blood supply to the arm. At which anatomical landmark does this artery begin as a continuation of the axillary artery? (Q848542)

A. Lower border of the teres minor

B. Upper border of the teres major

C. Lower border of the teres major

D. Upper border of the teres minor

Correct Answer: C. Lower border of the teres major

■ *Listen (English)*

■ *Listen (Hindi)*

Explanation: Brachial artery is a vital artery in the upper limb originating at the lower border of the teres major muscle and is a direct continuation of the axillary artery. Branches of Axillary artery: Subscapular artery runs along with nerve to latissimus dorsi/thoracodorsal nerve. Posterior Circumflex humeral artery runs along with the axillary nerve.

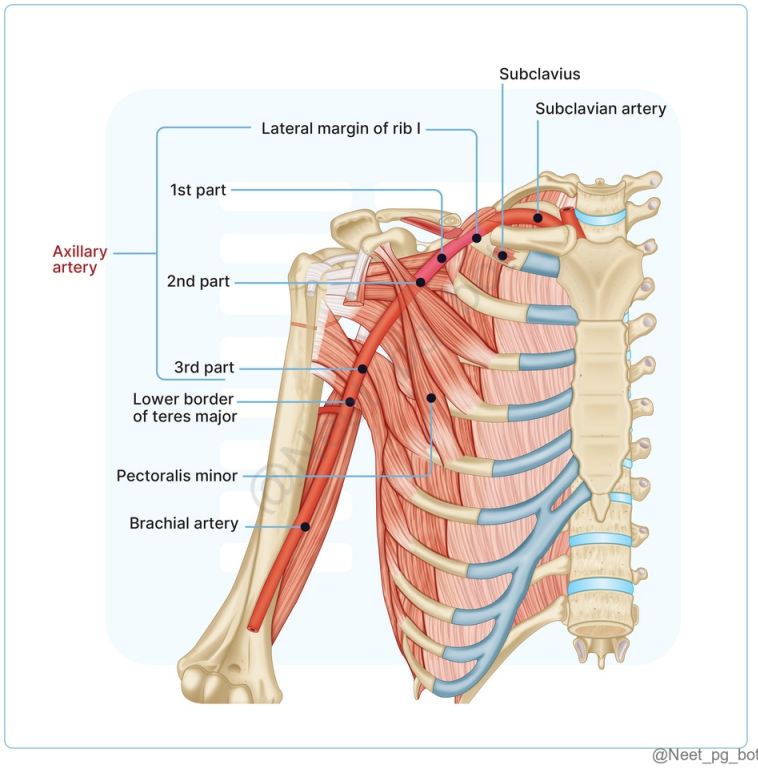

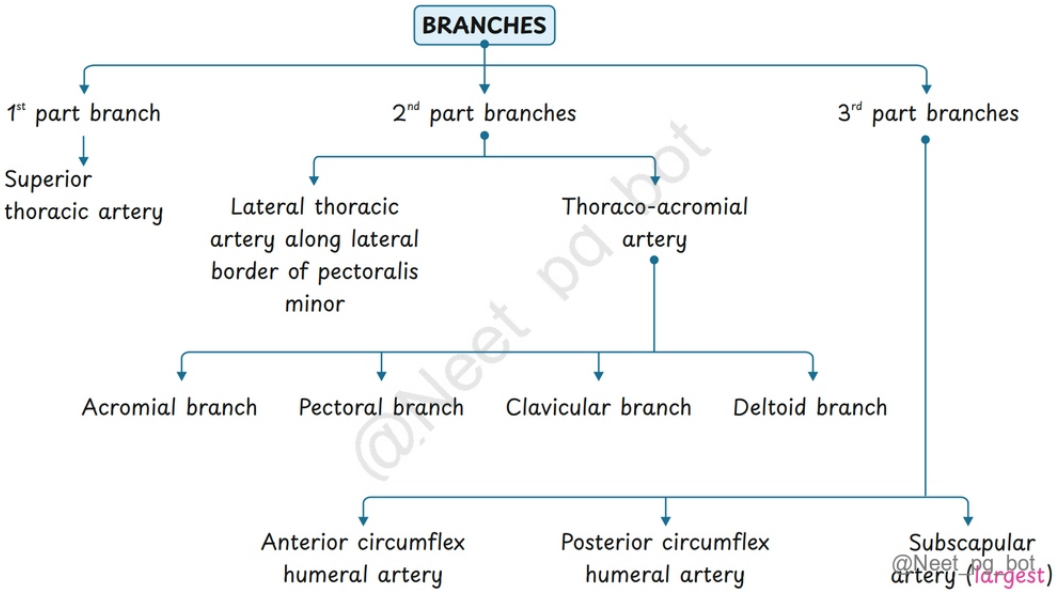

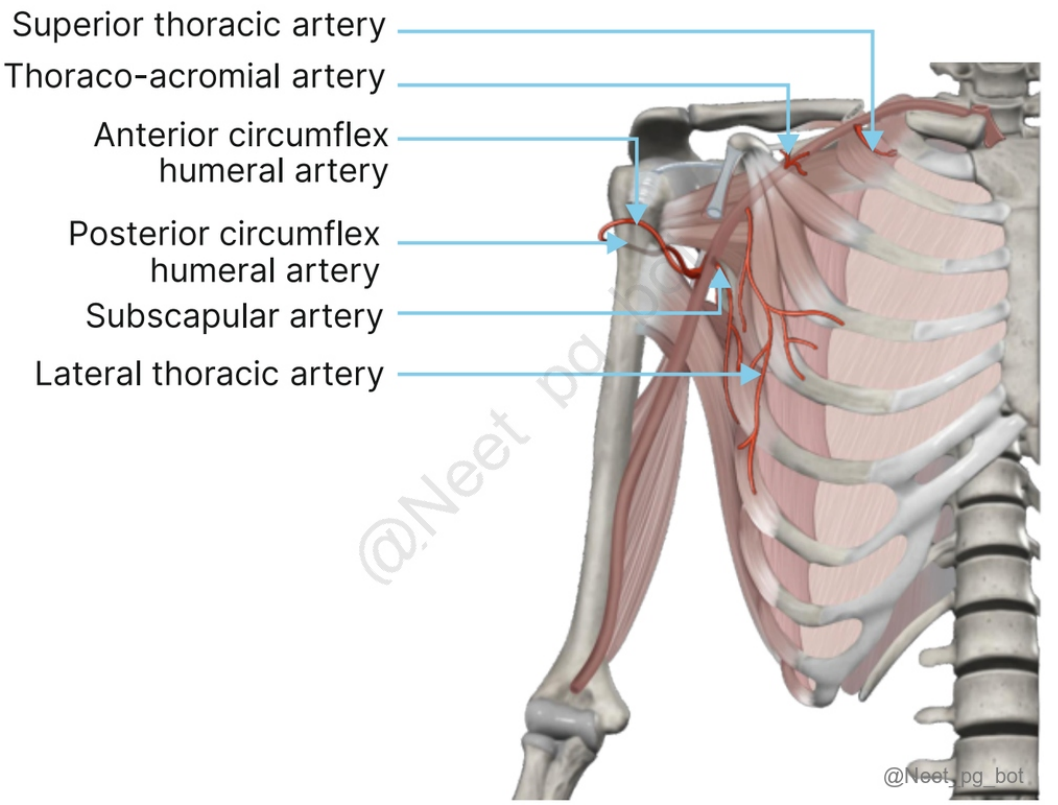

References:

Grey's Anatomy, 42nd Edition, Page 89

↑ *Back to this question in Part A*

@Neet_pg_bot

Q5: A 55-year-old male presents with intermittent pain and numbness in his right hand, especially after gripping. The physician suspects vascular insufficiency. Which test is the physician likely to perform to assess the blood supply to the hand? (Q848543)

A. Allen's test

B. Phalen's test

C. Tinel's sign

D. Capillary refill test

Correct Answer: A. Allen's test

■ *Listen (English)*

■ *Listen (Hindi)*

Explanation: Allen's test evaluates the patency of the radial and ulnar arteries supplying the hand. Allens test: The examiner compresses both arteries at the wrist while the patient clenches their fist to drain blood from the hand. Subsequently, pressure on one artery is released, and the return of hand colour is observed. A rapid colour return indicates an adequate blood supply from that artery. It ensures an adequate collateral circulation and is especially useful before procedures such as arterial blood gas sampling or harvesting the radial artery for grafting. Aspect Allen's Test Modified Allen's Test Primary goal Assessed if either artery was blocked Assesses if the Ulnar artery can support the hand alone. Hands Tested Both hands simultaneously for comparison One hand at a time Procedure Patient clenches both fists tightly (1 minute); occlude both radial and ulnar arteries on both hands; patient opens both hands; release all pressure and compare color return bilaterally (repeat occluding one artery pair)■ Patient clenches fist (30 seconds) on one hand; occlude both arteries; open hand (blanching); release ulnar pressure while holding radial, observe flush (5-15 sec); repeat for radial Purpose & Accuracy Assesses symmetry between hands; less precise for individual artery patency Evaluates unilateral collateral circulation (e.g., ulnar patency before radial puncture); more practical and preferred clinically Phalen's test (Option B) assesses carpal tunnel syndrome . The patient flexes their wrists by pressing the backs of their hands together for 60 seconds . A positive test results in tingling, numbness, or pain in the median nerve distribution, suggesting carpal tunnel compression. Tinel's sign (OptionC) is another test for carpal tunnel syndrome. The examiner taps over the median nerve at the wrist. If this elicits a tingling or "pins and needles" sensation in the fingers supplied by the median nerve , it indicates nerve irritation or damage. Capillary refill test (Option D) assesses peripheral perfusion and circulatory status . The examiner presses on the nail bed or skin until it blanches (turns white), then releases. A normal capillary refill time is less than 2 seconds , which indicates adequate blood flow.

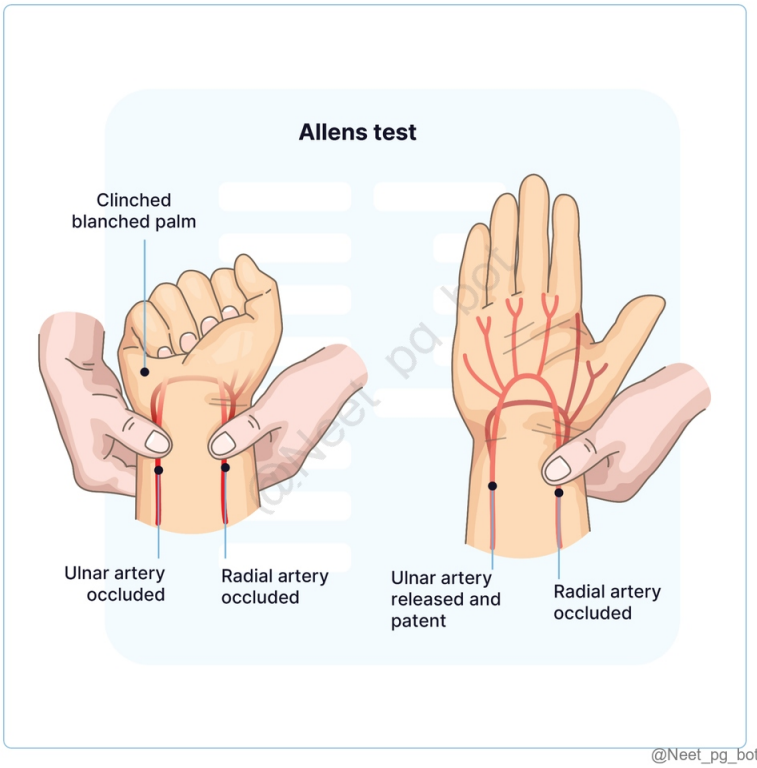

@Neet_pg_bot

Flexor of wrist compresses nerve inside carpal tunnel

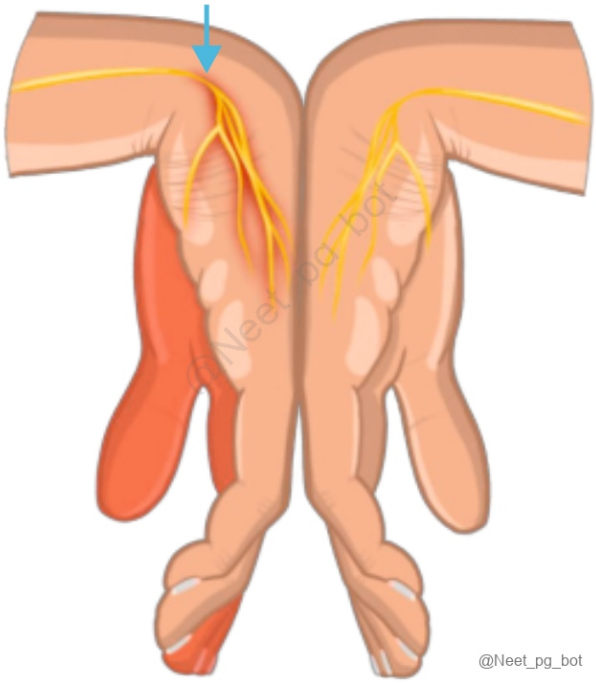

@Neet_pg_bot

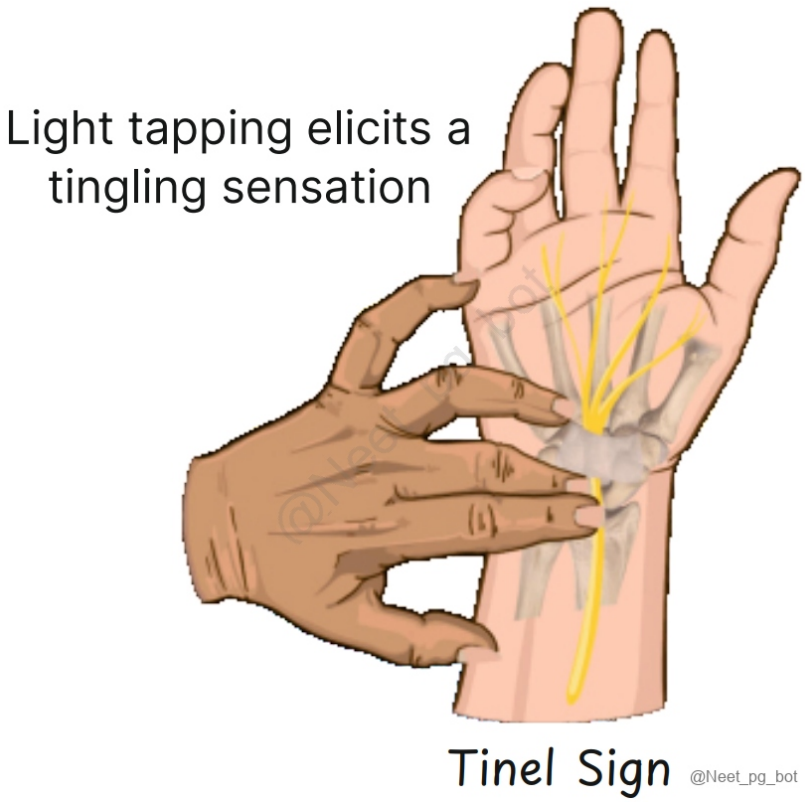

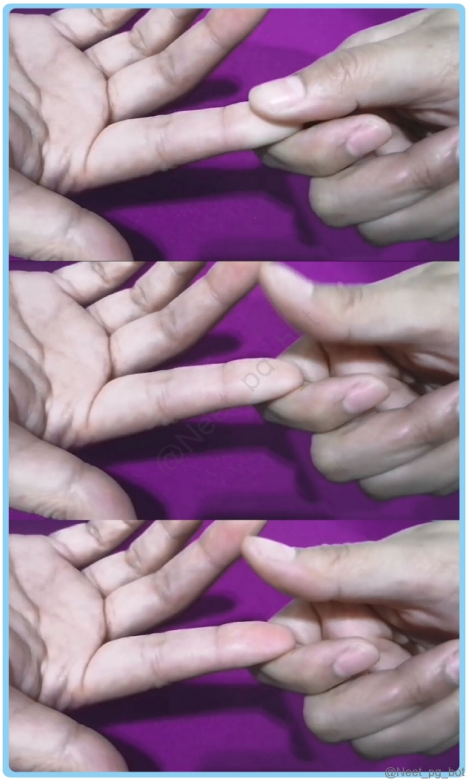

References:

Grey's Anatomy, 42nd Edition, Page 886

↑ *Back to this question in Part A*

@Neet_pg_bot

Q6: A 72-year-old male with a history of atherosclerosis and hypertension presents with sudden severe pain, numbness, and weakness in his left arm. Examination shows difficulty gripping and sensory loss in the hand. Which anastomosis is most critical for collateral blood flow to the left upper limb in this condition? (Q848544)

A. Suprascapular artery and dorsal scapular artery

B. Subscapular artery and circumflex scapular artery

C. Superior thoracic artery and acromiothoracic artery

D. Suprascapular artery and circumflex scapular artery

Correct Answer: D. Suprascapular artery and circumflex scapular artery

■ *Listen (English)*

■ *Listen (Hindi)*

Explanation: The scenario describes a case of subclavian artery occlusion , in which the suprascapular artery (branch of subclavian artery) and the circumflex scapular artery (branch of axillary artery) form the most critical anastomosis for ensuring collateral blood flow to the upper limb. Suprascapular artery and dorsal scapular artery (Option A) are the branches of the thyrocervical trunk and transverse cervical artery , respectively; both are subclavian artery branches. Subscapular and circumflex scapular arteries (Option B) are branches of the 3rd part of the axillary artery. Superior thoracic artery and acromiothoracic artery (Option C) are axillary artery branches from the 1st and 2nd part , respectively.

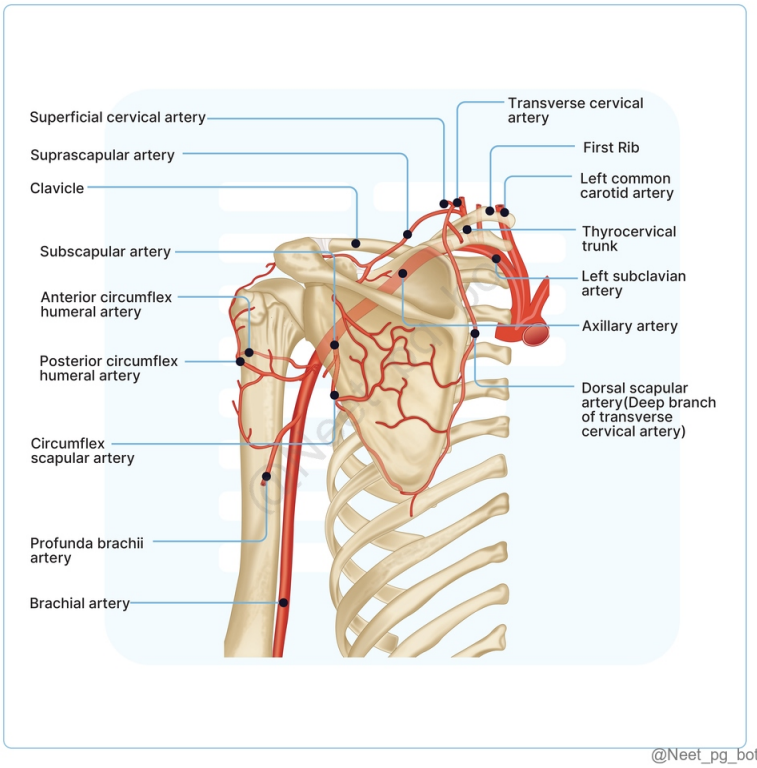

@Neet_pg_bot

References:

Gray's Anatomy, 42nd Edition, Page 919, 921

BD Chaurasia’s Human Anatomy, Volume-1, 8th Edition, Page 80-81

Vishram Singh Textbook of Anatomy, Volume-1, 2nd Edition, Page 51, 52

↑ *Back to this question in Part A*

@Neet_pg_bot

Q7: A patient with stage 5 chronic kidney disease is preparing for hemodialysis. During the examination, tenderness is noted in the right arm, and a prominent vein is visible. The doctor asks the intern to identify the vein, hinting that it pierces the clavipectoral fascia. What vein is being referenced? (Q848545)

A. Basilic vein

B. Brachial vein

C. Cephalic vein

D. Median cubital vein

Correct Answer: C. Cephalic vein

■ *Listen (English)*

■ *Listen (Hindi)*

Explanation: Cephalic vein is the preferred choice for hemodialysis in cases of renal failure. It pierces the clavipectoral fascia before its termination. Superficial veins of the upper limb: Deep veins of the upper limb: Begin as small venae comitantes alongside the digital veins, which then continue proximally to form the superficial and deep palmar arches . Venae comitantes , which accompany radial, ulnar, and brachial arteries Venae comitantes of the brachial artery Axillary vein (continuation of the basilic vein, drains into the subclavian vein)

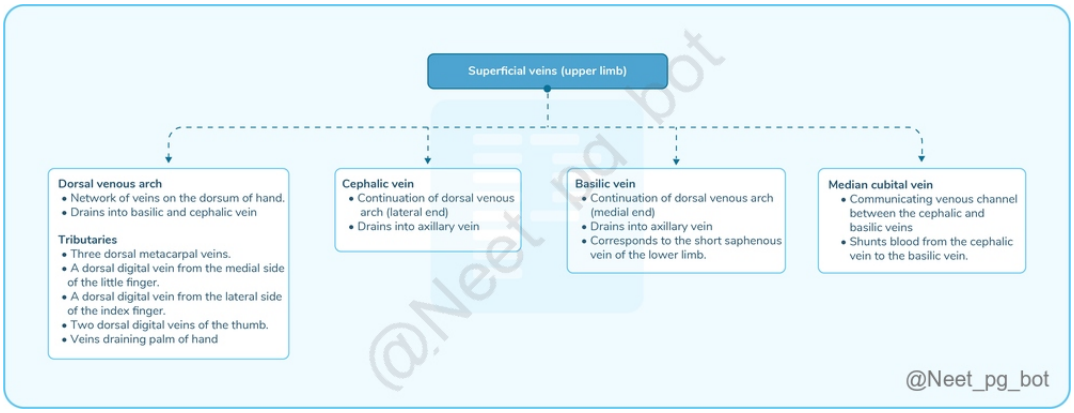

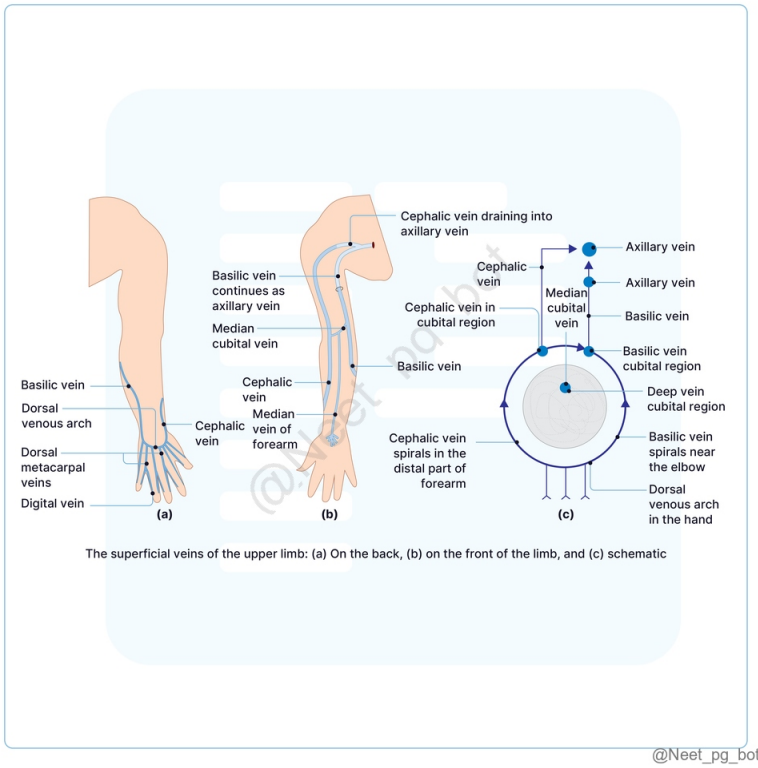

References:

Gray's Anatomy, 42nd Edition, Page 951

BD Chaurasia’s Human Anatomy, Volume-1, 8th Edition, Page 88,89,90

Vishram Singh Textbook of Anatomy, Volume-1, 2nd Edition, Page 86,87,88

↑ *Back to this question in Part A*

@Neet_pg_bot

Q8: A 45-year-old female presents to the clinic following her mammogram results, revealing a palpable mass in her left breast and mild discomfort. Examination shows enlarged lymph nodes in the left axilla. Which of the following is the terminal group of axillary lymph nodes? (Q848546)

A. Central

B. Pectoral

C. Apical

D. Supraclavicular

Correct Answer: C. Apical

■ *Listen (English)*

■ *Listen (Hindi)*

Explanation: The apical group of lymph nodes is the terminal group of axillary lymph nodes. Lymphatic Drainage of the Mammary Gland: It includes: Lymph nodes and lymphatic vessels Subdiaphragmatic and subperitoneal lymph plexuses Drainage: Lymph Nodes/Plexus Part of breast Anterior axillary or pectoral group of lymph nodes (Option B) Lateral quadrants Internal mammary lymph nodes Medial quadrants Posterior intercostal nodes Lower lateral quadrant Subdiaphragmatic and subperitoneal lymph plexuses Lower medial quadrant Apical group of axillary lymph nodes (Option C) Deep surface Subareolar plexus of Sappey is a network of lymphatic vessels located deep in the areola, which primarily drains lymphatic fluid from the breast into the anterior (pectoral) group of lymph nodes. Axillary lymph nodes drain into supraclavicular lymph nodes. (Option D) Central (Option A): While the central nodes are "central" in location (embedded in the axillary fat), they are intermediate , not terminal. They receive lymph from the three peripheral groups (Pectoral, Subscapular, and Lateral) and then they drain to the Apical group. They act as a collecting hub rather than the final exit point of the axilla. Clinical Significance: “Peau d’orange” appearance of the skin in the breast carcinoma due to obstruction of superficial lymphatics. Krukenberg’s tumour occurs when lymphatic vessels from the breast connect with the subperitoneal lymph plexus, allowing cancer cells to travel to the ovaries and form a secondary tumour.

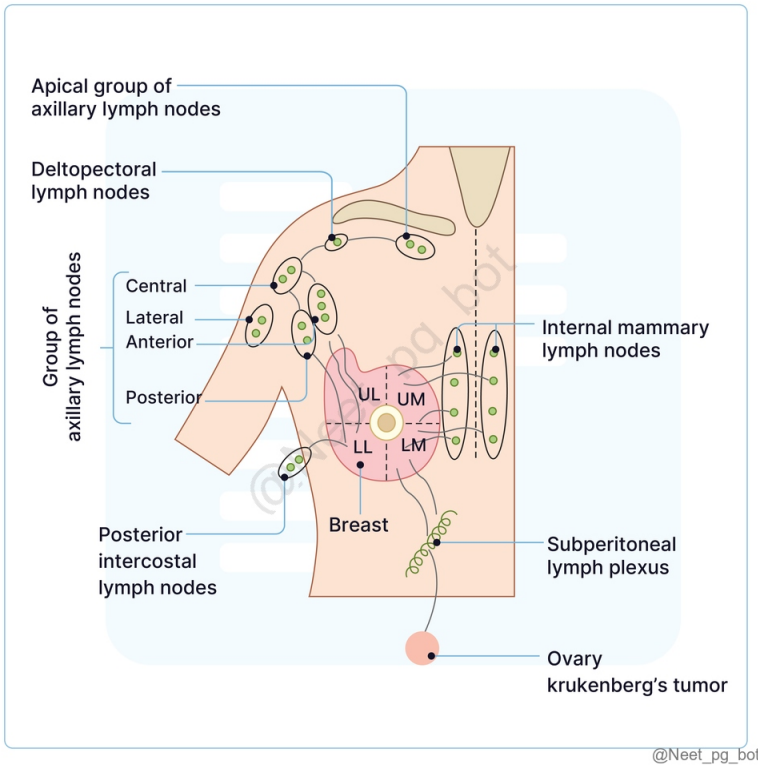

References:

Gray's Anatomy, 42nd Edition, Pages 1013,1015

BD Chaurasia's Human Anatomy, Volume-1, 8th Edition, Pages 41, 42

Vishram Singh Textbook of Anatomy, Volume-1, 2nd Edition, Pages 42-45

↑ *Back to this question in Part A*

@Neet_pg_bot

Q9: A 32-year-old male presents to the emergency department with swelling and pain in his right hand, particularly around the base of the thumb, after puncturing it with a nail. Examination shows tenderness, swelling, and limited thumb movement. An infection is diagnosed. Which statement about this space is incorrect? (Q848547)

A. It has a triangular shape

B. Infection can spread through the radial bursa

C. Associated short muscles of thumb anteriorly

D. Anterior wall is formed by the 2nd, 3rd, and 4th lumbricals

Correct Answer: D. Anterior wall is formed by the 2nd, 3rd, and 4th lumbricals

- *Listen (English)*
- *Listen (Hindi)*

Explanation: The case is diagnosed as an infection of the thenar space , where the 1st lumbrical forms the anterior wall , while the 2nd, 3rd, and 4th lumbricals constitute the anterior wall of the mid-palmar space. Midpalmar Space vs Thenar Space: Aspect Midpalmar Space Thenar Space Shape Triangular Triangular (Option A) Site Under the inner half of the hollow of the palm Under the outer half of the hollow of the palm Extent Distal margin of the flexor retinaculum (proximal) Distal palmar crease (distal) Distal margin of the flexor retinaculum (proximal) Proximal transverse palmar crease (distal) Communications Forearm space of Parona (proximal) Fascial sheaths of the 3rd and 4th lumbricals (distal) Forearm space of Parona (proximal) The fascial sheath of the first lumbrical (distal) Anterior wall Palmar aponeurosis Flexor tendons of 3rd, 4th and 5th digits Medial three (2nd, 3rd, and 4th) lumbricals (Option D) Short muscles of the thumb (Option C) Flexor tendons of the index finger 1st lumbrical Palmar aponeurosis Posterior wall Fascia covering interossei and metacarpals Transverse head of adductor pollicis Lateral wall Intermediate palmar septum Tendon of flexor pollicis longus with radial bursa Lateral palmar septum Medial wall Medial palmar septum Intermediate palmar septum Infection inlet Ulnar bursa Radial bursa (Option B) Synovial sheath of the index finger Incision for drainage 3rd or 4th web space 1st web (posteriorly)

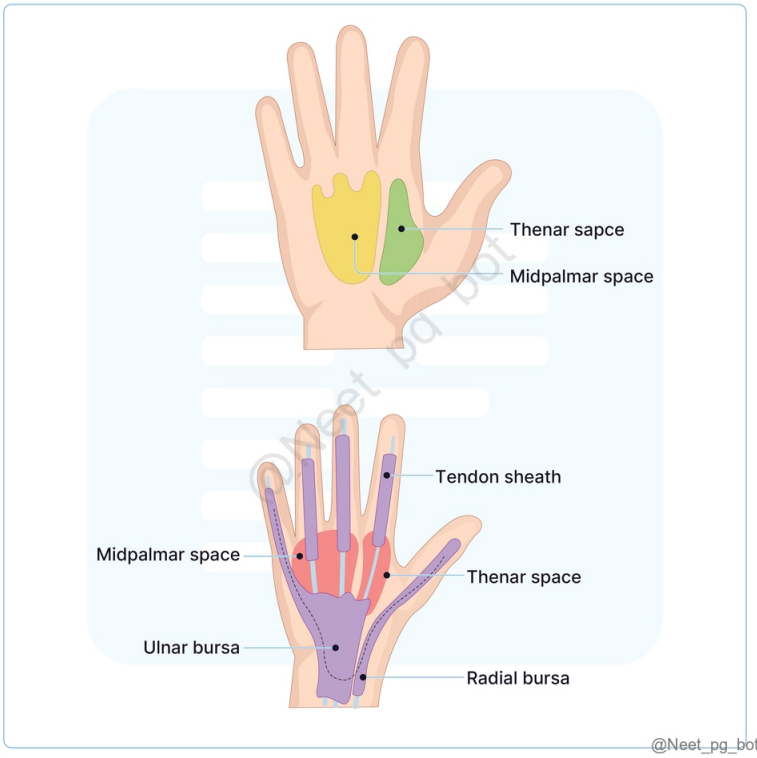

References:

BD Chaurasia’s Human Anatomy, Volume-1, 8th Edition, Page 141,142

Vishram Singh Textbook of Anatomy, Volume-1, 2nd Edition, Page 152,153,154

↑ *Back to this question in Part A*

@Neet_pg_bot

Q10: A teenager presents with severe pain and swelling in the tip of her right index finger after slamming it into a door. Examination reveals significant swelling, erythema, tenderness, increased sensitivity, and difficulty moving the finger. An infection of the structure marked 'X' is diagnosed. What is most likely? (Q848556)

A. Herpetic Whitlow

B. Felon

C. Paronychia

D. Tendon Sheath Infection

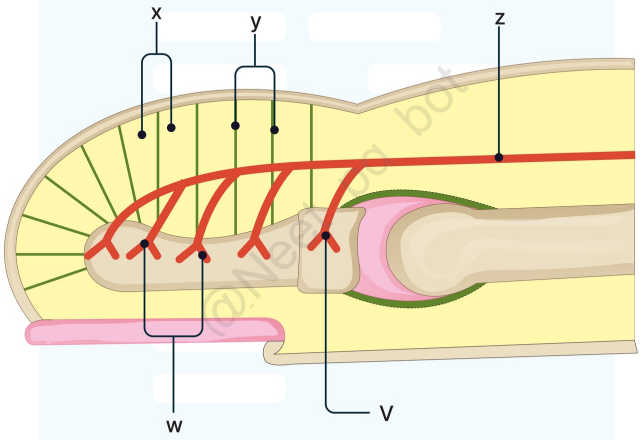

@Neet_pg_bot

Correct Answer: B. Felon

■ *Listen (English)*

■ *Listen (Hindi)*

Explanation: The given scenario is a case of Felon or infection in the Digital Pulp Space , labelled as “X” in the image. The tips of the fingers and thumb contain subcutaneous fat organised into compartments, separated by fibrous septa extending to the terminal phalanx's periosteum. Drainage procedure: A lateral incision should be made to access all loculi while carefully preserving tactile sensation on the dorsal aspect of the finger. Complication: AVN (avascular necrosis) of distal 4-5th of the terminal phalanx due to occlusion of the digital artery due to pressure. Herpetic Whitlow (Option A) is a viral infection characterised by painful blisters on the fingertip. It typically follows exposure to the herpes virus rather than trauma. It usually presents with vesicular lesions rather than localised swelling and tenderness. Paronychia (Option C) affects the nail fold and presents with redness, swelling, and pain around the nail margin. It does not involve the digital pulp space and is not typically associated with severe fingertip swelling. Tendon Sheath Infection (Option D) involves the flexor tendon sheath and presents with diffuse swelling, pain, and difficulty moving the entire finger. It generally does not cause localised tenderness at the fingertip, distinguishing it from a felon.

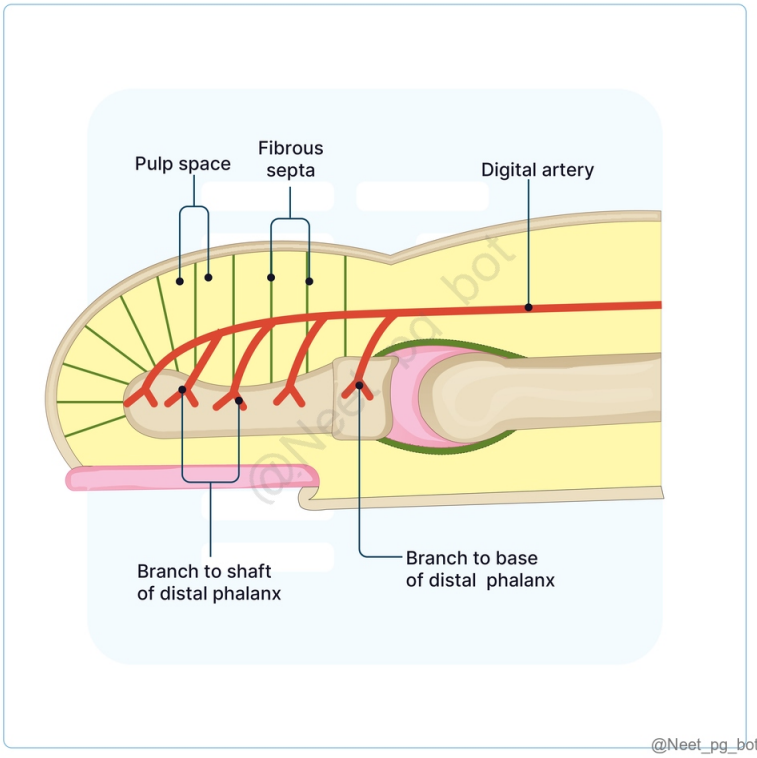

References:

BD Chaurasia’s Human Anatomy, Volume-1, 8th Edition, Page 141

Vishram Singh Textbook of Anatomy, Volume-1, 2nd Edition, Page 154

↑ *Back to this question in Part A*

@Neet_pg_bot

Q11: A 45-year-old patient is undergoing surgery on the forearm. During the procedure, the surgeon ligates the brachial artery near the elbow. Which anastomotic site helps maintain blood flow to the forearm? (Q848557)

A. In front of the lateral epicondyle

B. Behind the lateral epicondyle

C. In front of the medial epicondyle

D. Behind the medial epicondyle

Correct Answer: C. In front of the medial epicondyle

■ *Listen (English)*

■ *Listen (Hindi)*

Explanation: In front of the medial epicondyle : This anastomosis (inferior ulnar collateral ↔ anterior ulnar recurrent) ensures adequate blood flow to the forearm when the brachial artery is ligated near the elbow. Anastomoses Around the Elbow Joint: It Links brachial artery with upper ends of radial and ulnar arteries. Supply ligaments and bones of the elbow joint. Anastomotic Locations : In Front of the Lateral Epicondyle: Radial Collateral (Profunda Brachii) ↔ Radial Recurrent (Radial Artery). Behind the Lateral Epicondyle : Middle Collateral (Profunda Brachii) ↔ Interosseous Recurrent (Posterior Interosseous Artery). In Front of the Medial Epicondyle : Inferior Ulnar Collateral (Brachial Artery) ↔ Anterior Ulnar Recurrent (Ulnar Artery). Behind the Medial Epicondyle : Superior Ulnar Collateral (Brachial Artery) ↔ Posterior Ulnar Recurrent (Ulnar Artery). In front of the lateral epicondyle (Option A) : Involves radial collateral and radial recurrent arteries, which supply lateral elbow structures but not sufficient for forearm. Behind the lateral epicondyle (Option B) : Middle collateral and interosseous recurrent arteries provide supply behind the elbow but do not compensate fully for brachial artery ligation. Behind the medial epicondyle (Option D) : Superior ulnar collateral and posterior ulnar recurrent arteries supply posterior elbow , not anterior forearm structures.

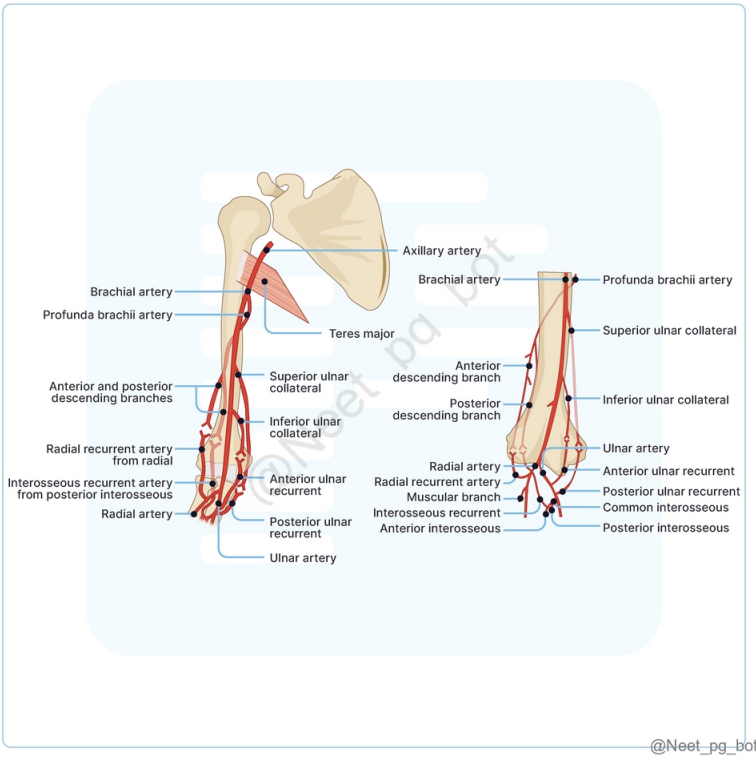

References:

BD Chaurasia’s Human Anatomy, Volume-1, 8th Edition, Page 101

Grey's Anatomy, 42nd Edition, Page 1464.e91

↑ *Back to this question in Part A*

@Neet_pg_bot

Q12: A patient sustains a deep laceration to the palm, resulting in significant bleeding. The surgeon identifies damage to an arterial structure located superficial to the flexor tendons and supplying the medial 3½ digits. Which arterial structure is most likely injured? (Q848558)

A. Superficial palmar arch

B. Deep palmar arch

C. Radial artery

D. Ulnar artery

Correct Answer: A. Superficial palmar arch

■ *Listen (English)*

■ *Listen (Hindi)*

Explanation: Superficial palmar arch is located deep to the palmar aponeurosis but superficial to the flexor tendons , and it supplies the medial 3½ digits via its common digital branches. Superficial Palmar Arch Deep Palmar Arch Anastomosis Between ulnar and radial arteries. Between radial and ulnar arteries. Location Deep to palmaris brevis and aponeurosis. Crosses palm over flexor tendons and median nerve Deep to flexor tendons, on proximal metacarpals and interossei. Formed by Ulnar artery (superficial branch) and radial artery (superficial branch). Radial artery (terminal part) and ulnar artery (deep branch). Branches Three common digital arteries (medial 3½ digits). One proper digital branch. Lateral digital branches join palmar metacarpal arteries from deep arch. Three palmar metacarpal arteries (supply medial metacarpals). Three perforating digital arteries (anastomose with dorsal metacarpal arteries). Recurrent branch (supplies carpal bones and joints, ends in palmar carpal arch). Deep palmar arch (Option B) : Lies deep to the flexor tendons and primarily supplies the proximal metacarpals, not the medial 3½ digits. Radial artery (Option C) : Supplies the lateral side of the forearm and hand but does not provide primary branches to the medial digits. Ulnar artery (Option D) : Contributes to the superficial palmar arch but does not directly supply the medial digits; damage here would involve the arch rather than the artery itself.

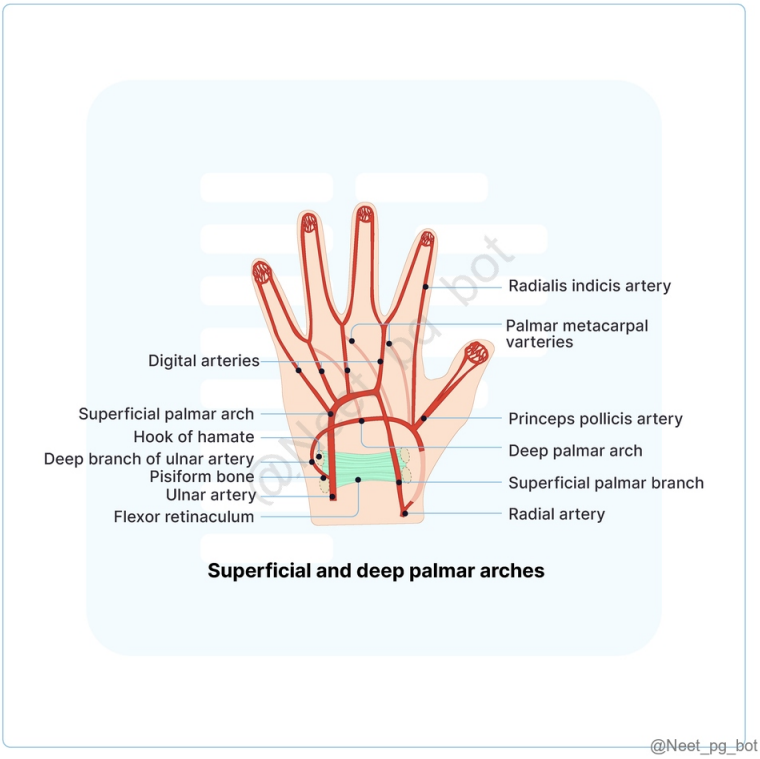

References:

BD Chaurasia’s Human Anatomy, Volume-1, 8th Edition, Page 133,135

Grey's Anatomy, 42nd Edition, Page 1464.e91

↑ *Back to this question in Part A*

@Neet_pg_bot

Q13: A 28-year-old patient presents with weakness in thumb flexion and loss of forearm pronation after a deep laceration to the anterior forearm. Imaging reveals disruption of an artery accompanying the anterior interosseous nerve. Which artery is most likely damaged? (Q848559)

A. Radial artery

B. Common interosseous artery

C. Anterior interosseous artery

D. Posterior interosseous artery

Correct Answer: C. Anterior interosseous artery

■ *Listen (English)*

■ *Listen (Hindi)*

Explanation: Anterior interosseous artery runs with the anterior interosseous nerve along the interosseous membrane, supplying deep forearm muscles like the flexor pollicis longus and pronator quadratus. Injury here matches the clinical findings of impaired thumb flexion and pronation. Interosseous Membrane and Arteries: Common Interosseous Artery : Arises below the radial tuberosity, divides into anterior and posterior interosseous arteries. Anterior Interosseous Artery : Deep artery on the forearm, runs along the interosseous membrane with the anterior interosseous nerve. Pierces the membrane at the pronator quadratus to enter the extensor compartment. Branches: Muscular branches, nutrient branches to radius and ulna, median artery with the median nerve. Posterior Interosseous Artery : Gives off interosseous recurrent artery (anastomoses with middle collateral artery). Passes through a gap in the interosseous membrane to the back of the forearm. Radial artery (Option A) : Supplies the lateral forearm and hand but does not accompany the anterior interosseous nerve or supply the affected muscles. Common interosseous artery (Option B) : Divides into anterior and posterior interosseous arteries early and does not accompany the nerve to the forearm. Posterior interosseous artery (Option D) : Supplies extensor muscles of the forearm and is unrelated to the anterior compartment or anterior interosseous nerve.

References:

BD Chaurasia’s Human Anatomy, Volume-1, 8th Edition, Page 121

Grey's Anatomy, 42nd Edition, Page 1464.e91

↑ *Back to this question in Part A*

@Neet_pg_bot

Q14: Which of the following statements regarding the median cubital vein is incorrect? (Q848560)

A. It connects the cephalic vein to the basilic vein.

B. It runs obliquely downward and laterally across the forearm.

C. It is superficial to the bicipital aponeurosis, which separates it from the brachial artery.

D. It is the primary choice for venipuncture and catheterization due to its stability.

Correct Answer: B. It runs obliquely downward and laterally across the forearm.

■ *Listen (English)*

■ *Listen (Hindi)*

Explanation: Median cubital vein runs obliquely upward and medially , not downward and laterally Median Cubital Vein: Anatomy : Connects cephalic to basilic vein. (Option A ruled out) Origin: Cephalic vein (2.5 cm below elbow). Ends: Basilic vein (2.5 cm above medial epicondyle). Runs obliquely upward and medially. Relations : Superficial to bicipital aponeurosis (separating it from brachial artery). (Option C ruled out) Receives tributaries from the median forearm vein. Stabilized by a perforator vein connecting to deep veins. Clinical Significance : Primary Choice : Ideal for venipuncture and catheterization due to stability. (Option D ruled out)

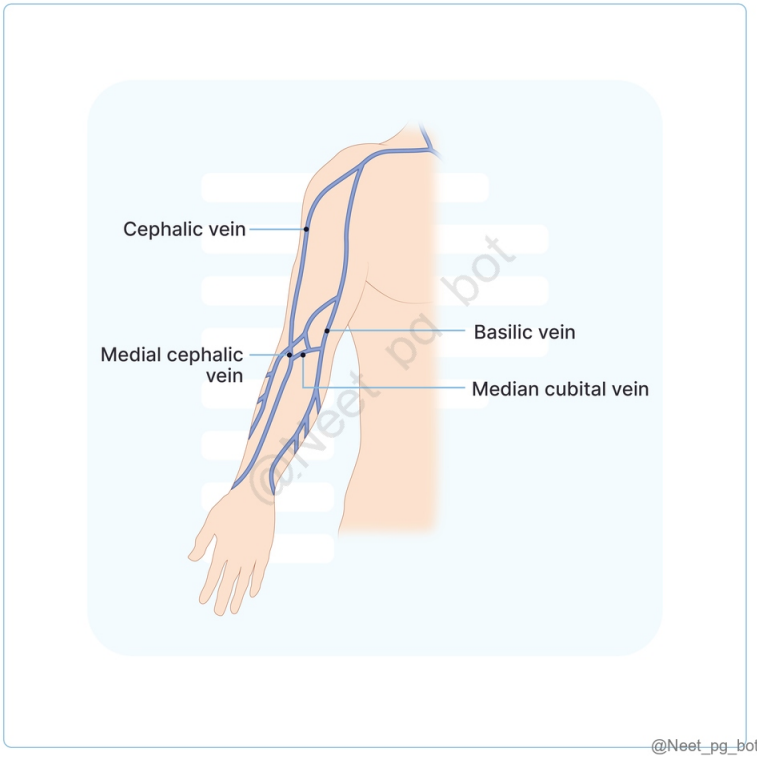

References:

BD Chaurasia’s Human Anatomy, Volume-1, 8th Edition, Page 89

↑ *Back to this question in Part A*

@Neet_pg_bot

Q15: A 35-year-old woman with breast cancer presents with enlarged lymph nodes in her axilla. Biopsy reveals metastatic spread. Which group of axillary lymph nodes is most likely the initial site of cancer drainage? (Q848561)

A. Anterior (Pectoral) nodes

B. Posterior (Scapular) nodes

C. Lateral nodes

D. Apical (Infraclavicular) nodes

Correct Answer: A. Anterior (Pectoral) nodes

■ *Listen (English)*

■ *Listen (Hindi)*

Explanation: Anterior (pectoral) nodes are located along the lateral thoracic vessels and primarily drain the anterior trunk wall and breast , making them the first site for lymphatic drainage from breast tissue. Clinical Importance of Axillary Lymph Nodes : Drains upper limb, breast, and body walls above the umbilicus. Common site for infections and malignancies (e.g., breast cancer). Axillary Abscess : Incision through axillary floor near medial wall to avoid vessels. Posterior (Scapular) nodes (Option B) : Drains the posterior trunk wall and the axillary tail of the breast; unlikely to be the first site of drainage for the main breast tissue. Lateral nodes (Option C) : Drains the upper limb and does not directly receive lymph from the breast. Apical (Infraclavicular) nodes (Option D) : Drains central nodes and other axillary groups but is not the initial site for primary breast lymphatic drainage.

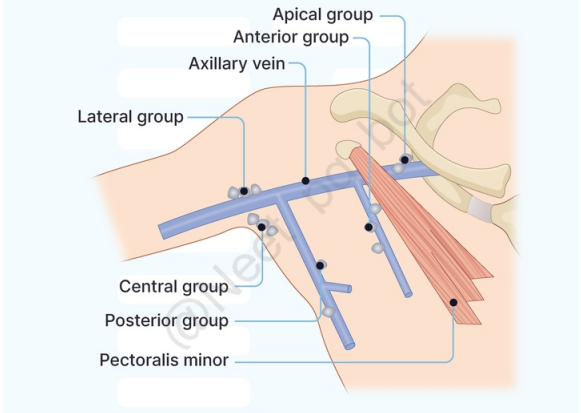

@Neet_pg_bot

References:

BD Chaurasia's Human Anatomy, Volume-1, 8th Edition, Pages 54,58,59

↑ *Back to this question in Part A*

@Neet_pg_bot

• [05_Upper Limb] 028 Previous Year Questions

« Back to Folder Directory

[05_Upper Limb] 028 Previous Year Questions — Quick Jump

Q1 (p. 1493)	*Q2 (p. 1495)*	*Q3 (p. 1495)*	*Q4 (p. 1497)*	*Q5 (p. 1500)*	*Q6 (p. 1502)*
Q7 (p. 1503)	*Q8 (p. 1505)*	*Q9 (p. 1506)*	*Q10 (p. 1507)*	*Q11 (p. 1508)*	*Q12 (p. 1510)*
Q13 (p. 1511)	*Q14 (p. 1512)*	*Q15 (p. 1513)*	*Q16 (p. 1516)*	*Q17 (p. 1517)*	*Q18 (p. 1519)*
Q19 (p. 1521)	*Q20 (p. 1523)*	*Q21 (p. 1524)*	*Q22 (p. 1525)*	*Q23 (p. 1526)*	*Q24 (p. 1528)*
Q25 (p. 1530)	*Q26 (p. 1532)*	*Q27 (p. 1534)*	*Q28 (p. 1535)*	*Q29 (p. 1536)*	*Q30 (p. 1537)*
Q31 (p. 1538)	*Q32 (p. 1540)*	*Q33 (p. 1541)*	*Q34 (p. 1542)*	*Q35 (p. 1545)*	*Q36 (p. 1546)*
Q37 (p. 1547)	*Q38 (p. 1549)*	*Q39 (p. 1551)*	*Q40 (p. 1552)*	*Q41 (p. 1554)*	*Q42 (p. 1555)*
Q43 (p. 1555)	*Q44 (p. 1556)*	*Q45 (p. 1558)*	*Q46 (p. 1559)*	*Q47 (p. 1561)*	

Q1: A 16-year-old boy came to the emergency room with the following X-ray. On examination, he had a sensory loss in the lateral arm and sensory loss in the posterior aspect of the forearm. Which of the following is true about his condition? (Q859909)

A. Fracture-dislocation of the elbow

B. Surgical neck humerus fracture with axillary nerve injury

C. Spine fracture with foot drop

D. Humerus shaft fracture with radial nerve palsy



Correct Answer: D. Humerus shaft fracture with radial nerve palsy

Explanation: The X-ray reveals a fracture in the shaft of the humerus, often accompanied by radial nerve damage, which affects wrist, finger, and thumb extension, along with sensation in the forearm and hand. Clinical signs like sensory loss in the lateral arm and posterior forearm support this diagnosis, possibly due to trauma or compression from the fracture. Nerve Root origin Common causes Features Radial C5-T1 Compression in axilla (crutches, "Saturday night palsy") Midshaft fracture of humerus Repetitive pronation/supination (screwdriver use, "finger drop") Above elbow injury: Loss of sensation over posterior arm/forearm and dorsal hand Wrist drop (loss of elbow, wrist, and finger extension) Decreased grip strength (wrist extension necessary for maximal action of flexors) Below elbow injury: Distal paresthesias without wrist drop Midshaft fracture: Tricep function and posterior arm sensation spared Median C5-T1 Supracondylar fracture of humerus (proximal lesion) Carpal tunnel syndrome and wrist laceration (distal lesion) "Ape hand" and "Hand of benediction" Loss of wrist flexion Loss of function of LOAF muscles (Lumbricals (lateral two), Opponens pollicis, Abductor pollicis brevis, Flexor pollicis brevis) Loss of sensation over thenar eminence and dorsal and palmar aspects of lateral 3 1/2 fingers with proximal lesion Ulnar C8-T1 Fracture of medial epicondyle of humerus (proximal lesion) Fractured hook of hamate (distal lesion) from fall on outstretched hand Compression of nerve against hamate during cycling "Ulnar claw" on digit extension Radial deviation of wrist upon flexion (proximal lesion) Decreased flexion of ulnar fingers Loss of abduction and adduction of fingers (interossei) Loss of thumb adduction Loss of action of ulnar 2 lumbrical muscles Loss of sensation over ulnar 1 1/2 fingers including hypothenar eminence Fracture-dislocation of the elbow (Option A): Typically affects the ulnar or median nerve , not the radial nerve. Surgical neck humerus fracture with axillary nerve injury (Option B): Would cause sensory loss over the lateral shoulder (regimental badge area) , not the posterior forearm. Spine fracture with foot drop (Option C): Would involve the common peroneal nerve , leading to sensory loss over the dorsum of the foot and foot drop , which is unrelated to the current sensory findings.

References:

https://www.ncbi.nlm.nih.gov/books/NBK448074/

↑ *Back to this question in Part A*

@Neet_pg_bot

Q2: Biceps brachii functions as which type of muscle for lifting the forearm ? (Q857635)

A. Synergistic

B. Fixator

C. Antagonist

D. Primary mover

Correct Answer: D. Primary mover

Explanation: The biceps brachii is the primary mover (agonist) for forearm flexion at the elbow joint. When lifting the forearm, it contracts to generate movement by pulling the radius upward. Muscle Roles in Movement Term Definition Example in Forearm Flexion Primary Mover (Agonist) Main muscle responsible for movement. Biceps brachii flexes the elbow. Antagonist Muscle that opposes the primary mover. Triceps brachii extends the elbow, opposing the biceps. Synergist Assists the primary mover by adding force or stability. Brachialis helps the biceps in flexion. Fixator Stabilizes the origin of the primary mover. Rotator cuff muscles stabilize the shoulder joint during flexion. Synergistic (Option A): Incorrect because the brachialis acts as a synergist, not the biceps brachii. Fixator (Option B): Incorrect because fixators stabilize joints, like the rotator cuff stabilizing the shoulder. Antagonist (Option C): Incorrect because the triceps brachii is the antagonist, opposing biceps action.

References:

BD Chaurasia’s Human Anatomy Vol-1 Upper limb & thorax page - 95,96.

↑ *Back to this question in Part A*

@Neet_pg_bot

Q3: A 25 year old male presented with symptoms of inability to flex the distal interphalangeal joint of the 4 th and 5 th digits. He was also not able to hold a piece of paper between his fingers. What is the likely site of injury? (Q855844)

A. A

B. B

C. C

D. D

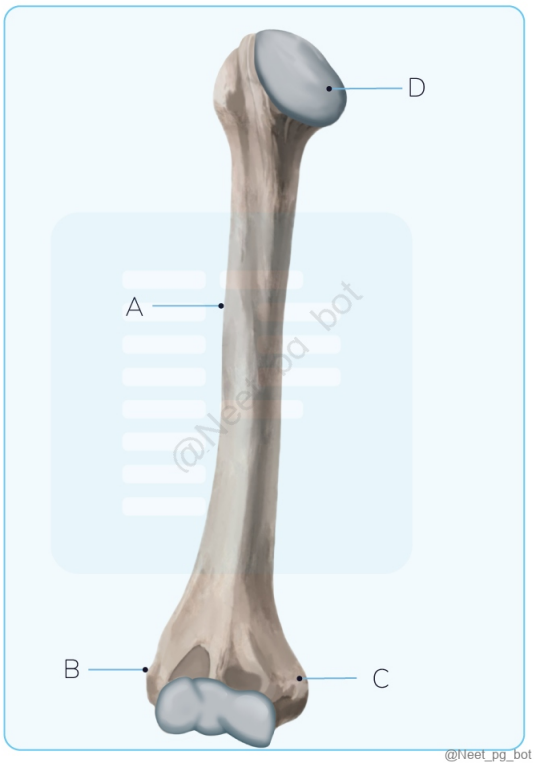

Correct Answer: C. C

Explanation: The patient presents with: Inability to flex the distal interphalangeal (DIP) joints of the 4th and 5th digits Weakness in finger adduction, causing difficulty in holding a piece of paper (Froment's sign positive) These findings suggest ulnar nerve injury affecting the medial half of flexor digitorum profundus (FDP) and intrinsic hand muscles , which occurs at the level of the medial epicondyle (cubital tunnel syndrome). Ulnar Nerve Injuries by Site Site of Injury Common Causes Clinical Features Key Signs Brachial Plexus (C8-T1 roots) Trauma, birth injury (Klumpke's palsy) Weakness in intrinsic hand muscles, forearm flexors, ± Horner's syndrome Claw hand, sensory loss in medial forearm/hand Cubital Tunnel (Elbow) Compression at medial epicondyle, prolonged flexion, trauma Weak grip, hypothenar atrophy, numbness in 4th/5th digits Positive Tinel's at elbow, Froment's sign Guyon's Canal (Wrist) Cyclists, repetitive trauma (handlebar palsy) Weak finger abduction/adduction, intrinsic muscle weakness No dorsal hand sensory loss, claw hand more pronounced Distal Ulnar Nerve (Hand) Lacerations, trauma Isolated intrinsic hand weakness, claw hand Froment's sign, Wartenberg's sign Shaft of Humerus (Option A): Incorrect because it affects the radial nerve, leading to wrist drop but not ulnar nerve dysfunction. Lateral Epicondyle (Option B): Incorrect because it affects the radial nerve and leads to weak wrist and finger extension (tennis elbow). Neck of Humerus (Option D): Incorrect because it affects the axillary nerve, leading to deltoid muscle weakness and loss of sensation over the lateral shoulder.

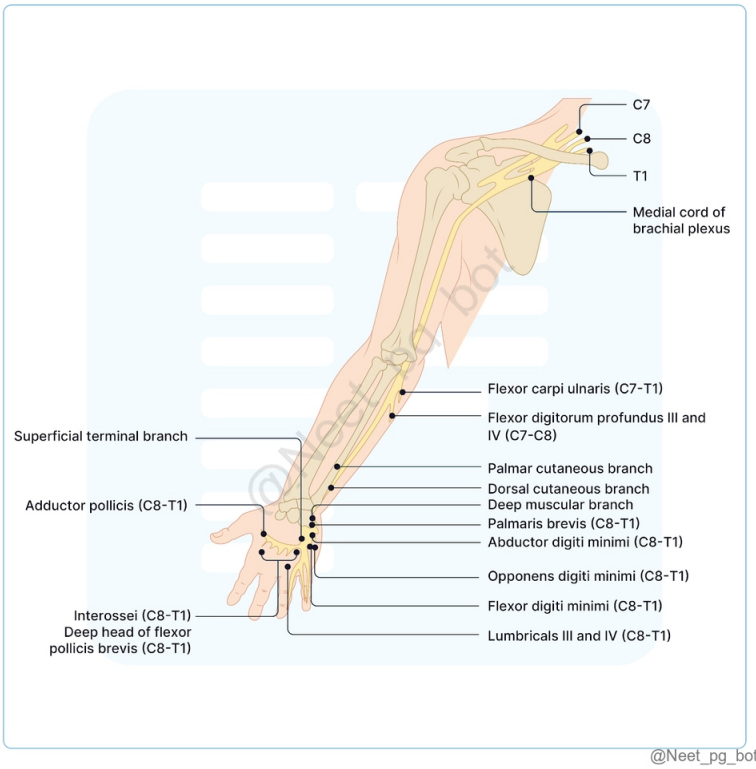

@Neet_pg_bot

References:

Gray's Anatomy: The Anatomical Basis of Clinical Practice, 41st Edition - Page no: 784, 785, 859, 860

Apley's System Of Orthopaedics And Fractures, 10th Edition, Page 296, 297

↑ *Back to this question in Part A*

@Neet_pg_bot

Q4: A patient who has taken the first COVID vaccine comes for the second dose. An astute nurse noticed that the shoulder was flabby, flat, and was asymmetrical. There was an associated loss of contour of the shoulder joint. Injury to which of the structures might have resulted and was avoidable? (Q856679)

A. Rotator cuff

B. Posterior circumflex artery

C. Lateral cutaneous nerve of arm

D. Axillary nerve

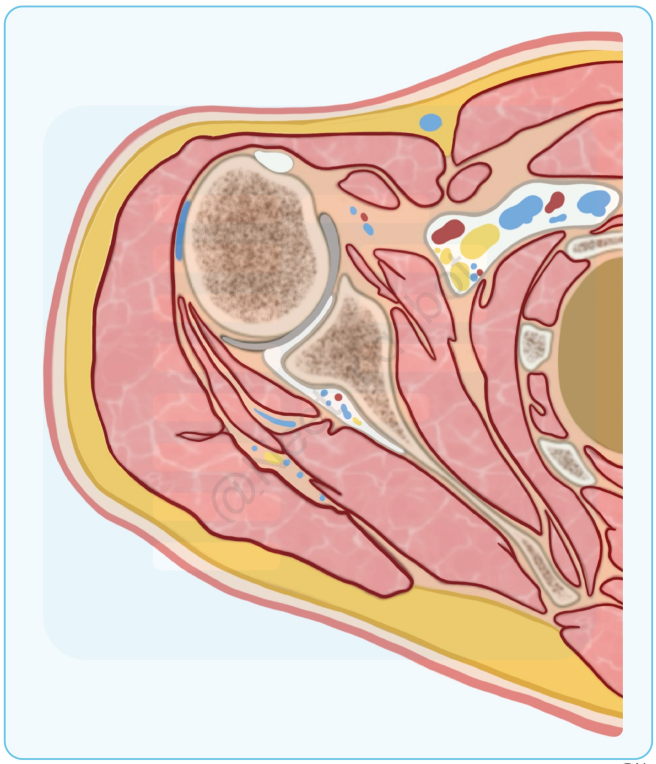

Correct Answer: D. Axillary nerve

Explanation: The axillary nerve (C5-C6) is vulnerable to injury during intramuscular injections in the deltoid muscle , especially if injected too low or too deep . Injury results in: Flattening of the shoulder (loss of deltoid muscle bulk). Loss of shoulder contour (due to deltoid atrophy). Weakness in abduction beyond 15° (deltoid function loss). Sensory loss over the lateral shoulder (regimental badge area). Prevention: Intramuscular injections should be given in the upper lateral quadrant of the deltoid to avoid axillary nerve injury . Axillary Nerve Injury Aspect Details Origin Arises from the posterior cord of the brachial plexus (C5-C6). Course Passes through quadrangular space with the posterior circumflex humeral artery . Motor Supply Deltoid muscle (shoulder abduction) and teres minor (external rotation). Sensory Supply Skin over the lateral shoulder (regimental badge area) via the superior lateral cutaneous nerve of the arm . Common Causes of Injury Improper intramuscular injection , shoulder dislocation, humeral surgical neck fracture . Clinical Features Shoulder atrophy, loss of contour , weakness in abduction , and sensory loss over the deltoid region . Rotator cuff (Option A) - Incorrect: Involved in shoulder stability but does not cause loss of shoulder contour when injured. Posterior circumflex artery (Option B) - Incorrect: Runs with the axillary nerve but its injury would cause vascular compromise , not motor weakness. Lateral cutaneous nerve of arm (Option C) - Incorrect: Only provides sensory innervation; it does not affect shoulder shape or movement .

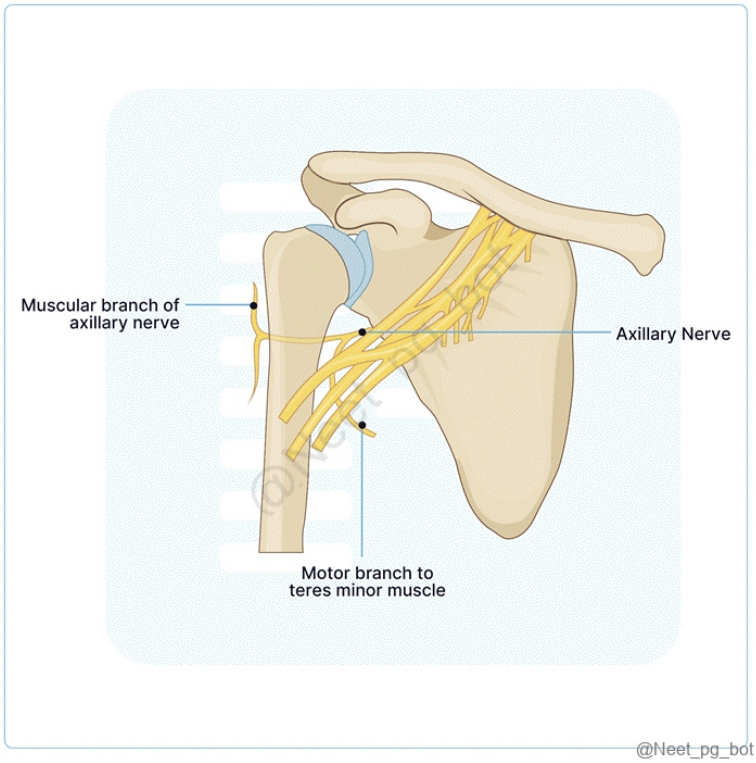

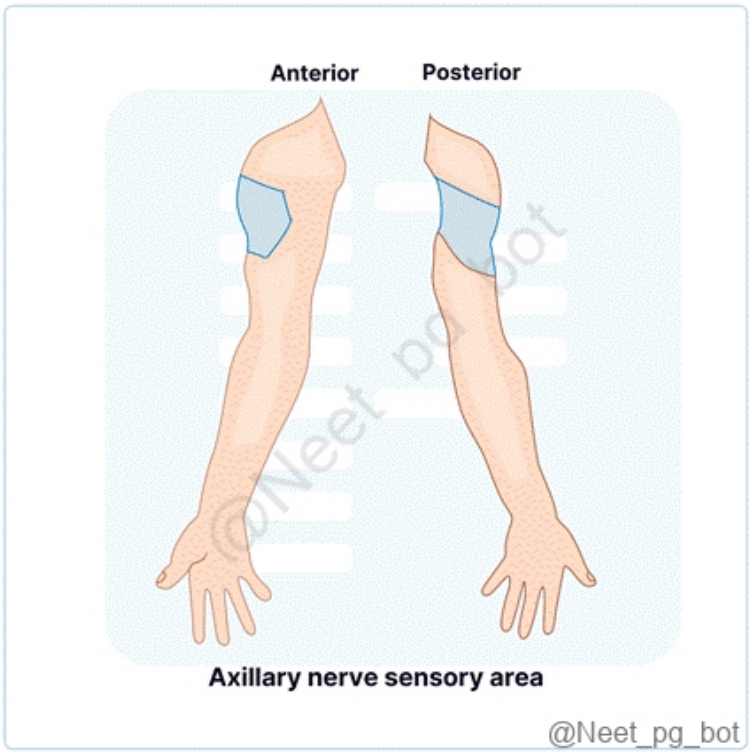

References:

Gray's Anatomy: The Anatomical Basis of Clinical Practice, 41st Edition - Page no: 783, 786, 791, 816

Apley & Solomon's System of Orthopaedics and Trauma, 10th Edition - Page no: 292, 293

https://www.ncbi.nlm.nih.gov/pmc/articles/PMC6347325/

https://pubmed.ncbi.nlm.nih.gov/17515691/

↑ *Back to this question in Part A*

@Neet_pg_bot

Q5: A 7-year-old boy was brought to the hospital with multiple fractures of the humerus secondary to a fall from height. On examination, there is difficulty in flexion of the elbow and supination of the forearm and associated loss of sensation over the lateral aspect of the forearm. Which is the nerve most likely to be injured? (Q856184)

A. Median nerve

B. Radial nerve

C. Musculocutaneous nerve

D. Ulnar nerve

Correct Answer: C. Musculocutaneous nerve

Explanation: Answer C - Musculocutaneous nerve: The musculocutaneous nerve (C5–C7) arises from the lateral cord of the brachial plexus and primarily supplies the flexor muscles of the arm . Key functions affected in this injury: Elbow flexion → Impaired due to paralysis of biceps brachii, brachialis, and coracobrachialis . Forearm supination → Weakened because biceps brachii is affected (but supination is not completely lost as the supinator muscle is intact). Sensory loss → Over the lateral aspect of the forearm due to involvement of the lateral cutaneous nerve of the forearm , which is a branch of the musculocutaneous nerve. Coracobrachialis: Origin: Medial coracoid process ; Insertion: Medial aspect of middle humerus Nerve supply: Musculocutaneous nerve (C5-C7) Action: Flexion (+adduction) of arm at shoulder joint May not be paralyzed in Erb's palsy, as in case of Erb's palsy: C5,C6 are compromised but C7 remains unaffected and hence Coracobrachialis is not paralyzed . {{caption_text}} Muscles of arm: Muscle Attachments Nerve supply Action Biceps brachii Origin: Short head- Coracoid process ; Long head- Supragelnoid tubercle Insertion: Radial tuberosity Musculocutaneous nerve (C5-C6) Flexion and supination of forearm Brachialis Origin: anterior humerus Insertion: coronoid process & ulnar tuberosity Motor: Musculocutaneous nerve Proprioceptive: Radial nerve Flexion of forearm Coraco- brachialis Origin: medial coracoid process Insertion: medial aspect of middle humerus Musculocutaneous nerve (C5-C7) Flexion of arm Median nerve (option A): Motor: Controls most forearm flexors and thenar muscles , but does not significantly affect elbow flexion or supination . Sensory: Supplies the lateral palm and first three fingers , not the lateral forearm . Radial nerve (option B): Motor: Affects wrist extension (wrist drop) and elbow extension , but not elbow flexion . Sensory: Supplies the posterior arm, forearm, and dorsum of the hand , not the lateral forearm . Ulnar nerve (option D): Motor: Controls intrinsic hand muscles and some forearm flexors , but does not significantly affect elbow flexion or supination . Sensory: Involves the medial hand and little finger , not the lateral forearm .

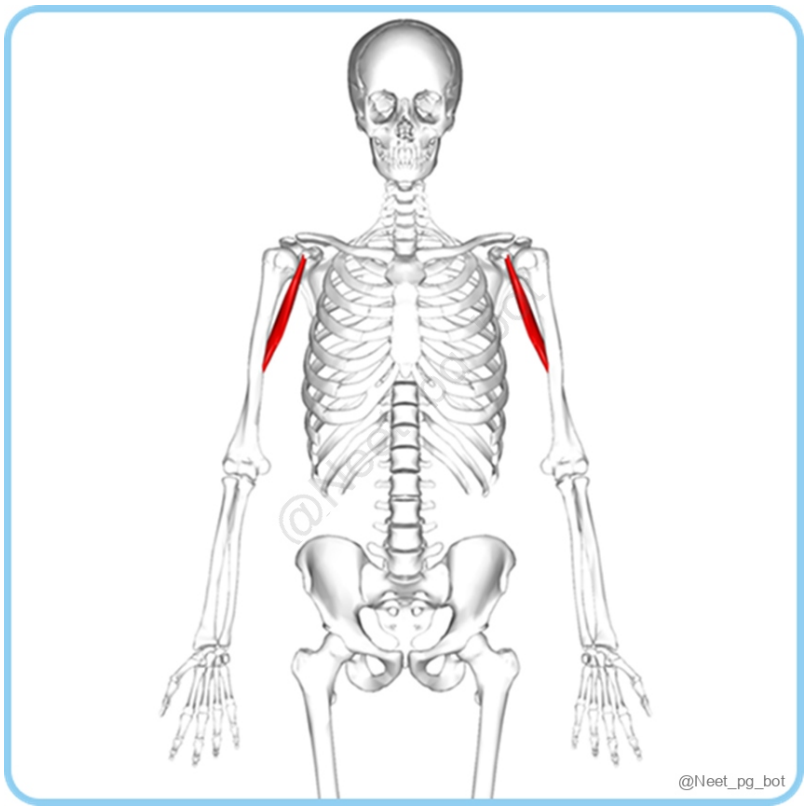

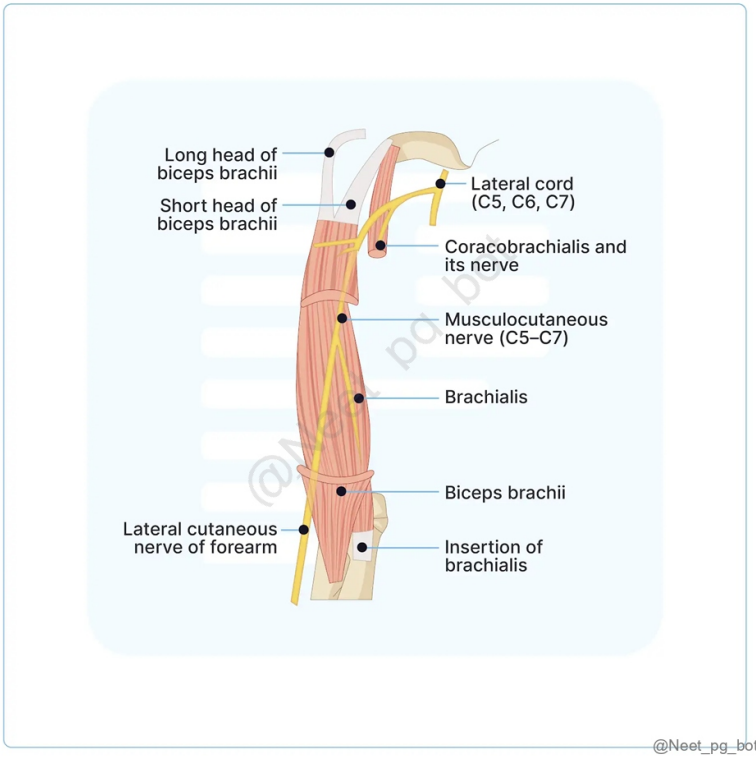

References:

BD Chaurasia’s Human Anatomy Vol-1 Upper limb & Thorax page - 95,96

↑ *Back to this question in Part A*

@Neet_pg_bot

Q6: Identify the muscle shown in the image below. (Q856374)

A. Abductor pollicis longus

B. Palmar interossei

C. Opponens pollicis

D. Flexor pollicis brevis

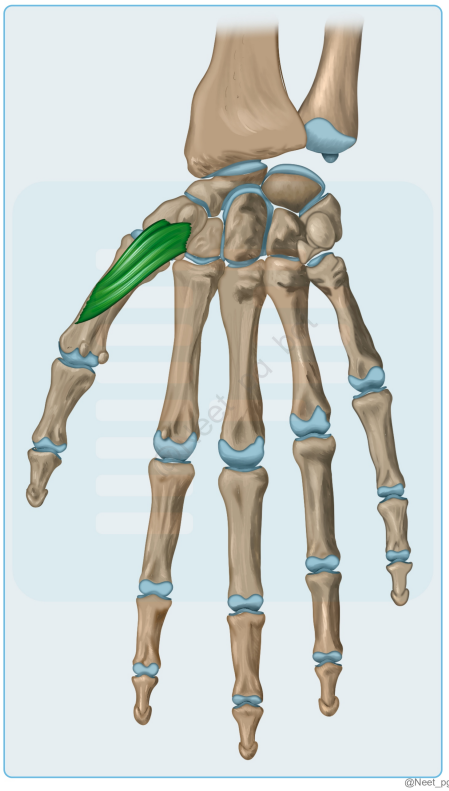

Correct Answer: C. Opponens pollicis

Explanation: The opponens pollicis muscle is attached to the palmar aspect of the first metacarpal. This muscle originates from the flexor retinaculum and the tubercles of the trapezium and scaphoid bones in the wrist. Its tendon inserts onto the palmar surface of the first metacarpal bone. The opponens pollicis muscle functions to oppose the thumb, allowing for its opposition to the other fingers, a key movement for precision grip. Muscles of the thenar eminence: Muscle Attachments Nerve supply Action Abductor pollicis brevis Origin: Scaphoid tubercle, crest of Trapezium, and flexor retinaculum Insertion: Base of the proximal phalanx of the thumb Median nerve Abduction of the thumb Flexor pollicis brevis (Option D) Origin: Capitate, crest of Trapezium, and flexor retinaculum Insertion: Base of the proximal phalanx of the thumb Median nerve Flexion of the

metacarpo-phalangeal joint of the thumb Opponens pollicis Origin: crest of the Trapezium and the flexor retinaculum Insertion: Lateral half of the palmar surface of the shaft of the thumb metacarpal Median nerve Opposition of thumb towards fingers Adductor pollicis (Option A) Origin: Oblique head- base of 2nd-3rd metacarpal ; transverse head- shaft of 3rd metacarpal Insertion: Base of the proximal phalanx of the thumb (medial aspect) Ulnar nerve Adduction of the thumb Palmar Interossei (Option B): While palmar interossei muscles are in the vicinity of the first metacarpal bone, they are not specifically attached to the palmar aspect of the first metacarpal.

References:

BD Chaurasia's Human Anatomy, 8th Edtion, Page no: 133

↑ *Back to this question in Part A*

@Neet_pg_bot

Q7: A 30-year-old female patient is presenting with wrist pain on the lateral side. On examination the following test was positive. Tendon sheaths of which two muscles have been involved? (Q854978)

A. Abductor pollicis longus and extensor pollicis brevis

B. Abductor pollicis longus and extensor pollicis longus

C. Abductor pollicis brevis and extensor pollicis brevis

D. Abductor pollicis brevis and extensor pollicis longus

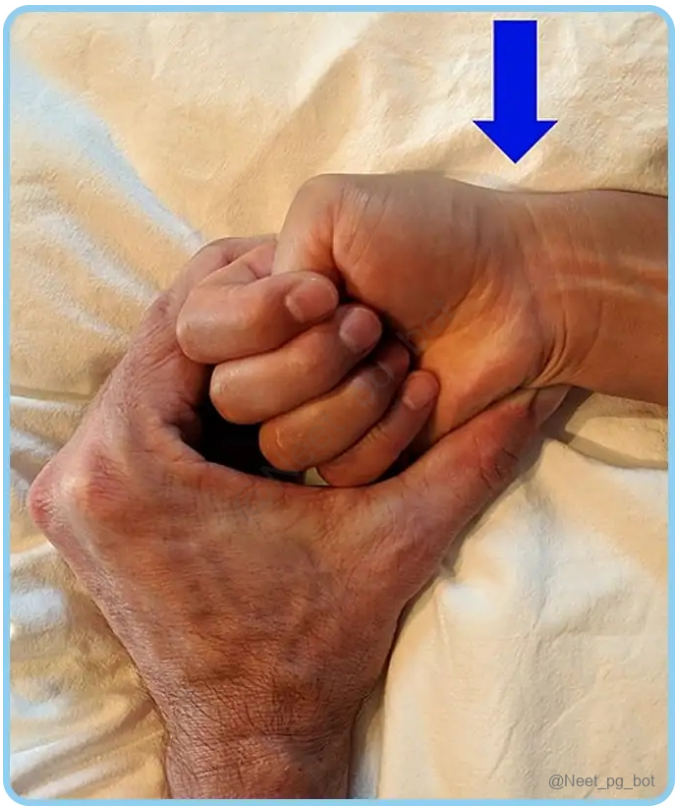

Correct Answer: A. Abductor pollicis longus and extensor pollicis brevis

Explanation: The patient presents with lateral wrist pain and a positive Finkelstein test (most commonly performed for diagnosing De Quervain’s tenosynovitis). {{caption_text}} De Quervain’s tenosynovitis involves the inflammation of the tendon sheaths of: Abductor pollicis longus (APL) Extensor pollicis brevis (EPB) These tendons pass through the first dorsal compartment of the wrist. Abductor pollicis longus and extensor pollicis longus (option B): Extensor pollicis longus (EPL) is located in the third dorsal compartment and is not involved in De Quervain’s tenosynovitis. Abductor pollicis brevis and extensor pollicis brevis (option C): Abductor pollicis brevis (APB) is part of the thenar muscles and does not pass through the first dorsal compartment. Abductor pollicis brevis and extensor pollicis longus (option D): Extensor pollicis longus (EPL) is not affected, and abductor pollicis brevis (APB) is a thenar muscle.

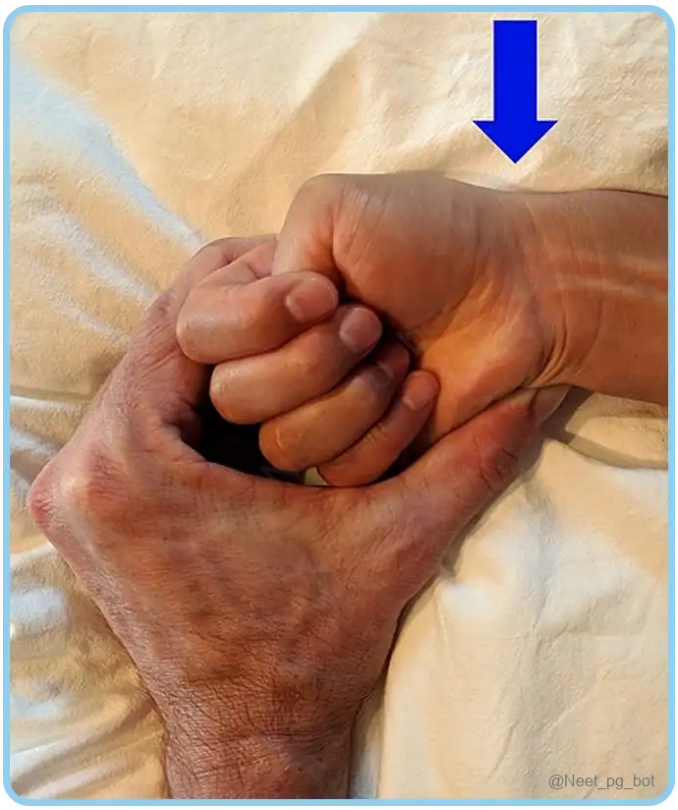

References:

Finkelstein Sign - PubMed Finkelstein Sign - StatPearls - NCBI Bookshelf

↑ *Back to this question in Part A*

@Neet_pg_bot

Q8: A patient presented with the extension of MCP joint and flexion of IP joints. Which muscle is affected? (Q854990)

A. Extensor digitorum

B. Interossei and lumbricals

C. Abductor pollicis longus

D. Abductor pollicis brevis

Correct Answer: B. Interossei and lumbricals

Explanation: This occurs when the muscles that normally flex the MCP joints and extend the IP joints are paralyzed . Muscles responsible for MCP flexion + IP extension : Lumbricals Palmar and dorsal interossei

Dysfunction of these muscles, such as in ulnar nerve damage, leads to the characteristic posture of MCP extension and IP flexion, known as "claw hand." Extensor digitorum (option A): This is incorrect because the extensor digitorum is primarily responsible for extending the MCP, PIP, and DIP joints. It does not cause the flexion of the IP joints with extension at the MCP joint. Abductor pollicis longus (option C): This is incorrect because the abductor pollicis longus is involved in the abduction and extension of the thumb , not the flexion or extension of the fingers. Abductor pollicis brevis (option D): This is incorrect because the abductor pollicis brevis is responsible for the abduction of the thumb and does not influence the MCP or IP joints of the fingers.

References:

BD Chaurasia’s Human Anatomy, 8th Edition, Page 141, 142.

Vishram Singh Textbook of Anatomy, 2nd Edition, Page 152, 153, 154

↑ *Back to this question in Part A*

@Neet_pg_bot

Q9: Identify the sign in the image given below: (Q858481)

A. Popeye sign

B. Hill-Sachs sign

C. Griesinger sign

D. Rising sun sign

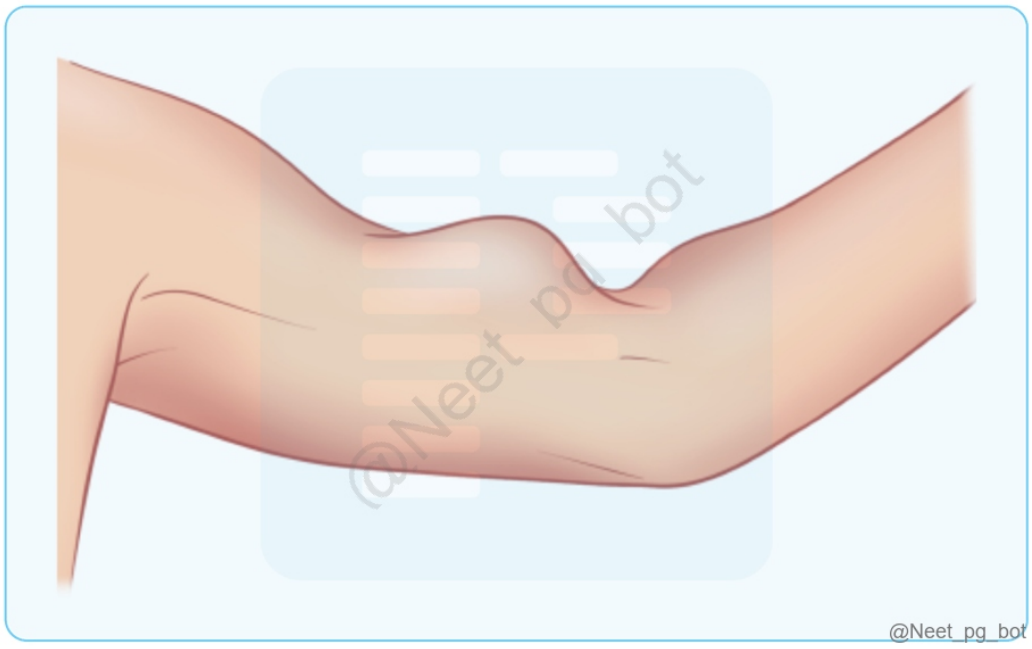

Correct Answer: A. Popeye sign

Explanation: Popeye sign refers to a characteristic bulging of the biceps muscle belly in the upper arm due to a rupture of the long head of the biceps tendon . The proximal portion of the tendon retracts , causing the muscle to bunch up in the mid-upper arm, resembling Popeye's biceps from the cartoon character. It is often seen in older adults , particularly in those with a history of repetitive overhead activity or degenerative tendon changes . Patients typically present with: Sudden pain in the shoulder Audible "pop" Bruising Weakness in elbow flexion and supination Incorrect Options: Hill-Sachs sign (option B): A cortical depression (compression fracture) in the posterolateral humeral head , caused by anterior shoulder dislocation . Best seen on X-ray or MRI , not a visible sign like Popeye sign. Griesinger sign (option C): Seen in lateral sinus thrombophlebitis (complication of otitis media or mastoiditis). Characterized by tenderness and swelling over the mastoid process due to venous congestion. Rising sun sign (option D): Seen in orbital floor fractures , indicating prolapse of orbital contents into the maxillary sinus, resembling a "rising sun" on imaging.

References:

Images in clinical medicine: Popeye's sign - PMC

↑ *Back to this question in Part A*

@Neet_pg_bot

Q10: Which of the following forms the lateral boundary of the anatomical snuff box? (Q858486)

A. Extensor pollicis brevis and abductor pollicis longus

B. Extensor pollicis longus and abductor pollicis brevis

C. Extensor pollicis longus and extensor pollicis brevis

D. Abductor pollicis longus and abductor pollicis brevis

Correct Answer: A. Extensor pollicis brevis and abductor pollicis longus

Explanation: The anatomical snuff box is a triangular depression on the lateral aspect of the wrist, best seen when the thumb is extended . It is bounded laterally by the tendons of: Abductor pollicis longus (APL) Extensor pollicis brevis (EPB) Boundaries of the Anatomical Snuff Box: Lateral (Radial) Boundary: Abductor pollicis longus (APL) Extensor pollicis brevis (EPB) Medial (Ulnar) Boundary: Extensor pollicis longus (EPL) Floor: Scaphoid & Trapezium bones Radial artery passes through Roof: Skin & Superficial branch of the radial nerve Contents Radial Artery: Crosses the floor of the anatomical snuff box. Tenderness in the anatomical snuff box following a fall on an outstretched hand strongly suggests a scaphoid fracture , as the scaphoid bone lies in the floor of the anatomical snuff box. This type of fracture is common and can have complications due to poor blood supply. Incorrect Options: Extensor pollicis longus and abductor pollicis brevis (option B): EPL forms the medial boundary , not lateral. Abductor pollicis brevis (APB) is not involved in the snuff box boundaries. Extensor pollicis longus and extensor pollicis brevis (option C): EPL is the medial boundary , while EPB is lateral. The second lateral tendon (

APL) is missing. Abductor pollicis longus and abductor pollicis brevis (option D): Abductor pollicis brevis (APB) is not part of the snuff box .

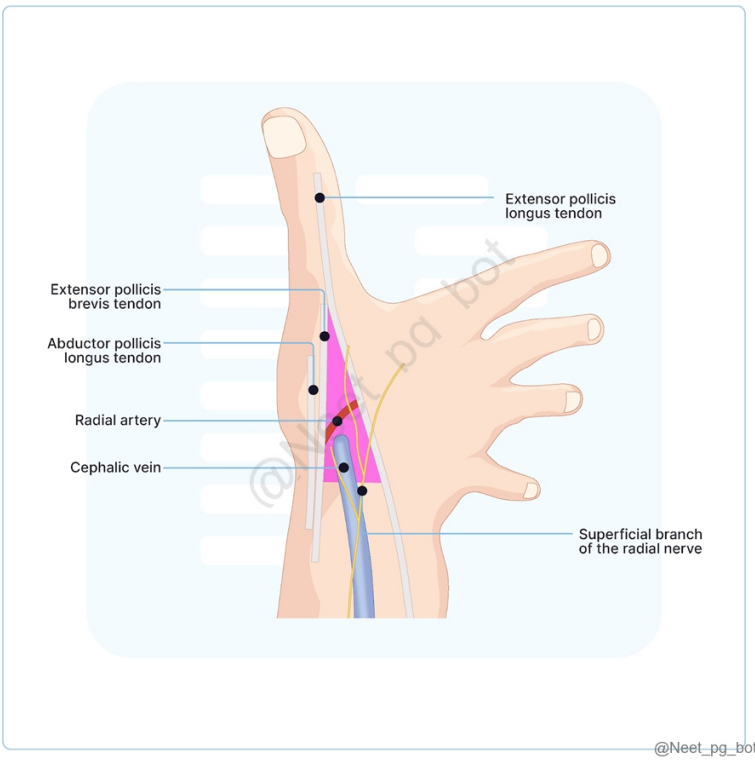

References:

Inderbir Singh, 6th Edition, Page 197

↑ *Back to this question in Part A*

@Neet_pg_bot

Q11: The image showed a normal elbow. What is the structure marked in the image called? (Q859519)

A. Capitulum

B. Trochlea

C. Olecranon

D. Head of radius

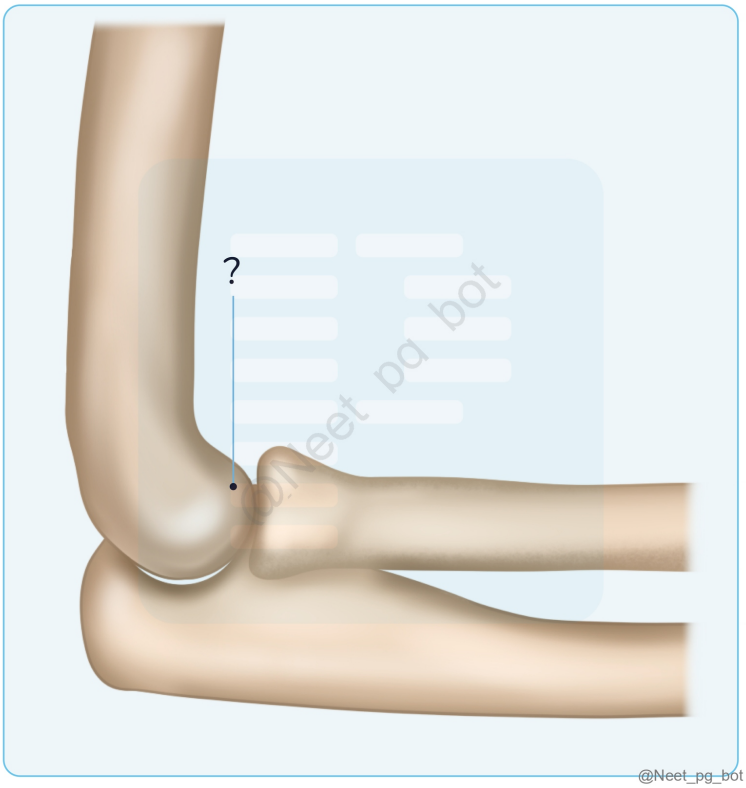

Correct Answer: A. Capitulum

Explanation: The capitulum is a rounded knob-like structure located on the distal end of the humerus bone. It articulates with the radius bone to form the radiocapitular joint, which allows for flexion and extension movements of the forearm at the elbow joint. {{caption_text}} Incorrect Options: Trochlea (Option B): The trochlea is a spool-shaped structure located on the distal end of the humerus bone, just medial to the capitulum. It forms the trochlear notch of the ulna bone, creating the ulnohumeral joint. The trochlea is responsible for the hinge-like movements of the elbow Joint, allowing flexion and extension of the forearm. Olecranon (Option C): The olecranon is a bony prominence located at the proximal end of the ulna bone, forming the bony tip of the elbow. It serves as an attachment point for muscles and ligaments, including the triceps brachii muscle and the triceps tendon. The olecranon helps stabilize the elbow joint and provides leverage for extension movements of the forearm. Head of radius (Option D): The head of the radius is the rounded, disc-shaped structure located at the proximal end of the radius bone. It articulates with the capitulum of the humerus, forming the radiocapitular joint. The head of the radius allows for rotation movements of the forearm, such as pronation and supination.

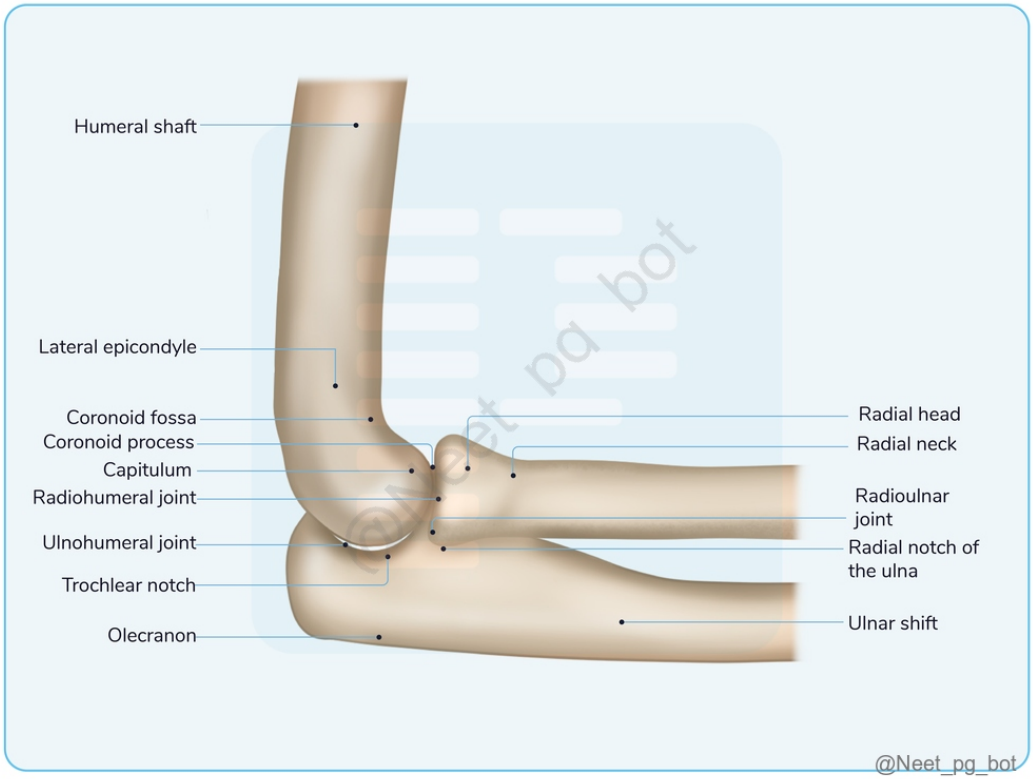

References:

https://www.ncbi.nlm.nih.gov/books/NBK544512/

↑ *Back to this question in Part A*

@Neet_pg_bot

Q12: Based on the clinical image below, what is the most probable nerve to be injured? (Q859526)

A. Thoracodorsal nerve

B. Axillary nerve

C. Intercostal nerve

D. Long thoracic nerve

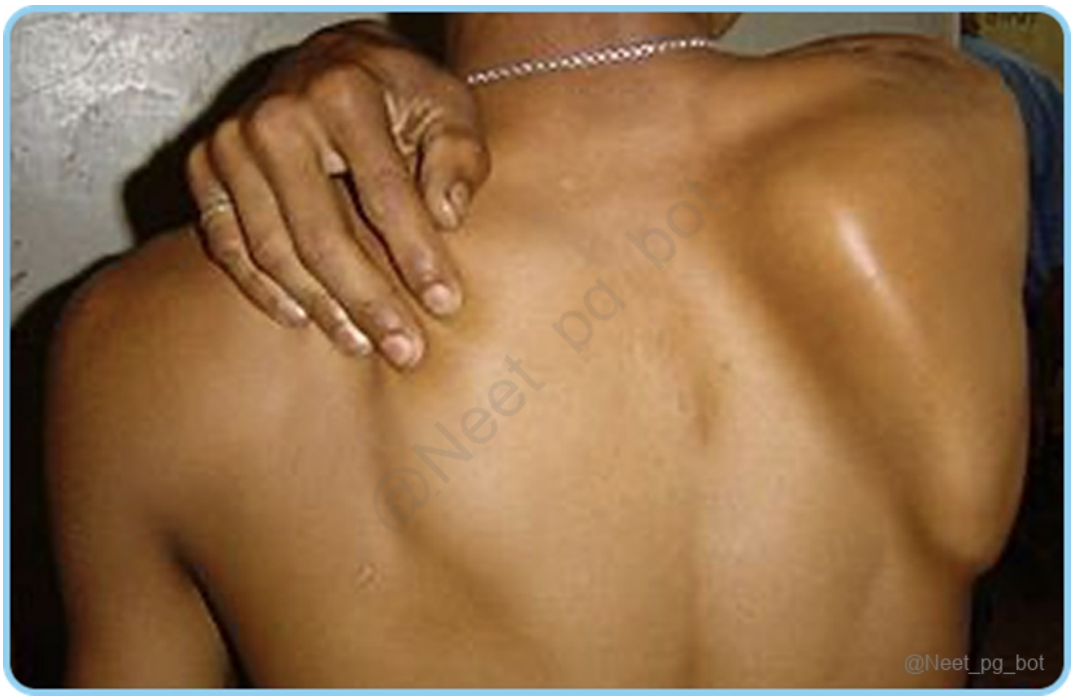

Correct Answer: D. Long thoracic nerve

Explanation: Injury to the long thoracic nerve results in weakness of the serratus anterior and winging of the scapula, as seen in the image. The long thoracic nerve, from the upper part of the brachial plexus's superior trunk, usually receives contributions from cervical nerves C5, C6, and C7. It innervates the serratus anterior muscle, weakness of which often causes scapular winging due to inadequate protraction countered by rhomboid and trapezius actions, leading to medial scapular winging. Long thoracic nerve Origin C5 - C7 Insertion Serratus anterior muscle , which is responsible for scapular protraction and upward rotation . Nerve actions (Motor function) Protracts the scapula (pulls it forward around the thorax). Assists in arm anteversion (moving the arm forward). Lifts the ribs , aiding in respiration. Responsible for the anterolateral motion of the scapula , which is necessary for arm elevation . Incorrect Options: Thoracodorsal nerve (Option A): mainly from C7 with contributions from C6 to C8, innervates the Latissimus dorsi muscle. It's often utilized as a nerve graft in surgeries. Axillary nerve (Option B): arising from the brachial plexus's posterior cord, controls the teres minor, deltoid muscles, shoulder skin, and glenohumeral joint, often injured in orthopedic surgeries, shoulder dislocations, and rotator cuff tears. Intercostal nerve (Option C): from T1 to T11 spinal nerves, provides sensory innervation to the chest wall and abdomen skin and motor innervation to intercostal and abdominalmuscles.

References:

B. D. Chaurasia’s Human Anatomy, VOL- 1 Edition 8, Pages 69, 74, 201

↑ *Back to this question in Part A*

@Neet_pg_bot

Q13: A patient presented with a history of chop injury to the right hand is undergoing surgical repairs . It is observed that the patient is unable to completely fold the right

ring finger, while making the fist , which structure injury results in this? (Q857228)

A. Median nerve

B. Flexor retinaculum

C. Flexor digitorum profundus

D. Flexor pollicis longus

Correct Answer: C. Flexor digitorum profundus

Explanation: The flexor digitorum profundus (FDP) is responsible for flexion at the distal interphalangeal (DIP) joints of the medial four fingers. If the FDP to the ring finger is injured , the patient will be unable to fully flex the ring finger when making a fist. Muscles Involved in the Movement of Interphalangeal Joints The interphalangeal (IP) joints include: Proximal interphalangeal (PIP) joints – between proximal and middle phalanges. Distal interphalangeal (DIP) joints – between middle and distal phalanges. Movement Muscles Involved Innervation Flexion of PIP joints Flexor digitorum superficialis (FDS) Median nerve Flexion of DIP joints Flexor digitorum profundus (FDP) Lateral part (index & middle fingers): Median nerve Medial part (ring & little fingers): Ulnar nerve Extension of PIP & DIP joints Extensor digitorum Extensor indicis (index finger only) Extensor digiti minimi (little finger only) Radial nerve (posterior interosseous branch) Assists in extension of PIP & DIP joints Lumbricals Palmar & dorsal interossei Lumbricals: Lateral 2 (median nerve), medial 2 (ulnar nerve) Interossei: Ulnar nerve Median nerve (Option A): Incorrect because median nerve injury would affect multiple fingers (thumb, index, middle), not just the ring finger alone. Flexor retinaculum (Option B): Incorrect because injury to the retinaculum leads to carpal tunnel syndrome , affecting the median nerve distribution, not isolated finger flexion. Flexor pollicis longus (Option D): Incorrect because this muscle only flexes the thumb , not the ring finger.

References:

Inderbir Singh edition 6, page- 176,177,179&180

↑ *Back to this question in Part A*

@Neet_pg_bot

Q14: A 34-year-old male patient presents to the OPD complaining of pain in the medial part of the elbow for the past 4-6 weeks. He states that the pain worsens while lifting weights in the gym. On examination, there is tenderness over the medial epicondyle, and reverse Cozen's test is positive. Which of the following nerves is most likely to be injured in this patient? (Q859916)

A. Median nerve

B. Ulnar nerve

C. Radial nerve

D. Axillary nerve

Correct Answer: B. Ulnar nerve

Explanation: The patient suffers from medial epicondylitis or golfer's elbow. The Ulnar nerve is posterior to the medial epicondyle within the cubital tunnel. The main symptom of medial epicondylitis is the 5 to 10 mm distal tenderness to the medial epicondyle. The pain is generally aggravated with resisted wrist flexion and pronation, known as reverse Cozen's test. Hand and Forearm Deformities: Mallet Finger (Baseball Finger): Permanent flexion of the distal phalanx due to lateral band avulsion of the extensor tendon. Boutonniere Deformity: Flexion of the middle phalanx and hyperextension of the distal phalanx due to central band avulsion of the extensor tendon. Tennis Elbow (Lateral Epicondylitis): Inflammation of extensor tendons from the lateral epicondyle (common in tennis players, violinists). Golfer’s Elbow (Medial Epicondylitis): Inflammation of flexor tendons from the medial epicondyle . Volkmann Ischemic Contracture: Flexion deformity of fingers due to ischemic necrosis of forearm flexor muscles (e.g., tight cast injury). Dupuytren Contracture: Progressive thickening of the palmar aponeurosis , pulling fingers into flexion. Swan Neck Deformity: Hyperextension of the PIP joint with flexion of the DIP joint . Nerve Root origin Common causes Features Radial (Option C) C5-T1 Compression in axilla (crutches, "Saturday night palsy") Midshaft fracture of humerus Repetitive pronation/supination (screwdriver use, "finger drop") Above elbow injury: Loss of sensation over posterior arm/forearm and dorsal hand Wrist drop (loss of elbow, wrist, and finger extension) Decreased grip strength (wrist extension necessary for maximal action of flexors) Below elbow injury: Distal paresthesias without wrist drop Midshaft fracture: Tricep function and posterior arm sensation spared Median (Option A) C5-T1 Supracondylar fracture of humerus (proximal lesion) Carpal tunnel syndrome and wrist laceration (distal lesion) "Ape hand" and "Hand of benediction" Loss of wrist flexion Loss of function of LOAF muscles (Lumbricals (lateral two), Opponens pollicis, Abductor pollicis brevis, Flexor pollicis brevis) Loss of sensation over thenar eminence and dorsal and palmar aspects of lateral 3 1/2 fingers with proximal lesion Ulnar C8-T1 Fracture of medial epicondyle of humerus (proximal lesion) Fractured hook of hamate (distal lesion) from fall on outstretched hand Compression of nerve against hamate during cycling "Ulnar claw" on digit extension Radial deviation of wrist upon flexion (proximal lesion) Decreased flexion of ulnar fingers Loss of abduction and adduction of fingers (interossei) Loss of thumb adduction Loss of action of ulnar 2 lumbrical muscles Loss of sensation over ulnar 1 1/2 fingers including hypothenar eminence Axillary nerve injury (Option D): Would cause sensory loss over the lateral shoulder (regimental badge area) , not the posterior forearm.

References:

https://www.ncbi.nlm.nih.gov/books/NBK557869/

↑ *Back to this question in Part A*

@Neet_pg_bot

Q15: Identify the tendon marked in the image (Q859920)

A. Flexor carpi radialis

B. Flexor carpi ulnaris

C. Palmaris longus

D. Median nerve

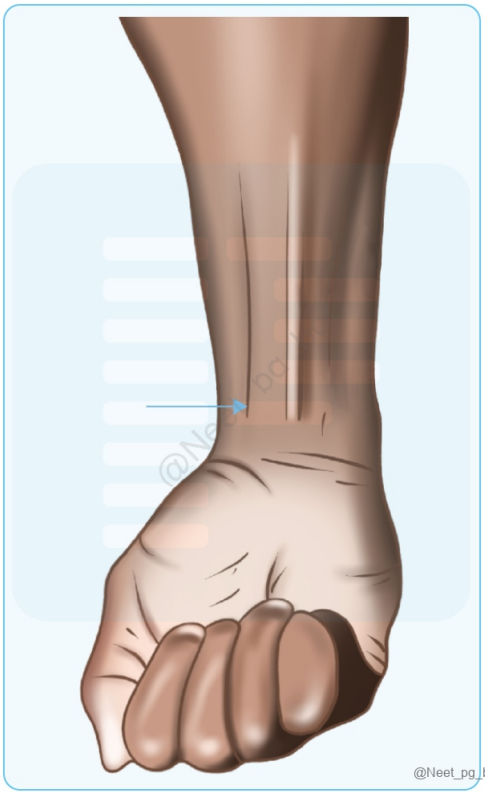

Correct Answer: A. Flexor carpi radialis

Explanation: The tendon marked in the image is the tendon of the flexor carpi radialis muscle. Flexor carpi radialis muscle is a long flexor muscle lying in the anterior compartment of the forearm. It arises in the humeral epicondyle, close to the wrist area. It is a superficial muscle that becomes visible as the wrist flexes. Muscles of Forearm: Superficial flexor muscles: Origin, insertion, nerve supply and action: (Options B, C) Deep flexor muscles–origin, insertion, nerve supply and action: Median nerve (Option D): Lies deep and does not appear as a tendon

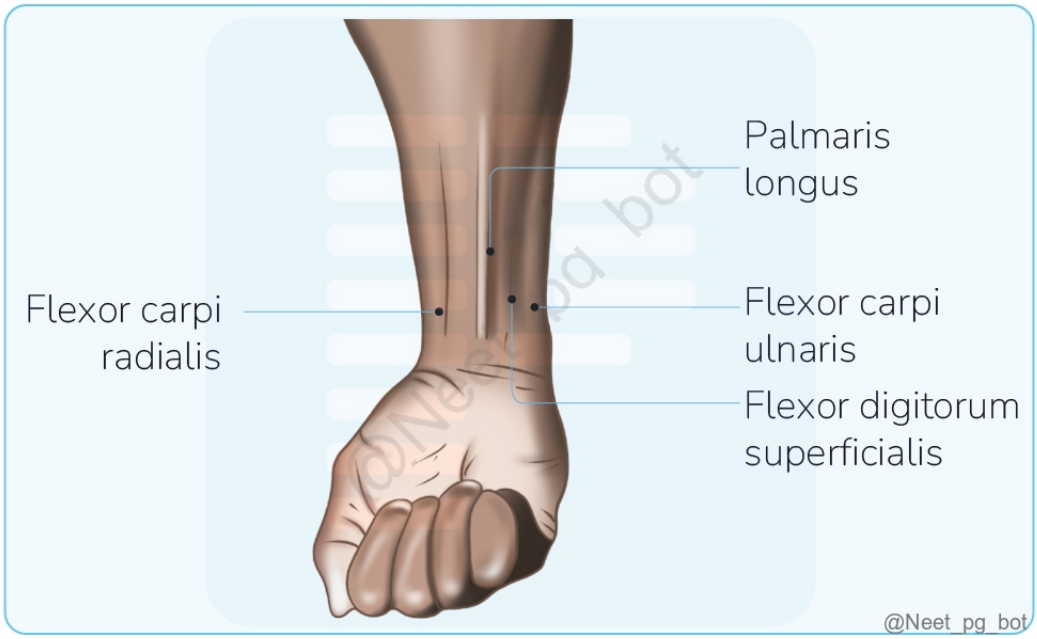

Muscles	Origin	Insertion	Nerve supply	Action
Pronator teres	Humeral head-medial supracondylar ridge and from ulna	Middle of radius	Median nerve	Pronation and weak flexor of forearm
Flexor carpi radialis	Medial epicondyle of humerus	Base of 2nd/3rd metacarpal bones	Median nerve	Weak flexor and abducts (radial deviation) the wrist
Palmaris longus	Medial epicondyle of humerus	Palmar aponeurosis and flexor retinaculum	Median nerve	Weak flexor of wrist
Flexor carpi ulnaris	Medial epicondyle of humerus and medial olecranon and posterior border of ulna	Pisiform bone and hook of hamate and 5th metacarpal	Ulnar nerve	Weak flexor and adducts (ulnar deviation) the wrist
Flexor digitorum superficialis	Medial epicondyle of humerus, coronoid process, oblique line of radius	Divides into 4 tendons and insert to middle phalanx	Median nerve	Flex the wrist, metacarpophalangeal and proximal interphalangeal joint

@Neet_pg_bot

Muscles	Origin	Insertion	Nerve supply	Action
Flexor digitorum profundus	Anteromedial surface of ulna and interosseus membrane	Divided into 4 tendons and Distal phalanx	Anterior interosseous nerve and ulnar nerve	Flex the wrist, metacarpophalangeal and proximal interphalangeal joint and distal interphalangeal joint
Flexor pollicis longus	Anterior surface of radius and interosseous membrane and coronoid process	Distal phalanx of thumb	Anterior interosseous nerve	Flex the wrist and interphalangeal joint of wrist
Pronator quadrantus	Anterior surface of distal ulna	Anterior surface of distal Radius	Anterior interosseous nerve	Pronates forearm

@Neet_pg_bot

References:

https://pmc.ncbi.nlm.nih.gov/articles/PMC9464466/

↑ *Back to this question in Part A*

@Neet_pg_bot

Q16: A man who was on crutches now presents with tingling and paraesthesia on the medial side of the arm, forearm, and hand. Which structure is most likely to be affected? (Q859924)

A. A

B. B

C. C

D. D

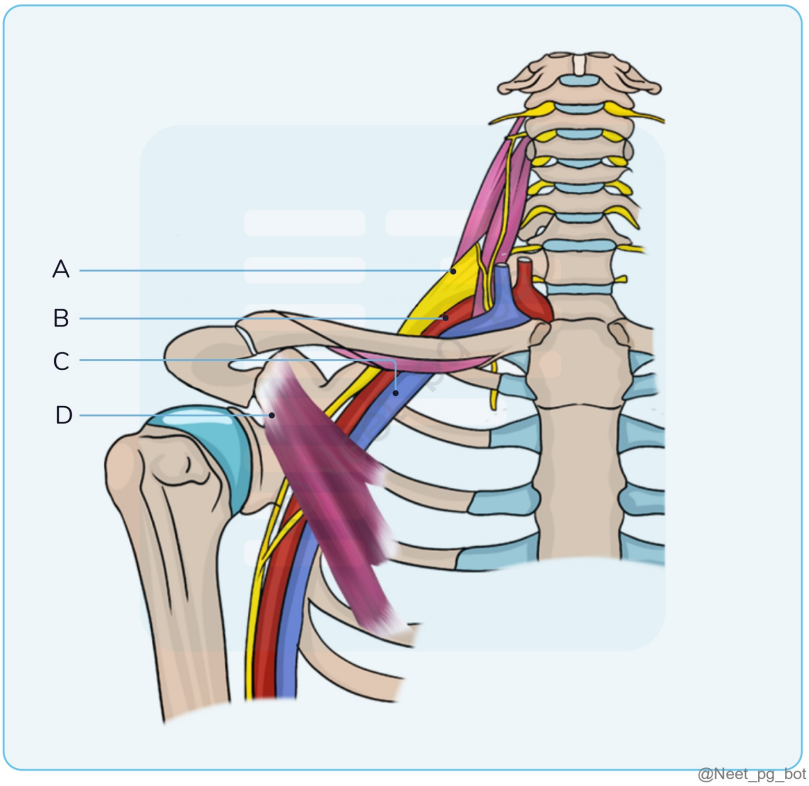

Correct Answer: A. A

Explanation: The patient has a history of using crutches , which can compress the Brachial plexus, indicated by A in the figure Nerve Root origin Common causes Features Radial C5-T1 Compression in axilla (crutches, "Saturday night palsy") Midshaft fracture of humerus Repetitive pronation/supination (screwdriver use, "finger drop") Above elbow injury: Loss of sensation over posterior arm/forearm and dorsal hand Wrist drop (loss of elbow, wrist, and finger extension) Decreased grip strength (wrist extension necessary for maximal action of flexors) Below elbow injury: Distal paresthesias without wrist drop Midshaft fracture: Tricep function and posterior arm sensation spared Median C5-T1 Supracondylar fracture of humerus (proximal lesion) Carpal tunnel syndrome and wrist laceration (distal lesion) "Ape hand" and "Hand of benediction" Loss of wrist flexion Loss of function of LOAF muscles (Lumbricals (lateral two), Opponens pollicis, Abductor pollicis brevis, Flexor pollicis brevis) Loss of

sensation over thenar eminence and dorsal and palmar aspects of lateral 3 1/2 fingers with proximal lesion Ulnar C8-T1 Fracture of medial epicondyle of humerus (proximal lesion) Fractured hook of hamate (distal lesion) from fall on outstretched hand Compression of nerve against hamate during cycling "Ulnar claw" on digit extension Radial deviation of wrist upon flexion (proximal lesion) Decreased flexion of ulnar fingers Loss of abduction and adduction of fingers (interossei) Loss of thumb adduction Loss of action of ulnar 2 lumbrical muscles Loss of sensation over ulnar 1 1/2 fingers including hypothenar eminence B (Option B): The structure in the figure is a Subclavian artery Compression would lead to vascular symptoms (cold, pale limb, weak pulses), not isolated tingling/paresthesia. C (Option C): The structure in the figure is a Subclavian Vein Affected veins would cause swelling and venous congestion, not sensory loss. D (Option D): The structure in the figure is a Scalenus Anterior While the scalene muscles can contribute to thoracic outlet syndrome, they mainly compress the subclavian vessels or brachial plexus at the root level, affecting more than just the medial arm.

References:

https://www.ncbi.nlm.nih.gov/books/NBK448074/

↑ *Back to this question in Part A*

@Neet_pg_bot

Q17: The marked structure serves as a surface landmark for which anatomical structure? (Q852990)

A. Pineal gland

B. Wernicke's area

C. Stem of lateral sulcus

D. Internal carotid artery siphon

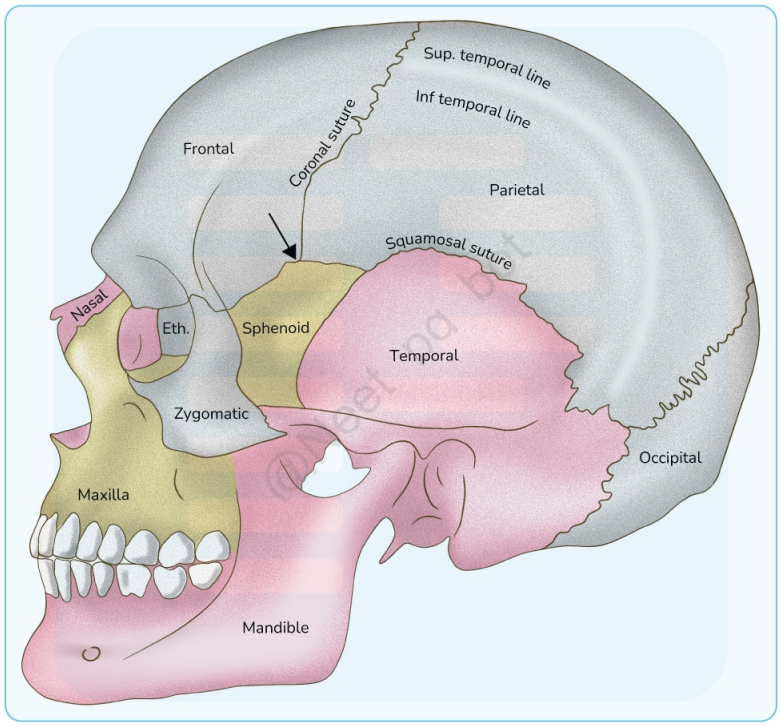

Correct Answer: C. Stem of lateral sulcus

Explanation: The stem of the lateral sulcus (Sylvian fissure) serves as a key surface landmark in the brain. It separates the frontal and temporal lobes and extends posteriorly towards the insular cortex . It is an important landmark for neurosurgical approaches and neurovascular structures. The middle cerebral artery (MCA) runs within the lateral sulcus, supplying a major portion of the cerebral cortex. Lateral Sulcus (Sylvian Fissure) and Its Anatomical Importance Feature Description Location Separates the frontal and temporal lobes Extends to Insular cortex and parietal lobe Contains Middle cerebral artery (MCA) Functions Landmark for neurosurgery, cortical mapping Related Clinical Importance MCA strokes affect motor, sensory, and language functions {{caption_text}} {{caption_text}} Pineal gland (Option A): Incorrect because the pineal gland is located near the posterior midline of the brain , not associated with the lateral sulcus. Wernicke’s area (Option B): Incorrect because Wernicke’s area is found in the posterior superior temporal gyrus , although related to the lateral sulcus, it is not its direct landmark. Internal carotid artery siphon (Option D): Incorrect because the ICA siphon is an S-shaped bend in the cavernous segment of the internal carotid artery , located near the base of the skull, not directly related to the lateral sulcus.

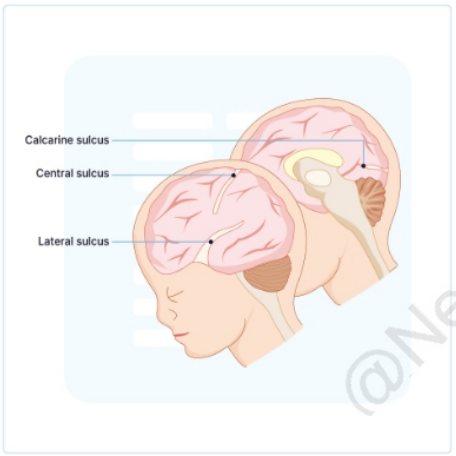

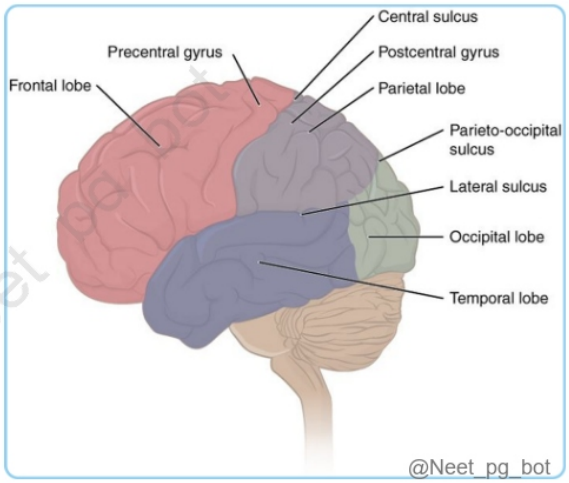

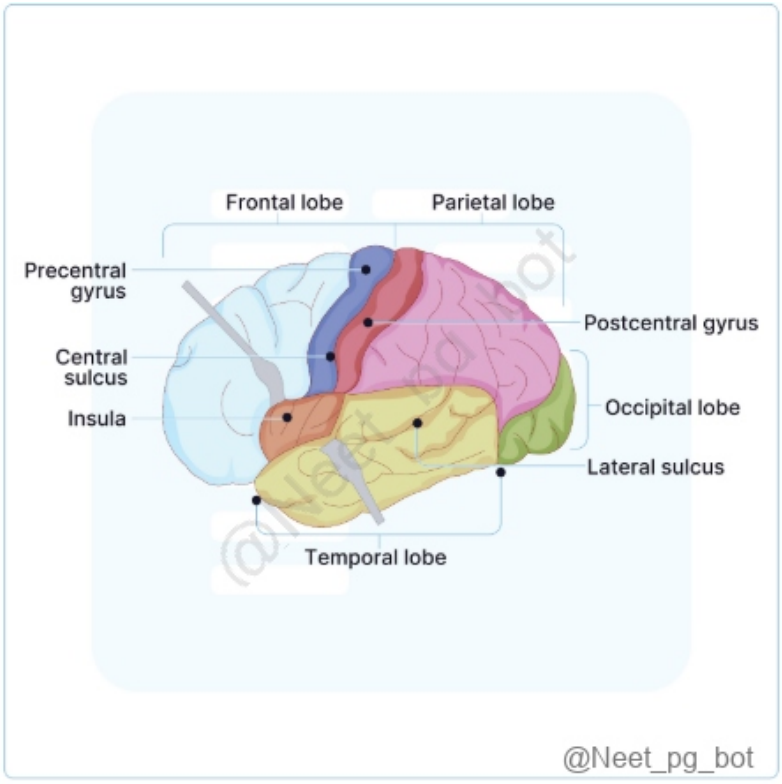

References:

Gray’s Anatomy, 42nd Edition, Pages 395, 396

Vishram Singh, Anatomy of Head, Neck, Brain, Volume 3, Pages 389-391

↑ *Back to this question in Part A*

@Neet_pg_bot

Q18: The bone shown in the image is not associated with which of the following types of joints? (Q839878)

A. Syndesmosis

B. Symphysis

C. Plane synovial joint

D. Synchondrosis



Correct Answer: D. Synchondrosis

Explanation: Correct Option D - Synchondrosis: The image shown above is of vertebra Synchondrosis is a type of joint where the bones are connected by hyaline cartilage. These joints are usually temporary and found in growing bones, such as the epiphyseal plates (growth plates) in children and the first sternocostal joint that unites the first rib to the sternum Synchondrosis or primary cartilaginous joints are not present in the given image Incorrect Options: Option A - Syndesmosis: Definition: A syndesmosis is a type of fibrous joint where bones are connected by a ligament or a sheet of connective tissue. The supraspinous ligament, interspinous ligament, ligamentum flavum (Connecting the lamina of adjacent bones). Posterior longitudinal ligament, anterior longitudinal ligament, these ligaments connects the adjacent vertebrae forming syndesmosis Option B - Symphysis: Definition : A symphysis is a type of cartilaginous joint where the bones are connected by fibrocartilage. Examples: The pubic symphysis. The intervertebral discs. Option C - Plane Synovial Joint: A plane synovial joint, also known as a gliding joint, involves flat or nearly flat articular surfaces that allow bones to slide over one another. The joint between the superior articular facet and inferior articular facet is plain synovial joint and thus makes it an incorrect

choice

↑ *Back to this question in Part A*

@Neet_pg_bot

Q19: Which of the following is the type of joint between epiphysis and diaphysis of a long bone? (Q860263)

A. Symphysis

B. Synchondrosis

C. Synostosis

D. Syndesmosis

Correct Answer: B. Synchondrosis

Explanation: Synchondrosis is a type of joint that is a primary cartilaginous joint where the epiphysis and diaphysis of a long bone are connected by a growth plate made of hyaline cartilage. Primary Cartilaginous Joints (Synchondrosis) Secondary Cartilaginous Joints (Symphysis) (Option A) Immobile Occur where ossification centres remain separated by hyaline cartilage. Found in bones that form from more than one ossification centre. Hyaline cartilage here can ossify with age, leading to fusion when growth is completed. Temporary and mainly for growth. Mostly associated with growth plates. The joint between the first rib and the manubrium is a permanent synchondrosis. Slightly mobile Defined by a pad or disc of fibrocartilage between articulating bones, e.g., intervertebral discs. Built to handle a variety of stresses (compression, tension, etc.). Permanent and provide limited movement. Found along the midline (e.g., pubic symphysis, intervertebral joints). Strong ligaments reinforce the joints and are key to stability and movement. Symphyses are built for durability and movement, but they also allow growth in areas like the intervertebral discs. Synostosis (Option C): Synostosis refers to the fusion of bones where the original cartilage is replaced entirely by bone. Syndesmosis (Option D): A syndesmosis is a fibrous joint where bones are connected by a ligament or an interosseous membrane, allowing for limited movement.

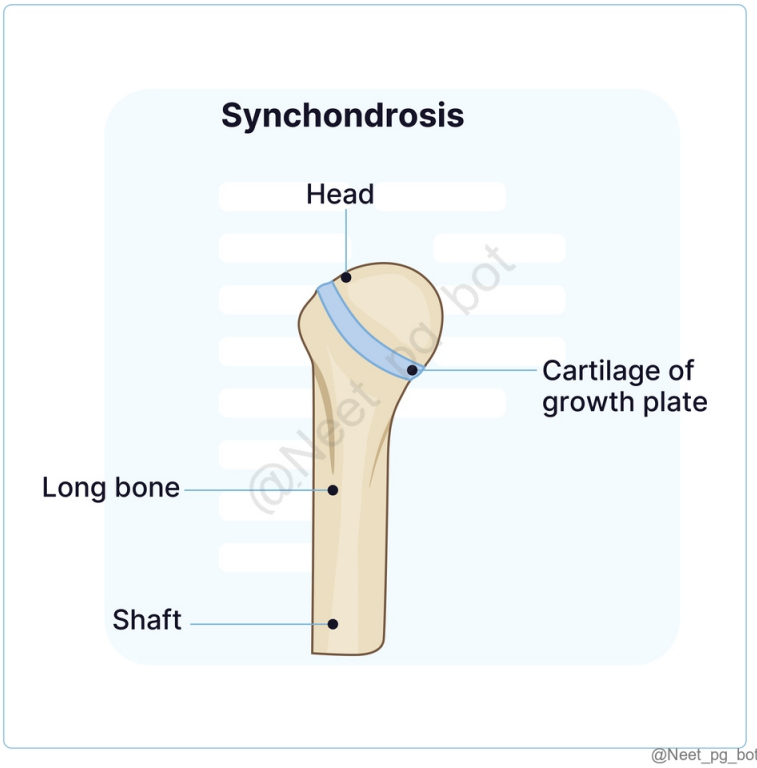

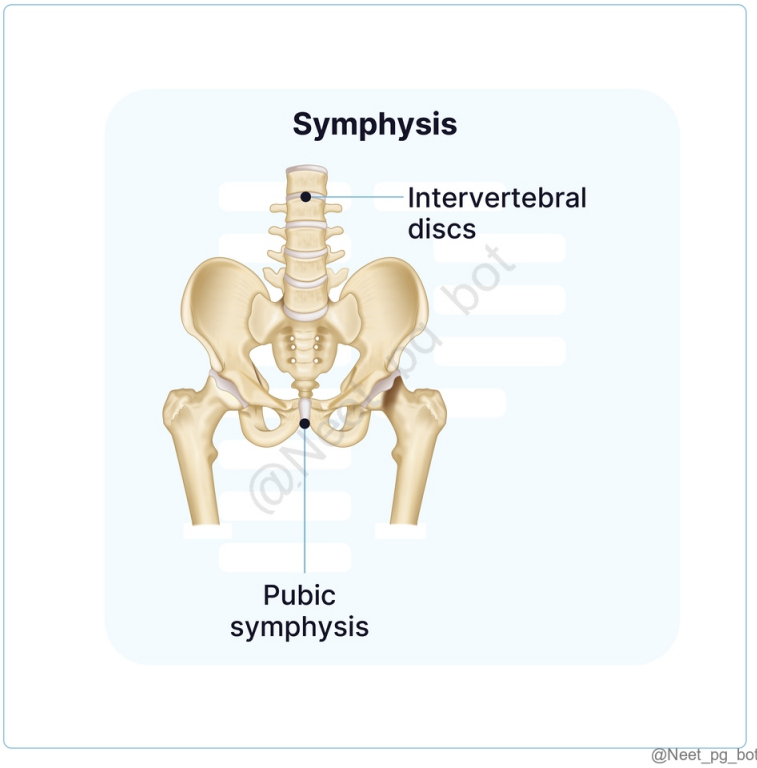

References:

Gray's Anatomy, 42nd Edition, Pg.102,106 BD Chaurasia 8th edition, volume 1, pg 155

↑ *Back to this question in Part A*

@Neet_pg_bot

Q20: Which part of this bone is palpable in the infraclavicular fossa? (Q855779)

A. 1

B. 2

C. 3

D. 4



Correct Answer: A. 1

Explanation: The coracoid process (1) is the only palpable part of the scapula in the infraclavicular fossa . It lies deep to the clavicle , but its tip can be felt by pressing below the lateral third of the clavicle. Palpable Bony Landmarks of the Scapula Structure Palpability Spine of scapula Easily palpable posteriorly. Acromion Most lateral and superior part, prominent. Coracoid process Palpable in the infraclavicular fossa , serves as an attachment site. Inferior angle Palpable at the lower medial end of the scapula. Acromion (Option B-2): Incorrect , as it is palpable over the shoulder , not in the infraclavicular fossa. Lateral angle of scapula (Option C-3): Incorrect , as it is posteriorly palpable , not infraclavicular. Inferior angle (Option D-4): Incorrect , as it is only palpable at the lower scapular border .

References:

Gray's Anatomy: The Anatomical Basis of Clinical Practice, 41st Edition - Page nos: 787, 803

Gray's Anatomy: The Anatomical Basis of Clinical Practice, 42nd Edition - Page no: 884, 896

↑ *Back to this question in Part A*

@Neet_pg_bot

Q21: What type of joint is seen in the labeled structure? (Q859517)

A. Syndesmosis

B. Primary cartilaginous joints

C. Fibrous joint

D. Secondary cartilaginous joint

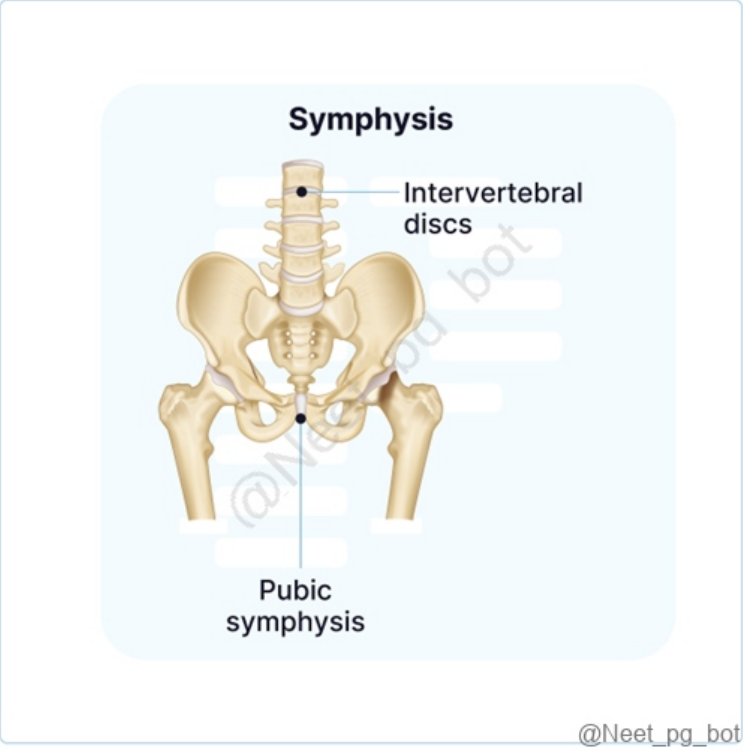

Correct Answer: D. Secondary cartilaginous joint

Explanation: The pubic symphysis is a joint sandwiched between your left pelvic bone and right pelvic bone. It is a secondary cartilaginous joint. The secondary cartilaginous joints are permanent joints, which are slightly movable

and their movements depend upon the sufficient amount of white-fibro cartilage tissues. Primary Cartilaginous Joint (Option B) Secondary Cartilaginous Joint Sutures Syndesmoses (Option A) Gomphosis Joint between epiphysis and diaphysis Between basiocciput and basisphenoid Symphysis menti Symphysis pubis Manubrio sternal Joint between vertebral bodies, xiphisternal joint, midline intervertebral joint Serrate : Sagittal Denticulate : Lambdoid Squamous :Temporoparietal Plane : Between palatine process of maxillae Schindylesis : Between rostrum of sphenoid and upper margin of vomer Inferior tibiofibular joint Tooth fit in the socket Fibrous joints are classified into: (Option C) Sutures, Syndesmoses Gomphosis

References:

Gray's Anatomy, 42nd Edition, Pg.101,102

Snells Anatomy, 10th edition, Pg 13

↑ *Back to this question in Part A*

@Neet_pg_bot

Q22: In the labeled structure, what kind of joint is present? (Q859522)

A. Sutures

B. Primary cartilaginous joints

C. Fibrous joint

D. Secondary cartilaginous joint

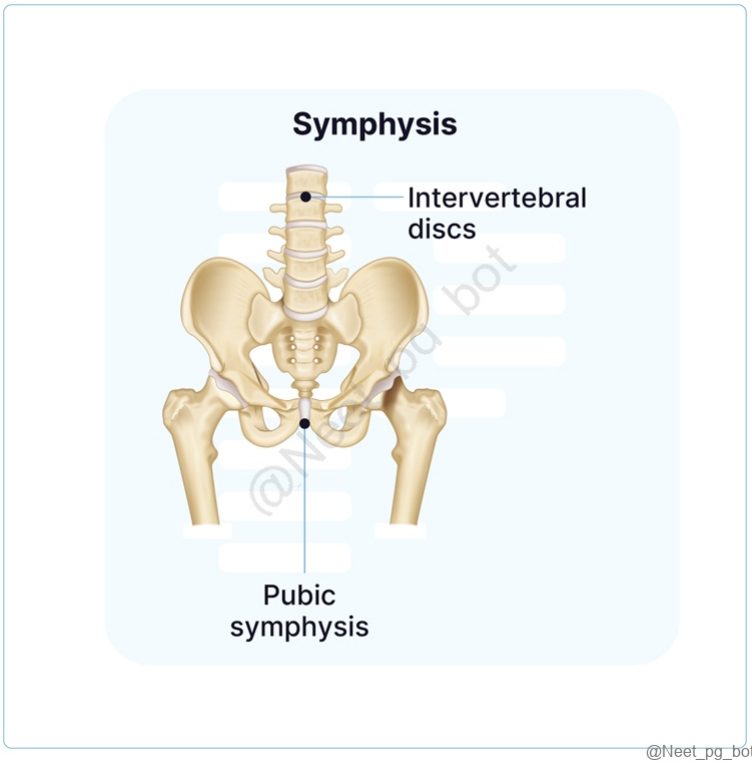

Correct Answer: D. Secondary cartilaginous joint

Explanation: The pubic symphysis is a joint sandwiched between your left pelvic bone and right pelvic bone. It is a secondary cartilaginous joint. The secondary cartilaginous joints are permanent joints, which are slightly movable and their movements depend upon the sufficient amount of white-fibro cartilage tissues. Primary Cartilaginous Joint (Option B) Secondary Cartilaginous Joint Sutures (Option A) Syndesmoses Gomphosis Joint between epiphysis and diaphysis Between basiocciput and basisphenoid Symphysis menti Symphysis pubis Manubrio sternal Joint between vertebral bodies, xiphisternal joint, midline intervertebral joint Serrate: Sagittal Denticulate: Lambdoid Squamous: Temporoparietal Plane: Between palatine process of maxillae Schindylesis: Between rostrum of sphenoid and upper margin of vomer Inferior tibiofibular joint Tooth fit in the socket Fibrous joints are classified into: (Option C) Sutures, Syndesmoses Gomphosis

References:

Gray’s Anatomy, 42nd Edition, Pg.101,102

Snells Anatomy, 10th edition, Pg 13

↑ *Back to this question in Part A*

@Neet_pg_bot

Q23: The given finding is associated with? (Q857932)

A. Trisomy 13

B. Trisomy 21

C. Klinefelter’s

D. Trisomy 18



Correct Answer: B. Trisomy 21

Explanation: Trisomy 21, commonly known as Down syndrome, results from an extra copy of chromosome 21. People with Down syndrome often have distinct facial features, intellectual disabilities, and certain medical problems. Approximately half of individuals with Down syndrome have a single transverse palmar crease, making this the correct answer. The simian crease is relatively common in Down syndrome. Down's syndrome , caused by trisomy 21, is associated with multiple systemic manifestations due to the presence of an extra copy of chromosome 21. This is due to meiotic nondisjunction in either maternal or paternal gamete. Occurs at a frequency of 1:800 to 1:1000 newborns. The overexpression of genes located on chromosome 21 contributes to the clinical features. Clinical Features and Diagnosis: General Features: Intellectual disability Flat facial profile, upward-slanting eyes with epicanthic folds, oblique palpebral fissure (visible when eyes are open). Small nose with flat nasal bridge Narrow palate, small teeth, and furrowed, protruding tongue Significant hypotonia Small, brachycephalic skull with flat occiput, and small, dysplastic ears Short, broad hands with clinodactyly (hypoplasia of the middle phalanx of the fifth finger) Simian crease on the palm A wide gap between the first and second toes (sandal gap) Comorbidities Congenital Heart Disease : 40% of children have congenital heart defects, primarily endocardial cushion defects (40-60% of cases) - AVSD, VSD, ASD, PDA, TOF. Early cardiac evaluation is crucial. Gastrointestinal Malformations : 12% have atresias, especially duodenal atresia. There is an increased risk of annular pancreas and Hirschsprung disease. Ophthalmic Problems : Increased risk of cataracts, nystagmus, strabismus, and visual acuity issues. Regular eye evaluations are advised from infancy onward. Hearing Defects :

40-60% experience conductive hearing loss, often due to serous otitis media in the first year. Routine hearing assessments are recommended before 6 months of age and annually. Thyroid Dysfunction : Hypothyroidism occurs in 13-54% of patients. Atlanto-occipital Subluxation : Incidence ranges from 10-30%. A lateral neck radiograph is recommended. Physical Growth : Linear growth is typically slower, and children may become obese with age. Muscle tone often improves, but regular monitoring of height and weight is necessary. Malignancies : Increased risk of lymphoproliferative disorders, such as acute lymphoblastic leukemia , acute myeloid leukemia, myelodysplasia, and transient lymphoproliferative syndrome. Early-Onset Alzheimer's Disease: The APP gene, located on chromosome 21, plays a significant role in amyloid plaque formation, a hallmark of Alzheimer's disease. Trisomy 13 (Option A): Trisomy 13, or Patau syndrome, results from an extra chromosome 13, leading to severe developmental issues and congenital abnormalities. While hand anomalies are common, a simian crease isn't typically present. Klinefelter's syndrome (Option C): Klinefelter's syndrome in males with an extra X chromosome (XXY) leads to male hypogonadism and physical differences, but it's not usually linked to a simian crease. Trisomy 18 (Option D): Trisomy 18, or Edwards syndrome, stems from an extra chromosome 18, leading to severe developmental delays, intellectual disabilities, and congenital anomalies. While hand abnormalities may occur, a simian crease isn't a defining trait.

References:

BD Chaurasia’s Human Anatomy, 8th Edtion, Page no: 987

↑ *Back to this question in Part A*

@Neet_pg_bot

Q24: The middle radioulnar joint is an example of a: (Q856401)

A. Plane synovial

B. Primary cartilaginous

C. Secondary cartilaginous

D. Fibrous joint

Correct Answer: D. Fibrous joint

Explanation: The middle radioulnar joint, located between the radius and ulna bones in the forearm, facilitates forearm rotation for pronation and supination. It's a fibrous joint known as a syndesmosis, characterized by dense connective tissue like ligaments or interosseous membranes holding the bones together. Fibrous joints connect bones with fibrous connective tissue, allowing minimal movement. They come in three main types: Sutures Gomphosis Syndesmosis Joints between two skull bones. Sutures are immobile in adults and slightly mobile in babies. Gomphosis is an immobile joint. Tooth-socket joints. Slightly mobile joint. Examples include the radioulnar joint and inferior tibiofibular joint. Plane synovial (Option A): Plane synovial joints, also known as gliding joints, are characterized by flat articular surfaces that allow sliding or gliding movements between bones. Primary cartilaginous (Option B): Primary cartilaginous joints, also known as synchondroses, are joints where the bones are connected by hyaline cartilage. Secondary cartilaginous (Option C): Secondary cartilaginous joints, also

known as symphyses, are joints where the bones are connected by fibrocartilage.

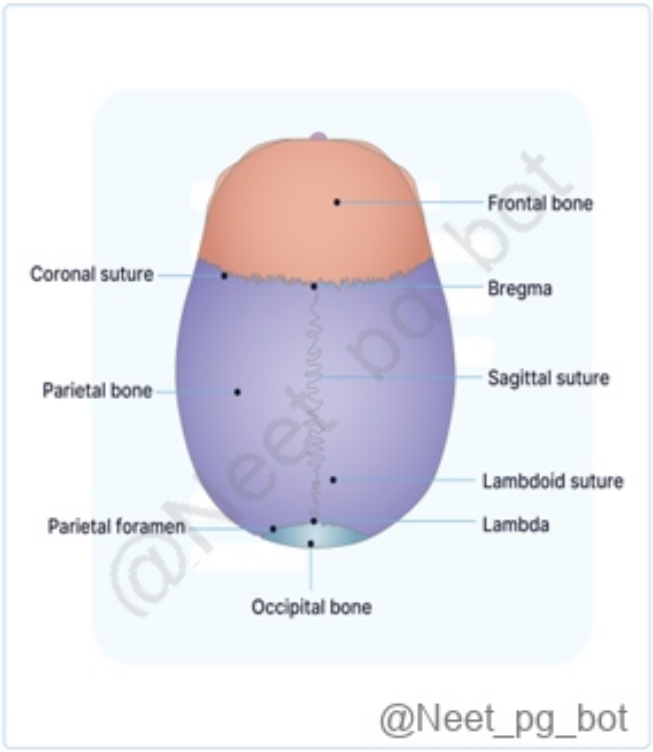

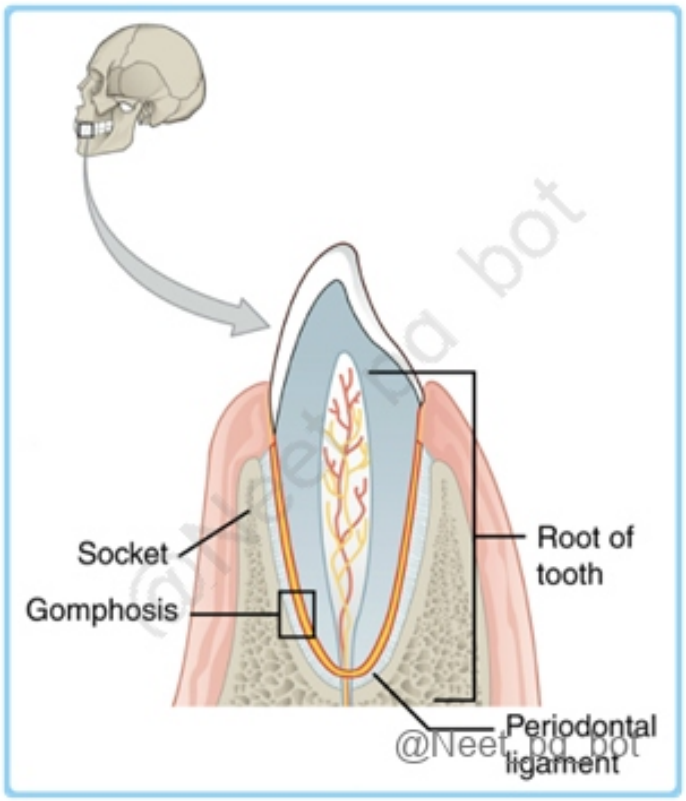

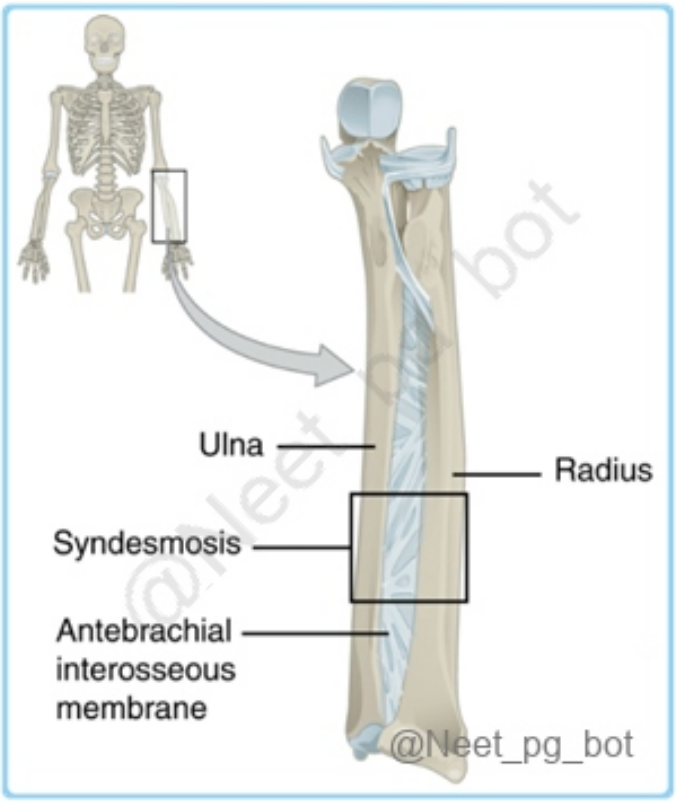

References:

BD Chaurasia's Human Anatomy, 8th Edtion, Page no: 234

↑ *Back to this question in Part A*

@Neet_pg_bot

Q25: A patient is referred to a higher center with the diagnosis of fracture. On examination, the forearm pulses were not palpable. An upper arm X-ray was done, which is given below. Which artery is most likely to be injured in this condition? (Q857902)

A. Radial artery

B. Ulnar artery

C. Brachial artery

D. Anterior interosseous artery



Correct Answer: C. Brachial artery

Explanation: The brachial artery is a major artery in the upper arm and runs along the anterior aspect of the upper arm. It is the main blood vessel that supplies blood to the arm. The brachial artery divides into the radial and ulnar arteries in the elbow region. An injury to the brachial artery can result in reduced blood flow to the entire arm, including the forearm and hand. This can cause a reduction or absence of pulses in the upper arm. Radial artery (Option A) : While an injury to the radial artery can result in reduced blood flow to the lateral aspect of the forearm and hand, it would not affect the pulses in the upper arm. Ulnar artery (Option B): Like the radial artery, an injury to the ulnar artery can result in reduced blood flow to the medial aspect of the forearm and hand but would not affect the pulses in the upper arm. Anterior interosseous artery (Option D) : An injury to the anterior interosseous artery can result in reduced blood flow to the muscles in the anterior compartment of the forearm but would not affect the pulses in the upper arm.

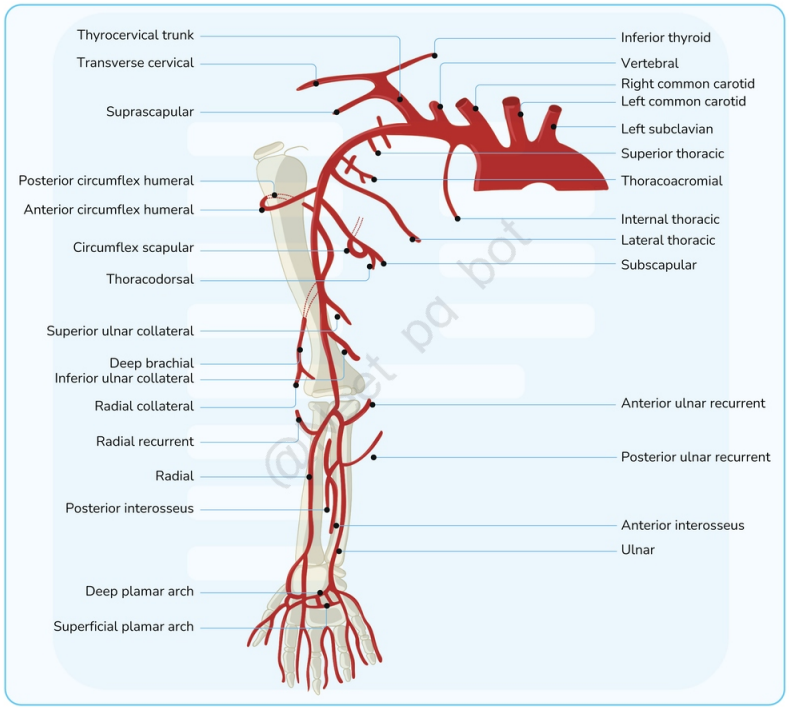

References:

BD Chaurasia's Human Anatomy, 8th Edtion, Page no: 876.

↑ *Back to this question in Part A*

@Neet_pg_bot

Q26: A diabetic worker sustains a stab injury to the central region of his palm. After 3 days, he develops swelling, severe pain, and inability to extend his middle and ring fingers. Pus accumulation is suspected in one of the palmar spaces. Which of the following spaces is most likely involved? (Q866624)

A. A

B. B

C. C

D. D

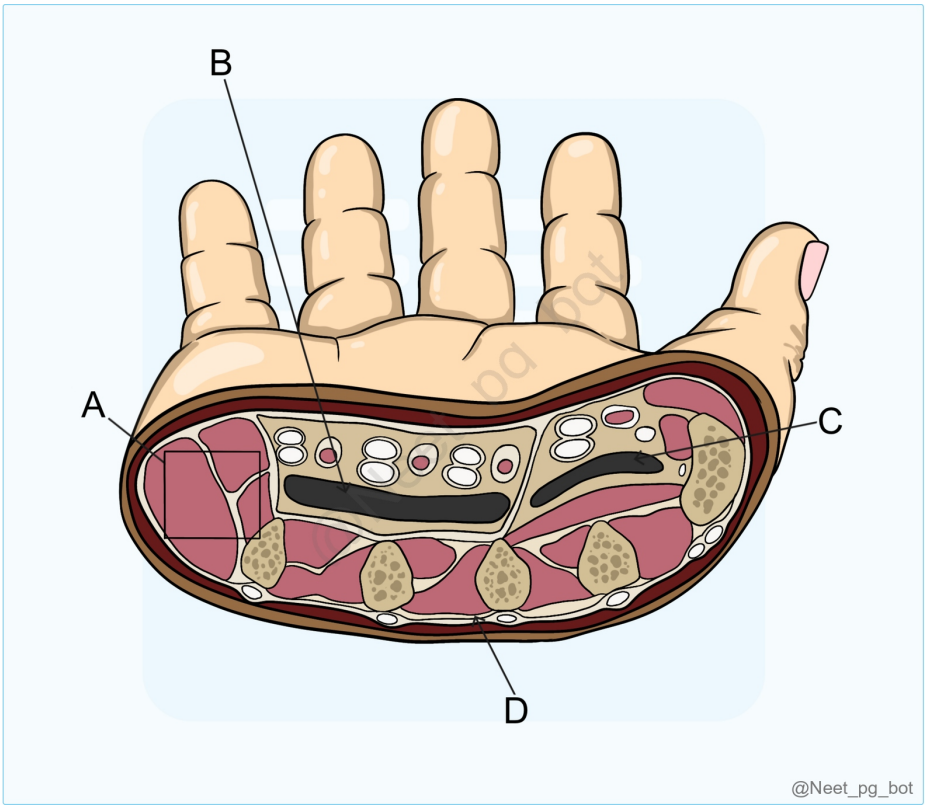

Correct Answer: B. B

Explanation: A stab injury to the central palm in a diabetic patient, followed by swelling, pain, and inability to extend the middle and ring fingers, suggests pus accumulation in the midpalmar space (B) - a deep space bounded by the palmar aponeurosis and metacarpals, commonly involved in deep hand infections affecting the 3rd and 4th digits. Incorrect Options: Hypothenar space (Option A): Located on the ulnar side of the palm, involving the little finger - not the middle and ring fingers. Thenar space (Option C): Found on the radial side of the palm, associated with the thumb and index finger, not the central palm. Dorsal subaponeurotic space (Option D): Located on the dorsum of the hand, not the palm - not relevant in this scenario.

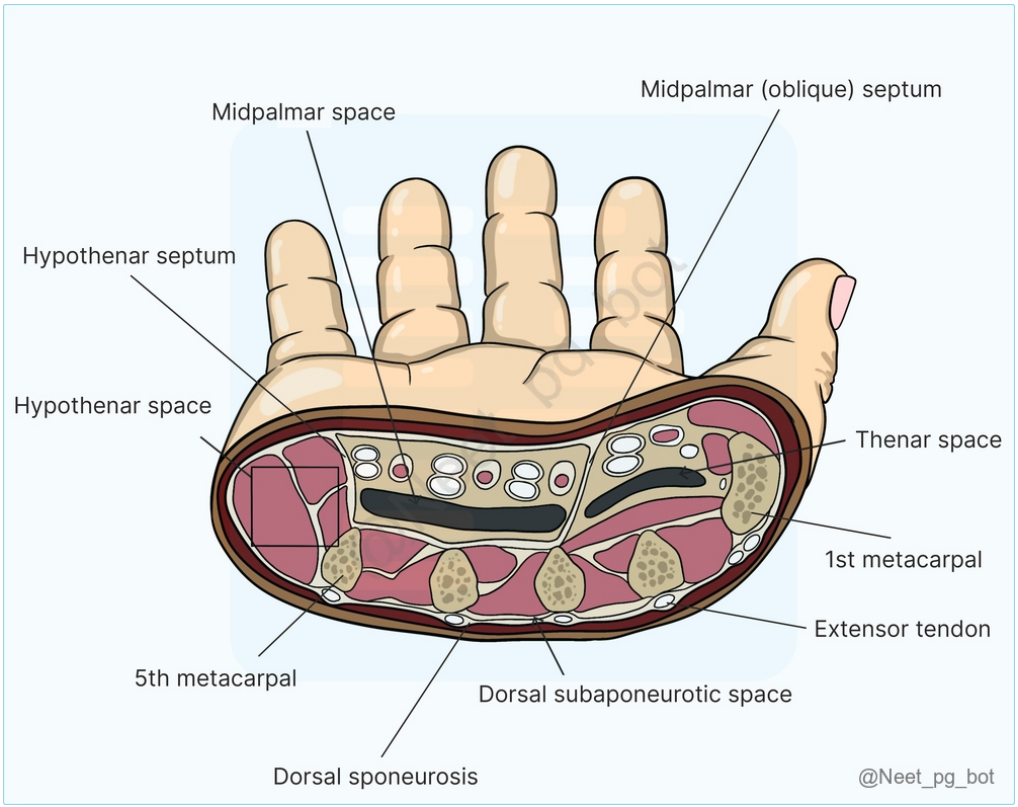

References:

.

↑ *Back to this question in Part A*

@Neet_pg_bot

Q27: All of the following muscles are supplied by the deep branch of the ulnar nerve, except? (Q865346)

A. 4 th lumbrical

B. Dorsal interossei

C. Abductor digiti minimi

D. Flexor carpi ulnaris

Correct Answer: D. Flexor carpi ulnaris

Explanation: The flexor carpi ulnaris (FCU) muscle is innervated by the muscular branches ulnar nerve. The deep branch of the ulnar nerve is primarily responsible for innervating the majority of the intrinsic muscles of the hand.

These include: Hypothenar muscles: These are the muscles that form the fleshy prominence on the medial side of the palm (at the base of the little finger). They include: Abductor digiti minimi (Option C) Flexor digiti minimi brevis Opponens digiti minimi Lumbricals (medial two): Specifically, the 3rd and 4th lumbricals (Option A) (which act on the ring and little fingers). The lateral two lumbricals are supplied by the median nerve. Interossei muscles: Both the: (Option B) Dorsal interossei (four muscles that abduct the fingers) Palmar interossei (three muscles that adduct the fingers) Adductor pollicis: This powerful muscle is responsible for adduction of the thumb. Flexor pollicis brevis (deep head): While the superficial head of the flexor pollicis brevis is supplied by the median nerve, the deep head typically receives innervation from the deep branch of the ulnar nerve.

References:

Inderbir Singh textbook of anatomy upper and lower limb, 6th edition, Page 165, 177, 189

↑ *Back to this question in Part A*

@Neet_pg_bot

Q28: During hyperextension, the long head of triceps gets detached from which site? (Q866310)

A. Infraglenoid tubercle

B. Supraglenoid tubercle

C. Shaft of humerus

D. Olecranon process

Correct Answer: A. Infraglenoid tubercle

Explanation: During hyperextension injuries, particularly with forceful backward arm movements as seen in overhead sports or trauma, the long head of the triceps may be stretched or avulsed from its origin at the infraglenoid tubercle. Triceps Brachii Origin Long Head: Infraglenoid tubercle of the scapula Lateral Head: Posterior surface of the humerus, above the radial (spiral) groove Medial Head: Posterior surface of the humerus, below the radial (spiral) groove. Insertion Olecranon process of the ulna (3 heads insert via a common tendon) Nerve supply Radial nerve (C6, C7, C8) Medial head often receives branches directly in the axilla. Function Primary extensor of the forearm at the elbow joint Shoulder extension and adduction Incorrect Options: Option B - Supraglenoid tubercle: Origin of the long head of the biceps brachii, not triceps. Option C - Shaft of humerus: Gives origin to the lateral and medial heads of the triceps, not the long head. Option D - Olecranon process: This is the insertion point of all three heads of the triceps, not the origin.

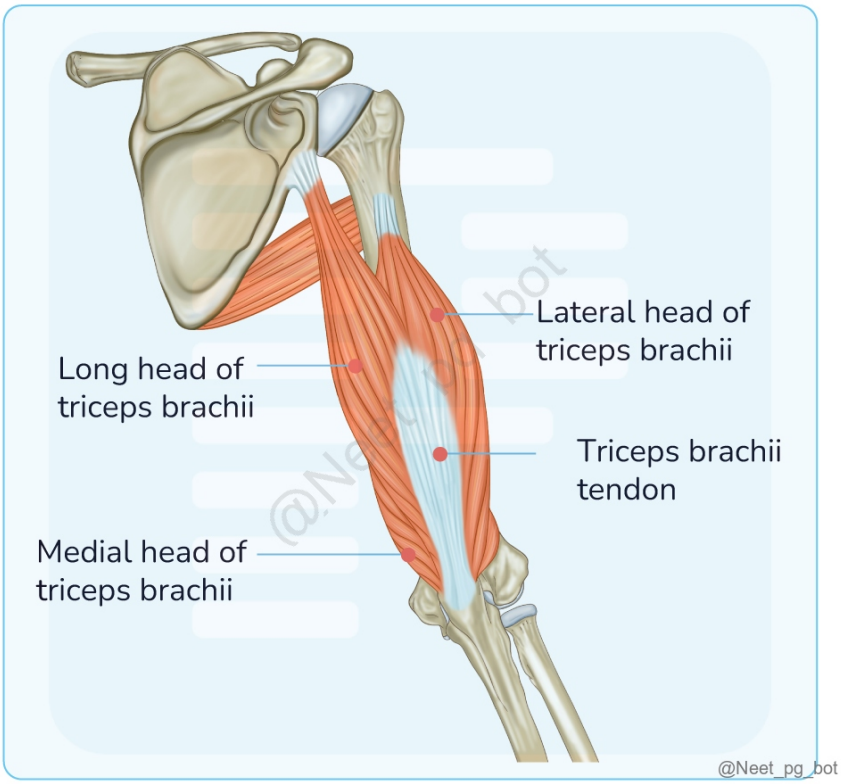

References:

.

↑ *Back to this question in Part A*

@Neet_pg_bot

Q29: Injury to the posterior interosseous nerve leads to? (Q852996)

A. Loss of extension of digits

B. Loss of extension of wrist

C. Loss of supination

D. Wrist drop

Correct Answer: A. Loss of extension of digits

Explanation: The posterior interosseous nerve (PIN) is a branch of the radial nerve , arising from the deep branch after passing through the supinator muscle . It supplies the extensor muscles of the forearm except for the brachioradialis, extensor carpi radialis longus, and anconeus. Injury to the PIN leads to inability to extend the fingers (digits) at the MCP joints while wrist extension is relatively preserved (due to intact ECRL). Sensory

function is not affected as the PIN is purely motor. Posterior Interosseous Nerve Palsy Feature Description Origin Deep branch of radial nerve (after supinator) Motor Supply Extensor digitorum, extensor pollicis longus & brevis, extensor indicis, ECU Sensory Supply None (purely motor) Clinical Features Weak finger extension, wrist extension intact (via ECRL) Common Causes Radial tunnel syndrome, trauma, compression at the arcade of Frohse Loss of extension of wrist (Option B): Incorrect because wrist extension is not completely lost , as the extensor carpi radialis longus (ECRL) (innervated by the radial nerve before the PIN) is still functional. Loss of supination (Option C): Incorrect because supination is mainly performed by the biceps brachii , with some contribution from the supinator (which is innervated by the PIN but has redundant function from the biceps). Wrist drop (Option D): Incorrect because wrist drop occurs in a proximal radial nerve injury , affecting all extensors, while PIN lesions primarily affect finger extension with wrist extension relatively spared.

References:

Vishram Singh Textbook of Anatomy, 2nd Edition, Pages 174,175

↑ *Back to this question in Part A*

@Neet_pg_bot

Q30: A 45-year-old woman presented with tingling sensation of lateral 3 digits with loss of sensation of base of thumb on the dorsal aspect of the hand. Which is the nerve involved? (Q852448)

A. Radial nerve

B. Ulnar nerve

C. Median nerve

D. AIN

Correct Answer: A. Radial nerve

Explanation: The patient presents with: Tingling of lateral 3 digits Loss of sensation at the base (root) of the thumb on the dorsal aspect These findings are best explained by involvement of the superficial branch of the radial nerve , which provides: Cutaneous sensation to the dorsum of the hand , especially the base of the thumb and proximal parts of the lateral 3½ fingers , excluding the fingertips . The tingling in the dorsal aspect of the lateral 3 digits may also be due to involvement of the proximal dorsal hand region , which is supplied by the radial nerve , not the median nerve. The median nerve supplies the palmar aspect and the distal dorsal phalanges (fingertips) of the lateral 3½ digits, not the base of the thumb dorsally . Sensory Supply of the Dorsal and Ventral Aspects of the Palm and Fingers: Region Nerve Area Supplied Ventral (Palmar) Aspect Lateral 3½ fingers + lateral palm Median nerve Palmar surface of thumb, index, middle, and lateral half of ring finger + palm Medial 1½ fingers + medial palm Ulnar nerve Palmar surface of little finger and medial half of ring finger + palm Thenar eminence (skin) Median nerve Over the base of thumb (root of thumb, palmar side) Hypothenar eminence Ulnar nerve Over the base of little finger Dorsal Aspect Lateral 3½ fingertips (nail beds) Median nerve Dorsal distal phalanges of thumb, index, middle, and lateral ring finger Medial 2½ fingers + hand dorsum Ulnar nerve Dorsal aspect of little

finger, medial half of ring finger, and medial hand Lateral 1½ dorsum + web space Radial nerve Dorsum of hand near base of thumb, lateral hand, and 1st web space Root (base) of thumb Radial nerve Dorsal aspect of thumb base and adjacent dorsum of hand Ulnar nerve (Option B): Incorrect. Supplies the medial 1½ digits , which are not involved in this case. Median nerve (Option C): Incorrect. Supplies palmar aspect and distal dorsal fingertips of lateral 3½ digits. It does not supply the dorsal root of the thumb , which is involved here. AIN (Option D): Incorrect. Purely motor nerve. No cutaneous distribution.

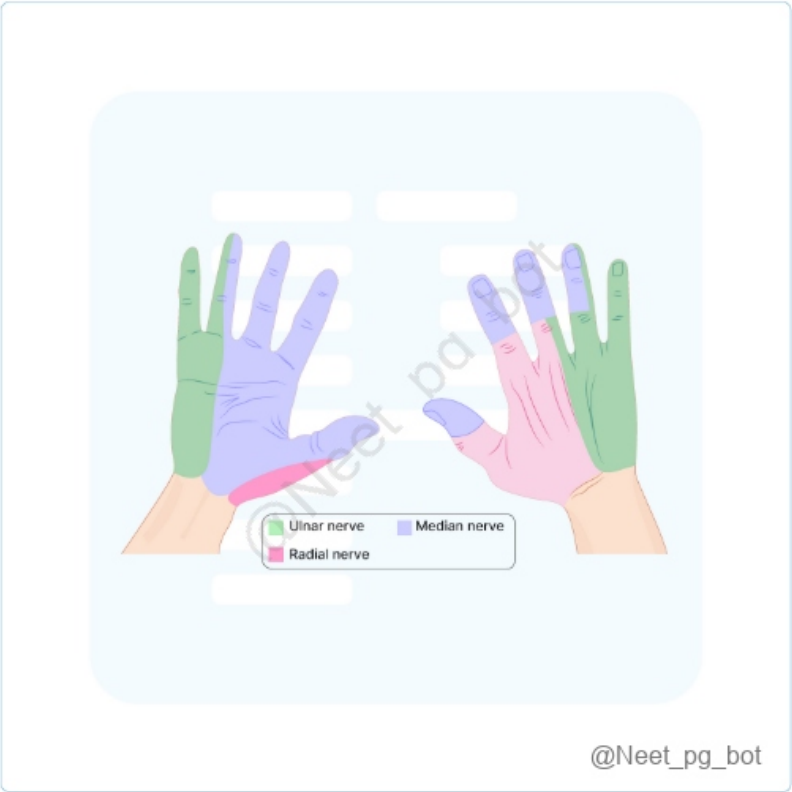

References:

Apley and Solomon’s System of Orthopaedics and Trauma, 10th Edition, Page 295-296 Campbell textbook of orthopedics, 14th edition - Page No. 3303

↑ *Back to this question in Part A*

@Neet_pg_bot

Q31: In the given image, the tendon marked by the arrow is? (Q860621)

A. Flexor carpi radialis

B. Flexor carpi ulnaris

C. Flexor digitorum superficialis

D. Palmaris longus

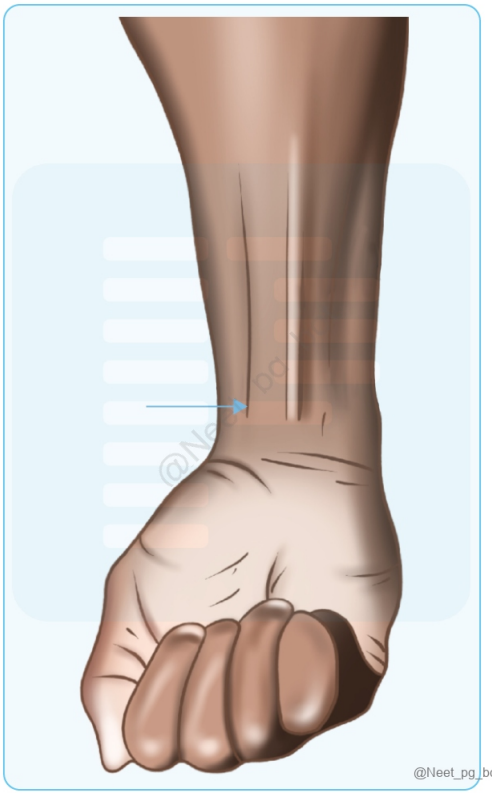

Correct Answer: A. Flexor carpi radialis

Explanation: The above-marked structure in the diagram is Flexor carpi radialis as it is present on the radial side of the forearm. Flexor carpi radialis originates from the medial epicondyle of the humerus and inserts into the bases of the second and third metacarpal bones. Muscles of Forearm: Superficial flexor muscles: Origin, insertion, nerve supply and action: Muscles Origin Insertion Nerve supply Action Pronator teres Humeral head - medial supracondylar ridge and from ulna Middle of radius Median nerve Pronation and weak flexor of forearm Flexor carpi radialis Medial epicondyle of humerus Base of 2nd /3rd metacarpal bones Median nerve Weak flexor and abducts (radial deviation)the wrist Palmaris longus Medial epicondyle of humerus Palmar aponeurosis and flexor retinaculum Median nerve Weak flexor of wrist Flexor carpi ulnaris Medial epicondyle of humerus and medial olecranon and posterior border of ulna Pisiform bone and hook of hamate and 5th metacarpal Ulnar nerve Weak flexor and adducts (ulnar deviation)the wrist Flexor digitorum superficialis Medial epicondyle of humerus, coronoid process, oblique line of radius Divides into 4 tendons and insert to middle phalanx Median nerve Flex the wrist, metacarpophalangeal and proximal interphalangeal joint Deep flexor muscles–origin, insertion, nerve supply and action Muscles Origin Insertion Nerve supply Action Flexor digitorum profundus Anteromedial surface of ulna and interosseous membrane Divided into 4 tendons and Distal phalanx Anterior interosseous nerve and ulnar nerve Flex the wrist, metacarpophalangeal and proximal interphalangeal joint and distal interphalangeal joint Flexor pollicis longus Anterior surface of radius and interosseous membrane and coronoid process Distal phalanx of thumb Anterior interosseous nerve Flex the wrist and interphalangeal joint of wrist Pronator quadratus Anterior surface of distal ulna Anterior surface of distal Radius Anterior interosseous nerve Pronates forearm

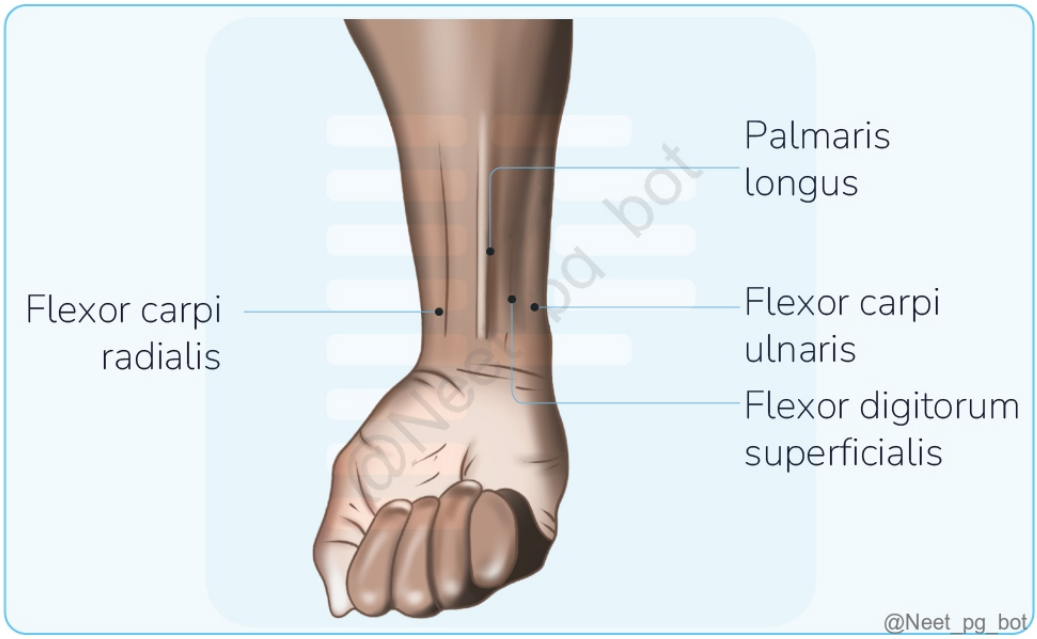

References:

https://pmc.ncbi.nlm.nih.gov/articles/PMC9464466/

↑ *Back to this question in Part A*

@Neet_pg_bot

Q32: A road traffic accident patient has presented to you with features of a nerve injury involving right upper limb. On examination, the patient is able to carry out flexion at metacarpo-phalangeal joint and extension at interphalangeal joint. The most likely nerve involved is? (Q860283)

A. Median nerve

B. Anterior interosseous nerve

C. Ulnar nerve

D. Radial nerve

Correct Answer: D. Radial nerve

Explanation: The most likely nerve involved is the posterior interosseous nerve, which is a branch of the radial nerve. The lumbricals and interossei can carry out flexion at MCP and extension at IP joints. Features of Posterior Interosseous Nerve (PIN) Palsy: (a branch of the radial nerve) Wrist extension not affected because extensor carpi

radialis longus and brevis are supplied by the radial nerve. Only one extension lost in PIN is extension at the metacarpophalangeal (MCP) joint. So, the patient has finger drop, not wrist drop. No sensory loss, because it is a motor nerve. common in Monteggia fracture dislocation Median nerve & Ulnar nerve (Options A & C): They supply the lumbricals and interossei, which are involved in flexion at metacarpophalangeal joint and extension at the interphalangeal joint Since these actions are present, these nerves are intact Anterior interosseous nerve (Options B): The anterior interosseous nerve supplies the Flexor Digitorum Profundus muscle and involved in the flexion and extension of the index and middle finger. Since the flexion of all the fingers is intact, this nerve is intact.

References:

https://pmc.ncbi.nlm.nih.gov/articles/PMC3919107/

↑ *Back to this question in Part A*

@Neet_pg_bot

Q33: A patient presents with abnormal sensations in the little finger and part of the ring finger with weakness of the hand. Also, there is a loss of coordination in the fingers. What is the nerve injured in the given scenario? (Q857315)

A. Ulnar nerve

B. Radial nerve

C. Median nerve

D. Axillary nerve

Correct Answer: A. Ulnar nerve

Explanation: The ulnar nerve supplies all the intrinsic muscles of the hand except the thenar muscles and lateral two lumbricals and is responsible for the sensations of the medial 11½ fingers of the hand. Hence abnormal sensations in the little finger and part of the ring finger with weakness on the palm side would be due to the ulnar nerve injury. Damage to the ulnar nerve leads to: Difficulty in flexing the fourth and fifth fingers due to paralysis of the flexor digitorum profundus (medial part) and the lumbricals (3rd and 4th). Inability to adduct the thumb, as the adductor pollicis is also innervated by the ulnar nerve. Motor branches of Ulnar nerve: Ulnar nerve (C7, C8 & T1- root values) Muscle Action Anterior Forearm Flexor carpi ulnaris Medial half of flexor digitorum profundus Flexion and adduction of hand at wrist Flexion of distal phalanges. Hand Hypothenar muscles Abducts little finger Flexes little finger Pulls fifth metacarpal forward as in cupping the palm 8 Interossei muscles Palmar Interossei Dorsal Interossei Ad ducts digits 2-5 (Mnemonic PAD) Ab duct digits 2-5 (Mnemonic DAB) Assists Lumbricals in MCP flexion and IP extension of digits 2-5 Lumbricals of Digits 4 & 5 Flexion of MCP Extension of PIP & DIP joints of digits 4 and 5 Adductor pollicis Adduction the thumb Ulnar nerve supply Radial nerve (Option B): The radial nerve injury is characterised by wrist drop and does not cause the symptoms mentioned in this case. Median nerve (Option C): the median nerve supplies the thenar muscles and is responsible for sensations on the medial side of the index finger, middle finger, and lateral side of the ring finger. Axillary nerve (Option D): Responsible

for the nerve supply of the deltoid muscle in the shoulder region.

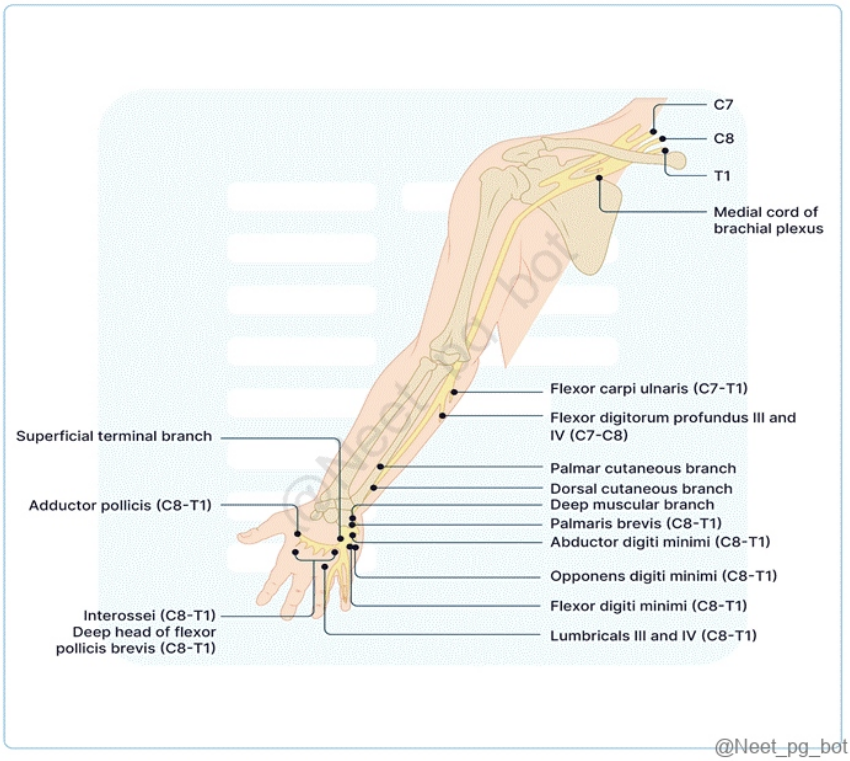

References:

B. D. Chaurasia's Human Anatomy, VOL- 1 Edition 8, Page 123, 116, 131, 79.

↑ *Back to this question in Part A*

@Neet_pg_bot

Q34: A man fell on his shoulder with his head pushed in the opposite direction. He presented with the following deformity. Which nerve root values are most likely affected? (Q866621)

A. C5 and C6

B. C6 and C7

C. C7 and C8

D. C8 and T1



Correct Answer: A. C5 and C6

Explanation: A fall on the shoulder with the head pushed to the opposite side suggests a traction injury to the upper brachial plexus, resulting in the characteristic posture seen in Erb's Palsy , most commonly affecting the C5 and C6 nerve roots. Erb's Palsy Definition Erb-Duchenne palsy results from damage to the upper trunk of the brachial plexus (C5 and C6 nerve roots). (Option A) Mechanism of Injury Traction or stretching of the neck during childbirth (shoulder dystocia) or traumatic separation of the head and shoulder. Anatomical Structures Involved Brachial Plexus: Formed by ventral rami of C5-T1 spinal nerves Upper Trunk: Union of C5 and C6 ventral rami Erb's Point: Located in the posterior triangle of the neck, where the upper trunk divides into anterior and posterior divisions. Clinical Presentation Muscle Weakness/ Paralysis Shoulder Abduction: Affected (supraspinatus, deltoid) External Rotation: Affected (infraspinatus, teres minor) Elbow Flexion: Affected (biceps brachii, brachialis) Forearm Supination: Affected (biceps brachii) Arm Position: Limp arm by the side, forearm pronated, hand inward ("waiter's tip" position). Sensory Deficits: Numbness or tingling along the lateral arm, forearm, and hand, corresponding to C5 and C6 dermatomes. Associated findings Horner's Syndrome: Involvement of T1 nerve root, indicating a more extensive injury. Skeletal abnormalities: Bone deformities (e.g., glenoid dysplasia, clavicular shortening) due to muscle imbalance. Incorrect Options: C6 and C7 (Option B) involves the middle trunk of the brachial plexus, which is not typically affected by traction injuries from shoulder falls; it doesn't produce the classic Erb's palsy posture. C7 and C8 (Option C) affects the lower part of the brachial plexus, leading to deficits in wrist and finger movements rather than the shoulder and elbow posture characteristic of Erb's palsy. C8 and T1 (Option D) involves the lower trunk, typically injured by upward traction of the arm, resulting in Klumpke's palsy with hand muscle weakness, not the upper limb findings seen here.

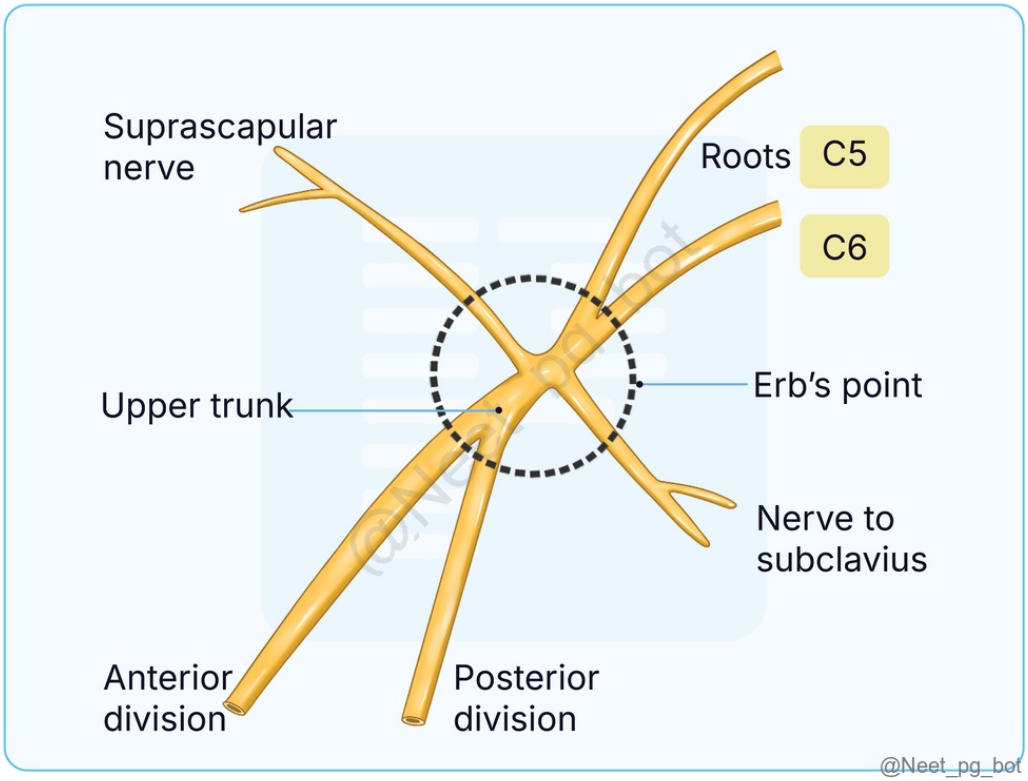
Suprascapular nerve
Roots
C5
C6
Upper trunk
Erb's point
Nerve to subclavius
Anterior division
Posterior division
@Neet_pg_bot


@Neet_pg_bot

References:

.

↑ *Back to this question in Part A*

@Neet_pg_bot

Q35: A 22-year-old male patient after an injury presented with a deformity as shown in the image. Which nerve will be damaged in the given condition? (Q857913)

A. Ulnar Nerve

B. Radial Nerve

C. Median Nerve

D. Musculocutaneous Nerve



Correct Answer: B. Radial Nerve

Explanation: In the given scenario, the image displaying wrist drop and a fracture of the shaft of the humerus is indicative of damage to the radial nerve Nerve Root origin Common causes Features Radial C5-T1 Compression in axilla (crutches, "Saturday night palsy") Midshaft fracture of humerus Repetitive pronation/supination (screwdriver use, "finger drop") Above elbow injury: Loss of sensation over posterior arm/forearm and dorsal hand Wrist drop (loss of elbow, wrist, and finger extension) Decreased grip strength (wrist extension necessary for maximal action of flexors) Below elbow injury: Distal paresthesias without wrist drop Midshaft fracture: Tricep

function and posterior arm sensation spared Ulnar Nerve (Option A): The ulnar nerve mainly innervates forearm and hand muscles for wrist flexion and finger abduction. It's not typically involved in wrist drop. Median Nerve (Option C): The median nerve innervates specific forearm muscles and the hand's anterior compartment but isn't heavily involved in wrist extension, the main problem in the image. Musculocutaneous Nerve (Option D): The musculocutaneous nerve mainly innervates the anterior arm muscles, like the biceps brachii, aiding in elbow flexion, not wrist extension.

References:

BD Chaurasia's Human Anatomy, 8th Edtion, Page no: 543

↑ *Back to this question in Part A*

@Neet_pg_bot

Q36: Which bone is most likely to be fractured in an injury to the anatomical snuff box? (Q857930)

A. Scaphoid

B. Lunar

C. Cuboid

D. Trapezius

Correct Answer: A. Scaphoid

Explanation: The anatomical snuff box is a dorsolateral wrist depression bordered by the tendons of APL, EPB (laterally) and EPL (medially). The scaphoid constitutes the primary osseous floor of this triangular fossa. A fall on an outstretched hand (FOOSH) transmits axial load through the radial column directly onto the scaphoid. Hence, the scaphoid is the most frequently fractured carpal bone in snuff-box trauma. Point tenderness over the anatomical snuff box is the hallmark clinical sign of a scaphoid fracture. The scaphoid receives retrograde vascular supply from branches of the radial artery, predisposing the proximal pole to avascular necrosis after fracture. Initial radiographs may be inconclusive, necessitating immobilization or advanced imaging (MRI/CT) if suspicion persists. Incorrect Options: Option B) Lunate : Primarily associated with volar dislocation and Kienböck's disease (avascular necrosis). It is not typically fractured in snuff-box injuries and does not produce snuff-box tenderness. Option C) Cuboid : A tarsal bone of the lateral foot, anatomically unrelated to the wrist and the anatomical snuff box. Option D) Trapezius : A superficial extrinsic muscle of the back and neck, not a carpal bone and unrelated to wrist biomechanics.

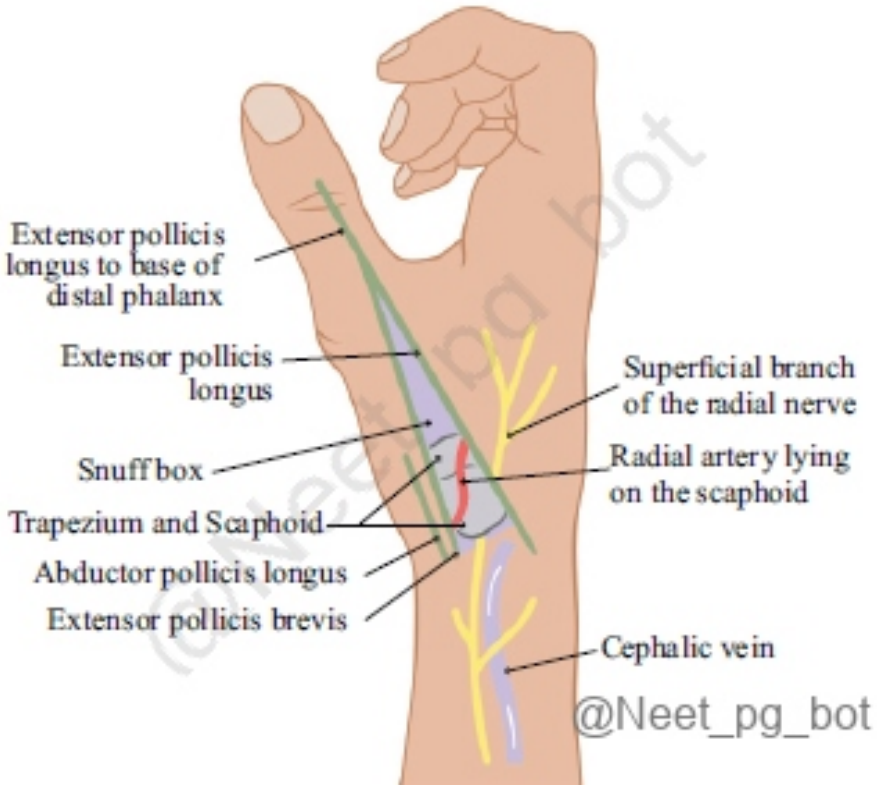

References:

BD Chaurasia's Human Anatomy, 8th Edtion, Page no: 987

↑ *Back to this question in Part A*

@Neet_pg_bot

Q37: Injury of the lower brachial plexus leads to Klumpke's paralysis. What is the characteristic clinical finding seen in this lesion? (Q855411)

A. Policeman tip hand

B. Wrist drop

C. Claw hand

D. Horner's syndrome

Correct Answer: C. Claw hand

Explanation: Klumpke's paralysis occurs due to injury of the lower brachial plexus (C8-T1) , which affects the intrinsic muscles of the hand , particularly the lumbricals, interossei , and thenar/hypothenar muscles . This results

in "claw hand" , where there is hyperextension of the metacarpophalangeal joints and flexion of the interphalangeal joints , leading to a characteristic clawed appearance of the fingers. Klumpke’s Paralysis Aspect Details Site of Injury Lower trunk of the brachial plexus Cause of Injury Undue arm abduction (e.g., clutching after a fall) Birth injury Nerve Roots Involved Primarily T1, partially C8 Muscles Affected Intrinsic muscles of the hand (T1) Ulnar flexors of the wrist and fingers (C8) Hand Deformity Claw hand: unopposed action of long flexors and extensors Hyperextension at metacarpophalangeal joints Flexion at interphalangeal joints Disabilities Associated Complete claw hand Cutaneous anesthesia and analgesia along the ulnar border of forearm and hand Horner’s Syndrome (if T1 injured near sympathetic ganglion) Symptoms: ptosis, miosis, anhidrosis, enophthalmos, loss of ciliospinal reflex Vasomotor Changes Warmer, drier skin in the sensory loss area due to arteriolar dilation and lack of sweating Trophic Changes Long-term paralysis results in dry, scaly skin, brittle nails, and atrophy of finger pulp Horner’s syndrome is also associated with lower brachial plexus injuries but is not the primary clinical finding. Policeman tip hand (option A): This is a sign of upper brachial plexus injury (C5-C6) , typically resulting in waiter's tip position due to paralysis of the deltoid , biceps , and brachioradialis . Wrist drop (option B): This is a feature of radial nerve injury , leading to the inability to extend the wrist and fingers. It is not a characteristic finding in Klumpke’s paralysis. Horner’s syndrome (option D) can occur in lower brachial plexus injury due to sympathetic fiber disruption, leading to ptosis, miosis , and anhidrosis on the same side. While present, it is not the primary clinical feature of Klumpke's paralysis.



References:

BD Chaurasia’s Human Anatomy, Vol 1, 8th Edition, Page 63

↑ *Back to this question in Part A*

@Neet_pg_bot

Q38: What is the nerve supply of the structure marked in the image? (Q855438)

A. Radial nerve

B. Median nerve

C. Ulnar nerve

D. Musculocutaneous nerve

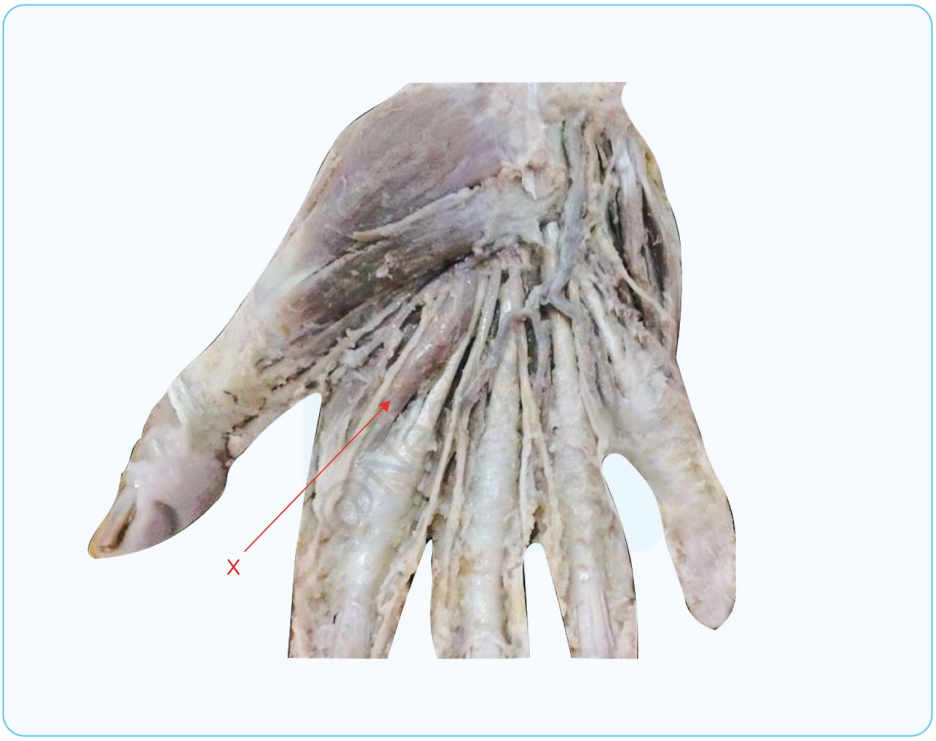

@Neet_pg_bot

Correct Answer: B. Median nerve

Explanation: The 1st lumbrical is primarily innervated by the median nerve . The first lumbrical is located in the hand , and it helps in flexing the metacarpophalangeal joint and extending the interphalangeal joints . It is innervated by the median nerve , which supplies the lumbricals 1 and 2 (the first two lumbricals). The median nerve , which innervates the muscles responsible for thumb abduction and opposition, is formed from the anterior rami of spinal nerves C5 to T1, derived from the brachial plexus. It primarily supplies the anterior forearm muscles and the t henar eminence of the hand, which includes: Muscles of the Thenar eminence: Abductor Pollicis Brevis: Responsible for thumb abduction. Flexor Pollicis Brevis: Assists in thumb flexion. Opponens Pollicis: Enables opposition of the thumb. Lumbricals (Lateral 2): Responsible for flexion at the metacarpophalangeal (MCP) joints and extension at the interphalangeal (IP) joints of the 2nd and 3rd digits Sensory supply: Lateral 3 1⁄2 digits in the palmar aspect & tip of same digits on the dorsum. . Brachial Plexus: The brachial plexus is a network of nerves formed by the anterior rami of the lower four cervical nerves (C5, C6, C7, C8) and the first thoracic nerve (T1) Components of the Brachial Plexus: Roots : Five roots (C5 to T1), deep to the scalenus anterior muscle. Trunks :

Upper trunk : C5 and C6, Middle trunk : C7, Lower trunk: C8 and T1 Divisions : Located behind the clavicle. Cords : Three cords form from the divisions Lateral cord: Anterior divisions of the upper and middle trunks. Medial cord: Anterior division of the lower trunk. Posterior cord: Posterior divisions of all three trunks. Branches: From Roots Long thoracic nerve (C5, C6, C7) Dorsal scapular nerve (C5) From Trunks Suprascapular nerve (C5, C6) Nerve to subclavius (C5, C6) Lateral Cord Lateral pectoral nerve (C5, C6, C7) Lateral root of median nerve (C5, C6, C7) Musculocutaneous nerve (C5, C6, C7) Medial Cord Medial pectoral nerve (C8, T1) Medial cutaneous nerve of arm (C8, T1) Medial cutaneous nerve of forearm (C8, T1) Medial root of median nerve (C8, T1) Ulnar nerve (C7, C8, T1) Posterior Cord Radial nerve (C5, C6, C7, C8, T1) Axillary nerve (C5, C6) Thoraco-dorsal nerve (C6, C7, C8) Upper subscapular nerve (C5, C6) Lower subscapular nerve (C5, C6) {{caption_text}} Radial nerve (option A): The radial nerve innervates the extensor muscles of the forearm and hand, not the lumbricals, which are responsible for flexion and extension of the fingers . Ulnar nerve (option C): The ulnar nerve innervates the lumbricals 3 and 4 (the last two lumbricals), not the first lumbrical. Musculocutaneous nerve (option D): The musculocutaneous nerve primarily innervates the flexor muscles of the upper arm (e.g., biceps brachii), not the lumbricals of the hand.

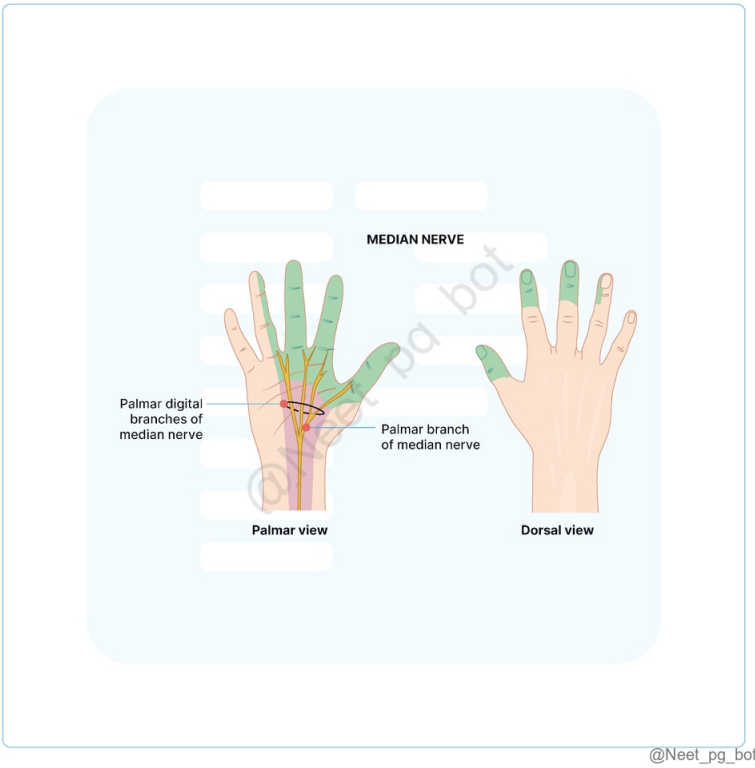

@Neet_pg_bot

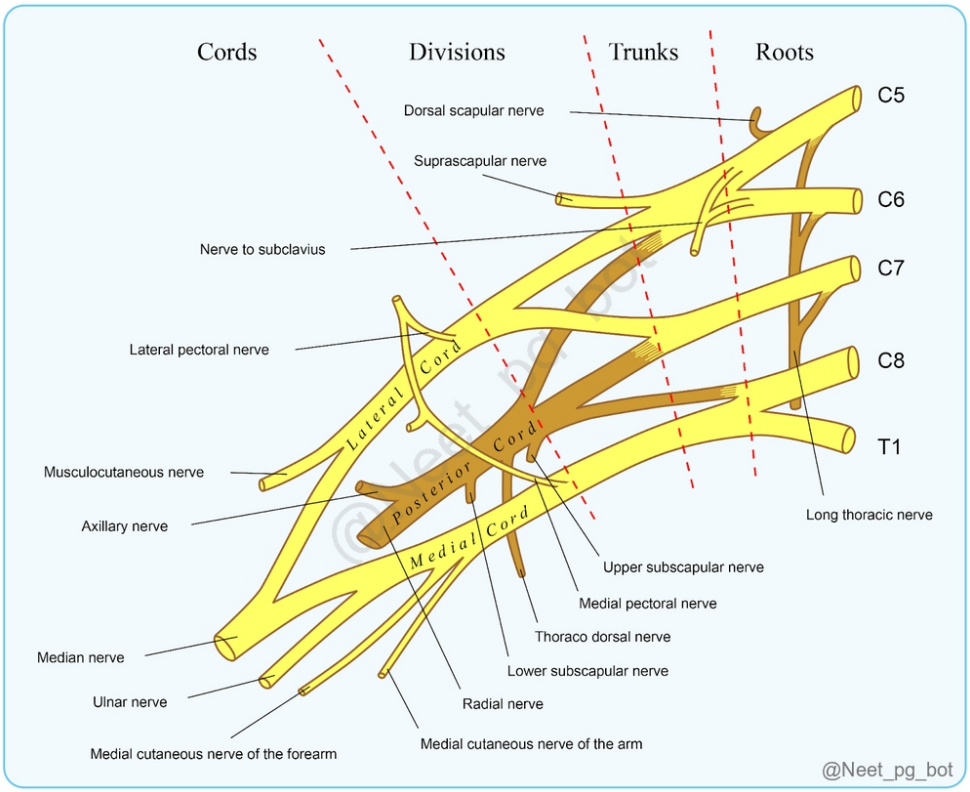

References:

B. D. Chaurasia's Human Anatomy, Volume 1, 8th Edition, Page 61, 62, 116, 131

↑ *Back to this question in Part A*

@Neet_pg_bot

Q39: Which nerve is affected in a 50-year-old male who has a positive Trendelenburg test on the right side? (Q855024)

A. Right inferior gluteal nerve

B. Right superior gluteal nerve

C. Left superior gluteal nerve

D. Left inferior gluteal nerve

Correct Answer: B. Right superior gluteal nerve

Explanation: A positive Trendelenburg test indicates weakness of the hip abductors , specifically the gluteus medius and gluteus minimus . These muscles are innervated by the superior gluteal nerve . In this case, the

right-sided Trendelenburg sign means the right gluteus medius and minimus are weak, which occurs due to damage to the right superior gluteal nerve . Trendelenberg sign: When the body's weight is balanced on one leg, the gluteal muscles on the supported side help elevate the opposite, unsupported side of the pelvis. However, if there is a malfunction in the abductor mechanism, the Sound side sinks, which is referred to as a positive Trendelenburg sign (uncompensated). This sign indicates issues with hip abductors, such as paralysis of the gluteus medius and minimus ; problems with the fulcrum, including congenital or pathological hip dislocations; and concerns related to body weight, such as an unhealed fracture of the femoral neck. When patients with the gluteus medius and minimus paralysis walk, they have a characteristic lurching gait ie, during the single leg supporting phase of walking, there is leaning of the trunk to the affected side known as the compensated Trendelenburg sign . Duck waddling gait is seen when both the sides are affected. {{caption_text}} Right inferior gluteal nerve (option A): The inferior gluteal nerve innervates the gluteus maximus , which is responsible for hip extension, not abduction. Damage here would cause difficulty rising from a seated position or climbing stairs , not a Trendelenburg sign. Left superior gluteal nerve (option C): If the left superior gluteal nerve were affected, the right hip would drop when standing on the left leg , not the right leg. Left inferior gluteal nerve (option D): The inferior gluteal nerve does not control hip abduction, and the left-sided nerve would not cause a right-sided Trendelenburg sign.

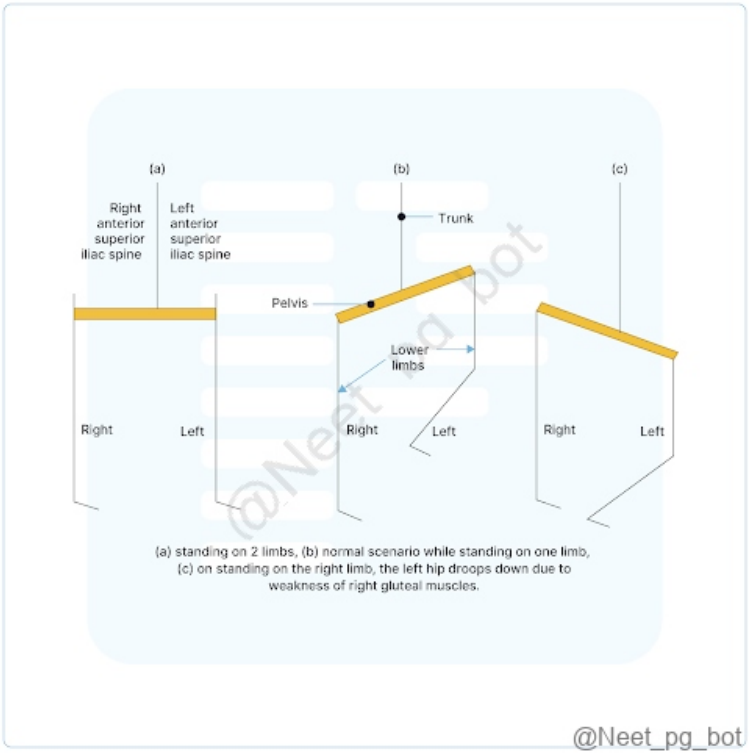

References:

Gray’s Anatomy, 42nd edition, Pages 1376-1379

↑ *Back to this question in Part A*

@Neet_pg_bot

Q40: A patient with leprosy presented with the deformity as shown below. Which nerve injury causes the given condition? (Q857225)

A. Ulnar nerve

B. Radial nerve

C. Median nerve

D. Posterior interosseous nerve



Correct Answer: A. Ulnar nerve

Explanation: The image shows "claw hand deformity" , which is characteristic of ulnar nerve injury . The deformity results from paralysis of the lumbricals (which flex the MCP joints and extend the IP joints of the 4th and 5th fingers). The 4th and 5th fingers are hyperextended at the MCP joints and flexed at the PIP & DIP joints, leading to a claw-like appearance . Common causes in leprosy: Ulnar nerve involvement due to nerve infiltration and fibrosis , leading to motor impairment . Ulnar Nerve Palsy and Claw Hand Feature Ulnar Nerve Palsy (Claw Hand) Affected Muscles Lumbricals (3rd & 4th), Interossei, Hypothenar muscles Deficit Seen MCP hyperextension, PIP & DIP flexion (mainly in 4th & 5th fingers) Common Causes Leprosy, trauma at the elbow (cubital tunnel) or wrist (Guyon's canal) Tests for Ulnar Nerve Froment’s sign (weak adductor pollicis) Treatment Physiotherapy, nerve grafting, claw correction surgery Radial nerve (Option B): Incorrect because its injury causes wrist drop , not claw hand. Median nerve (Option C): Incorrect because it causes ape hand deformity (loss of thumb opposition). Posterior interosseous nerve (Option D): Incorrect because it affects finger extension , leading to finger drop , not claw hand.

References:

B. D. Chaurasia’s Human Anatomy, VOL- 1 Edition 8, Page 123, 116, 131, 79.

↑ *Back to this question in Part A*

@Neet_pg_bot

Q41: The given finding is associated with ? (Q820329)

A. Trisomy 13

B. Trisomy 21

C. Klinefelter’s

D. Trisomy 18

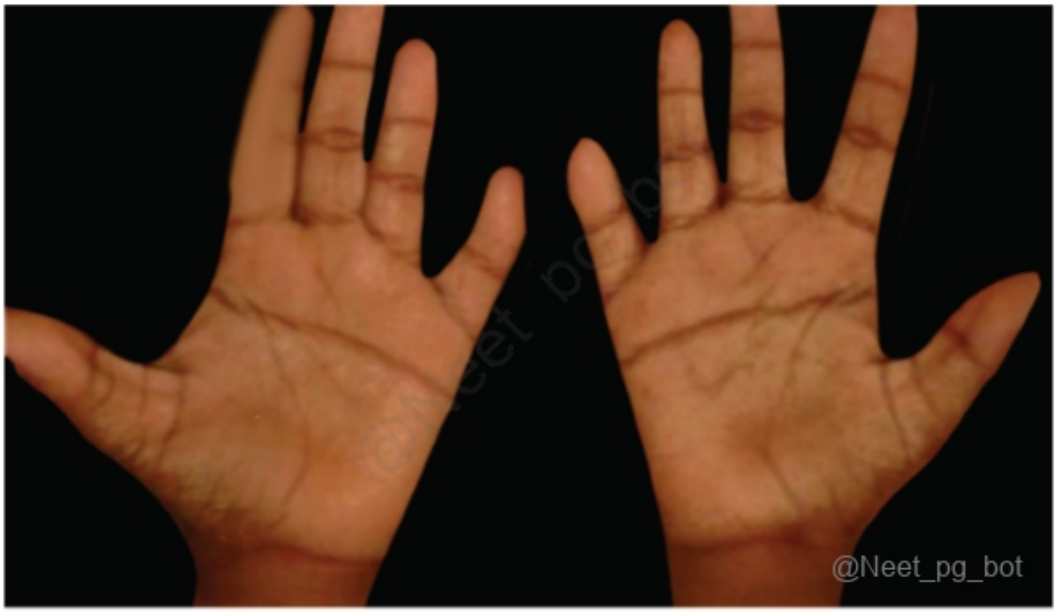

Correct Answer: B. Trisomy 21

Explanation: Correct Option B - Trisomy 21 Trisomy 21, commonly known as Down syndrome, results from an extra copy of chromosome 21. People with Down syndrome often have distinct facial features, intellectual disabilities, and certain medical problems. Approximately half of individuals with Down syndrome have a single transverse palmar crease, making this the correct answer. The simian crease is relatively common in Down syndrome. Incorrect Options: Option A - Trisomy 13: Trisomy 13, or Patau syndrome, results from an extra chromosome 13, leading to severe developmental issues and congenital abnormalities. While hand anomalies are common, a simian crease isn't typically present. Option C - Klinefelter's syndrome: Klinefelter's syndrome in males with an extra X chromosome (XXY) leads to male hypogonadism and physical differences, but it's not usually linked to a simian crease. Option D - Trisomy 18: Trisomy 18, or Edwards syndrome, stems from an extra

chromosome 18, leading to severe developmental delays, intellectual disabilities, and congenital anomalies. While hand abnormalities may occur, a simian crease isn't a defining trait.

↑ *Back to this question in Part A*

@Neet_pg_bot

Q42: Which bone is most likely to be fractured in an injury to the anatomical snuff box? (Q820325)

A. Scaphoid

B. Lunar

C. Cuboid

D. Trapezius

Correct Answer: A. Scaphoid

Explanation: Correct Option A - Scaphoid The anatomical snuff box is a triangular depression located on the radial aspect of the dorsum (back) of the hand. It is formed by the tendons of the extensor pollicis longus and extensor pollicis brevis muscles. Fractures within the anatomical snuff box are commonly associated with falls onto an outstretched hand, particularly with the wrist extended. The most fractured bone in this region is the scaphoid bone, also known as the navicular bone. Incorrect Options: Option B - Lunar (lunate) bone: The lunate bone, found in the wrist joint, rarely fractures in injuries to the anatomical snuff box and isn't usually part of its formation. Option C - Cuboid bone: The cuboid bone is one of the tarsal bones located in the foot. It is not related to the anatomical snuff box or the wrist region. Option D - Trapezius: The trapezius is a large muscle located in the upper back and neck area. It is not a bone and is not related to the anatomical snuff box or wrist injuries.

References:

.

↑ *Back to this question in Part A*

@Neet_pg_bot

Q43: A 22-year-old male patient after an injury presented with a deformity as shown in the image. Which nerve will be damaged in the given condition? (Q820304)

A. Ulnar Nerve

B. Radial Nerve

C. Median Nerve

D. Musculocutaneous Nerve



Correct Answer: B. Radial Nerve

Explanation: Correct Option B - Radial Nerve In the given scenario, the image displaying wrist drop and a fracture of the shaft of the humerus is indicative of damage to the radial nerve Incorrect Options: Option A - Ulnar Nerve: The ulnar nerve mainly innervates forearm and hand muscles for wrist flexion and finger abduction. It's not typically involved in wrist drop. Option C - Median Nerve: The median nerve innervates specific forearm muscles and the hand's anterior compartment but isn't heavily involved in wrist extension, the main problem in the image. Option D - Musculocutaneous Nerve: The musculocutaneous nerve mainly innervates the anterior arm muscles, like the biceps brachii, aiding in elbow flexion, not wrist extension.

References:

.

↑ *Back to this question in Part A*

@Neet_pg_bot

Q44: What is the function of the muscle indicated in the provided image? (Q793130)

A. Retraction of scapula

B. Protraction of scapula

C. Abduction of shoulder joint

D. Adduction of shoulder joint

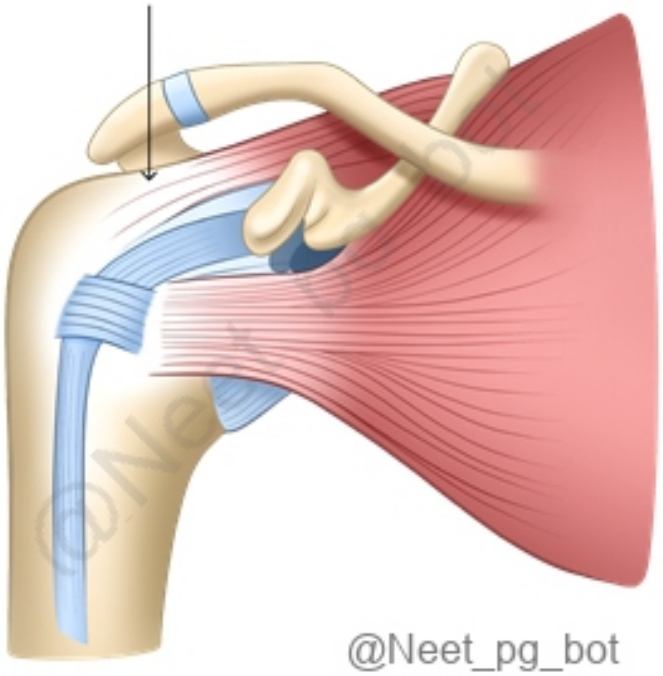

Correct Answer: C. Abduction of shoulder joint

Explanation: The muscle marked in the question is the supraspinatus, which is present above the spine of the scapula and helps abduct the shoulder joint. The muscles involved in abducting the shoulder joint are the deltoid muscle, the supraspinatus muscle, and the trapezius muscle Incorrect Options: Option A - Retraction of scapula: The muscles involved in retracting the scapula are the middle and lower trapezius muscles and the rhomboid major and minor muscles. Option B - Protraction of scapula: The muscles involved in protracting the scapula are the serratus anterior muscle. Option D - Adduction of shoulder joint: The muscles involved in adducting the shoulder joint are the latissimus dorsi muscle, pectoralis major muscle, and the teres major muscle.

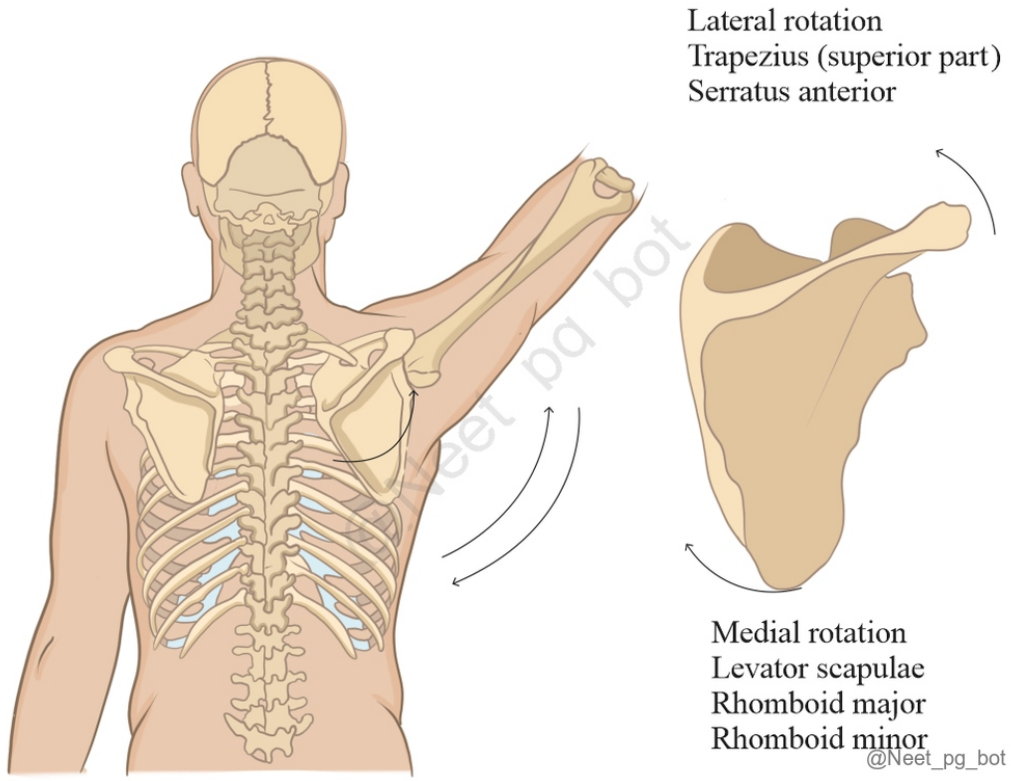

References:

.

↑ *Back to this question in Part A*

@Neet_pg_bot

Q45: Which among the following aids in supination and pronation of the forearm? (Q793134)

A. Pivot joint

B. Saddle joint

C. Ellipsoid joint

D. Ball and socket joint

Correct Answer: A. Pivot joint

Explanation: Correct Option A - Pivot joint: The forearm's radius and ulna bones are connected at the elbow joint to the upper arm's humerus bone. This joint allows for rotational movements like supination (palm up) and

pronation (palm down) as the radius rotates around the stationary ulna. It's a pivot joint, permitting movement around a single axis, supported by ligaments and muscles for stability and control of motion range. Incorrect Options: Option B - Saddle joint: A saddle joint in the thumb enables a wide range of motion in multiple directions but isn't involved in the forearm's rotational movement. Option C - Ellipsoid joint: An ellipsoid joint is a type of joint found in the wrist. It allows for movement in two planes but not rotation around a single axis. Option D - Ball and socket joint: A ball and socket joint is found in the hip and shoulder joints and does not play a significant role in the rotational movement of the forearm.

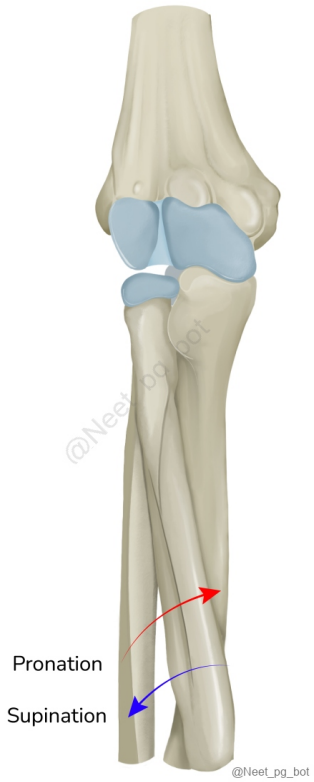

References:

.

↑ *Back to this question in Part A*

@Neet_pg_bot

Q46: Identify the anatomical structure marked in the given image. (Q793151)

A. Abductor pollicis brevis

B. Extensor pollicis brevis

C. Abductor pollicis longus

D. Extensor pollicis longus



Correct Answer: D. Extensor pollicis longus

Explanation: Correct Option D - Extensor pollicis longus: The pointed structure in the shown image is the medial boundary of the anatomical snuffbox which is away from the thumb formed by the extensor pollicis longus muscle. Incorrect Options: Option A - Abductor pollicis brevis: The abductor pollicis brevis muscle in the forearm assists in thumb abduction and borders the anatomical snuffbox. Option B - Extensor pollicis brevis: The extensor pollicis brevis muscle, situated in the forearm, extends the thumb and lies alongside the anatomical snuffbox. Option C - Abductor pollicis longus: The abductor pollicis longus muscle, in the forearm, aids in wrist abduction and lies near the proximal border of the anatomical snuffbox.

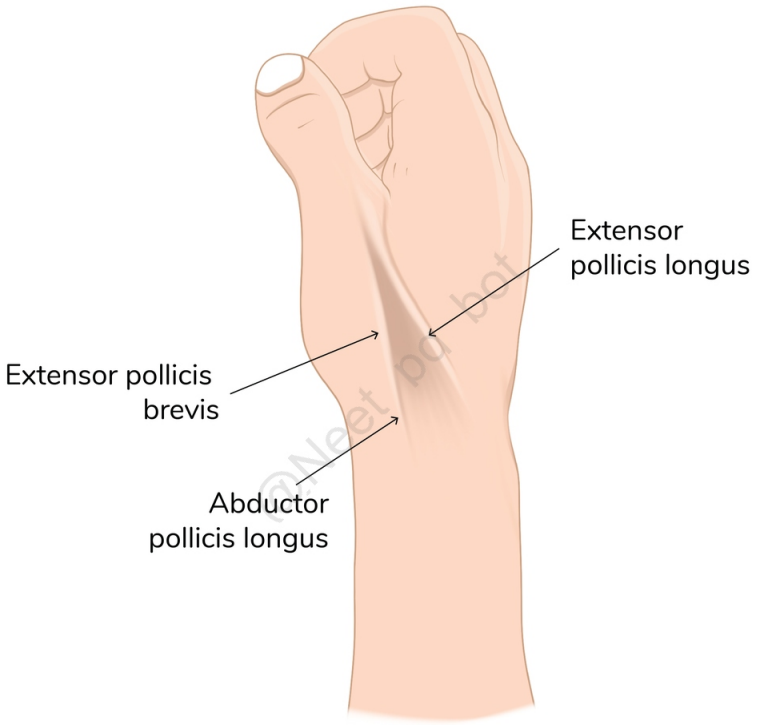

References:

.

↑ *Back to this question in Part A*

@Neet_pg_bot

Q47: Identify the type of joint shown in the given image. (Q793154)

A. Symphysis

B. Syndesmosis

C. Synchondrosis

D. Synostosis

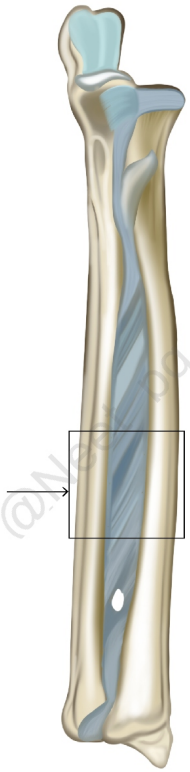

Correct Answer: B. Syndesmosis

Explanation: Correct Option B - Syndesmosis: The image is of the middle radio ulnar joint which is formed by the interosseous ligament. This is a type of fibrous joint which is syndesmosis. The syndesmosis is a type of joint that is formed by the union of two bones by a strong, fibrous tissue called a ligament. This type of joint is found in areas where stability is more important than mobility, such as the distal tibiofibular joint in the ankle and the distal radioulnar joint in the wrist. Incorrect Options: Option A - Symphysis: Symphysis joints fuse two bones with fibrocartilage, allowing limited movement crucial for shock absorption and flexibility, like in the pelvis and spine. Option C - Synchondrosis: Synchondrosis joints are formed by hyaline cartilage connecting two bones, commonly found in areas of growth and development like children's epiphyseal plates. Option D - Synostosis: Synostosis occurs when bones fuse due to various reasons like trauma or congenital conditions, leading to no mobility. Examples include cranial suture and radius-ulna fusion.

References:

.

↑ *Back to this question in Part A*

@Neet_pg_bot

• [06_Lower Limb] 029 Muscles And Nerve Supply Of The Hip Thigh And Gluteal Region

« Back to Folder Directory

[06_Lower Limb] 029 Muscles And Nerve Supply Of The Hip Thigh And Gluteal Region — Quick Jump

Q1 (p. 1563)	*Q2 (p. 1564)*	*Q3 (p. 1565)*	*Q4 (p. 1567)*	*Q5 (p. 1571)*	*Q6 (p. 1574)*
Q7 (p. 1575)	*Q8 (p. 1576)*	*Q9 (p. 1578)*	*Q10 (p. 1578)*	*Q11 (p. 1579)*	*Q12 (p. 1580)*
Q13 (p. 1582)	*Q14 (p. 1583)*	*Q15 (p. 1584)*	*Q16 (p. 1586)*	*Q17 (p. 1587)*	*Q18 (p. 1589)*
Q19 (p. 1591)	*Q20 (p. 1593)*	*Q21 (p. 1594)*	*Q22 (p. 1596)*	*Q23 (p. 1598)*	*Q24 (p. 1599)*
Q25 (p. 1600)					

Q1: Which of the following structures does not pass through the marked structure? (Q876248)

A. Piriformis muscle

B. Sciatic nerve

C. Tendon of obturator externus

D. Superior gluteal nerve and vessels

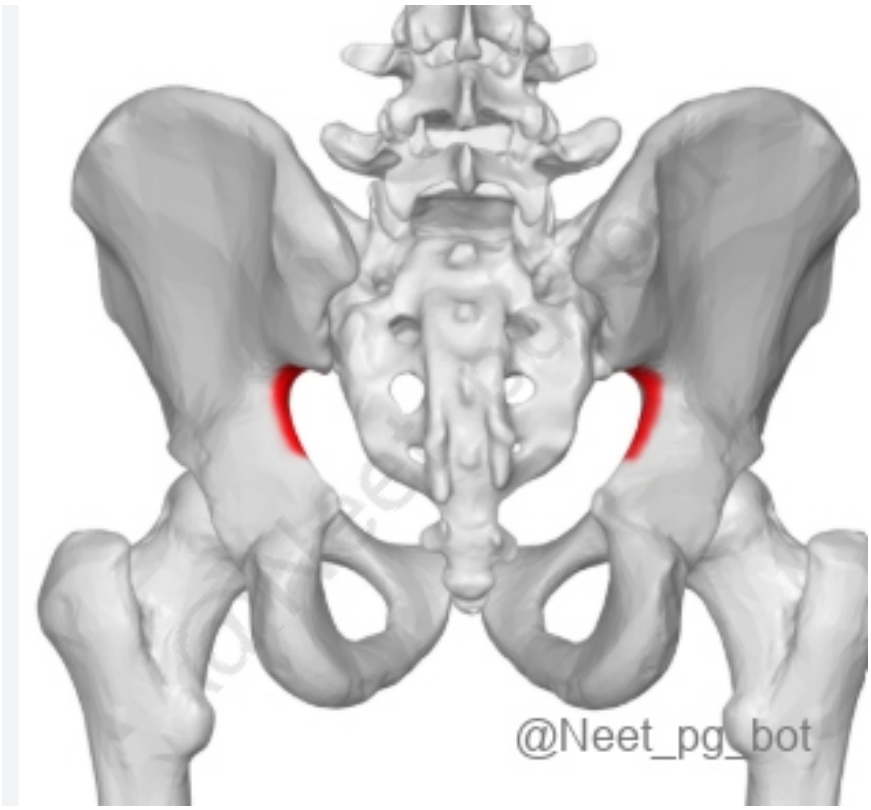

Correct Answer: C. Tendon of obturator externus

Explanation: Correct Option C - Tendon of obturator externus: Greater sciatic foramen: Formed by the greater sciatic notch, sacrospinous and sacrotuberous ligaments. Structures passing through include: Piriformis (divides the foramen into suprapiriform and infrapiriform spaces) Sciatic nerve Superior and inferior gluteal nerves and vessels Pudendal nerve, Posterior femoral cutaneous nerve Tendon of obturator externus: Does not pass through the greater sciatic foramen. Exits the pelvis through the obturator canal or lies deep in the medial thigh to insert on the femur.

↑ *Back to this question in Part A*

@Neet_pg_bot

Q2: Which of the following bones forms the posterior pillar of the medial longitudinal arch? (Q848243)

A. Talus

B. Navicular

C. Calcaneum

D. Metatarsals

Correct Answer: C. Calcaneum

■ *Listen (English)*

■ *Listen (Hindi)*

Explanation: Each longitudinal arch has: (a) two pillars, (b) a summit, and (c) joints. Medial Longitudinal Arch The medial longitudinal arch is made up of the calcaneum, talus, navicular, three cuneiform bones, and the medial three metatarsals. a) Pillars: The medial half of the calcaneum forms the posterior pillar of the medial longitudinal arch. The heads of the medial three metatarsals form the anterior pillar of the arch. b) Summit: The talus is located at the highest point (summit) of this arch and acts as its keystone. c) Joints: The main joints involved in the medial longitudinal arch are the talocalcaneonavicular joint and the subtalar joint.

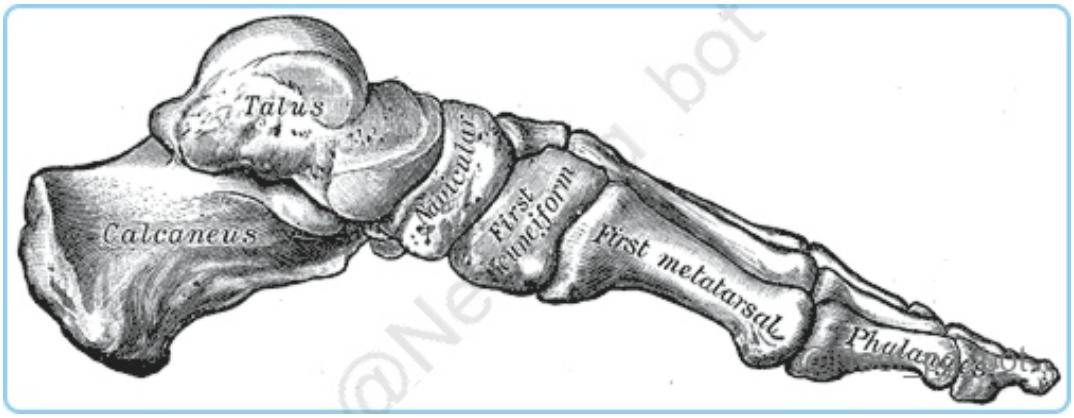

References:

Textbook of Anatomy, Abdomen and Lower Limb, Vishram Singh, Volume II, 2nd Edition, Page 433, 434

↑ *Back to this question in Part A*

@Neet_pg_bot

Q3: A 35-year-old male presents with a foot drop and weakness in the dorsiflexion of the great toe. He mentions a recent history of a herniated lumbar disc. There is decreased sensation over the dorsum of the foot and the first web space between the great toe and the second toe. Which dermatome and root value are most likely involved? (Q848223)

A. L5

B. S1

C. L4

D. L1

Correct Answer: A. L5

■ *Listen (English)*

■ *Listen (Hindi)*

Explanation: The L5 dermatome supplies sensation to the dorsum of the foot and the 1st web space between the great toe and the 2nd toe,the patient's decreased sensation in these areas indicates L5 nerve root involvement. Foot Drop indicates weakness in dorsiflexion , primarily controlled by the L5 nerve root through the deep peroneal nerve . A herniated lumbar disc (most common type—paradiscal), particularly between L4-L5 > L5-S1, can compress the L5 nerve root , leading to the symptoms described.

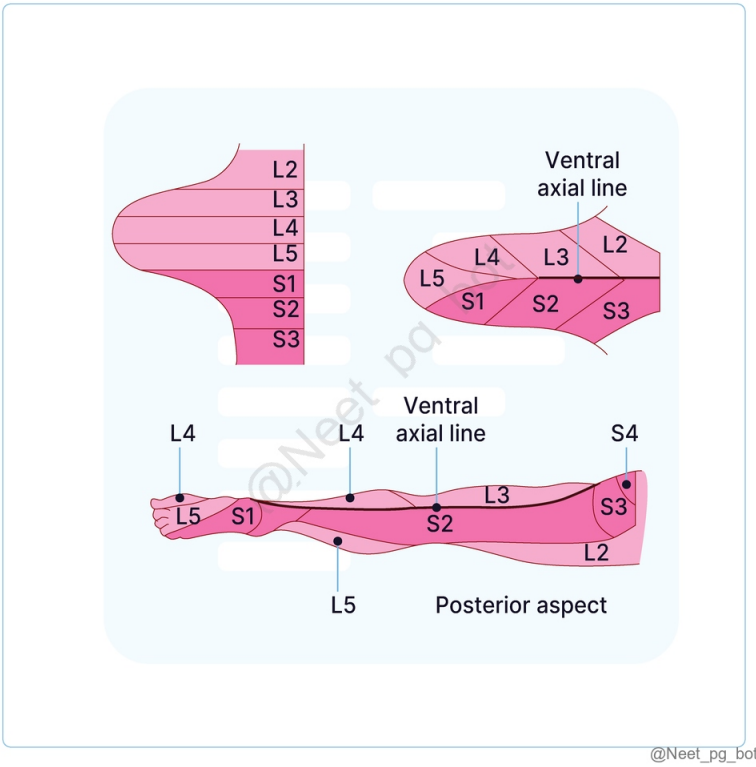

@Neet_pg_bot

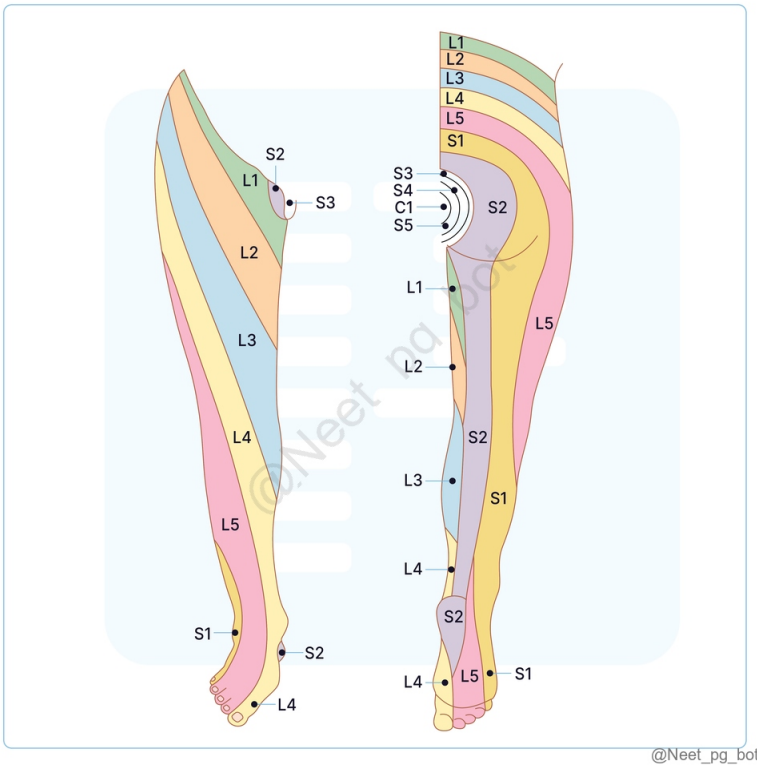

References:

Vishram Singh textbook of anatomy, 2nd Edition, Pages 468 - 474

↑ *Back to this question in Part A*

@Neet_pg_bot

Q4: Identify X. (Q848242)

A. Linea semilunaris

B. Linea alba

C. Spino-umbilical line

D. Addison’s plane

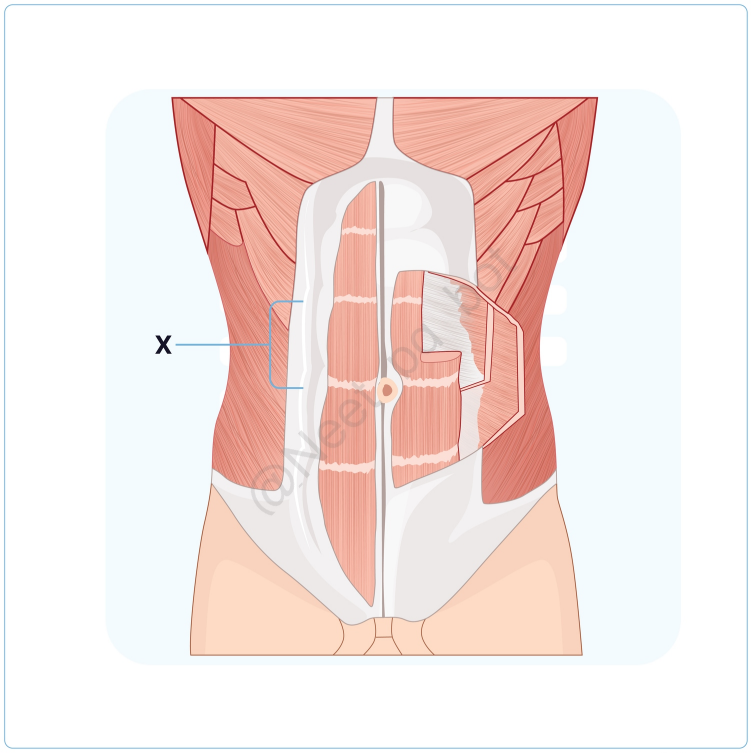

@Neet_pg_bot

Correct Answer: A. Linea semilunaris

- *Listen (English)*
- *Listen (Hindi)*

Explanation: The linea semilunaris is a curved groove that runs from the tip of the 9th costal cartilage to the pubic tubercle. It is located a few centimeters lateral to the midline and corresponds to the outer border of the rectus abdominis muscle. Linea alba (Option B): The linea alba is a tendinous raphe that separates the two rectus muscles. This midline groove divides the anterior abdominal wall into two halves, right and left. Spino-umbilical Line (Option C): Also known as the McBurney's line, is an imaginary line that extends from the umbilicus to the anterior superior iliac spine (ASIS) Addison's plane (Option D): Also known as the Transpyloric Plane , is an imaginary horizontal plane that passes through the midpoint of the line connecting the suprasternal notch to the pubic symphysis (roughly at the L1 vertebral level). Key structures present: Pylorus of the stomach Termination of the spinal cord Origin of the superior mesenteric artery Hilum of the kidney Fundus of the gallbladder Tip of the 9th costal cartilage Clinical Significance: Guides upper abdominal surgery (e.g., Whipple for pancreas), Separates supracolic/infracolic compartments Aids CT interpretation for masses/vascular issues. Subcostal plane: This plane is a horizontal line joining the lowest points of the costal margins (the bottom of the rib cage). It typically sits at the L3 vertebral level . It marks the upper boundary of the umbilical region . Key structures present: L3 Vertebra Third part of the Duodenum Origin of the Inferior Mesenteric Artery Clinical significance: Used to help define the boundaries of abdominal masses or to describe the extent of an enlarged liver (hepatomegaly) or spleen (splenomegaly). Transtubercular plane: Joins iliac crests tubercles (L5 level, intercristal line). This plane forms the boundary between the umbilical/lumbar regions (above) and the hypogastric/iliac regions (below). Key structures present: L5 Vertebra Confluence of Common Iliac Veins Cecum Clinical significance: It is a vital landmark for identifying the appendix (which sits just below this line in the right iliac fossa) and for performing certain vascular procedures near the bifurcation of the aorta. Supracristal Plane: Also known as the intercristal plane. It joins the

highest points of the iliac crests (L4 vertebral level), passing through the umbilical region. It is located ~1 cm below the transumbilical plane. Key structures present: Bifurcation of the Aorta L4 Vertebra Clinical significance: Primary landmark for lumbar puncture (L3/L4 interspace), spinal/epidural anesthesia, and dividing upper/lower abdominal quadrants It also guides vascular imaging for aneurysms.

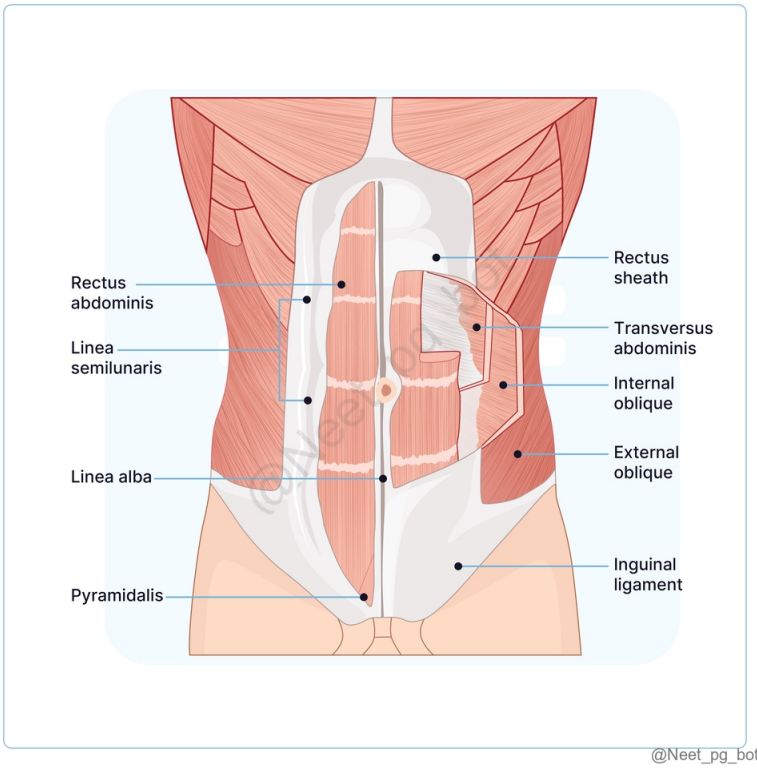

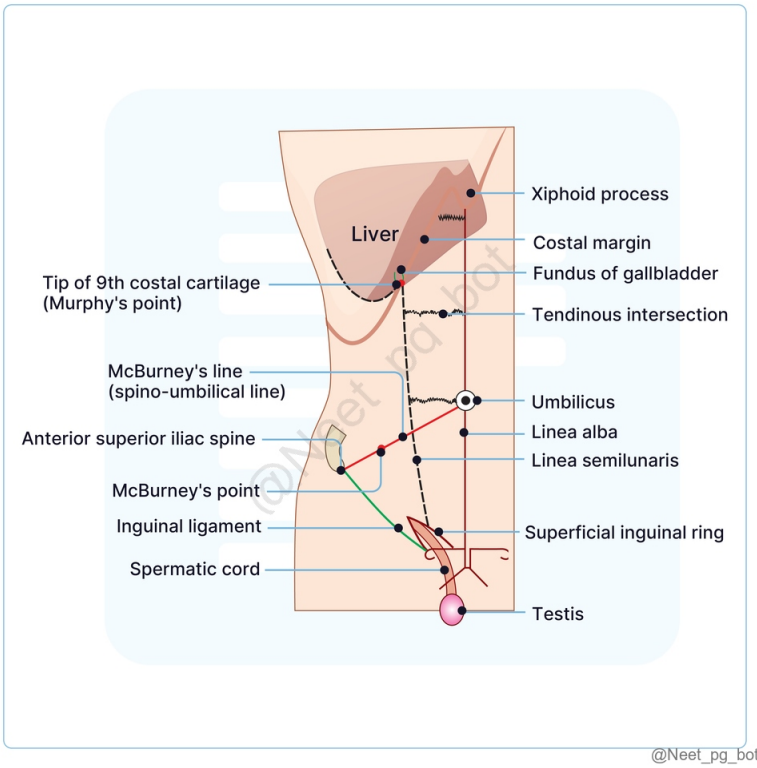

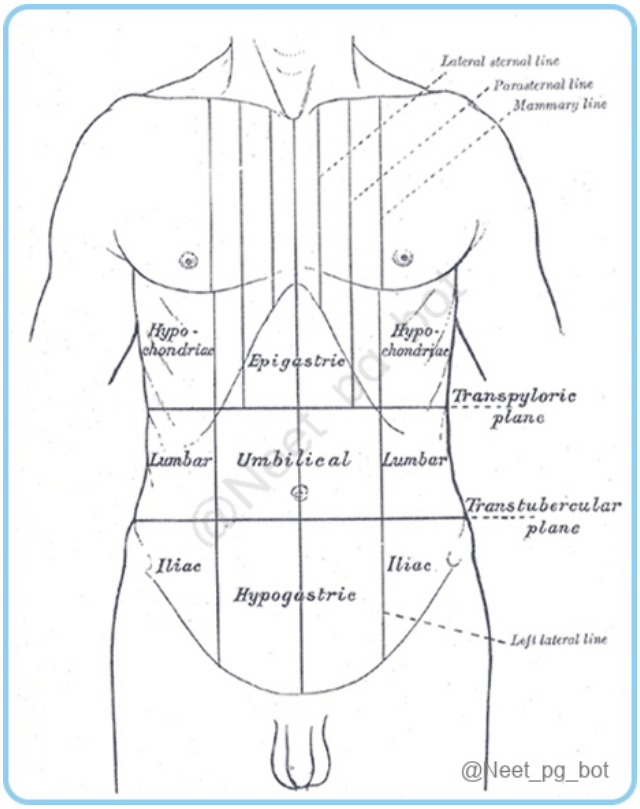

References:

Vishram Singh Textbook of Anatomy, Volume II, 2nd Edition, Pages 25, 26

↑ *Back to this question in Part A*

@Neet_pg_bot

Q5: Identify the muscle/muscle head that is not included in the hamstring group of muscles. (Q848227)

Correct Answer: Unknown

- *Listen (English)*
- *Listen (Hindi)*

Explanation: The part marked as “b” in the image is the short head of the biceps femoris, which is not a part of the hamstring group of muscles, it is supplied by common peroneal nerve (a) Long head of biceps femoris (b) Short head of biceps femoris (c) Semitendinosus (d) Semimembranosus Hamstrings include semitendinosus , semimembranosus, biceps femoris (long head) and ischial head (Hamstring portion) of adductor magnus The characteristic features of hamstring muscles are: All arise from the ischial tuberosity. All are inserted into one of the bones of the leg. All are supplied by tibial part of the sciatic nerve. All are flexors of the knee and extensors of the hip joint.

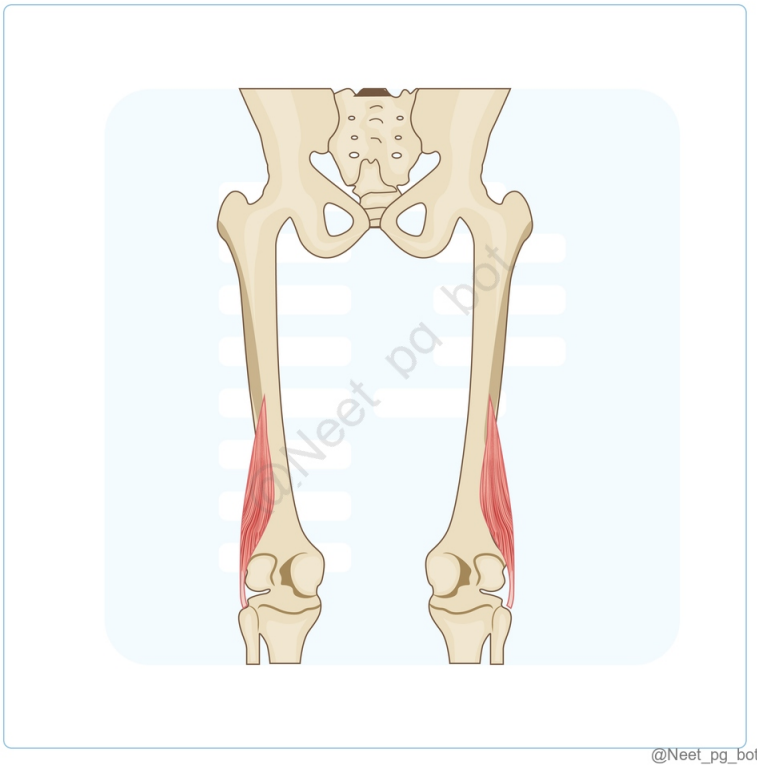

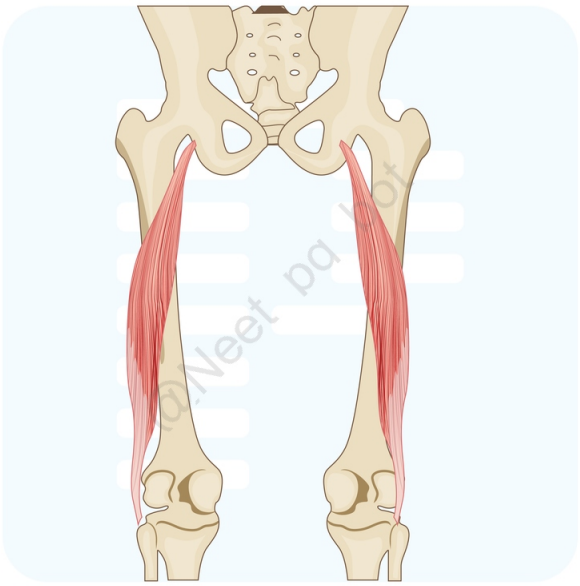

@Neet_pg_bot

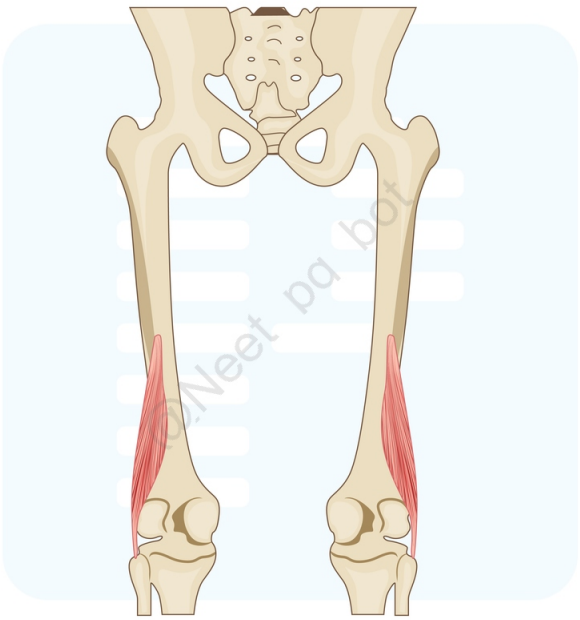

@Neet_pg_bot

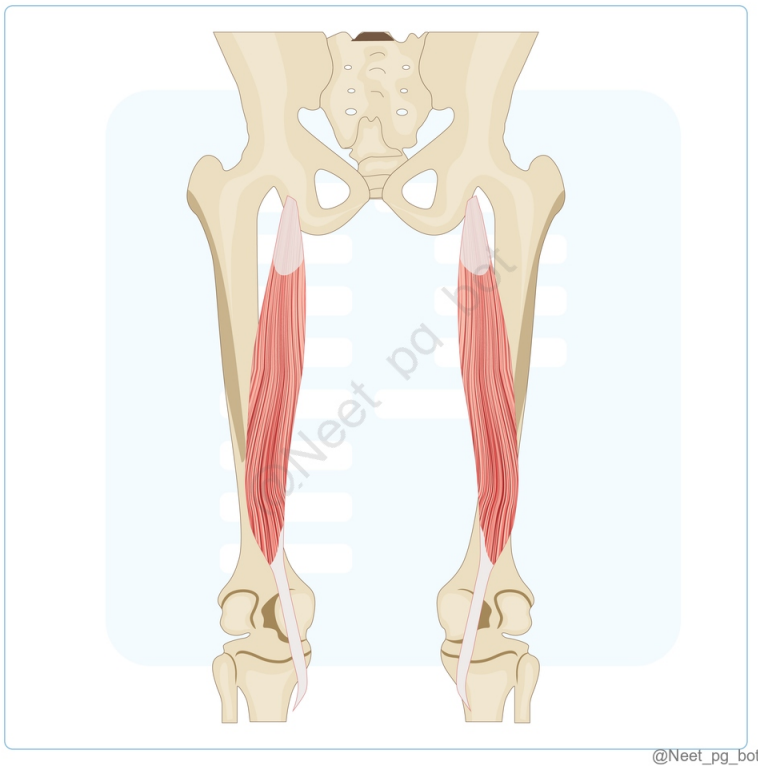

@Neet_pg_bot

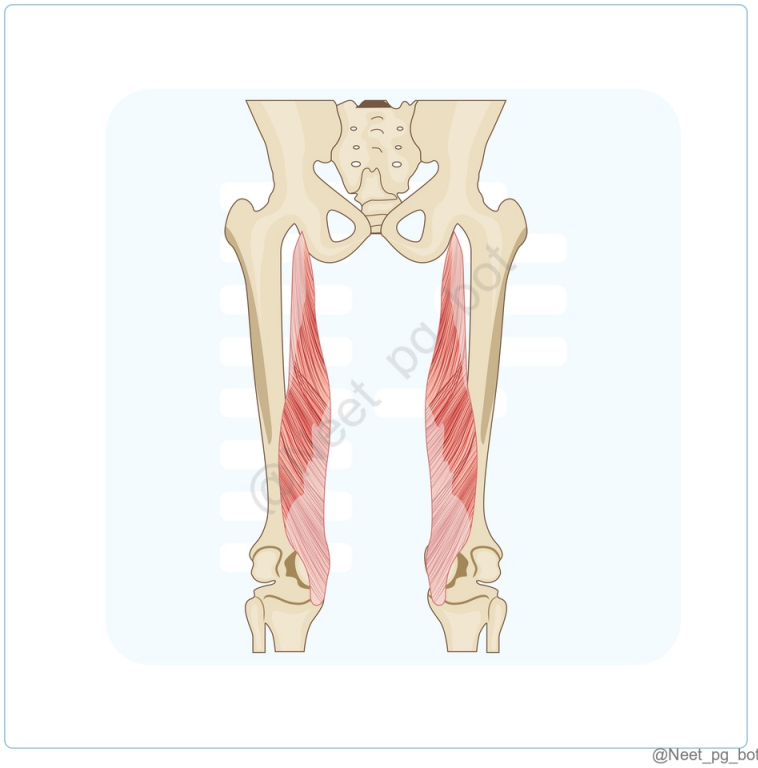

@Neet_pg_bot

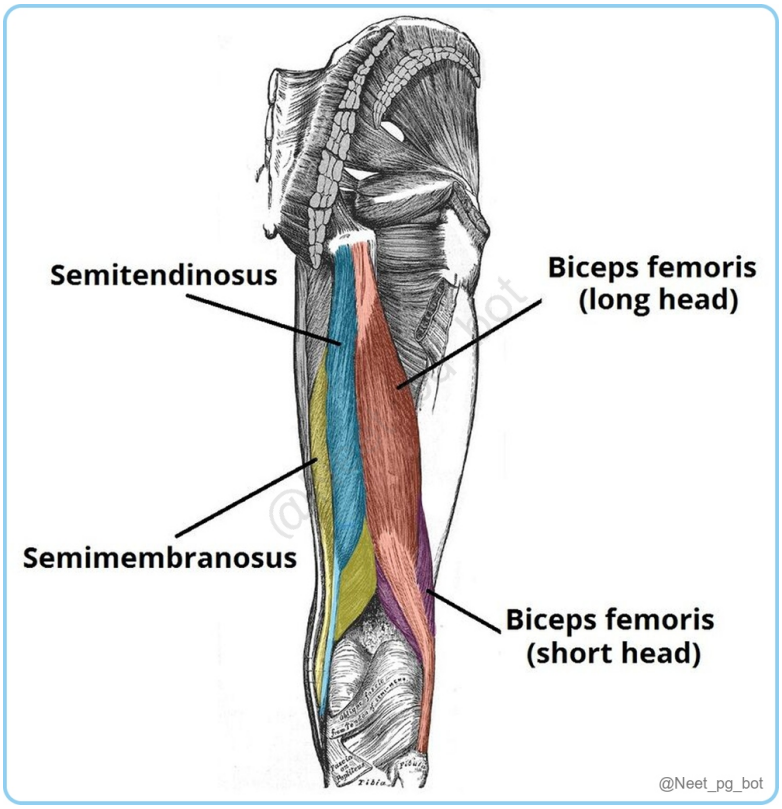

References:

Gray's Anatomy, 42nd Edition, Pages 1386, 1387

Vishram Singh Textbook of Anatomy, Abdomen and Lower Limb, 2nd Edition, Pages 364, 365

↑ *Back to this question in Part A*

@Neet_pg_bot

Q6: Which of the following muscles is/are supplied by the Nerve to the obturator internus? (Q848239)

A. Gamellus inferior and obturator internus

B. Gamellus superior and obturator internus

C. Quadratus femoris and obturator internus

D. Obturator internus only

Correct Answer: B. Gamellus superior and obturator internus

■ *Listen (English)*

■ *Listen (Hindi)*

Explanation: The nerve to obturator internus innervates both the obturator internus and superior gemellus muscles. It arises from the anterior divisions of the sacral plexus, originating from the L5, S1, and S2 nerve roots. Quadratus femoris and Gamellus inferior are supplied by Nerve to quadratus femoris (L4, 5, S1)

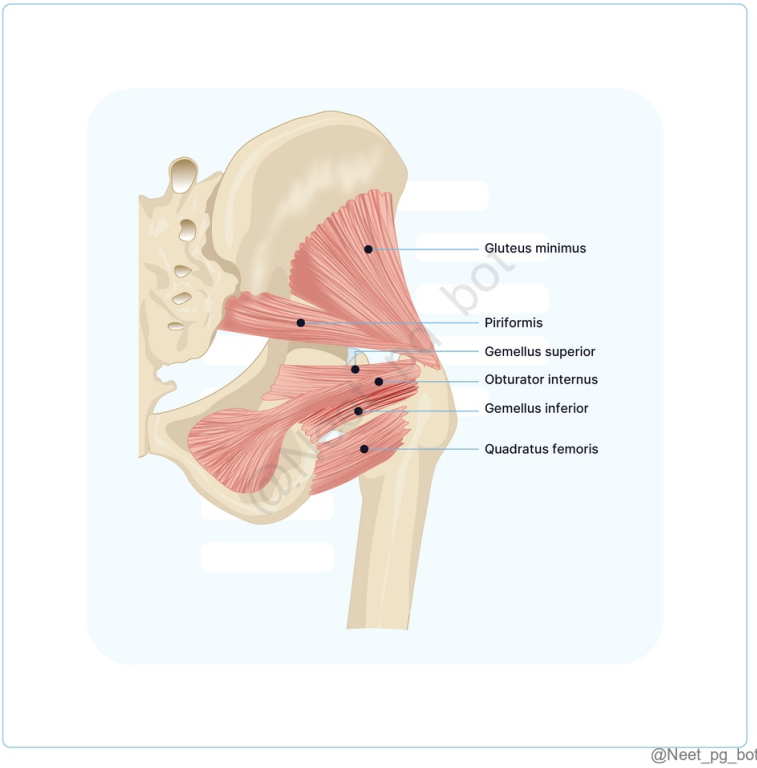

References:

Gray's Anatomy, 42nd Edition, Pages 1376 - 1380.

↑ *Back to this question in Part A*

@Neet_pg_bot

Q7: A 35-year-old athlete presents with difficulty climbing stairs and rising from a seated position. Upon examination, there is weakness in hip extension. Which muscle is most likely affected, and what is the nerve supply? (Q848231)

A. Psoas major; Anterior rami of L1, L2, L3

B. Gluteus maximus; Inferior gluteal nerve

C. Gluteus maximus; Superior gluteal nerve

D. Sartorius; Femoral nerve

Correct Answer: B. Gluteus maximus; Inferior gluteal nerve

■ *Listen (English)*

■ *Listen (Hindi)*

Explanation: Gluteus maximus is the chief extensor of the hip , and weakness would impair actions like rising from a seated position. Its nerve supply is the inferior gluteal nerve (L5, S1, S2). Origin: Posterior gluteal surface of ilium, behind the posterior gluteal line Dorsal surface of sacrum and coccyx Sacrotuberous ligament and thoracolumbar (lumbodorsal) fascia Insertion: Deep fibers: Gluteal tuberosity of the femur. Superficial fibers: Iliotibial tract (IT band). Action: Extension at Hip joint External Rotation of the thigh Muscles of Gluteal region: Action of the Hip joint, corresponding muscles and their innervation: Action Muscles Nerve supply Flexion Psoas major (chief flexor)■■■■■■■ (Option A) Anterior rami of L1, L2, L3 Iliacus (chief flexor) Sartorius (Option D) Rectus femoris Pectineus Femoral nerve (L2, L3) Extension Gluteus maximus (chief extensor) (Option B) Inferior gluteal nerve (L5, S1, S2) Hamstring muscles Tibial part of the sciatic nerve (L5, S1, S2) Abduction Gluteus medius and minimus (chief abductors) Tensor fasciae latae Superior gluteal nerve (L5, S1) (Option C) Adduction Adductor longus Adductor brevis Adductor magnus (chief adductors) Gracilis Obturator nerve (L2, L3, L4) Pectineus Double nerve supply (Femoral nerve and obturator nerve) Medial rotation Anterior fibres of gluteus minimus and medius (chief medial rotators) Tensor fasciae latae Superior gluteal nerve (L5, S1) Lateral rotation Piriformis Ventral rami of S1, S2 Obturator externus Posterior division of obturator nerve (L2, L3, L4) Obturator internus and Associated gemelli, Quadratus femoris (These muscles are generally termed short rotators) Nerve to obturator internus (L5, S1, S2)

<table>
<tr><th>MUSCLE</th><th>NERVE SUPPLY</th><th>ACTION</th></tr>
<tr><td>Gluteus Maximus</td><td>Inferior Gluteal Nerve (L5, S1, S2)</td><td>• Extension at Hip joint
• External Rotation</td></tr>
<tr><td>Gluteus Medius
Gluteus Minimus</td><td>Superior Gluteal Nerve (L4, L5, S1)</td><td>• Abduction at hip joint
• Stabilizes Pelvis
• Internal Rotation</td></tr>
<tr><td>Gemellus Superior
Obturator Internus</td><td>Nerve to Obturator Internus</td><td rowspan="2">Lateral Rotation at Hip joint</td></tr>
<tr><td>Gemellus Inferior
Quadratus Femoris</td><td>Nerve to Quadratus Femoris</td></tr>
</table>

@Neet_pg_bot

References:

Vishram Singh Textbook of Anatomy, 2nd Edition, Volume 2, Pages 382, 383

↑ *Back to this question in Part A*

@Neet_pg_bot

Q8: Which among the following structures do not pass through both the greater and lesser sciatic foramen? (Q848236)

A. Pudendal nerve

B. Internal pudendal artery

C. Nerve to obturator internus

D. Posterior cutaneous nerve of thigh

Correct Answer: D. Posterior cutaneous nerve of thigh

■ *Listen (English)*

■ *Listen (Hindi)*

Explanation: The posterior cutaneous nerve of the thigh only passes through the greater sciatic foramen and not the lesser foramen. Structures passing through greater and lesser sciatic foramen: Greater sciatic notch/foramen/gateway of gluteal region Lesser sciatic notch The piriformis, emerging from the pelvis, fills the foramen almost completely. It is the key muscle of the region. Structures passing above the piriformis are: Superior gluteal nerve Superior gluteal vessels Structures passing below the piriformis are: Inferior gluteal nerve Inferior gluteal vessels Sciatic nerve The posterior cutaneous nerve of the thigh Nerve to the quadratus femoris Pudendal nerve (Option A) Internal pudendal vessels (Option B) Nerve to obturator internus (Option C) Tendon of obturator internus Pudendal nerve (Option A) Internal pudendal vessels (Option B) Nerve to obturator internus (Option C) The upper and lower parts of the foramen are filled up by the origins of the two gemelli muscles.

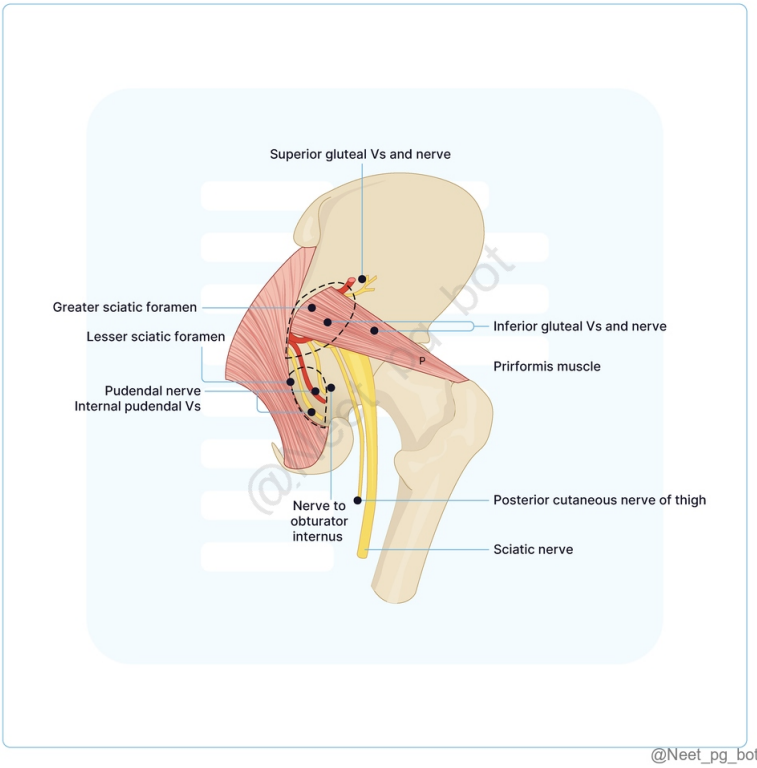

@Neet_pg_bot

References:

Gray’s Anatomy, 42nd Edition, Page 1252

BD Chaurasia Human Anatomy, 8th Edition, Page 85

↑ *Back to this question in Part A*

@Neet_pg_bot

Q9: In a clinical setting, a physician suspects a weakness in the gluteus maximus muscle. Which of the following functions would not be affected by this? (Q848233)

A. Extension of flexed thigh

B. Raising trunk after stooping

C. Lateral rotation and abduction of the thigh

D. Stabilization of pelvis during quiet standing

Correct Answer: D. Stabilization of pelvis during quiet standing

■ *Listen (English)*

■ *Listen (Hindi)*

Explanation: Gluteus maximus is minimally active during quiet standing. Pelvic stability in quiet standing is mainly maintained by gluteus medius and minimus, which prevent pelvic drop. Therefore, weakness of gluteus maximus does not significantly impair pelvic stability in standing. Incorrect Options: Option A) Extension of flexed thigh - Affected. Gluteus maximus is the principal extensor of the flexed thigh, especially during powerful movements like rising from a chair or climbing stairs. Option B) Raising trunk after stooping - Affected. This action requires strong hip extension, which is primarily performed by the gluteus maximus. Option C) Lateral rotation and abduction of the thigh - Affected. Gluteus maximus assists in lateral rotation and contributes to abduction of the thigh (upper fibers).

References:

Gray’s Anatomy, 42nd Edition, Page 1377

↑ *Back to this question in Part A*

@Neet_pg_bot

Q10: A 30-year-old runner complains of difficulty flexing his knee after long-distance running. He reports that once his knee locks in an extended position, it takes effort to

initiate flexion again. On examination, you notice that the patient struggles to begin flexion from full extension. Which muscle is likely impaired? (Q848232)

A. Quadriceps femoris

B. Popliteus

C. Biceps femoris

D. Vastus medialis

Correct Answer: B. Popliteus

■ *Listen (English)*

■ *Listen (Hindi)*

Explanation: The popliteus muscle is responsible for unlocking the knee by causing lateral rotation of the femur on the tibia during the initial phase of flexion. Impairment of this muscle would make it difficult to initiate flexion from full extension. Locking Unlocking Medial rotation of the femur on the tibia during the terminal phase of extension. Lateral rotation of the femur on the tibia during the initial phase of the flexion It is brought about by the quadriceps femoris It is brought about by the popliteus muscle Locked knee becomes rigid Unlocked knee can be further flexed All ligaments are taut All ligaments are relaxed

References:

Vishram Singh textbook of anatomy, 2nd Edition, Volume 2, Pages 447, 448.

↑ *Back to this question in Part A*

@Neet_pg_bot

Q11: The iliotibial tract provides attachment to which of the following muscles? (Q848241)

A. Gluteus medius

B. Tensor fasciae latae

C. Gluteus maximus

D. Both B and C

Correct Answer: D. Both B and C

■ *Listen (English)*

■ *Listen (Hindi)*

Explanation: The deep fascia of the thigh presents two modifications – iliotibial tract and saphenous opening. Iliotibial tract: The iliotibial tract splits into two layers to enclose the tensor fasciae latae and gluteus maximus muscles. Between these muscles, it forms a thickened sheet called the gluteal aponeurosis, which also covers the gluteus medius. The superficial lamina attaches to the tubercle of the iliac crest. The deep lamina attaches to the capsule of the hip joint. Inferiorly, the tract attaches to a smooth area on the anterior surface of the lateral condyle of the tibia. Function : Stabilizes the knee both in extension and in partial flexion. Used during walking and running. When leaning forward with slightly flexed knees, the iliotibial tract supports the knee against gravity, preventing the individual from falling forward.

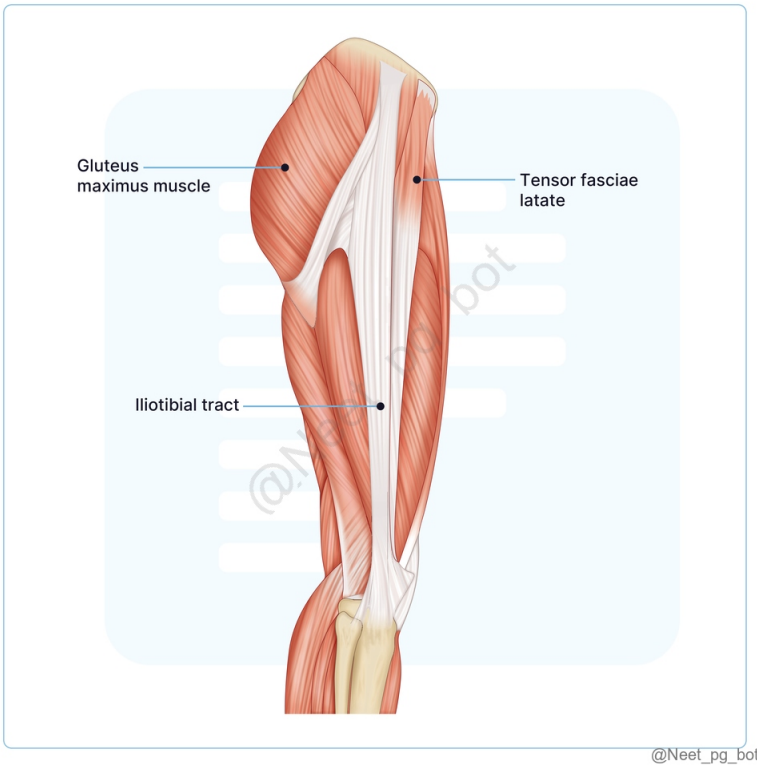

References:

Vishram Singh Textbook of Anatomy, Volume II, 2nd Edition, Page 331

↑ *Back to this question in Part A*

@Neet_pg_bot

Q12: Which of the following does not participate in the cruciate anastomosis? (Q848240)

A. Inferior gluteal artery

B. Medial circumflex femoral artery

C. Lateral circumflex femoral artery

D. Deep femoral artery

Correct Answer: D. Deep femoral artery

■ *Listen (English)*

■ *Listen (Hindi)*

Explanation: Cruciate anastomosis is situated at the upper part of the back of the femur at the level of lesser trochanter. It provides a bypass route if the femoral artery is blocked between the origin of the profunda femoris and the popliteal artery. The following arteries form the cruciate anastomosis: Transverse branch of the medial circumflex femoral artery . Transverse branch of the lateral circumflex femoral artery . Ascending branch of the first perforating artery . Descending branch of the inferior gluteal artery . Trochanteric Anastomosis: This is the "higher" network. It is clinically vital because its branches (retinacular arteries) are the primary source of blood for the femoral head. The following arteries form the cruciate anastomosis: Superior Gluteal Artery (Deep branch) Inferior Gluteal Artery Medial Circumflex Femoral Artery (Ascending branch) Lateral Circumflex Femoral Artery (Ascending branch)

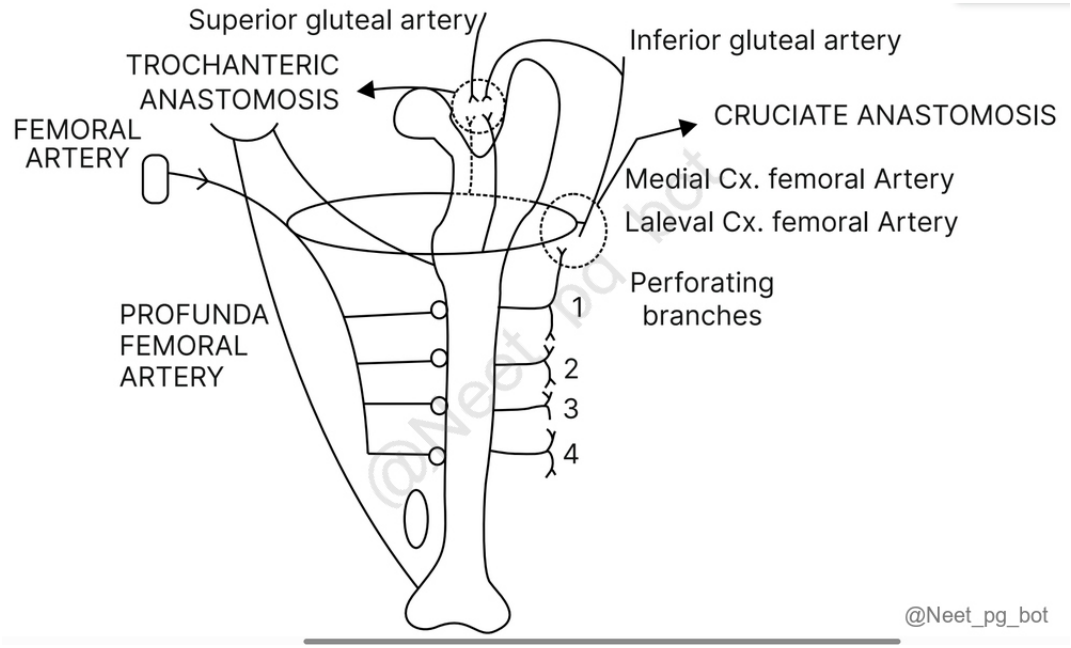

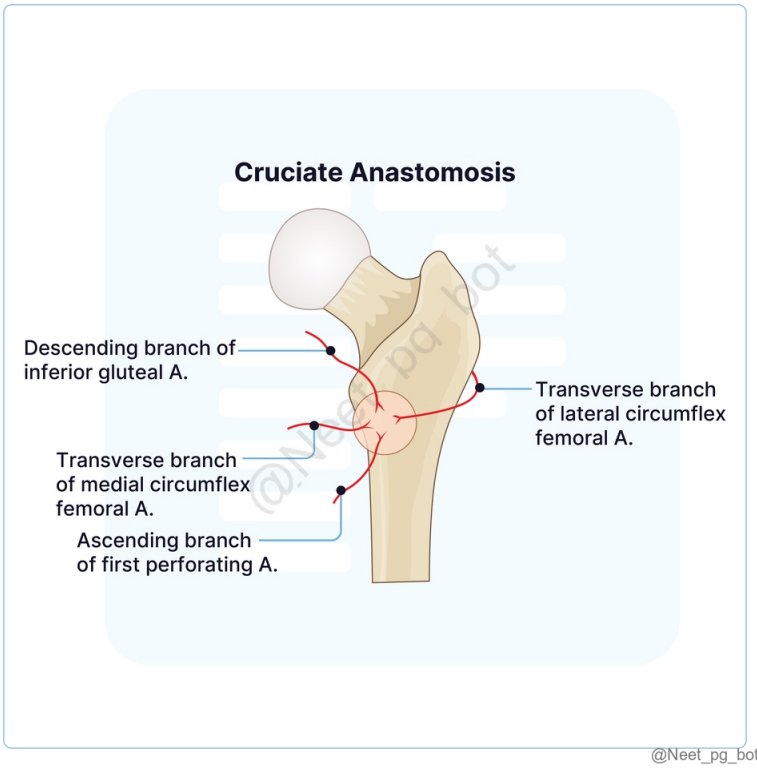

@Neet_pg_bot

References:

Vishram Singh Textbook of Anatomy, Volume II, 2nd Edition, Page 370

↑ *Back to this question in Part A*

@Neet_pg_bot

Q13: The femoral nerve splits into anterior and posterior divisions, which are separated by which of the following structures? (Q848238)

A. Femoral vein

B. Lateral circumflex femoral artery

C. Inguinal ligament

D. Obturator artery

Correct Answer: B. Lateral circumflex femoral artery

■ *Listen (English)*

■ *Listen (Hindi)*

Explanation: The chief nerve of the anterior compartment of the thigh is the femoral nerve. It is the largest branch of the lumbar plexus and arises from the dorsal divisions of the anterior primary rami of the L2, L3, and L4 nerves. The femoral nerve enters the thigh posterior to the inguinal ligament, just lateral to the femoral sheath. About 2 cm below the inguinal ligament, the femoral nerve divides into anterior and posterior divisions, separated by the lateral circumflex femoral artery.

References:

Vishram Singh Textbook of Anatomy, Volume II, 2nd Edition, Page 340

↑ *Back to this question in Part A*

@Neet_pg_bot

Q14: Which two nerves provide the dual innervation of the pectineus muscle? (Q848237)

A. Obturator Nerve and Femoral Nerve

B. Sciatic Nerve and Tibial Nerve

C. Medial Pectoral Nerve and Lateral Pectoral Nerve

D. Musculocutaneous Nerve and Radial Nerve

Correct Answer: A. Obturator Nerve and Femoral Nerve

■ *Listen (English)*

■ *Listen (Hindi)*

Explanation: The pectineus is considered a composite or hybrid muscle because it has dual nerve supply. The femoral nerve innervates the lateral part of the muscle, whereas the medial portion receives its innervation from the obturator nerve. Hybrid muscles: Composite or hybrid muscles contain multiple fiber types that perform the same function and are innervated by different nerves for each fiber set. Muscle Innervation Pectoralis Major (Option C) Sternocostal Head Medial Pectoral Nerve (C8, T1) Clavicular Head Lateral Pectoral Nerve (C5, 6, 7) Subscapularis Upper & Lower Subscapular Nerves (C5, 6) Brachialis (Option D) Musculocutaneous Nerve (C5, 6, 7) (medial) Radial Nerve (C5, 6, 7, 8, T1) (lateral) Flexor Digitorum Profundus Lateral Part Anterior Interosseous Branch of Median Nerve (C8, T1) Medial Part Ulnar Nerve (C8, T1) Pectineus (Option A) Obturator Nerve (L2, 3, 4) Femoral Nerve (L2, 3, 4) Adductor Magnus Adductor Part Posterior Division of Obturator Nerve (L2, 3, 4) Hamstring Part Tibial Branch of Sciatic Nerve (L4, 5, S1) Biceps Femoris Long Head Tibial Branch of Sciatic Nerve (L4, 5, S1) Short Head Common Peroneal Division of Sciatic Nerve (L4, 5, S1) Digastric muscle Anterior belly Nerve to mylohyoid Posterior belly Facial nerve

References:

https://orthopaedicprinciples.com/2021/03/muscles-with-dual-innervation/

↑ *Back to this question in Part A*

Q15: Which of the following regarding the marked structure is true? (Q848235)

A. Nerve to obturator internus passes above it

B. Innervated by L5, S1 nerve roots

C. Pudendal nerve passes below it

D. It is a medial rotator of the hip joint

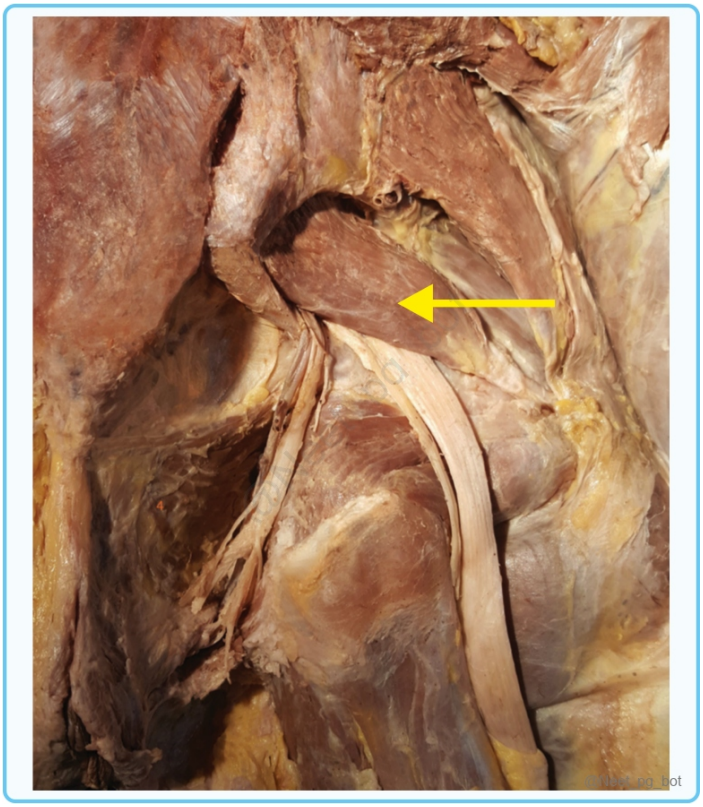

Correct Answer: C. Pudendal nerve passes below it

■ *Listen (English)*

■ *Listen (Hindi)*

Explanation: The structure marked here is the Piriformis muscle, and the Pudendal nerve passes inferior to it. Piriformis: The piriformis muscle emerges from the pelvis, almost filling the greater sciatic foramen completely and is the key muscle of the area. Structures running superior to piriformis : Superior gluteal nerve and vessel Structures running inferior to piriformis: Inferior gluteal nerve and vessels Greater trochanter Sciatic nerve Posterior cutaneous nerve of thigh Nerve to quadratus femoris Nerve to obturator internus (Option A) Internal pudendal vessels Pudendal nerve (Option C) Innervated by superior gluteal nerve and ventral rami of S1 and S2

(Option B) Actions: ■■■■ Laterally rotates extended thigh (Option D) Abducts flexed thigh Greater and lesser sciatic foramen:

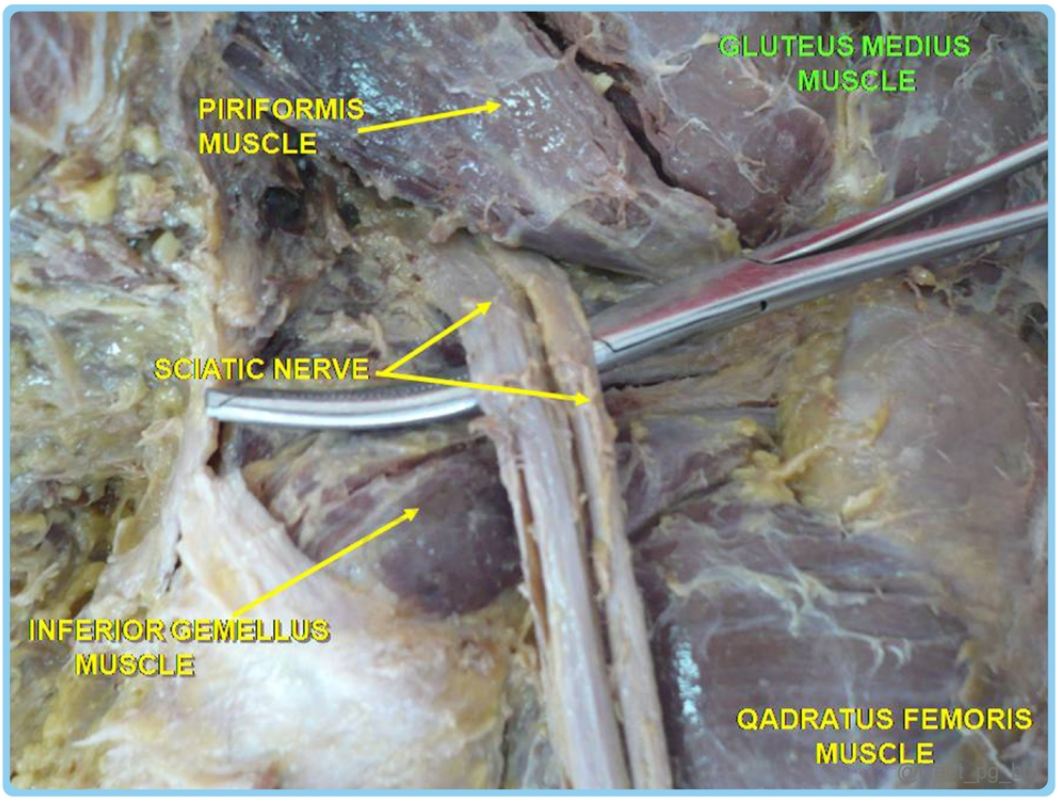

GREATER AND LESSER SCIATIC FORAMEN

Greater sciatic foramen - Piriformis muscle

- Structures passing above piriformis muscle:
  - Superior gluteal artery, nerve, vein
- All remaining structures pass below piriformis:
  - Inferior gluteal nerve, artery & vein
  - Nerve to obturator internus
  - Nerve to quadratus femoris
  - Sciatic nerve & posterior cutaneous nerve of thigh
  - Pudendal nerve
  - Internal pudendal artery & vein

Lesser sciatic foramen ~ obturator internus muscle

- Structures passing through lesser sciatic foramen:
  - Pudendal nerve
  - Internal pudendal artery & vein
  - Obturator internus muscle (tendon)

@Neet_pg_bot

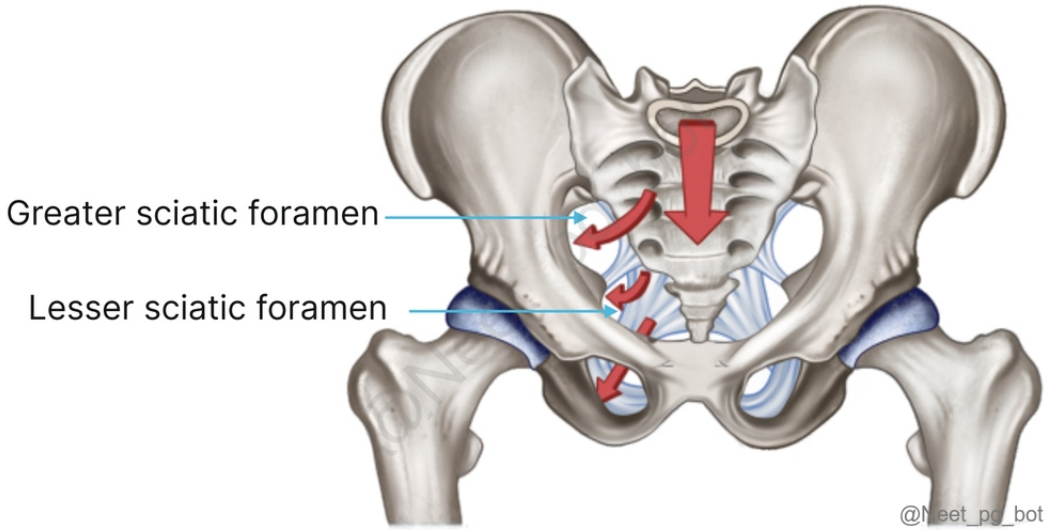

References:

Gray's Anatomy, 42nd Edition, Page 1379

BD Chaurasia Human Anatomy, Volume 2, 8th Edition, Page 85

↑ *Back to this question in Part A*

@Neet_pg_bot

Q16: A 30-year-old male is being examined for abnormal gait. His Trendelenberg sign is positive. What is false about testing for the Trendelenburg sign? (Q848234)

A. The side of the hip that droops down is the unaffected side

B. The gluteus medius and minimus muscles are affected

C. The patients have a characteristic lurching gait

D. The uncompensated Trendelenburg sign is elicited with a walking patient

Correct Answer: D. The uncompensated Trendelenburg sign is elicited with a walking patient

■ *Listen (English)*

■ *Listen (Hindi)*

Explanation: The uncompensated Trendelenburg sign is elicited in a patient in a standing position on one limb and the compensated is elicited in a walking patient. Trendelenberg sign: When the body's weight is balanced on one leg, the gluteal muscles on the supported side help elevate the opposite, unsupported side of the pelvis. However, if there is a malfunction in the abductor mechanism, the Sound side(unsupported side) sinks (Option A) , which is referred to as a positive Trendelenburg sign (uncompensated). This sign indicates issues with hip abductors, such

as paralysis of the gluteus medius and minimus (Option B) ; problems with the fulcrum, including congenital or pathological hip dislocations; and concerns related to body weight, such as an unhealed fracture of the femoral neck. When patients with the gluteus medius and minimus paralysis walk, they have a characteristic lurching gait (Option C) ie, during the single leg supporting phase of walking, there is leaning of the trunk to the affected side known as the compensated Trendelenburg sign . Duck waddling gait is seen when both the sides are affected.

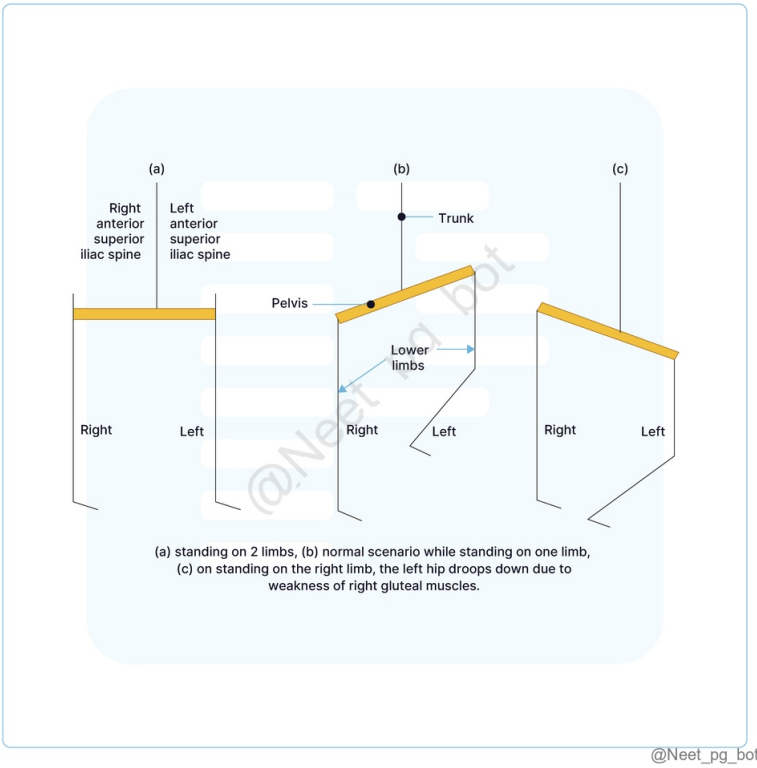

(a) standing on 2 limbs, (b) normal scenario while standing on one limb, (c) on standing on the right limb, the left hip droops down due to weakness of right gluteal muscles.

@Neet_pg_bot

References:

Gray’s Anatomy, 42nd Edition, Pages 1376-1379.

↑ *Back to this question in Part A*

@Neet_pg_bot

Q17: A patient reports pain and decreased sensation along the posterolateral aspect of the lower leg, extending onto the lateral side of the foot, following an ankle sprain. Which nerve is most likely injured? (Q848220)

A. Sural nerve

B. Saphenous nerve

C. Superficial peroneal nerve

D. Lateral femoral cutaneous nerve

Correct Answer: A. Sural nerve

■ *Listen (English)*

■ *Listen (Hindi)*

Explanation: The sural nerve innervates the posterolateral aspect of the leg . Injury can occur due to ankle sprains , fractures, or tight footwear, leading to pain and sensory loss in this region. Cutaneous Innervation of Lower Limb: Primarily from the lumbar and sacral plexuses. Except some proximal uni segmental nerves arise from T12 or L1 spinal nerves. Thigh Innervation: Main supply: Lateral and Posterior Cutaneous Nerves of the Thigh and Cutaneous Branch of Femoral Nerve. Leg Innervation: Anteromedial Aspect: Saphenous nerve (Option B) Posterolateral Aspect: Sural nerve Anterolateral Aspect: Superficial peroneal nerve (Option C) Lateral Femoral Cutaneous Nerve Injury: (Option D) Causes paresthesia or dysaesthesia (meralgia paresthetica) on the anterolateral aspect of the thigh, intensified by walking or hip extension. Clinical significance of Sural nerve: Patient Presentation: Numbness, tingling, or "burning" pain along the inner (medial) side of the leg and the medial arch of the foot. The "Gold Standard" for Nerve Grafts: Because it is a long, purely sensory nerve, it is the most common donor site for nerve autografts . If a patient has a major motor nerve severed elsewhere, surgeons "harvest" the Sural nerve to bridge the gap. Short Saphenous Vein Association: It runs alongside the Small (Short) Saphenous Vein . It can be damaged during procedures involving this vein or during lateral ankle surgeries (like Brostrom procedures for chronic instability). Sural Nerve Biopsy: This is the preferred site for diagnostic nerve biopsies to investigate peripheral neuropathies (like vasculitis or amyloidosis). Ankle Sprains: Severe inversion ankle sprains can occasionally stretch or compress the sural nerve, leading to persistent lateral foot pain. Clinical significance of Saphenous nerve: Patient Presentation: Numbness or pain along the outer (lateral) border of the foot and the small toe. Adductor Canal Syndrome: The nerve can be compressed as it exits the adductor canal (Hunter’s canal) by the vastoadductor membrane, causing pain or numbness on the medial knee and leg. Vulnerability during Surgery: Because it runs closely alongside the Great Saphenous Vein , it is the nerve most commonly injured during Varicose Vein stripping or Saphenous vein harvesting for CABG (heart bypass). Knee Surgery Complications: It is at high risk during medial meniscus repairs or ACL reconstructions using hamstring grafts. Saphenous Nerve Block: Often used for procedures on the medial foot or ankle, usually performed just above the medial malleolus.

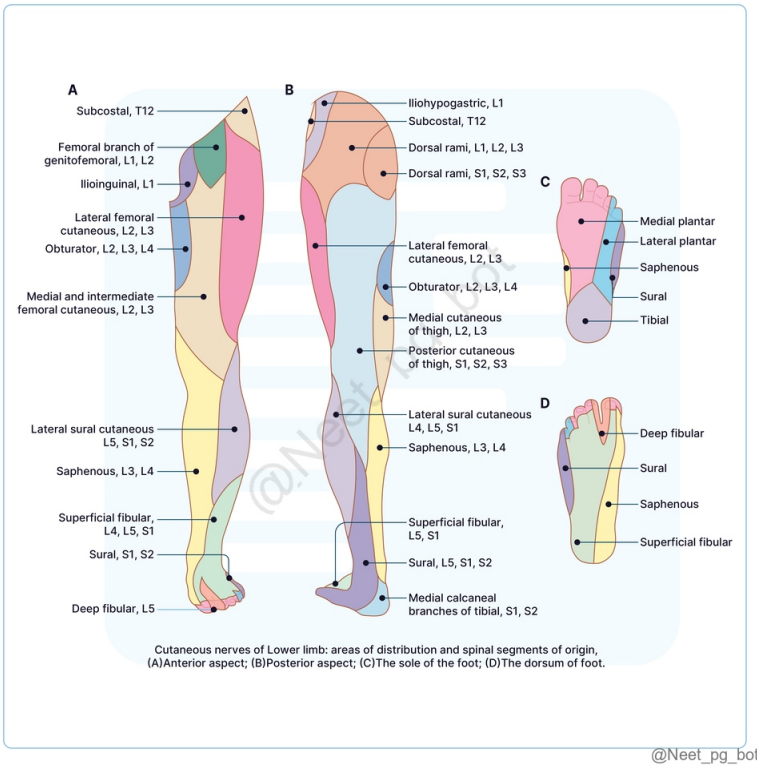

Cutaneous nerves of Lower limb: areas of distribution and spinal segments of origin, (A)Anterior aspect; (B)Posterior aspect; (C)The sole of the foot; (D)The dorsum of foot.

@Neet_pg_bot

References:

Vishram Singh Textbook of Anatomy, Abdomen and Lower Limb, 2nd Edition, Page 473

Gray's Anatomy, 42nd Edition, Pages 1341,1342

↑ *Back to this question in Part A*

@Neet_pg_bot

Q18: A 40-year-old man is involved in a car accident and sustains a fracture to the ischial tuberosity. He now presents with weakness in knee flexion and hip extension, with intact sensation. Which muscle group and nerve are likely involved? (Q848230)

A. Quadriceps; femoral nerve

B. Hamstrings; sciatic nerve

C. Adductors; obturator nerve

D. Gluteal muscles; superior gluteal nerve

Correct Answer: B. Hamstrings; sciatic nerve

■ *Listen (English)*

■ *Listen (Hindi)*

Explanation: The hamstrings , innervated by the sciatic nerve , are responsible for knee flexion and hip extension. A fracture of the ischial tuberosity can affect the attachment site of these muscles. Hamstring muscles: The hamstring muscle group comprises three main muscles in the posterior thigh that play key roles in lower limb movement and stability. Muscle Components: Biceps femoris (long and short heads): Lateral muscle; originates from ischial tuberosity (long head) and linea aspera (short head), inserts on fibular head. Semitendinosus : Medial, superficial; originates from ischial tuberosity, inserts on medial tibia via pes anserinus.■ Semimembranosus : Medial, deep; originates from ischial tuberosity, inserts on medial tibial condyle.■ Origins and Innervation: All three (except biceps short head) arise from the ischial tuberosity and are primarily innervated by the tibial division of the sciatic nerve (L5-S2); biceps short head by common peroneal. They cross both hip and knee joints as biarticular muscles. Primary Functions: Knee flexion (bending the knee).■ Hip extension (straightening the hip).■ Stabilize knee/hip during gait; assist in tibial rotation (medial for semitendinosus/semimembranosus, lateral for biceps). Sciatic nerve: Quadriceps; femoral nerve (Option A) : Quadriceps extend the knee, not flex it. Adductors; obturator nerve (Option C) : Adductors handle hip adduction, not knee flexion or hip extension. Gluteal muscles; superior gluteal nerve (Option D) : Gluteal muscles control hip abduction, not knee flexion or hip extension.

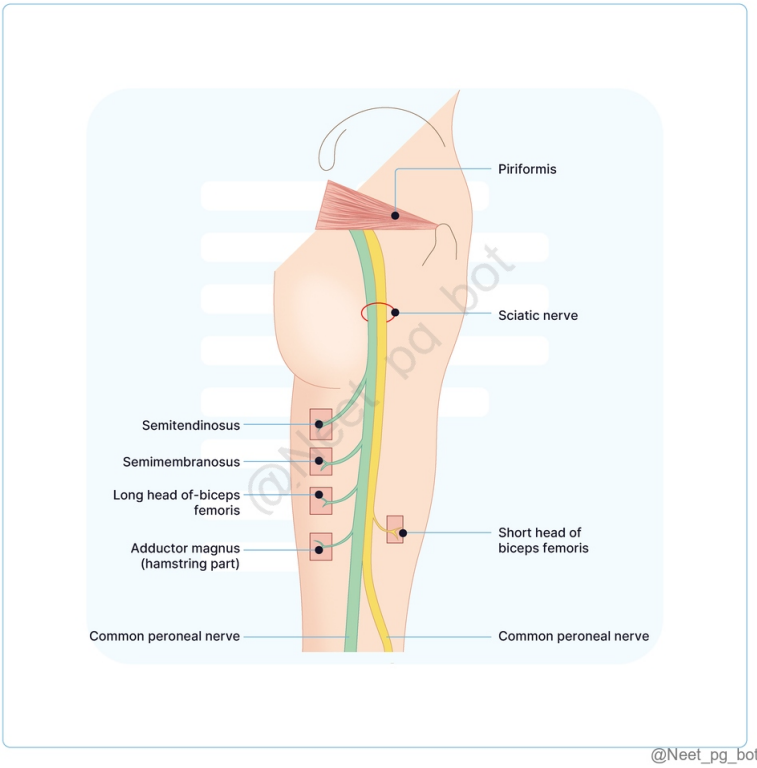

References:

Vishram Singh textbook of anatomy, 2nd Edition, Volume 2, Pages 367, 368, 369

↑ *Back to this question in Part A*

@Neet_pg_bot

Q19: Identify the marked structures in the given image: (Q848229)

A. a) Semitendinosus, b) Biceps femoris, c) Popliteal artery, d) Tibial nerve

B. a) Semitendinosus, b) Biceps femoris, c) Tibial nerve, d) Popliteal artery

C. a) Biceps femoris, b) Semitendinosus, c) Popliteal artery, d) Tibial nerve

D. a) Biceps femoris, b) Semitendinosus, c) Tibial nerve, d) Popliteal artery

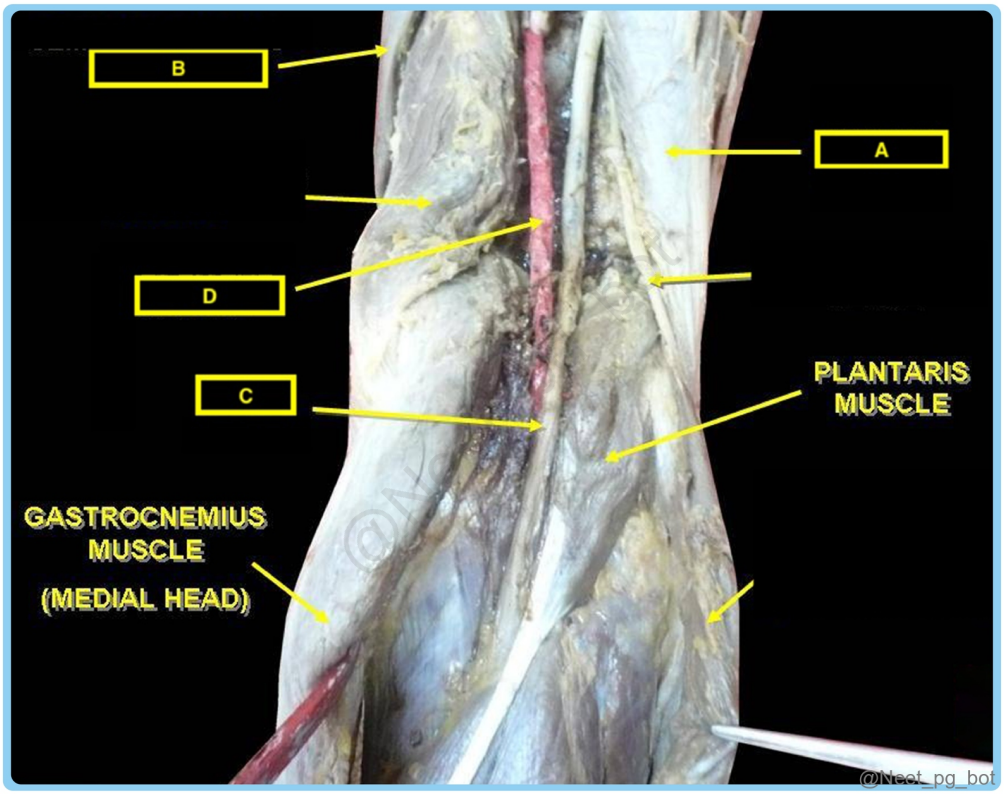

Correct Answer: D. a) Biceps femoris, b) Semitendinosus, c) Tibial nerve, d) Popliteal artery

- *Listen (English)*
- *Listen (Hindi)*

Explanation: The given image is the right popliteal fossa; therefore, The Superolateral boundary is formed by a) Biceps femoris The Superomedial boundary is formed by b) the Semitendinosus M arked structure c) is Tibial nerve and d) is Popliteal artery because in the upper part of the fossa, nerve is lateral and the artery is medial. Popliteal fossa

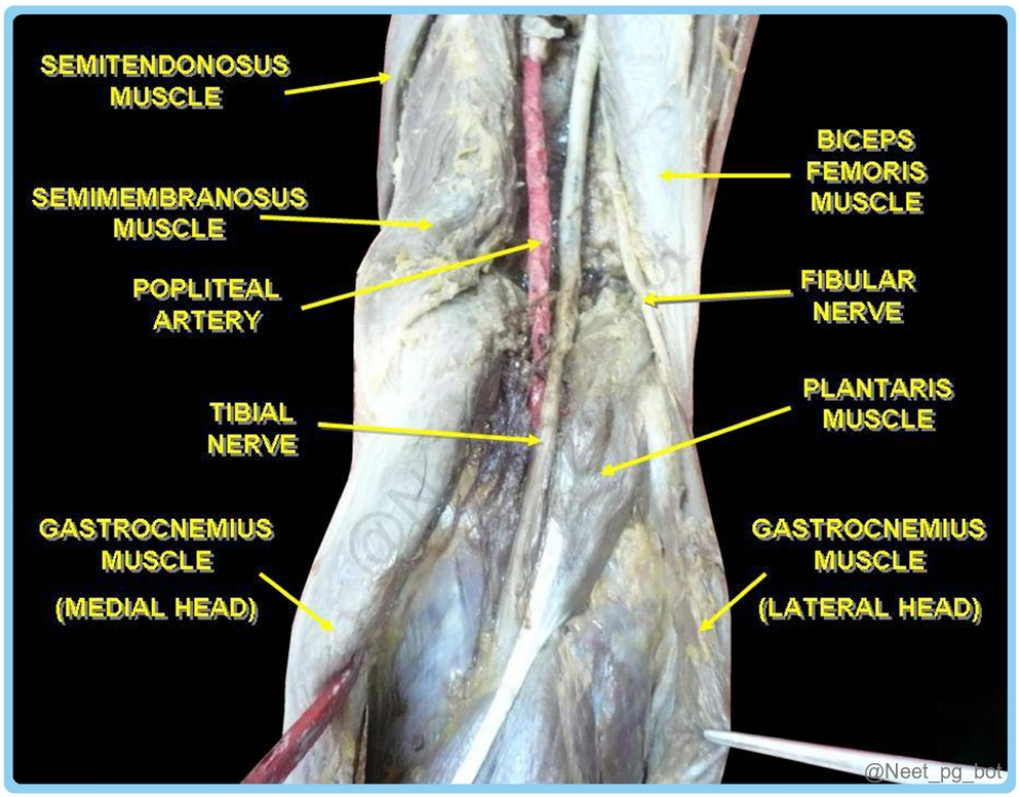

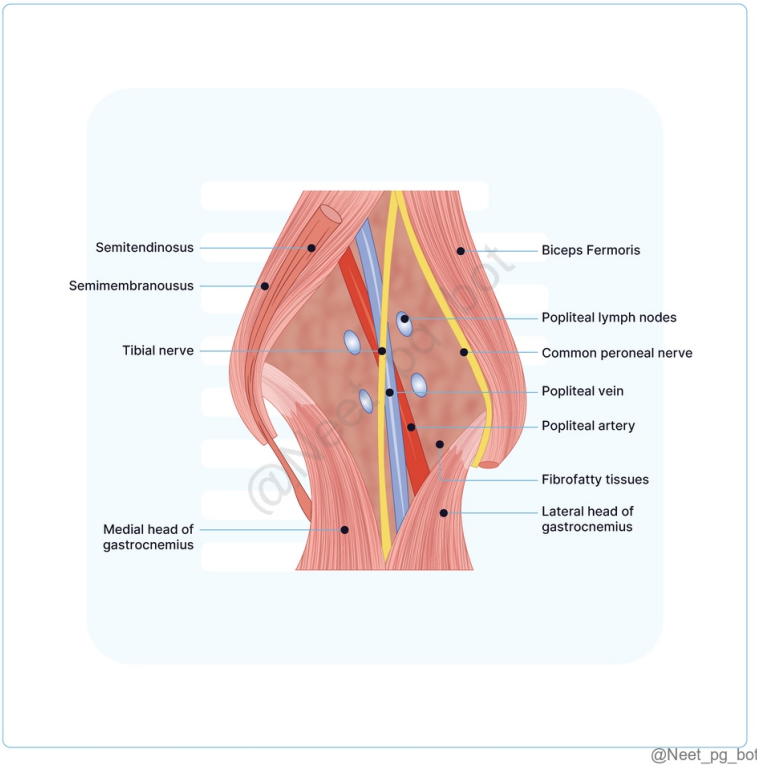

References:

Vishram Singh textbook of Anatomy, 2nd Edition, Pages 370, 371

↑ *Back to this question in Part A*

@Neet_pg_bot

Q20: Which of the following sets of muscles is referred to as "guy rope" muscles that stabilise the bony pelvis on the femur? (Q848228)

A. Semitendinosus, Semimembranosus, Gracilis

B. Sartorius, Gracilis, Semitendinosus

C. Semimembranosus, Sartorius, Adductor magnus

D. Semimembranosus, Gracilis, Sartorius

Correct Answer: B. Sartorius, Gracilis, Semitendinosus

■ *Listen (English)*

■ *Listen (Hindi)*

Explanation: The term "guy rope muscles" refers to the Sartorius, Gracilis, and Semitendinosus muscles, which each originate from different compartments of the thigh - anterior, medial, and posterior, respectively. These muscles play a crucial role in stabilizing the pelvis on the femur. Guy rope muscles 1. Sartorius 2. Gracilis 3. Semitendinosus Compartment Part of the anterior compartment Part of the medial compartment Part of the posterior compartment Origin Anterior superior iliac spine (ASIS) Inferior pubic ramus Ischial tuberosity Insertion Upper part of the medial surface of the tibia . (Pes anserinus or Goosefoot tendon is the broad, conjoined tendon formed by these 3 muscles, inserting on the medial surface of the proximal tibia) Together, these muscles anchor below at the tibia, spreading out above to support the pelvic structure, functioning effectively like "guy ropes" to maintain stability.

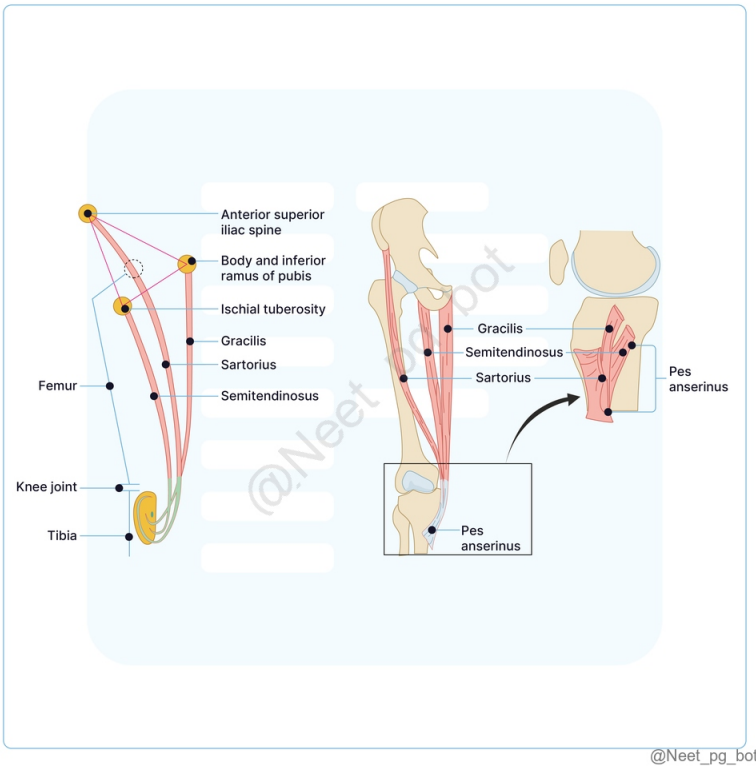

@Neet_pg_bot

References:

Vishram Singh Textbook of Anatomy, Abdomen and Lower Limb, 2nd Edition, Page 405

↑ *Back to this question in Part A*

@Neet_pg_bot

Q21: A 25-year-old male presents with difficulty in adducting his thigh after sustaining an injury during a soccer match. Upon examination, weakness in adduction and medial rotation of the thigh is noted. Which of the following muscles is primarily responsible for these actions, and what is its nerve supply? (Q848226)

A. Pectineus; Femoral nerve

B. Gracilis; Femoral nerve

C. Adductor longus; Obturator nerve (posterior division)

D. Adductor part of adductor magnus; Obturator nerve (posterior division)

Correct Answer: D. Adductor part of adductor magnus; Obturator nerve (posterior division)

■ *Listen (English)*

■ *Listen (Hindi)*

Explanation: The adductor part of the adductor magnus muscle is primarily responsible for thigh adduction and medial rotation. It is innervated by the obturator nerve, specifically the posterior division. The weakness observed in these actions following the injury indicates the involvement of adductor magnus. Muscle Origin Insertion Nerve Supply Actions Adductor magnus (largest muscle of this compartment) (Option D) Hamstring part: inferolateral part of the ischial tuberosity Adductor part: outer part of the ischiopubic ramus Adductor part: Medial margin of gluteal tuberosity , linea aspera, medial supracondylar line Hamstring part: Adductor tubercle Adductor part: By the obturator nerve Hamstring part : By the tibial part of sciatic nerve Adduction and medial rotation of thigh Weak extension of hip joint

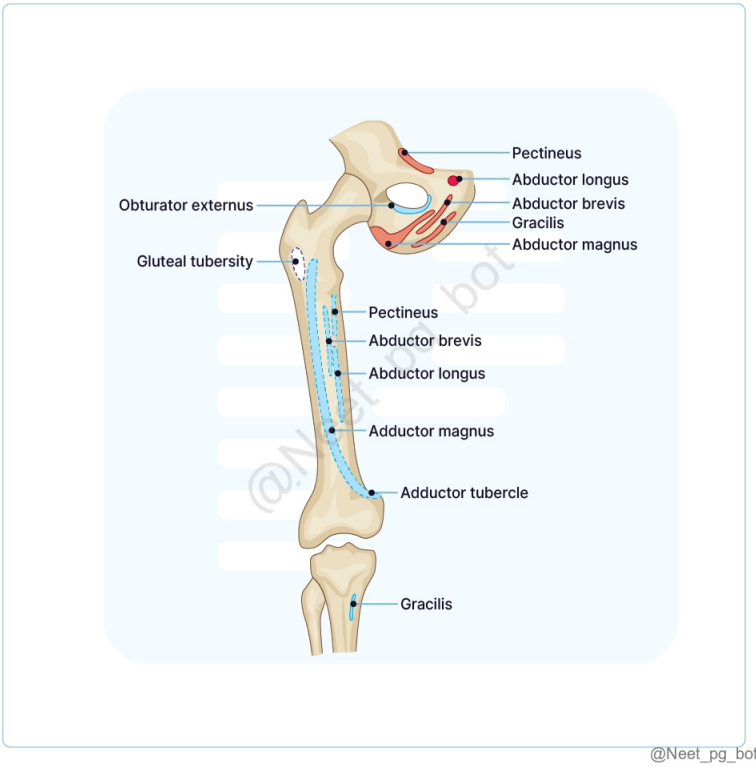

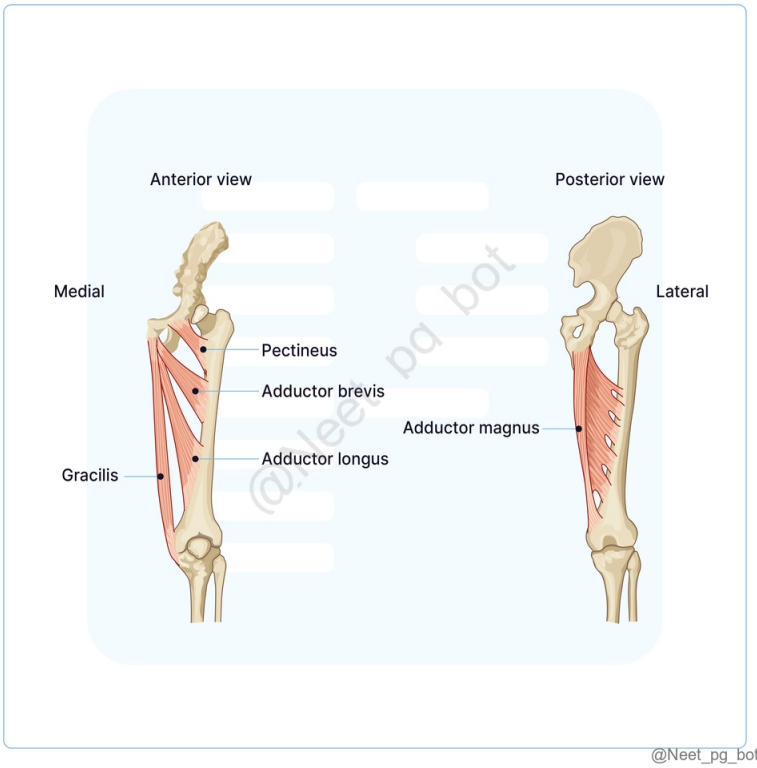

References:

BD Chaurasia's Human Anatomy, Volume 2, 8th Edition, Page 67

↑ *Back to this question in Part A*

@Neet_pg_bot

Q22: Which of the following is not the action of the marked structure? (Q848225)

A. Flexion of knee

B. Flexion of thigh

C. Extension of knee

D. Flexion of leg



Correct Answer: C. Extension of knee

- *Listen (English)*
- *Listen (Hindi)*

Explanation: The marked structure is Sartorius . It is responsible for flexing the thigh at the hip, flexing the knee , and aiding in the lateral rotation of the thigh . However, it does not perform knee extension; rather, it assists in knee flexion when the leg is raised. Sartorius Muscle: Originates from ASIS (anterior superior iliac spine). Inserts on medial aspect of tibia. Crosses both hip (flexion, abduction, lateral rotation) and knee joint (flexion), contributing to actions at both joints. Muscles of the front of the thigh: Muscle Nerve Supply Actions 1. Quadriceps femoris (a) Rectus femoris Femoral nerve Flexion of the hip joint and extension of the knee joint (b) Vastus lateralis Femoral nerve Extension of the knee joint (c) Vastus medialis Femoral nerve Extension of the knee joint (d) Vastus intermedius Femoral nerve Extension of the knee joint 2. Articularis genu Femoral nerve Pulls up the synovial membrane of the knee joint during its extension 3. Sartorius Femoral nerve Hip: Flexion, abduction and lateral rotation Knee: Flexion, medial rotation Leg: Flexion (Options A, B, D) 4. Tensor fasciae latae Superior gluteal nerve (different from the rest) Abduction of the hip joint

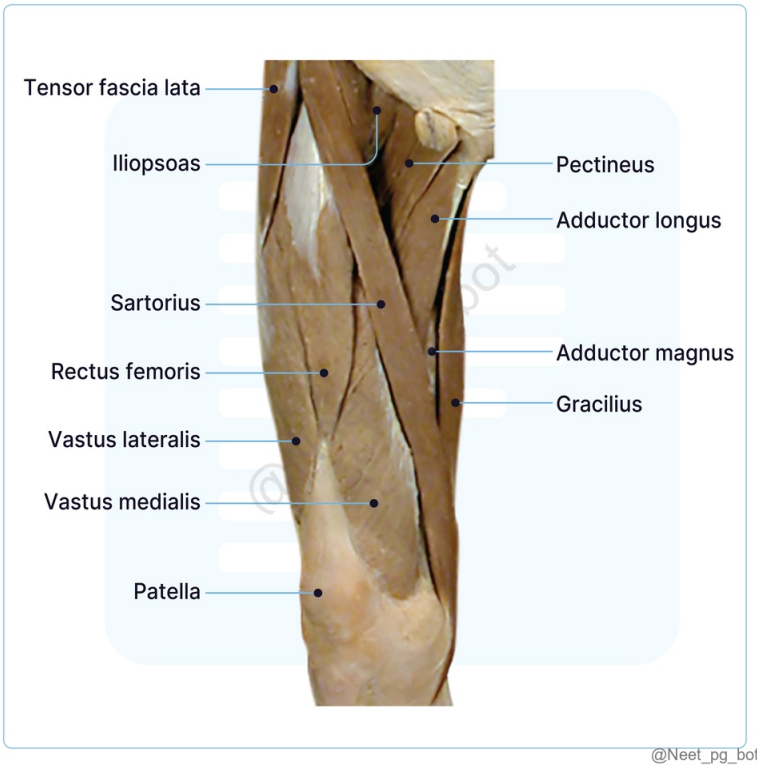

References:

BD Chaurasia's Human Anatomy, Volume 2, 8th Edition, Page 61

↑ *Back to this question in Part A*

@Neet_pg_bot

Q23: A 50-year-old male presents with leg pain and weakness after a heavy deadlift. He reports heaviness in his feet, difficulty standing on his toes, and performing calf raises. Neurological examination reveals weakness in plantar flexion, inability to flex his toes and diminished ankle reflexes. Which spinal cord segments are primarily involved in this patient's symptoms? (Q848224)

A. L4, L5

B. S1, S2

C. L2, L3

D. L3, L4

Correct Answer: B. S1, S2

■ *Listen (English)*

■ *Listen (Hindi)*

Explanation: The weakness in plantar flexion and difficulty in flexing the toes i ndicate involvement of the muscles innervated by the S1 and S2 spinal segments, primarily the gastrocnemius and soleus . Segmental innervation of joints of lower limb Joints Movements Hip joint Flexion, adduction, and medial rotation (L2, L3) Extension, abduction, and lateral rotation (L4, L5) Knee joint Extension (L3, L4) Flexion (L5; S1) Ankle joint Dorsiflexion (L4, L5) Plantar flexion (S1, S2) Foot Invertors (L4, L5) Evertors (L5, S1)

References:

Vishram Singh textbook of anatomy, 2nd Edition, Pages 475, 476

↑ *Back to this question in Part A*

@Neet_pg_bot

Q24: A 45-year-old patient presents with a foot drop following a recent knee injury. Which of the following nerves, part of the sacral plexus, is most likely injured, leading to the inability to dorsiflex the foot? (Q848222)

A. Posterior Femoral Cutaneous Nerve

B. Tibial nerve

C. Common peroneal nerve

D. Pudendal nerve

Correct Answer: C. Common peroneal nerve

■ *Listen (English)*

■ *Listen (Hindi)*

Explanation: The common peroneal nerve is a branch of the sciatic nerve. It divides into the deep and superficial peroneal nerves. The deep peroneal nerve supplies the muscles of the anterior compartment of the leg, including tibialis anterior, which are responsible for dorsiflexion of the foot. Injury to the common peroneal nerve therefore commonly results in foot drop.

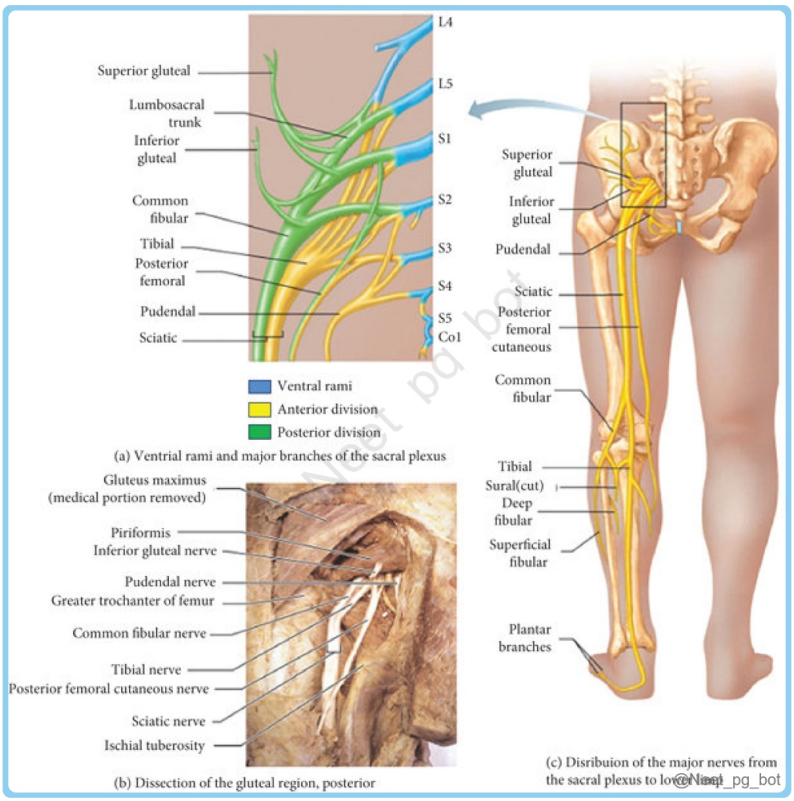

References:

Gray’s Anatomy, 42nd Edition, Pages 1252,1253.

BD Chaurasia's Human Anatomy, Volume 2, 8th Edition, Pages 491, 492.

↑ *Back to this question in Part A*

@Neet_pg_bot

Q25: A 45-year-old man presents to the clinic with complaints of tingling and numbness in the outer aspect of his right thigh. He reports that the symptoms worsen when he sits for prolonged periods and improves when he stands or walks. Upon examination, there is a sensory deficit in the lateral thigh region. Which nerve root value is primarily involved in this condition? (Q848221)

A. L1 and L2

B. L2 and L3

C. L2, L3 and L4

D. L4 and L5

Correct Answer: B. L2 and L3

■ *Listen (English)*

■ *Listen (Hindi)*

Explanation: Based on the clinical scenario, the patient's symptoms align with meralgia paresthetica, marked by tingling and numbness in the outer thigh that worsens with prolonged sitting and improves with standing or walking. This condition results from compression of the lateral femoral cutaneous nerve, which is primarily derived from the dorsal divisions of the L2 and L3 nerve roots.

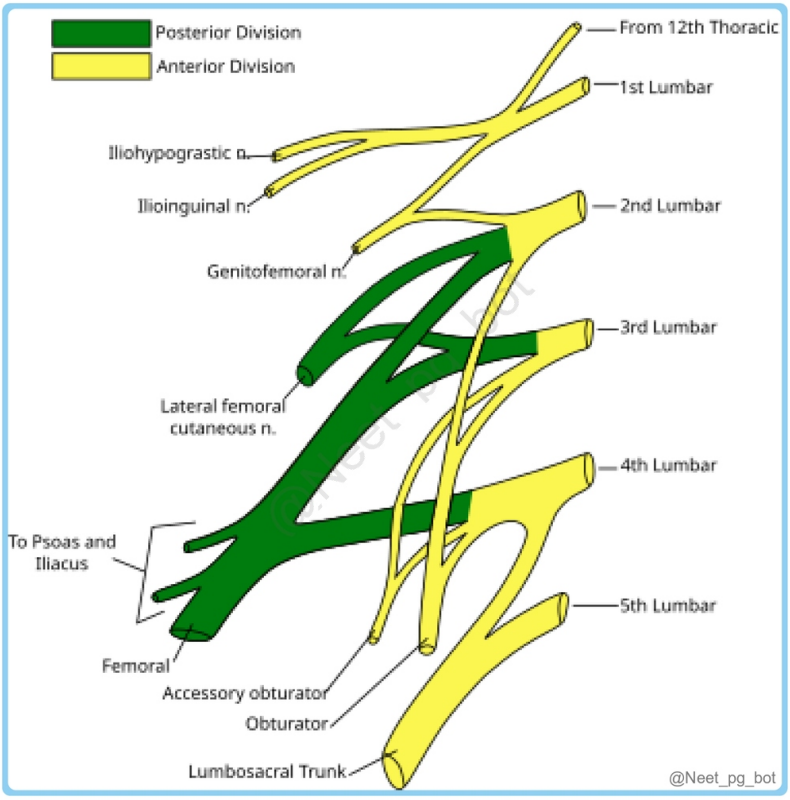

References:

Gray’s Anatomy, 42nd Edition, Pages 1146 - 1149

BD Chaurasia's Human Anatomy, Volume 2, 8th Edition, Pages 402, 403.

↑ *Back to this question in Part A*

@Neet_pg_bot

• [06_Lower Limb] 030 Lower Limb Anatomy Knee And Leg

« Back to Folder Directory

[06_Lower Limb] 030 Lower Limb Anatomy Knee And Leg — Quick Jump

Q1 (p. 1602)	*Q2 (p. 1603)*	*Q3 (p. 1604)*	*Q4 (p. 1605)*	*Q5 (p. 1607)*	*Q6 (p. 1608)*
Q7 (p. 1610)	*Q8 (p. 1611)*	*Q9 (p. 1612)*	*Q10 (p. 1613)*	*Q11 (p. 1614)*	*Q12 (p. 1615)*
Q13 (p. 1616)	*Q14 (p. 1618)*	*Q15 (p. 1620)*	*Q16 (p. 1621)*	*Q17 (p. 1622)*	*Q18 (p. 1623)*
Q19 (p. 1625)	*Q20 (p. 1627)*				

Q1: A 28 y/o football player experiences sudden pain on the inside of his left knee after getting tackled while running with the ball. He reports feeling a pop and is unable to continue playing. O/E, there is swelling, tenderness along the medial joint line, and pain when attempting to flex the knee. Which of the following injuries is most likely? (Q848265)

A. Lateral collateral ligament (LCL) sprain

B. Anterior cruciate ligament (ACL) tear

C. Medial meniscus tear

D. Posterior cruciate ligament (PCL) tear

Correct Answer: C. Medial meniscus tear

■ *Listen (English)*

■ *Listen (Hindi)*

Explanation: The mechanism of injury (sudden pain on the inside of the knee, feeling a pop, and tenderness along the medial joint line) is characteristic of a medial meniscus tear, which is often associated with twisting movements and trauma. Medial Meniscus is more prone to injury than the lateral meniscus. The medial meniscus attaches to the tibial collateral ligament- hence, it is more susceptible to tears from rotational forces. Bucket-handle tears are common in athletes and are characterised by longitudinal meniscus tears due to pivoting and twisting in a slightly flexed knee. Menisci

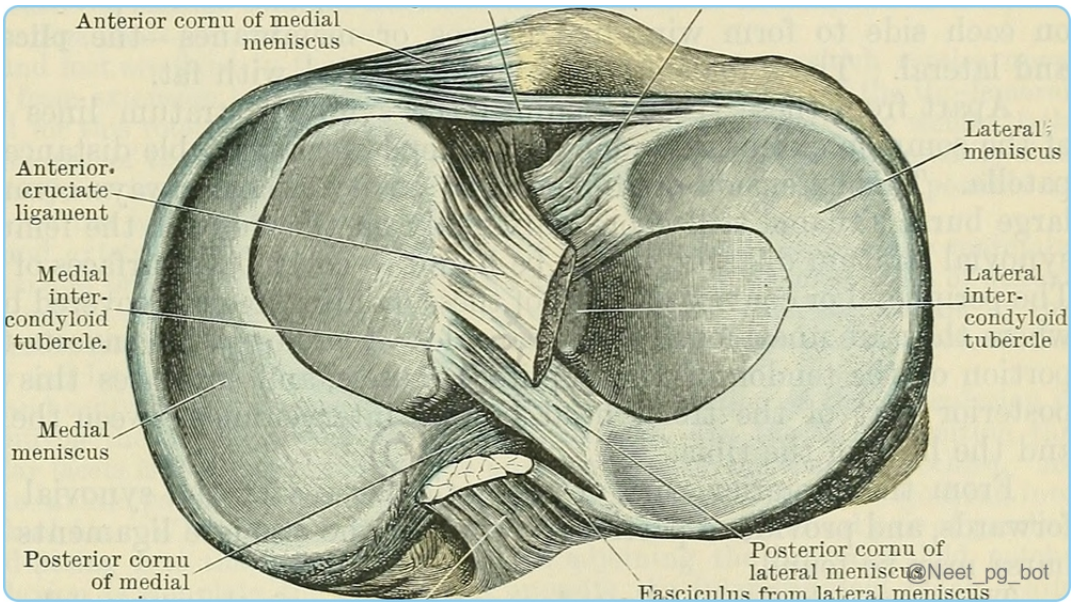

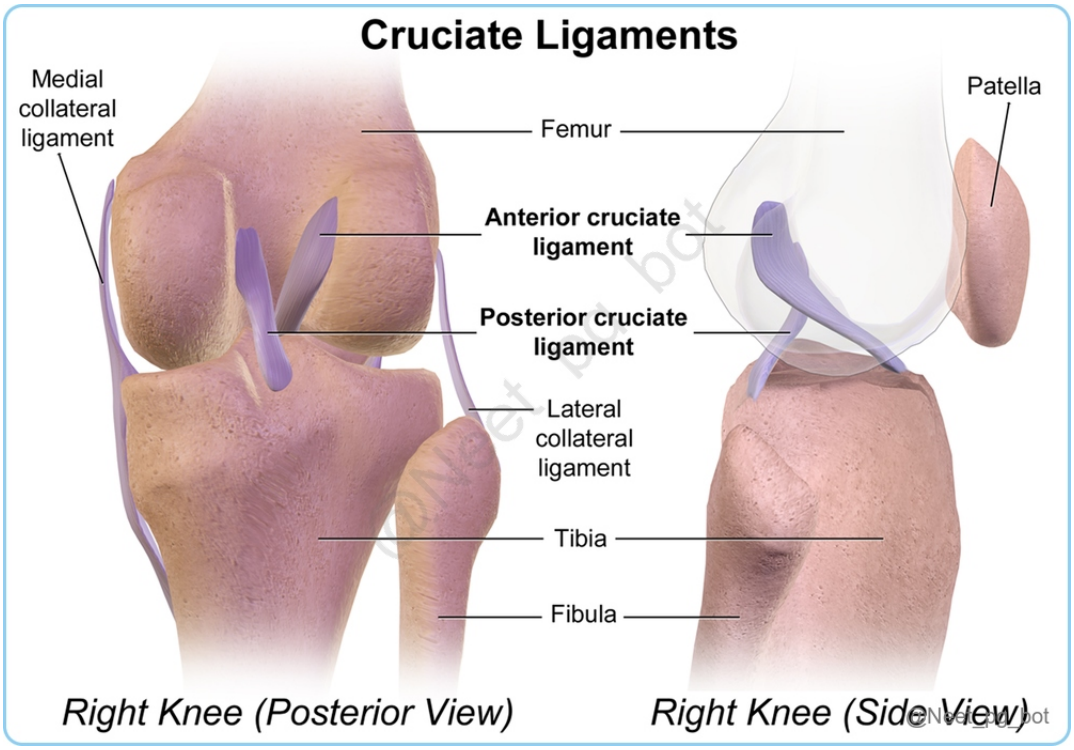

References:

B.D. Chaurasia's Human Anatomy, Volume 2, 8th Edition, Pages 174, 175

↑ *Back to this question in Part A*

@Neet_pg_bot

Q2: Which of the following statements regarding sustentaculum tali is correct: It is a shelf like projection, projecting from posterior surface of calcaneus. Superior surface of sustentaculum tali bears a facet for talus. Inferior surface of sustentaculum tali bears a groove for the tendon of flexor hallucis longus (Q848279)

A. Only 2

B. 1, 2, 3

C. 2 and 3

D. Only 3

Correct Answer: C. 2 and 3

■ *Listen (English)*

■ *Listen (Hindi)*

Explanation: Calcaneus: The calcaneus is the largest and strongest bone of the foot. It is situated below the talus and extends behind it. It is directed forward and laterally with an upward inclination Medial surface : It is concave from above downward A shelf-like projection called sustentaculum tali projects from its upper anterior part. (Statement 1) The superior surface of sustentaculum tali bears a facet for talus (Statement 2) while its inferior surface bears a groove for the tendon of flexor hallucis longus. (Statement 3) Tendon of flexor digitorum longus is related to the medial surface of sustentaculum tali. Medial surface of sustentaculum tali provides attachments to the following structures from anterior to posterior : (a) Spring ligament. (b) A slip from the tibialis posterior tendon. (c) Deltoid ligament (superficial fibres). (d) Medial talocalcaneal ligament.

References:

Vishram Singh’s Textbook of Anatomy, 2nd Edition, Volume 2, Pages 322-324

↑ *Back to this question in Part A*

@Neet_pg_bot

Q3: Which statement best describes the relationship of the tibial nerve in the popliteal fossa? (Q848277)

A. It is the most medial structure crossing to the lateral side of the fossa.

B. It is deep to the popliteal artery and vein.

C. It lies lateral to the popliteal vessels crossing to the medial side.

D. It does not enter the popliteal fossa.

Correct Answer: C. It lies lateral to the popliteal vessels crossing to the medial side.

■ *Listen (English)*

■ *Listen (Hindi)*

Explanation: The sciatic nerve enters the popliteal fossa at its apex , where it divides into the tibial nerve and the common peroneal (fibular) nerve . After the division, the tibial nerve initially lies lateral to the popliteal artery and vein . As it descends through the fossa, the tibial nerve crosses superficially over the vessels and comes to lie on their medial side . Tibial Nerve

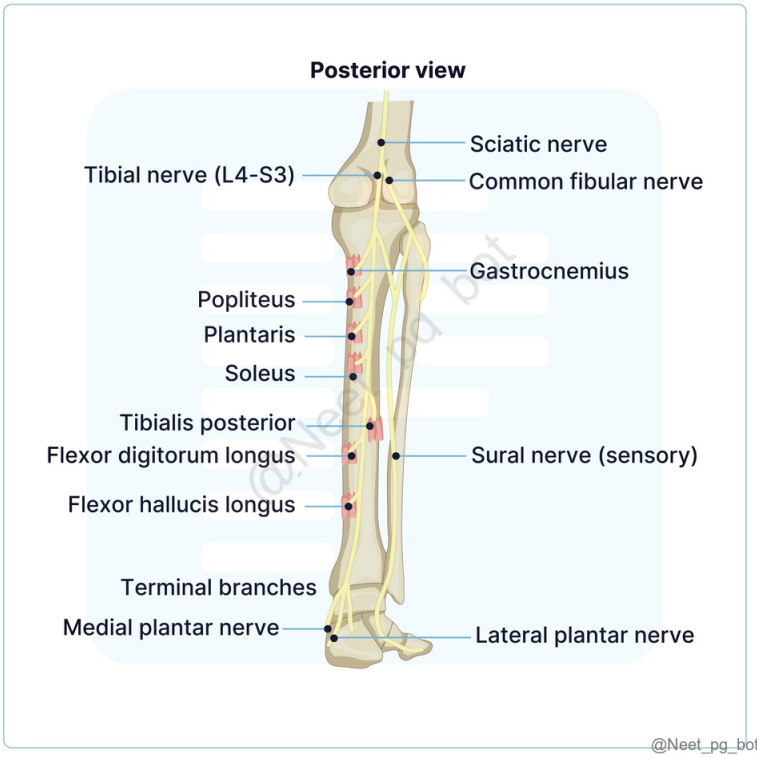

References:

Gray’s Anatomy, 42nd Edition, Pages 1427, 1428

Vishram Singh’s Textbook of Anatomy, Volume 2, 2nd Edition, Pages 418,471

↑ *Back to this question in Part A*

@Neet_pg_bot

Q4: A 35 y/o man is hiking on uneven terrain. As he steps on a rock with his right foot, his foot tilts inward, his medial arch elevates, and his foot becomes more rigid. This movement is best described as: (Q848275)

A. Pronation

B. Supination

C. Eversion

D. Dorsiflexion

Correct Answer: B. Supination

■ *Listen (English)*

■ *Listen (Hindi)*

Explanation: The described movement involves supination , a tri-planar motion that includes adduction, inversion, and plantar flexion , resulting in an elevated medial arch and a more rigid foot. This is commonly seen when standing or walking on uneven surfaces, such as a rock, where stability is needed. Supination: A tri-planar motion involving: Adduction Inversion Plantar flexion Occurs mainly at the talocalcaneonavicular and subtalar joints . Common in activities like standing with feet widely separated or standing on an inclined surface. The medial arch is elevated in supination, making the foot more rigid and stable. Pronation: The opposite tri-planar motion involves: Abduction Eversion (Option C ruled out) Dorsiflexion (Option D ruled out) It helps adapt the foot to uneven surfaces by making it more pliable. It occurs more when standing with feet close together. (Option A ruled out) Pronation flattens the medial longitudinal arch, spreading forces over a broader area of the foot.

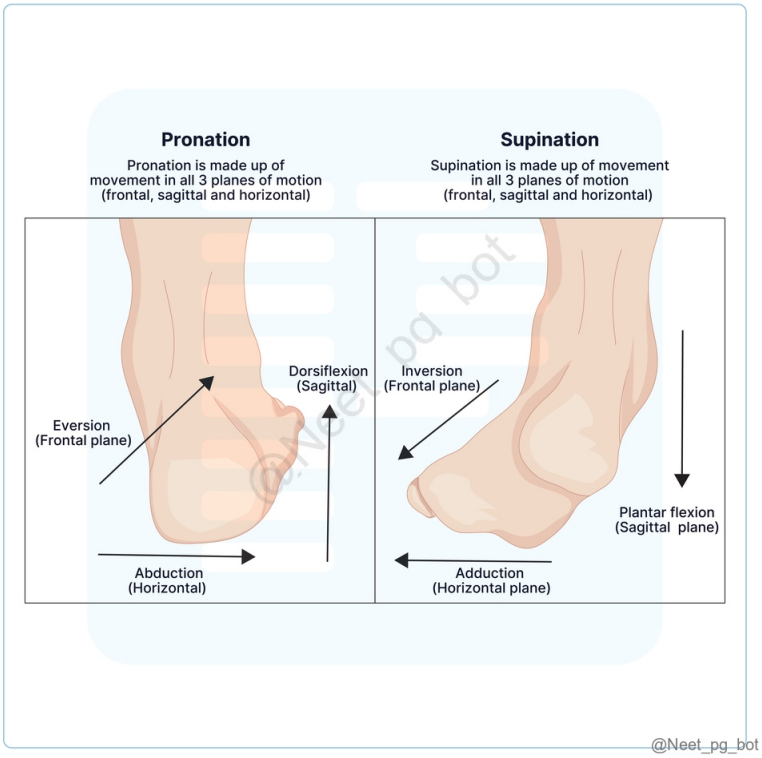

References:

Gray’s Anatomy, 42nd Edition, Pages 1463, 1464

↑ *Back to this question in Part A*

@Neet_pg_bot

Q5: A 30 y/o athlete reports sudden pain in the back of his left leg and an inability to push off the ground while sprinting. Examination reveals a significant weakness in plantar flexion. Which muscle is primarily responsible for the action of plantarflexion in this patient? (Q848271)

A. Tibialis Anterior

B. Gastrocnemius

C. Fibularis tertius

D. Fibularis Longus

Correct Answer: B. Gastrocnemius

■ *Listen (English)*

■ *Listen (Hindi)*

Explanation: Plantarflexion of the ankle joint is primarily produced by the triceps surae muscle group (gastrocnemius and soleus) acting through the Achilles tendon . The gastrocnemius is particularly important for powerful plantarflexion during activities such as sprinting and jumping . Sudden pain in the posterior leg with inability to push off the ground commonly occurs due to gastrocnemius strain (“tennis leg”) or Achilles tendon injury , leading to weakness of plantarflexion. Movement Major Muscles Nerve Dorsiflexion Tibialis anterior (Option A ruled out) , Extensor Digitorum Longus, Extensor Hallucis Longus, Fibularis tertius (Option C ruled out) Deep peroneal nerve Plantarflexion Gastrocnemius + Soleus (Triceps surae) , Tibialis posterior, Flexor Digitorum Longus, Flexor Hallucis Longus Tibial nerve Eversion Fibularis longus, Fibularis brevis (Option D ruled out) Superficial peroneal nerve Inversion Tibialis anterior + Tibialis posterior Deep peroneal + Tibial nerve

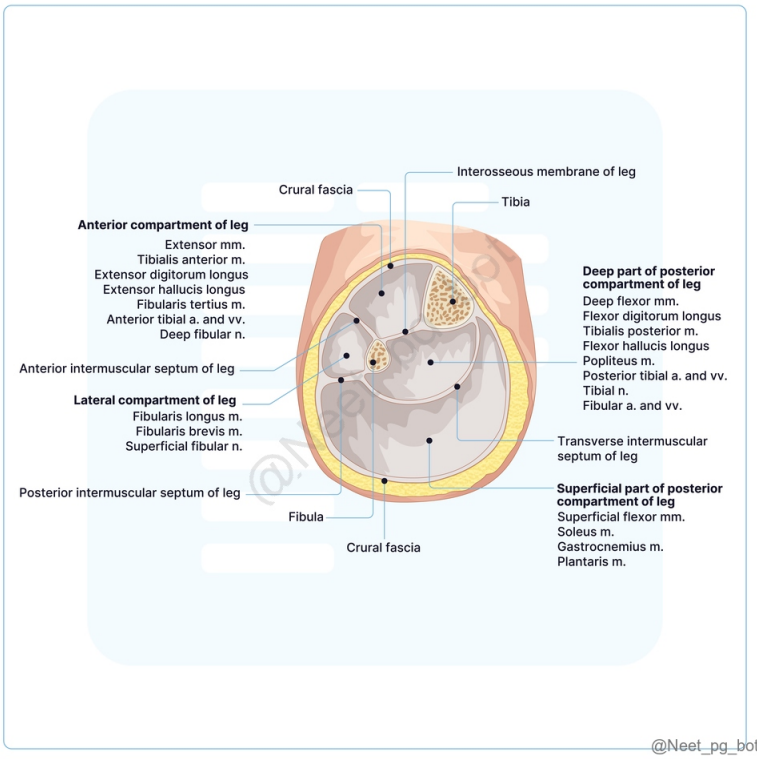

References:

Gray’s Anatomy, 42nd Edition, Pages 1416-1423

↑ *Back to this question in Part A*

@Neet_pg_bot

Q6: A 40 y/o woman presents with ankle instability and pain on the lateral side after rolling her ankle while walking on uneven ground. Examination reveals weakness in foot eversion and tenderness over the base of the fifth metatarsal. Which muscle is primarily responsible for foot eversion in this patient? (Q848273)

A. Tibialis Anterior

B. Fibularis Longus

C. Fibularis Brevis

D. Gastrocnemius

Correct Answer: B. Fibularis Longus

■ *Listen (English)*

■ *Listen (Hindi)*

Explanation: Fibularis Longus and brevis both are involved in eversion of foot but the Fibularis Longus muscle is one of the primary movers for foot eversion and supports the arches of the foot. The lateral compartment of the leg Muscles Fibularis/peroneus Longus Fibularis/peroneus Brevis Attachment Origin: Head and proximal two-thirds of the fibula, deep fascia, intermuscular septa, and sometimes the lateral condyle of the tibia. Insertion: Base of the first metatarsal and medial cuneiform. Origin: Distal two-thirds of the fibula, intermuscular septa. Insertion: Tuberosity on the base of the fifth metatarsal. Action Eversion of foot Plantar flexion of the ankle Supports longitudinal and transverse arches of foot Eversion of foot Limits inversion, relieving strain on lateral ankle ligaments Innervation Superficial fibular nerve (L5, S1) Superficial fibular nerve (L5, S1) Clinical aspects Risk of tendon dislocation if fibular retinaculum ruptures Limits inversion, relieving strain on lateral ankle ligaments. Lateral Compartment of Leg Muscles

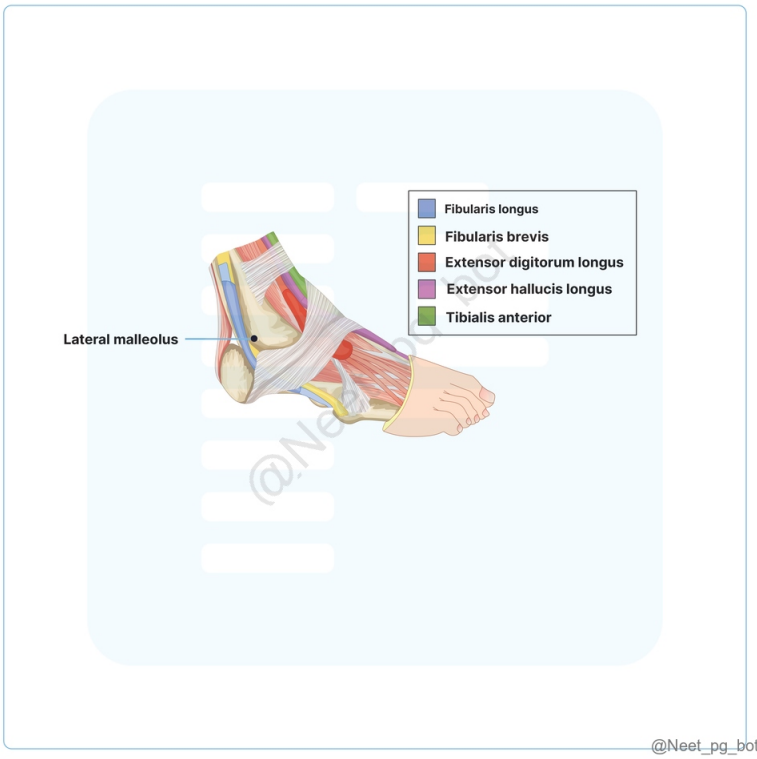

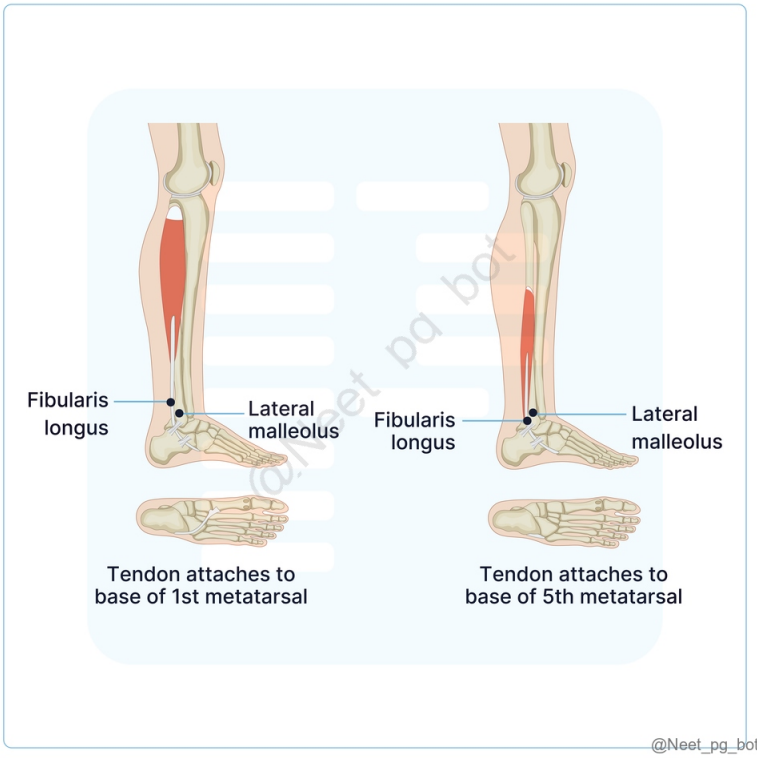

References:

Gray's Anatomy, 42nd Edition, Page 1419

↑ *Back to this question in Part A*

@Neet_pg_bot

Q7: A 25-year-old runner presents with pain along the front part of his right leg and difficulty in lifting the foot upwards after increasing his training intensity. O/E, he shows weakness in extending the big toe and foot drop. Which muscle is most likely affected in this patient, leading to his symptoms? (Q848272)

A. Tibialis Anterior

B. Extensor Hallucis Longus

C. Extensor Digitorum Longus

D. Fibularis Tertius

Correct Answer: B. Extensor Hallucis Longus

■ *Listen (English)*

■ *Listen (Hindi)*

Explanation: The patient presents with difficulty in dorsiflexing the foot and weakness in extending the big toe, which is primarily the function of the extensor hallucis longus. Anterior compartment of the leg Muscles Attachments Innervation Action Clinical aspects Extensor Hallucis Longus The middle half of the medial fibula and interosseous membrane. Inserts onto the dorsal base of the distal phalanx of the hallux. Deep fibular nerve (L5) Extends hallux Dorsiflexes foot Weakness: Difficulty extending the big toe.

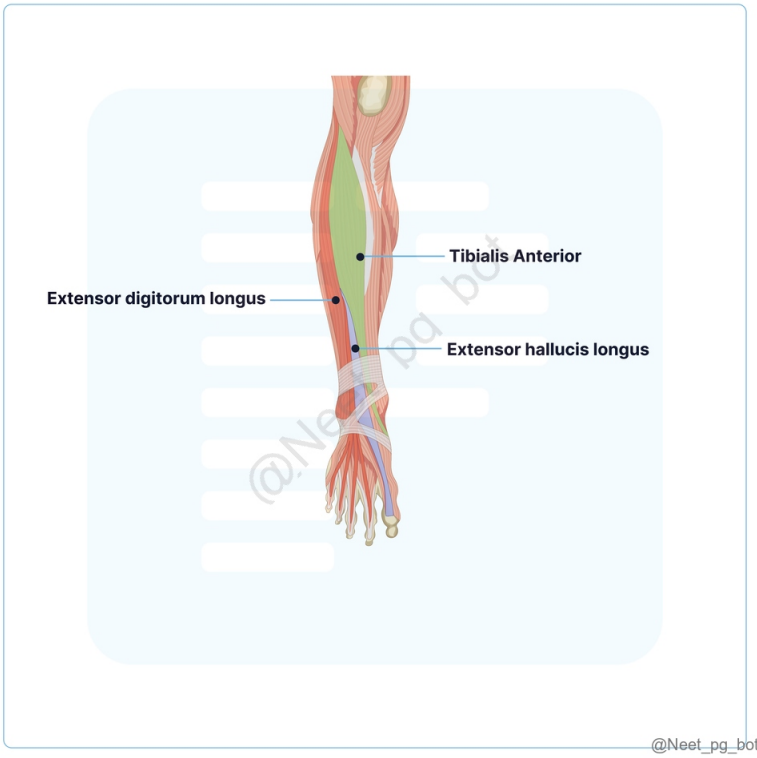

References:

Gray's Anatomy, 42nd Edition, Page 1416-1418

↑ *Back to this question in Part A*

@Neet_pg_bot

Q8: Which of the following is the correct statement regarding the ligaments of the hip joint. The fibrous capsule is made up of outer fibres which are longitudinal and inner circular fibres which are called zona orbicularis. Ligamentum teres femoris transmits the arteries to the head of femur. IIiofemoral ligament is inverted Y shaped ligament. The acetabular labrum helps in holding the femur in position. (Q848281)

A. 1,2,3,4

B. 1 and 4

C. Only 1

D. None of the above

Correct Answer: A. 1,2,3,4

■ *Listen (English)*

■ *Listen (Hindi)*

Explanation: The capsular ligament is a strong and dense fibrous sac which encloses the joint. The capsule is made up of two types of fibres—inner circular fibres and outer longitudinal fibres. The inner circular fibres form a collar around the femoral neck (zona orbicularis). These fibres are not directly attached to the bones (Statement 1) The outer longitudinal fibres are reflected along the neck toward the head to form the retinacula. The iliofemoral ligament is an inverted Y-shaped ligament, which lies anteriorly and intimately blended with the capsule.(Statement 3) Round ligament of head of femur : This ligament is also called ligamentum teres of the head of the femur. It transmits arteries to the head of the femur derived from the acetabular branches of the obturator and medial circumflex femoral arteries.(Statement 2) The acetabular labrum is a fibrocartilaginous rim attached to the acetabular margin. The labrum not only deepens the acetabulum (socket) but grasps the head of femur lightly to hold it in position.(Statement 4)

References:

Vishram Singh’s Textbook of Anatomy, 2nd Edition, Volume 2, Page 378-380

↑ *Back to this question in Part A*

@Neet_pg_bot

Q9: A 35-year-old woman presents with pain and swelling in the prepatellar region of her left knee, which developed gradually over the past few weeks. She works as a housemaid and spends long hours kneeling on hard surfaces while cleaning floors. On physical examination, the knee is swollen, and there is tenderness over the anterior part of the knee. The swelling is soft and fluctuant, and there is no redness or heat over the area. What is the most likely diagnosis? (Q848280)

A. Prepatellar bursitis

B. Baker’s cyst

C. Osteoarthritis of the knee

D. Clergyman’s knee

Correct Answer: A. Prepatellar bursitis

■ *Listen (English)*

■ *Listen (Hindi)*

Explanation: Prepatalar bursitis also known as Housemaid's knee is the inflammation of the prepatellar bursa (prepatellar bursitis). It occurs due to friction of bursa against the patella when it comes in contact with the ground during scrubbing of the floor by the housemaid. Such a bursa may get very large and drop by its weight too much below to its original position. Subcutaneous prepatellar bursa (bursa of housemaid's knee). It lies deep to the skin in front of the lower half of the patella and upper half of the ligamentum patellae and tibial tuberosity. Baker's cyst (Option B) : The chronic inflammation of bursa deep to semimembranosus may present as cystic swelling in the medial part of the popliteal fossa called Baker's cyst Osteoarthritis of the knee (Option C) : This is unlikely given the patient's relatively young age and the acute nature of the symptoms. Osteoarthritis typically presents with chronic pain, stiffness, and decreased range of motion in older individuals, especially those over the age of 50. The swelling in osteoarthritis is also typically associated with joint degeneration rather than soft, fluctuant swelling in the prepatellar region. Clergyman's knee (Option D) : It is the inflammation of subcutaneous infrapatellar bursa (subcutaneous infrapatellar bursitis). It occurs due to the friction of bursa against the tibial tuberosity due to kneeling (e.g., kneeling during prayer by Christian priests/clergymen, roofers, and floor tilers.

References:

Vishram Singh's Textbook of Anatomy, 2nd Edition, Volume 2, Pages 445, 446

↑ *Back to this question in Part A*

@Neet_pg_bot

Q10: Which dermatome supplies the middle of the back of the thigh and leg? (Q848278)

A. S1

B. S2

C. L4

D. L5

Correct Answer: B. S2

■ *Listen (English)*

■ *Listen (Hindi)*

Explanation: Segmental innervation of skin of Lower Limb Segments Area L1, L2, L3 The anterior aspect of the thigh from above downwards L4 (Option C ruled out) The medial aspect of the leg L5 (Option D ruled out) The lateral aspect of the leg and the medial side of the foot S1 (Option A ruled out) The lateral side of the foot and sole S2 (Option B) Middle of the back of the thigh and leg S3,S4 Buttocks Dermatomes of Lower Limb

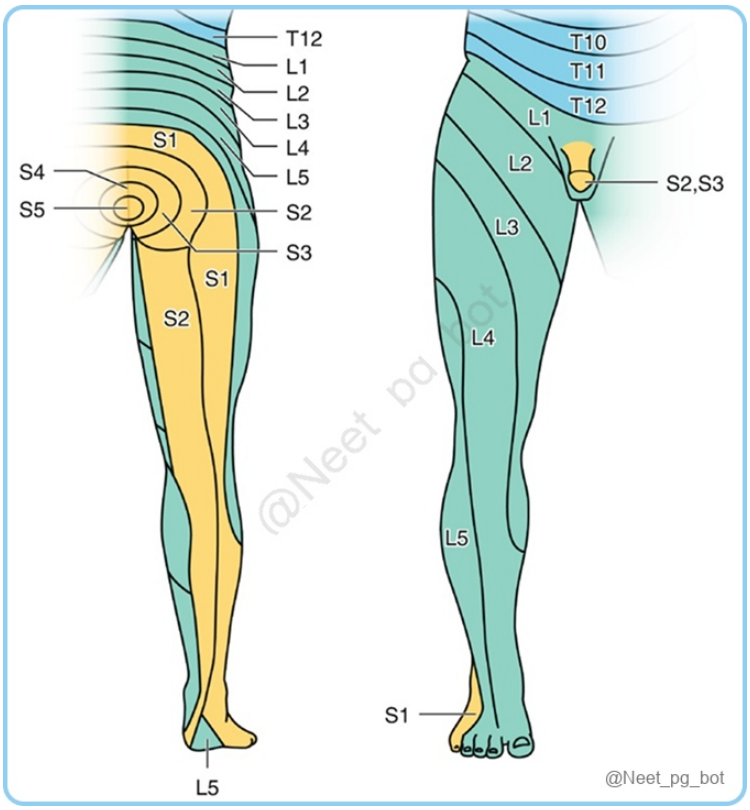

References:

Gray’s Anatomy, 42nd Edition, Pages 1342

Vishram Singh’s Textbook of Anatomy, 2nd Edition, Volume 2, Page 47

↑ *Back to this question in Part A*

@Neet_pg_bot

Q11: A 50 y/o man undergoes a total hip replacement. Postoperatively, he develops difficulty walking and reports numbness along the posterior thigh, lateral leg, and sole of the foot. O/E, he has weakness in extending the hip and flexing the knee. The injured nerve originates from which of the following spinal roots? (Q848276)

A. L2–L4

B. L4–S3

C. L5–S1

D. S1–S5

Correct Answer: B. L4–S3

■ *Listen (English)*

■ *Listen (Hindi)*

Explanation: The patient's symptoms, including weakness in hip extension, knee flexion, and sensory loss along the posterior thigh and leg, are indicative of sciatic nerve injury. The sciatic nerve originates from the ventral rami of the L4–S3 spinal roots. L2–L4 (Option A) forms the femoral/obturator nerves. L5–S1 (Option C) is part of the sacral plexus but not the full sciatic root S1–S5 (Option D) contributes to the pudendal and coccygeal nerves. Takeaway: Sciatic nerve = largest nerve, root value L4–S3, vulnerable in hip surgery/injections . Sciatic Nerve course

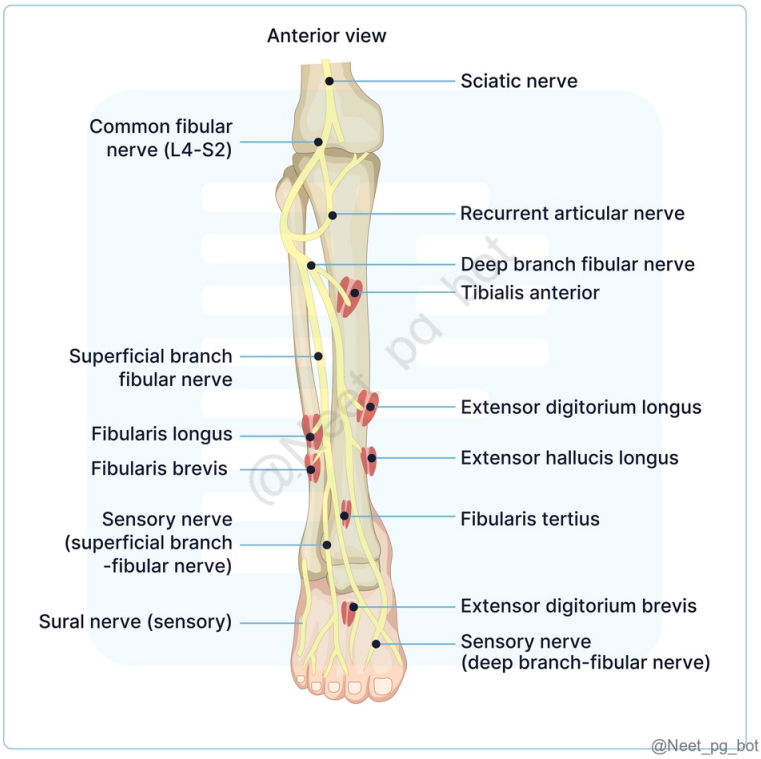

References:

Vishram Singh's Textbook of Anatomy, Volume 2, 2nd Edition, Pages 469, 470

↑ *Back to this question in Part A*

@Neet_pg_bot

Q12: A 55 y/o man presents with difficulty walking and reports pain along the medial aspect of his foot. Physical examination reveals weakness in inversion and signs of flatfoot. Which muscle is primarily responsible for the inversion of the foot in this patient? (Q848274)

A. Gastrocnemius

B. Soleus

C. Tibialis Posterior

D. Flexor Digitorum Longus

Correct Answer: C. Tibialis Posterior

■ *Listen (English)*

■ *Listen (Hindi)*

Explanation: Tibialis Posterior muscle is the principal inverter of the foot and supports the medial arch, which aligns with the patient's symptoms of flatfoot. Movements of Inversion and Eversion Inversion Eversion Tibialis anterior Tibialis posterior Flexor hallucis longus Flexor digitorum longus Peroneus brevis Peroneus longus Peroneus tertius Posterior compartment of Leg: Superficial group of muscles: Muscles Attachments Action Nerve Clinical aspects Gastrocnemius (Option A) Origin : Medial and lateral condyles of the femur Insertion :Calcaneal tendon Plantar flexion of the foot Flexion of knee Tibial nerve (S1, S2) Testing: Plantar flexion against resistance (knee extended). Soleus (Option B) Origin : Posterior head and proximal fibula, soleal line of tibia, tendinous arch of soleus Insertion : Calcaneal tendon Primary plantar flexor Stabilizes leg during standing Tibial nerve (S1, S2) Testing: Plantar flexion against resistance (hip and knee flexed). Plantaris Origin : Lower part of the lateral supracondylar line on the femur, oblique popliteal ligament Insertion : Calcaneus (medial to calcaneal tendon) Assists gastrocnemius in plantar flexion (less significant) Tibial nerve Minor role in foot mechanics. Deep group of muscles: Muscles Attachments Action Nerve Clinical aspects Popliteus Origin: Lateral femoral condyle Insertion: Posterior surface of tibia above the soleal line Unlocks the knee by laterally rotating the femur on the tibia Tibial nerve (L4, L5, S1,) Injury may lead to knee instability Important in knee biomechanics. Flexor Digitorum Longus (Option D) Origin: Posterior surface of the tibia (medial to tibialis posterior) Insertion: Plantar surfaces of distal phalanges of toes 2-5 Plantar flexion of the ankle Flexion of the distal phalanges of toes 2-5 Tibial nerve (L5, S1, S2) The aberrant function may contribute to toe deformities (e.g., hammer toe). Flexor Hallucis Longus Origin: Distal two-thirds of the posterior fibula, interosseus membrane. Insertion: Plantar surface of the base of the distal phalanx of the hallux Plantar flexion of the ankle Flexion of the hallux Tibial nerve (L5, S1, S2) Overuse in dancers may lead to tendinopathy (e.g., hallux saltans). Important surgical landmark at the ankle to avoid neurovascular injury. Tibialis Posterior (Option C) Origin: Interosseous membrane, posterior surface of tibia, fibula Insertion: Navicular tuberosity, cuneiforms, bases of metatarsals 2-4 The principal inverter of the foot Supports medial longitudinal arch Tibial nerve (L4, L5) Dysfunction can lead to a flat foot (pes planus) due to tendon elongation and attenuation of the spring ligament.

References:

Gray’s Anatomy, 42nd Edition, Pages 1419-1423

Textbook of Anatomy Vishram Singh, 2nd Edition, Volume 2, Page 456

↑ *Back to this question in Part A*

@Neet_pg_bot

Q13: Where does the popliteus muscle originate, and what is its nerve supply? (Q848262)

A. Medial condyle of femur; Femoral nerve

B. Lateral condyle of femur; Tibial nerve

C. Tibial tuberosity; Sciatic nerve

D. Fibular head; Peroneal nerve

Correct Answer: B. Lateral condyle of femur; Tibial nerve

- *Listen (English)*
- *Listen (Hindi)*

Explanation: The popliteus muscle originates from the anterior part of the popliteal groove on the lateral condyle of the femur and is supplied by a branch of the tibial nerve (L4, L5, S1). Popliteus Muscle Popliteus Muscle Origin Arises within the knee joint capsule from the anterior part of the popliteal groove located on the lateral condyle of the femur. Insertion The medial aspect of the head of the fibula via the popliteofibular ligament Medial two-thirds of the triangular area above the soleal line on the posterior surface of the tibia. Blood supply Inferior medial and lateral genicular arteries Posterior tibial artery and its branches. Nerve supply The branch of the tibial nerve (L4, L5, S1) . Actions Medially rotates the tibia on the femur; when the tibia is fixed, it laterally rotates the femur. It is the "unlocking" muscle of the knee by unlocking the locked knee by rotating the femur laterally during the initial stages of knee flexion. It pulls the lateral meniscus posteriorly, preventing it from becoming trapped and compressed between the femoral and tibial condyles.

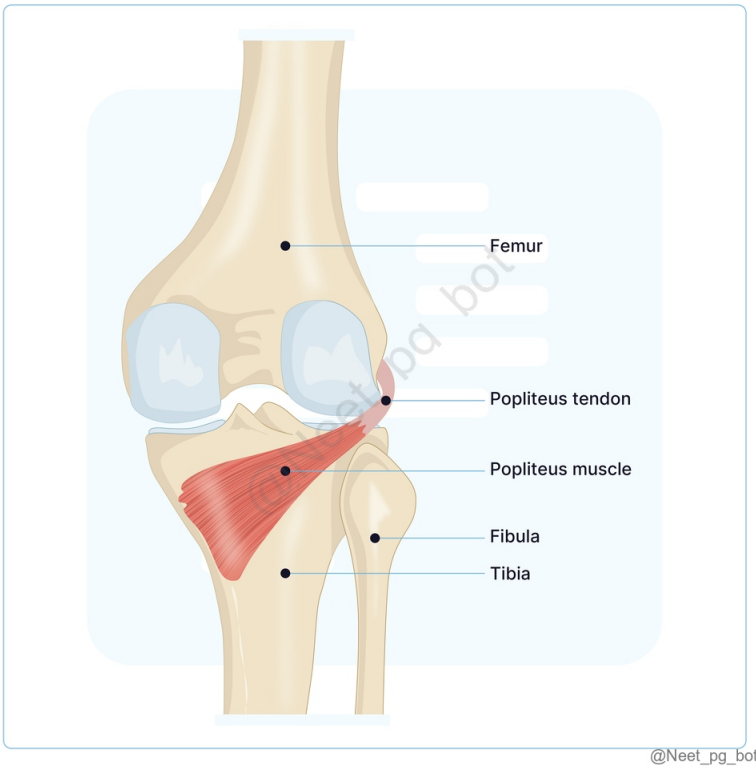

References:

Gray’s Anatomy, 42nd Edition, Page1416

Vishram Singh’s Textbook of Anatomy, Volume 2, 2nd Edition, Page 414

↑ *Back to this question in Part A*

@Neet_pg_bot

Q14: A 30-year-old runner comes in with weakness when trying to lift his foot and numbness on the outside of his right leg after hurting his knee. Examination reveals weakness in dorsiflexion and tenderness over the lateral aspect of the popliteal fossa. Which of the following structures is most likely compressed in the popliteal fossa, leading to the patient's symptoms? (Q848270)

A. Popliteal artery

B. Tibial nerve

C. Common peroneal nerve

D. Popliteal vein

Correct Answer: C. Common peroneal nerve

■ *Listen (English)*

■ *Listen (Hindi)*

Explanation: The common peroneal nerve runs obliquely through the lateral aspect of the popliteal fossa, and injury or compression can lead to weakness in dorsiflexion (foot drop) and sensory loss over the lateral leg. Contents of the Popliteal Fossa: Popliteal artery : Deepest structure, crossed posteriorly by the popliteal vein and tibial nerve. Popliteal vein : Located anterior to the tibial nerve, crosses the artery. Tibial nerve : Most superficial, runs vertically and crosses the fossa. Common peroneal nerve : Runs obliquely from the superior to the lateral angle of the fossa. The posterior cutaneous nerve of the thigh is located in the popliteal fossa. Genicular branch of the obturator nerve : Follows the popliteal artery to the knee. Popliteal lymph nodes : 6-7 nodes embedded in fat. Fat : Surrounds and supports all the structures. Relations: In the middle part of the fossa, Superficial to deep : Tibial nerve → Popliteal vein → Popliteal artery (NVA) In the upper part of the fossa, Lateral to Medial: Tibial nerve → Popliteal vein → Popliteal artery (NVA) In the lower part of the fossa, Lateral to Medial: Popliteal artery → Popliteal vein → Tibial Nerve (AVN)

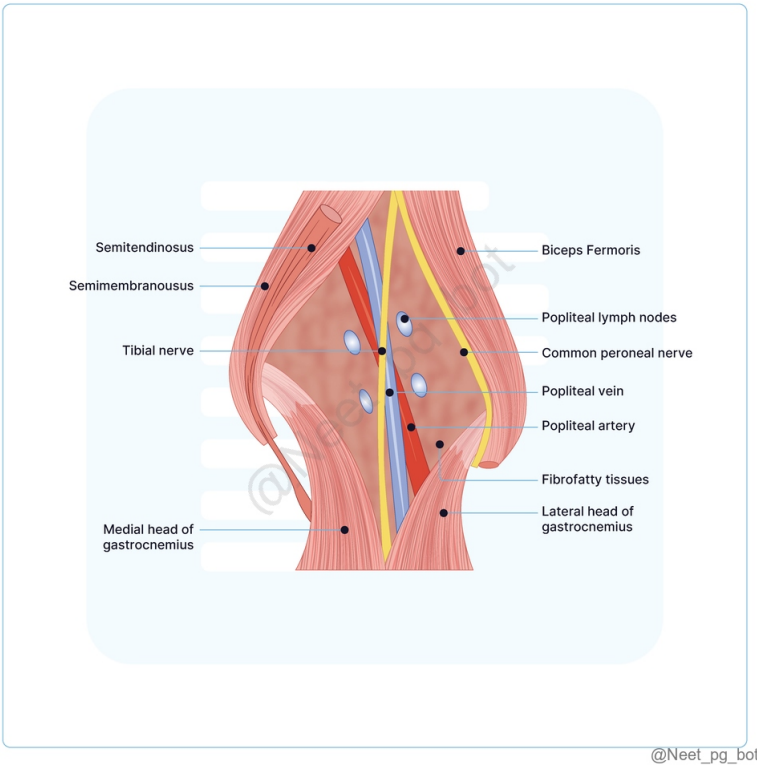

References:

Gray’s Anatomy, 42nd Edition, Pages 1396,1397

BD Chaurasia’s Human Anatomy, Volume 2, 8th Edition, Page 89

Textbook of Anatomy Vishram Singh, 2nd Edition, Volume 2, Page 372

↑ *Back to this question in Part A*

Q15: Which of the following correctly matches a boundary of the popliteal fossa with its associated structure? (Q848269)

A. Superolaterally - Semimembranosus and semitendinosus

B. Inferomedially - Medial head of the gastrocnemius

C. Roof of the popliteal fossa - Biceps femoris

D. Inferolaterally - Popliteal surface of the femur

Correct Answer: B. Inferomedially - Medial head of the gastrocnemius

■ *Listen (English)*

■ *Listen (Hindi)*

Explanation: The popliteal fossa is indeed bounded by the medial head of gastrocnemius inferomedially. Popliteal Fossa Shape : Diamond-shaped region located behind the knee. Boundaries of the Popliteal Fossa: Boundary Structure Superolaterally Biceps femoris muscle (Options A&C ruled out) Superomedially Semimembranosus, semitendinosus Inferomedially The medial head of the gastrocnemius muscle. Inferolaterally The lateral head of the gastrocnemius muscle and the plantaris muscle. Additional Features: Floor : (Option D ruled out) The popliteal surface of the femur Oblique popliteal ligament The posterior surface of the proximal tibia (covered by popliteus muscle and fascia) Roof : Deep fascia (continuous with fascia lata and deep fascia of the leg) Pierced by short saphenous vein and medial/lateral sural cutaneous nerves

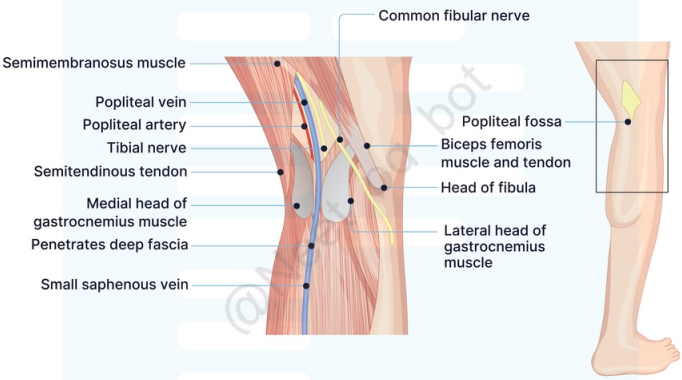

@Neet_pg_bot

References:

Gray's Anatomy, 42nd Edition, Page 1396

↑ *Back to this question in Part A*

@Neet_pg_bot

Q16: Which of the following accurately describes the boundaries of the adductor canal? (Q848268)

A. Anteriorly bounded by the sartorius muscle, laterally by the rectus femoris.

B. Posteromedially bounded by adductor longus and adductor magnus.

C. Roofed by the iliotibial band and bounded posteriorly by the adductor brevis.

D. Medially bounded by the gluteus maximus and anteriorly by the vastus lateralis.

Correct Answer: B. Posteromedially bounded by adductor longus and adductor magnus.

■ *Listen (English)*

■ *Listen (Hindi)*

Explanation: The canal is anterolaterally bounded by the vastus medialis and posteromedially by the adductor longus and adductor magnus. Adductor Canal (Subsartorial canal or Hunter's canal): Location : Distal two-thirds of the medial thigh Extent : Begins at apex of the femoral triangle; ends at adductor hiatus in the tendon of adductor magnus. Boundaries of the Adductor Canal: Boundary Structure Anterolaterally Vastus medialis muscle Posteromedially Adductor longus and adductor magnus muscles Anteromedially (Roof) Subsartorial fascia (dense fascia between vastus medialis and adductor muscles)

References:

Gray’s Anatomy, 42nd Edition, Page 1386.

↑ *Back to this question in Part A*

@Neet_pg_bot

Q17: Which of the following muscles forms the lateral part of the floor of the femoral triangle? (Q848267)

A. Pectineus

B. Iliacus

C. Adductor longus

D. Sartorius

Correct Answer: B. Iliacus

■ *Listen (English)*

■ *Listen (Hindi)*

Explanation: The iliacus, along with the psoas major, forms the lateral part of the floor of the femoral triangle. Femoral Triangle: Location : Anteromedial aspect of the proximal thigh Base : Inguinal ligament Borders: Lateral : Medial border of sartorius muscle (Option D ruled out) Medial : Medial border of adductor longus muscle Apex : Intersection of sartorius and adductor longus Floor Muscles: Lateral : Iliacus, psoas major Medial : Pectineus, adductor longus (Options A&C ruled out) Contents: Femoral artery & vein : Femoral nerve : Lateral to artery, outside the sheath, divides into branches Lateral femoral cutaneous nerve : Enters triangle 2.1-3.5 cm below the anterior superior iliac spine (ASIS) Lymph nodes & fat .

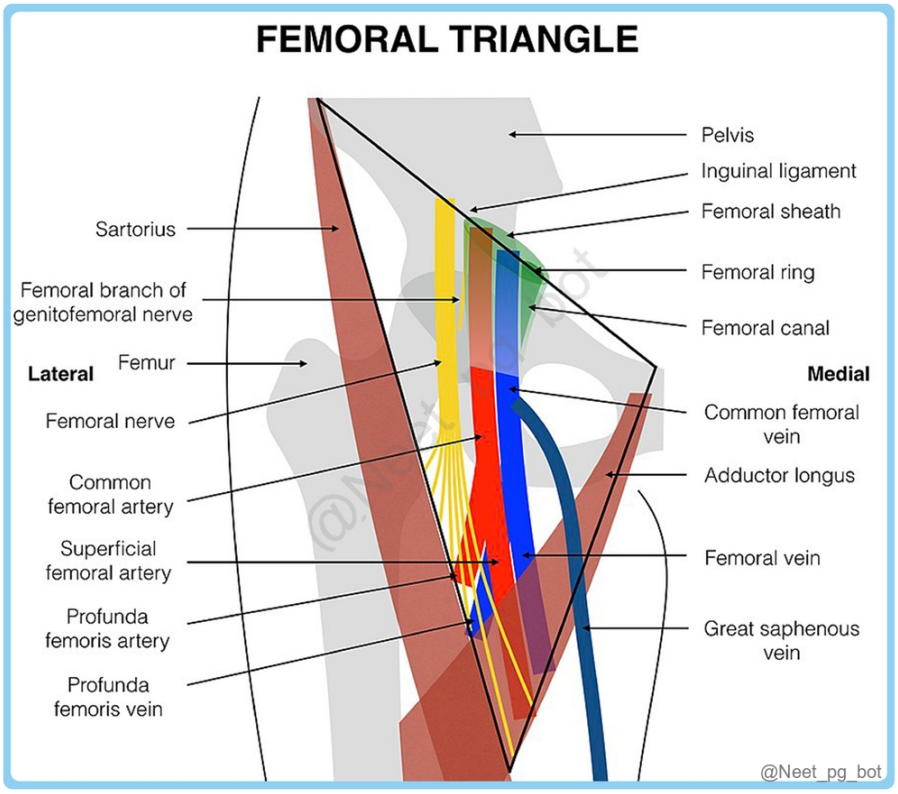

References:

Gray's Anatomy, 42nd Edition, Pages 1381, 1382, 1384

Textbook of Anatomy Vishram Singh, 2nd Edition, Volume 2, Pages 48, 338

↑ *Back to this question in Part A*

@Neet_pg_bot

Q18: A 28 y/o male presents with knee pain and instability after a football injury. The Lachmann Test is performed to assess for an ACL tear. At what degree of knee flexion is the Lachmann Test typically performed? (Q848266)

A. 0 degrees

B. 15-20 degrees

C. 60-70 degrees

D. 80-90 degrees

Correct Answer: B. 15-20 degrees

■ *Listen (English)*

■ *Listen (Hindi)*

Explanation: The Lachmann Test is typically performed with the knee flexed at 15-20 degrees to assess for ACL injuries. Anterior Cruciate Ligament (ACL) Injury Assessment Tests: Anterior Drawer Test Lachmann Test This is a test to detect injury to the anterior cruciate ligament. This is another test to detect injury to the anterior cruciate ligament. Procedure : The patient is positioned supine, with the knee being tested flexed to 80–90°, and passive forward traction is then applied to the tibia. (Option D ruled out) Procedure: This test is considered better than the anterior drawer test. In this test, the knee is maintained in 15° to 20° of flexion. One hand supports the thigh just above the knee, while the other holds the upper tibia. The degree of anterior glide assesses the integrity of the anterior cruciate ligament (ACL). Pivot Shift Test: Most specific clinical test for an ACL tear. Done to see if the tibia subluxates (pops out of place) and then reduces (pops back in) when the knee moves. The examiner lifts the leg and holds the knee in full extension. They apply a valgus stress (pushing the knee inward) and internal rotation (turning the shin bone inward). As they slowly bend (flex) the knee, they watch for a "clunk." At about 20–30° of flexion, the iliotibial (IT) band will pull the displaced tibia back into its proper spot with a noticeable "jerk" or shift. This test is difficult to perform on a conscious patient because it can be uncomfortable, causing the hamstrings to tense up and mask the result. It is often performed most accurately while the patient is under anesthesia before surgery. Posterior Cruciate Ligament (PCL) Injury Assessment Tests: 1. Posterior Drawer Test: Similar setup to the Anterior Drawer (knee at 90 degrees), but instead of pulling, the examiner pushes the tibia backward toward the table. If the tibia shifts backward excessively, it’s a positive sign for a PCL injury. 2. Posterior Sag Sign (Godfrey’s Test): This is the simplest test and often requires no physical manipulation. Patient lies on the back with both hips and knees flexed to 90 degrees (often supported by the examiner). The examiner looks at the profile of the knees from the side. If the PCL is torn, gravity causes the tibia on the injured side to "sag" or drop down lower than the healthy knee. 3. Quadriceps Active Test (PCL): To see if your quadriceps muscle can pull a "sagging" tibia back into its proper position.\ Patient lies on back with the knee bent at 90° (the "Drawer" position). If the PCL is torn, the tibia will already be "sagging" backward due to gravity. The examiner holds patient's foot down and asks them to try and slide their foot forward along the table (contracting your quads). If the PCL is torn, you will see the tibia shift forward to its neutral position as the quads pull on it. In a healthy knee, there is no shift because the tibia wasn't sagging to begin with.

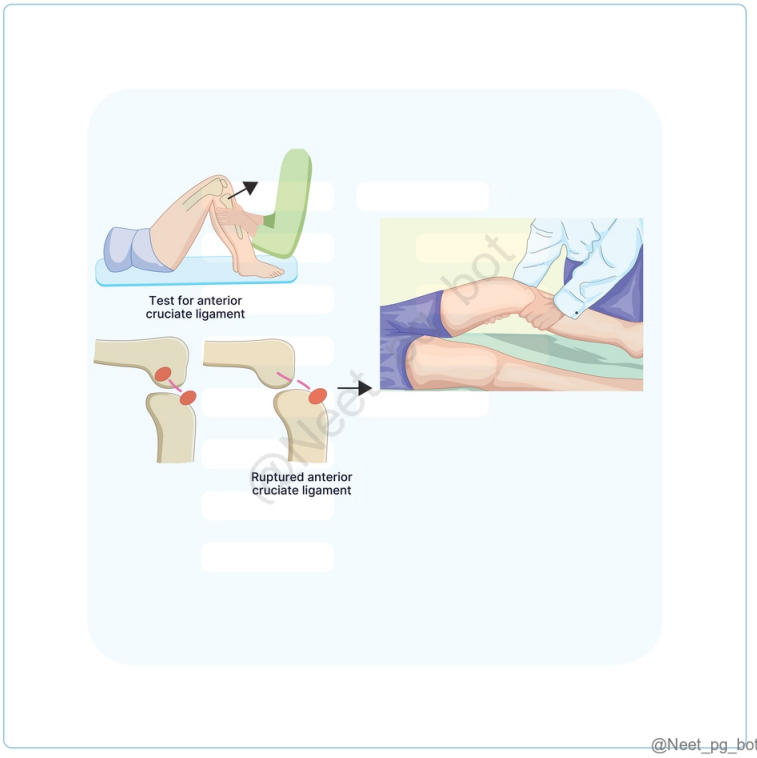

References:

Maheshwari Essentials of Orthopedics, 7th Edition, Page 356

www.ncbi.nlm.nih.gov/pmc/articles/PMC4151408/

↑ *Back to this question in Part A*

@Neet_pg_bot

Q19: A 25 y/o male presents to the emergency after a sports injury involving a sudden pivot on his left knee. An MRI reveals a tear in the anterior cruciate ligament (ACL). Which statement regarding the knee ligaments is true? (Q848264)

A. ACL is an extracapsular ligament.

B. Lateral collateral ligament attaches to the patella.

C. The medial meniscus is wider anteriorly.

D. PCL prevents anterior displacement of the femur.

Correct Answer: D. PCL prevents anterior displacement of the femur.

■ *Listen (English)*

■ *Listen (Hindi)*

Explanation: The PCL prevents anterior displacement of the femur and posterior displacement of the tibia when the knee is flexed, making it essential for knee stability. Extracapsular Ligaments Intracapsular Ligaments Ligamentum Patellae: Attaches from the lower border of the patella to the tibial tuberosity. Lateral (Fibular) Collateral Ligament: (Option B ruled out) Cord-like structure attaching from the femur's lateral condyle to the fibula's head. The Popliteus tendon is located between this ligament and the lateral meniscus. Medial (Tibial) Collateral Ligament: Flat band connecting the medial condyle of the femur to the medial surface of the tibia. Oblique Popliteal Ligament: Tendinous expansion from the semimembranosus muscle, strengthening the posterior capsule. Medial Meniscus Semicircular, wider posteriorly than anteriorly. (Option C ruled out) Lateral Meniscus Circular. The posterior end is attached to the medial condyle of the femur via two meniscofemoral ligaments; separated from the fibular collateral ligament by the popliteus tendon. Anterior Cruciate Ligament (ACL): (Option A ruled out) It attaches to the anterior intercondylar area of the tibia and ascends to the posterior part of the lateral femoral condyle. Prevents posterior displacement of the femur and anterior displacement of the tibia when the knee is flexed. It is extrasynovial. Posterior Cruciate Ligament (PCL): It attaches to the posterior intercondylar area of the tibia and extends to the anterior part of the medial femoral condyle. It is extrasynovial.

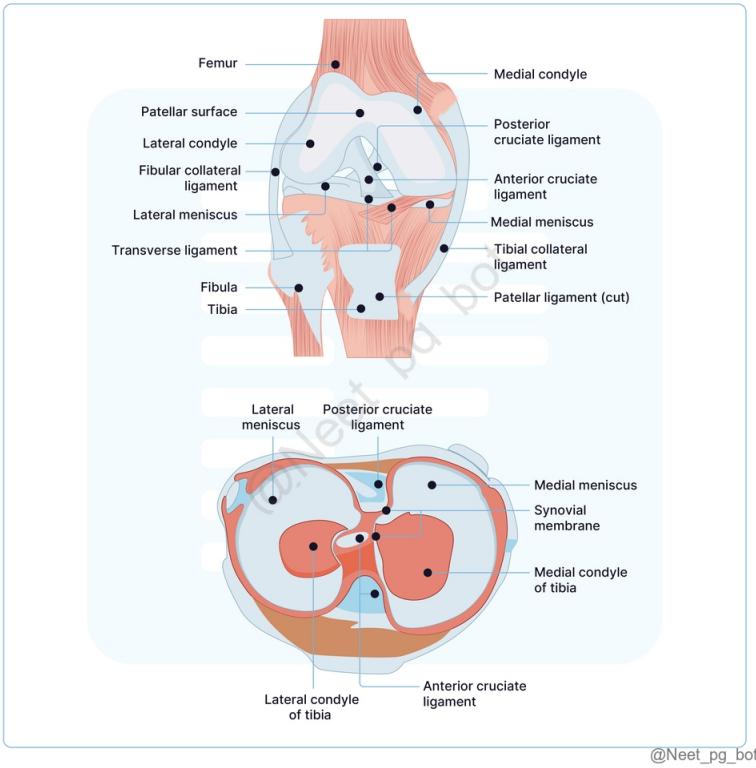

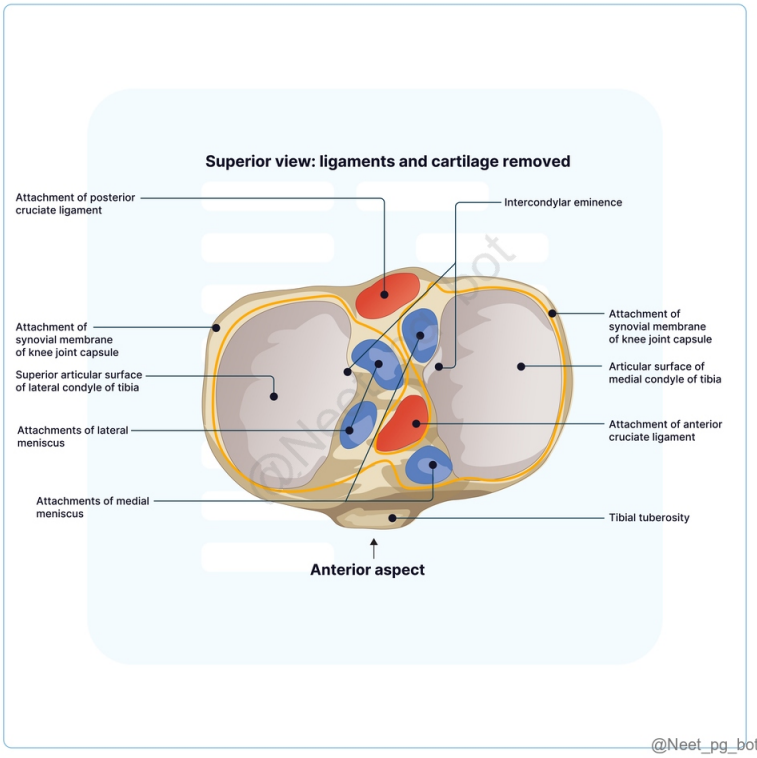

References:

Gray’s Anatomy, 42nd Edition, Pages 1406-1408

BD Chaurasia’s Human Anatomy, Volume 2, 8th Edition, Pages 169, 170, 171

Textbook of Anatomy Vishram Singh, 2nd Edition, Volume 2, Pages 443, 444

Snells Clinical Anatomy, 10th Edition, Pages 579, 580

↑ *Back to this question in Part A*

@Neet_pg_bot

Q20: Which muscles are involved in the locking and unlocking of the knee joint? (Q848263)

A. Hamstring muscles for both locking and unlocking

B. Quadriceps femoris for locking and popliteus for unlocking

C. Popliteus for both locking and unlocking

D. Soleus for unlocking and hamstring for locking

Correct Answer: B. Quadriceps femoris for locking and popliteus for unlocking

■ *Listen (English)*

■ *Listen (Hindi)*

Explanation: The quadriceps femoris muscle group extends the knee and helps in the locking mechanism when the knee is fully extended. The popliteus muscle is responsible for unlocking the knee by initiating flexion, particularly from a fully extended position. Aspect Locking of the Knee Joint Unlocking of the Knee Joint Phase of Motion Terminal phase of extension. Initial phase of flexion. Muscle Involved (Option A, C & D) Quadriceps femoris Popliteus muscle Knee Rigidity The locked knee becomes rigid. An unlocked knee can be further flexed. Ligament Tension All ligaments are taut. All ligaments are relaxed. Function Essential for bearing load during erect posture. Facilitates the progress of locomotion.

References:

Gray’s Anatomy, 42nd Edition, Page 1411

BD Chaurasia’s Human Anatomy, 8th Edition, Page 173

Vishram Singh’s Textbook of Anatomy, Volume 2, 2nd Edition, Page 447

↑ *Back to this question in Part A*

@Neet_pg_bot

• [06_Lower Limb] 031 Vascular Supply Of Lower Limb

« Back to Folder Directory

[06_Lower Limb] 031 Vascular Supply Of Lower Limb — Quick Jump

Q1 (p. 1629) *Q2 (p. 1631)* *Q3 (p. 1632)* *Q4 (p. 1633)* *Q5 (p. 1634)* *Q6 (p. 1635)*
Q7 (p. 1636) *Q8 (p. 1637)* *Q9 (p. 1639)* *Q10 (p. 1640)* *Q11 (p. 1643)* *Q12 (p. 1644)*
Q13 (p. 1646) *Q14 (p. 1647)* *Q15 (p. 1649)*

Q1: Which of the following is incorrect about the highlighted area? (Q848292)

A. It consists of a superficial part and a deep part.

B. Prone to injuries in eversion.

C. Excessive tensile forces cause avulsion fracture.

D. It's crossed by tibialis posterior and flexor digitorum longus.

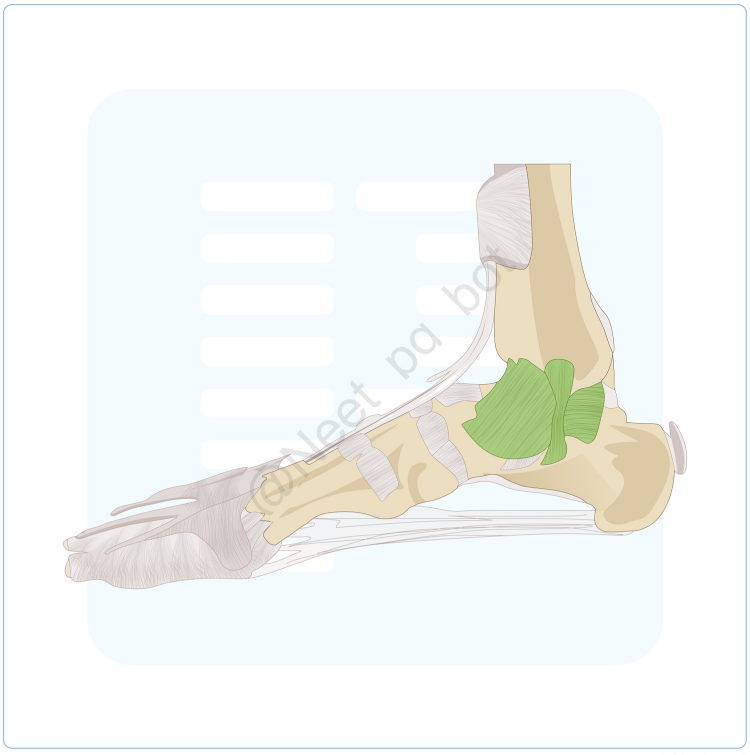

Correct Answer: B. Prone to injuries in eversion.

■ *Listen (English)*

■ *Listen (Hindi)*

Explanation: The ligament shown in the image is known as the deltoid ligament. It is prone to injuries in inversion, not eversion. Deltoid Ligament (Medial Ligament) Location: Medial side of the ankle ; triangular shape. Structure: Divided into superficial and deep parts, both attached to the medial malleolus. (Option A) Superficial Part: Anterior (Tibionavicular) Fibres Middle (Tibiocalcanean) Fibres Posterior (Tibiotalar) Fibres Deep Part: Anterior Tibiotalar Fibres: Attachments: Anterior part of the medial surface of the talus. Characteristics: Crossed by tendons of tibialis posterior and flexor digitorum longus (Option D) . Very strong; typically results in avulsion fracture rather than tear under excessive tensile forces (Option C) . Prone to injuries during inversion . Lateral Ligament Structure: Composed of three bands. Anterior Talofibular Ligament: A flat band from anterior margin of lateral malleolus to neck of talus (in front of fibular facet). Posterior Talofibular Ligament: Connects lower part of malleolar fossa of fibula to lateral tubercle of talus. Calcaneofibular Ligament: Long rounded cord from notch on lower border of lateral malleolus to tubercle on lateral surface of calcaneus. Characteristics: Crossed by tendons of peroneus longus and brevis.

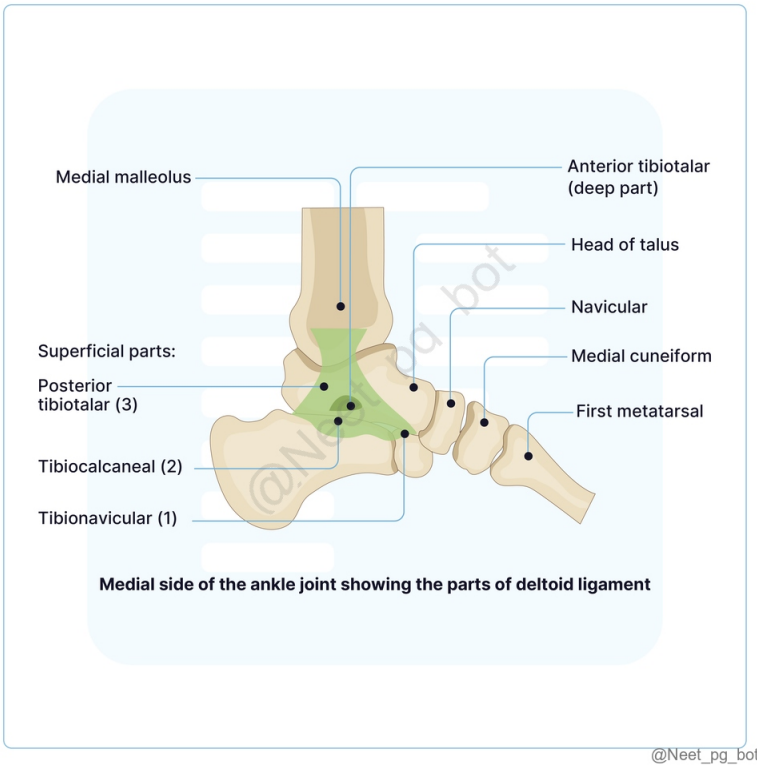

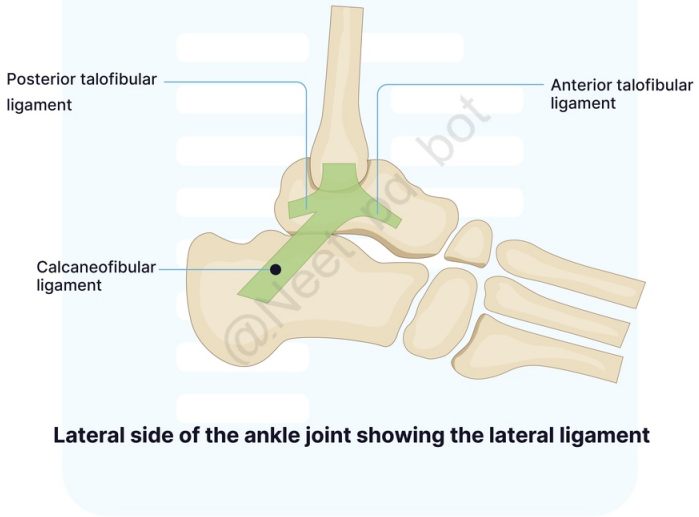

@Neet_pg_bot

References:

BD Chaurasia's Human Anatomy, Volume 2, 8th Edition, Page 177

↑ *Back to this question in Part A*

@Neet_pg_bot

Q2: A 42-year-old woman complains of difficulty adducting her toes. Which of the following muscles is primarily responsible for adducting the lateral three toes? (Q848294)

A. Adductor halucis

B. Dorsal interossei

C. Plantar interossei

D. Adductor digitorum brevis

Correct Answer: C. Plantar interossei

■ *Listen (English)*

■ *Listen (Hindi)*

Explanation: The plantar interossei (fourth layer) are responsible for adducting the 3rd–5th toes (PAD – Plantar Adduct) . Adductor hallucis (Option A) adducts the great toe at the metatarsophalangeal joint. The dorsal interossei (Option B) (fourth layer) performs abduction of the toes (DAB – Dorsal Abduct), not adduction. Adductor digitorum brevis (Option D) does not exist.

References:

Gray's Anatomy, 4th Edition, Pages 655, 656.

BD Chaurasia's Human Anatomy, Volume 2, 8th Edition, Pages 142, 143.

↑ *Back to this question in Part A*

@Neet_pg_bot

Q3: A 30-year-old athlete complains of difficulty in flexion at the metatarsophalangeal joint and extension at the interphalangeal joint of the second toe. Which of the following statements is correct? (Q848295)

A. First lumbrical is affected and is supplied by the lateral plantar nerve.

B. First lumbrical is affected and is supplied by the medial plantar nerve.

C. Second lumbrical is affected and is supplied by the lateral plantar nerve.

D. Second lumbrical is affected and is supplied by the medial plantar nerve.

Correct Answer: B. First lumbrical is affected and is supplied by the medial plantar nerve.

■ *Listen (English)*

■ *Listen (Hindi)*

Explanation: The first lumbrical, which acts on the second toe, is supplied by the medial plantar nerve . It facilitates flexion at the metatarsophalangeal joint and extension at the interphalangeal joints. The lumbricals of the foot show a pattern of dual innervation: The medial plantar nerve innervates the first lumbrical. The second, third, and fourth lumbricals are innervated by the lateral plantar nerve. This distribution mirrors the innervation seen in the hand , where a division between median and ulnar nerve innervation exists.

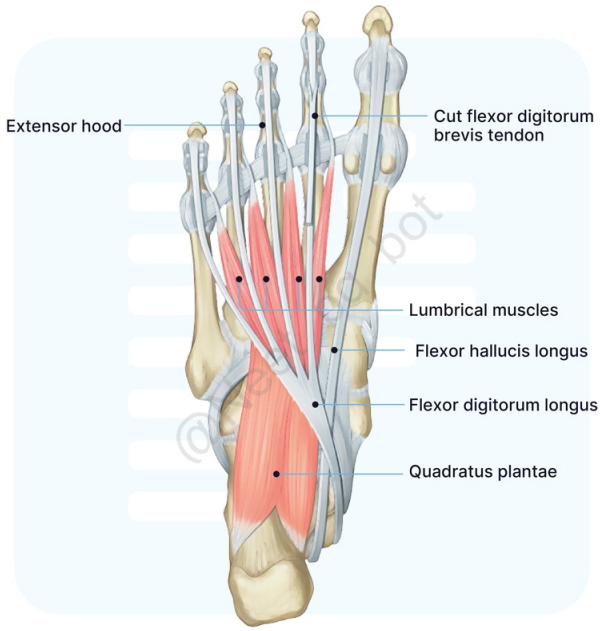

Second layer of muscles in the sole of the foot.

@Neet_pg_bot

References:

Gray’s Anatomy, 4th Edition, Pages 652, 653, 654.

BD Chaurasia’s Human Anatomy, Volume 2, 8th Edition, Pages 140, 141.

↑ *Back to this question in Part A*

@Neet_pg_bot

Q4: A 55-year-old man presents with complaints of claudication and cramping pain in his left lower limb while walking short distances, which is relieved by rest. On further examination, his left dorsalis pedis pulse is diminished, and he has cool skin on the affected leg. Doppler ultrasound reveals significant atherosclerosis at the bifurcation of the common iliac artery. Which of the following arteries, if most affected by this condition, is likely responsible for the reduced blood flow to his lower limb? (Q848296)

A. Internal iliac artery

B. Inferior epigastric artery

C. External iliac artery

D. Internal pudendal artery

Correct Answer: C. External iliac artery

■ *Listen (English)*

■ *Listen (Hindi)*

Explanation: External iliac artery is the primary artery that continues as the femoral artery to supply the lower limb. Atherosclerosis at the bifurcation of the common iliac artery directly affects the external iliac artery, reducing blood flow to the entire lower limb, causing claudication.

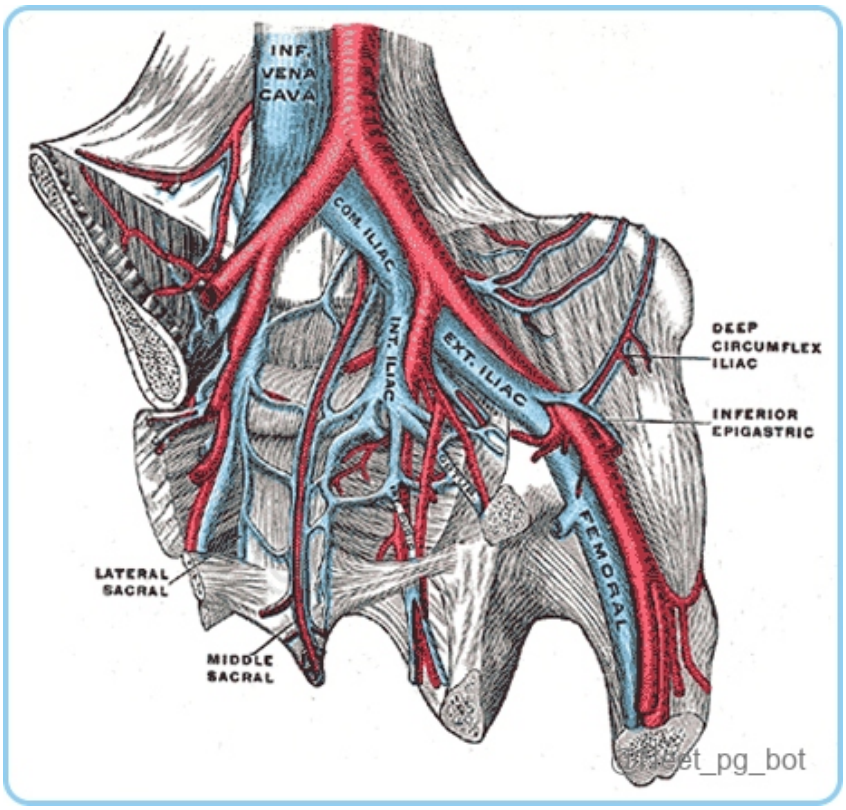

References:

BD Chaurasia's Human Anatomy, Volume 2, 8th Edition, Page 210, 211.

↑ *Back to this question in Part A*

@Neet_pg_bot

Q5: During surgery for a femoral shaft fracture, the surgeon notes damage to the vastus lateralis muscle. Which artery is primarily responsible for supplying the vastus lateralis? (Q848298)

A. Ascending branch of femoral circumflex artery

B. Ascending branch of medial femoral circumflex artery

C. Descending branch of lateral femoral circumflex artery

D. Transverse branch if medial femoral circumflex artery

Correct Answer: C. Descending branch of lateral femoral circumflex artery

■ *Listen (English)*

■ *Listen (Hindi)*

Explanation: The descending branch of the lateral femoral circumflex artery supplies the vastus lateralis muscle as it descends along its anterior border. Medial and Lateral Femoral Circumflex Arteries Branches of the profunda femoris artery (from the femoral artery) Lateral Femoral Circumflex Artery Branches near the root of profunda femoris, run laterally Divides into ascending, descending, and transverse branches Medial Femoral Circumflex Artery Typically branches from profunda femoris, sometimes from the femoral artery Supplies adductor muscles, runs medially around femur Divides into ascending and transverse

References:

Gray's Anatomy for Students, 42nd Edition, Pages 1389, 1390, 1464

↑ *Back to this question in Part A*

@Neet_pg_bot

Q6: A patient is experiencing discomfort in the lower limb due to venous insufficiency. Which of the following mechanisms aid in the venous return of blood from the lower limb to the heart? (Q848299)

A. Deep fascia limits muscle expansion

B. Contraction of calf muscles leads to compression of superficial veins

C. Increased intrathoracic pressure

D. Vasodilation of superficial veins

Correct Answer: A. Deep fascia limits muscle expansion

■ *Listen (English)*

■ *Listen (Hindi)*

Explanation: The deep fascia enhances the muscle pump by limiting outward muscle expansion, helping direct blood flow upwards through deep veins. Venous Drainage of the Lower Limb The venous system of the lower

limb returns deoxygenated blood to the heart. Factors Aiding Venous Return Valves: Ensure unidirectional flow towards the heart. Muscle Pump: Calf muscle contraction compresses deep veins , aiding blood propulsion. (Option B) Deep Fascia: Limits muscle expansion, enhancing pressure on deep veins during contraction. (Option A) Negative Intrathoracic Pressure: Assists in drawing blood upwards during inspiration. (Option C) Vasodilation of superficial veins (Option D) : Vasodilation would increase venous pressure and contribute to venous insufficiency, not aid in venous return.

References:

Gray's Anatomy for Students, 42nd Edition, Page 1464.

↑ *Back to this question in Part A*

@Neet_pg_bot

Q7: A 30-year-old female presents to the emergency department with a swollen right leg and pain following a long-haul flight. Doppler ultrasound confirms a deep vein thrombosis (DVT) in the right calf. Which statement about the anatomy of the deep veins of the lower limb is correct? (Q848300)

A. The anterior tibial vein runs alongside the fibular artery.

B. The medial and lateral plantar veins contribute to the formation of the popliteal vein.

C. Perforating veins carry blood from deep veins to superficial veins.

D. The fibular veins drain directly into the femoral vein.

Correct Answer: B. The medial and lateral plantar veins contribute to the formation of the popliteal vein.

■ *Listen (English)*

■ *Listen (Hindi)*

Explanation: The medial and lateral plantar veins unite to form the posterior tibial veins, which then contribute to the formation of the popliteal vein. Deep Veins of the Lower Limb Deep veins are located beneath the deep fascia of the lower limb, running alongside major arteries and are more numerous than superficial veins. They generally share names with their accompanying arteries and follow similar paths. Conditions: Deep Vein Thrombosis (DVT) : Formation of a thrombus in deep veins, often in the calf due to sluggish blood flow. Pulmonary Embolism : Thrombus fragments can dislodge, travel to the lungs, and cause a life-threatening blockage. The anterior tibial vein runs alongside the fibular artery (Option A): The anterior tibial vein runs alongside the anterior tibial artery. Perforating veins carry blood from deep veins to superficial veins (Option C): Perforating veins allow blood to flow from superficial veins to deep veins. The fibular veins drain directly into the femoral vein. (Option D) : The fibular veins drain into the popliteal vein, not directly into the femoral vein.

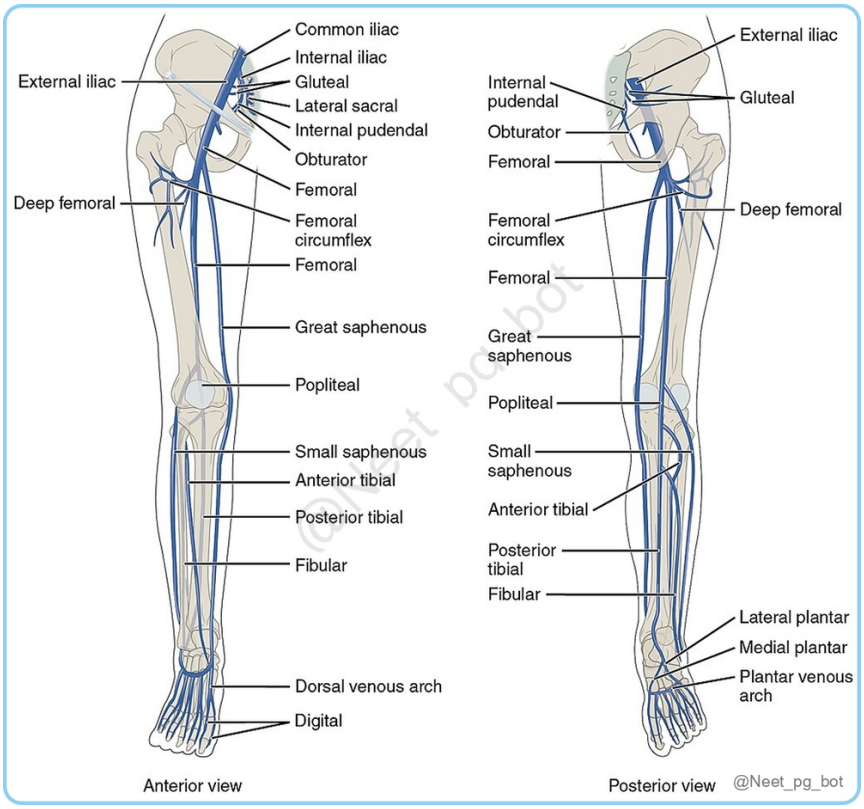

References:

Gray's Anatomy for Students, 42nd Edition, Page 1464

↑ *Back to this question in Part A*

@Neet_pg_bot

Q8: A 35-year-old female presents with symptoms of heaviness and visible varicose veins primarily affecting her left leg. Duplex ultrasonography reveals dilation of the great saphenous vein (GSV) with incompetent valves. She is scheduled for vein stripping surgery. Which of the following statements regarding the anatomical features of the GSV compared to the small saphenous vein (SSV) is correct? (Q848301)

A. The GSV has fewer valves than the SSV, making it less prone to varicosities

B. The GSV originates from the lateral end of the dorsal venous arch of the foot

C. The GSV is a continuation of the medial marginal vein.

D. The GSV pierces the deep fascia to drain into the popliteal vein.

Correct Answer: C. The GSV is a continuation of the medial marginal vein.

■ *Listen (English)*

■ *Listen (Hindi)*

Explanation: The GSV arises from the medial marginal vein on the dorsum of the foot. Important superficial veins: Great Saphenous Vein (GSV) and Small Saphenous Vein (SSV) Great Saphenous Vein (GSV): Arises on the dorsum of the foot, as a continuation of the medial marginal vein (Option C) Course: Ascends in front of the medial malleolus Runs along the medial leg Courses behind the knee Inclines forward in the thigh Passes through the saphenous opening into the femoral vein Contains 10-20 valves, more concentrated in the leg (Option A) Clinical Relevance of GSV: Coronary Artery Bypass Grafting (CABG): The GSV is the "gold standard" for venous autografts. Surgeons harvest sections of it to bypass blocked coronary arteries because it is long, accessible, and has a high wall thickness. Venous Cutdown: In trauma patients with collapsed veins, the GSV is the most reliable site for an emergency incision (cutdown). It is always found anterior to the medial malleolus . Varicose Veins: The GSV is the most common site for "incompetent valves," leading to visible varicosities on the medial leg and thigh. Surgical Risk: The Saphenous nerve runs closely with the GSV; injury during surgery causes numbness on the medial side of the leg/foot. Small Saphenous Vein (SSV): Forms on the dorsum of the foot from the lateral dorsal venous arch (Option B) Course: Ascends behind the lateral malleolus Runs along the calf Drains into the popliteal vein after piercing the deep fascia (Option D) Contains 7-13 valves, with one near its termination Clinical Relevance of SSV: Popliteal Connection: The SSV drains into the deep system (Popliteal vein) behind the knee. Incompetence here causes varicosities on the back of the calf . DVT/PE Risk: Because it connects directly to the deep popliteal vein, a superficial clot in the SSV can easily progress to a Deep Vein Thrombosis (DVT) or Pulmonary Embolism. Surgical Risk: The Sural nerve runs alongside the SSV; injury during procedures causes numbness on the lateral side of the foot. Anatomical Landmark: It is always found posterior to the lateral malleolus .

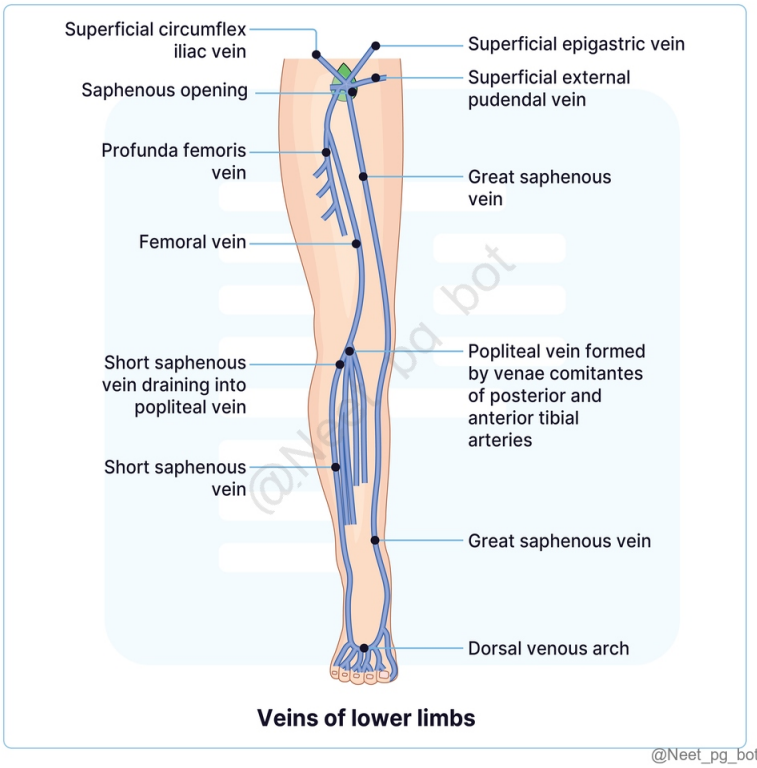

References:

Gray’s Anatomy for Students, 42nd Edition, Page 1464

↑ *Back to this question in Part A*

@Neet_pg_bot

Q9: A 45-year-old female presents with burning pain and tingling in the plantar aspect of her foot. She reports that the symptoms worsen with prolonged standing and improve with rest. You tap over the region just behind the medial malleolus, and the patient experiences tingling and numbness radiating into the sole of her foot. The underlying cause of her symptoms is likely related to? (Q848288)

A. Inadequate Blood Supply

B. Compressive Neuropathy

C. Morton’s neuroma

D. Arthritis

Correct Answer: B. Compressive Neuropathy

■ *Listen (English)*

■ *Listen (Hindi)*

Explanation: The clinical picture suggests tarsal tunnel syndrome, which results from a compressive neuropathy caused by pressure on the tibial nerve as it travels behind the medial malleolus through the tarsal tunnel. Tarsal tunnel: Present on the medial side of ankle Between medial malleolus and calcaneus → Flexor retinaculum Beneath the flexor retinaculum → tarsal tunnel Structures: (Mnemonic: Tom Dick and Harry): T om - Tendon of T ibialis Posterior D ick - Tendon of Flexor D igitorum Longus A - Posterior tibial A rtery N d -Tibial N erve H arry - Tendon of Flexor H allucis Longus Clinical application: Peripheral pulse: Posterior tibial artery can be palpated between the medial malleolus and calcaneus to measure the peripheral pulse

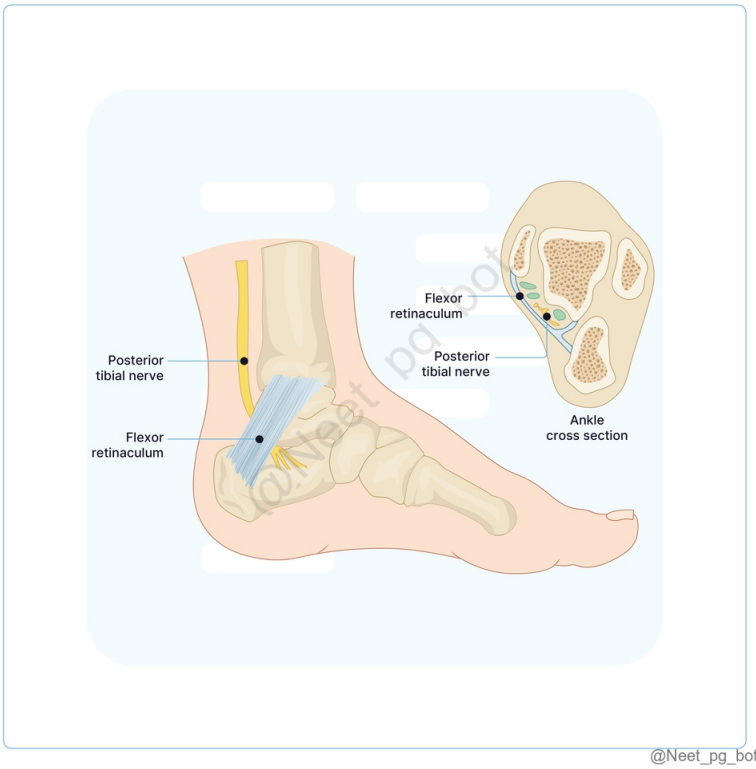

@Neet_pg_bot

References:

https://www.orthobullets.com/foot-and-ankle/7042/tarsal-tunnel-syndrome

BD Chaurasia's Human Anatomy, Volume 2, 8th Edition, Page 126

↑ *Back to this question in Part A*

@Neet_pg_bot

Q10: A 45-year-old woman presents with difficulty wearing shoes and discomfort in her toes. She reports pain in the forefoot and has noticed that the tips of her toes frequently press into the ground while walking. On physical examination, the toes are bent at the middle and distal joints, with hyperextension at the base. The deformity worsens when wearing tight shoes. What is the most likely diagnosis based on the description of the deformity?. (Q848289)

A. Claw toe

B. Hammer toe

C. Mallet toe

D. Bunion toe

Correct Answer: A. Claw toe

- *Listen (English)*
- *Listen (Hindi)*

Explanation: The given image is of a claw toe, a lesser toe deformity Characterised by hyperextension of the MTP joint, along with flexion at the proximal interphalangeal (PIP) and distal interphalangeal (DIP) joints. Claw Toe Other toe deformities: (Option B, C and D) Common Toe Deformities and Their Causes: Deformity Description Primary Reason/Cause Claw Toe The toe digs down into the sole of the shoe; it’s bent at the base and both joints. Nerve Damage: Often linked to underlying issues like diabetes or alcoholism, which weaken foot muscles and lead to "clawing." Hammer toe An abnormal bend in the middle joint of the toe (usually the second, third, or fourth toe). Muscle Imbalance: Often caused by tight shoes that force the toe into a bent position, eventually causing the tendons to shorten and "lock." Mallet Toe A bend that occurs only in the joint nearest the toenail (the distal joint). Trauma or Friction: Often caused by the toe stubbing against the front of a shoe that is too small. Bunions (Hallux Valgus) A bony bump that forms on the joint at the base of the big toe. Pressure & Mechanics: Often hereditary foot structure combined with narrow shoes. The big toe is pushed toward the others, forcing the joint out. Tailor's Bunion Similar to a regular bunion, but occurs on the outside of the foot at the base of the pinky toe. Foot Structure: Usually caused by a structural abnormality of the fifth metatarsal bone.




@Neet_pg_bot

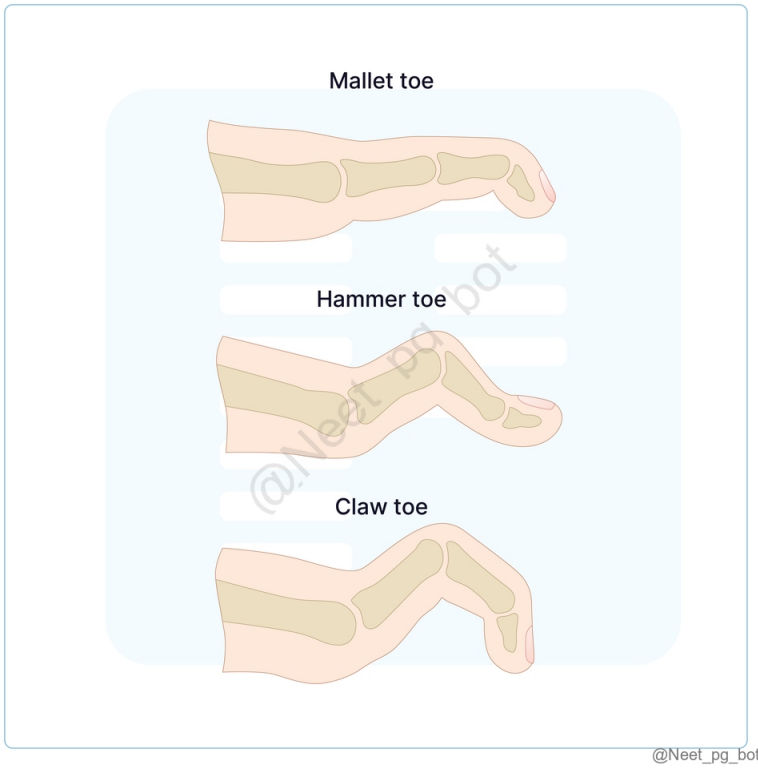
Mallet toe
Hammer toe
Claw toe
@Neet_pg_bot



References:

https://www.orthobullets.com/foot-and-ankle/7013/claw-toe?section=bullets

BD Chaurasia's Human Anatomy, Volume 2, 8th Edition, Page 184

↑ *Back to this question in Part A*

@Neet_pg_bot

Q11: A 32-year-old man presents to the emergency department after a fall from a height. He complains of severe pain in the heel and inability to bear weight on his foot. On physical examination, there is swelling and tenderness at the heel. Which bone is most likely affected?. (Q848290)

A. Calcaneus

B. Talus

C. Navicular

D. Cuboid

Correct Answer: A. Calcaneus

■ *Listen (English)*

■ *Listen (Hindi)*

Explanation: The calcaneus is the largest tarsal bone located in the heel and is the most commonly fractured tarsal bone following a fall from height.

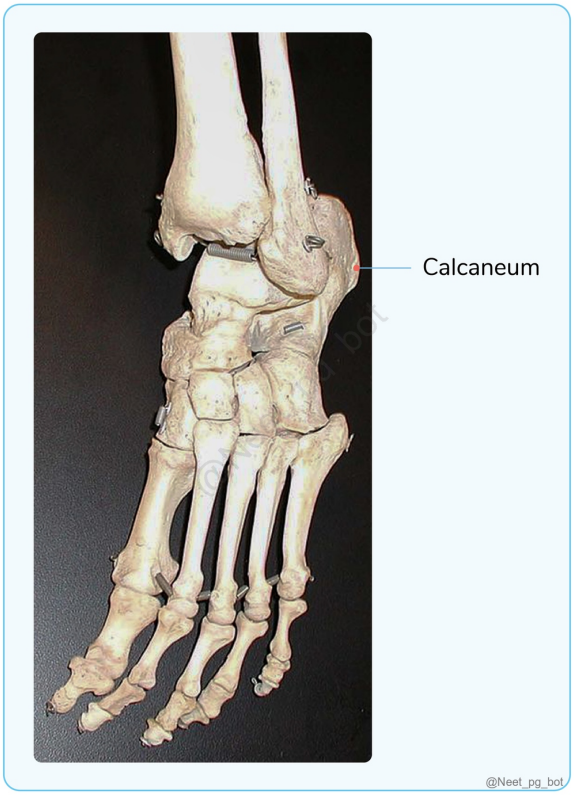

References:

https://teachmeanatomy.info/lower-limb/bones/bones-of-the-foot-tarsals-metatarsals-and-phalanges/

Inderbir Singh, Textbook of anatomy, General anatomy, upper and lower limb, 6th Edition, Pages 296-301

https://www.physio-pedia.com/Calcaneus

↑ *Back to this question in Part A*

@Neet_pg_bot

Q12: A 35-year-old male marathon runner presents with complaints of foot pain after long-distance runs. On examination, the foot shows a well-formed arch, and palpation reveals tenderness along the medial aspect of the foot. An X-ray confirms a normal medial longitudinal arch structure. Which of the following statements incorrectly

describes the function or anatomy of the medial longitudinal arch in this patient? (Q848291)

A. Provides better shock absorption.

B. The bony keystone is Talus

C. Has limited mobility

D. Main joint is Talocalcaneonavicular joint

Correct Answer: C. Has limited mobility

■ *Listen (English)*

■ *Listen (Hindi)*

Explanation: Medial longitudinal arch High and more mobile Functions primarily as a shock absorber Talus acts as the keystone The talocalcaneonavicular (TCN) joint is the key joint Lateral longitudinal arch Lower and more rigid Functions mainly in weight transmission Cuboid is the keystone The calcaneocuboid joint is the main joint

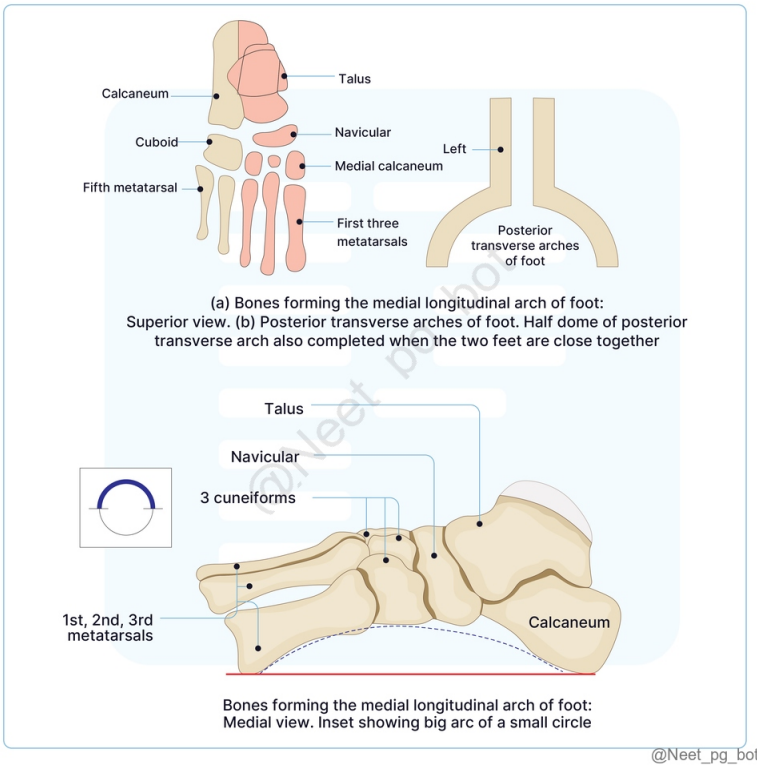

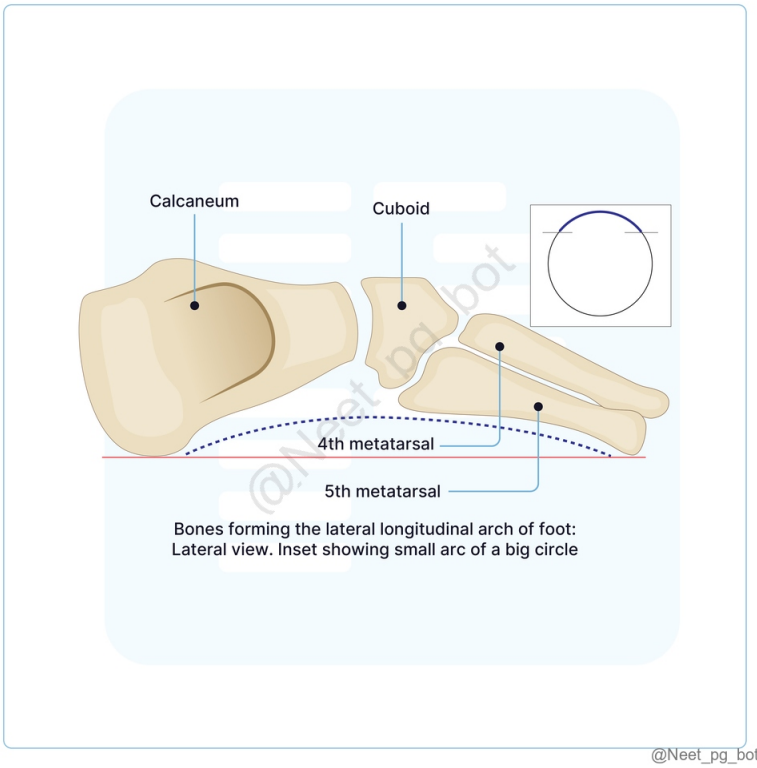

@Neet_pg_bot

References:

BD Chaurasia's Human Anatomy, Volume 2, 8th Edition, Page 192

↑ *Back to this question in Part A*

@Neet_pg_bot

Q13: A 35-year-old patient presents with difficulty in flexing the lateral four toes. On examination, it is noted that the action of the flexor digitorum longus tendon is intact. Which of the following muscles, in the second layer of the sole, assists the flexor digitorum longus during this action? (Q848293)

A. Abductor hallucis

B. Flexor digitorum brevis

C. Quadratus plantae

D. Lumbricals

Correct Answer: C. Quadratus plantae

■ *Listen (English)*

■ *Listen (Hindi)*

Explanation: The quadratus plantae in the second layer of the sole, assists the flexor digitorum longus by helping align and pull its tendon straight, thereby aiding in the flexion of the lateral four toes.

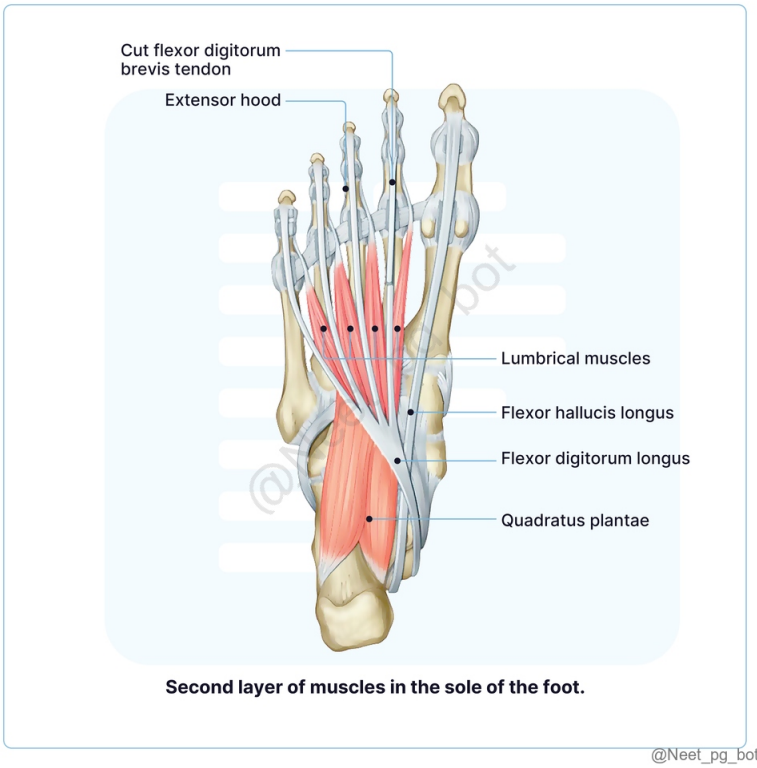

Second layer of muscles in the sole of the foot.

@Neet_pg_bot

References:

Gray’s Anatomy for Students, 4th Edition, Pages 652, 653, 654.

BD Chaurasia’s Human Anatomy, Volume 2, 8th Edition, Pages 140, 141.

↑ *Back to this question in Part A*

@Neet_pg_bot

Q14: A 35-year-old male presents with a deep laceration on the posterior aspect of his knee after a road traffic accident. On surgical exploration, the popliteal artery is injured. Which of the following is not a direct branch of the popliteal artery? (Q848297)

A. Superior medial genicular artery

B. Posterior tibial artery

C. Anterior tibial artery

D. Fibular artery

Correct Answer: D. Fibular artery

■ *Listen (English)*

■ *Listen (Hindi)*

Explanation: The fibular (peroneal) artery is a branch of the posterior tibial artery , not a direct branch of the popliteal artery. Branches of the Popliteal Artery Branch Supply Muscular branches Supply the adductor magnus and hamstrings, gastrocnemius, soleus, and plantaris. Cutaneous branches Arise from the popliteal artery or indirectly from its muscular branches. Genicular branches: Five branches in total: two superior, two inferior, one middle. Middle genicular artery Pierces the oblique popliteal ligament, supplies cruciate ligaments and synovial membrane of the knee. Medial and lateral superior genicular arteries (Option A) Wind around the femur above the condyles, pass deep to the hamstrings. Medial and lateral inferior genicular arteries Wind around the tibial condyles, pass deep to the collateral ligaments of the knee, form anastomoses around the knee. Terminal Branches: It terminates at the lower border of popliteus by dividing into the anterior (Option C) and posterior tibial arteries (Option B)

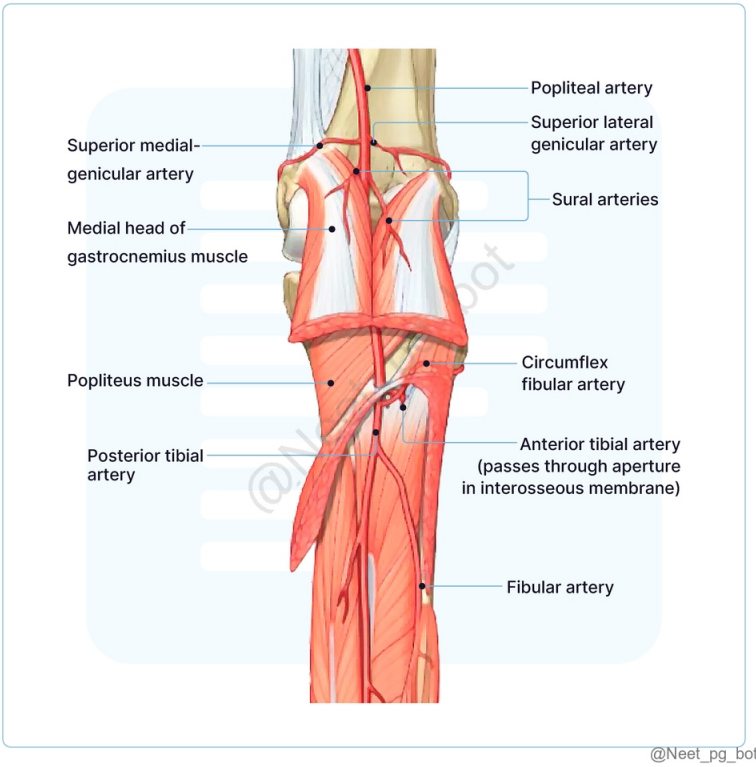

References:

BD Chaurasia’s Human Anatomy, Volume 2, 8th Edition, Page 90.

Gray’s Anatomy for Students, 4th Edition, Page 626.

↑ *Back to this question in Part A*

@Neet_pg_bot

Q15: During a surgical procedure involving the reconstruction of the lower limb, the surgeon plans to use a perforator flap. Which of the following statements about perforating arteries is correct? (Q848302)

A. Perforating arteries are exclusively found in the thigh region.

B. Musculocutaneous perforators run along intermuscular septa before supplying the skin.

C. Perforating arteries can originate from major source arteries or adjacent vessels and are essential for flap surgery.

D. Septocutaneous perforators only supply the periosteum of bones.

Correct Answer: C. Perforating arteries can originate from major source arteries or adjacent vessels and are essential for flap surgery.

■ *Listen (English)*

■ *Listen (Hindi)*

Explanation: Perforating arteries play a significant role in reconstructive flap surgeries as they can originate from major source arteries (e.g., femoral artery) or from vessels in adjacent tissues. This versatility is critical for ensuring adequate blood supply to the flap, which is necessary for successful healing and function. Perforating Arteries: Definition : Arteries that penetrate deep fascia to supply the suprafascial plexus (blood vessel network in subcutaneous tissue). Clinical Importance : Flap Surgery : Perforator flaps are used for wound coverage and reconstruction, supplied by perforating arteries. Donor Site : Lower limbs have an average of 90 perforating arteries, making them key for flap procedures. Perforating arteries are exclusively found in the thigh region (Option A): Perforating arteries are found throughout the lower limb, not exclusively in the thigh. Musculocutaneous perforators run along intermuscular septa before supplying the skin (Option B): Musculocutaneous perforators pass through muscles before reaching the skin, not along intermuscular septa. Septocutaneous perforators only supply the periosteum of bones (Option D): Septocutaneous perforators supply the skin after traveling along intermuscular septa.

References:

Gray’s Anatomy for Students, 42nd Edition, Pages 1335, 1336

BD Chaurasia’s Human Anatomy, Edition 8, Pages 150-152

↑ *Back to this question in Part A*

@Neet_pg_bot

• [06_Lower Limb] 032 Previous Year Questions

« Back to Folder Directory

[06_Lower Limb] 032 Previous Year Questions — Quick Jump

Q1 (p. 1650)	*Q2 (p. 1652)*	*Q3 (p. 1653)*	*Q4 (p. 1655)*	*Q5 (p. 1656)*	*Q6 (p. 1659)*
Q7 (p. 1661)	*Q8 (p. 1661)*	*Q9 (p. 1664)*	*Q10 (p. 1665)*	*Q11 (p. 1668)*	*Q12 (p. 1671)*
Q13 (p. 1672)	*Q14 (p. 1674)*	*Q15 (p. 1675)*	*Q16 (p. 1676)*	*Q17 (p. 1680)*	*Q18 (p. 1682)*
Q19 (p. 1683)	*Q20 (p. 1683)*	*Q21 (p. 1684)*	*Q22 (p. 1686)*	*Q23 (p. 1686)*	*Q24 (p. 1687)*
Q25 (p. 1689)	*Q26 (p. 1690)*	*Q27 (p. 1691)*	*Q28 (p. 1692)*	*Q29 (p. 1693)*	*Q30 (p. 1695)*
Q31 (p. 1697)	*Q32 (p. 1699)*	*Q33 (p. 1699)*	*Q34 (p. 1701)*	*Q35 (p. 1703)*	*Q36 (p. 1703)*

Q1: Which of the following branches of the anterior division of the internal iliac artery? 1. Superior gluteal artery 2. Inferior gluteal artery 3. Superior vesical artery 4. Middle rectal artery 5. Inferior vesical artery 6. Vaginal artery (Q855754)

A. 1,2,3,5

B. 2,3,4,6

C. 2,3,4,5,6

D. 1,4,5,6

Correct Answer: C. 2,3,4,5,6

Explanation: The anterior division of the internal iliac artery gives rise to multiple visceral and parietal branches supplying the pelvic organs, perineum, and lower limb. The correct answer includes all the relevant branches from this division. Branches of the Internal Iliac Artery: Division Branches Anterior Division (Primarily supplies pelvic organs, perineum, and medial thigh) Inferior gluteal artery, superior vesical artery, middle rectal artery, inferior vesical artery, vaginal artery, obturator artery, internal pudendal artery, uterine artery Posterior Division (Primarily supplies the pelvic wall and gluteal region) Superior gluteal artery, iliolumbar artery, lateral sacral artery 1,2,3,5- (Option A) : Incorrect because superior gluteal artery (1) belongs to the posterior division . 2,3,4,6- (Option B) : Incorrect because it excludes inferior vesical artery (5), which is an anterior division branch. 1,4,5,6- (Option D) : Incorrect because superior gluteal artery (1) belongs to the posterior division .

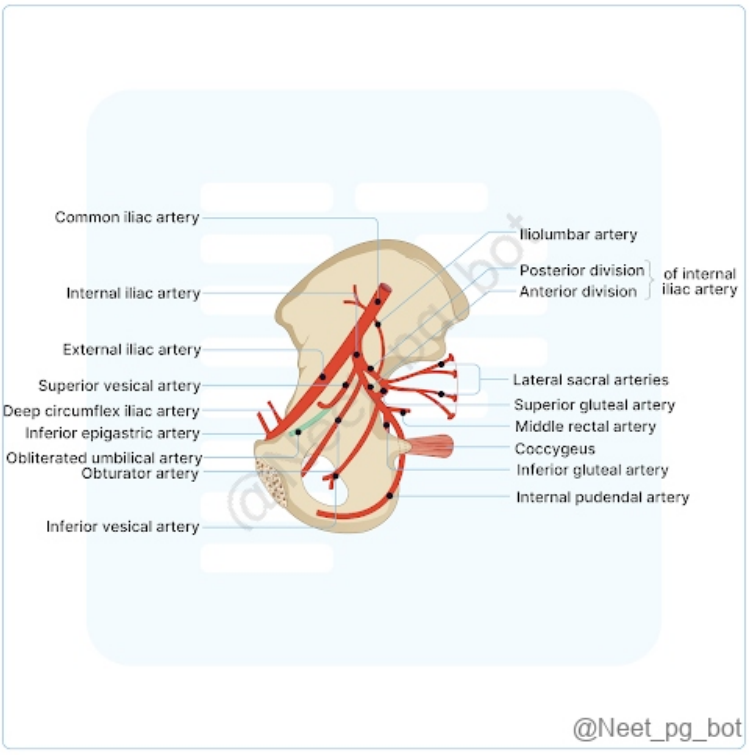

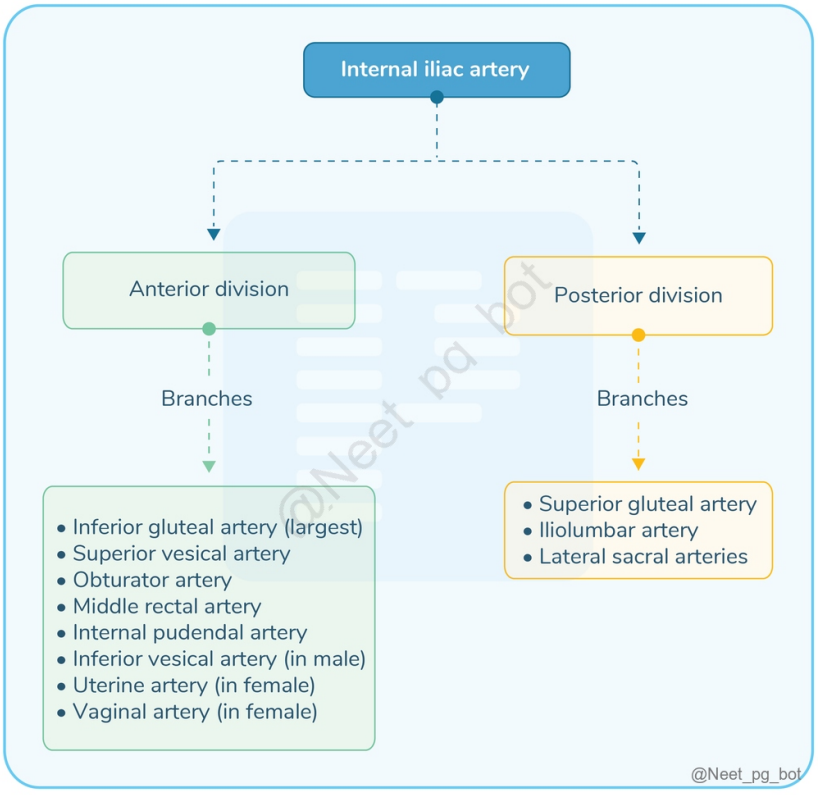

References:

Gray's Anatomy: The Anatomical Basis of Clinical Practice, 41st Edition, Page 1225-1227

↑ *Back to this question in Part A*

@Neet_pg_bot

Q2: A 34-year-old female, who works as a maid complained of knee pain and swelling. Which of the following area gets damaged in Housemaid's knee? (Q857918)

A. A

B. B

C. C

D. D

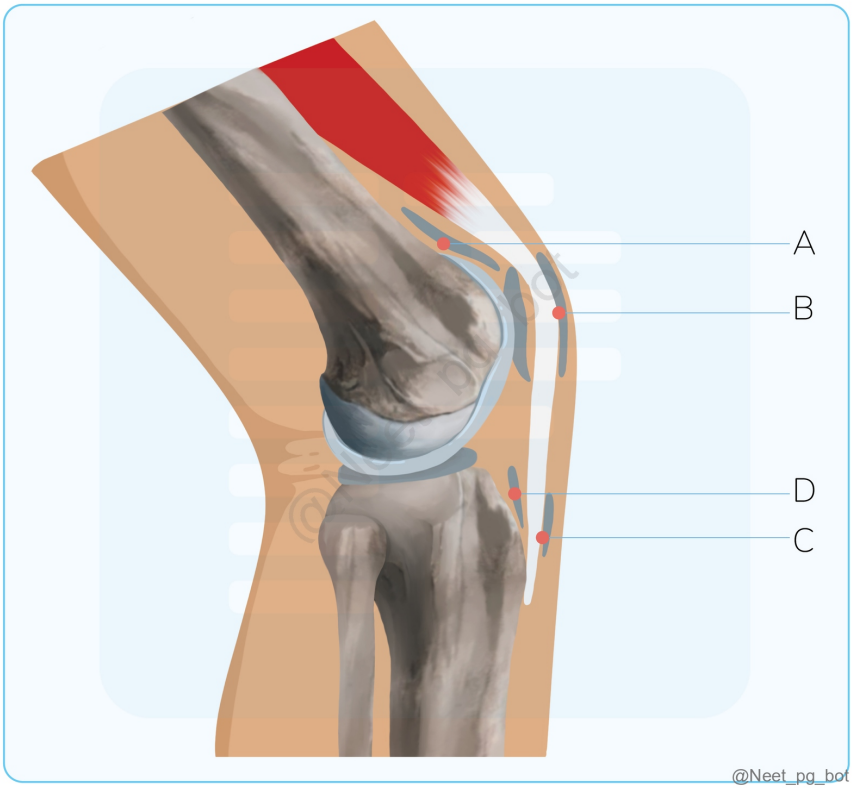

Correct Answer: B. B

Explanation: The correct answer is option b (Prepatellar bursa), as housemaid's knee involves inflammation of the prepatellar bursa due to repeated kneeling or trauma to the front of the knee. Housemaid's knee, also known as prepatellar bursitis, involves inflammation of the prepatellar bursa. The prepatellar bursa is located just in front of the patella (kneecap) and can become inflamed due to repetitive kneeling or trauma to the area. This condition is often seen in individuals who perform activities that involve prolonged kneeling, such as housemaids or carpet layers. Bursa Around Knee: Suprapatellar bursa: Deep to quadriceps femoris. Communicates with knee joint.

Prepatellar bursa: Lies over the superficial surface of patella. Housemaid’s knee – Prepatellar bursitis. Infrapatellar bursa: Lies over patellar ligament. Clergyman’s knee – Infrapatellar bursitis. Anserine bursa: Lies between tibial collateral ligament and tendons of sartorius, gracilis, and semitendinosus. A (Option A): The suprapatellar bursa is located above the patella (kneecap) and helps reduce friction between the femur (thigh bone) and the quadriceps tendon. This bursa is not commonly associated with housemaid's knee. C (Option C): The infrapatellar bursa is located below the patella, between the patellar ligament and the tibia (shin bone). It helps reduce friction during knee movements. Inflammation of this bursa is known as "clergyman's knee" or "Clergyman's bursitis," which is caused by excessive kneeling and friction. D (Option D): The pes anserine bursa is located on the inner side of the knee, just below the joint. It is situated between the tendons of the sartorius, gracilis, and semitendinosus muscles and the underlying tibia. Inflammation of this bursa can lead to pes anserine bursitis, which typically presents as pain and tenderness on the inner side of the knee. This condition is not directly related to housemaid's knee.

References:

BD Chaurasia’s Human Anatomy, 8th Edtion, Page no: 321

↑ *Back to this question in Part A*

@Neet_pg_bot

Q3: Which of the following arteries is palpated in the image shown below? (Q793152)

A. Anterior tibial artery

B. Posterior tibial artery

C. Dorsalis pedis artery

D. Popliteal artery



Correct Answer: B. Posterior tibial artery

Explanation: Correct Option B: The artery palpated in the image shown is the posterior tibial artery; it is palpated between the medial malleolus and Achilles tendon/tendocalcaneous. Locate the medial malleolus (the bony bump on the inside of the ankle). Place your index and middle fingers on the inside of the ankle and move your fingers behind the medial malleolus towards the back of the leg. You should be able to feel the posterior tibial artery pulsations in this area. Incorrect Options: Option A - Anterior tibial artery: To palpate the anterior tibial artery, ask the patient to lie down or sit with their legs slightly bent. Locate the ankle bones (medial malleolus and lateral malleolus) and identify the space between them. Place your index and middle fingers on the space between the ankle bones and move your fingers upwards towards the top of the foot. You should be able to feel the anterior tibial artery pulsations in this area. Option C - Dorsalis pedis artery: To palpate the dorsalis pedis artery, ask the patient to lie down or sit with their legs slightly bent. Locate the first and second metatarsal bones (the bones that connect to the big toe). Place your index and middle fingers on the top of the foot, just below the space between the first and second metatarsal bones, you can feel the pulsations there. Option D - Popliteal artery: To palpate the popliteal artery, ask the patient to lie down on their stomach or to sit with their legs hanging off the edge of the exam table. Flex the knee to about 90 degrees. Use your fingers to locate the popliteal fossa, which is the small depression behind the knee joint. Feel for the pulsation of the artery in the middle of the fossa. Press your fingers gently into the popliteal fossa and feel for the pulsation of the artery.

References:

.

↑ *Back to this question in Part A*

@Neet_pg_bot

Q4: Which of the following structures is not supplied by the superior gluteal nerve? (Q855034)

A. Gluteus medius

B. Gluteus minimus

C. Piriformis

D. Tensor fasciae latae

Correct Answer: C. Piriformis

Explanation: Piriformis is NOT supplied by the superior gluteal nerve. The piriformis is instead innervated by the nerve to piriformis , which arises from the sacral plexus (S1–S2) . Superior gluteal nerve (L4–S1) supplies: Gluteus medius Gluteus minimus Tensor fasciae latae Tensor Fasciae Latae Gluteus Medius Gluteus Minimus Attachments Origin : Outer lip of the iliac crest extending from the anterior superior iliac spine to the tubercle of the crest. Insertion : Iliotibial tract 3–5 cm below the level of the greater trochanter. Origin: Gluteal surface of the ilium between anterior and posterior gluteal lines Insertion: Oblique ridge on the lateral surface of the greater trochanter. Origin: Gluteal surfaces of the ilium between anterior & inferior gluteal lines. Insertion: Anterior aspect of the Greater trochanter Relations Between gluteus medius and sartorius Covered by fascia lata Covered by gluteus maximus (posterior third) Deep to gluteus minimus Deep to gluteus medius Related to hip joint capsule Vascular Supply Mainly from lateral circumflex femoral artery Supplied by superior gluteal artery Deep branch of superior gluteal artery Trochanteric anastomosis Main trunk and deep branch of superior gluteal arter y Trochanteric anastomosis Innervation Superior gluteal nerve (L4, L5, S1) Superior gluteal nerve (L4, L5, S1) Superior gluteal nerve (L4, L5, S1) Actions Hip flexor and abductor Stabilizes pelvis Helps maintain extended knee Abducts thigh Medial & lateral rotation of thigh Supports pelvis during single-leg stance Abducts thigh Medial and lateral rotation of thigh Testing Depression below anterior superior iliac spine Abduction against resistance Medial rotation against resistance Abduction against resistance Medial rotation against resistance Abduction against resistance {{caption_text}}

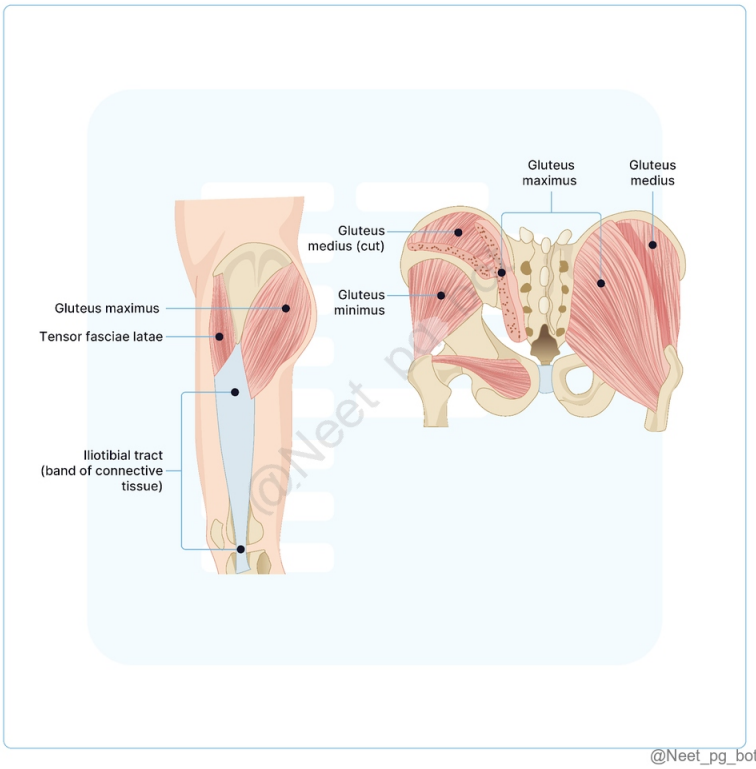

@Neet_pg_bot

References:

Gray’s Anatomy, 42nd Edition, Pages 1376 - 1380

↑ *Back to this question in Part A*

@Neet_pg_bot

Q5: What is the ligament that links the medial cuneiform bone to the base of the second metatarsal bone? (Q855036)

A. Chopart

B. Spring

C. Lisfranc

D. Deltoid

Correct Answer: C. Lisfranc

Explanation: The Lisfranc ligament is a strong oblique ligament extending from the medial cuneiform to the base of the 2nd metatarsal. It forms the key stabilizing structure of the tarsometatarsal (TMT) joint complex. This

ligament prevents separation between the 1st and 2nd metatarsals, preserving midfoot integrity. It plays a major role in maintaining alignment during weight-bearing and gait. Injury leads to the characteristic Lisfranc fracture-dislocation with midfoot pain and plantar bruising. Its unique attachment pattern is not shared by any other foot ligament. Thus, the ligament connecting medial cuneiform to 2nd metatarsal is the Lisfranc ligament. Incorrect Options: Option A) Chopart: Talonavicular–calcaneocuboid joint ligament, not cuneiform-metatarsal. Option B) Spring: Calcaneonavicular ligament supporting the talar head. Option D) Deltoid: Medial ankle ligament from tibia to tarsal bones, not to metatarsals.

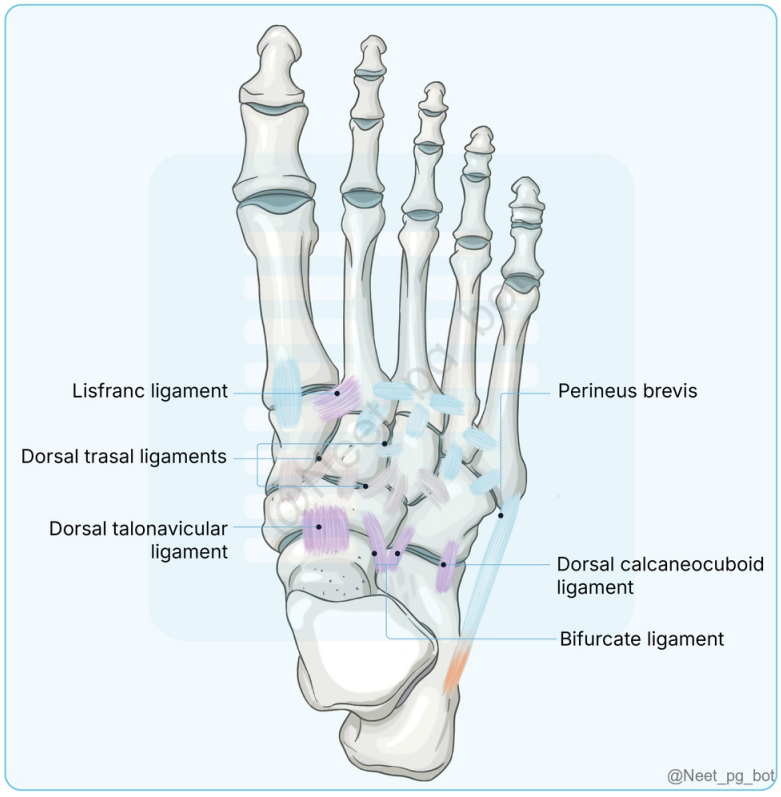

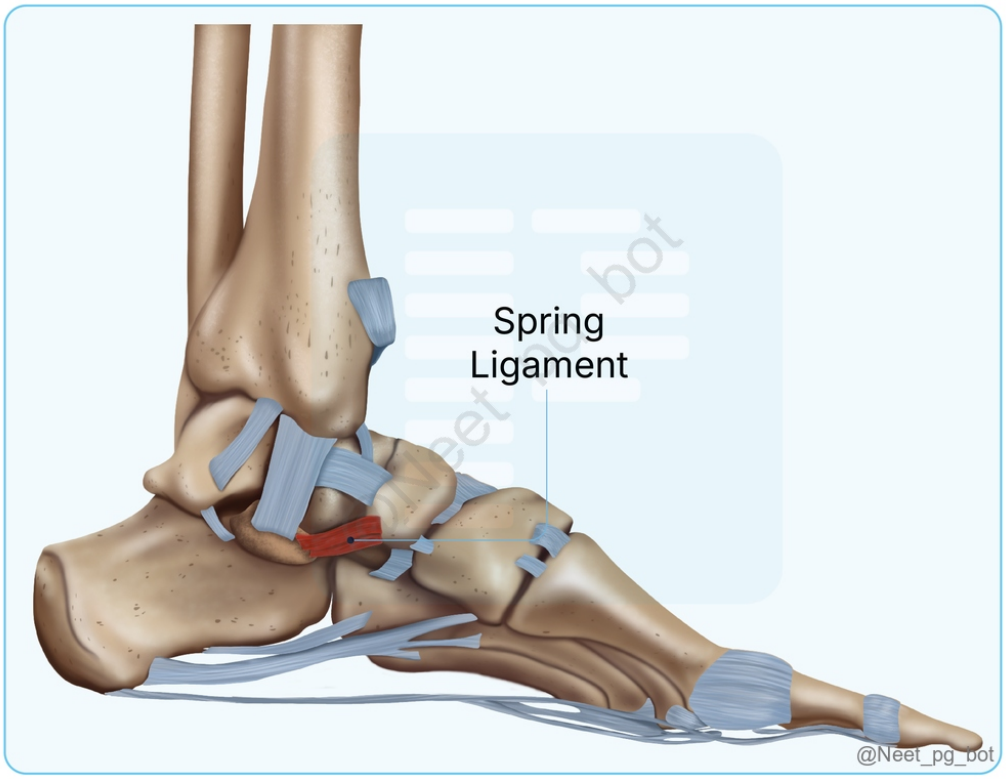

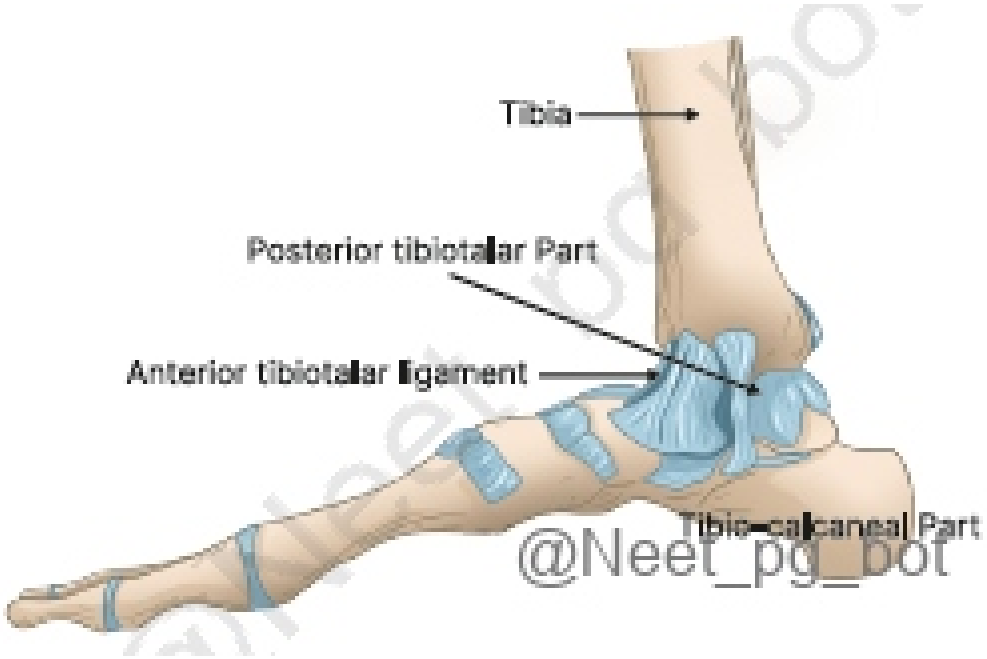

References:

Apley and Solomon’s System of Orthopaedics and Trauma, 10th Edition, Page 960.

https://www.ncbi.nlm.nih.gov/books/NBK448147/

↑ *Back to this question in Part A*

Q6: Identify the tarsal bone labeled in the image below. (Q857553)

A. Calcaneus

B. Cuboid

C. Navicular

D. Talus



Correct Answer: C. Navicular

Explanation: The navicular bone is a boat-shaped tarsal bone located on the medial side of the foot , between the talus (posteriorly) and the cuneiform bones (anteriorly) . The X-ray shows a lateral view of the foot, with the navicular bone labeled in its characteristic position between the talus and the midfoot structures. Tarsal Bones and Their Positions Bone Group Bones Description & Function Tarsals Provide mechanical support and structure to the foot. Proximal Group Talus Transmits body weight to the foot. Articulates at three joints: Superiorly: Ankle joint (tibia/fibula) Inferiorly: Subtalar joint (calcaneus) Anteriorly: Talonavicular joint (navicular) Calcaneus Largest tarsal bone, forms the heel. Articulates at two joints: Superiorly: Subtalar joint (talus) Anteriorly: Calcaneocuboid joint (cuboid) Intermediate Group Navicular Boat-shaped; articulates with talus, cuneiforms, and cuboid. Has a tuberosity for tibialis posterior tendon attachment. Distal Group Cuboid Lateral; articulates with calcaneus and fourth/fifth metatarsals. Features a groove for fibularis longus tendon. Cuneiforms (3) Medial, intermediate, lateral; wedge-shaped. Help form the transverse arch; attach to various muscles. Metatarsals I-V (1-5) Connect tarsals to phalanges; numbered medial to lateral. Have a head, neck, shaft, and base; facilitate movement and support. Phalanges Great Toe: 2 (proximal, distal) Toes 2-5: 3 each (proximal, intermediate, distal). Each phalanx has a base, shaft, and head; provide structure to toes. {{caption_text}} Calcaneus (Option A): Incorrect because the calcaneus is located posteriorly and is the largest tarsal bone forming the heel. Cuboid (Option B): Incorrect because the cuboid is on the lateral side of the foot, articulating with the 4th and 5th

metatarsals. Talus (Option D): Incorrect because the talus is superior to the navicular, articulating with the tibia and fibula to form the ankle joint.

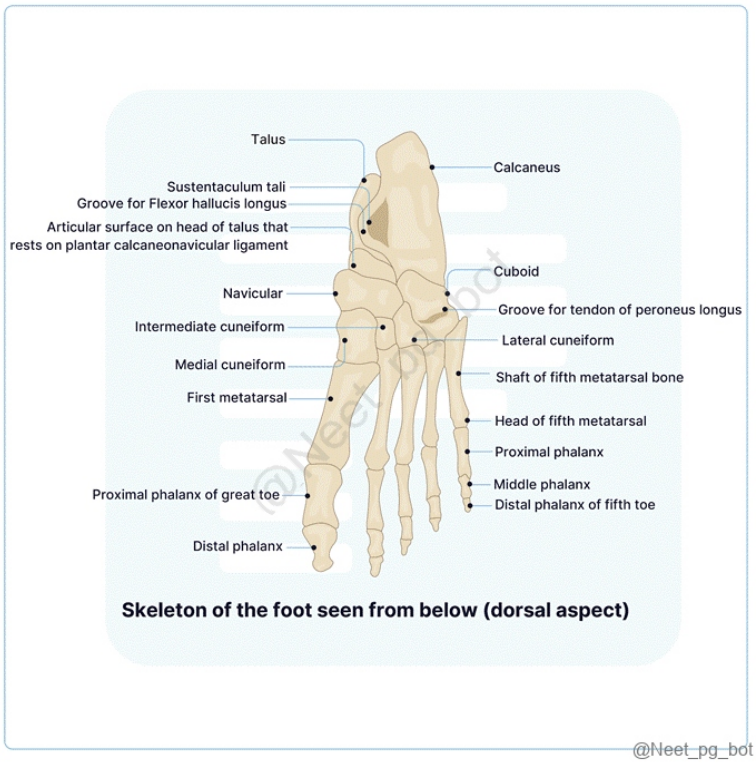

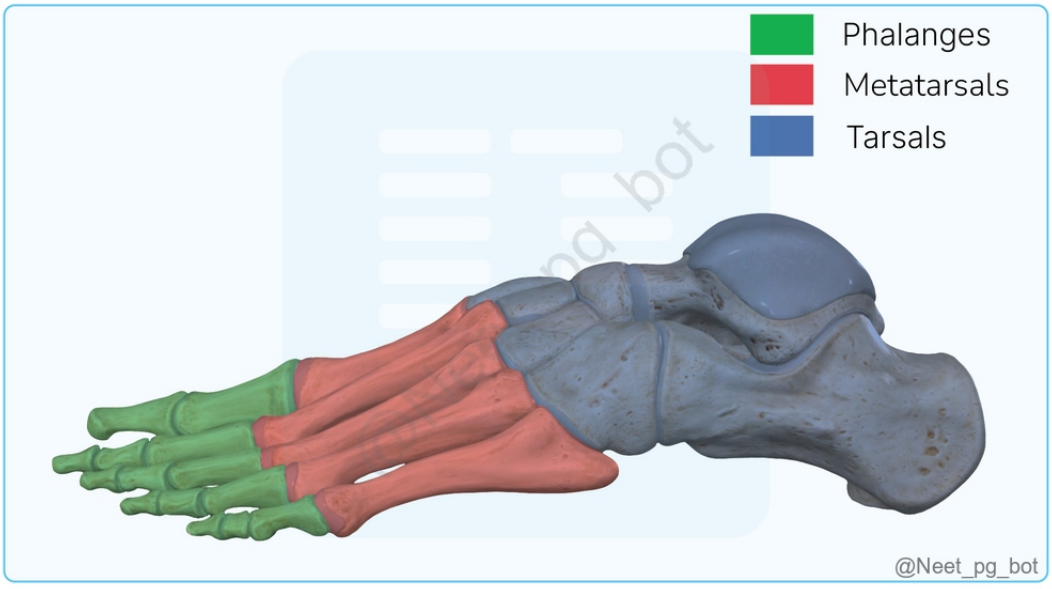

References:

Inderbir Singh- General anatomy, upper and lower limb 6e, pg,296-301

https://teachmeanatomy.info/lower-limb/bones/bones-of-the-foot-tarsals-metatarsals-and-phalanges/

https://www.physio-pedia.com/Calcaneus

↑ *Back to this question in Part A*

@Neet_pg_bot

Q7: The prevention of lateral dislocation of the patella during knee flexion is by- (Q857555)

A. Vastus medialis

B. Patellar ligament

C. Gracilis

D. Rectus femoris

Correct Answer: A. Vastus medialis

Explanation: The vastus medialis , particularly its oblique fibers (VMO - Vastus Medialis Obliquus) , plays a crucial role in preventing lateral dislocation of the patella by exerting a medial pull on the patella during knee flexion. This counteracts the lateral pull of the quadriceps , especially the vastus lateralis . Patellar Stability and Dislocation Prevention Structure Role in Patellar Stability Vastus Medialis (VMO) Exerts a medial pull on the patella, preventing lateral displacement Patellar Ligament Connects the patella to the tibial tuberosity but does not prevent lateral dislocation Gracilis A medial thigh muscle responsible for hip adduction, not involved in patellar stability Rectus Femoris A major knee extensor, but does not prevent lateral displacement Patellar Ligament (Option B): Incorrect because it primarily stabilizes the patella in the superior-inferior direction, not against lateral forces. Gracilis (Option C): Incorrect because it is a medial thigh muscle involved in hip adduction and does not influence patellar stability. Rectus Femoris (Option D): Incorrect because it is a knee extensor , contributing to overall quadriceps function but not directly preventing lateral patellar displacement.

References:

Vishram Singh textbook of anatomy, 2nd edition, Volume 2, Pages 447, 448

↑ *Back to this question in Part A*

@Neet_pg_bot

Q8: The dermatome of the area marked in the given below image is- (Q857565)

A. L4

B. L5

C. S1

D. S2

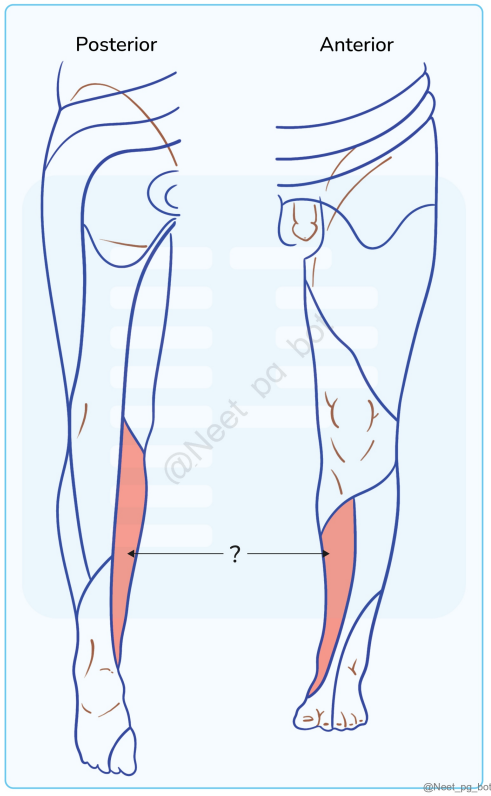

Correct Answer: A. L4

Explanation: The area marked in the image corresponds to the medial aspect of the leg , which is supplied by the L4 dermatome . The L4 dermatome extends from the anteromedial thigh, over the knee, and down to the medial malleolus. Dermatome Distribution of the Lower Limb Dermatome Region Supplied L1 Inguinal region L2 Anterior thigh L3 Lower anterior thigh and medial knee L4 Medial leg and medial malleolus L5 Lateral leg, dorsum of foot, great toe S1 Lateral foot, sole, little toe S2 Posterior thigh and leg S3-S5 Perineum and anal region {{caption_text}} {{caption_text}} L5 (Option B): incorrect because it supplies the dorsum of the foot and lateral leg, not the medial leg. S1 (Option C): incorrect because it supplies the lateral foot and sole, not the medial side. S2 (Option D): incorrect because it is distributed over the posterior thigh and leg, not the anterior or medial aspect.

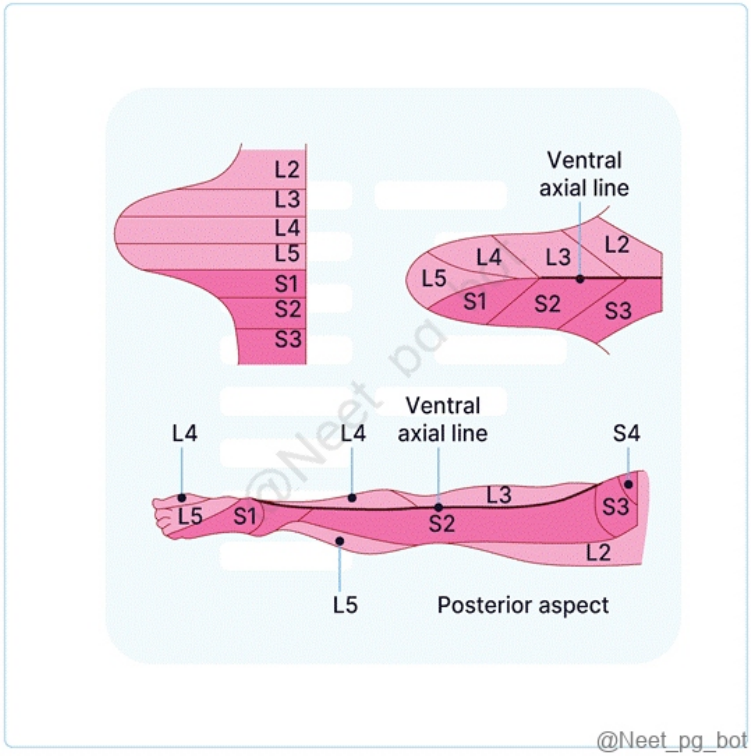

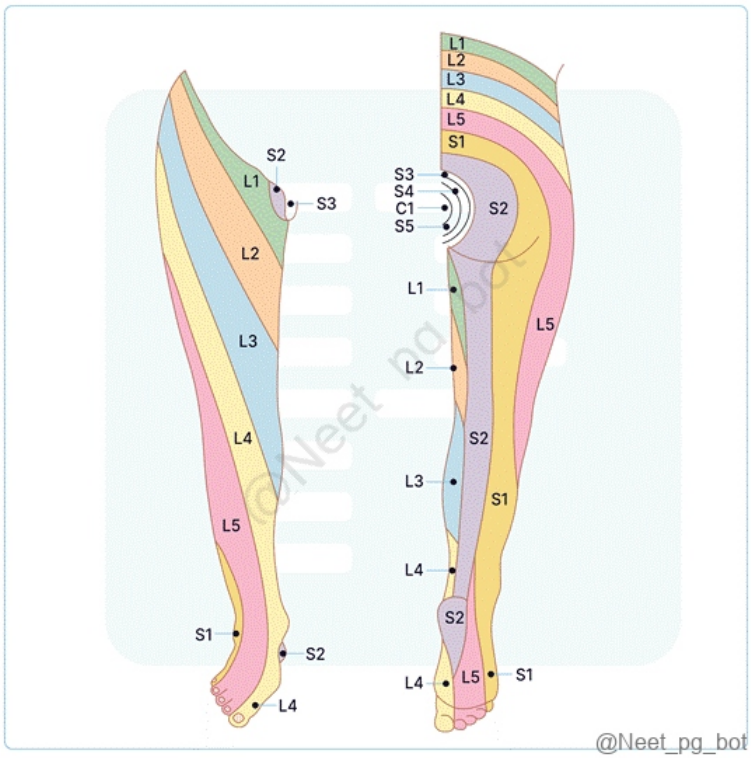

References:

Vishram Singh textbook of anatomy, 2nd Edition, Pages 468 - 474

↑ *Back to this question in Part A*

@Neet_pg_bot

Q9: Which artery is being palpated in the image shown below? (Q857569)

A. Anterior tibial artery

B. Posterior tibial artery

C. Dorsalis pedis artery

D. Popliteal artery

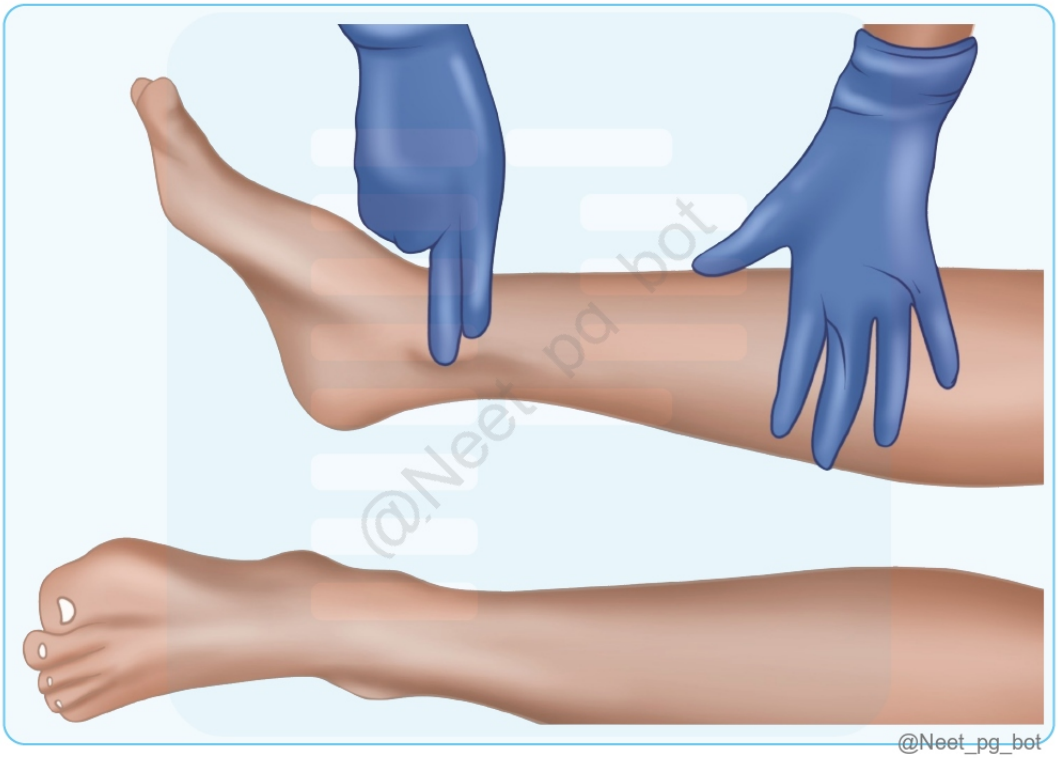

Correct Answer: B. Posterior tibial artery

Explanation: The image demonstrates palpation of the posterior tibial artery , which is typically assessed posterior to the medial malleolus , just behind the ankle joint. This pulse is an important clinical marker for peripheral circulation, especially in conditions like peripheral artery disease (PAD). Arterial Supply of the Lower Limb Artery Origin Course Palpation Site Clinical Importance Posterior Tibial Artery Popliteal artery Runs posterior to medial malleolus Behind medial malleolus Evaluated in PAD (absent in vascular diseases) Anterior Tibial Artery Popliteal artery Passes through interosseous membrane to anterior leg Difficult to palpate directly Supplies anterior compartment of the leg Dorsalis Pedis Artery Continuation of anterior tibial artery Runs along dorsum of foot Lateral to extensor hallucis longus tendon Commonly used in vascular assessments Popliteal Artery

Continuation of femoral artery Located in popliteal fossa Deep in the popliteal fossa Can be affected in popliteal artery entrapment syndrome {{caption_text}} Anterior tibial artery (Option A): incorrect because it is located in the anterior compartment of the leg and is not palpated posterior to the medial malleolus. Dorsalis pedis artery (Option C): incorrect because it is palpated on the dorsum of the foot, lateral to the extensor hallucis longus tendon. Popliteal artery (Option D): incorrect because it is located deep in the popliteal fossa and requires deep palpation behind the knee.

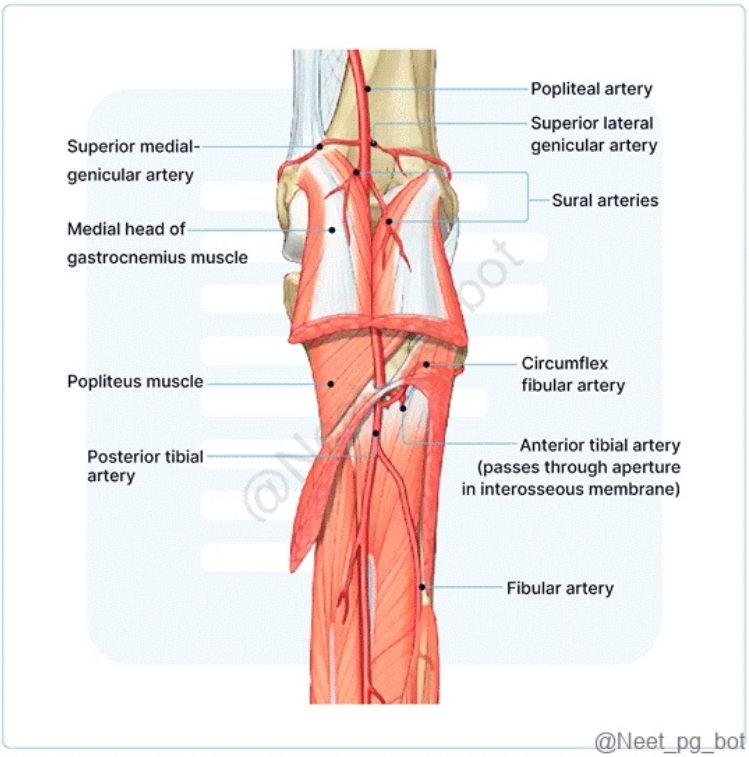

References:

BD Chaurasia's Human Anatomy Regional and Applied Dissection and Clinical, Lower limb, Abdomen and Pelvis, Vol 2, Edition 8th- Pg No. 90.

Gray's Anatomy for Students, Ed. 4, Page 626

↑ *Back to this question in Part A*

@Neet_pg_bot

Q10: Injury at which of the following marked sites causes failure of dorsiflexion? (Q855307)

A. 3

B. 2

C. 1

D. 4

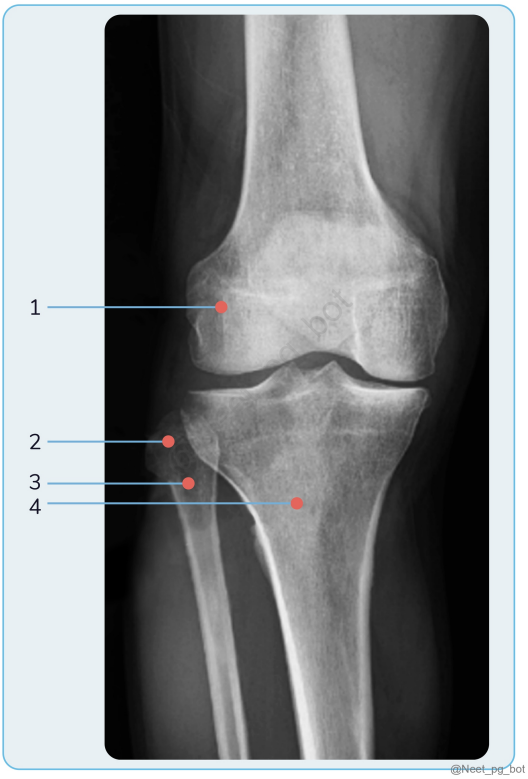

Correct Answer: A. 3

Explanation: The injury to common fibular nerve causes failure of dorsiflexion, thus the marked structure 3 i.e. neck of fibula is the right answer {{caption_text}} Sciatic Nerve Origin and Course The thickest nerve in the body. Arises from the ventral rami of L4–S3 spinal nerves. Exits the pelvis through the greater sciatic foramen below the piriformis and descends between the greater trochanter and ischial tuberosity along the back of the thigh. Divides into the tibial and common peroneal nerves above the popliteal fossa. Distribution Motor: Undivided Trunk: Supplies all muscles of the back of the thigh (hip extension, knee flexion). Tibial Nerve: Innervates leg muscles (flexion) and foot muscles (plantar flexion). Common Peroneal Nerve: Supplies leg muscles (dorsiflexion). Sensory: Tibial Nerve: Supplies skin on the back of the calf, heel, lateral border of the foot, and sole. Common Peroneal Nerve: Supplies skin on the anterolateral and lateral surfaces of the leg and dorsum of the foot (except for the deep peroneal nerve area). Clinical correlation Injury of the sciatic nerve: Causes: Penetrating wounds, posterior hip dislocation, pelvic fractures, total hip replacement, misplaced injections in the gluteal region. Clinical Features: Inability to extend the thigh and flex the knee (hamstring paralysis). Loss of all movements below the knee (foot drop) leading to flail foot and high-stepping gait. Loss of sensation on the back of the thigh, entire leg, and foot (except for the saphenous nerve area). Sciatica: Shooting pain along the sciatic nerve distribution (buttock, posterior thigh, lateral leg, dorsum of the foot). Compression/irritation of L4–S3 spinal nerve roots due to herniated lumbar discs. Neuropathy: Entrapment in the piriformis muscle can lead to piriformis syndrome. {{caption_text}} Sciatic Nerve Course {{caption_text}} Branches of Sciatic Nerve

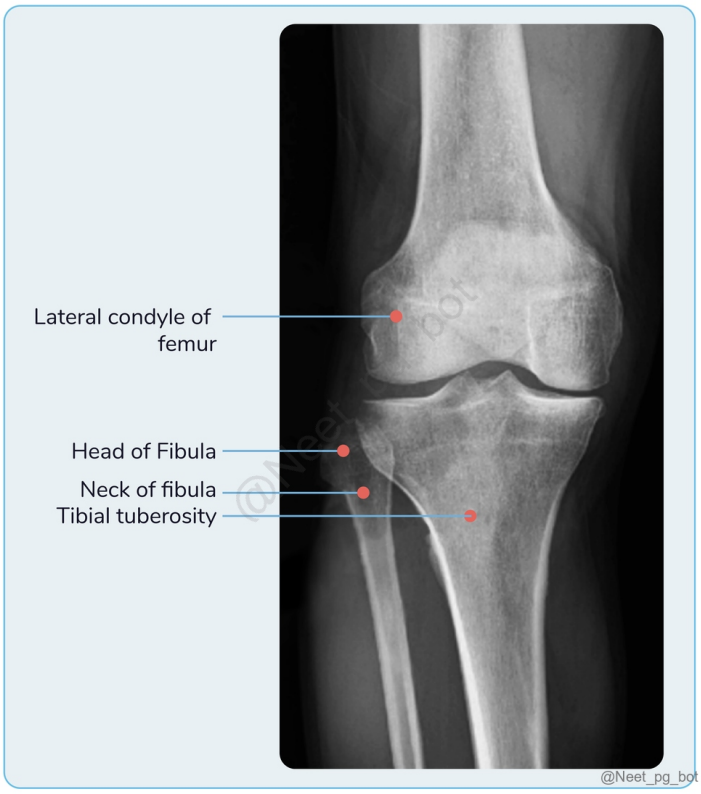
Lateral condyle of femur
Head of Fibula
Neck of fibula
Tibial tuberosity
@Neet_pg_bot

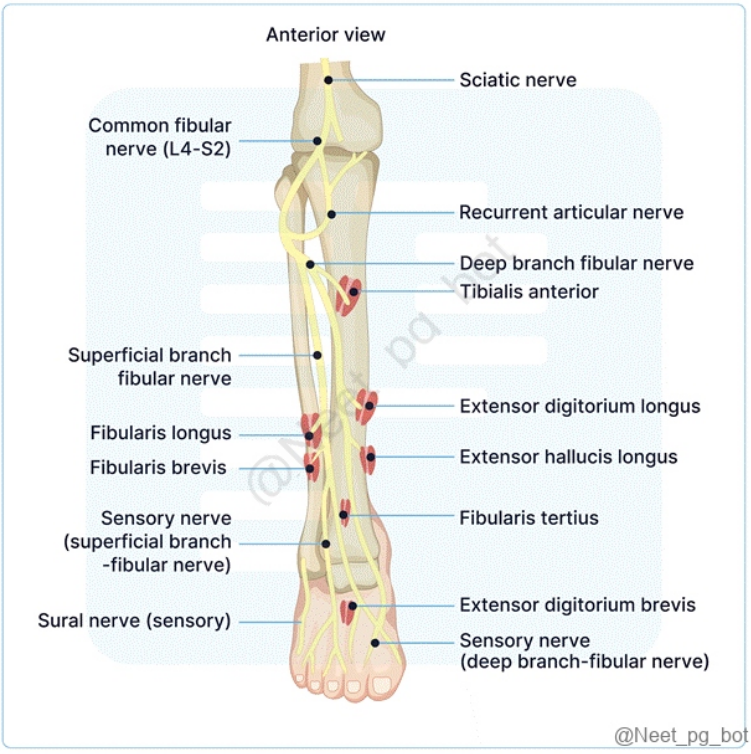
Anterior view
Sciatic nerve
Common fibular nerve (L4-S2)
Recurrent articular nerve
Deep branch fibular nerve
Tibialis anterior
Superficial branch fibular nerve
Extensor digitorium longus
Fibularis longus
Extensor hallucis longus
Fibularis brevis
Sensory nerve (superficial branch -fibular nerve)
Fibularis tertius
Extensor digitorium brevis
Sural nerve (sensory)
Sensory nerve (deep branch-fibular nerve)
@Neet_pg_bot

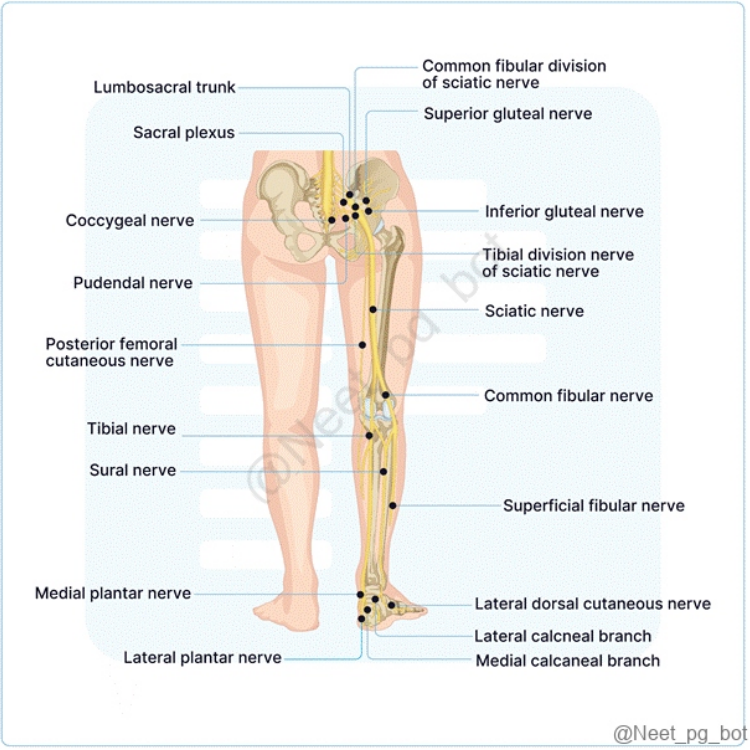

References:

Vishram Singh’s Textbook of Anatomy, Volume 2, 2nd Edition, Page 469, 470

↑ *Back to this question in Part A*

@Neet_pg_bot

Q11: A boy with a history of a fall from a tree presents with a lurching gait and dragging of his feet. Which of the following structures are involved? (Q856616)

A. 1

B. 2

C. 3

D. 4



Correct Answer: B. 2

Explanation: The gluteus medius is essential for stabilizing the pelvis during walking. Injury to this muscle or its innervation (superior gluteal nerve) leads to a lurching gait (Trendelenburg gait) where the patient compensates by shifting weight toward the affected side to prevent pelvic drop. Gluteus Muscles and Trendelenburg Gait Tensor Fasciae Latae Gluteus Medius Gluteus Minimus Attachments Origin : Outer lip of the iliac crest extending from the anterior superior iliac spine to the tubercle of the crest. Insertion : Iliotibial tract 3–5 cm below the level of the greater trochanter. Origin: Gluteal surface of the ilium between anterior and posterior gluteal lines Insertion: Oblique ridge on the lateral surface of the greater trochanter. Origin: Gluteal surfaces of the ilium between anterior & inferior gluteal lines. Insertion: Anterior aspect of the Greater trochanter Relations Between gluteus medius and sartorius Covered by fascia lata Covered by gluteus maximus (posterior third) Deep to gluteus minimus Deep to gluteus medius Related to hip joint capsule Vascular Supply Mainly from lateral circumflex femoral artery Supplied by superior gluteal artery Deep branch of superior gluteal artery Trochanteric anastomosis Main trunk and deep branch of superior gluteal arter y Trochanteric anastomosis Innervation Superior gluteal nerve (L4, L5, S1) Superior gluteal nerve (L4, L5, S1) Superior gluteal nerve (L4, L5, S1) Actions Hip flexor and abductor Stabilizes pelvis Helps maintain extended knee Abducts thigh Medial & lateral rotation of thigh Supports pelvis during single-leg stance Abducts thigh Medial and lateral rotation of thigh Testing Depression below anterior superior iliac spine Abduction against resistance Medial rotation against resistance Abduction against resistance Medial rotation against resistance Abduction against resistance Trendelenberg sign: When the body's weight is balanced on one leg, the gluteal muscles on the supported side help elevate the opposite, unsupported side of the pelvis. However, if there is a malfunction in the abductor mechanism, the Sound side sinks, which is referred to as a positive Trendelenburg sign (uncompensated). This sign indicates issues with hip abductors, such as paralysis of the gluteus medius and minimus ; problems with the fulcrum, including congenital or pathological hip dislocations; and concerns related to body weight, such as an unhealed fracture of the femoral neck. When patients with the gluteus medius and minimus paralysis walk, they have a characteristic lurching gait i.e., during the single leg supporting phase of walking, there is leaning of the trunk to the affected side known as the compensated Trendelenburg sign . Duck waddling gait is seen when both the sides are affected. 1 (Gluteus maximus) (Option

A): Incorrect – Gluteus maximus is responsible for hip extension. Injury causes difficulty in rising from a seated position but does not cause a lurching gait. 3 (Piriformis) (Option C): Incorrect – Piriformis primarily functions in hip external rotation. Injury leads to piriformis syndrome , which causes sciatica-like pain but does not cause a lurching gait. 4 (Sciatic nerve) (Option D): Incorrect – Sciatic nerve injury causes foot drop and weakness in knee flexion rather than a Trendelenburg gait.

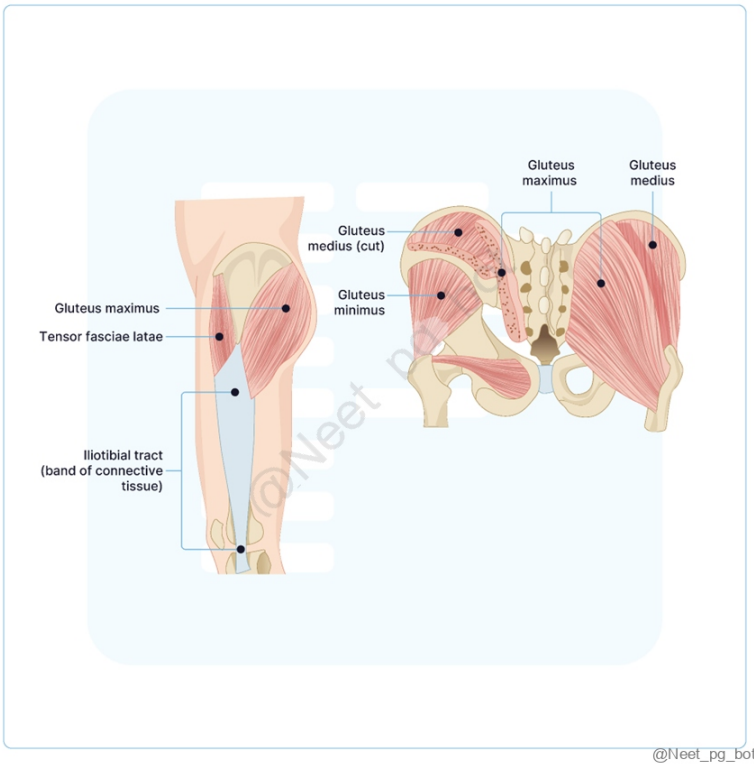

@Neet_pg_bot

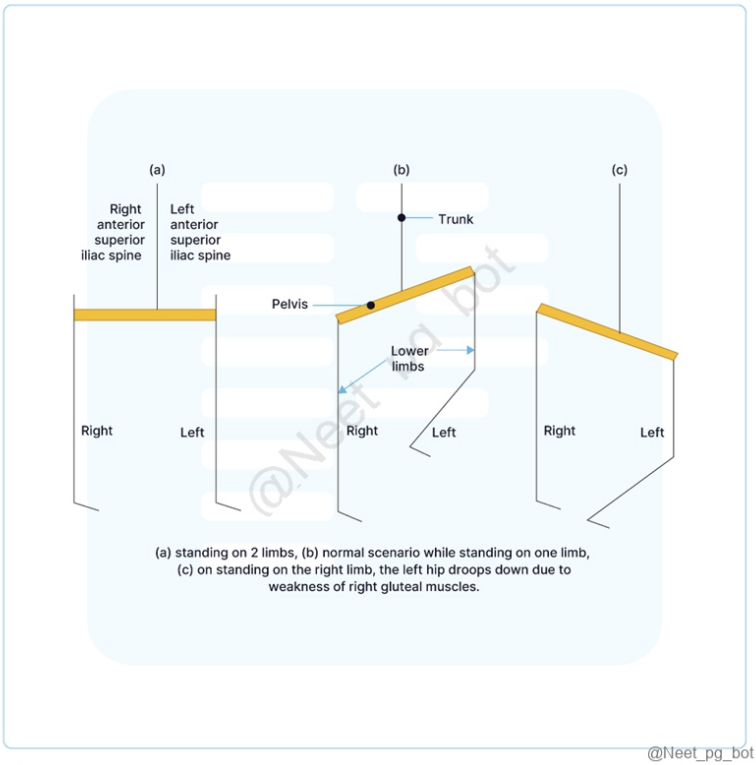

@Neet_pg_bot

References:

Gray's Anatomy: The Anatomical Basis of Clinical Practice, 41st Edition - Page no: 1357-1359, 1373

https://www.ncbi.nlm.nih.gov/books/NBK541094/

↑ *Back to this question in Part A*

@Neet_pg_bot

Q12: Which nerve is most likely to be affected in a patient who underwent a coronary bypass graft with the great saphenous vein and is now experiencing paresthesia and sensory loss over the inner side of the leg and foot? (Q856180)

A. Superficial peroneal nerve

B. Saphenous nerve

C. Femoral nerve

D. Sural nerve

Correct Answer: B. Saphenous nerve

Explanation: Answer B - Saphenous nerve The saphenous nerve is a purely sensory branch of the femoral nerve (L3-L4) that supplies sensation to the medial leg and foot . During coronary artery bypass grafting (CABG) , the great saphenous vein (GSV) is commonly harvested for the bypass procedure. Since the saphenous nerve runs alongside the GSV in the leg, it is highly susceptible to injury during vein harvesting, leading to paresthesia and sensory loss over the medial aspect of the leg and foot . Superficial peroneal nerve (option A): Provides sensory innervation to the anterolateral lower leg and dorsum of the foot . Unlikely to be affected in CABG as it is located in the lateral compartment of the leg. Femoral nerve (option C): Provides motor innervation to the anterior thigh muscles and sensory innervation to the anterior and medial thigh . Injury would cause weakness of quadriceps and loss of knee jerk reflex , which is not described in the question. Sural nerve (option D): Provides sensory innervation to the lateral foot and posterolateral calf . Not involved in medial leg and foot sensation, making it an unlikely option.

References:

Gray’s Anatomy, 42nd Edition, Page 1386

↑ *Back to this question in Part A*

@Neet_pg_bot

Q13: A muscle is attached to the area marked in the given Image. What is the action of this muscle on the hip joint? (Q856367)

A. Flexion and medial rotation

B. Adduction and lateral rotation

C. Abduction and medial rotation

D. Extension and lateral rotation



Correct Answer: D. Extension and lateral rotation

Explanation: The muscle attached to the area marked in the given image is the gluteus maximus. The gluteus maximus is the largest muscle in the gluteal region and is primarily responsible for extending the hip joint, which means it helps to move the thigh backward. This action is commonly referred to as hip extension. Additionally, the gluteus maximus also assists in lateral rotation of the hip joint. Lateral rotation refers to the outward rotation of the thigh away from the midline of the body. Action of the Hip joint, corresponding muscles and their innervation: Action Muscles Nerve supply Flexion Psoas major (chief flexor) Anterior rami of L1, L2, L3 Iliacus (chief flexor) Sartorius Rectus femoris Pectineus Femoral nerve (L2, L3) Extension Gluteus maximus (chief extensor) Inferior gluteal nerve (L5, S1, S2) Hamstring muscles Tibial part of the sciatic nerve (L5, S1, S2) Abduction Gluteus medius and minimus (chief abductors) Tensor fasciae latae Superior gluteal nerve (L5, S1) Adduction Adductor longus Adductor brevis Adductor magnus (chief adductors) Gracilis Obturator nerve (L2, L3, L4) Pectineus Double nerve supply (Femoral nerve and obturator nerve) Medial rotation Anterior fibres of gluteus minimus and medius (chief medial rotators) Tensor fasciae latae Superior gluteal nerve (L5, S1) Lateral rotation Piriformis Ventral rami of S1, S2 Obturator externus Posterior division of obturator nerve (L2, L3, L4) Obturator internus and Associated gemelli, Quadratus femoris (These muscles are generally termed short rotators) Nerve to obturator internus (L5, S1, S2) Flexion and medial rotation (Option A): Flexion of the hip joint involves bringing the thigh forward, towards the abdomen. The gluteus maximus acts opposite to this motion by extending the hip, so it is not involved in hip flexion. Medial rotation refers to the inward rotation of the thigh towards the midline of the body, which is also not a primary action of the gluteus maximus. Adduction and lateral rotation (Option B): Adduction involves bringing the thigh towards the midline of the body. The gluteus maximus is not directly involved in hip adduction. Lateral rotation is the correct action associated with the gluteus maximus, as explained earlier. Abduction and medial rotation (Option C): Abduction refers to moving the thigh away from the midline of the body, which is not a primary action of the gluteus maximus. Medial rotation, as mentioned earlier, is not a primary action of the gluteus maximus.

References:

BD Chaurasia’s Human Anatomy, 8th Edtion, Page no: 675

↑ *Back to this question in Part A*

@Neet_pg_bot

Q14: The artery that is palpated between the medial malleolus and the calcaneal tendon is? (Q859515)

A. Anterior tibial artery

B. Posterior tibial artery

C. Dorsalis pedis artery

D. Popliteal artery

Correct Answer: B. Posterior tibial artery

Explanation: The posterior tibial artery runs posterior to the medial malleolus, between the medial malleolus and the calcaneal (Achilles) tendon. It is commonly palpated at this location to assess peripheral circulation, especially in conditions like peripheral arterial disease (PAD). Arrangement of Structures Under the Flexor Retinaculum (Medial to Lateral) Mnemonic: Tom Dick ANd Harry T: Tibialis posterior D: Flexor Digitorum longus A: Posterior tibial Artery N: Tibial Nerve H: Flexor Hallucis longus {{caption_text}} Incorrect Options: Anterior tibial artery (Option A): The anterior tibial artery is located on the anterior aspect of the leg, and it travels through the anterior compartment. It is not palpated between the medial malleolus (inner ankle) and the calcaneal tendon (Achilles tendon). Dorsalis pedis artery (Option C): The dorsalis pedis artery is located on the dorsal (top) aspect of the foot, specifically between the first and second metatarsal bones. It is not palpated between the medial malleolus and the calcaneal tendon. Popliteal artery (Option D) : The popliteal artery is located behind the knee joint in the popliteal fossa. It is not palpated between the medial malleolus and the calcaneal tendon.

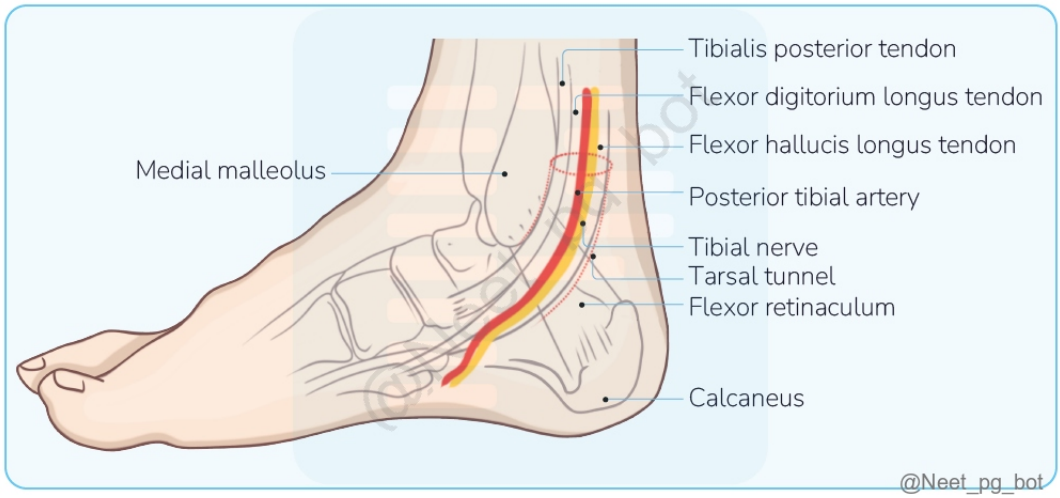

References:

https://www.ncbi.nlm.nih.gov/books/NBK539913/

↑ *Back to this question in Part A*

@Neet_pg_bot

Q15: A patient has lost sensation over the dorsum of the foot and medial four toes. There is the associated difficulty of eversion of the foot. Which nerve injury is likely to be the reason for this? (Q859516)

A. Deep peroneal nerve

B. Superficial peroneal nerve

C. Common peroneal nerve

D. Posterior tibial nerve

Correct Answer: B. Superficial peroneal nerve

Explanation: The superficial peroneal nerve provides sensory innervation to the dorsum of the foot and medial four toes, except for the web space between the first and second toes (which is supplied by the deep peroneal nerve). It also supplies the lateral compartment muscles (fibularis longus and brevis), which are responsible for foot eversion. Therefore, an injury to this nerve results in loss of sensation over the dorsum of the foot and difficulty with eversion. Fracture of the neck of fibula → Common peroneal nerve injury Features of Common Peroneal Nerve Injury: Loss of dorsiflexion → Foot drop Complete loss of eversion No loss of complete inversion (Tibialis posterior intact via tibial nerve) Loss of extension of great toe and lateral four toes Complete sensory loss on dorsum of foot (except lateral part) Injury of Tibial Nerve Injury of Superficial Peroneal Nerve Injury of Deep

Peroneal Nerve Loss of plantar flexion Eversion completely affected Loss of dorsiflexion – foot drop No loss of complete inversion (because of tibialis anterior supplied by deep peroneal nerve is intact) Loss of flexion of great toe Loss of flexion of lateral four toes Paralysis of all muscles of sole Loss of sensory supply over sole Sensory loss on major part of dorsum except medial side of foot and lateral side of foot and lateral side of little finger Inversion not completely affected because tibialis posterior functional Loss of extension of great toe Loss of extension of lateral four toes Sensory loss on the area between great and second toe Incorrect Options: Deep peroneal nerve (Option A): Supplies the anterior compartment of the leg Provides sensation only to the first web space between the first and second toes. Injury would cause foot drop , not loss of eversion. Common peroneal nerve (Option C): The common peroneal nerve branches into the superficial and deep peroneal nerves . Injury would cause a wider deficit , including foot drop (due to deep peroneal involvement) and loss of eversion and sensation over the dorsum of the foot . The given symptoms are specific to superficial peroneal nerve injury only . Posterior tibial nerve (Option D): Supplies the posterior compartment of the leg . Provides sensation to the sole of the foot , not the dorsum. Injury affects plantar flexion and sensation of the sole , not eversion .

References:

https://www.ncbi.nlm.nih.gov/books/NBK537292/#

↑ *Back to this question in Part A*

@Neet_pg_bot

Q16: Identify the labelled tarsal bone in the image below. (Q859520)

A. Calcaneus

B. Cuboid

C. Navicular

D. Talus



Correct Answer: C. Navicular

Explanation: There are 7 tarsal bones in the foot. The Navicular is located medially in the midfoot between the talus posteriorly and the 3 cuneiform bones anteriorly. {{caption_text}} Bone Group Bones Description & Function Tarsals Provide mechanical support and structure to the foot. Proximal Group Talus Transmits body weight to the foot. Articulates at three joints: Superiorly: Ankle joint (tibia/fibula) Inferiorly: Subtalar joint (calcaneus) Anteriorly: Talonavicular joint (navicular) Calcaneus Largest tarsal bone, forms the heel. Articulates at two joints: Superiorly: Subtalar joint (talus) Anteriorly: Calcaneocuboid joint (cuboid) Intermediate Group Navicular Boat-shaped; articulates with talus, cuneiforms, and cuboid. Has a tuberosity for tibialis posterior tendon attachment. Distal Group Cuboid Lateral; articulates with calcaneus and fourth/fifth metatarsals. Features a groove for fibularis longus tendon. Cuneiforms (3) Medial, intermediate, lateral; wedge-shaped. Help form the transverse arch; attach to various muscles. Metatarsals I-V (1-5) Connect tarsals to phalanges; numbered medial to lateral. Have a head, neck, shaft, and base; facilitate movement and support. Phalanges Great Toe: 2 (proximal, distal) Toes 2-5: 3 each (proximal, intermediate, distal). Each phalanx has a base, shaft, and head; provide structure to toes. {{caption_text}} {{caption_text}} {{caption_text}} Incorrect Options: Calcaneus (Option A): is the largest of the tarsal bones in the foot's heel. It bears the weight of the body as the heel touches the ground. Cuboid (Option B): is the lateral bone of the foot lying in front of the calcaneus and behind the fourth and fifth metatarsal bones. Talus (Option D): is the second largest tarsal bone, which lies above the calcaneus in the hindfoot.

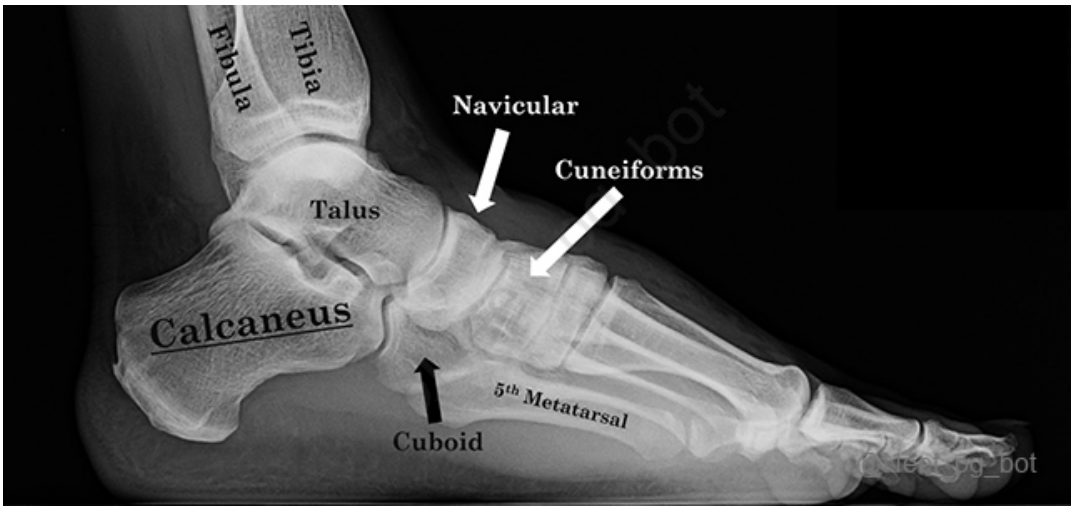

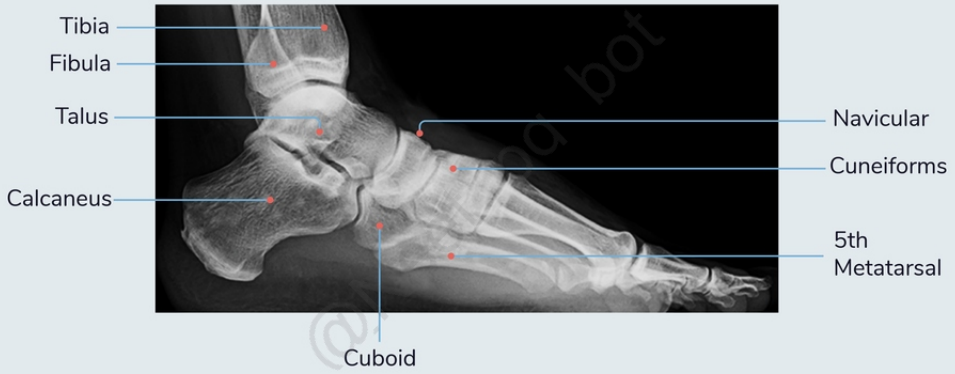

@Neet_pg_bot

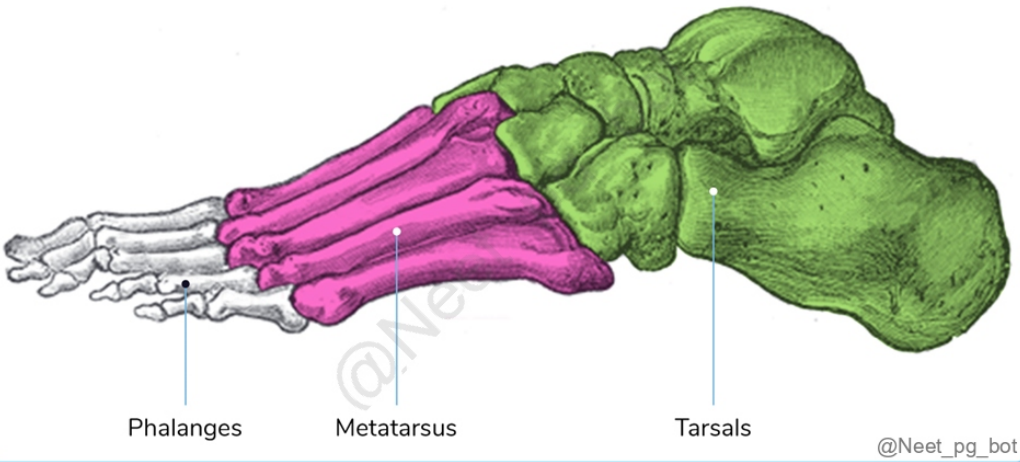

@Neet_pg_bot

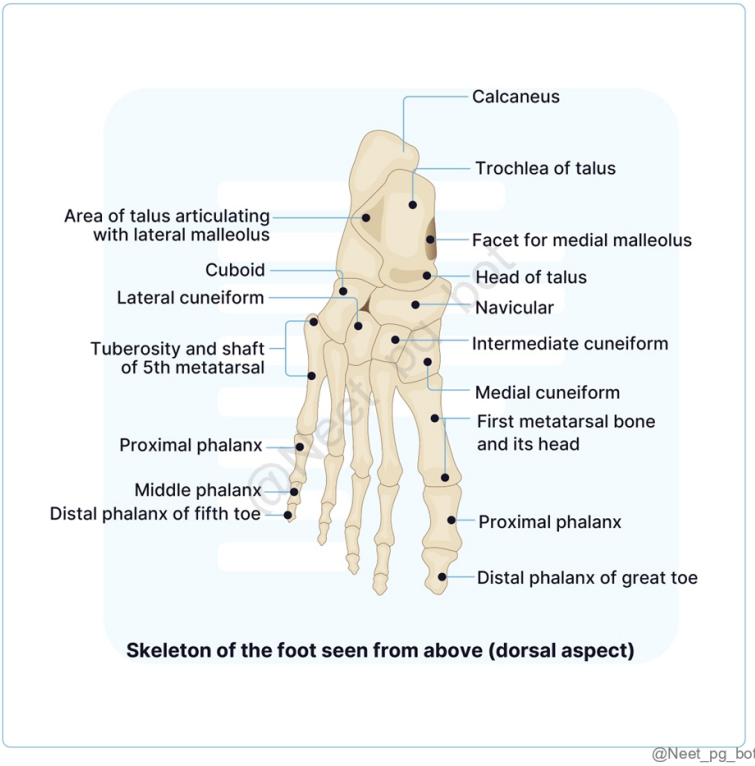

@Neet_pg_bot

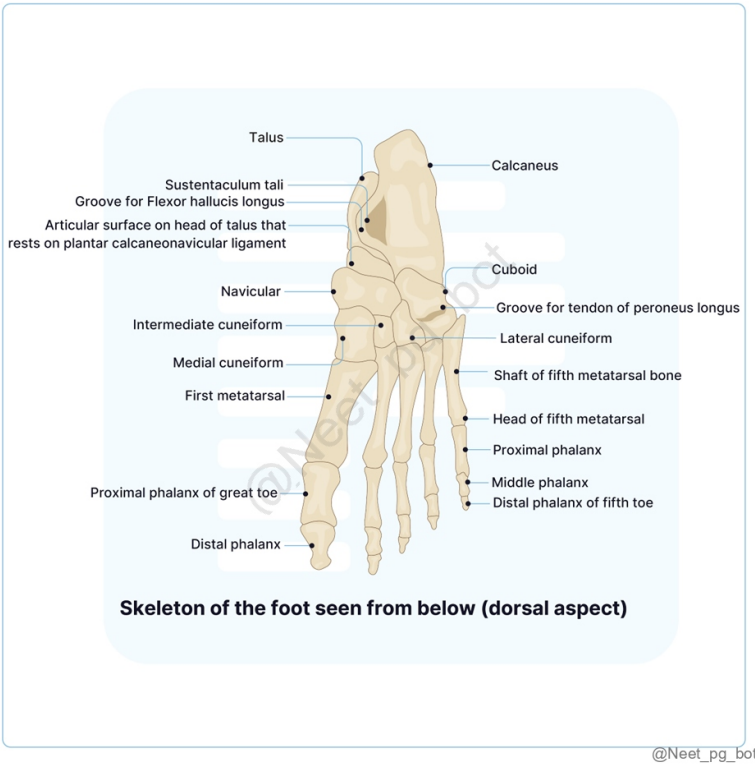

@Neet_pg_bot

References:

https://teachmeanatomy.info/lower-limb/bones/bones-of-the-foot-tarsals-metatarsals-and-phalanges/

Inderbir Singh- General anatomy, upper and lower limb 6e, pg,296-301

https://www.physio-pedia.com/Calcaneus

↑ *Back to this question in Part A*

@Neet_pg_bot

Q17: A patient underwent surgery for the varicose vein. He now complains of sensory loss over the medial aspect of the leg and foot. Which of the following nerves is most likely to be injured? (Q856063)

A. Sural nerve

B. Superficial peroneal nerve

C. Deep peroneal nerve

D. Saphenous nerve

Correct Answer: D. Saphenous nerve

Explanation: The saphenous nerve is a branch of the femoral nerve that provides sensory innervation to the medial aspect of the leg and foot. It is the largest cutaneous branch of the femoral nerve and runs alongside the great saphenous vein in the medial leg. During surgery for varicose veins (often involving the great saphenous vein), the saphenous nerve is at risk of being injured because of its close proximity to the vein. Region Dermatome Nerve Supply Heel (Skin on the heel) S1 The posterior tibial nerve has two branches Lateral plantar nerve S1 towards the little toe . Medial plantar nerve L5 towards the great toe . The popliteal region, posterior thigh (middle), calf, perineal region S2 Posterior cutaneous nerve Lateral foot, dorsum of the foot (Little toe) S1 Sural nerve (Option B) First web space (Dorsum) L5 Deep peroneal nerve (Option C) Medial aspect of leg (Medial malleolus) L4 Saphenous nerve Inguinal region (Proximal lower limb) L1 Ilioinguinal nerve, Genitofemoral nerve Anterior thigh L2, L3, L4 (Lateral to medial) Femoral nerve Medial thigh L2, L3, L4 Obturator nerve Perineum S2, S3, S4 Pudendal nerve Superficial peroneal nerve (Option B): Provides sensory innervation to the anterolateral lower leg and most of the dorsum of the foot , excluding the web space between the first and second toes.

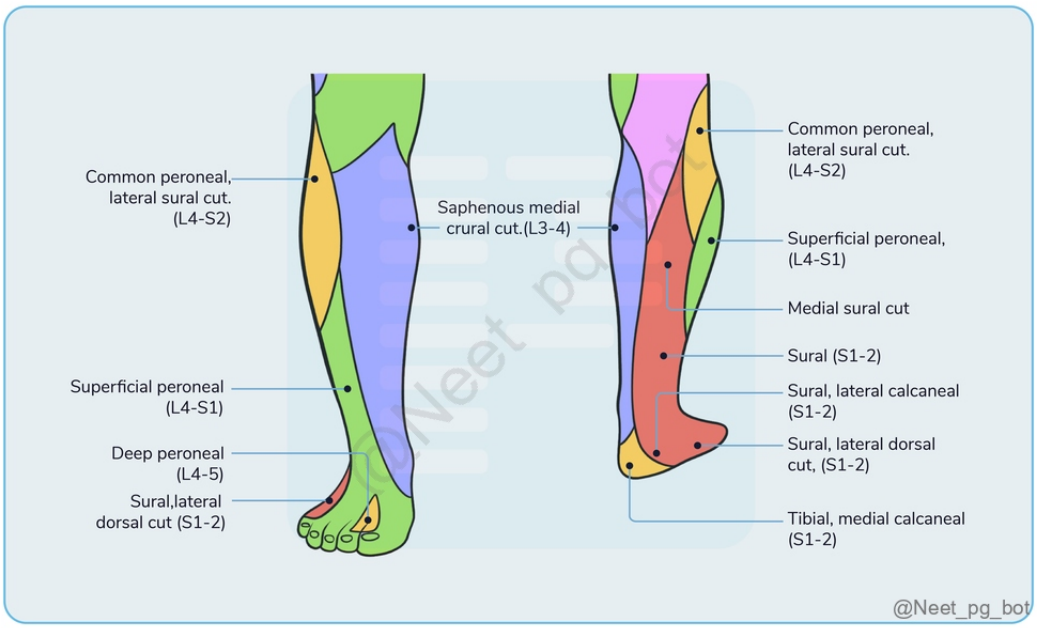

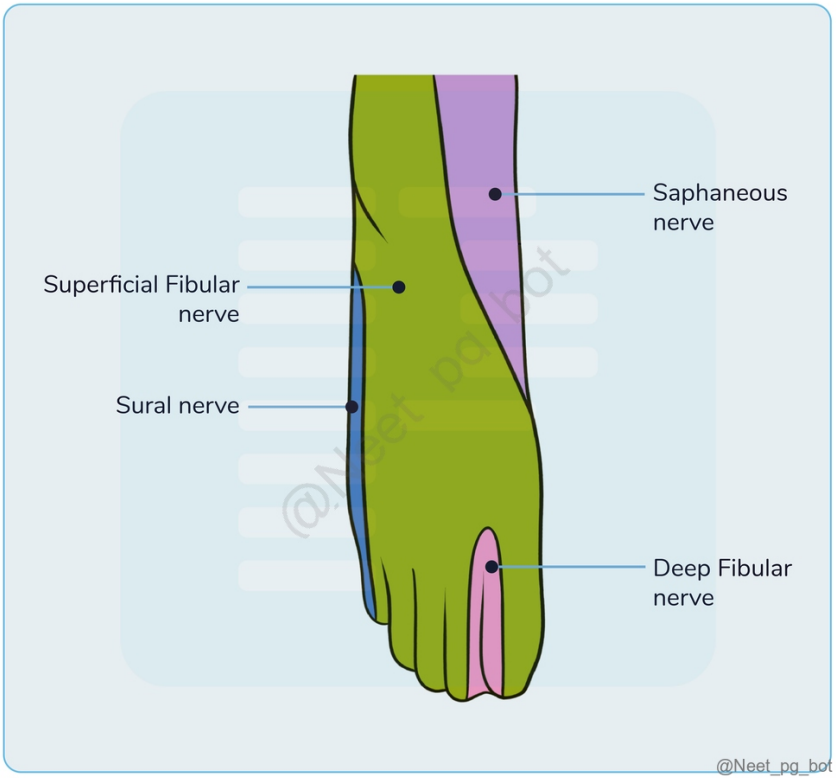

References:

Vishram Singh textbook of anatomy, 2nd Edition, Pages 468 to 474

↑ *Back to this question in Part A*

@Neet_pg_bot

Q18: Which of the following provides attachment to the muscle responsible for extension at the hip and the knee? (Q878935)

A. 1

B. 2

C. 3

D. 4

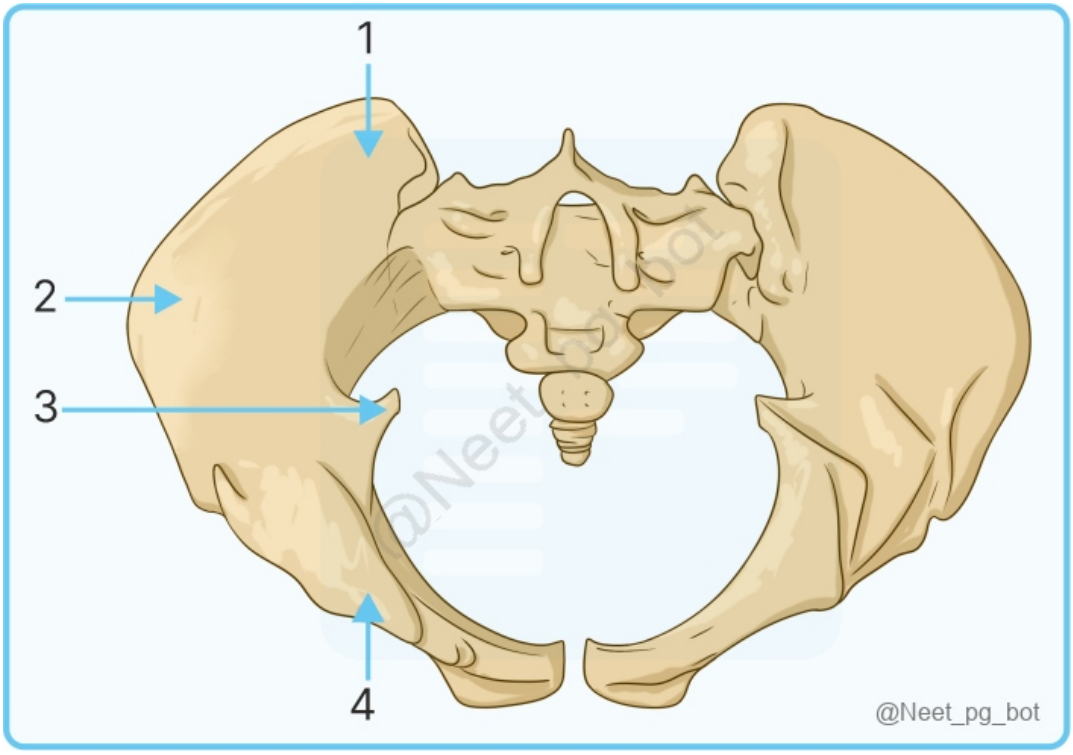

Correct Answer: A. 1

Explanation: The muscle described is gluteus maximus , the primary hip extensor that also maintains knee extension via tightening of the iliotibial band (ITB) . The structure labeled 1 corresponds to the posterior gluteal surface of the ilium , one of the major origins of the gluteus maximus. Main attachments of gluteus maximus: Posterior gluteal line of ilium Posterior gluteal surface of ilium Dorsal surface of sacrum and coccyx Sacrotuberous ligament Inserts into IT band and gluteal tuberosity Incorrect Options: 2 (Option B): Iliac fossa - Attachment of iliacus , a hip flexor , not an extensor 3 (Option C): Ischial spine - gives attachment to sacrospinous ligament & pelvic muscles , not gluteus maximus. 4 (Option D): Ischial tuberosity - Origin of hamstrings , which extend the hip but flex the knee.

References:

Gray’s Anatomy, 42nd Edition, Pages 1405–1407.

↑ *Back to this question in Part A*

@Neet_pg_bot

Q19: A patient diagnosed with sciatica had tender hamstrings. Which of the following supplies a hybrid muscle, which is spared in this patient? (Q844232)

A. Femoral nerve

B. Common peroneal nerve

C. Obturator nerve

D. Tibial nerve

Correct Answer: C. Obturator nerve

Explanation: Correct Option C - Obturator Nerve: This nerve supplies the adductor muscles of the thigh, which are part of the hybrid muscle group that is spared in sciatica. The obturator nerve is primarily responsible for innervating the adductor muscles (adductor longus, adductor brevis, adductor magnus, and gracilis) which are not affected in sciatica, as sciatica mainly involves the sciatic nerve and its branches. Incorrect Options: Option A - Femoral Nerve : This nerve innervates the quadriceps and other muscles of the anterior thigh. In sciatica, the femoral nerve is generally not directly involved, but the tender hamstrings are more related to the sciatic nerve and its branches. Option B - Common Peroneal Nerve : This is a branch of the sciatic nerve, and sciatica can affect it, leading to symptoms like foot drop. It does not provide significant innervation to the hybrid muscle group that is mentioned in this context. Option D - Tibial Nerve : This is another branch of the sciatic nerve, and it innervates the posterior compartment of the leg and the plantar aspect of the foot. It is involved in sciatica and is not spared in this condition.

References:

.

↑ *Back to this question in Part A*

@Neet_pg_bot

Q20: In the given image which vein is mainly affected? (Q866633)

A. Great saphenous vein

B. Short saphenous vein

C. Femoral vein

D. Perforator veins



Correct Answer: A. Great saphenous vein

Explanation: The image depicts varicose veins following the path of the great saphenous vein, the primary vein affected is the great saphenous vein. Great Saphenous Vein (GSV) Origin Arises on the dorsum of the foot, as a continuation of the medial marginal vein Course Ascends in front of the medial malleolus Runs along the medial leg Courses behind the knee Inclines forward in the thigh Passes through the saphenous opening into the femoral vein Tributaries Dorsal venous arch of the foot Medial marginal vein Posterior arch vein Calf vein Accessory saphenous vein Anterior cutaneous vein of the thigh Superficial epigastric, circumflex iliac, and external pudendal veins Valves Contains 10-20 valves, more concentrated in the leg Clinical Significance Commonly used in surgical grafting, especially for coronary artery bypass Varicose veins: Dilated, tortuous veins due to valve incompetence, commonly in GSV and tributaries Incorrect Options: Short saphenous vein (Option B) runs along the posterior leg and is less commonly affected. Femoral vein (Option C) is a deep vein, and varicosities usually involve superficial veins. Perforator veins (Option D) connect superficial veins to deep veins but are not the primary site of varicosities.

References:

.

↑ *Back to this question in Part A*

@Neet_pg_bot

Q21: The artery that is palpated between the medial malleolus and the calcaneal tendon is? (Q866640)

A. Anterior tibial artery

B. Posterior tibial artery

C. Dorsalis pedis artery

D. Popliteal artery

Correct Answer: B. Posterior tibial artery

Explanation: The posterior tibial artery runs posterior to the medial malleolus, between the medial malleolus and the calcaneal (Achilles) tendon. It is commonly palpated at this location to assess peripheral circulation, especially in conditions like peripheral arterial disease (PAD). Arrangement of Structures Under the Flexor Retinaculum (Medial to Lateral) Mnemonic: Tom Dick ANd Harry T: Tibialis posterior D: Flexor Digitorum longus A: Posterior tibial Artery N: Tibial Nerve H: Flexor Hallucis longus Incorrect Options: Anterior tibial artery (Option A): The anterior tibial artery is located on the anterior aspect of the leg, and it travels through the anterior compartment. It is not palpated between the medial malleolus (inner ankle) and the calcaneal tendon (Achilles tendon). Dorsalis pedis artery (Option C): The dorsalis pedis artery is located on the dorsal (top) aspect of the foot, specifically between the first and second metatarsal bones. It is not palpated between the medial malleolus and the calcaneal tendon. Popliteal artery (Option D) : The popliteal artery is located behind the knee joint in the popliteal fossa. It is not palpated between the medial malleolus and the calcaneal tendon.

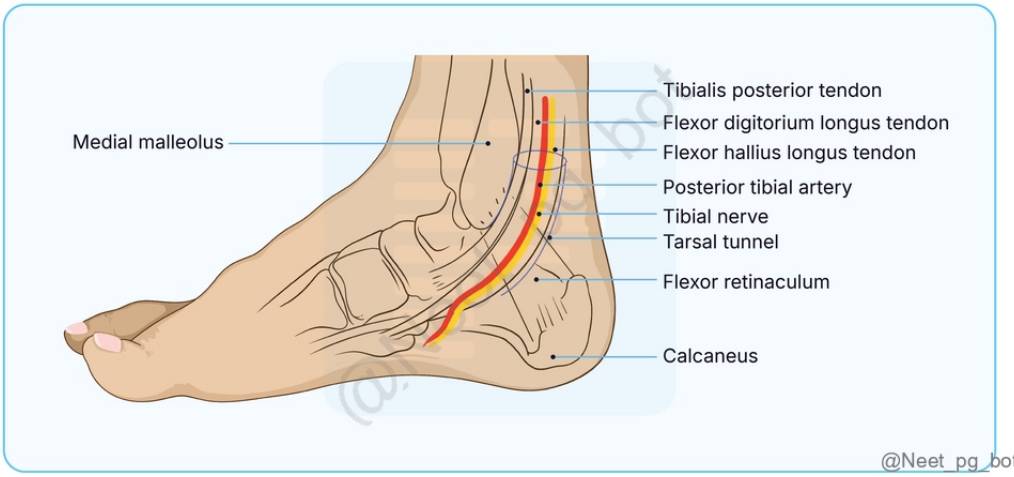

References:

.

↑ *Back to this question in Part A*

@Neet_pg_bot

Q22: Which of the following muscles is/are supplied by the superficial fibular (peroneal) nerve? (Q865266)

A. Peroneus longus &Peroneus brevis

B. Extensor digitorum longus

C. Tibialis anterior

D. None of the above

Correct Answer: A. Peroneus longus &Peroneus brevis

Explanation: Superficial peroneal nerve - Aka superficial fibular nerve. It is the nerve of the lateral compartment of the leg. It supplies peroneus longus and peroneus brevis. The extensor digitorum longus (EDL) (Option B ruled out) muscle is innervated by the deep fibular nerve, also known as the deep peroneal nerve. The tibialis anterior (Option C ruled out) muscle is supplied by the deep fibular nerve (also known as the deep peroneal nerve).

References:

Inderbir Singh textbook of anatomy upper limb and lower limb, 6th edition, Page 363

↑ *Back to this question in Part A*

@Neet_pg_bot

Q23: What is the primary action of this muscle attached to the area marked? (Q865282)

A. Abduction of the thigh

B. Flexion of the knee

C. Extension of the knee

D. Internal rotation of the thigh

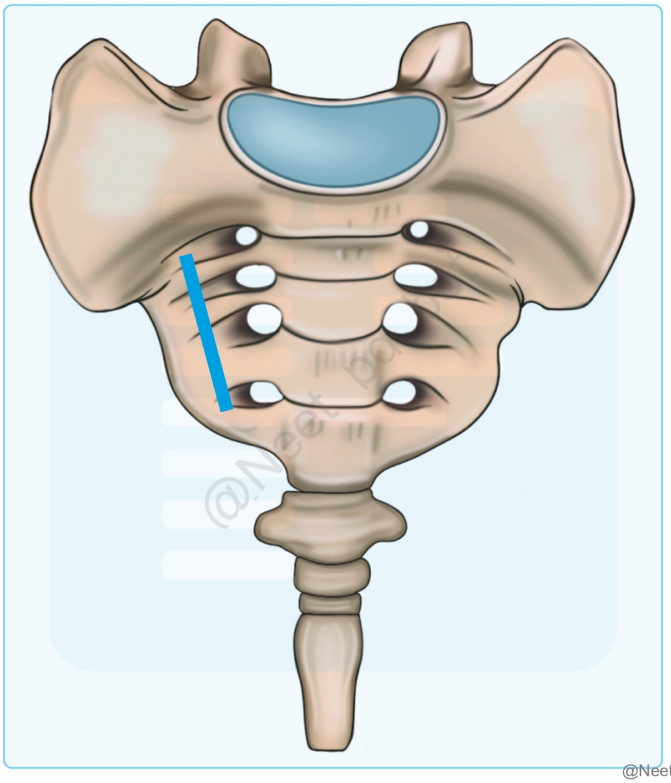

Correct Answer: A. Abduction of the thigh

Explanation: Piriformis Muscle Attachments: Origin: Anterior sacrum (3 parts), gluteal surface of ilium near posterior inferior iliac spine, sacroiliac joint capsule. Insertion: Medial upper border of the greater trochanter of the femur. Key Features: Fills most of the greater sciatic foramen, acting as a crucial landmark. Associated Structures: Superior: Superior gluteal nerve and vessel. Inferior: Inferior gluteal nerve and vessels, sciatic nerve, posterior cutaneous nerve of thigh, nerves to quadratus femoris and obturator internus, internal pudendal vessels, pudendal nerve. Vascular Supply: Primarily by the superior gluteal artery; also by gemellar branches of internal pudendal, inferior gluteal, and lateral sacral arteries. Innervation: Superior gluteal nerve and ventral rami of S1 and S2. Actions: Laterally rotates the extended thigh and abducts the flexed thigh.(Option A) Testing: No isolated test; dysfunction assessed by abducting thighs in a seated position, looking for buttock pain.

References:

Inderbir Singh textbook of anatomy upper and lower limb, 6th edition, Page 330, 332

↑ *Back to this question in Part A*

@Neet_pg_bot

Q24: A patient presents with meralgia paraesthetica. Based on the diagram, identify the nerve involved in this condition. (Q866308)

A. A

B. B

C. C

D. D

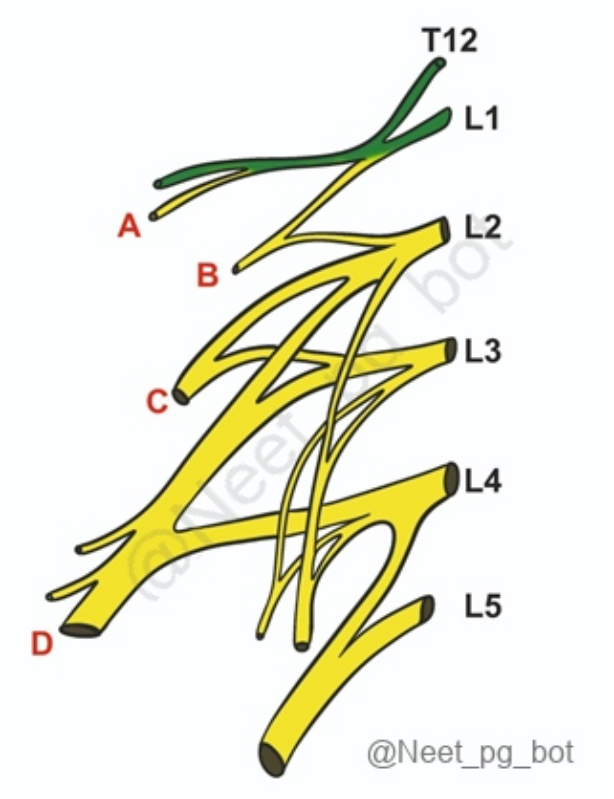

Correct Answer: C. C

Explanation: Meralgia Paraesthetica results from compression or irritation of the lateral femoral cutaneous nerve (L2-L3), which corresponds to the nerve labeled C in the diagram. It is marked by tingling and numbness in the outer thigh that worsens with prolonged sitting and improves with standing or walking. It results from compression of the lateral femoral cutaneous nerve → L2 and L3 nerve roots. Lateral Femoral Cutaneous Nerve Provides purely sensory innervation to the skin over the lateral aspect of the thigh. This nerve is significant in conditions such as meralgia paresthetica, where it can become compressed, leading to tingling and pain in the outer thigh. Most commonly injured during McRoberts manure & Laparoscopic hernia surgery. A: L1–T12 (Option A): These spinal levels correspond to the iliohypogastric and ilioinguinal nerves, which do not cause meralgia paraesthetica. B: L1–L2 (Option B): These roots form the genitofemoral nerve, unrelated to the lateral femoral cutaneous nerve involved in this condition. D: L2–L4 (Option D): These roots contribute to the femoral nerve, which is different from the lateral femoral cutaneous nerve responsible for meralgia paraesthetica.

↑ *Back to this question in Part A*

@Neet_pg_bot

Q25: A patients presents with ankle pain and swelling after a forceful eversion injury. Based on the mechanism of injury, which ligament is most likely to be damaged? (Q866309)

A. Anterior talofibular ligament

B. Calcaneofibular ligament

C. Deltoid ligament

D. Posterior talofibular ligament

Correct Answer: C. Deltoid ligament

Explanation: A forceful eversion injury causes the foot to twist outward, placing stress on the medial structures of the ankle, most commonly resulting in damage to the Deltoid Ligament , the strong medial stabilizer of the joint. A strong, fan-shaped ligament on the medial side of the ankle. Composed of four parts: Tibionavicular Tibiocalcaneal Posterior tibiotalar Anterior tibiotalar Function: Stabilizes the ankle joint and resists eversion forces. Damage to this ligament can lead to medial ankle pain, swelling, and instability. Injury (eversion): Occur: Foot is forcefully twisted outward (away from the midline) → Stresses the medial (inner) side of the ankle. Less common than inversion injuries. Incorrect Options: Option A : Anterior talofibular ligament is injured in inversion injuries, not eversion; part of the lateral ligament complex. Option B: Calcaneofibular ligament is also part of the lateral side, damaged in inversion injuries. Option D:Posterior talofibular ligament is rarely injured alone; involved in severe inversion injuries.

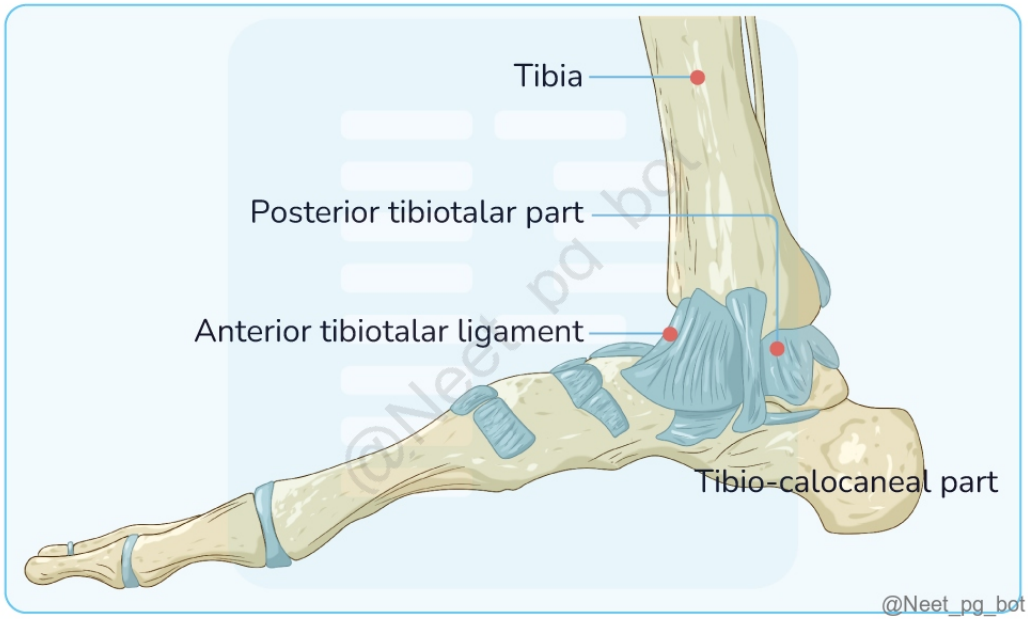

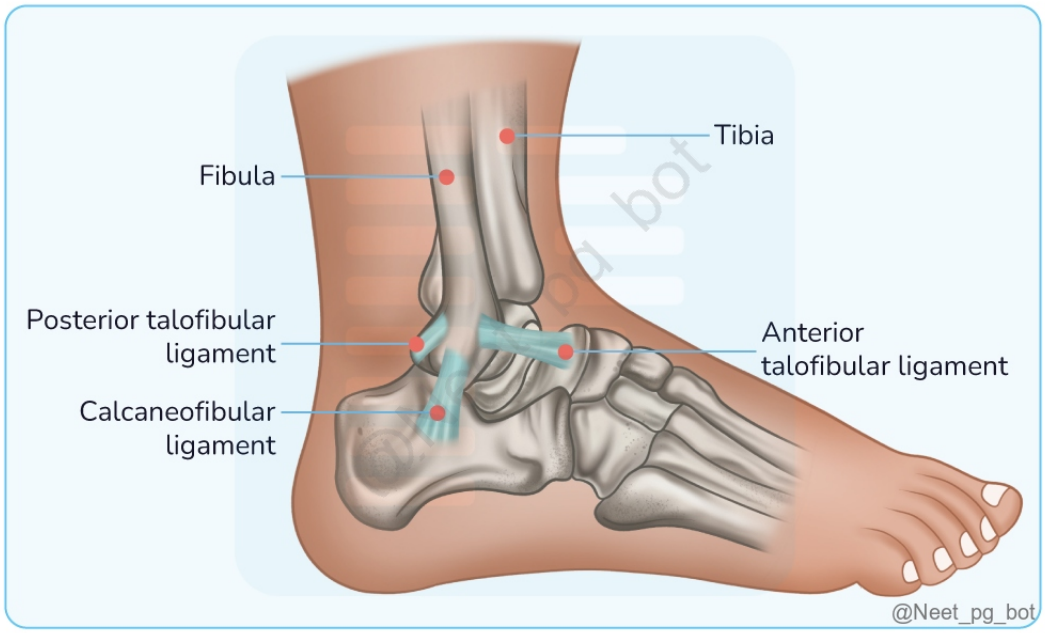

References:

.

↑ *Back to this question in Part A*

@Neet_pg_bot

Q26: Behind the medial malleolus and in front of Achilles which artery is present? (Q844160)

A. Posterior tibial artery

B. Peroneal artery

C. Anterior tibial artery

D. Dorsalis pedis artery

Correct Answer: A. Posterior tibial artery

Explanation: Correct Option A - Posterior tibial artery: Posterior tibial artery : The posterior tibial artery is located behind the medial malleolus and in front of the Achilles tendon. It runs posterior to the medial malleolus and can be palpated in this region. Incorrect Options: Option B - Peroneal artery : The peroneal artery (also known as the fibular artery) is located along the lateral side of the leg and is not found behind the medial malleolus. It supplies the lateral compartment of the leg. Option C - Anterior tibial artery : The anterior tibial artery runs down the anterior part of the leg, in front of the interosseous membrane, and becomes the dorsalis pedis artery at the ankle. It

is not located behind the medial malleolus. Option D - Dorsalis pedis artery : The dorsalis pedis artery is located on the dorsum (top) of the foot, not behind the medial malleolus.

↑ *Back to this question in Part A*

@Neet_pg_bot

Q27: Patient presenting with pain in back of thigh and leg after lifting heavy weights. Which segment is involved? (Q844229)

A. L4

B. L5

C. S1

D. S2

Correct Answer: D. S2

Explanation: Correct Option D - S2: Pain in the back of the thigh and leg after lifting heavy weights is most commonly associated with the S2 nerve root. The S2 nerve root contributes to the sensation in the posterior aspect of the thigh and leg and can be affected by conditions such as sciatica or disc herniation. Incorrect Options: Option A - L4 : The L4 nerve root typically affects the anterior and medial aspect of the thigh, as well as the medial side of the leg and foot. It is less likely to be associated with pain specifically in the back of the thigh and leg. Option B - L5 : The L5 nerve root affects the lateral aspect of the leg and the dorsum of the foot. While it can cause pain radiating down the leg, it is not typically associated with pain specifically in the back of the thigh. Option C - S1 : The S1 nerve root affects the posterior and lateral aspects of the leg and the heel. Pain in the back of the thigh and leg can be related to S1, but S2 is more directly associated with the described pain after heavy lifting.

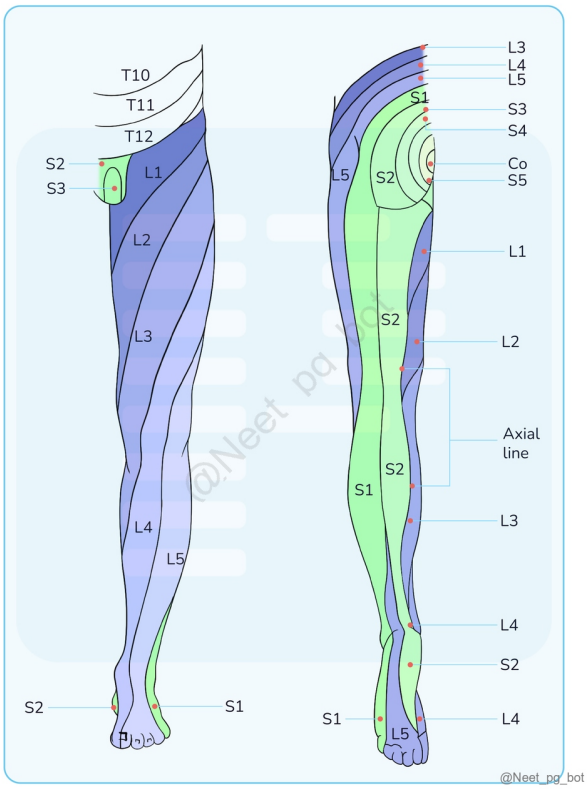

References:

.

↑ *Back to this question in Part A*

@Neet_pg_bot

Q28: A man sustained trauma on the lateral side of his right knee. Two days later, he complains of difficulty in walking, as his toes keep dragging on the ground. He also notices numbness over the upper lateral aspect of the leg and dorsum of the foot. Which nerve is most likely injured? (Q866627)

A. Tibial nerve

B. Common peroneal nerve

C. Deep peroneal nerve

D. Femoral nerve

Correct Answer: B. Common peroneal nerve

Explanation: A man with lateral right knee trauma now has foot drop and numbness over the upper lateral leg and dorsum of the foot, indicating injury to the Common Peroneal Nerve . Supply: Common peroneal nerve branches from the sciatic nerve. It wraps around the neck of the fibula and then divides into two major branches: Superficial peroneal nerve → Peroneus longus and Peroneus brevis (motor supply) → Eversion of the foot. Deep peroneal nerve → Dorsiflexion of the foot and toes and extension of the toes (motor supply) Tibialis anterior Extensor hallucis longus Extensor digitorum longus Peroneus tertius Extensor digitorum brevis Mechanism of Trauma: Trauma to the lateral side of the knee, especially around the fibular neck, is a common site of injury to the common peroneal nerve, where it is superficial and vulnerable. Symptoms: Foot drop (toes drag while walking) → due to loss of dorsiflexion (caused by paralysis of muscles innervated by the deep peroneal nerve). Numbness over the upper lateral leg and dorsum of foot → sensory supply of the common peroneal nerve and its superficial branch. Incorrect Options: Tibial nerve (Option A) affects plantarflexion and sensation on the sole of the foot - not consistent with symptoms. Deep peroneal nerve (Option C) controls dorsiflexion but doesn't explain sensory loss over the lateral leg and most of the dorsum of the foot. Femoral nerve (Option D) innervates anterior thigh muscles - not involved in foot dorsiflexion or lateral leg sensation.

↑ *Back to this question in Part A*

@Neet_pg_bot

Q29: The muscle attached to the marked bony structure is? (Q860617)

A. Ilio-psoas

B. Gluteus maximus

C. Gluteus medius

D. Sartorius



Correct Answer: A. Ilio-psoas

Explanation: The iliopsoas muscle consists of the illacus and psoas major muscles. It attaches to the lesser trochanter of the femur and primarily originates from the iliac fossa and lumbar vertebrae. The iliopsoas muscle is a major hip flexor and assists in anterior pelvic tilt. Gluteus maximus (Option B): Gluteus maximus is inserted into the iliotibial tract and gluteal tuberosity of the femur. Gluteus medius (Option C): Gluteus medius inserts into the lateral surface of the greater trochanter. Sartorius (Option D): Sartorius inserts into the medial side of the proximal tibia.

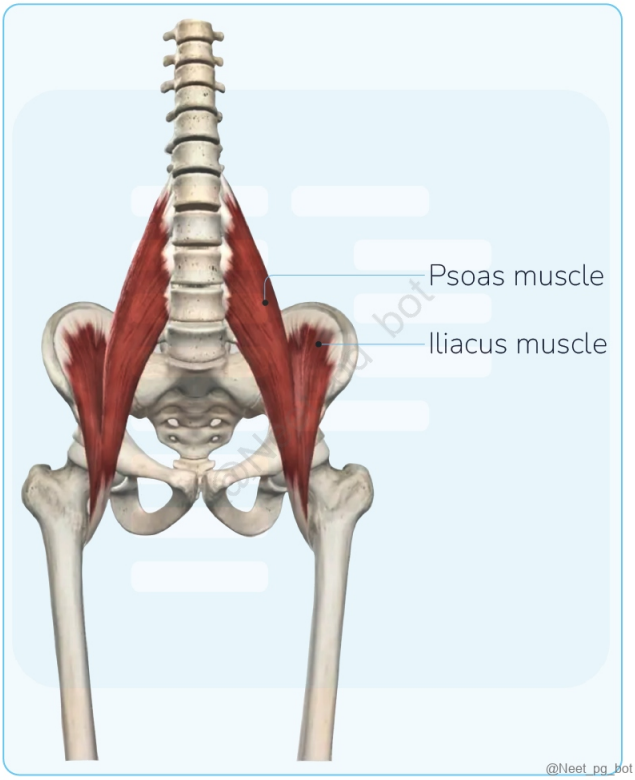

References:

https://www.ncbi.nlm.nih.gov/books/NBK531508/#:~:text

↑ *Back to this question in Part A*

@Neet_pg_bot

Q30: Muscle inserted on lesser trochanter? (Q860625)

A. Psoas major muscle

B. Psoas minor

C. Obturator internus

D. Piriformis

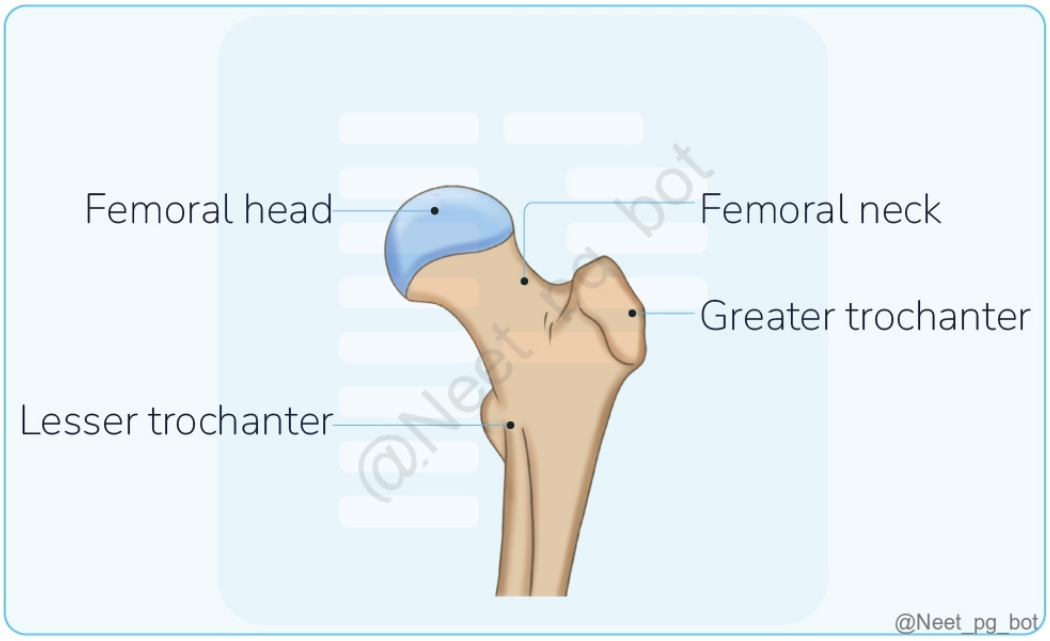

Correct Answer: A. Psoas major muscle

Explanation: Long muscle coming from the Lumbar vertebra Inserts into lesser trochanter - femur bone Innervated by anterior rami of L1, 2, 3 Flexes the thigh Psoas minor (Option B): Inserted into the illiopectinal eminence Innervated by the anterior rami of L1, 2 Flexes the thigh Obturator internus (Option C): Inserted into greater trochanter of the femur Innervated by the nerve to obturator internus (L5, S1) Laterally rotates extended thigh and abducts flexed hip Piriformis (Option D): Inserts superiorly into the tip of the greater trochanter. Innervated by the branches of anterior rami (S1, S2) Laterally rotates extended thigh and abducts flexed hip

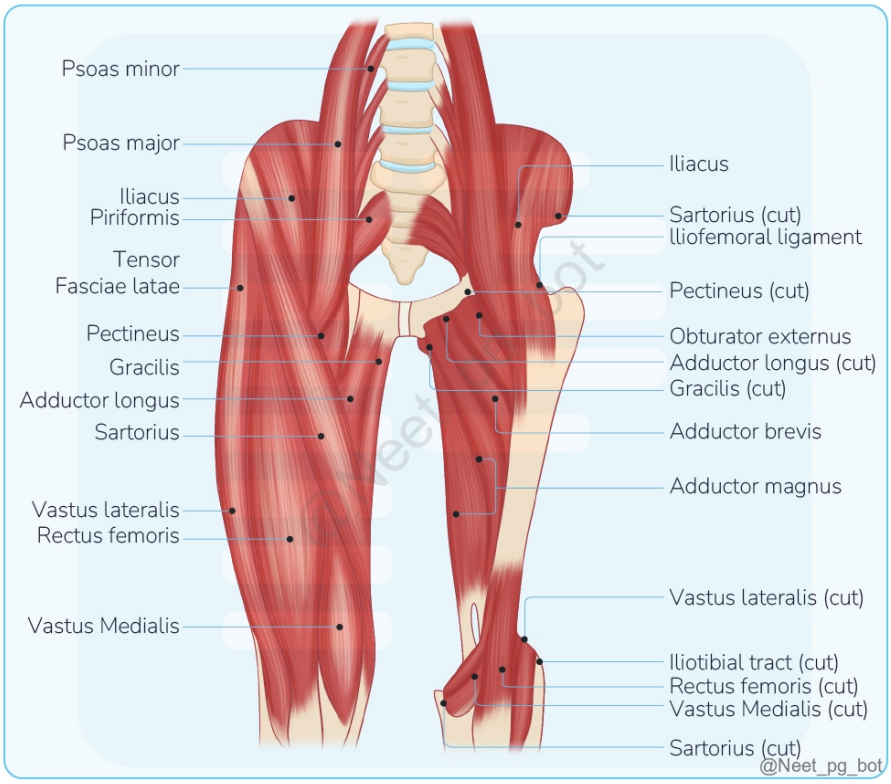

References:

https://www.ncbi.nlm.nih.gov/books/NBK535418/#:~:tex

↑ *Back to this question in Part A*

@Neet_pg_bot

Q31: Identify the muscle that is defective in the given image. (Q860261)

A. Gluteus medius and Gluteus minimus

B. Gluteus maximus

C. Piriformis

D. Obturator internus

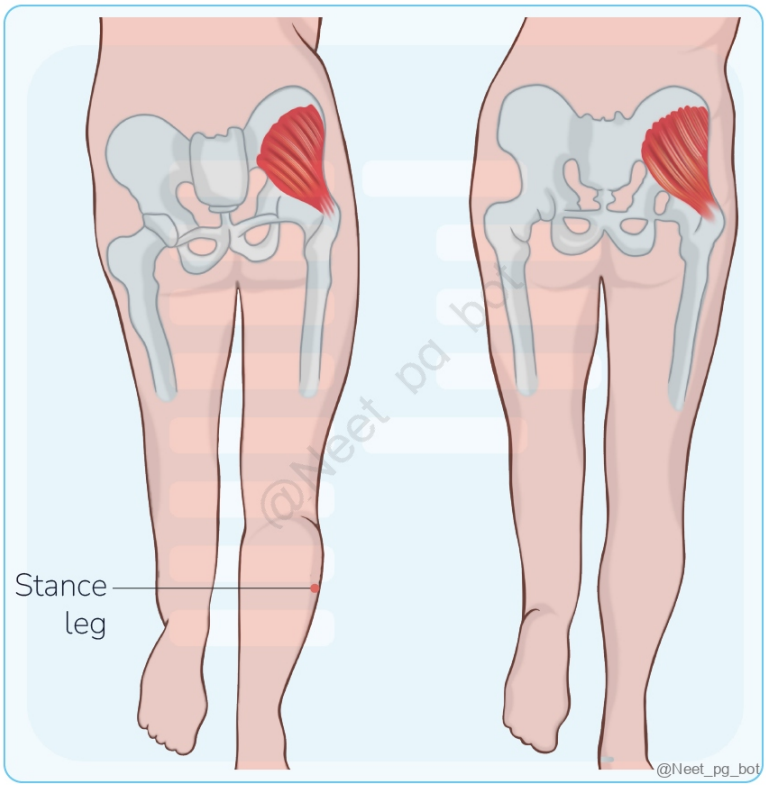

Correct Answer: A. Gluteus medius and Gluteus minimus

Explanation: The Gluteus medius and Gluteus minimus are responsible for the abduction and medial rotation of the thigh and are innervated by the superior gluteal nerve. A positive Trendelenburg test, which is indicated by a drop in the pelvic alignment when standing on one leg, is characteristic of a defect in these muscles. (as shown in the image) This condition suggests a superior gluteal nerve injury, which results in a lurching motion towards the side of the lesion.

Muscles	Innervations	Action
Gluteus Maximus	Inferior Gluteal nerve (L5,S1,S2)	Extends the thigh (especially from a flexed position) Assists in lateral rotation of the thigh Assists in raising from a sitting position
Gluteus medius	Superior gluteal nerve (L5,S1)	Abducts and medially rotates the thigh
Gluteus minimus	Superior gluteal nerve (L5,S1)	Abducts and medially rotates the thigh
Tensor fascia latae	Superior gluteal nerve (L5,S1)	Abducts and medially rotates the thigh
Piriformis	Branches of anterior rami (S1,S2)	Laterally rotates extended thigh and abducts flexes thigh
Obturator internus	Nerve to obturator internus (L5,S1)	Laterally rotates extended thigh and abducts flexes thigh

@Neet_pg_bot

References:

https://www.ncbi.nlm.nih.gov/books/NBK535408/

↑ *Back to this question in Part A*

@Neet_pg_bot

Q32: A surgical procedure is performed on the great saphenous vein, around 2.5 cm anterior to the medial malleolus. Which of the following structures is most likely to be injured? (Q860269)

A. Saphenous nerve

B. Sural nerve

C. Deep peroneal nerve

D. Tibial nerve

Correct Answer: A. Saphenous nerve

Explanation: The great saphenous vein passes anterior to the medial malleolus and is closely associated with the saphenous nerve; therefore, it is more prone to injury during this procedure. Great Saphenous Vein Origin : Begins at the medial end of the dorsal venous arch . Course : Ascends 2.5 cm in front of the medial malleolus , along the medial aspect of the tibia with the saphenous nerve . Passes posterior to the medial condyles of the tibia and femur. Runs posterior to the patella and ascends along the medial side of the femur . Pierces the cribriform fascia and passes through the saphenous opening . Drains into the femoral vein after piercing the femoral sheath . Clinical Aspects Venesection : Performed at the ankle in emergencies. Care must be taken to avoid damaging the saphenous nerve (as it accompanies the vein). Coronary Bypass Surgery : Commonly used as a graft for bypass surgery. The vein must be reversed to prevent its valves from obstructing blood flow in the graft.

References:

https://www.ncbi.nlm.nih.gov/books/NBK532880/#

↑ *Back to this question in Part A*

@Neet_pg_bot

Q33: In the given image, the physician is trying to palpate which of the following arteries? (Q860275)

A. Anterior tibial artery

B. Posterior tibial artery

C. Dorsalis pedis artery

D. Lateral plantar artery



Correct Answer: B. Posterior tibial artery

Explanation: The posterior tibial artery is present in the posterior aspect of the leg and, runs posterior to the tibia, and supplies the calf region. Arrangement of Structures Under the Flexor Retinaculum (Medial to Lateral) Mnemonic: Tom Dick ANd Harry T: Tibialis posterior D: Flexor Digitorum longus A: Posterior tibial Artery N: Tibial Nerve H: Flexor Hallucis longus Anterior tibial artery (Option A): Anterior tibial artery is present in the anterior aspect of the leg. Dorsalis pedis artery (Option C): The anterior tibial artery continuous as the dorsalis pedis artery Lateral plantar artery (Option D): The posterior tibial artery passes under the flexor retinaculum on the medial side of the ankle and divides into the medial and lateral plantar arteries to supply the sole.

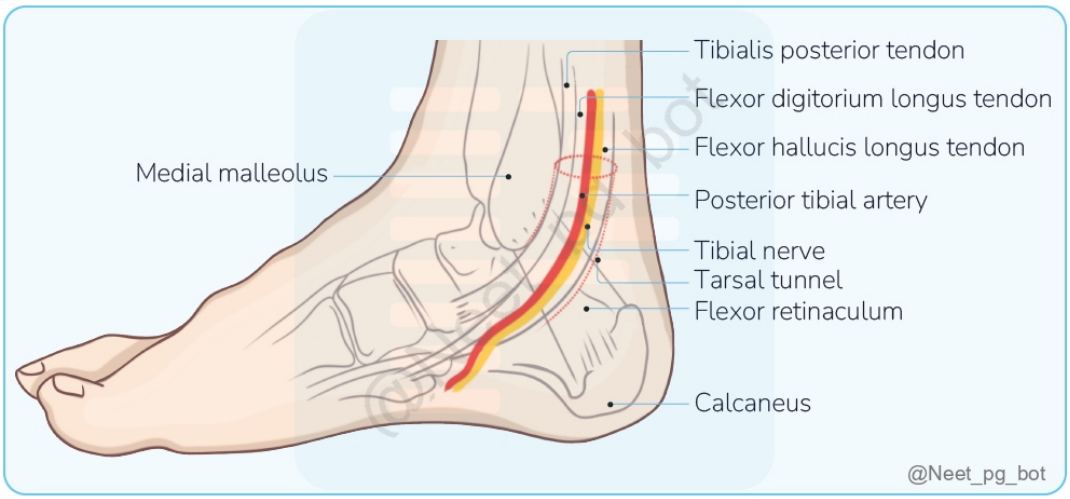

References:

https://www.ncbi.nlm.nih.gov/books/NBK536981/

↑ *Back to this question in Part A*

@Neet_pg_bot

Q34: A 34-year-old female, who works as a maid complained of knee pain and swelling. Which of the following area gets damaged in Housemaid's knee? (Q820318)

A. A

B. B

C. C

D. D

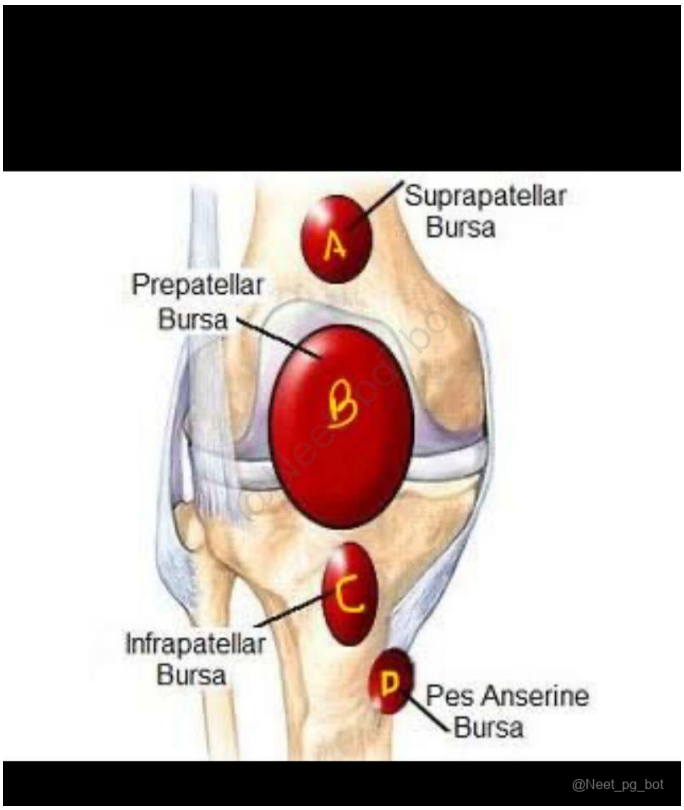

Correct Answer: B. B

Explanation: Correct Option B - B (Prepatellar bursa) The correct answer is option b (Prepatellar bursa), as housemaid's knee involves inflammation of the prepatellar bursa due to repeated kneeling or trauma to the front of the knee.Housemaid's knee, also known as prepatellar bursitis, involves inflammation of the prepatellar bursa. The prepatellar bursa is located just in front of the patella (kneecap) and can become inflamed due to repetitive kneeling or trauma to the area. This condition is often seen in individuals who perform activities that involve prolonged kneeling, such as housemaids or carpet layers. Incorrect Options: Option A - A (Suprapatellar bursa): The suprapatellar bursa is located above the patella (kneecap) and helps reduce friction between the femur (thigh bone) and the quadriceps tendon. This bursa is not commonly associated with housemaid's knee. Option C - C (Infrapatellar bursa): The infrapatellar bursa is located below the patella, between the patellar ligament and the tibia (shin bone). It helps reduce friction during knee movements. Inflammation of this bursa is known as "clergyman's knee" or "Clergyman's bursitis," which is caused by excessive kneeling and friction. Option D - D (Pes anserine bursa): The pes anserine bursa is located on the inner side of the knee, just below the joint. It is situated between the tendons of the sartorius, gracilis, and semitendinosus muscles and the underlying tibia. Inflammation of this bursa can lead to pes anserine bursitis, which typically presents as pain and tenderness on the inner side of the knee. This condition is not directly related to housemaid's knee.

References:

.

↑ *Back to this question in Part A*

@Neet_pg_bot

Q35: Which nerve supplies the Gluteus maximus? (Q854569)

A. Femoral nerve

B. Inferior gluteal nerve

C. Obturator nerve

D. Superior gluteal nerve

Correct Answer: B. Inferior gluteal nerve

Explanation: The inferior gluteal nerve (from the sacral plexus, specifically from L5, S1, and S2 nerve roots) primarily innervates the gluteus maximus muscle. It arises from the posterior division of the sacral plexus and passes through the greater sciatic foramen to reach the gluteal region. This nerve provides motor innervation to the gluteus maximus, which is the largest muscle in the buttocks and plays a significant role in movements such as hip extension and external rotation. Action of the Hip joint, corresponding muscles, and their innervation: Action Muscles Nerve supply Flexion Psoas major (chief flexor) Anterior rami of L1, L2, L3 Iliacus (chief flexor) Sartorius Rectus femoris Pectineus Femoral nerve (L2, L3) (Option A) Extension Gluteus maximus (chief extensor) Inferior gluteal nerve (L5, S1, S2) Hamstring muscles Tibial part of the sciatic nerve (L5, S1, S2) Abduction Gluteus medius and minimus (chief abductors) Tensor fasciae latae Superior gluteal nerve (L5, S1) Adduction Adductor longus Adductor brevis Adductor magnus (chief adductors) Gracilis Obturator nerve (L2, L3, L4) (Option C) Pectineus Double nerve supply (Femoral nerve and obturator nerve) Medial rotation Anterior fibres of gluteus minimus and medius (chief medial rotators) Tensor fasciae latae Superior gluteal nerve (L5, S1) (Option D) Lateral rotation Piriformis Ventral rami of S1, S2 Obturator externus Posterior division of obturator nerve (L2, L3, L4) Obturator internus and Associated gemelli, Quadratus femoris (These muscles are generally termed short rotators) Nerve to obturator internus (L5, S1, S2)

References:

Vishram Singh textbook of anatomy, 2nd Edition, volume II, Page 382, 383

↑ *Back to this question in Part A*

@Neet_pg_bot

Q36: Lateral plantar nerve supplies which of the following muscles? (Q854581)

A. Flexor digitorum brevis, Abductor hallucis, Flexor hallucis brevis

B. Flexor digitorum brevis, Abductor hallucis, Extensor digitorum brevis

C. Flexor digiti minimi brevis, Extensor digitorum brevis, Abductor digiti minimi

D. Flexor digiti minimi brevis, Abductor digiti minimi, Adductor hallucis

Correct Answer: D. Flexor digiti minimi brevis, Abductor digiti minimi, Adductor hallucis

Explanation: The lateral plantar nerve is a branch of the tibial nerve and supplies several muscles in the foot, mainly located in the lateral side and the deep layers of the sole. Muscles supplied by the lateral plantar nerve: Abductor digiti minimi Flexor digiti minimi brevis Adductor hallucis Quadratus plantae 2nd, 3rd, and 4th lumbricals Plantar interossei Dorsal interossei

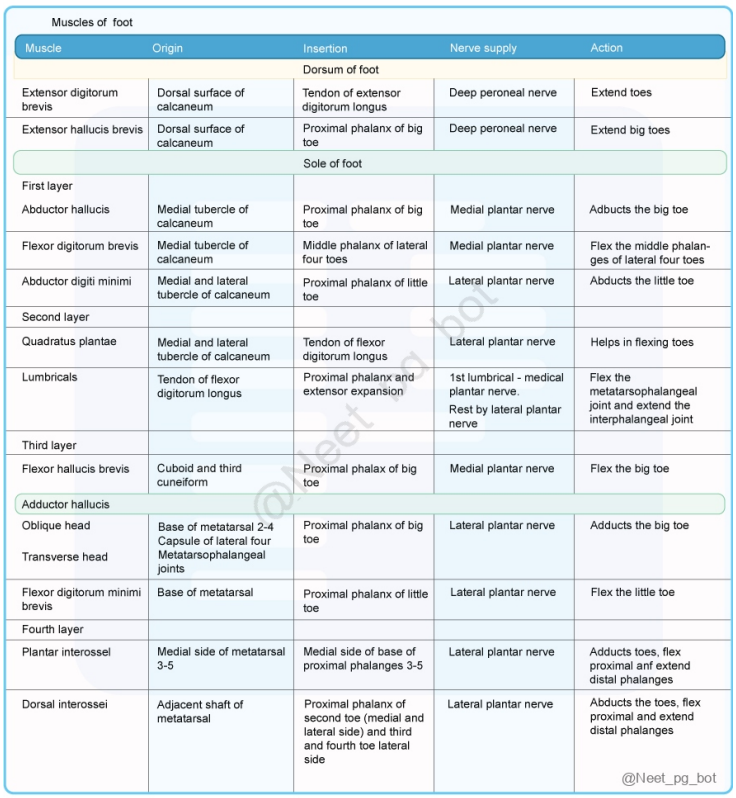

Muscles of foot

Muscle	Origin	Insertion	Nerve supply	Action
		Dorsum of foot		
Extensor digitorum brevis	Dorsal surface of calcaneum	Tendon of extensor digitorum longus	Deep peroneal nerve	Extend toes
Extensor hallucis brevis	Dorsal surface of calcaneum	Proximal phalanx of big toe	Deep peroneal nerve	Extend big toes
		Sole of foot		
First layer				
Abductor hallucis	Medial tubercle of calcaneum	Proximal phalanx of big toe	Medial plantar nerve	Adbucts the big toe
Flexor digitorum brevis	Medial tubercle of calcaneum	Middle phalanx of lateral four toes	Medial plantar nerve	Flex the middle phalanges of lateral four toes
Abductor digiti minimi	Medial and lateral tubercle of calcaneum	Proximal phalanx of little toe	Lateral plantar nerve	Abducts the little toe
Second layer				
Quadratus plantae	Medial and lateral tubercle of calcaneum	Tendon of flexor digitorum longus	Lateral plantar nerve	Helps in flexing toes
Lumbricals	Tendon of flexor digitorum longus	Proximal phalanx and extensor expansion	1st lumbrical - medical plantar nerve. Rest by lateral plantar nerve	Flex the metatarsophalangeal joint and extend the interphalangeal joint
Third layer				
Flexor hallucis brevis	Cuboid and third cuneiform	Proximal phalax of big toe	Medial plantar nerve	Flex the big toe
Adductor hallucis				
Oblique head Transverse head	Base of metatarsal 2-4 Capsule of lateral four Metatarsophalangeal joints	Proximal phalanx of big toe	Lateral plantar nerve	Adducts the big toe
Flexor digitorum minimi brevis	Base of metatarsal	Proximal phalanx of little toe	Lateral plantar nerve	Flex the little toe
Fourth layer				
Plantar interossel	Medial side of metatarsal 3-5	Medial side of base of proximal phalanges 3-5	Lateral plantar nerve	Adducts toes, flex proximal anf extend distal phalanges
Dorsal interossei	Adjacent shaft of metatarsal	Proximal phalanx of second toe (medial and lateral side) and third and fourth toe lateral side	Lateral plantar nerve	Abducts the toes, flex proximal and extend distal phalanges

@Neet_pg_bot

References:

https://www.ncbi.nlm.nih.gov/books/NBK546698/#:~:text

↑ *Back to this question in Part A*

@Neet_pg_bot

• [07_Thorax] 033 Development Of The Cardiovascular System And Fetal Circulation

« Back to Folder Directory

[07_Thorax] 033 Development Of The Cardiovascular System And Fetal Circulation — Quick Jump

Q1 (p. 1705)	*Q2 (p. 1708)*	*Q3 (p. 1712)*	*Q4 (p. 1714)*	*Q5 (p. 1715)*	*Q6 (p. 1720)*
Q7 (p. 1722)	*Q8 (p. 1724)*	*Q9 (p. 1725)*	*Q10 (p. 1728)*	*Q11 (p. 1729)*	*Q12 (p. 1731)*

Q1: Which of the following statements about the embryonic development of the heart is incorrect? (Q848244)

A. Heart tube is derived from the splanchnopleuric mesoderm.

B. Truncus arteriosus forms the ascending aorta and pulmonary trunk.

C. Bulbus cordis is located at the caudal end of the developing heart tube.

D. Disappearance of the dorsal mesocardium creates the transverse sinus.

Correct Answer: C. Bulbus cordis is located at the caudal end of the developing heart tube.

■ *Listen (English)*

■ *Listen (Hindi)*

Explanation: Bulbus cordis is located at the cranial end of the developing heart tube , not the caudal end. Formation of Heart Tubes: The endothelial heart tube is derived from the splanchnopleuric mesoderm, located near the pericardial cavity. (Option A) Initially, the heart appears as right and left endothelial heart tubes. These tubes fuse to form a single heart tube. The heart tube has 5 dilatations, which are: Truncus arteriosus Bulbus cordis Primitive ventricle Primitive atrium Sinus venosus Sinus venosus is located at the caudal (venous) end of the primitive heart tube. It consists of a body with two prolongations known as the right and left horns. Right horn: Forms smooth part of the right atrium (sinus venarum). Left horn: Forms coronary sinus. Each horn receives blood from three veins: Vitelline vein Umbilical vein Common cardinal vein Bulbus cordis is the cranial most part of the developing heart tube. (Option C) Forms outflow (smooth) parts of the right ventricle (conus arteriosus) and left ventricle (aortic vestibule). Primitive ventricle: Forms inflow (rough) parts of both ventricles. Primitive atrium: Forms trabeculated part of the right and left atrium. Truncus arteriosus: Forms ascending aorta and pulmonary trunk. (Option B) Formation of Transverse Pericardial Sinus: Heart Tube Folding: Brings the arterial and venous ends closer together. Disappearance of the dorsal mesocardium creates the transverse sinus of the pericardium. (Option D) Parietal and visceral layers of the serous pericardium become continuous at the arterial and venous ends of the heart. Pericardium forms two tubes: One enclosing the aorta and pulmonary trunk. Other enclosing the SVC, IVC, and four pulmonary veins. Two tubes are separated by the transverse sinus of the pericardium.

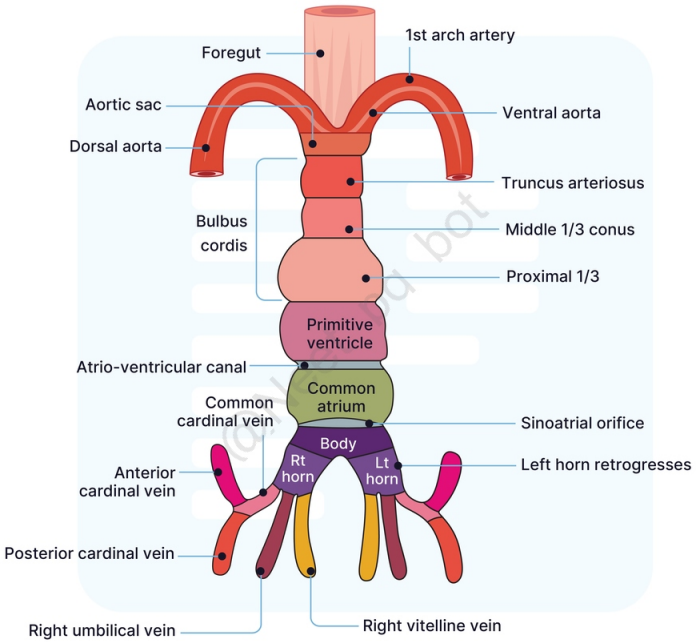

@Neet_pg_bot

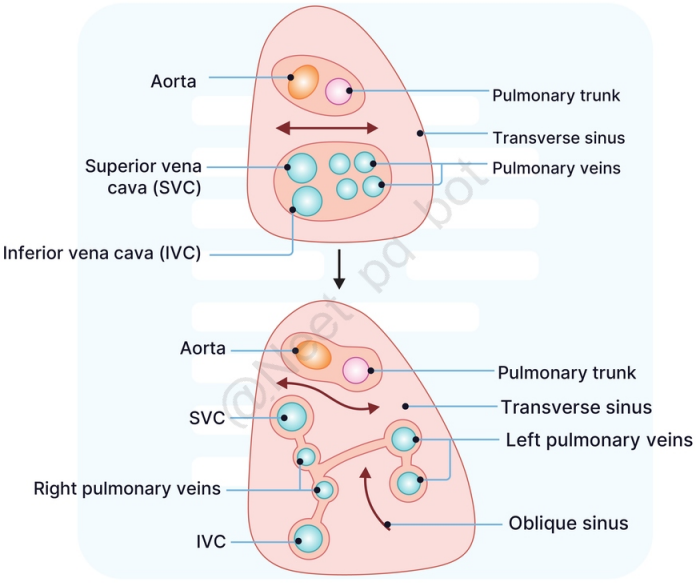

@Neet_pg_bot

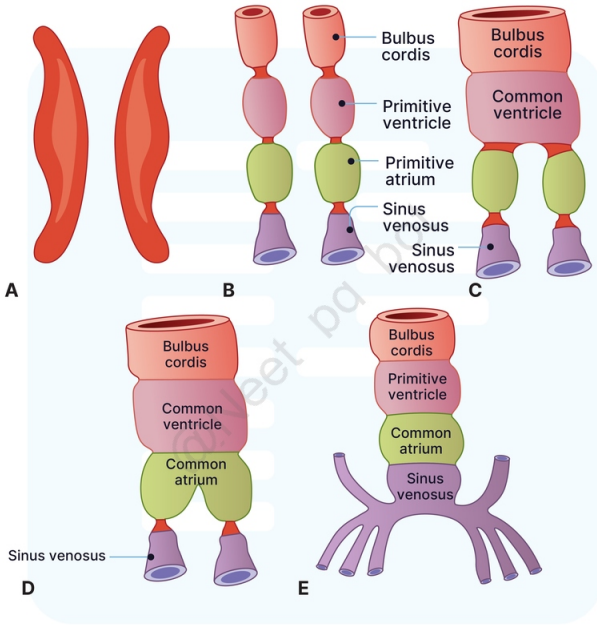

(A) Right and left heart tubes; (B to E) Progressive fusion of tubes from cranial to caudal end. Fusion of sinus venosus is partial

@Neet_pg_bot

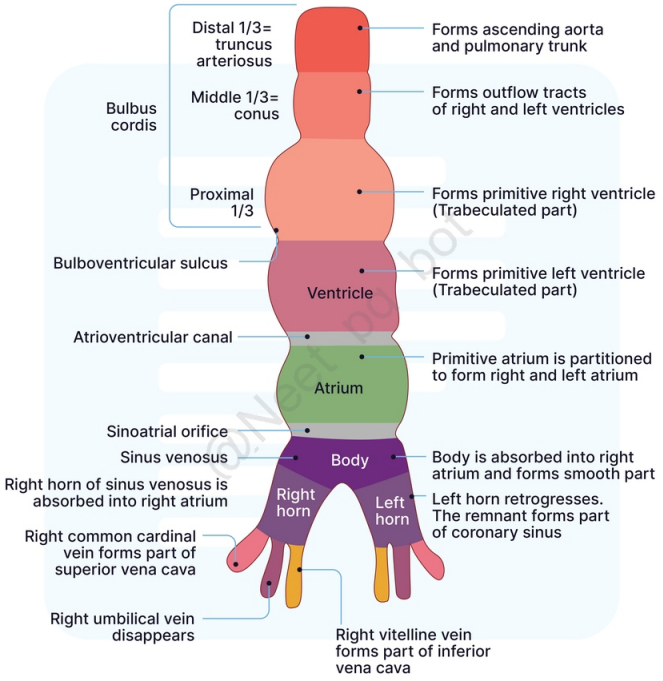

@Neet_pg_bot

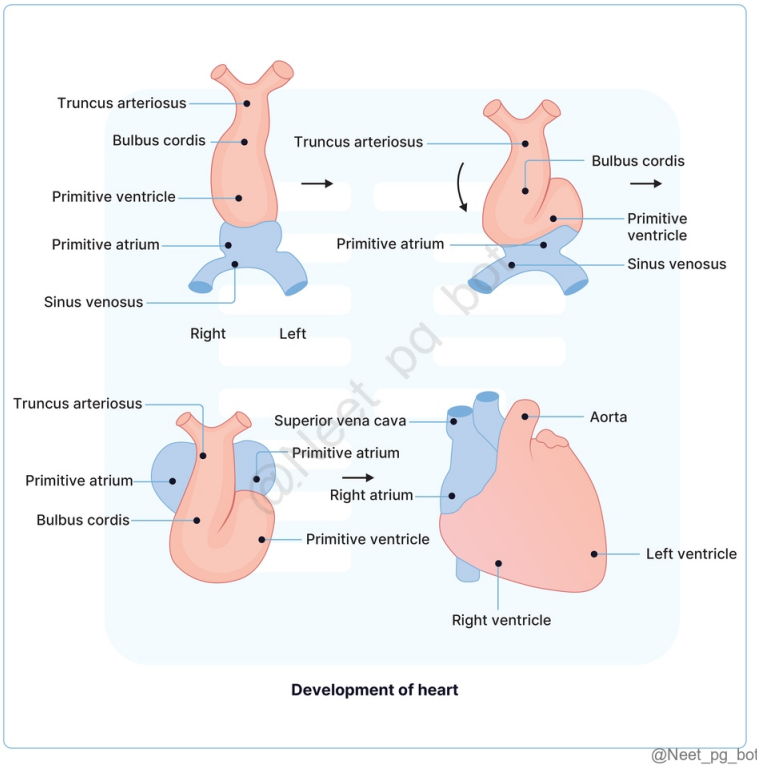

@Neet_pg_bot

References:

Langman's Medical Embryology, 14th Edition, Pages 185, 189.

Inderbir Singh's Human Embryology, 11th Edition, Pages 230, 231, 236, 239

Vishram Singh Textbook of Clinical Embryology, 2nd Edition, Pages 227, 228.

↑ *Back to this question in Part A*

@Neet_pg_bot

Q2: A newborn baby is found to have bluish discoloration of lips, tongue, and nails with poor feeding and signs of congestive heart failure. She is diagnosed with patent truncus arteriosus. What developmental error leads to this condition? (Q848245)

A. Overriding aorta and pulmonary stenosis

B. Switching of the aorta and pulmonary artery position.

C. Incomplete closure of interventricular septum

D. Complete absence of the spiral septum

Correct Answer: D. Complete absence of the spiral septum

- *Listen (English)*
- *Listen (Hindi)*

Explanation: The absence of spiral aorticopulmonary septum (AP septum) is a pathologic finding in truncus arteriosus (TA). Formation of the Bulbus Cordis: {{caption_text}} The bulbus cordis is the cranial-most region of the primitive heart tube, Originates from the cardiogenic area, a specialized mesoderm region cranial to the prochordal plate. Divides into 3 parts: Proximal one-third: Merges with the primitive ventricle to form the bulboventricular chamber. Contributes to the trabeculated part of the right ventricle. Middle part (Conus Cordis): Forms outflow tracts of both ventricles. Two septae are formed in this: proximal and distal bulbar septa. The proximal septum contributes to the interventricular septum . The distal septum divides the conus into the aortic vestibule and conus arteriosus. Distal part (Truncus Arteriosus): Divides into ascending aorta and pulmonary trunk via the spiral aortopulmonary septum Spiral septum is formed by the fusion of the right superior and left inferior truncus swellings or cushions. Responsible for distributing blood to the body and lungs. Clinical Significance: Persistent truncus arteriosus: Complete absence of spiral septum. (Option D) Ventricular Septal Defects (VSDs): Result from incomplete closure of the interventricular septum, leading to holes in the ventricular wall. (Option C) Symptoms may include shortness of breath and an increased risk of infections. {{caption_text}} Tetralogy of Fallot: Comprises four defects linked to abnormalities in the conus and truncus arteriosus: VSD Overriding aorta Pulmonary stenosis (Option A) Right ventricular hypertrophy Can cause cyanosis and impede blood flow to the lungs. {{caption_text}} Transposition of the Great Arteries (TGA): Occurs when the aorta and pulmonary artery are switched due to errors in truncus arteriosus division. (Option B) Requires surgical intervention to correct blood flow issues.

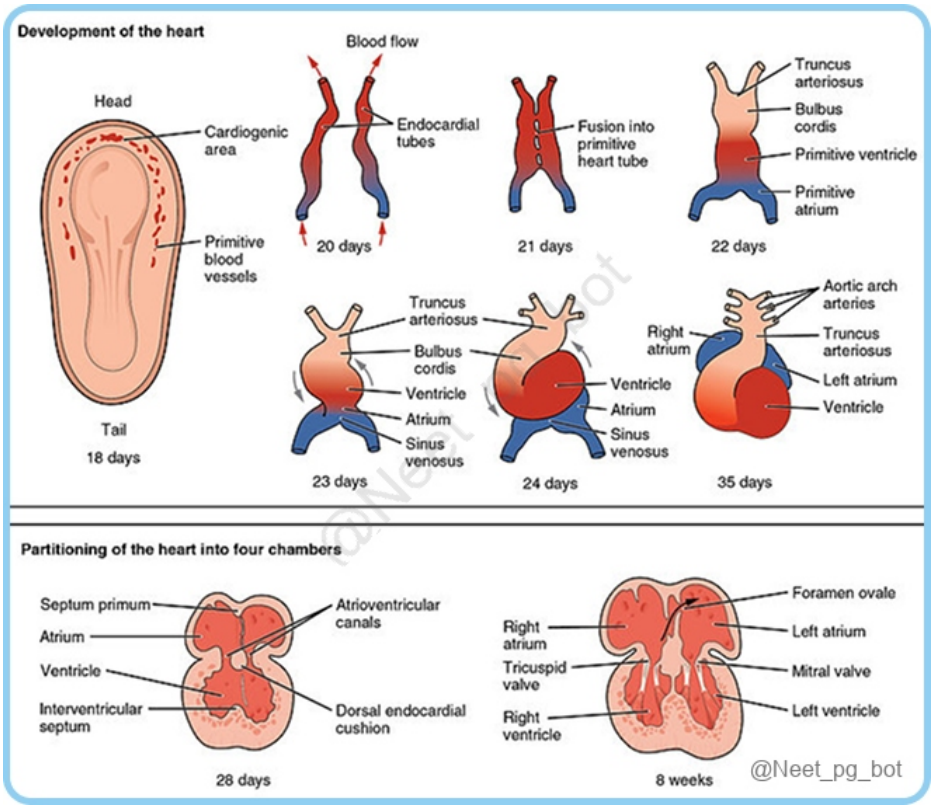

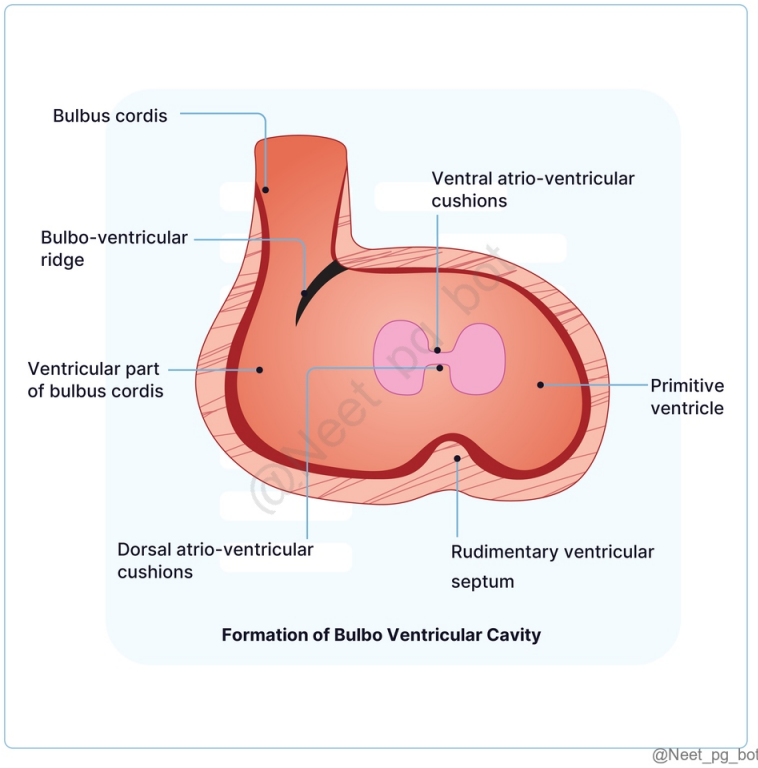

Formation of Bulbo Ventricular Cavity

@Neet_pg_bot

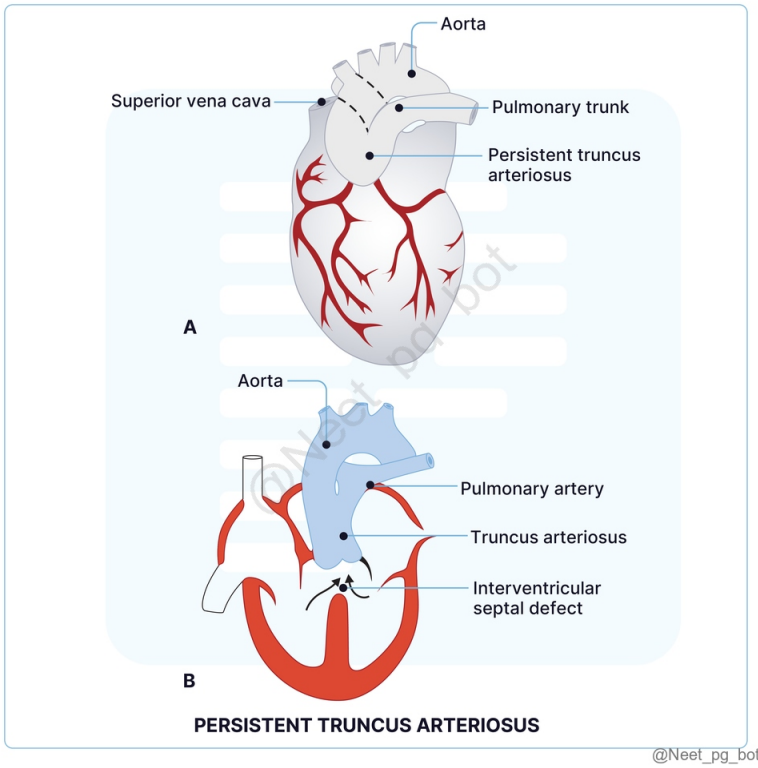

PERSISTENT TRUNCUS ARTERIOSUS

@Neet_pg_bot

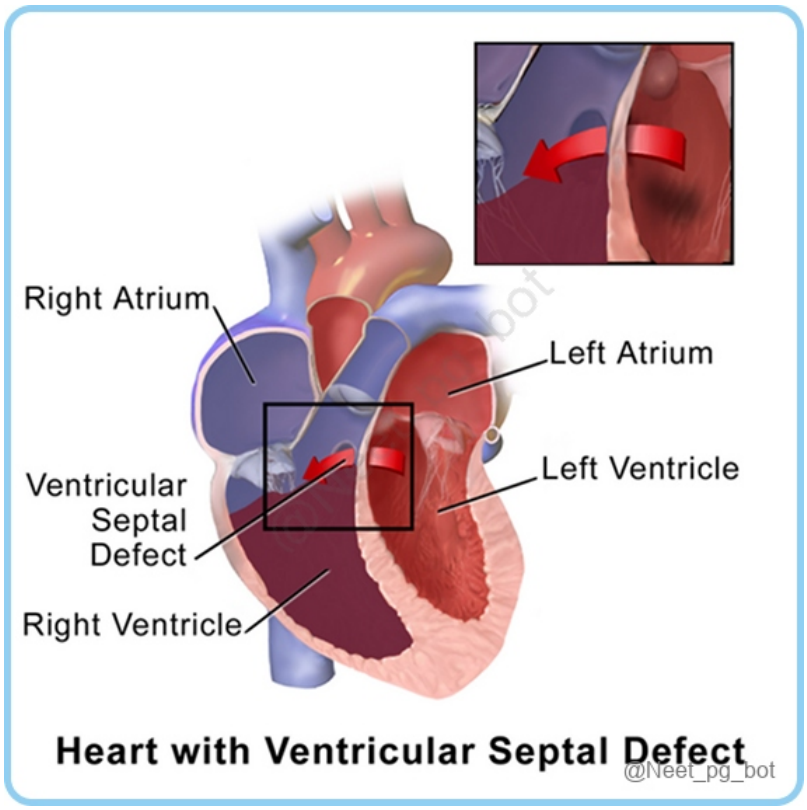
Right Atrium
Left Atrium
Ventricular Septal Defect
Left Ventricle
Right Ventricle
Heart with Ventricular Septal Defect
@Neet_pg_bot

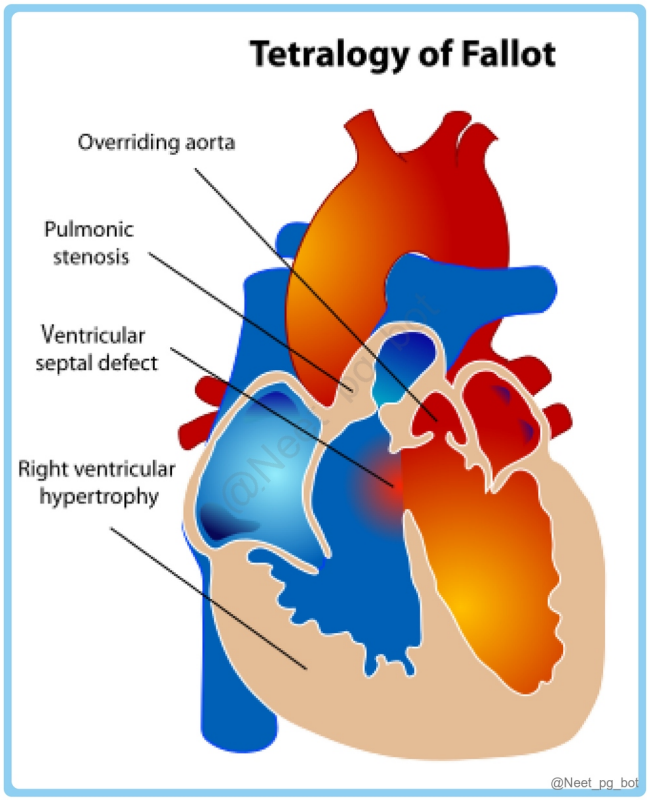
Tetralogy of Fallot
Overriding aorta
Pulmonic stenosis
Ventricular septal defect
Right ventricular hypertrophy
@Neet_pg_bot

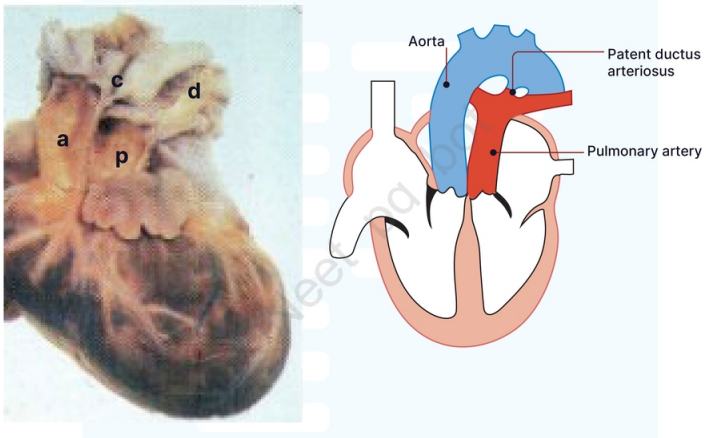

Transposition of Great Vessels

@Neet_pg_bot

References:

https://gmch.gov.in/sites/default/files/documents/Development-of-HEART-2-VENTRICLES-AND-CONG-ANOMALIES.pdf

https://www.ncbi.nlm.nih.gov/books/NBK534774/

↑ *Back to this question in Part A*

@Neet_pg_bot

Q3: An infant's echocardiogram reveals an enlarged coronary sinus. This finding most likely results from an abnormality in which embryological structure? (Q848246)

A. Right horn of the sinus venosus

B. Left horn of the sinus venosus

C. Right common cardinal vein

D. Right vitelline vein

Correct Answer: B. Left horn of the sinus venosus

■ *Listen (English)*

■ *Listen (Hindi)*

Explanation: Left horn of the sinus venosus regresses during development to form the coronary sinus , so a defect in this structure can result in an abnormal coronary sinus. Sinus Venosus: Structure of Sinus Venosus Sinus venosus is the caudal (venous) end of the primitive heart tube, consisting of a body with right and left horns. Each horn is connected to three major veins: Vitelline vein (from the yolk sac) Umbilical vein (from the placenta) Common cardinal vein (from the body wall) Communication with Atrial Chamber Sinus venosus initially communicates with the primitive atrium through a wide sinoatrial orifice. Grooves appear on the lateral walls of the heart, partially separating the sinus venosus from the atrium. Regression of the Left Horn Left horn and its tributaries become reduced in size and become part of the coronary sinus. Fate of Right Horn (Option A) Incorporated into the right atrium, forming the smooth-walled part of the right atrium (sinus venarum). Fate of Sinus Venosus Tributaries Right common cardinal vein becomes part of the superior vena cava. (Option C) Right vitelline vein forms the terminal part of the inferior vena cava. (Option D) Left horn regresses and becomes part of the coronary sinus. (Option B) Left common cardinal vein forms the oblique vein of the left atrium.
{{caption_text}}

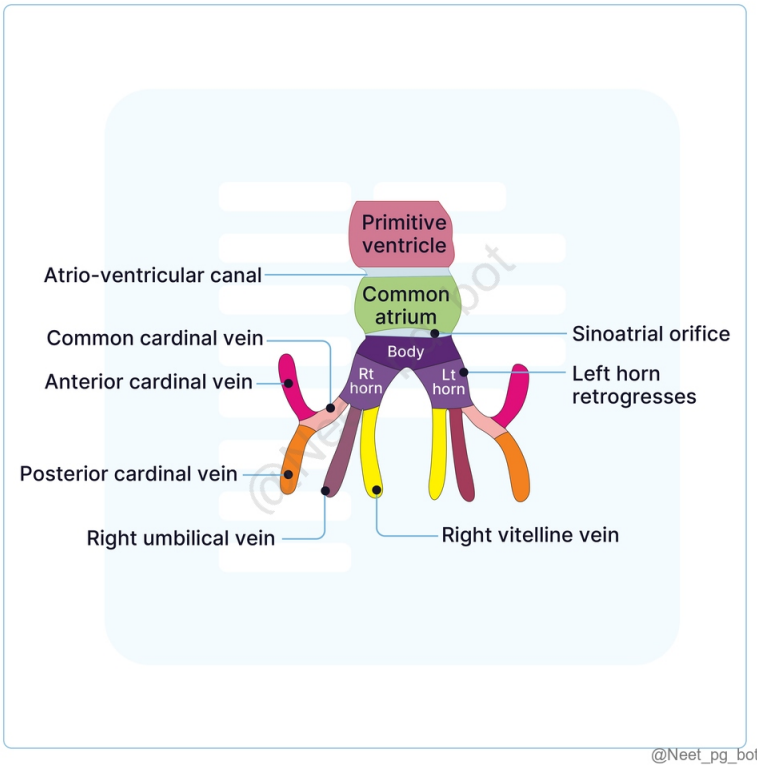

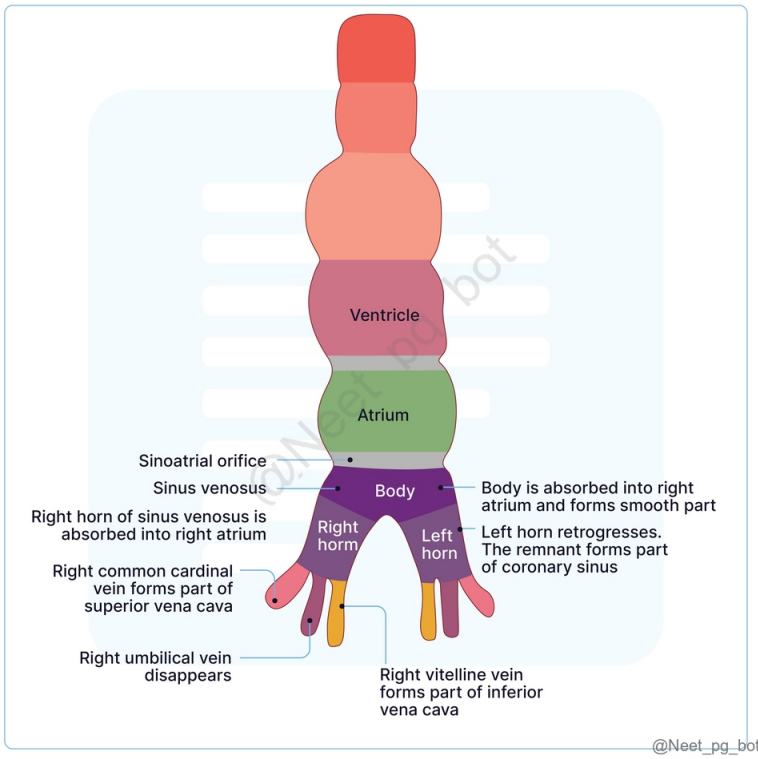

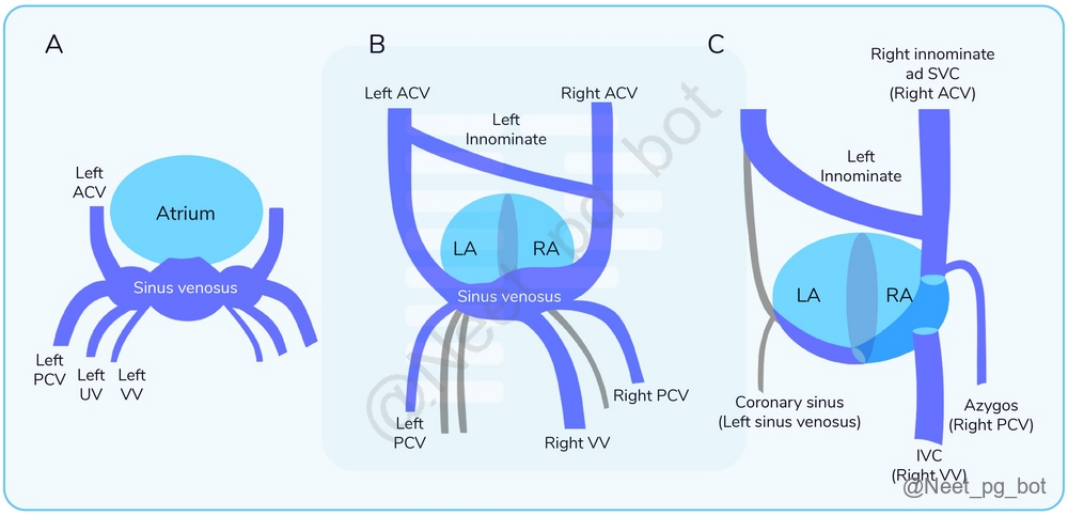

References:

Inderbir Singh's Human Embryology, 11th Edition, Pages 230,231,232,233,234

Langman's Medical Embryology, 14th Edition, Pages 187

↑ *Back to this question in Part A*

@Neet_pg_bot

Q4: Which of the following statements about cardiac jelly is incorrect? (Q848247)

A. Provide structural support during early heart development

B. Facilitates end-systolic occlusion, improving pumping efficiency

C. Store elastic energy during systole for the refilling phase of the heart.

D. Cellular matrix secreted by the endocardium in the developing heart.

Correct Answer: D. Cellular matrix secreted by the endocardium in the developing heart.

■ *Listen (English)*

■ *Listen (Hindi)*

Explanation: The cardiac jelly is an acellular matrix that is secreted by the myocardium in the developing heart. Cardiac Jelly (CJ): A gelatinous, cell-free extracellular matrix filling the myoendocardial space of the embryonic heart tube. Function : Acts as a hydraulic skeleton, providing structural support during early heart development. (Option A) Facilitates end-systolic occlusion of the embryonic heart lumen, improving pumping efficiency. (Option B) Stores elastic energy during systole, aiding the refilling phase of the heart. (Option C)

References:

https://www.ncbi.nlm.nih.gov/pmc/articles/PMC6463132/

Langman’s Medical Embryology, 14th Edition, Page 183.

↑ *Back to this question in Part A*

@Neet_pg_bot

Q5: In the image depicting fetal heart development, which structures are labelled as A and B, respectively? (Q848248)

A. A: Ostium primum, B: Ostium secundum

B. A: Foramen ovale, B: Ostium primum

C. A: Septum primum, B: Septum secundum

D. A: Septum secundum, B: Septum primum

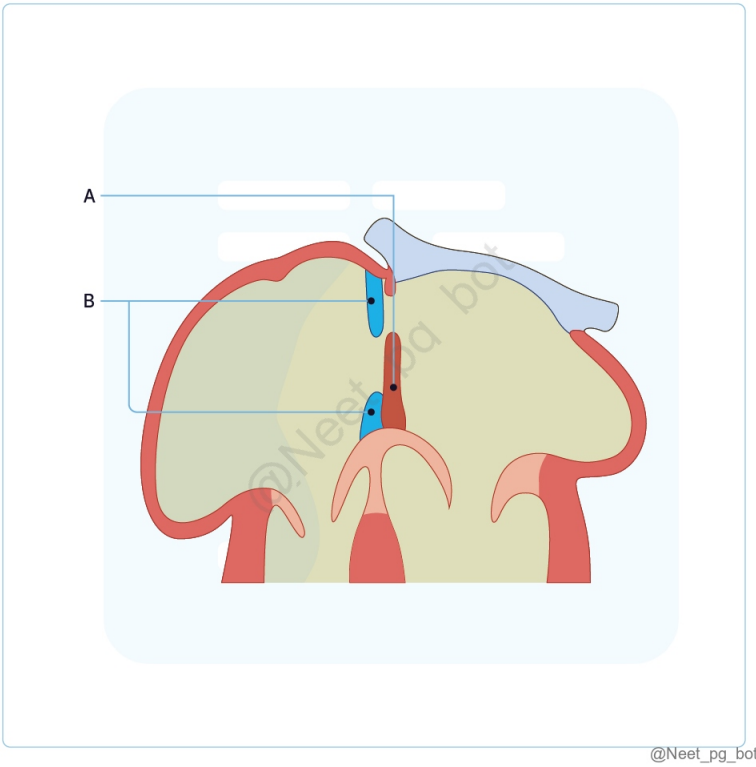

Correct Answer: C. A: Septum primum, B: Septum secundum

- *Listen (English)*
- *Listen (Hindi)*

Explanation: Septum primum (Label A) grows first and contributes to the division of the atria. The septum secundum (Label B) grows later and overlaps the septum primum, forming the foramen ovale, which allows right-to-left blood flow in fetal life. Septum Primum Formed as a sickle-shaped fold from the roof and dorsal wall of the primitive atrium due to pressure from the bulbus cordis. Grows downward toward the atrioventricular (AV) canal and septum intermedium, fusing with the latter. Ostium Primum Before the septum primum reaches and fuses with the septum intermedium, a gap (foramen primum) allows blood flow between the right and left atria. Ostium Secundum Upper part of the septum primum breaks down, creating a new gap (foramen secundum) before the foramen primum closes. The septum primum now has a free upper edge. Septum Secundum Grows down from the roof of the atrial chamber, to the right of the septum primum, overlapping the free upper edge of the septum primum as it grows. Foramen Ovale Formation Overlapping septa create the foramen ovale, allowing blood to flow from right to left atrium during fetal life, preventing left-to-right flow. Patent throughout fetal life. Obliteration of Foramen Ovale Post-birth, the left atrium receives oxygenated blood from the lungs, increasing pressure in this chamber greater than the right atrium, causing fusion of the septum primum and septum secundum, closing the foramen ovale. Annulus ovalis (adults) corresponds to the lower free edge of the septum secundum, while the fossa ovalis represents the septum primum.

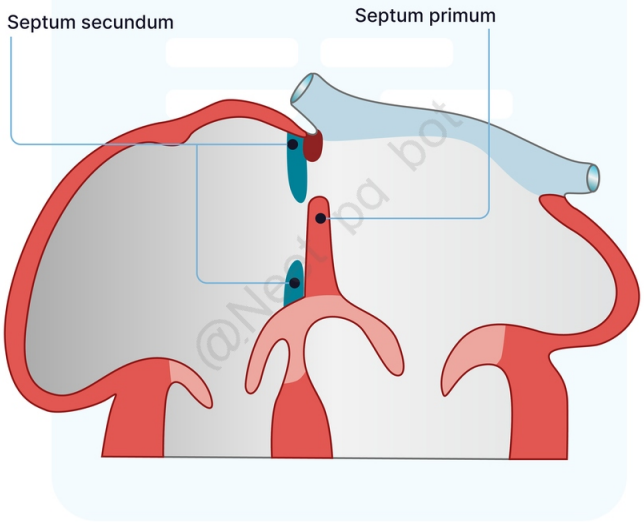

@Neet_pg_bot

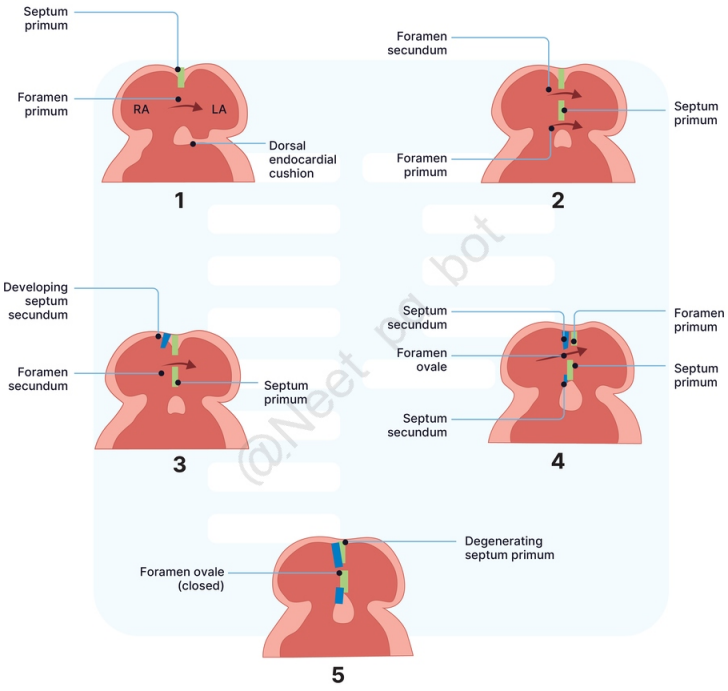

@Neet_pg_bot

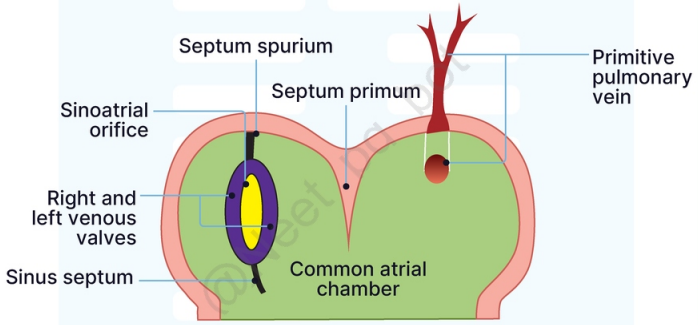

Septum primum appears

@Neet_pg_bot

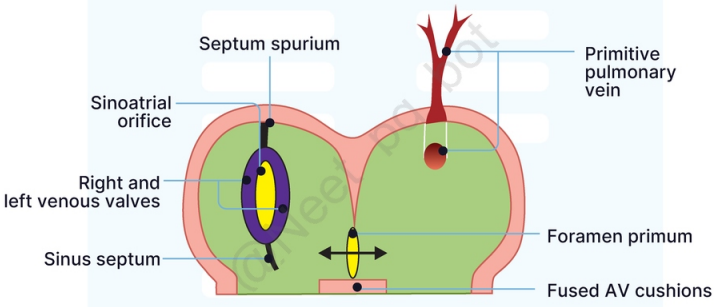

Septum primum grows towards fused AV cushions. The gap between them is foramen primum

@Neet_pg_bot

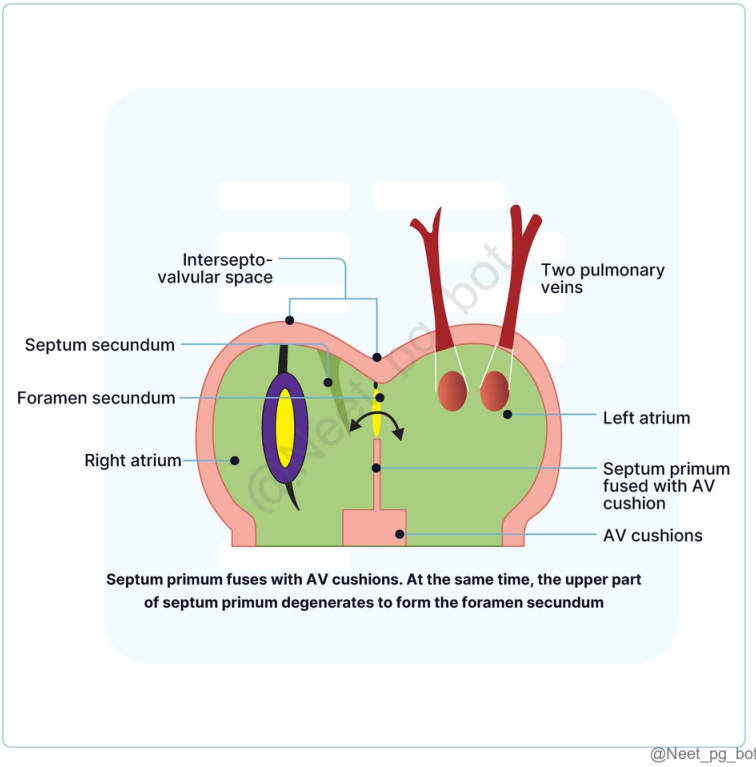

Septum primum fuses with AV cushions. At the same time, the upper part of septum primum degenerates to form the foramen secundum

@Neet_pg_bot

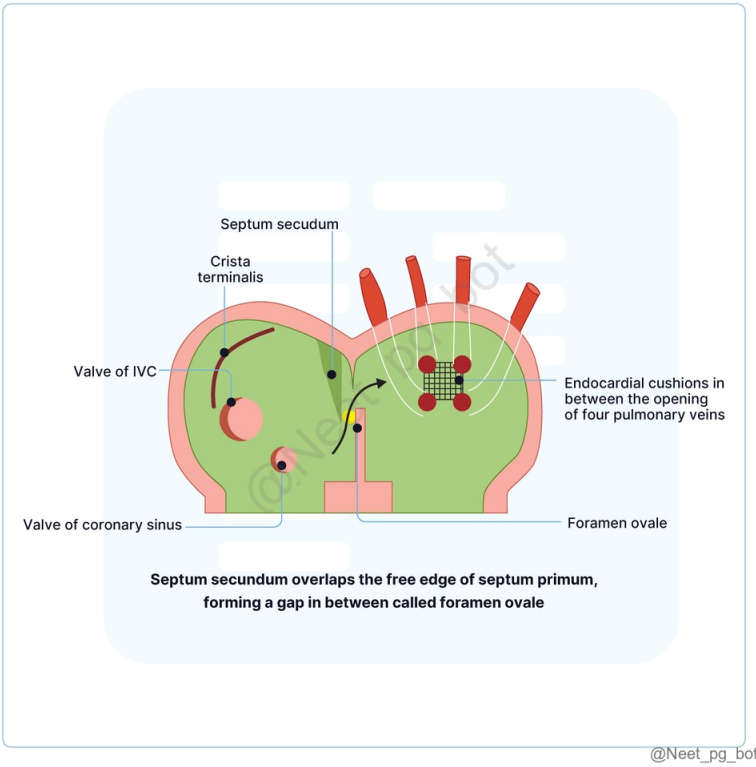

Septum secundum overlaps the free edge of septum primum, forming a gap in between called foramen ovale

@Neet_pg_bot

References:

Inderbir Singh’s Human Embryology, 11th Edition, Pages 233-235

↑ *Back to this question in Part A*

@Neet_pg_bot

Q6: A 5-year-old patient is diagnosed with an atrial septal defect (ASD) characterized by a large opening between the left and right atria. Which embryological defect is most commonly associated with this significant type of ASD? (Q848249)

A. Ostium primum defect

B. Ostium secundum defect

C. Sinus venosus defect

D. Coronary Sinus Defect

Correct Answer: B. Ostium secundum defect

■ *Listen (English)*

■ *Listen (Hindi)*

Explanation: Ostium secundum defect is the most common significant ASD characterized by a large atrial opening. Defects in Interatrial Septal Development Atrial Septal Defect (ASD): Varies from total absence of the atrial septum to small openings, such as probe patency of the oval foramen. Most significant defect: Ostium secundum defect , characterized by a large opening between the left and right atria. Causes: Excessive cell death and resorption of the septum primum. Inadequate development of the septum secundum. Complete Absence of Atrial Septum: Known as common atrium or cor triloculare biventriculare. Result from complete failure of the septum primum and septum secundum to form. Premature Closure of Foramen Ovale: It can occur during prenatal life. Results in: Massive hypertrophy of the right atrium and ventricle. Underdevelopment of the left side of the heart. Often leads to death shortly after birth. Ostium primum defect (Option A): Accounts for about 10% of septal defects and develops due to a deficiency in tissue near the atrioventricular valves, making it less common than ostium secundum. Sinus venosus defect (Option B) is located outside the fossa ovalis on the right septal surface. It is associated with anomalous right upper pulmonary venous return rather than a large atrial opening between the atria. Coronary Sinus Defect (Option C) is located in the wall separating the coronary sinus from the left atrium; it may be fenestrated or absent and does not create a significant opening between the left and right atria.

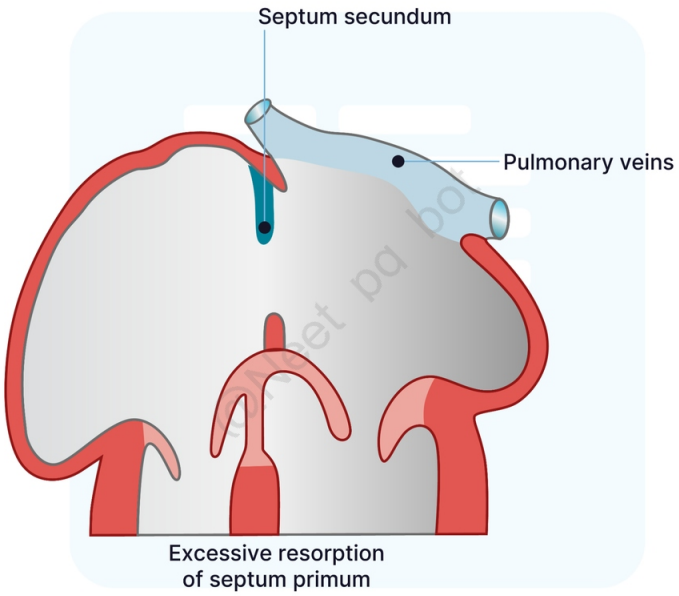

@Neet_pg_bot

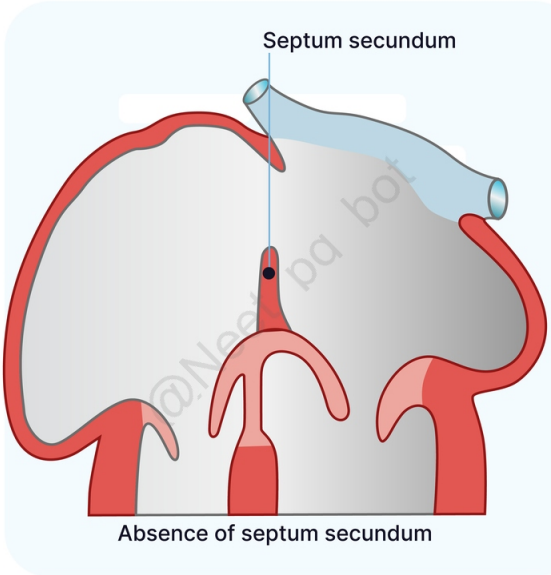

@Neet_pg_bot

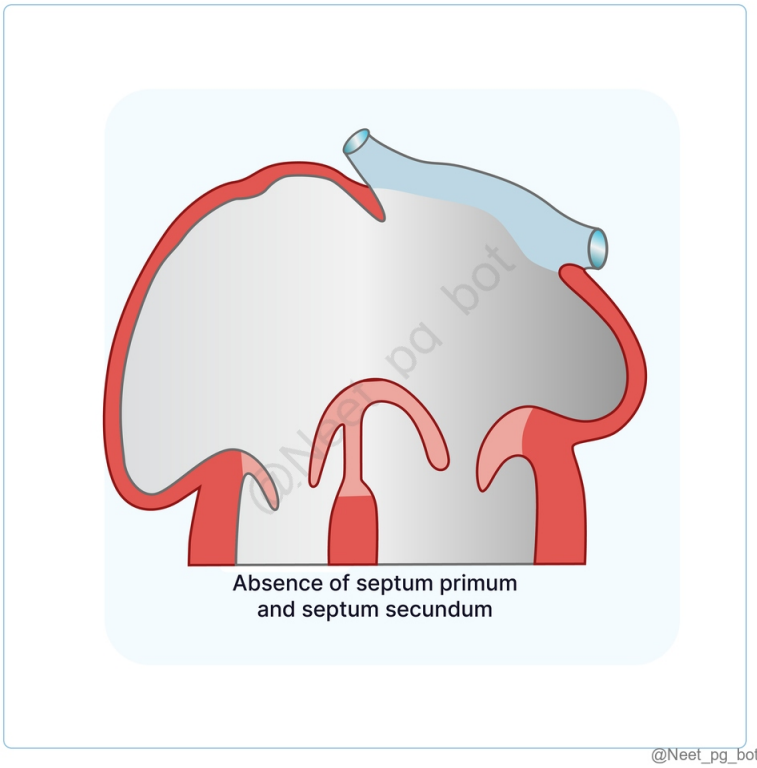

References:

Langman's Medical Embryology, 14th Edition, Pages 195, 197, 220

https://www.sciencedirect.com/science/article/abs/pii/S0733865120300242

https://www.sciencedirect.com/topics/medicine-and-dentistry/atrial-septal-defect

↑ *Back to this question in Part A*

@Neet_pg_bot

Q7: During an echocardiogram, a raised ridge is observed around a depression on the interatrial septum. Which structure is most likely involved? (Q848250)

A. Septum primum

B. Septum secundum

C. Fossa ovalis

D. Limbus fossa ovalis

Correct Answer: D. Limbus fossa ovalis

■ *Listen (English)*

■ *Listen (Hindi)*

Explanation: Limbus fossa ovalis is the raised ridge surrounding the fossa ovalis. Fossa Ovalis (Option C): Depressed area located in the lower portion of the right atrial side of the interatrial septum. Remnant of the foramen ovale. {{caption_text}} Septum primum which is on the left atrial side, forms the floor of the fossa ovalis. Limbus Fossa Ovalis (Option D): A raised ridge (annulus) that surrounds the perimeter of the fossa ovalis. It is formed from the septum secundum, an infolding of the atrial roof. Septum primum (Option A) forms the floor of the fossa ovalis, not the raised ridge surrounding it. Septum secundum (Option B) contributes to the formation of the limbus fossa ovalis but does not directly appear as a raised ridge itself.

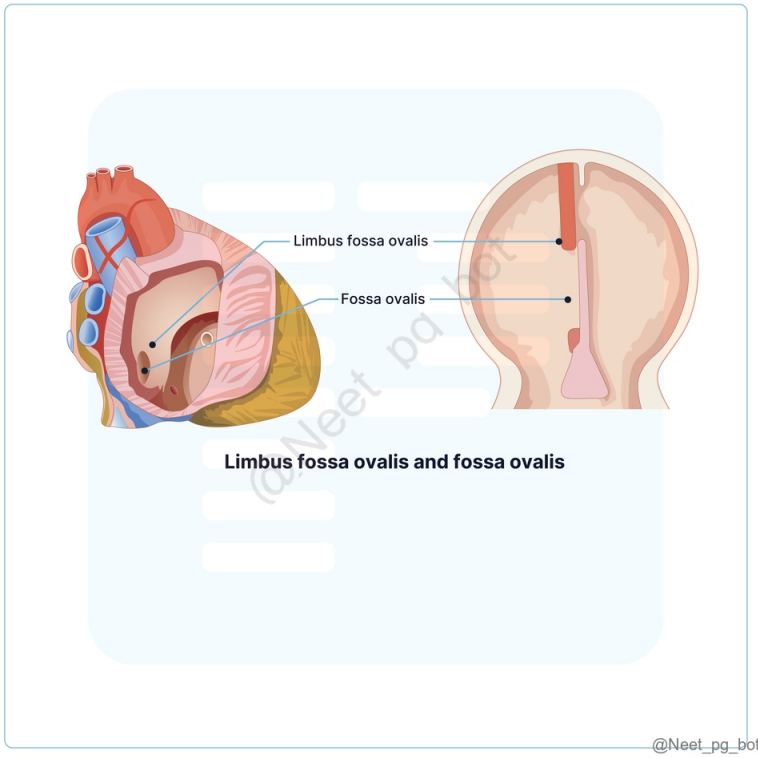

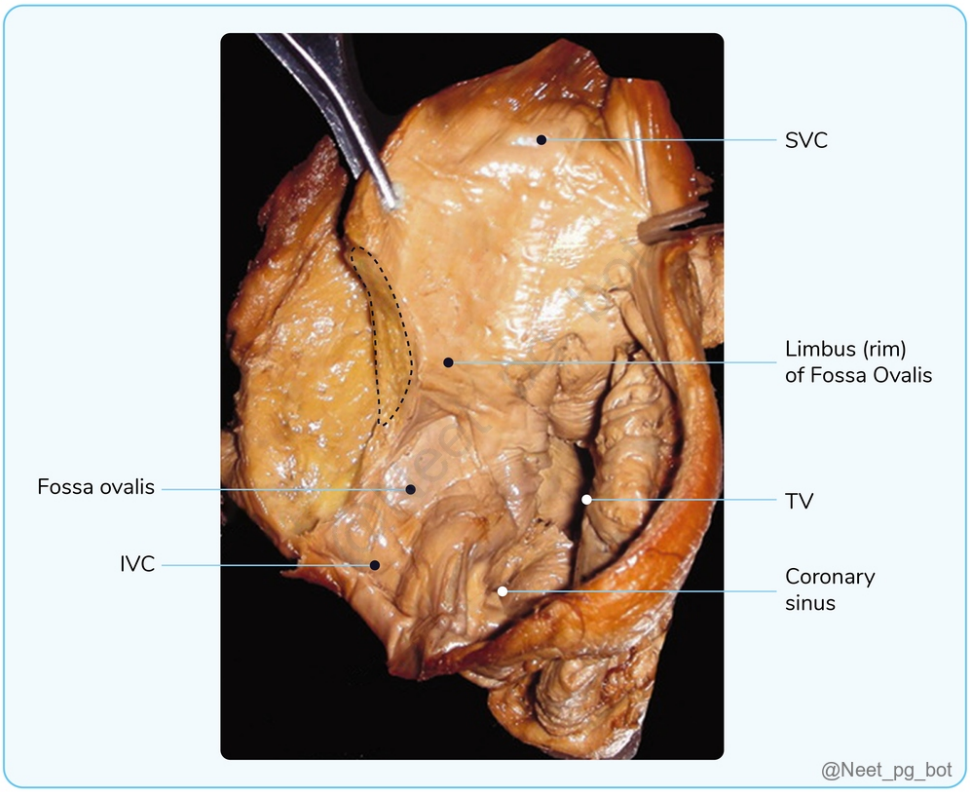

References:

https://www.ncbi.nlm.nih.gov/books/NBK538432/

↑ *Back to this question in Part A*

@Neet_pg_bot

Q8: During the spiraling process of the septum, what anatomical change occurs in relation to the pulmonary trunk and aorta? (Q848251)

A. The pulmonary trunk moves posteriorly.

B. The aorta moves to the right side of the body.

C. The pulmonary trunk crosses anteriorly and to the left of the aorta.

D. There is no change in the position of either vessel.

Correct Answer: C. The pulmonary trunk crosses anteriorly and to the left of the aorta.

■ *Listen (English)*

■ *Listen (Hindi)*

Explanation: The spiraling of the aorticopulmonary septum positions the pulmonary trunk anteriorly and to the left of the aorta . This arrangement is crucial for separating the pulmonary and systemic circulations. The bulbus cordis elongates into three segments: Proximal part forms bulboventricular chamber Middle part: Conus cordis (outflow tract) Distal part (Truncus arteriosus) develops into the ascending aorta and pulmonary trunk Truncus arteriosus undergoes septation and spiraling. There are two swellings along the truncus arteriosus- truncal swellings distally and conal swellings proximally. The truncal swellings, resembling endocardial cushions, divide the lumen into the proximal ascending aorta and the pulmonary trunk. The fusion of truncal and conal swellings establishes the pulmonary trunk's origin from the right ventricle and the aorta's origin from the left ventricle, with aortopulmonary valves forming at these fusion lines. Spiraling of the septum allows the pulmonary trunk to cross anterior and to the left of the aorta . (Option C) The pulmonary trunk moves posteriorly (Option A): The pulmonary trunk moves anteriorly. The aorta moves to the right side of the body (Option B): The aorta does end up in a more rightward position relative to the pulmonary trunk, but it does not specifically move to the right side of the body. There is no change in the position of either vessel (Option D) : The spiraling process specifically reorganizes the positions of the pulmonary trunk and aorta.

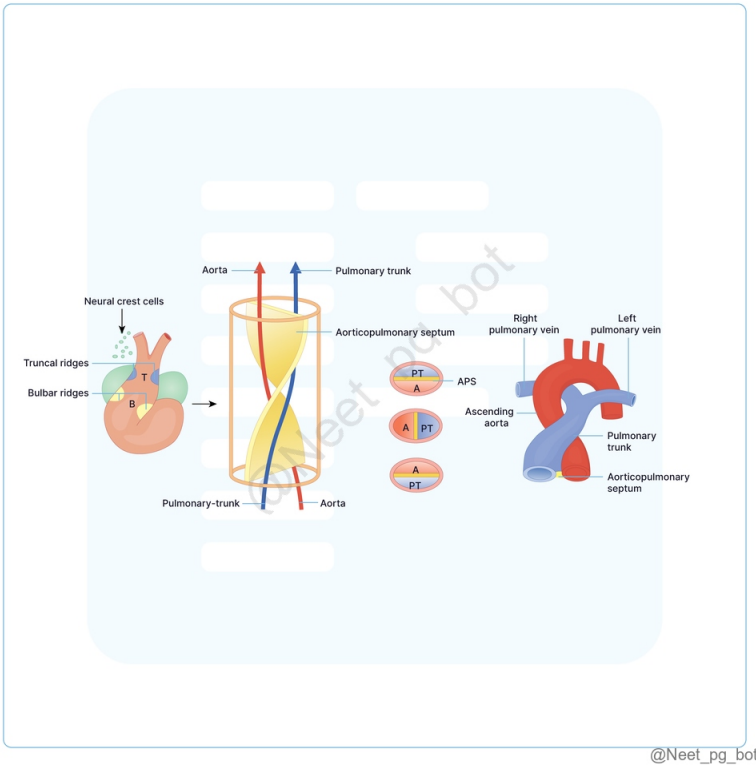

@Neet_pg_bot

References:

https://www.utmb.edu/Pedi_Ed/CoreV2/cardiology/Cardiology7.html

Inderbir Singh's Human Embryology, 11th Edition, Pages 236, 241, 243.

↑ *Back to this question in Part A*

@Neet_pg_bot

Q9: A newborn presents with significant cyanosis and a single large vessel exiting the heart on imaging studies. The echocardiogram shows a defect in the interventricular septum.What embryological failure led to this condition? (Q848254)

A. Failure of the atrioventricular septum to form.

B. Failure of the conotruncal ridges to form.

C. Failure of the aorticopulmonary septum to spiral.

D. Anterior displacement of the septum.

Correct Answer: B. Failure of the conotruncal ridges to form.

■ *Listen (English)*

■ *Listen (Hindi)*

Explanation: In this scenario, the newborn exhibits significant cyanosis and a single large vessel which is suggestive of persistent truncus arteriosus . It resulted from the failure of the conotruncal ridges to develop , which prevents the proper division of the outflow tracts into the aorta and pulmonary artery, leading to the mixing of oxygenated and deoxygenated blood. Aorticopulmonary septum anomalies: 1) Tetralogy of Fallot: Most common conotruncal heart defect. Cause: Due to unequal division of the conus and anterior displacement of the septum. (Option D) {{caption_text}} Features four cardiovascular issues: Pulmonary infundibular stenosis Overriding aorta Ventricular septal defect (VSD) Right ventricular hypertrophy 2) Persistent Truncus Arteriosus: Cause: Failure of conotruncal ridges to form. (Option B) {{caption_text}} Features: Leads to a single outflow tract and a defective interventricular septum. The truncus overrides both ventricles. Oxygenated and deoxygenated blood combine, with lung-bound blood entering systemic circulation.Results in congenital cyanotic heart disease. 3) Transposition of the Great Vessels: Cause: Occurs when the conotruncal septum fails to spiral correctly . (Option C) Features: Aorta connects to the right ventricle , pulmonary artery connects to the left ventricle . Patients cannot survive because deoxygenated blood from the body enters the right atrium through the superior and inferior vena cavae, then flows to the right ventricle and into the ascending aorta, bypassing the lungs completely. PDA is essential for survival, allowing blood flow to the lungs for oxygenation. Failure of the atrioventricular septum to form (Option A) refers to atrioventricular septal defects, which involve issues in the separation of the atria and ventricles, not the outflow tracts.

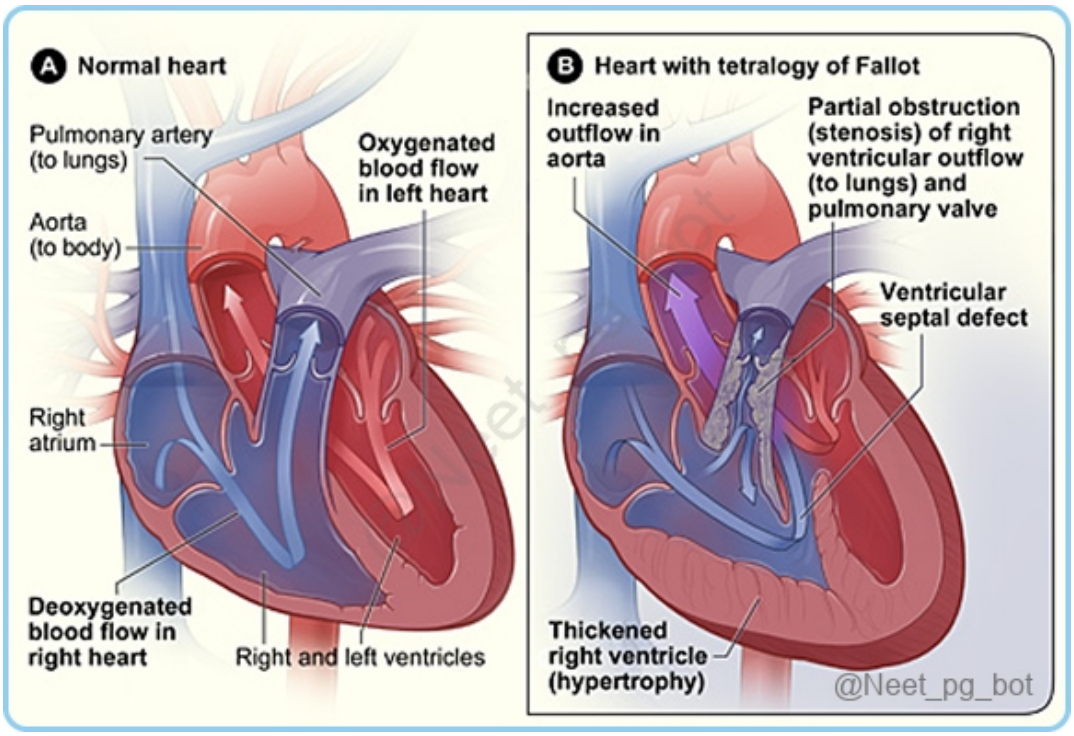
A Normal heart
Pulmonary artery (to lungs)
Oxygenated blood flow in left heart
Aorta (to body)
Right atrium
Deoxygenated blood flow in right heart
Right and left ventricles
B Heart with tetralogy of Fallot
Increased outflow in aorta
Partial obstruction (stenosis) of right ventricular outflow (to lungs) and pulmonary valve
Ventricular septal defect
Thickened right ventricle (hypertrophy)
@Neet_pg_bot

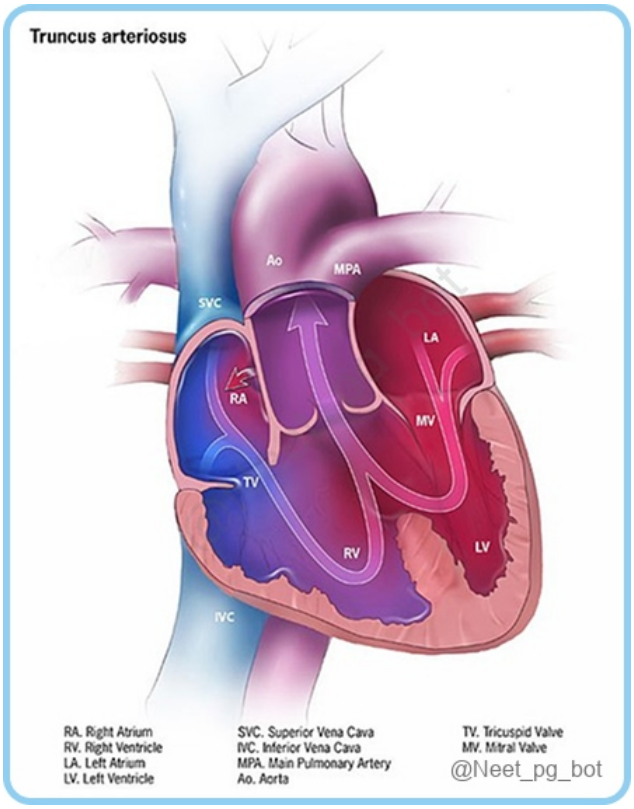
Truncus arteriosus
Ao
MPA
SVC
LA
RA
MV
TV
RV
LV
IVC
RA. Right Atrium
RV. Right Ventricle
LA. Left Atrium
LV. Left Ventricle
SVC. Superior Vena Cava
IVC. Inferior Vena Cava
MPA. Main Pulmonary Artery
Ao. Aorta
TV. Tricuspid Valve
MV. Mitral Valve
@Neet_pg_bot

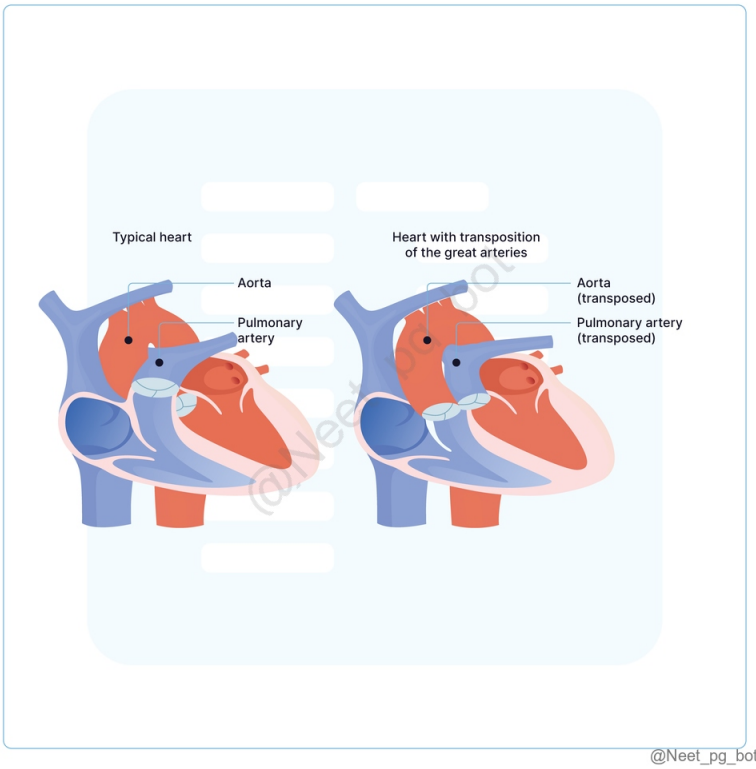

@Neet_pg_bot

References:

Langman's Medical Embryology, 14th Edition, Pages 202, 203, 204

↑ *Back to this question in Part A*

@Neet_pg_bot

Q10: Which of the following statements about the development of the interventricular septum is incorrect? (Q848255)

A. Muscular part grows from the floor of the bulboventricular cavity

B. Bulbar part forms from the fusion of two bulbar ridges.

C. Posterior part of the membranous septum separates the right ventricle from the left atrium.

D. Interventricular foramen forms above the muscular septum.

Correct Answer: C. Posterior part of the membranous septum separates the right ventricle from the left atrium.

■ *Listen (English)*

■ *Listen (Hindi)*

Explanation: The posterior part of the membranous septum separates the left ventricle from the right atrium , not the right ventricle from the left atrium. Formation of Interventricular Septum: The interventricular septum consists of three parts: Muscular part Bulbar part Membranous part 1. Muscular Part: Septum grows upward from the floor of the bulboventricular cavity, dividing it into right and left halves. (Option A) This growth is driven by passive dilation and hemodynamic forces. Septum fuses with the atrioventricular (AV) cushions (septum intermedium). Interventricular foramen forms between the two ventricles at the upper margin of the septum and is eventually closed by the septum intermedium and proximal bulbar septum. (Option D) 2. Bulbar Part: Two bulbar ridges (right and left) arise from the wall of the bulboventricular cavity. These ridges fuse to form the proximal bulbar septum, which grows downward toward the muscular septum but leaves a gap. (Option B) 3. Membranous Part: The gap between the muscular septum and the bulbar septum is filled by tissue from the AV cushions and bulbar ridges. Membranous septum consists of: Anterior part: Separates the right and left ventricles. Posterior part: Separates the left ventricle from the right atrium. (Option C) Mechanism of Septal Formation: Interventricular septum is likely formed by the downward enlargement of the right and left ventricular cavities on either side of the septum, rather than by active septal growth itself.

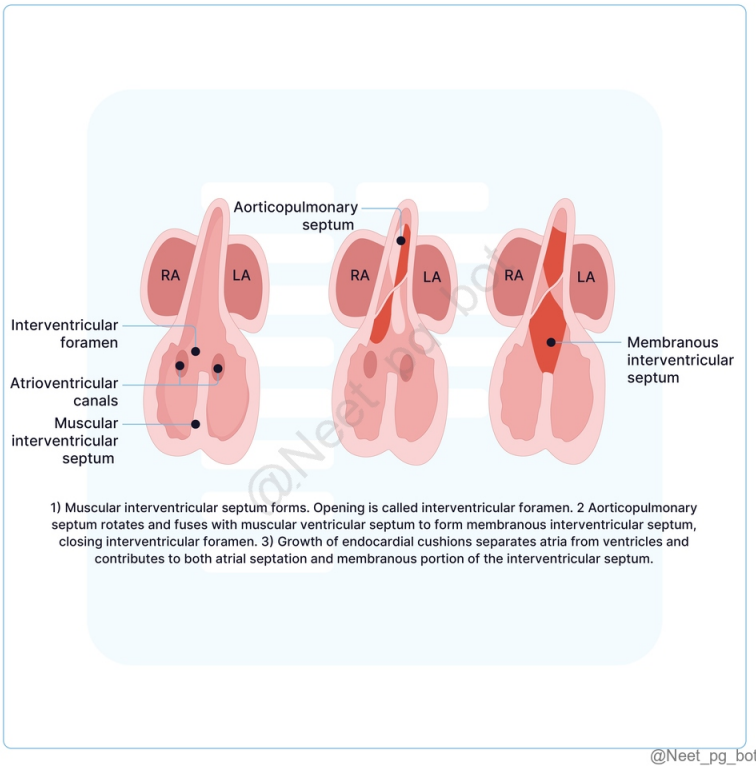

References:

Inderbir Singh’s Human Embryology, 11th Edition, Pages 237, 238

↑ *Back to this question in Part A*

@Neet_pg_bot

Q11: In fetal circulation, which structure allows oxygenated blood to bypass the lungs and directly enter the systemic circulation, ensuring oxygen delivery to the fetal brain and upper body? (Q848256)

A. Ductus venosus

B. Ductus arteriosus

C. Foramen ovale

D. Umbilical vein

Correct Answer: B. Ductus arteriosus

■ *Listen (English)*

■ *Listen (Hindi)*

Explanation: Ductus arteriosus allows most blood from the right ventricle to bypass the lungs by shunting it directly into the aorta, ensuring efficient delivery of oxygenated blood to the fetal brain and upper body. Fetal Circulation: Oxygenated Blood Flow: Placenta → Umbilical Vein → Ductus Venosus (bypasses liver) → Inferior Vena Cava → Right Atrium → Foramen Ovale → Left Atrium → Left Ventricle → Ascending Aorta → Oxygen to head, neck, and upper limbs Deoxygenated Blood Flow: Superior Vena Cava (SVC) → Right Atrium → Right Ventricle → Pulmonary Trunk → Ductus Arteriosus (bypass pulmonary circulation) → Descending Aorta → Lower body → Umbilical Arteries → Placenta (for oxygenation) Peculiarities of Fetal Circulation: Ductus Venosus: Directs blood to the inferior vena cava, bypassing the liver and preserving oxygen content. (Option A) Foramen Ovale: Allows equal distribution of blood to both sides of the heart, ensuring more oxygenated blood reaches vital organs in the upper body. (Option C) Ductus Arteriosus: Directs blood from the pulmonary trunk to the aorta, bypassing the lungs and allowing blood to flow to the placenta for oxygenation. (Option B) More oxygenated blood flows to the upper limbs, resulting in longer upper limbs compared to lower limbs in the fetus. Umbilical vein (Option D) carries oxygenated blood from the placenta to the fetus, but it doesn’t play a role in shunting blood past the lungs. Its function is to deliver oxygenated blood to the fetal circulation through the ductus venosus.

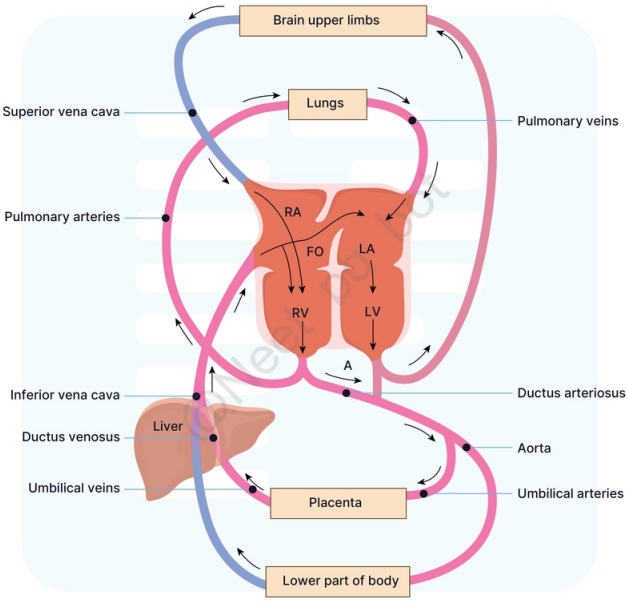

Scheme of the fetal circulation. The degree of deoxygenation is shown by the intensity of shading.
RA = right atrium; LA left atrium; RV = right ventricle; LV = left ventricle; FO foramen ovale

@Neet_pg_bot

References:

Langman's Medical embryology, 14th Edition, Pages 216, 217

Inderbir Singh's Human Embryology, 11th Edition, Page 260

↑ *Back to this question in Part A*

@Neet_pg_bot

Q12: A 3-day-old neonate presents with cyanosis, rapid breathing, and a machinery-like murmur on auscultation. Echocardiography reveals a left-to-right shunt at the level of the great vessels. Which of the following fetal circulatory changes is most likely responsible for this presentation? (Q848257)

A. Persistent foramen ovale

B. Patent ductus arteriosus

C. Closure of ductus venosus

D. Malrotation of the great arteries

Correct Answer: B. Patent ductus arteriosus

- *Listen (English)*
- *Listen (Hindi)*

Explanation: A machinery-like murmur in a neonate along with cyanosis and rapid breathing suggests patent ductus arteriosus (PDA) . PDA is a fetal vessel connecting the pulmonary artery to the aorta that normally closes soon after birth. If it remains open (patent), it causes a left-to-right shunt (oxygenated blood from the aorta flows back into the pulmonary artery), leading to volume overload in the lungs, causing cyanosis and respiratory distress. Persistent foramen ovale typically causes a different murmur and shunting pattern; closure of ductus venosus affects liver blood flow; malrotation of great arteries affects vessel positioning, not shunting or murmur. Fetal Circulatory Shunts and Their Changes After Birth Fetal Structure Function During Fetal Life Remnant Ductus arteriosus Shunts blood from the pulmonary artery to the aorta, bypassing pulmonary circulation. Ligamentum arteriosum Foramen ovale Shunts blood from the right atrium to the left atrium Fossa ovalis Ductus venosus Shunts blood from the umbilical vein to the inferior vena cava, bypassing the liver Ligamentum venosum Umbilical vein Carries oxygenated blood from the placenta to the fetus Ligamentum teres hepatis Umbilical arteries Carries deoxygenated blood from the fetus to the placenta Proximal part: Superior vesical artery Distal part: Medial umbilical ligaments Persistent foramen ovale (Option A) allows the shunting of blood from the right atrium to the left atrium, bypassing the lungs. While it can cause cyanosis, the clinical presentation usually doesn't include a machinery murmur, and it is typically asymptomatic or mild compared to PDA. Closure of ductus venosus (Option C) occurs normally after birth and redirects blood flow, but it does not cause shunting or significant symptoms like cyanosis or a murmur. Malrotation of the great arteries (Option D) is a form of congenital heart defect that can cause cyanosis, but it would typically be detected earlier, often with profound cyanosis from birth. Unlike PDA, it does not present with a machinery-like murmur and does not involve a left-to-right shunt.

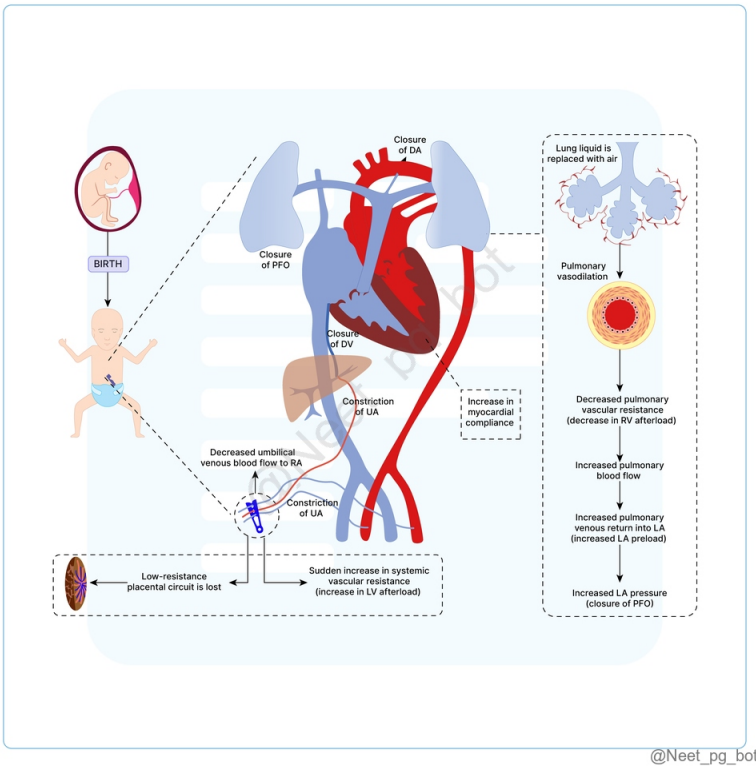

@Neet_pg_bot

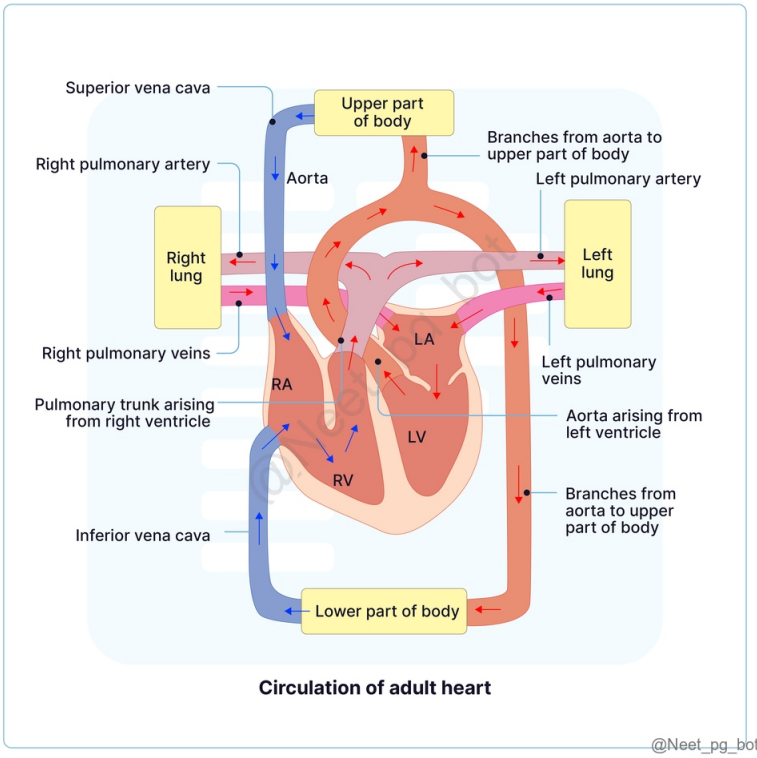

References:

Inderbir Singh’s Human Embryology, 11th Edition, Page 26

↑ *Back to this question in Part A*

@Neet_pg_bot

• [07_Thorax] 034 Heart And Thorax Anatomy - I

« Back to Folder Directory

[07_Thorax] 034 Heart And Thorax Anatomy - I — Quick Jump

Q1 (p. 1734)	*Q2 (p. 1736)*	*Q3 (p. 1737)*	*Q4 (p. 1737)*	*Q5 (p. 1739)*	*Q6 (p. 1741)*
Q7 (p. 1742)	*Q8 (p. 1744)*	*Q9 (p. 1746)*	*Q10 (p. 1748)*	*Q11 (p. 1749)*	*Q12 (p. 1750)*
Q13 (p. 1751)	*Q14 (p. 1752)*	*Q15 (p. 1753)*	*Q16 (p. 1756)*	*Q17 (p. 1757)*	*Q18 (p. 1758)*
Q19 (p. 1760)	*Q20 (p. 1761)*	*Q21 (p. 1762)*	*Q22 (p. 1764)*	*Q23 (p. 1766)*	*Q24 (p. 1768)*
Q25 (p. 1770)	*Q26 (p. 1771)*	*Q27 (p. 1773)*	*Q28 (p. 1773)*	*Q29 (p. 1775)*	*Q30 (p. 1776)*

Q1: In the given CT slice, A and B respectively represent? {{caption_text}} (Q848347)

A. Main bronchus, Ascending Aorta

B. Main bronchus, Descending Aorta

C. Ascending Aorta, Descending Aorta

D. Descending Aorta, Ascending Aorta

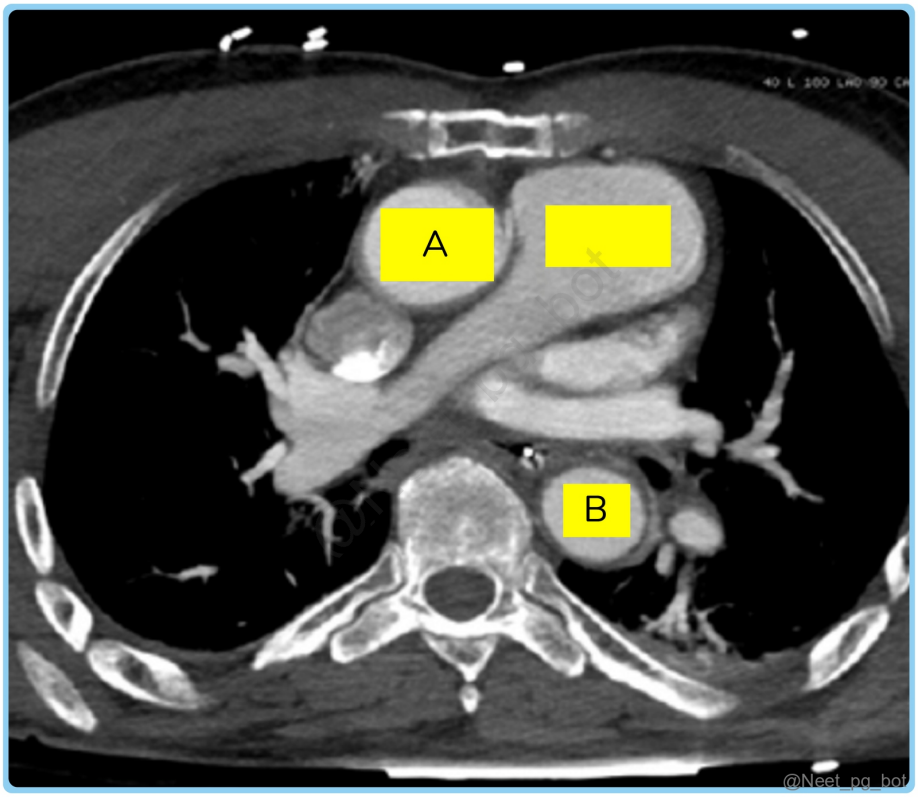

Correct Answer: C. Ascending Aorta, Descending Aorta

- *Listen (English)*
- *Listen (Hindi)*

Explanation: The CT slice is at the level of T5, in which A represents the ascending aorta & B represents descending aorta . {{caption_text}}

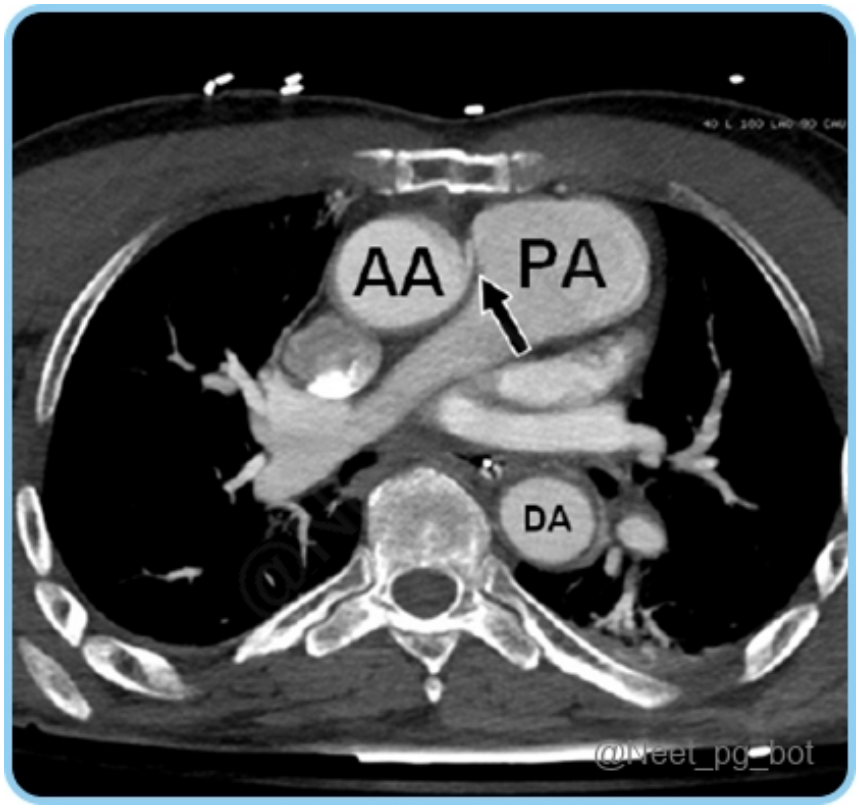

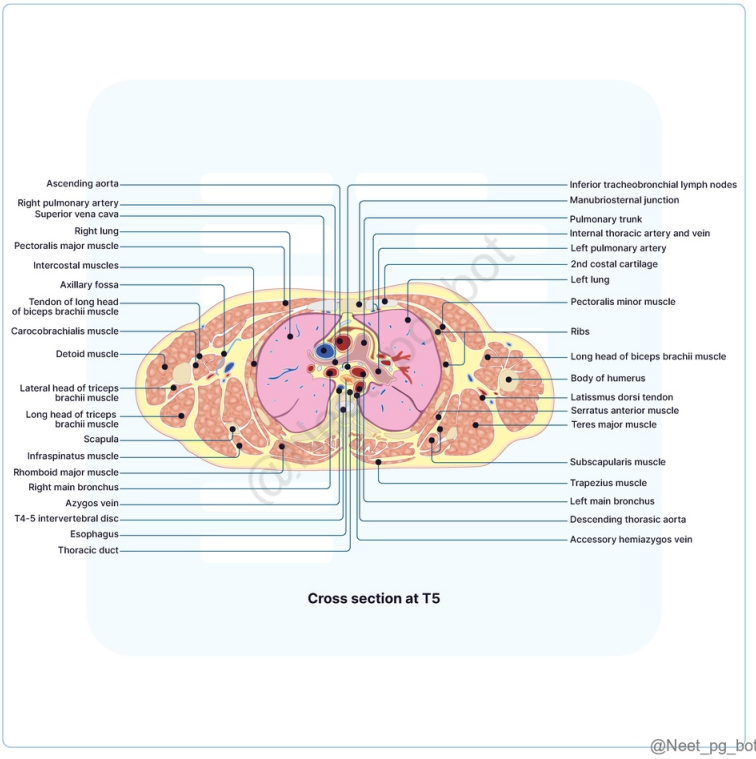

References:

Netter Atlas of Human Anatomy, 8th Edition, Page 292 Plate 265

↑ *Back to this question in Part A*

@Neet_pg_bot

Q2: The pleural cupola is located: (Q848361)

A. Above the diaphragm, covering the lower lung

B. Over the apex of the lung, reaching 2 to 3 cm above the clavicle

C. Near the midline of the chest at the level of the heart

D. At the base of the lungs, covered by the suprapleural membrane

Correct Answer: B. Over the apex of the lung, reaching 2 to 3 cm above the clavicle

■ *Listen (English)*

■ *Listen (Hindi)*

Explanation: Cervical Pleura Extends from the inner border of the 1st rib. Covers the apex of the lung. Passes downwards and medially to continue with the mediastinal pleura. Pleural Cupola Forms a cup-like dome over the apex of the lung. The summit of the dome reaches 2 to 3 cm higher than the medial third of the clavicle , at the level of the neck of the first rib. Suprapleural Membrane (Sibson's Fascia) Covers the cervical pleura from the scalenus minimus and the endothoracic fascia. Runs C7 transverse process → inner 1st rib; continuous medially with pretracheal fascia. Relation to Structures All structures related to the apex of the lung are superficial to the suprapleural membrane.

References:

Inderbir Singhs Textbook of Anatomy, Volume 1, 6th Edition, Page 56

↑ *Back to this question in Part A*

@Neet_pg_bot

Q3: Where is pain from the mediastinal pleura typically referred? (Q848360)

A. In the lower abdomen

B. Over the ipsilateral shoulder

C. In the lumbar region

D. In the lower back near the kidneys

Correct Answer: B. Over the ipsilateral shoulder

■ *Listen (English)*

■ *Listen (Hindi)*

Explanation: Pleura Structure and Function Visceral Pleura: Surrounds lung tissue. Composed of a single mesothelial cell layer. Blood supply from bronchial arteries. Innervation: No connective tissue; innervated by the vagus nerve, insensitive to pain. Parietal Pleura: Lines the inner chest wall. Contains stomata that drain pleural fluid into lymphatic capillaries. Connective tissue present; innervated by sensory nerve fibers. Innervation: Connective tissue; innervated by intercostal nerves and phrenic nerve. Phrenic Nerve: Predominantly innervates the central diaphragmatic region, referred pain to the ipsilateral shoulder.

References:

www.ncbi.nlm.nih.gov/books/NBK558958/#

↑ *Back to this question in Part A*

@Neet_pg_bot

Q4: Which of the following statements is correct regarding the cardiac plexuses? (Q848359)

A. The superficial cardiac plexus is located behind the arch of the aorta, in front of the bifurcation of the trachea.

B. The deep cardiac plexus receives cardiac branches from the vagus and recurrent laryngeal nerves, except the inferior cervical cardiac branch of the left vagus nerve.

C. The superficial cardiac plexus distributes to the left coronary artery and right anterior pulmonary plexus.

D. The deep cardiac plexus is formed only by the superior cervical cardiac branch of the left sympathetic chain.

Correct Answer: B. The deep cardiac plexus receives cardiac branches from the vagus and recurrent laryngeal nerves, except the inferior cervical cardiac branch of the left vagus nerve.

■ *Listen (English)*

■ *Listen (Hindi)*

Explanation: Cardiac ganglion of Wrisberg, also called the juxta ductal body or the aortico-pulmonary ganglionic mass. Cardiac Plexuses Superficial Cardiac Plexus: Location: Below the arch of the aorta, in front of the bifurcation of the pulmonary trunk, to the right of the ligamentum arteriosum (Option A) Cardiac Ganglion of Wrisberg : Located close to the ligamentum arteriosum. Formation: (a) Superior cervical cardiac branch of the left cervical sympathetic trunk. (b) Inferior cervical cardiac branch of the left vagus nerve. Distribution: (Option C) (a) Deep cardiac plexus. (b) Right coronary artery. (c) Left anterior pulmonary plexus. Deep Cardiac Plexus: Location: In front of the bifurcation of the trachea, behind the arch of the aorta. Formation: (a) Cardiac branches from three cervical and upper 4-5 thoracic ganglia of the sympathetic chains (except the superior cervical cardiac branch of the left sympathetic chain) (Option D) (b) Cardiac branches from the vagus and recurrent laryngeal nerves (except the inferior cervical cardiac branch of the left vagus nerve) (Option B) The illustration below shows Deep cardiac plexus

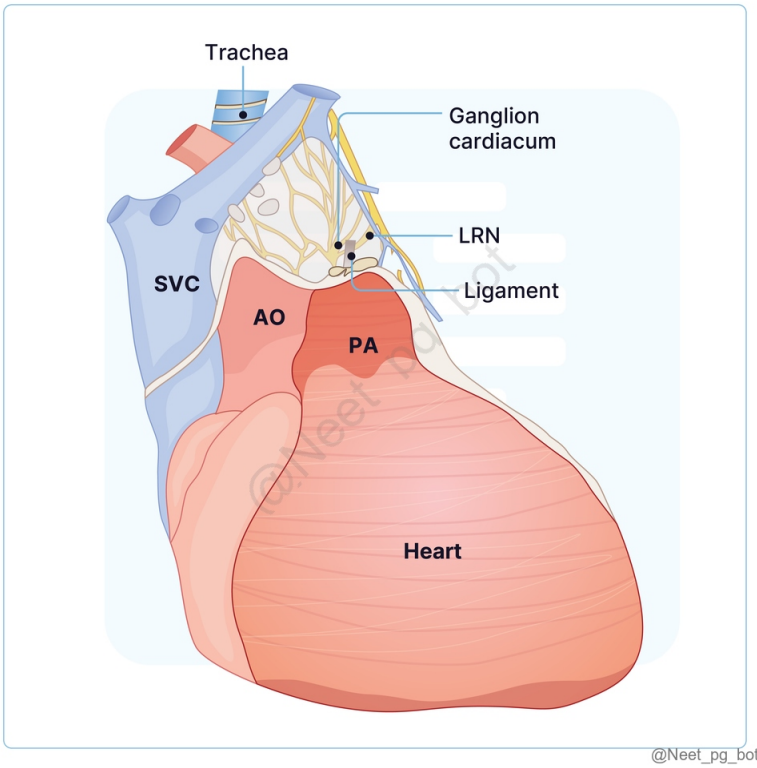

References:

Ganglia

Vishram Singh Textbook of Anatomy, Volume 1, 2nd Edition, Pages 278-279

↑ *Back to this question in Part A*

@Neet_pg_bot

Q5: An axial CT scan of the thorax shows a slice where the aortic arch is visible, along with the trachea bifurcating into the main bronchi. At which anatomical level is this axial section most likely taken? {{caption_text}} (Q848358)

A. T1-T2

B. T4-T5

C. T5-T6

D. T7-T8

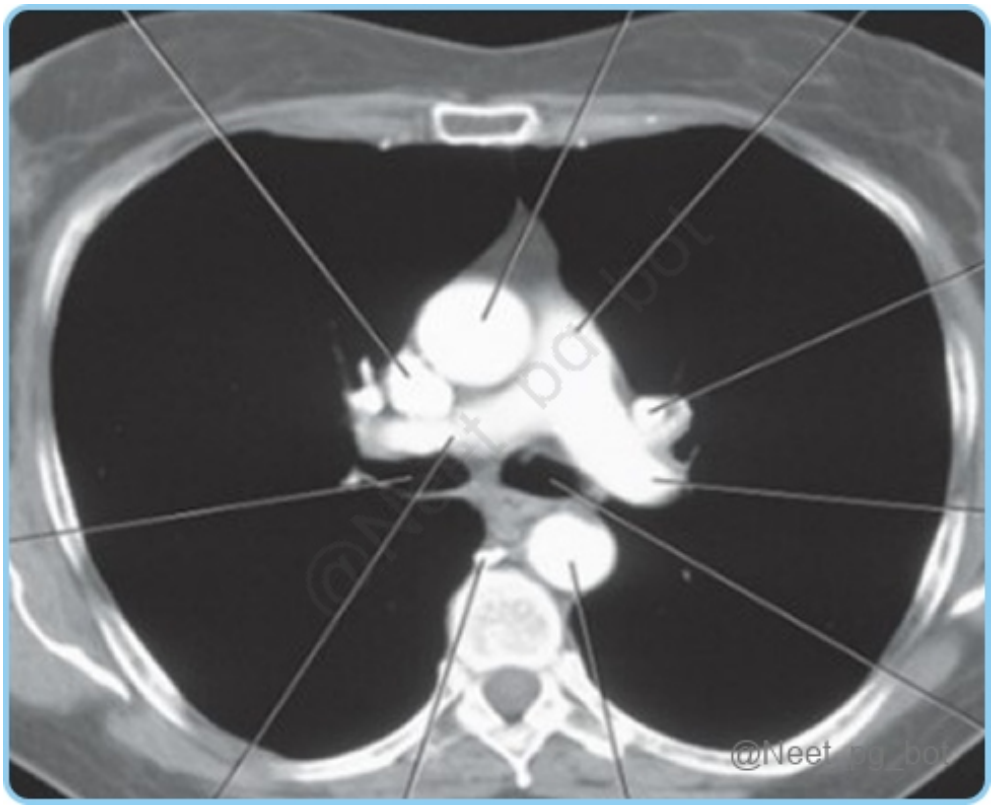

Correct Answer: B. T4-T5

- *Listen (English)*
- *Listen (Hindi)*

Explanation: At this level, the aortic arch is usually seen, and the trachea begins to bifurcate into the right and left main bronchi. Level of the Thoracic Inlet : This is at the top of the thoracic cavity, where the trachea and esophagus enter. Level of the Aortic Arch : Located around the T4-T5 vertebral level, where the aorta arches over the left main bronchus. Level of the Carina : At the T5-T6 level, this is where the trachea bifurcates into the right and left main bronchi. Level of the Heart : The heart is typically seen from T6 to T9 . You can identify the chambers (right atrium, left atrium, ventricles) and major vessels (aorta, pulmonary arteries). Level of the Diaphragm : The diaphragm typically corresponds to the T10 vertebral level, which can help in distinguishing between thoracic and abdominal structures. Level of the Esophagus : The esophagus runs along the midline and can be seen at various levels, usually starting from the cervical region down to T10. Level of the Thoracic Spine : The thoracic vertebrae can be used as references; typically, there are 12 thoracic vertebrae. {{caption_text}}

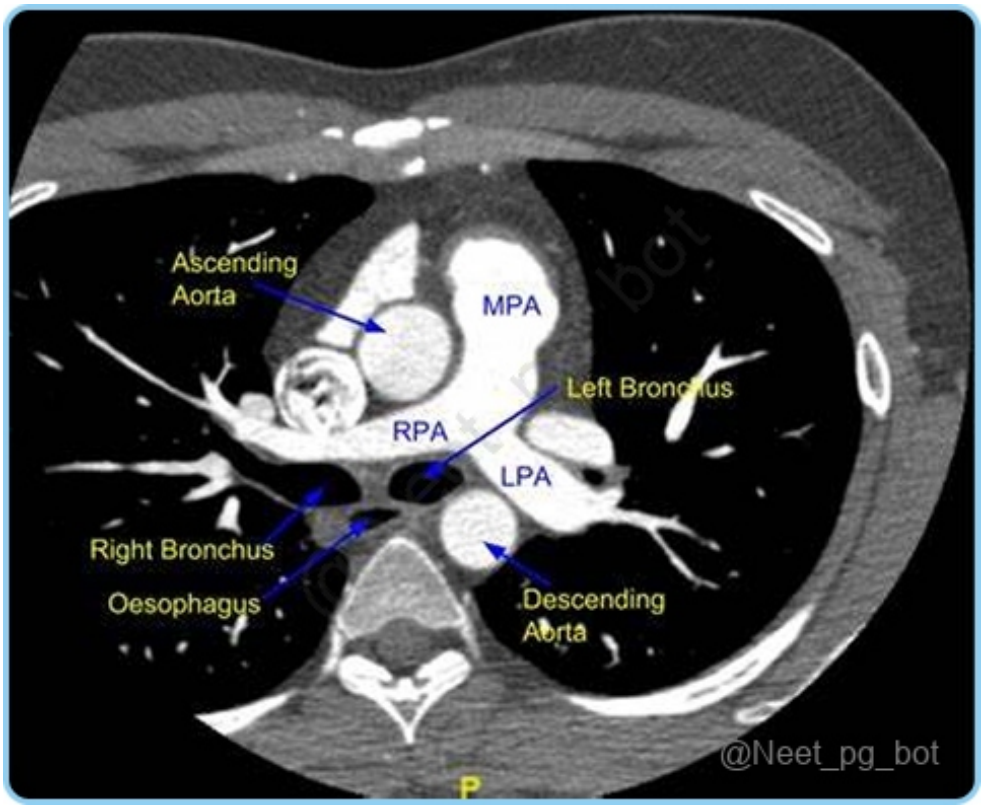

References:

https://www.ncbi.nlm.nih.gov/books/NBK557710/

https://www.imaios.com/en/e-anatomy/thorax/ct-axial-chest

↑ *Back to this question in Part A*

@Neet_pg_bot

Q6: Which of the following structures is commonly associated with a notable impression on the left lung? (Q848357)

A. Aorta

B. Superior vena cava

C. Oesophagus

D. Azygos vein

Correct Answer: A. Aorta

■ *Listen (English)*

■ *Listen (Hindi)*

Explanation: The left lung shows an impression from the aortic arch, which arches over the left main bronchus. Lung impressions refer to the indentations or impressions made on the surface of the lungs by adjacent structures in the thoracic cavity. Right lung impressions Left lung impressions Cardiac Impression (Right Atrium & Auricle) Superior Vena Cava (SVC) Impression (Option B) Right Ventricle (Small part) Right Brachiocephalic Vein (Lower part) Azygos Vein Impression (Option D) Esophageal Impression (Option C) Inferior Vena Cava (IVC) Impression Tracheal Impression Right Vagus Nerve Impression Right Phrenic Nerve Impression Cardiac Impression (Left Ventricle, Auricle, part of Right Ventricle) Pulmonary Trunk Impression Arch of Aorta Impression Descending Thoracic Aorta Impression Left Subclavian Artery Impression Thoracic Duct Impression Esophageal Impression Left Brachiocephalic Vein Impression Left Vagus Nerve Impression Left Phrenic Nerve Impression Left Recurrent Laryngeal Nerve Impression

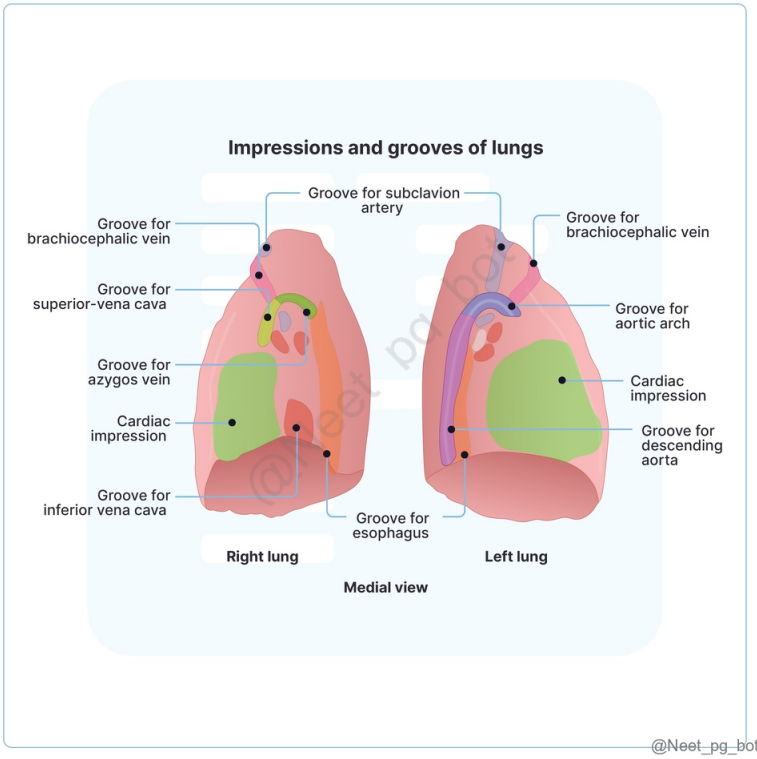

References:

BD Chaurasia Human Anatomy, 8th Edition, Page 267

↑ *Back to this question in Part A*

@Neet_pg_bot

Q7: A 60-year-old patient presents with a history of progressive shortness of breath and swelling in the neck. Imaging reveals distended chest wall veins and a mediastinal mass with known metastasis. Which of the following is the most likely cause of these

findings? {{caption_text}} (Q848356)

A. Right heart failure

B. Superior vena cava (SVC) obstruction

C. Pulmonary embolism

D. Thoracic aortic aneurysm



Correct Answer: B. Superior vena cava (SVC) obstruction

■ *Listen (English)*

■ *Listen (Hindi)*

Explanation: The presence of distended chest wall veins (collaterals) is highly indicative of increased venous pressure, commonly associated with superior vena cava (SVC) obstruction. In this case, the history of a mediastinal mass and metastasis suggests that the mass is compressing the SVC, leading to venous obstruction. This obstruction can cause the characteristic collateral circulation (distended chest wall veins) to develop, as the body attempts to reroute blood flow to bypass the obstruction. The illustration below shows signs of SVC obstruction Inferior Vena Cava (IVC) Obstruction: Inferior vena cava (IVC) obstruction, also known as IVC syndrome, results from compression, thrombosis, or invasion of the IVC, leading to impaired venous return from the lower body. Key Clinical Features: Bilateral lower extremity edema due to venous hypertension and pooling. Tachycardia, hypotension, and signs of shock from reduced preload.■ Abdominal pain, ascites, hepatomegaly from venous congestion. Associated Signs: Collateral vein dilation on abdomen or thighs (caput medusae-like).■ Dyspnea, hypoxia in severe cases; renal dysfunction if renal veins involved. In pregnancy: supine hypotensive

syndrome, fetal distress.

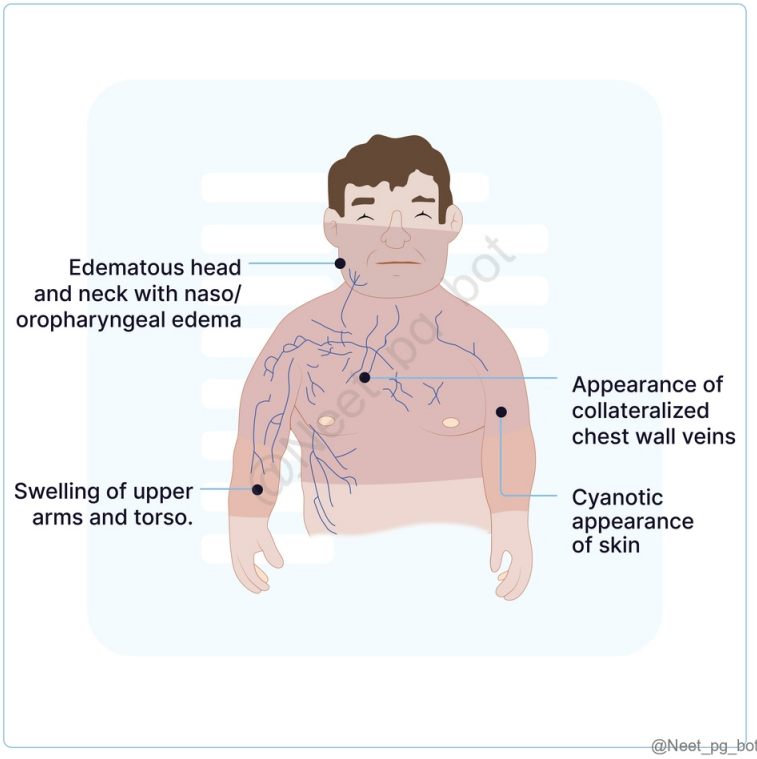

References:

https://www.ncbi.nlm.nih.gov/books/NBK441981/#

↑ *Back to this question in Part A*

@Neet_pg_bot

Q8: A 56-year-old male patient with a history of gastric carcinoma now presents with sharp or pleuritic pain that worsens with deep breaths or coughing. Pleural effusion is suspected and a pleural tap was done which showed the fluid shown in the image. Based on the knowledge of the course of thoracic duct, where does the thoracic duct drain lymph? {{caption_text}} (Q848355)

A. Into the right brachiocephalic vein

B. Into the junction of the left subclavian vein and left internal jugular vein

C. Directly into the inferior vena cava

D. Into the right lymphatic duct



Correct Answer: B. Into the junction of the left subclavian vein and left internal jugular vein

- *Listen (English)*
- *Listen (Hindi)*

Explanation: If the pleural effusion fluid is chylous (chyle), it indicates leakage of lymphatic fluid, often due to disruption or injury to the thoracic duct. Chylothorax is a condition where chyle accumulates in the pleural space, leading to pleural effusion. The thoracic duct drains lymph into the junction of the left subclavian vein and left internal jugular vein. Thoracic duct The thoracic duct starts as the cisterna chyli in the abdomen at the lower border of the T12 vertebra. It ascends through the aortic opening of the diaphragm. The duct collects lymph from the left jugular, subclavian, and bronchomediastinal trunks . It ends by draining into the junction of the left subclavian vein and the left internal jugular vein. (Option A, C, & D ruled out) The thoracic duct carries lymph from the lower limbs, pelvic cavity, abdominal cavity, and the left side of the thorax, head, neck, and arm.

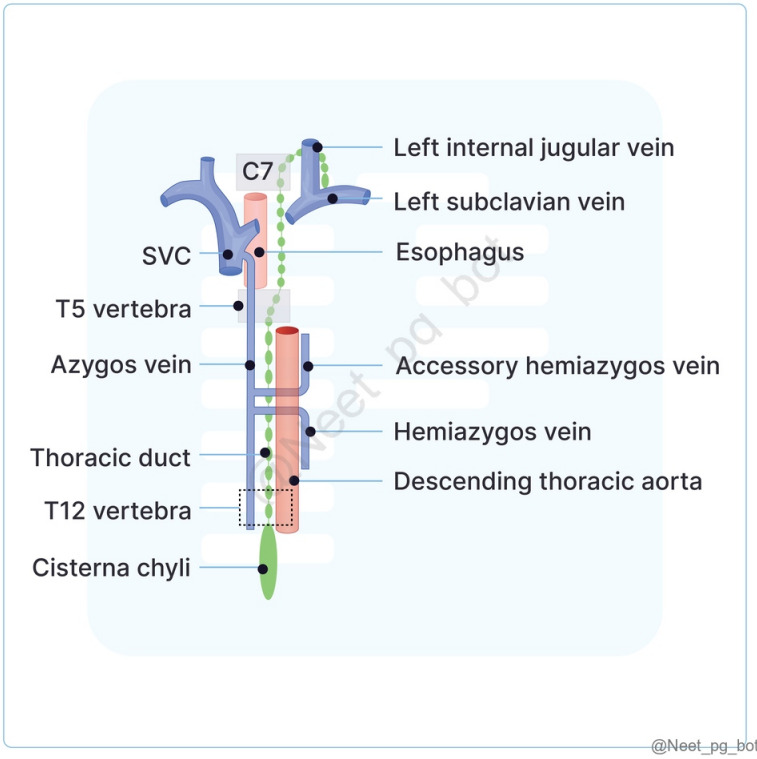

References:

Snell Clinical Anatomy by Regions, 10th Edition, Page 263, 264

Vishram Singh Textbook of Anatomy, Volume 1, 2nd Edition, Page 302, 303

↑ *Back to this question in Part A*

@Neet_pg_bot

Q9: Which part of the body is not drained by the right lymphatic duct? (Q848354)

A. Right side of the head and neck

B. Right upper limb

C. Right side of the thorax

D. Right abdomen

Correct Answer: D. Right abdomen

■ *Listen (English)*

■ *Listen (Hindi)*

Explanation: The right lymphatic duct does not drain the right abdomen; this region is typically drained by the thoracic duct, which handles lymph from the lower half of the body, including the abdomen. Right Lymphatic Duct The right lymphatic duct may form from the convergence of the right jugular, subclavian, and bronchomediastinal trunks. These trunks drain lymph from the right side of the head and neck, the right upper limb, and the right side of the thorax. It opens into the beginning of the right brachiocephalic vein. Alternatively, the lymphatic trunks may drain directly into the major veins at the root of the neck. Thoracic duct: Thoracic duct is the largest lymphatic duct → Drains lymph from the entire body Thoracic duct has a beaded appearance due to numerous valves Not drained by thoracic duct: Right side of head and neck Right side of thoracic wall Right lung Right half of heart Convex surface of liver Right upper limb

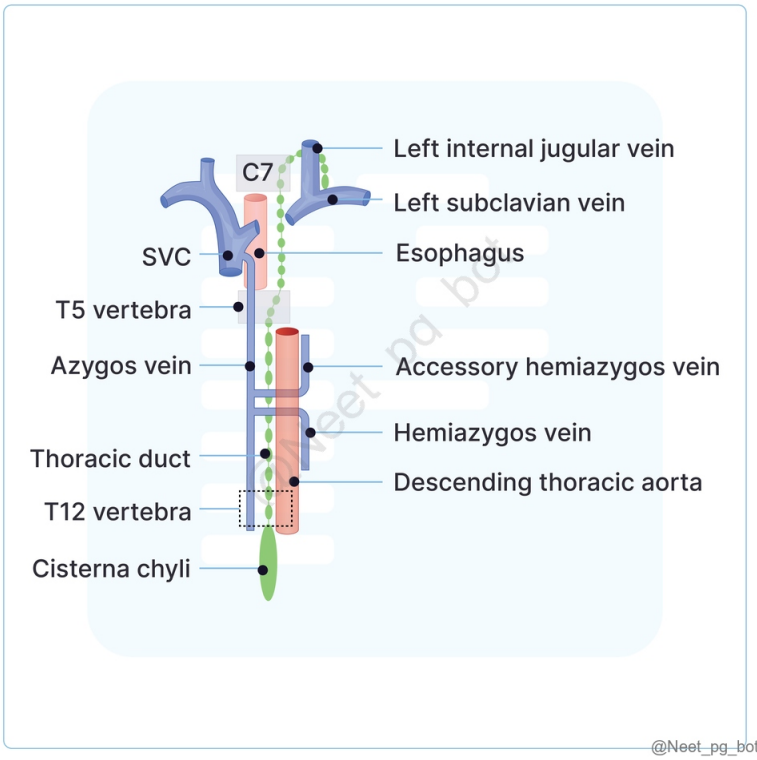

The thoracic duct ascends from the cisterna chyli (Lymphatic heart at the level of L1/L2)

↓

Crosses diaphragm through aortic opening (At the level of T12)

↓

Deviates to the left (at the level of T5)

↓

Drains lymph at the junction of left subclavian vein & left internal jugular vein (at the level of C7)

@Neet_pg_bot

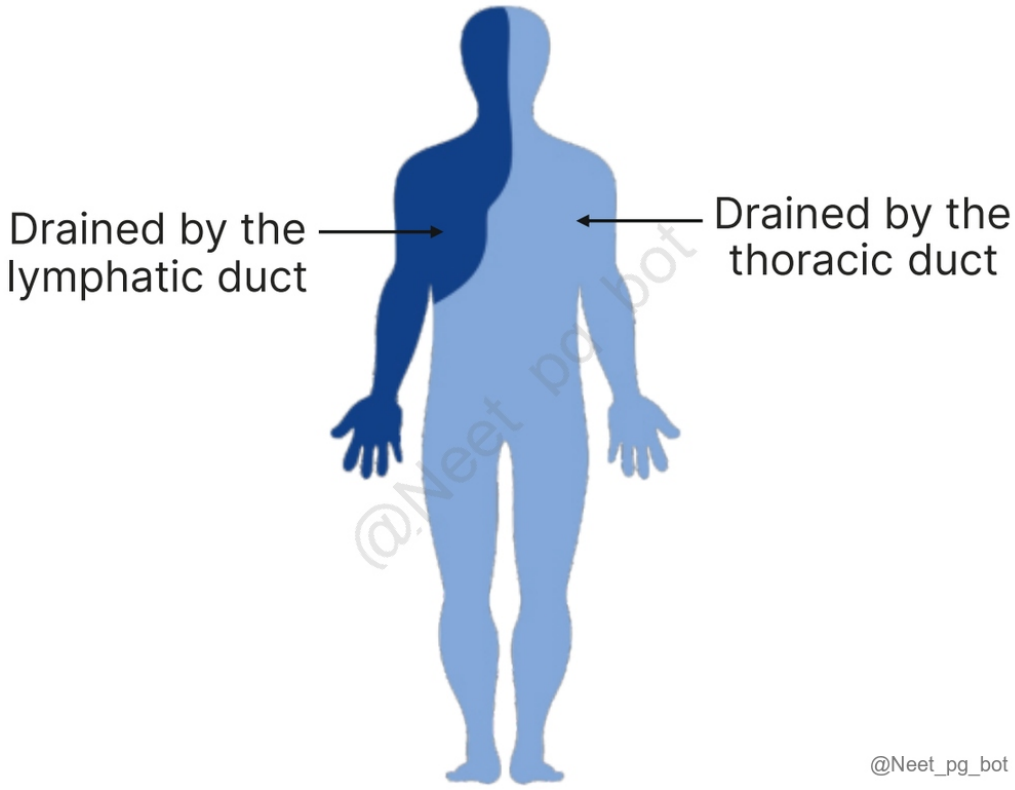

References:

Snell Clinical Anatomy by Region, 10th Edition, Page 264

↑ *Back to this question in Part A*

@Neet_pg_bot

Q10: Which of the following statements is true regarding the azygos and hemiazygos veins? (Q848353)

A. The azygos vein drains directly into the inferior vena cava.

B. The inferior hemiazygos vein drains into the superior vena cava.

C. The superior hemiazygos vein drains into the azygos vein.

D. In an obstruction of the SVC, the superior hemiazygos vein acts as the primary collateral pathway.

Correct Answer: C. The superior hemiazygos vein drains into the azygos vein.

■ *Listen (English)*

■ *Listen (Hindi)*

Explanation: The superior hemiazygos vein drains into the azygos vein at the level of the seventh thoracic vertebra. Azygos Vein Forms from the right ascending lumbar and subcostal veins. It drains into the posterior surface of the superior vena cava. (Option A ruled out) If there is an obstruction of the SVC, the azygos vein acts as the primary collateral pathway to redirect blood from the upper half of the body to the IVC. (Option D ruled out) Inferior Hemiazygos Vein Inferior hemiazygos forms from the left ascending lumbar and subcostal veins. Ascends through the left crus and at T8 crosses right to join the azygos receiving tributaries from the lower left intercostal and mediastinal veins. (Option B ruled out) Superior Hemiazygos Vein The superior hemiazygos vein is created by the union of the left superior intercostal vein and the fourth to eighth intercostal veins. It drains into the azygos vein at the level of the seventh thoracic vertebra.

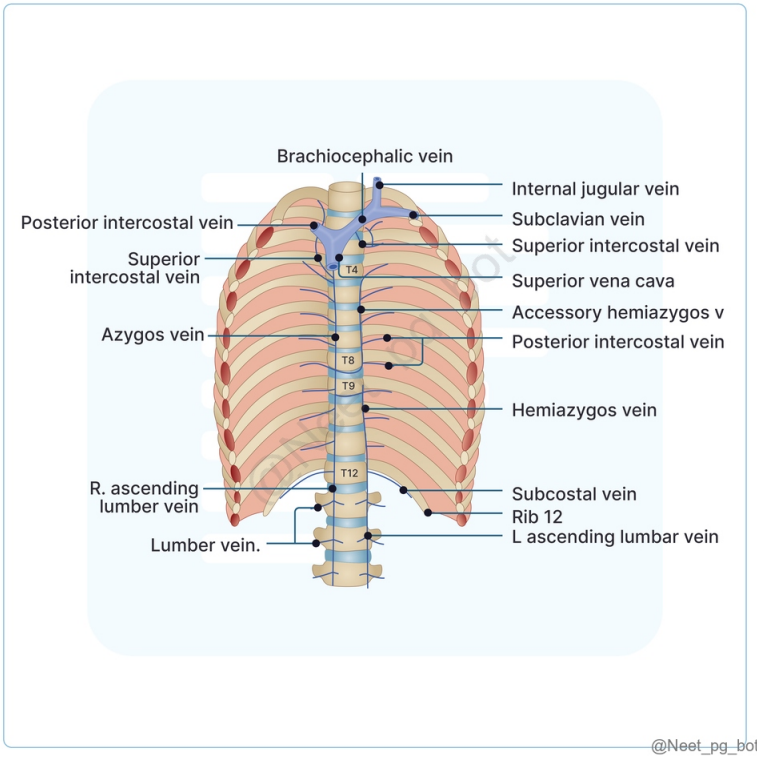

References:

Snell Clinical Anatomy by Regions, 10th Edition, Page 262

VVishram Singh Textbook of Anatomy, Volume 1, 2nd Edition, Page 306

↑ *Back to this question in Part A*

@Neet_pg_bot

Q11: Which of the following statements about the phrenic nerve is false? (Q848352)

A. The phrenic nerve contains both motor and sensory fibers.

B. Efferent fibers of the phrenic nerve supply the diaphragm muscle.

C. Afferent fibers transmit sensory information from the liver capsule.

D. Paralysis of the phrenic nerve can result from pressure from malignant tumors in the mediastinum.

Correct Answer: C. Afferent fibers transmit sensory information from the liver capsule.

■ *Listen (English)*

■ *Listen (Hindi)*

Explanation: Afferent fibers transmit sensory information from both the upper and lower surfaces of the diaphragm, as well as from the pericardium and mediastinal pleura and not from the liver capsule. Phrenic Nerve The phrenic nerves contain both efferent (motor) and afferent (sensory) fibers . (Option A ruled out) The efferent fibers provide the sole motor supply to the diaphragm muscle. (Option B ruled out) The afferent fibers transmit sensory information to the central nervous system from the peritoneum covering the diaphragm's undersurface, the pleura on the diaphragm's upper surface, and the pericardium and mediastinal parietal pleura. Paralysis of the phrenic nerve may result from pressure from malignant tumors in the mediastinum. (Option D ruled out) Historically, surgical methods like crushing or sectioning the nerve in the neck were used to treat lung tuberculosis affecting the lower lobes, leading to diaphragm paralysis on that side. This causes the elevated, immobile dome of the diaphragm to provide rest to the affected lung.

References:

Snell Clinical Anatomy by Region, 10th Edition, Page 265

Gray's Anatomy, 42nd Edition, Pages 1042-1044

↑ *Back to this question in Part A*

@Neet_pg_bot

Q12: Which of the following statements accurately describes a difference between the right and left phrenic nerves? (Q848351)

A. The left phrenic nerve is shorter than the right

B. The right phrenic nerve passes anterior to the aortic arch

C. The left phrenic nerve passes through the caval foramen of the diaphragm

D. The right phrenic nerve has a more vertical course in the thorax

Correct Answer: D. The right phrenic nerve has a more vertical course in the thorax

■ *Listen (English)*

■ *Listen (Hindi)*

Explanation: The right phrenic nerve (C3, C4, C5) has a more vertical and shorter course through the thorax compared to the left phrenic nerve. Feature Right Phrenic Nerve Left Phrenic Nerve Length and Course Shorter and more vertical Longer and less vertical Relation to Subclavian Artery Separated from second part by scalenus anterior Passes anterior to first part Relation to Major Vessels Passes lateral to superior vena cava Passes anterior to aortic arch Relation to Heart Passes lateral to right atrium Passes over left atrium and left ventricle Diaphragm Entry Through central tendon (caval foramen or just lateral) Through muscular part, anterior to central tendon Associated Ganglion Right phrenic ganglion, sometimes with accessory ganglion Left phrenic ganglion (less common)

References:

Gray's Anatomy, 42nd Edition, Pages 1042, 1043, 1044

↑ *Back to this question in Part A*

@Neet_pg_bot

Q13: Regarding intercostal nerve blocks, which of the following statements is incorrect? (Q848350)

A. The intercostal neurovascular bundle is arranged inferior to superior as vein, artery, nerve

B. The lateral cutaneous branch of the intercostal nerve arises anterior to the midaxillary line

C. The innermost intercostal muscle separates the intercostal nerve from the pleura

D. The angle of the rib, approximately 6 to 8 cm from the midline, is used as a landmark for needle insertion

Correct Answer: A. The intercostal neurovascular bundle is arranged inferior to superior as vein, artery, nerve

■ *Listen (English)*

■ *Listen (Hindi)*

Explanation: The intercostal neurovascular bundle follows a "VAN" arrangement from superior to inferior: Vein, Artery, Nerve. Intercostal nerve blocks Anatomical Feature Description Neurovascular Bundle Arrangement Superior to inferior: Vein, Artery, Nerve (VAN) Intercostal Nerve Location Inferior border of the rib, in the costal groove Separated from pleura by Innermost intercostal muscle between nerve and pleura (Option C) Landmark for Needle Insertion Angle of the rib, 6-8 cm from midline (Option D) Lateral Cutaneous Branch Arises anterior to the midaxillary line (Option B) Complications Pneumothorax (rare, 0.07% incidence), temporary intercostal muscle paralysis

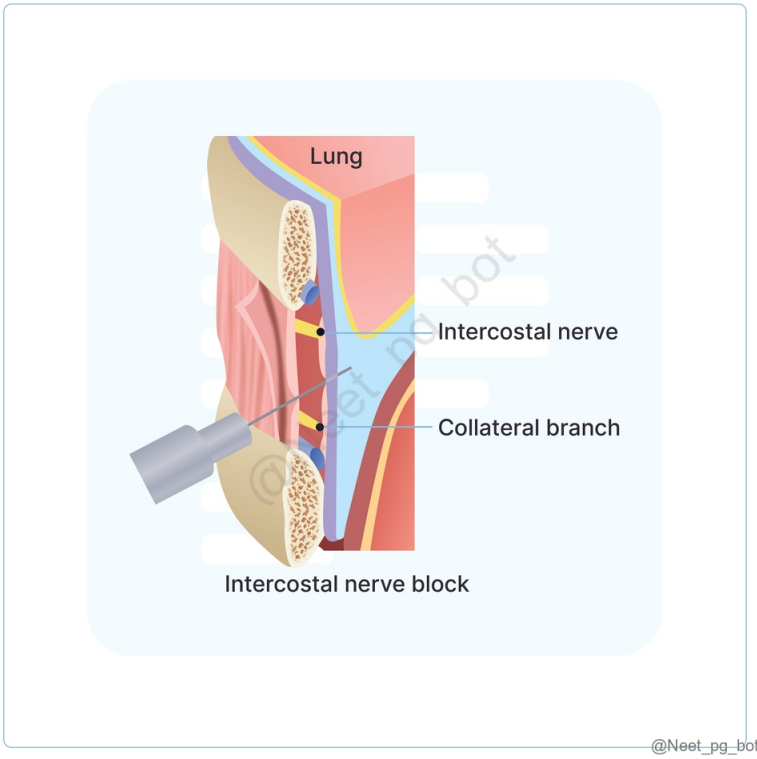

References:

Miller's Textbook of Anaesthesia, 9th Edition, Pages 1463, 1464, 1465

↑ *Back to this question in Part A*

@Neet_pg_bot

Q14: During a pleural tap procedure, which of the following structures is encountered immediately before reaching the parietal pleura? (Q848349)

A. Internal intercostal muscle

B. Endothoracic fascia

C. Serratus anterior muscle

D. Innermost intercostal muscle

Correct Answer: B. Endothoracic fascia

■ *Listen (English)*

■ *Listen (Hindi)*

Explanation: The endothoracic fascia is the layer encountered immediately before the parietal pleura during a pleural tap procedure. The endothoracic fascia lines the innermost intercostal muscle from inside and is fused with the parietal pleura , making it the last layer encountered before reaching the pleural space where fluid can be aspirated The order of structures punctured during a pleural tap, from superficial to deep: Skin Superficial fascia Serratus anterior (1st muscle to get punctured) External intercostal muscle Internal intercostal muscle Innermost intercostal muscle Endothoracic fascia (Fused with parietal pleura) Parietal pleura Pleural fluid (to be aspirated)

References:

www.ncbi.nlm.nih.gov/books/NBK538321/

↑ *Back to this question in Part A*

@Neet_pg_bot

Q15: A 65-year-old man with a history of congestive heart failure presents with increasing dyspnea. Chest X-ray is given below. The physician decides to perform a thoracentesis. Which of the following anatomical landmarks is most important to be identified, to prevent damage to important structures at its level? {{caption_text}} (Q848348)

A. Midclavicular line

B. Anterior axillary line

C. Midscapular line

D. Inferior border of the rib

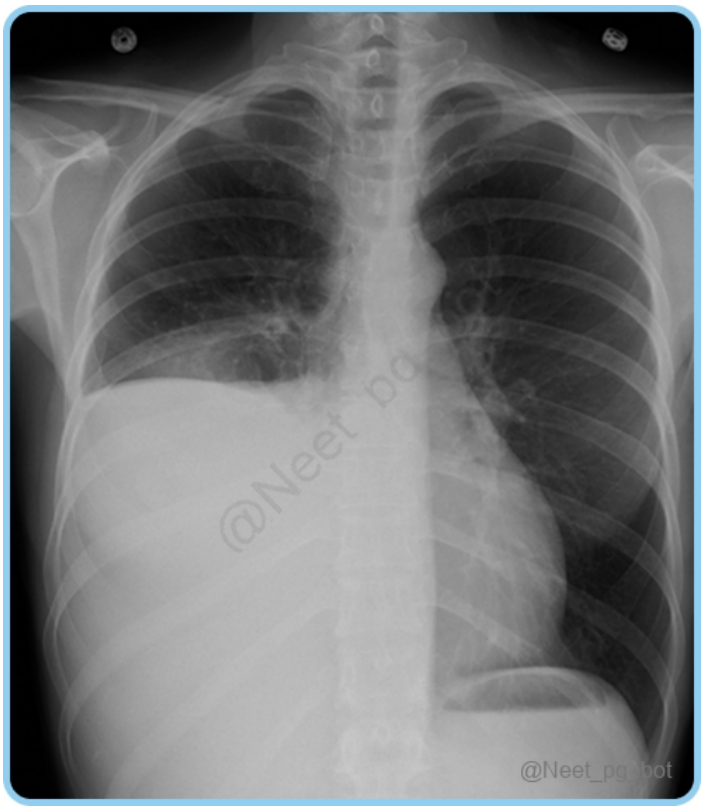

Correct Answer: D. Inferior border of the rib

- *Listen (English)*
- *Listen (Hindi)*

Explanation: The Chest X-ray shows a right sided pleural effusion for which the physician decides to perform thoracocentesis. The inferior border of the rib is the most important anatomical landmark to identify when performing a thoracentesis. This is because the intercostal neurovascular bundle (including the intercostal artery, vein, and nerve) runs along the inferior border of each rib. By inserting the needle just above the superior border of the rib below the intended intercostal space, the risk of damaging these structures is minimized. {{caption_text}} {{caption_text}}

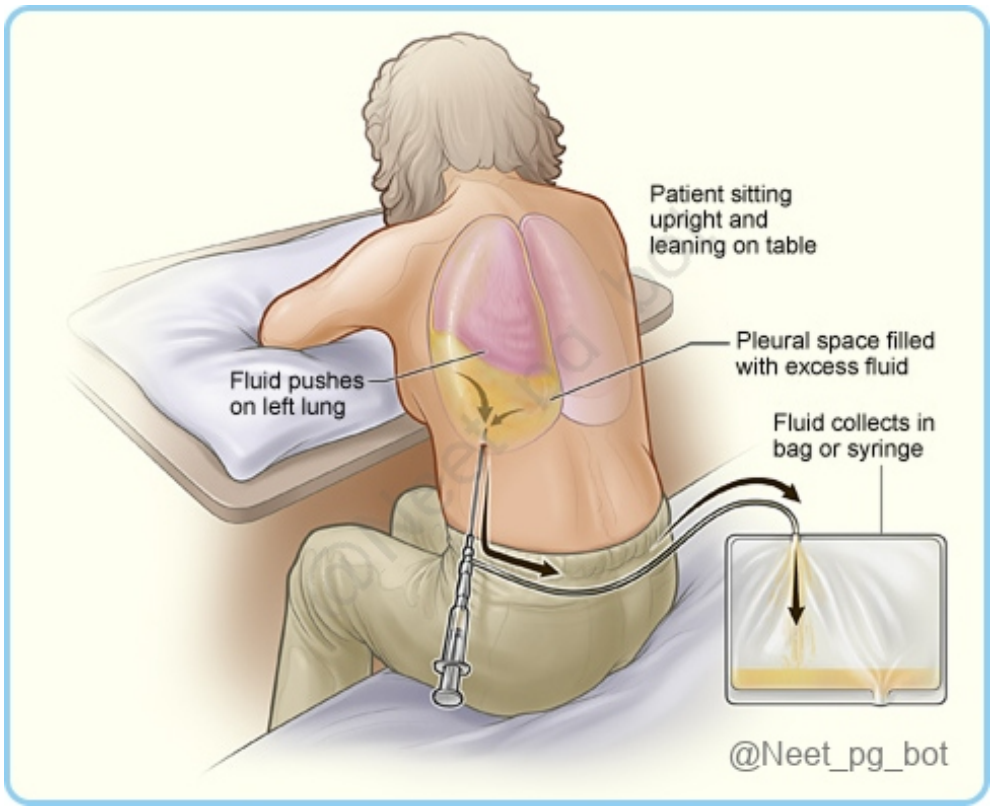

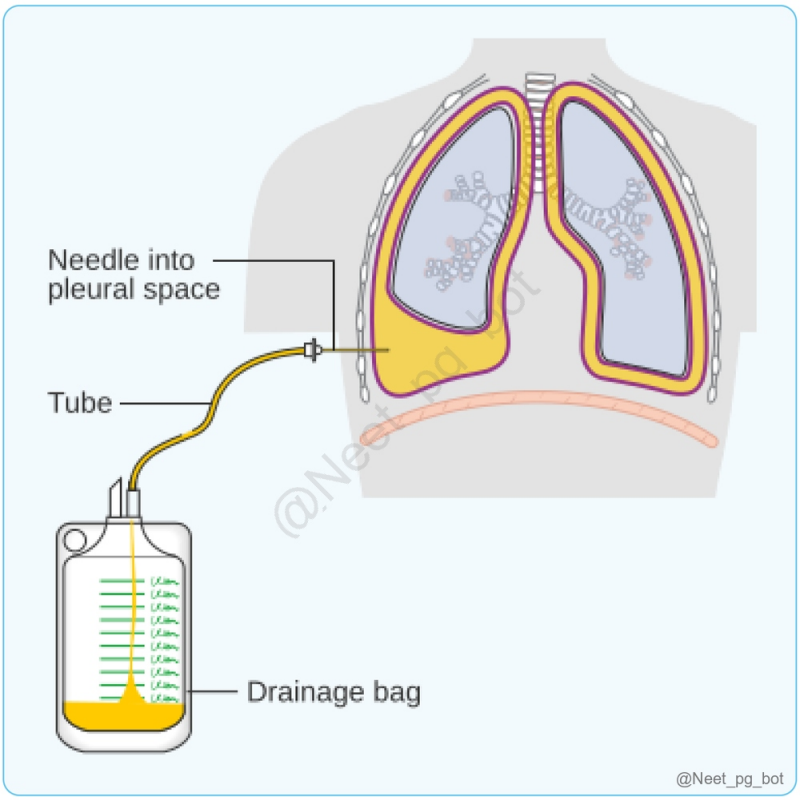

References:

SRB Manual of Surgery, 6th Edition , Pages 1102, 1103

www.ncbi.nlm.nih.gov/books/NBK441866/

↑ *Back to this question in Part A*

@Neet_pg_bot

Q16: Which of the following structures does not make up the anterior surface (sternocostal) of the heart? (Q848260)

A. Left atrium

B. Right ventricle

C. Left ventricle

D. Left auricle

Correct Answer: A. Left atrium

■ *Listen (English)*

■ *Listen (Hindi)*

Explanation: The left atrium is obscured by the ascending aorta and pulmonary trunk, and primarily forms part of the posterior surface, not the anterior surface. Anterior surface of heart (Sternocostal) Posterior View of Heart (Base) {{caption_text}} {{caption_text}} The anterior surface consists mainly of the right atrium and right ventricle separated by the anterior atrioventricular groove (coronary sulcus). (Option B) The left auricle and left ventricle also contribute. (Option C & D) The base of the heart is mainly formed by the left atrium (two-thirds) and right atrium (one-third). Major blood vessels like superior vena cava, ascending aorta, and pulmonary trunk attach to the base.

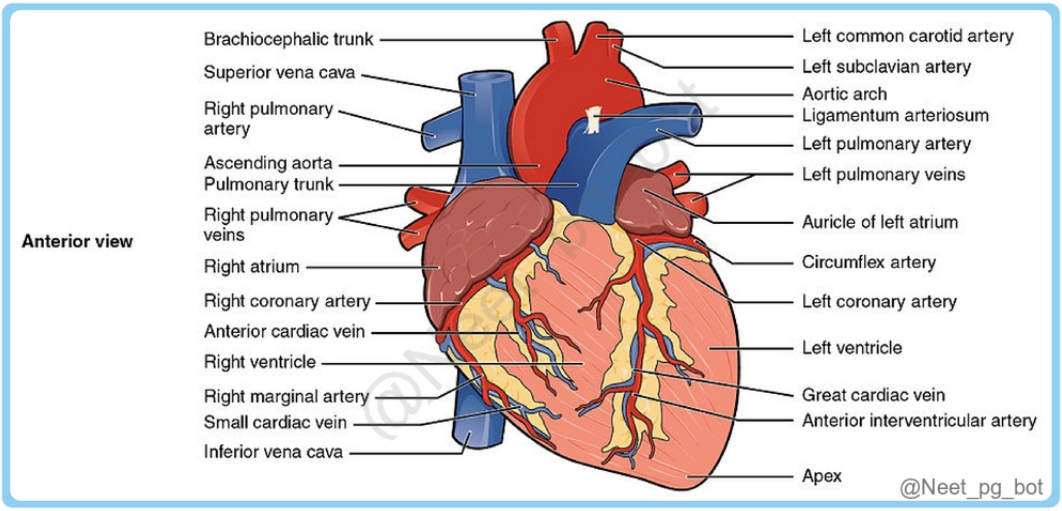

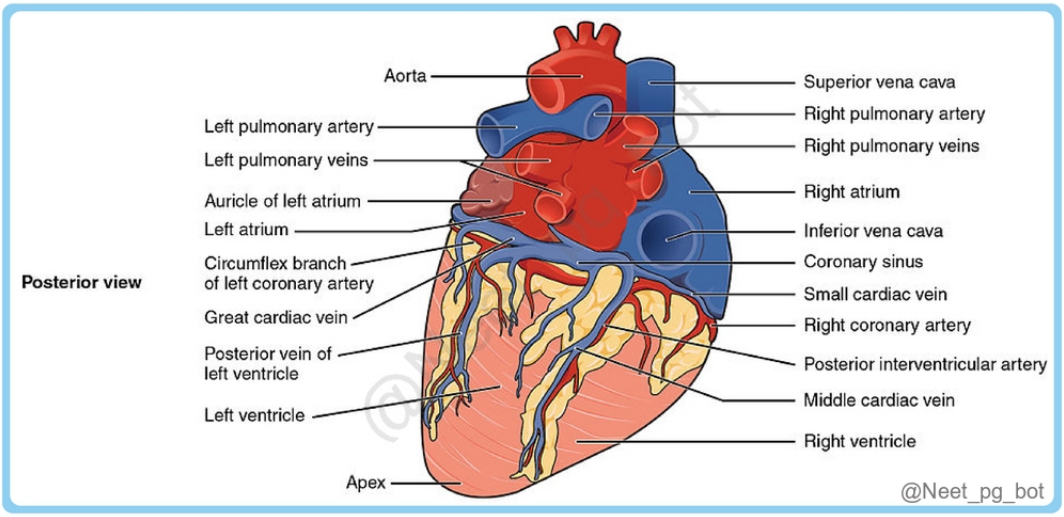

References:

Snell Clinical Anatomy by Regions, 10th Edition, Page 245

Vishram Singh Textbook of Anatomy, Volume 1, 2nd Edition, Page 261

Gray's Anatomy, 42nd Edition, Page 1073

↑ *Back to this question in Part A*

@Neet_pg_bot

Q17: A 65-year-old male presents with shortness of breath and chest pain. On examination, he has a prominent sternal angle. A CT scan reveals an enlarged mediastinal lymph node at the level of the tracheal bifurcation. Which of the following anatomical structures is most likely to be found at the same level as the bifurcation of the trachea? (Q848346)

A. Left atrium of the heart

B. Junction of the azygos vein and superior vena cava

C. Origin of the thoracic duct

D. Superior border of the aortic arch

Correct Answer: B. Junction of the azygos vein and superior vena cava

■ *Listen (English)*

■ *Listen (Hindi)*

Explanation: The sternal angle (angle of Louis) is a palpable, transverse ridge on the sternum located approximately 5 cm below the suprasternal notch. It serves as a critical anatomical landmark for various significant structures and anatomical events. These include: The second costal cartilage articulates with the sternum at this level on both sides, making it a key reference point for counting ribs. It corresponds to the level of the intervertebral disc between the T4 and T5 vertebrae . A horizontal plane passing through this level divides the superior mediastinum from the inferior mediastinum . The arch of the aorta both begins and ends at this level. The trachea bifurcates into the right and left principal bronchus at this level. The pulmonary trunk divides into the right and left pulmonary arteries here. The upper border of the heart is located at this level. The azygos vein arches over the root of the right lung and empties into the superior vena cava at this level. (Option B)

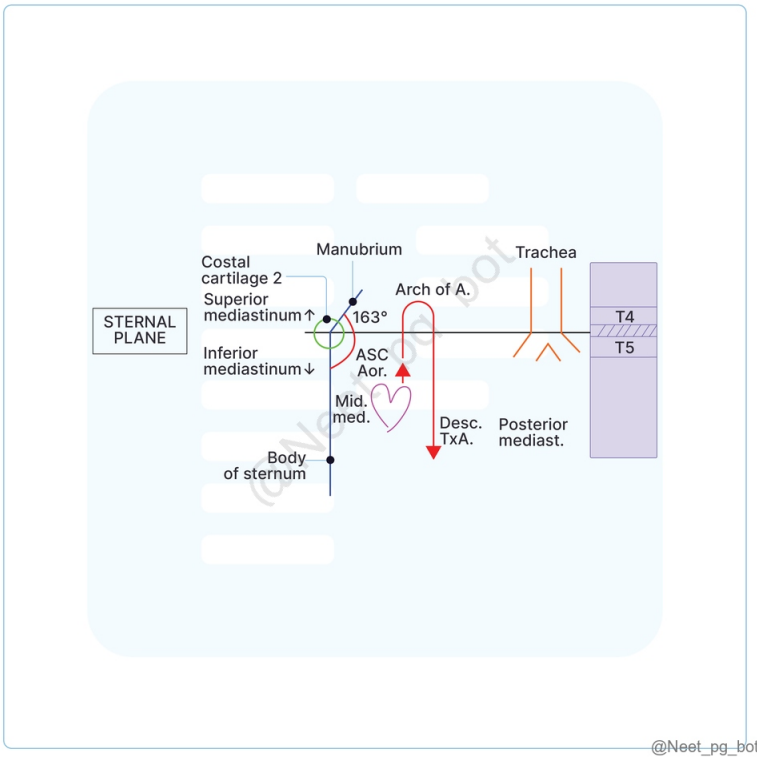

References:

Vishram Singh Textbook of Anatomy, Volume 1, 2nd Edition, Page 198

↑ *Back to this question in Part A*

@Neet_pg_bot

Q18: All the following are contents of the posterior mediastinum except: (Q848345)

A. Descending thoracic aorta

B. Esophagus

C. Azygos and hemiazygos veins

D. Pulmonary trunk

Correct Answer: D. Pulmonary trunk

- *Listen (English)*
- *Listen (Hindi)*

Explanation: Pulmonary trunk is the content of middle mediastinum. Mediastinum: The mediastinum is an anatomical region between the two lungs in the thoracic cavity. It is divided into superior and inferior mediastinum by the sternal plane which passes horizontally from the manubriosternal joint to T4 to T5 vertebra. Inferior Mediastinum- Located below the sternal angle and is further divided into anterior, middle, and posterior mediastinum. Anterior Mediastinum Middle Mediastinum Posterior Mediastinum Lies between the sternum and the pericardium Contains loose connective tissue, lymph nodes, and remnants of the thymus, sterno -pericardial ligaments. Provides surgical access to the heart and great vessels The broadest part of the inferior mediastinum Contains the heart enclosed in the pericardial sac Contains the roots of great vessels: ascending aorta, pulmonary trunk , and pulmonary veins, tracheal bifurcation and bronchi Includes the phrenic nerves and cardiac plexus Extends from the posterior pericardium to the vertebral column Contains important structures such as: (Option A, B, C) Descending thoracic aorta Esophagus Azygos and hemiazygos veins Thoracic duct Sympathetic trunks and splanchnic nerves Lymph nodes

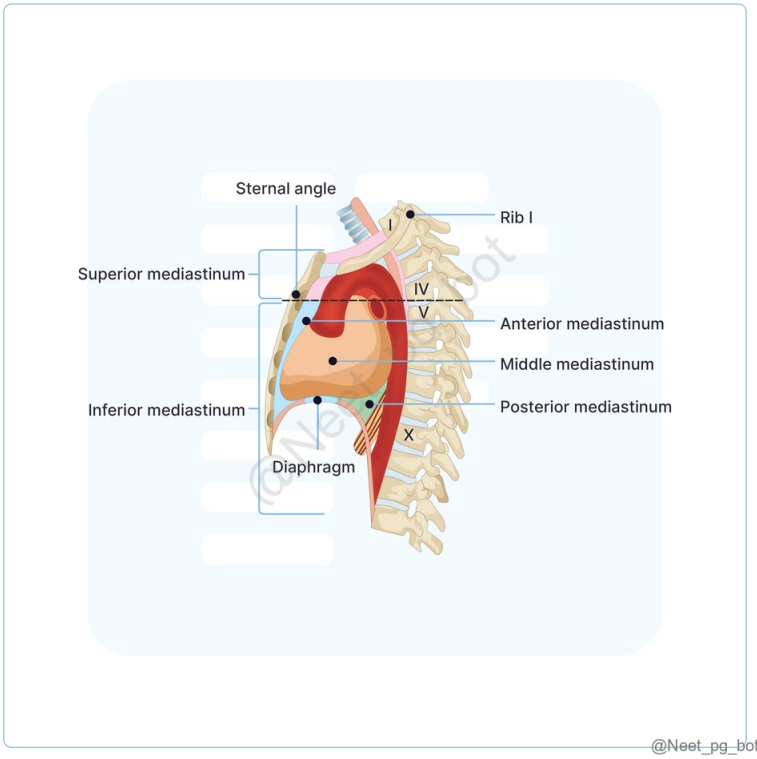

References:

Vishram Singh Textbook of Anatomy, Volume 1, 2nd Edition, Page 305

Gray’s Anatomy, 42nd Edition, Pages 1047, 1048.

↑ *Back to this question in Part A*

@Neet_pg_bot

Q19: A 55-year-old man presents with exertional chest pain radiating to his left arm. Coronary angiography reveals a significant blockage in the right coronary artery (RCA). Which of the following regions of the heart is most likely at risk of ischemia? (Q848344)

A. Anterior two-thirds of the interventricular septum

B. Lateral wall of the left ventricle

C. Posterior one-third of the interventricular septum

D. Apex of the heart

Correct Answer: C. Posterior one-third of the interventricular septum

■ *Listen (English)*

■ *Listen (Hindi)*

Explanation: The coronary arteries supply blood to specific regions of the heart. The right coronary artery (RCA) typically supplies the right atrium , right ventricle , part of the left ventricle , and the posterior one-third of the interventricular septum in individuals with right-dominant coronary circulation. The posterior descending artery (PDA) branches from the RCA in the right-dominant hearts and supplies the posterior part of the heart.

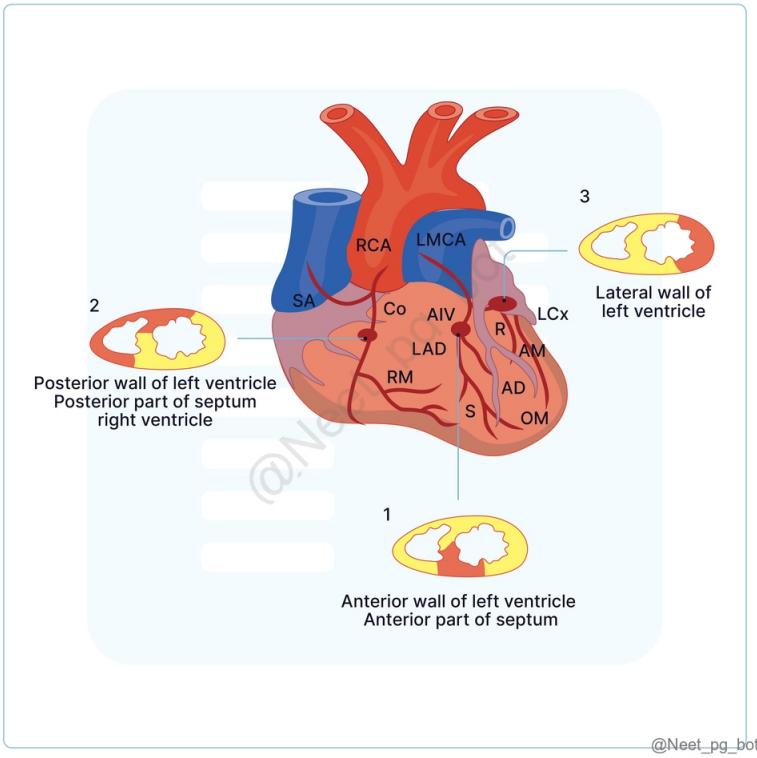

References:

Snell's Clinical Anatomy by Region, 10th Edition, Page 253

↑ *Back to this question in Part A*

@Neet_pg_bot

Q20: A 50-year-old male presents with inferior wall MI. Angiography shows occlusion in the artery supplying the SA node. Which of the following arteries is most likely affected? (Q848343)

A. Right coronary artery

B. Left coronary artery

C. Circumflex artery

D. Posterior interventricular artery

Correct Answer: A. Right coronary artery

■ *Listen (English)*

■ *Listen (Hindi)*

Explanation: The RCA supplies the SA node in ~60–70% of people. It travels in the coronary sulcus , then along the inferior border , so its blockage commonly causes inferior wall MI . RCA occlusion may produce SA node ischemia , leading to arrhythmias and conduction defects . Blood Supply to the Conducting system of the heart: {{caption_text}}

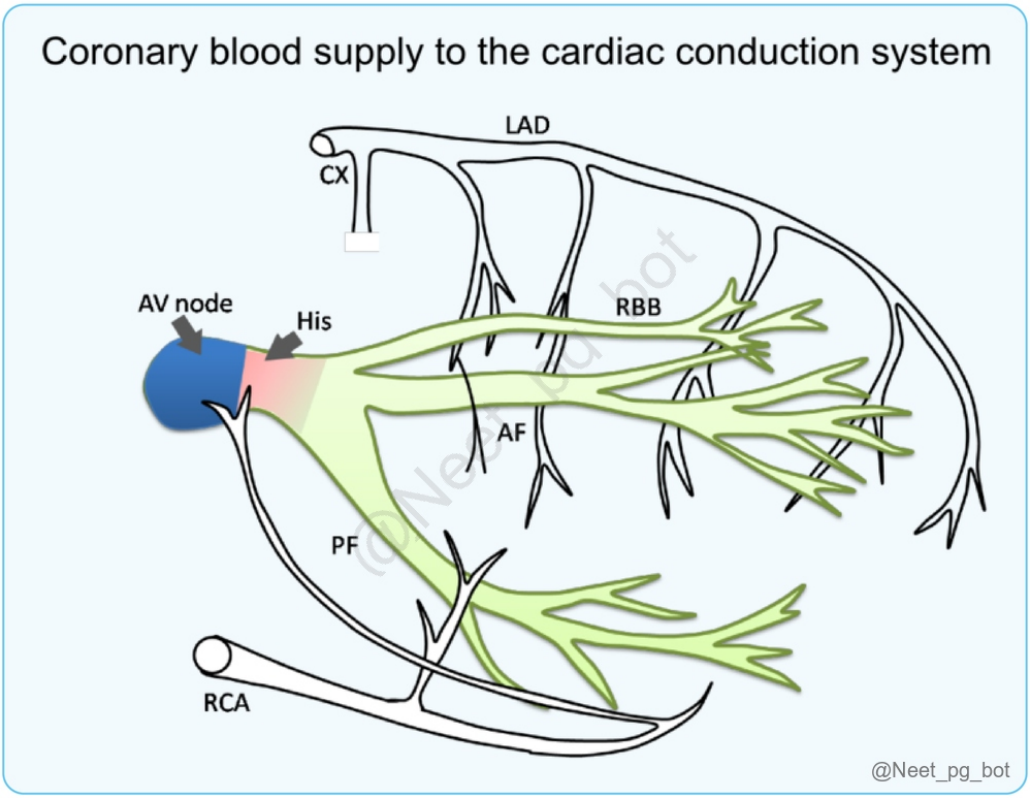

References:

Snell's Clinical Anatomy by Region, 10th Edition, Page 251

pubmed.ncbi.nlm.nih.gov/12819949/

↑ *Back to this question in Part A*

@Neet_pg_bot

Q21: A transverse section through the heart at the level of the ventricles reveals several anatomical structures. Which of the following structures is most likely to be observed in this section? (Q848342)

A. Left atrial appendage

B. Papillary muscles

C. Aortic arch

D. Superior vena cava

Correct Answer: B. Papillary muscles

■ *Listen (English)*

■ *Listen (Hindi)*

Explanation: A transverse section at the level of the heart's ventricles cuts through the middle of the ventricles, allowing visualization of internal structures within the ventricles themselves and parts of the surrounding structures. Structures visible in the transverse section of the ventricles of the heart are: Right and Left Ventricles Papillary muscles (Superoposterior, Inferoseptal)(They are clearly visible in a transverse section at the level of the ventricles, as they project into the ventricular chambers and anchor the chordae tendineae.) Arteries and Veins - Anterior and Posterior Interventricular, Left and Right marginal Sulcus - Anterior and Inferior interventricular Septomarginal trabecula (moderator band) Interventricular septum, muscular part Tricuspid valve, septal leaflet

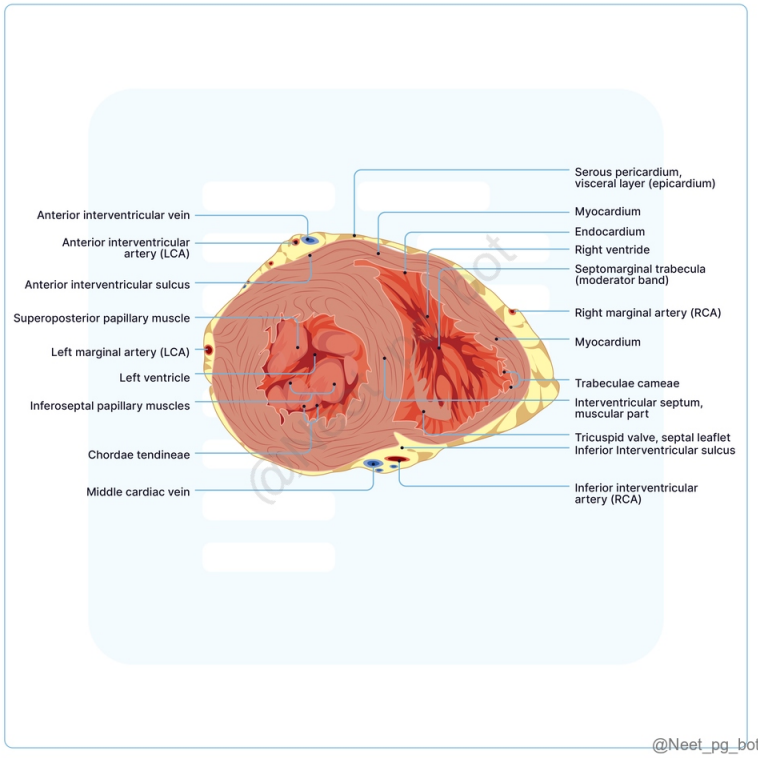

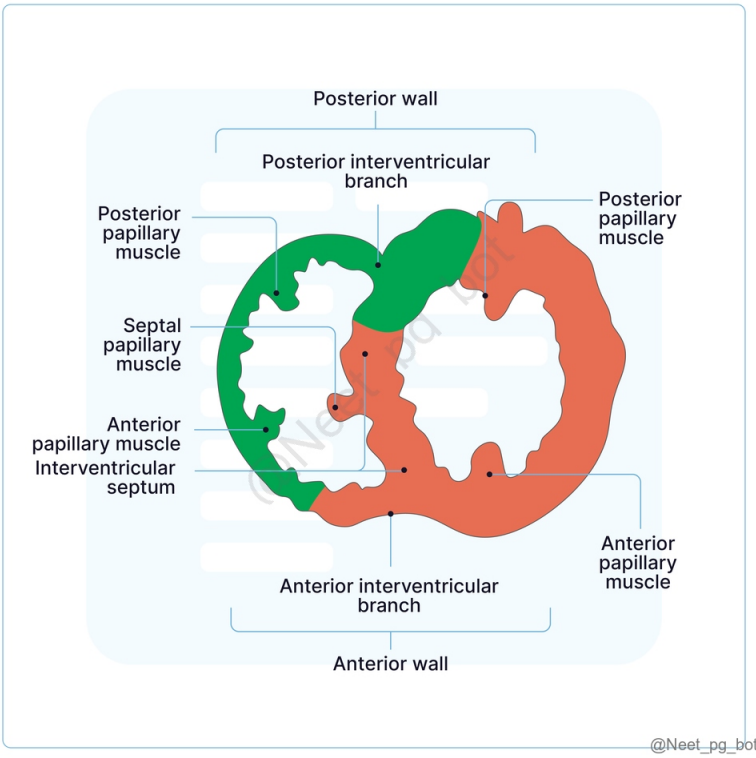

References:

Gray's Anatomy, 42nd Edition, Page 1082

↑ *Back to this question in Part A*

@Neet_pg_bot

Q22: A 45-year-old male patient is undergoing coronary angiography for chest pain evaluation. The angiogram reveals a dominant left coronary system, with the left coronary artery supplying the majority of the heart's posterior structures. Based on this finding, which of the following statements about cardiac dominance is most accurate? (Q848341)

A. In a left-dominant coronary system, RCA gives off the posterior descending artery (PDA) and the PDA supplies the right atrium.

B. In a right-dominant coronary system, the LCA gives off the PDA and the PDA supplies the left atrium.

C. In a left-dominant coronary system, the PDA is supplied by the left anterior descending artery, which arises from the left circumflex artery.

D. In a right-dominant coronary system, the RCA supplies the PDA, which in turn supplies the majority of the interventricular septum.

Correct Answer: D. In a right-dominant coronary system, the RCA supplies the PDA, which in turn supplies the majority of the interventricular septum.

- *Listen (English)*
- *Listen (Hindi)*

Explanation: Cardiac dominance refers to the variable blood supply pattern to the heart's posterior structures, especially the diaphragmatic surfaces of both ventricles, through the coronary artery that supplies the posterior descending artery (PDA) or posterior interventricular artery. Right Dominance (Option B) Left Dominance (Option A, C) Codominance The posterior interventricular artery (PDA) originates from the right coronary artery (RCA). Occurs in approximately 67% of individuals. The PDA arises from the left circumflex artery (LCX), a branch of the left coronary artery (LCA). Found in about 15% of individuals. Both the RCA and LCX contribute to the formation of the PDA or provide multiple branches serving similar functions. Occurs in approximately 18% of individuals.

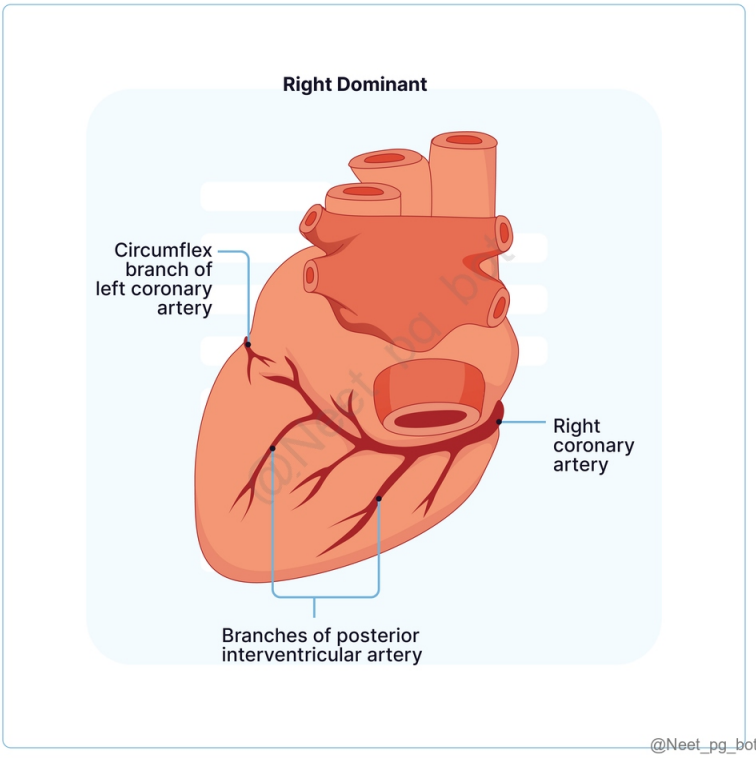

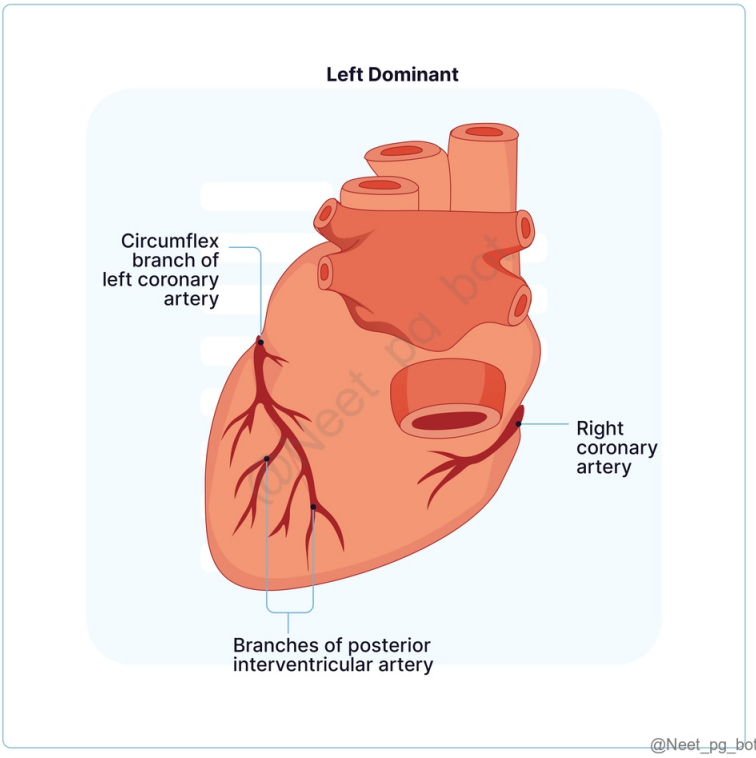

References:

Snell's Clinical Anatomy by Region, 10th Edition, Pages 250, 251

↑ *Back to this question in Part A*

@Neet_pg_bot

Q23: Match the following coronary arteries with the areas of the heart they predominantly supply: Coronary Arteries Supplied Areas 1) Right conus artery a) Anterior 2/3 of interventricular septum 2) Left anterior descending artery (LAD) b) Infundibulum of right ventricle 3) Left circumflex artery (LCX) c) Posterior interventricular septum 4) Posterior descending artery (PDA) d) Lateral wall of the left ventricle e) Apex of the heart (Q848340)

A. 1- c, 2- a, 3- d, 4- b

B. 1- b, 2- e, 3 - a, 4- d

C. 1- b, 2- a, 3- d, 4- c

D. 1-d, 2- e, 3- b, 4- a

Correct Answer: C. 1- b, 2- a, 3- d, 4- c

■ *Listen (English)*

■ *Listen (Hindi)*

Explanation: Artery Supplied Region Right Conus Artery (RCA) Infundibulum of the right ventricle Left Anterior Descending (LAD) Anterior 2/3 of the interventricular septum Left Circumflex Artery (LCX) Lateral wall of the left ventricle Posterior Descending Artery (PDA) Posterior interventricular septum Arterial Supply of the Heart: The arterial supply to the heart is primarily provided by two main coronary arteries: the right coronary artery (RCA) and the left coronary artery (LCA) . These arteries originate from the aortic sinus. {{caption_text}}

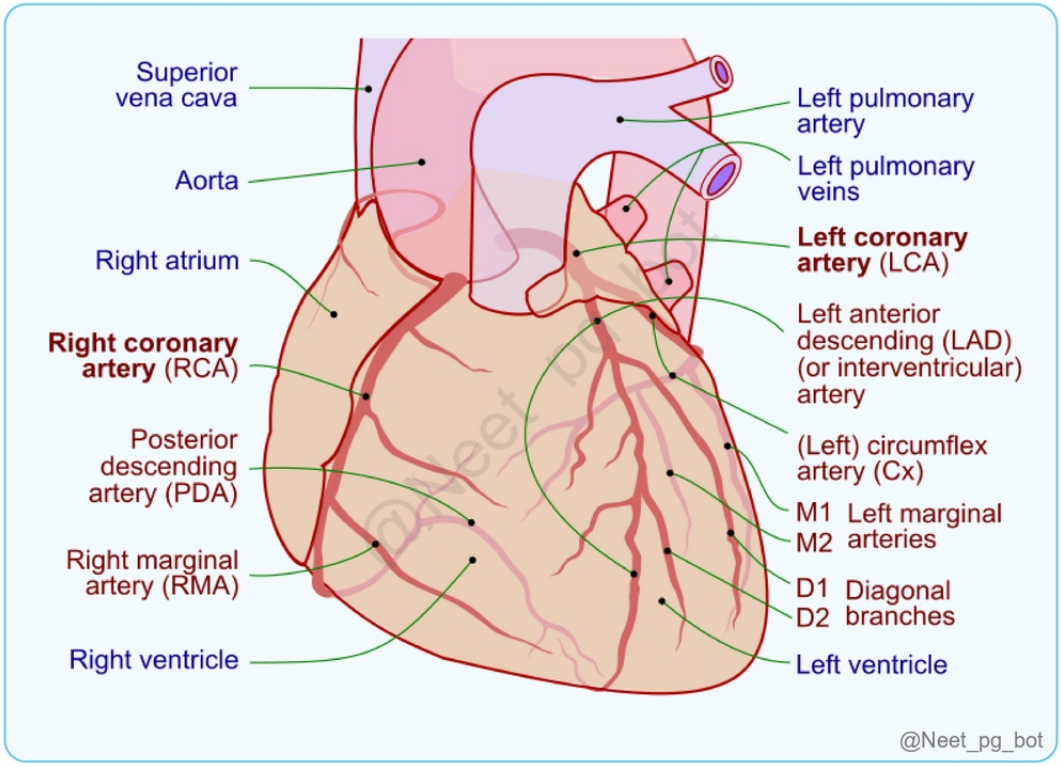

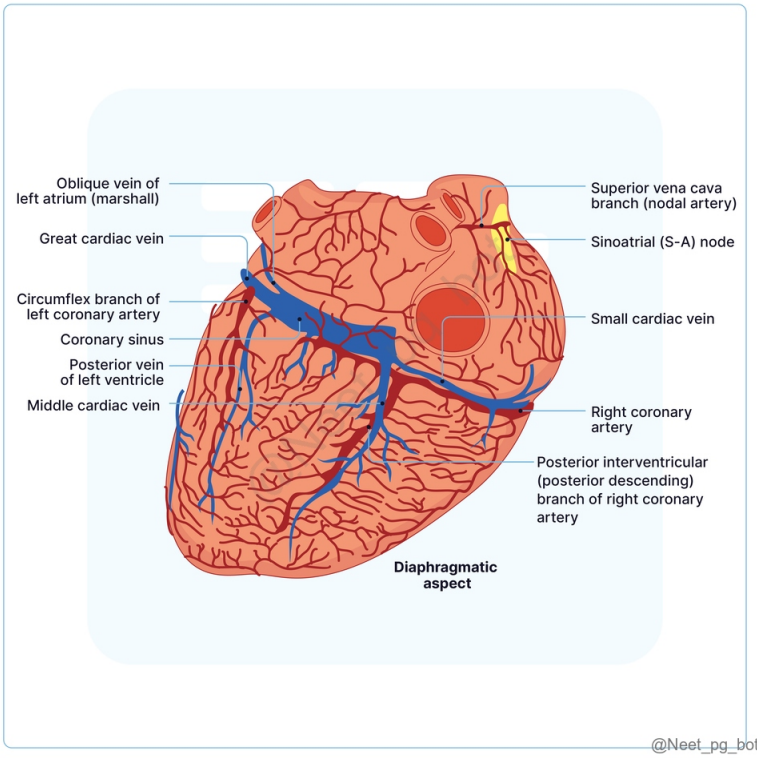

References:

Vishram Singh Textbook of Anatomy, Volume 1, 2nd Edition, Pages 273-275

Snell's Clinical Anatomy by Region, 10th Edition, Pages 250, 251

↑ *Back to this question in Part A*

@Neet_pg_bot

Q24: A 45-year-old man is undergoing evaluation for palpitations. ECG reveals a supraventricular tachycardia with HR of 190/min. An echocardiogram reveals hypertrophy of the right ventricle and enlargement of the right ventricular outflow tract. Which structure separates the inflow and outflow tracts in the right ventricle? (Q848287)

A. Crista terminalis

B. Supraventricular crest

C. Moderator band

D. Interventricular septum

Correct Answer: B. Supraventricular crest

- *Listen (English)*
- *Listen (Hindi)*

Explanation: The supraventricular crest is located within the right ventricle and separates the inflow tract , which carries blood from the right atrium through the tricuspid valve, from the outflow tract, which directs blood into the pulmonary trunk. It is a thick, muscular “U” shaped structure extending from the interventricular septum to the anterolateral wall of the right ventricle. The crest provides the main attachment for the anterosuperior leaflet of the tricuspid valve. The septal limb of the crest is connected to the septal limbs of the septomarginal trabeculation (moderator band).

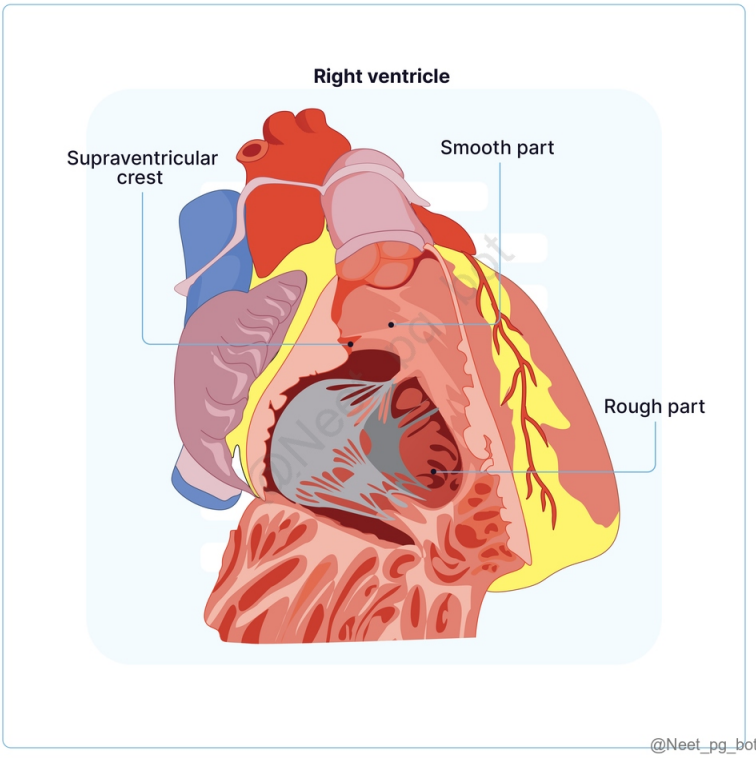

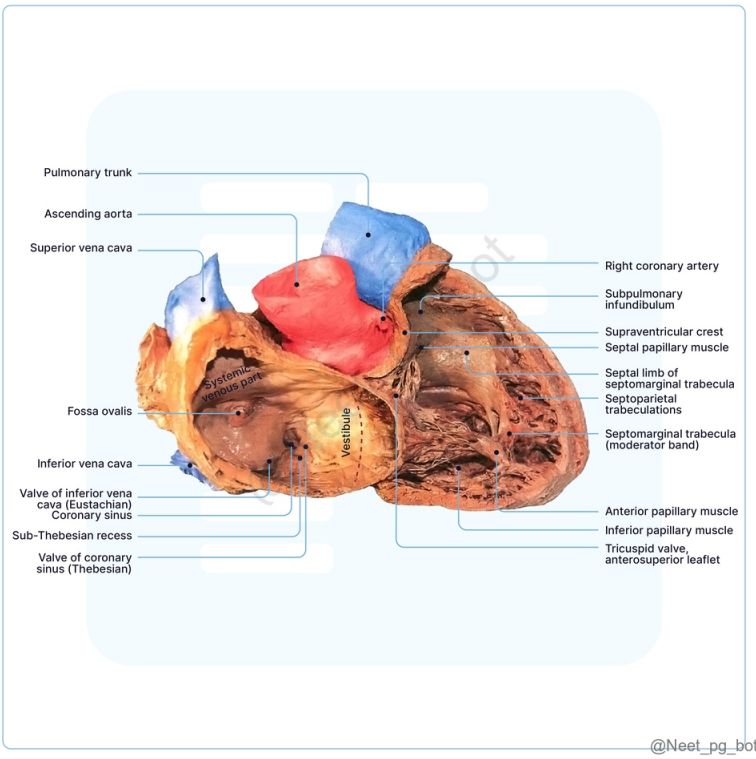

References:

Gray's Anatomy, 42nd Edition, Page 1075

Vishram Singh Textbook of Anatomy, Volume 1, 2nd Edition, Page 266

↑ *Back to this question in Part A*

@Neet_pg_bot

Q25: A 36-year-old woman presents with sudden-onset palpitations and lightheadedness. Her ECG shows a regular narrow complex tachycardia at 170 bpm. Vagal maneuvers temporarily relieve her symptoms. Atrioventricular Nodal Reentrant Tachycardia (AVNRT) is suspected. The reentrant circuit in AVNRT is most likely located in which anatomical region? (Q848286)

A. Crista terminalis

B. His bundle

C. Koch's triangle

D. Right atrial appendage

Correct Answer: C. Koch’s triangle

■ *Listen (English)*

■ *Listen (Hindi)*

Explanation: AVNRT is a common type of regular supraventricular tachycardia. It is characterized by a reentrant circuit involving fast and slow pathways, at the level of the AV node. Koch’s triangle is the anatomical region containing the AV node, which is critical in AVNRT. Pathways Involved: Slow pathway: posterior to the AV node. Fast pathway: anterior nodal extension. Anatomical Landmark: Triangle of Koch: Used for catheter ablation (CA), bordered by: Coronary sinus ostium (inferiorly). Septal leaflet of tricuspid valve (anteriorly). Tendon of Todaro (posterosuperiorly).

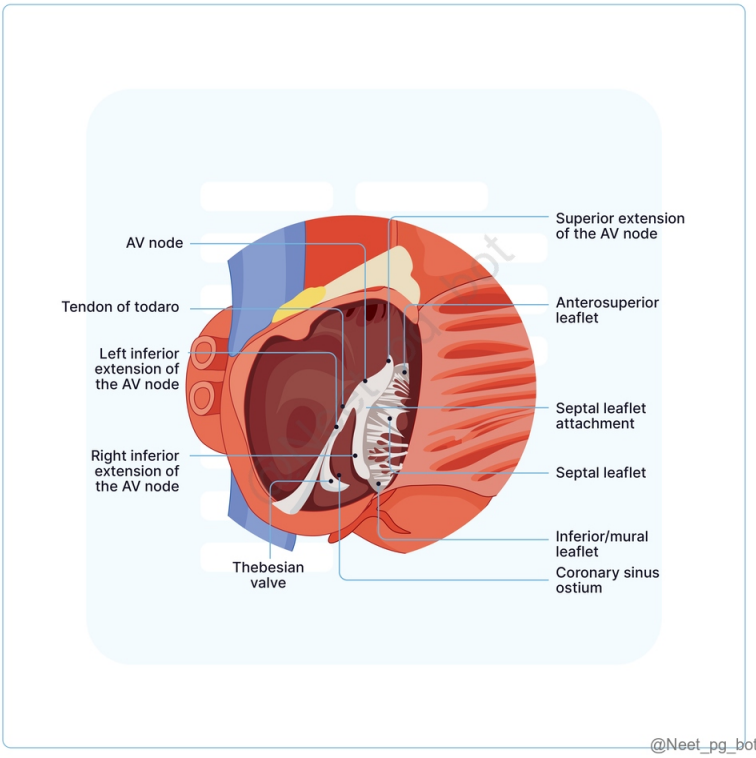

References:

www.ncbi.nlm.nih.gov/books/NBK594260/#

↑ *Back to this question in Part A*

@Neet_pg_bot

Q26: A 45-year-old patient presents with recurrent episodes of supraventricular tachycardia. The electrophysiologist plans to perform catheter ablation. Which of the following structures is most likely to be found at the apex of Koch's triangle?

(Q848285)

A. Sinoatrial node

B. Atrioventricular node

C. Bundle of His

D. Right bundle branch

Correct Answer: B. Atrioventricular node

Listen (English)

Listen (Hindi)

Explanation: The Triangle of Koch is situated on the right atrial aspect of the interatrial septum. Boundaries: Opening of the coronary sinus The Tendon of Todaro - a collagenous subendocardial band - runs from the central fibrous body to the Eustachian ridge - a part of the fibrous skeleton of the heart. Septal tricuspid leaflet Importance: It helps to localize the AV node - present at the apex of Koch's triangle . Localising the AV node is important to safely perform radiofrequency catheter ablation within the right atrium in cases of AVNRT.

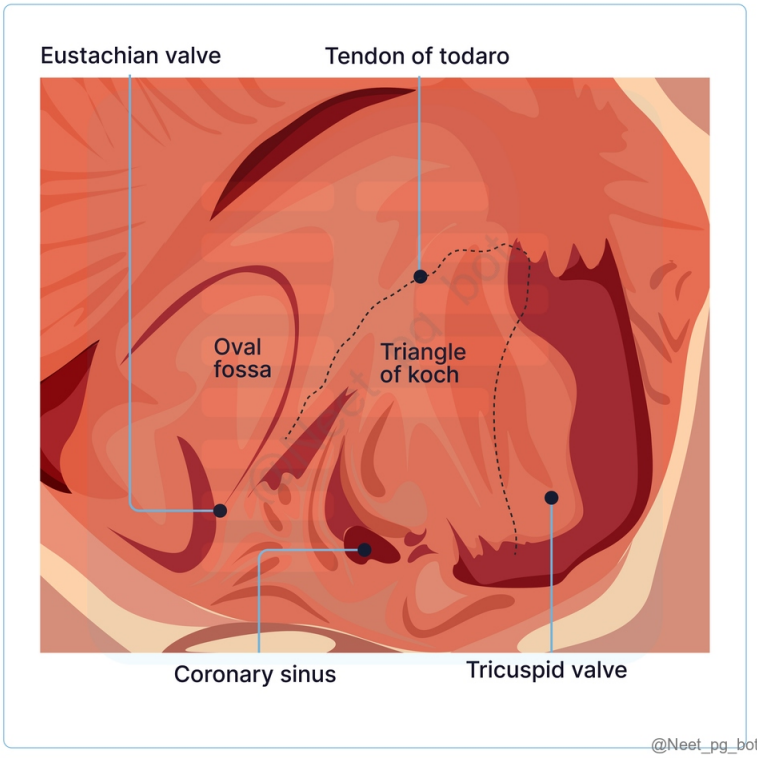

References:

Vishram Singh Textbook of Anatomy, Volume 1, 2nd Edition, Page 265

https://johnsonfrancis.org/professional/triangle-of-koch

↑ *Back to this question in Part A*

@Neet_pg_bot

Q27: A 32-year-old man undergoes a coronary angiography after presenting with chest pain. The cardiologist is explaining the venous drainage of the heart as observed in the angiographic images. Which of the following structures is primarily visible on the posterior view of the heart? (Q848284)

A. Great cardiac vein

B. Small cardiac vein

C. Coronary sinus

D. Anterior cardiac veins

Correct Answer: C. Coronary sinus

■ *Listen (English)*

■ *Listen (Hindi)*

Explanation: The coronary sinus is visible on the posterior surface of the heart and serves as the main venous channel, collecting blood from most cardiac veins and draining it into the right atrium. Venous drainage of the heart - anterior and posterior view: Anterior View of the Heart Posterior View of the Heart Anterior interventricular sulcus: LAD + Great cardiac vein Right coronary sulcus: RCA + Small cardiac vein Posterior interventricular sulcus: PDA + Middle cardiac vein Posterior coronary sulcus: Coronary sinus Great, small, middle cardiac veins → Coronary sinus Anterior cardiac veins → Right atrium directly Right marginal vein → Small cardiac vein or RA Posterior vein of LV, Oblique vein (Marshall), Left marginal vein → Coronary sinus Coronary sinus : Main venous collector on posterior heart; drains into RA.

References:

Vishram Singh Textbook of Anatomy, Volume 1, 2nd Edition, Pages 276, 277, 278

↑ *Back to this question in Part A*

@Neet_pg_bot

Q28: Which of the following veins does not drain into the coronary sinus but rather drains directly into the right atrium? (Q848283)

A. Great Cardiac Vein

B. Middle Cardiac Vein

C. Anterior Cardiac Veins

D. Small Cardiac Vein

Correct Answer: C. Anterior Cardiac Veins

■ *Listen (English)*

■ *Listen (Hindi)*

Explanation: Anterior cardiac veins are small veins that run parallel across the surface of the right ventricle and open directly into the right atrium, not into the coronary sinus. Venous Drainage of the Heart Venous blood from the heart is drained into the right atrium through: Coronary sinus Anterior cardiac veins Venae cordis minimae (Thebesian veins) Coronary Sinus The principal vein of the heart, draining most venous blood into the right atrium. Tributaries of the Coronary Sinus Great Cardiac Vein : Accompanies the anterior interventricular and circumflex arteries, joining the left end of the coronary sinus. (Option A) Middle Cardiac Vein : Accompanies the posterior interventricular artery, joining the coronary sinus near its termination. (Option B) Small Cardiac Vein : Accompanies the right ventricular artery in the right posterior coronary sulcus, draining into the right end of the coronary sinus. (Option D) Posterior Vein of the Left Ventricle Oblique Vein of the Left Atrium (Vein of Marshall) Right Marginal Vein Left Marginal Vein

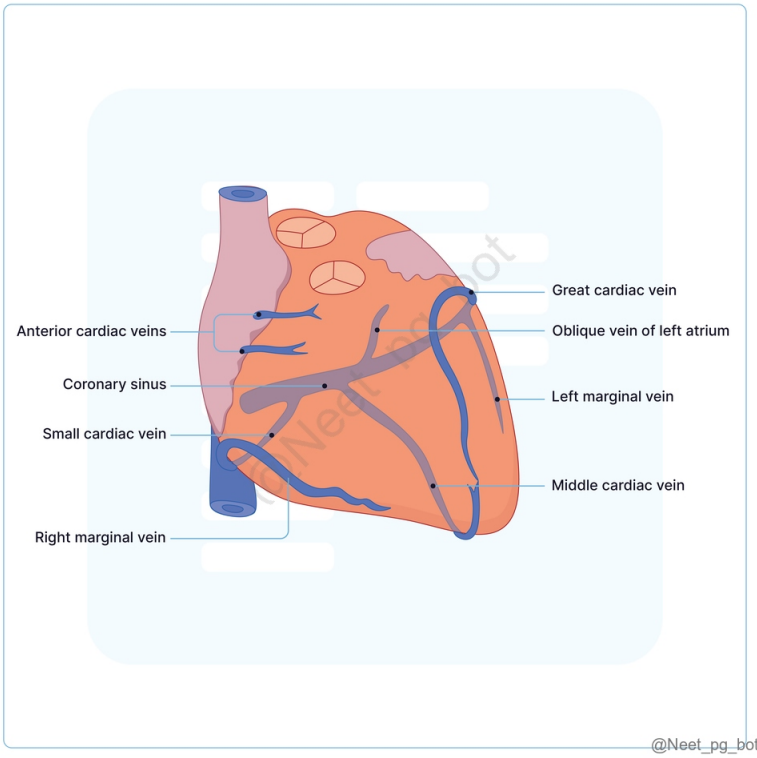

References:

Grays Anatomy, 42nd Edition, Pages 1092, 1093

Vishram Singh Textbook of Anatomy, Volume 1, 2nd Edition, Pages 276, 277, 278

↑ *Back to this question in Part A*

@Neet_pg_bot

Q29: In a chest X-ray given below, the inferior border of the heart is primarily contributed by which structure? {{caption_text}} (Q848282)

A. Right Atrium

B. Superior Vena Cava

C. Left Ventricle

D. Right Ventricle

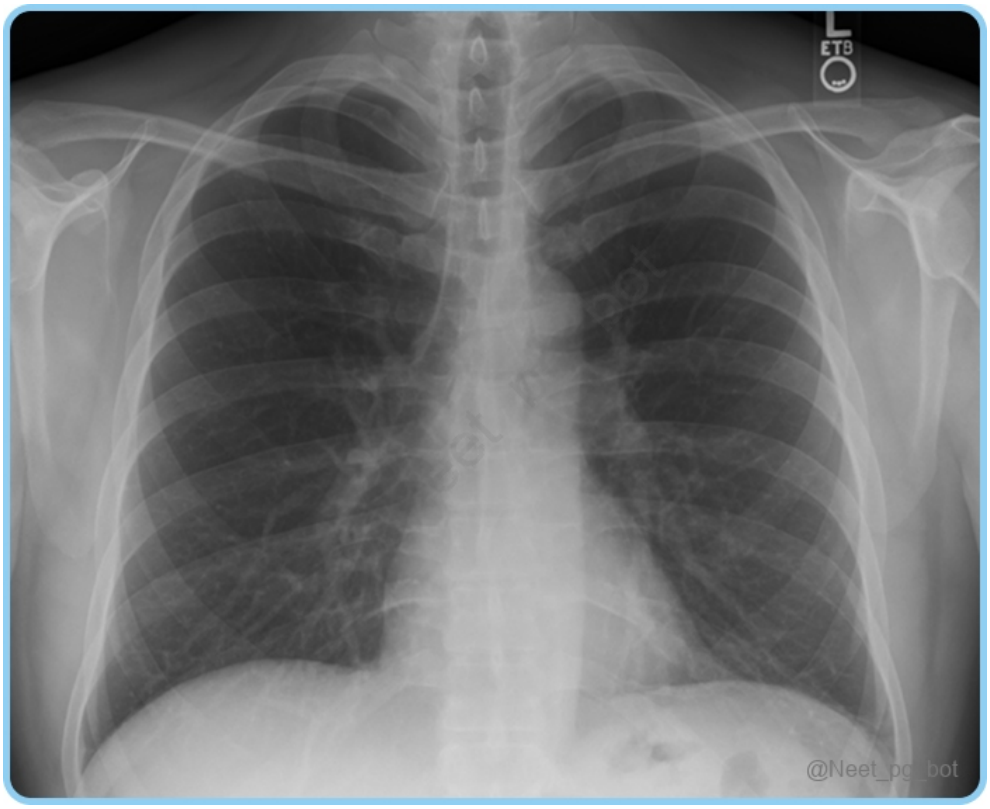

Correct Answer: D. Right Ventricle

■ *Listen (English)*

■ *Listen (Hindi)*

Explanation: The right ventricle forms the majority of the inferior border of the heart in a normal CXR, extending from the inferior vena cava (IVC) to the apex of the heart. {{caption_text}} Borders of the Heart Right Border : Formed by the right atrium. Extends from the opening of the superior vena cava (SVC) to the inferior vena cava (IVC). Left Border : Formed mainly by the left ventricle. Partly by the left auricle. Extends from the left auricle to

the apex of the heart. Inferior Border : Formed by the right ventricle. Partly by the right atrium and left ventricle(near apex). Extends from the opening of the IVC to the apex of the heart. Upper Border : Formed mainly by the left atrium. Partly by the right atrium. Also by the ascending aorta and pulmonary trunk.

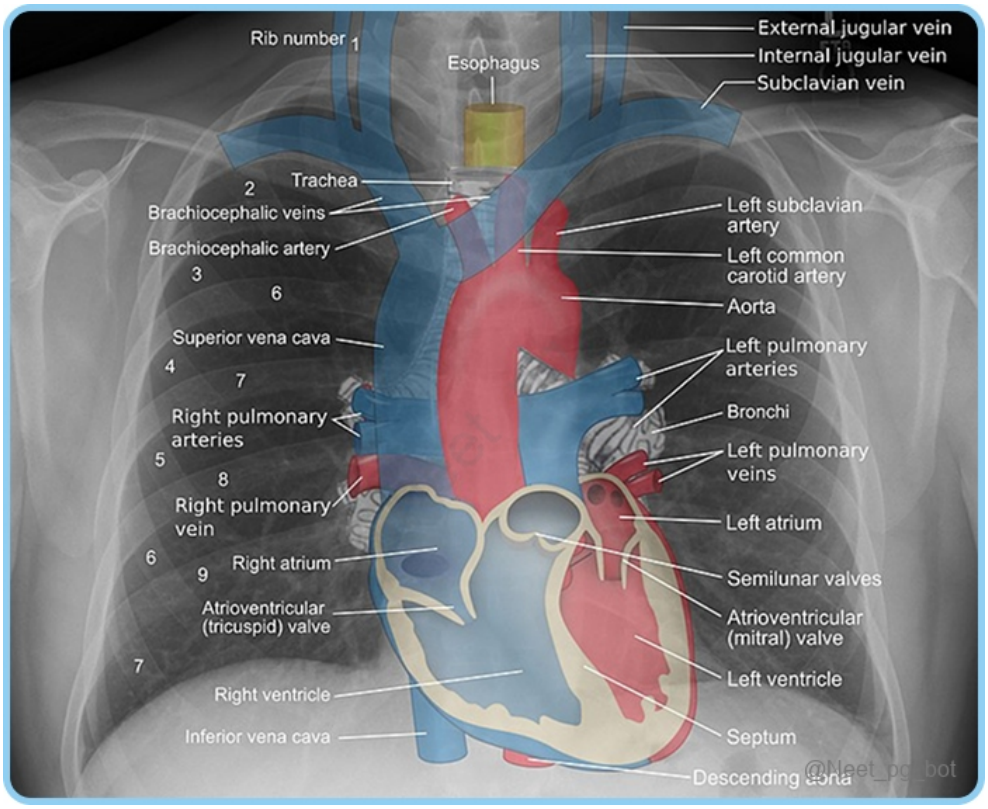

References:

Grays Anatomy, 42nd Edition, Page 1074

Vishram Singh Textbook of Anatomy, Volume 1, 2nd Edition, Page 262

↑ *Back to this question in Part A*

@Neet_pg_bot

Q30: Which sulcus contains major coronary arteries? (Q848261)

A. Sulcus of Waterston

B. Atrioventricular Sulcus

C. Anterior Interventricular Sulcus

D. Inferior Interventricular Sulcus

Correct Answer: B. Atrioventricular Sulcus

■ *Listen (English)*

■ *Listen (Hindi)*

Explanation: Atrioventricular (Coronary) Sulcus separates the atria from the ventricles and contains the major coronary arteries. Grooves of the Heart Interatrial Sulcus (of Waterston) : Separates the two atria. (Option A) Atrioventricular (Coronary) Sulcus : Separates the atria from the ventricles. Contains major coronary arteries. Anterior Interventricular Sulcus : (Option C) Located near the left border of the heart on the sternocostal surface. Contains the anterior interventricular artery and the great cardiac vein. Inferior Interventricular Sulcus : (Option D) Closer to the midpoint of the ventricular mass on the diaphragmatic surface. Contains the posterior interventricular artery and the middle cardiac vein.

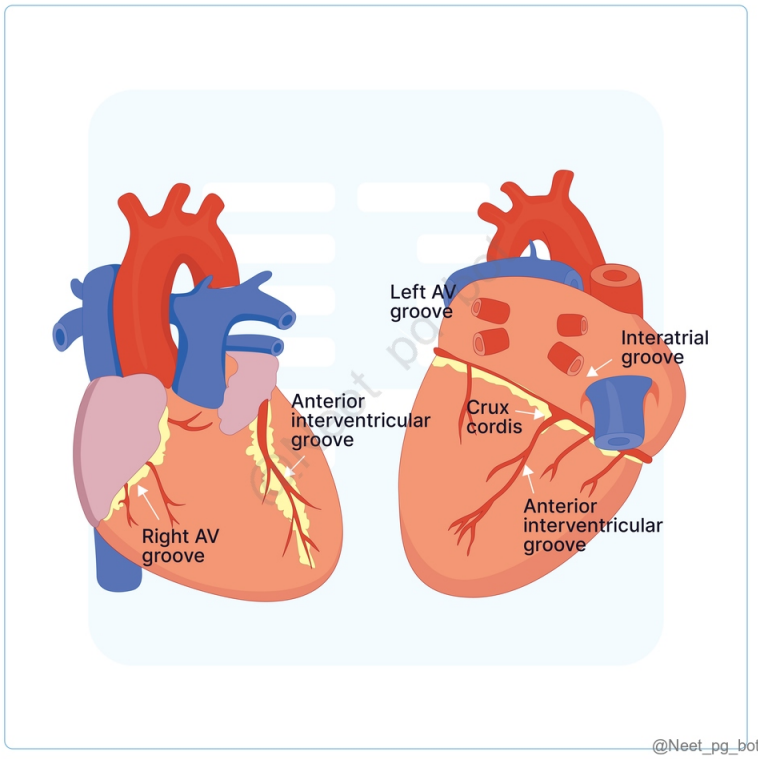

References:

Grays Anatomy, 42nd Edition, Page 1073

Vishram Singh Textbook of Anatomy, Volume 1, 2nd Edition, Page 263

↑ *Back to this question in Part A*

@Neet_pg_bot

• [07_Thorax] 035 Thorax Lungs Joints Respiratory Movements

« Back to Folder Directory

[07_Thorax] 035 Thorax Lungs Joints Respiratory Movements — Quick Jump

Q1 (p. 1778)	*Q2 (p. 1779)*	*Q3 (p. 1780)*	*Q4 (p. 1782)*	*Q5 (p. 1783)*	*Q6 (p. 1785)*
Q7 (p. 1787)	*Q8 (p. 1788)*	*Q9 (p. 1789)*	*Q10 (p. 1790)*	*Q11 (p. 1791)*	*Q12 (p. 1793)*
Q13 (p. 1794)	*Q14 (p. 1796)*	*Q15 (p. 1797)*	*Q16 (p. 1798)*	*Q17 (p. 1799)*	*Q18 (p. 1801)*
Q19 (p. 1802)	*Q20 (p. 1803)*				

Q1: The costal cartilages of which ribs attach directly to the sternum? (Q848374)

A. 1–7

B. 8-12

C. 11 and 12

D. 8-10

Correct Answer: A. 1–7

■ *Listen (English)*

■ *Listen (Hindi)*

Explanation: The first seven pairs of ribs (ribs 1–7) are true ribs as they are directly attached to the sternum via their costal cartilages. Ribs True ribs False ribs Attach to the sternum directly. AKA vertebrosternal ribs Arise from the vertebra. 1-7 are true ribs. (Option A) Do not attach to the sternum directly. They are indirectly attached to the sternum through the costal margin. Arise from the vertebra. 8-12 are false ribs. (Option B). 8,9,10 ribs form the costal margin. (Option D). AKA vertebrochondral ribs 11,12 are floating ribs (They are not attached to the sternum at all). (Option C)

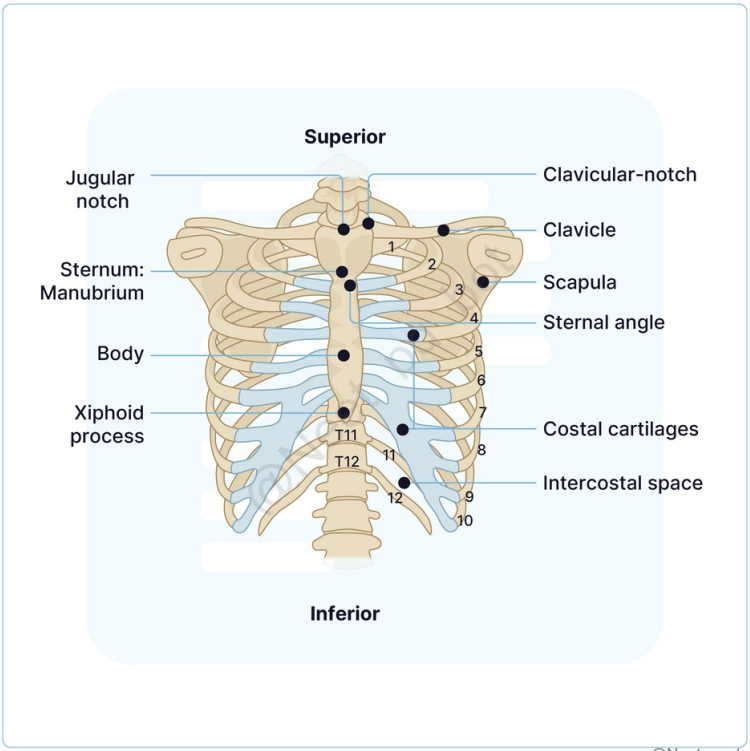

@Neet_pg_bot

References:

BD Chaurasia's Human Anatomy, Volume 1, 8th Edition, Page 220

↑ *Back to this question in Part A*

@Neet_pg_bot

Q2: Ductus venosus is an embryologic shunt that connects which of the following structures? (Q882121)

A. Pulmonary trunk and descending aorta

B. Right atrium and left atrium

C. Umbilical vein and IVC

D. Pulmonary trunk and ascending aorta

Correct Answer: C. Umbilical vein and IVC

Explanation: Option C: Umblical vein and IVC The umblical vein is connected to the IVC via ductus venosus. Ductus venosus: Fetal circulation is unlike adult circulation, which uses physiological shunts to carry oxygenated

blood to tissues and bypass developing organs. The fetus's viability heavily relies on these shunts to adequately perfuse developing tissues and organs, especially the brain and heart. The ductus venosus is a shunt that allows oxygenated blood in the umbilical vein to bypass the liver and is essential for normal fetal circulation. Blood becomes oxygenated in the placenta and travels to the right atrium via umbilical veins through the ductus venosus, then to the inferior vena cava. This oxygenated blood then passes through the foramen ovale, an opening between the atria, into the left atrium to be distributed systemically. Therefore, the ductus venosus plays a crucial role in maintaining this unique circulation pattern. Fetal circulation studies are done via Doppler ultrasound or MRI to ensure proper blood flow through these shunts. The impedance or absence of flow through these shunts may correlate with aneuploidies, cardiac defects, and/or other postpartum disease states. Postpartum, the ductus venosus closed, secondary to increased cardiac pressures and decreased circulating prostaglandins. The ductus venosus is critical for proper fetal circulation. Still, disruption of flow in utero or failure to close this shunt postpartum can lead to adverse antenatal and perinatal outcomes. Fig.: Fetal circulation Option A: Pulmonary trunk and descending aorta There is no structure that connects the descending aorta with the pulmonary trunk Option B: Right atrium and left atrium The right and left atriums are connected through the foramen ovale. Option D: Pulmonary trunk and ascending aorta The ductus arteriosus connects the Pulmonary trunk with ascending aorta.

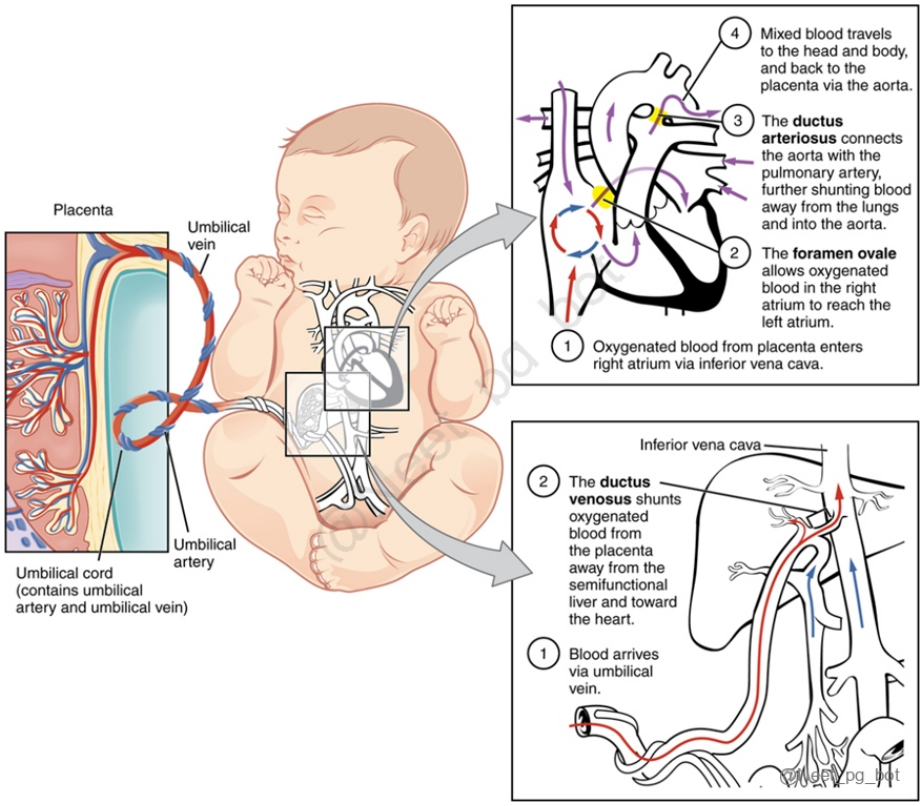

References:

Gray's anatomy Ed. 41 Ch. 56

↑ *Back to this question in Part A*

@Neet_pg_bot

Q3: A 36-year-old male presents with sharp, stabbing pain in the right upper abdomen for 2 weeks. The pain is aggravated by deep breathing and movement, especially when bending or twisting. There is tenderness over the right costal margin, but no signs of gastrointestinal distress, fever, or abdominal distension. His medical history is unremarkable. What is the most likely diagnosis? (Q848382)

A. Acute cholecystitis

B. Subcostal neuralgia

C. Appendicitis

D. Peptic ulcer disease

Correct Answer: B. Subcostal neuralgia

■ *Listen (English)*

■ *Listen (Hindi)*

Explanation: Subcostal neuralgia is caused by irritation or compression of the T12 (subcostal) nerve , which provides sensory innervation to the skin of the upper abdomen below the ribcage. It typically presents with sharp, localized pain along the costal margin , especially aggravated by deep breathing or movement (such as twisting or bending). The pain can be unilateral, as seen in this patient. The absence of gastrointestinal symptoms (like nausea, vomiting, or changes in bowel habits), along with localized tenderness over the right costal margin , supports the diagnosis of subcostal neuralgia .

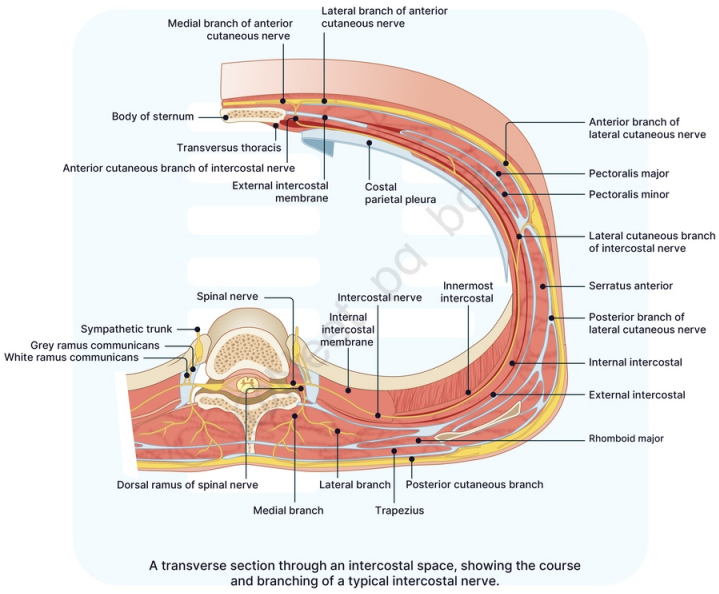

@Neet_pg_bot

References:

Gray’s Anatomy, 42nd edition, Pages 992, 1002, 1011, 1012

↑ *Back to this question in Part A*

@Neet_pg_bot

Q4: A 48-year-old woman presents to the clinic complaining of a burning, aching sensation on the inner side of her left upper arm. She mentions that about two weeks ago she underwent mastectomy with axillary clearance. She describes the pain as localized along the inner part of the upper arm, extending from the axilla (armpit) to the medial elbow. The pain seems to worsen when she raises her arm. On physical examination, there is tenderness over the left axillary region and the medial upper arm, but no signs of swelling or lymphadenopathy. Based on the patient's history of breast surgery and the clinical presentation, which of the following is the most likely diagnosis? (Q848381)

A. Radial nerve injury

B. Cervical radiculopathy (C7)

C. Intercostobrachial nerve injury

D. Thoracic outlet syndrome

Correct Answer: C. Intercostobrachial nerve injury

■ *Listen (English)*

■ *Listen (Hindi)*

Explanation: Intercostobrachial nerve injury is a well-known complication after breast surgery, particularly those involving the axillary region (such as axillary lymph node dissection or mastectomy). This condition is referred to as post-mastectomy pain syndrome when associated with breast cancer surgery. The pain may worsen with arm movements, and in some cases, hyperalgesia (heightened pain sensitivity) in the affected area is noted. The intercostobrachial nerve arises from the second intercostal nerve (T2) and provides sensory innervation to the inner upper arm, the medial side of the axilla, and part of the chest. It is a purely sensory nerve and does not affect motor function. Intercostobrachial nerve injury is a common complication following breast surgery—especially lumpectomy, mastectomy, or axillary lymph node dissection—due to the proximity of the nerve to the axillary region. During these procedures, the nerve can be cut, stretched, or irritated, leading to pain and sensory disturbances in its area of distribution.

References:

Gray's Anatomy, 42nd edition, Page 890, 891, 892.

↑ *Back to this question in Part A*

@Neet_pg_bot

Q5: Identify the structure marked as X in the image. {{caption_text}} (Q848380)

A. Subclavian vein

B. Subclavian artery

C. Median nerve

D. Ulnar nerve



Correct Answer: A. Subclavian vein

■ *Listen (English)*

■ *Listen (Hindi)*

Explanation: The subclavian vein is a key vessel in the venous system that drains blood from the upper limb, the neck, and part of the chest. It is located in the thoracic region and plays a crucial role in returning deoxygenated blood to the heart. The subclavian vein is positioned deep to the clavicle (collarbone) and lies within the thoracic inlet, a narrow space between the neck and the chest. It runs laterally and horizontally beneath the clavicle, crossing the first rib and passing anterior to the anterior scalene muscle. It continues to run towards the right or left sternoclavicular joint, where it drains into the brachiocephalic vein on both sides (right and left). {{caption_text}}

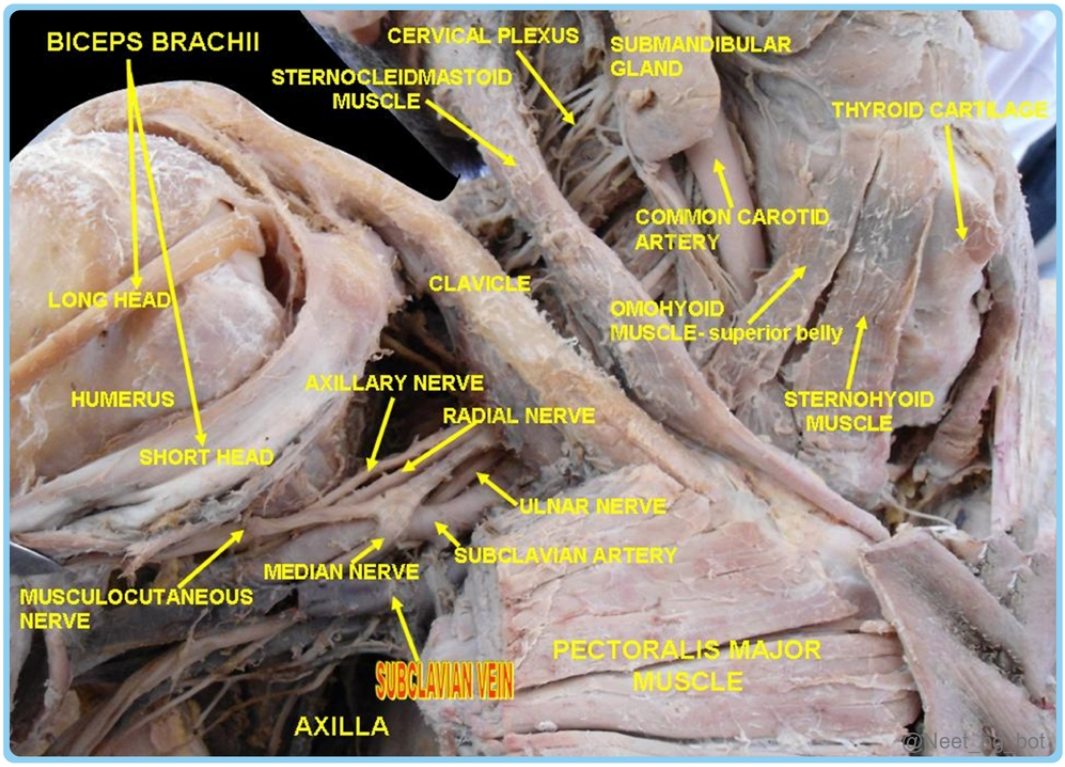

References:

BD Chaurasia's Human Anatomy, Volume 1, 8th Edition, Page 237, 266

↑ *Back to this question in Part A*

@Neet_pg_bot

Q6: Which of the following structures is the mediastinal surface of the right lung not related to? (Q848379)

A. Right atrium

B. Azygos vein

C. Thoracic aorta

D. Esophagus

Correct Answer: C. Thoracic aorta

■ *Listen (English)*

■ *Listen (Hindi)*

Explanation: Thoracic aorta is related to mediastinal surface of the left lung Mediastinal impression of right lung: Mediastinal impression of left lung: Mediastinal structures related to lungs: Right lung Left lung 1. Right atrium (Option A) 1. Left ventricle, left auricle, infundibulum and adjoining part of the right ventricle 2. A small part of the right ventricle 2. Pulmonary trunk 3. Superior vena cava 3. Arch of aorta 4. Lower part of the right brachiocephalic vein 4. Descending thoracic aorta (Option C) 5. Azygos vein (Option B) 5. Left subclavian artery 6. Esophagus (Option D) 6. Thoracic duct 7. Inferior vena cava 7. Oesophagus 8. Trachea 8. Left brachiocephalic vein 9. Right vagus nerve 9. Left vagus nerve 10. Right phrenic nerve 10. Left phrenic nerve 11. Left recurrent laryngeal nerve

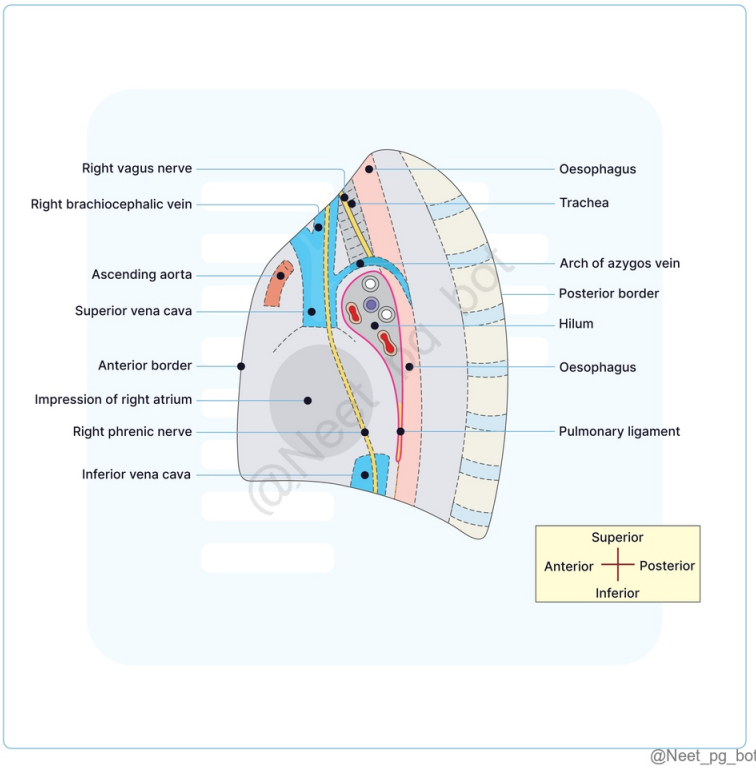

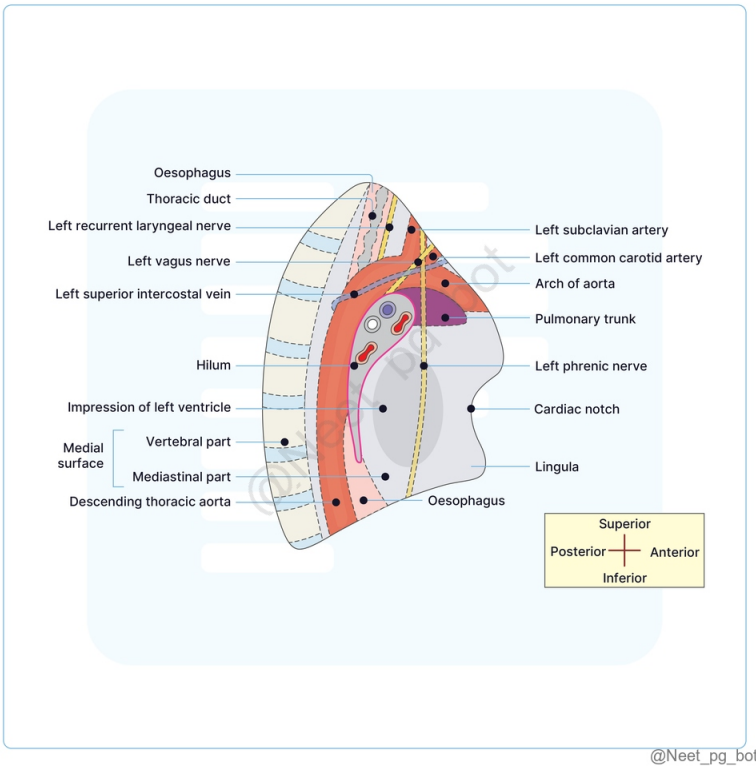

References:

BD Chaurasia's Human Anatomy, Volume 1, 8th Edition, Page 266

↑ *Back to this question in Part A*

@Neet_pg_bot

Q7: In a healthy individual at rest, which of the following is a primary muscle involved in expiration? (Q848378)

A. Diaphragm

B. External intercostal muscles

C. Scalene muscles

D. None of the above

Correct Answer: D. None of the above

■ *Listen (English)*

■ *Listen (Hindi)*

Explanation: Expiration is a passive process at rest due to elastic recoil of the lung and chest wall. Type of Breathing Muscles Involved Process Remarks Quiet Expiration Elastic recoil of chest wall and pulmonary alveoli Passive Mainly elastic recoil, aided by abdominal muscle tone Forced Expiration Abdominal muscles, Latissimus dorsi Active Strong contraction of abdominal muscles The diaphragm (Option A) is primarily involved in inspiration. External intercostal muscles (Option B) are used for inspiration. Scalene muscles (Option C) are accessory muscles of inspiration and do not play a role in expiration.

References:

BD Chaurasia's Human Anatomy, Volume 1, 8th Edition, Page237

↑ *Back to this question in Part A*

@Neet_pg_bot

Q8: Which of the following muscles plays the primary role in quiet inspiration? (Q848377)

A. Anterior abdominal wall muscles

B. External intercostal muscles

C. Scalene muscles

D. Sternocleidomastoid muscle

Correct Answer: B. External intercostal muscles

■ *Listen (English)*

■ *Listen (Hindi)*

Explanation: The external intercostal muscles are the primary muscles responsible for quiet inspiration, aiding in the elevation of the ribs and expansion of the thoracic cavity. Type of Breathing Muscles Involved Process Remarks Quiet Inspiration Diaphragm External Intercostal (Option B) Active Increase in A-P, transverse, and vertical diameters Forced Inspiration Scalene (Option C) Sternocleidomastoid (Option D) Erector Spinae, Pectoral muscles, Trapezius, Levator Scapulae, Rhomboids Active Exaggerated movements, Scapulae elevated and fixed Anterior abdominal wall muscles (Option A) and internal intercostal muscles are primarily involved in forced expiration. Scalene muscles (Option C) and the sternocleidomastoid muscle (Option D) are accessory muscles that come into play during deep or labored inspiration but not during quiet inspiration.

References:

BD Chaurasia's Human Anatomy, Volume 1, 8th Edition, Page 237

↑ *Back to this question in Part A*

@Neet_pg_bot

Q9: Which rib movements are responsible for increasing the anteroposterior diameter of the thoracic cavity during inspiration? (Q848376)

A. Pump-handle movement of ribs 1-6

B. Bucket-handle movement of ribs 7-10

C. Bucket-handle movement of ribs 1-6

D. Pump-handle movement of ribs 7-10

Correct Answer: A. Pump-handle movement of ribs 1-6

■ *Listen (English)*

■ *Listen (Hindi)*

Explanation: The pump-handle movement of the upper ribs (ribs 1-6) increases the anteroposterior (AP) diameter of the thoracic cavity during inspiration, elevating the sternum and ribs forward. Movements of the ribs during respiration: Mechanism Action Diameter Increased Ribs Involved Pump Handle (Option A) Elevation of ribs causing forward movement of the sternum Anteroposterior Diameter 2nd to 6th Ribs (Vertebrosternal) (Option D) Bucket Handle (Options B and C) Elevation of ribs causing outward movement of the rib shafts Transverse Diameter 7th to 10th Ribs (Vertebrochondral)

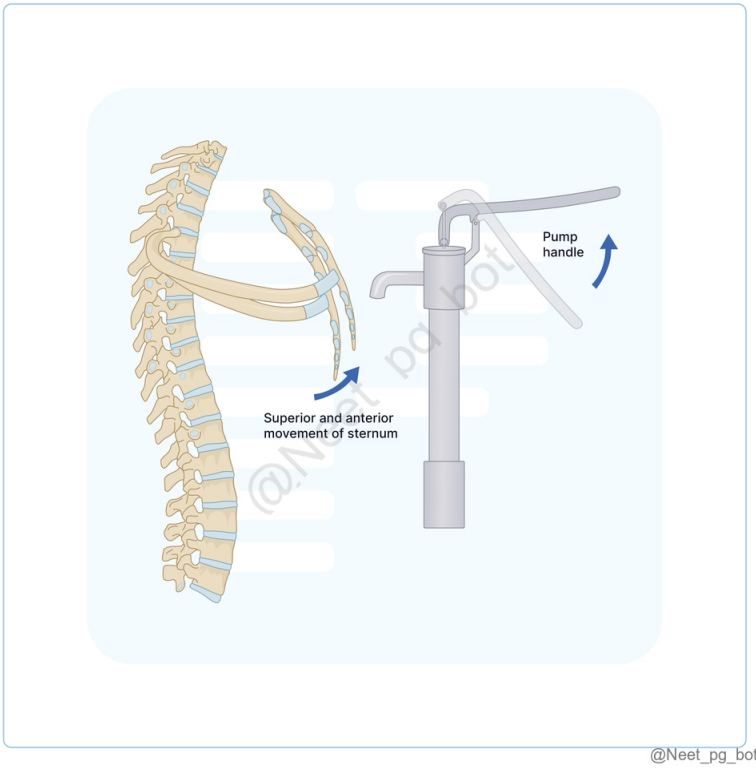

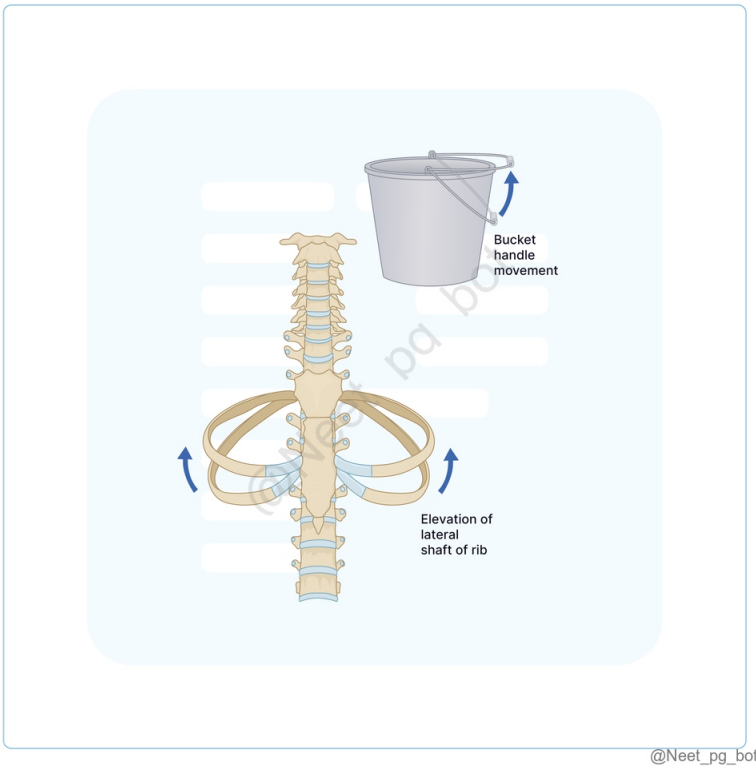

@Neet_pg_bot

References:

BD Chaurasia’s Human Anatomy, Volume 1, 8th Edition, Pages 235, 236

Gray’s Anatomy, 42nd edition, Page 185

↑ *Back to this question in Part A*

@Neet_pg_bot

Q10: The 2nd to 7th sternocostal joints are categorized as which type of joint? (Q848375)

A. Synovial

B. Symphysis

C. Synarthrosis

D. Synchondrosis

Correct Answer: A. Synovial

■ *Listen (English)*

■ *Listen (Hindi)*

Explanation: The second to seventh sternocostal joints are synovial joints. These are the joints between the costal cartilages of the ribs and the sternum. Thorax joints Manubriosternal Joint: It is between the manubrium and the body of the sternum. It lies in the midline. It is usually a symphysis Xiphisternal joint: It is between the xiphoid process and body of the sternum. It is a symphysis type of joint. (Option B) First sternocostal joint: It is a type of synarthrosis (fibrous joint) (Option C) It is inaccurately called synchondrosis. (Option D) The second to seventh sternocostal joints: It is a synovial type of joint. (Option A) Mobile joints for free movements. Helps in respiratory movements. Interchondral joints: Adjoining borders of the sixth to ninth costal cartilages articulate by apposition. Each articulation is lined by a synovial membrane.

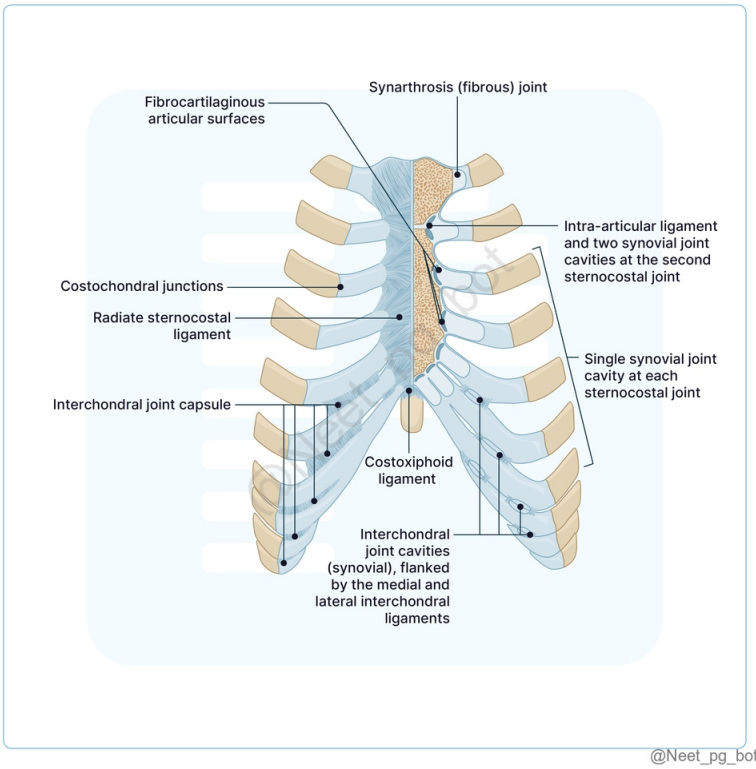

References:

Gray’s Anatomy, 42nd edition, Page 1006

↑ *Back to this question in Part A*

@Neet_pg_bot

Q11: Identify the correct labels. (Q848362)

A. A. Left main bronchus, B. Descending aorta, C. T5 vertebrae, D.Esophagus, H.Ascending aorta

B. A. Left main bronchus, B. Ascending aorta, C. T5 vertebrae, D. Esophagus, H. Descending aorta

C. A. Right main bronchus, B. Descending aorta, C. T5 vertebrae, D. Ascending aorta, H. Pulmonary artery

D. A. Right main bronchus, B. Descending aorta, C. T5 vertebrae, D. Esophagus, H. Ascending aorta

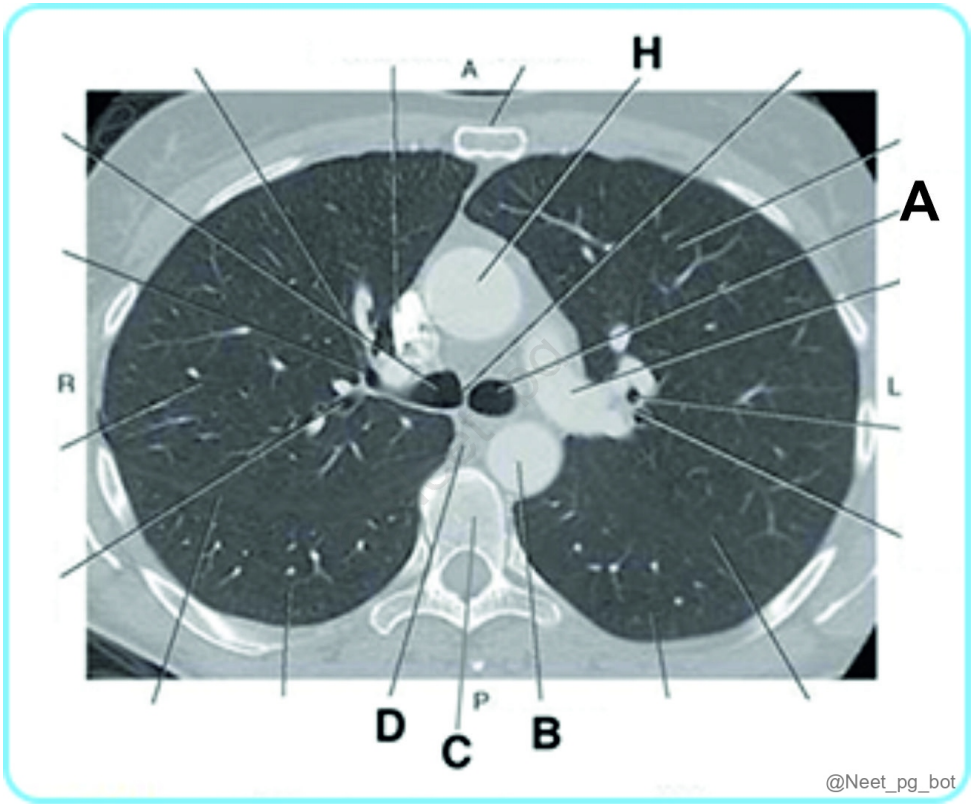

Correct Answer: A. A. Left main bronchus, B. Descending aorta, C. T5 vertebrae, D.Esophagus, H.Ascending aorta

■ *Listen (English)*

■ *Listen (Hindi)*

Explanation: The anatomical positions of the structures mentioned and how they typically appear in a CT image of the thorax is given below. {{caption_text}}

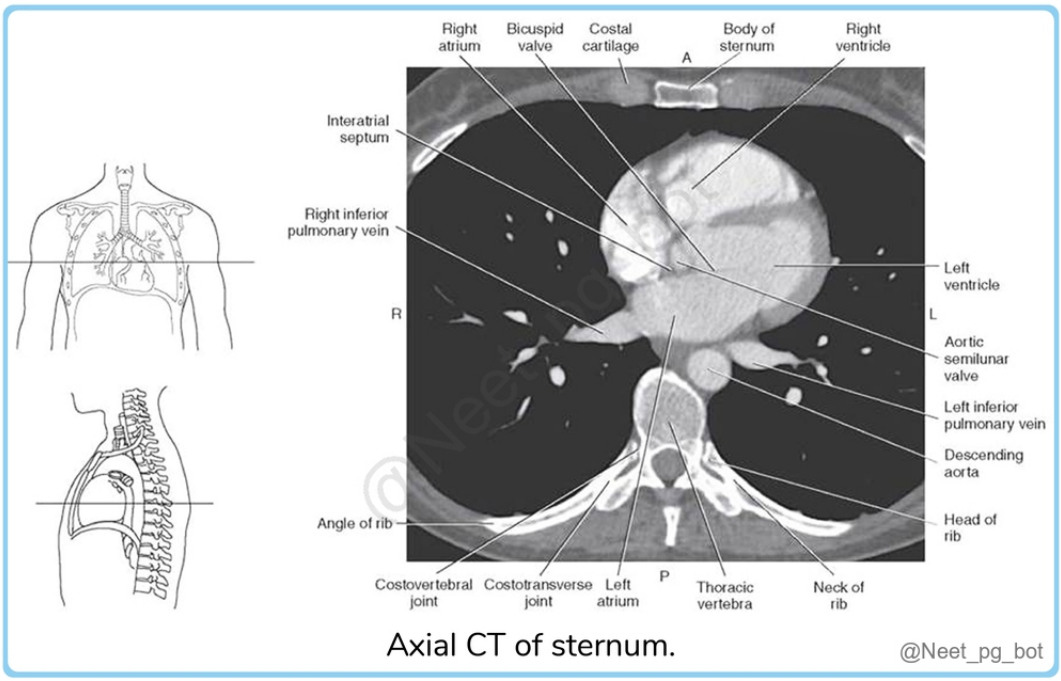

References:

doctorlib.info/anatomy/sectional-anatomy/6.html

↑ *Back to this question in Part A*

@Neet_pg_bot

Q12: At the midaxillary line, the inferior border of the right lung typically corresponds to which rib level? (Q848373)

A. 4th

B. 6th

C. 8th

D. 10th

Correct Answer: C. 8th

■ *Listen (English)*

■ *Listen (Hindi)*

Explanation: The lower border of each lung lies two ribs higher than the parietal pleural reflection. It crosses the eighth rib in the midaxillary line. Lung markings Anterior border: Right lung Left lung Corresponds to the anterior margin of the pleura up to the level of the 6th costal cartilage. Corresponds to the anterior margin of the pleura up

to the level of the 4th costal cartilage. (Option A) Curves downwards and medially to reach the sixth costal cartilage to form the cardiac notch. Lower border: Lies two ribs higher than the parietal pleural reflection. Same on both the lungs. At 6th rib - Midclavicular line (Option B) At 8th rib - Midaxillary line At 10 rib - Paravertebral line (Option D) The posterior border: Coincides with the posterior margin of the pleural reflection Lower end lies at the level of 10th thoracic spine (2 space higher than plerua) Pleural tapping: The "Safe Zone": Tapping is usually performed in the 8th or 9th intercostal space at the midaxillary line. This puts the needle in the costodiaphragmatic recess , where there is pleural fluid but the lung has not yet reached, minimizing the risk of a pneumothorax (lung puncture). Neurovascular Safety: The needle must always be inserted just above the lower rib of the intercostal space. This avoids the intercostal nerve, artery, and vein, which run in the costal groove along the inferior border of the upper rib. The Lower Limit: Tapping should not be done below the 9th rib to avoid penetrating the diaphragm or injuring abdominal organs like the liver (on the right) or spleen (on the left).

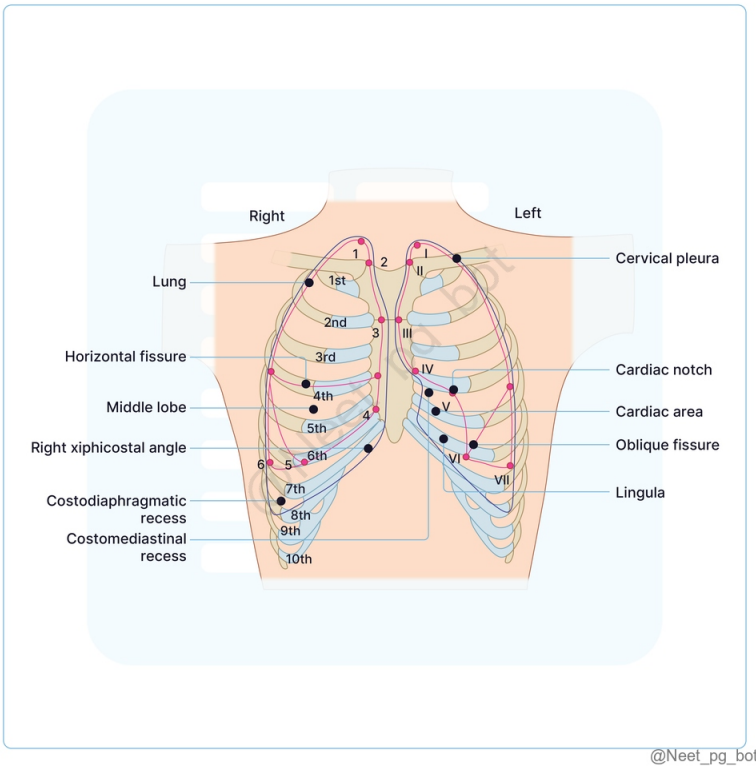

References:

Gray’s Anatomy, 42nd Edition, Page 1024

BD Chaurasia’s Human Anatomy, Volume 1, 8th Edition, Pages 331, 332

↑ *Back to this question in Part A*

@Neet_pg_bot

Q13: The pleura extends inferiorly to which rib at the midclavicular line in a normal adult? (Q848372)

A. 6th rib

B. 8th rib

C. 10th rib

D. 12th rib

Correct Answer: B. 8th rib

■ *Listen (English)*

■ *Listen (Hindi)*

Explanation: The costodiaphragmatic line of pleural reflection passes laterally from the lower limit of its anterior margin, crossing the eighth rib in the midclavicular line. Pleural markings Anterior margin: Right side Left side From the sternoclavicular joint vertically downwards to the midpoint of the xiphisternal joint (level of 6th costal cartilage). (Option A) Same as right side except at the level of 4 th costal cartilage it arches outwards and descends along the sternal margin up to the 6th costal cartilage. For cardiac notch. Inferior margin (costodiaphragmatic line of pleural reflection): From the lower limit of its anterior margin, it crosses 8th rib in the midclavicular line (Option B) 10th rib in the midaxillary line (Option C) 12th rib at the lateral border of the sacrospinalis muscle (Option D) Posterior margin: Extends from 2 cm lateral to the 12th thoracic spine to 2 cm lateral to the 7th cervical spine.



References:

Gray’s Anatomy, 42nd edition, Page1021

BD Chaurasia’s Human Anatomy, Volume 1, 8th Edition, Pages 330, 331

↑ *Back to this question in Part A*

@Neet_pg_bot

Q14: A 40-year-old patient with known dextrocardia comes for a routine checkup. Where would you expect to hear the loudest apex beat on physical examination? (Q848371)

A. Left 4th intercostal space

B. Right 5th intercostal space

C. Midline of the sternum

D. Right 3rd intercostal space

Correct Answer: B. Right 5th intercostal space

■ *Listen (English)*

■ *Listen (Hindi)*

Explanation: Dextrocardia is a congenital anomaly where the heart is placed on the right side of the thorax. The apex beat is heard in the right fifth intercostal space to the right of the inferior end of the sternum. Dextrocardia It is a rare congenital anomaly in which the heart is located on the right side of the thoracic cavity. {{caption_text}} Sometimes, the viscera of the abdomen and thorax including the heart are a mirror image of normal. This condition is called ‘situs inversus’. The apex beat is heard in the right fifth intercostal space to the right of the inferior end of the sternum (Option B) Kartagener syndrome (ciliary dyskinesia): Chronic sinusitis Bronchiectasis Dextrocardia

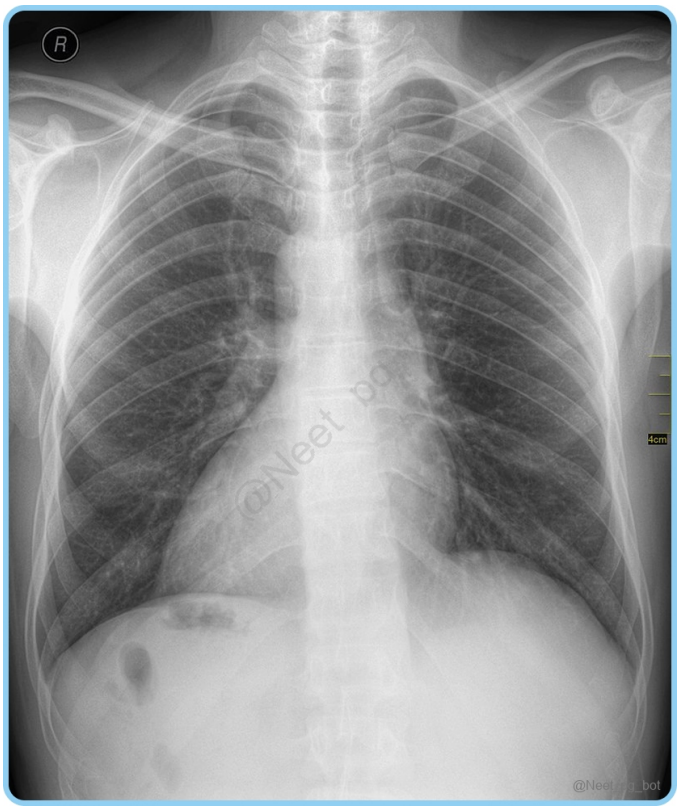

References:

Gray’s Anatomy, 42nd Edition, Page 1086.e1

BD Chaurasia’s Human Anatomy, Volume 1, 8th Edition, Page 307, 308

Dextrocardia - StatPearls - NCBI Bookshelf (nih.gov)

↑ *Back to this question in Part A*

@Neet_pg_bot

Q15: During bronchoscopy, the carina is an important landmark that separates the openings of the right and left main bronchi. Which of the following statements about the tracheal bifurcation is true? (Q848370)

A. The left main bronchus is shorter and more vertical than the right

B. The right main bronchus is wider and more horizontal than the left

C. The left main bronchus is longer and more horizontal than the right

D. The right main bronchus is narrower and more vertical than the left

Correct Answer: C. The left main bronchus is longer and more horizontal than the right

■ *Listen (English)*

■ *Listen (Hindi)*

Explanation: The right main bronchus is approximately 2.5 cm long, and is wider, shorter, and more vertical than the left. Bifurcation of trachea Level of bifurcation: T5–T6 intervertebral disc The angle between left and right principal bronchus - 70■ Bifurcates into left and right main (principal) bronchus Right main bronchus Shorter in length (Option C) Wider lumen More vertical (Option C) Inhaled foreign bodies and aspiration occurs at the right main bronchus more often than the left

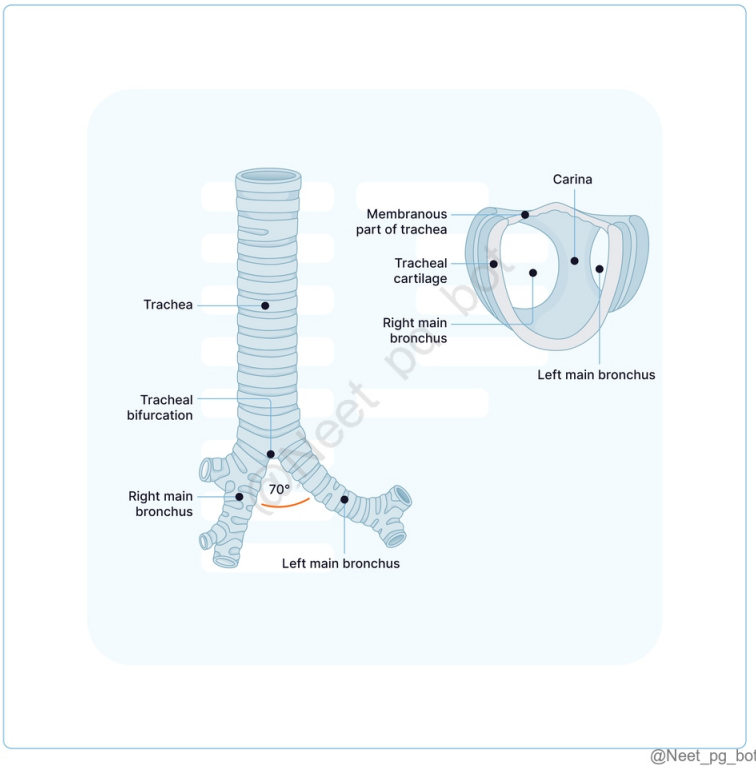

References:

Gray’s Anatomy, 42nd Edition, Pages 1025, 1026, 1027

↑ *Back to this question in Part A*

@Neet_pg_bot

Q16: Which segment of the left lung is located in the inferior lobe? (Q848369)

A. S5: Inferior Lingular

B. S3: Anterior

C. S10: Posterior Basal

D. S2: Posterior

Correct Answer: C. S10: Posterior Basal

■ *Listen (English)*

■ *Listen (Hindi)*

Explanation: S10: Posterior Basal is located in the inferior lobe of the left lung S5, S3, and S2 are also in the superior lobe. Left Lung Superior Lobe: S1: Apical S2: Posterior S3: Anterior S4: Superior Lingular S5: Inferior Lingular (Note: S1 and S2 may be fused) Inferior Lobe: S6: Superior (Apical) S7: Medial Basal S8: Anterior Basal S9: Lateral Basal S10: Posterior Basal (Note: S7 and S8 may be fused)

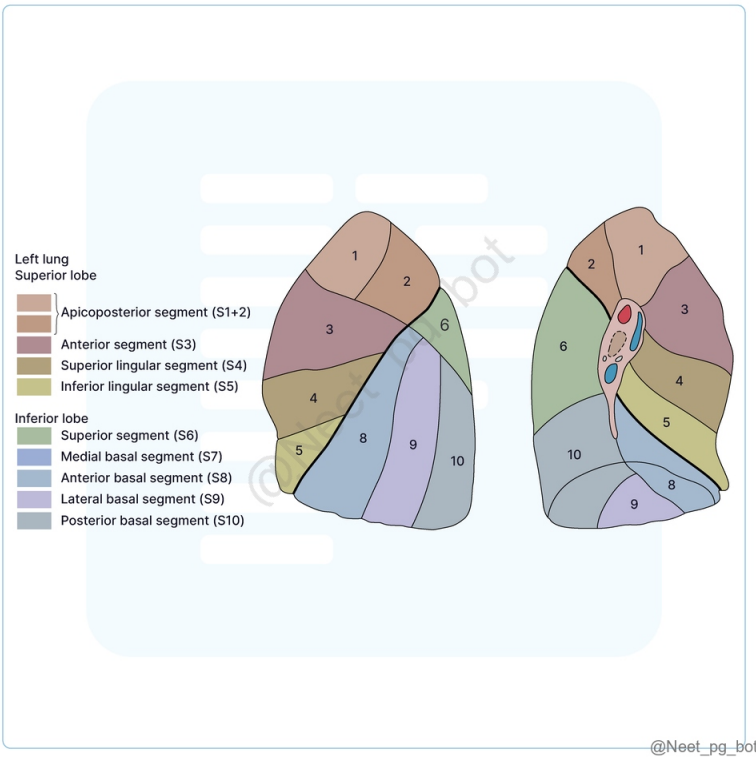

References:

Grays Anatomy, 42nd Edition, Page 1029

↑ *Back to this question in Part A*

@Neet_pg_bot

Q17: A 65-year-old male patient is admitted to the hospital after undergoing elective surgery. Post-anesthesia, he is found to be unconscious and placed in a supine position

for monitoring. The healthcare team is concerned about the risk of aspiration due to his current state. Which location is most likely to collect aspirated material in this patient? (Q848368)

A. Anterior Basal BPS of the right lower lobe

B. Posterior BPS of the right upper lobe

C. Apical Basal BPS of the right lower lobe

D. Lateral BPS of the right middle lobe

Correct Answer: C. Apical Basal BPS of the right lower lobe

■ *Listen (English)*

■ *Listen (Hindi)*

Explanation: The Apical Basal BPS of the right lower lobe is the most likely site for aspirated material in a supine, unconscious patient Due to its anatomical position and tendency to collect fluids. Other segments, while dependent, are less favorable for aspiration accumulation. (Option A, B, and D) Aspiration Sites by Patient Position: Patient Position Most Likely Aspiration Site Supine (Lying on back) Apical (Superior) segment of the Right Lower Lobe . Prone (Lying on front) Right Middle Lobe or Anterior segments of the upper lobes. Right Lateral Decubitus (Right side) Posterior segment of the Right Upper Lobe or Right Middle Lobe . Upright (Sitting/Standing) Posterior Basal segment of the Right Lower Lobe .

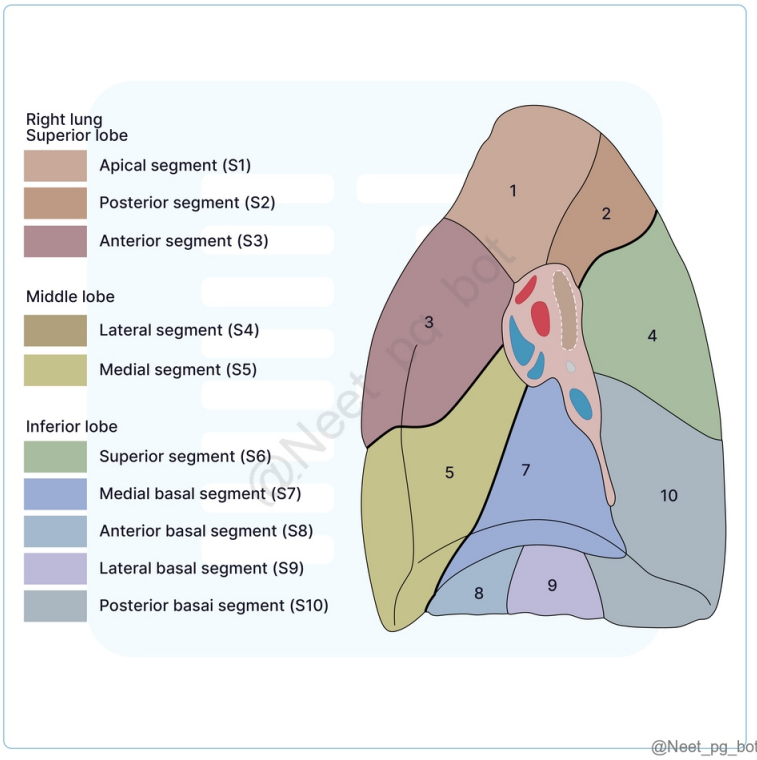

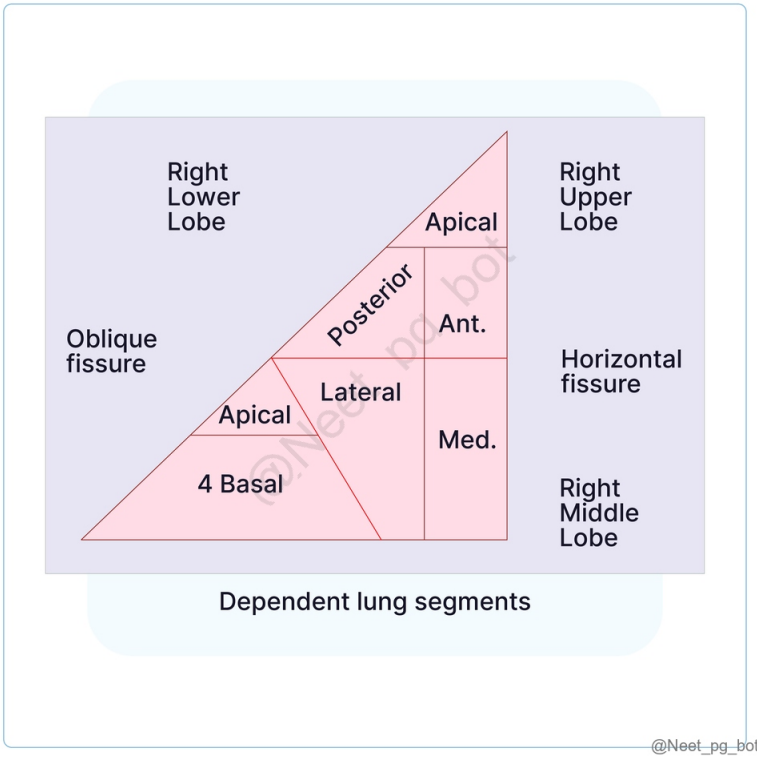

References:

BD Chaurasia's Human Anatomy, Volume 1, 8th Edition, Page 270

↑ *Back to this question in Part A*

@Neet_pg_bot

Q18: A 60-year-old female undergoes right lower lobe resection for a tumor. Which statement about bronchopulmonary segments is true? (Q848367)

A. Each segment shares a bronchus with adjacent segments.

B. Segments are supplied by segmental arteries and share venous drainage.

C. Each segment has independent arterial and venous supplies.

D. The shape is pyramidal with the base at the hilum.

Correct Answer: B. Segments are supplied by segmental arteries and share venous drainage.

■ *Listen (English)*

■ *Listen (Hindi)*

Explanation: Bronchopulmonary Segments Features: Well-defined anatomical segments of the lung, each aerated by a tertiary (segmental) bronchus. Each segment has its own arterial supply, but shares venous drainage with adjacent segments. (Option B) (Option C) Anatomical, Functional, and Surgical Units: Serve as distinct sectors of the lung. Aerosol Supply: Each segment is supplied by a tertiary (segmental) bronchus. (Option A) Shape: Pyramidal, with the apex oriented towards the root of the lung. (Option D) Vascular and Nerve Supply: Contains a segmental bronchus, segmental artery, autonomic nerves, and lymph vessels. Venous Drainage: Segmental venules are located in the connective tissue between adjacent segments. Surgical Resection: Surgeons isolate segments by working along the segmental veins during resection procedures.

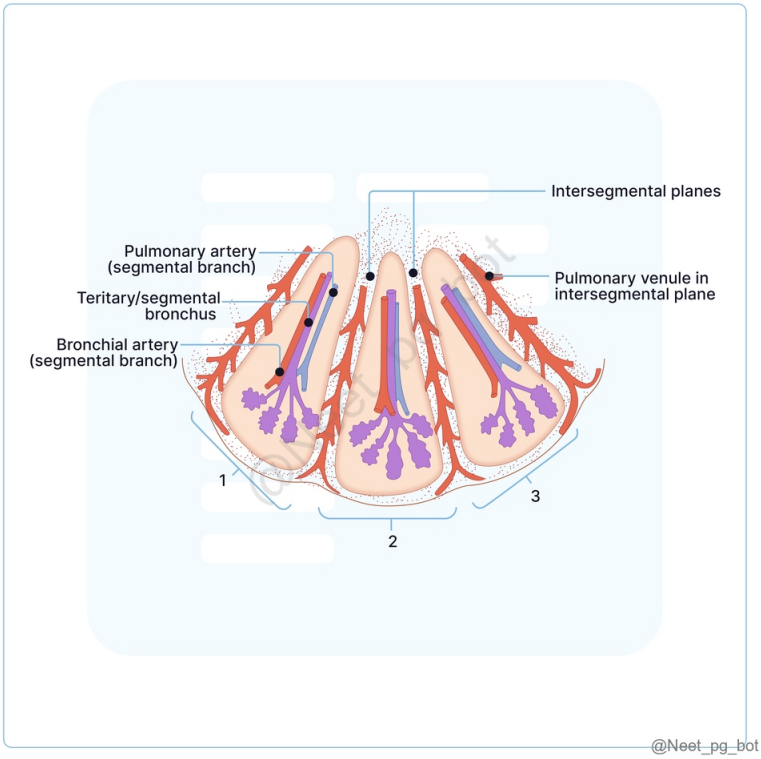

References:

BD Chaurasia's Human Anatomy, Volume 1, 8th Edition, Page 270

↑ *Back to this question in Part A*

@Neet_pg_bot

Q19: Which of the following statements correctly describes a difference between the right and left lungs? (Q848366)

A. The left lung is longer and narrower than the right lung.

B. The right lung has a cardiac notch.

C. The right lung has only one fissure and two lobes.

D. The left lung is larger and heavier than the right lung.

Correct Answer: A. The left lung is longer and narrower than the right lung.

■ *Listen (English)*

■ *Listen (Hindi)*

Explanation: The left lung is longer and narrower to accommodate the heart's position, with a cardiac notch. In contrast, the right lung is shorter and broader, allowing for a larger volume and more lobes. Feature Right Lung Left Lung Size Shorter and broader Longer and narrower (Option D) Weight Larger, about 700 g Smaller, about 600 g Anterior Border Straight Interrupted by a cardiac notch (Option B) Cardiac Impression Shallow/absent Deep Lingula Absent Present Lobes and Fissures 3 lobes, 2 fissures (Option C) 2 lobes, 1 fissure Bronchopulmonary segments 10 8 -10

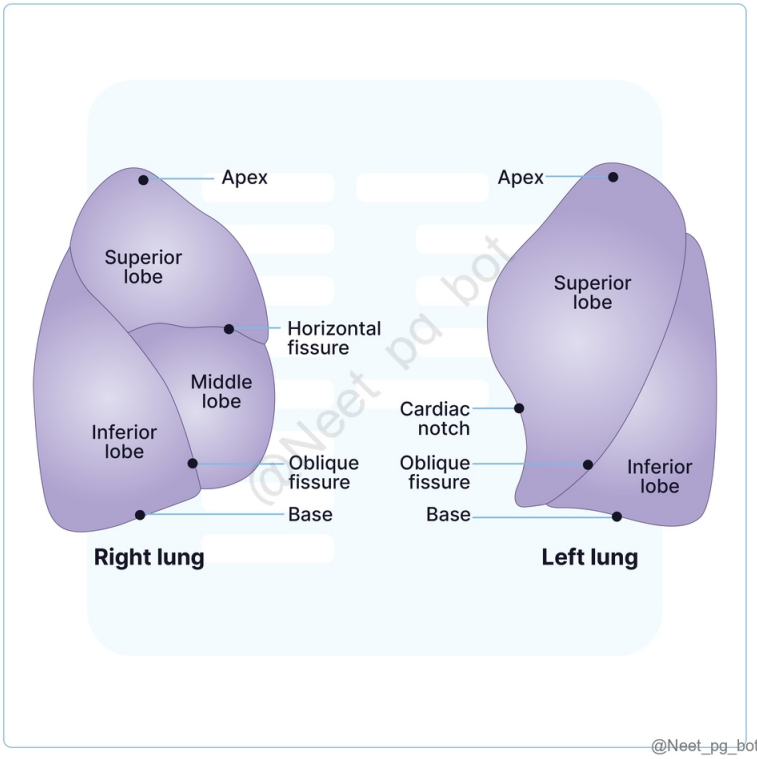

References:

BBD Chaurasia’s Human Anatomy, Volume 1, 8th Edition, Pages 268

↑ *Back to this question in Part A*

@Neet_pg_bot

Q20: A 55-year-old male patient presents with a persistent cough and shortness of breath. A chest X-ray shows a mass in the right lung. The attending physician is reviewing the anatomical structures relevant to potential surgical intervention. Which of the following statements about the anatomy of the right and left lungs is correct? (Q848363)

A. The right superior pulmonary vein is located posteriorly to the bronchus.

B. The eparterial bronchus in the right lung is found above the pulmonary artery.

C. The most superior structure of the left lung hilum is the Pulmonary vein.

D. The bronchus on the left side is shorter in length compared to the right bronchus.

Correct Answer: B. The eparterial bronchus in the right lung is found above the pulmonary artery.

■ *Listen (English)*

■ *Listen (Hindi)*

Explanation: In the right lung, the eparterial bronchus is anatomically located superior to the right pulmonary artery. This unique positioning is important for surgical considerations. Medial surface of the Lung Right Lung : Posterior Region : Bronchus is present. Anterior Region : Right superior pulmonary vein (Option A) Right inferior pulmonary vein Pulmonary Artery : More superior Eparterial Bronchus : Present above the artery. Hyparterial Bronchus : Present below the artery. Left Lung : Posterior Region : Bronchus is present. Anterior Region : Left superior pulmonary vein Left inferior pulmonary vein Pulmonary Artery : More superior in the superior region. Mnemonic (From Superior to Inferior) Atal Bihari Vajpayee : (Option C) A : Arteries B : Bronchus V : Veins NB: The eparterial bronchus is unique to the right lung's superior region. The right bronchus is shorter in length compared to the left (Option D)

References:

BD Chaurasia’s Human Anatomy, Volume 1, 8th Edition, Pages 265, 266, 267

↑ *Back to this question in Part A*

@Neet_pg_bot

• [07_Thorax] 036 Previous Year Questions

« Back to Folder Directory

[07_Thorax] 036 Previous Year Questions — Quick Jump

Q1 (p. 1805)	*Q2 (p. 1806)*	*Q3 (p. 1807)*	*Q4 (p. 1808)*	*Q5 (p. 1810)*	*Q6 (p. 1812)*
Q7 (p. 1813)	*Q8 (p. 1815)*	*Q9 (p. 1815)*	*Q10 (p. 1816)*	*Q11 (p. 1817)*	*Q12 (p. 1819)*
Q13 (p. 1821)	*Q14 (p. 1823)*	*Q15 (p. 1825)*	*Q16 (p. 1827)*	*Q17 (p. 1828)*	*Q18 (p. 1829)*
Q19 (p. 1830)	*Q20 (p. 1831)*	*Q21 (p. 1832)*	*Q22 (p. 1833)*	*Q23 (p. 1834)*	*Q24 (p. 1837)*
Q25 (p. 1838)	*Q26 (p. 1839)*				

Q1: Identify the labeling correctly: (Q844206)

A. A- Superior vena cava, B- Ascending aorta, C- Pulmonary trunk, D- Descending aorta

B. A- Ascending aorta, B- Descending aorta, C- Pulmonary trunk, D- Superior vena cava

C. A- Ascending aorta, B- Superior vena cava, C- Descending aorta, D- Pulmonary trunk,

D. A- Ascending aorta, B- Superior Vena Cava, C- Pulmonary trunk, D- Descending aorta

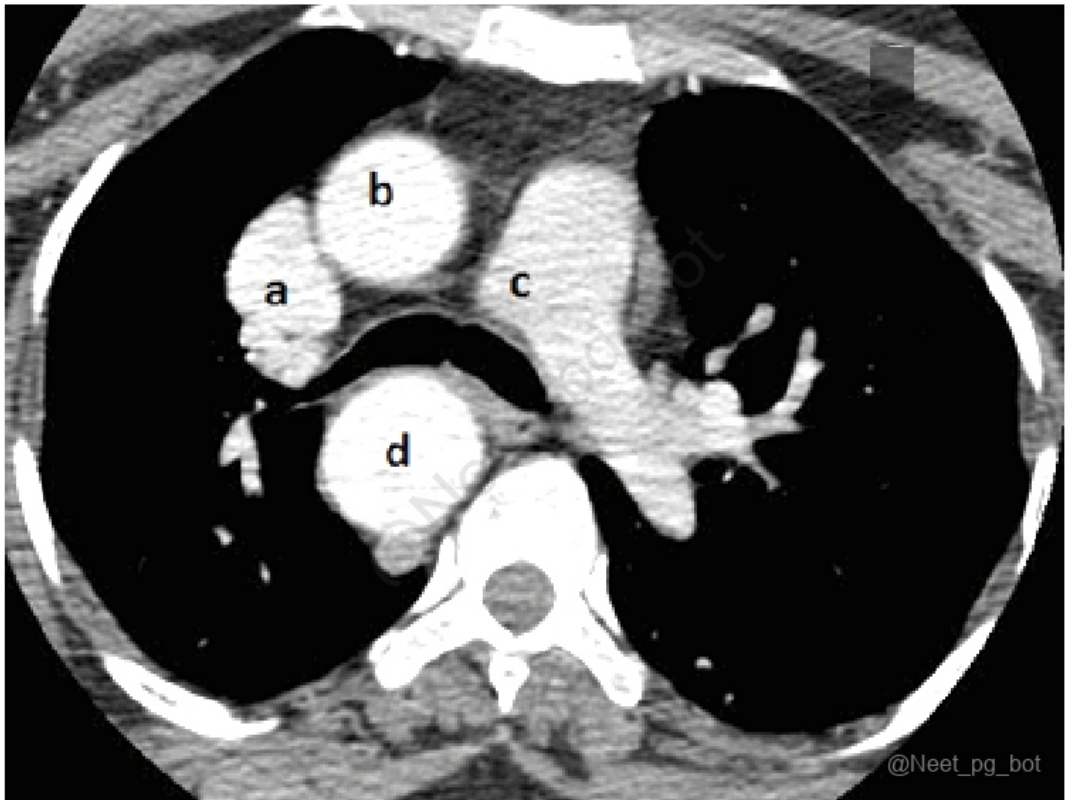

Correct Answer: A. A- Superior vena cava, B- Ascending aorta, C- Pulmonary trunk, D- Descending aorta

Explanation: Correct Option A - A- , B-Ascending aorta , C- Pulmonary trunk, D- Descending aorta: A. Superior vena cava: The superior vena cava is a large vein that carries deoxygenated blood from the upper half of the body to the right atrium of the heart. It is located anterior and slightly to the right of the ascending aorta. B. Ascending aorta: The ascending aorta arises from the left ventricle of the heart and is the initial portion of the aorta that moves upward before arching. C. Pulmonary Trunk: The pulmonary trunk is the vessel that arises from the right ventricle and bifurcates into the left and right pulmonary arteries, which carry deoxygenated blood to the lungs. It is positioned anterior to the ascending aorta and the superior vena cava. D. Descending Aorta: The descending aorta continues from the aortic arch and runs downwards behind the heart, supplying blood to the lower parts of the body. It is located posterior to the heart and more to the left in the thoracic cavity. Incorrect Options: Option B , C, D incorrectly labels the structures

References:

.

↑ *Back to this question in Part A*

@Neet_pg_bot

Q2: The subcostal line corresponds to which vertebrae level? (Q860619)

A. T12

B. L1

C. L2

D. L3

Correct Answer: D. L3

Explanation: The subcostal line corresponds to the L3 vertebrae. The subcostal plane refers to a horizontal (or transverse) plane which lies just below the level of the costal margin, i.e., connecting the 10th costal cartilages of right and left sides with each other. Posteriorly, the position of subcostal plane equates to the body of the third lumbar (L3) vertebrae. Incorrect Options: Option A) T12 – Level of origin of the celiac trunk, not the subcostal plane. Option B) L1 – Level of the transpyloric plane (passes SMA origin, pylorus). Option C) L2 – No major abdominal plane corresponds to this level.

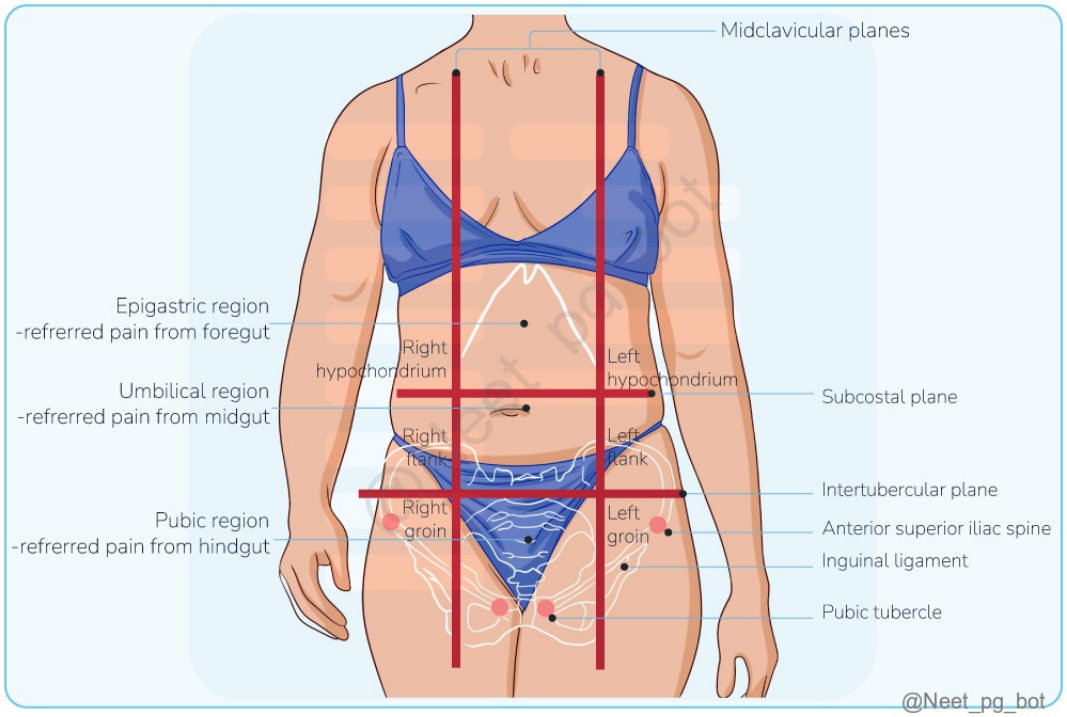

References:

https://www.ncbi.nlm.nih.gov/books/NBK553104/#

↑ *Back to this question in Part A*

@Neet_pg_bot

Q3: The structure marked in the image drains into: (Q859919)

A. Junction of superior vena cava and left brachiocephalic veins

B. Thoracic Duct

C. Directly into the coronary sinus

D. Azygos vein

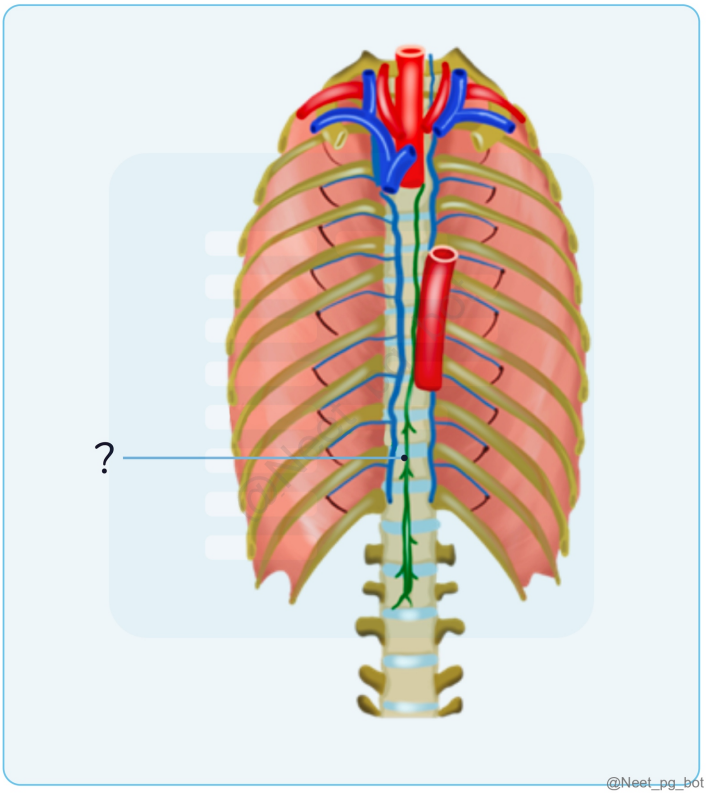

Correct Answer: B. Thoracic Duct

Explanation: The marked structure is the thoracic duct. The thoracic duct runs in the thorax and is the continuation of the cisterna chyli. It drains all body parts except the right half above the diaphragm. Left-sided trunks empty into it, and it ultimately drains into the left venous angle. Thoracic Duct: Function: Main lymphatic trunk, draining chyle and most lymph into the bloodstream. Drainage Area: Entire body except the right side of the head, neck, upper limb, lung, thoracic wall, right heart, and convex liver surface. Origin: Upper end of cisterna chyli (T12). Course: Enters thorax via aortic opening of the diaphragm. Ascends in posterior mediastinum behind the esophagus. At T5, inclines left and moves into the superior mediastinum. Termination: Ends at C7, draining into the left venous angle (junction of left internal jugular and subclavian veins). (Options A, C, and D ruled out)

References:

Snell Clinical Anatomy by Region. 10th edition. Pg. 264

↑ *Back to this question in Part A*

@Neet_pg_bot

Q4: A patient developed the following deformity, after overhead (weight-lifting) exercises. Which of the following muscles is involved? (Q859904)

A. Trapezius

B. Serratus anterior

C. Lattisimus dorsi

D. Supraspinatus



Correct Answer: B. Serratus anterior

Explanation: The Serratus Anterior muscle is located on the lateral aspect of the thorax and attaches to the medial border of the scapula. It is primarily responsible for protracting and stabilizing the scapula against the thoracic wall. Weakness or dysfunction of the Serratus Anterior can result in winged scapula, where the medial border of the scapula protrudes away from the thoracic wall. Serratus Anterior: Origin: Upper 8 ribs (anterolaterally) Insertion: Costal surface of the scapula Nerve Supply: Long thoracic nerve (C5, C6, C7 – "Wings to Heaven") Function: Protracts the scapula (pulls it forward) Holds scapula against the thoracic wall (prevents winging) Rotates the scapula laterally (turning the glenoid cavity upwards for full overhead abduction) Injury to Long Thoracic Nerve: Causes Winging of Scapula Seen in post-mastectomy cases, trauma, weightlifting injuries Patient has difficulty in overhead abduction (arm cannot be fully raised) Trapezius (Option A): Dysfunction of the trapezius (innervated by the spinal accessory nerve, CN XI) causes drooping of the shoulder, but not classic scapular winging. Latissimus dorsi (Option C): This muscle helps in adduction, extension, and medial rotation of the humerus. It is innervated by the thoracodorsal nerve and does not cause scapular winging. Supraspinatus (Option D): This muscle initiates arm abduction (first 15°) and is innervated by the suprascapular nerve. It is not responsible for scapular stability. Incorrect.

References:

https://pmc.ncbi.nlm.nih.gov/articles/PMC2684151/

↑ *Back to this question in Part A*

@Neet_pg_bot

Q5: The type of joint marked in the image below is: (Q858475)

A. Syndesmosis

B. Synarthrosis

C. Synchondrosis

D. Synovial

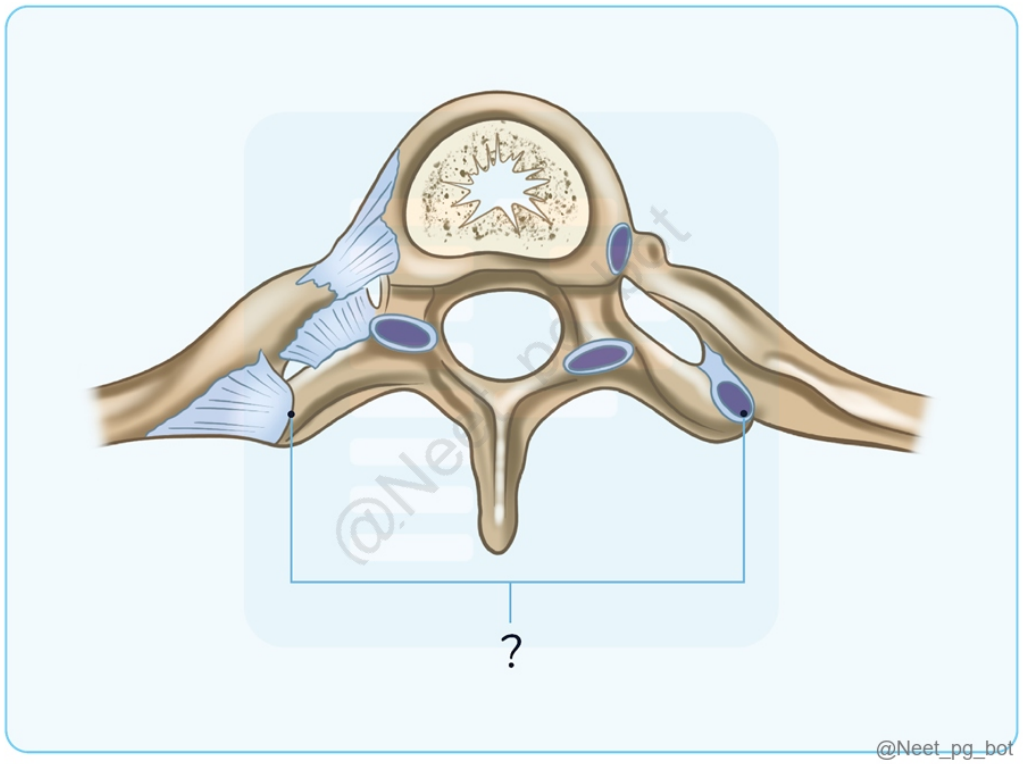

Correct Answer: D. Synovial

Explanation: The costotransverse joint is a synovial joint that forms between: The tubercle of the rib The transverse process of the corresponding thoracic vertebra It is a plane-type synovial joint , allowing slight gliding movements during respiration. Type of joint Examples Hinge Joint Elbow joint, Knee joint, Temporomandibular joint. Pivot Joint Superior radioulnar joint, C1 and C2 joint Ball-and-Socket Joint Shoulder (glenohumeral) joint, Hip joint Saddle Joint Sternoclavicular joint, Carpometacarpal joint of the thumb Ellipsoid (Condyloid) Joint Radiocarpal (wrist) joint, atlantooccipital joint, Metacarpophalangeal joints Aspect Hinge Joints (Bicondylar Joints) Pivot Joints (Trochoid Joints) Movement Predominantly uniaxial with limited rotation around a second orthogonal axis. Uniaxial rotation around an axis. Structure Formed by two convex condyles that articulate with concave or flat surfaces. Involves an osseous pivot rotating within an osteoligamentous ring, or vice versa. Examples Knee Joint- Condyles may be within a single fibrous capsule. Temporomandibular joint- In separate

capsules that work together.] Humeroulnar joint in the elbow. Superior radioulnar joint- The head of the radius rotates within the annular ligament and ulnar radial notch. Dens of the axis (C2 vertebra) project into altas. C1 and C2 joint that allows the head to move back and forth. Images {{caption_text}} {{caption_text}} Incorrect Options: Syndesmosis (option A): A fibrous joint with bones connected by ligaments or interosseous membranes (e.g., distal tibiofibular joint). Synarthrosis (option B): A non-movable joint , typically seen in skull sutures . Costotransverse joints allow movement , making this option incorrect. Synchondrosis (option C): A cartilaginous joint where bones are joined by hyaline cartilage (e.g., first costochondral joint). Costotransverse joints are not primarily cartilaginous .

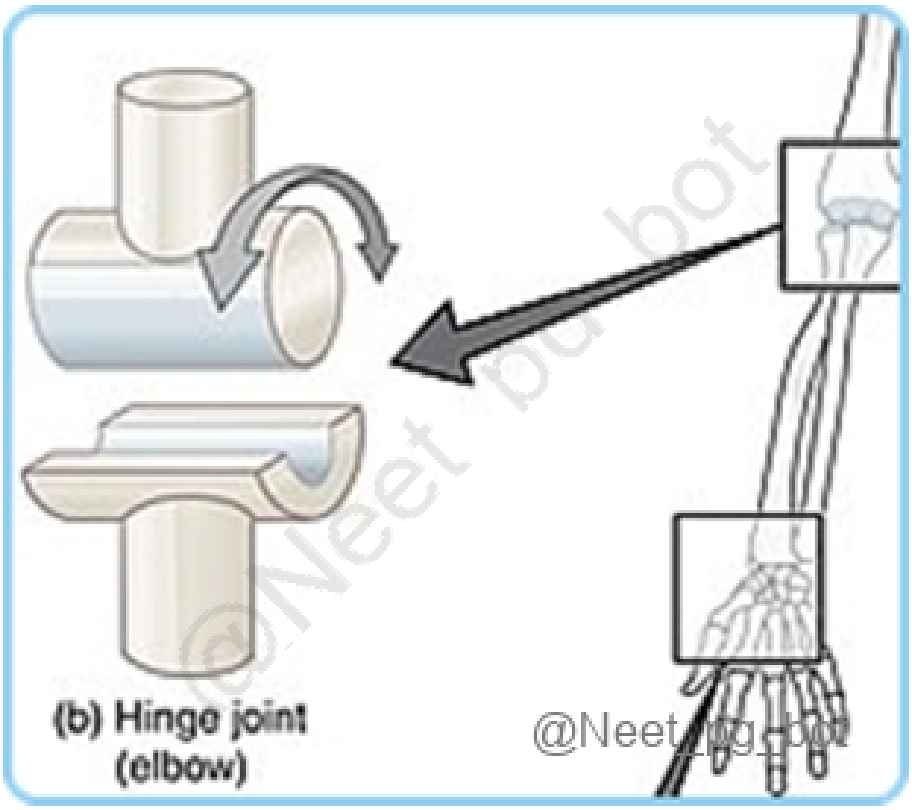

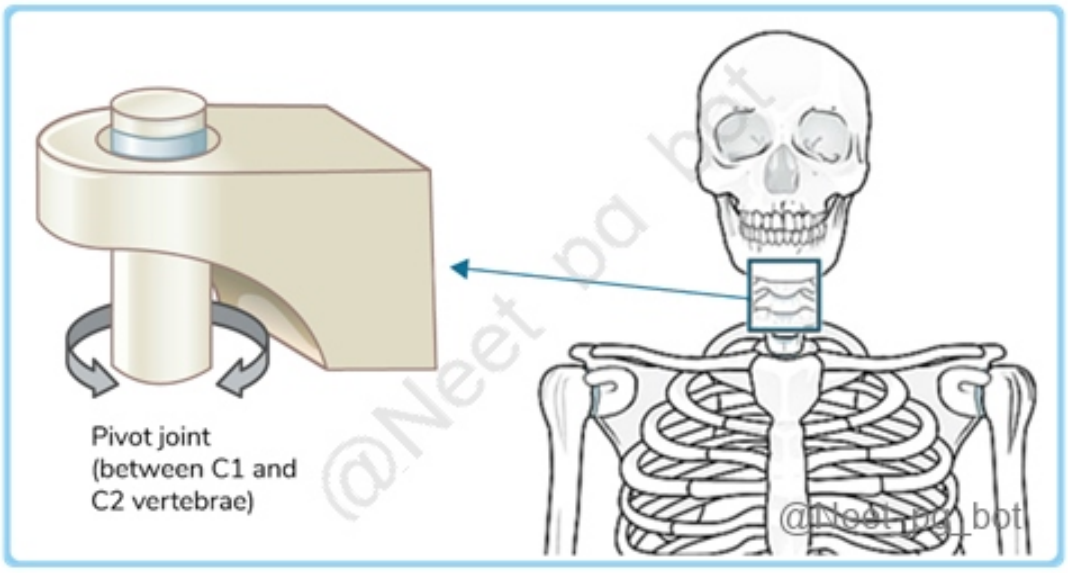

References:

Grey's Anatomy 42nd edition. Pg. 105

Snell's Clinical Anatomy by Regions 10th edition. Pg. 15

Types of Synovial Joints | Biology for Majors II

Types of joints

↑ *Back to this question in Part A*

@Neet_pg_bot

Q6: Identify the level of the cross-section shown in the image below:- (Q856403)

A. T1-T2

B. T2-T3

C. T3-T4

D. T4-T5

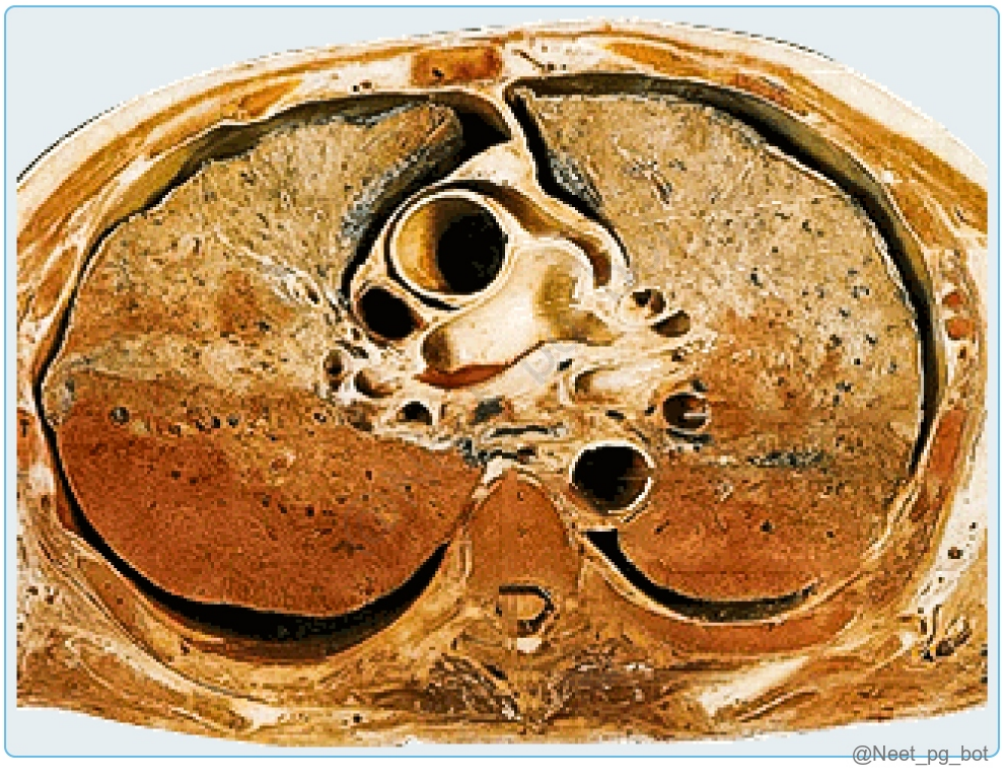

Correct Answer: D. T4-T5

Explanation: The transverse (axial) section shown in the image is through the thorax at the level of T4–T5 , which corresponds to the plane of the sternal angle (Angle of Louis) — a clinically and anatomically significant landmark Key identifying features: Tracheal bifurcation into right and left bronchi Arch of aorta beginning and ending Pulmonary trunk bifurcation Azygos vein arching over the right lung root to enter SVC Division between superior and inferior mediastinum {{caption_text}} Fig: Showing CT view of axial section of the thorax T1-T2 (Option A): Level of lung apex, superior mediastinum, and major neck vessels (brachiocephalic veins, trachea intact). No aortic arch or bronchial division seen. T2-T3 (Option B): Still above the sternal angle; aortic arch not yet visible in section. T3-T4 (Option C): Aortic arch may start appearing but trachea has not bifurcated yet; pulmonary trunk bifurcation not seen.

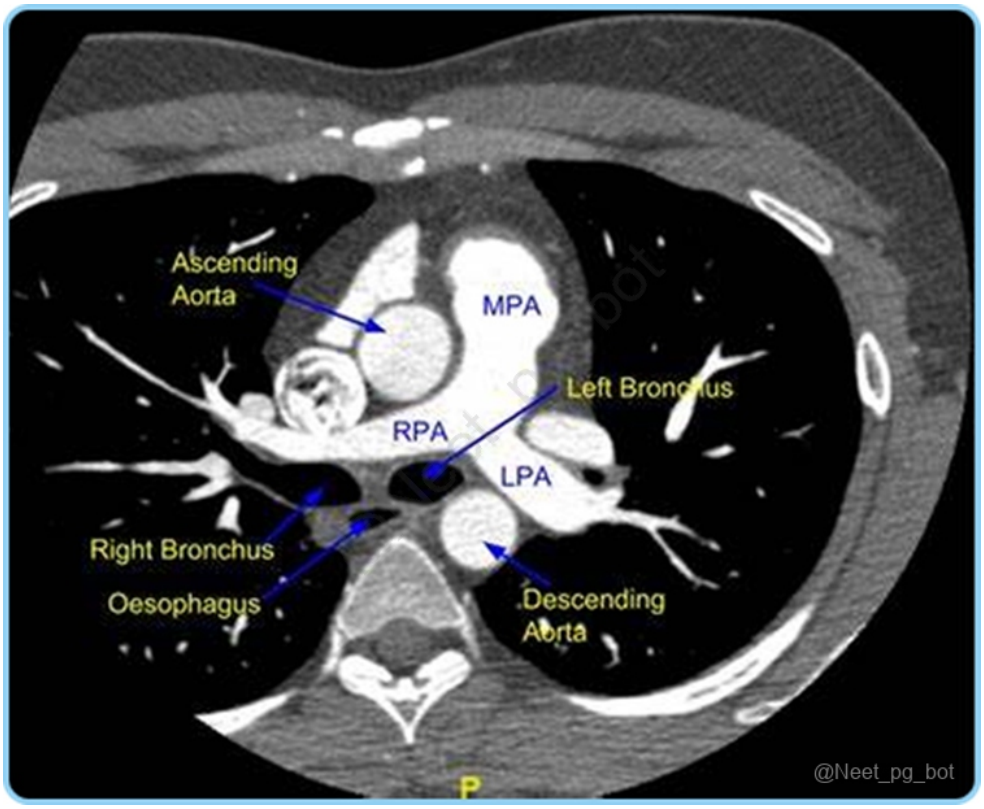

References:

BD Chaurasia’s Human Anatomy, 8th Edition, Page no: 145

↑ *Back to this question in Part A*

@Neet_pg_bot

Q7: Which of the following muscles is not involved in the overhead abduction of the arm? (Q856383)

A. Serratus anterior

B. Deltoid

C. Trapezius

D. Pectoralis major

Correct Answer: D. Pectoralis major

Explanation: Pectoralis major: The pectoralis major muscle is not directly involved in the overhead abduction of the arm. Its primary action is to adduct and internally rotate the arm, as in movements such as hugging or pressing the arms against the body. It does not play a significant role in raising the arm in an overhead position. Movement of the shoulder joint Muscle(s) Involved Other movements Adduction Pectoralis major Teres major Latissimus dorsi Coracobrachialis Short head of biceps brachii Long head of triceps brachii Medial rotation of scapula Abduction Supraspinatus (0-15) and deltoid (15-90) Serratus anterior (90°–180°) Upper and lower fibers of trapezius (90°–180°) Humerus elevation Clavicle axial rotation AC joint movement Lateral rotation of scapula Serratus anterior (Option A): The serratus anterior muscle plays an important role in stabilizing and upwardly rotating the scapula during arm abduction. Deltoid (Option B): The deltoid muscle, which is located on the shoulder, is a key muscle involved in the abduction of the arm. Trapezius (Option C): The trapezius muscle, a large muscle in the upper back and neck region, also contributes to the overhead abduction of the arm.

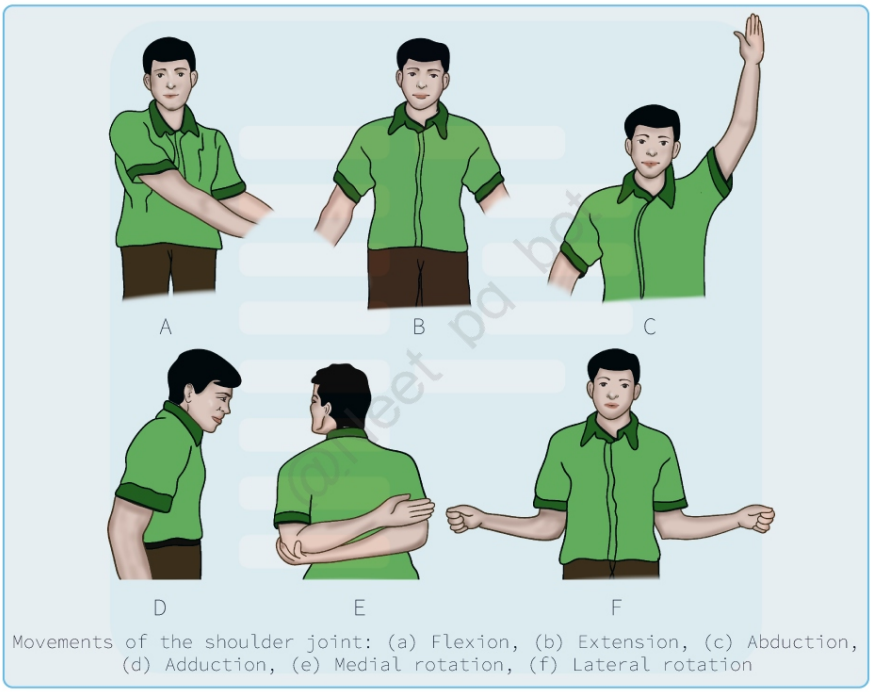

Movements of the shoulder joint: (a) Flexion, (b) Extension, (c) Abduction, (d) Adduction, (e) Medial rotation, (f) Lateral rotation

@Neet_pg_bot

References:

BD Chaurasia’s Human Anatomy, 8th Edtion, Page no: 890

↑ *Back to this question in Part A*

@Neet_pg_bot

Q8: A patient presented with paradoxical respiration. Which of the following nerves is most likely to be affected? (Q856967)

A. Right Vagus Nerve

B. Left Vagus Nerve

C. Recurrent Laryngeal Nerve

D. Phrenic Nerve

Correct Answer: D. Phrenic Nerve

Explanation: Phrenic Nerve: The phrenic nerve is indeed the most likely nerve to be affected in a patient with paradoxical respiration. The phrenic nerve plays a critical role in controlling the contraction of the diaphragm, the primary muscle involved in breathing. Damage or dysfunction of the phrenic nerve can result in weakened or paralyzed diaphragm movement, leading to paradoxical respiration where the chest moves inward during inhalation and outward during exhalation. Feature Right Phrenic Nerve Left Phrenic Nerve Length and Course Shorter and more vertical Longer and less vertical Relation to Subclavian Artery Separated from second part by scalenus anterior Passes anterior to first part Relation to Major Vessels Passes lateral to superior vena cava Passes anterior to aortic arch Relation to Heart Passes lateral to right atrium Passes over left atrium and ventricle Diaphragm Entry Through central tendon (caval foramen or just lateral) Through muscular part, anterior to central tendon Associated Ganglion Right phrenic ganglion, sometimes with accessory ganglion Left phrenic ganglion (less common) Right Vagus Nerve (Option A): While right vagus nerve injury can lead to respiratory issues, it doesn't directly control the diaphragm, reducing its likelihood as a cause of paradoxical respiration. Left Vagus Nerve (Option B): While the left vagus nerve regulates thoracic and abdominal functions, it's not the primary nerve for diaphragmatic control. Recurrent Laryngeal Nerve (Option C): While damage to the recurrent laryngeal nerve can result in vocal cord paralysis or weakness, it is not directly related to the innervation of the diaphragm.

References:

BD Chaurasia’s Human Anatomy, 8th Edtion, Page no: 133

↑ *Back to this question in Part A*

@Neet_pg_bot

Q9: Reticular fibers are not present in which of the following structures? (Q856954)

A. Thymus

B. Lymph node

C. Bone marrow

D. Spleen

Correct Answer: A. Thymus

Explanation: Reticular fibers are a type of connective tissue fibers composed of collagen type III. They form a delicate network of fibers that provide structural support to various organs and tissues. Reticular fibers are particularly abundant in lymphoid organs, where they form the framework for immune cell localization and function. Unlike other lymphoid organs, the thymus does not contain reticular fibers. Instead, it has a unique structural framework composed of epithelial cells called thymic epithelial cells. Reticular fibers: are fine, branching fibers composed of collagen, providing structural support to organs with a rich lymphoreticular or hepatocyte system. These fibers are found in: Lymph nodes Liver Spleen However, reticular fibers are absent in the thymus, despite it being part of the lymphatic system. Lymph node, Bone marrow, Spleen (Options B, C, and D): Reticular fibers are seen

References:

BD Chaurasia’s Human Anatomy, 8th Edtion, Page no: 133

↑ *Back to this question in Part A*

@Neet_pg_bot

Q10: What is the most common complication of the central line insertion below the marked bone? (Q855756)

A. Arterial puncture

B. Thrombophlebitis

C. Empyema

D. Chylothorax

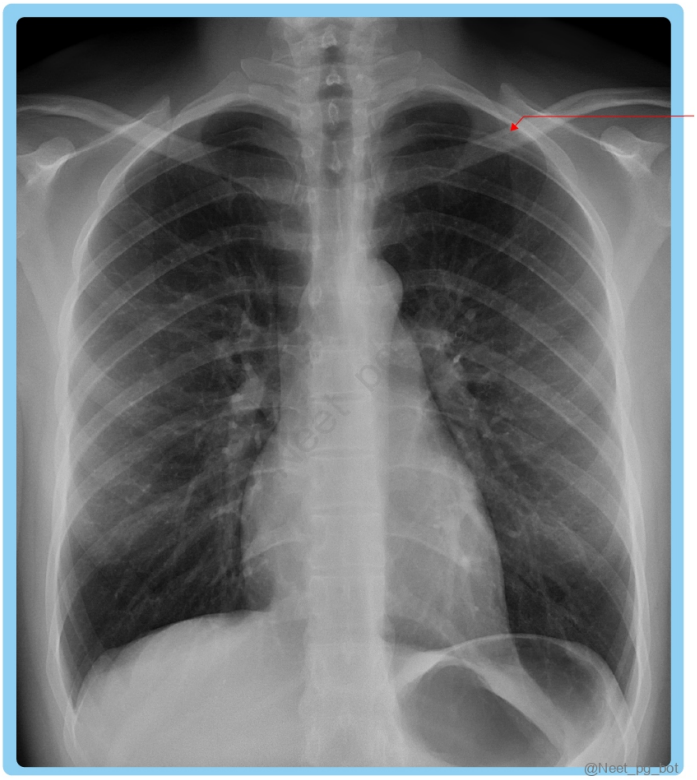

Correct Answer: A. Arterial puncture

Explanation: The most common complication of central line insertion below the clavicle (subclavian vein approach) is arterial puncture . This occurs when the subclavian artery is inadvertently punctured during the procedure. The subclavian vein lies posterior and inferior to the clavicle, making it prone to accidental arterial injury. Complications of Central Line Insertion (Subclavian Approach): Complication Description Arterial puncture The most common complication; can cause hematoma or hemorrhage. Pneumothorax Risk due to proximity to the lung apex. Thrombophlebitis Less common, but can occur due to catheter irritation. Chylothorax Rare, occurs if the thoracic duct (left side) is injured. Infection (Empyema, Sepsis) Can occur if strict aseptic precautions are not maintained. Thrombophlebitis (Option B): Incorrect , because it is less common compared to arterial puncture. Empyema (Option C): Incorrect , as infection-related complications occur later, not acutely. Chylothorax (Option D): Incorrect , as it is rare and occurs only on the left side due to thoracic duct injury.

References:

https://www.ncbi.nlm.nih.gov/books/NBK482224/

Miller's Anesthesia, 9th Edition - Page no: 1169-1171

↑ *Back to this question in Part A*

@Neet_pg_bot

Q11: Identify the arrow-marked chamber. (Q857560)

A. Right atrium

B. Left atrium

C. Right ventricle

D. Left ventricle

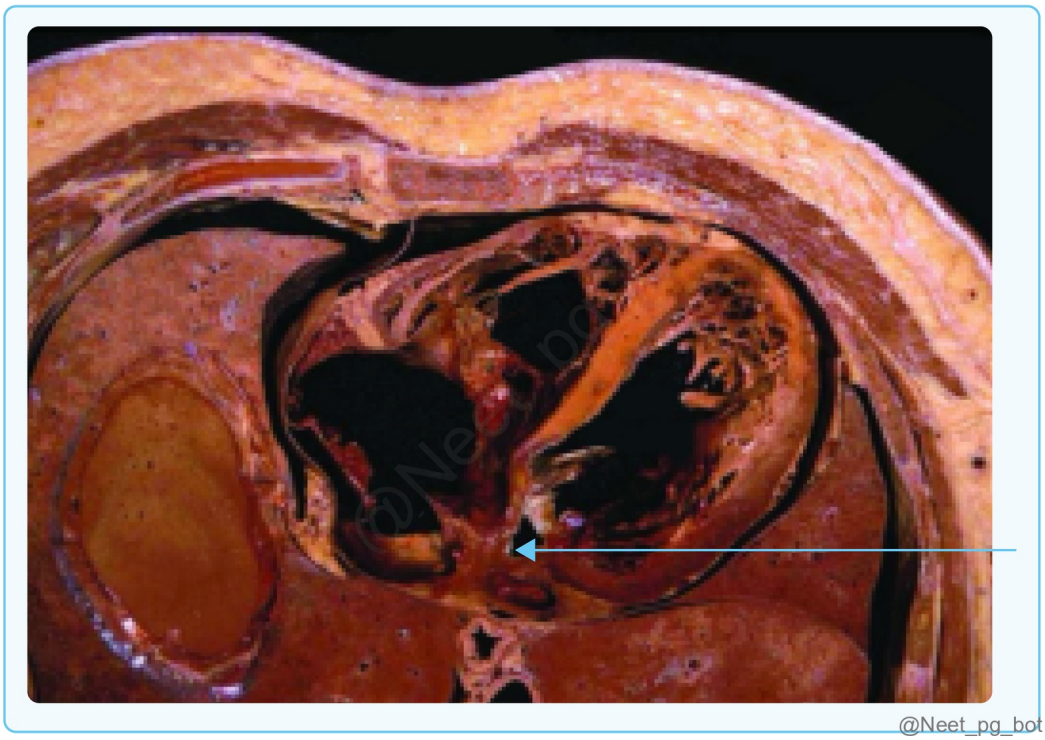

Correct Answer: B. Left atrium

Explanation: The left atrium is located posteriorly in the heart and receives oxygenated blood from the pulmonary veins. In cross-sectional imaging, it is centrally positioned and posterior to the right atrium and ventricles. The given image corresponds to a transverse section of the heart, showing the left atrium in its expected anatomical location. Anatomy of the Chambers of the Heart Feature Right Atrium Right Ventricle Left Atrium Left Ventricle Location Right, anterior Right, inferior Left, posterior Left, inferior Function Receives deoxygenated blood from vena cava Pumps deoxygenated blood to the lungs via pulmonary artery Receives oxygenated blood from pulmonary veins Pumps oxygenated blood to the body via aorta Wall Thickness Thin Thin Thin Thickest Valves Associated Tricuspid Valve Pulmonary Valve Mitral Valve Aortic Valve Key Structures Crista terminalis, fossa ovalis Trabeculae carneae, moderator band Pulmonary veins opening, interatrial septum Papillary muscles, chordae tendineae The left atrium lies posteriorly and superiorly, making it distinct in cross-sectional anatomy. It is crucial in pulmonary circulation, ensuring efficient oxygenated blood flow into the left ventricle. {{caption_text}} Right Atrium (Option A) : Incorrect because the right atrium is anterior and positioned to the right, unlike the marked posterior chamber. Right Ventricle (Option C) : Incorrect because the right ventricle is more anterior and lies inferior to the right atrium. Left Ventricle (Option D) : Incorrect because the left ventricle is thicker-walled and positioned inferiorly compared to the left atrium.

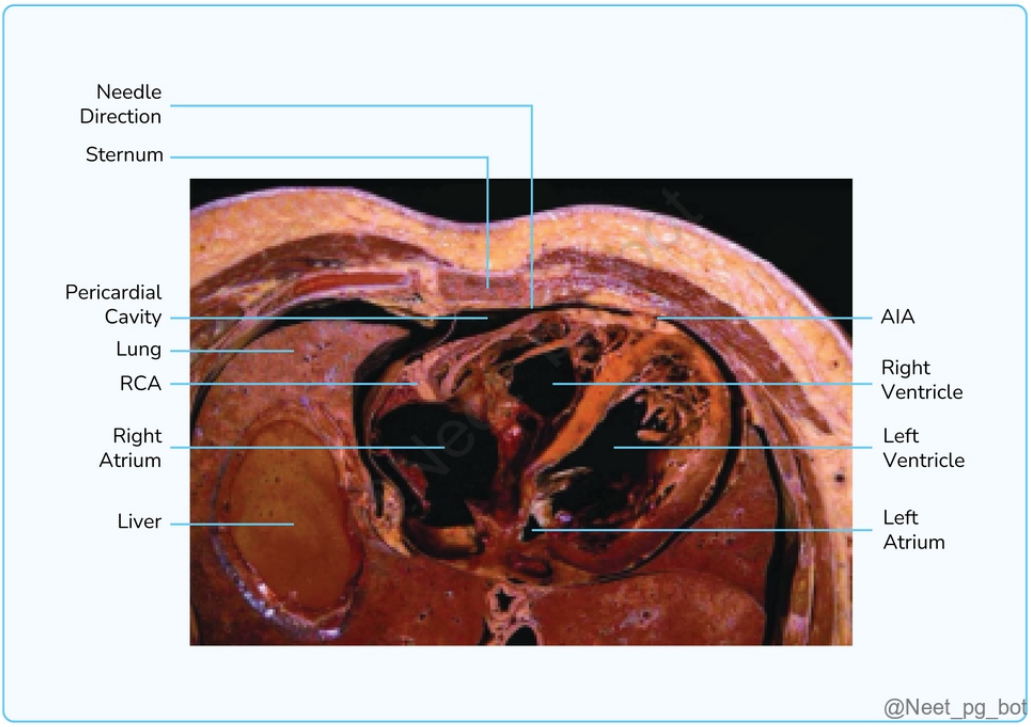

References:

Gray's Anatomy, 42nd Edition, Pg. 1082

↑ *Back to this question in Part A*

@Neet_pg_bot

Q12: Which of the following is wrongly labeled here? (Q857226)

A. A- Superior thoracic artery

B. B- Thoracoacromial artery

C. C- Subscapular artery

D. D- Posterior circumflex artery

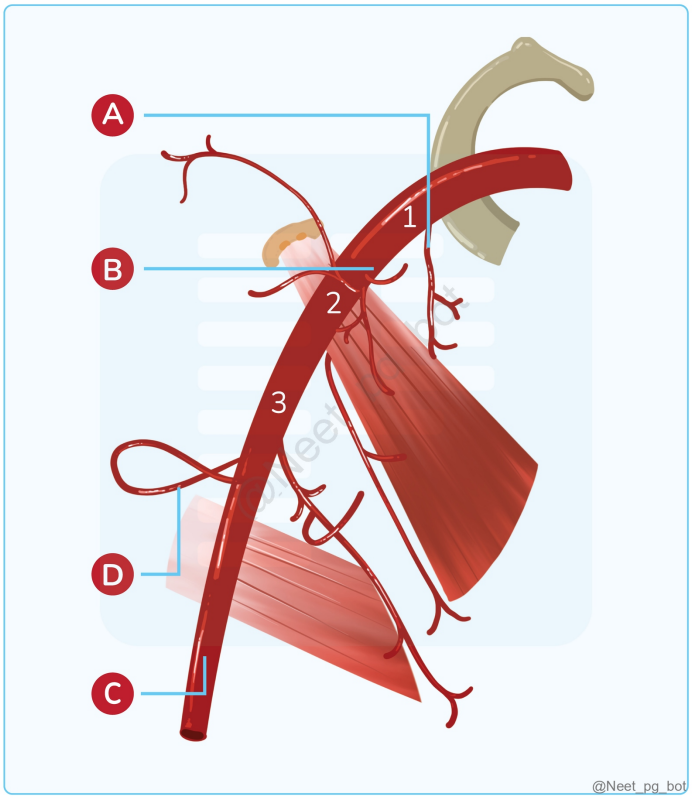

Correct Answer: C. C- Subscapular artery

Explanation: The subscapular artery is the largest branch of the axillary artery and arises from its third part . It soon divides into the circumflex scapular artery and thoracodorsal artery . In the given image, the structure labeled as the subscapular artery appears to be incorrectly marked, likely representing another artery. Branches of the Axillary Artery Part of Axillary Artery Branches First Part (proximal to pectoralis minor) Superior thoracic artery Second Part (behind pectoralis minor) Thoracoacromial artery, Lateral thoracic artery Third Part (distal to pectoralis minor) Subscapular artery, Anterior circumflex humeral artery, Posterior circumflex humeral artery Superior thoracic artery (Option A): Correctly labeled. Thoracoacromial artery (Option B): Correctly labeled. Posterior circumflex artery (Option D): Correctly labeled

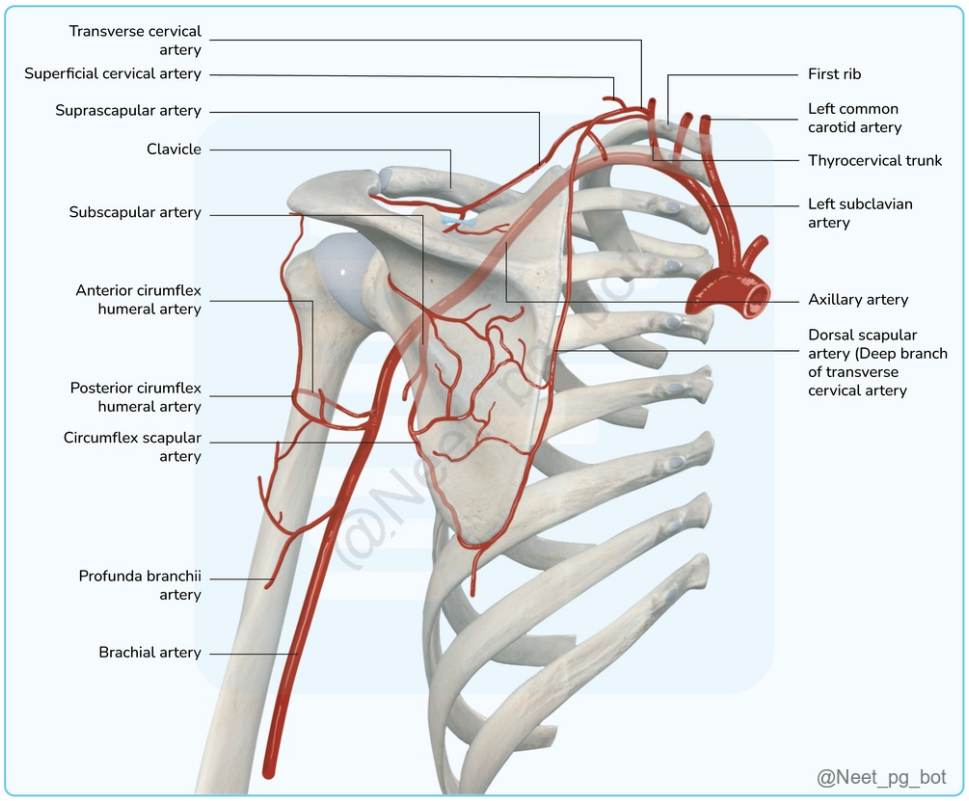

References:

Gray's Anatomy 42nd edition, pg 919, 921.

BD Chaurasia’s Human Anatomy, 8th edition, pg 80-81.

Vishram Singh Textbook of Anatomy, 2nd edition, pg 51, 52.

↑ *Back to this question in Part A*

@Neet_pg_bot

Q13: Match the auscultatory areas of the heart from the image given below. (Q857213)

A. 1-aortic, 2-pulmonary, 3-mitral, 4-tricuspid

B. 1-aortic, 2-pulmonary, 3- tricuspid, 4-mitral

C. 1-mitral, 2-pulmonary, 3- tricuspid, 4-aortic

D. 1-aortic,2-tricuspid, 3- pulmonary, 4-mitral

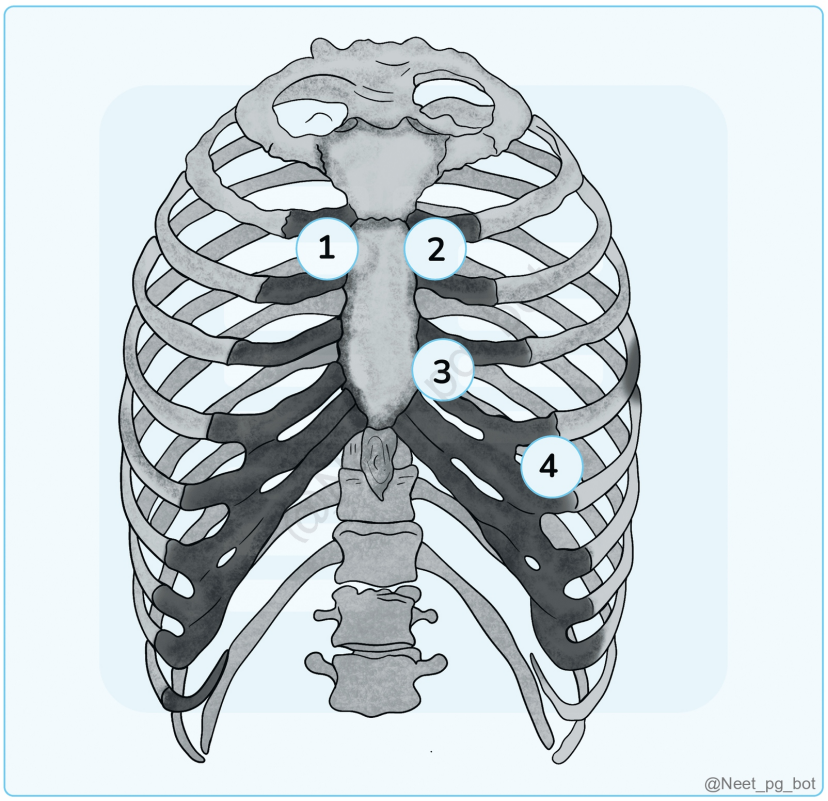

Correct Answer: B. 1-aortic, 2-pulmonary, 3- tricuspid, 4-mitral

Explanation: The auscultatory areas of the heart correspond to the locations where the heart valves' sounds are best heard: Aortic area - Right 2nd intercostal space (near the sternum). Pulmonary area - Left 2nd intercostal space (near the sternum). Tricuspid area - Left lower sternal border (around 4th intercostal space). Mitral area (Apex beat) - 5th intercostal space at the midclavicular line . Auscultation of Heart Sounds Valve Auscultation Site Location Aortic valve Right 2nd ICS, parasternal Best for aortic stenosis murmur Pulmonary valve Left 2nd ICS, parasternal Best for pulmonary stenosis murmur Tricuspid valve Left 4th ICS, parasternal Best for tricuspid regurgitation murmur Mitral valve Left 5th ICS, midclavicular line (apex beat) Best for mitral regurgitation/stenosis murmur

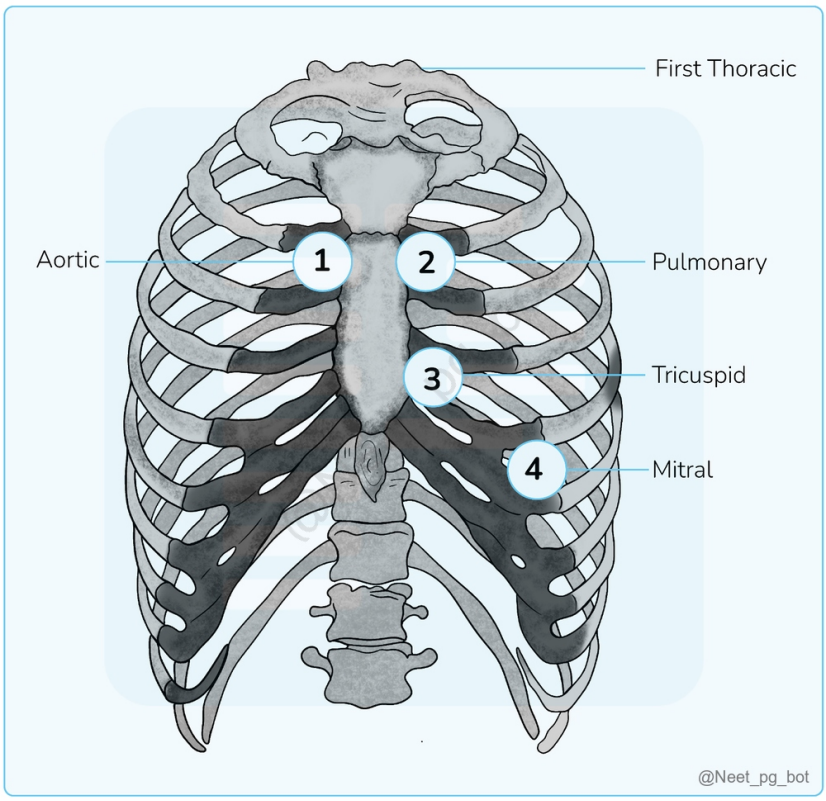

References:

https://www.ncbi.nlm.nih.gov/books/NBK541010/

https://pmc.ncbi.nlm.nih.gov/articles/PMC4518345/

↑ *Back to this question in Part A*

@Neet_pg_bot

Q14: A defect in which of the following pharyngeal arch artery causes the defect shown in the image? (Q855396)

A. Right 4th arch artery

B. Left 4th arch artery

C. Right 6th arch artery

D. Left 6th arch artery

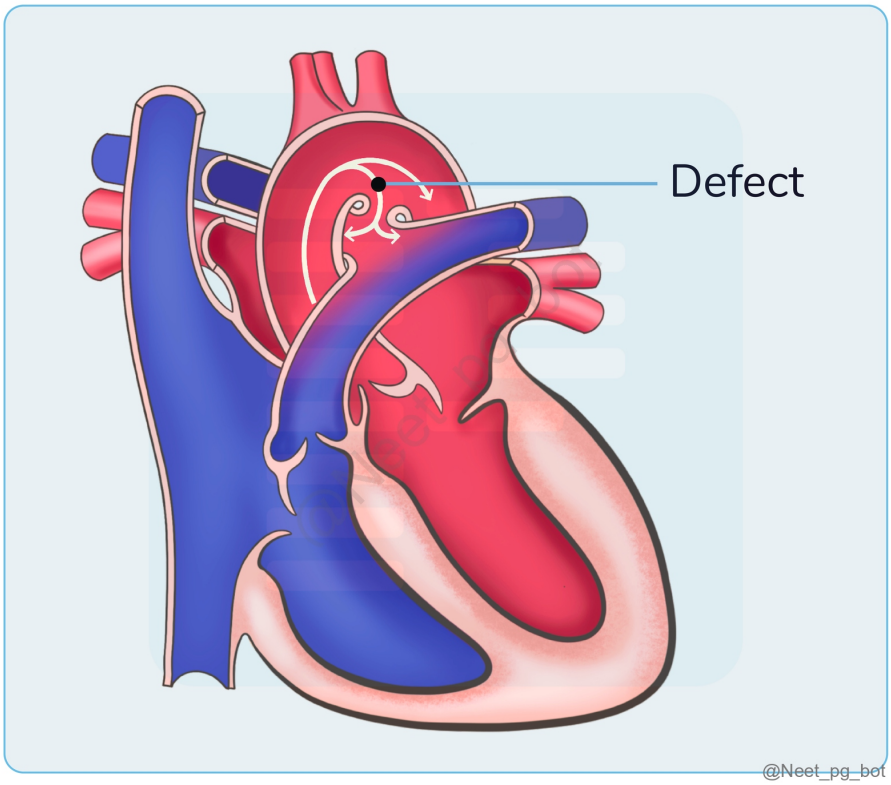

Correct Answer: D. Left 6th arch artery

Explanation: The condition shown in the image is Patent Ductus Arteriosus (PDA), a congenital heart defect where the ductus arteriosus (a fetal blood vessel connecting the pulmonary artery to the aorta) fails to close after birth. The ductus arteriosus is derived from the left 6th pharyngeal arch artery . {{caption_text}} Pharyngeal Arch Artery of Arch First Maxillary artery Second Hyoid artery, Stapedial artery Third Common carotid artery, Internal carotid artery Fourth Arch of aorta (left side), Subclavian artery (right side) Sixth Ductus arteriosus (left side) , Pulmonary artery (right side)

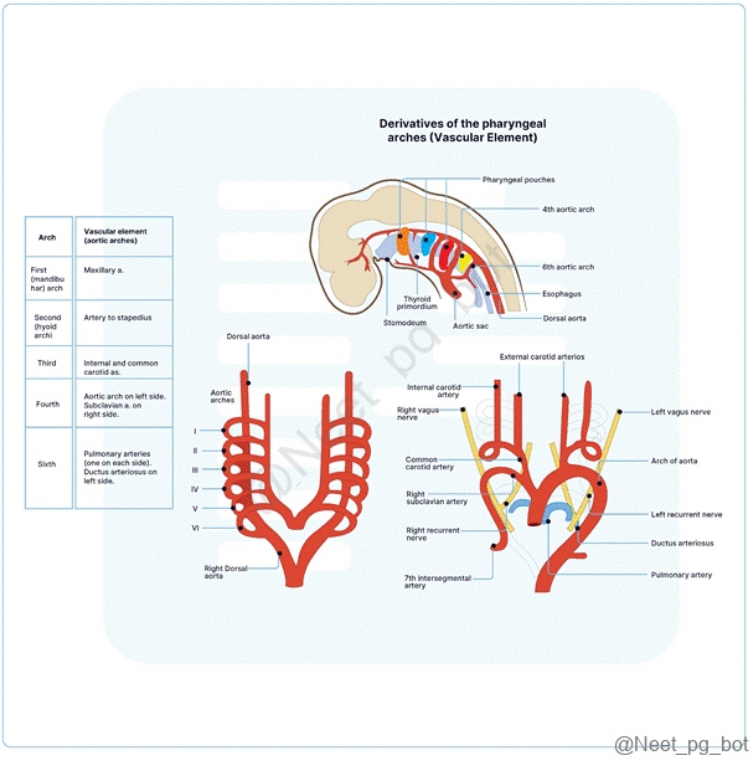

References:

Inderbir Singh’s Human Embryology 11th edition, page 130

↑ *Back to this question in Part A*

@Neet_pg_bot

Q15: Identify the structure marked in the given image (Q854583)

A. Bronchus

B. Arch of aorta

C. Brachiocephalic trunk

D. Pulmonary trunk

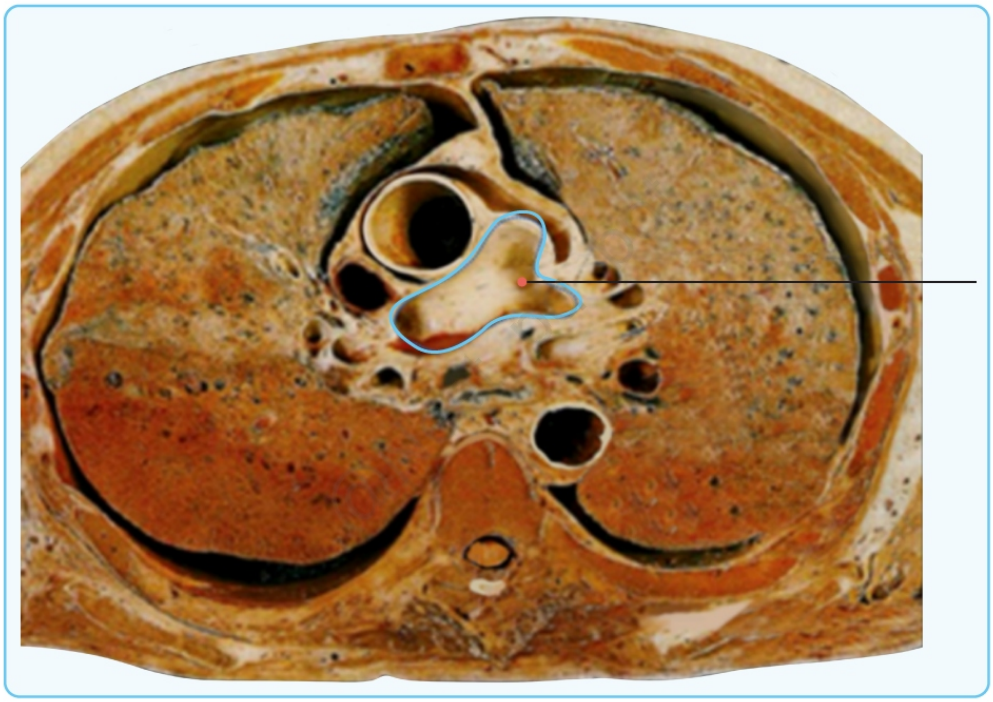

@Neet_pg_bot

Correct Answer: D. Pulmonary trunk

Explanation: The marked structure in the given image is the pulmonary trunk. The pulmonary trunk starts from the upper part of the right ventricle, near the left 3rd costal cartilage, and runs backward and leftward. It ends beneath the aortic arch, in front of the left principal bronchus, dividing into the right and left pulmonary arteries. (Options A, B, and C ruled out) Main pulmonary trunk: Pulmonary trunk - Carries blood to the pulmonary circulation. The pulmonary trunk, originating from the upper right ventricle, is approximately 5 cm long. It curves back and to the left through the middle mediastinum before dividing into the right and left pulmonary arteries below the aortic arch and in front of the left bronchus. Divides into left and right at the T4-T5 level. {{caption_text}}

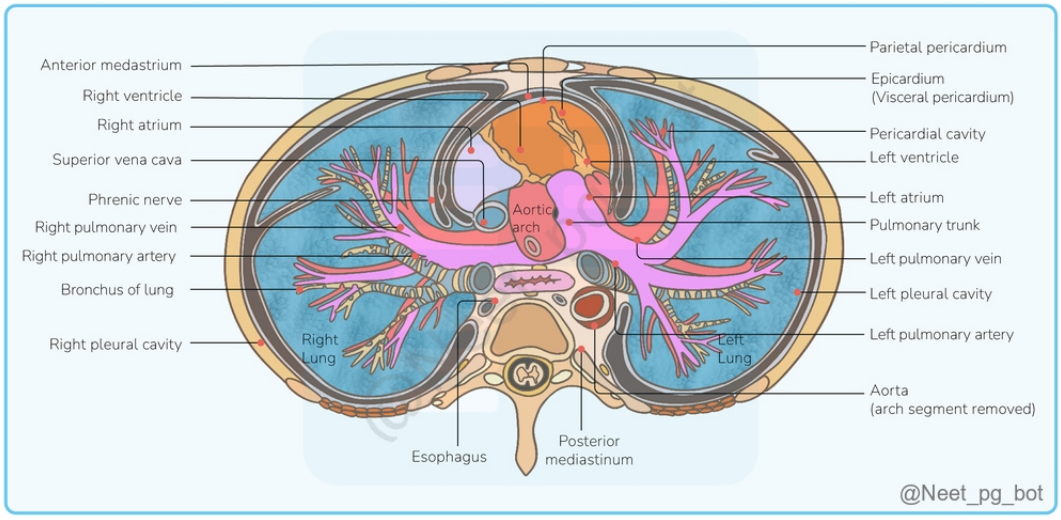

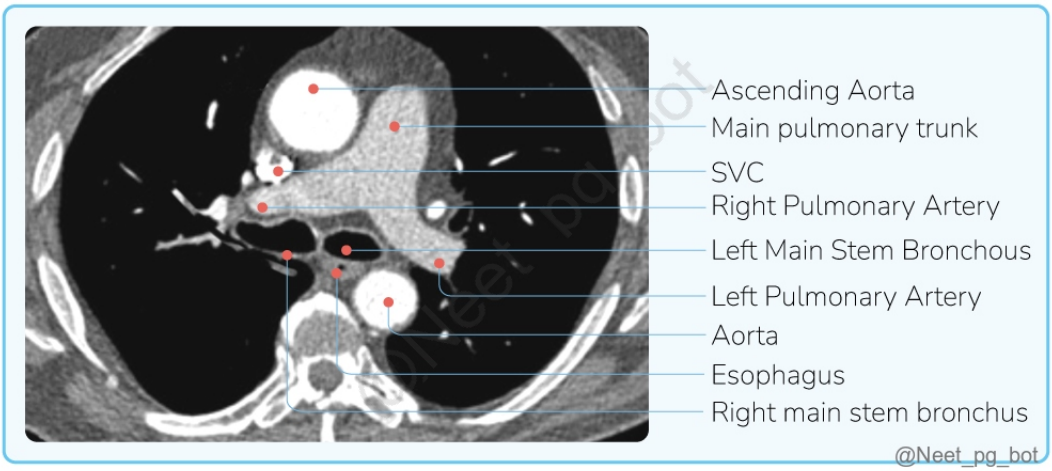

References:

1. https://www.ncbi.nlm.nih.gov/books/NBK557710/

↑ *Back to this question in Part A*

@Neet_pg_bot

Q16: During the surgical procedure for Patent Ductus Arteriosus, the structure that is in close relation to it can be damaged. Which of the following can be the structure? (Q860291)

A. Left recurrent laryngeal nerve

B. Right recurrent laryngeal nerve

C. Thoracic duct

D. Hemiazygos vein

Correct Answer: A. Left recurrent laryngeal nerve

Explanation: The left recurrent laryngeal nerve (a branch of the vagus nerve) loops around the arch of the aorta , near the ductus arteriosus (ligamentum arteriosum in adults) . Due to this close relationship, it is vulnerable to damage during PDA surgery. Feature Right Recurrent Laryngeal Nerve (Option B) Left Recurrent Laryngeal Nerve Pathway Loops around the right subclavian artery Loops around the arch of the aorta Relation to Inferior Thyroid Artery Lies between the branches of the inferior thyroid artery (can be anterior or posterior) Lies posterior to the inferior thyroid artery Course Shorter course in the neck Longer course in the neck Prone to Injury In Thyroid surgeries (more prone to injury than left side) Mediastinal pathologies (due to its longer course) Affected by Mediastinal Pathologies No, as it loops around the subclavian artery (outside the mediastinum) Yes, as it loops around the aortic arch (within the mediastinum) Clinical Condition Less affected by cardiac pathologies Ortner’s

Syndrome (Mitral stenosis → Left atrial enlargement → Compression of left recurrent laryngeal nerve → Hoarseness of voice) Thoracic duct (Option C): Located on the left side of the thorax, but it is not closely related to the PDA. Hemiazygos vein (Option D): Lies posteriorly in the thorax and is not in direct contact with the PDA.

References:

https://www.ncbi.nlm.nih.gov/books/NBK470179/

↑ *Back to this question in Part A*

@Neet_pg_bot

Q17: Which structure is located approximately 23 cm from the central incisor? (Q860286)

A. Cricopharynx

B. Arch of Aorta

C. Left principal bronchus

D. Diaphragm

Correct Answer: B. Arch of Aorta

Explanation: The arch of the aorta is positioned around the level of the T4 vertebra, which is roughly 23 cm from the central incisor.

Site of constriction	Vertebral level	Distance from upper incisor
Beginning (pharyngo-esophageal junction)	C6	15 cm
Aortic arch	T4	23 cm
Left principal bronchus	T6	28 cm
Esophageal hiatus	T10	40 cm

@Neet_pg_bot

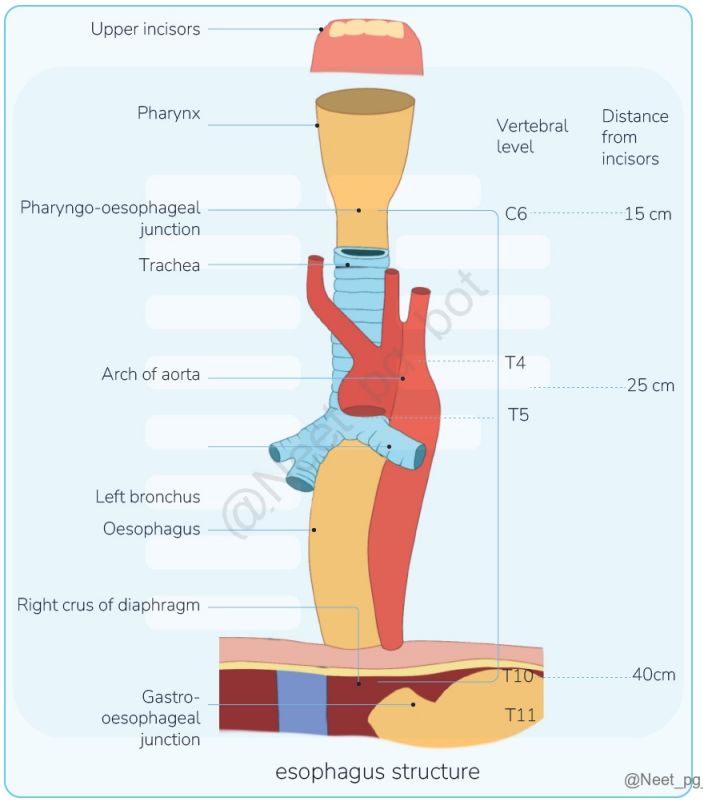

References:

BD Chaurasia's Human Anatomy Volume 1 - Upper Limb and Thorax, page 324

↑ *Back to this question in Part A*

@Neet_pg_bot

Q18: Identify the vascular structure marked in the given radiology image? (Q839934)

A. Aberrant right subclavian artery

B. Aberrant left subclavian artery

C. Ascending aorta

D. Main pulmonary artery



Correct Answer: A. Aberrant right subclavian artery

Explanation: Correct Option A - Aberrant right subclavian artery: This is a common vascular anomaly where the right subclavian artery arises abnormally from the aortic arch and travels behind the esophagus to the right arm. Incorrect Options: Option B - Aberrant left subclavian artery: An aberrant left subclavian artery is a rare anomaly compared to the right. It would arise from the right side and travel to the left, but this is not the typical presentation of aberrant subclavian arteries. Option C - Ascending aorta: The ascending aorta is the initial section of the aorta arising from the heart and extending upwards. It would not have the characteristic path seen in an aberrant subclavian artery. Option D - Main pulmonary artery: The main pulmonary artery carries deoxygenated blood from the right ventricle to the lungs. Its course and branching are distinct and do not resemble the path of an aberrant subclavian artery.

References:

.

↑ *Back to this question in Part A*

@Neet_pg_bot

Q19: Which of the following statements is true regarding the anatomy of the breast? (Q839893)

A. The superior medial quadrant has more tissue

B. There are 10 lobules present

C. The axillary tail of Spence crosses the anterior axillary fold

D. The nipple is located at the level of the fourth intercostal space in most women

Correct Answer: C. The axillary tail of Spence crosses the anterior axillary fold

Explanation: Correct Option C - The axillary tail of Spence crosses the anterior axillary fold: The axillary tail of Spence is an extension of the breast tissue that extends into the axilla, and it does cross the anterior axillary fold. Incorrect Options: Option A - The superior medial quadrant has more tissue: The superior lateral quadrant actually contains the most glandular tissue and is a common site for breast cancer. Option B - There are 10 lobules present: The human breast typically has 15-20 lobules, not just 10. Option D - The nipple is located at the level of the fourth intercostal space in most women: While the nipple is commonly said to be at the level of the fourth intercostal space, this can vary greatly among individuals and is not a definitive anatomical landmark for all women.

↑ *Back to this question in Part A*

@Neet_pg_bot

Q20: Identify the marked structure? (Q839890)

A. Anterior end of rib

B. Posterior end of rib

C. Right pulmonary artery

D. Costal cartilage



Correct Answer: B. Posterior end of rib

Explanation: The arrow in the chest X-ray is pointing to the posterior end of a rib. On a chest X-ray (PA view), the posterior ends of the ribs appear more horizontal and are seen more clearly compared to the anterior ends, which slope downward and are less distinct. The marked structure is bony (white, radiopaque), so it cannot be the pulmonary artery or costal cartilage (cartilage appears less radiodense and often isn't well visualized). (Option C & D Ruled out) It is not the anterior end because anterior ends are more anterior-inferior and less prominent. (Option A ruled out)

References:

.

↑ *Back to this question in Part A*

@Neet_pg_bot

Q21: Identify the artery that supplies the anatomical region of the heart shown in the provided image. (Q839884)

A. Anterior interventricular artery

B. left circumflex artery

C. Left marginal artery

D. Right coronary artery (RCA)

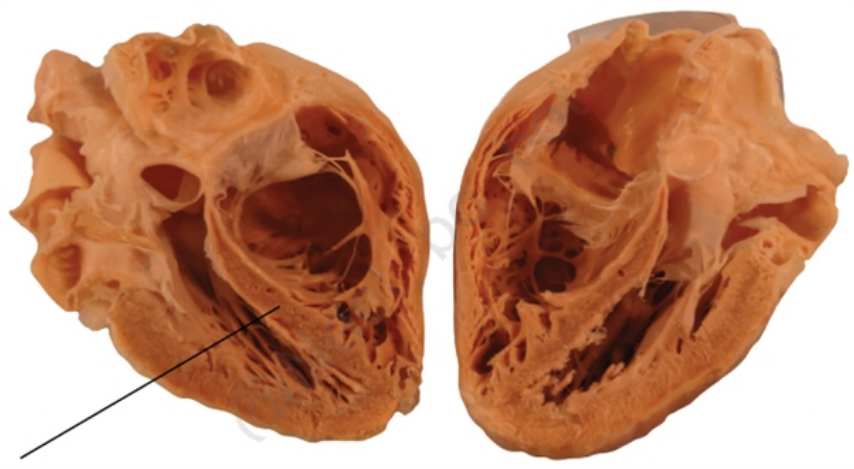

@Neet_pg_bot

Correct Answer: A. Anterior interventricular artery

Explanation: Correct Option A - Anterior Interventricular Artery (Left Anterior Descending Artery): The anterior interventricular artery, also known as the left anterior descending (LAD) artery, is responsible for supplying the anterior part of the interventricular septum and the anterior walls of both ventricles. Associated Regions: Anterior wall of the left ventricle. Part of the right ventricle. Anterior two-thirds of the interventricular septum. Incorrect Options: Option B - Left Circumflex Artery Supplies the lateral and posterior walls of the left ventricle and part of the left atrium. Associated Regions: Lateral wall of the left ventricle. Posterior wall of the left ventricle. Part of the left atrium. Option C - Left Marginal Artery: Function: Supplies the left margin (or border) of the heart. Details: It is a branch of the left circumflex artery and runs along the margin of the left ventricle. Associated Regions: Lateral wall of the left ventricle, especially along the margin. Option D - Right Coronary Artery (RCA): Supplies the right atrium, right ventricle, and part of the left ventricle, as well as the sinoatrial (SA) and atrioventricular (AV) nodes. Associated Regions: Right atrium. Right ventricle. Inferior wall of the left ventricle. SA and AV nodes.

↑ *Back to this question in Part A*

@Neet_pg_bot

Q22: At which vertebral level is the anatomical cross-section shown in the image provided? (Q839871)

A. T10

B. T12

C. T11

D. T9

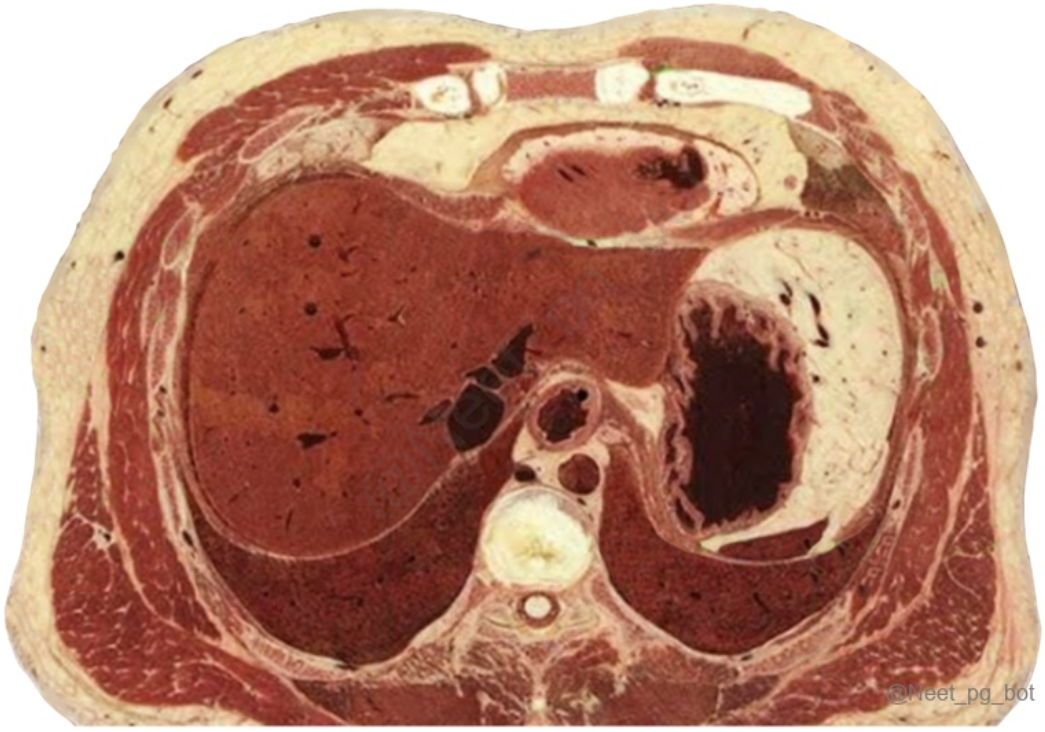

Correct Answer: A. T10

Explanation: At the T10 level, both lungs are visible, indicating the presence of thoracic structures. The liver, esophagus, and spleen are also visible, which is consistent with this level. At T11 and T12, the lungs start to taper off and may not be fully visible. The absence of the colon is also noted at this level, confirming T10 as the correct answer. Incorrect Options: Option B - T12: Visible Structures: Lungs are not visible. Liver Esophagus Spleen

↑ *Back to this question in Part A*

@Neet_pg_bot

Q23: Identify the arrow-marked chamber? (Q860624)

A. Right atrium

B. Left atrium

C. Right ventricle

D. Left ventricle



Correct Answer: C. Right ventricle

Explanation: The structure marked in the above scan is the right ventricle. Level of the Thoracic Inlet : This is at the top of the thoracic cavity, where the trachea and esophagus enter. Level of the Aortic Arch : Located around the T4-T5 vertebral level, where the aorta arches over the left main bronchus. Level of the Carina : At the T5-T6 level, this is where the trachea bifurcates into the right and left main bronchi. Level of the Heart : The heart is typically seen from T6 to T9 . You can identify the chambers (right atrium, left atrium, ventricles) and major vessels (aorta, pulmonary arteries). Level of the Diaphragm : The diaphragm typically corresponds to the T10 vertebral level, which can help in distinguishing between thoracic and abdominal structures. Level of the Esophagus : The esophagus runs along the midline and can be seen at various levels, usually starting from the cervical region down to T10. Level of the Thoracic Spine : The thoracic vertebrae can be used as references; typically, there are 12 thoracic vertebrae. {{caption_text}}

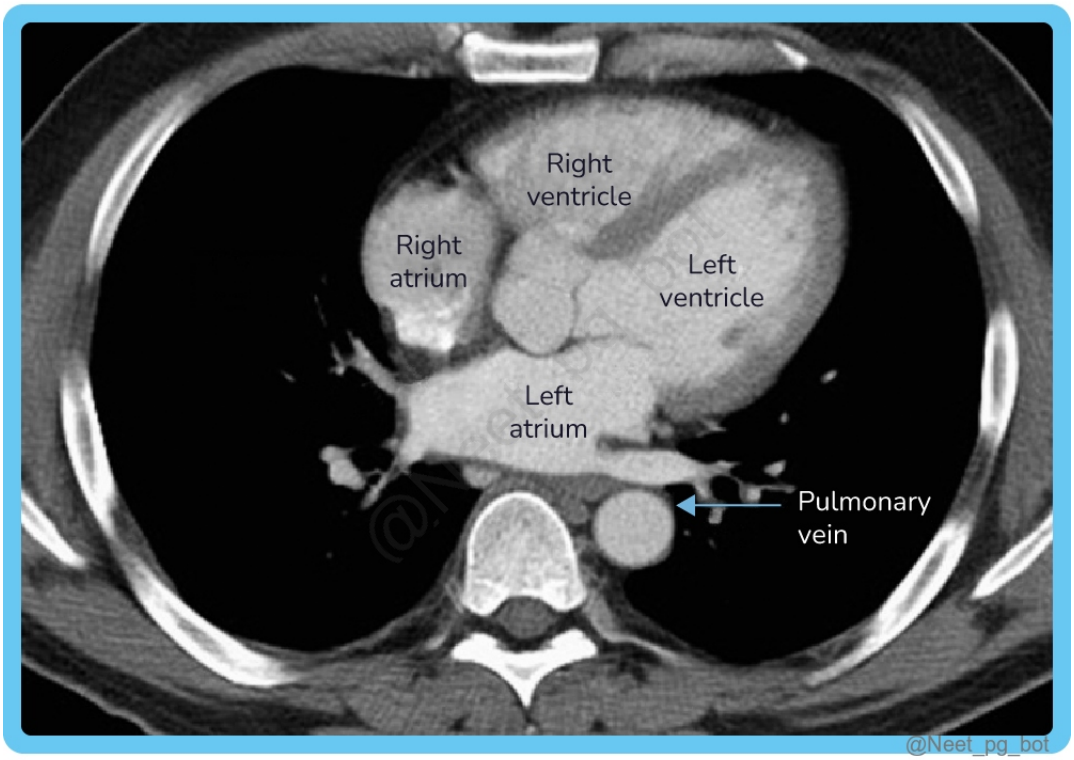

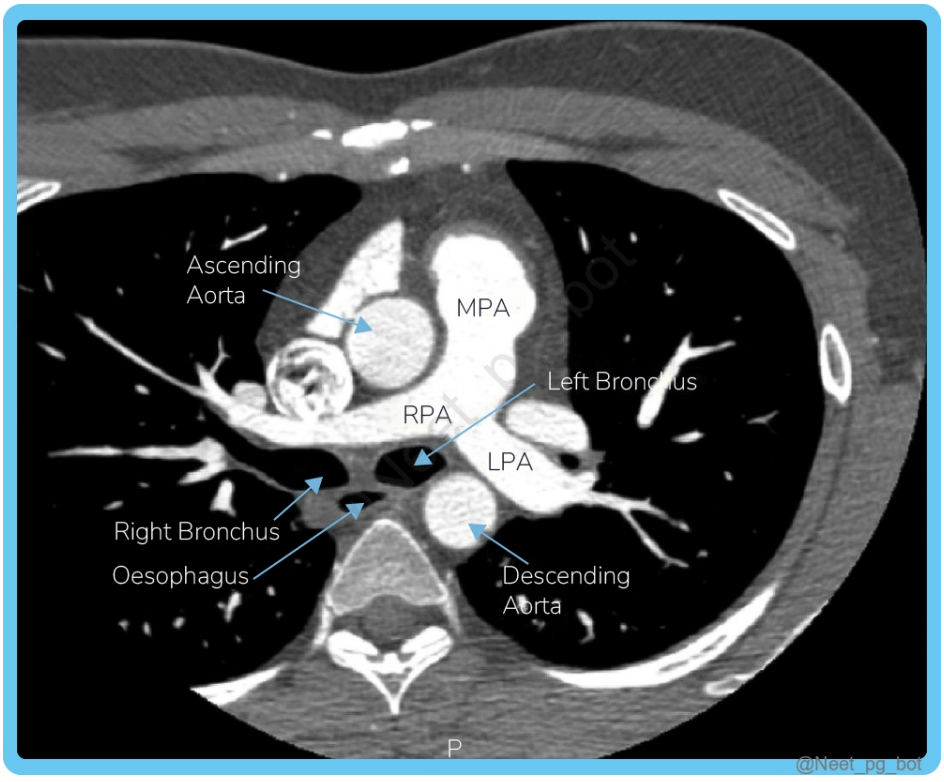

References:

https://www.ncbi.nlm.nih.gov/books/NBK557710/

https://www.imaios.com/en/e-anatomy/thorax/ct-axial-chest

↑ *Back to this question in Part A*

@Neet_pg_bot

Q24: Identify the part of the respiratory tract based on the image given below. (Q865297)

A. Bronchus

B. Respiratory bronchiole

C. Terminal bronchiole

D. Alveolar duct

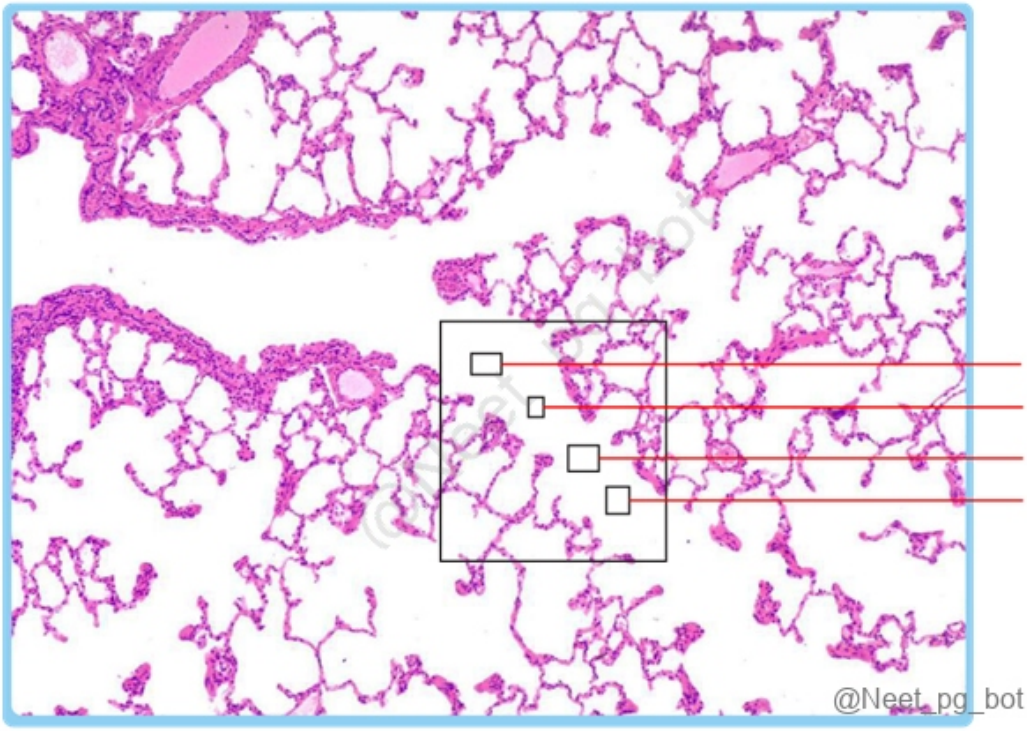

Correct Answer: B. Respiratory bronchiole

Explanation: Respiratory bronchiole Respiratory bronchiole First part of the respiratory zone Still has some bronchiolar lining, but with scattered alveoli opening directly into its wall . This matches the given histology image Bronchus (Option A): Contains cartilage plates and submucosal glands . The image does not show cartilage or large airway walls → ruled out . Terminal bronchiole (Option C) Last part of the conducting zone. Lined by ciliated cuboidal epithelium , no alveoli opening directly into its wall. In the image, alveoli are clearly budding from the walls → not terminal bronchiole . Alveolar duct (Option D) Lined almost completely by alveoli , with no

bronchiolar lining left. The image shows some intact bronchiolar wall → not purely an alveolar duct .

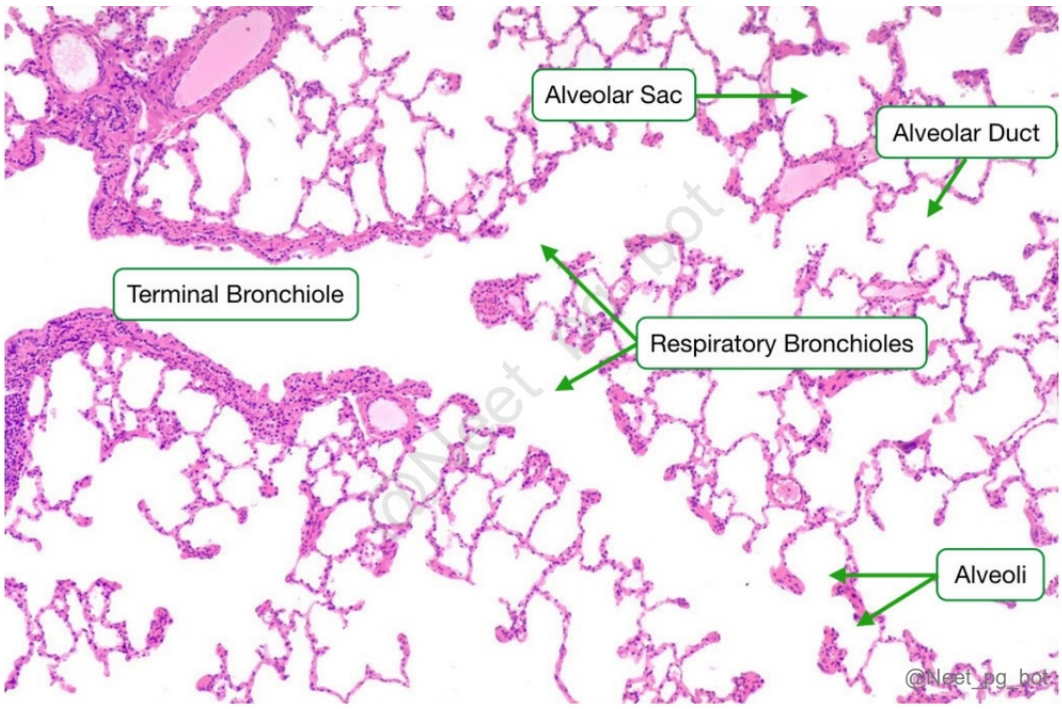

References:

Inderbir Singh textbook of anatomy thorax and abdomen, 6th edition, Page 68

↑ *Back to this question in Part A*

@Neet_pg_bot

Q25: After a fall from a height with his hand outstretched, a man is brought to the emergency department. An X-ray reveals a fracture in the clavicle. Which specific region of the clavicle is the most likely to be fractured? (Q793159)

A. Junction of medial 2/3rd and lateral 1/3rd

B. Junction of medial 1/3rd and lateral 2/3rd

C. Junction of middle 1/3rd and medial 1/3rd

D. Middle of the clavicle

Correct Answer: A. Junction of medial 2/3rd and lateral 1/3rd

Explanation: Correct Option A - Junction of medial 2/3rd and lateral 1/3rd The junction of medial 2/3rd and lateral 1/3rd of the clavicle. This is the most common site of clavicular fracture, accounting for approximately 80% of all

clavicular fractures. This area is also known as the "junction" or "transition zone" because it is where the clavicle changes from a thicker, more rounded bone to a thinner, flatter bone. Incorrect Options: Option B - Junction of medial 1/3rd and lateral 2/3rd: Clavicular fractures at this junction are rare due to its thickness and strength, needing considerable force to cause a fracture Option C - Junction of middle 1/3rd and medial 1/3rd: Fractures at the middle 1/3rd and medial 1/3rd junction of the clavicle are uncommon due to its thinner and more flexible nature. Option D - Middle of the clavicle: Mid-clavicular fractures are uncommon and typically result from direct trauma or a fall onto the shoulder, rather than a fall onto an outstretched hand.

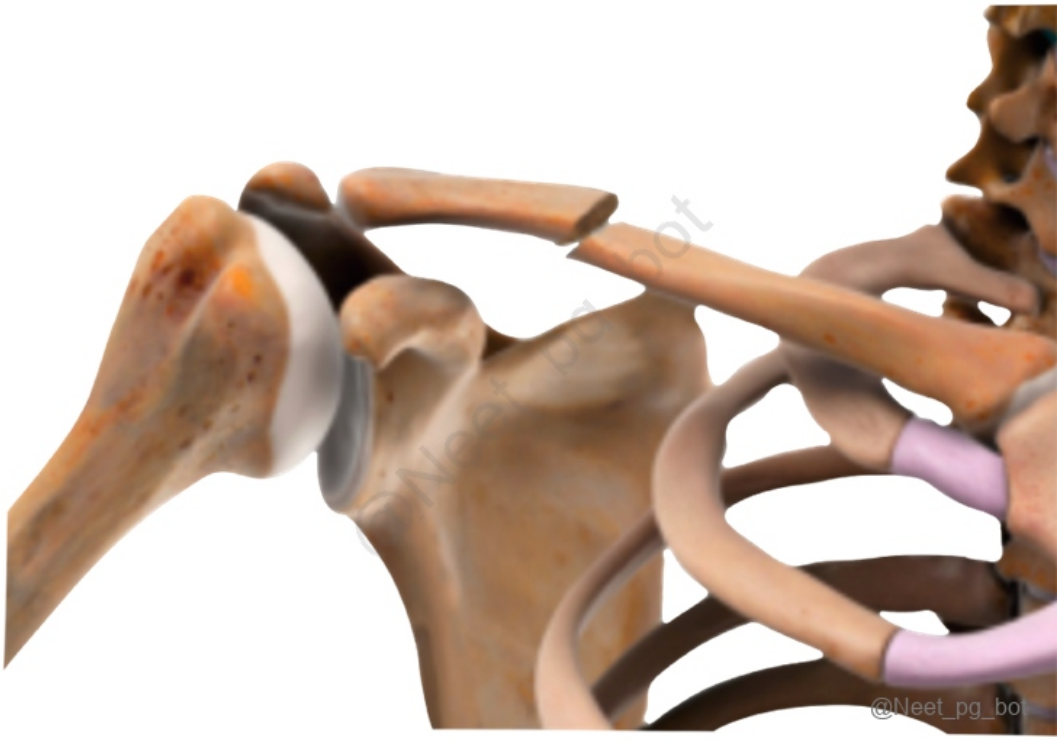

References:

.

↑ *Back to this question in Part A*

@Neet_pg_bot

Q26: The image shows the cross-section of the abdominal cavity. Identify the structure marked ‘A.’ (Q793144)

A. Descending aorta

B. Superior vena cava

C. Inferior vena cava

D. Ascending aorta

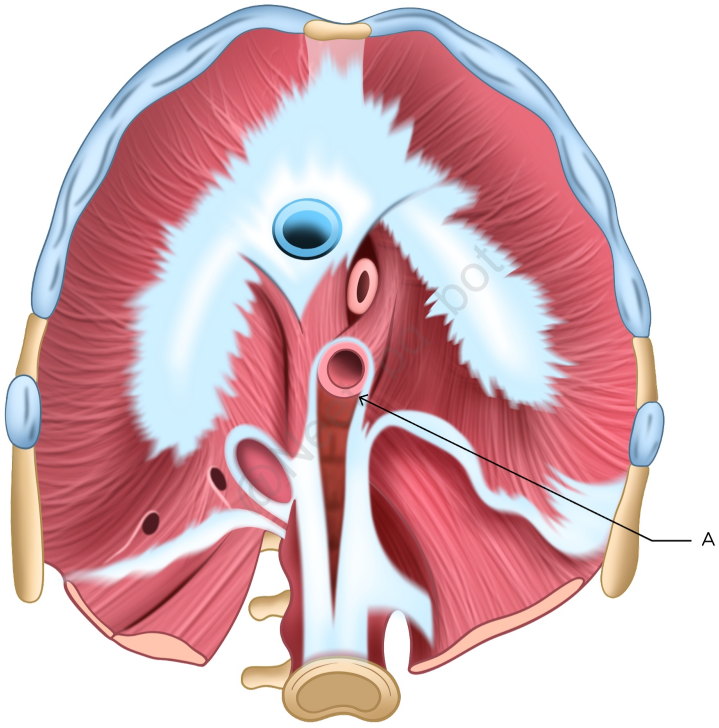

@Neet_pg_bot

Correct Answer: A. Descending aorta

Explanation: Correct Option A - Descending aorta: The diagram focuses on the posterior mediastinum, and the marked structure is descending aorta. The round structure just in front of the vertebral column is descending aorta, slightly towards the left. The descending aorta is located posterior to the diaphragm, in the midline of the body. It is a continuation of the thoracic aorta and descends along the vertebral column in the posterior mediastinum before entering the abdominal cavity. In the abdominal cavity, it descends along the posterior wall, slightly to the left of the midline, and gives off branches to the abdominal organs. Incorrect Options: Option B - Superior vena cava: The superior vena cava, found in the superior mediastinum, enters the right atrium of the heart. It is not visible in abdominal cavity cross-sections. Option C - Inferior vena cava: The inferior vena cava enters the right atrium from the posterior mediastinum, traveling along the back of the abdominal wall to the right of the midline, collecting blood from the lower body and abdominal organs. Option D - Ascending aorta: The ascending aorta begins at the left ventricle, ascends to the superior mediastinum, and branches into the brachiocephalic trunk, left common carotid artery, and left subclavian artery.

References:

.

↑ *Back to this question in Part A*

@Neet_pg_bot

• [08_Abdomen] 037 Embryology Of Abdominal Organs

« Back to Folder Directory

[08_Abdomen] 037 Embryology Of Abdominal Organs — Quick Jump

Q1 (p. 1841)	*Q2 (p. 1843)*	*Q3 (p. 1845)*	*Q4 (p. 1846)*	*Q5 (p. 1848)*	*Q6 (p. 1850)*
Q7 (p. 1852)	*Q8 (p. 1855)*	*Q9 (p. 1856)*	*Q10 (p. 1858)*	*Q11 (p. 1859)*	*Q12 (p. 1861)*
Q13 (p. 1862)	*Q14 (p. 1866)*	*Q15 (p. 1867)*	*Q16 (p. 1869)*	*Q17 (p. 1872)*	*Q18 (p. 1874)*
Q19 (p. 1877)	*Q20 (p. 1879)*	*Q21 (p. 1881)*	*Q22 (p. 1884)*	*Q23 (p. 1886)*	*Q24 (p. 1887)*

Q1: A newborn presents with bilious vomiting and abdominal distension. An abdominal X-ray shows signs of bowel obstruction. Intraoperatively, the surgeon finds multiple fibrous bands with the cecum on the left side and the small intestine on the right side. What is the most likely underlying anomaly? (Q848815)

A. Nonrotation of the midgut

B. Reversed rotation of the midgut

C. Incomplete midgut rotation

D. Midgut volvulus with normal rotation

Correct Answer: A. Nonrotation of the midgut

■ *Listen (English)*

■ *Listen (Hindi)*

Explanation: Nonrotation of the midgut refers to a congenital anomaly where the midgut only completes the first 90° of the normal 270° counterclockwise rotation, leaving the midgut improperly positioned within the abdomen. This leads to abnormal positioning of the small intestine on the right and the colon on the left, predisposing the infant to volvulus and obstruction, as seen in this case. The bilious vomiting and abdominal distension are typical presentations of midgut volvulus. Types of malrotation : Characteristic Non-Rotation Incomplete Rotation Reverse Rotation Features Failure of normal 270° counterclockwise rotation. Only the first 90° rotation occurs. Small intestine is on the right side and large intestine on the left. Incomplete rotation. Large intestine passes behind the duodenum and the superior mesenteric artery (SMA). SMA compresses the duodenum. Intestines rotate 90° clockwise instead of counterclockwise. Large intestine returns earlier and lies behind the duodenum and SMA. Small intestine misplaced anteriorly. Midgut volvulus with normal rotation (Option D): Midgut volvulus can still occur even with normal rotation, but it’s not the underlying cause here as the infant has abnormal rotation.

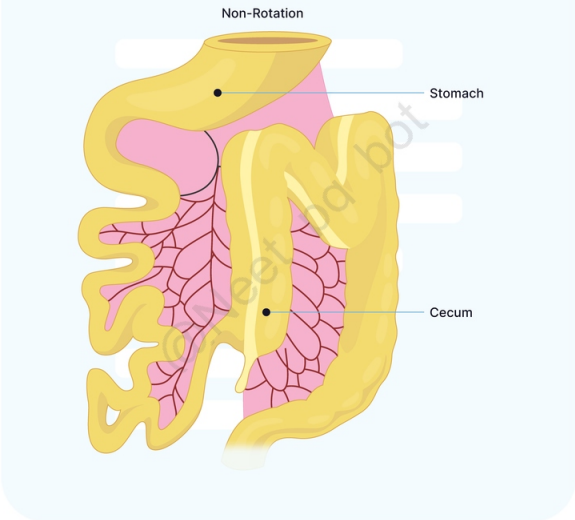

@Neet_pg_bot

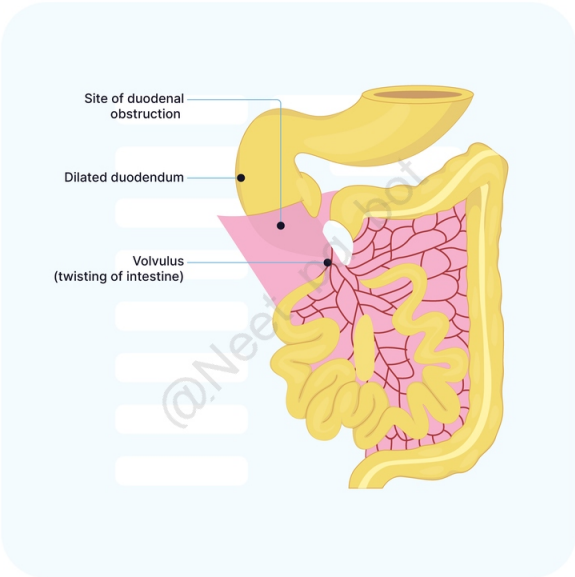

@Neet_pg_bot

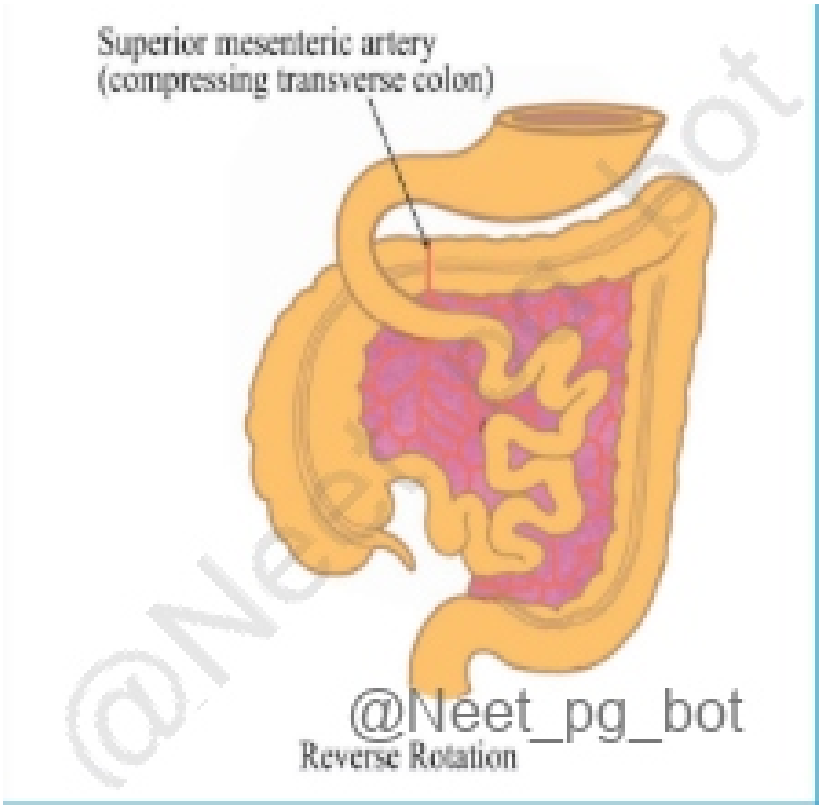

References:

https://www.ncbi.nlm.nih.gov/books/NBK560888/

↑ *Back to this question in Part A*

@Neet_pg_bot

Q2: A newborn presents with bilious vomiting shortly after birth. X-ray abdomen is taken and is shown below. Further evaluation reveals pancreatic tissue encircling and compressing the second part of the duodenum. Which embryological structure is primarily responsible for this congenital abnormality? (Q848811)

A. Dorsal pancreatic bud

B. Ventral pancreatic bud

C. Hepatic diverticulum

D. Vitelline duct

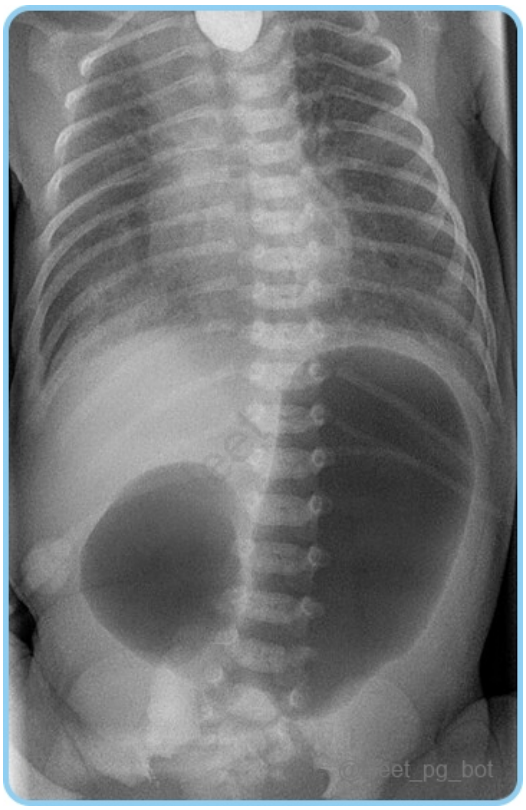

Correct Answer: B. Ventral pancreatic bud

- *Listen (English)*
- *Listen (Hindi)*

Explanation: Bilious vomiting, x-ray showing double bubble sign of duodenal obstruction and evaluation indicating presence of pancreatic tissue encircling and compressing the second part of the duodenum is suggestive of Annular pancreas, occurring due to abnormal rotation of the ventral pancreatic bud . Development of pancreas: Dorsal pancreatic bud (Option A): Forms parts of the pancreas (body, neck, and tail), but does not encircle the duodenum and is not involved in annular pancreas formation. Hepatic diverticulum (Option C): Develops into the liver and bile ducts, unrelated to pancreatic development or duodenal obstruction. Vitelline duct (Option D): Related to the yolk sac and conditions like Meckel's diverticulum, not involved in pancreatic or duodenal development.

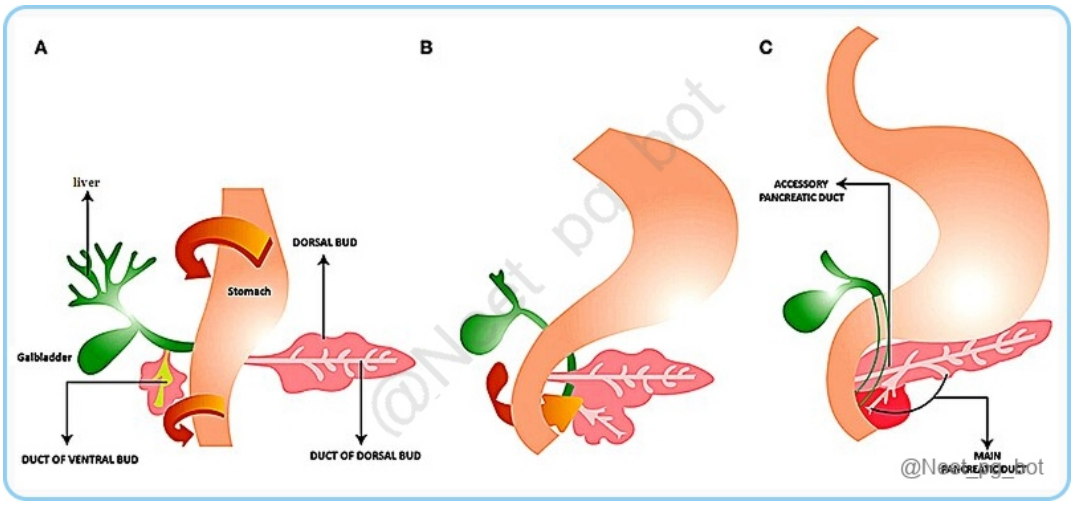

References:

Langman's Medical Embryology, 14th Edition, Pages 244 - 245

↑ *Back to this question in Part A*

@Neet_pg_bot

Q3: Which of the following statements is correct regarding the peritoneal folds of abdomen? (Q848822)

A. The greater omentum attaches to the lesser curvature of the stomach and the duodenum, providing a barrier to infections in the peritoneal cavity.

B. The lesser omentum connects the greater curvature of the stomach to the diaphragm and provides support to the liver

C. The greater omentum forms a fold between the liver and the diaphragm, providing structural support to the stomach.

D. The greater omentum is often used as a free flap in reconstructive surgeries based on gastro-omental vessels in gastrointestinal perforations.

Correct Answer: D. The greater omentum is often used as a free flap in reconstructive surgeries based on gastro-omental vessels in gastrointestinal perforations.

■ *Listen (English)*

■ *Listen (Hindi)*

Explanation: The remarkable capacity of the greater omentum to participate in reparative processes is highlighted by its use as an omental pedicle flap or free flap in reconstructive surgery: it has been used to support closure of gastrointestinal perforations, fill 'dead space' after surgical excision of pathology, and cover wound defects.
Peritoneum: The peritoneum consists of 2 layers: the superficial parietal layer and the deep visceral layer. The

peritoneal cavity contains the omentum, ligaments, and mesentery. The lesser omentum (or hepatogastric) is attached to the lesser curvature of the stomach and the liver. The greater omentum (or gastrocolic) hangs from the greater curvature of the stomach and loops down in front of the intestines before curving back upwards to attach to the transverse colon. In effect it is draped in front of the intestines like an apron and may serve as an insulating or protective layer.

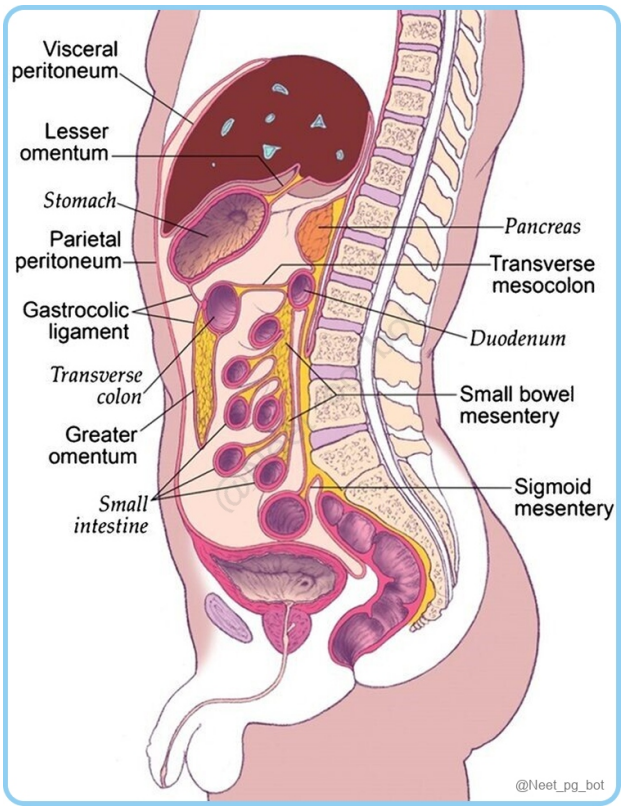

References:

Gray's Anatomy, 42nd Edition, Pages 1151-1157

https://en.wikipedia.org/wiki/Peritoneum

https://www.ncbi.nlm.nih.gov/books/NBK534788

↑ *Back to this question in Part A*

@Neet_pg_bot

Q4: Match the following with their corresponding dermatomal distribution: 1. Thumb 1) L3 2. Umblicus 2) L5 3. Knee 3) C6 4. Dorsum of foot 4) T10 (Q848821)

A. A-1, B-2, C-3, D-4

B. A-2, B-3, C-4, D-1

C. A-3, B-4, C-1, D-2

D. A-4, B-1, C-2, D-3

Correct Answer: C. A-3, B-4, C-1, D-2

- *Listen (English)*
- *Listen (Hindi)*

Explanation: Thumb 1) C6 Umblicus 2) T10 Knee 3) L3 Dorsum of foot 4) L5 Dermatomes: The sensory fibres in individual spinal and cranial nerves have characteristic, but often overlapping, peripheral (cutaneous) distributions. As far as the innervation of the body surface is concerned, the area of skin that is supplied by a particular spinal or cranial nerve is referred to as a dermatome, and the areas of skin supplied by named peripheral nerves are often referred to as the peripheral nerve field (or cutaneous nerve distribution) of that nerve.

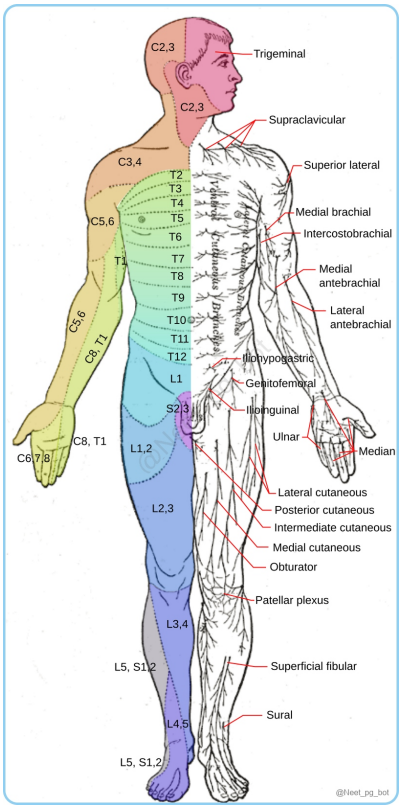

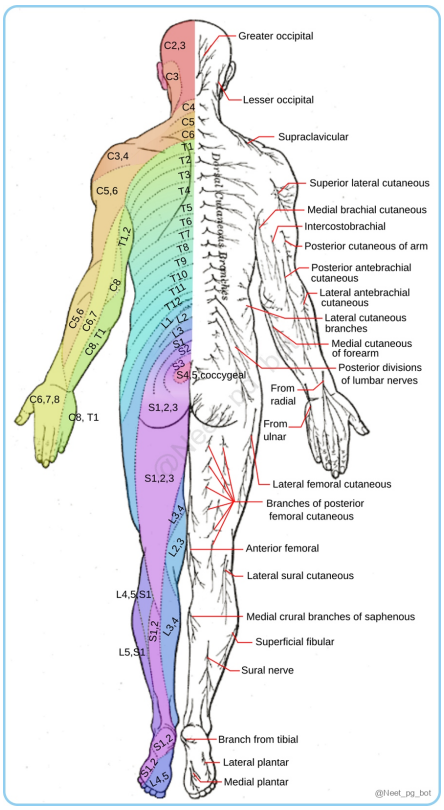

References:

Gray’s anatomy, 42nd Edition, Pages 390 - 392

https://www.physio-pedia.com/Dermatomes

https://en.wikipedia.org/wiki/Dermatome_(anatomy)

↑ *Back to this question in Part A*

@Neet_pg_bot

Q5: A 35-year-old male is involved in a high-speed motor vehicle accident and presents to the trauma unit with severe abdominal pain and hypotension. On examination, he has contusion on the left side of his abdomen. FAST reveals free fluid in the abdomen. CT scan shows a retroperitoneal hematoma and signs of injury to a retroperitoneal organ. Which of the following organs is most likely to be injured in this case? (Q848820)

A. Stomach

B. Small intestine

C. Left kidney

D. D) Spleen

Correct Answer: C. Left kidney

■ *Listen (English)*

■ *Listen (Hindi)*

Explanation: A retroperitoneal hematoma seen on CT scan, along with the clinical signs of severe abdominal pain, contusion, and hypotension, strongly suggests that the left kidney has been injured in this case. Retroperitoneal Space: The retroperitoneum is an anatomical space located behind the abdominal or peritoneal cavity. Abdominal organs that are not suspended by the mesentery and lie between the abdominal wall and parietal peritoneum are said to lie within the retroperitoneum. The retroperitoneum divides into three main anatomical spaces: The anterior pararenal space: contains the head, neck, and body of the pancreas (the tail of the pancreas is within the splenorenal ligament), ascending and descending colon, and the duodenum (except for the proximal first segment). The perirenal space: includes the adrenal gland, kidney, ureters, and renal vessels. The posterior pararenal space : It is surrounded by the posterior leaf of the renal fascia and muscles of the posterior abdominal wall, contains no major organs and is composed primarily of fat, blood vessels, and lymphatics. There is also a fourth, less well-defined space known as the great vessel space. It lies anterior to the vertebral bodies and psoas muscles and contains the aorta, inferior vena cava, and surrounding fat. Stomach (Option A) is an intraperitoneal organ. Trauma to the stomach would generally present with signs of peritoneal irritation and perforation, not retroperitoneal bleeding. Small intestine (Option C) is also an intraperitoneal organ. Injury to the small intestine would typically cause signs of peritonitis, but not a retroperitoneal hematoma. Spleen (Option D) is an intraperitoneal organ located in the left upper quadrant. Injury to the spleen would more commonly present with signs of intraperitoneal bleeding.

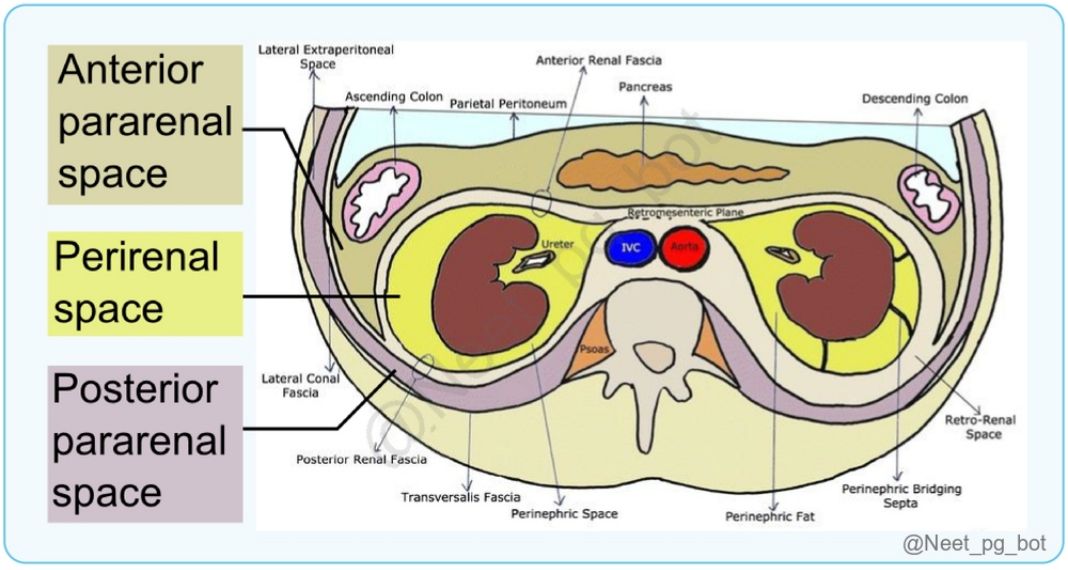

References:

Gray’s anatomy, 42nd Edition, Page 1119

https://www.ncbi.nlm.nih.gov/books/NBK549857/

↑ *Back to this question in Part A*

@Neet_pg_bot

Q6: Which of the following planes carries the origin of the hepatic portal vein and the termination of the spinal cord? (Q848819)

A. Subcostal plane

B. Supracristal plane

C. Intertubercular plane

D. Transpyloric plane

Correct Answer: D. Transpyloric plane

■ *Listen (English)*

■ *Listen (Hindi)*

Explanation: The origin of the hepatic portal vein and the termination of the spinal cord are in the transpyloric plane of the abdomen. Structures present: Pylorus of the stomach Termination of the spinal cord Origin of the superior mesenteric artery Hilum of the kidney Fundus of the gallbladder Tip of the 9th costal cartilage Vertical Planes Midline (Median Plane): Passes through the xiphoid process and pubic symphysis. Paramedian Lines: Left and right lines from midclavicular points to midway between the anterior superior iliac spine and the pubic symphysis. Horizontal Planes Xiphisternal Plane : Aligned with the T9 vertebral body; it often intersects the xiphisternal joint. Transpyloric Plane : Midway between the jugular notch and the superior pubic symphysis; intersects the L1-L2 intervertebral disc or superior half of L2. Key structures include: Subcostal Plane (Option A ruled out) : Joins the lowest points of the costal arch; typically intersects the vertebral body of L2. Supracristal Plane (Tuffier’s Line) (Option B ruled out) : Joins the superior points of the iliac crests; corresponds to the aortic bifurcation (L4-L5). Intertubercular Plane (Option C ruled out) : Joins iliac tubercles; commonly at the L5 vertebral body. Plane of the Pubic Crest : In line with the superior pubic symphysis; intersects the head of the femur and coccyx in supine individuals. Anatomical Landmarks for the Abdominal Planes: Plane Vertebral Level Surface Landmark Key Structures at this Level Transpyloric Lower border of L1 Midway between jugular notch & pubic symphysis Pylorus , Neck of Pancreas, Hila of Kidneys, Fundus of Gallbladder, Origin of SMA. Subcostal Lower border of L3 Inferior margin of 10th costal cartilage Origin of Inferior Mesenteric Artery (IMA), 3rd part of Duodenum. Transumbilical L3/L4 The Umbilicus Bifurcation of the Abdominal Aorta into Iliac Arteries (usually just below at L4). Supracristal Body of L4 Highest point of Iliac Crests Landmark for Lumbar Puncture (safe entry to subarachnoid space). Transtubercular Upper border of L5 Tubercles of Iliac Crests Formation of the Inferior Vena Cava (IVC) by common iliac veins.

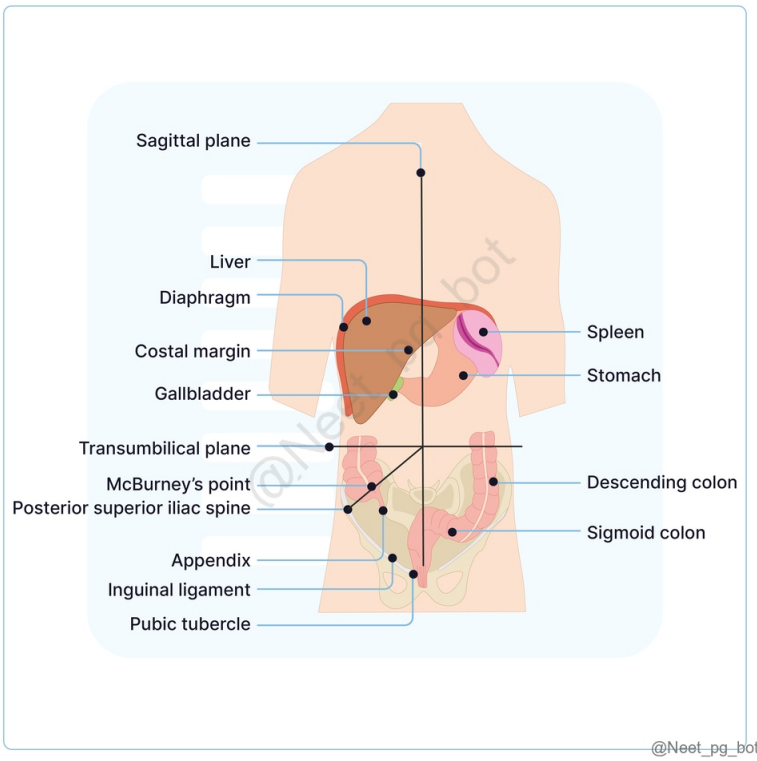

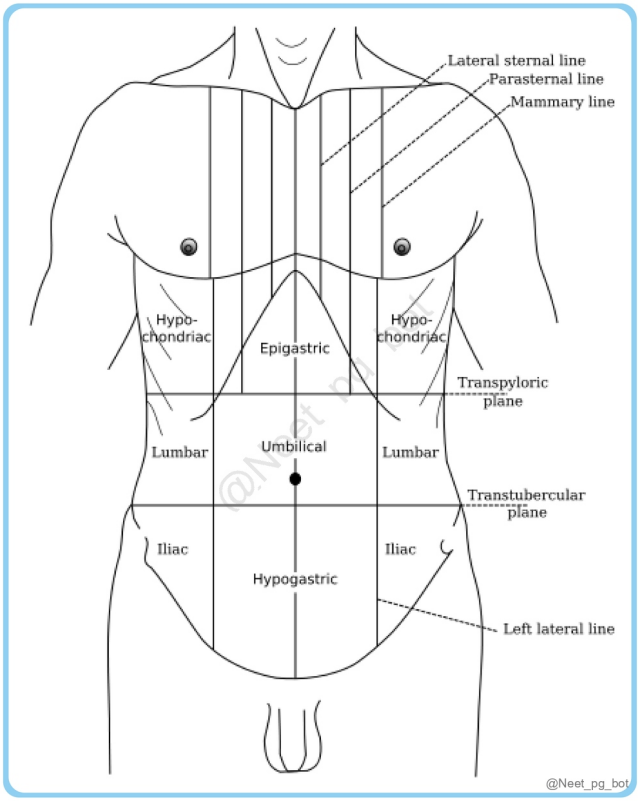

References:

Gray's Anatomy, 42nd Edition, Pages 1116-1118.

Vishram Singh Textbook of Anatomy, Abdomen and Pelvis, 2nd Edition, Page 75-76.

↑ *Back to this question in Part A*

@Neet_pg_bot

Q7: A triangular area formed in the bladder is called the trigone. Which of the following is the origin of the epithelium of the trigone? (Q848818)

A. Cranial vesicourethral canal

B. Mesonephric duct

C. Splanchnic mesoderm

D. Allantois

Correct Answer: B. Mesonephric duct

■ *Listen (English)*

■ *Listen (Hindi)*

Explanation: The epithelium of the trigone is from the endothelium of absorbed mesonephric ducts. Development of the Urinary Bladder: A Step-by-Step Process Formation of the Cloaca Cloaca: The terminal portion of the hindgut in the embryo. Urorectal Septum: a partition that divides the cloaca into: Dorsal Part: forms the primitive rectum, the later part of the large intestine. Ventral Part: becomes the primitive urogenital sinus Subdivisions of the Primitive Urogenital Sinus Cranial Part (Upper): Forms the vesicourethral canal, a precursor to the urinary bladder and urethra. Caudal Part (Lower): Develops into the definitive urogenital sinus, contributing to structures in both males and females. Development of the Vesicourethral Canal Regions of the Canal: Wider Upper Part: Expands to become the urinary bladder. Narrower Lower Part: Develops into the primitive urethra. Incorporation of the Mesonephric Ducts Mesonephric Ducts: Gradually absorbed into the posterior wall of the vesicourethral canal. Trigone Formation: Absorbed portions contribute to the formation of the trigone, a triangular area in the bladder wall. Fate of the Allantois Allantois (Option D) : Initially extends from the bladder apex and atrophies to form the urachus (median umbilical ligament), connecting the bladder to the umbilicus. Cellular Origins and Layers Epithelium: The inner lining originates from the endoderm of the cranial vesicourethral canal (Option A) ; trigone epithelium derives from the mesoderm of the absorbed mesonephric ducts. Muscular and Serous Walls: Develop from splanchnic mesoderm (Option C) surrounding the developing gut.

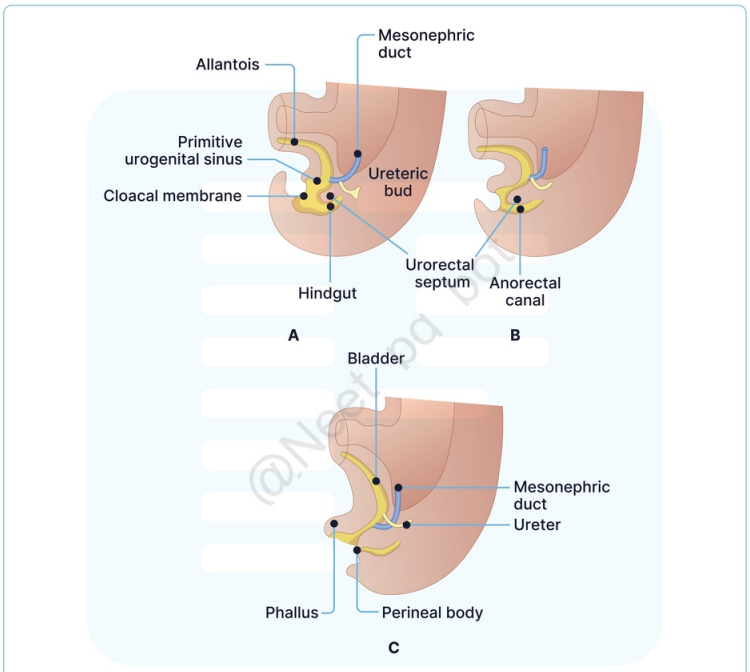

Divisions of the cloaca into the urogenital sinus and anorectal canal. The mesonephric duct is gradually absorbed into the wall of the urogenital sinus, and the ureters enter separately. A. At the end of the 5th week. B. 7 weeks. C. 8 weeks

@Neet_pg_bot

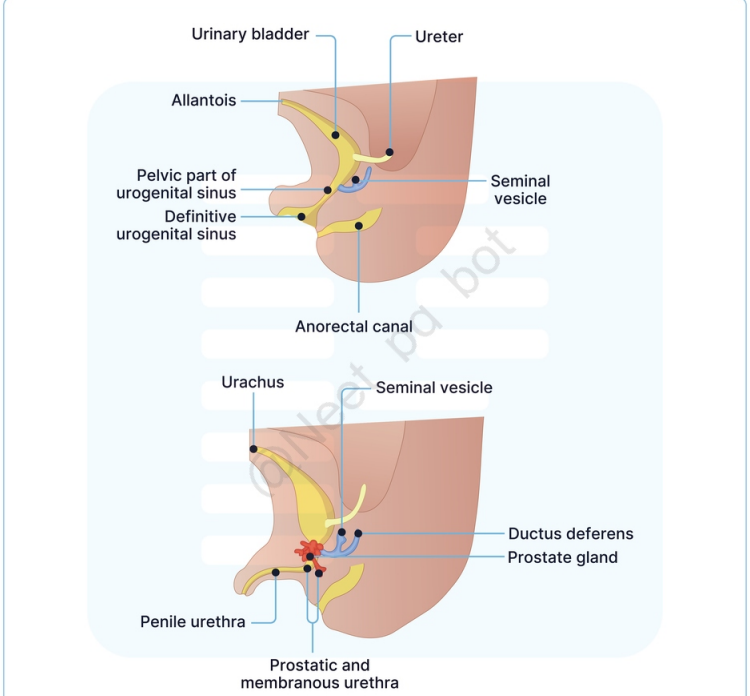

@Neet_pg_bot

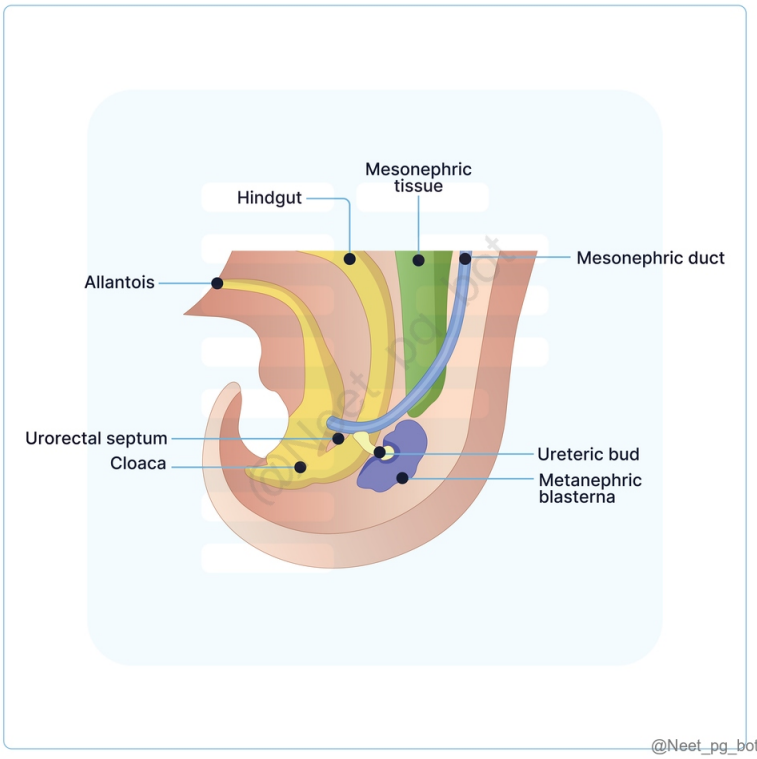

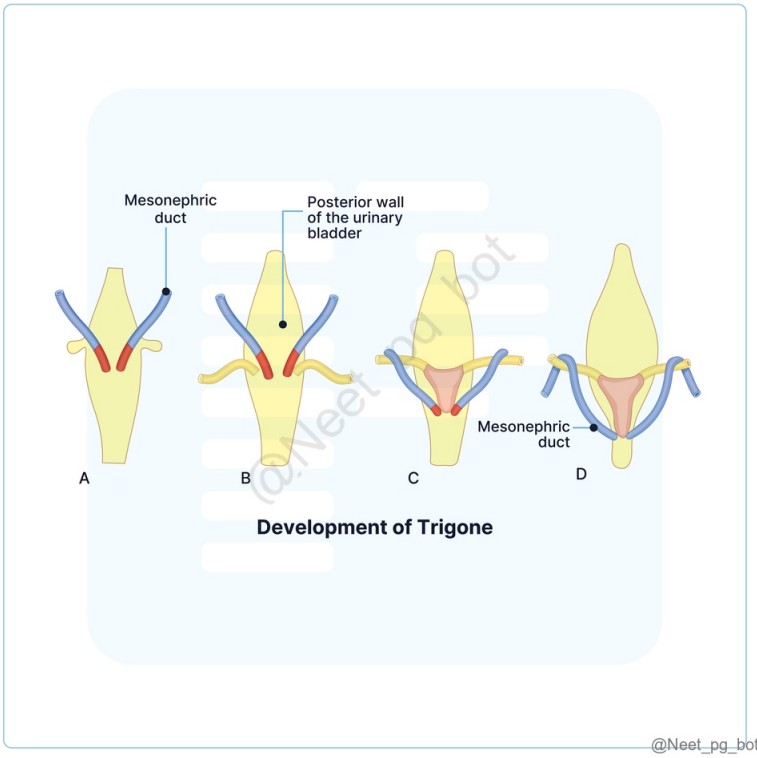

References:

Inderbir Singh’s Human Embryology, 11th Edition, Page 270, 271.

↑ *Back to this question in Part A*

@Neet_pg_bot

Q8: A newborn baby was found to have hydronephrosis. Which of the following would be the cause of this? (Q848817)

A. Obstruction by the umbilical arteries

B. Crossed ectopia

C. Malrotation of kidneys

D. Aberrant renal arteries

Correct Answer: D. Aberrant renal arteries

■ *Listen (English)*

■ *Listen (Hindi)*

Explanation: Aberrant renal arteries cause compression of the ureters and cause hydronephrosis. Ascent of Kidneys: Early Development and Position Metanephros: The definitive human kidney arises from the metanephros, initially located in the sacral region of the embryo. Blood Supply: Receives blood from the lateral sacral arteries at this stage. Ascent Process Differential Growth: As the embryo develops, significant growth of the abdominal wall causes the kidneys to ascend towards the lumbar region. This ascent results from surrounding structures changing positions, not physical movement of the kidneys. Change in Blood Supply: Ascent leads to a shift in blood supply from lateral sacral arteries to higher branches of the aorta. The definitive renal artery originates from the aorta at the second lumbar segment. Factors Influencing Ascent Abdominal Wall Growth: The primary driver of kidney ascent. Umbilical Arteries: During ascent, kidneys pass between the right and left umbilical arteries. Obstruction by these arteries can impede ascent, causing kidneys to remain in the pelvic region. (Option A) Rotation of the Kidney Hilum Reorientation: Initially, the hilum faces anteriorly; as the kidney ascends, it rotates to face medially (towards the midline). Clinical Significance of Anomalies Anomalies of Position: Pelvic Kidney: Kidney remains in the sacral region. Incomplete Ascent: Kidney lies opposite the lower lumbar vertebrae. Thoracic Kidney: Rare ascent into the thoracic cavity. Crossed Ectopia (Option B) : Both kidneys are located on the same side of the midline. Aberrant Renal Arteries: Abnormal kidney position can lead to unusual blood supply, potentially compressing the ureter and causing hydronephrosis (kidney swelling due to urine buildup). Malrotation (Option C) Abnormal hilum position due to incomplete rotation

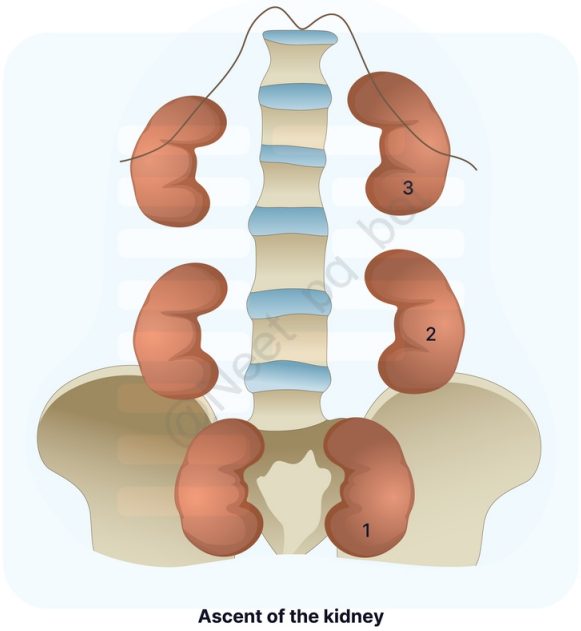

Ascent of the kidney

@Neet_pg_bot

References:

Inderbir Singh’s Human Embryology, 11th Edition, Page 268, 269.

↑ *Back to this question in Part A*

@Neet_pg_bot

Q9: A newborn presents with a congenital urinary tract anomaly. During evaluation, the physician explains the stages of kidney development and associated structures. Which of the following statements is true regarding the formation of the definitive kidney in mammals? (Q848816)

A. Pronephros is the functional kidney in humans and contributes to the urinary system.

B. Mesonephros develops in the cervical region and contains excretory tubules.

C. Metanephros arises from the metanephric blastema and the ureteric bud.

D. Lateral plate mesoderm forms the foundation of the urinary and genital systems.

Correct Answer: C. Metanephros arises from the metanephric blastema and the ureteric bud.

■ *Listen (English)*

■ *Listen (Hindi)*

Explanation: Metanephros is the definitive kidney that arises from both the metanephric blastema (forming nephrons) and the ureteric bud (forming the collecting system). Key Players in Development Intermediate Mesoderm: Forms the foundation of the urinary and genital systems. (Option D) Cloaca: Part of the hindgut; divides into the rectum and urogenital sinus . Urogenital Ridge: Develops from the intermediate mesoderm, giving rise to the genital ridge (gonads) and nephrogenic cord (future kidneys). Stages of Kidney Evolution Pronephros (Most Primitive): Develops in the cervical region of the nephrogenic cord. Nonfunctional in humans; associated duct persists as the mesonephric duct. (Option A) Mesonephros (Intermediate): Functional in amphibians; develops in the thoracolumbar region. (Option B) Consists of excretory tubules draining into the mesonephric duct; some tubules contribute to the male reproductive system. Metanephros (Definitive Kidney): (Option C) Functional kidney in mammals, birds, and reptiles; begins in the sacral region. Arises from two sources: 1. Excretory Tubules (Nephrons): Develop from the metanephric blastema. 2. Collecting System : Forms from the ureteric bud branching from the mesonephric duct. Step-by-Step Formation of the Kidney Ureteric Bud Branching: The ureteric bud grows towards metanephric blastema , forming an ampulla . Ampulla divides to form the renal pelvis, major and minor calyces, and collecting tubules. Nephron Formation: Ampulla induces differentiation in the metanephric blastema, leading to nephron formation. Cells form vesicles, elongate into S-shaped tubules , and develop glomeruli through capillary invasion. Ascent and Rotation of the Kidney Ascent: Initially located in the sacral region it ascends to the lumbar region as the abdominal wall grows. Acquires new blood supply from higher aortic branches. Rotation: Hilum faces anteriorly at first; and rotates medially during ascent.

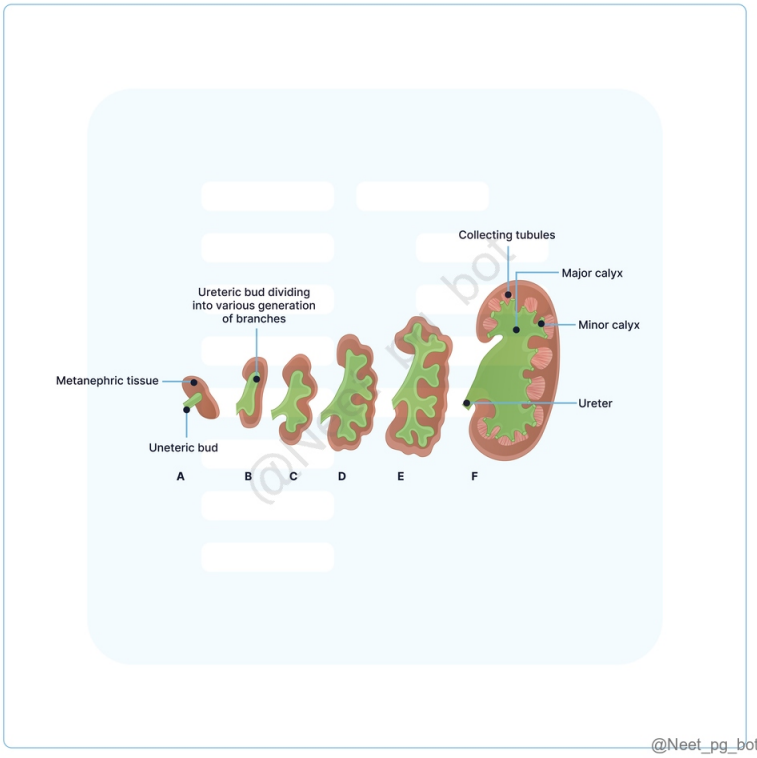

References:

Inderbir Singh’s Human Embryology, 11th Edition, Pages 265-269

↑ *Back to this question in Part A*

@Neet_pg_bot

Q10: A newborn presents with bilious vomiting and abdominal distension. Imaging reveals malrotation of the midgut. The pediatric surgeon explains that during normal embryological development, the midgut should rotate around a specific arterial axis to reach its anatomical position. How many degrees does the midgut rotate, and what is the axis of this rotation? (Q848814)

A. 180 degrees, Inferior Mesenteric Artery

B. 270 degrees, Superior Mesenteric Artery

C. 90 degrees, Inferior Mesenteric Artery

D. 360 degrees, Superior Mesenteric Artery

Correct Answer: B. 270 degrees, Superior Mesenteric Artery

■ *Listen (English)*

■ *Listen (Hindi)*

Explanation: During normal embryological development, the midgut undergoes a rotation of 270 degrees counterclockwise around the axis of the superior mesenteric artery (SMA). This rotation helps position the intestines correctly within the abdominal cavity. If this rotation does not occur properly, it can lead to malrotation. The midgut loop undergoes a counterclockwise rotation (approximately 270 degrees) around the superior mesenteric artery (SMA). This rotation occurs in two phases: Initial 90-degree Rotation: As the loop begins to retract from the umbilical cord, it rotates 90 degrees counterclockwise. Final 180-degree Rotation: Once retracted fully into the abdominal cavity, it completes an additional 180-degree rotation. Final Positioning: After the complete rotation, the small intestine is positioned predominantly in the upper left quadrant, while the colon occupies the right side of the abdomen. The duodenum becomes fixed to the posterior abdominal wall, which is important for its stability and function. Formation of Mesenteries: The rotation and positioning of the intestines also result in the development of mesenteries, which are double layers of peritoneum that support the intestines and provide blood supply and nerve connections.

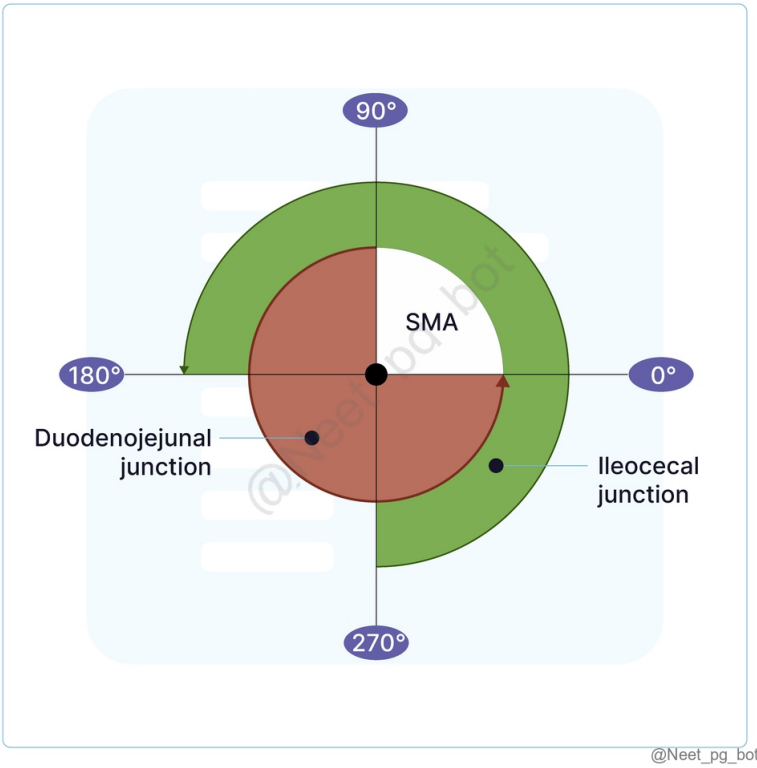

References:

Inderbir Singh's Human Embryology, 11th Edition, Page 181, 182, 183.

↑ *Back to this question in Part A*

@Neet_pg_bot

Q11: A 26-year-old woman with a history of recurrent abortion undergoes an ultrasound at 8 weeks of gestation and is found to have an abnormality in the fetus as shown below (arrow). The doctor reassures her that this condition typically resolves on its own. When should she schedule a follow-up ultrasound to monitor the resolution of the abnormality? (Q848813)

A. 12 weeks

B. 14 weeks

C. 16 weeks

D. 18 weeks

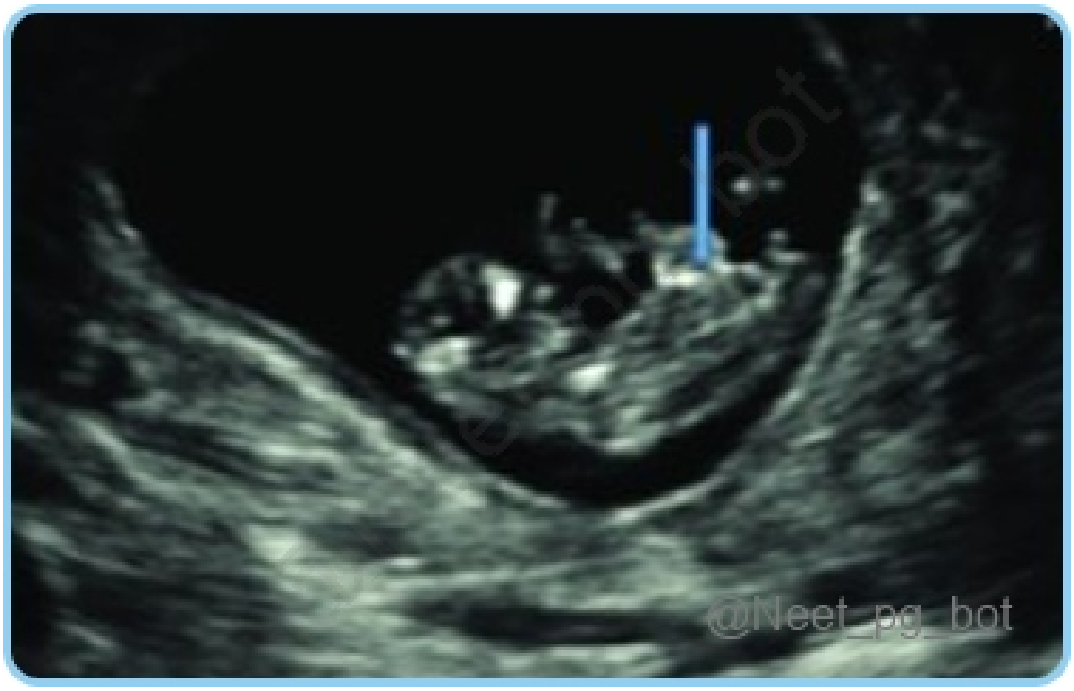

Correct Answer: A. 12 weeks

- *Listen (English)*
- *Listen (Hindi)*

Explanation: Ultrasound shows physiological umbilical hernia. A physiological umbilical hernia is a normal developmental process where the intestines temporarily protrude into the base of the umbilical cord during early pregnancy. This occurs as the fetal abdomen is too small to accommodate the rapidly growing intestines. By around 12 weeks of gestation, the intestines typically return to the abdominal cavity, and the umbilical hernia resolves on its own. A follow-up ultrasound around 12 weeks is recommended to ensure proper closure and development. Physiological Umbilical Hernia (PUH): Occurs during early embryogenesis due to rapid growth of the midgut and liver, temporarily exceeding the size of the abdominal cavity. Midgut Herniation (6th Week): The midgut herniates into the umbilical cord as the abdominal cavity is too small. It undergoes a 90-degree counterclockwise rotation around the superior mesenteric artery. Midgut Retraction (10th-12th Week): The abdominal cavity expands, allowing the midgut to return. During retraction, an additional 180-degree counterclockwise rotation completes the 270-degree total, positioning the intestines. Failure to Regress: Omphalocele: If the midgut doesn't return, omphalocele occurs, where organs remain herniated through the umbilical ring, covered by a membrane. It differs from Gastroschisis, where the organs protrude without a membrane. Feature Gastroschisis Omphalocele Location Usually to the right of the umbilical cord. Directly through the umbilical ring. Membrane Cover None. Bowel is exposed to amniotic fluid. Present. Covered by a sac (peritoneum and amnion). Umbilical Cord Attaches normally to the abdominal wall. Attaches to the top of the sac . Bowel Appearance Often "matted," edematous, or inflamed. Usually appears normal (protected by sac). Organs Involved Usually just small and large intestine. Can include liver, spleen, and bladder. Associated Anomalies Rare (usually limited to GI issues). Common (heart defects, trisomies, Beckwith-Wiedemann). Maternal Age Often associated with younger mothers. Often associated with older mothers.

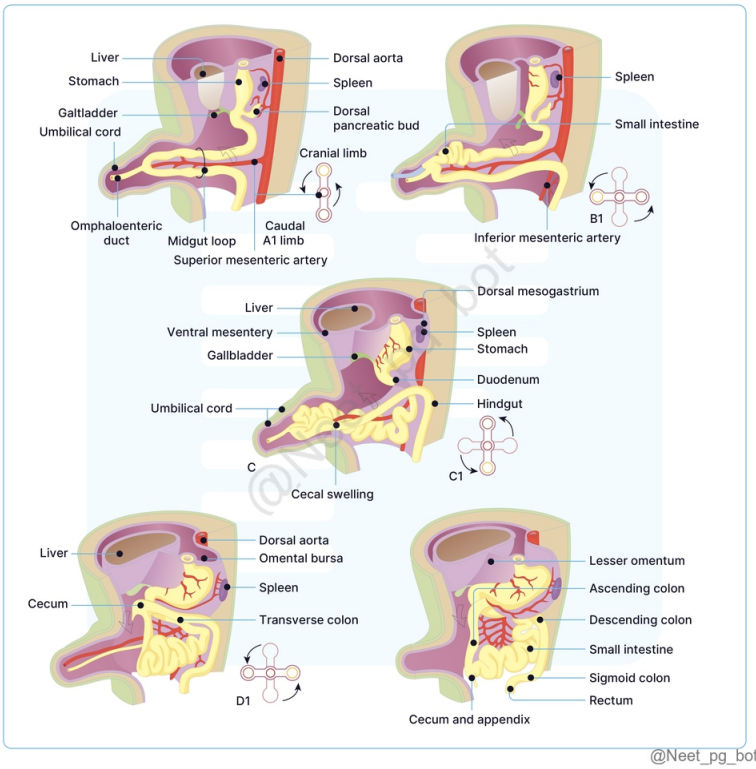

@Neet_pg_bot

References:

Inderbir Singh's Human Embryology, 11th Edition, Page 181.

https://www.ncbi.nlm.nih.gov/pmc/articles/PMC6549455/

↑ *Back to this question in Part A*

@Neet_pg_bot

Q12: Which of the following statements about the ligament of Treitz is not true? (Q848812)

A. It connects the duodenojejunal flexure to the right crus of the diaphragm.

B. It contains striated muscle fibers in its upper part.

C. It primarily serves as a conduit for blood supply to the small intestine.

D. It acts as a landmark in the diagnosis of intestinal malrotation.

Correct Answer: C. It primarily serves as a conduit for blood supply to the small intestine.

■ *Listen (English)*

■ *Listen (Hindi)*

Explanation: The ligament of Treitz does not serve as a conduit for blood supply to the small intestine ; it is done by the superior mesenteric arteries. The ligament primarily stabilizes the duodenojejunal flexure and serves as an anatomical landmark. Retention bands are ligaments that hold the gut in place during the primitive gut loop and rotation phase There are 2 types of retention band Superior retention band: Develops into ligament of Treitz. Inferior retention band: Undergoes atrophy. Ligament of Treitz It is a fibromuscular band that suspends the duodenojejunal flexure from the right crus of the diaphragm. (Option A) Attachments : Upper end connects to the right crus of the diaphragm. Lower end attaches to the posterior surface of the duodenojejunal flexure. Composition : Striated muscle fibers in the upper part. (Option B) Elastic fibers in the middle. Non-striated muscle fibers in the lower part. Clinical Relevance : Acts as an important landmark in radiological assessments for diagnosing incomplete rotation or malrotation of the small intestine. (Option D)

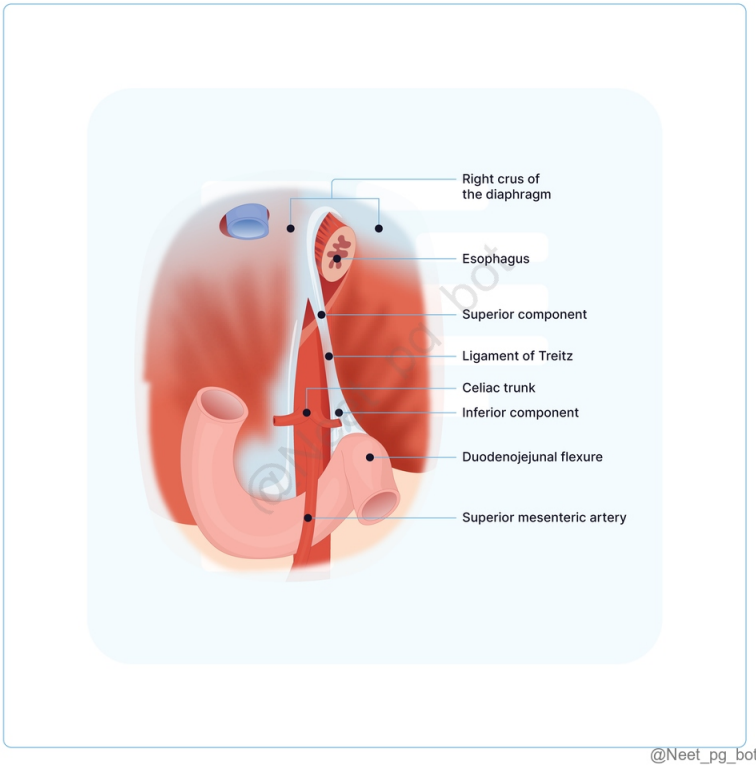

References:

https://pubmed.ncbi.nlm.nih.gov/6464646/

Vishram Singh textbook of anatomy, 2nd Edition, Page 130

↑ *Back to this question in Part A*

@Neet_pg_bot

Q13: A healthcare provider is discussing the anatomy of the umbilical cord with a medical student. How many arteries and veins are typically present in a normal umbilical cord? (Q848767)

A. 1 artery and 1 vein

B. 2 arteries and 1 vein

C. 2 arteries and 2 veins

D. 1 artery and 2 veins

Correct Answer: B. 2 arteries and 1 vein

- *Listen (English)*
- *Listen (Hindi)*

Explanation: Umbilical cord has one umbilical vein and two umbilical arteries. Contents of the Umbilical Cord Umbilical Arteries Two arteries transport deoxygenated blood from the fetus to the placenta. Umbilical Vein Initially, two veins are present; The right one disappears. The remaining left umbilical vein carries oxygenated blood from the placenta to the fetus. Wharton's Jelly A gelatinous substance derived from the mucoid degeneration of the mesoderm of the connecting stalk protects umbilical vessels. Allantoic Diverticulum Ventral projection of hindgut into the connecting stalk. It is incorporated into the urinary bladder proximally and forms the urachus distally. Vitellointestinal Duct Connection between the midgut and yolk sac; usually disappears but may leave remnants like cysts or fibrous cords. Intra and Extraembryonic Coelom Communication Exists at the fetal end around the vitellointestinal duct until week 10, allowing for a physiological hernia of the midgut loop.

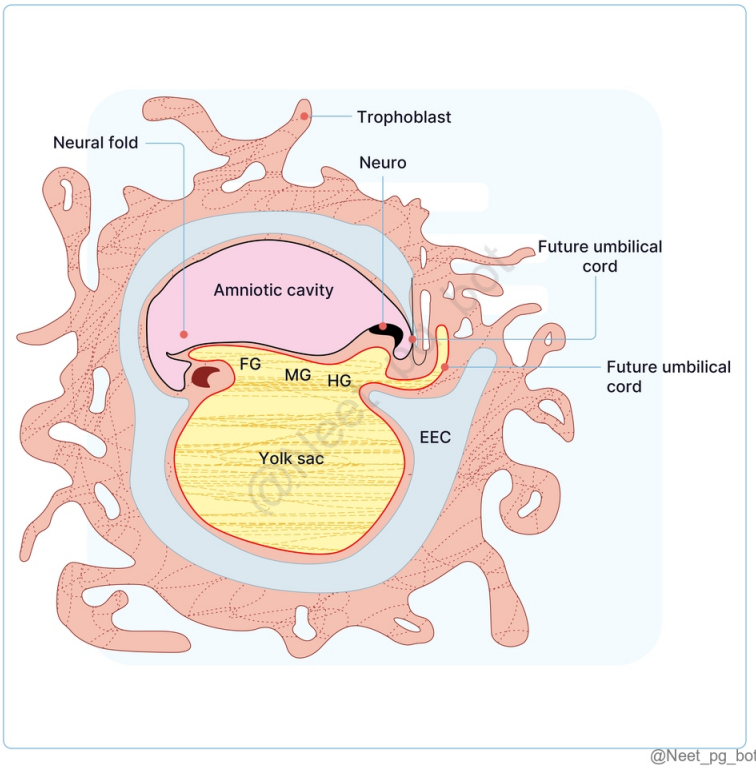

@Neet_pg_bot



@Neet_pg_bot

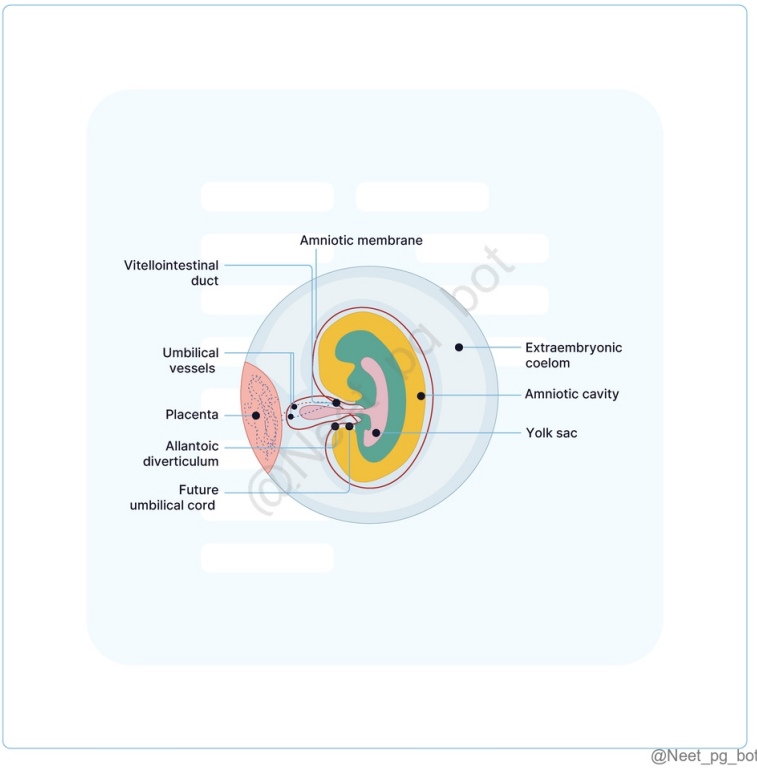

@Neet_pg_bot

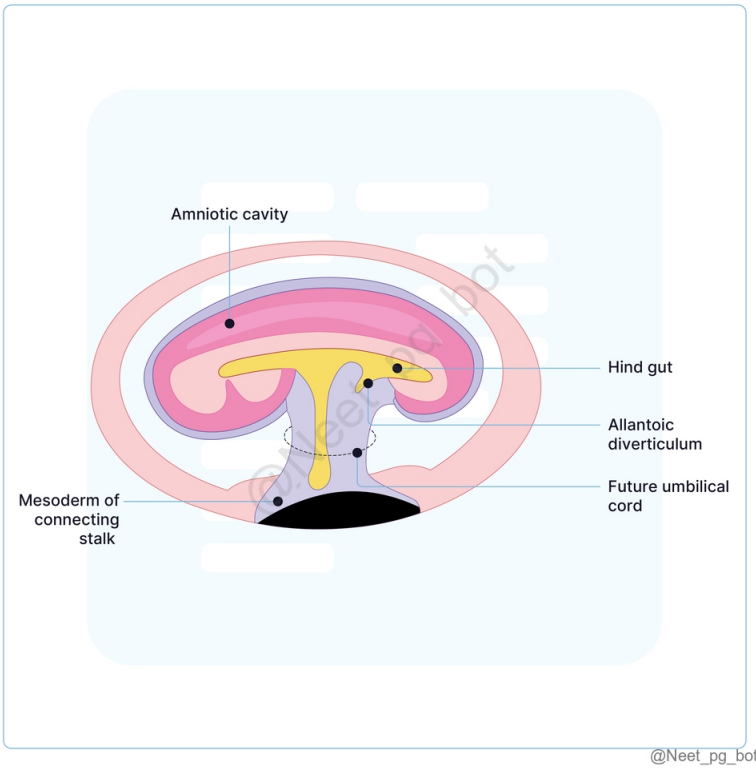

@Neet_pg_bot

References:

Inderbir Singh’s Human Embryology, 11th Edition, Pages 90-92.

↑ *Back to this question in Part A*

@Neet_pg_bot

Q14: Which of the following statements about the development of the liver and gallbladder is correct? (Q848810)

A. Liver develops from the mesodermal hepatic bud.

B. Cystic duct forms from the pars hepatica of the hepatic bud.

C. Bile duct initially opens on the dorsal aspect of the developing duodenum.

D. Vitelline and umbilical veins contribute to the formation of hepatic sinusoids.

Correct Answer: D. Vitelline and umbilical veins contribute to the formation of hepatic sinusoids.

■ *Listen (English)*

■ *Listen (Hindi)*

Explanation: Vitelline and umbilical veins within septum transversum get absorbed and broken to form hepatic sinusoids. Development of Liver: Develops from the endodermal hepatic bud.(Option A) Hepatic bud arises as an outgrowth from the ventral margin of the terminal part of the foregut. Hepatic bud grows ventrally and cranially into the ventral mesogastrium and through it into the septum transversum. Hepatic bud elongates and divides into: Pars hepatica: Forms the liver. Pars cystica: Forms the gallbladder and cystic duct. (Option B) Division of Pars Hepatica: Divides into right and left branches to form right and left hepatic ducts. Two termination of hepatic ducts forms: Right and left lobes of the liver. Formation of Hepatic Architecture: Hepatic bud (endoderm) forms: Hepatic cells Intrahepatic biliary apparatus (parenchyma). Vitelline and umbilical veins within septum transversum get absorbed and broken to form hepatic sinusoids. (Option C) Development of Gallbladder: Gallbladder and cystic duct develop from the pars cystica of the hepatic bud. Common bile duct forms from the narrow section of the hepatic bud between the pars cystica and the duodenum. Initially, the bile duct opens on the ventral aspect of the developing duodenum. (Option C) Due to differential growth and rotation of the duodenal loop, the bile duct shifts to open on the dorsomedial aspect, alongside the ventral pancreatic bud.

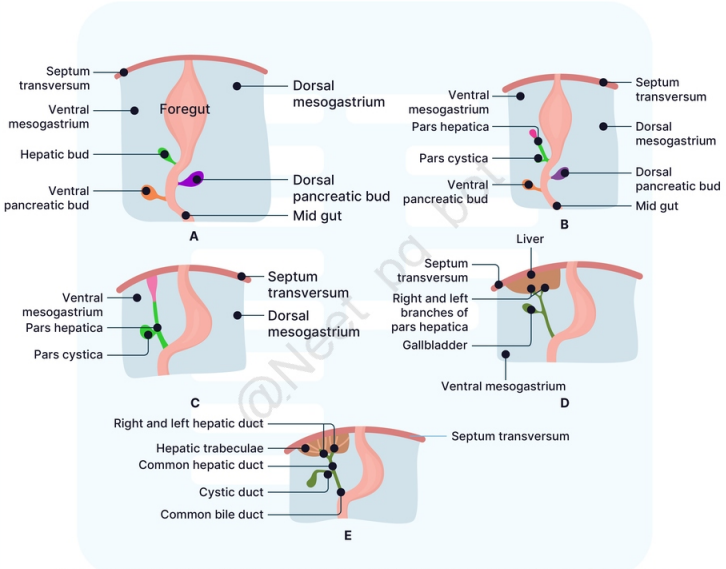

Development of liver: (A) Origin of hepatic bud from the ventral wall of terminal part of foregut, (B) Hepatic bud growing into the ventral mesogastrium and dividing into pars hepatica and pars cystica: (C) Pars hepatica growing toward septum transversum through ventral mesogastrium (D) Division of pars hepatica into right and left parts forming the right and left lobes of liver: (E) Formation of sheets of hepatic cells

@Neet_pg_bot

References:

Inderbir Singh's Human Embryology, 11th Edition, Page no: 190, 191,193, 194

↑ *Back to this question in Part A*

@Neet_pg_bot

Q15: A research study is conducted to understand the embryological development of gastrointestinal (GI) structures in an embryo. Which of the following statements about the normal embryological development of the GI tract is incorrect? (Q848809)

A. Esophagus develops entirely from the foregut.

B. Stomach initially forms as a fusiform dilation of the foregut.

C. Duodenum forms a C-shaped loop during stomach rotation.

D. Midgut-derived parts of the duodenum are supplied by the celiac artery

Correct Answer: D. Midgut-derived parts of the duodenum are supplied by the celiac artery

■ *Listen (English)*

■ *Listen (Hindi)*

Explanation: Midgut-derived parts of the duodenum are actually supplied by the superior mesenteric artery , not the celiac artery. Development of Esophagus: Develops from the foregut part between the pharynx and the stomach. (Option A) Initially short, it elongates with neck development, diaphragm descent, and pleural cavity expansion. Muscular coat of the esophagus is derived from the surrounding visceral mesenchyme. Upper two-thirds of the esophagus contains striated muscle, innervated by the vagus nerve. Lower one-third of the esophagus contains smooth muscle, innervated by the splanchnic plexus. Development of Stomach: Begins as a fusiform dilatation of the foregut , distal to the esophagus. (Option B) Dorsally attached to the posterior abdominal wall by the dorsal mesogastrium. Ventrally attached to the septum transversum by the ventral mesogastrium. Stomach Rotation: First rotation: 90■clockwise along the longitudinal axis, reorienting the stomach's surfaces and shifting the position of the vagus nerves. Second rotation: Along the anteroposterior axis, altering the position of the fundus, duodenum, and ends of the stomach. Development of Duodenum: Duodenum above the entry of the bile duct (first part and upper half of the second part) is derived from the foregut. Part below the entry of the bile duct (remaining portion of second part along with third and fourth part) is derived from the midgut. Rotation of stomach: Duodenum forms a C-shaped loop and rotates to the right. (Option C) Developing duodenum is initially attached to the posterior abdominal wall by the mesoduodenum, which later fuses with the peritoneum, making most of the duodenum retroperitoneal. Blood Supply of Duodenum: Foregut derived parts: Celiac artery Midgut derived parts: Superior mesenteric artery (Option D)

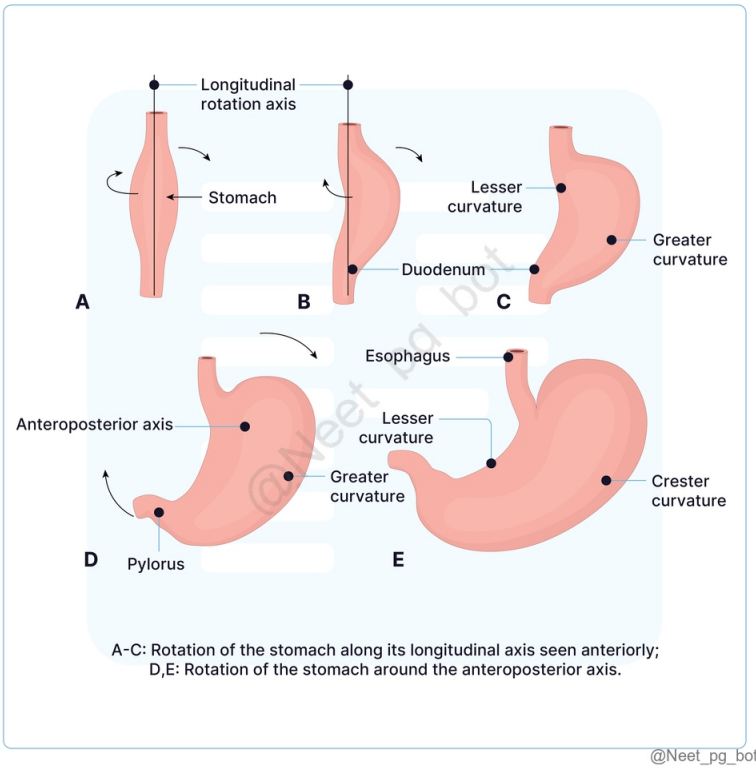



@Neet_pg_bot

References:

Inderbir Singh's Human Embryology, 11th Edition, Page no: 176,178,179

Langman's Medical Embryology, 14th Edition, Page no: 240

↑ *Back to this question in Part A*

@Neet_pg_bot

Q16: Which of the following statements about the development of mesentery is correct? (Q848808)

A. Dorsal mesentery is derived from the septum transversum.

B. Ventral mesentery gives rise to the greater omentum.

C. Dorsal mesentery extends from the lower esophagus to the rectum.

D. Ventral mesentery is continuous with the dorsal mesentery.

Correct Answer: C. Dorsal mesentery extends from the lower esophagus to the rectum.

■ *Listen (English)*

■ *Listen (Hindi)*

Explanation: Dorsal Mesentery is a collection of connective tissue that maintains the gut tube; it extends from the lower esophagus to the rectum. Mesentery: Initially, the foregut, midgut, and hindgut are in contact with the mesenchyme of the posterior abdominal wall. By the fifth week of development, the gut is suspended by the dorsal mesentery from the abdominal wall. Dorsal Mesentery: Collection of connective tissue that maintains the gut tube and its derivatives in anatomical position. It extends from the lower esophagus to the rectum, acting as a pathway for blood vessels, lymphatics and nerves to the gut tubes and their derivatives. (Option C) Its name varies based on the gut tube segment it attaches to: Dorsal mesogastrium Greater omentum (Option B) Mesoduodenum Mesentery proper (small intestine) Mesocolon Mesoappendix Mesosigmoid Mesorectum Ventral Mesentery: Derived from the septum transversum. (Option A) Growth of liver into septum divides it into: Ventral mesogastrium (lesser omentum): Extending from the stomach and most parts of the duodenum to the liver. Falciform ligament: Extending from the liver to the ventral body wall. Ventral mesentery is not continuous with the dorsal mesentery. (Option D) Derivatives of Ventral and Dorsal Mesogastrium:

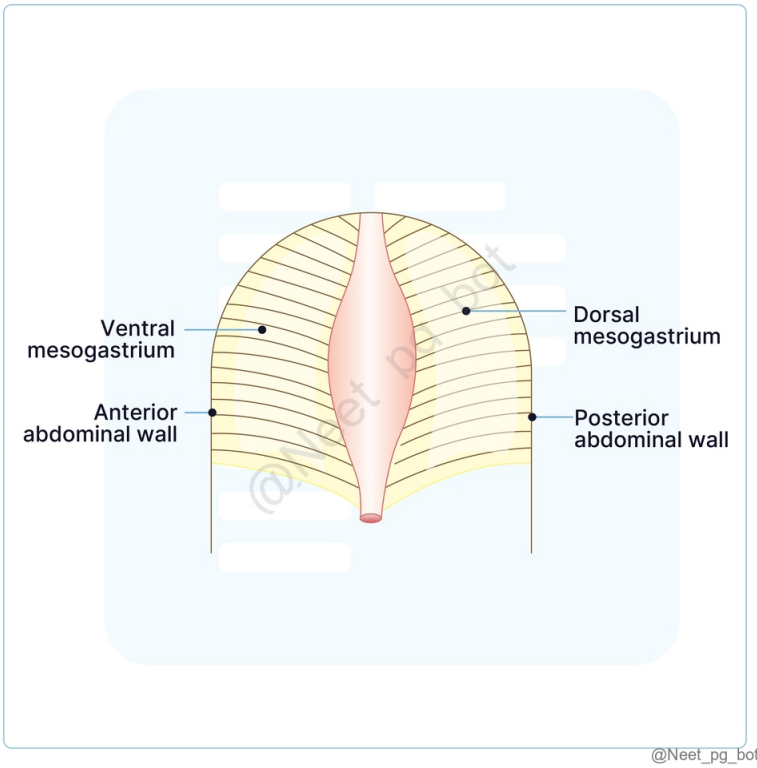

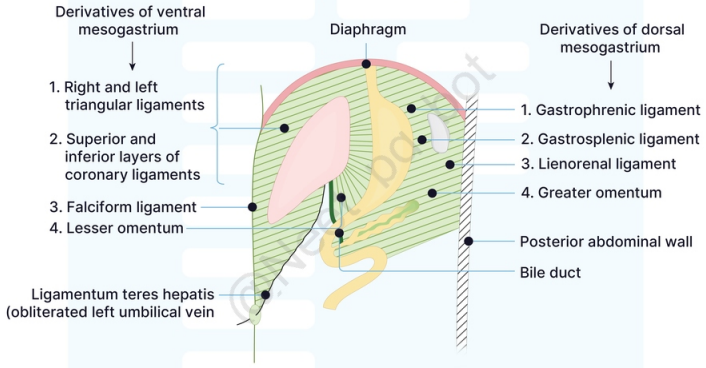

@Neet_pg_bot

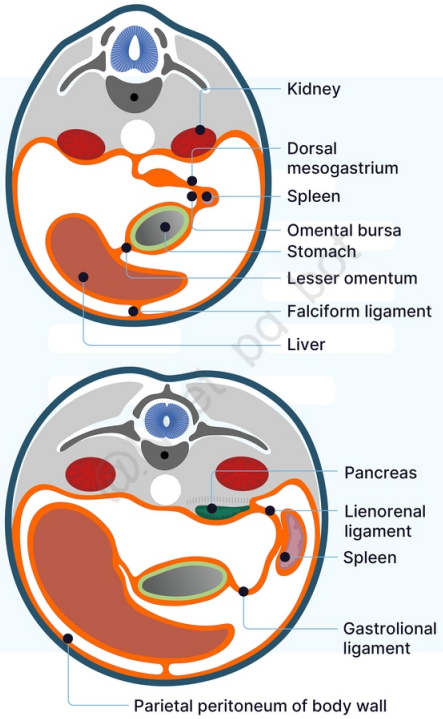

@Neet_pg_bot

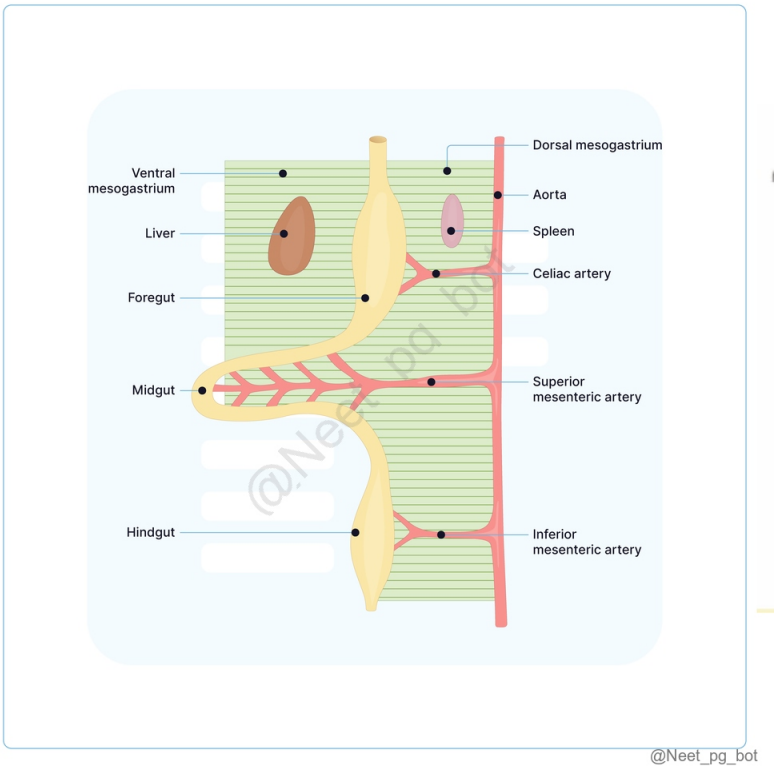

@Neet_pg_bot

References:

Langman’s Medical Embryology, 14th Edition, Page 232,233

Vishram Singh Textbook of Clinical Embryology, 2nd Edition, Page 153

↑ *Back to this question in Part A*

@Neet_pg_bot

Q17: A patient on examination and radiological imaging was found to have an absent gallbladder. Which gut tube structure is associated with this defect, and what is the primitive artery that supplies it? (Q848775)

A. Midgut, superior mesenteric artery

B. Foregut, celiac trunk

C. Midgut, celiac trunk

D. Hindgut, inferior mesenteric artery

Correct Answer: B. Foregut, celiac trunk

■ *Listen (English)*

■ *Listen (Hindi)*

Explanation: The gallbladder is derived from the foregut. The gallbladder develops as an outpouching from the hepatic diverticulum of the foregut during embryonic development. The foregut is primarily supplied by the celiac trunk, a major branch of the abdominal aorta. Foregut Extends from: Oropharyngeal membrane to the first part of the duodenum (distal to the bile duct) Derivatives: Pharynx Esophagus Stomach Proximal half of the duodenum (up to the bile duct) Liver Gallbladder Pancreas Respiratory system Arterial supply: Celiac trunk

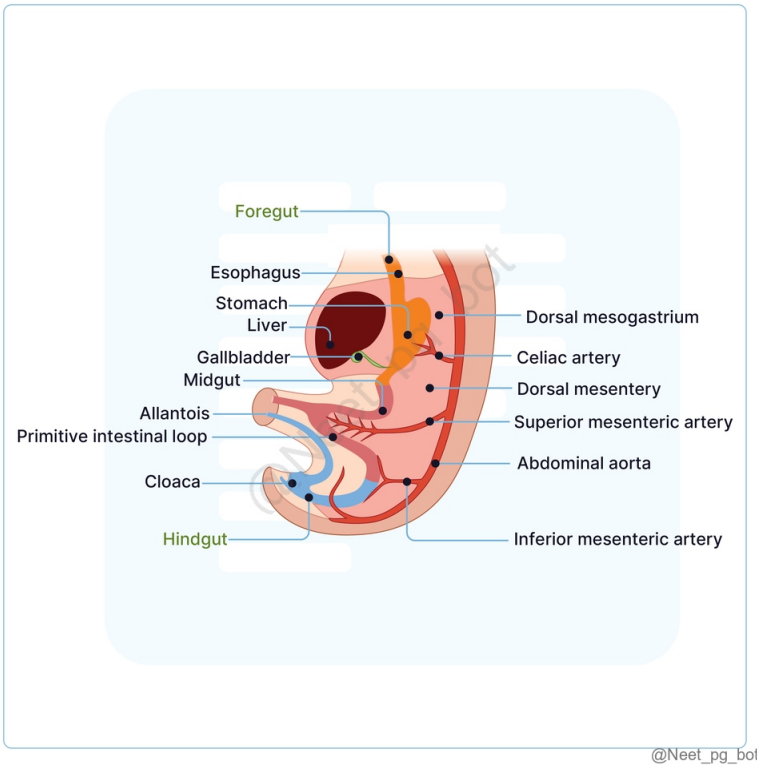

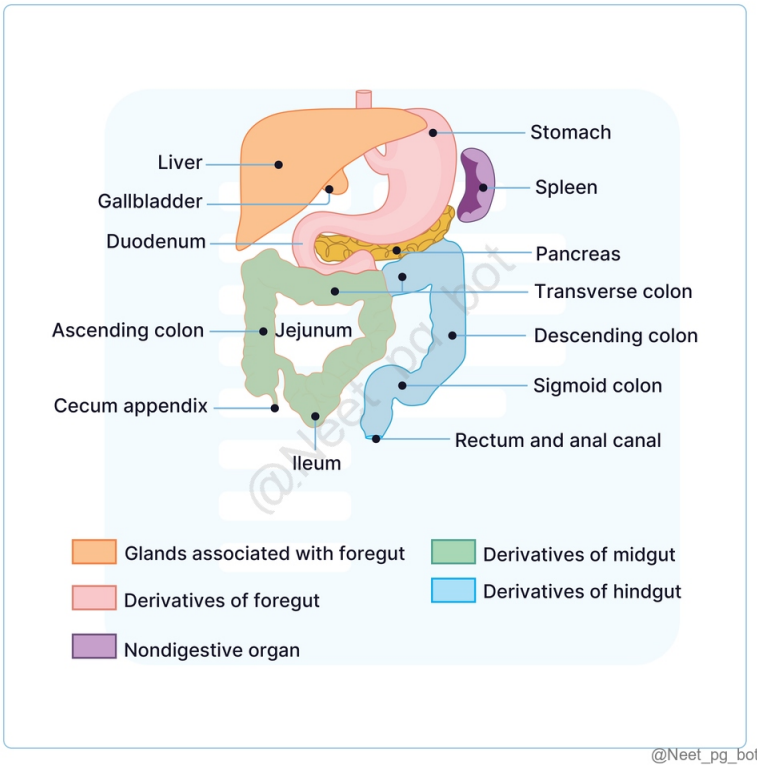

References:

Gray’s Anatomy, 42nd Edition, Page 204.

Inderbir Singh's Human Embryology, 11th Edition, Pages 174, 175, 176, 177, 178.

↑ *Back to this question in Part A*

@Neet_pg_bot

Q18: A 2-day-old infant is brought to the emergency department with severe respiratory distress. The physical examination reveals scaphoid abdomen, decreased breath sounds on the left side, and a chest X-ray shows a mediastinal shift to the right. Which type of hernia is most likely responsible for this presentation? (Q848774)

A. Morgagni hernia

B. Bochdalek hernia

C. Hiatal hernia

D. Umbilical hernia

Correct Answer: B. Bochdalek hernia

■ *Listen (English)*

■ *Listen (Hindi)*

Explanation: Given the age of the infant and the clinical presentation of severe respiratory distress, decreased breath sounds, and mediastinal shift, the most likely diagnosis is a Bochdalek hernia . It directly leads to lung compression and impaired respiratory function. Bochdalek hernia Morgagni hernia More common congenital diaphragmatic hernia (CDH) Less common CDH Often left sided Often right sided M/c site: Postero lateral M/c side: Anteromedial (retrosternal) Spleen and intestines enter the thoracic cavity. The transverse colon enters the thoracic cavity. Intestine passes through the left pleuroperitoneal membrane and makes the left lung small. The transverse colon passes through the right retrosternal space (space of Morgagni) behind the sternum but in front of the heart.



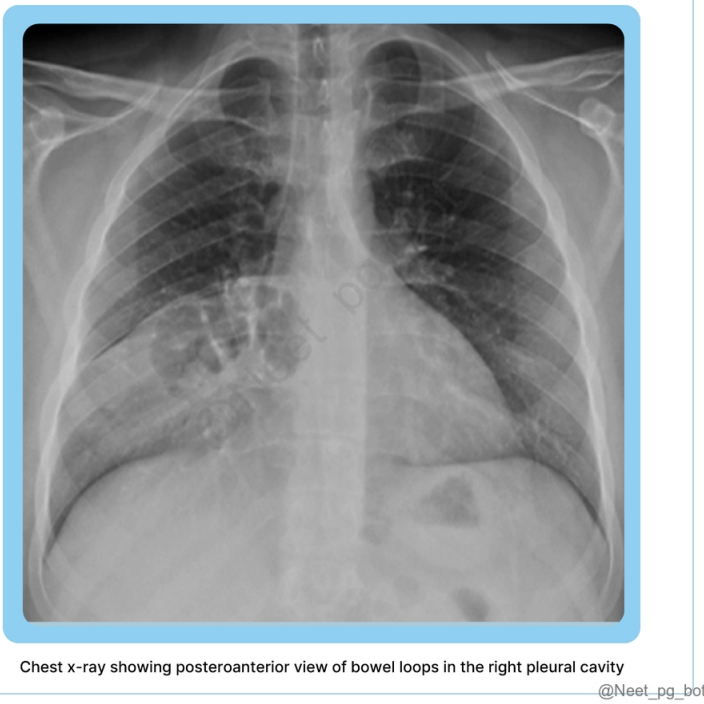

Chest x-ray showing posteroanterior view of bowel loops in the right pleural cavity

@Neet_pg_bot

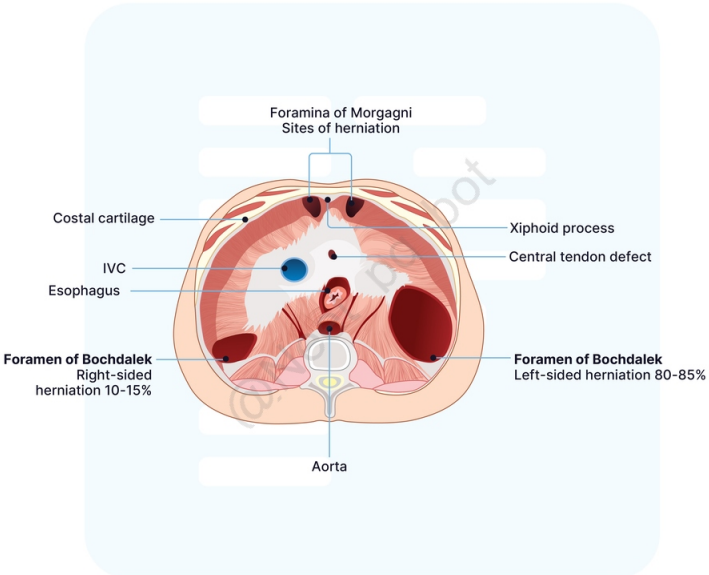

@Neet_pg_bot

References:

Gray’s Anatomy, 42nd Edition, Page 320.

↑ *Back to this question in Part A*

@Neet_pg_bot

Q19: What structures are transmitted through the marked opening of the diaphragm in the given image? (Q848773)

A. Oesophagus and gastric nerves

B. Aorta and thoracic duct

C. Inferior vena cava and right phrenic nerve

D. Inferior vena cava and left phrenic nerve



@Neet_pg_bot

Correct Answer: C. Inferior vena cava and right phrenic nerve

■ *Listen (English)*

■ *Listen (Hindi)*

Explanation: The marked opening in the above image is vena caval hiatus which contains inferior vena cava and right phrenic nerve . Major openings in the diaphragm Level of opening T8 T10 T12 Location In the central tendon In the muscular part In crus of the diaphragm Structures passing through the opening Inferior v ena cava Right phrenic nerve (Option C) (Option D) O esophagus (Option A) Right and left vagus nerve A orta (Option B)

Thoracic duct Azygous vein Hemiazygous vein

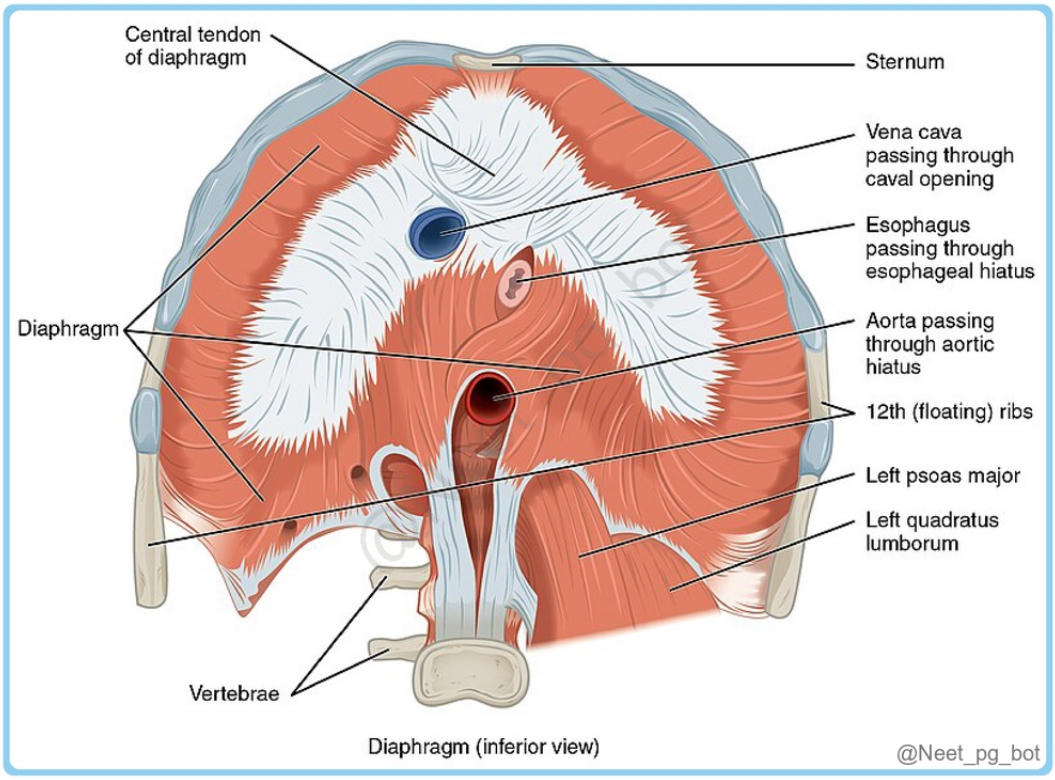

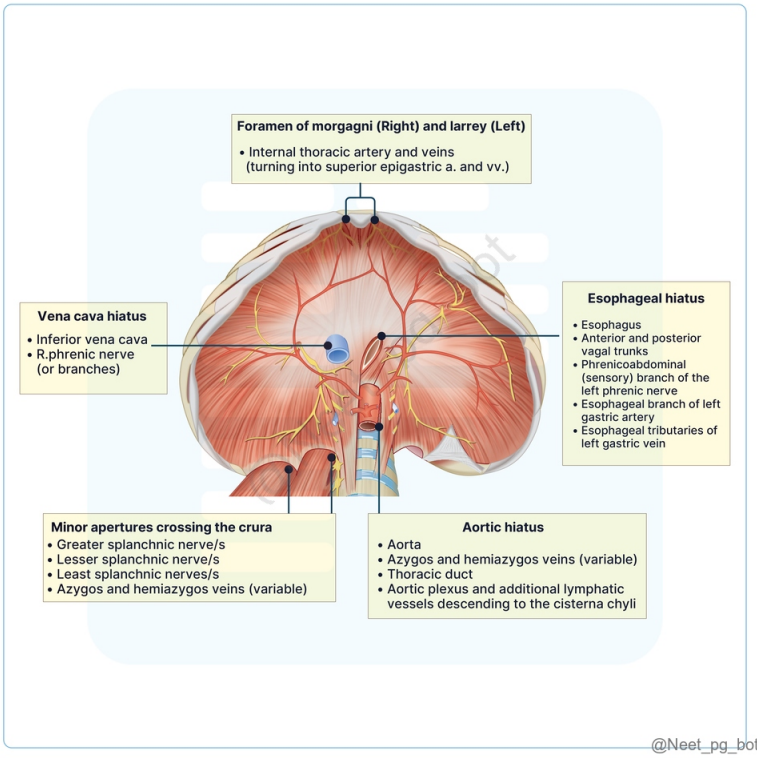

References:

BD Chaurasia's Human Anatomy, Volume 2, Page 390

↑ *Back to this question in Part A*

@Neet_pg_bot

Q20: All of the following are the derivatives of the structure labeled A in the image below, except: (Q848772)

A. Falciform ligament

B. Coronary ligament

C. Ligamentum teres

D. Lesser omentum

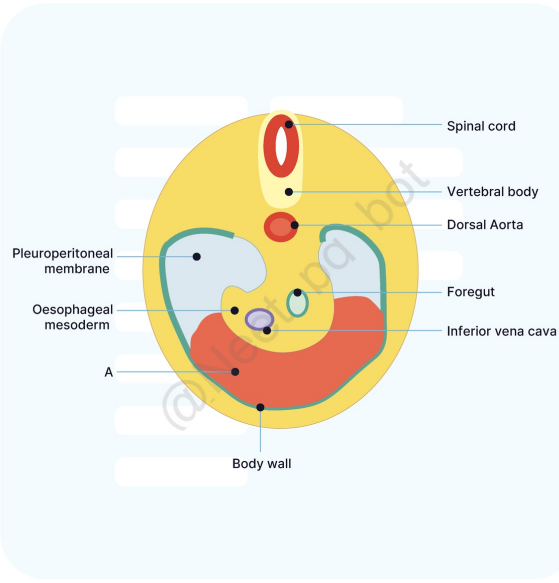

@Neet_pg_bot

Correct Answer: C. Ligamentum teres

■ *Listen (English)*

■ *Listen (Hindi)*

Explanation: Structure labeled A is septum transversum. Ligamentum teres (round ligament of the liver) is not derived from the septum transversum. It is a remnant of the left umbilical vein. Septum Transversum is a partial

barrier between the thoracic and abdominal cavities. Derivatives of the Septum Transversum 1. Central Tendon of Diaphragm (Diaphragm) 2.Portions of Liver Mesenchyme (Liver): Connective tissue stroma of the liver including Glisson’s capsule (fibrous capsule of the liver). Peritoneal coverings of liver Kupffer cells, Hemopoietic cells, sinusoids, etc 3. Ventral mesentery of the foregut. Derivatives of Ventral mesentery: Falciform ligament, Lesser omentum, Coronary ligament. (Options A, B and D) 4. Fibrous pericardium

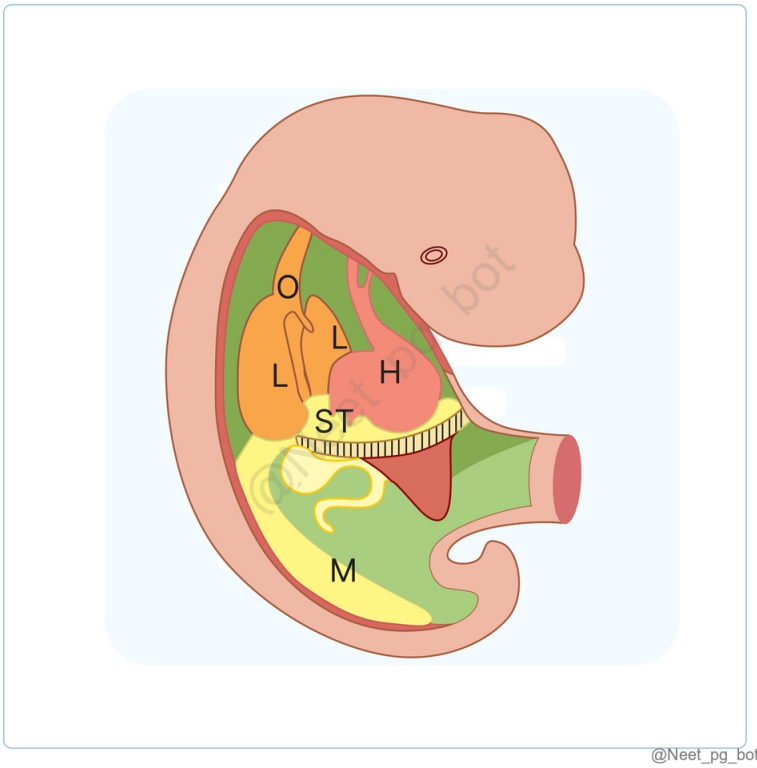

@Neet_pg_bot

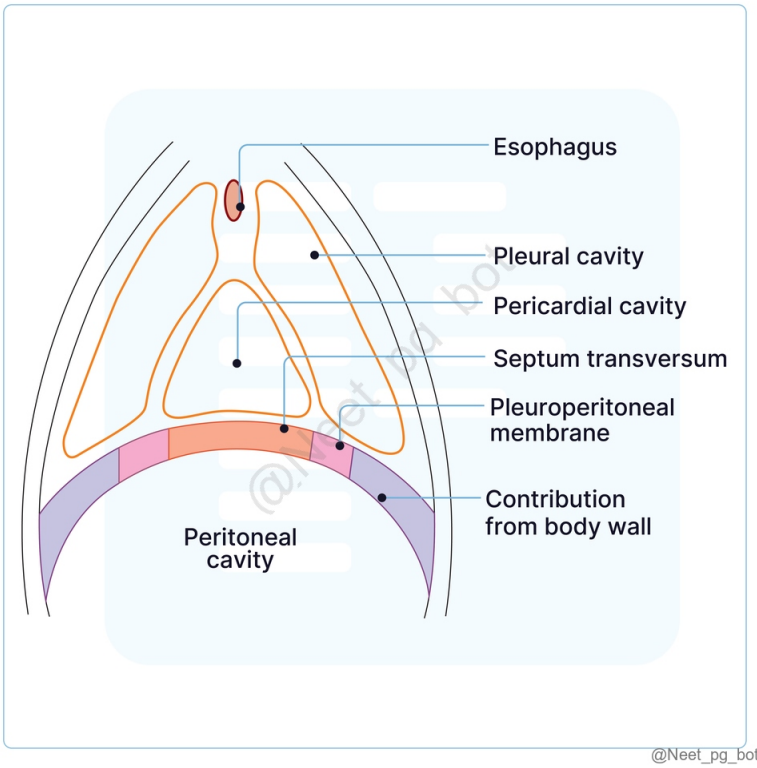

References:

Gray’s Anatomy, 42nd Edition, Page 205.

Inderbir Singh's Human Embryology, 11th Edition, Pages 212-213.

https://pubmed.ncbi.nlm.nih.gov/21294146/

↑ *Back to this question in Part A*

@Neet_pg_bot

Q21: Which of the following structures contributes to the formation of the marked part of the diaphragm (inferior view)? (Q848771)

A. Septum transversum

B. Pleuro-peritoneal membrane

C. Dorsal mesentery of esophagus

D. Mesoderm of body wall

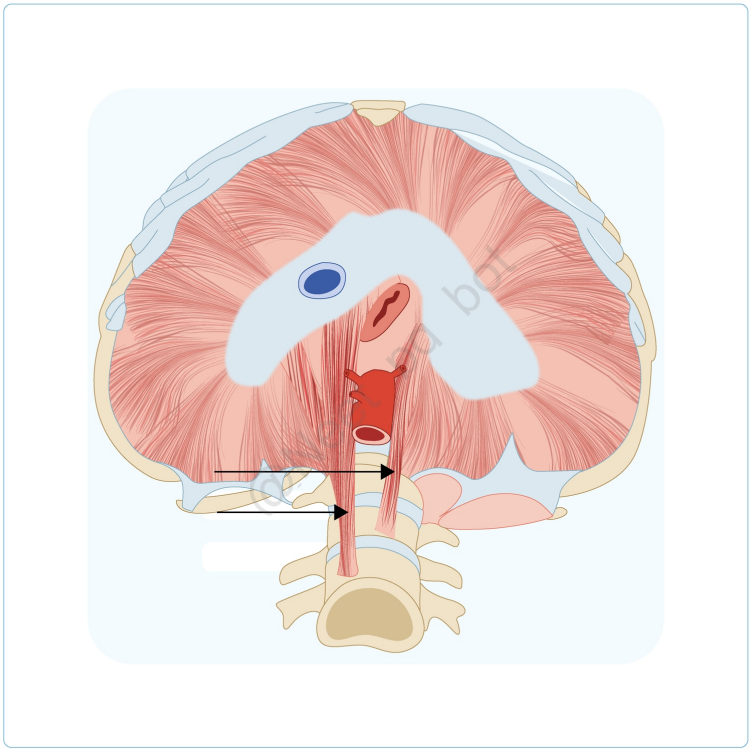

Correct Answer: C. Dorsal mesentery of esophagus

- *Listen (English)*
- *Listen (Hindi)*

Explanation: The marked part of the diaphragm corresponds to the crura of the diaphragm, which is primarily derived from the dorsal mesentery of the esophagus. Part of Diaphragm Source of Development 1. Central Tendon of Diaphragm Septum transversum 2. Small Peripheral Part Pleuroperitoneal Membrane 3. Crura of Diaphragm Dorsal Mesentery of Esophagus 4. Large Peripheral Part Mesoderm of Body Wall Structures passing through major openings of Diaphragm: Opening (Hiatus) Vertebral Level Primary Structures Passing Through Venacaval opening T8 Inferior Vena Cava Right Phrenic Nerve Oesophageal opening T10 Oesophagus Vagus Nerves Oesophageal branches of left gastric artery (LGA) (blood supply to lower part of oesophagus) Aortic opening T12 Aorta ((thoracic aorta becomes abdominal aorta at T12) Thoracic Duct Azygos Vein

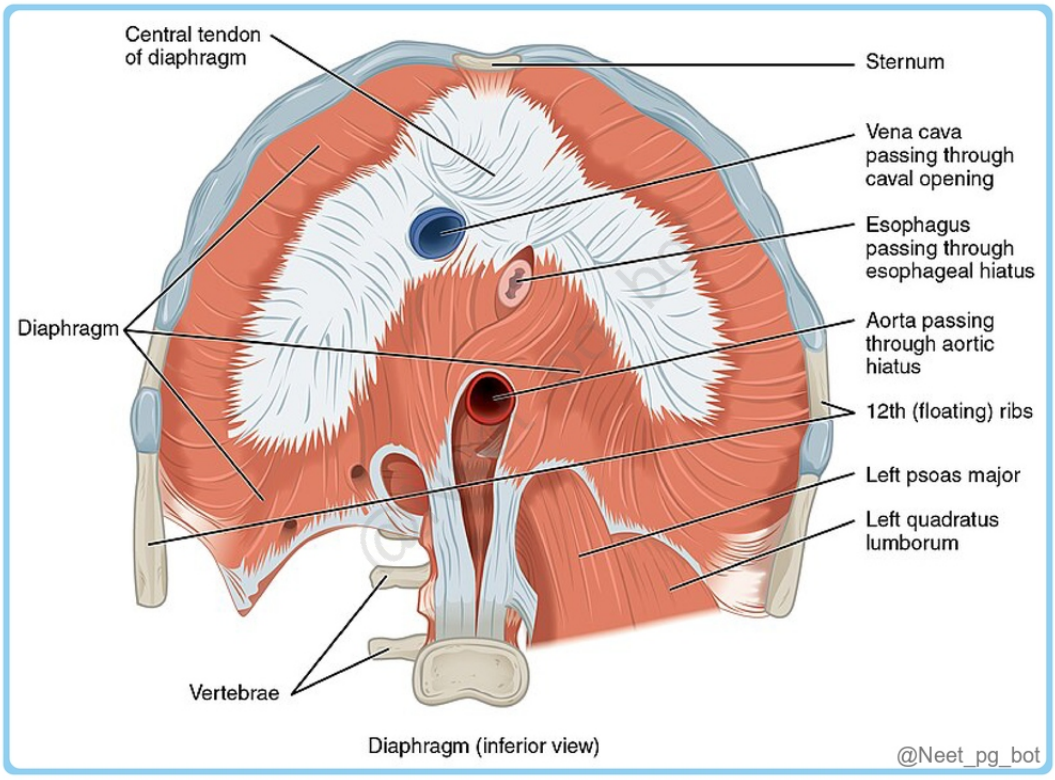

Diaphragm (inferior view)

@Neet_pg_bot

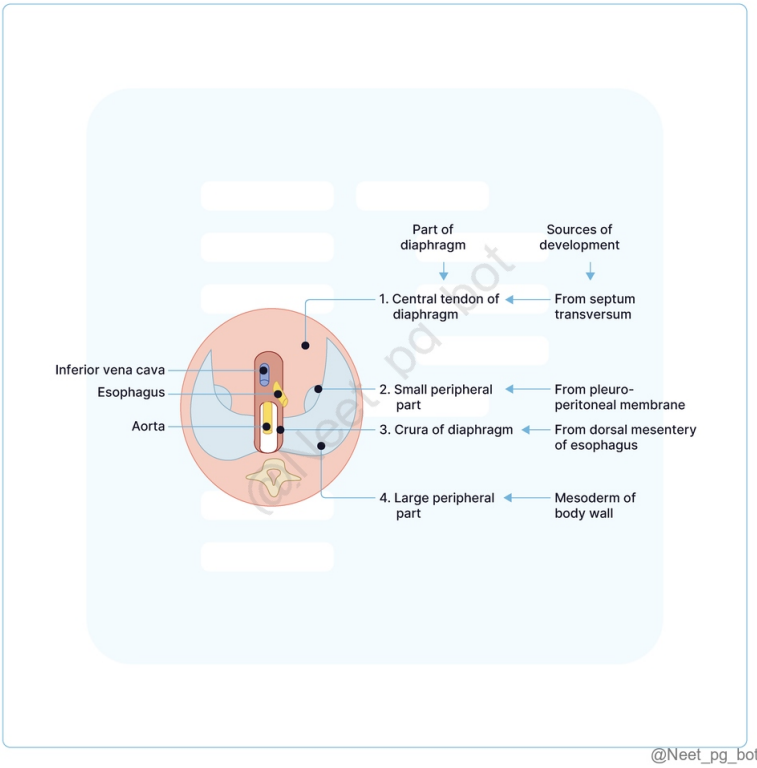

@Neet_pg_bot

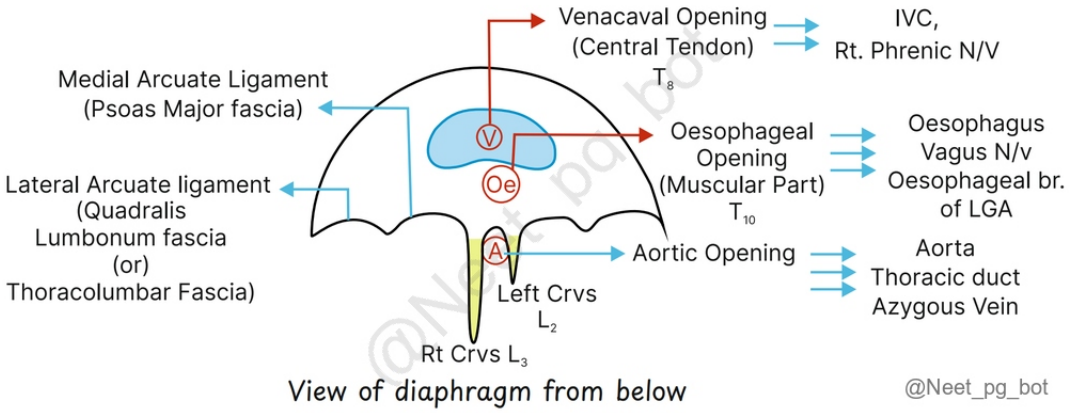

References:

Inderbir Singh's Human Embryology, 11th Edition, Page 211.

Gray’s Anatomy, 42nd Edition, Page 319.

↑ *Back to this question in Part A*

@Neet_pg_bot

Q22: Which of the following is true about gastroschisis as opposed to an omphalocele? (Q848770)

A. Has a covering of amnion around the herniated bowels

B. Is associated with chromosomal anomalies and cardiac anomalies

C. Due to the failure of the gut tube back to return into the abdomen

D. The herniated bowel loops are damaged due to amniotic fluid

Correct Answer: D. The herniated bowel loops are damaged due to amniotic fluid

■ *Listen (English)*

■ *Listen (Hindi)*

Explanation: The herniated loops of the bowel in gastroschisis are exposed as they lack any covering as in omphalocele and hence can be affected by the corrosive effect of amniotic fluid. Gastroschisis Omphalocele Definition A congenital defect where the abdominal wall fails to close, leading to herniation of intestinal loops into the amniotic cavity. M/c in premature/SGA babies A congenital ventral body wall defect where portions of the midgut fail to return to the abdominal cavity after physiological herniation. (Option C) Location of defect Right paraumbilical Central Sac Absent, bowel is exposed. Present (if not ruptured). Sac is made of amnion, Wharton's jelly and peritoneum (Option A) Description Free intestinal loops. (Liver is not usually herniated) Firm mass including liver, intestine and/ other organs (like stomach, spleen) Umbilical cord Adjacent to the defect Attached

to the sac Associated anomalies Associated anatomic defects are uncommon Associated abnormalities are common and include: Neural tube defect Cardiac abnormalities (Option B) Chromosomal defect Detection Identified through fetal ultrasound. Elevated alpha-fetoprotein (AFP) levels in maternal serum and amniotic fluid. Elevated alpha-fetoprotein (AFP) concentrations in maternal serum and amniotic fluid, similar to gastroschisis. Prognosis Favorable High mortality rates Image Fig: Omphalocele

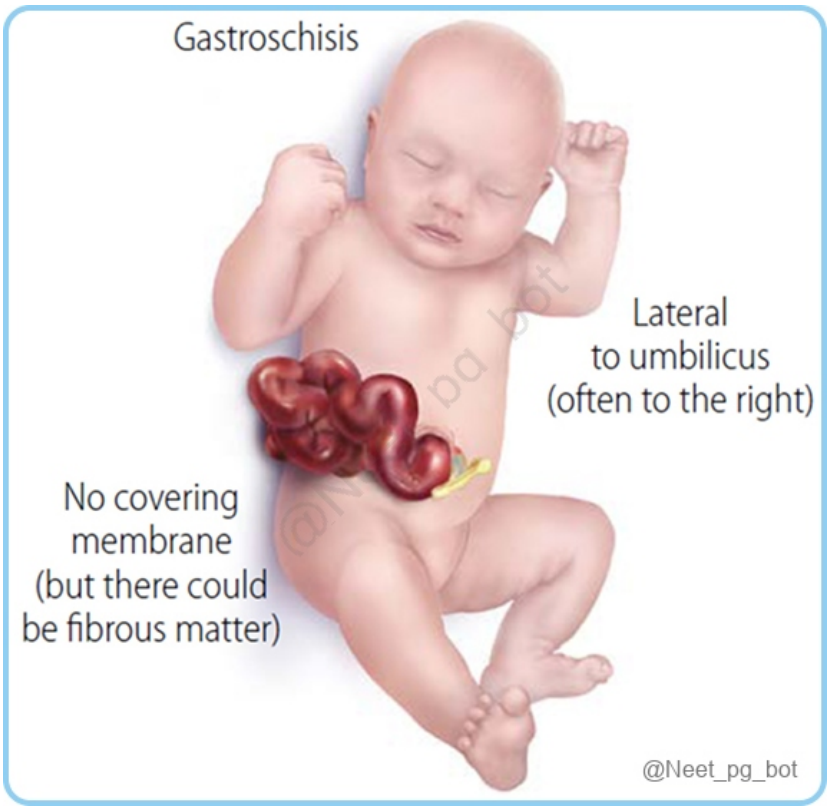

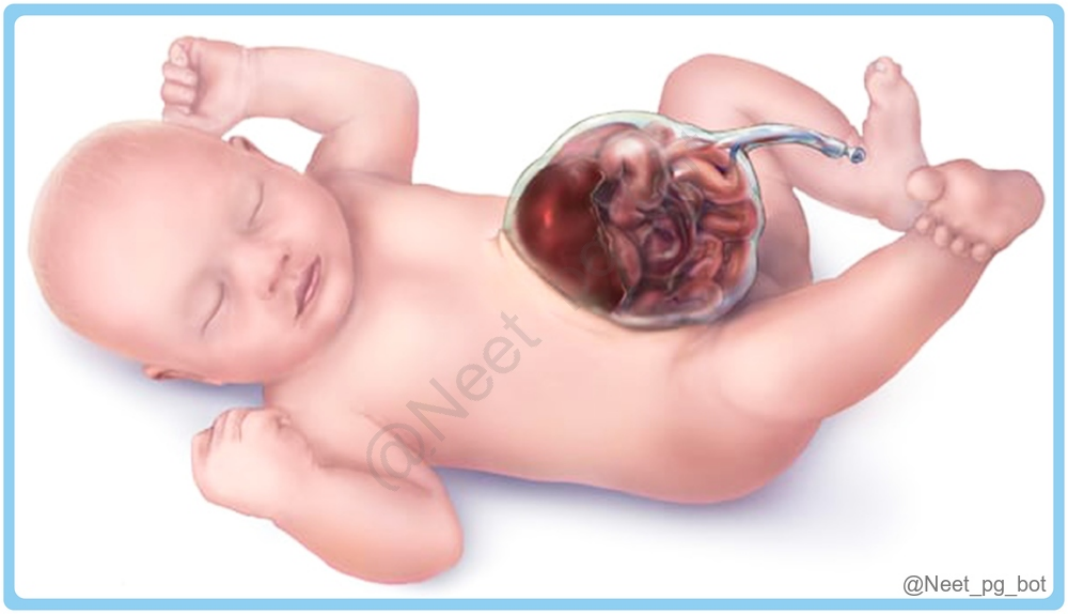

References:

Langman’s Medical Embryology, 14th Edition, Page 100.

https://www.ncbi.nlm.nih.gov/books/NBK519010/#

↑ *Back to this question in Part A*

@Neet_pg_bot

Q23: A neonate presents with dribbling of urine from the umbilicus. Which of the following statements is true regarding the affected structure? (Q848769)

A. Persistence of a small area of allantois

B. The lumen of the upper part of the urachus persists

C. Forms a cystic dilation due to secretions from the lining

D. Persistence of intraembryonic part of allantois

Correct Answer: D. Persistence of intraembryonic part of allantois

■ *Listen (English)*

■ *Listen (Hindi)*

Explanation: Dribbling of urine from the umbilicus is a finding in cases of urachal fistula. It is caused by the persistence of the intraembryonic portion of the allantois. Urachus is formed by fibrosis of the distal part of the allantoic diverticulum. Its proximal part joins the apex of the urinary bladder. Urachal anomalies lead to bladder defects like: Urachal fistula Caused by the persistence of the intraembryonic portion of allantois. Causes urine to drain from the umbilicus. Urachal cyst When only a small area of the allantois persists. (Option A) The secretory action from the lining results in a cystic dilation. (Option C) Urachal sinus When the lumen of the upper part persists and forms a sinus. (Option B) Usually continuous with the urinary bladder.

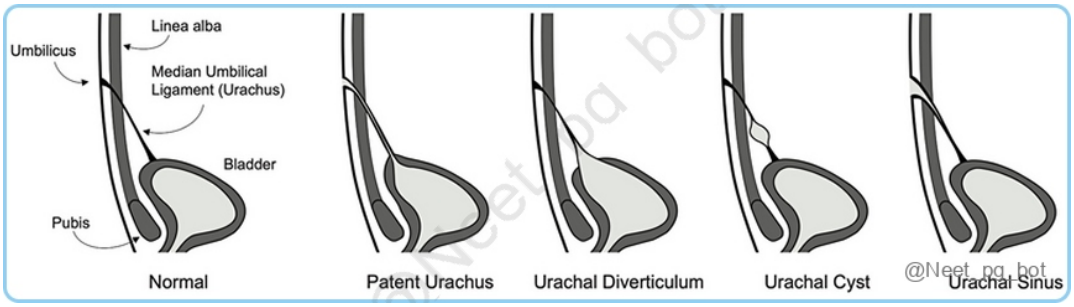

References:

Langman’s Medical embryology, 14th Edition, Page 249, 266.

Inderbir Singh’s Human Embryology, 11th Edition, Page 91.

↑ *Back to this question in Part A*

Q24: A newborn is scheduled for surgery after presenting with fecal discharge from the umbilicus. An intraoperative image is shown below. What is the most likely diagnosis? (Q848768)

A. Meckel’s diverticulum

B. Vitelline fistula

C. Vitelline sinus

D. Vitelline cyst

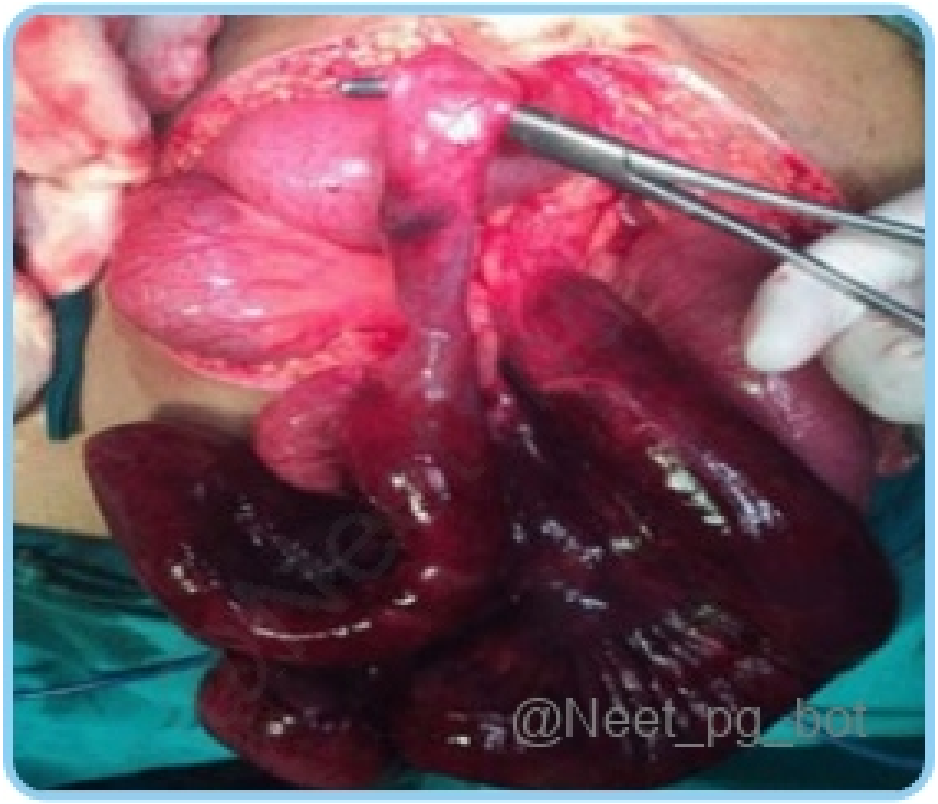

Correct Answer: B. Vitelline fistula

- *Listen (English)*
- *Listen (Hindi)*

Explanation: Newborn exhibiting fecal discharge from the umbilicus , along with intraoperative finding of vitelline duct joining umbilicus to small intestine point towards diagnosis of vitelline fistula or umbilical fistula . Vitelline duct The midgut during the early embryonic period communicates with the extraembryonic part of the yolk sac via the vitellointestinal duct or omphalomesenteric duct . It's involved in nutrient transfer and hematopoiesis It

disappears by the 5th week of development , and if it persists, it leads to the following anomalies: Vitelline duct anomalies Meckel’s diverticulum (Option A) It is the persistent proximal part of the embryonic Vitello intestinal duct. Key features: It occurs in about 2% of the population. Its length is around 2 inches (5 cm). It is located 2 feet (60 cm) proximal to the ileocecal junction . It is more common in males . Its wall structure and caliber resemble that of the ileum . It is a true diverticulum containing all the layers of ileum. The apex may be free or connected to the umbilicus by a fibrous band. It attaches to the antimesenteric border of the ileum. It can contain ectopic gastric mucosa and pancreatic tissue . Generally asymptomatic, but it can cause: Intestinal obstruction. Ulceration and bleeding if ectopic gastric mucosa or pancreatic tissue is present, mimicking acute abdomen. Symptoms resembling acute appendicitis when inflamed. Vitelline fistula (Option B) If the vitelline duct remains patent, it creates a direct connection between the umbilicus and the intestinal tract . This condition is called an umbilical fistula or vitelline fistula. It can lead to fecal discharge from the umbilicus. Vitelline sinus (Option C) If the distal segment of the vitelline duct remains patent, it can lead to the development of an umbilical sinus Vitelline cyst (Option D) When both ends of the vitelline duct become fibrous cords and the middle portion forms a large cyst, known as an enterocystoma or vitelline cyst. Fibrous cords can cause intestinal obstruction, strangulation, or volvulus.

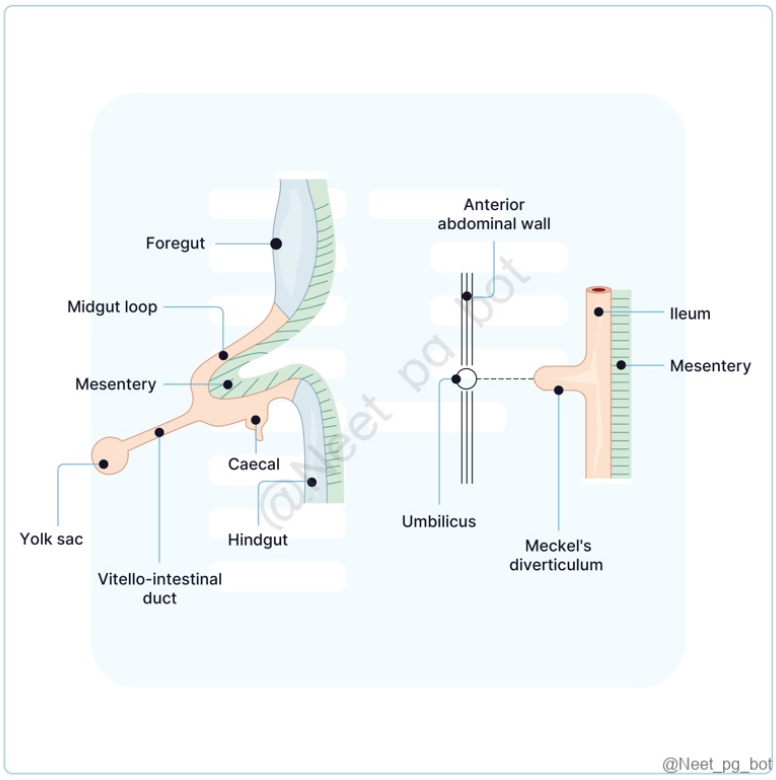

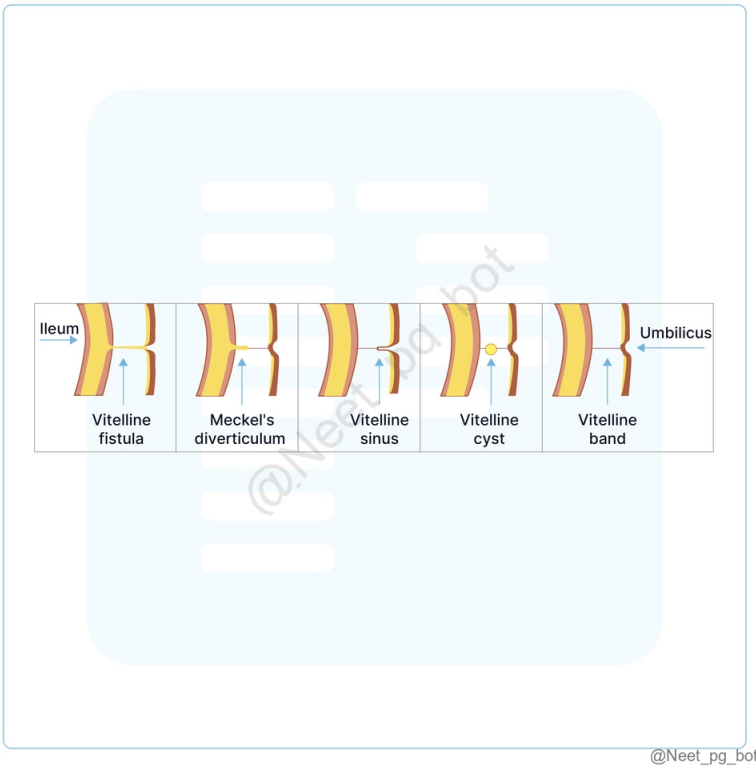

@Neet_pg_bot

References:

Vishram Singh textbook of anatomy, 2nd Edition, Page 148

Langman’s Medical Embryology, 14th Edition, Page 249

↑ *Back to this question in Part A*

@Neet_pg_bot

• [08_Abdomen] 038 Inguinal And Femoral Anatomy And Hernia Abdominal Wall Layers Peritoneal Cavity

« Back to Folder Directory

[08_Abdomen] 038 Inguinal And Femoral Anatomy And Hernia Abdominal Wall Layers Peritoneal Cavity — Quick Jump

Q1 (p. 1890) *Q2 (p. 1892)* *Q3 (p. 1892)* *Q4 (p. 1894)* *Q5 (p. 1895)* *Q6 (p. 1897)*
Q7 (p. 1898) *Q8 (p. 1900)* *Q9 (p. 1902)* *Q10 (p. 1903)* *Q11 (p. 1905)* *Q12 (p. 1907)*
Q13 (p. 1909) *Q14 (p. 1910)*

Q1: A 6-month-old boy is brought to the clinic by his parents due to a mass noticed in his right groin. An ultrasound confirms that it is an undescended testis, located just at the superficial inguinal ring Based on the normal developmental timeline of testicular descent, at which intrauterine period should the testis have normally reached the deep inguinal ring? (Q848777)

A. 8th week of gestation

B. 3rd month of gestation

C. 5th month of gestation

D. 7th month of gestation

Correct Answer: C. 5th month of gestation

■ *Listen (English)*

■ *Listen (Hindi)*

Explanation: The testis should have reached the deep inguinal ring by 5 months of gestation . Descent of testis: The developing testis is located in the upper abdomen, medial to the mesonephros during early intrauterine life, The processus vaginalis (peritoneal fold), extends in front of the testis toward the scrotum. Gubernaculum testis , a fibromuscular band, forms, connecting the mesonephric duct and the lower pole of the testis to the scrotum. The descent of the testis is driven by differential growth in the embryo, beginning in the 2nd month of intrauterine life. The normal timeline of testicular descent: 2nd month of gestation: The testis starts its descent from the posterior abdominal wall. 3rd month of gestation: The testis reaches the iliac fossa . (Option B) 4th to 6th month of gestation: The testis descends further and rests at the deep inguinal ring during this period. 7th month of gestation: The testis traverses the inguinal canal. (Option D) 8th month of gestation: The testis reaches the superficial inguinal ring. (Option A) 9th month of gestation: The testis enters the scrotum At or just after birth: reaches the base of the scrotum. Fig: Descent of testis

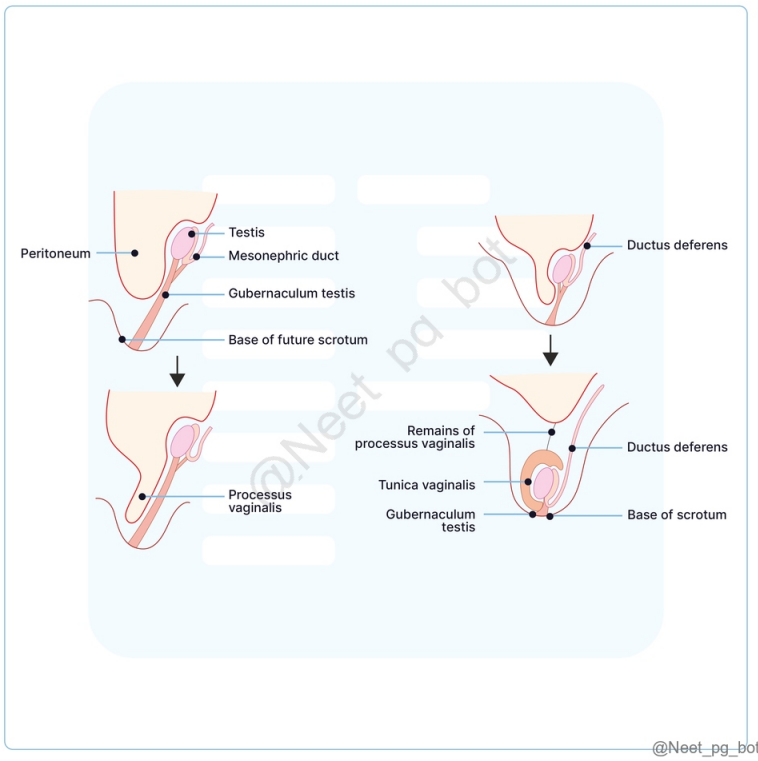

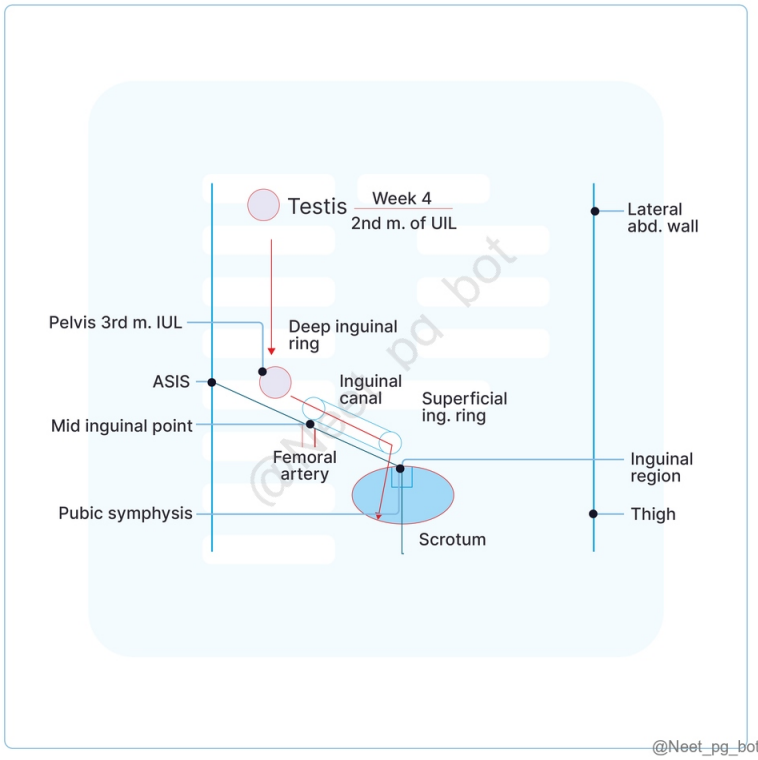

References:

Vishram Singh Textbook of Anatomy, Vol 2, Page. 71

↑ *Back to this question in Part A*

@Neet_pg_bot

Q2: Which of the following statements is FALSE regarding the peritoneal cavity? (Q848804)

A. The abdominal cavity is divided into supracolic and infracolic compartments.

B. The supracolic compartment is further divided into subphrenic spaces.

C. The infracolic compartment is divided into right and left parts by the falciform ligament.

D. The right paracolic gutter lies along the lateral side of the ascending colon.

Correct Answer: C. The infracolic compartment is divided into right and left parts by the falciform ligament.

■ *Listen (English)*

■ *Listen (Hindi)*

Explanation: The infracolic compartment is divided into right and left parts by the mesentery, not the falciform ligament. Peritoneal Cavity Peritoneal cavity is divided into two parts (Option A ruled out) Abdominal cavity Pelvic cavity Abdominal Cavity Divisions: Divided by the transverse colon and transverse mesocolon into: Supracolic Compartment: Subdivided into subphrenic spaces by peritoneal reflection around the liver. (Option B ruled out) Infracolic Compartment: Subdivided into right and left parts by the mesentery. Paracolic Gutters: Right Paracolic Gutter: Lateral side of the ascending colon. (Option D ruled out) Left Paracolic Gutter: Lateral side of the descending colon. Pelvic Cavity divisions: True Pelvis (Lesser Pelvis): The lower part that lies below the pelvic brim and contains the pelvic organs. Contents: Urinary bladder Reproductive organs (e.g., uterus, ovaries in females; prostate, seminal vesicles in males) Rectum and anal canal False Pelvis (Greater Pelvis): The upper part, technically part of the abdominal cavity but supports the intestines and provides some protection to pelvic organs.

References:

Grays anatomy 42nd Edition. Page. 1157

BD Chaurasia. Volume 2. 8th Edition. Page 284, 285

↑ *Back to this question in Part A*

@Neet_pg_bot

Q3: A 14-year-old girl presents with a mass in the right groin that is suspected to be an ovary. Imaging confirms that her ovary has been drawn into the inguinal canal.

Which structure is most likely responsible for the abnormal descent of the ovary into the inguinal canal? (Q848778)

A. Round ligament of the uterus

B. Suspensory ligament of the ovary

C. Broad ligament of the uterus

D. Uterosacral ligament

Correct Answer: A. Round ligament of the uterus

- *Listen (English)*
- *Listen (Hindi)*

Explanation: The ovary develops in the abdominal cavity from a genital ridge (formed from thickened coelomic epithelium) on the posterior abdominal wall, covering the mesonephros. It receives primordial germ cells from the yolk sac and then descends into the pelvis. During normal development, the descent is influenced by The gubernaculum (which later forms the round ligament of the ovary and the uterus) and The processus vaginalis , an evagination of the peritoneum. In rare cases, the ovary may follow the round ligament and be drawn into the inguinal canal. This condition, known as imperfect descent of the ovary , can present clinically as a groin mass. Suspensory ligament of the ovary (Option B): The suspensory ligament attaches the ovary to the lateral pelvic wall and contains the ovarian vessels. It is not involved in guiding the descent of the ovary into the inguinal canal. Broad ligament of the uterus (Option C): The broad ligament is a peritoneal fold that supports the uterus, fallopian tubes, and ovaries, but it is not responsible for pulling the ovary into the inguinal canal. Uterosacral ligament (Option D): This ligament connects the uterus to the sacrum and helps maintain the position of the uterus. It plays no role in the descent of the ovary.

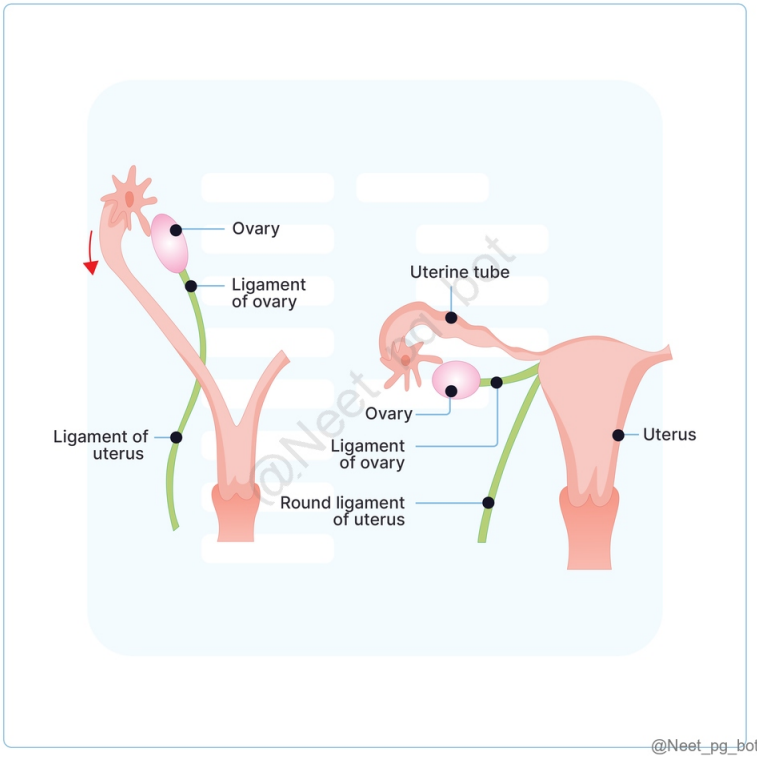

References:

Vishram Singh Textbook of Anatomy, Vol 2, Page. 263, 264

Snell's Clinical Anatomy by Regions, 10th Edition, Page. 460

↑ *Back to this question in Part A*

@Neet_pg_bot

Q4: Which of the following structures is NOT found in the spermatic cord? (Q848779)

A. Vas deferens

B. Testicular artery

C. Epididymis

D. Pampiniform plexus

Correct Answer: C. Epididymis

■ *Listen (English)*

■ *Listen (Hindi)*

Explanation: Epididymis is the structure where sperm mature and are stored but is not part of the spermatic cord; it is located on the surface of the testis. The spermatic cord is a collection of structures that pass to and from the testis through the inguinal canal. It extends from the deep inguinal ring to the posterior border of the testis and is covered by three fascial layers. Contents of the spermatic cord: Ductus deferens, in the posterior part (Option A) Three arteries: Testicular artery, from abdominal aorta (Option B) Cremasteric artery, from the inferior epigastric artery. Artery to ductus deferens, from inferior vesical artery The pampiniform venous plexus (Option D) Lymphatics, especially from testis draining into pre- and para-aortic nodes, and some from the coverings draining into external iliac nodes. Nerves: Genital branch of the genitofemoral nerve, and sympathetic fibers accompany the arteries. Remains of processus vaginalis Fig: Transverse section of the spermatic cord

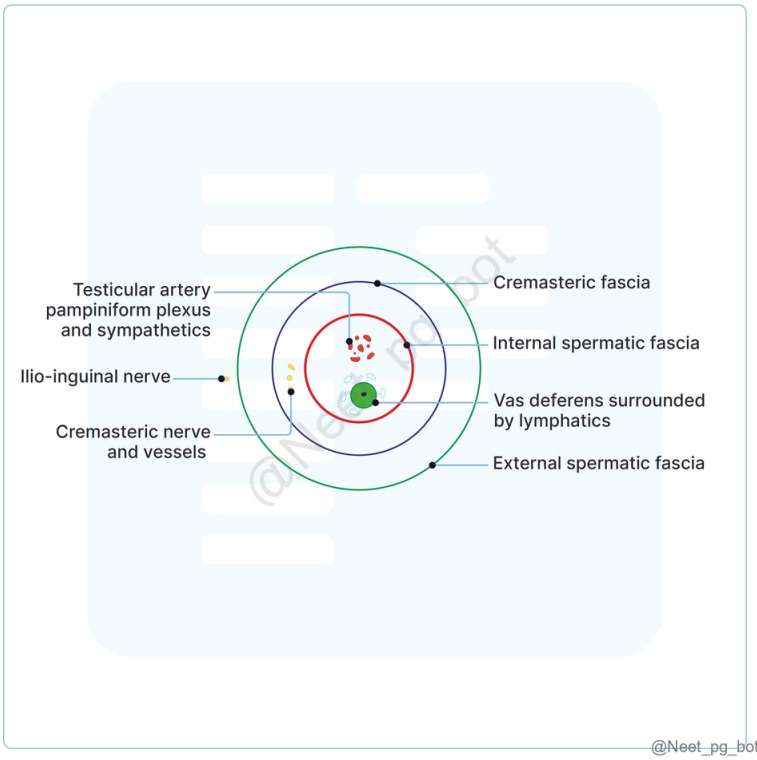

References:

Vishram Singh Textbook of Anatomy, Abdomen and lower-limb, Volume 2, 2nd Edition, Pages 51-53

↑ *Back to this question in Part A*

@Neet_pg_bot

Q5: What is the correct order of the layers of the anterior abdominal wall from superficial to deep? (Q848780)

A. Skin → Scarpa fascia → Internal oblique → External oblique → Transversalis fascia → Transversus abdominis → Peritoneum

B. Skin → Transversalis fascia → Internal oblique → External oblique → Transversus abdominis → Scarpa fascia → Peritoneum

C. Skin → Scarpa fascia → External oblique → Internal oblique → Transversus abdominis → Transversalis fascia → Peritoneum

D. Skin → External oblique → Scarpa fascia → Internal oblique → Transversus abdominis → Transversalis fascia → Peritoneum

Correct Answer: C. Skin → Scarpa fascia → External oblique → Internal oblique → Transversus abdominis → Transversalis fascia → Peritoneum

■ *Listen (English)*

■ *Listen (Hindi)*

Explanation: The most superficial layer is the skin. Deep to the skin is the superficial fascia, which has two layers. a. Camper fascia is called a fatty layer of subcutaneous tissue. b. Scarpa fascia is called the membranous layer of subcutaneous tissue. Muscles of the anterior abdominal wall a. External oblique muscle. b. Internal oblique muscle c. Transversus abdominis muscle TransversaIis fascia Extraperitoneal fat Parietal peritoneum.

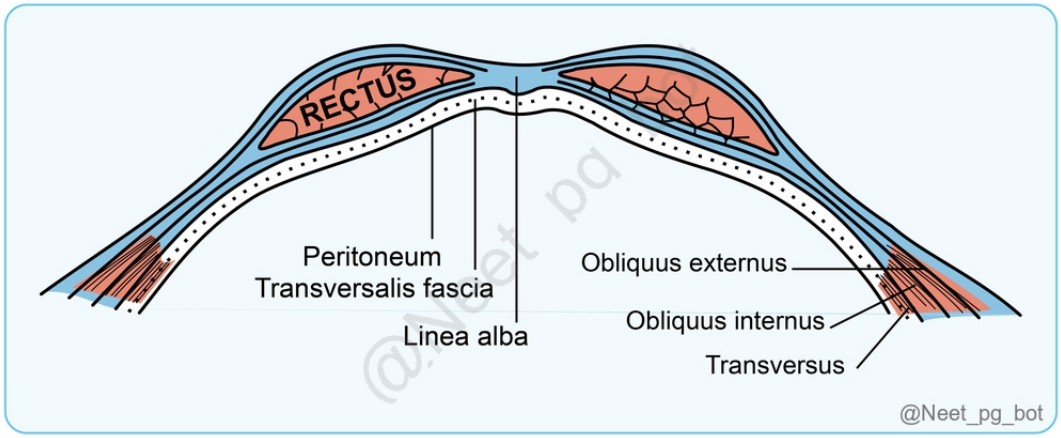

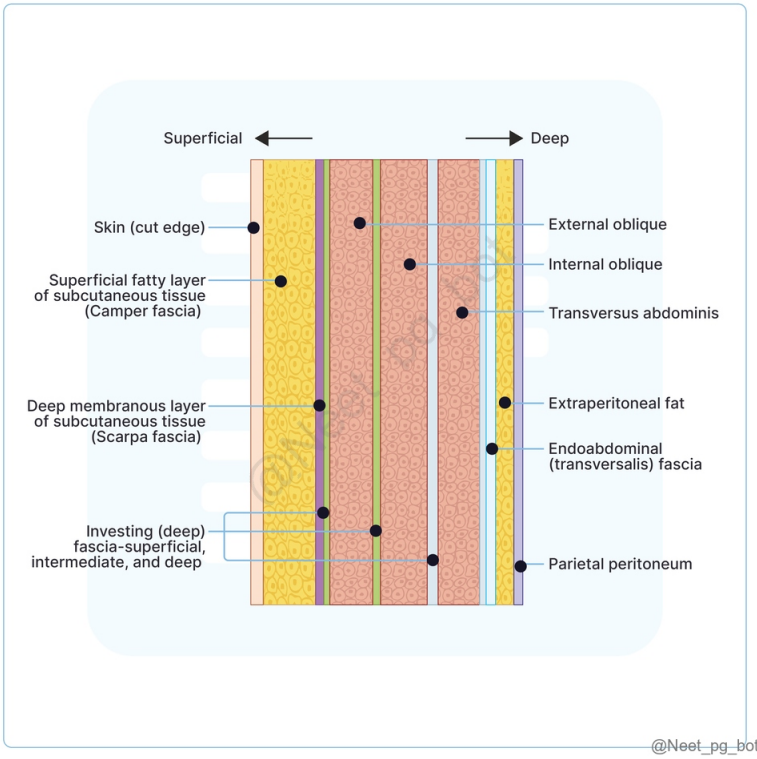

References:

Vishram Singh Textbook of Anatomy, Abdomen and lower-limb, Volume 2, Page. 27

↑ *Back to this question in Part A*

@Neet_pg_bot

Q6: At which level does the rectus sheath become entirely anterior to the rectus abdominis muscle due to absence of the posterior sheath? (Q848781)

A. At the level of the xiphoid process

B. At the level of umbilicus

C. Below the arcuate line

D. None of the above

Correct Answer: C. Below the arcuate line

■ *Listen (English)*

■ *Listen (Hindi)*

Explanation: Below the arcuate line, all three aponeuroses—external oblique, internal oblique, and transversus abdominis—pass anterior to the rectus abdominis, leaving no posterior rectus sheath. Fig: Rectus sheath at different levels The formation of rectus sheath differs from the above downward as follows: 1. Above the level of costal margin: The anterior wall is formed by the aponeurosis of the external oblique only. The posterior wall is deficient and muscle lies directly on the 5th, 6th, and 7th costal cartilage. 2. Between costal margin and arcuate line: Anterior wall is formed by the fusion of aponeurosis of external oblique with the anterior lamina of aponeurosis of internal oblique. The posterior wall is formed by the fusion of aponeurosis of the transversus abdominis with the posterior lamina of the aponeurosis of the internal oblique. 3. Below the level of the arcuate line: The anterior wall is formed by the aponeuroses of all three flat muscles (the aponeuroses of transversus abdominis and internal oblique are fused but the aponeurosis of external oblique remains separate). The posterior wall is deficient. At the level of the xiphoid process (Option A) : Above this level, the rectus sheath is made up of both the anterior and posterior layers formed by the aponeuroses of the abdominal muscles. At the level of the umbilicus (Option B) : Here, the rectus sheath still has anterior and posterior layers, but the arrangement starts to change as you move downward.

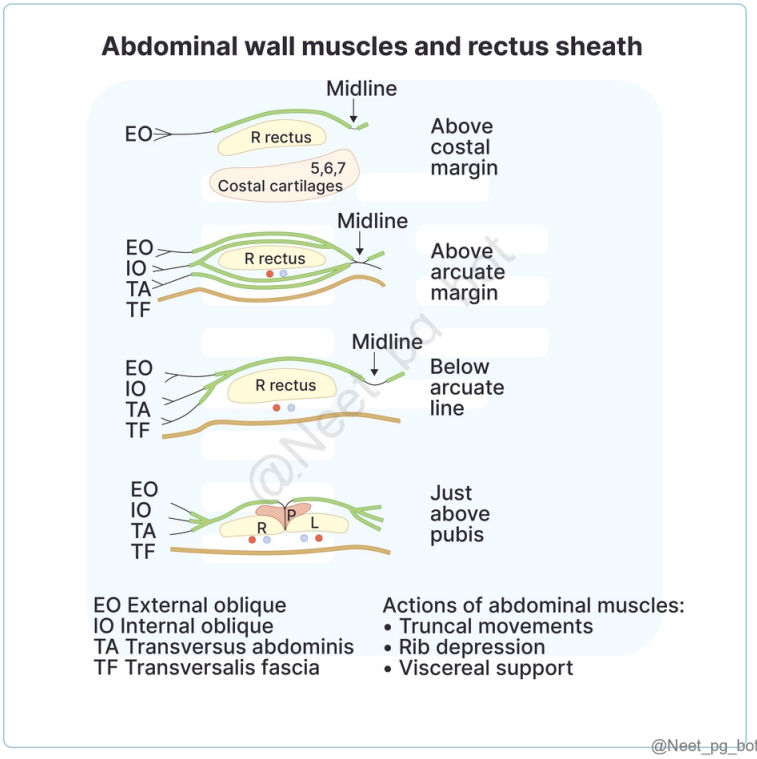

References:

Vishram Singh Textbook of Anatomy, Abdomen and lower-limb, Volume 2, Page. 39

↑ *Back to this question in Part A*

@Neet_pg_bot

Q7: Which of the following statements about the inguinal canal is false? (Q848782)

A. The posterior wall of the inguinal canal is formed by the transversalis fascia.

B. The inguinal canal contains the ilioinguinal nerve.

C. The aponeurosis of the external oblique muscle forms the roof of the inguinal canal.

D. In males, the inguinal canal contains the spermatic cord.

Correct Answer: C. The aponeurosis of the external oblique muscle forms the roof of the inguinal canal.

■ *Listen (English)*

■ *Listen (Hindi)*

Explanation: The roof of the inguinal canal is formed by the arching fibers of the internal oblique and the transversus abdominis muscles , not the external oblique aponeurosis. The inguinal canal is a passageway in the lower abdominal wall. Contents of inguinal canal: In males: Spermatic cord and ilioinguinal nerve (Options B and D) In females: Round ligament of the uterus and ilioinguinal nerve (Option B) The boundaries of the inguinal canal are: Anterior wall: It is formed from superficial to deep by: Skin Superficial fascia in the whole extent. External oblique aponeurosis Internal oblique muscle fibers, in lateral one-third. Posterior wall: It is formed from deep to superficial by: Fascia transversalis, in the whole extent (Option A) Conjoint tendon, in medial two-third Reflected part of the inguinal ligament, in the medial-most part. Roof: It is formed by the lower arched fibers of the internal oblique and transversus abdominis muscles. Floor: It is formed by: Grooved upper surface of the inguinal ligament in the whole extent Abdominal surface of the lacunar ligament at the medial end.

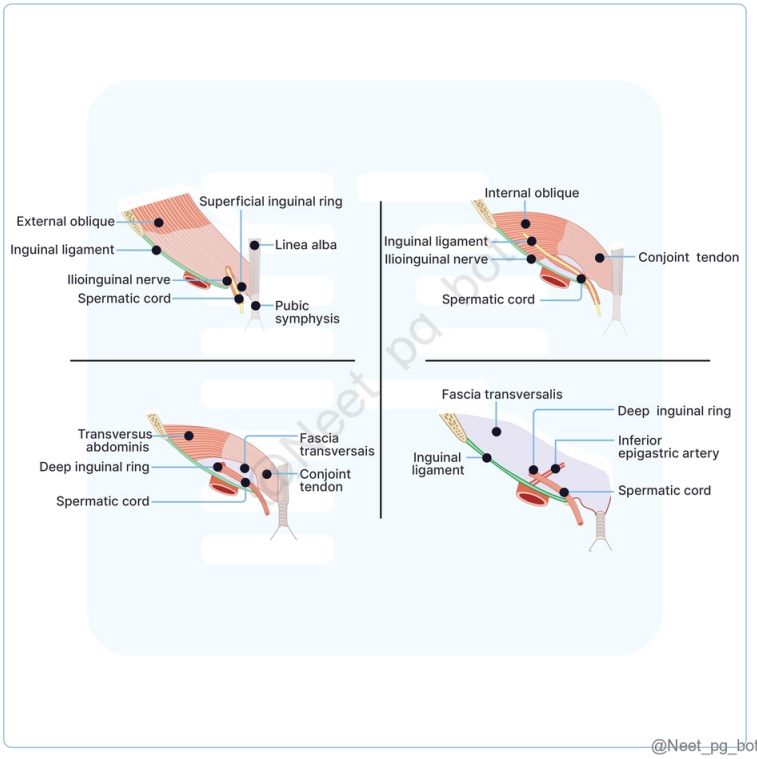

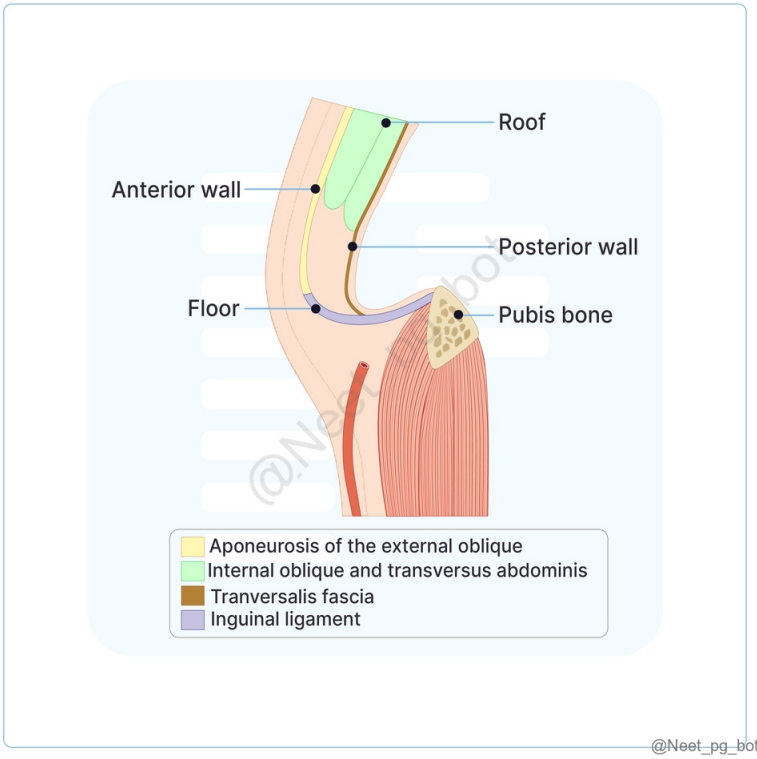

References:

Vishram Singh Textbook of Anatomy, Abdomen and lower-limb, Volume 2, 2nd Edition, Pages 50-51

↑ *Back to this question in Part A*

@Neet_pg_bot

Q8: A 45-year-old male presents with a swelling in the right inguinal region that increases in size on coughing or standing. Upon examination, a diagnosis of indirect inguinal hernia is made, and surgical repair is planned. While preparing for the surgery, the anatomical relations of the inguinal canal are reviewed. Which of the following correctly describes the anatomical relations of the inguinal canal? (Q848783)

A. The posterior wall of the inguinal canal is formed by the transversalis fascia.

B. The inguinal canal contains the inferior epigastric vessels.

C. The deep inguinal ring is located medial to the inferior epigastric vessels.

D. D) The floor of the inguinal canal is formed by the conjoint tendon

Correct Answer: A. The posterior wall of the inguinal canal is formed by the transversalis fascia.

■ *Listen (English)*

■ *Listen (Hindi)*

Explanation: The inguinal canal runs between these structures, with the inguinal ligament forming the inferior boundary and the iliopsoas muscle lying posterior. Relations of the inguinal canal: Structure Description Parietal peritoneum Most posterior structure. Transversalis fascia Has a defect called the deep inguinal ring, through which the testes and spermatic cord pass. Site for indirect inguinal hernias. Anterior to parietal peritoneum. Forms the posterior in the whole extent. (Option A) Lateral umbilical fold Formed by the inferior epigastric vessels. Median umbilical ligament Remnant of the urachus (from the allantois). Medial umbilical ligament Remnant of the obliterated umbilical artery. Pyramidalis muscle Small muscle attaching to the pubic bone. Rectus abdominis lies above it. Covered by the rectus sheath and supplied by the subcostal nerve (T12). Rectus abdominis muscle Receives segmental innervation from T6–T12. Transversus abdominis muscle Does not form the anterior wall of the inguinal canal. Contributes to the roof and posterior wall. Combines with internal oblique to form the conjoint tendon. Internal oblique muscle Forms parts of the anterior, roof, and posterior walls of the inguinal canal. Contributes to cremasteric muscle and fascia. External oblique muscle Aponeurosis forms the anterior wall of the inguinal canal and the superficial inguinal ring. Forms external spermatic fascia. Internal spermatic fascia Derived from the transversalis fascia. The inguinal canal does not contain the inferior epigastric vessels. The vessels are located medial to the deep inguinal ring, and the canal contains structures such as the spermatic cord (in males) or the round ligament (in females). (Option B) The deep inguinal ring is located lateral (not medial) to the inferior epigastric vessels. (Option C) The floor of the inguinal canal is not formed by the conjoint tendon. The floor is primarily formed by the inguinal ligament. (Option D)

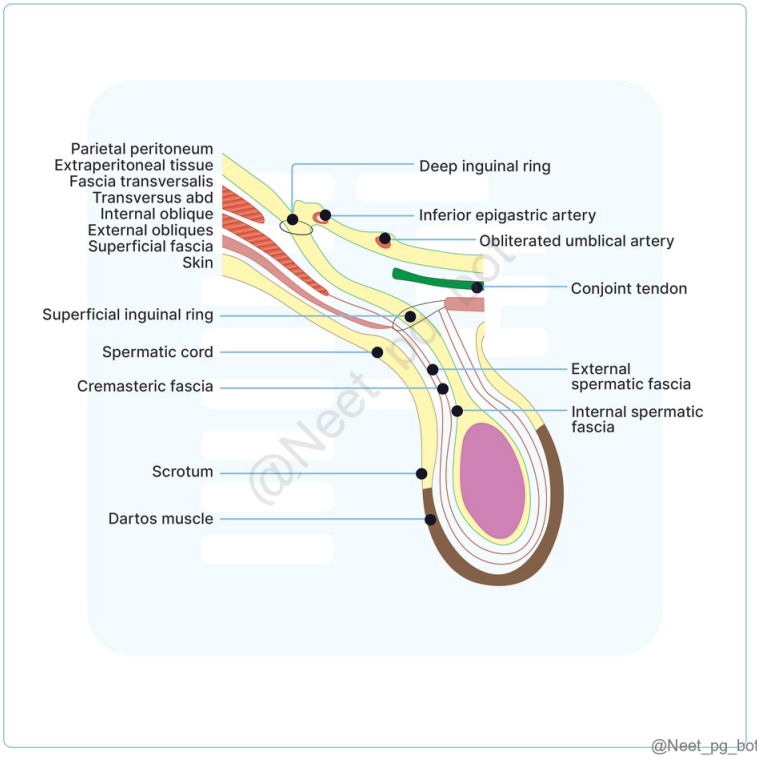

References:

Vishram Singh Textbook of Anatomy, Abdomen and lower-limb, Volume 2, Page. 51

↑ *Back to this question in Part A*

@Neet_pg_bot

Q9: Which of the following statements about the femoral triangle is FALSE? (Q848784)

A. The medial boundary of the femoral triangle is formed by the adductor longus muscle.

B. The lateral boundary of the femoral triangle is formed by the iliacus and psoas major muscles

C. The femoral nerve is one of the contents of the femoral triangle.

D. The anterior boundary of the femoral ring is the inguinal ligament.

Correct Answer: B. The lateral boundary of the femoral triangle is formed by the iliacus and psoas major muscles

■ *Listen (English)*

■ *Listen (Hindi)*

Explanation: The femoral triangle is an important anatomical region in the upper thigh, where key neurovascular structures pass, and it's clinically relevant for procedures like catheterization and palpating the femoral pulse. The lateral boundary of the femoral triangle is formed by the sartorius muscle . The iliacus and psoas major muscles form a part of the floor of the femoral triangle, not its lateral boundary. Femoral Triangle Boundaries Contents Lateral Boundary: Medial margin of the sartorius muscle. Medial Boundary: Medial margin of the adductor longus muscle. Apex: The point where the sartorius overlaps the adductor longus. Floor: Laterally: Iliacus and psoas major muscles. Medially: Pectineus and adductor longus muscles. Roof: Formed by the overlying fascia lata. The structures are arranged from medial to lateral in the following order (VAN): Femoral vein (most medial) and Its Tributaries Femoral artery and Its Branches Femoral nerve (most lateral) Femoral Sheath Nerves: Femoral Nerve Nerve to Pectineus Femoral Branch of Genitofemoral Nerve Lateral Cutaneous Nerve of the Thigh Deep Inguinal Lymph Nodes Femoral Ring- Base (upper end) of Femoral Canal Boundaries Contents Anterior: Inguinal ligament Posterior: Pectineus and its covering fascia Medial: Concave margin of lacunar ligament Lateral: Femoral vein Lymph node of Cloquet (Rosenmüller) Lymphatics Areolar tissue The femoral ring , surrounded by the inguinal ligament, lacunar ligament, pectineal ligament, and femoral vein , creates a narrow space. This makes femoral hernias highly prone to strangulation , as the herniated tissue can easily get trapped, leading to compromised blood supply and potential ischemia.

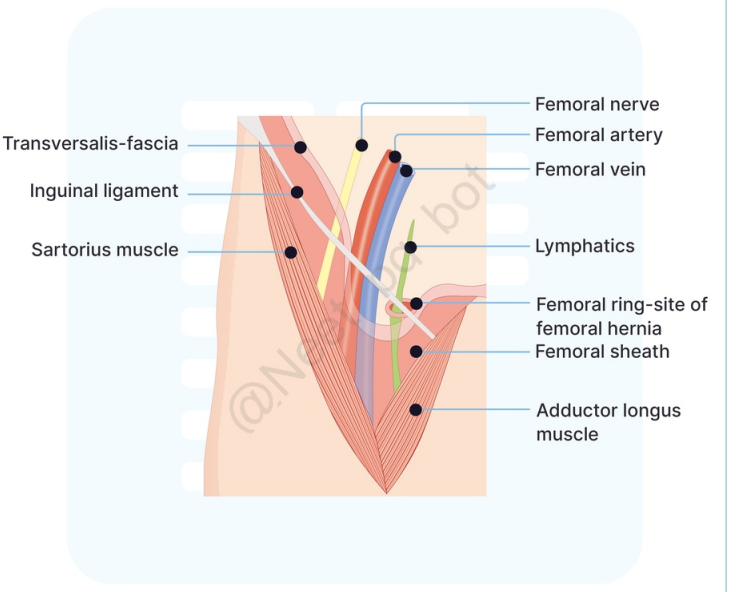

@Neet_pg_bot

References:

Grays anatomy 42nd edition. Pg. 1381

BD Chaurasia. Volume 2. 8th edition. Pg. 51,52, 53, 54

Vishram Singh Volume 2. Pg. 48

↑ *Back to this question in Part A*

@Neet_pg_bot

Q10: Which of the marked structures is formed directly by the rotation of the stomach and duodenum? (Q848802)

A. both a and b

B. both b and c

C. b only

D. d only

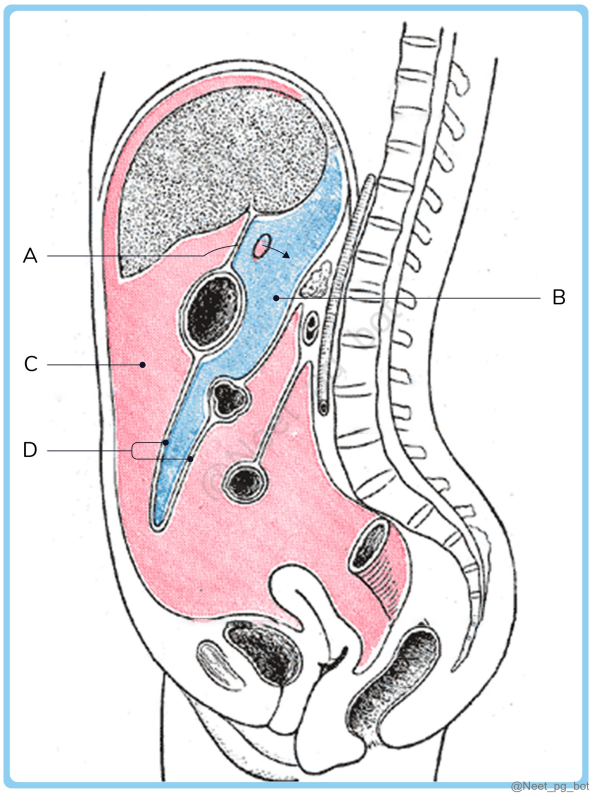

Correct Answer: C. b only

- *Listen (English)*
- *Listen (Hindi)*

Explanation: The rotation of the stomach and duodenum incorporates the upper right part of the peritoneal cavity into the lesser sac . In the given image, a- epiploic foramen b- lesser sac c- greater sac d- greater omentum. Formation of the Lesser Sac The growth of the right lobe of the liver pulls the ventral mesentery to the right, causing the rotation of the stomach and duodenum. This rotation incorporates the upper right part of the peritoneal cavity into the lesser sac. The right border of the ventral mesentery becomes the right border of the lesser omentum and forms the anterior boundary of the entrance into the lesser sac. Formation of the Greater Sac The remaining part of the peritoneal cavity, not included in the lesser sac, is called the greater sac. (Option C ruled out) The greater sac and lesser sac communicate through the epiploic foramen. (Option A ruled out) Formation of the Greater Omentum The spleen develops in the upper part of the dorsal mesentery, and the greater omentum forms from the rapid growth of the dorsal mesentery below the spleen. (Option D ruled out) Initially, it extends from the greater curvature of the stomach to the posterior abdominal wall above the transverse mesocolon. As it enlarges, it descends as a double apron-like layer in front of the transverse colon. The posterior layer later fuses with the transverse mesocolon, attaching it to the transverse colon. With time, it becomes fat-laden, and the inferior recess of the lesser sac extends between its layers.

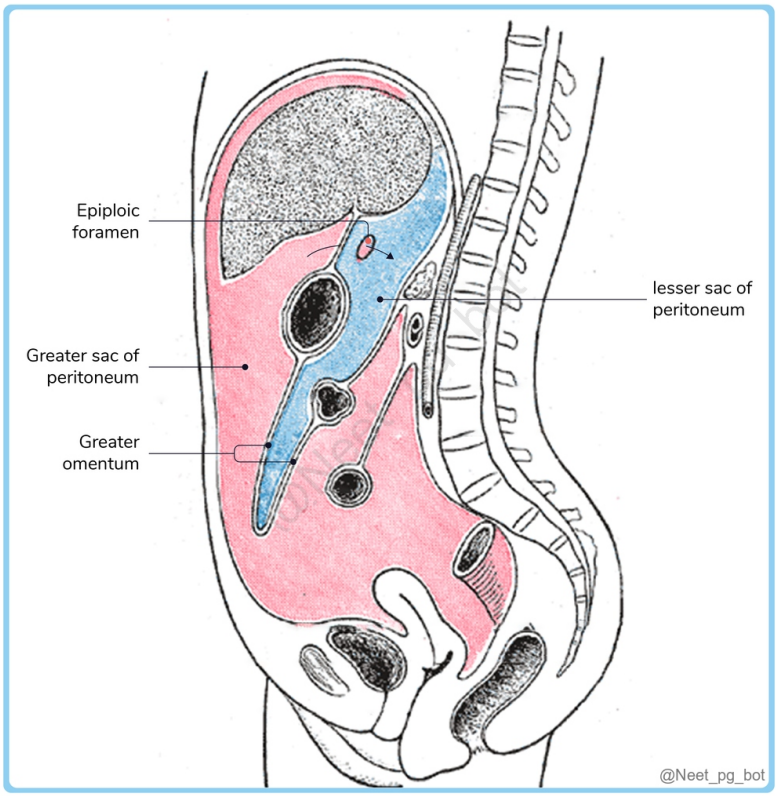

References:

Snells Clinical Anatomy. 10th Edition, Page. 338

↑ *Back to this question in Part A*

@Neet_pg_bot

Q11: A 50-year-old male undergoes an emergency laparotomy for severe upper abdominal bleeding after blunt abdominal trauma. During the procedure, the surgeon performs the Pringle maneuver by clamping the hepatoduodenal ligament to control hemorrhage. The clamp is applied to temporarily occlude the portal triad and assess the source of bleeding. Which structure forms the superior boundary of the anatomical space where the Pringle maneuver is performed? (Q848803)

A. Inferior vena cava

B. Caudate lobe of the liver

C. First part of the duodenum

D. Proper hepatic artery

Correct Answer: B. Caudate lobe of the liver

■ *Listen (English)*

■ *Listen (Hindi)*

Explanation: The Pringle maneuver involves clamping the hepatoduodenal ligament, which contains the portal triad, to control bleeding in the liver or surrounding structures. This maneuver is performed at the epiploic foramen (Foramen of Winslow) . The caudate lobe of the liver forms the superior boundary of the Epiploic Foramen. Epiploic Foramen / Omental Foramen / Foramen of Winslow: A vertical slit-like opening connecting the lesser sac with the greater sac, located behind the right free margin of the lesser omentum at the level of the 12th thoracic vertebra. Boundaries: Anterior: Right free margin of the lesser omentum (portal vein, proper hepatic artery, bile duct) (Option D ruled out) Posterior: Inferior vena cava, right suprarenal gland, T12 vertebra (Option A ruled out) Superior: Caudate process of the liver Inferior: First part of the duodenum, horizontal part of the hepatic artery (Option C ruled out) Clinical Relevance: Pringle Maneuver: A technique to control bleeding from the liver by compressing the free edge of the lesser omentum. Fluid Collections: The apposed walls of the foramen can lead to isolated fluid collections in the greater sac or omental bursa.

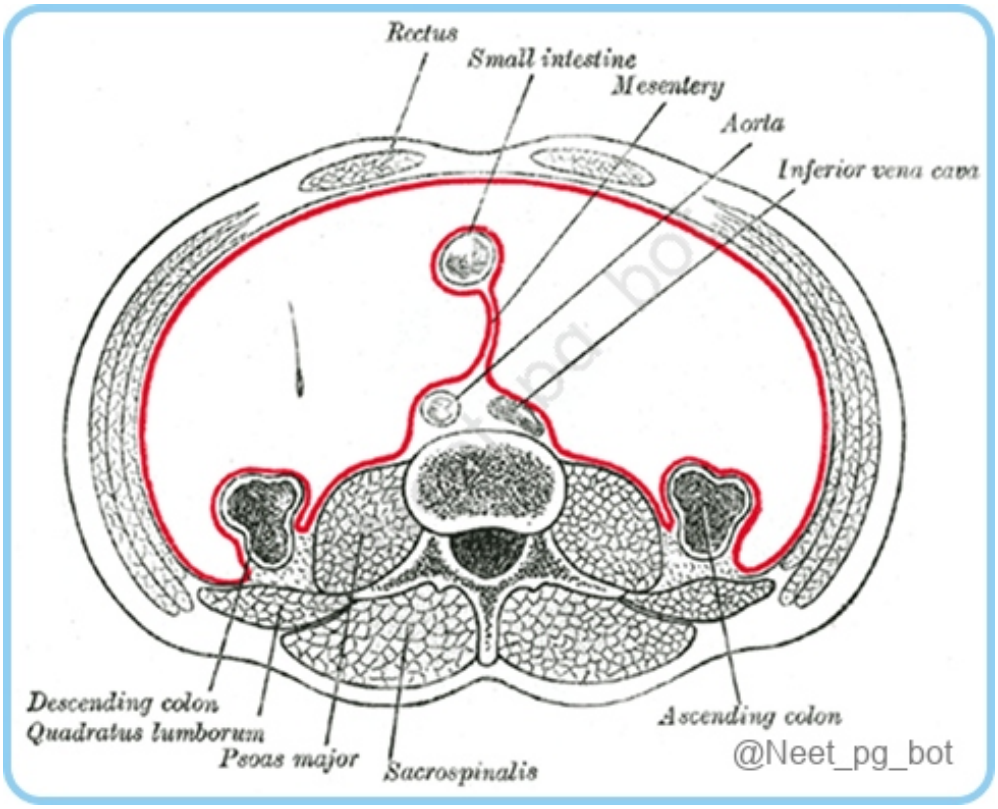

References:

Grays anatomy 42nd Edition. Page. 1157

BD Chaurasia. Volume 2. 8th Edition. Page. 282

Vishram Singh Volume 2. Page. 89

↑ *Back to this question in Part A*

Q12: A 35-year-old female presents with lower abdominal pain, high fever, and an elevated heart rate. She appears pale and diaphoretic on examination, with hypotension and a leukocytosis noted on laboratory tests. Imaging reveals a pelvic abscess. The surgeon suspects that pus has spread from an upper abdominal source. Which of the following sequences represents the correct flow of pus between important peritoneal spaces, leading to a pelvic abscess? (Q848805)

A. Rectouterine pouch → Hepatorenal pouch → Paracolic gutter → Lesser sac → Pelvic abscess

B. Lesser sac → Foramen of Winslow → Greater sac → Hepatorenal pouch → Paracolic gutter → Rectouterine pouch → Pelvic abscess

C. Greater sac → Foramen of Winslow → Hepatorenal pouch → Paracolic gutter → Lesser sac → Pelvic abscess

D. Hepatorenal pouch → Paracolic gutter → Lesser sac → Foramen of Winslow → Pelvic abscess

Correct Answer: B. Lesser sac → Foramen of Winslow → Greater sac → Hepatorenal pouch → Paracolic gutter → Rectouterine pouch → Pelvic abscess

■ *Listen (English)*

■ *Listen (Hindi)*

Explanation: Pus moves from the lesser sac through the foramen of Winslow into the greater sac, enters the hepatorenal pouch of Morrison, continues through the paracolic gutter, then reaches the rectouterine pouch of Douglas, where a pelvic abscess may form. Peritoneal Spaces: Greater Sac: Largest compartment of the peritoneal cavity, spanning the entire abdomen. Lesser Sac: Smaller compartment, located behind the stomach, liver, and lesser omentum, as a diverticulum from the greater sac. Both the sacs can be connected through the foramen of Winslow. Paracolic Gutters: Right Paracolic Gutter: Located lateral to the ascending colon, continuous with the hepatorenal pouch (Morrison’s pouch) above and pelvic cavity below. Infections may spread from the appendix or hepatorenal pouch. Left Paracolic Gutter: Located lateral to the descending colon, limited by the phrenicocolic ligament above, and continuous with the pelvic cavity below. Infections may spread upward from the pelvis. Subphrenic Spaces: Six spaces near the liver, important for surgeons due to frequent pus collection (subphrenic abscesses). Right side: Right posterior intraperitoneal compartment (Hepatorenal pouch or Morrison's pouch). Right anterior intraperitoneal compartment. Right extraperitoneal compartment. Left side: Left posterior intraperitoneal compartment. Left anterior intraperitoneal compartment. Left extraperitoneal compartment. Hepatorenal Pouch (Morison’s Pouch): Located between the liver and right kidney, communicates with the lesser sac through the epiploic foramen. Most dependent part in the supine position , often collecting pus after upper abdominal surgery (e.g., cholecystectomy). Communicates with the rectouterine pouch via the right paracolic gutter, serving as a route for infection from the abdomen to the pelvis.

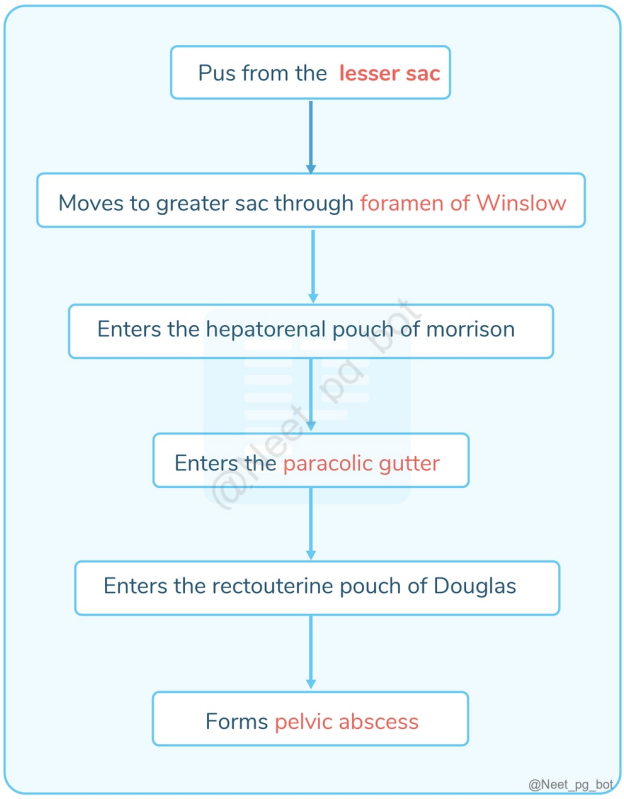

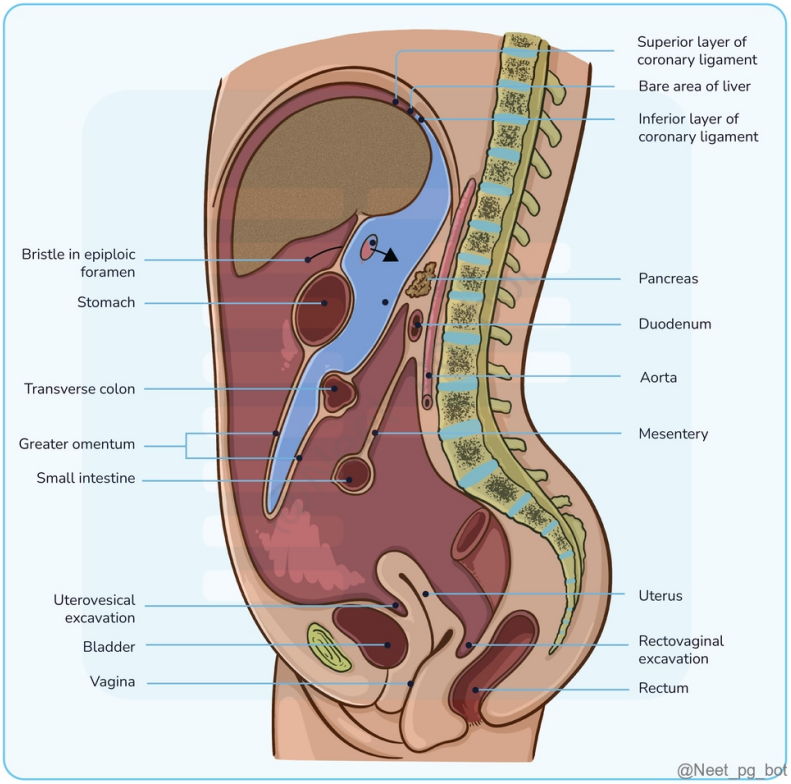

References:

Vishram Singh Textbook of Anatomy, Abdomen and lower-limb, Volume 2, 2nd Edition, Pages 84- 91

BD Chaurasia's Human Anatomy. Volume 2. 8th edition. Pages 282-286

↑ *Back to this question in Part A*

@Neet_pg_bot

Q13: Which muscle is primarily involved in a midline abdominal incision? (Q848806)

A. Rectus Abdominis

B. External Oblique

C. Internal Oblique

D. Transverse Abdominis

Correct Answer: A. Rectus Abdominis

■ *Listen (English)*

■ *Listen (Hindi)*

Explanation: The rectus abdominis is the primary muscle involved in a midline abdominal incision. The incision typically passes through the rectus sheath that encloses the rectus abdominis muscle. It may separate the muscle or retract it, but this muscle is directly related to the incision. The external oblique, Internal oblique, and Transverse abdominis muscles are located laterally and are not directly involved in the midline incision (Option B, C, and D).

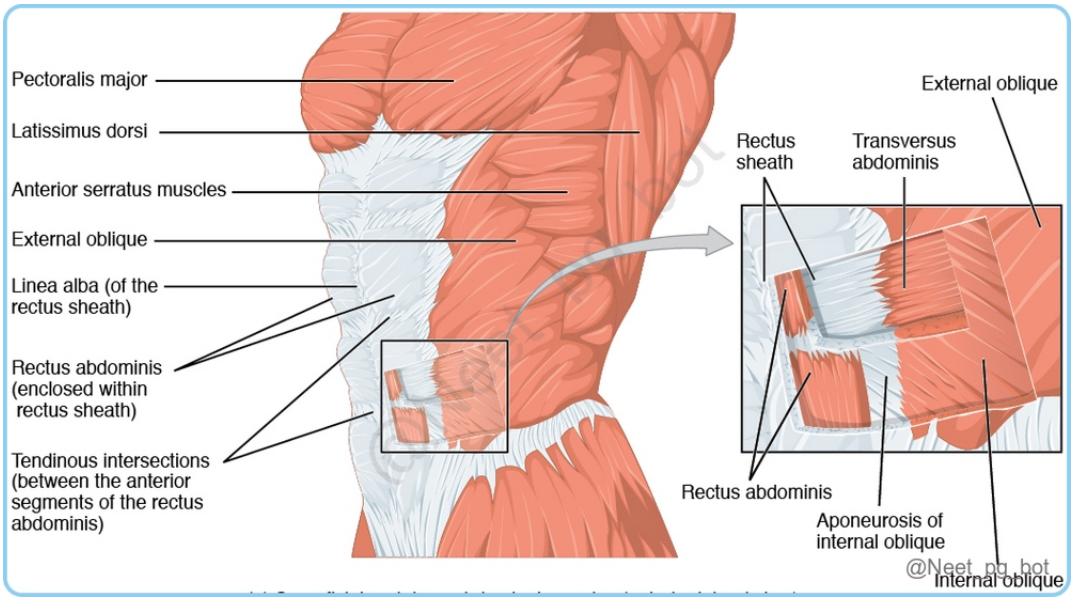

References:

Vishram Singh Textbook of Anatomy, Abdomen and lower-limb, Volume 2, 2nd Edition, Page 27

↑ *Back to this question in Part A*

@Neet_pg_bot

Q14: Which of the following statements about the conjoint tendon is false ? (Q848807)

A. The conjoint tendon is formed by the fusion of the internal oblique and transversus abdominis muscles.

B. The conjoint tendon contributes to the posterior wall of the inguinal canal.

C. The conjoint tendon is located in the anterior wall of the inguinal canal.

D. A weakness in the conjoint tendon can lead to a direct inguinal hernia.

Correct Answer: C. The conjoint tendon is located in the anterior wall of the inguinal canal.

■ *Listen (English)*

■ *Listen (Hindi)*

Explanation: The conjoint tendon, also known as the inguinal aponeurotic falx or Henle's ligament, is a condensation of tissue that runs through the lateral edge of the lower rectus sheath. It is located in the inferior abdomen and is formed from the common aponeurosis of the internal oblique muscle and transverse abdominis muscle .(Option A) The conjoint tendon makes up the main part of the medial portion of the posterior wall of the inguinal canal. (Option B) A weakness in the conjoint tendon can lead to a direct inguinal hernia, as it is an important structure in maintaining the integrity of the inguinal canal. (Option D)

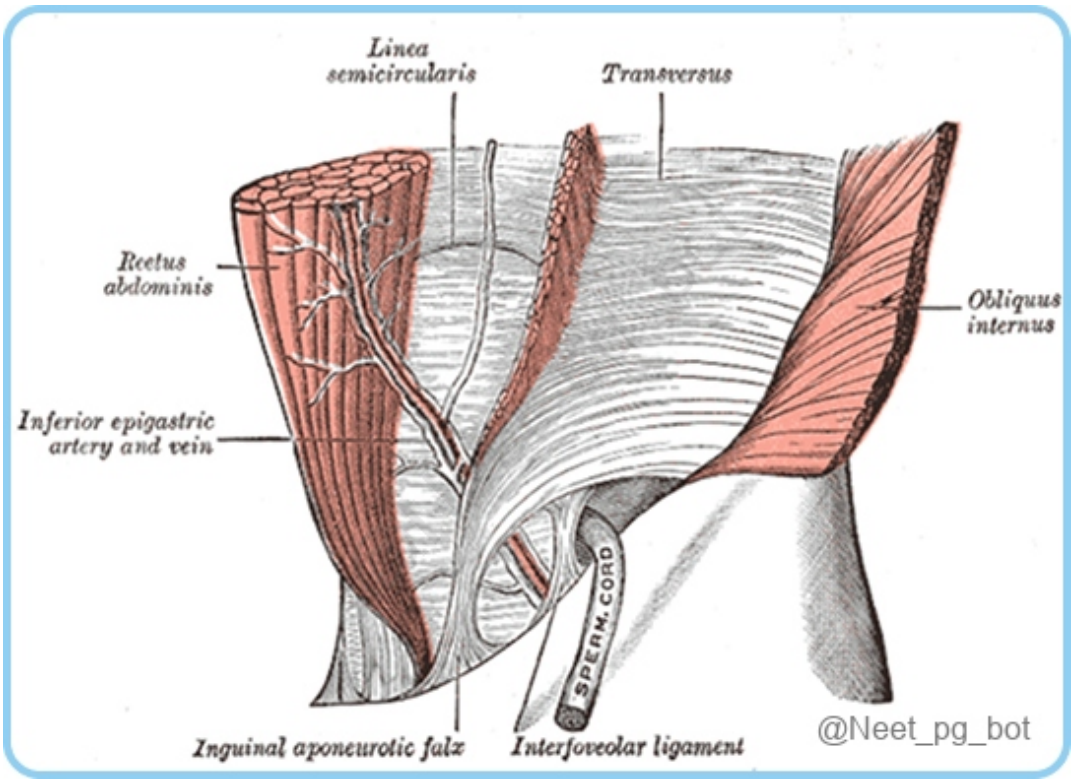

References:

Vishram Singh Textbook of Anatomy, Abdomen and lower-limb, Volume 2, Page. 50, 51

https://www.ncbi.nlm.nih.gov/books/NBK549772/

↑ *Back to this question in Part A*

@Neet_pg_bot

• [08_Abdomen] 039 Abdomen Arterial Supply Venous Drainage Of Thorax And Abdomen

« Back to Folder Directory

[08_Abdomen] 039 Abdomen Arterial Supply Venous Drainage Of Thorax And Abdomen — Quick Jump

Q1 (p. 1912)	*Q2 (p. 1913)*	*Q3 (p. 1914)*	*Q4 (p. 1915)*	*Q5 (p. 1917)*	*Q6 (p. 1918)*
Q7 (p. 1920)	*Q8 (p. 1921)*	*Q9 (p. 1923)*	*Q10 (p. 1923)*	*Q11 (p. 1925)*	*Q12 (p. 1926)*
Q13 (p. 1927)	*Q14 (p. 1929)*	*Q15 (p. 1930)*	*Q16 (p. 1932)*	*Q17 (p. 1933)*	

Q1: Which of the following is NOT a common collateral pathway for venous return in cases of IVC obstruction? (Q848708)

A. Vertebral venous plexus

B. Internal thoracic veins

C. Superficial veins of the anterior abdominal wall

D. Pulmonary veins

Correct Answer: D. Pulmonary veins

■ *Listen (English)*

■ *Listen (Hindi)*

Explanation: Pulmonary veins do not serve as a collateral pathway in cases of IVC obstruction. Vertebral venous plexus (Option A): True statement, the vertebral venous plexus is a common collateral pathway for venous return in cases of IVC obstruction. Internal thoracic veins (Option B): True statement, the internal thoracic veins (also called the internal mammary veins) are another common collateral route during IVC obstruction. They connect to the subclavian veins and can provide an alternative route for venous return to the heart. Superficial veins of the anterior abdominal wall (Option C): True statement, the superficial veins of the anterior abdominal wall, particularly the paraumbilical veins, form collateral pathways through the epigastric veins. In the case of IVC obstruction.

References:

Gray’s Anatomy: The Anatomical Basis of Clinical Practice, 42nd Edition, Page 1145

https://pubmed.ncbi.nlm.nih.gov/20083586/

↑ *Back to this question in Part A*

@Neet_pg_bot

Q2: How many Houston's valves are typically present in the human rectum? (Q848718)

A. 3

B. 4

C. 5

D. 6

Correct Answer: B. 4

- *Listen (English)*
- *Listen (Hindi)*

Explanation: There are typically 4 Houston's valves in the human rectum. Houston's valves (or permanent folds) are semilunar (crescentic) transverse folds in the rectum. They are located against the concavities of the lateral curvatures of the rectum. They are formed by the reduplication of the mucous membrane containing submucous tissue and thickening of circular smooth muscle of the rectal wall. Houston's valves are permanent and become more prominent when the rectum is distended. According to Houston, there are four valves numbered from above downward: 1st valve: Near rectosigmoid junction, from either wall. 2nd valve: ~2.5 cm above the third fold, projecting from the left wall. 3rd valve: Largest and most constant, on the anterior–right wall at the upper end of the ampulla. 4th valve: On the left wall, ~2.5 cm below the third valve.

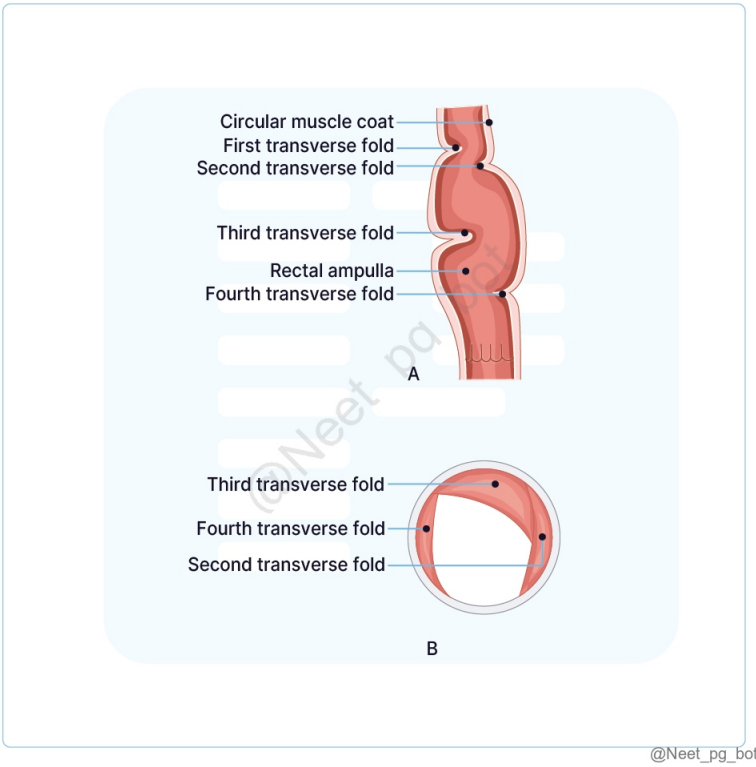

References:

Textbook of Anatomy, Abdomen and Lower Limb, Vishram Singh, Volume II, 2nd Edition, Page 282

↑ *Back to this question in Part A*

@Neet_pg_bot

Q3: Which of the following is not involved in the formation of the Marginal Artery of Drummond? (Q848717)

A. Ileocolic artery

B. Right colic artery

C. Left colic artery

D. Inferior epigastric artery

Correct Answer: D. Inferior epigastric artery

■ *Listen (English)*

■ *Listen (Hindi)*

Explanation: Marginal Artery of Drummond is a circumferential anastomotic arterial channel. It extends from the ileocaecal junction to the rectosigmoid junction. It is located approximately 3 cm from the inner margin of the colon. It is formed by the anastomoses between: Colic branches of the superior mesenteric artery (i.e., ileocolic artery, right colic artery, and middle colic artery). Colic branches of the inferior mesenteric artery (i.e., left colic artery and sigmoidal artery). The vasa recta (small vessels) arise from the Marginal Artery of Drummond and supply the colon. Splenic flexure: The splenic flexure of the colon is prone to ischemia → Due to poorly formed anastomoses in this region Also known as: Watershed Areas Griffith's Point Arc of Riolan: Additional arterial arc connecting: Middle colic artery and Left colic artery Suddeck's point: Sometimes no arcuate artery present at rectosigmoid junction

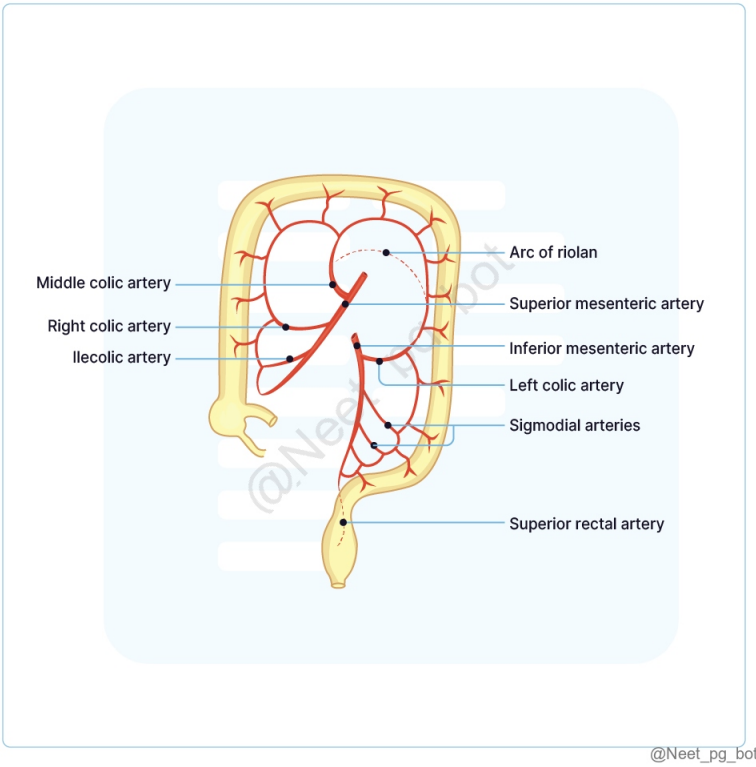

References:

Textbook of Anatomy, Abdomen and Lower Limb, Vishram Singh, Volume II, 2nd Edition, Page 158-159

↑ *Back to this question in Part A*

@Neet_pg_bot

Q4: Examine the image below showing a cross-section of the small intestine. Which part of the small intestine does this section belong to? (Q848716)

A. Duodenum

B. Jejunum

C. Ileum

D. Cecum



Correct Answer: B. Jejunum

■ *Listen (English)*

■ *Listen (Hindi)*

Explanation: Plicae circulares are circular folds of the mucous membrane found in the small intestine, particularly in the jejunum. These folds are more prominent, closely set, and contribute to the thicker feel of the jejunum when compared to the ileum, which has less prominent and more sparsely arranged folds. The plicae circulares increase the surface area, are more numerous in the jejunum, where the diameter of the intestine is slightly wider. In contrast, the ileum contains many more aggregated lymph follicles (Peyer's patches) but fewer plicae circulares. Anatomical comparison: Feature Jejunum (Proximal 2/5) Ileum (Distal 3/5) Location Upper left quadrant. Lower right quadrant / Pelvis. Diameter Wider and thicker-walled. Narrower and thinner-walled. Vascularity Highly vascular (deeper red). Less vascular (paler pink). Plicae Circulares Large, tall, and closely packed. Low, sparse, and absent distally. Vasa Recta Long straight arteries. Short straight arteries. Arterial Arcades Few, large loops. Many, short, complex loops. Mesenteric Fat Less fat; "windows" near bowel. More fat; "creeping" onto bowel. Lymphoid Tissue Sparse. Abundant (Peyer’s Patches). Key Differentiating Features: Internal Surface: The jejunum has prominent plicae circulares (circular folds) for intense absorption. These flatten out and eventually disappear in the distal ileum. Vascular Architecture: The jejunum has simple arterial arcades with long vasa recta (straight arteries). The ileum has complex, multi-tiered arcades with very short vasa recta. Mesenteric Windows: In the jejunum, the fat doesn't reach the bowel wall, leaving clear "windows" to see vessels. In the ileum, fat is

thicker and covers the vessels.

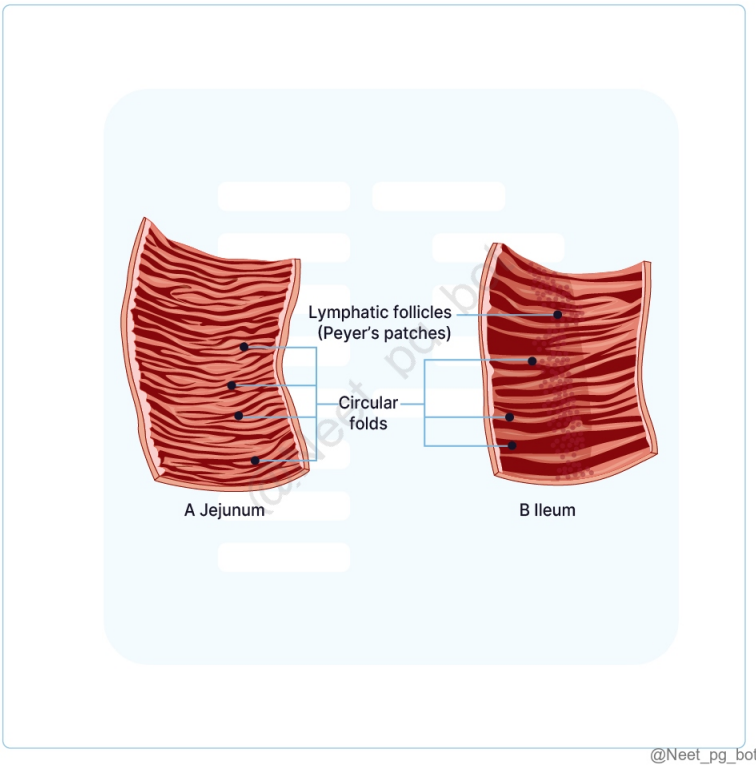

References:

Textbook of Anatomy, Abdomen and Lower Limb, Vishram Singh, Volume II, 2nd Edition, Page 147

↑ *Back to this question in Part A*

@Neet_pg_bot

Q5: Where is the paraduodenal recess located, and which structure is found in its fold? (Q848714)

A. To the right of the duodenum, contains the superior mesenteric artery.

B. To the left of the fourth part of the duodenum, contains the inferior mesenteric vein.

C. To the left of the fourth part of the duodenum, contains the superior mesenteric vein.

D. In front of the pancreas, contains the splenic vein.

Correct Answer: B. To the left of the fourth part of the duodenum, contains the inferior mesenteric vein.

■ *Listen (English)*

■ *Listen (Hindi)*

Explanation: The paraduodenal recess is an anatomical feature located to the left of the fourth part of the duodenum. It is situated behind the paraduodenal fold of the peritoneum. The key feature of this recess is that it contains the inferior mesenteric vein (IMV) in the free border of the paraduodenal fold.

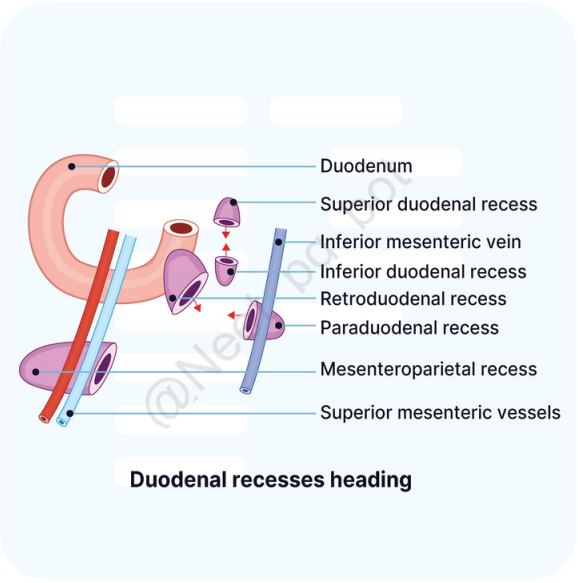

@Neet_pg_bot

References:

Textbook of Anatomy, Abdomen and Lower Limb, Vishram Singh, Volume II, 2nd Edition, Page 130

↑ *Back to this question in Part A*

@Neet_pg_bot

Q6: Which of the following statements accurately describes the anatomical extent of the attached border of the following structure? (Q848713)

A. Duodenojejunal flexure to the ileocecal junction

B. Pylorus of the stomach to the transverse colon

C. Duodenojejunal flexure to the right iliac fossa

D. Stomach to the appendix



Correct Answer: A. Duodenojejunal flexure to the ileocecal junction

■ *Listen (English)*

■ *Listen (Hindi)*

Explanation: The given image represents the mesentery. The attached border, or the root of mesentery, is attached to an oblique line across the posterior abdominal wall, extending from the duodenojejunal flexure to the ileocecal junction.

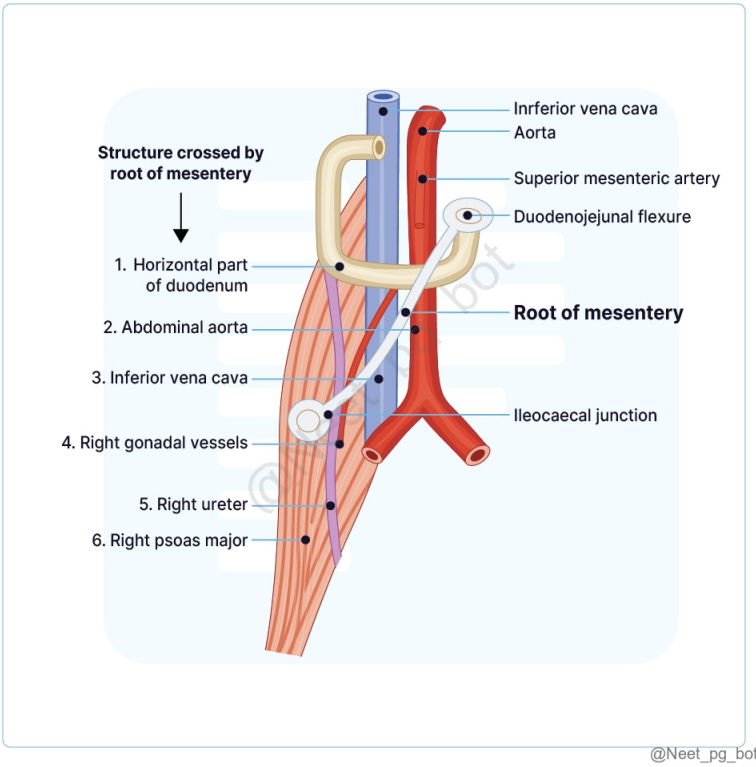

References:

Textbook of Anatomy, Abdomen and Lower Limb, Vishram Singh, Volume II, 2nd Edition, Page 82

↑ *Back to this question in Part A*

@Neet_pg_bot

Q7: A 55-year-old man with a history of chronic liver disease presents with increasing abdominal swelling, difficulty swallowing, and hematemesis. On examination, he has a distended abdomen, and upon palpation, his spleen is enlarged. Which anatomical feature is primarily responsible for his hematemesis? (Q848712)

A. Paraumbilical to epigastric vein connections

B. Left gastric to esophageal vein connections

C. Superior to middle rectal vein connections

D. Splenic to inferior mesenteric vein connections

Correct Answer: B. Left gastric to esophageal vein connections

■ *Listen (English)*

■ *Listen (Hindi)*

Explanation: This case is indicative of portal hypertension, a common consequence of chronic liver disease. left gastric to esophageal vein connections are primarily responsible for the hematemesis. Paraumbilical to epigastric vein connections (Option A): This refers to the formation of caput medusae, which is a characteristic sign of portal hypertension. While this is a visible finding in the abdominal wall, it is not directly responsible for hematemesis. Superior to middle rectal vein connections (Option C): This describes collateral circulation between the superior rectal vein (from the portal system) and the middle rectal vein (from the systemic circulation). While this can contribute to rectal varices, it is less likely to cause hematemesis compared to esophageal varices. Splenic to inferior mesenteric vein connection (Option D): Does not directly lead to hematemesis.

References:

1. BD Chaurasia's Human Anatomy, Lower limb Abdomen and Pelvis, Volume 2, 8th Edition, Page 331, 332, 333
2. Vishram Singh, Textbook of Anatomy, Abdomen and Lower Limb, Volume 2, 2nd Edition, Page 142

↑ *Back to this question in Part A*

@Neet_pg_bot

Q8: In cases of a strangulated internal hernia into the lesser sac through the epiploic foramen, the surgical approach is often made through the greater omentum as the epiploic foramen cannot be safely widened. Which of the following structures around the epiploic foramen restricts its enlargement during surgery? (Q848710)

A. Hepatic artery, bile duct, portal vein

B. Celiac trunk and splenic artery

C. Portal vein, duodenum, hepatic vein

D. Superior mesenteric artery, cystic duct, portal vein

Correct Answer: A. Hepatic artery, bile duct, portal vein

■ *Listen (English)*

■ *Listen (Hindi)*

Explanation: The epiploic foramen (of Winslow) is bordered anteriorly by the right free margin of lesser omentum which contains portal vein, hepatic artery, and common bile duct within the hepatoduodenal ligament. This makes it dangerous to enlarge the foramen during surgery. Therefore, surgeons typically access the lesser sac through the greater omentum to avoid damaging these structures.

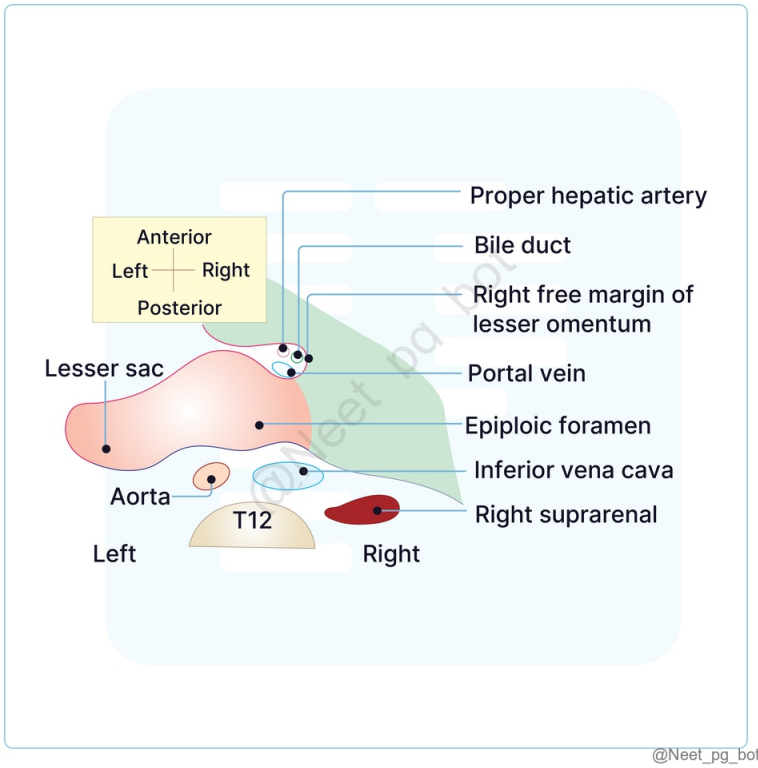

@Neet_pg_bot

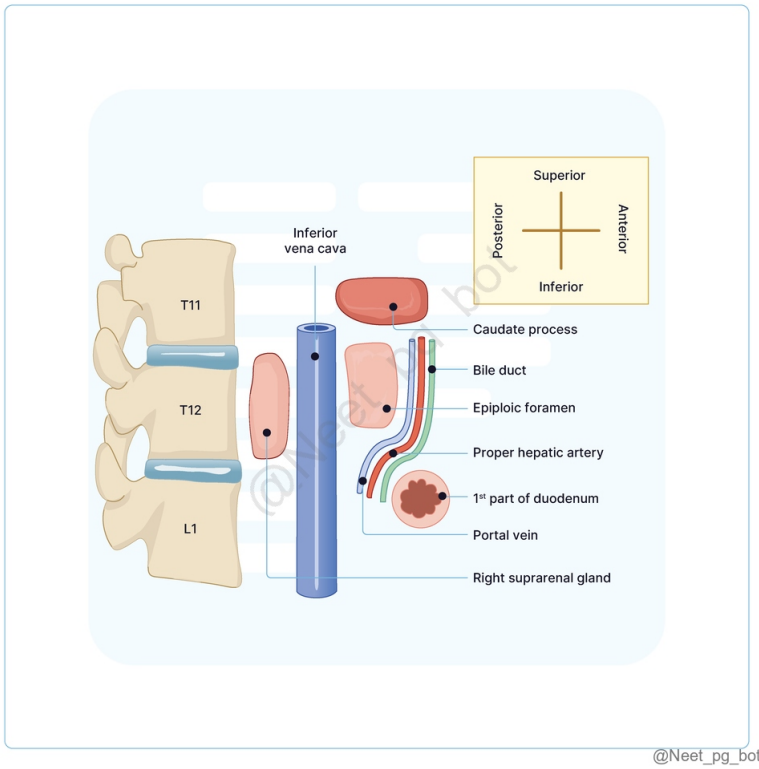

@Neet_pg_bot

References:

Gray’s Anatomy: The Anatomical Basis of Clinical Practice, 42nd Edition, Page 1158

BD Chaurasia’s Human Anatomy, Lower limb Abdomen and Pelvis, Volume 2, 8th Edition, Page 282, 283

↑ *Back to this question in Part A*

@Neet_pg_bot

Q9: Which of the following anatomical relationships is incorrect regarding portal venous circulation? (Q848709)

A. The portal vein is formed posterior to the neck of the pancreas

B. The splenic vein joins the superior mesenteric vein to form the portal vein

C. The portal vein ends at the porta hepatis

D. The portal vein is located posterior to the Inferior vena cava

Correct Answer: D. The portal vein is located posterior to the Inferior vena cava

■ *Listen (English)*

■ *Listen (Hindi)*

Explanation: The portal vein is always located anterior to the Inferior vena cava throughout its course from the origin to the termination. The portal vein is formed posterior to the neck of the pancreas (Option A): True statement, the portal vein is formed by the junction of the superior mesenteric vein (SMV) and the splenic vein. This junction occurs posterior to the neck of the pancreas, which is a correct anatomical description. The splenic vein joins the superior mesenteric vein to form the portal vein (Option B): True statement, the splenic vein and superior mesenteric vein join together to form the portal vein behind the neck of the pancreas, which is an accurate description of the portal venous system. The portal vein ends at the porta hepatis (Option C): True statement, the portal vein travels to the porta hepatis (the hilum of the liver), where it divides into right and left branches that supply the liver. This is the correct location for the termination of the portal vein.

References:

Gray’s Anatomy: The Anatomical Basis of Clinical Practice, 42nd Edition, Pages 1211-1212

BD Chaurasia’s Human Anatomy, Lower limb Abdomen and Pelvis, Volume 2, 8th Edition, Pages 330-331

↑ *Back to this question in Part A*

@Neet_pg_bot

Q10: A 55-year-old male presents with abdominal pain and constipation. A CT scan reveals a lesion affecting the distal third of the transverse colon and the descending colon. Which of the following arteries is most likely involved in the blood supply to this

region? (Q848700)

A. Celiac trunk

B. Superior mesenteric artery

C. Inferior mesenteric artery

D. Common hepatic artery

Correct Answer: C. Inferior mesenteric artery

Listen (English)

Listen (Hindi)

Explanation: The inferior mesenteric artery supplies the distal third of the transverse colon, descending colon, sigmoid colon, and rectum(Hindgut organs). Celiac trunk (Option A): Supplies the stomach, liver, spleen, but not the colon, making it incorrect. Superior mesenteric artery (SMA) (Option B): Supplies the small intestine, ascending colon, and proximal two-thirds of the transverse colon, not the distal third or descending colon. Common hepatic artery (Option D): A branch of the celiac trunk that supplies the liver and parts of the stomach, not the colon.

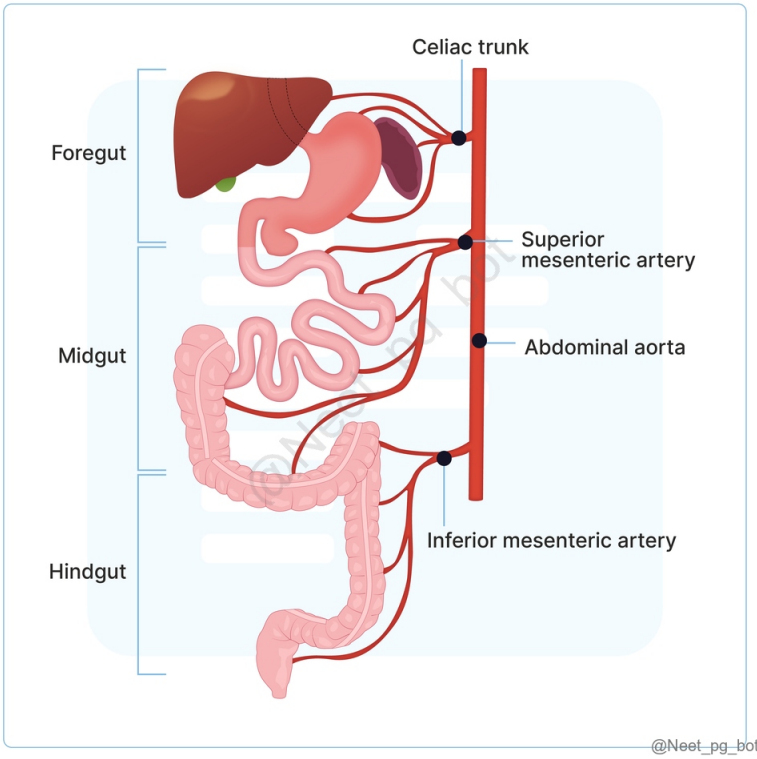

References:

Gray’s Anatomy: The Anatomical Basis of Clinical Practice, 42nd Edition, Page 1141

↑ *Back to this question in Part A*

@Neet_pg_bot

Q11: During abdominal surgery, the surgeon encounters a paired venous structure running vertically along the posterior abdominal wall continuing into the thoracic cavity, just lateral to the vertebral column as shown in the image below. What is this structure most likely? (Q848707)

A. Inferior vena cava

B. Hemiazygos vein

C. Ascending lumbar vein

D. Renal vein

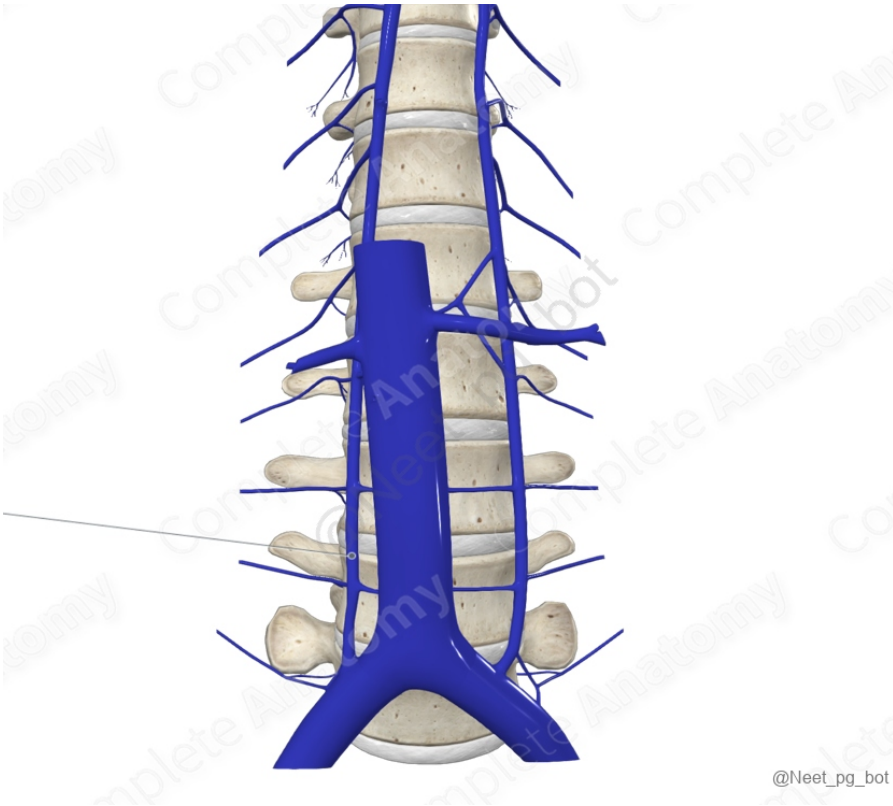

Correct Answer: C. Ascending lumbar vein

■ *Listen (English)*

■ *Listen (Hindi)*

Explanation: The paired ascending lumbar veins run vertically along the posterior abdominal wall medial to the psoas major. Inferior vena cava (Option A): It runs vertically and not a paired vein. Hence, not the correct option. Hemiazygos vein (Option B): The paired ascending lumbar veins join the subcostal vein to form the azygos vein on the right and the hemiazygos on the left. Renal vein (Option D): It is a paired venous structure that courses horizontally opening into the inferior vena cava almost at right angles. Hence, not the right option.

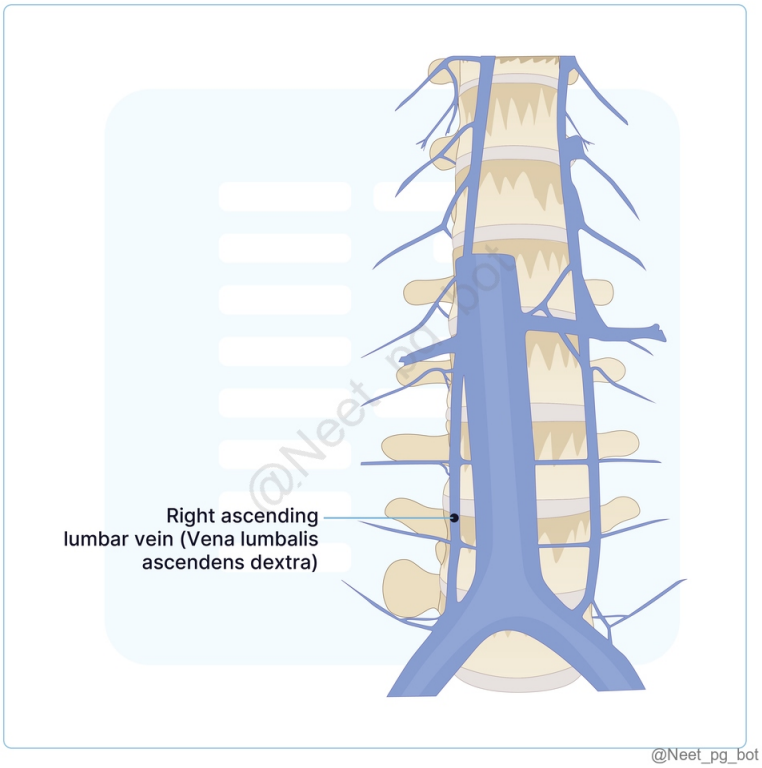

References:

Gray's Anatomy: The Anatomical Basis of Clinical Practice, 42nd Edition, Pages 1144, 1247

↑ *Back to this question in Part A*

@Neet_pg_bot

Q12: A surgeon must be careful with the inferior vena cava and its associated vessels during laparoscopic nephrectomy. Which of the following is true about IVC? (Q848706)

A. Left gonadal vein drains directly into IVC

B. Common iliac veins join to form the inferior vena cava at L3 vertebra level

C. Three large hepatic veins drain the liver into inferior vena cava

D. Right and left 5th lumbar veins drain into IVC

Correct Answer: C. Three large hepatic veins drain the liver into inferior vena cava

■ *Listen (English)*

■ *Listen (Hindi)*

Explanation: Three large and many small hepatic veins drain directly into the anterior surface of the inferior vena cava just before it pierces the diaphragm. Left gonadal vein drains directly into IVC (Option A): False. The left gonadal vein drains into the left renal vein, which then drains into the IVC, not directly into the IVC. Common iliac veins join to form the inferior vena cava at L3 vertebra level (Option B): False. The common iliac veins join to form the IVC at the L5 vertebral level, not L3. Right and left 5th lumbar veins drain into IVC (Option D): False. The lumbar veins are numbered from L1 to L4, and they drain into the IVC. The 5th lumbar segment does not have corresponding veins that drain into the IVC. Fig: Course and Tributaries of IVC

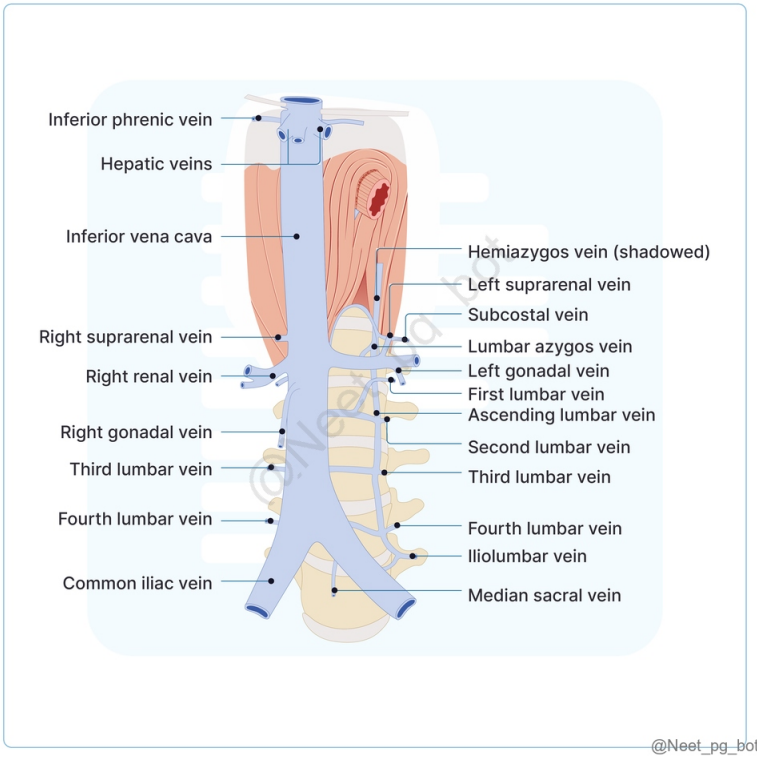

References:

Gray’s Anatomy: The Anatomical Basis of Clinical Practice, 42nd Edition, Pages 1143, 1144

↑ *Back to this question in Part A*

@Neet_pg_bot

Q13: Which of the following is/are NOT a branch of the anterior division of the internal iliac artery? Superior vesical Obturator Middle rectal Iliolumbar Inferior gluteal (Q848705)

A. 1, 2, and 5

B. 2, 4, and 5

C. Only 4

D. 1, and 2

Correct Answer: C. Only 4

■ *Listen (English)*

■ *Listen (Hindi)*

Explanation: The iliolumbar artery is a branch of the posterior division of the internal iliac artery. The others are branches of the anterior division. Internal iliac artery It is a branch of the common iliac artery. It supplies the pelvic viscera. Mnemonic: Posterior Division: S: Superior gluteal artery I: Iliolumbar artery L: Lateral sacral artery Note: Anterior division gives six branches in males and seven branches in females. The uterine artery is the 7th branch. In females inferior vesical artery is replaced by the vaginal artery.

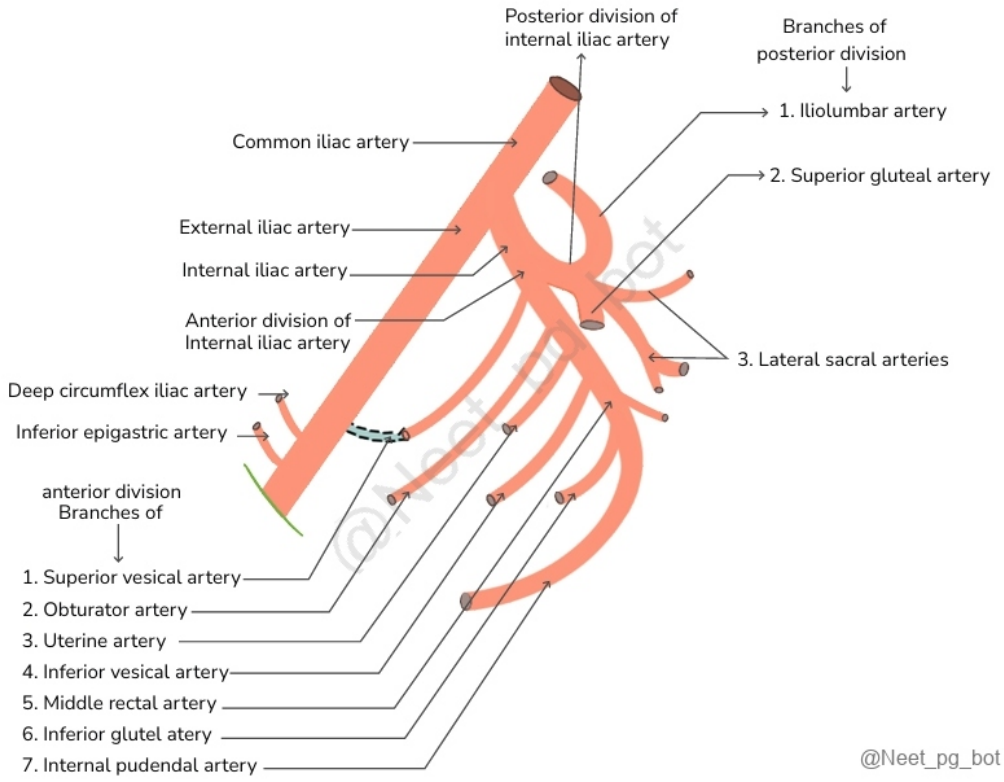

References:

Gray’s Anatomy: The Anatomical Basis of Clinical Practice, 42nd Edition, Page 1247, 1248, 1249, 1250

↑ *Back to this question in Part A*

@Neet_pg_bot

Q14: A medical student is reviewing the anatomy of the inferior mesenteric artery (IMA) and its branches. Which of the following statements about the IMA is false? (Q848704)

A. The IMA arises from the abdominal aorta at the level of the third lumbar vertebra (L3).

B. The IMA supplies the proximal segments of the small intestine.

C. The IMA gives rise to the superior rectal artery, which supplies the rectum.

D. IMA provides collateral circulation if SMA is stenosed

Correct Answer: B. The IMA supplies the proximal segments of the small intestine.

■ *Listen (English)*

■ *Listen (Hindi)*

Explanation: IMA does not supply the proximal segments of the small intestine. The proximal small intestine is primarily supplied by branches of the celiac trunk and SMA. The IMA arises from the abdominal aorta at the level of the third lumbar vertebra (L3) (Option A): This is a correct statement. The IMA typically arises from the abdominal aorta at L3, 3-4 cm above aortic bifurcation. The IMA gives rise to the superior rectal artery, which supplies the rectum (Option C): The IMA gives rise to the superior rectal artery, which supplies the rectum and proximal anal canal. IMA provides collateral circulation if SMA is stenosed (Option D): IMA provides collateral circulation if SMA is stenosed, preventing ischemia of the right side.

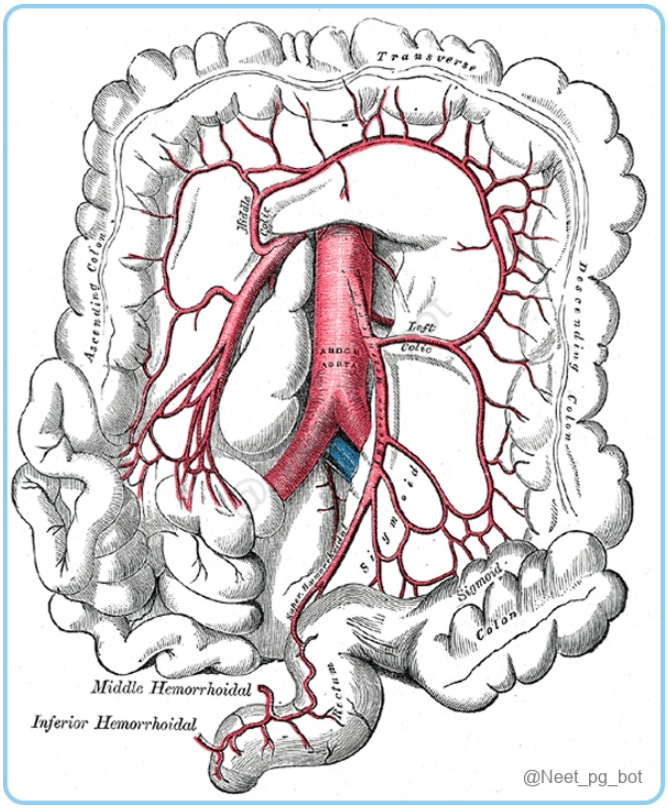

References:

Gray's Anatomy: The Anatomical Basis of Clinical Practice, 42nd Edition, Pages 1141, 1196-1197

↑ *Back to this question in Part A*

@Neet_pg_bot

Q15: A 50-year-old male presents with chronic postprandial abdominal pain and weight loss. Imaging reveals compression of the third part of the duodenum between the superior mesenteric artery and the aorta. Which of the following best explains the patient's condition? (Q848703)

A. Superior Mesenteric Artery Syndrome

B. Inferior Mesenteric Artery Syndrome

C. Mesenteric Arterial Thrombosis

D. Aortic Aneurysm

Correct Answer: A. Superior Mesenteric Artery Syndrome

■ *Listen (English)*

■ *Listen (Hindi)*

Explanation: This condition is caused by compression of the third part of the duodenum by the SMA, often due to weight loss leading to a loss of perivascular fat, which narrows the angle between the SMA and the aorta. Condition Description Superior Mesenteric Artery Syndrome Compression of the duodenum by the SMA due to weight loss, causing obstruction. Clinical Significance: Condition Description Surgical Importance Key for procedures like bypass or embolectomy in intestinal ischemia. Superior Mesenteric Artery Syndrome Compression of the duodenum by the SMA due to weight loss, causing obstruction. Collateral Circulation SMA anastomoses with celiac trunk and inferior mesenteric artery for backup blood flow. Inferior Mesenteric Artery Syndrome (Option B) : This is not a recognized condition; the inferior mesenteric artery does not compress the duodenum. Mesenteric Arterial Thrombosis (Option C) : This would present with acute ischemic symptoms, not chronic postprandial pain and duodenal obstruction. Aortic Aneurysm (Option D) : This would more likely cause back pain or pulsatile abdominal mass, not duodenal compression.

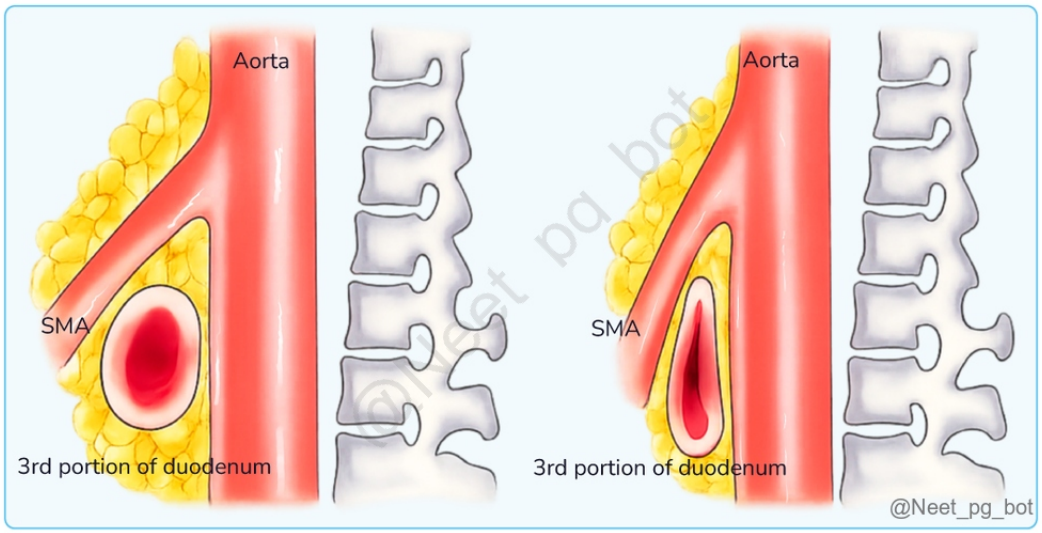

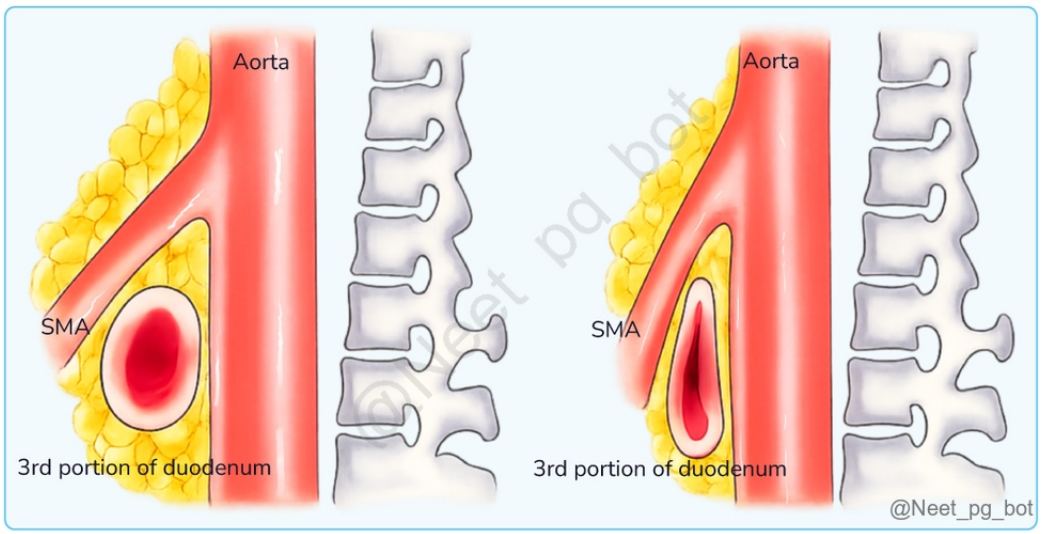

References:

Gray’s Anatomy: The Anatomical Basis of Clinical Practice, 42nd Edition, Pages 1141, 1178-1179, 1192-1193

↑ *Back to this question in Part A*

@Neet_pg_bot

Q16: A surgical procedure is planned to remove a tumor from the head of the pancreas. Which of the following arterial arcades is primarily responsible for supplying the posterior aspect of the head of the pancreas? (Q848702)

A. Anterior pancreaticoduodenal arcade

B. Posterior pancreaticoduodenal arcade

C. Kirk's arcade

D. Communicating artery

Correct Answer: B. Posterior pancreaticoduodenal arcade

■ *Listen (English)*

■ *Listen (Hindi)*

Explanation: The posterior pancreaticoduodenal arcade is formed by the anastomosis of the posterior superior and posterior inferior pancreaticoduodenal arteries, which supply the posterior aspect of the head of the pancreas. Arterial arcades encircle the head of the pancreas: Arcade Type Formed By Supplies Anterior Pancreaticoduodenal (Option A ruled out) Anastomosis of anterior superior and anterior inferior pancreaticoduodenal arteries Anterior duodenum, head of pancreas, uncinate process Posterior Pancreaticoduodenal Anastomosis of posterior superior and posterior inferior pancreaticoduodenal arteries Posterior head of pancreas, adjacent duodenum, distal bile duct Fig: Anterior and posterior pancreaticoduodenal arterial arcades, typical communicating artery

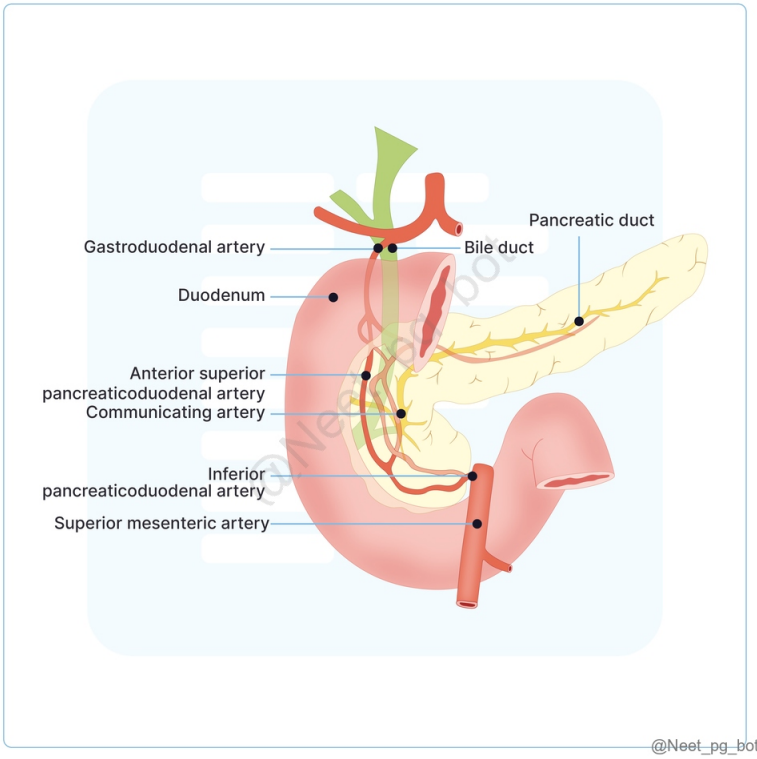

References:

Gray's Anatomy: The Anatomical Basis of Clinical Practice, 42nd Edition, Page 1226, 1227, 1228

↑ *Back to this question in Part A*

@Neet_pg_bot

Q17: A 45-year-old patient presents with chronic upper abdominal pain and is diagnosed with compression of the celiac trunk by the median arcuate ligament. Which of the following arteries is not a direct branch of the celiac trunk? (Q848701)

A. Left gastric artery

B. Splenic artery

C. Common hepatic artery

D. Inferior mesenteric artery

Correct Answer: D. Inferior mesenteric artery

■ *Listen (English)*

■ *Listen (Hindi)*

Explanation: Inferior mesenteric artery arises independently from the abdominal aorta and supplies the hindgut, not the foregut. Celiac Trunk: Origin : First major artery from the abdominal aorta, arises below the aortic hiatus at T12 level. Branches of the Celiac Trunk Left gastric artery. Common hepatic artery. Splenic artery. Compression (Dunbar Syndrome) Compression by the median arcuate ligament can cause visceral ischemia and abdominal pain. . Branches of Superior Mesenteric Artery (SMA): Branch Supplies Inferior pancreaticoduodenal Head of pancreas, duodenum Jejunal arteries Jejunum Ileal arteries Ileum Ileocolic artery Caecal artery Appendicular artery Terminal part of ileum Cecum Appendix (gives rise to cecal & appendicular arteries) Beginning part of colon Right colic artery Ascending colon Middle colic artery Transverse colon Branches of Inferior Mesenteric Artery (IMA): Branch Course & Anastomosis Supplied Regions Left Colic Artery Ascends within left colic mesentery; forms part of the marginal artery of Drummond Distal transverse colon, descending colon Sigmoidal Arteries Descend obliquely in sigmoid mesocolon; anastomose with left colic and superior rectal arteries Distal descending colon, S igmoid colon Superior Rectal Artery Crosses left common iliac vessels; descends to rectum, divides into two branches Rectum , proximal anal canal Left gastric artery (Option A): This is a direct branch of the celiac trunk and supplies the lesser curvature of the stomach and the lower esophagus. Splenic artery (Option B): This is also a direct branch of the celiac trunk and supplies the spleen, parts of the stomach, and pancreas. Common hepatic artery (Option C): This is another direct branch of the celiac trunk and supplies the liver, gallbladder, duodenum, and parts of the stomach.

References:

Gray’s Anatomy: The Anatomical Basis of Clinical Practice, 42nd Edition, Page 1141

↑ *Back to this question in Part A*

@Neet_pg_bot

• [08_Abdomen] 040 Anatomy Abdominal Organs

« Back to Folder Directory

[08_Abdomen] 040 Anatomy Abdominal Organs — Quick Jump

Q1 (p. 1935) *Q2 (p. 1936)* *Q3 (p. 1937)* *Q4 (p. 1939)* *Q5 (p. 1940)* *Q6 (p. 1942)*
Q7 (p. 1943) *Q8 (p. 1944)* *Q9 (p. 1945)* *Q10 (p. 1946)* *Q11 (p. 1948)* *Q12 (p. 1949)*

Q1: A 35-year-old man presents with abdominal pain and ascites. Imaging reveals obstruction of hepatic venous outflow consistent with Budd-Chiari syndrome. Which of the following statements best explains the preservation of the caudate lobe in this condition? (Q848788)

A. The caudate lobe has a separate arterial supply that protects it from hepatic venous obstruction.

B. The caudate lobe drains directly into the inferior vena cava via emissary veins, bypassing the obstructed hepatic veins.

C. The caudate lobe is less affected by portal hypertension due to its anatomical position.

D. The caudate lobe undergoes necrosis less frequently than other liver segments in Budd-Chiari syndrome.

Correct Answer: B. The caudate lobe drains directly into the inferior vena cava via emissary veins, bypassing the obstructed hepatic veins.

■ *Listen (English)*

■ *Listen (Hindi)*

Explanation: The direct drainage of the caudate lobe into the IVC via emissary veins is key to its preservation during hepatic venous obstruction. Budd-Chiari Syndrome Definition : Characterized by obstruction of hepatic venous outflow, leading to increased hepatic sinusoidal pressure. Causes portal hypertension and liver congestion due to impaired venous drainage. Most often associated with hypercoagulable or prothrombotic states. The caudate lobe shows increased contrast enhancement compared to the rest of the liver. Sparing of caudate lobe Separate Drainage : The caudate lobe is drained directly by emissary veins into the inferior vena cava (IVC), bypassing the obstructed hepatic veins. Caudate Hypertrophy : Due to its preserved drainage, the caudate lobe may undergo hypertrophy, compensating for the affected areas.

References:

Gray’s Anatomy: The Anatomical Basis of Clinical Practice, 42nd Edition, Page 1205

Budd-chiari

↑ *Back to this question in Part A*

Q2: During a surgical procedure involving the stomach, the surgeon needs to ensure adequate blood supply. Which artery should the surgeon be most concerned about when addressing the lesser curvature of the stomach? (Q848789)

A. Left gastroepiploic artery

B. Right gastric artery

C. Short gastric arteries

D. Right gastroepiploic artery

Correct Answer: B. Right gastric artery

■ *Listen (English)*

■ *Listen (Hindi)*

Explanation: The right gastric artery, a branch of the common hepatic artery, supplies the lesser curvature of the stomach, making it crucial during surgical interventions in that area. Left gastroepiploic artery (Option A): This artery supplies the greater curvature of the stomach, not the lesser curvature. It arises from the splenic artery . Short gastric arteries (Option C): These arteries also supply the greater curvature of the stomach and the fundus, and they arise from the splenic artery . They do not contribute significantly to the lesser curvature. Right gastroepiploic artery (Option D): This artery supplies the greater curvature of the stomach and arises from the gastroduodenal artery . It does not supply the lesser curvature. Arterial supply of stomach

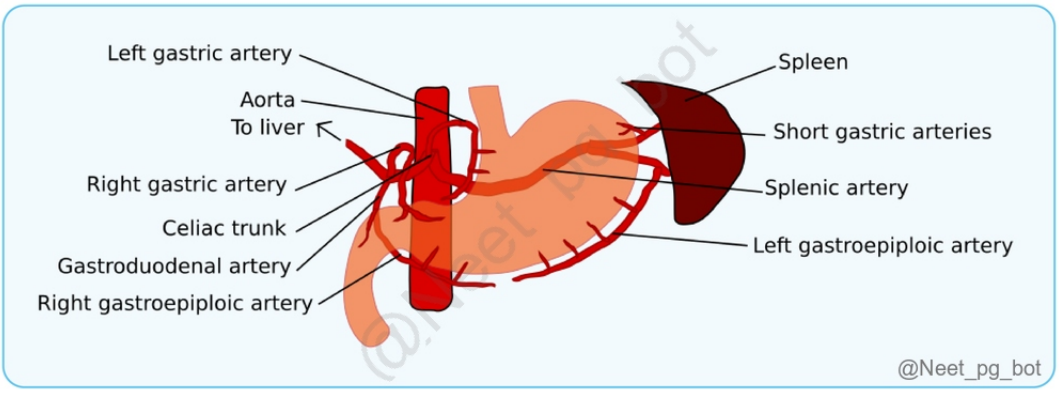

References:

1. BD Chaurasia’s Human Anatomy, Lower limb Abdomen and Pelvis, Volume 2, 8th Edition, Page 295 2. Vishram Singh Textbook of Anatomy, Abdomen and lower-limb, Volume 2, Page 99,100 3. Gray’s Anatomy: The Anatomical Basis of Clinical Practice, 42nd Edition, Pages 1164, 1165, 1166, 1167

↑ *Back to this question in Part A*

Q3: During a cholecystectomy, a surgeon encounters a variation in the biliary anatomy where the cystic duct is unusually short and close to the hepatic duct. Which of the following structures must the surgeon identify to avoid injury and ensure proper bile drainage? (Q848793)

A. Common bile duct

B. Sphincter of Oddi

C. Right hepatic duct

D. Pancreatic duct

Correct Answer: A. Common bile duct

■ *Listen (English)*

■ *Listen (Hindi)*

Explanation: The common bile duct is formed by the union of the common hepatic duct and the cystic duct, draining bile into the duodenum. Proper identification during surgery prevents injury and ensures bile drainage. The Biliary Apparatus: Function: Transports bile from the liver to the duodenum to aid fat digestion. Epiploic foramen: The epiploic foramen, also known as the foramen of Winslow or omental foramen, serves as a key anatomical landmark connecting the greater and lesser sacs of the peritoneum Epiploic foramen is situated behind the lesser sac. The lesser sac is also known as the omental bursa The epiploic foramen, has specific anterior and posterior anatomical relationships. Anterior Relations of Epiploic Foramen: Portal vein Bile duct Proper hepatic artery, which are components of the portal triad. Portal vein, Bile duct, and proper hepatic artery are components of the portal triad . Posterior Relations of Epiploic Foramen: Inferior vena cava Body of the T12 thoracic vertebra Right suprarenal gland. Superior Relation: Caudate lobe of the liver Inferior Relation: First part of the duodenum

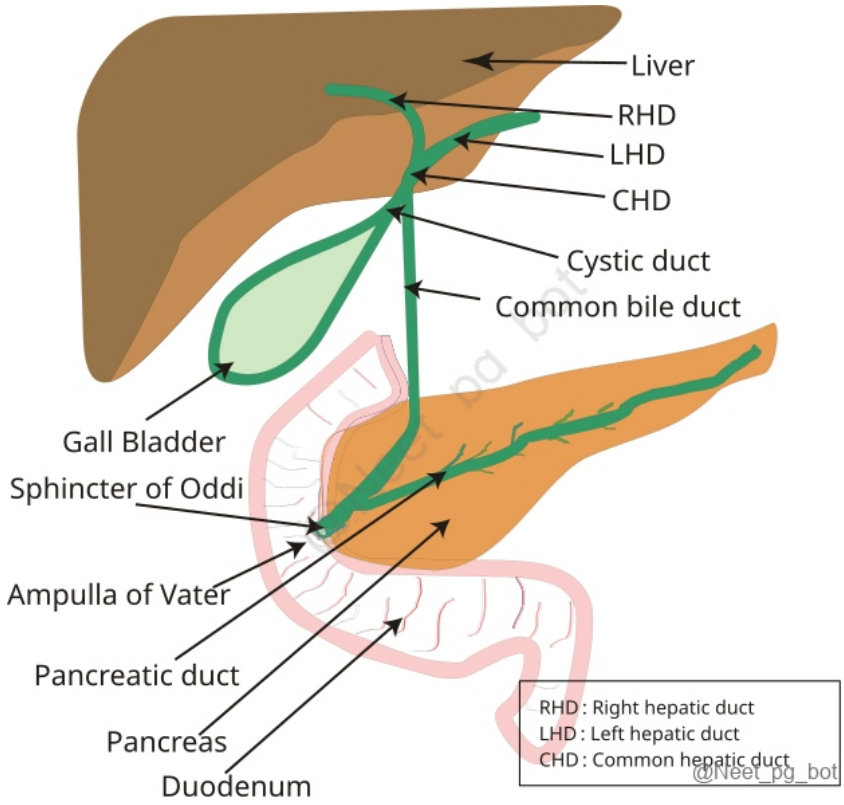

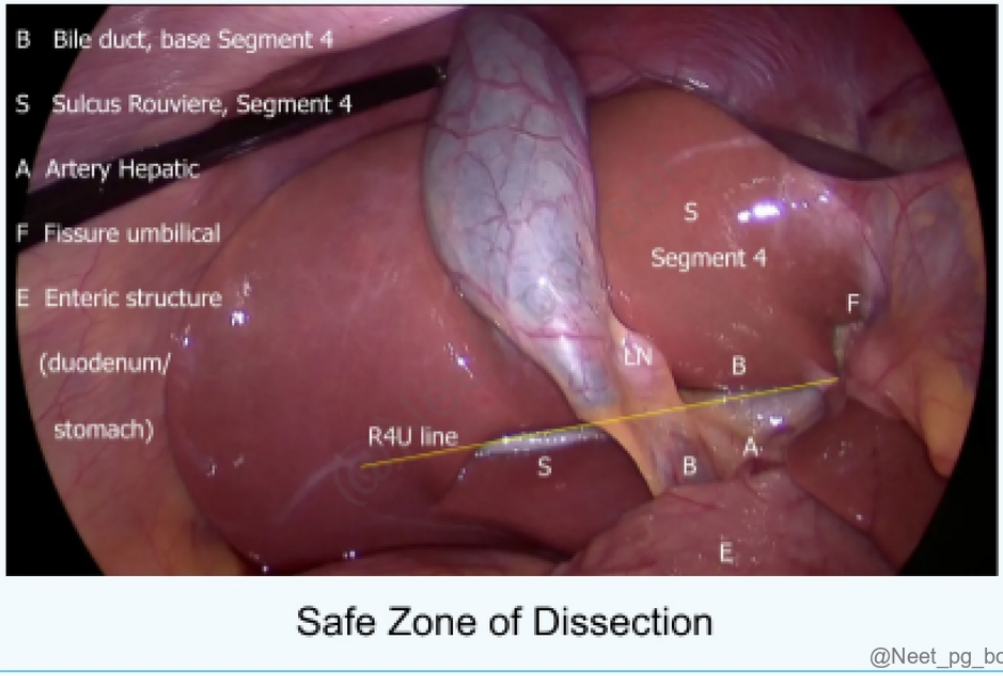

Safe Zone of Dissection

@Neet_pg_bot

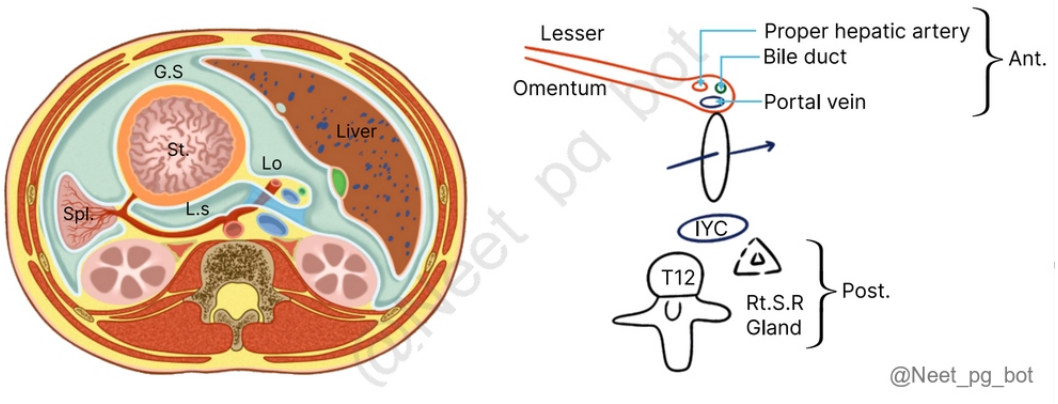

References:

Gray's Anatomy: The Anatomical Basis of Clinical Practice, 42nd Edition, Pages 1214-1221

↑ *Back to this question in Part A*

@Neet_pg_bot

Q4: Which of the following structures is not a component of the sphincter of Oddi? (Q848798)

A. Sphincter of the bile duct

B. Sphincter of the pancreatic duct

C. Sphincter of the ampulla

D. Sphincter of Rosenmuller

Correct Answer: D. Sphincter of Rosenmuller

■ *Listen (English)*

■ *Listen (Hindi)*

Explanation: The sphincter of Rosenmuller is located in the pharynx and is responsible for closing the nasopharynx during swallowing. It is not a part of the Sphincter of Oddi. Sphincter of Oddi The sphincter of Oddi is a smooth muscle complex located at the distal bile duct and pancreatic duct junction in the duodenum. Its function is to regulate bile and pancreatic secretion flow into the duodenum and prevent reflux from the duodenum into the ducts. It comprises three distinct components: Sphincter of the bile duct Sphincter of the ampulla Sphincter of the pancreatic duct

References:

Gray's Anatomy: The Anatomical Basis of Clinical Practice, 42nd Edition, Page 1219

↑ *Back to this question in Part A*

@Neet_pg_bot

Q5: A 45-year-old patient is scheduled for a liver imaging study. The radiologist explains that dividing the liver into physiological lobes is important for understanding liver anatomy and function. Which of the following is primarily responsible for dividing the liver into physiological lobes? (Q848785)

A. Falciform ligament

B. Cantlie's line

C. Ligamentum teres

D. Porta hepatis

Correct Answer: B. Cantlie's line

■ *Listen (English)*

■ *Listen (Hindi)*

Explanation: Cantlie's line is the imaginary line that divides the liver into right and left physiological lobes. Physiological Lobes of the Liver The liver is divided into right and left physiological lobes based on the intrahepatic distribution of the bile ducts, hepatic artery, and portal vein. This division follows an imaginary sagittal plane called Cantlie’s line (Main portal fissure) . Posteroinferior Surface: The plane runs through the fossa for the gallbladder to the groove for the inferior vena cava (IVC). Anterosuperior Surface: It extends from the IVC to the cystic notch, located slightly to the right of the falciform ligament.

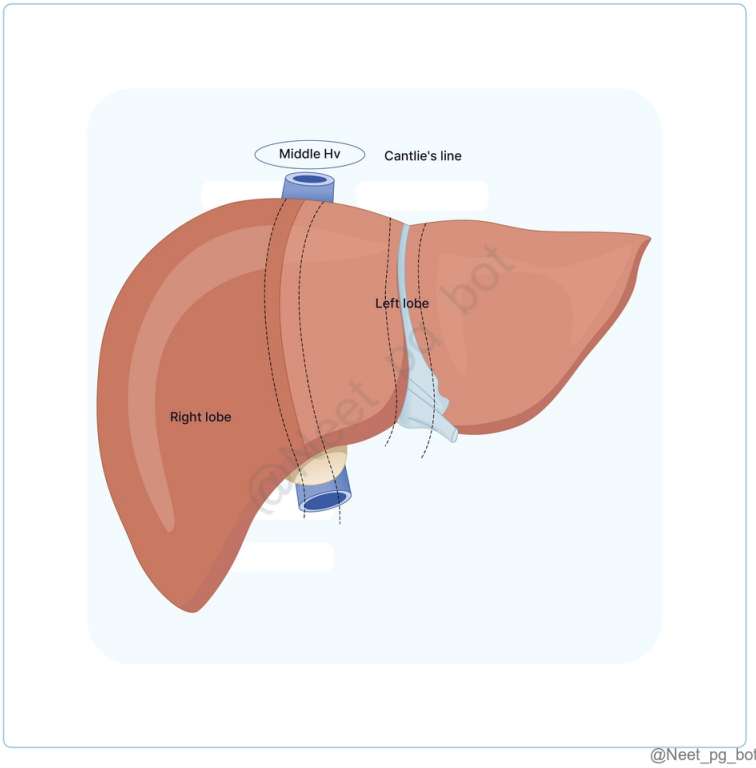

@Neet_pg_bot

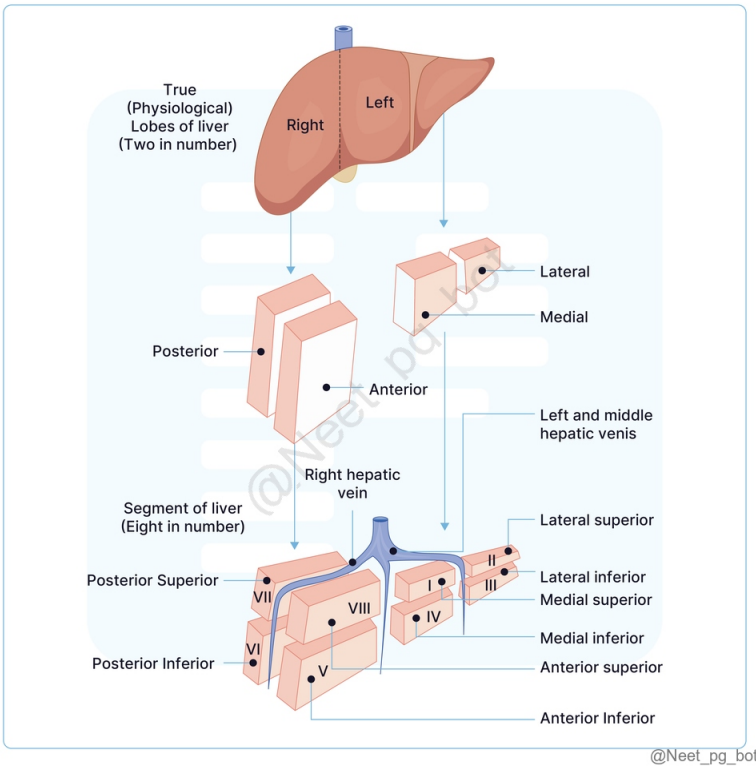

@Neet_pg_bot

References:

Vishram Singh Textbook of Anatomy, Abdomen and lower-limb, Volume 2, Pages111, 112

Gray’s Anatomy: The Anatomical Basis of Clinical Practice, 42nd Edition, Page 1207

↑ *Back to this question in Part A*

@Neet_pg_bot

Q6: Match the following Sectors of the liver with their respective segments. 1. Right Posterior Sector a) Segments IV 2. Right Anterior Sector b) Segments III 3. Left Medial Sector c) Segment VII 4. Left Lateral Sector d) Segments V (Q848786)

A. 1-a, 2-d, 3-c, 4-b

B. 1-a, 2-d, 3-b, 4-c

C. 1-d, 2-c, 3-b, 4-a

D. 1-c, 2-d, 3-a, 4-b

Correct Answer: D. 1-c, 2-d, 3-a, 4-b

■ *Listen (English)*

■ *Listen (Hindi)*

Explanation: The liver is divided into four portal sectors—right anterior, right posterior, left medial, and left lateral—by the main branches of the hepatic portal vein. The three main hepatic veins lie between these sectors, referred to as intersectoral veins, or portal fissures. Each sector is typically subdivided into segments based on the supply from tertiary divisions of the perivascular fibrous capsules (Glissonian sheaths). Sector Segments Right Posterior Sector Segments VI and VII Right Anterior Sector Segments V and VIII Left Medial Sector Segment IV (and part of I) Left Lateral Sector Segments II and III

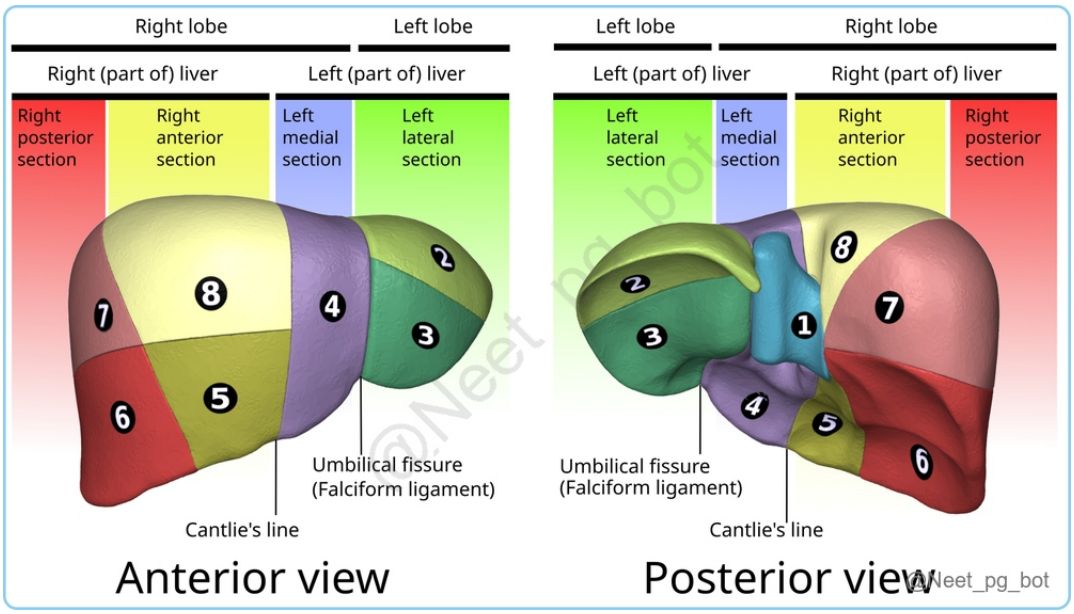

References:

Gray’s Anatomy: The Anatomical Basis of Clinical Practice, 42nd Edition, Pages 1207, 1208

BD Chaurasia’s Human Anatomy, Lower limb Abdomen and Pelvis, Volume 2, 8th Edition, Pages 359-360

↑ *Back to this question in Part A*

@Neet_pg_bot

Q7: A patient is undergoing imaging for liver evaluation. The radiologist describes a segment located posterior to the right hepatic vein and in the superior part of the right posterior sector. Which segment of the liver is being described? (Q848787)

A. Segment V

B. Segment III

C. Segment VII

D. Segment II

Correct Answer: C. Segment VII

■ *Listen (English)*

■ *Listen (Hindi)*

Explanation: Segment VII is the segment located in the superior part of the right posterior sector and posterior to the right hepatic vein. Segment V (Option A): Incorrect because this segment is located in the right anterior inferior sector of the liver, anterior to the right hepatic vein, so it does not match the description provided. Segment III (Option B): Incorrect because segment III is located in the left liver, specifically in the inferior part of the left lateral sector, which is far from the described location. Segment II (Option D): Incorrect because this segment is also located in the left liver, in the superior part of the left lateral sector, and does not correspond to the posterior location described. Segments I to IV (Left Lobe): Supply: Left branch of the hepatic artery and left branch of the portal vein. Drainage: Drained by the left hepatic duct. Segments V to VIII (Right Lobe): Supply: Right hepatic artery and right branch of the portal vein. Drainage: Drained by the right hepatic duct.

References:

Gray’s Anatomy: The Anatomical Basis of Clinical Practice, 42nd Edition, Page. 1209

Vishram Singh Textbook of Anatomy, Abdomen and lower-limb, Volume 2, 2nd Edition, Page 113

↑ *Back to this question in Part A*

@Neet_pg_bot

Q8: A 45 y/o man presents with symptoms of gastric dysmotility and increased acid secretion. Which structures are primarily involved in the parasympathetic innervation of the stomach? (Q848790)

A. Greater splanchnic nerves and coeliac plexus

B. Vagus nerves and their branches

C. T6 to T10 spinal segments

D. Lumbar sympathetic ganglia

Correct Answer: B. Vagus nerves and their branches

- *Listen (English)*
- *Listen (Hindi)*

Explanation: The parasympathetic innervation of the stomach is primarily provided by the vagus nerves and their branches. Nerve supply of stomach Sympathetic Innervation Parasympathetic Innervation Derived from T6 to T10 spinal segments via greater splanchnic nerves . Fibers run along arteries via coeliac and hepatic plexuses . Derived from vagus nerves . Anterior vagal trunk : Posterior vagal trunk : Neurovascular Supply of the Gut: Feature Foregut Midgut Hindgut Anatomical Extent Esophagus to proximal 1/2 of Duodenum Distal 1/2 of Duodenum to proximal 2/3 of Transverse Colon Distal 1/3 of Transverse Colon to upper Anal Canal Arterial Supply Celiac Trunk Superior Mesenteric Artery (SMA) Inferior Mesenteric Artery (IMA) Venous Drainage Splenic & Gastric veins (to Portal Vein) Superior Mesenteric Vein Inferior Mesenteric Vein Sympathetic Supply Greater Splanchnic nerves (T5–T9) Lesser Splanchnic nerves (T10–T11) Lumbar Splanchnic nerves (L1–L2) Sympathetic Ganglia Celiac Ganglion Superior Mesenteric Ganglion Inferior Mesenteric Ganglion Parasympathetic Vagus Nerve (CN X) Vagus Nerve (CN X) Pelvic Splanchnic nerves (S2–S4)

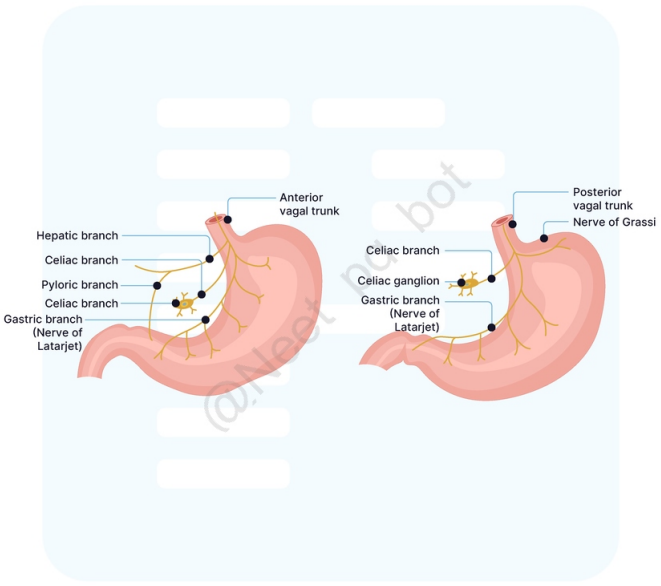

@Neet_pg_bot

References:

1. BD Chaurasia's Human Anatomy, Lower limb Abdomen and Pelvis, Volume 2, 8th Edition, Page 297 2. Vishram Singh Textbook of Anatomy, Abdomen and lower-limb, Volume 2, 2nd Edition, Page 101 3. Gray's Anatomy: The Anatomical Basis of Clinical Practice, 42nd Edition, Pages 1169

↑ *Back to this question in Part A*

@Neet_pg_bot

Q9: Which of the following structures is not part of the stomach bed? (Q848791)

A. Left kidney

B. Pancreas

C. Diaphragm

D. Right kidney

Correct Answer: D. Right kidney

■ *Listen (English)*

■ *Listen (Hindi)*

Explanation: The right kidney is not part of the stomach bed, as it is located on the right side of the body, far from the stomach. Stomach Bed: The stomach bed refers to the group of structures located behind the posterior surface of the stomach. These structures form the support for the stomach and are separated from it by the cavity of the lesser sac. Structures located in the stomach bed :(Mnemonic -DR SSS KILL) Diaphragm (Option C ruled out) Left kidney (Option A ruled out) Left suprarenal gland Pancreas (Option B ruled out) Transverse mesocolon Splenic flexure of the colon Splenic artery Note: The spleen is sometimes considered part of the stomach bed but is separated from the stomach by the greater sac.

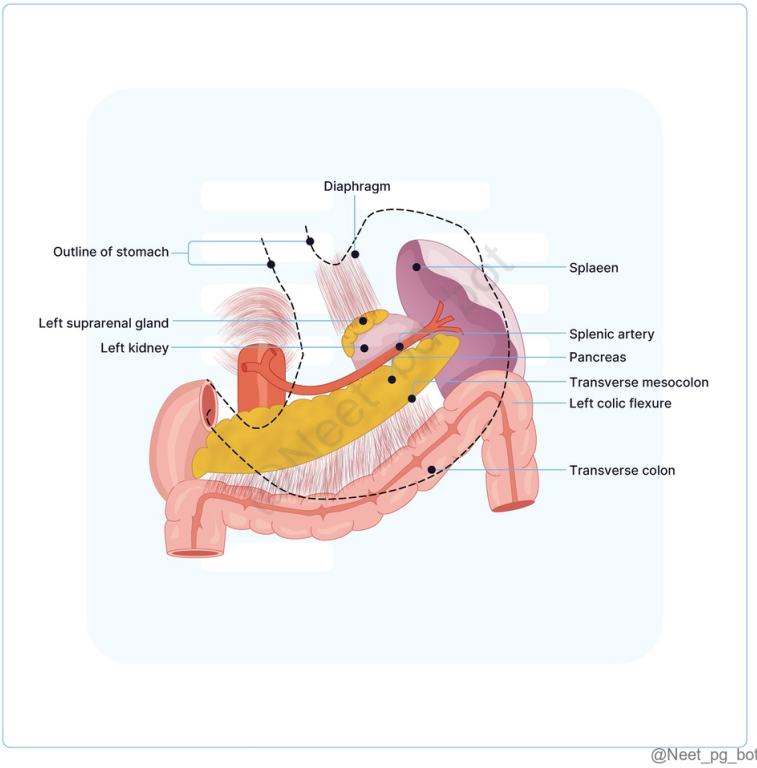

References:

B.D. Chaurasia's Human Anatomy, Edition 8, Volume 2, Page 295

↑ *Back to this question in Part A*

@Neet_pg_bot

Q10: A 60 y/o woman presents with abdominal pain localized to the upper right quadrant. Imaging reveals a mass adjacent to the uncinate process of the pancreas. Which part of the duodenum is most likely in direct relation to this mass? (Q848792)

A. First (superior) part

B. Second (descending) part

C. Third (horizontal) part

D. Fourth (ascending) part

Correct Answer: C. Third (horizontal) part

■ *Listen (English)*

■ *Listen (Hindi)*

Explanation: The third (horizontal) part is positioned horizontally and is more likely to be in contact with structures adjacent to the pancreas. Duodenum Relations of Duodenum First (superior) part (Option A) : While it is anteriorly related to the liver, it is not in direct contact with the pancreas. Second (descending) part (Option B): It is adjacent to the head of the pancreas but not directly to the uncinate process. Fourth (ascending) part (Option D) : It is more posterior and further from the pancreas

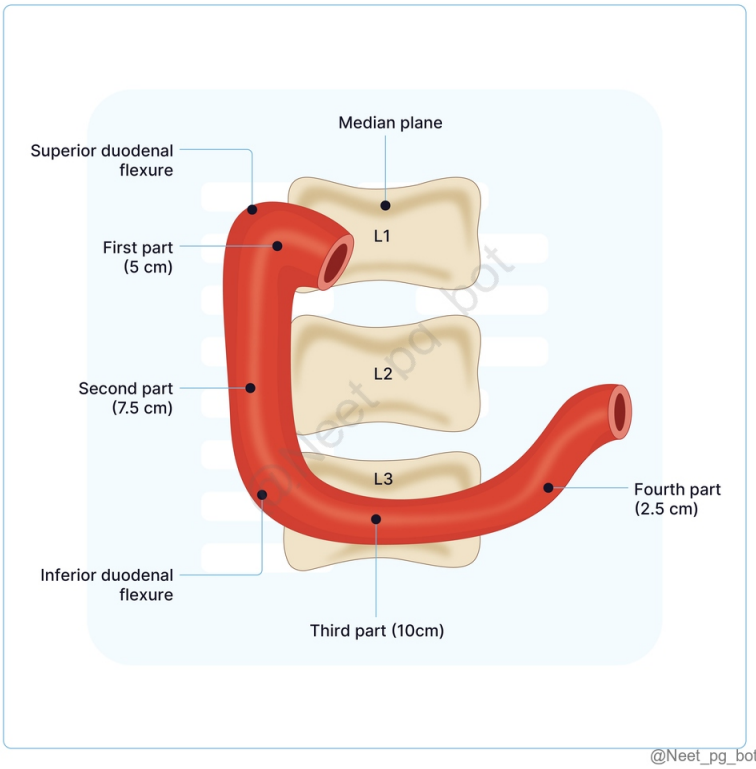

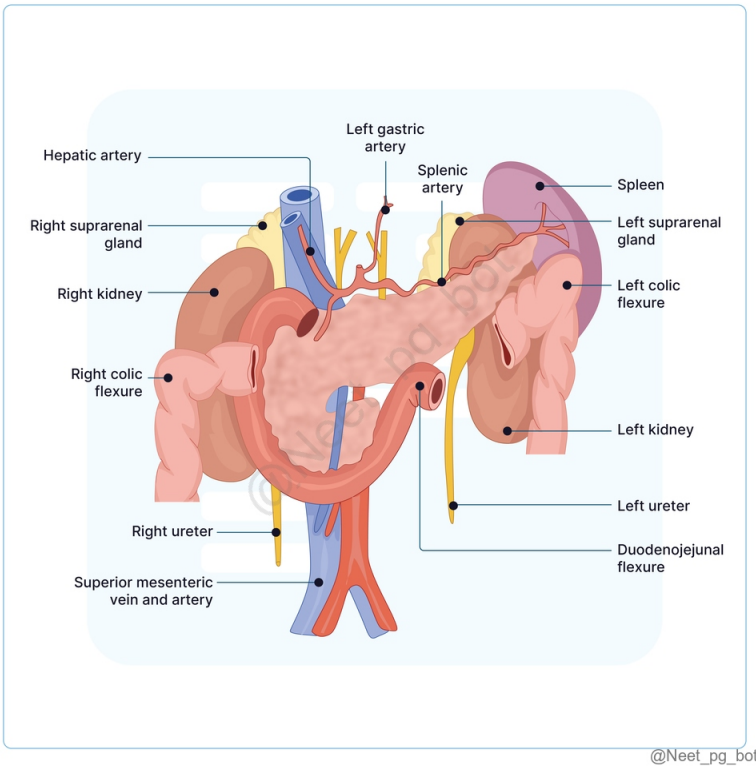

@Neet_pg_bot

References:

Gray's Anatomy: The Anatomical Basis of Clinical Practice, 42nd Edition, Pages 1173,1175

BD Chaurasia's Human Anatomy, Lower limb Abdomen and Pelvis, Volume 2, 8th Edition, Page 305, 306, 307, 308

Vishram Singh Textbook of Anatomy, Abdomen and lower-limb, Volume 2, Page 126,127, 128

↑ *Back to this question in Part A*

@Neet_pg_bot

Q11: Which of the following is a characteristic feature of the ileum compared to the jejunum? (Q848800)

A. Thicker and more vascular wall

B. Fewer Peyer's patches

C. More numerous straight arteries

D. Larger and more prominent circular folds

Correct Answer: C. More numerous straight arteries

■ *Listen (English)*

■ *Listen (Hindi)*

Explanation: The ileum has more numerous but shorter straight arteries compared to the jejunum. Comparison of Jejunum and Ileum: Feature Jejunum Ileum Diameter Larger (4 cm external, 3 cm internal) Smaller (3 cm external, 2.5 cm internal) Wall Thickness Thicker, more vascular Thinner, less vascular (Option A) Circular Folds Deeper, more numerous Flatter, less numerous distally (Option D) Mesentery Shorter Longer Straight Arteries Fewer, longer More numerous, shorter (Option C) Lymphoid Tissue Fewer Peyer's patches More Peyer's patches, especially in terminal 25 cm (Option B) Villi Taller, more numerous Shorter, fewer towards the distal end

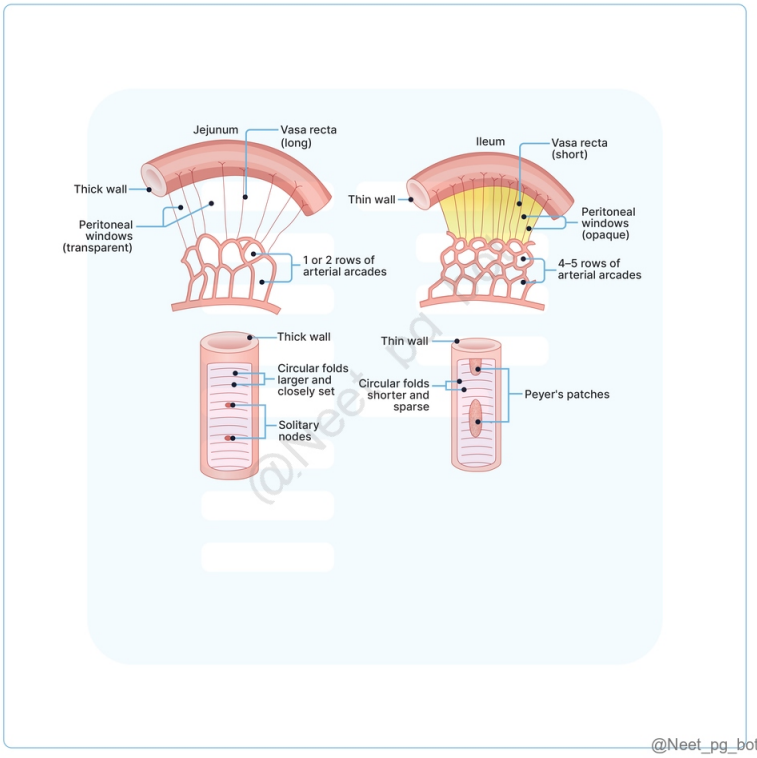

References:

Gray's Anatomy: The Anatomical Basis of Clinical Practice, 42nd Edition, Pages 1176, 1177

↑ *Back to this question in Part A*

@Neet_pg_bot

Q12: A 45 y/o male patient presents with abdominal pain and distension. A CT scan reveals multiple appendices epiploicae, particularly prominent in the sigmoid colon. Which of the following statements regarding the anatomy of the large intestine is false? (Q848801)

A. The caecum is typically 8-10 cm long and is a common site for appendices epiploicae.

B. The sigmoid colon, which is S-shaped, leads directly into the rectum.

C. The total length of the large intestine in adults ranges from 1 to 1.5 meters.

D. Appendices epiploicae are more common in the distal colon.

Correct Answer: A. The caecum is typically 8-10 cm long and is a common site for appendices epiploicae.

■ *Listen (English)*

■ *Listen (Hindi)*

Explanation: The caecum is not typically 8-10 cm long, and appendices epiploicae are more prevalent in the sigmoid colon and distal colon. Total Length of the Large intestine length in a living adult: 1 to 1.5 metres (Option C ruled out) Caecum (Option A) Blind pouch at the beginning of the large intestine and is approximately 6 cm long Sigmoid Colon: S-shaped segment leading to the rectum (Option B ruled out) Appendices Epiploicae: Feature Details Description Small, fat-filled pouches of peritoneum on the colon's surface. Location Few or absent on caecum and ascending colon (Option A). More common on the distal colon (Option D ruled out). Numerous on the sigmoid colon; can enlarge with obesity. Absent on rectum.

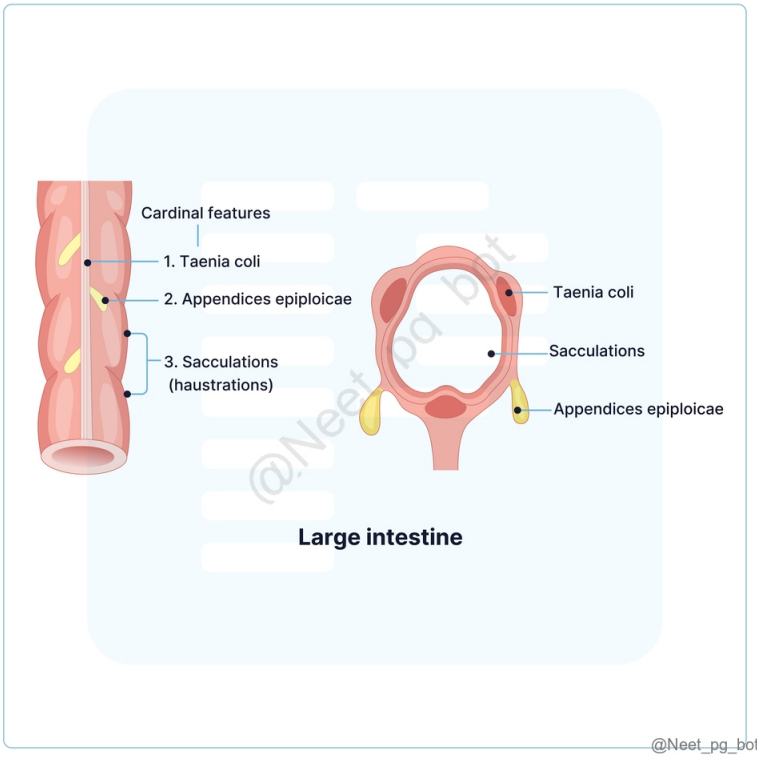

References:

Gray’s Anatomy: The Anatomical Basis of Clinical Practice, 42nd Edition, Pages 1115, 1185

↑ *Back to this question in Part A*

@Neet_pg_bot

• [08_Abdomen] 041 Anatomy Pancreas Kidney And Ureter

« Back to Folder Directory

[08_Abdomen] 041 Anatomy Pancreas Kidney And Ureter — Quick Jump

Q1 (p. 1952) *Q2 (p. 1953)* *Q3 (p. 1954)* *Q4 (p. 1955)* *Q5 (p. 1957)* *Q6 (p. 1957)*
Q7 (p. 1959) *Q8 (p. 1960)* *Q9 (p. 1962)* *Q10 (p. 1962)*

Q1: What structure crosses the ureter anteriorly on both sides during its abdominal course? (Q848669)

A. Inferior mesenteric artery

B. Gonadal vessels

C. Genitofemoral nerve

D. Duodenum

Correct Answer: B. Gonadal vessels

■ *Listen (English)*

■ *Listen (Hindi)*

Explanation: In both males and females, the ureter is crossed anteriorly by the gonadal vessels during its abdominal course. These vessels are the testicular artery and vein in males and the ovarian artery and vein in females. Relations of the abdominal part of the Ureter Anterior Relation Posterior Relation Right Ureter The second part of the Duodenum Right Colic vessels Ileocolic vessels Right testicular and ovarian vessels Root of mesentery Right Psoas Major Bifurcation of Right Common Iliac artery Left Ureter Left Colic vessels Sigmoidal vessels Left testicular and ovarian vessels Sigmoid mesocolon Left Psoas Major Bifurcation of Left Common Iliac artery

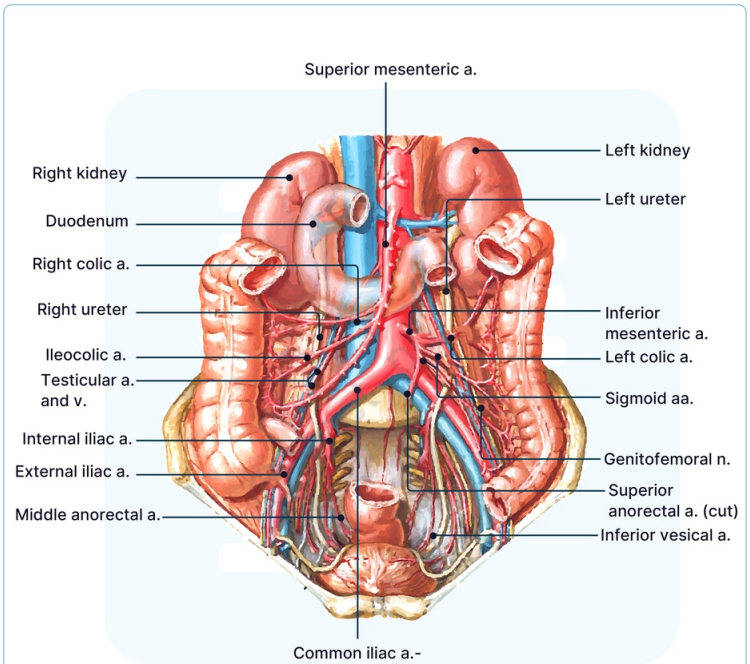

@Neet_pg_bot

References:

Gray's Anatomy, 42nd Edition, Page 1273

Netter Atlas of Human Anatomy, 8th Edition, Plate 335, Page 463

Textbook of Anatomy Vishram Singh, 2nd Edition, Volume 2, Page 178

↑ *Back to this question in Part A*

@Neet_pg_bot

Q2: Which vessels primarily supply the middle part of the ureter? (Q848671)

A. Renal artery

B. Vesical vessels

C. Aorta

D. Uterine vessels

Correct Answer: C. Aorta

■ *Listen (English)*

■ *Listen (Hindi)*

Explanation: The middle part of the ureter is primarily supplied by branches from the aorta. It can also receive blood from gonadal or iliac vessels, but the aorta is the key vessel for this segment. Blood Supply of the Ureter Arteries are closely associated with the peritoneum. They form a plexus on the ureter's surface with ascending and descending branches. The upper and middle parts receive blood from the medial side, while the pelvic part is supplied from the lateral side. Upper Part: Supplied by branches from the renal artery. (Option A ruled out) Middle Part: Receives branches from the aorta. Pelvic Part: Supplied by branches from vesical, middle rectal, or uterine vessels. (Options B & C ruled out) Fig: Blood Supply of the Ureter

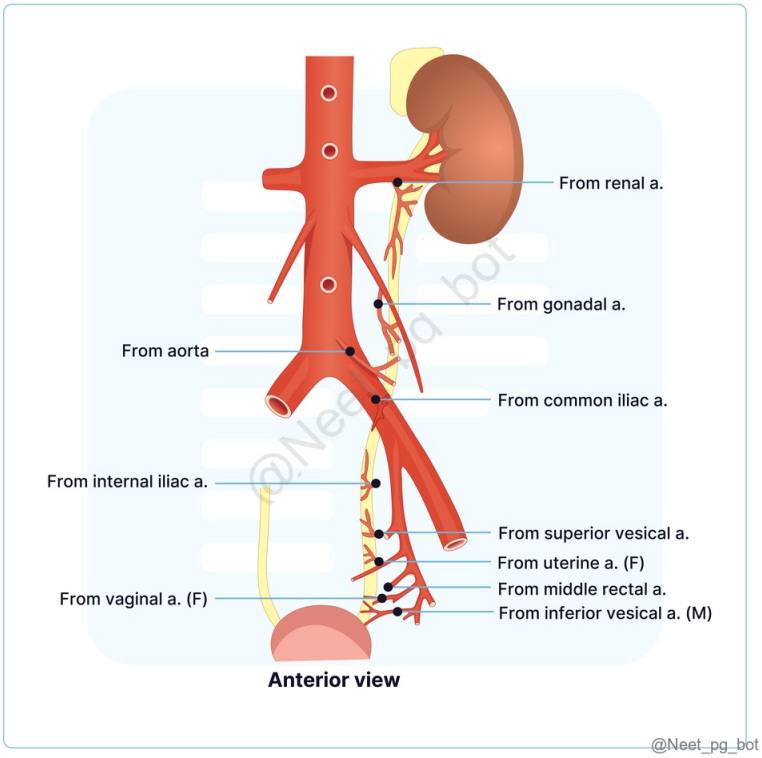

References:

Gray’s Anatomy, 42nd edition, Page 1273

BD Chaurasia’s Human Anatomy, Volume 2, 8th edition, Pages 377, 378

Snells Clinical Anatomy, 10th edition, Page 384

↑ *Back to this question in Part A*

@Neet_pg_bot

Q3: A 9 y/o child presents with abdominal pain and hematuria. Imaging reveals that the left renal vein is compressed between the abdominal aorta and the superior mesenteric artery. What is a key anatomical feature contributing to this condition? (Q848664)

A. The left renal vein passes behind the abdominal aorta.

B. The pancreas lies directly posterior to the superior mesenteric artery.

C. The left renal vein travels behind the pancreas before crossing the aorta.

D. The pancreas is situated inferior to the left renal vein.

Correct Answer: C. The left renal vein travels behind the pancreas before crossing the aorta.

■ *Listen (English)*

■ *Listen (Hindi)*

Explanation: The left renal vein's route behind the pancreas contributes to its susceptibility to compression. Relationship of the Pancreas, Veins, and Aorta in Nutcracker Syndrome Nutcracker Syndrome: A condition caused by compression of the left renal vein leading to the left renal vein hypertension. Highlights the anatomical relationship between the pancreas, veins, and aorta. Anatomical Features Description Left Renal Vein Originates from the hilum of the left kidney. Travels behind the pancreas and splenic vein. (Option C) (Option D ruled out) Crosses the abdominal aorta anteriorly below the superior mesenteric artery. (Option A ruled out) Nutcracker Analogy The left renal vein is compressed between the aorta and superior mesenteric artery, resembling a nutcracker. Symptoms Can lead to left renal vein hypertension. Symptoms include hematuria and varicocele, especially in children. Pancreas' Role in Nutcracker Syndrome: Positioned directly in front of the compression site, anterior to the SMA. (Option B ruled out) Proximity to vascular structures suggests the potential to worsen the condition. The uncinate process being close to the superior mesenteric artery and vein further emphasises the pancreas's proximity to major vessels.

References:

Gray’s Anatomy, 42nd Edition, Pages 1123, 1140, 1227, 1267

↑ *Back to this question in Part A*

@Neet_pg_bot

Q4: Which vein receives drainage from both the left gonadal and left adrenal veins? (Q848665)

A. Inferior vena cava

B. Right renal vein

C. Left renal vein

D. Right adrenal vein

Correct Answer: C. Left renal vein

■ *Listen (English)*

■ *Listen (Hindi)*

Explanation: Left gonadal and left adrenal veins drain into the left renal vein , emptying into the inferior vena cava. This is a key anatomical difference from the right side, where the veins drain directly into the inferior vena cava. Inferior vena cava (Option A): While the right gonadal and adrenal veins drain directly into the inferior vena cava, the left gonadal and adrenal veins drain into the left renal vein instead. Right renal vein (Option B): The right renal vein handles drainage from structures on the right side of the body, such as the right kidney. It does not receive blood from the left gonadal or adrenal veins. Right adrenal vein (Option D): The right adrenal vein is responsible for draining blood from the right adrenal gland into the inferior vena cava. It does not interact with the left gonadal or adrenal veins.

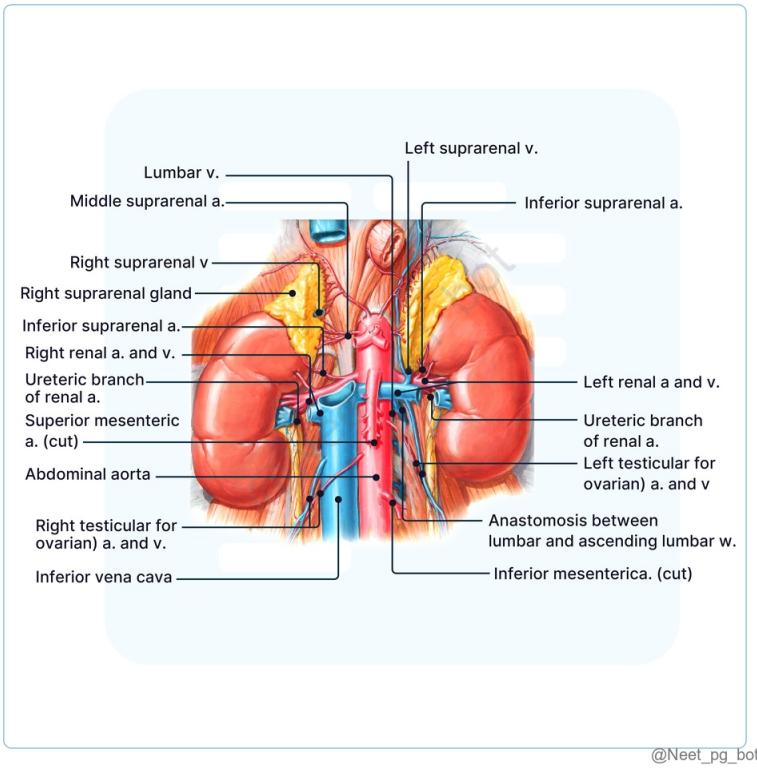

@Neet_pg_bot

References:

Gray’s Anatomy, 42nd Edition, Page 1267

Netter Atlas of Human Anatomy, 8th Edition, Plate 332, Page 460

Textbook of Anatomy Vishram Singh, 2nd Edition, Volume 2, Pages 194,69

↑ *Back to this question in Part A*

@Neet_pg_bot

Q5: Which of the following layers immediately surrounds the kidney and adheres closely to its surface? (Q848666)

A. Pararenal fat

B. Fibrous capsule

C. Renal fascia

D. Perirenal fat

Correct Answer: B. Fibrous capsule

■ *Listen (English)*

■ *Listen (Hindi)*

Explanation: The fibrous capsule, also known as the true capsule, is a thin, fibrous membrane that tightly adheres to the surface of the kidney. It is the kidney's immediate protective layer, safeguarding it from minor injuries. Coverings of the kidney (From inside out): Renal Capsule Perirenal Fat Renal Fascia Pararenal Fat

References:

Gray’s Anatomy, 42nd Edition, Page 1260

Netter Atlas of Human Anatomy, 8th Edition, Plate 333, Page 461

Textbook of Anatomy Vishram Singh, 2nd Edition, Volume 2, Pages 168,169

↑ *Back to this question in Part A*

@Neet_pg_bot

Q6: Which structure is in direct contact with the upper pole of the right kidney? (Q848667)

A. Right lobe of the liver

B. Duodenum

C. Right suprarenal gland

D. Right colic flexure

Correct Answer: C. Right suprarenal gland

■ *Listen (English)*

■ *Listen (Hindi)*

Explanation: The right suprarenal gland lies directly on the upper pole of the right kidney, potentially overlapping the kidney's medial border. There is no intervening peritoneum, making the gland and kidney directly connected. Anterior Relations of Kidney Right Kidney Left Kidney The right lobe of the Liver Right suprarenal gland The second part of the duodenum Jejunum Hepatic (Right colic) flexure Left suprarenal gland Stomach Spleen Jejunum Left colic flexure Pancreas and splenic vessels

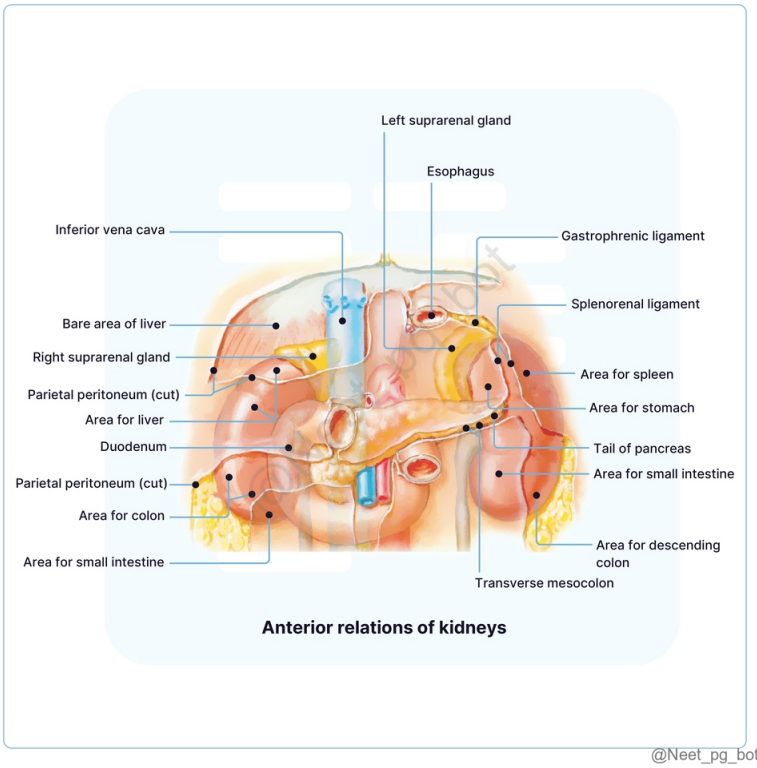

@Neet_pg_bot

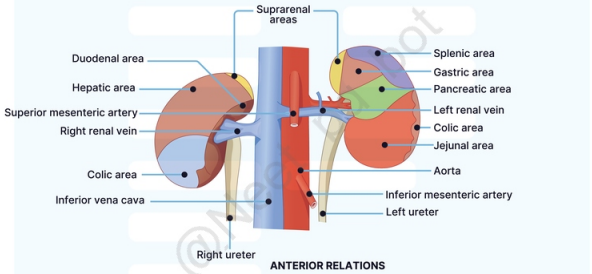

@Neet_pg_bot

References:

Gray's Anatomy, 42nd Edition, Page 1261

Netter Atlas of Human Anatomy, 8th Edition, Plate 330, Page 458

Textbook of Anatomy Vishram Singh, 2nd Edition, Volume 2, Pages 166,167

↑ *Back to this question in Part A*

@Neet_pg_bot

Q7: Which rib is related to the posterior surface of the left kidney but not the right kidney? (Q848668)

A. 7th rib

B. 8th rib

C. 12th rib

D. 11th rib

Correct Answer: D. 11th rib

■ *Listen (English)*

■ *Listen (Hindi)*

Explanation: The 11th rib is a posterior relation of the left kidney but not the right kidney . The kidneys are not positioned at the same level— the right kidney lies slightly lower due to the bulk of the liver. As a result, the right kidney is related only to the 12th rib, whereas the left kidney, which sits higher, is related to both the 11th and 12th ribs.

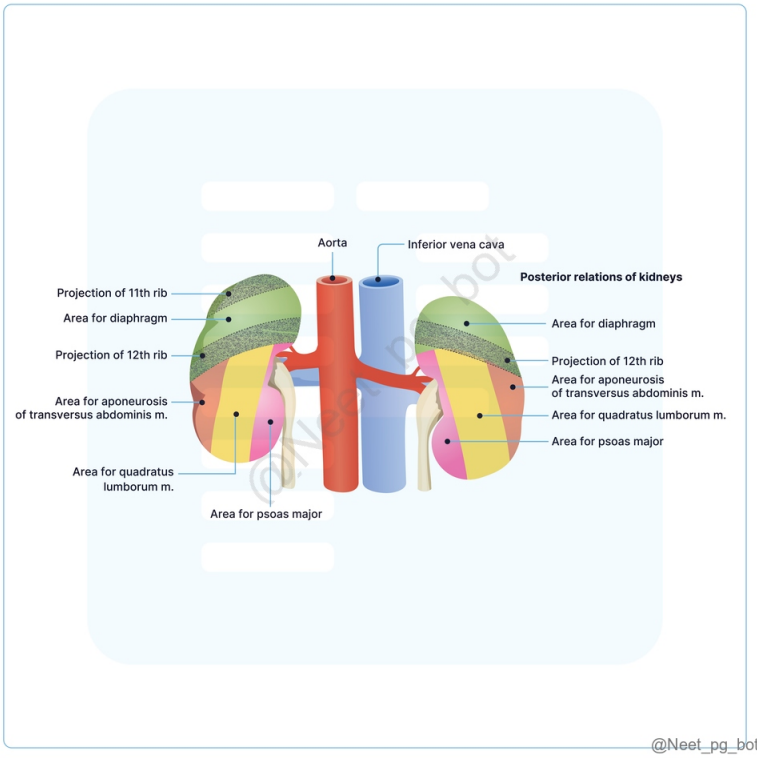

References:

Gray’s Anatomy, 42nd Edition, Page 1261

Netter Atlas of Human Anatomy, 8th Edition, Plate 331, Page 459

Textbook of Anatomy Vishram Singh, 2nd Edition, Volume 2, Pages 167,168

↑ *Back to this question in Part A*

@Neet_pg_bot

Q8: Which of the following is not a typical site of ureteric constriction? (Q848670)

A. Junction with the renal pelvis

B. Crossing by ductus deferens

C. At the pelvic outlet

D. Opening at the trigone

Correct Answer: C. At the pelvic outlet

■ *Listen (English)*

■ *Listen (Hindi)*

Explanation: The opening of the pelvic outlet is not typically recognized as a site of ureteric constriction. Ureteric constriction occurs at the pelvic inlet (pelvic brim) where it crosses the common iliac artery. Ureteric constrictions The ureters have several points of constriction that are clinically significant, particularly for renal stone impaction. The typical sites of constriction are: 1. Junction with the renal pelvis (Option A ruled out) 2. At the linea terminalis 3. Intramural segment 4. Crossing by ductus deferens or broad ligament (Option B ruled out) 5. Opening at the trigone (Option D ruled out)

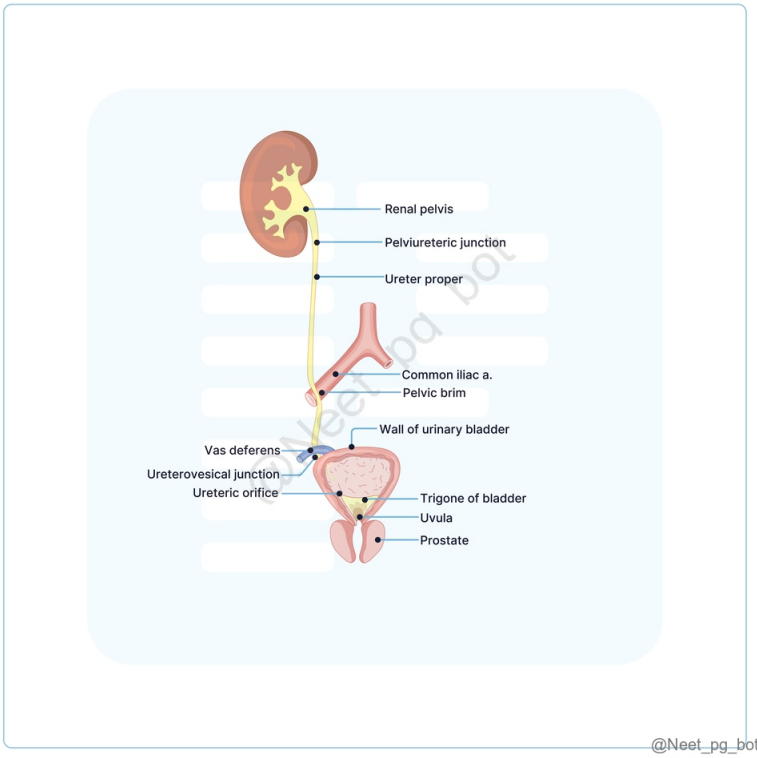

References:

Gray’s Anatomy, 42nd edition, Page 1273

BD Chaurasia’s Human Anatomy, Volume 2, 8th edition, Page 375

Snells Clinical Anatomy, 10th edition, Page 449

↑ *Back to this question in Part A*

@Neet_pg_bot

Q9: Which part of the pancreas is covered by the peritoneum? (Q848672)

A. Head of the pancreas

B. Body of the pancreas

C. Tail of the pancreas

D. Entire pancreas

Correct Answer: C. Tail of the pancreas

■ *Listen (English)*

■ *Listen (Hindi)*

Explanation: The tail of the pancreas is the only part of the pancreas that is covered by the peritoneum. It extends towards the spleen and is enclosed by the peritoneum, making it intraperitoneal. Retroperitoneal organs: Kidneys Duodenum Ascending and descending colon Rectum (lower ■) Adrenal glands Ureters Head and body of Pancreas (Options A, B) Aorta and Inferior venacava

References:

Textbook of Anatomy Vishram Singh, 2nd Edition, Volume 2, Page 132.

↑ *Back to this question in Part A*

@Neet_pg_bot

Q10: A 45-year-old male presents with complaints of a progressively enlarged abdomen and discomfort on the left side. Imaging studies reveal splenomegaly. Which structure is primarily responsible for preventing the downward displacement of the spleen in this case? (Q848673)

A. Phrenicocolic Ligament

B. Gastrosplenic Ligament

C. Splenorenal Ligament

D. Diaphragm

Correct Answer: A. Phrenicocolic Ligament

■ *Listen (English)*

■ *Listen (Hindi)*

Explanation: Downward displacement of the enlarged spleen is prevented by th e phrenicolic ligament. The phrenicolic ligament connects the splenic flexure of the colon to the diaphragm. It is not attached to the spleen. However, it lies below the spleen and supports its lower pole. When the spleen gets enlarged, phrenicolic ligaments along with the splenic flexure of the colon restrict its downward displacement. Hence, it is also called Sustentaculum lienis. Ligaments of the spleen:

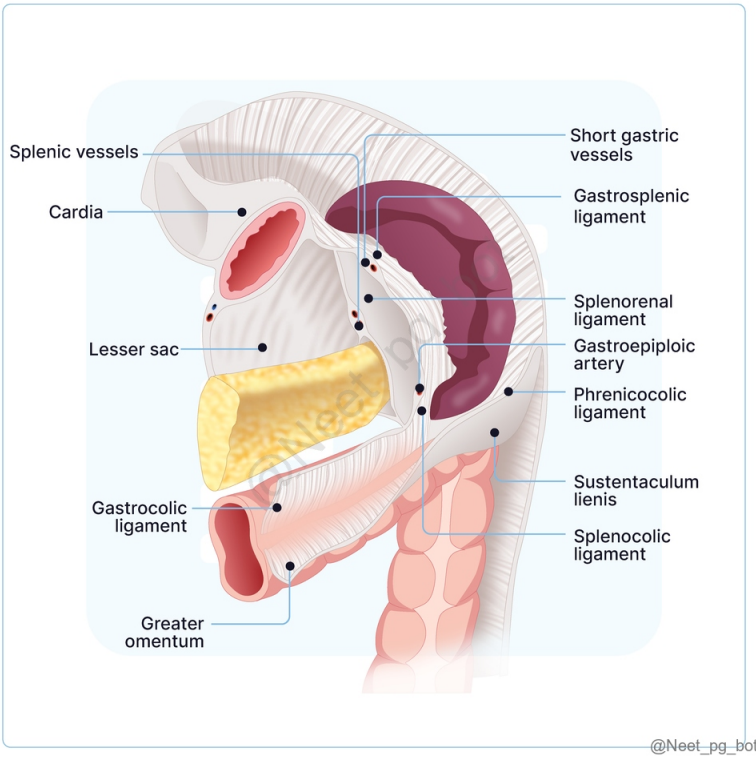

References:

Textbook of Anatomy Vishram Singh, 2nd Edition, Volume 2, Pages 104, 105.

↑ *Back to this question in Part A*

@Neet_pg_bot

• [08_Abdomen] 042 Abdominal Neurovascular Bundles

« Back to Folder Directory

[08_Abdomen] 042 Abdominal Neurovascular Bundles — Quick Jump

Q1 (p. 1964) *Q2 (p. 1964)* *Q3 (p. 1966)* *Q4 (p. 1967)* *Q5 (p. 1968)* *Q6 (p. 1969)*
Q7 (p. 1971) *Q8 (p. 1972)*

Q1: Which of the following statements about the autonomic innervation of the gastrointestinal tract is correct? (Q848676)

A. The vagus nerve provides parasympathetic innervation to the entire length of the gut.

B. The pelvic splanchnic nerves supply sympathetic innervation to the hindgut.

C. The greater splanchnic nerves provide sympathetic innervation primarily to the midgut.

D. The parasympathetic supply to the hindgut originates from the sacral spinal cord.

Correct Answer: D. The parasympathetic supply to the hindgut originates from the sacral spinal cord.

■ *Listen (English)*

■ *Listen (Hindi)*

Explanation: The parasympathetic supply to the hindgut originates from the sacral spinal cord , specifically from segments S2-S4 . These fibers form the pelvic splanchnic nerves. While the vagus nerve does provide parasympathetic innervation to a large portion of the gut, it does not supply the entire length. It innervates the foregut and midgut, extending approximately to the proximal two-thirds of the transverse colon. (Option A) The pelvic splanchnic nerves provide parasympathetic, not sympathetic, innervation to the hindgut. (Option B) The greater splanchnic nerves primarily provide sympathetic innervation to the foregut structures, not the midgut. (Option C)

References:

Gray’s Anatomy, 42nd Edition, Pages 1107, 1108, 1109, 1110, 1111, 1112, 1113, 1114, 1115, 1116, 1117, 1118, 1119, 1120, 1199

Snell’s Clinical Anatomy, 10th Edition, Pages 358, 359, 360, 361, 362, 363, 364, 365, 366

↑ *Back to this question in Part A*

@Neet_pg_bot

Q2: A 45-year-old male presents with severe epigastric pain radiating to the back. He reports that the pain worsens after eating and is associated with nausea. On examination, there is epigastric tenderness, but no rebound or guarding. The patient's past medical history is significant for chronic pancreatitis. You suspect autonomic involvement in his pain pattern. Which of the following nerves is most likely involved in transmitting the visceral pain signals from the pancreas? (Q848679)

A. Greater splanchnic nerve

B. Lesser splanchnic nerve

C. Pelvic splanchnic nerve

D. Vagus nerve

Correct Answer: A. Greater splanchnic nerve

■ *Listen (English)*

■ *Listen (Hindi)*

Explanation: Epigastric pain radiating to the back in case of chronic pancreatitis is due to autonomic innervation via the greater splanchnic nerve.

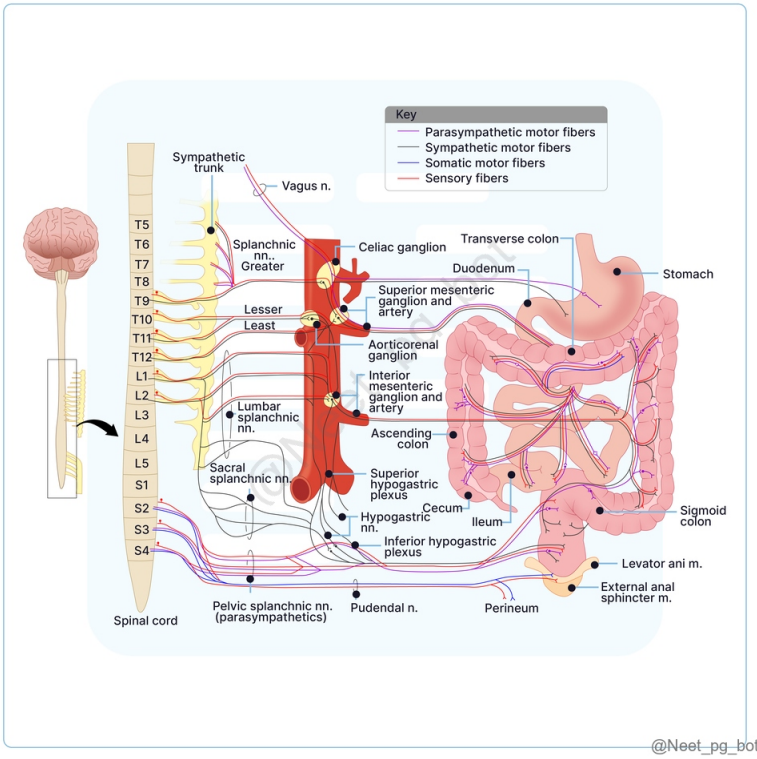

References:

Vishram Singh Textbook of Anatomy, Volume 2, 2nd Edition, Pages 198, 199

Moore’s Clinical Anatomy, 9th Edition, Pages 1300-1306

↑ *Back to this question in Part A*

@Neet_pg_bot

Q3: A 45-year-old man presents with dull, poorly localized abdominal pain that began 12 hours ago. Over time, the pain becomes sharper and more localized in the right lower quadrant. The patient also reports nausea and loss of appetite. On physical examination, tenderness is noted at McBurney's point. Which of the following best explains the initial presentation of the patient's pain? (Q848680)

A. Irritation of the peritoneum

B. Stimulation of visceral afferent fibers accompanying sympathetic nerves

C. Direct irritation of somatic nerves in the abdominal wall

D. Referred pain via the phrenic nerve (C3-C5)

Correct Answer: B. Stimulation of visceral afferent fibers accompanying sympathetic nerves

■ *Listen (English)*

■ *Listen (Hindi)*

Explanation: Referred pain occurs when visceral afferent fibers transmit pain signals to the spinal cord, which misinterprets these signals as originating from a somatic region innervated by the same spinal segment (same dermatome). Referred pain and associated dermatomes:

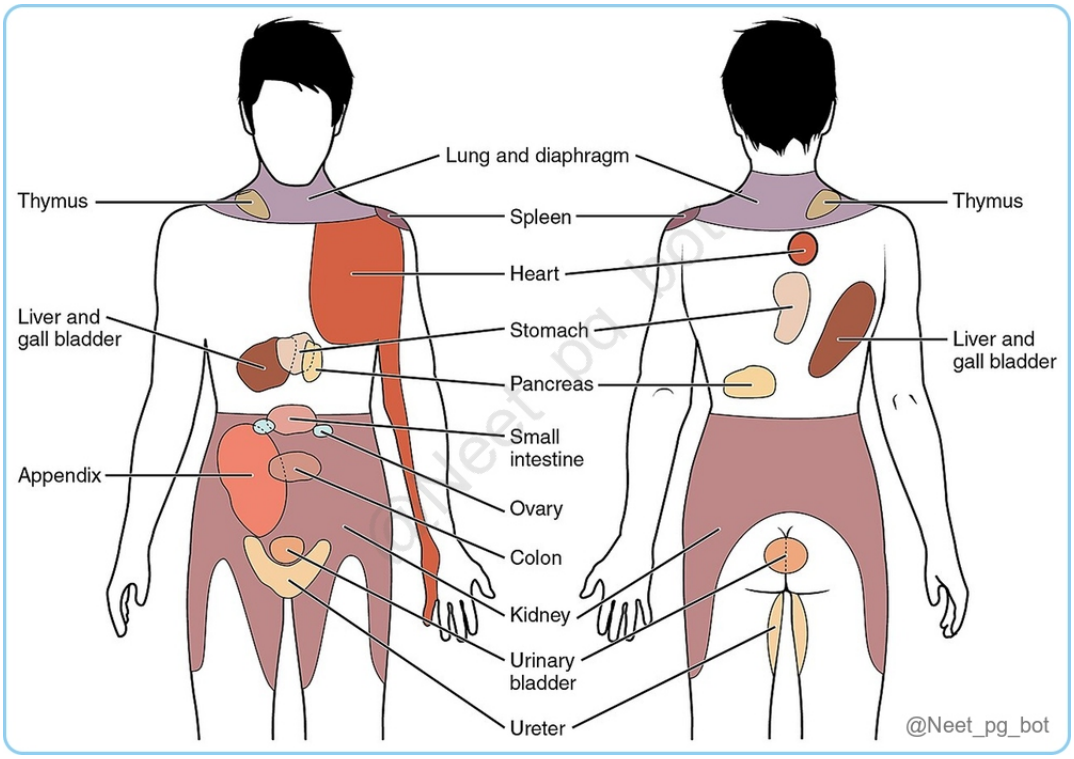

References:

Moore's Clinical Anatomy, 9th Edition, Pages 1195, 1196

↑ *Back to this question in Part A*

@Neet_pg_bot

Q4: At which vertebral level does the abdominal aorta typically bifurcate into the common iliac arteries? (Q848674)

A. T12

B. L2

C. L4

D. L5

Correct Answer: C. L4

■ *Listen (English)*

■ *Listen (Hindi)*

Explanation: The abdominal aorta typically bifurcates into the common iliac arteries at the level of the L4 vertebra. This bifurcation point is an important anatomical landmark in the abdomen.

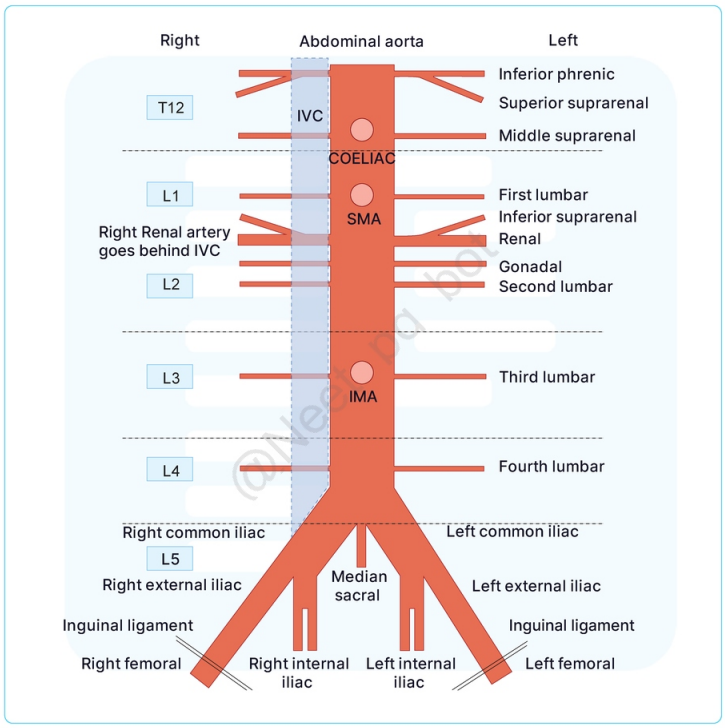

References:

Gray's Anatomy, 42nd Edition, Pages 1107- 1120

↑ *Back to this question in Part A*

@Neet_pg_bot

Q5: A 45-year-old patient presents with severe abdominal pain and bloody diarrhea. CT angiography reveals thrombosis of a major vein draining the distal transverse colon, descending colon, and sigmoid colon. Which of the following veins is most likely to be affected in this patient's condition? (Q848675)

A. Hepatic portal vein

B. Superior mesenteric vein

C. Inferior mesenteric vein

D. Celiac vein

Correct Answer: C. Inferior mesenteric vein

■ *Listen (English)*

■ *Listen (Hindi)*

Explanation: The patient's symptoms and the affected area (distal transverse colon, descending colon, and sigmoid colon) indicate an issue with the hindgut and its blood supply . Hindgut is drained by inferior mesenteric vein.

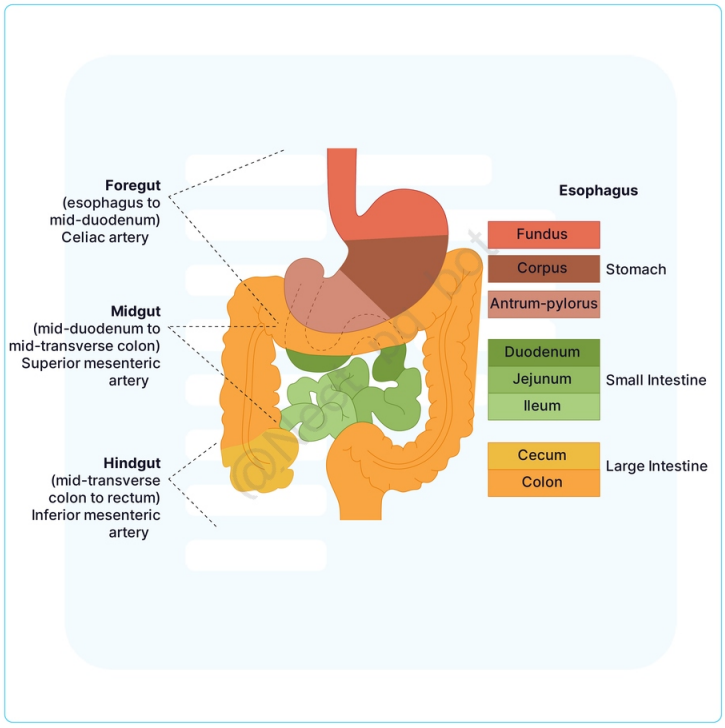

@Neet_pg_bot

References:

Gray’s Anatomy: The Anatomical Basis of Clinical Practice, 42nd Edition, Pages 1107-1120, 1199

Snell’s Clinical Anatomy, 10th Edition, Pages 358-366

↑ *Back to this question in Part A*

@Neet_pg_bot

Q6: Which of the following statements about the innervation and vascular supply of the uterus and vagina is correct? (Q848677)

A. The parasympathetic supply to the entire uterus and vagina comes from the pelvic splanchnic nerves (S2-S4)

B. The uterine artery is a branch of the external iliac artery

C. The vaginal venous plexus drains primarily into the internal pudendal vein

D. The superior part of the vagina receives its arterial supply from the vaginal artery, while the inferior part is supplied by branches of the internal pudendal artery

Correct Answer: D. The superior part of the vagina receives its arterial supply from the vaginal artery, while the inferior part is supplied by branches of the internal pudendal artery

■ *Listen (English)*

■ *Listen (Hindi)*

Explanation: The superior part of the vagina receives its arterial supply from the vaginal artery , while branches of the internal pudendal artery supply the inferior part . The neurovascular supply of the female reproductive system is given in the table below: Neurovascular supply of the female reproductive system Structure Arterial Supply Venous Drainage Sympathetic Innervation Parasympathetic Innervation Uterus Uterine artery (branch of internal iliac artery) Uterine venous plexus to internal iliac veins T12-L2 via superior hypogastric plexus Pelvic splanchnic nerves (S2-S4) Upper 2/3 of Vagina Vaginal artery (branch of internal iliac artery) Vaginal venous plexus to internal iliac veins T12-L2 via inferior hypogastric plexus Pelvic splanchnic nerves (S2-S4) Lower 1/3 of Vagina Branches of internal pudendal artery Vaginal venous plexus to internal iliac veins Pudendal nerve (S2-S4) Pudendal nerve (S2-S4) While the parasympathetic supply to the uterus and upper 2/3 of the vagina comes from the pelvic splanchnic nerves (S2-S4), the lower 1/3 of the vagina receives parasympathetic innervation via the pudendal nerve. (Option A) The uterine artery is a branch of the internal iliac artery, not the external iliac artery. (Option B) The vaginal venous plexus drains primarily into the internal iliac veins, not the internal pudendal vein. (Option C)

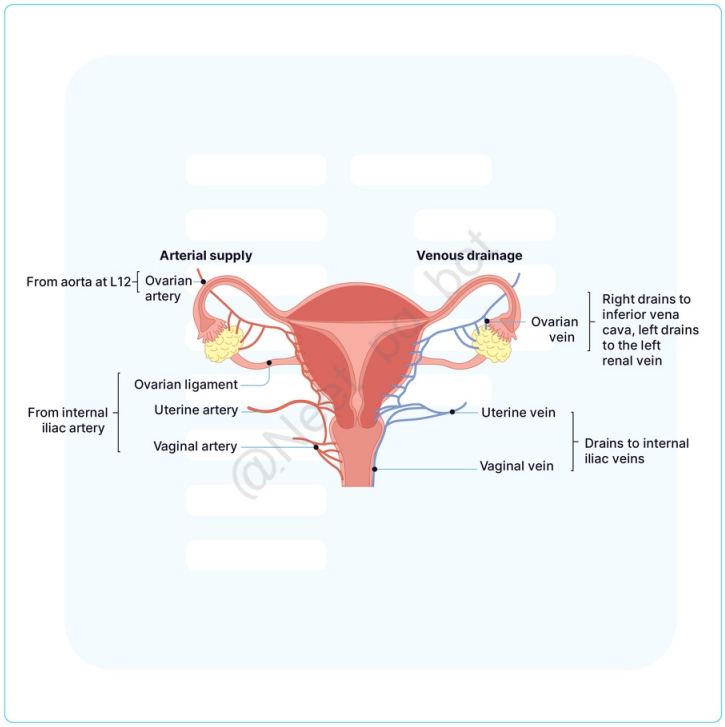

@Neet_pg_bot

References:

Gray’s Anatomy: The Anatomical Basis of Clinical Practice, 42nd Edition, Pages 1311-1312, 1316-1317, 1320

↑ *Back to this question in Part A*

@Neet_pg_bot

Q7: Which of the following statements about pre-aortic and para-aortic lymph nodes is correct? (Q848678)

A. Pre-aortic nodes primarily drain lymph from the lower limbs

B. Para-aortic nodes are located posterior to the abdominal aorta

C. Coeliac nodes are a subset of pre-aortic nodes

D. Lateral aortic nodes drain lymph from the stomach and pancreas

Correct Answer: C. Coeliac nodes are a subset of pre-aortic nodes

■ *Listen (English)*

■ *Listen (Hindi)*

Explanation: Coeliac nodes are a constituent of the pre-aortic group of lymph nodes. Pre-aortic nodes can be subdivided into coeliac, superior mesenteric and inferior mesenteric nodes. Pre-aortic and para-aortic lymph nodes Lymph Node Group Location Primary Drainage Subgroups Pre-aortic nodes Anterior to the abdominal aorta Gastrointestinal viscera including pancreas, liver, spleen Coeliac, superior mesenteric, inferior mesenteric nodes Para-aortic nodes (Lateral aortic) On either side of the abdominal aorta Deep layers of body wall, retroperitoneal pelvic viscera, gonads (testes and ovaries) Left and right lumbar (of the kidney), aortocaval, retrocaval, precaval groups

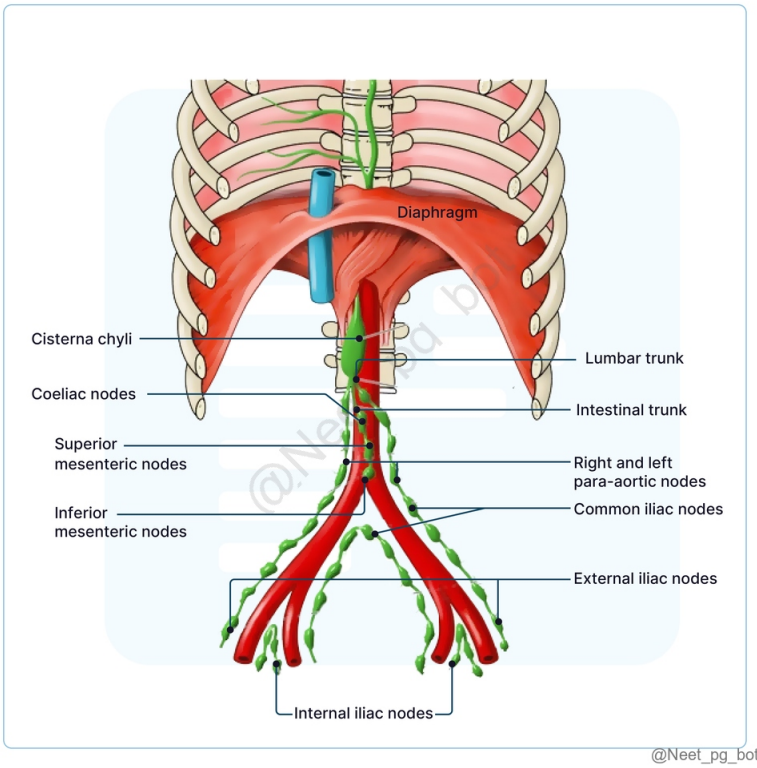

References:

Gray's Anatomy, 42nd Edition, Pages 1145, 1146

↑ *Back to this question in Part A*

@Neet_pg_bot

Q8: A 36-year-old male presents with pain in his right lower quadrant. Imaging reveals no abnormalities in the appendix, yet the patient experiences referred pain that radiates to the periumbilical region. Which of the following best explains this phenomenon? (Q848681)

A. Convergence of somatic and visceral afferent fibers in the dorsal horn of the spinal cord

B. Specific nerve injury affecting the parietal peritoneum

C. Direct stimulation of visceral pain fibers in the appendix

D. Local irritation of the somatic sensory nerves in the abdominal wall

Correct Answer: A. Convergence of somatic and visceral afferent fibers in the dorsal horn of the spinal cord

■ *Listen (English)*

■ *Listen (Hindi)*

Explanation: The Convergence Projection Hypothesis explains how visceral pain is often misinterpreted as somatic pain. Visceral organs are innervated by visceral afferent fibers, which enter the spinal cord at the same segmental level as somatic afferents. When these visceral fibers converge with somatic fibers in the dorsal horn of the spinal cord, the brain interprets the signal as originating from the somatic region, leading to referred pain. In the case of appendicitis, visceral afferents from the appendix converge with somatic afferents from the T10 dermatome, resulting in referred pain around the umbilicus.

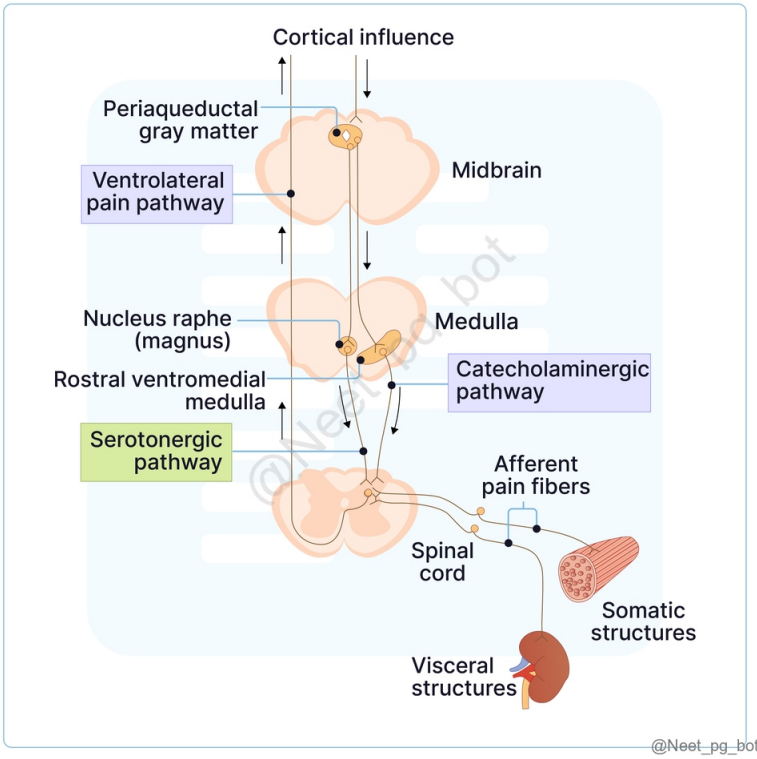

References:

https://www.ncbi.nlm.nih.gov/books/NBK219252/

↑ *Back to this question in Part A*

@Neet_pg_bot

• [08_Abdomen] 043 Previous Year Questions

« Back to Folder Directory

[08_Abdomen] 043 Previous Year Questions — Quick Jump

Q1 (p. 1974)	*Q2 (p. 1975)*	*Q3 (p. 1976)*	*Q4 (p. 1977)*	*Q5 (p. 1978)*	*Q6 (p. 1980)*
Q7 (p. 1981)	*Q8 (p. 1983)*	*Q9 (p. 1983)*	*Q10 (p. 1986)*	*Q11 (p. 1987)*	*Q12 (p. 1988)*
Q13 (p. 1989)	*Q14 (p. 1990)*	*Q15 (p. 1991)*	*Q16 (p. 1993)*	*Q17 (p. 1995)*	*Q18 (p. 1996)*
Q19 (p. 1998)	*Q20 (p. 1999)*	*Q21 (p. 2000)*	*Q22 (p. 2002)*	*Q23 (p. 2004)*	*Q24 (p. 2005)*
Q25 (p. 2006)	*Q26 (p. 2006)*	*Q27 (p. 2008)*	*Q28 (p. 2009)*	*Q29 (p. 2010)*	*Q30 (p. 2011)*

Q1: A patient with a medical history of liver cirrhosis now presents with abdominal pain, jaundice, and portal hypertension. Anastomosis between which of the following veins will be seen? (Q855402)

A. Left colic vein and middle colic veins

B. Esophageal veins and left gastric veins

C. Superior and phrenic veins

D. Sigmoid and superior rectal veins

Correct Answer: B. Esophageal veins and left gastric veins

Explanation: The patient has portal hypertension, which is commonly associated with liver cirrhosis. Portal hypertension leads to the development of portosystemic anastomoses, which are connections between the portal vein and systemic venous circulation. One significant site of such an anastomosis is between the esophageal veins (draining into the systemic circulation via the azygos vein) and the left gastric vein (draining into the portal vein). In portal hypertension, increased pressure in the portal vein causes blood to flow through these collateral veins, leading to esophageal varices. Portal Hypertension: Reversal of blood flow away from the portal vein due to high pressure. Clinical Features: Splenomegaly Ascites Esophageal varices Rectal varices Caput medusae Portal-Systemic Anastomoses Site of anastomosis Veins forming portocaval anastomosis Clinical signs Lower third of the esophagus Left gastric vein ↑ ↓ Esophageal veins draining into azygos vein Esophageal varices Umbilicus Paraumbilical veins ↑↓ Superficial veins of anterior abdominal wall Caput medusae Mid-anal canal Superior rectal vein ↑↓ Middle and inferior rectal veins Hemorrhoids Left colic vein and middle colic veins (Option A): These veins are part of the portal circulation and do not form portosystemic anastomoses. Superior and phrenic veins (Option C): These are systemic veins and do not involve the portal system. Sigmoid and superior rectal veins (Option D): both are part of the portal circulation but don't drain into the systemic circulation thus anastomoses between them aren't seen in portal hypertension.

References:

BD chaurasia 8e,vol-2,pg 331-333

Vishram Singh - Textbook of Anatomy Abdomen and Lower Limb, Volume 2,2E,Pg,142

↑ *Back to this question in Part A*

@Neet_pg_bot

Q2: Deep inguinal ring is a defect in (Q859524)

A. External oblique aponeurosis

B. Internal oblique aponeurosis

C. Fascia transversalis

D. Rectus sheath

Correct Answer: C. Fascia transversalis

Explanation: The deep inguinal ring is an opening in the fascia transversalis , located just above the midpoint of the inguinal ligament. This defect allows the passage of the spermatic cord in males and the round ligament of the uterus in females. {{caption_text}} Inguinal canal: Structure Description Parietal peritoneum Most posterior structure. Transversalis fascia Has a defect called the deep inguinal ring, through which the testes and spermatic cord pass. Site for indirect inguinal hernias. Anterior to parietal peritoneum. Forms the posterior in the whole extent. Lateral umbilical fold Formed by the inferior epigastric vessels. Median umbilical ligament Remnant of the urachus (from the allantois). Medial umbilical ligament Remnant of the obliterated umbilical artery. Pyramidalis muscle Small muscle attaching to the pubic bone. Rectus abdominis lies above it. Covered by the rectus sheath and supplied by the subcostal nerve (T12). Rectus abdominis muscle Receives segmental innervation from T6–T12. Transversus abdominis muscle Does not form the anterior wall of the inguinal canal. Contributes to the roof and posterior wall. Combines with internal oblique to form the conjoint tendon. Internal oblique muscle (Option B) Forms parts of the anterior, roof, and posterior walls of the inguinal canal. Contributes to cremasteric muscle and fascia. External oblique muscle (Option A) Aponeurosis forms the anterior wall of the inguinal canal and the superficial inguinal ring . Forms external spermatic fascia. Internal spermatic fascia Derived from the transversalis fascia. Rectus sheath (Option D): The rectus sheath encloses the rectus abdominis muscle and is not involved in the formation of the deep inguinal ring. This is incorrect.

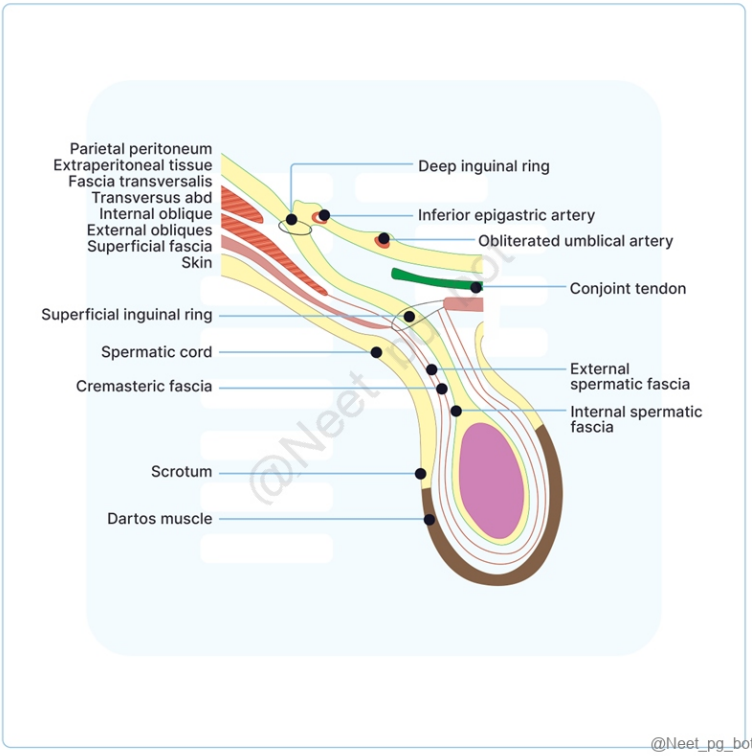

References:

Vishram Singh Textbook of Anatomy, Abdomen and lower-limb, Volume 2, pg.no: 51

↑ *Back to this question in Part A*

@Neet_pg_bot

Q3: A tumor of the uncinate process of the pancreas affects which of the following vessels? (Q854984)

A. Superior mesenteric artery

B. Portal vein

C. Common hepatic artery

D. Inferior mesenteric artery

Correct Answer: A. Superior mesenteric artery

Explanation: The uncinate process of the pancreas is a small, hook-like projection from the head of the pancreas that extends posteriorly and inferiorly , wrapping around the superior mesenteric vessels (SMA and SMV) . A

tumor in this region is likely to compress or invade the superior mesenteric artery (SMA) , which supplies blood to the midgut (small intestine and proximal colon). Relationship of the Pancreas, Veins, and Aorta in Nutcracker Syndrome Nutcracker Syndrome: A condition caused by compression of the left renal vein leading to the left renal vein hypertension. Highlights the anatomical relationship between the pancreas, veins, and aorta. Anatomical Features Description Left Renal Vein Originates from the hilum of the left kidney. Travels behind the pancreas and splenic vein. Crosses the abdominal aorta anteriorly below the superior mesenteric artery. Nutcracker Analogy The left renal vein is compressed between the aorta and superior mesenteric artery, resembling a nutcracker. Symptoms Can lead to left renal vein hypertension. Symptoms include hematuria and varicocele, especially in children. Pancreas' Role in Nutcracker Syndrome: Positioned directly in front of the compression site, anterior to the SMA. Proximity to vascular structures suggests the potential to worsen the condition. The uncinate process being close to the superior mesenteric artery and vein further emphasises the pancreas's proximity to major vessels. Portal vein (option B): Formed by the union of the superior mesenteric vein (SMV) and splenic vein , located posterior to the neck of the pancreas . The uncinate process is more inferior , so it typically does not directly compress the portal vein. Common hepatic artery (option C): Arises from the celiac trunk and gives rise to the proper hepatic artery and gastroduodenal artery . It runs superior to the pancreas and is not typically affected by tumors of the uncinate process. Inferior mesenteric artery (option D): Arises from the abdominal aorta at a lower level, supplying the hindgut (distal colon and rectum). It is too distant from the uncinate process to be affected.

References:

Gray’s Anatomy, 42nd Edition, Page 1123, 1140, 1227, 1267

↑ *Back to this question in Part A*

@Neet_pg_bot

Q4: Ligation of common hepatic artery will impair blood supply in: (Q854913)

A. Right gastric and right gastroepiploic artery

B. Right gastric and left gastric artery

C. Right gastroepiploic and short gastric vessels

D. Right gastric and short gastric vessels

Correct Answer: A. Right gastric and right gastroepiploic artery

Explanation: The common hepatic artery is a branch of the celiac trunk and gives rise to: Proper hepatic artery → Right gastric artery Gastroduodenal artery → Right gastroepiploic artery Ligation of the common hepatic artery will impair blood supply to: Right gastric artery (supplies the lesser curvature of the stomach) Right gastroepiploic artery (supplies the greater curvature of the stomach) Right gastric and left gastric artery (option B): The left gastric artery arises directly from the celiac trunk , so it will still receive blood despite common hepatic artery ligation. Right gastroepiploic and short gastric vessels (option C): The right gastroepiploic artery comes from the gastroduodenal artery (a branch of the common hepatic artery) and will be affected. Short gastric arteries , however, arise from the splenic artery , which remains intact. Right gastric and short gastric vessels (option D):

The right gastric artery is affected. The short gastric vessels come from the splenic artery and remain unaffected.

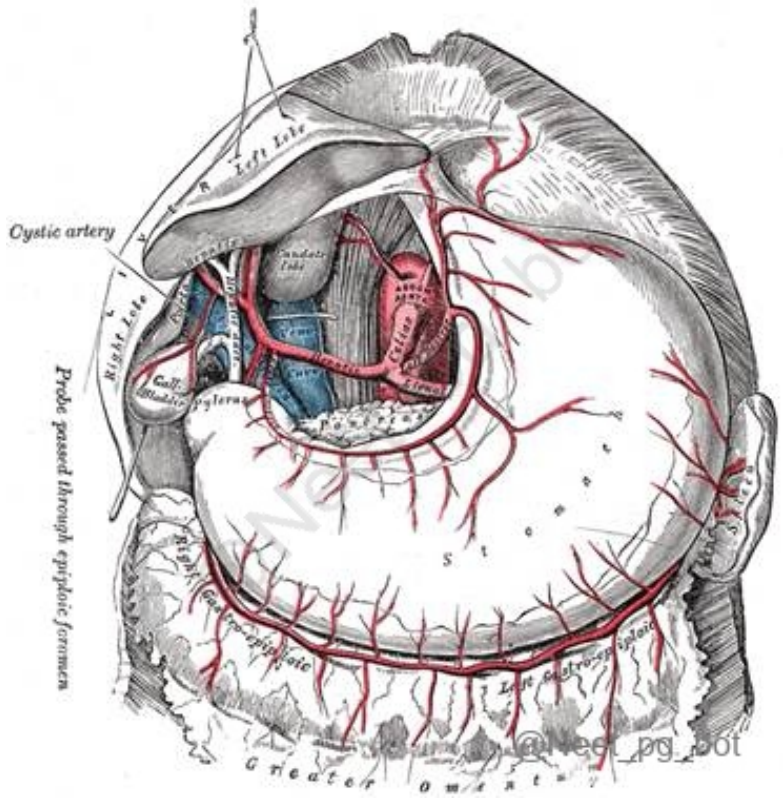

References:

Accidental Hepatic Artery Ligation in Humans - PMC

↑ *Back to this question in Part A*

@Neet_pg_bot

Q5: The patient exhibited an enlarged lymph node in the inguinal area. The primary cause that is most probable is (Q854911)

A. Testicular cancer

B. Anal cancer

C. Sigmoid colon cancer

D. Prostate cancer

Correct Answer: B. Anal cancer

Explanation: The inguinal lymph nodes primarily drain the lower limb, perineum, external genitalia, and anal canal below the dentate line . Anal cancer (especially if it arises below the pectinate/dentate line) spreads to the superficial inguinal lymph nodes , making it the most probable cause of an enlarged inguinal lymph node. Lymphatic Drainage of the Rectum and Anal Canal: Region Lymphatic Drainage Upper half of the rectum Inferior mesenteric nodes via pararectal and sigmoid nodes Lower half of the rectum & upper anal canal Internal iliac nodes Anal canal (below the pectinate line) Superficial inguinal lymph nodes Testicular cancer (option A): Testes drain to the para-aortic (retroperitoneal) lymph nodes , not the inguinal nodes. Inguinal node involvement is uncommon unless there is scrotal skin involvement. Sigmoid colon cancer (option C): The sigmoid colon drains to the inferior mesenteric and para-aortic lymph nodes , not the inguinal lymph nodes. Prostate cancer (option D): Prostate lymphatic drainage is primarily to the internal iliac and obturator lymph nodes , not the inguinal nodes.

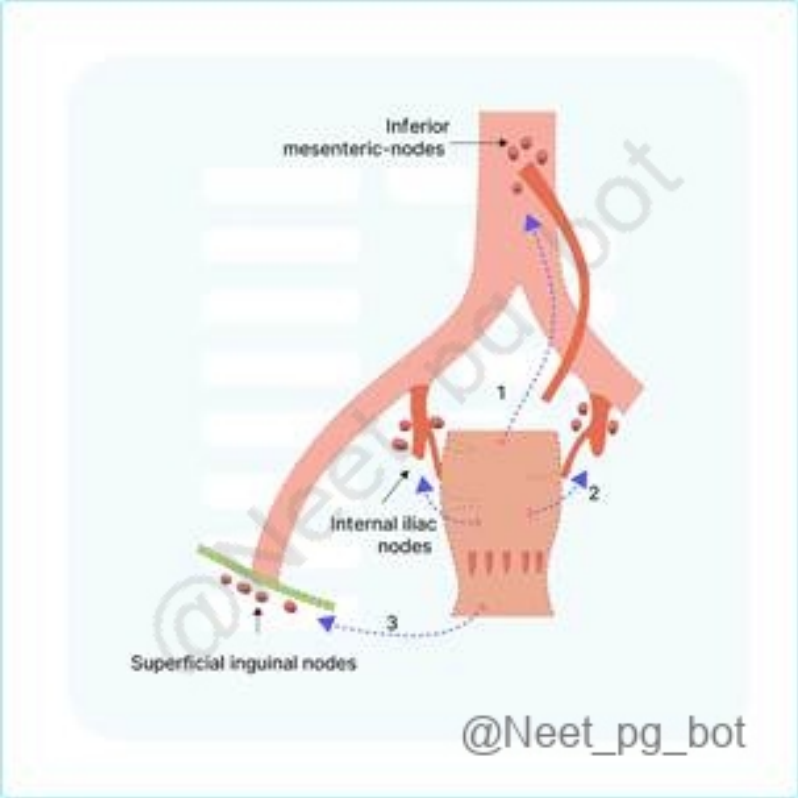

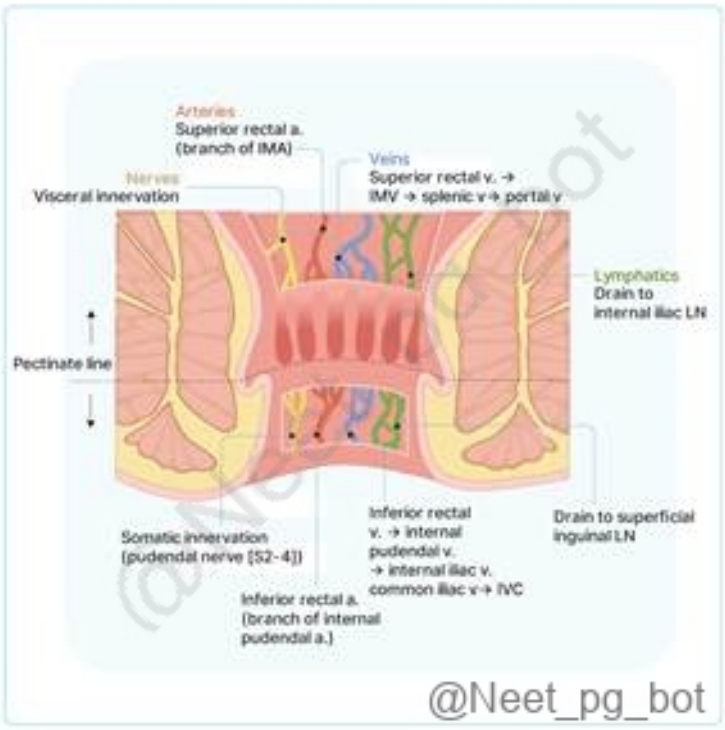

References:

B. D. Chaurasia's Human Anatomy, VOL-2, 8th Edition, Page 478, 479

↑ *Back to this question in Part A*

@Neet_pg_bot

Q6: Which of the following features differentiated the exocrine pancreas from the parotid gland? (Q856946)

A. Basal lamina lining the serous acini

B. Absence of striated duct

C. Presence of serous acini with acidophilic tip

D. Presence of apical acinar villi

Correct Answer: B. Absence of striated duct

Explanation: One key difference between the exocrine pancreas and the parotid gland is the absence of striated ducts in the pancreas. Striated ducts, found in glands like the parotid, modify secretions with characteristic basal

infoldings. In contrast, the pancreas relies on intercalated ducts, lacking these basal infoldings, to transport enzymes from acinar cells to the main duct. HISTOLOGY OF PANCREAS: The pancreas consists of exocrine and endocrine glands. The exocrine portion, made up of acini, secretes digestive enzymes and resembles a serous salivary gland. The endocrine portion , represented by the Islets of Langerhans, produces hormones like insulin and glucagon to regulate blood glucose levels. {{caption_text}} Histology of Pancreas. Beta cells (2) of the pancreatic islet (4) Serous acini (1) of the pancreas are stained with H and E. Centroacinar cells (3) can be seen in the serous acini Basal lamina lining the serous acini (Option B): Both the exocrine pancreas and the parotid gland have a basal lamina lining the serous acini. The basal lamina provides structural support to the acinar cells. Presence of serous acini with acidophilic tip (Option C): Both the exocrine pancreas and the parotid gland can have serous acini with acidophilic (eosinophilic) cytoplasmic granules at their apical (or luminal) ends. Presence of apical acinar villi (Option D): Neither the exocrine pancreas nor the parotid gland have apical acinar villi.

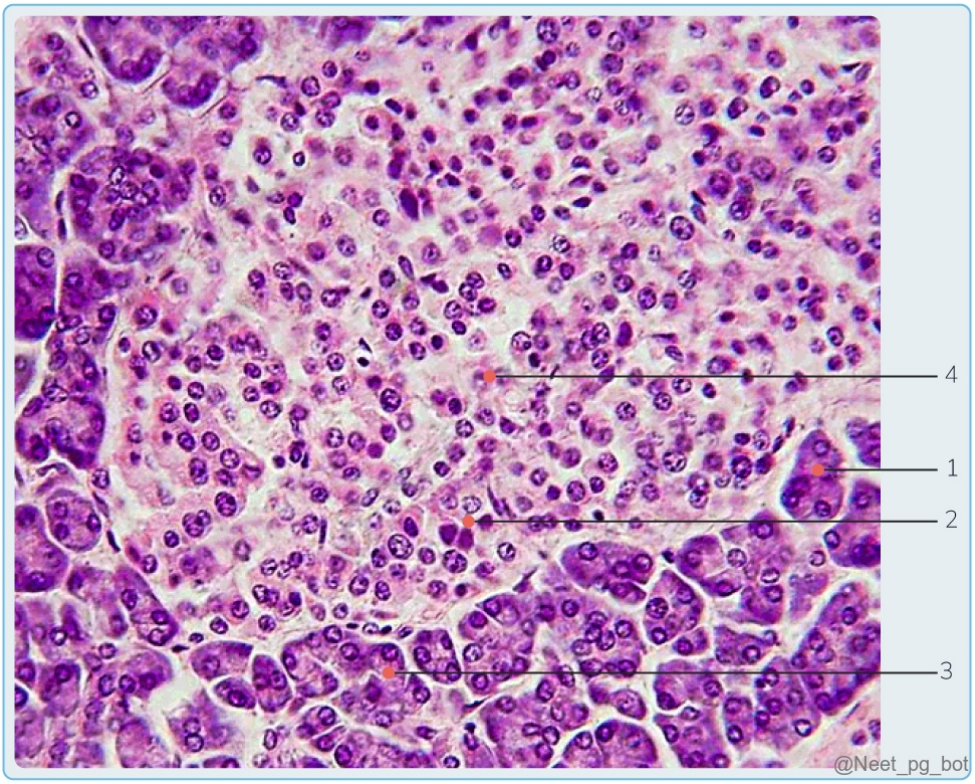

References:

BD Chaurasia’s Human Anatomy, 8th Edition, Page no: 133

↑ *Back to this question in Part A*

@Neet_pg_bot

Q7: Where are the Ito cells in the liver located? (Q856943)

A. Space of disse

B. Space of moll

C. Sinusoids

D. Bile canaliculi

Correct Answer: A. Space of disse

Explanation: Ito cells, or hepatic stellate cells, reside in the space of Disse within the liver, situated between sinusoidal endothelial cells and hepatocytes in liver lobules. This space holds extracellular matrix components, growth factors, and signaling molecules, creating a crucial microenvironment. Ito cells play a vital role in liver function and pathology. Hepatic stellate cells (or Ito cells): Located in the space of Disse, between hepatocytes and sinusoidal endothelial cells in the liver. In the healthy liver, these cells store vitamin A in lipid droplets. In response to injury, they activate and contribute to fibrosis by releasing TGFβ. {{caption_text}} Space of Moll (Option B): The space of Moll is a small space located between the posterior surface of the cornea and the anterior surface of the iris. It is not related to the location of Ito cells in the liver. Sinusoids (Option C): While Ito cells are located in close proximity to the sinusoids, they are specifically found within the space of Disse, which is a distinct anatomical space within the liver Bile canaliculi (Option D): Bile canaliculi are tiny channels between adjacent hepatocytes that transport bile towards the bile ducts. Ito cells are not located within the bile canaliculi.

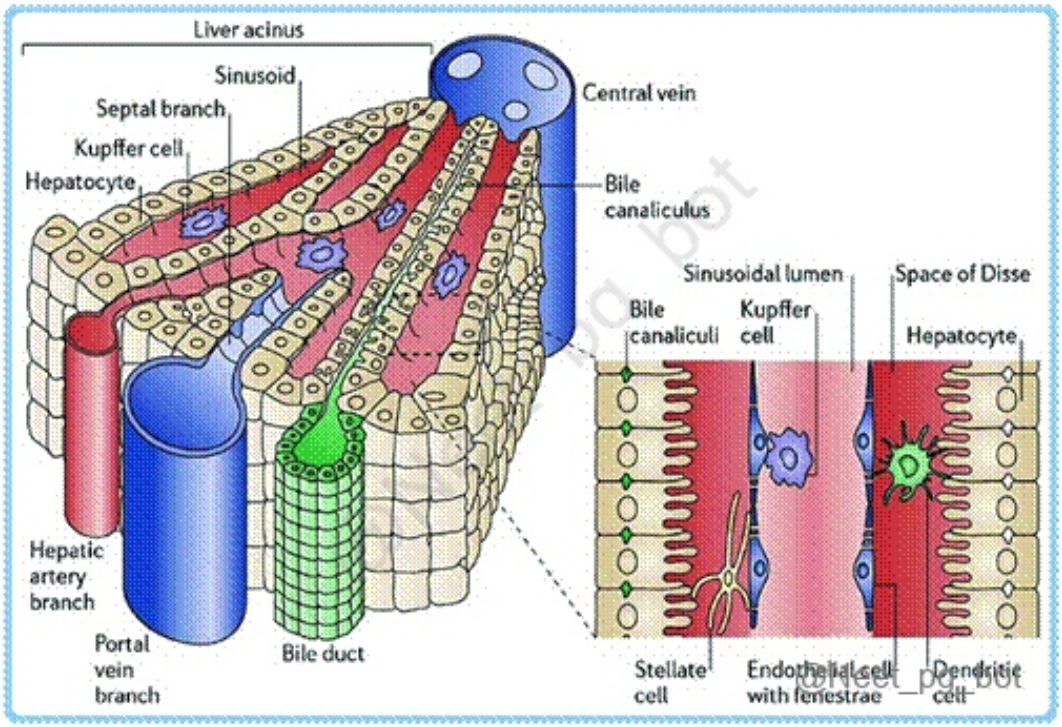

References:

BD Chaurasia’s Human Anatomy, 8th Edtion, Page no: 233

↑ *Back to this question in Part A*

@Neet_pg_bot

Q8: A 34-year-old man presented with a fever and massive splenomegaly. The spleen was 15 cm on palpation and directed obliquely when measured from the right iliac fossa. Which of the following structures prevent the vertical and downward descent of the spleen? (Q856182)

A. Lienorenal ligament

B. Gastrosplenic ligament

C. Phrenicocolic ligament

D. Lienophrenic ligament

Correct Answer: C. Phrenicocolic ligament

Explanation: - Phrenicocolic ligament: The phrenicocolic ligament is a peritoneal fold that extends from the left colic flexure to the diaphragm , supporting the spleen inferiorly . It acts as a shelf that prevents the spleen from descending vertically into the left lower quadrant , limiting downward displacement in conditions like massive splenomegaly . Lienorenal ligament (option A): Also called the splenorenal ligament , it connects the spleen to the left kidney and contains the splenic vessels and tail of the pancreas . It provides posterior support but does not prevent downward descent of the spleen. Gastrosplenic ligament (option B): This ligament connects the stomach to the spleen and contains the short gastric arteries and left gastroepiploic artery . It mainly stabilizes the spleen anteromedially but does not prevent downward movement . Lienophrenic ligament (option D): Also called the splenophrenic ligament , it attaches the spleen to the diaphragm and provides superior support . It prevents upward displacement , not downward movement.

References:

[The ligament system of the spleen and its significance for surgical interventions] - PubMed

Splenic Anomalies of Shape, Size, and Location: Pictorial Essay - PMC

↑ *Back to this question in Part A*

@Neet_pg_bot

Q9: The para-sagittal section of the abdomen is given below. What is the superior border of the marked structure? (Q855828)

A. Caudate lobe of liver

B. Duodenum

C. Lesser omentum

D. Inferior vena cava

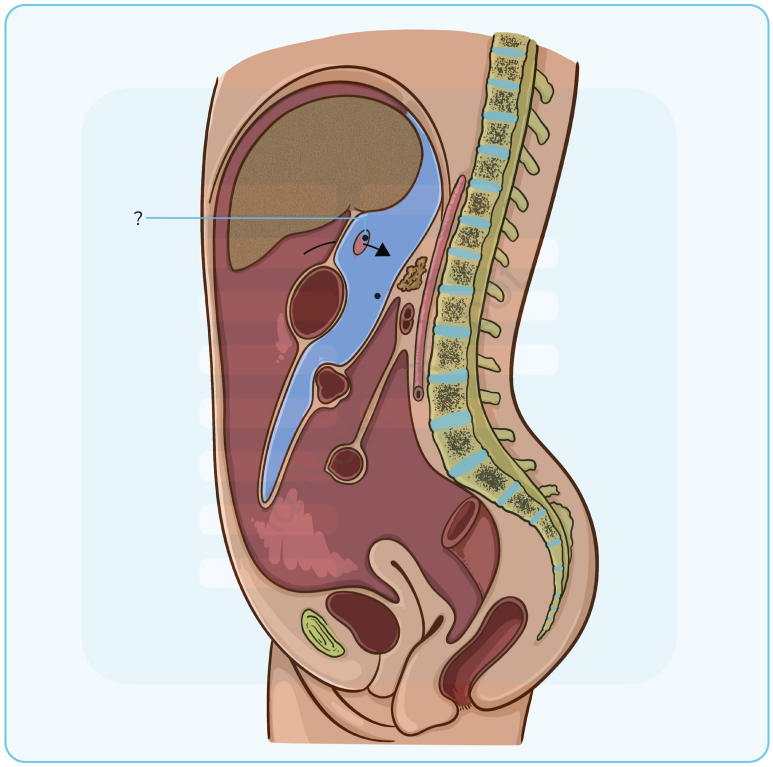

Correct Answer: A. Caudate lobe of liver

Explanation: The marked structure in the image is the epiploic foramen (of Winslow) , which connects the greater sac and the lesser sac (omental bursa) . It is an important anatomical passage located posterior to the free edge of the lesser omentum (hepatoduodenal ligament) . The superior border of the epiploic foramen is formed by the caudate lobe of the liver . Epiploic Foramen and Its Anatomical Borders Feature Details Definition Communication between greater sac and lesser sac Superior Border Caudate lobe of the liver Anterior Border Hepatoduodenal ligament (portal triad) Posterior Border Inferior vena cava Inferior Border First part of duodenum Clinical Importance Internal hernias, Pringle maneuver in hepatic trauma Clinical Relevance: The epiploic foramen is significant in internal herniation (e.g., herniation of bowel loops into the lesser sac). Surgical importance : It provides access to the portal triad in the Pringle maneuver, used to control hepatic bleeding. Duodenum (Option B): Incorrect because it forms the inferior border, not the superior. Lesser omentum (Option C): Incorrect because it forms the anterior border, not the superior. Inferior vena cava (Option D): Incorrect because it forms the posterior border, not the superior.

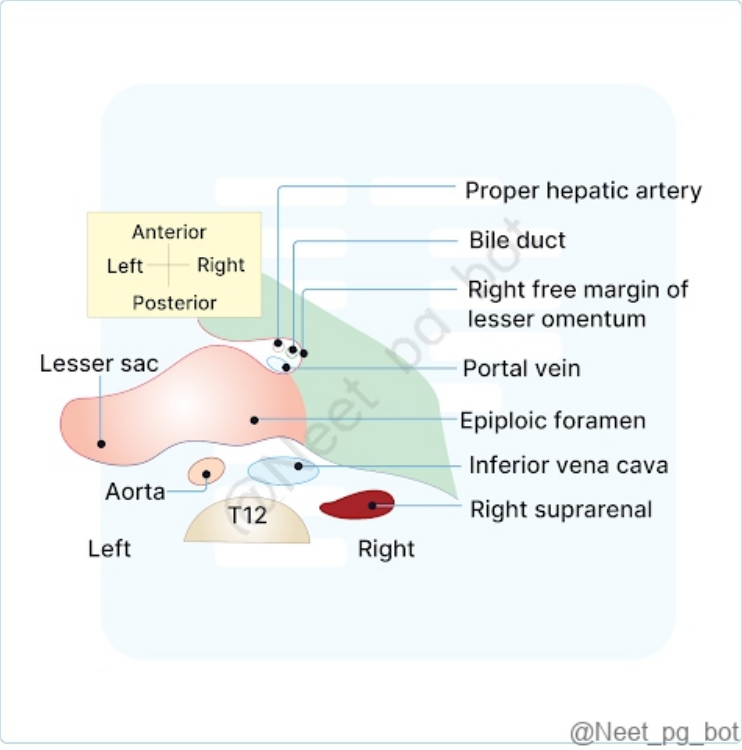

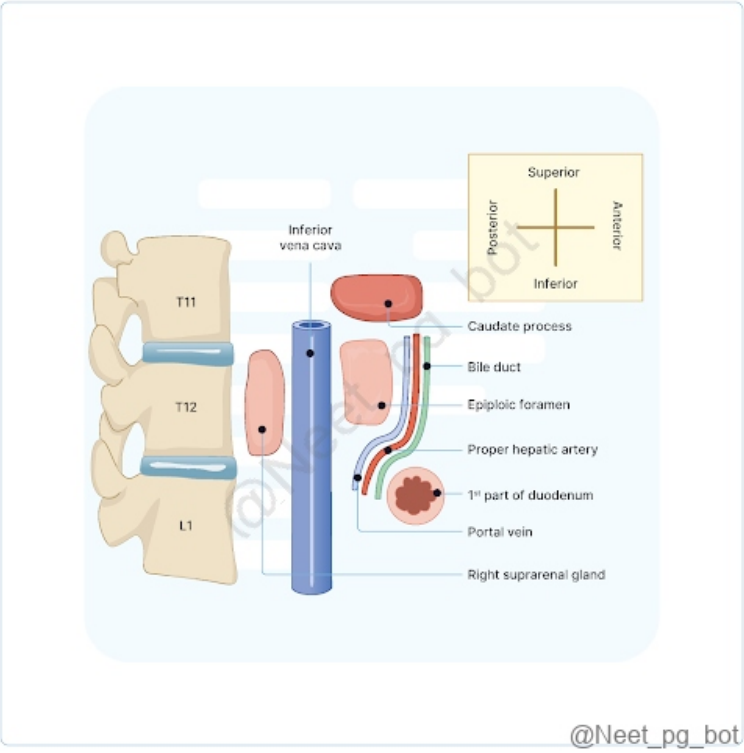

References:

Gray's Anatomy, The Anatomical Basis of Clinical Practice, 41st Edition, Page 1107

↑ *Back to this question in Part A*

@Neet_pg_bot

Q10: Which anatomical plane contains the neurovascular structures supplying the abdominal wall, located below the rectus abdominis muscle and above the transversalis fascia? (Q857643)

A. Between the internal oblique and external oblique

B. Deep to transversus abdominis

C. Between the internal oblique and rectus abdominis

D. Between the internal oblique and transversus abdominis

Correct Answer: D. Between the internal oblique and transversus abdominis

Explanation: The neurovascular plane of the anterior abdominal wall lies between the internal oblique and transversus abdominis muscles. This plane contains the intercostal nerves (T7-T11), subcostal nerve (T12), and branches of the lumbar plexus (L1), along with corresponding vessels. Neurovascular Plane of the Abdominal Wall Layer of Abdominal Wall Structures Present Between skin and external oblique Superficial fascia, cutaneous nerves. Between external oblique and internal oblique No major neurovascular structures. Between internal oblique and transversus abdominis Neurovascular plane (intercostal nerves, subcostal nerve, lumbar plexus branches, and segmental arteries). Deep to transversus abdominis Transversalis fascia, extraperitoneal fat, peritoneum. Deep to transversus abdominis (Option B): Incorrect because the neurovascular plane is located superficial to transversus abdominis, not deep to it. Between internal oblique and rectus abdominis (Option C): Incorrect because the rectus abdominis is enclosed by the rectus sheath, and the neurovascular structures run lateral to it, not between it and the internal oblique. Between internal oblique and external oblique (Option A): Incorrect because this plane does not contain major neurovascular structures.

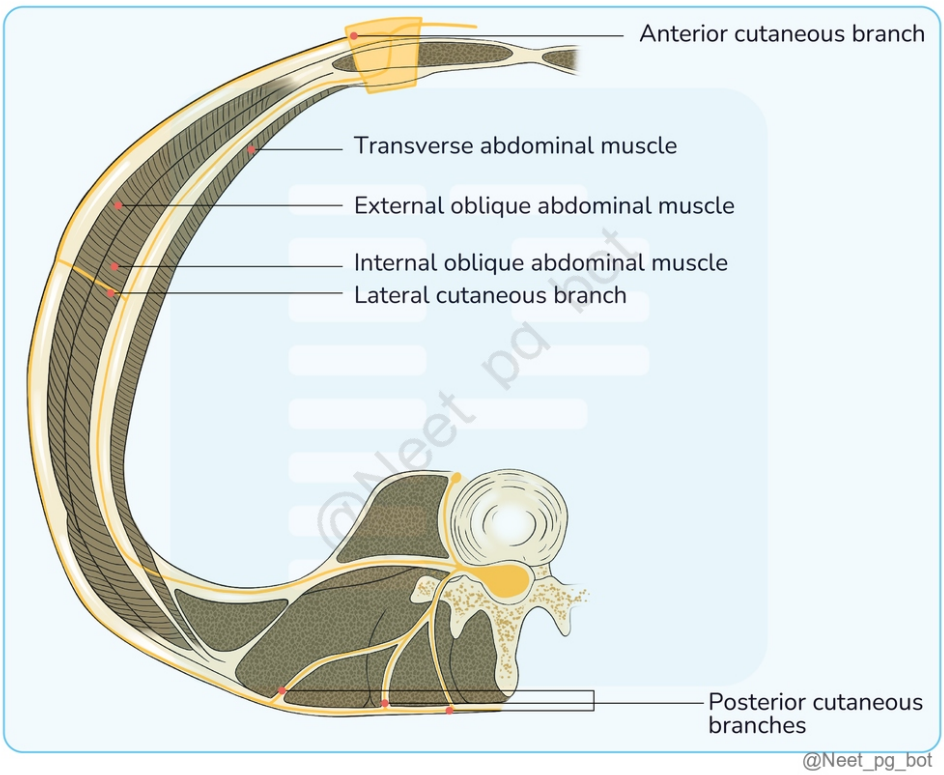

References:

Vishram Singh Textbook of Anatomy, Abdomen and lower-limb, Volume 2, pg.no: 50-51

https://www.ncbi.nlm.nih.gov/books/NBK557605/

https://www.ncbi.nlm.nih.gov/books/NBK560486/

↑ *Back to this question in Part A*

@Neet_pg_bot

Q11: What is the term used to describe the vertical plane that separates the body into anterior and posterior sections? (Q857568)

A. Coronal plane

B. Transverse plane

C. Axial plane

D. Median plane

Correct Answer: A. Coronal plane

Explanation: The coronal plane (frontal plane) is the vertical plane that divides the body into anterior (front) and posterior (back) sections . It runs perpendicular to the median plane and is commonly used in imaging and anatomical descriptions. Anatomical Planes of the Body Plane Description Division Clinical Relevance Coronal (Frontal) Plane Vertical plane passing side to side Anterior and Posterior Used in chest X-rays and CT scans Sagittal (Median) Plane Vertical plane passing front to back Left and Right MRI brain imaging, midline structures Transverse (Axial) Plane Horizontal plane Superior and Inferior Used in CT and MRI scans Oblique Plane Diagonal plane Varies Used in specialized imaging {{caption_text}} Transverse plane (Option B): incorrect because it divides the body into superior (upper) and inferior (lower) sections. Axial plane (Option C): incorrect because "axial" is another name for the transverse plane, which divides the body into top and bottom sections. Median plane (Option D): incorrect because it divides the body into equal left and right halves, not anterior and posterior sections.

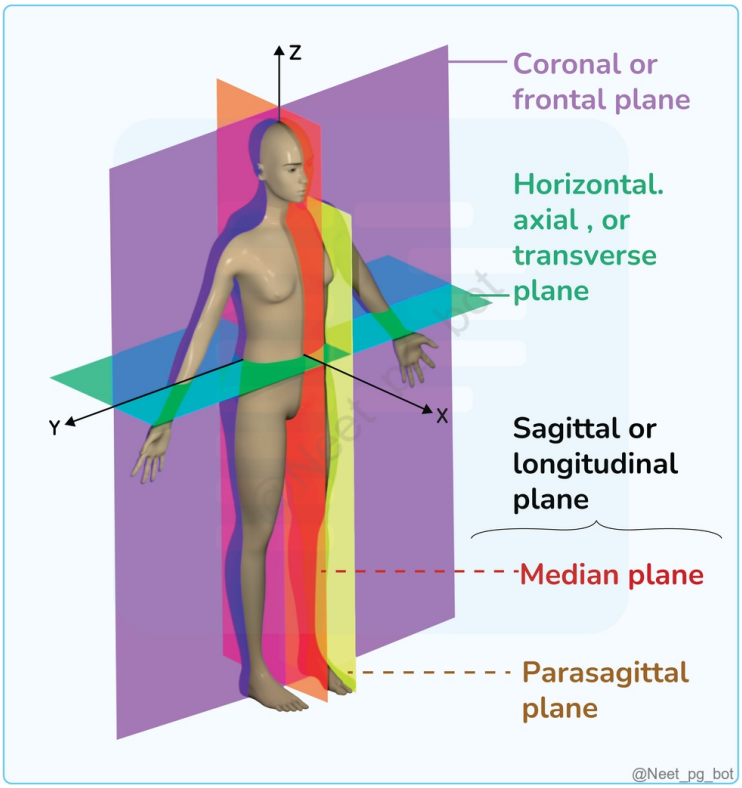

References:

https://pmc.ncbi.nlm.nih.gov/articles/PMC2800020/

↑ *Back to this question in Part A*

@Neet_pg_bot

Q12: Which of the following statements is false about thoracolumbar fascia? (Q857210)

A. They contain nociceptive nerve endings

B. In the lumbar region, it is in 4 layers

C. In the thoracic region, it is attached medially to the vertebrae

D. The anterior, posterior and middle join to form the aponeurotic origin of transversus abdominis

Correct Answer: B. In the lumbar region, it is in 4 layers

Explanation: The thoracolumbar fascia (TLF) is composed of three layers (anterior, middle, and posterior) in the lumbar region, not four. It provides attachment for various muscles and encloses the intrinsic back muscles. Thoracolumbar Fascia Region Layers Attachments Function Thoracic Single layer Medially to vertebrae, laterally to ribs Covers intrinsic back muscles Lumbar Three layers (anterior, middle, posterior) Encloses quadratus lumborum and erector spinae Supports lumbar spine, transmits forces They contain nociceptive nerve endings (Option A): Correct because thoracolumbar fascia has sensory nerve endings , including nociceptors, which are involved in pain perception. In the thoracic region, it is attached medially to the vertebrae (Option C): Correct as the fascia in the thoracic region attaches medially to the spinous processes and laterally to the ribs . The anterior, posterior, and middle join to form the aponeurotic origin of transversus abdominis (Option D): Correct as the three layers fuse laterally to form the aponeurotic origin of transversus abdominis .

References:

https://pubmed.ncbi.nlm.nih.gov/22630613/

↑ *Back to this question in Part A*

@Neet_pg_bot

Q13: To what level of vertebrae does the marked structure correspond? (Q857910)

A. At the junction of L1 & L2

B. At the junction of L2 & L3

C. At the junction of T12 & L1

D. At the junction of L3 & L4



Correct Answer: D. At the junction of L3 & L4

Explanation: The structure marked by the arrow is the umbilicus . Vertebral level of the umbilicus: L3–L4 vertebral level & Dermatome: T10 Associated structures at this level include the inferior vena cava, the renal veins, the gonadal arteries and veins, the ureters, and the descending colon. At the junction of L1 & L2 (Option A): Associated structures at this level include the spinal cord, the aorta, the inferior vena cava, the renal arteries and veins, and the ureters. At the junction of L2 & L3 (Option B): Associated structures at this level include the inferior vena cava, the renal veins, the gonadal arteries and veins, and the ascending colon. At the junction of T12 & L1 (Option C): Associated structures at this level include the aorta, the inferior vena cava, the celiac trunk, the superior mesenteric artery, and the renal arteries

References:

BD Chaurasia’s Human Anatomy, 8th Edtion, Page no: 244

↑ *Back to this question in Part A*

@Neet_pg_bot

Q14: Which of the following is not a boundary of the hepatocystic triangle ? (Q865261)

A. Cystic duct

B. Common hepatic duct

C. Cystic artery

D. Inferior border of liver

Correct Answer: C. Cystic artery

Explanation: The hepatocystic triangle, also widely known as Calot's triangle or the cystohepatic triangle, is a crucial anatomical landmark for surgeons, especially during gallbladder removal (cholecystectomy). Its boundaries are generally defined as: Medially: The common hepatic duct (Option B ruled out) Laterally (or Inferiorly): The cystic duct (Option A ruled out) Superiorly: The inferior surface of the liver (Option D ruled out) Within this triangle, typically find important structures such as: The cystic artery (Option C) (which usually arises from the right hepatic artery) The cystic lymph node (also known as Lund's node) Connective tissue and lymphatics Occasionally, an accessory right hepatic artery or anomalous sectoral bile duct

References:

Inderbir Singh textbook of anatomy Thorax and abdomen, 6th edition, Page 243

↑ *Back to this question in Part A*

@Neet_pg_bot

Q15: A defect in which of the following forms the structure marked below? (Q855296)

A. Internal oblique B) External oblique C) Parietal peritoneum D) Fascia transversalis

B. External oblique

C. Parietal peritoneum

D. Fascia transversalis

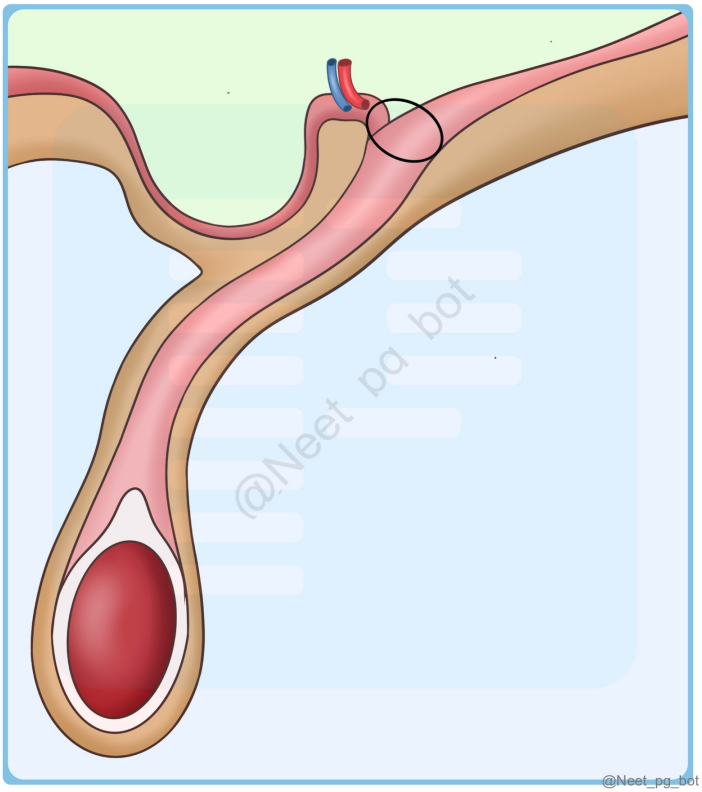

Correct Answer: D. Fascia transversalis

Explanation: The structure marked in the image corresponds to the deep inguinal ring , a key anatomical feature of the inguinal canal. The deep inguinal ring is an opening in the fascia transversalis , located just above the midpoint of the inguinal ligament. This defect allows the passage of the spermatic cord in males and the round ligament of the uterus in females. {{caption_text}} Structure Description Parietal peritoneum (Option C) Most posterior structure. Transversalis fascia Has a defect called the deep inguinal ring, through which the testes and spermatic cord pass. Site for indirect inguinal hernias. Anterior to parietal peritoneum. Forms the posterior in the whole extent. Lateral umbilical fold Formed by the inferior epigastric vessels. Median umbilical ligament Remnant of the urachus (from the allantois). Medial umbilical ligament Remnant of the obliterated umbilical artery. Pyramidalis muscle Small muscle attaching to the pubic bone. Rectus abdominis lies above it. Covered by the rectus sheath and supplied by the subcostal nerve (T12). Rectus abdominis muscle Receives segmental innervation from T6–T12. Transversus abdominis muscle Does not form the anterior wall of the inguinal canal. Contributes to the roof and posterior wall. Combines with internal oblique to form the conjoint tendon. Internal oblique muscle (Option A) Forms parts of the anterior, roof, and posterior walls of the inguinal canal. Contributes to cremasteric muscle and fascia. External oblique muscle (Option B) Aponeurosis forms the anterior wall of the inguinal canal and the superficial inguinal ring . Forms external spermatic fascia. Internal spermatic fascia Derived from the transversalis fascia.

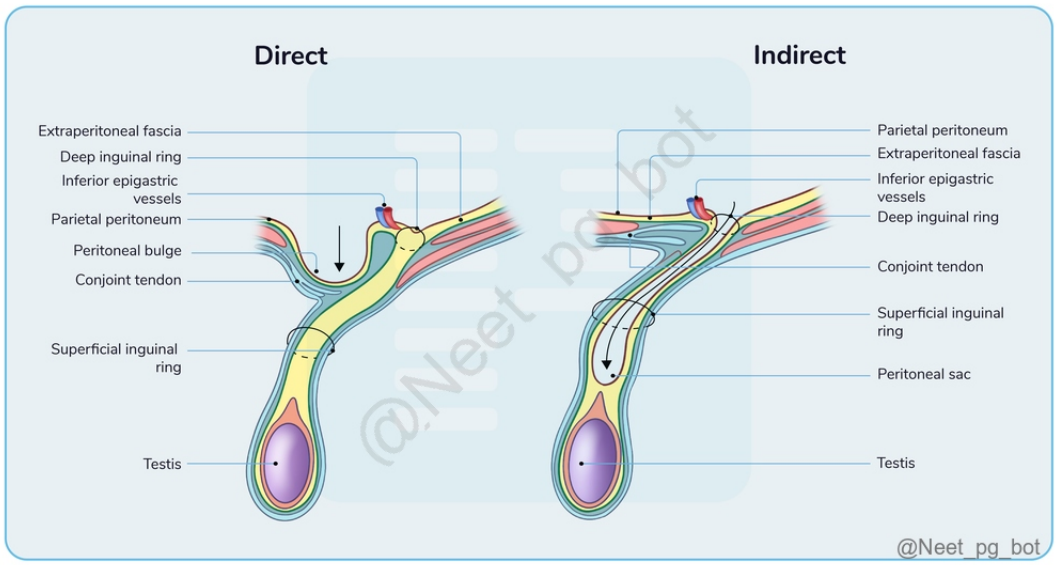

References:

Vishram Singh Textbook of Anatomy, Abdomen and lower-limb, Volume 2, pg.no: 51

↑ *Back to this question in Part A*

@Neet_pg_bot

Q16: Please identify the position of the appendix in the image provided . (Q854796)

A. A-Retrocecal; B-Preileal, C- Postileal, D-Pelvic; E- Subcecal

B. A- Retrocecal; B- Postileal; C Preileal; D-Pelvic: E-Paracecal

C. A- Retrocecal; B- Postileal; C- Preileal; D - Subcecal; E - Pelvic

D. A- Retrocecal; B- Postileal; C- Preileal; D-Pelvic; E- Subcecal

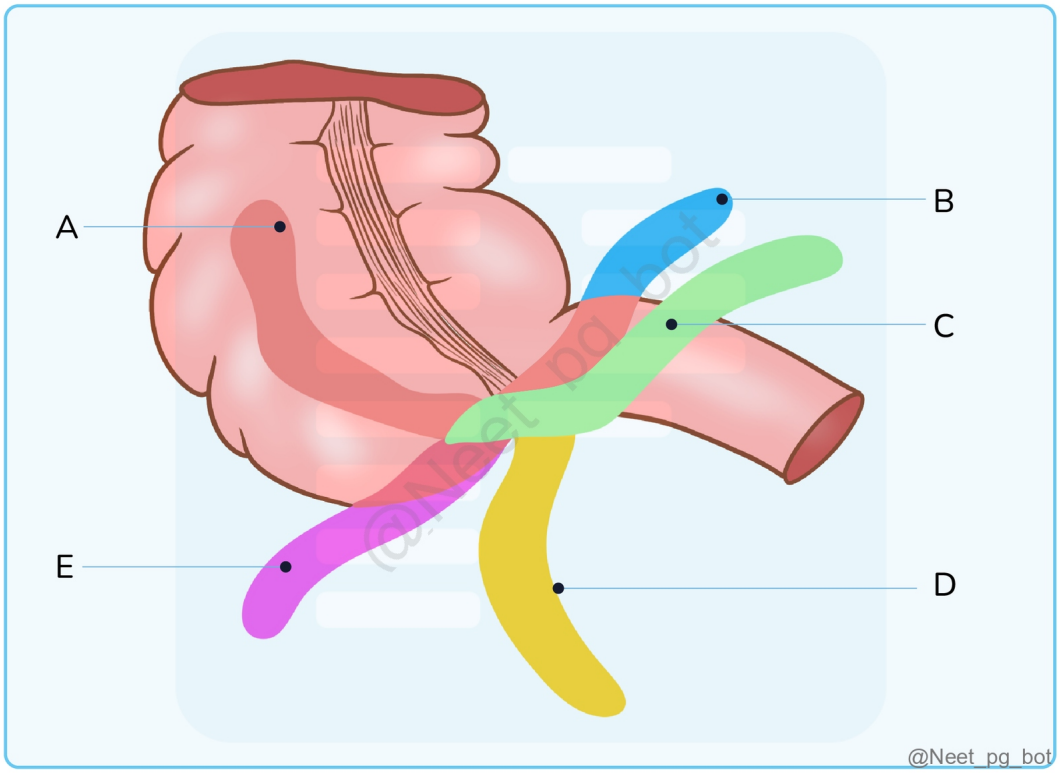

Correct Answer: D. A- Retrocecal; B- Postileal; C- Preileal; D-Pelvic; E- Subcecal

Explanation: A- Retrocecal; B- Postileal; C Preileal; D-Pelvic; E Subcecal Location Presentation Retrocecal May present with flank or back pain Subcecal Can mimic gynecological disorders or urinary tract infection Pre-ileal May cause small bowel obstruction symptoms Post-ileal May cause small bowel obstruction symptoms Paracecal Can present with typical right lower quadrant pain Subhepatic Can be mistaken for cholecystitis Pelvic Can mimic symptoms of pelvic inflammatory disease or ovarian pathology

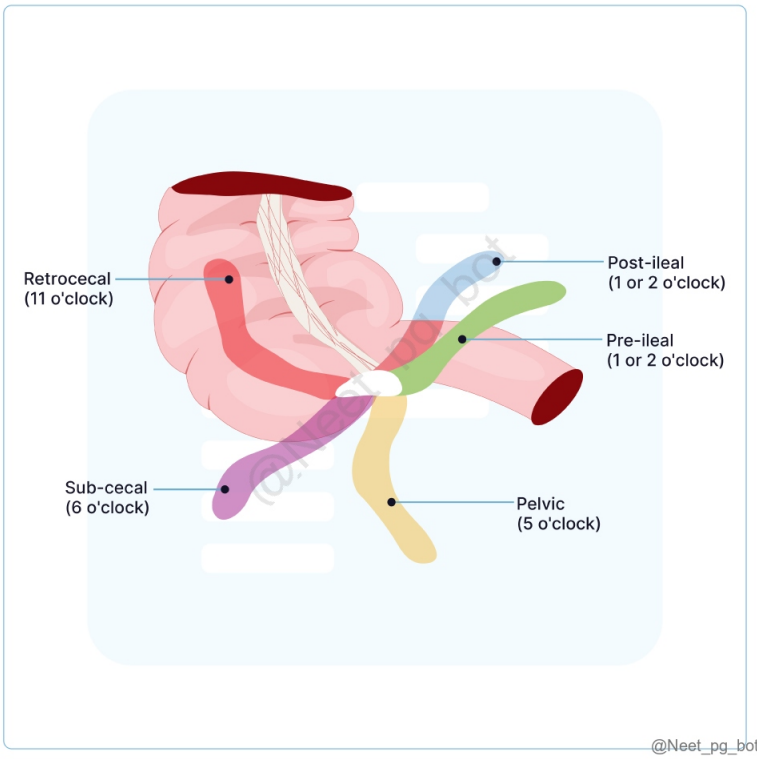

References:

Bailey & Love's Short Practice of Surgery, 28th Edition, pg.1339

↑ *Back to this question in Part A*

@Neet_pg_bot

Q17: During the examination of a patient with a hernia, a surgeon forcefully pushes the hernial sac back into the abdominal cavity without directly pushing back the contents first. What type of hernia has occurred as a result of this, which is depicted in the image below? (Q854794)

A. Strangulated hernia

B. Reduction en masse

C. Sliding hernia

D. Maydl's hernia

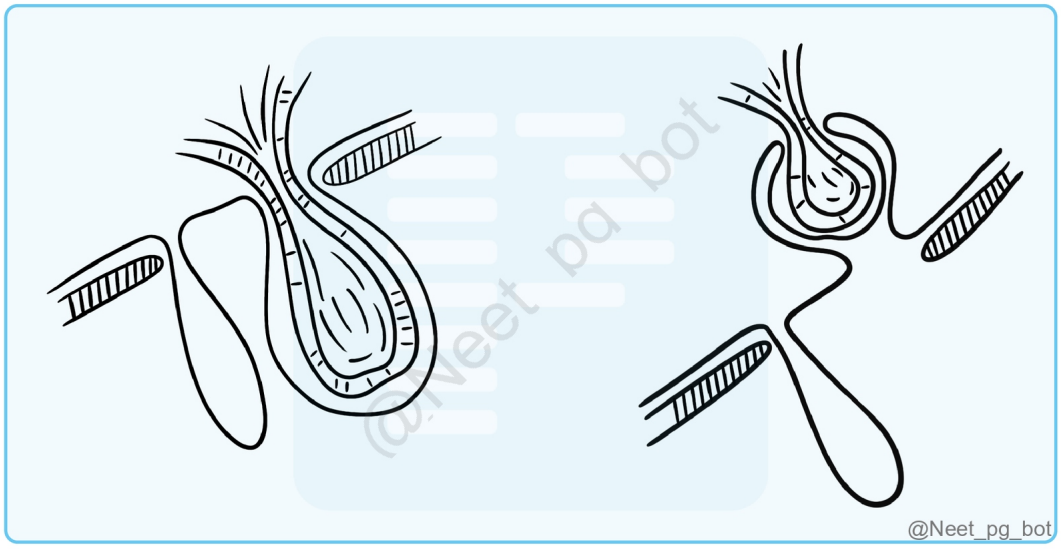

Correct Answer: B. Reduction en masse

Explanation: Reduction en masse refers to a situation where the hernia sac is forcibly pushed back into the abdominal cavity without properly reducing or returning the herniated contents to their normal position. This can occur when the hernia sac gets stuck or incarcerated within the abdominal wall opening. Reduction en masse: The condition reduction en masse is a complication associated with an inguinal hernia. In this condition, the herniated sac is inside the abdominal wall but its contents are strangulated. Clinical features: Persistent pain in the lower abdomen Localised or generalised peritonitis Absence of appreciable hernia externally Intestinal obstruction and strangulation Strangulated Hernia (Option A) : This occurs when the blood supply to the herniated contents is cut off, leading to ischemia. It is different from reduction en masse as the hernia contents remain in the hernial sac. Sliding hernia (Option C): Happens when part of the stomach slides up through the diaphragm opening (hiatus) into the chest cavity, essentially sharing a wall with the hernia sac formed by the diaphragm, causing it to protrude alongside the esophagus This is the most common type of hiatal hernia. Maydl's hernia (Option D): This is a rare hernia where two loops of bowel are within the hernial sac, with the loop between them (inside the abdomen) being at risk of strangulation.

References:

https://pmc.ncbi.nlm.nih.gov/articles/PMC5623225/#:~:text

↑ *Back to this question in Part A*

@Neet_pg_bot

Q18: All are anterior to the third part of the duodenum except? (Q854777)

A. Superior mesenteric artery

B. Root of mesentery

C. Jejunum

D. Fundus of gallbladder

Correct Answer: D. Fundus of gallbladder

Explanation: The third part of the duodenum (horizontal part) lies at the level of L3 and is retroperitoneal. Structures located anterior to it include: Superior mesenteric artery (SMA) Superior mesenteric vein Root of the mesentery Jejunum The fundus of the gallbladder, however, is located in the right hypochondrium, much higher than the third part of the duodenum, and thus is not anterior to it. Relations of Duodenum First Part Second Part Third Part Fourth part Anteriorly : Quadrate lobe of liver, gallbladder. Posteriorly : Portal vein, gastroduodenal artery, bile duct. Superiorly : Epiploic foramen. Inferiorly : Head and neck of the pancreas. Anteriorly : Liver, transverse colon, small intestine. Posteriorly : Right kidney, renal vessels, IVC, psoas major. Medially : Head of the pancreas, bile duct. Laterally : Right colic flexure. Anteriorly : Superior mesenteric vessels, the root of the mesentery. Posteriorly : IVC, abdominal aorta, right ureter, gonadal vessels. Superiorly : Head of the pancreas with the uncinate process. Inferiorly : Coils of jejunum. Anteriorly : Transverse colon, transverse mesocolon, stomach. Posteriorly : Left psoas major, left sympathetic chain, left renal artery. Superiorly : Body of pancreas. To the left : Left kidney, left ureter.

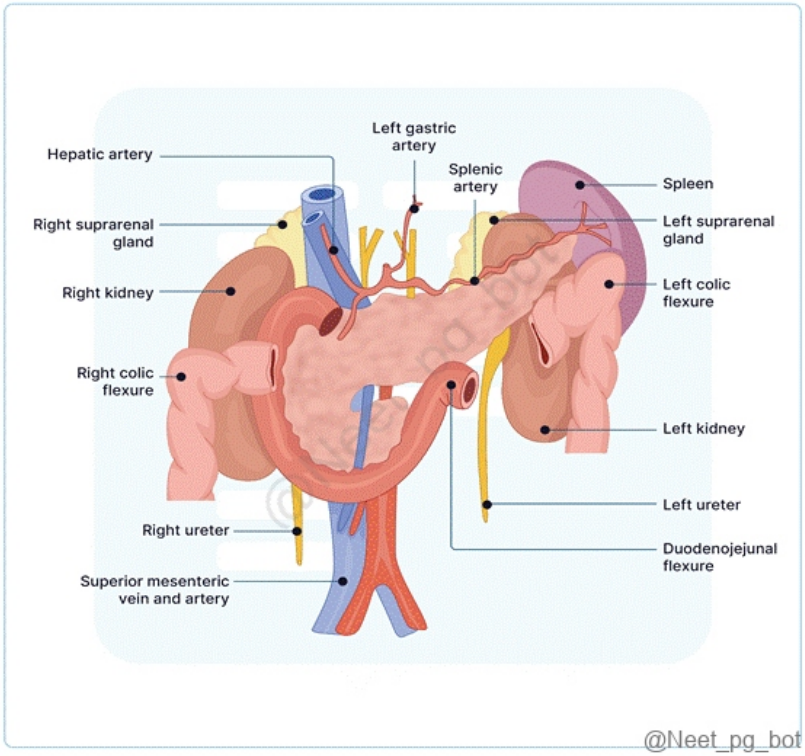

References:

Gray’s Anatomy 42nd edition. Pg. 1173,1175 BD Chaurasia , 8th edition , volume 2 pg 305-308 Vishram Singh Volume 2. Pg 126-128

↑ *Back to this question in Part A*

@Neet_pg_bot

Q19: Which of the following drains into the IVC? (Q854578)

A. Left gonadal vein

B. Left adrenal vein

C. Left renal vein

D. Right ascending lumbar

Correct Answer: C. Left renal vein

Explanation: Left Renal Vein directly drains into the Inferior Vena Cava (IVC). This vein receives blood from the left kidney and left gonadal vein. Inferior vena cava: Origin: Formed by the union of the right and left common iliac veins at the level of L5 vertebra. Termination: Opens into the lower and posterior part of the right atrium. Course: It ascends along the front of the vertebral column, positioned to the right of the aorta, creates a groove on the posterior surface of the liver, and passes through the central tendon of the diaphragm at the T8 vertebral level. Tributaries of IVC Key features Right and left 3rd and 4th lumbar veins It drains the posterior, lateral, and anterior abdominal walls into IVC. Right gonadal vein Left gonadal vein drains into the left renal vein, which drains into the inferior vena cava. Right suprarenal vein Left suprarenal vein drains into the left renal vein, which drains into the inferior vena cava. Right inferior phrenic vein Left inferior phrenic vein drains into the left suprarenal, or left renal vein. Right and left renal veins Left renal vein (7.5cm) is three times longer than right renal vein (2.5cm) Hepatic veins Three large and many small veins open directly into the anterior surface of the inferior vena cava just before it pierces the diaphragm. Left Gonadal Vein (Option A): The left gonadal vein (left testicular vein in males or left ovarian vein in females) drains into the left renal vein, and then the blood flows into the IVC. Left adrenal vein (Option B): The left adrenal vein also drains into the left renal vein, which eventually connects to the IVC. Right ascending lumbar vein (Option D): Right ascending lumbar vein drain into the azygous vein Azygous vein is on right side Azygous will drain in Superior Vena Cava (SVC) at T4 level

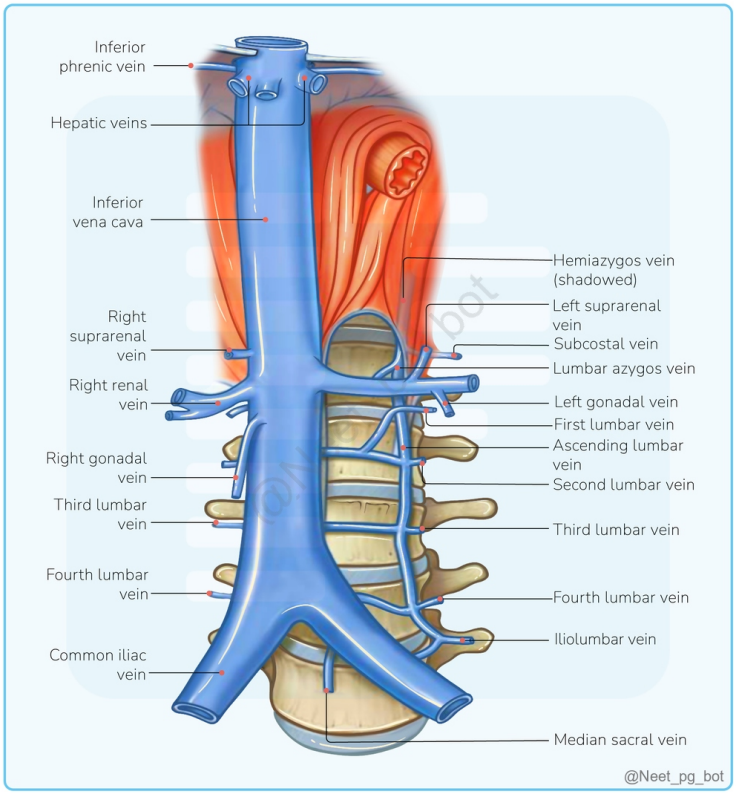

References:

Gray's Anatomy The Anatomical Basis of Clinical Practice, Edition 42nd- Pg No. 1143-44

Image: Gray's Anatomy The Anatomical Basis of Clinical Practice, Edition 42nd- Pg No. Pg No. 1144, Fig. 61.12

↑ *Back to this question in Part A*

@Neet_pg_bot

Q20: Which statement is incorrect regarding the Adrenal gland? (Q854577)

A. Yellow-colored structures

B. The left adrenal gland is present below the spleen

C. The right adrenal gland is crescent in shape

D. It is located retroperitoneally

Correct Answer: C. The right adrenal gland is crescent in shape

Explanation: The right adrenal gland is triangular or pyramidal, not crescent-shaped. Right Adrenal Gland Shape : Pyramidal Parts : Base : Below, overlaps the upper end of the right kidney. Apex : Above, anterior surface presents

a hilum. Anterior Surface : Medial area: Related to the inferior vena cava (IVC). Lateral area: Related to the liver. Posterior Surface : Upper area: Related to the diaphragm. Lower area: Related to the kidney. Borders : Lateral: Overlapped by the liver. Medial: Related to: Below: Celiac ganglion. Above: Inferior phrenic artery. Left Adrenal Gland Shape : Semilunar Parts : Lower End : Rounded, anterior surface presents hilum. Upper End : Narrow, related to the medial end of the spleen (Option B) Anterior Surface : Upper area: Related to the stomach bed. Lower area: Overlapped by the body of the pancreas and crossed by the tortuous splenic artery. Posterior Surface : Lateral area: Related to the left kidney. Medial area: Related to the left crus of the diaphragm. Borders : Lateral: Overlaps the left kidney. Medial: Related to: Below: Celiac ganglion. Above: Inferior phrenic artery. Yellow-colored structures (Option A): The adrenal cortex tends to exhibit a yellowish hue due to its higher fat content, while the adrenal medulla appears more reddish-brown in color. It is located retroperitoneally (Option D): The adrenal glands are situated on top of each kidney in the retroperitoneal space.

References:

https://www.ncbi.nlm.nih.gov/books/NBK482264/#:~:text

↑ *Back to this question in Part A*

@Neet_pg_bot

Q21: The fibers of the internal oblique and transversus abdominis contribute to which wall of the inguinal canal? (Q854573)

A. Anterior

B. Posterior

C. Roof

D. Floor

Correct Answer: C. Roof

Explanation: The roof of the inguinal canal is formed by the fibres of the internal oblique and transversus abdominis muscles. These muscles contribute to the structure that covers the canal from above. The inguinal canal is a passageway in the lower abdominal wall. Contents of the inguinal canal: In males: Spermatic cord and ilioinguinal nerve In females: Round ligament of the uterus and ilioinguinal nerve The boundaries of the inguinal canal are: Anterior wall: It is formed from superficial to deep by: (Option A) Skin Superficial fascia in its extent. External oblique aponeurosis Internal oblique muscle fibers, in lateral one-third. Posterior wall: It is formed from deep to superficial by: (Option B) Fascia transversalis, in the whole extent Conjoint tendon, in medial two-third Reflected part of the inguinal ligament, in the medial-most part. Roof: It is formed by the lower arched fibers of the internal oblique and transversus abdominis muscles. Floor: It is formed by: (Option D) Grooved upper surface of the inguinal ligament in the whole extent Abdominal surface of the lacunar ligament at the medial end. Fig: Contents of Inguinal canal Fig: Inguinal canal boundaries

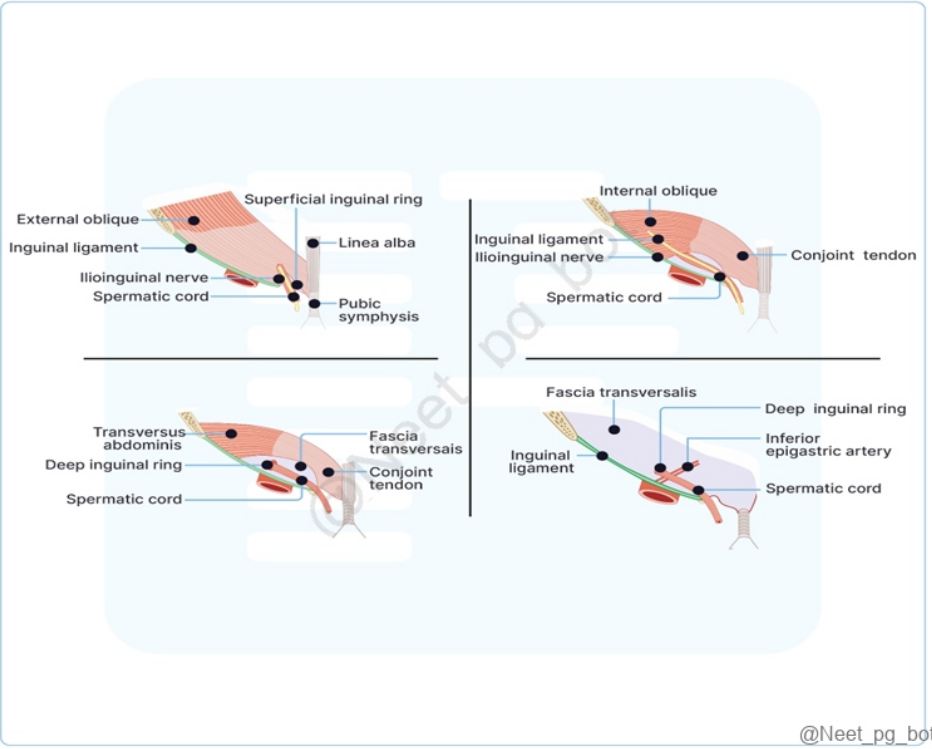

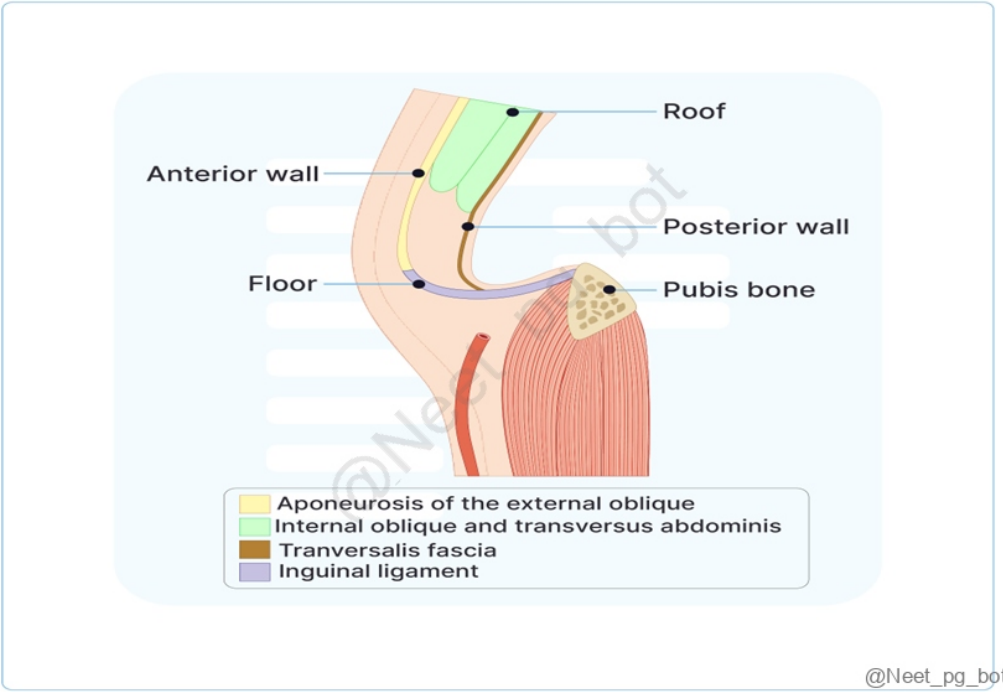

References:

Vishram Singh Textbook of Anatomy, Abdomen and lower-limb, Volume 2, pg.no: 50-51

↑ *Back to this question in Part A*

Q22: Identify the marked structure: (Q860255)

A. Splenogastric ligament

B. Lienorenal ligament

C. Greater omentum

D. Lesser omentum

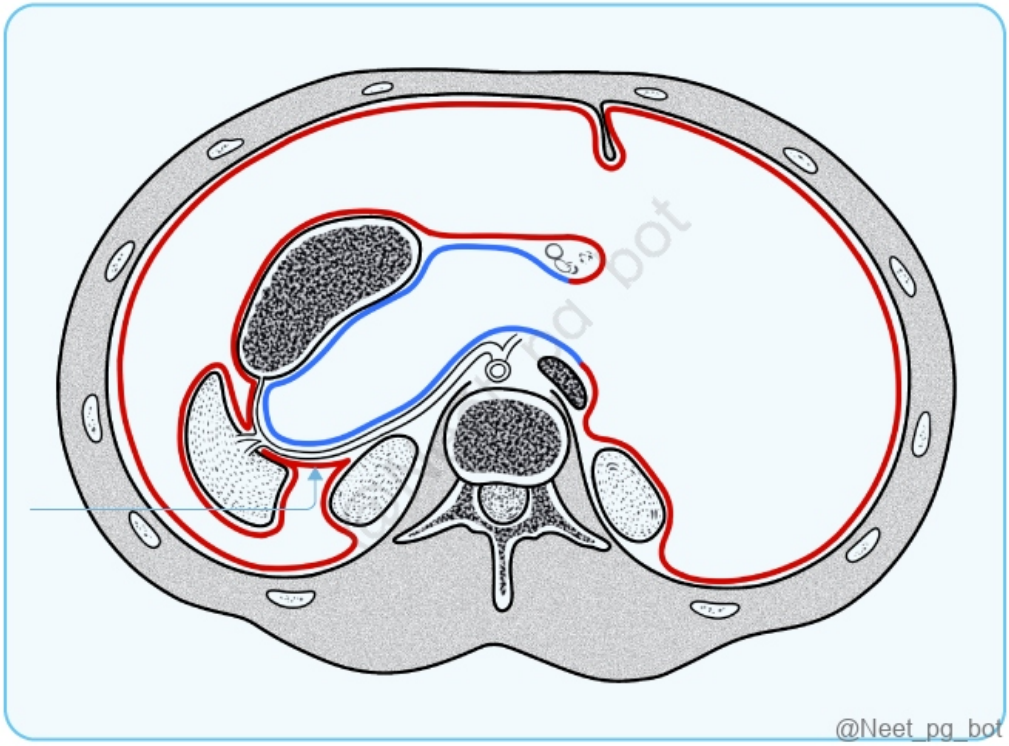

Correct Answer: B. Lienorenal ligament

Explanation: The marked structure is the Lienorenal ligament or the splenorenal ligament. It connects the spleen to the left kidney as the spleen has come to the left side due to the rotation of the stomach. It also carries the splenic artery. Omenta : Sources Structure From To Contains Dorsal mesentery Greater omentum Greater curvature of stomach (and spleen) Transverse colon right and left gastroepiploic vessels and fat Gastrosplenic ligament Stomach Spleen Short gastric artery, Left gastroepiploic artery Gastrophrenic ligament Stomach Diaphragm Left inferior phrenic artery Gastrocolic ligament Stomach Transverse colon Right gastroepiploic artery Splenorenal ligament Spleen Kidney Splenic artery, Tail of pancreas Ventral mesentery Lesser omentum Lesser curvature of the stomach (and duodenum) Liver The right free margin-hepatic artery, portal vein, and bile duct,lymph nodes and the lymph vessels,hepatic plexus of nerve,all enclosed in perivascular fibrous sheath. Along the lesser

curvature of the stomach-left and right gastric artery,the gastric group of lymph nodes and lymphatics, branches from the gastric nerve. Hepatogastric ligament Stomach Liver Right and left gastric artery Hepatoduodenal ligament Duodenum Liver Hepatic artery proper, hepatic portal vein, bile duct, autonomic nerves {{caption_text}} Horizontal disposition of the peritoneum in the upper part of the abdomen {{caption_text}} Horizontal disposition of the peritoneum in the lower part of the abdomen Mesenteries Sources Structure From To Contains Dorsal mesentery Mesentery proper Small intestine (jejunum and ileum) Posterior abdominal wall Superior mesenteric artery, accompanying veins, autonomic nerve plexuses, lymphatics, 100–200 lymph nodes and connective tissue with fat Transverse mesocolon Transverse colon Posterior abdominal wall Middle colic Sigmoid mesocolon Sigmoid colon Pelvic wall Sigmoid arteries and superior rectal artery Mesoappendix Mesentery of ileum Appendix Appendicular artery Other ligaments and folds Sources Structure From To Contains Ventral mesentery Falciform ligament Liver Thoracic diaphragm, anterior abdominal wall Round ligament of liver, paraumbilical vein Left umbilical vein Round ligament of liver Liver Umbilicus Ventral mesentery Coronary ligament Liver Thoracic diaphragm Ductus venosus Ligamentum venosum Liver Liver Phrenicocolic ligament Left colic flexure Thoracic diaphragm Ventral mesentery Left triangular ligament, right triangular ligament Liver Umbilical folds Urinary bladder Ileocecal fold Ileum Cecum Broad ligament of the uterus Uterus Pelvic wall Mesovarium, mesosalpinx, mesometrium Round ligament of uterus Uterus Inguinal canal Suspensory ligament of the ovary Ovary Pelvic wall Ovarian artery

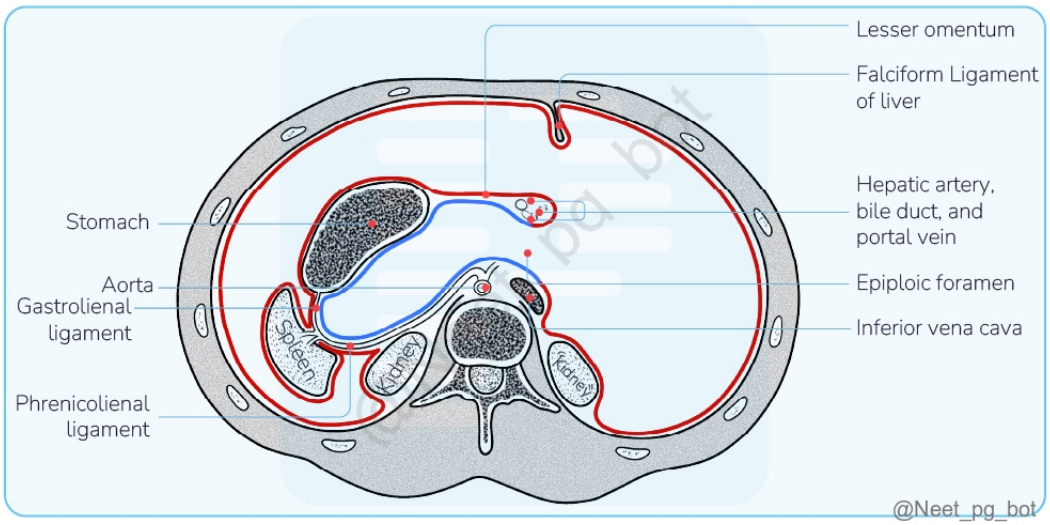

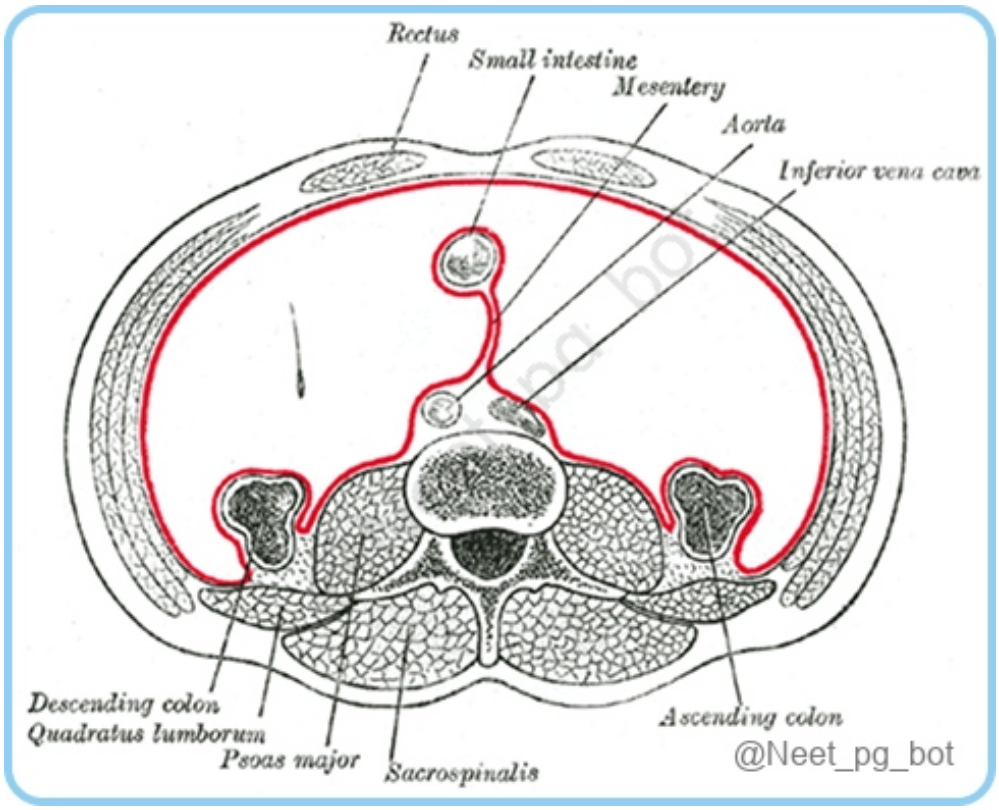

References:

Gray's anatomy, 42nd edition, Page 1151-1157

https://en.wikipedia.org/wiki/Peritoneum#:~:text=Peritoneal%20folds%20are%20omentums%2C%20mesenteries,red%20in%20the%20diagrams%20above.

https://www.ncbi.nlm.nih.gov/books/NBK534788/#:~:text=The%20peritoneum%20is%20comprised%20of,%2C%20transverse%2C%20and%20sigmoid%20colon.

↑ *Back to this question in Part A*

@Neet_pg_bot

Q23: What is the most common type of hernia in females? (Q839895)

A. Obturator hernia

B. Direct inguinal hernia

C. Indirect inguinal hernia

D. Femoral hernia

Correct Answer: C. Indirect inguinal hernia

Explanation: Inguinal hernias (direct + indirect) account for about 75% of all hernias and are the most common type overall. In females, indirect inguinal hernias are the most frequent due to incomplete closure of the processus vaginalis during fetal development. Although inguinal hernias are far more common in males, females can also develop them, and indirect inguinal hernias are still more common than femoral hernias in women. Femoral hernias are less common but are more likely in women than men because of the wider pelvic structure. Typical presentation is a groin swelling above the inguinal ligament, sometimes extending toward the labia majora. Incorrect Options: Option A - Obturator hernia: These are quite rare and occur through the obturator foramen. They are typically found in older, multiparous women and are not the most common type of hernia in females. Option B - Direct inguinal hernia: Direct inguinal hernias occur due to weakness in the abdominal wall in the inguinal (Hesselbach's) triangle. These are more common in men and are not the most common type in females. Option D - Femoral hernia: While femoral hernias are more common in females compared to males due to the wider female pelvis, they are still less common than indirect inguinal hernias in females.

References:

.

↑ *Back to this question in Part A*

@Neet_pg_bot

Q24: A patient presents with fecal discharge from the umbilicus. What's the most likely diagnosis? (Q844322)

A. Urachal fistula

B. Ileal diverticulum

C. Omphalocele

D. Gastroschisis

Correct Answer: B. Ileal diverticulum

Explanation: Correct Option B - Ileal diverticulum: Ileal diverticulum (Meckel's diverticulum) : This is a congenital anomaly resulting from incomplete obliteration of the vitelline duct. A vitelline fistula can form, leading to fecal discharge from the umbilicus, which is a characteristic sign. Incorrect Options: Option A - Urachal fistula : Involves a connection between the bladder and the umbilicus, typically resulting in urine discharge, not fecal material. Option C - Omphalocele : A congenital defect in the abdominal wall where abdominal contents herniate into the umbilical cord. There is no fecal discharge involved. Option D - Gastroschisis : A defect in the abdominal wall, usually to the right of the umbilicus, where the intestines protrude without a protective sac. It is not associated with fecal discharge from the umbilicus.

↑ *Back to this question in Part A*

@Neet_pg_bot

Q25: Most common site of Congenital diaphragmatic hernia is? (Q844237)

A. Central tendon

B. Posterolateral

C. Crural

D. Anterolateral

Correct Answer: B. Posterolateral

Explanation: Correct Option B – Posterolateral: The most common site for congenital diaphragmatic hernia is the posterolateral region of the diaphragm, specifically the left side. This area is where the foramen of Bochdalek is located, which is a common site for herniation of abdominal contents into the thoracic cavity Incorrect Options: Option A - Central Tendon : Hernias in this area are less common. The central tendon is a structure where the muscle fibers of the diaphragm converge, but it is not typically associated with congenital diaphragmatic hernias. Option C - Crural : This area refers to the portion of the diaphragm attaching to the lumbar vertebrae. Hernias in this region are not as common as those in the posterolateral area. Option D - Anterolateral : Hernias in the anterolateral region are rare compared to those in the posterolateral region. This region is less associated with congenital diaphragmatic hernias.

↑ *Back to this question in Part A*

@Neet_pg_bot

Q26: A 15-year-old boy underwent splenectomy for immune thrombocytopenic purpura. During the procedure, the surgeon noticed bleeding while separating the spleen from the stomach. Which vessel is most likely implicated in this bleeding? (Q852997)

A. Left gastric vessels

B. Short gastric vessels

C. Gastroepiploic vessels

D. Splenic vessels

Correct Answer: B. Short gastric vessels

Explanation: The short gastric vessels arise from the splenic artery and drain into the splenic vein . These vessels run within the gastrosplenic ligament , connecting the fundus of the stomach to the spleen. During splenectomy , when the spleen is being separated from the stomach, these vessels must be ligated to prevent bleeding. Since the short gastric arteries lack a collateral blood supply , their injury can lead to fundal ischemia . Blood Supply of the Stomach and Its Surgical Relevance Arterial Supply Origin Left gastric artery Branch of the celiac trunk , supplies the lesser curvature Right gastric artery Branch of the proper hepatic artery , supplies the lesser curvature Short gastric arteries Branches of the splenic artery , supply the fundus Right gastroepiploic artery Branch of the gastroduodenal artery , supplies the greater curvature Left gastroepiploic artery Branch of the splenic artery , supplies the greater curvature {{caption_text}} Left gastric vessels (Option A): Incorrect because these supply the lesser curvature of the stomach and are not directly involved in splenic separation. Gastroepiploic vessels (Option C): Incorrect because these supply the greater curvature and are located in the gastrocolic ligament , away from the spleen. Splenic vessels (Option D): Incorrect because these are major vessels supplying the spleen itself, but they do not cause significant bleeding when separating the spleen from the stomach .

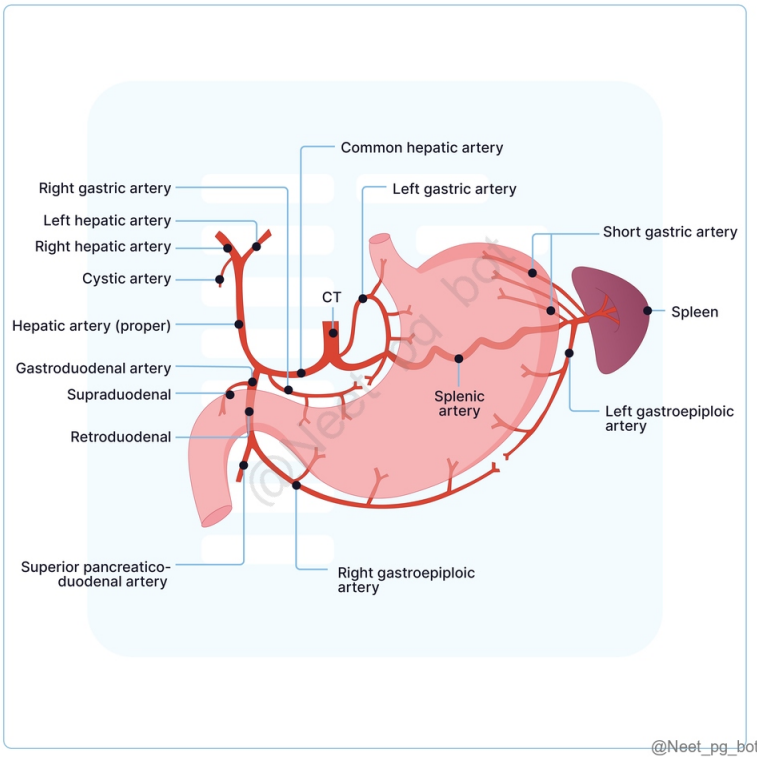

References:

BD Chaurasia’s Human Anatomy, 8th edition, Pages 295

Vishram Singh Textbook of Anatomy, 2nd Edition, PageS 99,100

Grey's Anatomy 42nd edition, Pages 1164-1167

↑ *Back to this question in Part A*

@Neet_pg_bot

Q27: A surgeon by mistake injures one structure posterio to epiploic foramen. Which of the following structure is most likely involved? (Q866325)

A. Abdominal aorta

B. Hepatic artery

C. Inferior vena cava

D. Portal vein

Correct Answer: C. Inferior vena cava

Explanation: The correct answer is the IVC (Inferior Vena Cava), as it forms the posterior boundary of the Epiploic Foramen and is therefore the most likely structure to be injured from behind. Epiploic Foramen / Omental Foramen / Foramen of Winslow A vertical slit-like opening connecting the lesser sac with the greater sac, located behind the right free margin of the lesser omentum at the level of the 12th thoracic vertebra. Boundaries Anterior: Right free margin of the lesser omentum (portal vein, proper hepatic artery, bile duct) Posterior: Inferior vena cava, right suprarenal gland, T12 vertebra (Option C) Superior: Caudate process of the liver Inferior: First part of the duodenum, horizontal part of the hepatic artery Clinical Relevance Pringle Maneuver: A technique to control bleeding from the liver by compressing the free edge of the lesser omentum. Fluid Collections: The apposed walls of the foramen can lead to isolated fluid collections in the greater sac or omental bursa. Incorrect Options: Option A: Abdominal aorta lies posterior to the IVC and is not in direct relation to the epiploic foramen. Option B: Hepatic artery is part of the anterior boundary within the portal triad. Option D: Portal vein is part of the anterior boundary within the portal triad, not posterior.

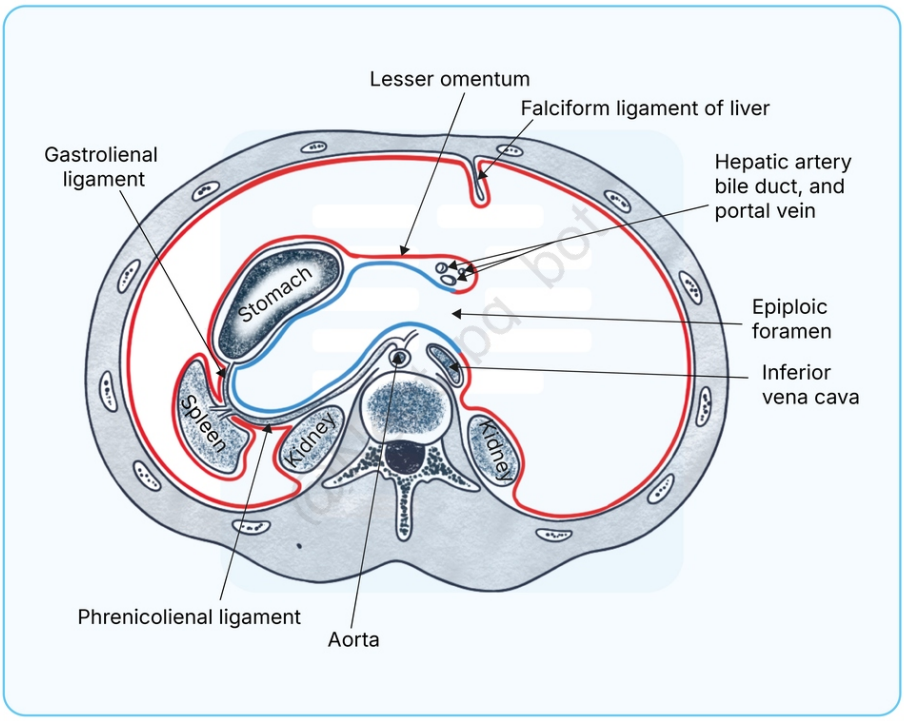

@Neet_pg_bot

References:

.

↑ *Back to this question in Part A*

@Neet_pg_bot

Q28: What is the vertebral level of the abdominal plane labelled 2? (Q793131)

A. Lower border of L1

B. Upper border of L1

C. Upper border of L3

D. Lower border of L4

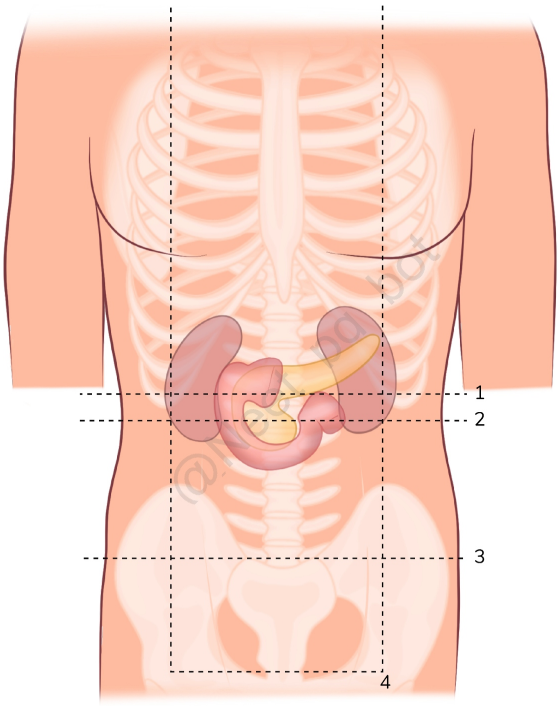

@Neet_pg_bot

Correct Answer: C. Upper border of L3

Explanation: Correct Option C: Upper border of L3 The abdominal plane labeled as 2 is the Subcostal plane, also known as the "plane of the superior mesenteric artery." It's located just below the costal margin, connecting the 10th costal cartilages bilaterally. In the posterior aspect, it corresponds to the upper border of the third lumbar (L3) vertebra. This plane intersects with the aorta, inferior vena cava, and the third part of the duodenum. Incorrect Options: Option A - lower border of L1 At the lower border of L1 is the location of the transpyloric plane, which is also known as the "plane of Addison." Option B - Upper border of L1 The upper border of L1 does not correspond to the subcostal plane. Option D - Lower border of L4 The lower border of L4 is the location of the intertubercular plane, which is also known as the "plane of the iliac crests.

References:

.

↑ *Back to this question in Part A*

@Neet_pg_bot

Q29: To what level of vertebrae does the given structure correspond? (Q793160)

A. At the junction of L1 & L2

B. At the junction of L2 & L3

C. At the junction of T12 & L1

D. At the junction of L3 & L4

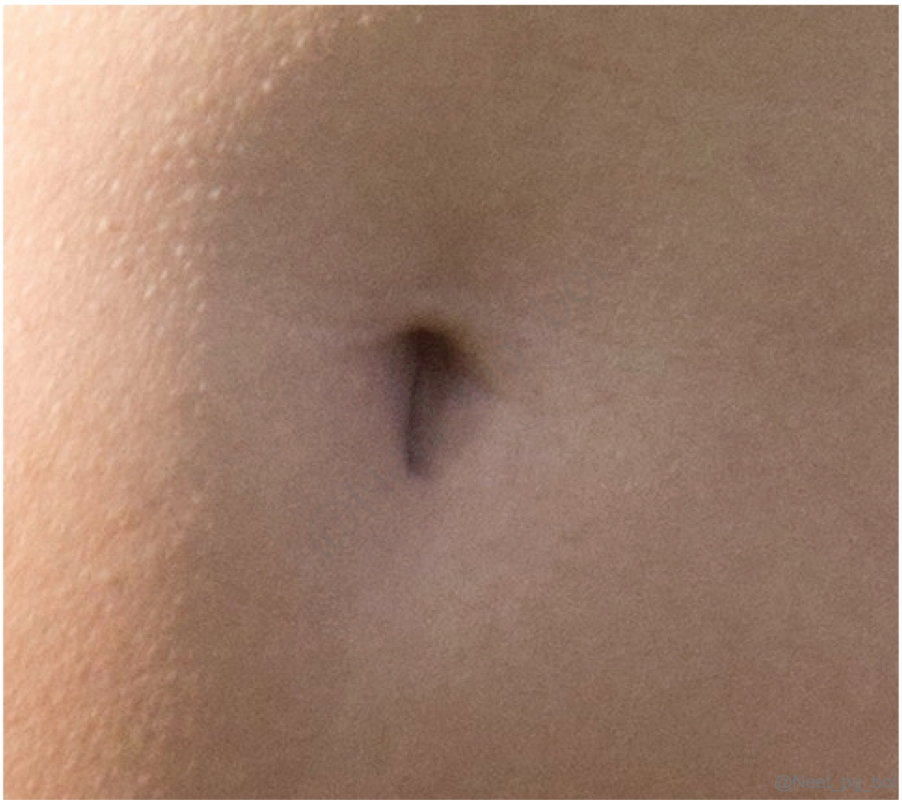

Correct Answer: D. At the junction of L3 & L4

Explanation: Correct Option D: The marked structure is the umbilicus which lies at the junction of L3 & L4. The umbilicus is located at the level of the intervertebral disc between the third lumbar vertebra (L3) and the fourth lumbar vertebra (L4). Associated structures at this level include the inferior vena cava, the renal veins, the gonadal arteries and veins, the ureters, and the descending colon. Incorrect Options: Option A - At the junction of L1 & L2: Associated structures at this level include the spinal cord, the aorta, the inferior vena cava, the renal arteries and veins, and the ureters. Option B - At the junction of L2 & L3: Associated structures at this level include the inferior vena cava, the renal veins, the gonadal arteries and veins, and the ascending colon. Option C - At the junction of T12 & L1: Associated structures at this level include the aorta, the inferior vena cava, the celiac trunk, the superior mesenteric artery, and the renal arteries.

References:

.

↑ *Back to this question in Part A*

@Neet_pg_bot

Q30: A 35-year-old patient underwent an endoscopic examination of the gastrointestinal tract due to recurrent abdominal discomfort and altered bowel habits. Identify the a rrow-marked structure in the given image . (Q820692)

A. Bruner gland

B. Intestinal cells of kajal

C. Crypts of lieberkuhn

D. Peyer's patch

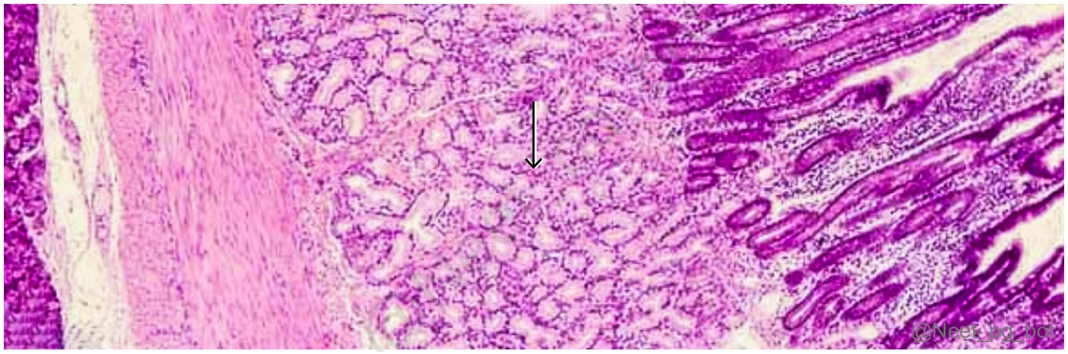

Correct Answer: A. Bruner gland

Explanation: .

References:

Prepladder Notes

↑ *Back to this question in Part A*

@Neet_pg_bot

• [09_Pelvis and Perineum] 044 Development Of Gut Pelvis Perineum

« Back to Folder Directory

[09_Pelvis and Perineum] 044 Development Of Gut Pelvis Perineum — Quick Jump

Q1 (p. 2013) *Q2 (p. 2014)* *Q3 (p. 2015)* *Q4 (p. 2017)* *Q5 (p. 2018)* *Q6 (p. 2019)*
Q7 (p. 2020) *Q8 (p. 2021)* *Q9 (p. 2023)* *Q10 (p. 2024)*

Q1: A 35-year-old female presents with persistent flank pain. An abdominal ultrasound reveals that the lower poles of both kidneys are fused. What is the most likely developmental cause of this condition? (Q848304)

A. Abnormal migration of the metanephros derivative

B. Failure of the ureteric bud to differentiate

C. Complete degeneration of the pronephros

D. Improper development of the urogenital sinus

Correct Answer: A. Abnormal migration of the metanephros derivative

■ *Listen (English)*

■ *Listen (Hindi)*

Explanation: This presentation is indicative of a horseshoe kidney. A condition where the lower poles of the kidney fuse during development. Normally, the Kidney ascends from the pelvis to its final position in the abdomen. Abnormal migration can prevent this ascent and lead to fusion. The ascent of the horseshoe kidney is blocked at the level of the inferior mesenteric artery. Development of the Renal System:

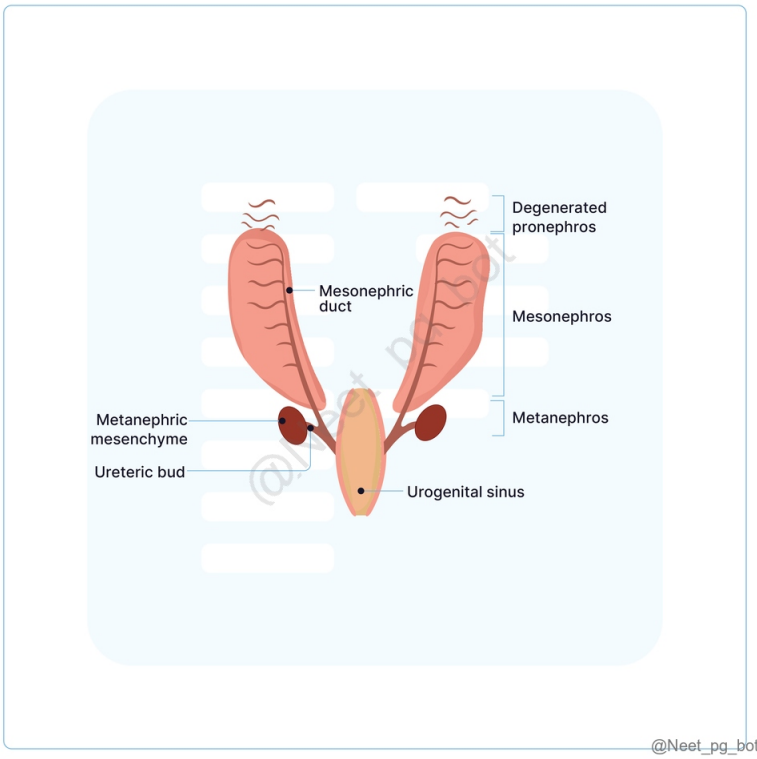

References:

Langman's Medical Embryology, 14th Edition, Page 282-283

↑ *Back to this question in Part A*

@Neet_pg_bot

Q2: A 17-year-old girl with primary amenorrhea is diagnosed with Mullerian agenesis. Which all structures are likely to be affected? (Q848308)

A. Fallopian tubes, uterus, and upper 1/3rd of the vagina

B. Uterus, epoophoron, and lower 2/3rd of the vagina

C. Fallopian tube, trigone of bladder, and clitoris

D. Ovaries, clitoris, and labia majora

Correct Answer: A. Fallopian tubes, uterus, and upper 1/3rd of the vagina

■ *Listen (English)*

■ *Listen (Hindi)*

Explanation: In females, the paramesonephric ducts , also known as Müllerian ducts give origin to the uterine tubes (fallopian tubes), the uterus , and the upper one-third of the vagina. Derivatives Müllerian Ducts (Paramesonephric Ducts) In males Remains rudimentary and forms an appendix of testis In females Uterine tubes Uterus Upper one-third of the vagina

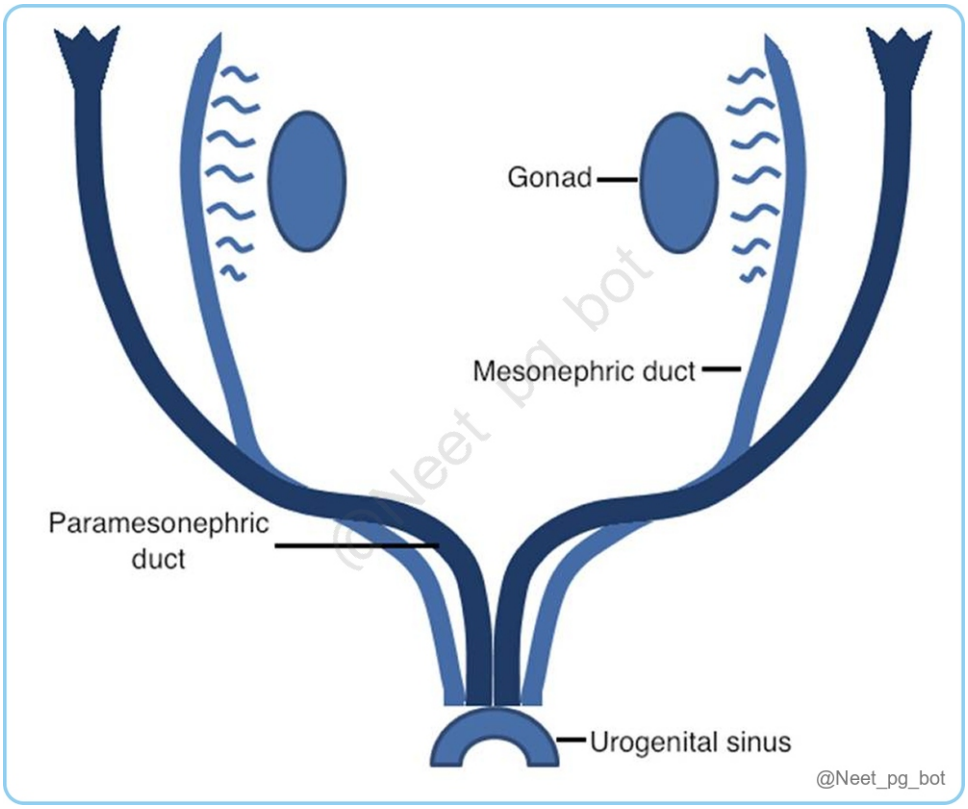

References:

Langman’s Medical Embryology, 14th Edition, Pages 270-272

Inderbir Singh's Human Embryology, 11th Edition, Pages 284-286

↑ *Back to this question in Part A*

@Neet_pg_bot

Q3: A 26-year-old female patient presents to the emergency department in active labour. The obstetrician is concerned about the size of the pelvic outlet and its implications for the delivery of the baby. Which of the following structures is NOT considered a boundary of the pelvic outlet? (Q848310)

A. Lower border of the pubic symphysis

B. Ischial tuberosities

C. Tip of the coccyx

D. Sacral promontory

Correct Answer: D. Sacral promontory

■ *Listen (English)*

■ *Listen (Hindi)*

Explanation: Sacral promontory is a part of the pelvic inlet , not the outlet. Pelvis Components: Structures from anterior to posterior are: Urinary bladder Uterus (in females) Rectum Note: These components are supported by the pelvic diaphragm (levator ani and coccygeus). Boundaries of the Perineum (same as pelvic outlet) : Anteriorly: Lower border of the pubic symphysis (Option A) Arcuate or inferior pubic ligament Posteriorly: Tip of the coccyx (Option C) On each side from anterior to posterior: Conjoined ischiopubic rami Ischial tuberosity (Option B) Sacrotuberous ligament

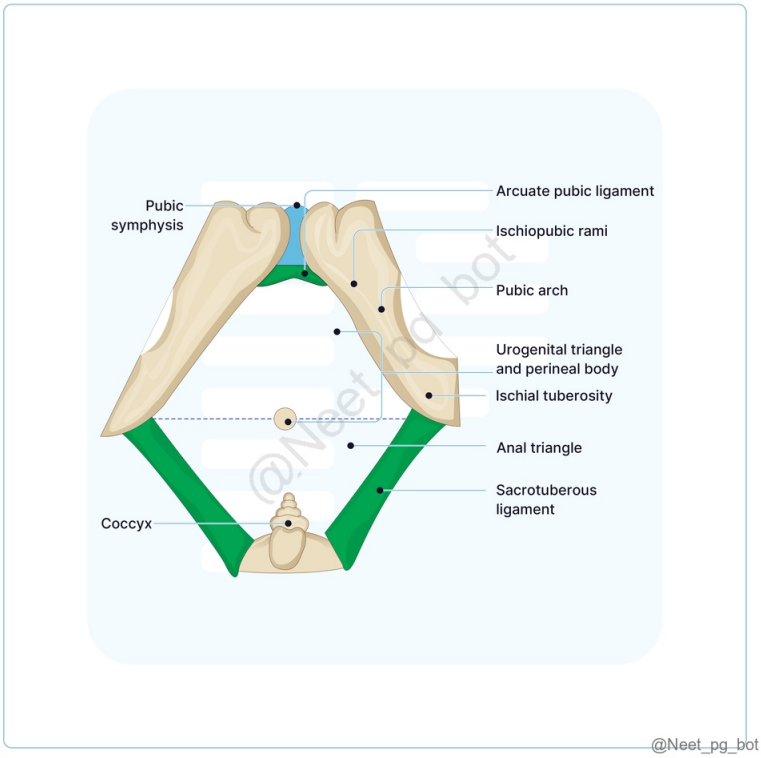

References:

Gray’s Anatomy, The Anatomical Basis of Clinical Practice, 42nd Edition, Page 1253-1255

BD Chaurasia’s Human Anatomy, Volume-2, 8th Edition, Page 431,409,410

↑ *Back to this question in Part A*

@Neet_pg_bot

Q4: A 35 yr old male with injury to the perineum, presented with blood collection in the perineal area extending to the mid-thigh. Which of the following correctly describes the location and characteristics of the perineal space involved in this patient? (Q848311)

A. Obturator fascia and inferior pelvic diaphragm fascia meet to form its apex

B. Located below the perineal membrane, open anteriorly, and continuous with spaces in the scrotum and penis

C. It contains the urethral sphincter within the wall of the urethra

D. Wedge-shaped spaces located below the pelvic diaphragm on either side of the anal canal

Correct Answer: B. Located below the perineal membrane, open anteriorly, and continuous with spaces in the scrotum and penis

■ *Listen (English)*

■ *Listen (Hindi)*

Explanation: Superficial perineal space is involved in this patient. Location: Superficial perineal space is situated below the perineal membrane, which separates it from the deep perineal space. Perineal Spaces: Space Description Superficial Perineal Space Located below the perineal membrane, open anteriorly, it connects with spaces in the scrotum/penis (males) or clitoris (females), enclosed posteriorly by Colles' fascia. (Option B) Deep Perineal Space Situated above the perineal membrane, previously thought to contain the urethral sphincter (now known to be within the urethra), it is thin and open above. (Option C) Ischioanal Fossa Wedge-shaped spaces in the anal triangle, located below the pelvic diaphragm, base formed by perineal skin, apex where obturator fascia and inferior pelvic diaphragm fascia meet. (Options A & D) Contents of Perineal Spaces: Contents of Superficial Perineal Space: Category Male Contents Female Contents Erectile Bodies Root of penis (Bulb and Crura) Root of clitoris (Bulbs of vestibule and Crura) Muscles Ischiocavernosus, Bulbospongiosus, Superficial transverse perineal Ischiocavernosus, Bulbospongiosus, Superficial transverse perineal Glands None Greater Vestibular (Bartholin's) Glands Vessels/Nerves Internal pudendal branches; Posterior scrotal nerves Internal pudendal branches; Posterior labial nerves Contents of Deep Perineal Space: Category Male Contents Female Contents Urethra Membranous Urethra Part of the Urethra Muscles Sphincter urethrae, Deep transverse perineal Sphincter urethrae, Deep transverse perineal, Compressor urethrae Glands Bulbourethral (Cowper's) Glands None (Bartholin's are superficial) Vessels/Nerves Internal pudendal artery and Dorsal nerve of penis Internal pudendal artery and Dorsal nerve of clitoris Contents of Ischioanal Fossa (Ischiorectal Fossa): Ischioanal Fat Pad: Large volume of fat that allows for the expansion of the anal canal during defecation. Pudendal Canal (Alcock’s Canal): A tunnel in the lateral wall (obturator fascia) containing: Pudendal Nerve Internal Pudendal Artery and Vein Inferior Rectal Neurovasculature: Branches of the pudendal nerve and internal pudendal vessels that "bridge" across the fat to supply the external anal sphincter and skin. Anterior Recess: A forward extension of the fossa that runs superior to the perineal membrane.

References:

Gray’s Anatomy, The Anatomical Basis of Clinical Practice, 42nd Edition, Page 1255

BD Chaurasia’s Human Anatomy, Lower limb Abdomen and Pelvis, Volume 2, 8th Edition, Pages 415-418

↑ *Back to this question in Part A*

@Neet_pg_bot

Q5: In a newborn presenting with ambiguous genitalia at birth, USG reveals the presence of a uterus. The karyotype was found to be XY. What is the most common cause? (Q848303)

A. Excessive production of DHT.

B. Mutation in the SRY gene.

C. Inadequate expression of WNT4.

D. Increased levels of estrogen.

Correct Answer: B. Mutation in the SRY gene.

■ *Listen (English)*

■ *Listen (Hindi)*

Explanation: Mutation in the SRY gene prevents the formation of testes Results in a lack of testosterone and Müllerian Inhibiting Substance (MIS). The absence of MIS leads to the proliferation of mullerian ducts (uterus present) and the lack of testosterone leads to degeneration of the wolfian duct. Excessive production of DHT (Option A) promotes the development of male external genitalia. Inadequate expression of WNT4 (Option C) : No role in male development. Increased levels of estrogen (Option D) : Do not present with functional Müllerian ducts alongside regressed Wolffian ducts in a genetically male infant.

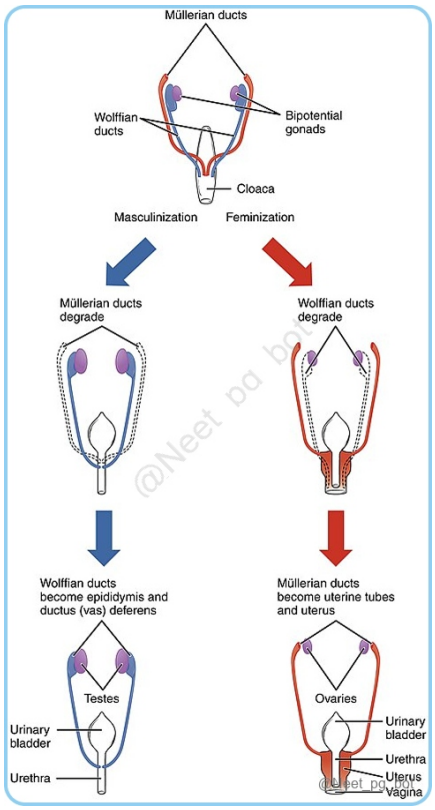

References:

Langman's Medical Embryology, 14th Edition, Page 283

https://www.ncbi.nlm.nih.gov/books/NBK557601/

↑ *Back to this question in Part A*

@Neet_pg_bot

Q6: A 16-year-old adolescent girl developed secondary sexual characteristics at 12 but has never menstruated. Ultrasound indicates no uterus. Karyotyping and hormone assays are normal. Which structure is most likely NOT affected in this patient? (Q848305)

A. Ovaries

B. Fallopian Tubes

C. Upper part of the Vagina

D. Cervix

Correct Answer: A. Ovaries

■ *Listen (English)*

■ *Listen (Hindi)*

Explanation: The presentation is consistent with Mayer-Rokitansky-Küster-Hauser (MRKH) syndrome , characterised by Müllerian agenesis. In Mullerian agenesis, Ovaries are not affected. Ovaries develop from the genito-urinary ridge. Müllerian (Paramesonephric) Ducts : Origin : Mesodermal derivative. Developmental Fate : Uterus Uterine (Fallopian) tubes (Options B) Cervix (Options D) Upper one-third of the vagina (Options C) Vaginal Development : Upper one-third : Derived from the fused Müllerian ducts. Lower two-thirds : Derived from the endoderm of the urogenital sinus.

References:

Langman's Medical Embryology, 14th Edition, Page 267-283

↑ *Back to this question in Part A*

@Neet_pg_bot

Q7: An 8-year-old male child presents with a history of recurrent urinary tract infections. Imaging studies reveal a significant dilation of the ureters and an abnormal configuration of the bladder trigone. The patient is diagnosed with vesicoureteral reflux (VUR). Urologists suspect that the anomaly is linked to the embryological development of the trigone of the bladder. Which of the following statements about the trigone of the urinary bladder is FALSE? (Q848306)

A. The trigone is formed from the mesonephric duct.

B. The trigone is composed of endodermal tissue.

C. The proximal part of the mesonephric duct is the Wolffian duct. Mucosal rugosities are absent in trigone region.

D. The trigone is formed on the posterior wall of the bladder.

Correct Answer: B. The trigone is composed of endodermal tissue.

■ *Listen (English)*

■ *Listen (Hindi)*

Explanation: The trigone of the urinary bladder is derived from mesodermal tissue. Development of the Trigone of the Urinary Bladder: Origin: The trigone is formed from the absorption of the tip of the mesonephric (Wolffian) duct into the posterior wall of the urogenital sinus . (Options A & D) Tissue Derivation: The trigone is composed of mesodermal tissue. (Option B) The remainder of the urinary bladder is derived from endoderm (urogenital sinus). Mesonephric Duct: After the formation of the trigone, the proximal part of the mesonephric duct is referred

to as the Wolffian duct. Unlike the rest of the bladder mucosa, which has rugae (folds) when empty, the trigone remains smooth regardless of bladder filling. (Option C) Clinical Significance: Anomalies in the development of the trigone can lead to urinary tract abnormalities. Anatomical Significance: The trigone is an important landmark within the bladder , delineating the area between the ureteric orifices and the internal urethral orifice.

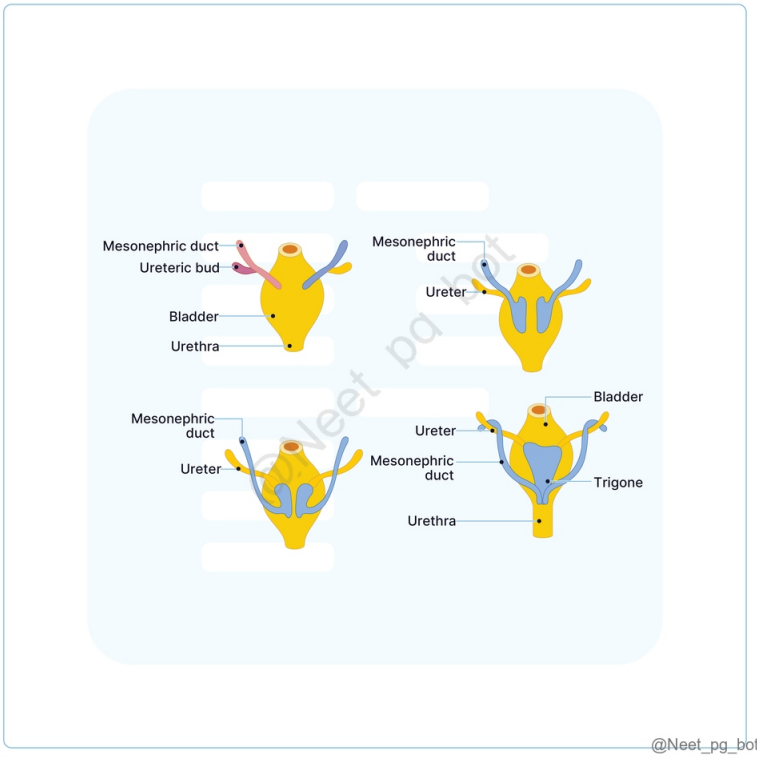

References:

1. Langman’s Medical Embryology, 14th Edition, Page 266 2. https://urology.ucsf.edu/sites/urology.ucsf.edu/files/uploaded-files/attachments/8_development_of_the_bladder_1-s2.0-s0301468118301038-main_copy.pdf

↑ *Back to this question in Part A*

@Neet_pg_bot

Q8: A one-day-old newborn is admitted to the neonatal intensive care unit (NICU) due to severe respiratory distress. Prenatal ultrasounds had revealed bilateral renal agenesis and severe oligohydramnios. The neonatologist explains that this malformation occurred early in gestation. Which of the following developmental processes is most likely responsible for the bilateral renal agenesis seen in this newborn? (Q848307)

A. Failure of the ureteric bud formation and induce the metanephric mesenchyme.

B. Failure of the pronephros development

C. Failure of the mesonephric duct to fuse with the urogenital sinus

D. Failure of the mesonephric duct to differentiate into kidney

Correct Answer: A. Failure of the ureteric bud formation and induce the metanephric mesenchyme.

■ *Listen (English)*

■ *Listen (Hindi)*

Explanation: The ureteric bud is an outgrowth from the mesonephric duct and induces the metanephric mesenchyme to differentiate into nephrons (the functional units of the kidney). Hence, failure of the ureteric bud formation or not properly inducing the metanephric mesenchyme leads to bilateral renal agenesis. Renal System Development Excretory Part Metanephrons Bowman's capsule, proximal convoluted tubules, loop of Henle, distal convoluted tubules. Collecting Part Ureteric bud Collecting duct, minor calyces, major calyces, ureter.

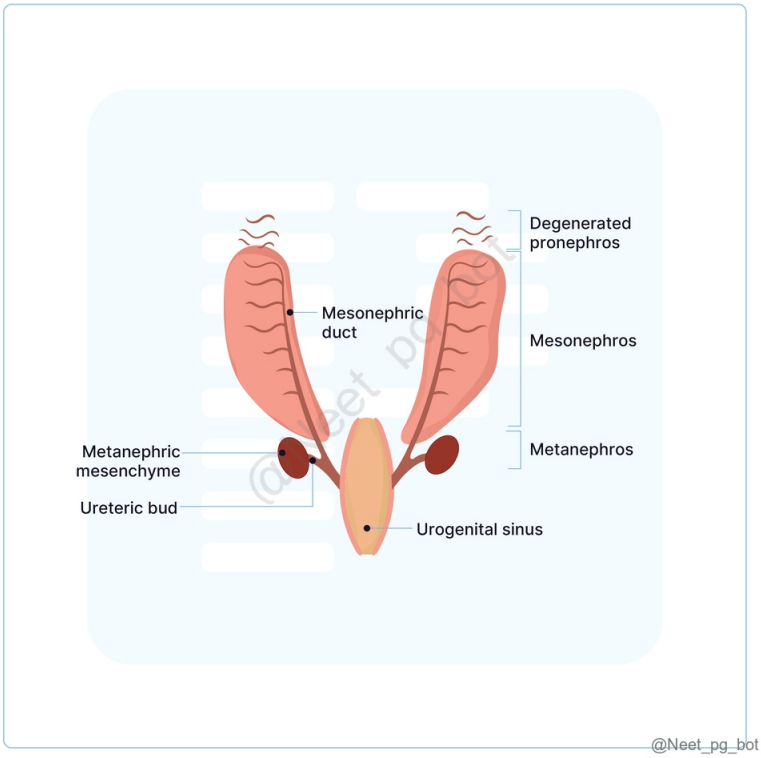

References:

Inderbir Singh's Human Embryology, 11th Edition, Page 266-288

https://teachmeanatomy.info/the-basics/embryology/urinary-system/

↑ *Back to this question in Part A*

@Neet_pg_bot

Q9: Which of the following pairs correctly matches the embryonic structure with its corresponding differentiated structure in males and females during the development of external genitalia? (Q848309)

A. Genital tubercle → Clitoris (Female), Glans penis (Male)

B. Genital fold → Labia majora (Female), Penoscrotal raphe (Male)

C. Genital swelling → Labia majora (Female), Glans penis (Male)

D. Genital fold → Labia minora (Female), Scrotum (Male)

Correct Answer: A. Genital tubercle → Clitoris (Female), Glans penis (Male)

■ *Listen (English)*

■ *Listen (Hindi)*

Explanation: The urethral folds (often referred to as genital folds) develop into the labia minora in females and contribute to the ventral urethra in males. Development of External Genitalia: Structure Female Male Genital tubercle (phallus) Clitoris Glans penis Genital fold (urethral fold) Labia minora Penoscrotal raphe Part of the ventral urethra Genital swelling (labioscrotal swelling) Labia majora Scrotum

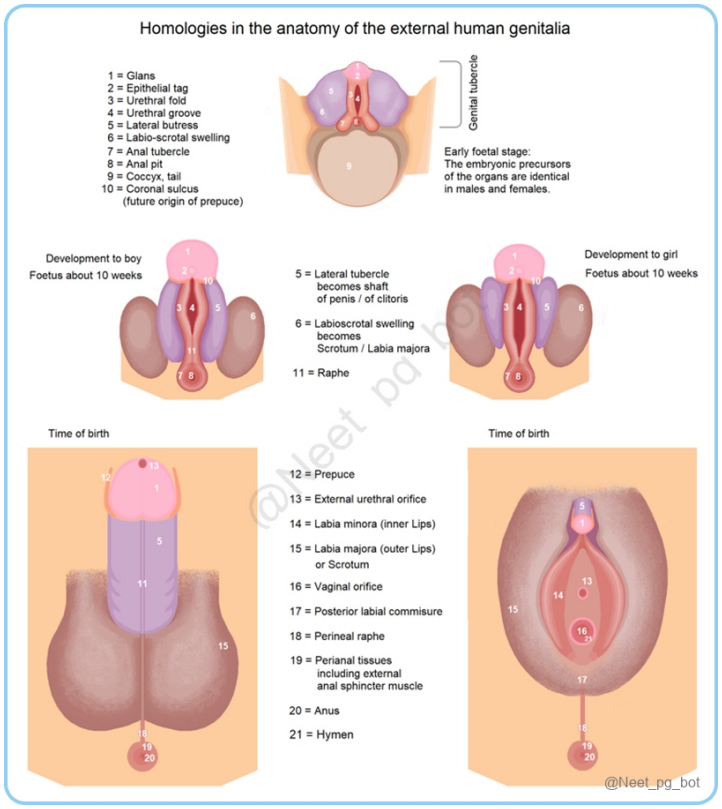

References:

Langman’s Medical Embryology, 14th Edition, Page 276-78

↑ *Back to this question in Part A*

@Neet_pg_bot

Q10: During a pelvic exam, a gynaecologist is teaching the medical students about the structures of the vestibule of the vagina. Which of the following structures is NOT located within the vestibule? (Q848312)

A. External urethral orifice

B. Vaginal orifice

C. Clitoral glans

D. Openings of the Bartholin glands

Correct Answer: C. Clitoral glans

■ *Listen (English)*

■ *Listen (Hindi)*

Explanation: Vestibule of Vagina: It is the area between the labia minora. It is a smooth area that starts just below the clitoris at the top and extends downward to the posterior junction of the labia minora. Contents: External urethral orifice (Option A) Vaginal orifice (Option B) Openings of the two greater vestibular glands (Bartholin gland) (Option D) Openings of numerous lesser vestibular glands (Skene's Glands) - mucous-secreting glands. The clitoral glans is not located within the vestibule.

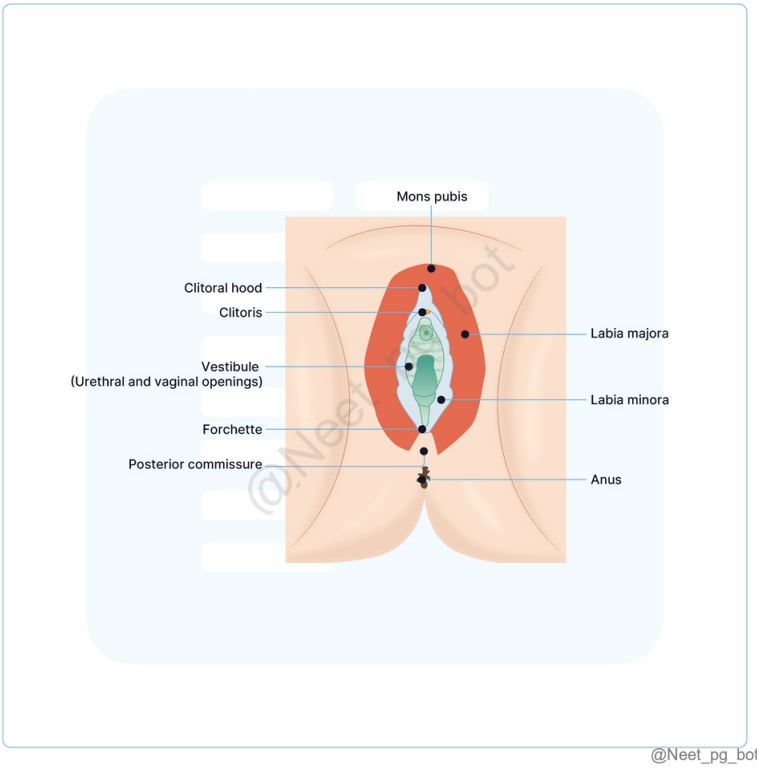

@Neet_pg_bot

References:

Gray’s Anatomy, The Anatomical Basis of Clinical Practice, 42nd Edition, Page 1307

https://www.ncbi.nlm.nih.gov/books/NBK547703/

↑ *Back to this question in Part A*

@Neet_pg_bot

• [09_Pelvis and Perineum] 045 Neurovascular Anatomy Of Pelvis Perineum Rectum And Anal Canal

« Back to Folder Directory

[09_Pelvis and Perineum] 045 Neurovascular Anatomy Of Pelvis Perineum Rectum And Anal Canal — Quick Jump

Q1 (p. 2026) *Q2 (p. 2028)* *Q3 (p. 2030)* *Q4 (p. 2033)* *Q5 (p. 2035)* *Q6 (p. 2037)*
Q7 (p. 2039) *Q8 (p. 2040)* *Q9 (p. 2042)* *Q10 (p. 2045)* *Q11 (p. 2047)* *Q12 (p. 2049)*
Q13 (p. 2050) *Q14 (p. 2052)*

Q1: A 58-year-old male patient presents with difficulty in urination and reports a sensation of incomplete bladder emptying. Upon examination, the neurologist suspects an issue with autonomic innervation to the urinary bladder. What are the root values for the sympathetic and parasympathetic innervation of the urinary bladder? (Q848316)

A. Sympathetic: S1-S2; Parasympathetic: T10-L2

B. Sympathetic: T12-L1; Parasympathetic: S3-S5

C. Sympathetic: L1-L3; Parasympathetic: S1-S3

D. Sympathetic: T10-L2; Parasympathetic: S2-S4

Correct Answer: D. Sympathetic: T10-L2; Parasympathetic: S2-S4

■ *Listen (English)*

■ *Listen (Hindi)*

Explanation: Urinary bladder is innervated by the vesical plexus, which comprises both sympathetic and parasympathetic fibers, involving both motor and sensory functions. Sympathetic innervation controls bladder filling , whereas the parasympathetic innervation controls bladder emptying. Somatic innervation is responsible for the voluntary control of urination. Type of Innervation Nerves Function Parasympathetic Nerve Fibers (S2, S3, S4) Pelvic splanchnic nerves Excitatory effect on Detrusor muscle Inhibitory to the vesical sphincter. Sympathetic Fibers (T10-L2) Inferior mesenteric plexus Hypogastric plexus Inhibitory effect on Detrusor muscle Motor action on vesical sphincter Somatic Nerve (S2, S3, S4) Pudendal nerve Supplies external urethral sphincter, which is under voluntary control

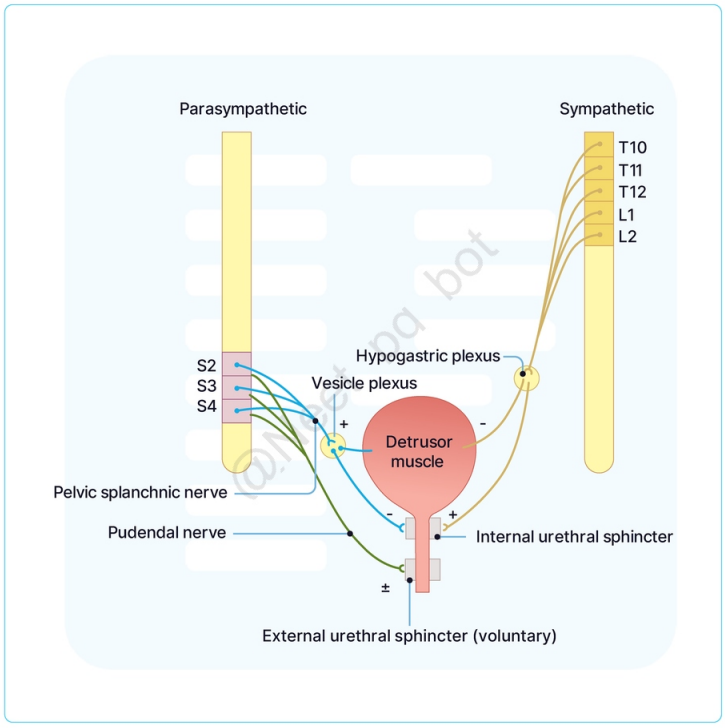

@Neet_pg_bot

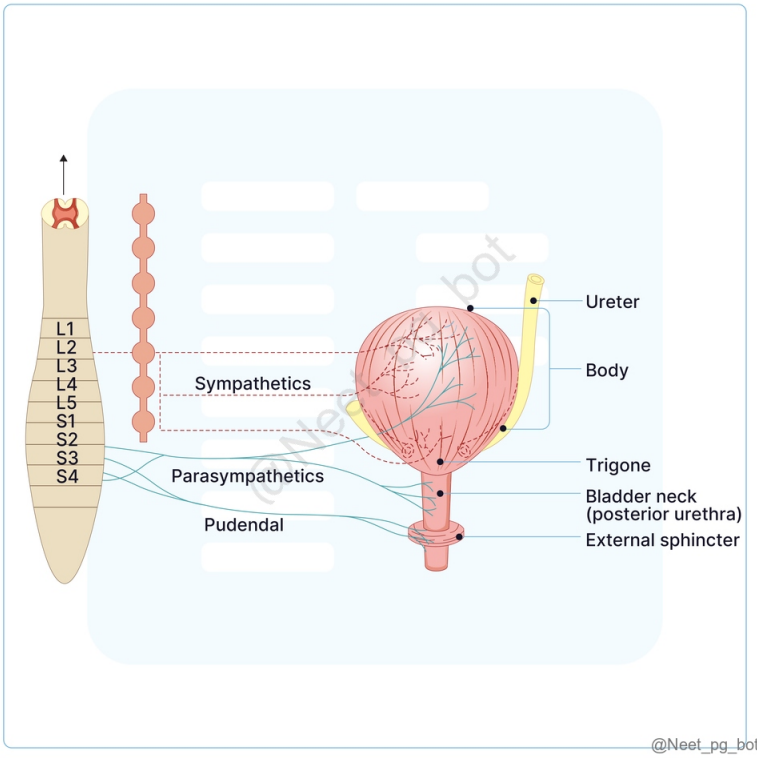

@Neet_pg_bot

References:

1. B. D. Chaurasia’s Human Anatomy, Volume-2, 8th Edition, Page 437 2. Vishram Singh Textbook of Anatomy, Volume-2, 2nd Edition, Page 243

↑ *Back to this question in Part A*

@Neet_pg_bot

Q2: A 45-year-old female presents with sharp pain and swelling in her right buttock and thigh after falling on her side, leading to difficulty sitting and walking. Examination shows swelling, tenderness, and bruising over the right buttock, with no deformity, dislocation, or neurological deficits, indicating a possible hematoma. What is the origin of the affected artery? (Q848318)

A. Anterior division of the internal iliac artery

B. Posterior division of the internal iliac artery

C. Anterior division of the obturator artery

D. Posterior division of the obturator artery

Correct Answer: B. Posterior division of the internal iliac artery

■ *Listen (English)*

■ *Listen (Hindi)*

Explanation: The scenario describes a hematoma resulting from trauma to the Superior gluteal artery , which is a branch of the posterior division of the internal iliac artery . Superior Gluteal Artery Origin Branch of the posterior division of the internal iliac artery. Course Supply Superficial Branch: Gluteus maximus Deep Branch: Gluteus medius Gluteus minimus Obturator artery : Branch of the internal iliac artery Divides (at obturator foramen) into: Anterior (medial) and posterior (lateral) branches. Acetabular branch (posterior division) passes through the acetabular notch (supplying the fat in the acetabular fossa) and sends a twig to the head of the femur along the round ligament.

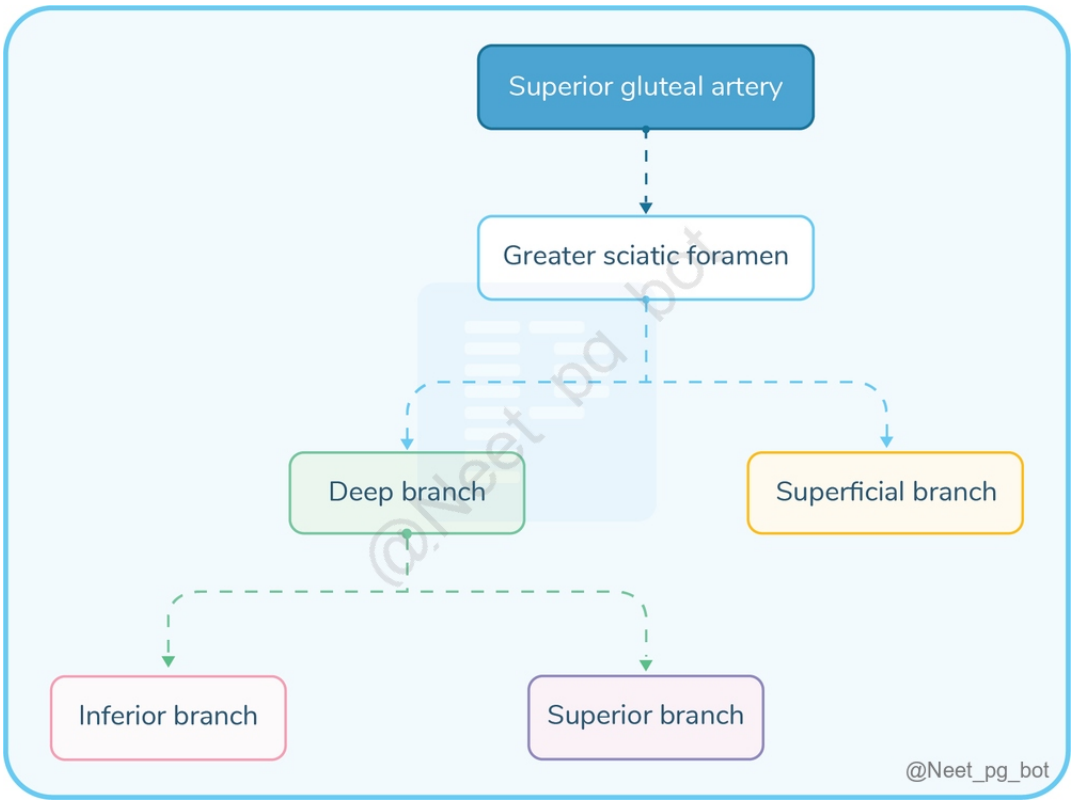
Superior gluteal artery
Greater sciatic foramen
Deep branch
Superficial branch
Inferior branch
Superior branch
@Neet_pg_bot

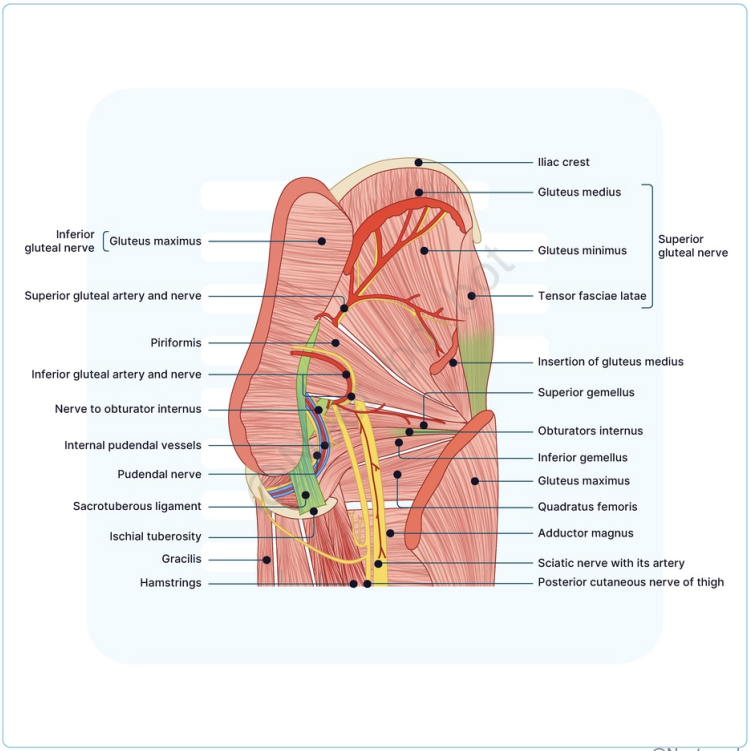
Iliac crest
Gluteus medius
Inferior gluteal nerve
Gluteus maximus
Gluteus minimus
Superior gluteal nerve
Superior gluteal artery and nerve
Tensor fasciae latae
Piriformis
Insertion of gluteus medius
Inferior gluteal artery and nerve
Superior gemellus
Nerve to obturator internus
Obturators internus
Internal pudendal vessels
Inferior gemellus
Pudendal nerve
Gluteus maximus
Sacrotuberous ligament
Quadratus femoris
Ischial tuberosity
Adductor magnus
Gracilis
Sciatic nerve with its artery
Hamstrings
Posterior cutaneous nerve of thigh

@Neet_pg_bot

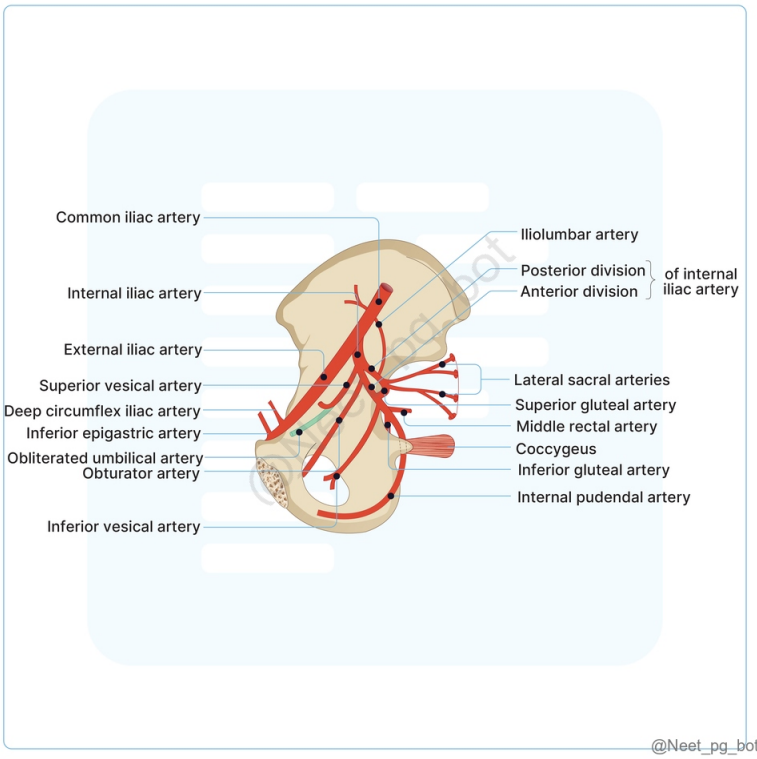

References:

1. Gray's Anatomy, 42nd Edition, Page 1248 2. BD Chaurasia’s Human Anatomy, Volume-2, 8th Edition, Page 84
3. Vishram Singh Textbook of Anatomy, Volume-2, 2nd Edition, Page 222, 223

↑ *Back to this question in Part A*

@Neet_pg_bot

Q3: A 55-year-old male presents with rectal bleeding and changes in bowel habits. The physician evaluates the rectal anatomy to determine the best surgical approach. Which part of the rectum is covered by peritoneum only on the anterior aspect? (Q848320)

A. Upper 1/3rd

B. Middle 1/3rd

C. Lower 1/3rd

D. Whole of the rectum

Correct Answer: B. Middle 1/3rd

■ *Listen (English)*

■ *Listen (Hindi)*

Explanation: Middle third of the Rectum is covered by the peritoneum only on the anterior aspect. Part of Rectum Peritoneal Relation Upper 1/3rd (Option A) Covered with peritoneum on the anterior and lateral aspects. Middle 1/3rd (Option B) Covered only on the anterior aspect. Lower 1/3rd (Option C) Devoid of peritoneum Visceral Relations of Rectum: Anterior Relations: Part of Rectum Male Female Upper 2/3rd Rectovesical pouch (coils of intestine and sigmoid colon) Rectouterine pouch (coils of intestine and sigmoid colon) Lower 1/3rd Base of the urinary bladder Ureters (terminal parts) Seminal vesicles Vas deferens (ampullae) Prostate Vagina (lower part)

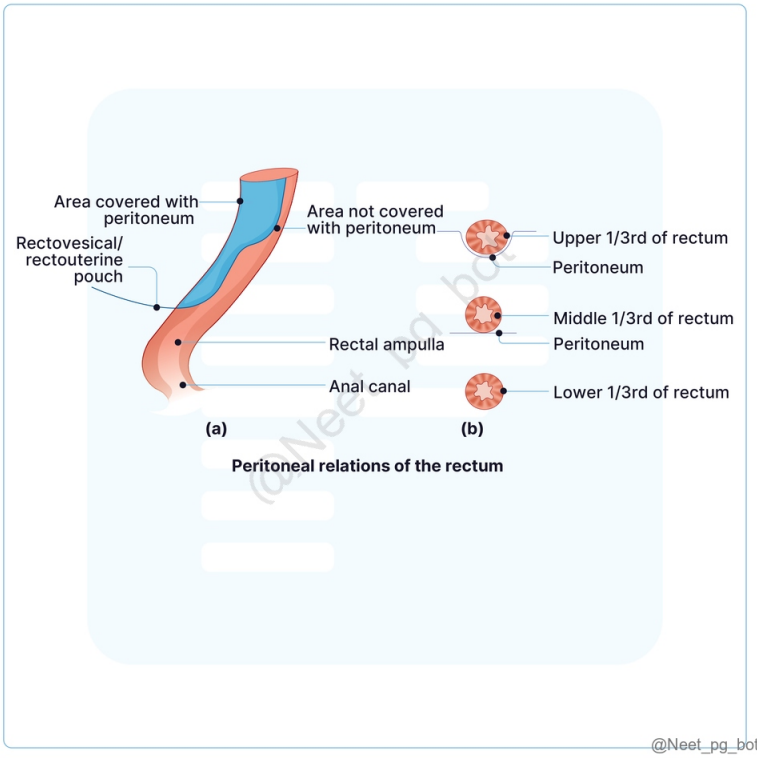

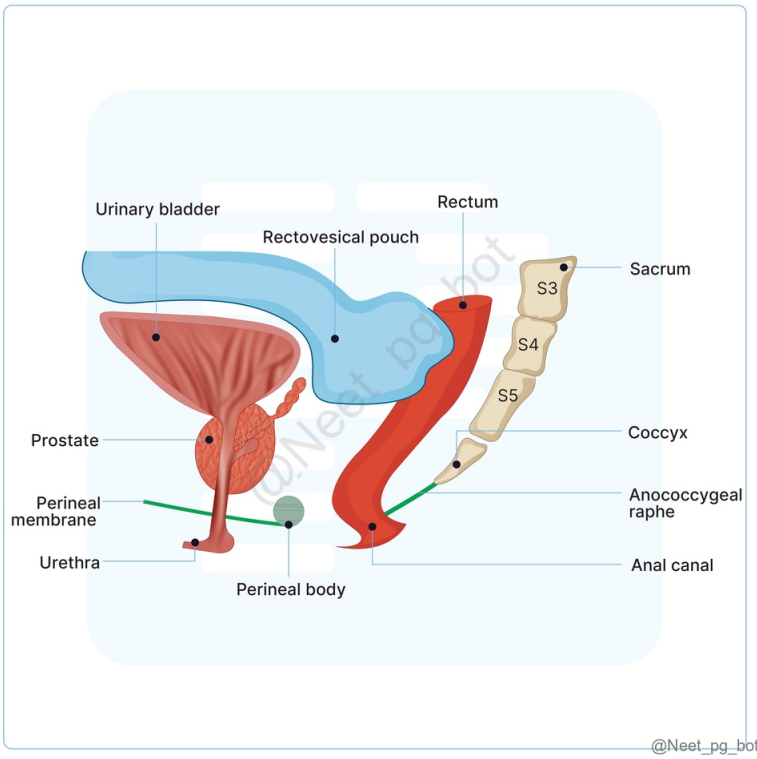
Urinary bladder
Rectum
Rectovesical pouch
Sacrum
S3
S4
S5
Coccyx
Prostate
Perineal membrane
Anococcygeal raphe
Urethra
Anal canal
Perineal body
@Neet_pg_bot

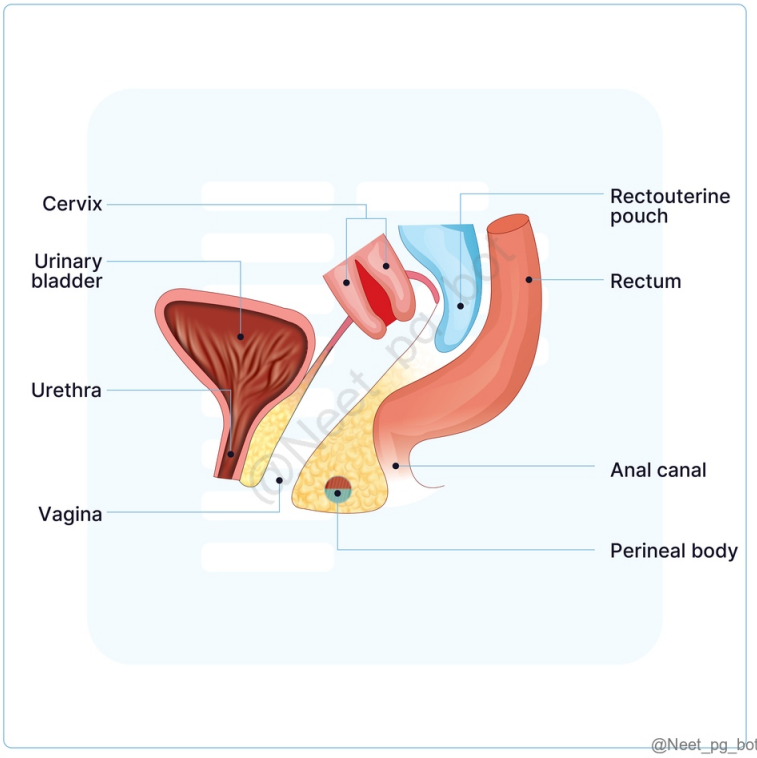
Cervix
Rectouterine pouch
Urinary bladder
Rectum
Urethra
Anal canal
Vagina
Perineal body
@Neet_pg_bot

References:

1. Gray's Anatomy, 42nd Edition, Page 1195 2. BD Chaurasia’s Human Anatomy, Volume-2, 8th Edition, Page 476,477 3. Vishram Singh Textbook of Anatomy, Volume-2, 2nd Edition, Page 281,282

↑ *Back to this question in Part A*

@Neet_pg_bot

Q4: A 58-year-old woman presents with faecal incontinence, particularly during activities that increase intra-abdominal pressure, such as coughing or lifting heavy objects. MRI reveals atrophy in a muscle responsible for maintaining the anorectal angle. What’s the likely muscle involved in this? (Q848323)

A. External anal sphincter

B. Conjoint longitudinal muscle

C. Puborectalis

D. Internal anal sphincter

Correct Answer: C. Puborectalis

■ *Listen (English)*

■ *Listen (Hindi)*

Explanation: Puborectalis muscle , part of the levator ani muscle, forms a sling around the anorectal junction and is crucial for maintaining the anorectal angle. Dysfunction or atrophy of this muscle can lead to faecal incontinence , especially during increases in intra-abdominal pressure. Resting Tone is mainly provided by Internal Anal Sphincter (IAS) Relaxed External anal sphincter (EAS) and Puborectalis muscle Weakness of External anal Sphincter, Internal anal Sphincter, Puborectalis muscle. Anorectal Ring Muscles Muscle Description Function Significance Internal Anal Sphincter (Option D) Thickened, terminal portion of the inner circular smooth muscle layer of the large intestine. Provides continuous resting tone to the anal canal through sympathetic innervation. Dysfunction can lead to faecal incontinence. External Anal Sphincter (Option A) Main bulk of the anal sphincter complex and is primarily made of striated muscle. Allows voluntary contro l over defecation; allows sustained contraction. Important for voluntary faecal control Conjoint Longitudinal Muscle (Option B) Layer between internal and external anal sphincters; continuous with the outer longitudinal smooth muscle of the rectum. Contracts during defecation , shortening and widening the anal canal, facilitating faecal passage. Plays a role in defecation; age-related decline in muscle fibres can impact function. Puborectalis (Option C) Sling muscle part of the levator ani muscle , surrounding the anorectal junction. Maintains the anorectal angle. Critical for faecal continence

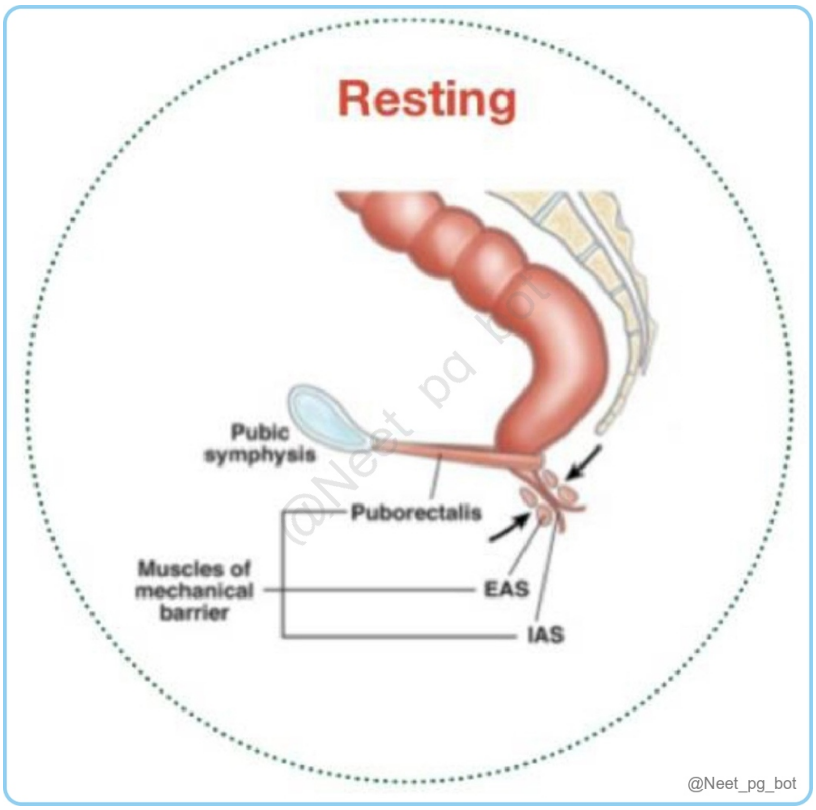
Resting
Pubic symphysis
Puborectalis
Muscles of mechanical barrier
EAS
IAS
@Neet_pg_bot

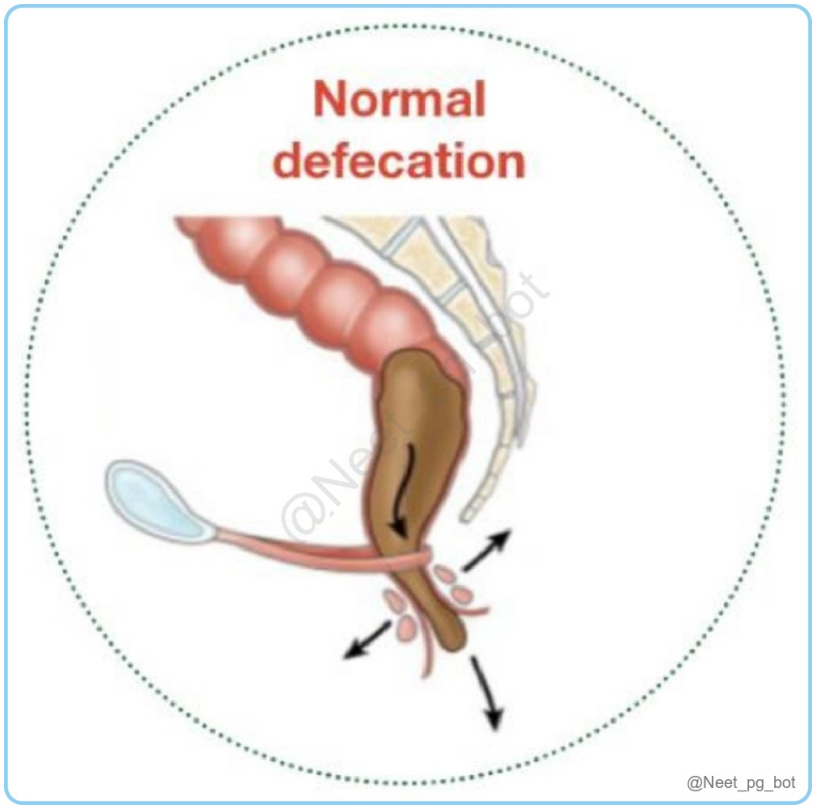
Normal defecation
@Neet_pg_bot

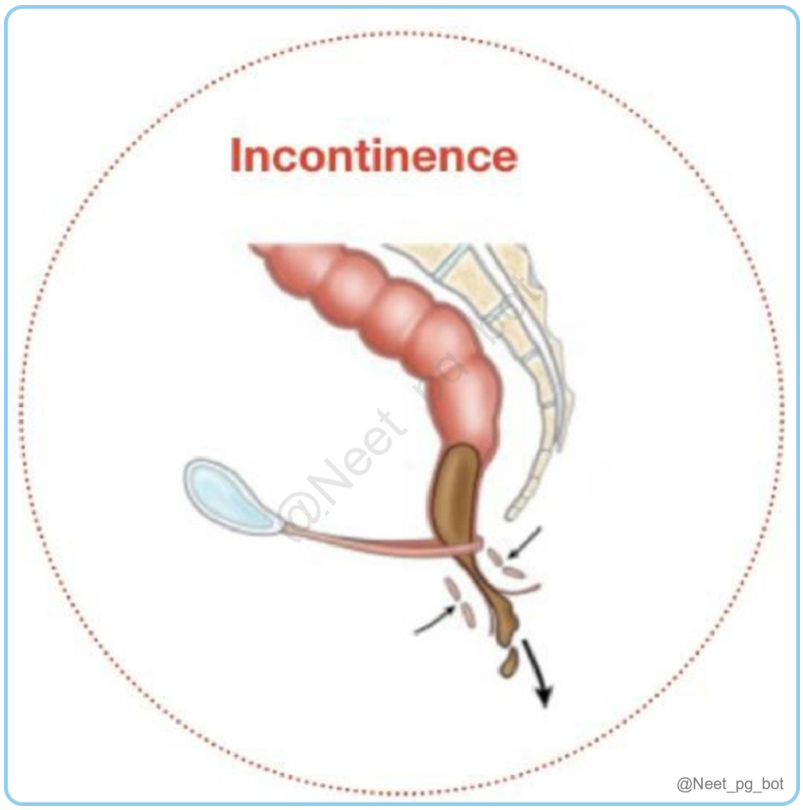

References:

Gray’s Anatomy, 42nd Edition, Page 1201,1245

↑ *Back to this question in Part A*

@Neet_pg_bot

Q5: A 46-year-old female reports intermittent rectal bleeding and a feeling of fullness during bowel movements. She has a history of constipation and obesity. Examination reveals internal haemorrhoids. Which of the following options correctly describes their characteristics concerning location and nerve supply? Presence of a visible thrombus in the anal region Ability to manually reduce the mass. Located below the dentate line, covered by anoderm. Innervated by pelvic splanchnic nerves; generally painless. (Q848325)

A. 1,2,3

B. 2,3

C. 1,2

D. 2,4

Correct Answer: D. 2,4

■ *Listen (English)*

■ *Listen (Hindi)*

Explanation: Hemorrhoids are variceal enlargement of the submucosal anal and perianal venous plexuses. They are divided into internal and external piles. Internal Hemorrhoids or True piles are usually painless and occur above the dentate line which bleed on straining during defecation. Type of piles Internal Hemorrhoids External Hemorrhoids Location Above pectinate line Below pectinate line Contributing Vein Main tributaries and radicals of Superior rectal vein Tributaries of Inferior rectal vein Common Site 3, 7 and 11 o'clock positions of the anal wall, in the lithotomy position No such common site. Pain Painless (as innervated by splanchnic nerves) (Statement 4) Painful (innervated by somatic nerves) Bleeding Bleeds on straining at stool Do not bleed on straining Points to know Initially, they are contained within the anal canal (1st degree) , later, they expand and protrude during defecation (2nd degree), and finally, they stay protruded (3rd degree). 2nd-degree piles can be manually reduced if they are prolapsed and not thrombosed. (Statement 2) A thrombosed external haemorrhoid appears as a painful, swollen, bluish lump at the anal verge resulting from the rupture of a subcutaneous vein. (Statement 1) These are located below the dentate line and present as tense hematomas at the anal margin (perianal hematomas). (Statement 3)

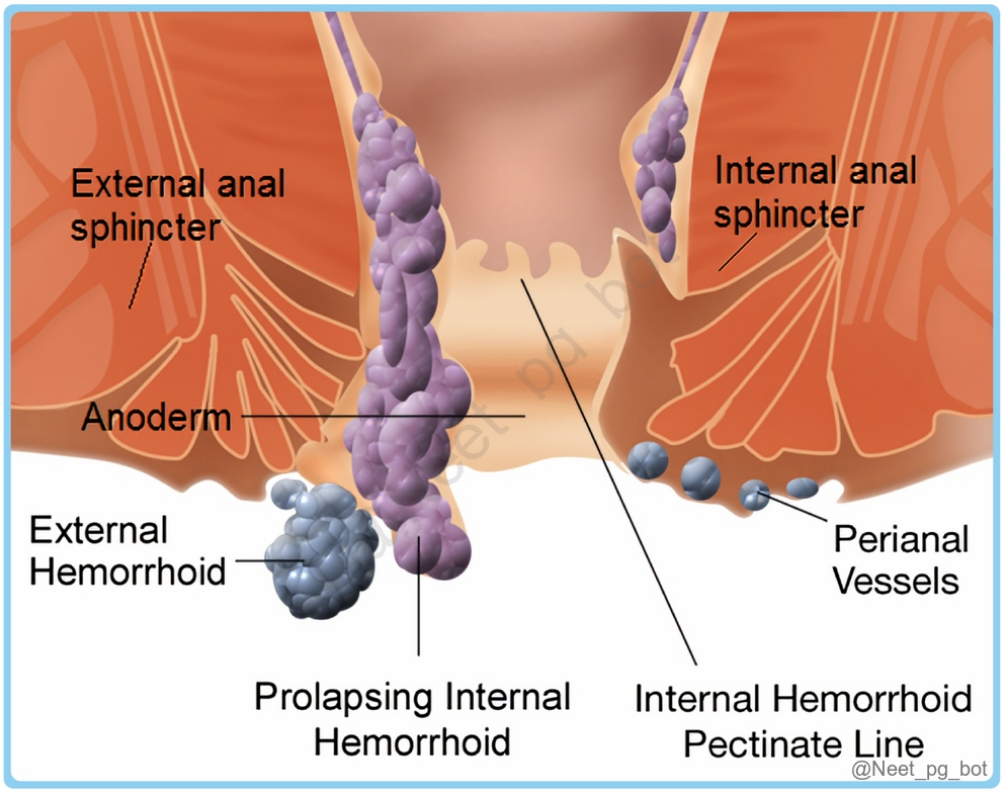

References:

1. Vishram Singh Textbook of Anatomy, Volume-2, 2nd Edition, Page 289 2. B. D. Chaurasia's Human Anatomy, Volume-2, 8th Edition, Page 484

↑ *Back to this question in Part A*

Q6: A 33-year-old woman in labour is experiencing discomfort and perianal pain and is scheduled to receive a pudendal nerve block. Which anatomical landmarks should the clinician identify to locate the pudendal nerve accurately? (Q848313)

A. Lesser sciatic notch

B. Pubic symphysis

C. Greater sciatic notch

D. Ischial spine

Correct Answer: D. Ischial spine

■ *Listen (English)*

■ *Listen (Hindi)*

Explanation: In the pudendal nerve block , the nerve is infiltrated with a local anaesthetic at the point where it crosses the ischial spine using a needle inserted through the vaginal wall, directed by a finger. It aids in achieving almost painless vaginal or forceps deliveries and is also helpful for minor surgeries involving the vagina and perineum. When a bilateral pudendal block is administered, it results in a loss of the anal reflex (saddle anaesthesia), relaxation of the pelvic floor muscles , and diminished sensation in the vulva and lower third of the vagina. Fig: Ischial spine landmark Fig: Pudendal nerve block Lesser sciatic notch (Option A) is the area where the pudendal nerve exits the gluteal region and enters the pudendal canal. It's not easily accessible for the nerve block. Pubic symphysis (Option B): Administering the block here would not accurately target the pudendal nerve and is unlikely to deliver the intended analgesic effect for perineal pain. Greater sciatic notch (Option C) is the point from which the pudendal nerve enters the gluteal region; it is not the preferred site for nerve block.

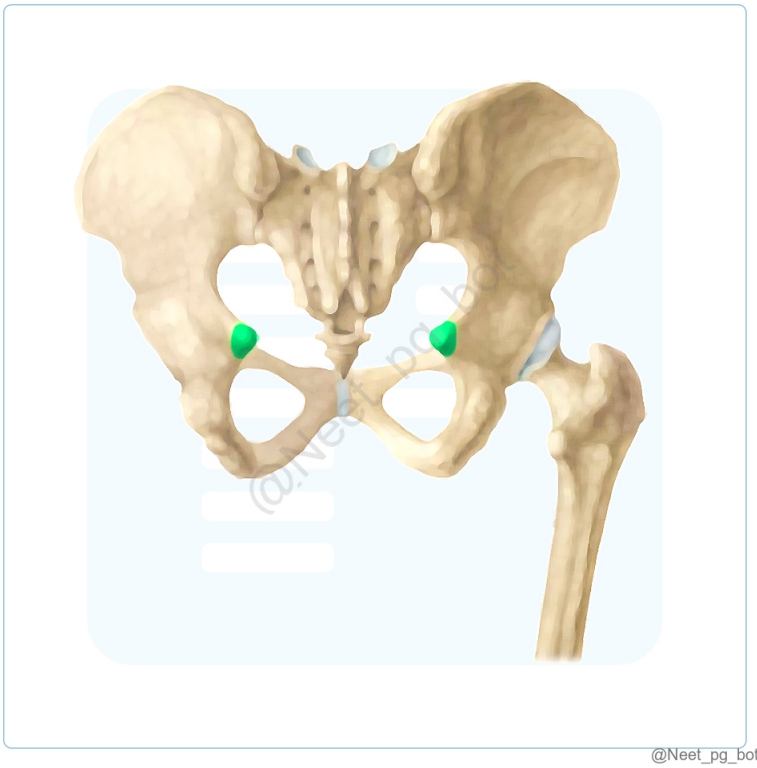

@Neet_pg_bot

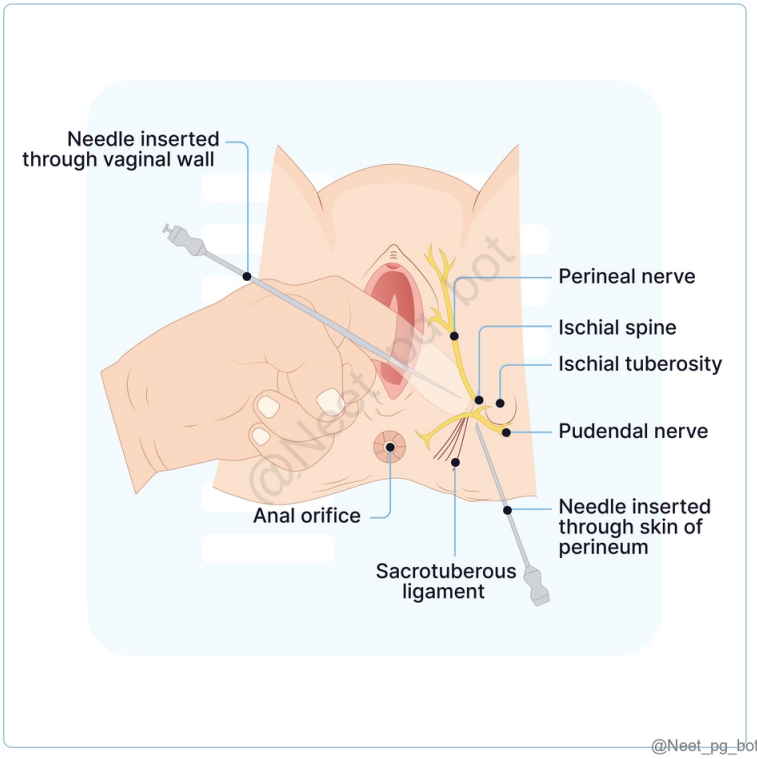

@Neet_pg_bot

References:

1. B. D. Chaurasia’s Human Anatomy, Volume-2, 8th Edition, Page 424, 520 2. Vishram Singh Textbook of Anatomy, Volume-2, 2nd Edition, Page 235

↑ *Back to this question in Part A*

@Neet_pg_bot

Q7: Which of the following accurately describes the X, Y, and Z listed below? (Q848314)

A. Posterior rami of S1, S2, S3

B. Anterior rami of S1, S2, S3

C. Posterior rami of S2, S3, S4

D. Anterior rami of S2, S3, S4

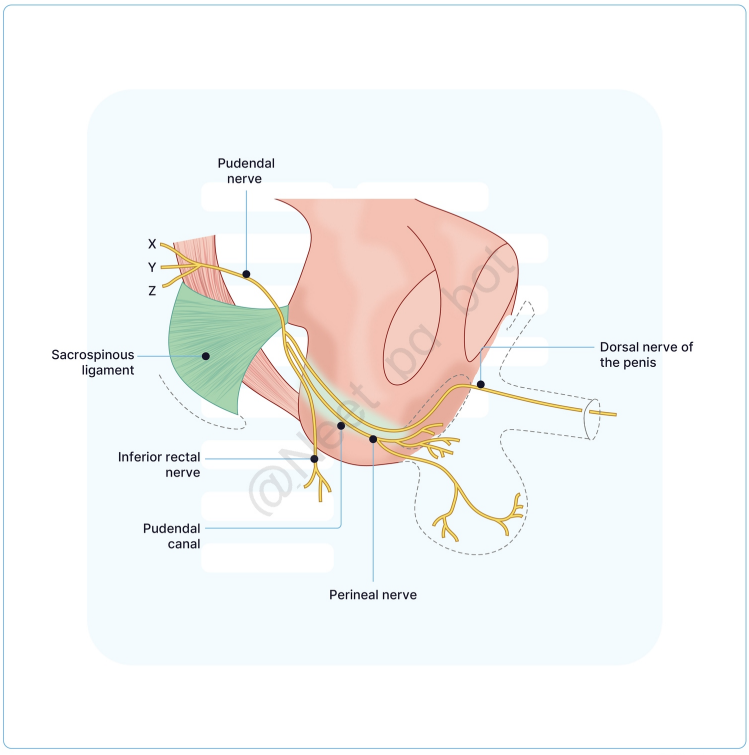

@Neet_pg_bot

Correct Answer: D. Anterior rami of S2, S3, S4

■ *Listen (English)*

■ *Listen (Hindi)*

Explanation: The given image depicts the origin of the pudendal nerve , which is formed in the pelvis by the anterior rami of sacral plexus S2, S3 and S4. Sacral plexus is formed by the anterior portion of the L4 nerve , the entire L5 nerve, and the S1, S2, and S3 nerves. These nerves then divide into anterior and posterior rami. Anterior rami: Nerve Root & Nerve To Supplies (L4, L5, S1) Nerve to Quadratus Femoris Quadratus femoris Inferior gemellus Hip joint (L5, S1, S2) Nerve to Obturator Internus Obturator internus Superior gemellus (S2, S3, S4) Pudendal nerve Genital skin, External genital organs Muscles of the perineum (S3, S4) Perforating cutaneous nerve Small area of skin in the gluteal area (L4, L5, S1, S2, S3) Tibial part of the sciatic nerve. Hamstrings All muscles of the calf and the sole (S1, S2) Posterior cutaneous nerve of thigh Skin at the back of the thigh

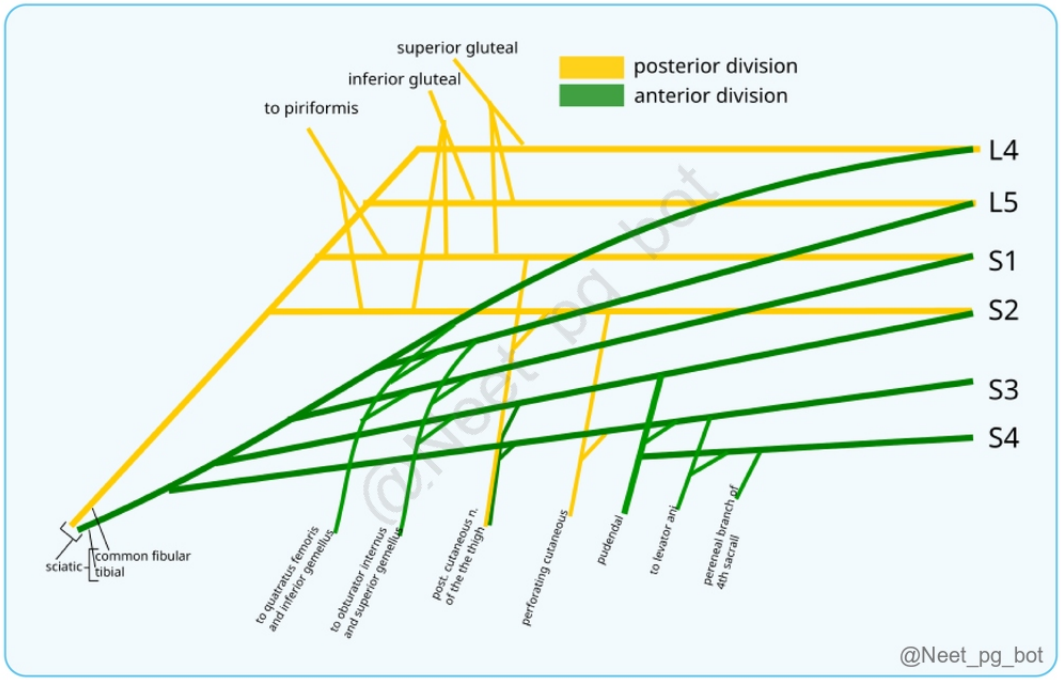

References:

B. D. Chaurasia's Human Anatomy, Volume-2, 8th Edition, Page 512

↑ *Back to this question in Part A*

@Neet_pg_bot

Q8: A 45-year-old woman presents with chronic perineal pain and numbness following a difficult vaginal delivery. The clinician suspects entrapment of the nerve supplying sensation to the perineum. Through which foramina does this nerve exit and re-enter the pelvis? (Q848315)

A. Greater sciatic foramen → Obturator foramen

B. Lesser sciatic foramen → Greater sciatic foramen

C. Obturator foramen → Lesser sciatic foramen

D. Greater sciatic foramen → Lesser sciatic foramen

Correct Answer: D. Greater sciatic foramen → Lesser sciatic foramen

■ *Listen (English)*

■ *Listen (Hindi)*

Explanation: Pudendal nerve originates in the pelvis from the anterior rami of the S2, S3 and S4 nerves of the sacral plexus. It enters the gluteal region through the greater sciatic notch, curves behind the ischial spine for a brief distance, and exits the gluteal area by passing into the lesser sciatic foramen. Greater sciatic foramen → Obturator foramen (Option A): O bturator foramen is related to the obturator nerve , not the pudendal nerve. Lesser sciatic foramen → Greater sciatic foramen (Option B): This reverses the actual order. The nerve first exits via the greater sciatic foramen and re-enters through the lesser , not the other way around. Obturator foramen → Lesser sciatic foramen (Option C): The pudendal nerve doesn't use the obturator foramen . The obturator nerve supplies the medial thigh , not the perineum.

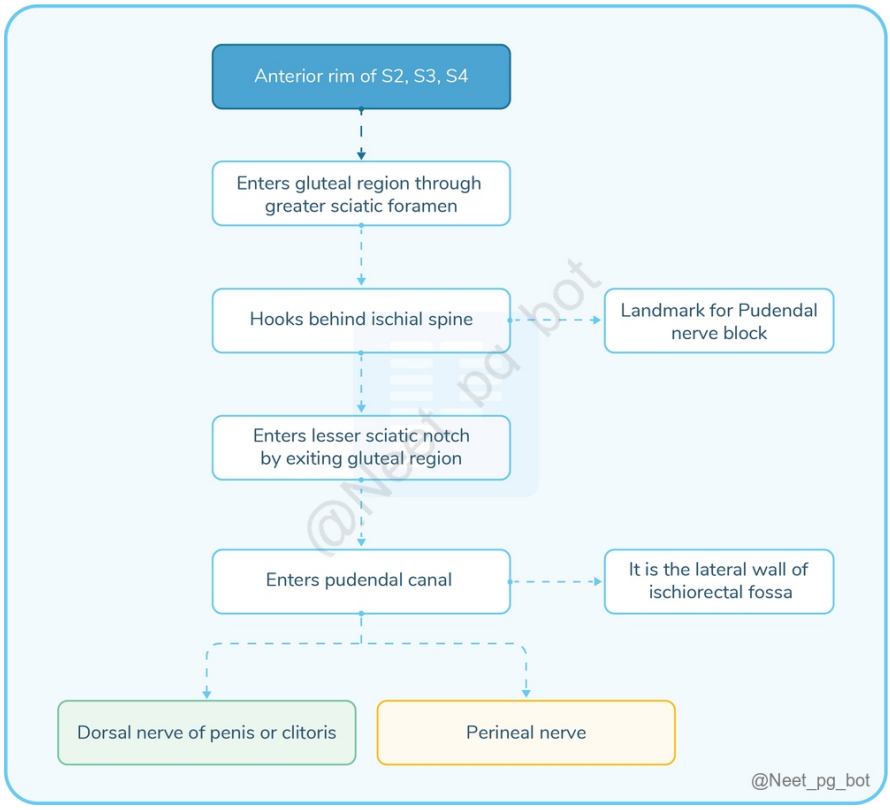

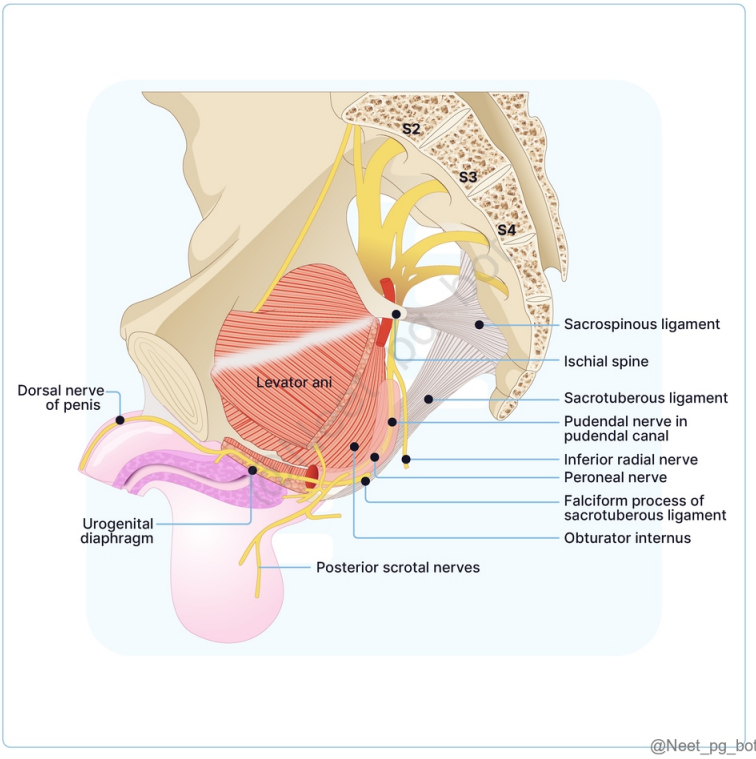

References:

1. Vishram Singh Textbook of Anatomy, Volume-2, 2nd Edition, Page 235 2. B. D. Chaurasia's Human Anatomy, Volume-2, 8th Edition, Page 424

↑ *Back to this question in Part A*

@Neet_pg_bot

Q9: A 62-year-old female presents with persistent pelvic pain and urinary incontinence. Imaging reveals a mass in the pelvic region compressing nearby vascular structures. During the surgical workup, the surgeon reviews the arterial supply of the pelvis. Which of the following is not a branch of the internal iliac artery? (Q848317)

A. Lateral sacral artery

B. Uterine artery

C. Internal pudendal artery

D. Deep circumflex iliac artery

Correct Answer: D. Deep circumflex iliac artery

■ *Listen (English)*

■ *Listen (Hindi)*

Explanation: The deep circumflex iliac artery arises from the external iliac artery (just proximal to the inguinal ligament), alongside the inferior epigastric artery. It does not originate from the internal iliac artery. The internal iliac artery is the primary blood supply to the pelvis and is typically divided into an Anterior and Posterior trunk. Branch Division Territory Supplied Lateral sacral artery (Option A) Posterior Sacral canal, skin, and muscles posterior to the sacrum. Uterine artery (Option B) Anterior Uterus and cervix (crosses superior to the ureter "water under the bridge"). Internal pudendal artery (Option C) Anterior Perineum and external genitalia.

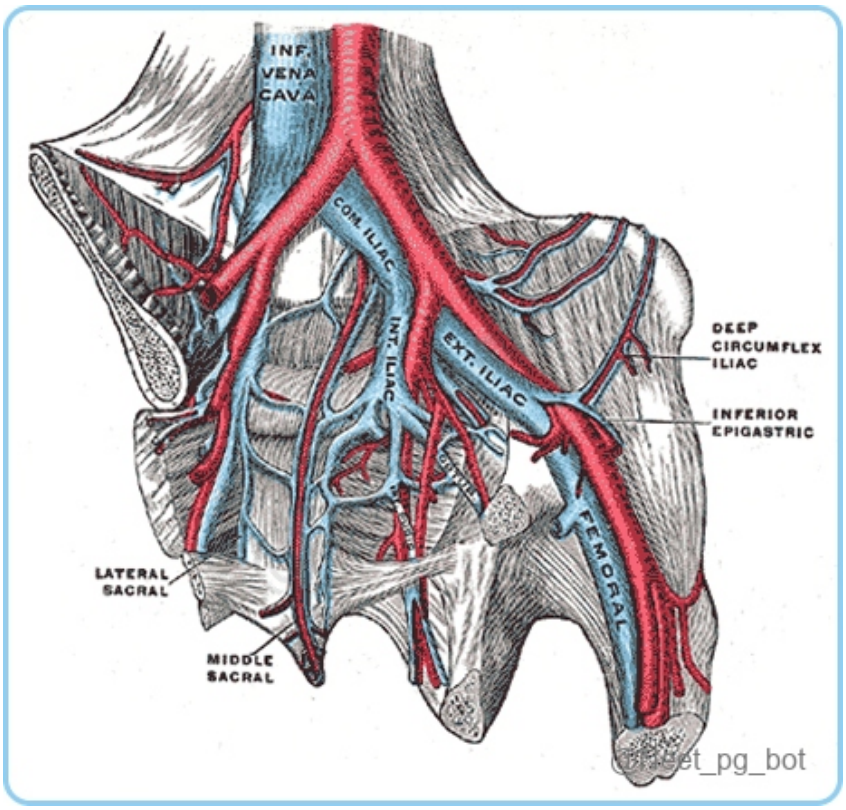

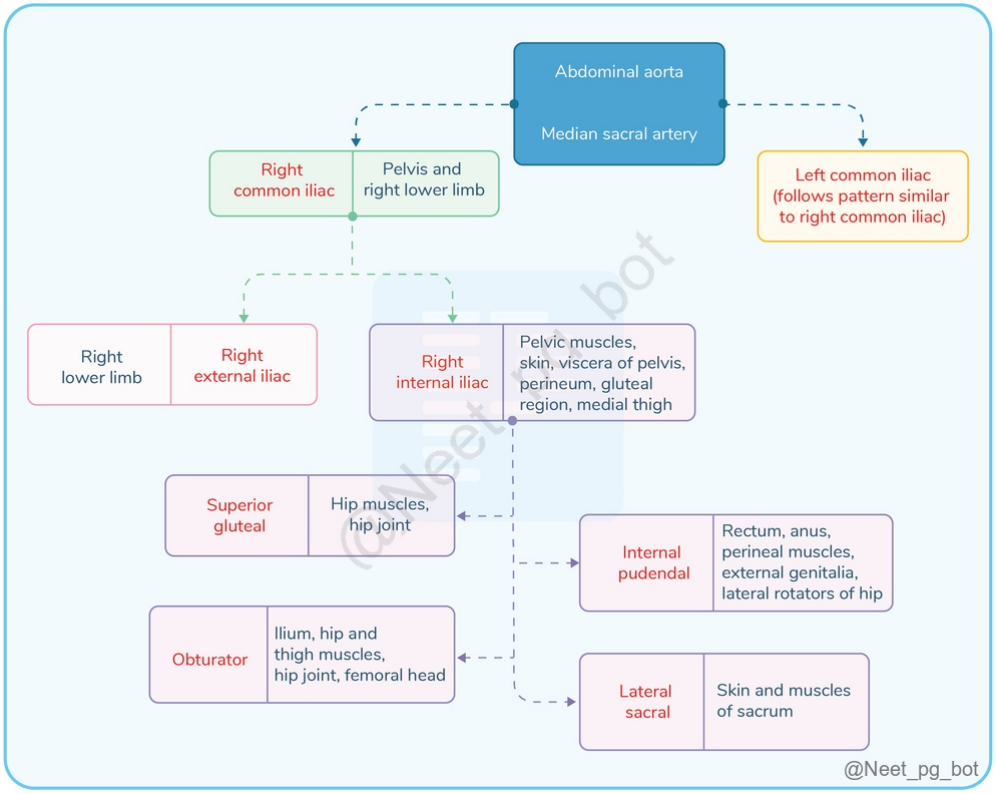

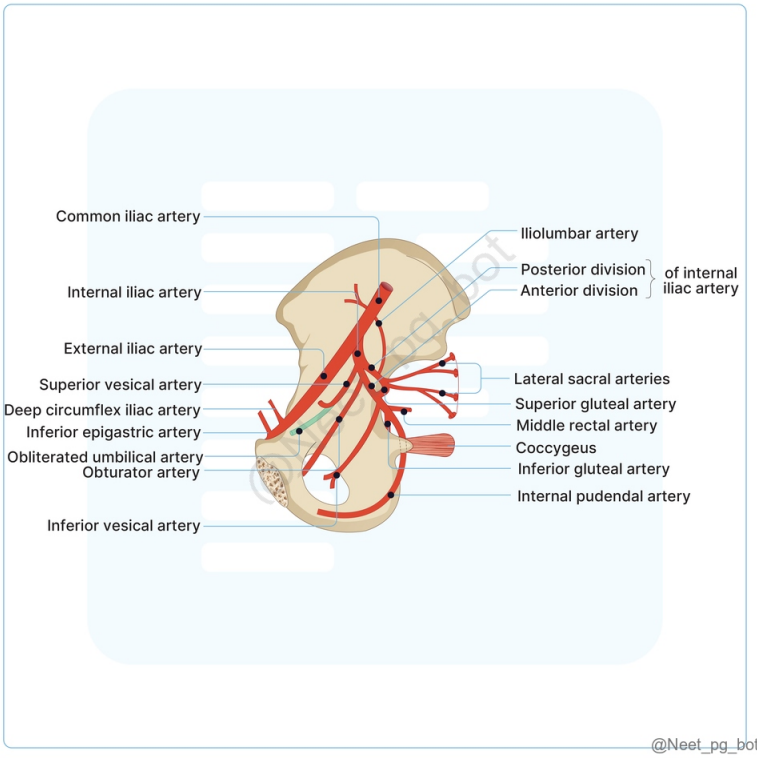

References:

B. D. Chaurasia's Human Anatomy, Volume-2, 8th Edition, Page 517,518,489

↑ *Back to this question in Part A*

@Neet_pg_bot

Q10: A 65-year-old male presents with urinary retention and pelvic discomfort. A digital rectal examination reveals an enlarged prostate gland. During surgery to relieve the obstruction, the urologist must take care to avoid damaging the structures that separate the prostate from the rectum. Which of the following structures separates the prostate gland from the rectum? (Q848319)

A. Waldeyer’s fascia

B. Scarpa’s fascia

C. Denonvilliers’ fascia

D. Camper’s fascia

Correct Answer: C. Denonvilliers’ fascia

■ *Listen (English)*

■ *Listen (Hindi)*

Explanation: The structure that separates the prostate gland from the rectum is the Rectovesical Fascia (also known as Denonvilliers' Fascia). It extends from the floor of the rectovesical pouch to the perineal body. Waldeyer’s fascia (Option A) is a connective tissue by which the rectum (ampulla) is attached to the sacrum and coccyx. The superficial fascia of the anterior abdominal wall is divided into: A superficial fatty layer, Camper’s fascia (Option D) A deep membranous layer, Scarpa’s fascia (Option B)

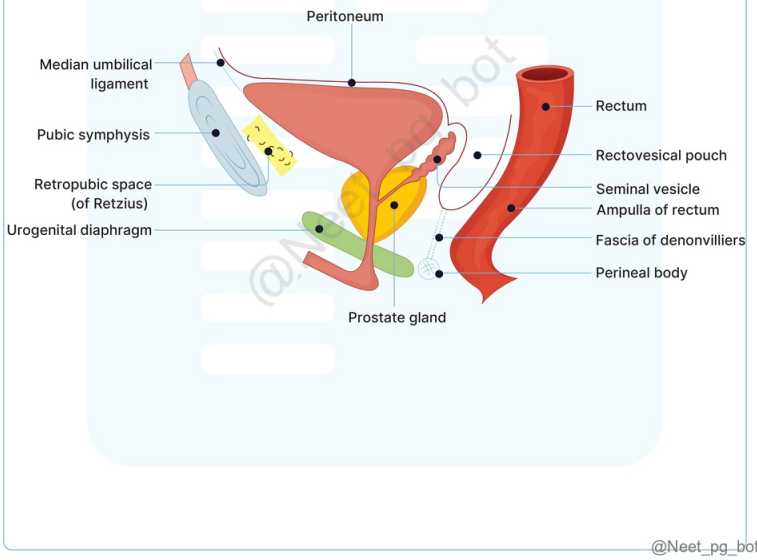

@Neet_pg_bot

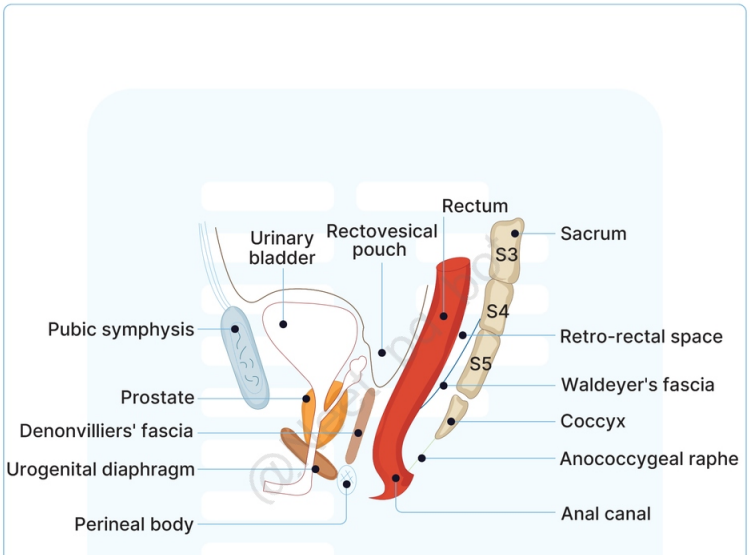

@Neet_pg_bot

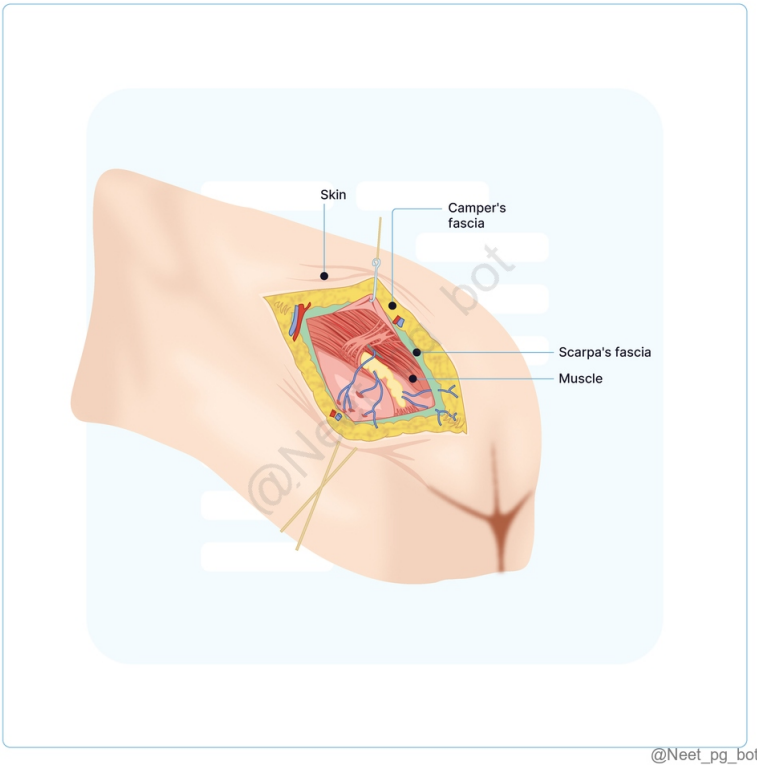

@Neet_pg_bot

References:

1. Gray's Anatomy, 42nd Edition, Page 1464 2. BD Chaurasia’s Human Anatomy, Volume-2, 8th Edition, Page 479 3. Vishram Singh Textbook of Anatomy, Volume-2, 2nd Edition, Page 255 4. Netter’s Atlas of Human Anatomy: Classic Regional Approach, 8th Edition, Page 270

↑ *Back to this question in Part A*

@Neet_pg_bot

Q11: A 55-year-old male with intermittent abdominal pain, changes in bowel habits, and occasional rectal bleeding is scheduled for a sigmoidoscopy. The cannula is inserted in the left lateral position to avoid injuring the rectal folds that are present against the concavities of the rectum. Which of the following statements regarding these folds is inaccurate? (Q848321)

A. First fold is situated near the rectosigmoid junction.

B. These folds are permanent.

C. Third fold is located at the upper end of the ampulla.

D. They are flattened in a distended rectum.

Correct Answer: D. They are flattened in a distended rectum.

■ *Listen (English)*

■ *Listen (Hindi)*

Explanation: In this case, the cannula is inserted laterally during the sigmoidoscopy to prevent injury to the permanent, transverse folds referred to as Houston's valves , which are more prominent during distension. Two Types of Folds in the Rectum: Longitudinal Houston’s valve (Transverse or horizontal folds or plicae transversales) Temporary folds Situated in the lower part of an empty rectum. Obliterated by distension Permanent folds (Option B) Situated against the concavities of the lateral curvatures of the rectum. More prominent by distension (Option D) Types of Houston’s Valves: Types First Transverse Fold Second Transverse Fold Third Transverse Fold Fourth Transverse Fold Site Near the upper end, close to the rectosigmoid junction. (Option A) Above the third fold (2.5cm) At the level of the upper end of the ampulla. (Option C) Below the third valve (2.5cm) Wall of Projection Right or left wall Left wall (upper lateral curvature) Anterior and right wall (middle lateral curvature) Left wall (lower lateral curvature)

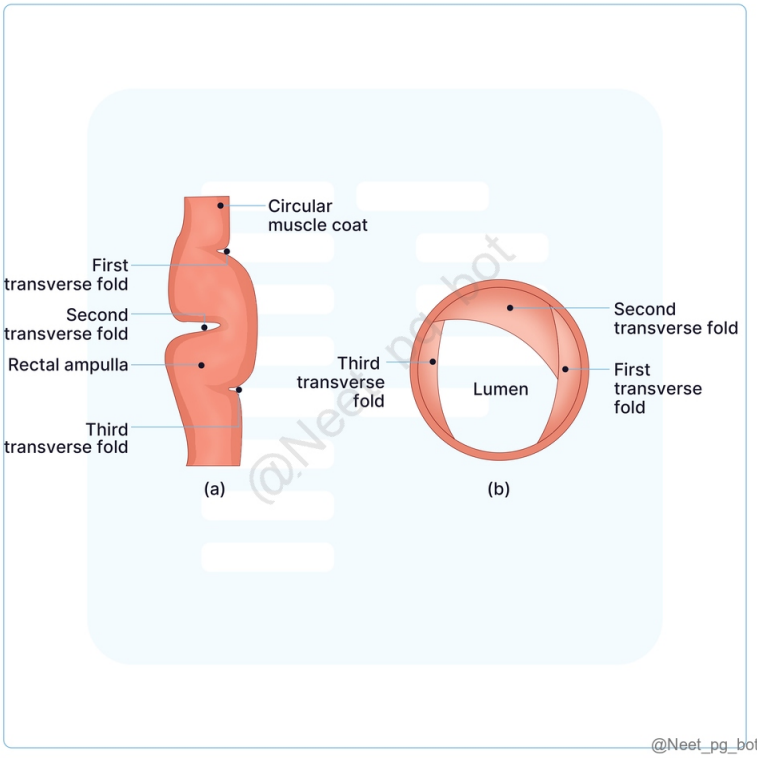

References:

1. Gray's Anatomy, 42nd Edition, Page 1185 2. BD Chaurasia’s Human Anatomy, Volume-2, 8th Edition, Page 476,477 3. Vishram Singh Textbook of Anatomy, Volume-2, 2nd Edition, Page 281,282

↑ *Back to this question in Part A*

@Neet_pg_bot

Q12: A 50-year-old man presents with perianal pain and bleeding during bowel movements. The region affected is supplied by a vessel that arises from the internal iliac system and supplies the lower anal canal. Which of the following arteries is the direct source of this vessel? (Q848322)

A. Inferior mesenteric artery

B. Internal pudendal artery

C. Obturator artery

D. Superior gluteal artery

Correct Answer: B. Internal pudendal artery

■ *Listen (English)*

■ *Listen (Hindi)*

Explanation: Internal pudendal artery is a branch of the anterior division of the internal iliac artery , and it gives rise to the inferior rectal artery that supplies the lower third of the rectum and the anal canal. Arterial Supply of the Rectum: Artery Source Supplies Superior Rectal Artery Branch of the inferior mesenteric artery (Option A) Upper two-thirds of the rectum Middle Rectal Artery Branch of the internal iliac artery Middle third of the rectum Inferior Rectal Artery Branch of the internal pudendal artery (Option B) Distal rectum & anal canal Venous Drainage of the Rectum: Vein Drains Into Region Drained Superior Rectal Vein Inferior mesenteric vein Upper two-thirds of the rectum Middle Rectal Vein Internal iliac vein Middle third of the rectum Inferior Rectal Vein Internal pudendal vein Anal canal & distal rectum Superior gluteal artery (Option D) is a branch of the internal iliac artery, supplying the gluteal muscles, but it does not directly contribute to the rectal blood supply.

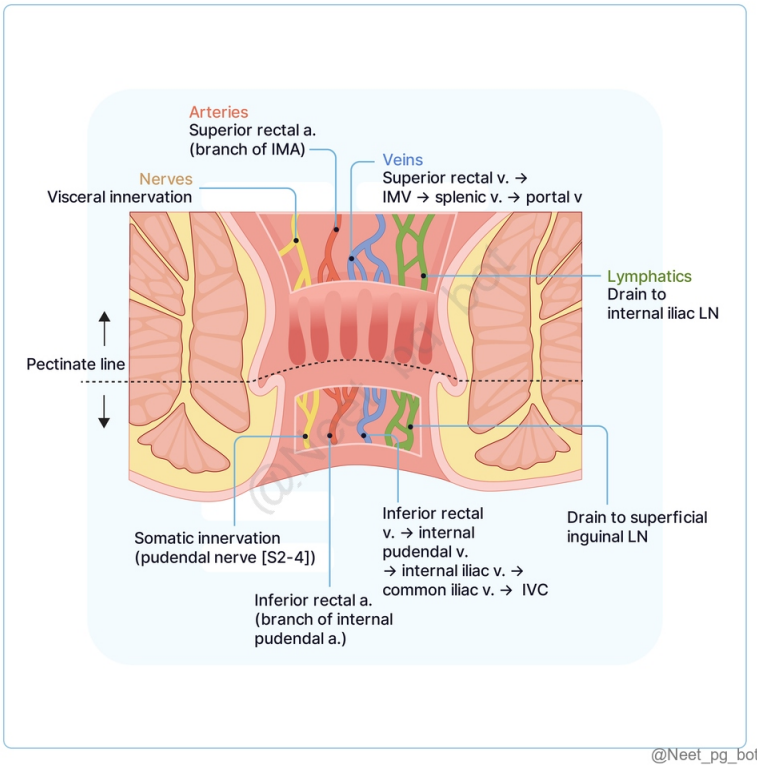

@Neet_pg_bot

References:

Gray's Anatomy, 42nd Edition, Page 1196,1197

↑ *Back to this question in Part A*

@Neet_pg_bot

Q13: A 50-year-old male presents with painful anal swelling and bleeding. External haemorrhoids are diagnosed, and the physician explains the pain is due to somatic innervation below a specific anatomical landmark in the anal canal. Which of the following separates the areas of somatic and visceral nerve supply in the anal canal? (Q848324)

A. White line of Hilton

B. Anorectal junction

C. Iliopectineal line

D. Pectinate line

Correct Answer: D. Pectinate line

- *Listen (English)*
- *Listen (Hindi)*

Explanation: Anal canal is divided into upper and lower parts by pectinate line or dentate line (teeth shaped), which forms embryological, neurovascular and histological boundaries. Upper part is supplied by the autonomic nervous system (painless) and the lower by somatic nerves (painful). Lower ends of the anal column are joined by short transverse folds of mucous membranes known as anal valves . Mucosal depressions above these valves are called anal sinuses. Together, the anal valves form a transverse line encircling the anal canal, known as the pectinate line. Features Upper Anal Canal Lower Anal Canal Development Endodermal Ectodermal Epithelium Simple columnar Stratified squamous Nerve supply Autonomic nerves Painless Sympathetic (L1, L2) Parasympathetic (S2, S3, S4) Somatic nerves Painful Sympathetic (S2, S, S4) Arterial supply Superior rectal artery Inferior rectal artery Venous drainage Superior rectal vein draining into the portal system Inferior rectal vein draining into caval system Lymphatic system Internal iliac nodes Superficial inguinal nodes Common Type of Hemorrhoids Internal hemorrhoids External hemorrhoids White line of Hilton (Option A) is located at the junction between the subcutaneous portion of the external anal sphincter and the lower border of the internal anal sphincter. It marks the boundary of the mucocutaneous junction. Anorectal junction (Option B) is defined by the forward convexity of the rectal perineal flexure, located just below the tip of the coccyx. Here, the rectal ampulla narrows as it passes through the pelvic diaphragm, aligning with the apex of the prostate in males. Iliopectineal line (Option C) is a ridge located on the inner surface of the pelvis, created by the fusion of the ilium and pubis, extending from the pubic symphysis to the arcuate line of the ilium. This anatomical landmark is significant in clinical practice for directing pelvic surgeries and evaluating conditions that impact the pelvic organs.

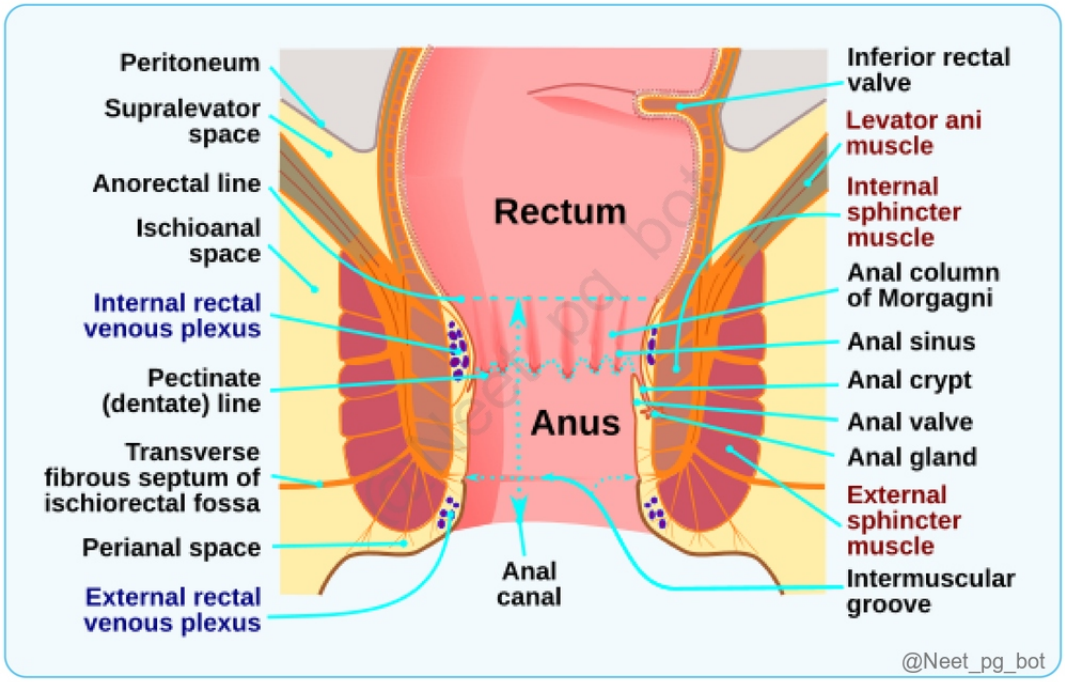

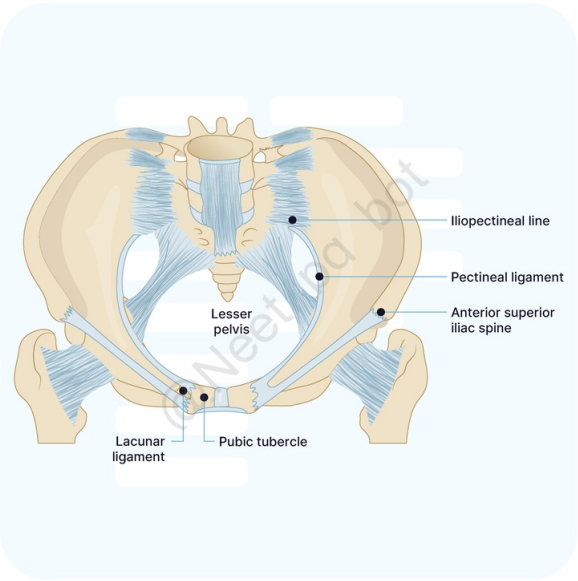

@Neet_pg_bot

References:

1. Vishram Singh Textbook of Anatomy, Volume-2, 2nd Edition, Page 286, 287 2. B. D. Chaurasia's Human Anatomy, Volume-2, 8th Edition, Page 481,483,484

↑ *Back to this question in Part A*

@Neet_pg_bot

Q14: A 73-year-old male presents with rectal pain, and there is concern for rectal metastasis, given his history of prostate cancer. Which lymph nodes are most likely involved in the lymphatic drainage of the region marked 'X' in the image? (Q848326)

A. Para-aortic lymph nodes

B. Inferior mesenteric lymph nodes

C. Superficial inguinal lymph nodes

D. Internal iliac lymph nodes

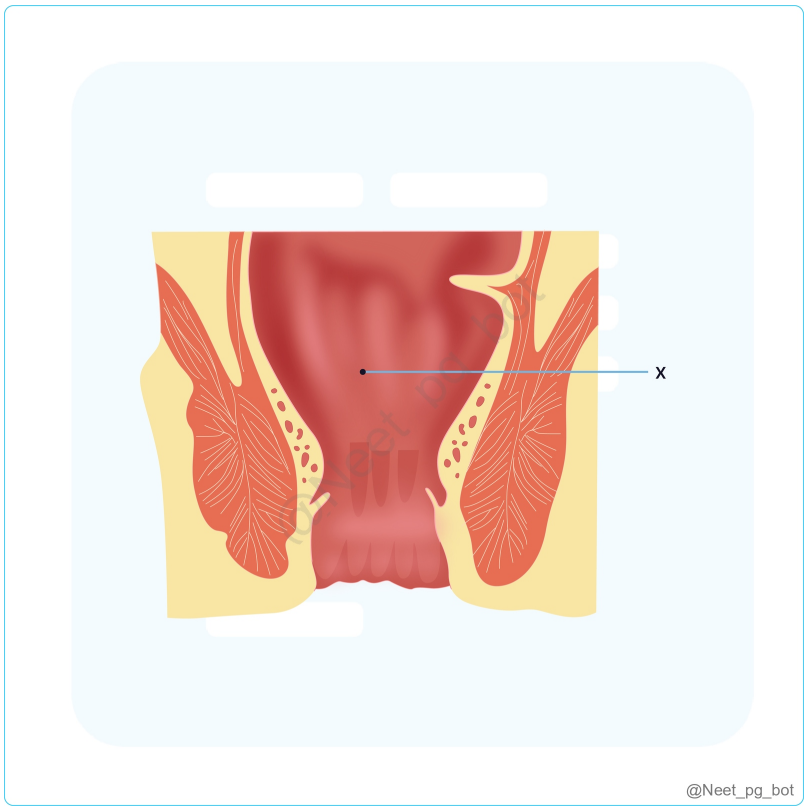

Correct Answer: D. Internal iliac lymph nodes

- *Listen (English)*
- *Listen (Hindi)*

Explanation: The ‘X’ marked region is the lower part of the rectum . Internal iliac lymph nodes are primarily involved in the lymphatic drainage of the lower part of the rectum. Lymphatic Drainage of the Rectum and Anal Canal: Region Lymphatic Drainage Upper half of the rectum Inferior mesenteric nodes via pararectal and sigmoid nodes (Option B) Lower half of the rectum & upper anal canal Internal iliac nodes Anal Canal (below the pectinate line) Superficial inguinal lymph nodes (Option C) Para-aortic lymph nodes (Option A) are situated along the abdominal aorta, mainly at the L1 and L2 vertebral levels. They are responsible for draining lymph from the pelvic organs, lower extremities, and abdominal viscera, including the kidneys, ureters, and sections of the gastrointestinal tract.

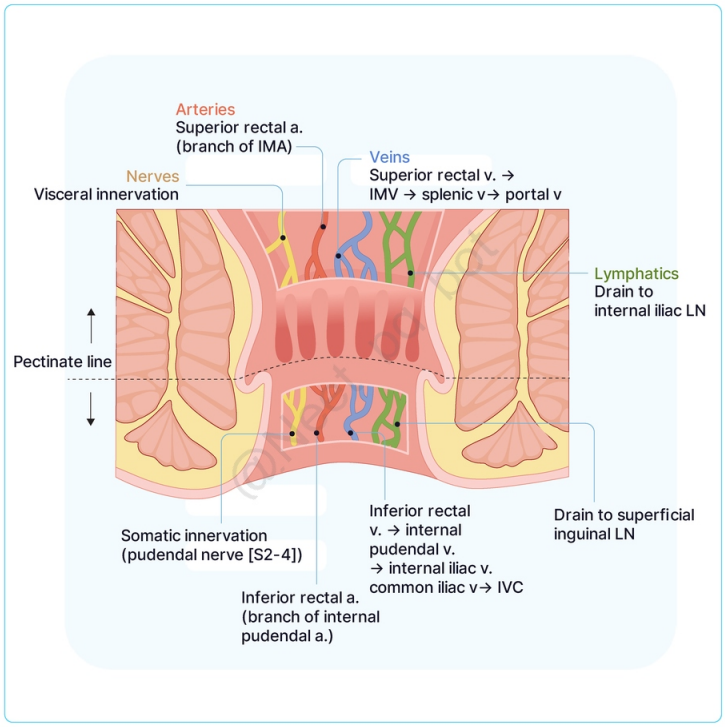

@Neet_pg_bot

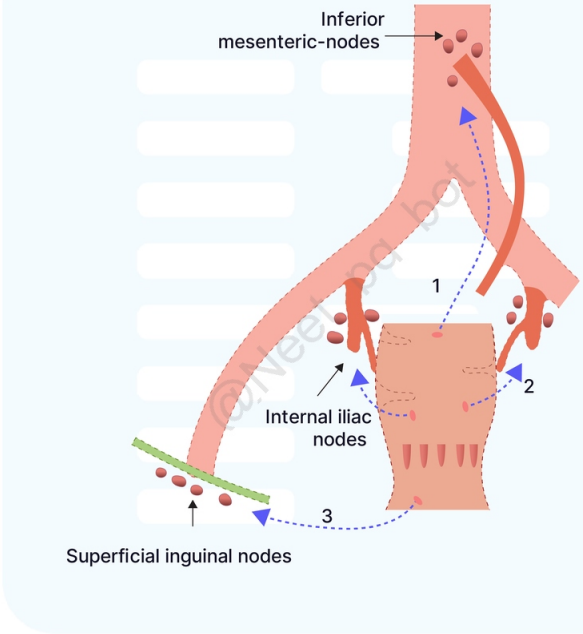

@Neet_pg_bot

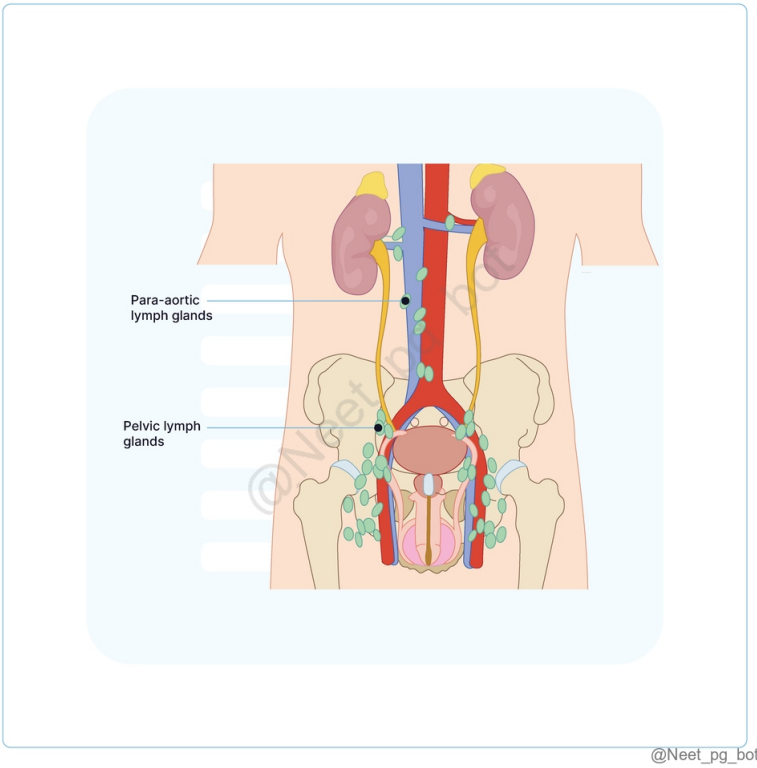

@Neet_pg_bot

References:

B. D. Chaurasia's Human Anatomy, Volume-2, 8th Edition, Page 478,479

↑ *Back to this question in Part A*

@Neet_pg_bot

• [09_Pelvis and Perineum] 046 Perineal Pouches And Ischiorectal Fossa Extravasation Of Urine

« Back to Folder Directory

[09_Pelvis and Perineum] 046 Perineal Pouches And Ischiorectal Fossa Extravasation Of Urine — Quick Jump

Q1 (p. 2056) *Q2 (p. 2057)* *Q3 (p. 2058)* *Q4 (p. 2060)* *Q5 (p. 2063)* *Q6 (p. 2064)*
Q7 (p. 2066) *Q8 (p. 2067)*

Q1: Which of the following best describes the boundaries of the ischiorectal fossa? (Q848398)

A. Medially by the obturator internus, laterally by the levator ani.

B. Medially by the external anal sphincter, laterally by the ischial tuberosity.

C. Medially by the coccyx, laterally by the sacrotuberous ligament.

D. Medially by the pubic symphysis, laterally by the ischial spine.

Correct Answer: B. Medially by the external anal sphincter, laterally by the ischial tuberosity.

■ *Listen (English)*

■ *Listen (Hindi)*

Explanation: Ischiorectal Fossa/Ischioanal Fossa: Is a space filled with fat lateral to the anal canal and just below the pelvic diaphragm. Has a shape of a triangular pyramid , with the apex at the boundary of the anal canal and the obturator fascia and the base directed towards the perineal surface. Divided into the perianal space and the ischiorectal space by the perineal fascia. Anatomy and Boundaries: Location : Situated on either side of the anal canal and extends from the skin of the perineum to the pelvic diaphragm. Boundaries : Medially External anal sphincter Levator ani (muscles of the pelvic floor) Laterally Obturator internus muscle Ischial tuberosity Anteriorly Pubic symphysis and puborectalis muscle. Posteriorly Sacrotuberous ligament and gluteus maximus muscle. Contents: Internal pudendal artery, vein, and nerve. Inferior rectal artery and vein Posterior scrotal vessels and nerves Perineal branch of S4 and perforating cutaneous nerve Lymphatics Inferior rectal nerve Subcutaneous fat is abundant on both sides of the anal canal, which permits distension of the anal canal during defecation. Clinical Significance: Abscess Formation: Ischioanal abscesses can occur due to infection, leading to significant pain and swelling in the perineal area. Surgical Access: Knowledge of the ischiorectal fossa is important for surgical procedures in the anal region, such as drainage of abscesses or repair of fistulas. Fecal Incontinence : Injury to the neurovascular structures in this area can lead to issues with anal control.

References:

https://www.ncbi.nlm.nih.gov/books/NBK535387/

↑ *Back to this question in Part A*

@Neet_pg_bot

Q2: Which of the following structures encloses all three masses of erectile tissue but does not extend into the glans penis? (Q848400)

A. Superficial fascia

B. Tunica albuginea

C. Bulbospongiosus muscle

D. Buck’s fascia

Correct Answer: D. Buck’s fascia

■ *Listen (English)*

■ *Listen (Hindi)*

Explanation: Deep fascia (Buck’s fascia) is a membranous fascia that encloses all three masses of erectile tissue (the corpora cavernosa and corpus spongiosum) but does not extend into the glans penis. Structure of Penis Root of the Penis Located in the superficial perineal pouch. Contains two crura and one bulb. Crura attach to the pubic arch, covered by ischiocavernosus muscle. Bulb attaches to the perineal membrane between the crura, covered by bulbospongiosus muscle. Urethra pierces the bulb to enter the corpus spongiosum. Body of the Penis Continues from the root and is covered by skin. Fills with blood during erection. Contains two corpora cavernosa and one corpus spongiosum. Corpora Cavernosa: Continuations of the crura. Run alongside each other, terminating beneath the glans penis. Encased in tunica albuginea , which has superficial fibers enclosing both corpora and deeper fibers enclosing each separately with a median septum. Corpus Spongiosum: Continues from the bulb of the penis. Expands to form the glans penis. Urethra runs through the corpus spongiosum. Surrounded by a fibrous sheath. Glans Penis Expanded terminal part of the corpus spongiosum. Base has a projecting edge (corona glandis), overhanging the neck of the penis. Urethra forms the navicular fossa within the glans. Skin and Fasciae Skin is thin, dark, loosely attached. Prepuce (foreskin) covers the glans and can be retracted. Frenulum is a median fold of skin on the underside of the glans. Preputial sac holds smegma from the preputial glands. Superficial fascia is loose areolar tissue without fat. Deep fascia (Buck's fascia) encloses all erectile tissues but doesn’t extend into the glans. Supporting Ligaments Fundiform ligament: Extends from the linea alba, splitting to enclose the penis. Suspensory ligament: Lies beneath the fundiform ligament, extends from the pubic symphysis, and merges with the penile fascia. Superficial fascia (Option A): Composed of loose areolar tissue, it covers the penis but lacks fat and is more superficial compared to Buck's fascia. Tunica albuginea (Option B): Encases only the corpora cavernosa, not the entire penis or the corpus spongiosum. Bulbospongiosus muscle (Option C): Covers the bulb of the penis, contributing to the function of the corpus spongiosum but does not enclose all three masses of erectile tissue.

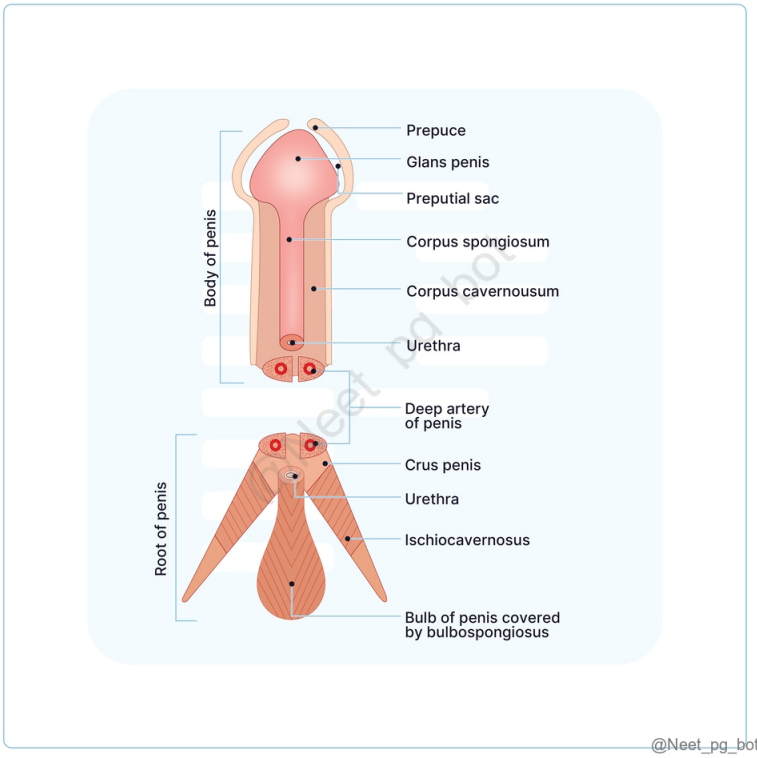

References:

BD Chaurasia's Human Anatomy, Volume-2, 8th Edition, Page 257-259

↑ *Back to this question in Part A*

@Neet_pg_bot

Q3: A 32-year-old man presents to the ER after falling onto a sharp object while riding a bicycle. He complains of difficulty urinating and swelling around his genital area. Examination reveals urine extravasation into the scrotum and anterior abdominal wall. What is the most likely site of urethral injury in this patient? (Q848401)

A. Membranous urethra

B. Prostatic urethra

C. Bulb of the penis

D. Can be any of the above

Correct Answer: C. Bulb of the penis

■ *Listen (English)*

■ *Listen (Hindi)*

Explanation: The most common site of urethral rupture is at the bulb of the penis , typically caused by trauma such as a fall onto a sharp object. In this case, the urethra is crushed against the pubic bones. Urine then leaks into the superficial perineal pouch and spreads over the scrotum, penis, and anterior abdominal wall beneath the membranous layer of the superficial fascia (superficial extravasation). Urethral Injury Causes Anterior Urethra Meatus Instrumentation, iatrogenic, hypospadias, skin disorders (lichen sclerosus) Pendulous Urethra Instrumentation, iatrogenic, hypospadias, skin disorders (lichen sclerosus), sexually transmitted infections, crush injury Bulbar Urethra Instrumentation, iatrogenic, skin disorders (lichen sclerosus), sexually transmitted infections, crush injury, straddle-type injury Membranous urethra (Option A): Located above the urogenital diaphragm, an injury here would cause urine to leak into the deep perineal pouch, not into the superficial perineal structures. Prostatic urethra (Option B): An injury to the prostatic urethra would involve the deep perineal structures and extraperitoneal space, not the scrotum or anterior abdominal wall.

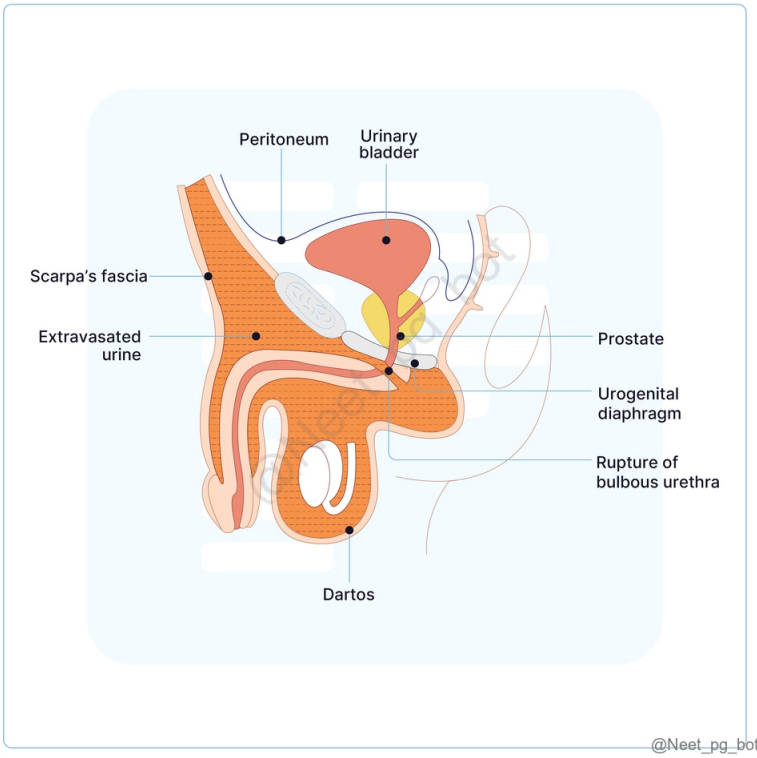

References:

Vishram Singh Textbook of Anatomy, Volume-2, 2nd Edition, Page 247

https://www.uptodate.com/contents/posterior-urethral-injuries-and-management

↑ *Back to this question in Part A*

@Neet_pg_bot

Q4: Which of the following muscles is NOT found in the superficial perineal pouch? (Q848395)

A. Bulbospongiosus

B. Ischiocavernosus

C. Superficial transverse perineal muscle

D. External urethral sphincter

Correct Answer: D. External urethral sphincter

■ *Listen (English)*

■ *Listen (Hindi)*

Explanation: Superficial Perineal Pouch: Perineum is a diamond-shaped space below the pelvic diaphragm and refers to the lowest region of the trunk. An imaginary line between the anterior ends of the ischial tuberosity divides the perineum into 2 triangular divisions. The anterior smaller triangle is known as the urogenital triangle , and the posterior larger division is called the anal triangle of the perineum. Urogenital triangle is further divided by a quadrangular fascial layer called the perineal membrane into a deep perineal pouch above the perineal membrane and a superficial perineal space below the membrane. Superficial perineal space is further divided into the subcutaneous and superficial perineal pouch by the 3 fascia layers: Superficial fascia of the perineum, deep perineal fascia, and the perineal membrane. Boundaries of the Superficial Perineal Pouch: Superior boundary (roof) Perineal membrane. Inferior boundary (floor) Colles' fascia (superficial fascia of the perineum) Lateral boundaries Ischiopubic rami Posterior boundary Fusion with the perineal body and the posterior edge of the perineal membrane. Anterior boundary The space is open and communicates with the potential space between the fascia of the anterior abdominal wall and the perineum. Contents of the Superficial Perineal Pouch: Muscles (Option A, B & C) Bulbospongiosus Ischiocavernosus Superficial transverse perineal muscles Erectile Tissues Crura of the penis (corpora cavernosa) Bulb of the penis (corpus spongiosum) Crura of the clitoris Vestibular bulbs Vessels and Nerves Branches of the internal pudendal vessels and pudendal nerve. Glands Greater vestibular (Bartholin’s) glands : Located at the posterior aspect of the vaginal opening, secreting mucus to lubricate the vagina. Functions : Provides a space for muscles that aid in the support of the pelvic floor and control of the external genitalia. Houses erectile tissues that play an important role in sexual function. It contains neurovascular structures that supply the external genitalia.

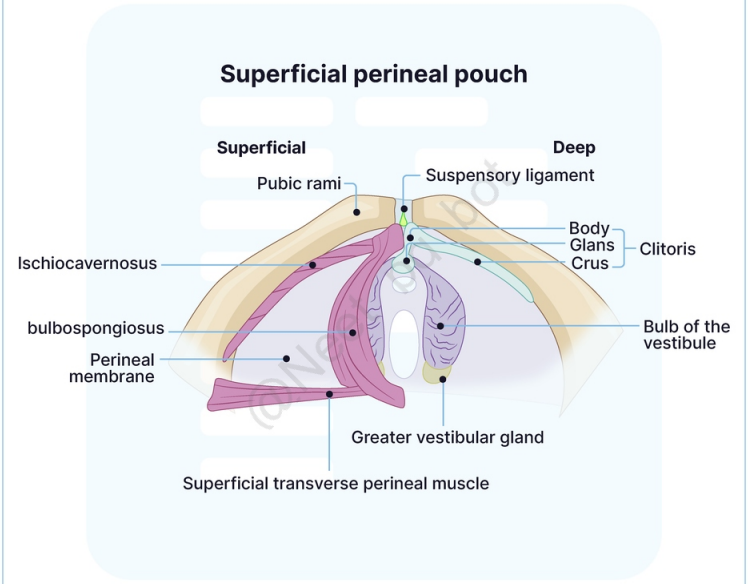

@Neet_pg_bot

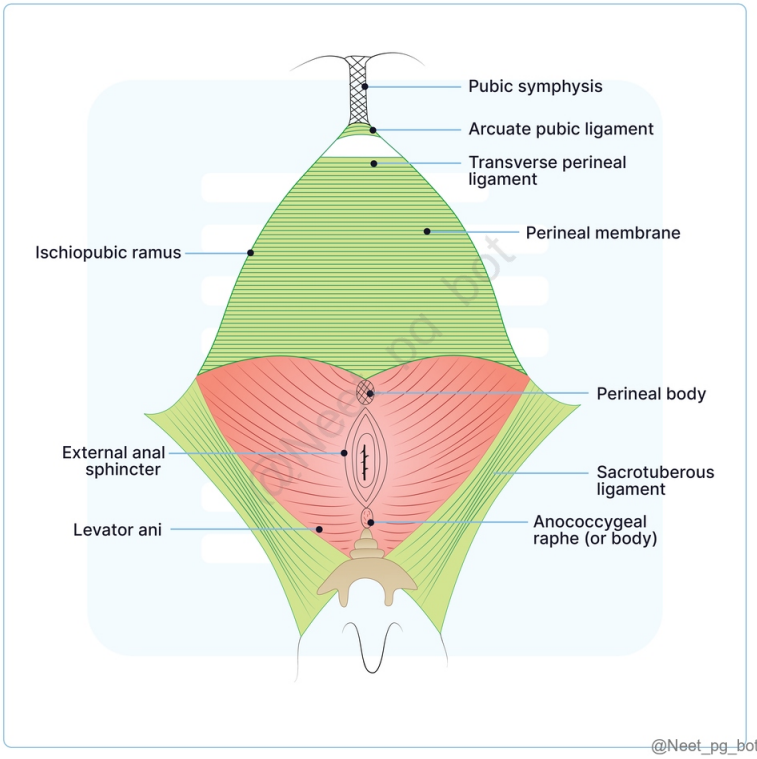

@Neet_pg_bot

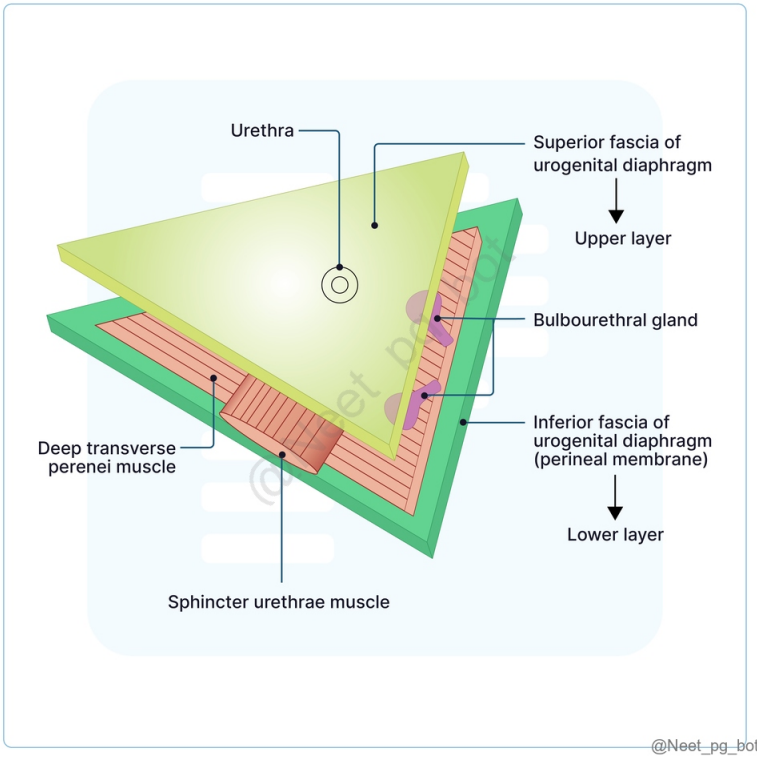

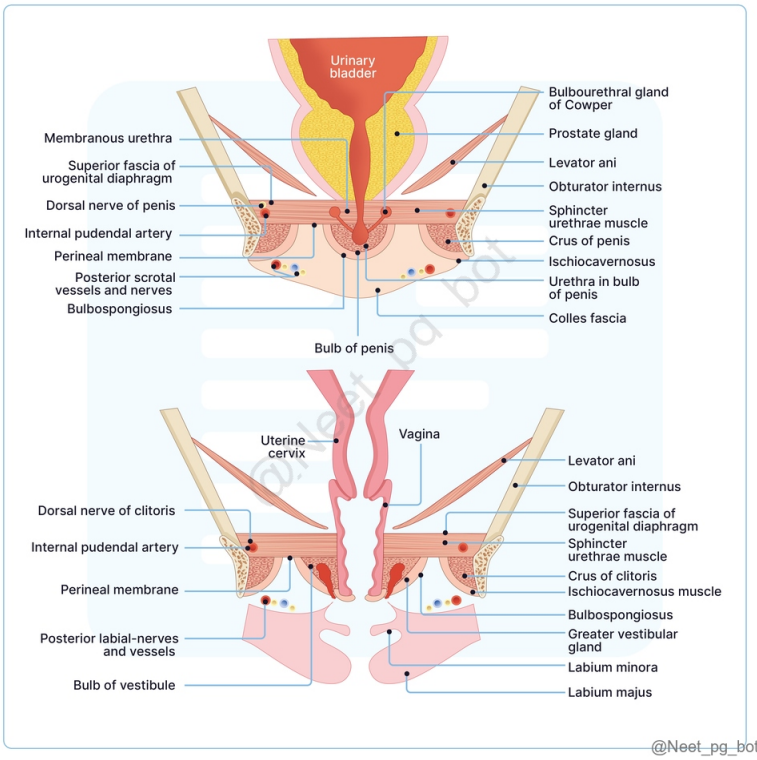

References:

https://www.ncbi.nlm.nih.gov/books/NBK542289/

↑ *Back to this question in Part A*

@Neet_pg_bot

Q5: A 40-year-old woman presents with stress urinary incontinence following childbirth. She reports leakage of urine during physical activity. Physical examination reveals no signs of infection or injury, but pelvic floor weakness is noted. The pelvic ultrasound shows damage to the muscles of the urogenital diaphragm. Which of the following muscles is most likely involved in this patient's condition? (Q848396)

A. Ischiocavernosus

B. Superficial transverse perineal muscle

C. External urethral sphincter

D. Bulbospongiosus

Correct Answer: C. External urethral sphincter

■ *Listen (English)*

■ *Listen (Hindi)*

Explanation: External urethral sphincter is located in the deep perineal pouch and plays a critical role in controlling urinary continence. Deep perineal pouch is in the urogenital triangle of the perineum below the pelvic diaphragm. It presents as a triangular, trilaminar space with sphincter urethrae [external urethral sphincter], deep transverse perineal, and compressor urethrae [in females]. Boundaries of the Deep Perineal Pouch: Superior boundary (roof): Pelvic diaphragm (levator ani). Inferior boundary (floor): Perineal membrane (inferior fascia of the urogenital diaphragm). Lateral boundary: Inferior portions of the obturator internus muscle and the ischiopubic rami. Contents of the Deep Perineal Pouch: In Males In Females Muscles and Glands External urethral sphincter: Surrounds the membranous part of the urethra and controls the voluntary release of urine. Deep transverse perineal muscle: Provides structural support to the perineum. Bulbourethral (Cowper's) glands: Small glands that secrete pre-ejaculate fluid into the urethra. Membranous urethra: Part of the urethra that passes through the deep perineal pouch. External urethral sphincter: Surrounds the urethra and controls voluntary urination. Deep transverse perineal muscle: Provides support to the perineum and helps maintain the integrity of the pelvic floor. Compressor urethrae muscle: Aids in urinary continence by compressing the urethra. Urethrovaginal sphincter: Wraps around the urethra and vagina, assisting in control over the urethra. Nerves and Vessels Branches of the dorsal nerve and artery of the penis, along with the pudendal nerve branches. Branches of the internal pudendal vessels and pudendal nerve supplying the clitoris and surrounding regions. Functions: Urinary continence: The external urethral sphincter plays a key role in controlling urination, helping to retain urine voluntarily. Support of pelvic structures: The muscles of the deep perineal pouch help support the perineum and pelvic organs. Sexual function: In males, the bulbourethral glands secrete fluid that lubricates the urethra during sexual arousal.

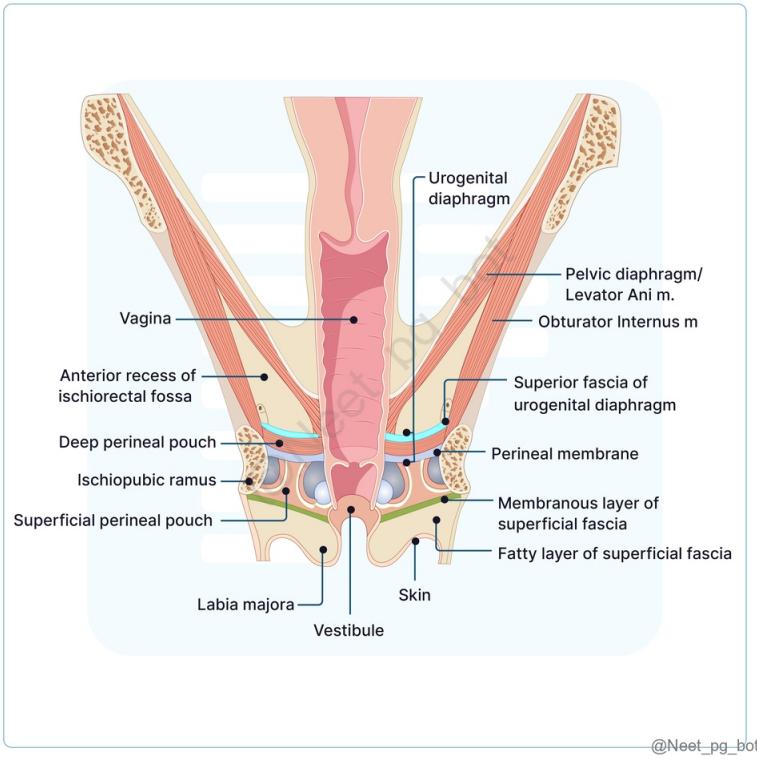

References:

https://www.ncbi.nlm.nih.gov/books/NBK538272/

↑ *Back to this question in Part A*

@Neet_pg_bot

Q6: A 45-year-old woman is undergoing a gynecological procedure in the lithotomy position. The surgeon is identifying the bony landmarks for access to the pelvic organs. During the examination, the surgeon palpates a bony structure near the midline at the anterior aspect of the perineum. Which of the following bony landmarks is the surgeon most likely palpating? (Q848397)

A. Ischial tuberosity

B. Sacrum

C. Pubic symphysis

D. Pubic tubercle

Correct Answer: C. Pubic symphysis

- *Listen (English)*
- *Listen (Hindi)*

Explanation: Pubic symphysis is located at the anterior aspect of the perineum and is easily palpated when the patient is in the lithotomy position. View from Lithotomy Position: Bones and Anatomical Landmarks: Pubic Symphysis: Located at the anterior aspect of the pelvis and acts as the anterior boundary of the perineum. Ischiopubic Rami: They form the lateral borders of the urogenital triangle and are important as attachment points for muscles like the ischiocavernosus and the deep and superficial perineal muscles. Ischial Tuberosities: They serve as the lateral borders of the anal triangle. In the lithotomy position, the ischial tuberosities can be palpated as they provide attachment points for the superficial transverse perineal muscles and are important in identifying the perineal body. Coccyx : The small, triangular bone at the base of the spine, forming the posterior border of the pelvic outlet and provides an attachment point for the coccygeus muscle. Sacrum : Lies posteriorly and superiorly, forming the posterior wall of the pelvic cavity. Obturator Foramen: A large opening formed by the pubis and ischium which allows the passage of the obturator nerve and vessels. Perineal Regions Related to Bones: From the lithotomy position, the perineal area can be divided into the urogenital triangle and the anal triangle. Muscles Attached to Bony Landmarks (Visible from Lithotomy Position) : Levator Ani (Pubococcygeus, Iliococcygeus): Support the pelvic organs and form part of the pelvic diaphragm. Ischiocavernosus and Bulbospongiosus: Attach to the ischiopubic rami and help in erection (males) and clitoral function (females). Superficial and Deep Transverse Perineal Muscles: Attach to the ischial tuberosities and the perineal body, providing support to the pelvic floor.

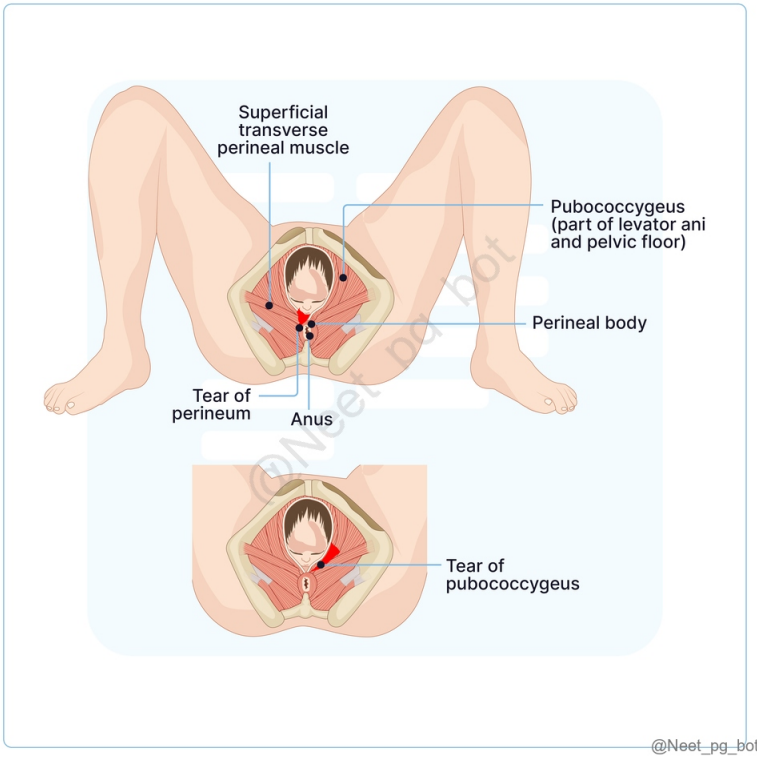

References:

https://www.ncbi.nlm.nih.gov/books/NBK513320/

↑ *Back to this question in Part A*

@Neet_pg_bot

Q7: Which of the following muscles is composed of the pelvic diaphragm? (Q848399)

A. Puborectalis, pubococcygeus

B. Obturator internus, piriformis

C. Levator ani, ischiococcygeus

D. Ischiocavernosus, bulbospongiosus

Correct Answer: C. Levator ani, ischiococcygeus

■ *Listen (English)*

■ *Listen (Hindi)*

Explanation: Pelvic Viscera Support: Pelvic diaphragm : The primary structure supporting the pelvic viscera consists mainly of the levator ani and ischiococcygeus muscles. Provides structural support for organs such as the bladder, uterus, rectum, and small bowel. It helps maintain continence by supporting the urethra and rectum. Levator ani muscles (puborectalis, pubococcygeus, and iliococcygeus) form the bulk of the pelvic diaphragm and are essential for maintaining pelvic organ support. Puborectalis muscle forms a sling around the rectum and is crucial in maintaining fecal continence by controlling the anorectal angle. Perineal Body: Perineal body is a fibromuscular mass located between the vagina and anus (or scrotum and anus in males). It serves as an anchoring point for several pelvic floor muscles, such as the external anal sphincter, bulbospongiosus, and transverse perineal muscles. It plays a critical role in maintaining the integrity of the pelvic floor , particularly during childbirth. Urogenital Diaphragm: Urogenital diaphragm consists of a layer of muscle and connective tissue located below the pelvic diaphragm, providing support to the urethra and vagina. It helps in maintaining continence and offers additional support to pelvic organs , though it plays a less prominent role compared to the pelvic diaphragm. Endopelvic Fascia: This connective tissue surrounds the pelvic organs and connects them to the pelvic walls, helping to stabilize and support these organs. Damage or weakening of the endopelvic fascia, often due to childbirth or aging, can lead to pelvic organ prolapse.

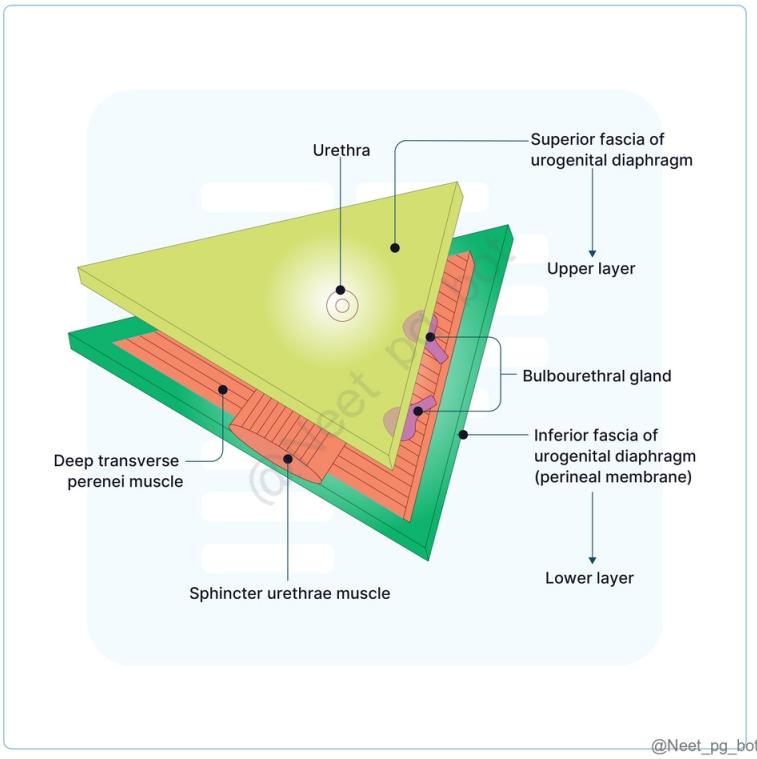

References:

https://www.ncbi.nlm.nih.gov/pmc/articles/PMC1472875/

↑ *Back to this question in Part A*

@Neet_pg_bot

Q8: A 40-year-old male presents to the emergency department after a motor vehicle accident. He has an inability to urinate and perineal pain. Physical examination reveals a high-riding prostate on digital rectal examination, and imaging confirms extravasation of urine around the bladder and prostate. What is the most likely site of urethral injury? (Q848402)

A. Membranous urethra

B. Penile urethra

C. Bulb of the penis

D. Can be any of the above

Correct Answer: A. Membranous urethra

■ *Listen (English)*

■ *Listen (Hindi)*

Explanation: If the rupture occurs above the urogenital diaphragm, urine escapes into the deep perineal pouch and may spread upward around the prostate and bladder into the extraperitoneal space (deep extravasation). Here, the membranous urethra is located above the urogenital diaphragm. A high-riding prostate could be further suggestive of posterior urethral injury , though not a reliable indicator. Urethral Injury Causes Posterior Urethra Membranous Urethra Instrumentation, pelvic fracture with urethral distraction defects Prostatic Urethra Instrumentation, radiation therapy for prostate cancer (external beam radiation therapy, brachytherapy) Bladder Neck Instrumentation, radiation therapy for prostate cancer (external beam radiation therapy, brachytherapy) Penile urethra (Option B) and Bulb of the penis (Option C) (Bulbar urethra) lie below the urogenital diaphragm, and thus, urine leaks into the superficial perineal pouch and spreads over the scrotum, penis, and anterior abdominal wall beneath the membranous layer of the superficial fascia (superficial extravasation).

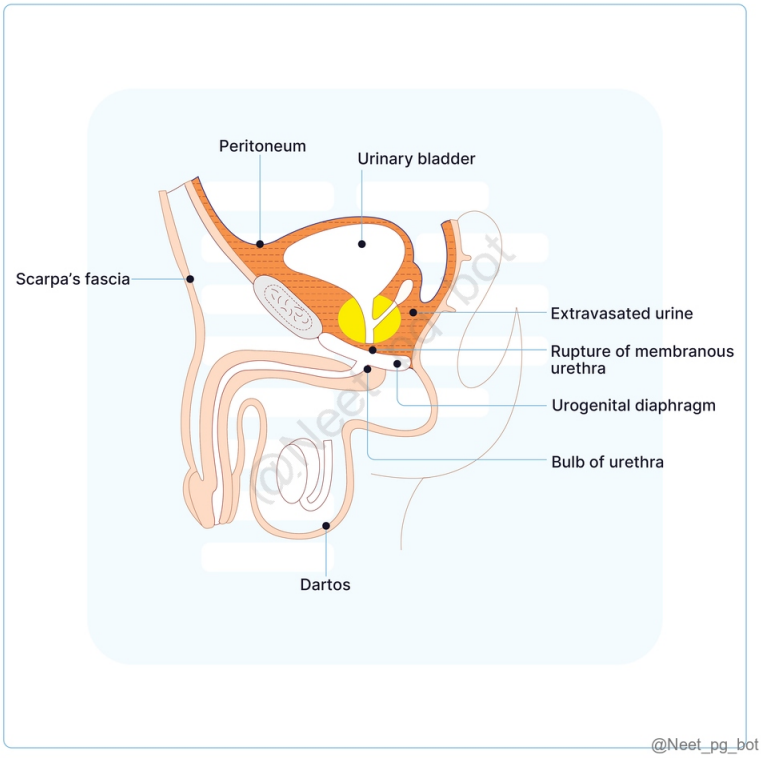

References:

Vishram Singh Textbook of Anatomy, Volume-2, 2nd Edition, Page 247

https://www.uptodate.com/contents/posterior-urethral-injuries-and-management

https://pubmed.ncbi.nlm.nih.gov/24158216/

↑ *Back to this question in Part A*

@Neet_pg_bot

• [09_Pelvis and Perineum] 047 Prostate Male Urethra And Female Reproductive System

« Back to Folder Directory

[09_Pelvis and Perineum] 047 Prostate Male Urethra And Female Reproductive System — Quick Jump

Q1 (p. 2070) *Q2 (p. 2071)* *Q3 (p. 2072)* *Q4 (p. 2073)* *Q5 (p. 2074)* *Q6 (p. 2076)*
Q7 (p. 2076) *Q8 (p. 2078)* *Q9 (p. 2079)* *Q10 (p. 2080)* *Q11 (p. 2082)* *Q12 (p. 2085)*

Q1: A 35 year old male presents with perineal pain and swelling after a traumatic injury during a sporting event. On examination, there is significant bruising over the scrotum and penis. Imaging confirms fluid collection in the superficial perineal space. Which of the following structures is most likely affected by the injury? (Q848403)

A. Sphincter urethrae muscle

B. Bulb of the penis

C. Dorsal nerve of the penis

D. Prostate gland

Correct Answer: B. Bulb of the penis

■ *Listen (English)*

■ *Listen (Hindi)*

Explanation: The bulb of the penis is located in the superficial perineal space, making it vulnerable to injury in this region. The bulb is covered by the bulbospongiosus muscle and contributes to the corpus spongiosum. Pouches in Perineum Superficial Perineal Space Deep Perineal Space Contents In males : Root of the penis (corpora cavernosa and corpus spongiosum) Muscles (ischiocavernosus, bulbospongiosus, superficial transverse perinei) Branches of the perineal nerve and artery Ducts of the bulbourethral glands In females: Body of the clitoris (corpora cavernosa) Bulbs of the vestibule Muscles (ischiocavernosus, bulbospongiosus, superficial transverse perinei) Branches of the perineal nerve and artery The greater vestibular glands and their ducts In males: Part of the urethra Muscles (sphincter urethrae in the urethral wall, deep transversus perinei) (Option A) Dorsal nerve of the penis (Option C) Muscular branches from the perineal nerve Artery of the penis Bulbourethral glands In females: Parts of the urethra and vagina Muscles (sphincter urethrae in the urethral wall, deep transversus perinei, compressor urethrae, sphincter urethrovaginalis), Dorsal nerve of the clitoris, Muscular branches from the perineal nerve, Artery of the clitoris, and no glands. Prostate gland (Option D) is located much higher, in the pelvic region, and is not part of the perineal spaces. Contents of Superficial and Deep Perineal Pouches:

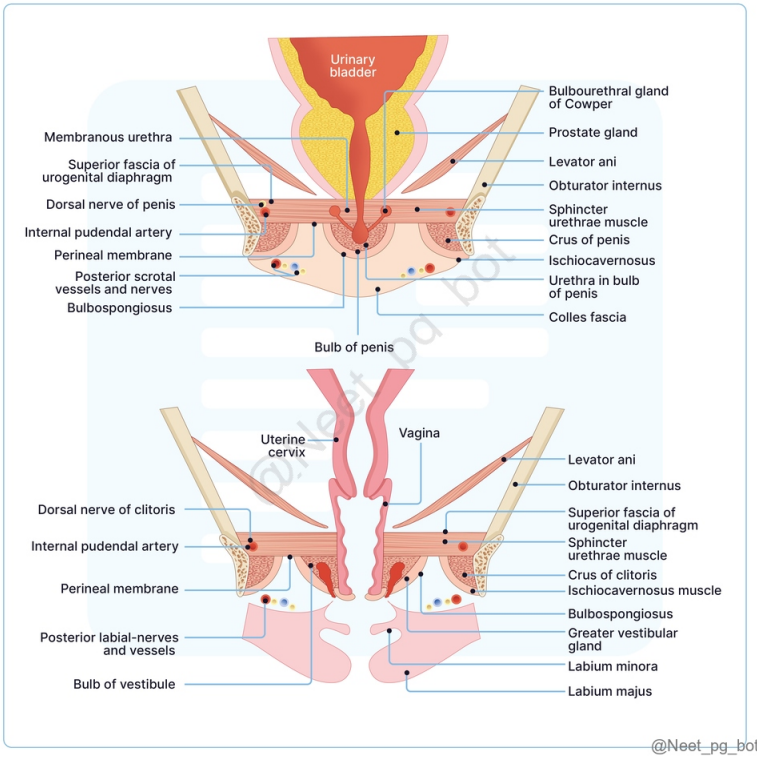

References:

BD Chaurasia's Human Anatomy, Lower limb Abdomen and Pelvis, Volume 2, 8th Edition, Pages 415-418,421-422

↑ *Back to this question in Part A*

@Neet_pg_bot

Q2: From the muscles given below, choose the muscles forming the pelvic diaphragm. Levator ani Coccygeus Bulbospongiosus Ischiocavernosus Superficial transverse perineal muscle Deep transverse perineal muscle (Q848404)

A. 1 and 2

B. 2 and 6

C. 3 and 4

D. 2 and 5

Correct Answer: A. 1 and 2

■ *Listen (English)*

■ *Listen (Hindi)*

Explanation: Levator ani and coccygeus muscles on both sides and their covering fasciae forms the pelvic diaphragm. Pelvic Diaphragm: The pelvic diaphragm (also called the pelvic floor) is formed by the following muscles: 1) Levator ani muscle group This is the main component and includes: Puborectalis Pubococcygeus Iliococcygeus 2) Coccygeus muscle (also called ischiococcygeus)

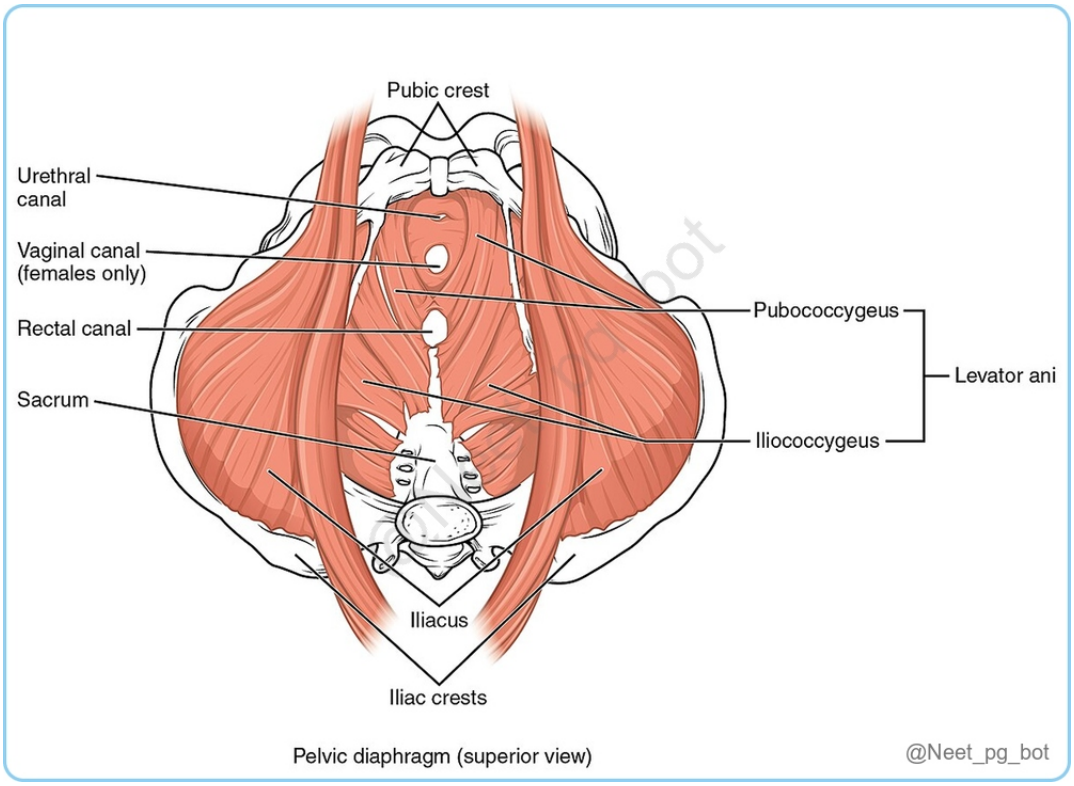

Pelvic diaphragm (superior view)

References:

Vishram Singh Textbook of Anatomy, Volume-2, 2nd Edition, Page 215

↑ *Back to this question in Part A*

@Neet_pg_bot

Q3: Choose the wrong pairing of fibers of pubococcygeus with its name. (Q848408)

A. Anterior fibers-levator prostatae

B. Anterior fibers-sphincter urethrovaginalis

C. Middle fibers-puborectalis

D. Posterior fibers-puborectalis

Correct Answer: D. Posterior fibers-puborectalis

■ *Listen (English)*

■ *Listen (Hindi)*

Explanation: The middle fibers of pubococcygeus are called puborectalis , not the posterior fibers

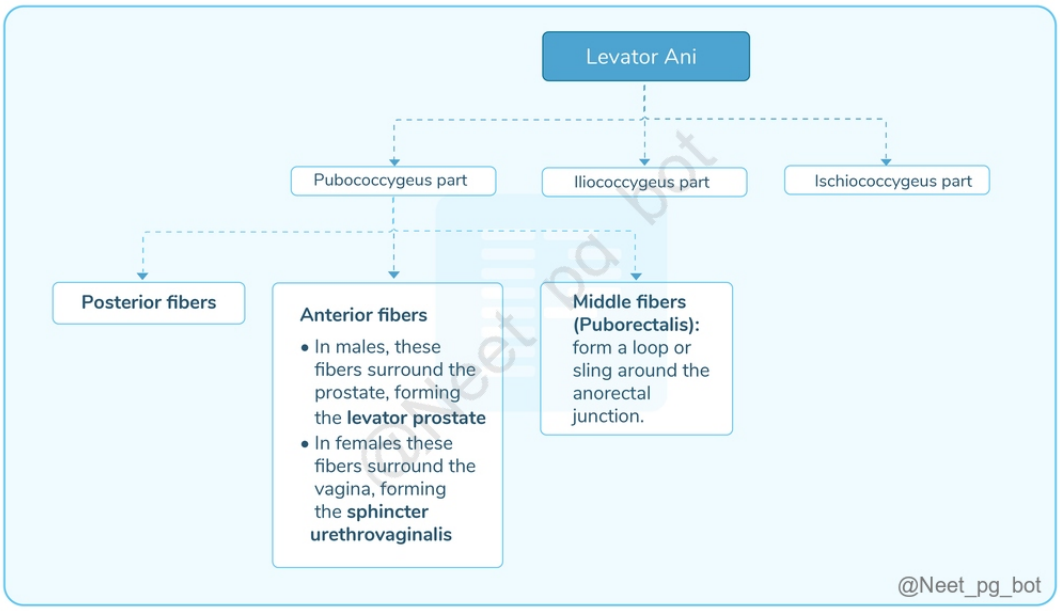

References:

BD Chaurasia's Human Anatomy, Volume-2, 8th Edition, Page 494

↑ *Back to this question in Part A*

@Neet_pg_bot

Q4: Which of the following lobes of the prostate is responsible for producing uvula vesicae? (Q848410)

A. Anterior lobe

B. Posterior lobe

C. Median lobe

D. Lateral lobe

Correct Answer: C. Median lobe

■ *Listen (English)*

■ *Listen (Hindi)*

Explanation: The median lobe of the prostate forms uvula vesicae. Median Lobe: Wedge-shaped Common site of adenoma Base produces an elevation at the apex of trigonum vesicae called uvula vesicae - A slight elevation in the mucous membrane of urinary bladder immediately above and behind the internal urethral orifice Most commonly enlarged in BPH

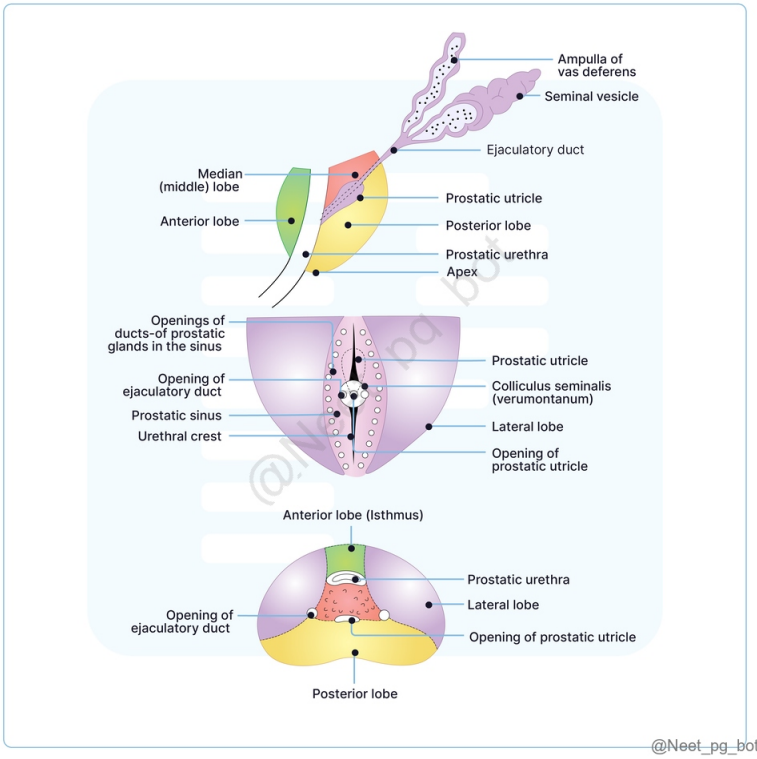

References:

Vishram Singh Textbook of Anatomy, Volume-2, 2nd Edition, Page 242,253

↑ *Back to this question in Part A*

@Neet_pg_bot

Q5: A 72-year-old man visits the clinic for evaluation of urinary symptoms, including nocturia, increased urgency, and a sensation of incomplete bladder emptying. During the examination, a digital rectal exam reveals a smooth, enlarged prostate without any palpable nodules. The patient's PSA level is slightly elevated at 5.5 ng/mL. In which zone of the prostate does this condition primarily occur? (Q848411)

A. Peripheral zone

B. Central zone

C. Transitional zone

D. Anterior fibromuscular stroma

Correct Answer: C. Transitional zone

■ *Listen (English)*

■ *Listen (Hindi)*

Explanation: The above mentioned condition is benign prostatic hyperplasia (BPH) and the transitional zone is primarily responsible for it.j Zones of Prostate gland: The prostate gland is divided into four main zones: Transitional zone Peripheral zone Central zone Fibromuscular zone Transitional Zone (TZ): This is the most clinically significant zone for Benign Prostatic Hyperplasia (BPH). Location: Surrounds the proximal part of the prostatic urethra. Importance: It is the primary site of BPH (Benign Prostatic Hyperplasia) . Because it encircles the urethra, growth in this zone leads to the obstructive urinary symptoms commonly seen in older men. Cancer Risk: Approximately 10–20% of prostate cancers originate here. Peripheral zone: This is the largest portion of the prostate, making up about 70% of the glandular tissue. Location: Located at the back (posterior) of the gland, closest to the rectum. Importance: This is the site where 70–80% of prostate cancers originate. Clinical Access: Because it is posterior, this is the area felt during a Digital Rectal Exam (DRE) . It is also the area most easily biopsied via ultrasound. Central Zone (CZ): This zone accounts for about 25% of the prostate volume. Location: Surrounds the ejaculatory ducts as they pass through the prostate to the urethra. Importance: It is histologically different from the other zones (more similar to the seminal vesicles). Cancer Risk: Only about 5% of prostate cancers start here, but when they do, they tend to be more aggressive. Anterior Fibromuscular Stroma: Unlike the others, this is a non-glandular zone. Location: The very front (anterior) surface of the prostate. Importance: It is composed of muscle and fibrous tissue rather than glandular tissue. It contains no "acini" (milk-producing-like glands), so it is virtually never a site for cancer or BPH.

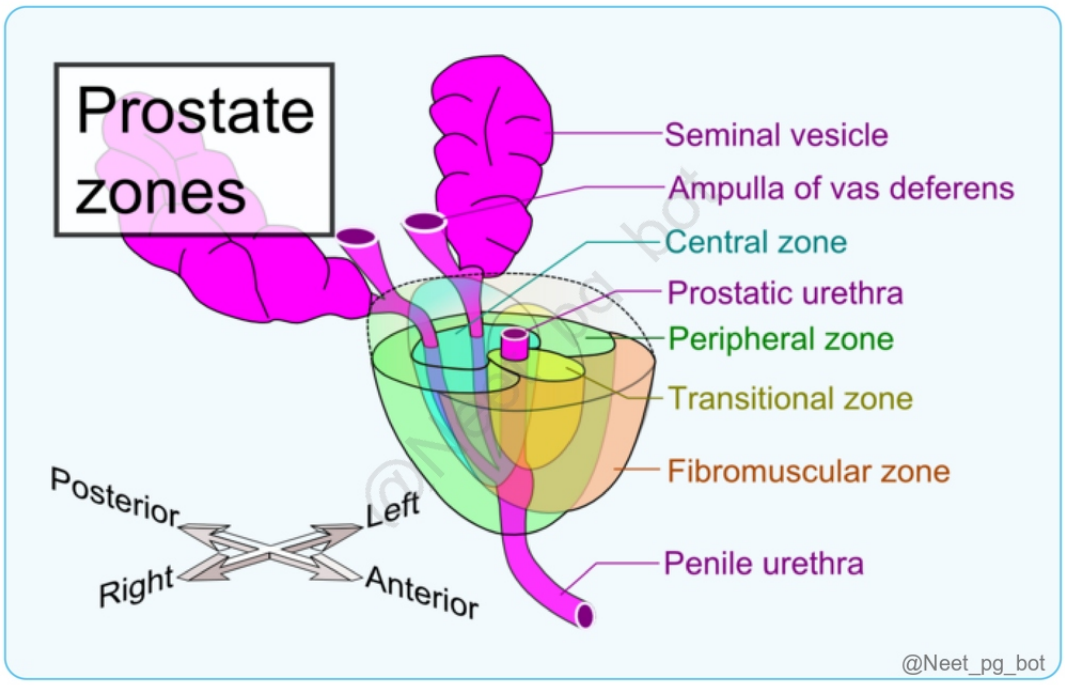

References:

https://www.ncbi.nlm.nih.gov/books/NBK13217/

↑ *Back to this question in Part A*

@Neet_pg_bot

Q6: A 65-year-old male presents to the clinic with complaints of frequent urination, especially at night, and difficulty initiating urination. He reports that he feels an urge to urinate but often has to wait before the stream begins. During the digital rectal exam, the physician notes a smooth, enlarged prostate. Patient has a medical history of diabetes and hyperlipidemia. What is the most likely diagnosis? (Q848412)

A. Prostate cancer

B. Prostatitis

C. Benign prostatic hyperplasia (BPH)

D. Urinary tract infection (UTI)

Correct Answer: C. Benign prostatic hyperplasia (BPH)

■ *Listen (English)*

■ *Listen (Hindi)*

Explanation: Patient’s symptoms of increased urinary frequency, nocturia, and difficulty initiating urination, along with the finding of an enlarged prostate, are classic signs of benign prostatic hyperplasia (BPH). Prostate cancer (Option A): presents similarly but would typically require further evaluation and would more likely present with nodularity or firmness rather than a smooth enlarged prostate. Prostatitis (Option B): causes urinary symptoms but usually associated with pain, fever or dysuria. Urinary tract infection (Option D): causes urinary frequency and urgency but would usually be associated with other symptoms like dysuria or fever.

References:

1. Robbins and Cotran's Pathological Basis of Diseases, 10th Edition, Page 976,977 2. https://www.ncbi.nlm.nih.gov/books/NBK558920/

↑ *Back to this question in Part A*

@Neet_pg_bot

Q7: Which of the following statements about the prostatic urethra is true? (Q848425)

A. It is primarily lined by stratified squamous epithelium.

B. It is the shortest segment of the male urethra.

C. It connects the bladder to the membranous urethra and receives the ejaculatory ducts.

D. It is solely responsible for the passage of urine, with no role in the reproductive system.

Correct Answer: C. It connects the bladder to the membranous urethra and receives the ejaculatory ducts.

■ *Listen (English)*

■ *Listen (Hindi)*

Explanation: Male Urethra is Divided into 4 Parts: Pre-prostatic urethra Prostatic urethra Membranous urethra Spongy urethra Prostatic Urethra: Segment of the male urethra that passes through the prostate gland. Location Widest part of male urethra. (Option B) Contains urethral crest, seminal colliculus, prostatic utricle and orifices of prostatic duct. Extends from the bladder neck to the beginning of the membranous urethra which is approximately 3-4 cm in length . (Option C) Histology Urothelium immediately surrounded by glandular and strong tissue of the periurethral zone of the prostate. (Option A) Functions Conducts urine from the bladder to the external urethral orifice and serves as a passage for semen during ejaculation. (Option D)

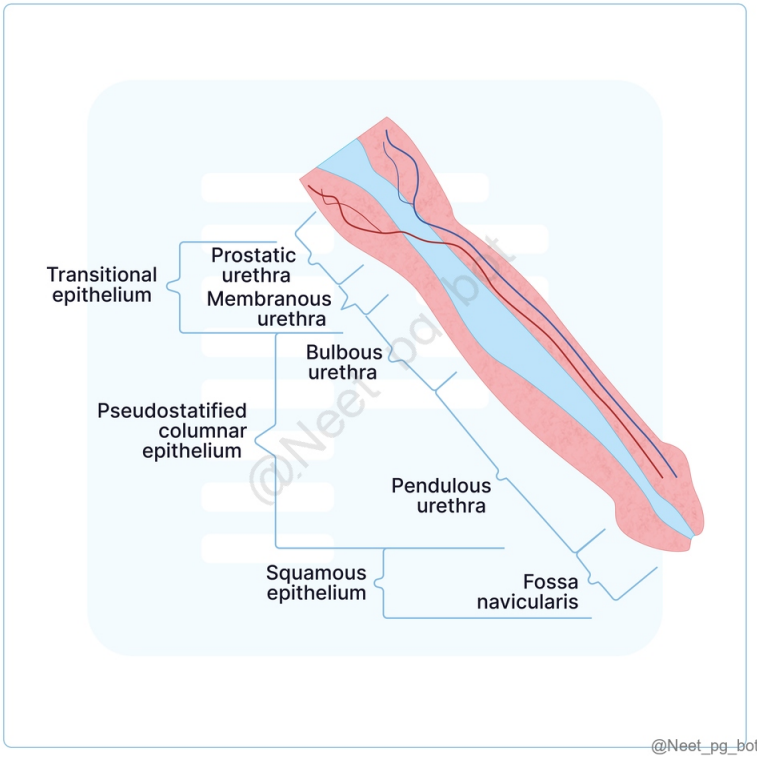

References:

https://www.ncbi.nlm.nih.gov/books/NBK542238/

↑ *Back to this question in Part A*

@Neet_pg_bot

Q8: Which of the following correctly lists the segments of the male urethra in the order they occur from the bladder to the external urethral orifice? (Q848426)

A. Prostatic urethra → Membranous urethra → Spongy urethra

B. Spongy urethra → Membranous urethra → Prostatic urethra

C. Membranous urethra → Spongy urethra → Prostatic urethra

D. Prostatic urethra → Spongy urethra → Membranous urethra

Correct Answer: A. Prostatic urethra → Membranous urethra → Spongy urethra

■ *Listen (English)*

■ *Listen (Hindi)*

Explanation: The correct order of the segments of the male urethra is Prostatic urethra → Membranous urethra → Spongy urethra Male Urethra: Divided into 4 parts: Pre-Prostatic Urethra Location : Extends inferiorly from urinary bladder and ends prior to entering the prostate gland. Prostatic Urethra Location : Completely encompassed within the prostate gland. Membranous Urethra Location : Begins immediately outside of the prostate and ends just prior to entering the bulb of the penis. Spongy Urethra/Penile Urethra Location : Travels the entire length of the penis via the corpus spongiosum.

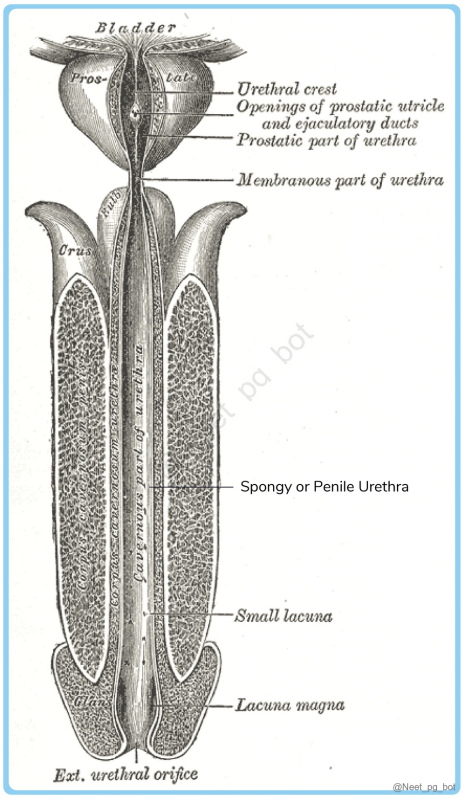

References:

https://www.ncbi.nlm.nih.gov/books/NBK542238/

↑ *Back to this question in Part A*

@Neet_pg_bot

Q9: Gynaecologist is planning to do uterine artery ligation. She must be careful while performing it due to the risk of injuring which structure? (Q848427)

A. Ureter, as it lies anterior to uterine artery

B. Ureter, as it lies posterior to uterine artery

C. Bladder, as it lies superior to uterine artery

D. Urethra, as it lies inferior to uterine artery

Correct Answer: B. Ureter, as it lies posterior to uterine artery

■ *Listen (English)*

■ *Listen (Hindi)*

Explanation: While performing uterine artery ligation, ‘ water under bridge ’ can occur due to injury to Ureter . ‘Water’ refers to urine, due to leak from the ureter and ‘bridge’ is formed by the uterine artery. Ureter lies posteroinferior to the uterine artery. Course of the ureter: 1. Abdominal Course: The ureter begins at the renal pelvis and descends retroperitoneally. Location: It runs vertically on the anterior surface of the psoas major muscle . Clinical Significance: During abdominal surgeries, the ureter is identified by its "vermicular" (worm-like) peristaltic movement when touched with forceps. 2. Pelvic Inlet (The Crossing): As it enters the true pelvis, the ureter crosses over the bifurcation of the common iliac artery (or the start of the external iliac artery). Clinical Significance: This is a common site for ureteral stones (calculi) to become lodged due to the slight narrowing at this junction. 3. Pelvic Course & The "Water Under the Bridge": The ureter travels along the lateral pelvic wall before turning medially toward the bladder. Relationship to Uterine Artery: In females, the ureter passes posteroinferior (underneath) the uterine artery. The uterine artery acts as the "bridge," while the ureter (carrying "water" or urine) passes under it. Clinical Significance: During a hysterectomy or uterine artery ligation , surgeons must be extremely careful not to accidentally clamp or cut the ureter when securing the uterine artery. An injury here can lead to a urine leak into the pelvic cavity. 4. Entry into the Bladder: The ureter enters the bladder wall obliquely at the vesicoureteric junction. This oblique entry creates a one-way valve mechanism. Clinical Significance: If this valve fails, it leads to Vesicoureteral Reflux (VUR) , where urine flows backward from the bladder toward the kidneys, increasing the risk of kidney infections (pyelonephritis). Summary of Constriction Sites: Ureteral stones most commonly lodge at these three points of natural narrowing: Ureteropelvic Junction (UPJ): Where the renal pelvis meets the ureter. Pelvic Brim: Where the ureter crosses the iliac vessels. Vesicoureteric Junction (VUJ): Where the ureter enters the bladder.

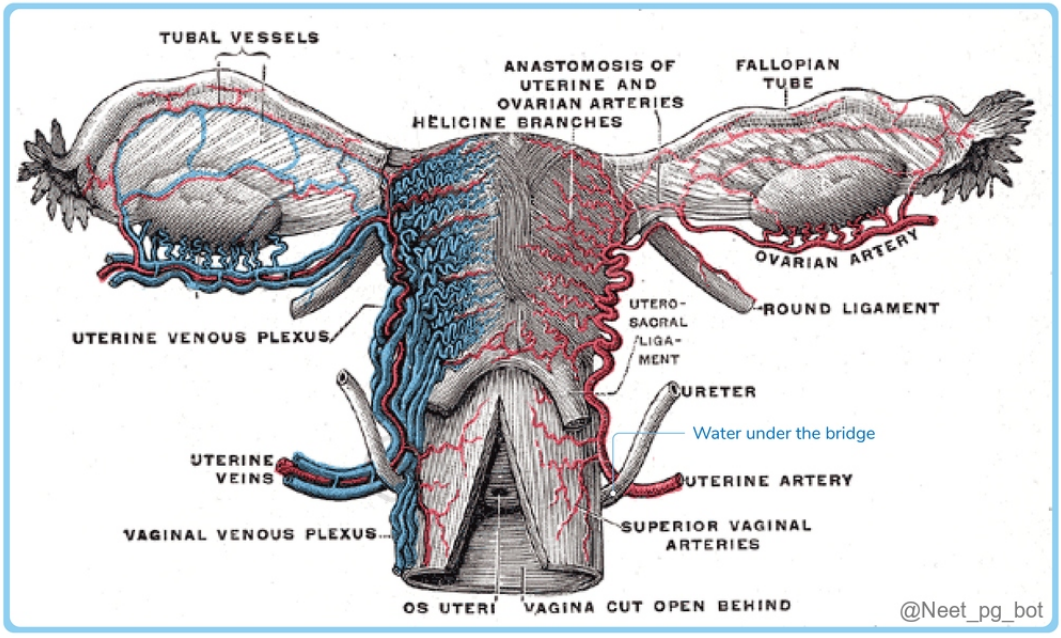

References:

BD Chaurasia’s Human Anatomy, Lower limb Abdomen and Pelvis, Volume 2, 8th Edition, Pages 380,453,459

↑ *Back to this question in Part A*

@Neet_pg_bot

Q10: Match the branches of uterine arteries with their names based on the image given: 1 a) Basal artery 2 b) Spiral artery 3 c) Arcuate artery 4 d) Radial artery (Q848428)

A. 1-c, 2-a, 3-d, 4-b

B. 1-a, 2-b, 3-c, 4-d

C. 1-a, 2-d, 3-c, 4-b

D. 1-c, 2-d, 3-a, 4-b

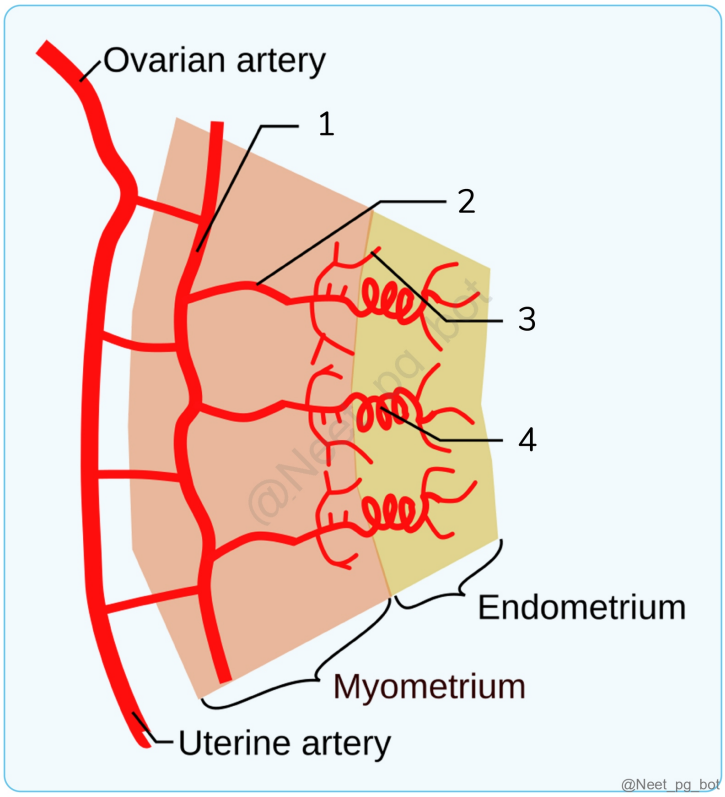

Correct Answer: D. 1-c, 2-d, 3-a, 4-b

- *Listen (English)*
- *Listen (Hindi)*

Explanation: Sequence of Uterine Artery: Artery Layer Supplied Role in Menstrual Cycle A Arcuate Artery Outer Myometrium Main distribution network. R Radial Artery Inner Myometrium Transports blood to the inner layers. B Basal Artery Stratum Basalis Remains stable; allows for regrowth. S Spiral Artery Stratum Functionalis Sheds during menstruation; crucial for pregnancy. Arcuate Artery: Location: These are found in the outer layer of the myometrium (the muscular wall of the uterus). Importance: They "encircle" the uterus (hence the name arcuate). They act as the primary distribution channels, ensuring that blood from the uterine and ovarian arteries is spread evenly around the organ's circumference. Area Supplied: The outer one-third of the myometrium. Radial Artery: Location: These branch off the arcuate arteries and penetrate deeply and perpendicularly into the uterine wall.

Importance: They bridge the gap between the outer muscular layer and the inner lining. They are the "connectors" that bring blood toward the endometrium. Area Supplied: The inner two-thirds of the myometrium. Basal Artery (Straight Artery): Location: These branch from the radial arteries and stay within the stratum basalis (the deep, permanent layer of the endometrium). Importance: These are not sensitive to hormonal changes. They do not constrict during menstruation, which is vital because they ensure the basal layer of the endometrium remains alive to "regrow" the lining for the next cycle. Area Supplied: The stratum basalis (basal layer) of the endometrium. Spiral Artery: Location: These also branch from the radial arteries but extend all the way into the stratum functionalis (the superficial layer of the endometrium). Importance: These are highly hormone-sensitive . During the menstrual cycle, they grow and become increasingly coiled (spiral). When progesterone levels drop, these arteries constrict and spasm, leading to the shedding of the uterine lining (menstruation) Area Supplied: The stratum functionalis (functional layer) of the endometrium.

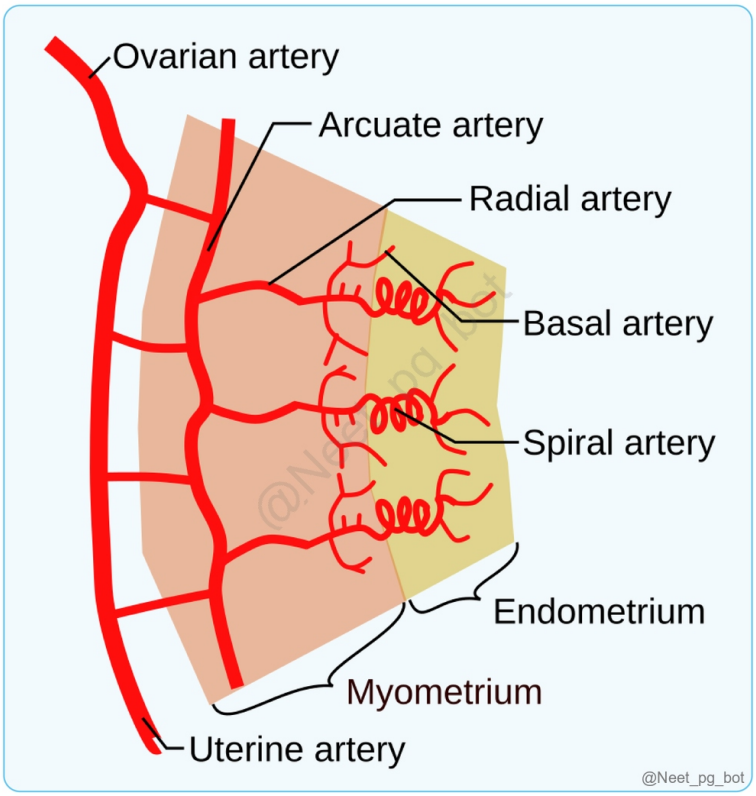

References:

BD Chaurasia’s Human Anatomy, Lower limb Abdomen and Pelvis, Volume 2, 8th Edition, Pages 458-459

https://www.ncbi.nlm.nih.gov/books/NBK482267/

↑ *Back to this question in Part A*

@Neet_pg_bot

Q11: A 30 year old female presented with post coital bleeding. Hysterectomy with lymph node dissection was done. Gross specimen of the uterus is shown below. Which

of the following nodes group is least likely to be positive for malignancy? (Q848429)

A. Superficial inguinal

B. Internal iliac

C. Obturator

D. Sacral



Correct Answer: A. Superficial inguinal

- *Listen (English)*
- *Listen (Hindi)*

Explanation: Clinical scenario and the gross specimen is diagnostic of Carcinoma cervix . Cervix belongs to the lower lymphatics of the uterus that drains into the Internal iliac, obturator & sacral group (never into the inguinal) . Lymphatic Drainage of Uterus: Lymphatics Region Draining Lymph Node Upper Fundus and upper half of uterine body including ovary and fallopian tube Aortic group (Pre- & Lateral aortic) Round ligament and uterine isthmus Superficial inguinal Middle Lower half of uterine body External iliac Lower Cervix Internal iliac, Sacral & Obturator group (never inguinal) Vagina Upper 1/3rd External iliac Middle 1/3rd Internal iliac Lower 1/3rd Superficial inguinal


@Neet_pg_bot

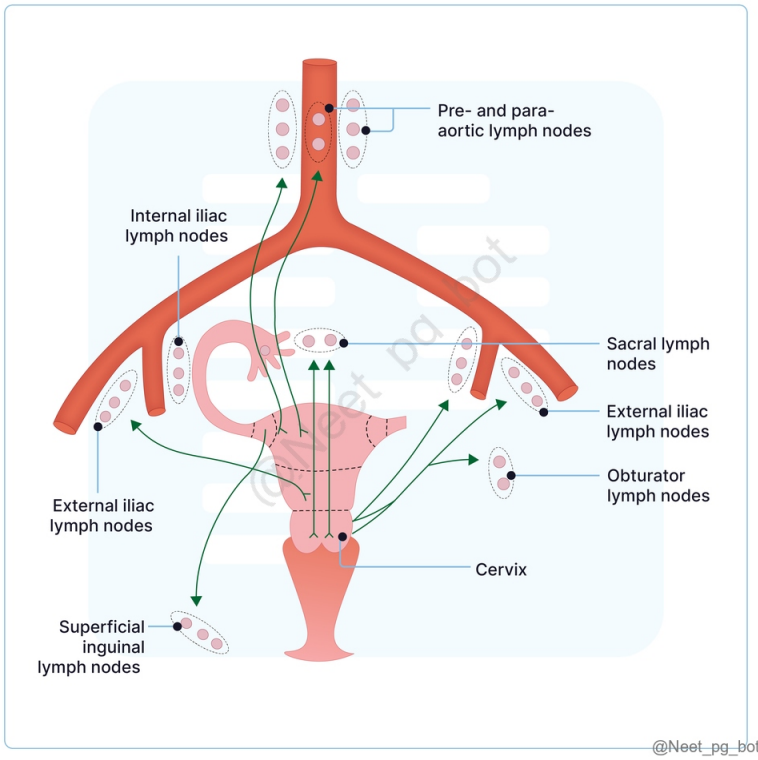
Pre- and para-
aortic lymph nodes
Internal iliac
lymph nodes
Sacral lymph
nodes
External iliac
lymph nodes
Obturator
lymph nodes
External iliac
lymph nodes
Cervix
Superficial
inguinal
lymph nodes
@Neet_pg_bot

References:

BD Chaurasia’s Human Anatomy, Lower limb Abdomen and Pelvis, Volume 2, 8th Edition, Pages 447,449,454,459

↑ *Back to this question in Part A*

@Neet_pg_bot

Q12: Angle shown in the image below in a non-gravid uterus is maintained by? (Q848430)

A. Round ligament

B. Uterosacral ligament

C. Both (A) and (B)

D. Pubocervical ligament

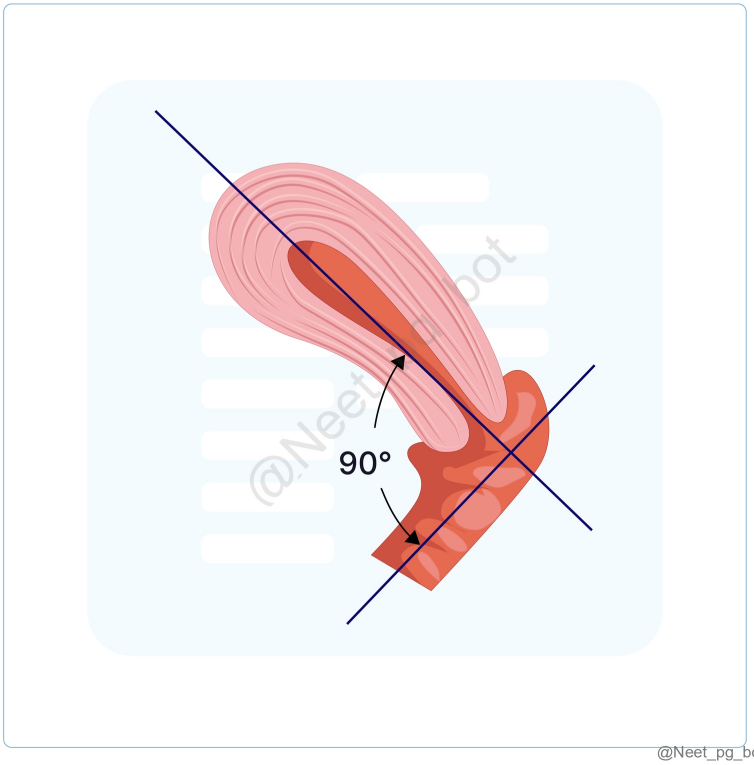

Correct Answer: C. Both (A) and (B)

■ *Listen (English)*

■ *Listen (Hindi)*

Explanation: Angle shown in the image between the cervix and vagina is known as the Angle of Anteversion. Angle between the uterus and cervix is known as the Angle of Anteflexion . Uterus is maintained in an anteverted state mainly by Round ligament with minor contribution from uterosacral ligament in non-pregnant female. (Hence, Option C would be most appropriate)

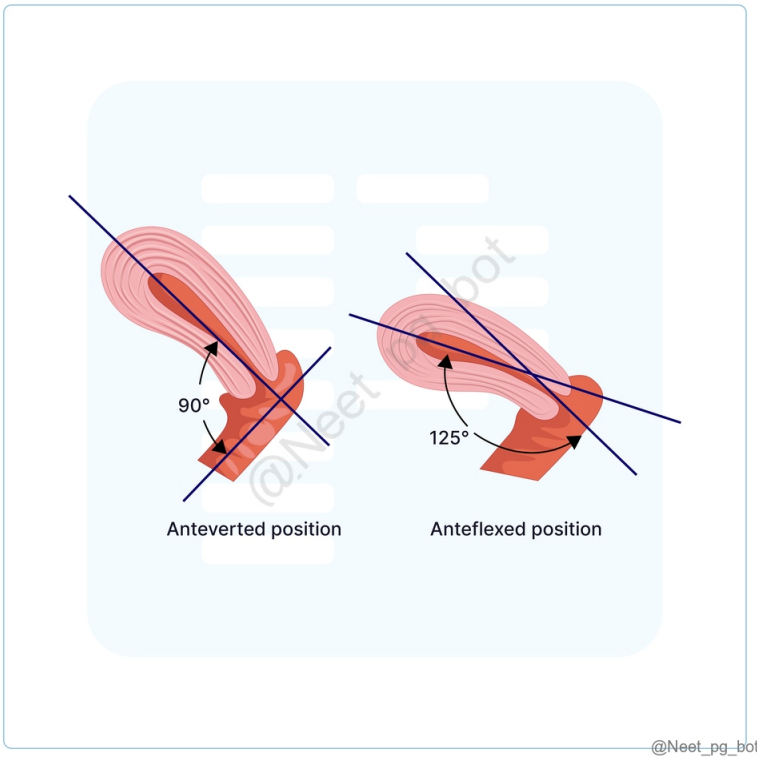

References:

DC Dutta's Textbook of Gynaecology, 8th Edition, Page 6,17,18

↑ *Back to this question in Part A*

@Neet_pg_bot

• [09_Pelvis and Perineum] 048 Previous Year Questions

« Back to Folder Directory

[09_Pelvis and Perineum] 048 Previous Year Questions — Quick Jump

Q1 (p. 2087)	*Q2 (p. 2088)*	*Q3 (p. 2089)*	*Q4 (p. 2091)*	*Q5 (p. 2092)*	*Q6 (p. 2094)*
Q7 (p. 2095)	*Q8 (p. 2097)*	*Q9 (p. 2098)*	*Q10 (p. 2099)*	*Q11 (p. 2100)*	*Q12 (p. 2102)*
Q13 (p. 2103)	*Q14 (p. 2104)*	*Q15 (p. 2105)*	*Q16 (p. 2106)*	*Q17 (p. 2107)*	*Q18 (p. 2107)*
Q19 (p. 2109)	*Q20 (p. 2109)*				

Q1: Which muscles are responsible for constituting the pelvic diaphragm? A. Iliococcygeus B. Pubococcygeus C. Obturator internus D. Deep transverse perinei (Q855033)

A. A and B

B. A, B, C and D

C. A, B and D

D. A and D

Correct Answer: A. A and B

Explanation: The pelvic diaphragm is the muscular structure that forms the floor of the pelvic cavity . It is composed of the levator ani muscles and the coccygeus muscle. Iliococcygeus (Muscle A) → Part of the levator ani , helps support pelvic organs. Pubococcygeus (Muscle B) → Another part of the levator ani , important for continence and pelvic floor integrity. The pelvic diaphragm is a muscular sheet that forms the inferior border of the pelvic cavity. It consists of several muscles that work together to support the pelvic organs and assist in various functions. The components of the pelvic diaphragm are: Levator ani muscle complex, which includes: Pubococcygeus Iliococcygeus Coccygeus muscle or Ischiococcygeus Functions: Supports pelvic viscera (bladder, uterus, rectum). Maintains urinary and faecal continence. Innervation: Primarily by the pudendal nerve (S2-S4). Clinical significance: Weakness can lead to prolapse and incontinence. Kegel exercises can improve function. {{caption_text}} Obturator internus (Muscle C) – Incorrect: This muscle is part of the lateral pelvic wall , not the pelvic diaphragm. It assists in hip rotation , not pelvic floor support. Deep transverse perinei (Muscle D) – Incorrect: This muscle is part of the urogenital diaphragm , which lies inferior to the pelvic diaphragm . It supports the perineal body but does not constitute the pelvic diaphragm.

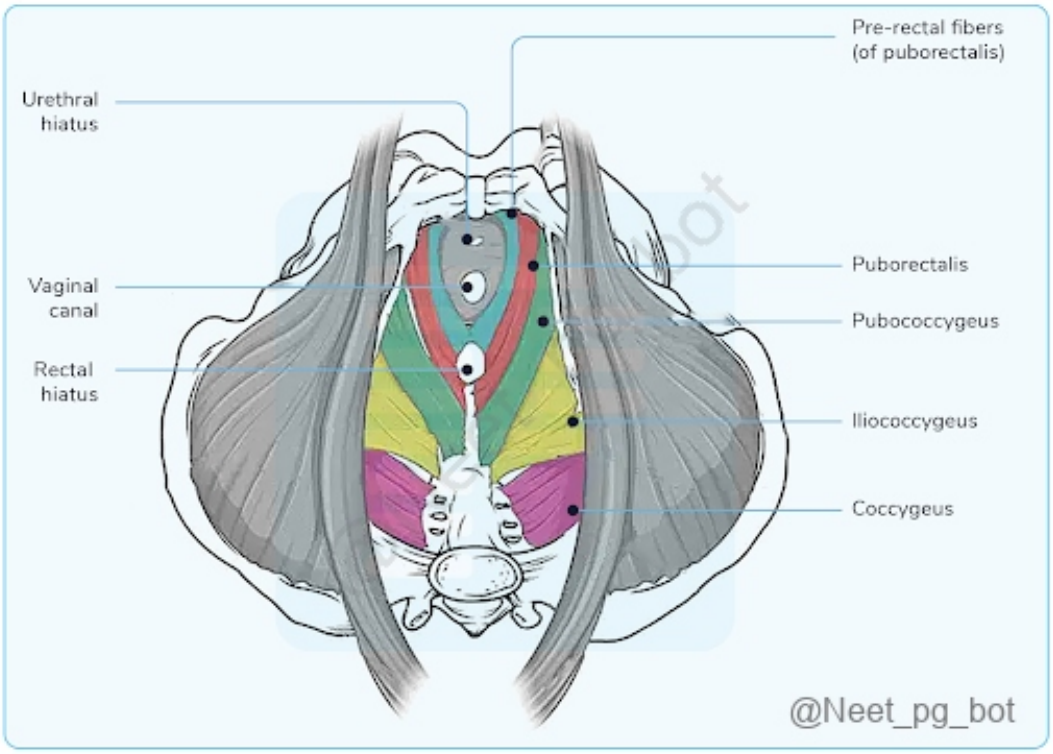

References:

Williams Gynecology, 4th edition, Page 798

↑ *Back to this question in Part A*

@Neet_pg_bot

Q2: In the given image which of the following structures is not associated with the marked area? (Q879187)

A. Pudendal nerve

B. Internal pudendal vessel

C. Tendon of obturator externus

D. Ischiococcygeus

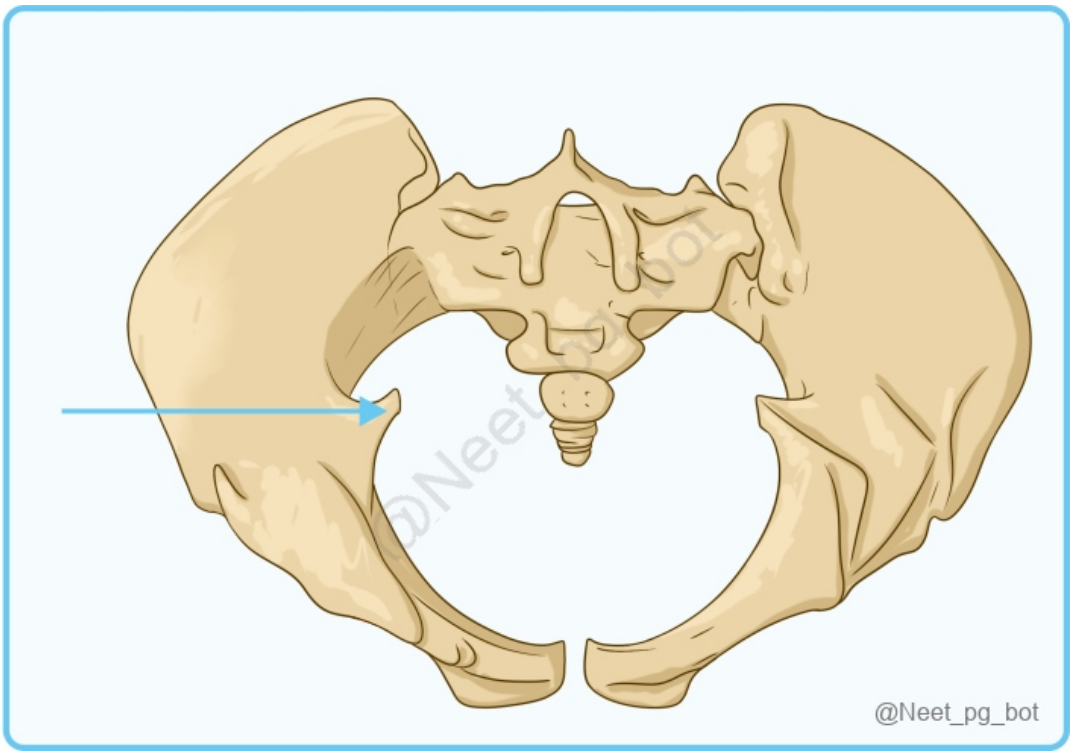

Correct Answer: C. Tendon of obturator externus

Explanation: The ischial spine is a bony projection separating the greater and lesser sciatic notches . Tendon of obturator externus is not related to the ischial spine; it lies anteriorly near the obturator foramen , not the sciatic notches. Ischial spine: Attachments: Sacrospinous ligament - attaches along its margins . Posterior fibers of levator ani - arise from its pelvic surface . Relations (Structures Crossing Dorsal Surface): Pudendal nerve Internal pudendal vessels Nerve to obturator internus

References:

BD Chaurasia’s Human Anatomy, 8th Edition, Volume 2, Page 13

↑ *Back to this question in Part A*

@Neet_pg_bot

Q3: The below image is of a femur bone. Which muscles are attached to "A"? (Q859518)

A. Gluteus maximus

B. Iliopsoas

C. Quadriceps femoris

D. Adductor magnus

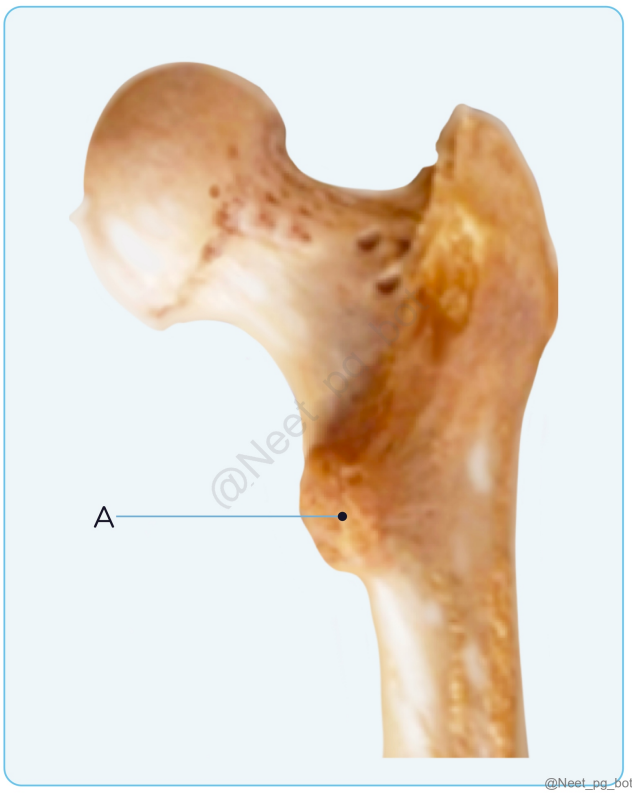

Correct Answer: B. Iliopsoas

Explanation: The A point marked on the image of the femur is the lesser trochanter of the femur. The Iliopsoas muscle arises from the Iliac fossa and lumbar spine and attaches to the lesser trochanter of the femur. Iliopsoas is a large compound muscle of the inner hip composed of the iliacus and psoas major muscles. It is situated on the posterior abdominal wall. The iliopsoas muscle is the primary flexor of the hip joint. It is also responsible for external hip rotation at the hip joint. It causes flexion of the trunk at the hip, lateral flexion of the trunk (psoas major only) Incorrect Options: Gluteus maximus (Option A): is the largest and heaviest muscle in the body. It takes its origin from the dorsum of the hip bone as well as from the dorsum of the sacrum and also has ligaments. Insertion is on the gluteal tuberosity on the posterior aspect of the upper femur bone. Quadriceps femoris (Option C): are the group of muscles in front of the thigh. Quadriceps perform a variety of movements, including running, jumping, kicking, and walking. There are 4 Quadriceps: Rectus femoris. Vastus lateralis Vastus medialis Vastus intermedius. When Quadriceps muscles contract, they extend the knee joint, straightening the leg. The quadriceps femoris attaches to the patella via the quadriceps tendon and does not attach to the lesser trochanter, so this is incorrect. Adductor Magnus (Option D): is a prime mover of the femur into adduction. One portion of the adductor muscle flexes the thigh and works as a medial rotator; the other extends the thigh and is a lateral rotator. The adductor magnus attaches to the adductor tubercle on the femur, not the lesser trochanter, so this is also incorrect.

References:

https://www.ncbi.nlm.nih.gov/books/NBK531508/#:~:text

↑ *Back to this question in Part A*

@Neet_pg_bot

Q4: Identify the foramen marked in the image below:- (Q856378)

A. Foramen rotundum

B. Foramen ovale

C. Vidian canal

D. Foramen spoinosum



Correct Answer: A. Foramen rotundum

Explanation: The foramen rotundum is indeed located in the sphenoid bone of the skull. It is a rounded opening that lies in the greater wing of the sphenoid bone, on the medial part of the infratemporal surface. The foramen rotundum serves as a passage for the maxillary nerve (V2), which is a branch of the trigeminal nerve (cranial nerve V). Foramen of Middle Cranial Fossa Structures Passing through Foramen Rotundum Maxillary Nerve Foramen Ovale M andibular nerve A ccessory meningeal artery L esser petrosal nerve E missary vein Occasionally, the Anterior trunk of the middle meningeal vein Foramen Spinosum M iddle meningeal artery and vein, E missary vein N ervus spinosus(Meningeal branch of mandibular nerve) Foramen Lacerum A triangular opening at the base of the skull, but in living individuals, it is filled with cartilage, and no major structures pass through it. Foramen lacerum contributed by 3 bones-temporal, occipital and sphenoid The internal carotid artery and nerve plexus traverse its superior end; The nerve to the pterygoid canal passes through its anterior wall. The meningeal branch

of the ascending pharyngeal artery and an emissary vein pass through it . Foramen Ovale (Option B): The foramen ovale is a separate opening in the sphenoid bone, located posterior and slightly lateral to the foramen rotundum. It is larger and oval-shaped. Vidian Canal (Option C): The vidian canal, or pterygoid canal, is a narrow bony passage in the sphenoid bone. It runs obliquely between the pterygopalatine fossa and the middle cranial fossa. Foramen Spinosum (Option D): The foramen spinosum, a small opening, is situated in the greater wing of the sphenoid bone, positioned posteriorly and laterally to the foramen ovale.

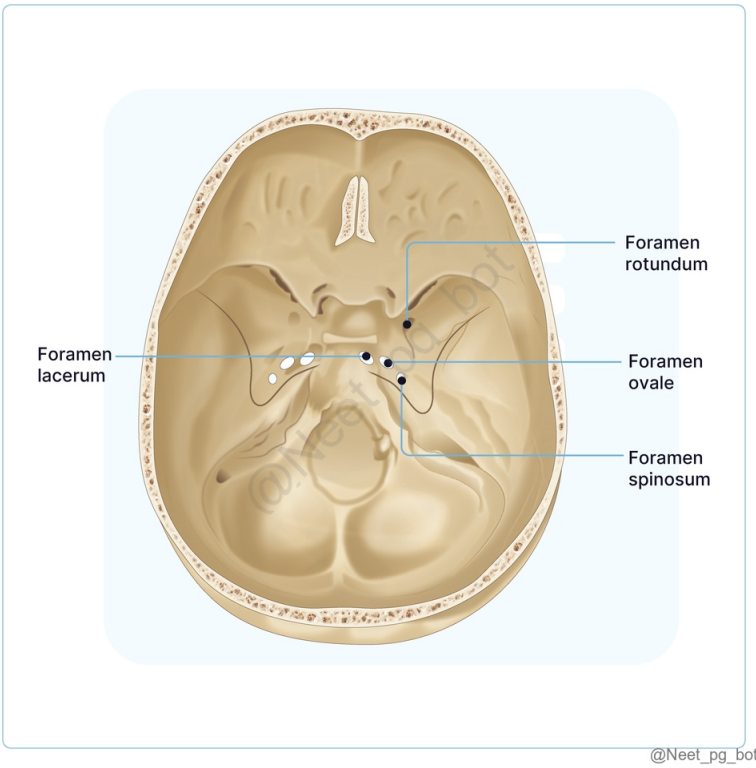

References:

BD Chaurasia's Human Anatomy, 8th Edtion, Page no: 124

↑ *Back to this question in Part A*

@Neet_pg_bot

Q5: What is the action of the muscle shown in the image below at the hip joint? (Q856991)

A. Abduction and external rotation

B. Extension, adduction, and lateral rotation

C. Flexion and abduction

D. Flexion and external rotation

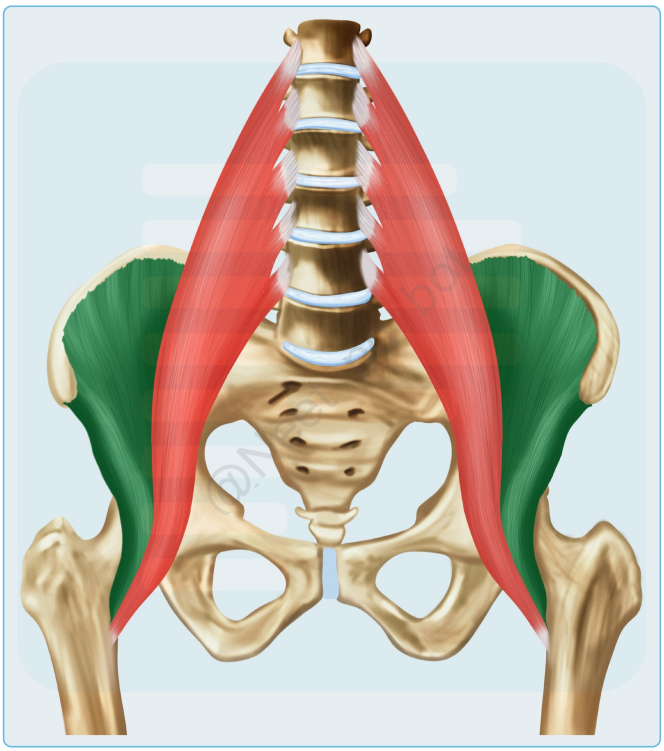

Correct Answer: D. Flexion and external rotation

Explanation: The muscle shown in the given image is the iliopsoas- (In the image: Red- Psoas major; Green- Iliacus) It is the largest and strongest inner hip thigh muscle and is primarily responsible for flexion and external rotation of the thigh at the hip joint. Iliopsoas: Iliopsoas is a large compound muscle of the inner hip composed of the iliacus and psoas major muscles. It is the chief flexor at the hip joint, assisted by sartorius and pectineus as the accessory muscles

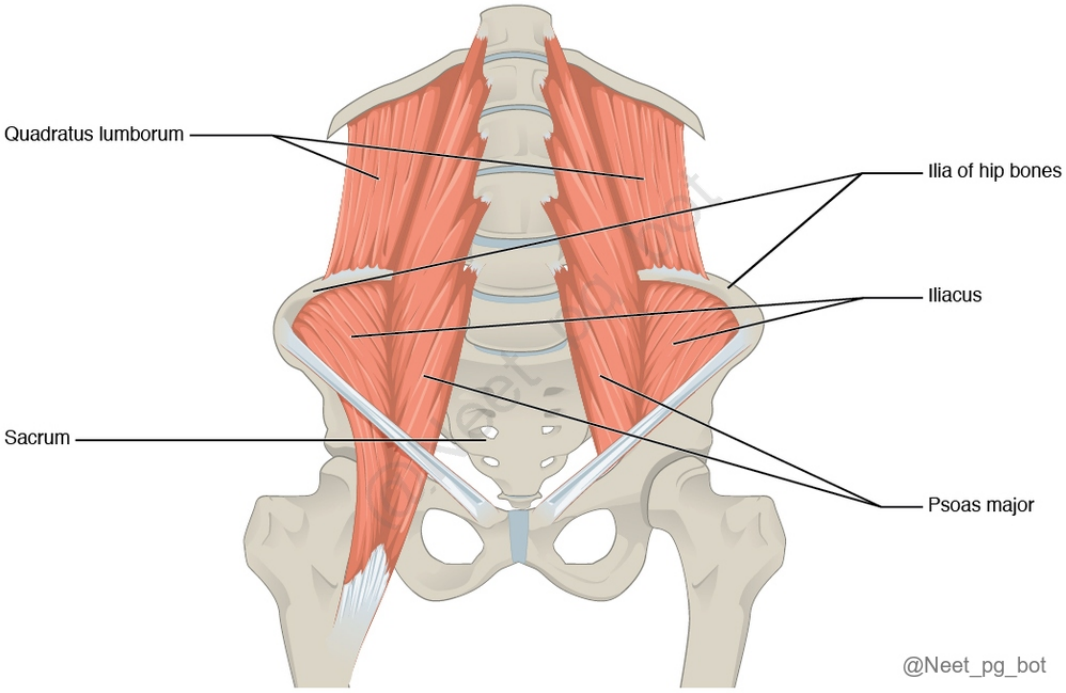

References:

BD Chaurasia's Human Anatomy, 8th Edition, Page no: 456

↑ *Back to this question in Part A*

@Neet_pg_bot

Q6: The structures marked in the image below are found in the epithelial lining of all of the following sites, except: (Q856956)

A. Oviduct

B. Epididymis

C. Bronchi

D. Ependyma

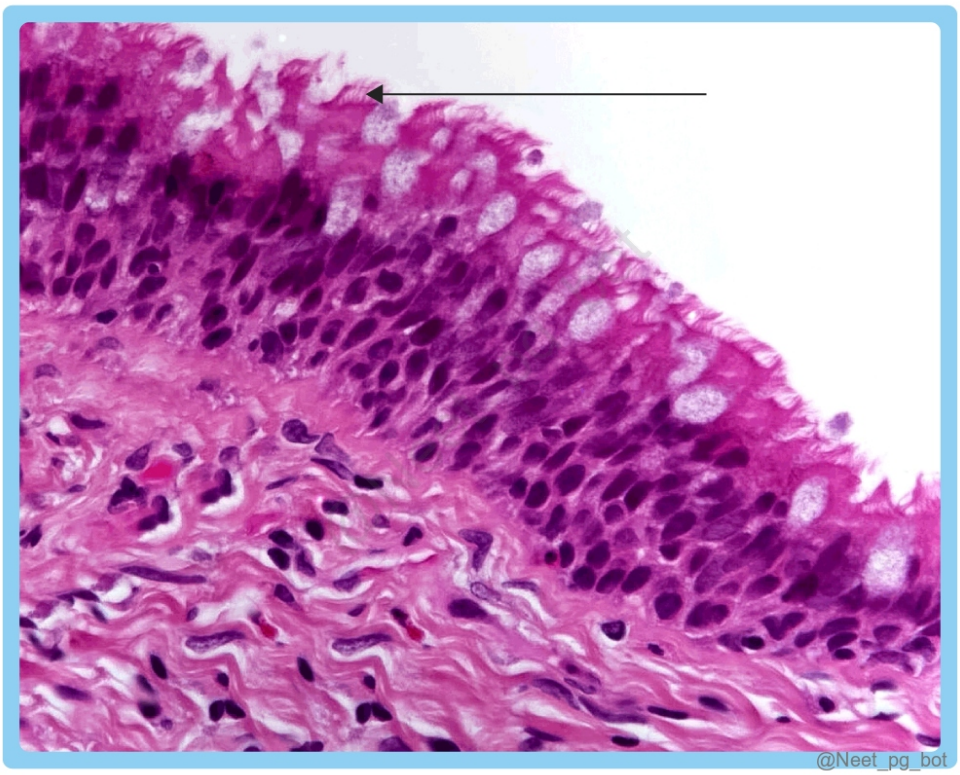

Correct Answer: B. Epididymis

Explanation: The marked structures in the histological image are cilia. Cilia are slender, hair-like structures found on the surface of many epithelial cells. They play a vital role in the movement of fluids and particles along various passageways in the body. While the epithelial lining of the epididymis does have stereocilia (long microvilli), it does not typically have cilia. Surface Projections Microvilli : Small finger-like projections (~1 micrometer) that increase surface area, found in the brush border of the kidney, gall bladder, and intestinal cells. Stereocilia : Long microvilli (15-20 micrometers) located in the hair cells of the inner ear and the epididymis in the male reproductive tract. Cilia : Motile cilia (7-10 micrometers) propel substances along the surface of certain epithelia. Non-motile cilia , present on nearly every cell in the G0 stage, were once considered nonfunctional but are now known to play a role in signaling pathways during both development and adulthood. Oviduct, Bronchi, Ependyma (Options A, C, and D): have cilia in their epithelial lining.

References:

BD Chaurasia’s Human Anatomy, 8th Edtion, Page no: 345

↑ *Back to this question in Part A*

@Neet_pg_bot

Q7: Identify the pelvic diaphragm in the given picture. (Q856615)

A. 1

B. 2

C. 3

D. 4

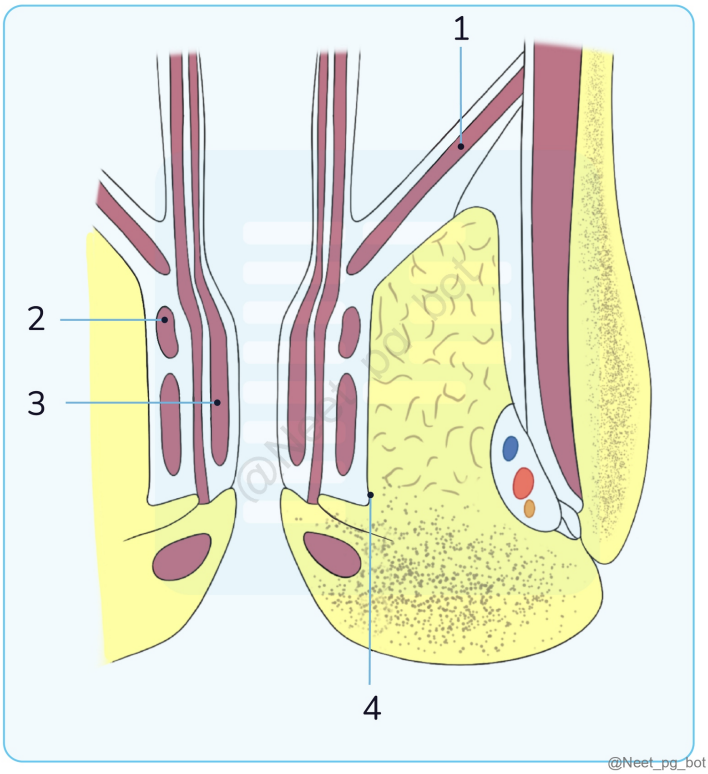

Correct Answer: A. 1

Explanation: The pelvic diaphragm forms the muscular floor of the pelvis and provides support to pelvic organs. It primarily consists of the levator ani (pubococcygeus, puborectalis, iliococcygeus) and coccygeus muscles . The marked Option 1 correctly identifies the pelvic diaphragm. Pelvic Diaphragm Feature Details Components Levator ani (pubococcygeus, puborectalis, iliococcygeus) Coccygeus Function Supports pelvic organs Aids in defecation, urination, and childbirth Maintains continence Openings Urogenital hiatus (for urethra and vagina) Anal hiatus (for rectum) Clinical Relevance Pelvic organ prolapse if weak Urinary/fecal incontinence Perineal tears in childbirth 2 (Option B): Incorrect – This marks the external anal sphincter , a voluntary muscle involved in anal continence but not part of the pelvic diaphragm. 3 (Option C): Incorrect – This marks the internal anal sphincter , an involuntary muscle that controls defecation, unrelated to the pelvic diaphragm. 4 (Option D): Incorrect – This marks the pudendal canal (Alcock's canal) , which transmits the pudendal nerve and vessels, but does not contribute to the pelvic diaphragm.

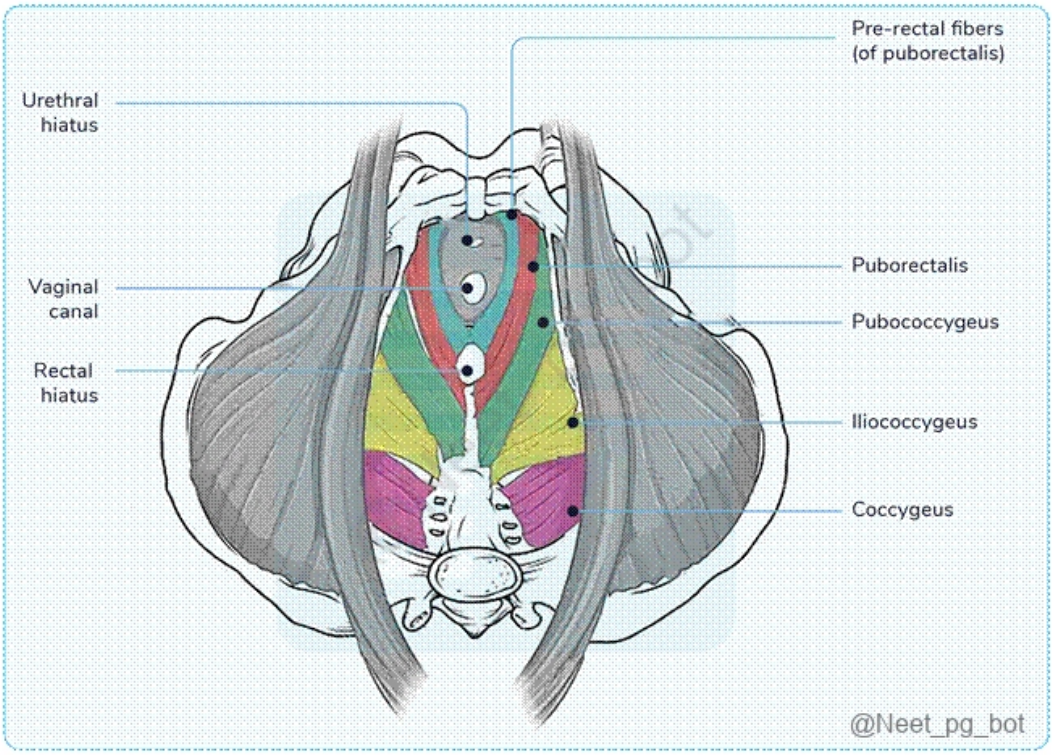

References:

Gray's Anatomy: The Anatomical Basis of Clinical Practice, 41st Edition - Pg 1223

Gray's Anatomy for Students, 4th Edition - Pg 446-448

↑ *Back to this question in Part A*

@Neet_pg_bot

Q8: In the scenario of a man who fell into a manhole and sustained perineal injury, leading to difficulty in urination and presence of blood at the urethral tip, a diagnosis of bulbar urethral injury was determined. In this particular case, where would the urine accumulation be the least expected? (Q857583)

A. Perineum

B. Anterior abdominal wall

C. The medial portion of thigh

D. Root of scrotum

Correct Answer: C. The medial portion of thigh

Explanation: In bulbar urethral injury , the spongy urethra is damaged, leading to extravasation of urine into the superficial perineal space . Urine can track into the perineum, scrotum, penis, and anterior abdominal wall due to the continuity of the Colles' fascia, Dartos fascia, and Scarpa's fascia . However, it does not spread into the thigh because Colles' fascia is firmly attached to the fascia lata of the thigh , preventing urine from tracking into the medial thigh. Perineum (Option A): incorrect because urine accumulates in the superficial perineal space due to the injury. Anterior abdominal wall (Option B): incorrect because urine can track upward via Scarpa’s fascia . Root of the scrotum (Option D): incorrect because urine spreads into the scrotum via continuity with Dartos fascia .

References:

https://pmc.ncbi.nlm.nih.gov/articles/PMC9192458/

https://pubmed.ncbi.nlm.nih.gov/7355317/

↑ *Back to this question in Part A*

@Neet_pg_bot

Q9: A woman delivered a healthy baby and to control her postpartum hemorrhage an artery was ligated. Then later she developed pain under her gluteus muscle. Which was the artery ligated ? (Q857577)

A. Uterine artery

B. Superior gluteal artery

C. Inferior gluteal artery

D. Internal iliac artery

Correct Answer: D. Internal iliac artery

Explanation: In cases of severe postpartum hemorrhage (PPH) , ligation of the internal iliac artery is a common life-saving procedure. However, this artery also supplies the gluteal region via the superior and inferior gluteal arteries . Ligation can lead to ischemia and pain in the gluteal region , which explains the symptoms seen in this patient. Internal Iliac Artery and Its Branches Artery Origin Major Branches Supply Clinical Significance Internal Iliac Artery Common iliac artery Anterior and posterior divisions Pelvic organs, gluteal region, perineum Ligation used in PPH management Uterine Artery Anterior division of internal iliac Anastomoses with ovarian artery Uterus, cervix, vagina Commonly ligated in hysterectomy Superior Gluteal Artery Posterior division of internal iliac Branches to gluteal muscles Gluteus medius, minimus, and tensor fascia lata Injury can cause Trendelenburg gait Inferior Gluteal Artery Anterior division of internal iliac Supplies deeper gluteal structures Gluteus maximus, sciatic nerve Injury affects hip extension {{caption_text}} Uterine artery (Option A): incorrect because it primarily supplies the uterus and is ligated in hysterectomy or uterine artery embolization , but does not directly cause gluteal pain. Superior gluteal artery (Option B): incorrect because while it supplies the gluteal muscles, it is a branch of the internal iliac artery and is not directly ligated in PPH. Inferior gluteal artery (Option C): incorrect

because, though it supplies the gluteal region, it is also a branch of the internal iliac artery and is rarely ligated alone.

References:

Gray’s Anatomy The Anatomical Basis of Clinical Practice, Edition 42nd- Pg No. 1247-50

Image: Prepladder notes (Pelvis and perineum arterial supply) Pg No. 1

↑ *Back to this question in Part A*

@Neet_pg_bot

Q10: The rupture of the penile urethra does not cause extravasation of blood into which of the following spaces? (Q855035)

A. Superficial perineal pouch

B. Anterior abdominal wall

C. Ischiorectal fossa

D. Skin around the scrotum

Correct Answer: C. Ischiorectal fossa

Explanation: The rupture of the penile urethra does NOT cause extravasation of blood into the ischiorectal fossa because this area is located deep to the perineal membrane and is separated from the superficial perineal structures by the deep perineal fascia . Pathway of Urine Extravasation in Penile Urethral Rupture: If the spongy (penile) urethra ruptures, urine and blood extravasate into the: Superficial perineal pouch → Because the Buck’s fascia (deep fascia of the penis) is torn. Skin around the scrotum → Due to continuity of the superficial perineal fascia (Colles’ fascia) . Anterior abdominal wall → Through the continuity of Scarpa’s fascia (superficial fascia of the lower abdomen) with Colles' fascia. Urethral injury causes Anterior urethra Meatus Instrumentation, iatrogenic, hypospadias, skin disorders (lichen sclerosus) Pendulous urethra Instrumentation, iatrogenic, hypospadias, skin disorders (lichen sclerosus), sexually transmitted infections, crush injury Bulbar urethra Instrumentation, iatrogenic, skin disorders (lichen sclerosus), sexually transmitted infections, crush injury, straddle-type injury Urethral injury causes Posterior urethra Membranous urethra Instrumentation, pelvic fracture with urethral distraction defects Prostatic urethra Instrumentation, radiation therapy for prostate cancer (external beam radiation therapy, brachytherapy) Bladder neck Instrumentation, radiation therapy for prostate cancer (external beam radiation therapy, brachytherapy) {{caption_text}} Superficial perineal pouch (option A): Rupture of the penile urethra with Buck’s fascia tear directly leads to urine extravasation here . Anterior abdominal wall (option B): Colles' fascia (superficial perineal fascia) is continuous with Scarpa's fascia , allowing urine and blood to spread upward into the anterior abdominal wall . Skin around the scrotum (option D): Urine spreads into the scrotal skin because the superficial perineal fascia (Colles’ fascia) extends over the scrotum .

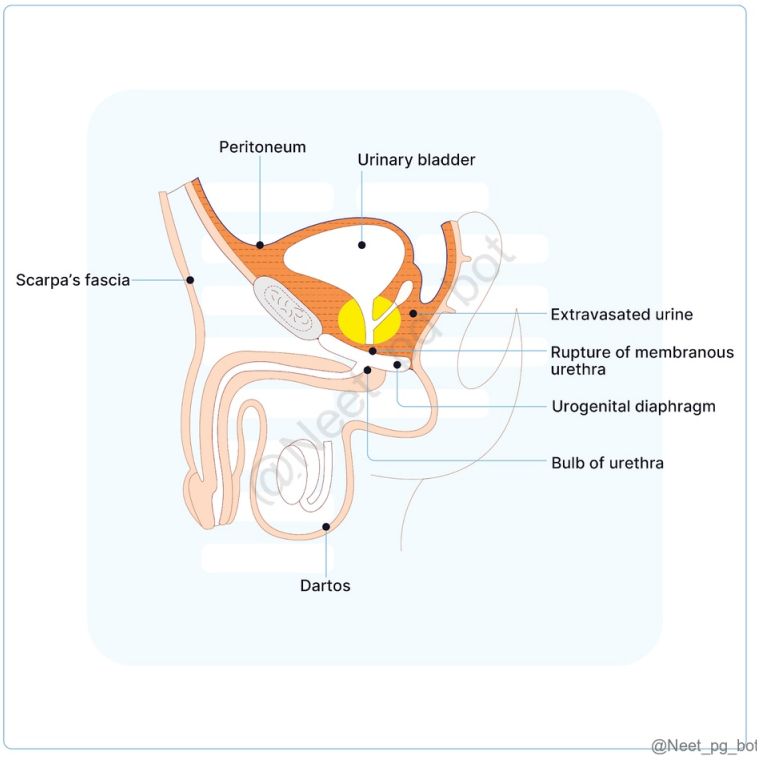

References:

https://www.uptodate.com/contents/posterior-urethral-injuries-and-management?search=Anterior%20urethral%20injury&source=search_result&selectedTitle=3~150&usage_type=default&display_rank=3#H3560650230

Vishram Singh textbook of anatomy Abdomen and Lower Limb, 2nd Edition, Page 247

The value of digital rectal examination in assessing for pelvic fracture-associated urethral injury: what defines a high-riding or nonpalpable prostate? - PubMed

↑ *Back to this question in Part A*

@Neet_pg_bot

Q11: Match the following (Q865302)

A. A- prostate, B- ureter, C- vas deferens , D- seminal vesicle

B. A- vas deferens, B- ureter, C- prostate , D- seminal vesicle

C. A- ureter, B-prostate, C- vas deferens , D- seminal vesicle

D. A- vas deferens, B- ureter, C-prostate , D- seminal vesicle

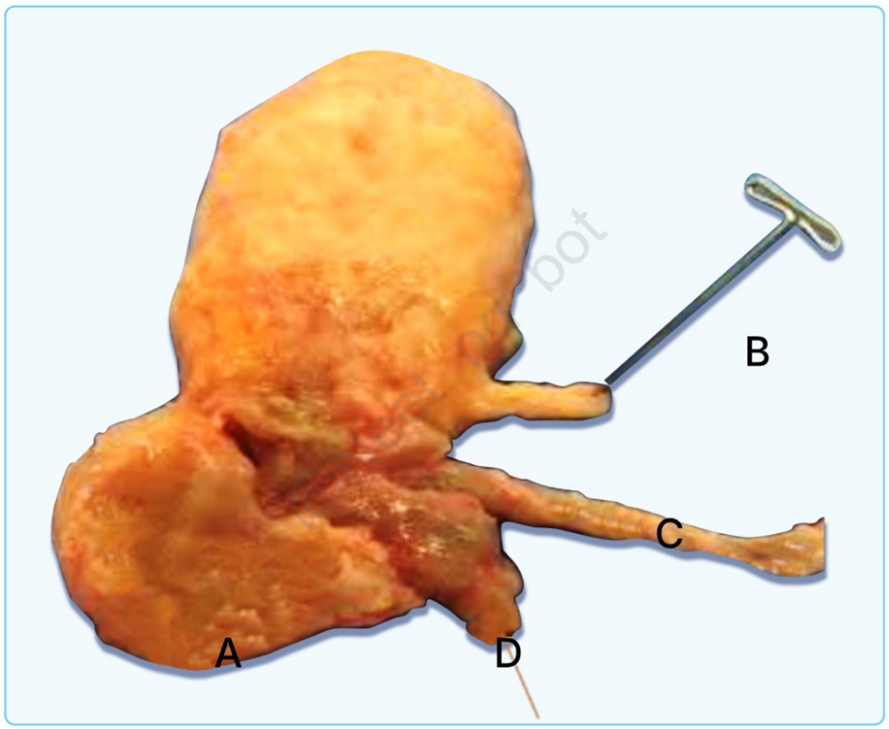

@Neet_pg_bot

Correct Answer: A. A- prostate, B- ureter, C- vas deferens , D- seminal vesicle

Explanation: Sperm travels from the epididymis through the vas deferens . The vas deferens joins with the seminal vesicle to form the ejaculatory duct. The ejaculatory duct then passes through the prostate gland , where the sperm mixes with fluids from the seminal vesicles and the prostate. This mixture, now called semen, is then expelled into the urethra and out of the body during ejaculation.

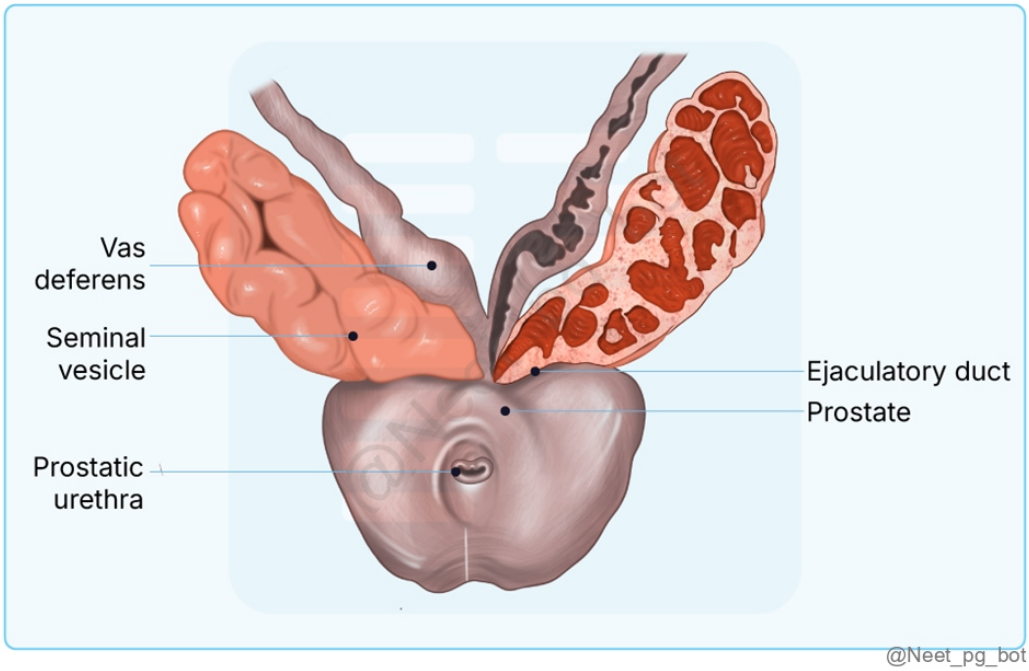

References:

Inderbir Singh textbook of anatomy thorax and abdomen, 6th edition, Page 313

↑ *Back to this question in Part A*

@Neet_pg_bot

Q12: What is the volume of the prostate in healthy adult males? (Q855006)

A. 20cc

B. 50cc

C. 75cc

D. 100cc

Correct Answer: A. 20cc

Explanation: The normal volume of the prostate in a healthy adult male is approximately 20–30 cc (cubic centimeters or mL). The prostate gland grows gradually with age, and an enlarged prostate (>30 cc) is often seen in benign prostatic hyperplasia (BPH) . Measurement of prostate volume is commonly done using transrectal ultrasound (TRUS) or MRI. The prostate gland weighs 20 gm in a normal adult male and is made up following zones: Zone Features Peripheral This zone makes up about 70% of the prostate gland and surrounds the urethra. The majority of prostate cancers (70-80%) originate in the peripheral zone, since it is rich in glandular tissue,

making it susceptible. Central It is situated at the base of the prostate gland, surrounding the ejaculatory ducts. Inflammation of the prostate gland (prostatitis) commonly affects the central zone. Transitional It is located near the urethra and accounts for about 5-10% of the prostate gland. BPH primarily affects the transitional zone, leading to urinary symptoms such as frequency, urgency, weak urine flow, and difficulty initiating or stopping urination. {{caption_text}} 50cc (option B): A prostate volume of >30 cc is usually indicative of benign prostatic hyperplasia (BPH) . 75cc (option C): A prostate volume of >40–50 cc is considered moderately enlarged , often seen in symptomatic BPH. 100cc (option D): Prostates exceeding 100 cc are considered severely enlarged , often leading to significant urinary obstruction and requiring medical or surgical intervention.

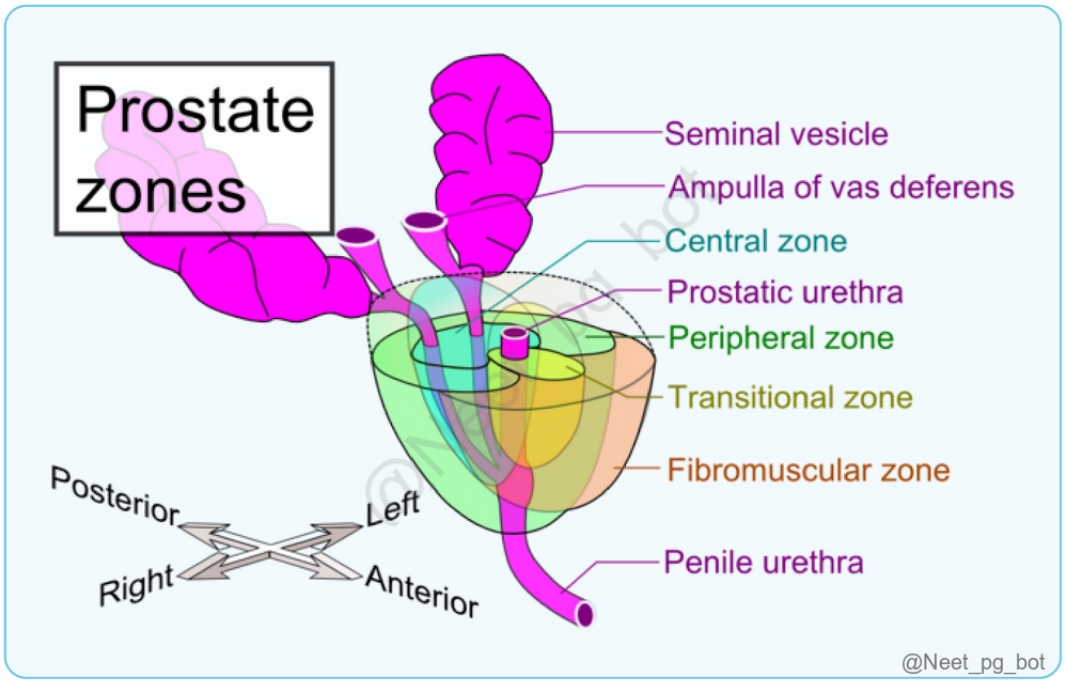

References:

Robbins Pathology, 10th Edition, Page 976

↑ *Back to this question in Part A*

@Neet_pg_bot

Q13: A person who had a road traffic accident presented to ER with injury to bulbar urethra. What can be the location of collection of the urine due to this injury? (Q857915)

A. Inguinal pouch

B. Peritoneal cavity

C. Ischiorectal fossa

D. Anterior abdominal wall

Correct Answer: D. Anterior abdominal wall

Explanation: The bulbar urethra is a part of the male urethra located just before the penile urethra. An injury to the bulbar urethra can lead to a urethral rupture, allowing urine to leak into the surrounding tissues. In the case of bulbar urethral rupture, the urine extravasates to Superficial perineal pouch Scrotum Penile region Anterior abdominal wall Extravasation of Urine: Due to rupture of spongy urethra below the perineal membrane causes urine to accumulate in – superficial extravasation. If Buck's fascia is intact, extravasation of blood and urine confined to penile shaft. If Buck's fascia is disrupted: Superficial perineal pouch Scrotum Around penis Lower part of anterior abdominal wall Urine cannot escape to: Deep perineal pouch (because of perineal membrane) Ischiorectal fossa (because of Colles' fascia) Thigh (fascia lata) Due to rupture of membranous urethra above the perineal membrane causes urine to accumulate in – deep extravasation. Deep perineal pouch Extraperitoneal space Space of Retzius (space around bladder and prostate) Superficial perineal space if perineal membrane also ruptured Inguinal pouch (Option A): The inguinal pouch is not a typical location for urine collection. It is an area in the groin region, and urine collection there wouldn't be directly related to a bulbar urethral injury. Peritoneal cavity (Option B): The peritoneal cavity is the abdominal cavity where various organs are located. It is not a common location for urine collection due to a bulbar urethral injury. Leakage of urine into the peritoneal cavity could result in a condition known as urinoma, but this is not the primary location of urine collection in cases of bulbar urethral injury. Ischiorectal fossa (Option C): The ischiorectal fossa is situated in the pelvic region, but it is not a usual site for urine collection due to a bulbar urethral injury. This fossa contains fat and connective tissue and is not directly connected to the urinary system.

References:

BD Chaurasia’s Human Anatomy, 8th Edtion, Page no: 324

↑ *Back to this question in Part A*

@Neet_pg_bot

Q14: A 55-year-old woman presents to the clinic complaining of blood in her stools. Physical exam reveals firm, enlarged inguinal lymph nodes. A contrast CT scan is performed and a possibly cancerous mass is visualized in the lower part of the gastrointestinal tract. In which location is the mass most likely located? (Q854571)

A. Anal canal inferior to the pectinate line

B. Distal rectum

C. Sigmoid colon

D. Proximal rectum

Correct Answer: A. Anal canal inferior to the pectinate line

Explanation: Lymphatic drainage from this region primarily goes to the superficial inguinal lymph nodes. A cancerous mass in this location would lead to enlargement of the inguinal lymph nodes, as seen in this patient. Distal rectum (Option B): This option is incorrect as lymph from the inferior part of the anal canal drains to the superficial inguinal nodes. Sigmoid colon (Option C): This option is incorrect as sigmoid colon lymph nodes drain to the inferior mesenteric nodes. Proximal rectum (Option D): This option is incorrect as the proximal rectum drains to the sacral nodes.

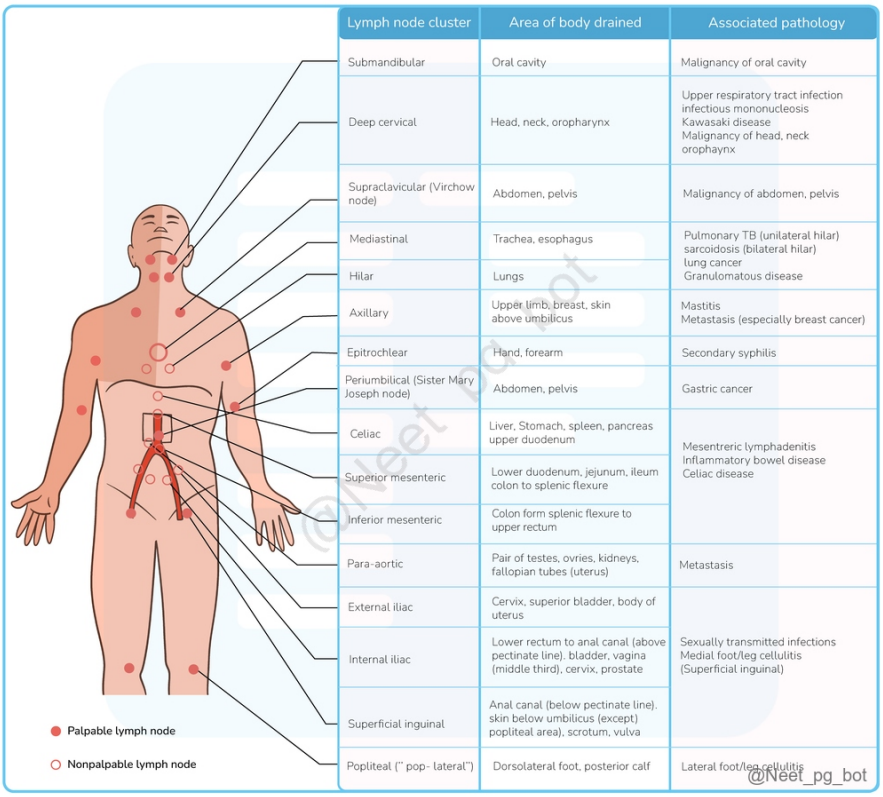

Lymph node cluster	Area of body drained	Associated pathology
Submandibular	Oral cavity	Malignancy of oral cavity
Deep cervical	Head, neck, oropharynx	Upper respiratory tract infection infectious mononucleosis Kawasaki disease Malignancy of head, neck orophaynx
Supraclavicular (Virchow node)	Abdomen, pelvis	Malignancy of abdomen, pelvis
Mediastinal	Trachea, esophagus	Pulmonary TB (unilateral hilar) sarcoidosis (bilateral hilar) lung cancer Granulomatous disease
Hilar	Lungs	
Axillary	Upper limb, breast, skin above umbilicus	Mastitis Metastasis (especially breast cancer)
Epitrochlear	Hand, forearm	Secondary syphilis
Periumbilical (Sister Mary Joseph node)	Abdomen, pelvis	Gastric cancer
Celiac	Liver, Stomach, spleen, pancreas upper duodenum	Mesentreric lymphadenitis Inflammatory bowel disease Celiac disease
Superior mesenteric	Lower duodenum, jejunum, ileum colon to splenic flexure	
Inferior mesenteric	Colon form splenic flexure to upper rectum	
Para-aortic	Pair of testes, ovries, kidneys, fallopian tubes (uterus)	Metastasis
External iliac	Cervix, superior bladder, body of uterus	Sexually transmitted infections Medial foot/leg cellulitis (Superficial inguinal)
Internal iliac	Lower rectum to anal canal (above pectinate line). bladder, vagina (middle third), cervix, prostate	
Superficial inguinal	Anal canal (below pectinate line). skin below umbilicus (except popliteal area), scrotum, vulva	
Popliteal (" pop- lateral")	Dorsolateral foot, posterior calf	Lateral foot/leg cellulitis

@Neet_pg_bot

References:

https://www.ncbi.nlm.nih.gov/books/NBK557720/#:~:text

↑ *Back to this question in Part A*

@Neet_pg_bot

Q15: What is the vertebral level shown by the blue line in the image? (Q820335)

A. L2-L3

B. L4-L5

C. L5-S1

D. L3-L4

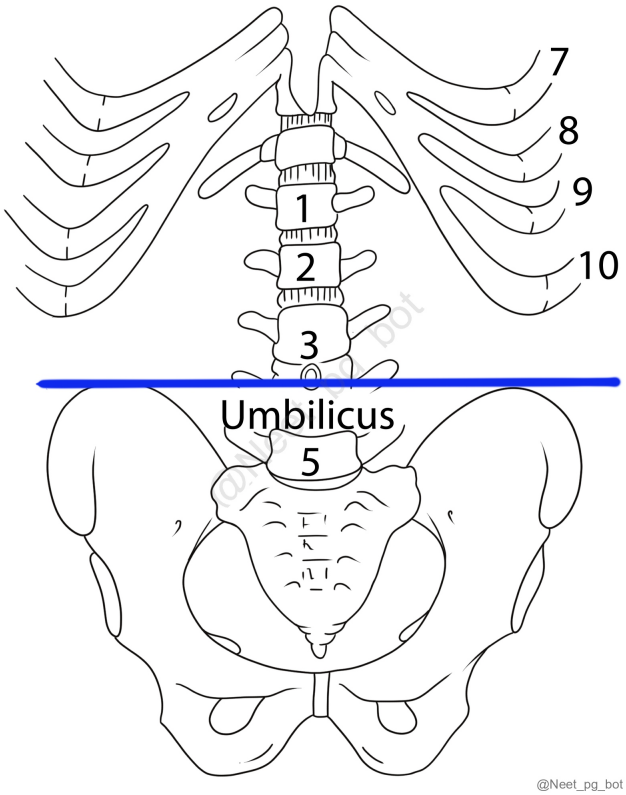

Correct Answer: D. L3-L4

Explanation: L3 - L4 The blue line corresponds to the umbilicus level, which classically lies at the L3–L4 intervertebral disc. The umbilicus lies at the level of the intervertebral disc between L3 and L4 in adults (supine position). This corresponds roughly to the transumbilical plane , an important horizontal surface landmark. Clinically, this level is important because: It helps estimate the positions of abdominal organs It is used as a reference point in imaging and surgery L2–L3 (Option A): Too high; closer to the upper abdomen (near the kidneys), not the umbilicus. L4–L5 (Option B): Too low; corresponds closer to the iliac crest level (L4) and below the umbilicus. L5–S1 (Option C): Much lower; corresponds to pelvic region / sacral promontory , far below the umbilicus.

↑ *Back to this question in Part A*

@Neet_pg_bot

Q16: A person who had a road traffic accident presented to ER with injury to bulbar urethra. What can be the location of collection of the urine due to this injury? (Q820309)

A. Inguinal pouch

B. Peritoneal cavity

C. Ischiorectal fossa

D. Anterior abdominal wall

Correct Answer: D. Anterior abdominal wall

Explanation: Correct Option D - Anterior abdominal wall The correct answer. The bulbar urethra is a part of the male urethra located just before the penile urethra. An injury to the bulbar urethra can lead to a urethral rupture, allowing urine to leak into the surrounding tissues. In the case of bulbar urethral rupture, the urine extravasates to Superficial perineal pouch Scrotum Penile region Anterior abdominal wall Incorrect Options: Option A - Inguinal pouch: The inguinal pouch is not a typical location for urine collection. It is an area in the groin region, and urine collection there wouldn't be directly related to a bulbar urethral injury. Option B - Peritoneal cavity: The peritoneal cavity is the abdominal cavity where various organs are located. It is not a common location for urine collection due to a bulbar urethral injury. Leakage of urine into the peritoneal cavity could result in a condition known as urinoma, but this is not the primary location of urine collection in cases of bulbar urethral injury. Option C - Ischiorectal fossa: The ischiorectal fossa is situated in the pelvic region, but it is not a usual site for urine collection due to a bulbar urethral injury. This fossa contains fat and connective tissue and is not directly connected to the urinary system.

↑ *Back to this question in Part A*

@Neet_pg_bot

Q17: The ischial spine corresponds to which level? (Q839931)

A. S3-S5

B. Tip of the coccyx

C. L4

D. S2

Correct Answer: B. Tip of the coccyx

Explanation: of Option B

↑ *Back to this question in Part A*

@Neet_pg_bot

Q18: Identify the marked area in the image given. (Q852526)

A. Morrison's pouch

B. Vesicouterine pouch

C. Pouch of Douglas

D. Ischioanal Fossa

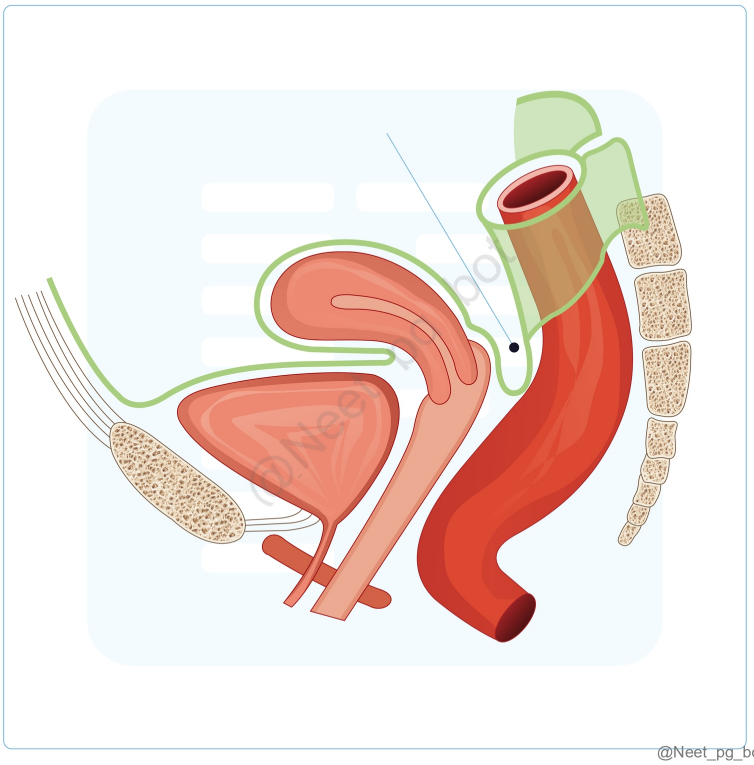

Correct Answer: C. Pouch of Douglas

Explanation: The marked area in the image is the Pouch of Douglas. The Pouch of Douglas, also known as the rectouterine pouch, is the lowest point of the peritoneal cavity in females. It is located between the posterior aspect of the uterus and the anterior aspect of the rectum. It is a common site for the accumulation of fluids, such as in the case of peritoneal infections or blood after pelvic surgeries. Rectouterine pouch (Pouch of Douglas): Pouch between rectum posteriorly and uterus anteriorly Most dependent part of the abdominal cavity in standing Most dependent part of the abdomen in the lying down position is the hepatorenal pouch of Morrison Morrison's pouch (Option A): This is the space between the liver and the right kidney. It is not located in the pelvic area but in the upper abdomen. Vesicouterine pouch (Option B): This is located between the uterus and the bladder, higher in the pelvic cavity, and is not the same as the Pouch of Douglas. Ischioanal Fossa (Option D) is a fat-filled space situated on either side of the anus, located just below the pelvic diaphragm, essentially acting as a cushion around the anal canal; it is considered part of the anal region and is sometimes referred to as the ischiorectal fossa.

References:

https://pmc.ncbi.nlm.nih.gov/articles/PMC5537103/

↑ *Back to this question in Part A*

@Neet_pg_bot

Q19: During walking, the hip bone on the side of the suspended leg is raised by the action of which muscle present in the supporting leg? (Q852998)

A. Gluteus medius

B. Gluteus maximus

C. Obturator internus

D. Quadratus femoris

Correct Answer: A. Gluteus medius

Explanation: The gluteus medius is the primary muscle responsible for hip abduction and stabilization of the pelvis during walking . During the stance phase , when one leg is on the ground and the other is lifted, the gluteus medius of the supporting leg contracts to prevent pelvic drop on the opposite side. This mechanism is known as the Trendelenburg mechanism , and dysfunction leads to a Trendelenburg gait . Gluteus Medius and Hip Stability Feature Description Origin Ilium (between anterior and posterior gluteal lines) Insertion Greater trochanter of femur Innervation Superior gluteal nerve (L4-S1) Function Hip abduction, pelvic stabilization during gait Clinical Relevance Weakness leads to Trendelenburg sign/gait , seen in superior gluteal nerve injury Action of the Hip joint, corresponding muscles and their innervation: Action Muscles Nerve supply Flexion Psoas major (chief flexor) Anterior rami of L1, L2, L3 Iliacus (chief flexor) Sartorius Rectus femoris Pectineus Femoral nerve (L2, L3) Extension Gluteus maximus (chief extensor) Inferior gluteal nerve (L5, S1, S2) Hamstring muscles Tibial part of the sciatic nerve (L5, S1, S2) Abduction Gluteus medius and minimus (chief abductors) Tensor fasciae latae Superior gluteal nerve (L5, S1) Adduction Adductor longus Adductor brevis Adductor magnus (chief adductors) Gracilis Obturator nerve (L2, L3, L4) Pectineus Double nerve supply (Femoral nerve and obturator nerve) Medial rotation Anterior fibres of gluteus minimus and medius (chief medial rotators) Tensor fasciae latae Superior gluteal nerve (L5, S1) Lateral rotation Piriformis Ventral rami of S1, S2 Obturator externus Posterior division of obturator nerve (L2, L3, L4) Obturator internus and Associated gemelli, Quadratus femoris (These muscles are generally termed short rotators) Nerve to obturator internus (L5, S1, S2) Gluteus maximus (Option B): Incorrect because it primarily functions in hip extension (e.g., rising from a seated position) rather than stabilizing the pelvis. Obturator internus (Option C): Incorrect because it mainly functions as a lateral rotator of the hip , not in pelvic stabilization. Quadratus femoris (Option D): Incorrect because it is a lateral rotator of the hip , not involved in abduction or pelvic stability.

References:

Vishram Singh textbook of anatomy, 2nd edition, Volume 2, Pages 382, 383

↑ *Back to this question in Part A*

@Neet_pg_bot

Q20: A patient presents with carcinoma near anal opening. Which of the following lymph node is most likely involved first? (Q866313)

A. Superficial inguinal lymph node

B. Deep inguinal lymph node

C. Paraaortic lymph node

D. Internal iliac lymph node

Correct Answer: A. Superficial inguinal lymph node

Explanation: Since the carcinoma is located near the anal opening referring to the perianal skin or anal verge, which lies below the pectinate line, it primarily drains to the superficial inguinal lymph nodes. Features Upper Anal Canal Lower Anal Canal Development Endodermal Ectodermal Epithelium Simple columnar Stratified squamous Nerve supply Autonomic nerves Painless Sympathetic (L1, L2) Parasympathetic (S2, S3, S4) Somatic nerves Painful Sympathetic (S2, S, S4) Arterial supply Superior rectal artery Inferior rectal artery Venous drainage Superior rectal vein draining into the portal system Inferior rectal vein draining into caval system Lymphatic system Internal iliac nodes (Option D ruled out) Superficial inguinal nodes (Option A) Common type of haemorrhoids Internal haemorrhoids External haemorrhoids Deep inguinal lymph node (Option B) receive lymph from the superficial inguinal nodes and are involved later, not as the first site of drainage from the anal verge. Paraaortic lymph node (Option C) drains lymph from deep abdominal and pelvic organs like the testes and ovaries, not from the anal region.

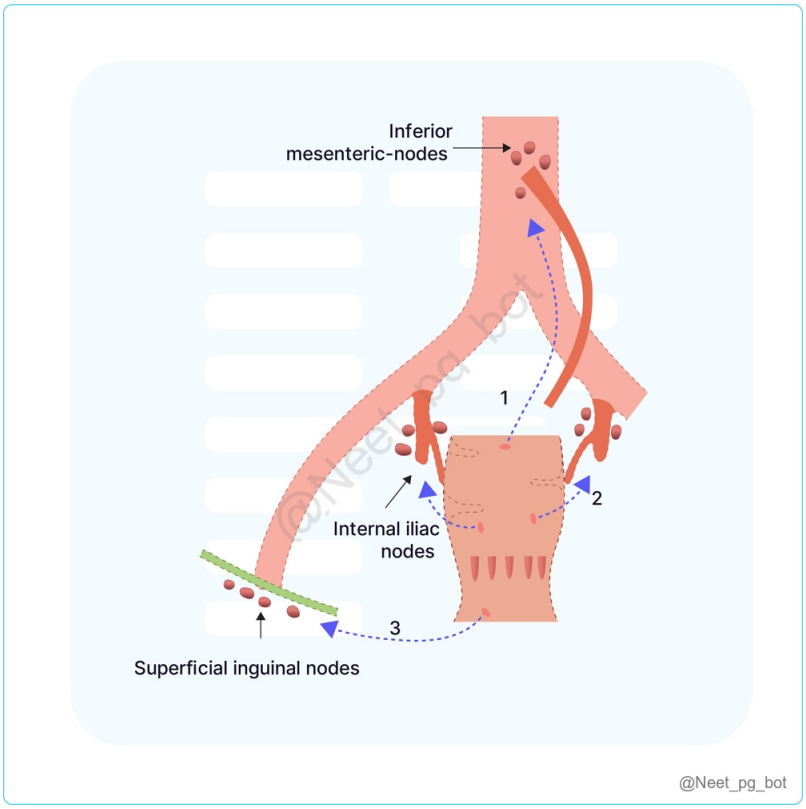

↑ *Back to this question in Part A*

@Neet_pg_bot

• [10_Systemic Embryology] 049 Previous Year Questions

« Back to Folder Directory

[10_Systemic Embryology] 049 Previous Year Questions — Quick Jump

Q1 (p. 2112) *Q2 (p. 2113)* *Q3 (p. 2117)* *Q4 (p. 2119)* *Q5 (p. 2121)* *Q6 (p. 2123)*
Q7 (p. 2126) *Q8 (p. 2130)* *Q9 (p. 2131)* *Q10 (p. 2132)*

Q1: The long left recurrent laryngeal nerve is due to the persistence of which arch artery? (Q854988)

A. 3rd arch

B. 4th arch

C. 5th arch

D. 6th arch

Correct Answer: D. 6th arch

Explanation: During embryonic development, the sixth arch contributes to the formation of the pulmonary arteries and the ductus arteriosus, and the recurrent laryngeal nerve loops around the aortic arch on the left side, giving it its characteristic long course. Recurrent laryngeal nerve anatomy : The right recurrent laryngeal nerve branches from the vagus at the level of the subclavian artery, looping around it before ascending between the trachea and esophagus. The left recurrent laryngeal nerve arises at the arch of the aorta, loops around it, and ascends along the tracheoesophageal groove, giving it a longer course compared to the right nerve, making it more prone to injury. Superior laryngeal nerve : Origin - from the inferior ganglion of the vagus nerve; courses behind the internal carotid artery; divides into external and internal branches at the level of the greater cornua of the hyoid bone. The external branch innervates the cricothyroid muscle. The internal branch provides sensory innervation to the larynx and hypopharynx after piercing through the thyrohyoid membrane. 3rd arch (Option A): This is incorrect because the 3rd arch gives rise to the common carotid artery and part of the internal carotid artery , but not the structures associated with the recurrent laryngeal nerve. 4th arch (Option B): This is incorrect for the left recurrent laryngeal nerve, as the right recurrent laryngeal nerve loops around the right subclavian artery , which is derived from the 4th arch . The left recurrent nerve loops around the aortic arch, which is from the sixth arch. 5th arch (Option C): This is incorrect because the 5th arch is rudimentary and does not contribute to the development of significant vascular structures or nerves.

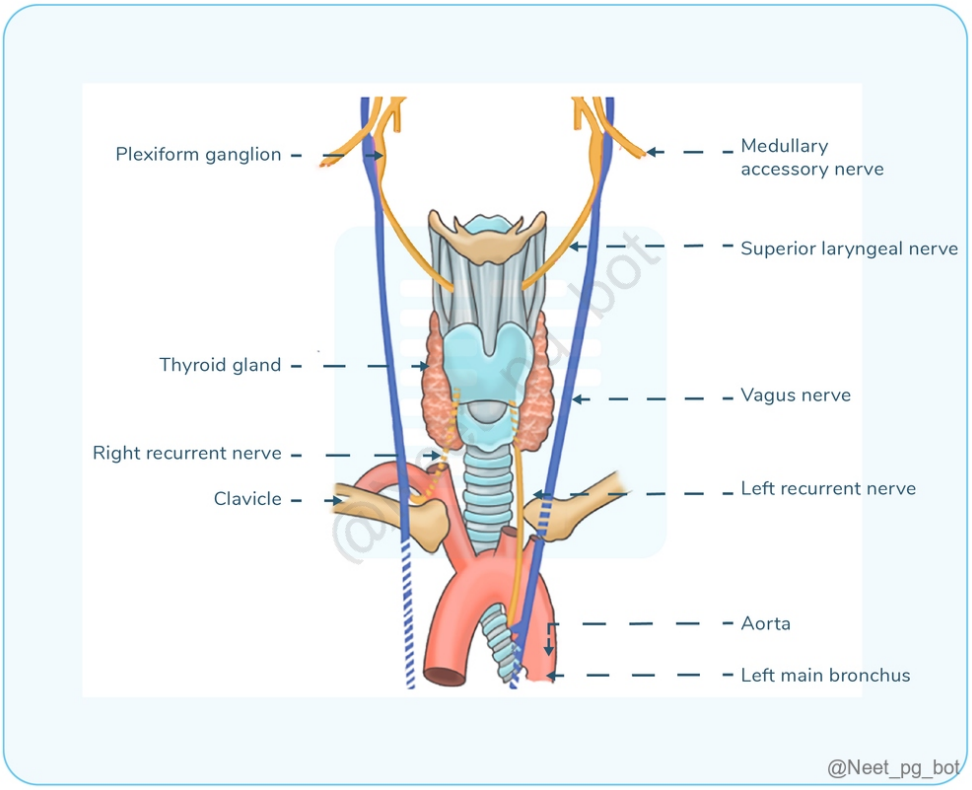

References:

Dhingra's Diseases Of Ear, Nose And Throat, & Head and Neck Surgery, 8th edition, Page 347

↑ *Back to this question in Part A*

@Neet_pg_bot

Q2: Which of the following statements regarding anatomical closure is incorrect? (Q854993)

A. Anatomical closure of foramen ovale is by 3 to 5 days

B. Anatomical closure of ductus venosus is by 2 to 3 weeks

C. Right umbilical vein is absent after birth

D. Anatomical closure of ductus arteriosus is by 2 to 3 weeks

Correct Answer: A. Anatomical closure of foramen ovale is by 3 to 5 days

Explanation: Foramen ovale does not anatomically close within 3 to 5 days . Functional closure occurs soon after birth due to increased left atrial pressure , but anatomical closure (fusion of the septum primum and septum

secundum) takes months to years . In some individuals, it may persist as a patent foramen ovale (PFO) . Anatomical closure of ductus venosus is by 2 to 3 weeks (option B): The ductus venosus shunts oxygenated blood from the umbilical vein to the inferior vena cava in fetal circulation. After birth, it functionally closes within hours and anatomically closes in 2 to 3 weeks , forming the ligamentum venosum . Formation of the Interatrial Septum: Septum Primum Formed as a sickle-shaped fold from the roof and dorsal wall of the primitive atrium due to pressure from the bulbus cordis. Grows downward toward the atrioventricular (AV) canal and septum intermedium, fusing with the latter. Ostium Primum Before the septum primum reaches and fuses with the septum intermedium, a gap (foramen primum) allows blood flow between the right and left atria. Ostium Secundum Upper part of the septum primum breaks down, creating a new gap (foramen secundum) before the foramen primum closes. The septum primum now has a free upper edge. Septum Secundum Grows down from the roof of the atrial chamber, to the right of the septum primum, overlapping the free upper edge of the septum primum as it grows. Foramen Ovale Formation Overlapping septa create the foramen ovale, allowing blood to flow from right to left atrium during fetal life, preventing left-to-right flow. Patent throughout fetal life. Obliteration of Foramen Ovale Post-birth, the left atrium receives oxygenated blood from the lungs, increasing pressure in this chamber greater than the right atrium, causing fusion of the septum primum and septum secundum, closing the foramen ovale. Annulus ovalis (adults) corresponds to the lower free edge of the septum secundum, while the fossa ovalis represents the septum primum. Right umbilical vein is absent after birth (option C): The right umbilical vein degenerates during fetal life , leaving only the left umbilical vein to carry blood from the placenta. After birth, the left umbilical vein also closes , forming the ligamentum teres (round ligament of the liver) . Anatomical closure of ductus arteriosus is by 2 to 3 weeks (option D): The ductus arteriosus functionally closes within 24 to 48 hours due to oxygenation and prostaglandin metabolism. Anatomical closure occurs by 2 to 3 weeks , forming the ligamentum arteriosum .

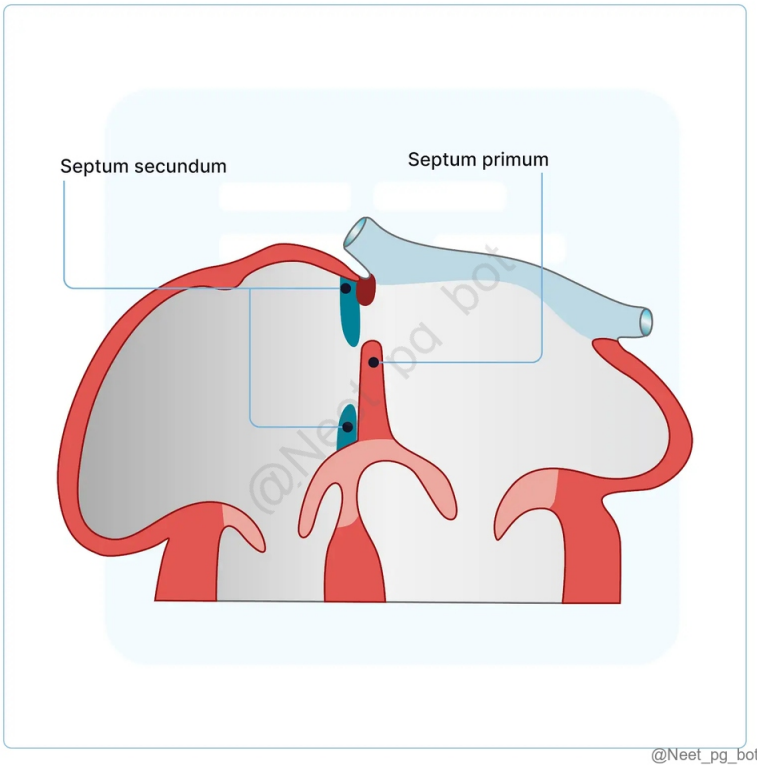

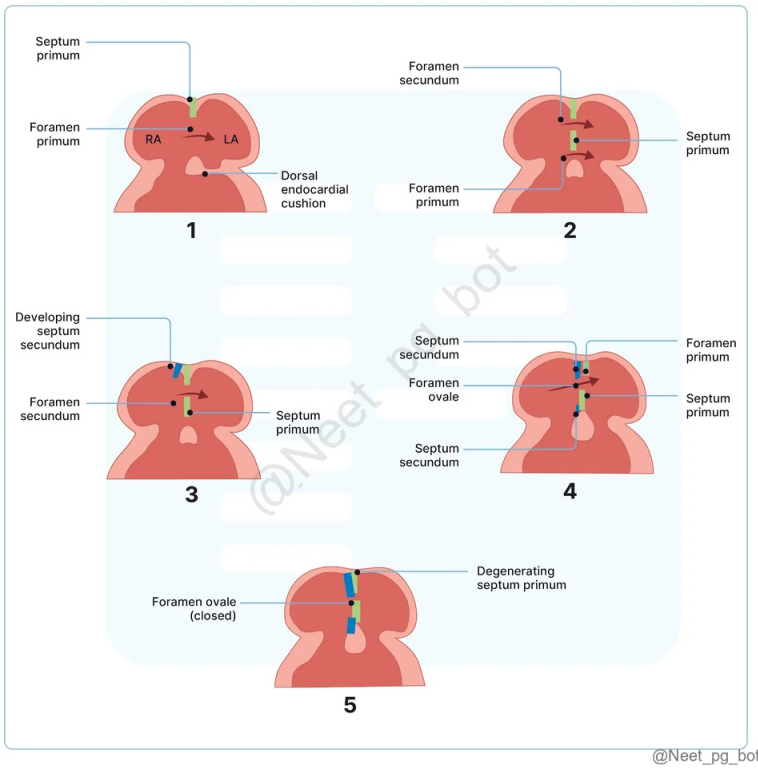

@Neet_pg_bot

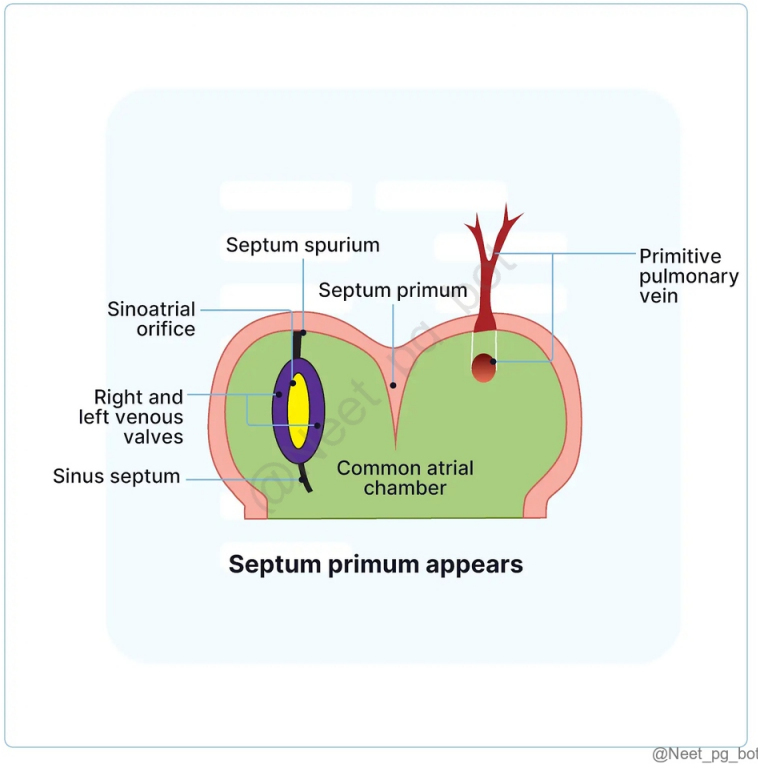

@Neet_pg_bot

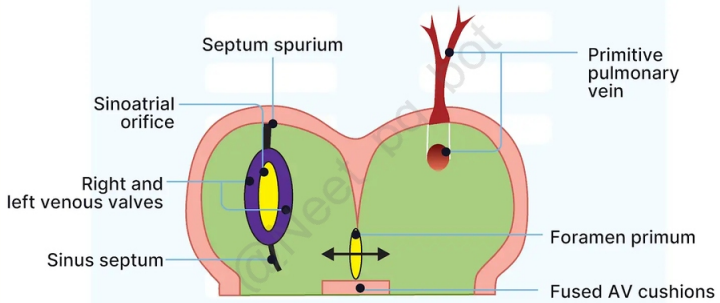

Septum primum grows towards fused AV cushions. The gap between them is foramen primum

@Neet_pg_bot

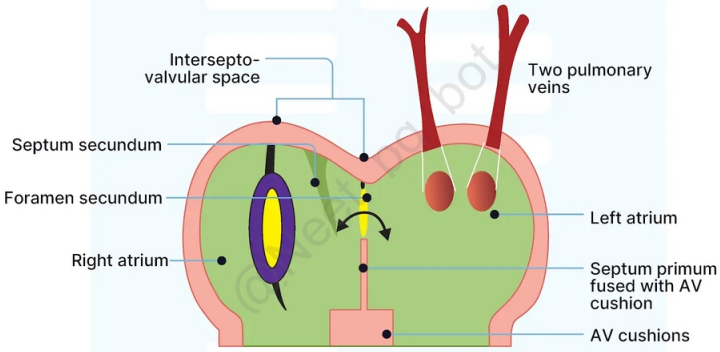

Septum primum fuses with AV cushions. At the same time, the upper part of septum primum degenerates to form the foramen secundum

@Neet_pg_bot

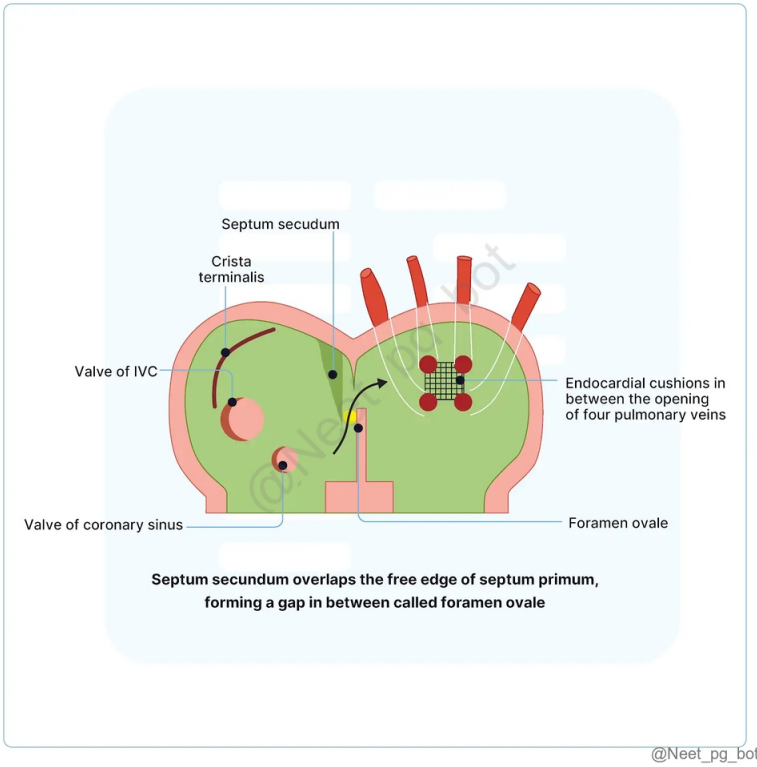

@Neet_pg_bot

References:

Inderbir Singh’s Human Embryology, 11th Edition, Page 233, 234, 235

↑ *Back to this question in Part A*

@Neet_pg_bot

Q3: Which of the following structures develops from the structure marked? (Q855401)

A. Medial umbilical ligament

B. Median umbilical ligament

C. Meckel's diverticulum

D. Ligamentum teres

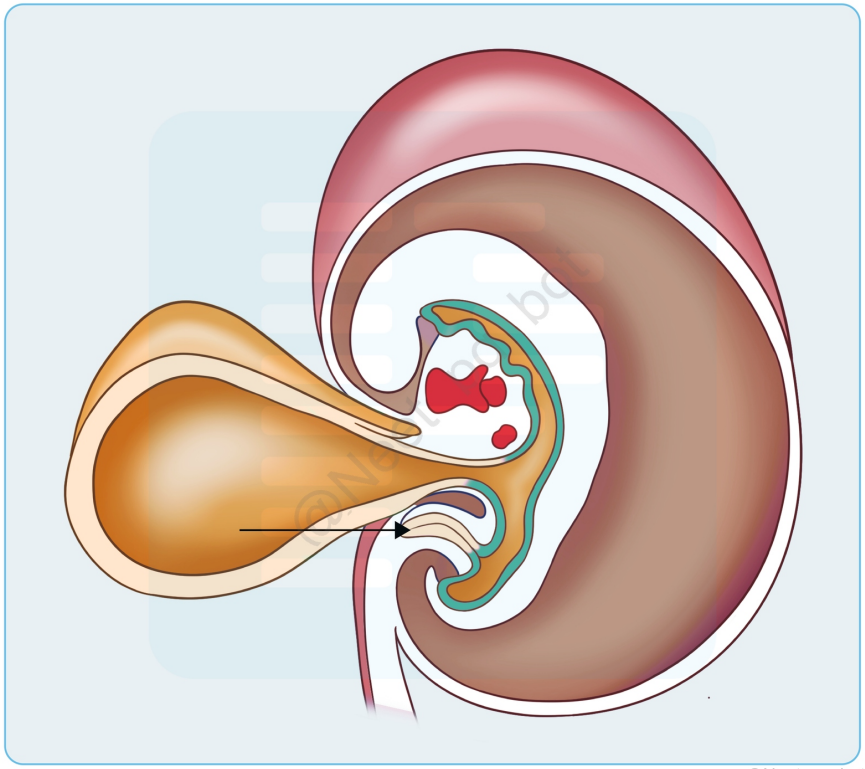

Correct Answer: B. Median umbilical ligament

Explanation: The marked structure is the allantois, a hindgut diverticulum. It forms the urachus during fetal development, connecting the bladder apex to the umbilicus, which later degenerates into the median umbilical ligament. This ligament runs along the midline of abdominal wall. {{caption_text}} Fetal Structure Postnatal derivative Notes Ductus arteriosus Ligamentum arteriosum Near the left recurrent laryngeal nerve Ductus venosus Ligamentum venosum - Foramen ovale Fossa ovalis - Allantois → urachus Median umbilical ligament Urachus is part of allantois between bladder and umbilicus Umbilical arteries Medial umbilical ligaments (Option A) - Umbilical vein Ligamentum teres hepatis (round ligament) (Option D) Contained in falciform ligament Meckel's diverticulum (Option C): This arises from the vitelline duct, not the urachus.

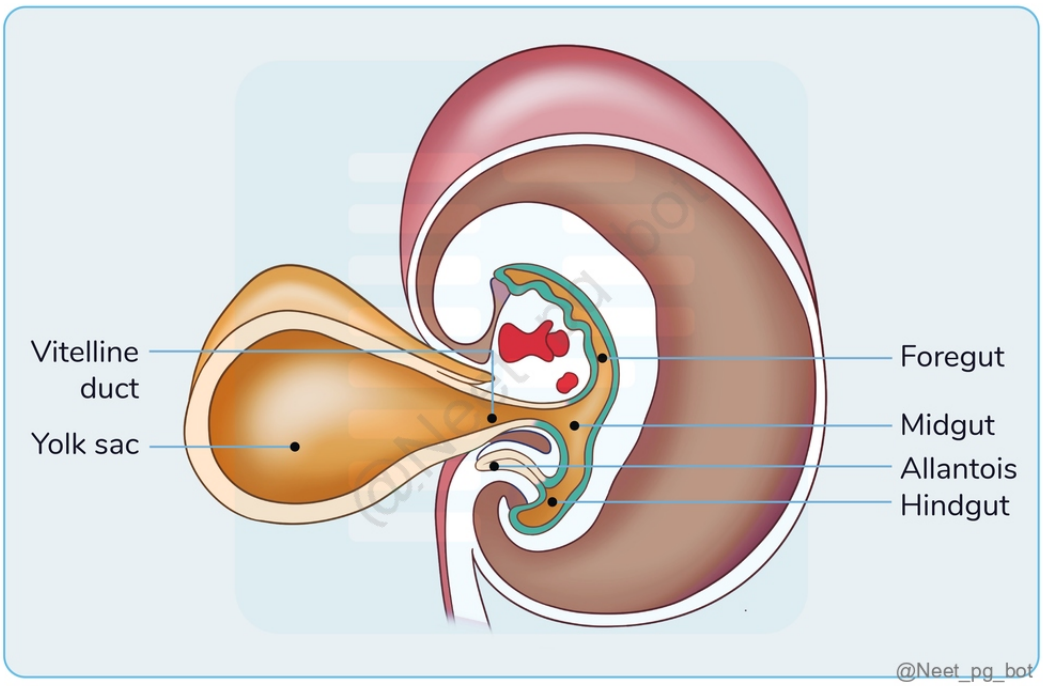

References:

https://pmc.ncbi.nlm.nih.gov/articles/PMC5838699/#:~:text

↑ *Back to this question in Part A*

@Neet_pg_bot

Q4: A child lacks thymus and inferior parathyroid glands. Defective development of which of the following structures is likely to be the cause? (Q855422)

A. 1

B. 2

C. 3

D. 4

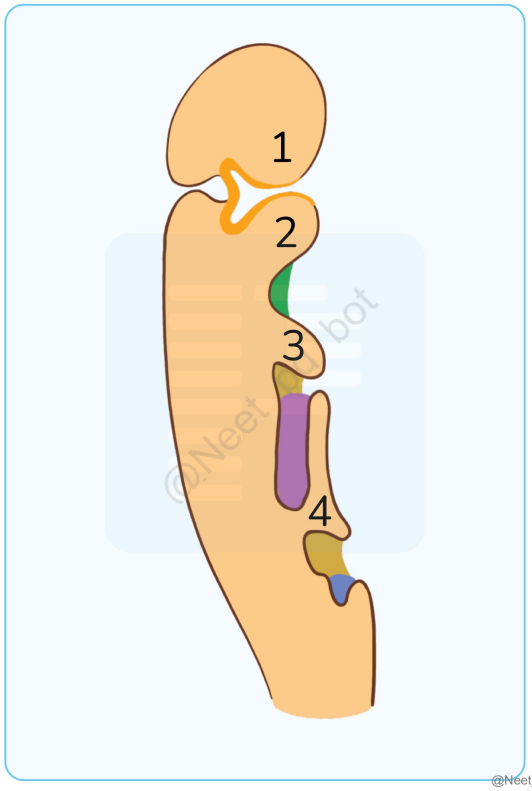

Correct Answer: C. 3

Explanation: The thymus and inferior parathyroid glands are both derived from the third pharyngeal pouch . Thymus : Forms from the endoderm of the third pharyngeal pouch , and is responsible for the development of T lymphocytes . Inferior parathyroid glands : Also arise from the third pharyngeal pouch , and are responsible for calcium homeostasis through parathyroid hormone (PTH) secretion. If there is a defect in the development of the third pharyngeal pouch , both the thymus and inferior parathyroid glands would fail to develop, leading to conditions such as DiGeorge syndrome , which is characterized by thymic hypoplasia and hypoparathyroidism . Pharyngeal arches, clefts and pouches Pharyngeal arches Pharyngeal arches are key structures in head and neck development, appearing in the fourth and fifth weeks as mesenchymal tissue bars. They resemble gills but do not function as such in humans. Pharyngeal arches are divided by pharyngeal clefts on the outside and pharyngeal pouches on the inside. Pharyngeal pouches develop as outpocketings from the lateral walls of the pharynx and do not connect to the exterior, playing crucial roles in organ development. Each arch incorporates neural crest cells essential for forming facial skeleton components, while mesoderm differentiates into facial and neck musculature. Each arch has its own cranial nerve and artery. Pharyngeal Pouches Four Pairs (fifth is rudimentary) First Pouch : Forms the middle ear cavity and Eustachian tube, contributing to the tympanic membrane. Second Pouch : Develops into palatine tonsils; remnants persist as the tonsillar fossa. Third Pouch: Dorsal wing becomes the inferior parathyroid gland; ventral wing forms the thymus, migrating to the thorax. Fourth Pouch : Dorsal region forms the superior parathyroid gland; ventral region becomes the ultimobranchial body, integrating into the thyroid. Pharyngeal Clefts Five-week-old Embryo: Four clefts are present. First Cleft: Does not form the external auditory meatus (EAM); instead, the EAM arises from surface ectoderm invagination. It eventually disappears due to overgrowth by the second arch. Second, Third, and Fourth Clefts: Overgrown by the second arch, they lose exterior contact and may temporarily form the cervical sinus, which ultimately disappears. First pharyngeal pouch (Option A) is incorrect because it gives rise to the auditory tube and middle ear cavity , not the thymus or parathyroid glands. Second pharyngeal pouch (Option B) is incorrect because it forms the palatine tonsils , not the

thymus or parathyroid glands. Fourth pharyngeal pouch (Option D) is incorrect because it gives rise to the superior parathyroid glands and parts of the ultimobranchial body , not the thymus or inferior parathyroid glands.

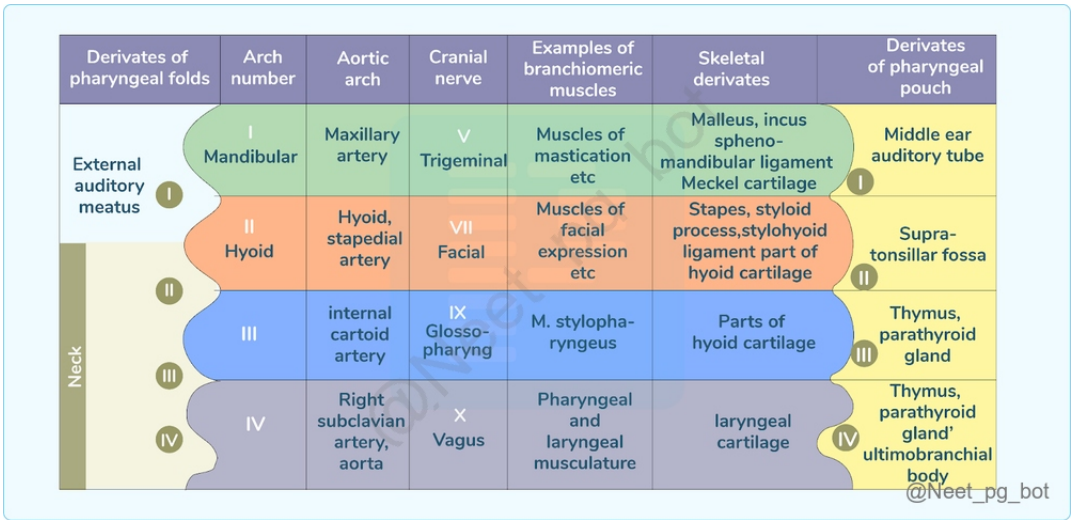

References:

Langman's Medical Embryology, 14th edition, Page 285, 286, 290, 291, 292

↑ *Back to this question in Part A*

@Neet_pg_bot

Q5: A young child with absent thymus is brought to the OPD with features of hypoparathyroidism and tetany. Which of the following marked areas in the picture is defective in this condition? (Q855837)

A. 1

B. 2

C. 3

D. 4

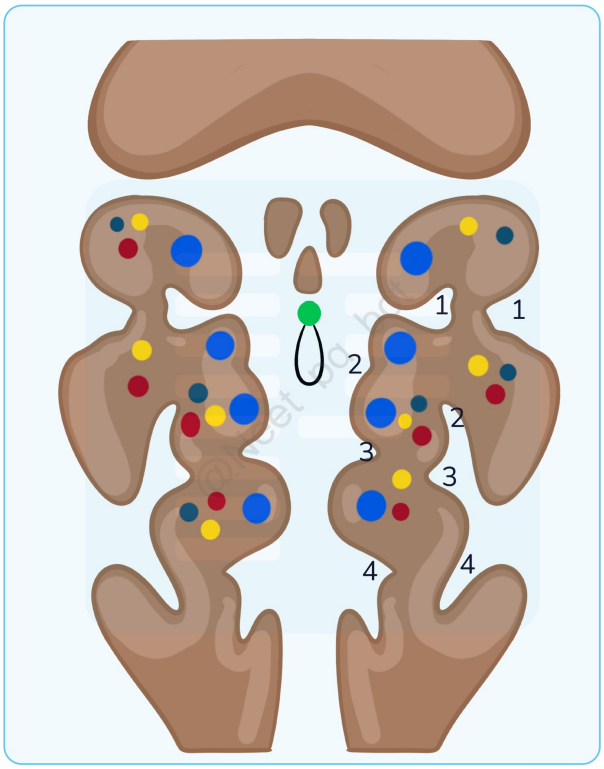

@Neet_pg_bot

Correct Answer: C. 3

Explanation: The given image represents the development of pharyngeal pouches . The condition described is DiGeorge syndrome , which is caused by defective development of the 3rd and 4th pharyngeal pouches , leading to: Absence of thymus → Immunodeficiency (T-cell deficiency) Hypoparathyroidism → Hypocalcemia and tetany The 3rd pharyngeal pouch (marked as 3) gives rise to: Thymus Inferior parathyroid glands The 4th pharyngeal pouch gives rise to: Superior parathyroid glands Ultimobranchial body (C-cells of thyroid) Since DiGeorge syndrome mainly affects the 3rd pouch , the correct answer is Option C (3) . Pharyngeal Pouch Derivatives Pharyngeal Pouch Derivatives 1st Pouch Eustachian tube (Auditory tube) Middle ear cavity Mastoid air cells 2nd Pouch Palatine tonsil (epithelial crypts) Tonsillar fossa 3rd Pouch Inferior parathyroid glands Thymus 4th Pouch Superior parathyroid glands Ultimobranchial body (forms C-cells of the thyroid) DiGeorge Syndrome: Cause: Deletion of 22q11.2, leading to defective neural crest migration CATCH-22 Cardiac defects (Tetralogy of Fallot, truncus arteriosus) Abnormal face Thymic aplasia (T-cell immunodeficiency) Cleft palate Hypocalcemia (due to parathyroid agenesis) 22q11.2 deletion 1- (Option A): Incorrect , as the 1st pouch develops into the Eustachian tube and middle ear cavity , unrelated to the thymus or parathyroid. 2- (Option B): Incorrect , as the 2nd pouch forms the palatine tonsils , not affected in DiGeorge syndrome. 4-(Option D): Incorrect , as while the 4th pouch forms the superior parathyroid glands, the major defect in DiGeorge syndrome is due to failure of 3rd pouch development.

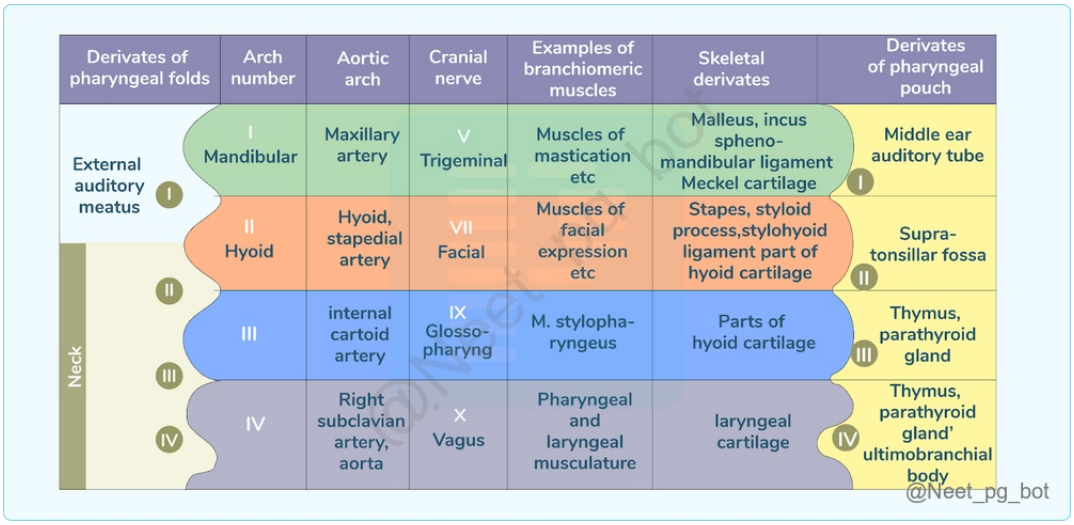

References:

Gray's Anatomy: The Anatomical Basis of Clinical Practice, 41st Edition - Page no: e37, e38, 619

Langman's Medical Embryology, 14th Edition - Page no: 211, 284, 285, 286, 296, 297

↑ *Back to this question in Part A*

@Neet_pg_bot

Q6: The structure marked A in the image below gives rise to which of the following structures? (Q856067)

A. Gastrosplenic ligament

B. Lienorenal ligament

C. Falciform ligament

D. Gastrophrenic ligament

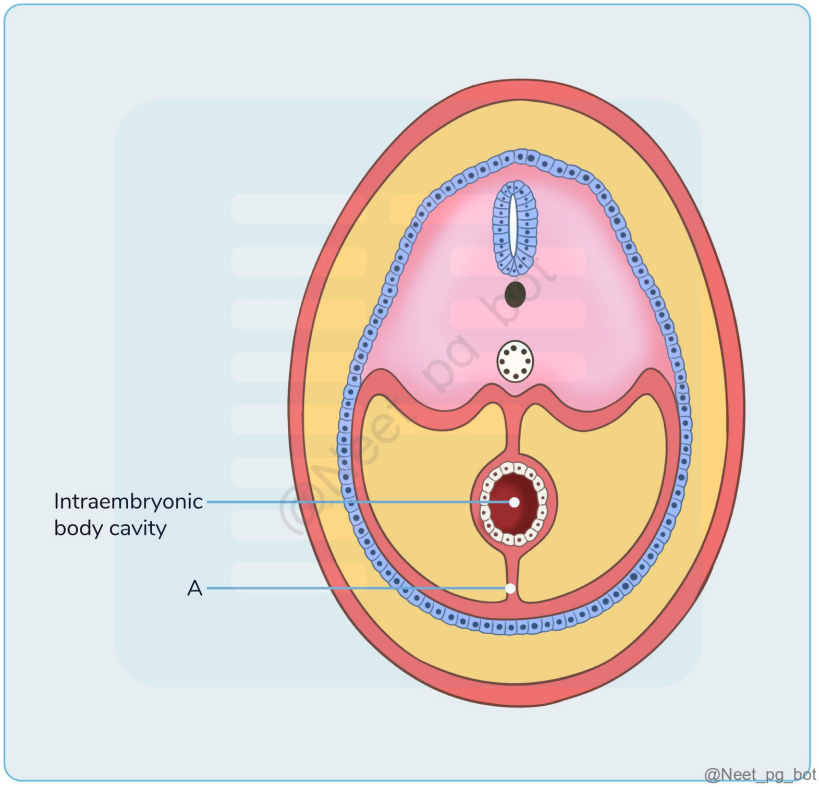

Correct Answer: C. Falciform ligament

Explanation: The structure marked A in the image is the Ventral mesentery, which gives rise to the falciform ligament. This broad, lean, mesentery-like structure connects the liver to the anterior abdominal wall and separates the right and left lobes of the liver. Omenta : Sources Structure From To Contains Dorsal mesentery Greater omentum Greater curvature of stomach (and spleen) Transverse colon right and left gastroepiploic vessels and fat Gastrosplenic ligament Stomach Spleen Short gastric artery, Left gastroepiploic artery Gastrophrenic ligament Stomach Diaphragm Left inferior phrenic artery Gastrocolic ligament Stomach Transverse colon Right gastroepiploic artery Splenorenal ligament Spleen Kidney Splenic artery, Tail of pancreas Ventral mesentery Lesser omentum Lesser curvature of the stomach (and duodenum) Liver The right free margin-hepatic artery, portal vein, and bile duct,lymph nodes and the lymph vessels,hepatic plexus of nerve,all enclosed in perivascular fibrous sheath. Along the lesser curvature of the stomach-left and right gastric artery,the gastric group of lymph nodes and lymphatics, branches from the gastric nerve. Hepatogastric ligament Stomach Liver Right and left gastric artery Hepatoduodenal ligament Duodenum Liver Hepatic artery proper, hepatic portal vein, bile duct, autonomic nerves {{caption_text}} Horizontal disposition of the peritoneum in the upper part of the abdomen {{caption_text}} Horizontal disposition of the peritoneum in the lower part of the abdomen Mesenteries Sources Structure From To Contains Dorsal mesentery Mesentery proper Small intestine (jejunum and ileum) Posterior abdominal wall Superior mesenteric artery, accompanying veins, autonomic nerve plexuses, lymphatics, 100–200 lymph nodes and connective tissue with fat Transverse mesocolon Transverse colon Posterior abdominal wall Middle colic Sigmoid mesocolon Sigmoid colon Pelvic wall Sigmoid arteries and superior rectal artery Mesoappendix Mesentery of ileum Appendix Appendicular artery Other ligaments and folds Sources Structure From To Contains Ventral mesentery Falciform ligament Liver Thoracic diaphragm, anterior abdominal wall Round ligament of liver, paraumbilical vein Left umbilical vein Round ligament of liver Liver Umbilicus Ventral mesentery Coronary ligament Liver Thoracic diaphragm Ductus venosus Ligamentum venosum Liver Liver Phrenicocolic ligament Left colic flexure Thoracic diaphragm Ventral mesentery Left triangular ligament, right

triangular ligament Liver Umbilical folds Urinary bladder Ileocecal fold Ileum Cecum Broad ligament of the uterus Uterus Pelvic wall Mesovarium, mesosalpinx, mesometrium Round ligament of uterus Uterus Inguinal canal Suspensory ligament of the ovary Ovary Pelvic wall Ovarian artery

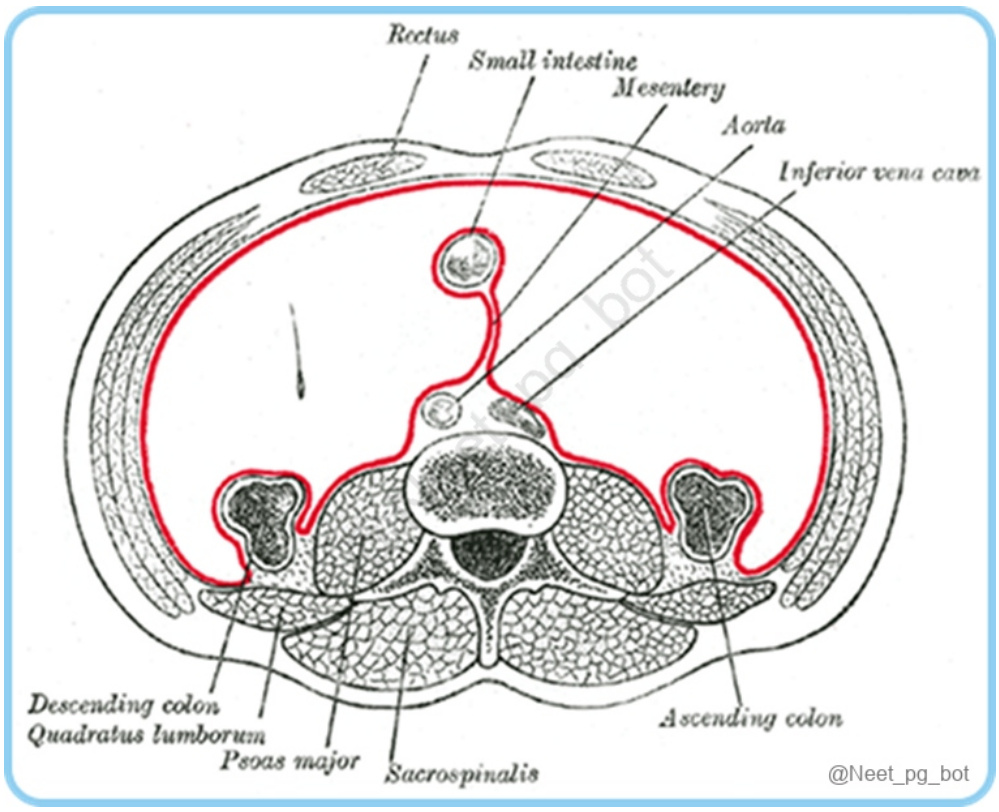

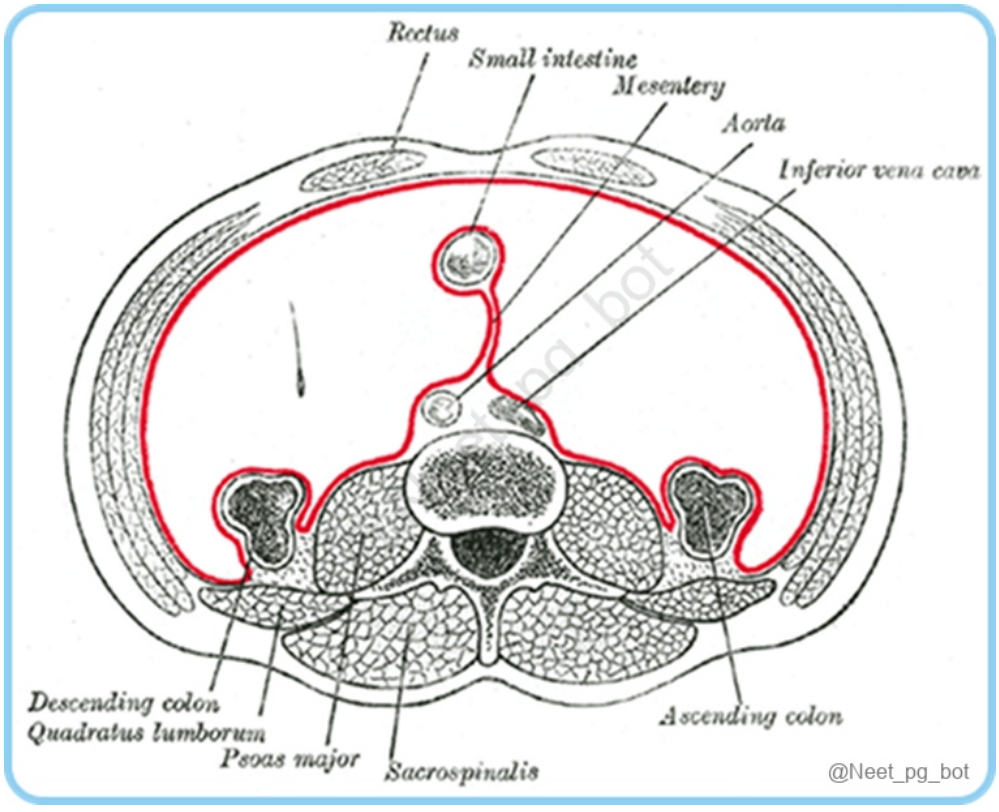

References:

Gray’s anatomy, 42nd edition, Page 1151-1157

https://en.wikipedia.org/wiki/Peritoneum#:~:text=Peritoneal%20folds%20are%20omentums%2C%20mesenteries,red%20in%20the%20diagrams%20above.

https://www.ncbi.nlm.nih.gov/books/NBK534788/#:~:text=The%20peritoneum%20is%20comprised%20of,%2C%20transverse%2C%20and%20sigmoid%20colon

↑ *Back to this question in Part A*

@Neet_pg_bot

Q7: What structure develops from the region labeled as "A" in the model of embryological heart development? (Q856363)

A. Atria

B. Left ventricle

C. Infundibulum

D. Interventricular septum

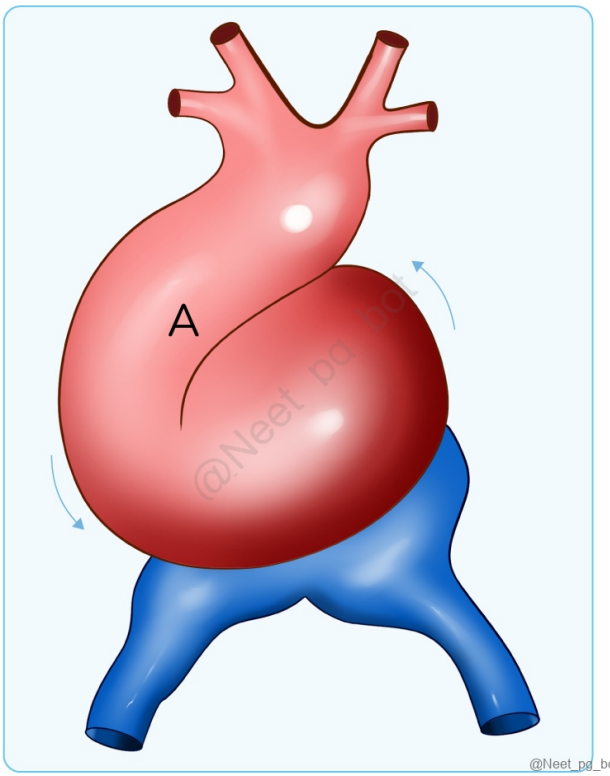

Correct Answer: C. Infundibulum

Explanation: In the embryological development of the heart, the area marked as "A" corresponds to the outflow tract of the developing heart. This outflow tract gives rise to several structures, including the infundibulum. The infundibulum is a conical structure located at the outflow of the right ventricle. It connects the right ventricle to the pulmonary artery and directs blood flow from the heart to the lungs. Formation of Heart Tubes: The endothelial heart tube is derived from the splanchnopleuric mesoderm, located near the pericardial cavity. Initially, the heart appears as right and left endothelial heart tubes. These tubes fuse to form a single heart tube. The heart tube has 5 dilatations, which are: Truncus arteriosus Bulbus cordis Primitive ventricle Primitive atrium Sinus venosus Sinus venosus is located at the caudal (venous) end of the primitive heart tube. It consists of a body with two prolongations known as the right and left horns. Right horn: Forms smooth part of the right atrium (sinus venarum). Left horn: Forms coronary sinus. Each horn receives blood from three veins: Vitelline vein Umbilical vein Common cardinal vein Bulbus cordis is the cranial most part of the developing heart tube. Forms outflow (smooth) parts of the right ventricle (conus arteriosus) and left ventricle (aortic vestibule). Primitive ventricle: Forms inflow (rough) parts of both ventricles. Primitive atrium: Forms trabeculated part of the right and left atrium. Truncus arteriosus: Forms ascending aorta and pulmonary trunk. Formation of Transverse Pericardial Sinus: Heart Tube Folding: Brings the arterial and venous ends closer together. Disappearance of the dorsal mesocardium creates the transverse sinus of the pericardium. Parietal and visceral layers of the serous pericardium become continuous at the arterial and venous ends of the heart. Pericardium forms two tubes: One enclosing the aorta and pulmonary trunk. Other enclosing the SVC, IVC, and four pulmonary veins. Two tubes are separated by the transverse sinus of the pericardium. Atria (Option A): The atria develop from the primitive heart tube, specifically from the regions known as the primitive atrium and sinus venosus. Left ventricle (Option B): The left ventricle develops from the primitive heart tube and forms the main pumping chamber of the heart that sends oxygenated blood to the systemic circulation. I nterventricular septum (Option D): The interventricular septum develops from the fusion of several components during heart development.

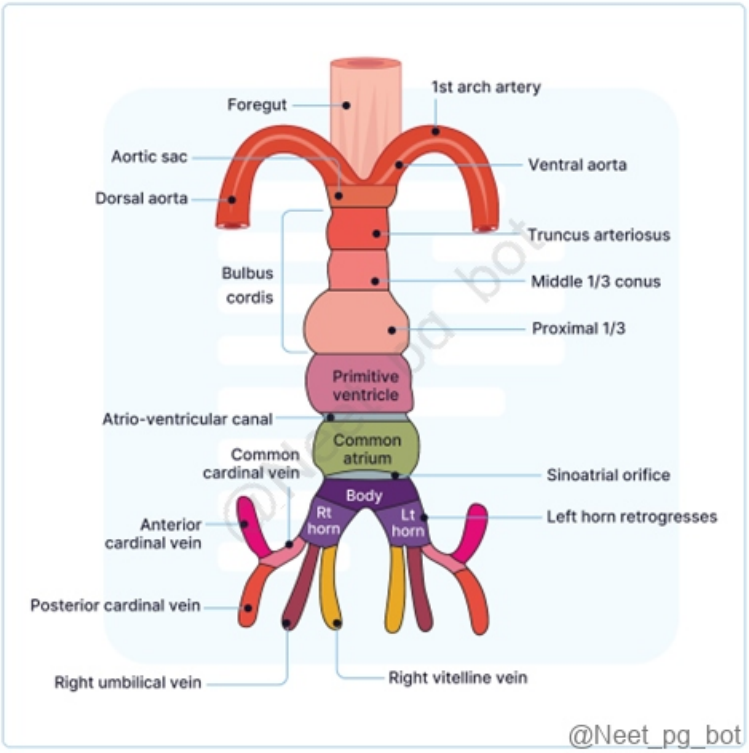

@Neet_pg_bot

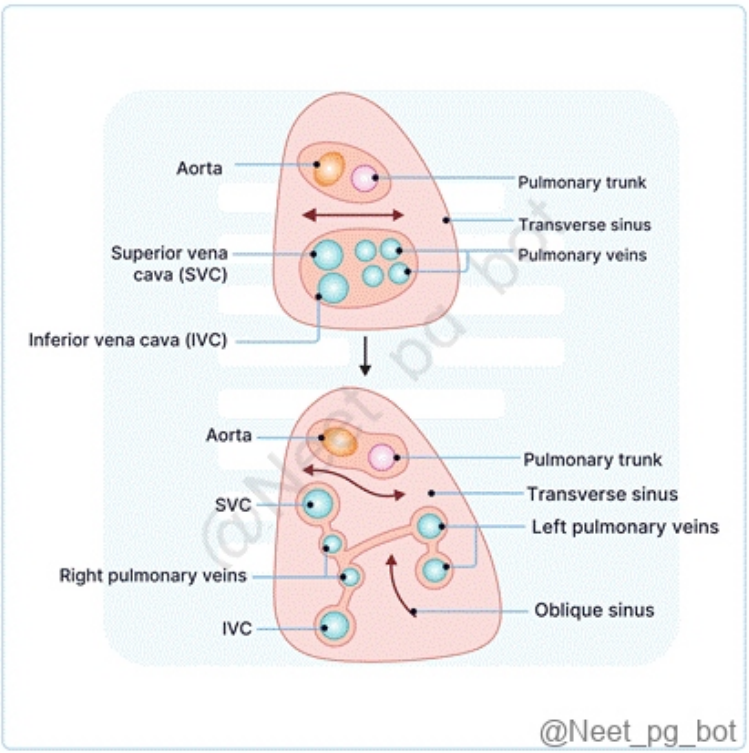

@Neet_pg_bot

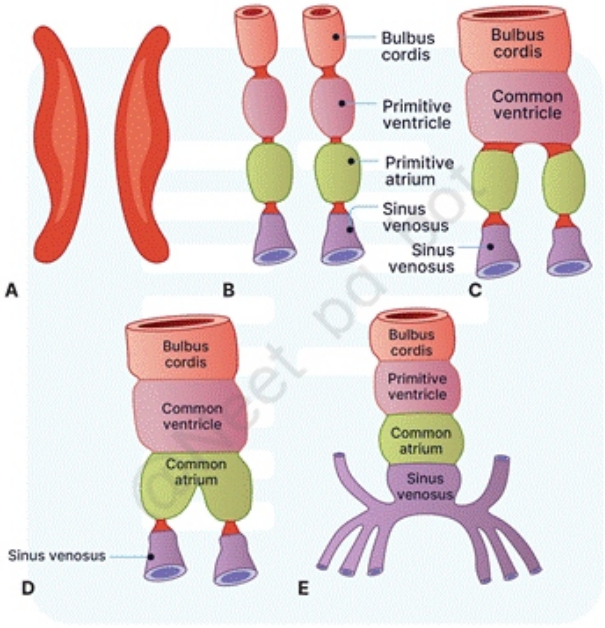

(A) Right and left heart tubes; (B to E) Progressive fusion of tubes from cranial to caudal end. Fusion of sinus venosus is partial

@Neet_pg_bot

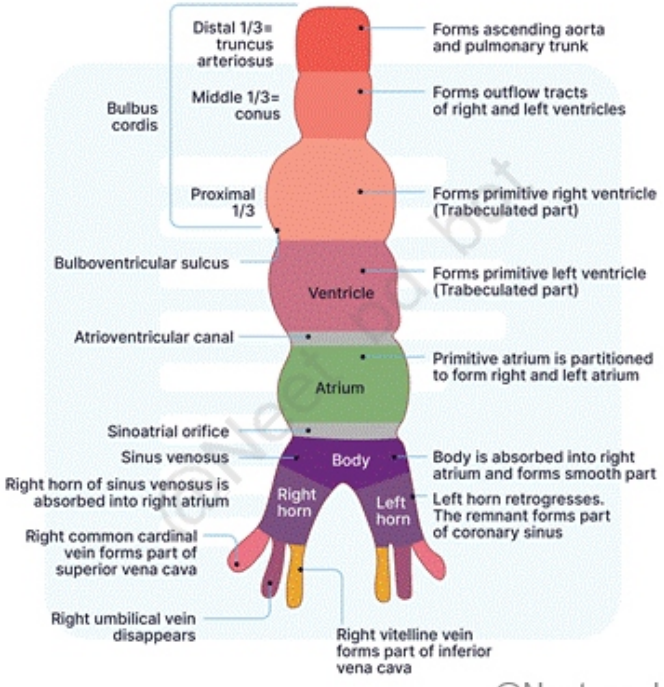

@Neet_pg_bot

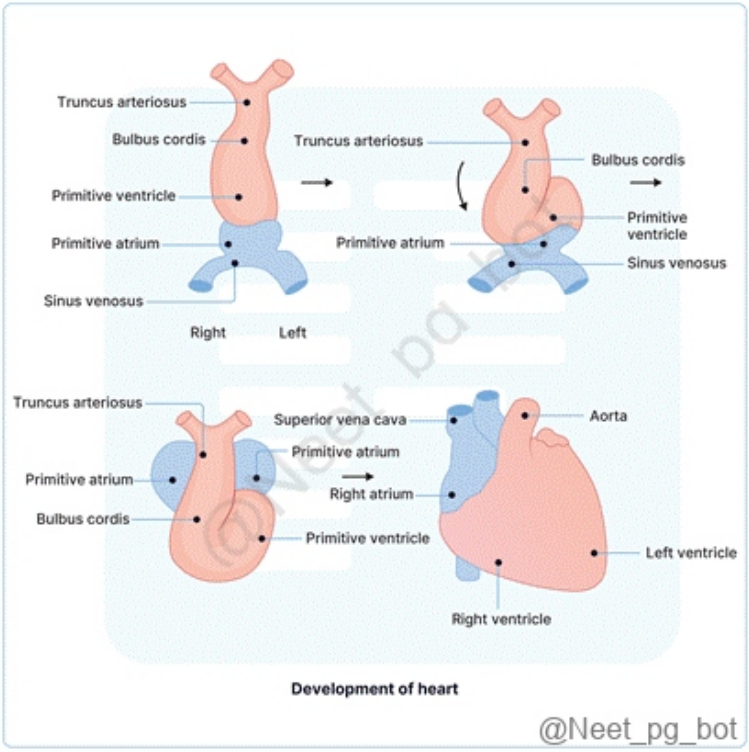

References:

BD Chaurasia's Human Anatomy, 8th Edtion, Page no: 123

↑ *Back to this question in Part A*

@Neet_pg_bot

Q8: The marked structure develops from which of the following structures? (Q856670)

A. Common cardinal vein

B. Anterior cardinal vein

C. Supracardinal vein

D. Subcardinal vein

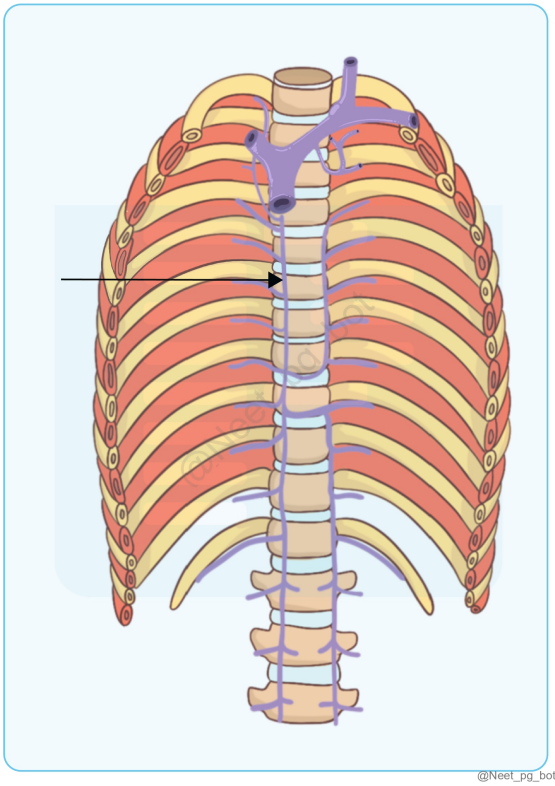

Correct Answer: C. Supracardinal vein

Explanation: The marked structure is the azygos vein , which develops primarily from the right supracardinal vein during embryogenesis. The supracardinal veins appear in the embryo as part of the venous system and contribute to the formation of azygos and hemiazygos veins . The right supracardinal vein persists to form the azygos vein , which drains blood from the posterior thoracic wall. The left supracardinal vein contributes to the hemiazygos vein , which drains into the azygos system. Thus, the correct answer is Option C (Supracardinal vein). Venous System Development Embryonic Vein Adult Derivative Common cardinal vein Contributes to superior vena cava (SVC) Anterior cardinal vein Forms jugular veins and part of SVC Supracardinal vein Azygos and hemiazygos veins Subcardinal vein Renal veins, gonadal veins, and part of IVC Common cardinal vein (Option A): Incorrect – Contributes to the formation of the superior vena cava (SVC) but not the azygos vein. Anterior cardinal vein (Option B): Incorrect – Develops into internal jugular veins and part of the SVC , not the azygos system. Subcardinal vein (Option D): Incorrect – Primarily forms renal veins and parts of the inferior vena cava (IVC) , not the azygos vein.

References:

Langman’s Medical Embryology, Edition 14, Page 214

BD Chaurasia’s Human Anatomy, Edition 6, Volume 1, Page 249

↑ *Back to this question in Part A*

@Neet_pg_bot

Q9: A newborn presented to the NICU with respiratory distress and meconium discharge from the umbilicus. The condition occurs due to the patency of which structure? (Q857217)

A. Mesonephric duct

B. Allantois

C. Urachus

D. Vitelline Fistula

Correct Answer: D. Vitelline Fistula

Explanation: A vitelline fistula occurs due to the failure of the vitelline duct (omphalomesenteric duct) to obliterate , leading to meconium discharge from the umbilicus . It connects the midgut to the yolk sac during fetal development, and its persistence results in fecal or intestinal content drainage from the umbilicus . Embryological Remnants of Umbilical Structures Structure Embryological Origin Failure of Obliteration Leads to Clinical Presentation Vitelline Duct Connects midgut to yolk sac Vitelline fistula Meconium discharge from the umbilicus Urachus Remnant of allantois (connects bladder to umbilicus) Patent urachus Urine discharge from umbilicus Allantois Contributes to bladder development Urachal cyst, urachal sinus Cystic swelling or umbilical urine leakage Mesonephric Duct Wolffian duct (forms male reproductive structures) No relation to umbilical anomalies Affects male genital development Mesonephric duct (Option A): Incorrect because it forms the male reproductive system (vas deferens, epididymis, seminal vesicles) and does not contribute to umbilical structures. Allantois (Option B): Incorrect because it contributes to bladder development , and its failure results in urachal anomalies (urine leakage, not meconium discharge). Urachus (Option C): Incorrect because a patent urachus leads to urinary discharge from the umbilicus , not meconium .

References:

https://pmc.ncbi.nlm.nih.gov/articles/PMC4601947/

https://pubmed.ncbi.nlm.nih.gov/29709845/

↑ *Back to this question in Part A*

@Neet_pg_bot

Q10: What is the embryological basis of the developmental defects shown in the image below? (Q857218)

A. Failure in closure of anterior neuropore of neural tube

B. Failure in closure of posterior neuropore of neural tube

C. Failure in closure of complete neural tube

D. Failure in closure of caudal neuropore of neural tube



Correct Answer: A. Failure in closure of anterior neuropore of neural tube

Explanation: The left image shows anencephaly , a severe neural tube defect (NTD) caused by failure of the anterior neuropore to close during embryogenesis (by day 25 of gestation). This leads to absence of the brain, skull, and scalp , with exposed brain tissue. The right image suggests difficulty in feeding, which is often associated with cranial NTDs . Neural Tube Defects (NTDs) and Neuropore Closure Defects Neuropore Failure of Closure Leads to Clinical Features Anterior Neuropore Anencephaly Absence of brain, skull, and scalp; open cranial vault; polyhydramnios (due to absent swallowing reflex) Posterior Neuropore Spina bifida (Occulta, Meningocele, Myelomeningocele) Defects in vertebral arch, meninges, or spinal cord; may present with tuft of hair, sac-like protrusion, or neurological deficits Complete Neural Tube Craniorachischisis Entire brain and spinal cord remain open, leading to lethal defects Caudal Neuropore Spina bifida occulta Mildest form of spina bifida, often asymptomatic, with a tuft of hair over the lumbar region Failure in closure of posterior neuropore (Option B): Incorrect because it causes spina bifida , affecting the spinal cord and vertebral column, not the brain. Failure in closure of the complete neural tube (Option C): Incorrect because it results in craniorachischisis , a lethal defect where both the brain and spinal cord remain open . Failure in closure of caudal neuropore (Option D): Incorrect because it leads to spina bifida occulta , a mild defect limited to the lower spine , not affecting brain development.

References:

Gray’s Anatomy, Ed 42, Pg 233

↑ *Back to this question in Part A*

@Neet_pg_bot

• [11_Osteology and Arthrology] 050 Previous Year Questions

« Back to Folder Directory

[11_Osteology and Arthrology] 050 Previous Year Questions — Quick Jump

Q1 (p. 2134) *Q2 (p. 2135)* *Q3 (p. 2137)* *Q4 (p. 2139)* *Q5 (p. 2140)* *Q6 (p. 2141)*

Q1: The bone shown in the image is not associated with which of the following types of joints? (Q839878)

A. Syndesmosis

B. Symphysis

C. Plane synovial joint

D. Synchondrosis



Correct Answer: D. Synchondrosis

Explanation: Correct Option D - Synchondrosis: The image shown above is of vertebra Synchondrosis is a type of joint where the bones are connected by hyaline cartilage. These joints are usually temporary and found in growing

bones, such as the epiphyseal plates (growth plates) in children and the first sternocostal joint that unites the first rib to the sternum Synchondrosis or primary cartilaginous joints are not present in the given image Incorrect Options: Option A - Syndesmosis: Definition: A syndesmosis is a type of fibrous joint where bones are connected by a ligament or a sheet of connective tissue. The supraspinous ligament, interspinous ligament, ligamentum flavum (Connecting the lamina of adjacent bones). Posterior longitudinal ligament, anterior longitudinal ligament, these ligaments connects the adjacent vertebrae forming syndesmosis Option B - Symphysis: Definition : A symphysis is a type of cartilaginous joint where the bones are connected by fibrocartilage. Examples: The pubic symphysis. The intervertebral discs. Option C - Plane Synovial Joint: A plane synovial joint, also known as a gliding joint, involves flat or nearly flat articular surfaces that allow bones to slide over one another. The joint between the superior articular facet and inferior articular facet is plain synovial joint and thus makes it an incorrect choice

↑ *Back to this question in Part A*

@Neet_pg_bot

Q2: The marked structure serves as a surface landmark for which anatomical structure? (Q852990)

A. Pineal gland

B. Wernicke's area

C. Stem of lateral sulcus

D. Internal carotid artery siphon

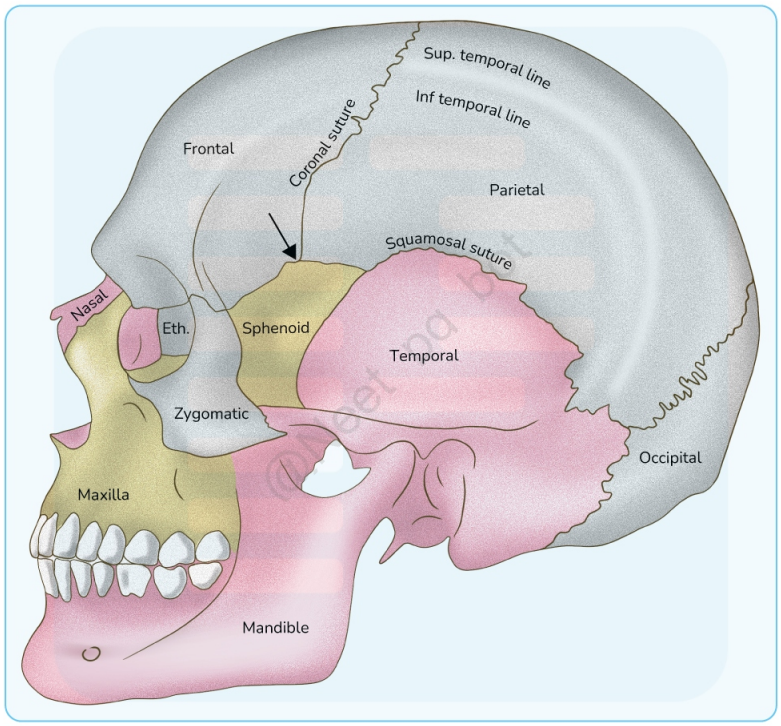

Correct Answer: C. Stem of lateral sulcus

Explanation: The stem of the lateral sulcus (Sylvian fissure) serves as a key surface landmark in the brain. It separates the frontal and temporal lobes and extends posteriorly towards the insular cortex . It is an important landmark for neurosurgical approaches and neurovascular structures. The middle cerebral artery (MCA) runs within the lateral sulcus, supplying a major portion of the cerebral cortex. Lateral Sulcus (Sylvian Fissure) and Its Anatomical Importance Feature Description Location Separates the frontal and temporal lobes Extends to Insular cortex and parietal lobe Contains Middle cerebral artery (MCA) Functions Landmark for neurosurgery, cortical mapping Related Clinical Importance MCA strokes affect motor, sensory, and language functions {{caption_text}} {{caption_text}} Pineal gland (Option A): Incorrect because the pineal gland is located near the posterior midline of the brain , not associated with the lateral sulcus. Wernicke’s area (Option B): Incorrect because Wernicke’s area is found in the posterior superior temporal gyrus , although related to the lateral sulcus, it is not its direct landmark. Internal carotid artery siphon (Option D): Incorrect because the ICA siphon is an S-shaped bend in the cavernous segment of the internal carotid artery , located near the base of the skull, not directly related to the lateral sulcus.

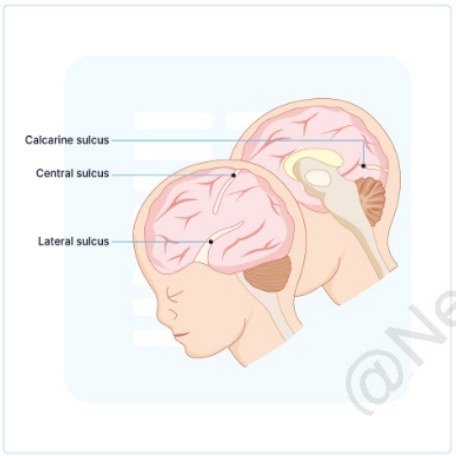

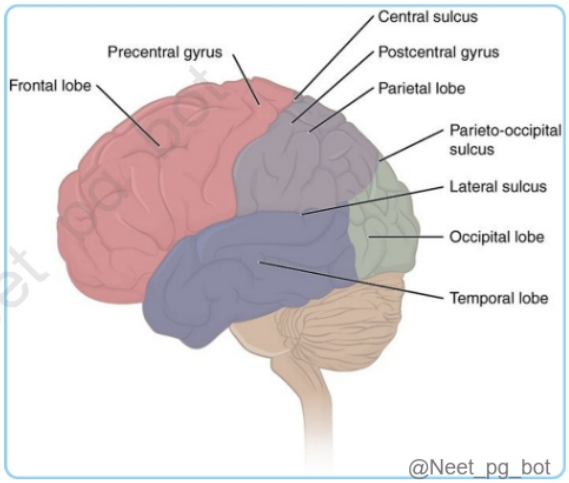

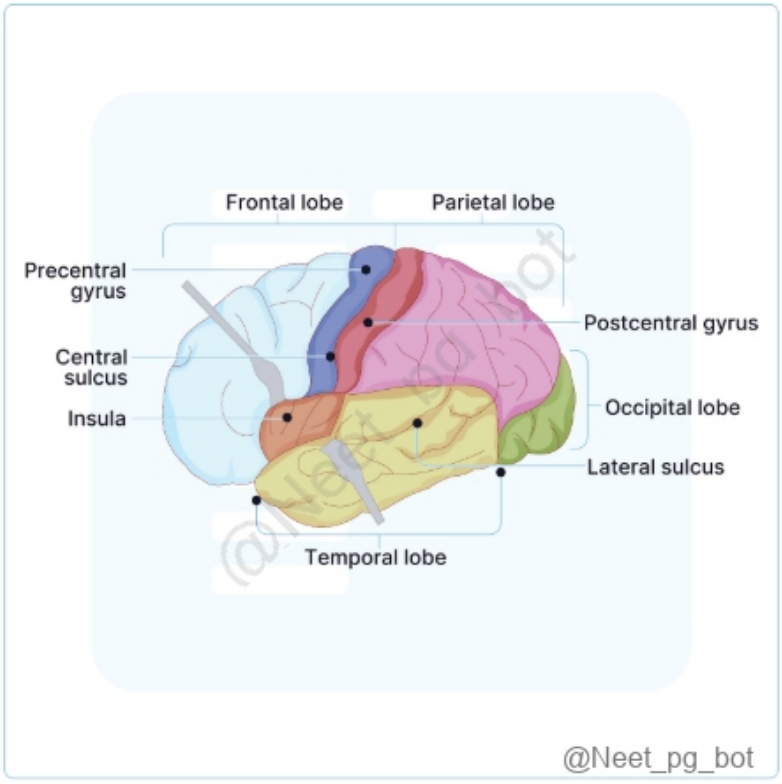

References:

Gray’s Anatomy, 42nd Edition, Pages 395, 396

Vishram Singh, Anatomy of Head, Neck, Brain, Volume 3, Pages 389-391

↑ *Back to this question in Part A*

@Neet_pg_bot

Q3: Which part of this bone is palpable in the infraclavicular fossa? (Q855779)

A. 1

B. 2

C. 3

D. 4



Correct Answer: A. 1

Explanation: The coracoid process (1) is the only palpable part of the scapula in the infraclavicular fossa . It lies deep to the clavicle , but its tip can be felt by pressing below the lateral third of the clavicle. Palpable Bony Landmarks of the Scapula Structure Palpability Spine of scapula Easily palpable posteriorly. Acromion Most lateral and superior part, prominent. Coracoid process Palpable in the infraclavicular fossa , serves as an attachment site. Inferior angle Palpable at the lower medial end of the scapula. Acromion (Option B-2): Incorrect , as it is palpable over the shoulder , not in the infraclavicular fossa. Lateral angle of scapula (Option C-3): Incorrect , as it is posteriorly palpable , not infraclavicular. Inferior angle (Option D-4): Incorrect , as it is only palpable at the lower scapular border .

References:

Gray's Anatomy: The Anatomical Basis of Clinical Practice, 41st Edition - Page nos: 787, 803

Gray's Anatomy: The Anatomical Basis of Clinical Practice, 42nd Edition - Page no: 884, 896

↑ *Back to this question in Part A*

@Neet_pg_bot

Q4: What type of joint is seen in the labeled structure? (Q859517)

A. Syndesmosis

B. Primary cartilaginous joints

C. Fibrous joint

D. Secondary cartilaginous joint

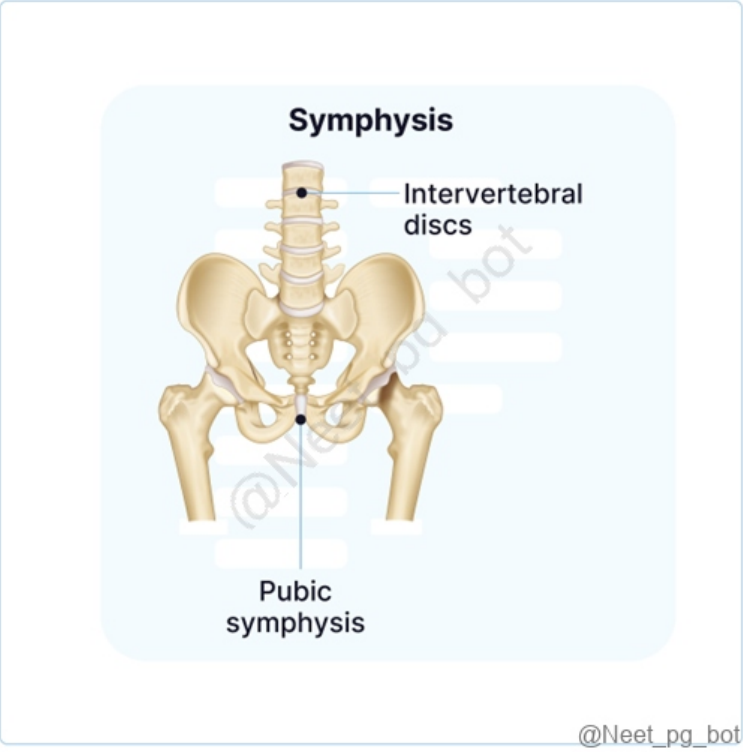

Correct Answer: D. Secondary cartilaginous joint

Explanation: The pubic symphysis is a joint sandwiched between your left pelvic bone and right pelvic bone. It is a secondary cartilaginous joint. The secondary cartilaginous joints are permanent joints, which are slightly movable and their movements depend upon the sufficient amount of white-fibro cartilage tissues. Primary Cartilaginous Joint (Option B) Secondary Cartilaginous Joint Sutures Syndesmoses (Option A) Gomphosis Joint between epiphysis and diaphysis Between basiocciput and basisphenoid Symphysis menti Symphysis pubis Manubrio sternal Joint between vertebral bodies, xiphisternal joint, midline intervertebral joint Serrate : Sagittal Denticulate : Lambdoid Squamous :Temporoparietal Plane : Between palatine process of maxillae Schindylesis : Between rostrum of sphenoid and upper margin of vomer Inferior tibiofibular joint Tooth fit in the socket Fibrous joints are

classified into: (Option C) Sutures, Syndesmoses Gomphosis

References:

Gray’s Anatomy, 42nd Edition, Pg.101,102

Snells Anatomy, 10th edition, Pg 13

↑ *Back to this question in Part A*

@Neet_pg_bot

Q5: In the labeled structure, what kind of joint is present? (Q859522)

A. Sutures

B. Primary cartilaginous joints

C. Fibrous joint

D. Secondary cartilaginous joint

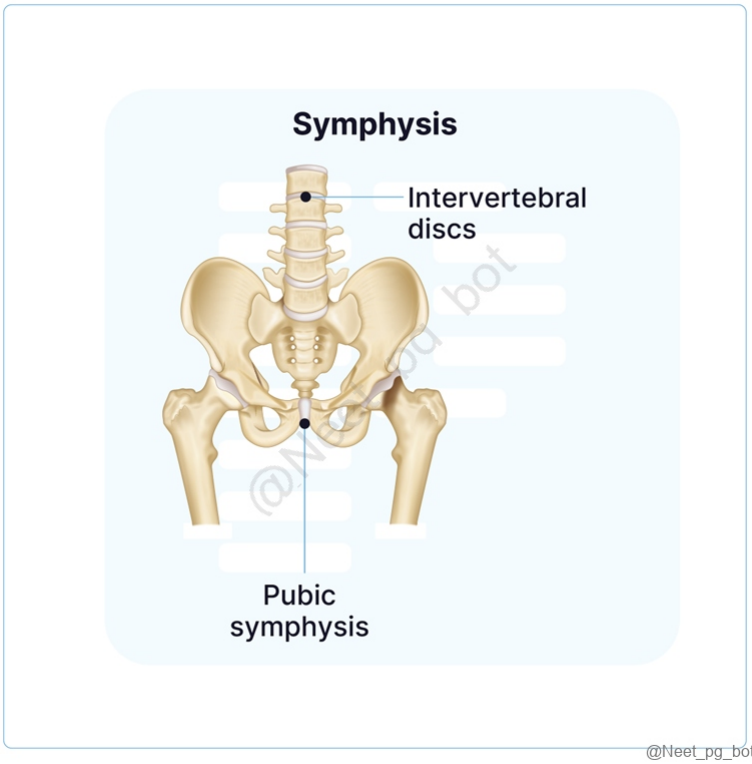

Correct Answer: D. Secondary cartilaginous joint

Explanation: The pubic symphysis is a joint sandwiched between your left pelvic bone and right pelvic bone. It is a secondary cartilaginous joint. The secondary cartilaginous joints are permanent joints, which are slightly movable and their movements depend upon the sufficient amount of white-fibro cartilage tissues. Primary Cartilaginous Joint (Option B) Secondary Cartilaginous Joint Sutures (Option A) Syndesmoses Gomphosis Joint between epiphysis and diaphysis Between basiocciput and basisphenoid Symphysis menti Symphysis pubis Manubrio sternal Joint between vertebral bodies, xiphisternal joint, midline intervertebral joint Serrate: Sagittal Denticulate: Lambdoid Squamous: Temporoparietal Plane: Between palatine process of maxillae Schindylesis: Between rostrum of sphenoid and upper margin of vomer Inferior tibiofibular joint Tooth fit in the socket Fibrous joints are classified into: (Option C) Sutures, Syndesmoses Gomphosis

References:

Gray's Anatomy, 42nd Edition, Pg.101,102

Snells Anatomy, 10th edition, Pg 13

↑ *Back to this question in Part A*

@Neet_pg_bot

Q6: Which of the following is the type of joint between epiphysis and diaphysis of a long bone? (Q860263)

A. Symphysis

B. Synchondrosis

C. Synostosis

D. Syndesmosis

Correct Answer: B. Synchondrosis

Explanation: Synchondrosis is a type of joint that is a primary cartilaginous joint where the epiphysis and diaphysis of a long bone are connected by a growth plate made of hyaline cartilage. Primary Cartilaginous Joints (Synchondrosis) Secondary Cartilaginous Joints (Symphysis) (Option A) Immobile Occur where ossification centres remain separated by hyaline cartilage. Found in bones that form from more than one ossification centre. Hyaline cartilage here can ossify with age, leading to fusion when growth is completed. Temporary and mainly for growth. Mostly associated with growth plates. The joint between the first rib and the manubrium is a permanent synchondrosis. Slightly mobile Defined by a pad or disc of fibrocartilage between articulating bones, e.g., intervertebral discs. Built to handle a variety of stresses (compression, tension, etc.). Permanent and provide limited movement. Found along the midline (e.g., pubic symphysis, intervertebral joints). Strong ligaments reinforce the joints and are key to stability and movement. Symphyses are built for durability and movement, but they also allow growth in areas like the intervertebral discs. Synostosis (Option C): Synostosis refers to the fusion of bones where the original cartilage is replaced entirely by bone. Syndesmosis (Option D): A syndesmosis is a fibrous joint where bones are connected by a ligament or an interosseous membrane, allowing for limited

movement.

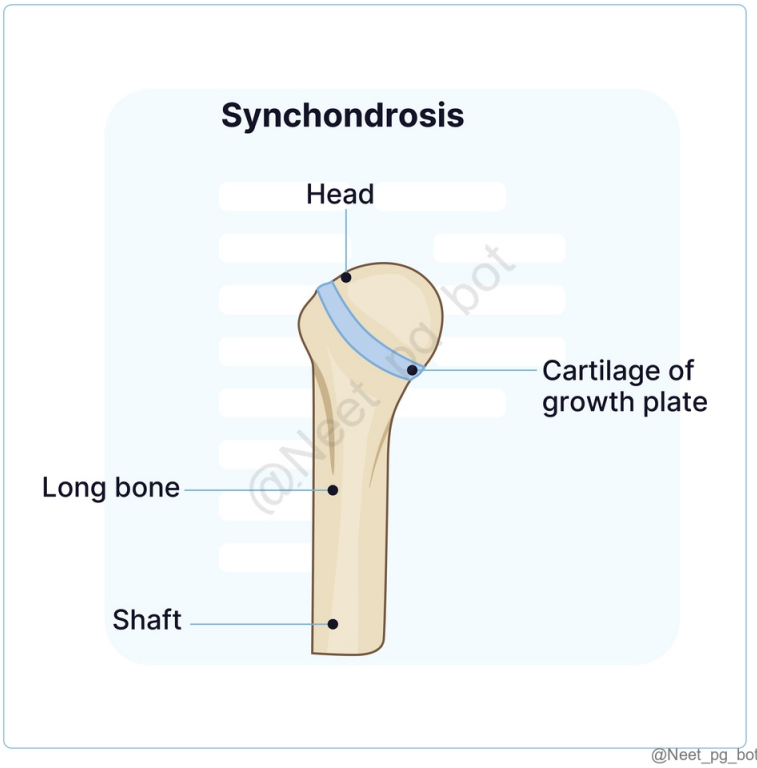

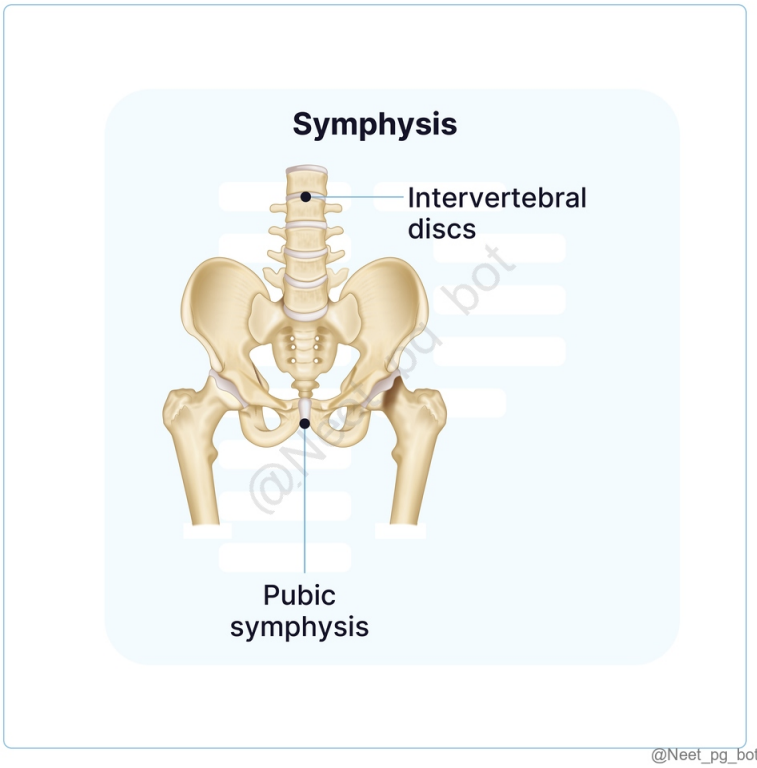

References:

Gray’s Anatomy, 42nd Edition, Pg.102,106 BD Chaurasia 8th edition, volume 1, pg 155

↑ *Back to this question in Part A*

@Neet_pg_bot

• [12_Back Region] 051 Back Region

« Back to Folder Directory

[12_Back Region] 051 Back Region — Quick Jump

Q1 (p. 2144)	*Q2 (p. 2146)*	*Q3 (p. 2149)*	*Q4 (p. 2153)*	*Q5 (p. 2156)*	*Q6 (p. 2157)*
Q7 (p. 2159)	*Q8 (p. 2160)*	*Q9 (p. 2162)*	*Q10 (p. 2164)*	*Q11 (p. 2165)*	*Q12 (p. 2167)*
Q13 (p. 2169)	*Q14 (p. 2170)*	*Q15 (p. 2174)*	*Q16 (p. 2177)*	*Q17 (p. 2179)*	

Q1: Which of the following muscles contributes to forming both Petit’s triangle and the triangle of auscultation? (Q848696)

A. Latissimus dorsi

B. Internal oblique

C. Rhomboid major

D. Trapezius

Correct Answer: A. Latissimus dorsi

■ *Listen (English)*

■ *Listen (Hindi)*

Explanation: The latissimus dorsi muscle contributes to the inferior border of the triangle of auscultation and posteriorly in Petit’s triangle. Triangle of auscultation Petit’s triangle Description The triangle of auscultation is a small gap in the musculature on the back of the thorax present near the inferior angle of the scapula. Also known as the inferior lumbar triangle . Borders and contents Superiorly by trapezius muscle (Option D) Inferiorly by latissimus dorsi Laterally by the medial border of scapula The floor has the 6th and 7th ribs and the sixth intercostal space Part of the rhomboid major muscle is exposed in the triangle (Option C) Posteriorly by latissimus dorsi Anteriorly by the posterior border of the external oblique The iliac crest inferiorly forms the base Floor has internal oblique muscle (Option B) Significance The apex of the lower lobe of the lung is found deep to it. When the scapulae move anteriorly (arms folded and trunk flexed), the triangle expands, allowing clear auscultation On the left side, the cardiac orifice of the stomach lies deep, previously used to detect esophageal tumors by auscultating swallowed liquids. A collection of pus from the abdomen may show up here. Site of lumbar hernia. M/c site for lumbar hernia: Superior lumbar triangle (Grynfeltt) > Inferior lumbar triangle (Petit) Detaching the fascia from the iliac crest enables access to the retroperitoneal space.

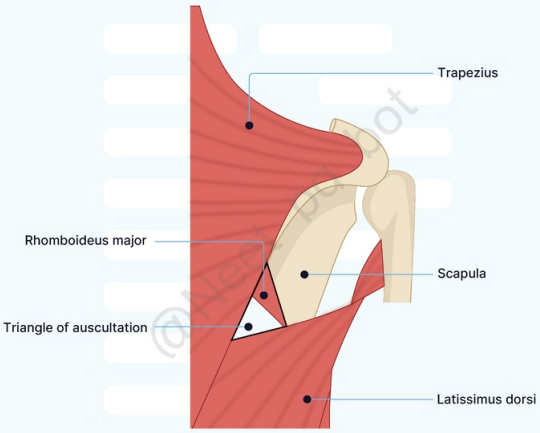

@Neet_pg_bot

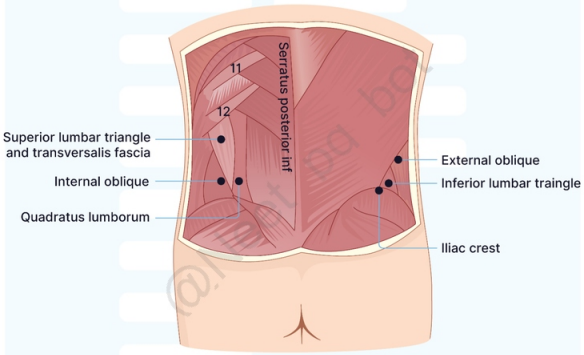

@Neet_pg_bot

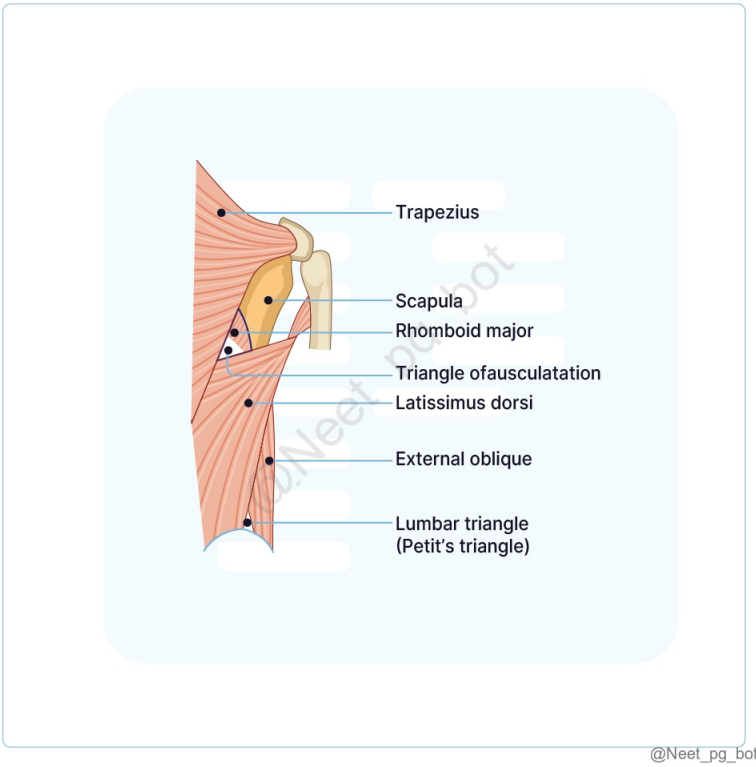

@Neet_pg_bot

References:

Gray's Anatomy, 42nd Edition, Page 915

Vishram Singh Textbook of Anatomy, 2nd Edition, Page 62

https://www.ncbi.nlm.nih.gov/pmc/articles/PMC6168328/

↑ *Back to this question in Part A*

@Neet_pg_bot

Q2: All of the following statements about the atlantooccipital joint is/are true except: 1. Allows for flexion and extension of the head 2. It is a synovial condyloid joint 3. Primarily responsible for lateral bending of the head 4. Formed by the articulation between the occipital condyles and the superior articular facets of the atlas 5. It facilitates rotational movement of the head (Q848694)

A. 1, 2, and 4

B. 2 and 3

C. 3 and 5

D. 3, 4, and 5

Correct Answer: C. 3 and 5

- *Listen (English)*
- *Listen (Hindi)*

Explanation: While the atlanto-occipital joint allows some lateral bending , it is not the primary joint responsible for this movement. Lateral bending of the head is more significantly facilitated by the atlantoaxial joint (between the atlas and axis, C1 and C2) and the cervical spine below. The atlantoaxial joint allows for rotational movements and contributes to lateral flexion. Atlanto-Occipital Joint The atlanto-occipital joint is a synovial joint formed between the atlas (C1) and the occipital bone of the skull. Here are key features: Structure: This joint consists of the superior articular facets of the atlas, which articulate with the occipital condyles of the skull. Function: It primarily allows for nodding movements (flexion and extension), often described as "yes" movements. {{caption_text}} Anatomy: The odontoid process (or dens) is a peg-like structure that projects from the body of the axis (C2). It is crucial for the stability and functionality of the cervical spine. The odontoid process is held in place by the transverse ligament of the atlas, which prevents excessive backward movement of the atlas relative to the dens. In the case of fusion, it can be assumed that the body of C1 and C2 may appear fused if there are pathological changes or congenital anomalies. Atlanto-Axial Joint {{caption_text}} The atlantoaxial joint is another synovial joint located between the atlas (C1) and axis (C2), and it has specific characteristics: Structure: This joint consists of the dens of the axis fitting into the anterior arch of the atlas. Function : It primarily facilitates rotational movements of the head, allowing for the "no" movement. Anatomy: The atlantoaxial joint is classified as a pivot or trochoid joint, enabling rotational movement around the central axis formed by the dens. The transverse ligament again plays a key role by stabilizing the odontoid process and allowing for controlled rotation of the skull and atlas around the dens.



@Neet_pg_bot

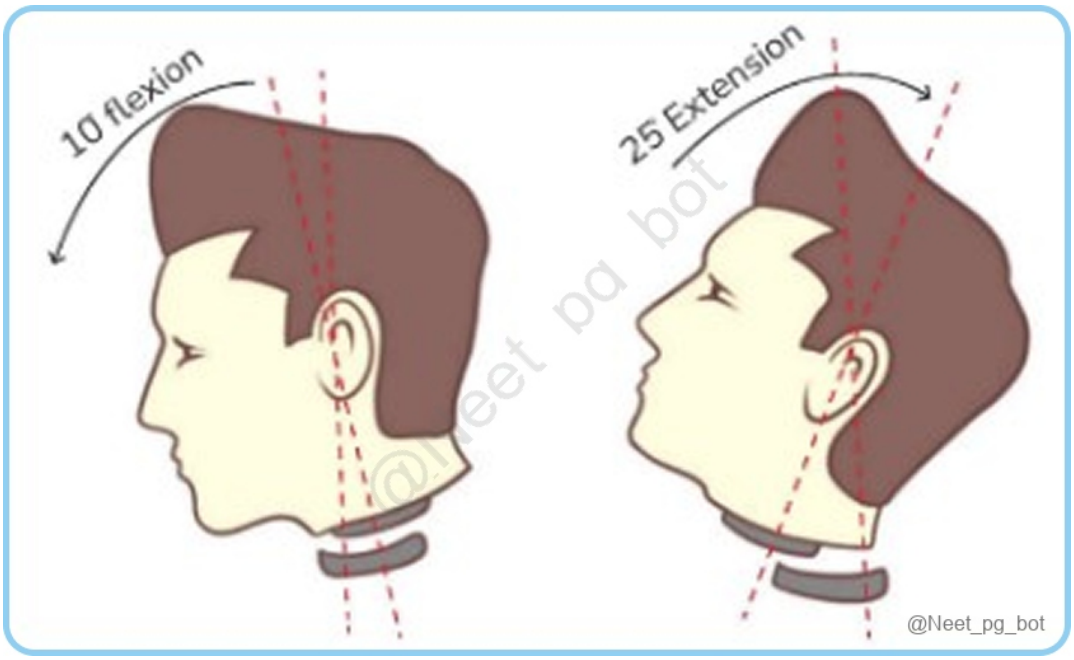
10 flexion
25 Extension
@Neet_pg_bot

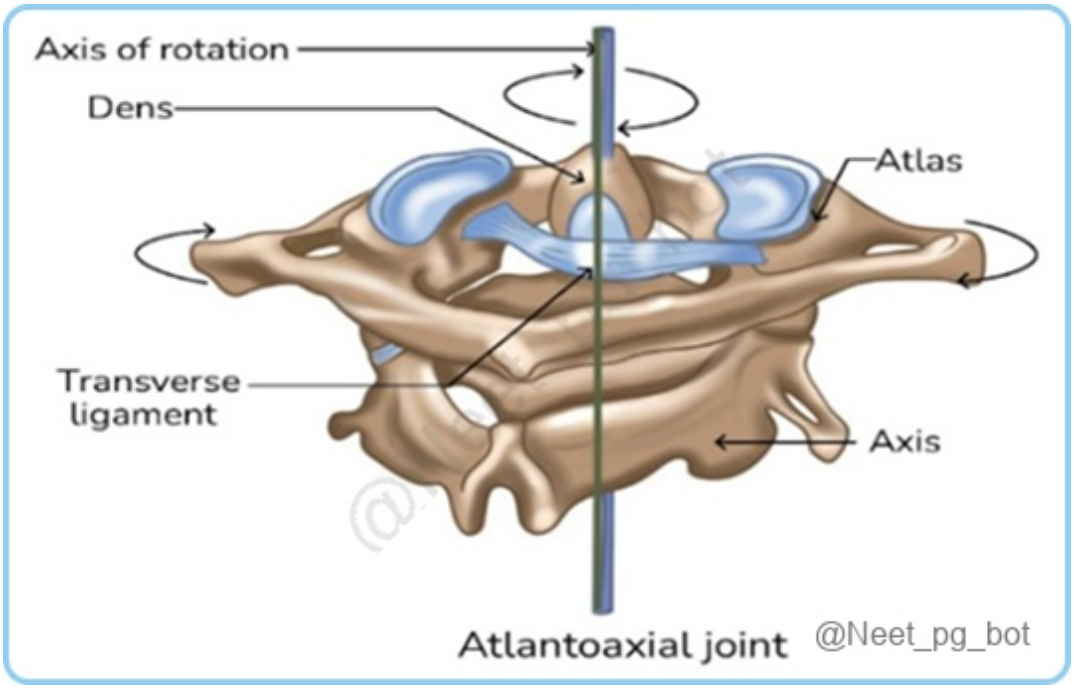
Axis of rotation
Dens
Atlas
Transverse ligament
Axis
Atlantoaxial joint
@Neet_pg_bot



References:

Gray’s Anatomy, 42nd Edition, Pages 840, 841

Vishram Singh, Textbook of Anatomy Head, Neck and Brain, Volume 3, 3rd Edition, Pages 106-108

BD Chaurasia's Human Anatomy, 8th Edition, Pages 185-188

↑ *Back to this question in Part A*

@Neet_pg_bot

Q3: A 5-month-old infant with suspected meningitis is scheduled for a lumbar puncture. Which of the following statements about lumbar puncture in infants is incorrect? (Q848688)

A. Procedure is typically done at the L3-L4 intervertebral space.

B. Procedure is preferably performed under ultrasound guidance.

C. Supracristal plane corresponds to the L4-L5 vertebral level.

D. Depth to the subarachnoid space is approximately 1.4 cm in neonates.

Correct Answer: C. Supracristal plane corresponds to the L4-L5 vertebral level.

■ *Listen (English)*

■ *Listen (Hindi)*

Explanation: In infants , the supracristal plane intersects the vertebral column at L3-L4, not L4-L5. Lumbar Puncture: Aspect Adults Neonates and infants Spinal Cord Termination Terminates at the level of L1-L2. Terminates between L1 and L3 in neonates. Conus Medullaris Location Around the L1 and L2 lumbar vertebra and can sometimes be lower. Commonly at the lower third of L1 vertebral body (range: lower third of T12 to L2/L3 intervertebral disc). Supracristal Plane A line between the highest points of the iliac crests intersects the vertebral column around L4 or the L4/L5 intervertebral disc; this may vary from the L2/L3 to L5/S1 level. In most adults, the plane intersects the vertebral column inferior to the termination of the spinal cord. Intersects the vertebral column at L3-L4 level in children. It may vary from L2/L3 to L5/S1 interspinous space. (Option C) Ultrasound Guidance Not routinely used. May be preferable to avoid overlap between the supracristal plane and the termination of the spinal cord. (Option B) Positioning Patients can be seated or lying on their side (lateral decubitus) on a firm, flat surface. Flex the lumbar spine to separate the vertebral spines maximally and expose the ligamentum flavum. {{caption_text}} Infants should be positioned to maximize convex curvature to the lumbar spine, either lying or sitting. {{caption_text}} Needle Insertion Insert the needle between the spines of L3 and L4 or L4 and L5, and anesthetize the skin and soft tissues. Performed between spinous processes of either L3 and L4 or L4 and L5, using a trocar needle and into subarachnoid space below the level of conus medullaris. (Option A) Depth to Subarachnoid Space: Approximately 1.4 cm in neonates, increasing with age. (Option D) Needle Puncturing {{caption_text}} Needle Path Technique Lumbar puncture needle inserted in the midline or just to one side. Angle the needle in the horizontal and sagittal planes to pierce the ligamentum flavum in or near the midline. Slight loss of resistance as the needle enters the epidural space. Careful advancement to pierce the dura and arachnoid to release CSF. {{caption_text}}

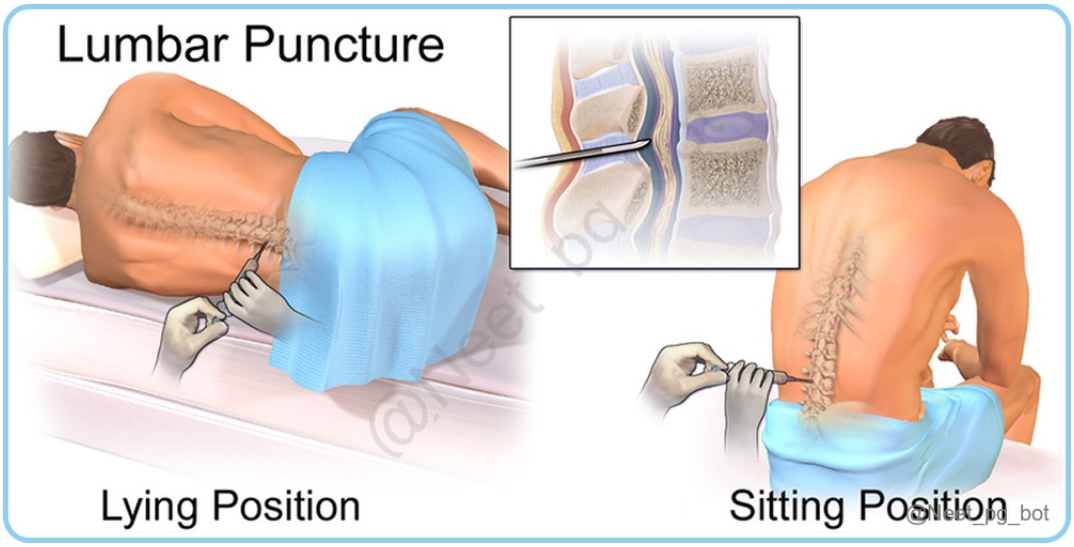

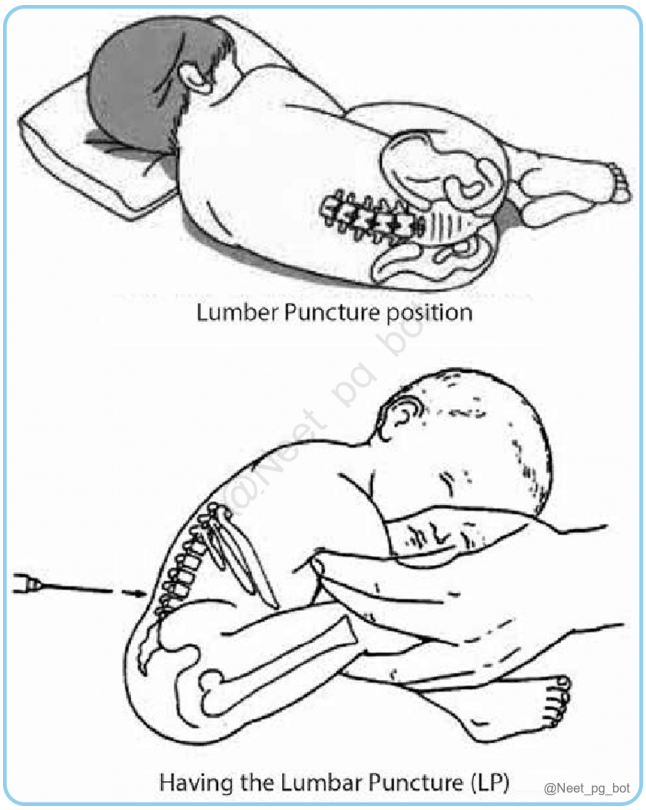
Lumber Puncture position
Having the Lumber Puncture (LP)
@Neet_pg_bot

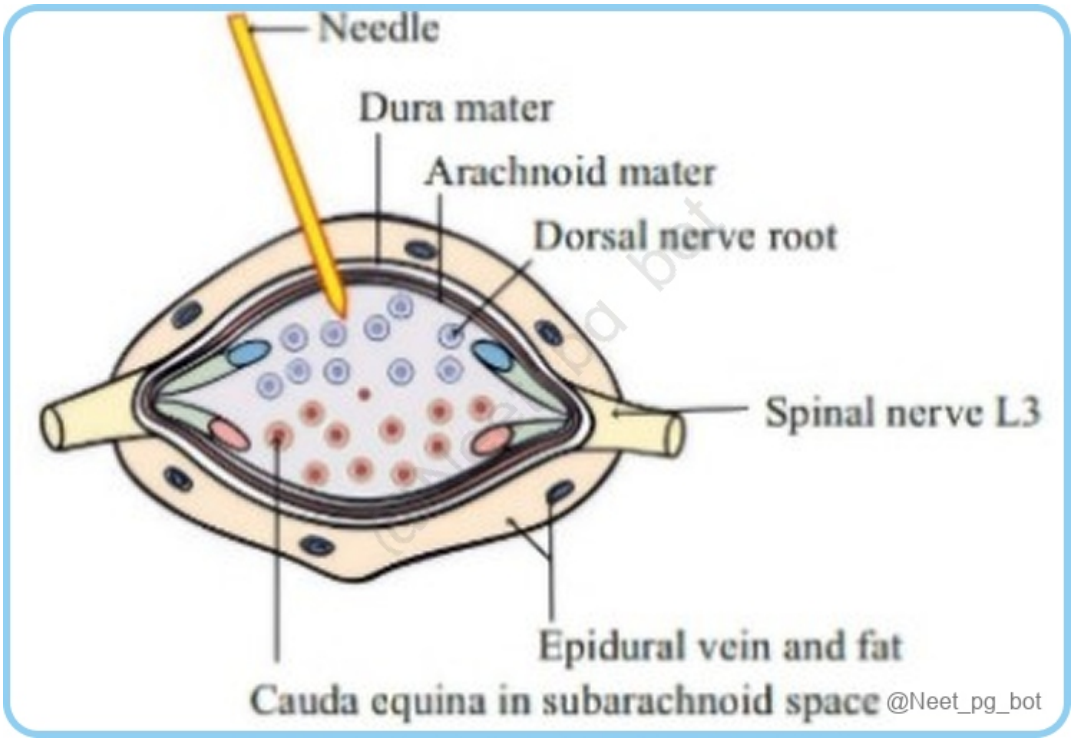
Needle
Dura mater
Arachnoid mater
Dorsal nerve root
Spinal nerve L3
Epidural vein and fat
Cauda equina in subarachnoid space
@Neet_pg_bot

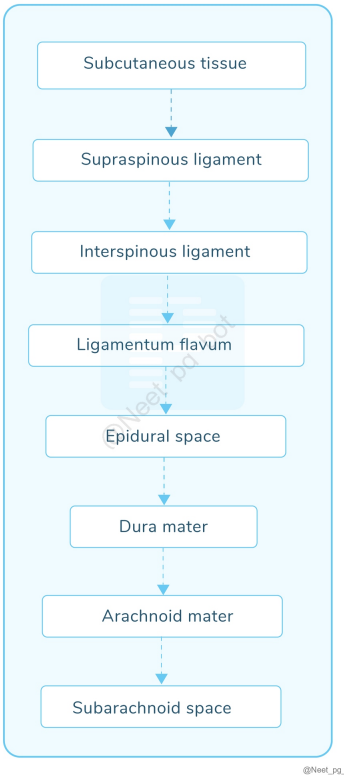

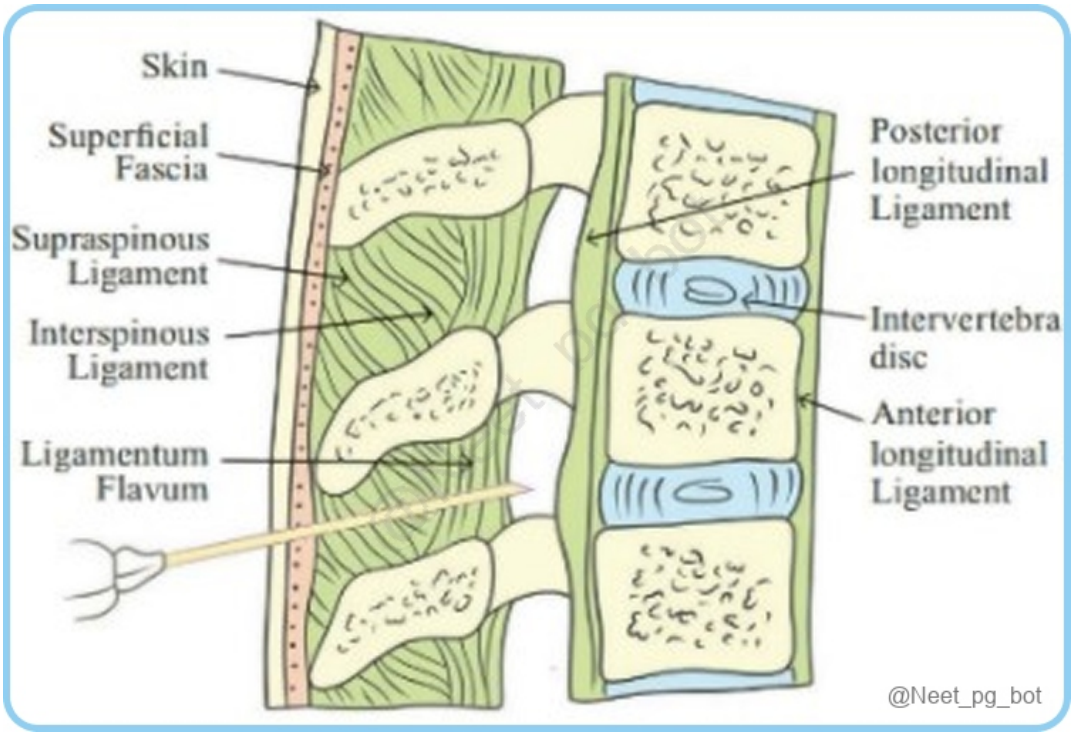

References:

Gray's Anatomy, 42nd Edition, Pages 866, 867

https://www.ncbi.nlm.nih.gov/books/NBK545206/

↑ *Back to this question in Part A*

@Neet_pg_bot

Q4: {{caption_text}} Based on the image, which of the following structures is primarily responsible for facilitating the described movement of the head? (Q848693)

A. Dens (Odontoid process) of C2

B. Transverse ligament of C1

C. Atlanto-occipital joint

D. Superior Articular Facet of C1

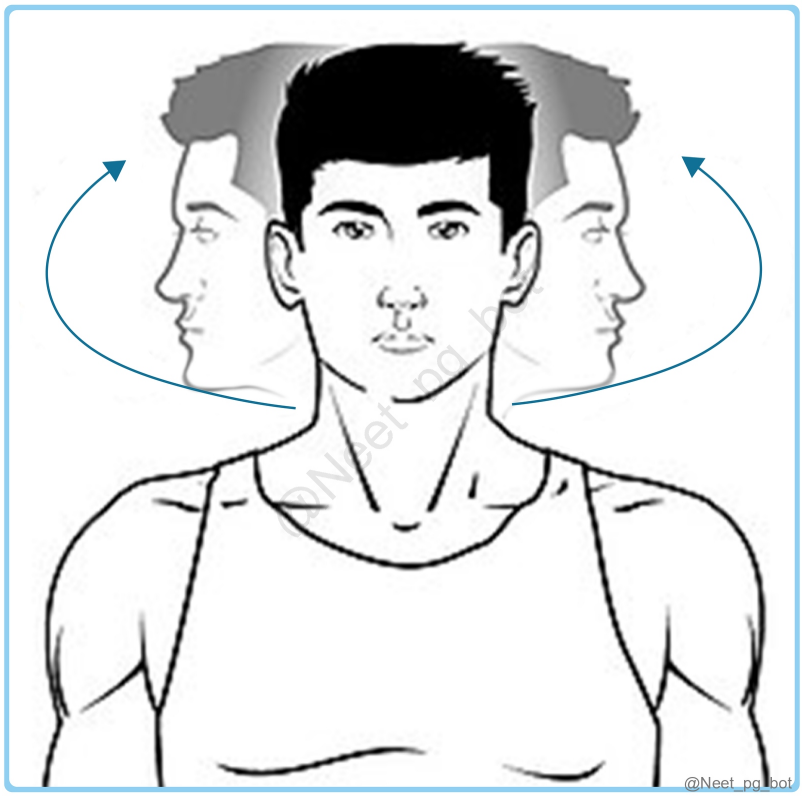

Correct Answer: A. Dens (Odontoid process) of C2

■ *Listen (English)*

■ *Listen (Hindi)*

Explanation: The dens (odontoid process) of C2 is the key structure facilitating head rotation. It projects upward from the axis and fits into the atlas (C1), allowing the atlas and skull to rotate around it. This pivot mechanism enables the characteristic side-to-side movement of the head. C1 Vertebra (Atlas) C2 Vertebra (Axis) {{caption_text}} Body Lacks a traditional vertebral body. Consists of an anterior and posterior arch. Prominent

body with a unique projection called the odontoid process (dens). Odontoid process: Bony projection that fits into the atlas ring, allowing for rotational movement of the head and neck. Spine Lacks spine The spine is massive with a bifid tip Superior Articular Facets Articulate with the occipital condyles of the skull (atlantooccipital joint) Articulate with the inferior facets of the atlas (atlantoaxial joint) ; oriented to permit head rotation. Inferior Articular Facets Articulates with C2 (atlantoaxial joint) Articulates with C3 Transverse process Long transverse process. Has anterior and posterior tubercles for ligament and muscle attachments. Small transverse processes. Lacks anterior tubercle. Transverse Foramen Contains a transverse foramen for the passage of the vertebral artery Role and Movement Supports the skull; allows nodding movements (flexion and extension) of the head. {{caption_text}} Yes movement Crucial for head rotation; the dens serves as the central pivot point. No movement Special Note Distinct for lacking a vertebral body and spinous process. Provides stability and acts as the primary pivot for head rotation.

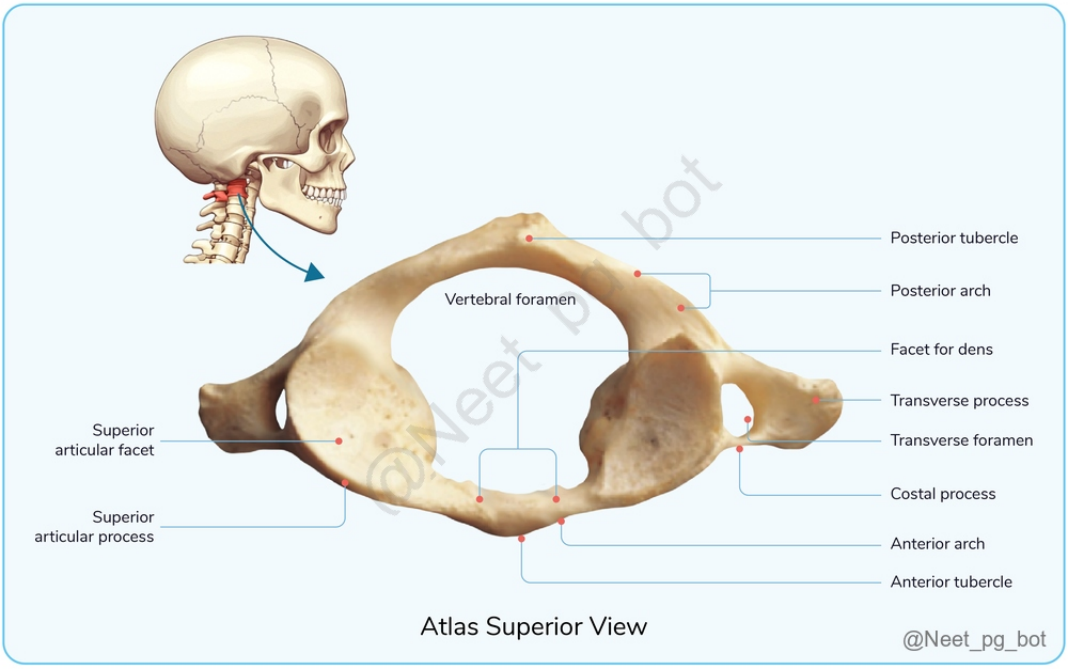

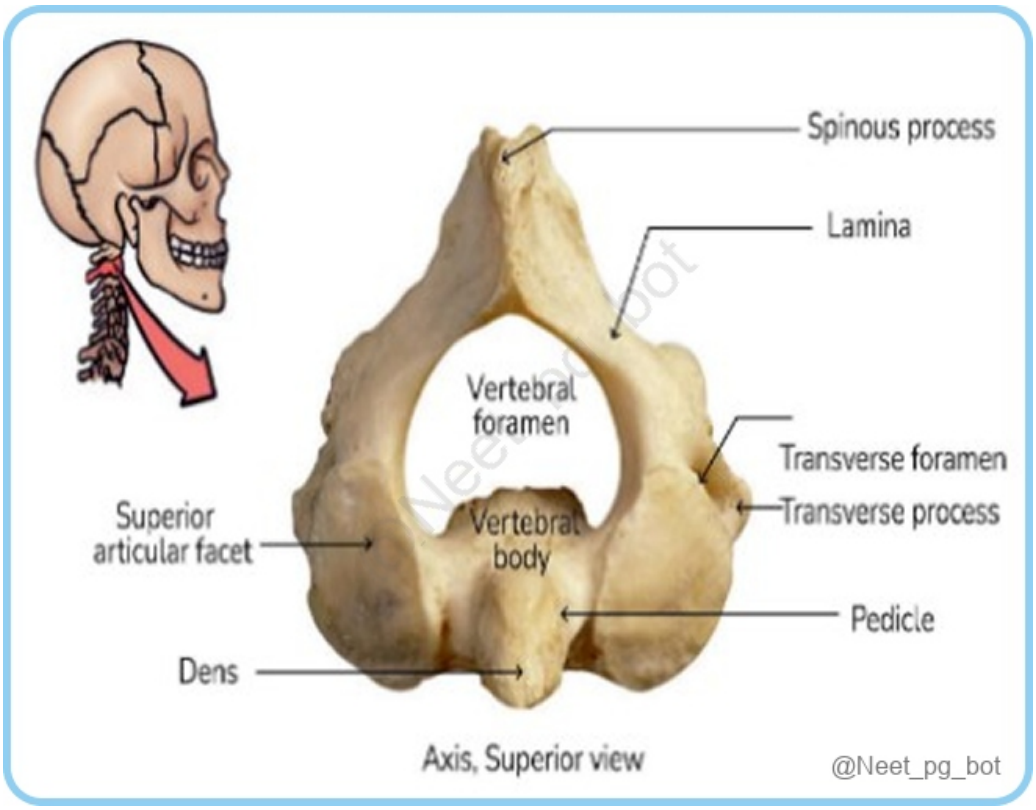
Spinous process
Lamina
Vertebral foramen
Transverse foramen
Transverse process
Superior articular facet
Vertebral body
Pedicle
Dens
Axis, Superior view
@Neet_pg_bot

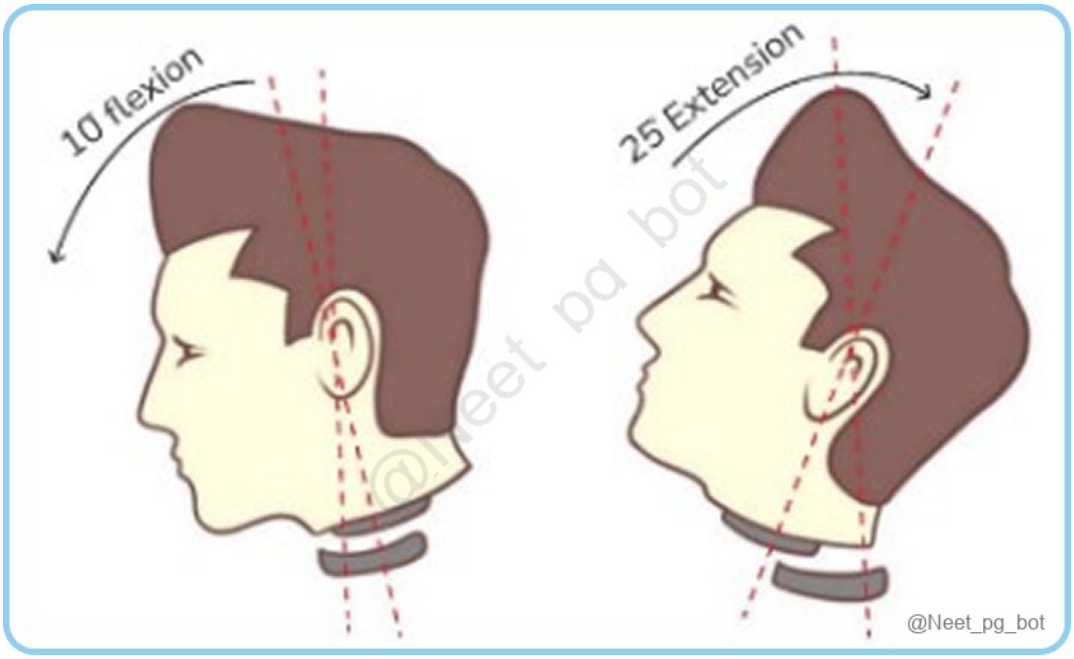
10 flexion
25 Extension
@Neet_pg_bot



References:

Gray’s Anatomy, 42nd Edition, Pages 826,827,828

BD Chaurasia's Human Anatomy, 8th Edition, Pages 53,54,55

↑ *Back to this question in Part A*

@Neet_pg_bot

Q5: Assertion (A): There are 8 cervical spinal nerves despite there being only 7 cervical vertebrae. Reason (R): The first cervical nerve exits above the first cervical vertebra, and the remaining nerves exit below their corresponding vertebrae. (Q848690)

A. Both Assertion and Reason are correct, and the Reason is the correct explanation for the Assertion

B. Both Assertion and Reason are correct, but the Reason is not the correct explanation for the Assertion

C. The Assertion is correct, but the Reason is incorrect

D. The Assertion is incorrect, but the Reason is correct

Correct Answer: C. The Assertion is correct, but the Reason is incorrect

■ *Listen (English)*

■ *Listen (Hindi)*

Explanation: The human cervical spine has 8 cervical spinal nerves, but only 7 cervical vertebrae. The first 7 cervical spinal nerves (C1–C7) exit above their corresponding vertebrae, while C8 exits below the 7th cervical vertebra (between C7 and T1). Regions Number of Vertebrae Spinal Nerves (Pairs) Cervical 7 8 Thoracic 12 12 Lumbar 5 5 Sacral 5 5 Coccygeal 4 (varies) 1 Total 33 vertebrae 31 pairs

References:

Gray's Anatomy, 42nd Edition, Pages 390, 425

Vishram Singh, Textbook of Anatomy: Head, Neck and Brain, Volume 3, 3rd Edition, Page 103

↑ *Back to this question in Part A*

@Neet_pg_bot

Q6: An anatomy professor presents an image of the back region and asks to identify the nerve innervation of muscle marked in green? (Q848698)

A. Dorsal scapular nerve

B. Suprascapular nerve

C. From the dorsal rami of C1

D. Subscapular nerve



Correct Answer: A. Dorsal scapular nerve

- *Listen (English)*
- *Listen (Hindi)*

Explanation: The muscle marked in above image is Levator scapulae, which is innervated by dorsal scapular nerve. Muscle Muscle connecting Origin Insertion Action Nerve supply Trapezius Vertebral column to scapula Thoracic vertebrae Spines of cervical and lateral 1/3 of clavicle + acromion and spine of scapula Rotation of the scapula during abduction of the humerus overhead. It is made up of 3 fibers: 1- Middle fibres: Retract scapula 2- Upper fibres: Elevate the scapula. 3- Lower fibres: Depress scapula. Accessory nerve (11th cranial nerve) Rhomboid major & minor Vertebral column to scapula Thoracic spines Medial border of the scapula. Retract scapula. Dorsal scapular nerve. Levator scapulae Vertebral column to scapula Cervical transverse processes Medial border of the scapula. Elevates scapula Dorsal scapular nerve. Latissimus dorsi Vertebral column to Humerus Spines of thoracic vertebrae Bicipital groove of the humerus. Extension, adduction & medial rotation of humerus. Thoracodorsal nerve

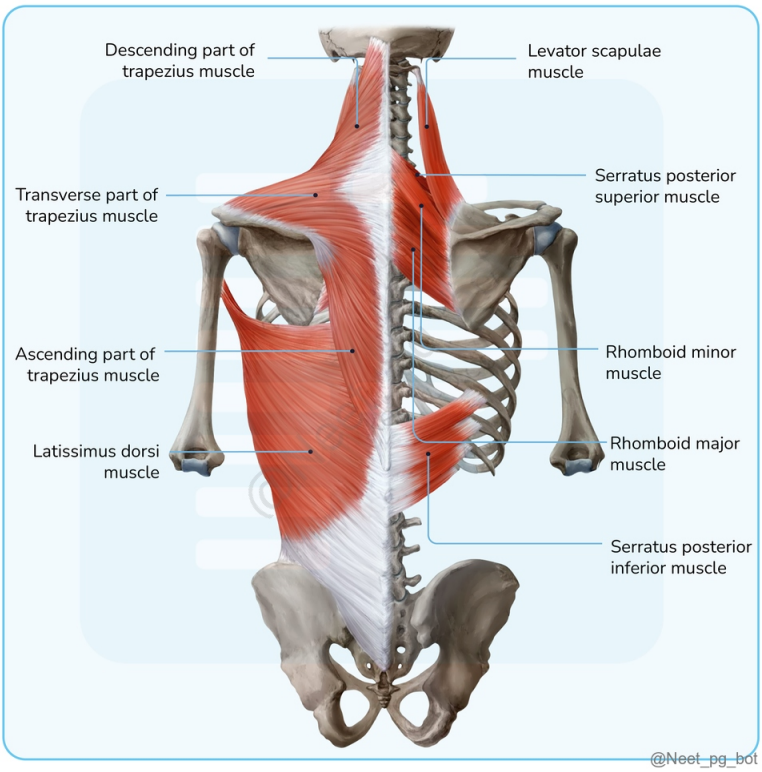

References:

Gray's Anatomy, 42nd Edition, Page 786

↑ *Back to this question in Part A*

@Neet_pg_bot

Q7: By the end of fetal development, at which vertebral level does the spinal cord terminate? (Q848682)

A. Lower border of L1

B. Lower border of L2

C. Upper border of L3

D. Lower border of L3

Correct Answer: C. Upper border of L3

■ *Listen (English)*

■ *Listen (Hindi)*

Explanation: By the end of fetal development, the spinal cord terminates at the upper border of the L3 vertebra. Fetus : Initially, the spinal cord and vertebral column are the same length. The vertebral column grows faster, causing the spinal cord to ascend. Ascent milestones: Begins around 9 weeks . Reaches the last sacral vertebra by 12 weeks. Attains the lower border of S1 by 15 weeks. Reaches the lower border of L4 at 6 months. Reaches the lower border of L3 at full term . (Option C) Child : The spinal cord terminates at the upper border of L3 . Adult : The spinal cord ends at the lower border of L1 (Option A) known as the conus medullaris. Below this level, the vertebral canal contains the cauda equina. Clinical significance: Lumbar puncture in adults must be done below L2 at the level of L3-L4 or L4-L5 laminae as this avoids injury to the spinal cord. In children, it is done at the lower level of L4.

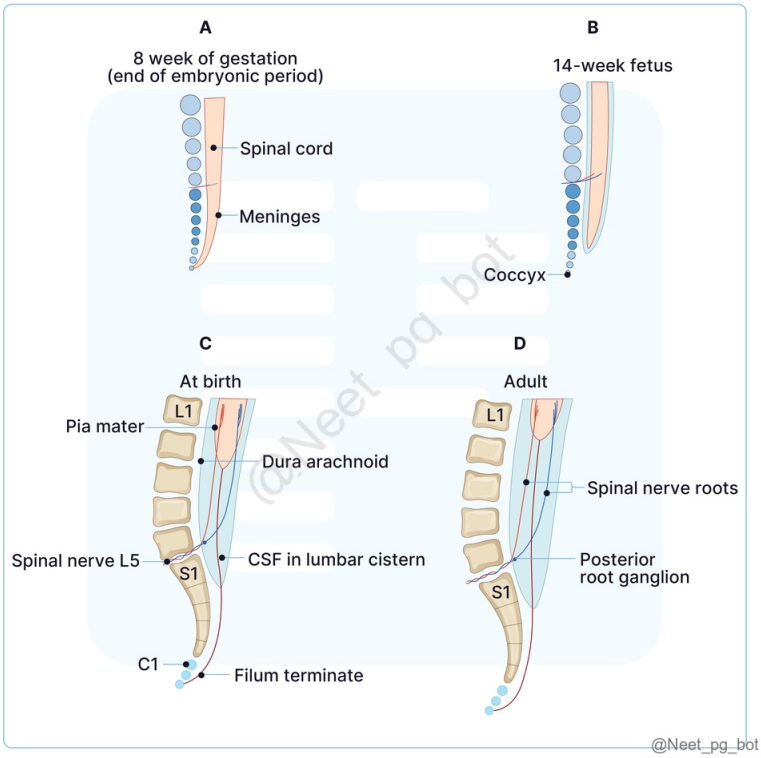

References:

https://www.ncbi.nlm.nih.gov/pmc/articles/PMC9671389/

↑ *Back to this question in Part A*

@Neet_pg_bot

Q8: A 54-year-old female is a known case of rheumatoid arthritis, underwent MRI which showed tectorial membrane thickening. This structure is derived from which of the following ligaments? (Q848697)

A. Anterior atlanto occipital membrane

B. Posterior atlanto occipital membrane

C. Anterior longitudinal ligament

D. Posterior longitudinal ligament

Correct Answer: D. Posterior longitudinal ligament

■ *Listen (English)*

■ *Listen (Hindi)*

Explanation: The membrana tectoria is a structure in the cervical spine that is part of the ligaments of the spinal cord. It is a continuation of the posterior longitudinal ligament (PLL) in the neck region and plays an important role in stabilizing the cervical spine It lies in the upper part of the cervical spine on the posterior surface of vertebral body, specifically in the area around the atlas (C1) and axis (C2), just below the level of the foramen magnum in the skull. Above the level of axis , the posterior longitudinal ligament continues as membrana tectoria. It extends from the axis to foramen magnum.

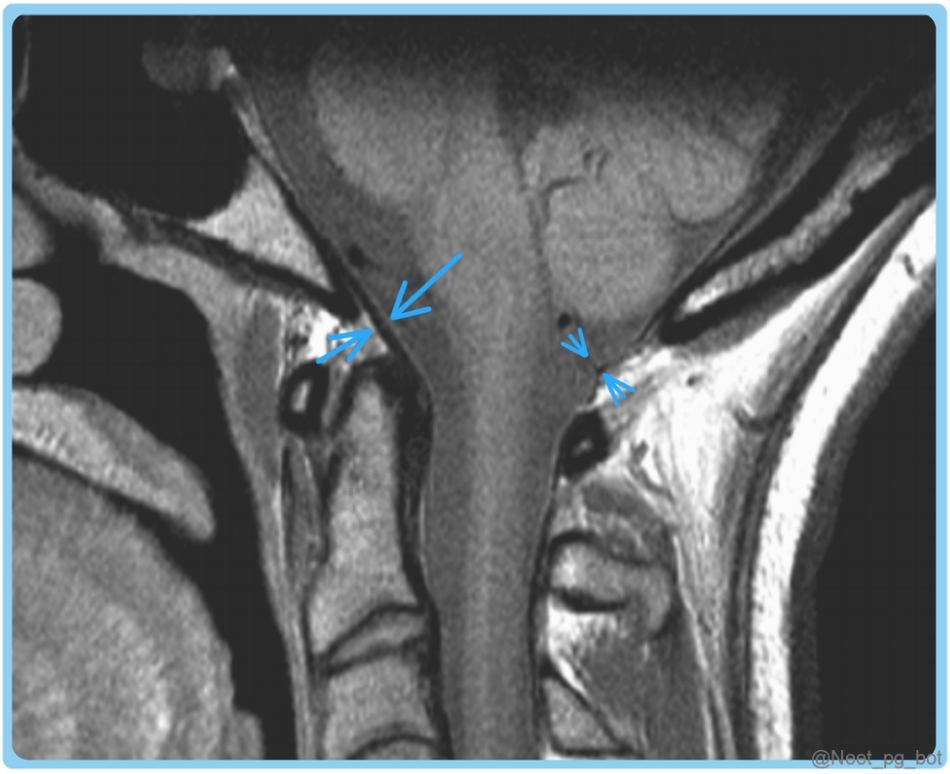

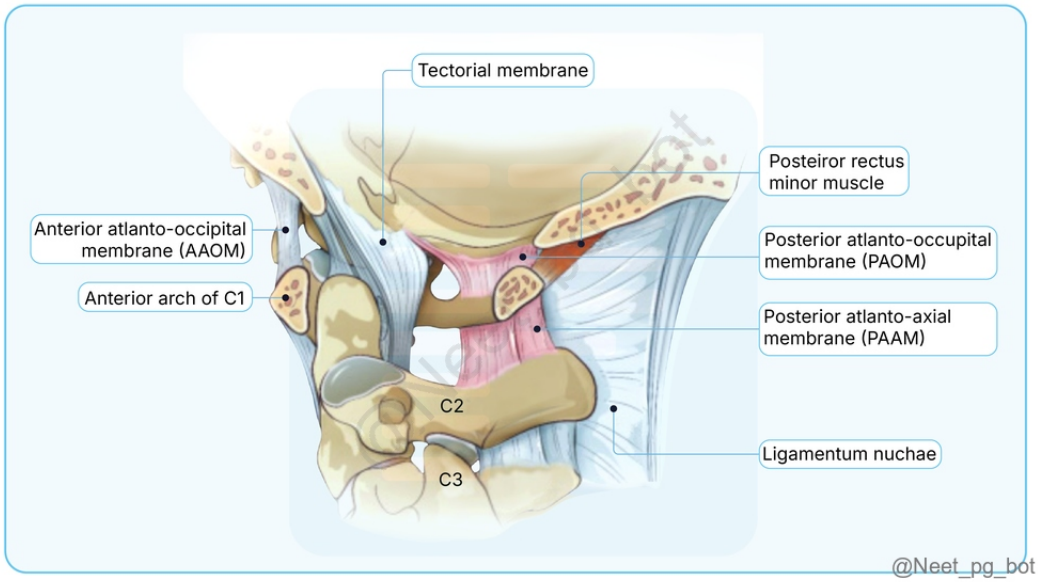

References:

Gray's Anatomy, 42nd Edition, Page 745

↑ *Back to this question in Part A*

@Neet_pg_bot

Q9: Match the right options. a Spine of scapula i T2 b Highest point of iliac crest ii T3 c Superior angle of scapula iii T7 d Inferior angle of scapula iv L4 (Q848695)

A. a-i, b-iii, c-ii, d-iv

B. a-ii, b-i, c-iv, d-iii

C. a-iv, b-ii, c-iii, d-i

D. a-ii, b-iv, c-i, d-iii

Correct Answer: D. a-ii, b-iv, c-i, d-iii

■ *Listen (English)*

■ *Listen (Hindi)*

Explanation: The scapula extends from rib 2 to rib 7 with its superior angle palpable over the trapezius and its inferior angle over the latissimus dorsi. These angles are connected to each other by the medial border of the scapula running vertically. The spine of the scapula is easily palpable as it runs subcutaneously. Parts of scapula Corresponding vertebrae Spine T3 (spinous process) Superior angle T2 Inferior angle T7 Other important landmarks Highest point of iliac crest L4 Posterior-superior iliac spine S2

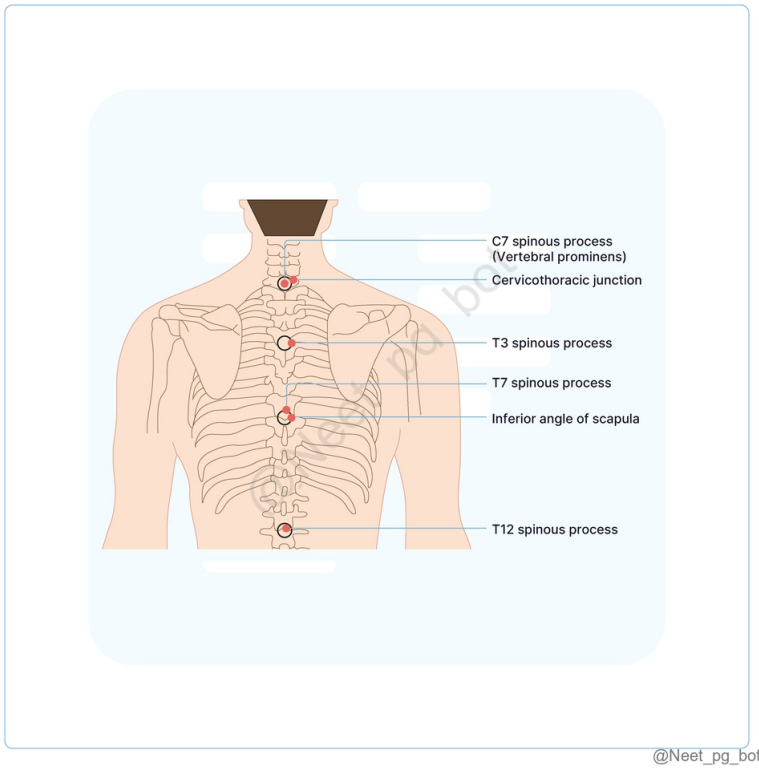

@Neet_pg_bot

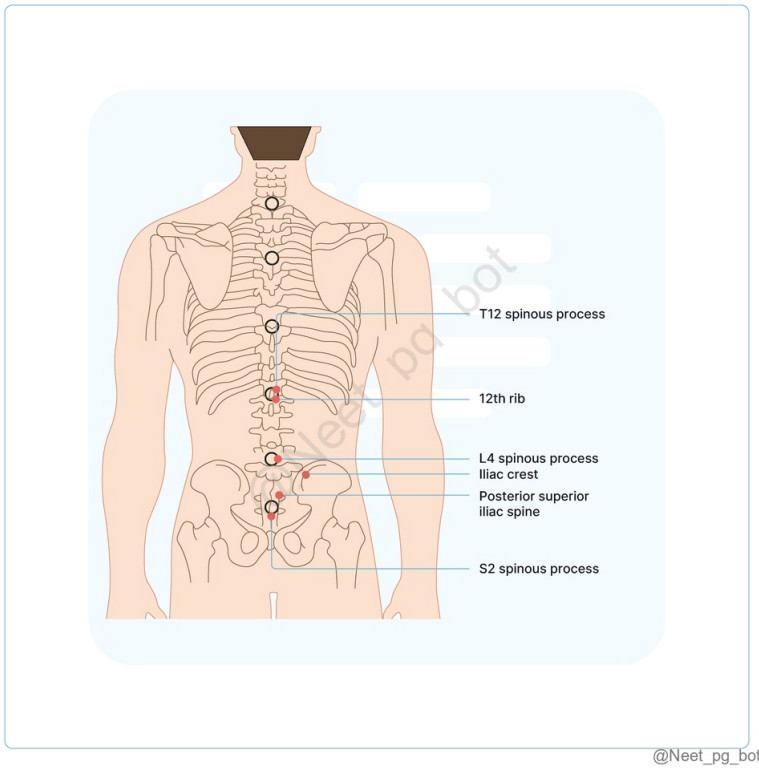

@Neet_pg_bot

References:

Gray’s Anatomy, 42nd Edition, Page 853

Vishram Singh Textbook of Anatomy, 2nd Edition, Page 59

↑ *Back to this question in Part A*

@Neet_pg_bot

Q10: Which of the following is true about cauda equina? (Q848692)

A. It is comprised of the terminal end of the spinal cord

B. Ends at L1-L2 vertebra in adults

C. Surrounded by CSF in the subarachnoid space

D. The filum terminale begins from the apex of cauda equina

Correct Answer: C. Surrounded by CSF in the subarachnoid space

■ *Listen (English)*

■ *Listen (Hindi)*

Explanation: The cauda equina is surrounded by the CSF in the subarachnoid space and is a bundle of spinal nerve roots (not the spinal cord's end) that extends into the sacral region surrounded by the filum terminale . Cauda Equina Conus Medullaris Definition A bundle of spinal nerve roots resembling a horse's tail (Option A) The tapered end of the spinal cord Location Below the conus medullaris, in the vertebral canal At the lower end of the spinal cord Structure Composed of dorsal and ventral nerve roots from L2 to S5 and Co1 Comprised of the terminal end of the spinal cord Number of Nerve Roots 40 nerve roots (16 lumbar, 20 sacral, 4 coccygeal) None; terminates without forming new roots Formation of Spinal Nerves Dorsal and ventral roots join at intervertebral foramina Does not contribute to new spinal nerves Filum Terminale Surrounds cauda equina Attached to the apex of conus medullaris (Option D) Clinical Relevance Site for lumbar puncture; potential for cauda equina syndrome Indicates termination of spinal cord; important for anatomical reference Length Extends to the sacral region, around 15-20 cm (Option B) Generally ends at L1-L2 vertebrae in adults Surrounding Structures Surrounded by cerebrospinal fluid in the subarachnoid space Encased by pia mater; continuous with filum terminale Anatomical Changes with Age Remains relatively constant Position shifts upward in younger individuals

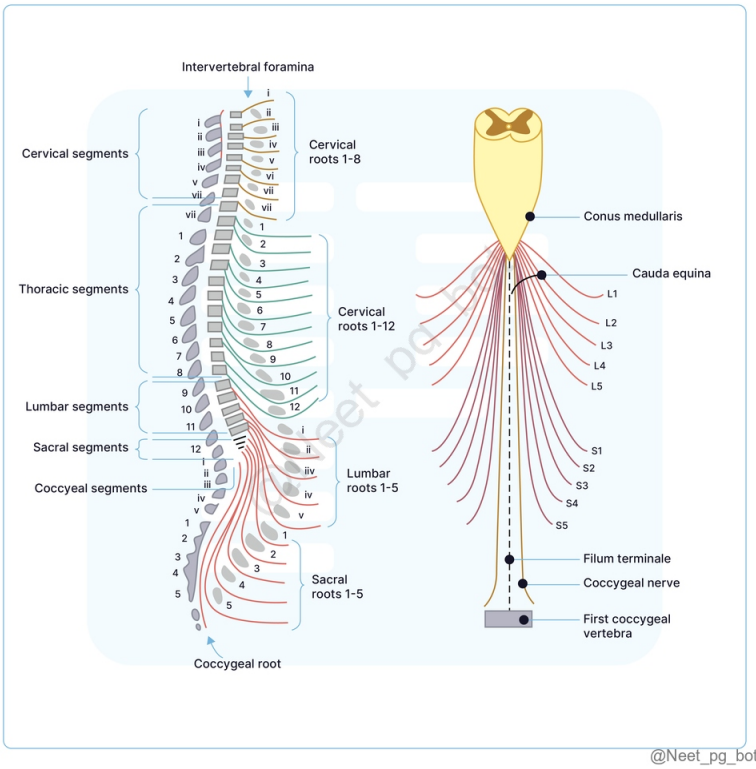

@Neet_pg_bot

References:

Gray's Anatomy, 42nd Edition, Page 856

BD Chaurasia's Human Anatomy, Volume 3, 8th Edition, Pages 36, 210

↑ *Back to this question in Part A*

@Neet_pg_bot

Q11: A 42-year-old male presents with complaints of lower back pain radiating down his left leg, associated with numbness over the top of his foot and difficulty in dorsiflexing his big toe. On examination, he has weakness in the extension of the great toe and decreased sensation along the dorsum of the foot. Reflexes are normal. Based on the symptoms, which vertebral level is most likely affected? (Q848691)

A. L3-L4

B. L4-L5

C. L5-S1

D. T12-L1

Correct Answer: B. L4-L5

- *Listen (English)*
- *Listen (Hindi)*

Explanation: The patient's symptoms suggest nerve root compression, commonly caused by a herniated disc. The key findings in this case include lower back pain radiating down the left leg, numbness over the top of the foot, and weakness in dorsiflexion of the great toe (extensor hallucis longus), without reflex abnormalities. These are classic signs of L5 nerve root involvement. Lumbar Slip Disc (Lower Limb Involvement) In the lumbar region, the nerves exit below their corresponding vertebrae. Therefore, when a disc herniation occurs between two vertebrae, the nerve root corresponding to the lower vertebra is usually compressed. Lumbar Slip Discs and Affected Nerve Roots Herniated Disc Between Compressed Nerve Root Symptoms (Lower Limb) L3 and L4 L4 Weakness in knee extension, reduced patellar reflex L4 and L5 L5 Weakness in foot dorsiflexion, difficulty walking L5 and S1 S1 Pain down the back of the leg, reduced Achilles reflex, foot drop L3-L4 (Option A): Compression at this level typically affects the L4 nerve root, causing weakness in knee extension (quadriceps) and decreased sensation over the medial side of the lower leg. This is not consistent with the patient's symptoms. L5-S1 (Option C): Compression here would affect the S1 nerve root, causing weakness in plantarflexion (gastrocnemius), decreased ankle reflex, and sensory loss along the lateral aspect of the foot. This does not match the patient's findings. T12-L1 (Option D): This is much higher in the vertebral column and would affect muscles and sensations around the lower abdomen and upper thighs, which are unrelated to the symptoms described in this case.



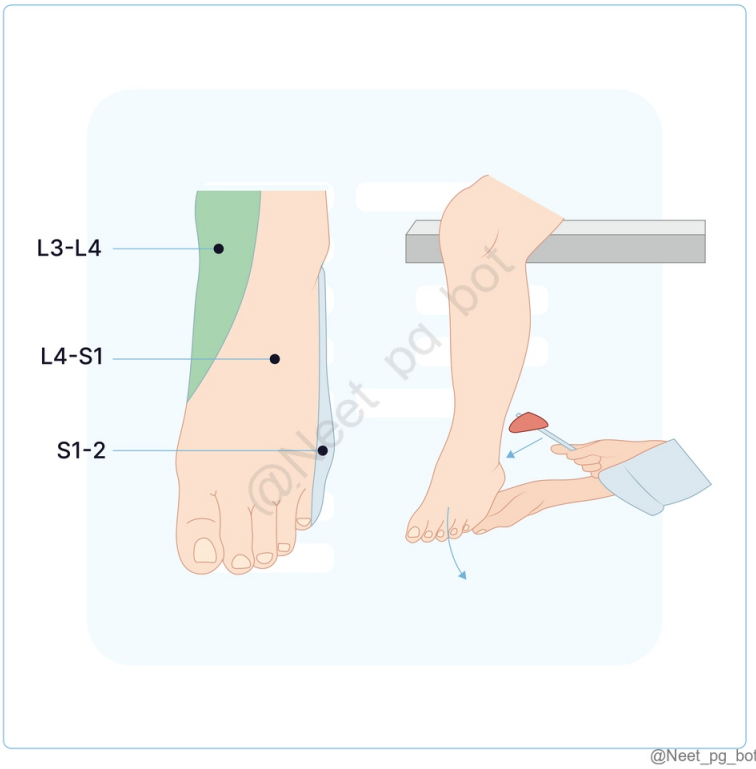

References:

Maheshwari- Essential Orthopaedics, 5th Edition, Pages 254, 255

↑ *Back to this question in Part A*

@Neet_pg_bot

Q12: A 2-year-old child is brought in for a routine check-up. The parents have noticed a pronounced lumbar curvature since the child began walking. Which of the following best describes this lumbar curvature? (Q848689)

A. Primary curvature

B. Secondary curvature

C. Compensatory curve from sacral kyphosis

D. Curvature related to increased abdominal weight

Correct Answer: B. Secondary curvature

■ *Listen (English)*

■ *Listen (Hindi)*

Explanation: Lumbar lordosis is a secondary curvature that becomes evident in infancy as the child begins to assume upright posture, stand and walk, contributing to normal posture development. Vertebral Curvature: Vertebral column in adults has 4 curvatures: Cervical lordosis Thoracic kyphosis Lumbar lordosis Sacral kyphosis Types of Vertebral Curvature: Primary Curvature Secondary Curvature Developmental. Thoracic and sacral kyphosis (both concave anteriorly) are primary curvatures. (Option A & C) Develop during the fetal period in response to the flexed fetal position. Are in the same direction as the main curvatures of the fetal vertebral column. Retained throughout life due to differences in height between the anterior and posterior parts of the vertebrae. Acquired in relation to the erect human posture. Cervical and lumbar lordosis (both concave posteriorly) are secondary curvatures. Result from extension from the flexed fetal position. Begin to appear during the late fetal period but do not become obvious until infancy (roughly, 1st year). Secondary curvatures are primarily maintained by differences in the thickness between the anterior and posterior parts of the intervertebral (IV) discs. Cervical lordosis becomes evident when an infant begins to raise (extend) the head while prone and to hold the head up while sitting. Lumbar lordosis appears when toddlers (children learning to walk) begin to assume upright posture, standing and walking. It is more pronounced in females. (Option B) Functional Importance: Curvatures of the vertebral column enhance flexibility (shock-absorbing resilience), augmenting the passive flexibility provided by the intervertebral (IV) discs. Response to Increased Load: When bearing heavy loads (e.g., carrying a heavy backpack), both the IV discs and curvatures are compressed, increasing the curvature. Impact of Additional Anterior Weight: Carrying weight in front of the body's normal gravitational axis (e.g., large breasts, obesity, pregnancy, or carrying a child) tends to increase these curvatures. (Option D)

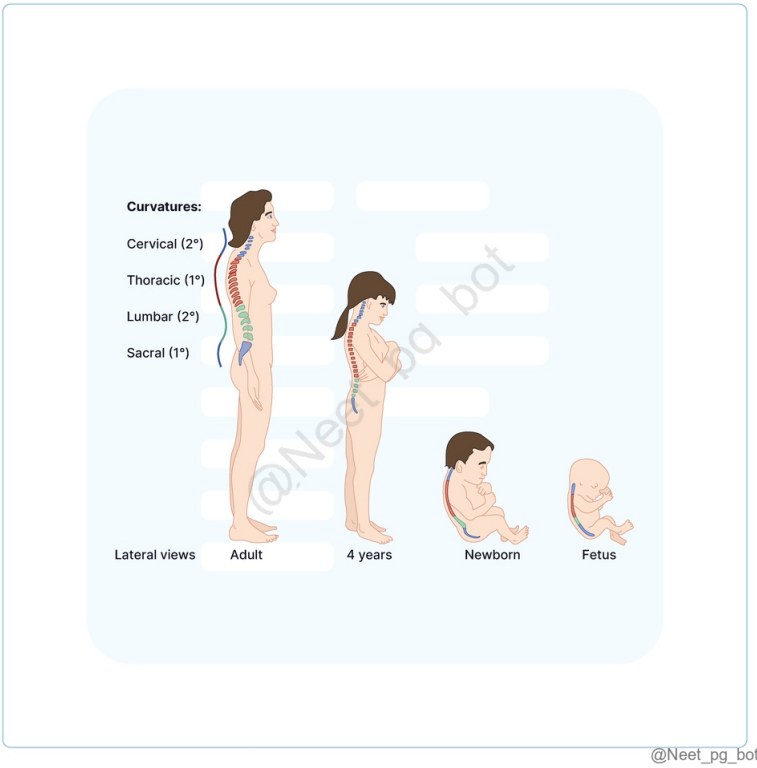

@Neet_pg_bot

References:

Moore's Clinically Oriented Anatomy, 9th Edition, Chapter: Vertebral Column

↑ *Back to this question in Part A*

@Neet_pg_bot

Q13: A patient has restricted spinal rotation and lateral flexion. Which vertebral structure primarily functions as a lever for these movements? (Q848687)

A. Spinous process

B. Superior articular process

C. Inferior articular process

D. Transverse process

Correct Answer: D. Transverse process

■ *Listen (English)*

■ *Listen (Hindi)*

Explanation: Transverse processes project laterally from the pediculolaminar junctions and serve as levers for muscles and ligaments mainly involved in spinal rotation and lateral flexion. Typical Vertebra Has a ventral body, dorsal arch with processes, and a vertebral foramen. Image {{caption_text}} Spinous Processes (Option A) Project dorsally from the junction of the lamina. Act as levers for muscles that control posture and active movements (flexion/extension, lateral flexion and rotation) of the vertebral column. Transverse Processes (Option D) Project laterally from the pediculolaminar junctions. Serve as levers for muscles and ligaments, mainly concerned with rotation and lateral flexion. Articular Processes (Option B & C) Superior articular processes project cranially with dorsal facets; inferior articular processes project caudally with ventral facets. They form zygapophysial or facet joints and form part of the posterior boundaries of intervertebral foramina, permitting only limited vertebral movement. Trabecular Structure Vertebrae are internally composed of trabecular bone with an outer shell of compact bone perforated by vascular foramina. Trabecular interior contains red bone marrow and basivertebral veins.

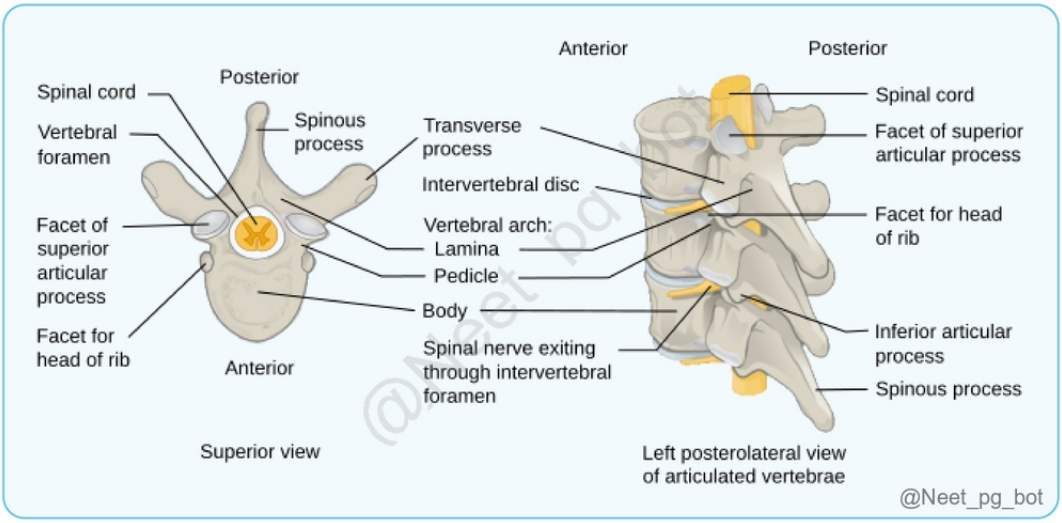

References:

Gray's Anatomy, 42nd Edition, Pages 822, 823

↑ *Back to this question in Part A*

@Neet_pg_bot

Q14: An anatomy professor presents an image of a vertebra in class and asks the students to identify its type. Which type of vertebra is depicted in the image? {{caption_text}} (Q848686)

A. Cervical vertebrae

B. Thoracic vertebrae

C. Lumbar vertebrae

D. Sacral vertebrae

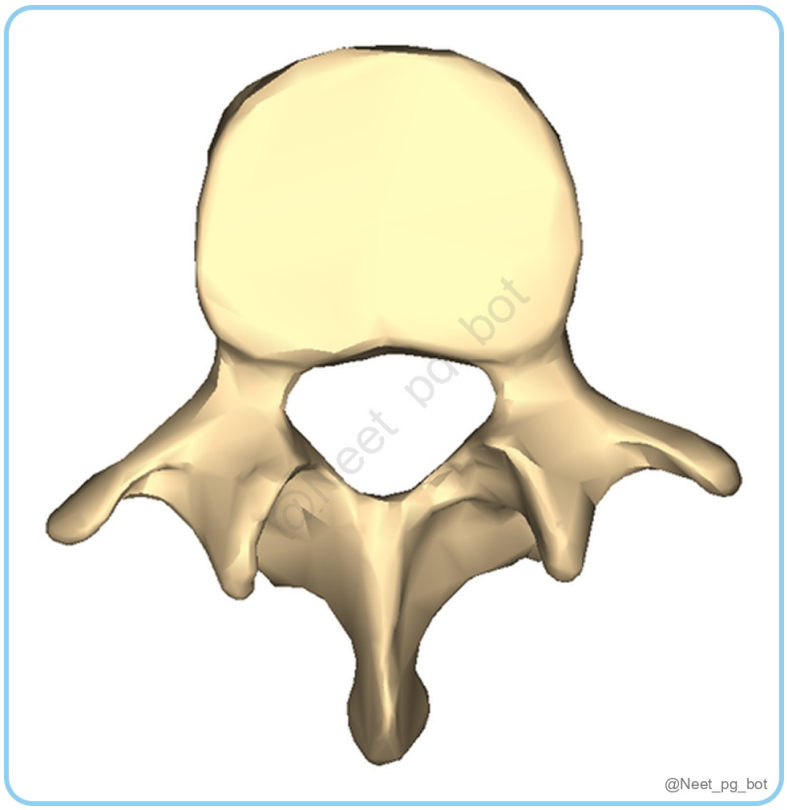

Correct Answer: C. Lumbar vertebrae

- *Listen (English)*
- *Listen (Hindi)*

Explanation: Lumbar vertebrae are characterized by their large size, thick and horizontal spinous processes , and the absence of transverse foramina (which are present in cervical vertebrae) or costal facets (which are found in thoracic vertebrae). Feature Cervical Vertebrae (Option A) Thoracic Vertebrae (Option B) Lumbar Vertebrae (Option C) Image {{caption_text}} Size Small size Intermediate-size Large size Body Small , broad with a convex anterior surface. Waisted cylinder ; nearly equal transverse and AP dimensions. Wider transversely Vertebral Canal Triangular Small and circular Triangular Pedicles and Laminae Pedicles: Attach midway between the discal surface of the vertebral body. Lamina: Thin , slightly curved . Pedicles: Do not diverge as the vertebral foramen is small and circular Lamina: Short , thick , and broad. Pedicles: Short Laminae: Broad and short . Spinous Process Short , bifid with two unequal tubercles. Slants downward. Almost horizontal, quadrangular, and thickened along its posterior and inferior borders. Transverse Process Composite structure Large, club-like. Long, thin. Superior Articular Facets Flat and ovoid, directed superoposteriorly . Directed posteriorly and slightly superolaterally . Bear vertical concave facets facing posteromedially . Inferior Articular Facets Directed mainly anteriorly . Directed forwards and slightly superomedially . Have vertical convex articular facets facing anterolaterally. Special Features Foramen Transversarium: Transmits the vertebral artery and vein, and a branch from the cervicothoracic ganglion (vertebral nerve) except in the seventh cervical vertebra. Have lateral costal facets and transverse process facets for rib articulation. Costal facets and transverse foramina are absent. Sacral vertebrae (Option D) are not considered individually because they fuse into a single immobile sacrum during adolescence, typically formed from five segments.

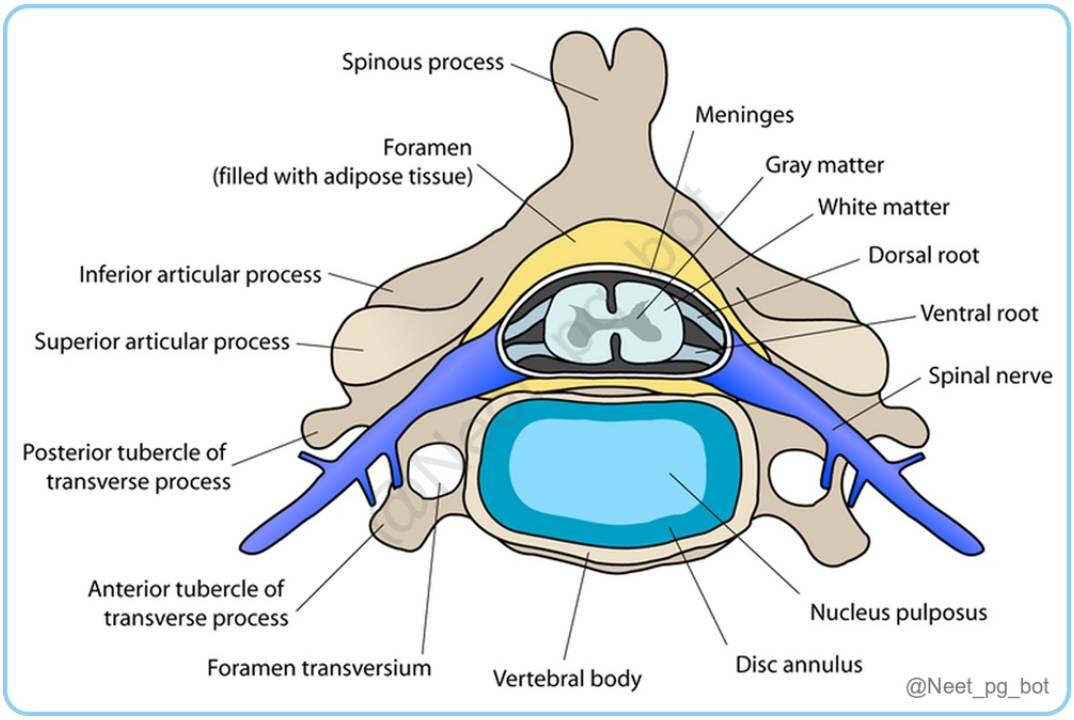
Spinous process
Meninges
Foramen
(filled with adipose tissue)
Gray matter
White matter
Dorsal root
Inferior articular process
Ventral root
Superior articular process
Spinal nerve
Posterior tubercle of
transverse process
Anterior tubercle of
transverse process
Nucleus pulposus
Foramen transversium
Vertebral body
Disc annulus
@Neet_pg_bot

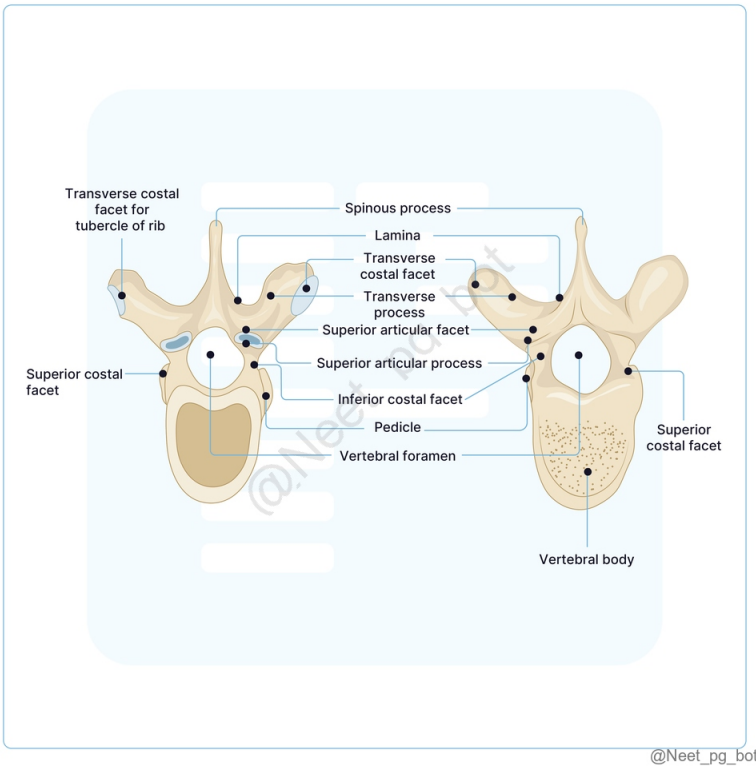
Transverse costal
facet for
tubercle of rib
Spinous process
Lamina
Transverse
costal facet
Transverse
process
Superior articular facet
Superior articular process
Superior costal
facet
Inferior costal facet
Pedicle
Vertebral foramen
Superior
costal facet
Vertebral body
@Neet_pg_bot

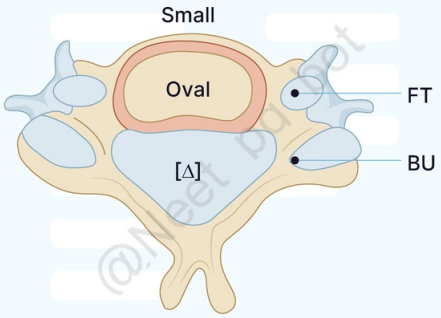

@Neet_pg_bot

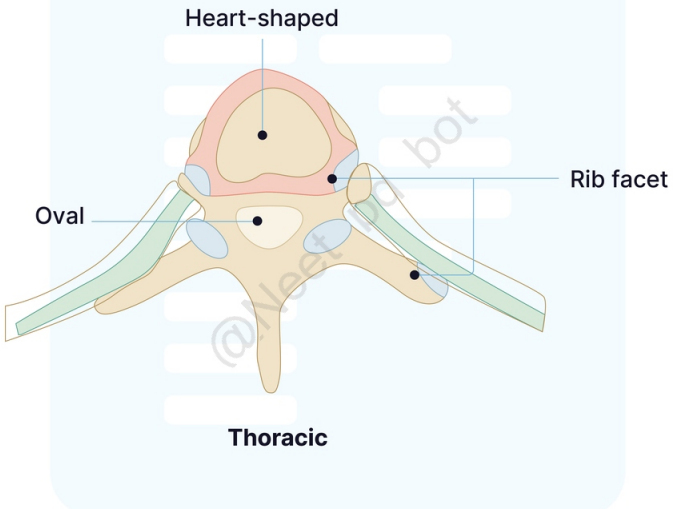

@Neet_pg_bot

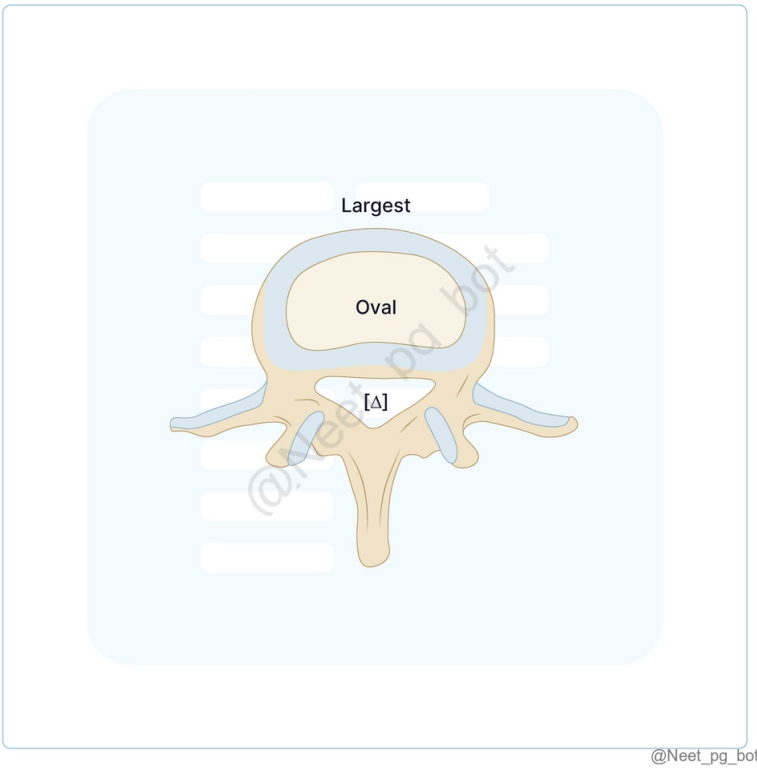

@Neet_pg_bot

References:

Gray’s Anatomy, 42nd Edition, Pages 824-830

https://www.sciencedirect.com/topics/immunology-and-microbiology/sacral-vertebra#

↑ *Back to this question in Part A*

@Neet_pg_bot

Q15: A 35-year-old patient undergoes spinal surgery. Postoperatively, he develops a cerebrospinal fluid leak. Which space is most likely compromised? (Q848685)

A. A

B. B

C. C

D. D

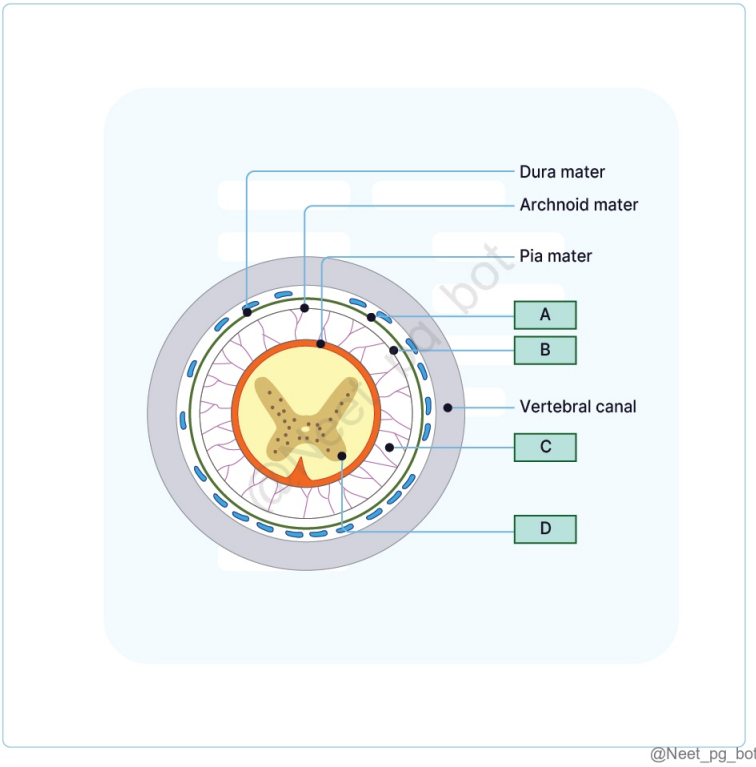

@Neet_pg_bot

Correct Answer: C. C

- *Listen (English)*
- *Listen (Hindi)*

Explanation: The subarachnoid space , which contains cerebrospinal fluid (CSF), is likely compromised after spinal surgery due to potential puncture of the dura or arachnoid. Epidural Space (Option A) Subdural Space Subarachnoid Space Located between the spinal dura mater and the periosteum. Contains: Loose areolar tissue Semiliquid fat Spinal arteries supplying deeper structures Internal vertebral venous plexus. Epidural anesthesia is given here Potential space between the dura and arachnoid mater. (Option B) Contains a thin layer of serous fluid. Allows movement of the dura over the arachnoid. Extends onto spinal nerves and connects with lymphatic spaces. Wide space between pia mater and arachnoid mater. Filled with cerebrospinal fluid (CSF) . (Option C) Cushions the brain and spinal cord. Wider in the spinal region, especially below the spinal cord where it encloses the cauda equina. Lumbar punctures are typically performed between L3 & L4 vertebrae. Periosteal space (Option D) is not a recognized anatomical space for CSF.

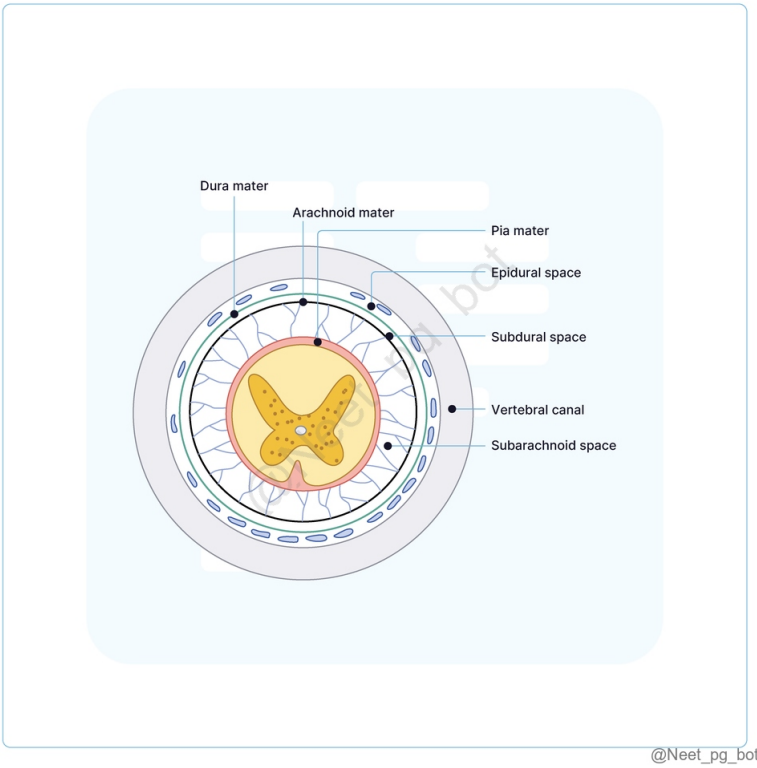

@Neet_pg_bot

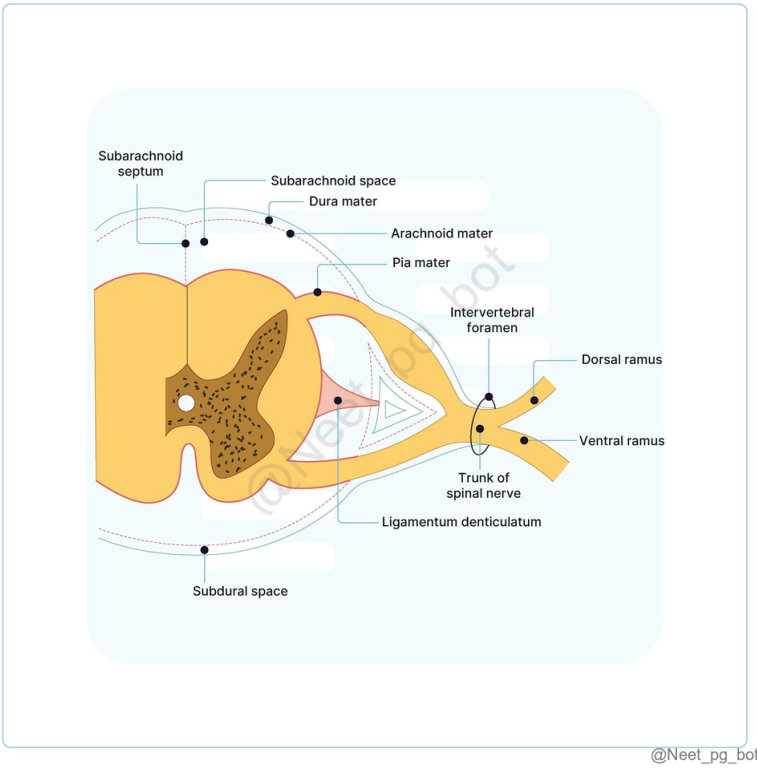

@Neet_pg_bot

References:

BD Chaurasia's Human Anatomy, Volume 3, 8th Edition, Page 207

↑ *Back to this question in Part A*

@Neet_pg_bot

Q16: A patient undergoes a procedure affecting a delicate, thread-like structure extending from the conus medullaris to the coccyx as marked in the figure. Which of the following statements regarding this structure is correct? {{caption_text}} (Q848684)

A. It is composed mainly of dura mater and contains no nerve fibers

B. Distal part of it is called the coccygeal ligament.

C. It does not extend beyond the sacral hiatus

D. It measures about 50 cm in length



Correct Answer: B. Distal part of it is called the coccygeal ligament.

■ *Listen (English)*

■ *Listen (Hindi)*

Explanation: The marked structure in the given image is the Filum terminale and it consists of 2 parts: filum terminale internum and the distal filum terminale externum, also known as the coccygeal ligament . {{caption_text}} Filum terminale is a thread-like extension of the pia mater (Option A) measuring about 20 cm in length. (Option D) Location : Extends from the tip of the conus medullaris to the base of the coccyx. Pathway : Pierces the dural tube, traverses the sacral canal and sacral hiatus (Option C) and attaches to the dorsal surface of the first coccygeal vertebra.

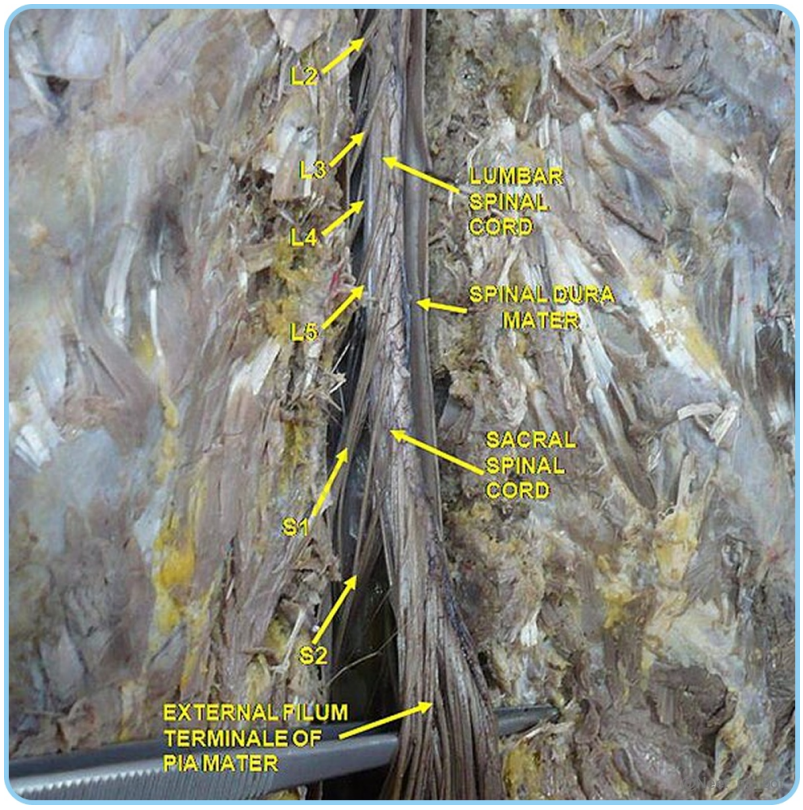

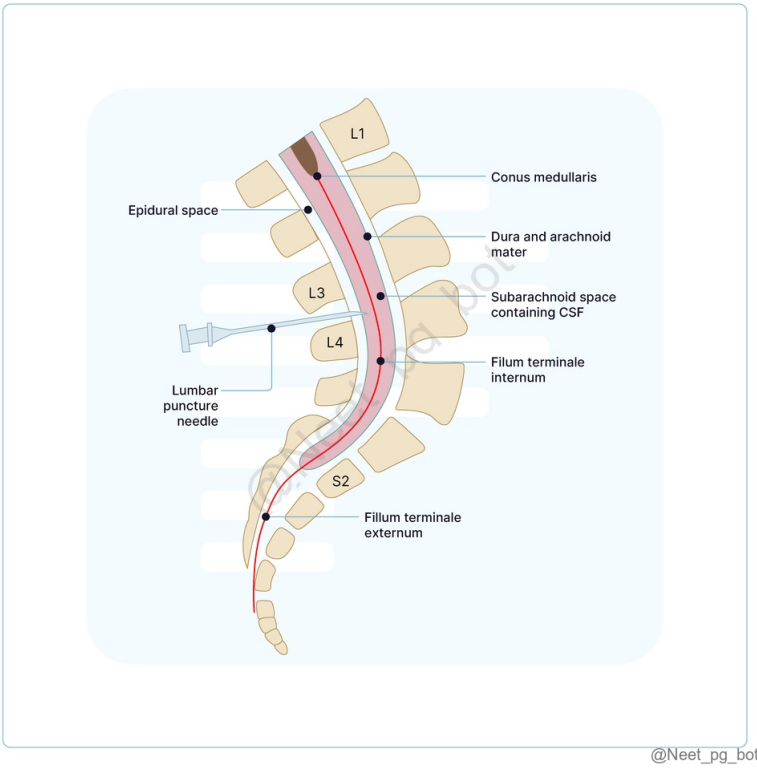

@Neet_pg_bot

References:

BD Chaurasia's Human Anatomy, Volume 3, 8th Edition, Pages 207, 208

Snell's Clinical Anatomy by Regions, 10th Edition, Page 69

↑ *Back to this question in Part A*

@Neet_pg_bot

Q17: Which of the following spinal segments is located between the cervical enlargement of the spinal cord? (Q848683)

A. T9 to L1

B. C5 to T1

C. L2 to S3

D. C3 to T1

Correct Answer: B. C5 to T1

■ *Listen (English)*

■ *Listen (Hindi)*

Explanation: The cervical enlargement is specifically found in the C5 to T1 spinal segments, providing nerves that form the brachial plexus . Cervical Enlargement Lumbar Enlargement Extent C5 to T1 spinal segments (Option B) L2 to S3 spinal segments (Option C) Function Gives rise to the brachial plexus Contributes to the lumbar plexus Corresponding vertebral level C3 to T1 vertebrae. (Option D) T9 to L1 vertebrae. (Option A)

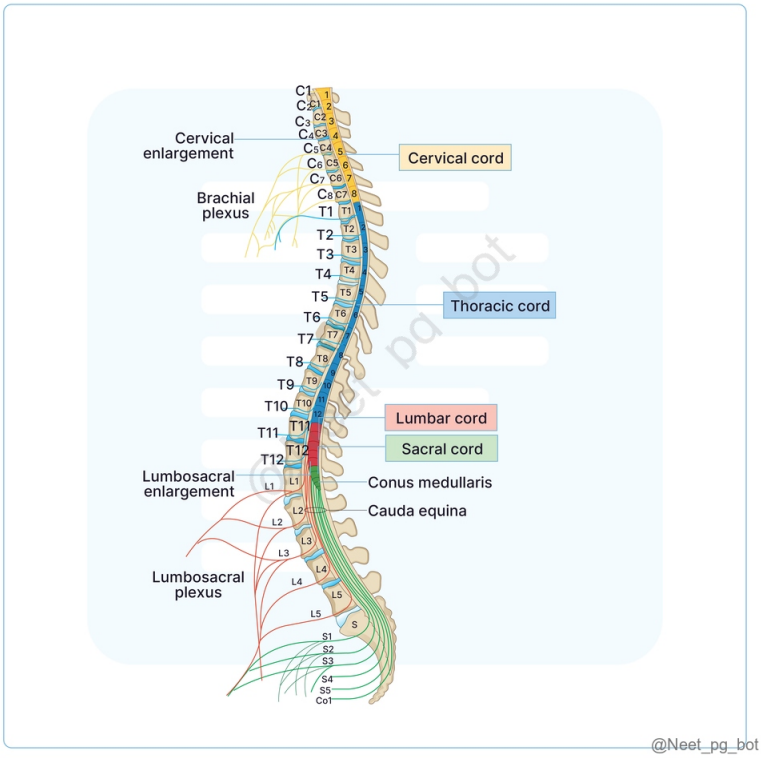

References:

Vishram Singh Textbook of Anatomy, 2nd Edition, Volume 3, Page 306

↑ *Back to this question in Part A*

@Neet_pg_bot

• [12_Back Region] 052 Previous Year Questions

« Back to Folder Directory

[12_Back Region] 052 Previous Year Questions — Quick Jump

Q1 (p. 2181) *Q2 (p. 2182)* *Q3 (p. 2184)*

Q1: Which of the following nerves supplies the muscle that is involved in the moment given below? (Q860271)

A. Spinal accessory nerve

B. Long thoracic nerve

C. Spinal branch of axillary nerve

D. Radial nerve



Correct Answer: A. Spinal accessory nerve

Explanation: The movement shown in the image is shrugging, which is carried out by the trapezius muscles and supplied by the spinal accessory nerve. Lesion of the accessory nerve or paralysis of the trapezius leads to

drooping of shoulders and difficulty in shrugging and weakness of overhead abduction. Trapezius Origin: Occipital bone and cervicothoracic spine Insertion: Scapula Bone and Clavicle Three sets of fiber: Upper: Insertion on clavicle (lateral 1/3posterior side) Middle: Insertion on acromion process anteriorly Lower: Insertion on the spine of the scapula Nerve Supply: Accessory nerve (CN XI) Action: Elevation (upper fiber) and depression (lower fiber) Retractor (Midline) Rotates the Glenoid cavity superiorly. Long thoracic nerve (Option B): Supplies serratus anterior, which is responsible for scapular protraction (not related to the given movement). Spinal branch of axillary nerve (Option C): Supplies deltoid and teres minor, involved in shoulder abduction and lateral rotation. Radial nerve (Option D): Innervates triceps, wrist extensors, and is involved in elbow extension and wrist extension.

References:

https://www.ncbi.nlm.nih.gov/books/NBK532245/# :

↑ *Back to this question in Part A*

@Neet_pg_bot

Q2: What is the action of the muscle shown in the image below? (Q857327)

A. Retracts the scapula

B. Adduction of the shoulder

C. Extension of the shoulder

D. Medial rotation of the shoulder

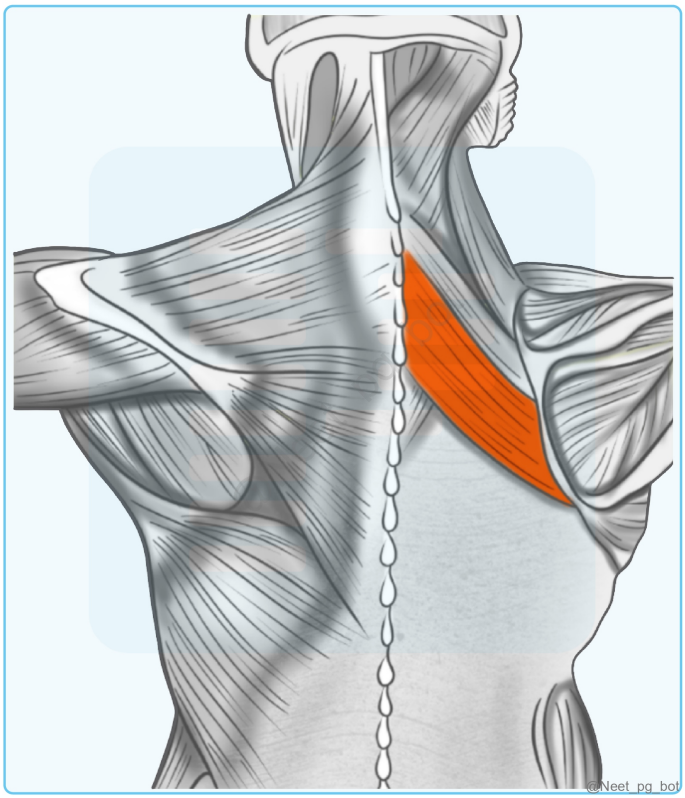

Correct Answer: A. Retracts the scapula

Explanation: The muscle identified in the image is the rhomboid major. Originating from the C7 and T1 vertebrae, it inserts along the medial border of the scapula. Primarily functioning as a retractor, the rhomboid major also plays roles in elevating the scapula and rotating it to depress the glenoid cavity. Muscle Muscle connecting Origin Insertion Action Nerve supply Trapezius vertebral column to scapula Spines of cervical and thoracic vertebrae lateral 1/3■ of clavicle + acromion and spine of scapula Rotation of scapula during abduction of humerus above horizontal. It is made up of 3 fibers: 1- Middle fibers: retract scapula 2- Upper fibers: elevate scapula. 3- Lower fibers: depress scapula. Accessory nerve (11th cranial nerve) Rhomboid major & minor Vertebral column to scapula Thoracic spines Medial border of scapula. Retract scapula. Dorsal scapular nerve Levator scapulae Vertebral column to scapula Cervical transverse processes Medial border of scapula Elevates scapula Dorsal scapular nerve Latissimus dorsi Vertebral column to Humerus Spines of thoracic vertebrae Bicipital groove of humerus Extension, adduction & medial rotation of humerus Thoracodorsal nerve

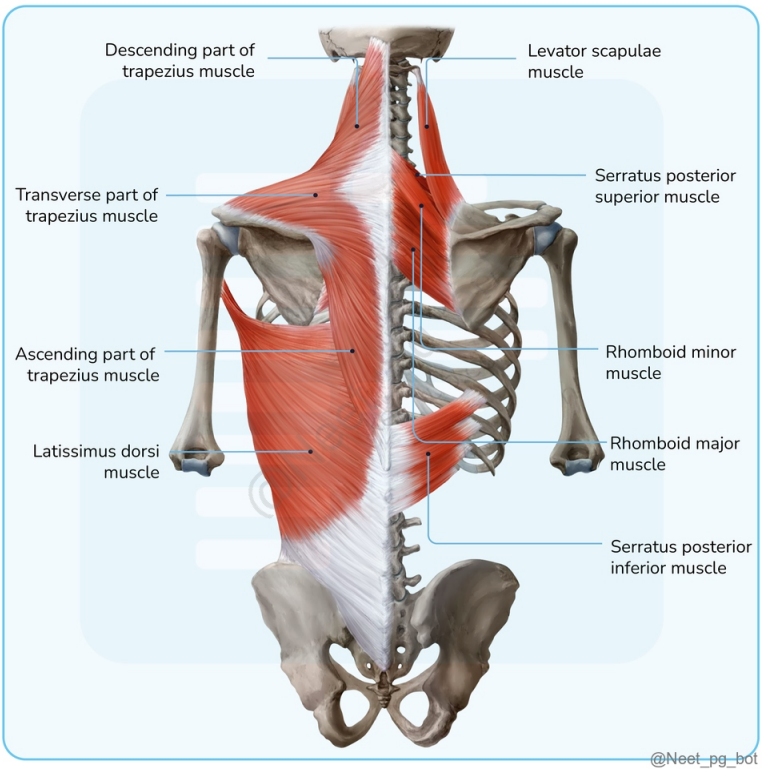

References:

Gray's Anatomy, 42nd edition, pg: 786

↑ *Back to this question in Part A*

@Neet_pg_bot

Q3: Match the following: Muscle Action a. Pectoralis major 1. Extension at shoulder b. Supraspinatus 2. Flexion at shoulder c. Infraspinatus 3. Lateral rotation of shoulder d. Latissimus dorsi 4. Abduction at shoulder (Q857330)

A. a-4, b-3, c-2, d-1

B. a-4, b-2, c-3, d-1

C. a-2, b-4, c-1, d-3

D. a-2, b-4, c-3, d-1

Correct Answer: D. a-2, b-4, c-3, d-1

Explanation: Correct Option: a-2, b-4, c-3, d-1 Muscle Action a. Pectoralis major 2. Flexion at shoulder b. Supraspinatus 4. Abduction at shoulder c. Infraspinatus 3. Lateral rotation of shoulder d. Latissimus dorsi 1. Extension at shoulder Muscles of the Anterior Axioappendicular Region Muscle Origin Insertion Nerve Supply Actions Pectoralis Major Anterior surface of the medial two-thirds of the clavicle Front of the manubrium and sternum up to the 6th costal cartilages Second to sixth costal cartilages and sternal end of the 6th rib Aponeurosis of the external oblique muscle Lateral lip of the bicipital groove of the humerus (via bilaminar tendon) Medial and lateral pectoral nerves Adducts and medially rotates the arm Flexes the arm (clavicular part) Extends the flexed arm against resistance (sternocostal part) Pectoralis Minor 3rd, 4th, and 5th ribs near the costochondral junction Medial border and upper surface of the coracoid process Medial and lateral pectoral nerves Protracts the scapula Lowers the point of the shoulder Subclavius First rib at the costochondral junction Subclavian groove on the middle third of the clavicle Nerve to subclavius (from upper trunk of brachial plexus) Stabilizes the clavicle during shoulder movements Protects axillary vessels and brachial plexus Serratus Anterior Eight digitations from the upper 8 ribs and fascia over the intercostal muscles Costal surface of the medial border of the scapula Long thoracic nerve (C5, C6, C7) Protracts scapula Rotates scapula upward for arm abduction beyond 90 degrees Stabilizes the scapula during weight-bearing activities Assists in forced inspiration {{caption_text}} Muscles of the posterior Axioappendicular Region Muscle Origin Insertion Nerve Supply Actions Trapezius Medial one-third of the superior nuchal line of the skull External occipital protuberance Ligamentum nuchae Spinous processes of C7 to T12 vertebrae Corresponding supraspinous ligaments Upper fibers: Posterior border of the lateral one-third of the clavicle Middle fibers: Medial margin of the acromion and upper lip of the spine of the scapula Lower fibers: Apex of a triangular area at the medial end of the spine of the scapula (intervening bursa) Spinal accessory nerve (CN XI) and proprioceptive fibers from C3 and C4. Upper fibers: Elevate the scapula (shoulder shrugging), extend the neck (bilaterally) Middle fibers: Retract the scapula Lower fibers: Rotate the scapula upward, aiding arm abduction beyond 90 degrees Trapezius with rhomboids: Retract scapula and tilt glenoid inferiorly. Trapezius with serratus anterior: Overhead abduction and tilt glenoid superiorly. All fibers together: Stabilize the scapula during arm movements Latissimus Dorsi Posterior one-third of the outer lip of the iliac crest Posterior layer of lumbar fascia (connecting to lumbar and sacral spines) Spinous processes of T7 to T12 Lower four ribs Inferior angle of the scapula Fibers twist to insert into the floor of the intertubercular sulcus of the humerus, wrapping around the lower border of the teres major. Thoracodorsal nerve (C6, C7, C8). Extends, adducts, and medially rotates the arm (e.g., swimming, climbing) Assists in forceful expiration (e.g., coughing, sneezing Levator Scapulae Transverse processes of C1 to C4 vertebrae Superior angle and upper part of the medial border of the scapula Dorsal scapular nerve (C5) and branches from C3 and C4 Elevates and stabilizes the scapula during arm movements. Rhomboid Minor Lower part of ligamentum nuchae and spinous processes of C7 and T1 Medial border of the scapula at the base of the triangular area at the root of the spine. Dorsal scapular nerve (C5) Retracts and stabilizes the scapula. Rhomboid Major Spinous processes of T2 to T5 and supraspinous ligaments Medial border of the scapula, below the root of the spine Dorsal scapular nerve (C5) Retracts and stabilizes the scapula.

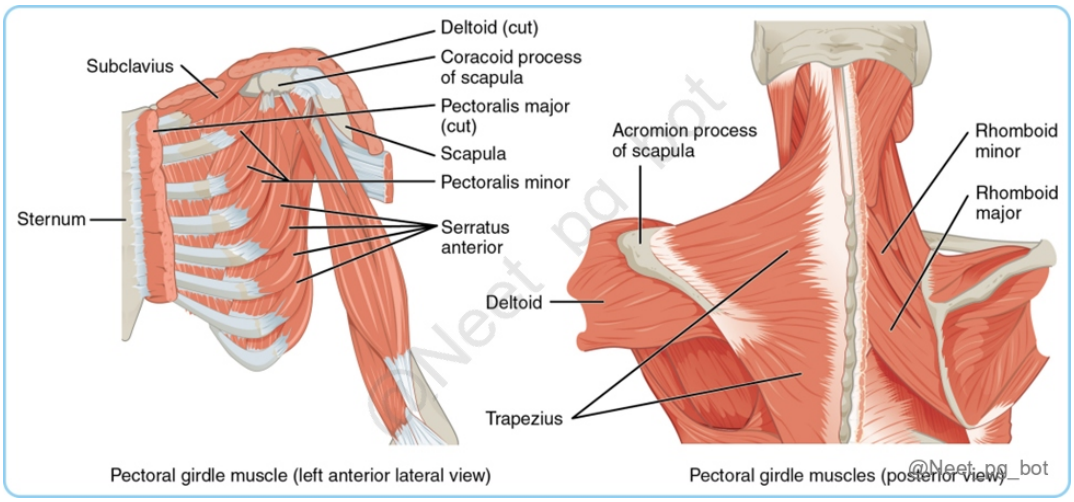

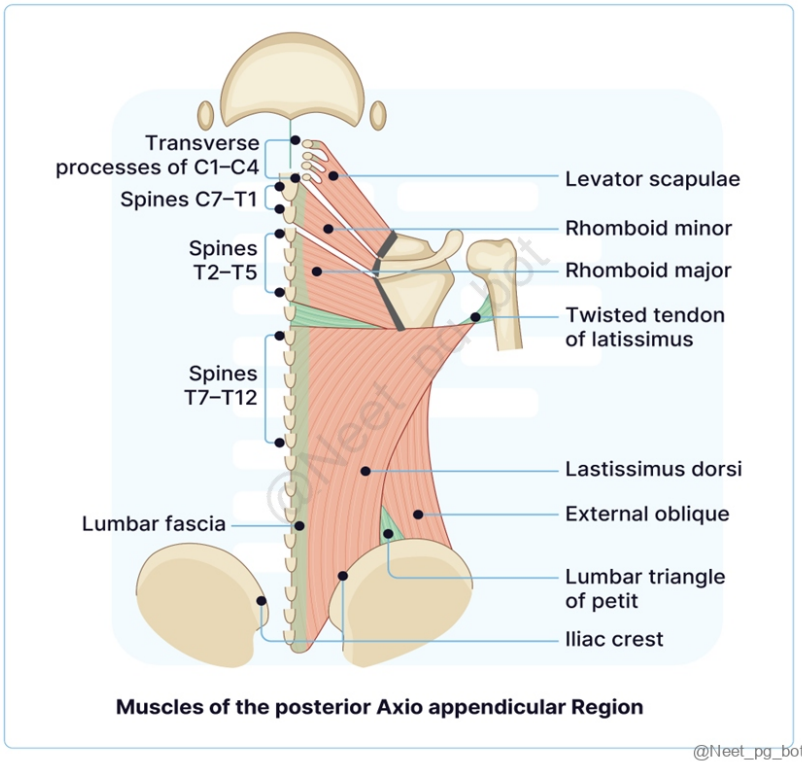

References:

BD Chaurasia's Human Anatomy Volume 1, 8th edition, page-45,46,48,49, 69

https://www.ncbi.nlm.nih.gov/books/NBK537216/

↑ *Back to this question in Part A*

@Neet_pg_bot