Dermatology Collection

Question Bank with Answers & Explanations

Generated on April 18, 2026

38 Topics • 581 Questions

Need help or updates?
■ *Click here to contact the creator of this PDF*

Viewer Guide

Navigation Tips:

- Use the outline/bookmarks pane (left side in most PDF viewers) to jump between sections.
- Click links at the bottom of each question to switch between Part A (questions) and Part B (answers).
- Master Index links take you to topic parts.

Viewer Settings:

- Adobe Reader: View > Show/Hide > Navigation Panes > Bookmarks
- Chrome: Install PDF viewer extension if needed.
- Mobile: Use apps like Adobe Acrobat or Xodo for outline support.

■ *For queries & support: Message @Neet_pg_bot on Telegram*

DIRECTORY EXPLORER

Click a folder below to open it.

» **01_Introduction to Dermatology**

» **02_Skin Appendages and their Disorders**

» **03_Pigmentary Disorders**

» **04_Dermatitis _ Eczema**

» **05_Papulosquamous Disorders**

» **06_Immunobullous Disorders**

» **07_Mycobacterial Infections**

» **08_Sexually Transmitted Infections**

» **09_Connective Tissue Disorders**

» **10_Skin Tumors**

» **11_Systemic Diseases and Skin**

» **12_Cutaneous Infections**

» **13_Miscellaneous Disorders**

» **14_Miscellaneous**

» **15_Bacterial Infections**

» **16_Viral Infections**

» **17_Fungal Infections**

» **18_Parasitic Infection**

» **19_Skin Tumours**

» 01_Introduction to Dermatology

« Back to Parent Directory

Path: 01_Introduction to Dermatology

• 001 Basics Of Dermatology	***Questions***	***Answers***
• 002 Skin Lesions In Dermatology	***Questions***	***Answers***

» 02_Skin Appendages and their Disorders

« Back to Parent Directory

Path: 02_Skin Appendages and their Disorders

• 003 Hair And Nail Disorders	***Questions***	***Answers***
• 004 Disorders Of Glands	***Questions***	***Answers***
• 005 Previous Year Questions	***Questions***	***Answers***

» 03_Pigmentary Disorders

« Back to Parent Directory

Path: 03_Pigmentary Disorders

• 006 Pigmentary Disorders - I	***Questions***	***Answers***
• 007 Previous Year Questions	***Questions***	***Answers***

» 04_Dermatitis _ Eczema

« Back to Parent Directory

Path: 04_Dermatitis _ Eczema

• 008 Eczema	***Questions***	***Answers***
• 009 Previous Year Questions	***Questions***	***Answers***

» 05_Papulosquamous Disorders

« Back to Parent Directory

Path: 05_Papulosquamous Disorders

• 010 Papulosquamous Disorders	***Questions***	***Answers***
• 011 Previous Year Questions	***Questions***	***Answers***

» 06_Immunobullous Disorders

« Back to Parent Directory

Path: 06_Immunobullous Disorders

• 012 Immunobullous Disorders	***Questions***	***Answers***
• 013 Previous Year Questions	***Questions***	***Answers***

» 07_Mycobacterial Infections

« Back to Parent Directory

Path: 07_Mycobacterial Infections

• 014 Cutaneous Tuberculosis	***Questions***	***Answers***
• 015 Leprosy	***Questions***	***Answers***
• 016 Previous Year Questions	***Questions***	***Answers***

» 08_Sexually Transmitted Infections

« Back to Parent Directory

Path: 08_Sexually Transmitted Infections

• 017 Non Syphilitic Std- I	***Questions***	***Answers***
• 018 Previous Year Questions	***Questions***	***Answers***

» 09_Connective Tissue Disorders

« Back to Parent Directory

Path: 09_Connective Tissue Disorders

• 019 Connective Tissue Disorders	***Questions***	***Answers***
• 020 Previous Year Questions	***Questions***	***Answers***

» 10_Skin Tumors

« Back to Parent Directory

Path: 10_Skin Tumors

	Questions	*Answers*
• 021 Previous Year Questions		

» 11_Systemic Diseases and Skin

« Back to Parent Directory

Path: 11_Systemic Diseases and Skin

• 022 Systemic Diseases And Skin - I	***Questions***	***Answers***
• 023 Previous Year Questions	***Questions***	***Answers***

» 12_Cutaneous Infections

« Back to Parent Directory

Path: 12_Cutaneous Infections

• 024 Previous Year Questions	***Questions***	***Answers***

» 13_Miscellaneous Disorders

« Back to Parent Directory

Path: 13_Miscellaneous Disorders

• 025 Adverse Drug Reactions Pediatric Dermatoses Urticaria And Angioedema	***Questions***	***Answers***
• 026 Genodermatoses Vector-Borne Diseases Bedside Tests In Dermatology	***Questions***	***Answers***
• 027 Previous Year Questions	***Questions***	***Answers***

» 14_Miscellaneous

« Back to Parent Directory

Path: 14_Miscellaneous

	Questions	*Answers*
• 028 Previous Year Questions		

» 15_Bacterial Infections

« Back to Parent Directory

Path: 15_Bacterial Infections

• 029 Bacterial Infections	***Questions***	***Answers***
• 030 Previous Year Questions	***Questions***	***Answers***

» 16_Viral Infections

« Back to Parent Directory

Path: 16_Viral Infections

• 031 Viral Infections	***Questions***	***Answers***
• 032 Previous Year Questions	***Questions***	***Answers***

» 17_Fungal Infections

« Back to Parent Directory

Path: 17_Fungal Infections

• 033 Fungal Infections - I	***Questions***	***Answers***
• 034 Previous Year Questions	***Questions***	***Answers***

» 18_Parasitic Infection

« Back to Parent Directory

Path: 18_Parasitic Infection

• 035 Parasitic Infestations Of Skin	***Questions***	***Answers***
• 036 Previous Year Questions	***Questions***	***Answers***

» 19_Skin Tumours

« Back to Parent Directory

Path: 19_Skin Tumours

• 037 Skin Tumors	***Questions***	***Answers***
• 038 Previous Year Questions	***Questions***	***Answers***

Part A — All Questions

• [01_Introduction to Dermatology] 001 Basics Of Dermatology

« Back to Folder Directory

[01_Introduction to Dermatology] 001 Basics Of Dermatology — Quick Jump

Q1 (p. 23) *Q2 (p. 23)* *Q3 (p. 24)* *Q4 (p. 24)* *Q5 (p. 25)* *Q6 (p. 25)*
Q7 (p. 25) *Q8 (p. 26)* *Q9 (p. 26)* *Q10 (p. 27)*

Q1: A 28-year-old primigravida delivers a baby at 30 weeks of gestation. The newborn skin appears very thin and translucent. Which of the following layers of epidermis will be absent in this baby? (Q841873)

A. Stratum Spinosum

B. Stratum Granulosum

C. Stratum Basale

D. Stratum Corneum

See Answer in Part B → Q1

@Neet_pg_bot

Q2: A 30-year-old woman presents to the dermatology clinic complaining of persistent dryness and itching on her hands and arms for several months which seem to worsen during the winter months. On examination, dry, scaly patches are observed on the dorsal aspects of her hands and arms. She denies any history of eczema or other skin conditions. What protein deficiency in the epidermis is most likely responsible for the observed skin manifestations in this patient? (Q841874)

A. Keratin

B. Filaggrin

C. Collagen

D. Elastin

See Answer in Part B → Q2

@Neet_pg_bot

Q3: A 74-year-old female presents with persistent dryness and itching on her shin for the past few weeks. Examination shows erythematous, exfoliated patches. Which of the following structures is primarily responsible for lipid secretion and maintaining skin barrier function? (Q841875)

A. Eleidin Granules

B. Keratohyaline Granules

C. Lamellar Granules

D. Birbeck Granules

See Answer in Part B → Q3

@Neet_pg_bot

Q4: A 35-year-old male presents to the dermatology clinic with complaints of thick, red plaques with silvery scales on his elbows, knees, and scalp for several months that have been worsening gradually. There is also pitting and discolouration of his fingernails and toenails. Which of the following pathological changes in the epidermis is associated with this condition? (Q841876)

A. Increased epidermal turnover time

B. Decreased epidermal turnover time

C. Increased thickness of granular layer

D. No change in the epidermal layer

See Answer in Part B → Q4

@Neet_pg_bot

Q5: Which of the following cells is exclusively present in the stratum spinosum layer of epidermis? (Q841877)

A. Keratinocytes

B. Langerhans cells

C. Merkel cells

D. Melanocytes

See Answer in Part B → Q5

@Neet_pg_bot

Q6: A 50-year-old female presents to the dermatology clinic with complaints of multiple erosions and blisters on her hands, face, and forearms. She was diagnosed with bullous pemphigoid. Which of the following structures is most directly implicated in the pathogenesis of this patient's condition? (Q841881)

A. Desmosomes

B. Hemidesmosomes

C. Keratin 5 and 14

D. Laminin

See Answer in Part B → Q6

@Neet_pg_bot

Q7: A 6-year-old child presents with a history of frequent fractures with minimal trauma. Physical examination reveals blue sclerae, triangular face, and short stature. Radiographic findings show multiple fractures in various stages of healing, thinning of long bones, and wormian bones in the skull. Which of the following is the correct combination regarding the defective protein and its location in the skin? (Q841882)

A. Collagen - Dermis

B. Elastin - Hypodermis

C. Collagen - Hypodermis

D. Elastin - Dermis

See Answer in Part B → Q7

@Neet_pg_bot

Q8: Which of the following conditions will not show the presence of nuclei retained in the stratum corneum as a pathological finding? (Q841883)

A. Eczema

B. Psoriasis

C. Lichen planus

D. Bowen’s disease

See Answer in Part B → Q8

@Neet_pg_bot

Q9: A 45-year-old female presents to the dermatology clinic with a complaint of pruritic, erythematous patches on her arms and legs. A skin biopsy specimen was done and microscopic examination shows intercellular oedema between keratinocytes within the epidermis. Which of the following terms best describes the microscopic finding in this patient? (Q841884)

A. Acantholysis

B. Basal cell degeneration

C. Acanthosis

D. Spongiosis

See Answer in Part B → Q9

@Neet_pg_bot

Q10: A 55-year-old man presents to the dermatology clinic with persistent red scaly patches on his scalp. On examination, erythematous plaques with adherent silver scales are noted on the scalp, particularly in the parietal and occipital regions. He was diagnosed with psoriasis. Which of the following histopathological changes is seen at the lower epidermis in this condition? (Q841981)

A. Munro’s micro abscess

B. Pautrier's microabscess

C. Elongation of rete ridges

D. Flattening of rete ridges

See Answer in Part B → Q10

@Neet_pg_bot

• [01_Introduction to Dermatology] 002 Skin Lesions In Dermatology

« Back to Folder Directory

[01_Introduction to Dermatology] 002 Skin Lesions In Dermatology — Quick Jump

Q1 (p. 28) *Q2 (p. 28)* *Q3 (p. 29)* *Q4 (p. 29)* *Q5 (p. 29)* *Q6 (p. 30)* *Q7 (p. 31)*

Q1: A 45-year-old patient presents with a small, flat, reddish-brown lesion on the palm of their hand. The lesion is non-palpable and measures approximately 5 mm in diameter. What is the most likely description of this lesion? (Q841984)

A. Papule

B. Plaque

C. Macule

D. Bulla

See Answer in Part B → Q1

@Neet_pg_bot

Q2: A 45-year-old male presents to the dermatology clinic with a complaint of red scaly lesion on his lower back. On examination, a well-demarcated, erythematous lesion measuring 4 cm in diameter with silvery scales on the surface is seen. What is the most likely diagnostic skin lesion present? (Q841986)

A. Pustule

B. Plaque

C. Nodule

D. Wheal

See Answer in Part B → Q2

@Neet_pg_bot

Q3: Which of the following skin lesions is a localized collection of pus within the epidermis or dermis? (Q841987)

A. Wheal

B. Pustule

C. Nodule

D. Bulla

See Answer in Part B → Q3

@Neet_pg_bot

Q4: Which of the following is a primary skin lesion? (Q842000)

A. Atrophy

B. Induration

C. Crust

D. Purpura

See Answer in Part B → Q4

@Neet_pg_bot

Q5: Identify the skin lesion and the disease associated with the image below. (Q842001)

A. Fissures - Seborrheic dermatitis

B. Atrophy - Pityriasis rosea

C. Target lesions - Pityriasis Versicolor

D. Scales - Seborrheic dermatitis



See Answer in Part B → Q5

@Neet_pg_bot

Q6: A 45-year-old male presents with complaints of severe itching and thickened skin on his lower legs. Upon examination, well-demarcated areas of thickened, leathery skin with exaggerated skin markings are seen. He mentions that he has a history of atopic dermatitis and has been using topical corticosteroids intermittently for the past few years to manage flare-ups. Which of the following lesions is present in this patient? (Q842003)

A. Erosion

B. Ulcer

C. Poikiloderma

D. Lichenification

See Answer in Part B → Q6

@Neet_pg_bot

Q7: Which among the following is the pathway of epidermal cell migration during embryonic development and the most common disease associated with it? (Q842004)

A. Langer lines - Gorlin syndrome

B. Blaschko lines - Incontinentia pigmenti

C. Langer lines - Neurofibromatosis type 1

D. Kraissl's lines - Linea Morphea

See Answer in Part B → Q7

@Neet_pg_bot

• [02_Skin Appendages and their Disorders] 003 Hair And Nail Disorders

« Back to Folder Directory

[02_Skin Appendages and their Disorders] 003 Hair And Nail Disorders — Quick Jump

Q1 (p. 32)	*Q2 (p. 32)*	*Q3 (p. 33)*	*Q4 (p. 33)*	*Q5 (p. 34)*	*Q6 (p. 35)*
Q7 (p. 36)	*Q8 (p. 37)*	*Q9 (p. 38)*	*Q10 (p. 39)*	*Q11 (p. 39)*	*Q12 (p. 40)*
Q13 (p. 41)	*Q14 (p. 42)*	*Q15 (p. 42)*	*Q16 (p. 43)*	*Q17 (p. 44)*	*Q18 (p. 44)*
Q19 (p. 45)	*Q20 (p. 45)*	*Q21 (p. 46)*	*Q22 (p. 47)*	*Q23 (p. 47)*	*Q24 (p. 48)*
Q25 (p. 49)	*Q26 (p. 50)*	*Q27 (p. 50)*	*Q28 (p. 52)*	*Q29 (p. 52)*	*Q30 (p. 53)*
Q31 (p. 54)	*Q32 (p. 55)*	*Q33 (p. 56)*	*Q34 (p. 57)*	*Q35 (p. 58)*	*Q36 (p. 59)*
Q37 (p. 59)	*Q38 (p. 60)*	*Q39 (p. 61)*	*Q40 (p. 62)*	*Q41 (p. 63)*	*Q42 (p. 63)*
Q43 (p. 63)	*Q44 (p. 64)*	*Q45 (p. 64)*	*Q46 (p. 64)*	*Q47 (p. 65)*	*Q48 (p. 66)*
Q49 (p. 66)	*Q50 (p. 67)*				

Q1: Match the following nail sign with its most likely cause A. Mee’s line 1. Chronic renal insufficiency B. Muehrcke's lines 2. Liver cirrhosis C. Lindsay's nails 3. Arsenic poisoning D. Terry’s nails 4. Hypoalbuminemia (Q841979)

A. A-3, B-4, C-1, D-2

B. A-4, B-2, C-1, D-3

C. A-4, B-1, C-2, D-3

D. A-1, B-3, C-2, D-4

See Answer in Part B → Q1

@Neet_pg_bot

Q2: Which of the following is a component of SAPHO syndrome? (Q886283)

A. Synovitis

B. Acanthosis nigricans

C. Seborrhea

D. Hyperandrogenism

See Answer in Part B → Q2

@Neet_pg_bot

Q3: Which of the following is used in the diagnosis of the condition as shown in the image? (Q884290)

A. Tzanck smear

B. Dermoscopy

C. KOH mount

D. Slit skin smear

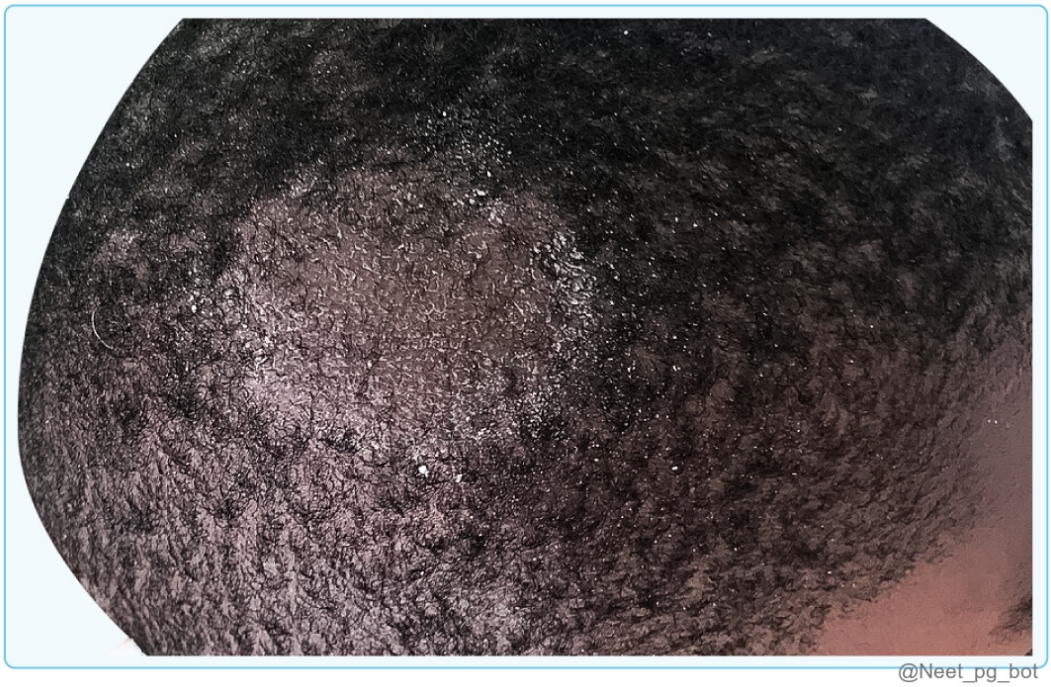

See Answer in Part B → Q3

@Neet_pg_bot

Q4: The following finding is classically seen in which of the following conditions? (Q884289)

A. Trichothiodystrophy

B. Netherton syndrome

C. Menkes disease

D. Trichiorexis nodosa



See Answer in Part B → Q4

@Neet_pg_bot

Q5: What is the structure marked in the given image? (Q884288)

A. Hyponychium

B. Lunula

C. Nail bed

D. Proximal nail fold

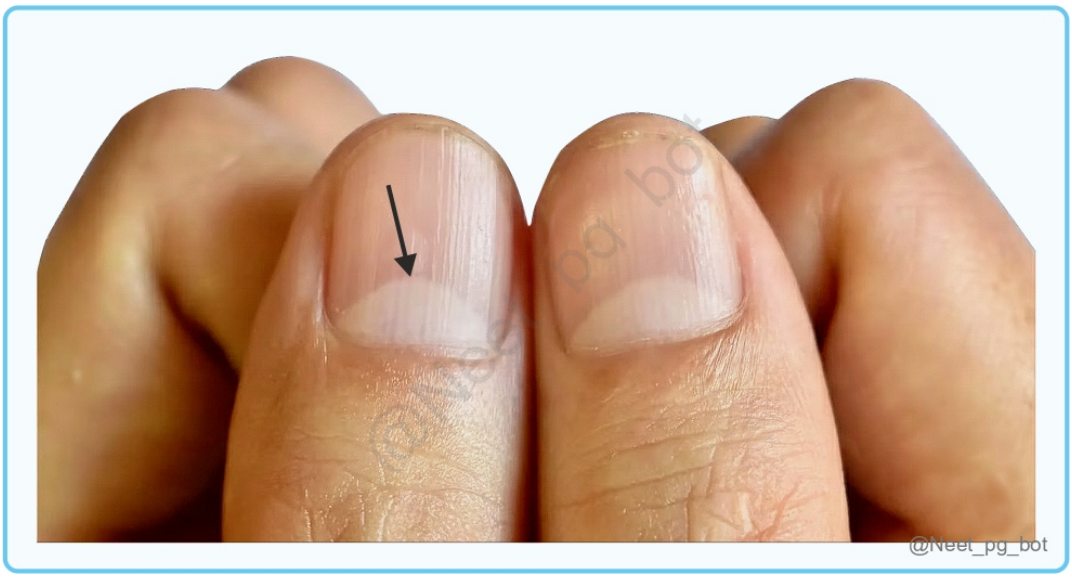

See Answer in Part B → Q5

@Neet_pg_bot

Q6: ■ A 55-year-old man presents with brittle, concave nails affecting his thumbs and great toes. Laboratory tests reveal elevated serum ferritin and transferrin saturation. What is the most likely underlying condition associated with this nail finding? (Q884287)

A. Hemochromatosis

B. Iron deficiency anaemia

C. Trauma

D. Nail infection



See Answer in Part B → Q6

@Neet_pg_bot

Q7: A 45-year-old man develops the following finding, as shown in the image on multiple fingernails 2 months after severe pneumonia. What is this finding called? (Q884310)

A. Mees’ lines

B. Beau’s lines

C. Onycholysis

D. Koilonychia



See Answer in Part B → Q7

@Neet_pg_bot

Q8: A 52-year-old man presents with slowly growing, thickened, yellow nails involving most fingers and toes. Examination shows loss of cuticle and an absent lunula. He also has chronic bilateral leg swelling and a history of recurrent pleural effusions and chronic cough. What is the most likely diagnosis? (Q884309)

A. Onychomycosis

B. Lichen planus

C. Yellow nail syndrome

D. Psoriasis



See Answer in Part B → Q8

@Neet_pg_bot

Q9: A 32-year-old woman presents with severe, localised pain at the tip of her right index finger for 8 months. The pain is excruciating on exposure to cold and is triggered by minimal pressure. Examination shows a tiny bluish-red discolouration beneath the nail plate. The nail appears otherwise normal. What is the most likely diagnosis? (Q884308)

A. Eccrine spiradenoma

B. Subungual glomus tumour

C. Pyogenic granuloma

D. Subungual melanoma



See Answer in Part B → Q9

@Neet_pg_bot

Q10: What is the inheritance pattern of Nail-patella syndrome? (Q884306)

A. Autosomal recessive

B. X-linked recessive

C. Autosomal dominant

D. Mitochondrial

See Answer in Part B → Q10

@Neet_pg_bot

Q11: A 22-year-old presents with greasy papules on the face, chest, and back, flexural plaques, and nail findings as shown in the image below. What is the most likely

diagnosis? (Q884305)

A. Hailey-Hailey disease

B. Darier disease

C. Pemphigus vulgaris

D. Seborrheic dermatitis



See Answer in Part B → Q11

@Neet_pg_bot

Q12: A 38-year-old homemaker presents with discolouration of a single fingernail for 3 weeks. Examination shows findings as shown in the image below. The nail is painless. She gives a history of frequent exposure to water and detergents. What is the most likely diagnosis? (Q884304)

A. Onychomycosis

B. Chloronychia

C. Subungual melanoma

D. Nail psoriasis



See Answer in Part B → Q12

@Neet_pg_bot

Q13: A 6-year-old child presents with sparse, brittle scalp hair since infancy. The polarised light microscopy image is given below. The child has short stature, developmental delay, and ichthyosis. Nails show dystrophic changes. What is the most likely diagnosis? (Q884303)

A. Netherton syndrome

B. Trichothiodystrophy

C. Menkes disease

D. Trichorrhexis nodosa



See Answer in Part B → Q13

@Neet_pg_bot

Q14: Which of the following conditions are causes of cicatricial (scarring) alopecia? Lichen planopilaris Alopecia areata Discoid lupus erythematosus Telogen effluvium Folliculitis decalvans (Q884291)

A. 1, 3 and 5

B. 1 and 3 only

C. 3, 4 and 5

D. 2 and 4 only

See Answer in Part B → Q14

@Neet_pg_bot

Q15: A 20-year-old male presents with findings as shown in the image, with scarring. What is the most appropriate treatment? (Q886284)

A. Topical benzoyl peroxide alone

B. Oral doxycycline

C. Oral isotretinoin

D. Topical retinoid with topical antibiotic



See Answer in Part B → Q15

@Neet_pg_bot

Q16: A 19-year-old patient has severe recalcitrant acne that has failed to respond to prolonged courses of oral antibiotics and topical therapy. What is the most appropriate treatment? (Q886285)

A. Long-term topical benzoyl peroxide

B. Oral doxycycline with topical retinoid

C. Oral isotretinoin

D. Intralesional corticosteroid injections

See Answer in Part B → Q16

@Neet_pg_bot

Q17: Which of the following is not an indication for hormonal therapy in acne? (Q886286)

A. Adult female with antibiotic-refractory papulopustular acne

B. Female requiring contraception along with acne treatment

C. Female with severe acne unresponsive to oral isotretinoin

D. Female with moderate acne where isotretinoin is contraindicated

See Answer in Part B → Q17

@Neet_pg_bot

Q18: A 17-year-old adolescent presents with the following findings, as shown in the image. What is the most likely diagnosis? ■ ■ (Q886287)

A. Acne vulgaris

B. Rosacea

C. Milia

D. Folliculitis



See Answer in Part B → Q18

@Neet_pg_bot

Q19: Which of the following drugs is not associated with acneiform eruptions ? (Q886288)

A. Prednisolone

B. Lithium

C. Isoniazid

D. Metformin

See Answer in Part B → Q19

@Neet_pg_bot

Q20: A 17-year-old girl has findings as shown, resulting from compulsively picking mild acne lesions, especially during stress. What is the most likely diagnosis? (Q886289)

A. Acne vulgaris

B. Acne excoriée

C. Acne conglobata

D. Perioral dermatitis



See Answer in Part B → Q20

@Neet_pg_bot

Q21: A 25-year-old patient with mild acne is being considered for a chemical peel to reduce comedones and superficial scarring. Which of the following is not commonly used as a chemical peeling agent? (Q886290)

A. Glycolic acid

B. Salicylic acid

C. Trichloroacetic acid

D. Retinol

See Answer in Part B → Q21

@Neet_pg_bot

Q22: A 55-year-old man presents with a slowly enlarging, bulbous, and red nose as shown in the image. What is the most likely diagnosis? ■ ■■■■■■■ (Q886291)

A. Acne vulgaris

B. Rhinophyma

C. Sebaceous hyperplasia

D. Lupus pernio



See Answer in Part B → Q22

@Neet_pg_bot

Q23: A 45-year-old patient presents with findings as shown. Which of the following is not associated with this condition? (Q886292)

A. Telangiectasia

B. Rhinophyma

C. Blepharitis

D. Alopecia areata



See Answer in Part B → Q23

@Neet_pg_bot

Q24: Which of the following statements is false regarding the condition shown in the image below? (Q886293)

A. Benign anatomical variant

B. No itching/pain

C. Caused by human papillomavirus

D. Reassurance is the treatment



See Answer in Part B → Q24

@Neet_pg_bot

Q25: Obstruction and rupture of the eccrine sweat duct at the dermo-epidermal junction leads to firm, flesh-colored papules without itching, usually following repeated episodes of prickly heat. What is the diagnosis? (Q886294)

A. Miliaria crystallina

B. Miliaria rubra

C. Miliaria profunda

D. Eccrine hidrocystoma

See Answer in Part B → Q25

@Neet_pg_bot

Q26: A 28-year-old man develops multiple erythematous papules with intense prickling sensation over the trunk and flexures after working in a hot, humid environment. The lesions worsen with sweating and improve with cooling. Obstruction of which skin gland is responsible for this condition? (Q886295)

A. Apocrine sweat gland

B. Sebaceous gland

C. Eccrine sweat gland

D. Ceruminous gland

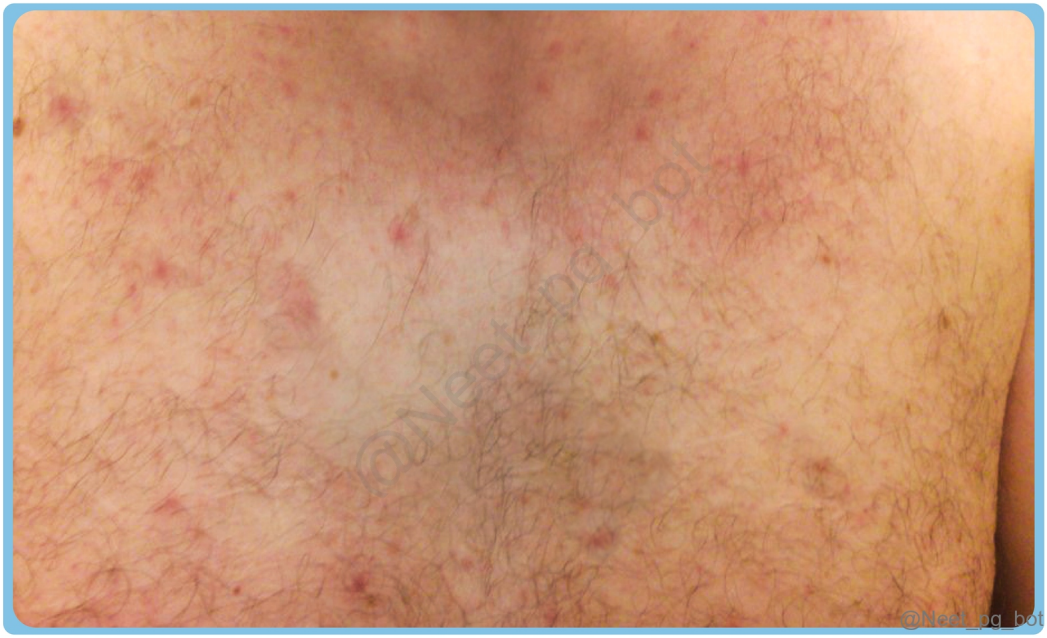

See Answer in Part B → Q26

@Neet_pg_bot

Q27: A 25 year old woman presents with complaints of the following nail lesions. Which among the following might be the most likely cause of the same? (Q841977)

A. Lichen planus

B. Burns

C. Blunt force trauma

D. Scleroderma





See Answer in Part B → Q27

@Neet_pg_bot

Q28: A 28-year-old man complains of progressive hair thinning over the temples and crown over the past two years. There is no history of sudden hair shedding, scarring, or itching. Examination shows a receding hairline and miniaturized hairs in the affected areas. What is the most likely diagnosis? (Q841869)

A. Frontal fibrosing alopecia

B. Telogen effluvium

C. Androgenic alopecia

D. Lupus erythematosus

See Answer in Part B → Q28

@Neet_pg_bot

Q29: A 32 year old man presents with a 5-week history of hair loss in a well-defined area as shown below. The hairs along the periphery of the lesion can be pulled with minimal traction. What is the most likely diagnosis? (Q841870)

A. Tractional alopecia

B. Alopecia areata

C. Tinea capitis

D. Telogen effluvium



@Neet_pg_bot

See Answer in Part B → Q29

@Neet_pg_bot

Q30: A 28 year old female presents with concerns about hair loss and decreased hair volume, as shown below. Many members of her family also have a similar history of significant hair loss. All of the following are true about the given condition except? (Q841968)

A. Frontal hairline preservation is seen.

B. It follows a polygenic mode of inheritance.

C. Ludwig’s grading system is used to assess severity.

D. Mitochondrial inheritance is the primary mode of transmission.

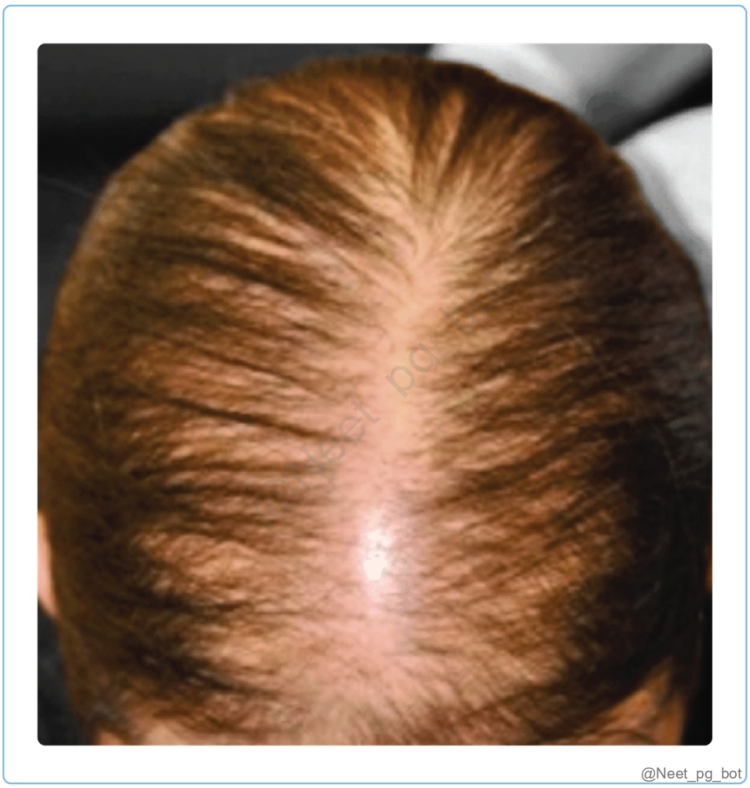

See Answer in Part B → Q30

@Neet_pg_bot

Q31: A 35 year old male presents with concern about hair loss and gradual thinning, as seen in the picture given below. He reports that all the male members of his family has lost their hair by 45 years, What is the most likely diagnosis? (Q841969)

A. Androgenic alopecia

B. Female pattern baldness

C. Alopecia areata

D. Pseudopelade of Brocq



See Answer in Part B → Q31

@Neet_pg_bot

Q32: A 30 year old woman has been complaining of patchy scalp hair loss for the past three weeks. Her past medical history is significant for vitiligo and thyroid disorders. On examination, she has a well-circumscribed area of hair loss over her occipital region, as shown below. Which among the following is not a feature of the disease described? (Q841970)

A. Ophiasis

B. Exclamation mark hair

C. Trichoclasis

D. Turning grey syndrome



See Answer in Part B → Q32

@Neet_pg_bot

Q33: The image shows a 16 year old boy brought to the clinic by his father with an unusual pattern of hair loss. History states that he has become increasingly reclusive, avoiding family gatherings and showing less interest in his usual hobbies spending most of his time alone in his room. The boy himself appears unaware of the issue and has no complaints. What is the possible diagnosis? (Q841971)

A. Trichotillomania

B. Alopecia areata

C. Pseudopelade of Brocq

D. Netherton Syndrome

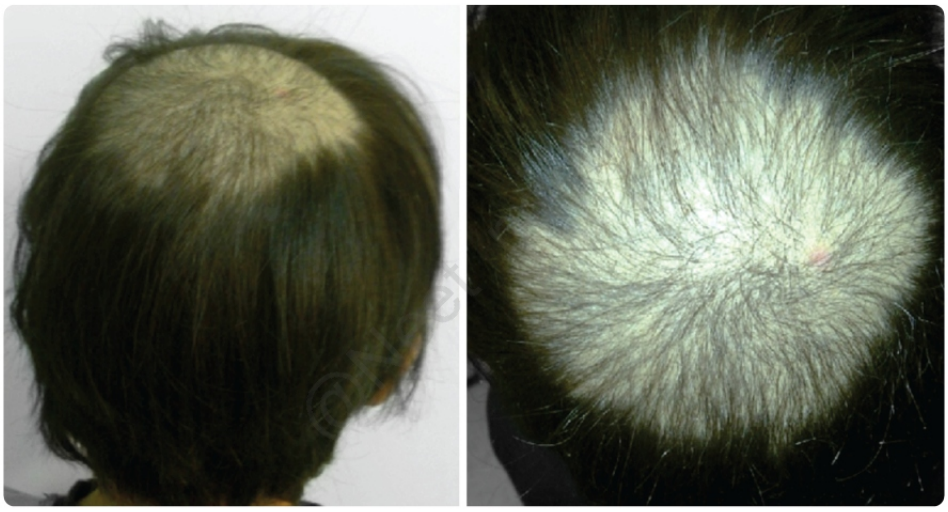

See Answer in Part B → Q33

@Neet_pg_bot

Q34: A middle-aged woman presents with a history of recurrent painful, pustular lesions on scalp which heals with scarring. She is healthy otherwise with no history of similar lesions. Which of the following is the most appropriate diagnostic test? (Q841972)

A. The culture of extracted hair alone.

B. Culture of extracted hair with patient-collected hair sheddings.

C. Shave biopsy of scalp and culture of extracted hair.

D. Punch biopsy of scalp and culture of extracted hair.



See Answer in Part B → Q34

@Neet_pg_bot

Q35: A 32 year old man complains of multiple inflamed, fluctuating nodules on his scalp. He also has patchy areas of hair loss. Upon examination, you notice interconnected sinus tracts and scarring with pustular discharge as shown below. Which of the following is not associated with this disease? (Q841973)

A. Acne conglobata

B. Pilonidal sinus

C. Pustular psoriasis

D. Hidradenitis suppurativa



See Answer in Part B → Q35

@Neet_pg_bot

Q36: Match the sign with its associated hair disorder: a. Pseudopelade of Brocq i. Scaly & itchy violaceous lesions b. Folliculitis decalvans ii. Doll's hair sign c. Follicular lichen planus iii. Patches with scales & follicular plugging d. Lupus erythematosus iv. Footprint in snow sign (Q841974)

A. a-ii, b-i, c-iv, d-iii

B. a-i, b-iv, c-iii, d-ii

C. a-iii, b-ii, c-i, d-iv

D. a-iv, b-ii, c-i, d-iii

See Answer in Part B → Q36

@Neet_pg_bot

Q37: A 32 year old woman presents with complaints of abnormal hair growth, as shown in the image. Which of the following drugs can be prescribed to her as oral therapy? (Q841975)

A. Danazol

B. Tamoxifen

C. Phenytoin

D. Spironolactone



See Answer in Part B → Q37

@Neet_pg_bot

Q38: A 32 year old female presents with complaints of breathlessness, weakness, and fatigue for the past few months. She has no significant past history. On examination, she appears to have some nail changes as depicted in the image below. What would be the most appropriate investigation to verify the diagnosis? (Q841976)

A. Liver function tests

B. Serum albumin

C. Chest X-ray

D. Serum iron level



See Answer in Part B → Q38

@Neet_pg_bot

Q39: A 70 year old man presents with complaints of recent hair loss. He is currently undergoing chemotherapy treatment for acute lymphoblastic leukaemia. Scalp examination reveals significantly decreased hair density compared to the previous visit. Which stage of his hair cycle is most likely affected? (Q841868)

A. Anagen

B. Catagen

C. Telogen

D. Exogen

See Answer in Part B → Q39

@Neet_pg_bot

Q40: A 42 year old male patient presents with numbness and tingling sensation over his soles. O/E, there are areas of hyperpigmentation, along with skin thickening on the palms and soles. The following findings are seen in his nails. Which of the following heavy metals could be responsible for his symptoms? (Q841978)

A. Lead

B. Arsenic

C. Mercury

D. Cadmium



See Answer in Part B → Q40

@Neet_pg_bot

Q41: A 30 year old woman reports experiencing diffuse hair loss starting about three months after a period of significant systemic stress, including a major life event and emotional strain. She notes increased hair shedding when washing or brushing her hair. What is the most likely cause of her diffuse hair loss, given the link between systemic stress and the condition? (Q842645)

A. Androgenetic alopecia

B. Alopecia areata

C. Telogen effluvium

D. Anagen effluvium

See Answer in Part B → Q41

@Neet_pg_bot

Q42: Which structure divides the permanent part of the hair follicle from the cycling part? (Q884279)

A. Opening of the sebaceous duct

B. Insertion of the arrector pili muscle

C. Dermal papilla

D. Hair bulb

See Answer in Part B → Q42

@Neet_pg_bot

Q43: In a healthy adult with a normal scalp hair cycle, the majority of hair follicles are found in which phase at any given time? (Q884280)

A. Catagen phase

B. Telogen phase

C. Exogen phase

D. Anagen phase

See Answer in Part B → Q43

@Neet_pg_bot

Q44: Which of the following statements regarding human hair is incorrect? (Q884283)

A. Vellus hair is soft and <2 cm long

B. Lanugo is shed after birth

C. Terminal hair develops after puberty under androgen influence

D. Humans lack vibrissae follicles

See Answer in Part B → Q44

@Neet_pg_bot

Q45: Which of the following 5α-reductase isoforms does finasteride not act upon? (Q884285)

A. Type 1 & 2

B. Type 2

C. Type 3

D. Type 1 & 3

See Answer in Part B → Q45

@Neet_pg_bot

Q46: The primary site of androgen action, determining hair growth and pattern baldness, is? (Q884296)

A. Hair shaft cortex

B. Outer root sheath

C. Dermal papilla

D. Epidermis

See Answer in Part B → Q46

@Neet_pg_bot

Q47: A 31-year-old woman presents with bitemporal recession and vertex thinning, giving a male-pattern distribution of hair loss as shown in the image. Which of the following statements regarding this condition is wrong? (Q884295)

A. It is often associated with hyperandrogenism

B. A scalp biopsy is routinely required to confirm the diagnosis

C. Hair loss occurs due to follicular miniaturisation

D. Topical minoxidil is useful in the management



See Answer in Part B → Q47

@Neet_pg_bot

Q48: A 26-year-old man presents with diffuse thinning over the central scalp with preservation of the frontal hairline. There is no bitemporal recession or vertex balding. Family history is negative. Scalp skin appears normal. What is the most likely diagnosis? (Q884294)

A. Male pattern androgenetic alopecia

B. Telogen effluvium

C. Female pattern hair loss

D. Alopecia areata

See Answer in Part B → Q48

@Neet_pg_bot

Q49: A 22-year-old patient presents with asymptomatic patchy hair loss on the scalp. Nail examination reveals findings as shown in the image. What is the most likely diagnosis? ■■■■■■■ (Q884293)

A. Lichen planus

B. Alopecia areata

C. Psoriasis

D. Onychomycosis



See Answer in Part B → Q49

@Neet_pg_bot

Q50: A 24-year-old patient presents with a single, well-defined patch of non-scarring hair loss on the scalp as shown. What is the most effective first-line treatment for this condition? (Q884292)

A. Topical minoxidil

B. Intralesional corticosteroid injections

C. Oral corticosteroids

D. Contact immunotherapy (DPCP)



See Answer in Part B → Q50

@Neet_pg_bot

• [02_Skin Appendages and their Disorders] 004 Disorders Of Glands

« Back to Folder Directory

[02_Skin Appendages and their Disorders] 004 Disorders Of Glands — Quick Jump

Q1 (p. 69) *Q2 (p. 69)* *Q3 (p. 70)* *Q4 (p. 71)* *Q5 (p. 71)* *Q6 (p. 72)*
Q7 (p. 73) *Q8 (p. 74)* *Q9 (p. 75)* *Q10 (p. 75)* *Q11 (p. 76)* *Q12 (p. 77)*

Q1: A 42 year old male who exercised vigorously presents to the emergency department with profuse sweating, flushed skin, and rapid breathing. His body temperature is elevated, and he appears dehydrated. Which of the following types of glandular secretion primarily contributes to the cooling mechanism observed in this patient? (Q841980)

A. Merocrine

B. Apocrine

C. Holocrine

D. Endocrine

See Answer in Part B → Q1

@Neet_pg_bot

Q2: A 55 year old male with a 10-year history of poorly controlled type 2 diabetes mellitus presents to the clinic with numbness and tingling sensation in the feet. He also reports no signs of sweating despite exposure to warm temperatures. Which of the following gland's functions is most likely to be impaired? (Q841982)

A. Eccrine sweat glands

B. Apocrine sweat glands

C. Sebaceous glands

D. Ceruminous glands

See Answer in Part B → Q2

@Neet_pg_bot

Q3: A 22 year old female presents to the dermatology clinic with complaints of recurrent episodes of profuse sweating, mainly involving her palms and soles. She reports sweating occurs even in cool environments, significantly impacting her daily activities and social interactions. The starch-iodine test is positive. What is the first-line management in this condition? (Q841983)

A. Aluminium chloride hexahydrate

B. Iontophoresis

C. Intradermal botulinum toxin

D. Removal or ablation of eccrine glands



See Answer in Part B → Q3

@Neet_pg_bot

Q4: A 32 year old man presents to the clinic with a rash on his neck and upper chest area after spending the day on his farm in hot and humid weather. He describes the rash as itchy and prickly. On examination, there are numerous small, erythematous papules present, as shown in the image. Which of the following is the most likely diagnosis? (Q841985)

A. Miliaria crystallina

B. Miliaria rubra

C. Miliaria profunda

D. Miliaria pustulosa



See Answer in Part B → Q4

@Neet_pg_bot

Q5: A 42 year old man presents with complaints of foul-smelling body odour, particularly in his axillae, despite maintaining good hygiene practices. On examination, there are no visible skin lesions or signs of inflammation in the affected area. What is the most likely diagnosis? (Q841988)

A. Fox-Fordyce disease

B. Chromhidrosis

C. Hyperhidrosis

D. Bromohidrosis

See Answer in Part B → Q5

@Neet_pg_bot

Q6: A 32 year old obese woman presents with multiple painful nodules and discharging sinuses in her axilla as shown in the image. She reports a history of similar lesions appearing and resolving intermittently over the past few years. Which of the following is a characteristic feature of this condition? (Q841989)

A. Pruritic, scaly patches on the extremities

B. Bridging scars indicate chronicity

C. Erythematous papules with central pustules

D. Painless nodules and the presence of comedones



See Answer in Part B → Q6

@Neet_pg_bot

Q7: A 25 year old man presents with small, painless papules on the inner surface of his lips. On examination, the papules are skin-coloured and located along the vermilion border. Which of the following is most likely the diagnosis? (Q841990)

A. Tyson glands

B. Meibomian gland dysfunction

C. Montgomery tubercles

D. Fordyce spots



@Neet_pg_bot

See Answer in Part B → Q7

@Neet_pg_bot

Q8: A 16 year old adolescent presents to the dermatology clinic with complaints of multiple papules, pustules, and comedones on her face and upper back. On examination, there are numerous open and closed comedones, inflamed papules, and a few pustules distributed primarily on her forehead, nose, and cheeks, with some involvement of the upper back. Which of the following statements regarding the characteristics of this condition is correct? (Q841991)

A. It primarily affects individuals over the age of 40 and is also seen in adolescents.

B. It is not influenced by hormonal factors.

C. Comedones are the hallmark lesion.

D. Genetic predisposition is not a contributing factor.

See Answer in Part B → Q8

@Neet_pg_bot

Q9: A 21 year old female presents to the dermatology clinic with complaints of persistent acne on her face. On examination, the lesions are as shown in the image below. Based on the grading of acne vulgaris, what is the most appropriate classification for this patient's acne, and what would be the initial treatment recommendation? (Q841992)

A. Grade I acne vulgaris; topical retinoids

B. Grade II acne vulgaris; topical antibiotics + topical retinoids

C. Grade III acne vulgaris; oral antibiotics + topical retinoids

D. Grade IV acne vulgaris; intralesional corticosteroid injections



See Answer in Part B → Q9

@Neet_pg_bot

Q10: A 45 year old woman presents to the dermatology clinic with complaints of persistent redness, flushing, and occasional papules and pustules on her face. She reports that her symptoms worsen with sun exposure and spicy foods. On

examination, diffuse erythema is present on the central face, predominantly on the cheeks shown in the image. Based on the clinical presentation, what is the most likely diagnosis? (Q841993)

A. Acne vulgaris

B. Lupus erythematosus

C. Atopic dermatitis

D. Rosacea



See Answer in Part B → Q10

@Neet_pg_bot

Q11: A 17 year old female with severe, resistant, nodular acne is prescribed isotretinoin. What is the appropriate initial dosage and important administration instruction? (Q842647)

A. 0.5 mg/kg/day; take with a fat-containing meal

B. 1.0 mg/kg/day; take on an empty stomach

C. 0.5 mg/kg/day; take on an empty stomach

D. 1.0 mg/kg/day; take with a fat-containing meal

See Answer in Part B → Q11

@Neet_pg_bot

Q12: A 20 year old female presents with severe acne and is prescribed isotretinoin 1 mg/kg. After two months of treatment, she reports dry skin, dry lips and dry eyes. Laboratory tests reveal mild elevation of liver enzymes. What is the most appropriate initial step in managing her side effects? (Q842751)

A. Discontinue isotretinoin immediately and switch to an alternative oral acne medication.

B. Advise the patient to use moisturizers, lip balm and artificial tears

C. Decrease the dosage of isotretinoin and monitor liver enzymes regularly

D. Both B and C

See Answer in Part B → Q12

@Neet_pg_bot

• [02_Skin Appendages and their Disorders] 005 Previous Year Questions

« Back to Folder Directory

[02_Skin Appendages and their Disorders] 005 Previous Year Questions — Quick Jump

Q1 (p. 78)	*Q2 (p. 79)*	*Q3 (p. 79)*	*Q4 (p. 80)*	*Q5 (p. 81)*	*Q6 (p. 82)*
Q7 (p. 82)	*Q8 (p. 83)*	*Q9 (p. 84)*	*Q10 (p. 85)*	*Q11 (p. 85)*	*Q12 (p. 85)*
Q13 (p. 86)	*Q14 (p. 86)*	*Q15 (p. 86)*	*Q16 (p. 87)*	*Q17 (p. 88)*	*Q18 (p. 88)*
Q19 (p. 89)					

Q1: A lady developed a skin reaction, as shown in the image after using a hair dye. Which of the following chemicals is responsible for this condition? (Q855289)

A. Pollen

B. Chromates

C. Balsam of Peru

D. p-Phenylenediamine



See Answer in Part B → Q1

@Neet_pg_bot

Q2: A 35-year-old woman presents to you with hair loss for the past three months. She tested positive for COVID-19 eight months ago. What is the most likely diagnosis? (Q855910)

A. Tinea capitis

B. Telogen effluvium

C. Trichotillomania

D. Female – pattern androgenetic alopecia

See Answer in Part B → Q2

@Neet_pg_bot

Q3: Irregular pitting of nails with subungual hyperkeratosis is seen in _____. (Q855906)

A. Lichen planus

B. Psoriasis

C. Atopic dermatitis

D. Alopecia areata

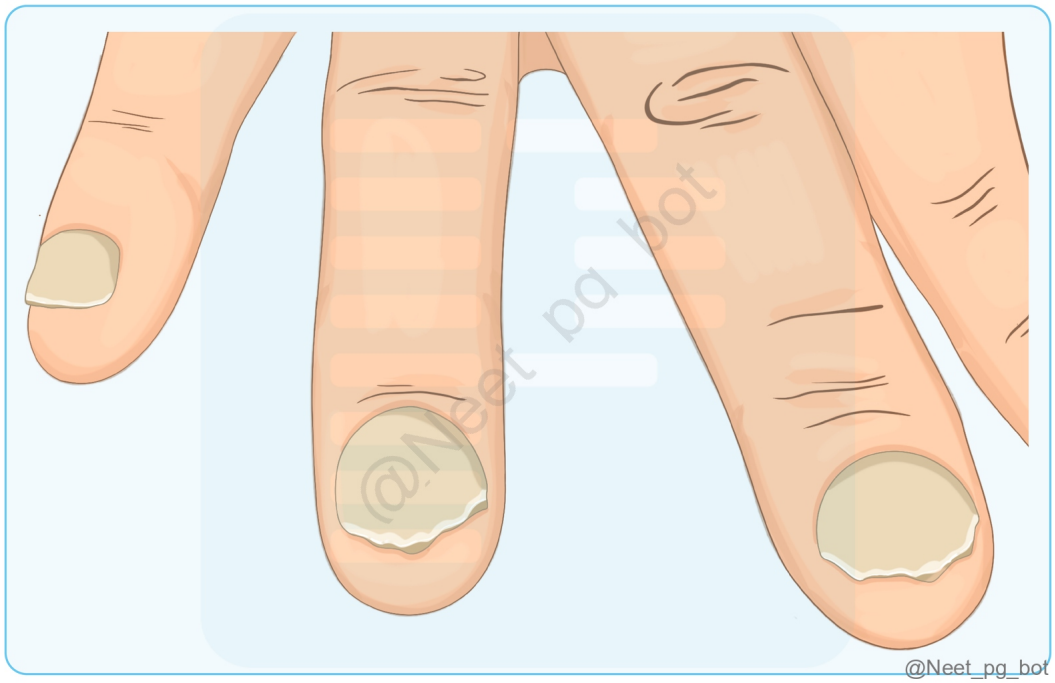

See Answer in Part B → Q3

@Neet_pg_bot

Q4: What is the term used to describe the distinctive finding shown in the image below, which is pathognomonic for Psoriasis? (Q859555)

A. Nail pitting

B. Subungual oil drop sign

C. Thinning of nails

D. Pterygium



See Answer in Part B → Q4

@Neet_pg_bot

Q5: A 40-year-old female comes with complaints of pain in her fingernail. On examination, nail folds were seen to be red and with erythema as shown in the picture. The most likely diagnosis is. (Q859551)

A. Paronychia

B. Yellow-nail syndrome

C. Psoriasis

D. Alopecia areata



See Answer in Part B → Q5

@Neet_pg_bot

Q6: Which of the morpholine drugs listed below is used as a nail lacquer? (Q858515)

A. Amorolfine

B. Oxiconazole

C. Ciclopirox olamine

D. Tioconazole

See Answer in Part B → Q6

@Neet_pg_bot

Q7: A young woman has presented to the OPD with facial symptoms (acne or pimple-like lesions). Which of the following options will not be effective for treating

these symptoms? (Q856671)

A. Topical benzoyl peroxide

B. Topical fluocinolone

C. Topical tazarotene

D. Topical antibiotics



See Answer in Part B → Q7

@Neet_pg_bot

Q8: A 25-year-old male presents with sudden onset, well-circumscribed patches of hair loss on the scalp. The affected areas are smooth, non-inflammatory, and the hair follicles appear intact. There is no scaling or erythema. On examination, exclamation-mark hairs are observed at the periphery of the lesions, and the pull test is positive. Nails show superficial, geometric pitting. Which of the following is the most likely diagnosis? (Q857587)

A. Tinea capitis

B. Kerion

C. Alopecia areata

D. Androgenic alopecia

See Answer in Part B → Q8

@Neet_pg_bot

Q9: A disorder is characterized by recurrent hair-pulling resulting in noticeable hair loss. Which of the following statements about this disorder is not accurate? [(Q857567)

A. Impulse control disorder

B. The onset is typically in adolescence or early adulthood

C. Associated with feelings of pleasure or relief after hair-pulling

D. Caused by a bacterial infection of the scalp



See Answer in Part B → Q9

@Neet_pg_bot

Q10: Which of the following factors is responsible for non-scarring alopecia in patients? 1. Alopecia areata 2. Telogen effluvium 3. Androgenic alopecia 4. Frontal fibrosing alopecia (Q855742)

A. 3 and 4

B. 1, 2 and 3

C. 2,3 and 4

D. Only 4

See Answer in Part B → Q10

@Neet_pg_bot

Q11: An elderly female undergoing chemotherapy for breast cancer is experiencing significant hair loss. What is the most likely cause of her condition? (Q852569)

A. Telogen Effluvium

B. Trichotillomania

C. Anagen Effluvium

D. Alopecia Areata

See Answer in Part B → Q11

@Neet_pg_bot

Q12: Where is the apocrine gland present? (Q854653)

A. Palm and soles

B. Face

C. Axilla

D. Scalp

See Answer in Part B → Q12

@Neet_pg_bot

Q13: Which of the following conditions causes non-scarring alopecia? 1. Alopecia areata 2. Telogen effluvium 3. Androgenic alopecia 4. Folliculitis Decalvans (Q854652)

A. 3 and 4

B. 1, 2 and 3

C. 2, 3 and 4

D. Only 4

See Answer in Part B → Q13

@Neet_pg_bot

Q14: Which of the following is not associated wIth non-scarring alopecia? (Q857389)

A. Alopecia areata

B. Androgenetic alopecia

C. Frontal fibrosing alopecia

D. Telogen effluvium

See Answer in Part B → Q14

@Neet_pg_bot

Q15: A hair shaft with arthroconidia is seen in the image below. Which fungi is most likely associated with this finding? (Q843984)

A. Trichophyton

B. Microsporum

C. Tenia

D. Epidermophyton

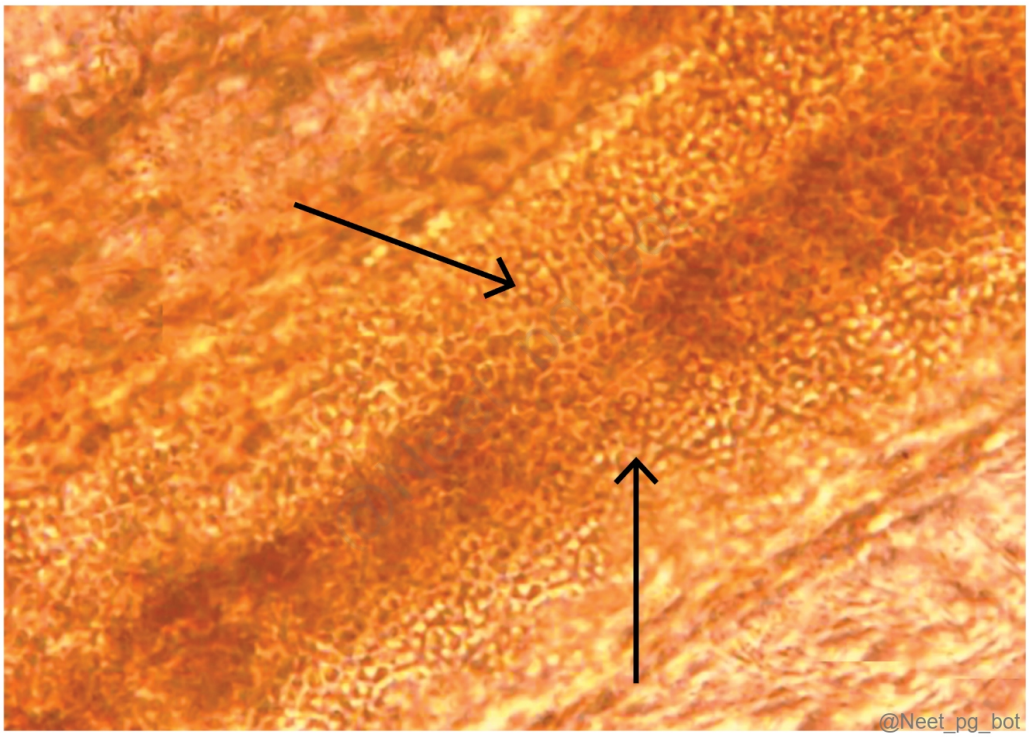

See Answer in Part B → Q15

@Neet_pg_bot

Q16: A 20-year-old male presents with numerous papules, pustules, and nodules on his face and trunk with evidence of scarring. He has a history of similar acne unresponsive to topical and oral antibiotic therapy. Which of the following drugs is the most appropriate treatment for this patient? (Q843982)

A. Topical tretinoin

B. Systemic doxycycline

C. Systemic minocycline

D. Systemic isotretinoin

See Answer in Part B → Q16

@Neet_pg_bot

Q17: A patient presents with a patch of hair loss on the scalp accompanied by scaling and itching, as depicted in the image. Their sibling had a similar scalp condition two years ago. What is the most likely diagnosis? (Q843975)

A. Tinea capitis

B. Alopecia areata

C. Pyoderma

D. Pediculosis capitis



See Answer in Part B → Q17

@Neet_pg_bot

Q18: Identify the structure marked with the arrow in the diagram provided: (Q843953)

A. Arrector pili

B. Sebaceous gland

C. Sweat gland

D. Hair papilla

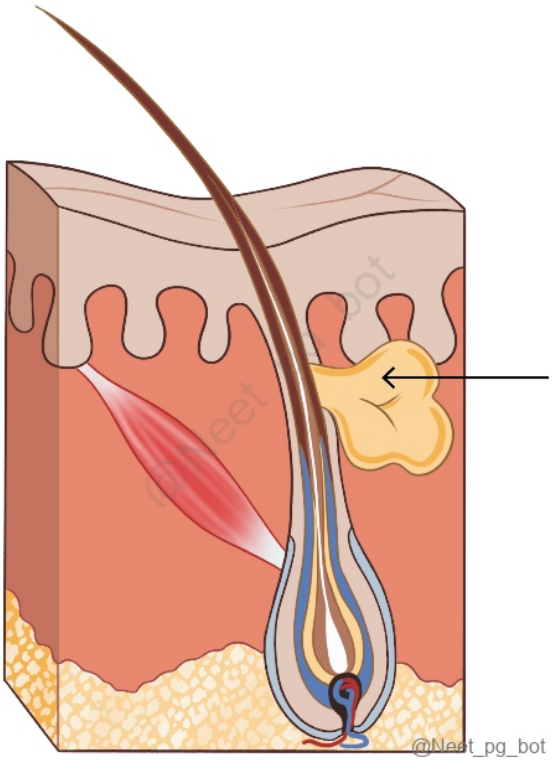

See Answer in Part B → Q18

@Neet_pg_bot

Q19: What is the most appropriate treatment for severe acne? (Q852711)

A. Topical Tretinoin

B. Isotretinoin

C. Steroids

D. Antibiotics

See Answer in Part B → Q19

@Neet_pg_bot

• [03_Pigmentary Disorders] 006 Pigmentary Disorders - I

« Back to Folder Directory

[03_Pigmentary Disorders] 006 Pigmentary Disorders - I — Quick Jump

Q1 (p. 91)	*Q2 (p. 92)*	*Q3 (p. 92)*	*Q4 (p. 93)*	*Q5 (p. 94)*	*Q6 (p. 94)*
Q7 (p. 95)	*Q8 (p. 96)*	*Q9 (p. 97)*	*Q10 (p. 97)*	*Q11 (p. 98)*	*Q12 (p. 99)*
Q13 (p. 100)	*Q14 (p. 100)*	*Q15 (p. 101)*	*Q16 (p. 102)*	*Q17 (p. 103)*	*Q18 (p. 104)*
Q19 (p. 105)	*Q20 (p. 105)*	*Q21 (p. 106)*	*Q22 (p. 107)*	*Q23 (p. 108)*	*Q24 (p. 108)*
Q25 (p. 109)	*Q26 (p. 110)*	*Q27 (p. 110)*	*Q28 (p. 110)*	*Q29 (p. 111)*	*Q30 (p. 112)*
Q31 (p. 112)	*Q32 (p. 113)*	*Q33 (p. 114)*	*Q34 (p. 115)*	*Q35 (p. 116)*	*Q36 (p. 116)*
Q37 (p. 116)	*Q38 (p. 117)*	*Q39 (p. 117)*	*Q40 (p. 118)*	*Q41 (p. 119)*	*Q42 (p. 120)*
Q43 (p. 120)	*Q44 (p. 121)*	*Q45 (p. 121)*	*Q46 (p. 122)*	*Q47 (p. 122)*	*Q48 (p. 122)*

Q1: A 20-year-old man takes NSAIDs and, within 2 hours, develops lesions as shown. Similar lesions occurred at the same site after previous NSAID use. What is the most likely diagnosis? (Q884807)

A. Fixed drug eruption

B. Drug-induced hyperpigmentation

C. Acute contact dermatitis

D. Chikungunya-related hyperpigmentation



@Neet_pg_bot

See Answer in Part B → Q1

@Neet_pg_bot

Q2: A 3-year-old child presents with pale skin, white hair, nystagmus, photophobia, and reduced visual acuity. Ophthalmological examination shows foveal hypoplasia and optic nerve misrouting. Which of the following statements about this condition is correct? (Q884746)

A. Melanocytes are abnormal

B. Autosomal recessive disorder

C. Sun protection is not necessary

D. No risk of skin cancer

See Answer in Part B → Q2

@Neet_pg_bot

Q3: Which of the following is the primary cause of the condition shown in the image below? (Q884747)

A. Defective migration of melanocytes during embryogenesis

B. Progressive loss of melanocytes

C. Decreased number of melanosomes in melanocytes

D. Reduced tyrosinase activity



See Answer in Part B → Q3

@Neet_pg_bot

Q4: A 25-year-old woman has progressive, well-defined depigmented patches over the hands and face. Which of the following is not associated with this condition? ■ (Q884748)

A. Autoimmune thyroid disease

B. Alopecia areata

C. Addison disease

D. Neurofibromatosis type 1



@Neet_pg_bot

See Answer in Part B → Q4

@Neet_pg_bot

Q5: A 30-year-old man with stable non-segmental vitiligo seeks treatment. Which of the following is not used in the management of vitiligo? (Q884749)

A. Excimer laser (308 nm)

B. Pimecrolimus

C. Autologous melanocyte grafting

D. Retinoids

See Answer in Part B → Q5

@Neet_pg_bot

Q6: Which of the following are the mechanisms of the treatment modality depicted in the image below: DNA cross-linking by psoralen photoadducts Inhibition of DNA replication Depletion of Langerhans cells Immunosuppressive effects on T-lymphocyte function and migration Restoration of Th17/regulatory T-cell imbalance (Q884765)

A. 1, 2 and 4

B. 2, 3 and 4

C. 1, 2, 3 and 4

D. 1, 2, 3, 4 and 5



See Answer in Part B → Q6

@Neet_pg_bot

Q7: A patient with non-segmental vitiligo is being counselled regarding disease prognosis. Which of the following is not considered a poor prognostic factor in vitiligo? (Q884769)

A. Koebner phenomenon

B. Mucosal involvement

C. Leukotrichia

D. Negative family history

See Answer in Part B → Q7

@Neet_pg_bot

Q8: An 8-year-old child presents with findings as shown in the image, with a history of seizures and developmental delay. Which of the following statements about this condition is wrong? (Q884778)

A. It represents a form of cutaneous mosaicism

B. It is commonly inherited in an autosomal dominant patterny

C. Along lines of Blashko

D. Skin lesions typically lack epidermal atroph



@Neet_pg_bot

See Answer in Part B → Q8

Q9: A newborn female presents with erythematous vesicular lesions arranged along Blaschko lines since birth. Over the next few months, the lesions become verrucous, followed later by swirled hyperpigmentation. She also has peg-shaped teeth & requires ophthalmologic follow-up. Which of the following statements about this condition is incorrect? (Q884782)

A. It is caused by mutations in the IKBKG (NEMO) gene

B. X-linked dominant disorder

C. Most of them have severe permanent neurological impairment

D. Ophthalmologic follow-up should be done



See Answer in Part B → Q9

Q10: A 14-year-old girl presents with findings as shown in the image. Her father has a history of similar lesions and gastrointestinal polyps. Imaging reveals a jejunal polyp causing intermittent abdominal pain. Which of the following statements about this condition is correct? (Q884784)

A. Hamartomatous polyps commonly undergo malignant transformation.

B. Lentigines typically appear in adulthood.

C. Granulosa cell ovarian tumours are a characteristic associated with tumours.

D. Inherited in an autosomal recessive pattern

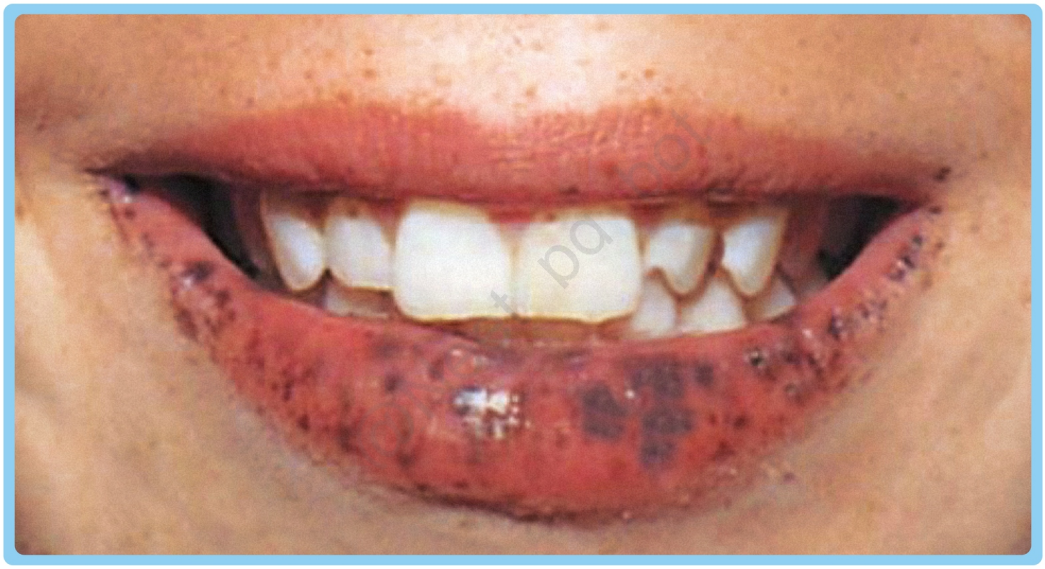

@Neet_pg_bot

See Answer in Part B → Q10

@Neet_pg_bot

Q11: Which of the following drugs are known to produce drug-induced hyperpigmentation? Amiodarone Chloroquine Paracetamol Minocycline Triamcinolone (Q884786)

A. 1, 2, 5

B. 1, 2, 4, 5

C. 1, 2, 4

D. 1, 4, 5

See Answer in Part B → Q11

@Neet_pg_bot

Q12: A 44-year-old woman presents with fever, severe bilateral joint pain, and headache for 5 days. She was taking NSAIDs under prescription. One week after her fever subsides, she develops findings as shown in the image. What is the most likely diagnosis? (Q884787)

A. Dengue fever

B. Chikungunya fever

C. Fixed drug eruption

D. Viral exanthem

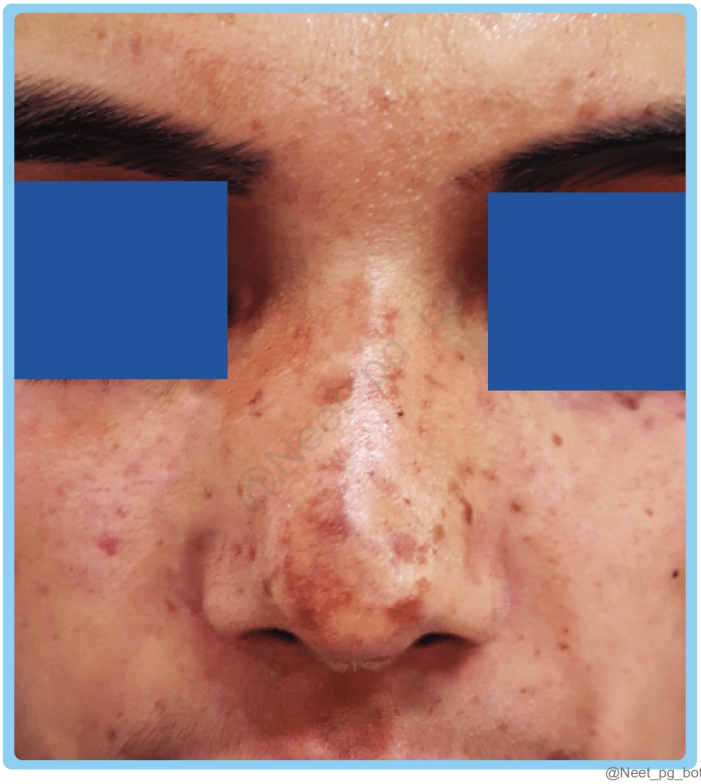

See Answer in Part B → Q12

Q13: A 5-year-old boy presents with silvery hair, fair skin, and pale irides. He has a history of recurrent bacterial infections and neutropenia. Peripheral smear shows findings as shown. Which of the following statements about this condition is correct? (Q884745)

A. It is inherited in an autosomal dominant pattern

B. Hypopigmentation is due to defective melanocyte trafficking

C. Phototherapy is the treatment of choice for pigmentation

D. Neutrophil function is normal in affected individuals

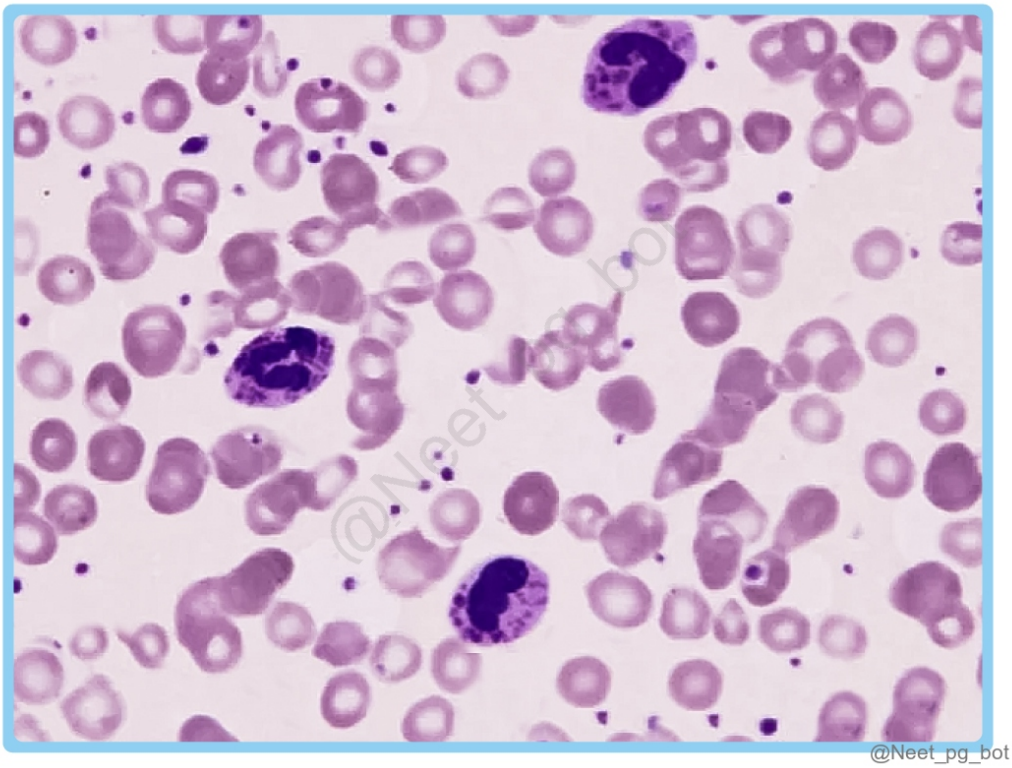

See Answer in Part B → Q13

Q14: Which of the following statements regarding Naevus of Ota is correct? (Q884821)

A. It is more common in males

B. Lesions are usually bilateral

C. It tends to regress spontaneously with age

D. It is distributed along the trigeminal nerve

See Answer in Part B → Q14

@Neet_pg_bot

Q15: A mother brings her 8-year-old child with a long-standing, asymptomatic blue-grey patch over the right shoulder and upper chest present since early childhood, as shown in the image. There is no ocular or mucosal involvement. What is the most likely diagnosis? (Q884822)

A. Naevus of Ota

B. Naevus of Ito

C. Becker naevus

D. Mongolian spot



See Answer in Part B → Q15

@Neet_pg_bot

Q16: A 9-year-old fair-skinned child presents with findings as shown in the image. The lesions become darker during summer and lighten in winter. Dermoscopy shows uniform pigmentation with a moth-eaten border. Which of the following statements regarding this condition is true? (Q884824)

A. Increased number of melanocytes

B. Non-benign

C. Increased melanin production with normal melanocyte number

D. No risk of melanoma



See Answer in Part B → Q16

@Neet_pg_bot

Q17: A 26-year-old woman presents with a long-standing mole on her neck. On examination, the lesion looks as shown in the image. There is no surrounding pigmentation. What is the most likely type of melanocytic naevus? (Q884825)

A. Junctional naevus

B. Compound naevus

C. Intradermal naevus

D. Blue naevus



See Answer in Part B → Q17

@Neet_pg_bot

Q18: A 17-year-old boy has a unilateral hyperpigmented patch as shown in the image below, with mild ipsilateral muscle hypoplasia. What is the diagnosis? (Q884828)

A. Naevus of Ito

B. Becker naevus

C. Congenital melanocytic naevus

D. Nevus spilus



See Answer in Part B → Q18

@Neet_pg_bot

Q19: Which of the following regarding nevus anemicus is incorrect? (Q884829)

A. Congenital lesion

B. Persistent vasoconstriction

C. Reduced melanocyte number

D. No erythema on rubbing

See Answer in Part B → Q19

@Neet_pg_bot

Q20: Which of the following statements regarding simple lentigo is incorrect? (Q884830)

A. It shows increased melanocytes at the dermo-epidermal junction

B. The lesion typically fades with reduced sun exposure

C. Melanocytes are increased without nest formation

D. It is a benign lesion that commonly appears in childhood

See Answer in Part B → Q20

@Neet_pg_bot

Q21: A 32-year-old pregnant woman presents with findings as shown in the image for 6 months. The pigmentation worsens after sun exposure. Wood's lamp shows enhanced pigmentation. What is the most likely diagnosis? (Q884832)

A. Chik sign

B. Melasma

C. Fixed drug eruption

D. Vitiligo



@Neet_pg_bot

See Answer in Part B → Q21

@Neet_pg_bot

Q22: A 3-month-old infant presents with a large pigmented patch covering the posterior trunk and extending to the upper thigh. The lesion has irregular borders, hypertrichosis, and some nodular areas. Neurologic examination is normal. Which of the following statements about this lesion is false? (Q884833)

A. This lesion is classified as a giant congenital melanocytic nevus.

B. The patient is at increased risk of neurocutaneous melanosis.

C. No risk of malignancy

D. Surgical excision may be considered.



See Answer in Part B → Q22

@Neet_pg_bot

Q23: A 2-week-old newborn is noted to have findings as shown in the image below. The infant is otherwise healthy. Which of the following statements about this lesion is correct? (Q884835)

A. Not associated with Down syndrome

B. Develops after birth

C. Usually resolves without treatment

D. Presence of fibrosis



See Answer in Part B → Q23

@Neet_pg_bot

Q24: Hyperpigmentation may be seen in which of the following conditions? Pheochromocytoma Hypothyroidism Cushing syndrome (ACTH-dependent) Haemochromatosis (Q884837)

A. 1, 3, 4

B. 2, 3

C. 3, 4

D. 1 only

See Answer in Part B → Q24

@Neet_pg_bot

Q25: A 16-year-old male presents with irregular hypopigmented macules on his forehead and anterior part of the body. Examination reveals a white forelock and V-shaped leukoderma on the mid-forehead. Small spots of hyperpigmentation are also noted within the hypopigmented lesions. Which of the following genetic abnormalities is most likely responsible for the observed clinical features? (Q841799)

A. Heterozygous mutations in the KIT gene

B. Autosomal dominant mutations in TERT gene

C. Heterozygous mutations in the SNAI2 gene

D. Autosomal recessive mutations in the NOLA3 gene

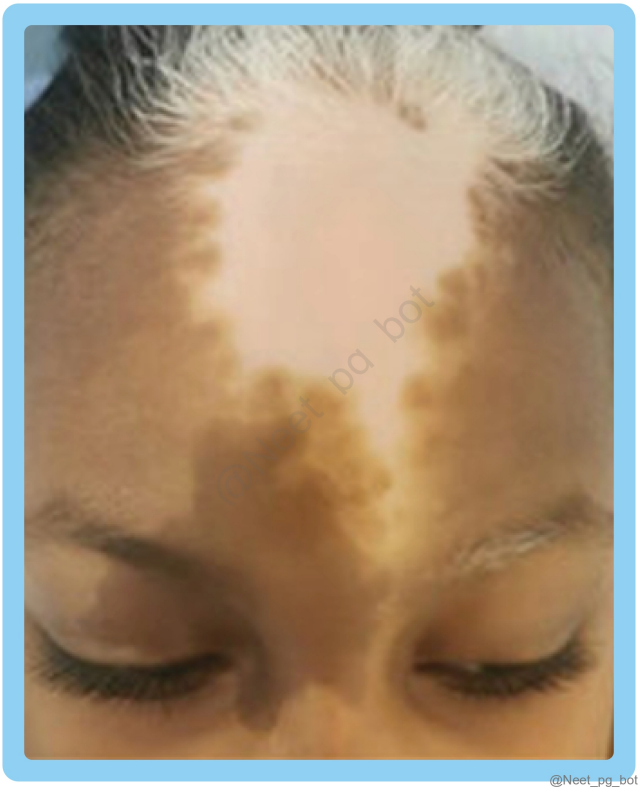

See Answer in Part B → Q25

@Neet_pg_bot

Q26: Which of the following statements accurately describes the role of melanosomes in determining skin pigmentation? (Q841787)

A. An increased number of melanocytes causes darker skin pigmentation.

B. Larger melanosomes are found in individuals with lighter skin tones.

C. The degradation rate of melanosomes is same across different skin types.

D. The arrangement of melanosomes influences skin pigmentation.

See Answer in Part B → Q26

@Neet_pg_bot

Q27: A 45-year-old fair-skinned woman presents with multiple tan to dark brown macules on her face and the dorsal aspect of her hands. These macules are 3 to 20 mm in size and have appeared after chronic sun exposure. Which of the following therapeutic options is not indicated for the treatment of these lesions? (Q841788)

A. Lightening agents

B. Cryotherapy

C. Antibiotic therapy

D. Trichloroacetic acid

See Answer in Part B → Q27

@Neet_pg_bot

Q28: A 7-year-old child presents with multiple hyperpigmented patches on the skin, as shown in the image below. These patches have been present since early childhood and are more than six in number. Which of the following skin lesions are seen in this

condition? (Q841789)

A. Vitiligo vulgaris

B. Café au lait macules

C. Freckles

D. Nevus depigmentosus



See Answer in Part B → Q28

@Neet_pg_bot

Q29: A 35 y/o female with a cosmetically concerning mole on her right cheek. It is a raised, skin-colored papule, approximately 4 mm in diameter. The patient reports no change in size, shape, or color of the mole, and it has been present for several years. What would be the most appropriate treatment approach for this patient? (Q841790)

A. Topical corticosteroids

B. Oral antibiotics

C. Laser treatment

D. Watchful waiting

See Answer in Part B → Q29

@Neet_pg_bot

Q30: A 5-month-old infant presents with a large, darkly pigmented lesion on their lower back. The lesion has been present since birth and has increased proportionally in size with the infant's growth. There is also the presence of hypertrichosis (excessive hair growth) within the lesion. What is the most likely diagnosis? (Q841791)

A. Congenital Melanocytic Nevus

B. Mongolian Spot

C. Nevus of Ota

D. Nevus Depigmentosus

See Answer in Part B → Q30

@Neet_pg_bot

Q31: A 28-year-old female on OCP presents with hyperpigmented macules on her cheeks and forehead. On examination, the lesions appear darker than the surrounding skin and have scalloped margins. There is no associated inflammation or itching. What is the most likely diagnosis based on the clinical presentation? (Q841792)

A. Melasma

B. Lentigo

C. Freckles

D. Chloasma

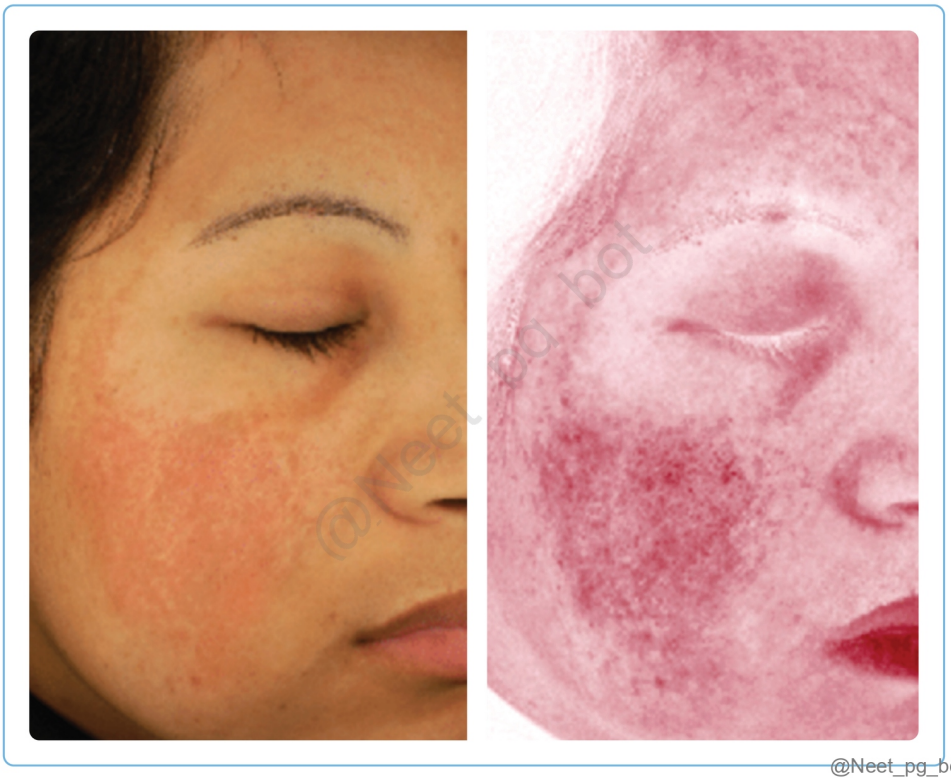

See Answer in Part B → Q31

@Neet_pg_bot

Q32: A 30-year-old woman develops dusky red to brown patches on her arms and legs as shown in the image below after taking a specific antibiotic for sinus infections. The patches, not painful but slightly itchy, leave hyperpigmented areas after resolving. She had a similar reaction to a same medication in the past. What is the most likely diagnosis? (Q841793)

A. Fixed drug eruptions (FDE)

B. Post-inflammatory hyperpigmentation

C. Lichen planus pigmentosus

D. Melasma



@Neet_pg_bot

See Answer in Part B → Q32

@Neet_pg_bot

Q33: A 5-year-old boy presents with hypopigmented macules distributed along the lines of Blaschko. The lesions are asymptomatic and have been present since birth. There is no history of progression or associated symptoms. Which condition is most likely to present with this clinical manifestation? (Q841794)

A. Nevus depigmentosus

B. Vitiligo

C. Nevus anemicus

D. Piebaldism



See Answer in Part B → Q33

@Neet_pg_bot

Q34: A 5-year-old child is brought to the dermatologist by concerned parents due to their child's extremely fair skin, white hair, and pale blue eyes. Upon examination, the dermatologist confirms the absence of melanin pigment in the child's skin, hair, and irises. The child also shows signs of photophobia and is noted to have nystagmus. Which of the following inheritance patterns is associated with this condition? (Q841795)

A. Autosomal dominant

B. X-linked dominant

C. Autosomal recessive

D. X-linked recessive

See Answer in Part B → Q34

@Neet_pg_bot

Q35: A 25-year-old female presents with hypopigmented patches on her skin and silvery-white hair. She also experiences easy bruising and prolonged bleeding following minor injuries. Examination reveals reduced iris pigmentation and visual impairment. Which primary pathological mechanism contributes to the hypopigmented skin observed in this patient? (Q841797)

A. Ceroid lipofuscin accumulation in epidermal cells

B. Dysfunctional Weibel-Palade bodies in keratinocytes

C. Defective melanosome formation, trafficking, or transfer to keratinocytes

D. Autophagocytosis and defective fission of large melanosomes

See Answer in Part B → Q35

@Neet_pg_bot

Q36: A 25-year-old female presents to the clinic with complaints of easy bruising, recurrent nosebleeds, and progressive shortness of breath over the past few years. Physical examination reveals hypopigmentation of the skin, hair, and eyes. Upon further inquiry, the patient mentions a family history of similar symptoms in her siblings. Which of the following diagnostic tests is most likely to confirm the suspected diagnosis in this patient? (Q841798)

A. Platelet aggregation assay

B. Pulmonary function tests

C. Whole-mount electron microscopy of platelets

D. Genetic sequencing of HPS-associated genes

See Answer in Part B → Q36

@Neet_pg_bot

Q37: A 30-year-old patient complains of increased skin pigmentation following prolonged sun exposure. Which of the following statements regarding melanin physiology is most accurate? (Q841786)

A. Melanocytes primarily produce eumelanin, responsible for skin pigmentation and protection against UV radiation.

B. Tyrosinase is an enzyme that converts tyrosine to melanin in keratinocytes.

C. Melanosome transfer from melanocytes to keratinocytes occurs via exocytosis.

D. Individuals with albinism have increased melanin production due to mutations in the MC1R gene.

See Answer in Part B → Q37

@Neet_pg_bot

Q38: A 7-year-old child presents with characteristic findings of Waardenburg syndrome, including wide-set eyes (hypertelorism), a broad nasal bridge, and a white forelock of hair. The child's father is also affected. What is the most likely inheritance pattern of Waardenburg syndrome in this case, and how would you counsel the parents regarding the risk of recurrence in future pregnancies? (Q841800)

A. Autosomal dominant inheritance; 50% risk of recurrence in each pregnancy

B. Autosomal recessive inheritance; 25% risk of recurrence in each pregnancy

C. X-linked recessive inheritance; 25% risk of recurrence in each pregnancy

D. Sporadic occurrence; negligible risk of recurrence in future pregnancies

See Answer in Part B → Q38

@Neet_pg_bot

Q39: A 30-year-old woman was diagnosed with vitiligo with lesions as shown below. They have been stable for the past few years, with no other lesions elsewhere. What is the most likely clinical subtype of vitiligo in this patient? (Q841801)

A. Acrofacial vitiligo

B. Mucosal vitiligo

C. Universal vitiligo

D. Generalized vitiligo



See Answer in Part B → Q39

@Neet_pg_bot

Q40: A 35-year-old patient presents with hypopigmented lesions shown below. There is no inflammation or textural changes associated with the lesions. The patient reports a family history of autoimmune diseases. Which of the following investigations is most likely to confirm the diagnosis in this patient? (Q841802)

A. Dermoscopy

B. Skin biopsy

C. Wood's lamp examination

D. KOH wet mount



See Answer in Part B → Q40

@Neet_pg_bot

Q41: A 25-year-old male presents with bilateral uveitis, dysacousia, and poliosis. On examination, there are areas of leukoderma observed on the skin. Which syndrome is associated with the clinical presentation described? (Q841803)

A. Waardenburg's syndrome

B. Vogt-Koyanagi-Harada syndrome

C. Hermansky-Pudlak syndrome

D. Chemical leukoderma

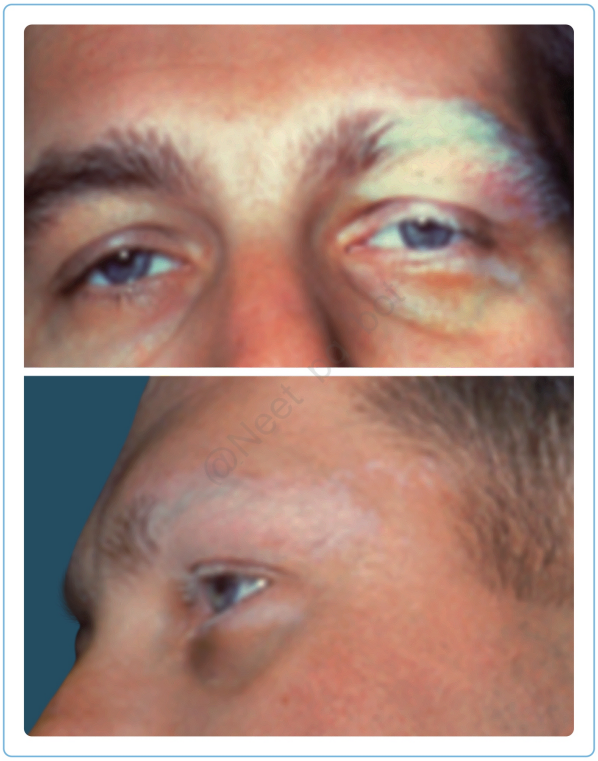

See Answer in Part B → Q41

@Neet_pg_bot

Q42: A 32 y/o female presents with gradually progressive, well-demarcated hypopigmented patches on her face. She has a history of melasma for which she has been using a triple-combination cream containing hydroquinone, tretinoin, and a corticosteroid for the past year. What is the most likely diagnosis? (Q841804)

A. Vitiligo

B. Drug induced Leukoderma

C. Post-inflammatory hypopigmentation

D. Melasma

See Answer in Part B → Q42

@Neet_pg_bot

Q43: A 32 y/o male presents to the clinic with progressively enlarging, hypopigmented patches on the backs of both hands. He has worked in a chemical factory for the past five years, handling various industrial solvents. Wood's lamp examination reveals well-demarcated depigmented patches with no fluorescence. What chemical is the most likely cause of the patient's condition? (Q841805)

A. Kojic acid

B. Azelaic acid

C. p-Tertiary-butylphenol

D. Mercury

See Answer in Part B → Q43

@Neet_pg_bot

Q44: A 30-year-old woman presents with hypopigmented patches on her chest and back after recovering from a severe rash caused by contact dermatitis. The affected areas are smooth, without any scaling, itching, or scarring. What is the most likely diagnosis? (Q841806)

A. Post-inflammatory hypopigmentation

B. Vitiligo

C. Pityriasis alba

D. Nevus depigmentosus

See Answer in Part B → Q44

@Neet_pg_bot

Q45: Which statement regarding skin colour is incorrect? (Q884741)

A. Melanocyte number is similar in all skin types

B. Melanin is transferred to keratinocytes via melanosomes

C. Skin colour is chiefly determined by the number of melanocytes

D. The type of melanin and melanosome size influence skin colour

See Answer in Part B → Q45

@Neet_pg_bot

Q46: The approximate keratinocyte to melanocyte ratio in normal human epidermis is? (Q884742)

A. 1: 1

B. 20: 1

C. 10: 1

D. 36: 1

See Answer in Part B → Q46

@Neet_pg_bot

Q47: Which of the following statements regarding piebaldism is correct? (Q884743)

A. Autosomal recessive disorder

B. Caused by a defect in melanocyte production

C. A white forelock is the characteristic clinical feature

D. Commonly presents with extracutaneous abnormalities

See Answer in Part B → Q47

@Neet_pg_bot

Q48: A 5-year-old has heterochromia irides, sensorineural deafness & the following skin findings. What is the most likely diagnosis? (Q884744)

A. Piebaldism

B. Waardenburg syndrome

C. Vitiligo

D. Tuberous sclerosis



@Neet_pg_bot

See Answer in Part B → Q48

@Neet_pg_bot

• [03_Pigmentary Disorders] 007 Previous Year Questions

« Back to Folder Directory

[03_Pigmentary Disorders] 007 Previous Year Questions — Quick Jump

Q1 (p. 124) *Q2 (p. 125)* *Q3 (p. 125)* *Q4 (p. 126)* *Q5 (p. 126)* *Q6 (p. 127)*
Q7 (p. 128) *Q8 (p. 129)* *Q9 (p. 129)* *Q10 (p. 130)*

Q1: A 20-year-old patient presents with a non-progressive hypopigmented patch on the trunk. On Wood's lamp examination, there is mild white accentuation. Diascopy is negative. There is no sensory loss. What is the most likely diagnosis? (Q866548)

A. Vitiligo

B. Nevus depigmentosus

C. Nevus anemicus

D. Indeterminate leprosy



See Answer in Part B → Q1

@Neet_pg_bot

Q2: Which type of vitiligo doesn't usually progress in the long term? (Q840083)

A. Segmental

B. Acrofacial

C. Focal

D. Mucosal

See Answer in Part B → Q2

@Neet_pg_bot

Q3: A 40-year-old female who had a history of chronic sun exposure presented to the OPD clinic with brownish pigmentation as shown in the image. Which of the following is the diagnosis? ' (Q860090)

A. Melasma

B. Freckles

C. Melanoma

D. Basal cell carcinoma



See Answer in Part B → Q3

@Neet_pg_bot

Q4: Match the following woods lamp findings: Column A Column B 1. Erythrasma a. Yellow 2. Pityriasis versicolor b. Coral red fluorescence 3. Tinea capitis c. Pink 4. Vitiligo d. Green e. Milky white (Q857388)

A. 1-b, 2-a, 3-d, 4-e

B. 1-b, 2-d, 3-a, 4-c

C. 1-d, 2-a, 3-c, 4-e

D. 1-a, 2-c, 3-e, 4-d

See Answer in Part B → Q4

@Neet_pg_bot

Q5: A 13-year-old patient presents with the velvety lesion shown in the image below. What is the diagnosis? (Q854654)

A. Acanthosis Nigricans

B. Tinea Versicolor

C. Seborrheic Keratosis

D. Atopic Dermatitis



See Answer in Part B → Q5

@Neet_pg_bot

Q6: A 22-year-old college student presents with small, depigmented lesions which have been there for over 2 years now as shown in the image below. What is the most likely diagnosis? (Q857572)

A. Melasma

B. Vitiligo

C. Psoriasis

D. Dermatitis herpetiformis



See Answer in Part B → Q6

@Neet_pg_bot

Q7: A young girl presents with leukotriosis and lesions as shown in the image. What is the most likely diagnosis? (Q855653)

A. Focal vitiligo

B. Segmental vitiligo

C. Piebaldism

D. Nevus depigmentosus



See Answer in Part B → Q7

@Neet_pg_bot

Q8: What is the purpose of using Methylisothiazolinone (MI) in cosmetics? (Q856830)

A. Surfactant

B. Humectant

C. Emulsifier

D. Preservative

See Answer in Part B → Q8

@Neet_pg_bot

Q9: What is the probable diagnosis for a pregnant woman of age 30 who visits the dermatology outpatient department (OPD) with the following condition? (Q793404)

A. Systemic lupus erythematosus

B. Viral infection

C. Rosacea

D. Chloasma



See Answer in Part B → Q9

@Neet_pg_bot

Q10: Which diagnostic tool is used to identify the condition depicted in the image below? (Q793447)

A. Culture

B. Wood’s lamp examination

C. Gram staining

D. Patch test



See Answer in Part B → Q10

@Neet_pg_bot

• [04_Dermatitis _ Eczema] 008 Eczema

« Back to Folder Directory

[04_Dermatitis _ Eczema] 008 Eczema — Quick Jump

Q1 (p. 132) *Q2 (p. 132)* *Q3 (p. 133)* *Q4 (p. 134)* *Q5 (p. 135)* *Q6 (p. 136)*
Q7 (p. 137) *Q8 (p. 137)* *Q9 (p. 138)* *Q10 (p. 139)* *Q11 (p. 140)* *Q12 (p. 140)*
Q13 (p. 141)

Q1: A 14-year-old girl presents with a flare-up of her atopic dermatitis which was previously well-controlled. Examination reveals erythematous lesions over the neck. Which of the following is the initial management? (Q841784)

A. Topical steroids

B. Cyclosporine

C. Oral steroids

D. Methotrexate

See Answer in Part B → Q1

@Neet_pg_bot

Q2: A 12-year-old girl presents with multiple hypopigmented patches, as shown below. She reports a prior history of asthma. Examination reveals lesions over her face as shown below. There is mild scaling over the lesions. What is the likely diagnosis? (Q841785)

A. Tinea versicolor

B. Indeterminate leprosy

C. Vitiligo

D. Pityriasis alba


@Neet_pg_bot

See Answer in Part B → Q2

@Neet_pg_bot

Q3: A 55-year-old female presents with multiple red, scaly patches with greasy, yellow scales in her hair. Which of the following represents an appropriate treatment option for her? (Q841878)

A. Azole-based shampoo

B. Oral ketoconazole

C. Topical corticosteroids

D. Avoiding topical creams

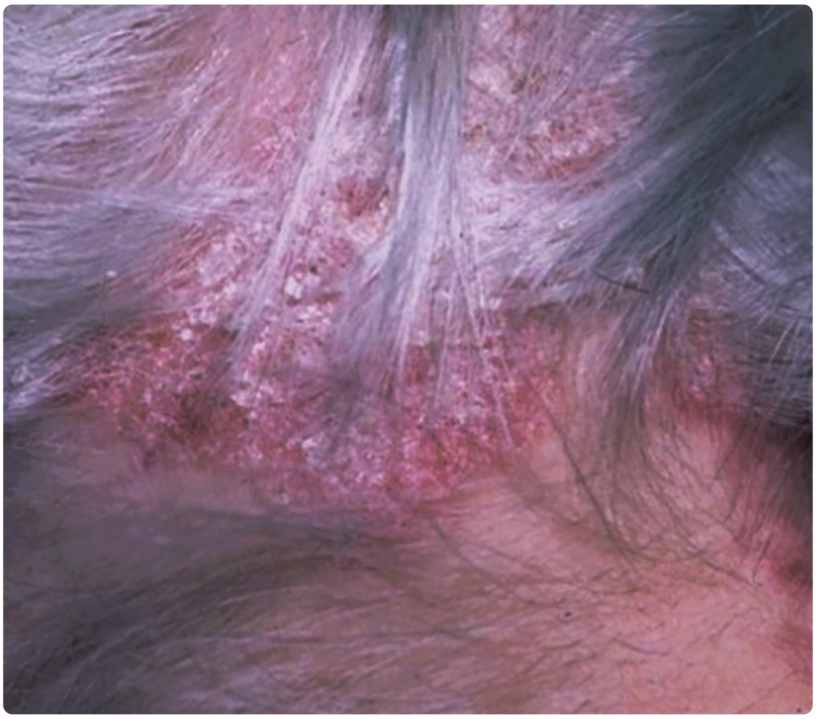

See Answer in Part B → Q3

@Neet_pg_bot

Q4: Which of the following examination findings would not be expected in acute eczema? (Q841776)

A. Erythema

B. Lichenification

C. Vesicles

D. Oozing



See Answer in Part B → Q4

@Neet_pg_bot

Q5: A 35-year-old housewife presents with itchy and burning lesions over her hands. She reports using a new detergent solution at home and lesions developed within few hours of usage. She has not had similar complaints in the past. Which of the following statements is correct regarding her diagnosis? (Q841777)

A. Occurs due to type IV hypersensitivity

B. Lesions may spread beyond the site of contact

C. Diagnosed by a patch test

D. Depends on intensity, duration and concentration of substance



See Answer in Part B → Q5

@Neet_pg_bot

Q6: A 29-year-old woman presents with an intensely pruritic, red rash over her neck as shown in the image. What is the most likely causative substance? (Q841778)

A. Nickel

B. Para tertiary butyl phenol

C. Para phenylene diamine

D. Latex

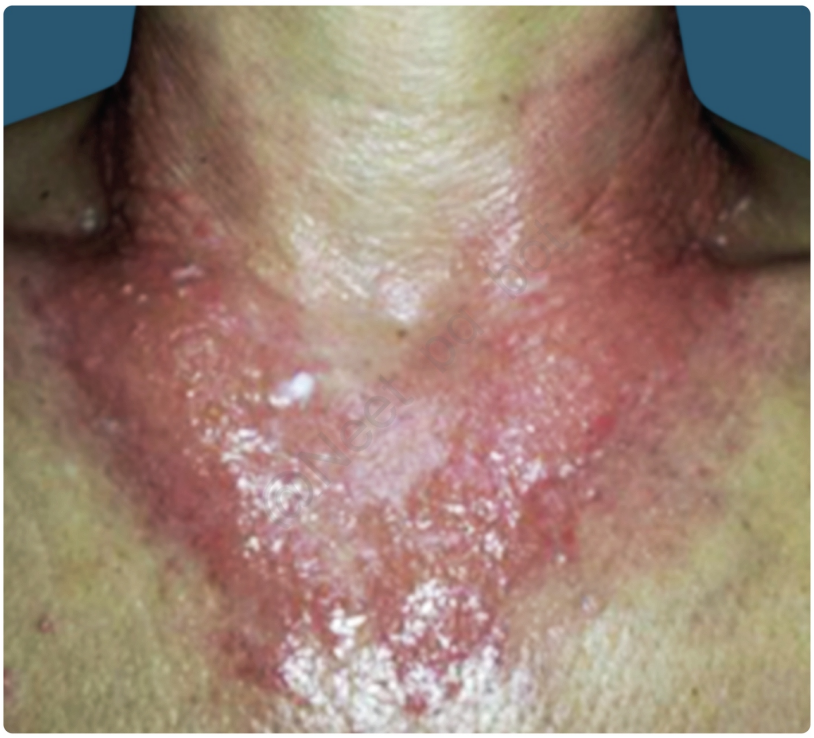

See Answer in Part B → Q6

@Neet_pg_bot

Q7: Interpret the following result of the photopatch test: Reaction on the non-irradiated side: Positive Reaction on the irradiated side: Negative (Q841779)

A. No allergy, no photoallergy

B. Pure photoallergy

C. Allergy, no photoallergy

D. Allergy, with photo exaggeration

See Answer in Part B → Q7

@Neet_pg_bot

Q8: What is the best time to visualize the results of the patch test? (Q841780)

A. 24 hours

B. 48 hours

C. 96 hours

D. 120 hours

See Answer in Part B → Q8

@Neet_pg_bot

Q9: A 45 year old gardener presents to the clinic with a persistent itchy rash on his exposed skin areas, including the face, neck, and arms. On examination, there are erythematous, scaly plaques with some vesicles and lichenification shown below. He mentions that he often works near a patch of wild plants that have small white flowers. Which of the following is the causative agent? (Q841781)

A. Parthenium hysterophorus

B. PTBP

C. Poison ivy

D. PPD

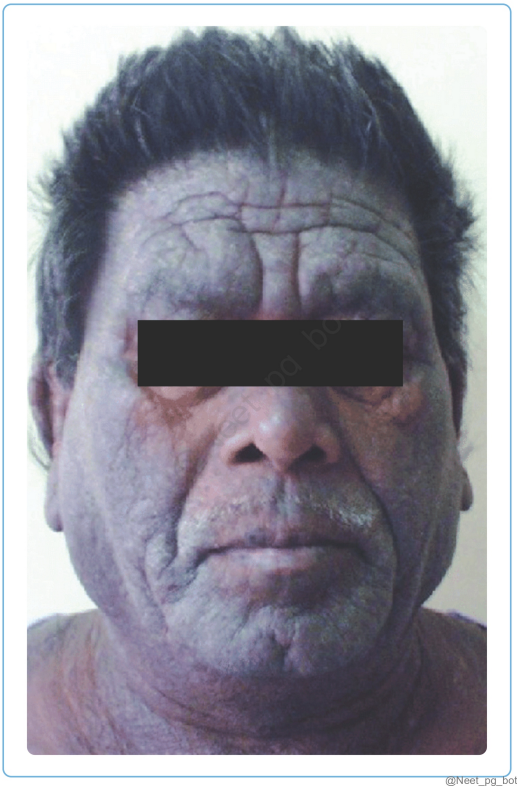

See Answer in Part B → Q9

@Neet_pg_bot

Q10: A 16-year-old boy presents with a rash over both his forearms as shown below. He states that he has had a relapsing, itchy rash since childhood. Family history is significant for asthma and allergic rhinitis in his father. Which of the following is not part of the diagnostic criteria for his disease? (Q841782)

A. Intense pruritus

B. Visible dermatitis involving flexural surfaces

C. Personal/ family history of dermatitis

D. Onset at 16 years of age



See Answer in Part B → Q10

@Neet_pg_bot

Q11: A 10-year-old boy has been recently diagnosed with atopic dermatitis(AD). Which of the following is not a minor feature of AD? (Q841783)

A. Lateral madarosis

B. Extra infraorbital fold of skin

C. Keratosis pilaris

D. Red dermatographism

See Answer in Part B → Q11

@Neet_pg_bot

Q12: An elderly male who works as a security guard presents with a chronic rash over his legs. Examination reveals a hyperpigmented rash with scaling over the medial aspect of both ankles, as shown below. What is the likely diagnosis? (Q841879)

A. Dyshidrotic eczema

B. Varicose eczema

C. Nummular eczema

D. Asteatotic eczema



@Neet_pg_bot

See Answer in Part B → Q12

@Neet_pg_bot

Q13: A 57-year-old male presents to you with an extensive erythematous rash that covers >90% of his body surface, as shown below. He is a known case of pemphigus foliaceous, requiring regular immunosuppressants but not adhering to medications. The skin is warm and tender to the touch. Which of the following is not a potential complication of his condition? (Q841880)

A. Bacterial infections

B. Hypothermia

C. Hypoproteinemia

D. Hyperproteinemia



See Answer in Part B → Q13

@Neet_pg_bot

• [04_Dermatitis _ Eczema] 009 Previous Year Questions

« Back to Folder Directory

[04_Dermatitis _ Eczema] 009 Previous Year Questions — Quick Jump

Q1 (p. 143) *Q2 (p. 144)* *Q3 (p. 144)* *Q4 (p. 145)* *Q5 (p. 146)* *Q6 (p. 146)*
Q7 (p. 147) *Q8 (p. 148)* *Q9 (p. 149)* *Q10 (p. 150)* *Q11 (p. 151)* *Q12 (p. 152)*
Q13 (p. 153) *Q14 (p. 154)* *Q15 (p. 155)* *Q16 (p. 156)* *Q17 (p. 156)* *Q18 (p. 157)*
Q19 (p. 157)

Q1: A 45 year old male patient from Bihar presented with normoanesthetic hypopigmented lesion as shown below. He had a history of fever for a long duration in his childhood. No thickened nerves were present. What is the probable diagnosis? (Q855521)

A. Tuberculoid leprosy

B. Lepromatous leprosy

C. Mycosis fungoides

D. Post kala-azar dermal leishmaniasis

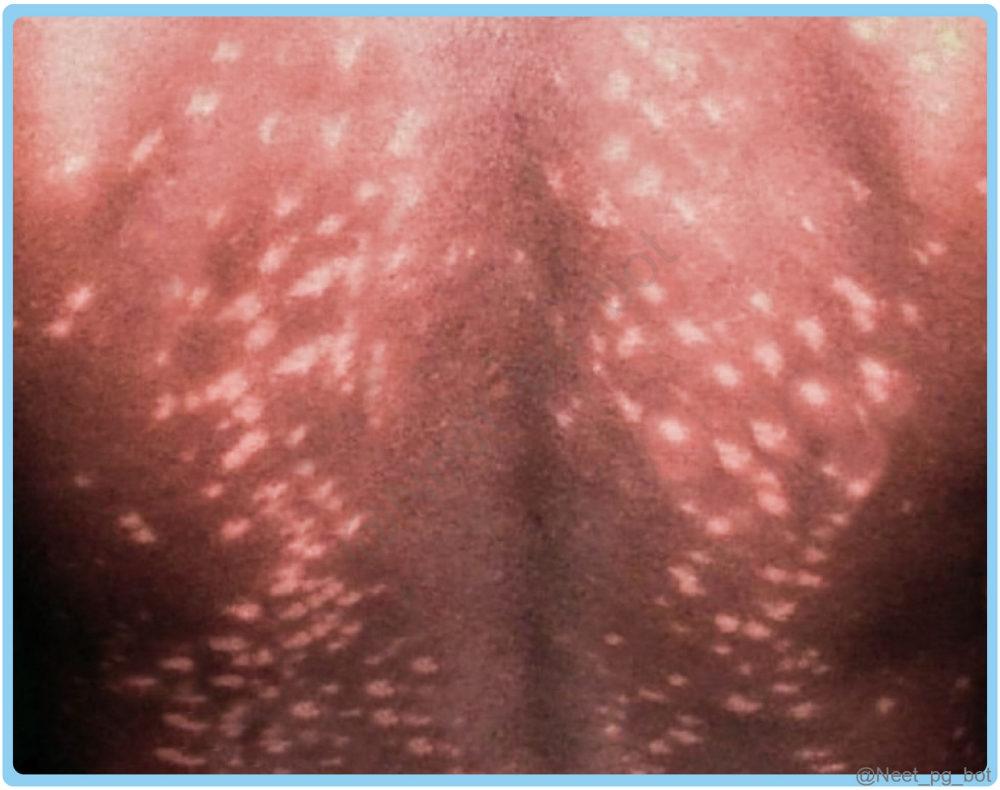

See Answer in Part B → Q1

@Neet_pg_bot

Q2: What is the probable diagnosis for a cauliflower-shaped mass on the foot of a farmer that appeared after a minor injury, with microscopy revealing copper penny bodies? (Q855903)

A. Chromoblastomycosis

B. Blastomycosis

C. Sporotrichosis

D. Phaeohyphomycosis

See Answer in Part B → Q2

@Neet_pg_bot

Q3: A farmer presents to you with swelling on foot and multiple discharging sinuses in the lower limb. Granules from the discharge were examined under the microscope, shown below. Which of the following is true regarding this condition? (Q855900)

A. Both bacteria and fungi can be causative

B. Undergoes lymphatic spread

C. There is lymphocyte accumulation

D. Involves only superficial tissues

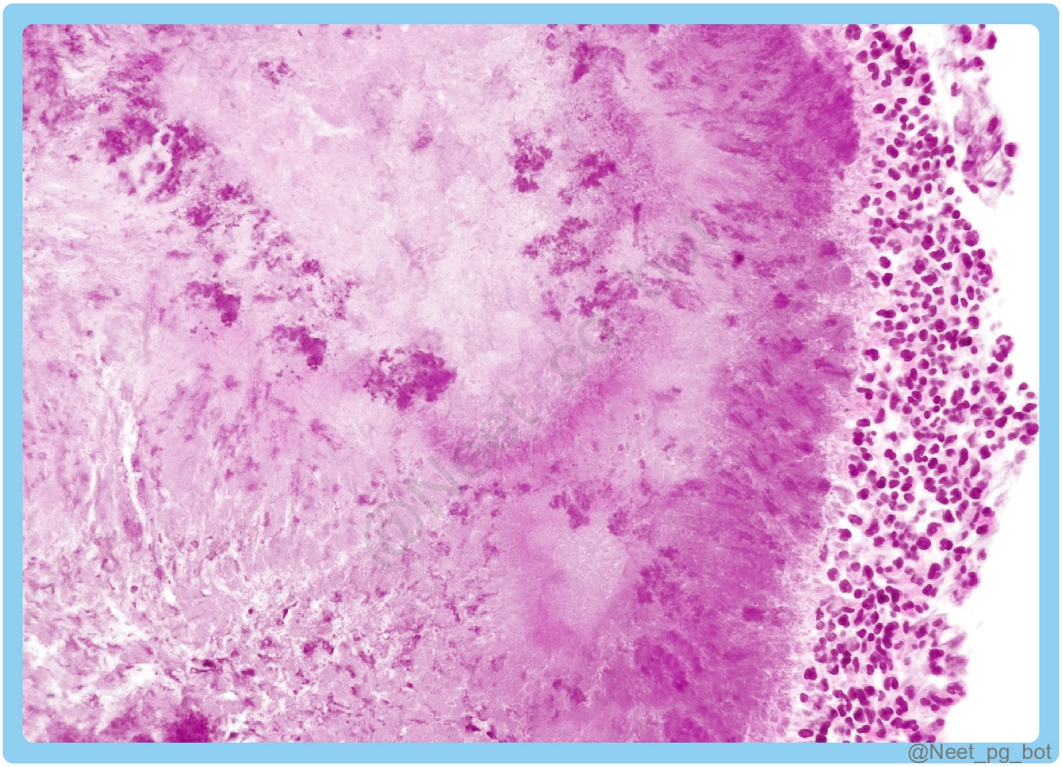

See Answer in Part B → Q3

@Neet_pg_bot

Q4: Identify the finding shown in the image below: (Q854902)

A. Herpes labialis

B. Herpangina

C. Molluscum contagiosum

D. Impetigo



See Answer in Part B → Q4

@Neet_pg_bot

Q5: A 28-year-old man took an antibiotic for a throat infection. Two days later, he noticed a single, round, dark red patch on his forearm that itched and burned. He recalls having a similar patch at the same spot last time he took the same antibiotic. What is the most likely diagnosis? (Q856372)

A. Psoriasis

B. Eczema

C. Fixed Drug Eruption

D. Contact Dermatitis

See Answer in Part B → Q5

@Neet_pg_bot

Q6: What could be the potential cause of the following lesions in a gardener who has a history of thorn pricks? (Q856368)

A. Streptococcus pyogenes

B. Sporothrix schenckii

C. Stronglyoides stercoralis

D. Staphylococcus aureus



See Answer in Part B → Q6

@Neet_pg_bot

Q7: Identify the type of skin lesion: (Q856836)

A. Nummular

B. Annular

C. Discoid

D. Target



See Answer in Part B → Q7

@Neet_pg_bot

Q8: Which of the following options should be excluded as a possible cause for the lesion seen in the image, developed by a forest officer? (Q856668)

A. Scrub typhus

B. KFD

C. Cutaneous anthrax

D. Healing brown recluse spider bite

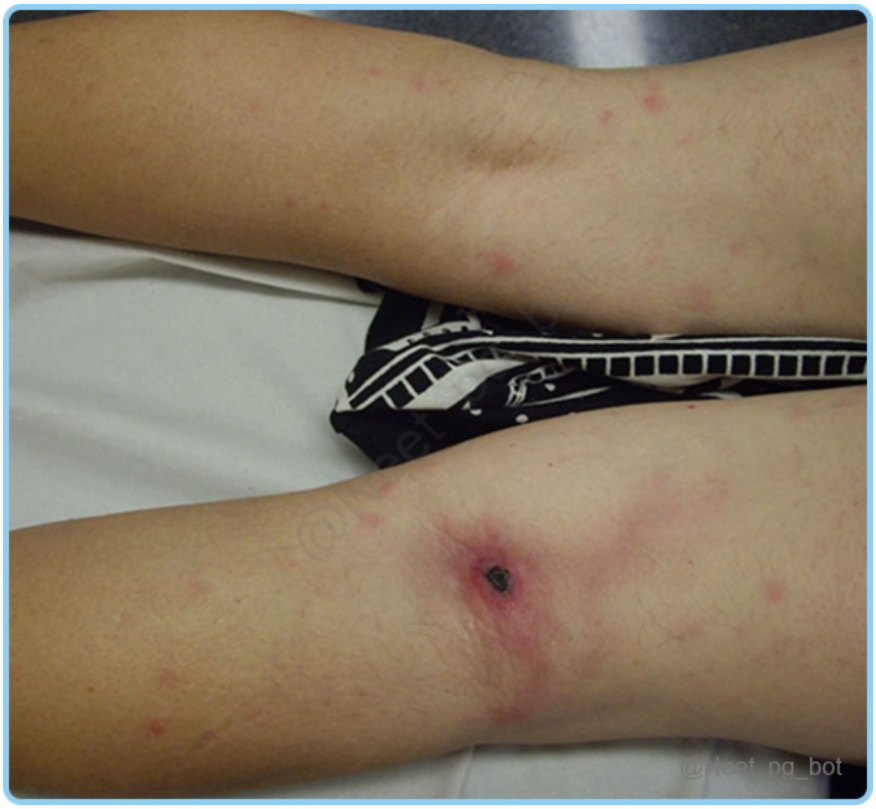

See Answer in Part B → Q8

@Neet_pg_bot

Q9: What is the probable diagnosis for a young man who has presented with painful lesions depicted in the image below? (Q855658)

A. Herpes Zoster

B. Molluscum contagiosum

C. Herpes simplex

D. Lymphangioma circumscriptum



See Answer in Part B → Q9

@Neet_pg_bot

Q10: What is the appropriate next course of action for a child who exhibits itchy scalp lesions and hair loss, as depicted in the image provided? (Q855655)

A. KOH mount

B. Slit skin mount

C. Gram staining

D. Biopsy



See Answer in Part B → Q10

@Neet_pg_bot

Q11: A child presented with itchy plaques over the neck, the bilateral popliteal and cubital fossa. What could be the diagnosis? (Q855656)

A. Atopic dermatitis

B. Dermatitis herpetiformis

C. Pemphigus vegetans

D. Psoriasis



See Answer in Part B → Q11

@Neet_pg_bot

Q12: What is the probable diagnosis for a farmer who has a swollen foot and multiple discharging sinuses, as depicted in the image below? (Q857581)

A. Mycetoma

B. Squamous cell carcinoma

C. Nocardia

D. Sporotrichosis



See Answer in Part B → Q12

@Neet_pg_bot

Q13: Identify the condition shown in the image below: (Q857059)

A. Impetigo

B. Chickenpox

C. Herpes Simplex

D. Molluscum contagiosum



See Answer in Part B → Q13

@Neet_pg_bot

Q14: What could be the potential diagnosis for a 7-year-old boy with intellectual disability who has developed extensive warty crusts on the trunk, hands, and feet, along with severe fissuring and scaling on the soles of his feet? (Q857057)

A. Scabies incognito

B. Animal scabies

C. Nodular scabies

D. Norwegian scabies



See Answer in Part B → Q14

@Neet_pg_bot

Q15: A 60-year-old male patient presents with the lesion given in the image below. He also mentions experiencing sensations like a spider crawling in the area of the lesion. Which of the following is the most likely diagnosis? (Q855741)

A. Herpes zoster infection

B. Irritant contact dermatitis

C. Allergic contact dermatitis

D. Herpes simplex infection



@Neet_pg_bot

See Answer in Part B → Q15

@Neet_pg_bot

Q16: A female patient presented with acne that is not resolving on oral isotretinoin and antibiotics therapy. Which of the following is the next best investigation? (Q855281)

A. Look for dietary triggers

B. Evaluate for hyperandrogenism

C. Check for antibiotic resistance

D. Look for drug triggers

See Answer in Part B → Q16

@Neet_pg_bot

Q17: Which among the following drug is not used in the treatment of acne vulgaris? (Q860622)

A. Topical Benzoyl peroxide

B. Topical Fluocinolone

C. Topical Tazarotene

D. Topical antibiotics

See Answer in Part B → Q17

@Neet_pg_bot

Q18: What is the diagnostic test used to identify allergic contact dermatitis which is a delayed hypersensitivity reaction caused by external substances? (Q856838)

A. Patch test

B. Radioimmunosorbent

C. Eosin-5′-maleimide binding test

D. Nitroblue tetrazolium test

See Answer in Part B → Q18

@Neet_pg_bot

Q19: What is the most probable diagnosis for a child who has displayed symptomless lesions on the elbow and shaft of the penis, as depicted in the image below? (Q855657)

A. Lichen planus

B. Lichen nitidus

C. Scrofuloderma

D. Scabies



See Answer in Part B → Q19

@Neet_pg_bot

• [05_Papulosquamous Disorders] 010 Papulosquamous Disorders

« Back to Folder Directory

[05_Papulosquamous Disorders] 010 Papulosquamous Disorders — Quick Jump

Q1 (p. 159)	*Q2 (p. 159)*	*Q3 (p. 160)*	*Q4 (p. 161)*	*Q5 (p. 161)*	*Q6 (p. 162)*
Q7 (p. 163)	*Q8 (p. 163)*	*Q9 (p. 164)*	*Q10 (p. 164)*	*Q11 (p. 165)*	*Q12 (p. 166)*
Q13 (p. 166)	*Q14 (p. 166)*	*Q15 (p. 167)*	*Q16 (p. 168)*	*Q17 (p. 169)*	*Q18 (p. 169)*
Q19 (p. 170)	*Q20 (p. 171)*	*Q21 (p. 172)*	*Q22 (p. 172)*	*Q23 (p. 173)*	*Q24 (p. 174)*

Q1: Which of the following is NOT one of the major criteria included in the CASPAR (Classification Criteria for Psoriatic Arthritis) for diagnosing psoriatic arthritis in patients with psoriasis? (Q841865)

A. Evidence of psoriasis (current history, or family history)

B. Nail lesions (onycholysis, pitting)

C. Negative rheumatoid factor.

D. Presence of rheumatoid nodules.

See Answer in Part B → Q1

@Neet_pg_bot

Q2: A 12y/o girl comes to the OPD with her parents complaining of multiple small, erythematous, scaly plaques on the trunk with a characteristic raindrop appearance 10 days after a streptococcal throat infection. An image of her lesions is given below. What is the appropriate treatment for this patient? (Q841860)

A. Topical corticosteroids

B. Reassurance

C. Penicillin

D. Doxycycline



@Neet_pg_bot

See Answer in Part B → Q2

@Neet_pg_bot

Q3: You are called by an ObGyn resident for the referral of care of a G2P1 woman with a known history of psoriasis, currently in her 2nd trimester. She is complaining of fever and malaise, and examination shows the following findings: What could be a possible fetal complication in this patient? (Q841862)

A. No complications

B. Renal agenesis

C. Low birth weight

D. Neonatal hypoglycemia



See Answer in Part B → Q3

@Neet_pg_bot

Q4: Which of the following is seen in pityriasis rosea? (Q886486)

A. Wickham striae

B. Auspitz sign

C. Collarette scale

D. Nail pitting

See Answer in Part B → Q4

@Neet_pg_bot

Q5: Which of the following is not a feature of lichen nitidus? (Q886485)

A. Mainly occurs in children

B. Associated with Crohn’s

C. Frequent mucosal involvement

D. Pinpoint to pinhead-sized papules

See Answer in Part B → Q5

@Neet_pg_bot

Q6: A patient with multiple shiny, pinhead-sized papules, as shown in the image, undergoes a skin biopsy. What is the characteristic histological feature? (Q886484)

A. Saw-tooth rete ridges with band-like infiltrate

B. Ball-in-claw appearance

C. Caseating granulomas

D. Follicular plugging



See Answer in Part B → Q6

@Neet_pg_bot

Q7: A 48-year-old patient presents with findings as shown in the image. There is no mucosal involvement. The dermatologist plans to start treatment according to standard guidelines. Which of the following medications is not routinely used in the management of the most likely condition? (Q886483)

A. Clobetasol ointment

B. Prednisolone

C. Methotrexate

D. Interferon



See Answer in Part B → Q7

@Neet_pg_bot

Q8: A patient with lichen planus presents with nail involvement. Which of the following findings are typical nail changes seen in Lichen Planus? Longitudinal ridging and linear depressions Pterygium formation (adhesion of the nail fold to the nail bed) Longitudinal melanonychia and onycholysis Clubbing of all fingernails Yellow, thickened nails with slow growth (Q886482)

A. 1, 2, 3

B. 2, 4, 5

C. 1, 4, 5

D. 3, 4, 5

See Answer in Part B → Q8

@Neet_pg_bot

Q9: Auspitz sign is seen in? (Q876199)

A. Psoriasis vulgaris

B. Pustular psoriasis

C. Pemphigus

D. Bullous pemphigoid

See Answer in Part B → Q9

@Neet_pg_bot

Q10: A 10 year old boy presents to you with scaly, red follicular plaques over his body. He also has areas near his axilla that are spared from these lesions . What is the most likely histopathological pattern that is characteristic of his disease? (Q841867)

A. Acanthosis and spongiosis

B. Elongation of rete ridges

C. Checkerboard pattern with alternate areas of hyperkeratosis and parakeratosis

D. Lichenoid infiltrate with Civatte bodies



See Answer in Part B → Q10

@Neet_pg_bot

Q11: A 24 year old girl with psoriatic skin lesions comes to the dermatology OPD with complaints of joint pain and worsening of her skin lesions. You want to use a single agent for managing both her skin disease and arthritis. Which of the following would you use? (Q841866)

A. Methotrexate

B. Oral corticosteroids

C. Cyclosporine

D. Leflunomide

See Answer in Part B → Q11

@Neet_pg_bot

Q12: Which of the following medications would not be used for treating a patient with moderate to severe psoriasis? (Q841864)

A. Adalimumab

B. Vitamin D analogs

C. Tazarotene

D. Tocilizumab

See Answer in Part B → Q12

@Neet_pg_bot

Q13: Which of the following spectrums of UV Light is most commonly used in the treatment of psoriasis? (Q841863)

A. UVA

B. UVB

C. UVC

D. UVD

See Answer in Part B → Q13

@Neet_pg_bot

Q14: A 20 year old male patient comes to your dermatology OPD complaining of non-itchy lesions on the back of his elbows, shins, and knees. On examination, you find scaly lesions that exhibit the Auspitz sign, as shown in the image below. Which of the following processes is responsible for this patient's lesions? {{caption_text}} (Q841850)

A. Th1-mediated disorder

B. Th2 mediated disorder

C. IgE response

D. Mast cell activation

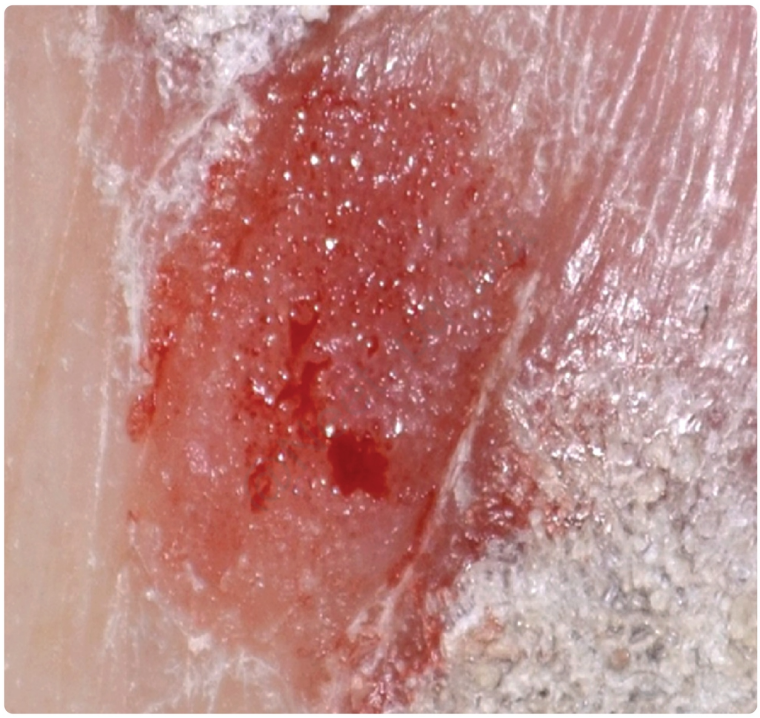

See Answer in Part B → Q14

@Neet_pg_bot

Q15: A patient with a fever of 103°C and pain all over his body comes to your clinic. He recently went to a high-profile medical spa, where he was treated with oral medication for his chronic psoriasis. He was elated with the complete resolution during treatment but woke up with a fever, malaise, and pain three days ago. Skin examination is given in the image below. What is your diagnosis? (Q841861)

A. Pustular psoriasis

B. Erythrodermic psoriasis

C. Psoriasis Vulgaris

D. Rupoid psoriasis



See Answer in Part B → Q15

@Neet_pg_bot

Q16: An orthopaedic surgeon shows you an X-ray of HLA B-27 positive female with seronegative arthritis and psoriatic skin lesions, and you observe the following deformity. What is the eponym given to this deformity? (Q841859)

A. Ivory phalanx

B. Pencil-in-cup deformity

C. Boutonniere deformity

D. Fraying



See Answer in Part B → Q16

@Neet_pg_bot

Q17: A 24 year old male patient presents to you with joint pain in his fingers. He is currently a fashion student at NIFT and shares that other students bully him for having a few 'sausage fingers.' There is no predominant DIP joint involvement noted. What type of arthritis would you most suspect in this patient? (Q841858)

A. Asymmetrical oligoarthritis

B. Distal interphalangeal arthritis

C. Spinal column or axial involvement

D. Arthritis mutilans

See Answer in Part B → Q17

@Neet_pg_bot

Q18: On examination of a specific finding in the nail, a dermatology professor confirms the presence of nail psoriasis. Which of these findings helped the professor establish this diagnosis? (Q841857)

A. Pitting of the nails

B. Oil drop sign

C. Onycholysis

D. Subungual hyperkeratosis

See Answer in Part B → Q18

@Neet_pg_bot

Q19: During your infectious disease rotation, you examine a 37 year old diabetic female with non-itchy lesions under both her breasts in the ward. The patient mentions that her lesions are non-itchy and exacerbate during the winter. They are salmon in colour, as shown in the image below. What is your next step in management? (Q841856)

A. Reassurance

B. Oral fluconazole

C. Local application of corticosteroids

D. Oral corticosteroids



See Answer in Part B → Q19

@Neet_pg_bot

Q20: An immigrant laborer comes to your Sunday volunteer clinic complaining of thickening of the skin on his scalp. The lesions are not itchy, cross the hairline, and are not associated with loss of hair as shown in the given image. What is your diagnosis? (Q841855)

A. Pityriasis amiantacea

B. Seborrheic dermatitis

C. Pityriasis rosea

D. Tinea barbae



See Answer in Part B → Q20

@Neet_pg_bot

Q21: During Dermatology grand rounds, a professor asks you to demonstrate the signs observed in patients with psoriasis. What is the order in which you will see these signs while scraping the lesion with the blunt end of a glass slide? (Q841854)

A. Grattage sign, Berkeley’s Membrane, Auspitz Sign

B. Auspitz Sign, Berkeley’s Membrane, Grattage Sign

C. Berkeley’s Membrane, Grattage Sign, Auspitz Sign

D. Berkeley’s Membrane, Auspitz Sign, Grattage Sign

See Answer in Part B → Q21

@Neet_pg_bot

Q22: While examining a patient with bilaterally symmetrical, silver-white scaly lesions during your Internal Medicine practical exam, you notice that each lesion is surrounded by an area of circumferential pallor as shown in the image below. What is this sign called? (Q841853)

A. Auspitz sign

B. Asboe-Hansen sign

C. Woronoff's ring

D. Nikolsky sign



@Neet_pg_bot

See Answer in Part B → Q22

@Neet_pg_bot

Q23: During a dermatology demonstration on the Koebner phenomenon, the professor also discusses the pseudo-Koebner phenomenon. Which of the following conditions typically shows a pseudo-Koebner response? (Q841852)

A. Lichen planus

B. Pemphigus vulgaris

C. Warts

D. Erythema multiforme



See Answer in Part B → Q23

@Neet_pg_bot

Q24: As a pathologist in a prestigious private clinic, a physician contacts you for urgent feedback on a skin biopsy from a prominent politician. Suspecting psoriasis, what histopathological findings in the stratum corneum would you communicate to the attending physician? (Q841851)

A. Hyperkeratosis, parakeratosis, and microabscesses

B. Kogoj's spongiform pustules

C. Camel foot appearance

D. Suprapapillary thinning

See Answer in Part B → Q24

@Neet_pg_bot

• [05_Papulosquamous Disorders] 011 Previous Year Questions

« Back to Folder Directory

[05_Papulosquamous Disorders] 011 Previous Year Questions — Quick Jump

Q1 (p. 176)	*Q2 (p. 177)*	*Q3 (p. 177)*	*Q4 (p. 178)*	*Q5 (p. 178)*	*Q6 (p. 179)*
Q7 (p. 180)	*Q8 (p. 180)*	*Q9 (p. 181)*	*Q10 (p. 182)*	*Q11 (p. 183)*	*Q12 (p. 183)*
Q13 (p. 184)	*Q14 (p. 185)*	*Q15 (p. 185)*	*Q16 (p. 187)*	*Q17 (p. 188)*	*Q18 (p. 188)*
Q19 (p. 190)	*Q20 (p. 191)*	*Q21 (p. 191)*	*Q22 (p. 192)*		

Q1: Which of the following tests is most appropriate for diagnosing this condition? (Q852570)

A. Nikolsky Test

B. Asboe-Hansen test

C. Grattage Test

D. Tzanck Smear



See Answer in Part B → Q1

@Neet_pg_bot

Q2: A 73-year-old female presents with severe pruritus and a white plaque in the genital region. Histopathological examination reveals loss of rete ridges, abundant collagen, and thinning of the epithelium. What is the most likely diagnosis? (Q879091)

A. Lichen planus

B. Lichen sclerosis

C. Candiasis

D. Vulvar leukoplakia

See Answer in Part B → Q2

@Neet_pg_bot

Q3: A 45-year-old male comes with recurrent blisters and oral ulcers for 3 years. The histology is as shown. What is the diagnosis of this patient? (Q854660)

A. Pemphigus vulgaris

B. Dermatitis herpetiformis

C. Bullous pemphigoid

D. Linear IgA disease

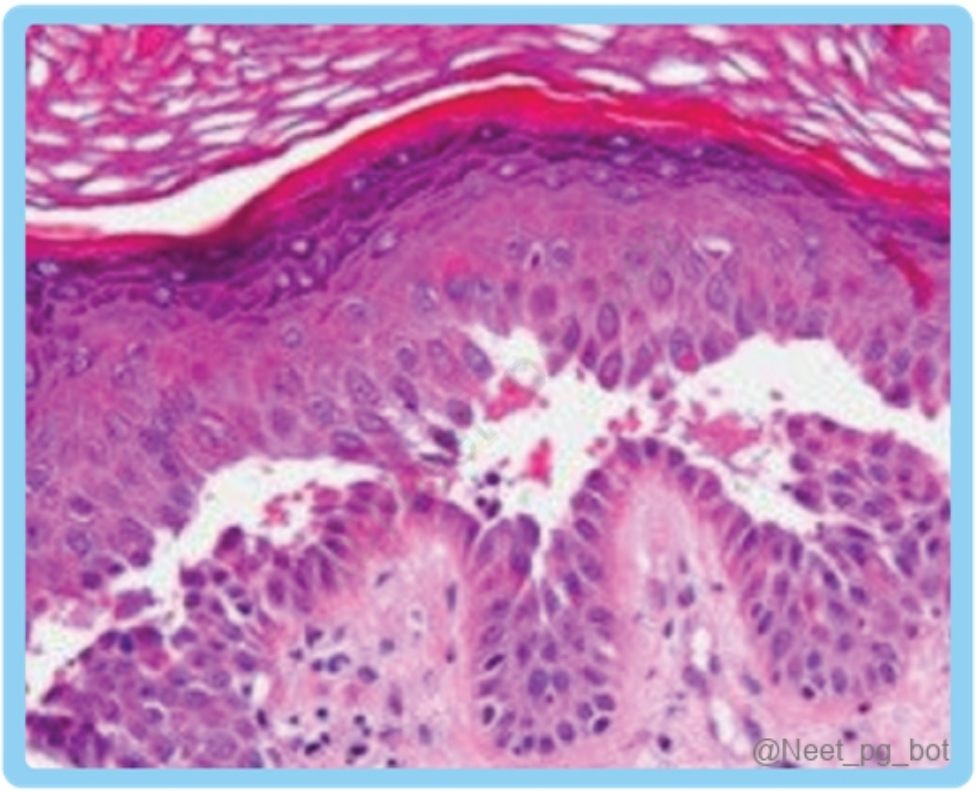

See Answer in Part B → Q3

@Neet_pg_bot

Q4: A patient on anti-PD1 immunotherapy (nivolumab) comes with pruritis, eczema, and urticarial rashes. Histopathological examination reveals a subepidermal blister and direct immunofluorescence of the lesions showed linear C3 and IgG on basement membrane. What isthe diagnosis? (Q854648)

A. Dermatitis herpetiformis

B. Pemphigus vulgaris

C. Pemphigus foliaceous

D. Bullous Pemphigoid

See Answer in Part B → Q4

@Neet_pg_bot

Q5: Auspitz sign is seen in? (Q859908)

A. Psoriasis vulgaris

B. Pustular psoriasis

C. Pemphigus

D. Bullous pemphigoid

See Answer in Part B → Q5

@Neet_pg_bot

Q6: Identify the finding associated with the condition shown in the image below: (Q858513)

A. Isomorphic phenomenon

B. Meyerson phenomenon

C. Gottron’s papule

D. Nikolsky’s sign



See Answer in Part B → Q6

@Neet_pg_bot

Q7: Which of the following would you not advise for a patient who is already diagnosed with chronic plaque psoriasis and has over 50% of their skin affected? (Q856386)

A. Oral methotrexate

B. NB UVB

C. Oral steroids

D. Oral cyclosporine

See Answer in Part B → Q7

@Neet_pg_bot

Q8: What is the most probable diagnosis for a 30-year-old woman who has lacy lesions in her mouth and genital area, while her proximal nail fold has extended onto the nail bed? (Q857591)

A. Pityriasis rubra pilaris

B. Psoriasis

C. Pityriasis rosea

D. Lichen planus

See Answer in Part B → Q8

@Neet_pg_bot

Q9: A patient presented with lesions, as shown in the image below, and later developed arthritis also. What is the treatment of choice for this condition? (Q857054)

A. PUVA

B. Steroids

C. Methotrexate

D. Infliximab



See Answer in Part B → Q9

@Neet_pg_bot

Q10: A 45-year-old male presents to the dermatology clinic with an itchy skin rash. Physical examination reveals flat-topped, polygonal, purplish papules with fine white lines on the surface. The lesions are primarily located on the inner wrists and forearms, as well as on the lower back. The patient reports that he has been experiencing oral discomfort and noticed white, lacy patches on the inside of his cheeks. There is no family history of similar conditions. What is the most likely diagnosis? (Q857051)

A. Psoriasis

B. Eczema

C. Lichen planus

D. Tinea corporis

See Answer in Part B → Q10

@Neet_pg_bot

Q11: Please match the following types of scales with their corresponding lesions. Scales Lesions 1. Collarette scales a. Pityriasis versicolour 2. Silvery scales b. Pityriasis rosea 3. Mica–like scales c. Psoriasis 4. Branny scales d. Pityriasis lichenoides (Q854965)

A. 1-b, 2-c, 3-d, 4-a

B. 1-a, 2-b, 3-d, 4-c

C. 1-d, 2-c, 3-a, 4-b

D. 1-c, 2-b, 3-d, 4-a

See Answer in Part B → Q11

@Neet_pg_bot

Q12: A patient presented with itchy lesions, as shown below. What is the diagnosis? (Q857975)

A. Scabies

B. Lichen planus

C. Psoriasis

D. Warts



See Answer in Part B → Q12

@Neet_pg_bot

Q13: A 26-year-old male presented with erythematous plaques covered with silvery scales over the extensor surfaces of both arms. Punctate pitting was noted on examining the nails. What is the most likely diagnosis? (Q857973)

A. Psoriasis

B. Lichen planus

C. Eczema

D. Pityriasis rosea



@Neet_pg_bot

See Answer in Part B → Q13

@Neet_pg_bot

Q14: A 25-year-old male presents with a 2-week history of mildly itchy skin lesions. On examination, there is a single, oval, pink plaque with a collarette of scale on the trunk arranged in a characteristic "Christmas tree" pattern. There is no history of fever, drug intake, or systemic illness. What is the most likely diagnosis? (Q854651)

A. Pityriasis rosea

B. Psoriasis

C. Tinea corporis

D. Secondary syphilis

See Answer in Part B → Q14

@Neet_pg_bot

Q15: A 24-year-old male presents with scaly lesions over the body, as shown in the Image below. No other associated symptoms are present. What is the likely diagnosis? (Q857399)

A. Lichen planus

B. Pityriasis Rosea

C. Seborrheic Dermatitis

D. Atopic Dermatitis





See Answer in Part B → Q15

@Neet_pg_bot

Q16: A child with a sore throat starts developing skin lesions as in the image below. Which of the following is the diagnosis? (Q860104)

A. Guttate psoriasis

B. Pustular psoriasis

C. Erythrodermic

D. Inverse psoriasis



See Answer in Part B → Q16

@Neet_pg_bot

Q17: A 45-year-old patient presents with itchy, flat-topped, polygonal, violaceous papules on the inner wrists and flexors surfaces of the forearms. The lesions have a characteristic shiny surface and are arranged in a linear pattern. The patient denies any recent medication changes. What is the treatment? (Q860609)

A. Topical steroids

B. Antibiotics

C. Immunosuppressants

D. Anti-fungal

See Answer in Part B → Q17

@Neet_pg_bot

Q18: A 25-year-old patient presents with rashes with an orange hue on his body and thickened palms and soles. Based on the histological image given, what is the diagnosis? (Q843964)

A. Pityriasis rubra pilaris

B. Keratosis follicularis

C. Follicular psoriasis

D. Cutaneous T-cell lymphoma







See Answer in Part B → Q18

@Neet_pg_bot

Q19: Diagnose the condition using the histological image provided. (Q843961)

A. Morphea

B. Lichen nitidus

C. Lichen planus

D. Lichen amyloidosis



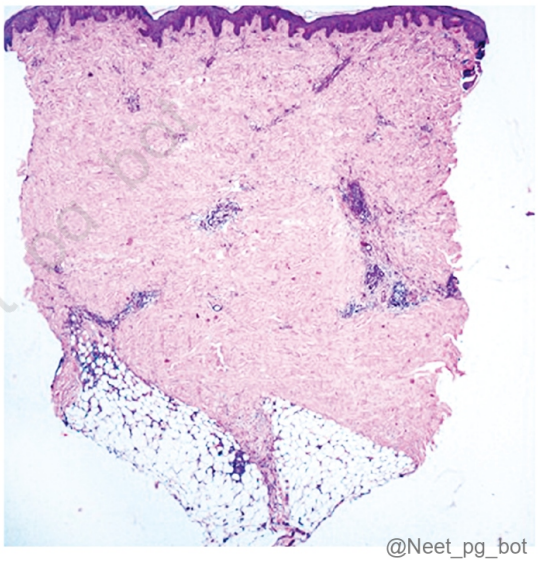

See Answer in Part B → Q19

@Neet_pg_bot

Q20: Which of the following does not distinguish Psoriasis from other arthropathies? (Q853197)

A. Diarrhoea

B. Dactylitis

C. Enthesitis

D. Nail pitting

See Answer in Part B → Q20

@Neet_pg_bot

Q21: Identify the type of psoriasis in the given picture. (Q793445)

A. Guttate

B. Erythrodermic

C. Pustular

D. Inverse



See Answer in Part B → Q21

@Neet_pg_bot

Q22: A 50-year-old patient presents with following skin lesions characterized by red and scaly patches. The patient also complains of a painful and swollen finger joint. On examination, the finger joint appears inflamed and tender to touch. What is the most likely diagnosis for this patient's condition? (Q820242)

A. Psoriatic Arthritis

B. Pseudo gout

C. Osteoarthritis

D. Reactive arthritis



See Answer in Part B → Q22

@Neet_pg_bot

• [06_Immunobullous Disorders] 012 Immunobullous Disorders

« Back to Folder Directory

[06_Immunobullous Disorders] 012 Immunobullous Disorders — Quick Jump

Q1 (p. 194)	*Q2 (p. 194)*	*Q3 (p. 195)*	*Q4 (p. 195)*	*Q5 (p. 195)*	*Q6 (p. 196)*
Q7 (p. 196)	*Q8 (p. 197)*	*Q9 (p. 198)*	*Q10 (p. 198)*	*Q11 (p. 198)*	*Q12 (p. 199)*
Q13 (p. 200)	*Q14 (p. 200)*	*Q15 (p. 201)*	*Q16 (p. 201)*	*Q17 (p. 204)*	*Q18 (p. 204)*
Q19 (p. 205)	*Q20 (p. 206)*	*Q21 (p. 206)*	*Q22 (p. 207)*		

Q1: Which of the following correctly matches the pemphigoid disease with its primary target antigen? (Q841959)

A. Bullous pemphigoid - BP180

B. Mucous membrane pemphigoid - BP230

C. Epidermolysis bullosa acquisita - Laminin

D. Linear IgA disease - Desmoglein 3

See Answer in Part B → Q1

@Neet_pg_bot

Q2: Arrange the following autoimmune blistering skin diseases in order from the most superficial to the deepest target antigen in the skin: Bullous pemphigoid Pemphigus vulgaris Epidermolysis bullosa acquisita Pemphigus foliaceus (Q842649)

A. 4, 2, 1, 3

B. 2, 4, 1, 3

C. 4, 2, 3, 1

D. 3, 1, 2, 4

See Answer in Part B → Q2

@Neet_pg_bot

Q3: Which of the following best describes the characteristic immunofluorescence pattern seen in pemphigus? (Q842648)

A. Linear band along the basement membrane zone

B. Granular deposits at the dermal-epidermal junction

C. Fish net-like or honeycomb pattern in the epidermis

D. Nuclear staining of keratinocytes

See Answer in Part B → Q3

@Neet_pg_bot

Q4: A patient presents with tense vesicles and bullae in sun■exposed areas like the neck, upper trunk, and proximal extremities. She has a history of systemic disease involving small joints of hands and feet. Immunofluorescence of the biopsied lesion shows granular + linear IgG and C3 deposits in the dermo-epidermal junction. Antibody against which of the following antigens is mainly associated with this patient's current condition? (Q841967)

A. Collagen VII

B. CCP

C. Ro La

D. Transglutaminase

See Answer in Part B → Q4

@Neet_pg_bot

Q5: A 14-year-old girl presents with complaints of pruritic papules on the elbows and knees as shown below. She also gives a history of chronic diarrhea which stopped after certain dietary restrictions. What is the immunofluorescence pattern seen on the biopsy of these lesions? (Q841966)

A. Epidermal intercellular deposition of IgG

B. Linear IgA deposition at the dermo-epidermal junction

C. Granular IgA deposition in the papillary dermis

D. Epidermal intercellular and subepidermal deposition of IgG



See Answer in Part B → Q5

@Neet_pg_bot

Q6: A biopsy is being performed to diagnose a skin lesion. The pathologist performs direct immunofluorescence microscopy on salt-split skin, which shows immunoglobulin depositing on the blister's floor. What is the most probable diagnosis? (Q841965)

A. Mucous membrane pemphigoid

B. Bullous pemphigoid

C. Linear IgA disease

D. Epidermolysis bullosa acquisita

See Answer in Part B → Q6

@Neet_pg_bot

Q7: A 45-year-old patient presents with erosions, blisters, and crusts in the groin and thigh region as shown below. His blood tests reveal he has antibodies against collagen VII. What is the most probable diagnosis? {{caption_text}} (Q841964)

A. Linear Ig A disease

B. Bullous pemphigoid

C. Epidermolysis bullosa aquisita

D. Pemphigus Vulgaris



See Answer in Part B → Q7

@Neet_pg_bot

Q8: Which of the following statements regarding Linear IgA disease is incorrect? (Q841963)

A. Common autoimmune blistering disease in infants and children

B. Crown of Jewels appearance

C. Subepidermal blistering on HPE

D. Oral steroids are first-line management

See Answer in Part B → Q8

@Neet_pg_bot

Q9: A 32 week pregnant lady presents with itching and erythematous plaques involving the periumbilical region. She is diagnosed with pemphigoid gestationis. What is the most common microscopy finding in this patient? (Q841962)

A. Intraepithelial Ig G Deposition

B. C3 deposit along the dermo-epidermal junction

C. Ig G deposit along the dermo-epidermal junction

D. Ig A deposit along the dermo-epidermal junction

See Answer in Part B → Q9

@Neet_pg_bot

Q10: A patient presented with blisters confined to the head, neck and upper trunk. Some of these blisters show scarring in the neck. The examination of the oral cavity is normal without any lesions. Electron microscopy shows a linear IgG deposition at the dermo-epidermal junction. What is the most probable diagnosis? (Q841961)

A. Mucous membrane pemphigoid

B. Pemphigus vulgaris

C. Cicatricial pemphigoid

D. Brunsting–Perry pemphigoid

See Answer in Part B → Q10

@Neet_pg_bot

Q11: A 75-year-old male patient came with skin lesions as shown below. Biopsy of the lesion shows a sub-epidermal split with linear deposition of C3 and IgG. Which of the following is true regarding this condition? (Q841960)

A. Antibodies directed against desmoglein 3

B. Nikolsky sign and bulla spread sign are positive

C. It has a non-bullous urticarial stage after the bullous stage

D. The lesions commonly heal without scarring



See Answer in Part B → Q11

@Neet_pg_bot

Q12: A 60-year-old male patient presented with ruptured vesicles and bullae on the skin and erosions in the mucous membrane. HPE of the skin biopsy revealed a row of tombstones. Antibodies against which of the following structures are most commonly present in this patient? (Q841947)

A. Desmoglein 1

B. Desmocolin

C. Desmoglein 3

D. Desmoplakin

See Answer in Part B → Q12

@Neet_pg_bot

Q13: Which of the following structure connects basal keratinocytes to the lamina lucida in the skin? (Q841958)

A. Hemidesmosomes

B. Keratin intermediate filaments

C. Lamina densa

D. Anchoring fibrils

See Answer in Part B → Q13

@Neet_pg_bot

Q14: A 60 old male patient presented with blisters involving >40% of body surface area. He was diagnosed with pemphigus vulgaris following a biopsy. The patient wants to know what is the best therapy to start for his condition. What would be the most appropriate solution to his question? (Q841957)

A. Prednisolone alone

B. Mycophenolate mophetil+ azathioprine

C. Prednisolone+ Azathioprine

D. Azathioprine+ Rituximab

See Answer in Part B → Q14

@Neet_pg_bot

Q15: A 45-year-old female patient presented with blisters in the oral cavity, arms, and trunk. A tzank smear of the epidermis was taken and is shown below. What is the characteristic finding and diagnosis? {{caption_text}} (Q841956)

A. Row of tombstone- Pemphigus vulgaris

B. Fishnet pattern- Pemphigus foliaceus

C. Acantholysis- Pemphigus foliaceus

D. Acantholysis- Pemphigus vulgaris

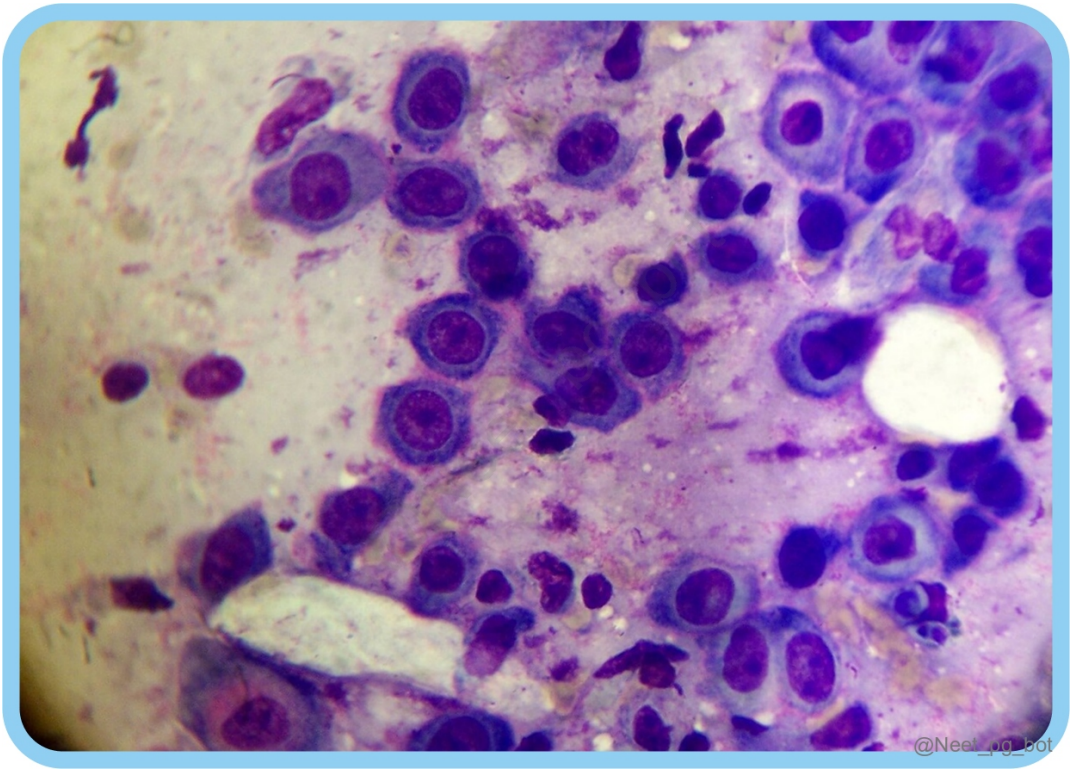

See Answer in Part B → Q15

@Neet_pg_bot

Q16: A middle aged female patient presented with vesicles and blisters over the skin and oral cavity. On examination, the blisters are flaccid with an erythematous base, and a firm sliding pressure with a finger separates the Superficial epidermis layers from basal epidermis, producing a new lesion. Which of the following microscopic

features is not seen in this patient? {{caption_text}} A {{caption_text}} B {{caption_text}} C {{caption_text}} D (Q841954)

A. A

B. B

C. C

D. D

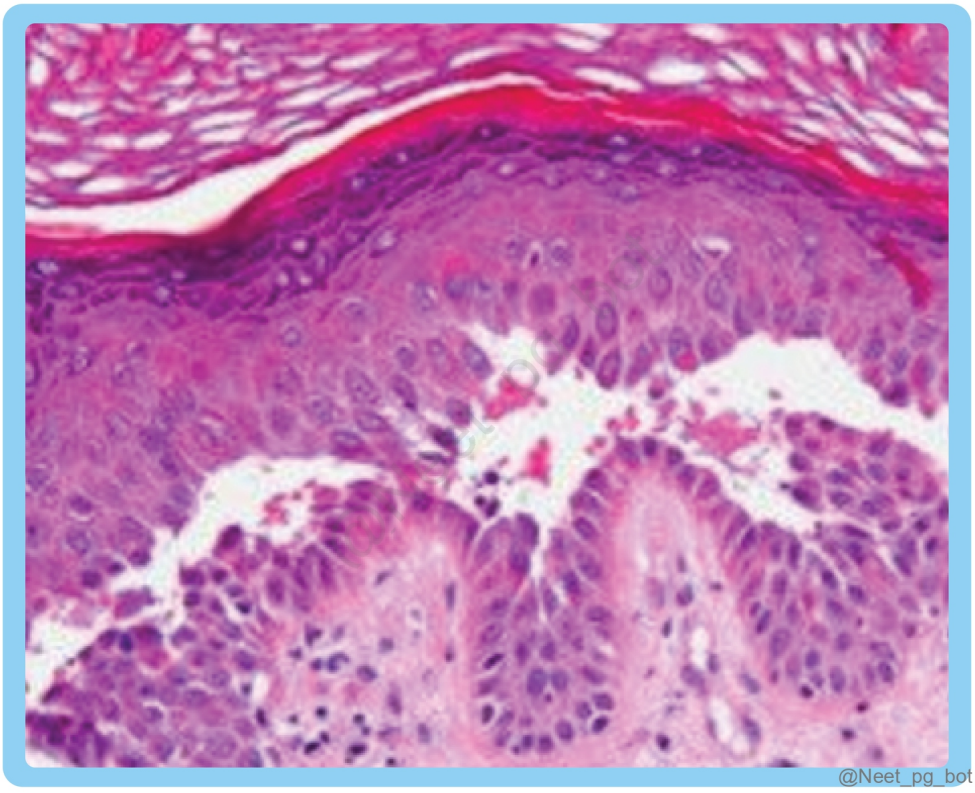

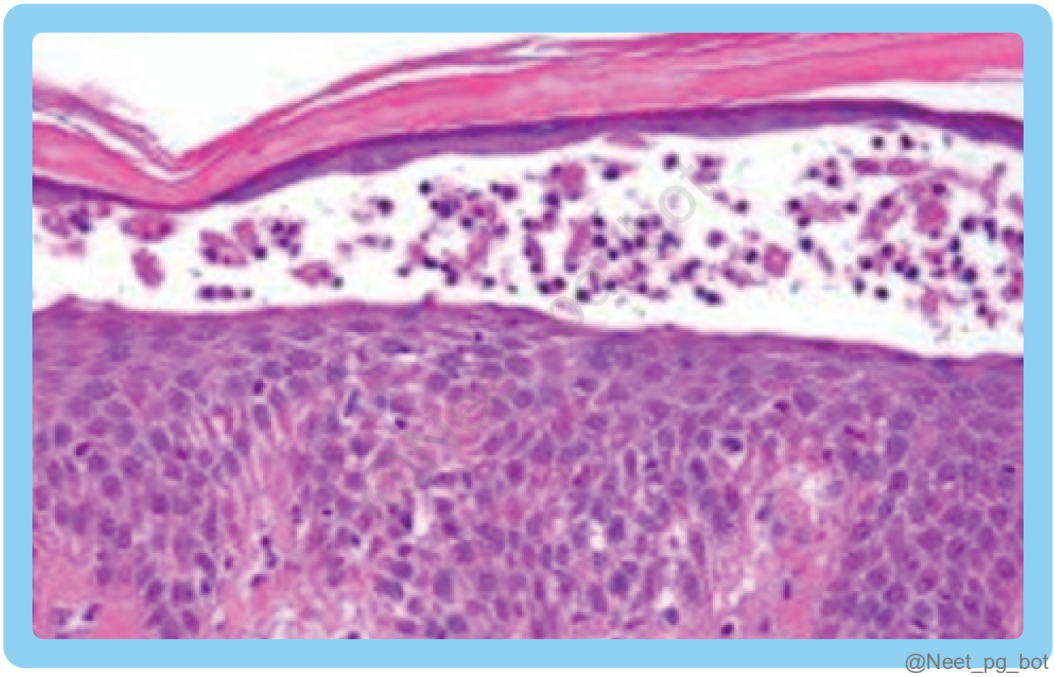

@Neet_pg_bot

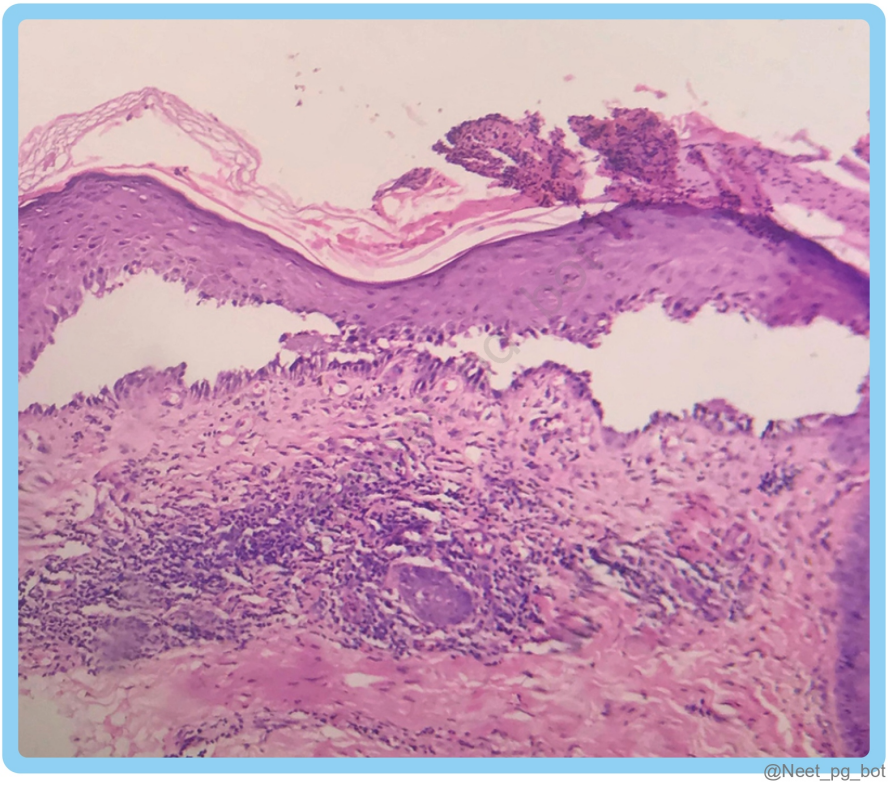

@Neet_pg_bot

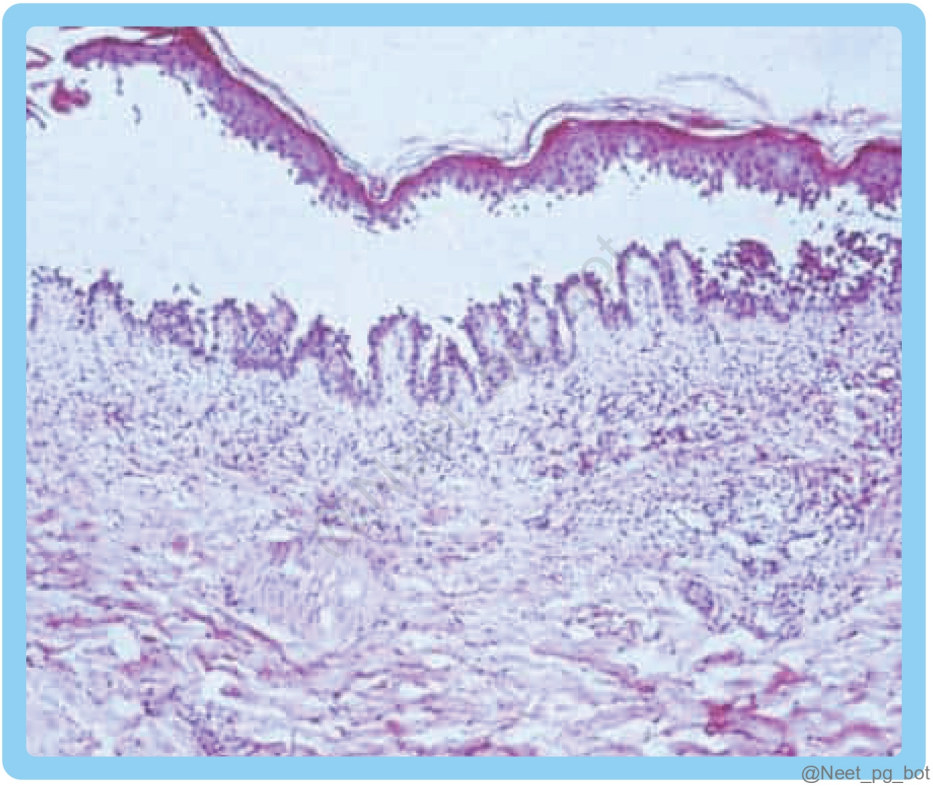

See Answer in Part B → Q16

@Neet_pg_bot

Q17: Which of the following statements about paraneoplastic pemphigus (PNP) is correct? (Q841953)

A. It is most commonly associated with lymphoma and leukemia

B. The oral mucosa is rarely involved

C. Autoantibodies in PNP exclusively target desmogleins

D. PNP typically has a better prognosis than other forms of pemphigus

See Answer in Part B → Q17

@Neet_pg_bot

Q18: A female patient came with a history of vesicles and bullae in the flexural parts one week ago. She presented to a dermatology clinic today because the lesion has changed. On examination, the following lesion is seen. What is the most likely diagnosis? {{caption_text}} (Q841952)

A. Pemphigus foliaceus

B. Endemic Pemphigus foliaceus

C. Condyloma accuminata

D. Pemphigus vegetans



See Answer in Part B → Q18

@Neet_pg_bot

Q19: A 45-year-old woman presents with pruritic, grouped vesicles and small blisters on her trunk and upper extremities. The patient reports that new lesions appear in waves, often in a herpetiform pattern. Biopsy shows eosinophilic spongiosis and acantholysis. DIF reveals intercellular IgG and C3 deposits. ELISA is positive for anti-desmoglein 1 antibodies. What is the most likely diagnosis? (Q841951)

A. Bullous pemphigoid

B. Dermatitis herpetiformis

C. Pemphigus vulgaris

D. Pemphigus herpetiformis

See Answer in Part B → Q19

@Neet_pg_bot

Q20: Which of the following statements is true regarding immunobullous disorders? (Q841950)

A. Skin is not affected in Pemphigus foliaceus.

B. Skin is not affected in Pemphigus vulgaris

C. Mucosa is not affected in Pemphigus foliaceus.

D. Mucosa is not affected in Pemphigus vulgaris

See Answer in Part B → Q20

@Neet_pg_bot

Q21: An elderly male patient presents with superficial vesicles and bullae seen in the face, scalp, and upper trunk. Most of the bullae have ruptured resulting in well-demarcated crusted erosions surrounded by erythema. Histopathological examination reveal following finding. What is the most likely diagnosis? {{caption_text}} (Q841949)

A. Pemphigus vulgaris (PV)

B. Pemphigus foliaceus (PF)

C. Staphylococcal Scalded Skin Syndrome (SSSS)

D. Steven Johnson Syndrome (SJS)

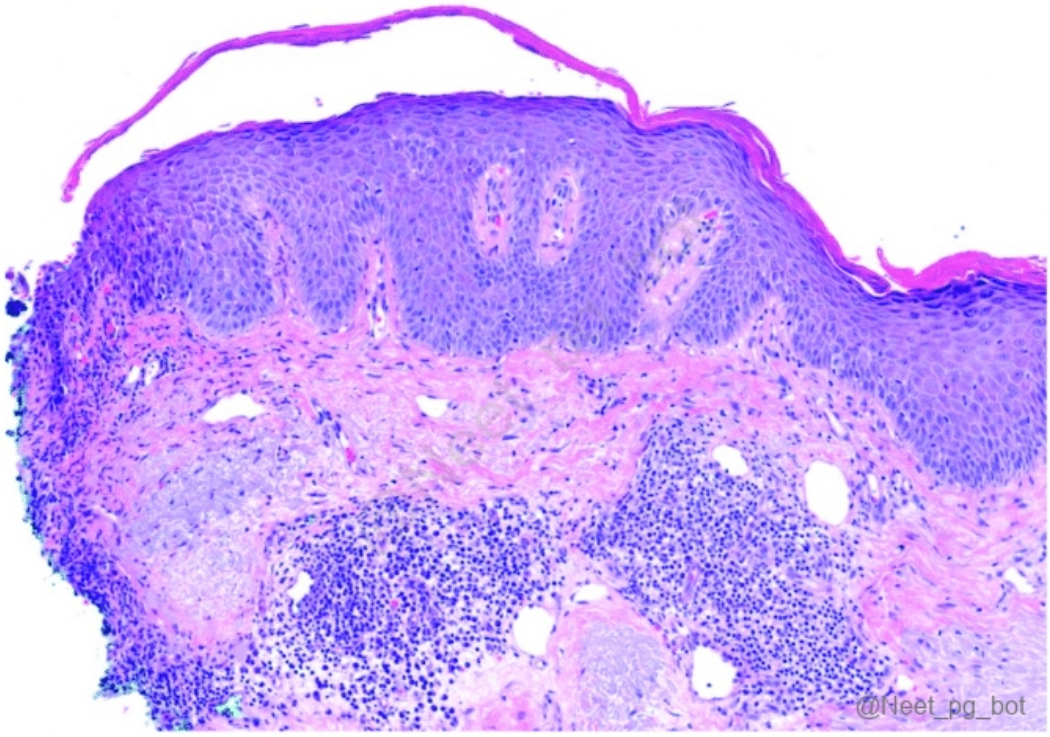

See Answer in Part B → Q21

@Neet_pg_bot

Q22: Which of the following is being demonstrated in the image given below? (Q841948)

A. Nikolsky's sign

B. Bulla spread sign

C. Auspitz sign

D. Koebner phenomenon



See Answer in Part B → Q22

@Neet_pg_bot

• [06_Immunobullous Disorders] 013 Previous Year Questions

« Back to Folder Directory

[06_Immunobullous Disorders] 013 Previous Year Questions — Quick Jump

Q1 (p. 209) *Q2 (p. 210)* *Q3 (p. 210)* *Q4 (p. 211)* *Q5 (p. 211)* *Q6 (p. 212)*
Q7 (p. 212) *Q8 (p. 212)*

Q1: A woman presents with a pruritic rash on the elbows, buttocks with recent diagnosis of gluten sensitive enteropathy. On immunofluorescence IgA deposition is seen as shown in the image. What is the most likely diagnosis? (Q866545)

A. Dermatitis herpetiformis

B. Pemphigus vulgaris

C. Bullous pemphigoid

D. Psoriasis

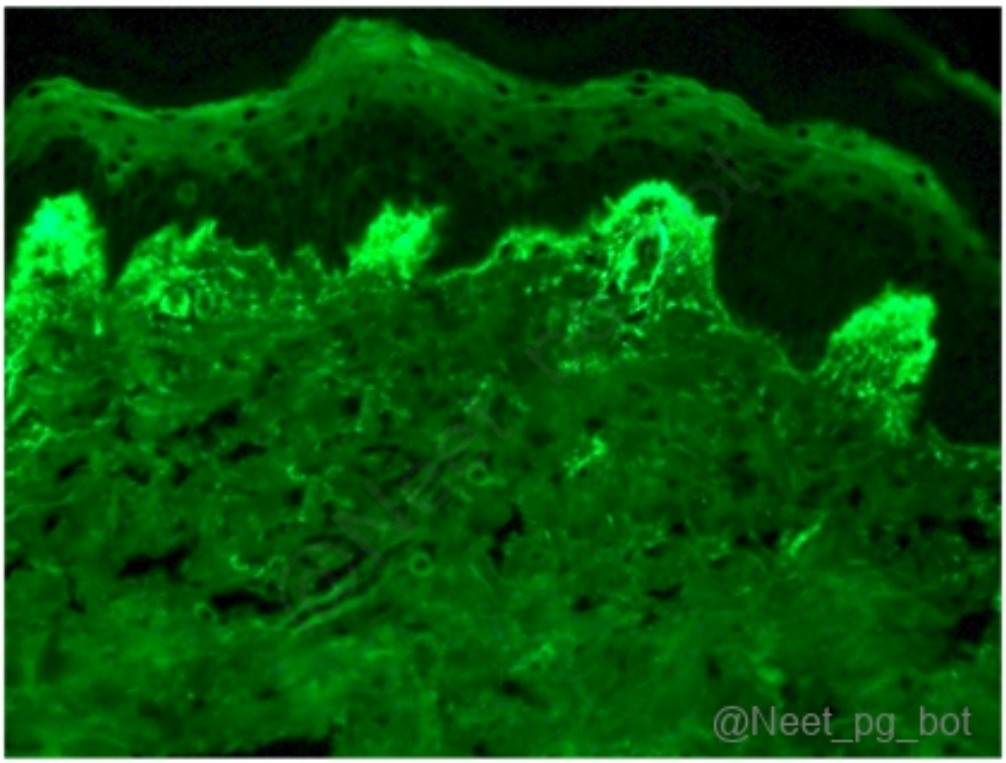

See Answer in Part B → Q1

@Neet_pg_bot

Q2: Identify the condition based on the immunofluorescence pattern shown in the image. (Q843974)

A. Lupus vulgaris

B. Pemphigus vulgaris

C. Bullous pemphigoid

D. Impetigo

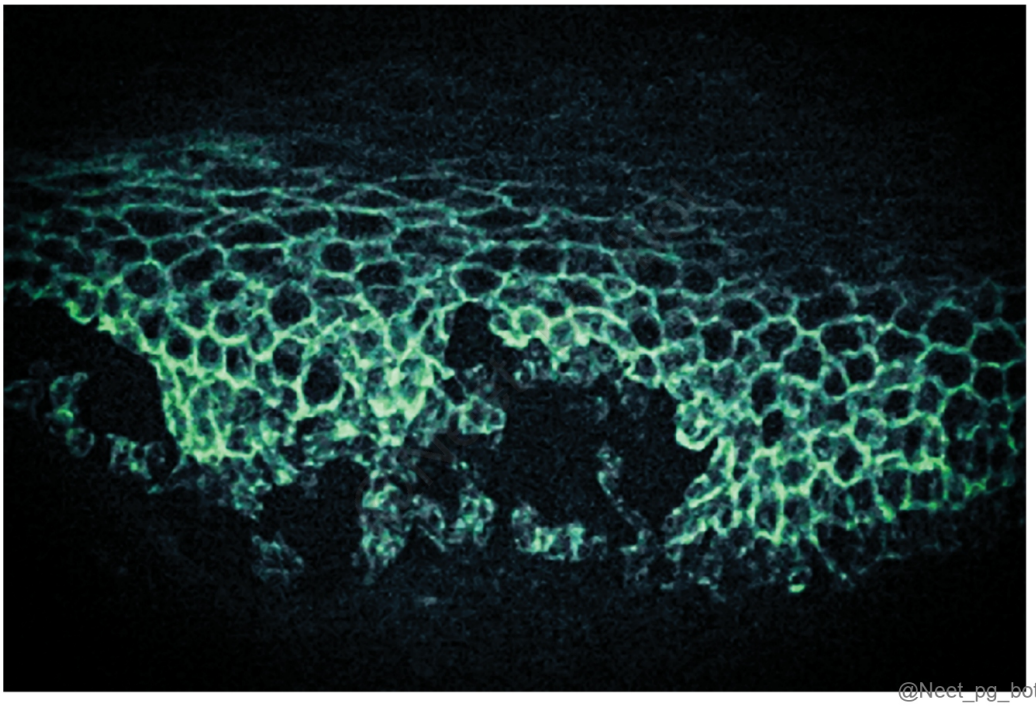

See Answer in Part B → Q2

@Neet_pg_bot

Q3: Statement 1 - A 59-year-old patient presents with flaccid bullae. Histopathology shows a suprabasal acantholytic split. Statement 2 - The row of tombstones' appearance is diagnostic of Pemphigus vulgaris. (Q857405)

A. Statements 1 & 2 are correct, 2 is not explaining 1

B. Statement 1 is incorrect

C. Statement 1 and 2 is incorrect

D. Statements 1 and 2 are correct and 2 is the correct explanation for 1

See Answer in Part B → Q3

@Neet_pg_bot

Q4: A 60-year-old female presents with eczematous itching lesions. Biopsy revealed a subepidermal cleft with direct immunofluorescence showing linear C3 & IgG deposition along the basement membrane zone. What is the likely diagnosis? (Q857410)

A. Pemphigus Vulgaris

B. Bullous Pemphigoid

C. Dermatitis herpetiformis

D. Pemphigus foliaceus

See Answer in Part B → Q4

@Neet_pg_bot

Q5: What is the probable diagnosis for a 30-year-old patient who has presented with flaccid bullae on her skin that are prone to easy rupture, with the biopsy showing a suprabasal split? (Q855941)

A. Pemphigus vulgaris

B. Pemphigus foliaceus

C. Pemphigus vegetans

D. Erythema multiforme

See Answer in Part B → Q5

@Neet_pg_bot

Q6: What is the diagnosis for a male baby, born to a non-consanguineous couple, who develops blisters on areas of friction, with a history of a previous child having similar complaints and dying at 2 weeks of age? (Q856824)

A. Epidermolysis bullosas

B. Chronic bullous disorder of childhood

C. Congenital syphilis

D. Neonatal pemphigu

See Answer in Part B → Q6

@Neet_pg_bot

Q7: What is the preferred treatment for the condition resulting in the formation of blisters beneath the epidermis, where neutrophils are found at the tips of the dermal papillae? (Q856840)

A. Rituximab

B. Dapsone

C. Cyclosporine

D. Azathioprine

See Answer in Part B → Q7

@Neet_pg_bot

Q8: A child presents to OPD with tense bullae over the torso. A biopsy of the lesion showed a subepidermal level of blistering and neutrophil infiltration. What is the drug of choice? (Q856382)

A. Rituximab

B. Dapsone

C. Cyclosporine

D. Azathioprine



See Answer in Part B → Q8

@Neet_pg_bot

• [07_Mycobacterial Infections] 014 Cutaneous Tuberculosis

« Back to Folder Directory

[07_Mycobacterial Infections] 014 Cutaneous Tuberculosis — Quick Jump

Q1 (p. 214) *Q2 (p. 215)* *Q3 (p. 216)* *Q4 (p. 216)* *Q5 (p. 217)* *Q6 (p. 218)*
Q7 (p. 219) *Q8 (p. 220)* *Q9 (p. 221)* *Q10 (p. 222)*

Q1: A 28-year-old swimming pool worker presents to the dermatology clinic with a lesion on his left hand which is mostly painless but has gradually increased in size as shown in the image. He recalls sustaining a minor cut while cleaning a pool about a month ago. Which of the following is a characteristic feature of this condition? (Q841842)

A. Erythematous nodules with central clearing

B. Non tender, erythematous nodules along lymphatic vessels

C. Vesicular rash with a linear distribution

D. Target-like lesions with central clearing



See Answer in Part B → Q1

@Neet_pg_bot

Q2: A 35-year-old construction worker presents with a painless lesion on his right forearm following sustaining a minor abrasion while working with bricks a few weeks ago. Physical examination reveals a shallow ulcer with undermined edges. Acid-fast bacilli staining of a biopsy specimen from the lesion is positive. Which of the following types of cutaneous tuberculosis is most likely responsible for this presentation? (Q841834)

A. Exogenous with previous exposure to MTB

B. Exogenous with no previous exposure to MTB

C. Endogenous cutaneous TB

D. Tuberculids

See Answer in Part B → Q2

@Neet_pg_bot

Q3: A 45-year-old female presents with a slowly progressive, verrucous plaque on her left foot. She has a history of pulmonary tuberculosis treated several years ago. On examination, the lesion appears well-defined, hyperkeratotic, and verrucous, with a papillomatous surface as shown in the image. All of the following statements are true about this condition except? (Q841835)

A. Anatomist's wart is the other name

B. Post-primary tuberculosis with poor immunity

C. It is a paucibacillary lesion

D. Antitubercular therapy is used in the management



@Neet_pg_bot

See Answer in Part B → Q3

@Neet_pg_bot

Q4: A 40-year-old woman presents with a slowly enlarging, painless lesion on the neck. She has a history of pulmonary tuberculosis with nodal involvement, treated 3 years ago. On examination, there is a firm, erythematous plaque with crusting and shallow ulceration. Ipsilateral, non-tender cervical lymphadenopathy is also noted. What is the most likely diagnosis? (Q841836)

A. Scrofuloderma

B. Actinomycosis

C. Sporotrichosis

D. Pyoderma gangrenosum



@Neet_pg_bot

See Answer in Part B → Q4

@Neet_pg_bot

Q5: A 20-year-old woman presents with a large erythematous, scaly plaque with deep-seated nodules on her buttock, as shown in the image. The lesion gradually progressed over 4 years, exhibiting scarring and atrophy in some areas. Diascopy of

the nodules reveals an "apple jelly" nodules. She has a history of a positive tuberculin skin test but no active tuberculosis. What is the likely diagnosis? (Q841837)

A. Lupus vulgaris

B. Psoriasis

C. Lupus pernio

D. Granuloma annulare



@Neet_pg_bot

See Answer in Part B → Q5

@Neet_pg_bot

Q6: A 24-year-old man presents with an erythematous plaque over the dorsum of hand that has been there for 4 years and is slowly progressing. Examination revealed a well-demarcated, indurated, annular-shaped plaque with irregular borders that was progressing towards one side and scarring on another border. Which of the following statements is FALSE about this condition? (Q841838)

A. It is a multibacillary lesion

B. It occurs in a previously sensitized patient

C. Lesions heal with central scarring

D. Apple jelly nodules can be seen



@Neet_pg_bot

See Answer in Part B → Q6

@Neet_pg_bot

Q7: An 11-year-old child presented in dermatology OPD with a micro papular rash on the trunk without any necrosis or itching. The Mantoux test is positive. Histopathology examination shows perifollicular non-caseating granulomas. Which of the following statements is false about its diagnosis? (Q841839)

A. Commonly seen in adults

B. The most common site is the trunk

C. It is not a type of lichen planus

D. Asymptomatic lichenoid papules are present



See Answer in Part B → Q7

@Neet_pg_bot

Q8: A 57-year-old female presented in dermatology OPD with bilateral nodular lesions and ulceration on her calf. On examination, tenderness was noticed. The Mantoux test was positive, and the culture for M. tuberculosis was negative. What is the likely diagnosis of this patient? (Q841840)

A. Erythema induratum of Bazin

B. Lichen scrofulosorum

C. Papulonecrotic tuberculid

D. Erythema nodosum



See Answer in Part B → Q8

@Neet_pg_bot

Q9: A 14-year-old girl presents with an erythematous plaque with central scarring and an advancing edge on her face. She reports a gradual progression of lesions over several months. Biopsy shows granulomatous inflammation. Which of the following drugs will be started as a part of treatment in this patient? (Q841841)

A. Amphotericin B

B. Itraconazole

C. Minocycline

D. Rifampicin



@Neet_pg_bot

See Answer in Part B → Q9

@Neet_pg_bot

Q10: A 15-year-old boy presents to the clinic with a large painless ulcer on the lower extremity with a necrotic base and undermined edges. His family reports that they live near a wetland area in a region known to have cases of similar ulcers. There has been no response to standard treatment for common bacterial skin infections. A smear from the lesion shows acid-fast bacilli. What is the most likely diagnosis? (Q841843)

A. Buruli ulcer

B. Cutaneous tuberculosis

C. Cutaneous leishmaniasis

D. Diabetic ulcer


@Neet_pg_bot

See Answer in Part B → Q10

@Neet_pg_bot

• [07_Mycobacterial Infections] 015 Leprosy

« Back to Folder Directory

[07_Mycobacterial Infections] 015 Leprosy — Quick Jump

Q1 (p. 224) *Q2 (p. 225)* *Q3 (p. 225)* *Q4 (p. 226)* *Q5 (p. 227)* *Q6 (p. 227)*
Q7 (p. 228) *Q8 (p. 229)* *Q9 (p. 229)* *Q10 (p. 230)*

Q1: A 45-year-old man from a leprosy endemic region presents with small, ill-defined, multiple symmetrically distributed skin nodules as depicted below. Additionally he also has thickened peripheral nerves. What type of T lymphocytes are predominantly involved here? (Q842011)

A. ■■■Predominantly CD8+ T-cells

B. Predominantly CD4+ T-cells

C. Both CD8+ and CD4+ T-cells

D. None of the above



See Answer in Part B → Q1

@Neet_pg_bot

Q2: A second-year medical student asks you to describe Lepromin Test in the dermatology ward. While reviewing the test together, she recalls several statements. Which of the following statements recalled by her is false? (Q842015)

A. An early reaction is called the Fernandez reaction

B. It is a diagnostic test

C. It is also called the Mitsuda test

D. It may be used to classify patients

See Answer in Part B → Q2

@Neet_pg_bot

Q3: What is the most likely diagnosis for a patient with hypoesthetic lesions as shown in the image? (Q842017)

A. Borderline lepromatous

B. Borderline tuberculoid

C. Lepromatous

D. Tuberculoid



See Answer in Part B → Q3

@Neet_pg_bot

Q4: A 6-year-old child presents with well demarcated hypopigmented lesions with fine scaling on the face and upper arms. The lesions are well-demarcated with fine scaling and have been present for several months. On examination, there is no erythema or induration. The child is otherwise healthy with no systemic symptoms. Which of the following is the most likely diagnosis for this presentation? (Q842019)

A. ■■■Pityriasis alba

B. ■■■Indeterminate leprosy

C. Atopic dermatitis

D. Niacin deficiency



See Answer in Part B → Q4

@Neet_pg_bot

Q5: A 40-years-old male presented with multiple hypopigmented macules on trunk. On examination, the lesions were non-scaly, shiny and hypoaesthetic. Which of the following tests should be performed to confirm the diagnosis? (Q842021)

A. Diascopy

B. Lepromin Test

C. Slit skin smear

D. Wood's lamp examination

See Answer in Part B → Q5

@Neet_pg_bot

Q6: A 12-year-old child presented with skin lesions, as shown in the image. On examination, bilateral ulnar and lateral popliteal nerves were enlarged. According to the National Leprosy Eradication Programme (NLEP) Guidelines, what would be the most appropriate treatment for the child on day 1? (Q842023)

A. ■■■Rifampicin 450 mg Clofazimine 150 mg Dapsone 50 mg

B. Rifampicin 600 mg Clofazimine 300 mg Dapsone 100 mg

C. ■■■Rifampicin 450 mg Clofazimine 150 mg Dapsone 100 mg

D. ■■■Rifampicin 300 mg Clofazimine 150 mg Dapsone 50 mg



@Neet_pg_bot

See Answer in Part B → Q6

@Neet_pg_bot

Q7: You are training a pharmacist at a local PHC to supply multi-drug therapy at regular intervals for patients with leprosy in a village. Which of the following statements would be incorrect regarding treatment of leprosy? (Q842026)

A. Fluoroquinolones are second-line drugs for the management of leprosy

B. Dapsone acts as an anti-leprosy medication by inhibiting folate synthesis.

C. Rifampicin acts by inhibiting RNA-dependent DNA polymerase

D. Clofazimine causes the deposition of crystals in the intestinal mucosa

See Answer in Part B → Q7

@Neet_pg_bot

Q8: A 30-year-old patient from an endemic region presents with weakness and numbness in the lower leg and foot. On examination, there is evidence of foot drop and sensory loss over the dorsum of the foot. Which nerve is most likely involved in a patient of leprosy, leading to these neurological deficits? (Q842028)

A. Median nerve

B. Ulnar nerve

C. Radial nerve

D. Common peroneal nerve

See Answer in Part B → Q8

@Neet_pg_bot

Q9: A 28-year-old woman presents with an erythematous, swollen patch in a skin lesion on the face, along with significant oedema of the hands and feet. She reports the patch has been present for several months now, but has only recently turned painful and red. Additionally, the patient experiences pain and tenderness along multiple nerves and reports a general feeling of fatigue and malaise. The patient has been on regular medications but is unsure about their names. What is the most likely diagnosis? (Q842029)

A. Pyoderma gangrenosum

B. Type 1 lepra reaction

C. Vasculitis

D. Psoriasis

See Answer in Part B → Q9

@Neet_pg_bot

Q10: A pregnant woman at 10 weeks of gestation, who is currently undergoing multidrug therapy (MDT) for leprosy, now presents with type 2 lepra reaction. What is the preferred treatment for this patient? (Q842032)

A. ■■■Stop MDT and start oral steroids

B. Antibiotics

C. ■■■Thalidomide

D. ■■■Continue MDT and add oral steroids

See Answer in Part B → Q10

@Neet_pg_bot

• [07_Mycobacterial Infections] 016 Previous Year Questions

« Back to Folder Directory

[07_Mycobacterial Infections] 016 Previous Year Questions — Quick Jump

Q1 (p. 231) *Q2 (p. 232)* *Q3 (p. 232)* *Q4 (p. 233)* *Q5 (p. 234)* *Q6 (p. 234)*
Q7 (p. 234) *Q8 (p. 235)* *Q9 (p. 236)* *Q10 (p. 237)* *Q11 (p. 237)*

Q1: A patient with borderline tuberculoid leprosy presents with the following findings. Which type of hypersensitivity reaction and nerve is enlarged? (Q866862)

A. Type 1 & greater auricular nerve

B. Type 2 & greater auricular nerve

C. Type 3 & anterior auricular nerve

D. Type 4 & greater auricular nerve



See Answer in Part B → Q1

@Neet_pg_bot

Q2: A patient presents with a progressive and asymptomatic lesion over the neck region and no systemic symptoms. Which of the following investigations would be helpful? KOH preparation Skin biopsy Chest X-ray (TB workup) HIV testing (Q865451)

A. 1, 2

B. 2, 3

C. 3, 4

D. 1, 4



See Answer in Part B → Q2

@Neet_pg_bot

Q3: A patient presents with an indurated plaque on the cheek with central atrophy. Chest X-ray reveals apical calcification. Which of the following tests is most appropriate to confirm the diagnosis? (Q866550)

A. Mantoux test

B. Slit skin smear

C. PCR

D. Probe test



See Answer in Part B → Q3

@Neet_pg_bot

Q4: A 38-year-old patient presents with hypopigmented nodular skin lesions and loss of sensation over the arm. On examination, there is thickening of the ulnar nerve. A skin biopsy reveals epithelioid cell granulomas, and an intradermal lepromin (antigen) test is performed. Which of the following statements most accurately describes this condition? (Q843957)

A. Tuberculoid leprosy with a positive antigen test

B. Lepromatous leprosy with a positive antigen test

C. Erythema nodosum leprosum with a negative antigen test

D. Lepromatous leprosy with a negative antigen test

See Answer in Part B → Q4

@Neet_pg_bot

Q5: What is the preferred treatment for a pregnant woman who is 12 weeks pregnant and undergoing multidrug therapy for leprosy but is now experiencing type 2 lepra reaction? (Q854964)

A. Stop MDT and start oral steroids

B. Antibiotics

C. Thalidomide

D. Continue MDT and add oral steroids

See Answer in Part B → Q5

@Neet_pg_bot

Q6: A 30-year-old patient presents to the clinic with hypopigmented patches on the skin. On examination, there are a few well-demarcated, slightly raised lesions with a loss of sensation. Skin smears reveal no acid-fast bacilli. Which of the following is the most likely diagnosis? (Q854966)

A. Multibacillary leprosy

B. Psoriasis

C. Tinea versicolor

D. Paucibacillary leprosy

See Answer in Part B → Q6

@Neet_pg_bot

Q7: The image given below is characteristically seen in which of the following types of leprosy? (Q856665)

A. Borderline lepromatous leprosy

B. Lepromatous leprosy

C. Borderline leprosy

D. Histoid leprosy



See Answer in Part B → Q7

@Neet_pg_bot

Q8: Which of the following will be the outcome of Leprosy , if left untreated. (Q856667)

A. No spontaneous remission is seen

B. Half of the cases resolve spontaneously after bacilli exposure

C. Spontaneous remission is more common in children than in adults

D. Indeterminate leprosy have more remission than tuberculoid

See Answer in Part B → Q8

@Neet_pg_bot

Q9: What would be your next best course of action when a patient undergoing multi-drug therapy (MDT) exhibits deterioration of preexisting lesions and nerve involvement? (Q855965)

A. Stop MDT, start systemic corticosteroids

B. Continue MDT, start systemic steroids

C. Stop MDT thalidomide Continue MDT, start thalidomide

D. Continue MDT, start thalidomide



See Answer in Part B → Q9

@Neet_pg_bot

Q10: Please determine the medication utilized for the management of the presented medical condition: (Q854901)

A. Anti-fungal therapy

B. Anti-tubercular therapy

C. Topical steroids therapy

D. Anti-leprosy treatment



See Answer in Part B → Q10

@Neet_pg_bot

Q11: A 45-year-old man presents with progressive facial weakness and difficulty closing his right eye. Examination reveals facial asymmetry, and early lagophthalmos. Facial swelling noted as shown in the image. There is also thickening of peripheral nerves. Which nerve is most commonly involved in this condition? (Q855876)

A. Abducens nuclei

B. Facial nerve

C. Optic nerve

D. Trigeminal nerve

See Answer in Part B → Q11

@Neet_pg_bot

• [08_Sexually Transmitted Infections] 017 Non Syphilitic Std- I

« Back to Folder Directory

[08_Sexually Transmitted Infections] 017 Non Syphilitic Std- I — Quick Jump

Q1 (p. 239)	*Q2 (p. 239)*	*Q3 (p. 240)*	*Q4 (p. 240)*	*Q5 (p. 241)*	*Q6 (p. 241)*
Q7 (p. 242)	*Q8 (p. 243)*	*Q9 (p. 244)*	*Q10 (p. 244)*	*Q11 (p. 245)*	*Q12 (p. 246)*
Q13 (p. 246)	*Q14 (p. 247)*	*Q15 (p. 247)*	*Q16 (p. 248)*	*Q17 (p. 248)*	

Q1: Match the following description of ulcers with their causative organisms. 1.Painful vesicular lesions a) Syphilis 2.Painless, beefy red ulcers with rolled edges. b) Chancroid 3.Painless genital ulcer with indurated base. c) Genital herpes 4.Soft, painful genital ulcer with irregular borders. d) Granuloma inguinale (Q841757)

A. 1-a, 2-b, 3-c, 4-d

B. 1-c, 2-d, 3-a, 4-b

C. 1-c, 2-d, 3-b, 4-a

D. 1-b, 2-a, 3-c, 4-d

See Answer in Part B → Q1

@Neet_pg_bot

Q2: A 28 year old female presents with vaginal discharge that is frothy, yellow-green in colour and has a foul odour. She reports mild vaginal itching and discomfort during urination. A per speculum reveals the image shown below. What is the most likely diagnosis? (Q841736)

A. Candida albicans

B. Trichomonas vaginalis

C. Neisseria gonorrhoeae

D. Gardnerella vaginalis



See Answer in Part B → Q2

@Neet_pg_bot

Q3: A 28 year old sexually active man presents with painful genital lesions. He reports a tingling sensation and burning pain in the genital area preceding the appearance of the ulcers. Which of the following is the most characteristic finding for his condition? (Q841775)

A. The presence of multinucleated giant cells on the Tzanck smear

B. Presence of bacterial colonies, "school of fish" appearance on Gram stain

C. Donovan bodies within Pund cells on Gram stain

D. Clue cells on saline mount

See Answer in Part B → Q3

@Neet_pg_bot

Q4: A 35 year old truck driver presents to the clinic with complaints of a painful genital lesion that has been progressively enlarging over the past few weeks. Upon examination, you note a tender ulcerative lesion with undermined edges and a base covered by a greyish exudate. Additionally, there are enlarged and tender inguinal lymph nodes palpable unilaterally. The patient reports a recent sexual encounter with another male truck driver. Which of the following sexually transmitted infections is most likely to present with this clinical manifestation (Q841770)

A. Syphilis

B. Donovanosis

C. Herpes simplex

D. Chancroid

See Answer in Part B → Q4

@Neet_pg_bot

Q5: A 45 year old male presents to the clinic with painless, beefy-red ulcers on his genitals. He reports that the lesions have been progressively enlarging over the past few weeks. What is the most appropriate treatment for this patient? (Q841755)

A. Oral Azithromycin

B. Intramuscular Penicillin G

C. Intramuscular Ceftriaxone

D. Oral Doxycycline

See Answer in Part B → Q5

@Neet_pg_bot

Q6: A 35 year old man presents to a clinic with complaints of painless genital ulcer. He reports that the ulcers have been present for several weeks and have been progressively increasing in size. He also mentions that the ulcers bleed easily upon touch and are not indurated. A picture of the ulcer is shown below. Based on the

clinical presentation, what is the most likely diagnosis? (Q841746)

A. Syphilis

B. Chancroid

C. Lymphogranuloma venereum

D. Donovanosis

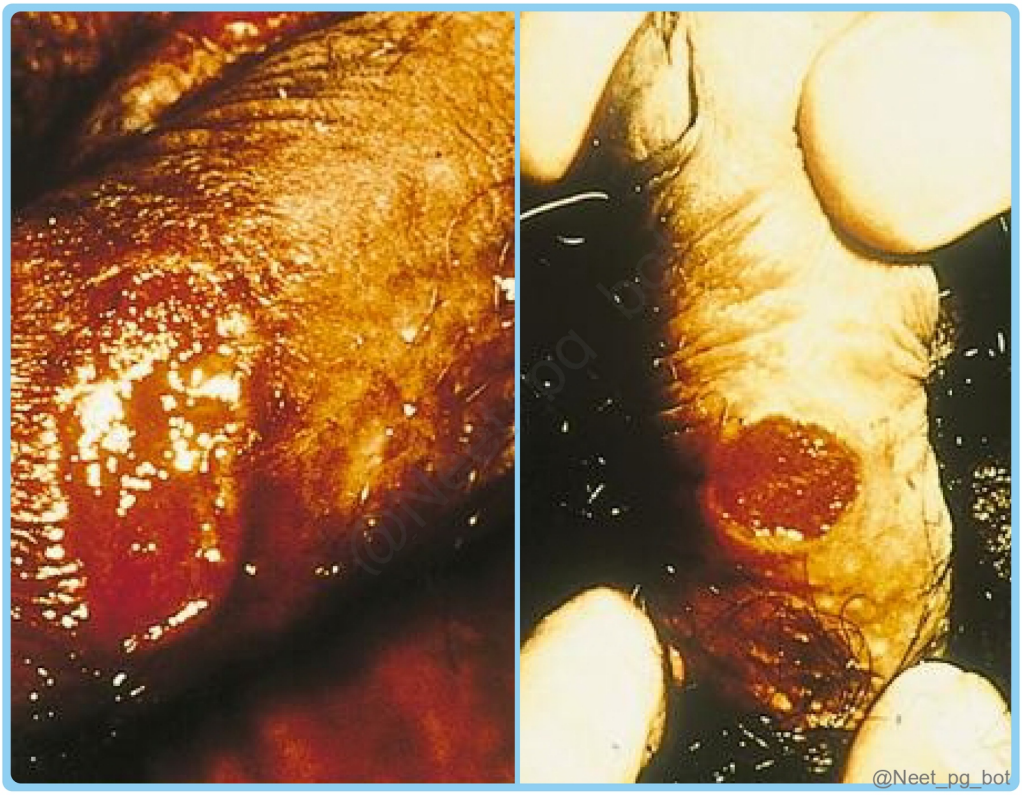

See Answer in Part B → Q6

@Neet_pg_bot

Q7: A 32 year old male presents to a primary care clinic with complaints of urethral discharge and dysuria. He reports having unprotected sexual intercourse with multiple partners. On examination, you note purulent discharge from the urethra. Which colour kit would be most appropriate for initial management in this patient? (Q841744)

A. Yellow

B. Blue

C. Grey

D. Red

See Answer in Part B → Q7

@Neet_pg_bot

Q8: A 32 year old woman presents with complaints of vaginal discharge and a fishy odour. She denies any genital itching or irritation. On examination, you notice the discharge coats the vaginal walls as shown in the image. There is no erythema or inflammation noted. Out of the following, which is the single most reliable predictor to support the diagnosis in this patient? (Q841741)

A. Presence of clue cells on wet mount microscopy

B. Thin, greyish-white vaginal discharge

C. Positive whiff test (amine odour) with 10% KOH solution

D. Vaginal pH of more than 4.5

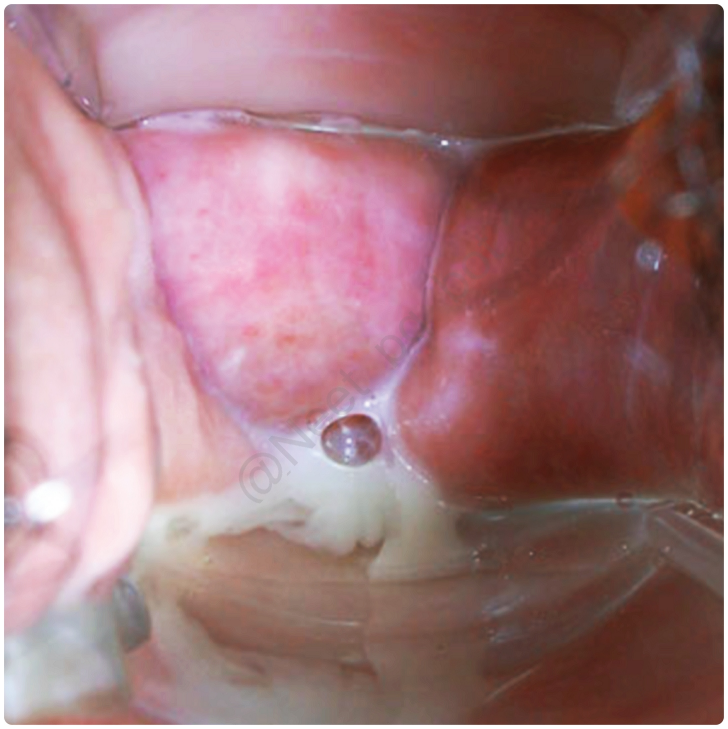

@Neet_pg_bot

See Answer in Part B → Q8

@Neet_pg_bot

Q9: A 30 year old woman with a medical history significant for diabetes mellitus presents to the clinic with complaints of vaginal itching and thick, white, curd-like discharge. Physical examination reveals no signs of inflammation or lesions. What is the most likely diagnosis? (Q841739)

A. Bacterial vaginosis

B. Trichomoniasis

C. Vaginal candidiasis

D. Chlamydia trachomatis infection

See Answer in Part B → Q9

@Neet_pg_bot

Q10: A 28 year old sexually active male presents to the clinic with a painless single lesion on his genitals. On examination, the healthcare provider observes single small, round, painless ulcer with raised edges and a clean base as shown below. The patient denies any recent travel, but he reports having unprotected sexual contact with multiple partners in the past month. What is the most appropriate treatment for this patient? (Q841721)

A. Oral Doxycycline

B. Oral Azithromycin

C. Intramuscular Penicillin G Benzathine

D. Topical Acyclovir



See Answer in Part B → Q10

@Neet_pg_bot

Q11: A 24-year-old sexually active female presents with dysuria, increased urinary frequency, and mild cervical discharge on per speculum examination. She denies fever or abdominal pain. A urinalysis reveals pyuria, but no bacteria are seen on Gram staining of the discharge. Which of the following agents is the first-line drug for this condition? (Q841735)

A. Azithromycin

B. Ceftriaxone

C. Fluconazole

D. Doxycycline

See Answer in Part B → Q11

@Neet_pg_bot

Q12: A 28 year old male presents to the STD clinic with a history of swelling in the inguinal region as shown in the image below. He has a history of unprotected sexual intercourse in the past few months and reports a painless ulcer, which healed without scarring. Which of the following is false regarding this condition? (Q841733)

A. Caused by Chlamydia trachomatis L1-L3

B. Can be associated with hepatitis C co-infection

C. Presents with an indurated ulcer and painless lymphadenopathy

D. Esthiomene is a complication in the tertiary stage of this disease



See Answer in Part B → Q12

@Neet_pg_bot

Q13: A 28 year old female presents with lower abdominal pain, dyspareunia, and cervical motion tenderness. She also reports that she has been unable to conceive despite actively trying for the past 18 months. What is the most likely diagnosis?

(Q841731)

A. Genital herpes

B. Chlamydia infection

C. Syphilis

D. Trichomoniasis

See Answer in Part B → Q13

@Neet_pg_bot

Q14: A 28 year old sexually active male presents with dysuria and urethral discharge which is purulent, profuse, thick and creamy. He reports having unprotected sexual intercourse with multiple partners. What is the most appropriate initial management? (Q841729)

A. Oral Fluconazole

B. Intramuscular Benzathine Penicillin G

C. Oral Azithromycin

D. IM Ceftriaxone

See Answer in Part B → Q14

@Neet_pg_bot

Q15: A 22 year old sexually active woman presents to the clinic with complaints of vaginal discharge and pelvic pain. She reports having multiple sexual partners and inconsistent use of condoms. On examination, the healthcare provider notices purulent vaginal discharge and tenderness on pelvic examination. A Gram stain of the discharge reveals intracellular gram-negative diplococci. What is the most likely diagnosis? (Q841726)

A. Bacterial vaginosis

B. Candidiasis

C. Trichomoniasis

D. Gonorrhea

See Answer in Part B → Q15

@Neet_pg_bot

Q16: A newborn infant presents with symptoms suggestive of congenital syphilis. The mother had untreated syphilis during pregnancy. Which of the following is not a manifestation of early-onset congenital syphilis in newborns? (Q841724)

A. Vesiculobullous rash

B. Inflammation of oral and nasal mucosa

C. Continous discharge from the nose

D. Hutchisons Triad

See Answer in Part B → Q16

@Neet_pg_bot

Q17: A 28 year old man presents to the clinic with a diffuse, maculopapular rash on his palms and soles, as well as fever and sore throat. He reports that the rash developed a few weeks after he noticed a painless ulcer on his genital area, which resolved on its own. The rash is not itchy and does not involve the face. The patient also has white patches in his mouth and a few small, red papules on his genitals. What is the most likely diagnosis? (Q841723)

A. Primary Syphilis

B. Tertiary Syphilis

C. Pitriyasis Rosea

D. Secondary Syphilis

See Answer in Part B → Q17

• [08_Sexually Transmitted Infections] 018 Previous Year Questions

« Back to Folder Directory

[08_Sexually Transmitted Infections] 018 Previous Year Questions — Quick Jump

Q1 (p. 250)	*Q2 (p. 250)*	*Q3 (p. 251)*	*Q4 (p. 251)*	*Q5 (p. 252)*	*Q6 (p. 253)*
Q7 (p. 253)	*Q8 (p. 254)*	*Q9 (p. 255)*	*Q10 (p. 256)*	*Q11 (p. 257)*	*Q12 (p. 257)*
Q13 (p. 258)	*Q14 (p. 259)*	*Q15 (p. 259)*	*Q16 (p. 260)*	*Q17 (p. 260)*	

Q1: What is the probable diagnosis for a young woman who presents with a painless ulcer in the genital region accompanied by pain less swelling of the lymph nodes in the groin? (Q855293)

A. Chancroid

B. Syphilis

C. Herpes genitalis

D. Granuloma inguinale

See Answer in Part B → Q1

@Neet_pg_bot

Q2: Which of the following conditions is not included in syndromic management for males? (Q879088)

A. Urethral discharge

B. Genital ulcer

C. Inguinal swelling

D. Lower abdominal pain

See Answer in Part B → Q2

@Neet_pg_bot

Q3: A patient presents to you with multiple anogenital warts. The biopsy of these lesions showed squamous atypia. Which of the following human papillomavirus types are considered high-risk? (Q855895)

A. HPV 2

B. HPV 18

C. HPV 6

D. HPV 11



See Answer in Part B → Q3

@Neet_pg_bot

Q4: A sexually active male presented with warts on his penis as shown below. Similar lesions were present near the anal canal. What is the most likely diagnosis? (Q859912)

A. Penile cancer

B. Condyloma acuminata

C. Bowen disease

D. Haemorrhoids



See Answer in Part B → Q4

@Neet_pg_bot

Q5: What advice would you provide to prevent the transmission of active genital warts in a female patient with a history of recurrence, despite her husband not being affected by it? (Q856365)

A. Give continuous prophylaxis to the patient

B. Give prophylactic antivirals to the husband

C. Give antivirals whenever active lesions are present

D. Don’t involve in intercourse when active lesions are present

See Answer in Part B → Q5

@Neet_pg_bot

Q6: Which of these options does not show symptoms of a maculopapular rash? (Q856833)

A. Zoster (shingles)

B. Rubella

C. Dengue (during the febrile phase)

D. Measles

See Answer in Part B → Q6

@Neet_pg_bot

Q7: A patient presents with the following lesions on the genitals. Scrapings from the lesion would show? (Q856676)

A. Tzanck cells

B. Cells with clear halo around the nucleus

C. Molluscum bodies

D. HP bodies



See Answer in Part B → Q7

@Neet_pg_bot

Q8: What does the presence of painless sores on the vulval area indicate? (Q857573)

A. Genital herpes

B. Condylomata acuminata

C. Gonococcal vulvovaginitis

D. Condyloma lata



See Answer in Part B → Q8

@Neet_pg_bot

Q9: A 45-year-old truck driver with a history of multiple sex partners presented to the dermatological department, as shown below. What is the likely diagnosis? (Q857977)

A. Secondary syphilis

B. Lichen planus

C. Scabies

D. Psoriasis



See Answer in Part B → Q9

@Neet_pg_bot

Q10: A male presents with lesions and a history of unprotected sexual intercourse a few months ago. What is the most appropriate investigation to confirm the diagnosis? (Q865444)

A. Serology

B. Tzanck smear

C. KOH

D. Biopsy



See Answer in Part B → Q10

@Neet_pg_bot

Q11: Bubo is seen in which of the following conditions? (Q860116)

A. LGV

B. Herpes

C. Syphilis

D. Donovanosis

See Answer in Part B → Q11

@Neet_pg_bot

Q12: A 40-year-old male presents to the OPD with painful genital ulcers along with painful bubos. And he had a history of multiple sexual partners. Which of the following is the diagnosis? (Q860106)

A. Chancroid

B. Donovanosis

C. Herpes genitalis

D. Chancre

See Answer in Part B → Q12

@Neet_pg_bot

Q13: A truck driver reports multiple painful genital ulcers on his scrotum following unprotected sexual intercourse, accompanied by painful lymph nodes. What is the most likely cause? (Q860097)

A. Chancre

B. Chancroid

C. Donovanosis

D. Herpes

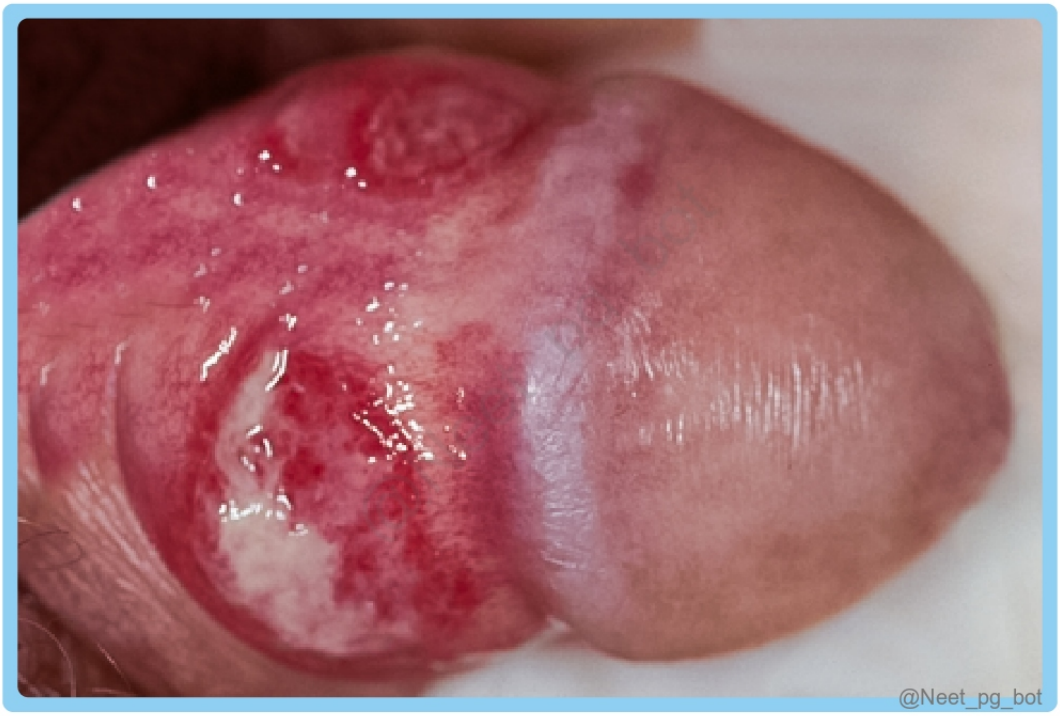

See Answer in Part B → Q13

@Neet_pg_bot

Q14: A 30-year-old patient presents with a history of flat lesions near the anal canal, rashes on the body, and hair loss that follows a particular pattern, as shown in the image. What is the diagnosis? (Q843949)

A. Trichotillomania

B. Alopecia areata

C. Secondary syphilis

D. Malassezia



See Answer in Part B → Q14

@Neet_pg_bot

Q15: A 30-year-old female presents with a painful, soft, red ulcer on the vulva that has a granular base. She also has tender, bilateral inguinal lymphadenopathy. Which of the following is the most likely diagnosis? (Q852730)

A. Chancroid

B. Neisseria Gonorrhoeae Infection

C. Granuloma Inguinale

D. Lymphogranuloma Venereum

See Answer in Part B → Q15

@Neet_pg_bot

Q16: Which organism is not associated with urethritis in men? (Q853201)

A. Neisseria gonorrhoea

B. Trichomonas vaginalis

C. Mycoplasma genitalium

D. Gardnerella vaginalis

See Answer in Part B → Q16

@Neet_pg_bot

Q17: A biopsy of a patient presenting with painful vesicular lesions and superficial erosions in the genital area is shown. What treatment would you initiate? (Q865447)

A. Acyclovir

B. Steroids

C. Penicillin

D. Azithromycin

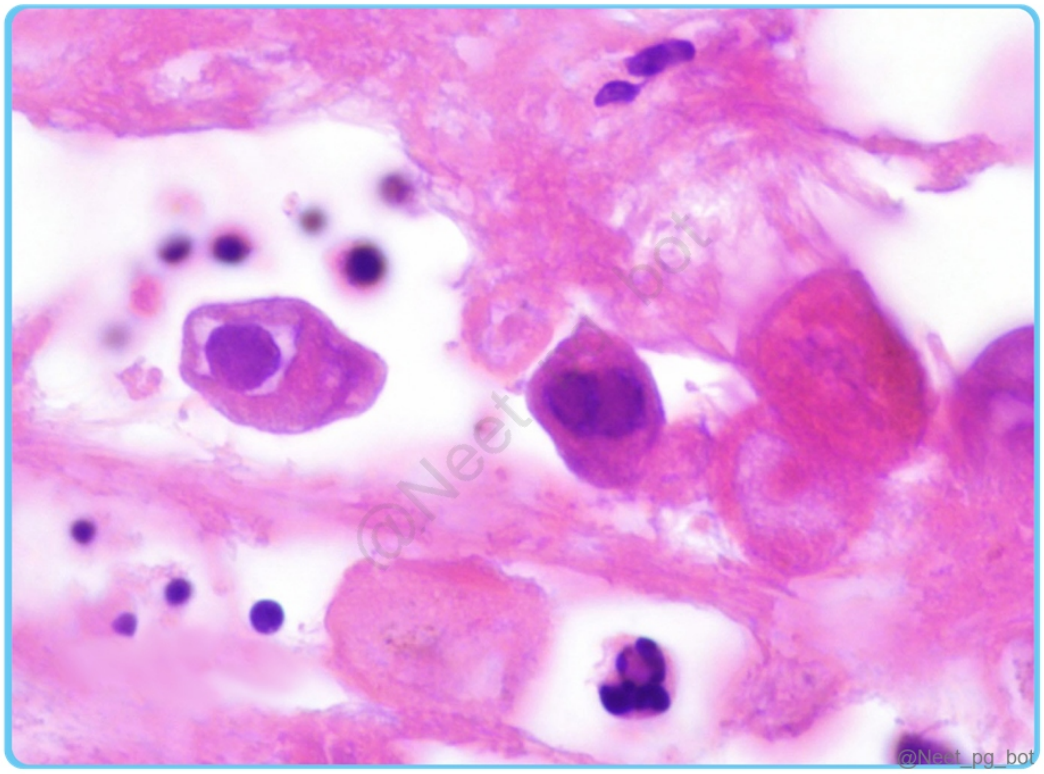

See Answer in Part B → Q17

@Neet_pg_bot

• [09_Connective Tissue Disorders] 019 Connective Tissue Disorders

« Back to Folder Directory

[09_Connective Tissue Disorders] 019 Connective Tissue Disorders — Quick Jump

Q1 (p. 262) *Q2 (p. 263)* *Q3 (p. 263)* *Q4 (p. 264)* *Q5 (p. 265)* *Q6 (p. 266)*
Q7 (p. 267) *Q8 (p. 268)* *Q9 (p. 269)*

Q1: A 32-year-old woman comes to the dermatology OPD with lesions on her cheeks that aggravate when exposed to sunlight, as shown in the image below. She has also had fatigue, myalgias, and arthralgias over the past four months. What would be the expected finding on direct immunofluorescence of a skin biopsy of a lesion from this patient? (Q841807)

A. Granular continuous deposit of IgG and C3 in the dermo-epidermal junction

B. Linear IgG and C3 deposits along the basement membrane zone

C. Granular IgA in dermal papillae

D. Intercellular IgG and C3 deposits in the epidermis



See Answer in Part B → Q1

Q2: A 42-year-old woman presented with complaints of a circular, scaly rash on her scalp, as shown in the image. On examination, you notice multiple small spikes over the underside of the rash. This presentation is most characteristic of which of the following conditions? (Q841808)

A. Psoriasis

B. Seborrheic dermatitis

C. Rosacea

D. Discoid lupus erythematosus



See Answer in Part B → Q2

Q3: A 3-week-old neonate is brought to the dermatology OPD with facial rashes exacerbated by sunlight exposure. Examination reveals erythematous, scaly papules around the eyes as shown in the image below. Maternal history includes positive anti-Ro/SSA antibodies. Which congenital cardiac anomaly is commonly associated with this condition? (Q841809)

A. Heart block

B. Patent ductus arteriosus

C. Coarctation of aorta

D. Aortic stenosis



See Answer in Part B → Q3

@Neet_pg_bot

Q4: A 32-year-old woman was recently diagnosed with cutaneous lupus erythematosus. During her review, she has come to you with a pamphlet and would like to discuss all her treatment options. Which of the following drugs are not used for

the treatment of cutaneous LE? (Q841844)

A. Leflunomide

B. Corticosteroids

C. Photoprotection

D. Chloroquine

See Answer in Part B → Q4

@Neet_pg_bot

Q5: A 50-year-old man was recently diagnosed with adenocarcinoma of the lung and started chemotherapy. During a follow-up visit, he complained of rashes over his face and hands, as shown in the image. He also reports fatigue and weakness in his legs while climbing stairs. What is the most likely diagnosis? (Q841845)

A. Polymyositis

B. Dermatomyositis

C. Lambert-Eaton syndrome

D. Drug reaction



@Neet_pg_bot



@Neet_pg_bot

See Answer in Part B → Q5

@Neet_pg_bot

Q6: A 60-year-old women comes to your OPD with her mother due to depressed linear lesion associated with hair loss on scalp for the past 3 years. She also has an area of progressive hypopigmentation and hair loss in her scalp as shown in the image below. Which of the following is the most likely diagnosis? (Q841846)

A. Atrophic scar

B. Gottron's Papule

C. En coup de sabre

D. Rowell Syndrome



See Answer in Part B → Q6

@Neet_pg_bot

Q7: A 54-year-old man with interstitial lung disease presents to you with complaints of a lesion over his chest. On examination, you notice the skin proximal to MCP joints appears thickened. There are also small ulcers over his fingertips. Which of the following would be the most specific investigation? (Q841847)

A. Anti-topoisomerase I antibodies (Anti-scl 70)

B. Anti-Ro (SS-A) antibodies

C. Antisynthetase antibodies

D. Antinuclear antibodies



See Answer in Part B → Q7

@Neet_pg_bot

Q8: A 32-year-old woman complains that the tips of her fingers are changing from pale white to bluish-red during winter. She states that it started five years ago but has worsened recently, along with difficulty swallowing food. Which of the following findings would you also expect to find in this patient? (Q841848)

A. Hypercalcemia

B. Calcinosis cutis

C. Malar Rash

D. Morphea

See Answer in Part B → Q8

@Neet_pg_bot

Q9: A 40-year-old woman presents with a history of Raynaud's phenomenon, arthritis, myalgia and fatigue. On examination, she has a rash on her face that spares her nasolabial folds. Her fingers appear puffy and sausage-shaped. Positive autoantibodies to anti-U1RNP along with her history are most indicative of which of the following diseases? (Q841849)

A. Scleroderma

B. Mixed connective tissue disease

C. Systemic lupus erythematosus

D. Dermatomyositis



See Answer in Part B → Q9

@Neet_pg_bot

• [09_Connective Tissue Disorders] 020 Previous Year Questions

« Back to Folder Directory

[09_Connective Tissue Disorders] 020 Previous Year Questions — Quick Jump

Q1 (p. 270) *Q2 (p. 270)* *Q3 (p. 271)* *Q4 (p. 272)* *Q5 (p. 273)*

Q1: What is the most probable diagnosis of the given image? (Q860620)

A. Polymyositis

B. Dermatomyositis

C. Inclusion body myositis

D. Discoid lupus erythematosus



See Answer in Part B → Q1

@Neet_pg_bot

Q2: A 50-year-old female patient with a known case of ovarian cancer presents with difficulty in activities like climbing stairs, getting up from a chair, combing hair, etc. The following characteristic sign was found on examination. The most probable diagnosis is: (Q857972)

A. Systemic lupus erythematosus

B. Dermatomyositis

C. Systemic sclerosis

D. Cushing syndrome





See Answer in Part B → Q2

@Neet_pg_bot

Q3: What is the observed condition in the image below, where a 10-year-old boy presents with muscle weakness in his lower limbs and a rash on his eyelids, with biopsy results indicating muscle inflammation? (Q855740)

A. Gottron’s papules

B. Shawl sign

C. Heliotrope rash

D. Scleroderma



See Answer in Part B → Q3

@Neet_pg_bot

Q4: A 10-year-old male child visits with symptoms of fever, joint pain, and a visible skin abnormality on his hand, as depicted in the provided image. Please identify the clinical observation and suggest a probable diagnosis. (Q854962)

A. Gottron’s papules – Juvenile dermatomyositis

B. Rheumatoid nodules – Juvenile rheumatic arthritis

C. Sclerodactyly-Systemic sclerosis

D. Mechanic’s hand – Systemic lupus erythematosus



See Answer in Part B → Q4

@Neet_pg_bot

Q5: In a 17-year-old patient, the most distinctive and characteristic indicator of juvenile dermatomyositis is (Q856678)

A. Photosensitive skin rash

B. Nail bed capillary changes

C. Gottron’s papules

D. Malar rash

See Answer in Part B → Q5

@Neet_pg_bot

• [10_Skin Tumors] 021 Previous Year Questions

« Back to Folder Directory

[10_Skin Tumors] 021 Previous Year Questions — Quick Jump

Q1 (p. 275) *Q2 (p. 275)* *Q3 (p. 276)* *Q4 (p. 277)* *Q5 (p. 278)* *Q6 (p. 279)*

Q1: Which carcinoma is the possible diagnosis in the image given below? (Q820214)

A. Basal cell carcinoma

B. Squamous cell carcinoma

C. Malignant melanoma

D. Hepatocellular carcinoma



See Answer in Part B → Q1

Q2: A 60-year-old person presented with an ulcer on the medial canthus. The ulcer has rolled-out, beaded margins. Histopathology shows nesting cells with peripheral palisading patterns. What is the most likely diagnosis? (Q852712)

A. Squamous Cell Carcinoma (SCC)

B. Nevus

C. Basal Cell Carcinoma (BCC)

D. Melanoma

See Answer in Part B → Q2

@Neet_pg_bot

Q3: A 60-year-old diabetic patient presents with a lesion on the nose as shown in the image below. The lesion bleeds on the touch. What is the diagnosis? (Q854645)

A. Squamous cell carcinoma

B. Basal cell carcinoma

C. Melanoma

D. Discoid lupus erythematosus



See Answer in Part B → Q3

@Neet_pg_bot

Q4: Which of the following is associated with the clinical condition shown in the image? (Q855295)

A. Condylomata lata

B. Mole

C. Malignant melanoma

D. Basal cell carcinoma



See Answer in Part B → Q4

@Neet_pg_bot

Q5: Identify the given disorder. (Q857048)

A. Melanoma

B. Hyperpigmentation

C. Basal cell carcinoma

D. Squamous cell carcinoma



See Answer in Part B → Q5

@Neet_pg_bot

Q6: A baby presents to the OPD; the image below shows the findings. What is the probable diagnosis? (Q857968)

A. Portwine stain

B. Cavernous hemangioma

C. Naevus simplex

D. Capillary hemangioma



See Answer in Part B → Q6

@Neet_pg_bot

• [11_Systemic Diseases and Skin] 022 Systemic Diseases And Skin - I

« Back to Folder Directory

[11_Systemic Diseases and Skin] 022 Systemic Diseases And Skin - I — Quick Jump

Q1 (p. 281) *Q2 (p. 281)* *Q3 (p. 282)* *Q4 (p. 283)* *Q5 (p. 283)* *Q6 (p. 284)*
Q7 (p. 285) *Q8 (p. 286)* *Q9 (p. 286)* *Q10 (p. 286)* *Q11 (p. 287)* *Q12 (p. 288)*
Q13 (p. 288) *Q14 (p. 289)* *Q15 (p. 290)*

Q1: A 3-year-old boy was brought to the clinic by his mother. She reports that the child has been irritable, lethargic, and refusing to eat for the past few weeks and had bilateral lower extremity swelling with a distended abdomen. Based on the clinical presentation, which dermatological manifestation is most likely to be associated with this condition? (Q841737)

A. Flaky paint dermatosis

B. Phrynoderma

C. Corkscrew hair

D. Casal’s necklace

See Answer in Part B → Q1

@Neet_pg_bot

Q2: A 45-year-old female presented to the dermatological OPD with complaints of painful cracks at the corners of her mouth. On examination, the doctor noticed a smooth magenta-coloured tongue. Which of the following supplements needs to be prescribed to the patient? (Q841738)

A. Thiamine

B. Methylcobalamin

C. Riboflavin

D. Folate

See Answer in Part B → Q2

@Neet_pg_bot

Q3: A 9-year-old child presents with a history of poor growth, intermittent episodes of confusion, and a skin rash after sun exposure. On examination, a pellagrous dermatitis rash is noted over the face, sparing eyelids, and the upper surface of the orbit, as shown in the image. Which of the following is the most likely diagnosis? (Q841740)

A. Kwashiorkor

B. Phenylketonuria

C. Hartnup disease

D. Maple syrup urine disease



See Answer in Part B → Q3

@Neet_pg_bot

Q4: A 6-month-old infant presents with irritability, diarrhoea, and a rash characterized by vesicles, pustules, and crusting around the mouth and anus. Which of the following conditions is most likely responsible for this presentation? (Q841742)

A. Scurvy

B. Zinc deficiency

C. Atopic dermatitis

D. Iron deficiency

See Answer in Part B → Q4

@Neet_pg_bot

Q5: A 45-year-old corporate office worker presents to the clinic after noticing the following skin changes with dull-red papules on his shin, as shown in the image. He reports no itching or pain and no history of trauma. Which of the following initial investigations would be the most relevant for confirming the diagnosis and guiding further management? (Q841743)

A. Skin biopsy

B. Fasting blood glucose

C. Haemoglobin

D. Lipid profile



See Answer in Part B → Q5

@Neet_pg_bot

Q6: A 38-year-old alcoholic patient presented to the OPD with atrophic scars and hyperpigmented lesions on the back of his hands, neck, face, and feet. Urine analysis revealed elevated uroporphyrin levels. On further evaluation, the patient was found to have a deficiency of uroporphyrinogen decarboxylase. What is the most likely diagnosis? (Q841745)

A. Acute intermittent porphyria

B. Erythropoietic porphyria

C. Variegate porphyria

D. Porphyria cutanea tarda



See Answer in Part B → Q6

@Neet_pg_bot

Q7: A 45-year-old obese woman presents to her primary care physician with complaints of dark patches on her neck and underarms that developed gradually over the past few months. On examination, velvety hyperpigmentation is seen over the affected areas. Which of the following statements regarding this condition is not correct? (Q841747)

A. Primarily caused by excessive melanin production in the affected areas

B. It is a cutaneous marker for underlying metabolic abnormalities

C. Seen in patients with gastrointestinal cancers

D. Skin tags are commonly associated with this condition

See Answer in Part B → Q7

@Neet_pg_bot

Q8: A 60-year-old woman presents with persistent unilateral nipple crusting and eczematous changes, with occasional bleeding. On examination, the affected nipple appears erythematous and flattened, with nipple retraction noted. There are no palpable breast masses. Which of the following conditions is most likely to be associated with these findings? (Q841753)

A. Eczematous dermatitis

B. Psoriasis

C. Mondor’s disease

D. Paget's disease

See Answer in Part B → Q8

@Neet_pg_bot

Q9: A 7-year-old boy has had recurrent abdominal pain, joint pain, and reddish-purple spots on his legs and buttocks for the past week. The spots don't fade when pressed, and he has swelling in his knees and ankles. He also has mild blood in his stools and had no sick contacts. What is the most likely diagnosis? (Q841754)

A. Henoch-Schönlein Purpura

B. Systemic Lupus Erythematosus

C. Rheumatic fever

D. Kawasaki disease

See Answer in Part B → Q9

@Neet_pg_bot

Q10: A 45-year-old woman presented to the clinic with painless nodular skin lesions on her cheeks and nose for the past three months which occasionally become tender and itchy on exposure to sunlight. She had intermittent episodes of dry cough, shortness of breath, and exercise intolerance. Chest X-ray revealed bilateral hilar

lymphadenopathy. What is the most likely diagnosis? (Q841756)

A. Acne vulgaris

B. Lupus pernio

C. Rosacea

D. Lupus vulgaris

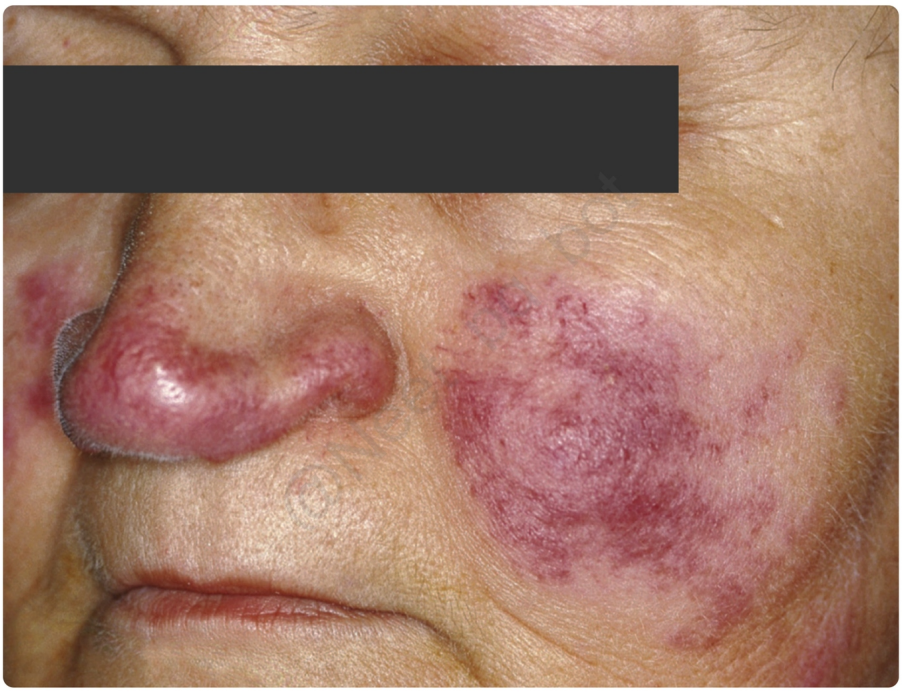

See Answer in Part B → Q10

@Neet_pg_bot

Q11: A 38-year-old woman presents to the dermatology clinic with sudden, painful, red nodules and plaques on her neck and upper arms as shown in the image. Additionally, pseudovesicular lesions are observed. She reports experiencing fever, sore throat, nasal congestion, and malaise for the past week. Skin biopsy reveals dense neutrophilic infiltrates without evidence of vasculitis. What is the most likely diagnosis? (Q841758)

A. Behcet’s disease

B. Erythema nodosum

C. Sweet syndrome

D. Pyoderma gangrenosum



See Answer in Part B → Q11

@Neet_pg_bot

Q12: Pathergy test is positive in all except? (Q841767)

A. Psoriasis

B. Crohn’s disease

C. Behcet’s disease

D. Genital herpes infection

See Answer in Part B → Q12

@Neet_pg_bot

Q13: A 25-year-old woman presents to the clinic with painful, raised lesions on her lower legs. Upon examination, tender, erythematous nodules ranging from 1 to 5 cm in diameter as shown in the image are noted bilaterally on the anterior aspects of her shins and are warm to the touch. She had a history of recent upper respiratory symptoms and fatigue. What is the most likely diagnosis? (Q841768)

A. Erythema marginatum

B. Erythema multiforme

C. Erythema nodosum

D. Erythema migrans



See Answer in Part B → Q13

@Neet_pg_bot

Q14: A 37-year-old male presents to the clinic with complaints of redness in the eyes, along with joint pain and stiffness. Further history revealed that he had vomiting and diarrhea one week back. On examination, erosions are seen on the glans penis. Which

of the following is the most likely diagnosis? (Q841769)

A. Rheumatoid arthritis

B. Systemic lupus erythematosus

C. Reiter’s disease

D. Ankylosing spondylitis

See Answer in Part B → Q14

@Neet_pg_bot

Q15: A 45-year-old female presents to the OPD with nodular skin lesions on dorsum of hand. She also gives a history of morning stiffness lasting for about an hour. Examination reveals multiple non-tender firm subcutaneous swellings over several metacarpals (as shown in the image), the left wrist, and both knees. Which of the following statements regarding the patient’s condition is incorrect? (Q841771)

A. More common in patients positive for HLA-DR4

B. Rituximab causes accelerated rheumatoid nodulosis

C. Nodules are painless in nature

D. Commonly found on extensor surfaces



See Answer in Part B → Q15

@Neet_pg_bot

• [11_Systemic Diseases and Skin] 023 Previous Year Questions

« Back to Folder Directory

[11_Systemic Diseases and Skin] 023 Previous Year Questions — Quick Jump

Q1 (p. 292) *Q2 (p. 292)* *Q3 (p. 293)* *Q4 (p. 294)* *Q5 (p. 294)* *Q6 (p. 295)*
Q7 (p. 296) *Q8 (p. 297)*

Q1: A baby presents with chronic diarrhea and a rash resembling acrodermatitis on the skin. Based on the clinical picture, what is the most likely deficiency? (Q852571)

A. Zinc deficiency

B. Selenium deficiency

C. Niacin deficiency

D. Magnesium deficiency



See Answer in Part B → Q1

@Neet_pg_bot

Q2: A 7-year-old boy is brought to the pediatric clinic by his parents with complaints of multiple soft, pedunculated masses scattered across his torso and limbs. The

parents mention that the child has recently developed some difficulty in reading and learning. Upon examination, the child has hyperpigmented macules with irregular borders on his back, and the ocular exam shows the findings below. What is the most likely diagnosis for this child? (Q860113)

A. NF2

B. TSC1

C. TSC2

D. NF1

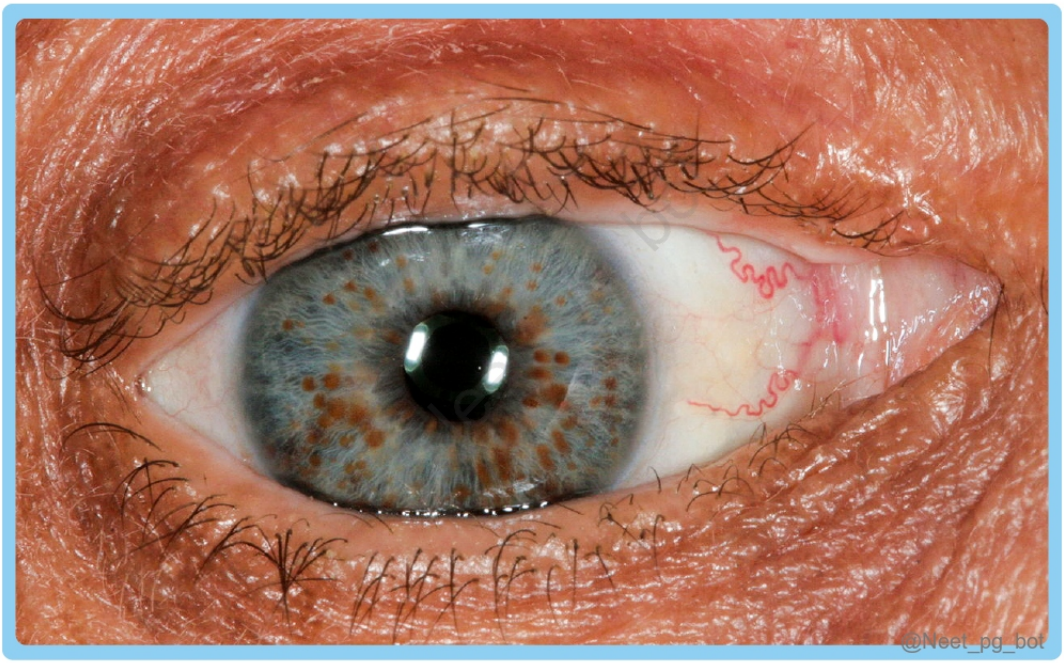

See Answer in Part B → Q2

@Neet_pg_bot

Q3: Match the Incubation periods of the following diseases: a. Syphilis 1. 16 days b. SARS 2. 90 days c. Hepatitis A 3. 6 days d. Chickenpox 4. 28 days (Q857416)

A. a-3, b-4, c-2, d-1

B. a-2, b-3, c-1, d-4

C. a-4, b3-, c-1, d-2

D. a-2, b-3, c-4, d-1

See Answer in Part B → Q3

@Neet_pg_bot

Q4: Which of the following mineral deficiency is associated with poor wound healing, dermatitis, diarrhoea and alopecia? (Q857978)

A. Iron

B. Calcium

C. Magnesium

D. Zinc

See Answer in Part B → Q4

@Neet_pg_bot

Q5: A 50-year-old patient presents with the following skin lesions characterized by red and scaly patches. The patient also complains of a painful and swollen finger joint. On examination, the finger joint appears inflamed and tender to touch. What is the most likely diagnosis for this patient's condition? (Q857979)

A. Psoriatic Arthritis

B. Pseudo gout

C. Osteoarthritis

D. Reactive arthritis



See Answer in Part B → Q5

@Neet_pg_bot

Q6: A child with a history of night-blindness presented to you with the following findings. What is the diagnosis? (Q855933)

A. Phrynoderma

B. Keratosis pilaris

C. Darier disease

D. Follicular eczema



See Answer in Part B → Q6

@Neet_pg_bot

Q7: A female patient with a body mass index of 30 kg/m2 presents to you with a lesion on the neck, as shown below. Which of the following conditions is the most likely to be suffering from? (Q855913)

A. Hypothyroidism

B. Metabolic syndrome

C. Addision’s disease

D. Hyperparathyroidism



See Answer in Part B → Q7

@Neet_pg_bot

Q8: Which of the following mineral deficiency is associated with poor wound healing, dermatitis, diarrhoea and alopecia? (Q820232)

A. Iron

B. Calcium

C. Magnesium

D. Zinc

See Answer in Part B → Q8

@Neet_pg_bot

• [12_Cutaneous Infections] 024 Previous Year Questions

« Back to Folder Directory

[12_Cutaneous Infections] 024 Previous Year Questions — Quick Jump

Q1 (p. 298) *Q2 (p. 298)* *Q3 (p. 299)* *Q4 (p. 300)* *Q5 (p. 301)* *Q6 (p. 302)*
Q7 (p. 303) *Q8 (p. 304)* *Q9 (p. 304)* *Q10 (p. 305)* *Q11 (p. 306)* *Q12 (p. 307)*
Q13 (p. 307) *Q14 (p. 308)* *Q15 (p. 309)* *Q16 (p. 310)*

Q1: Identify the finding shown in the image below: (Q854902)

A. Herpes labialis

B. Herpangina

C. Molluscum contagiosum

D. Impetigo



See Answer in Part B → Q1

@Neet_pg_bot

Q2: A female patient presented with acne that is not resolving on oral isotretinoin and antibiotics therapy. Which of the following is the next best investigation? (Q855281)

A. Look for dietary triggers

B. Evaluate for hyperandrogenism

C. Check for antibiotic resistance

D. Look for drug triggers

See Answer in Part B → Q2

@Neet_pg_bot

Q3: A 45 year old male patient from Bihar presented with normoanesthetic hypopigmented lesion as shown below. He had a history of fever for a long duration in his childhood. No thickened nerves were present. What is the probable diagnosis? (Q855521)

A. Tuberculoid leprosy

B. Lepromatous leprosy

C. Mycosis fungoides

D. Post kala-azar dermal leishmaniasis

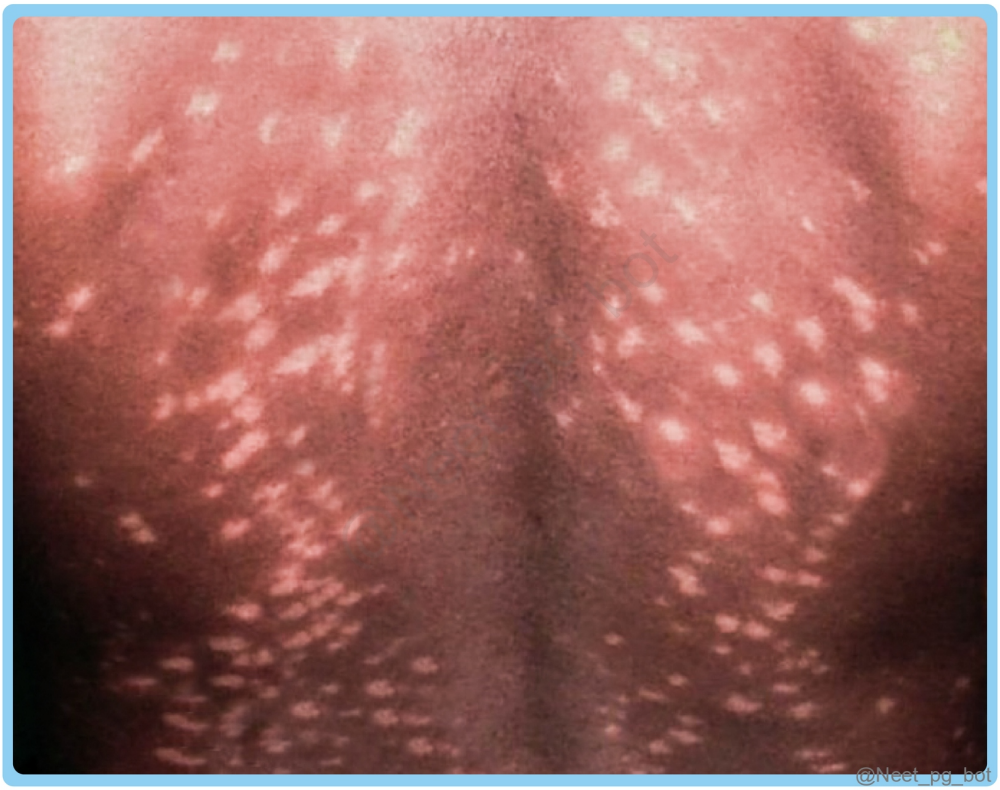

See Answer in Part B → Q3

@Neet_pg_bot

Q4: What is the appropriate next course of action for a child who exhibits itchy scalp lesions and hair loss, as depicted in the image provided? (Q855655)

A. KOH mount

B. Slit skin mount

C. Gram staining

D. Biopsy



See Answer in Part B → Q4

@Neet_pg_bot

Q5: What is the probable diagnosis for a young man who has presented with painful lesions depicted in the image below? (Q855658)

A. Herpes Zoster

B. Molluscum contagiosum

C. Herpes simplex

D. Lymphangioma circumscriptum



See Answer in Part B → Q5

@Neet_pg_bot

Q6: A 60-year-old male patient presents with the lesion given in the image below. He also mentions experiencing sensations like a spider crawling in the area of the lesion. Which of the following is the most likely diagnosis? (Q855741)

A. Herpes zoster infection

B. Irritant contact dermatitis

C. Allergic contact dermatitis

D. Herpes simplex infection



@Neet_pg_bot

See Answer in Part B → Q6

@Neet_pg_bot

Q7: A farmer presents to you with swelling on foot and multiple discharging sinuses in the lower limb. Granules from the discharge were examined under the microscope, shown below. Which of the following is true regarding this condition? (Q855900)

A. Both bacteria and fungi can be causative

B. Undergoes lymphatic spread

C. There is lymphocyte accumulation

D. Involves only superficial tissues

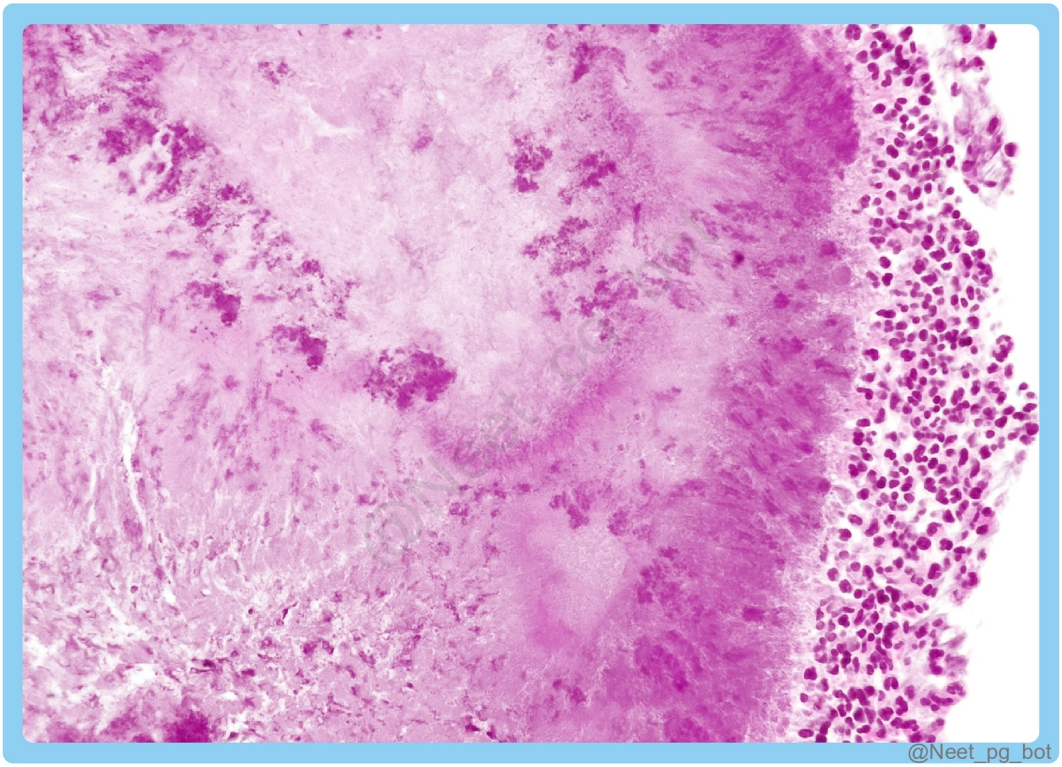

See Answer in Part B → Q7

@Neet_pg_bot

Q8: What is the probable diagnosis for a cauliflower-shaped mass on the foot of a farmer that appeared after a minor injury, with microscopy revealing copper penny bodies? (Q855903)

A. Chromoblastomycosis

B. Blastomycosis

C. Sporotrichosis

D. Phaeohyphomycosis

See Answer in Part B → Q8

@Neet_pg_bot

Q9: What could be the potential cause of the following lesions in a gardener who has a history of thorn pricks? (Q856368)

A. Streptococcus pyogenes

B. Sporothrix schenckii

C. Stronglyoides stercoralis

D. Staphylococcus aureus



See Answer in Part B → Q9

@Neet_pg_bot

Q10: A 28-year-old man took an antibiotic for a throat infection. Two days later, he noticed a single, round, dark red patch on his forearm that itched and burned. He recalls having a similar patch at the same spot last time he took the same antibiotic. What is the most likely diagnosis? (Q856372)

A. Psoriasis

B. Eczema

C. Fixed Drug Eruption

D. Contact Dermatitis

See Answer in Part B → Q10

@Neet_pg_bot

Q11: Which of the following options should be excluded as a possible cause for the lesion seen in the image, developed by a forest officer? (Q856668)

A. Scrub typhus

B. KFD

C. Cutaneous anthrax

D. Healing brown recluse spider bite

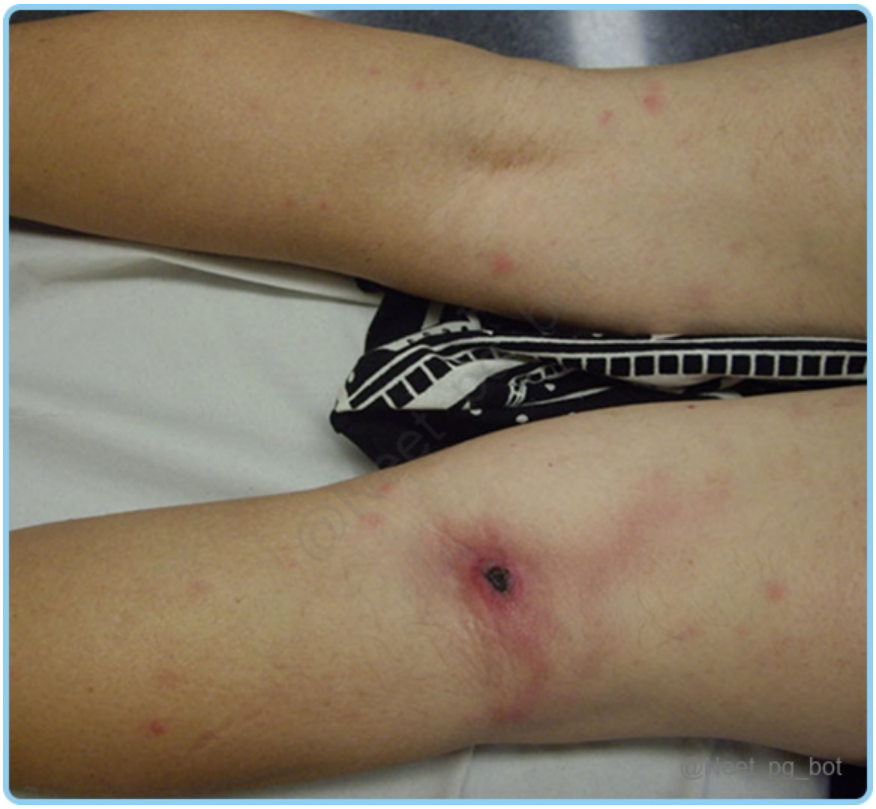

See Answer in Part B → Q11

@Neet_pg_bot

Q12: Identify the type of skin lesion: (Q856836)

A. Nummular

B. Annular

C. Discoid

D. Target



See Answer in Part B → Q12

@Neet_pg_bot

Q13: What could be the potential diagnosis for a 7-year-old boy with intellectual disability who has developed extensive warty crusts on the trunk, hands, and feet, along with severe fissuring and scaling on the soles of his feet? (Q857057)

A. Scabies incognito

B. Animal scabies

C. Nodular scabies

D. Norwegian scabies



See Answer in Part B → Q13

@Neet_pg_bot

Q14: Identify the condition shown in the image below: (Q857059)

A. Impetigo

B. Chickenpox

C. Herpes Simplex

D. Molluscum contagiosum



See Answer in Part B → Q14

@Neet_pg_bot

Q15: What is the probable diagnosis for a farmer who has a swollen foot and multiple discharging sinuses, as depicted in the image below? (Q857581)

A. Mycetoma

B. Squamous cell carcinoma

C. Nocardia

D. Sporotrichosis



See Answer in Part B → Q15

@Neet_pg_bot

Q16: Which among the following drug is not used in the treatment of acne vulgaris? (Q860622)

A. Topical Benzoyl peroxide

B. Topical Fluocinolone

C. Topical Tazarotene

D. Topical antibiotics

See Answer in Part B → Q16

@Neet_pg_bot

• [13_Miscellaneous Disorders] 025 Adverse Drug Reactions Pediatric Dermatoses Urticaria And Angioedema

« Back to Folder Directory

[13_Miscellaneous Disorders] 025 Adverse Drug Reactions Pediatric Dermatoses Urticaria And Angioedema — Quick Jump

Q1 (p. 311)	*Q2 (p. 312)*	*Q3 (p. 312)*	*Q4 (p. 313)*	*Q5 (p. 313)*	*Q6 (p. 314)*
Q7 (p. 314)	*Q8 (p. 315)*	*Q9 (p. 316)*	*Q10 (p. 316)*	*Q11 (p. 317)*	*Q12 (p. 318)*
Q13 (p. 319)	*Q14 (p. 319)*	*Q15 (p. 320)*	*Q16 (p. 321)*	*Q17 (p. 322)*	*Q18 (p. 322)*
Q19 (p. 323)	*Q20 (p. 324)*	*Q21 (p. 326)*	*Q22 (p. 326)*	*Q23 (p. 326)*	*Q24 (p. 327)*

Q1: A 7-year-old child with chronic itching is noted to develop a white linear streak as shown instead of erythema after the skin is stroked lightly with a blunt object. It is most commonly associated with which of the following conditions? (Q886424)

A. Chronic spontaneous urticaria

B. Atopic dermatitis

C. Psoriasis vulgaris

D. Lichen planus



See Answer in Part B → Q1

@Neet_pg_bot

Q2: A 40-year-old man develops fever and painful skin rash 2 weeks after starting allopurinol. He has widespread skin detachment (>30% BSA), severe oral erosions, and a positive Nikolsky sign. Biopsy shows full-thickness epidermal necrosis. What is the most likely diagnosis? (Q886446)

A. Erythema multiforme major

B. Pemphigus vulgaris

C. Stevens-Johnson syndrome

D. Lyell syndrome

See Answer in Part B → Q2

@Neet_pg_bot

Q3: Which statement about DRESS syndrome is incorrect? (Q886445)

A. Latency is typically 2-6 weeks

B. Kidney is the most commonly involved organ

C. Associated with HLA

D. Eosinophilia is a common finding

See Answer in Part B → Q3

@Neet_pg_bot

Q4: Which of the following conditions are classically associated with interface dermatitis? Lichen planus Psoriasis Lupus erythematosus Dermatomyositis Erythema multiforme (Q886444)

A. 1, 3 and 4

B. 1, 3, 4 and 5

C. 2, 3 and 5

D. 1, 2, 3, 4 and 5

See Answer in Part B → Q4

@Neet_pg_bot

Q5: Which of the following statements regarding erythema multiforme (EM) is correct? (Q886443)

A. Most commonly caused by drugs

B. Type 4 hypersensitivity reaction

C. Not self-limiting

D. Nikolsky sign is usually positive

See Answer in Part B → Q5

@Neet_pg_bot

Q6: A 20-year-old man develops a sudden onset of symmetric skin lesions 1 week after a febrile illness with oral ulcers. Examination shows lesions on the hands and forearms. Which is the most likely diagnosis? (Q886440)

A. Erythema multiforme

B. Stevens-Johnson syndrome

C. Toxic epidermal necrolysis

D. Urticaria



See Answer in Part B → Q6

@Neet_pg_bot

Q7: A 32-year-old woman develops sudden onset generalized itching, urticaria, facial swelling, wheezing, and hypotension within minutes of receiving an intravenous

antibiotic. She has no prior history of similar episodes. What is the most likely diagnosis? (Q886431)

A. Acute urticaria

B. Anaphylaxis

C. Hereditary angioedema

D. Vasovagal syncope

See Answer in Part B → Q7

@Neet_pg_bot

Q8: A 62-year-old woman presents with findings as shown in the image. He denies hives, itching, or abdominal pain. He started a new antihypertensive 2 weeks ago. Which of the following is the most likely cause? (Q886429)

A. Mast cell-mediated angioedema

B. Hereditary angioedema

C. ACE inhibitor-induced angioedema

D. Allergic reaction to food

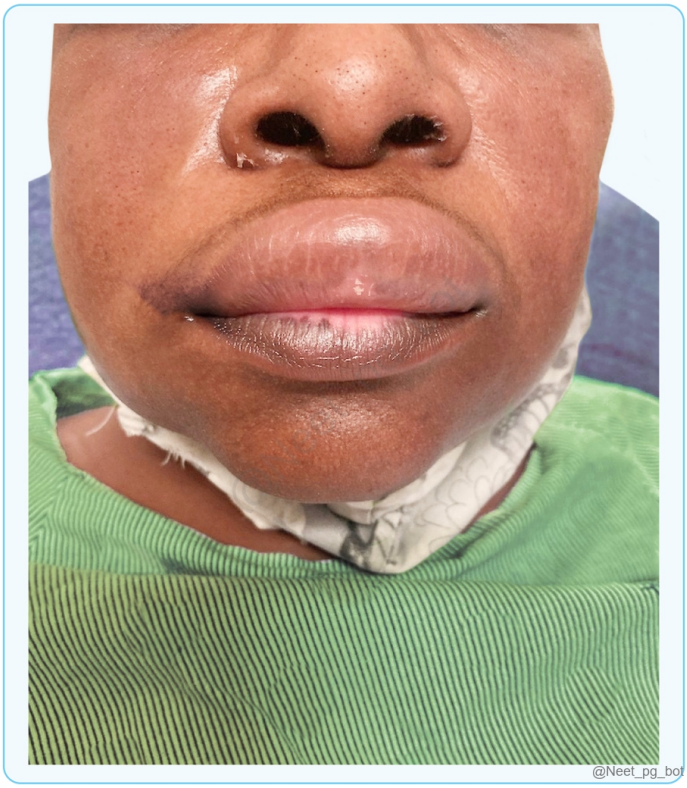

See Answer in Part B → Q8

@Neet_pg_bot

Q9: Which of the following statements is incorrect regarding hereditary angioedema type 1? (Q886428)

A. It is caused by mast cell degranulation

B. It is inherited in an autosomal dominant pattern

C. Reduced C1 INH levels

D. Most common type

See Answer in Part B → Q9

@Neet_pg_bot

Q10: A 5-year-old child presents with multiple reddish-brown maculopapular lesions on the trunk. Gentle rubbing of the lesions produces localized redness, itching, and wealing within minutes. It is characteristically seen in which of the following conditions? (Q886427)

A. Atopic dermatitis

B. Urticaria pigmentosa

C. Psoriasis vulgaris

D. Lichen planus



See Answer in Part B → Q10

@Neet_pg_bot

Q11: A 5-year-old child presents with multiple reddish-brown maculopapular lesions symmetrically distributed over the trunk, as shown in the image, sparing palms & soles. Which of the following statements is correct regarding the condition? (Q886426)

A. Lesions commonly involve the palms and soles

B. Associated with KIT mutations

C. Most common systemic mastocytosis

D. Lesions rarely regress in childhood



See Answer in Part B → Q11

@Neet_pg_bot

Q12: A 24-year-old man develops sudden-onset itchy lesions as shown after eating peanuts. He has no angio-oedema or breathing difficulty. The lesions have appeared over the last 2 hours. What is the first-line pharmacological treatment for this patient? (Q886425)

A. Oral corticosteroids

B. Antihistamines

C. Omalizumab

D. Epinephrine



See Answer in Part B → Q12

@Neet_pg_bot

Q13: A 25-year-old man presents with recurrent dark red plaques on his penis. He reports that these lesions appear shortly after taking certain medications. The patches are localized and recur in the same areas with each exposure. He denies any other symptoms or systemic involvement. Which of the following statements is correct regarding the diagnosis? (Q841994)

A. Resolution of lesions without any visible skin lesions.

B. It is a type 1 hypersensitivity reaction

C. Upon re-exposure Lesions develop on the 10th day.

D. Tetracyclines are commonly associated with FDE

See Answer in Part B → Q13

@Neet_pg_bot

Q14: A 26-year-old woman develops lesions as shown in the image within minutes of going outdoors. The lesions resolve completely within 1-2 hours without residual marks. Similar episodes occur with both natural sunlight and artificial light exposure. What is the most likely diagnosis? (Q886423)

A. Polymorphic light eruption

B. Solar urticaria

C. Cutaneous lupus erythematosus

D. Photoallergic dermatitis



See Answer in Part B → Q14

@Neet_pg_bot

Q15: An 18-year-old boy develops findings as shown in the image within minutes of exercise and emotional stress. Which statement is incorrect regarding the most probable diagnosis? (Q886421)

A. Triggered by spicy food

B. Weals persist for several hours to days

C. Associated with atopy

D. Provocation by hot bath can confirm the diagnosis



See Answer in Part B → Q15

@Neet_pg_bot

Q16: A 32-year-old woman presents with recurrent episodes of swelling in her face, lips, and throat, which she says occur intermittently and without any clear triggers. She has difficulty breathing during these episodes and She denies any rash or itching. She also reports a family history of similar symptoms affecting her mother and her maternal grandmother. Which of the following is the most likely diagnosis based on the patient's presentation and family history? (Q842008)

A. Aquagenic pruritis

B. Urticarial vasculitis

C. Hereditary angioedema

D. Anaphylaxis.

See Answer in Part B → Q16

@Neet_pg_bot

Q17: A 30-year-old man presents to the clinic with a sudden onset of red, raised, and itchy wheals on his arms, legs, and torso. The patient notes that the welts move around and change shape over time, resolving in one area and appearing in another. The patient denies any known allergies, recent illnesses, or new medications. Upon examination, you observe that there is no swelling of the lips, tongue, or throat. What is the most likely diagnosis? (Q842007)

A. Hereditary Angioedema

B. Erythema nodosum

C. Urticaria

D. Fixed drug eruption

See Answer in Part B → Q17

@Neet_pg_bot

Q18: A 3-year-old girl is brought to the clinic for evaluation of a prominent facial birthmark. Upon examination, you observe a port-wine stain covering most of the left side of her face, including the upper eyelid. The mother mentions that her daughter sometimes seems disoriented and has had a few brief seizures. A CT scan of the brain shows tram track calcification. What is the most likely diagnosis? (Q842005)

A. Tubercular Meningitis

B. Sturge-Weber Syndrome

C. Klippel-Trenaunay Syndrome

D. Cutis Marmorata Telangiectatica Congenita

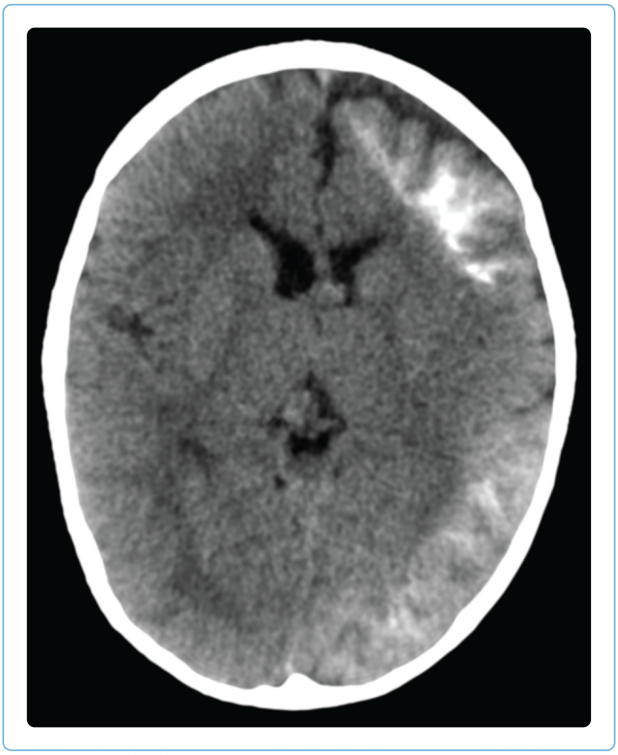

See Answer in Part B → Q18

@Neet_pg_bot

Q19: A 17-year-old male presents with a dark, irregularly pigmented patch on his right shoulder that he first noticed a few years ago. On examination, you see a large, unilateral patch of hyperpigmentation with a slightly irregular border and scattered areas of increased hair growth. The lesion has remained stable in size and shape over the years. The patient reports no associated symptoms such as itching or pain. Which of the following is the most likely diagnosis? (Q842002)

A. Seborrheic keratosis

B. Malignant melanoma

C. Becker's nevus

D. Nevus of Ito

See Answer in Part B → Q19

@Neet_pg_bot

Q20: Match the following: A. 1. Hydroxychloroquine B. 2. Clofazimine C. 3. Bleomycin D. 4. Amiodarone (Q841999)

A. A-3, B-1, C-4, D-2

B. A-3, B-4, C-2, D-1

C. A-4, B-3, C-2, D-1

D. A-4, B-2, C-3, D-1



@Neet_pg_bot



@Neet_pg_bot



@Neet_pg_bot



@Neet_pg_bot

See Answer in Part B → Q20

@Neet_pg_bot

Q21: A 38-year-old woman presents with a sudden onset of widespread, non-follicular pustules on an erythematous base. She reports having taken medication for a urinary tract infection two days ago. On examination, she appears febrile with diffuse erythema and multiple small, sterile pustules on her trunk and extremities. There is no mucosal involvement. What is the most likely cause of her presentation? (Q841998)

A. Staphylococcal scalded skin syndrome

B. Pemphigus vulgaris

C. Acute generalized exanthematous pustulosis

D. Milia

See Answer in Part B → Q21

@Neet_pg_bot

Q22: Which of the following factors is involved in the pathogenesis of Toxic Epidermal Necrolysis? (Q841997)

A. HLA polymorphism.

B. T cell-mediated response.

C. Necrosis of keratinocytes.

D. All of the above.

See Answer in Part B → Q22

@Neet_pg_bot

Q23: A 50-year-old patient presented to the emergency department with widespread blistering and skin detachment, along with mucosal involvement, after starting a new medication a week ago. On examination, there are large areas of epidermal detachment involving more than 30% of the body surface area. Nikolsky's sign is positive. Which of the following conditions is most likely to be responsible for this presentation? (Q841996)

A. Erythema multiforme

B. Stevens-Johnson syndrome

C. Pemphigus vulgaris

D. Toxic epidermal necrolysis

See Answer in Part B → Q23

@Neet_pg_bot

Q24: A 26-year-old male presents to the emergency department with a sudden onset of skin lesions. Upon examination, you notice distinct lesions with concentric rings resembling a "bull's eye" appearance. The patient reports a recent malarial infection. Which of the following conditions is most likely responsible for these skin lesions? (Q841995)

A. Fixed drug eruption

B. Nummular eczema

C. Urticaria

D. Erythema multiforme



See Answer in Part B → Q24

@Neet_pg_bot

• [13_Miscellaneous Disorders] 026 Genodermatoses Vector-Borne Diseases Bedside Tests In Dermatology

« Back to Folder Directory

[13_Miscellaneous Disorders] 026 Genodermatoses Vector-Borne Diseases Bedside Tests In Dermatology — Quick Jump

Q1 (p. 329) *Q2 (p. 330)* *Q3 (p. 330)* *Q4 (p. 331)* *Q5 (p. 332)* *Q6 (p. 333)*
Q7 (p. 333) *Q8 (p. 334)* *Q9 (p. 334)* *Q10 (p. 335)*

Q1: Which of the following condition presents with the characteristic skin lesion seen in this newborn? (Q841708)

A. Fish net ichthyosis

B. X-linked ichthyosis

C. Harlequin ichthyosis

D. Lamellar ichthyosis



See Answer in Part B → Q1

@Neet_pg_bot

Q2: An 11-year-old boy presents to the clinic with asymptomatic light brown-colored lesions on his body as shown in the image. On slit lamp examination, pigmented nodules on the iris were noted. What is the most common malignancy associated with this syndrome? (Q841703)

A. Optic nerve glioma

B. Renal cell carcinoma

C. Acoustic Schwannoma

D. Endolymphatic sac tumour





See Answer in Part B → Q2

@Neet_pg_bot

Q3: A 4-year-old boy presents to the paediatrician with a history of developmental delay, multiple hypopigmented macules on his trunk, and a history of infantile spasms. On examination, he also has facial angiofibroma. What is the most likely diagnosis? (Q841704)

A. Ataxia Telangiectasia

B. Sturge-Weber syndrome

C. Tuberous sclerosis

D. Von Hippel-Lindau syndrome



See Answer in Part B → Q3

@Neet_pg_bot

Q4: A 28-year-old male presents to the gastroenterologist with a history of recurrent abdominal pain and episodes of gastrointestinal bleeding. On examination, he has multiple pigmented macules on his lips and oral mucosa. A colonoscopy reveals numerous hamartomatous polyps throughout the gastrointestinal tract. What is the most likely diagnosis? (Q841705)

A. Gardner Syndrome

B. Familial Adenomatous Polyposis

C. Cowden Syndrome

D. Peutz-Jeghers Syndrome



See Answer in Part B → Q4

@Neet_pg_bot

Q5: A 10-year-old child presents to the dermatology clinic with a history of severe sunburns after minimal sun exposure. On examination, numerous freckle-like pigmented patches and atrophic areas were noted on the face and arms. Which of the following conditions is most likely responsible for the patient's presentation? (Q841706)

A. Vitiligo

B. Gorlin syndrome

C. Xeroderma Pigmentosum

D. Bloom Syndrome



@Neet_pg_bot

See Answer in Part B → Q5

@Neet_pg_bot

Q6: Which of the following best describes the pathophysiology underlying dystrophic epidermolysis bullosa? (Q841707)

A. Deficiency of type VII collagen

B. Mutations in genes KRT5 and KRT14

C. Malfunctioning laminin 332 protein

D. Faulty kindlin-1 proteins

See Answer in Part B → Q6

@Neet_pg_bot

Q7: A 3-month-old female infant presents with linear streaks of hyperpigmentation along Blaschko's lines on her trunk and extremities. The mother reports that the infant also experienced vesicular eruptions shortly after birth that resolved without scarring. What is the most likely diagnosis? (Q841709)

A. Hypomelanosis of Ito

B. Ichthyosis vulgaris

C. Incontinentia pigmenti

D. Epidermolysis bullosa

See Answer in Part B → Q7

@Neet_pg_bot

Q8: A 38-year-old male presents with persistent, rough lesions on his face. Examination reveals hyperkeratotic papules and plaques with a greasy, crusted appearance, predominantly on seborrheic areas. Nail abnormalities include longitudinal ridging and V-shaped notches. Based on histopathological findings showing acantholysis and dyskeratosis, what is the most likely diagnosis? (Q841712)

A. Darier's disease

B. Hailey-Hailey disease

C. Grover's disease

D. Seborrheic dermatitis

See Answer in Part B → Q8

@Neet_pg_bot

Q9: A 35-year-old male who had recently travelled to Rajasthan presented to the clinic with a complaint of a persistent skin lesion on his right forearm. About two months ago, it initially appeared as a small red bump, but it grew in size and became ulcerated. On examination, the lesion appears to have a raised border with central crusting. The surrounding skin shows signs of inflammation with erythema. What is

the diagnosis of this patient? (Q841715)

A. Lyme disease

B. Scrub typhus

C. Anthrax

D. Cutaneous Leishmaniasis



@Neet_pg_bot

See Answer in Part B → Q9

@Neet_pg_bot

Q10: Match the following Disease Colour on Wood's light A. Milky white 1. Erythrasma B. Coral pink 2. Pityriasis versicolor C. Yellow 3. Vitiligo D. Green 4. Tinea capitis (Q841718)

A. A-4, B-1, C-2, D-3

B. A-3, B-1, C-4, D-2

C. A-3, B-2, C-4, D-1

D. A-3, B-1, C-2, D-4

See Answer in Part B → Q10

@Neet_pg_bot

• [13_Miscellaneous Disorders] 027 Previous Year Questions

« Back to Folder Directory

[13_Miscellaneous Disorders] 027 Previous Year Questions — Quick Jump

Q1 (p. 337) *Q2 (p. 337)* *Q3 (p. 338)* *Q4 (p. 338)* *Q5 (p. 339)* *Q6 (p. 340)*
Q7 (p. 341) *Q8 (p. 342)* *Q9 (p. 342)*

Q1: A child accidentally took a bottle full of iron tablets. Which of the drugs is used as an antidote for iron poisoning? (Q866860)

A. Luspatercept

B. Deferoxamine

C. Deferiprone

D. DMSA

See Answer in Part B → Q1

@Neet_pg_bot

Q2: A patient presents to the dermatology clinic reporting recurrent skin lesions as seen on the image. He describes that these lesions emerge within hours each time he takes NSAIDs. What is the most likely diagnosis? (Q866865)

A. Fixed drug eruptions

B. Erythema multiforme

C. Drug Induced Pigmentation

D. Herpes



See Answer in Part B → Q2

@Neet_pg_bot

Q3: Annular lesions are seen in all of the following conditions except? (Q840076)

A. Tinea Corporis

B. Urticaria Pigmentosa

C. Pityriasis Rosea

D. Porokeratosis

See Answer in Part B → Q3

@Neet_pg_bot

Q4: The involvement of which of the following results in the given condition below? (Q857965)

A. Arteries

B. Vein

C. Lymphatics

D. DVT



See Answer in Part B → Q4

@Neet_pg_bot

Q5: A school-going child who had applied henna comes to dermatology OPD with the following lesions. Her mother also complains that she has a habit of scratching her hand whenever she is studying. What is the diagnosis for this child? (Q856828)

A. Contact dermatitis due to henna

B. Dermatitis artefacta

C. Polymorphous light eruption

D. Vitiligo



See Answer in Part B → Q5

@Neet_pg_bot

Q6: What is the probable diagnosis of the condition affecting the hair, resulting in the following appearance? (Q856835)

A. Trichorrhexis nodosa

B. Trichorexis invaginate

C. Trichothiodystrophy

D. Monilethrix



See Answer in Part B → Q6

@Neet_pg_bot

Q7: Which of the following is the most probable diagnosis for a child born with membranes around the body, ectropion, and eclabium, presenting with lesions on the face, trunk, and extremities, and brought to the OPD, what is the diagnosis? (Q854904)

A. Harlequin ichthyosis

B. Lamellar ichthyosis

C. Bathing suit ichthyosis

D. Ichthyosis vulgaris



See Answer in Part B → Q7

@Neet_pg_bot

Q8: What is the causative agent responsible for causing acne fulminans among the following options? (Q793394)

A. Actinomyces

B. Propionibacterium

C. Mobiluncus

D. Bifidobacterium

See Answer in Part B → Q8

@Neet_pg_bot

Q9: A 26-year-old male presented with a skin lesion as shown below. Biopsy shows the presence of hyperkeratosis . What is the most likely diagnosis? (Q793451)

A. Atopic dermatitis

B. Psoriasis

C. Pemphigus vulgaris

D. Pemphigus foliaceus



See Answer in Part B → Q9

@Neet_pg_bot

• [14_Miscellaneous] 028 Previous Year Questions

« Back to Folder Directory

[14_Miscellaneous] 028 Previous Year Questions — Quick Jump

Q1 (p. 344) *Q2 (p. 345)* *Q3 (p. 345)* *Q4 (p. 346)* *Q5 (p. 346)* *Q6 (p. 347)*
Q7 (p. 348) *Q8 (p. 349)* *Q9 (p. 350)* *Q10 (p. 351)* *Q11 (p. 352)* *Q12 (p. 353)*
Q13 (p. 354) *Q14 (p. 355)*

Q1: A neonate presents with a growing skin lesion, as shown in the image provided. The mother reports that the lesion has been increasing in size daily. What is the appropriate management? (Q852572)

A. Observation

B. Excision and Laser Therapy

C. Immediate Biopsy due to Malignancy Risk

D. Cryotherapy



See Answer in Part B → Q1

@Neet_pg_bot

Q2: A patient presents with a nodulo-ulcerative lesion on the lower lip, as shown in the image. What is the best way to take a biopsy in this case? (Q843968)

A. Superficial incisional with normal mucosa

B. Blush biopsy

C. Deep incisional with nodular part

D. Excisional biopsy



See Answer in Part B → Q2

@Neet_pg_bot

Q3: What nutritional deficiency is commonly associated with a chronic alcoholic presenting with a pruritic, eczematous rash on the neck and dorsum of the hands? (Q860608)

A. Vit B3

B. Vit B1

C. Vit D

D. Vit C

See Answer in Part B → Q3

@Neet_pg_bot

Q4: Which of the following deficiencies causes follicular hyperkeratosis? (Q860610)

A. Vitamin A

B. Vitamin C

C. Vitamin E

D. Vitamin B6

See Answer in Part B → Q4

@Neet_pg_bot

Q5: What is the most probable diagnosis of the given image? (Q860623)

A. Erythema toxicum neonatorum

B. Pustular melanosis

C. Mongolian spots

D. Milia



See Answer in Part B → Q5

@Neet_pg_bot

Q6: The condition shown in the image below is seen in which vitamin deficiency? (Q860125)

A. Pyridoxine

B. Cobalamin

C. Niacin

D. Riboflavin



See Answer in Part B → Q6

@Neet_pg_bot

Q7: The given condition is caused by which drug ? (Q856376)

A. Actinomycin

B. Bleomycin

C. Mitomycin C

D. Doxorubicin



See Answer in Part B → Q7

@Neet_pg_bot

Q8: A patient presents with the given rash after he had taken NSAIDs for his knee pain. He reported that he developed the same rash in the same location 6 months ago when he took the same drugs for back pain. What is the most likely diagnosis? (Q859554)

A. Drug hypersensitivity

B. Post inflammatory hyperpigmentation

C. Fixed drug eruption

D. Drug-induced hyper melanosis



See Answer in Part B → Q8

@Neet_pg_bot

Q9: What is the name of the clinical sign shown in the picture below? (Q859556)

A. Dermographism

B. Nikolsky sign

C. Koebner's phenomenon

D. Auspitz sign



See Answer in Part B → Q9

@Neet_pg_bot

Q10: A farmer presented to the outpatient department with a swelling over his palm as shown in the photo. A few months back he got injured with a thorn. What is the presentation given below? (Q859905)

A. Ameloblastoma

B. Embryogenic dermoid

C. Sequestration dermoid

D. Implantation dermoid



See Answer in Part B → Q10

@Neet_pg_bot

Q11: The girl seen in the image has had a history of severe sunburns after just a few minutes in the sun, severe freckling in the sun-exposed areas. The most likely diagnosis is. (Q859913)

A. Bloom syndrome

B. Xeroderma pigmentosum

C. Warts

D. Systemic lupus



See Answer in Part B → Q11

@Neet_pg_bot

Q12: The shown instrument is: (Q859914)

A. Single cutting razor

B. Double cutting razor

C. Humby’s knife

D. Finochietto knife



See Answer in Part B → Q12

@Neet_pg_bot

Q13: The given lesion is seen on 3 different occasions on the same site. What is the diagnosis? (Q878927)

A. Cutaneous mastocytosis

B. Fixed drug eruption

C. HSV1

D. Erythema multiforme



See Answer in Part B → Q13

@Neet_pg_bot

Q14: Match the following signs with their conditions: A. Auspitz sign i. Cutaneous mastocytosis B. Carpet track sign ii. Psoriasis C. Darier's sign iii. Kwashiorkor D. Flag sign iv. Discoid lupus erythematosus (Q879102)

A. A-ii, B-iv, C-i, D-iii

B. A-i, B-ii, C-iii, D-iv

C. A-iv, B-ii, C-i, D-iii

D. A-ii, B-i, C-iv, D-iii

See Answer in Part B → Q14

@Neet_pg_bot

• [15_Bacterial Infections] 029 Bacterial Infections

« Back to Folder Directory

[15_Bacterial Infections] 029 Bacterial Infections — Quick Jump

Q1 (p. 356)	*Q2 (p. 356)*	*Q3 (p. 357)*	*Q4 (p. 357)*	*Q5 (p. 358)*	*Q6 (p. 359)*
Q7 (p. 360)	*Q8 (p. 361)*	*Q9 (p. 362)*	*Q10 (p. 363)*	*Q11 (p. 364)*	*Q12 (p. 364)*
Q13 (p. 365)	*Q14 (p. 366)*	*Q15 (p. 367)*	*Q16 (p. 368)*	*Q17 (p. 369)*	*Q18 (p. 370)*
Q19 (p. 370)	*Q20 (p. 371)*	*Q21 (p. 372)*			

Q1: Which of the following would be the best initial test to diagnose erythrasma? (Q841817)

A. Microscopy with KOH preparation

B. Wood's lamp examination

C. Dermatoscope examination

D. Skin culture

See Answer in Part B → Q1

@Neet_pg_bot

Q2: Which of the following cutaneous conditions are associated with streptococcal infection? Guttate psoriasis Erythema nodosum Kawasaki disease Pemphigus vulgaris (Q887081)

A. 1 and 2 only

B. 1, 2 and 3 only

C. 2 and 4 only

D. 1, 2, 3 and 4

See Answer in Part B → Q2

@Neet_pg_bot

Q3: A 28-year-old man presents with asymptomatic brownish patches in the axilla. A Wood's lamp examination image is shown. What is the most likely diagnosis? (Q887233)

A. Tinea capitis

B. Pityriasis versicolor

C. Erythrasma

D. Vitiligo



See Answer in Part B → Q3

@Neet_pg_bot

Q4: Which of the following conditions are associated with the organism depicted in the image? Impetigo Folliculitis Ecthyma Staphylococcal scalded skin syndrome Toxic shock syndrome (Q887227)

A. 1,4 and 5 only

B. 1, 2 and 4 only

C. 1, 2, 3 and 4

D. 1, 2, 3, 4 and 5

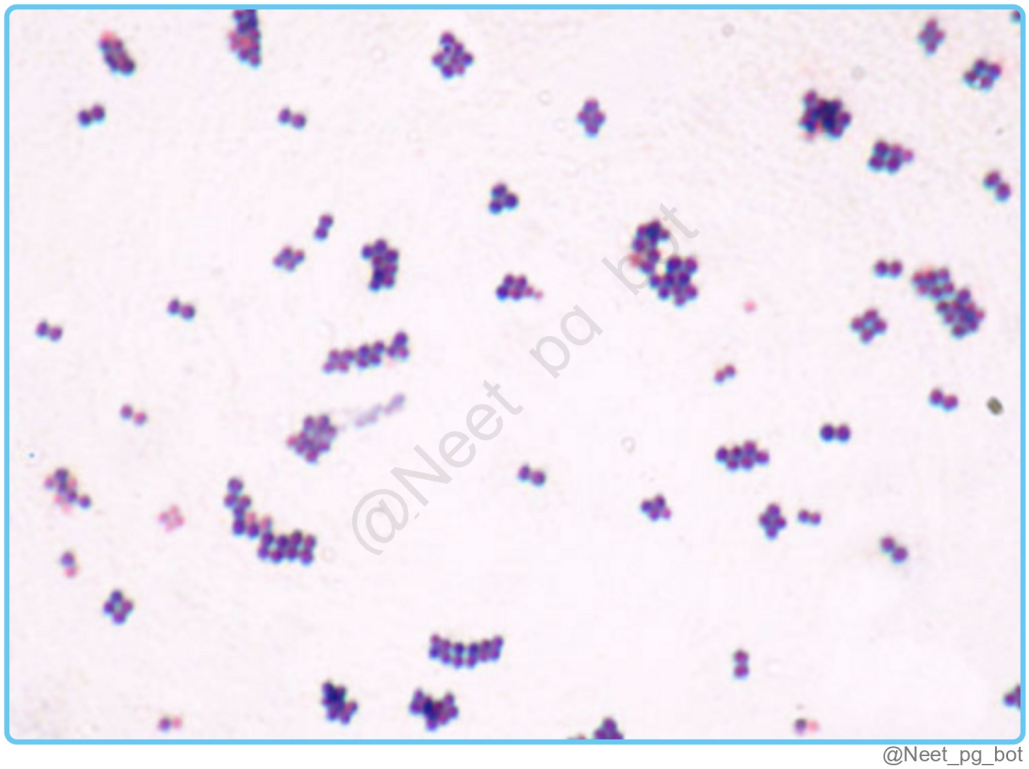

See Answer in Part B → Q4

@Neet_pg_bot

Q5: A 40-year-old man is diagnosed with erysipeloid and presents with a localised violaceous erythematous lesion on the finger with minimal systemic symptoms. What is the most likely mode of transmission of this condition? (Q887226)

A. Respiratory droplets

B. Animal bite

C. Inoculation through a skin breach from contaminated animal products

D. Human-to-human contact



See Answer in Part B → Q5

@Neet_pg_bot

Q6: A 25-year-old man presents with recurrent erythematous pustules and papules on his beard as shown for several months. Some areas show scarring at the margins. Which of the following statements about the condition is incorrect? (Q887224)

A. It primarily affects post-pubertal males

B. Staphylococcus aureus is the most common causative organism

C. It frequently resolves spontaneously without treatment

D. Lupoid sycosis involves follicular destruction with scarring



See Answer in Part B → Q6

@Neet_pg_bot

Q7: A 12-year-old girl presents with a painful, red swelling of the lateral nail fold after biting her nails. Which of the following statements about this condition is correct? (Q887223)

A. Staphylococcus aureus is the most common cause

B. Osteitis is not a complication

C. Radiography is needed for all patients

D. Commonly occurs in the elderly



See Answer in Part B → Q7

@Neet_pg_bot

Q8: A 45-year-old man with diabetes presents with multiple chronic abscesses on his leg. The lesions have drained through multiple sinuses over several months, leaving atrophic scars. Biopsy shows clusters of Gram-positive cocci. What is the most likely diagnosis? (Q887159)

A. Actinomycosis

B. Botryomycosis

C. Mycetoma

D. Furunculosis



See Answer in Part B → Q8

@Neet_pg_bot

Q9: A 55-year-old febrile diabetic man with neutropenia has rapidly developing necrotic ulcers with black eschars, as shown in the image. What is the most likely diagnosis? (Q887139)

A. Ecthyma

B. Ecthyma gangrenosum

C. Pyoderma gangrenosum

D. Gram-negative folliculitis



See Answer in Part B → Q9

@Neet_pg_bot

Q10: A 9-year-old girl has painful ulcers on her lower legs. Lesions started as pustules on a red base, developed thick crusts, and new lesions appeared nearby. What is the most likely diagnosis? (Q887135)

A. Impetigo

B. Ecthyma

C. Pyoderma gangrenosum

D. Ecthyma gangrenosum

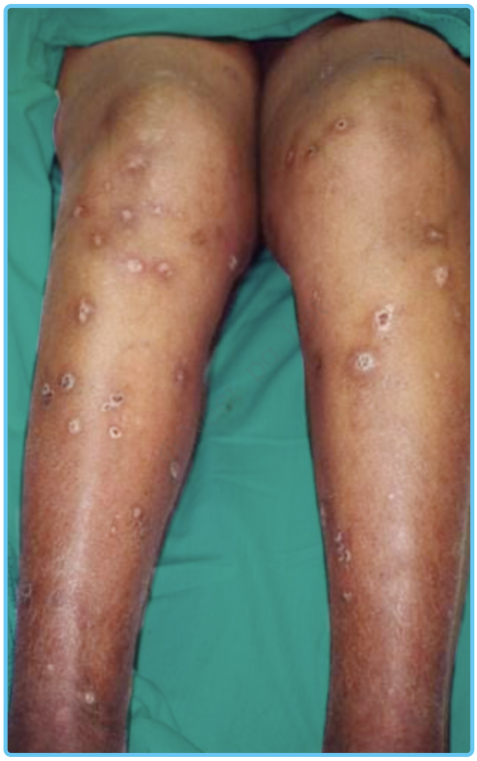

See Answer in Part B → Q10

@Neet_pg_bot

Q11: Which of the following conditions is caused by Corynebacterium minutissimum? (Q887131)

A. Tinea cruris

B. Erythrasma

C. Pityriasis versicolor

D. Intertrigo

See Answer in Part B → Q11

@Neet_pg_bot

Q12: A 7-year-old child presents with findings as shown. Culture from the lesion grows Streptococcus pyogenes. Which of the following complications are associated with this condition? Post-streptococcal acute glomerulonephritis Acute rheumatic fever Scarlet fever Erythema multiforme Chorea (Q887083)

A. 1, 3 and 4 only

B. 1 and 2 only

C. 2, 3 and 5 only

D. 1, 2, 3 and 4



See Answer in Part B → Q12

@Neet_pg_bot

Q13: The image shows a 2-year-old boy brought to the clinic with complaints of rashes on his face. On examination, he has plaques covered with honey-coloured crust. There is no history of fever or any constitutional symptoms. Which is the best stain to confirm the diagnosis? (Q841811)

A. Tzanck smear

B. Gram stain

C. KOH stain

D. Von Kossa stains

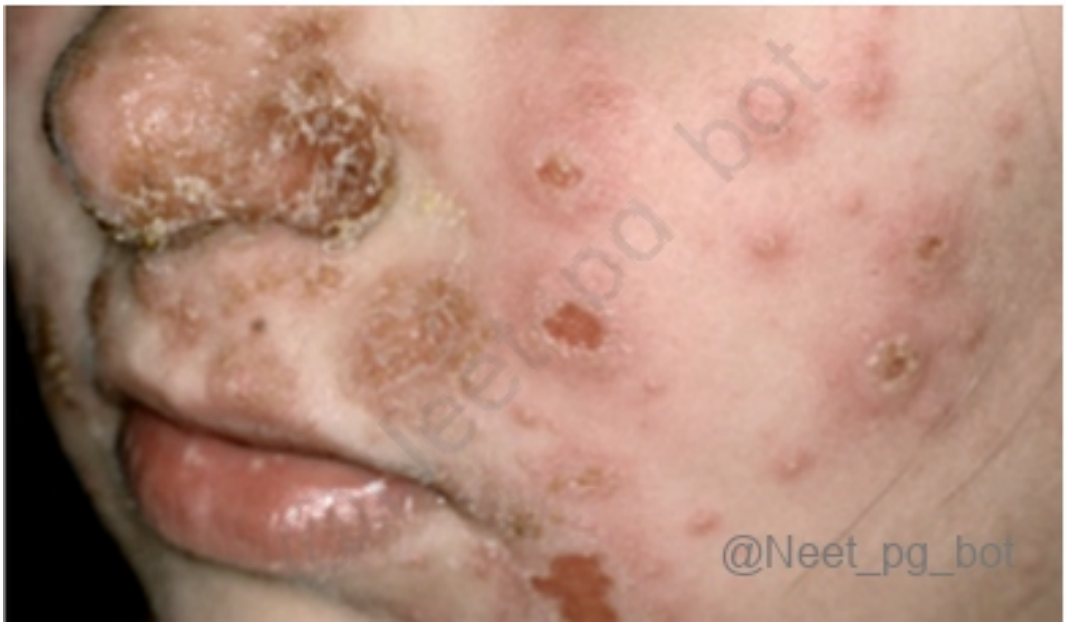

See Answer in Part B → Q13

@Neet_pg_bot

Q14: A 3-year-old child presents with a 2-day history of fever, irritability, and erythema starting around the perioral region, which quickly spreads to the face, trunk, and extremities. The child develops large, fragile bullae that rupture easily, leaving a moist, erythematous base. A positive Nikolsky sign is noted. There is no mucosal involvement, and the child has no recent history of medication use. What is the most likely diagnosis? {{caption_text}} (Q841820)

A. Staphylococcal scalded skin syndrome

B. Stevens-Johnson syndrome

C. Toxic epidermal necrolysis

D. Epidermolysis bullosa

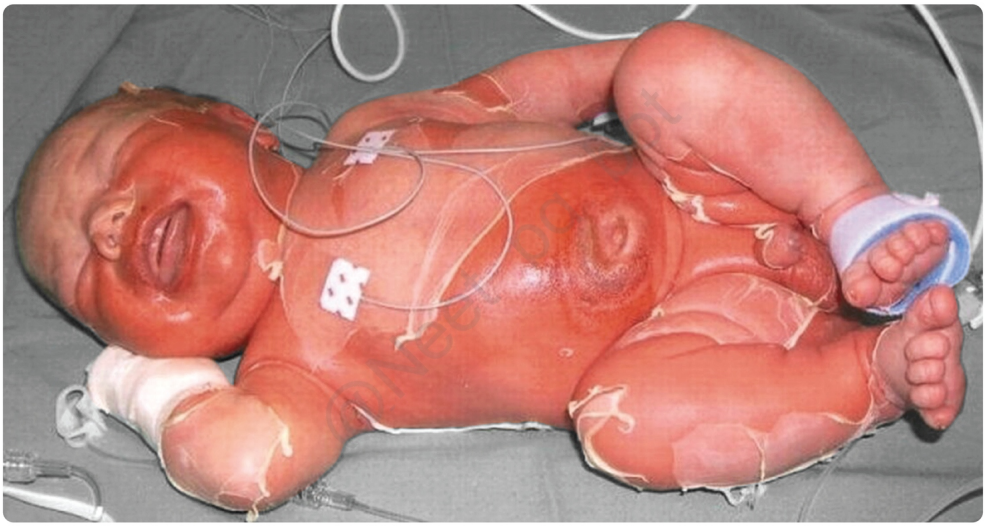

@Neet_pg_bot

See Answer in Part B → Q14

@Neet_pg_bot

Q15: A 35-year-old woman presents with nail discoloration, as shown in the image. She has a history of recurrent nail infections but has never noticed changes like these before. Which of the following diseases could be caused by the responsible pathogen? {{caption_text}} (Q841819)

A. Ecthyma gangrenosum

B. Hot tub folliculitis

C. Malignant external otitis

D. All the above



See Answer in Part B → Q15

@Neet_pg_bot

Q16: A young man presents with coarse axillary hair, foul-smelling sweat, and yellow, waxy nodules on the hair shafts that can be easily scraped off, with no pain or itching. What is the likely diagnosis? {{caption_text}} (Q841818)

A. Pediculosis

B. Pseudonits

C. Trichomycosis nodosa

D. None of the above

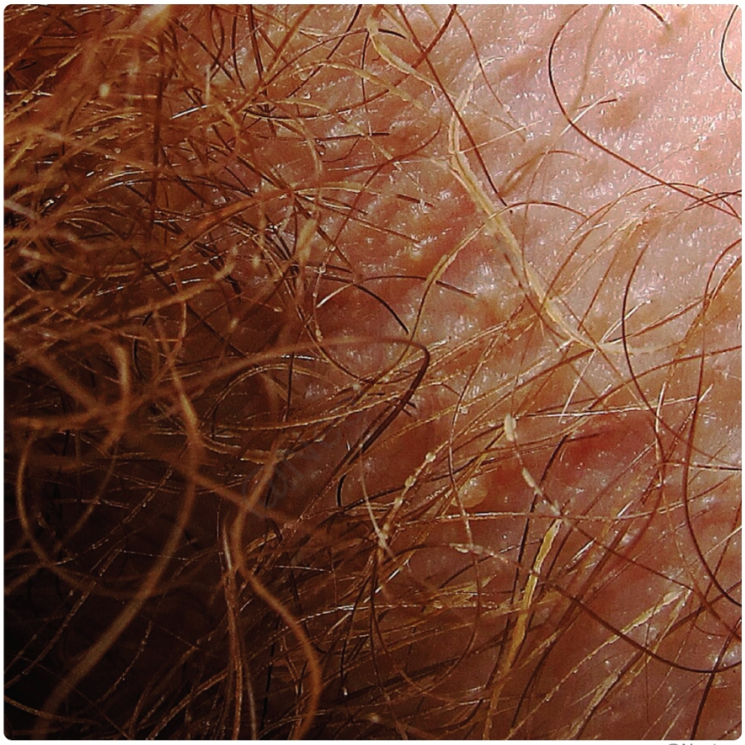

See Answer in Part B → Q16

@Neet_pg_bot

Q17: A 40-year-old male presents to his dermatologist with complaints of foul odor and discomfort on the soles of his feet when wearing closed shoes for prolonged periods. Upon examination, small, shallow pits on the heels and the balls of the feet are present. Which of the following features is not associated with this condition? {{caption_text}} (Q841816)

A. Associated with reduced or no sweat production

B. Occurs in weight-bearing areas

C. Common in swimmers

D. It is a superficial bacterial infection



@Neet_pg_bot

See Answer in Part B → Q17

@Neet_pg_bot

Q18: Which of the following best describes the typical progression of folliculitis? (Q841815)

A. Carbuncle, furuncle, folliculitis

B. Furuncle, folliculitis, carbuncle

C. Folliculitis, furuncle, carbuncle

D. Folliculitis, carbuncle, furuncle

See Answer in Part B → Q18

@Neet_pg_bot

Q19: A 27-year-old woman presents with complaints of severely itchy rashes all over her body that developed after she had used the hot tub in a hotel. On examination, she has multiple, monomorphic, erythematous papules and pinhead pustules over hair

follicles, predominantly over her trunk and buttocks. Which of the following is the most likely causative organism? (Q841814)

A. Staphylococcus aureus

B. Streptococcus pyogenes

C. Corynebacterium minutissimum

D. Pseudomonas aeruginosa

See Answer in Part B → Q19

@Neet_pg_bot

Q20: A 30-year-old man presents with a painful, erythematous skin rash over his leg that started two days ago and has been consistently increasing with a history of fever for the past two days. On examination, a tender, erythematous rash with ill-defined margins is visible. The local rise in temperature is present. There are no fluctuant nodules. Which is the most common causative organism for the infection? (Q841813)

A. Candida albicans

B. Pseudomonas aeruginosa

C. Beta-hemolytic streptococci

D. Clostridium perfringens



See Answer in Part B → Q20

@Neet_pg_bot

Q21: A 43-year-old man presents with a fever (100.4°F) and a skin lesion on the right leg that appeared 2 days ago. He also complains of redness over his ear since yesterday. He sustained a minor laceration in the same location 1 week ago when he fell into his rose bushes while gardening. What is the probable diagnosis? (Q841812)

A. Cellulitis

B. Erysipelas

C. Ecthyma

D. Impetigo



See Answer in Part B → Q21

@Neet_pg_bot

• [15_Bacterial Infections] 030 Previous Year Questions

« Back to Folder Directory

[15_Bacterial Infections] 030 Previous Year Questions — Quick Jump

Q1 (p. 374) *Q2 (p. 374)* *Q3 (p. 375)* *Q4 (p. 376)* *Q5 (p. 377)*

Q1: Identify the given condition and its treatment. (Q866858)

A. Staphylococcal scalded syndrome with Inj cephalexin

B. Epidermolysis bullosa with bandaging

C. Impetigo bullosa with antibiotics

D. Erythema multiforme with steroids



See Answer in Part B → Q1

@Neet_pg_bot

Q2: What skin condition is characterized by the presence of coral red fluorescence under a woods lamp? (Q860607)

A. Erythrasma

B. Acanthosis nigricans

C. Allergic contact dermatitis

D. Cutaneous candidiasis



See Answer in Part B → Q2

@Neet_pg_bot

Q3: A 45-year-old patient presents with a facial appearance that is marked by thickened, coarse, and deeply furrowed skin. The skin appears to be involved in the cheeks, forehead, and nose. The patient complains of numbness and weakness in the extremities. On examination, there are hypopigmented and erythematous patches with loss of sensation. What is the medical condition characterized by the term "Leonine facies"? (Q820234)

A. Lepromatous Leprosy

B. Acromegaly

C. Myasthenia gravis

D. Bells palsy

See Answer in Part B → Q3

@Neet_pg_bot

Q4: What is the treatment of choice for a patient with paronychia, as shown in the image below? (Q855953)

A. Amoxiclav

B. Metronidazole

C. Amikacin

D. Norfloxacin



See Answer in Part B → Q4

Q5: Which of the following organisms is most likely to be the cause of the leg lesion shown in the image below, as presented by a young man? The lesions exhibit pain, well-defined raised edges, and the patient also reports blisters on his body. Furthermore, the patient is in good health with no co-existing medical conditions. (Q859547)

A. Group B streptococcus

B. Group A streptococcus

C. Staphylococcus aureus

D. Haemophilus influenza type B



See Answer in Part B → Q5

• [16_Viral Infections] 031 Viral Infections

« Back to Folder Directory

[16_Viral Infections] 031 Viral Infections — Quick Jump

Q1 (p. 378)	*Q2 (p. 379)*	*Q3 (p. 379)*	*Q4 (p. 379)*	*Q5 (p. 380)*	*Q6 (p. 381)*
Q7 (p. 381)	*Q8 (p. 382)*	*Q9 (p. 382)*	*Q10 (p. 383)*	*Q11 (p. 384)*	*Q12 (p. 386)*
Q13 (p. 386)	*Q14 (p. 387)*	*Q15 (p. 388)*	*Q16 (p. 389)*	*Q17 (p. 390)*	

Q1: A 21-year-old medical student presented to the dermatology OPD with the following image on the sole and a diagnosis of warts is being made. All of the following statements are true except? {{caption_text}} (Q842031)

A. HPV 2 is the most common causative organism in Superficial plantar warts

B. Deep palmoplantar warts are also called Myrmecia warts

C. HPV 6 is the most common causative organism in Anogenital warts

D. Cryotherapy is a painless procedure



@Neet_pg_bot

See Answer in Part B → Q1

@Neet_pg_bot

Q2: A 26-year-old primigravida is living with her nephew, who has recently developed varicella. She has no history of varicella exposure or vaccination, and serological testing reveals that she is not immune to the varicella-zoster virus (VZV). Based on this information, which of the following is true? (Q842030)

A. She is susceptible to zoster

B. She is susceptible to chickenpox

C. She is immune to zoster

D. She is immune to chickenpox

See Answer in Part B → Q2

@Neet_pg_bot

Q3: Which of the following conditions are characteristically associated with a maculopapular rash ? Measles Erythema infectiosum Varicella Rubella Urticaria (Q887253)

A. 1, 2 and 4

B. 1, 3 and 5

C. 2, 4 and 5

D. 1, 2, 3 and 4

See Answer in Part B → Q3

@Neet_pg_bot

Q4: A 4-year-old child presents with a sudden onset of bright erythema over both cheeks with perioral pallor, followed 2 days later by a lace-like rash over the arms and

trunk. There was no significant prodrome. What is the causative agent? (Q887249)

A. Measles virus

B. Rubella virus

C. Parvovirus B19

D. Human herpesvirus-6



See Answer in Part B → Q4

@Neet_pg_bot

Q5: Imiquimod 5% cream is used in the treatment of which of the following conditions: Genital warts Superficial basal cell carcinoma Actinic keratoses Cutaneous warts Psoriasis (Q887246)

A. 1, 2 and 3 only

B. 1, 2, 3 and 4 only

C. 2, 4 and 5 only

D. 1, 3 and 5 only

See Answer in Part B → Q5

@Neet_pg_bot

Q6: Which statement regarding eczema herpeticum is incorrect? (Q887244)

A. Commonly occurs in atopic eczema

B. Usually caused by HSV-1

C. Produces monomorphic vesicles with punched-out erosions

D. Does not require antiviral therapy

See Answer in Part B → Q6

@Neet_pg_bot

Q7: A man presents with a haemorrhagic pustular lesion on the hand developing 5–7 days after animal contact. What is the most likely diagnosis? (Q887236)

A. Pyogenic granuloma

B. Cutaneous anthrax

C. Ecthyma contagiosum

D. Herpetic whitlow



See Answer in Part B → Q7

@Neet_pg_bot

Q8: Which statement regarding smallpox is incorrect? (Q887235)

A. Rash spreads centrifugally from the face to the extremities

B. Lesions in the same area are at different stages

C. Palms and soles are commonly involved

D. Healing often causes permanent scarring

See Answer in Part B → Q8

@Neet_pg_bot

Q9: What is the causative organism of the condition shown below? (Q842034)

A. Treponema pallidum

B. Human papillomavirus 6 and 11

C. Human papillomavirus 16 and 18

D. Haemophilus ducreyi



See Answer in Part B → Q9

@Neet_pg_bot

Q10: A 40-year-old woman presents with painful and pruritic lesions 2 days after developing a fever. She had a similar history of lesions in the past associated with fever which resolved gradually. What is the likely diagnosis? {{caption_text}} (Q842006)

A. Varicella

B. Cold sore

C. Molluscum contagiosum

D. Whitlow



@Neet_pg_bot

See Answer in Part B → Q10

@Neet_pg_bot

Q11: Three days ago, a mother brought her 1-year-old infant to the emergency room with a high fever. The infant was treated with acetaminophen. Today, the fever is gone, but the infant has developed a rash on the trunk that has spread to the limbs. The examination reveals red papules on the palate. What is the most probable diagnosis? {{caption_text}} (Q842027)

A. Rubella

B. Erythema infectiosum

C. Measles

D. Roseola infantum

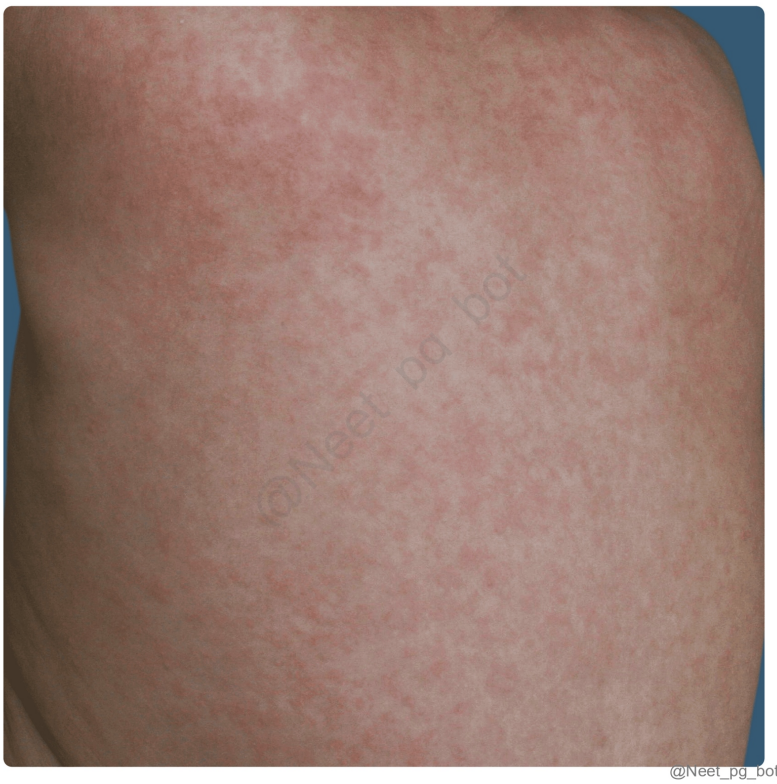



See Answer in Part B → Q11

@Neet_pg_bot

Q12: An immunocompromised individual presents with a corrugated white lesion on the side of the tongue as shown in the image below, which does not wipe off. The most likely causative agent is? {{caption_text}} (Q842025)

A. Candida

B. Epstein Barr Virus (EBV)

C. Human Herpes Virus (HHV7)

D. Human Herpesvirus 8 (HHV8)



See Answer in Part B → Q12

@Neet_pg_bot

Q13: Identify the incorrect statement regarding Herpes zoster (Shingles). (Q842024)

A. Varicella-zoster virus remains dormant in Dorsal root ganglion

B. A maculopapular rash is seen

C. Thoracic and lumbar dermatomes are most commonly involved

D. Mucous membranes within the affected dermatomes are involved

See Answer in Part B → Q13

@Neet_pg_bot

Q14: A 4-year-old child presents with sores in the mouth and a rash on the hands and feet, as shown in the image below. What is the causative organism for this? {{caption_text}} {{caption_text}} (Q842022)

A. Coxsackievirus A16

B. Pox virus

C. Herpes virus

D. Human papillomavirus



@Neet_pg_bot



@Neet_pg_bot

See Answer in Part B → Q14

@Neet_pg_bot

Q15: A 10-year-old child develops round, firm, and painless bumps over the face. All of the following statements about this disease are true except? {{caption_text}} (Q842020)

A. Spread direct skin-to-skin contact with an infected person

B. RNA virus is the causative agent

C. Auto inoculation can be seen

D. Lesions are not seen in palms & Soles generally



See Answer in Part B → Q15

@Neet_pg_bot

Q16: A primigravida at 38 weeks gestation presents to the emergency department in labor with symptoms of fever, headache, and genital itching. Upon examination, the cervix is found to be dilated at 7 cm, and small painful blisters with ulceration are observed around the vulva, along with inguinal lymphadenopathy. Select the incorrect statement regarding this presentation. (Q842013)

A. Cesarean section may reduce the risk of infection in the baby

B. In the case of neonatal transmission, mortality rates are typically low

C. This condition is commonly caused by HSV-2

D. Prophylactic acyclovir should be considered for her neonate.

See Answer in Part B → Q16

@Neet_pg_bot

Q17: A 30-year-old male visited the outpatient department with persistent vesicular eruptions on his lips as shown in the image. Despite multiple previous treatments with oral antiviral medication, the lesions have not shown signs of improvement. Considering acyclovir-resistant recurrent herpes labialis, which of the following alternative drugs could be considered for treatment? {{caption_text}} (Q842010)

A. Lamivudine

B. Foscarnet

C. Valacyclovir

D. Ganciclovir



@Neet_pg_bot

See Answer in Part B → Q17

@Neet_pg_bot

• [16_Viral Infections] 032 Previous Year Questions

« Back to Folder Directory

[16_Viral Infections] 032 Previous Year Questions — Quick Jump

Q1 (p. 391) *Q2 (p. 391)* *Q3 (p. 391)* *Q4 (p. 392)* *Q5 (p. 393)* *Q6 (p. 393)*
Q7 (p. 394) *Q8 (p. 395)*

Q1: A female presents with multiple small, pink, umbilicated papules on the face. What is the most likely diagnosis? (Q866857)

A. Molluscum contagiosum

B. Herpes simplex

C. HPV

D. Acne vulgaris

See Answer in Part B → Q1

@Neet_pg_bot

Q2: Which of the following best describes the characteristic lesion of Kaposi sarcoma? (Q866859)

A. A yellow lesion containing pus

B. A white, striated lesion that cannot be scraped off

C. A raised, purple-red lesion

D. Small, red erosions

See Answer in Part B → Q2

@Neet_pg_bot

Q3: A child was brought with c/o multiple lesions. O/E multiple vesicular lesions are seen on the palms, soles, and oral mucosa. Which of the following is the most likely etiological agent causing the disease? (Q866863)

A. Varicella-zoster virus

B. Human-herpesvirus 6

C. Enterovirus

D. Coxsackie virus



See Answer in Part B → Q3

@Neet_pg_bot

Q4: A patient presents with loss of sensation on the posterior surface of the ear along with a lesion. Which structure is most likely involved? (Q852739)

A. Greater Auricular Nerve

B. Internal Jugular Vein

C. External Jugular Vein

D. External Carotid Artery

See Answer in Part B → Q4

@Neet_pg_bot

Q5: A female patient presents to the OPD with complaints of recurrent lesions on lips as shown below, which is associated with fever. Which of the following is the characteristic feature seen in Tzanck smear? (Q860094)

A. Handerson patterson bodies

B. Multinucleated giant cells

C. Owl eye appearance

D. Acantholytic cells



See Answer in Part B → Q5

@Neet_pg_bot

Q6: A man presents with a rash on his flank, with Itching for the past 2 weeks. The patient has tried several over-the-counter medications without any improvement. In physical examination, the rash is seen on his palms and the sole of one foot, but no oral lesions are found. What is the Iikely diagnosis? (Q857387)

A. Urticaria

B. Viral exanthema

C. Erythema multiforme

D. Tinea manuum



See Answer in Part B → Q6

@Neet_pg_bot

Q7: A 3-year-old child is brought to the clinic with a generalized vesicular rash covering the entire body. The child's parents report that the rash started as red spots and quickly developed into fluid-filled blisters. The child also has a mild fever and is feeling irritable. What is the most likely diagnosis for this child's condition? (Q820220)

A. Varicella

B. Shingles

C. Smallpox

D. Dermatomyocytis



See Answer in Part B → Q7

@Neet_pg_bot

Q8: Which of the following does not exhibit the Koebner's phenomenon? (Q793414)

A. Vitiligo

B. Psoriasis

C. Lichen planus

D. Herpes

See Answer in Part B → Q8

@Neet_pg_bot

• [17_Fungal Infections] 033 Fungal Infections - I

« Back to Folder Directory

[17_Fungal Infections] 033 Fungal Infections - I — Quick Jump

Q1 (p. 396) *Q2 (p. 396)* *Q3 (p. 397)* *Q4 (p. 397)* *Q5 (p. 398)* *Q6 (p. 399)*
Q7 (p. 400) *Q8 (p. 401)* *Q9 (p. 401)* *Q10 (p. 402)* *Q11 (p. 403)* *Q12 (p. 404)*
Q13 (p. 404)

Q1: During your rural service, a patient arrives at the OPD with hypopigmented lesions on his trunk and back. A Wood's lamp examination of the lesions shows yellow fluorescence, and scales become prominent when the lesion is scratched with nails. Which of the following organisms causes this infection? (Q841821)

A. Malassezia furfur

B. Microsporum audouinii

C. Trichophyton rubrum

D. Epidermophyton floccosum

See Answer in Part B → Q1

@Neet_pg_bot

Q2: What would you expect to see on KOH examination of a scalp fleck from a patient with chronic dandruff? (Q841822)

A. Spaghetti and meatball appearance

B. Pilot wheel appearance

C. Conidia and conidiophores

D. Pseudohyphae

See Answer in Part B → Q2

@Neet_pg_bot

Q3: A 67-year-old actress, diagnosed with HIV 20 years ago, presents to your OPD with complaints of itching and flaking on her eyelids and scalp. The examination findings are shown in the image below. Which of the following conditions is not caused by the organism responsible for this patient's symptoms? (Q841823)

A. Folliculitis

B. Dandruff

C. Confluent Reticulate Papillomatosis

D. Piedra



@Neet_pg_bot

See Answer in Part B → Q3

@Neet_pg_bot

Q4: On your annual visit to the local orphanage in farmland to celebrate your birthday, you notice a 5-year-old boy crying due to a painful, boggy swelling on his scalp, shown in the image below. Multiple other boys in the orphanage also have areas of patchy, scaly hair loss. Which of the following is the causative organism of this

patient’s findings? (Q841824)

A. Tinea schoenleinii

B. Trichophyton verrucosum

C. Microsporum canis

D. Trichophyton concentricum

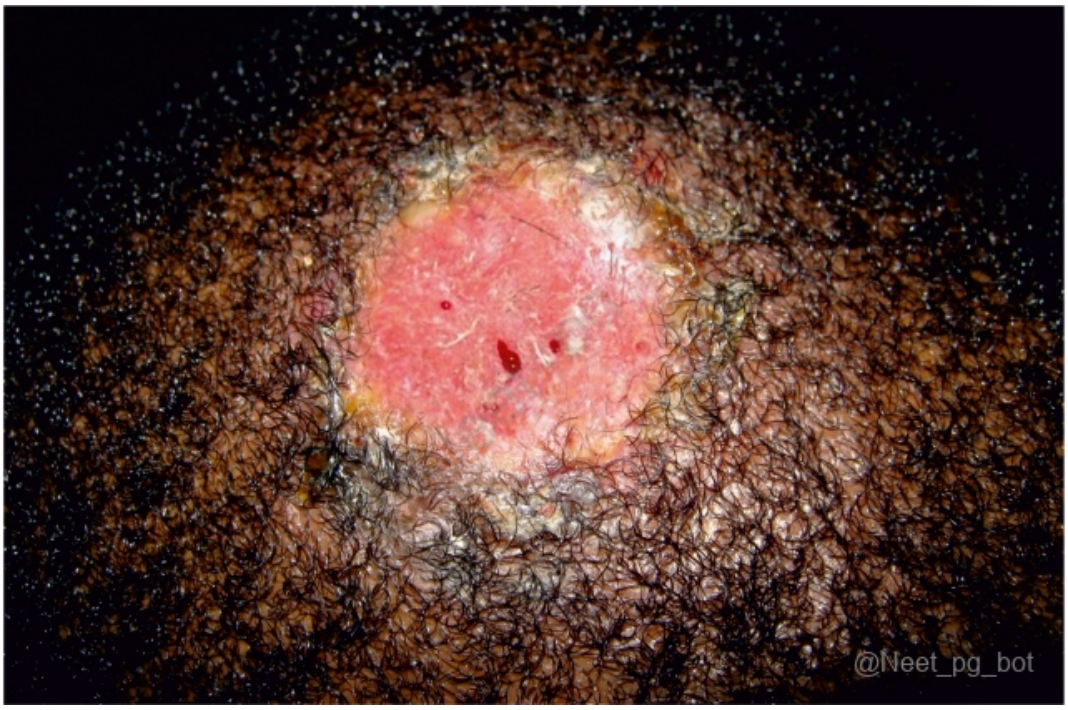

See Answer in Part B → Q4

@Neet_pg_bot

Q5: During a health check-up in a tropical coastal region, a 30-year-old patient presents with a well-demarcated, non-pruritic, dark brown macule on their palm. The lesion has gradually increased in size over the past few months. There is no associated pain or scaling. Based on the clinical findings, what is the most likely diagnosis? (Q841825)

A. Melanocytic nevus

B. Dermatofibroma

C. Tinea nigra

D. Lichen planus



See Answer in Part B → Q5

@Neet_pg_bot

Q6: A 27-year-old boy comes to your OPD complaining of an itchy rash over his forearm for the past 8 months. He gives history of unsupervised use of over the counter creams ,but it has only gotten worse after short-lived improvements. An image of the lesion is given below. What is the most likely diagnosis ? {{caption_text}} (Q841826)

A. Tinea manuum

B. Tinea incognito

C. Tinea profunda

D. Tinea corporis



See Answer in Part B → Q6

@Neet_pg_bot

Q7: A 62-year-old man with a history of diabetes mellitus presents to the dermatology clinic with discoloured nails. The examination findings are shown in the image below. What is the likely diagnosis? (Q841827)

A. Distal Lateral Subungual Onychomycosis

B. Paronychia

C. Nail Psoriasis

D. Onychogryphosis



See Answer in Part B → Q7

@Neet_pg_bot

Q8: A student from a hostel dormitory visits you with complaints of narrow nodules on her hair shafts. On examination, you find that these nodules are loosely attached to the surface of the hair, white in colour and soft in consistency. Which of the following organisms is the most likely cause of this condition? (Q841828)

A. Piedra horteii

B. Trichosporon beigelii

C. Trichosporon cutaneum

D. Trichophyton violaceum

See Answer in Part B → Q8

@Neet_pg_bot

Q9: A 67-year-old lady with diabetes comes to your OPD complaining of itching under her breasts. On examination, you see multiple erythematous, tender patches on the inferior surface of both breasts with multiple satellite lesions as shown in the image below. What is the causative organism and the diagnosis? {{caption_text}} (Q841829)

A. Candida albicans (Intertrigo)

B. Trichophyton Circinata (Tinea)

C. Streptococcus pyogenes (Erysipelas)

D. Malassezia furfur (Ptyriasis verciolor)



See Answer in Part B → Q9

@Neet_pg_bot

Q10: A 35-year-old uncircumcised male patient with a T-cell deficiency presents to your outpatient clinic. On examination, a frayed appearance and the presence of superficial pustules on the penis is noted. A KOH examination reveals the following findings. What is the most appropriate next step in management? (Q841830)

A. Local application of nystatin gel

B. Oral fluconazole

C. Local application of terbinafine ointment

D. Oral griseofulvin

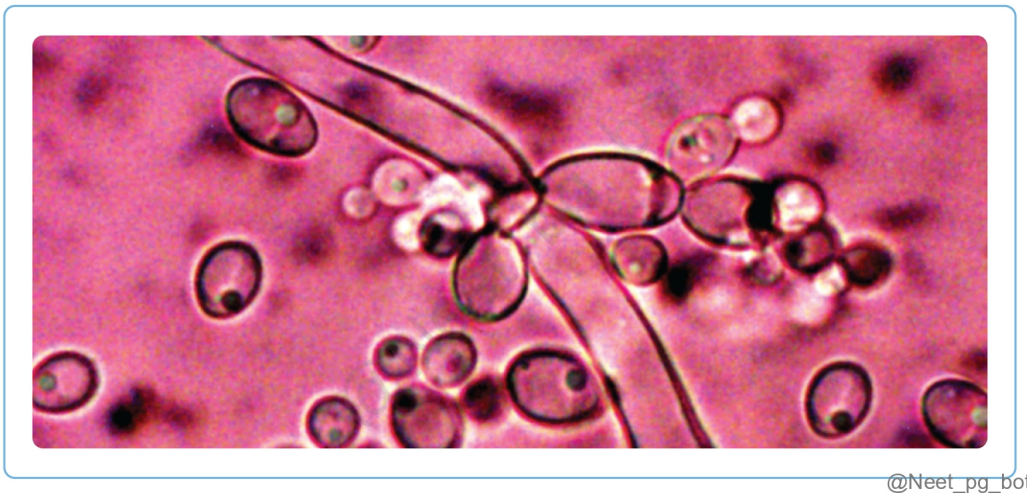

@Neet_pg_bot

See Answer in Part B → Q10

@Neet_pg_bot

Q11: A 40-year-old heroin and nicotine abuser with a 20-year history of untreated HIV comes to your community clinic complaining of a white patch on his tongue. You are unable to scrape the lesion off, and examination findings are given in the image below. What is the next best step of management? (Q841831)

A. Tongue biopsy

B. Nystatin gargle and Oral Fluconazole

C. Initiate Anti-Retroviral Therapy (ART)

D. Topical Corticosteroid therapy



See Answer in Part B → Q11

@Neet_pg_bot

Q12: Which pattern is most likely to be observed in the hair perforation test result of Trichophyton mentagrophytes infection? (Q841832)

A. Absence of hair perforation

B. Wedge-shaped hair perforations along the hair shaft

C. Circular perforations inside the hair shaft

D. Parallel perforations on either side of the hair shaft

See Answer in Part B → Q12

@Neet_pg_bot

Q13: At your community medicine posting, a farmer arrives complaining of multiple nodules over his right leg after being pricked by a thistle. Examination findings are given in the image below. What would you expect to find on a microscopic examination of tissue from one of his lesions? {{caption_text}} (Q841833)

A. Asteroid bodies

B. Black granules

C. Muriform bodies

D. Spherules containing endospores



See Answer in Part B → Q13

@Neet_pg_bot

• [17_Fungal Infections] 034 Previous Year Questions

« Back to Folder Directory

[17_Fungal Infections] 034 Previous Year Questions — Quick Jump

Q1 (p. 406) *Q2 (p. 407)* *Q3 (p. 407)* *Q4 (p. 407)* *Q5 (p. 408)* *Q6 (p. 409)*

Q1: A patient presents with irregular swelling over the foot, multiple discharging sinuses, and black granules. A KOH mount is performed on the discharge. What is the most likely observation? (Q866553)

A. Arthrospores

B. Slender dematiaceous fungi

C. Yeast

D. Septate hyphae 4-5 µm



See Answer in Part B → Q1

Q2: A 60-year-old female with a great toe infection. She had a significant discoloration with a subungual hyperkeratosis that caused surface changes. She was suspected of onychomycosis. Which is the topical drug given in toenail onychomycosis? (Q853198)

A. Itraconazole

B. Tavaborole

C. Griseofulvin

D. Caspofungin

See Answer in Part B → Q2

@Neet_pg_bot

Q3: A 35-year-old patient presents to the OPD with a history of prolonged use of steroids for a skin condition. The patient complains of an expanding rash that has become less red and itchy since using the steroids. On examination, there are well-defined, slightly raised, erythematous plaques with central clearing and a scaly border on various parts of the body. What is the most likely diagnosis for this patient's condition? (Q820216)

A. Tinea incognito

B. Tinea corporis

C. Tinea cruris

D. Tinea pedis

See Answer in Part B → Q3

@Neet_pg_bot

Q4: A 10-year-old boy, presented with a mild painful swelling over the scalp since 3 months, as depicted below. Additionally, the patient confirms having a pet dog in his household. What is the most appropriate diagnosis of this condition? (Q855926)

A. Furuncle

B. Epidermoid cyst

C. Kerion

D. Folliculitis



See Answer in Part B → Q4

@Neet_pg_bot

Q5: Which type of alopecia is commonly associated with inflammatory alopecia in a 30-year-old male patient who presents with tinea capitis infection? (Q855958)

A. Endothrix and Favus

B. Ectothrix and Endothrix

C. Favus and Kerion

D. Kerion and Endothrix

See Answer in Part B → Q5

Q6: A farmer presents to the outpatient department with the lesion shown. Examination of the discharge reveals black granules. What is the most likely causative organism? (Q879072)

A. Madurella mycetomatis

B. Actinomadura madurae

C. Nocardia brasiliensis

D. Streptomyces somaliensis



See Answer in Part B → Q6

• [18_Parasitic Infection] 035 Parasitic Infestations Of Skin

« Back to Folder Directory

[18_Parasitic Infection] 035 Parasitic Infestations Of Skin — Quick Jump

Q1 (p. 410)	*Q2 (p. 410)*	*Q3 (p. 411)*	*Q4 (p. 411)*	*Q5 (p. 412)*	*Q6 (p. 413)*
Q7 (p. 414)	*Q8 (p. 414)*	*Q9 (p. 415)*	*Q10 (p. 416)*	*Q11 (p. 416)*	*Q12 (p. 417)*
Q13 (p. 417)	*Q14 (p. 418)*	*Q15 (p. 418)*	*Q16 (p. 419)*	*Q17 (p. 420)*	*Q18 (p. 421)*
Q19 (p. 422)	*Q20 (p. 422)*	*Q21 (p. 423)*	*Q22 (p. 424)*	*Q23 (p. 425)*	

Q1: A 25-year-old man presents with an intensely pruritic, rapidly progressing, serpiginous rash over the trunk and proximal limbs. The lesion is noted to migrate quickly over hours to days. Which of the following organisms is the most likely causative agent? (Q882304)

A. Strongyloides stercoralis

B. Ancylostoma braziliense

C. Cutaneous larva migrans due to hookworm species

D. Sarcoptes scabiei

See Answer in Part B → Q1

@Neet_pg_bot

Q2: A patient with classical scabies has thin, serpiginous burrows on the finger web spaces. Which layer of the skin does the female mite create these burrows in? (Q887368)

A. Stratum basale

B. Stratum spinosum

C. Stratum corneum

D. Dermis

See Answer in Part B → Q2

@Neet_pg_bot

Q3: A 24-year-old man presents with intensely pruritic, erythematous serpiginous tracks on his foot that have been slowly migrating over several days. He recently walked barefoot on a beach. What is the most likely causative organism? (Q887391)

A. Ancylostoma duodenale

B. Ancylostoma braziliense

C. Enterobius vermicularis

D. Sarcoptes scabiei



See Answer in Part B → Q3

@Neet_pg_bot

Q4: Pediculosis pubis is caused by which parasite? (Q887388)

A. Head louse

B. Body louse

C. Crab louse

D. Scabies mite

See Answer in Part B → Q4

@Neet_pg_bot

Q5: A 28-year-old man presents with intense itching in the pubic region for 2 weeks. Examination shows excoriations and multiple blue-grey macules on the lower abdomen and thighs. Close inspection reveals findings as shown. What is the most likely diagnosis? (Q887387)

A. Pediculosis corporis

B. Scabies

C. Pediculosis pubis

D. Tinea cruris



See Answer in Part B → Q5

@Neet_pg_bot

Q6: A 60-year-old homeless man presents with findings as shown. Lice and nits are seen in clothing seams, not on the scalp. What is the most likely diagnosis? (Q887386)

A. Scabies incognito

B. Pediculosis capitis

C. Vagabond’s disease

D. Post-inflammatory hyperpigmentation

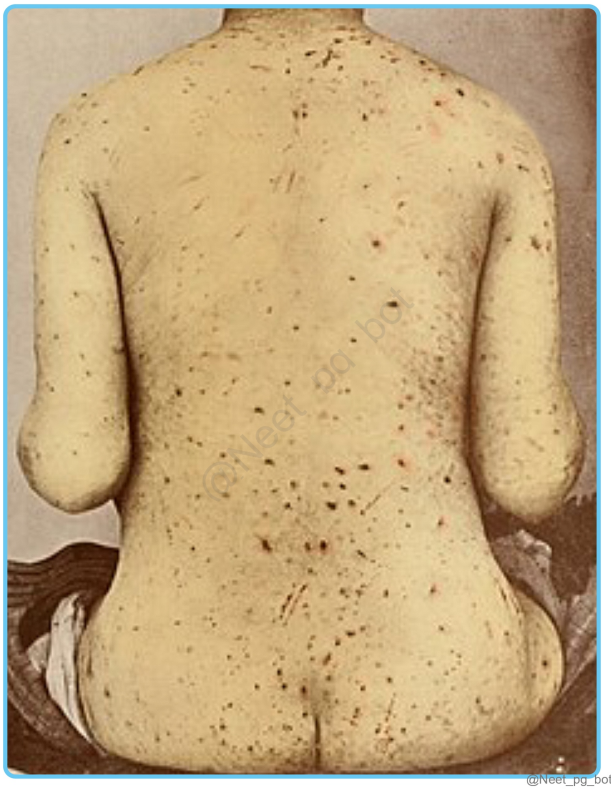

See Answer in Part B → Q6

@Neet_pg_bot

Q7: A 58-year-old immunocompromised man has thick hyperkeratotic crusts on hands and feet, nail debris, minimal itching, and contact with pruritus. Skin scrapings show numerous mites. What is the diagnosis? (Q887384)

A. Nodular scabies

B. Animal scabies

C. Norwegian scabies

D. Darier disease

See Answer in Part B → Q7

@Neet_pg_bot

Q8: Which of the following statements regarding nodular scabies is incorrect? (Q887381)

A. Lesions are violaceous and intensely pruritic

B. Commonly involves the groin, axillae, and male genitalia

C. Nodules contain large numbers of live mites

D. Lesions may persist for weeks or months after treatment

See Answer in Part B → Q8

@Neet_pg_bot

Q9: A 22-year-old man presents with intense nocturnal itching and pruritic papules as shown. Two family members have similar symptoms. Which of the following tests are useful to confirm the diagnosis? Skin scraping with mineral oil microscopy. Dermoscopy Adhesive tape test Patch testing (Q887379)

A. 1, 2 and 3

B. 1 and 4

C. 2 and 4

D. 3 and 4



See Answer in Part B → Q9

@Neet_pg_bot

Q10: A patient with nocturnal pruritus and burrows is diagnosed with scabies. Which statement regarding management is incorrect? (Q887376)

A. Treat all close contacts simultaneously

B. Apply permethrin only to visible lesions

C. Wash clothes and bedding in hot water or seal for 72 h

D. Itching may persist after treatment

See Answer in Part B → Q10

@Neet_pg_bot

Q11: A 6-month-old infant presents with intense itching, irritability, and a generalised papulovesicular rash. Lesions involve the scalp, face, palms, and soles. The mother also complains of nocturnal itching. Examination shows excoriations and crusted papules. What is the most likely diagnosis? (Q887374)

A. Atopic dermatitis

B. Infantile scabies

C. Impetigo

D. Papular urticaria

See Answer in Part B → Q11

@Neet_pg_bot

Q12: Which of the following statements about scabies is incorrect? (Q887371)

A. Burrows are absent in animal scabies

B. Permethrin is the drug of choice for scabies

C. Crusted scabies is highly contagious

D. Animal scabies commonly causes persistent human infestation

See Answer in Part B → Q12

@Neet_pg_bot

Q13: A patient acquires scabies for the first time. After how long do symptoms typically begin? (Q887369)

A. Within 24-48 hours

B. 3-4 weeks

C. 6-8 weeks

D. Immediate

See Answer in Part B → Q13

@Neet_pg_bot

Q14: A 25-year-old male presents with complaints of severe itching in both his hands for the last 2 weeks. He reports that the itching is significantly worse at night and disturbs his sleep. His hands show lesions characteristic of scabies. Which body site is usually not affected by this condition? {{caption_text}} (Q842037)

A. Face

B. Axilla

C. Groin/genitalia

D. Umbilicus



@Neet_pg_bot

See Answer in Part B → Q14

@Neet_pg_bot

Q15: A 22-year-old man presents with intense itching, worse at night, for 3 weeks. Examination shows multiple excoriated papules and thin serpiginous burrows as shown in the finger web spaces and flexor wrists. His roommate also has similar symptoms. What is the most likely diagnosis? (Q887364)

A. Pediculosis corporis

B. Atopic dermatitis

C. Scabies

D. Prurigo nodularis



See Answer in Part B → Q15

@Neet_pg_bot

Q16: A 50-year-old female who recently migrated from Bihar presents for evaluation of a new rash. Her history is significant for low-grade fever and fatigue over the last few months. She reports receiving some treatment at the local government hospital, but cannot recount any more details. Examination reveals hundreds of

hypopigmented macules over her back and arms. She also has palpable splenomegaly. What is the likely diagnosis? (Q842063)

A. Post-kala-azar dermal leishmaniasis

B. Cutaneous leishmaniasis

C. Lepromatous leprosy

D. Pityriasis versicolor



See Answer in Part B → Q16

@Neet_pg_bot

Q17: A 30-year-old male soldier who had recently been deployed to Iraq presents with a mildly itchy, raised rash on his neck. He has no other systemic complaints. Examination revealed a painless plaque with ulceration and overlying crusting associated with tender posterior lymphadenopathy. What is the likely causative organism? (Q842062)

A. Leishmania mexicana

B. Leishmania braziliensis

C. Leishmania major

D. Leishmania donovani

See Answer in Part B → Q17

@Neet_pg_bot

Q18: As shown in the figure, a 10-year-old boy presents with a painless swelling over his left lower eyelid. He reports visiting the Amazon forest on vacation with his family recently. If left untreated, which of the following is not a long-term risk? (Q842061)

A. Sleeping sickness

B. Heart failure

C. Megaesophagus

D. Megacolon



See Answer in Part B → Q18

@Neet_pg_bot

Q19: A 20-year-old female presents with an itchy lesion as shown below. She reports that it started as a small, red, itchy spot, then progressed over the next few days to its current form. She also reveals a recent beach holiday. What is the causative organism? {{caption_text}} (Q842060)

A. Loa loa

B. Ancylostoma caninus

C. Strongyloides stercoralis

D. Ascaris lumbricoides



@Neet_pg_bot

See Answer in Part B → Q19

@Neet_pg_bot

Q20: A 9-year-old girl presents with complaints of an itchy scalp for the last few days. Local inspection reveals mild crusting in areas of the scalp, with multiple white nits along the hair shafts. What is the causative organism? {{caption_text}} (Q842059)

A. Pediculus humanus corporis

B. Pthirus pubis

C. Sarcopteis scabei

D. Pediculus humanus capitis



See Answer in Part B → Q20

@Neet_pg_bot

Q21: A 6-month-old girl is brought by her parents for evaluation of a rash. On examination, she appears uncomfortable, and there are multiple small red papules on her face, palms, and soles. Multiple small burrows are also seen. Microscopy of skin scrapings is shown below. What is the causative organism? (Q842058)

A. Phthiris pubis

B. Sarcoptes scabiei

C. Trichophyton

D. Staphylococcus aureus

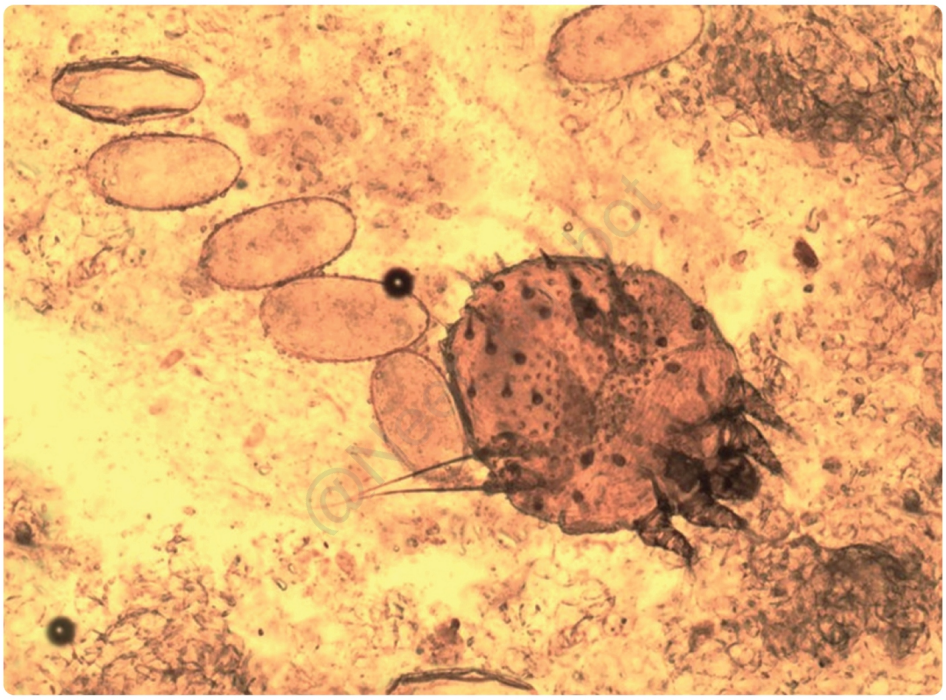

See Answer in Part B → Q21

@Neet_pg_bot

Q22: A 30-year-old female with lymphoma on chemotherapy presents with large, crusted plaques over her entire torso, arm, and legs. She reports minimal itching. What is the optimal treatment regimen for this patient? (Q842057)

A. Oral ivermectin alone

B. Topical permethrin alone

C. Ivermectin + Permethrin

D. Topical steroids



See Answer in Part B → Q22

@Neet_pg_bot

Q23: A 10-year-old boy is diagnosed with scabies after presenting with severe itching lesions, predominantly over his wrists and hands. What is the first-line treatment for his condition? (Q842040)

A. 5 % Permethrin

B. Gamma benzene hexachloride (GBHC)

C. Precipitated sulfur

D. Ivermectin

See Answer in Part B → Q23

@Neet_pg_bot

• [18_Parasitic Infection] 036 Previous Year Questions

« Back to Folder Directory

[18_Parasitic Infection] 036 Previous Year Questions — Quick Jump

Q1 (p. 426) *Q2 (p. 426)* *Q3 (p. 426)* *Q4 (p. 427)* *Q5 (p. 428)*

Q1: Which of the following treatments are appropriate for scabies in infants? a. 5% Permethrin cream b. 10% Crotamitron c. Ivermectin d. 25% Benzyl benzoate lotion (Q865457)

A. a, b, c

B. a, b, d

C. a, c, d

D. b, c, d

See Answer in Part B → Q1

@Neet_pg_bot

Q2: A pregnant woman presents with lymph node swelling. She has a history of toxoplasmosis infection 5 years ago and is IgG positive. What should be the next step? (Q866558)

A. Congenital anomalies risk is high

B. Reassurance, continue pregnancy

C. Do amniotic sampling to find if fetus is infected or not

D. Start treatment

See Answer in Part B → Q2

@Neet_pg_bot

Q3: A young boy came to the OPD with complaints of severe itching at night. On examination, burrows are seen over intertriginous areas, axillae, umbilicus, and between digits. Which ofthe following transmits the condition described in the scenario? (Q860618)

A. Louse

B. Tick

C. Mite

D. Flea

See Answer in Part B → Q3

@Neet_pg_bot

Q4: The involvement of which of the following results in the given condition below? (Q820238)

A. Arteries

B. Vein

C. Lymphatics

D. DVT



See Answer in Part B → Q4

@Neet_pg_bot

Q5: Identify the disease shown in the image below (Q859897)

A. Syphilis

B. Leprosy

C. Elephantiasis

D. Leishmaniasis



See Answer in Part B → Q5

@Neet_pg_bot

• [19_Skin Tumours] 037 Skin Tumors

« Back to Folder Directory

[19_Skin Tumours] 037 Skin Tumors — Quick Jump

Q1 (p. 430)	*Q2 (p. 430)*	*Q3 (p. 431)*	*Q4 (p. 431)*	*Q5 (p. 432)*	*Q6 (p. 433)*
Q7 (p. 434)	*Q8 (p. 434)*	*Q9 (p. 435)*	*Q10 (p. 436)*	*Q11 (p. 437)*	*Q12 (p. 437)*
Q13 (p. 438)	*Q14 (p. 439)*	*Q15 (p. 440)*	*Q16 (p. 440)*	*Q17 (p. 441)*	*Q18 (p. 441)*
Q19 (p. 442)	*Q20 (p. 442)*	*Q21 (p. 443)*	*Q22 (p. 444)*	*Q23 (p. 445)*	*Q24 (p. 445)*
Q25 (p. 446)	*Q26 (p. 446)*	*Q27 (p. 447)*	*Q28 (p. 448)*	*Q29 (p. 449)*	*Q30 (p. 449)*
Q31 (p. 450)					

Q1: Which of the following is NOT a cutaneous marker of underlying internal malignancy? (Q841734)

A. Necrolytic migratory erythema

B. Acanthosis nigricans

C. Erythroderma

D. Erythema chronicum migrans

See Answer in Part B → Q1

@Neet_pg_bot

Q2: Which of the following is not included in the clinical triad of sezary syndrome? (Q841730)

A. Erythroderma

B. Peripheral lymphadenopathy

C. Atypical mononuclear cells >20% of total lymphocytes

D. Follicular Mucinosis

See Answer in Part B → Q2

@Neet_pg_bot

Q3: A 50-year-old construction worker presents to the dermatology OPD with a black mole over his back as shown in the image. Which of the following investigations is the gold standard for diagnosis of this condition? (Q841722)

A. Dermoscopy

B. Clinical examination

C. Biopsy

D. CT



See Answer in Part B → Q3

@Neet_pg_bot

Q4: Extracorporeal photopheresis is most useful in which of the following conditions? (Q887632)

A. Plaque psoriasis

B. Sezary syndrome

C. Atopic dermatitis

D. Vitiligo

See Answer in Part B → Q4

@Neet_pg_bot

Q5: A 32-year-old man with untreated HIV infection presents with findings as shown over the hard palate and lower limbs. Biopsy shows spindle cell proliferation with slit-like vascular spaces and extravasated erythrocytes. Which of the following statements regarding this condition is incorrect? (Q887593)

A. It is caused by Human Herpesvirus-8 infection

B. The gastrointestinal tract is a common site of visceral involvement

C. It is poorly responsive to radiotherapy

D. Risk markedly increases in immunocompromised individuals



See Answer in Part B → Q5

Q6: What is the most likely diagnosis based on the histopathology slide? ■ ■■ (Q887635)

A. Squamous cell carcinoma

B. Melanoma

C. Basal cell carcinoma

D. Keratoacanthoma

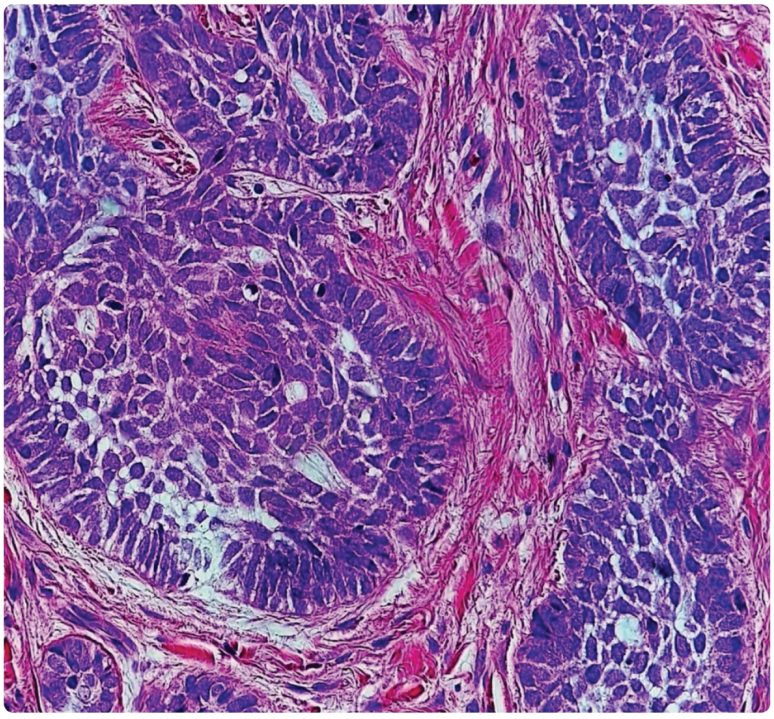



See Answer in Part B → Q6

@Neet_pg_bot

Q7: A 72-year-old man presents with a slowly enlarging lesion on the lateral nose. It appears as a pearly papule with surface telangiectasia and occasional central ulceration. A biopsy confirms a diagnosis of basal cell carcinoma. Which of the following is the most common histological subtype of basal cell carcinoma? (Q887639)

A. Superficial

B. Morpheaform

C. Nodular

D. Infiltrative

See Answer in Part B → Q7

@Neet_pg_bot

Q8: Which of the following is not a recognised risk factor for basal cell carcinoma? (Q887640)

A. Fitzpatrick skin type I-II

B. Chronic arsenic exposure

C. Immunosuppression

D. Chronic mechanical friction

See Answer in Part B → Q8

@Neet_pg_bot

Q9: A 72-year-old woman presents with findings as shown for 10 months. It is asymptomatic. Biopsy shows atypical keratinocytes involving the entire thickness of the epidermis with an intact basement membrane. Which of the following statements regarding this condition is correct? (Q887642)

A. It is more common in males

B. It is typically a rapidly enlarging lesion

C. There is a risk of progression to invasive SCC

D. It is not associated with prior radiation exposure



See Answer in Part B → Q9

@Neet_pg_bot

Q10: A 58-year-old man presents with a slowly enlarging lesion on the plantar surface of his foot for 2 years. It is painless but progressively increasing in size with no regional lymphadenopathy. What is the most likely diagnosis? (Q887643)

A. Keratoacanthoma

B. Verrucous carcinoma

C. Conventional invasive squamous cell carcinoma

D. Viral wart (verruca vulgaris)



See Answer in Part B → Q10

@Neet_pg_bot

Q11: A 48-year-old man presents with multiple yellowish papules and nodules on the face and trunk for 3 years. Histopathology of one lesion shows a sebaceous adenoma. He also has a history of right-sided colon carcinoma diagnosed at age 45. His father died of colorectal cancer. What is the most likely diagnosis? (Q887644)

A. Gardner syndrome

B. Turcot syndrome

C. Muir-Torre syndrome

D. Cowden syndrome

See Answer in Part B → Q11

@Neet_pg_bot

Q12: Which gene mutation is most commonly associated with Gorlin syndrome? (Q887646)

A. PTCH1

B. PTEN

C. MLH1

D. TP53

See Answer in Part B → Q12

@Neet_pg_bot

Q13: A 50-year-old man presents with a progressively widening dark streak on his thumbnail. Examination shows longitudinal melanonychia with brown-black pigmentation extending onto the proximal nail fold, visible to the naked eye. What is this sign called? (Q887647)

A. Pseudo-Hutchinson sign

B. Micro-Hutchinson sign

C. Hutchinson sign

D. Parallel ridge pattern



See Answer in Part B → Q13

@Neet_pg_bot

Q14: Which of the following statements regarding risk factors of the most probable condition depicted in the image below is incorrect? (Q887648)

A. Intermittent sun exposure and sunburns increase melanoma risk.

B. Having ≥5 atypical/dysplastic naevi significantly increases melanoma risk.

C. Most cutaneous melanomas arise from pre-existing naevi.

D. Red hair independently confers increased melanoma risk.

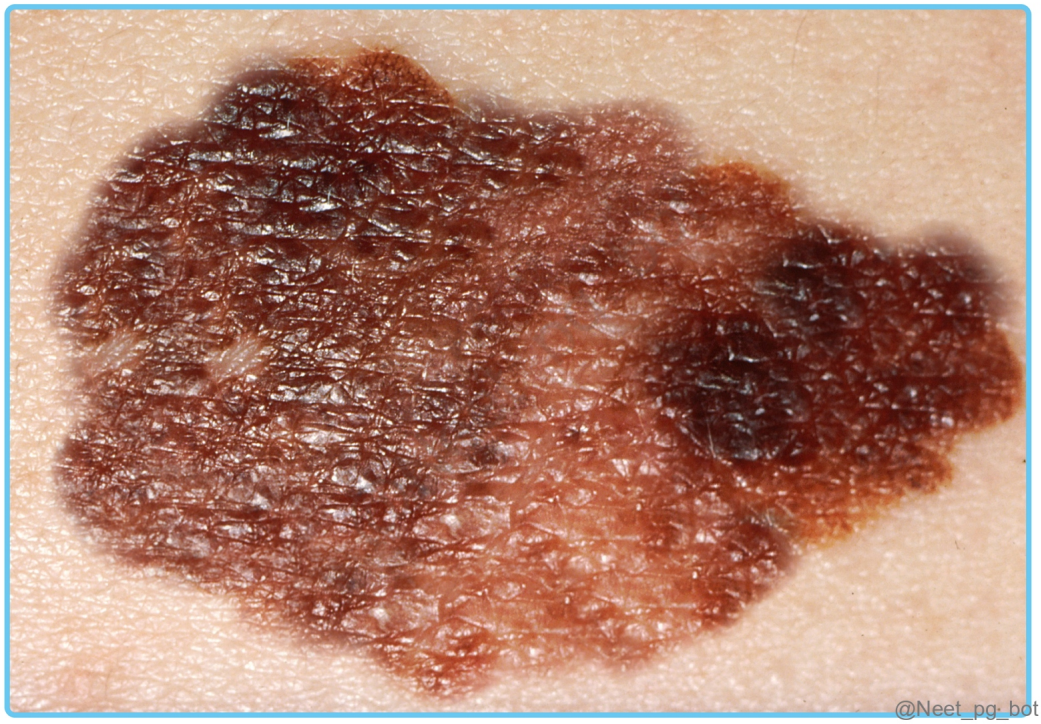

See Answer in Part B → Q14

@Neet_pg_bot

Q15: Which of the following genes is the most important high-penetrance susceptibility gene for familial melanoma? (Q887649)

A. CDKN2A

B. CDK4

C. MC1R

D. BAP1

See Answer in Part B → Q15

@Neet_pg_bot

Q16: Which of the following is the most important prognostic factor for predicting melanoma recurrence and overall survival? (Q887650)

A. Size of the melanoma

B. Breslow thickness

C. Mitotic rate

D. Colour of lesion

See Answer in Part B → Q16

@Neet_pg_bot

Q17: A 28-year-old woman has multiple firm, pink nodules on her scalp. Family history is positive. Histology shows lobules in a "jigsaw-puzzle" pattern with a hyaline basal membrane. What is the most likely diagnosis? (Q887651)

A. Trichoepithelioma

B. Cylindroma

C. Basal cell carcinoma

D. Trichilemmal cyst

See Answer in Part B → Q17

@Neet_pg_bot

Q18: A 60-year-old man has chronic pruritic patches over the trunk progressing to plaques. Skin biopsy shows epidermotropism and findings as shown. What is the diagnosis? (Q887627)

A. Sézary syndrome

B. Mycosis fungoides

C. Pagetoid reticulosis

D. Adult T-cell leukaemia/lymphoma

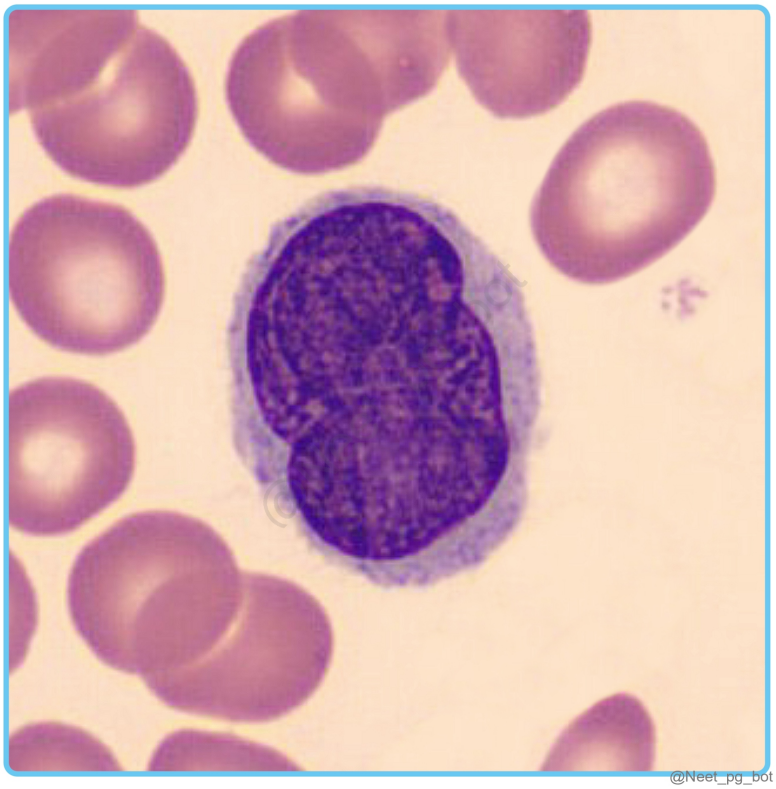

See Answer in Part B → Q18

@Neet_pg_bot

Q19: Which of the following is the most common cutaneous T-cell lymphoma (CTCL)? (Q887597)

A. Sézary syndrome

B. Mycosis fungoides

C. Pagetoid reticulosis

D. Follicular mucinosis

See Answer in Part B → Q19

@Neet_pg_bot

Q20: A 50-year-old female presented with sudden eruption of asymptomatic lesions as shown in the image below. The lesions have a stuck-on appearance suggestive of a diagnosis of Seborrheic keratosis. Which of the following malignancies is commonly suspected in the given scenario? (Q841710)

A. Gastric

B. Intestinal

C. Pulmonary

D. Cardiac

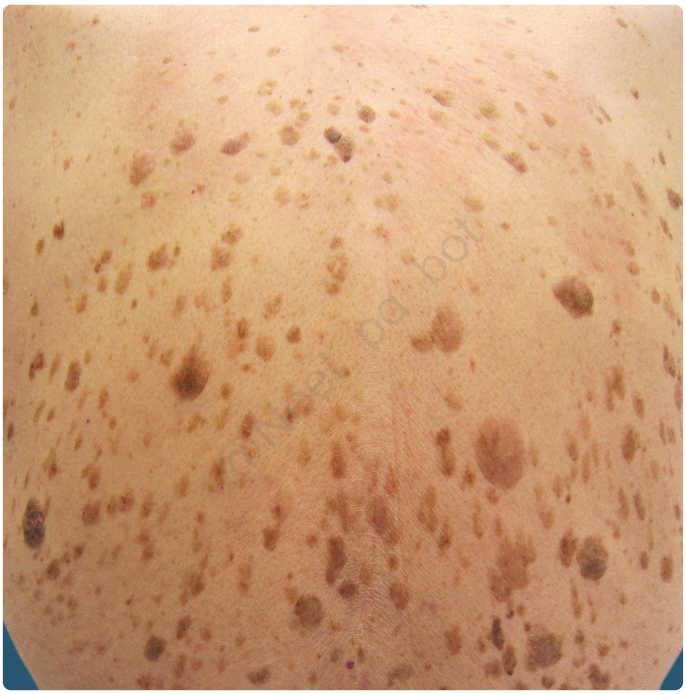

@Neet_pg_bot

See Answer in Part B → Q20

@Neet_pg_bot

Q21: A 25-year-old homosexual male presents with the following lesion on his legs which have progressed in size. Which of the following is the most common organism associated with this condition? (Q841732)

A. HHV-4

B. HHV-6

C. HHV-8

D. HHV-5

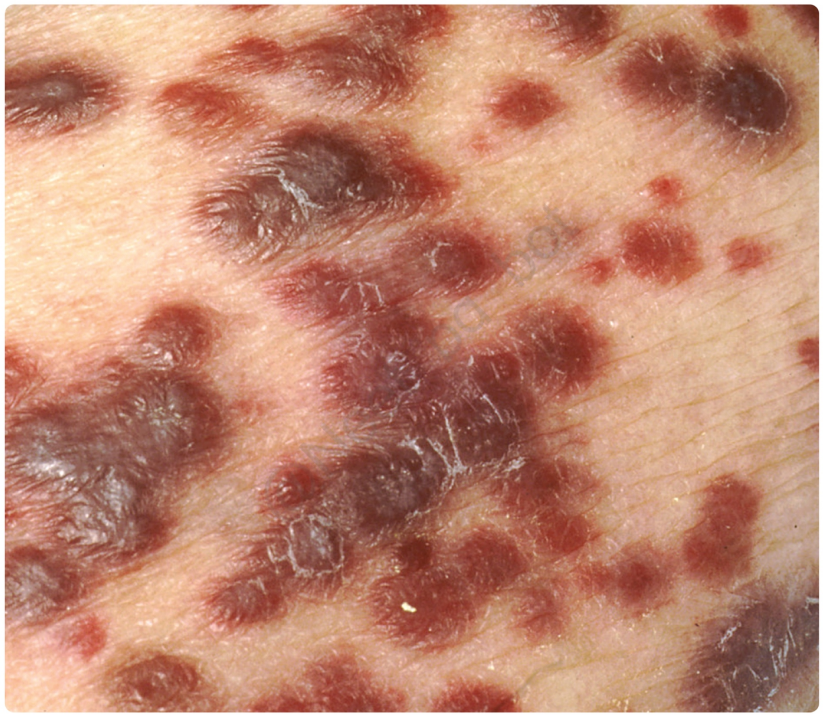

See Answer in Part B → Q21

@Neet_pg_bot

Q22: A 52-year-old male has a slow-growing, scaly, reddish patch on his lower back that has become a thickened plaque over several months. He reports no itching, pain, or discomfort. Examination reveals similar plaques on his abdomen. A biopsy shows a monoclonal proliferation of CD4+/CD45R0+ helper T cells. Which of the following is the most likely diagnosis for this patient? (Q841728)

A. Sezary syndrome

B. Psoriasis

C. Basal Cell Carcinoma

D. Mycosis Fungoides

See Answer in Part B → Q22

@Neet_pg_bot

Q23: A 45-year-old male presents with a slow-growing lesion on the face as shown in the image. What is the best indicator for the prognosis of this condition? (Q841727)

A. Tumor thickness

B. Tumor size

C. Regularity of margins

D. Symmetry of tumour



See Answer in Part B → Q23

@Neet_pg_bot

Q24: A 65-year-old woman with fair skin and a history of teenage sunburns presents with a mole on her upper back that has become larger and darker over the past few months. The lesion is pigmented with irregular borders, color variation, asymmetry, slight elevation, and measures 1.5 cm in diameter. She reports occasional itching and tenderness but denies bleeding or ulceration. Identify the true statements regarding this condition. The most common type is nodular melanoma. CDKN2A mutation is most commonly involved in sporadic melanoma. Depth > 6 mm is suggestive of melanoma. Clark's classification is used in malignant melanoma. Interferon-5ü can be used for the prevention of metastasis. (Q841725)

A. 1,2

B. 4,5

C. 3,4

D. 1,3,5

See Answer in Part B → Q24

@Neet_pg_bot

Q25: A 38-year-old female presents with an increasing size of a mole. A lesion with irregular borders and variegated colours is noted, histopathologically confirmed as atypical melanocytes invading the dermis. Which nevus type is most commonly associated with malignant transformation to melanoma? (Q841720)

A. Dermal nevus

B. Compound nevus

C. Large congenital melanocytic nevus

D. Beckers nevus

See Answer in Part B → Q25

@Neet_pg_bot

Q26: A 65-year-old female presented with a slow-growing, painless lesion on her face that has been present for several months. Physical examination reveals an ulcerated lesion with rolled borders and telangiectasias. The lesion is non-tender. What is the most likely diagnosis? (Q841719)

A. Squamous cell carcinoma

B. Basal cell carcinoma

C. Malignant melanoma

D. Dermatofibroma



See Answer in Part B → Q26

@Neet_pg_bot

Q27: Which among the following is false regarding Marjolin's Ulcer? (Q841717)

A. It has a tendency to convert into SCC and BCC.

B. It doesn't commonly have lymphatic spread.

C. It has cauliflower-like edges.

D. It occurs within a few days of surgery.

See Answer in Part B → Q27

@Neet_pg_bot

Q28: A 65-year-old female came with complaints of a painless nodule on the right palm for the past 3 weeks. She gave a history of sustaining a thorn prick injury to the palm 4 weeks ago. On examination, the lesions appear as shown below. What is the most likely diagnosis? (Q841716)

A. Keratoacanthoma

B. Bowens disease

C. Mycosis fungoides

D. Actinic keratosis



See Answer in Part B → Q28

@Neet_pg_bot

Q29: Identify the FALSE statement among the following regarding SCC? (Q841714)

A. It arises from keratinocytes.

B. It occurs in sun-exposed and also over sun-protected sites including mucosa.

C. It is most common in transplant recipients.

D. It has pearly rolled-out edges.

See Answer in Part B → Q29

@Neet_pg_bot

Q30: A 60-year-old male presents with a slowly growing lesion on his left forearm, occasionally bleeding post-trauma, and had a lot of sun exposure throughout his life. The biopsy of the lesion is shown below. What is the likely diagnosis? (Q841713)

A. Actinic keratosis

B. Basal cell carcinoma

C. Cutaneous squamous cell carcinoma

D. Melanoma

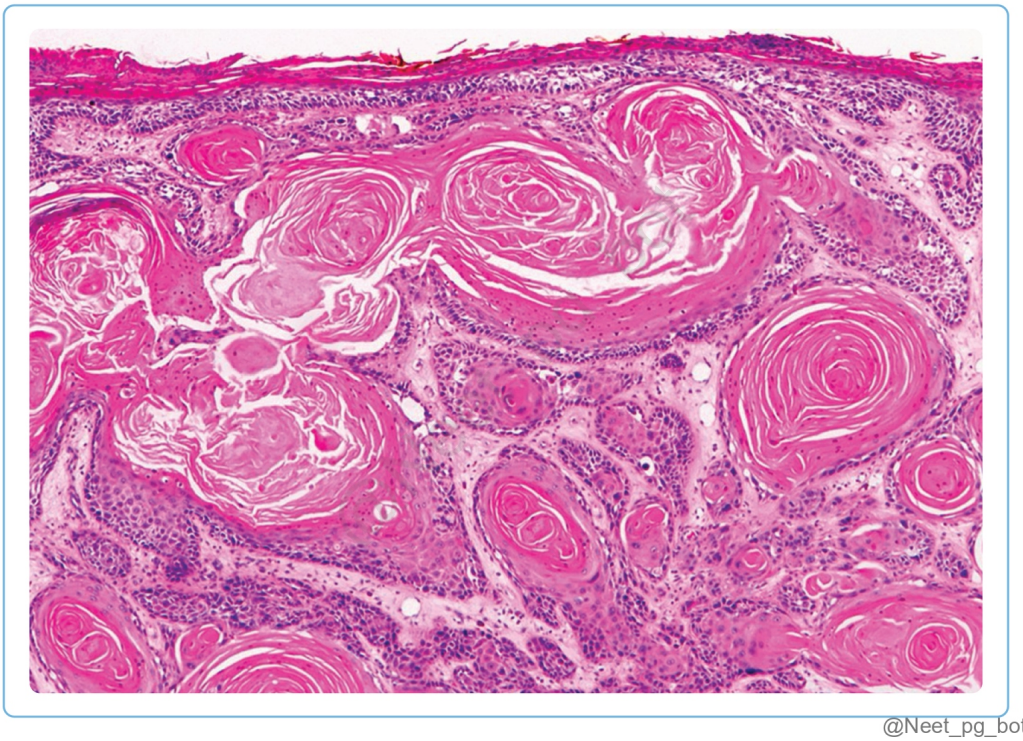

See Answer in Part B → Q30

@Neet_pg_bot

Q31: A 65-year-old woman presents to the dermatology clinic with a persistent, non-elevated, red, scaly plaque on her lower leg. The lesion has been slowly enlarging over the past several months. She reports no pain or bleeding from the lesion. Her medical history includes a solid-organ transplant five years ago, for which she is on immunosuppressive therapy.Which statement about this condition is NOT true? (Q841711)

A. Intraepidermal squamous cell carcinoma

B. HPV16 and HPV18 are commonly implicated, especially in genital lesions.

C. High potential for invasive malignancy

D. Occasionally it may undergo spontaneous partial resolution

See Answer in Part B → Q31

@Neet_pg_bot

• [19_Skin Tumours] 038 Previous Year Questions

« Back to Folder Directory

[19_Skin Tumours] 038 Previous Year Questions — Quick Jump

Q1 (p. 451) *Q2 (p. 451)* *Q3 (p. 451)* *Q4 (p. 452)* *Q5 (p. 453)* *Q6 (p. 454)*
Q7 (p. 455)

Q1: A patient is diagnosed with squamous cell carcinoma at the base of the tongue. What is the most common causative agent? (Q866556)

A. EBV

B. HPV

C. HCV

D. CMV

See Answer in Part B → Q1

@Neet_pg_bot

Q2: A 60-year-old person presented with an ulcer on the medial canthus. The ulcer has rolled-out, beaded margins. Histopathology shows nesting cells with peripheral palisading patterns. What is the most likely diagnosis? (Q852712)

A. Squamous Cell Carcinoma (SCC)

B. Nevus

C. Basal Cell Carcinoma (BCC)

D. Melanoma

See Answer in Part B → Q2

@Neet_pg_bot

Q3: Which carcinoma is the possible diagnosis in the image given below? (Q820214)

A. Basal cell carcinoma

B. Squamous cell carcinoma

C. Malignant melanoma

D. Hepatocellular carcinoma



See Answer in Part B → Q3

@Neet_pg_bot

Q4: A 60-year-old diabetic patient presents with a lesion on the nose as shown in the image below. The lesion bleeds on the touch. What is the diagnosis? (Q854645)

A. Squamous cell carcinoma

B. Basal cell carcinoma

C. Melanoma

D. Discoid lupus erythematosus



See Answer in Part B → Q4

@Neet_pg_bot

Q5: Which of the following is associated with the clinical condition shown in the image? (Q855295)

A. Condylomata lata

B. Mole

C. Malignant melanoma

D. Basal cell carcinoma



See Answer in Part B → Q5

@Neet_pg_bot

Q6: A baby presents to the OPD; the image below shows the findings. What is the probable diagnosis? (Q857968)

A. Portwine stain

B. Cavernous hemangioma

C. Naevus simplex

D. Capillary hemangioma



See Answer in Part B → Q6

@Neet_pg_bot

Q7: Identify the given disorder. (Q857048)

A. Melanoma

B. Hyperpigmentation

C. Basal cell carcinoma

D. Squamous cell carcinoma



See Answer in Part B → Q7

@Neet_pg_bot

Part B — All Answers & Explanations

• [01_Introduction to Dermatology] 001 Basics Of Dermatology

« Back to Folder Directory

[01_Introduction to Dermatology] 001 Basics Of Dermatology — Quick Jump

Q1 (p. 457) *Q2 (p. 458)* *Q3 (p. 459)* *Q4 (p. 460)* *Q5 (p. 461)* *Q6 (p. 464)*
Q7 (p. 465) *Q8 (p. 466)* *Q9 (p. 468)* *Q10 (p. 471)*

Q1: A 28-year-old primigravida delivers a baby at 30 weeks of gestation. The newborn skin appears very thin and translucent. Which of the following layers of epidermis will be absent in this baby? (Q841873)

A. Stratum Spinosum

B. Stratum Granulosum

C. Stratum Basale

D. Stratum Corneum

Correct Answer: D. Stratum Corneum

■ *Listen (English)*

■ *Listen (Hindi)*

Explanation: A newborn delivered at 30 weeks of gestation is preterm , and the skin shows typical features such as: Thin, translucent appearance Increased permeability and fluid loss Poor barrier protection These are due to the immature development of the epidermis , specifically the stratum corneum . Stratum Corneum is absent or poorly developed in infants <32–34 weeks. Begins forming around 24–26 weeks , but by 30 weeks, it's still only a few thin layers . Fully developed only by 34–37 weeks gestation . Its absence leads to impaired barrier function , making the skin look shiny, red, and gelatinous . Layers of epidermis (from superficial to deep): Stratum corneum Stratum lucidum Stratum granulosum Stratum spinosum Stratum basale

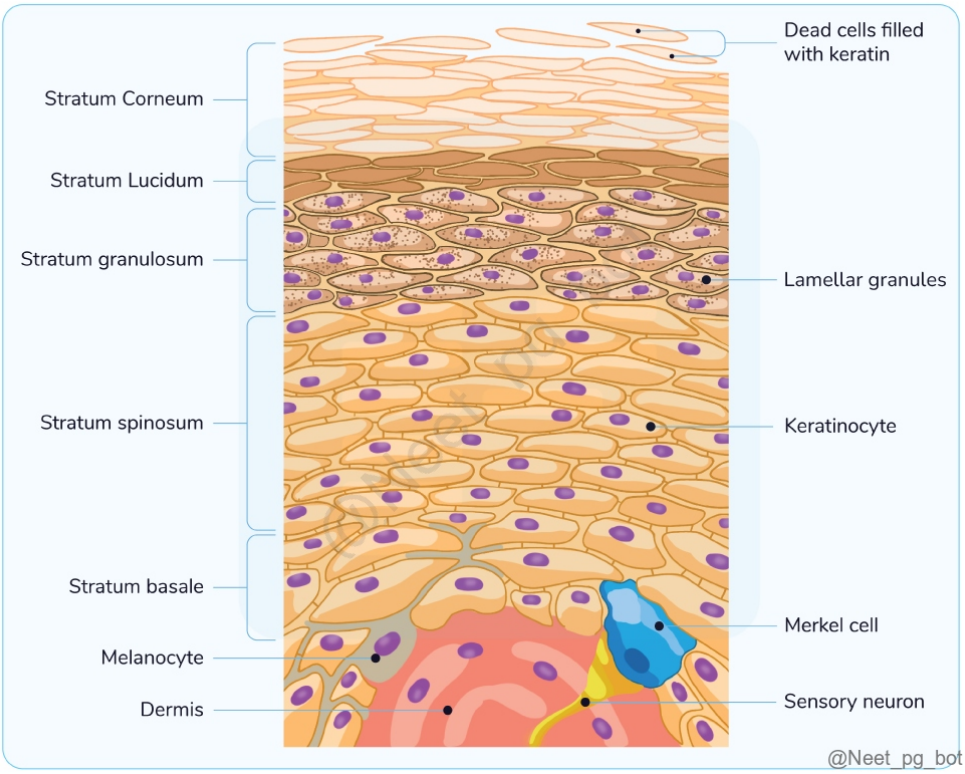

References:

Rook's Textbook of Dermatology, 9th Edition, Page 31

↑ *Back to this question in Part A*

@Neet_pg_bot

Q2: A 30-year-old woman presents to the dermatology clinic complaining of persistent dryness and itching on her hands and arms for several months which seem to worsen during the winter months. On examination, dry, scaly patches are observed on the dorsal aspects of her hands and arms. She denies any history of eczema or other skin conditions. What protein deficiency in the epidermis is most likely responsible for the observed skin manifestations in this patient? (Q841874)

A. Keratin

B. Filaggrin

C. Collagen

D. Elastin

Correct Answer: B. Filaggrin

■ *Listen (English)*

■ *Listen (Hindi)*

Explanation: Filaggrin helps in keratin filament aggregation in stratum corneum and is subsequently broken down into individual hygroscopic amino acids that form the basis of the natural moisturizing factor within corneocytes. Filaggrin is formed from profilaggrin in the stratum corneum, which is derived from keratohyalin granules of stratum granulosum. Deficiency leads to dryness, scaling, and itching, especially in winter when humidity is low. The patient's chronic xerosis with scaly patches directly reflects impaired filaggrin-NMF function. Thus, filaggrin deficiency is the most likely cause of her skin manifestations. Incorrect Options : Option A) Keratin : Provides structural strength; keratin filaments require filaggrin for proper aggregation, so keratin deficiency alone does not cause xerosis. Option C) Collagen : A dermal protein responsible for tensile strength; abnormalities lead to scarring or laxity, not defective NMF production or dry skin. Option D) Elastin : Provides elasticity in the dermis; its deficiency causes sagging, not impaired keratin aggregation or loss of NMFs.

References:

Rook's Textbook of Dermatology, 9th Edition, Page 39

↑ *Back to this question in Part A*

@Neet_pg_bot

Q3: A 74-year-old female presents with persistent dryness and itching on her shin for the past few weeks. Examination shows erythematous, exfoliated patches. Which of the following structures is primarily responsible for lipid secretion and maintaining skin barrier function? (Q841875)

A. Eleidin Granules

B. Keratohyaline Granules

C. Lamellar Granules

D. Birbeck Granules

Correct Answer: C. Lamellar Granules

■ *Listen (English)*

■ *Listen (Hindi)*

Explanation: Lamellar Granules: Lamellar granules, also known as Odland bodies or Membrane-coating granules, are present in the stratum granulosum. They are secreted into intercellular space to play a major role in barrier function by producing the lipid content in the epidermis and intercellular cohesion within the stratum corneum. Dysfunction or abnormalities of Odland bodies lead to conditions disrupting the skin barrier such as Eczema and

Icthyosis. Eleidin Granules (Option A): Eleidin granules are specialized organelles found in stratum lucidum which is present only in palms and soles. They contribute to the keratinization, translucency, and barrier function. Keratohyalin Granules (Option B): These granules are found primarily in the stratum granulosum and secrete a protein called profilaggrin, which transforms into filaggrin. This protein helps keratin filaments aggregate and maintains skin hydration and barrier. Birbeck Granules (Option D): These granules are found in Langerhans cells in the stratum spinosum of the epidermis. On electron microscopy, they appear to be 'tennis racquet'-shaped.Birbeck granules facilitate antigen processing and presentation in Langerhans cells, aiding in immune response.

References:

Rook's Textbook of Dermatology, 9th Edition, Page 39

↑ *Back to this question in Part A*

@Neet_pg_bot

Q4: A 35-year-old male presents to the dermatology clinic with complaints of thick, red plaques with silvery scales on his elbows, knees, and scalp for several months that have been worsening gradually. There is also pitting and discolouration of his fingernails and toenails. Which of the following pathological changes in the epidermis is associated with this condition? (Q841876)

A. Increased epidermal turnover time

B. Decreased epidermal turnover time

C. Increased thickness of granular layer

D. No change in the epidermal layer

Correct Answer: B. Decreased epidermal turnover time

■ *Listen (English)*

■ *Listen (Hindi)*

Explanation: Epidermal turnover or transit time or Keratinocyte transit time is the time taken by the keratinocytes to migrate from the basal layer to the surface of the skin as fully matured Keratinocytes. Cells take 14 days to migrate from the Stratum Basale to the Stratum Corneum. They stay at Stratum Corneum for another 14 days. After which Cells exfoliate. It takes approximately 28 days. The total duration may range between 52-75 days. In psoriasis, the rate of cell proliferation in the basal layer of the epidermis increases significantly. This results in the rapid turnover and migration of epidermal cells towards the skin surface, which decreases epidermal transit time to 4 days. Increased epidermal turnover time (Option A): The epidermal turnover is decreased in psoriasis due to the rapid proliferation of cells in the epidermis. This accelerated turnover contributes to the formation of characteristic plaques, erythema, and scaling in psoriatic lesions. Increased thickness of granular layer (Option C): In psoriasis, the thickness of the granular layer in the skin is typically reduced or absent. No change in the epidermal layer

(Option D): In psoriasis, the epidermis undergoes several distinct changes that contribute to the disease's clinical manifestations.

References:

Fitzpatrick’s Dermatology, 9th Edition, Page 232

↑ *Back to this question in Part A*

@Neet_pg_bot

Q5: Which of the following cells is exclusively present in the stratum spinosum layer of epidermis? (Q841877)

A. Keratinocytes

B. Langerhans cells

C. Merkel cells

D. Melanocytes

Correct Answer: B. Langerhans cells

■ *Listen (English)*

■ *Listen (Hindi)*

Explanation: Langerhans cells are exclusively found in the Stratum spinosum layer of the epidermis. Cell Type Location in Epidermis Origin Key Features Associated Diseases Markers Keratinocytes Present in all layers Ectoderm Most abundant Contain keratin intermediate filaments Form skin barrier Involved in wound healing Psoriasis, Eczema, Ichthyosis Cytokeratins Langerhans Cells Stratum spinosum (exclusive) Mesenchymal (bone marrow-derived monocytes) Antigen-presenting dendritic cells Contain Birbeck granules ("tennis racquet" appearance) Involved in cutaneous immune responses Langerhans cell histiocytosis S100 , CD1a , CD207 (Langerin) Merkel Cells Stratum basale Neural crest Mechanoreceptors Involved in slow-adapting touch sensation Contain neuropeptides Associated with nerve endings Merkel cell carcinoma CK20 Melanocytes Stratum basale Neural crest Dendritic-shaped pigment cells Produce melanin stored in melanosomes Each melanocyte serves ~36 keratinocytes (epidermal melanin unit) Melanoma S100 , HMB-45 , Melan-A {{caption_text}} Keratinocytes {{caption_text}} Langerhans cell in Epidermis {{caption_text}} The above image is an electron microscopic image of Birbek granules of Langerhans cells. {{caption_text}} Layers of skin {{caption_text}} Melanocytes

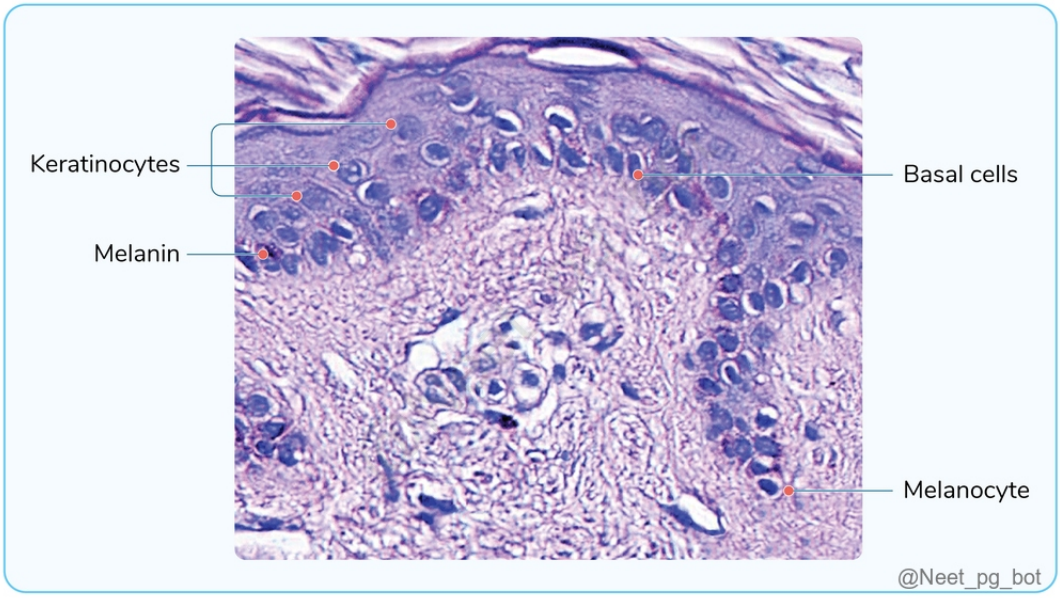
Keratinocytes
Melanin
Basal cells
Melanocyte
@Neet_pg_bot

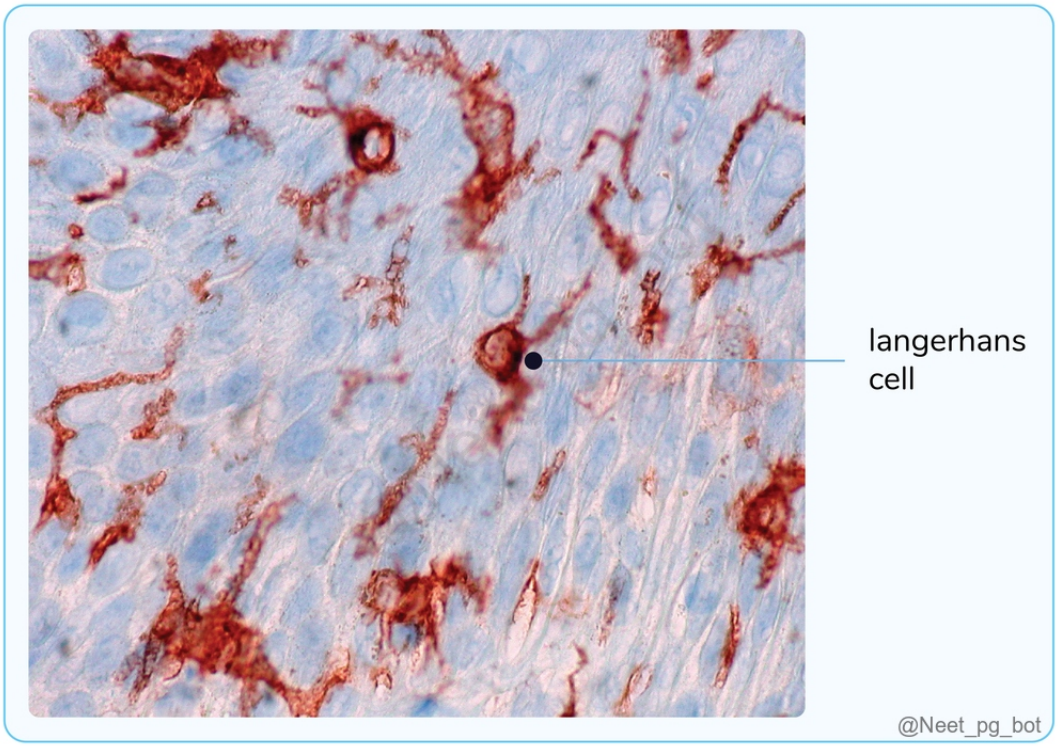
langerhans cell
@Neet_pg_bot


Vesicles
0.5 µ
@Neet_pg_bot

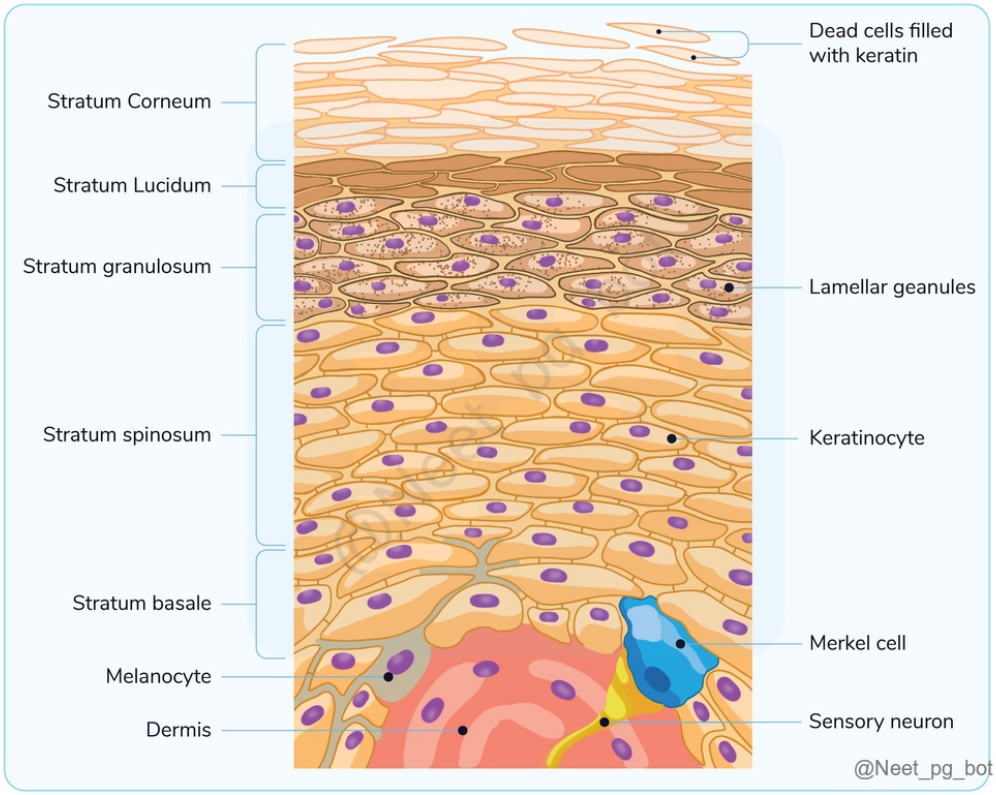
Dead cells filled with keratin
Stratum Corneum
Stratum Lucidum
Stratum granulosum
Lamellar geanules
Stratum spinosum
Keratinocyte
Stratum basale
Merkel cell
Melanocyte
Dermis
Sensory neuron
@Neet_pg_bot

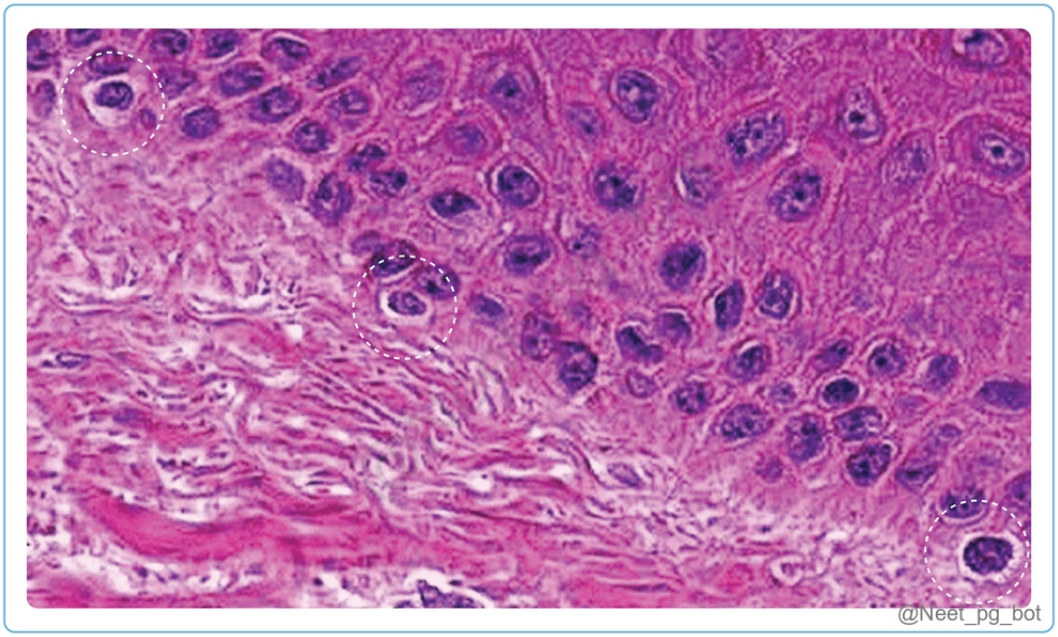

References:

Rook’s Textbook of Dermatology, 9th Edition, Page 216

↑ *Back to this question in Part A*

@Neet_pg_bot

Q6: A 50-year-old female presents to the dermatology clinic with complaints of multiple erosions and blisters on her hands, face, and forearms. She was diagnosed with bullous pemphigoid. Which of the following structures is most directly implicated in the pathogenesis of this patient's condition? (Q841881)

A. Desmosomes

B. Hemidesmosomes

C. Keratin 5 and 14

D. Laminin

Correct Answer: B. Hemidesmosomes

■ *Listen (English)*

■ *Listen (Hindi)*

Explanation: Hemidesmosomes: Hemidesmosomes are specialized cell junctions that anchor epithelial cells to the basement membrane. Dysfunction of hemidesmosomes can lead to blistering disorders, such as: Bullous Pemphigoid (BP): The most common disorder, where autoantibodies target hemidesmosome components, particularly BP180 (collagen XVII) and BP230, which are integral proteins anchoring epithelial cells to the basement membrane. Cicatricial (Mucous Membrane) Pemphigoid: Also targets BP180 but primarily affects mucous membranes (eyes, mouth), often leading to significant scarring. Pemphigoid Gestationis: A rare, pregnancy-associated variant that specifically targets the BP180 antigen. Desmosomes (Desmogleins) (Option A): Pemphigus Vulgaris: Autoantibodies target both Desmoglein 1 (Dsg1) and Desmoglein 3 (Dsg3) . This causes deep blisters just above the basal layer (suprabasal). Pemphigus Foliaceus: Autoantibodies target only Desmoglein 1 (Dsg1) . This leads to very superficial blisters because Dsg1 is primarily expressed in the upper layers of the epidermis. Keratin 5 and 14 (Option C): Mutations in these proteins result in weakened keratin filaments, leading to Epidermolysis Bullosa Simplex (EBS) . The skin "shatters" at the basal cell level under minor friction. Laminin (Option D): Dysregulation or absence of Laminin (specifically Laminin 332) is associated with Junctional Epidermolysis Bullosa , where the blister forms within the basement membrane zone.

References:

Rooks’s Textbook of Dermatology, 9th Edition, Page 2.21, 2.25, 50.10

↑ *Back to this question in Part A*

@Neet_pg_bot

Q7: A 6-year-old child presents with a history of frequent fractures with minimal trauma. Physical examination reveals blue sclerae, triangular face, and short stature. Radiographic findings show multiple fractures in various stages of healing, thinning of long bones, and wormian bones in the skull. Which of the following is the correct combination regarding the defective protein and its location in the skin? (Q841882)

A. Collagen - Dermis

B. Elastin - Hypodermis

C. Collagen - Hypodermis

D. Elastin - Dermis

Correct Answer: A. Collagen - Dermis

■ *Listen (English)*

■ *Listen (Hindi)*

Explanation: The given clinical scenario suggests Osteogenesis imperfecta, also known as brittle bone disease. This genetic disorder is characterized by defective collagen (Type I) synthesis. The dermis is a connective tissue layer present between the epidermis and hypodermis and is mainly composed of collagen and some elastin. It plays a major role in maintaining the structural integrity, elasticity, and functionality of the skin. Collagen Elastin

Contribution to skin It makes up 70% of connective tissue in the dermis It makes up 2 - 4% of the dermis. (Option B) Function Responsible for the tensile strength. Responsible for elasticity, allowing to stretch and recoil. Other locations Type I collagen is the most common type in the skin which is also present in bone, tendons, and ligaments. Also present in the blood vessels, lungs, and ligaments contributing to their resilience and flexibility Special stains Masson's trichrome Verhoeff's van Gieson (VVG) Disorders associated Osteogenesis imperfecta (Type I) Ehlers-Danlos syndromes (Type III -2nd most common collagen in the skin). Alport Syndrome (Type IV) Cutis laxa. Pseudoxanthoma elasticum. Supravalvular aortic stenosis. The hypodermis is primarily composed of subcutaneous fat, which provides thermal insulation and helps regulate body temperature. (Option C) Elastin - Dermis (Option D): This combination is true, but in the clinical scenario, the defective protein is collagen. Organization of basement membrane:

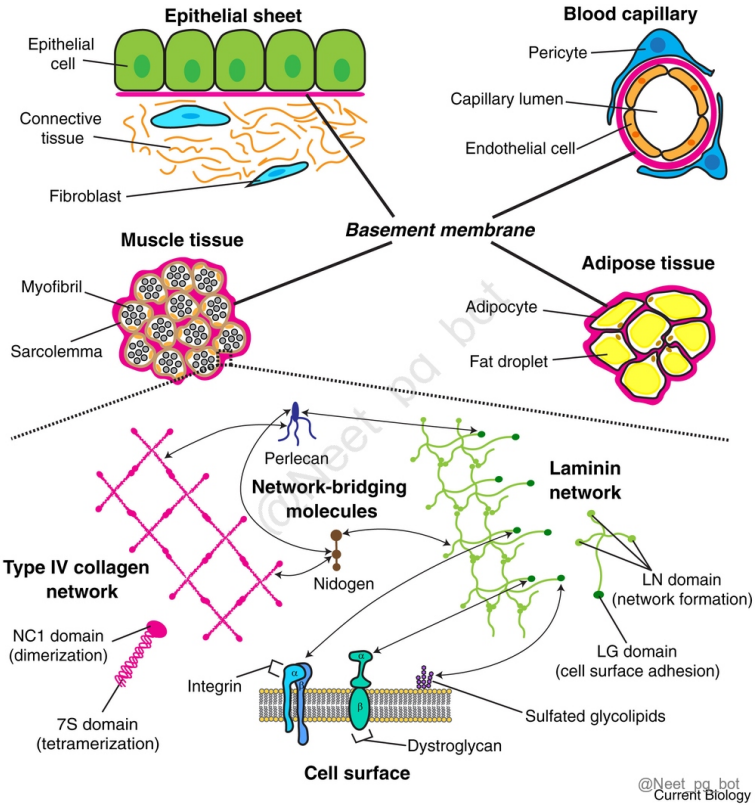

References:

Rook’s Text Book of Dermatology, 9th Edition, Page 2.28, 2.33

↑ *Back to this question in Part A*

@Neet_pg_bot

Q8: Which of the following conditions will not show the presence of nuclei retained in the stratum corneum as a pathological finding? (Q841883)

A. Eczema

B. Psoriasis

C. Lichen planus

D. Bowen’s disease

Correct Answer: C. Lichen planus

■ *Listen (English)*

■ *Listen (Hindi)*

Explanation: Since epidermal turnover is not affected in lichenoid reactions, parakeratosis is not commonly seen in lichen planus. Instead, it is associated with hyperkeratosis, which is the thickening of the stratum corneum. The stratum corneum is the topmost layer of the epidermis, where cells (keratinocytes/corneocytes) have lost the nuclei and cytoplasmic organelles. Parakeratosis: The retention of nuclei in the keratinocyte of the stratum corneum, known as Parakeratosis, is associated either with increased epidermal cell turnover or with inflammatory changes in the epidermis itself. It is seen in psoriasis, sub-acute eczema, squamous cell carcinoma, and actinic keratoses. Parakeratosis is physiological in oral mucosa and vaginal mucosa. Both Parakeratosis and Hyperkeratosis are pathological findings that can be seen in the Stratum corneum. Eczema (Option A): Parakeratosis is seen as a pathological finding in sub-acute eczematous reactions. Psoriasis (Option B): In psoriasis, both parakeratosis and hyperkeratosis can be seen. Bowen’s disease (Option D): Bowen’s disease is an in-situ squamous cell carcinoma of the epidermis. In this condition, nuclei retention (due to incomplete maturation of epidermal keratinocytes) in the stratum corneum can be seen as a pathological finding. Parakeratosis: {{caption_text}} {{caption_text}}

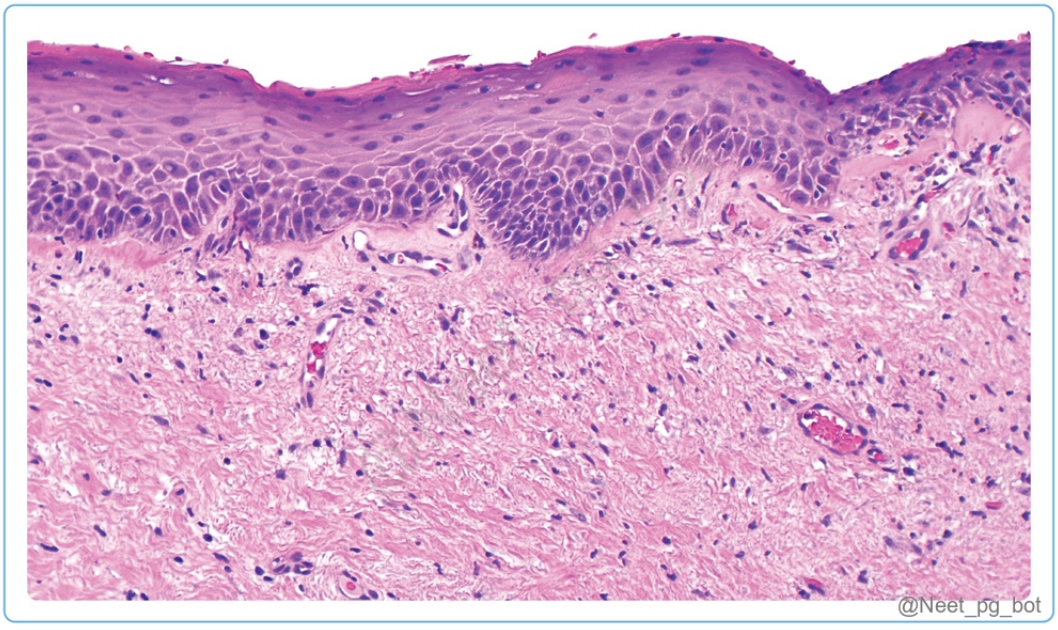

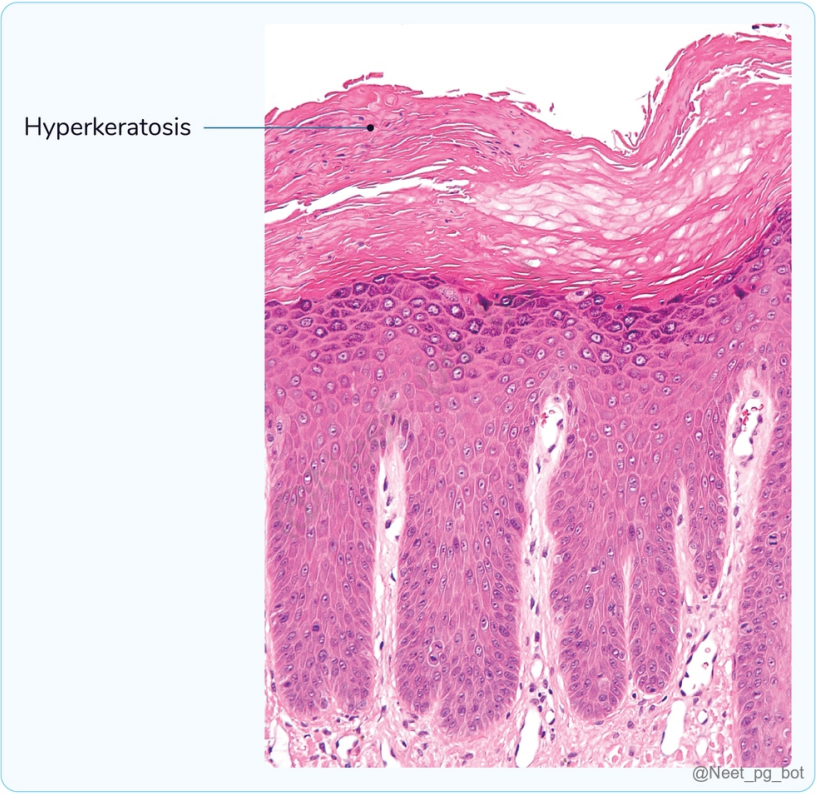

References:

Rook’s Textbook of Dermatology, 9th edition, Page 34

↑ *Back to this question in Part A*

@Neet_pg_bot

Q9: A 45-year-old female presents to the dermatology clinic with a complaint of pruritic, erythematous patches on her arms and legs. A skin biopsy specimen was done and microscopic examination shows intercellular oedema between keratinocytes within the epidermis. Which of the following terms best describes the microscopic finding in this patient? (Q841884)

A. Acantholysis

B. Basal cell degeneration

C. Acanthosis

D. Spongiosis

Correct Answer: D. Spongiosis

■ *Listen (English)*

■ *Listen (Hindi)*

Explanation: The condition given in the clinical scenario is Acute eczema. Spongiosis, also known as Intercellular oedema, is the widening of intercellular spaces between keratinocytes caused by fluid accumulation. It is the characteristic histopathological change seen in acute and subacute eczematous reactions. It primarily occurs in the stratum spinosum layer of the epidermis and may extend to the stratum granulosum depending on the severity and extent of an inflammatory process. {{caption_text}} Acantholysis (Option A): Acantholysis refers to the loss of intercellular connections between keratinocytes within the epidermis, leading to the formation of intraepidermal blisters or erosions. This phenomenon is characteristic of diseases such as pemphigus vulgaris and Pemphigus foliaceus {{caption_text}} Basal cell degeneration (Option B): Degeneration of the basal cell layer is one of the characteristic changes seen in Lichen planus. {{caption_text}} Acanthosis (Option C): Acanthosis refers to epidermal hyperplasia characterized by thickening of the stratum spinosum layer of the epidermis. It is often observed in conditions such as chronic eczemas. {{caption_text}}

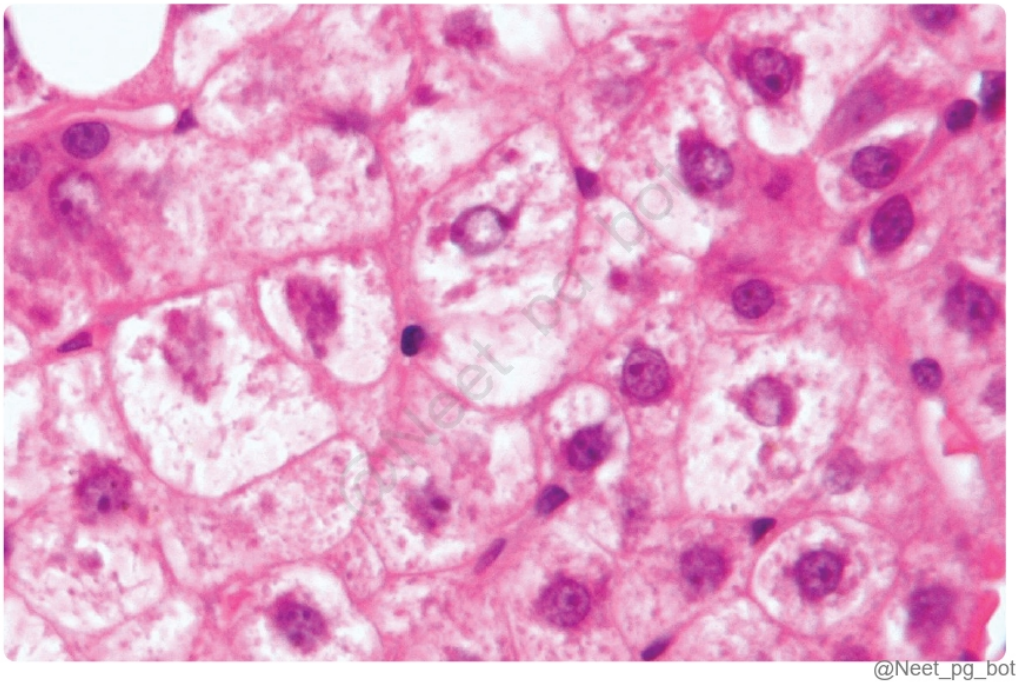

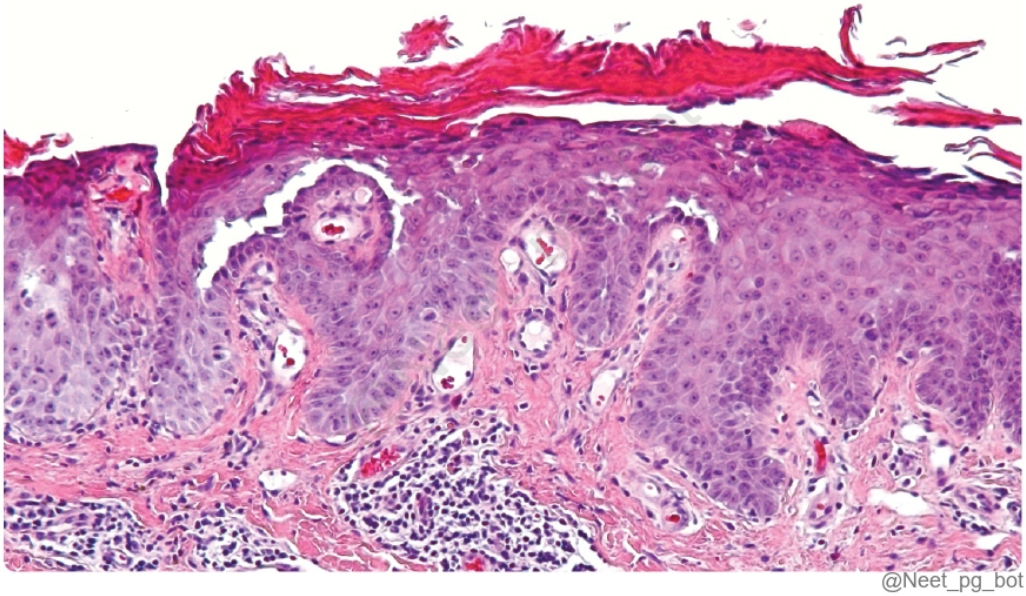
@Neet_pg_bot

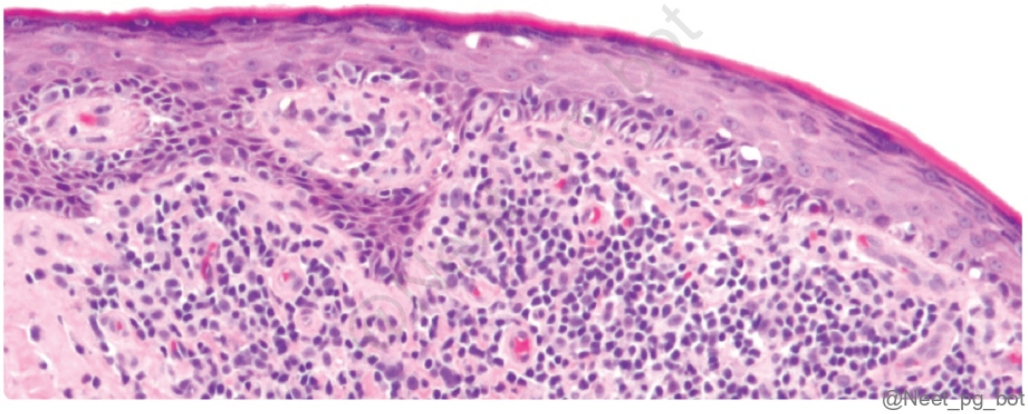
@Neet_pg_bot

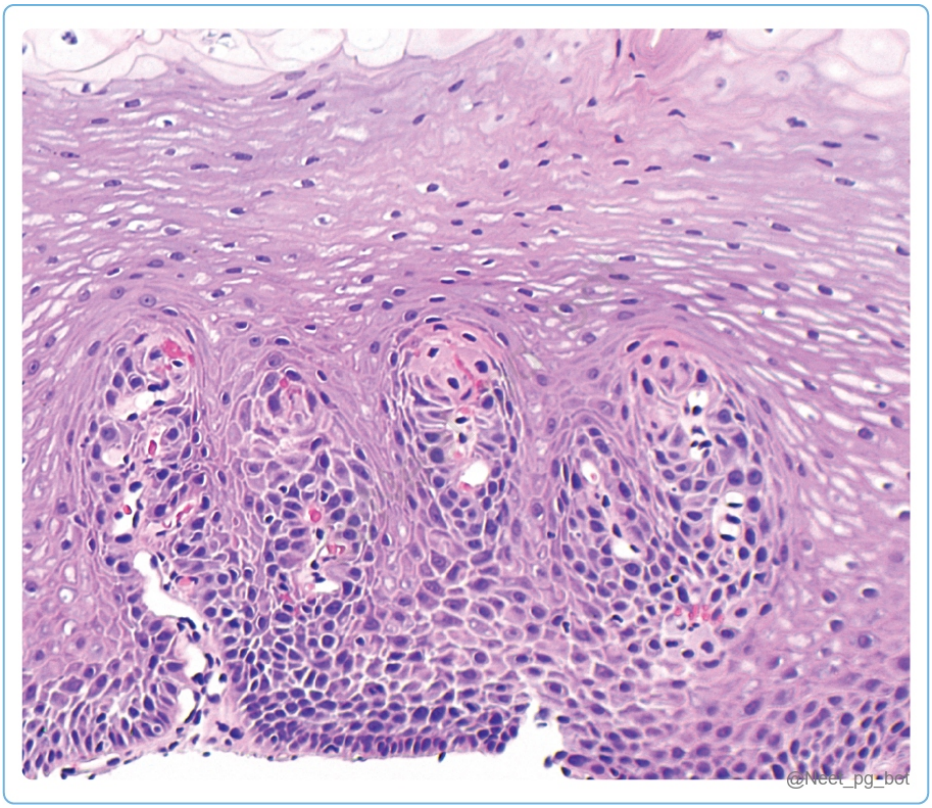

References:

Rook’s Textbook of Dermatology, 9th Edition, Page 119

↑ *Back to this question in Part A*

@Neet_pg_bot

Q10: A 55-year-old man presents to the dermatology clinic with persistent red scaly patches on his scalp. On examination, erythematous plaques with adherent silver scales are noted on the scalp, particularly in the parietal and occipital regions. He was diagnosed with psoriasis. Which of the following histopathological changes is seen at the lower epidermis in this condition? (Q841981)

A. Munro’s micro abscess

B. Pautrier's microabscess

C. Elongation of rete ridges

D. Flattening of rete ridges

Correct Answer: C. Elongation of rete ridges

■ *Listen (English)*

■ *Listen (Hindi)*

Explanation: Rete ridges are extensions of the epidermis that project downward into the dermis, forming finger-like projections. They play a crucial role in maintaining the skin's structural integrity and function by increasing the surface area of the dermal-epidermal junction and enhancing adhesion between the skin layers. In psoriasis, regular elongation of rete ridges is seen The part of the dermis that invaginates into the epidermis is the ‘papillary dermis’, which carries capillaries between the rete ridges (pinpoint bleeding spots in Auspitz sign are due to rupture of these dilated blood vessels). {{caption_text}} Munro’s micro abscess (Option A) : It is also seen in psoriasis but it is the collection of neutrophils at the level of stratum corneum. Another collection of neutrophils at the level of stratum spinosum in psoriasis is the ‘Spongiform pustule of kogoj’. {{caption_text}} Pautrier's microabscess (Option B): In Cutaneous T cell Lymphoma/ Mycosis fungoides, the atypical lymphocytes infiltrate the epidermis and form clusters within these layers, leading to the formation of Pautrier's microabscesses. {{caption_text}} Flattening of rete ridges (Option D): It is seen in conditions characterized by epidermis atrophy, such as lichen sclerosis and atrophic dermatitis. {{caption_text}}

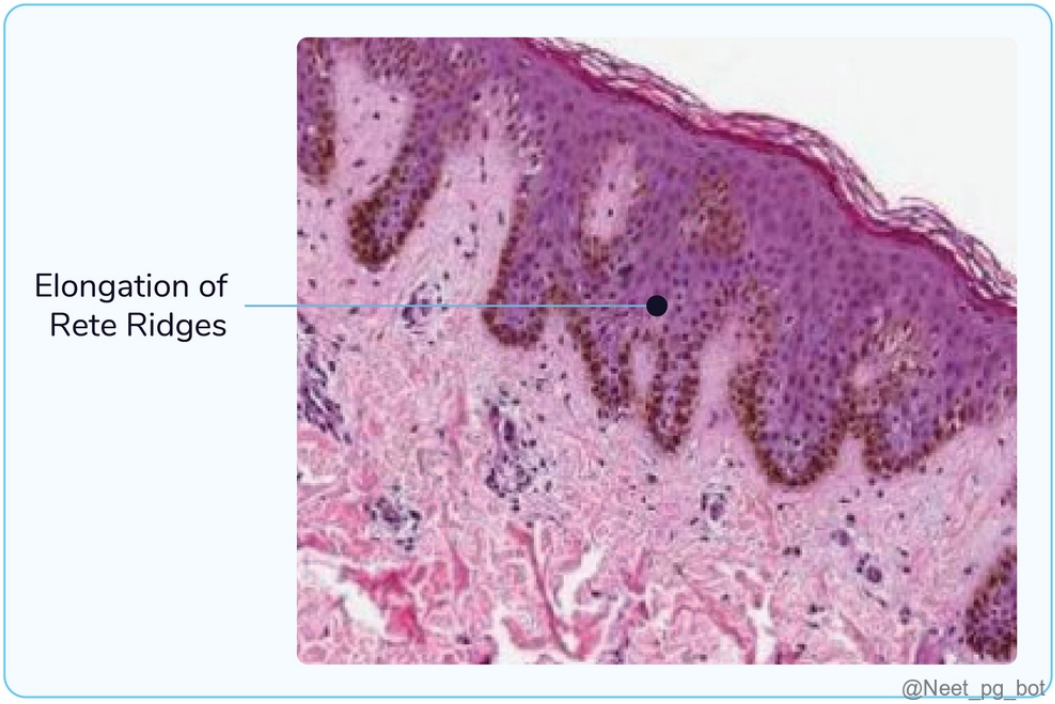

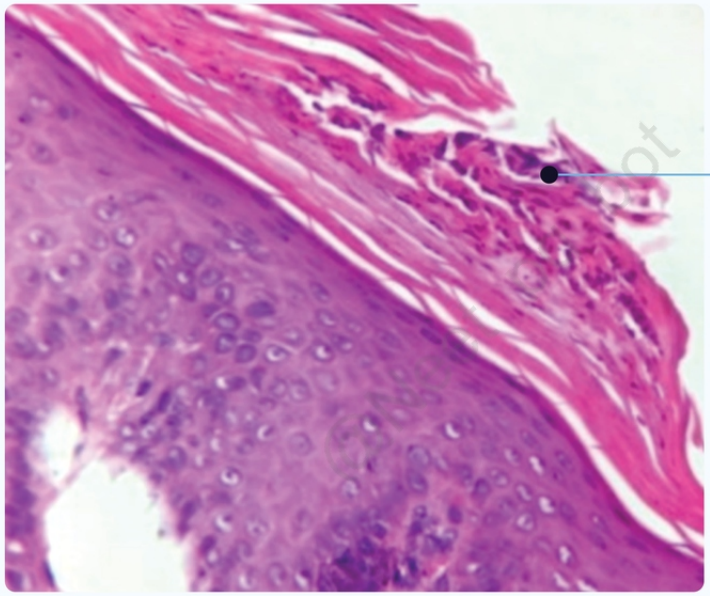

@Neet_pg_bot

Pautrier's
microabcess

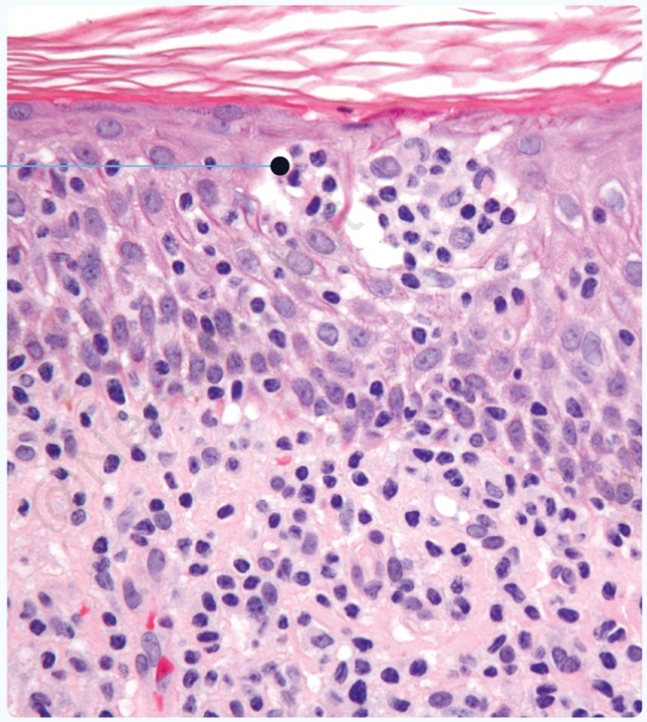

@Neet_pg_bot

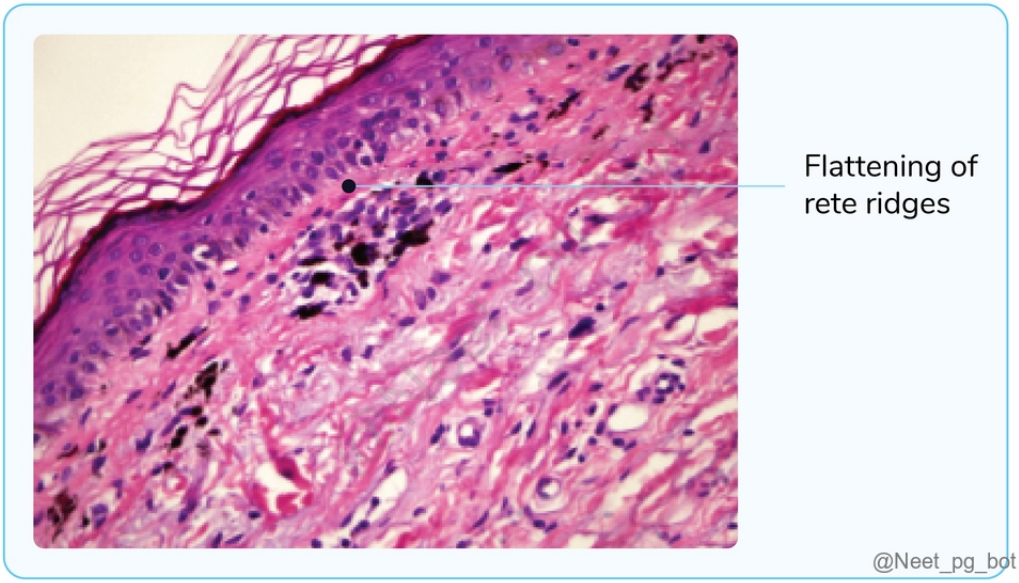

References:

Rook’s Textbook of Dermatology, 9th Edition, Page 74

↑ *Back to this question in Part A*

@Neet_pg_bot

• [01_Introduction to Dermatology] 002 Skin Lesions In Dermatology

« Back to Folder Directory

[01_Introduction to Dermatology] 002 Skin Lesions In Dermatology — Quick Jump

Q1 (p. 475) *Q2 (p. 480)* *Q3 (p. 483)* *Q4 (p. 485)* *Q5 (p. 487)* *Q6 (p. 491)* *Q7 (p. 493)*

Q1: A 45-year-old patient presents with a small, flat, reddish-brown lesion on the palm of their hand. The lesion is non-palpable and measures approximately 5 mm in diameter. What is the most likely description of this lesion? (Q841984)

A. Papule

B. Plaque

C. Macule

D. Bulla

Correct Answer: C. Macule

■ *Listen (English)*

■ *Listen (Hindi)*

Explanation: A macule is a flat, non-raised lesion less than 0.5 cm in diameter characterized by a change in skin colour or pigmentation. {{caption_text}} Skin Lesions <1 cm Skin Lesions >1 cm Macule: Flat, non-raised lesion (Option C) {{caption_text}} Patch: Flat, non-raised lesion {{caption_text}} Papule: Raised, circumscribed, solid lesion (Option A ruled out) < 1cm {{caption_text}} Plaque: Elevated circumscribed lesion (Option B ruled out) > 1cm {{caption_text}} Vesicle: Circumscribed elevation less than < 1cm in diameter that contains fluid (clear, serous or haemorrhagic) and is often grouped {{caption_text}} Bullae: Bullae are more than > 1cm in diameter (Option D ruled out). {{caption_text}} Petechiae: Punctate haemorrhagic spot, approximately 1–2 mm in diameter. {{caption_text}} Ecchymoses: A macular area of haemorrhage more than 1cm (bruise) in diameter. {{caption_text}} Purpura: Haemorrhagic spots more than 3mm but less than 1cm caused by bleeding underneath the skin

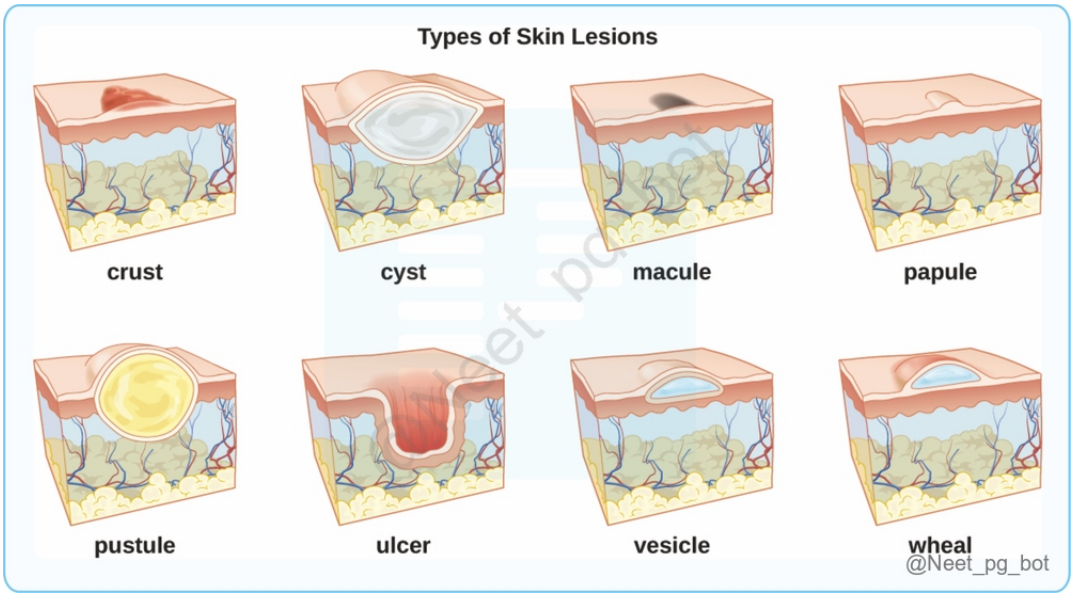
Types of Skin Lesions
crust
cyst
macule
papule
pustule
ulcer
vesicle
wheal
@Neet_pg_bot

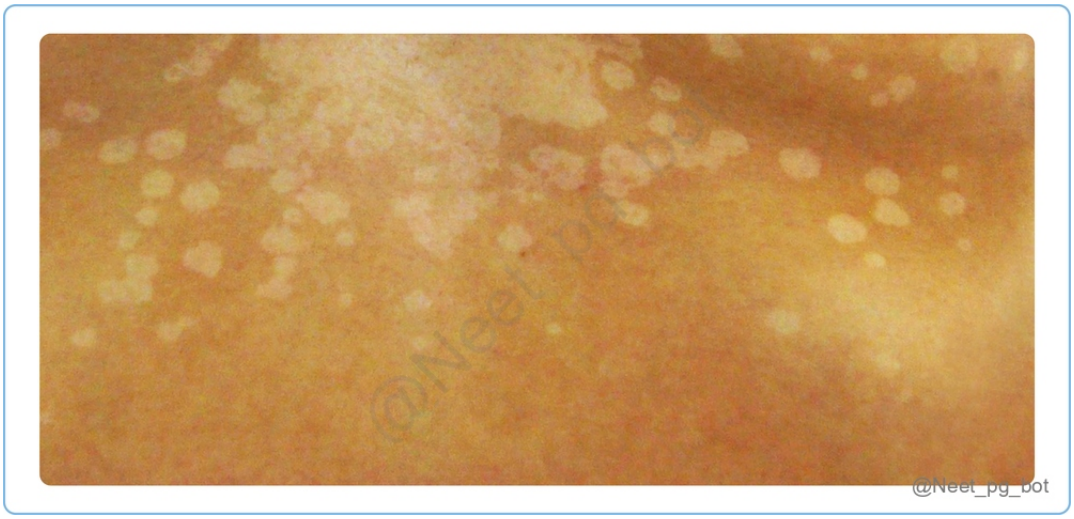
@Neet_pg_bot

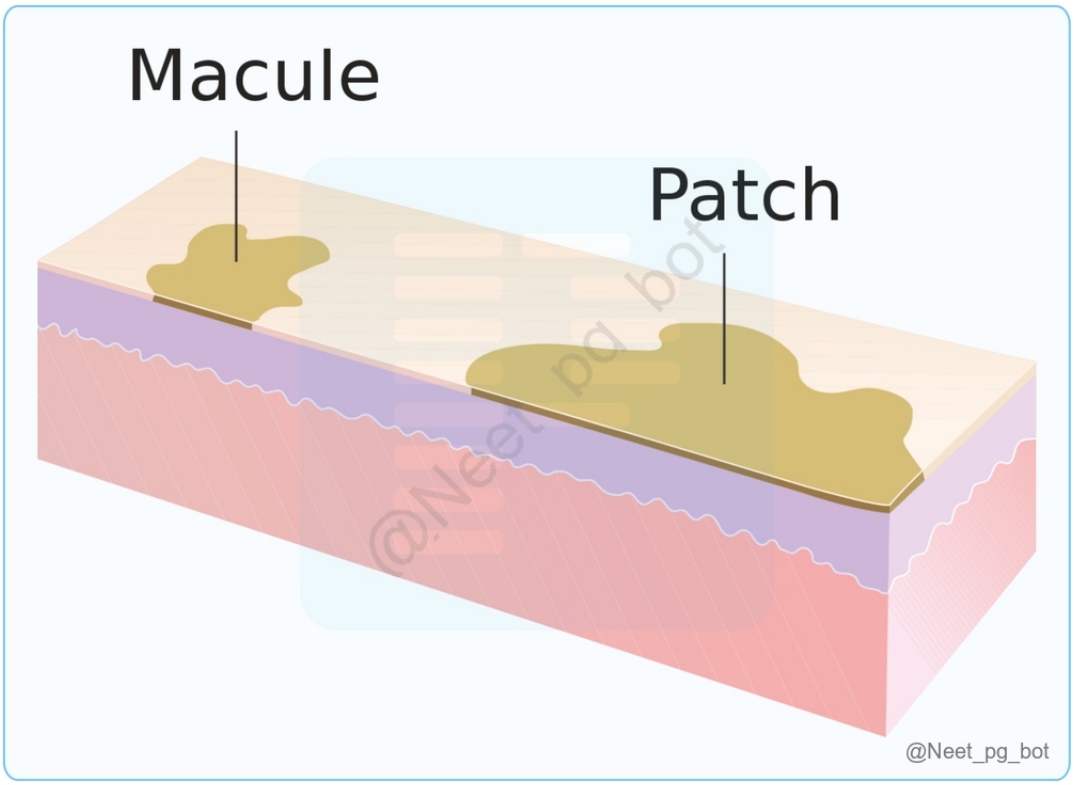
Macule
Patch
@Neet_pg_bot

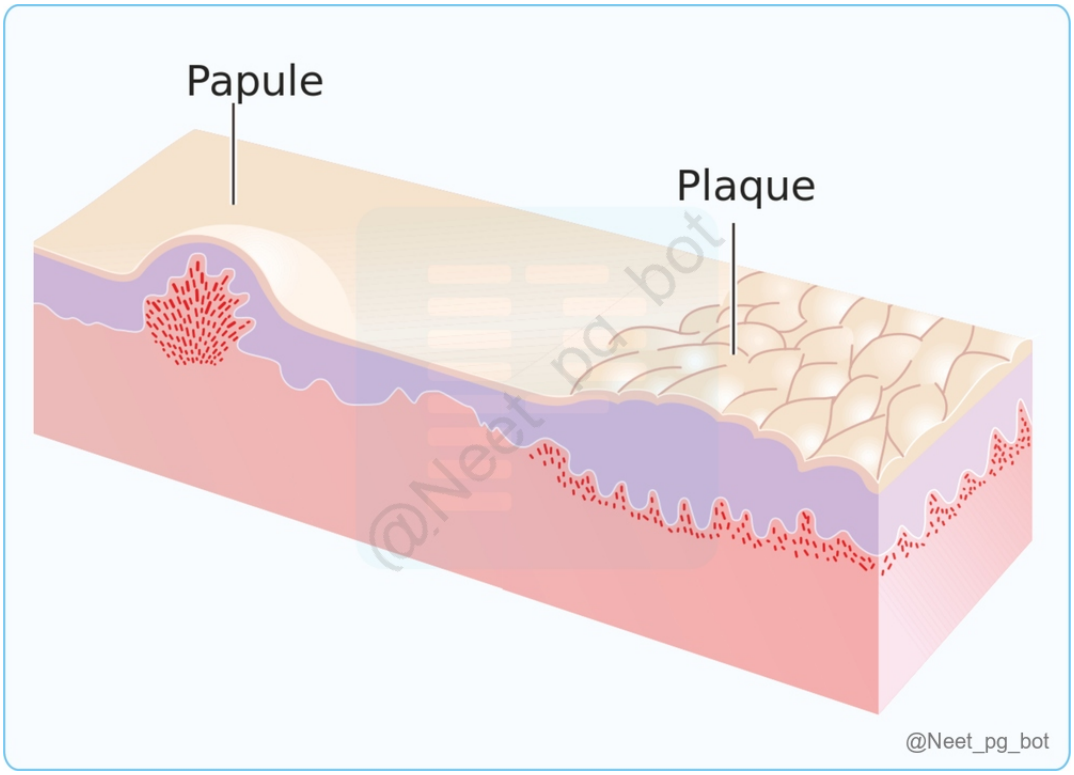
Papule
Plaque
@Neet_pg_bot

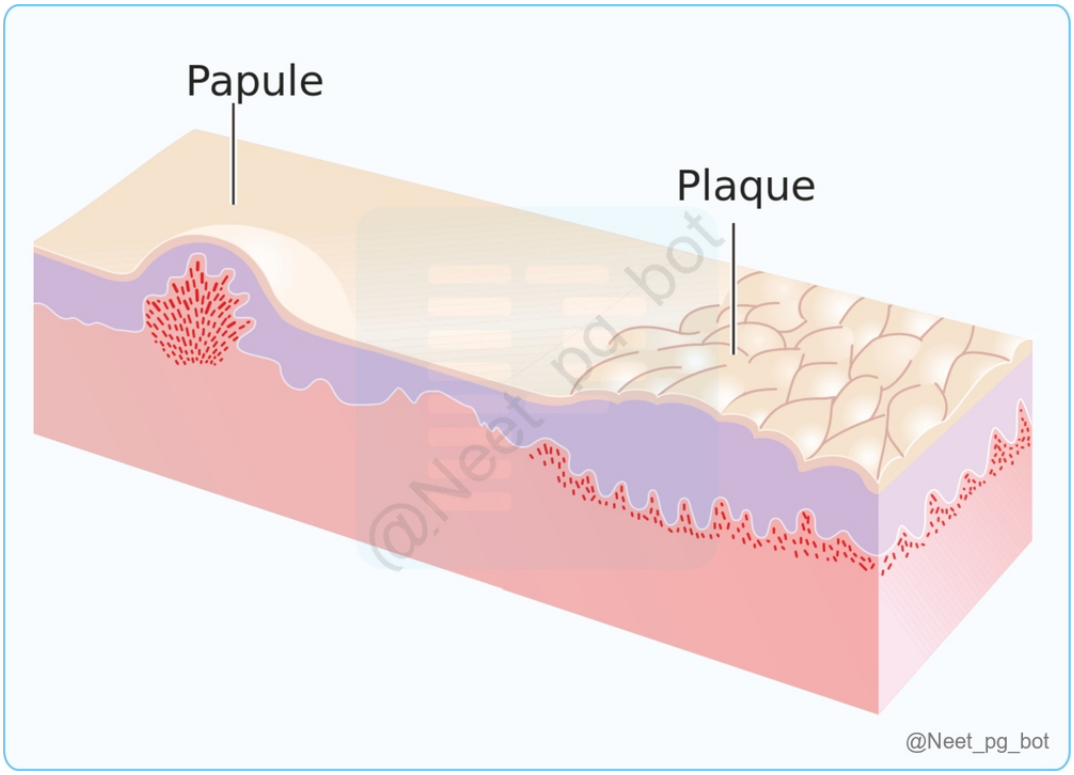
Papule
Plaque
@Neet_pg_bot


@Neet_pg_bot


@Neet_pg_bot


@Neet_pg_bot



References:

Rook’s Textbook of Dermatology, 9th Edition, Page 4.11, 4.12, 4.13

↑ *Back to this question in Part A*

@Neet_pg_bot

Q2: A 45-year-old male presents to the dermatology clinic with a complaint of red scaly lesion on his lower back. On examination, a well-demarcated, erythematous lesion measuring 4 cm in diameter with silvery scales on the surface is seen. What is the most likely diagnostic skin lesion present? (Q841986)

A. Pustule

B. Plaque

C. Nodule

D. Wheal

Correct Answer: B. Plaque

■ *Listen (English)*

■ *Listen (Hindi)*

Explanation: The lesion is suggestive of plaque in psoriasis. Plaques are elevated circumscribed lesions > 1cm, Plaque in psoriasis is characterized by silvery scales on a thickened, erythematous base. Depending on the underlying cause, these lesions can be pink, red, brown, or skin-colored. Some common causes of plaques include: Psoriasis Eczema (specifically nummular eczema) Lichen planus Seborrheic dermatitis {{caption_text}} Pustule (Option A): A pustule is a type of skin lesion characterized by a small, circumscribed elevation of the skin that contains pus. Pustules are usually < 1cm in size {{caption_text}} Nodule (Option C): Nodules are a type of skin lesion characterized by solid, palpable, elevated masses that extend into the dermis or subcutaneous tissue. They are >1 cm in size and range in depth from 1 to 10 mm. {{caption_text}} Wheal (Option D): Wheals are a type of skin lesion characterized by transient, edematous (swollen), elevated areas on the skin. These areas are typically pink or red and have well-defined borders. {{caption_text}}




@Neet_pg_bot


@Neet_pg_bot
@Neet_pg_bot



References:

Rook’s Textbook of Dermatology, 9th Edition, Page 4.11, 4.12, 4.13

↑ *Back to this question in Part A*

@Neet_pg_bot

Q3: Which of the following skin lesions is a localized collection of pus within the epidermis or dermis? (Q841987)

A. Wheal

B. Pustule

C. Nodule

D. Bulla

Correct Answer: B. Pustule

■ *Listen (English)*

■ *Listen (Hindi)*

Explanation: A pustule is a small, circumscribed elevation of the skin containing pus. They typically appear as small, white or yellowish bumps on the skin's surface. Pustules may have a visible central point where the pus is located. {{caption_text}} Wheal (Option A): Wheal is a transient type of skin lesion characterized by edematous,

swollen and elevated dermis and hypodermis. {{caption_text}} Nodules (Option C): Nodules are solid, palpable, elevated masses that extend into the dermis or subcutaneous tissue. They are larger and deeper than papules, which are similar in appearance but smaller. They are >1 cm in size and range in depth from 1 to 10 mm. Bullae (Option D): Bullae are blisters more than 1 cm on the skin that are filled with clear fluid







References:

Rook's Textbook of Dermatology, 9th Edition, Page 4.11, 4.12, 4.13

↑ *Back to this question in Part A*

@Neet_pg_bot

Q4: Which of the following is a primary skin lesion? (Q842000)

A. Atrophy

B. Induration

C. Crust

D. Purpura

Correct Answer: D. Purpura

■ *Listen (English)*

■ *Listen (Hindi)*

Explanation: Purpura is a primary skin lesion. It is a condition with red, discoloured spots on the skin that do not blanch on pressure. The spots are caused by bleeding underneath the skin. {{caption_text}} Purpura measure between 4 and 10 mm in diameter. When purpura spots are less than 4 mm in diameter, they are called Petechiae. Purpura spots larger than 1 cm are called Ecchymoses . All the below lesions are secondary skin lesions: Atrophy (Option A): Atrophy refers to the loss of tissue from either or all the layers of skin (Epidermis, Dermis, Subcutaneous tissue). If the process is superficial, there may be fine wrinkling and translucency. Induration (Option B): Induration refers to the dermal thickening that clinically appears firmer than normal on palpation. Crust (Option C): The crust consists of dried-up discharge from the lesions. {{caption_text}}





References:

Rook's Textbook of Dermatology, 9th Edition, Page 4.11, 4.12, 4.13

↑ *Back to this question in Part A*

@Neet_pg_bot

Q5: Identify the skin lesion and the disease associated with the image below. (Q842001)

A. Fissures - Seborrheic dermatitis

B. Atrophy - Pityriasis rosea

C. Target lesions - Pityriasis Versicolor

D. Scales - Seborrheic dermatitis



Correct Answer: D. Scales - Seborrheic dermatitis

■ *Listen (English)*

■ *Listen (Hindi)*

Explanation: Scales are visible exfoliation of the skin containing flakes of stratum corneum. Seborrheic dermatitis: Seborrheic dermatitis is characterized by yellow, greasy scales covering the scalp , extending to the hairline and behind the ears. Seborrheic dermatitis is a common inflammatory skin condition primarily affecting areas rich in sebaceous glands, such as the scalp, face, and trunk. It is characterized by erythematous plaques with adherent, greasy scales, often associated with itching and mild redness. Fissures - Seborrheic dermatitis (Option A) are linear breaks or cracks in the skin that are not typically associated with seborrheic dermatitis. Atrophy - Pityriasis rosea (Option B) describes the thinning of the skin, resulting in a decrease in the thickness of the epidermis and dermis. Pityriasis rosea is not typically associated with atrophy. Target lesions - Pityriasis Versicolor■■■■■■■ (Option C) are less than 3 cm in diameter and have three or more zones, usually a central area of dusky erythema or purpura, a middle paler zone of oedema, and an outer ring of erythema with a well■defined edge. {{caption_text}} Pityriasis versicolor presents with hypo- or hyperpigmented macules with fine scaling, but it is not typically associated with target lesions. {{caption_text}}





Fissure

Crack or split



Ivory white atrophy

@Neet_pg_bot



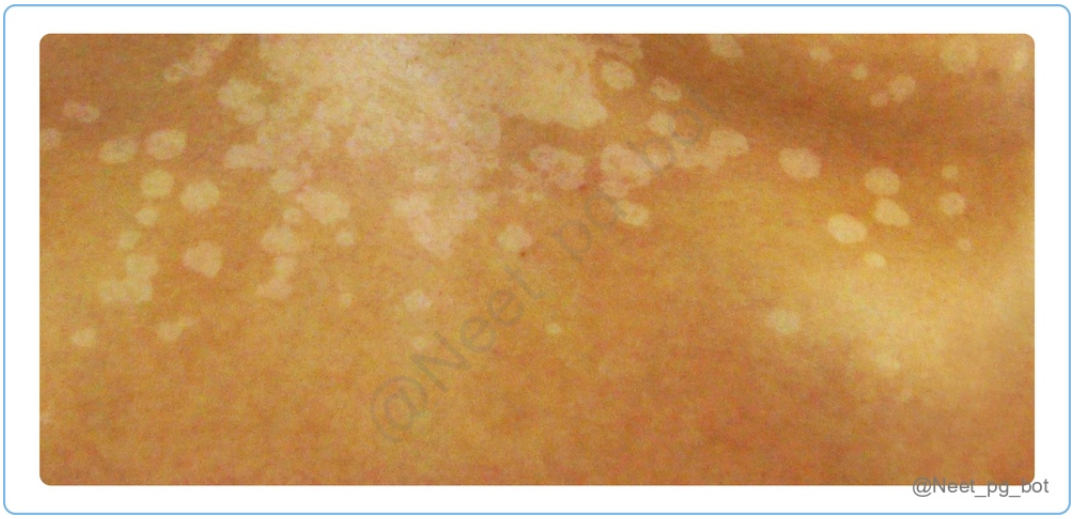

References:

Rook’s Textbook of Dermatology, 9th Edition, Page 4.13

↑ *Back to this question in Part A*

@Neet_pg_bot

Q6: A 45-year-old male presents with complaints of severe itching and thickened skin on his lower legs. Upon examination, well-demarcated areas of thickened, leathery skin with exaggerated skin markings are seen. He mentions that he has a history of atopic dermatitis and has been using topical corticosteroids intermittently for the past few years to manage flare-ups. Which of the following lesions is present in this patient? (Q842003)

A. Erosion

B. Ulcer

C. Poikiloderma

D. Lichenification

Correct Answer: D. Lichenification

■ *Listen (English)*

■ *Listen (Hindi)*

Explanation: Lichenification is characterised by the thickening of the Epidermis and dermis due to prolonged scratching. It is a secondary skin lesion associated with thick skin, hyperpigmentation and exaggerated skin

markings. It is associated with the following characteristic features in HPE Acanthosis (thickening of the epidermis) Hyperkeratosis (thickening of the stratum corneum) Elongation of rete ridges Chronic inflammatory infiltrate in the dermis. {{caption_text}} Erosion (Option A) is a loss of the epidermis, which heals without scarring. {{caption_text}} Ulcer (Option B) is a loss of the dermis and epidermis, often with loss of the underlying tissues. Poikiloderma (Option A) is an association of Cutaneous pigmentation (Hypo or Hyper pigmentation) Atrophy Telangiectasia (Visible dilatation of small blood vessels, particularly the capillaries, in the dermal layer of the skin). {{caption_text}}



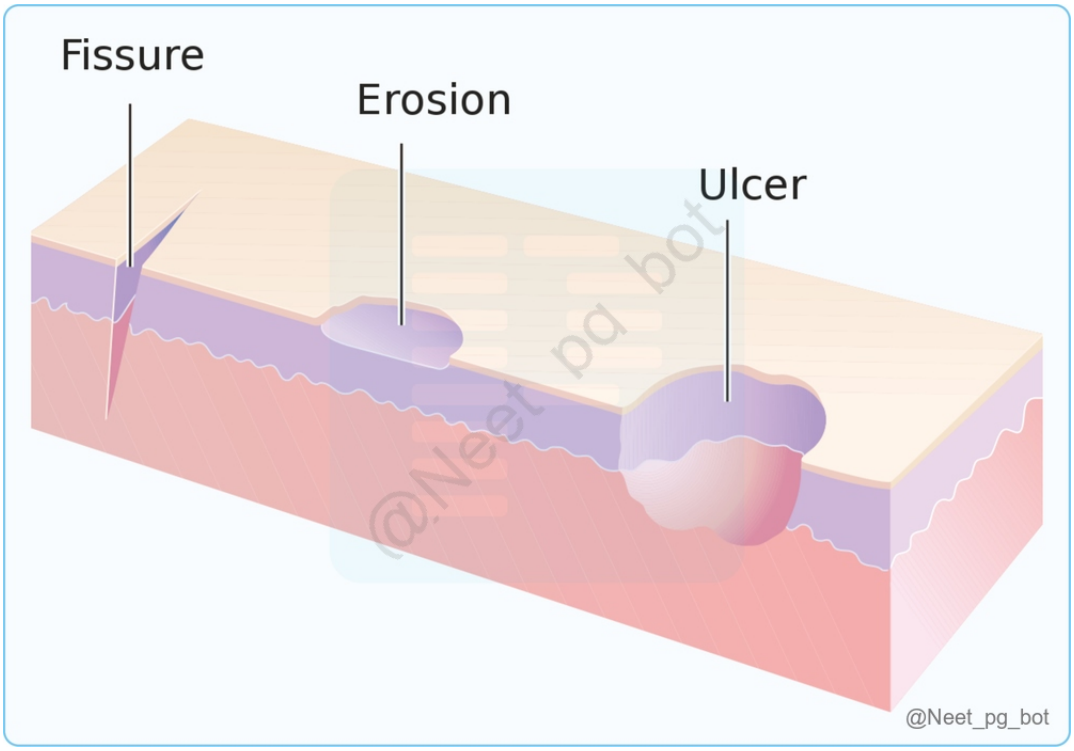



References:

Rook’s Textbook of Dermatology, 9th Edition, Page 4.11, 4.12, 4.13

↑ *Back to this question in Part A*

@Neet_pg_bot

Q7: Which among the following is the pathway of epidermal cell migration during embryonic development and the most common disease associated with it? (Q842004)

A. Langer lines - Gorlin syndrome

B. Blaschko lines - Incontinentia pigmenti

C. Langer lines - Neurofibromatosis type 1

D. Kraissl's lines - Linea Morphea

Correct Answer: B. Blaschko lines - Incontinentia pigmenti

■ *Listen (English)*

■ *Listen (Hindi)*

Explanation: The described linear rash following a distinct geometric pattern with parallel lines, often in a V-shaped distribution over the spine, is characteristic of Blaschko lines. Blaschko lines represent a pathway of

normal epidermal cell migration during embryonic development. Incontinentia pigmenti is an X-linked dominant disorder associated with Blaschko lines. It presents distinctive cutaneous findings, including linear vesicles, papules, and hyperpigmentation following the distribution of these lines. Other diseases associated with Blaschko disease are Epidermal naevi and Hypomelanosis of Ito. {{caption_text}} Langer lines - Gorlin syndrome(Option A): Langer’s lines : Represent skin tension lines (used in surgery to guide incisions for better healing and minimal scarring). Not related to embryonic cell migration. Gorlin syndrome (basal cell nevus syndrome) is associated with multiple basal cell carcinomas, jaw cysts, and skeletal abnormalities - not with Langer lines. Langer lines - Neurofibromatosis type 1 (Option C): Again, Langer lines are about mechanical skin tension , not embryology. NF1 manifests with café-au-lait spots, neurofibromas, Lisch nodules - these do not follow Langer’s lines . Kraissl's lines (Option D) represent the relaxed skin tension lines of the breast and are pertinent in breast surgery planning. Linear morphea is a form of localized scleroderma characterized by linear patches of sclerosis, but it is not associated with Kraissl's lines.

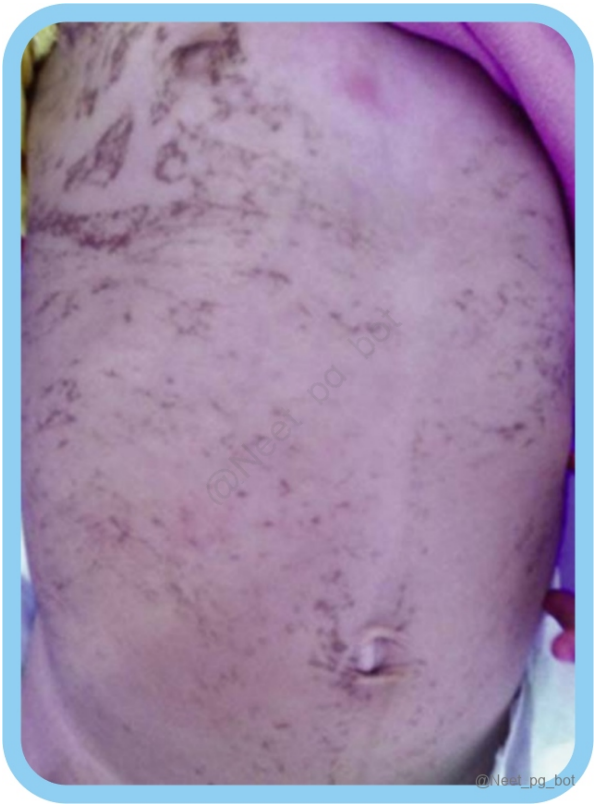

References:

Rook’s Textbook of Dermatology, 9th Edition, Page 4.12

↑ *Back to this question in Part A*

@Neet_pg_bot

• [02_Skin Appendages and their Disorders] 003 Hair And Nail Disorders

« Back to Folder Directory

[02_Skin Appendages and their Disorders] 003 Hair And Nail Disorders — Quick Jump

Q1 (p. 495)	*Q2 (p. 498)*	*Q3 (p. 499)*	*Q4 (p. 500)*	*Q5 (p. 503)*	*Q6 (p. 504)*
Q7 (p. 506)	*Q8 (p. 508)*	*Q9 (p. 510)*	*Q10 (p. 511)*	*Q11 (p. 512)*	*Q12 (p. 514)*
Q13 (p. 517)	*Q14 (p. 520)*	*Q15 (p. 521)*	*Q16 (p. 522)*	*Q17 (p. 523)*	*Q18 (p. 523)*
Q19 (p. 526)	*Q20 (p. 527)*	*Q21 (p. 528)*	*Q22 (p. 529)*	*Q23 (p. 533)*	*Q24 (p. 534)*
Q25 (p. 535)	*Q26 (p. 538)*	*Q27 (p. 539)*	*Q28 (p. 543)*	*Q29 (p. 543)*	*Q30 (p. 547)*
Q31 (p. 550)	*Q32 (p. 552)*	*Q33 (p. 556)*	*Q34 (p. 558)*	*Q35 (p. 561)*	*Q36 (p. 563)*
Q37 (p. 566)	*Q38 (p. 567)*	*Q39 (p. 570)*	*Q40 (p. 571)*	*Q41 (p. 574)*	*Q42 (p. 575)*
Q43 (p. 576)	*Q44 (p. 577)*	*Q45 (p. 578)*	*Q46 (p. 578)*	*Q47 (p. 579)*	*Q48 (p. 580)*
Q49 (p. 582)	*Q50 (p. 587)*				

Q1: Match the following nail sign with its most likely cause A. Mee’s line 1. Chronic renal insufficiency B. Muehrcke's lines 2. Liver cirrhosis C. Lindsay's nails 3. Arsenic poisoning D. Terry’s nails 4. Hypoalbuminemia (Q841979)

A. A-3, B-4, C-1, D-2

B. A-4, B-2, C-1, D-3

C. A-4, B-1, C-2, D-3

D. A-1, B-3, C-2, D-4

Correct Answer: A. A-3, B-4, C-1, D-2

■ *Listen (English)*

■ *Listen (Hindi)*

Explanation: These conditions are examples of leukonychia Nail sign Causes Mees’ lines Also known as transverse leukonychia. Horizontal, transverse white lines. Seen in, Arsenic poisoning Chemotherapy Muehrcke’s lines Pairs of transverse white bands. Seen in Hypoalbuminemia. Lindsay's nails Also known as half-and-half nails. See in: Chronic renal failure Uremia Terry’s nails The proximal part is white and the distal nail appears normal and red. Seen in: Liver cirrhosis Congestive heart failure Diabetes Punctate leukonychia Seen in: Trauma Alopecia areata



@Neet_pg_bot



@Neet_pg_bot

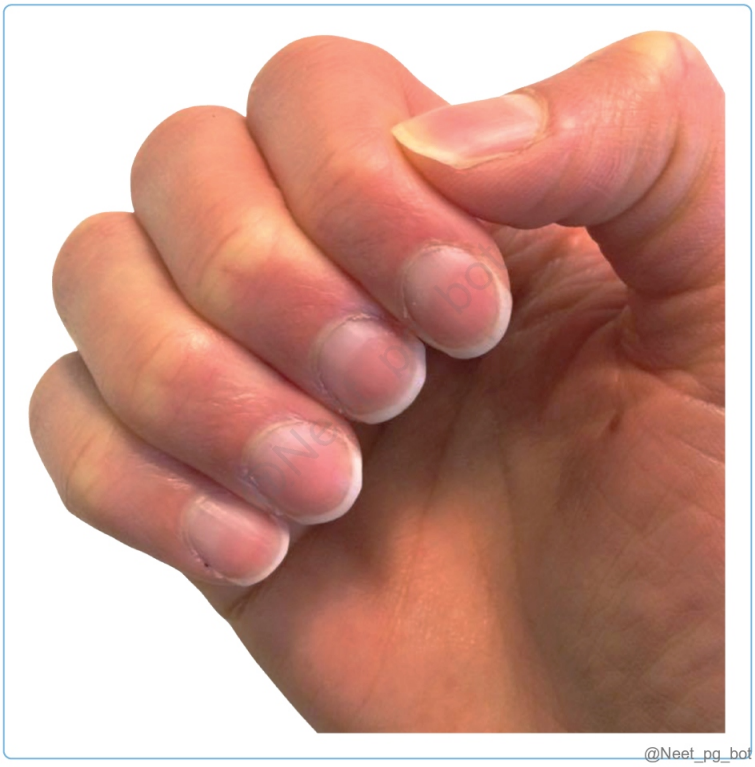
@Neet_pg_bot


@Neet_pg_bot



References:

1. Rook’s Textbook of Dermatology, 9th Edition, Page 95.13-95.14 2. Rich P. 2022. Overview of nail disorders, UpToDate

↑ *Back to this question in Part A*

@Neet_pg_bot

Q2: Which of the following is a component of SAPHO syndrome? (Q886283)

A. Synovitis

B. Acanthosis nigricans

C. Seborrhea

D. Hyperandrogenism

Correct Answer: A. Synovitis

Explanation: SAPHO syndrome is characterised by a combination of osteoarticular and cutaneous manifestations . The acronym SAPHO stands for: S - Synovitis A - Acne (severe acne forms such as acne conglobata, acne fulminans) P - Pustulosis (especially palmoplantar pustulosis) H - Hyperostosis O - Osteitis

References:

Rook’s Textbook of Dermatology, 9th Edition, Page 90.6

↑ *Back to this question in Part A*

@Neet_pg_bot

Q3: Which of the following is used in the diagnosis of the condition as shown in the image? (Q884290)

A. Tzanck smear

B. Dermoscopy

C. KOH mount

D. Slit skin smear

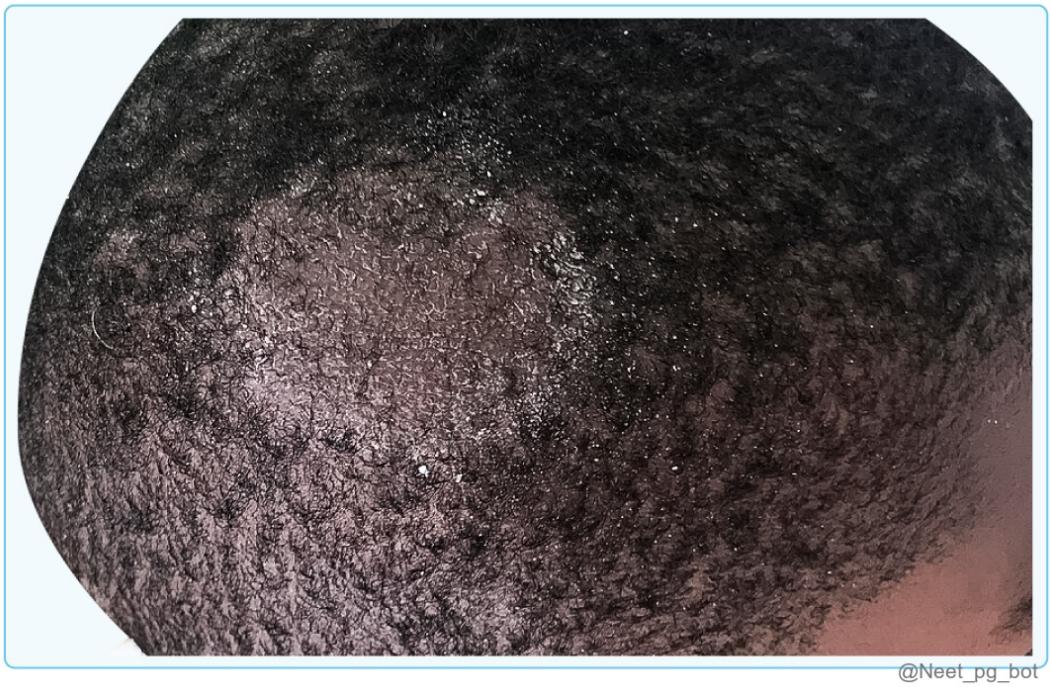

Correct Answer: C. KOH mount

Explanation: The given image depicts tinea capitis . KOH mount of plucked hair or scalp scales demonstrates fungal hyphae/arthroconidia , making it the confirmatory diagnostic test for tinea capitis. Tinea capitis: Dermatophyte fungal infection of the scalp hair shafts (ringworm of scalp). Requires stratum corneum invasion first Hair invasion occurs ~ 3 weeks after inoculation Spread to adjacent follicles → persistence → regression ± inflammation Clinical features: Partial hair loss + scaling ± inflammation Broken hairs, grey patches Itching variable Management: First line: Terbinafine (4 weeks) Itraconazole (4-6 weeks) Griseofulvin 10 mg/kg for 6 weeks (20 mg/kg for T. tonsurans , T. schoenleinii) Adjuncts: Ketoconazole/selenium sulphide shampoo (reduce spread) Remove crusts (kerion) Antibiotics for secondary bacterial infection Tzanck smear (Option A) : Used for herpes infections Dermoscopy (Option B) : Supportive (comma/corkscrew hairs) but not confirmatory Slit skin smear (Option D) : Used in leprosy.



References:

Rook’s Textbook of Dermatology, 9th Edition, Pages 32.8, 32.38-32.40.

↑ *Back to this question in Part A*

@Neet_pg_bot

Q4: The following finding is classically seen in which of the following conditions? (Q884289)

A. Trichothiodystrophy

B. Netherton syndrome

C. Menkes disease

D. Trichiorexis nodosa



Correct Answer: B. Netherton syndrome

Explanation: Bamboo hair refers to trichorrhexis invaginata , which is a hallmark feature of Netherton syndrome , along with ichthyosis linearis circumflexa and atopy. Netherton syndrome: Triad: Trichorrhexis invaginata (bamboo hair) Ichthyosis linearis circumflexa Atopy (↑ IgE, eczema) Hair findings: Fragile, short, brittle hair Sparse/absent eyebrows & eyelashes Diagnosis: Light microscopy of hair (gold standard) Single trichorrhexis invaginata = diagnostic Dermoscopy: golf-tee appearance Skin features: Erythema & scaling from infancy Serpiginous, polycyclic plaques Management: No specific hair treatment Avoid physical/chemical trauma Trichothiodystrophy (Option A) is characterised by sulfur-deficient brittle hair with “tiger-tail” banding on polarised light, not bamboo hair. Menkes disease (Option C) shows pili torti (twisted hair) due to a copper metabolism defect. Trichorrhexis nodosa (Option D) involves nodes and fraying of the hair shaft, not invagination.



A



B



@Neet_pg_bot



@Neet_pg_bot



References:

Rook’s Textbook of Dermatology, 9th Edition, Pages 89.53, 89.54.

↑ *Back to this question in Part A*

@Neet_pg_bot

Q5: What is the structure marked in the given image? (Q884288)

A. Hyponychium

B. Lunula

C. Nail bed

D. Proximal nail fold

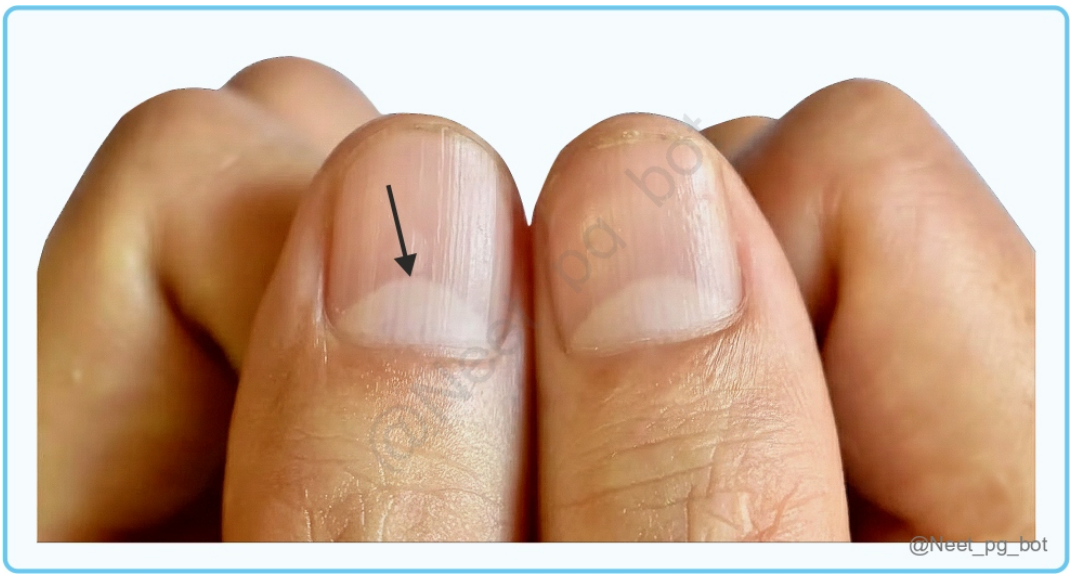

Correct Answer: B. Lunula

Explanation: The lunula is the whitish, crescent-shaped area at the proximal portion of the nail plate, representing the distal part of the nail matrix. It is most visible on the thumb and great toe. The white colour is due to the matrix cells and obscured underlying vasculature. Parts of nail: Nail plate : firmly attached to nail bed; proximal quarter covered by proximal nail fold Lunula : white distal part of matrix ; most visible on thumb/great toe Pink colour of nail: due to the translucent plate over the vascular nail bed Cuticle : from the junction of the dorsal & ventral proximal nail fold Matrix (main nail producer): Dorsal-ventral proximal nail fold Intermediate - germinal matrix Ventral - nail bed (sterile matrix) Nail bed (Option C) : role in nail formation is minimal; disease may form false nail Hyponychium (Option A) : beneath the free nail edge Onychodermal band (nail isthmus) : distal attachment of nail to bed; damage → onycholysis Proximal nail fold (Option D) : Skin fold covering the nail's proximal part

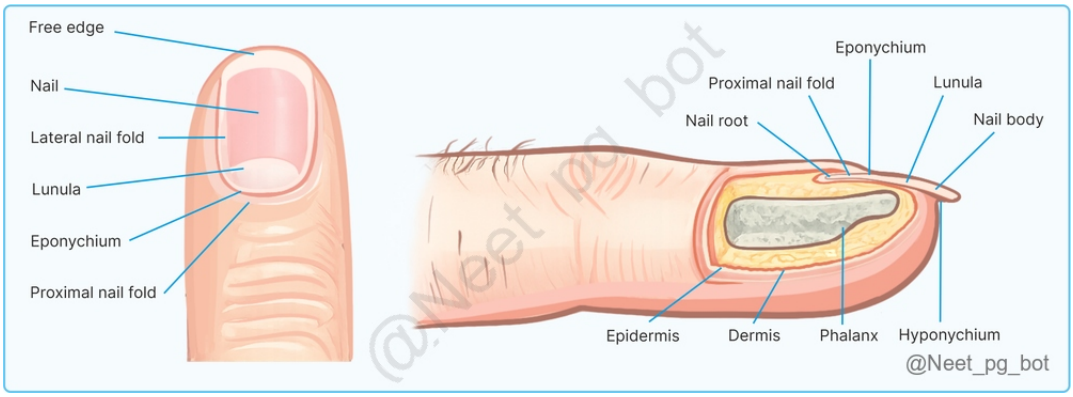

References:

Rook's Textbook of Dermatology, 9th Edition, Pages 95.2, 95.3.

↑ *Back to this question in Part A*

@Neet_pg_bot

Q6: ■ A 55-year-old man presents with brittle, concave nails affecting his thumbs and great toes. Laboratory tests reveal elevated serum ferritin and transferrin saturation. What is the most likely underlying condition associated with this nail finding? (Q884287)

A. Hemochromatosis

B. Iron deficiency anaemia

C. Trauma

D. Nail infection



Correct Answer: A. Hemochromatosis

Explanation: Koilonychia (spoon-shaped nails) is classically seen in hemochromatosis due to iron overload affecting nail structure. Concave, hollow nails with reverse curvature in both transverse and longitudinal axes. Most prominent in the thumbs and great toes. Common in infancy as a benign feature of the great toenail. Can persist in infants with cysteine■rich keratin deficiency (e.g., trichothiodystrophy). Familial cases are usually autosomal dominant . Systemic association: Iron deficiency anaemia (most common) Haemochromatosis Dermatoses & external factors: Psoriasis or dermatophyte infection → nail bed hyperkeratosis pushes nail distally Mechanical/chemical trauma → nail softening (e.g., hairdressers, oil exposure, permanent wave solutions) Iron deficiency anaemia (Option B) : Can also cause koilonychia, but lab tests here indicate iron excess, not deficiency. Trauma (Option C) : May deform nails but does not typically cause concave nails. Nail infection (Option D) :

Usually causes thickening, discolouration, or brittleness, not spooning.

References:

Rook’s Textbook of Dermatology, 9th Edition, Page 95.7.

↑ *Back to this question in Part A*

@Neet_pg_bot

Q7: A 45-year-old man develops the following finding, as shown in the image on multiple fingernails 2 months after severe pneumonia. What is this finding called? (Q884310)

A. Mees’ lines

B. Beau’s lines

C. Onycholysis

D. Koilonychia



Correct Answer: B. Beau’s lines

Explanation: Beau’s lines are transverse (horizontal) depressions across the nail plate caused by a temporary interruption of nail matrix growth . This arrest is most commonly due to an acute systemic illness such as severe infections (e.g., pneumonia), myocardial infarction , or drug reactions . When the cause is generalised , the condition is specifically termed Beau’s lines , reflecting a temporary nail matrix arrest . The transverse grooves may be classified based on aetiology. Endogenous causes produce arcuate grooves that parallel the lunula , whereas exogenous causes, such as manicure-related trauma or habit-tic deformity, produce grooves that match the contour of the proximal nail fold and are often multiple , giving rise to the appearance of “washboard nails.” Localised causes include trauma, inflammation, and neurological events. The timing of the insult can be estimated by measuring the distance of the groove from the proximal nail fold , as this reflects the time elapsed since the growth arrest. The severity of the insult correlates with the depth of the groove, while the duration of the insult is reflected by the width of the depression. Beau’s lines are often most prominent on the thumbs and great toes . In severe cases, when the growth arrest involves the full thickness of the nail plate , the nail may shed completely, a complication known as onychomadesis . Mees’ lines (Option A) are transverse white lines due to abnormal nail plate keratinisation (e.g., arsenic poisoning), not grooves. ■ Onycholysis (Option C) refers to the separation of the nail plate from the nail bed , usually distally. Koilonychia (Option D) describes spoon-shaped nails , classically associated with iron deficiency or hemochromatosis.







References:

Rook's Textbook of Dermatology, 9th Edition, Page 95.11

↑ *Back to this question in Part A*

@Neet_pg_bot

Q8: A 52-year-old man presents with slowly growing, thickened, yellow nails involving most fingers and toes. Examination shows loss of cuticle and an absent lunula. He also has chronic bilateral leg swelling and a history of recurrent pleural effusions and chronic cough. What is the most likely diagnosis? (Q884309)

A. Onychomycosis

B. Lichen planus

C. Yellow nail syndrome

D. Psoriasis



Correct Answer: C. Yellow nail syndrome

Explanation: Yellow nail syndrome is characterised by the classic triad of yellow, slow-growing nails, lymphedema, and respiratory disease (e.g., pleural effusions, bronchiectasis). Nails : Yellow, thickened, ↑ curvatures, lunula absent , cuticle lost, very slow growth Classic triad : Yellow nails Lymphedema Respiratory disease: Pleural effusions, bronchiectasis, chronic sinusitis Epidemiology : Adults; non-inherited Pathogenesis : Lymphatic dysfunction with fibrous subungual tissue Associations : Malignancy, D-penicillamine, nephrotic syndrome Treatment : Variable; Vitamin E ± azoles, treat infections Onychomycosis (Option A) : Causes yellow, thickened nails but is usually associated with subungual debris and fungal elements; it does not cause lymphedema or respiratory involvement. Lichen planus (Option B) : Nail LP may cause thinning, ridging, or pterygium formation, but yellow discolouration with systemic lymphatic and respiratory features is not typical . Psoriasis (Option D) : Produces nail pitting, onycholysis, and subungual hyperkeratosis; lymphedema and pleural effusions are not features .

References:

Rook’s Textbook of Dermatology, 9th Edition, Pages 95.14, 95.15.

↑ *Back to this question in Part A*

@Neet_pg_bot

Q9: A 32-year-old woman presents with severe, localised pain at the tip of her right index finger for 8 months. The pain is excruciating on exposure to cold and is triggered by minimal pressure. Examination shows a tiny bluish-red discolouration beneath the nail plate. The nail appears otherwise normal. What is the most likely diagnosis? (Q884308)

A. Eccrine spiradenoma

B. Subungual glomus tumour

C. Pyogenic granuloma

D. Subungual melanoma



Correct Answer: B. Subungual glomus tumour

Explanation: A subungual glomus tumour presents as a small bluish lesion under the nail with severe paroxysmal pain , marked cold sensitivity , and point tenderness , which are classic diagnostic features. Glomus tumour: Tumour of the glomus body (myoarterial), composed of glomus cells and vascular channels Types: Solid glomus tumour, glomangioma (commonest), glomangiomyoma Epidemiology: Uncommon; ↑ after 7 yrs; adults in 3rd-4th decade ; no sex predilection Genetics: AD inheritance (multiple lesions); glomulin gene , chr 1p21 22 Clinical (Solitary): Small pink/blue nodule, severe pain , cold sensitivity; subungual common Clinical (Multiple): Larger, dark blue, deep dermal, usually painless Pathology: Well-circumscribed dermal tumour; SMA+, desmin– Differential: Leiomyoma, eccrine spiradenoma, hemangioma Treatment: Surgical excision (curative) Eccrine spiradenoma (Option A) : Painful dermal tumour, but not characteristically subungual or cold-sensitive Pyogenic granuloma (Option C) : Friable, bleeding vascular lesion without severe pain Subungual melanoma (Option D) : Pigmented lesion with nail dystrophy, usually painless initially

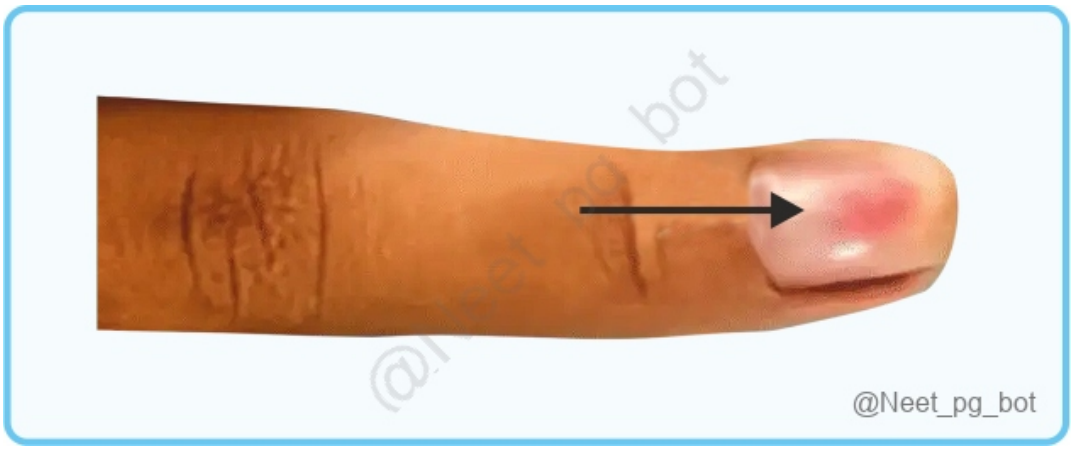

References:

Rook’s Textbook of Dermatology, 9th Edition, Pages 137.43-137.45.

↑ *Back to this question in Part A*

@Neet_pg_bot

Q10: What is the inheritance pattern of Nail-patella syndrome? (Q884306)

A. Autosomal recessive

B. X-linked recessive

C. Autosomal dominant

D. Mitochondrial

Correct Answer: C. Autosomal dominant

Explanation: Nail-patella syndrome is caused by mutations in the LMX1B gene and follows an autosomal dominant inheritance pattern, often showing vertical transmission with variable expressivity. Nail-patella

syndrome: Inheritance: Autosomal dominant Gene: LMX1B (9q33.3) Nail findings: Nails: Congenital, bilateral nail dysplasia with a triangular lunula (often the only feature); fingernails, especially thumbnails, are most affected, with greater severity on the ulnar side. Pattern: Changes are symmetrical, present at birth, and affect fingernails more than toenails, with severity decreasing from index to little finger. Digits: Swan-neck deformity (DIP flexion, PIP hyperextension) with absent DIP creases. Key skeletal features: Small/absent patella Elbow deformities Iliac horns (pathognomonic) Systemic associations: Renal disease (proteinuria, HTN) Open-angle glaucoma Diagnosis: Clinical + X-ray pelvis (iliac horns) Management: Supportive; monitor kidneys, BP, eyes



References:

Rook's Textbook of Dermatology, 9th Edition, Pages 69.15, 69.16.

↑ *Back to this question in Part A*

@Neet_pg_bot

Q11: A 22-year-old presents with greasy papules on the face, chest, and back, flexural plaques, and nail findings as shown in the image below. What is the most likely diagnosis? (Q884305)

A. Hailey-Hailey disease

B. Darier disease

C. Pemphigus vulgaris

D. Seborrheic dermatitis



Correct Answer: B. Darier disease

Explanation: A young adult with greasy, hyperkeratotic papules over the seborrhoeic areas (face, chest, back), involvement of flexures , and characteristic nail changes strongly points to Darier disease (keratosis follicularis) . Inheritance: Autosomal dominant Gene: ATP2A2 → encodes SERCA2 (sarco/endoplasmic reticulum Ca^{2}■-ATPase) Pathophysiology: Defective calcium pump → immature desmosomes & adherens junctions → loss of cell adhesion and abnormal keratinocyte differentiation Histology: Acantholytic dyskeratosis Clinical features: Greasy papules/plaques in seborrheic areas & flexures Nail abnormalities: V-shaped notches , longitudinal violaceous or white streaks Hailey-Hailey disease (Option A) : Painful erosions at friction sites, flexural involvement, no hyperkeratotic papules, and less prominent nail changes. Pemphigus vulgaris (Option C) : Flaccid bullae and erosions, oral mucosa involvement, positive Nikolsky sign, histology shows intraepidermal acantholysis without dyskeratosis. Seborrheic dermatitis (Option D) : Erythematous, scaly patches in seborrheic areas, not associated with nail changes or acantholytic dyskeratosis.



References:

Rook's Textbook of Dermatology, 9th Edition, Page 71.24.

↑ *Back to this question in Part A*

@Neet_pg_bot

Q12: A 38-year-old homemaker presents with discolouration of a single fingernail for 3 weeks. Examination shows findings as shown in the image below. The nail is painless. She gives a history of frequent exposure to water and detergents. What is the most likely diagnosis? (Q884304)

A. Onychomycosis

B. Chloronychia

C. Subungual melanoma

D. Nail psoriasis



Correct Answer: B. Chloronychia

Explanation: Chloronychia (green nail syndrome) is caused by Pseudomonas aeruginosa , producing green pigments in a moist environment , typically associated with onycholysis and minimal symptoms. Green to green-black discolouration of the nail due to Pseudomonas aeruginosa infection. Bacterial pigments (pyocyanin, pyoverdin) stain the nail plate. Occurs in a moist environment , often with onycholysis . Predisposing factors: Repeated water exposure (dishwashers, cleaners) Nail trauma Pre-existing nail disease (onychomycosis, psoriasis) Occlusive gloves, artificial nails Clinical features: Green/green-black nail discolouration (hallmark) Usually distal nail involvement & often painless May have distal onycholysis ± chronic paronychia Diagnosis: Clinical Treatment: Keep nail dry + topical antibiotics (gentamicin); oral ciprofloxacin if severe Onychomycosis (Option A) : Usually yellow-white discolouration with subungual debris Subungual melanoma (Option C) : Brown-black pigment, often longitudinal, may involve the nail fold Nail psoriasis (Option D) : Pitting, onycholysis, oil-drop sign, not green discolouration



@Neet_pg_bot



@Neet_pg_bot



References:

Rook’s Textbook of Dermatology, 9th Edition, Pages 95.12, 95.13.

https://pmc.ncbi.nlm.nih.gov/articles/PMC4298286/

↑ *Back to this question in Part A*

@Neet_pg_bot

Q13: A 6-year-old child presents with sparse, brittle scalp hair since infancy. The polarised light microscopy image is given below. The child has short stature, developmental delay, and ichthyosis. Nails show dystrophic changes. What is the most likely diagnosis? (Q884303)

A. Netherton syndrome

B. Trichothiodystrophy

C. Menkes disease

D. Trichorrhexis nodosa



Correct Answer: B. Trichothiodystrophy

Explanation: The clinical features and the polarised microscopy image are suggestive of Trichothiodystrophy. Trichothiodystrophy is characterised by brittle hair with tiger-tail banding , due to low sulfur content in the hair shaft. Associated systemic features include short stature, photosensitivity, ichthyosis, and intellectual impairment (PIBIDS syndrome). Key feature: Brittle hair with tiger-tail banding on polarised microscopy Hair defects: Pili torti, trichorrhexis nodosa; hypotrichosis (scalp, eyebrows, eyelashes) Nails: Dystrophic changes Systemic features: Short stature, progeroid facies, microcephaly, cataracts, joint contractures, asthma Subtypes: Sabinas - intellectual disability, dental caries Hair-brain - infertility, developmental delay Tay - ichthyosis PIBIDS - photosensitivity, ichthyosis, brittle hair, intellectual impairment, ↓ fertility, short stature Pathogenesis: ↓ high-sulfur hair proteins Genes: Non-photosensitive: C7ORF11 (MPLKIP) Photosensitive (NER defect): ERCC2, ERCC3, GTF2H5 Netherton syndrome (Option A) : Characterised by trichorrhexis invaginata (bamboo hair) and atopic features, not tiger-tail banding. Menkes disease (Option C) : Presents with kinky, hypopigmented hair and neurodegeneration due to copper deficiency, without tiger-tail banding. Trichorrhexis nodosa (Option D) : A localised hair shaft defect without systemic features such as ichthyosis or developmental delay.



@Neet_pg_bot



@Neet_pg_bot



References:

Rook’s Textbook of Dermatology, 9th Edition, Pages 68.21, 68.22.

↑ *Back to this question in Part A*

@Neet_pg_bot

Q14: Which of the following conditions are causes of cicatricial (scarring) alopecia? Lichen planopilaris Alopecia areata Discoid lupus erythematosus Telogen effluvium Folliculitis decalvans (Q884291)

A. 1, 3 and 5

B. 1 and 3 only

C. 3, 4 and 5

D. 2 and 4 only

Correct Answer: A. 1, 3 and 5

Explanation: Lichen planopilaris, discoid lupus erythematosus, and folliculitis decalvans cause permanent follicular destruction , leading to cicatricial alopecia. Alopecia areata and telogen effluvium are non-scarring

alopecias. The most important conditions causing cicatricial (scarring) alopecia are: Primary causes: Lichen planopilaris (LPP) Frontal fibrosing alopecia (FFA) Central centrifugal cicatricial alopecia (CCCA) Discoid lupus erythematosus (DLE) Folliculitis decalvans Dissecting cellulitis of the scalp Pseudopelade of Brocq Secondary causes: Tinea capitis (Kerion & favus) Traction alopecia (advanced stage) Thermal or chemical burns Radiodermatitis (post-radiation therapy) Scalp neoplasms (e.g., Basal Cell Carcinoma)

References:

Rook's Textbook of Dermatology, 9th Edition, Page 89.35 .

↑ *Back to this question in Part A*

@Neet_pg_bot

Q15: A 20-year-old male presents with findings as shown in the image, with scarring. What is the most appropriate treatment? (Q886284)

A. Topical benzoyl peroxide alone

B. Oral doxycycline

C. Oral isotretinoin

D. Topical retinoid with topical antibiotic



Correct Answer: C. Oral isotretinoin

Explanation: Nodulocystic acne is a severe form of acne with deep inflammatory nodules and cysts and a high risk of scarring. Oral isotretinoin is the treatment of choice as it reduces sebaceous gland size, sebum production, follicular keratinisation, and inflammation. Oral isotretinoin (13-cis-retinoic acid) is a synthetic vitamin A analogue Indications: Used for severe recalcitrant acne and moderate acne unresponsive to conventional antibiotic therapy . Most effective anti-acne drug; produces long-term remission in many patients after 4-6 months , dose-dependent. Laboratory monitoring: Liver function tests and lipid profile should be monitored; elevations are usually mild, asymptomatic, and reversible . Rare thrombocytopenia and neutropenia reported; CBC, triglycerides, cholesterol, and transaminases should be monitored. Highly teratogenic → strict Pregnancy Prevention Programme (PPP) mandatory for all females of child-bearing potential. Pregnancy testing: Required before starting, monthly during treatment, and 5 weeks after stopping isotretinoin. Contraception: At least one (preferably two) effective contraceptive methods are advised; prescription limited to 30 days and valid for 7 days ; treatment ideally starts on day 3 of the menstrual cycle . Treatment of acne: Grades Lesions Treatment Grade I Non-inflammatory lesions such as open (blackheads) and closed comedones (whiteheads) Topical retinoids (Tretinoin, Adapalene) Grade II Non-inflammatory lesions (comedones) + inflammatory lesions such as papules and a few pustules. Topical retinoids + Topical antibiotics Grade III Multiple inflammatory papules and pustules ± nodules (moderate) Topical retinoids + Oral antibiotics ± Benzoyl peroxide Grade IV Nodules + Cysts (Most severe form) Oral retinoids (Isotretinoin)

References:

Rook’s Textbook of Dermatology, 9th Edition, Pages 90.37, 90.44, 90.45.

https://pmc.ncbi.nlm.nih.gov/articles/PMC9180136/

↑ *Back to this question in Part A*

@Neet_pg_bot

Q16: A 19-year-old patient has severe recalcitrant acne that has failed to respond to prolonged courses of oral antibiotics and topical therapy. What is the most appropriate treatment? (Q886285)

A. Long-term topical benzoyl peroxide

B. Oral doxycycline with topical retinoid

C. Oral isotretinoin

D. Intralesional corticosteroid injections

Correct Answer: C. Oral isotretinoin

Explanation: Oral isotretinoin is the treatment of choice for severe recalcitrant acne that does not respond to conventional antibiotic therapies. Isotretinoin (13-cis-retinoic acid) , a synthetic vitamin A analogue Indications: Severe acne unresponsive to conventional antibiotic therapy European S3 guidelines: Severe recalcitrant acne Moderate acne failing standard antibiotics Efficacy: Most effective acne therapy available Duration: ~ 4-6 months (dose-dependent) Produces long-term remission or marked improvement Relapse: More common in younger patients

References:

Rook's Textbook of Dermatology, 9th Edition, Page 90.44

↑ *Back to this question in Part A*

@Neet_pg_bot

Q17: Which of the following is not an indication for hormonal therapy in acne? (Q886286)

A. Adult female with antibiotic-refractory papulopustular acne

B. Female requiring contraception along with acne treatment

C. Female with severe acne unresponsive to oral isotretinoin

D. Female with moderate acne where isotretinoin is contraindicated

Correct Answer: C. Female with severe acne unresponsive to oral isotretinoin

Explanation: Hormonal therapy is used in women with antibiotic failure, need for contraception, or when isotretinoin is contraindicated. Failure of isotretinoin indicates severe disease where hormonal therapy alone is not appropriate. Mechanisms of Action: ↓ Androgen production (ovary/adrenal) Androgen receptor blockade ↓ Androgen effect on sebaceous glands ↑ Sex hormone-binding globulin (SHBG) → ↓ free testosterone Combined Oral Contraceptives (COCs) ↑ SHBG → ↓ free testosterone Suppress ovulation → ↓ ovarian androgens → ↓ sebum Indications: Failure of standard antibiotic/combination therapy (Option A) Need for contraception and/or menstrual regulation (Option B) Isotretinoin contraindicated or unavailable (Option D) Can be combined with topical therapy

References:

Rook's Textbook of Dermatology, 9th Edition, Page 90.43

↑ *Back to this question in Part A*

@Neet_pg_bot

Q18: A 17-year-old adolescent presents with the following findings, as shown in the image. What is the most likely diagnosis? ■ ■ (Q886287)

A. Acne vulgaris

B. Rosacea

C. Milia

D. Folliculitis



Correct Answer: A. Acne vulgaris

Explanation: Based on the clinical presentation and image provided, the most likely diagnosis is Acne vulgaris . The patient displays a polymorphic eruption featuring inflammatory papules, pustules, and notably, whiteheads (closed comedones) . Acne Vulgaris: Chronic disease of adolescence (average duration ~ 7 years) Can begin as early as 6 years (adrenarche-related) Distribution: Face: ~99% (most common) > Back: ~60% > Chest: ~15% Often associated with seborrhoea , scarring , and post-inflammatory erythema/pigmentation Types of lesions: Non-inflammatory (Comedonal): Open comedones (blackheads): Often mid-facial Early presence → poor prognosis Closed comedones (whiteheads): ~1 mm, skin-coloured No visible follicular opening Require good lighting and skin stretching to detect Rosacea (Option B) typically presents in older adults (30s-50s) and often includes telangiectasia (visible blood vessels) and flushing, which are not the primary features in this case. ■ Milia (Option C) are small, firm, white keratin-filled cysts without the significant inflammation or pustule formation seen in this patient. Folliculitis (Option D) : While it presents with pustules, they are typically centred strictly on hair follicles and often appear more uniform and widespread than the clustered, varying lesions of acne.


Papulopustular rosacea
Erythematotelangiectatic rosacea
Ocular rosacea
Rhinophyma (phymatous rosacea)
@Neet_pg_bot


@Neet_pg_bot



References:

Rook’s Textbook of Dermatology, 9th Edition, Pages 90.20 - 90.23

↑ *Back to this question in Part A*

@Neet_pg_bot

Q19: Which of the following drugs is not associated with acneiform eruptions ? (Q886288)

A. Prednisolone

B. Lithium

C. Isoniazid

D. Metformin

Correct Answer: D. Metformin

Explanation: Acneiform eruptions are commonly associated with corticosteroids , lithium , and antitubercular drugs such as isoniazid. Metformin is not known to cause acneiform eruptions. Important Drug Classes Associated with Acne: Corticosteroids: Betamethasone, Prednisolone (Option A) , Budesonide ACTH: ACTH, synthetic ACTH Anabolic steroids / synthetic androgens: Danazol, Nandrolone, Stanozolol Anticonvulsants:

Carbamazepine, Phenytoin, Phenobarbitone, Gabapentin, Topiramate Antidepressants: Lithium (Option B) , Sertraline Neuroleptics/antipsychotics: Pimozide, Risperidone Antitubercular drugs: Isoniazid (Option C) , Pyrazinamide Antiviral drugs: Ritonavir, Ganciclovir Calcium channel blockers: Nilvadipine, Nimodipine Vitamins: Vitamin B■■ (± other B vitamins) Miscellaneous: Buserelin, Cabergoline, Ciclosporin, Sirolimus, Tacrolimus, Clofazimine, Dantrolene, Disulfiram

References:

Rook’s Textbook of Dermatology, 9th Edition, Page 90.10

↑ *Back to this question in Part A*

@Neet_pg_bot

Q20: A 17-year-old girl has findings as shown, resulting from compulsively picking mild acne lesions, especially during stress. What is the most likely diagnosis? (Q886289)

A. Acne vulgaris

B. Acne excoriée

C. Acne conglobata

D. Perioral dermatitis



@Neet_pg_bot

Correct Answer: B. Acne excoriée

Explanation: Acne excoriée is a self-inflicted variant of acne, characterised by compulsive picking of minimal or imagined acne lesions. Adolescent girls > adults Stress related Compulsive picking of acne lesions (face) Linear erosions, excoriations → scarring Associated with OCD, anxiety, and BDD Treat acne gently + CBT/SSRIs if compulsive Acne vulgaris (Option A) : Typically shows comedones, papules, and pustules without predominant excoriations. Acne conglobata (Option C) : Severe nodulocystic acne with abscesses and sinus tracts. Perioral dermatitis (Option D) : Papulopustular eruption around the mouth, sparing the vermilion border.

References:

Rook's Textbook of Dermatology, 9th Edition, Page 90.23.

↑ *Back to this question in Part A*

@Neet_pg_bot

Q21: A 25-year-old patient with mild acne is being considered for a chemical peel to reduce comedones and superficial scarring. Which of the following is not commonly used as a chemical peeling agent? (Q886290)

A. Glycolic acid

B. Salicylic acid

C. Trichloroacetic acid

D. Retinol

Correct Answer: D. Retinol

Explanation: Retinol is a topical retinoid that regulates keratinocyte turnover but is not used as a chemical peeling agent . Chemical Peels: Promote desquamation by reducing corneocyte cohesion and keratinocyte plugging, facilitating extrusion of inflammatory contents. Common agents: α■Hydroxy acids (e.g., glycolic acid) Salicylic acid Trichloroacetic acid Clinical use: Evidence for acne treatment is limited. Generally safe and inexpensive. Widely used to reduce comedones, superficial scarring, and hyperpigmentation.

References:

Rook’s Textbook of Dermatology, 9th Edition, Page 90.50.

↑ *Back to this question in Part A*

@Neet_pg_bot

Q22: A 55-year-old man presents with a slowly enlarging, bulbous, and red nose as shown in the image. What is the most likely diagnosis? ■ ■■■■■■■ (Q886291)

A. Acne vulgaris

B. Rhinophyma

C. Sebaceous hyperplasia

D. Lupus pernio



Correct Answer: B. Rhinophyma

Explanation: The above clinical image and presentation are suggestive of Rhinophyma. Rhinophyma is a subtype of rosacea, specifically characterised by thickening of the skin on the nose. It often leads to a bulbous, irregular appearance and can affect the shape and texture of the nose. Pathophysiology: Chronic Inflammation: Long-standing rosacea can lead to inflammation of the sebaceous glands, causing them to enlarge. Fibrosis: Over time, collagen and connective tissue build up in the skin, contributing to the thickened appearance. Vascular Changes: The blood vessels may become more prominent, leading to the reddish hue often observed. Risk factors: Middle-aged Men. History of Rosacea Genetics Appearance: The patient's nose shows a bulbous, bumpy, and red appearance, which is characteristic of rhinophyma. The "cobblestone" texture is due to the enlarged sebaceous glands and increased connective tissue. Acne vulgaris (Option A) : Typically presents with comedones, papules, and pustules; does not cause bulbous nasal enlargement. Sebaceous hyperplasia (Option C) : Presents as small, yellowish papules with central umbilication, usually not causing nasal deformity. Lupus pernio (Option D) : Chronic violaceous plaques on the nose and cheeks seen in sarcoidosis; does not cause nodular, bulbous nasal enlargement typical of rhinophyma.


@Neet_pg_bot


@Neet_pg_bot





References:

Rook’s Textbook of Dermatology, 9th Edition, Page 91.7.

Dhingra Diseases of Ear, Nose and Throat, 8th Edition, Pages 165, 166, 204.

↑ *Back to this question in Part A*

@Neet_pg_bot

Q23: A 45-year-old patient presents with findings as shown. Which of the following is not associated with this condition? (Q886292)

A. Telangiectasia

B. Rhinophyma

C. Blepharitis

D. Alopecia areata



Correct Answer: D. Alopecia areata

Explanation: The given image depicts Acne rosacea. Rosacea is associated with ocular involvement (blepharitis), phymatous changes such as rhinophyma, and telangiectasia. Alopecia areata is not associated with rosacea. Presentations of rosacea: 1. Erythematotelangiectatic Rosacea (ETTR) Gradual facial erythema (central face ± ears, neck) Telangiectasia (Option A) , flushing Triggers: heat, hot drinks, spicy food, alcohol Sensitive skin, burning/stinging Associated actinic damage 2. Papulopustular Rosacea: Papules ± pustules on cheeks, nose, chin, forehead Prominent erythema may form plaques Lesions superficial; no nodules or cysts No pain or itch Heals without scarring (± post-inflammatory erythema) 3. Phymatous Rosacea: Rhinophyma (Option B) (common, males): thickened, bulbous nose, enlarged pores Oily skin, sebaceous discharge Other forms: Otophyma, Metophyma 4. Ocular Rosacea: Dryness, grittiness, burning Blepharitis (Option C) , styes, contact lens intolerance

Severe: conjunctival redness, photophobia, keratitis (rare) Usually bilateral

References:

Rook’s Textbook of Dermatology, 9th Edition, Page 91.6-91.8

↑ *Back to this question in Part A*

@Neet_pg_bot

Q24: Which of the following statements is false regarding the condition shown in the image below? (Q886293)

A. Benign anatomical variant

B. No itching/pain

C. Caused by human papillomavirus

D. Reassurance is the treatment



Correct Answer: C. Caused by human papillomavirus

Explanation: Pearly penile papules are not HPV-related or sexually transmitted; they are a normal anatomical variant , and reassurance alone is the treatment . Pearly penile papules: A benign anatomical variant of the penis, not a disease. It mostly affects males, especially during adolescence and early adulthood. Appearance: Flesh-colored or white , dome-shaped or filiform (thread-like) papules. Arranged in rows around the corona of the glans penis. Usually asymptomatic - no pain or itch. Management: Reassurance that it's benign and not sexually transmitted. Can be removed for cosmetic reasons if desired. Procedures include cryotherapy or laser ablation , but these are optional and may have side effects.

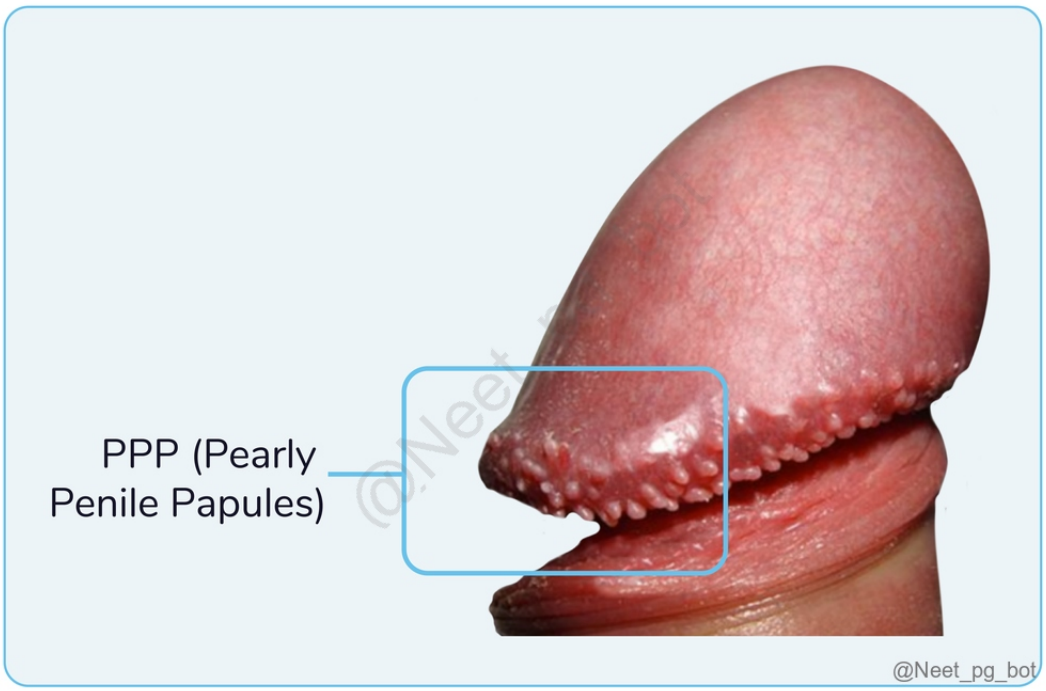

References:

https://www.ncbi.nlm.nih.gov/books/NBK442028/

https://emedicine.medscape.com/article/1058826-overview?form=fpf

↑ *Back to this question in Part A*

@Neet_pg_bot

Q25: Obstruction and rupture of the eccrine sweat duct at the dermo-epidermal junction leads to firm, flesh-colored papules without itching, usually following repeated episodes of prickly heat. What is the diagnosis? (Q886294)

A. Miliaria crystallina

B. Miliaria rubra

C. Miliaria profunda

D. Eccrine hidrocystoma

Correct Answer: C. Miliaria profunda

Explanation: Miliaria profunda results from eccrine duct rupture at or below the dermo-epidermal junction , producing firm, asymptomatic papules, often after recurrent miliaria rubra. Miliaria: Acute or subacute disorder due to occlusion or disruption of eccrine sweat ducts in hot, humid conditions Leads to leakage of sweat into: Epidermis → crystallina, rubra Dermis → profunda ■ Types: ■ Miliaria crystallina (Option A) Miliaria rubra (Option B) Miliaria profunda Obstruction of the eccrine sweat duct at the level of the stratum corneum. Seen in infants and are characterised by clear fluid thin vesicles that may rupture easily, leaving behind superficial peeling or desquamation. ■ Obstruction at intra-epidermal duct. Typical lesions develop on the body, especially in areas of friction with clothing, and in flexures. Uniformly minute erythematous papules, which may be present in very large numbers. Intense discomfort in the form of an unbearable prickling sensation, with instant relief when triggers are removed. Obstruction of the eccrine sweat duct at the Dermo-epidermal junction. It is characterised by firm, flesh-coloured lesions or bumps beneath the skin's surface. It follows repeated attacks of miliaria rubra . Eccrine hidrocystoma (Option D) : Benign cystic dilation of eccrine ducts presenting as translucent cysts , usually on the face, unrelated to prickly heat.




@Neet_pg_bot


@Neet_pg_bot

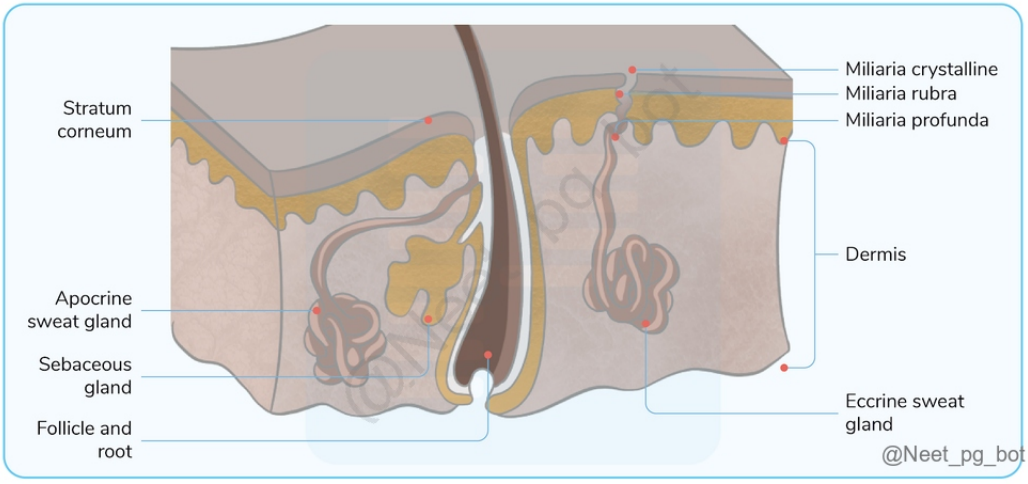

References:

Rook's Textbook of Dermatology, 9th Edition, Pages 94.12, 94.13.

↑ *Back to this question in Part A*

@Neet_pg_bot

Q26: A 28-year-old man develops multiple erythematous papules with intense prickling sensation over the trunk and flexures after working in a hot, humid environment. The lesions worsen with sweating and improve with cooling. Obstruction of which skin gland is responsible for this condition? (Q886295)

A. Apocrine sweat gland

B. Sebaceous gland

C. Eccrine sweat gland

D. Ceruminous gland

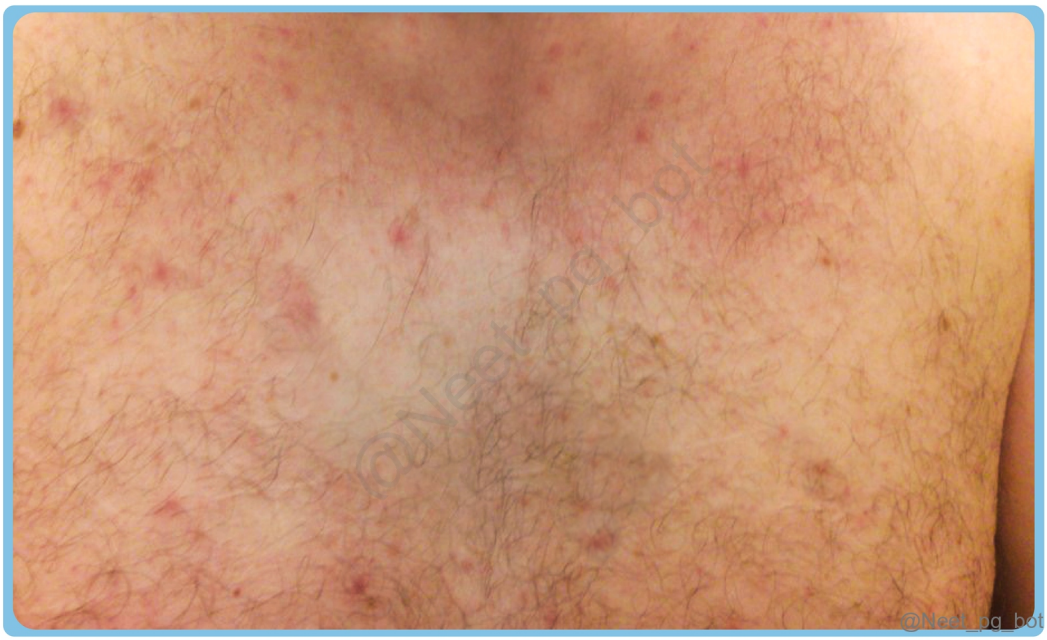

Correct Answer: C. Eccrine sweat gland

Explanation: Miliaria occurs due to occlusion or rupture of eccrine sweat ducts in hot, humid conditions. Trapped sweat leaks into the skin, producing erythematous papules with a prickling sensation that worsens with sweating and improves with cooling. Miliaria: Acute or subacute disorder due to occlusion or disruption of eccrine sweat ducts in hot, humid conditions Leads to leakage of sweat into: Epidermis → crystallina, rubra Dermis → profunda Apocrine sweat gland (Option A) : Involved in disorders like hidradenitis suppurativa and Fox-Fordyce disease , not miliaria. Sebaceous gland (Option B) : Causes acne and seborrhea; obstruction does not produce prickly heat. Ceruminous gland (Option D) : Modified apocrine glands of the external ear canal; unrelated to miliaria.

References:

Rook's Textbook of Dermatology, 9th Edition, Page 94.12.

↑ *Back to this question in Part A*

@Neet_pg_bot

Q27: A 25 year old woman presents with complaints of the following nail lesions. Which among the following might be the most likely cause of the same? (Q841977)

A. Lichen planus

B. Burns

C. Blunt force trauma

D. Scleroderma





Correct Answer: A. Lichen planus

■ *Listen (English)*

■ *Listen (Hindi)*

Explanation: The above image shows a wing-shaped extension of the proximal nail fold on the nail plate suggestive of pterygium seen in the Lichen planus (LP) of the nail. The other image shows Trachyonychia of the nail. It presents as a rough surface affecting all of the nail plate (sand-blasted nails). Nail presentation in LP includes: Longitudinal ridging, nail plate thinning, longitudinal fissuring. Pterygium occurs secondary to scarring of the nail matrix. Trachonychia: Other causes of trachyonychia include idiopathic changes and alopecia areata. Burns and Blunt force trauma (Option B and Option C) present with Pterygium but not Trachyonychia. Scleroderma (Option D) presents with Inverse Pterygium . In this condition, the hyponychium attaches to the nail distally. Other causes include connective tissue disorders, trauma, scleroderma, SLE, and Raynaud's syndrome.







References:

Rich P. 2022. Overview of nail disorders, UpToDate Rook's Textbook of Dermatology, 9th Edition, Page 95.10-95.11

↑ *Back to this question in Part A*

@Neet_pg_bot

Q28: A 28-year-old man complains of progressive hair thinning over the temples and crown over the past two years. There is no history of sudden hair shedding, scarring, or itching. Examination shows a receding hairline and miniaturized hairs in the affected areas. What is the most likely diagnosis? (Q841869)

A. Frontal fibrosing alopecia

B. Telogen effluvium

C. Androgenic alopecia

D. Lupus erythematosus

Correct Answer: C. Androgenic alopecia

Explanation: Androgenic alopecia , a type of non-scarring alopecia, characterized by progressive hair thinning especially at the temples and crown is typical of male-pattern baldness . Hair loss is divided into cicatricial and non-cicatricial alopecias: Cicatricial alopecias Non-cicatricial alopecias Loss of hair follicle stem cells. Stem cells are not affected. Irreversible cessation of hair cycle. Damage to the hair cycle can be reversed. Dermoscopy: Absent follicular ostia. Dermoscopy: Ostia is present. Black dots may be seen. Examples: Frontal fibrosing alopecia (Option A) Folliculitis Lupus erythematosus (Option D) Scleroderma Types: Patterned: Androgenic alopecia Diffuse: Effluvium (Option B) Patchy: Alopecia areata Trichotillomania. Tinea capitis Moth-eaten alopecia. Telogen effluvium (Option B) is a nonscarring alopecia marked by diffuse, often acute hair shedding due to metabolic stress, hormonal changes, or medication. It typically resolves once the underlying cause is addressed.

References:

Rook’s Textbook of Dermatology, 9th Edition, Pages 86.47, 89.10

https://www.ncbi.nlm.nih.gov/books/NBK430848/

↑ *Back to this question in Part A*

@Neet_pg_bot

Q29: A 32 year old man presents with a 5-week history of hair loss in a well-defined area as shown below. The hairs along the periphery of the lesion can be pulled with minimal traction. What is the most likely diagnosis? (Q841870)

A. Tractional alopecia

B. Alopecia areata

C. Tinea capitis

D. Telogen effluvium



Correct Answer: B. Alopecia areata

- *Listen (English)*
- *Listen (Hindi)*

Explanation: This patient with a positive hair pull test and patchy hair loss has alopecia areata. Alopecia areata is a T-cell-mediated autoimmune condition targeting the anagen hair bulb causing non-scarring hair loss. Clinical features include, Localized patches of hair loss on the scalp that emerge over a few weeks. It can also affect other areas, such as the beard, eyebrows, eyelashes, and extremities. Variants: Alopecia Totalis: Complete hair loss from the scalp. Alopecia Universalis: Complete hair loss from all over the body. Ophiasis: Occipital hair loss. Alopecia Totalis Exclamation-mark hair, with a narrower proximal end than the distal end, is commonly observed at the periphery of lesions and is a pathognomonic finding in patients with alopecia areata. Pitting of nails that is superficial, geometric and regular Patchy hair loss Yellow dots and exclamation mark hair Pitting of nails The pull test is positive, Very gentle traction on the unaffected hair at the margin of the patch of hair loss can remove all of the hair from the roots painlessly. It is a distinguishing feature of alopecia areata Traction alopecia (Option A): Because of traction, there is an excess force applied to the hair follicle causing traction alopecia. On the hair pull test, it is not possible to remove the hair with a gentle tug. The patient will have a previous history of hairstyling or wearing wigs. Tinea capitis (Option C): Pull test, Hair may break off, but it is not removed completely. There will be other symptoms like irritation and itching. Telogen effluvium (Option D): During stress, hair in the anagen phase prematurely converts into the telogen phase, causing hair loss. Only a fraction of the hair can be removed by

gentle traction and past history is significant for stress.





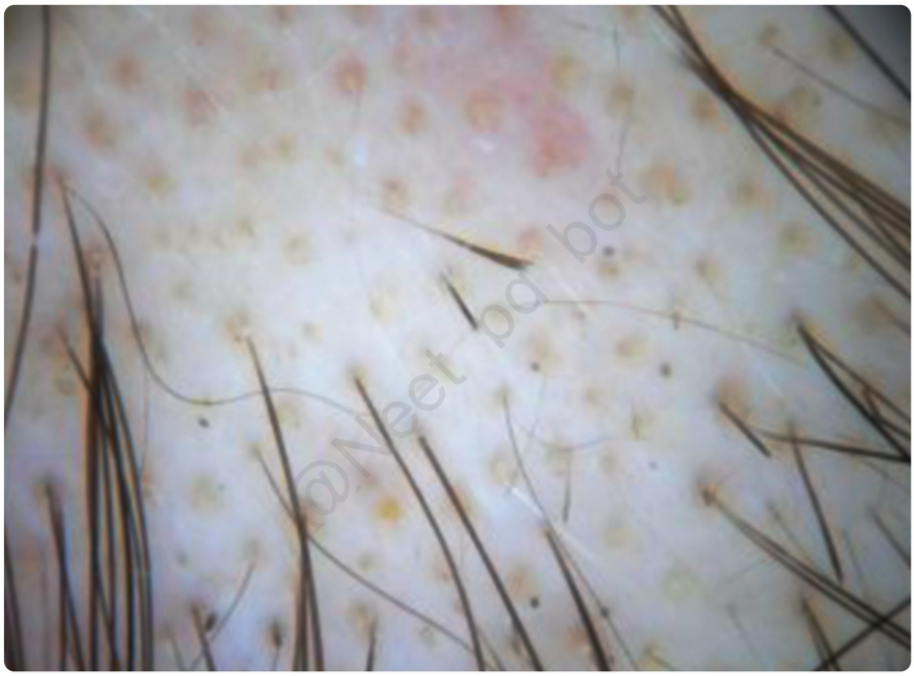

@Neet_pg_bot



@Neet_pg_bot

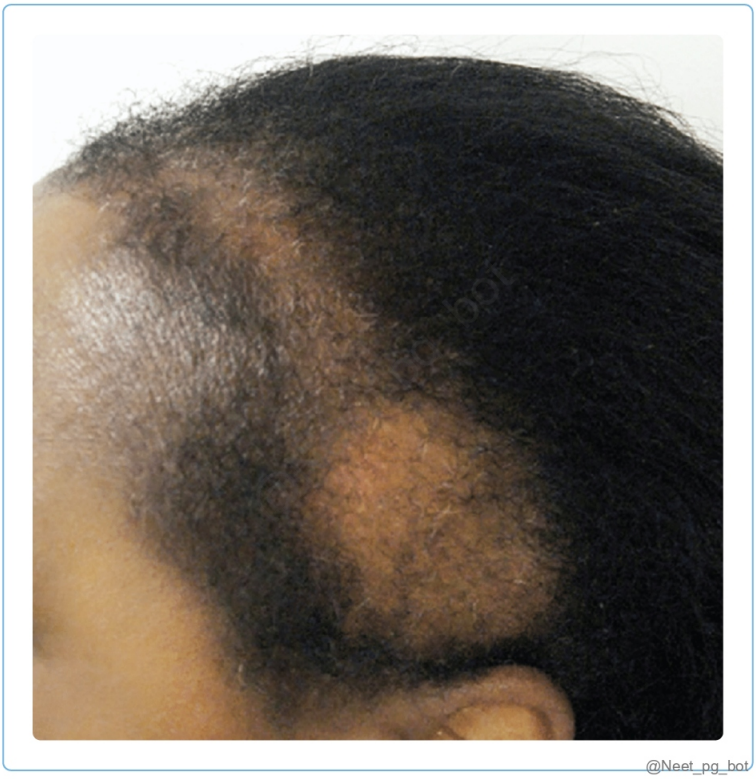

References:

Rook's Textbook of Dermatology, 9th Edition, Section 89.10

↑ *Back to this question in Part A*

@Neet_pg_bot

Q30: A 28 year old female presents with concerns about hair loss and decreased hair volume, as shown below. Many members of her family also have a similar history of significant hair loss. All of the following are true about the given condition except? (Q841968)

A. Frontal hairline preservation is seen.

B. It follows a polygenic mode of inheritance.

C. Ludwig’s grading system is used to assess severity.

D. Mitochondrial inheritance is the primary mode of transmission.

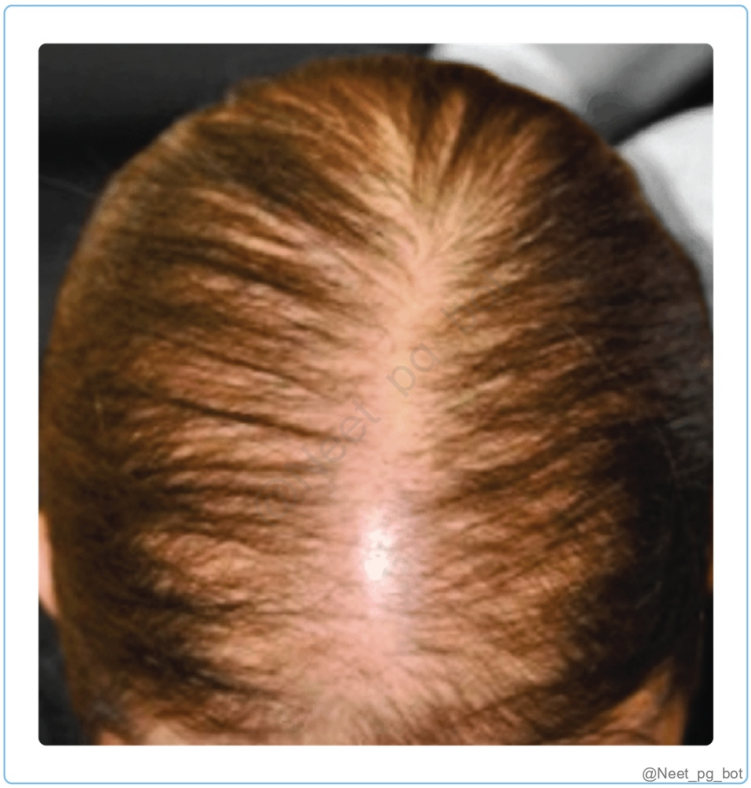

Correct Answer: D. Mitochondrial inheritance is the primary mode of transmission.

- *Listen (English)*
- *Listen (Hindi)*

Explanation: Hair loss with increased central parting and decreased hair volume is considered to be female pattern hair loss (FPHL). It is different from female pattern baldness as there is no loss of front hairline (Option A) . It is seen in androgenetic alopecia which occurs due to the involvement of multiple hormonal and genetic factors. Multiple genes have been identified for the same and hence it is considered to be of polygenic inheritance (Option B). It is commonly seen in middle-aged women with progressive loss of terminal hair over the vertex of the scalp. It presents with diffuse thinning of hair, increased hair shedding, decreased hair volume, and widening of hair partition. Grade 3 FPHL is also called the ‘Fir tree / Christmas tree’ pattern. Ludwig’s grading for female androgenic alopecia. (Option C) Treatment: Topical 2% minoxidil is the first line of treatment, with or without adjuncts like spironolactone in women and finasteride in men.

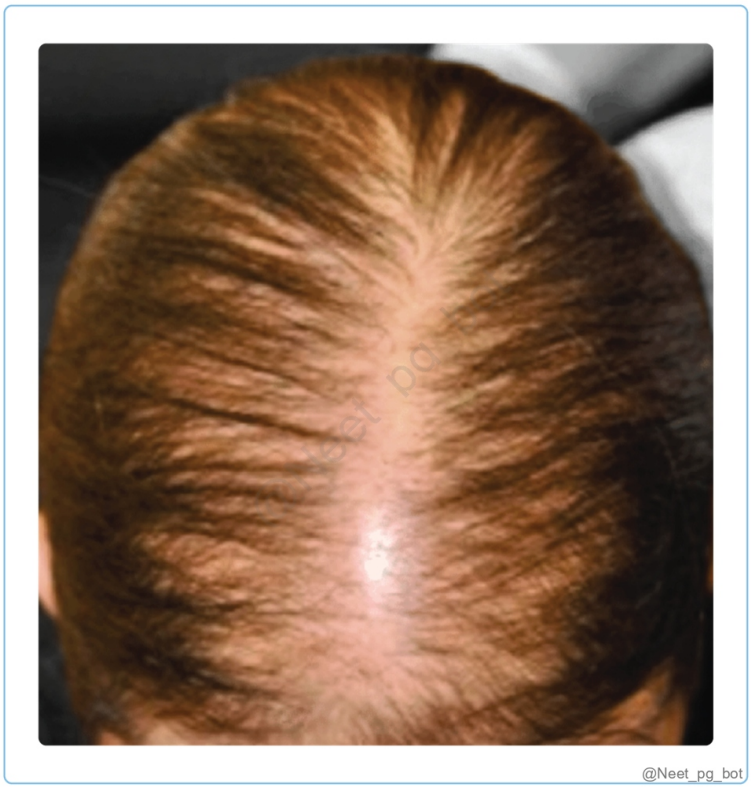

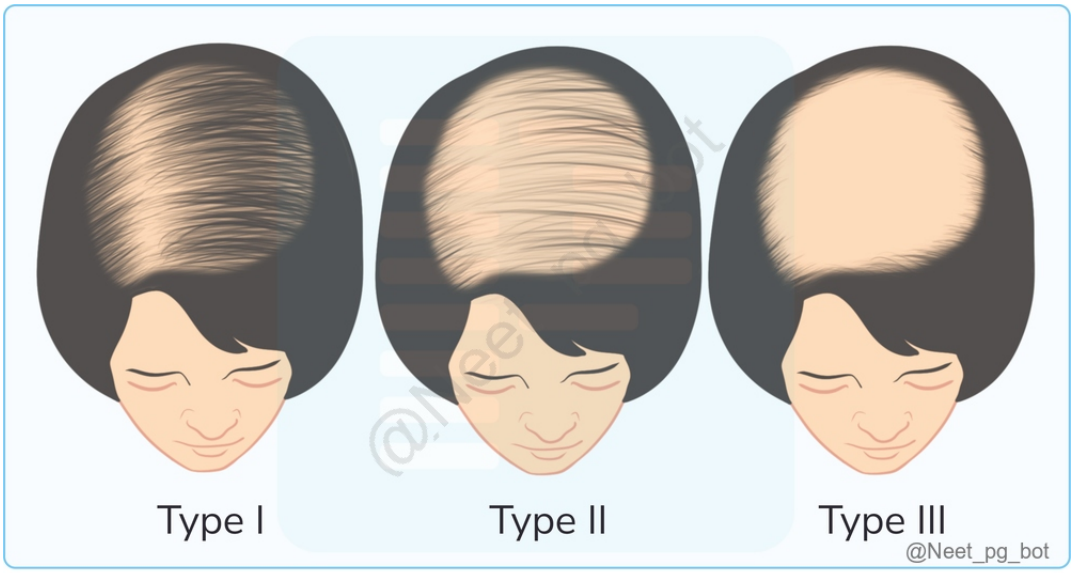

References:

Rook's Textbook of Dermatology, 9th Edition, Page 89.14-86.24. Female pattern hair loss (androgenetic alopecia in females): Management - UpToDate

↑ *Back to this question in Part A*

@Neet_pg_bot

Q31: A 35 year old male presents with concern about hair loss and gradual thinning, as seen in the picture given below. He reports that all the male members of his family has lost their hair by 45 years, What is the most likely diagnosis? (Q841969)

A. Androgenic alopecia

B. Female pattern baldness

C. Alopecia areata

D. Pseudopelade of Brocq



Correct Answer: A. Androgenic alopecia

■ *Listen (English)*

■ *Listen (Hindi)*

Explanation: The patient presents with concerns about hair loss and hair thinning, with the family history suggesting the diagnosis of male pattern baldness in this patient. Male pattern hair loss (androgenetic alopecia) is common in men, characterized by progressive loss of terminal hairs on the scalp, influenced by genetics and hormones. It typically begins at the temples and crown, progressing with age. Dihydrotestosterone (DHT), derived from testosterone, shrinks hair follicles, reducing the anagen phase and miniaturizing hair. This leads to the transformation of thick terminal hair into finer, vellus hair. Symptoms include hair thinning and bitemporal recession of the hairline Bitemporal recession → vertex balding → Finally left with a band of hair in the occipital

region because this area is androgen-independent. Grading: Hamilton Norwood grading Treatment: Topical treatment: Minoxidil 5% Systemic: Oral 5-alpha reductase inhibitors(finasteride, dutasteride) Surgical: Hair transplantation Alopecia areata (Option C) is an autoimmune condition where the immune system mistakenly attacks hair follicles, leading to sudden, round patches of hair loss. This is not consistent with the given clinical scenario. Pseudopelade of Brocq (Option D): Pseudopelade of Brocq (PPB) is a rare, idiopathic self-limiting hair disorder resulting in progressive cicatricial alopecia. Footprints in snow appearance.

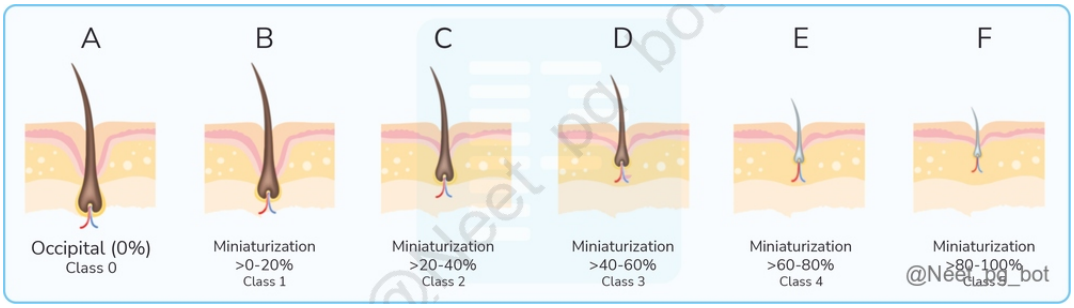

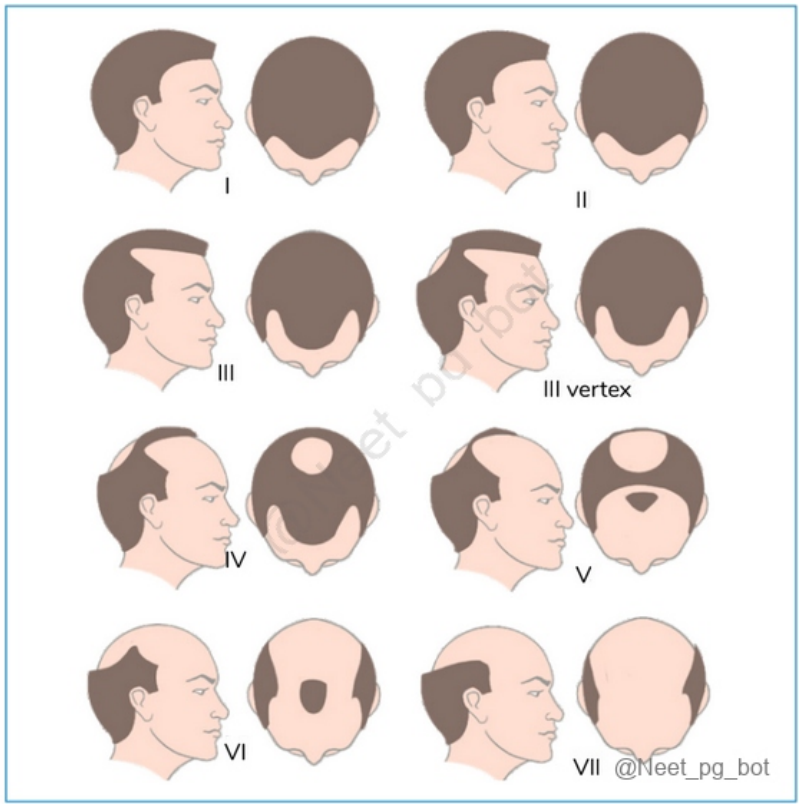



References:

Rook’s Textbook of Dermatology, 9th Edition, Page 89.14-86.24.

Diwan, N., Gohil, S., & Nair, P. A. (2014). Primary Idiopathic Pseudopelade of Brocq: Five Case Reports.International Journal of Trichology,6(1), 27-30.

https://doi.org/10.4103/0974-7753.136759

↑ *Back to this question in Part A*

@Neet_pg_bot

Q32: A 30 year old woman has been complaining of patchy scalp hair loss for the past three weeks. Her past medical history is significant for vitiligo and thyroid disorders. On examination, she has a well-circumscribed area of hair loss over her occipital region, as shown below. Which among the following is not a feature of the disease described? (Q841970)

A. Ophiasis

B. Exclamation mark hair

C. Trichoclasis

D. Turning grey syndrome



Correct Answer: C. Trichoclasis

■ *Listen (English)*

■ *Listen (Hindi)*

Explanation: This patient with a history of autoimmune diseases and patchy hair loss as described in the question and image is suggestive of alopecia areata. Trichoclasis is a feature of a feature of trichorrhexis nodosa, not alopecia areata. Trichoclasis: It is a transverse break in the hair shaft through a node seen in Trichorrhexis nodosa . It is a hair shaft disorder where the hair shaft is excessively fragile due to the presence of nodes. The end of the hair resembles a small paint brush with cortical fibers extruding through the fracture as shown in the image. The proximal end of the hair shaft is normal, unlike in alopecia areata. It is associated with rare genetic diseases like argininosuccinate lyase deficiency. Clinical features : Sparse, brittle, and lustreless hair Diagnosis is through physical examination and hair shaft microscopy Treatment includes avoiding trauma to the hair and management of the medical cause. The features of alopecia areata include Ophiasis (Option A) is scalp hair loss in the occipital region, whereas sisaipho is the opposite of this variant, with scalp hair loss sparing the temporal and occipital areas. Ophiasis Sisaipho Exclamation mark hair (Option B) Turning grey syndrome (Option D): It is a feature of alopecia areata where white hair are typically spared by immune cells, leading to loss of black hair with sparing of white hair Nail pitting : Regular, geometric pitting of the nail bed as shown below. Note: Psoriasis shows irregular pitting. Treatment depends on the extent of the disease. Topical therapy for limited disease is done using intralesional steroids and contact immunotherapy whereas systemic therapy, Levamisole or Cyclosporine is used for extensive disease.

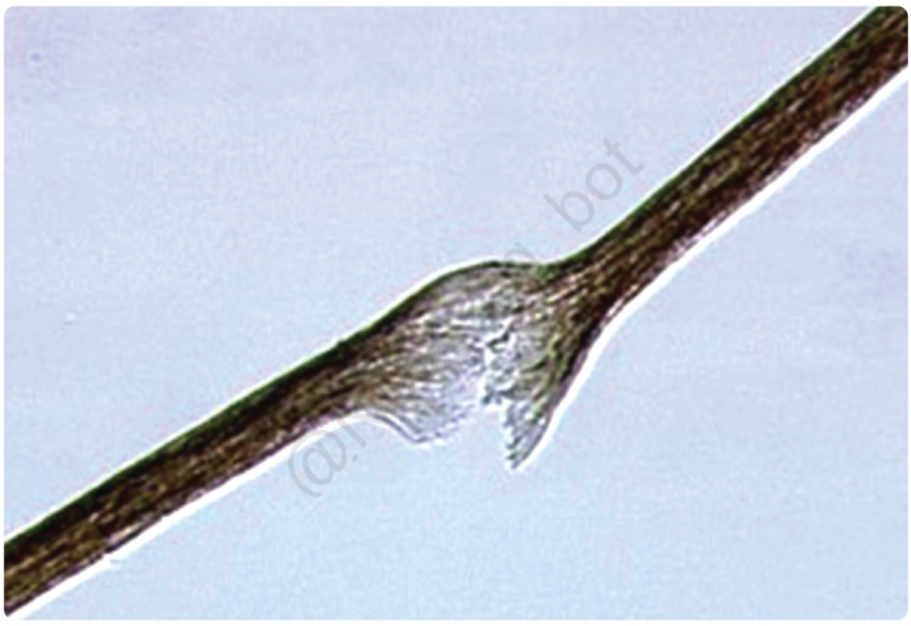

@Neet_pg_bot



@Neet_pg_bot

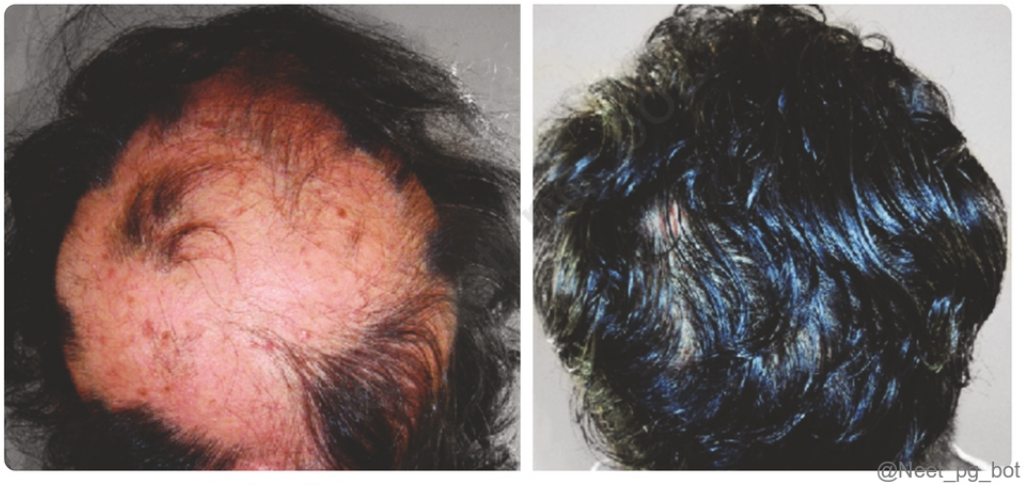
@Neet_pg_bot


@Neet_pg_bot

Regular pitting

Irregular pitting



References:

Spano F, Donovan JC. Alopecia areata: Part 1: pathogenesis, diagnosis, and prognosis. Can Fam Physician. 2015 Sep;61(9):751-5. PMID: 26371097; PMCID: PMC4569104.

Rook's Textbook of Dermatology, 9th Edition, Page 89.28 - 86.34.

pubmed.ncbi.nlm.nih.gov/30630022/

https://www.ncbi.nlm.nih.gov/books/NBK537000/

↑ *Back to this question in Part A*

@Neet_pg_bot

Q33: The image shows a 16 year old boy brought to the clinic by his father with an unusual pattern of hair loss. History states that he has become increasingly reclusive, avoiding family gatherings and showing less interest in his usual hobbies spending most of his time alone in his room. The boy himself appears unaware of the issue and has no complaints. What is the possible diagnosis? (Q841971)

A. Trichotillomania

B. Alopecia areata

C. Pseudopelade of Brocq

D. Netherton Syndrome

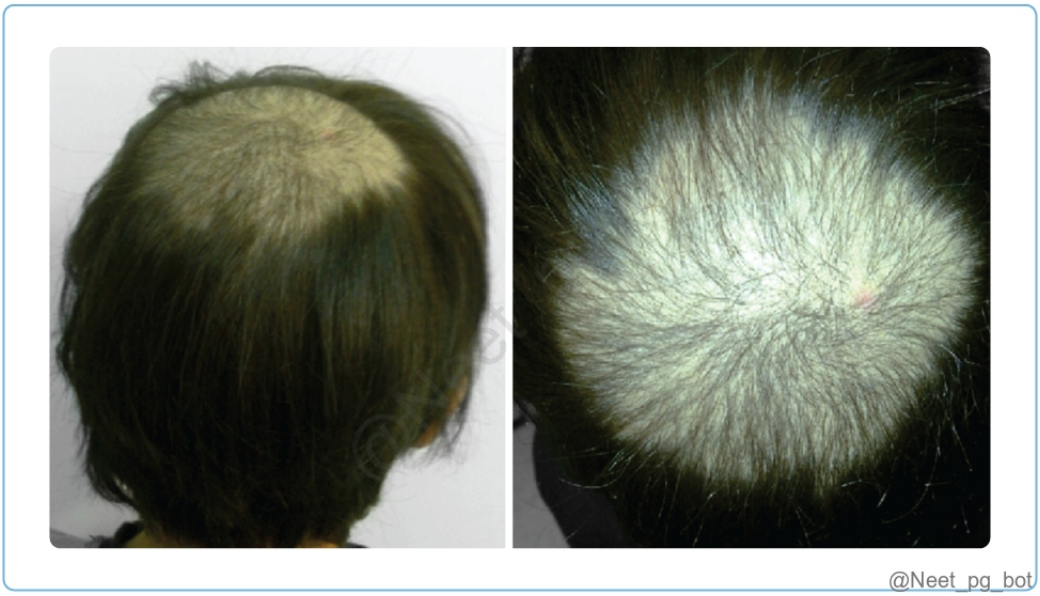

Correct Answer: A. Trichotillomania

■ *Listen (English)*

■ *Listen (Hindi)*

Explanation: The boy with the above history and a characteristic Friar Tuck hair loss pattern has trichotillomania. Trichotillomania: It is a psychiatric disorder in which obsessive, recurrent pulling of one's hair results in hair loss. It is seen in adolescents or young adults, more commonly in girls. Patchy hair loss with broken hair of variable lengths is seen in commonly accessible sites like the frontoparietal area of the scalp. In the Friar Tuck sign or Tonsure pattern, there is uneven hair loss in a circular pattern with surrounding hairs remaining unaffected. Perifollicular hemorrhages can also be seen because of trauma to the scalp. Skin biopsy shows empty hair follicles, with some forming soft twisted hairs described as trichomalacia. Treatment includes cognitive behavioral therapy and antipsychotic medications like SSRI and paroxetine. Trichobezoar/ Rapunzel syndrome is caused by chronic ingestion of hair ; it is commonly seen in young females who may have psychological disorders, such as trichophagia and trichotillomania. Common symptoms are abdominal pain, nausea, vomiting, and weight loss. Netherton syndrome (Option D) is an autosomal recessive disorder caused by a mutation in the serine protease inhibitor. Characteristic triad includes, Congenital Ichtyosiform erythroderma. Trichorrhexis invaginata (Bamboo hair). Atopic diathesis. Alopecia areata (Option B) is an autoimmune condition where the immune system mistakenly attacks hair follicles, leading to sudden, round patches of hair loss. This is not consistent with the given clinical scenario. Pseudopelade of Brocq (Option C) is a chronic and slowly progressive idiopathic condition with no inflammation, scaling, or erythema. Smooth patches due to scarring alopecia. Footprint in snow appearance-spreading patches of cicatricial alopecia.

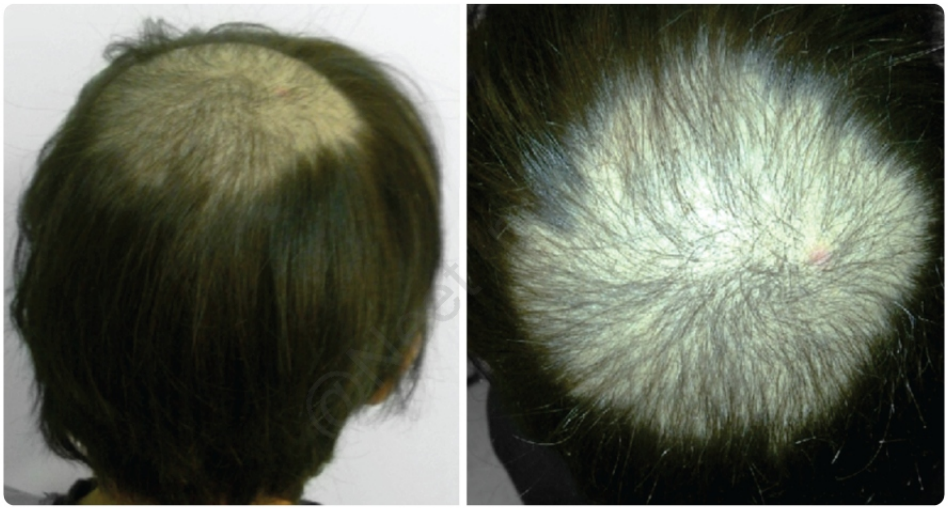



References:

Rook’s Textbook of Dermatology, 9th Edition, Page 86.17- 86.19.

↑ *Back to this question in Part A*

@Neet_pg_bot

Q34: A middle-aged woman presents with a history of recurrent painful, pustular lesions on scalp which heals with scarring. She is healthy otherwise with no history of similar lesions. Which of the following is the most appropriate diagnostic test? (Q841972)

A. The culture of extracted hair alone.

B. Culture of extracted hair with patient-collected hair sheddings.

C. Shave biopsy of scalp and culture of extracted hair.

D. Punch biopsy of scalp and culture of extracted hair.



Correct Answer: D. Punch biopsy of scalp and culture of extracted hair.

■ *Listen (English)*

■ *Listen (Hindi)*

Explanation: The patient presented with a history of recurrent painful, pustular lesions on the scalp which heal with scarring suggests the diagnosis of Folliculitis decalvans . A punch biopsy of the scalp and culture of extracted hair is the most appropriate investigation. Folliculitis decalvans: Folliculitis decalvans or tufted hair folliculitis is a progressive pattern of cicatricial alopecia of the scalp. Its characteristic feature is the presence of multiple tufts of hair emerging from a single follicular opening also known as Doll's hair appearance The images below depict the scaring alopecia seen in Folliculitis decalvans. Diagnosis is based on clinical and histological findings. Ideal biopsy tissue should contain clinical signs of scarring, no follicular ostia, and active inflammation (pustules,

erythema, etc.). Hence, a punch biopsy that extends into the subcutaneous fat is our preferred procedure for the pathologic evaluation of FD. Oral antibiotics (Tetracyclines) are the mainstay treatment.


@Neet_pg_bot


@Neet_pg_bot

References:

Goldberg J L. 2022.Folliculitis decalvans, UpToDate

↑ *Back to this question in Part A*

@Neet_pg_bot

Q35: A 32 year old man complains of multiple inflamed, fluctuating nodules on his scalp. He also has patchy areas of hair loss. Upon examination, you notice interconnected sinus tracts and scarring with pustular discharge as shown below. Which of the following is not associated with this disease? (Q841973)

A. Acne conglobata

B. Pilonidal sinus

C. Pustular psoriasis

D. Hidradenitis suppurativa



@Neet_pg_bot

Correct Answer: C. Pustular psoriasis

■ *Listen (English)*

■ *Listen (Hindi)*

Explanation: The above scenario with scalp lesions is seen in dissecting cellulitis of the scalp, which is part of the follicular occlusion tetrad. Pustular psoriasis is not part of the tetrad. Follicular occlusion tetrad is a group of four disorders where follicular occlusion is thought to be a key pathogenic event. The components of this tetrad are:

Dissecting cellulitis of the scalp Hidradenitis suppurativa (Option D) Acne conglobata (Option A) Pilonidal sinus (Option B) Pilonidal sinus Dissecting cellulitis of the scalp: Dissecting cellulitis of the scalp (Hoffman disease) is a type of cicatricial alopecia characterized by multiple suppurative nodular lesions over the scalp. Follicular occlusion by accumulation of sebaceous and keratinous materials causes an intense neutrophilic inflammatory reaction which is exacerbated by secondary bacterial infection. The patient presents with boggy, suppurative pustules and nodules that later form sinus tracts. This leads to patchy and scarring alopecia over the scalp as shown below. Diagnosis is mainly clinical through history and examination. Cultures are done to determine the organism causing secondary infection. Treatment: Treatment is started with oral antibiotics and/or oral isotretinoin. Biologic tumor necrosis factor (TNF)-alpha inhibitors and surgical excision are options in patients who don't respond to earlier treatment.





References:

Rook's Textbook of Dermatology, 9th Edition, Page 107.8 - 107.9.

https://www.ncbi.nlm.nih.gov/pmc/articles/PMC10613185/

↑ *Back to this question in Part A*

@Neet_pg_bot

Q36: Match the sign with its associated hair disorder: a. Pseudopelade of Brocq i. Scaly & itchy violaceous lesions b. Folliculitis decalvans ii. Doll’s hair sign c. Follicular lichen planus iii. Patches with scales & follicular plugging d. Lupus erythematosus iv. Footprint in snow sign (Q841974)

A. a-ii, b-i, c-iv, d-iii

B. a-i, b-iv, c-iii, d-ii

C. a-iii, b-ii, c-i, d-iv

D. a-iv, b-ii, c-i, d-iii

Correct Answer: D. a-iv, b-ii, c-i, d-iii

■ *Listen (English)*

■ *Listen (Hindi)*

Explanation: Pseudopelade of Brocq Chronic and slowly progressive idiopathic condition with no inflammation, scaling, or erythema. Smooth patches due to scarring alopecia. Footprint in snow appearance-spreading patches of cicatricial alopecia. Footprint in snow sign Folliculitis decalvans Deep folliculitis caused by bacteria. Pustules with neutrophilic infiltrate damage the stem cells causing cicatricial alopecia. Doll’s hair sign - Multiple hair tufts emerge from the common dilated follicular opening. Doll’s hair sign Follicular LP / Lichen plano pilaris Violaceous plaques in the perifollicular distribution. Itching present. Scaly & itchy violaceous lesions Lupus erythematosus Scarred patches of alopecia are associated with scaling and follicular plugging. A positive history of lupus may be present. Patches with scales & follicular plugging



@Neet_pg_bot



@Neet_pg_bot





References:

Rook’s Textbook of Dermatology, 9th Edition, Page 89, 89, 107

↑ *Back to this question in Part A*

Q37: A 32 year old woman presents with complaints of abnormal hair growth, as shown in the image. Which of the following drugs can be prescribed to her as oral therapy? (Q841975)

A. Danazol

B. Tamoxifen

C. Phenytoin

D. Spironolactone



Correct Answer: D. Spironolactone

Listen (English)

Listen (Hindi)

Explanation: The given image shows coarse terminal hair in the face region of a woman, which suggests hirsutism. Among the given options, spironolactone is a popular treatment for hirsutism. It interferes with the production of testosterone and increases its metabolic clearance. Management of hirsutism- Topical Eflornithine Anti-androgen drugs Spironolactone OCPs If the patient has PCOS. Dutasteride Flutamide Cyproterone acetate Physical Hair

removal lasers Diode and long pulse ND Yag laser Danazol. Tamoxifen & Phenytoin (Options A, B & C) are drugs responsible for causing hirsutism.

References:

Rook's Textbook of Dermatology, 9th Edition, Page 89.64-86.68

↑ *Back to this question in Part A*

@Neet_pg_bot

Q38: A 32 year old female presents with complaints of breathlessness, weakness, and fatigue for the past few months. She has no significant past history. On examination, she appears to have some nail changes as depicted in the image below. What would be the most appropriate investigation to verify the diagnosis? (Q841976)

A. Liver function tests

B. Serum albumin

C. Chest X-ray

D. Serum iron level



Correct Answer: D. Serum iron level

■ *Listen (English)*

■ *Listen (Hindi)*

Explanation: The patient presented with complaints of breathlessness, weakness, and fatigue for the past few weeks and has spoon-shaped nails (koilonychia), as shown in the image, suggesting iron deficiency anemia.Koilonychia is most commonly a manifestation of chronic iron deficiency.Iron deficiency anemia is primarily a laboratory diagnosis. Low serum iron and ferritin levels plus an elevated total iron binding capacity (TIBC) are diagnostic of iron deficiency. Other causes of koilonychia include Pulmonary and thoracic causes- Bronchogenic carcinoma, suppurative lung disease (bronchiectasis, cystic fibrosis, lung abscess, empyema), interstitial lung disease, long-standing pulmonary TB. Gastrointestinal causes- Cirrhosis of the liver, UC, Crohn’s disease. Cardiovascular causes- Cyanotic congenital heart disease, bacterial endocarditis, atrial myxoma, and Eisenmeger’s syndrome. LFTs (Option A) are useful in diagnosing Terry’s nails. It's a type of leukonychia, where the proximal part is white and the distal nail appears normal and red. It is seen in alcoholic cirrhosis, T2DM, and some other autoimmune diseases. Serum albumin (Option B) can be useful in the diagnosis of Muehrcke's lines on nails, which are transverse, white bands that run across the nail. These are typically associated with hypoalbuminemia in nephrotic syndrome. Chest X-ray (Option C): Clubbing refers to increased longitudinal and transverse curvatures of the nail plate. Clubbing is commonly associated with pulmonary and cardiovascular diseases such as lung cancer, congenital heart disease, pulmonary fibrosis, asbestosis, and infective endocarditis.







References:

Rooks Textbook of Dermatology, 9th Edition, Chapter 69

↑ *Back to this question in Part A*

@Neet_pg_bot

Q39: A 70 year old man presents with complaints of recent hair loss. He is currently undergoing chemotherapy treatment for acute lymphoblastic leukaemia. Scalp examination reveals significantly decreased hair density compared to the previous visit. Which stage of his hair cycle is most likely affected? (Q841868)

A. Anagen

B. Catagen

C. Telogen

D. Exogen

Correct Answer: A. Anagen

■ *Listen (English)*

■ *Listen (Hindi)*

Explanation: The most likely diagnosis in this patient undergoing chemotherapy is Anagen effluvium, which refers to hair shedding during the anagen or growth stage of the hair cycle. Hair goes through 3 stages in its life cycle. These stages are the Anagen phase (growth phase): 86% of hair, 3 years. Catagen phase (transition phase): 1% of hair, 3 weeks. Telogen phase (falling phase): 10-13% of hair, 3 months. Anagen effluvium: Anagen effluvium refers to hair shedding in the growth phase of the hair cycle. In this phase, the affected hairs have a cessation in their mitotic activity, causing damage to the hair shaft that results in breakage and complete hair loss if the bulb is affected. The main causes of anagen effluvium are toxic or inflammatory insults from drugs, toxins, radiation, and autoimmune diseases. Infections may interrupt hair growth, resulting in a single or several bald patches. Onset is rapid after 2–3 weeks after exposure to the cause. It is a diffuse, non-scarring type of alopecia that is completely reversible after the stoppage of cause, with a delay of 3–6 months. It requires no particular treatment. Catagen (Option B) is incorrect because it is the transitional phase (2–3 weeks) when hair growth slows and follicular regression begins. It is not the primary target in chemotherapy-related hair loss. Telogen (Option C) is incorrect because telogen effluvium refers to hair shedding due to premature shift into the resting phase , typically seen after stress, fever, or childbirth , not chemotherapy. Onset is delayed (2–3 months) after the insult. Exogen (Option D) : is incorrect because this is the shedding phase of telogen hairs. It is a passive process and not directly disrupted by chemotherapy agents.

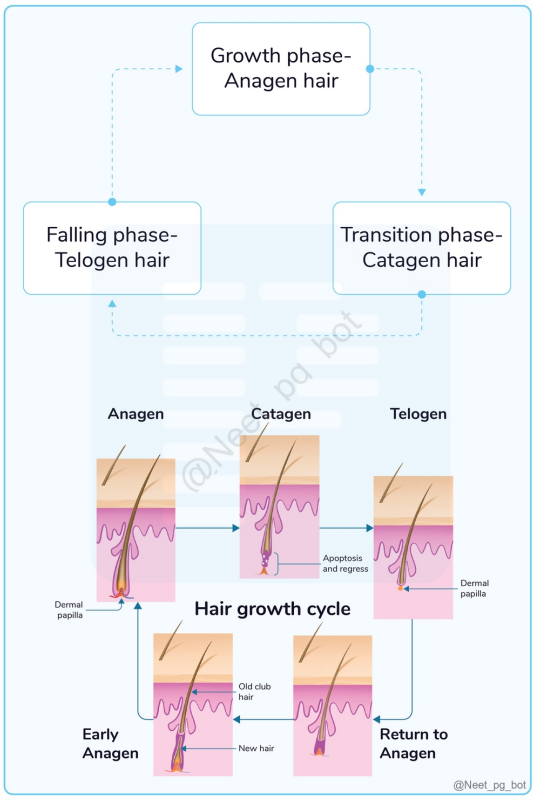

References:

1. Rugo H S. 2023. Alopecia related to systemic cancer therapy, UpToDate 2. Rook's Textbook of Dermatology, 9th Edition, Page 89.6 - 86.27.

↑ *Back to this question in Part A*

@Neet_pg_bot

Q40: A 42 year old male patient presents with numbness and tingling sensation over his soles. O/E, there are areas of hyperpigmentation, along with skin thickening on the palms and soles. The following findings are seen in his nails. Which of the following heavy metals could be responsible for his symptoms? (Q841978)

A. Lead

B. Arsenic

C. Mercury

D. Cadmium



Correct Answer: B. Arsenic

- *Listen (English)*
- *Listen (Hindi)*

Explanation: The given scenario with transverse, white bands that run parallel on the nail suggests a case of chronic arsenic poisoning. Chronic exposure to arsenic results in peripheral neuropathy, vascular insufficiency and various malignancies. Cutaneous manifestations include Mee's lines, arsenic keratosis, eczema and gangrene. Arsenic keratosis Mee's lines Acute arsenic poisoning presents with severe nausea, vomiting, abdominal pain and diarrhoea. Lead (Option B): Lead is a common heavy metal additive found in paints, and chronic exposure can lead to lead poisoning. It presents with features of nausea, diarrhoea, weakness, tremors anaemia, headache, memory disturbances and visual defects. Burton's line is a classical sign on examination. It is a bluish line present on the gums in chronic lead poisoning. Mercury (Option C): Poisoning from mercury can occur due to inorganic sources like thermometers or organic mercury in fish (Minamata disease in Japan). Mercury poisoning presents with tremors, excessive salivation, Erethism (Personality and memory disorders), and membranous glomerulopathy. Cadmium (Option D): Cadmium toxicity occurs commonly in people handling old metal pipes, batteries, polluted water, electric cigarettes, and areas with high air pollution. Symptoms include nausea, vomiting, chest pain, flu-like symptoms, and shortness of breath. It can also lead to pneumonitis, osteoporosis, and chronic kidney disease.



@Neet_pg_bot



@Neet_pg_bot



References:

Harrison's Principles of Internal Medicine, 21st Edition, Page 472e-2, 472e-3.

↑ *Back to this question in Part A*

@Neet_pg_bot

Q41: A 30 year old woman reports experiencing diffuse hair loss starting about three months after a period of significant systemic stress, including a major life event and emotional strain. She notes increased hair shedding when washing or brushing her hair. What is the most likely cause of her diffuse hair loss, given the link between systemic stress and the condition? (Q842645)

A. Androgenetic alopecia

B. Alopecia areata

C. Telogen effluvium

D. Anagen effluvium

Correct Answer: C. Telogen effluvium

Explanation: Telogen effluvium is commonly associated with systemic stress, leading to diffuse hair loss due to a disruption in the hair growth cycle, which results in increased shedding. Telogen effluvium: This is a type of diffuse hair loss triggered by systemic stress, which disrupts the normal hair growth cycle. Stress causes hair follicles to prematurely enter the resting phase (Telogen) instead of the growth phase (Anagen), leading to hair shedding after about three months. Chronic TE can be caused by factors like iron deficiency, thyroid disorders, crash dieting, or malnutrition. Prolonged exposure to stressors can result in long-term hair loss. Androgenic

alopecia (Option A) : This is a genetic condition characterized by gradual, patterned hair loss. In men, it usually results in a receding hairline and thinning at the crown. In women, it often causes diffuse thinning over the crown but preserves the frontal hairline. Alopecia areata (Option B): This is an autoimmune condition where the immune system mistakenly attacks hair follicles, leading to sudden, round patches of hair loss. Anagen effluvium (Option D): This type of hair loss occurs during the anagen (growth) phase of the hair cycle and is often caused by exposure to toxic substances like chemotherapy agents. Seen due to a disorder of the anagen phase of the hair cycle. The main causes of anagen effluvium are infection, drugs, toxins, radiation, and autoimmune disease. Infections may interrupt hair growth, resulting in a single or several bald patches. Onset is rapid after 2–3 weeks after exposure to the cause.

References:

Rook's Textbook of Dermatology, 9th Edition, Page 89.24

↑ *Back to this question in Part A*

@Neet_pg_bot

Q42: Which structure divides the permanent part of the hair follicle from the cycling part? (Q884279)

A. Opening of the sebaceous duct

B. Insertion of the arrector pili muscle

C. Dermal papilla

D. Hair bulb

Correct Answer: B. Insertion of the arrector pili muscle

Explanation: The arrector pili muscle insertion marks the boundary between the upper follicle (infundibulum + isthmus, relatively permanent) and the lower follicle (suprabulbar region + hair bulb, cycling during the hair cycle). The follicle is obliquely placed in the dermis Arrector pili muscle : papillary dermis → mid-follicle wall Sebaceous glands (± apocrine glands) open into the follicle above the arrector insertion Regions of Hair Follicle: Upper Follicle (Permanent): Infundibulum: From the skin surface → sebaceous duct opening Epidermis-like keratinisation Isthmus: From sebaceous duct → arrector pili insertion Trichilemmal keratinization Hair follicle stem cells are located here (bulge area) Lower Follicle (Cycling): Suprabulbar region: Outer root sheath (ORS) Inner root sheath (IRS) Hair shaft Hair bulb: Deepest part (often in subcutis) Contains matrix cells and dermal papilla

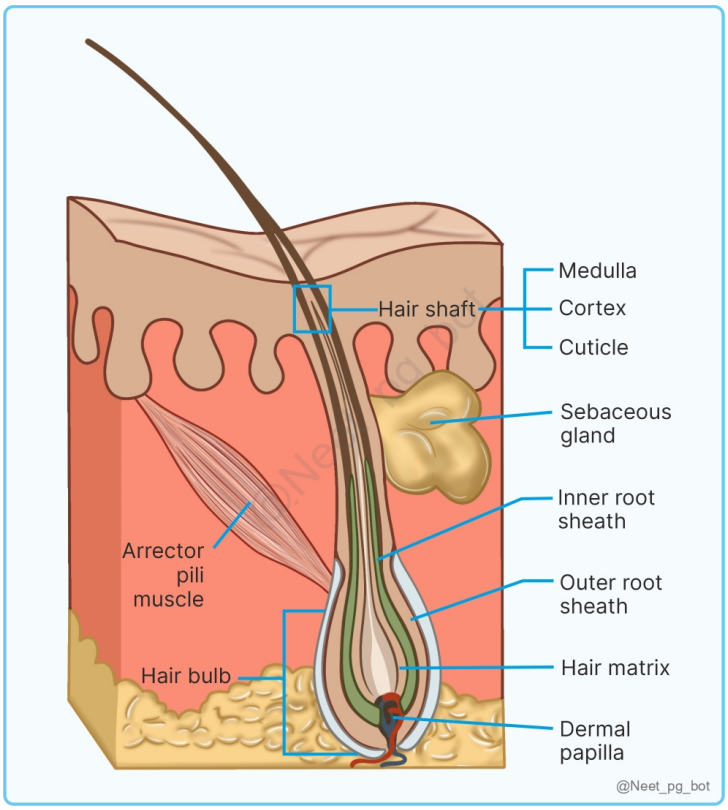

References:

Rook's Textbook of Dermatology, 9th Edition, Pages 89.3, 89.4.

↑ *Back to this question in Part A*

@Neet_pg_bot

Q43: In a healthy adult with a normal scalp hair cycle, the majority of hair follicles are found in which phase at any given time? (Q884280)

A. Catagen phase

B. Telogen phase

C. Exogen phase

D. Anagen phase

Correct Answer: D. Anagen phase

Explanation: Most scalp follicles are actively growing (anagen) at any given time. Hair cycle: Hair follicles undergo a cyclic pattern of growth and rest . Anagen (Growth): Active hair growth determines hair length Weeks

(body hair) to years (scalp) 80-90% of scalp follicles are in anagen Mitotic activity in the hair bulb; formation of hair shaft and inner root sheath Catagen (Option A) (Regression): Short involution phase Cell division stops, and the follicle undergoes apoptosis Hair shaft forms club hair The dermal papilla moves up to the arrector pili level Telogen (Option B) (Rest): Follicle inactive Club hair is retained in the epithelial sac Exogen (Option C) : Active shedding of club hair Kenogen (Human scalp): Latent phase after shedding before new anagen

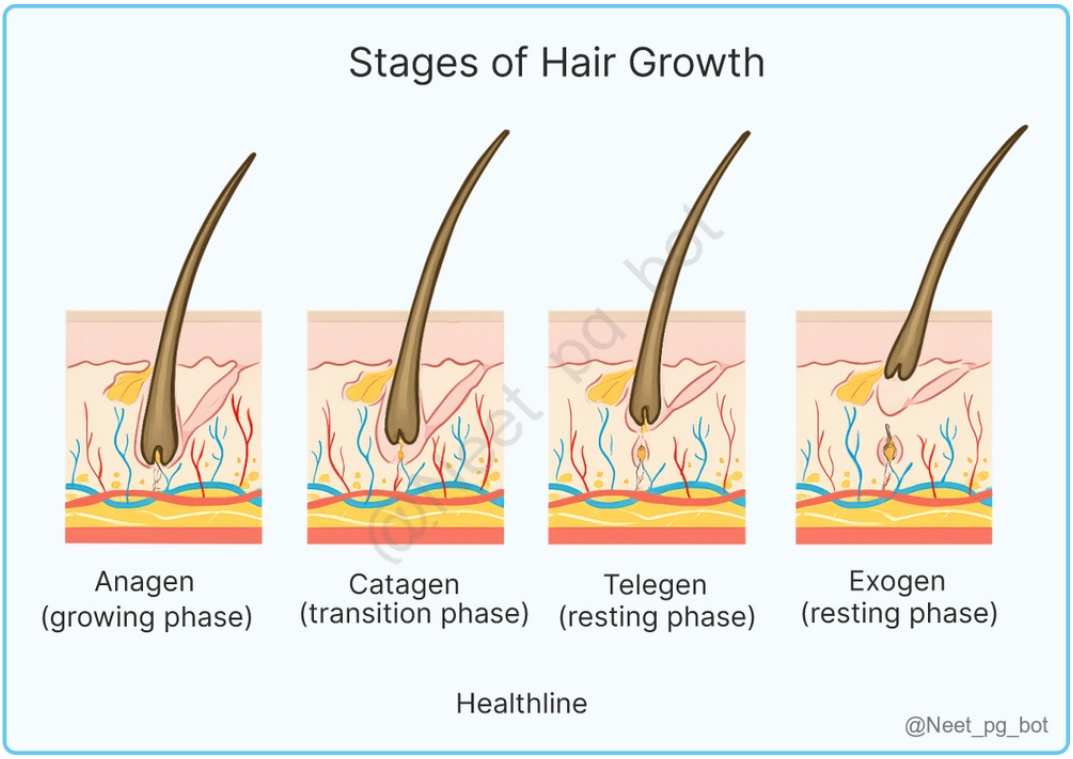

References:

Rook's Textbook of Dermatology, 9th Edition, Page 89.7.

↑ *Back to this question in Part A*

@Neet_pg_bot

Q44: Which of the following statements regarding human hair is incorrect? (Q884283)

A. Vellus hair is soft and <2 cm long

B. Lanugo is shed after birth

C. Terminal hair develops after puberty under androgen influence

D. Humans lack vibrissae follicles

Correct Answer: B. Lanugo is shed after birth

Explanation: Lanugo is prenatal hair that is normally shed in utero (8-9 months of gestation), not after birth. Types of Hair: Hair type depends on the kind of follicle and can change with age or hormonal fluctuations. Lanugo: prenatal, fine, soft, unmedullated, usually unpigmented; shed in utero (~8-9 months) Postnatal hair: Vellus: soft, fine, unmedullated, sometimes pigmented, ≤2 cm (Option A) Terminal: longer, coarse, medullated, pigmented Intermediate types exist Distribution: Pre-puberty: terminal hair on scalp, eyebrows, eyelashes Post-puberty: androgen-driven terminal hair develops from vellus in secondary sexual areas (Option C) Animals: Guard hairs: stiff, protective overcoat Undercoat: fine, soft hairs Vibrissae (sinus hairs): sensory, with erectile tissue (not in humans) (Option D)

References:

Rook's Textbook of Dermatology, 9th Edition, Page 89.2.

↑ *Back to this question in Part A*

@Neet_pg_bot

Q45: Which of the following 5α-reductase isoforms does finasteride not act upon? (Q884285)

A. Type 1 & 2

B. Type 2

C. Type 3

D. Type 1 & 3

Correct Answer: D. Type 1 & 3

Explanation: Finasteride selectively inhibits 5α-reductase type 2 , the key isoform involved in androgen-dependent hair growth. Testosterone → DHT via 5α-reductase Isoforms: Type 1: widespread in the skin Type 2: androgen-target tissues (key for hair growth) Type 3: role unclear Finasteride inhibits type 2 → ↓ alopecia & hirsutism.

References:

Rook's Textbook of Dermatology, 9th Edition, Page 89.9.

↑ *Back to this question in Part A*

@Neet_pg_bot

Q46: The primary site of androgen action, determining hair growth and pattern baldness, is? (Q884296)

A. Hair shaft cortex

B. Outer root sheath

C. Dermal papilla

D. Epidermis

Correct Answer: C. Dermal papilla

Explanation: Dermal papilla expresses androgen receptors and 5α-reductase type 2 and controls follicle size and response to androgens. Mechanism of Androgen Action on Hair Follicle: Androgen response is follicle-specific Androgen receptors are present only in dermal papilla cells Follicle size depends on dermal papilla volume Dermal papilla expresses 5α-reductase type 2 Androgens alter dermal papilla cell number & ECM Dermal papilla releases: Growth-promoting factors (beard hair) TGF-β (in balding scalp) → inhibits hair growth Androgens stimulate terminal hair growth in some sites but cause follicular miniaturisation and hair loss on the scalp. This paradox is determined at the level of the dermal papilla .

References:

Rook's Textbook of Dermatology, 9th Edition, Page 89.9, 89.10

↑ *Back to this question in Part A*

@Neet_pg_bot

Q47: A 31-year-old woman presents with bitemporal recession and vertex thinning, giving a male-pattern distribution of hair loss as shown in the image. Which of the following statements regarding this condition is wrong? (Q884295)

A. It is often associated with hyperandrogenism

B. A scalp biopsy is routinely required to confirm the diagnosis

C. Hair loss occurs due to follicular miniaturisation

D. Topical minoxidil is useful in the management



Correct Answer: B. A scalp biopsy is routinely required to confirm the diagnosis

Explanation: Androgenetic alopecia is a clinical diagnosis. A scalp biopsy is done only if the diagnosis is unclear or to rule out scarring alopecia. Androgenic alopecia: Pattern hair loss : Progressive, patterned scalp hair thinning due to follicular miniaturisation . (Option C) Men Women Pattern of hair loss Predominantly androgen-dependent → Androgenetic alopecia (AGA) . Women : Termed Female Pattern Hair Loss (FPHL) ; the androgen role is less consistent. Male-pattern hair loss can occur in women and vice versa. Associated conditions Men : Possible association with coronary artery disease Women : PCOS, hyperandrogenism (Option A) , hypertension, diabetes Trichodynia may coexist Investigations Men: usually not required If hyperandrogenism is suspected: Testosterone, DHEAS, androstenedione Pelvic USG ± adrenal imaging Scalp biopsy if diagnosis is unclear Medical Treatment Topical minoxidil (2-5%) Oral finasteride 1 mg/day (5α-reductase type 2 inhibitor) Dutasteride (type 1 & 2 inhibitor; more potent, more side effects) Topical minoxidil - first line (Option D) Antiandrogens (selected cases): Spironolactone Cyproterone acetate Finasteride (limited evidence; teratogenic)

References:

Rook’s Textbook of Dermatology, 9th Edition, Pages 89.17 - 89.23.

↑ *Back to this question in Part A*

@Neet_pg_bot

Q48: A 26-year-old man presents with diffuse thinning over the central scalp with preservation of the frontal hairline. There is no bitemporal recession or vertex balding. Family history is negative. Scalp skin appears normal. What is the most likely

diagnosis? (Q884294)

A. Male pattern androgenetic alopecia

B. Telogen effluvium

C. Female pattern hair loss

D. Alopecia areata

Correct Answer: C. Female pattern hair loss

Explanation: Female pattern hair loss (FPHL) can occur in males and presents as central diffuse thinning with preserved frontal hairline , unlike classic male pattern baldness. Clinical Patterns of Hair Loss: Men: Bitemporal recession → vertex thinning → frontal-vertex baldness Classified by the Hamilton-Norwood scale Occipital scalp is usually spared. ■■ Women:■■ Diffuse crown thinning with preserved frontal hairline " Christmas-tree " widening of the central part Classified by Ludwig / Sinclair scales True vertex baldness is uncommon. ■■ Male pattern androgenetic alopecia (Option A) : Typically shows bitemporal recession and vertex balding. Telogen effluvium (Option B) : Causes diffuse shedding, not patterned thinning. Alopecia areata (Option D) : Presents with well-defined patches.



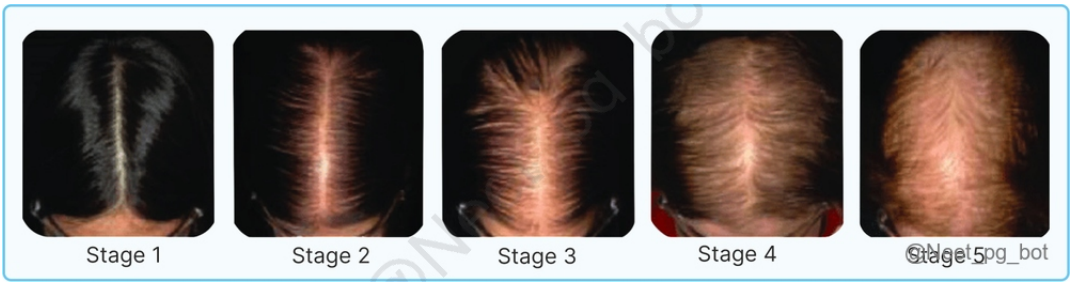

References:

Rook's Textbook of Dermatology, 9th Edition, Pages 89.14-89.17.

↑ *Back to this question in Part A*

@Neet_pg_bot

Q49: A 22-year-old patient presents with asymptomatic patchy hair loss on the scalp. Nail examination reveals findings as shown in the image. What is the most likely diagnosis? ■■■■■■■ (Q884293)

A. Lichen planus

B. Alopecia areata

C. Psoriasis

D. Onychomycosis



Correct Answer: B. Alopecia areata

Explanation: Alopecia areata is classically associated with nail pitting (thimble pitting) due to involvement of the nail matrix. Nail involvement (10-15%): Fine stippled (thimble) pitting - classic Trachyonychia (rough nails) Non-specific nail dystrophy Alopecia Areata - Clinical Features: Lesion: Smooth, well-defined bald patch; normal skin Edge sign: Exclamation mark hairs Course: Unpredictable; regrowth or progression Severe forms: Alopecia totalis - complete scalp hair loss Alopecia universalis - complete body hair loss Pattern: Ophiasis (occipital band) Sites: Scalp, beard, eyebrows, eyelashes Regrowth: Initially fine, non-pigmented Pigment: White hair spared ■ ■ ■■ Lichen planus (Option A) : Shows longitudinal ridging and pterygium. ■■ Psoriasis (Option C) : Nail pitting is coarse and irregular with onycholysis and oil-drop sign. Onychomycosis (Option D) : Causes discolouration, subungual debris, and no pitting.



@Neet_pg_bot



@Neet_pg_bot





@Neet_pg_bot





@Neet_pg_bot



References:

Rook’s Textbook of Dermatology, 9th Edition, Pages 89.31, 89.32.

↑ *Back to this question in Part A*

@Neet_pg_bot

Q50: A 24-year-old patient presents with a single, well-defined patch of non-scarring hair loss on the scalp as shown. What is the most effective first-line treatment for this condition? (Q884292)

A. Topical minoxidil

B. Intralesional corticosteroid injections

C. Oral corticosteroids

D. Contact immunotherapy (DPCP)



Correct Answer: B. Intralesional corticosteroid injections

Explanation: The given image & features indicates Alopecia areata. Intralesional corticosteroids (e.g., triamcinolone acetonide) are the most effective first-line treatment for limited patchy alopecia areata, producing localised hair regrowth. Alopecia Areata - Management: No curative therapy Spontaneous remission in ≤80% of limited patchy AA (<1 year) First-Line (Limited Patchy AA): Topical potent steroids (e.g. clobetasol): Use ≥3 months Ineffective in totalis/universalis Intralesional corticosteroids (most effective) : Triamcinolone 5-10 mg/mL (multiple injections) Side effect: transient skin atrophy Not for rapidly progressive or extensive AA Other options (limited benefit): Minoxidil (Option A) Anthralin (dithranol) Second line: Oral / pulse corticosteroids - temporary benefit, high relapse (Option C) Third line: Contact immunotherapy (DPCP) (Option D) Best documented (≈50-60%) Agent: DPCP (preferred) Weekly application → mild dermatitis Poor prognosis if: Nail changes Early onset Family history Totalis/universalis PUVA therapy

References:

Rook’s Textbook of Dermatology, 9th Edition, Pages 89.33, 89.34.

↑ *Back to this question in Part A*

@Neet_pg_bot

• [02_Skin Appendages and their Disorders] 004 Disorders Of Glands

« Back to Folder Directory

[02_Skin Appendages and their Disorders] 004 Disorders Of Glands — Quick Jump

Q1 (p. 589) *Q2 (p. 590)* *Q3 (p. 591)* *Q4 (p. 593)* *Q5 (p. 596)* *Q6 (p. 597)*
Q7 (p. 600) *Q8 (p. 601)* *Q9 (p. 604)* *Q10 (p. 605)* *Q11 (p. 609)* *Q12 (p. 609)*

Q1: A 42 year old male who exercised vigorously presents to the emergency department with profuse sweating, flushed skin, and rapid breathing. His body temperature is elevated, and he appears dehydrated. Which of the following types of glandular secretion primarily contributes to the cooling mechanism observed in this patient? (Q841980)

A. Merocrine

B. Apocrine

C. Holocrine

D. Endocrine

Correct Answer: A. Merocrine

■ *Listen (English)*

■ *Listen (Hindi)*

Explanation: Merocrine secretion involves the release of secretory products through exocytosis without loss of cellular material. Thermoregulation is primarily done by eccrine sweat glands which typically have merocrine secretion. Eccrine sweat glands produce watery sweat by merocrine secretion directly onto the skin's surface. The sweat then evaporates, dissipating heat and aiding in the body's cooling. Some other examples of merocrine secretion include salivary glands and goblet cells in the intestinal epithelium. Apocrine (Option B): Apocrine secretion involves the release of cellular products along with portions of the cytoplasm. Apocrine sweat glands present in the axilla, perineum, and groin regions secrete their secretion into hail follicles by apocrine mechanism and are primarily responsible for producing body odour. The mammary gland (Modified apocrine gland) produces milk by apocrine secretion. Holocrine (Option C): Holocrine secretion involves the disintegration of entire cells filled with secretory products. Sebaceous glands in the skin utilize holocrine secretion to produce sebum, an oily substance that lubricates and waterproofs the skin and hair. Endocrine (Option C): Ductless glands secrete hormones directly into the bloodstream. They are involved in regulating various physiological processes and maintaining homeostasis within the the body.

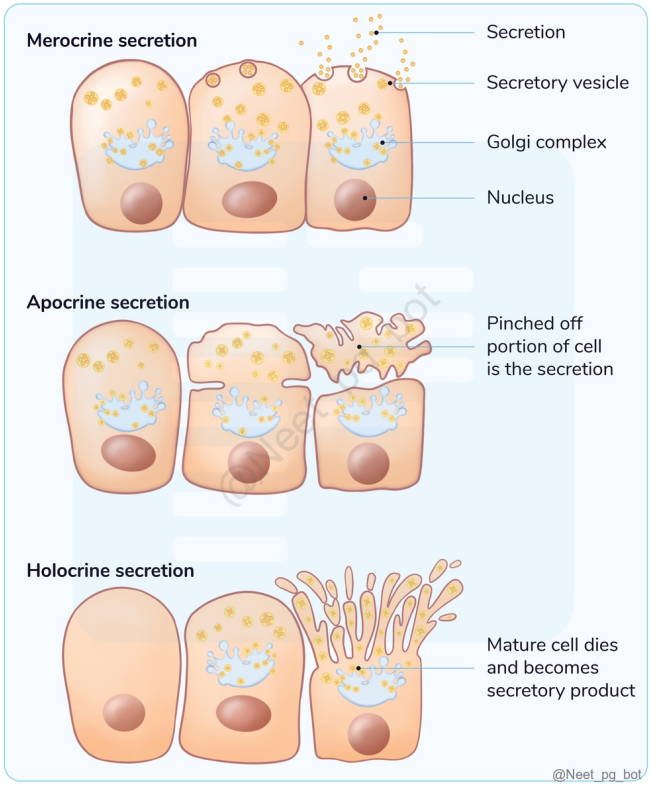

References:

Fitzpatrick's Dermatology, 9th Edition, Page 104

↑ *Back to this question in Part A*

@Neet_pg_bot

Q2: A 55 year old male with a 10-year history of poorly controlled type 2 diabetes mellitus presents to the clinic with numbness and tingling sensation in the feet. He also reports no signs of sweating despite exposure to warm temperatures. Which of the following gland's functions is most likely to be impaired? (Q841982)

A. Eccrine sweat glands

B. Apocrine sweat glands

C. Sebaceous glands

D. Ceruminous glands

Correct Answer: A. Eccrine sweat glands

■ *Listen (English)*

■ *Listen (Hindi)*

Explanation: The clinical scenario suggests diabetic peripheral neuropathy in which autonomic dysfunction results in impaired sweat production. It may be partial (hypohidrosis) or complete (anhidrosis). Eccrine sweat glands are responsible for sweat production and thermoregulation. They are located all over the body (more in palms and soles), open directly into the skin, and are innervated by sympathetic cholinergic nerves. These glands have been active since childhood. Disorders of eccrine sweat glands include Hyperhidrosis, Hypo/Anhydrosis, Miliaria, and Neutrophilic eccrine hidradenitis. Apocrine glands (Option B): The apocrine sweat glands are responsible for producing body odor, and they have no role in thermoregulation. They are located in the axilla, groin, and perineum, open into the hair follicle above the sebaceous duct (pilosebaceous unit), and are innervated by adrenergic nerves. They become active at puberty. Disorders of Apocrine sweat glands include Bromhidrosis, Chromhidrosis, Fox Fordyce disease/ Apocrine miliaria, and Hidradenitis suppurativa. Sebaceous glands (Option C): These glands are responsible for the secretion of sebum into hair follicles that helps in moisturizing and lubricating the skin and hair. Disorders of the sebaceous gland include Acne vulgaris, Rosacea, and Seborrheic dermatitis. Ceruminous glands (Option D): Ceruminous glands are modified sweat glands located in the external auditory canal. They secrete a wax-like substance called cerumen, which helps moisturize and protect the ear canal from foreign particles.

References:

Rooks's Textbook of Dermatology, 9th Edition, Page 94.10

↑ *Back to this question in Part A*

@Neet_pg_bot

Q3: A 22 year old female presents to the dermatology clinic with complaints of recurrent episodes of profuse sweating, mainly involving her palms and soles. She reports sweating occurs even in cool environments, significantly impacting her daily activities and social interactions. The starch-iodine test is positive. What is the first-line management in this condition? (Q841983)

A. Aluminium chloride hexahydrate

B. Iontophoresis

C. Intradermal botulinum toxin

D. Removal or ablation of eccrine glands



Correct Answer: A. Aluminium chloride hexahydrate

■ *Listen (English)*

■ *Listen (Hindi)*

Explanation: The given clinical condition is Hyperhidrosis, a disorder of eccrine sweat glands characterized by profuse sweating of palms and soles (palmoplantar hyperhidrosis) or axilla (axillary hyperhidrosis). Minor's starch-iodine test is a non-invasive diagnostic test used to confirm the presence of hyperhidrosis in which skin is cleaned with povidone-iodine solution and then sprinkled with starch, the hyperhidrosis areas will be seen in blue■black colour. First-line management includes Aluminium chloride hexahydrate (Eccrine duct■blocking agents) and Topical anticholinergics (glycopyrrolate). Iontophoresis (Option B): It is second-line management for hyperhidrosis in which each hand is treated for 30 min by placing it into a bowl filled with tap water or anticholinergics drugs such as 0.05% glycopyrronium bromide solution and 20mA of direct current is passed. Intradermal botulinum toxin (Option C): It is also second-line management for hyperhidrosis. It acts by prolonged blockade of neuronal acetylcholine release at the neuromuscular junction and in cholinergic autonomic neurons of eccrine sweat glands. Removal or ablation of eccrine glands (Option D): It is a third-line management of hyperhidrosis and is done for axillary hyperhidrosis.

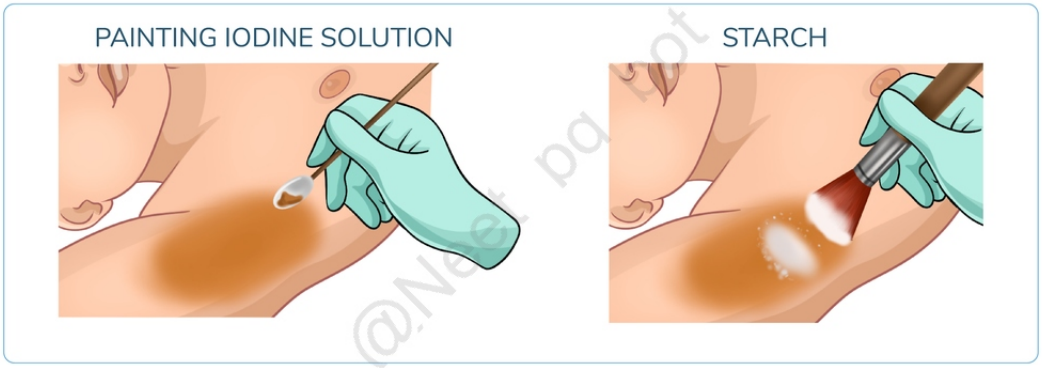

@Neet_pg_bot

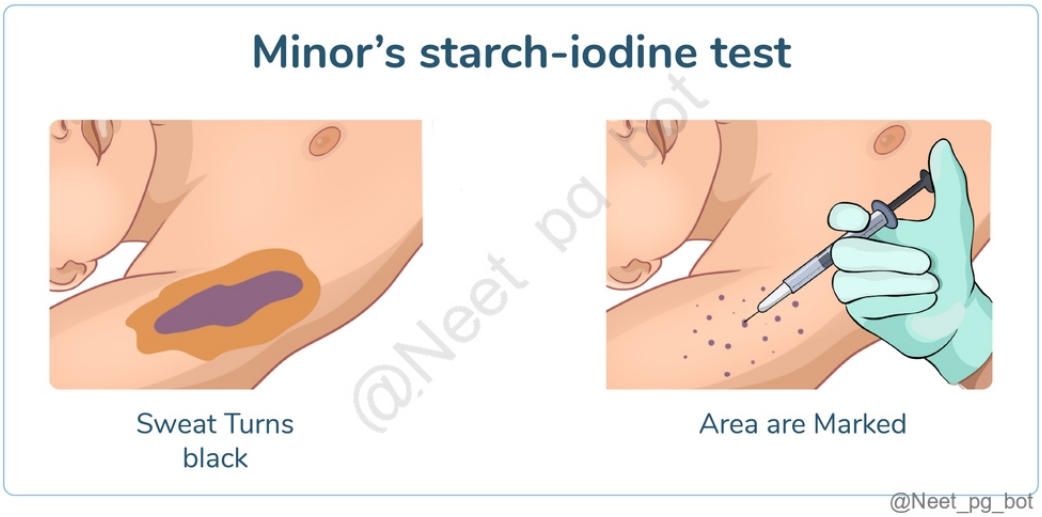

@Neet_pg_bot

References:

Rook's Textbook of Dermatology, 9th Edition, Page 94.10

↑ *Back to this question in Part A*

@Neet_pg_bot

Q4: A 32 year old man presents to the clinic with a rash on his neck and upper chest area after spending the day on his farm in hot and humid weather. He describes the rash as itchy and prickly. On examination, there are numerous small, erythematous papules present, as shown in the image. Which of the following is the most likely diagnosis? (Q841985)

A. Miliaria crystallina

B. Miliaria rubra

C. Miliaria profunda

D. Miliaria pustulosa



Correct Answer: B. Miliaria rubra

■ *Listen (English)*

■ *Listen (Hindi)*

Explanation: Miliaria rubra (prickly heat or heat rash) arises due to the occlusion or disruption of eccrine sweat ducts at the level of stratum spinosum in hot, humid conditions, resulting in sweat leakage into the epidermis. It is characterized by small, red papules or vesicles accompanied by itching or a prickling sensation. It typically occurs in areas of the body prone to sweating and friction during hot and humid weather. Miliaria crystallina (Option A) Miliaria profunda (Option C) Miliaria pustulosa (Option D) Obstruction of eccrine sweat duct at the level of stratum corneum. Seen in infants and are characterized by clear fluid thin vesicles that may rupture easily, leaving behind superficial peeling or desquamation. Obstruction of eccrine sweat duct at Dermo-epidermal junction. It is characterized by firm, flesh-coloured lesions or bumps beneath the skin's surface. It follows repeated attacks of miliaria rubra. It is an infected variant of miliaria rubra by Staphylococcus aureus. It is characterized by pustules or pus-filled lesions in addition to the typical features of miliaria rubra.

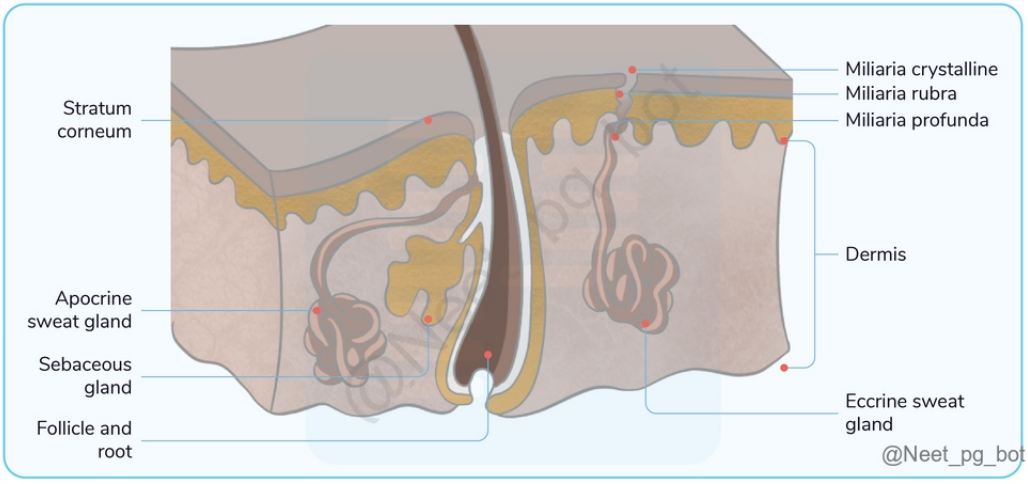
Miliaria crystalline
Miliaria rubra
Miliaria profunda
Stratum corneum
Dermis
Apocrine sweat gland
Sebaceous gland
Follicle and root
Eccrine sweat gland
@Neet_pg_bot


@Neet_pg_bot



@Neet_pg_bot

References:

Rooks’s Textbook of Dermatology, 9th Edition, Page 116.16

↑ *Back to this question in Part A*

@Neet_pg_bot

Q5: A 42 year old man presents with complaints of foul-smelling body odour, particularly in his axillae, despite maintaining good hygiene practices. On examination, there are no visible skin lesions or signs of inflammation in the affected area. What is the most likely diagnosis? (Q841988)

A. Fox-Fordyce disease

B. Chromhidrosis

C. Hyperhidrosis

D. Bromohidrosis

Correct Answer: D. Bromohidrosis

■ *Listen (English)*

■ *Listen (Hindi)*

Explanation: Bromohidrosis, also known as malodor or osmidrosis, is a condition characterized by foul-smelling body odour caused by bacteria such as staphylococcus, micrococcus, corynebacterium, and propionibacterium breaking down apocrine secretion. It often occurs in areas with a high density of apocrine glands, such as the axillae and groin. Fox-Fordyce disease (Option A): Fox-Fordyce disease, also known as Apocrine miliaria, presents with multiple small, skin-coloured, or yellowish pruritic papules in areas with apocrine glands, such as the axillae, groin, perineum, and areolae of the breasts. Chromhidrosis (Option B): Chromhidrosis is the secretion of vividly coloured apocrine sweat, most commonly blue, yellow, or green, due to the secretion of lipofuscins in the apocrine sweat. Hyperhidrosis (Option C): It is a disorder of eccrine sweat glands characterized by profuse watery sweating of the axilla or palms and soles. Eccrine sweat glands are primarily involved in thermoregulation.



References:

Rooks's Textbook of Dermatology, 9th Edition, Page 94

↑ *Back to this question in Part A*

@Neet_pg_bot

Q6: A 32 year old obese woman presents with multiple painful nodules and discharging sinuses in her axilla as shown in the image. She reports a history of similar lesions appearing and resolving intermittently over the past few years. Which of the

following is a characteristic feature of this condition? (Q841989)

A. Pruritic, scaly patches on the extremities

B. Bridging scars indicate chronicity

C. Erythematous papules with central pustules

D. Painless nodules and the presence of comedones



Correct Answer: B. Bridging scars indicate chronicity

■ *Listen (English)*

■ *Listen (Hindi)*

Explanation: The given clinical condition is diagnosed as Hidradenitis Suppurativa, which occurs due to the occlusion of hair follicles and apocrine glands. It is characterized by recurrent, painful, deep■seated nodules, abscesses, and multiple discharging sinuses in intertriginous areas. It typically affects the anogenital region in men and the axillae in women. Recurrent episodes of inflammation and tissue damage lead to the formation of bridging scars/rope scars, which indicate the chronicity of the disease. Pruritic, scaly patches on the extremities (Option A): This is more indicative of conditions like eczema or psoriasis, which present with pruritic (itchy) and scaly patches on the extremities. Hidradenitis Suppurativa typically does not present with pruritic or scaly lesions. Erythematous papules with central pustules on trunk (Option C): Disorders like acne vulgaris present with red erythematous papules and pustules, commonly seen on the face, chest, and back. Hidradenitis Suppurativa typically presents with nodules and abscesses in intertriginous areas rather than on the trunk. Painless nodules and the presence of comedones (Option D): Hidradenitis Suppurativa is characterized by painful nodules and abscesses and is

associated with polyporous comedones. Comedones are non-inflammatory lesions that result from the blockage of hair follicles by sebum and dead skin cells seen in Acne Vulgaris.



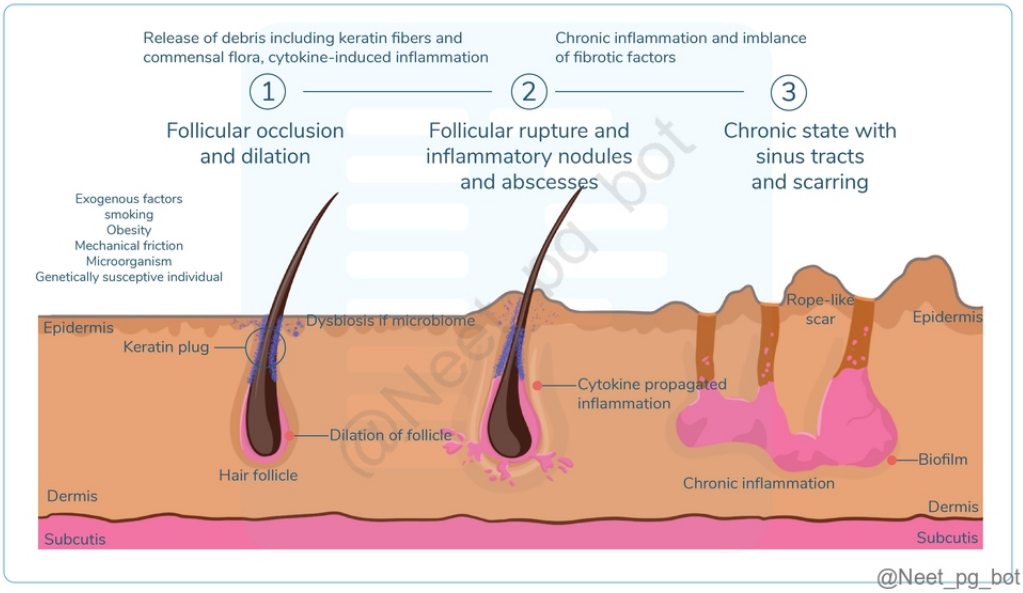

References:

Rooks's Textbook of Dermatology, 9th Edition, Page 113.21

↑ *Back to this question in Part A*

Q7: A 25 year old man presents with small, painless papules on the inner surface of his lips. On examination, the papules are skin-coloured and located along the vermilion border. Which of the following is most likely the diagnosis? (Q841990)

A. Tyson glands

B. Meibomian gland dysfunction

C. Montgomery tubercles

D. Fordyce spots



@Neet_pg_bot

Correct Answer: D. Fordyce spots

■ *Listen (English)*

■ *Listen (Hindi)*

Explanation: Fordyce spots are ectopic sebaceous glands that can occur around the vermilion border of the lips or within the oral mucosa. They present as small, painless papules and are typically asymptomatic. These are also modified sebaceous glands but vary in their location. Ectopic sebaceous glands are specialized sebaceous glands which open into the skin surface and are confined to particular locations, unlike the normal sebaceous glands

which are primarily found in association with hair follicles on the skin throughout the body, with higher concentrations on the face, scalp, chest, and back. Ectopic sebaceous glands Location Tyson glands or Preputial glands (Option A) The inner surface of the foreskin (prepuce) in males. Meibomian glands (Option B) Along the rim of the eyelids. Glands of Zeis The base of the eyelashes. Montgomery tubercles (Option C) Areola of the breast. Fordyce spots The vermilion border of the lips or within the oral mucosa.



@Neet_pg_bot

References:

Rooks's Textbook of Dermatology, 9th Edition, Page 90.25

↑ *Back to this question in Part A*

@Neet_pg_bot

Q8: A 16 year old adolescent presents to the dermatology clinic with complaints of multiple papules, pustules, and comedones on her face and upper back. On examination, there are numerous open and closed comedones, inflamed papules, and a few pustules distributed primarily on her forehead, nose, and cheeks, with some involvement of the upper back. Which of the following statements regarding the characteristics of this condition is correct? (Q841991)

A. It primarily affects individuals over the age of 40 and is also seen in adolescents.

B. It is not influenced by hormonal factors.

C. Comedones are the hallmark lesion.

D. Genetic predisposition is not a contributing factor.

Correct Answer: C. Comedones are the hallmark lesion.

- *Listen (English)*
- *Listen (Hindi)*

Explanation: The given clinical condition is diagnosed as Acne vulgaris, a chronic inflammatory skin condition associated with increased sebum production and the accumulation of dead skin cells within the follicles. Comedones are clogged hair follicles (pores) that contain a mixture of oil (sebum) and dead skin cells. They are the hallmark lesions of acne vulgaris. They are non-inflammatory lesions and are of two types: Open comedones (blackheads): These are follicles with a wider opening to the skin's surface and are not covered by the epidermis. When exposed to air, the keratin plug becomes oxidized and appears black. Closed comedones (whiteheads): These are follicles with a narrower opening to the skin's surface and are covered by the epidermis. The accumulation of sebum and dead skin cells creates a white or flesh-coloured bump beneath the skin's surface. It primarily affects individuals over the age of 40 and is also seen in adolescents (Option A): Acne vulgaris is typically seen in puberty and adolescence, not above the age of 40 years. It is not influenced by hormonal factors (Option B): Hormonal fluctuations, particularly increased levels of androgens (such as testosterone), can stimulate sebaceous gland activity, leading to increased sebum production. They are often associated with hormonal conditions like polycystic ovary syndrome (PCOS) and congenital Adrenal Hyperplasia (CAH). Genetic predisposition is not a contributing factor (Option D) : Genetic factors influence various aspects of acne development, including sebum production, follicular hyperkeratinization, and inflammatory responses. Thus, Genetic predisposition is a contributing factor to the development of acne vulgaris.



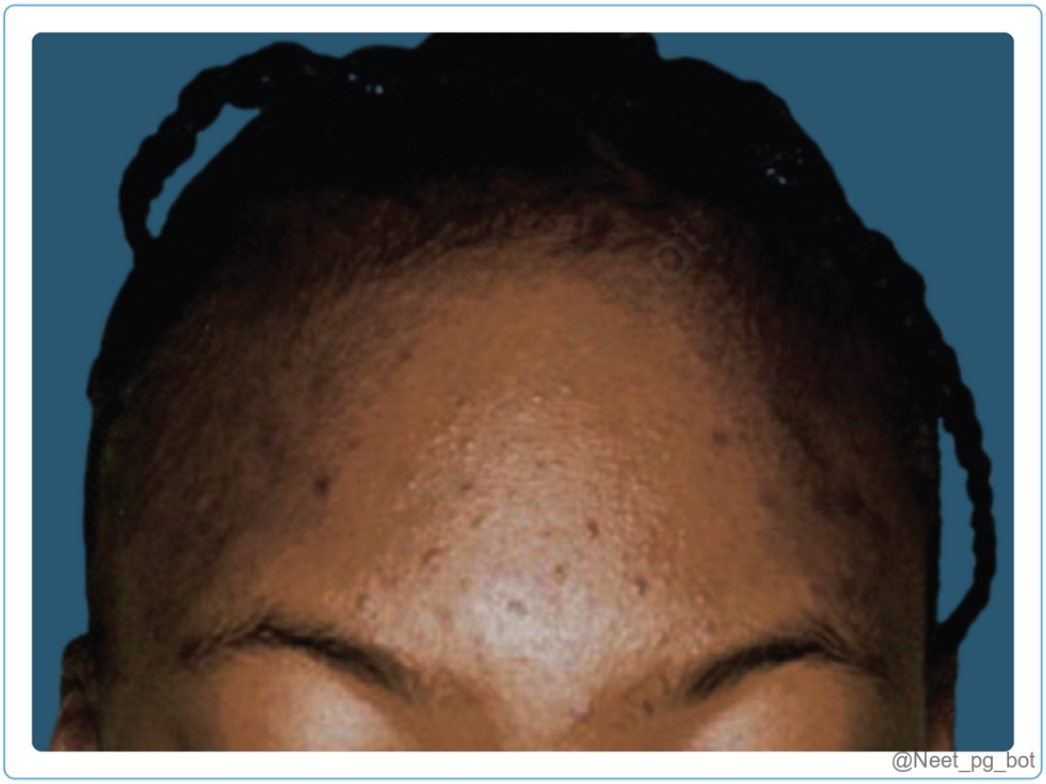

References:

Rooks’s Textbook of Dermatology, 9th Edition, Page 90.1

↑ *Back to this question in Part A*

@Neet_pg_bot

Q9: A 21 year old female presents to the dermatology clinic with complaints of persistent acne on her face. On examination, the lesions are as shown in the image below. Based on the grading of acne vulgaris, what is the most appropriate classification for this patient's acne, and what would be the initial treatment recommendation? (Q841992)

A. Grade I acne vulgaris; topical retinoids

B. Grade II acne vulgaris; topical antibiotics + topical retinoids

C. Grade III acne vulgaris; oral antibiotics + topical retinoids

D. Grade IV acne vulgaris; intralesional corticosteroid injections



Correct Answer: C. Grade III acne vulgaris; oral antibiotics + topical retinoids

■ *Listen to Audio 1*

Explanation: Grade of acne vulgaris Lesions Treatment Grade I Non-inflammatory lesions such as open (blackheads) and closed comedones (whiteheads) Topical retinoids (Tretinoin, Adapalene) Grade II Non-inflammatory lesions (comedones) + inflammatory lesions such as papules and few pustules. Topical

retinoids + Topical antibiotics Grade III Multiple inflammatory papules and pustules ± nodules (moderate) Topical retinoids + Oral antibiotics ± Benzoyl peroxide Grade IV Nodules + Cysts (Most severe form) Oral retinoids (Isotretinoin)

References:

Rooks’s Textbook of Dermatology, 9th Edition, Page 90.37

↑ *Back to this question in Part A*

@Neet_pg_bot

Q10: A 45 year old woman presents to the dermatology clinic with complaints of persistent redness, flushing, and occasional papules and pustules on her face. She reports that her symptoms worsen with sun exposure and spicy foods. On examination, diffuse erythema is present on the central face, predominantly on the cheeks shown in the image. Based on the clinical presentation, what is the most likely diagnosis? (Q841993)

A. Acne vulgaris

B. Lupus erythematosus

C. Atopic dermatitis

D. Rosacea



Correct Answer: D. Rosacea

- *Listen (English)*
- *Listen (Hindi)*

Explanation: Rosacea is a chronic inflammatory skin condition characterized by persistent diffuse erythema, facial flushing due to vascular hyper-reactivity, and the development of papules and pustules affecting the central face. Triggers such as sun exposure, spicy foods, alcohol, and temperature extremes can exacerbate symptoms. Four subtypes: Subtype Characteristics Erythematotelangiectatic rosacea Erythema and telangiectasia. Papulopustular rosace Papules and pustules. Phymatous rosacea Rhinophyma (thickening of the skin and enlargement of sebaceous glands on the nose). Ocular rosacea Affects the eyes and eyelids, causing symptoms such as dryness, burning, itching, foreign body sensation, redness, and sensitivity to light (photophobia). Acne vulgaris (Option A): While acne vulgaris can also present with papules and pustules on the face, it typically involves comedones (open and closed) which are characteristically absent in Rosacea. Lupus erythematosus (Option B): It encompasses a group of autoimmune diseases that can affect the skin and various organs. Cutaneous lupus erythematosus may present with facial erythema, but it typically has distinct features such as a butterfly rash (malar rash) over the cheeks and nose, which is different from the diffuse erythema seen in rosacea. Also, papules and pustules are not seen. Atopic dermatitis (Option C): Atopic dermatitis presents with pruritic, erythematous papules and plaques, often with a flexural distribution, in individuals with a personal or family history of atopy. It does not typically present with persistent facial erythema and flushing which is characteristic of rosacea.

Papulopustular rosacea

Erythematotelangiectatic rosacea



Ocular rosacea

Rhinophyma (phymatous rosacea)

@Neet_pg_bot



@Neet_pg_bot





References:

Rooks's Textbook of Dermatology, 9th Edition, Page 91.1

↑ *Back to this question in Part A*

@Neet_pg_bot

Q11: A 17 year old female with severe, resistant, nodular acne is prescribed isotretinoin. What is the appropriate initial dosage and important administration instruction? (Q842647)

A. 0.5 mg/kg/day; take with a fat-containing meal

B. 1.0 mg/kg/day; take on an empty stomach

C. 0.5 mg/kg/day; take on an empty stomach

D. 1.0 mg/kg/day; take with a fat-containing meal

Correct Answer: A. 0.5 mg/kg/day; take with a fat-containing meal

Explanation: Isotretinoin Primary Indication Severe, resistant, nodular acne Dosage Initial: 0.5 mg/kg/day Adjustment: Upto 1.0 mg/kg/day based on tolerance Treatment Duration 15-20 weeks Cumulative Dose 120–150 mg/kg Administration Oral with water and fat-containing meal Contraindication Contraindicated in females who plan on conceiving as it is teratogenic

References:

Adverse Events in Isotretinoin Therapy: A Single-Arm Meta-Analysis - PMC

↑ *Back to this question in Part A*

@Neet_pg_bot

Q12: A 20 year old female presents with severe acne and is prescribed isotretinoin 1 mg/kg. After two months of treatment, she reports dry skin, dry lips and dry eyes. Laboratory tests reveal mild elevation of liver enzymes. What is the most appropriate initial step in managing her side effects? (Q842751)

A. Discontinue isotretinoin immediately and switch to an alternative oral acne medication.

B. Advise the patient to use moisturizers, lip balm and artificial tears

C. Decrease the dosage of isotretinoin and monitor liver enzymes regularly

D. Both B and C

Correct Answer: D. Both B and C

Explanation: Reducing the dosage and monitoring liver enzymes is a prudent approach to managing elevated liver enzymes, while moisturizers and artificial tears can manage dryness. The initial dose is 0.5 mg/kg/day which can

be increased upto 1mg/kg/day if well tolerated only. Discontinuing isotretinoin and switching medications should be considered only for severe or persistent adverse effects. Side Effects of Isotretinoin Side Effect Treatment Solution Xerosis (dryness) Use moisturizers and hydrating agents (Option B) Cheilitis (dry lips) Use moisturizers and lip balms (Option B) Skin fragility and dermatitis Avoid irritants and use gentle skin care products Rashes and erythema Topical corticosteroids if necessary Dry eyes Use artificial tears and lubricating eye drops (Option B) Depression Discontinue isotretinoin and seek health professionals' advice as psychiatric side effects may occur in acne patients regardless of isotretinoin use. Liver test abnormalities Monitor liver function tests regularly, consider dose adjustment (Option C) Increased creatine phosphokinase (CPK) levels Monitor levels, adjust physical activity, and consider dose reduction Increased homocysteine levels Monitor levels, dietary modifications, and consider supplementation Stevens-Johnson syndrome Discontinue isotretinoin and seek immediate medical attention

References:

Adverse Events in Isotretinoin Therapy: A Single-Arm Meta-Analysis - PMC

↑ *Back to this question in Part A*

@Neet_pg_bot

• [02_Skin Appendages and their Disorders] 005 Previous Year Questions

« Back to Folder Directory

[02_Skin Appendages and their Disorders] 005 Previous Year Questions — Quick Jump

Q1 (p. 611) *Q2 (p. 612)* *Q3 (p. 613)* *Q4 (p. 617)* *Q5 (p. 619)* *Q6 (p. 620)*
Q7 (p. 621) *Q8 (p. 622)* *Q9 (p. 626)* *Q10 (p. 627)* *Q11 (p. 628)* *Q12 (p. 629)*
Q13 (p. 629) *Q14 (p. 630)* *Q15 (p. 631)* *Q16 (p. 632)* *Q17 (p. 633)* *Q18 (p. 634)*
Q19 (p. 635)

Q1: A lady developed a skin reaction, as shown in the image after using a hair dye. Which of the following chemicals is responsible for this condition? (Q855289)

A. Pollen

B. Chromates

C. Balsam of Peru

D. p-Phenylenediamine



Correct Answer: D. p-Phenylenediamine

Explanation: p-Phenylenediamine (PPD) is a chemical commonly found in hair dyes. It is known to cause allergic reactions in some people, and symptoms can include itching, redness, swelling, and skin blistering. PPD allergies are fairly common and can be quite severe, so it is important to be cautious when using hair dyes that contain this chemical. Incorrect Options: Pollen (Option A): Pollen is a common allergen that can cause allergic reactions like hay fever. However, it is not typically found in hair dyes, so it is unlikely to be the cause of a skin reaction from hair dye. Chromates (Option B): Chromates are chemicals that are sometimes used in hair dyes. They cause allergic reactions in some people, especially those with a history of eczema or other skin conditions. Symptoms of a chromate allergy can include itching, redness, and skin swelling. Balsam of Peru (Option C): Balsam of Peru is a fragrance commonly used in perfumes, cosmetics, and other personal care products. It is known to cause allergic reactions in some people, and symptoms can include itching, redness, and skin swelling. However, it is not typically found in hair dyes.

References:

Prepladder PYQ

↑ *Back to this question in Part A*

@Neet_pg_bot

Q2: A 35-year-old woman presents to you with hair loss for the past three months. She tested positive for COVID-19 eight months ago. What is the most likely diagnosis?

(Q855910)

A. Tinea capitis

B. Telogen effluvium

C. Trichotillomania

D. Female – pattern androgenetic alopecia

Correct Answer: B. Telogen effluvium

Explanation: History of COVID-19: The patient had COVID-19 eight months ago , a known trigger for telogen effluvium . Telogen effluvium is a stress-induced hair loss condition occurring 2-3 months after a triggering event . Clinical Features of Telogen Effluvium: Diffuse, non-scarring hair loss Increased hair shedding during combing/washing Resolves spontaneously in 6-12 months Telogen Effluvium Feature Telogen Effluvium Trigger Stress, infection (COVID-19), surgery, postpartum, drugs Onset 2-3 months after stressor Hair Loss Pattern Diffuse thinning, shedding >100 hairs/day Scalp Examination Normal, no inflammation or scarring Prognosis Self-limiting, resolves in 6-12 months Tinea Capitis (Option A): Incorrect because it presents with patchy hair loss, scaling, and inflammation, often with black dot hairs . Trichotillomania (Option C): Incorrect because it causes irregular patches of broken hair due to self-induced pulling . Female Pattern Androgenetic Alopecia (Option D): Incorrect because it has a gradual onset with hair thinning in the central scalp, without sudden shedding .

References:

Rook’s Textbook of Dermatology 89.24

↑ *Back to this question in Part A*

@Neet_pg_bot

Q3: Irregular pitting of nails with subungual hyperkeratosis is seen in _____. (Q855906)

A. Lichen planus

B. Psoriasis

C. Atopic dermatitis

D. Alopecia areata

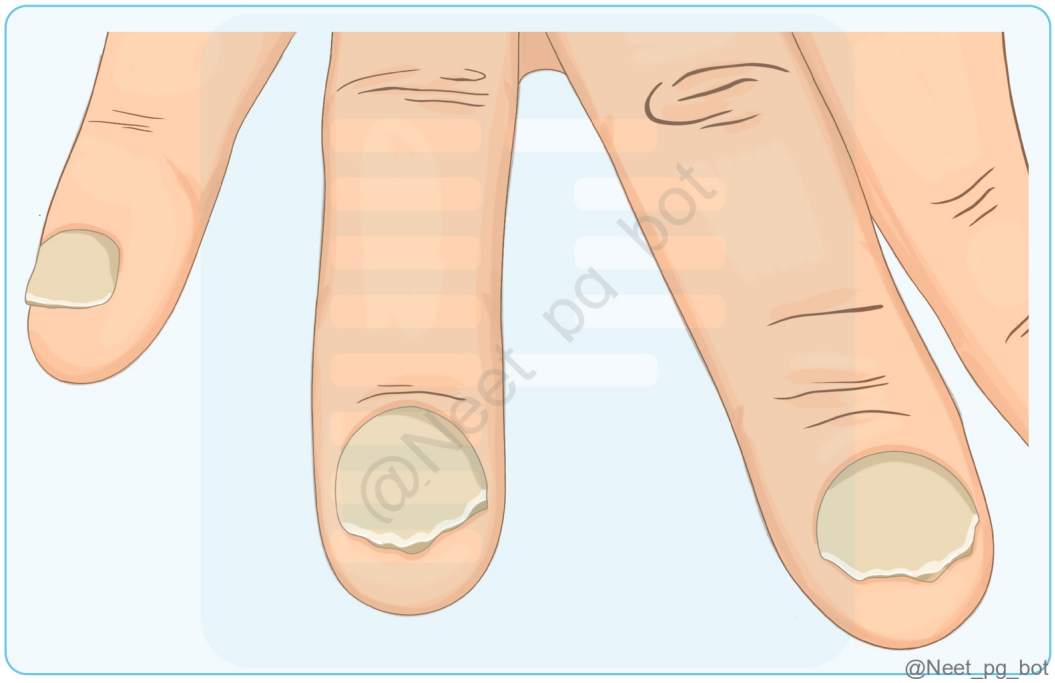

Correct Answer: B. Psoriasis

Explanation: Nail Features in Psoriasis: Irregular pitting of nails (small depressions in the nail plate) {{caption_text}} Subungual hyperkeratosis (thickening under the nail) {{caption_text}} Onycholysis (nail separation from the bed) {{caption_text}} Oil drop sign (yellow-brown discoloration) {{caption_text}} Psoriasis Nail Involvement: Seen in 10-55% of psoriasis cases More common in psoriatic arthritis Nail Changes in Different Dermatological Conditions Condition Nail Changes Psoriasis Irregular pitting , subungual hyperkeratosis , oil drop sign, onycholysis, splinter hemorrhages Lichen Planus Pterygium formation (wing-shaped scar), nail thinning, ridging, longitudinal striations Atopic Dermatitis Shiny, brittle nails , exaggerated longitudinal ridging Alopecia Areata Regular, geometric pitting , trachyonychia (rough, sandpaper-like nails) Lichen Planus (Option A): Incorrect because it causes longitudinal ridging, pterygium formation, and thinning, but not pitting . Atopic Dermatitis (Option C): Incorrect because nail changes are uncommon; if present, they show ridging and brittle nails, not pitting . Alopecia Areata (Option D): Incorrect because it has regular, geometric nail pitting, unlike psoriasis, which is irregular .


@Neet_pg_bot

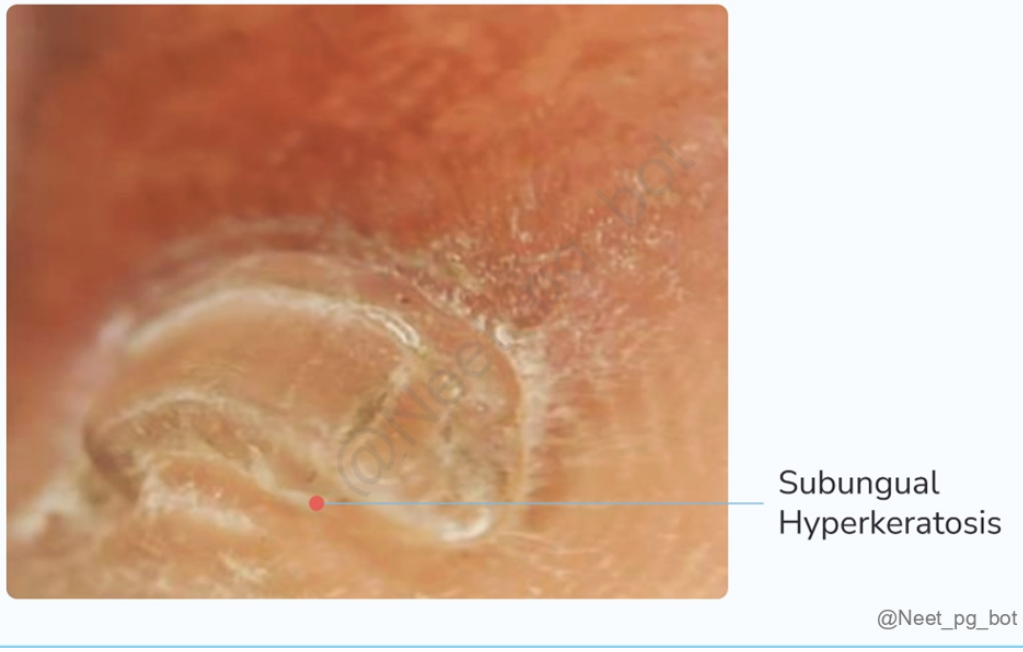
Subungual
Hyperkeratosis
@Neet_pg_bot



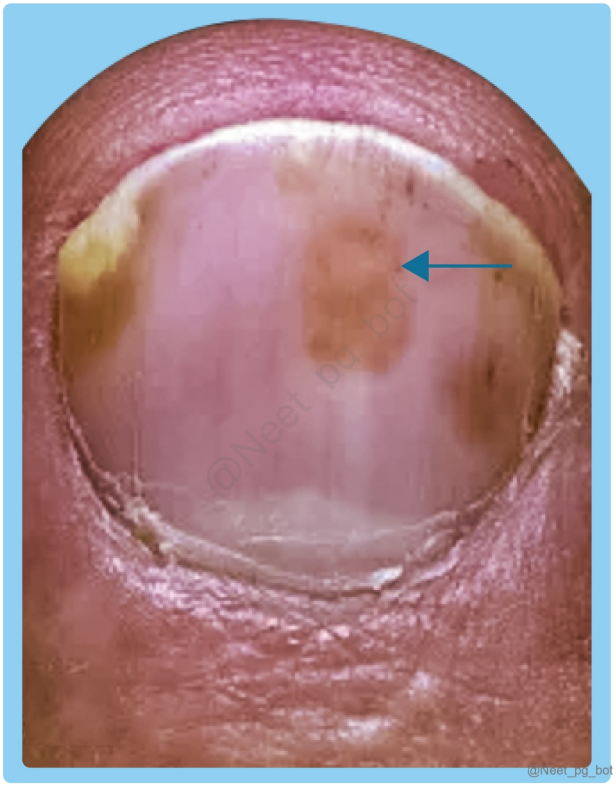

References:

Rook’s Textbook of Dermatology, 9th Edition, Chapter 35, Section 14

↑ *Back to this question in Part A*

@Neet_pg_bot

Q4: What is the term used to describe the distinctive finding shown in the image below, which is pathognomonic for Psoriasis? (Q859555)

A. Nail pitting

B. Subungual oil drop sign

C. Thinning of nails

D. Pterygium



Correct Answer: B. Subungual oil drop sign

Explanation: This sign refers to small, yellowish-orange discolourations seen beneath the nail plate, resembling drops of oil, and is highly specific for nail psoriasis. It is the most specific sign of psoriasis with a specificity of ~98% It occurs due to nail bed parakeratosis and psoriasiform hyperplasia It occurs just before onycholysis {{caption_text}} Important findings in nail psoriasis are (Mnemonic: POLISH) Pits Onycholysis Leukonychia Salmon patch (Subungual oil drop sign) Subungual Hyperkeratosis Incorrect Options: Nail Pitting (Option A): Although nail pitting is common in psoriasis, it is not pathognomonic, as it can also be seen in alopecia areata and eczema. {{caption_text}} Thinning of Nails (Option C): Nail thinning is more commonly associated with lichen planus or trauma-related nail dystrophy, rather than psoriasis. Pterygium (Option D): Pterygium (dorsal or ventral) occurs due to scarring of the nail matrix, commonly seen in lichen planus, not psoriasis.





References:

Rook's Textbook of Dermatology, 9th Edition, Chapter 35, Section 14

↑ *Back to this question in Part A*

@Neet_pg_bot

Q5: A 40-year-old female comes with complaints of pain in her fingernail. On examination, nail folds were seen to be red and with erythema as shown in the picture. The most likely diagnosis is. (Q859551)

A. Paronychia

B. Yellow-nail syndrome

C. Psoriasis

D. Alopecia areata



Correct Answer: A. Paronychia

Explanation: The most likely diagnosis for the described symptoms of a 40-year-old female with pain in her fingernail, along with redness and erythema of the nail folds, is paronychia. Paronychia: is an infection or inflammation of the skin around the nail, specifically the nail folds. It can occur acutely or chronically. Acute paronychia is typically caused by bacterial infection, often by Staphylococcus aureus or Streptococcus pyogenes. Chronic paronychia is often associated with fungal infections, particularly Candida species. Symptoms: redness, swelling, tenderness, and pain around the nail. The affected area may also appear warm and may develop pus-filled abscesses. Commonly seen in: Individuals who frequently immerse their hands in water Who engage in activities that cause minor trauma to the skin around the nails, such as nail biting, picking, or manicuring.

Diagnosis: Physical examination of the affected area and evaluate the patient's symptoms. a sample of the pus or discharge may be sent for laboratory analysis to determine the causative organism. Treatment: Warm water soaks, topical antibiotic ointments or creams, and, if necessary, oral antibiotics. In cases of chronic paronychia associated with fungal infection, antifungal medications. In some instances, incision and drainage of abscesses may be required. Incorrect Options: Yellow-nail syndrome (Option B): is a condition characterized by yellowish discoloration, thickening, and slow growth of the nails. It is usually associated with underlying respiratory or lymphatic disorders and is not consistent with the described symptoms. Psoriasis (Option C): is a chronic inflammatory skin condition that can affect the nails, causing pitting, discoloration, separation of the nail from the nail bed (onycholysis), and thickening of the nails. Alopecia areata (Option D): is an autoimmune condition characterized by hair loss, typically in patches. It does not involve the nails and is not related to the described symptoms.

References:

https://www.ncbi.nlm.nih.gov/books/NBK544307/

↑ *Back to this question in Part A*

@Neet_pg_bot

Q6: Which of the morpholine drugs listed below is used as a nail lacquer? (Q858515)

A. Amorolfine

B. Oxiconazole

C. Ciclopirox olamine

D. Tioconazole

Correct Answer: A. Amorolfine

Explanation: Amorolfine is an antifungal medication that belongs to the class of drugs known as morpholines. It is commonly used as a topical nail lacquer for the treatment of fungal infections of the nails, known as onychomycosis. Amorolfine works by inhibiting the growth of fungi, including dermatophytes and yeasts, which are responsible for causing nail infections. Morpholines are a class of organic compounds that contain a morpholine ring structure, which is a saturated heterocycle consisting of a six-membered ring with one oxygen atom and one nitrogen atom. These compounds have diverse applications in the field of pharmaceuticals due to their unique chemical properties. Incorrect Options: Oxiconazole (Option B) : Oxiconazole is not the correct choice for the drug belonging to the morpholines and used as a nail lacquer. It is an antifungal medication, but it belongs to a different class of drugs called imidazoles. Oxiconazole is available in various formulations, including creams and lotions, and is used for the treatment of various fungal skin infections. Ciclopirox olamine (Option C) : Ciclopirox olamine is not the correct choice for the drug belonging to the morpholines and used as a nail lacquer. Although it is an antifungal medication, it belongs to a different class of drugs called hydroxypyridones. Ciclopirox olamine is available as a nail lacquer and is used for the treatment of fungal infections of the nails, including onychomycosis. Tioconazole (Option D) : Tioconazole is not the correct choice for the drug belonging

to the morpholines and used as a nail lacquer. It is an antifungal medication that belongs to the class of drugs called imidazoles. Tioconazole is commonly used for the treatment of vaginal yeast infections and is available in various formulations, including creams and ointments.

References:

https://pubmed.ncbi.nlm.nih.gov/1532336/

↑ *Back to this question in Part A*

@Neet_pg_bot

Q7: A young woman has presented to the OPD with facial symptoms (acne or pimple-like lesions). Which of the following options will not be effective for treating these symptoms? (Q856671)

A. Topical benzoyl peroxide

B. Topical fluocinolone

C. Topical tazarotene

D. Topical antibiotics



Correct Answer: B. Topical fluocinolone

Explanation: Fluocinolone is a topical corticosteroid , which is not recommended for acne . Corticosteroids can worsen acne by promoting follicular occlusion, increasing sebum production, and causing steroid-induced acne . Acne treatment focuses on reducing inflammation, controlling bacterial overgrowth, and regulating keratinisation , which fluocinolone does not address. Acne vulgaris is a chronic inflammatory condition affecting the pilosebaceous units. Pathophysiology: Increased sebum production (hormonal influence). Follicular hyperkeratinisation (plug formation). Bacterial colonisation (Cutibacterium acnes proliferation). Inflammation (leading to papules, pustules, nodules). Treatment Approach: Type of Acne Treatment Comedonal acne Topical retinoids (tretinoin, adapalene, tazarotene) Mild inflammatory acne Topical benzoyl peroxide, topical antibiotics (clindamycin, erythromycin) Moderate-severe acne Oral antibiotics (doxycycline, minocycline), combination therapy Severe nodulocystic acne Oral isotretinoin (vitamin A derivative) Why Steroids Are Not Recommended: Topical corticosteroids (like fluocinolone) can lead to: Steroid-induced acne (monomorphic papules, no comedones). Skin atrophy and telangiectasia with long-term use. Rebound flare-ups upon discontinuation. Topical benzoyl peroxide (Option A) is incorrect because benzoyl peroxide is an effective first-line treatment for acne. It has antibacterial properties (against Cutibacterium acnes) , reduces inflammation, and prevents antibiotic resistance when used with topical antibiotics. Topical tazarotene (Option C) is incorrect because tazarotene is a topical retinoid that promotes keratinocyte turnover , prevents comedone formation, and reduces acne lesions. It is highly effective in treating acne . Topical antibiotics (Option D) is incorrect because antibiotics like clindamycin and erythromycin reduce C. acnes growth and inflammation. They are commonly used in combination with benzoyl peroxide to prevent resistance .

References:

Rooks’s Textbook of Dermatology 9th edition, 90.1

↑ *Back to this question in Part A*

@Neet_pg_bot

Q8: A 25-year-old male presents with sudden onset, well-circumscribed patches of hair loss on the scalp. The affected areas are smooth, non-inflammatory, and the hair follicles appear intact. There is no scaling or erythema. On examination, exclamation-mark hairs are observed at the periphery of the lesions, and the pull test is positive. Nails show superficial, geometric pitting. Which of the following is the most likely diagnosis? (Q857587)

A. Tinea capitis

B. Kerion

C. Alopecia areata

D. Androgenic alopecia

Correct Answer: C. Alopecia areata

Explanation: The given scenario with sudden, smooth, well-circumscribed patches of non-scarring hair loss, exclamation-mark hairs, positive pull test, and regular nail pitting indicates Alopecia areata . A T-cell-mediated autoimmune condition targeting the anagen hair bulb, causing non-scarring hair loss. Clinical features: Localized patches of hair loss on the scalp that emerge over a few weeks. It can also affect other areas, such as the beard, eyebrows, eyelashes, and extremities. Pull test - Positive - very gentle traction on the unaffected hair at the margin of the patch of hair loss can remove all of the hair from the roots painlessly (distinguishing feature). Variants: Alopecia Totalis: Complete hair loss from the scalp. Alopecia Universalis: Complete hair loss from all over the body. Ophiasis: Occipital hair loss. {{caption_text}} {{caption_text}} Exclamation-mark hair, with a narrower proximal end than the distal end, is commonly observed at the periphery of lesions and is a pathognomonic finding in patients with alopecia areata. Pitting of nails that is superficial, geometric and regular {{caption_text}} Non-scarring alopecia {{caption_text}} Exclamation mark hair {{caption_text}} Regular nail pitting Tinea capitis (Scalp Ringworm) (Option A): Fungal scalp infection in children presenting with scaly patches, broken hairs, and black dots; KOH mount shows fungal hyphae. Kerion (Option B): Painful, boggy, pus-filled inflammatory swelling of the scalp representing severe tinea capitis, common in children. Androgenic alopecia (Male Pattern Baldness) (Option D): Gradual, patterned hair loss due to DHT sensitivity, showing bitemporal and vertex thinning without discrete patches.




@Neet_pg_bot


@Neet_pg_bot





References:

Chapter 89: Acquired disorders of hair. In: Rook’s Textbook of Dermatology. 9th ed. Blackwell; 2016. p. 89.14-86.24.

↑ *Back to this question in Part A*

@Neet_pg_bot

Q9: A disorder is characterized by recurrent hair-pulling resulting in noticeable hair loss. Which of the following statements about this disorder is not accurate? [(Q857567)

A. Impulse control disorder

B. The onset is typically in adolescence or early adulthood

C. Associated with feelings of pleasure or relief after hair-pulling

D. Caused by a bacterial infection of the scalp



Correct Answer: D. Caused by a bacterial infection of the scalp

Explanation: The disorder depicted in the image appears to be Trichotillomania (Hair-Pulling Disorder), which is characterized by recurrent hair-pulling leading to hair loss. Trichotillomania is not due to a bacterial infection but

rather a psychiatric disorder Trichotillomania: It is a psychiatric disorder in which obsessive, recurrent pulling of one's hair results in hair loss (Options A, C) It is seen in adolescents or young adults, more commonly in girls (Option B) Patchy hair loss with broken hair of variable lengths is seen in commonly accessible sites like the frontoparietal area of the scalp. In the Friar Tuck sign or Tonsure pattern, there is uneven hair loss in a circular pattern with surrounding hairs remaining unaffected. {{caption_text}} Perifollicular haemorrhages can also be seen because of trauma to the scalp. Skin biopsy shows empty hair follicles, with some forming soft twisted hairs described as tracheomalacia. Treatment includes cognitive behavioural therapy and antipsychotic medications like SSRI and paroxetine.

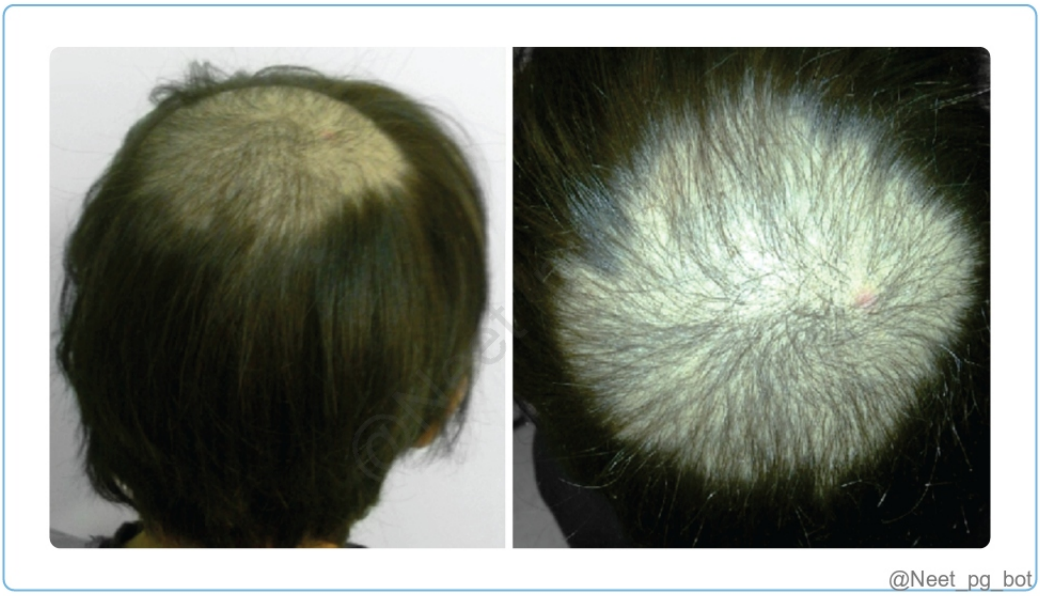

References:

Bewley A, Taylor RE. Chapter 86: Psychodermatology and Psychocutaneous Disease. In: Rook's Textbook of Dermatology. 9th ed. Blackwell; 2016. p. 86.17-86.19.

Image: https://www.semanticscholar.org/paper/Photoletter-to-the-editor%3A-The-Friar-Tuck-sign-in-Peralta-Morais/e7e84be909cdf23d406f5aade551833e6edfa365

↑ *Back to this question in Part A*

@Neet_pg_bot

Q10: Which of the following factors is responsible for non-scarring alopecia in patients? 1. Alopecia areata 2. Telogen effluvium 3. Androgenic alopecia 4. Frontal fibrosing alopecia (Q855742)

A. 3 and 4

B. 1, 2 and 3

C. 2,3 and 4

D. Only 4

Correct Answer: B. 1, 2 and 3

Explanation: Non-scarring alopecia refers to hair loss without permanent follicular destruction , meaning hair regrowth is possible. Alopecia areata (immune-mediated hair follicle attack), Telogen effluvium (stress-induced shedding), and Androgenic alopecia (genetic hair thinning) are all non-scarring causes . Frontal fibrosing alopecia (FFA) is a scarring alopecia , meaning it causes permanent hair loss with fibrosis . Non-Scarring vs. Scarring Alopecia: Feature Non-Scarring Alopecia Scarring Alopecia Pathophysiology Hair follicles remain intact; regrowth is possible. Follicular destruction with fibrosis; irreversible loss. Examples Alopecia areata (autoimmune) Telogen effluvium (stress-related shedding) Androgenic alopecia (hormonal, genetic) Frontal fibrosing alopecia (FFA) (lichen planopilaris variant) (Option 4 ruled out) Lupus erythematosus Folliculitis decalvans Clinical Findings Smooth scalp , no scarring Can have exclamation mark hairs (alopecia areata) Inflammation, erythema, follicular plugging Scalp atrophy or fibrosis Prognosis Usually reversible Permanent hair loss Treatment Alopecia areata: Intralesional steroids, JAK inhibitors Telogen effluvium: Treat underlying cause Androgenic alopecia: Minoxidil, finasteride Frontal fibrosing alopecia: Immunosuppressants, topical corticosteroids

References:

Rook’s Dermatology, 9th Edition, Volume 1, Section 32

↑ *Back to this question in Part A*

@Neet_pg_bot

Q11: An elderly female undergoing chemotherapy for breast cancer is experiencing significant hair loss. What is the most likely cause of her condition? (Q852569)

A. Telogen Effluvium

B. Trichotillomania

C. Anagen Effluvium

D. Alopecia Areata

Correct Answer: C. Anagen Effluvium

Explanation: The most likely cause of significant hair loss in an elderly female undergoing chemotherapy is Anagen Effluvium . This type of hair loss occurs due to damage to the hair follicle during the anagen (growth) phase . It is commonly caused by chemotherapy, radiation therapy, or toxic agents that impair rapidly dividing cells, including hair follicle matrix cells. Hair loss is usually sudden, diffuse, and non-scarring , occurring within days to weeks after starting chemotherapy. Other Options: Telogen Effluvium (Option A) : A temporary hair loss

condition caused by stress, illness, or hormonal changes, leading to excessive shedding in the telogen (resting) phase . It is not a primary side effect of chemotherapy. Trichotillomania (Option B) : A psychiatric disorder characterized by compulsive hair pulling , leading to patchy hair loss with irregular borders. It is behavioral rather than treatment-induced. Alopecia Areata (Option C) : An autoimmune condition that causes sudden, patchy hair loss due to immune system attacks on hair follicles. It is unrelated to chemotherapy.

References:

Neena Khanna, Textbook of Dermatology, 7th Edition, Page no: 324

↑ *Back to this question in Part A*

@Neet_pg_bot

Q12: Where is the apocrine gland present? (Q854653)

A. Palm and soles

B. Face

C. Axilla

D. Scalp

Correct Answer: C. Axilla

Explanation: Apocrine secretion involves the release of cellular products along with portions of the cytoplasm. Apocrine sweat glands present in the axilla, perineum, and groin regions secrete their secretion into hail follicles by apocrine mechanism and are primarily responsible for producing body odour. The mammary gland (Modified apocrine gland) produces milk by apocrine secretion. Types of glandular secretion Merocrine Apocrine Holocrine Mechanism By exocytosis The apical part of the cell is pinched off. Whole-cell is disintegrated while secretion Examples Eccrine sweat glands. Salivary glands. Globlet cells. Apocrine sweat glands. Mammary glands. Sebaceous glands Palm and soles (Option A) are free of apocrine glands. These areas primarily contain eccrine sweat glands, which are responsible for thermoregulation through merocrine secretion. Face (Option B): While the face contains sebaceous glands and eccrine sweat glands, apocrine glands are absent from the face. The sebaceous glands in the face use holocrine secretion to release sebum, not apocrine mechanisms. Scalp (Option D): While the scalp has eccrine sweat glands and sebaceous glands, apocrine glands are not located on the scalp.

References:

Fitzpatrick’s Dermatology 9th edition, Pg. 104

↑ *Back to this question in Part A*

@Neet_pg_bot

Q13: Which of the following conditions causes non-scarring alopecia? 1. Alopecia areata 2. Telogen effluvium 3. Androgenic alopecia 4. Folliculitis Decalvans (Q854652)

A. 3 and 4

B. 1, 2 and 3

C. 2, 3 and 4

D. Only 4

Correct Answer: B. 1, 2 and 3

Explanation: Cicatricial alopecias Non-cicatricial alopecias Loss of hair follicle stem cells Stem cells are not affected Irreversible cessation of hair cycle Damage to hair cycle can be reversed Dermoscopy: Absent follicular ostia Dermoscopy: Ostia are present. Black dots may be seen Examples: Frontal fibrosing alopecia. Folliculitis. Lupus erythematosus Scleroderma Types: Patterned: Androgenetic alopecia Diffuse: Effluvium Patchy: Alopecia areata, Trichotillomania. Tinea capitis, Moth-eaten alopecia Correct Optlon B- 1, 2 and 3: 1. Alopecia areata: Alopecia areata is an autoimmune condition that can cause non-scarring alopecia. It typically presents as well-defined, round or oval patches of hair loss on the scalp or other areas of the body. While it can lead to non-scarring alopecia, in some cases, it may progress to involve the entire scalp or body, resulting in complete hair loss. 2. Telogen effluvium: Telogen effluvium is a form of non-scarring alopecia characterized by diffuse hair shedding. It occurs when a large number of hair follicles enter the telogen (resting) phase simultaneously, leading to increased hair loss. It is often triggered by various factors such as childbirth, surgery, illness, or significant stress. 3. Androgenic alopecia: Androgenic alopecia, also known as male-pattern baldness or female-pattern baldness, is a genetic condition that leads to progressive hair thinning. It is a common cause of non-scarring alopecia, especially in a specific pattern on the scalp. Folllculltis Decalvans (Option D): Folliculitis decalvans is a type of scarring alopecia. Folliculitis decalvans typically presents as clusters of small, red, inflamed papules or pustules atthe site of hair follicles, often accompanied by crusting and scaling. Over time, the affected area may progress to form patches of smooth, bald skin with visible scarring.

References:

Chapter 89: Acquired disorders of hair. In: Rook’s Textbook of Dermatology. 9th ed. Blackwell; 2016. p. 89.10 -86.47.

Rook’s Textbook of Dermatology 89.24

↑ *Back to this question in Part A*

@Neet_pg_bot

Q14: Which of the following is not associated wIth non-scarring alopecia? (Q857389)

A. Alopecia areata

B. Androgenetic alopecia

C. Frontal fibrosing alopecia

D. Telogen effluvium

Correct Answer: C. Frontal fibrosing alopecia

Explanation: Frontal fibrosing alopecia is scarring alopecia , not non-scarring. It leads to permanent hair loss due to fibrosis and destruction of hair follicles, unlike non-scarring alopecia, where hair loss is reversible if the underlying cause is addressed. Cicatricial alopecias Non-cicatricial alopecias Loss of hair follicle stem cells Stem cells are not affected Irreversible cessation of hair cycle Damage to hair cycle can be reversed Dermoscopy: Absent follicular ostia Dermoscopy: Ostia are present. Black dots may be seen Examples: Frontal fibrosing alopecia. Folliculitis. Lupus erythematosus Scleroderma Types: Patterned: Androgenetic alopecia (Option B) Diffuse: Effluvium (Option D) Patchy: Alopecia areata (Option A) Trichotillomania Tinea capitis Moth-eaten alopecia Telogen Effluvium (Option D) is hair loss triggered by physical stressors like surgery, trauma, or illnesses such as dengue, malaria, COVID-19, TB, or chikungunya. TE can also occur during pregnancy, known as Telogen gravidarum. Here, stress causes hair follicles to prematurely enter the resting phase (Telogen) instead of the growth phase (Anagen), leading to hair shedding after about three months. Chronic TE can be caused by factors like iron deficiency, thyroid disorders, crash dieting, or malnutrition. Prolonged exposure to stressors can result in long-term hair loss.

References:

Chapter 89: Acquired disorders of hair. In: Rook’s Textbook of Dermatology. 9th ed. Blackwell; 2016. p. 89.10 -86.47.

↑ *Back to this question in Part A*

@Neet_pg_bot

Q15: A hair shaft with arthroconidia is seen in the image below. Which fungi is most likely associated with this finding? (Q843984)

A. Trichophyton

B. Microsporum

C. Tenia

D. Epidermophyton

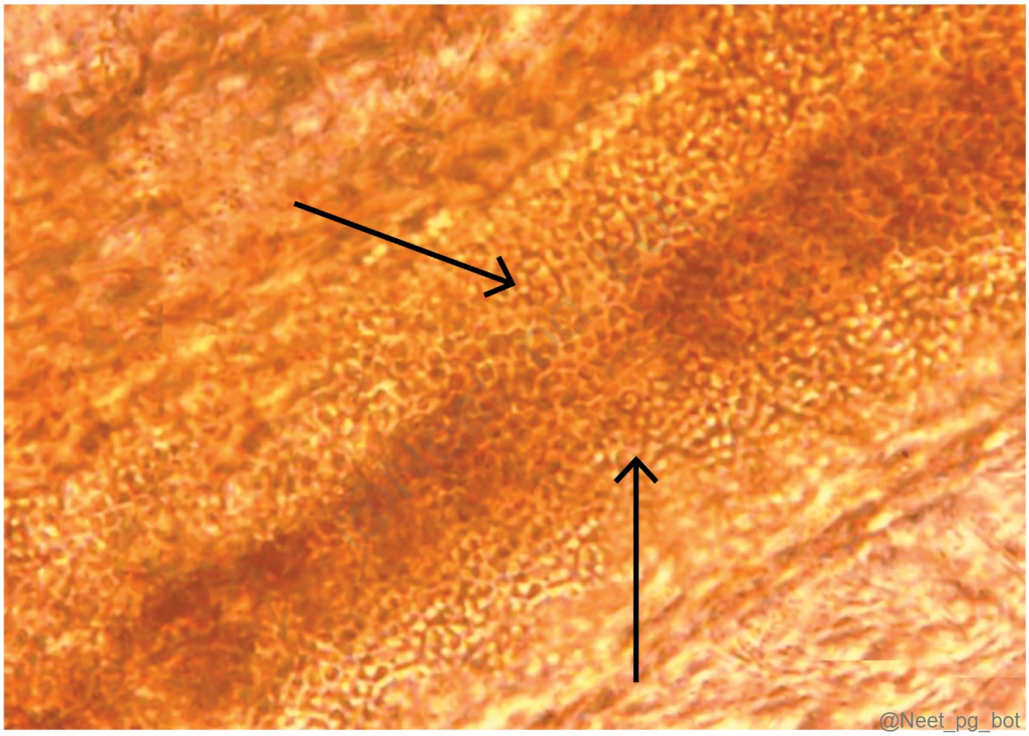

Correct Answer: A. Trichophyton

Explanation: Correct Option A - Trichophyton: The given image shows a chain of arthrospores inside the hair shaft, known as endothrix. They are seen in trichophyton infection. Incorrect Options: Options A, C, and D do not affect the hair shaft.

↑ *Back to this question in Part A*

@Neet_pg_bot

Q16: A 20-year-old male presents with numerous papules, pustules, and nodules on his face and trunk with evidence of scarring. He has a history of similar acne unresponsive to topical and oral antibiotic therapy. Which of the following drugs is the most appropriate treatment for this patient? (Q843982)

A. Topical tretinoin

B. Systemic doxycycline

C. Systemic minocycline

D. Systemic isotretinoin

Correct Answer: D. Systemic isotretinoin

Explanation: Systemic isotretinoin is the most effective treatment for moderate to severe nodulocystic acne, especially when there is scarring, and when the acne fails to respond to topical drugs and antibiotics. It works by reducing sebaceous gland size, normalizing keratinization, and decreasing inflammation and Cutibacterium acnes colonization. Topical tretinoin (Option A): Effective for mild to moderate acne but inadequate for severe, nodulocystic, or scarring acne. Systemic doxycycline (Option B): Useful for moderate inflammatory acne, but insufficient for severe, treatment-resistant cases. Systemic minocycline (Option C): Also for moderate acne; less effective alone in severe, scarring acne and carries additional side-effect risks.

References:

Neena Khanna, Textbook of Dermatology, 7th Edition, Page no: 300

↑ *Back to this question in Part A*

@Neet_pg_bot

Q17: A patient presents with a patch of hair loss on the scalp accompanied by scaling and itching, as depicted in the image. Their sibling had a similar scalp condition two years ago. What is the most likely diagnosis? (Q843975)

A. Tinea capitis

B. Alopecia areata

C. Pyoderma

D. Pediculosis capitis



Correct Answer: A. Tinea capitis

Explanation: The patient’s patchy hair loss with scaling and itching is characteristic of tinea capitis , a fungal infection of the scalp caused by dermatophytes. A history of a similar condition in a sibling supports transmission through close contact. Alopecia areata (Option B): Causes smooth, well-defined patches of hair loss without scaling or itching. Pyoderma (Option C): A bacterial skin infection that typically presents with pustules or ulcers, not scaling. Pediculosis capitis (Option D): Head lice infestation, characterized by itching and nits, not focal hair loss with scaling.

References:

.

↑ *Back to this question in Part A*

@Neet_pg_bot

Q18: Identify the structure marked with the arrow in the diagram provided: (Q843953)

A. Arrector pili

B. Sebaceous gland

C. Sweat gland

D. Hair papilla

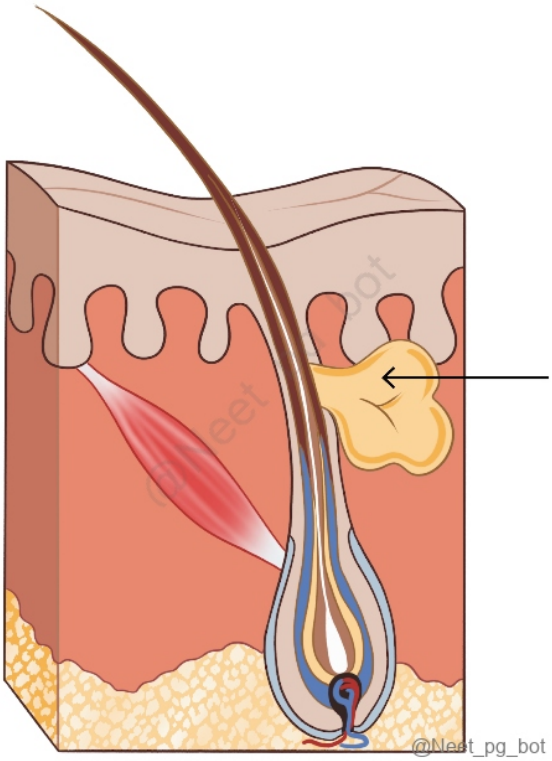

Correct Answer: B. Sebaceous gland

Explanation: Correct Option B - Sebaceous gland: The structure marked with an arrow shows a gland opening into the hair follicle, which is a sebaceous gland. Incorrect Options: Options A, C, and D are not marked in the given image.

↑ *Back to this question in Part A*

@Neet_pg_bot

Q19: What is the most appropriate treatment for severe acne? (Q852711)

A. Topical Tretinoin

B. Isotretinoin

C. Steroids

D. Antibiotics

Correct Answer: B. Isotretinoin

Explanation: Isotretinoin is the most effective treatment for severe, nodulocystic, or treatment-resistant acne . It is a systemic retinoid that reduces sebum production, keratinization, and bacterial colonization , leading to long-term remission in many cases. Acne Severity Treatment Options Mild Acne Over-the-counter topical treatments (benzoyl peroxide, salicylic acid) Topical retinoids (adapalene) (Option A ruled out) Moderate Acne Topical antibiotics (clindamycin, erythromycin) Oral antibiotics (doxycycline, minocycline) Topical retinoids (Option A ruled out) Hormonal therapy (for females) Severe Acne Oral isotretinoin (Most effective) (Option B) Oral antibiotics Topical retinoids Hormonal therapy (for females) Intralesional corticosteroids (for cystic acne) Other Options: Steroids (Option C) : Not used for acne treatment as systemic steroids can worsen acne (steroid-induced acne) . Intralesional steroids can be used on a per lesion basis but is not the most appropriate treatment option to cure severe acne. Antibiotics (Option D) : Topical or oral antibiotics (e.g., doxycycline, clindamycin) are useful for inflammatory acne , but they are not as effective as isotretinoin for severe or resistant cases.

References:

Neena Khanna, Textbook of Dermatology, 7th Edition, Page no: 300

↑ *Back to this question in Part A*

@Neet_pg_bot

• [03_Pigmentary Disorders] 006 Pigmentary Disorders - I

« Back to Folder Directory

[03_Pigmentary Disorders] 006 Pigmentary Disorders - I — Quick Jump

Q1 (p. 637)	*Q2 (p. 639)*	*Q3 (p. 640)*	*Q4 (p. 642)*	*Q5 (p. 643)*	*Q6 (p. 644)*
Q7 (p. 646)	*Q8 (p. 647)*	*Q9 (p. 648)*	*Q10 (p. 649)*	*Q11 (p. 651)*	*Q12 (p. 652)*
Q13 (p. 654)	*Q14 (p. 656)*	*Q15 (p. 657)*	*Q16 (p. 659)*	*Q17 (p. 660)*	*Q18 (p. 662)*
Q19 (p. 665)	*Q20 (p. 666)*	*Q21 (p. 667)*	*Q22 (p. 670)*	*Q23 (p. 671)*	*Q24 (p. 673)*
Q25 (p. 673)	*Q26 (p. 675)*	*Q27 (p. 676)*	*Q28 (p. 677)*	*Q29 (p. 680)*	*Q30 (p. 680)*
Q31 (p. 683)	*Q32 (p. 685)*	*Q33 (p. 686)*	*Q34 (p. 689)*	*Q35 (p. 691)*	*Q36 (p. 692)*
Q37 (p. 694)	*Q38 (p. 694)*	*Q39 (p. 696)*	*Q40 (p. 699)*	*Q41 (p. 701)*	*Q42 (p. 703)*
Q43 (p. 704)	*Q44 (p. 705)*	*Q45 (p. 706)*	*Q46 (p. 706)*	*Q47 (p. 707)*	*Q48 (p. 708)*

Q1: A 20-year-old man takes NSAIDs and, within 2 hours, develops lesions as shown. Similar lesions occurred at the same site after previous NSAID use. What is the most likely diagnosis? (Q884807)

A. Fixed drug eruption

B. Drug-induced hyperpigmentation

C. Acute contact dermatitis

D. Chikungunya-related hyperpigmentation



@Neet_pg_bot

Correct Answer: A. Fixed drug eruption

Explanation: The most likely diagnosis is Fixed Drug Eruption (FDE) . The clinical presentation of a recurrent lesion appearing at the same site shortly after drug ingestion is the hallmark of this condition. Fixed Drug Eruption (FDE): Recurrent, well-defined cutaneous lesions at the same site after exposure to a drug. Benign, self-limiting; post-inflammatory hyperpigmentation is common. Common drugs: NSAIDs , Paracetamol, Co-trimoxazole, Tetracyclines Others: Penicillins, Metronidazole, Carbamazepine, ACE inhibitors, food/herbals Pathophysiology: Delayed-type hypersensitivity via CD8+ skin-resident T cells . Rechallenge → T cell activation → keratinocyte apoptosis → lesion formation. Clinical features: Onset: 30 min-8 h after drug exposure Lesion: Round/oval, erythematous → dusky/violaceous; may be vesicular/bullous Sites: Lips, genitals, palms, soles , occasionally face Recurrence: Same site on re-exposure Variant: GBFDE (Generalised Bullous Fixed Drug Eruption) mimics TEN, but the mucosa is usually spared Investigation: Oral provocation (gold standard if safe) Patch test : ~50% positive at previous lesion sites Management: Stop offending the drug Topical corticosteroids; systemic if multiple lesions GBFDE: ICU/burns unit care Usually self-limiting; hyperpigmentation may persist GBFDE mortality ~20% Drug-induced hyperpigmentation (Option B) : Usually diffuse or patchy , develops gradually over weeks/months , not rapid and site-specific. Acute contact dermatitis (Option C) : Localised rash at the contact site , often itchy , not rapidly recurring with drug re-exposure. Chikungunya-related hyperpigmentation (Option D) : Appears days after fever , typically on the nasal dorsum , not immediately post-drug.



References:

Rook's Textbook of Dermatology, 9th Edition, Pages 118.11-118.14.

↑ *Back to this question in Part A*

@Neet_pg_bot

Q2: A 3-year-old child presents with pale skin, white hair, nystagmus, photophobia, and reduced visual acuity. Ophthalmological examination shows foveal hypoplasia and optic nerve misrouting. Which of the following statements about this condition is correct? (Q884746)

A. Melanocytes are abnormal

B. Autosomal recessive disorder

C. Sun protection is not necessary

D. No risk of skin cancer

Correct Answer: B. Autosomal recessive disorder

Explanation: The clinical presentation of pale skin, white hair, nystagmus, and specific ocular findings like foveal hypoplasia and optic nerve misrouting is diagnostic of Oculocutaneous Albinism . Oculocutaneous albinism is an autosomal recessive disorder caused by defects in melanin biosynthesis , with normal melanocyte number. Oculocutaneous Albinism: Definition: Genetic hypopigmentation of skin, hair, and eyes due to a melanin

biosynthesis defect ; melanocytes are normal (Option A) Inheritance: Autosomal recessive; subtypes OCA1-OCA7 (TYR, OCA2, TYRP1, SLC45A2, SLC24A5, C10orf11) Clinical Features: Skin & hair: pale; severity varies by subtype Eyes: nystagmus, iris translucency, foveal hypoplasia, optic nerve misrouting, photophobia, reduced visual acuity OCA1A: complete pigment absence; OCA1B & others: variable pigmentation Increased risk of skin cancers (squamous cell carcinoma in OCA2) (Option D) Normal lifespan, development, intelligence, and fertility ■■■■■■■ Management: Sun protection to prevent burns and skin cancer (Option C) Ophthalmology referral: Corrective lenses, eye patching, or surgery for strabismus; sunglasses for photophobia

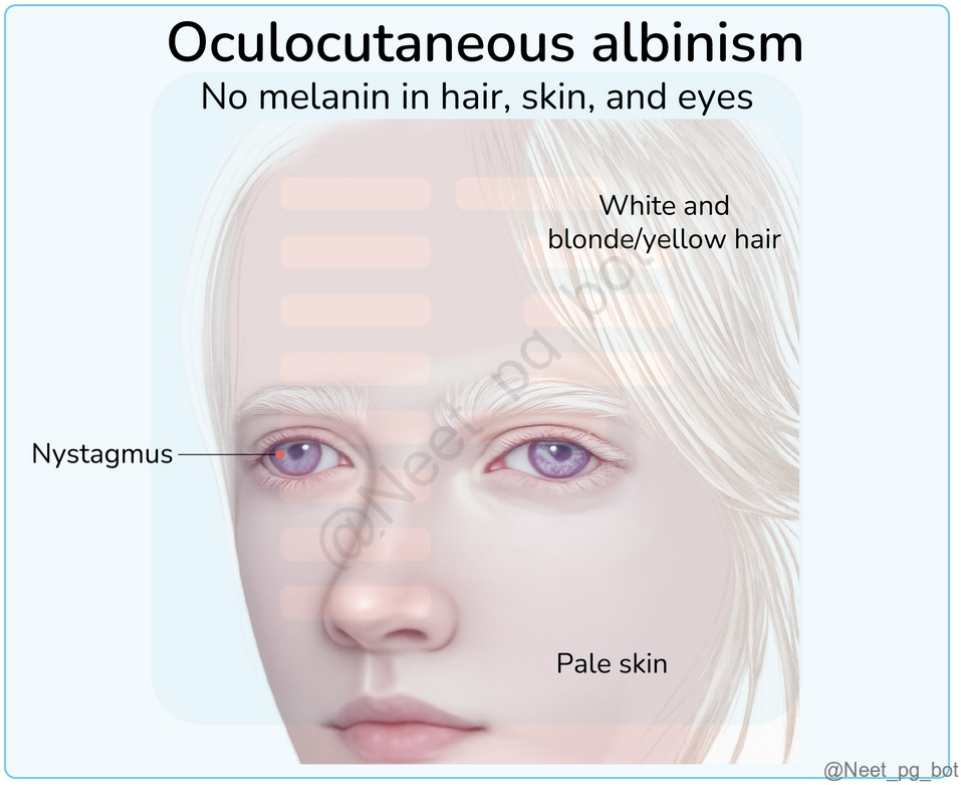

References:

Rook’s Textbook of Dermatology, 9th Edition, Pages 70.6-70.8.

↑ *Back to this question in Part A*

@Neet_pg_bot

Q3: Which of the following is the primary cause of the condition shown in the image below? (Q884747)

A. Defective migration of melanocytes during embryogenesis

B. Progressive loss of melanocytes

C. Decreased number of melanosomes in melanocytes

D. Reduced tyrosinase activity



Correct Answer: B. Progressive loss of melanocytes

Explanation: Vitiligo is an acquired depigmentation disorder caused by progressive loss of melanocytes , presenting as milky-white, sharply demarcated macules . Pathophysiology: Autoimmune/autoinflammatory mechanism: cytotoxic T cells target melanocytes. Oxidative stress: generates neoantigens triggering autoimmunity. Other mechanisms: melanocyte self-destruction, defective keratinocytes, melanocytorrhagy, and neurogenic factors. Genetics: polygenic; ~30% have a family history. Key genes include TYR . Vitiligo is an acquired depigmenting disorder characterised by well-defined depigmented macules and patches due to loss of melanocytes. Lesions are usually asymptomatic , symmetrical, and commonly involve the face, hands, genitalia, and body orifices. Hair within lesions may turn white (leukotrichia), and the disease may be associated with other autoimmune disorders. True Koebner's phenomenon is seen. Diagnosis is primarily clinical , based on the typical appearance of depigmented patches. Wood's lamp examination shows milky-white fluorescence. Defective migration of melanocytes during embryogenesis (Option A) : This describes piebaldism or Waardenburg syndrome, which are congenital. Decreased number of melanosomes in melanocytes (Option C) : Melanosome number is normal initially; melanocytes themselves are lost. Reduced tyrosinase activity (Option D) : This is seen in oculocutaneous albinism, where melanin synthesis is defective but melanocyte number is normal.



References:

Rook's Textbook of Dermatology, 9th Edition, Pages 88.34, 88.36, 88.37.

↑ *Back to this question in Part A*

@Neet_pg_bot

Q4: A 25-year-old woman has progressive, well-defined depigmented patches over the hands and face. Which of the following is not associated with this condition? ■ (Q884748)

A. Autoimmune thyroid disease

B. Alopecia areata

C. Addison disease

D. Neurofibromatosis type 1



@Neet_pg_bot

Correct Answer: D. Neurofibromatosis type 1

Explanation: Vitiligo is frequently associated with other autoimmune disorders due to shared genetic susceptibility and common pathways of immune-mediated destruction. Neurofibromatosis type 1 (NF1) , however, is a genetic neurocutaneous syndrome and is not autoimmune in nature. Associated conditions of vitiligo: Thyroid disease: Hyperthyroidism & hypothyroidism (Option A) Pernicious anemia Addison's (Option C) Diabetes Myasthenia gravis. Alopecia areata (Option B) Morphoea Lichen sclerosus Halo naevi Malignant melanoma.

References:

Rook's Textbook of Dermatology, 9th Edition, Page 88.35

↑ *Back to this question in Part A*

@Neet_pg_bot

Q5: A 30-year-old man with stable non-segmental vitiligo seeks treatment. Which of the following is not used in the management of vitiligo? (Q884749)

A. Excimer laser (308 nm)

B. Pimecrolimus

C. Autologous melanocyte grafting

D. Retinoids

Correct Answer: D. Retinoids

Explanation: While retinoids (like tretinoin) are used for many skin conditions, such as acne, psoriasis, and photoaging, they are not a standard treatment for vitiligo. Management of vitiligo: First line: Topical corticosteroids (e.g., 0.1% betamethasone, 0.05% clobetasol) Topical calcineurin inhibitors (tacrolimus, pimecrolimus) (Option B) - mainly for face/neck Second line: Phototherapy (PUVA, NB-UVB, excimer laser 308 nm) (Option A) Third line: Tissue grafts: punch, split-thickness, suction blister Cellular grafts : cultured melanocytes/epithelial sheets (Option C) Hair follicle outer root sheath cell transplantation Depigmentation therapy: For extensive residual pigmentation: monobenzyl ether of hydroquinone, Q-switched lasers, cryotherapy Supportive: Sunscreen for sun-exposed areas Cosmetic camouflage

References:

Rook’s Textbook of Dermatology, 9th Edition, Pages 88.39, 88.40.

↑ *Back to this question in Part A*

@Neet_pg_bot

Q6: Which of the following are the mechanisms of the treatment modality depicted in the image below: DNA cross-linking by psoralen photoadducts Inhibition of DNA replication Depletion of Langerhans cells Immunosuppressive effects on T-lymphocyte function and migration Restoration of Th17/regulatory T-cell imbalance (Q884765)

A. 1, 2 and 4

B. 2, 3 and 4

C. 1, 2, 3 and 4

D. 1, 2, 3, 4 and 5



Correct Answer: D. 1, 2, 3, 4 and 5

Explanation: The image depicts a newborn receiving phototherapy for jaundice at the hospital. Phototherapy = controlled use of non-ionising ultraviolet (UV) radiation to treat skin diseases. PUVA therapy: PUVA = Psoralen + UVA Psoralen given oral/topical , followed by UVA exposure Mechanism: DNA cross-linking by psoralen photoadducts Inhibition of DNA replication Langerhans cell depletion Immunosuppression of T-lymphocyte function and migration Restoration of Th17 / regulatory T-cell imbalance



References:

Rook’s Textbook of Dermatology, 9th Edition, Page 21.1.

↑ *Back to this question in Part A*

@Neet_pg_bot

Q7: A patient with non-segmental vitiligo is being counselled regarding disease prognosis. Which of the following is not considered a poor prognostic factor in vitiligo? (Q884769)

A. Koebner phenomenon

B. Mucosal involvement

C. Leukotrichia

D. Negative family history

Correct Answer: D. Negative family history

Explanation: Negative family history is not associated with worse disease outcomes and, therefore, it is not a poor prognostic factor in vitiligo. Poor prognostic factors for vitiligo: Family history of vitiligo Mucosal involvement (Option B) Koebner phenomenon (skin lesions at sites of trauma) (Option A) Adverse clinical markers

Confetti-like lesions (limited evidence) Longer disease duration and leukotrichia (Option C) correlated with greater body surface area involvement and poor repigmentation. Age of onset showed inconsistent associations.

References:

Vitiligo- prognosis

↑ *Back to this question in Part A*

@Neet_pg_bot

Q8: An 8-year-old child presents with findings as shown in the image, with a history of seizures and developmental delay. Which of the following statements about this condition is wrong? (Q884778)

A. It represents a form of cutaneous mosaicism

B. It is commonly inherited in an autosomal dominant patterny

C. Along lines of Blashko

D. Skin lesions typically lack epidermal atroph



@Neet_pg_bot

Correct Answer: B. It is commonly inherited in an autosomal dominant patterny

Explanation: Hypomelanosis of Ito is usually sporadic , resulting from postzygotic mutations leading to mosaicism , and is not commonly inherited . Hypomelanosis of Ito: A rare neuroectodermal mosaic disorder characterised by hypopigmented skin lesions along the lines of Blaschko . (Option C) Present as macular hypopigmentation No skin atrophy (helps differentiate from focal dermal hypoplasia) (Option D) Extracutaneous associations: Neurological: intellectual disability, epilepsy Ophthalmological abnormalities Skeletal defects Overall marked phenotypic variability Genetics & pathogenesis: Caused by postzygotic mutations Represents cutaneous mosaicism (Option A) : May be monogenic or chromosomal Transmission to offspring presumed lethal , explaining sporadic occurrence Current concept: Not a single disease entity Represents a phenotypic pattern of mosaicism manifesting as hypo- or hyperpigmentation along the Blaschko line.

References:

Rook’s Textbook of Dermatology, 9th Edition, Page 70.10

↑ *Back to this question in Part A*

@Neet_pg_bot

Q9: A newborn female presents with erythematous vesicular lesions arranged along Blaschko lines since birth. Over the next few months, the lesions become verrucous, followed later by swirled hyperpigmentation. She also has peg-shaped teeth & requires ophthalmologic follow-up. Which of the following statements about this condition is incorrect? (Q884782)

A. It is caused by mutations in the IKBKG (NEMO) gene

B. X-linked dominant disorder

C. Most of them have severe permanent neurological impairment

D. Ophthalmologic follow-up should be done



Correct Answer: C. Most of them have severe permanent neurological impairment

Explanation: The child is presenting with Incontinentia Pigmenti (IP) , also known as Bloch-Sulzberger syndrome. The majority (>60%) of patients with incontinentia pigmenti are neurologically normal . Incontinentia Pigmenti (IP): Rare X-linked dominant (Option B) multisystem ectodermal dysplasia Usually lethal in males & affects mainly females Involves skin, teeth, hair, nails, eyes, and CNS Genetics & pathophysiology: Caused by IKBKG (NEMO / IKK-γ) gene mutation (Option A) Impaired NF-κB activation → ↑ TNF-α-induced apoptosis Exon 4-10 deletion in ~85% cases Inherited or de novo & affected males usually miscarried Cutaneous Stages (along Blaschko lines): Stage I (Vesicular): Erythematous vesicles at birth Stage II (Verrucous): Hyperkeratotic, wart-like lesions (limbs) Stage III (Pigmented): Swirled hyperpigmentation (fades by adolescence) Stage IV (Atrophic): Hypopigmented, hairless, atrophic streaks (adolescence) Extras: Peg/missing teeth, alopecia, nail dystrophy, retinal neovascularisation, ± seizures >60% neurologically normal Prognosis: Normal life expectancy Management: Supportive; mandatory ophthalmologic follow-up (Option D)

References:

Rook’s Textbook of Dermatology, 9th Edition, Page 70.11.

↑ *Back to this question in Part A*

@Neet_pg_bot

Q10: A 14-year-old girl presents with findings as shown in the image. Her father has a history of similar lesions and gastrointestinal polyps. Imaging reveals a jejunal polyp

causing intermittent abdominal pain. Which of the following statements about this condition is correct? (Q884784)

A. Hamartomatous polyps commonly undergo malignant transformation.

B. Lentigines typically appear in adulthood.

C. Granulosa cell ovarian tumours are a characteristic associated with tumours.

D. Inherited in an autosomal recessive pattern

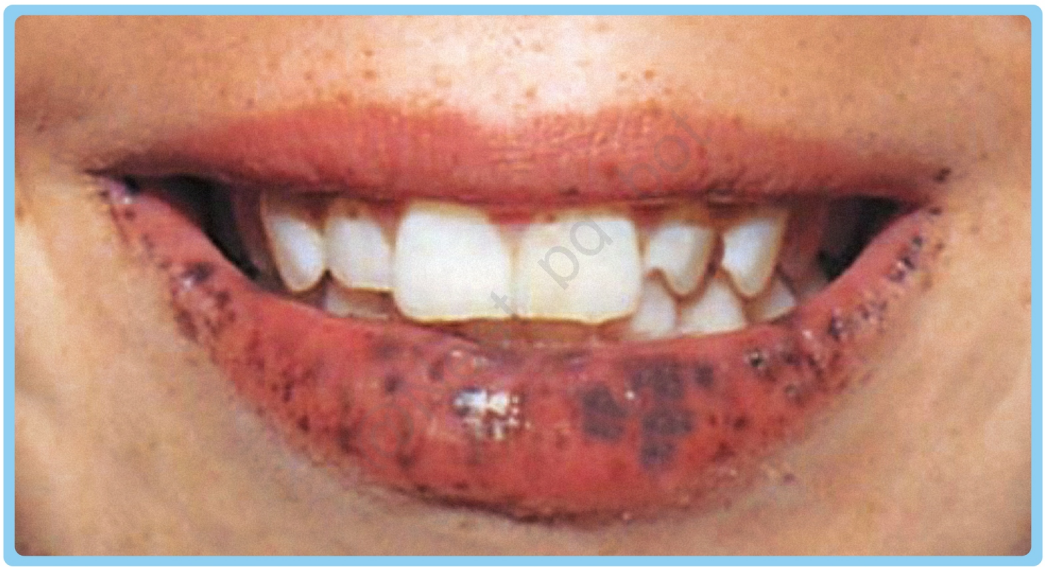

@Neet_pg_bot

Correct Answer: C. Granulosa cell ovarian tumours are a characteristic associated with tumours.

Explanation: The clinical presentation- mucocutaneous lentigines (dark spots on the lips/fingers), hamartomatous gastrointestinal polyps , and a positive family history -points directly to Peutz-Jeghers Syndrome (PJS) . Granulosa cell ovarian tumors are the most distinctive non-GI tumor associated with Peutz-Jeghers-Touraine syndrome. Peutz-Jeghers-Touraine Syndrome (PJT): Inheritance: Autosomal dominant (Option D) Gene: STK11 (LKB1) Skin & Mucosa Early-onset (Option B) lentigines on the lips Buccal mucosa and digits involved GI features: Hamartomatous polyps (most common in the jejunum) Complications: intussusception, bleeding Malignant change of small-bowel polyps: rare (Option A) Associated tumours: Granulosa cell ovarian tumour (characteristic) ↑ risk: breast, pancreas Histology: GI polyps: arborising smooth muscle , frond-like epithelium Acral lesions: pigment block Genotype-Cancer Risk: Substrate-recognition domain mutations → ↑ malignancy Truncating mutations → common in breast cancer cases

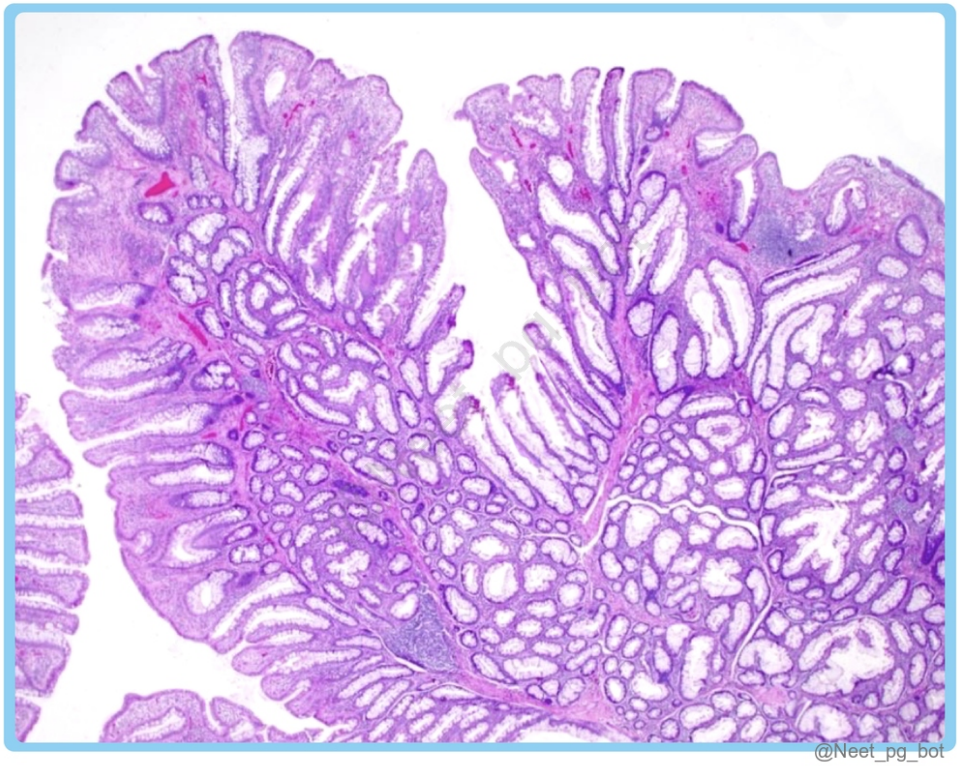

References:

Rook's Textbook of Dermatology, 9th Edition, Pages 70.14, 70.15.

↑ *Back to this question in Part A*

@Neet_pg_bot

Q11: Which of the following drugs are known to produce drug-induced hyperpigmentation? Amiodarone Chloroquine Paracetamol Minocycline Triamcinolone (Q884786)

A. 1, 2, 5

B. 1, 2, 4, 5

C. 1, 2, 4

D. 1, 4, 5

Correct Answer: C. 1, 2, 4

Explanation: The correct answer is 1, 2, 4 (Amiodarone, Chloroquine, and Minocycline). Paracetamol: Not associated with hyperpigmentation. Triamcinolone: Corticosteroid; may cause skin atrophy or striae but not hyperpigmentation . Drug-Induced Hyperpigmentation: Skin hyperpigmentation caused by medications via melanin/lipofuscin accumulation, drug deposition, or post-inflammatory changes . Onset: 1 week → years Risk ↑ with high dose/long duration Sun exposure and drug history guide diagnosis Common Drugs & Patterns: Amiodarone: Slate-grey/purple; sun-exposed areas; dose- and duration-dependent; lipofuscin + drug in macrophages. Antimalarials (Chloroquine, Mepacrine): Yellowish or bluish-grey; face, extremities, nails, hard palate; melanin + drug/iron complexes. Clofazimine: Violaceous-brown; lesional skin; ceroid-lipofuscin in macrophages. Cytotoxic drugs (Busulfan, Doxorubicin, Cyclophosphamide, etc.): Localised/diffuse; skin, nails, mucosa, hair; mimics Addison's disease. Hydantoins (Phenytoin), Barbiturates: Basal epidermal hyperpigmentation; diffuse or melasma-like. Psychotropics (Chlorpromazine, Trifluoperazine, Imipramine): Blue-grey sun-exposed areas; may involve nails, cornea, conjunctiva. Tetracyclines (Minocycline): Skin, nails, oral cavity, sclera; 4 patterns (acne scars, inflammation, muddy-brown, lip vermilion); partially reversible.

References:

Rook’s Textbook of Dermatology, 9th Edition, Pages 88.25-88.27.

↑ *Back to this question in Part A*

@Neet_pg_bot

Q12: A 44-year-old woman presents with fever, severe bilateral joint pain, and headache for 5 days. She was taking NSAIDs under prescription. One week after her fever subsides, she develops findings as shown in the image. What is the most likely diagnosis? (Q884787)

A. Dengue fever

B. Chikungunya fever

C. Fixed drug eruption

D. Viral exanthem

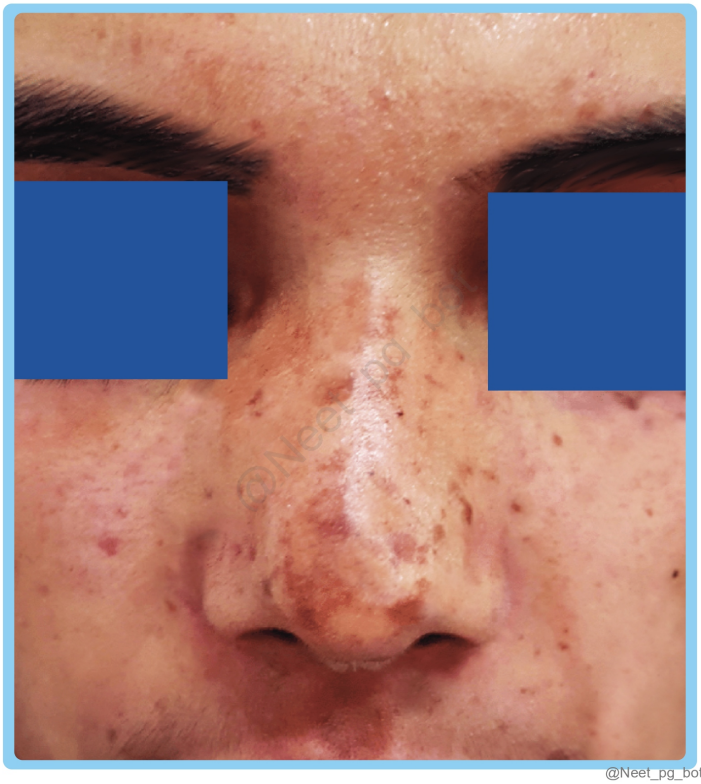

Correct Answer: B. Chikungunya fever

Explanation: The correct answer is Chikungunya fever . The patient shows the “chik sign” , which is brownish hyperpigmentation over the nasal dorsum appearing after the acute febrile phase , a hallmark of chikungunya. Severe arthralgia supports this diagnosis. Chikungunya fever is a mosquito■borne viral illness characterised by fever, severe joint pain (arthralgia), and skin symptoms . The “chik sign” refers to distinctive hyperpigmentation over the nose seen in some chikungunya patients. This mucocutaneous sign may appear during the disease’s recovery phase and can look similar to melasma or freckles , which makes recognition important. Dengue fever (Option A) : Fever and myalgia are common, but localised nasal hyperpigmentation is not seen . Fixed drug eruption (Option C) : Typically appears within hours of drug exposure as well-demarcated erythematous/violaceous patches that recur at the same site ; in this case, the timing (1 week after fever resolution) and location (nasal dorsum) make FDE unlikely. Viral exanthem (Option D) : Causes generalised rashes , but does not produce localised nasal pigmentation like the chik sign.



References:

https://pmc.ncbi.nlm.nih.gov/articles/PMC11979963/

↑ *Back to this question in Part A*

@Neet_pg_bot

Q13: A 5-year-old boy presents with silvery hair, fair skin, and pale irides. He has a history of recurrent bacterial infections and neutropenia. Peripheral smear shows findings as shown. Which of the following statements about this condition is correct? (Q884745)

A. It is inherited in an autosomal dominant pattern

B. Hypopigmentation is due to defective melanocyte trafficking

C. Phototherapy is the treatment of choice for pigmentation

D. Neutrophil function is normal in affected individuals

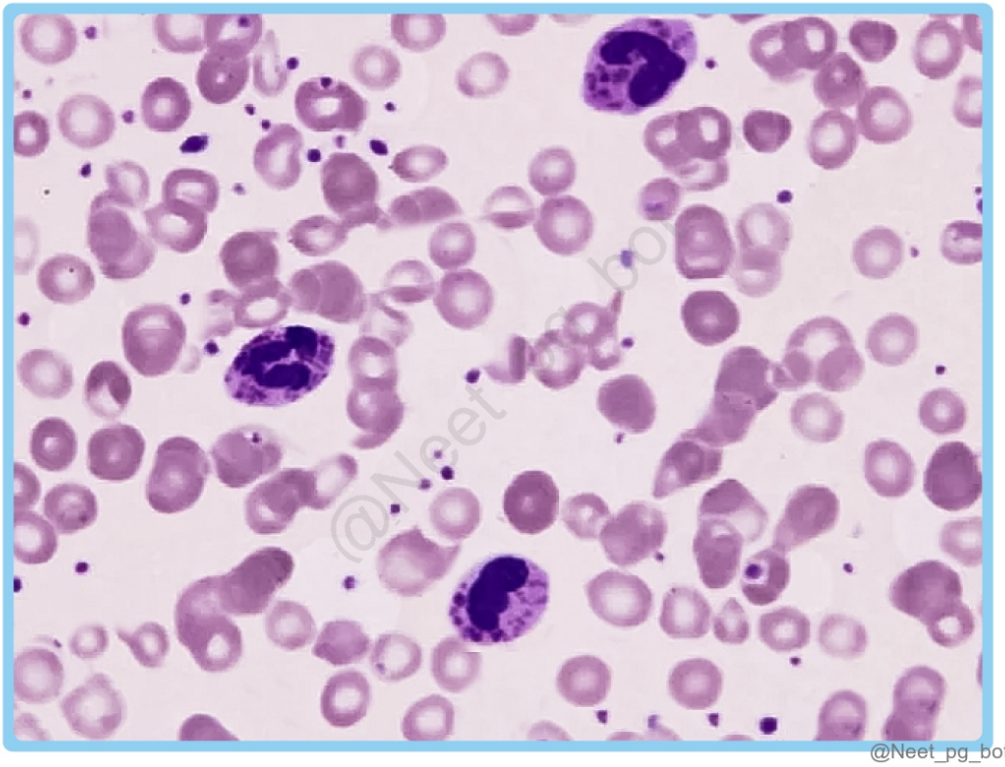

Correct Answer: B. Hypopigmentation is due to defective melanocyte trafficking

Explanation: The child is presenting with Chédiak-Higashi Syndrome (CHS) , a rare multisystem disorder characterised by partial oculocutaneous albinism, immunodeficiency, and unique cellular abnormalities. The disorder results from mutations in LYST , causing giant melanosomes in melanocytes due to defective trafficking. Chédiak-Higashi Syndrome (CHS): Inheritance: Autosomal recessive (Option A) Gene: CHS1 (LYST) → defective lysosomal trafficking Pathology: Giant melanosomes in melanocytes; giant inclusions in neutrophils Neutrophil function is impaired , leading to recurrent infections (Option D) Clinical Features: Hypopigmented skin, hair, and eyes Recurrent infections, neutropenia Neurological symptoms (intellectual decline, tremor, cranial nerve palsies) Accelerated phase: hemophagocytic lymphohistiocytosis Investigations: Giant peroxidase-positive leukocyte inclusions; hair pigment clumping Management: Bone marrow transplantation (curative) Phototherapy does not correct pigmentation (Option C)



References:

Rook’s Textbook of Dermatology, 9th Edition, Pages 70.8, 70.9.

↑ *Back to this question in Part A*

@Neet_pg_bot

Q14: Which of the following statements regarding Naevus of Ota is correct? (Q884821)

A. It is more common in males

B. Lesions are usually bilateral

C. It tends to regress spontaneously with age

D. It is distributed along the trigeminal nerve

Correct Answer: D. It is distributed along the trigeminal nerve

Explanation: Naevus of Ota classically follows the V1 and V2 divisions of the trigeminal nerve . Naevus of Ota: (Oculodermal melanocytosis, Naevus fuscoceruleus ophthalmomaxillaris) Congenital bluish-brown dermal

melanocytosis involving periocular skin and sclera , along V1 & V2 trigeminal distribution. Asians , females > males (Option A) Present at birth/early childhood (rare pubertal onset) Clinical features: Blue (deep) + brown (superficial) pigmentation Sites: Periorbital skin, sclera/conjunctiva , temple, forehead, malar area Usually unilateral (Option B) Pathology: Dermal dendritic melanocytes , no epidermal involvement GNAQ mutation (subset) D/D: Hori naevus - acquired, bilateral, no mucosal involvement Complications: Rare uveal/meningeal melanoma Does not regress & Persists lifelong (unlike Mongolian spot) (Option C) Management: Q-switched lasers - treatment of choice Cosmetic camouflage as an adjunct Regular ophthalmologic follow-up is essential Any new nodule → biopsy to rule out melanoma



References:

Rook's Textbook of Dermatology, 9th Edition, Pages 132.13, 132.14.

↑ *Back to this question in Part A*

@Neet_pg_bot

Q15: A mother brings her 8-year-old child with a long-standing, asymptomatic blue-grey patch over the right shoulder and upper chest present since early childhood, as shown in the image. There is no ocular or mucosal involvement. What is the most likely diagnosis? (Q884822)

A. Naevus of Ota

B. Naevus of Ito

C. Becker naevus

D. Mongolian spot



Correct Answer: B. Naevus of Ito

Explanation: The most likely diagnosis is Naevus of Ito . This clinical presentation describes a classic dermal melanocytosis located in the distribution of the posterior supraclavicular and lateral cutaneous brachial nerves . Naevus of Ito: (Naevus fusco-ceruleus acromiodeltoideus) Dermal melanocytosis involving the acromioclavicular region, shoulder, upper chest, and upper back . More common in Asians (especially Chinese and Japanese) Less common than naevus of Ota Pathology: Identical to naevus of Ota Dermal dendritic melanocytes are scattered among collagen bundles Clinical features: Unilateral blue-grey macular pigmentation Distribution along the posterior supraclavicular and lateral cutaneous brachial nerves Bilateral lesions uncommon Complications: Benign Very rare malignant transformation (few reported melanoma cases) Course: Persistent, similar to naevus of Ota Management: Q-switched pigment-targeting lasers (treatment of choice)

References:

Rook’s Textbook of Dermatology, 9th Edition, Pages 132.14, 132.15.

↑ *Back to this question in Part A*

@Neet_pg_bot

Q16: A 9-year-old fair-skinned child presents with findings as shown in the image. The lesions become darker during summer and lighten in winter. Dermoscopy shows uniform pigmentation with a moth-eaten border. Which of the following statements regarding this condition is true? (Q884824)

A. Increased number of melanocytes

B. Non-benign

C. Increased melanin production with normal melanocyte number

D. No risk of melanoma

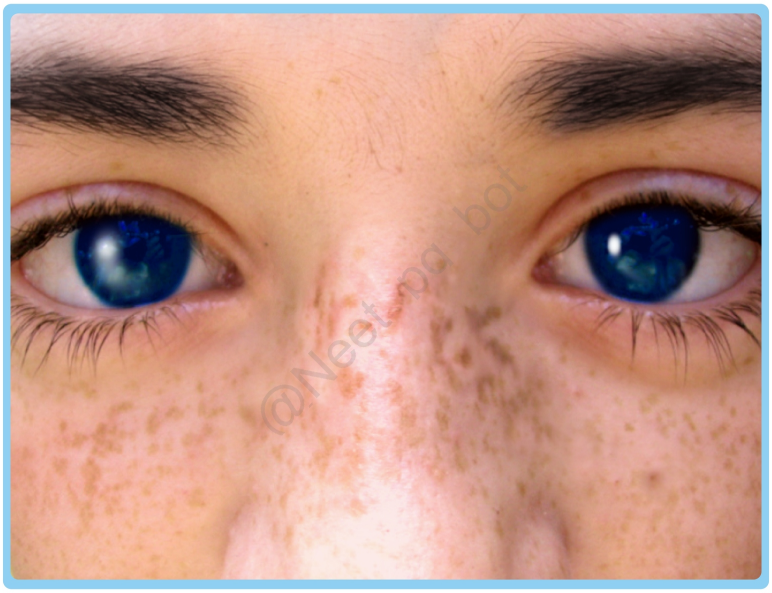

@Neet_pg_bot

Correct Answer: C. Increased melanin production with normal melanocyte number

Explanation: The child is presenting with Ephelides (commonly known as freckles). The diagnosis is based on the early age of onset, the seasonal variation (darkening in summer, lightening in winter), and the characteristic "moth-eaten" border seen on dermoscopy. Freckles (ephelides) result from UV-induced increased melanin production by melanocytes with a normal melanocyte count , leading to reversible hyperpigmented macules. Freckles: Small brown macules , ill-defined, on sun-exposed skin Darken with UV , fade in winter Common in children , fair skin , red hair, blue eyes Pathogenesis: ↑ melanin production, normal melanocyte number (Option A) Histology: Basal layer hyperpigmentation only Genetics: MC1R variants Differential: Solar lentigines:

Persistent, older age, ↑ melanocytes NF1 freckling: Axilla/groin Risk: ↑ melanoma risk (Option D) Course: Benign (Option B) , may fade with age Dermoscopy: Uniform pigment, moth-eaten edge Management: Reassurance + photoprotection

References:

Rook's Textbook of Dermatology, 9th Edition, Pages 132.1-132.3.

↑ *Back to this question in Part A*

@Neet_pg_bot

Q17: A 26-year-old woman presents with a long-standing mole on her neck. On examination, the lesion looks as shown in the image. There is no surrounding pigmentation. What is the most likely type of melanocytic naevus? (Q884825)

A. Junctional naevus

B. Compound naevus

C. Intradermal naevus

D. Blue naevus



Correct Answer: C. Intradermal naevus

Explanation: An intradermal naevus is characterised by a flesh-coloured, dome-shaped lesion , often with hair growth , due to naevus cells being located entirely within the dermis and producing little melanin. Acquired Melanocytic Naevi: Benign melanocytic tumours (moles) Start at the dermo-epidermal junction → migrate to dermis → senesce Types: Junctional naevus (Option A) - melanocytes at DE junction → flat brown macule Compound naevus (Option B) - junctional + dermal component → slightly raised papule Intradermal naevus - dermal only → flesh-coloured dome-shaped papule Blue naevus (Option D) : Blue-black lesion due to deep dermal melanocytes, not flesh-coloured.

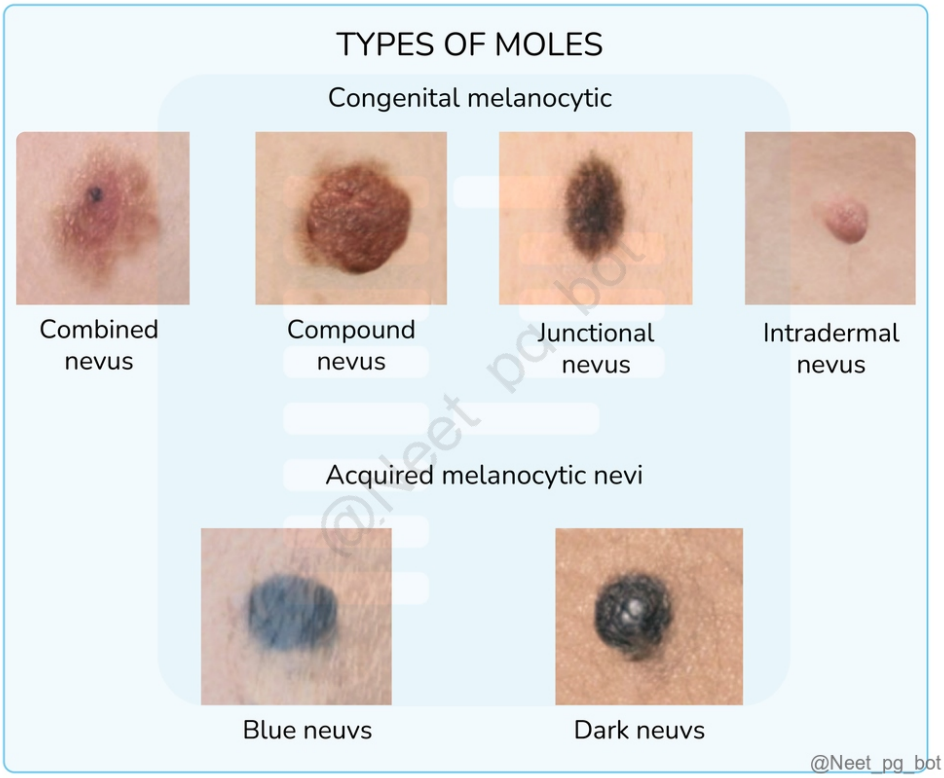

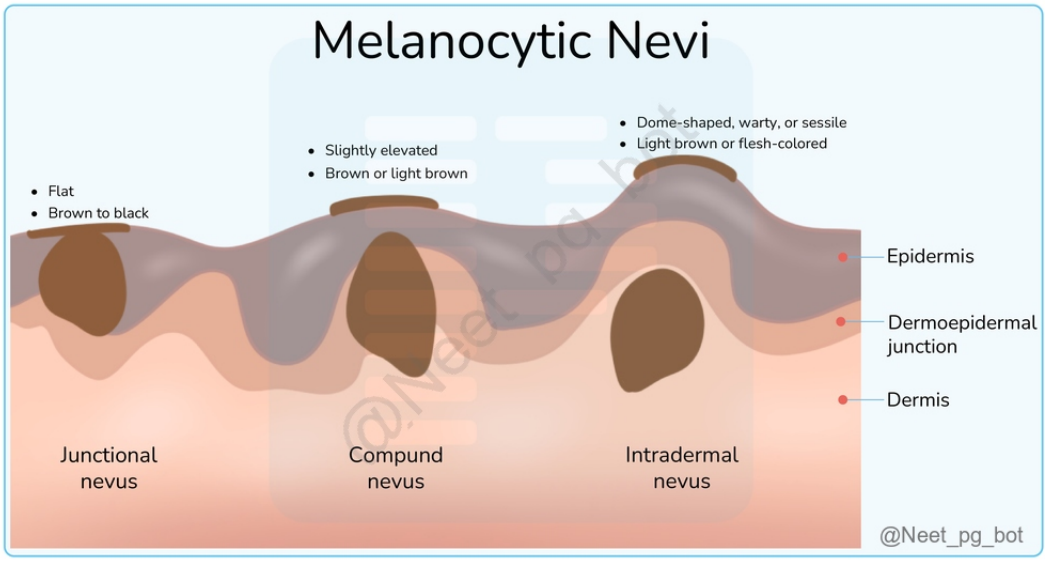

References:

Rook’s Textbook of Dermatology, 9th Edition, Pages 132.18-132.22 .

↑ *Back to this question in Part A*

@Neet_pg_bot

Q18: A 17-year-old boy has a unilateral hyperpigmented patch as shown in the image below, with mild ipsilateral muscle hypoplasia. What is the diagnosis? (Q884828)

A. Naevus of Ito

B. Becker naevus

C. Congenital melanocytic naevus

D. Nevus spilus



Correct Answer: B. Becker naevus

Explanation: The correct diagnosis is Becker naevus . Becker naevus typically presents in adolescent males as a unilateral hyperpigmented patch , often on the upper trunk , and may be associated with ipsilateral muscle or breast hypoplasia (Becker naevus syndrome). Becker Naevus (Becker Melanosis): Definition: Common benign

hyperpigmented naevus, often hypertrichotic Sex: More common in males Onset: Usually peripubertal ; rarely congenital Site: Upper trunk most common Pathology: Lentiginous melanocytic hyperplasia Epidermal hyperplasia Smooth muscle hyperplasia Classification: Does not fit neatly into standard melanocytic naevus categories Associations (Becker Naevus Syndrome): Ipsilateral breast hypoplasia/aplasia Pectoralis major / shoulder muscle hypoplasia Lipoatrophy Limb growth disturbance Supernumerary nipple Scoliosis Naevus of Ito (Option A) : This is a blue-grey dermal melanocytosis. It lacks the brown colour and hair overgrowth of Becker naevus and does not involve underlying muscle defects. Congenital Melanocytic Naevus (Option C) : This is present at birth and contains nests of melanocytes (naevus cells). Becker naevus is acquired in adolescence and lacks these nests. Nevus Spilus (Option D) : This is a "speckled" lesion with dark spots on a tan background. It does not present as a large uniform patch or involve muscle hypoplasia.





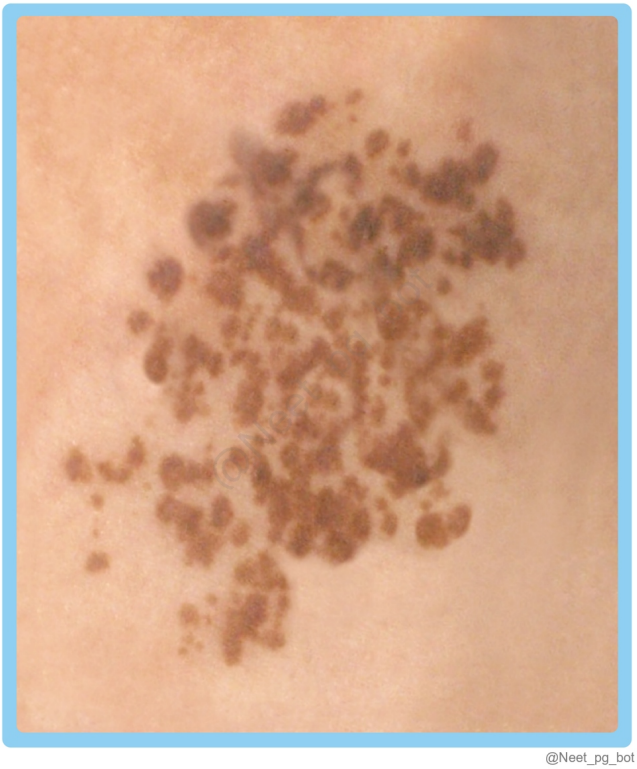

References:

Rook’s Textbook of Dermatology, 9th Edition, Pages 75.19, 132.15.

↑ *Back to this question in Part A*

@Neet_pg_bot

Q19: Which of the following regarding nevus anemicus is incorrect? (Q884829)

A. Congenital lesion

B. Persistent vasoconstriction

C. Reduced melanocyte number

D. No erythema on rubbing

Correct Answer: C. Reduced melanocyte number

Explanation: Nevus anemicus is not a pigmentary disorder . Melanocyte number and melanin content are normal; the pale appearance results from persistent vasoconstriction , not hypopigmentation. Nevus anemicus: Congenital vascular anomaly causing a pale patch due to persistent vasoconstriction Onset: Present at birth (Option A) Key Feature: Does not redden with rubbing, heat, or cold (Option D) Pathogenesis: Local hypersensitivity of dermal vessels to catecholamines (Option B) Diagnosis: Clinical; Wood lamp/diascopy helpful Differential: Vitiligo, nevus depigmentosus, pityriasis alba Associations: May be seen with NF1 Treatment: None required (benign) Prognosis: Excellent, lifelong stability



References:

Rook’s Textbook of Dermatology, 9th Edition, Page 4.20

https://www.ncbi.nlm.nih.gov/books/NBK459139/

↑ *Back to this question in Part A*

@Neet_pg_bot

Q20: Which of the following statements regarding simple lentigo is incorrect? (Q884830)

A. It shows increased melanocytes at the dermo-epidermal junction

B. The lesion typically fades with reduced sun exposure

C. Melanocytes are increased without nest formation

D. It is a benign lesion that commonly appears in childhood

Correct Answer: B. The lesion typically fades with reduced sun exposure

Explanation: Simple lentigo does not fade once it appears, unlike freckles. Simple lentigo: Light- to dark-brown/black macule that does not fade Histology: increased melanocytes at the dermo-epidermal junction (no nesting) (Option A, C) Risk factors: UV exposure is the most important environmental factor Reported after topical immunotherapy: tacrolimus, SADBE, DPCP Genetics: No BRAF/FGFR3/PIK3CA mutations; multiple lesions → syndromic (RAS-MAPK, mTOR) Pathology: Mild ↑ melanocytes, basal hyperpigmentation, elongated rete ridges Clinical features: Uniformly pigmented , poorly circumscribed macules Round/oval, ≤ 5 mm, pale to deep brown Common in sun-exposed areas D/D: Freckles: Fade with sun; no ↑ melanocytes Junctional naevus: Shows nests of naevus cells “Jentigo” pattern: Features of lentigo + junctional naevus Dermoscopy: Scalloped borders, faint irregular network Management: None; photoprotection; cosmetic treatments if needed Prognosis: Benign, stable (Option D)

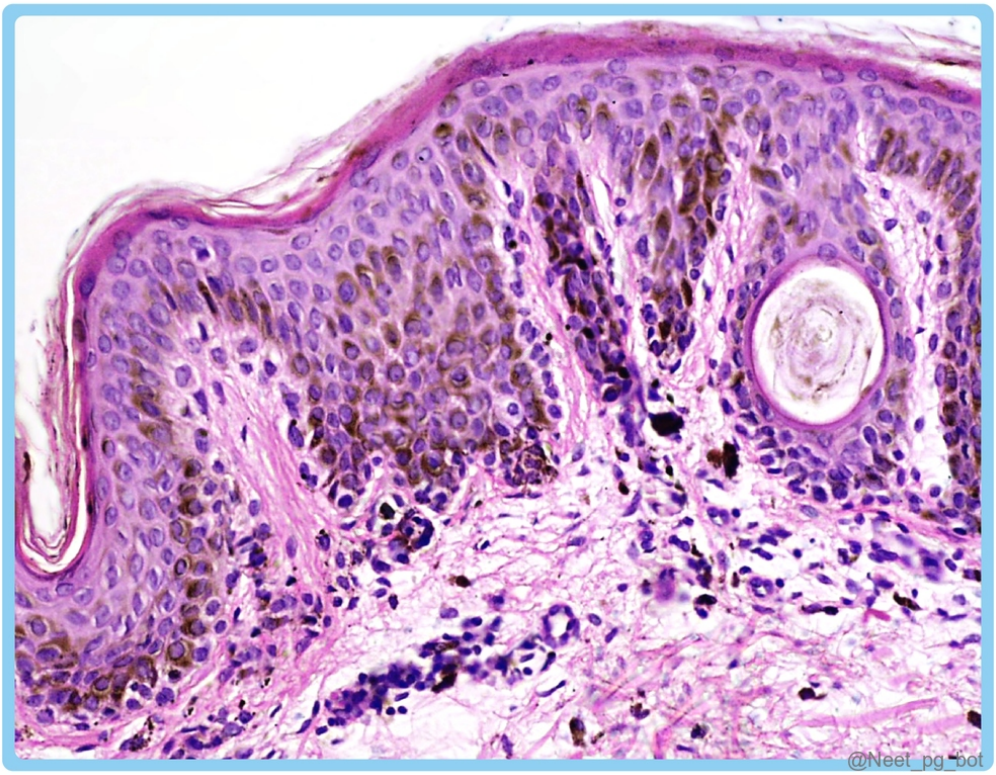

References:

Rook’s Textbook of Dermatology, 9th Edition, Pages 132.4-132.6.

↑ *Back to this question in Part A*

@Neet_pg_bot

Q21: A 32-year-old pregnant woman presents with findings as shown in the image for 6 months. The pigmentation worsens after sun exposure. Wood’s lamp shows enhanced pigmentation. What is the most likely diagnosis? (Q884832)

A. Chik sign

B. Melasma

C. Fixed drug eruption

D. Vitiligo



Correct Answer: B. Melasma

Explanation: Melasma presents as symmetrical facial hyperpigmentation , commonly during pregnancy , aggravated by UV exposure , with epidermal enhancement on Wood's lamp examination. Melasma: Symmetric hyperpigmented macules on the face, worsened by sun exposure Synonyms: Chloasma, mask of pregnancy Epidemiology: F > M; age 20-40; pregnancy & OCPs; darker skin types Predisposing factors: UV exposure (most important) Hormonal factors: pregnancy, oral contraceptives Estrogen, progesterone, ↑ MSH (especially 3rd trimester) Pathology: Normal melanocyte number , ↑ melanin (epidermal ± dermal) Sites: Upper lip, malar area, forehead, chin Types (Wood's Lamp): Epidermal: light brown, enhanced contrast Dermal: grey/blue, poor contrast Mixed Course: Often fades postpartum; may persist Investigations: None; Wood's lamp helpful Treatment: Sun protection; triple therapy (hydroquinone + retinoid + steroid); peels/lasers if needed Chik sign (Option A) : Hyperpigmentation after chikungunya infection; not pregnancy-related and differs in distribution. Fixed drug eruption (Option C) : Presents as recurrent, well-circumscribed lesions at the same site after drug exposure, often with erythema or blistering; does not worsen with sunlight. Vitiligo (Option D) : Causes depigmented white patches due to melanocyte loss; not brown hyperpigmentation and not influenced by sun exposure.

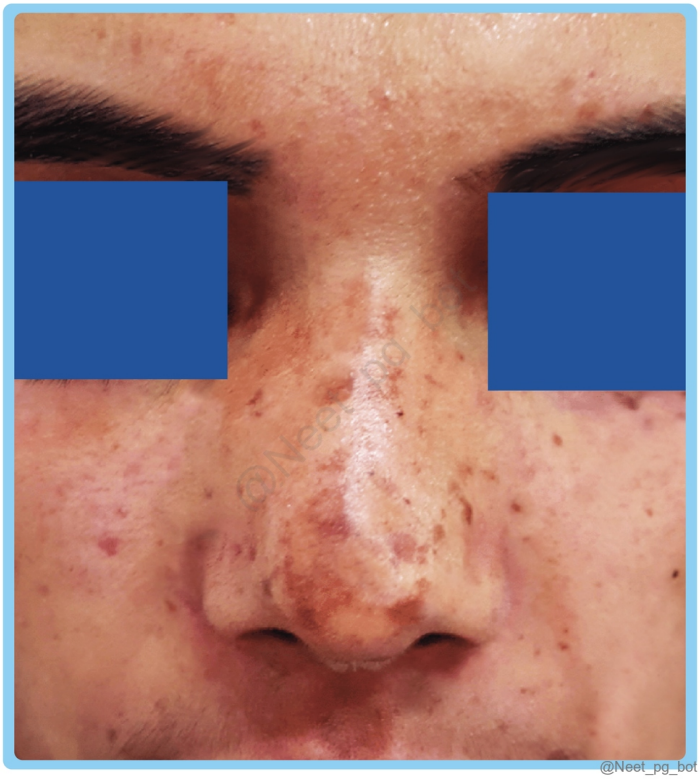
@Neet_pg_bot


@Neet_pg_bot



References:

Rook's Textbook of Dermatology, 9th Edition, Pages 88.10-88.12

↑ *Back to this question in Part A*

@Neet_pg_bot

Q22: A 3-month-old infant presents with a large pigmented patch covering the posterior trunk and extending to the upper thigh. The lesion has irregular borders, hypertrichosis, and some nodular areas. Neurologic examination is normal. Which of the following statements about this lesion is false? (Q884833)

A. This lesion is classified as a giant congenital melanocytic nevus.

B. The patient is at increased risk of neurocutaneous melanosis.

C. No risk of malignancy

D. Surgical excision may be considered.



Correct Answer: C. No risk of malignancy

Explanation: Giant CMN carry a significant risk of malignant transformation. Congenital Naevi: Subtypes: Small (<1.5 cm), Medium (1.5-20 cm), and Giant (>20 cm). (Option A) Clinical Presentation: Present at birth, light to dark brown; flat or elevated. Texture ranges from smooth to mammillated or verrucous. Features well-defined borders and may develop coarse hair. Pathology: Deeper naevus cells tend to extend deeply around skin appendages. Dermoscopy: Reticular, globular, or mixed patterns. May show milia-like cysts, perifollicular pigment changes, dots/globules, and hypertrichosis (excess hair). Pathogenesis: NRAS mutations; melanocyte migration/proliferation defect in utero. Diagnosis: Clinical; dermatoscopy or biopsy if uncertain. Management: Observation, surgical excision (staged if large) (Option D) , laser/dermal techniques for cosmetic reasons. Complications: Malignant melanoma (esp. large), neurocutaneous melanosis (Option B) , cosmetic/psychological impact. Prognosis: Good for small/medium; higher risk for large/giant lesions.

References:

Rook’s Textbook of Dermatology, 9th Edition, Page 132.16

Giant melanocytic nevus

↑ *Back to this question in Part A*

@Neet_pg_bot

Q23: A 2-week-old newborn is noted to have findings as shown in the image below. The infant is otherwise healthy. Which of the following statements about this lesion is correct? (Q884835)

A. Not associated with Down syndrome

B. Develops after birth

C. Usually resolves without treatment

D. Presence of fibrosis



Correct Answer: C. Usually resolves without treatment

Explanation: Mongolian spots are benign dermal melanocytoses that typically fade spontaneously in childhood; no treatment is required. Mongolian spot: Congenital blue-grey macular pigmentation is usually present on the sacrum of infants. Age: Develops in utero (Option B) , deepens in infancy, then fades. Associations: Down syndrome (Option A) , Hurler syndrome, GM1 gangliosidosis, mucolipidosis II, naevus of Ota. Pathophysiology: Elongated dendritic melanocytes in mid-to-lower dermis along neurovascular bundles. No fibrosis (Option D) or dermal melanophages (distinguishes from blue naevus). Clinical features: Diffuse, uniform blue-grey macule; round or oval; usually <10 cm. Common location: lumbosacral area. Can be multiple; generalised lesions may involve the buttocks, flanks, shoulders, and lower legs. Course: Typically resolves in childhood. Management: No treatment required. Persistent lesions: Q-switched laser, intense pulsed light, bleaching creams (mainly in adults).

References:

Rook’s Textbook of Dermatology, 9th Edition, Pages 132.12, 132.13.

↑ *Back to this question in Part A*

@Neet_pg_bot

Q24: Hyperpigmentation may be seen in which of the following conditions? Pheochromocytoma Hypothyroidism Cushing syndrome (ACTH-dependent) Haemochromatosis (Q884837)

A. 1, 3, 4

B. 2, 3

C. 3, 4

D. 1 only

Correct Answer: A. 1, 3, 4

Explanation: Hyperpigmentation is associated with hyperthyroidism, not hypothyroidism. Conditions associated with hyperpigmentation: Addison disease Cushing syndrome (ACTH-dependent) Nelson syndrome (post-adrenalectomy) Acromegaly Hyperthyroidism Carcinoid syndrome Lymphomas (Hodgkin > Non-Hodgkin) Phaeochromocytoma Systemic sclerosis Systemic lupus erythematosus Rheumatoid arthritis Chronic renal failure & chronic liver disease Haemochromatosis Vitamin B12 deficiency & folate deficiency Vitamin A deficiency POEMS syndrome

References:

Rook’s Textbook of Dermatology, 9th Edition, Pages 88.17-88.25.

↑ *Back to this question in Part A*

@Neet_pg_bot

Q25: A 16-year-old male presents with irregular hypopigmented macules on his forehead and anterior part of the body. Examination reveals a white forelock and V-shaped leukoderma on the mid-forehead. Small spots of hyperpigmentation are also noted within the hypopigmented lesions. Which of the following genetic abnormalities is most likely responsible for the observed clinical features? (Q841799)

A. Heterozygous mutations in the KIT gene

B. Autosomal dominant mutations in TERT gene

C. Heterozygous mutations in the SNAI2 gene

D. Autosomal recessive mutations in the NOLA3 gene

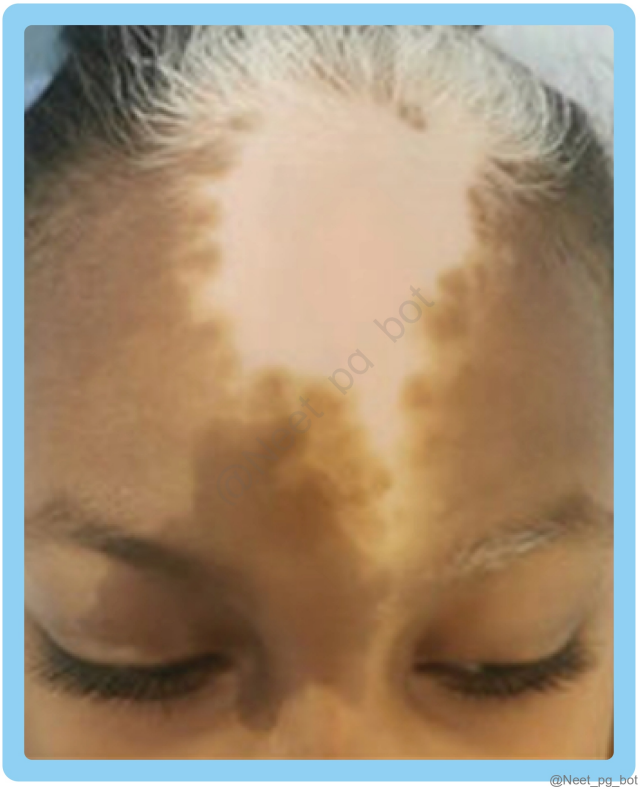

Correct Answer: A. Heterozygous mutations in the KIT gene

■ *Listen (English)*

■ *Listen (Hindi)*

Explanation: The given clinical scenario of hypopigmented macules with white forelock and V-shaped leukoderma on the forehead is suggestive of piebaldism . It is associated with heterozygous mutations in the KIT gene. Piebaldism is a rare autosomal dominant disorder with congenital white patches that results from impairment of melanoblast migration in embryonal development. The KIT gene encodes for the c-KIT protein , a receptor with tyrosine kinase activity, essential for various cellular processes, including melanocyte migration and proliferation, and throughout life. When mutations occur in one allele of the KIT gene, it disrupts the normal function of c-KIT, leading to impaired melanocyte migration and proliferation. This disruption leads to the formation of hypopigmented patches on the skin, which occur due to the absence of melanocytes in certain areas. The forehead , chest, abdomen, and extremities are typically involved. The distribution of the lesions remains for the entire life of affected individuals. The TERT gene (Option B) encodes for telomerase reverse transcriptase , which plays a crucial role in maintaining telomere length and genomic stability. The SNAI2 gene (Option C) encodes for the zinc finger transcription factor Snail family transcriptional repressor 2 (SNAI2), also known as SLUG. Autosomal recessive mutations in the NOLA3 (Option D) gene are incorrect, as piebaldism typically follows an autosomal dominant inheritance pattern.

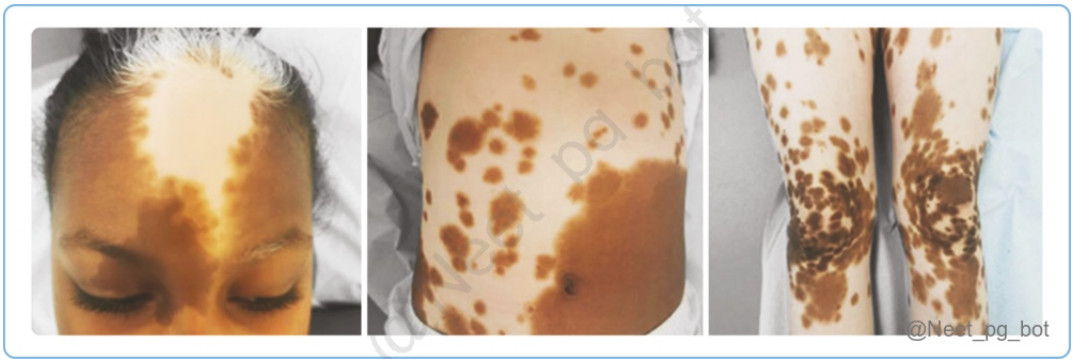

References:

Rook's Textbook of Dermatology, 9th Edition, Page 70.3

↑ *Back to this question in Part A*

@Neet_pg_bot

Q26: Which of the following statements accurately describes the role of melanosomes in determining skin pigmentation? (Q841787)

A. An increased number of melanocytes causes darker skin pigmentation.

B. Larger melanosomes are found in individuals with lighter skin tones.

C. The degradation rate of melanosomes is same across different skin types.

D. The arrangement of melanosomes influences skin pigmentation.

Correct Answer: D. The arrangement of melanosomes influences skin pigmentation.

■ *Listen (English)*

■ *Listen (Hindi)*

Explanation: Size of melanosomes influences their arrangement within keratinocytes, which in turn affects skin pigmentation. Larger melanosomes, observed in darker skin tones, are typically dispersed individually. Melanin Types and Production: Two main types: Eumelanin : Brownish-black, responsible for darker skin tones. Pheomelanin : Orangish-red, found in lighter skin tones. Synthesis process (Melanogenesis): Melanosomes : Melanin is stored within specialized organelles called melanosomes, which are produced by melanocytes. Size and Distribution: Darker skin: Larger melanosomes (Option A) Lighter skin: Smaller melanosomes (Option B) Degradation: (Option C) Varies between skin types. Lighter skin: Melanosome complexes show degradative changes due to lysosomal enzymes. Darker skin: Larger melanosomes can remain intact up to the stratum corneum. Melanin and Skin Color: Key factors: Type of melanin, Melanosome size, Melanosome distribution (dispersed vs. aggregated), Skin color is NOT solely determined by the number of melanocytes. Regulation of Pigmentation : UV radiation Hormones: Estrogens - increase pigmentation; Melanocortins - melanin production.

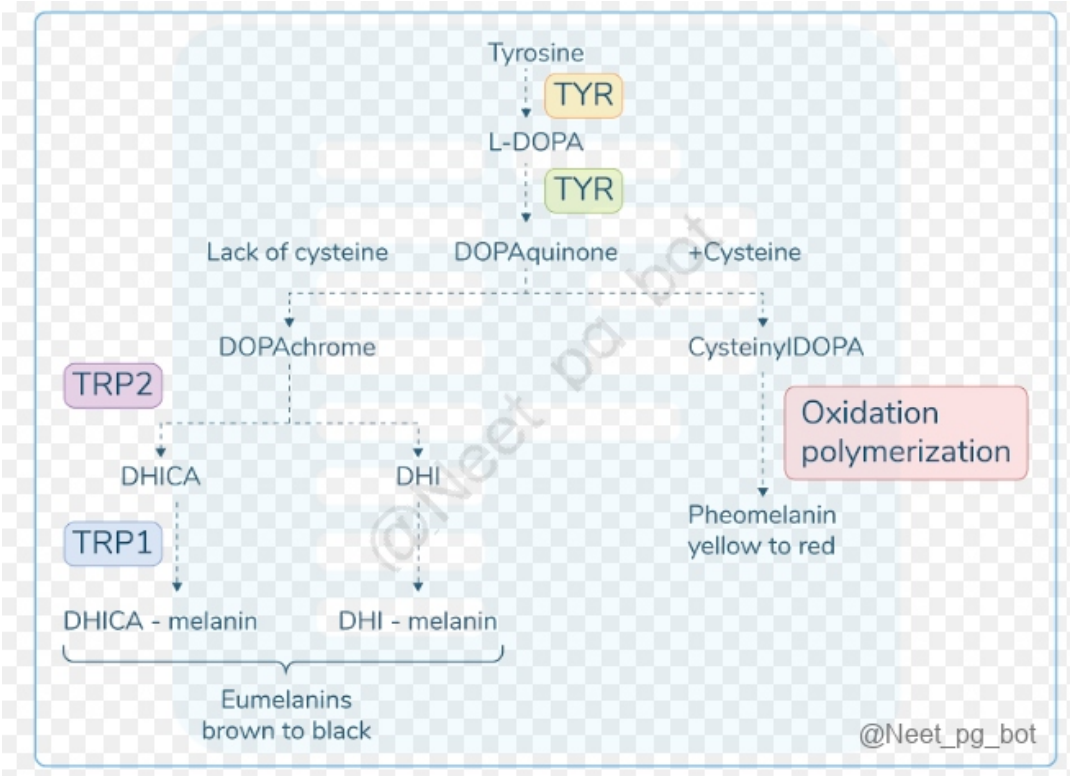

References:

Rook's Textbook of Dermatology 9th edition page no 88.1 -88.8

↑ *Back to this question in Part A*

@Neet_pg_bot

Q27: A 45-year-old fair-skinned woman presents with multiple tan to dark brown macules on her face and the dorsal aspect of her hands. These macules are 3 to 20 mm in size and have appeared after chronic sun exposure. Which of the following therapeutic options is not indicated for the treatment of these lesions? (Q841788)

A. Lightening agents

B. Cryotherapy

C. Antibiotic therapy

D. Trichloroacetic acid

Correct Answer: C. Antibiotic therapy

■ *Listen (English)*

■ *Listen (Hindi)*

Explanation: The patient presented with multiple tan to dark brown macules on her face and the dorsal aspect of her hands. These macules are 3 to 20 mm in size and have appeared after chronic sun exposure which can be diagnosed as solar lentigines Solar lentigines are benign pigmented skin lesions that occur in response to excessive or chronic sun exposure. Treatment for solar lentigines is generally unnecessary unless for cosmetic purposes. Therapeutic options include lightening agents, retinoic acid, trichloroacetic acid, cryotherapy, and laser therapy. However, antibiotic therapy is not indicated for the treatment of solar lentigines. Cryotherapy involves using extreme cold to destroy abnormal tissues such as solar lentigines. It works by freezing the affected area, leading to cellular destruction and subsequent sloughing off of the lesion. Trichloroacetic acid (TCA) is used for chemical peels and treating conditions like solar lentigines. It induces controlled skin injury, leading to exfoliation and skin regeneration. TCA effectively removes superficial skin layers, including pigmented lesions.



References:

https://www.uptodate.com/contents/acquired-hyperpigmentation-disorders?

↑ *Back to this question in Part A*

@Neet_pg_bot

Q28: A 7-year-old child presents with multiple hyperpigmented patches on the skin, as shown in the image below. These patches have been present since early childhood and are more than six in number. Which of the following skin lesions are seen in this

condition? (Q841789)

A. Vitiligo vulgaris

B. Café au lait macules

C. Freckles

D. Nevus depigmentosus



Correct Answer: B. Café au lait macules

■ *Listen (English)*

■ *Listen (Hindi)*

Explanation: The clinical history and skin findings suggest a diagnosis of Neurofibromatosis type 1 (NF-1), which is associated with Café au lait macules. Café au lait macules are hyperpigmented macules with smooth or serrated borders, resembling coffee stains on milk. Congenital or early-onset pigmented macules, light to dark brown, solitary or multiple, commonly on trunk/extremities, sometimes linked to NF-1, NF-2, or McCune-Albright syndrome.



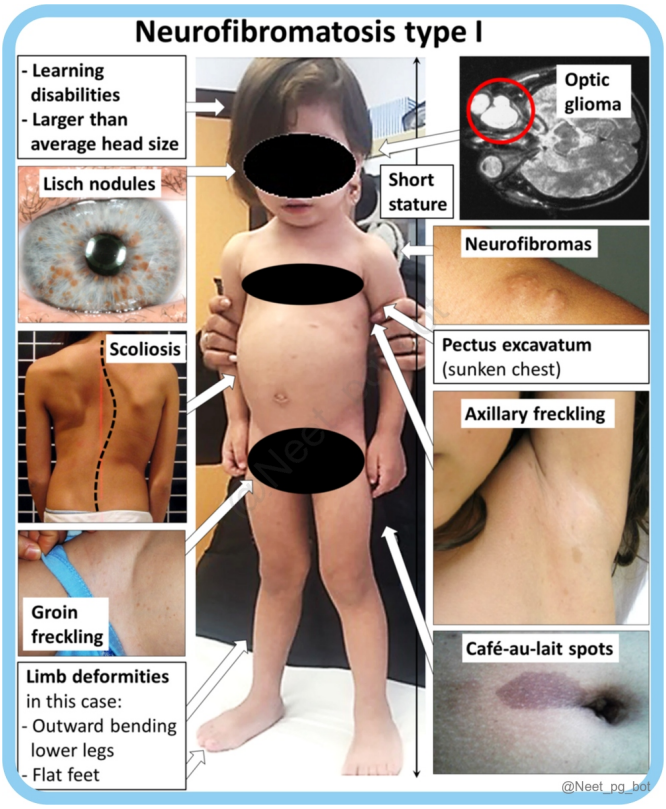

References:

www.ncbi.nlm.nih.gov/books/NBK557492/

↑ *Back to this question in Part A*

@Neet_pg_bot

Q29: A 35 y/o female with a cosmetically concerning mole on her right cheek. It is a raised, skin-colored papule, approximately 4 mm in diameter. The patient reports no change in size, shape, or color of the mole, and it has been present for several years. What would be the most appropriate treatment approach for this patient? (Q841790)

A. Topical corticosteroids

B. Oral antibiotics

C. Laser treatment

D. Watchful waiting

Correct Answer: C. Laser treatment

■ *Listen (English)*

■ *Listen (Hindi)*

Explanation: Melanocytic nevi: Also called moles. They are proliferating nevus cells derived from the neural crest. Acquired melanocytic nevi are nests of proliferating nevus cells and are classified into three types: Junctional nevi : Present at the dermo-epidermal junction which are small and dark brown. Compound nevi : Present at the dermo-epidermal junction and the dermis as these are slightly raised and lighter in color than junctional nevi. Intradermal nevi : Present in the dermis are raised papules that are either skin-colored or red. Treatment is usually done for cosmetic reasons, if indicative of malignancy, treatment options include electrocautery, laser treatment, and surgical excision. Congenital melanocytic nevi are present at birth. Giant congenital melanocytic nevi (also called bathing trunk/garment nevi) may have malignant potential. Halo nevi presents as a nevus with a halo around it which is caused by the autoimmune destruction of melanocytes surrounding the mole.

References:

https://www.uptodate.com/contents/benign-pigmented-skin-lesions-other-than-melanocytic-nevi-moles?

↑ *Back to this question in Part A*

@Neet_pg_bot

Q30: A 5-month-old infant presents with a large, darkly pigmented lesion on their lower back. The lesion has been present since birth and has increased proportionally in size with the infant's growth. There is also the presence of hypertrichosis (excessive

hair growth) within the lesion. What is the most likely diagnosis? (Q841791)

A. Congenital Melanocytic Nevus

B. Mongolian Spot

C. Nevus of Ota

D. Nevus Depigmentosus

Correct Answer: A. Congenital Melanocytic Nevus

■ *Listen (English)*

■ *Listen (Hindi)*

Explanation: In the above scenario, nevi are present at birth and are associated with hypertrichosis and rugosities. Congenital Melanocytic Nevus is the most likely diagnosis. Congenital Melanocytic Nevi (CMN): These are benign growths of melanocytes (pigment-producing cells), present at birth. CMN arise from the neural crest, a temporary group of cells in embryonic development. Characteristics : A single lesion. Exhibit hypertrichosis (increased hair growth) and rugosities (a wrinkled appearance). Classification : Congenital : Present at birth. Acquired : Develop after birth. Size and Malignant Potential : Small to Medium CMN: Benign. Large/Giant CMN (Bathing Trunk/Garment Nevi): Higher risk of developing melanoma (skin cancer). Treatment : Surgical removal, laser therapy, or other therapies. Mongolian spots (Option B) are typically bluish macules found in the sacral area. They tend to fade over time and are not associated with hypertrichosis. Nevus of Ota (Option C) a bluish/slate-gray patch affecting ophthalmic (V1) and maxillary (V2) branches of the trigeminal nerve, face, eyes, oral mucosa. Nevus Depigmentosus (Option D) presents as a single hypopigmented (lighter) macule, typically present at birth.





References:

Rook’s Textbook of Dermatology, 9th Edition, Page 75.9-75.10

https://www.ncbi.nlm.nih.gov/books/NBK560574/

↑ *Back to this question in Part A*

@Neet_pg_bot

Q31: A 28-year-old female on OCP presents with hyperpigmented macules on her cheeks and forehead. On examination, the lesions appear darker than the surrounding skin and have scalloped margins. There is no associated inflammation or itching. What is the most likely diagnosis based on the clinical presentation? (Q841792)

A. Melasma

B. Lentigo

C. Freckles

D. Chloasma

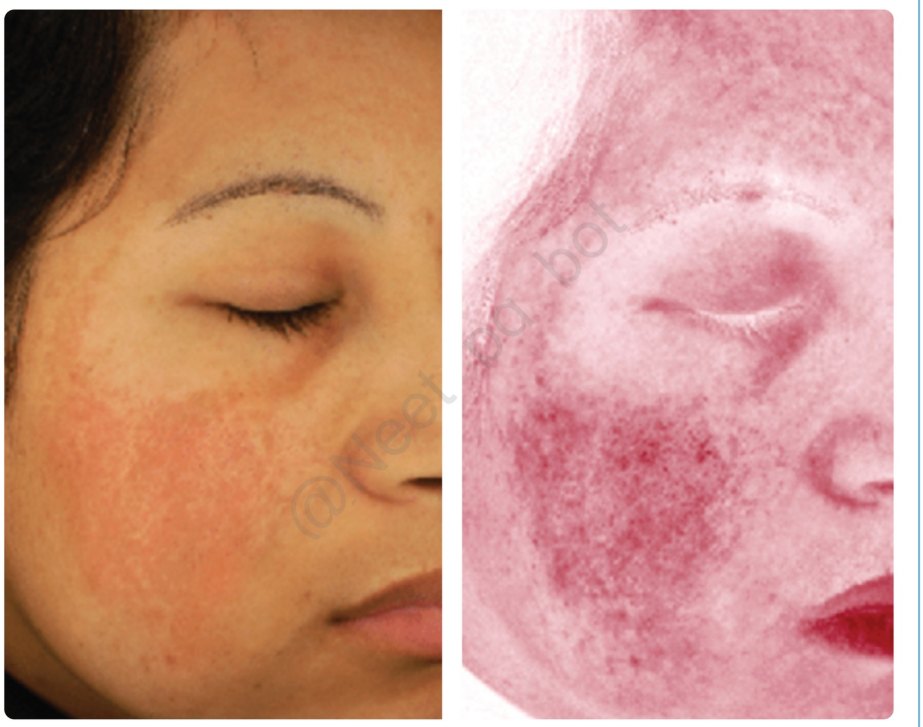

Correct Answer: A. Melasma

■ *Listen (English)*

■ *Listen (Hindi)*

Explanation: This woman with hyperpigmented patches on her cheek and a history of OCP use most likely has melasma. Melasma: hyperpigmented facial macules with irregular margins, commonly on cheeks, forehead, and chin. Causes: genetics, UV exposure, pregnancy, hormones (OCPs), cosmetics, phototoxic drugs. Prevention: broad-spectrum sunscreen, protective clothing, avoid sun. Treatment: topical hydroquinone, triple combination (hydroquinone + retinoid + corticosteroid), chemical peels, azelaic acid, lasers. Lentigo (Option B) A dark brown macule from increased melanocytes, appearing in childhood, uniformly pigmented, round/oval, ≤5 mm, increasing with age.. Freckles (Option C) are pale to dark brown macules on sun-exposed skin that darken with UV-induced melanin overproduction. Chloasma(Option D:) is a hypermelanosis of sun-exposed areas that occurs during pregnancy and affects 50-70% of pregnant women. It presents similar to melasma but in pregnant women. It tends to improve spontaneously postpartum, and treatment may not be necessary.





References:

Fitzpatrick Textbook of Dermatology, 9th Edition

Rook's Textbook of Dermatology, 9th Edition, Page 88.10-88.13, 131.1

↑ *Back to this question in Part A*

@Neet_pg_bot

Q32: A 30-year-old woman develops dusky red to brown patches on her arms and legs as shown in the image below after taking a specific antibiotic for sinus infections. The patches, not painful but slightly itchy, leave hyperpigmented areas after resolving. She had a similar reaction to a same medication in the past. What is the most likely diagnosis? (Q841793)

A. Fixed drug eruptions (FDE)

B. Post-inflammatory hyperpigmentation

C. Lichen planus pigmentosus

D. Melasma



@Neet_pg_bot

Correct Answer: A. Fixed drug eruptions (FDE)

■ *Listen (English)*

■ *Listen (Hindi)*

Explanation: In the described clinical scenario, the patient's presentation of reddish-brown macules on her hands and legs after initiating antibiotic therapy, along with a history of similar macules following the use of other medications, indicates a likely diagnosis of fixed drug eruptions. Fixed drug eruption: Well-defined slate-brown lesions recurring at the same site after drug exposure. Mechanism: type IV hypersensitivity; ICAM-1 expression in keratinocytes; pigmentation from dermal macrophages. Triggers: tetracyclines, NSAIDs, sulfonamides, sedatives. Course: lesions may be erythematous or bullous initially, recur at same sites, sometimes new areas with re-exposure.

References:

Rook’s Textbook of Dermatology, 9th edition, Page no. 88.28

↑ *Back to this question in Part A*

@Neet_pg_bot

Q33: A 5-year-old boy presents with hypopigmented macules distributed along the lines of Blaschko. The lesions are asymptomatic and have been present since birth. There is no history of progression or associated symptoms. Which condition is most

likely to present with this clinical manifestation? (Q841794)

A. Nevus depigmentosus

B. Vitiligo

C. Nevus anemicus

D. Piebaldism



Correct Answer: A. Nevus depigmentosus

- *Listen (English)*
- *Listen (Hindi)*

Explanation: The image and clinical description point towards Nevus depigmentosus , a non-progressive hypopigmented congenital skin disorder . Key Clinical Features of Nevus Depigmentosus: Present at or shortly after birth Hypopigmented macules with irregular but well-defined margins Distributed in a segmental or Blaschkoid pattern Non-progressive and asymptomatic No scaling, erythema, or associated systemic abnormalities Vitiligo (Option B) presents with depigmented macules that may increase in size and number over time due to autoimmune destruction of melanocytes and are not restricted to dermatomal distribution. Nevus anemicus (Option C) typically presents as hypopigmented macules due to persistent cutaneous vasoconstriction resulting from hypersensitivity to catecholamines that become more pronounced with rubbing or trauma. It does not follow the lines of Blaschko. Piebaldism (Option D) is an autosomal dominant condition that presents with depigmented patches on the skin and a characteristic white forelock of hair. However, it is usually present at birth and does not follow the lines of Blaschko.



@Neet_pg_bot



@Neet_pg_bot



References:

Fitzpatrick, Richard E., et al. "Disorders of Hyperpigmentation: Melanocytes, Melanogenesis, and Pigmentary Disorders.

↑ *Back to this question in Part A*

@Neet_pg_bot

Q34: A 5-year-old child is brought to the dermatologist by concerned parents due to their child's extremely fair skin, white hair, and pale blue eyes. Upon examination, the dermatologist confirms the absence of melanin pigment in the child's skin, hair, and irises. The child also shows signs of photophobia and is noted to have nystagmus. Which of the following inheritance patterns is associated with this condition? (Q841795)

A. Autosomal dominant

B. X-linked dominant

C. Autosomal recessive

D. X-linked recessive

Correct Answer: C. Autosomal recessive

■ *Listen (English)*

■ *Listen (Hindi)*

Explanation: The given clinical scenario of hypopigmentation of the skin and hair, ocular manifestations such as nystagmus and photophobia suggest oculocutaneous albinism. It is associated with an autosomal recessive pattern. Oculocutaneous albinism (OCA) is a rare genetic disorder characterized by generalized hypopigmentation and ophthalmological anomalies caused by a deficiency in melanin biosynthesis with normal melanocyte count. There are seven types of OCA, all of which are associated with an autosomal recessive inheritance pattern. There can be either failure of synthesis of tyrosinase enzyme or defect in tyrosinase activity. Clinical features include hypopigmentation of skin, hair, and eyes and ocular findings such as photophobia (which may be prominent). Iris translucency can be demonstrated by slit-lamp examination. A characteristic finding is the misrouting of the optic nerves, consisting of an excessive crossing of the fibres in the optic chiasma, which can result in strabismus and reduced stereoscopic vision. Note: Ocular albinism has an X-linked recessive inheritance pattern.



References:

Rook's Textbook of Dermatology - 9th Edition page no 70.7

Fitzpatrick Textbook of Dermatology, 9th edition, page no 1310

↑ *Back to this question in Part A*

@Neet_pg_bot

Q35: A 25-year-old female presents with hypopigmented patches on her skin and silvery-white hair. She also experiences easy bruising and prolonged bleeding following minor injuries. Examination reveals reduced iris pigmentation and visual impairment. Which primary pathological mechanism contributes to the hypopigmented skin observed in this patient? (Q841797)

A. Ceroid lipofuscin accumulation in epidermal cells

B. Dysfunctional Weibel-Palade bodies in keratinocytes

C. Defective melanosome formation, trafficking, or transfer to keratinocytes

D. Autophagocytosis and defective fission of large melanosomes

Correct Answer: C. Defective melanosome formation, trafficking, or transfer to keratinocytes

■ *Listen (English)*

■ *Listen (Hindi)*

Explanation: The given clinical scenario of a patient with symptoms of bleeding diathesis (easy bruising, prolonged bleeding following minor injuries), hypopigmentation of skin, hair & eyes with visual impairment & reduced iris pigmentation (oculocutaneous albinism), is suggestive of Hermansky-Pudlak syndrome. Hermansky–Pudlak syndrome (HPS) is a rare autosomal recessive oculocutaneous albinism with bleeding tendency. Caused by mutations affecting lysosome-related organelle biogenesis, impairing melanosome maturation and platelet dense bodies. Clinical features: hypopigmentation of skin, hair, and eyes; easy bruising; pulmonary fibrosis; granulomatous colitis in severe cases. Platelet granule defect: delta granules in HPS; alpha granules defect seen in Grey platelet syndrome.. Hermansky-Pudlak vs. Grey Platelet Syndrome: Feature Hermansky-Pudlak Syndrome (HPS) Grey Platelet Syndrome (GPS) Primary Defect Absence of Dense (δ) granules Absence of Alpha (α) granules Genetics Autosomal Recessive Typically Autosomal Recessive (NBEAL2 gene) Appearance Normal platelet color; normal size Large, pale/grey platelets on peripheral smear Albinism Present (Oculocutaneous albinism) Absent Systemic Features Pulmonary fibrosis, granulomatous colitis Progressive Myelofibrosis (bone marrow scarring) Bleeding Risk Mild to severe Mild to moderate Ceroid lipofuscin accumulation in epidermal cells(Option A) Ceroid lipofuscin accumulates in lysosomes of organs like lung macrophages, not skin epidermis. Dysfunctional Weibel-Palade bodies in keratinocytes(Option B) Weibel-Palade bodies in endothelial cells regulate vascular function; their dysfunction can impair hemostasis and promote thrombosis. Autophagocytosis and defective fission of large melanosomes(Option D) Chediak-Higashi syndrome features autophagocytosis and defective melanosome fission due to LYST gene mutations.



References:

Rook’s Textbook of Dermatology, 9th edition, page no. 70.8

https://www.uptodate.com/contents/hermansky-pudlak-syndrome?

↑ *Back to this question in Part A*

@Neet_pg_bot

Q36: A 25-year-old female presents to the clinic with complaints of easy bruising, recurrent nosebleeds, and progressive shortness of breath over the past few years. Physical examination reveals hypopigmentation of the skin, hair, and eyes. Upon further inquiry, the patient mentions a family history of similar symptoms in her siblings. Which of the following diagnostic tests is most likely to confirm the suspected diagnosis in this patient? (Q841798)

A. Platelet aggregation assay

B. Pulmonary function tests

C. Whole-mount electron microscopy of platelets

D. Genetic sequencing of HPS-associated genes

Correct Answer: C. Whole-mount electron microscopy of platelets

■ *Listen (English)*

■ *Listen (Hindi)*

Explanation: The given clinical scenario of a patient with symptoms of bleeding diathesis (easy bruising, recurrent nosebleeds), hypopigmentation of skin, hair & eyes (oculocutaneous albinism), shortness of breath, and family history of similar symptoms is suggestive of Hermansky-Pudlak syndrome. Diagnostic evaluation involves electron microscopy of platelets to detect absent dense bodies, which serves as a standard diagnostic test. Upon platelet stimulation, dense bodies containing ADP, ATP, serotonin, calcium, and phosphate release their contents to attract other platelets. Platelet aggregation assay(Option A) is not typically used to diagnose Hermansky–Pudlak syndrome (HPS). While bleeding tendencies are characteristic, the primary diagnostic test for HPS involves assessing platelet morphology rather than function. Pulmonary function tests (Option B) may aid in the diagnosis and monitoring of complications such as interstitial pulmonary fibrosis in Hermansky–Pudlak syndrome. Genetic sequencing of HPS-associated genes (Option D) can confirm the diagnosis by identifying mutations in genes associated with HPS. However, compared to the direct observation of platelet morphology, it is not always readily available or necessary for initial diagnosis.



@Neet_pg_bot

References:

Rook's Textbook of Dermatology - 9th Edition page no 70.8

↑ *Back to this question in Part A*

@Neet_pg_bot

Q37: A 30-year-old patient complains of increased skin pigmentation following prolonged sun exposure. Which of the following statements regarding melanin physiology is most accurate? (Q841786)

A. Melanocytes primarily produce eumelanin, responsible for skin pigmentation and protection against UV radiation.

B. Tyrosinase is an enzyme that converts tyrosine to melanin in keratinocytes.

C. Melanosome transfer from melanocytes to keratinocytes occurs via exocytosis.

D. Individuals with albinism have increased melanin production due to mutations in the MC1R gene.

Correct Answer: A. Melanocytes primarily produce eumelanin, responsible for skin pigmentation and protection against UV radiation.

■ *Listen (English)*

■ *Listen (Hindi)*

Explanation: Melanocytes are specialised cells that produce melanin, a pigment responsible for skin colouration, hair, and eyes. Eumelanin, along with pheomelanin, is one of the two main types of melanin produced by melanocytes. It ranges from brown to black and protects against harmful ultraviolet (UV) radiation by absorbing and scattering UV light, thereby reducing the risk of DNA damage and skin cancer. Tyrosinase is an enzyme that converts tyrosine to melanin in keratinocytes.(Option B): Tyrosinase, in melanocyte melanosomes, converts tyrosine to dopaquinone for melanin synthesis, not active in keratinocytes. Melanosome transfer from melanocytes to keratinocytes occurs via exocytosis.(Option C): Melanosomes transfer from melanocytes to keratinocytes via dendrites (1:36 ratio), enhancing pigmentation and UV protection. Individuals with albinism have increased melanin production due to mutations in the MC1R gene(Option D): Albinism is caused by mutations in melanin-synthesizing enzymes, leading to reduced pigmentation, not by MC1R mutations.

References:

Fitzpatrick's Dermatology in General Medicine, 9th Edition, Chapter 75, Page 1205.

↑ *Back to this question in Part A*

@Neet_pg_bot

Q38: A 7-year-old child presents with characteristic findings of Waardenburg syndrome, including wide-set eyes (hypertelorism), a broad nasal bridge, and a white forelock of hair. The child's father is also affected. What is the most likely inheritance pattern of Waardenburg syndrome in this case, and how would you counsel the

parents regarding the risk of recurrence in future pregnancies? (Q841800)

A. Autosomal dominant inheritance; 50% risk of recurrence in each pregnancy

B. Autosomal recessive inheritance; 25% risk of recurrence in each pregnancy

C. X-linked recessive inheritance; 25% risk of recurrence in each pregnancy

D. Sporadic occurrence; negligible risk of recurrence in future pregnancies

Correct Answer: A. Autosomal dominant inheritance; 50% risk of recurrence in each pregnancy

■ *Listen (English)*

■ *Listen (Hindi)*

Explanation: Autosomal dominant inheritance; 50% risk of recurrence in each pregnancy. Waardenburg syndrome (WS) is a group of genetic conditions inherited in an autosomal dominant fashion. Autosomal dominant inheritance means that a child only needs to inherit one copy of the mutated gene from either parent to express the trait. This means that if one parent carries the mutated gene, there's a 50% chance of passing it on to each child. Hence, in each pregnancy where one parent carries the gene, there's a 50% risk of the child having Waardenburg syndrome.



References:

Rooks textbook of Dermatology, 9th edition page no 70.4

↑ *Back to this question in Part A*

@Neet_pg_bot

Q39: A 30-year-old woman was diagnosed with vitiligo with lesions as shown below. They have been stable for the past few years, with no other lesions elsewhere. What is the most likely clinical subtype of vitiligo in this patient? (Q841801)

A. Acrofacial vitiligo

B. Mucosal vitiligo

C. Universal vitiligo

D. Generalized vitiligo



Correct Answer: A. Acrofacial vitiligo

■ *Listen (English)*

■ *Listen (Hindi)*

Explanation: The image and clinical description suggest vitiligo lesions localised to the face , particularly around the perioral and periorbital areas, which is characteristic of acrofacial vitiligo . Vitiligo can be classified as

segmental and non-segmental types. Segmental vitiligo involves depigmentation along a specific segment/dermatome with one or more white macules on one side of the body, usually not crossing the midline. It often begins during childhood or early adulthood and usually stabilizes within a year, with limited spread beyond the affected dermatome. Non-segmental vitiligo includes: Acrofacial -Affects face, head, hands, and feet, and preferably involves the perioral region and the extremities of digits Mucosal - Affects the oral and genital mucosae. (Option B ruled out) Generalized or Common - Often symmetrical, can affect any part of the tegument, mainly hands, fingers, face, and trauma-exposed areas. (Option D ruled out) Universal - Affects 80-90% of the body surface, the most common form in adulthood. (Option C ruled out) Mixed - Simultaneous involvement of segmental and non-segmental vitiligo




@Neet_pg_bot


@Neet_pg_bot

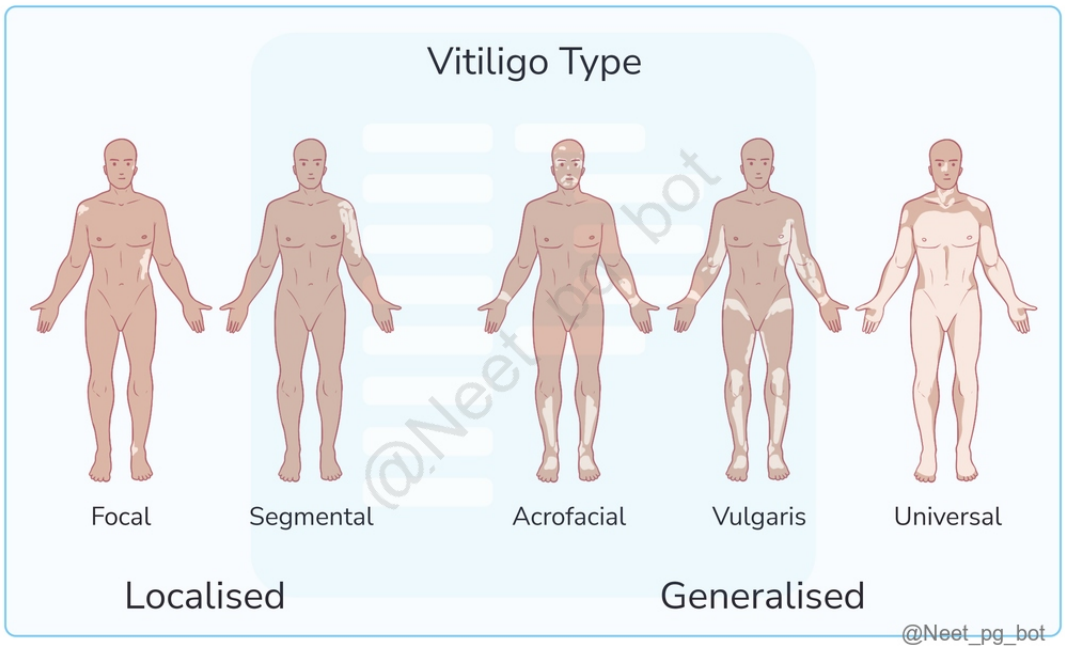

References:

www.uptodate.com/contents/vitiligo-pathogenesis-clinical-features-and-diagnosis?

www.ncbi.nlm.nih.gov/pmc/articles/PMC4155957/

↑ *Back to this question in Part A*

@Neet_pg_bot

Q40: A 35-year-old patient presents with hypopigmented lesions shown below. There is no inflammation or textural changes associated with the lesions. The patient reports a family history of autoimmune diseases. Which of the following investigations is most likely to confirm the diagnosis in this patient? (Q841802)

A. Dermoscopy

B. Skin biopsy

C. Wood's lamp examination

D. KOH wet mount



Correct Answer: C. Wood's lamp examination

- *Listen (English)*
- *Listen (Hindi)*

Explanation: The clinical scenario illustrates a patient with depigmented patches on their face and neck, without inflammation or itching. This manifestation, coupled with a family history of autoimmune conditions (most commonly thyroid abnormalities), suggests the presence of vitiligo. Vitiligo is a common acquired pigmentation disorder characterized by developing well-defined, depigmented macules on the skin. Lesional skin biopsies reveal a loss of epidermal melanocytes. Lesions may occur in a localized or generalized distribution and coalesce into large, depigmented areas. Wood's lamp emits ultraviolet A(UV-A) light and is particularly useful in identifying depigmented areas in patients with vitiligo. It exhibits a bright blue-white fluorescence with sharply demarcated borders. Dermoscopy (Option A) may help differentiate evolving vitiligo patches from other hypopigmentation disorders. However, it is not necessary for the initial diagnosis of vitiligo. While a skin biopsy may be performed to confirm hypopigmented or depigmented lesions with questionable aetiology, it is not routinely required to diagnose vitiligo, especially when clinical features are characteristic. (Option B ruled out) KOH wet mount(Option D) is used to diagnose fungal infections, it has no role in the diagnosis of vitiligo



References:

www.uptodate.com/contents/vitiligo-pathogenesis-clinical-features-and-diagnosis?

↑ *Back to this question in Part A*

@Neet_pg_bot

Q41: A 25-year-old male presents with bilateral uveitis, dysacousia, and poliosis. On examination, there are areas of leukoderma observed on the skin. Which syndrome is associated with the clinical presentation described? (Q841803)

A. Waardenburg's syndrome

B. Vogt-Koyanagi-Harada syndrome

C. Hermansky-Pudlak syndrome

D. Chemical leukoderma

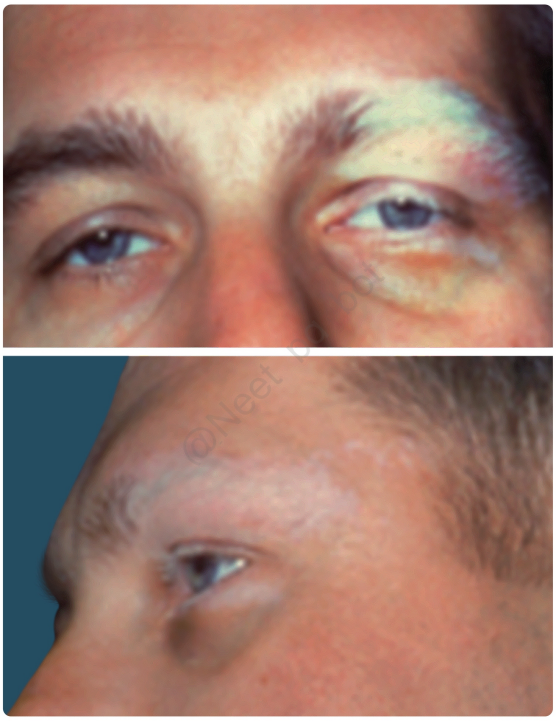

Correct Answer: B. Vogt-Koyanagi-Harada syndrome

■ *Listen (English)*

■ *Listen (Hindi)*

Explanation: This patient with the above symptoms most likely has Vogt-Koyanagi-Harada syndrome. Vogt-Koyanagi-Harada (VKH) syndrome is a rare autoimmune disorder that primarily affects melanocytes. It manifests with a range of symptoms that typically involve the eyes, ears, skin, and central nervous system. The underlying cause of VKH syndrome is thought to be an autoimmune reaction against melanocytes. Genetic predisposition and environmental factors may contribute to the development of the condition. The hallmark features of VKH syndrome include: Bilateral uveitis. Dysacousia. Poliosis : Depigmentation or whitening of the hair, particularly noticeable in the eyelashes, eyebrows, or scalp. This occurs due to the autoimmune destruction of melanocytes, which results in the loss of pigment production in affected hair follicles. Leukoderma: Hypopigmented patches or areas of lighter skin that arise due to the disruption of melanin production by melanocytes. These patches may appear on various parts of the body and can vary in size and distribution. Features: vitiligo, neurological symptoms, and ocular issues like sunset glow fundus and retinal detachment. Diagnosis is clinical; treatment uses immunosuppressants to control inflammation and preserve vision.

References:

Fitzpatrick Dermatology 9th edition

↑ *Back to this question in Part A*

@Neet_pg_bot

Q42: A 32 y/o female presents with gradually progressive, well-demarcated hypopigmented patches on her face. She has a history of melasma for which she has been using a triple-combination cream containing hydroquinone, tretinoin, and a corticosteroid for the past year. What is the most likely diagnosis? (Q841804)

A. Vitiligo

B. Drug induced Leukoderma

C. Post-inflammatory hypopigmentation

D. Melasma

Correct Answer: B. Drug induced Leukoderma

■ *Listen (English)*

■ *Listen (Hindi)*

Explanation: Given the patient's history of using a hydroquinone-containing cream and the clinical presentation of hypopigmented patches the most likely diagnosis is drug induced Leukoderma. Topical or Intralesional Corticosteroids Gefitinib (EGFR inhibitor) Imatinib Mesylate (Tyrosine kinase inhibitor) Pegylated Interferon (Immunomodulator) Topical Imiquimod (Immunomodulator) Transdermal Methylphenidate (CNS stimulant) Localized hypopigmentation/depigmentation can be seen at the site of application. Chemical leukoderma : Cause: Toxic chemicals in drugs (e.g., p-tertiary-butylphenol, monobenzylether of hydroquinone) damage melanocytes. Presentation: Well-defined depigmented patches, commonly on dorsal hands; lesions may expand or recur. Mechanism: Selective melanocyte destruction. Treatment: Avoid the causative chemical; repigmentation may occur over time. Vitiligo (Option A) presents with depigmented patches, it is characterized by a complete absence of melanocytes and typically presents with milky-white macules. Post-inflammatory hypopigmentation (Option C) : This type of hypopigmentation occurs following skin inflammation, but it is not typically associated with the use of triple-combination creams for melasma. Melasma (Option D) is characterized by hyperpigmentation, not hypopigmentation.



References:

https://www.uptodate.com/contents/acquired-hypopigmentation-disorders-other-than-vitiligo?

↑ *Back to this question in Part A*

@Neet_pg_bot

Q43: A 32 y/o male presents to the clinic with progressively enlarging, hypopigmented patches on the backs of both hands. He has worked in a chemical factory for the past five years, handling various industrial solvents. Wood's lamp examination reveals well-demarcated depigmented patches with no fluorescence. What chemical is the most likely cause of the patient's condition? (Q841805)

A. Kojic acid

B. Azelaic acid

C. p-Tertiary-butylphenol

D. Mercury

Correct Answer: C. p-Tertiary-butylphenol

■ *Listen to Audio 1*

Explanation: The scenario describes a typical presentation of chemical leukoderma in the context of occupational exposure to a substituted phenol. p-Tertiary-butylphenol substituted phenol is a known cause of the chemical leukoderma. Chemical Clinical Presentation Monobenzylether of hydroquinone Confetti-like areas of depigmentation, typically where it is applied. 4-Tertiary-butyl-catechol Depigmentation, particularly on the hands; areas may enlarge, and new ones may appear even after contact has ceased. Phenolic germicides Depigmentation Para tertiary butyl phenol Bindi dermatitis MBEH (mercaptobenzothiazole) Rubber chappals dermatitis Kojic acid (Option A) is a skin-lightening agent used in some cosmetic products, it is not typically associated with chemical leukoderma. Azelaic acid (Option B) is another compound used in treating hyperpigmentation, it is not a common cause of chemical leukoderma. Mercury (Option D) can cause skin discoloration, it typically presents as a blue-grey or purplish pigmentation on light-exposed skin and the sclerae.

References:

https://www.uptodate.com/contents/acquired-hypopigmentation-disorders-other-than-vitiligo?

↑ *Back to this question in Part A*

@Neet_pg_bot

Q44: A 30-year-old woman presents with hypopigmented patches on her chest and back after recovering from a severe rash caused by contact dermatitis. The affected areas are smooth, without any scaling, itching, or scarring. What is the most likely diagnosis? (Q841806)

A. Post-inflammatory hypopigmentation

B. Vitiligo

C. Pityriasis alba

D. Nevus depigmentosus

Correct Answer: A. Post-inflammatory hypopigmentation

Explanation: Post-inflammatory hypopigmentation can occur after any skin condition, particularly in darker skin, and is caused by decreased melanin production or transfer to keratinocytes. Post-inflammatory hypopigmentation (PIH): Definition: Loss of normal skin color after inflammation resolves, causing lighter patches. Epidemiology: Most common cause of acquired hypopigmentation; more frequent in darker skin types. Causes/Factors: Impaired melanin transfer from melanocytes to keratinocytes. Melanocyte damage or loss due to inflammation. Potent topical corticosteroids inhibiting melanin production. Reversibility: Often reversible if melanin production and transfer are restored. Management: Avoid triggers. Protect skin from sun exposure to prevent worsening. Vitiligo (Option B) is autoimmune, unrelated to prior inflammation, often progressive. Pityriasis alba (Option C) hypopigmented patches with mild scaling , mostly on the face, often in children/atopic individuals. Nevus depigmentosus (Option D) is a congenital, stable, hypopigmented macule that is usually present at birth and does

not change in size or shape.

References:

https://www.uptodate.com/contents/acquired-hypopigmentation-disorders-other-than-vitiligo?

↑ *Back to this question in Part A*

@Neet_pg_bot

Q45: Which statement regarding skin colour is incorrect? (Q884741)

A. Melanocyte number is similar in all skin types

B. Melanin is transferred to keratinocytes via melanosomes

C. Skin colour is chiefly determined by the number of melanocytes

D. The type of melanin and melanosome size influence skin colour

Correct Answer: C. Skin colour is chiefly determined by the number of melanocytes

Explanation: Skin colour differences are not due to the number of melanocytes, which is relatively constant across populations. Instead, the type of melanin produced and the size, number, and distribution of melanosomes determine skin colour. The colour of the skin depends on the amount of melanin inside melanocytes, the number and size of melanosomes, and the degree of melanin transfer to ketrtinocytes Racial and ethnic differences in skin colour are related to the number, size, shape, distribution and degradation of melanin■laden organelles called melanosomes. These are produced by melanocytes and are transferred to the surrounding epidermal keratinocytes. Two types of melanin pigmentation occur in humans. Constitutive skin colour: The amount of melanin pigment that is genetically determined in the absence of sun exposure and other influences. Facultative (inducible) skin colour or ‘tan’: Results from sun exposure.

References:

Rook’s Textbook of Dermatology, 9th Edition, Pages 2.1, 2.2, 88.1, 88.2.

↑ *Back to this question in Part A*

@Neet_pg_bot

Q46: The approximate keratinocyte to melanocyte ratio in normal human epidermis is? (Q884742)

A. 1: 1

B. 20: 1

C. 10: 1

D. 36: 1

Correct Answer: D. 36: 1

Explanation: In normal epidermis, one melanocyte supplies melanin to ~36 keratinocytes , maintaining pigmentation. This ratio is constant across skin types. Skin colour varies due to melanosome size, number, and melanin type.

References:

Rook’s Textbook of Dermatology, 9th Edition, Page 88.3.

↑ *Back to this question in Part A*

@Neet_pg_bot

Q47: Which of the following statements regarding piebaldism is correct? (Q884743)

A. Autosomal recessive disorder

B. Caused by a defect in melanocyte production

C. A white forelock is the characteristic clinical feature

D. Commonly presents with extracutaneous abnormalities

Correct Answer: C. A white forelock is the characteristic clinical feature

Explanation: Piebaldism is classically marked by a white forelock and stable congenital hypopigmented patches. Piebaldism: Rare autosomal dominant pigmentary disorder (Option A) Well-demarcated congenital hypopigmented macules Pathophysiology: KIT gene mutation → defective c-KIT tyrosine kinase receptor → Failure of melanocyte migration to the skin (Option B) Result: Absent melanocytes and melanin in white patches Less commonly: SNAI2 mutation Clinical features: White forelock (most characteristic) V-shaped leukoderma on mid-forehead & hypopigmented patches Hands, feet, and back spared Islands of hyperpigmentation within depigmented areas Extent variable; sometimes only white forelock Usually, no extracutaneous involvement (Option D) Rare: deafness or intellectual disability (large deletions) Management: Sun protection (amelanotic skin burns easily) Skin/epidermal grafting - effective Phototherapy & topical steroids: ineffective



References:

Rook's Textbook of Dermatology, 9th Edition, Pages 70.3, 70.4.

↑ *Back to this question in Part A*

@Neet_pg_bot

Q48: A 5-year-old has heterochromia irides, sensorineural deafness & the following skin findings. What is the most likely diagnosis? (Q884744)

A. Piebaldism

B. Waardenburg syndrome

C. Vitiligo

D. Tuberous sclerosis



@Neet_pg_bot

Correct Answer: B. Waardenburg syndrome

Explanation: White forelock, congenital hypopigmentation, heterochromia, dystopia canthorum, and sensorineural deafness are characteristic of Waardenburg syndrome. Waardenburg Syndrome: Definition: Genetic disorder of neural crest → white forelock, hypopigmented patches, sensorineural deafness Inheritance: Autosomal dominant (WS1-3), autosomal recessive (WS4) Genes: WS1/3 - PAX3 ; WS2 - MITF/SLUG ; WS4 - EDNRB, EDN3, SOX10 Clinical Features: White forelock (hallmark) Hypopigmented patches (may partially repigment) Heterochromia irides WS1: dystopia canthorum, facial dysmorphism WS3: musculoskeletal anomalies WS4: Hirschsprung disease Management: Hearing loss: Non-progressive; manage based on severity Audiogram: Usually a one-time evaluation unless indicated Piebaldism (Option A) : White forelock + hypopigmented patches, but no deafness or dystopia canthorum Vitiligo (Option C) : Acquired, progressive depigmentation ; lesions appear after birth Tuberous sclerosis (Option D) : Hypopigmented “ash leaf” macules, not associated with white forelock or deafness

References:

Rook’s Textbook of Dermatology, 9th Edition, Pages 70.4, 70.5.

↑ *Back to this question in Part A*

@Neet_pg_bot

• [03_Pigmentary Disorders] 007 Previous Year Questions

« Back to Folder Directory

[03_Pigmentary Disorders] 007 Previous Year Questions — Quick Jump

Q1 (p. 710) *Q2 (p. 711)* *Q3 (p. 712)* *Q4 (p. 715)* *Q5 (p. 717)* *Q6 (p. 719)*
Q7 (p. 720) *Q8 (p. 722)* *Q9 (p. 722)* *Q10 (p. 724)*

Q1: A 20-year-old patient presents with a non-progressive hypopigmented patch on the trunk. On Wood's lamp examination, there is mild white accentuation. Diascopy is negative. There is no sensory loss. What is the most likely diagnosis? (Q866548)

A. Vitiligo

B. Nevus depigmentosus

C. Nevus anemicus

D. Indeterminate leprosy



Correct Answer: B. Nevus depigmentosus

Explanation: Nevus depigmentosus is a congenital, stable, non-progressive hypopigmented macule or patch, present from early life. Lesion is usually solitary, well-defined, and does not spread over time. Wood's lamp shows an off-white accentuation (less bright than vitiligo). Diascopy is negative because the hypopigmentation is due to reduced melanin, not vascular changes. No sensory loss or scaling is present. Management is generally reassurance; no effective repigmentation treatment is required unless for cosmetic concerns. Vitiligo (Option A): An acquired progressive depigmentation with complete loss of melanin; Wood's lamp shows bright chalk-white fluorescence; lesions tend to enlarge over time. Nevus anemicus (Option C): A vascular anomaly where skin appears pale due to localized increased vasoconstriction; diascopy causes the lesion to blend with surrounding skin (positive diascopy), unlike nevus depigmentosus. Indeterminate leprosy (Option D): Hypopigmented patch with impaired sensation and possible nerve thickening; would not be stable for years without progression, and diagnosis requires sensory loss or skin smear evidence.



↑ *Back to this question in Part A*

@Neet_pg_bot

Q2: Which type of vitiligo doesn't usually progress in the long term? (Q840083)

A. Segmental

B. Acrofacial

C. Focal

D. Mucosal

Correct Answer: A. Segmental

Explanation: Correct Option A - Segmental: Segmental vitiligo is present along a segment/dermatome. It develops after birth during childhood. Depigmented macules are seen in particular dermatomes and are unilateral with midline demarcation. These have relatively stable courses and are not amenable to medical treatment; hence, surgical treatment is required. Incorrect Options: Option B, C, and D: These are non-segmental types of vitiligo. They are not along the segment/dermatome but can be focal and limited to one area. These are autoimmune and have a tendency to progress long-term.

References:

.

↑ *Back to this question in Part A*

@Neet_pg_bot

Q3: A 40-year-old female who had a history of chronic sun exposure presented to the OPD clinic with brownish pigmentation as shown in the image. Which of the following is the diagnosis? ' (Q860090)

A. Melasma

B. Freckles

C. Melanoma

D. Basal cell carcinoma



Correct Answer: A. Melasma

Explanation: This woman with hyperpigmented patches on her cheek and a history of chronic sun exposure most likely has melasma. Melasma: It is characterized by hyperpigmented macules with scalloped or irregular margins that are darker than the surrounding areas. These patches typically appear on the face, with common locations being the cheeks, forehead, and chin. It is more common in females. Etiologic factors include: Genetic influences, ultraviolet (UV) radiation, pregnancy, hormonal therapies (Ex-OCPs), cosmetics, and phototoxic drugs. Sun protection with broad-spectrum sunscreen with a high SPF, wearing protective clothing, and avoiding prolonged sun exposure aim to prevent further pigmentation. Topical hydroquinone inhibits tyrosinase, an enzyme responsible for pigment production in melanocytes, and is a common depigmenting agent. Triple combination therapy of hydroquinone, retinoid, and corticosteroid is highly effective for melasma. Chemical peels, azelaic acid, and laser therapy are other options. Freckles (Option B): Freckles (ephelides) are small, light-brown macules that darken with sun exposure and fade in winter. They are more common in fair-skinned individuals and appear in childhood. {{caption_text}} Melanoma (Option C): Melanoma presents as an irregularly shaped, rapidly growing pigmented lesion with asymmetry, border irregularity, color variation, and possible ulceration. It does not typically present as uniform brown pigmentation. {{caption_text}} Basal Cell Carcinoma (BCC) (Option D): BCC commonly appears as a pearly, translucent nodule with telangiectasia, central ulceration, or rolled borders, rather than diffuse pigmentation. {{caption_text}}


@Neet_pg_bot

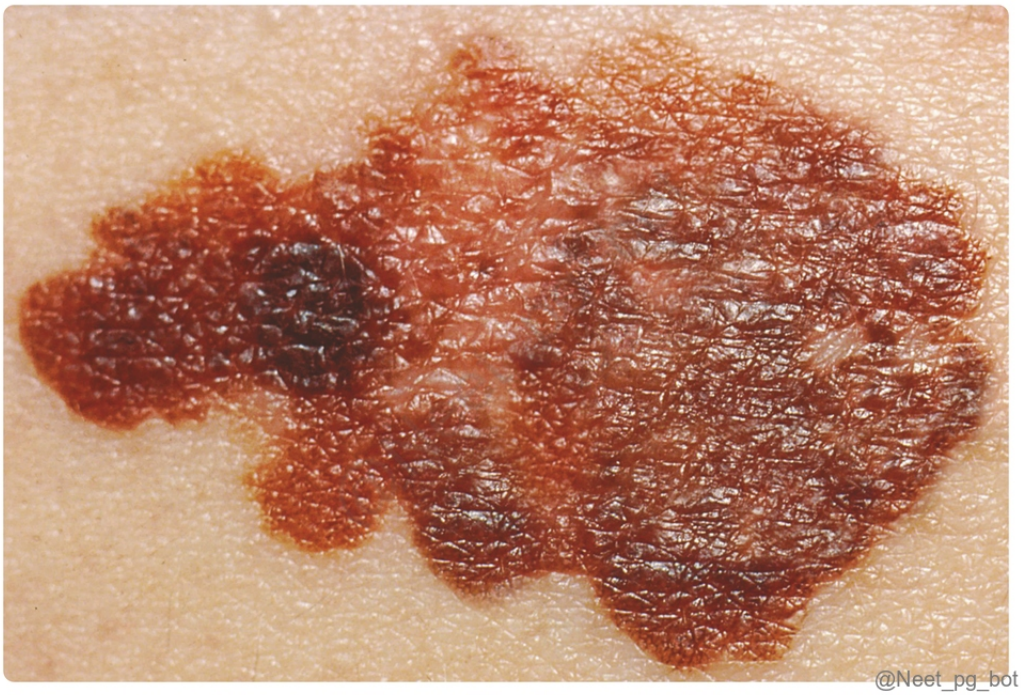
@Neet_pg_bot



References:

Fitzpatrick Textbook of Dermatology, 9th edition

Rook's Textbook of Dermatology, 9th edition, page no. 88.10-88.13, 131.1

https://www.google.com/url?sa=i&url=https%3A%2F%2Fwww.aocd.org%2Fpage%2FLentigoMaligna&psig=AOvVaw0CXAX57Oxcmfq6q_msOXOT&ust=1711954688334000&source=images&cd=vfe&opi=89978449&ved=0CBIQjRxqFwoTCMjqtqz2nYUDFQAAAAAdAAAAABAD

↑ *Back to this question in Part A*

@Neet_pg_bot

Q4: Match the following woods lamp findings: Column A Column B 1. Erythrasma a. Yellow 2. Pityriasis versicolor b. Coral red fluorescence 3. Tinea capitis c. Pink 4. Vitiligo d. Green e. Milky white (Q857388)

A. 1-b, 2-a, 3-d, 4-e

B. 1-b, 2-d, 3-a, 4-c

C. 1-d, 2-a, 3-c, 4-e

D. 1-a, 2-c, 3-e, 4-d

Correct Answer: A. 1-b, 2-a, 3-d, 4-e

Explanation: Wood's lamp examination is a diagnostic procedure used to observe fluorescence patterns in the skin under ultraviolet light. It helps identify fungal infections, bacterial infections, pigmentary disorders, and other skin conditions based on characteristic fluorescence reactions This non-invasive test is conducted in a darkened room, emitting light of wavelength 320-450nm. Disease Colour on Wood’s light Vitiligo Milky white Erythrasma Coral pink Pityriasis versicolor Yellow Tinea capitis Green Pseudomonas Green Scabies Fluorescein solution fills the burrows and is viewed with Wood’s light Porphyria Fluorescence observed in urine, teeth and blood Tuberous sclerosis Ash-leaf macules {{caption_text}} The image below shows milky-white fluorescence in vitiligo. {{caption_text}}





References:

Rook’s Textbook of Dermatology - page 4.20

↑ *Back to this question in Part A*

@Neet_pg_bot

Q5: A 13-year-old patient presents with the velvety lesion shown in the image below. What is the diagnosis? (Q854654)

A. Acanthosis Nigricans

B. Tinea Versicolor

C. Seborrheic Keratosis

D. Atopic Dermatitis



Correct Answer: A. Acanthosis Nigricans

Explanation: The presence of velvety, hyperpigmented lesions is characteristic of Acanthosis Nigricans. This condition is caused by hyperkeratosis (thickening of the skin) without an increase in melanocyte or melanin production. It commonly affects intertriginous areas (skin folds such as the neck, axillae, groins, and submammary folds) and is associated with obesity, insulin resistance, hypothyroidism, polycystic ovary syndrome (PCOS), acromegaly, and other metabolic disturbances. {{caption_text}} Pathogenesis: The condition is linked to increased production of IGF-1 (insulin-like growth factor 1). Types: Benign Acanthosis Nigricans: Associated with diabetes, obesity, or metabolic syndrome. Malignant Acanthosis Nigricans: Rapid onset and linked to visceral malignancies , such as adenocarcinomas of the gastrointestinal tract. Clinical Features: Velvety, asymptomatic, symmetrical darkening of the skin. Often begins in the neck, axillae, groins, or other intertriginous areas. May lead to the development of skin tags in affected regions. The presence of these lesions is a cutaneous marker for underlying metabolic abnormalities and insulin resistance. Treatment involves addressing the underlying condition with lifestyle modifications and, if necessary, topical treatments like keratolytics or retinoids. Tinea Versicolor (Option B) Caused by a fungal infection (Malassezia species). Presents as hypopigmented or hyperpigmented scaly macules/patches, not velvety lesions. Typically has a scaly appearance, especially after sun exposure. Seborrheic Keratosis (Option C) A benign skin lesion that appears as well-demarcated, warty, or "stuck-on" plaques. Common in older adults. Does not have the velvety texture characteristic of Acanthosis Nigricans. Atopic Dermatitis (Option D) Also known as eczema, it appears as dry, itchy, scaly, and inflamed patches of skin. Typically affects flexural surfaces (e.g., behind knees, elbows) rather than intertriginous areas. Velvety hyperpigmented patches are not a feature of atopic dermatitis.



References:

Rook’s Textbook of Dermatology 9 th edition - page 87.2

↑ *Back to this question in Part A*

@Neet_pg_bot

Q6: A 22-year-old college student presents with small, depigmented lesions which have been there for over 2 years now as shown in the image below. What is the most likely diagnosis? (Q857572)

A. Melasma

B. Vitiligo

C. Psoriasis

D. Dermatitis herpetiformis



Correct Answer: B. Vitiligo

Explanation: The image shows depigmented patches on the arm, which are characteristic of Vitiligo. Vitiligo: Vitiligo is an acquired pigmentation disorder featuring well-defined depigmented macules on the skin. Biopsies show epidermal melanocyte loss. Lesions may be localized or generalized, coalescing into large depigmented areas. Wood's lamp, emitting ultraviolet A (UV-A) light, aids in diagnosis by revealing bright blue-white fluorescence with sharply demarcated borders in vitiligo lesions, particularly in individuals with pale skin. Melasma (Option A): Melasma presents as hyperpigmented (brownish) patches, often on sun-exposed areas like the face. It is associated with pregnancy, oral contraceptive use, and sun exposure. Psoriasis (Option C): Psoriasis features erythematous plaques with silvery-white scales, usually on extensor surfaces like elbows and knees. It does not cause depigmentation. Dermatitis Herpetiformis (Option D): This is a chronic, intensely pruritic vesicular disease associated with celiac disease. It presents as grouped vesicles and papules rather than depigmented patches.

References:

https://www.uptodate.com/contents/vitiligo-pathogenesis-clinical-features-and-diagnosis?search=vitiligo&source=search_result&selectedTitle=2%7E150&usage_type=default&display_rank=2

↑ *Back to this question in Part A*

@Neet_pg_bot

Q7: A young girl presents with leukotriosis and lesions as shown in the image. What is the most likely diagnosis? (Q855653)

A. Focal vitiligo

B. Segmental vitiligo

C. Piebaldism

D. Nevus depigmentosus



Correct Answer: B. Segmental vitiligo

Explanation: The presence of leukotrichia (white hair) along with depigmented patches suggests vitiligo , as leukotrichia is uncommon in congenital disorders like piebaldism or nevus depigmentosus . Segmental vitiligo affects one side of the body and follows a dermatomal or unilateral pattern . It occurs early in life , progresses rapidly , and then stabilises , unlike generalised vitiligo, which progresses over time. Focal Vitiligo (Option A) is incorrect because focal vitiligo presents as small, isolated patches but does not follow a segmental/dermatomal distribution. It often progresses into generalised vitiligo, unlike segmental vitiligo, which remains localized . Piebaldism (Option C) is incorrect because it is a congenital disorder (present from birth) due to c-KIT gene mutations . Typically associated with a white forelock (poliosis) and symmetrical patches, not segmental . Nevus Depigmentosus (Option D) is incorrect because it is a stable hypopigmented patch present from birth . Unlike vitiligo, it does not progress or show leukotrichia .

References:

https://www.uptodate.com/contents/vitiligo-pathogenesis-clinical-features-and-diagnosis?search=vitiligo&source=search_result&selectedTitle=2%7E150&usage_type=default&display_rank=2

Vitiligo - Part 2 - classification, histopathology and treatment - PMC (nih.gov)

↑ *Back to this question in Part A*

@Neet_pg_bot

Q8: What is the purpose of using Methylisothiazolinone (MI) in cosmetics? (Q856830)

A. Surfactant

B. Humectant

C. Emulsifier

D. Preservative

Correct Answer: D. Preservative

Explanation: - Preservative Methylisothiazolinone (MI) is commonly used as a preservative in cosmetics. It helps prevent the growth of bacteria, fungi, and other microorganisms in cosmetic products, thereby extending their shelf life and maintaining their safety and efficacy. Incorrect Options: Surfactant (Option A) : Surfactants are commonly used in cosmetic products to enhance foaming, cleansing, and emulsifying properties. While surfactants are frequently used in cosmetics, methylisothiazolinone is not primarily used as a surfactant. Humectant (Option B) : Humectants are commonly used in skincare and cosmetic products to prevent dryness and maintain moisture balance. Methylisothiazolinone is not typically used as a humectant. Emulsifier (Option C) : Emulsifiers are commonly used in cosmetic formulations to create stable emulsions, such as creams and lotions. Methylisothiazolinone is not primarily used as an emulsifier.

References:

https://pubmed.ncbi.nlm.nih.gov/23340392/

↑ *Back to this question in Part A*

@Neet_pg_bot

Q9: What is the probable diagnosis for a pregnant woman of age 30 who visits the dermatology outpatient department (OPD) with the following condition? (Q793404)

A. Systemic lupus erythematosus

B. Viral infection

C. Rosacea

D. Chloasma



Correct Answer: D. Chloasma

Explanation: Correct answer: Option D Chloasma A common skin condition that can occur during pregnancy is chloasma, also known as the "mask of pregnancy." The appearance of brownish or grayish patches on the face, particularly on the cheeks, nose, forehead, and upper lip, is a hallmark of this condition. Chloasma is brought on by hormonal changes during pregnancy, particularly an increase in estrogen and progesterone levels, both of which can encourage the skin to produce more melanin. Incorrect choices: Option a. Systemic lupus erythematosus: Lupus, also known as systemic lupus erythematosus (SLE), is a chronic autoimmune disease that can affect a variety of body organs and tissues. It is characterized by the production of autoantibodies that damage and inflame the body's own tissues and cells. SLE is more common in ladies, and side effects can shift generally from one individual to another, contingent upon which organs and tissues are impacted. Option b. Viral infection: The given image is not of viral infection Option c. Rosacea: Rosacea is a long-term condition of the skin that mostly affects the face and causes redness, flushing, and blood vessels to show up. It can likewise cause pimple-like knocks and thickened skin on the cheeks, and brow. Rosacea typically affects fair-skinned adults over the age of 30 who have a family history of the condition.

References:

.

↑ *Back to this question in Part A*

Q10: Which diagnostic tool is used to identify the condition depicted in the image below? (Q793447)

A. Culture

B. Wood’s lamp examination

C. Gram staining

D. Patch test



Correct Answer: B. Wood’s lamp examination

Explanation: Wood's light assessment is a symptomatic test utilized in dermatology to assist with recognizing different skin conditions, including contagious contaminations, bacterial diseases, and color problems like vitiligo. Dermatologists are able to observe subtle changes in the skin that might not be apparent under normal lighting conditions thanks to the use of ultraviolet light to highlight fluorescent substances in the skin. The patient's skin is first cleansed, and any cosmetics or lotions are removed during a Wood's lamp examination. The dermatologist applies the UV light from Wood's lamp to the patient's skin in a room that is darkened. The fluorescent substances in the skin mirror the light, making the skin seem an alternate tone, it is inspected to rely upon the condition. For instance, fungal infections can have a yellow-green appearance, while pigment disorders can have a white or

blue-green appearance. Incorrect choices: Option a. Culture: Microorganisms like bacteria, viruses, and fungi can be identified and grown from a sample of tissue or bodily fluid with the help of a culture test in the laboratory. Cultures are frequently utilized in dermatology to diagnose fungal or bacterial skin infections like cellulitis, impetigo, or fungal skin infections. Option c. Gram staining: A laboratory test known as "gram staining" is used to determine the kind of bacteria that is present in a sample of bodily fluid or tissue. In dermatology, it is frequently used to diagnose bacterial skin infections like folliculitis, cellulitis, and impetigo. Option d. Patch test: A diagnostic test known as patch testing is used to pinpoint the substances or allergens that may be triggering allergic contact dermatitis. When the skin comes into contact with a substance that the immune system perceives as foreign and reacts against, this type of dermatitis is a delayed hypersensitivity reaction.

References:

.

↑ *Back to this question in Part A*

@Neet_pg_bot

• [04_Dermatitis _ Eczema] 008 Eczema

« Back to Folder Directory

[04_Dermatitis _ Eczema] 008 Eczema — Quick Jump

Q1 (p. 726) *Q2 (p. 727)* *Q3 (p. 730)* *Q4 (p. 732)* *Q5 (p. 735)* *Q6 (p. 736)*
Q7 (p. 740) *Q8 (p. 741)* *Q9 (p. 743)* *Q10 (p. 746)* *Q11 (p. 747)* *Q12 (p. 752)*
Q13 (p. 756)

Q1: A 14-year-old girl presents with a flare-up of her atopic dermatitis which was previously well-controlled. Examination reveals erythematous lesions over the neck. Which of the following is the initial management? (Q841784)

A. Topical steroids

B. Cyclosporine

C. Oral steroids

D. Methotrexate

Correct Answer: A. Topical steroids

■ *Listen (English)*

■ *Listen (Hindi)*

Explanation: The patient presents with a mild flare of AD for which the initial management is topical steroids (ointment if lichenified; cream if scaly/oozy) along with emollients. Management of atopic dermatitis includes Controlling environmental factors like removing triggers (example- dust), avoiding extreme temperatures, detergents, and harsh soaps. Restoring the compromised barrier: Hydration using emollients and moisturizers) Emollients soften the skin, reduce itch, and enhance the effect of topical corticosteroids. Persistent use of emollients when the inflammation is in remission may reduce the time and frequency of flare-ups. Pharmacological treatment:- Localized condition: Topical corticosteroids +/- antihistamines +/- antibiotics For face: Calcineurin inhibitors (pimecrolimus and tacrolimus) Severe disease (systemic management): Oral corticosteroids, cyclosporine, and azathioprine. Newer drugs : Crisabole: PDE-4 inhibitor (topical). Dupilumab: IL-4 receptor alpha antagonist (systemic). Tofacitinib: JAK kinase inhibitors Apremilast: PDE-4 inhibitor (also used in psoriasis) Atopic eczema treatment algorithm: TCI- topical calcineurin inhibitors; TCS, topical corticosteroids.

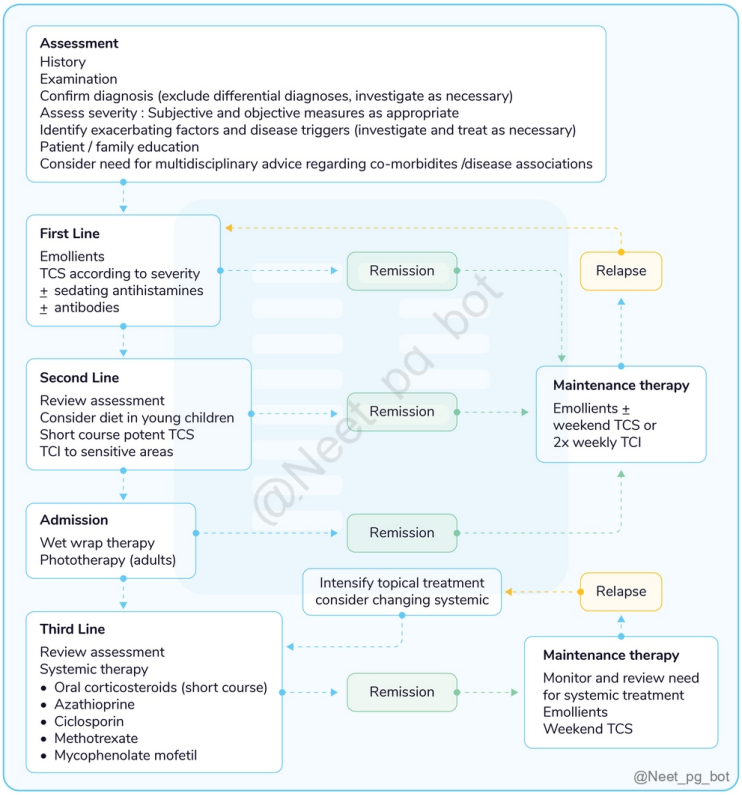

References:

Rook’s textbook of dermatology, 9th Edition, Page 41.26, 41.27, 41.28

↑ *Back to this question in Part A*

@Neet_pg_bot

Q2: A 12-year-old girl presents with multiple hypopigmented patches, as shown below. She reports a prior history of asthma. Examination reveals lesions over her face as shown below. There is mild scaling over the lesions. What is the likely diagnosis? (Q841785)

A. Tinea versicolor

B. Indeterminate leprosy

C. Vitiligo

D. Pityriasis alba



Correct Answer: D. Pityriasis alba

- *Listen (English)*
- *Listen (Hindi)*

Explanation: This patient with a history of asthma and above lesions most likely has pityriasis alba (PA). Pityriasis alba is a benign condition that predominantly affects children and adolescents and is associated with atopic asthma. The classical presentation is multiple hypopigmented, scaly, round, or oval macules and patches, predominantly over the face, upper trunk, and upper limbs. These may be associated with mild erythema or scaling. On Wood's lamp examination, lesions are nonfluorescent. It is a self-limited condition, treatment options include emollients, low-potency topical corticosteroids, and topical calcineurin inhibitors. Tinea versicolor (Option A): It is caused by Malasezzia species and is more common in the truncal region. It presents with hypo or hyperpigmentation in patients with oily and sweaty skin and fine scales on scratching. There may be mild pruritus and erythema with yellow to green fluorescence on Wood’s lamp . The KOH mount shows a spaghetti and meatball appearance. Treatment includes antifungal agents like topical selenium sulfide and topical ketoconazole. KOH mount: Wood's lamp: Indeterminate leprosy (Option B) lacks scales on examination. Indeterminate Hansen presents with a single lesion. Vitiligo (Option C) presents with depigmented milky white patches without scaling.


@Neet_pg_bot

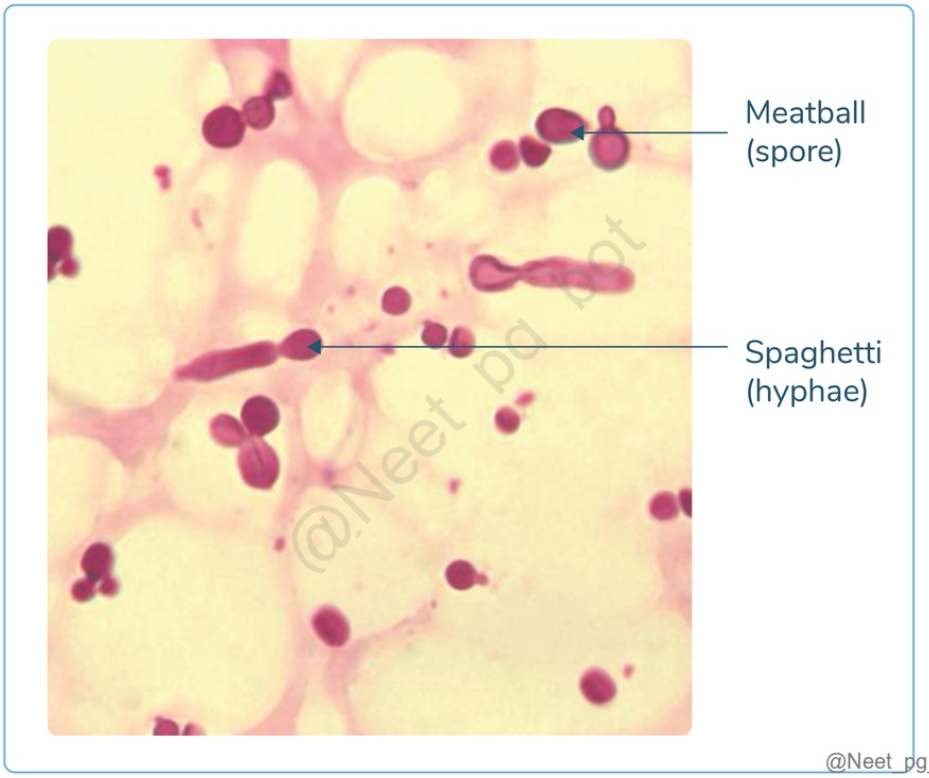
Meatball
(spore)
Spaghetti
(hyphae)
@Neet_pg_bot

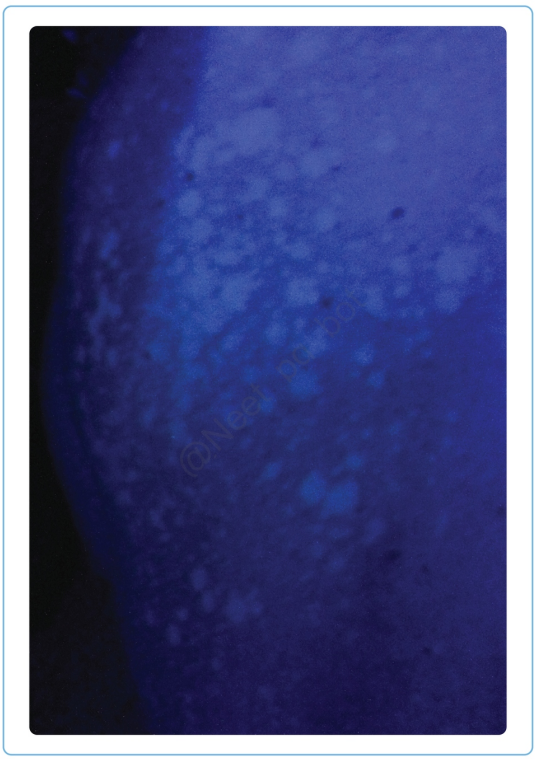

References:

Rook’s textbook of dermatology, 9th Edition, Page 39.25

http://uptodate.com/contents/acquired-hypopigmentation-disorders-other-than-vitiligo

↑ *Back to this question in Part A*

@Neet_pg_bot

Q3: A 55-year-old female presents with multiple red, scaly patches with greasy, yellow scales in her hair. Which of the following represents an appropriate treatment option for her? (Q841878)

A. Azole-based shampoo

B. Oral ketoconazole

C. Topical corticosteroids

D. Avoiding topical creams

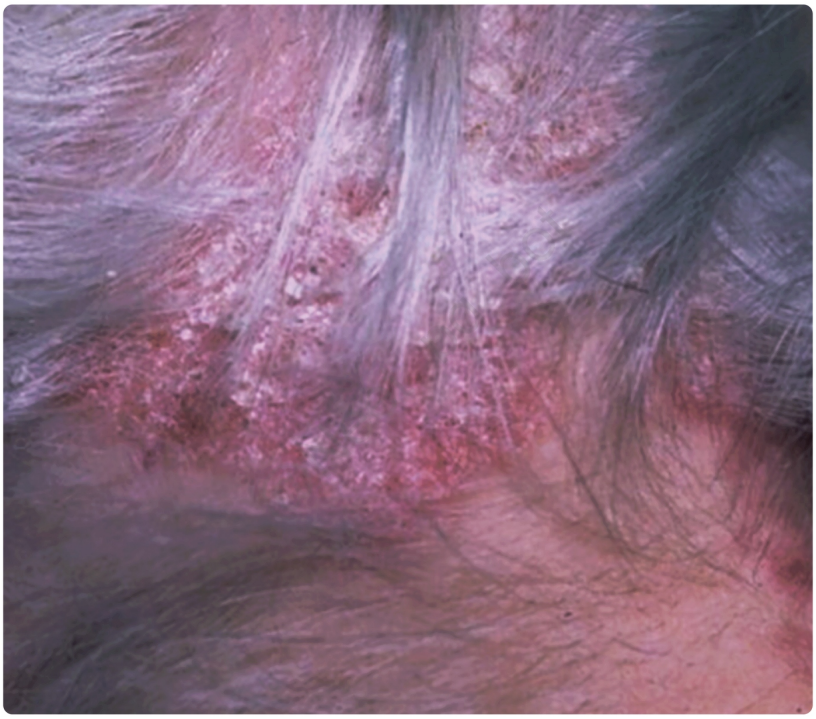

Correct Answer: A. Azole-based shampoo

- *Listen (English)*
- *Listen (Hindi)*

Explanation: The given case scenario describes seborrheic dermatitis (SD) , an inflammatory response to colonization by the Malassezia fungal species. In adults and adolescents, it is characterized by yellow, greasy scales involving the face, scalp (dandruff), nasolabial folds, and retro auricular region due to the major activity of sebaceous glands here leading to increased sebum production. It is also seen in infants < 3 months old due to presence of maternal androgens. Involvement of the scalp and face leads to a characteristic finding called cradle cap. It is also called infantile seborrheic dermatitis. Management includes stopping Malassezia growth using antifungals like Topical creams: Azoles (Sertaconazole, Propiconazole, Luliconazole) · Azole, zinc pyrithione (ZPTO), ciclopirox olamine, and selenium sulfide-based shampoo Topical corticosteroids or Topical calcineurin inhibitors + Shampoo or Azoles for dry erythema Antihistamines for itching Oral antifungals (itraconazole, fluconazole) for severe and unresponsive disease No oil application, as sebaceous gland activity is already increased. For contact dermatitis, it may be recommended to avoid topical creams (Option D) to remove exposure to the offending substances. In the case of SD, organic oils may be avoided as they can worsen the condition.



References:

https://www.uptodate.com/contents/seborrheic-dermatitis-in-adolescents-and-adults

Rook’s textbook for dermatology, 9th Edition, Page 107.2

↑ *Back to this question in Part A*

@Neet_pg_bot

Q4: Which of the following examination findings would not be expected in acute eczema? (Q841776)

A. Erythema

B. Lichenification

C. Vesicles

D. Oozing



Correct Answer: B. Lichenification

- *Listen (English)*
- *Listen (Hindi)*

Explanation: The given clinical scenario likely describes acute eczema that does not show lichenification, which is a feature of chronic eczema. Eczema or atopic dermatitis is a chronic, pruritic, inflammatory condition of the skin. The pattern of the rash varies with age Infantile phase (<2 years): The lesions are present on the face and extensor aspect of the knees and elbows consisting of erythema and discrete or confluent oedematous papules. The papules may become exudative and crusted. Childhood phase (2 years to puberty): Presents as erythema, crusting, excoriation, hyper and hypopigmentation, and warty lichenification involving the elbow and knee flexures. Adult phase : Similar to the childhood phase with more localized and lichenified lesions. Based on the duration of complaints, eczema may be acute, subacute, or chronic. Acute eczema presents with itching and dryness of the skin. Examination findings include signs of inflammation - erythema, oedema, vesicles, oozing, and crusting. Chronic eczema results from long-term untreated or inadequately treated eczema. Exam findings include lichenification, increased skin markings, hyperpigmentation, and thickening of the skin as shown below. Subacute eczema lies in between acute and chronic eczema - erythema and scaling may be seen.





References:

https://www.uptodate.com/contents/atopic-dermatitis-eczema-pathogenesis-clinical-manifestations-and-diagnosis

Rook’s Textbook of Dermatology, 9th Edition, Page 41.2, 49.16-49.9

↑ *Back to this question in Part A*

@Neet_pg_bot

Q5: A 35-year-old housewife presents with itchy and burning lesions over her hands. She reports using a new detergent solution at home and lesions developed within few hours of usage. She has not had similar complaints in the past. Which of the following statements is correct regarding her diagnosis? (Q841777)

A. Occurs due to type IV hypersensitivity

B. Lesions may spread beyond the site of contact

C. Diagnosed by a patch test

D. Depends on intensity, duration and concentration of substance



Correct Answer: D. Depends on intensity, duration and concentration of substance

■ *Listen (English)*

■ *Listen (Hindi)*

Explanation: This patient presents with: Acute onset of itchy and burning lesions Confined to the area of contact (hands) After exposure to a new detergent No prior sensitisation history These features are most consistent with Irritant Contact Dermatitis (ICD) . ICD depends on: Intensity of the irritant (e.g., detergent chemicals) Duration of

contact Concentration of the substance used Irritant contact dermatitis Allergic contact dermatitis Onset Within minutes to hours of exposure Sensitization with first exposure, lesions with subsequent exposure - may be days/ weeks later Pathogenesis Direct disruption of the epidermal barrier, inflammation, and cellular immunity activation. Type IV hypersensitivity Predisposition No genetic predisposition Genetic/ family predisposition present Distribution Site of contact May extend beyond the site of contact Causes Detergents, Alkalis, cement, Acids, Cutting oils, Organic solvents Nickel (watches), PPD - paraphenyl diamine(hair dye), topical neomycin, Parthenium plants Occurs due to type IV hypersensitivity (Option A): This is true for allergic contact dermatitis , not irritant type. Lesions may spread beyond the site of contact (Option B): Again, a feature of allergic contact dermatitis , not ICD. Diagnosed by a patch test (Option C): Patch testing is used to diagnose allergic contact dermatitis , not ICD.

References:

Rook’s Textbook of Dermatology, 9th Edition, Page 129.1

https://www.uptodate.com/contents/irritant-contact-dermatitis-in-adults

https://www.uptodate.com/contents/clinical-features-and-diagnosis-of-allergic-contact-dermatitis

↑ *Back to this question in Part A*

@Neet_pg_bot

Q6: A 29-year-old woman presents with an intensely pruritic, red rash over her neck as shown in the image. What is the most likely causative substance? (Q841778)

A. Nickel

B. Para tertiary butyl phenol

C. Para phenylene diamine

D. Latex

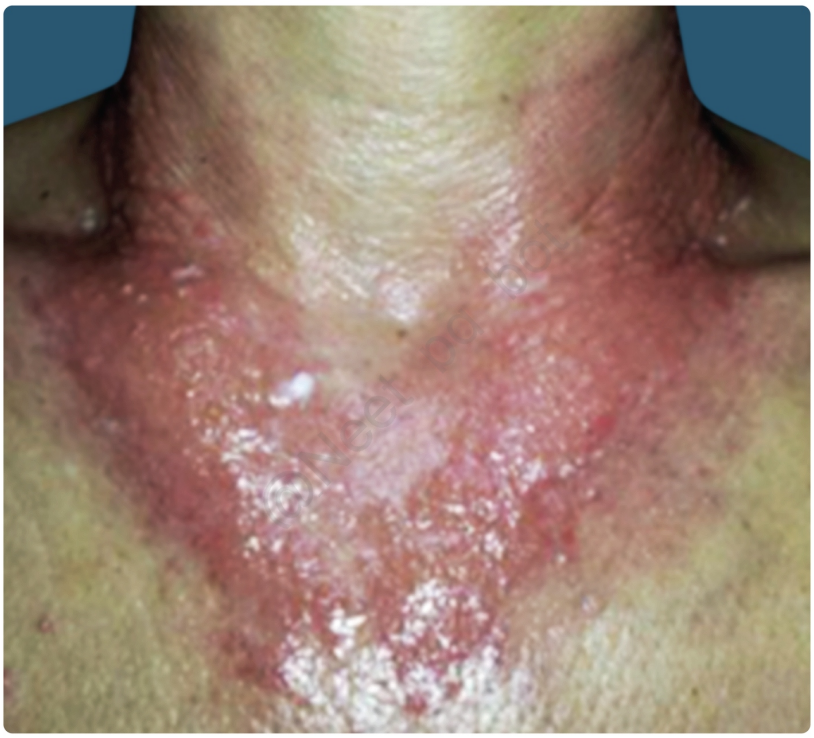

Correct Answer: A. Nickel

■ *Listen (English)*

■ *Listen (Hindi)*

Explanation: This patient presents with ACD over the neck, likely due to a new artificial jewelry . Artificial jewellery typically contains nickel , which can cause ACD. Other sites of ACD due to Nickel include wrists (watches) and waist (belt buckle). Other causative substances of ACD include: Allergens Sources Nickel, cobalt Artificial jewellery, jean buttons, wristwatches Chromium Cement, paintings Potassium dichromate Leather, detergents Epoxy resins, phenols Plastics Parthenium Parthenium plants - airborne ACD Propylene glycol Cosmetics, Medicaments Paraphenyl diamine(PPD) Hair dyes Neomycin, gentamycin Topical medications Latex/rubber Gloves, shoes, belts Para Tertiary Butyl Phenol (PTBP) Bindi ■■■■Allergic contact dermatitis on forehead: Allergic contact dermatitis due to hair dye:



@Neet_pg_bot

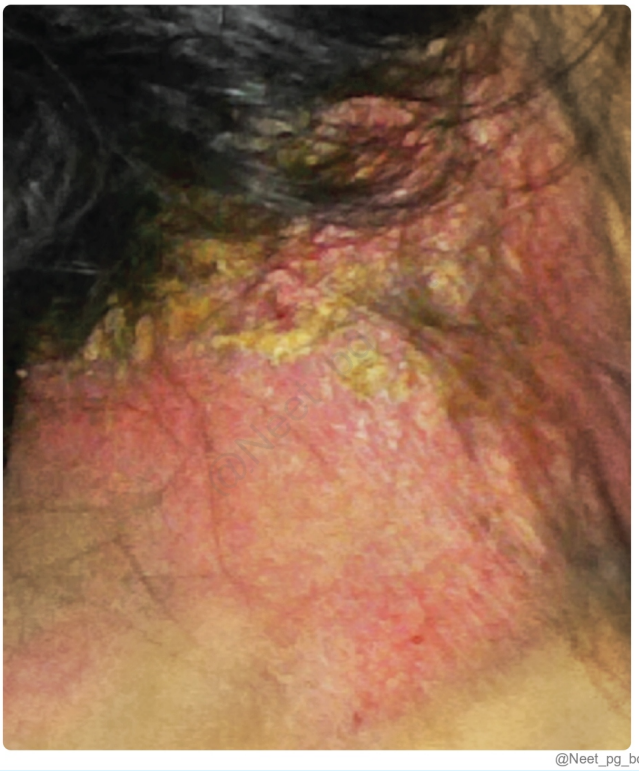

@Neet_pg_bot

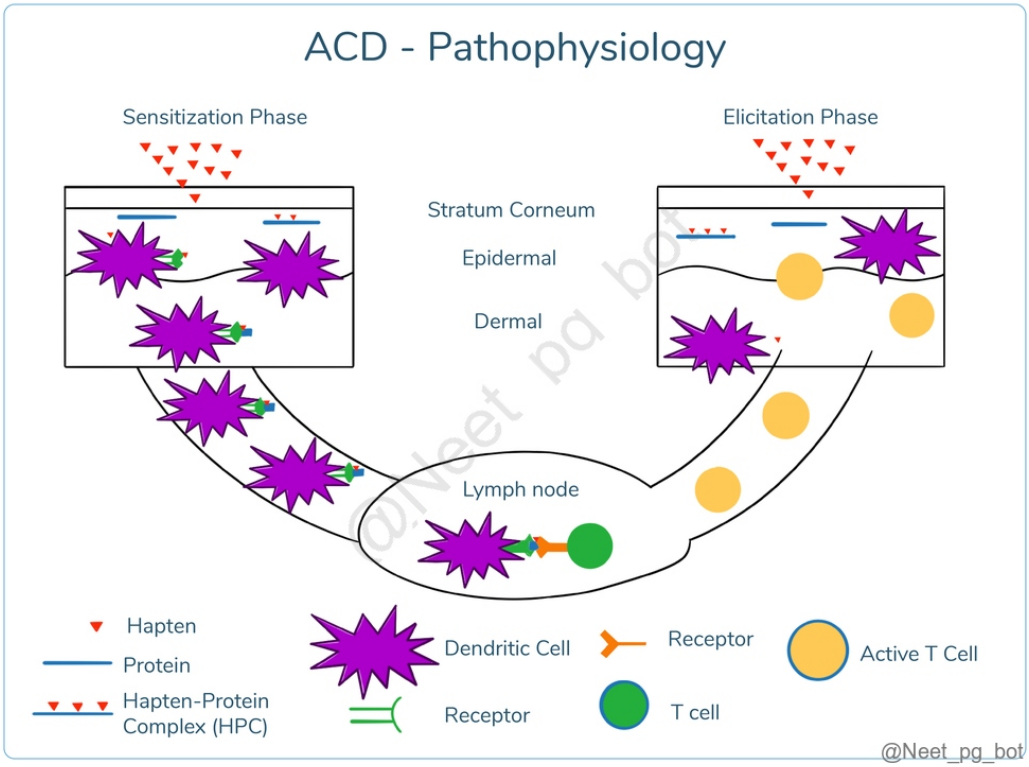
ACD - Pathophysiology
Sensitization Phase
Elicitation Phase
Stratum Corneum
Epidermal
Dermal
Lymph node
Hapten
Protein
Hapten-Protein Complex (HPC)
Dendritic Cell
Receptor
Receptor
T cell
Active T Cell
@Neet_pg_bot



@Neet_pg_bot



References:

https://www.uptodate.com/contents/clinical-features-and-diagnosis-of-allergic-contact-dermatitis

↑ *Back to this question in Part A*

@Neet_pg_bot

Q7: Interpret the following result of the photopatch test: Reaction on the non-irradiated side: Positive Reaction on the irradiated side: Negative (Q841779)

A. No allergy, no photoallergy

B. Pure photoallergy

C. Allergy, no photoallergy

D. Allergy, with photo exaggeration

Correct Answer: C. Allergy, no photoallergy

■ *Listen (English)*

■ *Listen (Hindi)*

Explanation: A patient who shows a positive reaction to a patch test on the non-irradiated side is allergic, while a negative reaction on the irradiated side indicates no photo allergy. A photo patch test is a diagnostic procedure that combines patch testing with UV irradiation. Antigen patches are applied in duplicate, with one patch covered with opaque material. The Patient is called back after 48 hours, and the patches are irradiated with UVA light (5 J/cm^2). Exposing the patches to UV light simulates real-life conditions where the skin is exposed to sunlight. It is mainly used for Photoallergic dermatitis. Interpretation of photo patch test in photoallergic dermatitis Reaction on non-irradiated side Reaction on the irradiated side Interpretation Positive Negative Allergy, no photo allergy Positive Positive Allergy, with photo exaggeration Negative Positive Pure photo allergy Negative Negative No allergy, no photo allergy

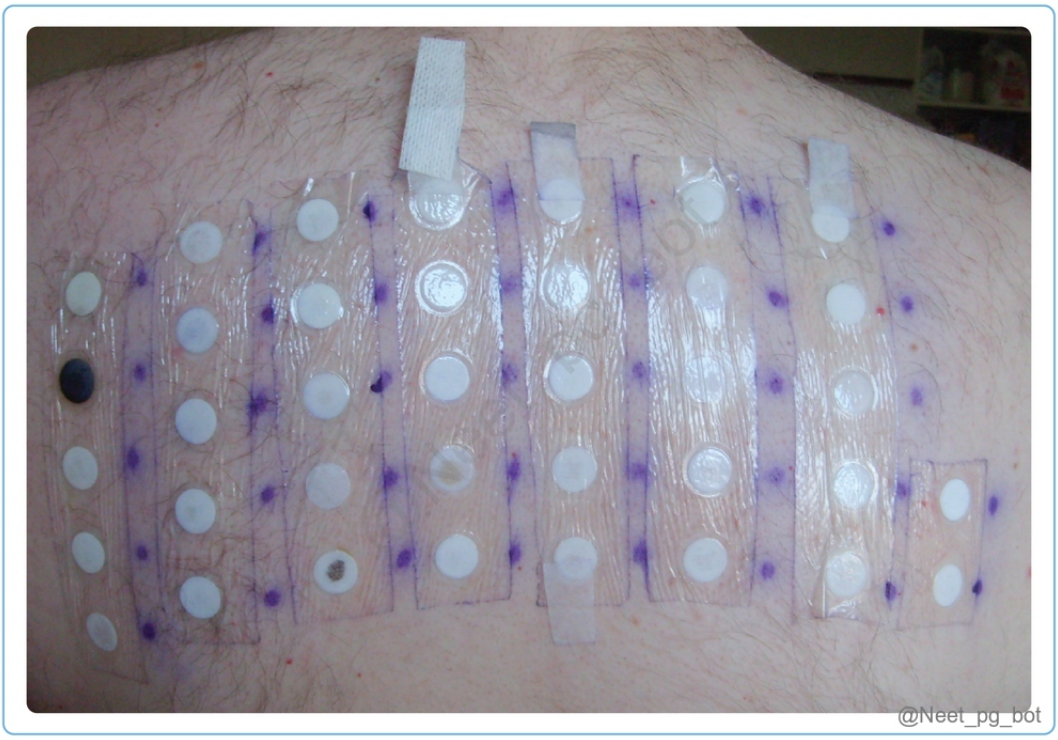

References:

Rook's textbook of dermatology, Pg No. 128.80

↑ *Back to this question in Part A*

@Neet_pg_bot

Q8: What is the best time to visualize the results of the patch test? (Q841780)

A. 24 hours

B. 48 hours

C. 96 hours

D. 120 hours

Correct Answer: C. 96 hours

■ *Listen (English)*

■ *Listen (Hindi)*

Explanation: The best time to visualize the results of the patch test is after 96 hours. Patch tests are usually used to detect contact allergy of the delayed hypersensitivity type. They are usually read at 48–72 h, 96 h and again after 1 week, but can also be read at 15–30 min to detect contact urticaria. If only one patch test reading is possible, a day 4 reading has been recommended. Indications for patch testing Allergic contact dermatitis Eczematous disorders failing to respond to treatment (including occupational) The back is the most commonly used site. Before testing, the site should be free of eczema. Finn chambers or discs are used to ensure the allergen contacts the skin. The discs are applied and removed after 48 hours. A typical regimen is a 48 h application time, with readings taken 1 h after removal and again 48 h later (that is day 2 and day 4). A single day 2 reading is not advised as it may lead to the labelling of some marginal irritants as allergens and positive reactions to more poorly absorbed allergens may be missed. If only one patch test reading is possible, a day 4 reading has been recommended. The positive result might include erythema, papule, pustule, and vesicles at the site of application. It might also lead to thickening of the dermis.

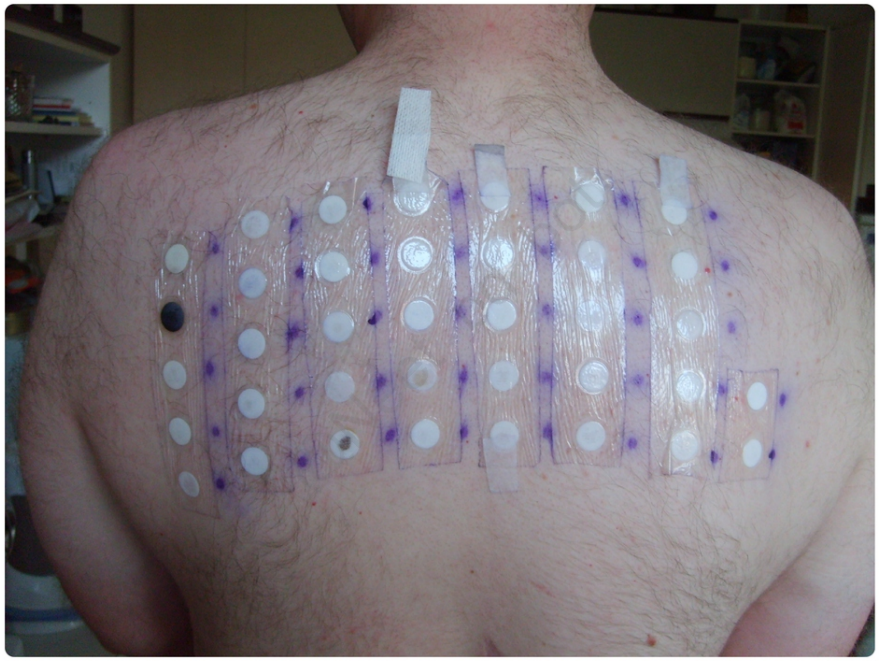

@Neet_pg_bot

References:

Rook’s Textbook of Dermatology, 9th Edition, Page128.64

↑ *Back to this question in Part A*

Q9: A 45 year old gardener presents to the clinic with a persistent itchy rash on his exposed skin areas, including the face, neck, and arms. On examination, there are erythematous, scaly plaques with some vesicles and lichenification shown below. He mentions that he often works near a patch of wild plants that have small white flowers. Which of the following is the causative agent? (Q841781)

A. Parthenium hysterophorus

B. PTBP

C. Poison ivy

D. PPD

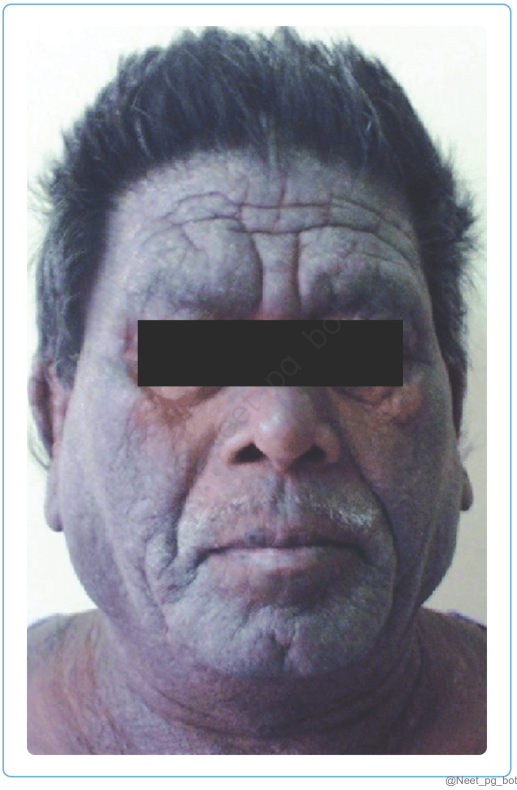

Correct Answer: A. Parthenium hysterophorus

■ *Listen (English)*

■ *Listen (Hindi)*

Explanation: The given clinical scenario shows leonine facies due to chronic airborne contact dermatitis. Given his occupation as a farmer, this is likely phytophotodermatitis (PPD) caused by Parthenium hysterophorus. Parthenium hysterophorus Parthenium dermatitis : Caused by airborne sesquiterpene lactone from Parthenium (congress grass) . Affects exposed areas (face, neck, hands) in farmers/outdoor workers. Presents as subacute eczema ; chronic cases may develop leonine facies . Leonine faces Lesions on the back of hand Other causes of Phytodermatitis (dermatitis due to plants) are:- Xanthium Strumarium Chrysanthemums Sunflowers Dahlia. Treatment includes covering the body from exposure and taking a bath when returning home. Pharmacotherapy includes antihistamines, corticosteroids, and azathioprine. PTBP (Option B): Para-tert-butylphenol is found in the adhesive of bindi which acts as an allergen and causes allergic contact dermatitis. Poison ivy (Option C) can cause acute ACD. However, this would present with erythematous, intensely itchy lesions in the area of contact with the plant leaf/ branch. PPD (Option D): Para-phenylenediamine is an allergen found in hair dyes causing allergic contact dermatitis.



@Neet_pg_bot

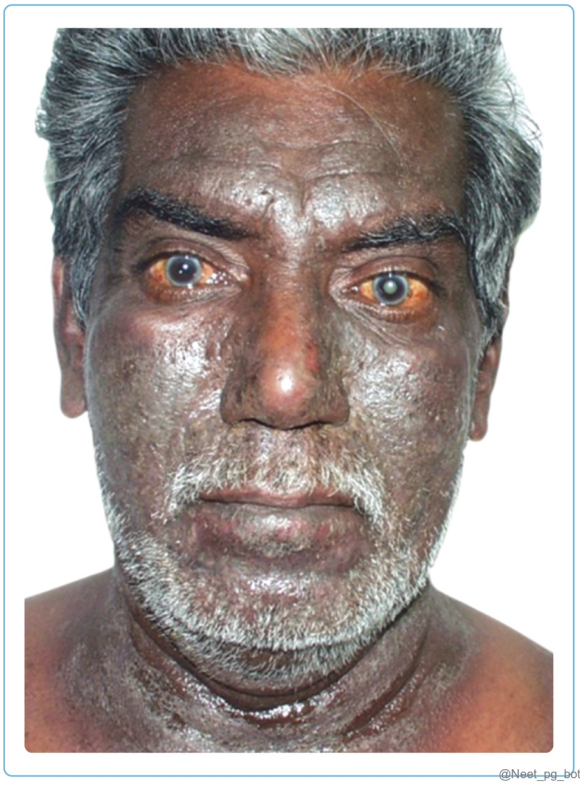



References:

https://www.ncbi.nlm.nih.gov/pmc/articles/PMC3481864

↑ *Back to this question in Part A*

@Neet_pg_bot

Q10: A 16-year-old boy presents with a rash over both his forearms as shown below. He states that he has had a relapsing, itchy rash since childhood. Family history is significant for asthma and allergic rhinitis in his father. Which of the following is not part of the diagnostic criteria for his disease? (Q841782)

A. Intense pruritus

B. Visible dermatitis involving flexural surfaces

C. Personal/ family history of dermatitis

D. Onset at 16 years of age



Correct Answer: D. Onset at 16 years of age

■ *Listen (English)*

■ *Listen (Hindi)*

Explanation: The given clinical scenario is suggestive of atopic dermatitis (AD), and its onset at 20 years of age is not a diagnostic criterion. Onset below the age of 2 years is used as a criterion. Dermatitis in different age groups with site of involvement: 1. Infantile dermatitis :[0-2 years]: extensors and face . 2. Childhood[2 years - puberty]: flexors and cubital fossa 3. Adult [puberty]: mainly flexors. Atopic dermatitis is a chronic, relapsing dermatitis that is classified as endogenous eczema. The pathogenesis includes multiple mechanisms like The refined Hanifin and Rajka criteria include one mandatory and five major criteria: Mandatory criteria: Evidence of pruritic skin, including that report by a parent or caregiver

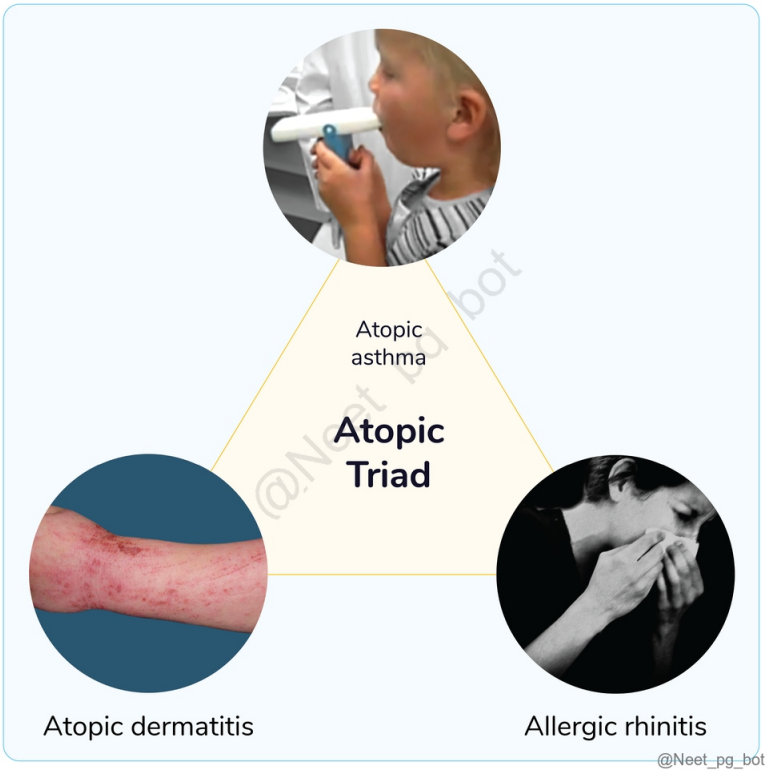

References:

https://www.uptodate.com/contents/atopic-dermatitis-eczema-pathogenesis-clinical-manifestations-and-diagnosis

Rook’s Textbook of Dermatology, 9th Edition, Page 41.2

↑ *Back to this question in Part A*

@Neet_pg_bot

Q11: A 10-year-old boy has been recently diagnosed with atopic dermatitis(AD). Which of the following is not a minor feature of AD? (Q841783)

A. Lateral madarosis

B. Extra infraorbital fold of skin

C. Keratosis pilaris

D. Red dermatographism

Correct Answer: D. Red dermatographism

■ *Listen (English)*

■ *Listen (Hindi)*

Explanation: Among the given options, red dermatographism is not considered a minor feature of atopic dermatitis (AD). It describes the presence of red streaks on the skin upon stroking as shown below and is commonly associated with urticaria. White dermatographism refers to a white line on the stroking of the skin due to vasoconstriction as seen in AD. Black dermatographism is due to metal deposition in the skin surface, as shown below. Minor features of AD include: Eye: Periorbital dermatitis Hertoghe’s sign - lateral madarosis due to continuous rubbing Dennie Morgan fold - extra infraorbital fold of skin Allergic shiners Papillary conjunctivitis Anterior subcapsular cataract Keratoconus Skin: Cheilitis & perioral dermatitis - lip inflammation surrounded by area of pallor, and perioral dermatitis (headlight sign) Ichthyosis (dry skin) Keratosis pilaris - due to occluded hair follicles, with coiled hair White dermatographism - white line on stroking of skin due to vasoconstriction Hyperlinear palms and soles




@Neet_pg_bot


@Neet_pg_bot



@Neet_pg_bot

PERIORAL DERMATITIS

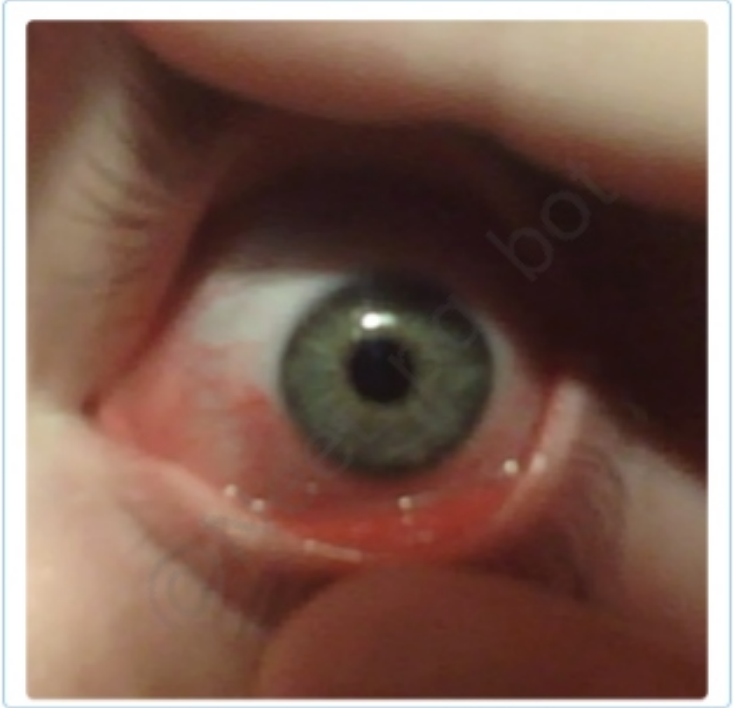

@Neet_pg_bot

PAPILLARY CONJUNCTIVITIS

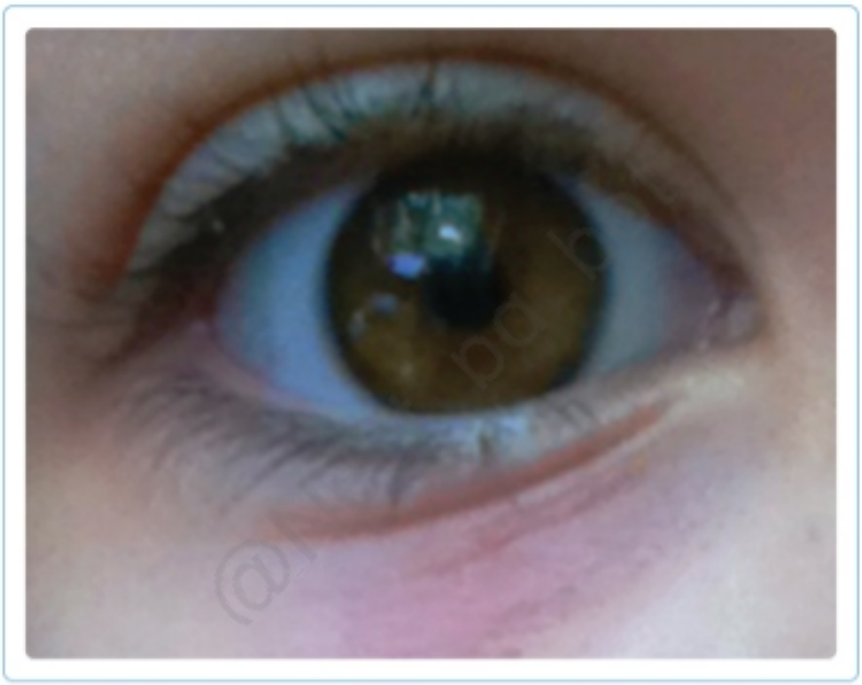

DENNIE-MORGAN FOLD

@Neet_pg_bot

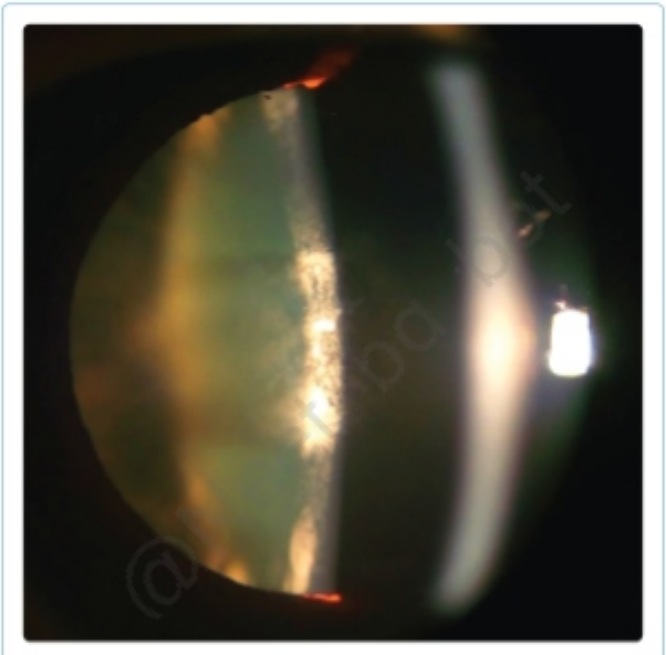

ANTERIOR SUBCAPSULAR CATARACT

@Neet_pg_bot

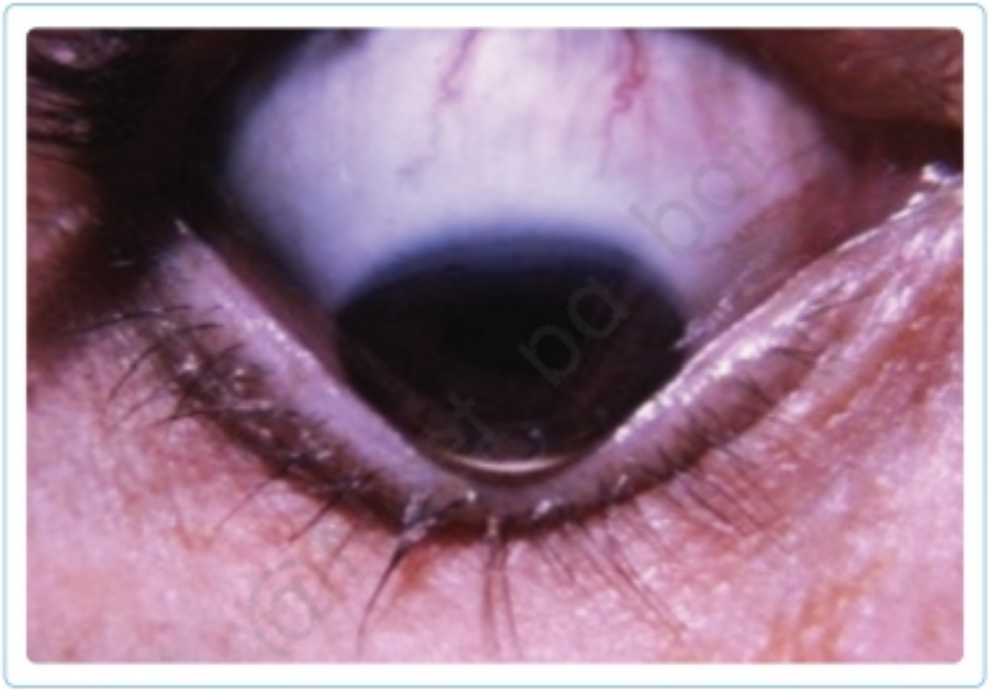

References:

https://www.uptodate.com/contents/atopic-dermatitis-eczema-pathogenesis-clinical-manifestations-and-diagnosis

↑ *Back to this question in Part A*

@Neet_pg_bot

Q12: An elderly male who works as a security guard presents with a chronic rash over his legs. Examination reveals a hyperpigmented rash with scaling over the medial aspect of both ankles, as shown below. What is the likely diagnosis? (Q841879)

A. Dyshidrotic eczema

B. Varicose eczema

C. Nummular eczema

D. Asteatotic eczema



@Neet_pg_bot

Correct Answer: B. Varicose eczema

- *Listen (English)*
- *Listen (Hindi)*

Explanation: This patient with a chronic hyperpigmented lesion over the medial side of the ankle and a risk factor of venous stasis (standing-security guard) most likely has varicose eczema(VE) / venous stasis dermatitis. It is typically seen in patients with long-standing varicose veins/ venous insufficiency. Risk factors include a family history of venous disease, standing occupations (security guard), obesity, female sex, and prior deep vein thrombosis. Chronic pooling of blood/ venous hypertension leads to circulatory changes in the dermis including dilated capillaries and increased permeability that lead to pericapillary fibrin cuffs, oedema, leucocyte accumulation, and hemosiderin deposits. VE is characterized by erythematous, scaling patches/ plaques over a background of chronic oedema. The medial ankle is most commonly involved, and the changes may extend up to the knee. With time, due to pruritus, there may be lichenification, scaling, and even ulceration. Varicose ulcer most commonly involves gaiter area[lower 1/3rd of leg] Dyshidrotic eczema (aka Pompholyx) (Option A): This is a condition associated with atopic dermatitis that presents with vesicles over the palms and fingers (classically on sides of fingers). Nummular eczema (Option C): This is a type of endogenous eczema characterised by sharply defined, round or coin-shaped, erythematous, and eczematous plaques. It commonly involves lower extremities. Pruritus is common, and lesions may ooze fluid. Asteatotic eczema (Option D): This is seen in the elderly and occurs due to decrease of lipid coating granules in epidermis. It may be more prominent in dry seasons (winter). It is characterized by cracked, dry skin called cracked porcelain or crazy paving pattern.


@Neet_pg_bot


@Neet_pg_bot

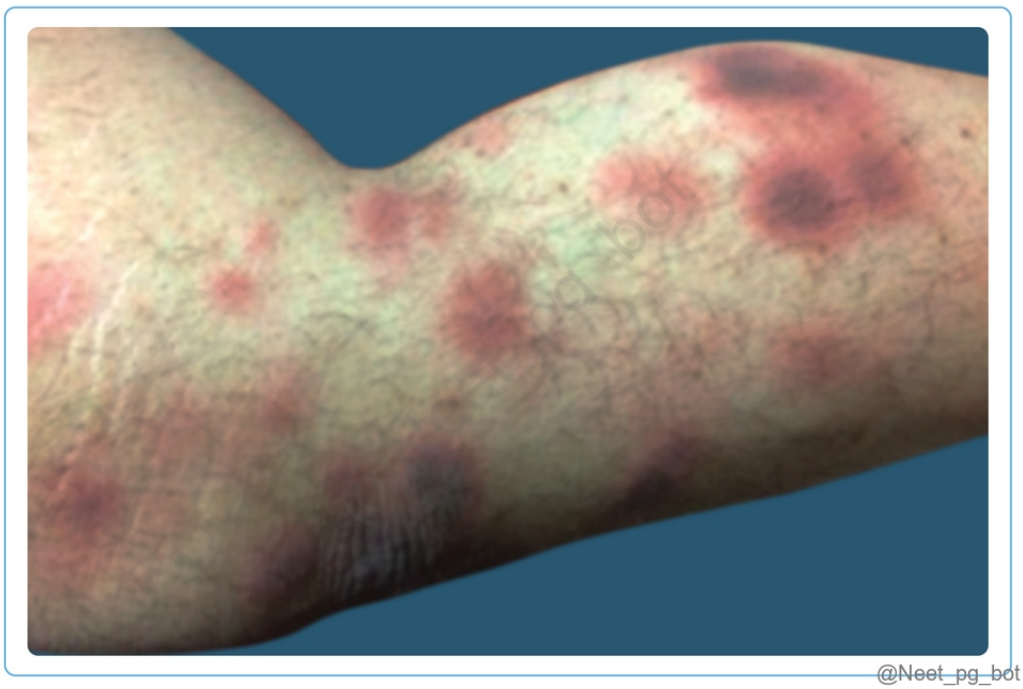

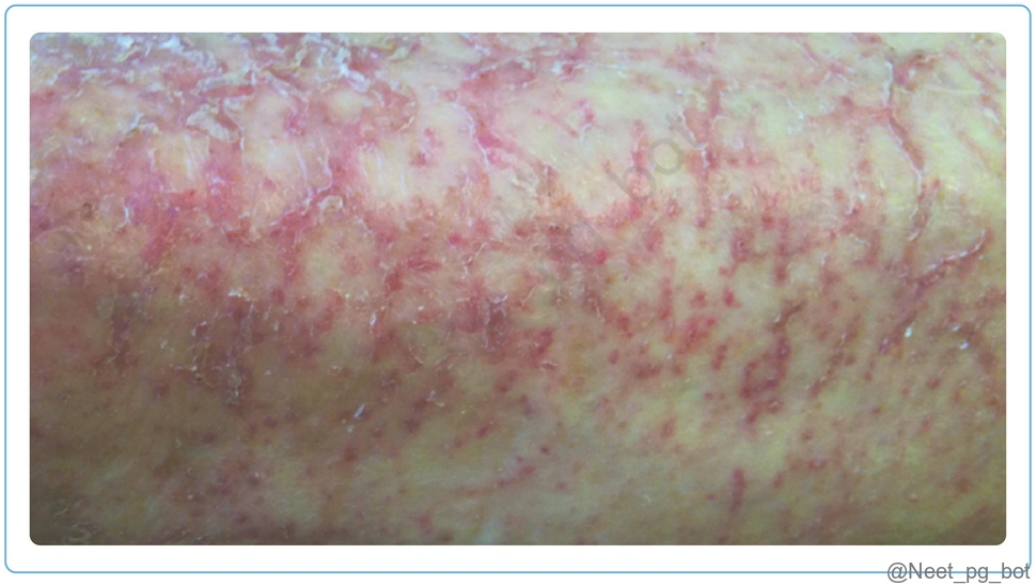

References:

Rook’s Textbook of Dermatology, 9th Edition, Pages 39.18 - 39.20

https://www.nhs.uk/conditions/varicose-eczema/

↑ *Back to this question in Part A*

@Neet_pg_bot

Q13: A 57-year-old male presents to you with an extensive erythematous rash that covers >90% of his body surface, as shown below. He is a known case of pemphigus foliaceous, requiring regular immunosuppressants but not adhering to medications. The skin is warm and tender to the touch. Which of the following is not a potential complication of his condition? (Q841880)

A. Bacterial infections

B. Hypothermia

C. Hypoproteinemia

D. Hyperproteinemia



Correct Answer: D. Hyperproteinemia

■ *Listen (English)*

■ *Listen (Hindi)*

Explanation: This patient likely has exfoliative dermatitis (ED) due to inadequate treatment of his pemphigus, which can lead to high-output heart failure and not heart failure with reduced ejection fraction. Erythroderma, or exfoliative dermatitis, is a severe complication of other underlying diseases. It is characterized by diffuse erythema and scaling involving >90% of the skin surface area, which may be tender and/ or pruritic. There may be

associated systemic features like lymphadenopathy and hepatosplenomegaly. Complications include: Bacterial infections of the skin - especially MRSA Increased skin transpiration causes thermoregulation issues, dehydration, and dyselectrolytemia, which results in extensive water and protein loss. Blood shunting to the skin may lead to high-output cardiac failure in patients with pre-existing cardiac issues (not HFrEF). Hypoproteinemia (oedema, muscle wasting) in those with extensive exfoliation

References:

Rook’s textbook of dermatology, 9th Edition, Page 119.12

↑ *Back to this question in Part A*

@Neet_pg_bot

• [04_Dermatitis _ Eczema] 009 Previous Year Questions

« Back to Folder Directory

[04_Dermatitis _ Eczema] 009 Previous Year Questions — Quick Jump

Q1 (p. 758) *Q2 (p. 760)* *Q3 (p. 762)* *Q4 (p. 764)* *Q5 (p. 765)* *Q6 (p. 766)*
Q7 (p. 768) *Q8 (p. 769)* *Q9 (p. 771)* *Q10 (p. 773)* *Q11 (p. 774)* *Q12 (p. 775)*
Q13 (p. 779) *Q14 (p. 781)* *Q15 (p. 782)* *Q16 (p. 784)* *Q17 (p. 784)* *Q18 (p. 785)*
Q19 (p. 786)

Q1: A 45 year old male patient from Bihar presented with normoanesthetic hypopigmented lesion as shown below. He had a history of fever for a long duration in his childhood. No thickened nerves were present. What is the probable diagnosis? (Q855521)

A. Tuberculoid leprosy

B. Lepromatous leprosy

C. Mycosis fungoides

D. Post kala-azar dermal leishmaniasis

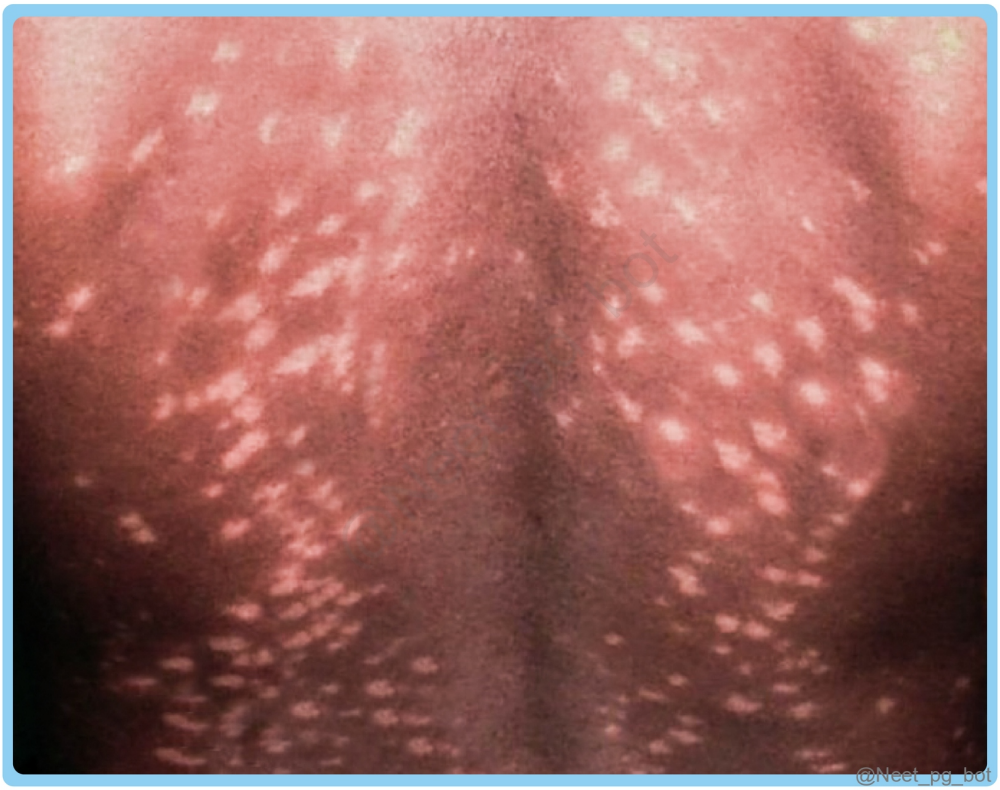

Correct Answer: D. Post kala-azar dermal leishmaniasis

Explanation: The patient is from Bihar, an endemic region for visceral leishmaniasis (kala-azar) . The image shows multiple hypopigmented macules over the back, characteristic of PKDL . History of prolonged fever in childhood suggests prior kala-azar infection , which is a prerequisite for developing PKDL. No thickened nerves rule out leprosy. Post Kala-Azar Dermal Leishmaniasis (PKDL): PKDL is a chronic dermal complication of visceral leishmaniasis caused by Leishmania donovani . Endemic in India, Nepal, and Sudan , especially in Bihar, West Bengal, and Uttar Pradesh . Clinical Features: Occurs months to years after treated visceral leishmaniasis . Hypopigmented macules, erythematous papules, or nodules on the face, trunk, and extremities. No loss of sensation or thickened nerves (differentiating from leprosy). Histopathology: Presence of Leishman-Donovan (LD) bodies . Diagnosis: Slit-skin smear or skin biopsy showing Leishmania donovani bodies . PCR or rK39 serology can confirm diagnosis. Management: First-line treatment: Miltefosine for 12 weeks. Alternatives: Liposomal amphotericin B or paromomycin . Tuberculoid leprosy (Option A) is incorrect because it presents with single or few hypopigmented macules with loss of sensation . Thickened peripheral nerves are a hallmark feature, which is absent in this case. Lepromatous leprosy (Option B) is incorrect because it presents with multiple ill-defined hypopigmented macules with symmetric distribution . Thickened nerves and sensation loss are typical, but they are absent in this patient . Mycosis fungoides (Option C) is incorrect because it presents as erythematous scaly plaques rather than hypopigmented macules . It is a form of cutaneous T-cell lymphoma , which is not related to prior fever or endemic infections .

References:

Post Kala-Azar Dermal Leishmaniasis: Clinical Features and Differential Diagnosis - PMC

↑ *Back to this question in Part A*

@Neet_pg_bot

Q2: What is the probable diagnosis for a cauliflower-shaped mass on the foot of a farmer that appeared after a minor injury, with microscopy revealing copper penny bodies? (Q855903)

A. Chromoblastomycosis

B. Blastomycosis

C. Sporotrichosis

D. Phaeohyphomycosis

Correct Answer: A. Chromoblastomycosis

Explanation: Clinical Presentation: Cauliflower-shaped mass on the foot Farmer with a history of minor trauma Slow-growing lesion Microscopy Findings: Copper penny bodies (Medlar bodies) → Characteristic of Chromoblastomycosis Chromoblastomycosis Feature Chromoblastomycosis Causative Organisms Fonsecaea, Cladophialophora, Phialophora Risk Factor Trauma (especially in farmers) Clinical Appearance Cauliflower-like verrucous lesion Microscopy Copper penny bodies (Medlar bodies/ muriform bodies) {{caption_text}} Spread Slow, localized spread Treatment Itraconazole, surgery if severe {{caption_text}} Blastomycosis (Option B): Incorrect because Blastomycosis presents as pulmonary or skin ulcers, not a cauliflower-like lesion . Sporotrichosis (Option C): Incorrect because Sporotrichosis follows a lymphatic spread (rose gardener's disease), not a localized verrucous lesion . Phaeohyphomycosis (Option D): Incorrect because it involves dark-pigmented fungi but does not show copper penny bodies .

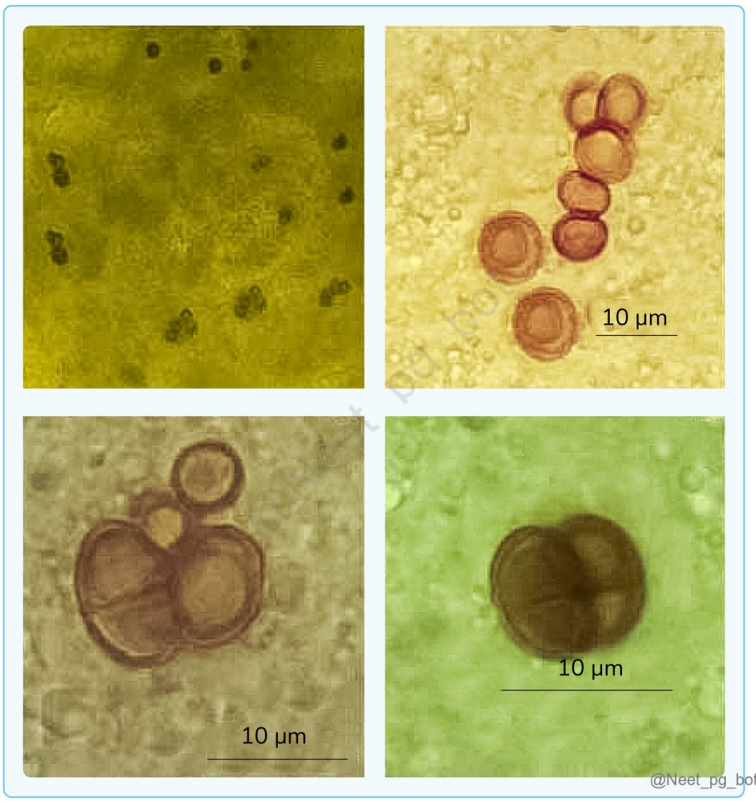

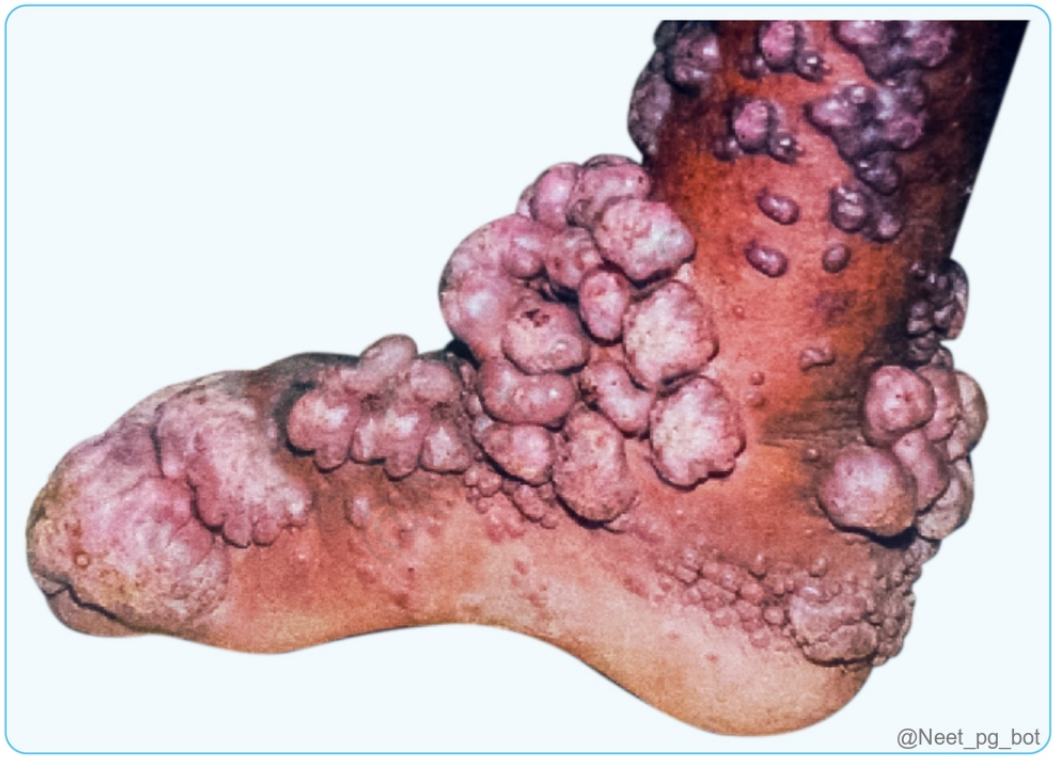

References:

Chromoblastomycosis - StatPearls - NCBI Bookshelf

Textbook of Microbiology, Ananthanarayan & Paniker, 6th Edition, Page 604, 605, 606, 607

↑ *Back to this question in Part A*

@Neet_pg_bot

Q3: A farmer presents to you with swelling on foot and multiple discharging sinuses in the lower limb. Granules from the discharge were examined under the microscope, shown below. Which of the following is true regarding this condition? (Q855900)

A. Both bacteria and fungi can be causative

B. Undergoes lymphatic spread

C. There is lymphocyte accumulation

D. Involves only superficial tissues

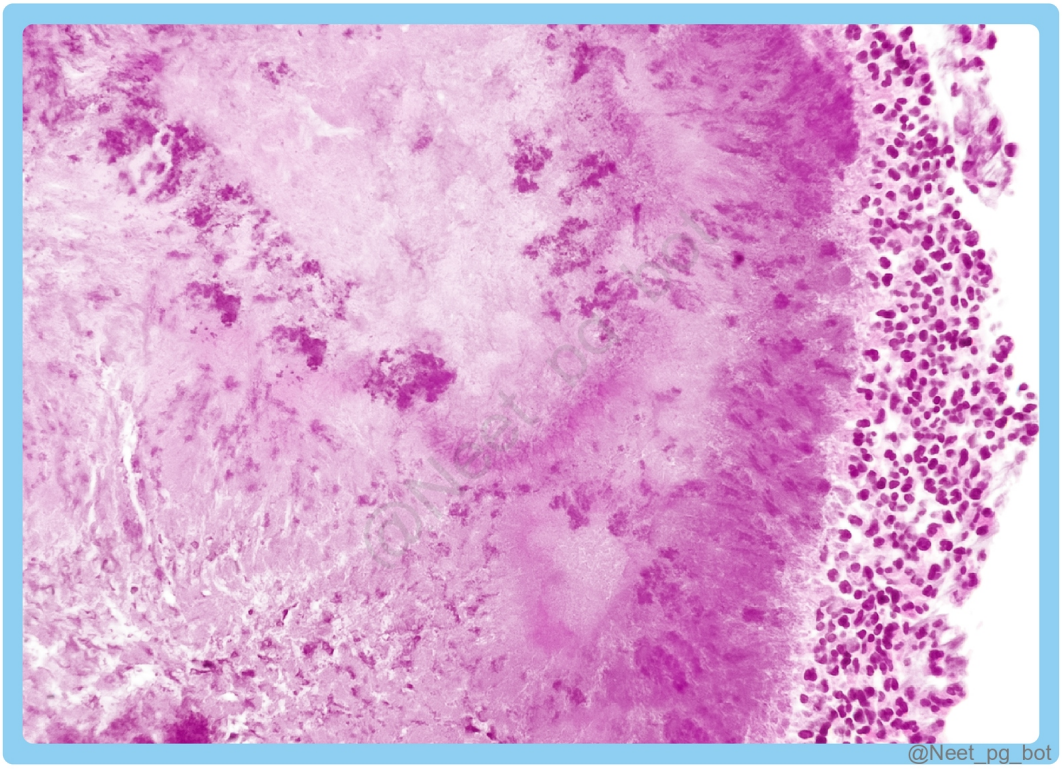

Correct Answer: A. Both bacteria and fungi can be causative

Explanation: Clinical Presentation: Swelling on the foot , multiple discharging sinuses , and granules in discharge are characteristic of mycetoma . Farmers are commonly affected due to trauma with contaminated soil . Microscopic Features in the Image: The granules seen in the image are sulfur granules , which are commonly found in mycetoma . Mycetoma can be caused by both bacteria (Actinomycetoma) and fungi (Eumycetoma).

Mycetoma Feature Actinomycetoma (Bacterial) Eumycetoma (Fungal) Causative Agents Actinomyces, Nocardia Madurella, Exophiala Granule Color White, yellow, red Black, brown Tissue Involvement Deep tissue destruction Deep tissue involvement Spread Hematogenous, but not lymphatic Hematogenous, but not lymphatic Treatment Long-term antibiotics Antifungals, surgery {{caption_text}} {{caption_text}} Undergoes lymphatic spread (Option B): Incorrect because mycetoma spreads via direct extension and hematogenous routes , not through lymphatics. There is lymphocyte accumulation (Option C): Incorrect because mycetoma is granulomatous, not predominantly lymphocytic . Involves only superficial tissues (Option D): Incorrect because mycetoma extends deeply into subcutaneous and bone tissue over time.

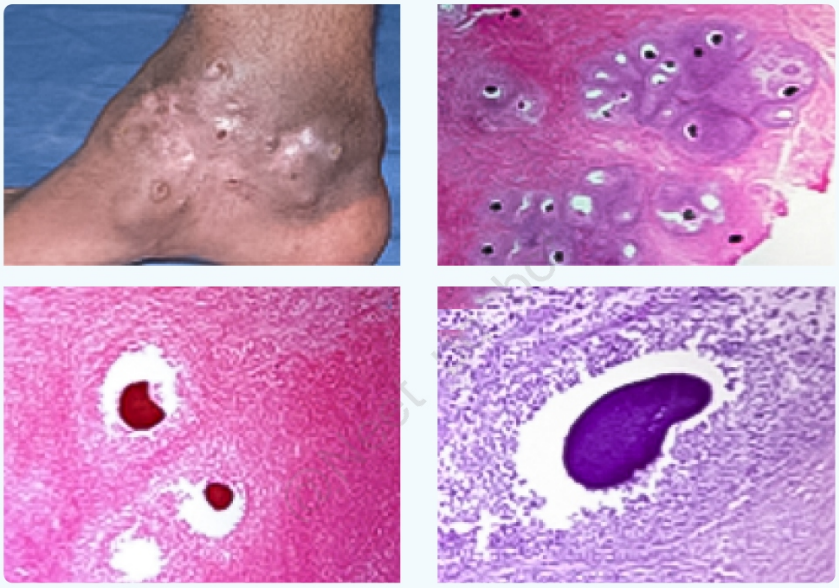

A case of eumycetoma showing (A) a large plaque with atrophic surface studded with multiple sinuses on the lower leg, (B) a deep dermal granulomatous infiltrate with multiple colonies (H&E section, Â2), (C) Gram-negative staining (Â20), and (D) periodic acid -Schiff-positive staining (Â40)

@Neet_pg_bot

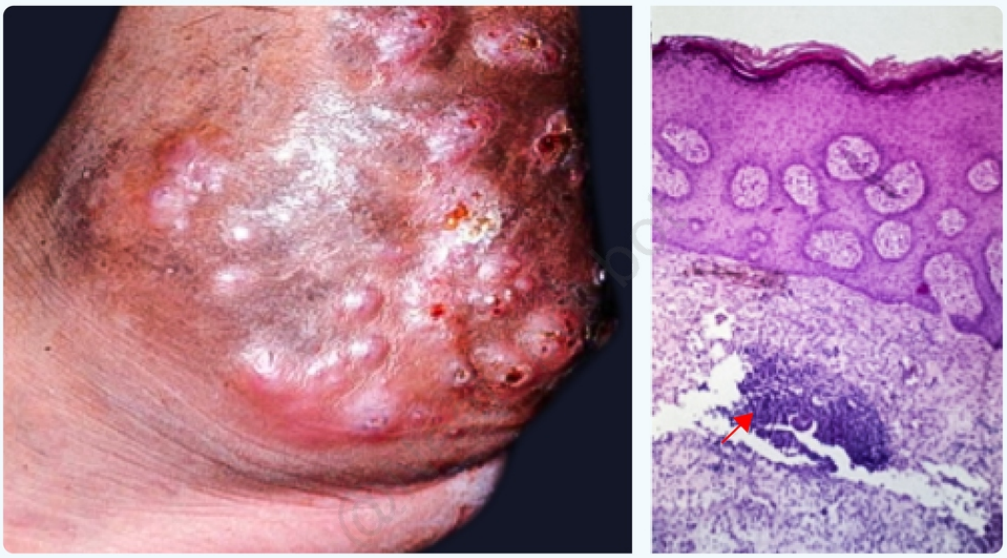

A) Initial presentation of multiple erythematous nodules with pus formation over the left ankle; (B) histopathology of a section of the nodule showed one sulfur granule (arrow) surrounded by inflammatory cells present in the deep dermis (hematoxylin-eosin stain, x100).

@Neet_pg_bot

References:

https://pmc.ncbi.nlm.nih.gov/articles/PMC2840937/

↑ *Back to this question in Part A*

@Neet_pg_bot

Q4: Identify the finding shown in the image below: (Q854902)

A. Herpes labialis

B. Herpangina

C. Molluscum contagiosum

D. Impetigo



Correct Answer: A. Herpes labialis

Explanation: Herpes labialis, commonly known as cold sores or fever blisters, is a viral infection caused by the herpes simplex virus type 1 (HSV-1). The characteristic presentation of multiple vesicles and crusts clustered on an inflamed base around the lips is indicative of a herpes simplex virus infection. Occurs on the vermillion border of lips. Recurrent outbreaks are common, often triggered by factors such as stress, sun exposure, or fever. Incorrect Options: Herpangina (Option B) : It typically presents as small, painful ulcers or vesicles on the back of the throat, soft palate, or tonsillar pillars. Molluscum contagiosum (Option C): It typically presents as small, raised, dome-shaped papules with a central indentation (umbilication). The lesions are usually flesh-colored Impetigo (Option D): It commonly presents as honey-colored crusts or bullae on an erythematous base.

References:

Reference: Illustrated Synopsis of Dermatology and Sexually Transmitted Diseases, Fifth Edition – Neena Khanna Pg 298

↑ *Back to this question in Part A*

@Neet_pg_bot

Q5: A 28-year-old man took an antibiotic for a throat infection. Two days later, he noticed a single, round, dark red patch on his forearm that itched and burned. He recalls having a similar patch at the same spot last time he took the same antibiotic. What is the most likely diagnosis? (Q856372)

A. Psoriasis

B. Eczema

C. Fixed Drug Eruption

D. Contact Dermatitis

Correct Answer: C. Fixed Drug Eruption

Explanation: Fixed drug eruption presents as a well-circumscribed, round or oval lesion that recurs at the same site upon re-exposure to the causative drug. Common drugs include antibiotics (like sulfonamides, tetracyclines), NSAIDs, and barbiturates. Lesions appear 1–2 days after drug ingestion and may be itchy or burn. After healing, the site often shows post-inflammatory hyperpigmentation. The history of recurrence at the same location is key for diagnosis. Treatment is discontinuation of the offending drug and supportive care, sometimes with topical corticosteroids. Unlike eczema or contact dermatitis, FDE has a sudden onset after drug exposure and recurs at identical sites. Incorrect Options : Option A) Psoriasis: Chronic, scaly plaques, not sudden onset after drug exposure. Option B) Eczema: Usually widespread, itchy, often chronic, not fixed to a single site after drug intake. Option D) Contact Dermatitis: Requires direct contact with allergen and usually spreads beyond a single recurring spot.

References:

https://jcdr.net/articles/PDF/19493/70377_CE%5BRa1%5D_F%28SS%29_QC_REF_PAT%28AN_IS%29_PF1%28AKA_DK%29_PFA_NC%28KM%29_PN_%28KM%29.pdf

↑ *Back to this question in Part A*

@Neet_pg_bot

Q6: What could be the potential cause of the following lesions in a gardener who has a history of thorn pricks? (Q856368)

A. Streptococcus pyogenes

B. Sporothrix schenckii

C. Stronglyoides stercoralis

D. Staphylococcus aureus



Correct Answer: B. Sporothrix schenckii

Explanation: The lesions described in the question, following a thorn prick, are suggestive of a condition known as sporotrichosis or rose gardener's disease. The characteristic feature of sporotrichosis is the distribution of the lesions along the lymphatic vessels. The infection typically starts as a small, painless bump or nodule at the site of the inoculation, and it then spreads along the lymphatic vessels, forming a chain of nodules or ulcers. Sporotrichosis Sporotrichosis is a chronic fungal infection caused by Sporothrix schenckii , commonly known as “rose gardener’s disease.” It occurs through trauma-induced inoculation from soil, plants, or organic matter. Pathophysiology Sporothrix schenckii is a dimorphic fungus that exists as a mold in the environment and yeast in human tissue . The fungus spreads via lymphatics , causing characteristic nodular lymphangitis . Features Cutaneous (most common) : Painless nodules and ulcers along lymphatic channels (lymphocutaneous form). Pulmonary : Chronic cough, fever, weight loss (inhalation exposure). Disseminated (rare, immunocompromised patients) : Systemic involvement affecting bones, joints, and CNS. Investigations & Diagnosis Culture (gold standard) : Grows Sporothrix schenckii on Sabouraud’s agar . Microscopy : Shows cigar-shaped yeast on tissue samples. Histopathology : Granulomatous inflammation with fungal elements. Treatment First-line : Itraconazole (100-200 mg/day) for cutaneous cases. Severe/disseminated cases : Amphotericin B , followed by itraconazole. Potassium iodide (older treatment) : Still used in some regions. Incorrect Options: Streptococcus pyogenes (Option A) : It is not the causative agent for the described presentation of lesions following a thorn prick. Strongyloides stercoralis (Option C) : Strongyloides stercoralis does not typically present with the specific lesion distribution described in the question. Staphylococcus aureus (Option D) : Staphylococcus aureus is not the primary causative agent for the described presentation. Sporothrix schenckii is more commonly associated with the development of sporotrichosis in this context.

References:

https://www.ncbi.nlm.nih.gov/books/NBK532255/

↑ *Back to this question in Part A*

@Neet_pg_bot

Q7: Identify the type of skin lesion: (Q856836)

A. Nummular

B. Annular

C. Discoid

D. Target



Correct Answer: B. Annular

Explanation: n annular skin lesion refers to a ring-shaped lesion with a clear or normal-looking center. It typically has a raised border or edge. This pattern is commonly seen in conditions such as ringworm (tinea corporis), granuloma annulare, and erythema migrans (associated with Lyme disease). Some other types of skin lesions: Skin Lesion Description Examples Macule Flat, discolored spot on the skin with no palpable elevation or depression. Freckles, flat moles Patch Large, flat, maculopapular area of skin discoloration. Vitiligo, café-au-lait spots Papule Small, solid, elevated lesion with a palpable surface. Acne, warts Plaque Elevated, flat-topped lesion with a broad, flat surface. Psoriasis plaques, seborrheic keratosis Vesicle Small, fluid-filled blister, usually less than 5mm in diameter. Chickenpox blisters, herpes simplex Bulla Large, fluid-filled blister, typically more than 5mm in diameter. Bullous pemphigoid, second-degree burns Pustule Small, elevated lesion filled with pus. Acne pustules,

impetigo Wheal Transient, raised, and edematous lesion with irregular borders, often associated with itching or allergic reactions. Insect bite reactions, hives (urticaria) Nodule Solid, palpable lesion, often deeper in the skin layers. Dermatofibroma, lipoma Tumor Solid, elevated lesion larger than a few centimeters in diameter. Basal cell carcinoma, melanoma Plaque Large, flat, elevated lesion with a flat surface and a diameter greater than its height. Psoriasis plaques, lichen planus Burrow Linear or serpignious tunnel in the skin caused by infestation or burrowing of parasites. Scabies burrows Scale Dry, flaky, or thickened skin with shedding of dead skin cells. Psoriasis scales, seborrheic dermatitis Crust Dried exudate or secretion on the skin surface. Impetigo crusts, dried blood crusts Erosion Loss of the superficial epidermis, resulting in a moist, shallow depression. Aphthous ulcers, erosion due to scratching Ulcer Loss of the entire epidermis and at least part of the dermis, resulting in a deep, open lesion. Pressure ulcers, venous ulcers Fissure Linear crack or slit-like split in the skin. Athlete's foot fissures, anal fissures Scar Fibrous tissue that replaces normal skin after injury or surgery. Surgical scars, keloids Atrophy Thinning or depression of the skin with loss of normal skin markings. Striae (stretch marks), aged skin Incorrect Options: Nummular lesions (Option A) : These are coin-shaped or circular lesions with distinct borders and a flat or slightly elevated surface. They are usually smaller and do not have the characteristic ring shape. Discoid lesions (Option C) : These are circular or oval-shaped lesions with well-defined borders, but they do not necessarily have a ring shape or central clearing. Target lesions (Option D) : Target or "bull's eye" lesions have concentric rings or circles of different colors. They typically have three zones—an outer ring, an intermediate ring, and a central clearing. This pattern is seen in conditions such as erythema multiforme and Lyme disease.

References:

https://pmc.ncbi.nlm.nih.gov/articles/PMC3657228/

↑ *Back to this question in Part A*

@Neet_pg_bot

Q8: Which of the following options should be excluded as a possible cause for the lesion seen in the image, developed by a forest officer? (Q856668)

A. Scrub typhus

B. KFD

C. Cutaneous anthrax

D. Healing brown recluse spider bite

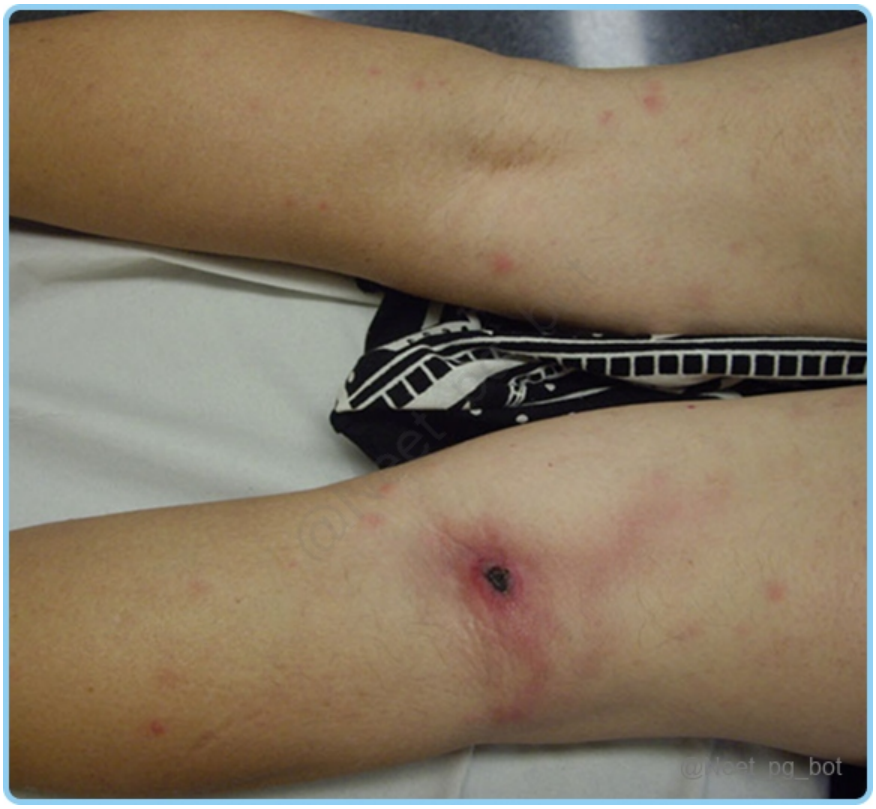

Correct Answer: B. KFD

Explanation: The lesion described by a forest officer suggests an eschar-like lesion , which is commonly seen in scrub typhus, cutaneous anthrax, and brown recluse spider bites . KFD (Kyasanur Forest Disease) is a viral hemorrhagic fever caused by a Flavivirus , transmitted by ticks . It primarily affects forest workers but does not cause eschar formation . Instead, it presents with fever, myalgia, haemorrhagic manifestations, and meningoencephalitis . Kyasanur Forest Disease (KFD) is a tick-borne viral disease (Flavivirus) endemic to forests in South India . Transmission: By Haemaphysalis ticks from infected rodents, monkeys, and livestock. Monkey fever/Kyasanur forest disease: General features: Virus Characteristics : Enveloped virus belonging to the family Flaviviridae ; contains single-stranded RNA (ssRNA). Vector : Hard ticks (Haemaphysalis spinigera) Hosts : Monkeys, rodents, and squirrels are common hosts; monkeys act as amplifier hosts where the virus multiplies exponentially. Seasonality : KFD cases peak during dry months (November to June), coinciding with increased human activity in forests. The life cycle of Kyasanur forest disease {{caption_text}} Clinical features: Incubation Period: 3-8 days. First Stage (Hemorrhagic Fever): Acute high fever with malaise and frontal headaches. Hemorrhagic symptoms: bleeding from the nasal cavity, throat, gums, and gastrointestinal tract. Second Stage: Meningoencephalitis may occur 7–21 days after the first stage. Lab diagnosis: Diagnosis Methods : Virus isolation from blood. IgM antibody detection by ELISA. RT-PCR. Vaccination: Vaccine Type : Killed KFD vaccine (formalin-inactivated chick embryo) developed at Haffkine Institute, Mumbai. Vaccination Schedule : Initial two doses at 2-month intervals. Booster doses at 6–9 months, then every 5 years. Target Area : Recommended for endemic areas of Karnataka. Vector Diseases transmitted Sandfly Kala-azar Oriental sore Sandfly fever (Papatasi fever) Flea Hymenolepis diminuta Hymenolepis nana Bubonic plague Endemic typhus Louse Epidemic relapsing fever Epidemic typhus Trench fever Hard tick Babesiosis Kyasanur Forest disease virus (Option B) Colorado tick fever virus Russian spring-summer encephalitis virus Omsk hemorrhagic fever virus Crimean Congo hemorrhagic fever virus Tularemia Lyme disease Rocky Mountain spotted fever Indian tick typhus Ehrlichiosis Soft tick Endemic relapsing fever Reduvid bug Chagas’ disease Scrub typhus (Option A) is incorrect because it is caused by

Orientia tsutsugamushi and commonly presents with an eschar at the site of a chigger bite. This is a hallmark of the disease. Cutaneous anthrax (Option C) is incorrect because Bacillus anthracis causes painless black eschars with surrounding oedema. It is common in individuals handling animal products or exposed to spores in the environment. Healing brown recluse spider bite (Option D) is incorrect because brown recluse spider bites can cause necrotic ulcers that heal over time, mimicking an eschar.

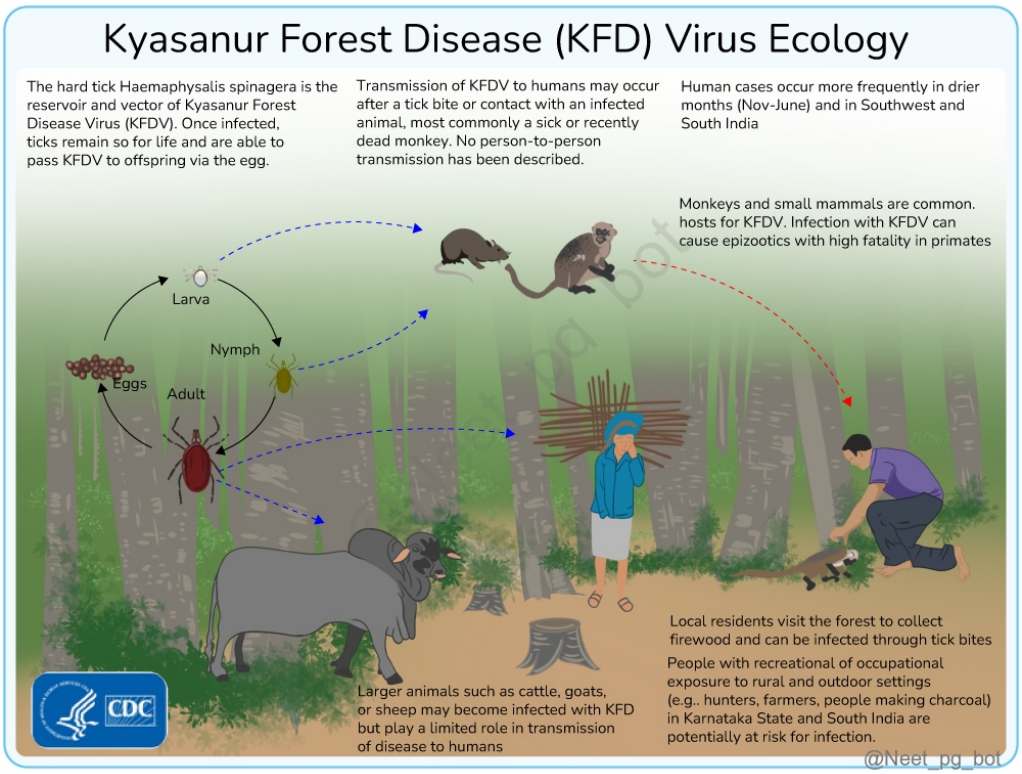

References:

Apurba Sastry Essentials of Medical Microbiology, 3rd Edition Page 343, 825

↑ *Back to this question in Part A*

@Neet_pg_bot

Q9: What is the probable diagnosis for a young man who has presented with painful lesions depicted in the image below? (Q855658)

A. Herpes Zoster

B. Molluscum contagiosum

C. Herpes simplex

D. Lymphangioma circumscriptum



Correct Answer: A. Herpes Zoster

Explanation: The image shows a unilateral, dermatomal eruption of grouped vesicles on an erythematous base . The patient has painful lesions , which is a key feature of Herpes Zoster (Shingles) . The lesions appear in a band-like distribution , following the sensory nerve dermatome . Herpes Zoster (Shingles): Cause: Reactivation of Varicella-Zoster Virus (VZV) in the dorsal root ganglion. Risk Factors: Immunosuppression (HIV, malignancies) Elderly individuals Stress and trauma Clinical Features: Painful, grouped vesicles on an erythematous base in a unilateral dermatomal pattern . Pre-eruptive phase (burning, tingling pain) 48–72 hours before rash onset. Thoracic dermatomes are most commonly involved. Postherpetic neuralgia (persistent pain after healing) may develop in older adults. Diagnosis: Clinical, confirmed by Tzanck smear (multinucleated giant cells) or PCR for VZV DNA . Treatment: Antiviral therapy (Acyclovir, Valacyclovir) within 72 hours of rash onset. Analgesics for pain control. Corticosteroids in severe cases. Molluscum Contagiosum (Option B) is incorrect because Molluscum contagiosum presents as small, umbilicated, pearly white papules , not as vesicular eruptions . It is usually asymptomatic and not painful . Herpes Simplex (Option C) is incorrect because Herpes simplex virus (HSV) causes clusters of vesicles but does not usually follow a dermatomal distribution . HSV infections typically affect the oral (HSV-1) or genital (HSV-2) regions rather than the thoracic dermatomes . Lymphangioma Circumscriptum (Option D) is incorrect because lymphangioma circumscriptum is a benign lymphatic malformation , presenting as clusters of small, translucent vesicles ("frog spawn" appearance) . It is not painful and does not appear in a dermatomal pattern .

References:

Ananthanarayan and Paniker’s Textbook of Microbiology, 10th Edition, Pages 478, 479.

↑ *Back to this question in Part A*

@Neet_pg_bot

Q10: What is the appropriate next course of action for a child who exhibits itchy scalp lesions and hair loss, as depicted in the image provided? (Q855655)

A. KOH mount

B. Slit skin mount

C. Gram staining

D. Biopsy



Correct Answer: A. KOH mount

Explanation: The image depicts a scaly, inflamed, well-demarcated lesion on the scalp with hair loss , suggestive of Tinea Capitis (scalp ringworm) . KOH (potassium hydroxide) mount is the gold standard for diagnosing superficial fungal infections , including Tinea Capitis , by detecting fungal hyphae in hair shafts and skin scrapings. Tinea Capitis: Caused by: Trichophyton and Microsporum species. Common in children , especially in warm, humid climates . Types: Non-inflammatory: Scaly patches with broken hairs . Inflammatory (Kerion): Painful, boggy swelling with pustules and crusting (as seen in the image). Diagnosis: KOH Mount: Detects fungal hyphae in hair shafts and skin scrapings . Fungal Culture: Confirms the fungal species. Wood's Lamp Examination: Fluorescence in Microsporum infections. Management: Systemic antifungals (Griseofulvin or Terbinafine) for 6–8 weeks (topical antifungals alone are ineffective). Antifungal shampoos (ketoconazole or selenium sulfide) reduce fungal shedding . Kerion cases may need corticosteroids to reduce inflammation. Slit

Skin Mount (Option B) is incorrect because it is used for leprosy diagnosis by identifying acid-fast bacilli from skin lesions, which is not relevant in this case. Gram Staining (Option C) is incorrect because it is useful for diagnosing bacterial infections (e.g., impetigo, folliculitis) but not fungal infections like Tinea Capitis . Biopsy (Option D) is incorrect because skin biopsy is rarely needed for diagnosing Tinea Capitis and is usually reserved for atypical or unclear cases .

References:

Rook's Textbook of Dermatology. 9th ed. Blackwell; 2016. p. 89.10 -86.47.-89.24

↑ *Back to this question in Part A*

@Neet_pg_bot

Q11: A child presented with itchy plaques over the neck, the bilateral popliteal and cubital fossa. What could be the diagnosis? (Q855656)

A. Atopic dermatitis

B. Dermatitis herpetiformis

C. Pemphigus vegetans

D. Psoriasis



Correct Answer: A. Atopic dermatitis

Explanation: The image shows lichenified, scaly, and hyperpigmented plaques over the popliteal fossae (behind the knees) . The history of itching and involvement of flexural areas (neck, popliteal, and cubital fossae) is highly characteristic of Atopic Dermatitis (Eczema) . Atopic Dermatitis: Common in children , associated with atopy (asthma, allergic rhinitis, eczema) . Hallmark features: Chronic pruritus and inflammation . Flexural involvement in children and adults. Lichenification due to chronic scratching . Infants: More likely to have cheeks, trunk, and extensor limb involvement . Exacerbating factors: Irritants, allergens, weather changes, infections. Diagnosis: Clinical diagnosis based on chronic relapsing course and typical distribution . No specific lab test required . Elevated IgE levels may be seen but are not diagnostic . Management: Moisturisation (Emollients) – cornerstone of therapy. Topical corticosteroids – for flare-ups (mild to moderate strength). Antihistamines – for pruritus relief. Avoid triggers (harsh soaps, allergens, irritants). Severe cases: Topical calcineurin inhibitors (Tacrolimus), systemic immunosuppressants if needed. Dermatitis Herpetiformis (Option B) is incorrect because it presents as intensely itchy, grouped vesicles on extensor surfaces (elbows, knees, buttocks) , not flexural areas. Strongly associated with coeliac disease . Pemphigus Vegetans (Option C) is incorrect because a rare variant of pemphigus , characterised by moist, verrucous plaques in intertriginous areas (axilla, groin) , unlike the dry, lichenified lesions seen here. Psoriasis (Option D) is incorrect because psoriasis in children often affects extensor surfaces (knees, elbows) , not flexures. Lesions are well-demarcated, erythematous plaques with silvery scales , unlike the ill-defined, lichenified plaques seen here.

References:

Atopic dermatitis (eczema): Pathogenesis, clinical manifestations, and diagnosis - UpToDate

Rook’s Textbook of Dermatology. 9th ed: 41.2

↑ *Back to this question in Part A*

@Neet_pg_bot

Q12: What is the probable diagnosis for a farmer who has a swollen foot and multiple discharging sinuses, as depicted in the image below? (Q857581)

A. Mycetoma

B. Squamous cell carcinoma

C. Nocardia

D. Sporotrichosis



Correct Answer: A. Mycetoma

Explanation: The most probable diagnosis for a farmer with a swollen foot and multiple discharging sinuses is Mycetoma Mycetoma (Madura Foot) Definition : Chronic granulomatous infection with subcutaneous masses, draining sinuses, and grains in exudates Types : Eumycetoma (fungal) Actinomycetoma (bacterial) {{caption_text}} {{caption_text}} Clinical Presentation Initial Lesion : Painless nodule; may be asymptomatic for years Progression : Leads to swelling, ulceration, and pus discharge from sinuses containing grains Complications : Severe deformities, osteomyelitis, potential amputation due to extensive tissue damage Microscopic Examination Type Causative Agents Microscopic Features Eumycetoma Madurella mycetomatis , Curvularia lunata , Scedosporium spp. , Acremonium spp. Hyphae or thick-walled grains (black/white). {{caption_text}} Histology shows suppurative granulomas with neutrophils. Actinomycetoma Actinomadura madurae , Nocardia spp. Thin, branching filaments visible with Gram staining. Similar granulomas to eumycetoma but distinct morphology. {{caption_text}} Diagnostic Techniques Biopsy and Culture : Tissue biopsy for visualization of pathogens. Culturing exudates for specific organism identification. Special stains to differentiate fungal and bacterial infections. Imaging Studies : X-rays and MRI to assess bone involvement in advanced cases. Treatment Type Treatment Approach Eumycetoma Surgical excision with antifungals (itraconazole, ketoconazole). High recurrence rates. Actinomycetoma Prolonged antibiotic therapy (e.g., trimethoprim-sulfamethoxazole, dapsone) along with surgical intervention. Squamous Cell Carcinoma (SCC) (Option B): SCC can develop in chronic ulcers or scars but is not characterized by multiple discharging sinuses with granules. Nocardia (Option C): While Nocardia can cause actinomycetoma , which is a type of mycetoma, Nocardia alone does not fully describe the condition seen in the image . The term mycetoma broadly refers to both eumycetoma (fungal) and actinomycetoma (bacterial) , including those caused by Nocardia . Sporotrichosis (Option D): A subcutaneous fungal infection (Sporothrix schenckii) that spreads along lymphatics (sporotrichoid spread) but does not present with multiple sinus tracts and granules.

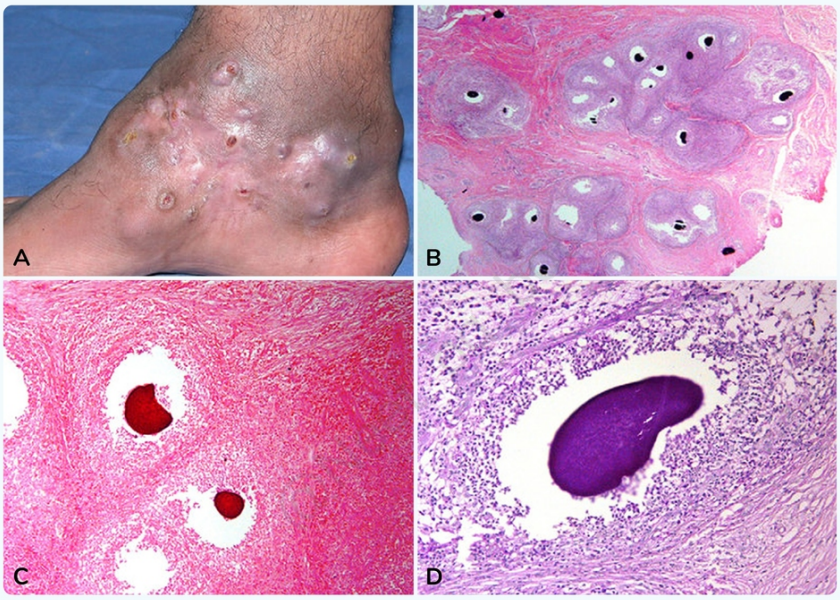

A case of eumycetoma showing

A. A large plaque with atrophic surface studded with multiple sinuses on the lower leg
B. A deep dermal granulomatous infiltrate with multiple colonies (H and E section)
C. Gram negative staining
D. Periodic acid-Schiff-positive staining

@Neet_pg_bot

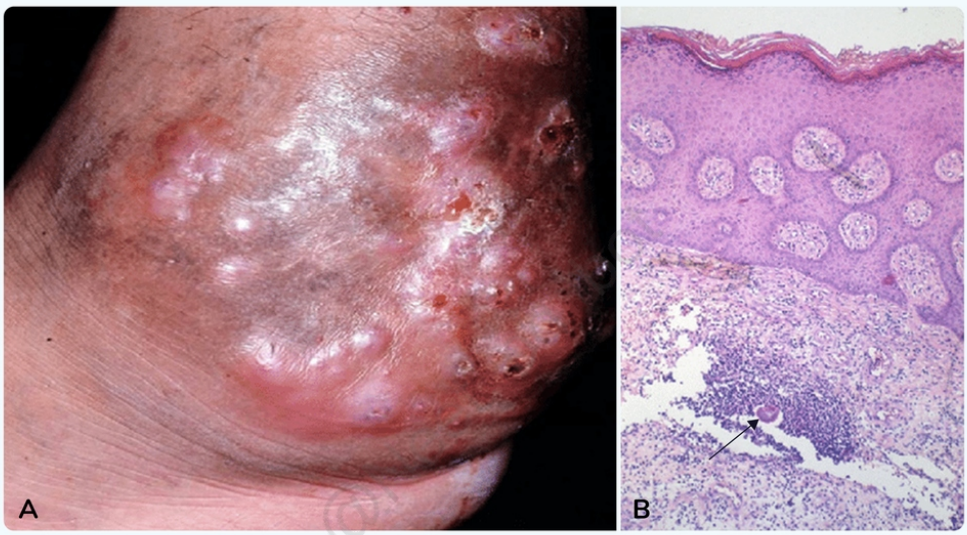

Actinomycetoma

A. Initial presentation of multiple erythematous nodules with pus formation over the left ankle.

B. Histopathology of a section of the nodule showed one sulfur granule (arrow) surrounded by inflammatory cells present in the deep dermis.

@Neet_pg_bot



KOH wet mount direct microscopic examination of
M. mycetomatis grains showing its hyphal structure

@Neet_pg_bot

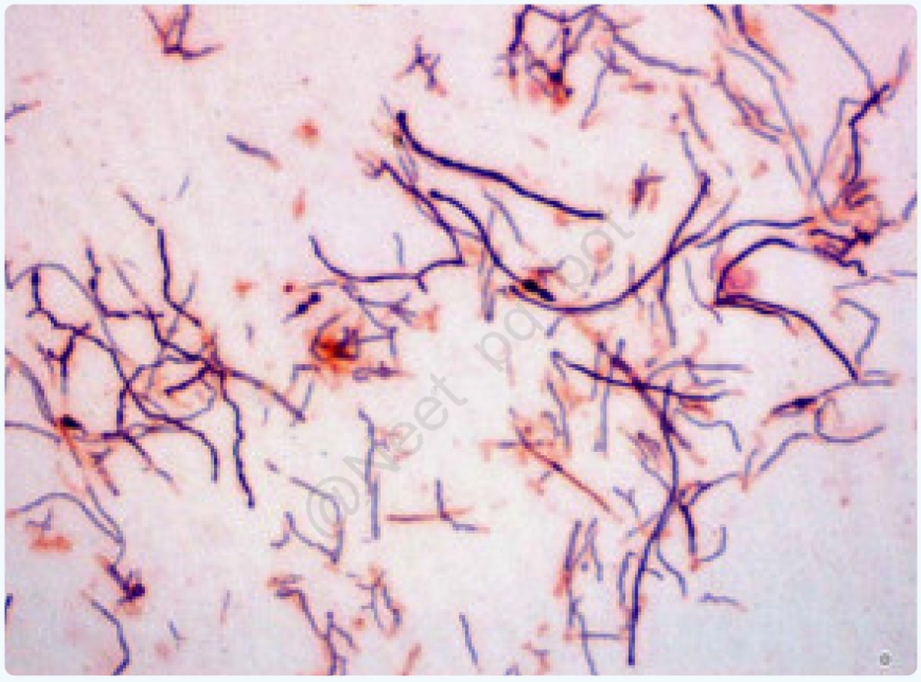

Gram staining of an A. meyerae colony

@Neet_pg_bot

References:

https://pmc.ncbi.nlm.nih.gov/articles/PMC2840937/

↑ *Back to this question in Part A*

@Neet_pg_bot

Q13: Identify the condition shown in the image below: (Q857059)

A. Impetigo

B. Chickenpox

C. Herpes Simplex

D. Molluscum contagiosum



Correct Answer: A. Impetigo

Explanation: The image shows honey-colored, crusted lesions around the mouth, characteristic of non-bullous impetigo . Impetigo is a superficial bacterial skin infection caused by Staphylococcus aureus or Streptococcus pyogenes . Common in children and spreads via direct contact . Impetigo Feature Details Etiology Staphylococcus aureus , Streptococcus pyogenes Types Non-bullous (crusted), Bullous Lesion Honey-colored crusts, vesicles, erosions Common Sites Face (perioral, perinasal), extremities Treatment Topical mupirocin, oral antibiotics if extensive Bullous impetigo {{caption_text}} Non-bullous impetigo/Impetigo contagiosa {{caption_text}} Incorrect Options: Chickenpox (Option B) - Incorrect because vesicles appear in crops and have a dew-drop on a rose petal appearance , unlike the honey-colored crusts seen in impetigo. Herpes Simplex (Option C) - Incorrect

because it presents as grouped vesicles on an erythematous base , often with pain and recurrence , whereas impetigo shows crusted lesions . Molluscum Contagiosum (Option D) - Incorrect because it presents as pearly, dome-shaped papules with central umbilication , not crusted erosions .





References:

Chapter 26: Bacterial infections. In: Rook's Textbook of Dermatology. 9th ed. Blackwell; 2016. p. 26.13-26.16.

↑ *Back to this question in Part A*

@Neet_pg_bot

Q14: What could be the potential diagnosis for a 7-year-old boy with intellectual disability who has developed extensive warty crusts on the trunk, hands, and feet, along with severe fissuring and scaling on the soles of his feet? (Q857057)

A. Scabies incognito

B. Animal scabies

C. Nodular scabies

D. Norwegian scabies



Correct Answer: D. Norwegian scabies

Explanation: Norwegian scabies (crusted scabies) is a severe, highly contagious form of scabies, seen in immunocompromised individuals, elderly patients, or those with neurological disorders (e.g., intellectual disability). Feature Classic Scabies Crusted (Norwegian) Scabies Prevalence More common Less common Skin Lesions Small erythematous papules, "knots on a rope" Erythematous, scaling, crusting, and fissuring Pruritus Severe, worse at night Usually mild or absent due to nerve damage Onset 3-6 weeks after initial colonization, 1-3 days after reinfestation Gradual but progressive Risk Factors No specific immunosuppression required Occurs in immunosuppressed patients (HIV, elderly, cancer, etc.) Mite Burden Low mite burden High mite burden Transmission Direct skin-to-skin contact More commonly transmitted via fomites (objects) Common Sites Webs of fingers, axillae, areola, genitalia Hands, feet, and scalp Incorrect Options: Scabies incognito (Option A): Occurs due to misuse of topical steroids, modifying typical scabies lesions. Presents as diffuse eczema-like plaques rather than thick crusts. Animal scabies (Option B): It is usually seen in animals and is rarely transmitted to humans Nodular scabies (Option C): a less common form of scabies that causes firm, itchy, red bumps. It's often found in the groin and genital area.

References:

https://pmc.ncbi.nlm.nih.gov/articles/PMC9223105/

↑ *Back to this question in Part A*

@Neet_pg_bot

Q15: A 60-year-old male patient presents with the lesion given in the image below. He also mentions experiencing sensations like a spider crawling in the area of the lesion. Which of the following is the most likely diagnosis? (Q855741)

A. Herpes zoster infection

B. Irritant contact dermatitis

C. Allergic contact dermatitis

D. Herpes simplex infection



@Neet_pg_bot

Correct Answer: A. Herpes zoster infection

Explanation: The image shows a dermatomal distribution of grouped vesicles on an erythematous base, which is characteristic of Herpes zoster (shingles) . The patient reports paresthesia ("spider crawling sensation") , a common prodromal symptom due to viral reactivation affecting sensory nerves. The lesion pattern is unilateral , consistent with reactivation of Varicella-zoster virus (VZV) from dorsal root ganglia. Herpes Zoster: Feature Details Etiology Reactivation of Varicella-Zoster Virus (VZV) from latency in sensory ganglia. Risk Factors Immunosuppression, aging (>50 years), stress, malignancy, chronic diseases (diabetes). Clinical Features Painful, grouped vesicles on an erythematous base along a single dermatome (usually thoracic, lumbar, or trigeminal). Prodromal Symptoms Burning, tingling, paresthesia ("spider crawling sensation") , fever, malaise before rash appears. Complications Postherpetic neuralgia (PHN), bacterial superinfection, ophthalmic zoster (if V1 of trigeminal nerve is involved). Diagnosis Clinical; Tzanck smear (multinucleated giant cells), PCR for VZV in doubtful cases. Treatment Antiviral therapy (acyclovir, valacyclovir, famciclovir) within 72 hours , analgesics, corticosteroids (if severe pain). Prevention Zoster vaccine for elderly and immunocompromised individuals. Irritant contact dermatitis (Option B) is incorrect because it results from direct skin damage due to chemical exposure , leading to erythema, scaling, and burning , rather than a vesicular dermatomal rash with neuropathic pain. Allergic contact dermatitis (Option C) is incorrect because it is a delayed hypersensitivity reaction (Type IV), presenting as itchy, erythematous, and vesicular plaques in areas of contact , but lacks dermatomal distribution and prodromal neuralgia . Herpes simplex infection (Option D) is incorrect because HSV causes grouped vesicles on an erythematous base , but these typically appear around the mouth (HSV-1) or genital region (HSV-2) and do not follow a dermatomal pattern .

References:

Ananthanarayan and Paniker’s Textbook of Microbiology, 10th Edition, Page 478, 479.

↑ *Back to this question in Part A*

@Neet_pg_bot

Q16: A female patient presented with acne that is not resolving on oral isotretinoin and antibiotics therapy. Which of the following is the next best investigation? (Q855281)

A. Look for dietary triggers

B. Evaluate for hyperandrogenism

C. Check for antibiotic resistance

D. Look for drug triggers

Correct Answer: B. Evaluate for hyperandrogenism

Explanation: The patient presents with acne that is not responding to oral isotretinoin and antibiotics, which suggests that a more systemic or hormonal cause could be contributing to the acne. Hyperandrogenism is commonly associated with conditions like polycystic ovary syndrome (PCOS) and congenital adrenal hyperplasia (CAH) , both of which can lead to increased sebum production and hormonal imbalances , exacerbating acne. Evaluating for hyperandrogenism through tests like testosterone levels , dehydroepiandrosterone sulfate (DHEAS) , and other hormonal markers is crucial to rule out these underlying causes. Hyperandrogenism is when the body produces too much androgen, a male hormone. This can contribute to the development of acne in women and other symptoms such as hirsutism and irregular periods. Treatment may involve medications such as oral contraceptives or anti-androgen drugs. Look for dietary triggers (Option A): Acne can be affected by diet in some people, particularly those with a high glycemic index or a diet high in dairy products. However, this is typically considered after other causes of acne have been ruled out. Additionally, dietary changes may not be sufficient to treat acne on their own, but rather they can be used in conjunction with other treatments. Check for antibiotic resistance (Option C): Antibiotics are often used to treat acne, but over time, the bacteria that causes acne can become resistant to the antibiotics. If a patient's acne is not improving with antibiotics, checking for antibiotic resistance can help determine if a different treatment approach is needed. Look for drug triggers (Option D): Certain medications can contribute to the development of acne. For example, corticosteroids, anticonvulsants, and some hormonal medications can cause acne as a side effect. If a patient takes any medications that may increase the risk of acne, it is important to evaluate their treatment plan and consider alternative medications if necessary.

References:

Rooks’s Textbook of Dermatology 9th edition, 90.1

↑ *Back to this question in Part A*

@Neet_pg_bot

Q17: Which among the following drug is not used in the treatment of acne vulgaris? (Q860622)

A. Topical Benzoyl peroxide

B. Topical Fluocinolone

C. Topical Tazarotene

D. Topical antibiotics

Correct Answer: B. Topical Fluocinolone

Explanation: Fluocinolone is a corticosteroid, which can cause steroid-induced acne (pustular eruptions). Steroids exacerbate acne rather than treat it. Grades Lesions Treatment Grade I Non-inflammatory lesions such as open (blackheads) and closed comedones (whiteheads) Topical retinoids (Tretinoin, Adapalene) Grade II Non-inflammatory lesions (comedones) + inflammatory lesions such as papules and few pustules. Topical retinoids + Topical antibiotics Grade III Multiple inflammatory papules and pustules ± nodules (moderate) Topical retinoids + Oral antibiotics ± Benzoyl peroxide Grade IV Nodules + Cysts (Most severe form) Oral retinoids (Isotretinoin)

References:

Rooks's Textbook of Dermatology 9th edition, 90.37

↑ *Back to this question in Part A*

@Neet_pg_bot

Q18: What is the diagnostic test used to identify allergic contact dermatitis which is a delayed hypersensitivity reaction caused by external substances? (Q856838)

A. Patch test

B. Radioimmunosorbent

C. Eosin-5′-maleimide binding test

D. Nitroblue tetrazolium test

Correct Answer: A. Patch test

Explanation: in blood Food, environmental, drug allergies Incorrect Options: Radioimmunosorbent (RAST) (Option B) : The RAST test is a blood test used to measure specific IgE antibodies in the serum. Allergic contact dermatitis is a delayed-type hypersensitivity reaction mediated by T-cells, and it does not involve IgE antibodies. Therefore, the RAST test is not appropriate for diagnosing allergic contact dermatitis. Eosin-5′-maleimide binding test (Option C) : The eosin-5′-maleimide binding test is a laboratory test used to assess the presence of hereditary spherocytosis, a congenital hemolytic anemia. It is not relevant for diagnosing allergic contact dermatitis. Nitroblue tetrazolium (NBT) test (Option D) : It is primarily used in the diagnosis of chronic granulomatous

disease, an inherited disorder characterized by defective neutrophil function. This test is not related to the diagnosis of allergic contact dermatitis.

References:

https://www.ncbi.nlm.nih.gov/books/NBK537020/

↑ *Back to this question in Part A*

@Neet_pg_bot

Q19: What is the most probable diagnosis for a child who has displayed symptomless lesions on the elbow and shaft of the penis, as depicted in the image below? (Q855657)

A. Lichen planus

B. Lichen nitidus

C. Scrofuloderma

D. Scabies



Correct Answer: B. Lichen nitidus

Explanation: The image shows multiple, tiny, discrete, dome-shaped, shiny papules on the forearm. The history of symptomless lesions on the forearm and shaft of the penis is characteristic of Lichen Nitidus . Lichen Nitidus: Rare chronic inflammatory disorder . Presents as multiple, asymptomatic, tiny, uniform, skin-coloured to hypopigmented, dome-shaped papules . Common sites: Forearms Dorsum of hands Shaft of the penis (pathognomonic location) Trunk Aetiology: Unknown, but associated with atopic dermatitis, Crohn’s disease, and lichen planus . Diagnosis: Clinical; biopsy if needed shows lymphocytic infiltrate in a "claw clutching a ball"

pattern . Management: No treatment required if asymptomatic. If symptomatic, topical steroids, emollients, or calcineurin inhibitors can be used. Usually self-limiting but may persist for months to years. Incorrect Options: Lichen Planus (Option A) is incorrect because Lichen planus presents as violaceous, flat-topped, pruritic papules with Wickham's striae . Usually involves flexor wrists, oral mucosa, and lower back but not commonly the shaft of the penis . Scrofuloderma (Option C) is incorrect because it is a tuberculous skin infection that presents as cold abscesses and sinus tracts overlying lymph nodes or bones, not as discrete, shiny papules . Scabies (Option D) is incorrect because scabies causes intensely pruritic papules, vesicles, and burrows , commonly found in finger webs, axillae, and genital areas . The absence of itching and burrows makes scabies unlikely .

References:

https://pubmed.ncbi.nlm.nih.gov/31869173/

↑ *Back to this question in Part A*

@Neet_pg_bot

• [05_Papulosquamous Disorders] 010 Papulosquamous Disorders

« Back to Folder Directory

[05_Papulosquamous Disorders] 010 Papulosquamous Disorders — Quick Jump

Q1 (p. 788)	*Q2 (p. 788)*	*Q3 (p. 790)*	*Q4 (p. 792)*	*Q5 (p. 794)*	*Q6 (p. 795)*
Q7 (p. 796)	*Q8 (p. 798)*	*Q9 (p. 800)*	*Q10 (p. 800)*	*Q11 (p. 803)*	*Q12 (p. 804)*
Q13 (p. 805)	*Q14 (p. 806)*	*Q15 (p. 808)*	*Q16 (p. 812)*	*Q17 (p. 817)*	*Q18 (p. 818)*
Q19 (p. 821)	*Q20 (p. 823)*	*Q21 (p. 827)*	*Q22 (p. 828)*	*Q23 (p. 831)*	*Q24 (p. 835)*

Q1: Which of the following is NOT one of the major criteria included in the CASPAR (Classification Criteria for Psoriatic Arthritis) for diagnosing psoriatic arthritis in patients with psoriasis? (Q841865)

A. Evidence of psoriasis (current history, or family history)

B. Nail lesions (onycholysis, pitting)

C. Negative rheumatoid factor.

D. Presence of rheumatoid nodules.

Correct Answer: D. Presence of rheumatoid nodules.

■ *Listen (English)*

■ *Listen (Hindi)*

Explanation: According to the Classification of Psoriatic Arthritis (CASPAR) criteria for diagnosing psoriatic arthritis, a patient must accumulate 3 or more points from the given categories CASPAR criteria Criteria Points Current Psoriasis 2 History of psoriasis 1 Psoriasis in a first or second■degree relative. 1 Typical psoriatic nail involvement. 1 A negative test for rheumatoid factor. 1 Current dactylitis. 1 History of dactylitis. 1 Radiological evidence of juxta■articular new bone formation. 1

References:

Rook’s Textbook of Dermatology, 9th Edition, Chapter 35, Section 45

↑ *Back to this question in Part A*

@Neet_pg_bot

Q2: A 12y/o girl comes to the OPD with her parents complaining of multiple small, erythematous, scaly plaques on the trunk with a characteristic raindrop appearance 10 days after a streptococcal throat infection. An image of her lesions is given below. What is the appropriate treatment for this patient? (Q841860)

A. Topical corticosteroids

B. Reassurance

C. Penicillin

D. Doxycycline



@Neet_pg_bot

Correct Answer: C. Penicillin

■ *Listen (English)*

■ *Listen (Hindi)*

Explanation: The presentation is classical of guttate psoriasis , often seen in children and adolescents . It typically occurs 1–3 weeks after a streptococcal pharyngitis or upper respiratory tract infection. The appropriate treatment includes: Eradication of the triggering streptococcal infection using penicillin (or amoxicillin) . Topical therapies (like corticosteroids or emollients) may help skin symptoms but do not address the underlying cause. Reassurance may be needed, but antibiotic therapy is essential in acute, post-streptococcal guttate psoriasis. Clinical Features of Guttate Psoriasis Age group Common in children and young adults Trigger Post-streptococcal pharyngitis (esp. Streptococcus pyogenes) Lesion morphology Multiple, small (<1 cm), erythematous, scaly plaques ("drop-like")

Distribution Trunk, proximal limbs Course May resolve spontaneously or evolve into chronic plaque psoriasis Topical corticosteroids (Option A) : Incorrect as first-line monotherapy in acute guttate psoriasis post-infection. Can be used adjunctively , but antibiotic therapy is essential to treat the underlying streptococcal cause. Reassurance (Option B) : Incorrect as sole treatment . Although guttate psoriasis may be self-limited, reassurance alone is not adequate when a recent streptococcal infection is present. Doxycycline (Option D) : Incorrect because it is not the first-line agent against streptococcal infection in children. Penicillin or amoxicillin is preferred.

References:

Rook's Textbook of Dermatology, 9th Edition, Chapter 35, Section 16

↑ *Back to this question in Part A*

@Neet_pg_bot

Q3: You are called by an ObGyn resident for the referral of care of a G2P1 woman with a known history of psoriasis, currently in her 2nd trimester. She is complaining of fever and malaise, and examination shows the following findings: What could be a possible fetal complication in this patient? (Q841862)

A. No complications

B. Renal agenesis

C. Low birth weight

D. Neonatal hypoglycemia



Correct Answer: C. Low birth weight

■ *Listen (English)*

■ *Listen (Hindi)*

Explanation: This patient with a known history of psoriasis and an image showing healing pustular lesions most likely has impetigo herpetifromis. Impetigo herpetiformis is a rare and severe form of pustular psoriasis that typically occurs during pregnancy or postpartum. It is characterized by widespread pustular eruptions with systemic symptoms such as fever, malaise, and electrolyte imbalances. A possible fetal complication in this patient with impetigo herpetiformis during the third trimester could be low birth weight , as the condition is associated with significant maternal and fetal risks, including i ntrauterine growth restriction and placental insufficiency . Treatment includes Admit the patient IV Steroids/ Cyclosporine Strict monitoring with appropriate IV fluids Avoiding aggravating factors No complications (Option A): Impetigo herpetiformis usually presents with fetal complications such as low birth weight and increased perinatal mortality. Renal Agenesis (Option B): It refers to the absence of one or both kidneys at birth, often leading to severe complications such as oligohydramnios, pulmonary hypoplasia, and an increased risk of urinary tract infections. It is usually genetically inherited (Potter's sequence) but could also be a complication of intake of ACE inhibitors or reno-toxic drugs during pregnancy. Neonatal hypoglycemia (Option D): It is characterized by low blood sugar levels in newborns, often due to inadequate glycogen stores or impaired glucose production. It can lead to seizures, neurologic impairment, and long-term developmental issues if left untreated. It is usually caused due to gestational diabetes mellitus.

References:

Rook's Textbook of Dermatology, 9th Edition, Chapter 35, Section 35

↑ *Back to this question in Part A*

Q4: Which of the following is seen in pityriasis rosea? (Q886486)

A. Wickham striae

B. Auspitz sign

C. Collarette scale

D. Nail pitting

Correct Answer: C. Collarette scale

Explanation: Pityriasis rosea characteristically shows collarette scaling , which is a fine rim of scale attached at the periphery of the lesion and free toward the center. This follows the initial herald patch and is seen in the subsequent oval lesions distributed along cleavage lines on the trunk. Pityriasis rosea: Acute, self-limiting papulosquamous eruption (young adults) Likely viral (HHV-6/7) Herald patch → 1-2 weeks later generalised eruption Oval scaly lesions with collarette scale Christmas-tree pattern on trunk Resolves in 3-6 weeks ; symptomatic treatment only Wickham striae (Option A) : Fine white reticular lines seen on papules of lichen planus , not in pityriasis rosea. Auspitz sign (Option B) : Pinpoint bleeding after scale removal, characteristic of psoriasis . Nail pitting (Option D) : Small depressions on the nail plate seen in psoriasis and alopecia areata , not pityriasis rosea.

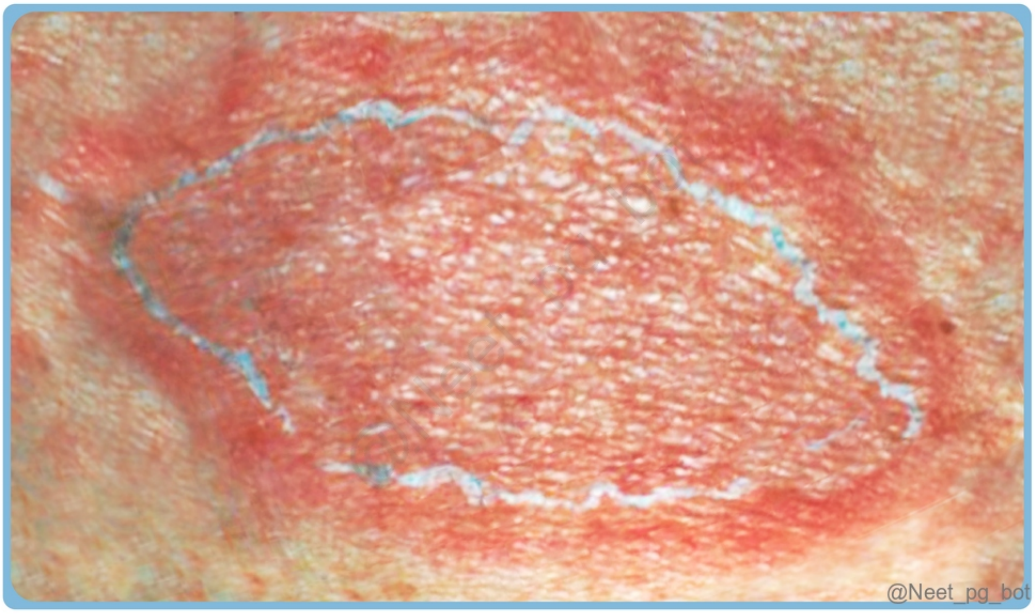


@Neet_pg_bot


@Neet_pg_bot

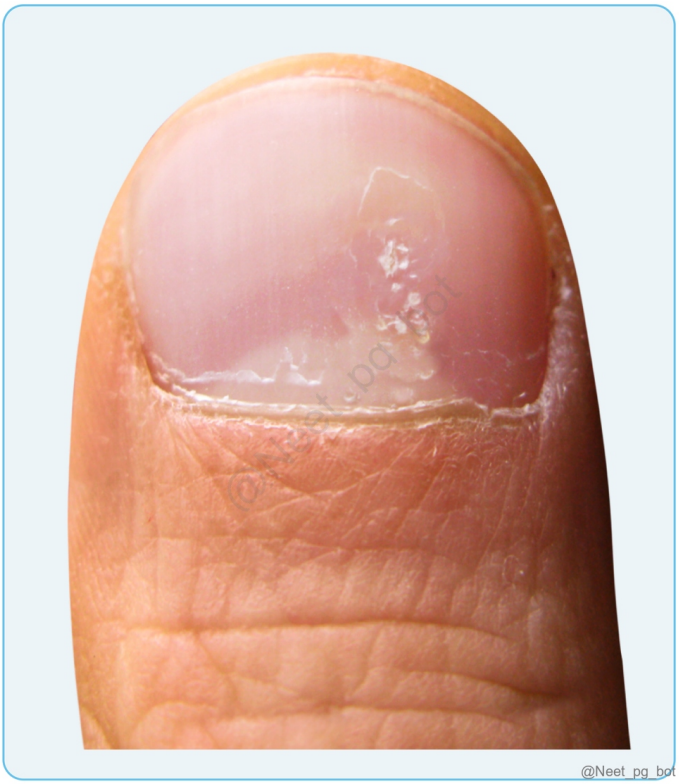

References:

Rook's Textbook of Dermatology, 9th Edition, Page 25.91

↑ *Back to this question in Part A*

@Neet_pg_bot

Q5: Which of the following is not a feature of lichen nitidus? (Q886485)

A. Mainly occurs in children

B. Associated with Crohn's

C. Frequent mucosal involvement

D. Pinpoint to pinhead-sized papules

Correct Answer: C. Frequent mucosal involvement

Explanation: Mucosal involvement is rare in lichen nitidus (much less common than in lichen planus). Lichen nitidus: Epidemiology: Rare; mainly children/young adults (Option A) ; familial cases uncommon. Lesions: Pinpoint to pinhead-sized (Option D) , flat or dome-shaped, shiny papules; usually asymptomatic. Distribution: Forearms, penis, abdomen, chest, buttocks; palms/soles may show hyperkeratosis or purpuric papules. Variants:

Linear, perforating, actinic; nail pitting or ridging possible; mucosal involvement rare. Associations: Crohn disease (Option B) , trisomy 21, congenital megacolon, Niemann-Pick type B. Differentials: Lichen planus, lichen scrofulosorum, keratosis pilaris; biopsy confirms diagnosis .

References:

Rook’s Textbook of Dermatology, 9th Edition, Page 37.10

↑ *Back to this question in Part A*

@Neet_pg_bot

Q6: A patient with multiple shiny, pinhead-sized papules, as shown in the image, undergoes a skin biopsy. What is the characteristic histological feature? (Q886484)

A. Saw-tooth rete ridges with band-like infiltrate

B. Ball-in-claw appearance

C. Caseating granulomas

D. Follicular plugging



Correct Answer: B. Ball-in-claw appearance

Explanation: Lichen nitidus is characterized by pinpoint, shiny papules and histologically shows a well-circumscribed lymphohistiocytic infiltrate beneath the epidermis , with rete ridges encircling the infiltrate (ball-in-claw appearance). Histology: Characteristic papule: Well-circumscribed lymphohistiocytic infiltrate immediately below the epidermis; sometimes Langhans giant cells or plasma cells. The overlying epidermis may show flattening and basal cell liquefaction . Rete ridges encircle infiltrate. Palmar lesions: deep parakeratotic plug (distinguishes from LP). Perifollicular granulomas may mimic lichen scrofulosorum. Sharp infiltration with surrounding epidermal ridges produces a “ball■in■claw” (ball■in■clutch) configuration. Saw-tooth rete ridges with band-like infiltrate (Option A): This is characteristic of lichen planus , not lichen nitidus. Lichen planus shows a dense, continuous band-like lymphocytic infiltrate with saw-tooth acanthosis. Caseating granulomas (Option C): Seen in tuberculosis and other granulomatous infections , not in lichen nitidus. Follicular plugging (Option D): A typical feature of discoid lupus erythematosus , not lichen nitidus.

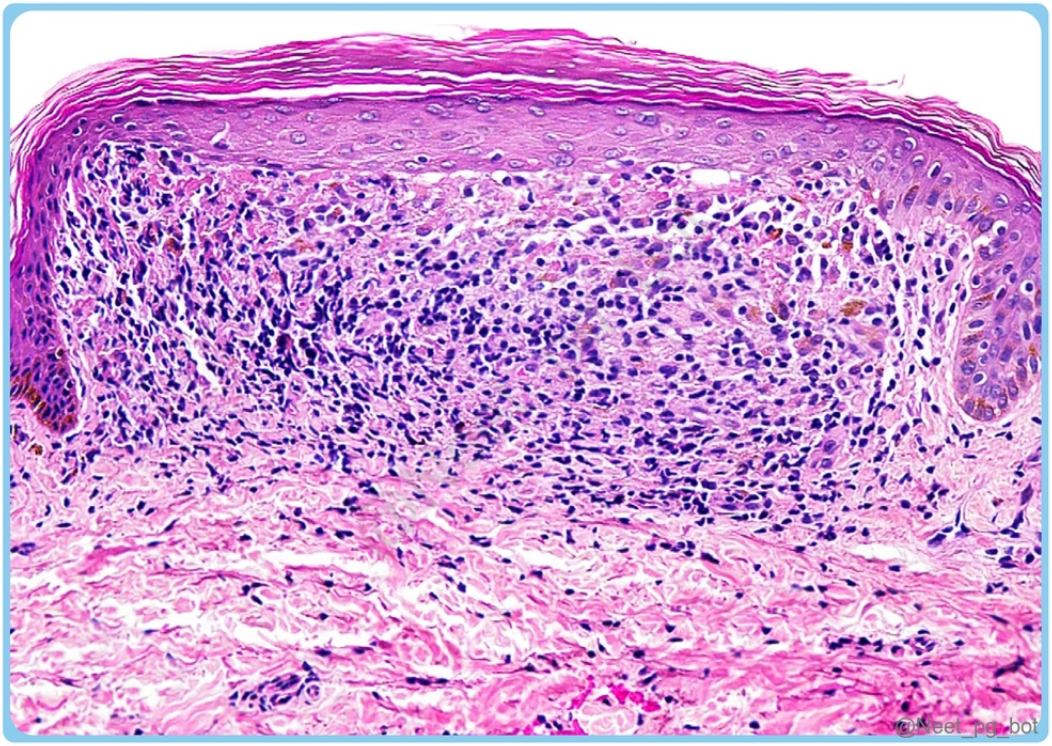

References:

Rook’s Textbook of Dermatology, 9th Edition, Page 37.10

https://www.ncbi.nlm.nih.gov/books/NBK551709/

↑ *Back to this question in Part A*

@Neet_pg_bot

Q7: A 48-year-old patient presents with findings as shown in the image. There is no mucosal involvement. The dermatologist plans to start treatment according to

standard guidelines. Which of the following medications is not routinely used in the management of the most likely condition? (Q886483)

A. Clobetasol ointment

B. Prednisolone

C. Methotrexate

D. Interferon



Correct Answer: D. Interferon

Explanation: The image shows violaceous (purplish), flat-topped, polygonal papules and plaques with fine white streaks on the surface, pointing towards lichen planus. Interferon is not used in the standard management of cutaneous LP. Lichen Planus Management: Treatment guided by site, severity, and symptoms . Cutaneous LP: reduce itching, speed resolution; may clear spontaneously. High-risk sites (nail, scalp, genital, oesophageal, ocular): early treatment to prevent scarring. First line: Limited: potent topical corticosteroids (clobetasol 0.05%) (Option A) Widespread: oral prednisolone 0.5-1 mg/kg/day (Option B) Second line: Acitretin 30 mg/day PUVA or narrow-band UVB ± retinoids Oral steroids + phototherapy Third line: Methotrexate (generalised LP) (Option C) Other agents are not routinely recommended

References:

Rook’s Textbook of Dermatology, 9th Edition, Page 37.16

↑ *Back to this question in Part A*

@Neet_pg_bot

Q8: A patient with lichen planus presents with nail involvement. Which of the following findings are typical nail changes seen in Lichen Planus? Longitudinal ridging and linear depressions Pterygium formation (adhesion of the nail fold to the nail bed) Longitudinal melanonychia and onycholysis Clubbing of all fingernails Yellow, thickened nails with slow growth (Q886482)

A. 1, 2, 3

B. 2, 4, 5

C. 1, 4, 5

D. 3, 4, 5

Correct Answer: A. 1, 2, 3

Explanation: Nail Involvement in Lichen Planus (LP): Occurs in up to 10% of LP cases. Fingernails>toenails. Pattern & Progression: Initial involvement of 2-3 fingernails, progressing to other digits. Often seen in severe generalised LP, skin lesions may be absent near the nail. Common nail changes: Longitudinal lines and linear depressions (thinning of the nail plate). (Statement 1) Elevated ridges on nails. Pterygium unguis (adhesion of dorsal nail fold to nail bed → partial destruction). (Statement 2) Rare complete nail shedding, usually preceded by LP at the nail base. Partial regrowth is possible; permanent loss mainly in the great toenails. Other Nail Bed Changes: Longitudinal melanonychia, hyperpigmentation. Subungual hyperkeratosis or onycholysis. (Statement 3) Changes may mimic yellow nail syndrome . Ulcerative LP of the soles can lead to permanent toenail destruction.

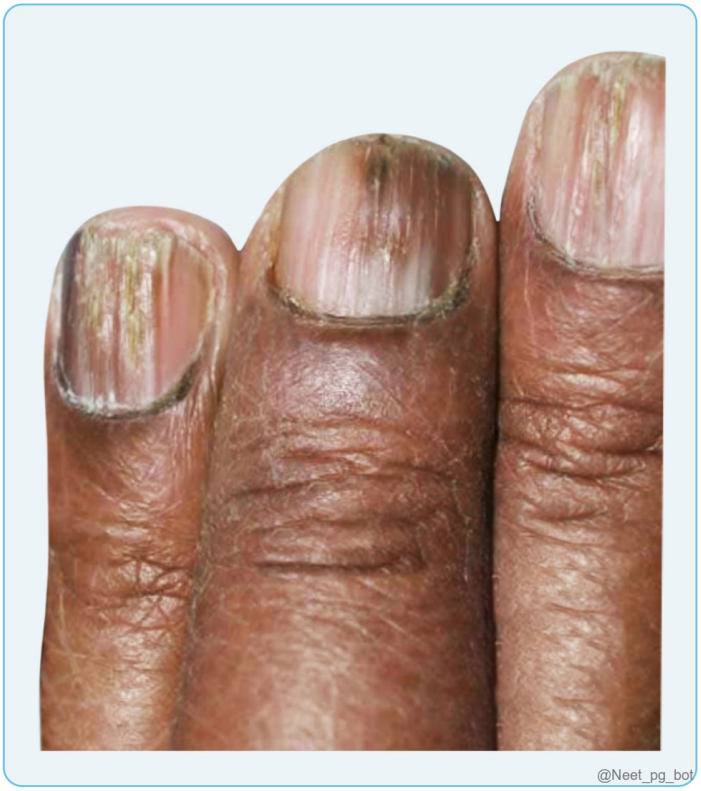



References:

Rook’s Textbook of Dermatology, 9th Edition, Page 37.12

↑ *Back to this question in Part A*

@Neet_pg_bot

Q9: Auspitz sign is seen in? (Q876199)

A. Psoriasis vulgaris

B. Pustular psoriasis

C. Pemphigus

D. Bullous pemphigoid

Correct Answer: A. Psoriasis vulgaris

Explanation: Correct Option A - Psoriasis vulgaris: Auspitz sign is seen in Psoriasis vulgaris. Auspitz sign refers to the appearance of pinpoint bleeding spots when scales are removed from the skin lesions. It is a characteristic finding in Psoriasis vulgaris This phenomenon is due to the abnormal growth and turnover of skin cells in psoriasis, leading to an increased vascularity and fragility of the skin. Incorrect Options: Option B, C & D are incorrect Pustular psoriasis, pemphigus, and bullous pemphigoid are different skin conditions with distinct clinical features and mechanisms. Auspitz sign is not typically observed in these conditions.

References:

Prepladder Notes

↑ *Back to this question in Part A*

@Neet_pg_bot

Q10: A 10 year old boy presents to you with scaly, red follicular plaques over his body. He also has areas near his axilla that are spared from these lesions . What is the most likely histopathological pattern that is characteristic of his disease? (Q841867)

A. Acanthosis and spongiosis

B. Elongation of rete ridges

C. Checkerboard pattern with alternate areas of hyperkeratosis and parakeratosis

D. Lichenoid infiltrate with Civatte bodies



Correct Answer: C. Checkerboard pattern with alternate areas of hyperkeratosis and parakeratosis

- *Listen (English)*
- *Listen (Hindi)*

Explanation: Based on the clinical presentation of scaly, red follicular plaques with areas of sparing near the axilla also called islands of sparing , the diagnosis is Pityriasis Rubra Pilaris (PRP) . Pityriasis Rubra Pilaris is characterized by a histopathological finding known as the checkerboard pattern, which consists of alternate areas of hyperkeratosis (thickening of the stratum corneum) and parakeratosis (retention of nuclei in the stratum corneum). Treatment includes topical agents, the same as that used in psoriasis including topical corticosteroids and emollients. Hyperkeratosis Parakeratosis Acanthosis and spongiosis (Option A) are histopathological findings commonly seen in conditions such as psoriasis and eczema, but they are not characteristic of PRP. Elongation of rete ridges (Option B) is a histological feature typically associated with psoriasis rather than PRP. Lichenoid infiltrate with Civatte bodies (Option D) is a histopathological finding seen in lichen planus, which is a different dermatological disorder unrelated to PRP.

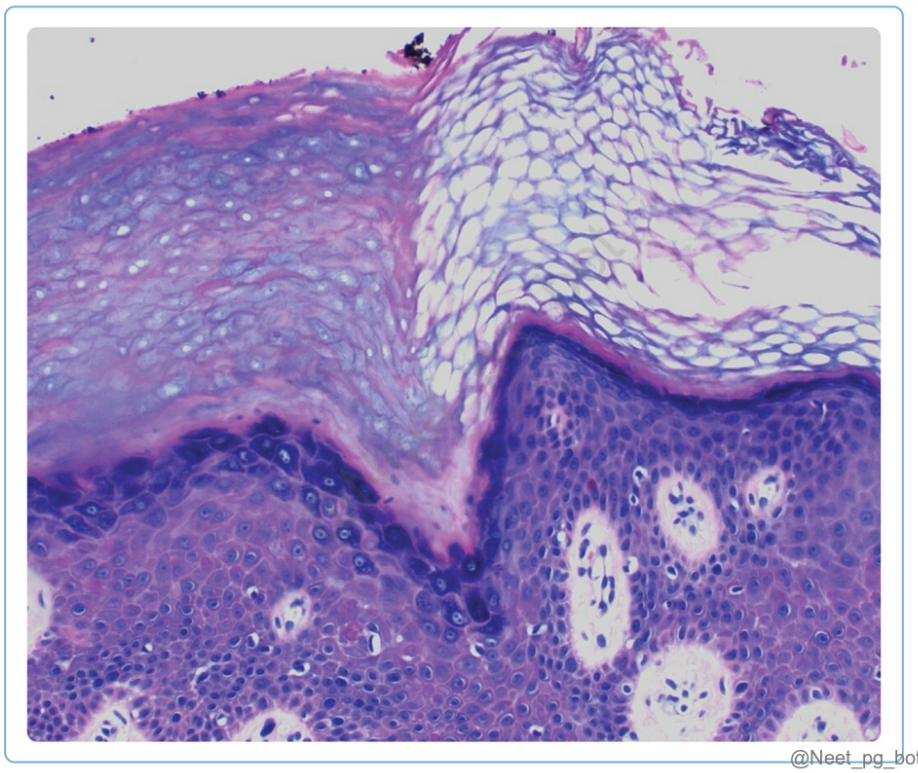

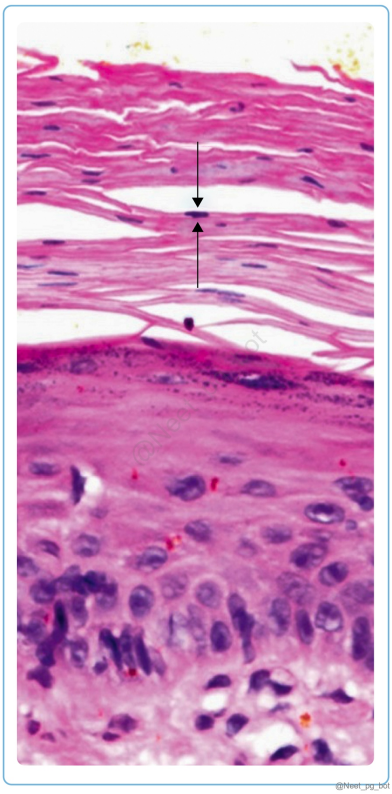

References:

Rook’s Textbook of Dermatology, 9th Edition, Chapter 36

↑ *Back to this question in Part A*

@Neet_pg_bot

Q11: A 24 year old girl with psoriatic skin lesions comes to the dermatology OPD with complaints of joint pain and worsening of her skin lesions. You want to use a single agent for managing both her skin disease and arthritis. Which of the following would you use? (Q841866)

A. Methotrexate

B. Oral corticosteroids

C. Cyclosporine

D. Leflunomide

Correct Answer: A. Methotrexate

■ *Listen (English)*

■ *Listen (Hindi)*

Explanation: Methotrexate inhibit s dihydrofolate reductase, thereby disrupting folate metabolism and interfering with DNA synthesis, leading to decreased proliferation of skin cells. It also decreases the production of inflammatory cytokines eg. TNF-alpha and ILs, thereby reducing inflammation in the joints. It is currently the most recommended single agent for managing both psoriatic arthritis and skin lesions. Dosage: 7.5-25 mg/week via oral/subcutaneous route. Common side effects of methotrexate include: Gastrointestinal symptoms such as nausea, vomiting, and diarrhea. Hepatotoxicity necessitates regular monitoring of liver function tests. Bone marrow suppression leads to anemia, leukopenia, and thrombocytopenia and requires monitoring through regular blood counts. Long-term use: hepatotoxicity, pulmonary toxicity (including interstitial pneumonitis), and renal toxicity. Oral corticosteroids (Option B): They are used at times to control acute flares of psoriatic arthritis. However, they are not preferred as a single agent for managing both skin disease and arthritis, considering their potential to cause instability of cutaneous psoriasis due to reactivation after stopping. Cyclosporine (Option C): It acts by inhibiting IL-2, a key cytokine involved in immune response modulation. Often termed a " crisis drug ," it is utilized to manage severe acute episodes of various immune-mediated disorders. Due to its potential for adverse effects like hyperlipidemia and hypertension, cyclosporin is not used long-term for psoriasis with psoriatic arthritis. Leflunomide (Option D) may be effective for arthritis, but it does not adequately address the skin disease aspect.

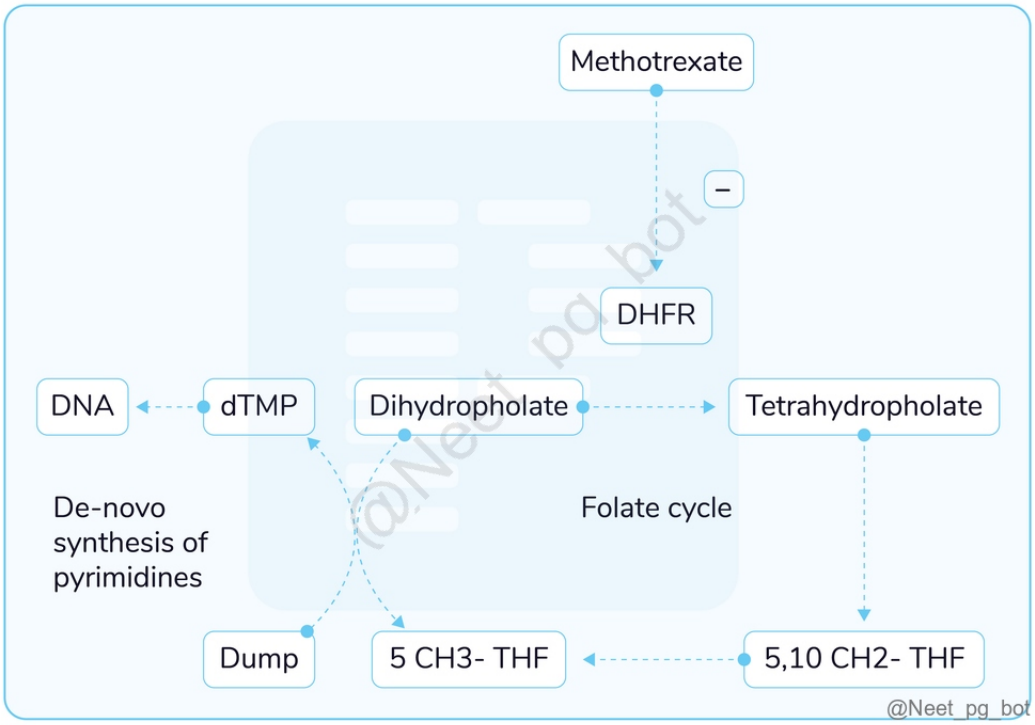

References:

Rook's Textbook of Dermatology, 9th Edition, Chapter 35, Section 26

↑ *Back to this question in Part A*

@Neet_pg_bot

Q12: Which of the following medications would not be used for treating a patient with moderate to severe psoriasis? (Q841864)

A. Adalimumab

B. Vitamin D analogs

C. Tazarotene

D. Tocilizumab

Correct Answer: D. Tocilizumab

■ *Listen (English)*

■ *Listen (Hindi)*

Explanation: Tocilizumab - It is a biological drug that targets the interleukin-6(IL-6) receptor, used primarily in the treatment of rheumatoid arthritis, giant cell arteritis, and juvenile idiopathic arthritis. The characteristics of various topical treatments are shown in the table below Aspect Topical Corticosteroids Vitamin D analogues (Option B) Tazarotene (Option C) Coal tar Mechanism of Action Local anti-inflammatory action Regulate epidermal keratinocyte proliferation. Regulate immune cell function. Modulating keratinocyte differentiation and proliferation. Anti-inflammatory Antiproliferative Frequency Once daily Once or twice daily Side Effects Cutaneous atrophy Tachyphylaxis Rebound flare Systemic absorption Local irritation Erythema Scaling. Odor Staining properties Inconvenience of application Calcipotriene (also known as calcipotriol) and dithranol are examples of vitamin D analogs commonly used to treat psoriasis. Adalimumab (Option A) is a tumor necrosis factor (TNF) inhibitor. It works by blocking the action of TNF. It is used to treat various autoimmune conditions such as psoriasis, psoriatic arthritis, rheumatoid arthritis, and ankylosing spondylitis.

References:

Rook's Textbook of Dermatology, 9th Edition, Chapter 35, Section 23

↑ *Back to this question in Part A*

@Neet_pg_bot

Q13: Which of the following spectrums of UV Light is most commonly used in the treatment of psoriasis? (Q841863)

A. UVA

B. UVB

C. UVC

D. UVD

Correct Answer: B. UVB

■ *Listen (English)*

■ *Listen (Hindi)*

Explanation: UVB therapy, particularly narrow-band UVB , is the recommended first-line and most commonly used therapy for most patients with moderate to severe psoriasis. Narrow-band UVB has a high effectiveness and tolerability compared to other UV spectra, such as broadband UVB and UVA (PUVA therapy). The mechanism of NB-UVB is cutaneous immunomodulation by Increasing vitamin D Induction of apoptosis of T cells Reduction of epidermal hyperproliferation Wavelengths of various UV spectra are given in the image below. UVA (Option A): While UVA therapy (PUVA) has been used in the treatment of psoriasis, narrow-band UVB is preferred now. PUVA therapy is associated with concerns regarding long-term side effects, including an increased risk of skin cancer. UVC (Option C) exposure can be harmful to the skin and is not indicated for therapeutic purposes in psoriasis management. UVD (Option D): "UVD light" is not a recognized term in the context of ultraviolet radiation. The standard terminology for ultraviolet radiation includes UVA, UVB, and UVC.

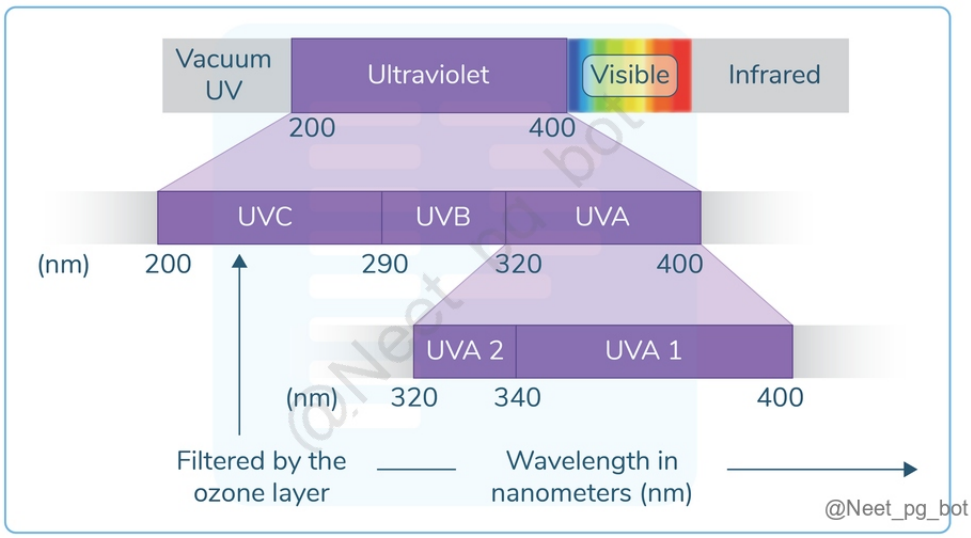

References:

Rook's Textbook of Dermatology, 9th Edition, Chapter 35, Section 25

↑ *Back to this question in Part A*

@Neet_pg_bot

Q14: A 20 year old male patient comes to your dermatology OPD complaining of non-itchy lesions on the back of his elbows, shins, and knees. On examination, you find scaly lesions that exhibit the Auspitz sign, as shown in the image below. Which of the following processes is responsible for this patient's lesions? {{caption_text}} (Q841850)

A. Th1-mediated disorder

B. Th2 mediated disorder

C. IgE response

D. Mast cell activation

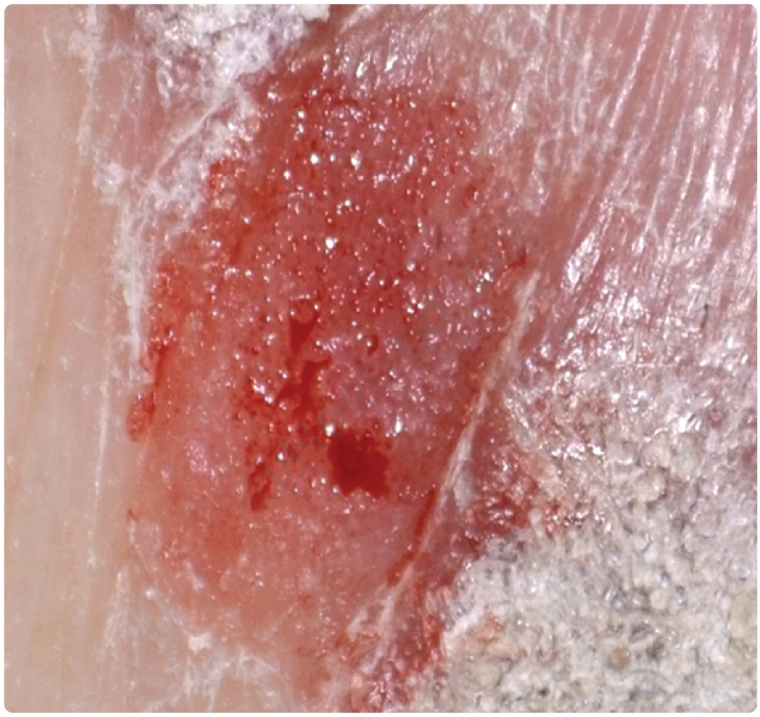

Correct Answer: A. Th1-mediated disorder

- *Listen (English)*
- *Listen (Hindi)*

Explanation: The Auspitz sign, characterized by pinpoint bleeding in the areas where the lesion is scraped with a glass slide, is commonly associated with psoriasis, as depicted in the image above. Psoriasis occurs via Th1-mediated immune responses , which are also involved in the pathogenesis of lichen planus. The inflammatory modulators involved in a Th1 response are: INF-γ (Th1 cells) TNF-α (Th1 cells) Th-17 (IL-17) (Th17 cells) Th-22 (IL-22) (Th22 cells) A detailed depiction of the pathogenesis is given in the image below. {{caption_text}} Immune cells Immunomodulators Examples Th2 response (Option B) T helper 2 (Th2) cells Eosinophils Mast cells IL-4 IL-13 Atopic dermatitis (eczema) IgE response (Option C) B cells (producing IgE antibodies) Mast cells IL-10 Allergic contact dermatitis Mast cell activation (Option D) Mast cells IL-10 Urticaria (hives)

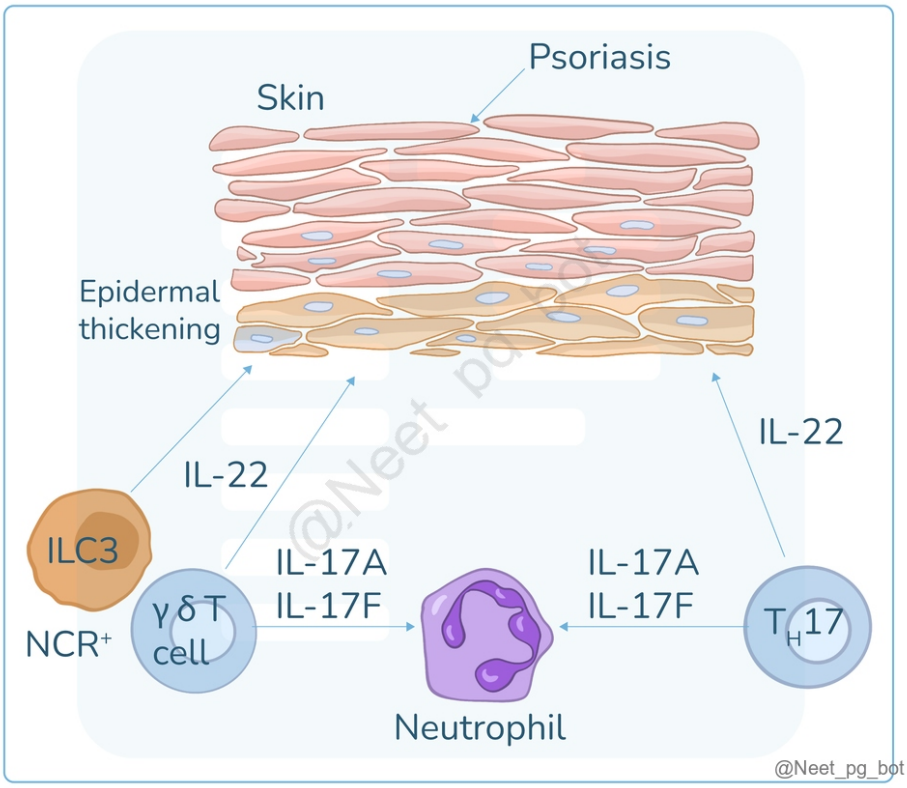

References:

Rook's Textbook of Dermatology, 9th Edition, Chapter 35, Section 6

↑ *Back to this question in Part A*

@Neet_pg_bot

Q15: A patient with a fever of 103°C and pain all over his body comes to your clinic. He recently went to a high-profile medical spa, where he was treated with oral medication for his chronic psoriasis. He was elated with the complete resolution during treatment but woke up with a fever, malaise, and pain three days ago. Skin examination is given in the image below. What is your diagnosis? (Q841861)

A. Pustular psoriasis

B. Erythrodermic psoriasis

C. Psoriasis Vulgaris

D. Rupoid psoriasis



Correct Answer: A. Pustular psoriasis

- *Listen (English)*
- *Listen (Hindi)*

Explanation: The diagnosis of the image is pustular psoriasis (a type of unstable psoriasis) characterized by the presence of multiple sterile, non-infectious pus-filled blisters on erythematous skin, forming a characteristic 'Lakes of pus' appearance. This condition can occur due to the abrupt cessation of systemic corticosteroids , leading to rebound flare-ups of psoriasis. Since it affects the whole body, it is also called Acute generalized pustular psoriasis or Von Zumbusch psoriasis. Aggravating factors: Withdrawal of steroids Coal tar Pregnancy Stress Classification of Unstable Psoriasis: Erythrodermic psoriasis (Option B) is another variant of unstable psoriasis that presents with erythema and scales covering more than 90% of the body surface. Psoriasis Vulgaris (Option C) also known as plaque psoriasis, is the most common form of psoriasis. It is characterized by raised, red patches of skin covered with silvery scales. Rupioid psoriasis (Option D) is a severe form of psoriasis characterized by the development of large, thick, adherent, and waxy scales resembling limpet shells or oyster shells.


@Neet_pg_bot

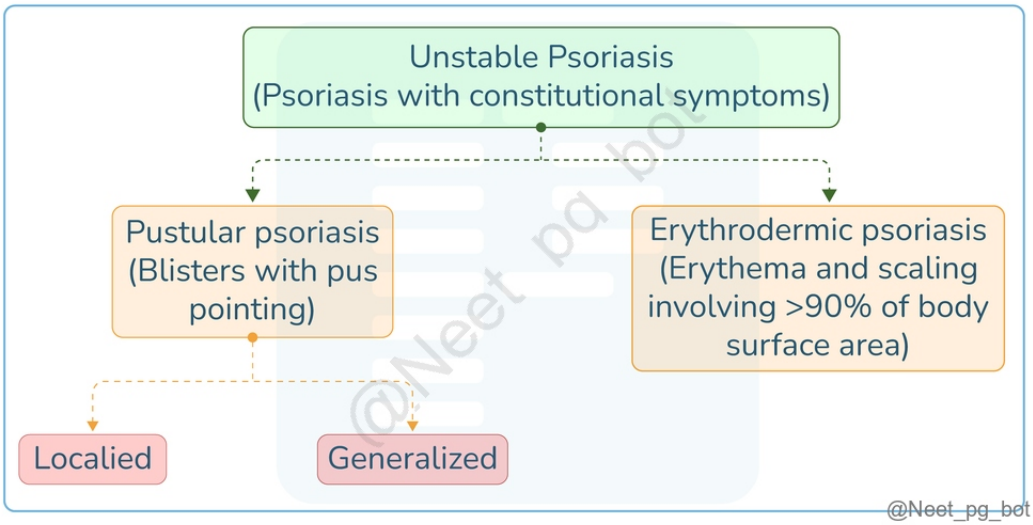
Unstable Psoriasis
(Psoriasis with constitutional symptoms)
Pustular psoriasis
(Blisters with pus pointing)
Erythrodermic psoriasis
(Erythema and scaling involving >90% of body surface area)
Localied
Generalized
@Neet_pg_bot

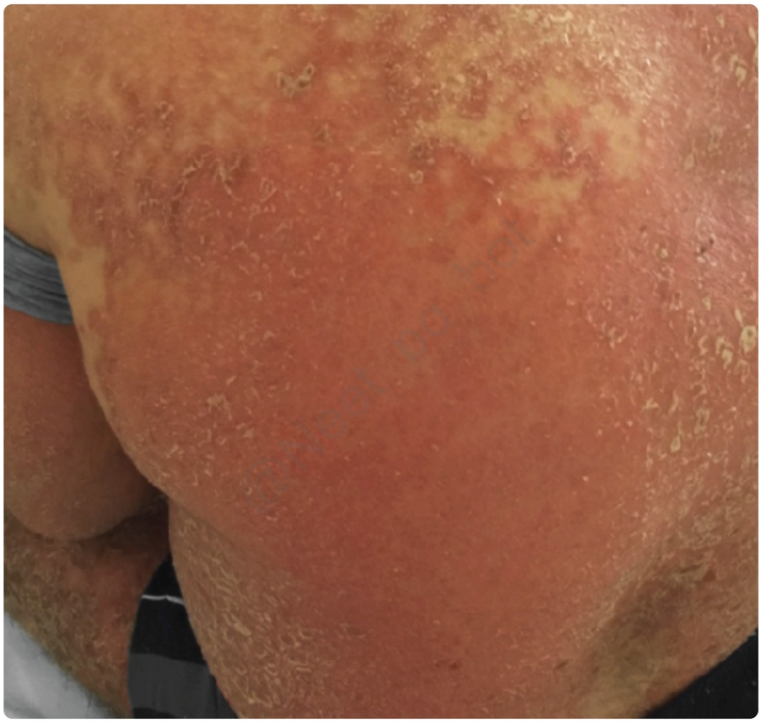

@Neet_pg_bot



@Neet_pg_bot

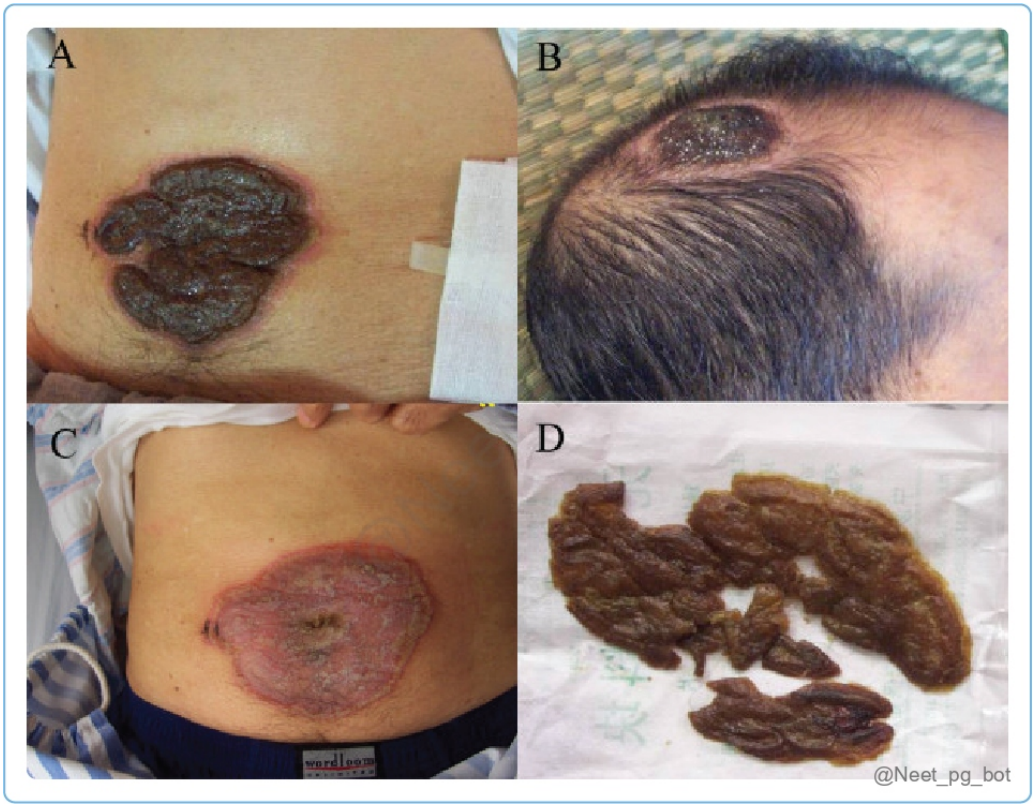

References:

Rook's Textbook of Dermatology, 9th Edition, Chapter 35, Section 34

↑ *Back to this question in Part A*

@Neet_pg_bot

Q16: An orthopaedic surgeon shows you an X-ray of HLA B-27 positive female with seronegative arthritis and psoriatic skin lesions, and you observe the following deformity. What is the eponym given to this deformity? (Q841859)

A. Ivory phalanx

B. Pencil-in-cup deformity

C. Boutonniere deformity

D. Fraying



Correct Answer: B. Pencil-in-cup deformity

- *Listen (English)*
- *Listen (Hindi)*

Explanation: Pencil-in-cup deformity The "pencil-in-cup" deformity is a characteristic radiographic finding in patients with psoriatic arthritis. Psoriatic arthritis occurs mainly in HLA B-27 positive patients and is seronegative . It results from erosive changes at the joint margins, leading to bony proliferation and destruction, causing the proximal bone to taper into the distal bone. It is often seen in the distal interphalangeal (DIP) joints and is indicative of severe joint damage in psoriatic arthritis. The tapered phalanx is also called the ‘mouse ear deformity.’ Ivory phalanx (Option A) occurs due to new bone formation in psoriatic arthritis ; the phalanx may appear whiter due to sclerosis. Boutonniere deformity (Option C) is commonly seen in rheumatoid arthritis, and involves flexion of the proximal interphalangeal (PIP) joint with hyperextension of the distal interphalangeal (DIP) joint. Fraying (Option D): Irregularity and thinning of the cortex of long bones, particularly at the metaphyses, resulting in a fuzzy or frayed appearance seen in vitamin C deficiency/ Scurvy.


@Neet_pg_bot


@Neet_pg_bot


@Neet_pg_bot


@Neet_pg_bot





References:

Psoriatic Arthritis, (Gladman, Rosan, and Chandran) Chapter 6

↑ *Back to this question in Part A*

@Neet_pg_bot

Q17: A 24 year old male patient presents to you with joint pain in his fingers. He is currently a fashion student at NIFT and shares that other students bully him for having a few ‘sausage fingers.’ There is no predominant DIP joint involvement noted. What type of arthritis would you most suspect in this patient? (Q841858)

A. Asymmetrical oligoarthritis

B. Distal interphalangeal arthritis

C. Spinal column or axial involvement

D. Arthritis mutilans

Correct Answer: A. Asymmetrical oligoarthritis

■ *Listen (English)*

■ *Listen (Hindi)*

Explanation: In psoriatic arthritis (PsA), inflammation can affect the joints closest to the fingernails and toenails (DIP), resulting in swelling and inflammation. This inflammation can lead to the characteristic appearance of swollen and sausage-like fingers or toes. The image below is that of sausage toes. The most common type of arthritis associated with psoriasis is asymmetric oligoarthritis (50%). Distal interphalangeal arthritis (Option B) affects 5% of patients with psoriatic arthritis. This subtype specifically targets DIP joints predominantly, often with nail involvement. Spinal column or axial involvement (Option C) affects 40% of patients. Arthritis mutilans (Option D) is a severe form of PsA characterized by destructive joint changes, but it is relatively rare with a prevalence of 5%.



References:

Psoriatic Arthritis, (Gladman, Rosan, and Chandran) Chapter 2

↑ *Back to this question in Part A*

@Neet_pg_bot

Q18: On examination of a specific finding in the nail, a dermatology professor confirms the presence of nail psoriasis. Which of these findings helped the professor establish this diagnosis? (Q841857)

A. Pitting of the nails

B. Oil drop sign

C. Onycholysis

D. Subungual hyperkeratosis

Correct Answer: B. Oil drop sign

■ *Listen (English)*

■ *Listen (Hindi)*

Explanation: The Oil drop sign refers to small, yellowish-orange discolorations seen beneath the nail plate, resembling drops of oil, and is highly specific for nail psoriasis. It is the most specific sign of psoriasis with a specificity of ~98% It occurs due to nail bed parakeratosis and psoriasiform hyperplasia It occurs just before onycholysis Important findings in nail psoriasis are (Mnemonic: POLISH) Pits Onycholysis Leukonychia Salmon patch Subungual Hyperkeratosis Pitting of the nails (Option A): While pitting is the most common finding in nail psoriasis, it is not as specific as the oil drop sign. Other diseases where pitting of nails is seen are : Alopecia Areata , Onychomycosis , Darier's disease , Hailey-Hailey disease etc. Onycholysis (Option C) or separation of the nail plate from the nail bed, can occur in various nail conditions including trauma and onychomycosis (fungal nail infection), not just nail psoriasis. Subungual hyperkeratosis (Option D) refers to the thickening of the skin under the nail, which can also be seen in other nail disorders including eczema and hyperkeratosis, and is not specific to nail psoriasis.





@Neet_pg_bot



@Neet_pg_bot



References:

Rook's Textbook of Dermatology, 9th Edition, Chapter 35, Section 14

↑ *Back to this question in Part A*

@Neet_pg_bot

Q19: During your infectious disease rotation, you examine a 37 year old diabetic female with non-itchy lesions under both her breasts in the ward. The patient mentions that her lesions are non-itchy and exacerbate during the winter. They are salmon in colour, as shown in the image below. What is your next step in management? (Q841856)

A. Reassurance

B. Oral fluconazole

C. Local application of corticosteroids

D. Oral corticosteroids



Correct Answer: C. Local application of corticosteroids

- *Listen (English)*
- *Listen (Hindi)*

Explanation: These lesions are consistent with flexural or inverse psoriasis, characterized by non-itchy, salmon-coloured plaques in flexural areas like under the breasts. As it is a variant of psoriasis, local corticosteroids help reduce inflammation and alleviate symptoms. It's important to differentiate flexural psoriasis from candidal intertrigo, which is also common in similar areas but is itchy and lacks the characteristic bilaterally symmetrical scaly appearance. Characteristics Flexural Psoriasis Candidal Intertrigo Image Colour Salmon Red, erythematous Symmetry Bilaterally symmetrical Asymmetrical Satellite lesions are seen Symptoms Not pruritic Pruritic Exacerbation Cold environment Warm, humid environment Treatment Topical corticosteroids and emollients Topical and oral antifungals Reassurance (Option A) alone may not be sufficient as the patient's condition requires treatment to alleviate symptoms and prevent exacerbations. Oral fluconazole (Option B) is not the appropriate choice because the lesions are not indicative of a fungal infection; they lack the typical features of candidiasis or tinea. Oral corticosteroids (Option D) are not needed as the lesion is restricted to her breast region. Topical steroids can be applied to the specific site to resolve the lesion.





References:

Rook's Textbook of Dermatology, 9th Edition, Chapter 35, Section 11

↑ *Back to this question in Part A*

@Neet_pg_bot

Q20: An immigrant laborer comes to your Sunday volunteer clinic complaining of thickening of the skin on his scalp. The lesions are not itchy, cross the hairline, and are not associated with loss of hair as shown in the given image. What is your diagnosis? (Q841855)

A. Pityriasis amiantacea

B. Seborrheic dermatitis

C. Pityriasis rosea

D. Tinea barbae



Correct Answer: A. Pityriasis amiantacea

■ *Listen (English)*

■ *Listen (Hindi)*

Explanation: Pityriasis amiantacea is a scalp condition characterized by th e formation of thick, asbestos-like scales that adhere to the hair shafts. While the lesions are typically not itchy , they could cause hair loss if left untreated. Can be secondary to an underlying inflammatory skin disorder such as: Psoriasis Lichen simplex Scalp infections Treatment Topical corticosteroids Keratolytic agents Seborrheic dermatitis (Option B) is a scalp condition with red, itchy , greasy scales that affects areas rich in sebaceous glands, like the scalp, face, and upper trunk it can be caused by the fungi Malassezia furfur. Pityriasis rosea (Option C) presents with oval-shaped, pink, or red patches on the trunk, arms, or legs. It doesn't involve the scalp , and the lesions don't cross the hairline . It is also caused by Malassezia furfur. Tinea barbae (Option D) is a fungal infection of the beard area in men, characterized by erythematous plaques and pustules.



@Neet_pg_bot



@Neet_pg_bot



@Neet_pg_bot



@Neet_pg_bot

References:

Rook’s Textbook of Dermatology, 9th Edition, Chapter 35, Section 10

↑ *Back to this question in Part A*

Q21: During Dermatology grand rounds, a professor asks you to demonstrate the signs observed in patients with psoriasis. What is the order in which you will see these signs while scraping the lesion with the blunt end of a glass slide? (Q841854)

A. Grattage sign, Berkeley’s Membrane, Auspitz Sign

B. Auspitz Sign, Berkeley’s Membrane, Grattage Sign

C. Berkeley’s Membrane, Grattage Sign, Auspitz Sign

D. Berkeley’s Membrane, Auspitz Sign, Grattage Sign

Correct Answer: A. Grattage sign, Berkeley’s Membrane, Auspitz Sign

■ *Listen (English)*

■ *Listen (Hindi)*

Explanation: While examining a patient’s psoriatic lesions during scraping with a blunt object such as the blunt edge of a glass slide, the following signs are seen. Grattage Sign/ Candle sign : Accentuation of scaling when the lesion is scraped with the blunt edge of a glass slide. ↓ Berkeley’s membrane: Formation of a thin membrane on further scraping. ↓ Auspitz sign: Formation of pin-point bleeding on scraping the Berkeley’s membrane. Another sign, "Sign of the last Hauchen" or "Sign of the Last Scale," refers to the presence of small, raised, erythematous papules that become visible after the last scale is removed from a psoriatic plaque, i.e., before the formation of Berkeley’s membrane .

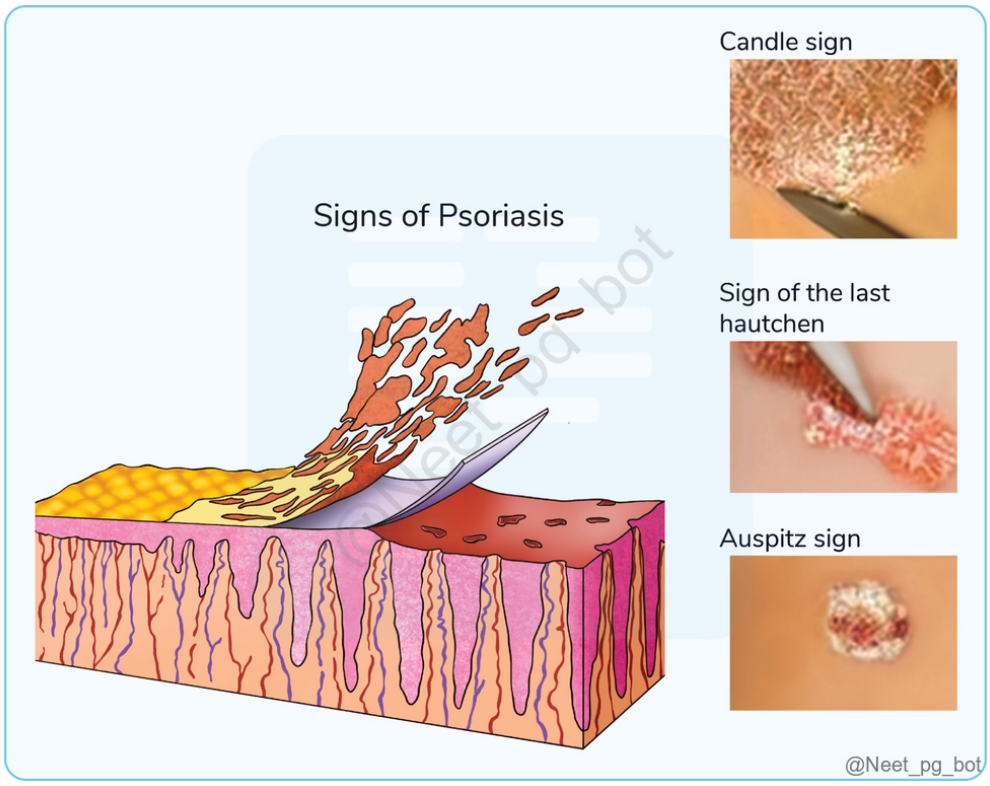

References:

Rook's Textbook of Dermatology, 9th Edition, Chapter 35, Section 9

↑ *Back to this question in Part A*

@Neet_pg_bot

Q22: While examining a patient with bilaterally symmetrical, silver-white scaly lesions during your Internal Medicine practical exam, you notice that each lesion is surrounded by an area of circumferential pallor as shown in the image below. What is this sign called? (Q841853)

A. Auspitz sign

B. Asboe-Hansen sign

C. Woronoff's ring

D. Nikolsky sign



@Neet_pg_bot

Correct Answer: C. Woronoff’s ring

- *Listen (English)*
- *Listen (Hindi)*

Explanation: Woronoff 's ring is a phenomenon where a ring-like area of lighter skin encircles fading psoriasis lesions. As described above it is seen due to vasoconstriction (due to the absence of PGE2) and disruption of melanogenesis (autoimmunity). It is characteristically seen in healing lesions. Auspitz sign (Option A) is seen in psoriasis, referring to pinpoint bleeding when scales are removed by scraping. Asboe-Hansen sign (Option B) can be demonstrated by the spreading of a blister by applying pressure at its edge, as seen in bullous pemphigoid Nikolsky sign (Option D) indicates the detachment of the epidermis from the dermis with slight rubbing pressure, seen in pemphigus vulgaris , SSSS , Toxic epidermal necrolysis or Lyell's disease and other blistering disorders.

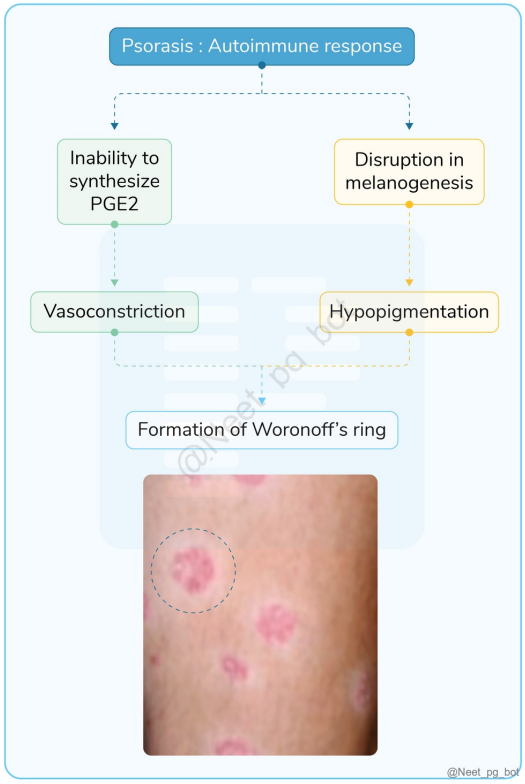
Psorasis : Autoimmune response
Inability to synthesize PGE2
Disruption in melanogenesis
Vasoconstriction
Hypopigmentation
Formation of Woronoff's ring
@Neet_pg_bot


@Neet_pg_bot





References:

Rook’s Textbook of Dermatology, 9th Edition, Chapter 35, Image 35.6

↑ *Back to this question in Part A*

@Neet_pg_bot

Q23: During a dermatology demonstration on the Koebner phenomenon, the professor also discusses the pseudo-Koebner phenomenon. Which of the following conditions typically shows a pseudo-Koebner response? (Q841852)

A. Lichen planus

B. Pemphigus vulgaris

C. Warts

D. Erythema multiforme



Correct Answer: C. Warts

■ *Listen (English)*

■ *Listen (Hindi)*

Explanation: Koebner phenomenon (isomorphic response): Appearance of new lesions at sites of skin trauma in diseases like psoriasis and lichen planus . Pseudo-Koebnerization : Seen in warts (verruca vulgaris) due to autoinoculation from trauma or seeding of microorgaisms Types of Koebnerisation- Category Cause Examples Images Category 1 (True koebnerization) Development of lesions at sites of trauma. Psoriasis Lichen planus (Option A) Vitiligo Psoriasis Category 2 (Pseudo koebnerization) Non-immunological and occurs due to auto-inoculation and not trauma. Verruca vulgaris (warts) Molluscum Warts Category 3 (Occasional koebnerization) The phenomenon is infrequent or occurs only in specific circumstances. Darier disease Erythema multiforme (Option D) . Erythema multiforme Category 4 (Dubious association with trauma) Limited evidence or

conflicting reports regarding the role of trauma in lesion formation. Pemphigus vulgaris (Option B) Lupus erythematosus Pemphigus vulgaris









References:

Rook’s Textbook of Dermatology, 9th Edition, Chapter 35, Section 9

↑ *Back to this question in Part A*

@Neet_pg_bot

Q24: As a pathologist in a prestigious private clinic, a physician contacts you for urgent feedback on a skin biopsy from a prominent politician. Suspecting psoriasis, what histopathological findings in the stratum corneum would you communicate to the attending physician? (Q841851)

A. Hyperkeratosis, parakeratosis, and microabscesses

B. Kogoj’s spongiform pustules

C. Camel foot appearance

D. Suprapapillary thinning

Correct Answer: A. Hyperkeratosis, parakeratosis, and microabscesses

■ *Listen (English)*

■ *Listen (Hindi)*

Explanation: The various histopathological findings in the different skin layers seen in a patient with psoriasis are as follows. Layer Findings Image Stratum Corneum Hyperkeratosis (increased thickening of stratum corneum) Parakeratosis (retention of nuclei in stratum corneum) Munro's microabscess (collection of neutrophils Stratum Granulosum Agranulocytosis / Agranulosis (absent granular layer) Malpighian layer (Stratum Spinosum and Basale) Acanthosis (increased thickness) of stratum spinosum Kogoj's Spongiform pustules (collection of neutrophils) Rete ridges They are elongated and club-shaped (Camel foot appearance). Dermis Suprapapillary thinning is seen as the first histopathological sign . Dilated tortuous blood vessels. Inflammation Kogoj’s spongiform pustules (Option B) is a collection of neutrophils seen in the Malphigian layer. Camel foot appearance (Option C) is seen in Rete ridges, which are elongated. Suprapapillary thinning (Option D) is seen in the dermis.

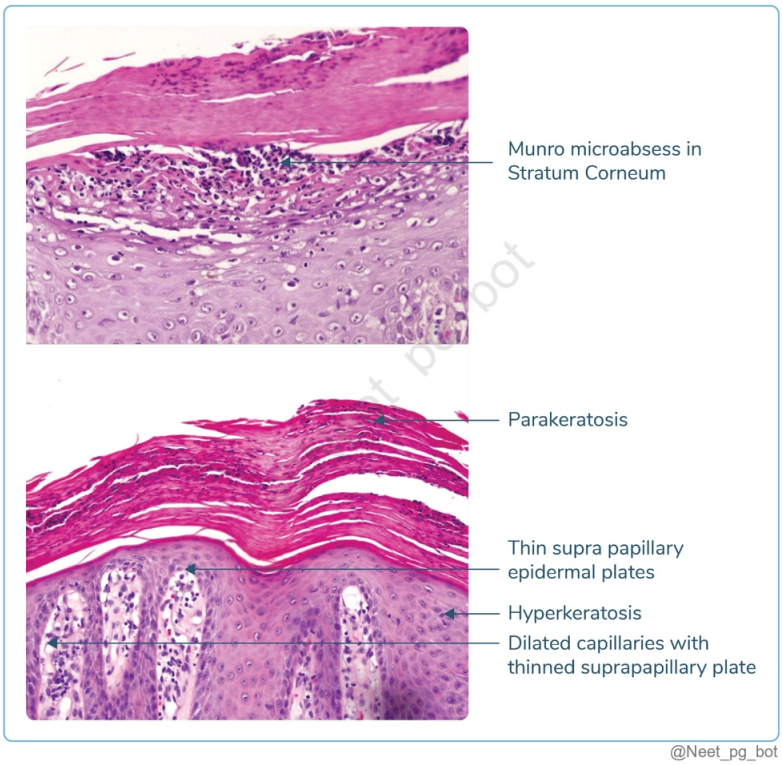

@Neet_pg_bot

References:

Rook's Textbook of Dermatology, 9th Edition, Chapter 35, Section 6

↑ *Back to this question in Part A*

@Neet_pg_bot

• [05_Papulosquamous Disorders] 011 Previous Year Questions

« Back to Folder Directory

[05_Papulosquamous Disorders] 011 Previous Year Questions — Quick Jump

Q1 (p. 837)	*Q2 (p. 838)*	*Q3 (p. 839)*	*Q4 (p. 840)*	*Q5 (p. 842)*	*Q6 (p. 844)*
Q7 (p. 845)	*Q8 (p. 846)*	*Q9 (p. 848)*	*Q10 (p. 849)*	*Q11 (p. 850)*	*Q12 (p. 854)*
Q13 (p. 855)	*Q14 (p. 856)*	*Q15 (p. 857)*	*Q16 (p. 861)*	*Q17 (p. 864)*	*Q18 (p. 865)*
Q19 (p. 867)	*Q20 (p. 868)*	*Q21 (p. 869)*	*Q22 (p. 870)*		

Q1: Which of the following tests is most appropriate for diagnosing this condition? (Q852570)

A. Nikolsky Test

B. Asboe-Hansen test

C. Grattage Test

D. Tzanck Smear



Correct Answer: C. Grattage Test

Explanation: Grattage Test is used to diagnose psoriasis , a condition characterized by scaly plaques on the skin. In this test, gentle scraping of the lesion leads to removal of scales in a characteristic manner, revealing a shiny, thin membrane (Auspitz sign) and pinpoint bleeding. Other Options: Nikolsky Test (Option A) : Used to diagnose conditions like pemphigus vulgaris and toxic epidermal necrolysis . It involves applying lateral pressure to the skin, which causes the epidermis to slough off. Asboe-Hansen Test (Option B) : Also known as the bulla spread sign , it helps diagnose pemphigus vulgaris by checking if pressure on a blister spreads it to adjacent skin. Tzanck Smear(Option D) : Used to diagnose herpes infections by detecting multinucleated giant cells in skin lesions.

References:

Neena Khanna, Textbook of Dermatology, 7th Edition, Page no: 124

↑ *Back to this question in Part A*

@Neet_pg_bot

Q2: A 73-year-old female presents with severe pruritus and a white plaque in the genital region. Histopathological examination reveals loss of rete ridges, abundant collagen, and thinning of the epithelium. What is the most likely diagnosis? (Q879091)

A. Lichen planus

B. Lichen sclerosis

C. Candiasis

D. Vulvar leukoplakia

Correct Answer: B. Lichen sclerosis

Explanation: The clinical presentation of a white plaque with intense pruritus in the genital region of an elderly woman, along with histopathology showing loss of rete ridges, abundant collagen, and thinning of the epithelium , is characteristic of Lichen Sclerosus . It commonly affects elderly women, presenting with intense itching and white atrophic plaques in the genital region. Histopathology shows loss of rete ridges, thinned epithelium, and a broad zone of dense collagen (sclerosis) in the upper dermis—classic findings described in LS. Incorrect Options: Lichen planus (Option A) shows saw-toothing of rete ridges, band-like lymphocytic infiltrate, and violaceous lesions, not white sclerotic plaques. Candidiasis (Option C) presents with erythema, curdy white discharge, and pseudohyphae on microscopy; not sclerosis or epithelial thinning. Vulvar leukoplakia (Option D) is a descriptive term for white patches; does not show the classic sclerosis with loss of rete ridges seen in LS.

References:

Lichen Sclerosus—Presentation, Diagnosis and Management - PMC

↑ *Back to this question in Part A*

Q3: A 45-year-old male comes with recurrent blisters and oral ulcers for 3 years. The histology is as shown. What is the diagnosis of this patient? (Q854660)

A. Pemphigus vulgaris

B. Dermatitis herpetiformis

C. Bullous pemphigoid

D. Linear IgA disease

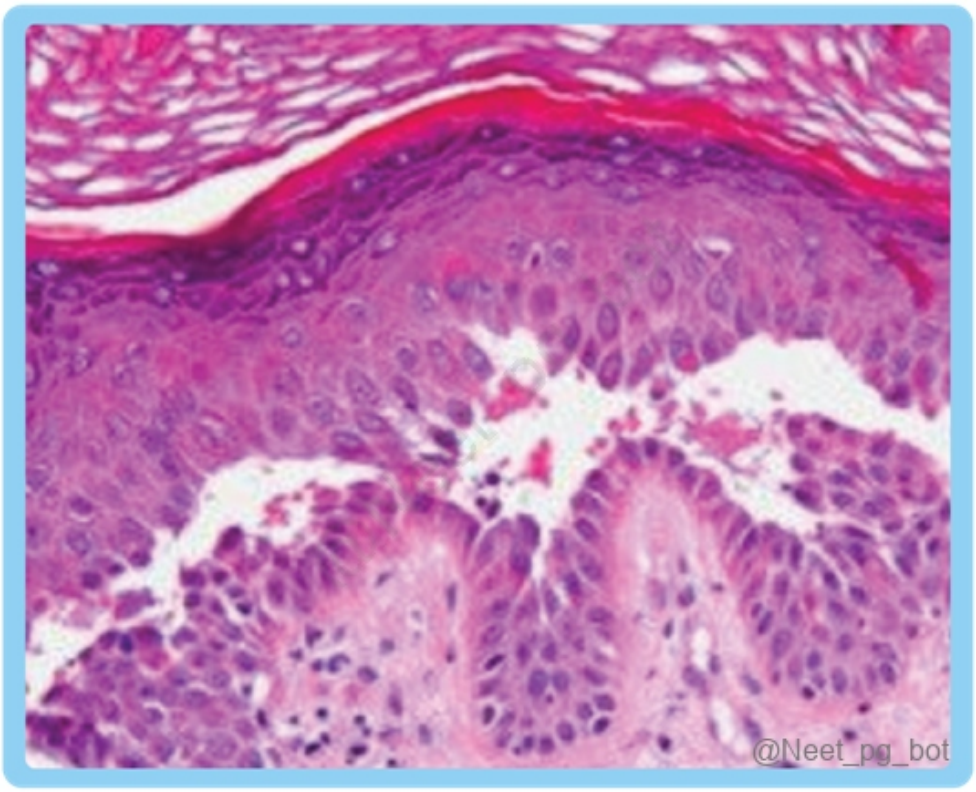

Correct Answer: A. Pemphigus vulgaris

Explanation: The above clinical features and HPE findings in this patient suggest the diagnosis of Pemphigus vulgaris (PV), which most commonly has antibodies against Desmoglein 3. Pemphigus vulgaris: PV is the most common chronic autoimmune blistering disease caused by antibodies against desmosomal adhesion proteins. They are characterized by the presence of flaccid blisters filled with clear fluid present on normal skin or an erythematous base. The blisters rupture producing painful erosion. Mucosal involvement is a very important and one of the distinguishing features of PV. Histopathology: Intraepidermal cleavage with acantholysis (detached keratinocytes) primarily localized to the suprabasal region Separation of basal keratinocytes along the basement membrane zone, resulting in an appearance that resembles a "row of tombstones" The target antigens for PV are

most commonly Desmoglein 3 and sometimes Desmoglein 1. The image below shows the common target antigen in Intraepidermal Immunobullous Disorders. Dermatitis herpetiformis (Option B) Associated with celiac disease and characterized by intensely pruritic, grouped vesicles typically on extensor surfaces. Shows granular IgA deposits on immunofluorescence, not intercellular IgG. Bullous pemphigoid (Option C) Causes subepidermal blisters and does not commonly present with oral ulcers. Immunofluorescence shows linear IgG and C3 at the dermal-epidermal junction. Linear IgA disease (Option D) Characterized by linear IgA deposits at the basement membrane zone. Typically causes subepidermal blistering, not intraepidermal, and oral ulcers are less common.

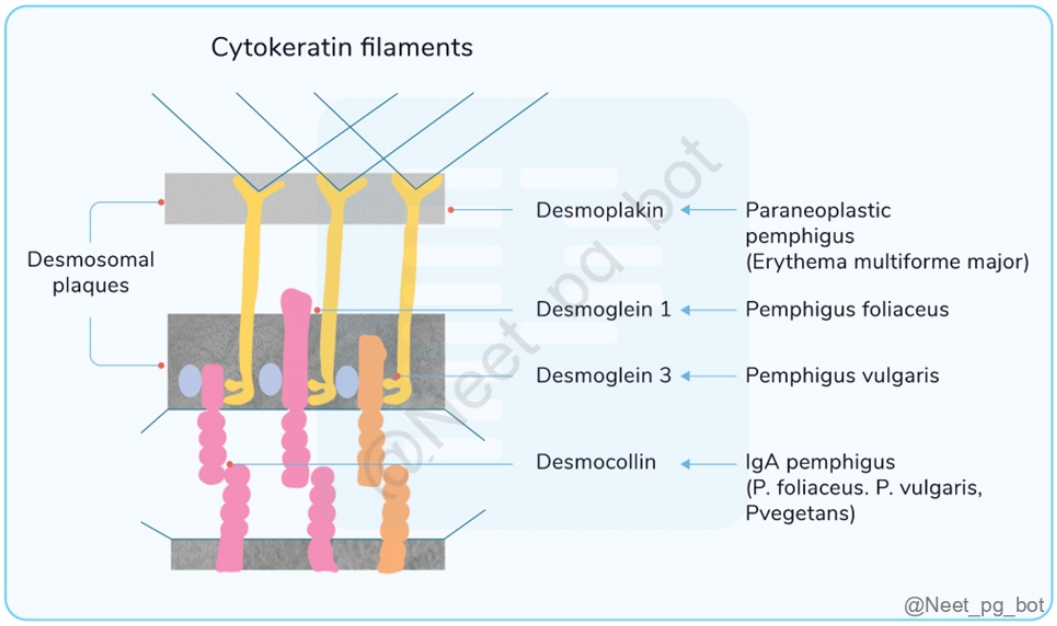

References:

Pathogenesis, clinical manifestations, and diagnosis of pemphigus - UpToDate

Rooks textbook of dermatology, 9th ed, page no.50.1-50.4

↑ *Back to this question in Part A*

@Neet_pg_bot

Q4: A patient on anti-PD1 immunotherapy (nivolumab) comes with pruritis, eczema, and urticarial rashes. Histopathological examination reveals a subepidermal blister and direct immunofluorescence of the lesions showed linear C3 and IgG on basement membrane. What isthe diagnosis? (Q854648)

A. Dermatitis herpetiformis

B. Pemphigus vulgaris

C. Pemphigus foliaceous

D. Bullous Pemphigoid

Correct Answer: D. Bullous Pemphigoid

Explanation: Bullous Pemphigoid: BP is a common subepidermal immunobullous disorder mainly affecting elder people. Autoantibodies against hemidesmosomal target proteins BP230(BPAG1) and BP180(BPAG2) which finally leads to bullae formation. It is characterised by a prodromal non bullous stage with pruritis which is followed by a bullous stage. The later has intense pruritus with tense blisters and vesicles. These blisters show a negative Nikolsky sign but a positive Bulla spread sign. The rupture of blisters leads to yellow or hemorrhagic crust formation, which later heal without any scar. Oral lesions can occur sometimes. HPE shows a subepidermal split with inflammatory infiltrate, immunofluorescence shows a linear binding of immunoglobulin (IgG and C3) at the dermo-epidermal junction. Topical and systemic steroids are the mainstay of treatment. {{caption_text}} Dermatitis herpetiformis (Option A) DH is a gluten-sensitive enteropathy associated with deposition of IgA in the dermal papillae, not linear IgG or C3 at the basement membrane. DH typically shows granular IgA deposition in immunofluorescence and not the linear patterns seen here. Pemphigus vulgaris (Option B) PV is characterized by intraepidermal blistering and acantholysis (loss of cell-to-cell adhesion between keratinocytes). Immunofluorescence shows intercellular IgG (not linear staining at the basement membrane zone). The presence of subepidermal blisters here excludes PV. Pemphigus foliaceous (Option C) PF is another type of pemphigus that features intraepidermal blistering and acantholysis but lacks subepidermal blistering. Immunofluorescence in PF typically shows intercellular IgG, not the linear IgG and C3 at the basement membrane observed in this case.

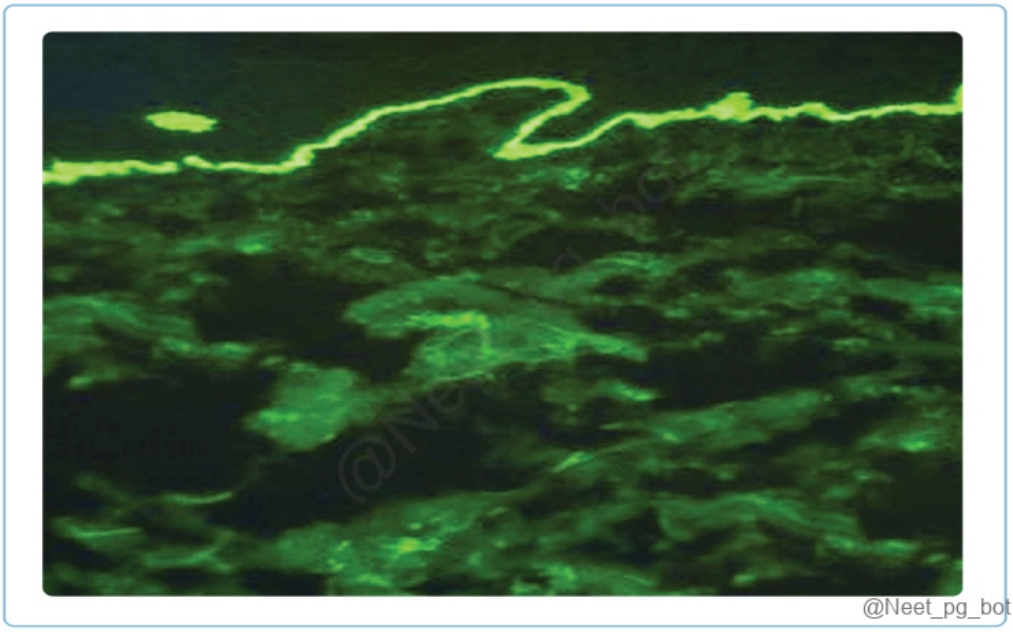

References:

Rooks textbook of dermatology 9th ed, page no. 50.10-50.17, 50.7, 50.53, 3.33-3.34, 50.3 , 50.7-50.8

Eponymous Dermatological Signs in Bullous Dermatoses - PMC (nih.gov)

Pathogenesis, clinical manifestations, and diagnosis of pemphigus - UpToDate

Dermatitis Herpetiformis - StatPearls - NCBI Bookshelf (nih.gov)

↑ *Back to this question in Part A*

@Neet_pg_bot

Q5: Auspitz sign is seen in? (Q859908)

A. Psoriasis vulgaris

B. Pustular psoriasis

C. Pemphigus

D. Bullous pemphigoid

Correct Answer: A. Psoriasis vulgaris

Explanation: The Auspitz sign, characterized by the development of pinpoint bleeding in the areas where the lesion is scraped with a glass slide, is commonly associated with psoriasis vulgaris {{caption_text}} While examining a patient’s psoriatic lesions during scraping with a blunt object such as the blunt edge of a glass slide, the following signs are seen: Grattage Sign/ Cadle sign : Accentuation of scaling when the lesion is scraped with the blunt edge of a glass slide ↓ Berkeley’s membrane: Formation of a thin membrane on further scraping ↓ Auspitz sign: Formation of pin-point bleeding on scraping the Berkeley’s membrane in patients with psoriasis. Another sign, "Sign of the last Hautchen" or "Sign of the Last Scale," refers to the presence of small, raised, erythematous papules that become visible after the last scale is removed from a psoriatic plaque, i.e., before the formation of Berkeley’s membrane .



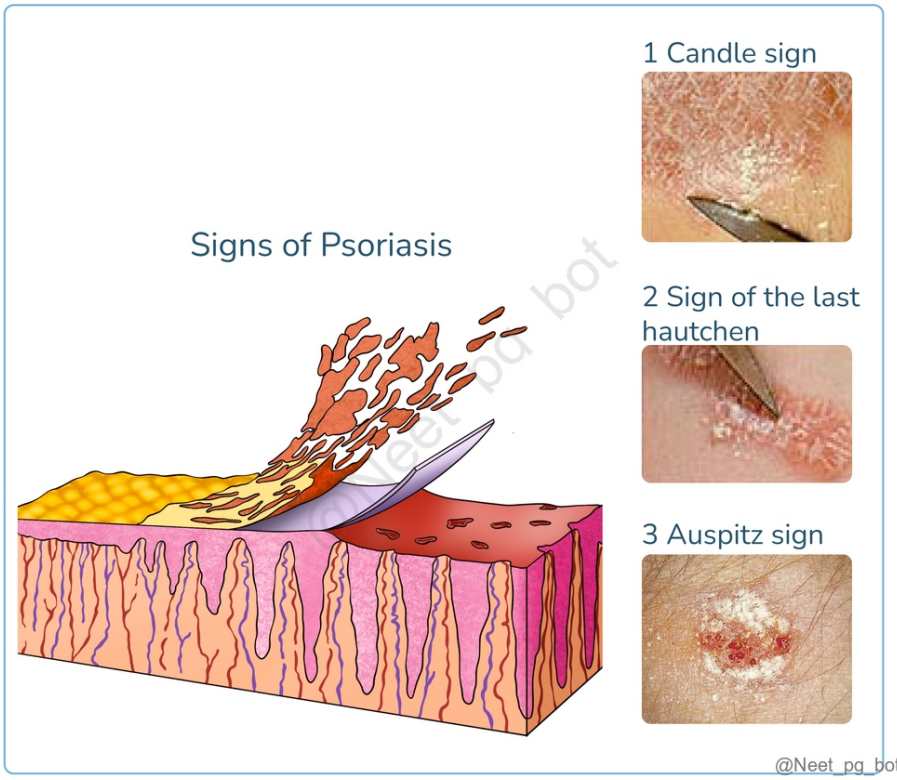

References:

Rook’s Textbook of Dermatology, 9th Edition, Chapter 35, Section 9

↑ *Back to this question in Part A*

@Neet_pg_bot

Q6: Identify the finding associated with the condition shown in the image below: (Q858513)

A. Isomorphic phenomenon

B. Meyerson phenomenon

C. Gottron’s papule

D. Nikolsky’s sign



Correct Answer: A. Isomorphic phenomenon

Explanation: The above image depicts Pustular psoriasis, which is a chronic inflammatory skin condition characterized by well-demarcated, erythematous plaques covered with silvery-white scales. Isomorphic phenomenon: The isomorphic phenomenon is the correct finding associated with the image. In individuals with psoriasis, new psoriatic lesions can appear at sites of skin trauma, such as scratches, cuts, or other forms of injury. Koebner's Phenomenon Psoriatic lesions develop along the lines of trauma. Isomorphic response All or none phenomenon {{caption_text}} Category Examples Category 1 (True koebnerization) Psoriasis, Lichen planus,

Vitiligo Category 2 (Pseudo koebnerization) Warts, Molluscum Category 3 (Occasional koebnerization) Darier disease, Erythema multiforme Category 4 (Dubious association with trauma) Pemphigus vulgaris, Lupus erythematosus Incorrect Options: Meyerson phenomenon (Option B): The Meyerson phenomenon refers to the development of psoriatic lesions after light tapping or pressure on a psoriatic plaque. Gottron's papule (Option C): Gottron's papule appear as flat-topped, violaceous eruptions overlying the joints of the fingers and elbows. Nikolsky's sign (Option D): Nikolsky's sign refers to the ability to induce blistering or detachment of the superficial skin layers by lateral pressure or rubbing (positive Nikolsky's sign). This sign is not relevant to plaque psoriasis.



References:

Illustrated Synopsis of Dermatology and Sexually Transmitted Diseases, Fifth Edition – Neena Khanna Pg 45

↑ *Back to this question in Part A*

@Neet_pg_bot

Q7: Which of the following would you not advise for a patient who is already diagnosed with chronic plaque psoriasis and has over 50% of their skin affected? (Q856386)

A. Oral methotrexate

B. NB UVB

C. Oral steroids

D. Oral cyclosporine

Correct Answer: C. Oral steroids

Explanation: In the case of a patient with chronic plaque psoriasis involving more than 50% of the skin, oral steroids are generally not recommended as a long-term treatment option due to the risk of severe rebound flares and pustular psoriasis upon withdrawal. Reasons Why Oral Steroids Are Avoided Rebound Phenomenon Sudden discontinuation can cause severe exacerbation of psoriasis, leading to erythroderma or pustular psoriasis (potentially life-threatening). Risk of Pustular Psoriasis Systemic steroids can trigger generalized pustular psoriasis (GPP) , characterized by widespread sterile pustules, fever, and systemic illness. Limited Long-Term Efficacy While steroids provide short-term relief , they do not alter disease progression and often require higher doses over time , leading to dependency. Preferred Long-Term Treatment Options Biologics (e.g., IL-17, IL-23, TNF inhibitors) Methotrexate, cyclosporine, or apremilast (for systemic therapy) (Option A and C) Phototherapy (NB-UVB- Narrowband ultraviolet B) (Option B) Topical therapies (vitamin D analogs, corticosteroids, calcineurin inhibitors) for localized disease

References:

Illustrated Synopsis of Dermatology and Sexually Transmitted Diseases, Fifth Edition – Neena Khanna Pg 55-60

↑ *Back to this question in Part A*

@Neet_pg_bot

Q8: What is the most probable diagnosis for a 30-year-old woman who has lacy lesions in her mouth and genital area, while her proximal nail fold has extended onto the nail bed? (Q857591)

A. Pityriasis rubra pilaris

B. Psoriasis

C. Pityriasis rosea

D. Lichen planus

Correct Answer: D. Lichen planus

Explanation: The combination of lacy lesions in the mouth and genital area, along with nail changes, strongly suggests lichen planus. Lichen Planus: Clinical Features 6 P's → Pruritic, Purple, Polygonal, Planar Papules & Plaques Mucosal involvement → Wickham striae (reticular white lines) Koebner phenomenon : This phenomenon refers to the development of lesions at sites of trauma to uninvolved skin Histology → Sawtooth infiltrate of lymphocytes at the dermal-epidermal junction Association → Hepatitis C Treatment Topical (First-line for mild

cases) Corticosteroids (Clobetasol, Betamethasone) Calcineurin Inhibitors (Tacrolimus, Pimecrolimus) – for oral/genital LP Antihistamines – for pruritus relief Local anesthetics (Lidocaine gel) – for painful oral lesions Intralesional (For hypertrophic LP) Intralesional corticosteroids (Triamcinolone injections) Systemic (For severe, widespread, or refractory cases) Oral corticosteroids (Prednisolone) Dapsone Hydroxychloroquine (HCQS) Azathioprine, Mycophenolate mofetil (MMF) Phototherapy (For generalized LP, especially in children) Narrow-band UVB (NBUVB) phototherapy Pityriasis Rubra Pilaris (Option A): Pityriasis Rubra Pilaris (PRP) typically presents with scaly, red follicular plaques and islands of sparing near the axilla called islands of sparing It histopathologically exhibits a distinctive checkerboard pattern marked by alternating areas of hyperkeratosis and parakeratosis. {{caption_text}} Psoriasis (Option B): Features silvery scales on erythematous plaques, commonly on extensor surfaces. Nail changes include pitting, oil-drop sign, and onycholysis, but not pterygium formation. Oral lesions are rare. Pityriasis rosea (Option C): Starts with a herald patch followed by oval, scaly lesions in a "Christmas tree" pattern. No oral/genital lesions or nail involvement. {{caption_text}}





References:

Rook’s Textbook of Dermatology, 9th Edition, Chapter 35, Section 9

↑ *Back to this question in Part A*

@Neet_pg_bot

Q9: A patient presented with lesions, as shown in the image below, and later developed arthritis also. What is the treatment of choice for this condition? (Q857054)

A. PUVA

B. Steroids

C. Methotrexate

D. Infliximab



Correct Answer: C. Methotrexate

Explanation: The patient has psoriasis (as indicated by the psoriatic plaque in the image) and later developed arthritis , suggesting psoriatic arthritis The drug of choice used to treat Psoriatic arthritis is methotrexate Methotrexate belongs to a class of drugs called disease-modifying anti-rheumatoid drugs (DMARDs). It reduces inflammation and alleviates the symptoms of arthritis. Treatment: Medical: NSAIDs Immuno suppressive agents- methotrexate and TNF inhibitors Local glucocorticoid injections Physiotherapy Surgery: For unstable joints. Arthrodesis procedure. Incorrect Options: PUVA (Option A): PUVA does not work effectively in reducing the arthritic condition. Methotrexate is preferred over PUVA for the treatment of Psoriatic arthritis. Steroids (Option B): Oral and topical corticosteroids can be used for short-term therapy but are not recommended for long-term use due to their many adverse effects. Infliximab (Option D): Infliximab is preferred in moderate to severe cases of Psoriatic arthritis but is not the first drug of choice due to it being more expensive.

References:

Apley and Solomon’s System of Orthopaedics and Trauma, 10th Edition, Pages 66, 78, 79.

Psoriatic Arthritis - StatPearls - NCBI Bookshelf (nih.gov)

↑ *Back to this question in Part A*

@Neet_pg_bot

Q10: A 45-year-old male presents to the dermatology clinic with an itchy skin rash. Physical examination reveals flat-topped, polygonal, purplish papules with fine white lines on the surface. The lesions are primarily located on the inner wrists and forearms, as well as on the lower back. The patient reports that he has been experiencing oral discomfort and noticed white, lacy patches on the inside of his cheeks. There is no family history of similar conditions. What is the most likely diagnosis? (Q857051)

A. Psoriasis

B. Eczema

C. Lichen planus

D. Tinea corporis

Correct Answer: C. Lichen planus

Explanation: Lichen planus is a chronic inflammatory skin disorder characterized by pruritic, violaceous, flat-topped papules. It frequently affects the flexor surfaces of the wrists, forearms, lower back, and mucosal surfaces. Lichen Planus: Clinical Features 6 P's → Pruritic, Purple, Polygonal, Planar Papules & Plaques Mucosal involvement → Wickham striae (reticular white lines) Koebner phenomenon : This phenomenon refers to the development of lesions at sites of trauma to uninvolved skin Histology → Sawtooth infiltrate of lymphocytes at the dermal-epidermal junction Association → Hepatitis C Treatment Topical (First-line for mild cases) Corticosteroids (Clobetasol, Betamethasone) Calcineurin Inhibitors (Tacrolimus, Pimecrolimus) – for oral/genital LP Antihistamines – for pruritus relief Local anesthetics (Lidocaine gel) – for painful oral lesions Intralesional (For hypertrophic LP) Intralesional corticosteroids (Triamcinolone injections) Systemic (For severe, widespread, or refractory cases) Oral corticosteroids (Prednisolone) Dapsone Hydroxychloroquine (HCQS) Azathioprine, Mycophenolate mofetil (MMF) Phototherapy (For generalized LP, especially in children) Narrow-band UVB (NBUVB) phototherapy Incorrect Options: Psoriasis (Option A): Characterized by silvery-white scales on erythematous plaques, mostly on extensor surfaces. Nail pitting and onycholysis are common. Eczema (Atopic Dermatitis) (Option B): Poorly demarcated, erythematous, weeping lesions with crusting and lichenification. Typically affects flexural surfaces (e.g., antecubital, popliteal fossae). Tinea Corporis (Option D): Annular (ring-shaped) lesions with a central clearing and scaly border. Fungal infection, confirmed by KOH preparation showing hyphae.

References:

Rook's Textbook of Dermatology, 9th Edition, Chapter 35, Section 9

↑ *Back to this question in Part A*

@Neet_pg_bot

Q11: Please match the following types of scales with their corresponding lesions. Scales Lesions 1. Collarette scales a. Pityriasis versicolour 2. Silvery scales b. Pityriasis rosea 3. Mica–like scales c. Psoriasis 4. Branny scales d. Pityriasis lichenoides (Q854965)

A. 1-b, 2-c, 3-d, 4-a

B. 1-a, 2-b, 3-d, 4-c

C. 1-d, 2-c, 3-a, 4-b

D. 1-c, 2-b, 3-d, 4-a

Correct Answer: A. 1-b, 2-c, 3-d, 4-a

Explanation: Each type of scale is associated with a characteristic dermatological condition: Collarette scales – Pityriasis rosea (1-b) Fine, trailing collarette of scales surrounding oval, salmon-coloured plaques seen in pityriasis rosea . Most prominent around the edges of herald patches . Silvery scales – Psoriasis (2-c) Thick, silvery-white scales over erythematous plaques , classically seen in psoriasis . Removal may lead to Auspitz sign (pinpoint bleeding). Mica-like scales – Pityriasis lichenoides (3-d) Fine, adherent mica-like scales covering small, erythematous papules. Seen in pityriasis lichenoides , a chronic inflammatory skin condition. Branny scales – Pityriasis versicolour (4-a) Fine, powdery, branny scales seen in pityriasis versicolour , a superficial fungal infection caused by Malassezia . Often reveals yellow-green fluorescence under Wood’s lamp. Scales in Dermatology: Scales are abnormal accumulations of keratinized cells on the skin surface and are characteristic of various dermatological conditions. They can vary in thickness, texture, and pattern based on the underlying disease. Type of Scale Description Associated Disease Key Clinical Features Collarette scales Thin, peripheral scales arranged in a collarette pattern, often seen in annular lesions. Pityriasis rosea Herald patch followed by a "Christmas tree" distribution of lesions. Silvery scales Thick, silvery-white, adherent scales that bleed upon removal (Auspitz sign). Psoriasis Well-demarcated erythematous plaques on extensor surfaces, scalp, and lower back. Mica-like scales Fine, thin, shiny scales resembling mica. Pityriasis lichenoides Chronic or recurrent papulosquamous eruptions. Branny scales Fine, powdery, furfuraceous (bran-like) scaling. Pityriasis versicolor Hypo- or hyperpigmented macules caused by Malassezia, commonly on the trunk.


@Neet_pg_bot


@Neet_pg_bot



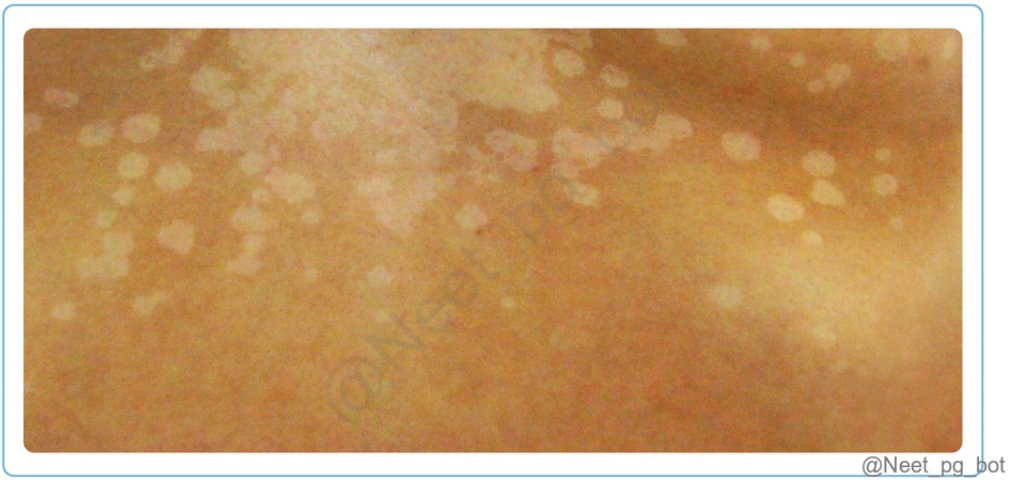

References:

https://pmc.ncbi.nlm.nih.gov/articles/PMC4961504/

https://pmc.ncbi.nlm.nih.gov/articles/PMC9319552/

https://www.ncbi.nlm.nih.gov/books/NBK459240/

https://www.ncbi.nlm.nih.gov/books/NBK448091/

https://www.ncbi.nlm.nih.gov/books/NBK557401/

↑ *Back to this question in Part A*

@Neet_pg_bot

Q12: A patient presented with itchy lesions, as shown below. What is the diagnosis? (Q857975)

A. Scabies

B. Lichen planus

C. Psoriasis

D. Warts



Correct Answer: B. Lichen planus

Explanation: : Incorrect because scabies presents with burrows, interdigital involvement, and nocturnal itching . Psoriasis (Option C): Incorrect because psoriasis has silvery scales on erythematous plaques, usually on extensor surfaces . Warts (Option D): Incorrect because warts are hyperkeratotic papules caused by HPV, without pruritus or Wickham striae .

References:

Robbin’s Pathology, 10th edition, pg 1159

↑ *Back to this question in Part A*

@Neet_pg_bot

Q13: A 26-year-old male presented with erythematous plaques covered with silvery scales over the extensor surfaces of both arms. Punctate pitting was noted on examining the nails. What is the most likely diagnosis? (Q857973)

A. Psoriasis

B. Lichen planus

C. Eczema

D. Pityriasis rosea



@Neet_pg_bot

Correct Answer: A. Psoriasis

Explanation: : Incorrect because lichen planus presents with purple, pruritic, polygonal papules and Wickham striae, not silvery scales. Eczema (Option C): Incorrect because eczema involves flexural surfaces and is associated with intense pruritus and weeping lesions. Pityriasis rosea (Option D): Incorrect because it presents

with a herald patch followed by a Christmas-tree distribution of lesions, not thick silvery scales.

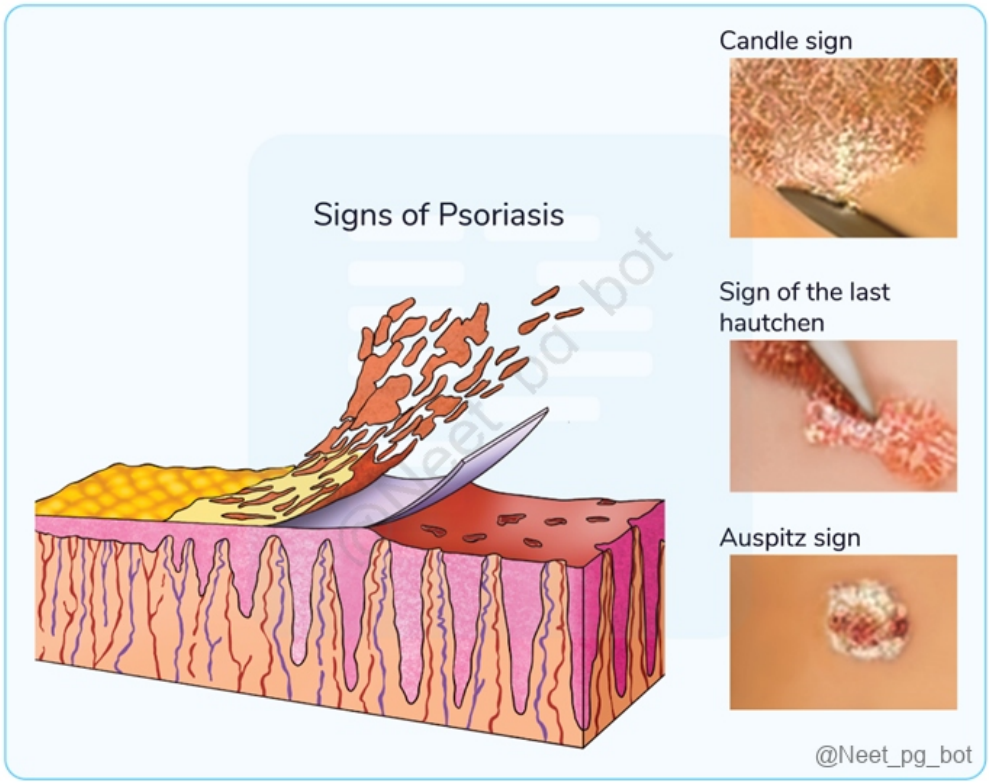

References:

Rook’s Textbook of Dermatology, 9th Edition, Chapter 35, Section 9

↑ *Back to this question in Part A*

@Neet_pg_bot

Q14: A 25-year-old male presents with a 2-week history of mildly itchy skin lesions. On examination, there is a single, oval, pink plaque with a collarette of scale on the trunk arranged in a characteristic "Christmas tree" pattern. There is no history of fever, drug intake, or systemic illness. What is the most likely diagnosis? (Q854651)

A. Pityriasis rosea

B. Psoriasis

C. Tinea corporis

D. Secondary syphilis

Correct Answer: A. Pityriasis rosea

Explanation: The case scenario with a 2-week history of mildly itchy, oval, pink plaques with a collarette of scale and a "Christmas tree" pattern on the trunk is suggestive of P ityriasis rosea . It begins with a single, oval, pink plaque with a collarette of scale (herald patch), followed by smaller, scaly oval lesions along skin cleavage lines forming a "Christmas tree" pattern on the trunk . It mainly affects young adults (15–35 years), causes mild itching, and lacks systemic symptoms. The condition is self-limiting and usually resolves within weeks to months without treatment. Psoriasis (Option B): Usually presents with thick, well-defined red plaques with silvery scales, often on extensor surfaces, and can have nail and joint involvement, unlike the milder, self-limiting rash of pityriasis rosea. Tinea corporis (Option C): Characterized by annular, scaly plaques with central clearing, typically associated with fungal infection, and does not follow a Christmas tree pattern. Secondary syphilis (Option D): Presents with a generalized rash including palms and soles, often with systemic symptoms and positive serology, not a solitary herald patch or Christmas tree pattern typical of pityriasis rosea.

References:

From PYQ

Rook’s Textbook of Dermatology, 9th Edition, Chapter 35, Image 35.6

Psoariasis

↑ *Back to this question in Part A*

@Neet_pg_bot

Q15: A 24-year-old male presents with scaly lesions over the body, as shown in the Image below. No other associated symptoms are present. What is the likely diagnosis? (Q857399)

A. Lichen planus

B. Pityriasis Rosea

C. Seborrheic Dermatitis

D. Atopic Dermatitis





Correct Answer: B. Pityriasis Rosea

Explanation: Pityriasis Rosea is a scaly red lesion that usually occurs on the trunk. They are scaly heralds patches and a collarette of scales can be seen. It usually presents 2-3 weeks after URTI and Gl infections. {{caption_text}} Lichen planus (Option A): Presents as papulosquamous disorder which affects the skin, mucosa, hair, and nails. It is pruritic and it affects flexure surfaces. {{caption_text}} Seborrheic dermatitis (Option C): Usually seen as red itchy, scaly patches on the skin. Since in this case, it is asymptomatic it cannot be this option. {{caption_text}} Atopic dermatitis (Option D): Atopic dermatitis is dry, itchy, and erythematous. It is not asymptomatic. Hence the incorrect choice. {{caption_text}}




@Neet_pg_bot


@Neet_pg_bot



References:

https://www.ncbi.nlm.nih.gov/books/NBK448091/

↑ *Back to this question in Part A*

@Neet_pg_bot

Q16: A child with a sore throat starts developing skin lesions as in the image below. Which of the following is the diagnosis? (Q860104)

A. Guttate psoriasis

B. Pustular psoriasis

C. Erythrodermic

D. Inverse psoriasis



Correct Answer: A. Guttate psoriasis

Explanation: The image given above is of Guttate psoriasis It is commonly seen in children. It is usually preceded by streptococcal infection Small, erythematous, scaly plaques on the trunk which gives raindrop-like appearance are seen Treatment: Antibiotics (penicillin, amoxicillin) Pustular Psoriasis (Option B): Pustular psoriasis (a type of unstable psoriasis) characterized by the presence of multiple sterile, non-infectious pus-filled blisters on erythematous skin, forming a characteristic 'Lakes of pus' appearance. {{caption_text}} Erythrodermic Psoriasis (Option C): It is another variant of unstable psoriasis that presents with erythema and scales covering more than 90% of the body surface. {{caption_text}} Inverse Psoriasis (Option D): Affects intertriginous areas (axilla, groin, inframammary folds) and presents with shiny, erythematous plaques without scaling, unlike guttate psoriasis. {{caption_text}}


@Neet_pg_bot

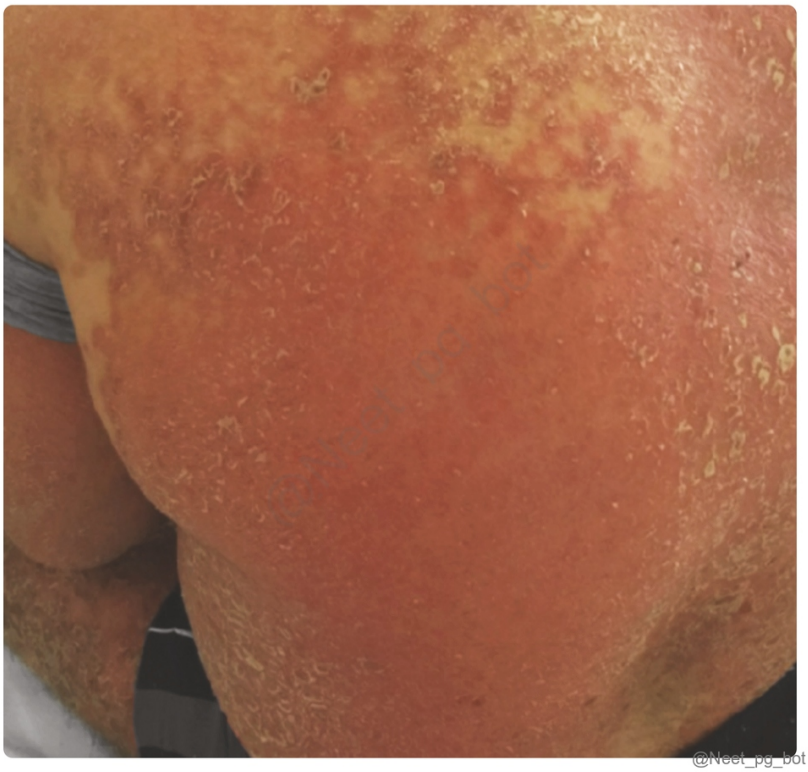
@Neet_pg_bot



References:

Rook’s Textbook of Dermatology, 9th Edition, Chapter 35, Section 16

↑ *Back to this question in Part A*

@Neet_pg_bot

Q17: A 45-year-old patient presents with itchy, flat-topped, polygonal, violaceous papules on the inner wrists and flexors surfaces of the forearms. The lesions have a characteristic shiny surface and are arranged in a linear pattern. The patient denies any recent medication changes. What is the treatment? (Q860609)

A. Topical steroids

B. Antibiotics

C. Immunosuppressants

D. Anti-fungal

Correct Answer: A. Topical steroids

Explanation: The patient's itchy, flat-topped, polygonal, violaceous papules on the inner wrists and flexor surfaces of the forearms are characteristic of Lichen Planus (LP). Lichen Planus: Clinical Features 6 P’s → Pruritic, Purple, Polygonal, Planar Papules & Plaques Mucosal involvement → Wickham striae (reticular white lines) Koebner phenomenon : This phenomenon refers to the development of lesions at sites of trauma to uninvolved skin Histology → Sawtooth infiltrate of lymphocytes at the dermal-epidermal junction Association → Hepatitis C Treatment Topical (First-line for mild cases) Corticosteroids (Clobetasol, Betamethasone) Calcineurin Inhibitors

(Tacrolimus, Pimecrolimus) – for oral/genital LP Antihistamines – for pruritus relief Local anesthetics (Lidocaine gel) – for painful oral lesions Intralesional (For hypertrophic LP) Intralesional corticosteroids (Triamcinolone injections) Systemic (For severe, widespread, or refractory cases) Oral corticosteroids (Prednisolone) Dapsone Hydroxychloroquine (HCQS) Azathioprine, Mycophenolate mofetil (MMF) Phototherapy (For generalized LP, especially in children) Narrow-band UVB (NBUVB) phototherapy

References:

Rook’s Textbook of Dermatology, 9th Edition, Chapter 35, Section 9

↑ *Back to this question in Part A*

@Neet_pg_bot

Q18: A 25-year-old patient presents with rashes with an orange hue on his body and thickened palms and soles. Based on the histological image given, what is the diagnosis? (Q843964)

A. Pityriasis rubra pilaris

B. Keratosis follicularis

C. Follicular psoriasis

D. Cutaneous T-cell lymphoma







Correct Answer: A. Pityriasis rubra pilaris

Explanation: Correct Option A - Pityriasis rubra pilaris: The patient’s presentation with orange-hued rashes, thickened palms and soles, and the histological findings (checkerboard pattern of hyperkeratosis and parakeratosis) are characteristic of Pityriasis Rubra Pilaris (PRP). Incorrect Options: Options B, C, and D show a different histopathological pattern.

↑ *Back to this question in Part A*

@Neet_pg_bot

Q19: Diagnose the condition using the histological image provided. (Q843961)

A. Morphea

B. Lichen nitidus

C. Lichen planus

D. Lichen amyloidosis

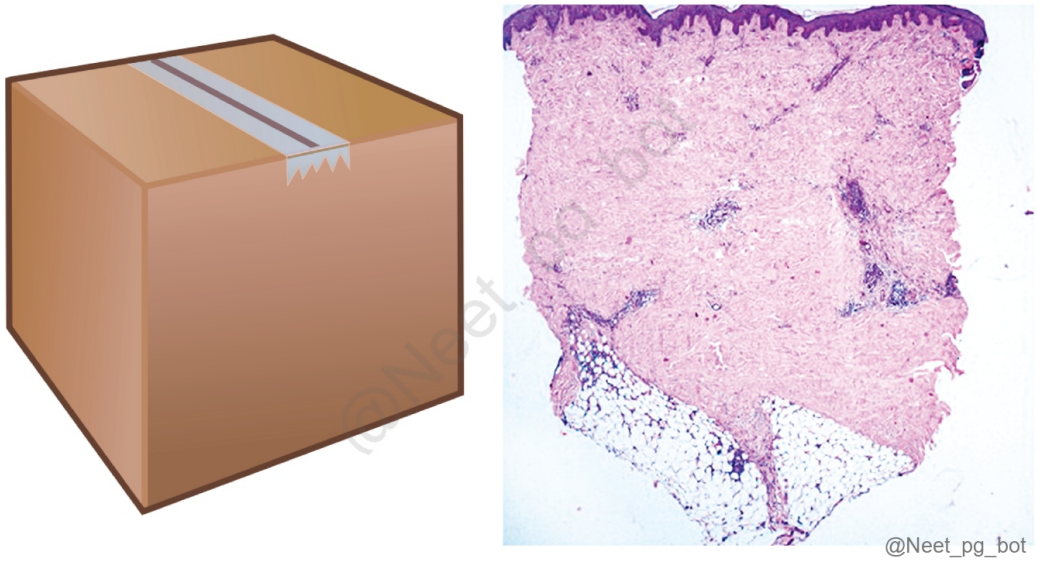

Correct Answer: A. Morphea

Explanation: Correct option A - Morphea Biopsy from the indurative stage of morphea (localized scleroderma) is squared off at the edges, giving the appearance of box-shaped (or boxed dermis appearance) This boxing of the dermis probably happens due to the marked sclerosis of collagen throughout the reticular dermis and extending to the septa of subcutaneous fat. Morphea-lichen sclerosus overlap and scleredema can also similarly show squared off edges of biopsy specimen. Incorrect Options Option B - Lichen nitidus : Histology of lichen nitidus showing well-defined granuloma enclosed by rete pegs giving the appearance of "claw clutching a ball" Option C - Lichen planus: The histological image is consistent with lichen planus, showing a dense band-like lymphocytic infiltrate at the dermo-epidermal junction and saw-toothing of the rete ridges.

Stratum Corneum	Hyperkeratosis (increased thickening). 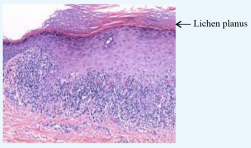
Stratum Granulosum	Typically focal, wedge-shaped hypergranulosis is seen. 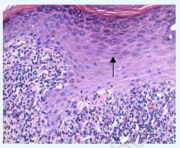
Stratum Spinosum	Acanthosis
Stratum Basale	• Basal cell degeneration occurs and keratinocytes transform into apoptotic bodies (civatte bodies) • The melanocytes release melanin leading to melanin incontinence, this melanin gets engulfed by the macrophages leading to formation of melanophages.
Rete Ridges	Saw-toothed rete ridges 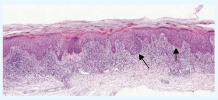
Between epidermis and dermis	Max Joseph Space
Dermis	Band-like infiltrate of lymphocytes. 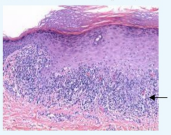
The basal cell degeneration and infiltrate in the dermis are together referred to as Interface dermatitis.	

↑ *Back to this question in Part A*

@Neet_pg_bot

Q20: Which of the following does not distinguish Psoriasis from other arthropathies? (Q853197)

A. Diarrhoea

B. Dactylitis

C. Enthesitis

D. Nail pitting

Correct Answer: A. Diarrhoea

Explanation: Diarrhea is not a distinguishing feature of psoriatic arthritis; it is more commonly associated with inflammatory bowel disease (IBD)-related arthritis. CASPAR Criteria for Psoriatic Arthritis (PsA): To classify a patient as having PsA, they must have inflammatory joint disease (affecting joints, spine, or entheses) plus ≥3 of the following 5 criteria: Evidence of Psoriasis (Any one of the following): Current psoriasis Personal history of psoriasis Family history of psoriasis Psoriatic nail dystrophy (Option C ruled out) Negative Rheumatoid Factor (RF) Dactylitis (Current or past history) (Option B ruled out) Radiological evidence of juxta-articular new bone

formation Enthesitis (Option C): which is inflammation of tendons and ligaments, though not part of CASPAR criteria for PsA, is commonly found in PsA. Note: Psoriatic arthritis is a seronegative polyarthritis with erosive arthritis .

References:

https://www.frontiersin.org/journals/medicine/articles/10.3389/fmed.2018.00246/full

↑ *Back to this question in Part A*

@Neet_pg_bot

Q21: Identify the type of psoriasis in the given picture. (Q793445)

A. Guttate

B. Erythrodermic

C. Pustular

D. Inverse



Correct Answer: A. Guttate

Explanation: Correct Option A - Guttate psoriasis: A type of psoriasis known as guttate psoriasis is characterized by skin lesions in the shape of small drops. These sores are generally under 1 centimeter in measurement and show up on the storage compartment, appendages, and scalp. Incorrect Options: Option B - Erythrodermic: Erythrodermic psoriasis is characterized by widespread skin scaling, inflammation, and redness, frequently accompanied by pain and itchiness. Option C - Pustular: A form of psoriasis known as pustular psoriasis results in pus-filled blisters on plaques, which are scaly, flaky patches of skin. Option D - Inverse: Converse psoriasis.

Presents with smooth, red, and inflamed patches of skin that may be itchy, painful, and susceptible to infection are its hallmarks.

References:

Prepladder Notes

↑ *Back to this question in Part A*

@Neet_pg_bot

Q22: A 50-year-old patient presents with following skin lesions characterized by red and scaly patches. The patient also complains of a painful and swollen finger joint. On examination, the finger joint appears inflamed and tender to touch. What is the most likely diagnosis for this patient's condition? (Q820242)

A. Psoriatic Arthritis

B. Pseudo gout

C. Osteoarthritis

D. Reactive arthritis



Correct Answer: A. Psoriatic Arthritis

Explanation: The patient’s red, scaly skin lesions and painful, swollen distal finger joints are indicative of P soriatic Arthritis Swelling of the DIP joint plus skin psoriasis signs. Pain, swelling, and tenderness in affected joints. Nail changes like pitting or ridges support diagnosis. Often involves the fingers with "sausage digits" and can cause deformities over time. Pseudo gout (Option B) is a type of arthritis caused by the deposition of calcium pyrophosphate crystals in the joints. It can also lead to joint inflammation and pain, but it typically doesn't have an association with skin lesions like psoriasis. The symptoms described in the case, including the skin lesions, make psoriatic arthritis a more likely diagnosis. Osteoarthritis (Option C) is a degenerative joint disease characterized by the breakdown of cartilage in the joints. It is more common in older individuals and typically presents with joint pain and stiffness. However, it does not usually involve the red and scaly skin lesions mentioned in the case. Reactive arthritis (Option D) , also known as Reiter's syndrome, is an inflammatory condition that typically develops as a response to an infection in another part of the body. It often involves joint inflammation, especially in the lower limbs, and can be associated with skin lesions. However, the case description of red and scaly patches on the skin, along with finger joint DIP involvement, is more suggestive of psoriatic arthritis.

References:

.

↑ *Back to this question in Part A*

@Neet_pg_bot

• [06_Immunobullous Disorders] 012 Immunobullous Disorders

« Back to Folder Directory

[06_Immunobullous Disorders] 012 Immunobullous Disorders — Quick Jump

Q1 (p. 872)	*Q2 (p. 873)*	*Q3 (p. 874)*	*Q4 (p. 875)*	*Q5 (p. 876)*	*Q6 (p. 879)*
Q7 (p. 880)	*Q8 (p. 882)*	*Q9 (p. 883)*	*Q10 (p. 885)*	*Q11 (p. 885)*	*Q12 (p. 888)*
Q13 (p. 890)	*Q14 (p. 891)*	*Q15 (p. 892)*	*Q16 (p. 895)*	*Q17 (p. 900)*	*Q18 (p. 901)*
Q19 (p. 904)	*Q20 (p. 905)*	*Q21 (p. 906)*	*Q22 (p. 911)*		

Q1: Which of the following correctly matches the pemphigoid disease with its primary target antigen? (Q841959)

A. Bullous pemphigoid - BP180

B. Mucous membrane pemphigoid - BP230

C. Epidermolysis bullosa acquisita - Laminin

D. Linear IgA disease - Desmoglein 3

Correct Answer: A. Bullous pemphigoid - BP180

■ *Listen (English)*

■ *Listen (Hindi)*

Explanation: Pemphigoid diseases are characterized by autoantibodies against structural proteins of the dermal–epidermal junction. These proteins link the cytoskeleton of the basal keratinocytes to the extracellular matrix of the dermis. The binding of autoantibodies leads to the separation of epidermis and dermis and the formation of blisters. These can be summarised in the table below. Disease Target antigens Bullous pemphigoid (Option A) BP 180 (BP2) > BP 230 (BP1) Pemphigoid gestationis BP 180 > BP 230 Linear IgA disease (Option D) BP 180 and LAD 1 Epidermolysis bullosa acquisita (Option C) Collagen VII Bullous systemic lupus erythematosus Collagen VII Cicatricial pemphigoid BP 180 Mucous Membrane Pemphigoid (Option B) BP 180, laminin 332 Dermatitis Herpetiformis Epidermal transglutaminase

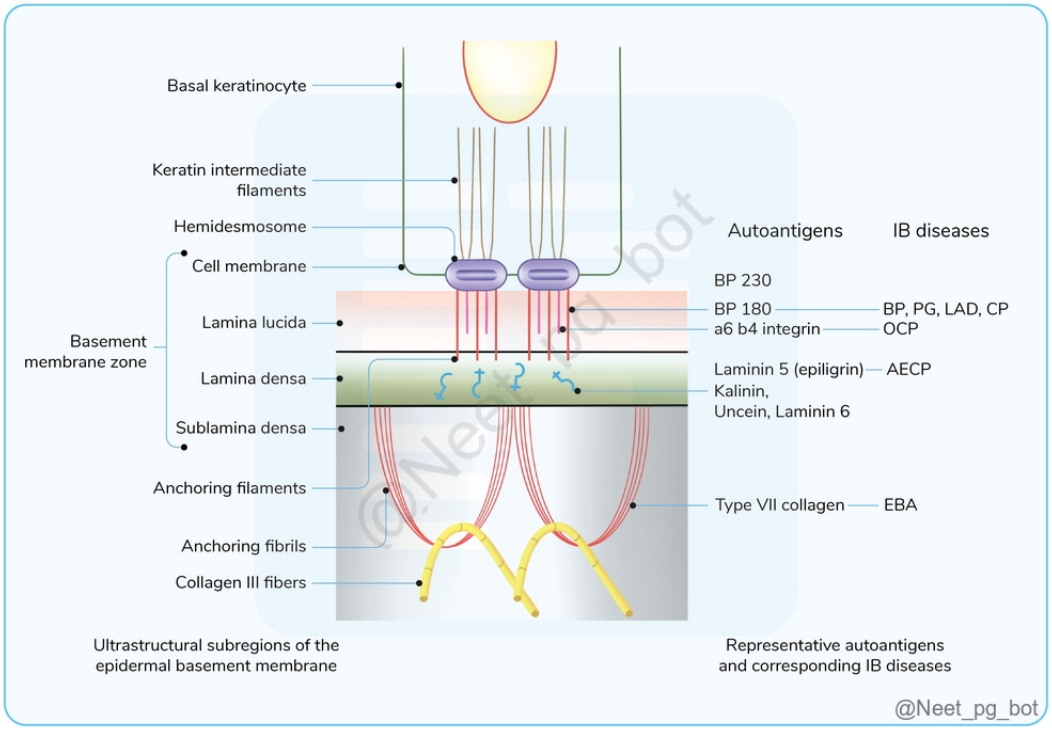

References:

Rooks textbook of dermatology 9th ed, page no. 50.9-50.10

↑ *Back to this question in Part A*

@Neet_pg_bot

Q2: Arrange the following autoimmune blistering skin diseases in order from the most superficial to the deepest target antigen in the skin: Bullous pemphigoid Pemphigus vulgaris Epidermolysis bullosa acquisita Pemphigus foliaceus (Q842649)

A. 4, 2, 1, 3

B. 2, 4, 1, 3

C. 4, 2, 3, 1

D. 3, 1, 2, 4

Correct Answer: A. 4, 2, 1, 3

Explanation: Disease Target Antigen(s) Location Pemphigus foliaceus (4) Desmoglein 1 Upper layers of epidermis (stratum granulosum and upper spinosum) Pemphigus vulgaris (2) Primarily Desmoglein 3, sometimes also Desmoglein 1 Throughout epidermis, mainly in lower layers (suprabasal) Bullous pemphigoid (1) BP180

(BPAG2) BP230 (BPAG1) Hemidesmosomes at the dermal-epidermal junction Epidermolysis bullosa acquisita (3) Type VII collagen Anchoring fibrils in upper dermis, below lamina densa Clinical Presentation: Pemphigus foliaceus presents with very superficial blisters that easily break. Pemphigus vulgaris causes deeper blisters within the epidermis. Bullous pemphigoid produces tense blisters at the dermal-epidermal junction. Epidermolysis bullosa acquisita leads to blisters that heal with scarring and milia formation due to the deeper level of blister formation

References:

Rooks textbook of dermatology 9th ed, page no. 50.2

↑ *Back to this question in Part A*

@Neet_pg_bot

Q3: Which of the following best describes the characteristic immunofluorescence pattern seen in pemphigus? (Q842648)

A. Linear band along the basement membrane zone

B. Granular deposits at the dermal-epidermal junction

C. Fish net-like or honeycomb pattern in the epidermis

D. Nuclear staining of keratinocytes

Correct Answer: C. Fish net-like or honeycomb pattern in the epidermis

Explanation: The characteristic immunofluorescence pattern seen in pemphigus is indeed a fish net-like or honeycomb pattern in the epidermis (Option C). Pemphigus : It is an autoimmune blistering disease affecting the skin and mucous membranes. The two main types are pemphigus vulgaris and pemphigus foliaceus. Autoantibodies : In pemphigus, autoantibodies target desmoglein proteins Immunofluorescence pattern: When a skin biopsy from a pemphigus patient is subjected to direct immunofluorescence (DIF), it reveals a distinctive pattern: The autoantibodies (usually IgG) bind to the cell surface of keratinocytes throughout the epidermis. This creates a pattern that resembles a fish net or honeycomb when viewed under a fluorescence microscope. {{caption_text}} Linear band (Option A) is typically seen in bullous pemphigoid, not pemphigus. Granular deposits (Option B) are more characteristic of lupus erythematosus. Pemphigus erythematosus (a/w SLE) has both intercellular IgG Deposits in epidermis and granular IgG Deposits in Dermo Epidermal Junction Nuclear staining (Option D) is more commonly seen in SLE, Scleroderma.

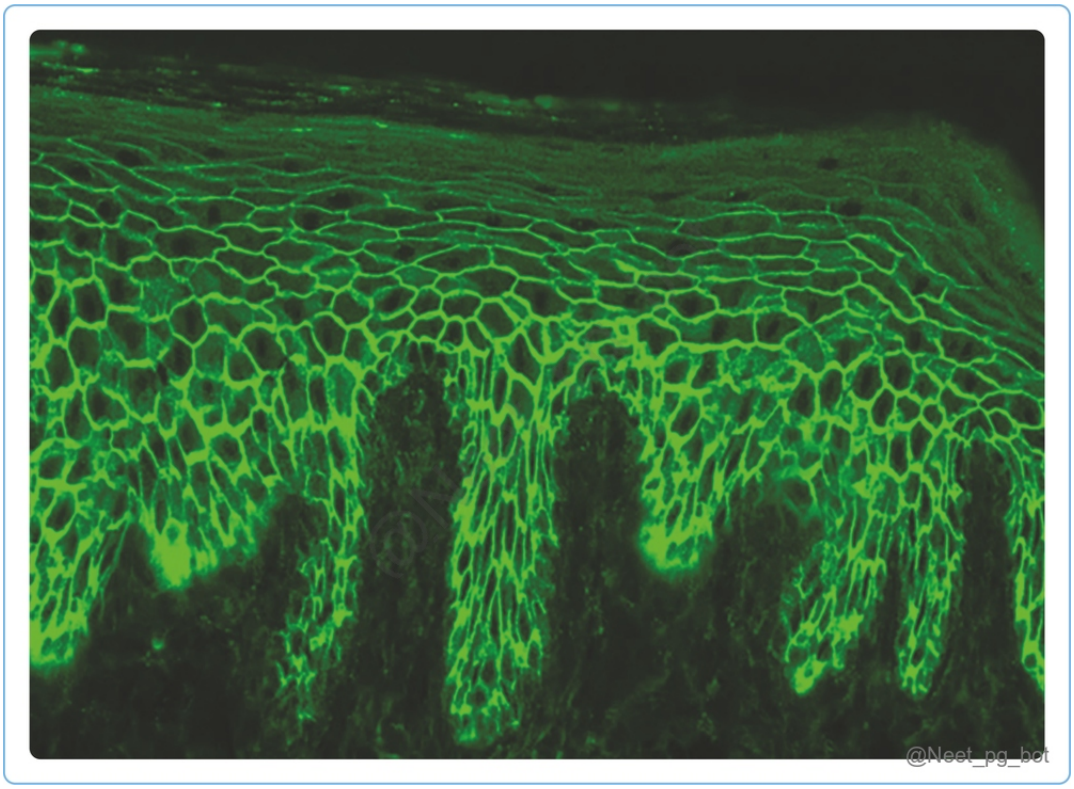

References:

Rooks textbook of dermatology 9th ed, page no. 3.17, 3.18

↑ *Back to this question in Part A*

@Neet_pg_bot

Q4: A patient presents with tense vesicles and bullae in sun■exposed areas like the neck, upper trunk, and proximal extremities. She has a history of systemic disease involving small joints of hands and feet. Immunofluorescence of the biopsied lesion shows granular + linear IgG and C3 deposits in the dermo-epidermal junction. Antibody against which of the following antigens is mainly associated with this patient's current condition? (Q841967)

A. Collagen VII

B. CCP

C. Ro La

D. Transglutaminase

Correct Answer: A. Collagen VII

■ *Listen (English)*

■ *Listen (Hindi)*

Explanation: The above clinical scenario and immunofluorescence showing granular + linear IgG and C3 deposits in the dermo-epidermal junction suggest bullous systemic lupus erythematosus(BSLE). The main antibodies in this case are directed against collagen VII. Bullous systemic lupus erythematosus(BSLE): BSLE is an autoimmune subepidermal blistering disease that occurs in patients with SLE. The target antigen here is type VII collagen. On top of the SLE symptoms, patients with BSLE present with acute-onset vesicles and blisters, with a predilection for sun■exposed areas like neck, upper trunk, and proximal extremities. HPE would show subepidermal splitting with immunofluorescence showing granular + linear IgG and C3 deposits in the dermo-epidermal like other related bullous disorders. Anti-CCP antibodies (Option B) are seen in patients with rheumatoid arthritis. Ro La antibodies (Option C) are classical of SCLE. But this patient's current condition is BSLE which mainly has antibodies against collagen VII causing the above skin lesions. Anti-transglutaminase antibodies (Option D) are seen in dermatitis herpetiformis, which presents with pruritic vesicles and erosions involving the extensor surfaces. Patient will have a history of chronic diarrhoea

References:

Rooks textbook of dermatology 9th ed, page no. 50.46-50.48, 56.8, 50.53

↑ *Back to this question in Part A*

@Neet_pg_bot

Q5: A 14-year-old girl presents with complaints of pruritic papules on the elbows and knees as shown below. She also gives a history of chronic diarrhea which stopped after certain dietary restrictions. What is the immunofluorescence pattern seen on the biopsy of these lesions? (Q841966)

A. Epidermal intercellular deposition of IgG

B. Linear IgA deposition at the dermo-epidermal junction

C. Granular IgA deposition in the papillary dermis

D. Epidermal intercellular and subepidermal deposition of IgG



Correct Answer: C. Granular IgA deposition in the papillary dermis

■ *Listen (English)*

■ *Listen (Hindi)*

Explanation: The girl with the above lesions associated with chronic diarrhea most likely has dermatitis herpetiformis, which shows granular IgA deposition in the papillary dermis. Dermatitis herpetiformis(DH): ■■■■■■■ Dermatitis herpetiformis (DH) is linked to celiac disease and gluten sensitivity. Gluten triggers chronic diarrhea and malabsorption; gluten-free diet resolves symptoms. Associated with HLA-DQ2/DQ8 and IgA autoantibodies against transglutaminase. Presents as pruritic, grouped papules/vesicles on extensor surfaces; excoriations common. Histology: subepidermal blisters with neutrophils at dermal papillae tips. Immunofluorescence: granular/fibrillar IgA in papillary dermis (“picket fence” pattern). {{caption_text}} {{caption_text}} HPE with papillary abscess and infiltrate Immunofluorescence with IgA in papillary dermis {{caption_text}} Management includes a gluten■free diet that improves diarrhoea as well as skin lesions. Dapsone is given for targeting pruritis and skin lesions.

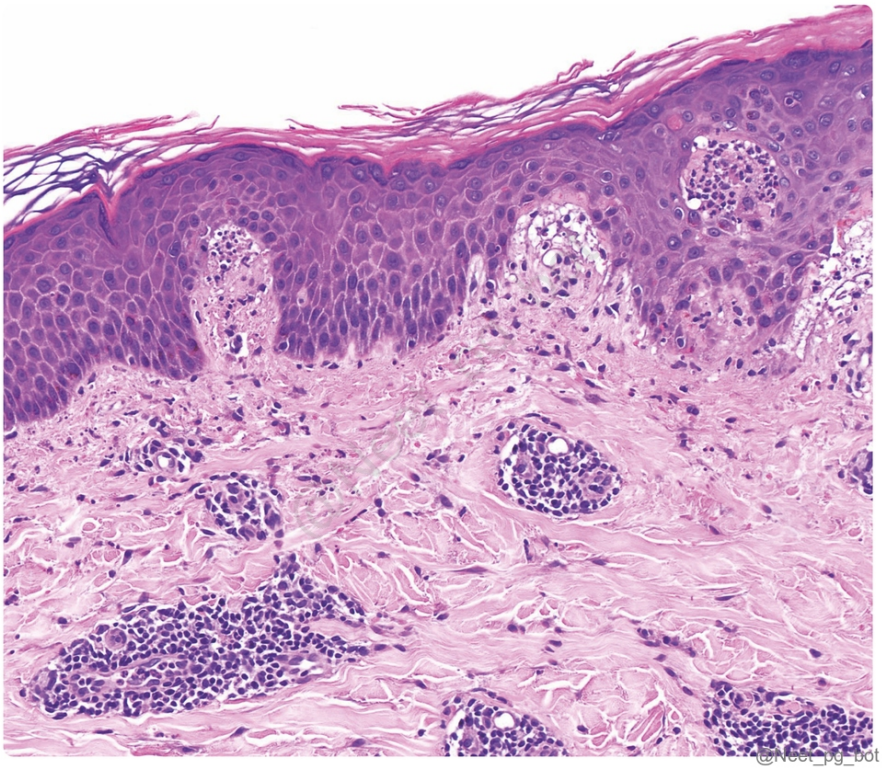
@Neet_pg_bot

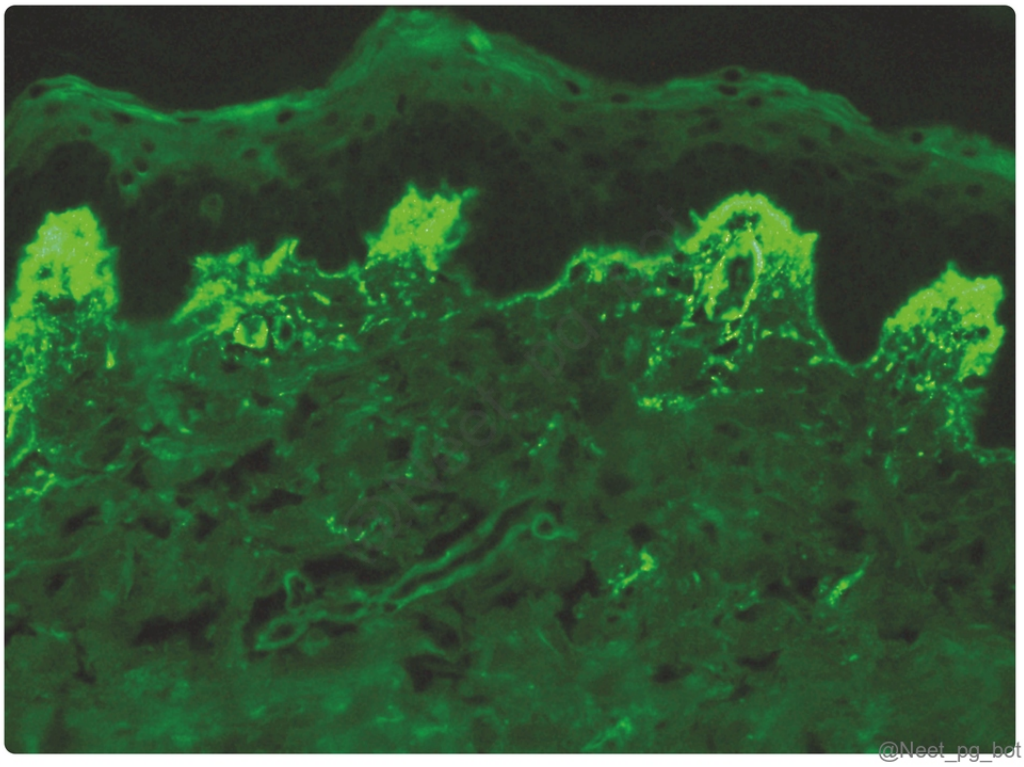
@Neet_pg_bot



References:

Rooks textbook of dermatology 9th ed, page no.50.52-50.54, 50.2 Utility of immunofluorescence in dermatology - PMC (nih.gov)

↑ *Back to this question in Part A*

@Neet_pg_bot

Q6: A biopsy is being performed to diagnose a skin lesion. The pathologist performs direct immunofluorescence microscopy on salt-split skin, which shows immunoglobulin depositing on the blister's floor. What is the most probable diagnosis? (Q841965)

A. Mucous membrane pemphigoid

B. Bullous pemphigoid

C. Linear IgA disease

D. Epidermolysis bullosa acquisita

Correct Answer: D. Epidermolysis bullosa acquisita

■ *Listen (English)*

■ *Listen (Hindi)*

Explanation: Among the given options, the only condition that shows antibodies on the blister floor during salt-split skin immunofluorescence is epidermolysis bullosa acquisita. Salt split technique(SST): To a skin biopsy specimen, 1 molar of NaCl is added and left to sit for some time. This splits the basement membrane at the level of lamina lucida, leaving 2 different targets for antibodies to be visualized on immunofluorescence microscopy. This is used to differentiate and diagnose blistering disorders. Immunofluorescence at the blister roof is seen in Mucous membrane pemphigoid Bullous pemphigoid Linear IgA disease Whereas immunofluorescence on the blister floor

is seen in epidermolysis bullosa acquisita.

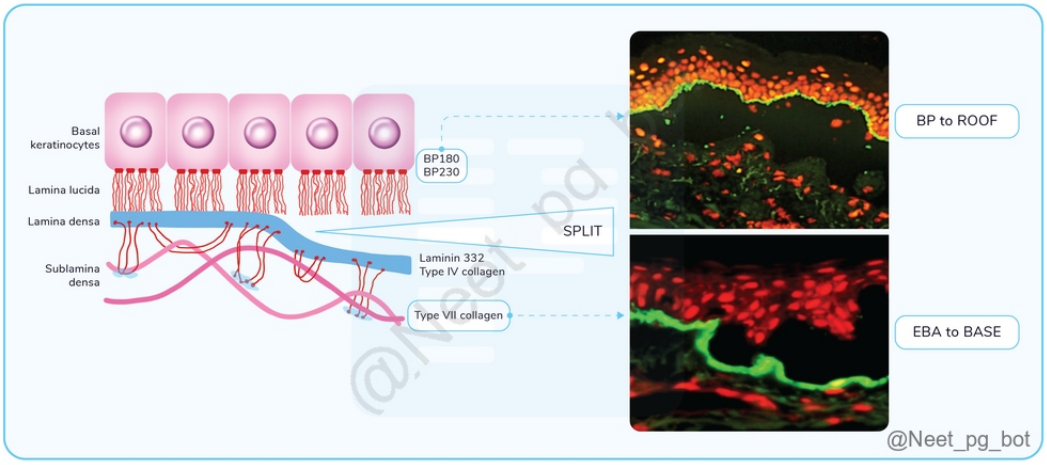

References:

Rooks textbook of dermatology 9th ed, page no.50.45 Salt-Split Skin for Evaluating Autoimmune Blistering Diseases (jwatch.org)

↑ *Back to this question in Part A*

@Neet_pg_bot

Q7: A 45-year-old patient presents with erosions, blisters, and crusts in the groin and thigh region as shown below. His blood tests reveal he has antibodies against collagen VII. What is the most probable diagnosis? {{caption_text}} (Q841964)

A. Linear Ig A disease

B. Bullous pemphigoid

C. Epidermolysis bullosa aquisita

D. Pemphigus Vulgaris



Correct Answer: C. Epidermolysis bullosa aquisita

■ *Listen to Audio 1*

Explanation: This clinical scenario and the presence of antibodies against collagen VII suggest a diagnosis of epidermolysis bullosa aquisita (EBA). Epidermolysis bullosa aquisita: It is a subepidermal blistering disease defined by autoantibodies against type VII collagen. It has two forms: Mechanobullous variant: Skin fragility, erosions, blisters, crusts, and scars on trauma■prone areas such as the hands, knuckles, elbows, knees, and toes {{caption_text}} Inflammatory varian t: present similar to bullous pemphigoid. HPE examination will show subepidermal blistering with immunofluorescence showing linear deposition of IgG at the dermal-epidermal junction. Patients have antibodies against collagen VII. Pemphigoid diseases and target antigen: Disease Target antigens Bullous pemphigoid BP 180, BP 230 Pemphigoid gestationis BP 180, BP 230 Linear IgA disease LAD1 Epidermolysis bullosa acquisita Collagen VII Bullous systemic lupus erythematosus Collagen VII Cicatricial pemphigoid BP 180 Mucous Membrane Pemphigoid BP 180, laminin 332 Dermatitis Herpetiformis Epidermal transglutaminase Linear IgA disease (Option A): Characterized by linear deposition of IgA at the basement membrane zone. Common in children (chronic bullous disease of childhood) but also occurs in adults. Not associated with anti-collagen VII antibodies . Typically shows “ string of pearls ” arrangement of blisters. Bullous pemphigoid (Option B): Involves IgG antibodies against BP180 (collagen XVII) and BP230 , not collagen VII. Causes tense subepidermal blisters , usually in the elderly. Common on trunk and extremities , less often in groin. Not associated with anti-collagen VII antibodies. Pemphigus vulgaris (Option D): Caused by IgG antibodies against desmoglein 3 (and sometimes desmoglein 1). Leads to intraepidermal (suprabasal) blisters , which are fragile and rupture easily. Mucosal involvement is common. Not associated with collagen VII.



References:

https://www.ncbi.nlm.nih.gov/books/NBK554512/

https://dermnetnz.org/topics/epidermolysis-bullosa-acquisita

↑ *Back to this question in Part A*

@Neet_pg_bot

Q8: Which of the following statements regarding Linear IgA disease is incorrect? (Q841963)

A. Common autoimmune blistering disease in infants and children

B. Crown of Jewels appearance

C. Subepidermal blistering on HPE

D. Oral steroids are first-line management

Correct Answer: D. Oral steroids are first-line management

■ *Listen (English)*

■ *Listen (Hindi)*

Explanation: The incorrect statement about linear IgA disease is that oral steroids are the first line of management, as the first line of management includes topical steroids or Dapsone. Linear IgA disease: It is an autoimmune blistering disorder with bimodal distribution in pediatric (peak<5 years) and adult patients (60 years). It is the most common autoimmune blistering disease in infants and children. The antigens BP 180 and LAD are targetted by IgA antibodies. Blisters and vesicles are formed in an annular pattern with blistering along the edges forming a string■of■pearls/crown of jewels appearance. It commonly affects the trunk and limbs but starts as perioral and perennial lesions in children. Mucosal involvement may be seen. {{caption_text}} HPE will show subepidermal blistering. Immunofluorescence will reveal a linear deposit of predominant or exclusive IgA at the dermo-epidermal junction. Dapsone is the first line of treatment. Oral steroids are used only in some cases to suppress blister formation.



References:

Rooks textbook of dermatology 9th ed, page no. 50.33-50.37

↑ *Back to this question in Part A*

@Neet_pg_bot

Q9: A 32 week pregnant lady presents with itching and erythematous plaques involving the periumbilical region. She is diagnosed with pemphigoid gestationis. What is the most common microscopy finding in this patient? (Q841962)

A. Intraepithelial Ig G Deposition

B. C3 deposit along the dermo-epidermal junction

C. Ig G deposit along the dermo-epidermal junction

D. Ig A deposit along the dermo-epidermal junction

Correct Answer: B. C3 deposit along the dermo-epidermal junction

■ *Listen (English)*

■ *Listen (Hindi)*

Explanation: The most common microscopy finding in many cases of pemphigoid gestationis is the C3 deposit along the dermo-epidermal junction. {{caption_text}} Pemphigoid gestationis: It is a bullous disorder presenting mainly in late pregnancy or the immediate postpartum period. Circulating complement■fixing IgG antibodies bind to a BP■180 in hemidesmosomes of the dermo-epidermal junction causing blisters. These blisters are formed in the subepidermal. It presents as intense pruritis with erythematous papules and plaques starting on the abdomen which later become tense blisters. The lesions show remission and exacerbation with most of them usually resolving after pregnancy Immunofluorescence is the gold standard test showing linear C3 deposition along the dermo-epidermal junction in 100% of cases and additional IgG deposition in 30% of cases. Management is done using topical and systemic steroids. Intraepithelial IgG Deposition (Option A) is a feature of pemphigus vulgaris and related disorders. Ig A deposit along the dermo-epidermal junction (Option D) is a feature of linear IgA disease.



References:

Rooks textbook of dermatology 9th ed, page no.115.13-15.14, 50.35

↑ *Back to this question in Part A*

@Neet_pg_bot

Q10: A patient presented with blisters confined to the head, neck and upper trunk. Some of these blisters show scarring in the neck. The examination of the oral cavity is normal without any lesions. Electron microscopy shows a linear IgG deposition at the dermo-epidermal junction. What is the most probable diagnosis? (Q841961)

A. Mucous membrane pemphigoid

B. Pemphigus vulgaris

C. Cicatricial pemphigoid

D. Brunsting–Perry pemphigoid

Correct Answer: C. Cicatricial pemphigoid

■ *Listen (English)*

■ *Listen (Hindi)*

Explanation: The above clinical features and immunofluorescence pattern suggests a diagnosis of cicatricial pemphigoid. Cicatricial pemphigoid: It is a variant of pemphigoid disease in which skin lesions heal with scarring. They are positive for BP180. They present with blisters, erosions, haemorrhagic crusts and atrophic scars on the head, neck and upper trunk. The mucous membrane may rarely be involved, but it is not predominant. Pemphigus vulgaris (Option B): PV never heals with scarring Mucous membrane pemphigoid (Option A) predominantly affects the mucous membranes like the oral cavity, conjunctivae, nasopharynx, skin, anogenital region, larynx and oesophagus. Brunsting Perry pemphigoid (Option D) is a variant with lesions predominantly in head and neck with no mucosal involvement. The presence of involvement extending to upper trunk favors cicatricial pemphigoid instead.

References:

Rooks textbook of dermatology 9th ed, page no. 50.10, 50.49

↑ *Back to this question in Part A*

@Neet_pg_bot

Q11: A 75-year-old male patient came with skin lesions as shown below. Biopsy of the lesion shows a sub-epidermal split with linear deposition of C3 and IgG. Which of the following is true regarding this condition? (Q841960)

A. Antibodies directed against desmoglein 3

B. Nikolsky sign and bulla spread sign are positive

C. It has a non-bullous urticarial stage after the bullous stage

D. The lesions commonly heal without scarring



Correct Answer: D. The lesions commonly heal without scarring

■ *Listen (English)*

■ *Listen (Hindi)*

Explanation: {{caption_text}} The image showing tense bullae and the biopsy findings suggest a diagnosis of bullous pemphigoid (BP), which commonly heals without scarring. Bullous Pemphigoid: BP is a common subepidermal immunobullous disorder mainly affecting elder people. Autoantibodies against hemidesmosomal target proteins BP230 (BPAG1) and BP180 (BPAG2) which finally leads to bullae formation. It is characterised by a prodromal non bullous stage with pruritis which is followed by a bullous stage. The later has intense pruritus with tense blisters and vesicles. These blisters show a negative Nikolsky sign but a positive Bulla spread sign. The rupture of blisters leads to yellow or hemorrhagic crust formation, which later heal without any scar. Oral lesions can occur sometimes. HPE shows a subepidermal split with inflammatory infiltrate, immunofluorescence shows a linear binding of immunoglobulin (IgG and C3) at the dermo-epidermal junction. Topical and systemic steroids are the mainstay of treatment. {{caption_text}}



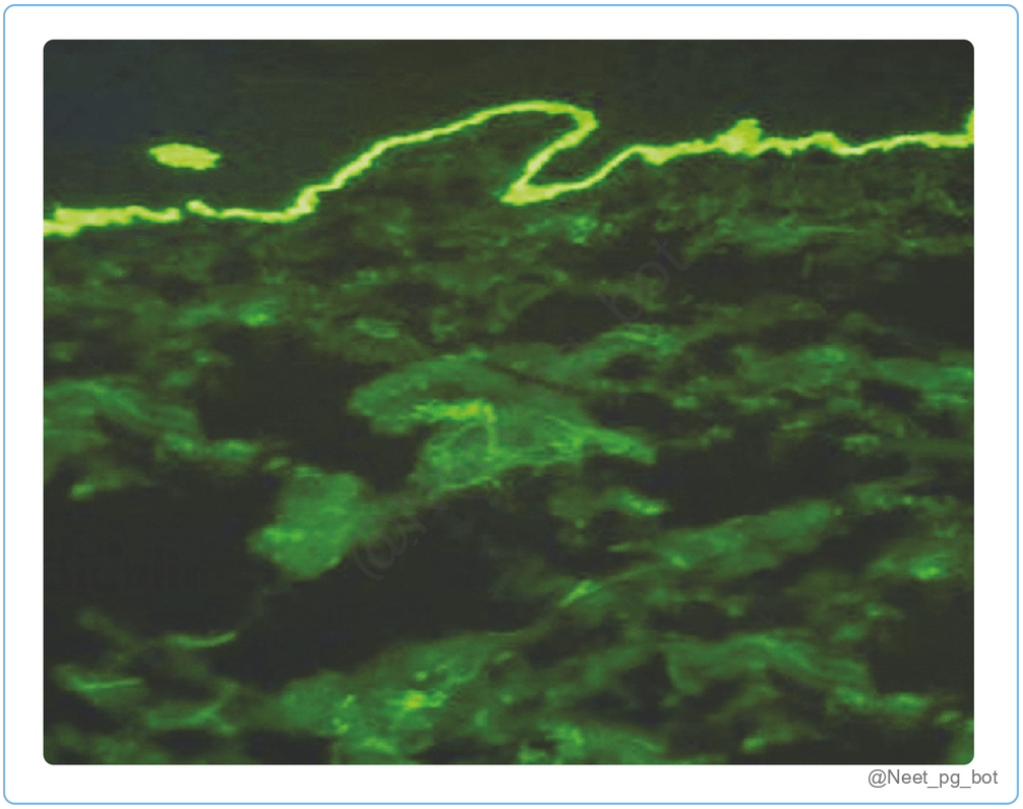

References:

Rooks textbook of dermatology, 9th edition, pages 50.10-50.17

Eponymous Dermatological Signs in Bullous Dermatoses - PMC (nih.gov)

↑ *Back to this question in Part A*

@Neet_pg_bot

Q12: A 60-year-old male patient presented with ruptured vesicles and bullae on the skin and erosions in the mucous membrane. HPE of the skin biopsy revealed a row of tombstones. Antibodies against which of the following structures are most commonly present in this patient? (Q841947)

A. Desmoglein 1

B. Desmocolin

C. Desmoglein 3

D. Desmoplakin

Correct Answer: C. Desmoglein 3

■ *Listen (English)*

■ *Listen (Hindi)*

Explanation: The above clinical features and HPE findings in this patient suggest the diagnosis of Pemphigus vulgaris (PV), which most commonly has antibodies against Desmoglein 3. Pemphigus vulgaris: PV is the most common chronic autoimmune blistering disease caused by antibodies against desmosomal adhesion proteins. (Desmoglein 3>1) They are characterized by the presence of flaccid blisters filled with clear fluid present on normal skin or an erythematous base. The blisters rupture producing painful erosion. Mucosal involvement is a very important and one of the distinguishing features of PV. {{caption_text}} Histopathology: Suprabasal intraepidermal cleavage with acantholysis, basal cells form a “row of tombstones.” {{caption_text}} {{caption_text}} Antigen affected Immunobullous disease-associated Desmoglein 1 Pemphigus foliaceous (Subcorneal split) (Option A) Desmoglein 3 > 1 Pemphigus Vulgaris (Suprabasal split) Desmocolin IgA pemphigus (Option B) (Aka Subcorneal pustular dermatosis) Desmoplakin Paraneoplastic pemphigus (Option D) M/c associated malignancy is NHL



@Neet_pg_bot

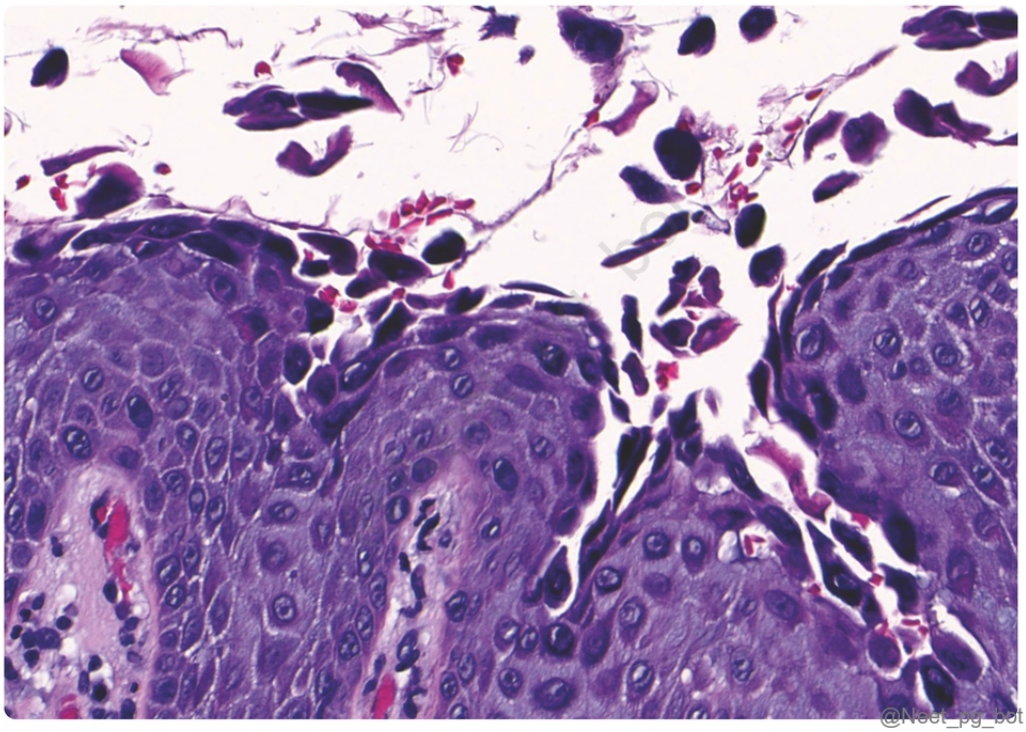

@Neet_pg_bot

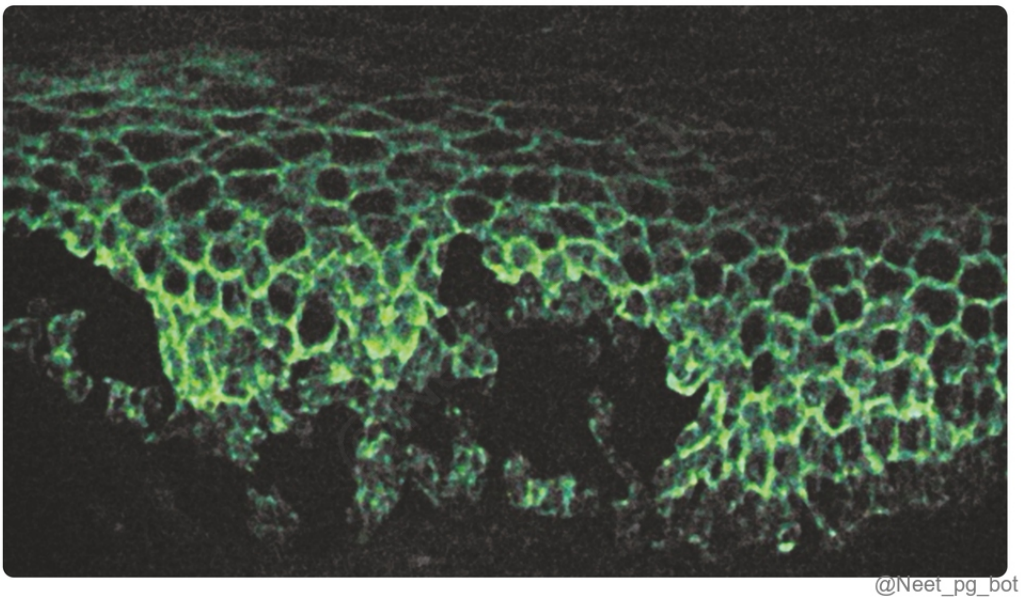

References:

Pathogenesis, clinical manifestations, and diagnosis of pemphigus - UpToDate Rooks textbook of dermatology 9th ed, page no.50.1-50.4

↑ *Back to this question in Part A*

@Neet_pg_bot

Q13: Which of the following structure connects basal keratinocytes to the lamina lucida in the skin? (Q841958)

A. Hemidesmosomes

B. Keratin intermediate filaments

C. Lamina densa

D. Anchoring fibrils

Correct Answer: A. Hemidesmosomes

■ *Listen (English)*

■ *Listen (Hindi)*

Explanation: Hemidesmosomes(HD), anchoring filaments, and anchoring fibrils are present at the dermal-epidermal junction and maintain the integrity of the skin. The lower end of the epidermis is made up of basal keratinocytes. Hemidesmosomes are attachment complexes that connect the keratin intermediate filaments

within the basal keratinocytes to the lamina lucida with the help of anchoring filaments (Option B). Lamina lucida(LL) and densa(LD) are part of dermal–epidermal basement membrane forming the interface between the two (Option C). The anchoring filaments are thread-like structures passing under the HD and merge with the lamina densa. Whereas anchoring fibrils are U■shaped structures extending from lamina densa to the upper reticular dermis (Option D).

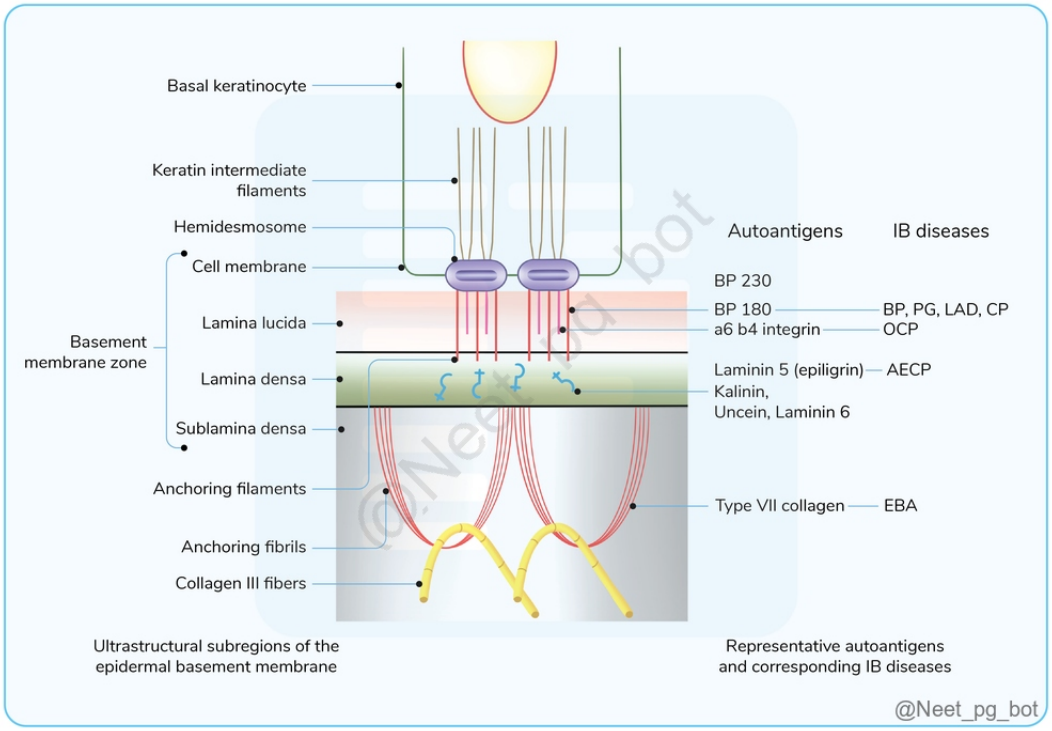

References:

Rooks textbook of dermatology 9th ed, page no. 2.25-2.27, 2.20, 2.21.

↑ *Back to this question in Part A*

@Neet_pg_bot

Q14: A 60 old male patient presented with blisters involving >40% of body surface area. He was diagnosed with pemphigus vulgaris following a biopsy. The patient wants to know what is the best therapy to start for his condition. What would be the most appropriate solution to his question? (Q841957)

A. Prednisolone alone

B. Mycophenolate mophetil+ azathioprine

C. Prednisolone+ Azathioprine

D. Azathioprine+ Rituximab

Correct Answer: C. Prednisolone+ Azathioprine

■ *Listen (English)*

■ *Listen (Hindi)*

Explanation: The recommended therapy to be initiated in this patient with a pemphigus group of disorders is steroids in combination with adjuvant immunosuppression like prednisolone+ azathioprine. Since pemphigus is related to autoantibodies against desmogleins, management includes immunosuppression. Topical or intralesional steroids can be used to manage patients who present with oral disease and mild cutaneous involvement. However, in most cases with extensive involvement, the initial management is systemic corticosteroid therapy in combination with steroid■sparing agents(SSA). Prednisolone with SSA like azathioprine, mycophenolate mofetil, and rituximab. Intravenous immune globulin (IVIG), immunoadsorption, and cyclophosphamide are options reserved for patients with refractory disease

References:

Rooks textbook of dermatology 9th ed, page no. 50.8-50.9 Initial management of pemphigus vulgaris and pemphigus foliaceus - UpToDate

↑ *Back to this question in Part A*

@Neet_pg_bot

Q15: A 45-year-old female patient presented with blisters in the oral cavity, arms, and trunk. A tzank smear of the epidermis was taken and is shown below. What is the characteristic finding and diagnosis? {{caption_text}} (Q841956)

A. Row of tombstone- Pemphigus vulgaris

B. Fishnet pattern- Pemphigus foliaceus

C. Acantholysis- Pemphigus foliaceus

D. Acantholysis- Pemphigus vulgaris

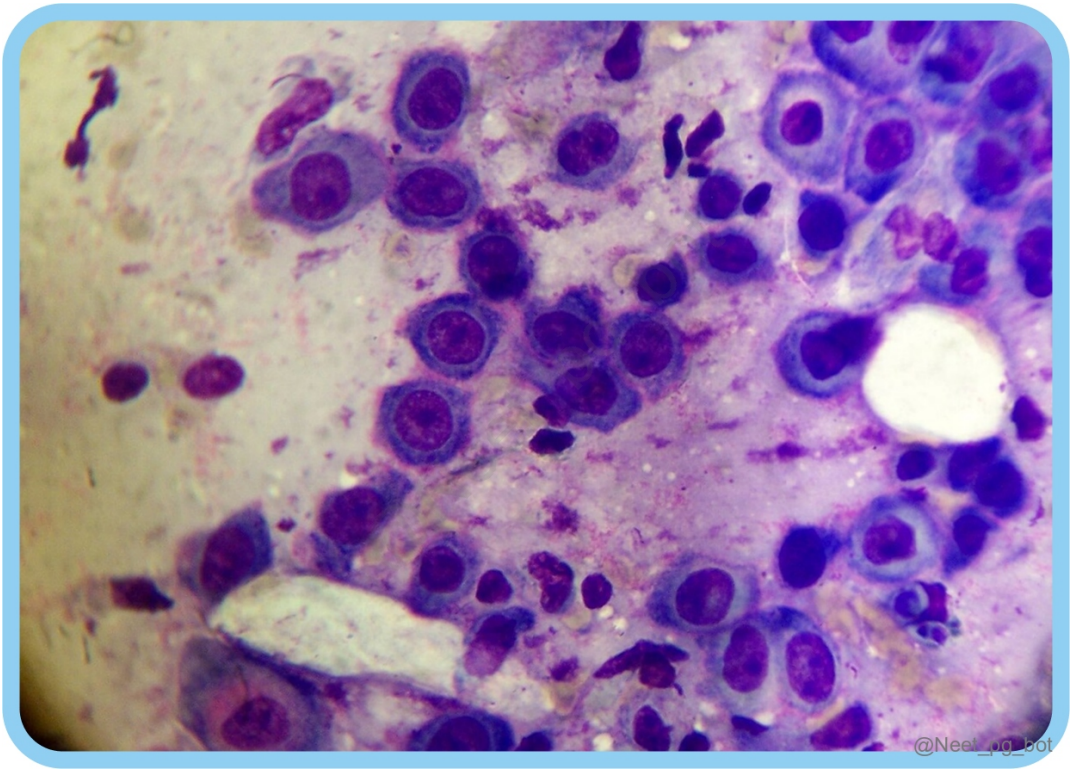

Correct Answer: D. Acantholysis- Pemphigus vulgaris

- *Listen (English)*
- *Listen (Hindi)*

Explanation: The above clinical features and Tzank smear showing separated keratinocytes or acantholytic cells is a feature of Pemphigus group of disorders and can be seen in PV or PF. However since the question mentions oral mucosa involvement, PV would be the answer as the mucosa is not involved in PF. Pemphigus Vulgaris: Pemphigus vulgaris is an autoimmune blistering disease (anti-Desmoglein 3) with lower epidermal acantholysis; acantholysis occurs in other pemphigus variants and acantholytic disorders. {{caption_text}} Separation of basal keratinocytes along the basement membrane in PV results in the appearance of a row of tombstones as shown below. (Option A) {{caption_text}} Pemphigus shows intercellular IgG deposition in a “chicken-wire” pattern on immunofluorescence. (Option B) {{caption_text}} Acantholysis as shown in the image can be seen in pemphigus foliaceus (PF) as well. But PF does not have mucosal involvement, unlike PV which is seen in this patient. (Option C)

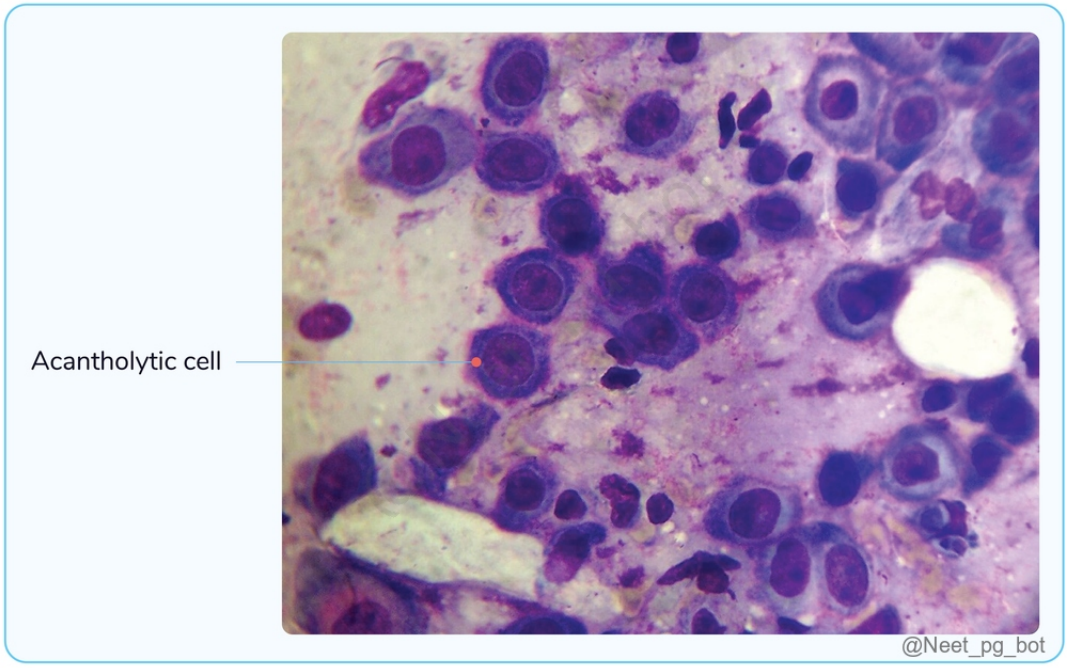
Acantholytic cell
@Neet_pg_bot

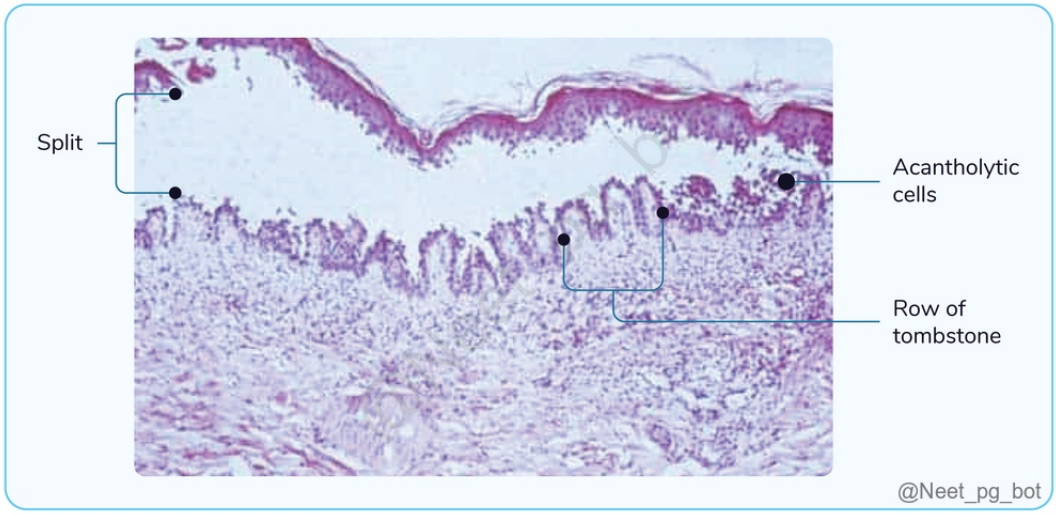
Split
Acantholytic cells
Row of tombstone
@Neet_pg_bot

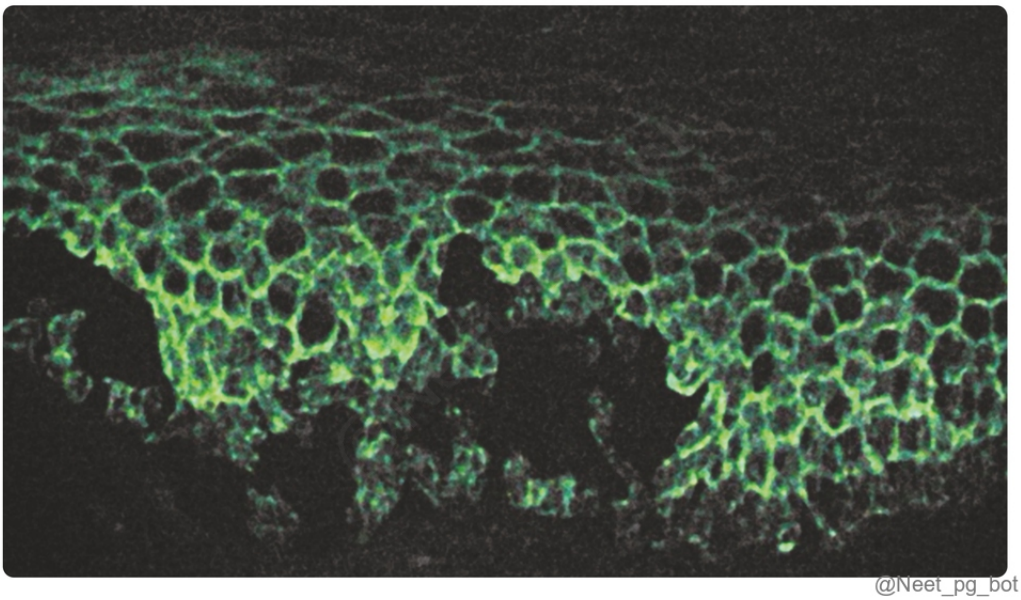

References:

Rooks textbook of dermatology 9th ed, page no. 3.33-3.34, 50.3 , 50.7-50.8

↑ *Back to this question in Part A*

@Neet_pg_bot

Q16: A middle aged female patient presented with vesicles and blisters over the skin and oral cavity. On examination, the blisters are flaccid with an erythematous base, and a firm sliding pressure with a finger separates the Superficial epidermis layers from basal epidermis, producing a new lesion. Which of the following microscopic features is not seen in this patient? {{caption_text}} A {{caption_text}} B {{caption_text}} C {{caption_text}} D (Q841954)

A. A

B. B

C. C

D. D

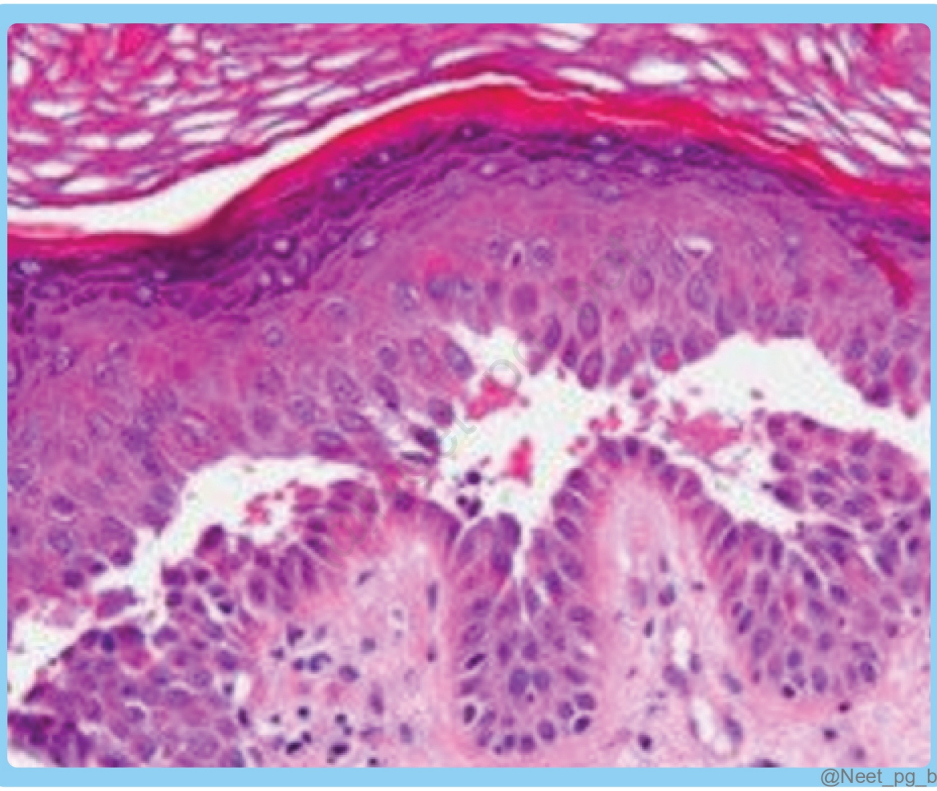

@Neet_pg_bot

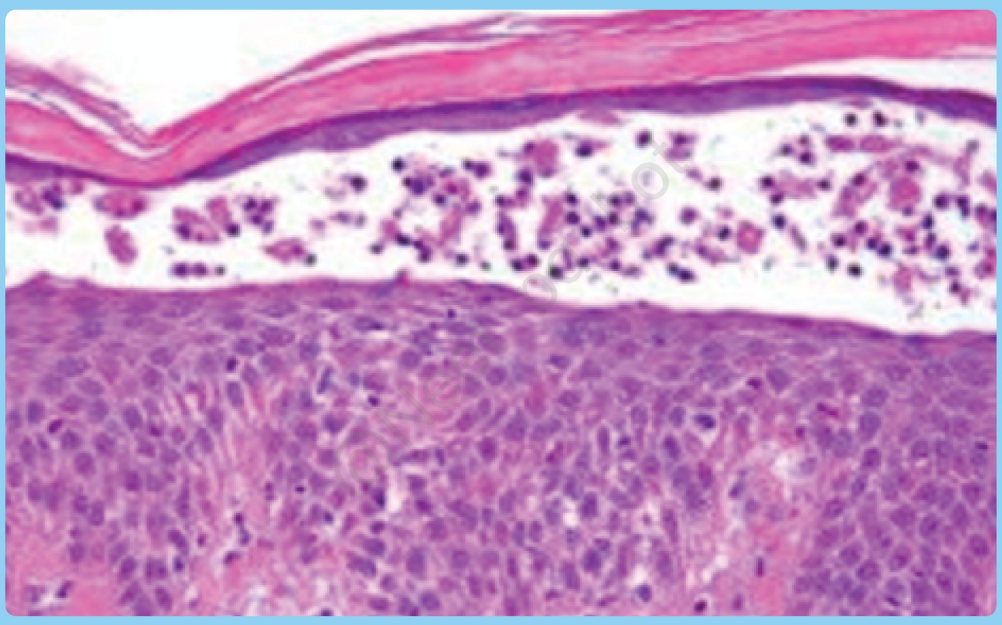

@Neet_pg_bot

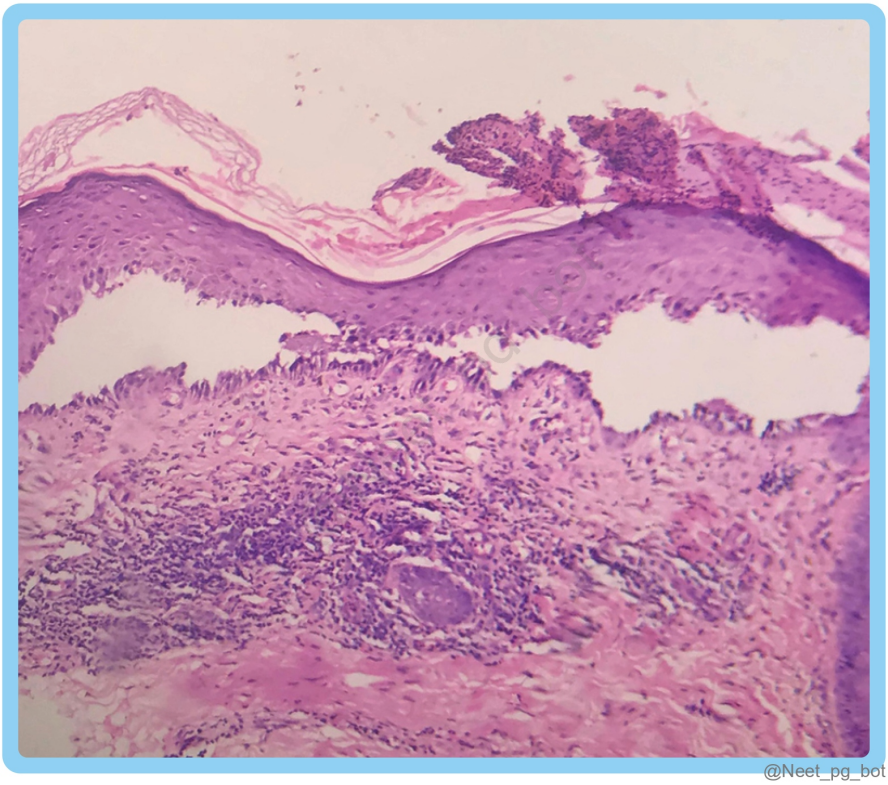

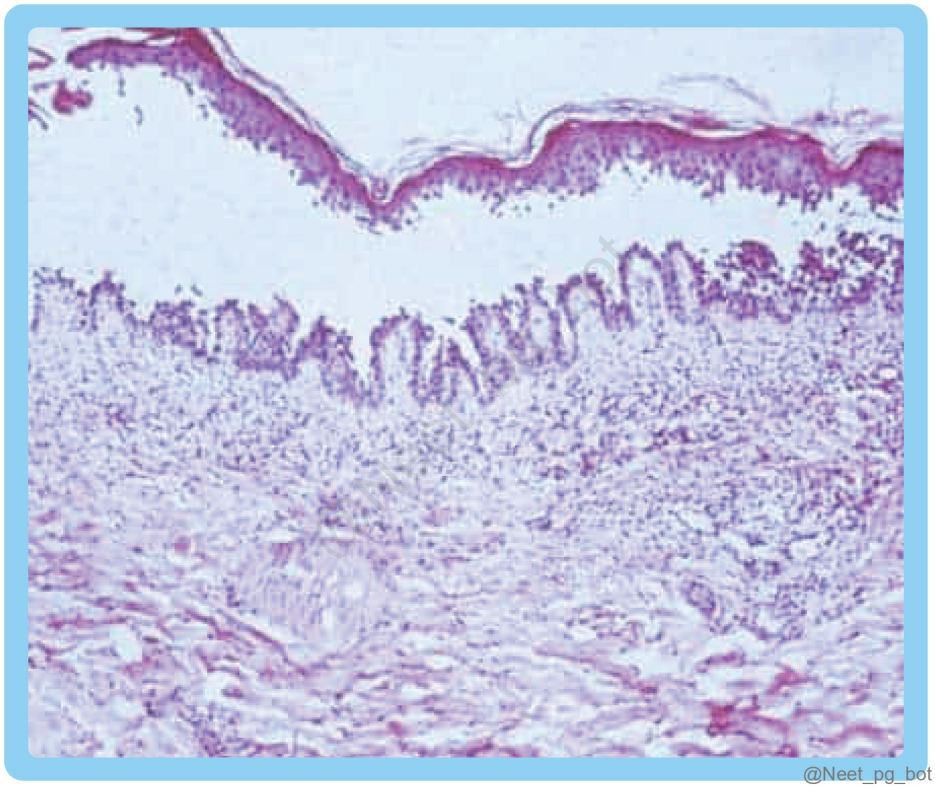

Correct Answer: B. B

■ *Listen (English)*

■ *Listen (Hindi)*

Explanation: The clinical scenario suggests pemphigus vulgaris, whose microscopic features are shown in images A, C, and D. Image B shows the HPE of pemphigus foliaceus. Image A shows Intraepidermal cleavage with a suprabasal splitting in the epidermis. {{caption_text}} Image C shows suprabasal acantholytic cells-detached keratinocytes {{caption_text}} Image D shows the retention of basal keratinocytes along the basement membrane, resulting in a row of tombstones appearance. All the above features are characteristic of Pemphigus vulgaris. {{caption_text}} Image B shows intraepidermal cleavage with acantholysis beneath the stratum corneum (subcorneal splitting) or within the granular layer; seen in PF. {{caption_text}}

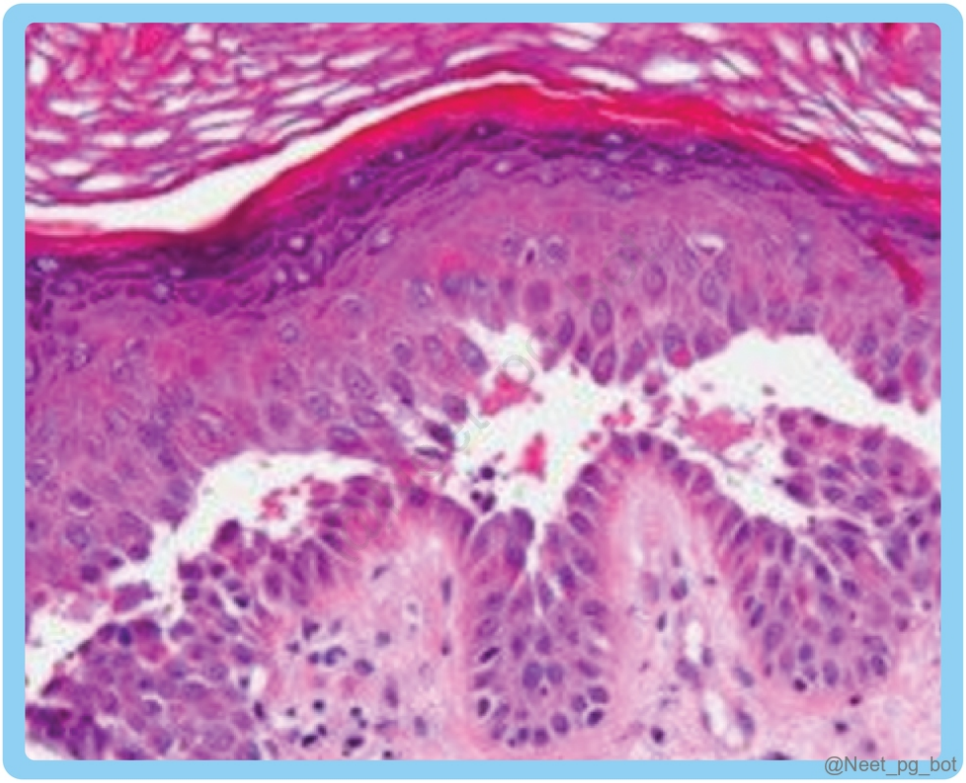

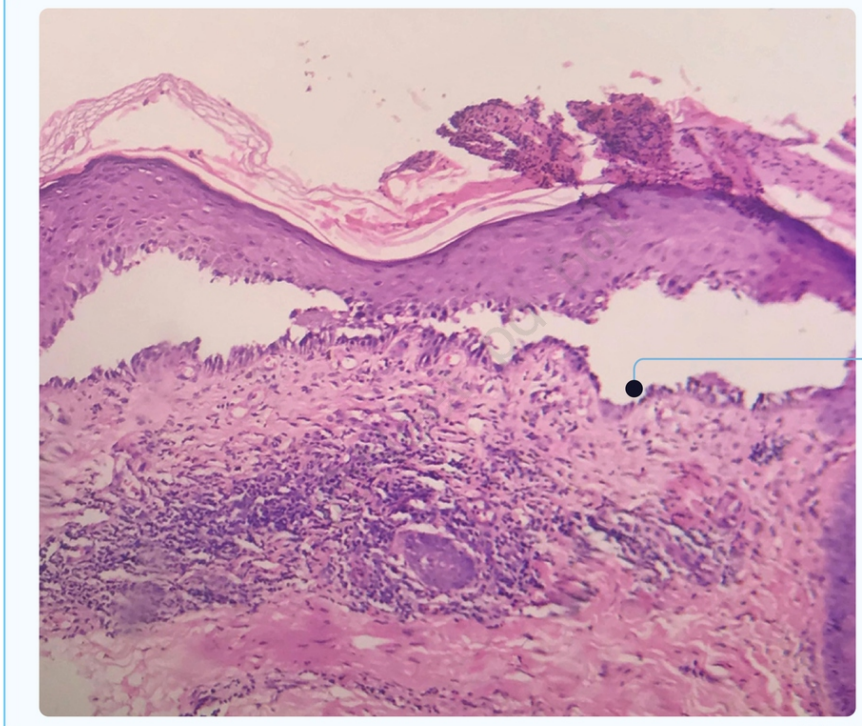

@Neet_pg_bot

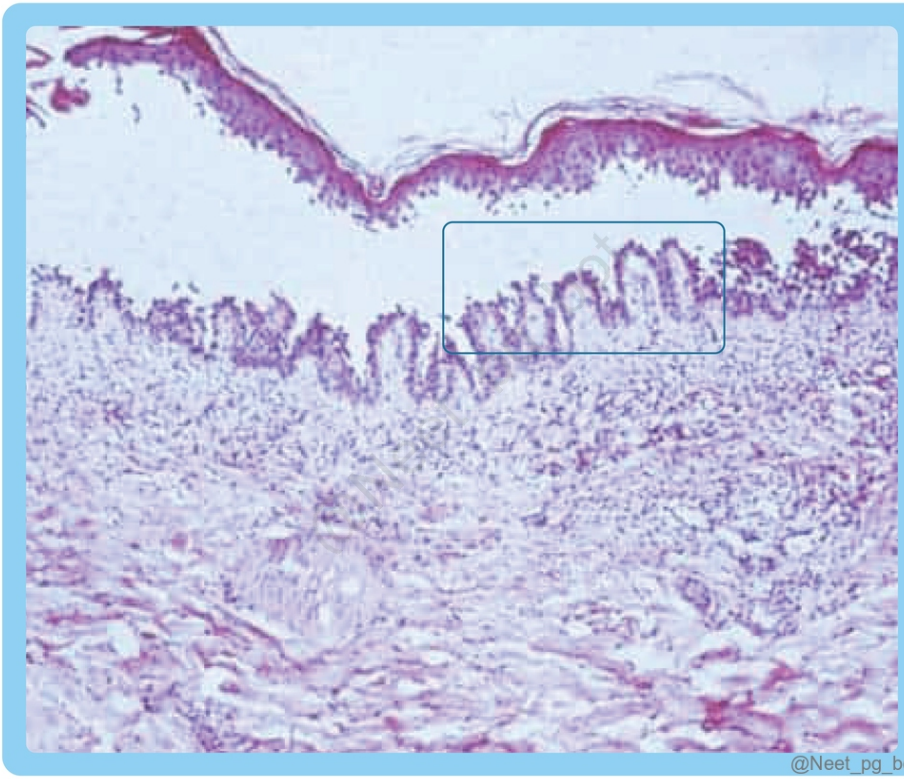

@Neet_pg_bot

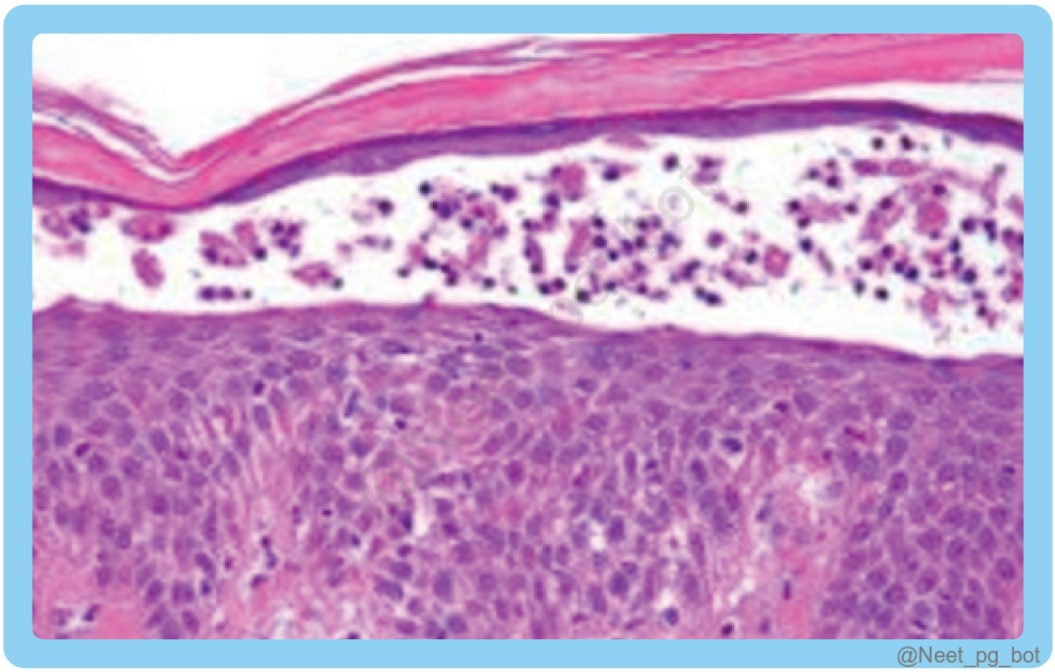

References:

www.uptodate.com/contents/pathogenesis-clinical-manifestations-and-diagnosis-of-pemphigus?search=pemphigus%20vulgaris&source=search_result&selectedTitle=2%7E53&usage_type=default&display_rank=2

↑ *Back to this question in Part A*

@Neet_pg_bot

Q17: Which of the following statements about paraneoplastic pemphigus (PNP) is correct? (Q841953)

A. It is most commonly associated with lymphoma and leukemia

B. The oral mucosa is rarely involved

C. Autoantibodies in PNP exclusively target desmogleins

D. PNP typically has a better prognosis than other forms of pemphigus

Correct Answer: A. It is most commonly associated with lymphoma and leukemia

■ *Listen (English)*

■ *Listen (Hindi)*

Explanation: PNP is most frequently associated with hematologic malignancies, particularly non-Hodgkin lymphoma and other B cell lymphomas. Other associated neoplasms can include Castleman's disease, thymoma,

chronic lymphocytic leukemia and sarcomas. The antigens associated include Envoplakin and Periplakin (most specific) Desmoglein1 and 3 Desmoplakin 1 and 2 Epiplakin and Plectin Bullous pemphigoid (BP) antigen 1 Oral mucosal involvement is actually a hallmark of PNP and is often severe and resistant to treatment. It can be one of the earliest and most persistent manifestations of the disease. (Option B) While autoantibodies against desmogleins (particularly desmoglein 3) can be present in PNP, they are not exclusive targets. PNP is characterized by autoantibodies against multiple antigens, predominantly members of the plakin family (including desmoplakin, envoplakin, and periplakin). (Option C) PNP generally has a worse prognosis compared to other forms of pemphigus. It is often more resistant to treatment and can be associated with significant morbidity and mortality, partly due to the underlying malignancy. (Option D)

References:

www.uptodate.com/contents/paraneoplastic-pemphigus?

www.ncbi.nlm.nih.gov/books/NBK546694/

↑ *Back to this question in Part A*

@Neet_pg_bot

Q18: A female patient came with a history of vesicles and bullae in the flexural parts one week ago. She presented to a dermatology clinic today because the lesion has changed. On examination, the following lesion is seen. What is the most likely diagnosis? {{caption_text}} (Q841952)

A. Pemphigus foliaceus

B. Endemic Pemphigus foliaceus

C. Condyloma accuminata

D. Pemphigus vegetans



Correct Answer: D. Pemphigus vegetans

■ *Listen (English)*

■ *Listen (Hindi)*

Explanation: {{caption_text}} The image shows moist, vegetative, hypertrophic plaques located in a flexural region , which is characteristic of pemphigus vegetans . The patient has a history of vesicles and bullae , which later ruptured to form vegetative erosions in intertriginous areas- supporting the diagnosis. This is a rare variant of pemphigus vulgaris , often misdiagnosed without considering the specific morphology and location of lesions. Pemphigus Vegetans: A variant of pemphigus vulgaris , characterized by vegetating plaques . Flexural involvement is typical- especially in areas like groin, axillae, inframammary region. Develops after bullae or pustules rupture , leading to: Hypertrophic , granulating , exudative erosions. Lesions may become foul-smelling and infected. Oral mucosa may be involved: Cerebriform tongue (called Premlata sign) {{caption_text}} Two subtypes : Neumann type – more severe , vesiculobullous onset. Hallopeau type – milder , pustular onset leading to vegetative growth. Differential Diagnoses: Diagnosis Key Features Pemphigus vegetans (Option D) Vegetating erosions in flexures; post-vesicular phase; cerebriform tongue (Premlata sign); Neumann/Hallopeau types. Pemphigus foliaceus (Option A) Crusted erosions in seborrheic areas (face, chest, scalp); no mucosal involvement; superficial blistering. Endemic PF (fogo selvagem) (Option B) Seen in rural Brazil/Colombia; associated with black fly bites (Simulium); affects children/young adults. Condyloma acuminata (Option C) HPV-related genital warts; soft, pink, verrucous or filiform lesions; no vesicle-bullae history. Condyloma lata (secondary syphilis) Flat, moist, broad-based lesions in groin/perineum; painless; seen in syphilis- not relevant here.





References:

Rooks textbook of dermatology 9th ed, page no. 50.6, 50.1, 50.4, 25.56

↑ *Back to this question in Part A*

Q19: A 45-year-old woman presents with pruritic, grouped vesicles and small blisters on her trunk and upper extremities. The patient reports that new lesions appear in waves, often in a herpetiform pattern. Biopsy shows eosinophilic spongiosis and acantholysis. DIF reveals intercellular IgG and C3 deposits. ELISA is positive for anti-desmoglein 1 antibodies. What is the most likely diagnosis? (Q841951)

A. Bullous pemphigoid

B. Dermatitis herpetiformis

C. Pemphigus vulgaris

D. Pemphigus herpetiformis

Correct Answer: D. Pemphigus herpetiformis

■ *Listen (English)*

■ *Listen (Hindi)*

Explanation: The given scenario is of pemphigus herpetiformis due to the presence of circulating IgG and C3 autoantibodies against DSG 1 or DSG 3. Pemphigus herpetiformis is a variant of pemphigus that resembles dermatitis herpetiformis(DH) clinically It is characterized by clusters of pruritic that develop on an erythematous background. Pruritis is due to eosinophils in the epidermis. Pemphigus herpetiformis has acantholysis while DH is intradermal pathology with papillary dermis involvement Immunofluorescence revealing intercellular staining is the key to diagnosis. Patients possess circulating IgG autoantibodies against DSG 1 or 3 and desmocollins 1 or 3 in some individuals. It may progress to PV or classical PF. Treatment of both PH and DH Is Dapsone {{caption_text}} Papules and vesicles of pemphigus herpetiformis which are similar to DH



References:

Rooks textbook of dermatology 9th ed, page no. 50.7, 50.53 Pathogenesis, clinical manifestations, and diagnosis of pemphigus - UpToDate Dermatitis Herpetiformis - StatPearls - NCBI Bookshelf (nih.gov)

↑ *Back to this question in Part A*

@Neet_pg_bot

Q20: Which of the following statements is true regarding immunobullous disorders? (Q841950)

A. Skin is not affected in Pemphigus foliaceus.

B. Skin is not affected in Pemphigus vulgaris

C. Mucosa is not affected in Pemphigus foliaceus.

D. Mucosa is not affected in Pemphigus vulgaris

Correct Answer: C. Mucosa is not affected in Pemphigus foliaceus.

■ *Listen (English)*

■ *Listen (Hindi)*

Explanation: Pemphigus foliaceus (PF) is a blistering disorder that typically affects the skin and spares the mucosa. Pemphigus vulgaris(PV) and foliaceus are autoimmune blistering disorders caused by antibodies against structural protein desmosomes (DSG). They affect the skin and mucosa in a unique way, which is explained by the

distribution of DSG1 and 3 in the skin and mucosa. In skin, DSG1 is present throughout the epidermis whereas DSG3 is found only in the basal and immediate suprabasal layers. In mucosa, DSG 3 is expressed through all layers whereas DSG 1 is found only at low levels. Because DSG1 and 3 work together, antibodies against DSG1 cannot destabilize the oral mucosa, but they can significantly affect the skin. As a result, skin blistering without mucosal involvement is seen in PF patients who only have anti-DSG 1 antibodies. As PV has both DSG 3 and DSG 1 antibodies, both skin and mucosal lesions are seen.

References:

Rooks textbook of dermatology 9th Edition, Page 50

↑ *Back to this question in Part A*

@Neet_pg_bot

Q21: An elderly male patient presents with superficial vesicles and bullae seen in the face, scalp, and upper trunk. Most of the bullae have ruptured resulting in well-demarcated crusted erosions surrounded by erythema. Histopathological examination reveal following finding. What is the most likely diagnosis? {{caption_text}} (Q841949)

A. Pemphigus vulgaris (PV)

B. Pemphigus foliaceus (PF)

C. Staphylococcal Scalded Skin Syndrome (SSSS)

D. Steven Johnson Syndrome (SJS)

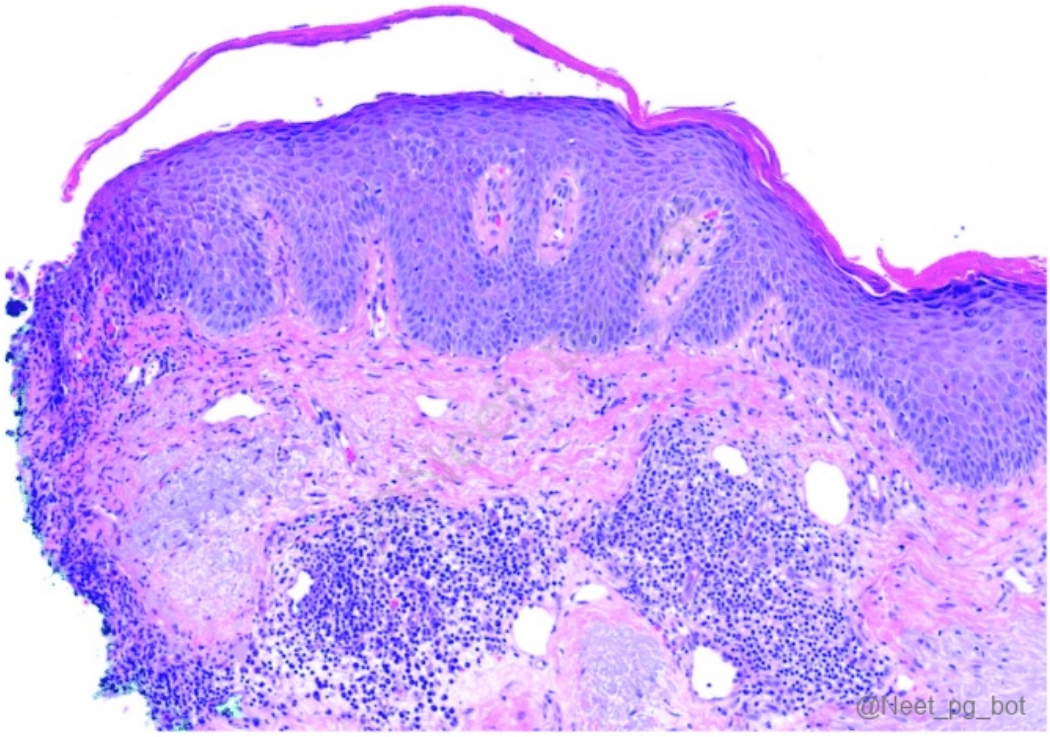

Correct Answer: B. Pemphigus foliaceus (PF)

- *Listen (English)*
- *Listen (Hindi)*

Explanation: The clinical features and imaging showing intraepidermal cleavage with acantholysis beneath the stratum corneum (subcorneal splitting) point to a diagnosis of Pemphigus Foliaceus. Pemphigus foliaceus is a group of immunobullous disorders caused by antibodies against desmosomal proteins mainly Desmosome-1. Desmosomes maintain the structure of the epidermis through their adhesive function. It presents as superficial vesicles or bullae that rupture easily, causing eroded skin lesions with surrounding erythema and crusting. {{caption_text}} Pemphigus Vulgaris (Option A) presents as flaccid blisters and erosions involving both the skin and mucous membrane. The target antigens for PV is most commonly Desmoglein 3, sometimes desmoglein 1 {{caption_text}} {{caption_text}} {{caption_text}} Staphylococcal Scalded Skin Syndrome (SSSS) (Option C) Caused by Staph. aureus toxins (A/B), seen in neonates with flaccid bullae and crusting on face, axillae, groin. No mucosal involvement (unlike PV); targets desmoglein 1. {{caption_text}} Stevens-Johnson syndrome (SJS) (Option D) and toxic epidermal necrolysis (TEN) are severe drug reactions causing mucocutaneous blistering, starting on face and flexures, followed by skin sloughing. {{caption_text}}



@Neet_pg_bot



@Neet_pg_bot



@Neet_pg_bot



@Neet_pg_bot





References:

Rooks Textbook of Dermatology, 9th Edition, Pages 50.2, 50.5, 116.24, 119.13

↑ *Back to this question in Part A*

@Neet_pg_bot

Q22: Which of the following is being demonstrated in the image given below? (Q841948)

A. Nikolsky's sign

B. Bulla spread sign

C. Auspitz sign

D. Koebner phenomenon



Correct Answer: A. Nikolsky's sign

■ *Listen (English)*

■ *Listen (Hindi)*

Explanation: The above image shows a firm sliding tangential pressure with a finger separating superficial epidermis layer from basal epidermis , producing an erosion called the Nikolsky sign. Disease process Associated diseases True Nikolsky’s sign Acantholysis Pemphigus foliaceous, Pemphigus Vulgaris, staphylococcal scalded skin syndrome. Pseudo-Nikolsky’s sign Necrosis of keratinocytes Toxic epidermal Necrolysis Stevens-Johnson syndrome Bulla spread (Option B): Gentle pressure extends bullae: V-shaped in pemphigus vulgaris, oval in bullous pemphigoid. {{caption_text}} Auspitz sign (Option C): Gentle scraping of psoriatic scales reveals bleeding points from inflamed papillary dermal vessels. {{caption_text}} Koebner phenomenon (Option D) Koebner phenomenon: lesions appear at trauma sites in diseases like psoriasis; pseudokoebner occurs via autoinoculation in warts or molluscum. {{caption_text}}


@Neet_pg_bot


@Neet_pg_bot



References:

Rooks textbook of dermatology 9th ed, page no. 50.4, 110.48, 35.10, 83.36 Eponymous Dermatological Signs in Bullous Dermatoses - PMC (nih.gov) Koebner Phenomenon - StatPearls - NCBI Bookshelf (nih.gov)

↑ *Back to this question in Part A*

@Neet_pg_bot

• [06_Immunobullous Disorders] 013 Previous Year Questions

« Back to Folder Directory

[06_Immunobullous Disorders] 013 Previous Year Questions — Quick Jump

Q1 (p. 914) *Q2 (p. 915)* *Q3 (p. 916)* *Q4 (p. 917)* *Q5 (p. 918)* *Q6 (p. 919)*
Q7 (p. 921) *Q8 (p. 921)*

Q1: A woman presents with a pruritic rash on the elbows, buttocks with recent diagnosis of gluten sensitive enteropathy. On immunofluorescence IgA deposition is seen as shown in the image. What is the most likely diagnosis? (Q866545)

A. Dermatitis herpetiformis

B. Pemphigus vulgaris

C. Bullous pemphigoid

D. Psoriasis

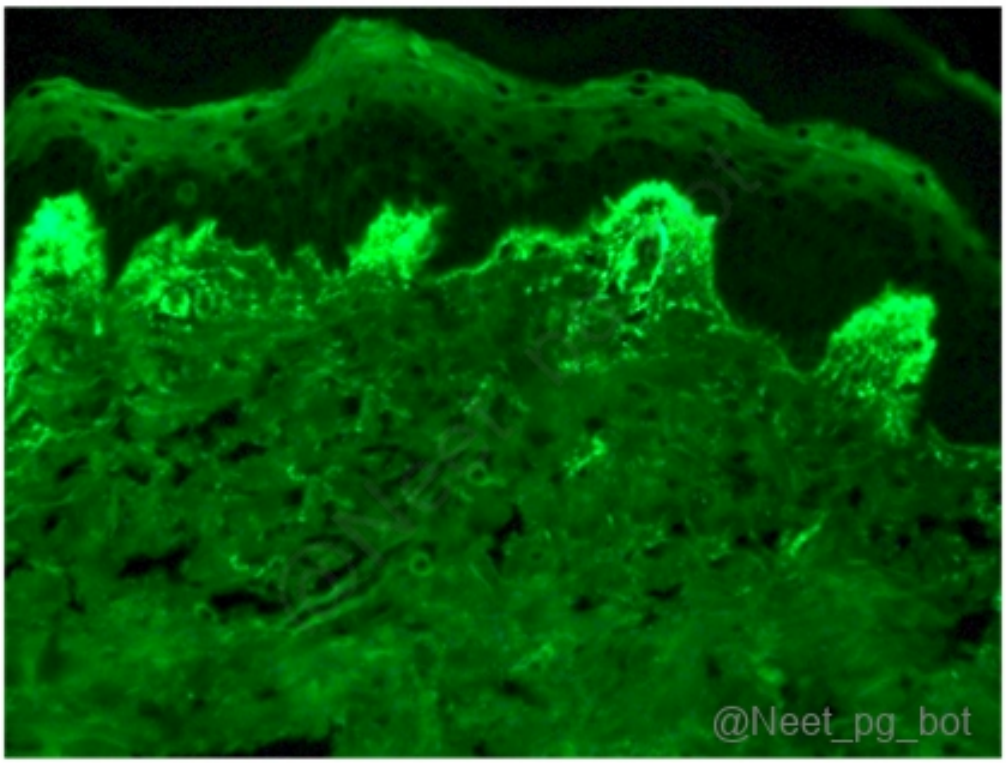

Correct Answer: A. Dermatitis herpetiformis

Explanation: Dermatitis herpetiformis is a chronic, intensely pruritic blistering skin condition strongly associated with celiac disease (gluten-sensitive enteropathy) . It presents with grouped vesicles and papules on extensor surfaces such as elbows, knees, buttocks, and scalp. Direct immunofluorescence of perilesional skin shows granular IgA deposits at the dermal papillae —this is diagnostic. Pathogenesis involves IgA antibodies against epidermal transglutaminase, triggered by gluten exposure. First-line treatment is a gluten-free diet ; dapsone can provide rapid symptom relief. ■■■■■■■ Pemphigus vulgaris (Option B): An autoimmune blistering disease with flaccid bullae, oral mucosal involvement, and IgG antibodies against desmoglein; immunofluorescence shows intercellular IgG in a “fish-net” pattern, not granular IgA at dermal papillae. Bullous pemphigoid (Option C): Presents with tense bullae in elderly patients, due to IgG antibodies against hemidesmosomes; immunofluorescence shows linear IgG and C3 along the basement membrane, not IgA deposits. Psoriasis (Option D): A chronic inflammatory skin disease with erythematous plaques and silvery scales, no vesicles, and no IgA deposition on immunofluorescence.

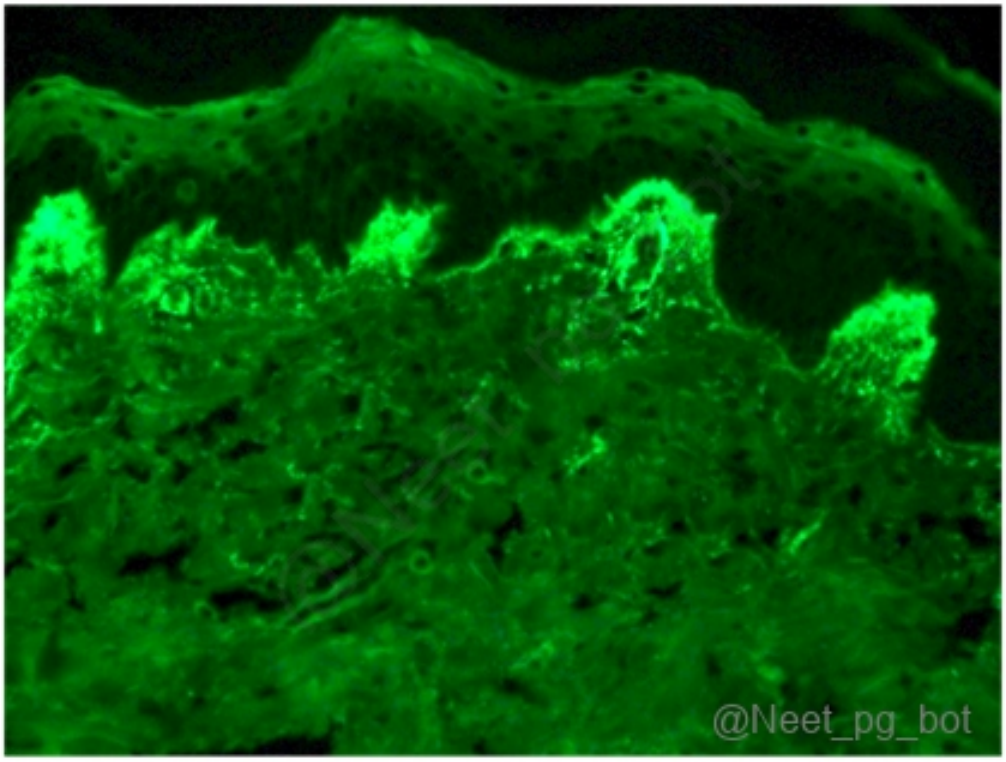

↑ *Back to this question in Part A*

@Neet_pg_bot

Q2: Identify the condition based on the immunofluorescence pattern shown in the image. (Q843974)

A. Lupus vulgaris

B. Pemphigus vulgaris

C. Bullous pemphigoid

D. Impetigo

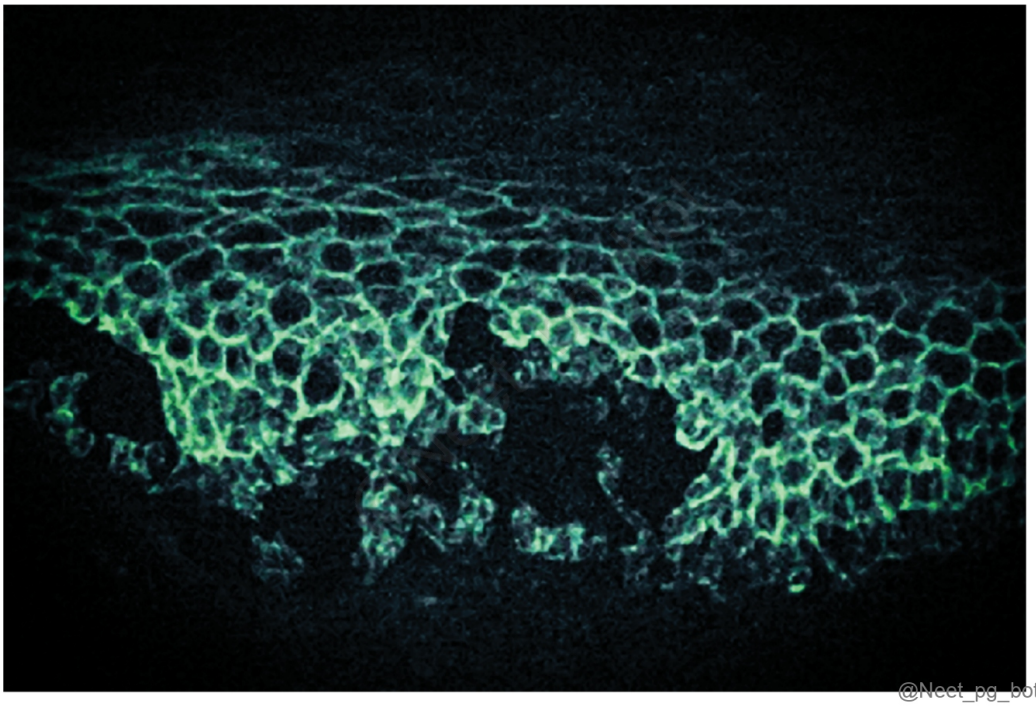

Correct Answer: B. Pemphigus vulgaris

Explanation: Correct Option B - Pemphigus vulgaris: The fishnet pattern of immunofluorescence observed between keratinocytes in the image is diagnostic of pemphigus vulgaris, an autoimmune blistering disorder. Incorrect Options: Options A, C, and D do not show fishnet pattern on immunofluorescence.

↑ *Back to this question in Part A*

@Neet_pg_bot

Q3: Statement 1 - A 59-year-old patient presents with flaccid bullae. Histopathology shows a suprabasal acantholytic split. Statement 2 - The row of tombstones' appearance is diagnostic of Pemphigus vulgaris. (Q857405)

A. Statements 1 & 2 are correct, 2 is not explaining 1

B. Statement 1 is incorrect

C. Statement 1 and 2 is incorrect

D. Statements 1 and 2 are correct and 2 is the correct explanation for 1

Correct Answer: A. Statements 1 & 2 are correct, 2 is not explaining 1

Explanation: Correct Option A - Statements 1 & 2 are correct, 2 Is not explaining 1: In pemphigus vulgaris, both flaccid blisters and suprabasal acantholytic split, as well as rows of tombstones, are seen. The row of tombstones' appearance is seen due to the detached basal cells from the basement membrane. Statement 1 describes suprabasal acantholytic split (mechanism = anti-Dsg3 antibodies). Statement 2 describes a morphological consequence seen on histopathology. Although both occur in PV, the presence of tombstones does not explain why the split is suprabasal. The pathophysiology (anti-Dsg3 antibodies) explains Statement 1, not Statement 2. Incorrect Options: Statement 1 Is Incorrect (Option B): this choice is incorrect as there is the presence of flaccid blisters and suprabasal acantholytic split seen in PV Statement 1 and 2 Is Incorrect (Option C): both statements correctly describe pemphigus vulgaris. Statement 1 and 2 are correct and 2 Is the correct

References:

https://pmc.ncbi.nlm.nih.gov/articles/PMC5901732/

↑ *Back to this question in Part A*

@Neet_pg_bot

Q4: A 60-year-old female presents with eczematous itching lesions. Biopsy revealed a subepidermal cleft with direct immunofluorescence showing linear C3 & IgG deposition along the basement membrane zone. What is the likely diagnosis? (Q857410)

A. Pemphigus Vulgaris

B. Bullous Pemphigoid

C. Dermatitis herpetiformis

D. Pemphigus foliaceus

Correct Answer: B. Bullous Pemphigoid

Explanation: Bullous Pemphigoid: In prodromal phase of Bullous Pemphigoid itchy eczematous lesions can be seen. The associated antibody is IgG. Direct immunofluorescence linear deposition shows IgG and C3. Hence, this option is correct. BP is a common subepidermal immunobullous disorder mainly affecting elder people. Autoantibodies against hemidesmosomal target proteins BP230(BPAG1) and BP180(BPAG2) which finally leads to bullae formation. It is characterised by a prodromal non bullous stage with pruritis which is followed by a bullous stage. The later has intense pruritus with tense blisters and vesicles. These blisters show a negative Nikolsky sign but a positive Bulla spread sign. The rupture of blisters leads to yellow or hemorrhagic crust formation, which later heal without any scar. Oral lesions can occur sometimes. HPE shows a subepidermal split with inflammatory infiltrate, immunofluorescence shows a linear binding of immunoglobulin (IgG and C3) at the dermo-epidermal junction. Topical and systemic steroids are the mainstay of treatment. {{caption_text}}

Pemphigus vulgaris (Option A) PV is characterized by intraepidermal blistering and acantholysis (loss of cell-to-cell adhesion between keratinocytes). Immunofluorescence shows intercellular IgG (not linear staining at the basement membrane zone). The presence of subepidermal blisters here excludes PV. Dermatitis herpetiformis (Option C) DH is a gluten-sensitive enteropathy associated with deposition of IgA in the dermal papillae, not linear IgG or C3 at the basement membrane. DH typically shows granular IgA deposition in immunofluorescence and not the linear patterns seen here. Pemphigus foliaceous (Option D) PF is another type of pemphigus that features intraepidermal blistering and acantholysis but lacks subepidermal blistering. Immunofluorescence in PF typically shows intercellular IgG, not the linear IgG and C3 at the basement membrane observed in this case.

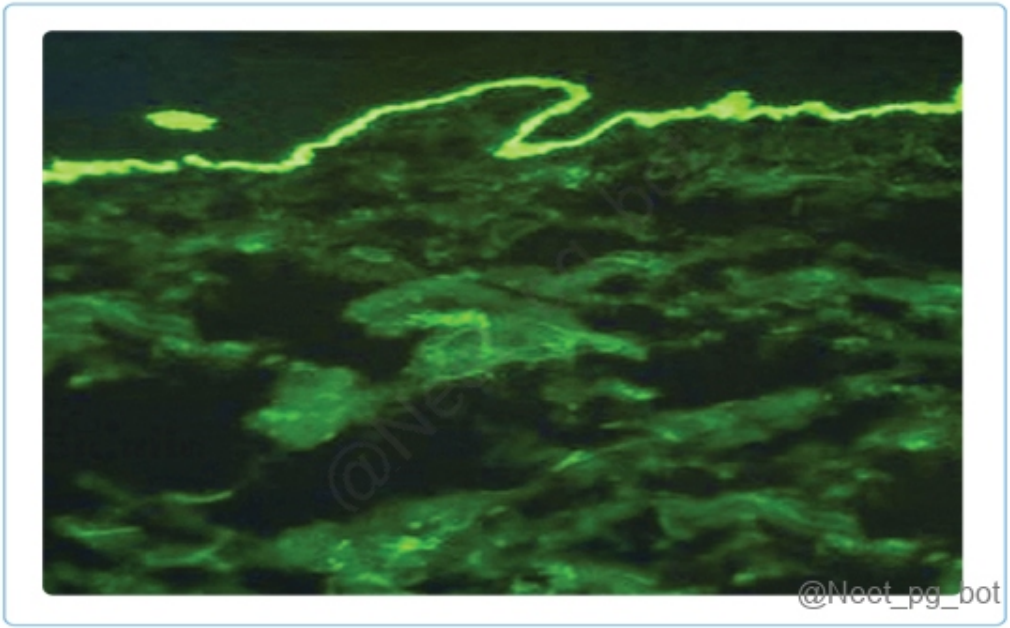

References:

Rooks textbook of dermatology 9th ed, page no. 50.10-50.17, 50.7, 50.53, 3.33-3.34, 50.3 , 50.7-50.8

Eponymous Dermatological Signs in Bullous Dermatoses - PMC (nih.gov)

Pathogenesis, clinical manifestations, and diagnosis of pemphigus - UpToDate

Dermatitis Herpetiformis - StatPearls - NCBI Bookshelf (nih.gov)

↑ *Back to this question in Part A*

@Neet_pg_bot

Q5: What is the probable diagnosis for a 30-year-old patient who has presented with flaccid bullae on her skin that are prone to easy rupture, with the biopsy showing a suprabasal split? (Q855941)

A. Pemphigus vulgaris

B. Pemphigus foliaceus

C. Pemphigus vegetans

D. Erythema multiforme

Correct Answer: A. Pemphigus vulgaris

Explanation: Clinical Presentation: Flaccid bullae (easily rupturing blisters). Mucosal involvement is often present. Histopathology Findings: Suprabasal split (acantholysis within the epidermis). Row of tombstones appearance (basal keratinocytes remain attached to the basement membrane). Confirmatory Test: Direct Immunofluorescence (DIF): IgG deposition in an intercellular pattern. Most Likely Diagnosis: Pemphigus vulgaris (PV) . Pemphigus and Other Blistering Disorders Condition Blister Type Histopathology Immunofluorescence Pemphigus vulgaris Flaccid bullae, oral lesions Suprabasal split, acantholysis IgG in intercellular spaces (fishnet pattern) Pemphigus foliaceus (Option B ruled out) Superficial, crusted lesions Subcorneal split Similar IgG deposits Bullous pemphigoid Tense bullae, no mucosal involvement Subepidermal split Linear IgG at BMZ Dermatitis herpetiformis Grouped vesicles, pruritic Neutrophilic abscesses in dermal papillae IgA at dermal papillae Pemphigus vegetans (Option C): Incorrect because it presents with verrucous plaques rather than flaccid bullae. Erythema multiforme (Option D): Incorrect because it presents with target lesions , not bullous formations with acantholysis.

References:

Rooks textbook of dermatology 9th ed, page no.50.1-50.4\

Pathogenesis, clinical manifestations, and diagnosis of pemphigus - UpToDate

↑ *Back to this question in Part A*

@Neet_pg_bot

Q6: What is the diagnosis for a male baby, born to a non-consanguineous couple, who develops blisters on areas of friction, with a history of a previous child having similar complaints and dying at 2 weeks of age? (Q856824)

A. Epidermolysis bullosas

B. Chronic bullous disorder of childhood

C. Congenital syphilis

D. Neonatal pemphigu

Correct Answer: A. Epidermolysis bullosas

Explanation: B simplex, junctional EB, dystrophic EB, and Kindler syndrome . Pathophysiology Caused by mutations in genes encoding skin structural proteins (keratins, laminins, collagen). Leads to weakened dermal-epidermal adhesion , resulting in blister formation with minor friction or trauma. Features Fragile skin with fluid-filled blisters , erosions, and scarring. Mucosal involvement (oral, esophageal, ocular, and genitourinary). Severe forms can lead to deformities, malnutrition, and infections . Dystrophic EB may cause mitten-hand deformities due to fusion of digits. Investigations & Diagnosis Skin biopsy with immunofluorescence mapping – Identifies the defective protein. Genetic testing – Confirms mutation type. Electron microscopy – Assesses ultrastructural defects. Classification and Antigen Disease Target antigens Bullous pemphigoid BP 180, BP 230 Pemphigoid gestationis BP 180, BP 230 Linear IgA bullous dermatosis (LABD) BP 180 (LAD1) Epidermolysis bullosa acquisita Collagen VII Bullous lupus erythematosus Collagen VII Cicatricial pemphigoid BP 180, laminin, α4 and β6 subunits of integrin MMP (Mucous Membrane Pemphigoid) BP 180, laminin 332 Linear IgA LAD1 DH (Dermatitis Herpetiformis) Epidermal Transglutaminase (not from basement membrane) Incorrect Options: Chronic bullous disorder of childhood (Option B): This condition is characterized by recurrent blistering and typically occurs in older children, not in infancy. Congenital syphilis (Option C): While syphilis can cause skin manifestations, it typically presents with other symptoms as well and can be confirmed through specific diagnostic tests. Neonatal pemphigus (Option D): Neonatal pemphigus is a rare autoimmune condition in which autoantibodies are transferred from the mother to the baby, resulting in blistering.

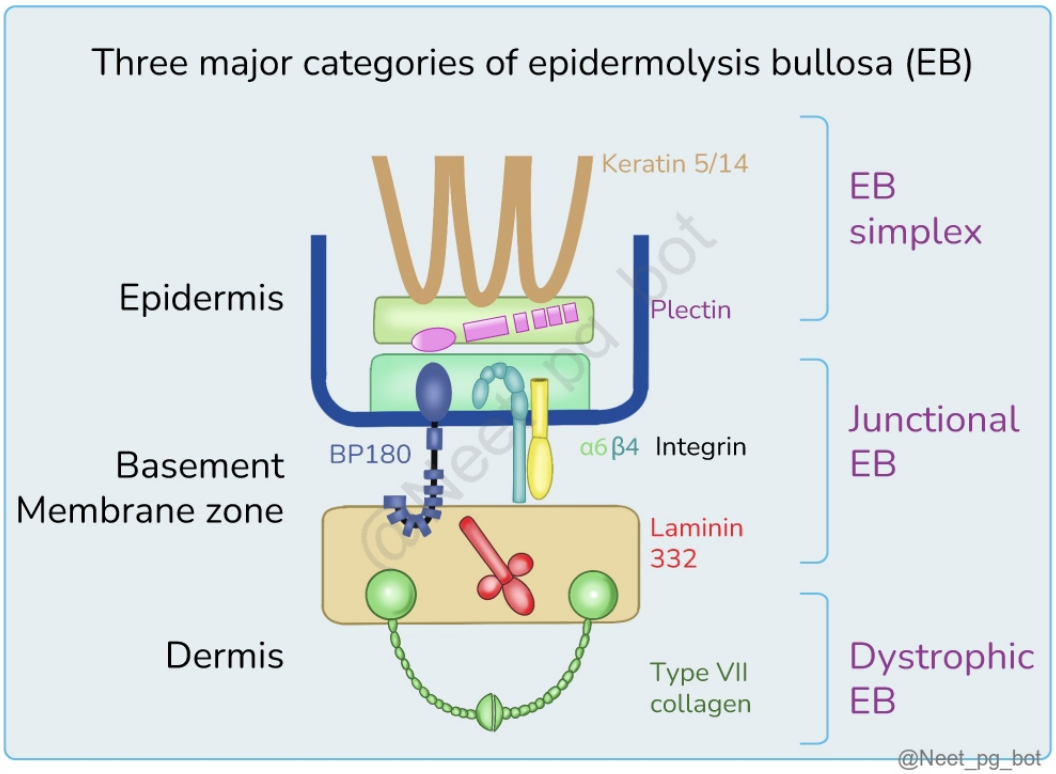

References:

Illustrated Synopsis of Dermatology and Sexually Transmitted Diseases, Fifth Edition – Neena Khanna Pg 31-34

↑ *Back to this question in Part A*

@Neet_pg_bot

Q7: What is the preferred treatment for the condition resulting in the formation of blisters beneath the epidermis, where neutrophils are found at the tips of the dermal papillae? (Q856840)

A. Rituximab

B. Dapsone

C. Cyclosporine

D. Azathioprine

Correct Answer: B. Dapsone

Explanation: – Occasionally used as adjunct therapy Incorrect Options: Rituximab (Option A) : Rituximab is not the treatment of choice for sub-epidermal blister formation with neutrophils located at the tips of the dermal papillae. Cyclosporine (Option C) : Cyclosporine can be effective in managing certain blistering diseases, it is not the treatment of choice Azathioprine (Option D) : Azathioprine may be beneficial in some cases of autoimmune blistering diseases, it is not the treatment of choice.

References:

Illustrated Synopsis of Dermatology and Sexually Transmitted Diseases, Fifth Edition – Neena Khanna Pg 449

↑ *Back to this question in Part A*

@Neet_pg_bot

Q8: A child presents to OPD with tense bullae over the torso. A biopsy of the lesion showed a subepidermal level of blistering and neutrophil infiltration. What is the drug of choice? (Q856382)

A. Rituximab

B. Dapsone

C. Cyclosporine

D. Azathioprine



Correct Answer: B. Dapsone

Explanation: Based on the given information of a child presenting with tense bullae over the torso and a biopsy showing subepidermal blistering and neutrophil infiltration, the most likely diagnosis is Bullous Pemphigoid. The primary treatment for Bullous Pemphigoid is systemic immunosuppressive therapy, and Dapsone is one of the drugs of choice for this condition. Mechanism of Action of Dapsone Inhibits neutrophil chemotaxis and reactive oxygen species (ROS) production , reducing blister formation. Suppresses inflammatory mediators , leading to decreased skin damage. Indications in Subepidermal Autoimmune Bullous Diseases Dermatitis Herpetiformis (DH) - First-line treatment Linear IgA Bullous Dermatosis (LABD) - Effective in most cases Bullous Systemic Lupus Erythematosus (BSLE) - Used in resistant cases Epidermolysis Bullosa Acquisita (EBA) - Occasionally used as adjunct therapy Incorrect Options: Rituximab (Option A) : Rituximab can be used in some cases of autoimmune blistering disorders, it is not typically the drug of choice for Bullous Pemphigoid. Cyclosporine (Option C) : Cyclosporine it is not the first-line drug of choice. Azathioprine (Option D) : Azathioprine is usually reserved for cases that are refractory to first-line treatments or as a steroid-sparing agent. It is not the initial drug of choice.

References:

Illustrated Synopsis of Dermatology and Sexually Transmitted Diseases, Fifth Edition – Neena Khanna Pg 449

↑ *Back to this question in Part A*

@Neet_pg_bot

• [07_Mycobacterial Infections] 014 Cutaneous Tuberculosis

« Back to Folder Directory

[07_Mycobacterial Infections] 014 Cutaneous Tuberculosis — Quick Jump

Q1 (p. 923) *Q2 (p. 926)* *Q3 (p. 927)* *Q4 (p. 929)* *Q5 (p. 932)* *Q6 (p. 936)*
Q7 (p. 937) *Q8 (p. 940)* *Q9 (p. 943)* *Q10 (p. 944)*

Q1: A 28-year-old swimming pool worker presents to the dermatology clinic with a lesion on his left hand which is mostly painless but has gradually increased in size as shown in the image. He recalls sustaining a minor cut while cleaning a pool about a month ago. Which of the following is a characteristic feature of this condition? (Q841842)

A. Erythematous nodules with central clearing

B. Non tender, erythematous nodules along lymphatic vessels

C. Vesicular rash with a linear distribution

D. Target-like lesions with central clearing



Correct Answer: B. Non tender, erythematous nodules along lymphatic vessels

- *Listen (English)*
- *Listen (Hindi)*

Explanation: The given clinical scenario suggests Swimming pool granuloma or Fish tank granuloma, which is caused by Mycobacterium marinum following exposure to contaminated water sources such as swimming pools or aquariums. It is characterized by erythematous, painless nodules along lymphatic vessels of the affected area. Histopathological examination of the biopsy specimen may reveal granulomatous inflammation. Treated with clarithromycin + ethambutol. Erythematous nodules with central clearing (Option A) present as expanding red nodules with central clearing, a bull's-eye rash typical of Lyme disease. Vesicular rash with a linear distribution (Option C) is a characteristic feature of herpes zoster (shingles), a viral infection caused by the reactivation of the varicella-zoster virus. It typically presents with a painful vesicular rash that follows a dermatomal distribution (i.e., along the path of a sensory nerve). Target-like lesions with central clearing (Option D) are a characteristic feature of erythema multiforme , which various factors, including infections, medications, and autoimmune disorders can trigger.



@Neet_pg_bot



@Neet_pg_bot



References:

Rook's Textbook of Dermatology, 9th Edition, Page 27.33

↑ *Back to this question in Part A*

@Neet_pg_bot

Q2: A 35-year-old construction worker presents with a painless lesion on his right forearm following sustaining a minor abrasion while working with bricks a few weeks ago. Physical examination reveals a shallow ulcer with undermined edges. Acid-fast bacilli staining of a biopsy specimen from the lesion is positive. Which of the following types of cutaneous tuberculosis is most likely responsible for this presentation? (Q841834)

A. Exogenous with previous exposure to MTB

B. Exogenous with no previous exposure to MTB

C. Endogenous cutaneous TB

D. Tuberculids

Correct Answer: B. Exogenous with no previous exposure to MTB

■ *Listen to Audio 1*

Explanation: The given clinical scenario suggests Tuberculosis chancre, a multibacillary, exogenous cutaneous TB that occurs in individuals with no previous sensitization to TB. It presents with an ulcer with undermined edges and is analogous to Ghon's focus on pulmonary TB. Cutaneous TB is classified into three categories: Exogenous: The source of TB is outside the body. It is further divided into two types based on previous exposure to MTB. Tuberculosis chancre Tuberculosis verrucosa cutis No previous exposure to MTB No immunity present Multibacillary Previous exposure to MTB Strong immunity is present Paucibacillary Endogenous: The source of TB is inside the body Tuberculids: Cutaneous hypersensitivity response to mycobacteria



References:

Rook's Textbook of Dermatology, 9th Edition, Page27.12

↑ *Back to this question in Part A*

@Neet_pg_bot

Q3: A 45-year-old female presents with a slowly progressive, verrucous plaque on her left foot. She has a history of pulmonary tuberculosis treated several years ago. On examination, the lesion appears well-defined, hyperkeratotic, and verrucous, with a

papillomatous surface as shown in the image. All of the following statements are true about this condition except? (Q841835)

A. Anatomist's wart is the other name

B. Post-primary tuberculosis with poor immunity

C. It is a paucibacillary lesion

D. Antitubercular therapy is used in the management



@Neet_pg_bot

Correct Answer: B. Post-primary tuberculosis with poor immunity

■ *Listen (English)*

■ *Listen (Hindi)*

Explanation: The given clinical scenario and the image suggest the diagnosis of Tuberculosis verrucous cutis which is also known as Prosecutor's wart, Anatomist's wart (Option A) , Verruca necrogenica, and Warty tuberculosis. It is a form of Cutaneous tuberculosis that occurs after direct inoculation of the mycobacteria into the skin of a previously sensitized host with good immunity against the bacillus. (Option B) It is a paucibacillary lesion (Option C) , and inoculation typically occurs from an exogenous source. In adults, TBVC most frequently develops on the acral extremities; the fingers and dorsum of the hands are commonly affected, while in children, the ankles or buttocks are frequent sites for lesion occurrence. It presents as a painless, slowly progressive, red or brown warty, hyperkeratotic plaque with a verrucous or papillomatous surface and it grows via peripheral extension. On histopathological examination, it is characterized by granulomatous inflammation with epithelioid

histiocytes, giant cells, and caseous necrosis(caseating granulomas). It can be treated with Antitubercular drugs (Option D).



@Neet_pg_bot

References:

Rook's Textbook of Dermatology, 9th Edition, Page 27

↑ *Back to this question in Part A*

@Neet_pg_bot

Q4: A 40-year-old woman presents with a slowly enlarging, painless lesion on the neck. She has a history of pulmonary tuberculosis with nodal involvement, treated 3 years ago. On examination, there is a firm, erythematous plaque with crusting and shallow ulceration. Ipsilateral, non-tender cervical lymphadenopathy is also noted. What is the most likely diagnosis? (Q841836)

A. Scrofuloderma

B. Actinomycosis

C. Sporotrichosis

D. Pyoderma gangrenosum



Correct Answer: A. Scrofuloderma

- *Listen (English)*
- *Listen (Hindi)*

Explanation: The given clinical scenario and the image suggest a diagnosis of Scrofuloderma, which is caused by the direct extension of an infection (endogenous spread) to the skin from the underlying TB focus (Lymph node, bone joint). It is a multibacillary manifestation and is the most common form of cutaneous TB in children, although it can occur in any age group. It often presents as painless subcutaneous swellings and ruptures into the overlying skin, resulting in discharging sinuses or undermined ulcers or fibrotic scars. The most common focus of infection is the cervical lymph node. The most common sites are the neck and axilla. Biopsy reveals positive staining for acid-fast bacilli and characteristic caseating granulomas seen. Actinomycosis (Option B): Chronic bacterial infection causing indurated nodules or abscesses with sinus tracts and sulfur granules. Unlike scrofuloderma, it lacks caseating nodules. Sporotrichosis (Option C): Fungal infection presenting as painless papules/nodules after trauma, spreading linearly along lymphatics. Unlike scrofuloderma, it lacks central caseation. Pyoderma gangrenosum (Option D) : Rare, non-infectious ulcers with undermined borders, linked to systemic diseases (IBD, RA, hematologic malignancies). Histology shows neutrophilic infiltrate without infection, vasculitis, or granulomas



@Neet_pg_bot



@Neet_pg_bot



@Neet_pg_bot

References:

Rook’s Textbook of Dermatology, 9th Edition, Page 27.13

↑ *Back to this question in Part A*

@Neet_pg_bot

Q5: A 20-year-old woman presents with a large erythematous, scaly plaque with deep-seated nodules on her buttock, as shown in the image. The lesion gradually progressed over 4 years, exhibiting scarring and atrophy in some areas. Diascopy of the nodules reveals an "apple jelly" nodules. She has a history of a positive tuberculin skin test but no active tuberculosis. What is the likely diagnosis? (Q841837)

A. Lupus vulgaris

B. Psoriasis

C. Lupus pernio

D. Granuloma annulare



@Neet_pg_bot

Correct Answer: A. Lupus vulgaris

- *Listen (English)*
- *Listen (Hindi)*

Explanation: The clinical scenario is suggestive of Lupus vulgaris which is a chronic form of cutaneous tuberculosis that occurs in previously sensitized individuals with moderate immunity to Mycobacterium tuberculosis. These lesions usually appear as well-defined, erythematous to reddish-brown plaques or nodules with smooth, slightly scaly, or verrucous surfaces and may have active, raised margins. They may initially appear as small papules or nodules that gradually enlarge and coalesce to form larger plaques. Often exhibits induration due to the underlying granulomatous inflammation and atrophy due to underlying tissue destruction by the tuberculosis infection. The center of the lesion may show atrophy and scarring. Diagnosis is often confirmed by histopathological examination of skin biopsy specimens, which typically show caseating granulomas with acid-fast bacilli. Diascopy shows characteristic ‘apple jelly nodules’. Treated with Antitubercular therapy. Fig. Apple Jelly Nodule on diascopy Psoriasis (Option B): This typically presents as well-demarcated, erythematous plaques with silvery scales, most commonly on extensor surfaces and scalp. It is associated with systemic manifestations such as psoriatic arthritis and does not produce apple jelly nodules on diascopy, spitz sign positive. Fig. Psoriasis Lupus pernio (Option C): It is a distinctive form of chronic cutaneous sarcoidosis, a multisystem inflammatory disorder characterized by the formation of non-caseating granulomas. It typically presents as persistent, violaceous or dusky-red, indurated plaques or nodules, often involving the nose, cheeks, lips, and ears. It can present with apple jelly nodules on diascopy, but histopathological examination reveals non-caseating granuloma. Fig. Lupus pernio Granuloma Annulare (Option D): It is a benign, self-limiting dermatosis characterized by the formation of dermal granulomas, which are typically devoid of necrosis. Typically presents as asymptomatic or minimally pruritic, erythematous to skin-coloured papules or plaques. Fig . Granuloma Annulare



@Neet_pg_bot



@Neet_pg_bot

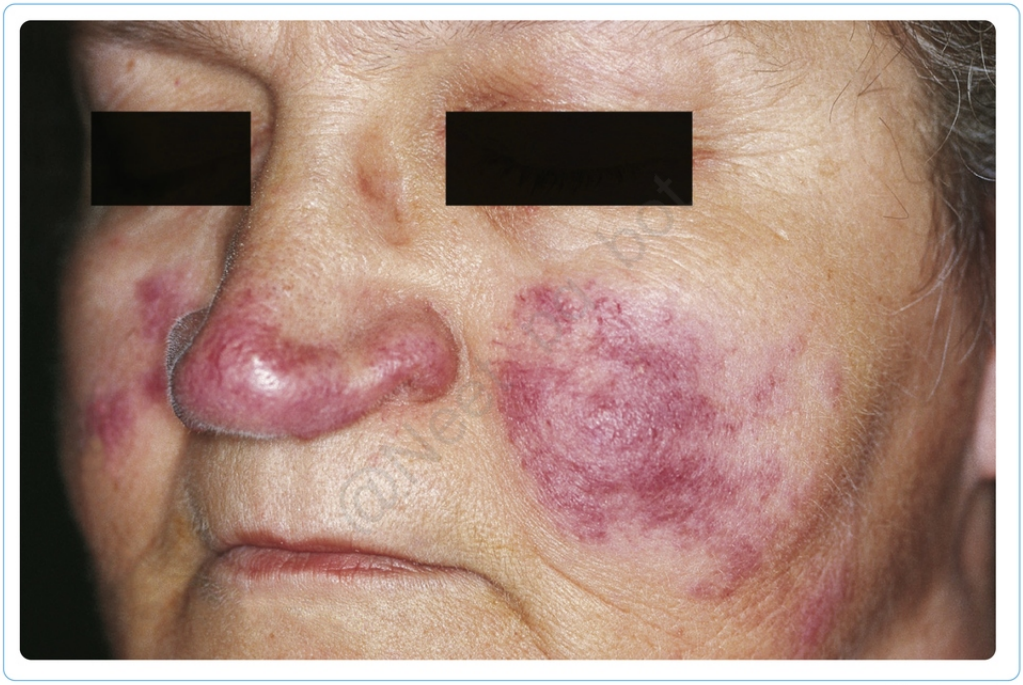

@Neet_pg_bot



@Neet_pg_bot

References:

Rook’s Textbook of Dermatology, 9th Edition, Page 27.21 27.22

Jean L. Bolognia, Dermatology, 4th Edition, Page 1306

↑ *Back to this question in Part A*

@Neet_pg_bot

Q6: A 24-year-old man presents with an erythematous plaque over the dorsum of hand that has been there for 4 years and is slowly progressing. Examination revealed a well-demarcated, indurated, annular-shaped plaque with irregular borders that was progressing towards one side and scarring on another border. Which of the following statements is FALSE about this condition? (Q841838)

A. It is a multibacillary lesion

B. It occurs in a previously sensitized patient

C. Lesions heal with central scarring

D. Apple jelly nodules can be seen



@Neet_pg_bot

Correct Answer: A. It is a multibacillary lesion

■ *Listen (English)*

■ *Listen (Hindi)*

Explanation: Based on the history and the image provided, the diagnosis is Lupus vulgaris and it is a chronic, progressive, paucibacillary (not multibacillary) form of cutaneous tuberculosis. Lupus vulgaris is the most common form of cutaneous TB seen in adults (Most common in females). Causative organisms: Mycobacterium tuberculosis, Mycobacterium bovis. Pathogenesis : Route of spread: Endogenous spread or from exogenous inoculation. It occurs in a previously sensitized individual with an increased cell-mediated immunity to tuberculin. (Option B) Clinical features: Presents as a single or a group of erythematous violaceous annular plaques with central scarring and atrophy with active margins. (Option C) The periphery shows erythematous deep-seated nodules which on diascopy may stand out as apple jelly nodules. (Option D) Most commonly seen in the buttocks, upper extremities, and face. Papules may recur within scarred areas, enlarging and coalescing into large, firm, elevated plaques. Complications: Secondary scarring and squamous cell carcinoma may develop rarely. Treatment : Anti-tubercular drugs.

References:

Rook's Textbook of Dermatology, 9th Edition, Page 27.21, 27.22

↑ *Back to this question in Part A*

@Neet_pg_bot

Q7: An 11-year-old child presented in dermatology OPD with a micro papular rash on the trunk without any necrosis or itching. The Mantoux test is positive. Histopathology examination shows perifollicular non-caseating granulomas. Which of the following statements is false about its diagnosis? (Q841839)

A. Commonly seen in adults

B. The most common site is the trunk

C. It is not a type of lichen planus

D. Asymptomatic lichenoid papules are present



Correct Answer: A. Commonly seen in adults

■ *Listen (English)*

■ *Listen (Hindi)*

Explanation: Based on the clinical history and image, the diagnosis points to Lichen scrofulosorum , a rare form of tuberculid (Option C) , commonly seen in children (not in adults). Fig. Lichen Scrofulosorum showing annular and plaque■like lesions with strong tuberculin reaction Lichenoid variety of Lichen Scrofulosorum Lichen scrofulosorum presents with asymptomatic, lichenoid-grouped papules, often perifollicular in distribution. (Option D) The trunk is the most common site for these lesions. (Option B) Healing typically occurs without scarring. Positive Mantoux test indicates previous exposure to tuberculosis antigens. Biopsy reveals superficial dermal granulomas surrounding hair follicles. These granulomas contain epithelioid cells, lymphocytes, and occasional giant cells, typically without caseation. Treatment involves a course of antitubercular therapy: 2 months of HRZE followed by 4 months of HRE.





References:

Rook’s Textbook of Dermatology, 9th Edition, Page 27.26

↑ *Back to this question in Part A*

Q8: A 57-year-old female presented in dermatology OPD with bilateral nodular lesions and ulceration on her calf. On examination, tenderness was noticed. The Mantoux test was positive, and the culture for M. tuberculosis was negative. What is the likely diagnosis of this patient? (Q841840)

A. Erythema induratum of Bazin

B. Lichen scrofulosorum

C. Papulonecrotic tuberculid

D. Erythema nodosum



Correct Answer: A. Erythema induratum of Bazin

■ *Listen (English)*

■ *Listen (Hindi)*

Explanation: The given clinical history suggests a diagnosis of Erythema induratum of Bazin. It is a type of tuberculid whose cause is not fully understood. It is believed to be a hypersensitivity reaction to Mycobacterium tuberculosis antigens. It is most common in middle-aged females. It presents as recurrent nodular and ulcerative

lesions that are usually localized to the lower legs(posterior calves). Biopsy reveals Lobular panniculitis and vasculitis. Tuberculids can be considered to be cutaneous hypersensitivity reactions to hematogenous dissemination of M. tuberculosis or its antigens from a primary source in an individual with strong anti-tuberculous cell■mediated immunity. Patients with tuberculids typically have a good response to anti-tuberculous therapy. Lichen Scrofulosorum (Option B): A tuberculid with grouped perifollicular lichenoid papules on the trunk, common in children, healing without scars. Papulonecrotic tuberculid (Option C) : A tuberculid with necrotic papules on extremities, seen in adults, showing obliterative vasculitis and thrombosis on biopsy. Erythema nodosum(Option D): Erythema nodosum presents with tender red nodules on extensor limbs, without ulceration or scarring. .





@Neet_pg_bot

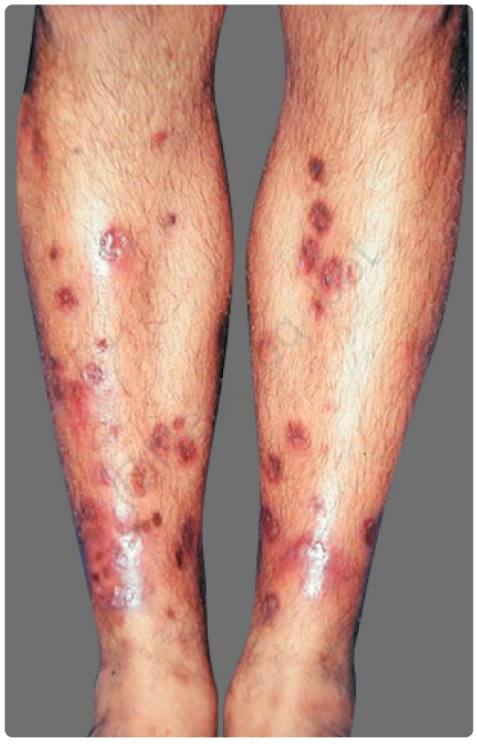

@Neet_pg_bot



@Neet_pg_bot

References:

Rook’s Textbook of Dermatology, 9th Edition, Page 27.25, 99.21

↑ *Back to this question in Part A*

@Neet_pg_bot

Q9: A 14-year-old girl presents with an erythematous plaque with central scarring and an advancing edge on her face. She reports a gradual progression of lesions over several months. Biopsy shows granulomatous inflammation. Which of the following drugs will be started as a part of treatment in this patient? (Q841841)

A. Amphotericin B

B. Itraconazole

C. Minocycline

D. Rifampicin



@Neet_pg_bot

Correct Answer: D. Rifampicin

■ *Listen (English)*

■ *Listen (Hindi)*

Explanation: The clinical picture shows an erythematous plaque with central scarring and an advancing edge, which suggests a clinical diagnosis of Lupus vulgaris. Rifampicin is an antibiotic that is part of the standard Anti-Tuberculous Therapy (ATT), started in this patient. It is used in combination with other medications, such as Isoniazid, Pyrazinamide, and Ethambutol, to treat cutaneous tuberculosis, such as lupus vulgaris. Amphotericin B (Option A): Amphotericin B treats serious systemic fungal infections but not cutaneous tuberculosis. Itraconazole (Option B): Itraconazole treats skin fungal infections but is ineffective against Mycobacterium tuberculosis. Minocycline (Option D) : It is a tetracycline used for acne, not effective for mycobacterial infections.

References:

Rook’s Textbook of Dermatology, 9th Edition, Page 27.22

↑ *Back to this question in Part A*

@Neet_pg_bot

Q10: A 15-year-old boy presents to the clinic with a large painless ulcer on the lower extremity with a necrotic base and undermined edges. His family reports that they live near a wetland area in a region known to have cases of similar ulcers. There has been

no response to standard treatment for common bacterial skin infections. A smear from the lesion shows acid-fast bacilli. What is the most likely diagnosis? (Q841843)

A. Buruli ulcer

B. Cutaneous tuberculosis

C. Cutaneous leishmaniasis

D. Diabetic ulcer



Correct Answer: A. Buruli ulcer

■ *Listen (English)*

■ *Listen (Hindi)*

Explanation: It is caused by Mycobacterium ulcerans , which is endemic to wetland areas. It presents as a painless ulcer with necrosis and undermined edges. Necrosis is due to a cytotoxin, Myolactone, released by the organism ■Acid-fast bacilli in a smear from the lesion support the diagnosis. The four main diagnostic laboratory tests for Buruli ulcer are direct smear (with acid■fast stains, auramine O or Ziehl–Neelsen), culture at 32°C, histopathology (lympho-epithelioid cell proliferation and panniculitis with characteristic fat necrotic changes), PCR (highest sensitivity). Treatment: Small ulcers(<5cm) Rifampicin + Clarithromycin/Streptomycin for 8 weeks Large ulcers (>5cm) Surgery is recommended along with antibiotic therapy. Cutaneous Tuberculosis (Option B) : Although cutaneous tuberculosis is caused by an acid-fast bacillus (Mycobacterium tuberculosis), it typically presents in areas with a high prevalence of tuberculosis. Cutaneous Leishmaniasis (Option C): causes painful ulcers with Leishmania parasites, often after travel to endemic areas. Diabetic Ulcer (Option D) : Diabetic ulcers are typically found on pressure points of the feet, are associated with neuropathy and vascular disease, and do not

usually present with undermined edges or a necrotic base unless secondarily infected.

References:

Rook’s Textbook of Dermatology, 9th Edition, Page 27.38

↑ *Back to this question in Part A*

@Neet_pg_bot

• [07_Mycobacterial Infections] 015 Leprosy

« Back to Folder Directory

[07_Mycobacterial Infections] 015 Leprosy — Quick Jump

Q1 (p. 947) *Q2 (p. 948)* *Q3 (p. 949)* *Q4 (p. 950)* *Q5 (p. 954)* *Q6 (p. 954)*
Q7 (p. 956) *Q8 (p. 957)* *Q9 (p. 960)* *Q10 (p. 962)*

Q1: A 45-year-old man from a leprosy endemic region presents with small, ill-defined, multiple symmetrically distributed skin nodules as depicted below. Additionally he also has thickened peripheral nerves. What type of T lymphocytes are predominantly involved here? (Q842011)

A. ■■■Predominantly CD8+ T-cells

B. Predominantly CD4+ T-cells

C. Both CD8+ and CD4+ T-cells

D. None of the above



Correct Answer: A. ■■■Predominantly CD8+ T-cells

■ *Listen (English)*

■ *Listen (Hindi)*

Explanation: The clinical presentation described, characterized by small, symmetric, ill-defined skin nodules and thickened peripheral nerves, is typical of lepromatous leprosy. In lepromatous leprosy, there is a failure of cell-mediated immunity to control the Mycobacterium Leprae infection and a predominant CD8 cellular response. This leads to widespread dissemination of the bacteria and the characteristic skin nodules, and thickened peripheral nerves , as described in the case. Clinical features that differentiate lepromatous and tuberculoid leprosy: Tuberculoid Lepromatous Number of lesions Less More Margins Well-defined Ill-defined Glands Dry lesions Shiny lesions Sensation Localized or lesional loss Widespread loss Glove and stocking anaesthesia Nerve Involvement Localized / single nerve trunk involvement Multiple nerve trunk involvement Bacterial load Less More Histopathology: Tuberculoid Lepromatous Granuloma Well-formed elongated granuloma Ill-defined/loose Granuloma Epithelioid cells More Fewer Macrophages Less More(foamy aka lepra / virchow cells) T-Lymphocytes CD4 cells (Option A,C) CD8 cells Giant cells Langerhans giant cells Foreign body giant cells Grenz zone Absent Present Perineural lamination/ Onion skin appearance Absent Present

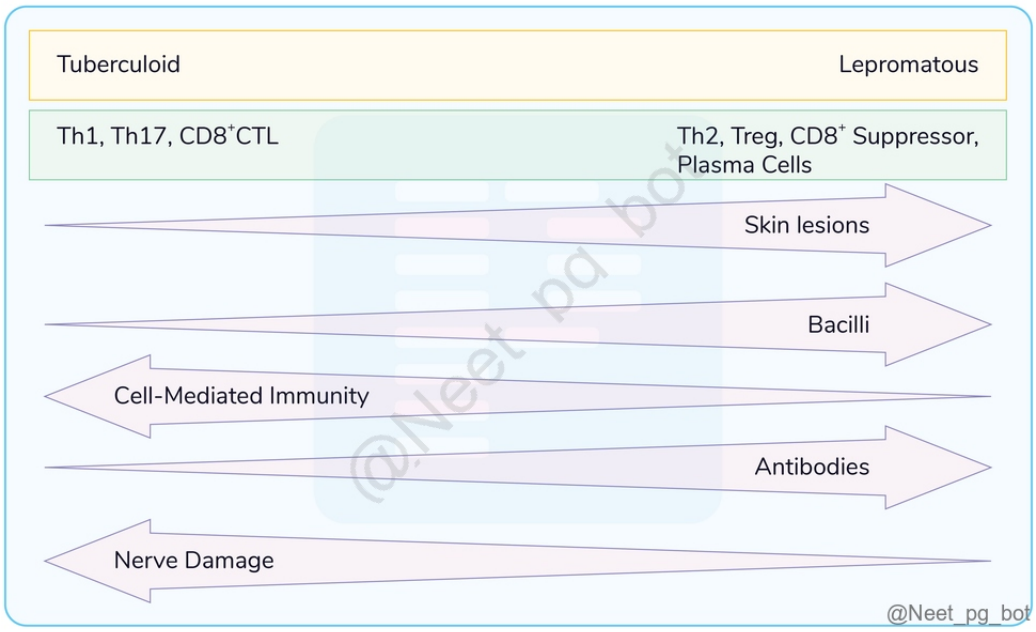

References:

Rook’s Textbook of Dermatology, 9th Edition, Page28.8

↑ *Back to this question in Part A*

@Neet_pg_bot

Q2: A second-year medical student asks you to describe Lepromin Test in the dermatology ward. While reviewing the test together, she recalls several statements.

Which of the following statements recalled by her is false? (Q842015)

A. An early reaction is called the Fernandez reaction

B. It is a diagnostic test

C. It is also called the Mitsuda test

D. It may be used to classify patients

Correct Answer: B. It is a diagnostic test

■ *Listen (English)*

■ *Listen (Hindi)*

Explanation: The Lepromin test does not detect leprosy, because many confirmed patients especially lepromatous cases show no reaction. A test that is negative in diseased individuals cannot be used for diagnosis. It is primarily a measure of cell-mediated immunity, not an indicator of infection. Diagnosis of leprosy depends on clinical signs and slit-skin smear, not Lepromin. So, lepromin test is not a diagnostic test. Incorrect Options: Option A) An early reaction is called the Fernandez reaction: The initial response within 48 hours is known as the Fernandez reaction, reflecting early cellular hypersensitivity. Option C) It is also called the Mitsuda test : The test's delayed response at 3–4 weeks is known as the Mitsuda reaction, giving the procedure its alternative name. Option D) It may be used to classify patients: The test assists in grading disease along the immunological spectrum, helping differentiate tuberculoid from lepromatous forms.

References:

Rook's Textbook of Dermatology, 9th Edition, Page 28.6,11,12,13,14

↑ *Back to this question in Part A*

@Neet_pg_bot

Q3: What is the most likely diagnosis for a patient with hypoesthetic lesions as shown in the image? (Q842017)

A. Borderline lepromatous

B. Borderline tuberculoid

C. Lepromatous

D. Tuberculoid



Correct Answer: B. Borderline tuberculoid

■ *Listen (English)*

■ *Listen (Hindi)*

Explanation: The image shows a single large hypopigmented patch with clear but slightly irregular margins. Satellite lesions around the main patch indicate a spreading nature typical of borderline forms. Pseudopodia (finger-like extensions) from the main lesion are characteristic of Borderline Tuberculoid (BT) leprosy. BT usually presents with few lesions (1–5), matching the image pattern. Lesions are typically dry, well-defined, and hypoesthetic, consistent with BT leprosy. Incorrect Options: Option A) Borderline Lepromatous (BL): Presents with multiple, ill-defined lesions spread across the body. The image shows only one major lesion with satellites, not widespread disease. Option C)Lepromatous Leprosy (LL): Has numerous, symmetrical, poorly defined lesions with late sensory loss. The solitary large lesion with clear borders and satellites is not typical of LL. Option D) Tuberculoid Leprosy (TT): Shows a single, sharply defined lesion without satellite lesions or pseudopodia. This does not match the irregular margin and spreading pattern seen in the image.

References:

Rook's Textbook of Dermatology, 9nd Edition Chapter 28 Page No 28.11

↑ *Back to this question in Part A*

@Neet_pg_bot

Q4: A 6-year-old child presents with well demarcated hypopigmented lesions with fine scaling on the face and upper arms. The lesions are well-demarcated with fine scaling

and have been present for several months. On examination, there is no erythema or induration. The child is otherwise healthy with no systemic symptoms. Which of the following is the most likely diagnosis for this presentation? (Q842019)

A. ■■■Pityriasis alba

B. ■■■Indeterminate leprosy

C. Atopic dermatitis

D. Niacin deficiency



Correct Answer: A. ■■■Pityriasis alba

■ *Listen (English)*

■ *Listen (Hindi)*

Explanation: Pityriasis alba typically presents as multiple, ill-defined, hypopigmented patches primarily on the face and is often associated with a history of atopy. It occurs predominantly in children between the ages of 3 -16 years . The lesions are mildly scaly and non-atrophic, and the sensation is intact. It lacks peripheral nerve involvement or raised skin lesions Treatment:- First line- Emollient Second line- Mild topical corticosteroids Third line- Topical tacrolimus or pimecrolimus (Option B) Indeterminate Leprosy: ■■Indeterminate leprosy presents with a single, hypopigmented, slightly atrophic patch. Histologically there is a scattered non■specific histiocytic and lymphocytic infiltration with some concentration around skin appendages, usually no bacilli are found. Difference between pityriasis alba and indeterminate leprosy:- Child, with facial hypopigmented patches Pityriasis

alba Indeterminate leprosy Lesions Multiple Single Scaling + - Atopy + - Sensation Intact Normal Skin atrophy Absent May or may not be Present (Option C) Atopic Dermatitis: Atopic dermatitis usually presents with pruritic, eczematous lesions, often in flexural areas, not typically as a single hypopigmented atrophic patch. (Option D) Niacin Deficiency: Niacin deficiency, or pellagra, typically presents with dermatitis in sun-exposed areas, diarrhoea, and dementia, not as a single hypopigmented atrophic patch on the face.







References:

Rook's textbook of dermatology 9th edition page no.- 28.5, 28.6

↑ *Back to this question in Part A*

@Neet_pg_bot

Q5: A 40-years-old male presented with multiple hypopigmented macules on trunk. On examination, the lesions were non-scaly, shiny and hypoaesthetic. Which of the following tests should be performed to confirm the diagnosis? (Q842021)

A. Diascopy

B. Lepromin Test

C. Slit skin smear

D. Wood’s lamp examination

Correct Answer: C. Slit skin smear

■ *Listen (English)*

■ *Listen (Hindi)*

Explanation: This clinical vignette is suggestive of a patient with Leprosy A slit skin smear is performed by taking a sample from the earlobes or lesions and staining for acid-fast bacilli is done, which is diagnostic for leprosy. Diascopy(Option A): Diascopy is used to determine the nature of erythema or lesions by applying pressure with a glass slide. It helps to differentiate erythema from purpura but is not useful for diagnosing hypopigmented, anaesthetic lesions in leprosy. Lepromin Test(Option B): The Lepromin test is not a diagnostic test for leprosy. It is used to determine the type of immune response (cell-mediated immunity) a person has to Mycobacterium leprae. It can help classify the form of leprosy and give an estimate of the patient's prognosis, but it does not confirm the presence of the disease itself. Wood’s Lamp Examination(Option D): This examination is primarily used to assess for fluorescent pigments or substances in the skin, such as in the case of fungal infections or certain pigmentation disorder s, but it may not be specific enough to confirm the diagnosis in this case.

References:

Rook’s Textbook of Dermatology- 9th Edition Chapter 28 Page No 28.1, 28.3, 28.12

↑ *Back to this question in Part A*

@Neet_pg_bot

Q6: A 12-year-old child presented with skin lesions, as shown in the image. On examination, bilateral ulnar and lateral popliteal nerves were enlarged. According to the National Leprosy Eradication Programme (NLEP) Guidelines, what would be the

most appropriate treatment for the child on day 1? (Q842023)

A. ■■■Rifampicin 450 mg Clofazimine 150 mg Dapsone 50 mg

B. Rifampicin 600 mg Clofazimine 300 mg Dapsone 100 mg

C. ■■■Rifampicin 450 mg Clofazimine 150 mg Dapsone 100 mg

D. ■■■Rifampicin 300 mg Clofazimine 150 mg Dapsone 50 mg



@Neet_pg_bot

Correct Answer: A. ■■■Rifampicin 450 mg Clofazimine 150 mg Dapsone 50 mg

■ *Listen (English)*

■ *Listen (Hindi)*

Explanation: A 12-year-old child presents with clinical features suggestive of multibacillary (MB) leprosy : Multiple papules and nodules on the face Nodular thickening of the earlobes These are classical features of MB leprosy (high bacterial load and involvement of skin and nerves), requiring multibacillary multidrug therapy (MB-MDT) as per National Leprosy Eradication Programme (NLEP) guidelines in India. NATIONAL LEPROSY ERADICATION PROGRAMME (NLEP) Cardinal Features Paucibacillary Multibacillary Skin: Hypopigmented/hypo-anaesthetic patches 1-5 >1 Nerves Thickened +/- Tenderness No nerve / only one nerve with or without 1 to 5 lesions >1 SSS AFB Absent Present ■■The presence of one of the three signs can establish the diagnosis of leprosy. Treatment TREATMENT OF HANSEN'S DISEASE (WHO REGIME) Age or weight group Medicine Dosage and frequency MB PB Adult Rifampicin 600 mg once a month 12 months 6 Months Clofazimine 300 mg once a month and 50 mg daily Dapsone 100 mg daily Children (10–14 years) Rifampicin 450 mg once a month 12 months 6 Months Clofazimine 150 mg once a month and 50 mg on alternate days Dapsone 50 mg daily Children (< 10 years old or < 40 kg) Rifampicin 10 mg/kg once a month 12 months 6 months

Clofazimine 100 mg once a month, 50 mg twice weekly Dapsone 2 mg/kg daily

References:

Rook's Textbook of Dermatology- 9th Edition Chapter 28 Page No 28.14,15,16

https://cdn.who.int/media/docs/default-source/ntds/leprosy/recommended-treatment-regimens-for-leprosy.pdf?sfvrsn=ac6de2af_3

www.flickr.com/photos/communityeyehealth/5683310963

↑ *Back to this question in Part A*

@Neet_pg_bot

Q7: You are training a pharmacist at a local PHC to supply multi-drug therapy at regular intervals for patients with leprosy in a village. Which of the following statements would be incorrect regarding treatment of leprosy? (Q842026)

A. Fluoroquinolones are second-line drugs for the management of leprosy

B. Dapsone acts as an anti-leprosy medication by inhibiting folate synthesis.

C. Rifampicin acts by inhibiting RNA-dependent DNA polymerase

D. Clofazimine causes the deposition of crystals in the intestinal mucosa

Correct Answer: C. Rifampicin acts by inhibiting RNA-dependent DNA polymerase

■ *Listen (English)*

■ *Listen (Hindi)*

Explanation: Rifampicin inhibits DNA-dependent RNA polymerase , not RNA-dependent DNA polymerase. This inhibition interferes with bacterial RNA synthesis, ultimately leading to bactericidal activity against Mycobacterium leprae. Fluoroquinolones (Option A) , such as pefloxacin and ofloxacin have remarkable bactericidal activity against M. leprae, and they are considered potential second-line drugs Dapsone (Option B) also known as DDS (4,4-diaminodiphenylsulphone), acts by blocking folic acid synthesis in bacteria. It is weakly bactericidal against Mycobacterium leprae. Clofazimine (Option D): ■■It has weak bactericidal activity against mycobacterium leprae & causes the deposition of crystals in the intestinal mucosa, liver, lymph nodes & spleen ■■Other adverse effects of Clofazimine are: ■■Ichthyosis of skin. ■■Skin discoloration (red to purple-black) TREATMENT OF HANSEN'S DISEASE (WHO REGIME) Drugs PB MB Rifampicin 600 mg once a month 600 mg once a month Dapsone 100mg daily 100mg daily Clofazimine 300mg once a month 50mg daily 300mg once a month 50mg daily Duration 6 months 12 months

References:

Rook's Textbook of Dermatology 9th Edition Chapter 28 Page No. 28.1- 28.15

↑ *Back to this question in Part A*

@Neet_pg_bot

Q8: A 30-year-old patient from an endemic region presents with weakness and numbness in the lower leg and foot. On examination, there is evidence of foot drop and sensory loss over the dorsum of the foot. Which nerve is most likely involved in a patient of leprosy, leading to these neurological deficits? (Q842028)

A. Median nerve

B. Ulnar nerve

C. Radial nerve

D. Common peroneal nerve

Correct Answer: D. Common peroneal nerve

■ *Listen (English)*

■ *Listen (Hindi)*

Explanation: The common peroneal nerve , located in the leg, is commonly affected in leprosy. This nerve involvement can significantly impact mobility and function in affected individuals, resulting in neurological deficits such as foot drop and sensory loss over the dorsum of the foot. Common peroneal nerve lesions cause difficulty in dorsiflexion and eversion of the foot and anaesthesia of the outer border of the foot, a combination which predisposes to traumatic damage and plantar ulceration Motor nerve deficits in leprosy:- Surface markings of all the nerves commonly affected in Leprosy:- Median nerve(Option A) :Median nerve involvement causes hand weakness and sensory loss, leading to claw hand, not foot drop. Ulnar nerve(Option B): Ulnar nerve involvement causes hand weakness and sensory loss, leading to partial claw hand; it is the most commonly affected peripheral nerve in leprosy. Radial nerve(Option C) : Radial nerve involvement in leprosy causes wrist drop; less common than common peroneal nerve, with radial cutaneous nerve most often biopsied.

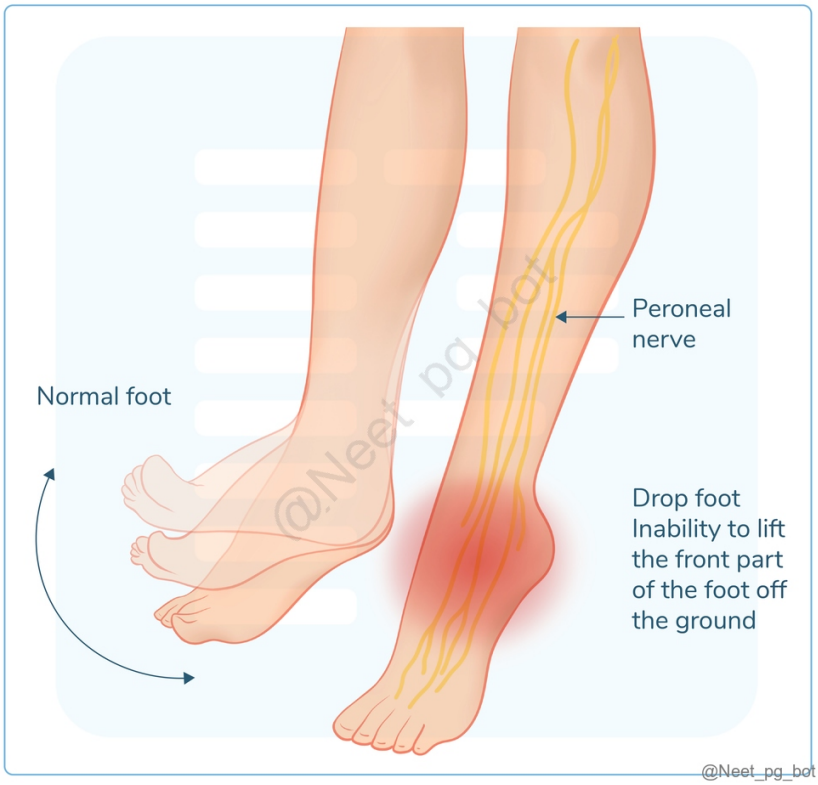
Peroneal nerve
Normal foot
Drop foot
Inability to lift the front part of the foot off the ground
@Neet_pg_bot

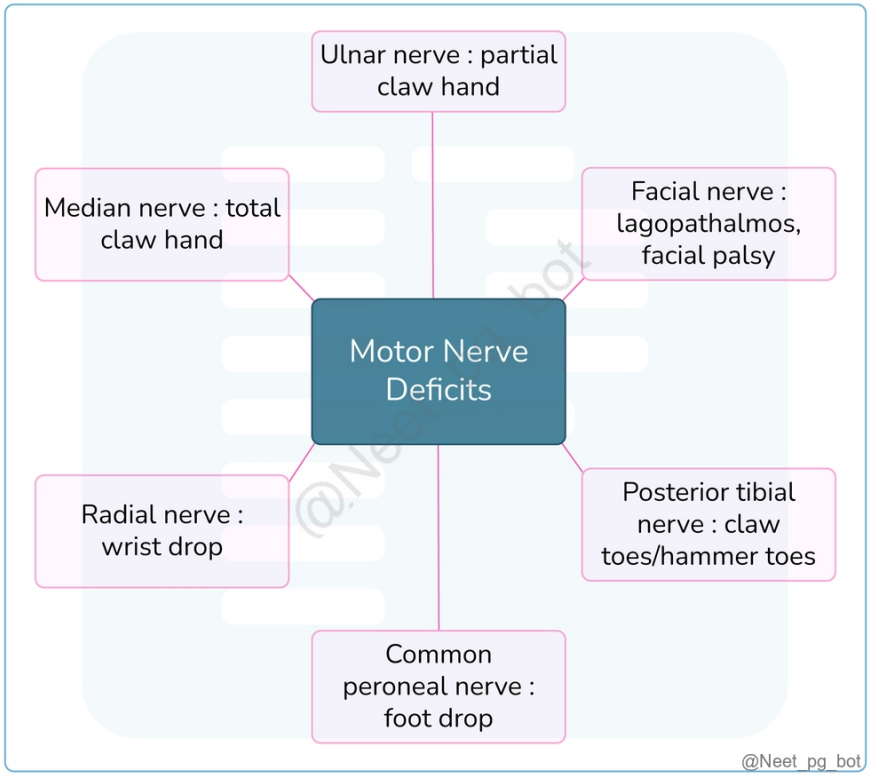
Ulnar nerve : partial claw hand
Median nerve : total claw hand
Facial nerve : lagopathalmos, facial palsy
Motor Nerve Deficits
Radial nerve : wrist drop
Posterior tibial nerve : claw toes/hammer toes
Common peroneal nerve : foot drop
@Neet_pg_bot

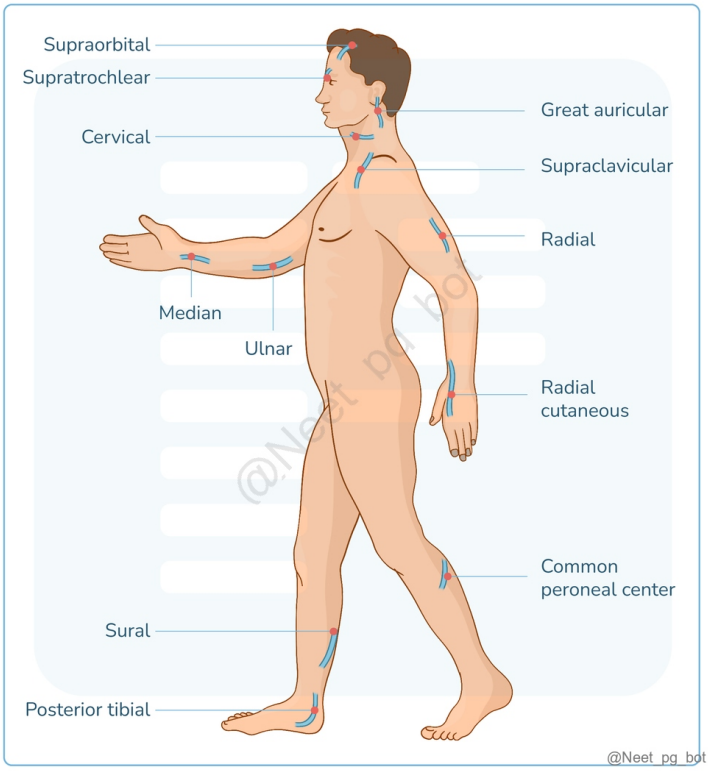

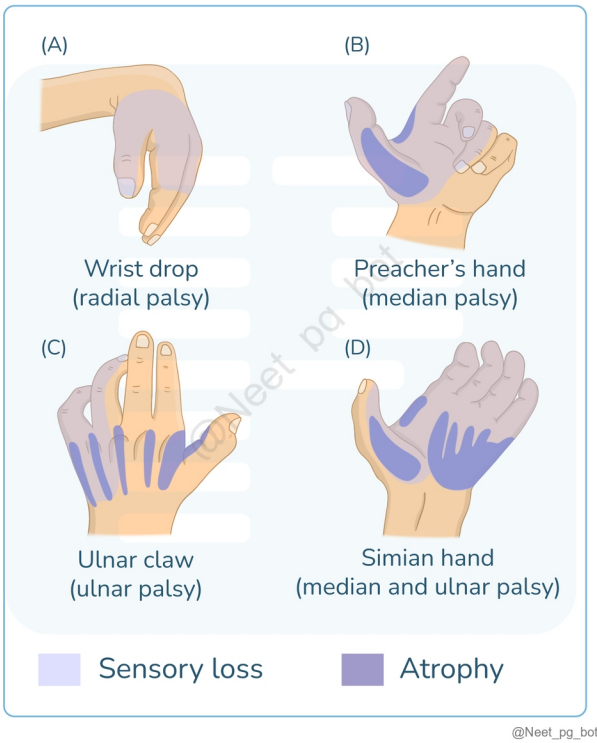

References:

Rook's textbook of leprosy 9th edition page no.-28.13

↑ *Back to this question in Part A*

@Neet_pg_bot

Q9: A 28-year-old woman presents with an erythematous, swollen patch in a skin lesion on the face, along with significant oedema of the hands and feet. She reports the patch has been present for several months now, but has only recently turned painful and red. Additionally, the patient experiences pain and tenderness along multiple nerves and reports a general feeling of fatigue and malaise. The patient has been on regular medications but is unsure about their names. What is the most likely diagnosis? (Q842029)

A. Pyoderma gangrenosum

B. Type 1 lepra reaction

C. Vasculitis

D. Psoriasis

Correct Answer: B. Type 1 lepra reaction

■ *Listen (English)*

■ *Listen (Hindi)*

Explanation: History of a pre-existing skin lesion on the face turning red and swollen, along with significant oedema of the hands and feet, is indicative of Type 1 lepra reaction Pain and tenderness over multiple nerves are other characteristic features of Type 1 lepra reaction. Type 1 lepra reaction is a type IV hypersensitivity reaction , that typically occurs in patients with borderline leprosy (BT, BB, or BL disease). It is characterized by an inflammatory response to Mycobacterium leprae antigens usually seen on starting MDT, resulting in a sudden exacerbation of pre-existing skin lesions and nerve involvement. Cellulitis (Option A): Acute, painful, red swelling of skin and subcutis, usually post-injury; differs from lepra reaction in presentation. Psoriasis (Option C): It is a chronic autoimmune skin condition characterized by red, scaly patches on the skin, over the elbows, knees, scalp, and lower back. Erythema multiforme (Option D): Hypersensitivity reaction with target lesions , often post-infection or drug-related; not consistent with leprosy reaction.



@Neet_pg_bot



@Neet_pg_bot



@Neet_pg_bot

References:

Rook’s textbook of dermatology, 9th edition, Pages 28.15 to 28.16

↑ *Back to this question in Part A*

@Neet_pg_bot

Q10: A pregnant woman at 10 weeks of gestation, who is currently undergoing multidrug therapy (MDT) for leprosy, now presents with type 2 lepra reaction. What is the preferred treatment for this patient? (Q842032)

A. ■■■Stop MDT and start oral steroids

B. Antibiotics

C. ■■■Thalidomide

D. ■■■Continue MDT and add oral steroids

Correct Answer: D. ■■■Continue MDT and add oral steroids

■ *Listen (English)*

■ *Listen (Hindi)*

Explanation: Corticosteroids and thalidomide are mainstay treatments for type 2 lepra reactions ■■In patients with lepra reactions, MDT is never discontinued in order to prevent the development of drug resistance and further progression of the disease. MDT is considered safe in pregnancy. A Type 2 lepra reaction, also known as Erythema Nodosum Leprosum (ENL) , is a type 3 hypersensitivity reaction that occurs in lepromatous and borderline lepromatous leprosy, which can present with painful nodules, fever, malaise, and other systemic symptoms. ■■Corticosteroids: Treatment of choice. They help reduce inflammation and immune response. Thalidomide: ■■Only severe cases of type-2 lepra reaction or erythema nodosum leprosum are treated with Thalidomide. Thalidomide is the gold standard for type II Lepra reaction, but it is NOT the drug of choice due to its cost factor & also its adverse drug reaction profile. Alternative drugs: Methotrexate, clofazimine, or tumour necrosis factor-alpha (TNF-a) inhibitors ■■■ Stop MDT and start oral steroids (Option A): Stopping MDT is not advisable because it can increase the bacterial load and risk the development of drug resistance. Antibiotics (Option B): While antibiotics are a part of MDT to treat the bacterial infection, they alone are not sufficient to address the acute inflammatory symptoms of a Type 2 lepra reaction. Thalidomide (Option C): ■■Thalidomide is an effective treatment for Type 2 lepra reactions due to its potent anti-inflammatory properties. However, it is absolutely contraindicated in pregnant women due to the risk of phocomelia in the first trimester.

References:

Rook's Textbook of Dermatology, 9th Edition, Chapter 28, Page 28.16

↑ *Back to this question in Part A*

@Neet_pg_bot

• [07_Mycobacterial Infections] 016 Previous Year Questions

« Back to Folder Directory

[07_Mycobacterial Infections] 016 Previous Year Questions — Quick Jump

Q1 (p. 964) *Q2 (p. 965)* *Q3 (p. 967)* *Q4 (p. 970)* *Q5 (p. 970)* *Q6 (p. 971)*
Q7 (p. 973) *Q8 (p. 974)* *Q9 (p. 975)* *Q10 (p. 976)* *Q11 (p. 981)*

Q1: A patient with borderline tuberculoid leprosy presents with the following findings. Which type of hypersensitivity reaction and nerve is enlarged? (Q866862)

A. Type 1 & greater auricular nerve

B. Type 2 & greater auricular nerve

C. Type 3 & anterior auricular nerve

D. Type 4 & greater auricular nerve



Correct Answer: D. Type 4 & greater auricular nerve

Explanation: The image shows a patient with a visibly thickened and enlarged nerve in the neck region, which is the greater auricular nerve. The question also mentions that the patient has borderline tuberculoid leprosy and is experiencing a reaction. Leprosy Reactions: Leprosy reactions are episodes of acute inflammation that occur during the course of the disease. Type 1 (reversal) reactions are a form of delayed-type hypersensitivity (Type IV) reaction. They are caused by a sudden increase in the cell-mediated immune response to the Mycobacterium leprae bacteria. Clinical Presentation: These reactions often involve inflammation of existing skin lesions and, most importantly, acute neuritis , which is the painful inflammation and enlargement of peripheral nerves. The greater auricular nerve is a common site for this nerve enlargement. Therefore, the correct pairing is a Type 4 hypersensitivity reaction and the greater auricular nerve . Incorrect Options: Type 1 & greater auricular nerve (Option A) is an immediate, IgE-mediated reaction (e.g., an allergic reaction), which is not what causes leprosy reactions. Type 2 & greater auricular nerve (Option B) is a cytotoxic, antibody-mediated reaction. A Type 2 leprosy reaction is known as erythema nodosum leprosum (ENL), which presents with painful red nodules and is a Type III hypersensitivity reaction. Type 3 & anterior auricular nerve (Option C) is an immune complex-mediated reaction. A Type 2 leprosy reaction (ENL) is an example of this. The anterior auricular nerve is not the most commonly affected nerve.

References:

.

↑ *Back to this question in Part A*

@Neet_pg_bot

Q2: A patient presents with a progressive and asymptomatic lesion over the neck region and no systemic symptoms. Which of the following investigations would be helpful? KOH preparation Skin biopsy Chest X-ray (TB workup) HIV testing (Q865451)

A. 1, 2

B. 2, 3

C. 3, 4

D. 1, 4



Correct Answer: B. 2, 3

Explanation: In a patient with a progressive, asymptomatic lesion over the neck, clinically suggestive of Lupus Vulgaris (a form of cutaneous tuberculosis), the most helpful investigation would be skin biopsy and TB workup. It is a chronic, progressive, paucibacillary (not multibacillary) form of cutaneous tuberculosis. Lupus vulgaris is the most common form of cutaneous TB seen in adults (M/C in females). Causative organisms: Mycobacterium tuberculosis, Mycobacterium bovis. Pathogenesis : Route of spread: Endogenous spread or from exogenous inoculation. It occurs in a previously sensitized individual with an increased cell-mediated immunity to tuberculin. Clinical features: Presents as a single or a group of erythematous violaceous annular plaques with central scarring and atrophy with active margins. The periphery shows erythematous deep-seated nodules which on diascopy may stand out as apple jelly nodules. Most commonly seen in the buttocks, upper extremities, and face. Papules may recur within scarred areas, enlarging and coalescing into large, firm, elevated plaques. Treatment: Antitibercular therapy. Complication: Secondary scarring and squamous cell carcinoma may develop rarely. KOH preparation (Option 1) is used to detect superficial fungal infections like tinea or candidiasis by identifying fungal elements in skin scrapings. Since lupus vulgaris is a form of cutaneous tuberculosis, KOH is not helpful for its diagnosis. HIV testing (Option 4) is useful in immunocompromised patients or atypical infections, but this patient has a localized, slow-growing lesion without systemic signs. It doesn't directly help diagnose lupus vulgaris and isn't a first-line test.

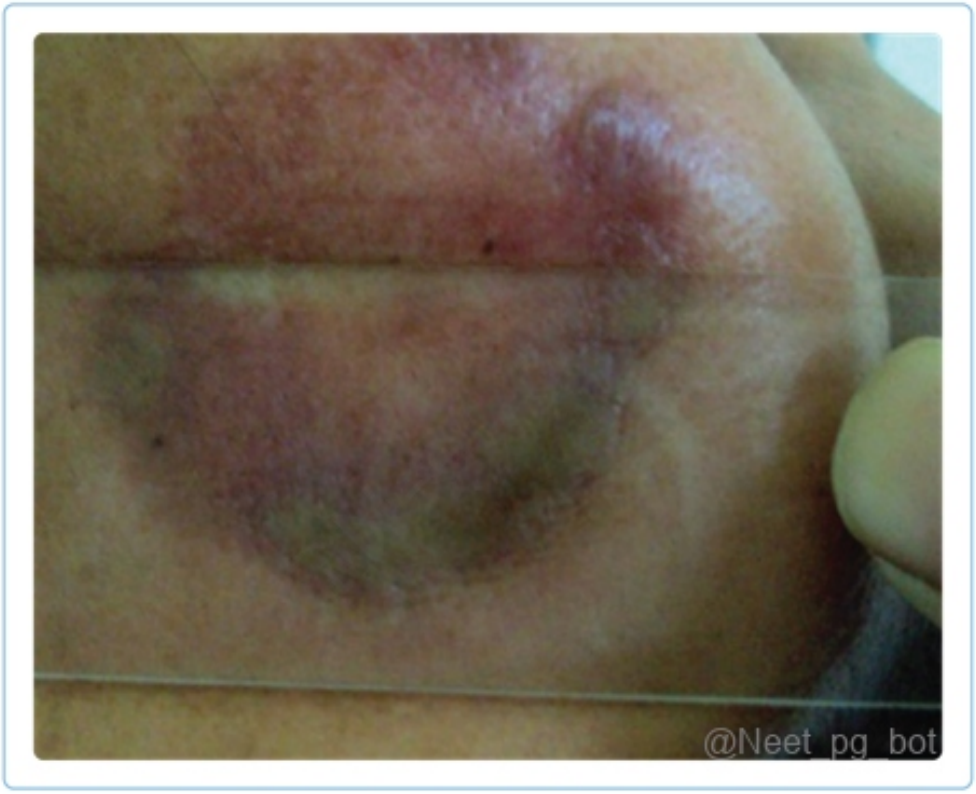

References:

Rooks Textbook of Dermatology, 9th Edition, Page 27.21 27.22

Bolognia Textbook of Dermatology, 4th Edition, Page 1306.

↑ *Back to this question in Part A*

@Neet_pg_bot

Q3: A patient presents with an indurated plaque on the cheek with central atrophy. Chest X-ray reveals apical calcification. Which of the following tests is most appropriate to confirm the diagnosis? (Q866550)

A. Mantoux test

B. Slit skin smear

C. PCR

D. Probe test



Correct Answer: C. PCR

Explanation: Lupus vulgaris is the most common form of cutaneous tuberculosis, often arising from hematogenous or lymphatic spread from a latent pulmonary focus. Clinical clue: indurated plaque with central atrophy on the face + old TB lesion in the lung (apical calcification). PCR for Mycobacterium tuberculosis DNA is the most sensitive and specific test to confirm cutaneous TB. PCR detects bacterial DNA even when bacillary load is low (as in lupus vulgaris, which is paucibacillary). While Mantoux may support diagnosis, it is not confirmatory Lupus vulgaris Chronic, progressive, paucibacillary (not multibacillary) form of cutaneous tuberculosis. Lupus vulgaris is the most common form of cutaneous TB seen in adults (M/C in females). Causative organisms: Mycobacterium tuberculosis, Mycobacterium bovis. Pathogenesis : Route of spread: Endogenous spread or from exogenous inoculation. It occurs in a previously sensitized individual with an increased cell-mediated immunity to tuberculin. Clinical features: Presents as a single or a group of erythematous violaceous annular plaques with central scarring and atrophy with active margins. The periphery shows erythematous deep-seated nodules which on diascopy may stand out as apple jelly nodules. Most commonly seen in the buttocks, upper extremities, and face. Papules may recur within scarred areas, enlarging and coalescing into large, firm, elevated plaques. Diagnosis is often confirmed by histopathological examination of skin biopsy specimens, which typically show caseating granulomas with acid-fast bacilli. The above image depicts the Apple Jelly Nodule Complication: Secondary scarring and squamous cell carcinoma may develop rarely. Treatment : Anti-tubercular drugs. Mantoux test (Option A): Indicates prior sensitization to TB but cannot confirm active disease; may be positive in BCG-vaccinated individuals and other mycobacterial infections. Slit skin smear (Option B): Useful for detecting acid-fast bacilli in leprosy, not for cutaneous TB where bacillary load is very low. Probe test (Option D): Used in oral submucous fibrosis to assess fibrous bands in the oral mucosa; not related to lupus vulgaris diagnosis.



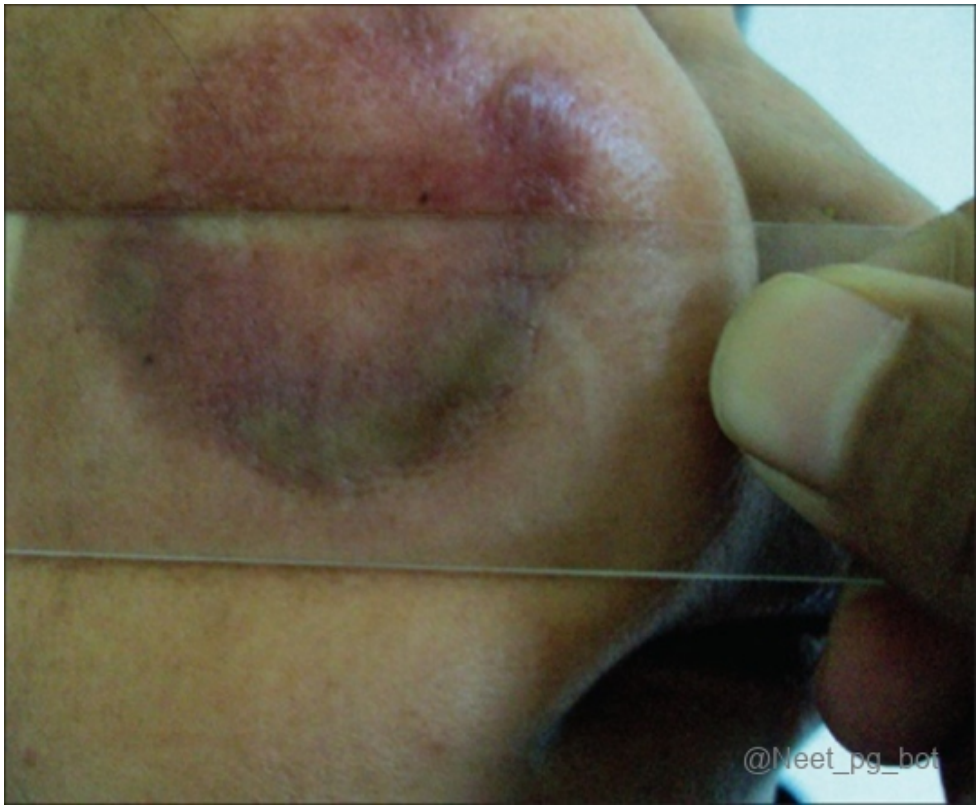

↑ *Back to this question in Part A*

Q4: A 38-year-old patient presents with hypopigmented nodular skin lesions and loss of sensation over the arm. On examination, there is thickening of the ulnar nerve. A skin biopsy reveals epithelioid cell granulomas, and an intradermal lepromin (antigen) test is performed. Which of the following statements most accurately describes this condition? (Q843957)

A. Tuberculoid leprosy with a positive antigen test

B. Lepromatous leprosy with a positive antigen test

C. Erythema nodosum leprosum with a negative antigen test

D. Lepromatous leprosy with a negative antigen test

Correct Answer: A. Tuberculoid leprosy with a positive antigen test

Explanation: The presentation of hypopigmented nodular lesions with sensory loss , ulnar nerve thickening , and biopsy showing epithelioid cell granulomas is characteristic of tuberculoid leprosy . Lesions are well-defined with anesthesia due to nerve involvement. Non-caseating granulomas with epithelioid cells are seen histologically. The Lepromin (intradermal antigen) test is positive , indicating strong cell-mediated immunity . Lepromatous leprosy with a positive antigen test (Option B): Lepromatous leprosy shows a negative lepromin test due to poor cell-mediated immunity. Erythema nodosum leprosum with a negative antigen test (Option C): ENL is a Type II lepra reaction , not a primary form of leprosy. Lepromatous leprosy with a negative antigen test (Option D): Although the test result fits, the clinical features (few anesthetic lesions, nerve thickening, granulomas) indicate tuberculoid , not lepromatous, leprosy.

References:

https://www.ncbi.nlm.nih.gov/books/NBK559307/

↑ *Back to this question in Part A*

@Neet_pg_bot

Q5: What is the preferred treatment for a pregnant woman who is 12 weeks pregnant and undergoing multidrug therapy for leprosy but is now experiencing type 2 lepra reaction? (Q854964)

A. Stop MDT and start oral steroids

B. Antibiotics

C. Thalidomide

D. Continue MDT and add oral steroids

Correct Answer: D. Continue MDT and add oral steroids

Explanation: Type 2 lepra reaction (erythema nodosum leprosum, ENL) is an immune complex-mediated reaction seen in multibacillary leprosy. Pregnancy does not alter the management of leprosy itself, and stopping multidrug therapy (MDT) is not recommended. The preferred treatment for type 2 reactions includes oral corticosteroids , which are safe in pregnancy. Thalidomide is strictly contraindicated due to teratogenicity. Leprosy and Its Management in Pregnancy Aspect Details Cause of Leprosy Mycobacterium leprae Types of Reactions Type 1 (Reversal), Type 2 (Erythema Nodosum Leprosum) Type 2 Lepra Reaction Immune complex-mediated (Type III hypersensitivity) Common Symptoms Painful nodules, fever, malaise, neuritis Management of Type 2 Reaction Corticosteroids (safe in pregnancy) Role of MDT in Pregnancy Must be continued to prevent relapse Drugs to Avoid Thalidomide (teratogenic) Management of Type 2 Lepra Reaction in Pregnancy Aspect Details Continue MDT Essential to prevent disease relapse Preferred drug Oral steroids (prednisolone) Avoid in pregnancy Thalidomide (teratogenic, causes phocomelia) Supportive therapy Analgesics, wound care if ulcerated lesions present Alternative options Clofazimine has mild immunomodulatory effects Stop MDT and start oral steroids (Option A) is incorrect because stopping MDT can lead to disease relapse and worsening nerve damage . MDT must be continued while managing the reaction with steroids. Antibiotics (Option B) is incorrect because type 2 lepra reaction is an inflammatory immune response , not an infectious complication. Antibiotics have no role in managing ENL itself. Thalidomide (Option C) is incorrect because thalidomide is highly teratogenic (causing phocomelia and limb defects) and is absolutely contraindicated in pregnancy. Although thalidomide is an effective treatment for ENL, it should never be used in pregnant women.

References:

Rook’s textbook of dermatology 9th edition page no.- 28.15 to 28.16

Robbins & Cotran Pathologic Basis of Disease, 10th Edition, Pages 211, 212

↑ *Back to this question in Part A*

@Neet_pg_bot

Q6: A 30-year-old patient presents to the clinic with hypopigmented patches on the skin. On examination, there are a few well-demarcated, slightly raised lesions with a loss of sensation. Skin smears reveal no acid-fast bacilli. Which of the following is the most likely diagnosis? (Q854966)

A. Multibacillary leprosy

B. Psoriasis

C. Tinea versicolor

D. Paucibacillary leprosy

Correct Answer: D. Paucibacillary leprosy

Explanation: Hypopigmented patches with sensory loss strongly suggest leprosy rather than other dermatological conditions. Well-demarcated, slightly raised lesions are characteristic of paucibacillary leprosy , which presents with five or fewer skin lesions with nerve involvement. Skin smears revealing no acid-fast bacilli indicate a low bacterial load , confirming paucibacillary leprosy rather than multibacillary leprosy . Leprosy: Leprosy (Hansen's disease) is a chronic infectious disease caused by Mycobacterium leprae , primarily affecting the skin, peripheral nerves, and mucosa of the upper respiratory tract . It presents in a spectrum based on bacterial load and immune response. Classification of Leprosy (Ridley-Jopling & WHO Classification) Type Immune Response Skin Lesions Nerve Involvement AFB Smear WHO Classification Tuberculoid (TT) Strong (Th1) Few, well-defined, anesthetic Single nerve thickening Negative Paucibacillary (PB) Borderline Tuberculoid (BT) Moderate Multiple, asymmetric, anesthetic Multiple nerves affected Variable Paucibacillary (PB) Borderline Borderline (BB) Unstable Numerous, irregular plaques Moderate nerve involvement Positive Multibacillary (MB) Borderline Lepromatous (BL) Weak (Th2) Diffuse, infiltrative lesions Severe nerve damage Strongly Positive Multibacillary (MB) Lepromatous (LL) Absent Diffuse, nodular, leonine facies Symmetric nerve thickening Strongly Positive Multibacillary (MB) Clinical Features of Leprosy System Involved Clinical Features Skin Hypopigmented or erythematous macules, plaques, nodules, loss of sweating (anhidrosis) Nerves Thickened peripheral nerves, sensory loss (glove and stocking pattern) Eyes Lagophthalmos, keratitis, blindness Musculoskeletal Claw hand, foot drop, joint deformities Systemic Testicular atrophy, gynecomastia (LL type) Diagnosis of Leprosy Diagnostic Method Findings Clinical Diagnosis Hypopigmented/anesthetic skin lesions, nerve thickening Skin Smear (Ziehl-Neelsen Stain) AFB seen in multibacillary leprosy but not in paucibacillary leprosy Lepromin Test Positive in tuberculoid leprosy , negative in lepromatous leprosy Skin Biopsy Granulomas in tuberculoid leprosy, foam cells in lepromatous leprosy Nerve Biopsy Shows caseation necrosis in tuberculoid type Treatment of Leprosy (WHO Multidrug Therapy – MDT) Type First-Line Treatment (Duration) Paucibacillary (PB) Rifampicin + Dapsone (6 months) Multibacillary (MB) Rifampicin + Dapsone + Clofazimine (12 months) Pregnancy & lactation : MDT is safe. Children : Treated with adjusted doses based on weight. Leprosy Reactions & Management Reaction Type Features Treatment Type 1 (Reversal) Inflammatory response in existing lesions, nerve damage Steroids (Prednisolone) Type 2 (Erythema Nodosum Leprosum - ENL) Painful nodules, fever, neuritis, systemic involvement Steroids, Clofazimine , avoid Thalidomide in pregnancy Lucio Phenomenon Ulcerative necrotizing lesions Rifampicin, Clofazimine Prevention & Public Health Measures BCG vaccine offers partial protection. Early diagnosis & MDT prevents transmission. Household contacts should be screened regularly. Reconstructive surgery for deformities in chronic cases. Multibacillary leprosy (Option A) is incorrect because MB leprosy presents with multiple lesions , often widespread, with no sensory impairment in early stages and a positive skin smear for Mycobacterium leprae (acid-fast bacilli). This patient's negative smear and limited lesion count favour paucibacillary leprosy . Psoriasis (Option B) is incorrect because psoriatic plaques are erythematous with silvery scales , not hypopigmented. Sensory loss is not a feature of psoriasis , and skin smears do not play a role in its diagnosis. Tinea versicolor (Option C) is incorrect because pityriasis (tinea) versicolor , caused by Malassezia spp., presents with hypo- or hyperpigmented macules , but there is no sensory loss . The lesions are typically scaly , and a KOH mount would reveal spaghetti and meatballs appearance (yeast and hyphae).

References:

Rook's Textbook of Dermatology- 9th Edition Chapter 28 Page No 28.14,15,16

↑ *Back to this question in Part A*

Q7: The image given below is characteristically seen in which of the following types of leprosy? (Q856665)

A. Borderline lepromatous leprosy

B. Lepromatous leprosy

C. Borderline leprosy

D. Histoid leprosy

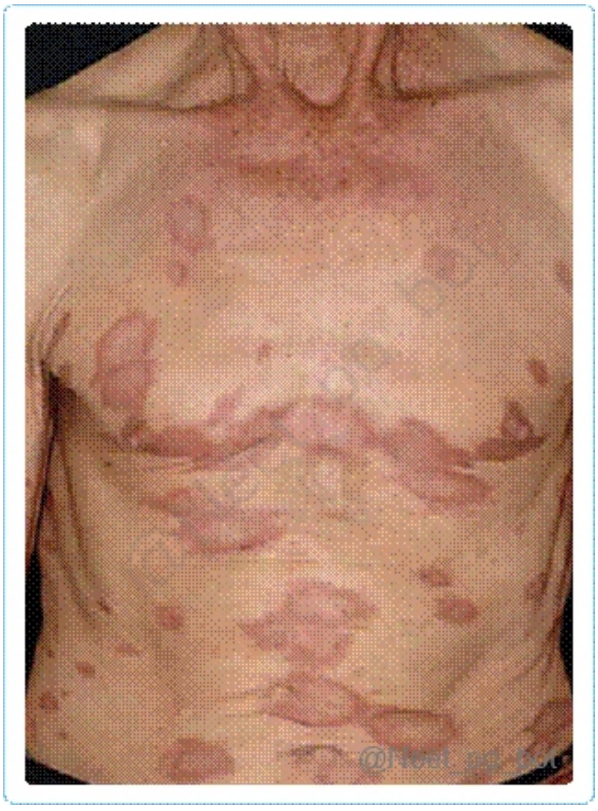

Correct Answer: A. Borderline lepromatous leprosy

Explanation: The image shows multiple, irregular, erythematous plaques and lesions distributed on the trunk, which are characteristically seen in borderline lepromatous leprosy . It typically presents with numerous, asymmetrical plaques and infiltrated lesions of varying sizes and shapes across the trunk and limbs. In BL Leprosy, the bacilli are trying to invade the surrounding area, and there is a central invasion called an inverted saucer appearance . Ridley-Jopling Classification of Leprosy: Tuberculoid leprosy (TT) – Few well-demarcated hypopigmented patches with complete loss of sensation . Strong cell-mediated immunity (CMI) . Borderline tuberculoid (BT) – Multiple asymmetrical lesions, less well-defined than TT, with some sensory loss. Borderline leprosy (BB) – Intermediate form, variable lesions with partial sensory loss , and patchy nerve involvement .

Borderline lepromatous (BL) – Numerous lesions resembling LL but with some sensory impairment. Lepromatous leprosy (LL) – Diffuse, symmetrical lesions with loss of eyebrows, leonine facies, and late nerve damage. Poor CMI response . Lepromatous leprosy (Option B): Usually shows numerous, symmetric, small nodules, papules, or diffuse infiltration. The lesions are more uniform and widespread, commonly involving the face and earlobes. Borderline leprosy (Option C): Fewer lesions than BL but with more defined margins. Histoid leprosy (Option D): Characterized by firm, nodular lesions that are often shiny and dome-shaped, usually on a background of lepromatous leprosy.

References:

Rook's Textbook of Dermatology, 9nd Edition Chapter 28 Page No 28.11

↑ *Back to this question in Part A*

@Neet_pg_bot

Q8: Which of the following will be the outcome of Leprosy , if left untreated. (Q856667)

A. No spontaneous remission is seen

B. Half of the cases resolve spontaneously after bacilli exposure

C. Spontaneous remission is more common in children than in adults

D. Indeterminate leprosy have more remission than tuberculoid

Correct Answer: D. Indeterminate leprosy have more remission than tuberculoid

Explanation: Indeterminate leprosy is the earliest form of leprosy, presenting with a single or few ill-defined hypopigmented macules and minimal sensory loss. In many cases, spontaneous remission occurs , particularly in individuals with a strong cell-mediated immune (CMI) response . Tuberculoid leprosy , while having a strong immune response, tends to be chronic and persistent , with less likelihood of spontaneous remission. Indeterminate Leprosy: Early, undifferentiated form of leprosy . Few hypopigmented macules with slight sensory impairment. Histopathology : Mild inflammation, sparse acid-fast bacilli (AFB) . Fate : Can resolve spontaneously (~25–75% of cases) . May progress to tuberculoid or lepromatous forms, depending on immune response. Tuberculoid Leprosy: Well-demarcated plaques with sensory loss , few lesions. Strong CMI response , granuloma formation. Less likely to remit spontaneously , tends to persist unless treated. Outcomes if Untreated: Indeterminate leprosy has a higher chance of spontaneous remission compared to tuberculoid leprosy. If it does not resolve, it may progress toward the tuberculoid or lepromatous spectrum based on immune status. No spontaneous remission is seen (Option A) is incorrect because spontaneous remission does occur , particularly in indeterminate and early tuberculoid leprosy , especially in individuals with good immunity. Half of the cases resolve spontaneously after bacilli exposure (Option B) is incorrect because while some individuals clear the infection, the proportion is variable and not as high as 50% in all populations . Spontaneous remission is more common in children than in adults (Option C) is incorrect because although children may have a higher rate of spontaneous resolution , the likelihood of remission is more dependent on the type of leprosy (indeterminate vs tuberculoid) rather than age

alone .

References:

Rook's textbook of dermatology 9th edition page no.- 28.5, 28.6

↑ *Back to this question in Part A*

@Neet_pg_bot

Q9: What would be your next best course of action when a patient undergoing multi-drug therapy (MDT) exhibits deterioration of preexisting lesions and nerve involvement? (Q855965)

A. Stop MDT, start systemic corticosteroids

B. Continue MDT, start systemic steroids

C. Stop MDT thalidomide Continue MDT, start thalidomide

D. Continue MDT, start thalidomide



Correct Answer: B. Continue MDT, start systemic steroids

Explanation: Deterioration of preexisting lesions + nerve involvement in a patient on MDT suggests Type 1 Lepra Reaction (Reversal Reaction) . Type 1 Reaction is a delayed hypersensitivity reaction in borderline leprosy due to increased cell-mediated immunity . Management: Continue MDT : The reaction is due to immune response, not drug failure. Start systemic corticosteroids (prednisolone) to reduce inflammation and prevent permanent nerve damage. Lepra Reactions Type Mechanism Clinical Features Management Type 1 (Reversal Reaction) Increased cell-mediated immunity (CMI) Worsening of existing lesions , erythema, edema, nerve pain Continue MDT , start systemic steroids (prednisolone) Type 2 (Erythema Nodosum Leprosum - ENL) Immune complex deposition (TNF-α mediated) Painful nodules , fever, neuritis, systemic symptoms Continue MDT , start thalidomide or steroids Stop MDT, start systemic corticosteroids (Option A): Incorrect because MDT should not be stopped ; the reaction is due to immune response, not drug toxicity. Stop MDT, start thalidomide (Option C): Incorrect because thalidomide is used for Type 2 reaction (ENL), not Type 1 reaction . Continue MDT, start thalidomide (Option D): Incorrect because thalidomide is ineffective for Type 1 reactions; steroids are preferred .

References:

Rook’s textbook of dermatology 9th edition page no.- 28.15 to 28.16

↑ *Back to this question in Part A*

@Neet_pg_bot

Q10: Please determine the medication utilized for the management of the presented medical condition: (Q854901)

A. Anti-fungal therapy

B. Anti-tubercular therapy

C. Topical steroids therapy

D. Anti-leprosy treatment



Correct Answer: B. Anti-tubercular therapy

Explanation: The image shows annular plaque with central scarring which is suggestive of Lupus vulgaris, a form of cutaneous tuberculosis caused by Mycobacterium tuberculosis infection. It presents as a chronic, slowly progressive skin lesion with an annular (ring-shaped) plaque and central scarring. Anti-tubercular therapy: Anti-tubercular therapy is the treatment of choice for lupus vulgaris. It consists of a combination of drugs, including isoniazid, rifampicin, ethambutol, and pyrazinamide. These medications target Mycobacterium tuberculosis, the causative organism, and aim to eradicate the infection. Cutaneous TB: Exogenous: Endogenous: Source of MTB is from outside the body First exposure to TB - new to TB infection is Naive infection Called TB chance No immunity Once had TB but now recurred due to Exogenous causes: Tuberculosis Verrucous cutis (TBVC) Immunity present Source is within the body Transmitted to skin by: Contiguous (ex: lymphatic TB breaking into skin) - Scrofuloderma Hematogenous - Lupus vulgaris, TB gumma and miliary TB Auto miliary TB Auto inoculation - or Orificial TB 1. TB Chancre / Primary Inoculation TB {{caption_text}} 2. TBVC or Tuberculosis verrucosa cutis {{caption_text}} 1. Lupus Vulgaris {{caption_text}} {{caption_text}} Apple jelly nodules on diascopy 2. Scrofuloderma {{caption_text}} 3. Orificial Tuberculosis {{caption_text}} Management All forms of cutaneous TB have the same treatment. Total 6 months treatment: 2 months: Intensive phase = HERZ for 2 months. 4 months: Maintenance phase = HRE for 4 months. HERZ = Isoniazid, ethambutol, rifampicin and pyrazinamide. Doses Isoniazid (H): 5mg/kg/day Rifampicin = 10 mg/kg/day Ethambutol (E): 15 mg/kg/day Streptomycin (S): 15 mg/kg/day Pyrazinamide (P): 25 mg/kg/day Incorrect Options: Anti-fungal therapy (Option A) is not the appropriate treatment for lupus vulgaris. While superficial fungal infections can also present as annular lesions, the clinical presentation and diagnostic criteria mentioned in the question suggest a mycobacterial infection rather than a fungal infection. Topical steroids therapy (Option C): Topical steroid therapy is not the primary treatment for lupus vulgaris. While topical steroids may be used in some cases to alleviate inflammation and itching, they do not address the underlying mycobacterial infection and are not the mainstay of treatment. Anti-leprosy treatment (Option D): Anti-leprosy treatment is not the correct choice for lupus vulgaris. Leprosy,

caused by Mycobacterium leprae, is a separate disease entity and requires specific anti-leprosy drugs for treatment. It is not indicated for the management of lupus vulgaris.






@Neet_pg_bot

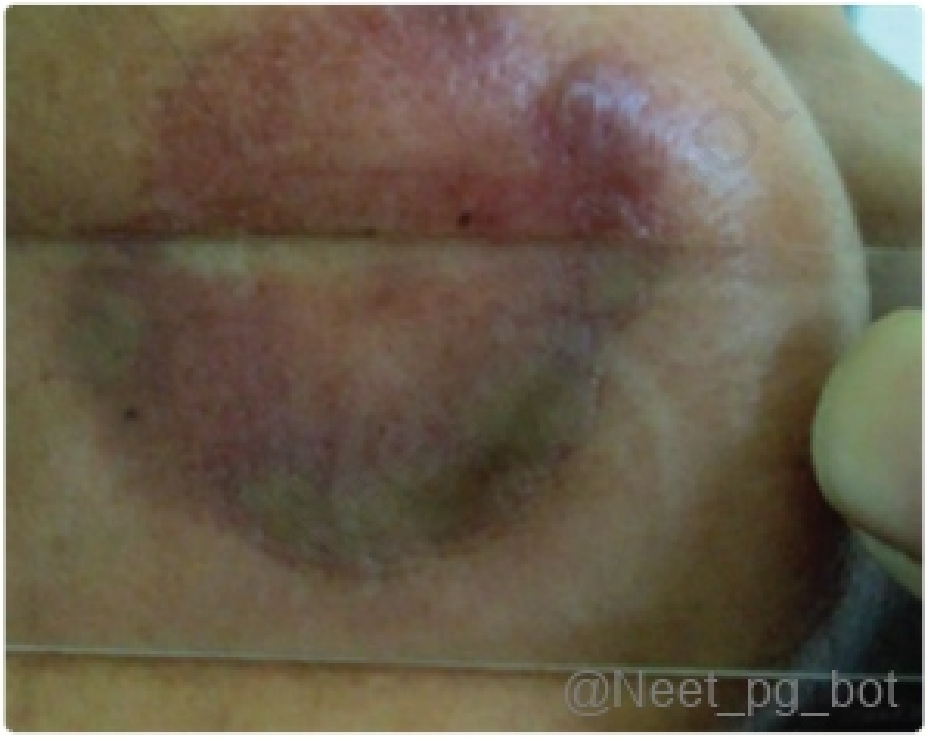
@Neet_pg_bot





References:

Illustrated Synopsis of Dermatology and Sexually Transmitted Diseases, Fifth Edition – Neena Khanna Pg 268-271

https://www.ncbi.nlm.nih.gov/books/NBK482220/

↑ *Back to this question in Part A*

@Neet_pg_bot

Q11: A 45-year-old man presents with progressive facial weakness and difficulty closing his right eye. Examination reveals facial asymmetry, and early lagophthalmos. Facial swelling noted as shown in the image. There is also thickening of peripheral nerves. Which nerve is most commonly involved in this condition? (Q855876)

A. Abducens nuclei

B. Facial nerve

C. Optic nerve

D. Trigeminal nerve

Correct Answer: B. Facial nerve

Explanation: Clinical Features in the question/ image: The image suggests facial swelling with muscle weakness , commonly seen in leprosy (Hansen's disease) . The Facial Nerve (CN VII) is commonly involved in lepromatous leprosy , leading to facial palsy and lagophthalmos (inability to close the eye). Facial Nerve Involvement in Leprosy: Mycobacterium leprae infiltrates Schwann cells , causing neuropathy . This leads to weakness of facial muscles , particularly affecting the orbicularis oculi , resulting in lagophthalmos . Loss of motor control can contribute to facial asymmetry and trophic ulcers . Facial Nerve Involvement in Leprosy Feature Facial Nerve (CN VII) Involvement Function Motor to facial muscles, taste from anterior 2/3 of tongue Affected Branches Zygomatic & Buccal branches Symptoms in Leprosy Facial weakness, inability to close eye (lagophthalmos), drooping face Complications Corneal ulcers, facial deformity Abducens nuclei (Option A): Incorrect because CN VI controls lateral eye movement , not facial sensation or motor function. Optic nerve (Option C): Incorrect because CN II controls vision , not facial movement or sensation. Trigeminal nerve (Option D): Incorrect because CN V mainly controls sensation , whereas the image suggests a motor deficit affecting facial expressions.

References:

Rook's Textbook of Dermatology 9th Edition Chapter 28 Page No. 28.1- 28.15

↑ *Back to this question in Part A*

@Neet_pg_bot

• [08_Sexually Transmitted Infections] 017 Non Syphilitic Std- I

« Back to Folder Directory

[08_Sexually Transmitted Infections] 017 Non Syphilitic Std- I — Quick Jump

Q1 (p. 982)	*Q2 (p. 985)*	*Q3 (p. 987)*	*Q4 (p. 991)*	*Q5 (p. 994)*	*Q6 (p. 995)*
Q7 (p. 999)	*Q8 (p. 1000)*	*Q9 (p. 1002)*	*Q10 (p. 1004)*	*Q11 (p. 1006)*	*Q12 (p. 1007)*
Q13 (p. 1009)	*Q14 (p. 1011)*	*Q15 (p. 1012)*	*Q16 (p. 1015)*	*Q17 (p. 1016)*	

Q1: Match the following description of ulcers with their causative organisms. 1.Painful vesicular lesions a) Syphilis 2.Painless, beefy red ulcers with rolled edges. b) Chancroid 3.Painless genital ulcer with indurated base. c) Genital herpes 4.Soft, painful genital ulcer with irregular borders. d) Granuloma inguinale (Q841757)

A. 1-a, 2-b, 3-c, 4-d

B. 1-c, 2-d, 3-a, 4-b

C. 1-c, 2-d, 3-b, 4-a

D. 1-b, 2-a, 3-c, 4-d

Correct Answer: B. 1-c, 2-d, 3-a, 4-b

■ *Listen (English)*

■ *Listen (Hindi)*

Explanation: The correct match of the clinical description with their disease is shown below. Ulcer Description Causative Organism 1. Painful vesicular lesions c) Genital herpes 2. Painless, beefy red ulcers with rolled edges d) Granuloma inguinale 3. Painless genital ulcer with indurated base a) Syphilis 4. Soft, painful genital ulcer with irregular borders b) Chancroid Genital herpes presents with painful vesicular lesions & blisters which can burst and cause ulcer formation. It is most commonly caused by HSV-2 > HSV-1. The given image below shows genital herpes. Granuloma inguinale is caused by Klebsiella granulomatis. It presents with painless, beefy ulcers that may bleed on touch. Microscopically, it shows Donovan body with a safety-pin appearance. The given image shows the clinical picture of the ulcer and Donovan bodies. Syphilis is caused by Treponema pallidum. It occurs in various stages such as primary, secondary, and tertiary. The primary lesion appears as a regularly edged, regularly based, hard , painless , and button■like ulceration measuring up to 1 cm in diameter. The ulcer is often surrounded by a narrow, red border 1–2 mm wide. The given image shows the primary ulcer. Chancroid is caused by Haemophilus ducreyi. multiple, superficial, tender, soft, ragged ulcers which bleed on manipulation.



Herpes genitalis female @Neet_pg_bot



Granuloma inguinale

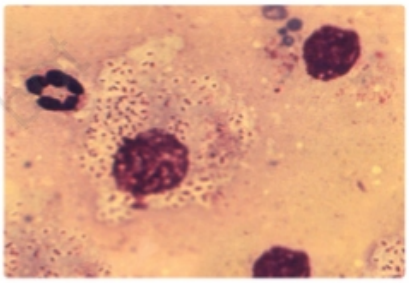

Donovan body-Klebsiella granulomatis

@Neet_pg_bot



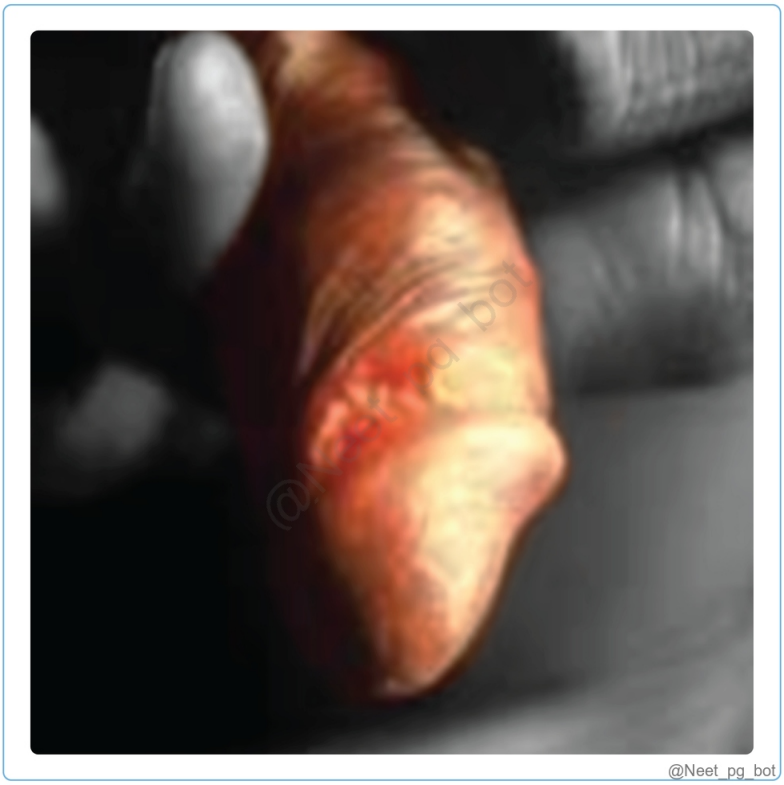

References:

Rook’s Textbook of Dermatology, 9th Edition, Page 29.3-30.24

↑ *Back to this question in Part A*

@Neet_pg_bot

Q2: A 28 year old female presents with vaginal discharge that is frothy, yellow-green in colour and has a foul odour. She reports mild vaginal itching and discomfort during urination. A per speculum reveals the image shown below. What is the most likely diagnosis? (Q841736)

A. Candida albicans

B. Trichomonas vaginalis

C. Neisseria gonorrhoeae

D. Gardnerella vaginalis

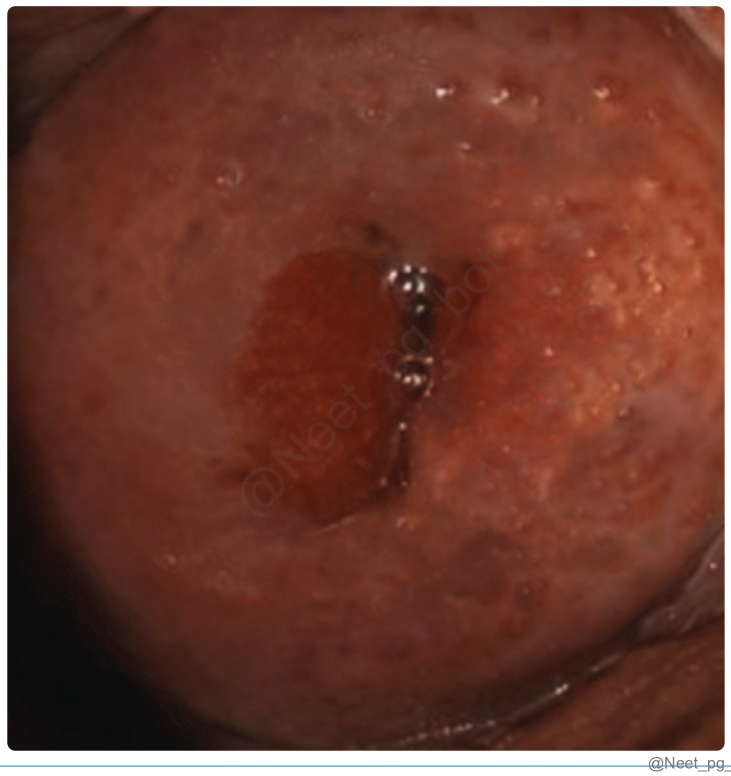

Correct Answer: B. Trichomonas vaginalis

■ *Listen (English)*

■ *Listen (Hindi)*

Explanation: Trichomoniasis is a sexually transmitted infection caused by Trichomonas vaginalis. It typically presents with the frothy, yellow-green vaginal discharge with a foul odor, along with vaginal itching and discomfort during urination. The characteristic appearance seen is ‘Strawberry cervix,’ an erythematous and edematous cervical mucosa with characteristic punctate red papules. It is caused by microscopic punctate haemorrhages of the cervix. The standard treatment is Metronidazole 2g PO single dose . Features Bacterial Vaginosis Trichomoniasis Candidiasis (Yeast Infection) Discharge Thin, greyish-white, homogenous discharge Frothy, yellow-green, often malodorous discharge Thick, white, cottage cheese-like discharge, often odourless Odor Fishy odour, particularly noticeable after intercourse A foul odour can be strong and unpleasant Usually no significant odor Genital Itching/Irritation May or may not be present Common Common, along with redness and swelling of the vulva pH of Vaginal Discharge Elevated (usually above 4.5) Elevated (usually above 4.5) Acidic (4.0 to 4.5) Clue Cells on Microscopy Present (epithelial cells with adherent bacteria) Absent Absent Microscopic Pathogen Overgrowth of anaerobic bacteria (Gardnerella vaginalis)(Option D) Protozoan parasite (Trichomonas vaginalis) Overgrowth of Candida species (Candida albicans most common) (Option A) Treatment Secnidazole 2g SOD Metronidazole 2g single dose PO Secnidazole 2g +fluconazole 150mg Neisseria gonorrhoeae (Option C) infection can present with vaginal discharge (which may be yellow or green), pelvic pain, and dysuria.

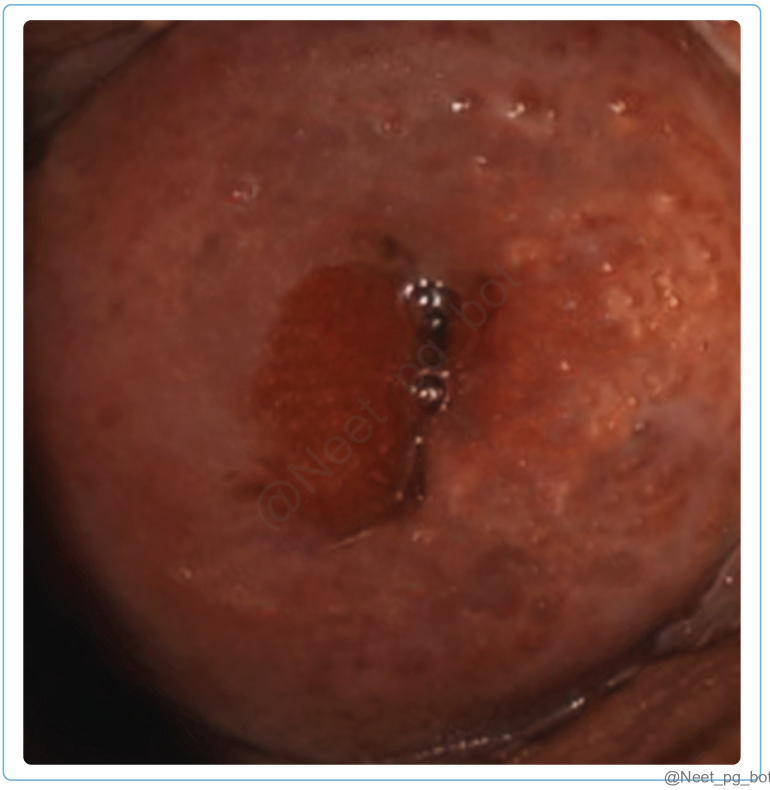



References:

Rooks Textbook of Dermatology, 9th Edition, Chapter 113

↑ *Back to this question in Part A*

@Neet_pg_bot

Q3: A 28 year old sexually active man presents with painful genital lesions. He reports a tingling sensation and burning pain in the genital area preceding the appearance of the ulcers. Which of the following is the most characteristic finding for his condition? (Q841775)

A. The presence of multinucleated giant cells on the Tzanck smear

B. Presence of bacterial colonies, "school of fish" appearance on Gram stain

C. Donovan bodies within Pund cells on Gram stain

D. Clue cells on saline mount

Correct Answer: A. The presence of multinucleated giant cells on the Tzanck smear

■ *Listen (English)*

■ *Listen (Hindi)*

Explanation: Multinucleated giant cells on a Tzanck smear are characteristic of herpes simplex virus (HSV) infection, particularly herpes genitalis TZANCK smear The presence of painful genital lesions, along with a tingling sensation and burning pain preceding the appearance of ulcers, is highly suggestive of HSV infection. The image shows multiple vesicles and pustules with a coalescing vesicles and erosions as seen in herpes genitalis Herpes genitalis is a sexually transmitted infection caused primarily by HSV-2, although HSV-1 can also be responsible. It is characterised by the infection of genital skin or mucosa Clinical features: Multiple, painful, non-indurated vesicles that may rupture, forming coalescing vesicles or polycyclic erosions. Bilateral tender lymphadenopathy is common. Males: Painful penile ulcerations affecting the glans, prepuce and shaft of the penis Females: Involves external genitalia, vulva, vagina and cervix. Accompanied by dysuria Diagnosis: Tzanck smear, revealing multinucleated giant cells, a characteristic feature. Serological testing , such as ELISA for HSV glycoprotein, can also aid in diagnosis. Treatment typically involves antiviral medications like acyclovir (400mg TDS), administered for 7-10 days for primary infection and 5 days for secondary infection. Presence of bacterial colonies, "school of fish" appearance on Gram stain (Option B): This finding is characteristic of chancroid caused by Haemophilus ducreyi, which leads to the formation of painful genital ulcers. Donovan bodies within Pund cells on Gram stain (Option C) : This finding is characteristic of granuloma inguinale, also known as Donovanosis, caused by the bacterium Klebsiella granulomatis. Donovan bodies are intracellular inclusions seen within macrophages, representing aggregates of the causative organism giving safety pin appearence. Clue cells on saline mount (Option D): Clue cells are epithelial cells covered with bacteria, typically seen in bacterial vaginosis (BV), caused by Gardenella vaginalis.



Herpes genitalis female@Neet_pg_bot

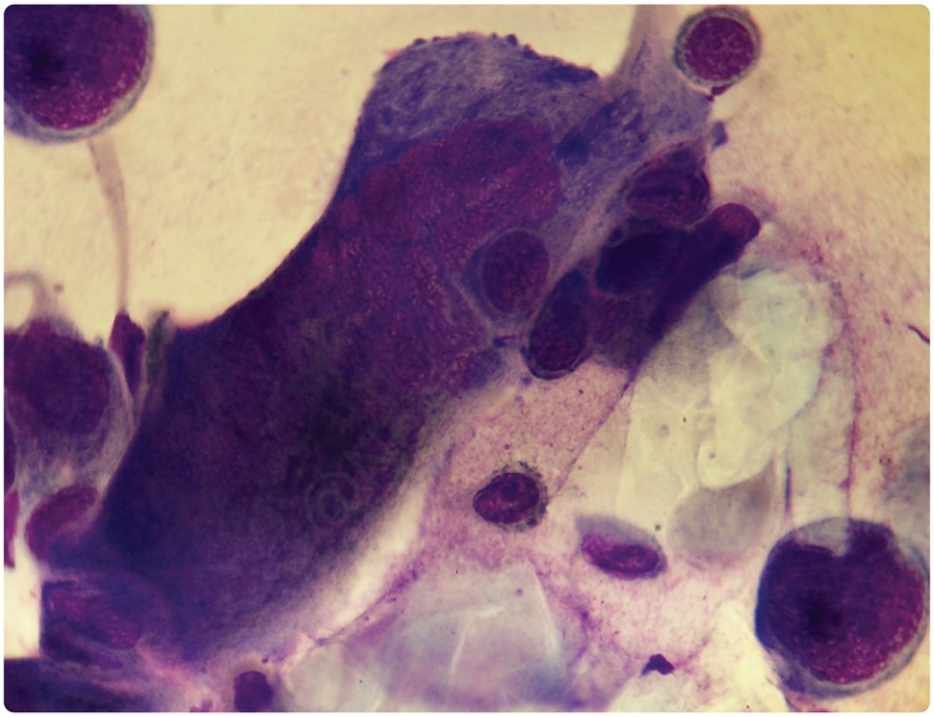

@Neet_pg_bot



Chancroid due to Haemophilus ducreyi



Chancroid on microscopy- railway track appearance

@Neet_pg_bot

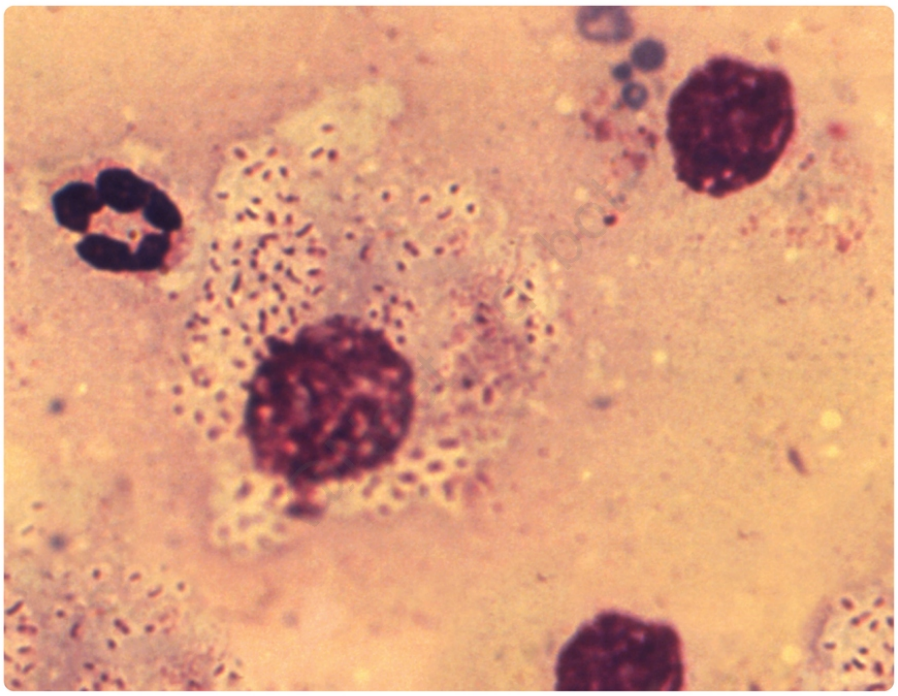
@Neet_pg_bot

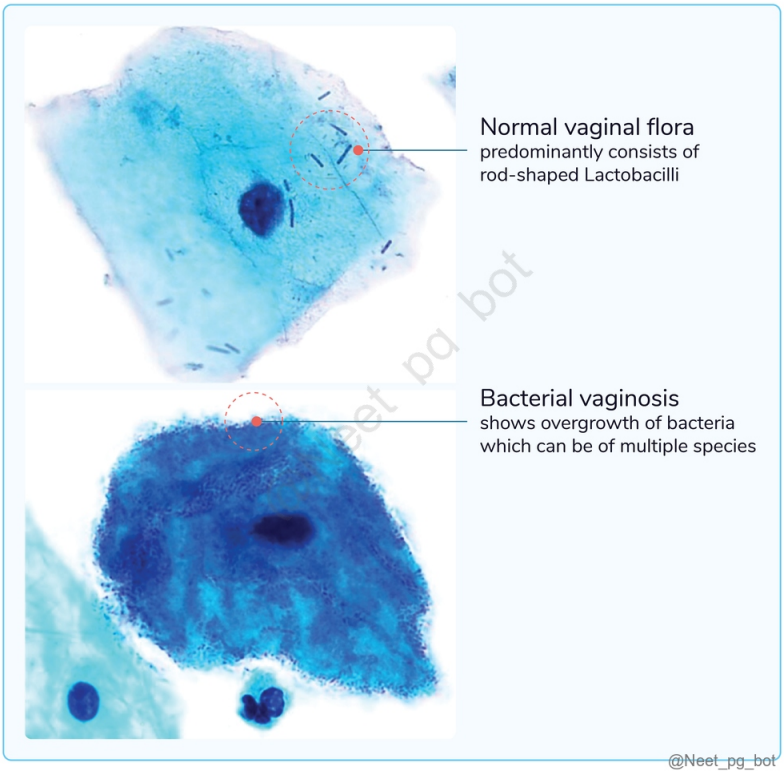

References:

Rooks Textbook of Dermatology, 9th Edition, Page 25.20 - 25.22

↑ *Back to this question in Part A*

@Neet_pg_bot

Q4: A 35 year old truck driver presents to the clinic with complaints of a painful genital lesion that has been progressively enlarging over the past few weeks. Upon examination, you note a tender ulcerative lesion with undermined edges and a base covered by a greyish exudate. Additionally, there are enlarged and tender inguinal lymph nodes palpable unilaterally. The patient reports a recent sexual encounter with another male truck driver. Which of the following sexually transmitted infections is most likely to present with this clinical manifestation (Q841770)

A. Syphilis

B. Donovanosis

C. Herpes simplex

D. Chancroid

Correct Answer: D. Chancroid

■ *Listen (English)*

■ *Listen (Hindi)*

Explanation: Chancroid caused by Haemophilus ducreyi manifests as multiple ulcers in the genital area, characterized by their non-indurated nature, undermined edges, greyish slough, and tendency to bleed on touch. Individuals with chancroid may develop unilateral, painful lymphadenopathy. The suppurative lymphadenopathy observed in chancroid is termed bubo. Diagnosis Gram staining reveals Gram-negative bacilli arranged in chains, often referred to as "railway tracks" or "school of fish" appearance. Culturing specimens on Mueller Hinton Agar supplemented with chocolate horse blood aids in the identification of Haemophilus ducreyi. Treatment. Azithromycin is administered orally in a single dose of 1 gram OR intramuscular injection of Ceftriaxone at a dosage of 250 mg (single dose) Ulcer Lymph Node Image Syphilis - treponema Pallidum (Option A) Painless genital ulcer called a chancre Non-tender and rubbery in consistency. Donovanosis - Klebsiella granulomatis (Option B) Painless, beefy red ulcers known as granulomas Pseudo-bubo (enlarged and tender but occurs due to inflammation and not infection) Herpes Simplex (Option C) Grouped vesicles or shallow erosions Multiple, enlarged and inflamed. Lymphogranuloma Venerum (Chlamydia) Solitary and painless. Swollen, inflamed, and fluctuant lymph nodes containing purulent material. Palpable groove or furrow that may be felt in the inguinal region due to the enlargement and fusion of the inguinal lymph nodes. (Groove of Greenlat)



Chancroid due to Haemophilus ducreyi



Chancroid on microscopy- railway track appearance

@Neet_pg_bot



@Neet_pg_bot

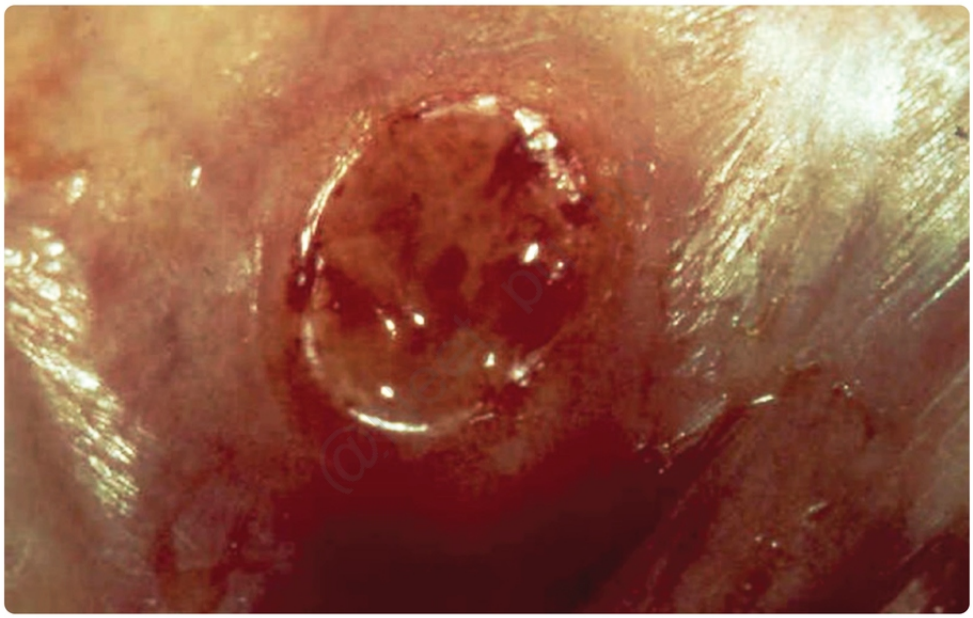

@Neet_pg_bot



@Neet_pg_bot



References:

Rooks Textbook of Dermatology, 9th Edition, Chapter 113

↑ *Back to this question in Part A*

@Neet_pg_bot

Q5: A 45 year old male presents to the clinic with painless, beefy-red ulcers on his genitals. He reports that the lesions have been progressively enlarging over the past few weeks. What is the most appropriate treatment for this patient? (Q841755)

A. Oral Azithromycin

B. Intramuscular Penicillin G

C. Intramuscular Ceftriaxone

D. Oral Doxycycline

Correct Answer: A. Oral Azithromycin

■ *Listen (English)*

■ *Listen (Hindi)*

Explanation: The given clinical presentation of a male with painless, beefy-red ulcers on his genitals with progressive enlargement is suggestive of granuloma inguinale caused by Klebsiella granulomatis. The drug of choice for this condition is oral azithromycin . Donovanosis , also known as granuloma inguinale, is caused by Klebsiella granulomatis bacteria. The characteristic clinical presentation includes painless, beefy-red ulcers that can bleed on touch, with rolled edges and a granular base. Prolonged antibiotic treatment is often necessary. Antibiotics must be given for 3-6 weeks till the ulcer is healed. Drugs include First-line Azithromycin 1g once weekly (or) Azithromycin 500mg daily Second-line Doxycycline 100mg BD (or) Erythromycin 500mg QID (or) Cotrimoxazole 960mg BD Intramuscular penicillin G (Option B) is used in the treatment of syphilis . Intramuscular ceftriaxone (Option C) is used in the treatment of gonococcal infections. Oral doxycycline (Option D) can be used in the second-line treatment of donovanosis .

References:

Rooks Textbook of Dermatology, 9th Edition, Page 30.25

https://www.cdc.gov/std/treatment-guidelines/donovanosis.htm

↑ *Back to this question in Part A*

@Neet_pg_bot

Q6: A 35 year old man presents to a clinic with complaints of painless genital ulcer. He reports that the ulcers have been present for several weeks and have been progressively increasing in size. He also mentions that the ulcers bleed easily upon touch and are not indurated. A picture of the ulcer is shown below. Based on the clinical presentation, what is the most likely diagnosis? (Q841746)

A. Syphilis

B. Chancroid

C. Lymphogranuloma venereum

D. Donovanosis

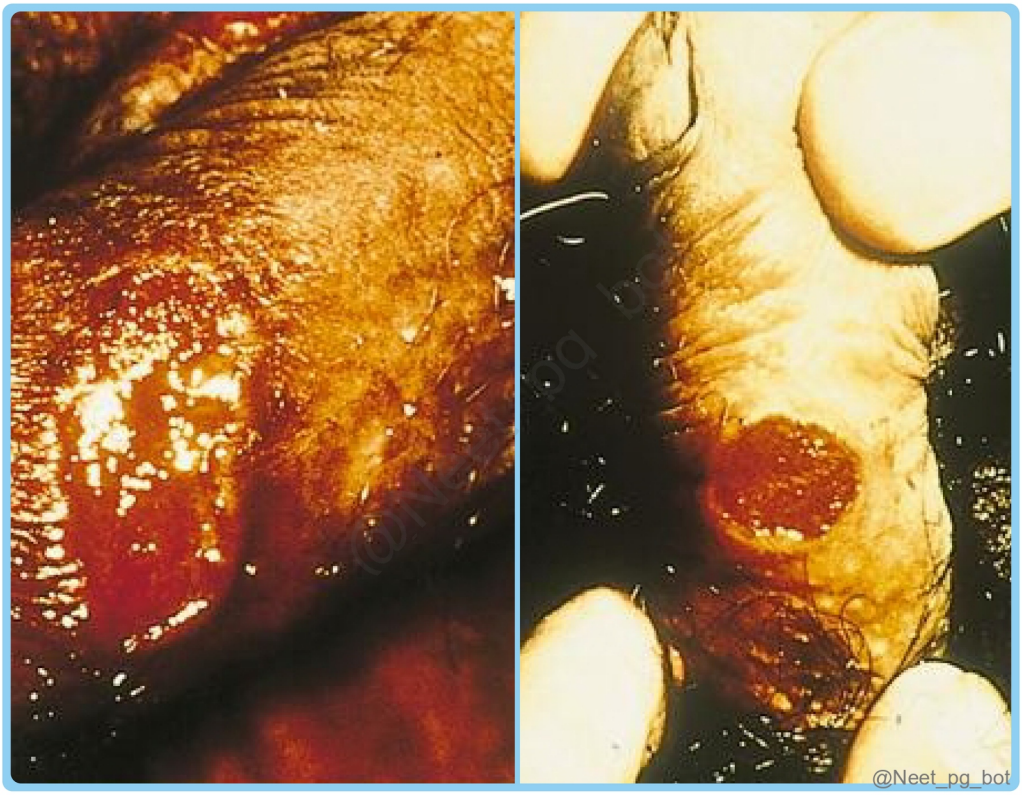

Correct Answer: D. Donovanosis

- *Listen (English)*
- *Listen (Hindi)*

Explanation: The image depicts a beefy-red ulcer with a granulomatous base. The presence of a painless, beefy-red ulcer with a granulomatous base that bleeds easily on touch, indicates a diagnosis of Donovanosis . Donovanosis Causative Agent Klebsiella granulomatis bacterium Clinical Presentation Painless ulcers or nodules in genital, perianal, or inguinal regions; ulceration with beefy red, granular base Progression Slowly progressive, may lead to extensive tissue destruction if untreated Complications Genital deformity, lymphatic obstruction, secondary bacterial infections Diagnostic Tests Tissue biopsy, Wright or Giemsa staining of tissue samples, PCR for bacterial DNA Treatment Doxycycline (200mg daily) or azithromycin (1g once a week)for 3 weeks Characteristic Donovanosis Syphilis (Option A) Chancroid (Option B) LGV (Option C) Causative Agent Klebsiella granulomatis bacterium Treponema pallidum bacterium Haemophilus ducreyi bacterium Chlamydia trachomatis (serovars L1-L3) Appearance of Ulcer Beefy red, painless, exuberant granulation tissue Painless, solitary, firm, round ulcer Multiple necrotic based non indurated with undermined edges and bleeds on touch Painless herpetiform transient ulcer I mages


@Neet_pg_bot


@Neet_pg_bot

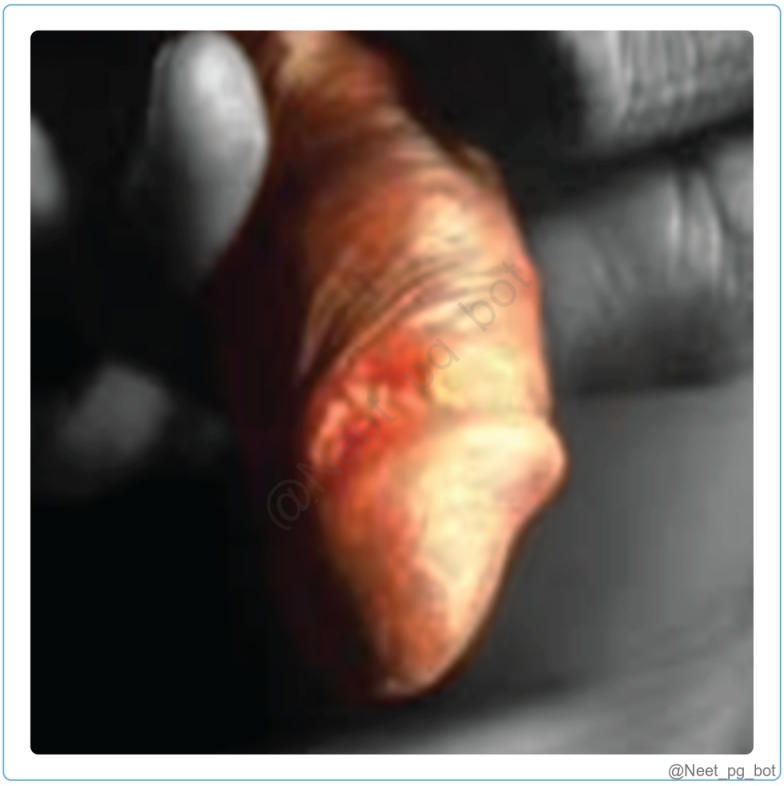



References:

Neena Khanna’s Illustrated Synopsis of Dermatology and Sexually Transmitted Diseases, 1st Edition, Page 300

↑ *Back to this question in Part A*

@Neet_pg_bot

Q7: A 32 year old male presents to a primary care clinic with complaints of urethral discharge and dysuria. He reports having unprotected sexual intercourse with multiple partners. On examination, you note purulent discharge from the urethra. Which colour kit would be most appropriate for initial management in this patient? (Q841744)

A. Yellow

B. Blue

C. Grey

D. Red

Correct Answer: C. Grey

■ *Listen (English)*

■ *Listen (Hindi)*

Explanation: The grey colour kit in the NACO syndromic management approach is used for urethral discharge in males, which is suggestive of possible gonococcal infection (gonorrhoea). STI Color Coded Kits under NACP-2024:

Kit	Composition	Targetted syndrome
Grey (Kit 1)	• Tab. Azithromycin 1000 mg • Tab. Cefixime 800 mg single dose	• Urethral discharge syndrome • Vaginal discharge syndrome (for cervicitis) • Painful scrotal swelling • Presumptive treatment (PT)
Green (Kit 2)	• Tab. Secnidazole 2000 mg • Tab. Fluconazole 150 mg single dose	• Vaginal discharge syndrome (for vaginitis)
White (Kit 3)	• Inj. Benzathine penicillin G 2.4 MU • Tab. Azithromycin 1000 mg single dose • Disposable syringe 10 ml with 21-gauge needle and sterile water 10 ml	• Genital ulcer disease syndrome (for Syphilis and Chancroid)
Blue (Kit 4)	• Tab. Doxycycline 100 mg (28 capsules twice / day dose for 14 days) • Tab. Azithromycin 1 g single dose	• Genital ulcer disease syndrome (for Syphilis and Chancroid when unavailability or history of allergy to Benzathine penicillin G)
Red (Kit 5)	• Tab. Acyclovir 400 mg (21 tablets as three times / per day dose for 7 days)	• Genital ulcer disease syndrome (for Herpetic ulcers)
Yellow (Kit 6)	• Tab. Cefixime 800 mg single dose • Tab. Metronidazole 400 mg (28 tablets twice / day dose for 14 days) • Cap. Dxycycline 100 mg (28 capsules twice / day dose for 14 days)	• Lower abdomen pain • PID
Black (Kit 7)	• Tab. Dxycycline 100 mg (42 capsules twice / day dose for 21 days)	• Inguinal bubo under genital ulcer disease syndrome • LGV Proctitis under anorectal discharge syndrome
Brown (Kit 8)	• Tab. Cefixime 800 mg stat dose • Tab. Doxycycline 100 mg (14 capsules twice / day dose for 7 days)	• Anorectal discharge syndrome

@Neet_pg_bot

References:

https://naco.gov.in/sites/default/files/National%20Technical%20Guidelines%20on%20STI%20and%20RTI_Final.pdf

↑ *Back to this question in Part A*

@Neet_pg_bot

Q8: A 32 year old woman presents with complaints of vaginal discharge and a fishy odour. She denies any genital itching or irritation. On examination, you notice the discharge coats the vaginal walls as shown in the image. There is no erythema or inflammation noted. Out of the following, which is the single most reliable predictor to support the diagnosis in this patient? (Q841741)

A. Presence of clue cells on wet mount microscopy

B. Thin, greyish-white vaginal discharge

C. Positive whiff test (amine odour) with 10% KOH solution

D. Vaginal pH of more than 4.5

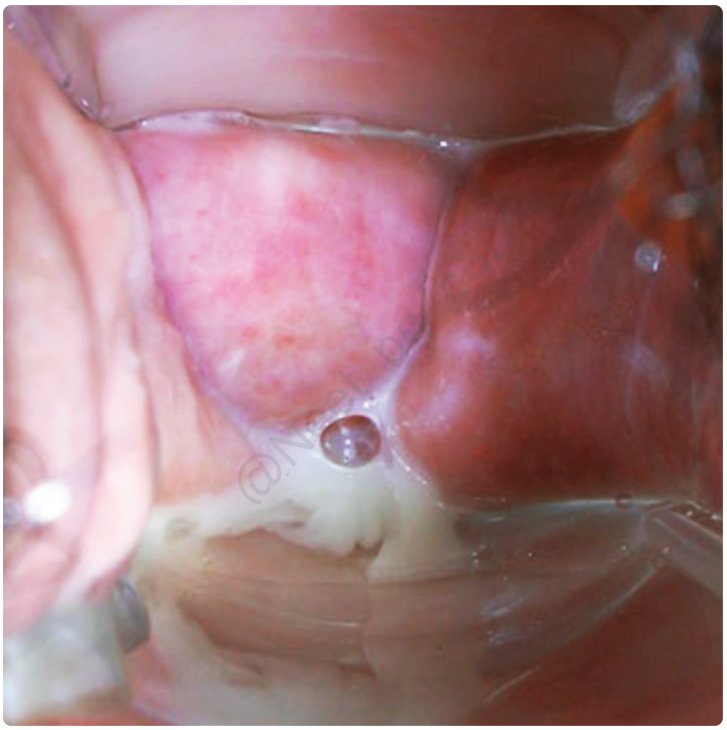

Correct Answer: A. Presence of clue cells on wet mount microscopy

- *Listen (English)*
- *Listen (Hindi)*

Explanation: The presence of clue cells on saline wet mount is the single most reliable predictor of bacterial vaginosis. Indicators towards the diagnosis: Presence of fishy-smelling, vaginal discharge without a history of pruritus The image shows a thin, homogenous whitish discharge that coats the walls, characteristic of bacterial vaginosis Clue cells are vaginal epithelial cells that are studded with adherent coccobacilli. This gives the cells a stippled, fuzzy appearance. The presence of these cells indicates bacterial infection of the vagina. Clue cells in bacterial vaginosis: Amsel's criteria for bacterial vaginosis (BV): Thin, greyish-white vaginal discharge. Vaginal pH greater than 4.5 Presence of clue cells on wet mount microscopy and Positive whiff test (amine odour) with 10% potassium hydroxide (KOH) solution. Presence of at least three of the above findings is needed to make a diagnosis of bacterial vaginosis Nugent’s score It is the gold standard test for bacterial vaginosis but is not used in clinical practice as it requires more expertise. This score involves a gram stain smear of vaginal discharge. Score Lactobacillus morphotype/ hpf Gardnerella and Bacteroides morphotypes/ hpf Curved bacteria (Mobiluncus)/ hpf 0 >30 0 0 1 5-30 <1 1-5 2 1-4 1-4 >5 3 <1 5-30 4 0 >30 Interpretation: 7 to 10: Bacterial vaginosis 4 to 6: Indeterminate 0 to 3: Normal. While all the other options are part of Amsel's criteria, presence of clue cells is most diagnostic, as other features may be seen with other types of vaginal discharge. Presence of clue cells >20% is diagnostic.

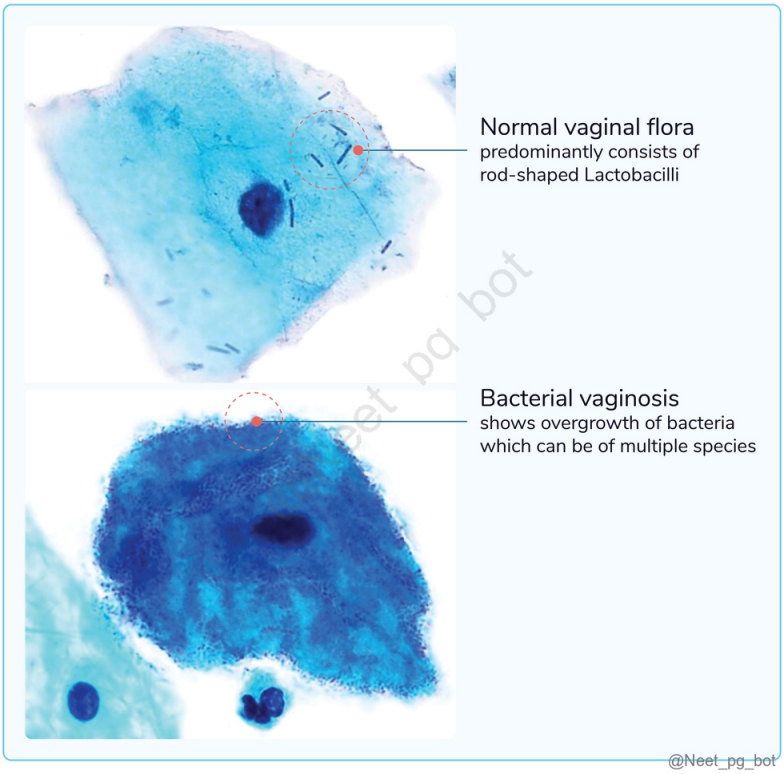

References:

Rooks Textbook of Dermatology, 9th Edition, Page 112.23

Sobel J D. 2023, Bacterial vaginosis: Clinical manifestations and diagnosis, UpToDate

↑ *Back to this question in Part A*

@Neet_pg_bot

Q9: A 30 year old woman with a medical history significant for diabetes mellitus presents to the clinic with complaints of vaginal itching and thick, white, curd-like discharge. Physical examination reveals no signs of inflammation or lesions. What is the most likely diagnosis? (Q841739)

A. Bacterial vaginosis

B. Trichomoniasis

C. Vaginal candidiasis

D. Chlamydia trachomatis infection

Correct Answer: C. Vaginal candidiasis

■ *Listen (English)*

■ *Listen (Hindi)*

Explanation: Vaginal candidiasis, (yeast infection/ vaginal thrush) is caused by overgrowth of the fungus Candida albicans . Women with diabetes are at higher risk of developing yeast infections due to elevated blood sugar levels, which provide a favourable environment for yeast growth. The symptoms typically include vaginal itching, thick, white, curd-like discharge , and sometimes redness and swelling of the vulva. The absence of inflammation or lesions on examination further supports the diagnosis of vaginal candidiasis Unlike other vaginal discharges, Vaginal pH is usually acidic . Treatment: Topical azole antifungals: Clotrimazole, miconazole, econazole, or tioconazole creams or suppositories Oral azole antifungals: Fluconazole is an effective oral antifungal medication that may be prescribed as a single-dose regimen (150 mg) or as multiple doses depending on the severity of the infection. Bacterial vaginosis (BV) (Option A): It is characterized by a thin, greyish-white discharge with a characteristic fishy odour, known as "whiff test" positivity. Trichomoniasis (Option B): Trichomonal vaginitis typically presents with a frothy, yellow-green vaginal discharge with a characteristic foul odour, often described as "musty." Additionally, patients with trichomoniasis may experience vulvar itching, dyspareunia, and dysuria. Chlamydia trachomatis infection (Option D): Chlamydia trachomatis infection typically presents with mucopurulent cervical discharge. It may lead to complications such as pelvic inflammatory disease (PID) if left untreated.

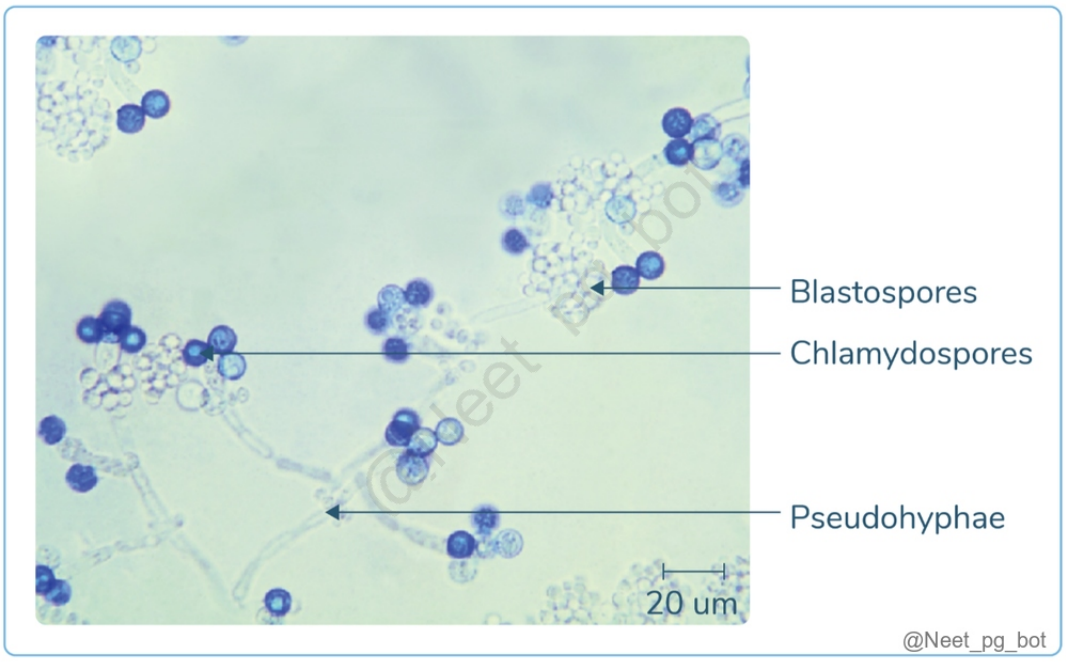



@Neet_pg_bot

References:

Rooks Textbook of Dermatology, 9th Edition, Chapter 113

Harrison’s Principles of Internal Medicine, 21st Edition, Chapter 216

↑ *Back to this question in Part A*

@Neet_pg_bot

Q10: A 28 year old sexually active male presents to the clinic with a painless single lesion on his genitals. On examination, the healthcare provider observes single small, round, painless ulcer with raised edges and a clean base as shown below. The patient denies any recent travel, but he reports having unprotected sexual contact with multiple partners in the past month. What is the most appropriate treatment for this patient? (Q841721)

A. Oral Doxycycline

B. Oral Azithromycin

C. Intramuscular Penicillin G Benzathine

D. Topical Acyclovir



Correct Answer: C. Intramuscular Penicillin G Benzathine

- *Listen (English)*
- *Listen (Hindi)*

Explanation: Based on the clinical presentation of single painless genital ulcer with raised edges and a clean base in a sexually active individual, the most likely diagnosis is syphilis, specifically primary syphilis. Syphilis is a sexually transmitted infection caused by the bacterium Treponema pallidum. The treatment of choice for all stages of syphilis, including primary syphilis, is penicillin. In this case, intramuscular Penicillin G Benzathine is the recommended treatment. Syphilis treatment: Counselling and Education: Very important component of treatment and should include: Avoidance of sex till healing of lesions. Presumptive treatment of partners. Advice on safe sex including use of condoms and encouraging single-partner relationship. Follow up testing for HIV, hepatitis B virus and VDRL at 3 months and further if necessary. Specific Treatment: Injectable penicillin is the treatment of choice, unless patient is sensitive to it when either erythromycin (in pregnant women sensitive to penicillin) or doxycycline are used. Doxycycline (Option A) is effective for treating genital ulcers like donovosis . Oral Azithromycin (Option B) is not the first-line treatment for primary syphilis. Azithromycin is also used for the treatment of Chlamydia and Gonorrhoea . Oral Acyclovir (Option D) is used to treat herpes simplex virus (HSV) infections that present with multiple painful ulcers.

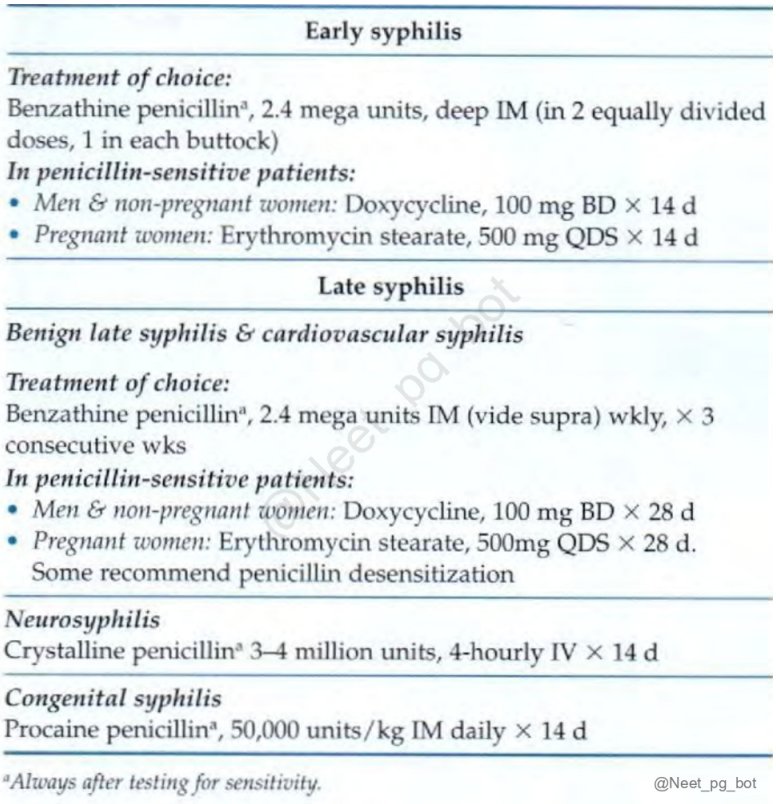

Early syphilis
Treatment of choice: Benzathine penicillin[a], 2.4 mega units, deep IM (in 2 equally divided doses, 1 in each buttock) ***In penicillin-sensitive patients:*** • *Men & non-pregnant women:* Doxycycline, 100 mg BD × 14 d • *Pregnant women:* Erythromycin stearate, 500 mg QDS × 14 d
Late syphilis
Benign late syphilis & cardiovascular syphilis ***Treatment of choice:*** Benzathine penicillin[a], 2.4 mega units IM (vide supra) wkly, × 3 consecutive wks ***In penicillin-sensitive patients:*** • *Men & non-pregnant women:* Doxycycline, 100 mg BD × 28 d • *Pregnant women:* Erythromycin stearate, 500mg QDS × 28 d. Some recommend penicillin desensitization
Neurosyphilis Crystalline penicillin[a] 3–4 million units, 4-hourly IV × 14 d
Congenital syphilis Procaine penicillin[a], 50,000 units/kg IM daily × 14 d
[a]*Always after testing for sensitivity.*

@Neet_pg_bot

References:

Neena Khanna's Illustrated Synopsis of Dermatology and Sexually Transmitted Diseases, 7th Edition, Page 300

↑ *Back to this question in Part A*

@Neet_pg_bot

Q11: A 24-year-old sexually active female presents with dysuria, increased urinary frequency, and mild cervical discharge on per speculum examination. She denies fever or abdominal pain. A urinalysis reveals pyuria, but no bacteria are seen on Gram staining of the discharge. Which of the following agents is the first-line drug for this condition? (Q841735)

A. Azithromycin

B. Ceftriaxone

C. Fluconazole

D. Doxycycline

Correct Answer: A. Azithromycin

Explanation: The clinical presentation and absence of bacteria on Gram stain suggest Chlamydia trachomatis as the likely cause of non-gonococcal cervicitis . The first-line treatment is a single dose of Azithromycin (1g orally). The diagnosis of NGU/NGC requires the exclusion of gonorrheal infection. This can be achieved with a gram stain that lacks gram-negative diplococci or by any negative gonorrhea test (culture, nucleic acid testing, among others). Chlamydia trachomatis serovars D-K are the most common cause of non-gonococcal urethritis. In females, it can cause various manifestations such as: Mucopurulent cervicitis (most common). It may progress to endometritis, salpingitis (fallopian tube), pelvic inflammatory disease, and finally pelvic peritonitis. Perihepatitis (Fitz–Hugh–Curtis syndrome). First-line management involves a single oral dose of azithromycin 1g stat. It is preferred due to its greater effectiveness and lower cost . The table below shows the management of uncomplicated chlamydial infections: Non-pregnant First line: Azithromycin 1g single dose Second line: Doxycycline 100mg BD x 7 days Third line: Ofloxacin 200-300mg BD x 7 days Pregnancy First line: Azithromycin 1g oral single dose Second line: Amoxicillin 500mg TDS x 7 days Ceftriaxone (Option B) is used for the treatment of gonococcal infections. Fluconazole (Option C) is used for the treatment of vaginal candidiasis. Doxycycline (Option D) is also highly effective for treating uncomplicated chlamydial infections. It is used when azithromycin is not available or there is a history of allergies. The recommended dose is 100 mg BD x 7 days.

References:

Rook’s Textbook of Dermatology, 9th Edition, Page 30.10-15

Harrison’s Principles of Internal Medicine, 21st Edition Page 1449-50

Essentials of Medical Microbiology, Apurba Sastry, 4th Edition, Page 768, 770

https://www.ncbi.nlm.nih.gov/books/NBK535411/

↑ *Back to this question in Part A*

@Neet_pg_bot

Q12: A 28 year old male presents to the STD clinic with a history of swelling in the inguinal region as shown in the image below. He has a history of unprotected sexual intercourse in the past few months and reports a painless ulcer, which healed without scarring. Which of the following is false regarding this condition? (Q841733)

A. Caused by Chlamydia trachomatis L1-L3

B. Can be associated with hepatitis C co-infection

C. Presents with an indurated ulcer and painless lymphadenopathy

D. Esthiomene is a complication in the tertiary stage of this disease



Correct Answer: C. Presents with an indurated ulcer and painless lymphadenopathy

- *Listen (English)*
- *Listen (Hindi)*

Explanation: The given clinical presentation of a male with a history of unprotected sexual intercourse , swelling in the inguinal region (inguinal lymphadenopathy) and a painless ulcer that has healed without scarring is suggestive of lymphogranuloma venerum, caused by Chlamydia trachomatis. The incorrect statement is that it presents with an indurated ulcer and painless lymphadenopathy. Lymphogranuloma venerum (LGV): It is a sexually transmitted disease caused by serovars L1-L3 of Chlamydia trachomatis (M/C strain causing LGV: L2). It occurs in sexually active adults of all ages. It can cause LGV-associated proctitis in homosexuals, associated with HIV and hepatitis C co-infection. The incubation period of LGV is around 3-30 days , and the disease presents in three stages, described in the table below: Primary Secondary Tertiary 3-30 days Days-weeks Years after a chronic, untreated infection Small papule/pustule/ Non-indurated ulcer at the site of inoculation which heals spontaneously with no scarring. Lymphatic involvement of nodes that drain the primary lesion. Classic form: Tender unilateral or bilateral inguinal and/or femoral adenopathy (Groove sign of Greenblatt). The lymph nodes may coalesce to form a bubo or abscesses that may rupture spontaneously with the development of Fistulae or sinus tracts. There may be systemic features such as malaise and fever. Lymphatic obstruction due to chronic inflammation leads to fistula formation, strictures, and disfiguring conditions such as genital elephantiasis and esthiomene , which refers to hypertrophic enlargement with ulceration of the external genitalia. Diagnosis of LGV can be confirmed by the Nucelic Acid Amplification Test (NAAT). Antibody detection by real-time PCR can also be done. Treatment includes: First line: Doxycycline 100mg BD x 21 days. Second line: Erythromycin 500mg 4 times a day x 21 days. Third line: Azithromycin 1g weekly once x 21 days. Caused by Chlamydia trachomatis L1-L3 (Option A): This statement is true; these specific serovars are the causative agents of LGV. Can be associated with hepatitis C co-infection (Option B): This statement is true; co-infections with other STIs, including

HCV, are possible in individuals with LGV. Esthiomene is a complication in the tertiary stage of this disease (Option D): This statement is true; esthiomene (genital elephantiasis) is a recognized chronic complication of untreated or persistent LGV infection.

References:

Rook's Textbook of Dermatology, 9th Edition, Page 30.15-30.20

↑ *Back to this question in Part A*

@Neet_pg_bot

Q13: A 28 year old female presents with lower abdominal pain, dyspareunia, and cervical motion tenderness. She also reports that she has been unable to conceive despite actively trying for the past 18 months. What is the most likely diagnosis? (Q841731)

A. Genital herpes

B. Chlamydia infection

C. Syphilis

D. Trichomoniasis

Correct Answer: B. Chlamydia infection

■ *Listen (English)*

■ *Listen (Hindi)*

Explanation: The symptoms described in the stem, along with the patient's inability to conceive despite actively trying, raise suspicion of chlamydia infection . Chlamydial pelvic inflammatory disease often presents asymptomatically but can cause symptoms such as lower abdominal pain, dyspareunia, and cervical motion tenderness. These symptoms, along with the patient's reported inability to conceive despite actively trying for the past 18 months, raise suspicion for chlamydial pelvic inflammatory disease (PID), which can lead to fallopian tube damage and subsequent infertility . Chlamydia trachomatis is the most common cause of bacterial sexually transmitted infections (STIs). It is caused by the bacterium Chlamydia trachomatis Clinical features in females: Although it is mostly asymptomatic, it can present in the following forms: Cervicitis Urethritis Pelvic inflammatory disease Perihepatitis Pregnancy complications Clinical features in males: Urethritis Epididymitis Prostatitis Common features: Conjunctivitis Pharyngitis Proctitis Genital lymphogranuloma venereum Diagnosis is made through nucleic acid amplification testing (NAAT) of genital samples. Genital herpes (Option A) presents with multiple, painful, non-indurated, umbilicated vesicles that rupture to form coalescing vesicles or polycyclic erosions. Syphilis (Option C) presents as painless genital ulcers (chancre). Trichomoniasis (Option D) presents with frothy discharge, vulvar itching, and strawberry cervix.



@Neet_pg_bot



@Neet_pg_bot

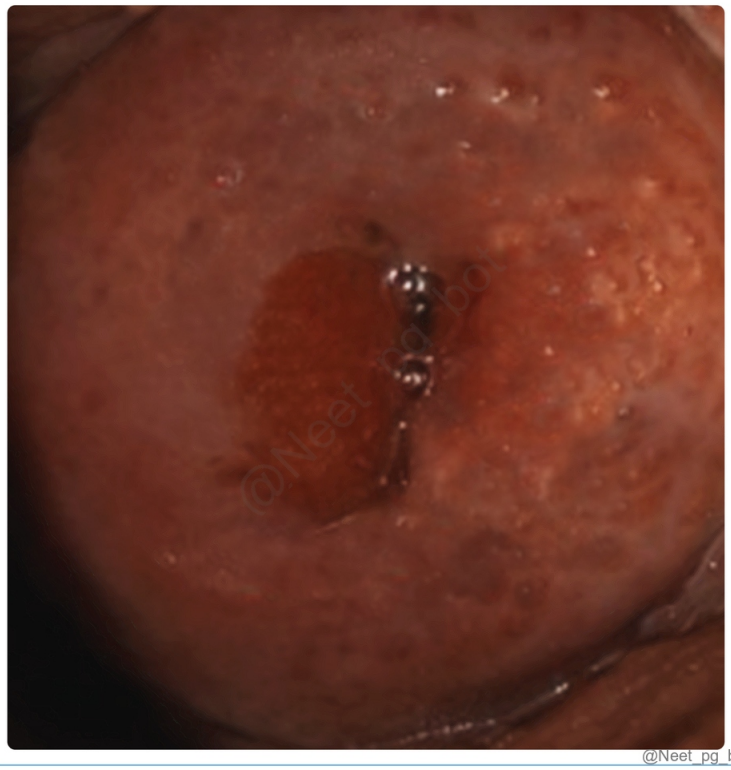

References:

Rooks Textbook of Dermatology, 9th Edition, Chapter 113

↑ *Back to this question in Part A*

@Neet_pg_bot

Q14: A 28 year old sexually active male presents with dysuria and urethral discharge which is purulent, profuse, thick and creamy. He reports having unprotected sexual intercourse with multiple partners. What is the most appropriate initial management? (Q841729)

A. Oral Fluconazole

B. Intramuscular Benzathine Penicillin G

C. Oral Azithromycin

D. IM Ceftriaxone

Correct Answer: D. IM Ceftriaxone

■ *Listen (English)*

■ *Listen (Hindi)*

Explanation: Given the symptoms and risk factors, the most likely diagnosis is gonorrhoea. IM ceftriaxone, a third-generation cephalosporin antibiotic, is the recommended treatment. Ceftriaxone is typically given as a single dose, often combined with azithromycin to cover potential co-infection with Chlamydia trachomatis. In case of chlamydia the urethral discharge is mucoid/mucopurulent. Treatment regimens in Neisseria infection: Treatment Regimen Dosage/Duration Uncomplicated Gonorrhea Ceftriaxone 250 mg IM (intramuscular) + Azithromycin 1 g orally Single dose OR Doxycycline 100 mg orally twice daily, Erythromycin 500mg orally QDS daily For 7 days Note: Azithromycin is preferred if chlamydia coinfection is suspected. Alternative Regimen Cefixime 400 mg orally + Azithromycin 1 g orally Single dose OR Doxycycline 100 mg orally twice daily Erythromycin 500mg orally QDS daily For 7 days Extragenital Gonorrhea (Pharyngeal or Rectal) Ceftriaxone 250 mg IM (intramuscular) + Azithromycin 1 g orally Single dose Single dose OR Doxycycline 100 mg orally twice daily For 7 days Oral fluconazole (Option A) is used for treating fungal infections like vaginal candidiasis. Intramuscular benzathine penicillin G (Option B) is used for treating syphilis, not gonorrhoea. Oral Azithromycin (Option C) is an alternative treatment for gonorrhoea but is not the first-line treatment.

References:

Rook's Textbook of Dermatology, 9th Edition , Page 30.7 - 30.8

↑ *Back to this question in Part A*

@Neet_pg_bot

Q15: A 22 year old sexually active woman presents to the clinic with complaints of vaginal discharge and pelvic pain. She reports having multiple sexual partners and inconsistent use of condoms. On examination, the healthcare provider notices purulent vaginal discharge and tenderness on pelvic examination. A Gram stain of the discharge reveals intracellular gram-negative diplococci. What is the most likely diagnosis? (Q841726)

A. Bacterial vaginosis

B. Candidiasis

C. Trichomoniasis

D. Gonorrhea

Correct Answer: D. Gonorrhea

■ *Listen (English)*

■ *Listen (Hindi)*

Explanation: Gonorrhea is a sexually transmitted infection (STI) caused by the bacterium Neisseria gonorrhoeae. Additionally, the history of multiple sexual partners and inconsistent condom use is suggestive of a higher risk for STIs, including gonorrhoea. Gram stain showing Neisseria gonorrhoeae Neisseria Gonorrhoea Bacterium Gram-negative diplococcus Clinical Presentation Genital discharge (purulent), dysuria, pelvic pain, rectal symptoms Complications Pelvic inflammatory disease (PID), epididymitis, prostatitis, disseminated gonococcal infection (DGI) Transmission Primarily through sexual contact (vaginal, anal, oral) with an infected individual Risk Factors Unprotected sex, multiple sexual partners, history of gonorrhoea Diagnosis In males, by gram stain(gram negative intracellular diplococci) and culture and in females by culture. Multiplex PCR Treatment SOD cefixime 400mg or intramuscular ceftriaxone 125/250mg as SD Bacterial vaginosis (Option A) is characterized by a thin, greyish-white vaginal discharge with a fishy odour, but it does not present with purulent discharge or intracellular gram-negative diplococci on Gram stain. Candidiasis (Option B) is a fungal infection that causes vaginal itching and thick, white, cottage cheese-like discharge. Trichomoniasis (Option C) is caused by the protozoan parasite Trichomonas vaginalis and typically presents with frothy, yellow-green, malodorous discharge.

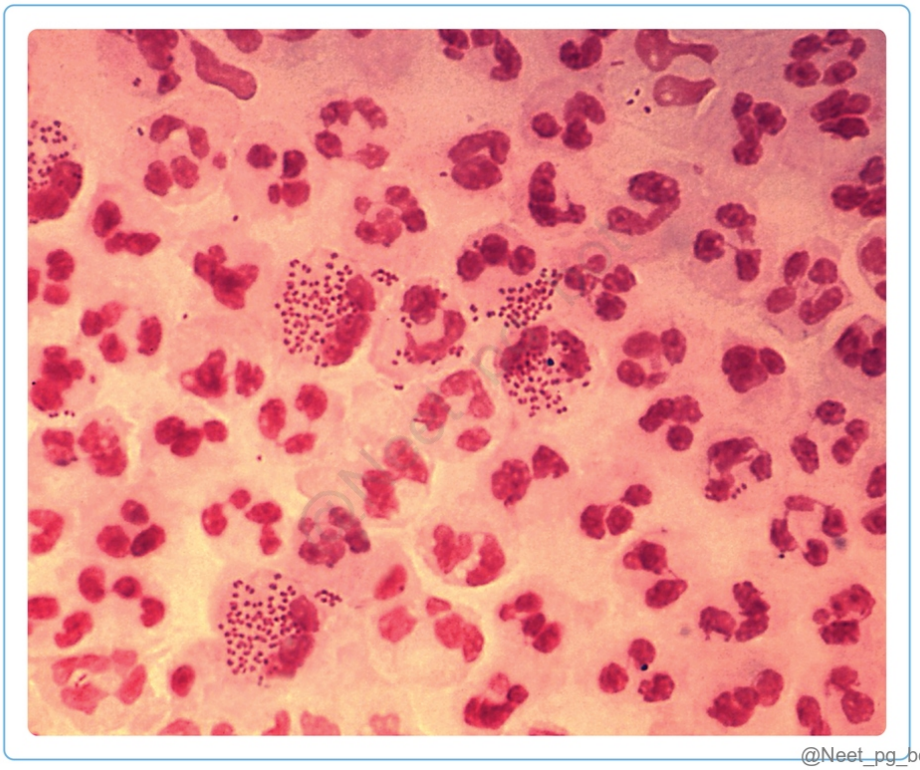

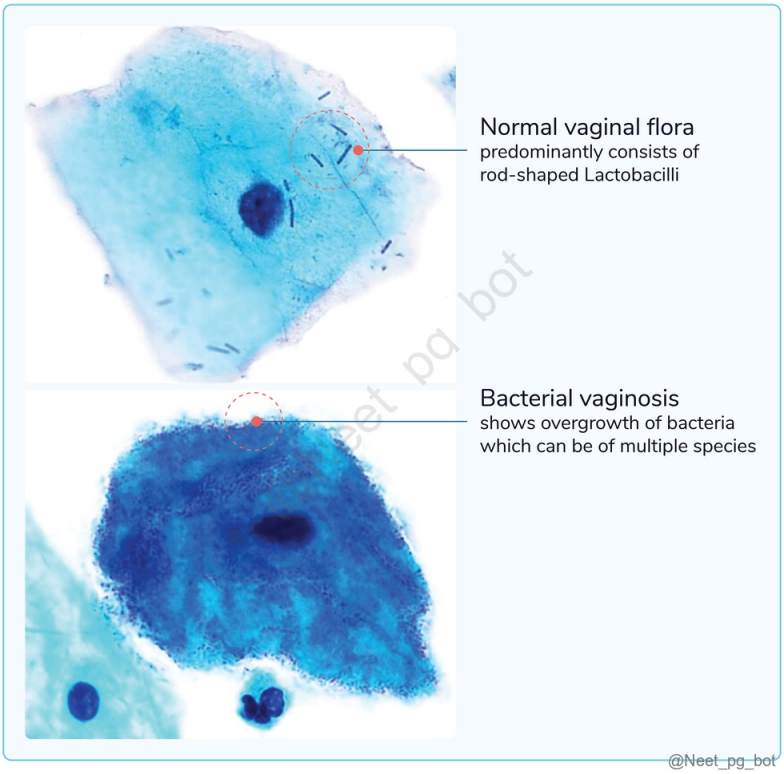
Normal vaginal flora
predominantly consists of
rod-shaped Lactobacilli
Bacterial vaginosis
shows overgrowth of bacteria
which can be of multiple species
@Neet_pg_bot

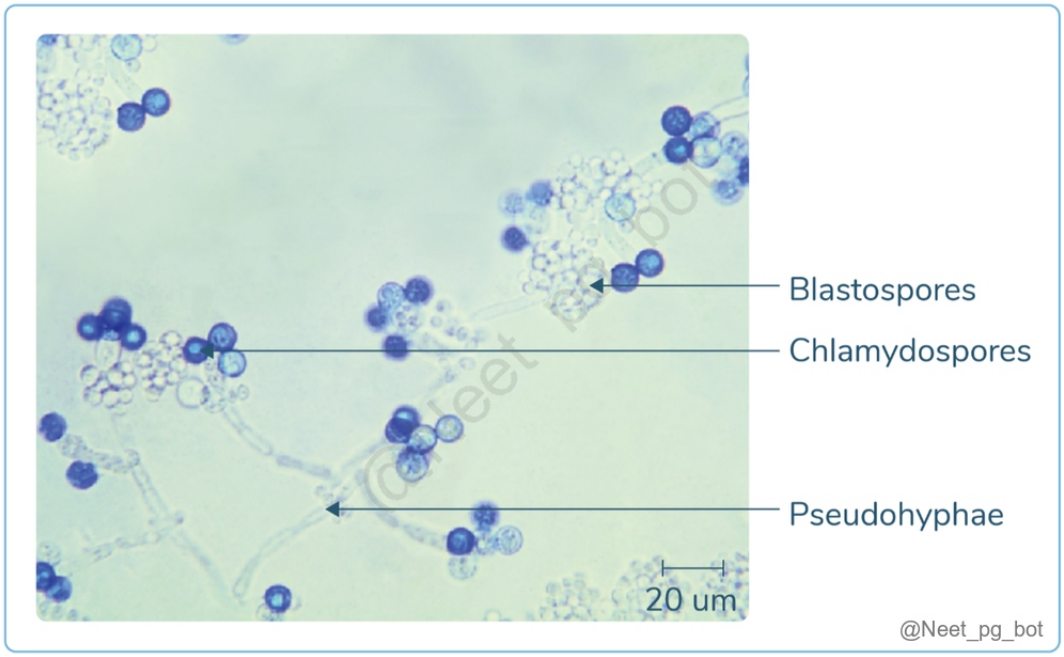
Blastospores
Chlamydospores
Pseudohyphae
20 um
@Neet_pg_bot



References:

Neena Khanna’s Illustrated Synopsis of Dermatology and Sexually Transmitted Diseases, 1st Edition, Page 300

↑ *Back to this question in Part A*

@Neet_pg_bot

Q16: A newborn infant presents with symptoms suggestive of congenital syphilis. The mother had untreated syphilis during pregnancy. Which of the following is not a manifestation of early-onset congenital syphilis in newborns? (Q841724)

A. Vesiculobullous rash

B. Inflammation of oral and nasal mucosa

C. Continous discharge from the nose

D. Hutchisons Triad

Correct Answer: D. Hutchisons Triad

■ *Listen (English)*

■ *Listen (Hindi)*

Explanation: Hutchinson’s Triad is a feature of the late-onset congenital syphilis. Congenital syphilis occurs when a pregnant woman with untreated syphilis passes the infection to her fetus during pregnancy. The bacterium Treponema pallidum can affect various organ systems in the newborn. The lesions in Congenital syphilis can be classified as Early onset (within 2 years after birth) and Late onset (after 2 years of birth). Lesions in Early Onset Congenital Syphilis: (Options A, B, C ruled out) Vesiculo Bullous rash - Over palms & soles (aka SYPHILITIC PEMPHIGUS) Inflammation of oral and nasal mucosa Continuous discharge from the nose is called snuffles. Wimberger Sign (Bilateral Medial Tibial Erosions) Osteochondritis & Peri Osteochondritis (Pseudo Paralysis of Parrot - Child not able to move) Lesions in Late Onset Congenital Syphilis Hutchison’s Triad: Peg-shaped incisors, interstitial keratitis, and deafness Mulberry Molars Deformed nose Rhagades: Fissures around the mouth Frontal bossing / Olympian bow Higoumenakis Sign (Unilateral Medial Clavicle Periostitis) Cluttons Joint (Painless) Sabre Tibia (Anterior Tibia Periostitis)

References:

Neena Khanna’s Illustrated Synopsis of Dermatology and Sexually Transmitted Diseases, 7th Edition, Page 300

↑ *Back to this question in Part A*

@Neet_pg_bot

Q17: A 28 year old man presents to the clinic with a diffuse, maculopapular rash on his palms and soles, as well as fever and sore throat. He reports that the rash developed a few weeks after he noticed a painless ulcer on his genital area, which resolved on its own. The rash is not itchy and does not involve the face. The patient also has white patches in his mouth and a few small, red papules on his genitals. What is the most likely diagnosis? (Q841723)

A. Primary Syphilis

B. Tertiary Syphilis

C. Pitriyasis Rosea

D. Secondary Syphilis

Correct Answer: D. Secondary Syphilis

■ *Listen (English)*

■ *Listen (Hindi)*

Explanation: The most likely diagnosis for this patient's presentation is secondary syphilis. Secondary syphilis occurs a few weeks to months after the initial infection (primary syphilis) and is characterized by a variety of symptoms, including a diffuse maculopapular rash involving the palms and soles. Other common features of secondary syphilis include fever, sore throat, and mucous membrane involvement (such as white patches in the

mouth). The presence of a painless genital ulcer (chancre) in the history supports the diagnosis. Lesions of Primary Syphilis Lesions of Secondary Syphilis Primary Syphilis genital ulcer Primary syphilis - Penile chancre Chancre - secondary syphilis Characteristic Primary Syphilis Secondary Syphilis Tertiary Syphilis Causative Agent Treponema pallidum bacterium Incubation period 9-90 days after sexual contact 3-12 weeks 24 months Clinical features Single, indurated (button like),painless, clean ulcer which oozes serum on pressure Coppery hyperpigmented, scaly macules or hyperkeratotic papules on palms and soles. condyloma lata in perianal and other intertriginous regions Gumma formation on skin and mucosa ,neurosyphilis, uncomplicated aortitis ,aortic insufficiency ,aneurysm ,coronary stenosis, hepatic gumma Diagnostic Tests Darkground microscopy(cork-screw appearance) Darkground microscopy Blood tests (RPR, VDRL), imaging studies Treatment Benzathine penicillin 2.4 megaunits deep IM In penicillin -sensitive patients- Men and non -pregnant women-Doxycycline 100mg BD x 14d. pregnant women-Erythromycin stearate 500mg QDS x 14d Benzathine penicillin 2.4 megaunits deep IM In penicillin -sensitive patients- Men and non -pregnant women-Doxycycline 100mg BD x 14d. pregnant women-Erythromycin stearate 500mg QDS x 14 Benzathine penicillin 2.4 megaunits IM weekly,x 3 consecutive weeks. In penicillin -sensitive patients- Men and non -pregnant women-Doxycycline 100mg BD x 28d. pregnant women-Erythromycin stearate 500mg QDS x 28d Neurosyphilis-Crystalline penicillin 3-4 units ,4 hourly IV x 14d. Congenital syphilis-Procaine penicillin 50,000units/kg IM daily x 14d.



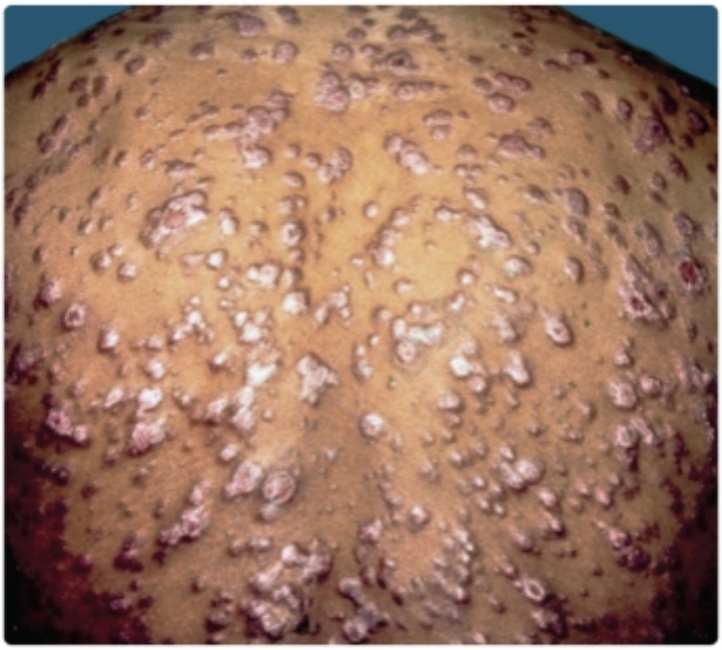

Reddish papules and nodules on the back
to secondary syphilis

@Neet_pg_bot



secondary syphilis with a rash on
the palms of the hands

@Neet_pg_bot



@Neet_pg_bot



@Neet_pg_bot

References:

Neena Khanna’s Illustrated Synopsis of Dermatology and Sexually Transmitted Diseases, 7th Edition, Page 300.

↑ *Back to this question in Part A*

@Neet_pg_bot

• [08_Sexually Transmitted Infections] 018 Previous Year Questions

« Back to Folder Directory

[08_Sexually Transmitted Infections] 018 Previous Year Questions — Quick Jump

Q1 (p. 1021)	*Q2 (p. 1022)*	*Q3 (p. 1022)*	*Q4 (p. 1024)*	*Q5 (p. 1025)*	*Q6 (p. 1026)*
Q7 (p. 1027)	*Q8 (p. 1029)*	*Q9 (p. 1030)*	*Q10 (p. 1033)*	*Q11 (p. 1034)*	*Q12 (p. 1037)*
Q13 (p. 1039)	*Q14 (p. 1042)*	*Q15 (p. 1043)*	*Q16 (p. 1044)*	*Q17 (p. 1045)*	

Q1: What is the probable diagnosis for a young woman who presents with a painless ulcer in the genital region accompanied by pain less swelling of the lymph nodes in the groin? (Q855293)

A. Chancroid

B. Syphilis

C. Herpes genitalis

D. Granuloma inguinale

Correct Answer: B. Syphilis

Explanation: The clinical presentation of a single painless genital ulcer with raised edges and a clean base, accompanied by painless swelling of the inguinal lymph nodes , strongly suggests P rimary Syphilis . Syphilis is a sexually transmitted infection caused by the spirochete bacterium Treponema pallidum . Primary syphilis typically manifests as a chancre , which is a painless ulcer appearing at the site of inoculation. The associated lymphadenopathy is also painless, helping to differentiate syphilis from other sexually transmitted infections. Treatment of syphilis: Primary, secondary, and early latent syphilis: A single intramuscular injection of benzathine penicillin G 2.4 million units . Late latent syphilis or tertiary syphilis (excluding neurosyphilis): Benzathine penicillin G 2.4 million units IM weekly for 3 weeks . Neurosyphilis: Intravenous aqueous crystalline penicillin G at 18–24 million units daily, divided into doses every 4 hours or by continuous infusion for 10–14 days . Chancroid (Option A) is caused by Haemophilus ducreyi and presents as a painful genital ulcer with irregular edges, often accompanied by tender, suppurative inguinal lymphadenopathy (buboes). Herpes genitalis (Option C) is caused by Herpes simplex virus (HSV) , it presents with multiple painful vesicles or ulcers on the genital area, often associated with burning or itching sensations. Granuloma inguinale (Option D) is caused by Klebsiella granulomatis , it presents as beefy red ulcers that bleed easily on touch, with no associated lymphadenopathy. The ulcers are typically painless but have a different appearance than the chancre of syphilis.

References:

Fitzpatrick Dermatology, 9th Edition, Page 3160.

Rook’s textbook of Dermatology, 9th Edition, Page 30.7

↑ *Back to this question in Part A*

@Neet_pg_bot

Q2: Which of the following conditions is not included in syndromic management for males? (Q879088)

A. Urethral discharge

B. Genital ulcer

C. Inguinal swelling

D. Lower abdominal pain

Correct Answer: D. Lower abdominal pain

Explanation: Lower abdominal pain is not part of male syndrome management in STI programs. It is a female-specific syndrome , usually related to PID (Pelvic Inflammatory Disease) , and therefore not included in male STI syndromic case management algorithms . Incorrect Options: Urethral discharge (Option A) is included in male STI syndromic management; usually due to gonorrhea or chlamydia. Genital ulcer (Option B) is included as a major syndrome; covers HSV, syphilis, chancroid. Inguinal swelling (Option C) represents bubo syndrome (LGV, chancroid).

References:

Advantages and disadvantages of syndromic case management | Download Table

Universal Screening for Sexually Transmitted Infections among Asymptomatic Adolescents in an Urban Emergency Department: High Acceptance but Low Prevalence of Infection - PMC.

↑ *Back to this question in Part A*

@Neet_pg_bot

Q3: A patient presents to you with multiple anogenital warts. The biopsy of these lesions showed squamous atypia. Which of the following human papillomavirus types are considered high-risk? (Q855895)

A. HPV 2

B. HPV 18

C. HPV 6

D. HPV 11



Correct Answer: B. HPV 18

Explanation: Clinical Features in the Image: The image shows anogenital warts (condyloma acuminata) , which are commonly caused by human papillomavirus (HPV) . The presence of squamous atypia on biopsy suggests a risk of progression to high-grade squamous intraepithelial lesions (HSIL) or malignancy . HPV and Oncogenic Potential: Low-risk HPV types (HPV 6 & 11) : Cause benign anogenital warts. High-risk HPV types (HPV 16 & 18) : Associated with cervical, anal, and anogenital cancers . HPV 18 is one of the most oncogenic strains , particularly linked to cervical adenocarcinoma . High-Risk HPV and Cancer Association HPV Type Risk Level Associated Conditions HPV 6, 11 Low-risk Anogenital warts, respiratory papillomatosis HPV 16, 18 High-risk Cervical, anal, oropharyngeal, and penile cancers HPV 31, 33, 45 High-risk Cervical and vulvar cancers HPV 2 (Option A): Incorrect because it is associated with common warts (verruca vulgaris) , not anogenital warts. HPV 6 (Option C): Incorrect because it is a low-risk type that causes benign genital warts. HPV 11 (Option D): Incorrect because it is also low-risk , causing anogenital warts but not linked to cancer.

References:

Robbins and Cotran, Pathologic Basis of Disease, 10th Edition, Page no-991.

https://www.ncbi.nlm.nih.gov/pmc/articles/PMC145302/

↑ *Back to this question in Part A*

@Neet_pg_bot

Q4: A sexually active male presented with warts on his penis as shown below. Similar lesions were present near the anal canal. What is the most likely diagnosis? (Q859912)

A. Penile cancer

B. Condyloma acuminata

C. Bowen disease

D. Haemorrhoids



Correct Answer: B. Condyloma acuminata

Explanation: The most likely diagnosis based on the given presentation is Condyloma acuminata, commonly known as genital warts. Genital warts are caused by certain strains of the human papillomavirus (HPV), which is a sexually transmitted infection. They typically appear as raised, flesh-colored or grayish growths on or around the genitals, including the penis in males. In some cases, they can also be found near the anal canal, as mentioned in the scenario. Condyloma acuminata (anogenital warts): Benign, moist, soft, pedunculated wart found on the external genitalia and has low malignant potential. Site: They may be found in the genital area such as the penile shaft, scrotum, or labia majora of the vagina, or in the anal area. Appearance: They are generally pink and project out from the surface of the skin. Size may vary; they usually appear small but can merge into large masses. Microscopy: A branching villous structure with connective tissue stroma. Epidermis showing hyperkeratosis and

acanthosis (thickening). Cytoplasmic vacuolization of the squamous cells (koilocytosis) is Characteristic. No evidence of dysplasia. {{caption_text}} The table below shows the clinical features of HPV and the types responsible for various lesions: Clinical lesion Oncogenic potential HPV types Plantar warts Benign 1 Common skin warts Benign 2, 4, 27, 57 Epidermodysplasia verrucosa Mostly benign, rarely progresses to malignancy 5, 8, 9, 12, 17 Anogenital warts Laryngeal papilloma Intraepithelial neoplasia Low malignant potential 6, 11 Palmar warts in butchers Low malignant potential 7 Carcinomas of the cervix & other genital mucosa/larynx/oesophagus High malignant potential 16, 18, 31, 33, 45, 51, 52, 56, 58, 59, 68 Penile cancer (Option A): Penile cancer refers to the malignant growth of cells in the penis. It may present as changes in the skin, ulcerations, or lumps, but it is distinct from the appearance of genital warts. Bowen disease (Option C): Bowen disease is an intraepidermal carcinoma that appears as a red, scaly patch on the skin, typically caused by prolonged exposure to sunlight. Hemorrhoids (Option D): Hemorrhoids are swollen blood vessels in the anal canal that can cause discomfort, itching, and pain.

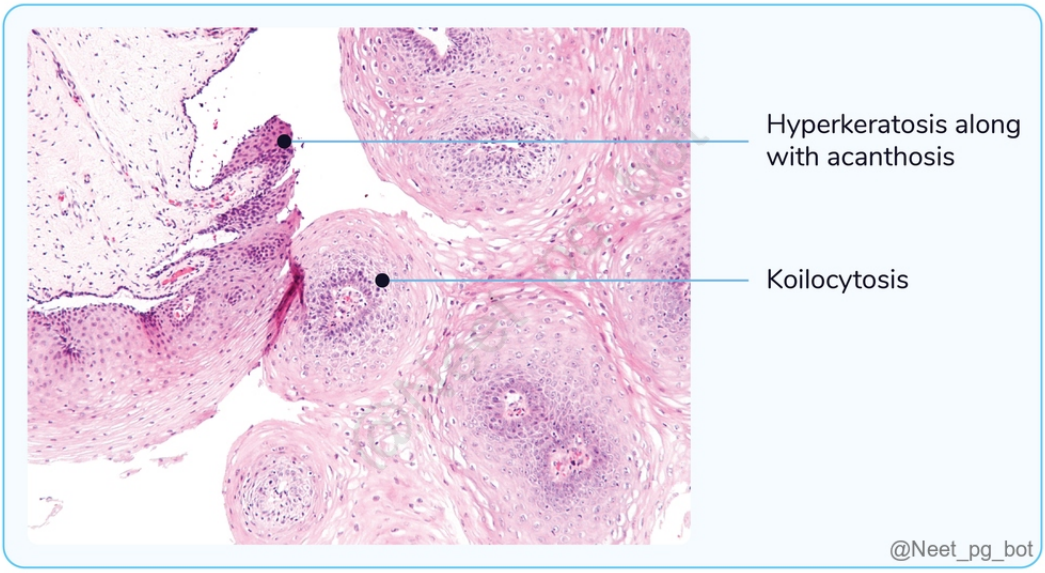

References:

Ananthanarayan and Paniker's microbiology,10 ed page no. 557

Essentials of Medical Microbiology, 3rd edition, 3rd edition, page no. 804

↑ *Back to this question in Part A*

@Neet_pg_bot

Q5: What advice would you provide to prevent the transmission of active genital warts in a female patient with a history of recurrence, despite her husband not being affected by it? (Q856365)

A. Give continuous prophylaxis to the patient

B. Give prophylactic antivirals to the husband

C. Give antivirals whenever active lesions are present

D. Don’t involve in intercourse when active lesions are present

Correct Answer: D. Don’t involve in intercourse when active lesions are present

Explanation: Genital warts are caused by the human papillomavirus (HPV) and can be transmitted through sexual contact. When a female patient presents with active genital warts and a history of recurrence, it is important to provide appropriate advice to prevent transmission to her partner. The most effective measure to prevent transmission of genital warts is to avoid sexual intercourse when active lesions are present. This is because the virus is most contagious and easily transmitted when the warts are actively present Treatment for genital warts involves both individual and partner management Individual Treatment: Topical Medications: Various topical medications can be prescribed to treat genital warts. These include: Imiquimod cream/Trichloroacetic acid (TCA) or bichloroacetic acid (BCA): These acids are applied directly to the warts to destroy them. Surgical Procedures These procedures include: Cryotherapy Electrocautery Surgical excision Partner Management: It is important to inform the partner about the presence of genital warts so that they can also seek appropriate medical evaluation and treatment if necessary. It is best to avoid sexual activity, especially during active wart outbreaks, to prevent transmission to the partner. Incorrect Options: Give continuous prophylaxis to the patient (Option A) : Prophylactic treatments such as topical creams or vaccines are typically used for individuals who have not yet contracted the virus or to prevent future outbreaks. Give prophylactic antivirals to the husband (Option B) : Antiviral medications are primarily used for the treatment of active infections or to reduce the severity and duration of outbreaks, but they do not provide long-term protection against transmission. Give antivirals whenever active lesions are present (Option C) : While antiviral medications can be used to treat active genital warts and reduce the duration of outbreaks, using them solely when active lesions are present is not the most effective approach to prevent transmission.

References:

Illustrated Synopsis of Dermatology and Sexually Transmitted Diseases, Fifth Edition – Neena Khanna Pg 339-341

↑ *Back to this question in Part A*

@Neet_pg_bot

Q6: Which of these options does not show symptoms of a maculopapular rash? (Q856833)

A. Zoster (shingles)

B. Rubella

C. Dengue (during the febrile phase)

D. Measles

Correct Answer: A. Zoster (shingles)

Explanation: maculopapular rash can be seen in various conditions, including: Rubella (German measles) Measles (Rubeola) Fifth disease (Erythema infectiosum) Roseola (Sixth disease) Drug reactions: Certain medications can cause a maculopapular rash as an adverse reaction. Incorrect Options: Rubella (Option B) : Rubella infection typically presents with a maculopapular rash that starts on the face and spreads to the rest of the body. Dengue (Option C) : During the febrile phase of dengue fever, patients may develop a maculopapular rash. Measles (Option D) : Measles infection is associated with a maculopapular rash that usually starts on the face and spreads downward to the rest of the body. The rashmay be accompanied by other symptoms such as cough, fever, and conjunctivitis.

References:

Illustrated Synopsis of Dermatology and Sexually Transmitted Diseases, Fifth Edition – Neena Khanna Pg 300

↑ *Back to this question in Part A*

@Neet_pg_bot

Q7: A patient presents with the following lesions on the genitals. Scrapings from the lesion would show? (Q856676)

A. Tzanck cells

B. Cells with clear halo around the nucleus

C. Molluscum bodies

D. HP bodies



Correct Answer: A. Tzanck cells

Explanation: Tzanck cells are multinucleated giant cells seen in herpes simplex virus (HSV) and varicella-zoster virus (VZV) infections . Genital lesions caused by HSV-1 or HSV-2 typically present as painful vesicles that rupture to form ulcers . Tzanck smear from lesion scrapings shows multinucleated giant cells with acantholysis , confirming HSV infection. HSV-1 and HSV-2 cause genital and orolabial herpes , with HSV-2 being more commonly associated with genital lesions . Clinical Features of Genital Herpes: Painful grouped vesicles on an erythematous base Vesicles rupture to form shallow ulcers Pain, burning, dysuria Recurrent episodes (especially in immunocompromised individuals) Diagnosis of HSV: Tzanck smear: Shows multinucleated giant cells (Tzanck cells) but cannot differentiate between HSV-1 and HSV-2. PCR: Most sensitive and specific test for HSV. DFA (Direct Fluorescent Antibody test): Detects viral antigens. Management of HSV: First-line therapy: Oral antivirals (acyclovir, valacyclovir, famciclovir). Supportive care: Pain relief, hydration, avoiding triggers for recurrence. Cells with clear halo around the nucleus (Option B) is incorrect because this refers to koilocytes , which are seen in human papillomavirus (HPV) infections (genital warts). Molluscum bodies (Option C) is incorrect because these are Henderson-Patterson bodies , seen in molluscum contagiosum . They appear as intracytoplasmic eosinophilic inclusions in affected keratinocytes. HP bodies (Option D) is incorrect because HP (Hailey-Penrose) bodies are associated with Hailey-Hailey disease , a rare genetic blistering disorder, and are not found in genital lesions.

References:

Ananthanarayan and Paniker’s Textbook of Microbiology, 10th edition, Page 476, 480, 482

↑ *Back to this question in Part A*

@Neet_pg_bot

Q8: What does the presence of painless sores on the vulval area indicate? (Q857573)

A. Genital herpes

B. Condylomata acuminata

C. Gonococcal vulvovaginitis

D. Condyloma lata



Correct Answer: B. Condylomata acuminata

Explanation: The above image shows rough finger-like, cauliflower-like growth over the vulva is suggestive of condyloma accuminata , caused by human papillomavirus (HPV 6 > HPV 11). Condyloma acuminata (anogenital warts): Benign, moist, soft, pedunculated wart found on the external genitalia and has low malignant potential. Site: They may be found in the genital area such as the penile shaft, scrotum, or labia majora of the vagina, or in the anal area. Appearance: They are generally pink and project out from the surface of the skin. Size may vary; they usually appear small but can merge into large masses. Microscopy: A branching villous structure with connective tissue stroma. Epidermis showing hyperkeratosis and acanthosis (thickening). Cytoplasmic vacuolization of the squamous cells (koilocytosis) is Characteristic. No evidence of dysplasia. {{caption_text}} The table below shows the clinical features of HPV and the types responsible for various lesions: Clinical lesion Oncogenic potential HPV types Plantar warts Benign 1 Common skin warts Benign 2, 4, 27, 57 Epidermodysplasia verrucosa Mostly benign, rarely progresses to malignancy 5, 8, 9, 12, 17 Anogenital warts Laryngeal papilloma Intraepithelial neoplasia Low malignant potential 6, 11 Palmar warts in butchers Low

malignant potential 7 Carcinomas of the cervix & other genital mucosa/larynx/oesophagus High malignant potential 16, 18, 31, 33, 45, 51, 52, 56, 58, 59, 68 Genital herpes (HSV-2) (Option A): Presents with painful vesicles and ulcers, not large warty growths. Associated with burning, itching, and systemic symptoms (fever, malaise). Gonococcal vulvovaginitis (Option C): Presents with purulent vaginal discharge, dysuria, and irritation, not warty lesions. Condyloma lata (Secondary Syphilis) (Option D): Presents as flat, moist, velvety, painless plaques rather than exophytic growths. Associated with generalized lymphadenopathy and systemic symptoms.

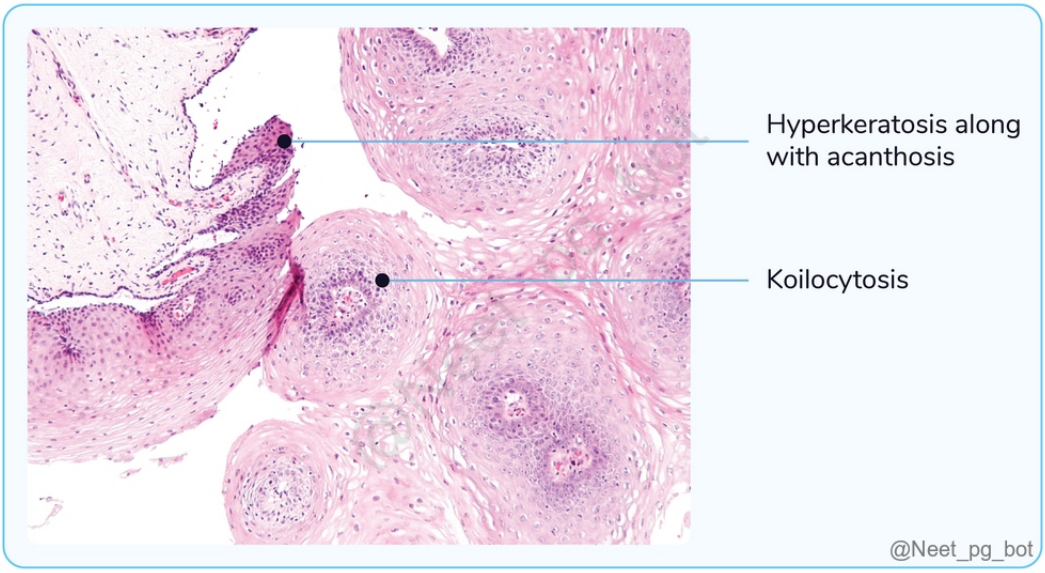

References:

Ananthanarayan and Paniker's microbiology,10 ed page no. 557

Essentials of Medical Microbiology, 3rd edition, 3rd edition, page no. 804

↑ *Back to this question in Part A*

@Neet_pg_bot

Q9: A 45-year-old truck driver with a history of multiple sex partners presented to the dermatological department, as shown below. What is the likely diagnosis? (Q857977)

A. Secondary syphilis

B. Lichen planus

C. Scabies

D. Psoriasis



Correct Answer: A. Secondary syphilis

Explanation: Answer A - Secondary Syphilis The image shows bilateral, non-pruritic, reddish-brown maculopapular lesions on the palms , characteristic of secondary syphilis . The patient's history of multiple sex partners increases the likelihood of Treponema pallidum infection . Associated systemic signs include lymphadenopathy, fever, and mucous membrane involvement . Secondary Syphilis Feature Secondary Syphilis Etiology Treponema pallidum (spirochete) Transmission Sexual contact, vertical transmission Clinical Features Maculopapular rash on palms/soles, condylomata lata, lymphadenopathy Systemic Symptoms Fever, malaise, sore throat Diagnosis Serology (VDRL, RPR, FTA-ABS, TPPA) Treatment Benzathine penicillin G (single dose IM) {{caption_text}} {{caption_text}} Lichen Planus (Option B): Incorrect because lichen planus has violaceous, polygonal papules with Wickham striae , not palmoplantar rash. Scabies (Option C): Incorrect because scabies presents with burrows in interdigital spaces with severe nocturnal pruritus . Psoriasis (Option D): Incorrect because palmoplantar psoriasis has silvery scales and well-defined plaques rather than a diffuse maculopapular rash.





References:

Apurba S Sastry’s Essentials of Medical Microbiology, 3rd Edition, Pg 756-763

Features of Rash

↑ *Back to this question in Part A*

Q10: A male presents with lesions and a history of unprotected sexual intercourse a few months ago. What is the most appropriate investigation to confirm the diagnosis? (Q865444)

A. Serology

B. Tzanck smear

C. KOH

D. Biopsy



Correct Answer: A. Serology

Explanation: The lesions depicted in the image, along with a history of unprotected sexual intercourse, suggest a diagnosis of Secondary Syphilis , which is best confirmed through serological testing. It is the second stage of syphilis, which occurs if primary syphilis is left untreated. It presents a few weeks to several months after the initial chancre has healed. It is marked by systemic manifestations and can affect multiple organ systems. Clinical Features: Diffuse, non-pruritic rash, often reddish-brown macules or papules, that is polymorphous and non-vesicular . Mucous membrane lesions, such as condylomata lata , appear in moist areas like the oral cavity and genitals and are highly infectious. Oral signs may include mucous patches or snail track ulcers. “Moth-eaten" alopecia: A patchy, non-scarring hair loss. Buschke-Ollendorff sign: Deep tenderness over lesions. Painless generalized lymphadenopathy (especially epitrochlear nodes)l. Systemic symptoms include fever, malaise, and fatigue, with rare cases showing neurological or ocular involvement. Diagnosis : By serological testing: (Option

A) Non-Treponemal Tests : RPR (Rapid Plasma Reagin) and VDRL (Venereal Disease Research Laboratory) are used for screening. These tests detect nonspecific antibodies and can be positive in other conditions. Treponemal Tests : FTA-ABS (Fluorescent Treponemal Antibody Absorption) confirms the diagnosis by detecting antibodies specific to Treponema pallidum. Treatment: Standard treatment: Benzathine penicillin G . Dosage: 2.4 million units intramuscularly in a single dose. For those allergic to penicillin, alternatives such as doxycycline or tetracycline can be used. Complications : If left untreated, secondary syphilis can progress to the latent stage and eventually tertiary syphilis, which can lead to serious complications, including cardiovascular, neurological, and systemic damage. Incorrect Options: Tzanck smear (Option B) is a diagnostic test primarily used for identifying infections caused by Herpes Simplex Virus (HSV) and Varicella-Zoster Virus. It involves examining cells scraped from a lesion under a microscope. However, this test has no role in diagnosing syphilis, as it does not detect Treponema pallidum, the bacterium responsible for the disease. KOH preparation (Option C) is commonly employed to diagnose superficial fungal infections such as dermatophytosis or candidiasis. A sample from the skin, hair, or nails is treated with potassium hydroxide, which dissolves keratin and allows for the visualization of fungal elements under a microscope. Since syphilis is a bacterial infection, this test is irrelevant in its diagnosis. Biopsy (Option D) is used to evaluate suspicious skin lesions when the diagnosis is unclear, and it can sometimes reveal histopathological features suggestive of syphilis. It is invasive and nonspecific, whereas serological tests are more sensitive, specific, and the preferred method for diagnosing secondary syphilis.

References:

Essentials of Medical Microbiology by Apurba S. Sastry, 3rd Edition, Page 78-79

↑ *Back to this question in Part A*

@Neet_pg_bot

Q11: Bubo is seen in which of the following conditions? (Q860116)

A. LGV

B. Herpes

C. Syphilis

D. Donovanosis

Correct Answer: A. LGV

Explanation: A bubo is an enlarged, tender, and suppurative lymph node commonly associated with Lymphogranuloma Venereum (LGV), a sexually transmitted infection caused by Chlamydia trachomatis Lymphogranuloma venerum (LGV): It is a sexually transmitted disease caused by serovars L1-L3 of Chlamydia trachomatis (M/C strain causing LGV: L2). It occurs in sexually active adults of all ages. It can cause LGV-associated proctitis in homosexuals, associated with HIV and hepatitis C co-infection. The incubation period of LGV is around 3-30 days , and the disease presents in three stages, described in the table below: Primary Secondary Tertiary 3-30 days Days-weeks Years after a chronic, untreated infection Small papule/pustule/ Non-indurated ulcer at the site of inoculation which heals spontaneously with no scarring. Lymphatic involvement

of nodes that drain the primary lesion. Classic form: Tender unilateral or bilateral inguinal and/or femoral adenopathy (Groove sign of Greenblatt). The lymph nodes may coalesce to form a bubo or abscesses that may rupture spontaneously with the development of Fistulae or sinus tracts. There may be systemic features such as malaise and fever. Lymphatic obstruction due to chronic inflammation leads to fistula formation, strictures, and disfiguring conditions such as genital elephantiasis and esthiomene , which refers to hypertrophic enlargement with ulceration of the external genitalia. Diagnosis of LGV can be confirmed by the Nucelic Acid Amplification Test (NAAT). Antibody detection by real-time PCR can also be done. Treatment includes: First line: Doxycycline 100mg BD x 21 days. Second line: Erythromycin 500mg 4 times a day x 21 days. Third line: Azithromycin 1g weekly once x 21 days. Ulcer Lymph Node Syphilis - treponema Pallidum (Option C) Painless genital ulcer called a chancre Non-tender and rubbery in consistency. Donovanosis- Klebsiella granulomatis (Option D) Painless, beefy red ulcers known as granulomas Pseudo-bubo (enlarged and tender but occurs due to inflammation and not infection) {{caption_text}} Herpes Simplex (Option B) Grouped vesicles or shallow erosions Multiple, enlarged and inflamed. {{caption_text}} Lymphogranuloma Venerum (Chlamydia) Solitary and painless. Swollen, inflamed, and fluctuant lymph nodes containing purulent material. Palpable groove or furrow that may be felt in the inguinal region due to the enlargement and fusion of the inguinal lymph nodes. (Groove of Greenlat) {{caption_text}}





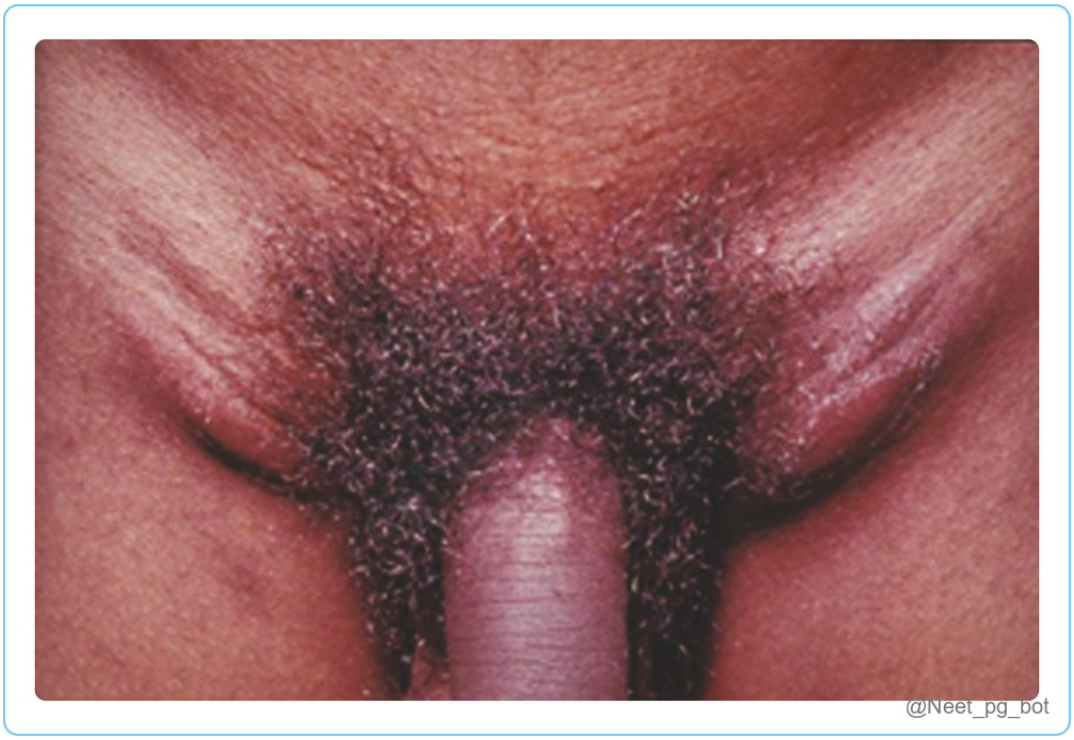

References:

Rook's Textbook of Dermatology, 9th edition, Page no. 30.15-30.20

↑ *Back to this question in Part A*

@Neet_pg_bot

Q12: A 40-year-old male presents to the OPD with painful genital ulcers along with painful bubos. And he had a history of multiple sexual partners. Which of the following is the diagnosis? (Q860106)

A. Chancroid

B. Donovanosis

C. Herpes genitalis

D. Chancre

Correct Answer: A. Chancroid

Explanation: The patient's presentation of multiple painful genital ulcers with painful inguinal lymphadenopathy is highly suggestive of chancroid, which is caused by Haemophilus ducreyi. Chancroid: Caused by Haemophilus ducreyi manifests as multiple ulcers in the genital area, characterized by their non-indurated nature, undermined edges, greyish slough, and tendency to bleed on touch. Individuals with chancroid may develop unilateral, painful lymphadenopathy. The suppurative lymphadenopathy observed in chancroid is termed bubo . Diagnosis: Gram staining reveals Gram-negative bacilli arranged in chains, often referred to as "railway tracks" or "school of fish" appearance. Culturing specimens on Mueller Hinton Agar supplemented with chocolate horse blood aids in the identification of Haemophilus ducreyi. Treatment: Azithromycin is administered orally in a single dose of 1 gram OR intramuscular injection of Ceftriaxone at a dosage of 250 mg (single dose) Ulcer Lymph Node Syphilis - treponema Pallidum (Option D) Painless genital ulcer called a chancre Non-tender and rubbery in consistency. Donovanosis- Klebsiella granulomatis (Option B) Painless, beefy red ulcers known as granulomas Pseudo-bubo (enlarged and tender but occurs due to inflammation and not infection) {{caption_text}} Herpes Simplex (Option C) Grouped vesicles or shallow erosions Multiple, enlarged and inflamed. {{caption_text}} Lymphogranuloma Venerum (Chlamydia) Solitary and painless. Swollen, inflamed, and fluctuant lymph nodes containing purulent material. Palpable groove or furrow that may be felt in the inguinal region due to the enlargement and fusion of the inguinal lymph nodes. (Groove of Greenlat) {{caption_text}}


@_feet_pg_bot





References:

Rooks textbook of Dermatology, 9th Edition, Chapter 113

↑ *Back to this question in Part A*

@Neet_pg_bot

Q13: A truck driver reports multiple painful genital ulcers on his scrotum following unprotected sexual intercourse, accompanied by painful lymph nodes. What is the most likely cause? (Q860097)

A. Chancre

B. Chancroid

C. Donovanosis

D. Herpes

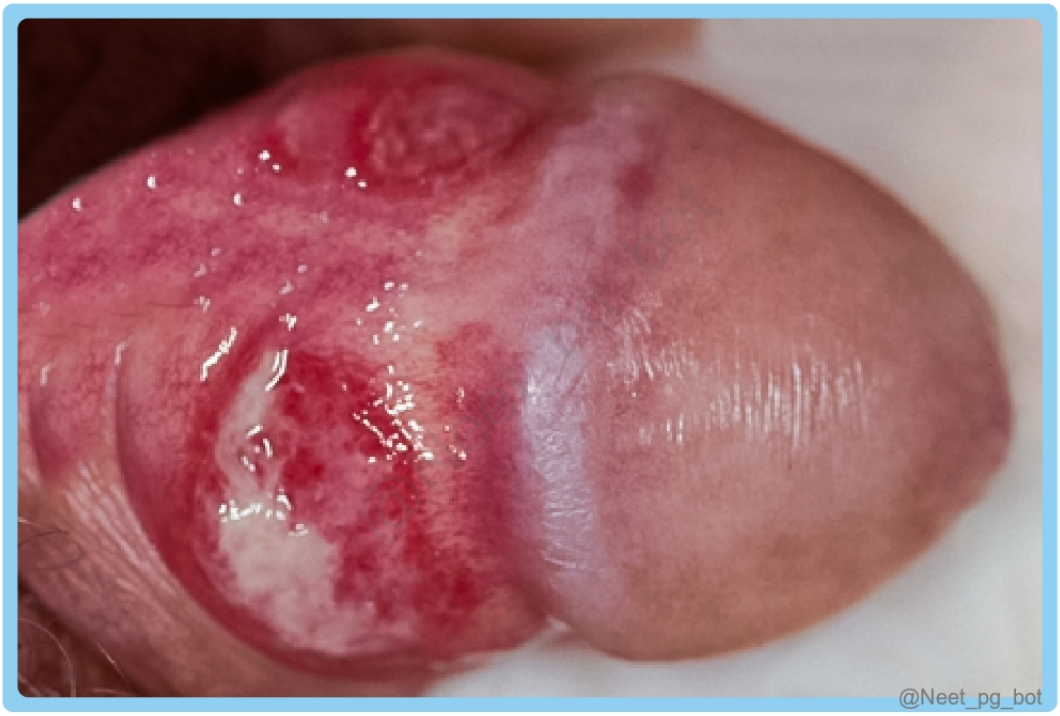

Correct Answer: B. Chancroid

Explanation: The patient's presentation of multiple painful genital ulcers with painful inguinal lymphadenopathy is highly suggestive of chancroid, which is caused by Haemophilus ducreyi. Chancroid: Caused by Haemophilus ducreyi manifests as multiple ulcers in the genital area, characterized by their non-indurated nature, undermined edges, greyish slough, and tendency to bleed on touch. Individuals with chancroid may develop unilateral, painful lymphadenopathy. The suppurative lymphadenopathy observed in chancroid is termed bubo . Diagnosis Gram staining reveals Gram-negative bacilli arranged in chains, often referred to as "railway tracks" or "school of fish" appearance. Culturing specimens on Mueller Hinton Agar supplemented with chocolate horse blood aids in the identification of Haemophilus ducreyi. Treatment. Azithromycin is administered orally in a single dose of 1 gram OR intramuscular injection of Ceftriaxone at a dosage of 250 mg (single dose) Ulcer Lymph Node Syphilis - treponema Pallidum (Option A) Painless genital ulcer called a chancre Non-tender and rubbery in consistency. Donovanosis- Klebsiella granulomatis (Option C) Painless, beefy red ulcers known as granulomas Pseudo-bubo (enlarged and tender but occurs due to inflammation and not infection) {{caption_text}} Herpes Simplex (Option D) Grouped vesicles or shallow erosions Multiple, enlarged and inflamed. {{caption_text}} Lymphogranuloma Venerum (Chlamydia) Solitary and painless. Swollen, inflamed, and fluctuant lymph nodes containing purulent material. Palpable groove or furrow that may be felt in the inguinal region due to the enlargement and fusion of the inguinal lymph nodes. (Groove of Greenlat) {{caption_text}}


@Neet_pg_bot


@Neet_pg_bot

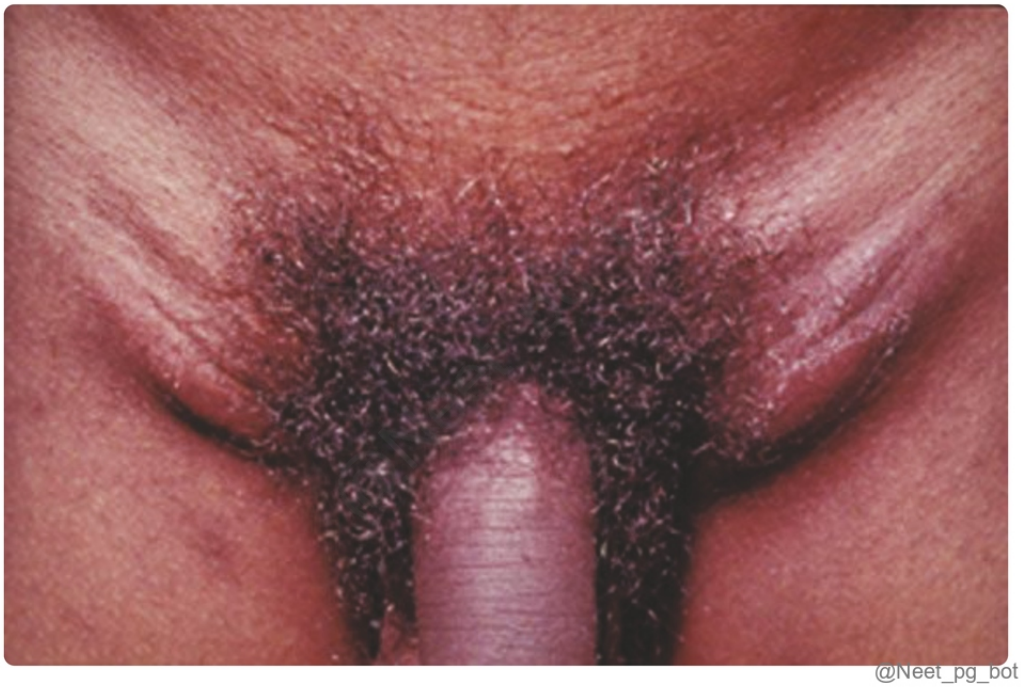

References:

Rooks textbook of Dermatology, 9th Edition, Chapter 113

↑ *Back to this question in Part A*

@Neet_pg_bot

Q14: A 30-year-old patient presents with a history of flat lesions near the anal canal, rashes on the body, and hair loss that follows a particular pattern, as shown in the image. What is the diagnosis? (Q843949)

A. Trichotillomania

B. Alopecia areata

C. Secondary syphilis

D. Malassezia



Correct Answer: C. Secondary syphilis

Explanation: Correct Option C - Secondary syphilis: The flat lesions near the anal canal are likely condyloma lata, which are broad, flat; moist papules and the moth-eaten alopecia given in the image, along with rashes, are suggestive of secondary syphilis. Incorrect Options: Options A, B, and D are incorrect, as explained above.

↑ *Back to this question in Part A*

@Neet_pg_bot

Q15: A 30-year-old female presents with a painful, soft, red ulcer on the vulva that has a granular base. She also has tender, bilateral inguinal lymphadenopathy. Which of the following is the most likely diagnosis? (Q852730)

A. Chancroid

B. Neisseria Gonorrhoeae Infection

C. Granuloma Inguinale

D. Lymphogranuloma Venereum

Correct Answer: A. Chancroid

Explanation: The most likely diagnosis for a 30-year-old female with a painful, soft, red vulvar ulcer with a granular base and tender bilateral inguinal lymphadenopathy is Chancroid . Feature Chancroid Causative organism Haemophilus ducreyi Incubation period 3–10 days Ulcer Painful , non-indurated, soft ulcer with irregular borders and granular base Number of ulcers Often multiple Lymphadenopathy Painful , unilateral or bilateral, may form buboes (fluctuant lymph nodes) Base of ulcer Necrotic, purulent, bleeds on contact Tenderness Marked Neisseria Gonorrhoeae Infection (Option B) causes urethritis, cervicitis, or pelvic inflammatory disease (PID) , but not painful genital ulcers . Granuloma Inguinale (Donovanosis) (Option C) caused by Klebsiella granulomatis . Presents with painless, beefy-red ulcers that slowly enlarge and lack lymphadenopathy . Donovan bodies seen on microscopy. Lymphogranuloma Venereum (LGV) (Option D) caused by Chlamydia trachomatis (L1-L3 serotypes) . Typically presents with small, painless ulcers followed by painful inguinal lymphadenopathy (buboes) , which can lead to groove sign (inguinal ligament indentation).

References:

Neena Khanna, Textbook of Dermatology, 7th Edition, Page no: 789

↑ *Back to this question in Part A*

@Neet_pg_bot

Q16: Which organism is not associated with urethritis in men? (Q853201)

A. Neisseria gonorrhoea

B. Trichomonas vaginalis

C. Mycoplasma genitalium

D. Gardnerella vaginalis

Correct Answer: D. Gardnerella vaginalis

Explanation: Gardnerella vaginalis is primarily associated with bacterial vaginosis (BV) in women and does not commonly cause urethritis in men. Neisseria gonorrhoeae (Option A): A gram-negative diplococcus that causes gonococcal urethritis, characterized by purulent discharge and dysuria. Trichomonas vaginalis (Option B): A flagellated protozoan causing non-gonococcal urethritis, often presenting with mild discharge and dysuria. It is detected by wet mount microscopy or NAAT. Mycoplasma genitalium (Option C): A small, cell wall-lacking bacterium responsible for persistent or recurrent non-gonococcal urethritis. It is difficult to culture and is diagnosed using NAAT.

References:

https://www.ncbi.nlm.nih.gov/books/NBK537282/#

↑ *Back to this question in Part A*

@Neet_pg_bot

Q17: A biopsy of a patient presenting with painful vesicular lesions and superficial erosions in the genital area is shown. What treatment would you initiate? (Q865447)

A. Acyclovir

B. Steroids

C. Penicillin

D. Azithromycin

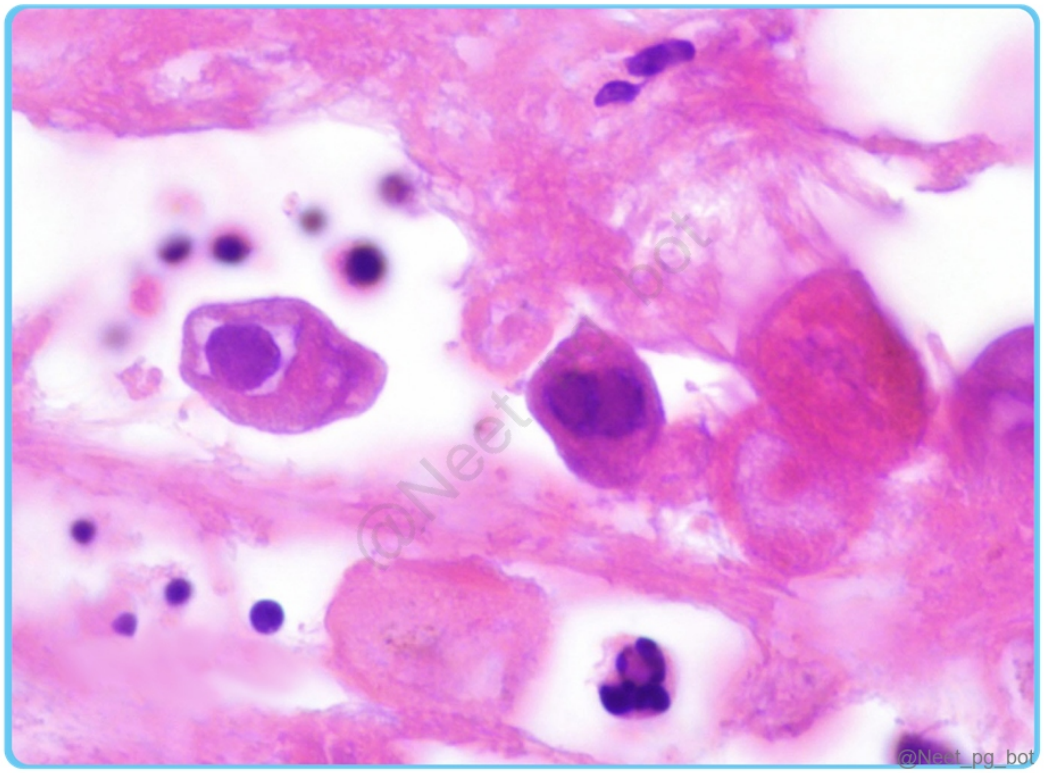

Correct Answer: A. Acyclovir

Explanation: The biopsy image, along with the presence of painful vesicular lesions and superficial erosions in the genital area, is indicative of Genital Herpes , most commonly caused by the Herpes Simplex Virus (HSV). The appropriate treatment for this condition is acyclovir. Treatment : First line Acyclovir (topical/oral) (Option A) Hydrocolloid dressing Topical penciclovir Second line Long-term prophylactic acyclovir Third line IV acyclovir Penciclovir Foscarnet IV cidofovir Topical imiquimod Incorrect Options: Steroids (Option B) are not suitable for treating genital herpes because they suppress the immune response. While steroids can be useful in managing inflammatory or autoimmune conditions, using them during an active viral infection like herpes simplex virus (HSV) can worsen the condition. Penicillin (Option C) is an antibiotic used primarily to treat bacterial infections, such as syphilis. Syphilis typically presents with a painless ulcer (chancre), in contrast to the painful vesicular lesions and superficial erosions seen in genital herpes. Azithromycin (Option D) is another antibiotic, commonly

used to treat bacterial sexually transmitted infections (STIs) such as chlamydia and, in some cases, gonorrhea. However, like penicillin, azithromycin has no antiviral activity and is ineffective against HSV.

References:

Rook's Textbook of Dermatology, 9th Edition, Page 17-25.

↑ *Back to this question in Part A*

@Neet_pg_bot

• [09_Connective Tissue Disorders] 019 Connective Tissue Disorders

« Back to Folder Directory

[09_Connective Tissue Disorders] 019 Connective Tissue Disorders — Quick Jump

Q1 (p. 1047) *Q2 (p. 1051)* *Q3 (p. 1054)* *Q4 (p. 1055)* *Q5 (p. 1056)* *Q6 (p. 1062)*
Q7 (p. 1064) *Q8 (p. 1067)* *Q9 (p. 1069)*

Q1: A 32-year-old woman comes to the dermatology OPD with lesions on her cheeks that aggravate when exposed to sunlight, as shown in the image below. She has also had fatigue, myalgias, and arthralgias over the past four months. What would be the expected finding on direct immunofluorescence of a skin biopsy of a lesion from this patient? (Q841807)

A. Granular continuous deposit of IgG and C3 in the dermo-epidermal junction

B. Linear IgG and C3 deposits along the basement membrane zone

C. Granular IgA in dermal papillae

D. Intercellular IgG and C3 deposits in the epidermis



Correct Answer: A. Granular continuous deposit of IgG and C3 in the dermo-epidermal junction

■ *Listen (English)*

■ *Listen (Hindi)*

Explanation: Based on the clinical presentation described, with a typical “malar rash/butterfly rash ” aggravated by sunlight exposure along with systemic symptoms such as fatigue, myalgias, and arthralgias, the patient likely has systemic lupus erythematosus (SLE). Malar rash with sparing of nasolabial folds. The lupus band test (LBT) is a diagnostic tool where immunofluorescence reveals homogenous deposits along the dermo-epidermal junction. These deposits contain Predominantly IgG, but also occasionally IgM and IgA, Complement components (C1q, C3) Present both in lesions and normal skin. Present in 80% of patients with SLE and DLE. Option Direct Immunofluorescence Test - Image Linear IgG and C3 deposits along the BMZ (Option B) : Also known as shoreline fluorescence pattern Seen in epidermolysis bullosa Granular IgA in dermal papillae (Option C) : Papillary tip immunofluorescence is seen in dermatitis herpetiformis Intercellular IgG and C3 deposits in the epidermis (Option D): Characteristic fish-net pattern of immunofluorescence is seen in pemphigous vulgaris



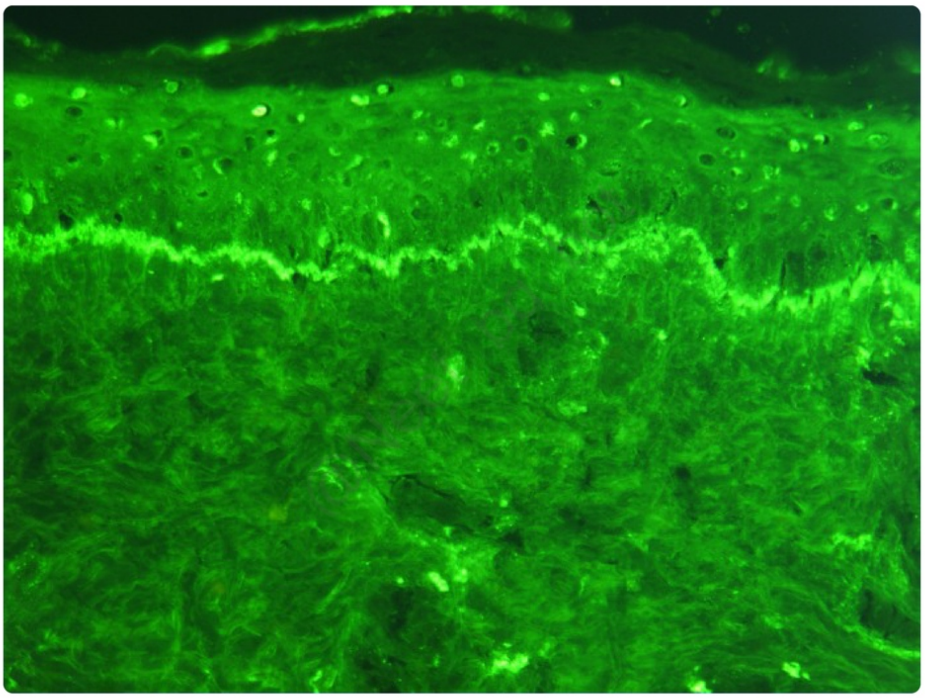

@Neet_pg_bot

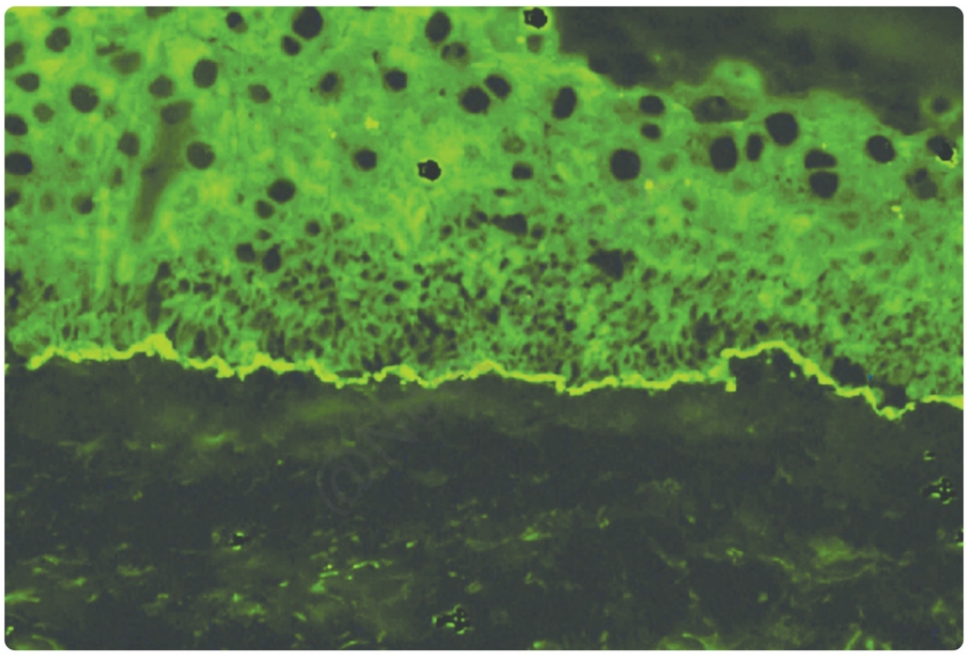

@Neet_pg_bot

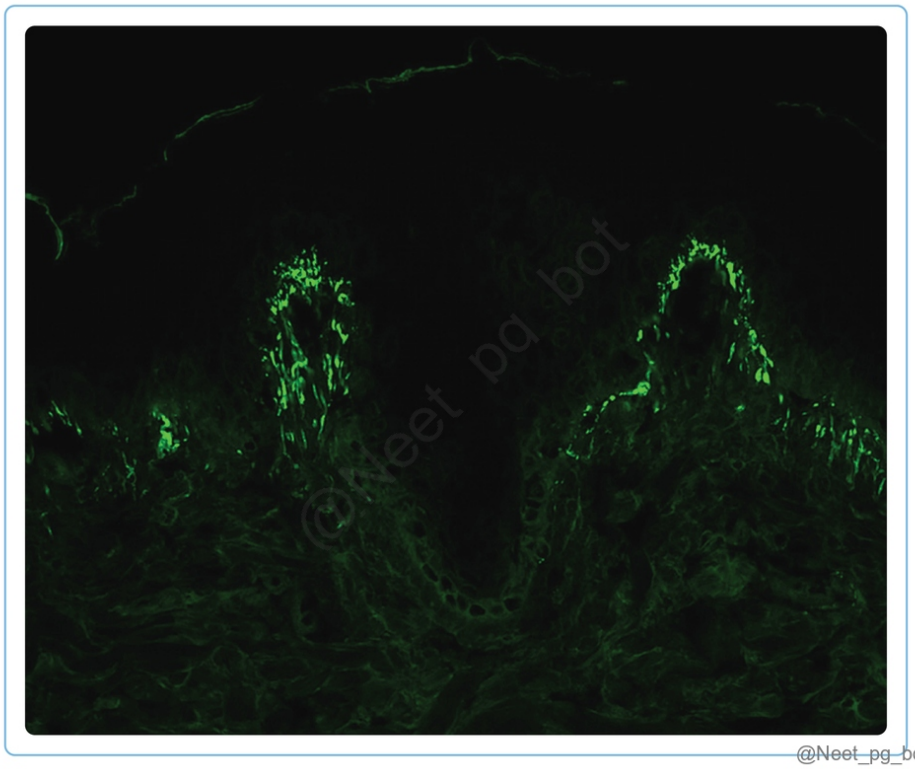

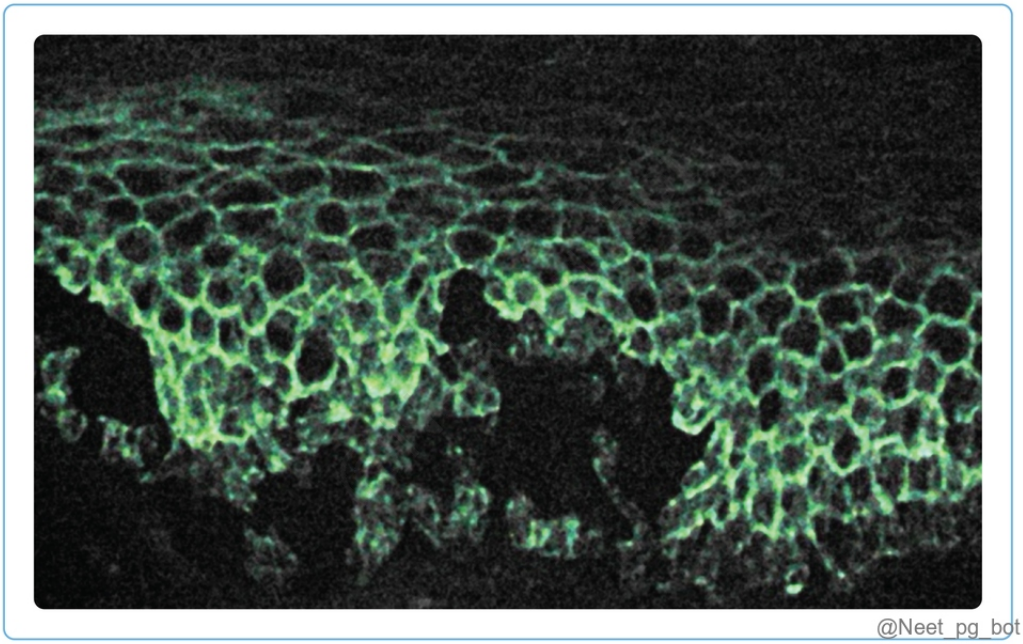

References:

Rook's Textbook of Dermatology, 9th Edition, Page 51.16-51.17 and 50.21-51.22.

↑ *Back to this question in Part A*

@Neet_pg_bot

Q2: A 42-year-old woman presented with complaints of a circular, scaly rash on her scalp, as shown in the image. On examination, you notice multiple small spikes over the underside of the rash. This presentation is most characteristic of which of the following conditions? (Q841808)

A. Psoriasis

B. Seborrheic dermatitis

C. Rosacea

D. Discoid lupus erythematosus



Correct Answer: D. Discoid lupus erythematosus

■ *Listen (English)*

■ *Listen (Hindi)*

Explanation: ‘ Carpet tack sign,’ as shown in the image, is seen in discoid lupus erythematosus (DLE). Scales on the undersurface of the lesion appear like tin tacks penetrated on carpets. Discoid lupus erythematosus is the most common type of chronic cutaneous lupus erythematosus. Clinical features: Localized Skin Involvement: Predominantly affects the face and scalp, presenting as circumscribed/ discoid erythematous patches on cheeks, nose bridge, ears, neck, and scalp Lesions exhibit adherent scale with underlying horny plugs (“tin-tack” sign) due

to follicular plugging. Characterized by three zones: Central Atrophy area Middle activity - perifollicular plugging, scaling, telangiectasias Zone of hyperpigmentation Schuster sign : Lesions over the ear conchae Cicatricial alopecia Scarring and pigmentary changes: Scarring (atrophic, hypertrophic, cribriform) is common. Hyper/Hypo pigmentation is also seen, especially in dark-skinned individuals. Psoriasis (Option A) typically presents with silvery scales and found on the extensor surface such as elbow and knees Seborrheic dermatitis (Option B) presents with greasy scales and erythema affecting scalp, eyebrows and nasolabial folds. Rosacea (Option C) is characterized by facial erythema, telangiectasia, but not with scaly plaques





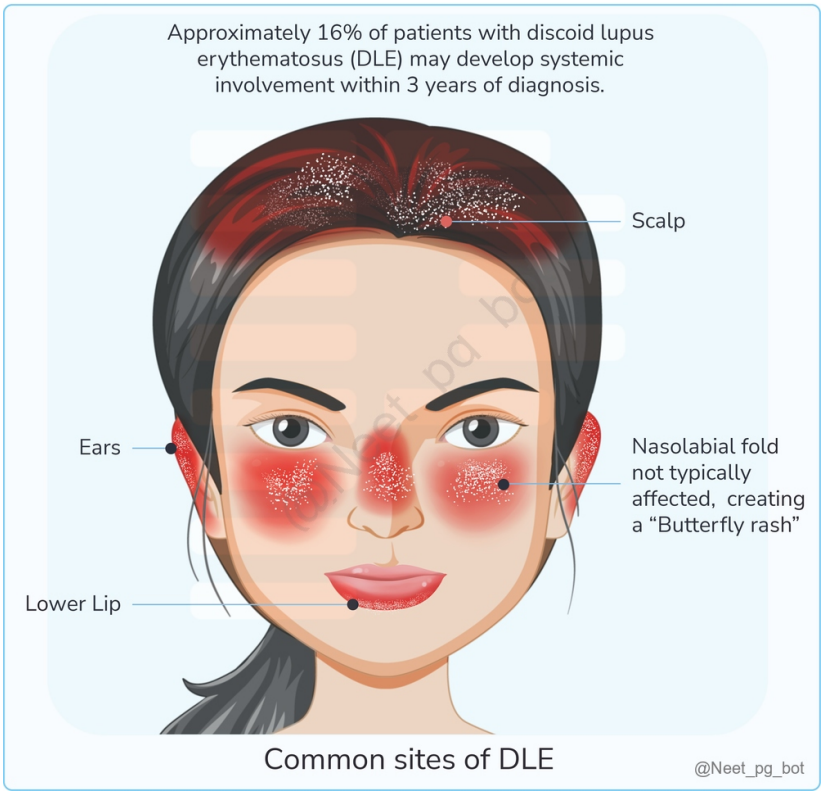



References:

Rook’s Textbook of Dermatology, 9th Edition, Page 51.2-51.9

https://www.aocd.org/page/DiscoidLupusErythe

↑ *Back to this question in Part A*

@Neet_pg_bot

Q3: A 3-week-old neonate is brought to the dermatology OPD with facial rashes exacerbated by sunlight exposure. Examination reveals erythematous, scaly papules around the eyes as shown in the image below. Maternal history includes positive anti-Ro/SSA antibodies. Which congenital cardiac anomaly is commonly associated with this condition? (Q841809)

A. Heart block

B. Patent ductus arteriosus

C. Coarctation of aorta

D. Aortic stenosis



Correct Answer: A. Heart block

■ *Listen (English)*

■ *Listen (Hindi)*

Explanation: A neonate presenting with facial rashes exacerbated by sunlight exposure, along with a maternal history of positive anti-Ro/SSA antibodies, is highly suggestive of neonatal lupus erythematosus (NLE). NLE occurs when maternal autoantibodies, particularly anti-Ro/SSA antibodies, cross the placenta and affect the fetus. Clinical features of Neonatal Lupus Erythematosus are: Cutaneous: Rash resembling subacute cutaneous lupus erythematosus (SCLE) or discoid lupus erythematosus (DLE). Owl's eye sign or Racoon sign- Erythematous, slightly scaly eruption on the face and periorbital skin Cardiac: Various degrees of heart block, including first-degree, second-degree, or complete heart block. A complete heart block may require pacemaker placement. Hepatic involvement: Hepatitis cholestasis, Hematological abnormalities: Thrombocytopenia Anemia Neurological manifestations: seizures Developmental delay. Respiratory manifestations: Respiratory distress syndrome (RDS) Transient tachypnea of the newborn (TTN), Anti-Ro and anti-La antibodies, also known as anti-SSA and anti-SSB antibodies are commonly implicated in neonatal systemic lupus erythematosus (SLE) and also Sjögren's syndrome. Patent ductus arteriosus (PDA) (Option B) is commonly seen in premature infants and is associated with conditions such as respiratory distress syndrome (RDS), necrotizing enterocolitis (NEC), and bronchopulmonary dysplasia (BPD). Coarctation of the aorta (Option C) can occur in the context of Turner syndrome. Aortic stenosis (Option D) occurs in Williams Syndrome (Chromosome 7 defect)

References:

Rook's Textbook of Dermatology, 9th Edition, Page 51.37-51.39.

↑ *Back to this question in Part A*

@Neet_pg_bot

Q4: A 32-year-old woman was recently diagnosed with cutaneous lupus erythematosus. During her review, she has come to you with a pamphlet and would like to discuss all her treatment options. Which of the following drugs are not used for the treatment of cutaneous LE? (Q841844)

A. Leflunomide

B. Corticosteroids

C. Photoprotection

D. Chloroquine

Correct Answer: A. Leflunomide

■ *Listen (English)*

■ *Listen (Hindi)*

Explanation: Leflunomide is an immunomodulatory drug that can cause drug-induced lupus erythematosus, and hence, it is contraindicated in the treatment of cutaneous LE. It acts via the inhibition of dihydroorotate dehydrogenase. It is used to treat rheumatoid and psoriatic arthritis. Some of the most commonly implicated drugs

in drug-induced LE (DILE) include: Procainamide Hydralazine Isoniazid Minocycline Quinidine Anti-TNF agents (e.g., infliximab, adalimumab) Methyldopa Propylthiouracil TNF-α inhibitors Usually, withdrawal of causative drug resolves the disease Positive anti-histone antibodies are particularly specific for DILE Corticosteroids (Option B): These are the preferred first-line drugs for cutaneous lupus erythematosus due to their potent anti-inflammatory effect. They can be applied topically or administered intralesionally. Cutaneous atrophy is a common side effect of this drug, and the patient should be carefully instructed to limit the application over the skin only. Photoprotection (Option C): UV radiation is directly responsible for inducing lesions and hence, should be avoided. Sunscreens and protective clothing should be worn daily. Photoprotection also includes avoiding drugs that cause photosensitivity (e.g., Tetracyclines, Metformin, Hydrochlorothiazides, sulfonamides, etc.) Chloroquine (Option D): Antimalarial agents like chloroquine and hydroxychloroquine agents for cutaneous lupus. These drugs have an immune-modulating and photoprotective effect. Ocular toxicity, specifically retinopathy, is a common side effect

References:

Rook's Textbook of Dermatology, 9th Edition, Page 51.10-51.36.

https://www.uptodate.cn/contents/initial-management-of-discoid-lupus-erythematosus-and-subacute-cutaneous-lupus-erythematosus

https://pubmed.ncbi.nlm.nih.gov/35186126/

https://www.uptodate.cn/contents/overview-of-cutaneous-lupus-erythematosus

↑ *Back to this question in Part A*

@Neet_pg_bot

Q5: A 50-year-old man was recently diagnosed with adenocarcinoma of the lung and started chemotherapy. During a follow-up visit, he complained of rashes over his face and hands, as shown in the image. He also reports fatigue and weakness in his legs while climbing stairs. What is the most likely diagnosis? (Q841845)

A. Polymyositis

B. Dermatomyositis

C. Lambert-Eaton syndrome

D. Drug reaction



@Neet_pg_bot



@Neet_pg_bot

Correct Answer: B. Dermatomyositis

- *Listen (English)*
- *Listen (Hindi)*

Explanation: The presence of limb weakness and cutaneous manifestations in association with a malignancy indicate a diagnosis of dermatomyositis . Inflammatory myopathies like dermatomyositis have an association with

malignancies such as ovarian, lung, gastrointestinal, and breast cancer. Dermatomyositis is a chronic, inflammatory myositis seen in adults around 50-60 years of age. Clinical features It presents as symmetrical muscle weakness (proximal > distal) Gottron's papules (erythematous scaly papules over knuckles) are pathognomonic of the disease. Gottron's sign : Symmetric, confluent, violaceous macular erythema (CMVE) on the back of fingers (interphalangeal and metacarpophalangeal joints) , on the extensor surfaces of joints of the elbows, knees, or ankles. CMVE is seen over other sites too, and is named accordingly. Heliotrope rash: CMVE over the periorbital skin V-Sign: CMVE over the anterior aspect of the neck Shawl sign: Involvement of upper back Holster sign: Rash over the lateral aspect of the thigh Mechanic's hand: Hyperkeratosis and fissuring on the edges of the fingers. ■■■■ Holtser Sign Mechanics Hands Shawl Sign Polymyositis (Option A): Differences between dermatomyositis and polymyositis are as follows: Dermatomyositis Polymyositis Skin Involvement Present Typically lacks characteristic skin manifestations Associated Conditions More frequently associated with malignancies Less frequently associated with malignancies Muscle Biopsy Findings May show perifascicular atrophy pattern Typically shows endomysial inflammation pattern Lambert-Eaton syndrome (Option C) is a neuromuscular disorder that presents with proximal muscle weakness but no cutaneous manifestations , it is also associated with adenocarcinoma of the lung . Unlike dermatomyositis, deep tendon reflexes are lost in this syndrome. Drug reaction (Option D): Acute presentation of generalized urticaria/ drug reaction does not present with characteristic features of Grotton's papules and the V- Sign.

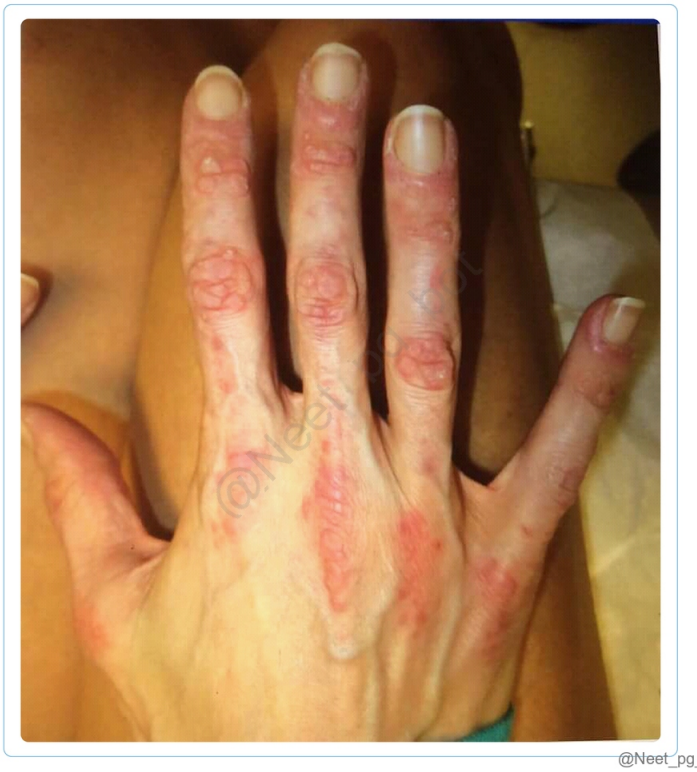



@Neet_pg_bot



HELIOTROPE RASH

@Neet_pg_bot



V SIGN

@Neet_pg_bot







References:

Rook’s Textbook of Dermatology, 9th Edition, Page 53.2-53.10

↑ *Back to this question in Part A*

@Neet_pg_bot

Q6: A 60-year-old women comes to your OPD with her mother due to depressed linear lesion associated with hair loss on scalp for the past 3 years. She also has an area of progressive hypopigmentation and hair loss in her scalp as shown in the image below. Which of the following is the most likely diagnosis? (Q841846)

A. Atrophic scar

B. Gottron's Papule

C. En coup de sabre

D. Rowell Syndrome



Correct Answer: C. En coup de sabre

■ *Listen (English)*

■ *Listen (Hindi)*

Explanation: "En coup de sabre" is a French term meaning " struck by the sword ." It refers to a specific subtype of localized scleroderma called morphea , characterized by excessive collagen deposition leading to thickening and hardening of the skin and underlying tissues. This linear lesion typically extends vertically from the hairline downward , resembling a stroke from a sabre or sword. It may vary in width and depth and often results in a visible depression or indentation in the skin. This may resemble the appearance of the fictional character "Kakashi Hatake" from the anime series Naruto, who has a similar linear scar on his forehead. Scleroderma is a chronic autoimmune disease characterized by excessive collagen production, leading to the thickening and hardening of the skin and other connective tissues The types of scleroderma are described below, Localized Scleroderma: This type of scleroderma primarily affects the skin and underlying tissues in specific areas of the body. Morphea Linear Scleroderma En coup de sabre alopecia. Systemic Sclerosis (Systemic Scleroderma): Systemic sclerosis is a more severe form of scleroderma that not only affects the skin but also involves internal organs such as the lungs, heart, kidneys, and gastrointestinal tract. Limited Cutaneous Systemic Sclerosis (lcSSc) Diffuse Cutaneous Systemic Sclerosis (dcSSc) Atrophic scar (Option A) usually occurs following injury or surgery, which is not present in this patient. Gottron’s papules (Option B) are raised, violaceous to erythematous lesions typically found over the extensor surfaces of the joints, such as the knuckles, elbows, and knees in dermatomyositis. Rowell syndrome (Option D) , also known as lupus erythematosus overlap syndrome, is a rare condition characterized by features of both systemic lupus erythematosus (SLE) and erythema multiforme



(This relation has been made solely to help the reader understand and remember the eponym)

@Neet_pg_bot

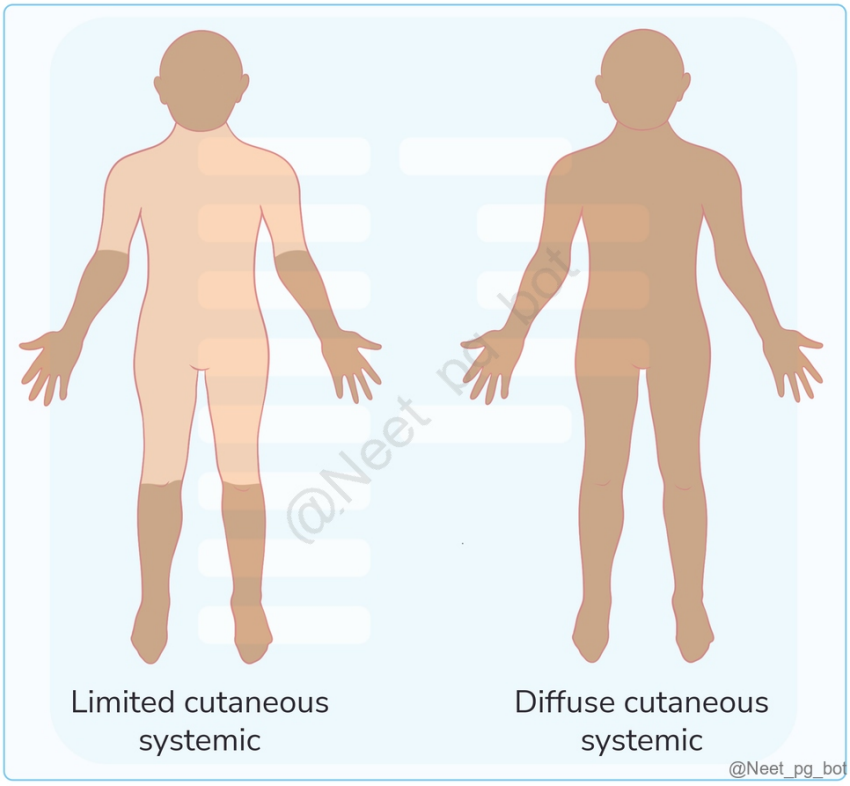

References:

1. Zulian F. 2023. Juvenile localized scleroderma. UpToDate 2. Rook's Textbook of Dermatology. 9th Edition, Page 57.11-57.20

↑ *Back to this question in Part A*

@Neet_pg_bot

Q7: A 54-year-old man with interstitial lung disease presents to you with complaints of a lesion over his chest. On examination, you notice the skin proximal to MCP joints appears thickened. There are also small ulcers over his fingertips. Which of the following would be the most specific investigation? (Q841847)

A. Anti-topoisomerase I antibodies (Anti-scl 70)

B. Anti-Ro (SS-A) antibodies

C. Antisynthetase antibodies

D. Antinuclear antibodies



Correct Answer: A. Anti-topoisomerase I antibodies (Anti-scl 70)

- *Listen (English)*
- *Listen (Hindi)*

Explanation: Anti-topoisomerase I antibody , also known as anti-Scl-70 antibody, is positive in systemic sclerosis. It is part of the diagnostic criteria for systemic sclerosis. The image depicts the ‘ salt and pepper appearance ’ of skin seen in scleroderma This in combination with a history of ILD, thickened skin proximal to MCP joints or sclerodactyly (see image), and digital tip ulcers indicates a diagnosis of scleroderma . ‘ salt and pepper appearance ’ of skin thickened skin proximal to MCP joints or sclerodactyly Mask-like face in scleroderma. Other antibodies include: Anticentromere and Anti-RNA polymerase III antibodies Anti-Ro (SS-A) antibodies (Option B): Most commonly positive in discoid lupus erythematosus, especially neonatal lupus. Antisynthetase antibodies (Option C): Seen in Dermatomyositis Antinuclear antibodies (Option D): Positive in multiple autoimmune connective tissue diseases, including systemic lupus erythematosus (SLE), Sjogren's syndrome, and polymyositis/dermatomyositis.



@Neet_pg_bot



@Neet_pg_bot



References:

1. Rook’s Textbook of Dermatology, 9th Edition, Page 56.2-56.18. 2. Varga J. 2023. Clinical manifestations and diagnosis of systemic sclerosis (scleroderma) in adults. UpToDate

↑ *Back to this question in Part A*

@Neet_pg_bot

Q8: A 32-year-old woman complains that the tips of her fingers are changing from pale white to bluish-red during winter. She states that it started five years ago but has worsened recently, along with difficulty swallowing food. Which of the following findings would you also expect to find in this patient? (Q841848)

A. Hypercalcemia

B. Calcinosis cutis

C. Malar Rash

D. Morphea

Correct Answer: B. Calcinosis cutis

■ *Listen (English)*

■ *Listen (Hindi)*

Explanation: Cold-associated colour changes in the fingers, such as bluish-red discoloration, along with dysphagia (difficulty swallowing), are classic symptoms associated with Raynaud's phenomenon and oesophagal dysfunction, respectively, which are features of scleroderma. CREST syndrome is a type of limited scleroderma that consists of calcinosis cutis, Raynaud phenomenon, oesophageal dysmotility, sclerodactyly, and telangiectasia Calcinosis cutis, the deposition of calcium in the skin and subcutaneous tissues is a common complication of systemic sclerosis. Von Kossa stain used for calcinosis cutis: Pitted scar on fingertips in Raynaud's phenomenon: Hypercalcemia (Option A): While hypercalcemia can occur in certain conditions, such as hyperparathyroidism or malignancies, it is not a characteristic feature of systemic sclerosis. Malar Rash (Option C): A malar rash, a rash that appears on the cheeks and resembles a butterfly shape, is characteristic of systemic lupus erythematosus (SLE), not systemic sclerosis. Morphea (Option D): Morphea, a localized form of scleroderma, primarily affects the skin and does not typically involve the oesophagus or cause dysphagia (systemic sclerosis)

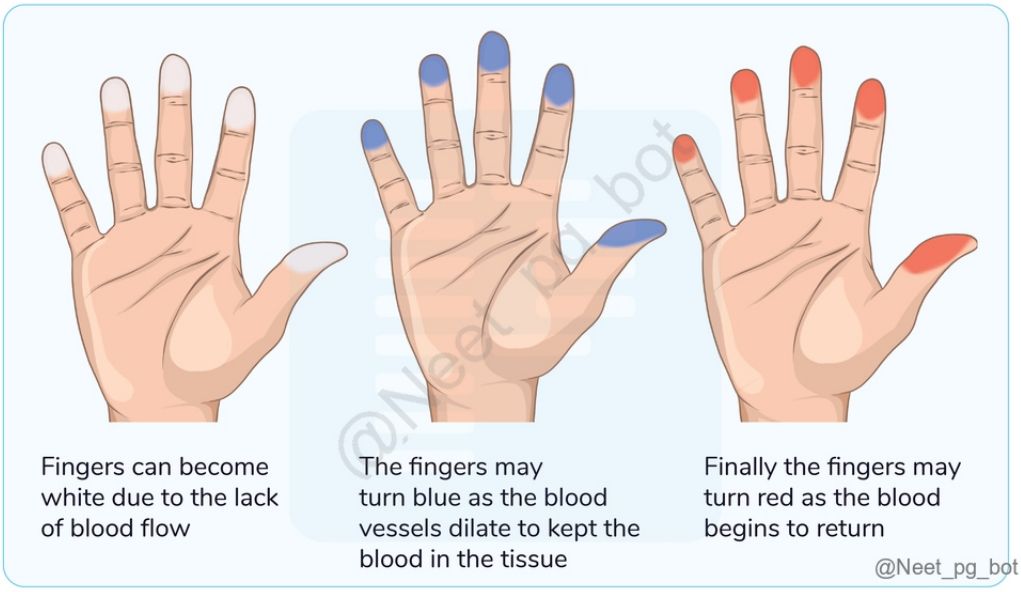



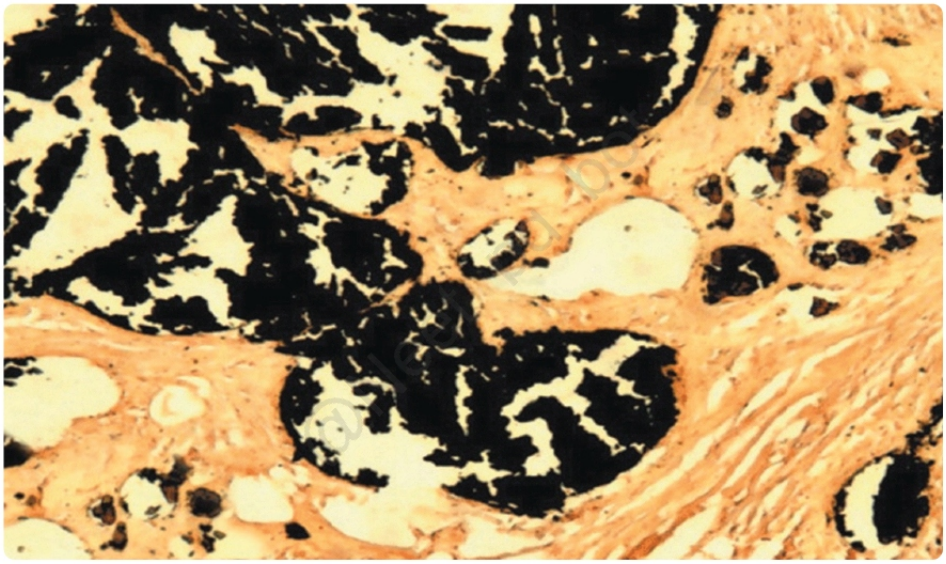



References:

https://www.verywellhealth.com/raynauds-phenomenon-8643512

↑ *Back to this question in Part A*

@Neet_pg_bot

Q9: A 40-year-old woman presents with a history of Raynaud's phenomenon, arthritis, myalgia and fatigue. On examination, she has a rash on her face that spares her nasolabial folds. Her fingers appear puffy and sausage-shaped. Positive autoantibodies to anti-U1RNP along with her history are most indicative of which of the following diseases? (Q841849)

A. Scleroderma

B. Mixed connective tissue disease

C. Systemic lupus erythematosus

D. Dermatomyositis



Correct Answer: B. Mixed connective tissue disease

■ *Listen (English)*

■ *Listen (Hindi)*

Explanation: Mixed connective tissue disease presents a combination of features of cutaneous LE, scleroderma, and dermatomyositis . Anti-U1RNP antibody (anti-U1RNP) is a specific serological marker for mixed connective tissue disease (MCTD). Mixed connective tissue disease is a type of overlap syndrome where one patient will have features of multiple connective tissue diseases. Due to its non-specific presentation, autoantibody testing is fundamental. Treatment: First line: Corticosteroids show good response Second line: Hydroxychloroquine and methotrexate Scleroderma (Option A): While scleroderma is associated with various autoantibodies, including anti-centromere antibodies and anti-topoisomerase I (anti-Scl-70) antibodies, it is not typically associated with anti-U1 ribonucleoprotein antibodies. Scleroderma primarily presents with skin thickening, Raynaud phenomenon, and internal organ involvement.Malar rash is not a feature. Systemic Lupus Erythematosus (LE) (Option C): Systemic lupus erythematosus is primarily associated with anti-nuclear antibodies (ANA - Most sensitive),

anti-dsDNA antibodies, and anti-Smith (anti-Sm - Most specific) antibodies. Dermatomyositis (Option D): Dermatomyositis is associated with various autoantibodies, including anti-Jo-1 antibodies and anti-Mi-2 antibodies. Dermatomyositis is characterized by muscle weakness and skin involvement, including a characteristic skin rash.

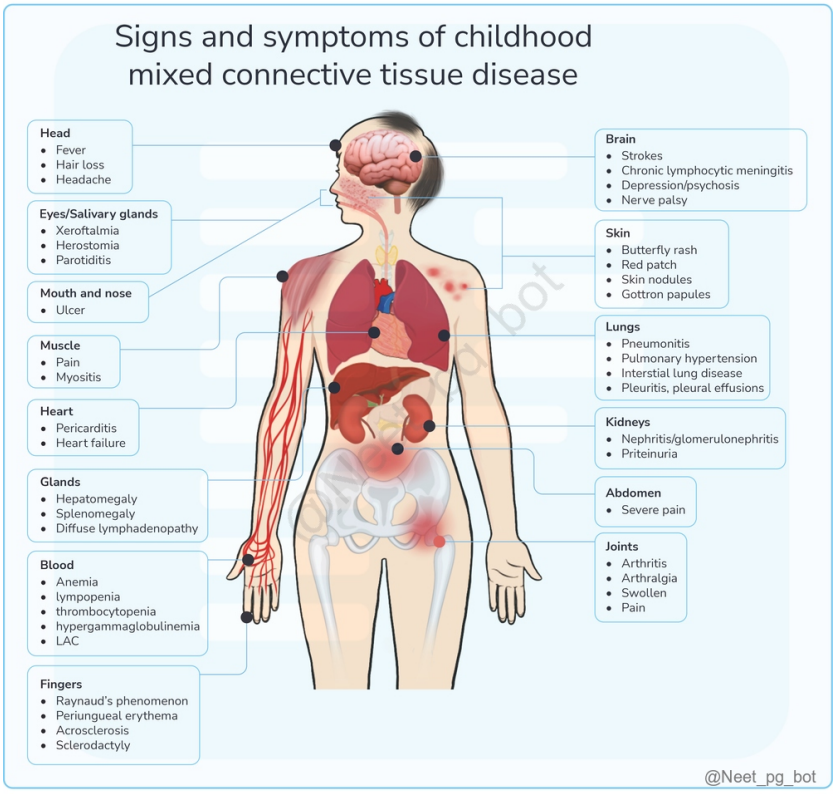

References:

Rook's Textbook of Dermatology, 9th Edition, Page 54.1-54.3.

↑ *Back to this question in Part A*

@Neet_pg_bot

• [09_Connective Tissue Disorders] 020 Previous Year Questions

« Back to Folder Directory

[09_Connective Tissue Disorders] 020 Previous Year Questions — Quick Jump

Q1 (p. 1072) *Q2 (p. 1075)* *Q3 (p. 1079)* *Q4 (p. 1084)* *Q5 (p. 1086)*

Q1: What is the most probable diagnosis of the given image? (Q860620)

A. Polymyositis

B. Dermatomyositis

C. Inclusion body myositis

D. Discoid lupus erythematosus



Correct Answer: B. Dermatomyositis

Explanation: The given image shows a heliotrope rash, which is a characteristic feature of Dermatomyositis. Clinical Features of Dermatomyositis Weakness : Symmetric, proximal greater than distal. Rash : Characteristic rashes include: Heliotrope rash: Erythematous eyelid discolouration with periorbital edema. Gottron sign: Erythematous rash over extensor surfaces (knuckles, elbows, knees, ankles). Gottron papules: Raised erythematous rash over knuckles. V-sign: Rash on sun-exposed anterior neck and chest. Shawl sign: Rash over the back of the neck and shoulders. Nail bed telangiectasias: Dilated capillaries at nail beds. Subcutaneous calcium deposits. Weakness and rash can appear together or be separated by months. Some patients may present with only a rash (amyopathic DM), while others may show mainly weakness. Additional Symptoms: Myalgias, arthralgias, dysphagia, and dysarthria. Skin symptoms significantly affect overall life quality; pruritus can be debilitating. Pulmonary Issues: Dyspnea from ventilatory muscle weakness or intrinsic lung problems (interstitial lung disease, bronchopneumonia, alveolitis). Malignancy Risk: Higher risk (~15%) in adult-onset cases within the first 2–3 years. {{caption_text}} Heliotrope rash {{caption_text}} Gottron’s Papules {{caption_text}} Shawl sign

{{caption_text}} V Sign Polymyositis (Option A): Muscle involvement similar to dermatomyositis but lacks skin manifestations. Inclusion body myositis (Option C): Does not present with a heliotrope rash. The feature distinguishing inclusion body myosistis from dermatomyositis and polymyositis is the lack of responsiveness to immunosuppressive treatment. Discoid lupus erythematosus (Option D): Carpet track or Tin tack sign, also called Cat's tongue is characteristic of DLE.









References:

Harrison’s Principles of Internal Medicine, 21st Edition, Page 2820

Davidson’s Principles and Practice of Medicine, 24th Edition, Page 1039

↑ *Back to this question in Part A*

@Neet_pg_bot

Q2: A 50-year-old female patient with a known case of ovarian cancer presents with difficulty in activities like climbing stairs, getting up from a chair, combing hair, etc. The following characteristic sign was found on examination. The most probable diagnosis is: (Q857972)

A. Systemic lupus erythematosus

B. Dermatomyositis

C. Systemic sclerosis

D. Cushing syndrome





Correct Answer: B. Dermatomyositis

Explanation: : Incorrect because SLE presents with malar rash, arthritis, and systemic involvement, but not prominent muscle weakness . Systemic sclerosis (Option C): Incorrect because systemic sclerosis causes skin tightening, Raynaud's phenomenon, and esophageal dysmotility, not proximal muscle weakness . Cushing syndrome (Option D): Incorrect because Cushing’s causes proximal weakness due to steroid myopathy, but lacks the classic skin rash seen in dermatomyositis .




@Neet_pg_bot


@Neet_pg_bot


@Neet_pg_bot


@Neet_pg_bot



References:

Chapter 53: Dermatomyositis. In: Rook's Textbook of Dermatology. 9th ed; 2016. p. 53.2-53.10.

↑ *Back to this question in Part A*

@Neet_pg_bot

Q3: What is the observed condition in the image below, where a 10-year-old boy presents with muscle weakness in his lower limbs and a rash on his eyelids, with biopsy results indicating muscle inflammation? (Q855740)

A. Gottron's papules

B. Shawl sign

C. Heliotrope rash

D. Scleroderma



Correct Answer: A. Gottron’s papules

Explanation: Gottron’s papules are erythematous to violaceous plaques over the extensor surfaces of the knuckles, elbows, and knees . They are characteristic of juvenile dermatomyositis (JDM) , an autoimmune inflammatory myopathy. The clinical triad includes proximal muscle weakness, heliotrope rash (violaceous rash on eyelids), and Gottron’s papules . Muscle biopsy typically shows perivascular and perimysial inflammation with CD4+ T-cell infiltration . Diagnosis is confirmed with elevated muscle enzymes (CK, aldolase), electromyography, and MRI findings of myositis . Treatment involves high-dose corticosteroids and immunosuppressants (methotrexate, IVIG). {{caption_text}} Juvenile Dermatomyositis (JDM) Feature Description Definition Autoimmune inflammatory myopathy affecting muscles and skin in children Age Group Common in children aged 5–15 years Muscle Weakness Proximal muscle weakness (difficulty climbing stairs, getting up from a chair) Skin Findings Gottron’s papules (erythematous plaques over knuckles) Heliotrope rash (violaceous periorbital rash) Shawl/V-sign (rash over shoulders and chest) Lab Findings ↑ CK, aldolase, ANA, anti-Mi-2, anti-Jo-1 antibodies Diagnostic Tests Muscle biopsy (perifascicular atrophy, inflammatory infiltrates), MRI, EMG Treatment Corticosteroids, methotrexate, IVIG Mechanic Hands {{caption_text}} Holster sign {{caption_text}} Shawl sign (Option B) is incorrect because the Shawl sign is a macular erythematous rash over the shoulders, neck, and upper back , typically seen in Dermatomyositis (DM) but does not specifically describe the lesions over the hands. {{caption_text}} {{caption_text}} Heliotrope rash (Option C) is incorrect because a heliotrope rash refers specifically to a purplish rash on the eyelids . While present in JDM , it is not the primary observation being asked in the question. {{caption_text}} Scleroderma (Option D) is incorrect because scleroderma presents with skin thickening, tightness, and Raynaud’s phenomenon , not inflammatory myopathy with characteristic rashes like Gottron’s papules. {{caption_text}}



@Neet_pg_bot



@Neet_pg_bot

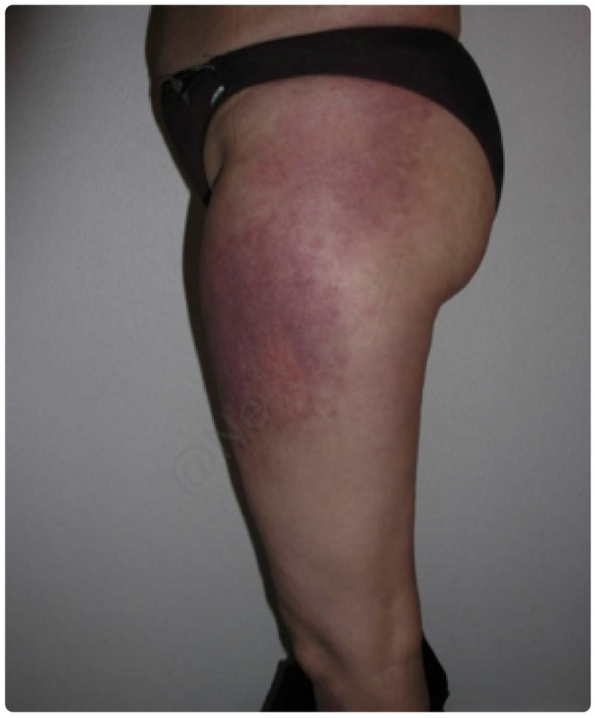

@Neet_pg_bot



@Neet_pg_bot


@Neet_pg_bot


@Neet_pg_bot



References:

Rook's Textbook of Dermatology, Chapter 53: Dermatomyositis, 9th Edition 2016, Page 53.2-53.10.

↑ *Back to this question in Part A*

@Neet_pg_bot

Q4: A 10-year-old male child visits with symptoms of fever, joint pain, and a visible skin abnormality on his hand, as depicted in the provided image. Please identify the clinical observation and suggest a probable diagnosis. (Q854962)

A. Gottron's papules – Juvenile dermatomyositis

B. Rheumatoid nodules – Juvenile rheumatic arthritis

C. Sclerodactyly-Systemic sclerosis

D. Mechanic's hand – Systemic lupus erythematosus



Correct Answer: A. Gottron’s papules – Juvenile dermatomyositis

Explanation: The image shows erythematous, scaly plaques over the knuckles (MCP and PIP joints) , which are characteristic of Gottron’s papules . Juvenile Dermatomyositis (JDM) is an autoimmune inflammatory myopathy affecting children. Associated features include proximal muscle weakness, heliotrope rash, and systemic symptoms like fever and arthritis. Diagnosis is based on clinical findings, muscle enzymes (CK), EMG, and muscle biopsy . Juvenile Dermatomyositis: Feature Description Skin findings Gottron’s papules (erythematous scaly plaques on knuckles), heliotrope rash (violaceous eyelid discoloration) Muscle involvement Proximal muscle weakness (difficulty climbing stairs, combing hair) Systemic symptoms Fever, arthritis, fatigue Investigations Elevated CK, aldolase, anti-Jo-1 antibodies, EMG, muscle biopsy Treatment Corticosteroids, methotrexate, IVIG in severe cases Rheumatoid nodules – Juvenile rheumatoid arthritis (Option B) is incorrect because rheumatoid nodules are firm, non-tender subcutaneous nodules over pressure points (e.g., elbows, fingers) in juvenile idiopathic arthritis (JIA) . These nodules are not scaly or violaceous and do not appear over joint extensor surfaces like Gottron’s papules. Sclerodactyly – Systemic sclerosis (Option C) is incorrect because sclerodactyly refers to thickened, tight skin over the fingers due to dermal fibrosis, seen in systemic sclerosis (scleroderma) . It is not associated with Gottron’s papules or muscle weakness. Mechanic’s hand – Systemic lupus erythematosus (Option D) is incorrect because mechanic’s hands (hyperkeratotic, cracked palmar skin) are seen in antisynthetase syndrome , often associated with dermatomyositis and polymyositis, but not systemic lupus erythematosus (SLE).

References:

Chapter 53: Dermatomyositis. In: Rook’s Textbook of Dermatology. 9th ed; 2016. p. 53.2-53.10.

↑ *Back to this question in Part A*

@Neet_pg_bot

Q5: In a 17-year-old patient, the most distinctive and characteristic indicator of juvenile dermatomyositis is (Q856678)

A. Photosensitive skin rash

B. Nail bed capillary changes

C. Gottron’s papules

D. Malar rash

Correct Answer: C. Gottron’s papules

Explanation: Gottron’s papules are the most distinctive and characteristic feature of juvenile dermatomyositis (JDM) . They appear as violaceous, scaly papules symmetrically distributed over bony prominences , especially the knuckles, elbows, and knees . This is a hallmark finding in both juvenile and adult dermatomyositis and helps distinguish it from other connective tissue diseases. JDM is a rare autoimmune inflammatory myopathy affecting children, characterised by proximal muscle weakness and distinctive skin rashes . Clinical Features: Muscle involvement: Symmetrical proximal muscle weakness (difficulty climbing stairs, rising from a chair). Gower’s sign may be positive in severe cases. Cutaneous manifestations: Gottron’s papules (violaceous papules over knuckles, elbows, knees). Heliotrope rash (violaceous discolouration around eyelids). Nailfold capillary abnormalities (dilated capillary loops, dropout). Photosensitivity and facial erythema . Systemic involvement: Dysphagia, interstitial lung disease, calcinosis cutis (in chronic cases). Diagnosis: Raised muscle enzymes: CK, aldolase. MRI (muscle oedema) , EMG (myopathic changes). Muscle biopsy: Perifascicular atrophy, inflammatory infiltrates. ANA, anti-Mi-2, anti-MDA5 antibodies (useful in subtypes). Management: First-line: Corticosteroids (prednisolone) with methotrexate or azathioprine . IVIG, rituximab in refractory cases. Physiotherapy to prevent contractures. Photosensitive skin rash (Option A) is incorrect because while photosensitivity is common in JDM, it is not specific and can be seen in other autoimmune conditions like lupus erythematosus . Nail bed capillary changes (Option B) is incorrect because abnormal nailfold capillaries (dilated capillary loops, dropout) occur in JDM but are not as distinctive as Gottron’s papules. They are also seen in systemic sclerosis . Malar rash (Option D) is incorrect because a malar rash is more characteristic of systemic lupus erythematosus (SLE) , not JDM. Although JDM can have facial erythema , it does not spare the nasolabial folds , unlike the butterfly rash in lupus.

References:

Rook’s Textbook of Dermatology. 9th ed; 2016. p. 53.2-53.10

↑ *Back to this question in Part A*

@Neet_pg_bot

• [10_Skin Tumors] 021 Previous Year Questions

« Back to Folder Directory

[10_Skin Tumors] 021 Previous Year Questions — Quick Jump

Q1 (p. 1087) *Q2 (p. 1088)* *Q3 (p. 1088)* *Q4 (p. 1092)* *Q5 (p. 1096)* *Q6 (p. 1100)*

Q1: Which carcinoma is the possible diagnosis in the image given below? (Q820214)

A. Basal cell carcinoma

B. Squamous cell carcinoma

C. Malignant melanoma

D. Hepatocellular carcinoma



Correct Answer: C. Malignant melanoma

Explanation: Correct option C - Malignant melanoma It presents as an irregularly shaped, dark-colored lesion with uneven borders. Malignant melanoma has a higher potential to metastasize if not detected and treated early. It is crucial to catch it at an early stage for a better prognosis. Incorrect options: Option A - Basal cell carcinoma: It

appears as a flesh-colored or pinkish bump with a central depression and raised edges. It is slow-growing and rarely metastasizes. It is common in areas exposed to the sun. Option B - Squamous cell carcinoma: It is also linked to sun exposure. It presents as a firm, red nodule or a scaly, crusted lesion. It has a higher potential to metastasize if left untreated. Option D - Hepatocellular carcinoma: Hepatocellular carcinoma is a type of liver cancer that originates from hepatocytes.

↑ *Back to this question in Part A*

@Neet_pg_bot

Q2: A 60-year-old person presented with an ulcer on the medial canthus. The ulcer has rolled-out, beaded margins. Histopathology shows nesting cells with peripheral palisading patterns. What is the most likely diagnosis? (Q852712)

A. Squamous Cell Carcinoma (SCC)

B. Nevus

C. Basal Cell Carcinoma (BCC)

D. Melanoma

Correct Answer: C. Basal Cell Carcinoma (BCC)

Explanation: Basal Cell Carcinoma (BCC) is the most common skin cancer and typically occurs in sun-exposed areas such as the face, particularly around the medial canthus of the eye . The classic clinical description includes: Ulceration with rolled-out, beaded margins . A pearly or translucent appearance with visible telangiectasia. Histopathology findings include: Nesting of basaloid cells . Peripheral palisading of nuclei. Clefting artifact between tumor cells and surrounding stroma. Other Options: Squamous Cell Carcinoma (SCC) (Option A) : Typically presents with a scaly, keratinized lesion that may ulcerate but lacks the rolled, pearly margins and palisading pattern seen in BCC. Nevus (Option B) : A benign lesion that does not typically ulcerate or have invasive histological features. Melanoma (Option D) : Usually presents with irregular pigmentation, asymmetry, and rapid growth , rather than a rolled-margin ulcer.

References:

Neena Khanna, Textbook of Dermatology, 5th Edition, Page no: 388-390
https://pubmed.ncbi.nlm.nih.gov/29494046/

↑ *Back to this question in Part A*

@Neet_pg_bot

Q3: A 60-year-old diabetic patient presents with a lesion on the nose as shown in the image below. The lesion bleeds on the touch. What is the diagnosis? (Q854645)

A. Squamous cell carcinoma

B. Basal cell carcinoma

C. Melanoma

D. Discoid lupus erythematosus



Correct Answer: B. Basal cell carcinoma

Explanation: Basal cell carcinoma (BCC), aka rodent ulcer is a slow-growing, locally invasive tumor and it rarely metastasizes. It arises from pluripotent cells within the basal layer of the epidermis or follicular structures. Clinical Features It presents initially small, scaly plaque Slow progressive course of peripheral extension Develops into nodular-ulcerative lesions, it has a thread-like margin, telangiectasia and it bleeds on touch. Site: Face, Around eyes, Nose Histopathology: peripheral palisading of tumour cells (shown in the image), the cells resemble cells of stratum basale that have grown into the dermis. This cluster of cells is surrounded at the periphery by perpendicularly arranged cells . It also has a well-organized stroma surrounding it. {{caption_text}} Treatment Medical: Imiquimod, 5-FU,Intralesional interferon α-2b Hedgehog pathway inhibitors:(Vismodegib) Surgical: Mohs micrographic surgery, Done in recurrent BCCs. Squamous cell carcinoma (Option A): Clinical Features: There is a presence of a papule, nodule, or plaque with induration, accompanied by signs of photodamage such as crusting and scaling. Histopathology: Keratin pearls. {{caption_text}} {{caption_text}} Melanoma (Option C): The image presented above doesn't meet the diagnostic criteria of malignant melanoma (ABCDE) Asymmetry: Irregular shapes. Border: Irregular. Colour: Various colours present or uneven distribution. Diameter: > 6 mm. Evolution: Changes in lesion over time (size, shape, itching, or bleeding). {{caption_text}} Discoid lupus erythematosus (Option D): This is a chronic inflammatory skin condition characterized by red, scaly, and atrophic

lesions, typically without a tendency to bleed. Discoid lupus has distinct features like a well-demarcated, scaly plaque, and it usually lacks the ulcerative appearance seen in this case.



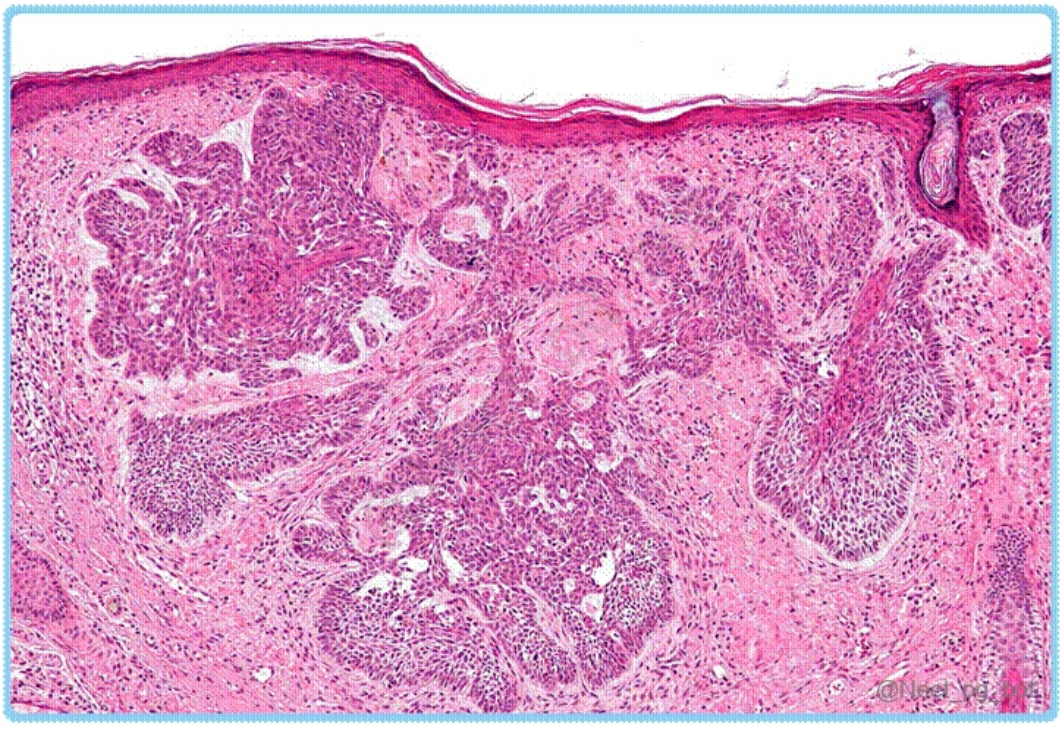

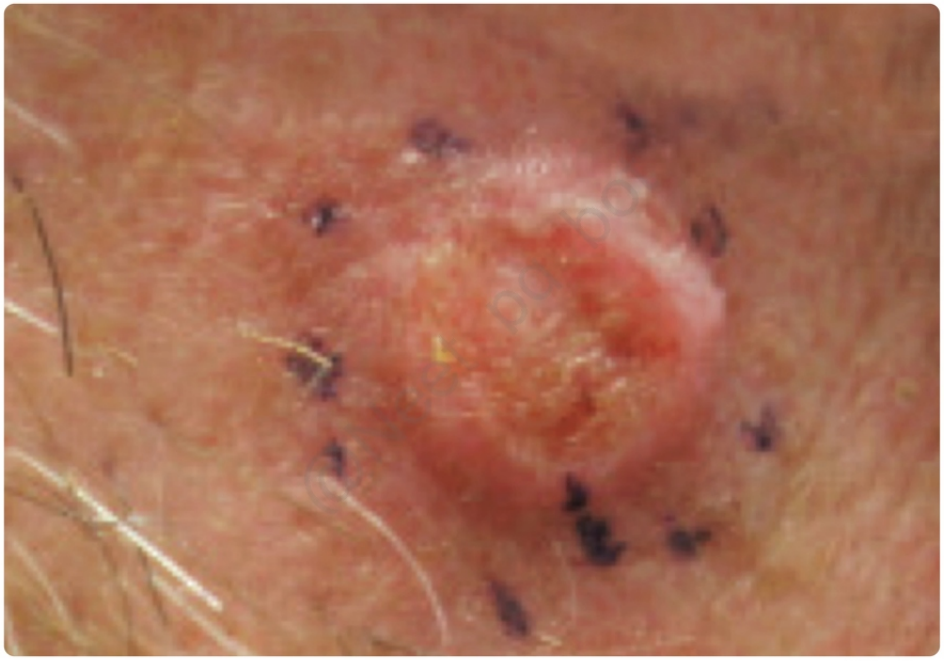

@Neet_pg_bot

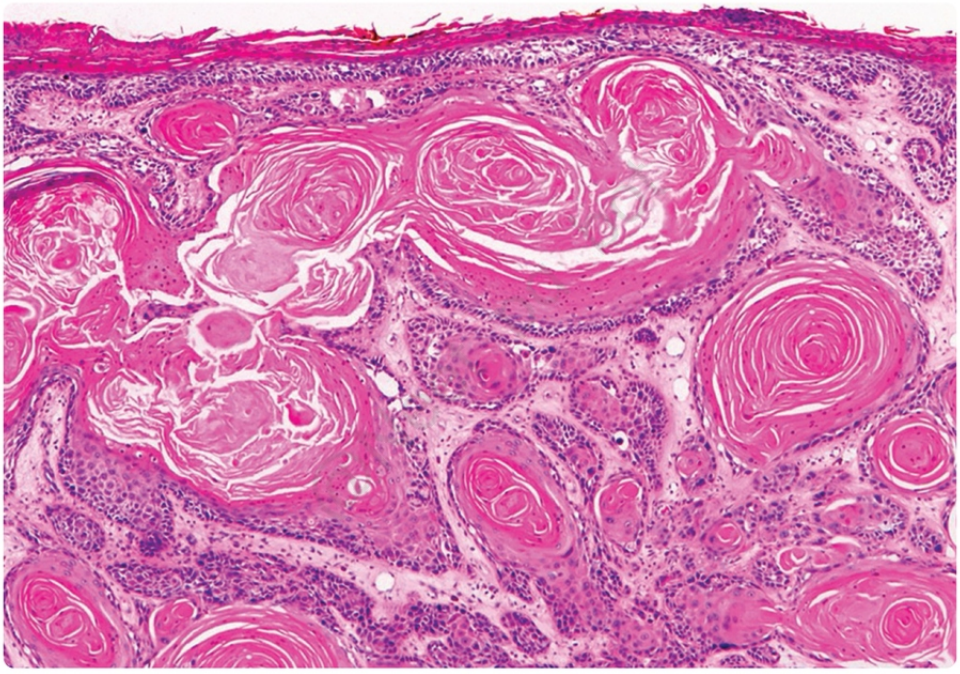

@Neet_pg_bot



References:

Rooks textbook of dermatology, 9th edition page no.141.4-141.6

↑ *Back to this question in Part A*

@Neet_pg_bot

Q4: Which of the following is associated with the clinical condition shown in the image? (Q855295)

A. Condylomata lata

B. Mole

C. Malignant melanoma

D. Basal cell carcinoma



Correct Answer: C. Malignant melanoma

Explanation: The image showing a lesion with irregular borders, asymmetry, and uneven distribution of colors , strongly suggests malignant melanoma . This is a malignant tumor arising from melanocytes located at the epidermal-dermal junction. Though rare, melanoma is highly aggressive with a significant risk of metastasis if not diagnosed early. Key Diagnostic Features of Malignant Melanoma ABCDE criteria : A symmetry. B order irregularity. C olor variation (brown, black, red, white, or blue). D iameter >6 mm. E volving lesion (changes in size, shape, or symptoms like bleeding or itching). Biopsy Findings: Large melanoma cells with enlarged nuclei , irregular contours, and clumped chromatin. Prominent eosinophilic nucleoli . Similar cellular appearance in both radial and vertical growth phases: Radial phase : Horizontal spread of melanoma within the epidermis and superficial dermis. Vertical phase : Deep invasion into dermal layers, forming an expansile mass. Risk Factors: Fair skin and history of sunburns . Family history or genetic mutations (e.g., CDKN2A mutation on chromosome 9p21). UV exposure and pre-existing nevi (e.g., dysplastic or congenital nevi). Types of Melanoma: Type Site Description Image Superficial spreading (M/C type) Any (more common on the upper back and, in women, lower legs) Brown mixed with bluish-red, bluish-black, reddish brown, and often whitish pink. The lesion border is often visibly and/or palpably raised {{caption_text}} Lentigo maligna Sun-exposed surfaces, particularly malar region and temple In flat portions, brown and tan predominate, but whitish grey sometimes present; in nodules, reddish brown, bluish grey, bluish-black. {{caption_text}} Acral lentiginous Palm, sole, nail bed, mucous membrane In flat portions, dark brown; in raised lesions (plaques), brown-black or blue-black. {{caption_text}} Nodular Any Reddish blue, purple, or bluish-black; can be uniform or mixed with brown and black. {{caption_text}} Staging and Classification: Breslow thickness : Measures depth of tumor invasion. Clark level : Describes the anatomical level of invasion. Stage Classification Clarke Breslow I Involvement of epidermis ≤ 0.75 mm II Involvement of epidermis + dermis 0.76-1.5 mm III Involvement of dermal papillae 1.5-4 mm IV Involvement of reticular dermis >4 mm V Involvement of subcutaneous tissue - Management: Early detection and histopathological confirmation via biopsy are critical for improving outcomes. Wide local excision : Margins depend on Breslow thickness. Sentinel lymph node biopsy : Indicated for lesions >1 mm in thickness. Advanced cases : Immunotherapy (e.g.,

immune checkpoint inhibitors). Targeted therapy (BRAF/MEK inhibitors for BRAF-mutant melanoma). Interferon-α : Prevents metastasis in high-risk cases. Incorrect Options: Option A) Condylomata lata: Associated with secondary syphilis, these are smooth, moist, flat-topped, and highly contagious warty lesions, typically found in the anogenital region or mucous membranes. They lack the asymmetry, irregular borders, and color variations seen in malignant melanoma. Option B) Mole: Moles (benign melanocytic nevi) are symmetric lesions with uniform color, smooth borders, and no significant changes over time. They do not exhibit the irregular and evolving features of malignant melanoma. Option D) Basal cell carcinoma: This is the most common skin cancer, presenting as a pearly or translucent papule with telangiectasias, often on sun-exposed areas. It rarely shows pigmentation or the asymmetry and color variation seen in malignant melanoma.



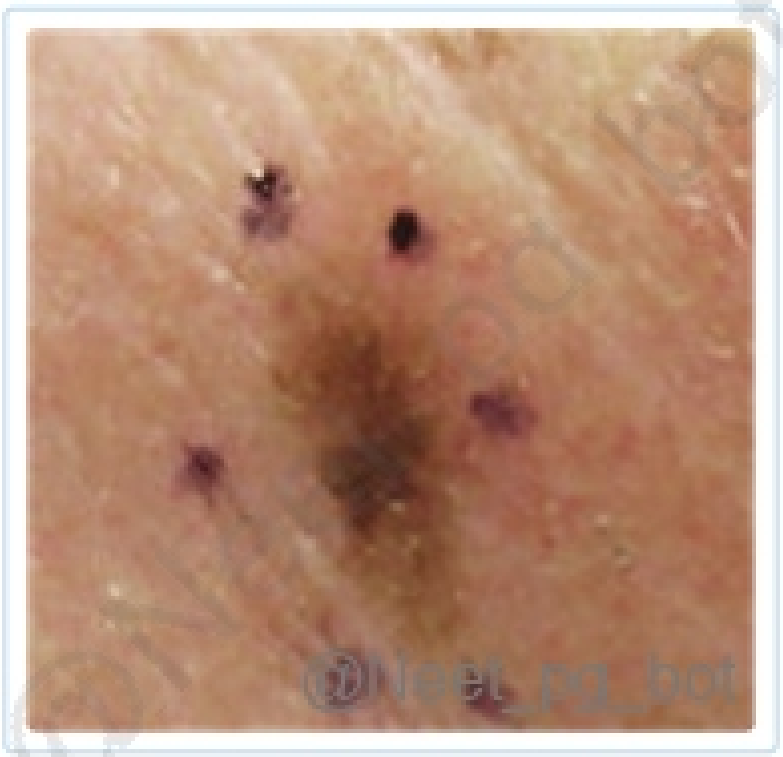
@Neet_pg_bot


@Neet_pg_bot



References:

Rook’s Textbook of Dermatology, 9th edition, page no. 143.7-143.28

Harrison’s Principles of Internal Medicine, 21st edition, page no. 587

↑ *Back to this question in Part A*

@Neet_pg_bot

Q5: Identify the given disorder. (Q857048)

A. Melanoma

B. Hyperpigmentation

C. Basal cell carcinoma

D. Squamous cell carcinoma



Correct Answer: A. Melanoma

Explanation: The given image showing a lesion with irregular borders , asymmetry , and uneven distribution of colors in the lesion is suggestive of malignant melanoma . Malignant melanoma: Melanoma is a malignant tumour arising from melanocytes at the epidermal-dermal junction. Though it is a rare skin cancer, it has a high mortality rate. It presents as a pigmented lesion that enlarges, ulcerates, or bleeds. Risk factors: Positive family history. Fair skin. Genetics: CDKN2A (chromosome 9p21), MC1R, and TYR genes. Nevus: Congenital melanocytic nevi. Junctional nevi. Atypical nevi. Dysplastic nevi. Fitzpatrick Type 1 skin. UV light. Types of Melanoma: Type Site Description Image Superficial spreading (M/C type) Any (more common on the upper back and, in women, lower legs) Brown mixed with bluish-red, bluish-black, reddish brown, and often whitish pink. The lesion border is often visibly and/or palpably raised {{caption_text}} Lentigo maligna Sun-exposed surfaces, particularly malar region and temple In flat portions, brown and tan predominate, but whitish grey sometimes present; in nodules, reddish brown, bluish grey, bluish-black. {{caption_text}} Acral lentiginous Palm, sole, nail bed, mucous membrane In flat portions, dark brown; in raised lesions (plaques), brown-black or blue-black. {{caption_text}} Nodular Any Reddish blue, purple, or bluish-black; can be uniform or mixed with brown and black. {{caption_text}} Investigations: Clinical examination. Dermoscopy. Biopsy. Immunohistochemistry: The markers are S-100, HMB-45 (the most specific), Melan-A (MART-1), and MITF. CT scan. Breslow's and Clarke's Classifications of Malignant Melanoma: Stage Classification Clarke Breslow I Involvement of epidermis ≤ 0.75 mm II Involvement of epidermis + dermis 0.76-1.5 mm III Involvement of dermal papillae 1.5-4 mm IV Involvement of reticular dermis >4 mm V Involvement of subcutaneous tissue - Management: Wide local excision (with margins measured before excision and determined by Breslow depth, sentinel lymph node biopsy indicated for tumours with a depth of >1.0 mm). If the tumour is aggressive: Immunotherapy. Chemotherapy. Targeted therapy. Interferon-■ is the only adjuvant treatment that has documented beneficial effects on overall survival. Incorrect Options: Hyperpigmentation (Option B): Generalized or localized increased skin pigmentation due to conditions like melasma, Addison's disease, or post-inflammatory hyperpigmentation. Does not present with an irregular, evolving lesion. Basal Cell Carcinoma (Option C): Pearly, translucent nodule with telangiectasia. Slow-growing

and rarely metastasizes. May have central ulceration ("rodent ulcer"). Squamous Cell Carcinoma (Option D): Scaly, erythematous plaque or ulcer with crusting. Often seen in chronically sun-exposed areas. More locally invasive, with some potential for metastasis.

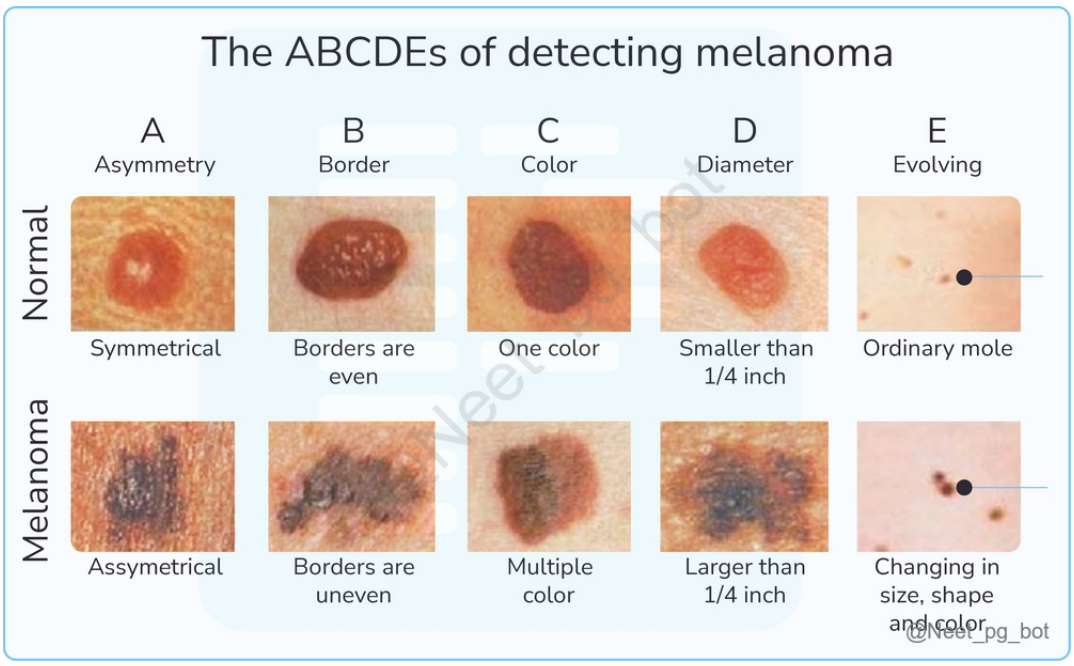



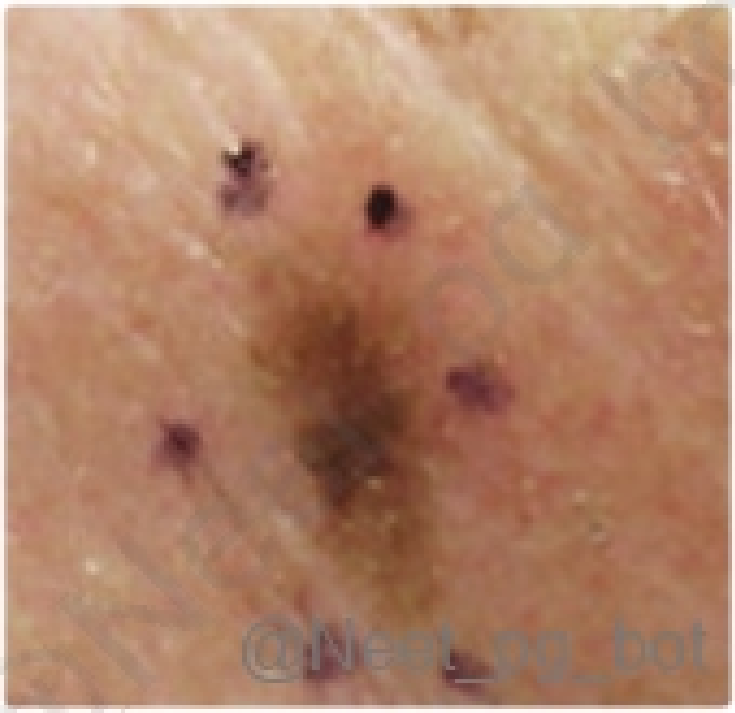
@Neet_pg_bot


@Neet_pg_bot



References:

Rook’s Textbook of Dermatology, 9th edition, page no. 143.7-143.28

Harrison’s Principles of Internal Medicine, 21st edition, page no. 587

↑ *Back to this question in Part A*

@Neet_pg_bot

Q6: A baby presents to the OPD; the image below shows the findings. What is the probable diagnosis? (Q857968)

A. Portwine stain

B. Cavernous hemangioma

C. Naevus simplex

D. Capillary hemangioma



Correct Answer: D. Capillary hemangioma

Explanation: Answer D - Capillary Hemangioma: The images show a bright red, raised, well-demarcated lesion commonly seen in infants. Capillary hemangiomas (strawberry hemangiomas) are benign vascular tumors that typically appear after birth, grow rapidly, and regress spontaneously . They are superficial hemangiomas composed of proliferating endothelial cells . Commonly occur on the face, scalp, trunk, or extremities . Most resolve by 5–7 years of age without treatment. Infantile Hemangioma (Capillary Hemangioma) Feature Capillary Hemangioma Cause Proliferation of immature endothelial cells Appearance Bright red, raised lesion with a well-demarcated border Onset Appears within first few weeks after birth Growth Pattern Rapid growth for months, then gradual involution Resolution 90% regress by 5–7 years of age Treatment Observation, propranolol (if complications occur) {{caption_text}} {{caption_text}} Portwine stain (Option A): Incorrect because port-wine stains (nevus flammeus) are flat, non-proliferative vascular malformations that do not regress . Cavernous hemangioma (Option B): Incorrect because cavernous hemangiomas are deeper, bluish, and less well-defined . Naevus simplex (Option C): Incorrect because naevus simplex ("salmon patch") is a flat, pink-red blanching lesion commonly seen on the forehead and nape of the neck .



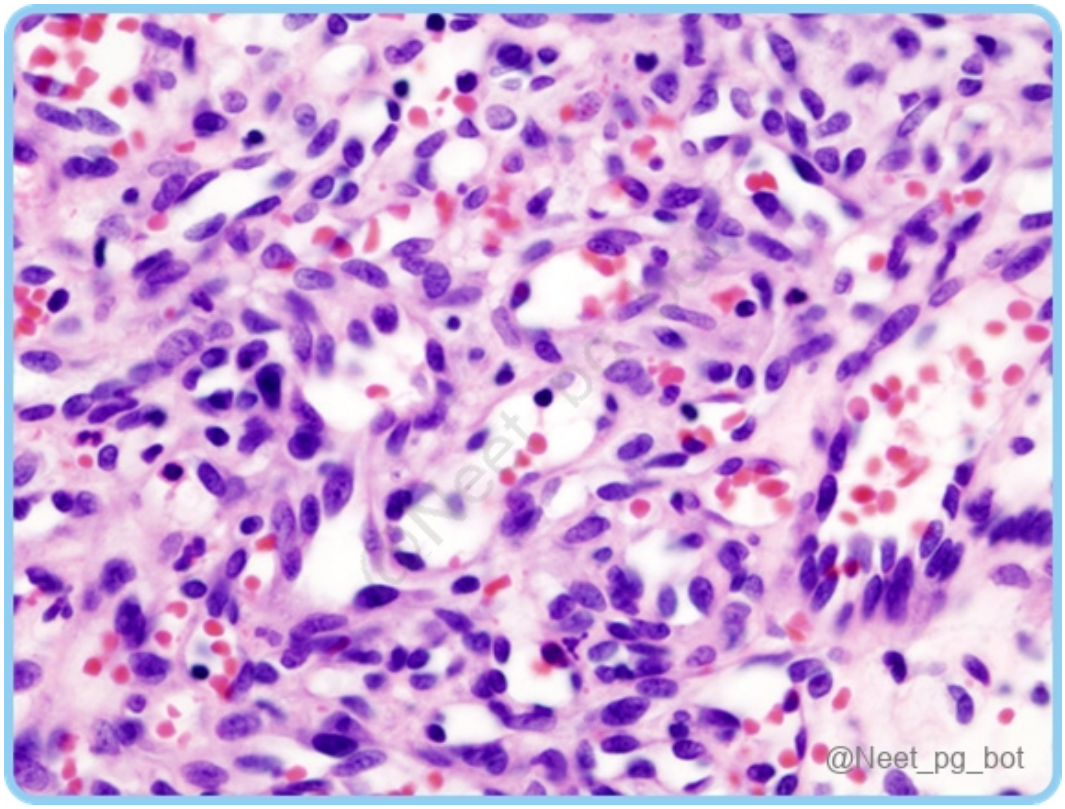

References:

Robbins Pathology 10th edition, Pg 519, 520

↑ *Back to this question in Part A*

@Neet_pg_bot

• [11_Systemic Diseases and Skin] 022 Systemic Diseases And Skin - I

« Back to Folder Directory

[11_Systemic Diseases and Skin] 022 Systemic Diseases And Skin - I — Quick Jump

Q1 (p. 1104) *Q2 (p. 1107)* *Q3 (p. 1108)* *Q4 (p. 1110)* *Q5 (p. 1112)* *Q6 (p. 1115)*
Q7 (p. 1117) *Q8 (p. 1118)* *Q9 (p. 1119)* *Q10 (p. 1121)* *Q11 (p. 1124)* *Q12 (p. 1126)*
Q13 (p. 1128) *Q14 (p. 1131)* *Q15 (p. 1134)*

Q1: A 3-year-old boy was brought to the clinic by his mother. She reports that the child has been irritable, lethargic, and refusing to eat for the past few weeks and had bilateral lower extremity swelling with a distended abdomen. Based on the clinical presentation, which dermatological manifestation is most likely to be associated with this condition? (Q841737)

A. Flaky paint dermatosis

B. Phrynoderma

C. Corkscrew hair

D. Casal’s necklace

Correct Answer: A. Flaky paint dermatosis

■ *Listen (English)*

■ *Listen (Hindi)*

Explanation: The given clinical picture suggests the diagnosis of Kwashiorkor, a form of severe acute malnutrition characterized by oedema resulting from a deficiency of dietary protein despite sufficient caloric intake. This condition may present with peripheral pitting oedema, muscle atrophy, abdominal distension (hepatomegaly), moon facies, hair and skin changes, anorexia, apathy, and growth retardation. The skin manifestations are distinctive and often described as resembling "cracked skin," "peeling paint," "enamel paint," "flaky paint," or "crazy paving" due to the characteristic scaling and irregular fissures observed during examination.Over time, more defined plaques may develop, particularly in areas prone to friction such as skin folds. The hair frequently takes on a dull, reddish-brown hue that may alternate with more normal colouring, referred to as the "flag sign." Inflammatory changes of the mucous membranes, such as xerophthalmia, cheilitis, stomatitis, and vulvovaginitis, may develop alongside other concurrent deficiencies in vitamins and mineral micronutrients. Treatment focuses on slowly restoring nutrients to prevent refeeding syndrome and related electrolyte imbalances and micronutrient deficiencies. Phrynoderma (Option B) , derived from "toad skin," is a dermatological manifestation linked to vitamin A deficiency, although it can also occur in conjunction with other nutritional deficiencies. Corkscrew hair

(Option C) represents fractured and coiled hairs due to disruption in the formation of keratin cross-links through disulfide bonds. It is commonly seen in deficiencies of vitamins C. Casal's necklace (Option D) is V-shaped eczematous, hyperkeratotic lesions on the anterior aspect of the neck, manifesting as a part of dermatitis in pellagra due to Vitamin B3 (Niacin) deficiency. Other sites of these eczematous lesions include the dorsum of the hand and face.

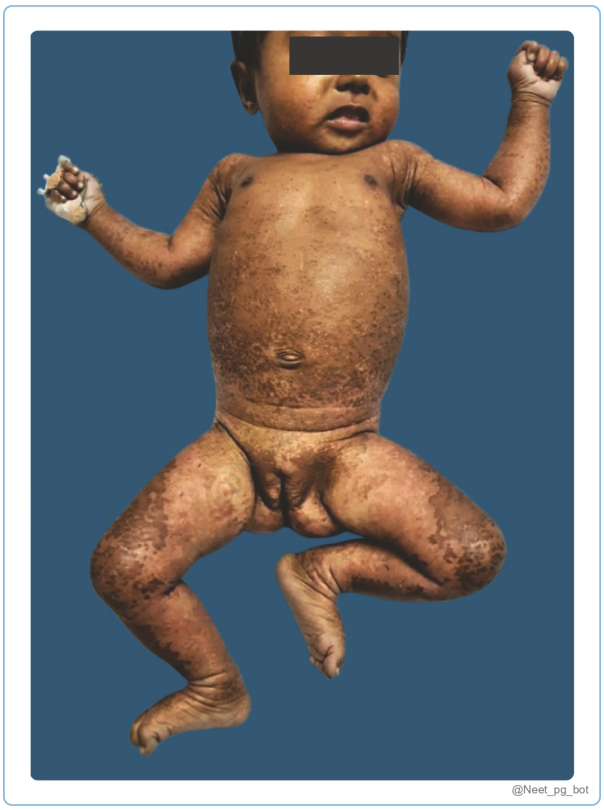



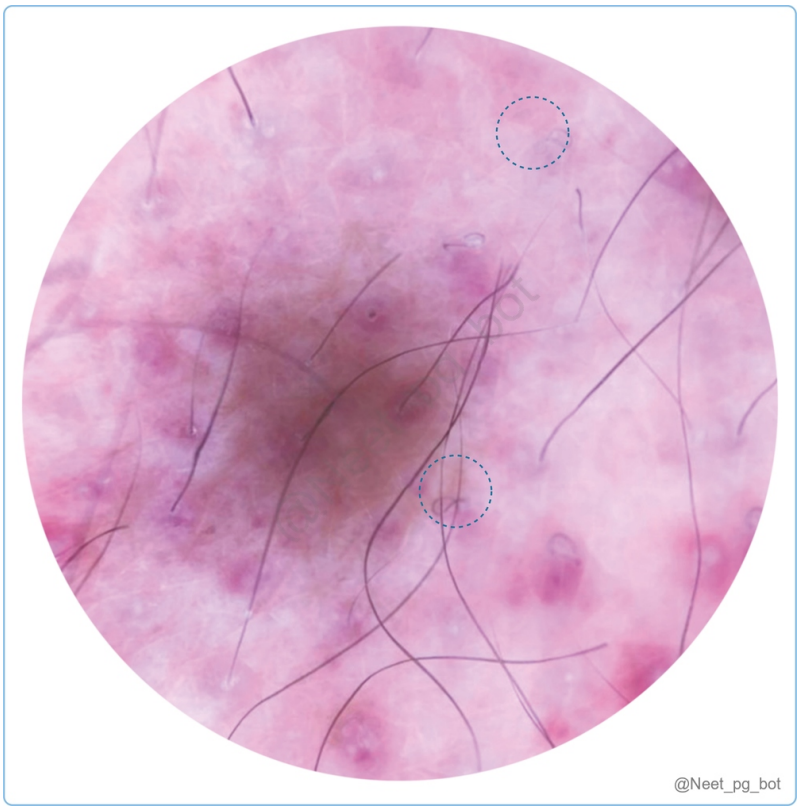



References:

Rook’s Textbook of Dermatology, 9thEdition, Page 63.3-63.5, 87.13

www.ncbi.nlm.nih.gov/books/NBK507876/

↑ *Back to this question in Part A*

@Neet_pg_bot

Q2: A 45-year-old female presented to the dermatological OPD with complaints of painful cracks at the corners of her mouth. On examination, the doctor noticed a smooth magenta-coloured tongue. Which of the following supplements needs to be prescribed to the patient? (Q841738)

A. Thiamine

B. Methylcobalamin

C. Riboflavin

D. Folate

Correct Answer: C. Riboflavin

■ *Listen (English)*

■ *Listen (Hindi)*

Explanation: Based on the clinical presentation of painful cracks at the corners of the mouth (angular stomatitis) and a smooth magenta-coloured tongue, the most likely deficiency is of Riboflavin (Vitamin B2). Vitamin B2 is a water-soluble B-complex vitamin. The recommended daily intake of riboflavin is 0.3–1.6 mg, depending on age and gender. A deficiency in riboflavin can arise due to reduced dietary consumption, impaired absorption, or exposure to phototherapy. Clinical presentations include angular stomatitis, cheilitis, glossitis, and Seborrhoeic dermatitis-like eruption. The ocular manifestation of riboflavin deficiency is corneal vascularization, which presents as itching and burning in the eyes and increased sensitivity to light. Treatment is with riboflavin supplementation of 1–2 mg/day in infants and children and 10–20 mg/day in adults. Thiamine (Option A): Thiamine (vitamin B1) deficiency primarily leads to a condition known as Beriberi, which is of two types: Wet beriberi has predominant cardiovascular involvement, including cardiomegaly and congestive heart failure. Dry beriberi causes neurological manifestations including peripheral neuropathy and Wernicke’s encephalopathy. It can result in the development of skin lesions, including patches of redness, scaling, or hyperpigmentation. Methylcobalamin (Option B): Vitamin B12 (Methylcobalamin) deficiency presents with haematological manifestations, including megaloblastic anaemia, and dermatological manifestations such as pallor, jaundice, hyperpigmentation, and angular cheilitis. Although B12 deficiency also causes angular cheilitis, riboflavin deficiency most commonly and primarily affects mucous membranes, which can result in the development of angular cheilitis. Folate (Option D): Folate (vitamin B9) deficiency also presents with megaloblastic anaemia. While angular stomatitis and cheilitis are also seen in folate deficiency, the smooth magenta-coloured tongue is commonly associated with riboflavin deficiency.



References:

Rook’s Textbook of Dermatology, 9 th Edition, Page 63.13-63.18

↑ *Back to this question in Part A*

@Neet_pg_bot

Q3: A 9-year-old child presents with a history of poor growth, intermittent episodes of confusion, and a skin rash after sun exposure. On examination, a pellagrous dermatitis rash is noted over the face, sparing eyelids, and the upper surface of the orbit, as shown in the image. Which of the following is the most likely diagnosis? (Q841740)

A. Kwashiorkor

B. Phenylketonuria

C. Hartnup disease

D. Maple syrup urine disease



Correct Answer: C. Hartnup disease

■ *Listen (English)*

■ *Listen (Hindi)*

Explanation: The above clinical presentation points towards the diagnosis of Hartnup disease, a rare autosomal recessive condition, which is marked by a faulty transport system for neutral amino acids, leading to inadequate absorption of tryptophan and subsequent niacin deficiency. Mutations in the SLC6A19 gene , which encodes a neutral amino acid transporter found in the intestine and kidneys, responsible for this condition. Clinical manifestations include cerebellar ataxia, psychiatric manifestations, aminoaciduria, and pellagra. Niacin deficiency leads to dermatitis on sun-exposed parts of the body. Management includes intake of a high-protein diet and nicotinamide supplementation. Other common causes of niacin deficiency are inadequate dietary intake, carcinoid syndrome, excess maize consumption, and treatment with isoniazid. The tetrad associated with Niacin defieceincy: Dermatitis, Diarrhea, Dementia and Death. Kwashiorkor (Option A): Kwashiorkor is a form of severe malnutrition due to a disproportionate intake of carbohydrates (energy or calories) in excess of other macronutrients, specifically proteins. Characteristic features include oedema, muscle atrophy, abdominal distension (hepatomegaly), growth retardation, flaky paint dermatosis, and flag sign. Phenylketonuria (Option B): Phenylketonuria (PKU) is an inborn error of metabolism caused by mutations in the gene encoding phenylalanine hydroxylase, which catalyzes the conversion of phenylalanine to tyrosine. It presents with delayed developmental milestones, microcephaly, hypopigmentation, hyperactivity/behaviour problems, seizures, and a musty odour to skin and urine. Maple syrup urine disease (Option D): Maple syrup urine disease is a rare inborn metabolic disorder characterized by diminished activity of the branched-chain ketoacid dehydrogenase enzyme. Its classic presentation in the neonatal period includes failure to thrive, delayed developmental milestones, feeding difficulties, and the presence of a maple syrup odor in the urine.

References:

Rook’s Textbook of Dermatology, 9thEdition, Page 63.16

Kwashiorkor - StatPearls - NCBI Bookshelf (nih.gov)

Phenylketonuria - StatPearls - NCBI Bookshelf (nih.gov)

Maple Syrup Urine Disease - StatPearls - NCBI Bookshelf (nih.gov)

↑ *Back to this question in Part A*

@Neet_pg_bot

Q4: A 6-month-old infant presents with irritability, diarrhoea, and a rash characterized by vesicles, pustules, and crusting around the mouth and anus. Which of the following conditions is most likely responsible for this presentation? (Q841742)

A. Scurvy

B. Zinc deficiency

C. Atopic dermatitis

D. Iron deficiency

Correct Answer: B. Zinc deficiency

■ *Listen (English)*

■ *Listen (Hindi)*

Explanation: The infant in this clinical vignette with diarrhoea and peri-oral and peri-genital rashes is probably suffering from Acrodermatitis enteropathica due to zinc deficiency. It is an autosomal recessive disorder caused by a mutation in the gene SLC39A4 , which encodes the intestinal zinc transporter ZIP4 on enterocytes. The characteristic clinical triad of symptoms comprises diarrhoea, dermatitis, and alopecia. It presents with eczematous rash in periorificial, peri-genital, and acral areas. Onset is usually after 6 months of age (Weaning of the child). Treated with zinc supplements. Scurvy (Option A): Scurvy is caused by vitamin C deficiency, which manifestations involve the skin and oral cavity. Symptoms include bleeding gums, easy bruising, perifollicular haemorrhages (bleeding around hair follicles), corkscrew hair, petechiae, ecchymoses, delayed wound healing, and bone and joint aches. Atopic dermatitis (Option C): Atopic dermatitis is a pruritic inflammatory skin disorder that typically begins in infancy, often before the age of 2. The rash is marked by erythema, itchy papules, or papulovesicles that can progress to become excoriated and thickened (lichenified) and frequently have a flexural distribution. {{caption_text}} Iron deficiency (Option D) Iron deficiency can result in reduced haemoglobin levels, leading to the pallor of the skin and mucous membranes. Brittle nails and Koilonychia (spoon-shaped nails) due to the thinning of nail plates can be seen. Iron deficiency may also contribute to hair loss or thinning of the hair.


@Neet_pg_bot


@Neet_pg_bot



References:

Rook’s Textbook of Dermatology, 9 th Edition, Page 41.1, 63.16, 63.25 Vitamin C Deficiency - StatPearls - NCBI Bookshelf (nih.gov)

↑ *Back to this question in Part A*

@Neet_pg_bot

Q5: A 45-year-old corporate office worker presents to the clinic after noticing the following skin changes with dull-red papules on his shin, as shown in the image. He reports no itching or pain and no history of trauma. Which of the following initial investigations would be the most relevant for confirming the diagnosis and guiding further management? (Q841743)

A. Skin biopsy

B. Fasting blood glucose

C. Haemoglobin

D. Lipid profile


@Neet_pg_bot

Correct Answer: B. Fasting blood glucose

Explanation: The image depicts the presence of asymptomatic, oval, dull-red papules over the shin with no history of trauma suggests that the patient might have Diabetic dermopathy and hence needs to be evaluated for diabetes mellitus with fasting blood glucose levels and HbA1c levels. Diabetes can lead to many skin manifestations such as Acanthosis nigricans, Diabetic dermopathy, Necrobiosis lipoidica, Granuloma annulare, Scleredema diabeticorum, Eruptive xanthomas, Bullous diabeticorum, Pruritus and diabetic bulla. Diabetic dermopathy initially presents as rounded, dull, red papules that progressively evolve over 1-2 weeks into well-circumscribed, atrophic, brown macules, which are distributed bilaterally. The pretibial area is commonly affected, but other bony prominences like forearms or lateral malleoli may also be involved. These patients often exhibit concomitant nephropathy, neuropathy, and retinopathy. Histological examination indicates that the pigmentation results from the dermal deposition of haemosiderin and melanin.


@Neet_pg_bot


@Neet_pg_bot



References:

Rook's Textbook of Dermatology, 9thEdition, Page 64.2

https://diabetes.co.in/media/uploads/2020/06/diabetic-dermopathy-pictures.jpg

↑ *Back to this question in Part A*

@Neet_pg_bot

Q6: A 38-year-old alcoholic patient presented to the OPD with atrophic scars and hyperpigmented lesions on the back of his hands, neck, face, and feet. Urine analysis revealed elevated uroporphyrin levels. On further evaluation, the patient was found to have a deficiency of uroporphyrinogen decarboxylase. What is the most likely diagnosis? (Q841745)

A. Acute intermittent porphyria

B. Erythropoietic porphyria

C. Variegate porphyria

D. Porphyria cutanea tarda



Correct Answer: D. Porphyria cutanea tarda

■ *Listen (English)*

■ *Listen (Hindi)*

Explanation: The image showing atrophic scars and hyperpigmented patches along with the uroporphyrinogen decarboxylase enzyme deficiency indicates that the likely diagnosis is Porphyria cutanea tarda (PCT). It is the most common porphyria, has a complex inheritance pattern, and is of three types: Type I (sporadic) Type II (familial) Type III The enzyme deficiency is acquired and restricted to hepatocytes due to the inhibition of a normal UROD enzyme. The enzyme deficiency is hereditary, present in all tissues, and associated with a UROD gene mutation. Rare type and is characterized by a hereditary enzyme deficiency localized to the liver. The major risk factors are subclinical genetic hemochromatosis, hepatitis C infection, alcohol , and estrogens. Patients exhibit increased fragility of light-exposed skin, presenting with painful bullae formation, subsequent crusting, and resulting in atrophic scarring, milia, and alterations in pigmentation, either hyper- or hypopigmentation. Histopathology reveals subepidermal bullae with a sparse inflammatory infiltrate and ‘festooning’ of dermal papillae into the bullae. Management includes photoprotection and eliminating the risk factors. Definitive treatment with venesection or low■dose antimalarials is required in almost all cases. Acute intermittent porphyria (Option A): Acute intermittent porphyria is a rare autosomal dominant disorder marked by hydroxymethylbilane synthase deficiency. Clinical manifestations include abdominal pain, nausea, vomiting, peripheral neuropathy, and seizures. Erythropoietic porphyria (Option B): Erythropoietic protoporphyria (EPP) is a hereditary porphyria characterized by chronic photosensitivity and occasional liver disease. It typically arises from deficient ferrochelatase activity, the final enzyme of heme biosynthesis. It manifests most commonly in the first year of life, with excruciating pains on exposure to sunlight. Variegate porphyria (Option C): It is an autosomal dominant inherited deficiency of protoporphyrinogen oxidase. Clinical manifestations include cutaneous blistering lesions (subepidermal vesicles, bullae, and erosions that crust over and heal slowly) of sun-exposed skin, especially the

hands and face.

References:

Rook’s Textbook of Dermatology, 9 th Edition, Page 60.9-60.18 Acute Intermittent Porphyria - StatPearls - NCBI Bookshelf (nih.gov)

↑ *Back to this question in Part A*

@Neet_pg_bot

Q7: A 45-year-old obese woman presents to her primary care physician with complaints of dark patches on her neck and underarms that developed gradually over the past few months. On examination, velvety hyperpigmentation is seen over the affected areas. Which of the following statements regarding this condition is not correct? (Q841747)

A. Primarily caused by excessive melanin production in the affected areas

B. It is a cutaneous marker for underlying metabolic abnormalities

C. Seen in patients with gastrointestinal cancers

D. Skin tags are commonly associated with this condition

Correct Answer: A. Primarily caused by excessive melanin production in the affected areas

■ *Listen (English)*

■ *Listen (Hindi)*

Explanation: The presence of velvety hyperpigmentation hints at the condition of Acanthosis nigricans. The pigmentation is due to hyperkeratosis; there is no increase in melanocytes or melanin production. Therefore, this statement is incorrect. Acanthosis nigricans is a velvety, darkening of the skin that usually occurs in intertriginous areas. It typically occurs in individuals younger than the age of 40 years and is associated with obesity, hypothyroidism, acromegaly, PCOS, insulin-resistant diabetes, and Cushing and Addison diseases. It manifests as asymptomatic, symmetrical darkening of the skin, particularly in the axillae, groins, sub mammary folds, and neck. Pathogenesis: Increased production of IGF-1 (Insulin-like growth factor 1). Acanthosis nigricans is of two types: Benign: Mild, localized, and associated with obesity, diabetes mellitus and other metabolic syndromes. Malignant: Rapid in onset, generalized, and associated with visceral malignancy like Adenocarcinoma of GIT (Option C). The goal of treatment is to treat the underlying disease; Keratolytics, such as topical retinoids and podophyllin can be used. It is a cutaneous marker for underlying metabolic abnormalities (Option B): This statement is correct as Acanthosis nigricans is commonly seen in associated metabolic conditions like DM, obesity, metabolic syndrome, OCP use, and insulin resistance. Skin tags are commonly associated with this condition (Option D): Acanthosis nigricans typically begins with asymptomatic darkening of the skin in the neck, axillae, and groin regions. Over time, these patches thicken and may lead to the formation of skin tags in the affected areas.



References:

Rook’s Textbook of Dermatology, 9 th Edition, Page 87.2

↑ *Back to this question in Part A*

@Neet_pg_bot

Q8: A 60-year-old woman presents with persistent unilateral nipple crusting and eczematous changes, with occasional bleeding. On examination, the affected nipple appears erythematous and flattened, with nipple retraction noted. There are no palpable breast masses. Which of the following conditions is most likely to be associated with these findings? (Q841753)

A. Eczematous dermatitis

B. Psoriasis

C. Mondor’s disease

D. Paget's disease

Correct Answer: D. Paget's disease

■ *Listen (English)*

■ *Listen (Hindi)*

Explanation: The above clinical vignette suggests that the patient is suffering from Paget's disease of the nipple. A progressive, marginated scaling or crusting of the nipple and areola due to invasion of the epidermis by malignant cells, which usually originate from an intraductal carcinoma of the breast. Unilateral eczematous lesions, with a typical well-demarcated border seen on the nipple. Biopsy shows characteristic Paget cells that are present in the stratum spinosum. Surgery should be carried out for carcinoma of the breast. Eczematous dermatitis (Option A): Typically bilateral and not associated with nipple retraction or bleeding. Can present with a scaly, itchy rash and typically does not have well-demarcated borders Psoriasis (Option B): Psoriasis is characterized by well-defined, scaly plaques but usually affects the skin elsewhere on the body and does not typically involve the nipple. Psoriasis would be characterized by hyperkeratosis, acanthosis, and Munro microabscesses, rather than the atypical Paget cells found in Paget's disease. Mondor's disease (Option C): Mondor's disease manifests as thrombophlebitis of the superficial veins of the breast and anterior chest wall. A characteristic feature is the presence of a tender, thrombosed subcutaneous cord, often adherent to the skin.

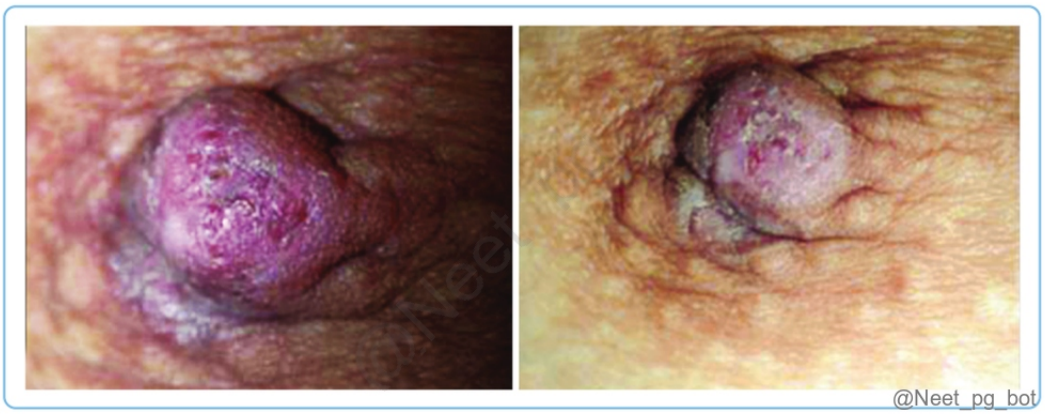

References:

Rook's Textbook of Dermatology, 9 th Edition, Page 138.40 Bailey & Love's Short Practice of Surgery 28 th Edition, Page 919

↑ *Back to this question in Part A*

@Neet_pg_bot

Q9: A 7-year-old boy has had recurrent abdominal pain, joint pain, and reddish-purple spots on his legs and buttocks for the past week. The spots don't fade when pressed, and he has swelling in his knees and ankles. He also has mild blood in his stools and had no sick contacts. What is the most likely diagnosis? (Q841754)

A. Henoch-Schönlein Purpura

B. Systemic Lupus Erythematosus

C. Rheumatic fever

D. Kawasaki disease

Correct Answer: A. Henoch-Schönlein Purpura

■ *Listen (English)*

■ *Listen (Hindi)*

Explanation: The given clinical scenario and lab investigations support the diagnosis of Henoch-Schönlein Purpura. IgA vasculitis, formerly known as Henoch-Schönlein Purpura , primarily affects the small vessels of the joints, kidneys, gastrointestinal tract, and skin. Cutaneous findings include erythematous, urticarial papules, which may evolve into palpable purpura with haemorrhage within 24 hours. This condition typically involves the extensor aspect of limbs and buttocks but can also involve the trunk, hands, and face. Renal involvement: Gross/microscopic hematuria with proteinuria. Gastrointestinal involvement: Abdominal pain, gastrointestinal bleeding. Painful arthritis. Less common manifestations include pancreatitis, orchitis, neurological abnormalities, carditis, and pulmonary haemorrhage. Biopsy reveals IgA-containing immune complexes in the walls of small blood vessels. Treatment: In children, the condition is self-limiting whereas in adults, colchicine and steroids can be given. Systemic Lupus Erythematosus (Option B): Systemic lupus erythematosus (SLE) can present with a variety of symptoms, including skin rashes and joint pain. Butterfly Rash (Malar Rash): A characteristic facial rash that appears as a butterfly-shaped erythematous rash across the cheeks and nose bridge. It often has a “slapped cheek” appearance. Discoid Rash: Chronic, disk-shaped lesions that are scaly and often appear on sun-exposed areas. These rashes can lead to scarring and are distinct from the malar rash. Rheumatic fever (Option C): Rheumatic fever is associated with a history of streptococcal throat infection and primarily affects the heart, joints, and skin (e.g., erythema marginatum). Erythema Marginatum: This is a key dermatological feature of rheumatic fever, characterized by erythematous, ring-shaped lesions with a pale center and raised edges. Kawasaki disease (Option D) Kawasaki disease typically presents with prolonged fever, erythematous rash, conjunctivitis, and mucosal changes (e.g., strawberry tongue) rather than purpura and joint swelling. It usually does not cause abdominal pain or blood in stools.



@Neet_pg_bot

References:

Rook’s Textbook of Dermatology, 9 th Edition, Page 102.13, 151.3

↑ *Back to this question in Part A*

@Neet_pg_bot

Q10: A 45-year-old woman presented to the clinic with painless nodular skin lesions on her cheeks and nose for the past three months which occasionally become tender and itchy on exposure to sunlight. She had intermittent episodes of dry cough, shortness of breath, and exercise intolerance. Chest X-ray revealed bilateral hilar lymphadenopathy. What is the most likely diagnosis? (Q841756)

A. Acne vulgaris

B. Lupus pernio

C. Rosacea

D. Lupus vulgaris

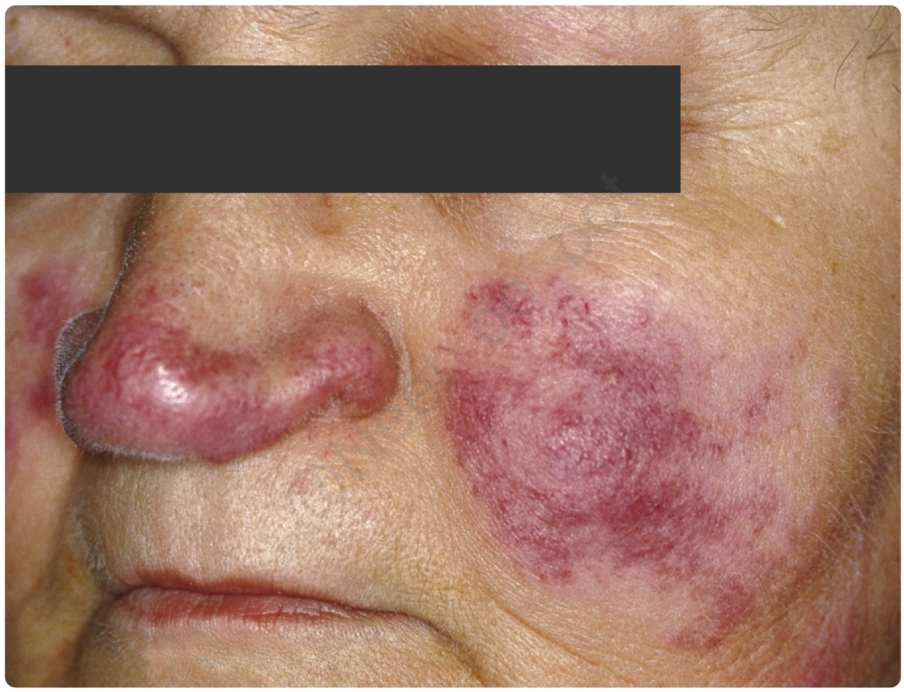

@Neet_pg_bot

Correct Answer: B. Lupus pernio

■ *Listen (English)*

■ *Listen (Hindi)*

Explanation: The clinical presentation of reddish-purple nodules along with systemic illness suggests the diagnosis of Lupus pernio which is a chronic specific cutaneous manifestation of sarcoidosis, a multisystem granulomatous disorder. Lupus Pernio: It is characterized by the presence of violaceous infiltrative plaques with telangiectasia on the convexities of the face. It is often associated with disorders of the upper respiratory tract and can also be associated with pulmonary fibrosis, chronic uveitis, and bony cysts, particularly affecting terminal phalanges. Diagnosis can be made by classical clinical findings and histopathology showing non-caseating epithelioid cell granuloma. Treatment involves topical and systemic steroids, hydroxychloroquine, and methotrexate. Acne vulgaris (Option A): It is a chronic inflammatory disease of the pilosebaceous unit. The clinical lesions include non■inflammatory open and closed comedones with or without papules, pustules, and nodules of varying degrees of inflammation and depth. Treated with retinoids and antibiotics. Rosacea (Option C): Rosacea is a common chronic inflammatory condition marked by recurrent episodes of flushing, erythema, telangiectasia, papules, or pustules. It primarily affects the nose, chin, cheeks, and forehead but spares the perioral area. It is usually triggered by certain factors like environmental temperature and other dietary factors. No pulmonary involvement or BHL. Lupus vulgaris (Option D): It represents a chronic, progressive, paucibacillary variant of cutaneous tuberculosis. The characteristic lesion manifests as a plaque, comprising soft, reddish-brown papules, exhibiting a diascopic appearance resembling apple jelly.



@Neet_pg_bot



@Neet_pg_bot



References:

Rook’s Textbook of Dermatology, 9thEdition, Page 91.1

www.ncbi.nlm.nih.gov/books/NBK557574/#article-28642.s8

↑ *Back to this question in Part A*

@Neet_pg_bot

Q11: A 38-year-old woman presents to the dermatology clinic with sudden, painful, red nodules and plaques on her neck and upper arms as shown in the image. Additionally, pseudovesicular lesions are observed. She reports experiencing fever, sore throat, nasal congestion, and malaise for the past week. Skin biopsy reveals dense neutrophilic infiltrates without evidence of vasculitis. What is the most likely diagnosis? (Q841758)

A. Behcet’s disease

B. Erythema nodosum

C. Sweet syndrome

D. Pyoderma gangrenosum



Correct Answer: C. Sweet syndrome

■ *Listen (English)*

■ *Listen (Hindi)*

Explanation: The given clinical presentation of nodules and plaques on the neck and upper arm, with neutrophilic infiltrates on biopsy, supports the diagnosis of Sweet syndrome which is also called Acute febrile neutrophilic dermatosis. It is more common in females. It is associated with: Infections: Streptococcal, URTI, GI infections (Salmonella, Yersinia) Pregnancy IBD, Sjögren's syndrome Haematological malignancies (AML) Drugs (contraceptives, propylthiouracil) It presents with fever and the sudden appearance of tender, red papules on the face, chest, and trunk; because of prominent dermal oedema, the lesions may appear pseudovesicular, but no fluid is present. Biopsy shows neutrophilic infiltrate without vasculitis is seen. Treated with steroids and potassium iodide. Behcet's disease (Option A) is less likely in this case due to the absence of characteristic recurrent oral and genital ulcers, lack of vasculitis on biopsy and the presence of pseudovesicular lesions, which are not typical of Behcet's disease. Erythema nodosum (Option B): Erythema nodosum (EN) is a common acute nodular septal panniculitis characterized by the sudden onset of erythematous, firm, solid, deep nodules or plaques that are tender and typically located on the shins; they heal without scarring. Most common triggers: Bacterial infections, Inflammatory bowel disease, URTI by group Aβ-hemolytic streptococcus, and Tuberculosis It is also associated with Lofgren's syndrome, an acute form of sarcoidosis. Pyoderma gangrenosum (Option D): It is also a neutrophilic dermatosis but not a bacterial infection (misnomer) and is associated with diseases like Rheumatoid arthritis and IBD. The patient presents with painful papules or lesions on the lower limbs that break down to form ulcers that have a violaceous undermined margin. Pathergy test is positive and heals with atrophic cribriform scarring.



References:

Rook’s Textbook of Dermatology, 9 th Edition, Page 49.6, 99.18, 48.3-48.7

↑ *Back to this question in Part A*

@Neet_pg_bot

Q12: Pathergy test is positive in all except? (Q841767)

A. Psoriasis

B. Crohn’s disease

C. Behcet’s disease

D. Genital herpes infection

Correct Answer: A. Psoriasis

■ *Listen (English)*

■ *Listen (Hindi)*

Explanation: Psoriasis shows Koebner’s phenomenon, not positive pathergy. Koebner phenomenon (Isomorphic phenomenon) Pathergy It refers to the development of new lesions of the original disease at sites of skin injury or trauma (scratches, cuts, burns, or even friction) Pathergy-induced lesions typically manifest as non-specific papules or pustules or enlargement of pre-existing wounds, occurring at sites of minor trauma. Koebner’s phenomenon is positive in Psoriasis Lichen planus Vitiligo Pathergy test is positive in Bechet's disease Pyoderma gangrenosum Rheumatoid arthritis Crohn's disease Genital herpes infection Pathergy test: A positive pathergy test

indicates hyperreactivity, which is manifested as an erythematous papule or pustule (>2 mm) within 48 hours of a skin needle prick or intracutaneous injection of 0.1 mL isotonic salt solution. The prick is typically made at a 45-degree angle, 3–5 mm, intracutaneously on the volar forearm. Erythema without infiltration is considered negative. Histopathologically, a monocytic infiltrate is often observed at the positive site.



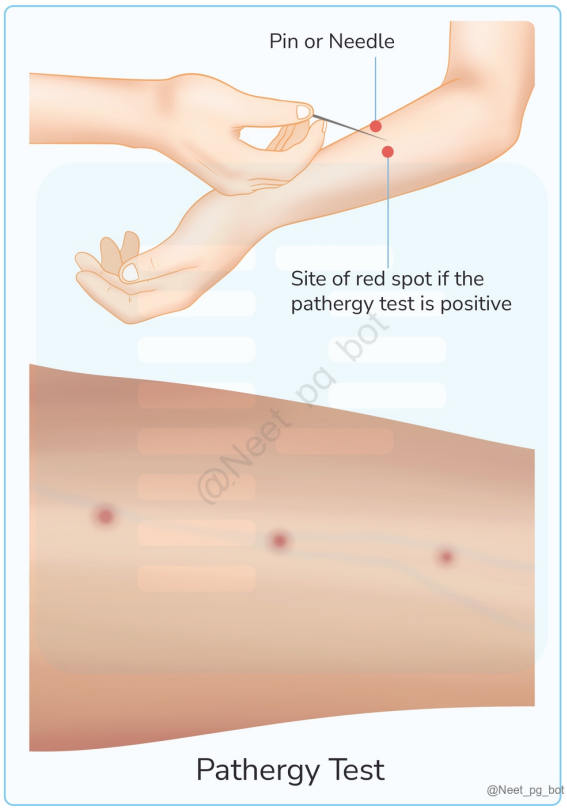

References:

Rook's Textbook of Dermatology, 9 th Edition, Page 48.1

↑ *Back to this question in Part A*

@Neet_pg_bot

Q13: A 25-year-old woman presents to the clinic with painful, raised lesions on her lower legs. Upon examination, tender, erythematous nodules ranging from 1 to 5 cm in diameter as shown in the image are noted bilaterally on the anterior aspects of her shins and are warm to the touch. She had a history of recent upper respiratory symptoms and fatigue. What is the most likely diagnosis? (Q841768)

A. Erythema marginatum

B. Erythema multiforme

C. Erythema nodosum

D. Erythema migrans



Correct Answer: C. Erythema nodosum

- *Listen (English)*
- *Listen (Hindi)*

Explanation: Based on the clinical features and the provided image, the most likely diagnosis is Erythema nodosum. Erythema nodosum is a type of septal panniculitis characterized by the abrupt onset of bilaterally symmetrical, erythematous, firm, subcutaneous nodules or plaques that are tender and predominantly localized on the extensor surfaces of the lower extremities. It is symptomatic, acute in onset, and self-limiting but it can recur. The most common triggers are: Bacterial infections (Streptococcus) Sarcoidosis, TB, IBD URTI by group A β-hemolytic streptococcus (common in children and young adults) Biopsy (confirmatory) shows septal panniculitis without vasculitis and Miescher's radial granulomas. Treatment includes leg elevation, NSAIDS, and colchicine; Steroids are not given. Erythema marginatum (Option A): It presents as an annular rash that typically appears on the trunk, inner aspects of the upper arms, and thighs but seldom on the face. It is non-painful and non-pruritic and commonly occurs in children. The rash is transient, blanches under pressure, and exhibits migratory patterns across the body, lasting from hours to several days. Associated with Rheumatic fever (1–18% of cases). Erythema multiforme (Optio n B): It is a self-limiting cytotoxic dermatitis stemming from cell-mediated hypersensitivity, most frequently induced by medications (NSAIDs, sulfonamides, antiepileptics) or infections like HSV (most common) and Mycoplasma pneumoniae. Clinically, it presents with a variety of macular, papular, or urticarial lesions, along with the characteristic acral iris or "target lesions." These lesions may involve the palms, trunk, and mucous membranes of the oral and genital regions, often associated with erosions. The image shows the ‘target lesion’ (3 zones: Central dusky erythema, surrounded by a pale edematous ring which is in turn surrounded by an erythematous halo). Erythema migrans (Option D) It represents an initial cutaneous manifestation of Lyme disease, typically appearing at the site of a tick bite. A central spot surrounded by clear skin that is in turn ringed by an expanding red rash is the most typical appearance.



@Neet_pg_bot



@Neet_pg_bot



References:

Rook's Textbook of Dermatology, 9 th Edition, Page 47.1, 47.11-16, 99.1 Management (erythema migrans) - Evidence review for the management of erythema migrans - NCBI Bookshelf (nih.gov)

↑ *Back to this question in Part A*

@Neet_pg_bot

Q14: A 37-year-old male presents to the clinic with complaints of redness in the eyes, along with joint pain and stiffness. Further history revealed that he had vomiting and diarrhea one week back. On examination, erosions are seen on the glans penis. Which of the following is the most likely diagnosis? (Q841769)

A. Rheumatoid arthritis

B. Systemic lupus erythematosus

C. Reiter's disease

D. Ankylosing spondylitis

Correct Answer: C. Reiter's disease

■ *Listen (English)*

■ *Listen (Hindi)*

Explanation: The triad of polyarthritis, urethritis, and conjunctivitis, suggests that the patient has Reiter’s disease which is also known as Reactive arthritis. It is usually preceded by a gastrointestinal or lower genital tract infection. The triggers include: GI infection: Shigella, Yersinia, Campylobacter Chlamydia trachomatis HIV HLA association: HLA-B27, HLA-B51 Reactive arthritis has 2 skin manifestations: Keratoderma Blennorrhagicum Circinate Balanitis Small vesicles on the hand/palms, covered by hyperkeratotic heaped-up crusts. Moist, well-defined erosions with a slightly raised micro pustular circinate border on the glans penis. It is not as painful as herpes. Renal involvement is usually asymptomatic but sometimes presents with proteinuria, microscopic haematuria, and aseptic pyuria. Treated with topical steroids (first line), methotrexate, and acitretin (in HIV patients). Rheumatoid arthritis (Option A): Rheumatoid arthritis (RA) is a systemic autoimmune disease characterized by inflammatory arthritis and extra-articular involvement, like rheumatoid nodules. Rheumatoid nodules are firm, non-tender subcutaneous nodules that typically develop over pressure points or areas of repeated trauma, such as the elbows, fingers, heels, and occiput. Systemic lupus erythematosus (Option B): SLE is a systemic condition marked by inflammation of multiple organs, typically affecting the skin, joints, and blood vessels, accompanied by immune system irregularities. Malar rash, or butterfly rash, is a characteristic rash that appears over the cheeks and bridge of the nose and is often associated with photosensitivity. Nonscarring alopecia may occur in individuals with SLE. Ankylosing spondylitis (Option D) Ankylosing spondylitis is a persistent inflammatory condition primarily affecting the axial spine. The predominant symptoms include chronic back pain and gradual restriction of spinal mobility.





@Neet_pg_bot



@Neet_pg_bot

References:

Rook’s Textbook of Dermatology, 9 th Edition, Page 112.17, 55.1, 51.14

↑ *Back to this question in Part A*

@Neet_pg_bot

Q15: A 45-year-old female presents to the OPD with nodular skin lesions on dorsum of hand. She also gives a history of morning stiffness lasting for about an hour. Examination reveals multiple non-tender firm subcutaneous swellings over several metacarpals (as shown in the image), the left wrist, and both knees. Which of the following statements regarding the patient's condition is incorrect? (Q841771)

A. More common in patients positive for HLA-DR4

B. Rituximab causes accelerated rheumatoid nodulosis

C. Nodules are painless in nature

D. Commonly found on extensor surfaces



Correct Answer: B. Rituximab causes accelerated rheumatoid nodulosis

■ *Listen (English)*

■ *Listen (Hindi)*

Explanation: The image shown above of rheumatoid nodules, along with the clinical history of morning stiffness, suggests that the patient is suffering from Rheumatoid arthritis. Methotrexate causes accelerated rheumatoid nodulosis, not Rituximab. Rheumatoid nodules are palpable subcutaneous nodules, often multiple, and are present in over 20% of individuals with Rheumatoid arthritis, particularly in males, those with seropositive disease, and patients with HLA-DR4 positivity (Option A is true) Typically asymptomatic, they are commonly found on extensor surfaces like the elbows and knees, as well as areas prone to repetitive trauma like sacrum, buttocks, or heels (Options C and D are true) These nodules are firm in consistency and may ulcerate with trauma, particularly on the sacrum, potentially eroding underlying bone. In some cases, nodules may precede the onset of RA by several years. Histologically, they exhibit characteristic palisading granuloma surrounding a central region of fibrinoid necrosis. Diagnosis is by measurement of anti■citrullinated peptide antibodies (more specific) and rheumatoid factor. Treatment often involves Rituximab, but drugs like Methotrexate can exacerbate the condition, leading to accelerated rheumatoid nodulosis characterized by rapidly progressive painful nodules on previously unaffected sites.



References:

Rook’s Textbook of Dermatology, 9 th Edition, Page 154.6

↑ *Back to this question in Part A*

@Neet_pg_bot

• [11_Systemic Diseases and Skin] 023 Previous Year Questions

« Back to Folder Directory

[11_Systemic Diseases and Skin] 023 Previous Year Questions — Quick Jump

Q1 (p. 1136) *Q2 (p. 1137)* *Q3 (p. 1139)* *Q4 (p. 1139)* *Q5 (p. 1140)* *Q6 (p. 1142)*
Q7 (p. 1143) *Q8 (p. 1144)*

Q1: A baby presents with chronic diarrhea and a rash resembling acrodermatitis on the skin. Based on the clinical picture, what is the most likely deficiency? (Q852571)

A. Zinc deficiency

B. Selenium deficiency

C. Niacin deficiency

D. Magnesium deficiency



Correct Answer: A. Zinc deficiency

Explanation: Zinc deficiency can lead to acrodermatitis enteropathica , a rare genetic disorder that presents with: Chronic diarrhea Periorificial and acral dermatitis (rash around the mouth, hands, feet, and perineal area) Alopecia Failure to thrive and immune dysfunction It occurs due to impaired zinc absorption and can also be seen in cases of inadequate dietary intake or prolonged parenteral nutrition without zinc supplementation. Other Options: Selenium deficiency (Option B) : Causes cardiomyopathy (Keshan disease) and muscle weakness , but not chronic diarrhea or acrodermatitis. Niacin deficiency (Option C) : Leads to pellagra , which is characterized by the "3

D’s"— diarrhea, dermatitis, and dementia —but the rash is typically photosensitive , unlike acrodermatitis.
Magnesium deficiency(Option D) : Presents with neuromuscular symptoms like tetany, seizures, and arrhythmias rather than a characteristic rash and chronic diarrhea.

References:

Rook’s Textbook of Dermatology 9 th edition - page 41.1, 63.16, 63.25
https://www.ncbi.nlm.nih.gov/books/NBK493187/#article-28798.s7

↑ *Back to this question in Part A*

@Neet_pg_bot

Q2: A 7-year-old boy is brought to the pediatric clinic by his parents with complaints of multiple soft, pedunculated masses scattered across his torso and limbs. The parents mention that the child has recently developed some difficulty in reading and learning. Upon examination, the child has hyperpigmented macules with irregular borders on his back, and the ocular exam shows the findings below. What is the most likely diagnosis for this child? (Q860113)

A. NF2

B. TSC1

C. TSC2

D. NF1

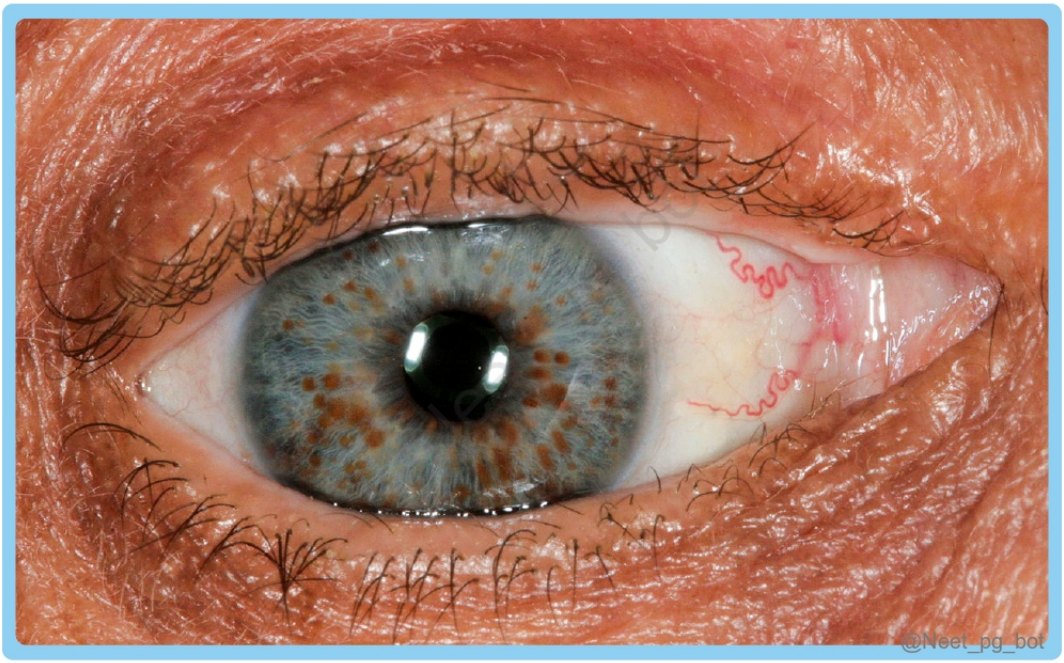

Correct Answer: D. NF1

Explanation: The child presents with: Multiple soft, pedunculated masses → Likely neurofibromas Hyperpigmented macules with irregular borders → Café-au-lait spots Ocular findings (likely Lisch nodules on iris examination) Learning difficulties These findings are characteristic of Neurofibromatosis Type 1 (NF1), an autosomal dominant disorder caused by a mutation in the NF1 gene on chromosome 17, which encodes neurofibromin (a tumor suppressor protein). Neurofibromatosis Type 1 (NF1) Incidence: 1 in 3,000 live births. Inheritance: 50% of cases are inherited from a parent. 50% due to spontaneous mutations. Genetics: Autosomal dominant loss-of-function mutations in the NF1 gene on chromosome 17q11.2. The gene encodes neurofibromin, which inhibits the oncogene Ras. Diagnosis Criteria (Two or more required) Feature Description Café-au-lait macules (CALMs) >5 mm in prepubertal, >15 mm in postpubertal. 6 or more needed for diagnosis Axillary/Inguinal Freckling Multiple hyperpigmented areas, 2-3 mm in diameter. Iris Lisch Nodules Hamartomas in the iris, best seen with a slit-lamp. 2 or more needed for diagnosis Neurofibromas Two or more neurofibromas or one plexiform neurofibroma. Osseous Lesion Sphenoid dysplasia or cortical thinning of long bones. Congenital pseudarthrosis of the tibia. Optic Gliomas CNS tumor affecting the optic nerve. Family History First-degree relative with an NF1 diagnosis based on these criteria. Management Regular Monitoring: Treatment Considerations: Avoid routine brain/optic tract imaging unless symptomatic. Selumetinib: Effective in children with inoperable plexiform neurofibromas . Neuropsychological and Educational Support. Genetic Counseling Inheritance: Autosomal dominant; over 50% of cases are de novo mutations. Molecular Testing: Useful in cases with unclear clinical diagnosis or severe disease. Prenatal/preimplantation diagnosis may be considered. NF2 (Neurofibromatosis Type 2) (Option A): NF2 is associated with bilateral vestibular schwannomas , hearing loss, and juvenile cataracts , rather than café-au-lait spots and Lisch nodules. It is caused by a mutation in the NF2 gene (Merlin protein) on chromosome 22 . TSC1 (Tuberous Sclerosis Complex 1) (Option B): TSC1 is associated with hamartomas, facial angiofibromas, hypopigmented “ash-leaf” macules, and cortical tubers , not café-au-lait spots and neurofibromas. It is due to a mutation in the TSC1 gene (hamartin) on chromosome 9 . TSC2 (Tuberous Sclerosis Complex 2) (Option C): Similar to TSC1, TSC2 presents with hypopigmented macules, facial angiofibromas, and neurological issues like epilepsy but is due to a mutation in the TSC2 gene (tuberin) on chromosome 16 .

References:

Nelson Textbook of Pediatrics, Ed.21 Pg 3140- 3134, 3142-3 https://www.ncbi.nlm.nih.gov/pmc/articles/PMC3543877/#:~:text=Congenital%20pseudarthrosis%20of%20the%20tibia%20(CPT)%20is%20a%20rare%20pathology,the%20lesion%20to%20heal%20spontaneously .

↑ *Back to this question in Part A*

@Neet_pg_bot

Q3: Match the Incubation periods of the following diseases: a. Syphilis 1. 16 days b. SARS 2. 90 days c. Hepatitis A 3. 6 days d. Chickenpox 4. 28 days (Q857416)

A. a-3, b-4, c-2, d-1

B. a-2, b-3, c-1, d-4

C. a-4, b3-, c-1, d-2

D. a-2, b-3, c-4, d-1

Correct Answer: D. a-2, b-3, c-4, d-1

Explanation: Disease Incubation period a. Syphilis 2. 90 days b. SARS 3. 6 days c. Hepatitis A 4. 28 days d. Chickenpox 1. 16 days

References:

https://www.ncbi.nlm.nih.gov/books/NBK534780/

https://www.who.int/news-room/fact-sheets/detail/hepatitis-a

https://www.who.int/health-topics/severe-acute-respiratory-syndrome#:~:text=The%20incubation%20period%20of%20SARS,headache%2C%20malaise%20and%20muscle%20pain.

https://www.ncid.sg/Health-Professionals/Diseases-and-Conditions/Pages/Chickenpox.aspx

↑ *Back to this question in Part A*

@Neet_pg_bot

Q4: Which of the following mineral deficiency is associated with poor wound healing, dermatitis, diarrhoea and alopecia? (Q857978)

A. Iron

B. Calcium

C. Magnesium

D. Zinc

Correct Answer: D. Zinc

Explanation: : Incorrect because iron deficiency causes anemia, fatigue, koilonychia, and glossitis , not dermatitis and diarrhea. Calcium (Option B): Incorrect because calcium deficiency leads to tetany, muscle spasms, and osteomalacia , not alopecia or poor wound healing. Magnesium (Option C): Incorrect because magnesium deficiency causes neuromuscular excitability, tremors, and cardiac arrhythmias , not dermatitis or alopecia.

References:

Vasudevan 7th edition , pg no 497, 522

↑ *Back to this question in Part A*

@Neet_pg_bot

Q5: A 50-year-old patient presents with the following skin lesions characterized by red and scaly patches. The patient also complains of a painful and swollen finger joint. On examination, the finger joint appears inflamed and tender to touch. What is the most likely diagnosis for this patient's condition? (Q857979)

A. Psoriatic Arthritis

B. Pseudo gout

C. Osteoarthritis

D. Reactive arthritis



Correct Answer: A. Psoriatic Arthritis

Explanation: : Incorrect because pseudo gout presents with acute monoarthritis (e.g., knee) due to calcium pyrophosphate deposition , but does not cause dactylitis or skin lesions. Osteoarthritis (Option C): Incorrect because OA affects weight-bearing joints, spares DIP, and lacks systemic inflammation like psoriasis. Reactive Arthritis (Option D): Incorrect because reactive arthritis follows an infection (e.g., GI or GU) and presents with conjunctivitis, urethritis, and arthritis (Reiter's syndrome) , but lacks dactylitis and psoriasis.



References:

Apley and Solomon’s System of Orthopaedics and Trauma, 10th Edition, Page 78.

Psoriasis: Overview and Diagnosis - PMC (nih.gov)

Psoriatic Arthritis - StatPearls - NCBI Bookshelf (nih.gov)

↑ *Back to this question in Part A*

@Neet_pg_bot

Q6: A child with a history of night-blindness presented to you with the following findings. What is the diagnosis? (Q855933)

A. Phrynoderma

B. Keratosis pilaris

C. Darier disease

D. Follicular eczema



Correct Answer: A. Phrynoderma

Explanation: Clinical Presentation: History of night blindness (suggests vitamin A deficiency). Follicular hyperkeratotic papules , typically on extensor surfaces. Classic Appearance: Resembles "toad skin" (hence, phrynoderma). Associated with malnutrition and vitamin A deficiency . Most Likely Diagnosis: Phrynoderma (Follicular hyperkeratosis due to vitamin A deficiency) . {{caption_text}} Phrynoderma (Vitamin A Deficiency)

Feature Details Definition Follicular hyperkeratosis due to Vitamin A deficiency Causes Malnutrition, fat malabsorption, chronic diarrhea Clinical Features Keratotic papules on extensor surfaces, rough skin, night blindness Diagnosis Clinical, serum Vitamin A levels Treatment Vitamin A supplementation, improved nutrition Keratosis pilaris (Option B): Incorrect because it is a benign genetic condition without a history of vitamin A deficiency . Darier disease (Option C): Incorrect because it presents with greasy crusted papules , not vitamin A-related follicular hyperkeratosis . Follicular eczema (Option D): Incorrect because eczema is associated with itching, scaling , and lichenification , not night blindness.



References:

https://pubmed.ncbi.nlm.nih.gov/16918630/

https://pmc.ncbi.nlm.nih.gov/articles/PMC1995140/

↑ *Back to this question in Part A*

@Neet_pg_bot

Q7: A female patient with a body mass index of 30 kg/m2 presents to you with a lesion on the neck, as shown below. Which of the following conditions is the most likely to be suffering from? (Q855913)

A. Hypothyroidism

B. Metabolic syndrome

C. Addision’s disease

D. Hyperparathyroidism



Correct Answer: B. Metabolic syndrome

Explanation: Clinical Presentation: The image shows velvety, hyperpigmented thickening of the skin , likely Acanthosis Nigricans (AN) . It is commonly seen in patients with obesity (BMI 30 kg/m²) and insulin resistance . Metabolic Syndrome Association: Acanthosis nigricans is strongly linked to insulin resistance , which is a key component of metabolic syndrome . Metabolic Syndrome = Central obesity + Insulin resistance + Hypertension + Dyslipidemia . Metabolic Syndrome & Acanthosis Nigricans Feature Metabolic Syndrome Key Components Insulin resistance, obesity, hypertension, hyperlipidemia Clinical Signs Acanthosis nigricans, central obesity, skin tags Pathophysiology Chronic hyperinsulinemia stimulates epidermal growth, leading to Acanthosis Nigricans Associated Risks Type 2 diabetes, cardiovascular disease Management Lifestyle changes (weight loss, exercise), Metformin Hypothyroidism (Option A): Incorrect because it causes dry skin, myxedema, and weight gain, but not Acanthosis Nigricans . Addison's Disease (Option C): Incorrect because it causes generalized hyperpigmentation due to ACTH excess, not localized velvety thickening . Hyperparathyroidism (Option D): Incorrect because it presents with hypercalcemia, bone pain, and kidney stones, but not Acanthosis Nigricans .

References:

Rook's Textbook of Dermatology 9 th edition - page 64.2, 87.2

↑ *Back to this question in Part A*

@Neet_pg_bot

Q8: Which of the following mineral deficiency is associated with poor wound healing, dermatitis, diarrhoea and alopecia? (Q820232)

A. Iron

B. Calcium

C. Magnesium

D. Zinc

Correct Answer: D. Zinc

Explanation: Correct Option D - Zinc Zinc deficiency can indeed cause poor wound healing, dermatitis (inflammation of the skin), diarrhea, and alopecia (hair loss). Zinc is essential for immune function, wound healing, and maintaining healthy skin and hair. Incorrect Options: Option A - Iron: Iron deficiency is associated with anemia, fatigue, weakness, and pale skin. It can lead to reduced oxygen transport in the body, causing symptoms like tiredness, shortness of breath, and cold extremities. Option B - Calcium: Calcium deficiency can result in weak bones, brittle nails, and muscle cramps. It's crucial for maintaining bone health and proper muscle function. Option C - Magnesium: Magnesium deficiency may lead to muscle spasms, irregular heartbeat, and weakness. It plays a role in nerve transmission and muscle contraction.

↑ *Back to this question in Part A*

@Neet_pg_bot

• [12_Cutaneous Infections] 024 Previous Year Questions

« Back to Folder Directory

[12_Cutaneous Infections] 024 Previous Year Questions — Quick Jump

Q1 (p. 1146) *Q2 (p. 1147)* *Q3 (p. 1148)* *Q4 (p. 1149)* *Q5 (p. 1151)* *Q6 (p. 1152)*
Q7 (p. 1153) *Q8 (p. 1156)* *Q9 (p. 1158)* *Q10 (p. 1159)* *Q11 (p. 1160)* *Q12 (p. 1162)*
Q13 (p. 1164) *Q14 (p. 1165)* *Q15 (p. 1168)* *Q16 (p. 1171)*

Q1: Identify the finding shown in the image below: (Q854902)

A. Herpes labialis

B. Herpangina

C. Molluscum contagiosum

D. Impetigo



Correct Answer: A. Herpes labialis

Explanation: Herpes labialis, commonly known as cold sores or fever blisters, is a viral infection caused by the herpes simplex virus type 1 (HSV-1). The characteristic presentation of multiple vesicles and crusts clustered on an inflamed base around the lips is indicative of a herpes simplex virus infection. Occurs on the vermillion border of lips. Recurrent outbreaks are common, often triggered by factors such as stress, sun exposure, or fever. Incorrect

Options: Herpangina (Option B) : It typically presents as small, painful ulcers or vesicles on the back of the throat, soft palate, or tonsillar pillars. Molluscum contagiosum (Option C): It typically presents as small, raised, dome-shaped papules with a central indentation (umbilication). The lesions are usually flesh-colored Impetigo (Option D): It commonly presents as honey-colored crusts or bullae on an erythematous base.

References:

Reference: Illustrated Synopsis of Dermatology and Sexually Transmitted Diseases, Fifth Edition – Neena Khanna Pg 298

↑ *Back to this question in Part A*

@Neet_pg_bot

Q2: A female patient presented with acne that is not resolving on oral isotretinoin and antibiotics therapy. Which of the following is the next best investigation? (Q855281)

A. Look for dietary triggers

B. Evaluate for hyperandrogenism

C. Check for antibiotic resistance

D. Look for drug triggers

Correct Answer: B. Evaluate for hyperandrogenism

Explanation: The patient presents with acne that is not responding to oral isotretinoin and antibiotics, which suggests that a more systemic or hormonal cause could be contributing to the acne. Hyperandrogenism is commonly associated with conditions like polycystic ovary syndrome (PCOS) and congenital adrenal hyperplasia (CAH) , both of which can lead to increased sebum production and hormonal imbalances , exacerbating acne. Evaluating for hyperandrogenism through tests like testosterone levels , dehydroepiandrosterone sulfate (DHEAS) , and other hormonal markers is crucial to rule out these underlying causes. Hyperandrogenism is when the body produces too much androgen, a male hormone. This can contribute to the development of acne in women and other symptoms such as hirsutism and irregular periods. Treatment may involve medications such as oral contraceptives or anti-androgen drugs. Look for dietary triggers (Option A): Acne can be affected by diet in some people, particularly those with a high glycemic index or a diet high in dairy products. However, this is typically considered after other causes of acne have been ruled out. Additionally, dietary changes may not be sufficient to treat acne on their own, but rather they can be used in conjunction with other treatments. Check for antibiotic resistance (Option C): Antibiotics are often used to treat acne, but over time, the bacteria that causes acne can become resistant to the antibiotics. If a patient's acne is not improving with antibiotics, checking for antibiotic resistance can help determine if a different treatment approach is needed. Look for drug triggers (Option D): Certain medications can contribute to the development of acne. For example, corticosteroids, anticonvulsants, and some hormonal medications can cause acne as a side effect. If a patient takes any medications that may increase the risk of acne, it is important to evaluate their treatment plan and consider alternative medications if necessary.

References:

Rooks’s Textbook of Dermatology 9th edition, 90.1

↑ *Back to this question in Part A*

@Neet_pg_bot

Q3: A 45 year old male patient from Bihar presented with normoanesthetic hypopigmented lesion as shown below. He had a history of fever for a long duration in his childhood. No thickened nerves were present. What is the probable diagnosis? (Q855521)

A. Tuberculoid leprosy

B. Lepromatous leprosy

C. Mycosis fungoides

D. Post kala-azar dermal leishmaniasis

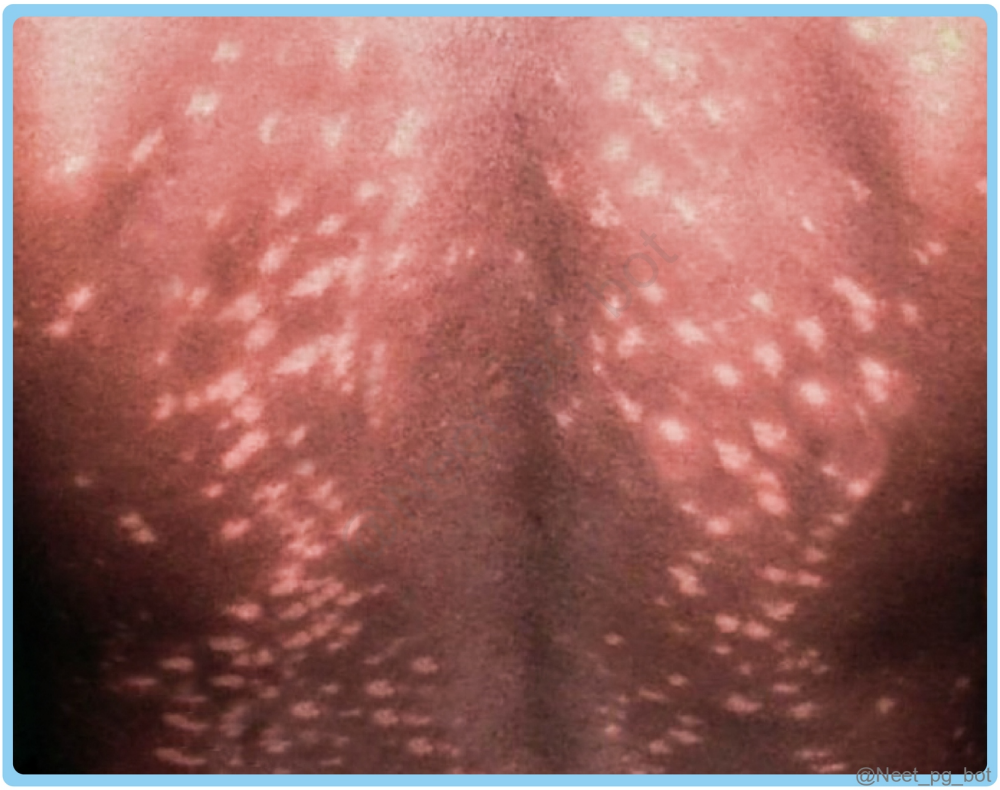

Correct Answer: D. Post kala-azar dermal leishmaniasis

Explanation: The patient is from Bihar, an endemic region for visceral leishmaniasis (kala-azar) . The image shows multiple hypopigmented macules over the back, characteristic of PKDL . History of prolonged fever in childhood

suggests prior kala-azar infection , which is a prerequisite for developing PKDL. No thickened nerves rule out leprosy. Post Kala-Azar Dermal Leishmaniasis (PKDL): PKDL is a chronic dermal complication of visceral leishmaniasis caused by Leishmania donovani . Endemic in India, Nepal, and Sudan , especially in Bihar, West Bengal, and Uttar Pradesh . Clinical Features: Occurs months to years after treated visceral leishmaniasis . Hypopigmented macules, erythematous papules, or nodules on the face, trunk, and extremities. No loss of sensation or thickened nerves (differentiating from leprosy). Histopathology: Presence of Leishman-Donovan (LD) bodies . Diagnosis: Slit-skin smear or skin biopsy showing Leishmania donovani bodies . PCR or rK39 serology can confirm diagnosis. Management: First-line treatment: Miltefosine for 12 weeks. Alternatives: Liposomal amphotericin B or paromomycin . Tuberculoid leprosy (Option A) is incorrect because it presents with single or few hypopigmented macules with loss of sensation . Thickened peripheral nerves are a hallmark feature, which is absent in this case. Lepromatous leprosy (Option B) is incorrect because it presents with multiple ill-defined hypopigmented macules with symmetric distribution . Thickened nerves and sensation loss are typical, but they are absent in this patient . Mycosis fungoides (Option C) is incorrect because it presents as erythematous scaly plaques rather than hypopigmented macules . It is a form of cutaneous T-cell lymphoma , which is not related to prior fever or endemic infections .

References:

Post Kala-Azar Dermal Leishmaniasis: Clinical Features and Differential Diagnosis - PMC

↑ *Back to this question in Part A*

@Neet_pg_bot

Q4: What is the appropriate next course of action for a child who exhibits itchy scalp lesions and hair loss, as depicted in the image provided? (Q855655)

A. KOH mount

B. Slit skin mount

C. Gram staining

D. Biopsy



Correct Answer: A. KOH mount

Explanation: The image depicts a scaly, inflamed, well-demarcated lesion on the scalp with hair loss , suggestive of Tinea Capitis (scalp ringworm) . KOH (potassium hydroxide) mount is the gold standard for diagnosing superficial fungal infections , including Tinea Capitis , by detecting fungal hyphae in hair shafts and skin scrapings. Tinea Capitis: Caused by: Trichophyton and Microsporum species. Common in children , especially in warm, humid climates . Types: Non-inflammatory: Scaly patches with broken hairs . Inflammatory (Kerion): Painful, boggy swelling with pustules and crusting (as seen in the image). Diagnosis: KOH Mount: Detects fungal hyphae in hair shafts and skin scrapings . Fungal Culture: Confirms the fungal species. Wood's Lamp Examination: Fluorescence in Microsporum infections. Management: Systemic antifungals (Griseofulvin or Terbinafine) for 6–8 weeks (topical antifungals alone are ineffective). Antifungal shampoos (ketoconazole or selenium sulfide) reduce fungal shedding . Kerion cases may need corticosteroids to reduce inflammation. Slit Skin Mount (Option B) is incorrect because it is used for leprosy diagnosis by identifying acid-fast bacilli from skin lesions, which is not relevant in this case. Gram Staining (Option C) is incorrect because it is useful for diagnosing bacterial infections (e.g., impetigo, folliculitis) but not fungal infections like Tinea Capitis . Biopsy (Option D) is incorrect because skin biopsy is rarely needed for diagnosing Tinea Capitis and is usually reserved for atypical or unclear cases .

References:

Rook's Textbook of Dermatology. 9th ed. Blackwell; 2016. p. 89.10 -86.47.-89.24

↑ *Back to this question in Part A*

@Neet_pg_bot

Q5: What is the probable diagnosis for a young man who has presented with painful lesions depicted in the image below? (Q855658)

A. Herpes Zoster

B. Molluscum contagiosum

C. Herpes simplex

D. Lymphangioma circumscriptum



Correct Answer: A. Herpes Zoster

Explanation: The image shows a unilateral, dermatomal eruption of grouped vesicles on an erythematous base . The patient has painful lesions , which is a key feature of Herpes Zoster (Shingles) . The lesions appear in a band-like distribution , following the sensory nerve dermatome . Herpes Zoster (Shingles): Cause: Reactivation of Varicella-Zoster Virus (VZV) in the dorsal root ganglion. Risk Factors: Immunosuppression (HIV, malignancies) Elderly individuals Stress and trauma Clinical Features: Painful, grouped vesicles on an erythematous base in a unilateral dermatomal pattern . Pre-eruptive phase (burning, tingling pain) 48–72 hours before rash onset. Thoracic dermatomes are most commonly involved. Postherpetic neuralgia (persistent pain after healing) may develop in older adults. Diagnosis: Clinical, confirmed by Tzanck smear (multinucleated giant cells) or PCR for VZV DNA . Treatment: Antiviral therapy (Acyclovir, Valacyclovir) within 72 hours of rash onset. Analgesics for pain control. Corticosteroids in severe cases. Molluscum Contagiosum (Option B) is incorrect because Molluscum contagiosum presents as small, umbilicated, pearly white papules , not as vesicular eruptions . It is usually asymptomatic and not painful . Herpes Simplex (Option C) is incorrect because Herpes simplex virus (HSV) causes clusters of vesicles but does not usually follow a dermatomal distribution . HSV infections typically affect the oral (HSV-1) or genital (HSV-2) regions rather than the thoracic dermatomes . Lymphangioma Circumscriptum (Option D) is

incorrect because lymphangioma circumscriptum is a benign lymphatic malformation , presenting as clusters of small, translucent vesicles ("frog spawn" appearance) . It is not painful and does not appear in a dermatomal pattern .

References:

Ananthanarayan and Paniker's Textbook of Microbiology, 10th Edition, Pages 478, 479.

↑ *Back to this question in Part A*

@Neet_pg_bot

Q6: A 60-year-old male patient presents with the lesion given in the image below. He also mentions experiencing sensations like a spider crawling in the area of the lesion. Which of the following is the most likely diagnosis? (Q855741)

A. Herpes zoster infection

B. Irritant contact dermatitis

C. Allergic contact dermatitis

D. Herpes simplex infection



@Neet_pg_bot

Correct Answer: A. Herpes zoster infection

Explanation: The image shows a dermatomal distribution of grouped vesicles on an erythematous base, which is characteristic of Herpes zoster (shingles) . The patient reports paresthesia ("spider crawling sensation") , a common prodromal symptom due to viral reactivation affecting sensory nerves. The lesion pattern is unilateral , consistent with reactivation of Varicella-zoster virus (VZV) from dorsal root ganglia. Herpes Zoster: Feature Details Etiology Reactivation of Varicella-Zoster Virus (VZV) from latency in sensory ganglia. Risk Factors Immunosuppression, aging (>50 years), stress, malignancy, chronic diseases (diabetes). Clinical Features Painful, grouped vesicles on an erythematous base along a single dermatome (usually thoracic, lumbar, or trigeminal). Prodromal Symptoms Burning, tingling, paresthesia ("spider crawling sensation") , fever, malaise before rash appears. Complications Postherpetic neuralgia (PHN), bacterial superinfection, ophthalmic zoster (if V1 of trigeminal nerve is involved). Diagnosis Clinical; Tzanck smear (multinucleated giant cells), PCR for VZV in doubtful cases. Treatment Antiviral therapy (acyclovir, valacyclovir, famciclovir) within 72 hours , analgesics, corticosteroids (if severe pain). Prevention Zoster vaccine for elderly and immunocompromised individuals. Irritant contact dermatitis (Option B) is incorrect because it results from direct skin damage due to chemical exposure , leading to erythema, scaling, and burning , rather than a vesicular dermatomal rash with neuropathic pain. Allergic contact dermatitis (Option C) is incorrect because it is a delayed hypersensitivity reaction (Type IV), presenting as itchy, erythematous, and vesicular plaques in areas of contact , but lacks dermatomal distribution and prodromal neuralgia . Herpes simplex infection (Option D) is incorrect because HSV causes grouped vesicles on an erythematous base , but these typically appear around the mouth (HSV-1) or genital region (HSV-2) and do not follow a dermatomal pattern .

References:

Ananthanarayan and Paniker’s Textbook of Microbiology, 10th Edition, Page 478, 479.

↑ *Back to this question in Part A*

@Neet_pg_bot

Q7: A farmer presents to you with swelling on foot and multiple discharging sinuses in the lower limb. Granules from the discharge were examined under the microscope, shown below. Which of the following is true regarding this condition? (Q855900)

A. Both bacteria and fungi can be causative

B. Undergoes lymphatic spread

C. There is lymphocyte accumulation

D. Involves only superficial tissues

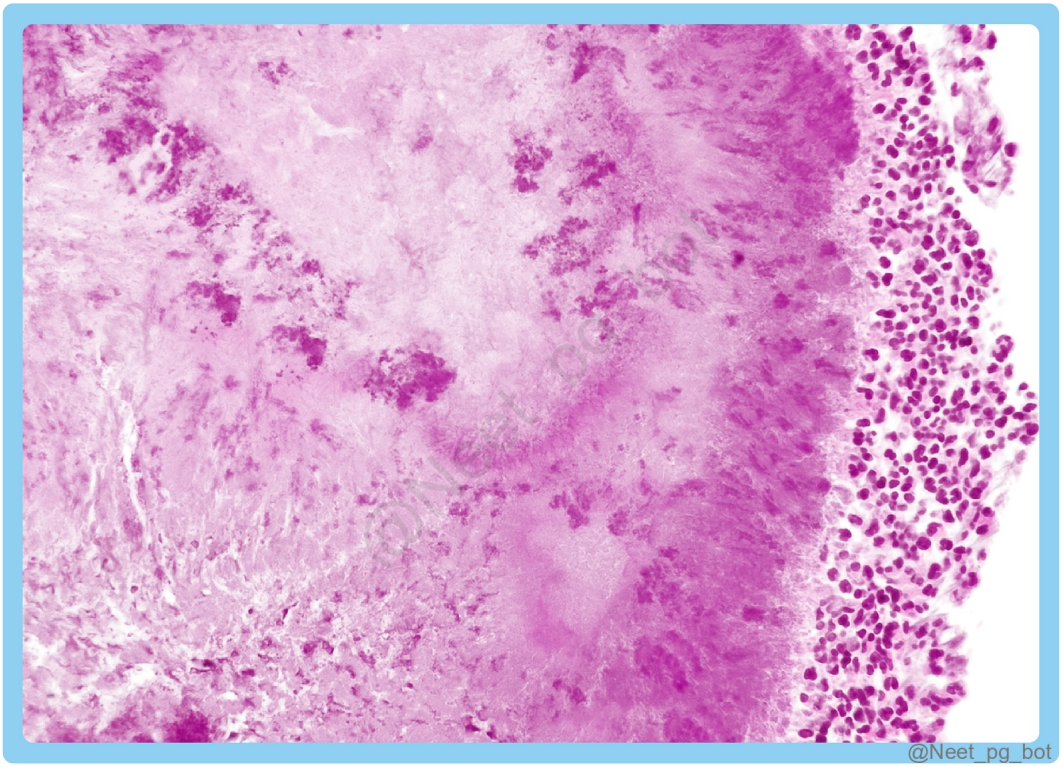

Correct Answer: A. Both bacteria and fungi can be causative

Explanation: Clinical Presentation: Swelling on the foot , multiple discharging sinuses , and granules in discharge are characteristic of mycetoma . Farmers are commonly affected due to trauma with contaminated soil . Microscopic Features in the Image: The granules seen in the image are sulfur granules , which are commonly found in mycetoma . Mycetoma can be caused by both bacteria (Actinomycetoma) and fungi (Eumycetoma). Mycetoma Feature Actinomycetoma (Bacterial) Eumycetoma (Fungal) Causative Agents Actinomyces, Nocardia Madurella, Exophiala Granule Color White, yellow, red Black, brown Tissue Involvement Deep tissue destruction Deep tissue involvement Spread Hematogenous, but not lymphatic Hematogenous, but not lymphatic Treatment Long-term antibiotics Antifungals, surgery {{caption_text}} {{caption_text}} Undergoes lymphatic spread (Option B): Incorrect because mycetoma spreads via direct extension and hematogenous routes , not through lymphatics. There is lymphocyte accumulation (Option C): Incorrect because mycetoma is granulomatous, not predominantly lymphocytic . Involves only superficial tissues (Option D): Incorrect because mycetoma extends deeply into subcutaneous and bone tissue over time.

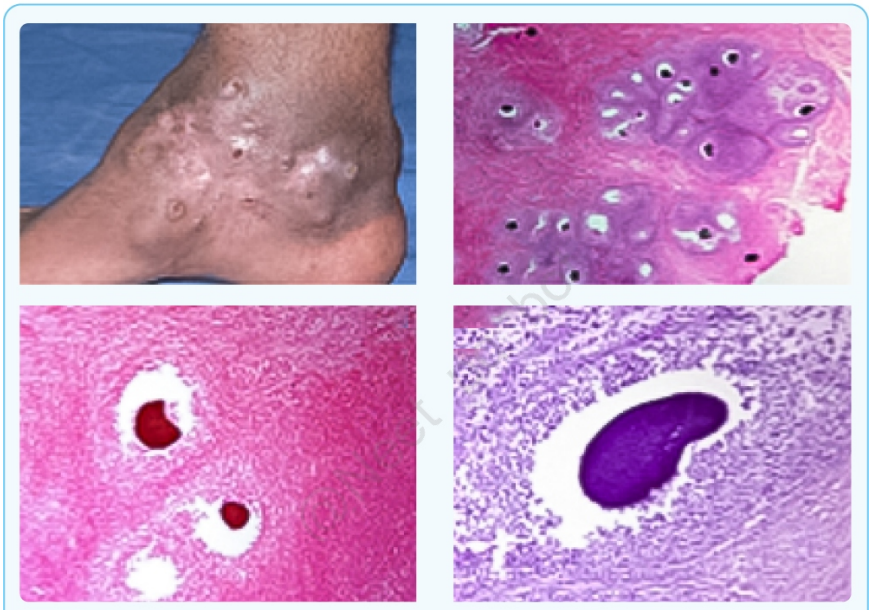

A case of eumycetoma showing (A) a large plaque with atrophic surface studded with multiple sinuses on the lower leg, (B) a deep dermal granulomatous infiltrate with multiple colonies (H&E section, Â2), (C) Gram-negative staining (Â20), and (D) periodic acid -Schiff-positive staining (Â40)

@Neet_pg_bot

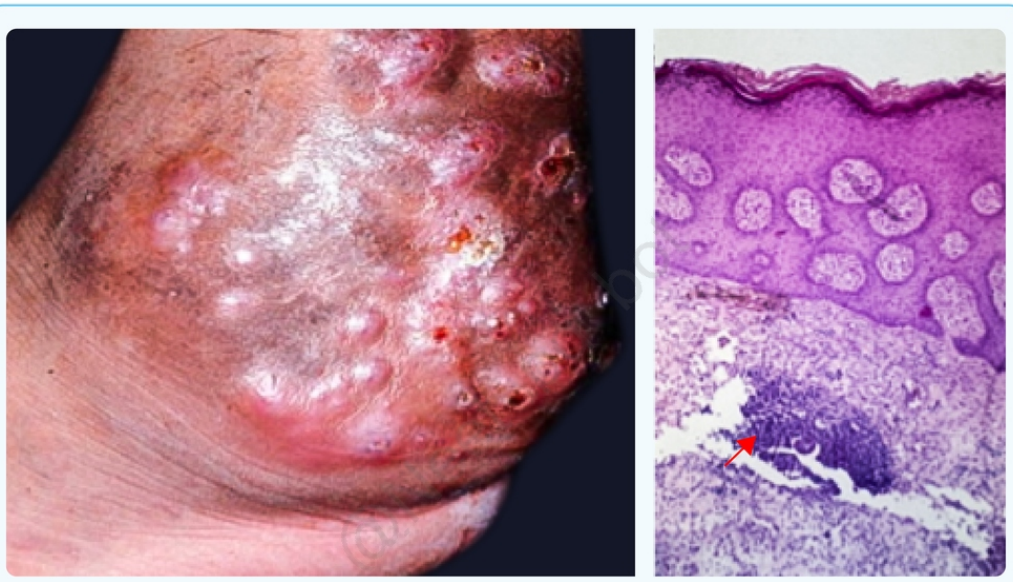

A) Initial presentation of multiple erythematous nodules with pus formation over the left ankle; (B) histopathology of a section of the nodule showed one sulfur granule (arrow) surrounded by inflammatory cells present in the deep dermis (hematoxylin-eosin stain, x100).

@Neet_pg_bot

References:

https://pmc.ncbi.nlm.nih.gov/articles/PMC2840937/

↑ *Back to this question in Part A*

@Neet_pg_bot

Q8: What is the probable diagnosis for a cauliflower-shaped mass on the foot of a farmer that appeared after a minor injury, with microscopy revealing copper penny bodies? (Q855903)

A. Chromoblastomycosis

B. Blastomycosis

C. Sporotrichosis

D. Phaeohyphomycosis

Correct Answer: A. Chromoblastomycosis

Explanation: Clinical Presentation: Cauliflower-shaped mass on the foot Farmer with a history of minor trauma Slow-growing lesion Microscopy Findings: Copper penny bodies (Medlar bodies) → Characteristic of Chromoblastomycosis Chromoblastomycosis Feature Chromoblastomycosis Causative Organisms Fonsecaea, Cladophialophora, Phialophora Risk Factor Trauma (especially in farmers) Clinical Appearance Cauliflower-like verrucous lesion Microscopy Copper penny bodies (Medlar bodies/ muriform bodies) {{caption_text}} Spread Slow, localized spread Treatment Itraconazole, surgery if severe {{caption_text}} Blastomycosis (Option B): Incorrect because Blastomycosis presents as pulmonary or skin ulcers, not a cauliflower-like lesion . Sporotrichosis (Option C): Incorrect because Sporotrichosis follows a lymphatic spread (rose gardener's disease), not a localized verrucous lesion . Phaeohyphomycosis (Option D): Incorrect because it involves dark-pigmented fungi but does not show copper penny bodies .

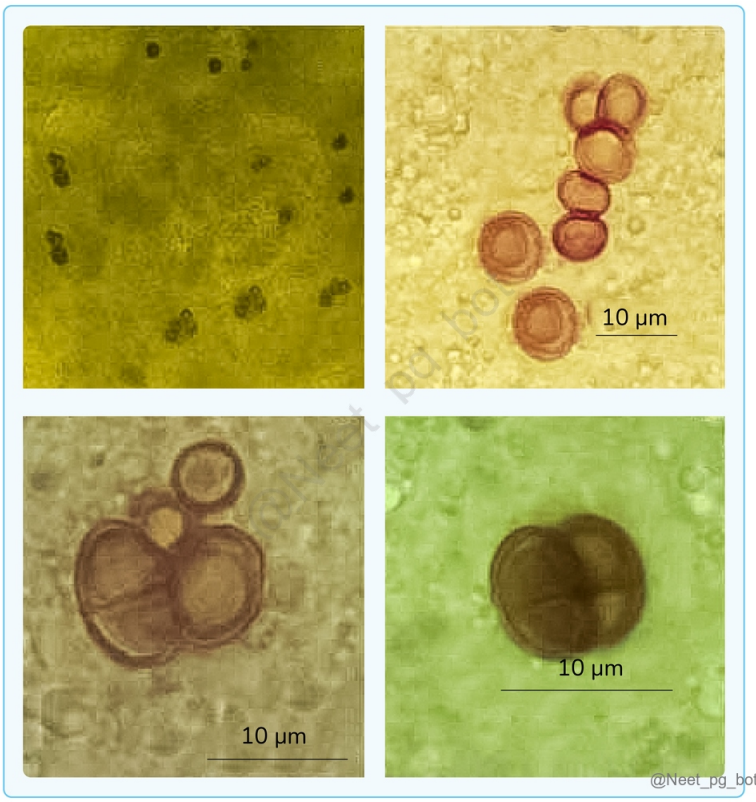

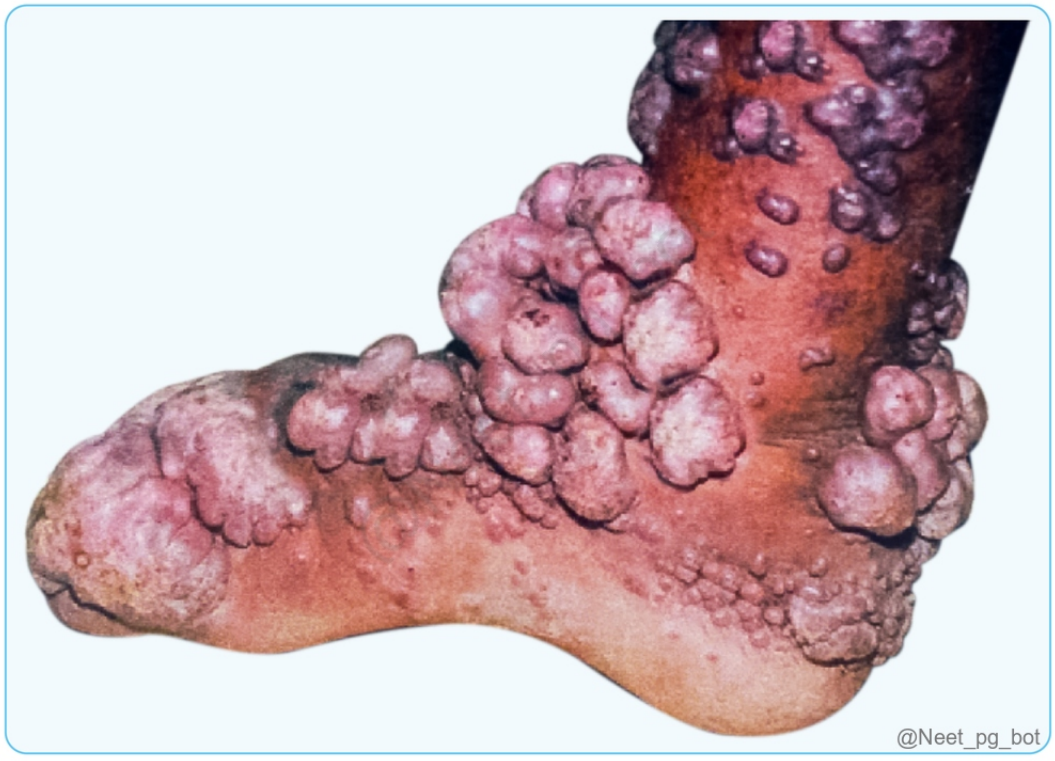

References:

Chromoblastomycosis - StatPearls - NCBI Bookshelf

Textbook of Microbiology, Ananthanarayan & Paniker, 6th Edition, Page 604, 605, 606, 607

↑ *Back to this question in Part A*

@Neet_pg_bot

Q9: What could be the potential cause of the following lesions in a gardener who has a history of thorn pricks? (Q856368)

A. Streptococcus pyogenes

B. Sporothrix schenckii

C. Stronglyoides stercoralis

D. Staphylococcus aureus



Correct Answer: B. Sporothrix schenckii

Explanation: The lesions described in the question, following a thorn prick, are suggestive of a condition known as sporotrichosis or rose gardener's disease. The characteristic feature of sporotrichosis is the distribution of the lesions along the lymphatic vessels. The infection typically starts as a small, painless bump or nodule at the site of the inoculation, and it then spreads along the lymphatic vessels, forming a chain of nodules or ulcers. Sporotrichosis Sporotrichosis is a chronic fungal infection caused by Sporothrix schenckii , commonly known as

“rose gardener’s disease.” It occurs through trauma-induced inoculation from soil, plants, or organic matter. Pathophysiology Sporothrix schenckii is a dimorphic fungus that exists as a mold in the environment and yeast in human tissue . The fungus spreads via lymphatics , causing characteristic nodular lymphangitis . Features Cutaneous (most common) : Painless nodules and ulcers along lymphatic channels (lymphocutaneous form). Pulmonary : Chronic cough, fever, weight loss (inhalation exposure). Disseminated (rare, immunocompromised patients) : Systemic involvement affecting bones, joints, and CNS. Investigations & Diagnosis Culture (gold standard) : Grows Sporothrix schenckii on Sabouraud’s agar . Microscopy : Shows cigar-shaped yeast on tissue samples. Histopathology : Granulomatous inflammation with fungal elements. Treatment First-line : Itraconazole (100-200 mg/day) for cutaneous cases. Severe/disseminated cases : Amphotericin B , followed by itraconazole. Potassium iodide (older treatment) : Still used in some regions. Incorrect Options: Streptococcus pyogenes (Option A) : It is not the causative agent for the described presentation of lesions following a thorn prick. Strongyloides stercoralis (Option C) : Strongyloides stercoralis does not typically present with the specific lesion distribution described in the question. Staphylococcus aureus (Option D) : Staphylococcus aureus is not the primary causative agent for the described presentation. Sporothrix schenckii is more commonly associated with the development of sporotrichosis in this context.

References:

https://www.ncbi.nlm.nih.gov/books/NBK532255/

↑ *Back to this question in Part A*

@Neet_pg_bot

Q10: A 28-year-old man took an antibiotic for a throat infection. Two days later, he noticed a single, round, dark red patch on his forearm that itched and burned. He recalls having a similar patch at the same spot last time he took the same antibiotic. What is the most likely diagnosis? (Q856372)

A. Psoriasis

B. Eczema

C. Fixed Drug Eruption

D. Contact Dermatitis

Correct Answer: C. Fixed Drug Eruption

Explanation: Fixed drug eruption presents as a well-circumscribed, round or oval lesion that recurs at the same site upon re-exposure to the causative drug. Common drugs include antibiotics (like sulfonamides, tetracyclines), NSAIDs, and barbiturates. Lesions appear 1–2 days after drug ingestion and may be itchy or burn. After healing, the site often shows post-inflammatory hyperpigmentation. The history of recurrence at the same location is key for diagnosis. Treatment is discontinuation of the offending drug and supportive care, sometimes with topical corticosteroids. Unlike eczema or contact dermatitis, FDE has a sudden onset after drug exposure and recurs at identical sites. Incorrect Options : Option A) Psoriasis: Chronic, scaly plaques, not sudden onset after drug

exposure. Option B) Eczema: Usually widespread, itchy, often chronic, not fixed to a single site after drug intake. Option D) Contact Dermatitis: Requires direct contact with allergen and usually spreads beyond a single recurring spot.

References:

https://jcdr.net/articles/PDF/19493/70377_CE%5BRa1%5D_F%28SS%29_QC_REF_PAT%28AN_IS%29_PF1%28AKA_DK%29_PFA_NC%28KM%29_PN_%28KM%29.pdf

↑ *Back to this question in Part A*

@Neet_pg_bot

Q11: Which of the following options should be excluded as a possible cause for the lesion seen in the image, developed by a forest officer? (Q856668)

A. Scrub typhus

B. KFD

C. Cutaneous anthrax

D. Healing brown recluse spider bite

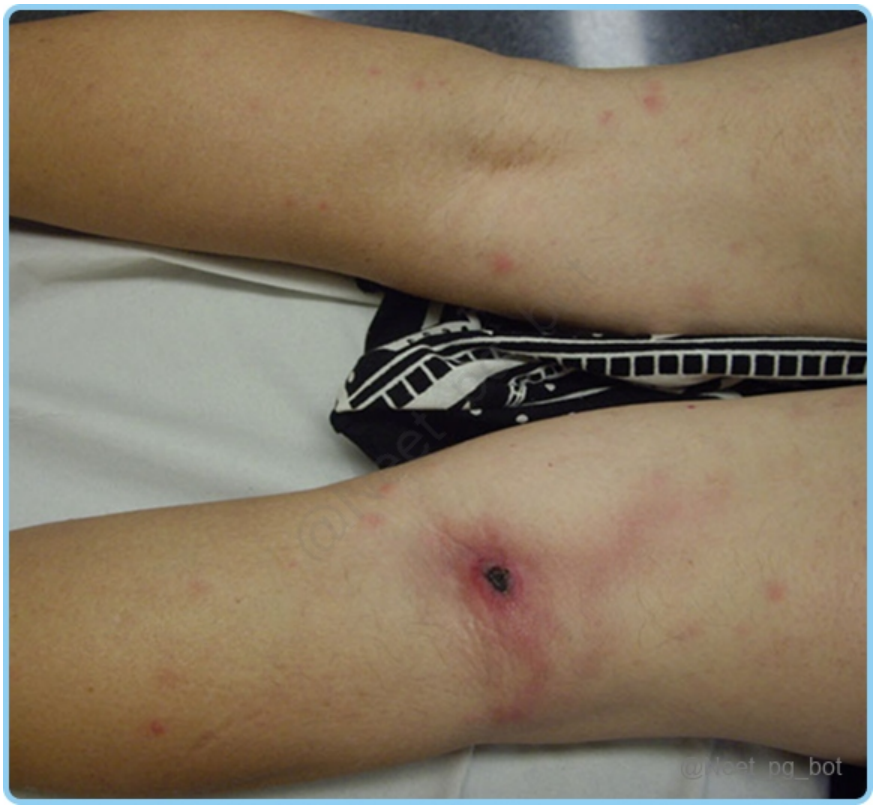

Correct Answer: B. KFD

Explanation: The lesion described by a forest officer suggests an eschar-like lesion , which is commonly seen in scrub typhus, cutaneous anthrax, and brown recluse spider bites . KFD (Kyasanur Forest Disease) is a viral hemorrhagic fever caused by a Flavivirus , transmitted by ticks . It primarily affects forest workers but does not cause eschar formation . Instead, it presents with fever, myalgia, haemorrhagic manifestations, and meningoencephalitis . Kyasanur Forest Disease (KFD) is a tick-borne viral disease (Flavivirus) endemic to forests in South India . Transmission: By Haemaphysalis ticks from infected rodents, monkeys, and livestock. Monkey fever/Kyasanur forest disease: General features: Virus Characteristics : Enveloped virus belonging to the family Flaviviridae ; contains single-stranded RNA (ssRNA). Vector : Hard ticks (Haemaphysalis spinigera) Hosts : Monkeys, rodents, and squirrels are common hosts; monkeys act as amplifier hosts where the virus multiplies exponentially. Seasonality : KFD cases peak during dry months (November to June), coinciding with increased human activity in forests. The life cycle of Kyasanur forest disease {{caption_text}} Clinical features: Incubation Period: 3-8 days. First Stage (Hemorrhagic Fever): Acute high fever with malaise and frontal headaches. Hemorrhagic symptoms: bleeding from the nasal cavity, throat, gums, and gastrointestinal tract. Second Stage: Meningoencephalitis may occur 7–21 days after the first stage. Lab diagnosis: Diagnosis Methods : Virus isolation from blood. IgM antibody detection by ELISA. RT-PCR. Vaccination: Vaccine Type : Killed KFD vaccine (formalin-inactivated chick embryo) developed at Haffkine Institute, Mumbai. Vaccination Schedule : Initial two doses at 2-month intervals. Booster doses at 6–9 months, then every 5 years. Target Area : Recommended for endemic areas of Karnataka. Vector Diseases transmitted Sandfly Kala-azar Oriental sore Sandfly fever (Papatasi fever) Flea Hymenolepis diminuta Hymenolepis nana Bubonic plague Endemic typhus Louse Epidemic relapsing fever Epidemic typhus Trench fever Hard tick Babesiosis Kyasanur Forest disease virus (Option B) Colorado tick fever virus Russian spring-summer encephalitis virus Omsk hemorrhagic fever virus Crimean Congo hemorrhagic fever virus Tularemia Lyme disease Rocky Mountain spotted fever Indian tick typhus Ehrlichiosis Soft tick Endemic relapsing fever Reduvid bug Chagas’ disease Scrub typhus (Option A) is incorrect because it is caused by Orientia tsutsugamushi and commonly presents with an eschar at the site of a chigger bite. This is a hallmark of the disease. Cutaneous anthrax (Option C) is incorrect because Bacillus anthracis causes painless black eschars with surrounding oedema. It is common in individuals handling animal products or exposed to spores in the environment. Healing brown recluse spider bite (Option D) is incorrect because brown recluse spider bites can cause necrotic ulcers that heal over time, mimicking an eschar.

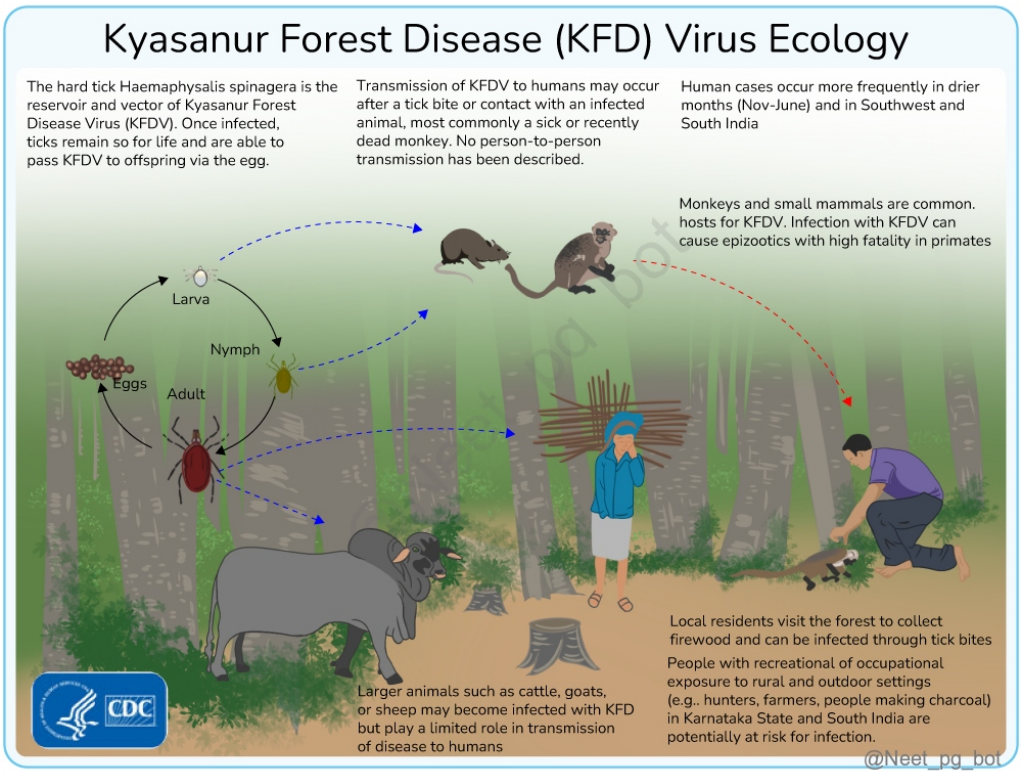

References:

Apurba Sastry Essentials of Medical Microbiology, 3rd Edition Page 343, 825

↑ *Back to this question in Part A*

@Neet_pg_bot

Q12: Identify the type of skin lesion: (Q856836)

A. Nummular

B. Annular

C. Discoid

D. Target



Correct Answer: B. Annular

Explanation: n annular skin lesion refers to a ring-shaped lesion with a clear or normal-looking center. It typically has a raised border or edge. This pattern is commonly seen in conditions such as ringworm (tinea corporis), granuloma annulare, and erythema migrans (associated with Lyme disease). Some other types of skin lesions: Skin Lesion Description Examples Macule Flat, discolored spot on the skin with no palpable elevation or depression. Freckles, flat moles Patch Large, flat, maculopapular area of skin discoloration. Vitiligo, café-au-lait spots Papule Small, solid, elevated lesion with a palpable surface. Acne, warts Plaque Elevated, flat-topped lesion with a broad, flat surface. Psoriasis plaques, seborrheic keratosis Vesicle Small, fluid-filled blister, usually less than 5mm in diameter. Chickenpox blisters, herpes simplex Bulla Large, fluid-filled blister, typically more than 5mm in diameter. Bullous pemphigoid, second-degree burns Pustule Small, elevated lesion filled with pus. Acne pustules, impetigo Wheal Transient, raised, and edematous lesion with irregular borders, often associated with itching or allergic reactions. Insect bite reactions, hives (urticaria) Nodule Solid, palpable lesion, often deeper in the skin layers. Dermatofibroma, lipoma Tumor Solid, elevated lesion larger than a few centimeters in diameter. Basal cell carcinoma, melanoma Plaque Large, flat, elevated lesion with a flat surface and a diameter greater than its height. Psoriasis plaques, lichen planus Burrow Linear or serpignious tunnel in the skin caused by infestation or burrowing of parasites. Scabies burrows Scale Dry, flaky, or thickened skin with shedding of dead skin cells. Psoriasis scales, seborrheic dermatitis Crust Dried exudate or secretion on the skin surface. Impetigo crusts, dried blood crusts Erosion Loss of the superficial epidermis, resulting in a moist, shallow depression. Aphthous ulcers, erosion due to scratching Ulcer Loss of the entire epidermis and at least part of the dermis, resulting in a deep, open lesion. Pressure ulcers, venous ulcers Fissure Linear crack or slit-like split in the skin. Athlete's foot fissures, anal fissures Scar Fibrous tissue that replaces normal skin after injury or surgery. Surgical scars, keloids Atrophy Thinning or depression of the skin with loss of normal skin markings. Striae (stretch marks), aged skin Incorrect Options: Nummular lesions (Option A) : These are coin-shaped or circular lesions with distinct borders and a flat or slightly elevated surface. They are usually smaller and do not have the characteristic ring shape. Discoid lesions (Option C) : These are circular or oval-shaped lesions with well-defined borders, but they do not necessarily have a

ring shape or central clearing. Target lesions (Option D) : Target or "bull's eye" lesions have concentric rings or circles of different colors. They typically have three zones—an outer ring, an intermediate ring, and a central clearing. This pattern is seen in conditions such as erythema multiforme and Lyme disease.

References:

https://pmc.ncbi.nlm.nih.gov/articles/PMC3657228/

↑ *Back to this question in Part A*

@Neet_pg_bot

Q13: What could be the potential diagnosis for a 7-year-old boy with intellectual disability who has developed extensive warty crusts on the trunk, hands, and feet, along with severe fissuring and scaling on the soles of his feet? (Q857057)

A. Scabies incognito

B. Animal scabies

C. Nodular scabies

D. Norwegian scabies



Correct Answer: D. Norwegian scabies

Explanation: Norwegian scabies (crusted scabies) is a severe, highly contagious form of scabies, seen in immunocompromised individuals, elderly patients, or those with neurological disorders (e.g., intellectual disability). Feature Classic Scabies Crusted (Norwegian) Scabies Prevalence More common Less common Skin Lesions Small erythematous papules, "knots on a rope" Erythematous, scaling, crusting, and fissuring Pruritus Severe, worse at night Usually mild or absent due to nerve damage Onset 3-6 weeks after initial colonization, 1-3 days after reinfestation Gradual but progressive Risk Factors No specific immunosuppression required Occurs in immunosuppressed patients (HIV, elderly, cancer, etc.) Mite Burden Low mite burden High mite burden Transmission Direct skin-to-skin contact More commonly transmitted via fomites (objects) Common Sites Webs of fingers, axillae, areola, genitalia Hands, feet, and scalp Incorrect Options: Scabies incognito (Option A): Occurs due to misuse of topical steroids, modifying typical scabies lesions. Presents as diffuse eczema-like plaques rather than thick crusts. Animal scabies (Option B): It is usually seen in animals and is rarely transmitted to humans Nodular scabies (Option C): a less common form of scabies that causes firm, itchy, red bumps. It's often found in the groin and genital area.

References:

https://pmc.ncbi.nlm.nih.gov/articles/PMC9223105/

↑ *Back to this question in Part A*

@Neet_pg_bot

Q14: Identify the condition shown in the image below: (Q857059)

A. Impetigo

B. Chickenpox

C. Herpes Simplex

D. Molluscum contagiosum



Correct Answer: A. Impetigo

Explanation: The image shows honey-colored, crusted lesions around the mouth, characteristic of non-bullous impetigo . Impetigo is a superficial bacterial skin infection caused by Staphylococcus aureus or Streptococcus pyogenes . Common in children and spreads via direct contact . Impetigo Feature Details Etiology Staphylococcus aureus , Streptococcus pyogenes Types Non-bullous (crusted), Bullous Lesion Honey-colored crusts, vesicles, erosions Common Sites Face (perioral, perinasal), extremities Treatment Topical mupirocin, oral antibiotics if extensive Bullous impetigo {{caption_text}} Non-bullous impetigo/Impetigo contagiosa {{caption_text}} Incorrect Options: Chickenpox (Option B) - Incorrect because vesicles appear in crops and have a dew-drop on a rose petal appearance , unlike the honey-colored crusts seen in impetigo. Herpes Simplex (Option C) - Incorrect because it presents as grouped vesicles on an erythematous base , often with pain and recurrence , whereas impetigo shows crusted lesions . Molluscum Contagiosum (Option D) - Incorrect because it presents as pearly, dome-shaped papules with central umbilication , not crusted erosions .





References:

Chapter 26: Bacterial infections. In: Rook's Textbook of Dermatology. 9th ed. Blackwell; 2016. p. 26.13-26.16.

↑ *Back to this question in Part A*

@Neet_pg_bot

Q15: What is the probable diagnosis for a farmer who has a swollen foot and multiple discharging sinuses, as depicted in the image below? (Q857581)

A. Mycetoma

B. Squamous cell carcinoma

C. Nocardia

D. Sporotrichosis



Correct Answer: A. Mycetoma

Explanation: The most probable diagnosis for a farmer with a swollen foot and multiple discharging sinuses is Mycetoma Mycetoma (Madura Foot) Definition : Chronic granulomatous infection with subcutaneous masses, draining sinuses, and grains in exudates Types : Eumycetoma (fungal) Actinomycetoma (bacterial) {{caption_text}} {{caption_text}} Clinical Presentation Initial Lesion : Painless nodule; may be asymptomatic for years Progression : Leads to swelling, ulceration, and pus discharge from sinuses containing grains Complications : Severe deformities, osteomyelitis, potential amputation due to extensive tissue damage Microscopic Examination

Type Causative Agents Microscopic Features Eumycetoma Madurella mycetomatis , Curvularia lunata , Scedosporium spp. , Acremonium spp. Hyphae or thick-walled grains (black/white). {{caption_text}} Histology shows suppurative granulomas with neutrophils. Actinomycetoma Actinomadura madurae , Nocardia spp. Thin, branching filaments visible with Gram staining. Similar granulomas to eumycetoma but distinct morphology. {{caption_text}} Diagnostic Techniques Biopsy and Culture : Tissue biopsy for visualization of pathogens. Culturing exudates for specific organism identification. Special stains to differentiate fungal and bacterial infections. Imaging Studies : X-rays and MRI to assess bone involvement in advanced cases. Treatment Type Treatment Approach Eumycetoma Surgical excision with antifungals (itraconazole, ketoconazole). High recurrence rates. Actinomycetoma Prolonged antibiotic therapy (e.g., trimethoprim-sulfamethoxazole, dapsone) along with surgical intervention. Squamous Cell Carcinoma (SCC) (Option B): SCC can develop in chronic ulcers or scars but is not characterized by multiple discharging sinuses with granules. Nocardia (Option C): While Nocardia can cause actinomycetoma , which is a type of mycetoma, Nocardia alone does not fully describe the condition seen in the image . The term mycetoma broadly refers to both eumycetoma (fungal) and actinomycetoma (bacterial) , including those caused by Nocardia . Sporotrichosis (Option D): A subcutaneous fungal infection (Sporothrix schenckii) that spreads along lymphatics (sporotrichoid spread) but does not present with multiple sinus tracts and granules.

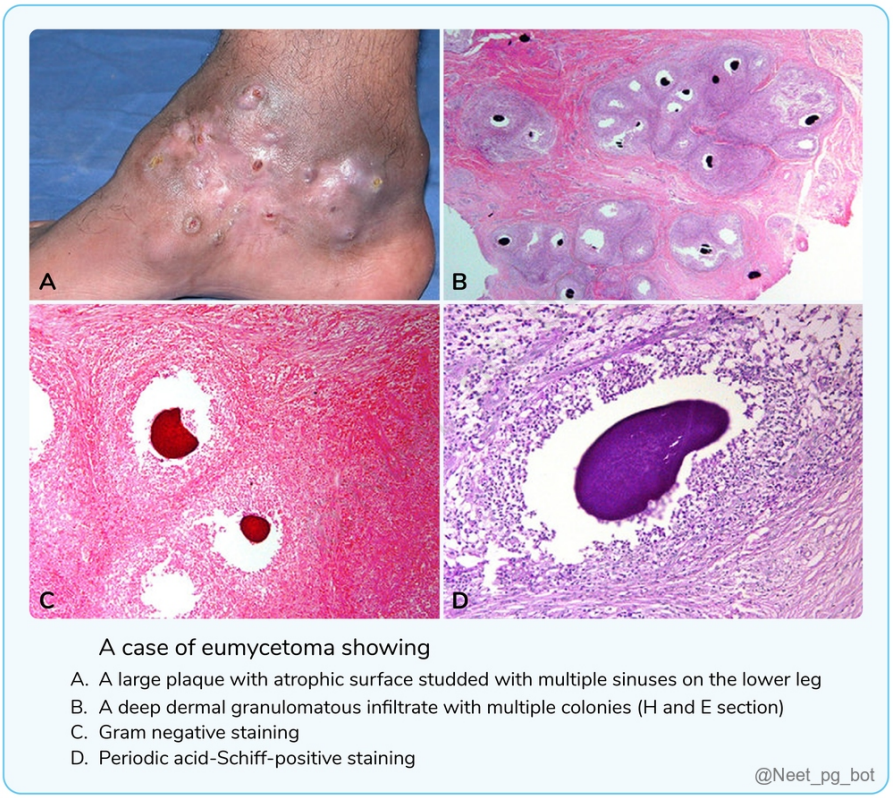

A case of eumycetoma showing

A. A large plaque with atrophic surface studded with multiple sinuses on the lower leg
B. A deep dermal granulomatous infiltrate with multiple colonies (H and E section)
C. Gram negative staining
D. Periodic acid-Schiff-positive staining

@Neet_pg_bot

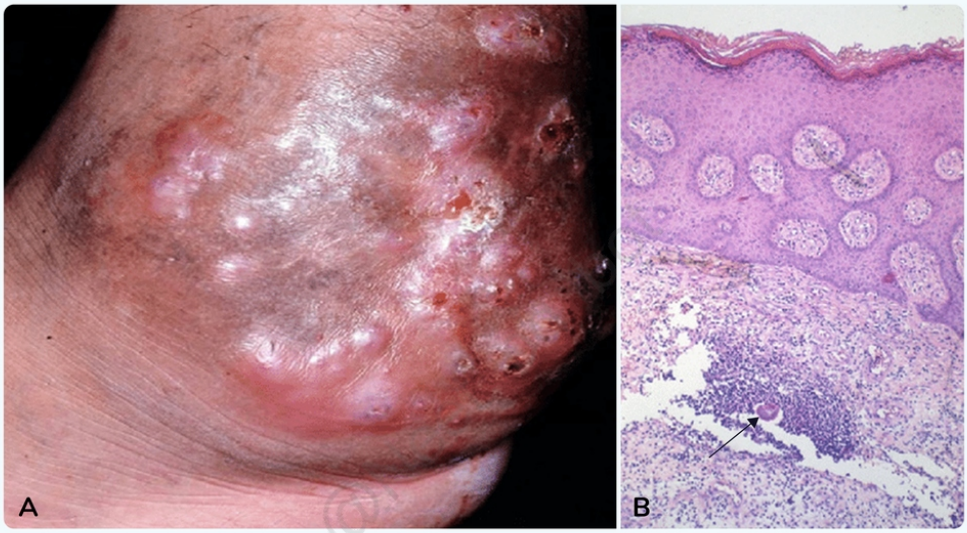

Actinomycetoma

A. Initial presentation of multiple erythematous nodules with pus formation over the left ankle.

B. Histopathology of a section of the nodule showed one sulfur granule (arrow) surrounded by inflammatory cells present in the deep dermis.

@Neet_pg_bot



KOH wet mount direct microscopic examination of M. mycetomatis grains showing its hyphal structure

@Neet_pg_bot

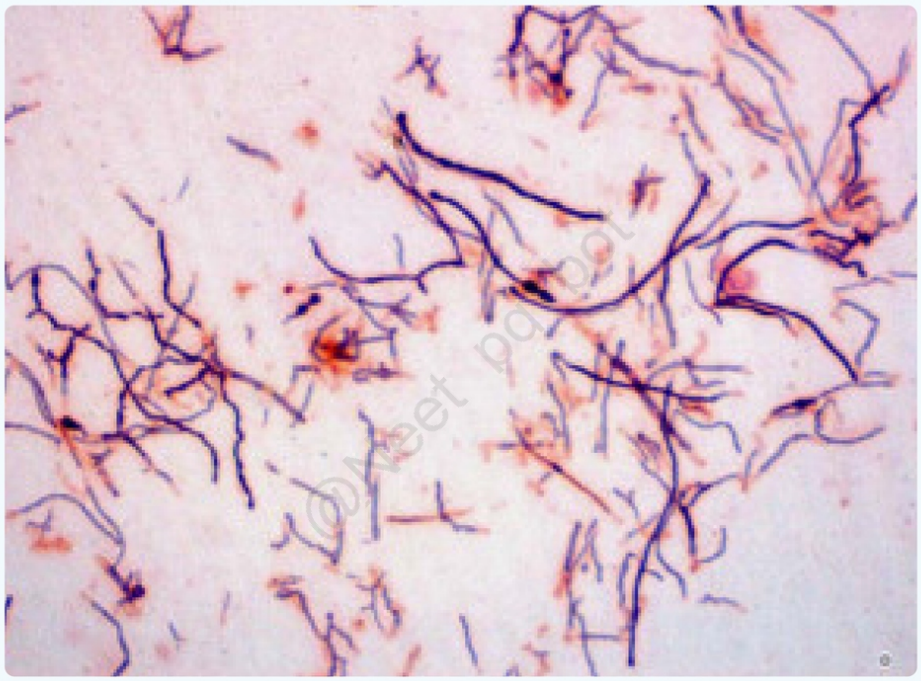

Gram staining of an A. meyerae colony

@Neet_pg_bot

References:

https://pmc.ncbi.nlm.nih.gov/articles/PMC2840937/

↑ *Back to this question in Part A*

@Neet_pg_bot

Q16: Which among the following drug is not used in the treatment of acne vulgaris? (Q860622)

A. Topical Benzoyl peroxide

B. Topical Fluocinolone

C. Topical Tazarotene

D. Topical antibiotics

Correct Answer: B. Topical Fluocinolone

Explanation: Fluocinolone is a corticosteroid, which can cause steroid-induced acne (pustular eruptions). Steroids exacerbate acne rather than treat it. Grades Lesions Treatment Grade I Non-inflammatory lesions such as open

(blackheads) and closed comedones (whiteheads) Topical retinoids (Tretinoin, Adapalene) Grade II Non-inflammatory lesions (comedones) + inflammatory lesions such as papules and few pustules. Topical retinoids + Topical antibiotics Grade III Multiple inflammatory papules and pustules ± nodules (moderate) Topical retinoids + Oral antibiotics ± Benzoyl peroxide Grade IV Nodules + Cysts (Most severe form) Oral retinoids (Isotretinoin)

References:

Rooks's Textbook of Dermatology 9th edition, 90.37

↑ *Back to this question in Part A*

@Neet_pg_bot

• [13_Miscellaneous Disorders] 025 Adverse Drug Reactions Pediatric Dermatoses Urticaria And Angioedema

« Back to Folder Directory

[13_Miscellaneous Disorders] 025 Adverse Drug Reactions Pediatric Dermatoses Urticaria And Angioedema — Quick Jump

Q1 (p. 1173)	*Q2 (p. 1175)*	*Q3 (p. 1176)*	*Q4 (p. 1177)*	*Q5 (p. 1178)*	*Q6 (p. 1179)*
Q7 (p. 1181)	*Q8 (p. 1182)*	*Q9 (p. 1183)*	*Q10 (p. 1185)*	*Q11 (p. 1187)*	*Q12 (p. 1188)*
Q13 (p. 1189)	*Q14 (p. 1191)*	*Q15 (p. 1192)*	*Q16 (p. 1194)*	*Q17 (p. 1195)*	*Q18 (p. 1198)*
Q19 (p. 1201)	*Q20 (p. 1203)*	*Q21 (p. 1207)*	*Q22 (p. 1208)*	*Q23 (p. 1209)*	*Q24 (p. 1210)*

Q1: A 7-year-old child with chronic itching is noted to develop a white linear streak as shown instead of erythema after the skin is stroked lightly with a blunt object. It is most commonly associated with which of the following conditions? (Q886424)

A. Chronic spontaneous urticaria

B. Atopic dermatitis

C. Psoriasis vulgaris

D. Lichen planus



Correct Answer: B. Atopic dermatitis

Explanation: White dermographism is a characteristic feature of atopic dermatitis . Instead of the normal red wheal-and-flare response , the skin shows a white linear streak after stroking due to an abnormal vasoconstrictive response of cutaneous blood vessels in atopic skin. It is commonly seen in children with chronic pruritus and eczema and reflects altered autonomic vascular reactivity in atopic individuals. Chronic spontaneous urticaria (Option A): In urticaria, stroking the skin produces red dermographism (erythematous, raised wheals due to histamine-mediated vasodilation), not a white line. Psoriasis vulgaris (Option C): Psoriasis is associated with Auspitz sign (pinpoint bleeding on scale removal) and Koebner phenomenon , not white dermographism. Lichen planus (Opyion D): Lichen planus shows Koebner phenomenon and Wickham striae , but white dermographism is not a feature .



References:

Rook’s Textbook of Dermatology, 9th Edition, Page 42.10

↑ *Back to this question in Part A*

@Neet_pg_bot

Q2: A 40-year-old man develops fever and painful skin rash 2 weeks after starting allopurinol. He has widespread skin detachment (>30% BSA), severe oral erosions, and a positive Nikolsky sign. Biopsy shows full-thickness epidermal necrosis. What is the most likely diagnosis? (Q886446)

A. Erythema multiforme major

B. Pemphigus vulgaris

C. Stevens-Johnson syndrome

D. Lyell syndrome

Correct Answer: D. Lyell syndrome

Explanation: Lyell syndrome is another name for Toxic Epidermal Necrolysis (TEN). It represents the most severe end of the SJS-TEN spectrum , defined by >30% body surface area epidermal detachment , extensive mucosal involvement, positive Nikolsky sign, and full-thickness epidermal necrosis , most often drug-induced . Stevens-Johnson Syndrome / Toxic Epidermal Necrolysis (SJS/TEN): Definition: Severe drug-induced mucocutaneous reaction with epidermal necrosis and sloughing Spectrum: SJS <10% BSA (Option C) SJS-TEN overlap 10-30% TEN >30% Etiology: Drugs (most common): allopurinol, anticonvulsants, sulfonamides, nevirapine Clinical: Prodrome: fever, malaise, sore throat Skin: painful erythema → blisters → sheet-like detachment, +ve Nikolsky Mucosa: oral (>95%), ocular, genital (early, severe) Histology: Full-thickness epidermal necrosis Subepidermal split, minimal inflammation Management: Immediate drug withdrawal ICU/burns unit care Supportive care IVIG / steroids/ciclosporin (selected cases) Mortality ~20-30% Sepsis = most common cause of death Pemphigus vulgaris (Option B) : An autoimmune blistering disorder with suprabasal acantholysis , chronic course, and no acute drug-related onset or massive epidermal necrosis. Erythema multiforme major (Option A) : Usually infection-related (HSV) with typical target lesions; epidermal necrosis and extensive skin detachment are absent .



References:

Rook’s Textbook of Dermatology, 9th Edition, Pages 119.13 - 119.22

↑ *Back to this question in Part A*

@Neet_pg_bot

Q3: Which statement about DRESS syndrome is incorrect? (Q886445)

A. Latency is typically 2-6 weeks

B. Kidney is the most commonly involved organ

C. Associated with HLA

D. Eosinophilia is a common finding

Correct Answer: B. Kidney is the most commonly involved organ

Explanation: The liver , not the kidney, is the most commonly involved organ in DRESS. Renal involvement occurs but is less frequent. DRESS syndrome (Drug Reaction with Eosinophilia and Systemic Symptoms): Severe cutaneous adverse reaction (SCAR) with rash + systemic involvement + eosinophilia Delayed, multisystem drug hypersensitivity Latency: 2-6 weeks after starting drug (key discriminator) (Option A) Common drugs: Allopurinol Antiepileptics: carbamazepine, phenytoin, lamotrigine Antibiotics: vancomycin, amoxicillin, minocycline Sulfonamides, NSAIDs Pathogenesis: Drug-specific T-cell reaction Herpesvirus reactivation (HHV-6 → EBV → CMV) HLA associations (e.g., B1502 carbamazepine, B5801 allopurinol) (Option C) Clinical features: Fever, facial/head-neck edema, Lymphadenopathy (≥2 sites) Widespread rash (urticated papules, morbilliform, erythroderma, EM-like) Eosinophilia (hallmark) (Option D) Atypical lymphocytes, leukocytosis / cytopenias Liver (most common, 70-95%) → main cause of death Diagnosis: RegiSCAR criteria Management: Immediate drug withdrawal Systemic corticosteroids (prednisolone ~1 mg/kg/day) Refractory: ciclosporin, IVIg (selected cases)

References:

Rook’s Textbook of Dermatology, 9th Edition, Pages 119.4 - 119.11

↑ *Back to this question in Part A*

@Neet_pg_bot

Q4: Which of the following conditions are classically associated with interface dermatitis? Lichen planus Psoriasis Lupus erythematosus Dermatomyositis Erythema multiforme (Q886444)

A. 1, 3 and 4

B. 1, 3, 4 and 5

C. 2, 3 and 5

D. 1, 2, 3, 4 and 5

Correct Answer: B. 1, 3, 4 and 5

Explanation: Psoriasis is classified as a psoriasiform dermatitis , not interface dermatitis. Interface dermatitis describes a group of skin conditions where inflammation affects the dermo-epidermal junction , leading to

characteristic histologic changes Histological features: Basal cell vacuolization Apoptotic keratinocytes (also called colloid or Civatte bodies) Inflammatory cell infiltrates obscuring the junction Conditions associated: Lupus erythematosus Dermatomyositis Lichen planus Graft-versus-host disease Erythema multiforme Fixed drug eruptions Lichen striatus Pityriasis lichenoides

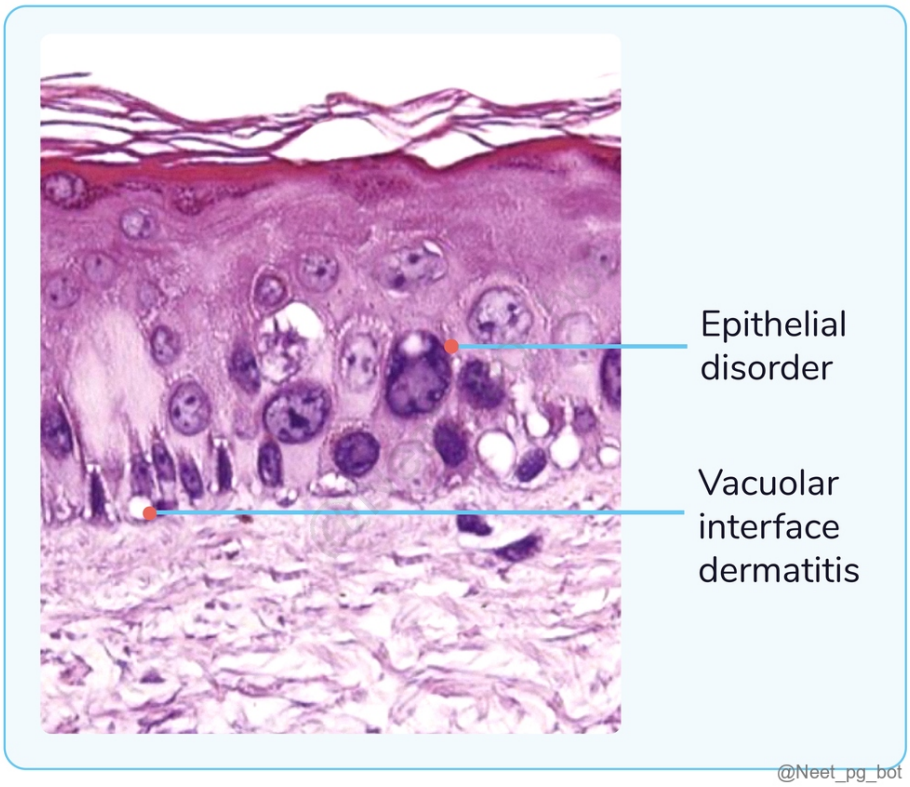

References:

https://pubmed.ncbi.nlm.nih.gov/23619439/

↑ *Back to this question in Part A*

@Neet_pg_bot

Q5: Which of the following statements regarding erythema multiforme (EM) is correct? (Q886443)

A. Most commonly caused by drugs

B. Type 4 hypersensitivity reaction

C. Not self-limiting

D. Nikolsky sign is usually positive

Correct Answer: B. Type 4 hypersensitivity reaction

Explanation: Erythema multiforme is a cell-mediated (Type IV) hypersensitivity reaction , most often triggered by infections, especially herpes simplex virus . Erythema multiforme: Immune-mediated, self-limiting (Option C) cytotoxic dermatitis Triggers: HSV (most common), Mycoplasma, infections, drugs (less common) (Option A) Pathogenesis: Type IV hypersensitivity, CD8-mediated keratinocyte apoptosis Lesions: Classic target (iris) lesions , <3 cm Distribution: Acral (hands, feet, extensor surfaces) Mucosa: Mild in EM minor, significant in EM major Course: Resolves in 2-3 weeks , may recur Management: Supportive; acyclovir prophylaxis for recurrent HSV-associated EM Nikolsky sign is negative in EM (Option D) ; it is positive in SJS/TEN.



References:

Rook’s Textbook of Dermatology, 9th Edition, Pages 47.1 - 47.6

↑ *Back to this question in Part A*

@Neet_pg_bot

Q6: A 20-year-old man develops a sudden onset of symmetric skin lesions 1 week after a febrile illness with oral ulcers. Examination shows lesions on the hands and forearms. Which is the most likely diagnosis? (Q886440)

A. Erythema multiforme

B. Stevens-Johnson syndrome

C. Toxic epidermal necrolysis

D. Urticaria



Correct Answer: A. Erythema multiforme

Explanation: The most likely diagnosis is Erythema multiforme (EM) . A febrile illness with oral ulcers is the classic presentation of Herpes Simplex Virus (HSV) , which is the most common cause of Erythema multiforme. Erythema multiforme: Erythema multiforme (EM) is a self-limiting, immune-mediated cytotoxic dermatitis . EM minor and EM major form a spectrum. Etiology: Most commonly triggered by infections , especially herpes simplex virus (HSV) . Other triggers: Mycoplasma pneumoniae , other viral/bacterial infections. Drugs cause a minority of EM cases compared with SJS/TEN. Stevens-Johnson syndrome (Option B) : Drug-induced; shows widespread atypical targets, significant mucosal erosion , and systemic toxicity. Toxic epidermal necrolysis (Option C) : Severe drug reaction with extensive epidermal necrosis, positive Nikolsky sign , and large body surface area involvement. Urticaria (Option D) : While sudden and itchy, urticarial weals are transient (lasting <24 hours) and do not follow a viral prodrome with specific acral targeting like EM.



References:

Rook’s Textbook of Dermatology, 9th Edition, Pages 47.2, 47.3

↑ *Back to this question in Part A*

@Neet_pg_bot

Q7: A 32-year-old woman develops sudden onset generalized itching, urticaria, facial swelling, wheezing, and hypotension within minutes of receiving an intravenous antibiotic. She has no prior history of similar episodes. What is the most likely diagnosis? (Q886431)

A. Acute urticaria

B. Anaphylaxis

C. Hereditary angioedema

D. Vasovagal syncope

Correct Answer: B. Anaphylaxis

Explanation: This patient’s combination of urticaria + angioedema + wheezing + hypotension immediately after an IV antibiotic is classic for anaphylaxis . Anaphylaxis is an acute, life-threatening systemic hypersensitivity reaction caused by mast cell and basophil mediator release (e.g., histamine, leukotrienes, prostaglandins). It can be IgE-mediated (allergic) or non-IgE-mediated and typically occurs within minutes of exposure to a trigger such as a drug, food, or insect sting. Key clinical features include: Skin/mucosal involvement: Urticaria, flushing, angioedema, pruritus Respiratory compromise: Wheezing, bronchospasm, stridor Cardiovascular involvement: Hypotension, shock, syncope Rapid onset and progression Acute urticaria (Option A) : Causes weals and itching but does not cause hypotension or bronchospasm . Hereditary angioedema (Option C) : Non-mast cell mediated , lacks urticaria, and does not present acutely after drug exposure . Vasovagal syncope (Option D) : Causes transient hypotension and bradycardia but no urticaria, wheeze, or angioedema .

References:

Rook’s Textbook of Dermatology, 9th Edition, Page 42.1

↑ *Back to this question in Part A*

@Neet_pg_bot

Q8: A 62-year-old woman presents with findings as shown in the image. He denies hives, itching, or abdominal pain. He started a new antihypertensive 2 weeks ago. Which of the following is the most likely cause? (Q886429)

A. Mast cell-mediated angioedema

B. Hereditary angioedema

C. ACE inhibitor-induced angioedema

D. Allergic reaction to food

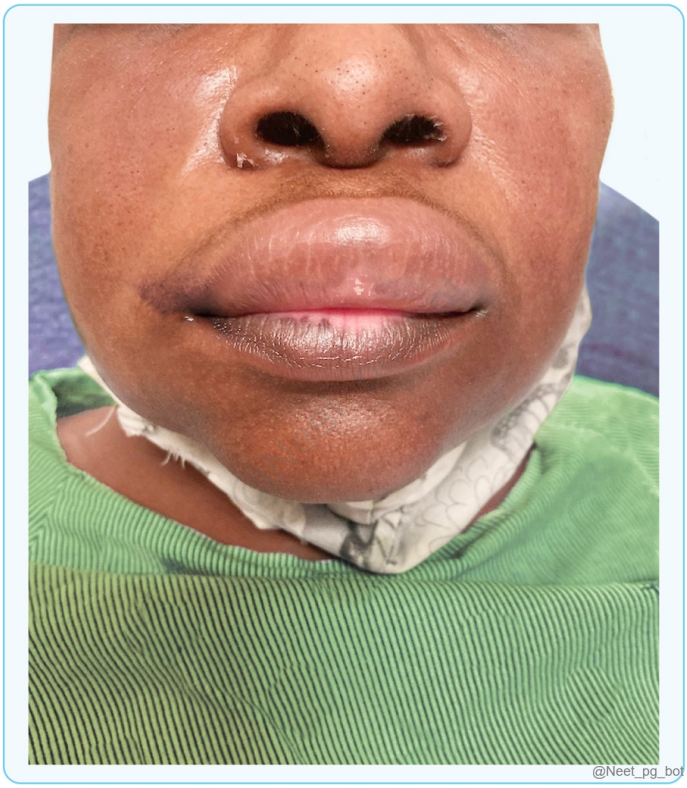

Correct Answer: C. ACE inhibitor-induced angioedema

Explanation: ACE inhibitor-induced angioedema typically presents with facial and oropharyngeal swelling , often without hives , and can occur within weeks to years of starting therapy. Angiotensin-Converting Enzyme (ACE) is responsible for breaking down bradykinin . When a patient takes an ACE inhibitor, bradykinin levels rise. In susceptible individuals, this excess bradykinin causes significant vasodilation and fluid leakage into the tissues, resulting in deep-seated swelling. ACE inhibitor-induced angioedema: Sites affected: Mainly face and oropharynx . Laryngeal involvement: Can occur and may be life-threatening . Abdominal symptoms: Rare. Mechanism: Bradykinin accumulation due to ACE inhibition. Clinical pearl: Can occur anytime during therapy , even years after starting the drug. Mast cell-mediated angioedema (Option A) : Usually associated with hives, itching , and may involve other body sites. Hereditary angioedema (Option B) : Often starts in childhood/adolescence and is C1-INH related ; family history is typical. Allergic reaction to food (Option D) : Usually associated with rapid onset, hives, itching, GI symptoms , and often follows ingestion of a specific food.

References:

Rook’s Textbook of Dermatology, 9th Edition, Page 43.4

↑ *Back to this question in Part A*

@Neet_pg_bot

Q9: Which of the following statements is incorrect regarding hereditary angioedema type 1? (Q886428)

A. It is caused by mast cell degranulation

B. It is inherited in an autosomal dominant pattern

C. Reduced C1 INH levels

D. Most common type

Correct Answer: A. It is caused by mast cell degranulation

Explanation: Hereditary Angioedema is fundamentally different from "allergic" angioedema. It is a bradykinin-mediated condition, not a histamine-mediated one.\ Hereditary Angioedema (HAE): Type 1: Most common (~85%). (Option D) Reduced C1-INH levels and function. (Option C) Autosomal dominant (Option B) , onset usually <15 yrs Symptoms: Recurrent skin/mucosal swelling, abdominal pain. Type 2: Dysfunctional C1-INH (Normal levels but inactive) Similar clinical features to Type I. Type 3: Often estrogen-dependent, mainly in women Normal C1-INH Investigations: C4 : Screening for HAE (low in Types I & II, acquired C1-INH deficiency). C1-INH antigen & function : Confirms HAE Type I/II or acquired deficiency. C1q : Low in acquired C1-INH deficiency. Normal labs: HAE Type III.



References:

Rook’s Textbook of Dermatology, 9th Edition, Pages 43.4, 43.5

↑ *Back to this question in Part A*

@Neet_pg_bot

Q10: A 5-year-old child presents with multiple reddish-brown maculopapular lesions on the trunk. Gentle rubbing of the lesions produces localized redness, itching, and wealing within minutes. It is characteristically seen in which of the following conditions? (Q886427)

A. Atopic dermatitis

B. Urticaria pigmentosa

C. Psoriasis vulgaris

D. Lichen planus



Correct Answer: B. Urticaria pigmentosa

Explanation: The clinical finding described is the Darier sign , which is the pathognomonic feature of Urticaria pigmentosa . Darier's sign : Lesions urticate with gentle rubbing , causing localized pruritus, redness, and wealing , which usually subsides within an hour. Wealing is confined to lesions , not intervening skin. Darier's sign is diagnostic in children, but not always present in adults. Atopic dermatitis (Option A) : Presents with ill-defined erythematous, scaly patches. Rubbing the skin results in excoriations (scratches) or lichenification (thickening), not a localized weal (Darier sign). Psoriasis vulgaris (Option C) : Rubbing or scraping a psoriasis plaque leads to pinpoint bleeding points, a phenomenon known as the Auspitz sign , rather than wealing. Lichen planus (Option D) : Characterized by the "6 Ps" (Planar, Purple, Polygonal, Pruritic, Papules, and Plaques). Scratching can cause

new lesions to form in a linear pattern (Koebner phenomenon), but it does not elicit a Darier sign.





References:

Rook’s Textbook of Dermatology, 9th Edition, Page 46.4

↑ *Back to this question in Part A*

@Neet_pg_bot

Q11: A 5-year-old child presents with multiple reddish-brown maculopapular lesions symmetrically distributed over the trunk, as shown in the image, sparing palms & soles. Which of the following statements is correct regarding the condition? (Q886426)

A. Lesions commonly involve the palms and soles

B. Associated with KIT mutations

C. Most common systemic mastocytosis

D. Lesions rarely regress in childhood



Correct Answer: B. Associated with KIT mutations

Explanation: Urticaria pigmentosa is associated with activating KIT mutations (commonly D816V in adults), leading to mast cell accumulation. Urticaria pigmentosa: Most common cutaneous mastocytosis (Option C) in adults and children Lesions: Reddish-brown or pale maculopapules/plaques, symmetrically on trunk/thighs;

sparing palms and soles (Option A) Darier’s sign: Lesions urticate with gentle rubbing → pruritus, redness, wealing (confined to lesions) Symptoms: Flushing, pruritus, GI upset; rare anaphylaxis Pathophysiology: Increased dermal mast cells; KIT mutations (D816V common in adults) Course: Childhood lesions often resolve (Option D) ; adults usually have systemic involvement (indolent systemic mastocytosis) Variants: TMEP (red macules, may not urticate), mastocytoma (solitary nodules in children, often involutes)



References:

Rook’s Textbook of Dermatology, 9th Edition, Pages 46.1 - 46.6

↑ *Back to this question in Part A*

@Neet_pg_bot

Q12: A 24-year-old man develops sudden-onset itchy lesions as shown after eating peanuts. He has no angio-oedema or breathing difficulty. The lesions have appeared over the last 2 hours. What is the first-line pharmacological treatment for this patient? (Q886425)

A. Oral corticosteroids

B. Antihistamines

C. Omalizumab

D. Epinephrine



Correct Answer: B. Antihistamines

Explanation: The patient is experiencing acute urticaria following a known trigger (peanuts). The first-line pharmacological treatment for this patient is antihistamines . Urticaria Management: First line: Second-generation H1 antihistamines (cetirizine, loratadine, fexofenadine, rupatadine) Can increase up to 4× dose if inadequate Sedating antihistamines generally avoided Second line: Short-course oral corticosteroids (rescue) (Option A) Leukotriene antagonists, doxepin, danazol (selected cases) Dapsone, sulfasalazine, tranexamic acid, phototherapy, cold desensitization Emergency: IM epinephrine (Option D) for airway-compromising angio-oedema Third line: Immunomodulators : ciclosporin, tacrolimus, mycophenolate, methotrexate, cyclophosphamide IVIG / plasmapheresis - limited use Fourth line: Omalizumab (Option C) (anti-IgE) for antihistamine-resistant chronic urticaria

References:

Rook’s Textbook of Dermatology, 9th Edition, Pages 42.16 - 42.18

↑ *Back to this question in Part A*

@Neet_pg_bot

Q13: A 25-year-old man presents with recurrent dark red plaques on his penis. He reports that these lesions appear shortly after taking certain medications. The patches are localized and recur in the same areas with each exposure. He denies any other symptoms or systemic involvement. Which of the following statements is correct

regarding the diagnosis? (Q841994)

A. Resolution of lesions without any visible skin lesions.

B. It is a type 1 hypersensitivity reaction

C. Upon re-exposure Lesions develop on the 10th day.

D. Tetracyclines are commonly associated with FDE

Correct Answer: D. Tetracyclines are commonly associated with FDE

■ *Listen (English)*

■ *Listen (Hindi)*

Explanation: Fixed drug eruption is a distinctive cutaneous allergic reaction that characteristically recurs at the same sites with the same morphology on re-exposure to the medication or other chemical agent. Type 4 hypersen sitivity reaction (Option B ruled out) Causative drugs: Co - trimoxazole , NSAIDs , tetracyclines , sulfonamides . Mediated by memory T-cells. Acutely, erythematous and bullous phases of fixed eruptions, followed by well-circumscribed areas of slate-brown pigmentation Site of lesions: Mucous membrane (Lips, tongues, Glans penis), face and acral areas although can occur anywhere on the skin surface. Leaves residual hyperpigmentation on healing (Option A ruled out). Upon reexposure, lesions develop within 30 minutes to 8 hours (Option C ruled out). Treatment: Stop the causative drug. Topical steroids and antibiotics combinations





References:

Rook’s Textbook of Dermatology 9 th edition - page 88.28, UpToDate.

↑ *Back to this question in Part A*

Q14: A 26-year-old woman develops lesions as shown in the image within minutes of going outdoors. The lesions resolve completely within 1-2 hours without residual marks. Similar episodes occur with both natural sunlight and artificial light exposure. What is the most likely diagnosis? (Q886423)

A. Polymorphic light eruption

B. Solar urticaria

C. Cutaneous lupus erythematosus

D. Photoallergic dermatitis



Correct Answer: B. Solar urticaria

Explanation: This case presents the classic "rapid onset and rapid resolution" pattern that distinguishes solar urticaria from other photodermatoses Solar urticaria presents with immediate weals (minutes) after exposure to visible or UV light and resolves within hours . Solar urticaria: Usually idiopathic Rarely secondary to porphyrias Type: Inducible urticaria Trigger: Visible light, UVA, or UVB radiation Onset: Within minutes of sun exposure Lesions: Itchy weals at exposed sites Duration: Usually fades within 2 hours Rare variant: Delayed-onset solar urticaria Polymorphic light eruption (Option A) : Delayed onset (hours) and lasts days. Cutaneous lupus erythematosus (Option C) : Persistent photosensitive rash, not transient weals. Photoallergic dermatitis (Option D) : Eczematous, delayed reaction.





References:

Rook’s Textbook of Dermatology, 9th Edition, Page 42.12

↑ *Back to this question in Part A*

@Neet_pg_bot

Q15: An 18-year-old boy develops findings as shown in the image within minutes of exercise and emotional stress. Which statement is incorrect regarding the most probable diagnosis? (Q886421)

A. Triggered by spicy food

B. Weals persist for several hours to days

C. Associated with atopy

D. Provocation by hot bath can confirm the diagnosis



Correct Answer: B. Weals persist for several hours to days

Explanation: Based on the triggers (exercise, emotional stress) and the age of the patient, the most probable diagnosis is cholinergic urticaria . In cholinergic urticaria, weals are short-lived , lasting minutes to 1-2 hours , not several hours to days. Cholinergic Urticaria: Type: Inducible urticaria Frequency: ~5% of chronic urticaria; common in adolescents Trigger: Sweating (exercise, heat, emotion, spicy food) (Option A) Pathogenesis: Cholinergic nerve stimulation → mast cell activation; ↑ histamine; possible sweat allergy / circulating Ig Clinical: 1-3 mm itchy micropapular weals Appear within minutes With/without erythematous flare Last minutes-1-2 h Associations: Atopy (Option C) ; may coexist with spontaneous urticaria Variants: Cholinergic angio-oedema, persistent cholinergic erythema, pruritus without weals Diagnosis: Provocation (hot bath 42°C × 15 min or exercise → ↑ core temp 0.7-1°C) (Option D)

References:

Rook’s Textbook of Dermatology, 9th Edition, Pages 42.11, 42.12

↑ *Back to this question in Part A*

@Neet_pg_bot

Q16: A 32-year-old woman presents with recurrent episodes of swelling in her face, lips, and throat, which she says occur intermittently and without any clear triggers. She has difficulty breathing during these episodes and She denies any rash or itching. She also reports a family history of similar symptoms affecting her mother and her maternal grandmother. Which of the following is the most likely diagnosis based on the patient's presentation and family history? (Q842008)

A. Aquagenic pruritis

B. Urticarial vasculitis

C. Hereditary angioedema

D. Anaphylaxis.

Correct Answer: C. Hereditary angioedema

■ *Listen (English)*

■ *Listen (Hindi)*

Explanation: Recurrent episodes of swelling, lack of rash (wheals) or itching, Difficulty breathing, and family history suggest a diagnosis of Hereditary angioedema. Hereditary angioedema: Definition: Recurrent angioedema without urticaria or pruritus. Cause: C1 inhibitor (C1-INH) deficiency or dysfunction. Mechanism: Excess bradykinin production causes vasodilation and swelling. Sites affected: Skin, upper respiratory tract, gastrointestinal tract. Key feature: Non-histamine-mediated; no wheals. Types: Type 1: Deficiency in C1 inhibitor. Type 2: Defect in C1 inhibitor. Type 3: Normal levels and function of C1 inhibitor. Management: C1 inhibitor concentrate (plasma-derived) Recombinant C1 inhibitor Bradykinin B2-receptor antagonist: Icatibant Kallikrein inhibitor: Ecallantide Fresh frozen plasma. Aquagenic pruritus (Option A) : Intense water-induced itching without wheals, may be linked to polycythemia vera. Urticarial vasculitis (Option B): Chronic hives >24 h with bruising/hyperpigmentation; involves leukocytoclastic vasculitis, associated with connective tissue/hematologic diseases. Anaphylaxis (Option D): Acute, life-threatening; features urticaria, angioedema, hypotension, bronchoconstriction.



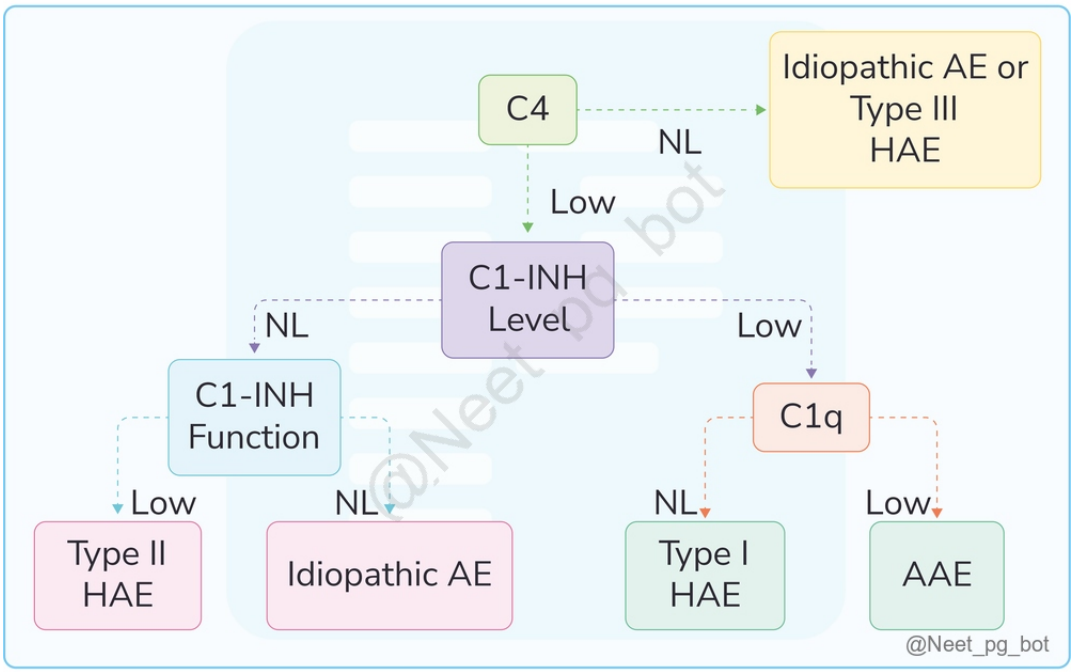

References:

https://www.uptodate.com/contents/hereditary-angioedema-acute-treatment-of-angioedema-attacks

↑ *Back to this question in Part A*

@Neet_pg_bot

Q17: A 30-year-old man presents to the clinic with a sudden onset of red, raised, and itchy wheals on his arms, legs, and torso. The patient notes that the welts move around and change shape over time, resolving in one area and appearing in another. The patient denies any known allergies, recent illnesses, or new medications. Upon examination, you observe that there is no swelling of the lips, tongue, or throat. What is the most likely diagnosis? (Q842007)

A. Hereditary Angioedema

B. Erythema nodosum

C. Urticaria

D. Fixed drug eruption

Correct Answer: C. Urticaria

■ *Listen (English)*

■ *Listen (Hindi)*

Explanation: Urticarial lesions are intensely pruritic, circumscribed, raised, and erythematous plaques, often with central pallor. They are due to vasodilation and increased vascular permeability causing dermal edema. Mostly Mast cell-dependent, can also be Bradykinin mediated. Urticarial lesions typically develop over minutes to hours and resolve in hours to a day without residual markings. There may be accompanying angioedema, which is a non-pitting submucosal or subcutaneous oedema commonly seen in lips and eyelids. Classification: Urticaria is classified as either acute or chronic. Acute Urticaria Chronic urticaria Periodic outbreaks of urticarial lesions that resolve within six weeks. Urticaria that persists beyond six weeks Infections: Viral infections. Drugs: Penicillin, sulfa drugs. Ingestion: Food items Inhalation: Pollen. Idiopathic. Chronic spontaneous urticaria (autoimmune, pseudo allergic, infection, and idiopathic). Physical/ inducible urticaria. Urticarial vasculitis. Salient features of physical/inducible Urticaria: Management: 2nd generation antihistamines (Dose can be increased up to 4 folds) The biological agent used in Urticaria is Omalizumab. Monteleukast and Cyclosporine can also be used.



@Neet_pg_bot

Type of Physical Urticaria	Eliciting Factors
Urticaria factitial/dermographism **Most common type**, red, itchy, linear wheal appearing immediately after light stroking of the skin.	Mechanical shearing forces (wheals arising within 1-5 mins)
Cold contact urticaria	Cold objects, air, fluids, wind
Heat contact urticaria	Localised heat
Solar urticaria	UV and/or visible light
Delayed pressure urticaria (poor prognosis)	Vertical pressure (wheals arise with 3-12 hours latency)
Aquagenic	Water
Cholinergic	Increase in core body temperature by exercise or spicy food

@Neet_pg_bot

References:

Rook’s Textbook of Dermatology 9thedition, Pages 42.1, 42.7

https://www.aafp.org/pubs/afp/issues/2017/0601/p717.html

↑ *Back to this question in Part A*

@Neet_pg_bot

Q18: A 3-year-old girl is brought to the clinic for evaluation of a prominent facial birthmark. Upon examination, you observe a port-wine stain covering most of the left side of her face, including the upper eyelid. The mother mentions that her daughter sometimes seems disoriented and has had a few brief seizures. A CT scan of the brain shows tram track calcification. What is the most likely diagnosis? (Q842005)

A. Tubercular Meningitis

B. Sturge-Weber Syndrome

C. Klippel-Trenaunay Syndrome

D. Cutis Marmorata Telangiectatica Congenita

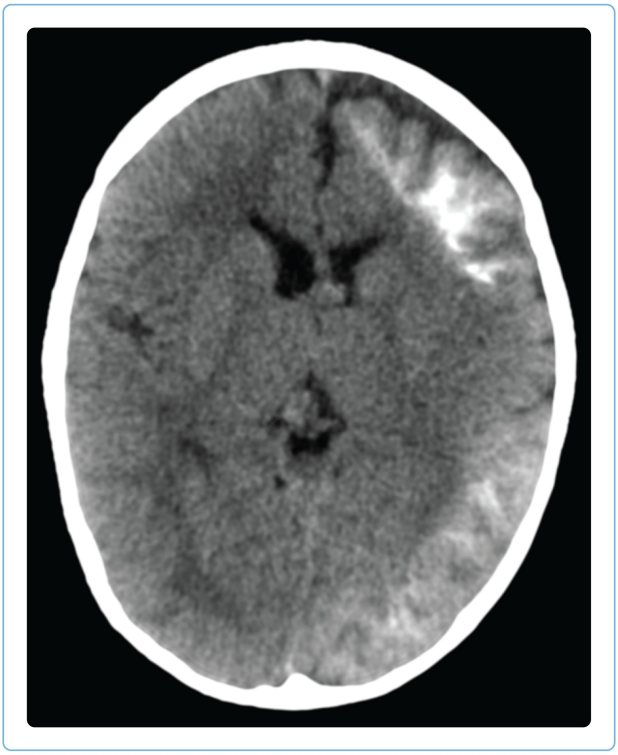

Correct Answer: B. Sturge-Weber Syndrome

■ *Listen (English)*

■ *Listen (Hindi)*

Explanation: The clinical presentation of port-wine stain along with the CT findings of Tram track calcification suggests the diagnosis of Sturge Weber syndrome. Sturge Weber syndrome is a neurocutaneous syndrome characterized by the triad of port-wine stain in the trigeminal distribution, ipsilateral leptomeningeal angiomatosis and ocular complications. Neurological manifestations include convulsions, behavioural problems, subnormal

intelligence. Ocular complications include ipsilateral glaucoma, buphthalmos, congestion, strabismus. Plain radiograph of skull shows the characteristic tram-track sign. CT is the best to detect the calcifications and MRI (Preferred diagnostic neuroimaging) shows changes such as cortical atrophy and leptomeningeal enhancement. Tubercular Meningitis (Option A): While TB meningitis can cause intracranial calcifications, they are usually found in the basal cisterns (basal exudates) rather than the cerebral cortex. It would present with systemic symptoms like fever, weight loss, and meningeal signs (neck stiffness), and it lacks the characteristic facial port-wine stain. Klippel-Trenaunay Syndrome (KTS) (Option C) : It is characterized by three features: Port wine stain Venous and lymphatic malformation Bony and soft tissue hypertrophy of an extremity It is diagnosed only if at least 2 out of the 3 features are present. Radiological imaging shows soft tissue overgrowth. Cutis Marmorata Telangiectatica Congenita (Option D): Also termed congenital livedo reticularis, is a rare condition present at birth, characterized by a red-purple vascular pattern. Typically appears on limbs, intensifies with cold, crying, or physical activity. Skin atrophy may occur alongside. While often isolated, congenital livedo reticularis can also coincide with other congenital anomalies.



Port wine stain

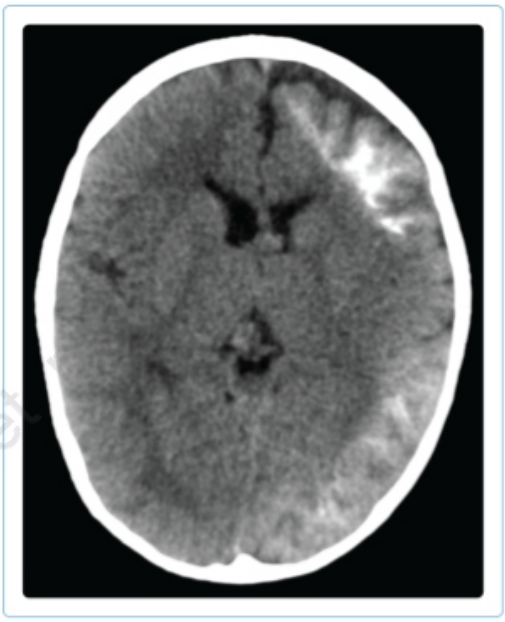

MRI - Leptomeningeal enhancement

@Neet_pg_bot

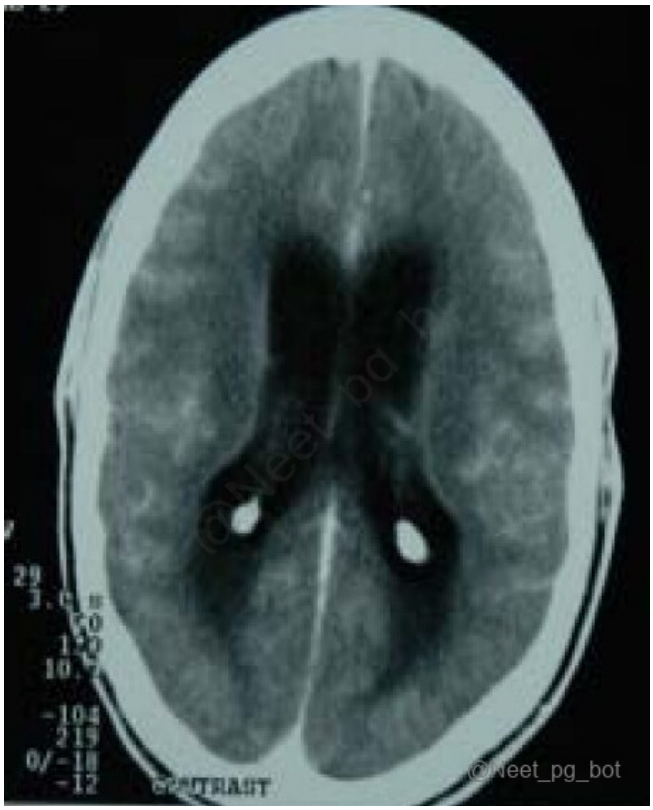
@Neet_pg_bot

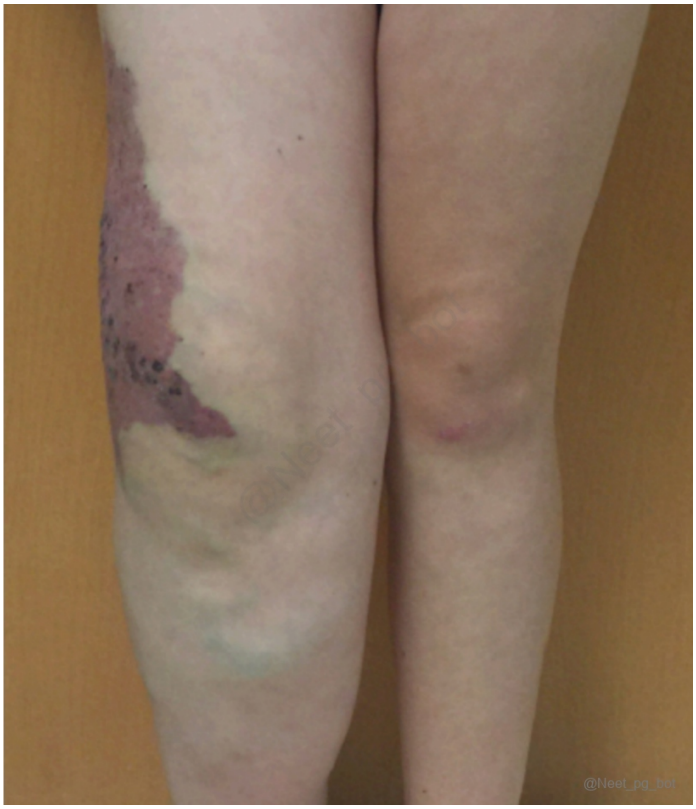
@Neet_pg_bot

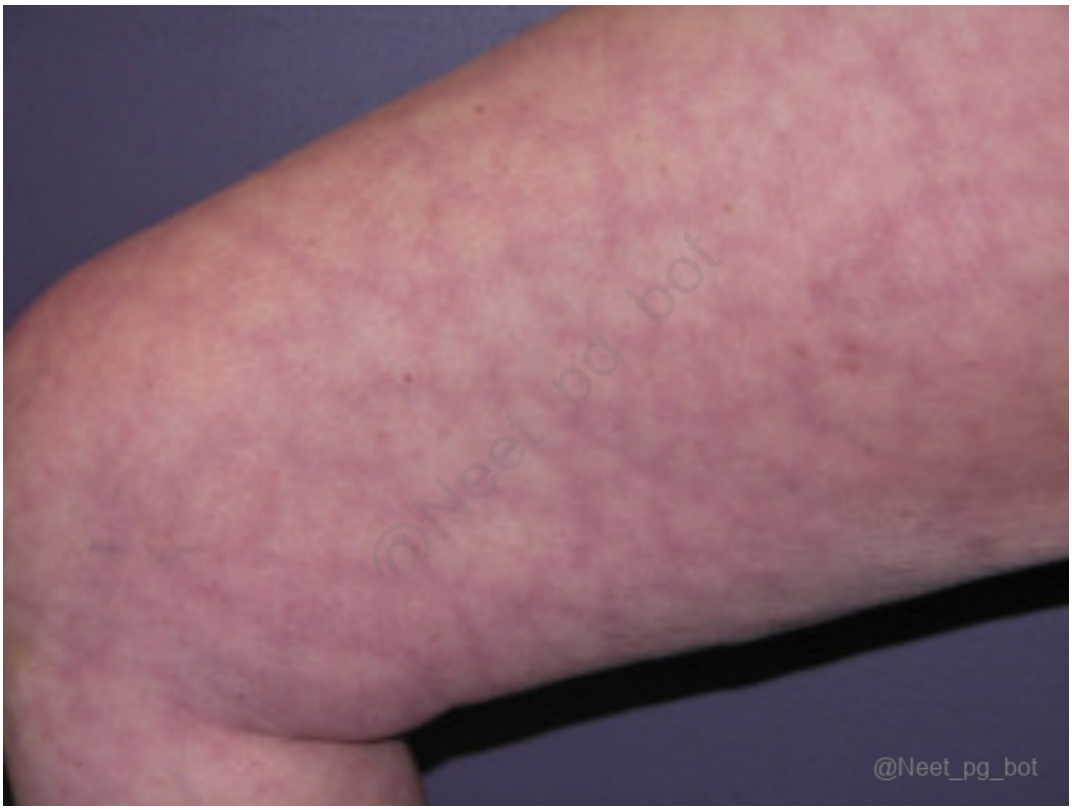

References:

Rook’s Textbook of Dermatology 9thedition - page 75.22, 103.24

www.ncbi.nlm.nih.gov/books/NBK541015/

radiopaedia.org/articles/tram-track-sign-brain-1

www.ncbi.nlm.nih.gov/books/NBK459163/#article-29590.s7

↑ *Back to this question in Part A*

@Neet_pg_bot

Q19: A 17-year-old male presents with a dark, irregularly pigmented patch on his right shoulder that he first noticed a few years ago. On examination, you see a large, unilateral patch of hyperpigmentation with a slightly irregular border and scattered areas of increased hair growth. The lesion has remained stable in size and shape over the years. The patient reports no associated symptoms such as itching or pain. Which of the following is the most likely diagnosis? (Q842002)

A. Seborrheic keratosis

B. Malignant melanoma

C. Becker's nevus

D. Nevus of Ito

Correct Answer: C. Becker's nevus

■ *Listen (English)*

■ *Listen (Hindi)*

Explanation: Becker's nevus, (or Becker melanosis), is a hyperpigmented skin lesion, commonly seen in adolescent males. While hypertrichosis is frequently observed, it is not consistently present. Commonly found on the Shoulders and the upper trunk. Becker's nevus may also be associated with extracutaneous abnormalities, collectively referred to as Becker's nevus syndrome. These abnormalities can involve underlying structures such as aplasia or hypoplasia of breast tissue, pectoralis major muscle, or lipoatrophy.



References:

Rook’s Textbook of Dermatology 9thedition - page 75.19, 132.15

https://www.ncbi.nlm.nih.gov/books/NBK435999/(Histopathology of Becker’s nevus)

Nevus of Ota and Ito - StatPearls - NCBI Bookshelf (nih.gov)

Malignant Melanoma - StatPearls - NCBI Bookshelf (nih.gov)

Seborrheic Keratosis - StatPearls - NCBI Bookshelf (nih.gov)

↑ *Back to this question in Part A*

@Neet_pg_bot

Q20: Match the following: A. 1. Hydroxychloroquine B. 2. Clofazimine C. 3. Bleomycin D. 4. Amiodarone (Q841999)

A. A-3, B-1, C-4, D-2

B. A-3, B-4, C-2, D-1

C. A-4, B-3, C-2, D-1

D. A-4, B-2, C-3, D-1

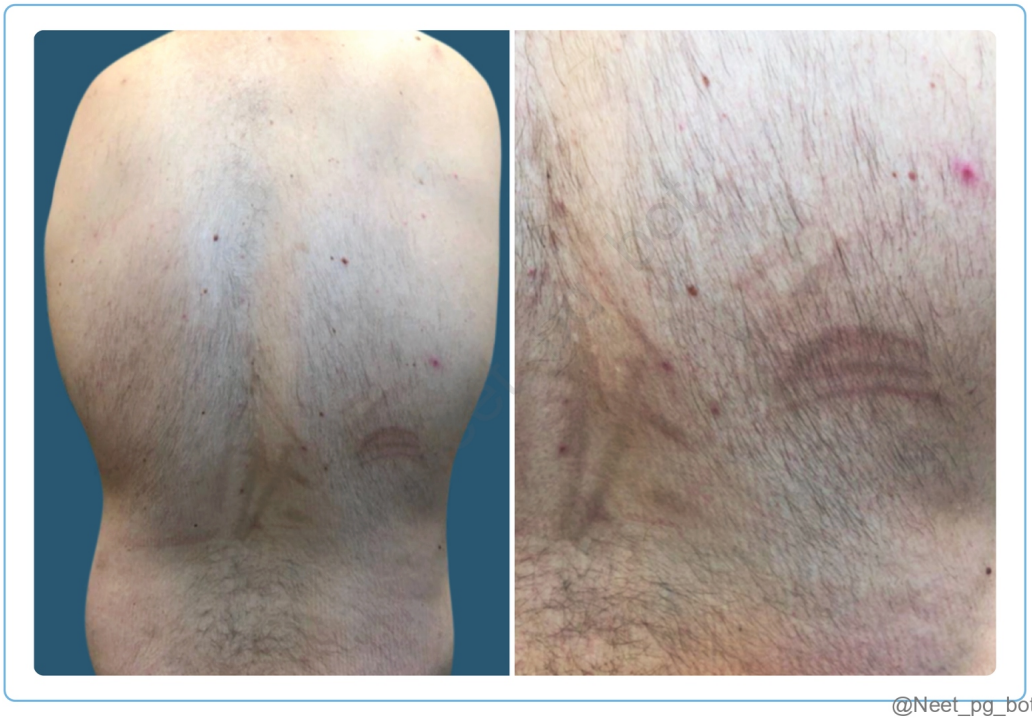

@Neet_pg_bot



@Neet_pg_bot



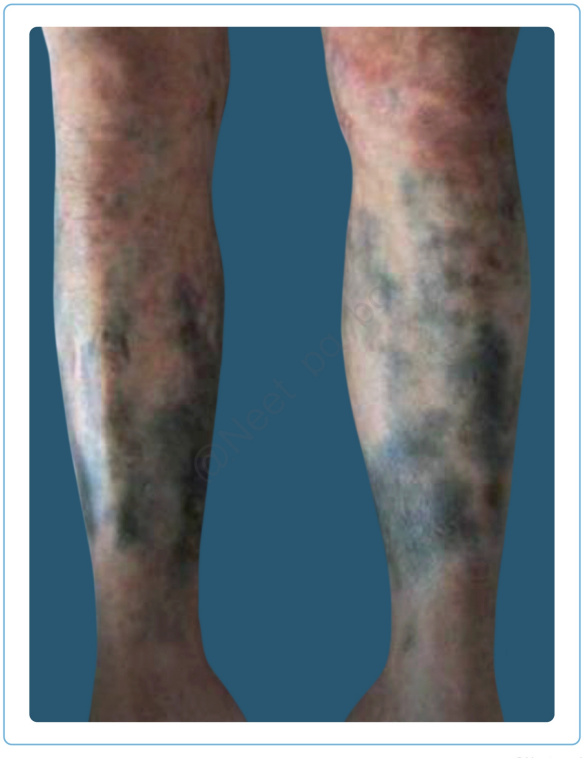

Correct Answer: B. A-3, B-4, C-2, D-1

Explanation: A. Bleomycin Flagellate hyperpigmentation — characteristic cutaneous reaction. Presents as multiple linear, erythematous streaks at sites of minor trauma or scratching. B. Amiodarone Photosensitivity. Blue man

syndrome: Bluish slate grey discolouration of the skin, predominantly in the face due to deposition of lipofuscin in the dermis C. Clofazimine (In leprosy patients) Ichthyosis. Photosensitivity. Brownish skin discoloration. D. Hydroxychloroquine Brown, Blue-gray and/or slate grey hyperpigmentation most commonly on shins, but can also be seen in arms, forearms, face, oral mucosa, trunk, nails, and axilla. The involvement is typically bilateral.

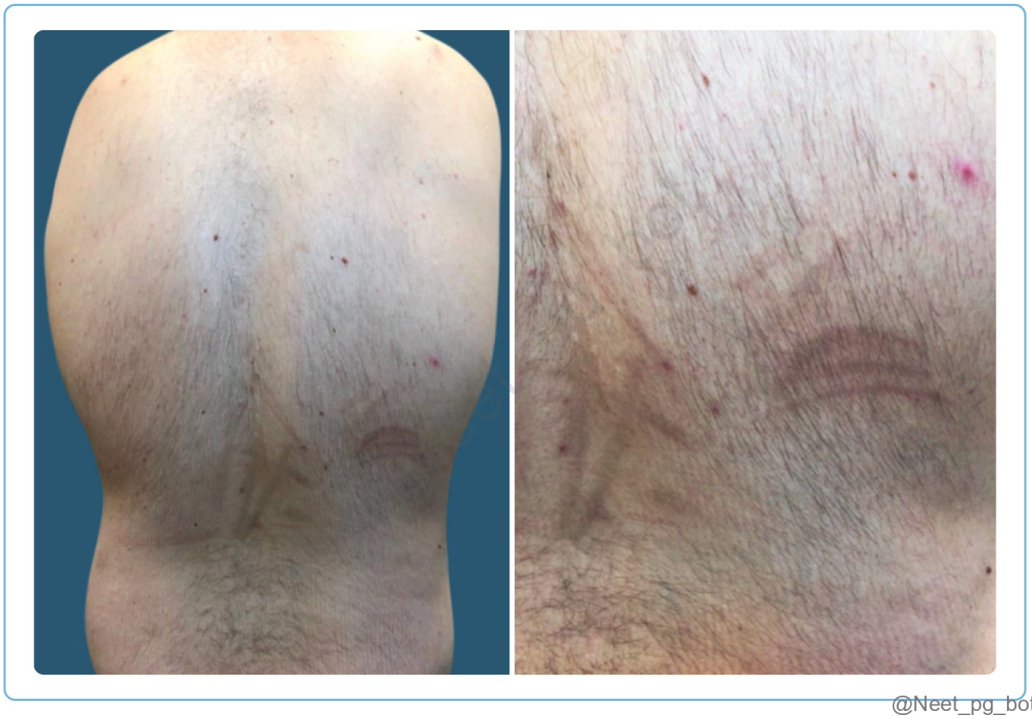





@Neet_pg_bot

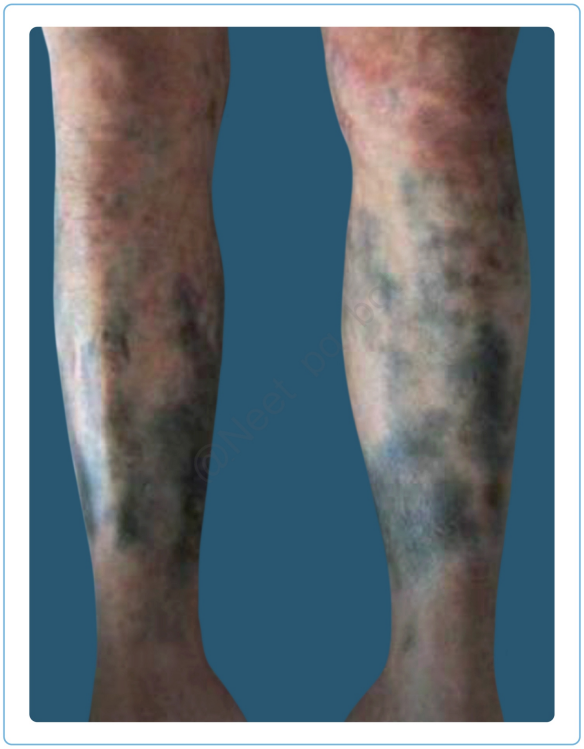

@Neet_pg_bot

References:

Rook’s Textbook of Dermatology, 9thEdition.

https://www.uptodate.com/contents/minocycline-systemic-drug-information?search=minocycline%20side%20effects&source=panel_search_result&selectedTitle=1%7E145&usage_type=panel&showDrugLabel=true&display_rank=1#F57426561

https://pmc.ncbi.nlm.nih.gov/articles/PMC7375853/

↑ *Back to this question in Part A*

@Neet_pg_bot

Q21: A 38-year-old woman presents with a sudden onset of widespread, non-follicular pustules on an erythematous base. She reports having taken medication for a urinary tract infection two days ago. On examination, she appears febrile with diffuse erythema and multiple small, sterile pustules on her trunk and extremities. There is no mucosal involvement. What is the most likely cause of her presentation? (Q841998)

A. Staphylococcal scalded skin syndrome

B. Pemphigus vulgaris

C. Acute generalized exanthematous pustulosis

D. Milia

Correct Answer: C. Acute generalized exanthematous pustulosis

■ *Listen (English)*

■ *Listen (Hindi)*

Explanation: Acute generalized exanthematous pustulosis (AGEP) is a rare, acute hypersensitivity reaction caused in approximately 90 per cent of cases by drugs, most often antibiotics, calcium channel blockers, and antimalarials. AGEP is characterized by the development of numerous nonfollicular, sterile, small pustules on a background of edematous erythema with flexural accentuation. Fever above 38°C (100.4°F) and leukocytosis with a neutrophil count >7000/microL are usually present. The eruption usually occurs a few hours to a few days after the administration of the offending drug. The eruption resolves spontaneously in one to two weeks after the discontinuation of the offending drug Features which distinguish acute generalized exanthematous pustulosis (AGEP) from psoriasis: AGEP Psoriasis History of psoriasis Possible Common Distribution pattern Predominance in the folds More generalized Duration of pustules Shorter Longer Duration of fever Shorter Longer History of drug reaction Usual Uncommon Recent drug administration Very frequent Less frequent Arthritis Rare ~30% Histology Spongiform subcorneal and/ or intraepidermal pustules, Oedema of papillary dermis, Vasculitis, Exocytosis of eosinophils, Single■cell necrosis of keratinocytes Subcorneal and/or intraepidermal pustules, Papillomatosis, Acanthosis



References:

Rook’s Textbook of Dermatology 9thedition, Page 119.4

https://www.uptodate.com/contents/acute-generalized-exanthematous-pustulosis-agep?

↑ *Back to this question in Part A*

@Neet_pg_bot

Q22: Which of the following factors is involved in the pathogenesis of Toxic Epidermal Necrolysis? (Q841997)

A. HLA polymorphism.

B. T cell-mediated response.

C. Necrosis of keratinocytes.

D. All of the above.

Correct Answer: D. All of the above.

■ *Listen (English)*

■ *Listen (Hindi)*

Explanation: Toxic epidermal necrolysis (TEN) are severe cutaneous adverse reaction characterized by extensive necrosis and detachment of the epidermis. The pathophysiology behind TEN is as follows, Genetic predisposition:

HLA variants, pharmacogenetics. Drug antigen presentation: Drugs bind self-proteins/HLA, activating T cells. T cell response: CD8■ T cells release cytotoxic proteins; immune dysregulation. Keratinocyte death: Granulysin, perforin/granzyme, FasL induce apoptosis/necrosis. Other mediators: NK/T cells, Th17, neutrophils, cytokines (TNF-α, IL-15), alarmins. Pathologic Sequelae: Epidermal necrolysis, full-thickness detachment, mucosal involvement.

References:

Rook's Textbook of Dermatology 9thedition.

https://www.uptodate.com/contents/stevens-johnson-syndrome-and-toxic-epidermal-necrolysis-pathogenesis-clinical-manifestations-and-diagnosis

↑ *Back to this question in Part A*

@Neet_pg_bot

Q23: A 50-year-old patient presented to the emergency department with widespread blistering and skin detachment, along with mucosal involvement, after starting a new medication a week ago. On examination, there are large areas of epidermal detachment involving more than 30% of the body surface area. Nikolsky's sign is positive. Which of the following conditions is most likely to be responsible for this presentation? (Q841996)

A. Erythema multiforme

B. Stevens-Johnson syndrome

C. Pemphigus vulgaris

D. Toxic epidermal necrolysis

Correct Answer: D. Toxic epidermal necrolysis

■ *Listen (English)*

■ *Listen (Hindi)*

Explanation: Stevens-Johnson syndrome (SJS) and toxic epidermal necrolysis (TEN) are severe cutaneous adverse reactions characterized by extensive necrosis and detachment of the epidermis. Classification based on Body surface area involvement (BSA) SJS : <10 % of BSA detached (Option B ruled out) SJS/TEN overlap: 10 to 30 % of BSA detached TEN: >30 percent of BSA detached The term "epidermal necrolysis" collectively refers to SJS, SJS/TEN overlap, and TEN. Cause: Drugs (NSAIDs, allopurinol, antiepileptics, sulfonamides, antiretrovirals); T cell-mediated, HLA-linked keratinocyte necrosis. Clinical: Prodrome → atypical target lesions → diffuse erythema → bullae → sheet-like skin peeling; positive pseudo-Nikolsky; mucosal involvement common. Management : stop offending drug, provide supportive care, consider cyclosporine or IV immunoglobulins. Prognosis: SCORTEN predicts mortality. Erythema multiforme(Option A): Mild, target lesions, <10% BSA,

limited mucosal involvement; unlike TEN. Pemphigus vulgaris (Option C): Autoimmune intraepidermal blisters (anti-desmoglein 3>1); lacks widespread epidermal detachment seen in TEN.



References:

Rook’s Textbook of Dermatology 9thedition.

https://www.uptodate.com/contents/stevens-johnson-syndrome-and-toxic-epidermal-necrolysis-pathogenesis-clinical-manifestations-and-diagnosis

↑ *Back to this question in Part A*

@Neet_pg_bot

Q24: A 26-year-old male presents to the emergency department with a sudden onset of skin lesions. Upon examination, you notice distinct lesions with concentric rings resembling a "bull's eye" appearance. The patient reports a recent malarial infection. Which of the following conditions is most likely responsible for these skin lesions? (Q841995)

A. Fixed drug eruption

B. Nummular eczema

C. Urticaria

D. Erythema multiforme



Correct Answer: D. Erythema multiforme

■ *Listen (English)*

■ *Listen (Hindi)*

Explanation: Erythema multiforme Explanantion : Based on the history provided and the Target lesions seen in the image, the diagnosis is erythema multiforme. Erythema Multiforme (EM) is an acute, immune-mediated condition characterized by distinctive target-like skin lesions accompanied by erosions or bullae involving the oral, genital, and/or ocular mucosa. Types: EM Major (severe mucosal/systemic involvement), EM Minor (mild/no mucosal/systemic symptoms). Causes: Infections (HSV-1, Mycoplasma), drugs (NSAIDs, sulfonamides, antimalarials), SLE, leukemia. Clinical: Target lesions on distal extremities, possible mucosal involvement; prodrome rare in mild cases. Target lesion zones: central dusky/blistered area, dark red middle zone, pale outer ring, possible peripheral erythematous halo. Treatment: Stop offending drug, acyclovir, short course of systemic steroids if needed. Fixed drug eruption(Option A): Recurrent lesions at same site, acutely erythematous/bullous, later slate-brown; commonly affects mucous membranes, face, acral areas. Nummular eczema(Option B): Coin-shaped lesions, lacks EM's concentric rings. Urticaria(Option C): Transient pruritic wheals with central pallor, not targetoid. Has transient wheals lasting <24 hours, not fixed target lesions. Lacks the characteristic three-zone concentric rings seen in EM



Erythema multiforme on oral mucosa



Erythema multiforme skin lesions

@Neet_pg_bot

References:

Rook’s Textbook of Dermatology, 9 th Edition.

↑ *Back to this question in Part A*

@Neet_pg_bot

• [13_Miscellaneous Disorders] 026 Genodermatoses Vector-Borne Diseases Bedside Tests In Dermatology

« Back to Folder Directory

[13_Miscellaneous Disorders] 026 Genodermatoses Vector-Borne Diseases Bedside Tests In Dermatology — Quick Jump

Q1 (p. 1213) *Q2 (p. 1215)* *Q3 (p. 1217)* *Q4 (p. 1220)* *Q5 (p. 1221)* *Q6 (p. 1224)*
Q7 (p. 1225) *Q8 (p. 1226)* *Q9 (p. 1227)* *Q10 (p. 1230)*

Q1: Which of the following condition presents with the characteristic skin lesion seen in this newborn? (Q841708)

A. Fish net ichthyosis

B. X-linked ichthyosis

C. Harlequin ichthyosis

D. Lamellar ichthyosis



Correct Answer: D. Lamellar ichthyosis

Explanation: The image shows a newborn with a taut and glistening membrane, which suggests a diagnosis of colloidion baby , which is a feature of lamellar icthyosis. Lamellar ichthyosis is autosomal recessive , usually caused by TGM1 gene mutation (Transglutaminase 1). Clinical features: collodion membrane, fish-like scales, ectropion , eclabium , deformed ears, palmoplantar keratoderma, and nasal blockage. Ichthyosis vulgaris (Option A) develops later (not at birth), mostly spares flexures, and is due to filaggrin gene defect . X-linked ichthyosis (Option B) occurs in males, presents with fine scales and a “dirty” appearance later; flexures spared. Harlequin ichthyosis (Option C) is more severe with thick, armor-like plates, severe ectropion/eclabium, risk of respiratory failure, and often lethal.



@Neet_pg_bot



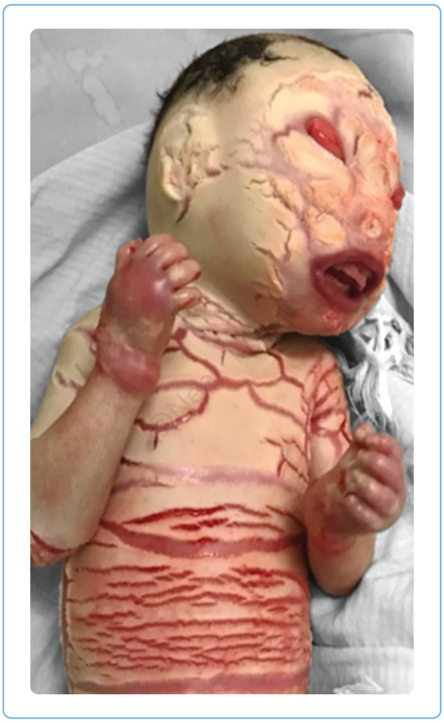

References:

Rook’s Textbook of Dermatology, 9 th Edition, Page 65.2, 65.7, 65.9-13

↑ *Back to this question in Part A*

@Neet_pg_bot

Q2: An 11-year-old boy presents to the clinic with asymptomatic light brown-colored lesions on his body as shown in the image. On slit lamp examination, pigmented nodules on the iris were noted. What is the most common malignancy associated with this syndrome? (Q841703)

A. Optic nerve glioma

B. Renal cell carcinoma

C. Acoustic Schwannoma

D. Endolymphatic sac tumour





Correct Answer: A. Optic nerve glioma

■ *Listen (English)*

■ *Listen (Hindi)*

Explanation: The brown-pigmented lesions shown in the image are café au lait macules, and the presence of pigmented nodules on the iris, known as Lisch nodules, suggests the diagnosis of Neurofibromatosis type-1(NF-1), also known as Von Recklinghausen's disease. It is an autosomal dominant neurocutaneous syndrome. The gene for NF-1 is located on chromosome 17 and encodes for neurofibromin. Malignancies associated with this syndrome are Optic nerve gliomas and astrocytoma. In NF1, optic nerve gliomas typically present in children and are often associated with specific clinical features such as café-au-lait spots (light brown skin patches), Lisch nodules (pigmented nodules in the iris), and axillary freckling (freckling in the armpits). Other characteristic features of the syndrome include Buttonhole sign: Lesions invaginate when pressed with a finger. Bag of worms: Plexiform neurofibroma has a lot of nerves which feels like a bag of worms.



Lisch nodules



Café-au-lait spots

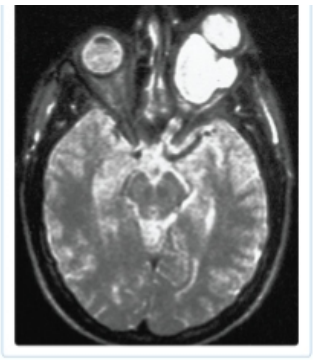

Optic nerve glioma

@Neet_pg_bot

References:

Rook's Textbook of Dermatology 9 th edition, Page 80.1

↑ *Back to this question in Part A*

@Neet_pg_bot

Q3: A 4-year-old boy presents to the paediatrician with a history of developmental delay, multiple hypopigmented macules on his trunk, and a history of infantile spasms. On examination, he also has facial angiofibroma. What is the most likely diagnosis? (Q841704)

A. Ataxia Telangiectasia

B. Sturge-Weber syndrome

C. Tuberous sclerosis

D. Von Hippel-Lindau syndrome



Correct Answer: C. Tuberous sclerosis

- *Listen (English)*
- *Listen (Hindi)*

Explanation: The given clinical presentation suggests the diagnosis of Tuberous Sclerosis (TSC), an autosomal dominant neurocutaneous syndrome. This syndrome is caused by mutations in the genes TSC 1(Chromosome 9) and TSC 2 (Chromosome 16), which encode the proteins hamartin and tuberin, respectively. There are four pathognomic skin lesions associated with this condition: Ash-leaf macules are characterized by oval or irregularly shaped hypopigmented (lighter than surrounding skin) patches and are accentuated on Wood's lamp examination. Angiofibroma, previously misnamed adenoma sebaceum, consists of hyperplastic blood vessels and sebaceous glands in immature hair follicles. Periungual fibroma (Koenen tumours) emerge from the nail folds. A Shagreen patch is characterized by thickened, leathery skin and typically appears as irregularly shaped plaques with a rough, raised surface, commonly located on the lower back. Angiofibroma Infantile spasms, also known as West syndrome, can occur in infants and young children with tuberous sclerosis complex.



Ash leaf macule

Shagreen patch

Periungual fibroma

@Neet_pg_bot



@Neet_pg_bot

References:

Rook’s Textbook of Dermatology 9thedition - page 80.9

www.ncbi.nlm.nih.gov/books/NBK519542/

www.ncbi.nlm.nih.gov/books/NBK459163/

www.ncbi.nlm.nih.gov/books/NBK459242/

↑ *Back to this question in Part A*

@Neet_pg_bot

Q4: A 28-year-old male presents to the gastroenterologist with a history of recurrent abdominal pain and episodes of gastrointestinal bleeding. On examination, he has multiple pigmented macules on his lips and oral mucosa. A colonoscopy reveals numerous hamartomatous polyps throughout the gastrointestinal tract. What is the most likely diagnosis? (Q841705)

A. Gardner Syndrome

B. Familial Adenomatous Polyposis

C. Cowden Syndrome

D. Peutz-Jeghers Syndrome



@Neet_pg_bot

Correct Answer: D. Peutz-Jeghers Syndrome

■ *Listen (English)*

■ *Listen (Hindi)*

Explanation: The history of recurrent abdominal pain with GI bleed and multiple pigmented macules on lips with hamartomatous polyps suggests the diagnosis of Peutz-Jeghers Syndrome, an autosomal dominant disorder characterized by mutations in the STK11 gene located on the short arm of chromosome 19. Gardner Syndrome (Option A) is a phenotypic variant of familial adenomatous polyposis (FAP), an inherited condition characterized by the development of numerous adenomatous polyps in the colon, along with extracolonic manifestations such as osteomas, epidermal cysts, fibromas, and dental abnormalities. Familial Adenomatous Polyposis (Option B) is an inherited genetic disorder characterized by the development of numerous adenomatous polyps in the colon and rectum. Cowden Syndrome (Option C) or multiple hamartoma syndrome, is a genodermatosis linked to mutations in the PTEN gene located on the long arm of chromosome 10. It manifests as multiple benign hamartomas affecting various organs, with mucocutaneous lesions and macrocephaly being characteristic features. Individuals with Cowden syndrome have an elevated risk of developing malignant neoplasms, particularly thyroid, endometrial, or breast cancers.

References:

Rook’s Textbook of Dermatology 9 th edition - page 110.13, 80.13 Familial Adenomatous Polyposis - StatPearls - NCBI Bookshelf (nih.gov)

↑ *Back to this question in Part A*

@Neet_pg_bot

Q5: A 10-year-old child presents to the dermatology clinic with a history of severe sunburns after minimal sun exposure. On examination, numerous freckle-like pigmented patches and atrophic areas were noted on the face and arms. Which of the following conditions is most likely responsible for the patient's presentation? (Q841706)

A. Vitiligo

B. Gorlin syndrome

C. Xeroderma Pigmentosum

D. Bloom Syndrome



@Neet_pg_bot

Correct Answer: C. Xeroderma Pigmentosum

- *Listen (English)*
- *Listen (Hindi)*

Explanation: The clinical presentation described in the question is typical of Xeroderma Pigmentosum. Xeroderma Pigmentosum: A rare autosomal recessive NER defect causing extreme UV sensitivity, freckling, ocular damage, neurological deficits, and early skin cancers (melanoma, SCC, BCC). Vitiligo (Option A) is an acquired depigmentation disorder resulting from the absence of melanocytes in the epidermis, which causes white macules and patches on the body. Gorlin syndrome (Option B) or nevoid basal cell carcinoma syndrome, is a rare genetic disorder caused by mutations in the PTCH1 gene, which is involved in the Hedgehog signalling pathway. It is characterized by multiple basal cell carcinomas, along with jaw cysts, skeletal abnormalities, facial deformities, and an increased risk of other cancers like medulloblastoma. Bloom syndrome (Option D) is a rare autosomal recessive genetic disorder caused by mutations in the BLM gene. It presents with short stature, photosensitivity, and characteristic facial features including a long, narrow face and prominent nose, along with other physical anomalies such as micrognathia and cafe-au-lait spots. Increased risk of various cancers, particularly leukaemia and lymphoma, at an early age.



@Neet_pg_bot



@Neet_pg_bot

References:

Rook’s Textbook of Dermatology - page 78.1, 79.3

www.ncbi.nlm.nih.gov/books/NBK559149/

www.ncbi.nlm.nih.gov/books/NBK430921/#article-22375.s6

↑ *Back to this question in Part A*

@Neet_pg_bot

Q6: Which of the following best describes the pathophysiology underlying dystrophic epidermolysis bullosa? (Q841707)

A. Deficiency of type VII collagen

B. Mutations in genes KRT5 and KRT14

C. Malfunctioning laminin 332 protein

D. Faulty kindlin-1 proteins

Correct Answer: A. Deficiency of type VII collagen

■ *Listen (English)*

■ *Listen (Hindi)*

Explanation: Epidermolysis bullosa (EB) refers to a group of rare genetic disorders characterized by fragile skin that blisters and ulcerates easily with minor friction or trauma and is also known as mechanobullous disease. Dystrophic epidermolysis bullosa is caused by mutations in the COL7A1 gene, which encodes type VII collagen resulting in Subepidermal bulla. Depending on the specific type of DEB and the inheritance pattern of the mutated gene, it can be inherited in an autosomal dominant or autosomal recessive manner. A positive family history is present. Common presenting complaints include blistering, skin fragility, and non-healing wounds disproportionate to mechanical trauma. Diagnosis is made with transmission electron microscopy, immunofluorescence antigen mapping using biopsy specimens, and genetic sequencing to confirm the subtype. Treatment mainly focuses on wound care, prevention of infection, and symptomatic management of skin and mucosal complications. The major forms of EB include: Level of skin cleavage EB type Defective protein Intraepidermal EB simplex Keratin 5 & 14 Intra lamina lucida Junctional EB Laminin 332 Sublamina densa Dystrophic EB Type VII collagen Mixed Kindler syndrome Kindlin-1



References:

Rook’s Textbook of Dermatology 9 th edition - page 71.2 Epidermolysis Bullosa - StatPearls - NCBI Bookshelf (nih.gov)

↑ *Back to this question in Part A*

@Neet_pg_bot

Q7: A 3-month-old female infant presents with linear streaks of hyperpigmentation along Blaschko's lines on her trunk and extremities. The mother reports that the infant also experienced vesicular eruptions shortly after birth that resolved without scarring. What is the most likely diagnosis? (Q841709)

A. Hypomelanosis of Ito

B. Ichthyosis vulgaris

C. Incontinentia pigmenti

D. Epidermolysis bullosa

Correct Answer: C. Incontinentia pigmenti

■ *Listen (English)*

■ *Listen (Hindi)*

Explanation: The clinical presentation of linear streaks of hyperpigmentation along Blaschko's lines suggests the diagnosis of Incontinentia Pigmenti, also known as Bloch-Sulzberger syndrome The condition is characterized by X-linked dominant inheritance with a mutation in the NEMO gene. It predominantly affects females while resulting in in-utero lethality in males. Presents in 4 stages: Stage I Vesicular Erythematous vesicular rash at birth Stage II Verrucous Mainly on the limbs Stage III Hyperpigmentation Hyperpigmented streaks and whorls along Blaschko's lines Stage IV Hypopigmentation Pale, hairless, atrophic linear streaks on the lower extremities Extracutaneous features: Alopecia Dental: Peg/cone-shaped crowns Ocular: Retinal neovascularisation CNS: Microcephaly, seizures, motor impairments Treatment is typically symptomatic

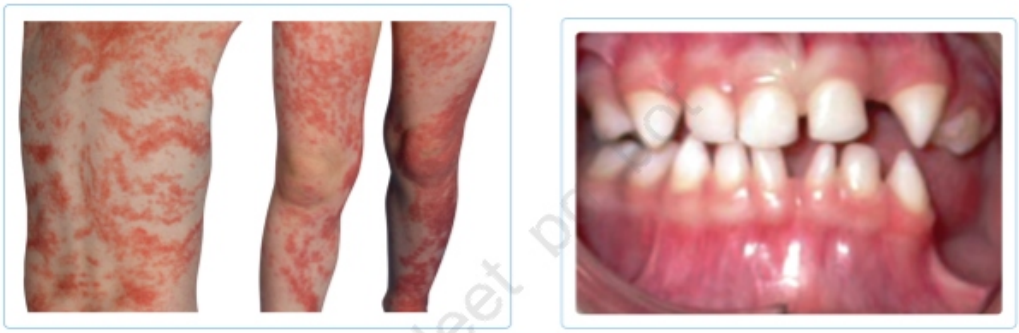

Hyperpigmented streaks along Blaschko's lines

Peg-shaped crowns

@Neet_pg_bot

References:

Rook's Textbook of Dermatology - page 70.11

↑ *Back to this question in Part A*

@Neet_pg_bot

Q8: A 38-year-old male presents with persistent, rough lesions on his face. Examination reveals hyperkeratotic papules and plaques with a greasy, crusted appearance, predominantly on seborrheic areas. Nail abnormalities include longitudinal ridging and V-shaped notches. Based on histopathological findings showing acantholysis and dyskeratosis, what is the most likely diagnosis? (Q841712)

A. Darier's disease

B. Hailey-Hailey disease

C. Grover's disease

D. Seborrheic dermatitis

Correct Answer: A. Darier's disease

■ *Listen (English)*

■ *Listen (Hindi)*

Explanation: The clinical presentation given in the question suggests Darier's disease, an autosomal dominant disorder with an ATP2A2 gene defect (chromosome 12) responsible for calcium-bound ATPase type 2. Darier's disease Its onset is typically in childhood, exacerbated during summer and monsoon. It presents as warty, dirty, foul-smelling papules in seborrheic areas like the scalp, forehead, nasolabial folds, retro auricular region, chest, middle of the back, axillae, and groins and they are covered with a crust, causing discomfort and itching (No bulla or vesicles are observed). Nails exhibit alternate longitudinal white and red bands (erythro-leukonychia) with distal notching (V sign). Cobblestone lesions on the palate can be seen. HPE shows suprabasal acantholysis and dyskeratosis, leading to the formation of dyskeratotic cells known as Corps ronds and grains.

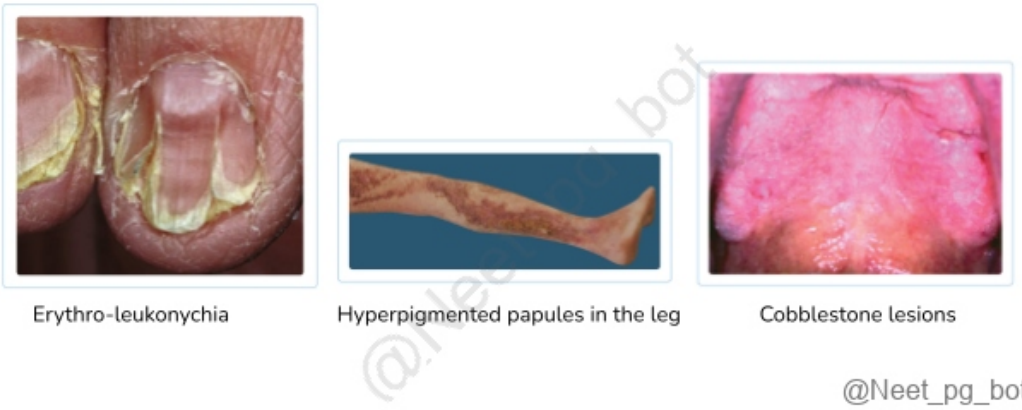

References:

Rook's Textbook of Dermatology - pages 66.1 to 66.14

↑ *Back to this question in Part A*

@Neet_pg_bot

Q9: A 35-year-old male who had recently travelled to Rajasthan presented to the clinic with a complaint of a persistent skin lesion on his right forearm. About two months ago, it initially appeared as a small red bump, but it grew in size and became ulcerated. On examination, the lesion appears to have a raised border with central crusting. The surrounding skin shows signs of inflammation with erythema. What is the diagnosis of this patient? (Q841715)

A. Lyme disease

B. Scrub typhus

C. Anthrax

D. Cutaneous Leishmaniasis



Correct Answer: D. Cutaneous Leishmaniasis

■ *Listen (English)*

■ *Listen (Hindi)*

Explanation: The characteristic lesion on the forearm, which suggests a recent travel history to Rajasthan, suggests the diagnosis of Leishmaniasis, caused by protozoan parasites transmitted by the bite of infected female phlebotomine sandflies. Cutaneous leishmaniasis (Delhi boil/Chiclero ulcer) causes annular crusted ulcers after endemic travel; Giemsa smear shows amastigotes, NNN culture promastigotes; treated with liposomal amphotericin B or miltefosine. Lyme disease (Option A): Erythema chronicum migrans, the bull's-eye rash of Lyme disease, is caused by Borrelia burgdorferi via Ixodid ticks and may include flu-like symptoms. Erythema Migrans in Lyme disease Scrub typhus (Option B): caused by Orientia tsutsugamushi via chigger bites, shows a characteristic black eschar at the bite site. Cutaneous Anthrax (Option C): It appears 1–10 days post-exposure as a painless ulcer with a black necrotic center, satellite vesicles, and surrounding edema.



@Neet_pg_bot

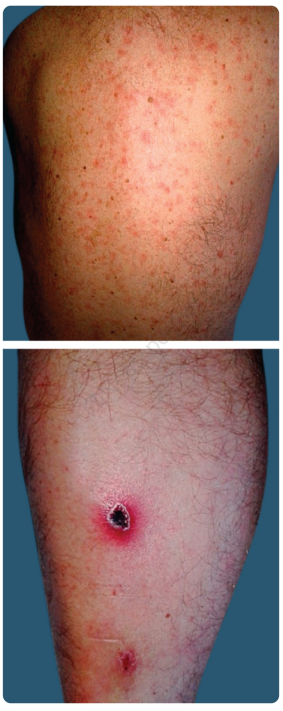

@Neet_pg_bot

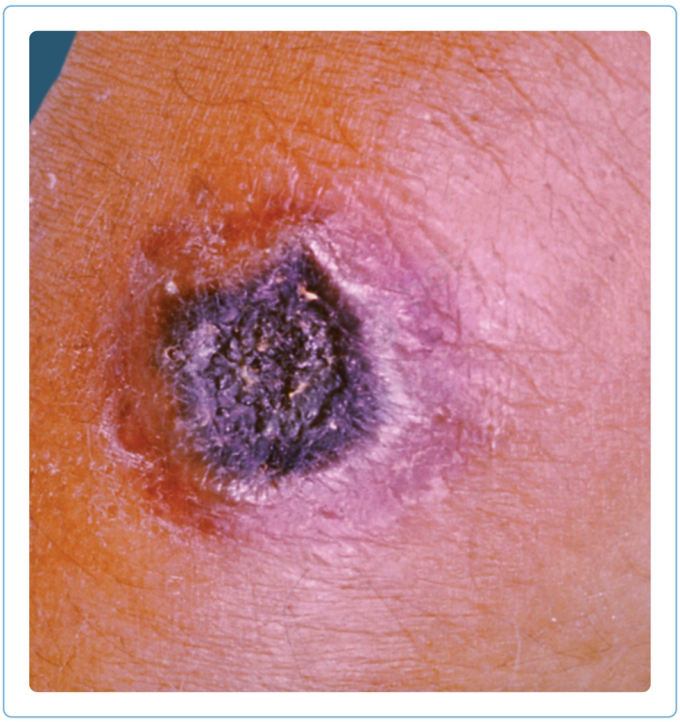

@Neet_pg_bot

References:

Rook’s Textbook of Dermatology - page 33.47

↑ *Back to this question in Part A*

@Neet_pg_bot

Q10: Match the following Disease Colour on Wood’s light A. Milky white 1. Erythrasma B. Coral pink 2. Pityriasis versicolor C. Yellow 3. Vitiligo D. Green 4. Tinea capitis (Q841718)

A. A-4, B-1, C-2, D-3

B. A-3, B-1, C-4, D-2

C. A-3, B-2, C-4, D-1

D. A-3, B-1, C-2, D-4

Correct Answer: D. A-3, B-1, C-2, D-4

■ *Listen (English)*

■ *Listen (Hindi)*

Explanation: Wood's lamp examination is a diagnostic procedure used to observe fluorescence patterns in the skin under ultraviolet light. It helps identify fungal infections, bacterial infections, pigmentary disorders, and other skin conditions based on characteristic fluorescence reactions This non-invasive test is conducted in a darkened room, emitting light of wavelength 320-450nm. Disease Colour on Wood’s light Vitiligo Milky white Erythrasma Coral pink Pityriasis versicolor Yellow Tinea capitis Green Pseudomonas Green Scabies Fluorescein solution fills the burrows and is viewed with Wood’s light Porphyria Fluorescence observed in urine, teeth and blood Tuberous sclerosis Ash-leaf macules



References:

Rook’s Textbook of Dermatology - page 4.20

↑ *Back to this question in Part A*

@Neet_pg_bot

• [13_Miscellaneous Disorders] 027 Previous Year Questions

« Back to Folder Directory

[13_Miscellaneous Disorders] 027 Previous Year Questions — Quick Jump

Q1 (p. 1232) *Q2 (p. 1232)* *Q3 (p. 1235)* *Q4 (p. 1236)* *Q5 (p. 1237)* *Q6 (p. 1238)*
Q7 (p. 1240) *Q8 (p. 1241)* *Q9 (p. 1242)*

Q1: A child accidentally took a bottle full of iron tablets. Which of the drugs is used as an antidote for iron poisoning? (Q866860)

A. Luspatercept

B. Deferoxamine

C. Deferiprone

D. DMSA

Correct Answer: B. Deferoxamine

Explanation: Acute iron poisoning can occur when a person ingests a toxic amount of iron tablets or other iron-containing substances. Deferoxamine is a chelating agent that is used as the antidote for Acute iron poisoning. Mechanism: Binds iron in the body and forms a stable complex that can be excreted through urine and faeces. Deferoxamine helps to remove excess iron from the body and prevent its toxic effects. Incorrect Options: Luspatercept (Option B) is a medication used for the treatment of anemia in certain blood disorders and is not indicated for the treatment of iron poisoning. Deferiprone (Option C) is an oral chelating agent used to treat iron overload in disorders like thalassemia. However, deferoxamine is the preferred antidote for acute iron poisoning. DMSA (Dimercaptosuccinic acid) (Option D) is another chelating agent used for heavy metal poisoning, but it is not the preferred antidote for iron poisoning. It is more commonly used for lead or mercury poisoning.

↑ *Back to this question in Part A*

@Neet_pg_bot

Q2: A patient presents to the dermatology clinic reporting recurrent skin lesions as seen on the image. He describes that these lesions emerge within hours each time he takes NSAIDs. What is the most likely diagnosis? (Q866865)

A. Fixed drug eruptions

B. Erythema multiforme

C. Drug Induced Pigmentation

D. Herpes



Correct Answer: A. Fixed drug eruptions

Explanation: Fixed drug eruption features: Recurrent lesions that appear within hours of taking NSAIDs well-demarcated, erythematous patch They recur at the same site upon re-exposure to the offending drug Common triggers: NSAIDs, sulfa drugs, antibiotics They heal with hyperpigmentation Incorrect Options: Erythema multiforme (Option B): Shows "target" or "iris" lesions with three zones of color, typically triggered by infections or drugs. But it does not typically recur on the same site after drug exposure and resolves differently . Drug Induced Pigmentation (Option C): They present as persistent pigment changes (blue-grey, brown), not the acute, recurrent red plaques described here. Herpes (Option D): Herpes produces blistering grouped lesions, often painful, and is unrelated to NSAID intake or this typical recurrence pattern.

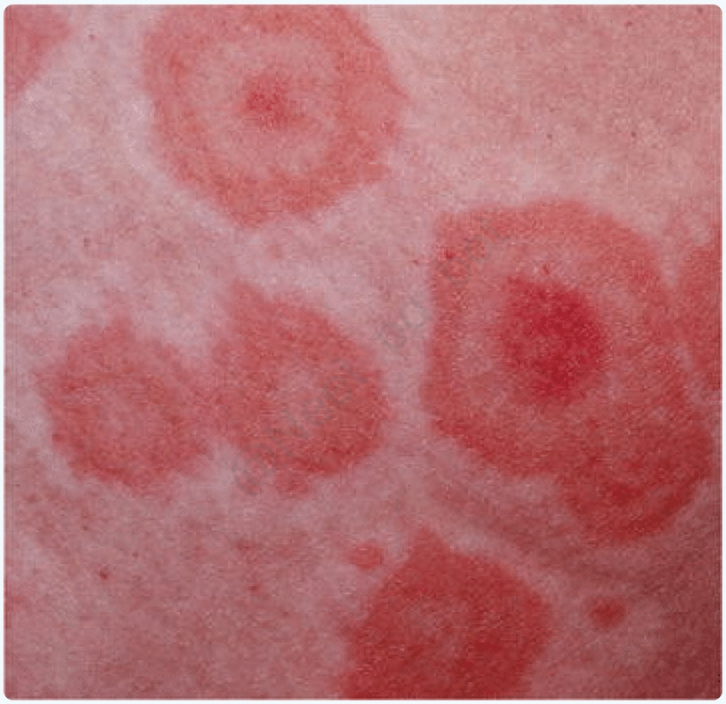

@Neet_pg_bot



@Neet_pg_bot



References:

.

↑ *Back to this question in Part A*

@Neet_pg_bot

Q3: Annular lesions are seen in all of the following conditions except? (Q840076)

A. Tinea Corporis

B. Urticaria Pigmentosa

C. Pityriasis Rosea

D. Porokeratosis

Correct Answer: B. Urticaria Pigmentosa

Explanation: Correct Option B - Urticaria Pigmentosa: Urticaria pigmentosa is a form of mastocytosis that primarily affects the skin. It presents with urticarial lesions that heal with hyperpigmentation. Any minute trauma or stroking of lesions leads to the development of urticarial lesions. However, these lesions are not annular. Incorrect Options: Options A, C, and D: Annular lesions are seen in Tinea corporis, Pityriasis Rosea, and

Porokeratosis.



References:

Prepladder notes

↑ *Back to this question in Part A*

@Neet_pg_bot

Q4: The involvement of which of the following results in the given condition below? (Q857965)

A. Arteries

B. Vein

C. Lymphatics

D. DVT



Correct Answer: C. Lymphatics

Explanation: : Incorrect because arterial disease causes ischemia, pain, and ulceration, not massive swelling . Vein (Option B): Incorrect because venous insufficiency leads to varicose veins and stasis ulcers, not elephantiasis . DVT (Option D): Incorrect because deep vein thrombosis (DVT) presents with acute unilateral swelling, pain, and erythema, not chronic massive lymphedema .

References:

Park's Textbook of Preventive and Social Medicine 27th Edition Pg: 315-317

↑ *Back to this question in Part A*

@Neet_pg_bot

Q5: A school-going child who had applied henna comes to dermatology OPD with the following lesions. Her mother also complains that she has a habit of scratching her hand whenever she is studying. What is the diagnosis for this child? (Q856828)

A. Contact dermatitis due to henna

B. Dermatitis artefacta

C. Polymorphous light eruption

D. Vitiligo



Correct Answer: B. Dermatitis artefacta

Explanation: ontact dermatitis due to henna (Option A) : Could be a possible differential diagnosis, as henna can sometimes cause an allergic reaction in certain individuals. However, in this case, the option "dermatitis artefacta" suggests that the lesions are self-induced rather than a true allergic contact dermatitis. Polymorphous light eruption (Option C) : (PMLE) is a type of photodermatitis that occurs in response to exposure to sunlight or artificial ultraviolet (UV) light. However, the given information about henna application does not align with the characteristic triggers of PMLE. Vitiligo (Option D) : Vitiligo is an autoimmune disorder and does not involve the intentional or self-inflicted creation of skin lesions.

References:

https://www.ncbi.nlm.nih.gov/books/NBK430936/

↑ *Back to this question in Part A*

@Neet_pg_bot

Q6: What is the probable diagnosis of the condition affecting the hair, resulting in the following appearance? (Q856835)

A. Trichorrhexis nodosa

B. Trichorexis invaginate

C. Trichothiodystrophy

D. Monilethrix



Correct Answer: C. Trichothiodystrophy

Explanation: rittle Hair Tiger Tail Banding Variable Hair Color Intellectual and Developmental Disabilities Additional features may include dry and scaly skin, brittle nails, photosensitivity (sensitivity to sunlight), and ocular abnormalities. Incorrect Options: Trichorhexis nodosa (Option A) : Trichorhexis nodosa is a hair shaft disorder characterized by nodules or nodes along the hair shaft. It does not typically show the specific "tiger tail banding" pattern seen in Trichothiodystrophy. Trichorexis invaginata (Option B) : Trichorexis invaginata, also known as "bamboo hair," is a condition in which the hair shaft is characterized by multiple invaginations or nodules. It does not present with the specific banding pattern seen in Trichothiodystrophy. Monilethrix (Option D) : Monilethrix is a hereditary hair disorder characterized by beaded hair shafts that resemble a necklace. It does not show the specific "tiger tail banding" pattern seen in Trichothiodystrophy.

References:

https://linkinghub.elsevier.com/retrieve/pii/S0190962204024880

https://www.ncbi.nlm.nih.gov/books/NBK6285/

↑ *Back to this question in Part A*

Q7: Which of the following is the most probable diagnosis for a child born with membranes around the body, ectropion, and eclabium, presenting with lesions on the face, trunk, and extremities, and brought to the OPD, what is the diagnosis? (Q854904)

A. Harlequin ichthyosis

B. Lamellar ichthyosis

C. Bathing suit ichthyosis

D. Ichthyosis vulgaris

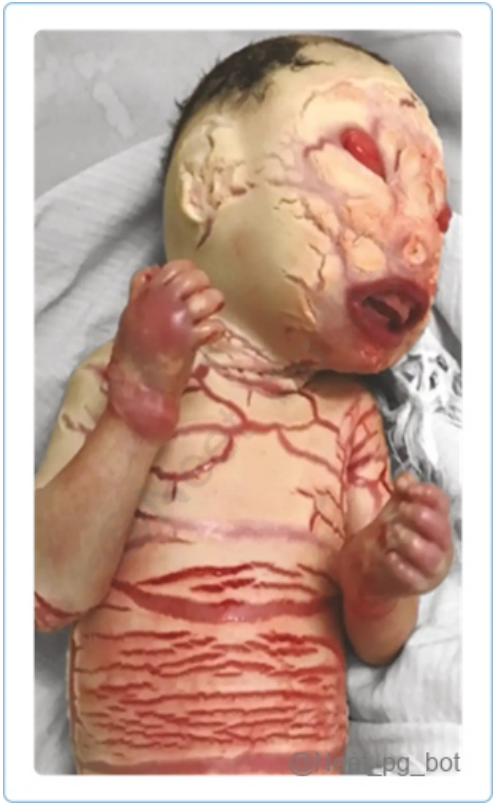

Correct Answer: A. Harlequin ichthyosis

Explanation: Harlequin ichthyosis is likely a diagnosis based on the image shown. Harlequin Ichthyosis Introduction Harlequin ichthyosis is a rare, severe genetic skin disorder characterized by thick, armor-like scales covering the body at birth. It is an autosomal recessive condition caused by mutations in the ABCA12 gene, affecting lipid transport in the epidermis. Pathophysiology ABCA12 gene mutation leads to defective lipid transport, disrupting the skin barrier. This results in thickened, hyperkeratotic plates with deep fissures, severe

dehydration, and increased infection risk. Features Thick, diamond-shaped scales covering the body Ectropion (everted eyelids) and eclabium (everted lips) Contracted digits (hypoplastic fingers and toes) Risk of severe dehydration, infections, and respiratory distress Delayed skin shedding , improving with time but requiring lifelong care Investigations & Diagnosis Clinical examination based on characteristic features at birth Genetic testing to confirm ABCA12 mutation Skin biopsy (rarely needed) shows massive hyperkeratosis Treatment Neonatal intensive care (hydration, temperature regulation) Emollients and keratolytics (e.g., petrolatum, urea, lactic acid) to soften scales Oral retinoids (e.g., acitretin, isotretinoin) to reduce hyperkeratosis Antibiotics for secondary infections Lifelong skin care with moisturization and gentle exfoliation Autosomal recessive congenital ichthyosis: Subtype Clinical Features Genetic Defect Harlequin ichthyosis Thick, plate-like scales covering the entire body ABCA12 gene mutations Lamellar ichthyosis (Option B) Large thick scales, often present at birth TGM1, ALOX12B, ALOXE3, or NIPAL4 gene mutations Congenital ichthyosiform erythroderma (CIE) Generalized redness, fine white scales TGM1, ALOX12B, ALOXE3, or NIPAL4 gene mutations Self-healing collodion baby Membrane-like encasement at birth, followed by shedding TGM1, ALOX12B, ALOXE3, or NIPAL4 gene mutations Harlequin ichthyosis-like phenotypes Variations resembling harlequin ichthyosis Different genetic mutations, including PNPLA1, CYPF22, CASP14, CERS3, etc. Incorrect Options: Bathing suit ichthyosis (Option C) : A rare variant of lamellar ichthyosis where scaling predominantly affects the trunk and proximal limbs , sparing other areas, resembling a "bathing suit" pattern. Ichthyosis vulgaris (Option D) : A common inherited skin disorder characterized by fine, dry, scaly skin, especially on the extensor surfaces, due to filaggrin gene mutations leading to impaired skin barrier function.

References:

Illustrated Synopsis of Dermatology and Sexually Transmitted Diseases, Fifth Edition – Neena Khanna Pg 27

https://www.ncbi.nlm.nih.gov/books/NBK562318/

↑ *Back to this question in Part A*

@Neet_pg_bot

Q8: What is the causative agent responsible for causing acne fulminans among the following options? (Q793394)

A. Actinomyces

B. Propionibacterium

C. Mobiluncus

D. Bifidobacterium

Correct Answer: B. Propionibacterium

Explanation: An abnormal immune response to the bacterium Propionibacterium acnes is thought to be the cause of the rare and severe form of acne known as acne fulminans. The exact cause of acne fulminans, on the other hand, is still poorly understood. Genetic predisposition, hormonal imbalances, and certain medications like

isotretinoin are additional factors that could contribute to the onset of this condition. The genus of bacteria known as Propionibacterium is commonly found on human skin, particularly in areas of the face, scalp, and upper back that produce a lot of oil. These Gram-positive bacteria are anaerobic or facultatively anaerobic and do not produce spores. Propionibacterium acnes is known to be engaged with the improvement of skin breakout, in spite of the fact that it is likewise a typical occupant of the skin microbiome and plays other helpful parts in the body. Incorrect choices: Option a. Actinomyces: The bacteria of the genus Actinomyces are typically found in the gastrointestinal tract, throat, and mouth of humans and other animals. Gram-positive, anaerobic or microaerophilic, and filamentous, these bacteria produce long, branching structures that are known as filaments. Actinomyces species are essential members of the human body's normal microbiota and contribute to oral and digestive health. Option c. Mobiluncus: The bacteria in the genus Mobiluncus are anaerobic, Gram-variable, and curved or comma-shaped, like shrimps. These bacteria are frequently found in the female genital tract and are linked to bacterial vaginosis (BV), a condition characterized by an overgrowth of certain bacteria in the vagina that can result in itching, odor, and discharge. Mobiluncus microorganisms are much of the time present in big numbers in females with BV, alongside different microscopic organisms, for example, Gardnerella vaginalis. Option d. Bifidobacterium: Bifidobacterium is a variety of microscopic organisms that are normally tracked down in the human gastrointestinal parcel and different pieces of the body, like the mouth and vagina. These microorganisms are anaerobic, Gram-positive, and non-spore-framing, and they have a trademark Y-or Angular shape. Due to their crucial role in maintaining gut health and immunity, Bifidobacterium species are regarded as beneficial or "friendly" bacteria.

References:

.

↑ *Back to this question in Part A*

@Neet_pg_bot

Q9: A 26-year-old male presented with a skin lesion as shown below. Biopsy shows the presence of hyperkeratosis . What is the most likely diagnosis? (Q793451)

A. Atopic dermatitis

B. Psoriasis

C. Pemphigus vulgaris

D. Pemphigus foliaceus



Correct Answer: B. Psoriasis

Explanation: Option b. Psoriasis is a persistent immune system skin jumble that is portrayed by the fast development and shedding of skin cells. As a result, thick, scaly skin patches are often reddish or pink in color and covered in silvery-white scales. Psoriasis can affect any part of the body, but the scalp, elbows, knees, lower back, and genitals are the most common locations Incorrect choices: Option a -Atopic dermatitis A group of conditions known as neutrophilic dermatoses (NDs) are characterized by skin lesions for which a histological examination reveals a significant inflammatory infiltrate, primarily composed of neutrophils, without evidence of infection.Red, crusty, itchy, and flaky patches, resembling oval or circular patches on the skin, are typical manifestations of atopic dermatitis. Option c. Pemphigus vulgaris is an uncommon immune system problem that influences the skin and mucous layers. Painful blisters and sores form on the skin as well as inside the mouth, nose, and genital area, indicating this condition. Option d. Pemphigus foliaceus is a skin and mucous membrane-affecting autoimmune disease. The development of crusty, scaly lesions or blisters on the skin, particularly on the face, scalp, and chest, is a sign of this condition. An autoimmune reaction in which the immune system makes antibodies that attack the proteins that hold skin cells(desmoglein-1) together is what causes pemphigus foliaceus.

References:

ref

↑ *Back to this question in Part A*

@Neet_pg_bot

• [14_Miscellaneous] 028 Previous Year Questions

« Back to Folder Directory

[14_Miscellaneous] 028 Previous Year Questions — Quick Jump

Q1 (p. 1244) *Q2 (p. 1245)* *Q3 (p. 1246)* *Q4 (p. 1248)* *Q5 (p. 1248)* *Q6 (p. 1253)*
Q7 (p. 1254) *Q8 (p. 1256)* *Q9 (p. 1258)* *Q10 (p. 1259)* *Q11 (p. 1261)* *Q12 (p. 1262)*
Q13 (p. 1264) *Q14 (p. 1265)*

Q1: A neonate presents with a growing skin lesion, as shown in the image provided. The mother reports that the lesion has been increasing in size daily. What is the appropriate management? (Q852572)

A. Observation

B. Excision and Laser Therapy

C. Immediate Biopsy due to Malignancy Risk

D. Cryotherapy



Correct Answer: A. Observation

Explanation: Infantile hemangiomas are benign vascular tumors that commonly appear within the first few weeks of life. They typically grow rapidly during the first few months (proliferative phase) before undergoing spontaneous involution over several years. Most do not require intervention unless they cause complications such as airway obstruction, ulceration, or vision impairment . Other options: Excision and Laser Therapy (Option B) : Reserved for complicated hemangiomas (e.g., ulcerated, functionally impairing, or rapidly growing in critical areas like the airway or eyes). Immediate Biopsy due to Malignancy Risk (Option C) : Unnecessary, as infantile hemangiomas are benign and diagnosed clinically. Cryotherapy (Option D) : Not an appropriate treatment for hemangiomas, as they typically regress without intervention.

References:

Neena Khanna, Textbook of Dermatology, 7th Edition, Page no: 290

↑ *Back to this question in Part A*

@Neet_pg_bot

Q2: A patient presents with a nodulo-ulcerative lesion on the lower lip, as shown in the image. What is the best way to take a biopsy in this case? (Q843968)

A. Superficial incisional with normal mucosa

B. Blush biopsy

C. Deep incisional with nodular part

D. Excisional biopsy



Correct Answer: D. Excisional biopsy

Explanation: Correct Option D - Excisional biopsy: For a suspicious lesion on the lip, which may be pre-cancerous, an excisional biopsy is the most appropriate method, allowing for complete removal and histopathological examination. Incorrect Options: Options A, B, and C are insufficient.

↑ *Back to this question in Part A*

@Neet_pg_bot

Q3: What nutritional deficiency is commonly associated with a chronic alcoholic presenting with a pruritic, eczematous rash on the neck and dorsum of the hands? (Q860608)

A. Vit B3

B. Vit B1

C. Vit D

D. Vit C

Correct Answer: A. Vit B3

Explanation: The patient is a chronic alcoholic with a pruritic, eczematous rash on the neck and dorsum of the hands, which is characteristic of pellagra—a disease caused by niacin (Vitamin B3) deficiency. Pellagra is characterized by the classic triad of symptoms: Dermatitis Bright red erythema- in sun-exposed areas (face, ankles, feet) Casal's necklace - ↑pigmentation around the neck Diarrhoea, and Dementia. {{caption_text}} Causes of pellagra : Dietary Deficiency- Maize and Sorghum based diet Impaired Tryptophan Metabolism Factors Affecting Tryptophan to Niacin Conversion: Vitamin B6 Deficiency Medications: Isoniazid (INH), OCPs Hormonal Influences: Estrogen metabolites hinder tryptophan metabolism. Genetic Disorders: Inherited conditions like Hartnup disease can impede tryptophan absorption in the intestines and reabsorption in the kidneys Carcinoid Syndrome Other Contributing Factors: Alcoholism: Interferes with nutrient absorption, including niacin and tryptophan. Malabsorption Syndromes Incorrect Options: Vitamin B1 (Thiamine) Deficiency (Option B): Leads to Beriberi (wet/dry) and Wernicke-Korsakoff syndrome , which primarily causes neurological and cardiac symptoms rather than a rash. Vitamin D Deficiency (Option C): Causes rickets in children and osteomalacia in adults , presenting with bone pain and muscle weakness , but no skin rash. Vitamin C Deficiency (Option D): Leads to scurvy , characterized by bleeding gums, petechiae, impaired wound healing , and corkscrew hairs, but not the photosensitive rash seen in pellagra.



References:

Harper's Illustrated Biochemistry, 32nd Edition, Pg.542,543

Textbook of Biochemistry- Vasudevan, 7th Edition, Pg. 481,482

↑ *Back to this question in Part A*

@Neet_pg_bot

Q4: Which of the following deficiencies causes follicular hyperkeratosis? (Q860610)

A. Vitamin A

B. Vitamin C

C. Vitamin E

D. Vitamin B6

Correct Answer: A. Vitamin A

Explanation: Follicular hyperkeratosis is characterized by dry, rough skin with small, keratotic papules around hair follicles, often seen in Vitamin A deficiency. This occurs due to abnormal keratinization of epithelial cells. Vitamin A Deficiency Manifestations : 1) Ocular manifestations : Vitamin A deficiency is the most significant preventable cause of blindness, especially in children below 5 in developing countries. Early Signs: Loss of sensitivity to green light. Difficulty adapting to dim light. Night blindness. Prolonged Deficiency: Xerophthalmia: Dry, thick, keratinized conjunctiva and cornea. If untreated, it leads to corneal ulceration and ultimately results in blindness due to the formation of opaque scar tissue. WHO grading of xerophthalmia: XN Night blindness. X1 X1A: Conjunctival xerosis. X1B: Bitot spots. X2 Corneal xerosis. X3 X3A: Corneal ulceration, less than one-third. X3B: Corneal ulceration, more than one-third. XS Corneal scar. XF Xerophthalmic fundus. Bitot's Spots: Grayish-white triangular plaques firmly adherent to the conjunctiva. Keratomalacia: When xerophthalmia persists for a longer time, it progresses to keratomalacia (corneal softening). 2) Immune Function: Deficiency increases susceptibility to infections. Infection reduces retinol-binding protein synthesis, lowering vitamin A levels and impairing immune responses. 3) Skin and Mucous Membrane Lesions: Follicular Hyperkeratosis (Phrynoderma): Causes rough skin due to hyperkeratinization of the follicular epithelium. Keratinizing Metaplasia: Affects respiratory, gastrointestinal, and genitourinary tracts. Epithelium is atrophied. 4) Other General Manifestation : Growth retardation due to defective synthesis of chondroitin sulfate. Decreased protein synthesis. Incorrect Options: Vitamin C Deficiency (Option B): Causes scurvy, leading to corkscrew hairs, perifollicular hemorrhages, and poor wound healing, but not follicular hyperkeratosis. Vitamin E Deficiency (Option C): Causes neurological symptoms (ataxia, peripheral neuropathy, hemolytic anemia) but does not affect keratinization. Vitamin B6 Deficiency (Option D): Leads to cheilitis, glossitis, irritability, and neuropathy, but not follicular hyperkeratosis.

References:

Harper Textbook of Biochemistry, 32nd edition, pg: 538

Lippincott’s Illustrated Reviews biochemistry, 7th edition, pgs: 1112, 1113

↑ *Back to this question in Part A*

@Neet_pg_bot

Q5: What is the most probable diagnosis of the given image? (Q860623)

A. Erythema toxicum neonatorum

B. Pustular melanosis

C. Mongolian spots

D. Milia



Correct Answer: D. Milia

Explanation: The most probable diagnosis based on the image is Milia. Disease of the newborn not requiring treatment Sebaceous hyperplasia Minute, profuse, yellow-white papules are frequently found on the forehead, nose, upper lip, and cheeks. Hyperplastic sebaceous glands. {{caption_text}} Milia Firm cyst, pearly, and opalescent white lesions. Superficial epidermal inclusion cysts that contain laminated keratinized material. {{caption_text}} Epstein pearls Milia on the midline of the palate. {{caption_text}} Sucking blisters Solitary or scattered superficial bullae present at birth on the upper limbs. Induced by vigorous sucking on the affected part in utero. Salmon patch (Nevus simplex) Small, pale pink, ill-defined, vascular macule that occurs most commonly on the glabella, eyelids, upper lip, and nuchal area. {{caption_text}} Mongolian spots (Dermal melanocytosis) (Option C) Blue or slate-grey macular lesions most commonly in the sacral area. {{caption_text}} Erythema toxicum(Option A) Firm, yellow-white, papules or pustules with a surrounding erythematous flare. Eosinophils are seen in Wright-stained smears Unknown cause. {{caption_text}} Pustular melanosis (Option B): It is an idiopathic pustular eruption that heals with brown pigmented macules. It is more common in black neonates.


@Neet_pg_bot


@Neet_pg_bot


@Neet_pg_bot


@Neet_pg_bot





References:

Nelson textbook of pediatrics, 21st Edition, Page 3453-55.

↑ *Back to this question in Part A*

@Neet_pg_bot

Q6: The condition shown in the image below is seen in which vitamin deficiency? (Q860125)

A. Pyridoxine

B. Cobalamin

C. Niacin

D. Riboflavin



Correct Answer: C. Niacin

Explanation: The condition described in the image is Pellagra , which is caused by niacin (Vitamin B3) deficiency . Pellagra is characterized by the classic triad of symptoms: Dermatitis Bright red erythema- in sun-exposed areas (face, ankles, feet) Casal's necklace - ↑pigmentation around the neck Diarrhoea, and Dementia. {{caption_text}} Causes of pellagra : Dietary Deficiency- Maize and Sorghum based diet Impaired Tryptophan Metabolism Factors Affecting Tryptophan to Niacin Conversion: Vitamin B6 Deficiency Medications: Isoniazid (INH), OCPs Hormonal Influences: Estrogen metabolites hinder tryptophan metabolism. Genetic Disorders: Inherited conditions

like Hartnup disease can impede tryptophan absorption in the intestines and reabsorption in the kidneys Carcinoid Syndrome Other Contributing Factors: Alcoholism: Interferes with nutrient absorption, including niacin and tryptophan. Malabsorption Syndromes Pyridoxine (Vitamin B6) Deficiency (Option A): Causes cheilitis, glossitis, irritability, and peripheral neuropathy , but not the characteristic photosensitive rash. Cobalamin (Vitamin B12) Deficiency (Option B): Leads to megaloblastic anemia, neuropathy, and glossitis , but not pellagra. Riboflavin (Vitamin B2) Deficiency (Option D): Presents with angular cheilitis, glossitis.



References:

Harper's Illustrated Biochemistry, 32nd Edition, Pg.542,543

Textbook of Biochemistry- Vasudevan, 7th Edition, Pg. 481,482

↑ *Back to this question in Part A*

@Neet_pg_bot

Q7: The given condition is caused by which drug ? (Q856376)

A. Actinomycin

B. Bleomycin

C. Mitomycin C

D. Doxorubicin



Correct Answer: B. Bleomycin

Explanation: Flagellate dermatitis, also known as "flagellate erythema," is a distinctive skin reaction that can occur as a side effect of certain medications. Among the given options, the most commonly associated drug with flagellate dermatitis is Bleomycin, which is an antineoplastic medication used in the treatment of various cancers. Flagellate dermatitis typically appears as linear or streak-like red or brownish patches on the skin, resembling the marks left by a whip or a scratch. It usually occurs on the trunk, extremities, or face and is believed to be an idiosyncratic reaction to Bleomycin. Bleomycin-induced flagellate dermatitis is thought to be related to the drug's ability to induce the release of inflammatory mediators, resulting in the characteristic skin reaction. It typically occurs within a few days to weeks after the administration of Bleomycin and tends to resolve spontaneously once the drug is discontinued. Some common side effects associated with the use of Bleomycin: Side Effect Description Pulmonary Toxicity Bleomycin is known to cause lung damage, which can lead to pulmonary fibrosis and respiratory symptoms such as cough, shortness of breath, and decreased lung function. Skin Toxicity Bleomycin can cause skin reactions, including flagellate dermatitis (linear streaks on the skin), erythema (redness), and skin desquamation (peeling). Mucosal Toxicity Bleomycin can cause mucosal damage, resulting in mouth sores, sore throat, and inflammation of the oral and nasal mucosa. Fever Fever is a common side effect of Bleomycin treatment and can occur shortly after administration. Hematologic Toxicity Bleomycin can suppress bone marrow function, leading to decreased production of blood cells, including red blood cells, white blood cells, and platelets. Nail Changes Bleomycin can cause nail abnormalities, including nail discoloration, brittle nails, and nail bed inflammation. Allergic Reactions Allergic reactions to Bleomycin can occur, ranging from mild rash to severe hypersensitivity reactions, including anaphylaxis. Incorrrect Options: Actinomycin (Option A) : Actinomycin is an antibiotic medication used in chemotherapy. While it can cause various dermatological side effects, flagellate dermatitis is not commonly associated with Actinomycin use. Mitomycin C (Option C) : Mitomycin C is an

antineoplastic medication used in the treatment of certain cancers. While it can cause skin reactions, flagellate dermatitis is not a recognized side effect commonly associated with Mitomycin C use. Doxorubicin (Option D) : Doxorubicin is an anthracycline chemotherapy drug used to treat various types of cancer. While it can cause skin-related side effects, flagellate dermatitis is not a well-known or commonly reported side effect of Doxorubicin use.

References:

https://pmc.ncbi.nlm.nih.gov/articles/PMC4668964/

↑ *Back to this question in Part A*

@Neet_pg_bot

Q8: A patient presents with the given rash after he had taken NSAIDs for his knee pain. He reported that he developed the same rash in the same location 6 months ago when he took the same drugs for back pain. What is the most likely diagnosis? (Q859554)

A. Drug hypersensitivity

B. Post inflammatory hyperpigmentation

C. Fixed drug eruption

D. Drug-induced hyper melanosis



Correct Answer: C. Fixed drug eruption

Explanation: The recurrent nature of the rash in the same location after taking NSAIDs strongly supports Fixed Drug Eruption (FDE). Fixed drug eruption: Fixed drug eruption is a distinctive cutaneous allergic reaction that characteristically recurs at the same sites with the same morphology on re-exposure to the medication or other chemical agent. {{caption_text}} Type 4 hypersensitivity reaction (Option B ruled out) Causative drugs: Co-trimoxazole, NSAIDs, tetracyclines, sulfonamides. Mediated by memory T-cells. Acutely, erythematous and bullous phases of fixed eruptions, followed by well-circumscribed areas of slate-brown pigmentation Site of lesions: Mucous membrane (Lips, tongues, Glans penis), face and acral areas although can occur anywhere on the skin surface. Leaves residual hyperpigmentation on healing (Option A ruled out). Upon reexposure, lesions develop within 30 minutes to 8 hours (Option C ruled out). Treatment: Stop the causative drug. Topical steroids and antibiotics combinations Incorrect Options Drug hypersensitivity (Option A): While this is a broad term for adverse drug reactions, it doesn't specify the unique characteristic of recurrence at the same site. Post-inflammatory hyperpigmentation (PIH) (Option B): PIH is a result of inflammation or injury to the skin, but it wouldn't consistently reappear in the same location with each exposure to the same drug. Drug-induced hypermelanosis (Option D): This is a general term for increased melanin production due to drugs, but it doesn't fit the specific pattern of a solitary lesion recurring at the same site with each drug exposure.



References:

Rook’s Textbook of Dermatology 9 th edition - page 88.28, UpToDate.

↑ *Back to this question in Part A*

@Neet_pg_bot

Q9: What is the name of the clinical sign shown in the picture below? (Q859556)

A. Dermographism

B. Nikolsky sign

C. Koebner's phenomenon

D. Auspitz sign



Correct Answer: A. Dermographism

Explanation: Dermographism (also called dermatographia or skin writing) is a condition where firm stroking of the skin induces an urticarial wheal within minutes. Type of Physical Urticaria Eliciting Factors Urticaria factitial / Dermographism Most common type, red, itchy, linear wheal appearing immediately after light stroking of the skin. Mechanical shearing forces (wheals arising within 1-5 mins) Cold contact urticaria Cold objects, air, fluids, wind Heat contact urticaria Localized heat Solar urticaria UV and/or visible light Delayed pressure urticaria (poor prognosis) Vertical pressure (wheals arise with 3-12 hours latency) Aquagenic urticaria Water Cholinergic urticaria Increase in core body temperature by exercise or spicy food Nikolsky Sign (Option B): Nikolsky sign is seen in pemphigus vulgaris, toxic epidermal necrolysis (TEN), and staphylococcal scalded skin syndrome (SSSS). It refers to the sloughing of epidermis upon slight rubbing of the skin. Koebner's Phenomenon (Option C): This describes the development of new skin lesions at sites of trauma in diseases like psoriasis, lichen planus, and vitiligo. Unlike dermographism, it is not immediate and takes days to develop. Option D: Auspitz Sign (Option D): Seen in psoriasis, where removal of scales leads to pinpoint bleeding due to exposure of dermal papillary capillaries.

References:

https://www.ncbi.nlm.nih.gov/books/NBK531496/

↑ *Back to this question in Part A*

@Neet_pg_bot

Q10: A farmer presented to the outpatient department with a swelling over his palm as shown in the photo. A few months back he got injured with a thorn. What is the presentation given below? (Q859905)

A. Ameloblastoma

B. Embryogenic dermoid

C. Sequestration dermoid

D. Implantation dermoid



Correct Answer: D. Implantation dermoid

Explanation: An implantation dermoid is a type of dermoid cyst that occurs due to the accidental implantation of epidermal cells into the deeper tissues following trauma, such as thorn pricks, puncture wounds, or surgical procedures. Dermoid Cyst: Pathophysiology: Formed when epithelial tissue is trapped along the lines of embryonic fusion. Common Sites: Outer canthus of the eye Post-auricular region Clinical Features: Cystic swelling (Fluctuation test positive) Skin can be pinched over the swelling Investigations: X-ray/CT must be done to rule out intracranial extension before surgery Management: Surgical excision Implantation Dermoid: Occurs due to injury Most common after ear piercing Management: Surgical excision Ameloblastoma (Option A): is a benign odontogenic tumor generally present in the jawbone. Embryogenic dermoid (Option B): A dermoid cyst is a benign cutaneous developmental anomaly that arises from the entrapment of ectodermal elements along the lines of embryonic closure. Sequestration dermoid (Option C): Dermoid cysts result from an abnormal alteration in fetal development. They occur due to the abnormal sequestration and inclusion of the surface ectoderm along the lines

of skin fusion during embryologic development.

References:

https://www.ncbi.nlm.nih.gov/books/NBK560573/

↑ *Back to this question in Part A*

@Neet_pg_bot

Q11: The girl seen in the image has had a history of severe sunburns after just a few minutes in the sun, severe freckling in the sun-exposed areas. The most likely diagnosis is. (Q859913)

A. Bloom syndrome

B. Xeroderma pigmentosum

C. Warts

D. Systemic lupus



Correct Answer: B. Xeroderma pigmentosum

Explanation: The correct answer is Xeroderma pigmentosum, as the girl has severe sunburns with minimal exposure, freckling, and sun-induced skin damage, which are hallmark features of XP. Xeroderma Pigmentosum: It is a rare autosomal recessive disorder characterized by extreme sensitivity to ultraviolet (UV) radiation from sunlight. It arises due to genetic mutations affecting genes responsible for the nucleotide excision repair (NER) pathway. It presents with freckle-like pigmented patches, atrophic areas, and other skin abnormalities in sun-exposed areas. Additionally, patients may experience ocular manifestations such as photophobia, conjunctival injection, and corneal ulcers due to UV-induced damage. Systemic manifestations can include mental retardation and low intelligence. Increased risk of developing skin cancers, including melanoma, squamous cell carcinoma, and basal cell carcinoma, at a young age. {{caption_text}} Bloom Syndrome (Option A): It is a rare autosomal recessive genetic disorder caused by mutations in the BLM gene. It presents with short stature, photosensitivity, and characteristic facial features including a long, narrow face and prominent nose, along with other physical anomalies such as micrognathia and cafe-au-lait spots. Increased risk of various cancers, particularly leukaemia and lymphoma, at an early age. Warts (Option C): Warts (caused by HPV) present as localized verrucous lesions, not widespread freckling and sun sensitivity. Systemic Lupus Erythematosus (SLE) (Option D): SLE can cause photosensitivity, but it presents with a malar rash, systemic symptoms (fatigue, arthritis, renal involvement), and autoantibodies. XP causes DNA repair defects, not an autoimmune reaction.



References:

Rook’s Textbook of Dermatology - page 78.1, 79.3

↑ *Back to this question in Part A*

@Neet_pg_bot

Q12: The shown instrument is: (Q859914)

A. Single cutting razor

B. Double cutting razor

C. Humby’s knife

D. Finochietto knife



Correct Answer: C. Humby’s knife

Explanation: Identification : The image shows a Humby’s knife , a surgical instrument used for harvesting split-thickness skin grafts (STSGs) . Structure : A handle for grip. An adjustable blade for controlling the thickness of the graft. A roller to maintain uniform graft thickness. Usage : Used in plastic and reconstructive surgery for covering wounds, burns, and ulcers. Humby’s Knife Feature Details Purpose Harvesting split-thickness skin grafts (STSGs) . Blade Type Single cutting blade , adjustable for thickness. Alternative Instruments Watson’s knife, Padgett dermatome, and Brown’s dermatome . Advantages Cost-effective, reusable, allows controlled thickness. Disadvantages Requires manual skill , risk of irregular graft thickness . {{caption_text}} Single cutting razor (Option A): Incorrect because Humby’s knife has an adjustable blade for controlled cutting, unlike a simple razor. Double cutting razor (Option B): Incorrect because Humby’s knife has a single cutting edge . Finochietto knife (Option D): Incorrect because Finochietto is a rib spreader , not a skin grafting knife.



References:

SRB's Surgical Operations: Text and Atlas, Ed 1, Pg. 86, 115, 116

↑ *Back to this question in Part A*

@Neet_pg_bot

Q13: The given lesion is seen on 3 different occasions on the same site. What is the diagnosis? (Q878927)

A. Cutaneous mastocytosis

B. Fixed drug eruption

C. HSV1

D. Erythema multiforme



Correct Answer: B. Fixed drug eruption

Explanation: FDE characteristically reappears at the same site each time the offending drug is taken , producing a well-defined dusky red/violaceous plaque → heals with post-inflammatory hyperpigmentation . Shows same-site recurrence due to persistent lesional T-cells / ICAM-1 expression . Leaves slate-brown residual hyperpigmentation , especially in darker skin. Common triggers: tetracyclines, NSAIDs, sulfonamides, sedatives . Lesions often occur on genital/perianal areas , but may occur anywhere. Incorrect Options: Cutaneous Mastocytosis (Option A): Lesions are persistent with urtication on stroking (Darier sign); they do not recur at the same site only after drug exposure. HSV-1 (Herpes Simplex Virus-1) (Option C): Causes grouped painful vesicles that may recur but not exclusively at the same fixed site, and do not leave persistent slate-brown pigmentation. Erythema Multiforme (Option D): Shows target lesions on multiple sites, related to infections (often HSV), and does not show same-site fixed recurrence with pigmentation.

References:

Rook’s Textbook of Dermatology, 9th Edition, Page 2233.

↑ *Back to this question in Part A*

@Neet_pg_bot

Q14: Match the following signs with their conditions: A. Auspitz sign i. Cutaneous mastocytosis B. Carpet track sign ii. Psoriasis C. Darier’s sign iii. Kwashiorkor D.

Flag sign iv. Discoid lupus erythematosus (Q879102)

A. A-ii, B-iv, C-i, D-iii

B. A-i, B-ii, C-iii, D-iv

C. A-iv, B-ii, C-i, D-iii

D. A-ii, B-i, C-iv, D-iii

Correct Answer: A. A-ii, B-iv, C-i, D-iii

Explanation: The signs and their associated conditions are: Sign Description Associated Condition Auspitz sign Appearance of pinpoint bleeding when scales are removed Psoriasis Darier’s sign Urtication on stroking the lesion due to mast cell degranulation Cutaneous mastocytosis Carpet tack sign Keratotic plugs on the underside of scales resembling carpet tacks Discoid lupus erythematosus (DLE) Flag sign Alternating bands of light and dark color in hair due to episodic protein malnutrition Kwashiorkor

References:

Carpet Tack Sign - PMC.

Darier's sign

Auspitz Sign and Psoriasis: What You Need to Know

Flaky Paint Dermatosis in Kwashiorkor - PMC

↑ *Back to this question in Part A*

@Neet_pg_bot

• [15_Bacterial Infections] 029 Bacterial Infections

« Back to Folder Directory

[15_Bacterial Infections] 029 Bacterial Infections — Quick Jump

Q1 (p. 1267)	*Q2 (p. 1269)*	*Q3 (p. 1270)*	*Q4 (p. 1271)*	*Q5 (p. 1272)*	*Q6 (p. 1274)*
Q7 (p. 1275)	*Q8 (p. 1276)*	*Q9 (p. 1278)*	*Q10 (p. 1279)*	*Q11 (p. 1280)*	*Q12 (p. 1281)*
Q13 (p. 1282)	*Q14 (p. 1287)*	*Q15 (p. 1288)*	*Q16 (p. 1292)*	*Q17 (p. 1293)*	*Q18 (p. 1294)*
Q19 (p. 1296)	*Q20 (p. 1296)*	*Q21 (p. 1299)*			

Q1: Which of the following would be the best initial test to diagnose erythrasma? (Q841817)

A. Microscopy with KOH preparation

B. Wood's lamp examination

C. Dermatoscope examination

D. Skin culture

Correct Answer: B. Wood's lamp examination

■ *Listen (English)*

■ *Listen (Hindi)*

Explanation: Wood's lamp examination is the initial diagnostic tool used to confirm Erythrasma . It is a superficial skin infection caused by Corynebacterium minutissimum. Risk factors include diabetes mellitus, obesity, immunocompromised state, hyperhidrosis, and older adults. It usually presents as asymptomatic lesions in the following areas: Interdigital: Scaling, fissuring plaques, maceration. Intertriginous (between skin folds): Hyperpigmented patches, mild scaling, wrinkling. Genital/perianal: Pruritis ani Interdigital erythrasma commonly occurs with dermatophyte or candidal infections. Wood's lamp examination shows coral-red fluorescence from coproporphyrin III produced by Corynebacterium minutissimum. Treatment: First line: Topical antibacterials (Fusidic acid, Clarithromycin) or topical antifungal (Miconazole) Second line: Photodynamic therapy using porphyrin {{caption_text}} {{caption_text}} Microscopy with KOH (Option A): It is commonly used to diagnose fungal infections like dermatophyte or candidal infection. (Images : Left - Candidal infection; Right - Tinea versicolor) {{caption_text}} Dermatoscope Examination (Option C) : This tool is primarily used for evaluating pigmented skin lesions. It is not diagnostic for erythrasma but is useful for identifying melanomas and other skin cancers and tumours. Skin Culture (Option D) : Small shiny, whitish-grey colonies with coral-red fluorescence would be observed in a culture. However, a Wood's lamp examination can be performed in the clinic, offering a more immediate diagnosis and treatment.



@Neet_pg_bot

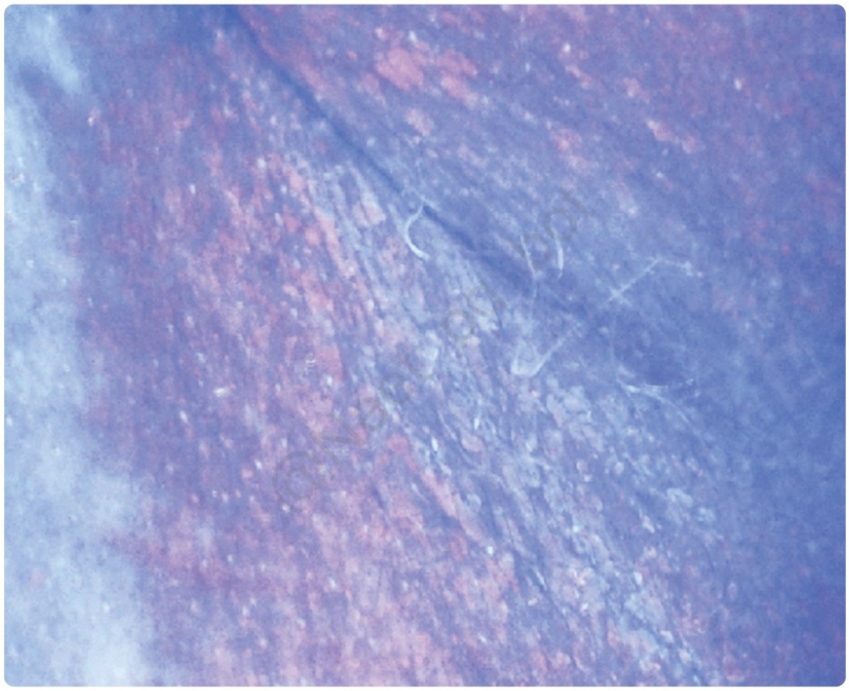

@Neet_pg_bot

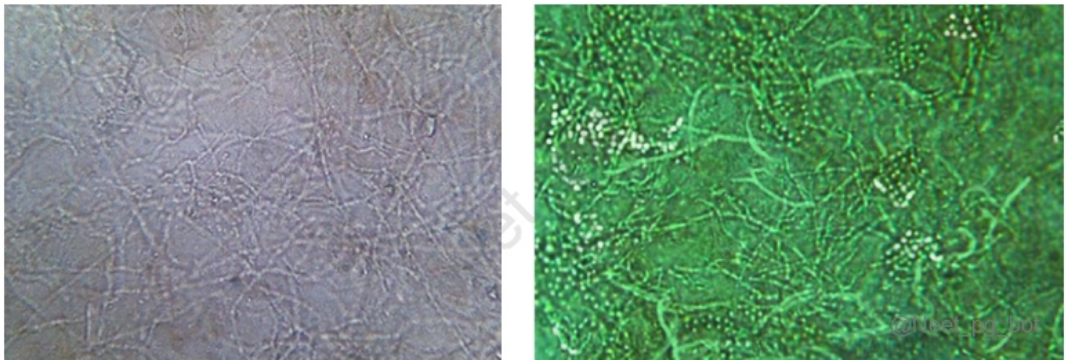

References:

Rook’s Textbook of Dermatology, 9th Edition, Blackwell; 2016, Chapter 26: Bacterial infections, Pages 26.39-26.41

↑ *Back to this question in Part A*

@Neet_pg_bot

Q2: Which of the following cutaneous conditions are associated with streptococcal infection? Guttate psoriasis Erythema nodosum Kawasaki disease Pemphigus vulgaris (Q887081)

A. 1 and 2 only

B. 1, 2 and 3 only

C. 2 and 4 only

D. 1, 2, 3 and 4

Correct Answer: B. 1, 2 and 3 only

Explanation: Streptococcal infection is known to trigger guttate psoriasis , cause hypersensitivity reactions such as erythema nodosum , and has an epidemiological association with Kawasaki disease . Cutaneous Manifestations of Streptococcal Infection: Direct skin / subcutaneous infections (Group A streptococci): Impetigo Ecthyma Erysipelas Cellulitis Necrotizing fasciitis Streptococcal ulcers Blistering distal dactylitis Vulvovaginitis Perianal infection Secondary infection: Eczema & infestations Chronic ulcers Toxin-mediated disease: Scarlet fever Toxic shock-like syndrome Recurrent toxin-mediated perineal erythema Hypersensitivity reactions: Erythema nodosum Vasculitis Diseases triggered or influenced by streptococcal infection Psoriasis (especially guttate) Kawasaki disease

References:

Rook’s Textbook of Dermatology, 9th Edition, Page 26.10

↑ *Back to this question in Part A*

@Neet_pg_bot

Q3: A 28-year-old man presents with asymptomatic brownish patches in the axilla. A Wood's lamp examination image is shown. What is the most likely diagnosis? (Q887233)

A. Tinea capitis

B. Pityriasis versicolor

C. Erythrasma

D. Vitiligo

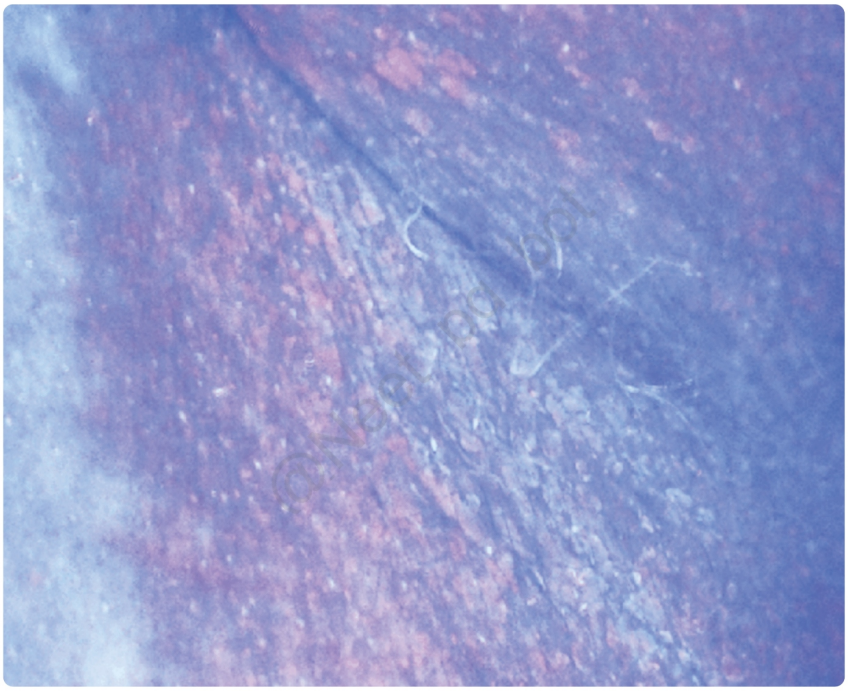

@Neet_pg_bot

Correct Answer: C. Erythrasma

Explanation: Erythrasma is caused by Corynebacterium minutissimum, which produces porphyrins , leading to coral pink/red fluorescence under Wood's lamp. ■ ■ Erythrasma: It is a superficial skin infection caused by Corynebacterium minutissimum. Risk factors include diabetes mellitus, obesity, immunocompromised state , hyperhidrosis, and older adults. It usually presents as asymptomatic lesions in the interdigital, intertriginous, and genital/perianal areas. Wood's lamp examination shows coral-red fluorescence from coproporphyrin III produced

by Corynebacterium minutissimum. Treatment: First line: Topical azoles (e.g., clotrimazole, miconazole) for ~2 weeks. Extensive disease: Oral erythromycin. Second line: Photodynamic therapy using porphyrin Condition/Substance Fluorescence Colour / Observation Tinea capitis (Microspora/favus) (Option A) Green Pityriasis versicolor (Option B) Yellow Erythrasma Coral pink (due to porphyrins) Pseudomonas pyocyanea Yellowish green (due to pyocyanin) Vitiligo (Option D) Accentuated (dermal pigment becomes less apparent) - Ivory/milky white Tuberous sclerosis Detection of ash leaf macules



References:

Rook's Textbook of Dermatology, 9th Edition, Pages 4.20, 26.39 - 26.41

↑ *Back to this question in Part A*

@Neet_pg_bot

Q4: Which of the following conditions are associated with the organism depicted in the image? Impetigo Folliculitis Ecthyma Staphylococcal scalded skin syndrome Toxic shock syndrome (Q887227)

A. 1,4 and 5 only

B. 1, 2 and 4 only

C. 1, 2, 3 and 4

D. 1, 2, 3, 4 and 5

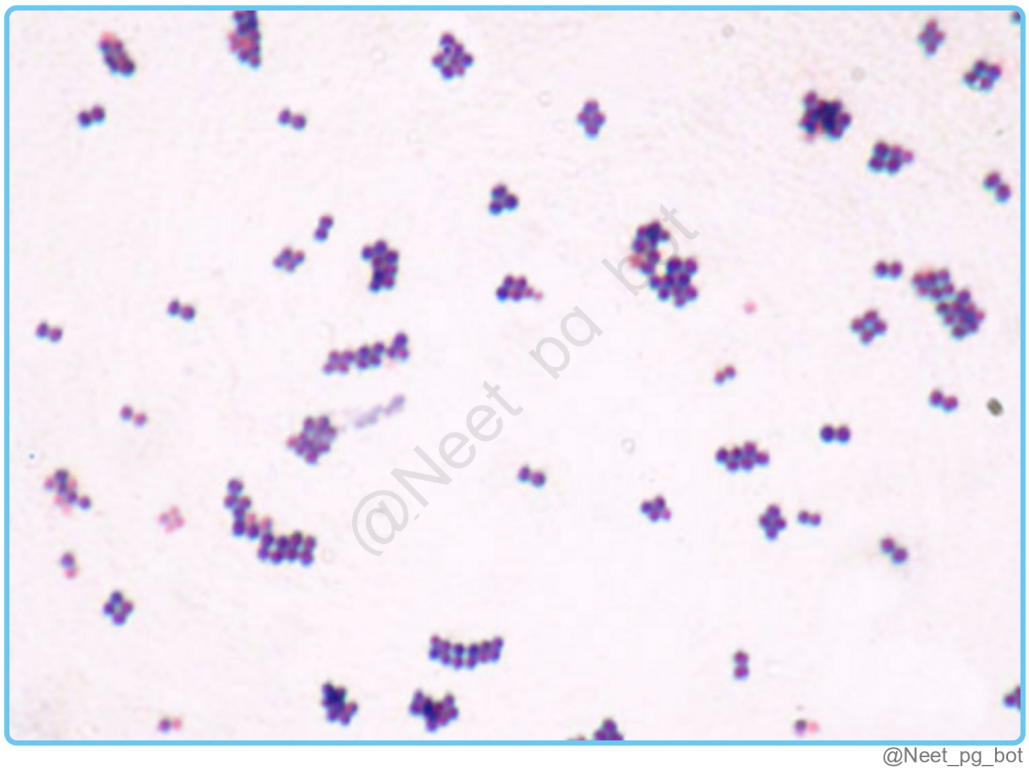

Correct Answer: D. 1, 2, 3, 4 and 5

Explanation: The image shows Gram-positive organisms arranged in grape-like clusters, indicative of Staphylococcus aureus. S. aureus causes direct skin infections , secondary infections , and toxin-mediated diseases , making all listed conditions associated with it. Cutaneous Diseases Caused by Staphylococcus aureus: 1. Direct infection of skin & adjacent tissues Impetigo Ecthyma Folliculitis Furunculosis Carbuncle Sycosis Occasionally cellulitis 2. Secondary infection: Eczema Infestations Chronic ulcers, wounds 3. Toxin-mediated cutaneous disease: Staphylococcal scalded skin syndrome (SSSS) Toxic shock syndrome (TSS) Staphylococcal scarlatina Recurrent toxin-mediated perineal erythema

References:

Rook’s Textbook of Dermatology, 9th Edition, Page 26.6

↑ *Back to this question in Part A*

@Neet_pg_bot

Q5: A 40-year-old man is diagnosed with erysipeloid and presents with a localised violaceous erythematous lesion on the finger with minimal systemic symptoms. What

is the most likely mode of transmission of this condition? (Q887226)

A. Respiratory droplets

B. Animal bite

C. Inoculation through a skin breach from contaminated animal products

D. Human-to-human contact



Correct Answer: C. Inoculation through a skin breach from contaminated animal products

Explanation: The most likely mode of transmission is inoculation through a skin breach from contaminated animal products . Erysipeloid: Erysipeloid (also known as "whale finger" or "seal finger" in specific industries) is an occupational zoonosis caused by the bacterium Erysipelothrix rhusiopathiae. Organism persists in soil for months Reservoirs: pigs (most important), fish, shellfish, birds, mammals Occupational disease : Butchers, fishermen, cooks, farmers, veterinarians Transmission: Direct inoculation through skin breaks More commonly from animal carcasses than live animals Clinical forms: Localized cutaneous (most common): 3 days post-injury Tender violaceous erythema , sharp border Hands/fingers; minimal fever Self-limiting (≈2 weeks) Generalized cutaneous: Multiple violaceous lesions, central clearing Blood cultures negative Systemic (rare): Aortic valve endocarditis , joints, bone, CNS Blood cultures positive Treatment: First line: Penicillin Alternatives: Ciprofloxacin, Erythromycin Second line: Tetracyclines Severe/systemic → IV penicillin

References:

Rook’s Textbook of Dermatology, 9th Edition, Pages 26.46, 26.47

↑ *Back to this question in Part A*

@Neet_pg_bot

Q6: A 25-year-old man presents with recurrent erythematous pustules and papules on his beard as shown for several months. Some areas show scarring at the margins. Which of the following statements about the condition is incorrect? (Q887224)

A. It primarily affects post-pubertal males

B. Staphylococcus aureus is the most common causative organism

C. It frequently resolves spontaneously without treatment

D. Lupoid sycosis involves follicular destruction with scarring



Correct Answer: C. It frequently resolves spontaneously without treatment

Explanation: Sycosis barbae is a deep-seated, chronic inflammatory infection of the hair follicles in the beard area. Unlike simple superficial folliculitis (often called "barber's itch"), sycosis barbae is persistent and notoriously difficult to eradicate without medical intervention. Sycosis barbae: Chronic or subacute bacterial folliculitis of the beard; lupoid sycosis involves scarring. Epidemiology: Post-pubertal males (Option A) ; often seborrheic or indoor workers. Cause: Staphylococcus aureus (often a nasal carrier). (Option B) Clinical: Erythematous follicular papules/pustules on the beard; chronic forms form plaques; lupoid sycosis shows scarring with active pustules at margins (Option D) . Investigations: Skin and nasal swabs; biopsy if uncertain. Management: Topical antibiotics ± steroids; treat nasal carriage. Systemic antibiotics or oral retinoids for chronic cases. Laser or photodynamic therapy for resistant disease. Course: Relapsing/remitting; chronic forms may persist indefinitely.



References:

Rook’s Textbook of Dermatology, 9th Edition, Pages 26.26, 26.27

↑ *Back to this question in Part A*

@Neet_pg_bot

Q7: A 12-year-old girl presents with a painful, red swelling of the lateral nail fold after biting her nails. Which of the following statements about this condition is correct? (Q887223)

A. Staphylococcus aureus is the most common cause

B. Osteitis is not a complication

C. Radiography is needed for all patients

D. Commonly occurs in the elderly



Correct Answer: A. Staphylococcus aureus is the most common cause

Explanation: Acute paronychia is an acute bacterial infection of the nail fold , most often occurring after minor trauma such as nail biting, hangnails, or manicuring. The most common causative organism is Staphylococcus aureus (Option A) Clinically, it presents with a painful, red, swollen lateral nail fold , sometimes with pus or a subungual abscess . It is more common in children and adolescents than in the elderly (Option D) Complications can include abscess formation, cellulitis, and rarely osteomyelitis (osteitis) of the distal phalanx (Option B) Radiography is not required for all patients . An X-ray is considered only when there is a history of trauma , suspicion of a foreign body , fracture , or bone involvement (Option C) Management is based on the stage of disease: Early/superficial cases: warm soaks and local care ± topical/systemic antibiotics Abscess present: incision and drainage ± antibiotics

References:

Rook’s Textbook of Dermatology, 9th Edition, Page 95.58

↑ *Back to this question in Part A*

@Neet_pg_bot

Q8: A 45-year-old man with diabetes presents with multiple chronic abscesses on his leg. The lesions have drained through multiple sinuses over several months, leaving atrophic scars. Biopsy shows clusters of Gram-positive cocci. What is the most likely diagnosis? (Q887159)

A. Actinomycosis

B. Botryomycosis

C. Mycetoma

D. Furunculosis



Correct Answer: B. Botryomycosis

Explanation: Based on the clinical presentation, the most likely diagnosis is Botryomycosis . Botryomycosis: Chronic granulomatous bacterial infection forming granules resembling actinomycosis. Synonyms: Actinophytosis, Bacterial pseudomycosis Epidemiology: Rare, any age/sex; associated with diabetes, AIDS, follicular mucinosis Aetiology: Mainly Staphylococcus aureus; occasionally Pseudomonas or others Pathophysiology: Often follows trauma/foreign body; chronic abscesses and sinus formation Clinical features: Limbs most affected; also face, perianal region Cutaneous: abscess → multiple sinuses → atrophic scars Pulmonary: masses with sinuses Investigations: Biopsy: bacterial granules Methenamine silver stain is useful Culture for organism identification Management: First-line: Flucloxacillin or erythromycin Extensive lesions: Flucloxacillin + fusidic acid Chronic if untreated; outcome affected by comorbidities Actinomycosis (Option A) : Caused by Actinomyces (anaerobic), often cervicofacial; histology shows true sulphur granules, not cocci. Mycetoma (Option C) : Usually painless swelling with sinus tracts on the feet; caused by fungi or actinomycetes; grains differ in appearance. Furunculosis (Option D) : Acute, painful boils; typically single lesions; does not cause chronic sinuses or granules.

References:

Rook’s Textbook of Dermatology, 9th Edition, Pages 26.72, 26.73

↑ *Back to this question in Part A*

@Neet_pg_bot

Q9: A 55-year-old febrile diabetic man with neutropenia has rapidly developing necrotic ulcers with black eschars, as shown in the image. What is the most likely diagnosis? (Q887139)

A. Ecthyma

B. Ecthyma gangrenosum

C. Pyoderma gangrenosum

D. Gram-negative folliculitis



Correct Answer: B. Ecthyma gangrenosum

Explanation: Necrotic ulcers with black eschars in immunocompromised patients are characteristic of Pseudomonas infection (ecthyma gangrenosum). Risk factors: Neutropenia, diabetes, HIV/AIDS Critically ill or septic patients Begins as erythematous macules or papules Rapidly progresses to necrotic ulcers with black eschars Common sites: axillae, buttocks, perineum Often associated with fever and systemic infection Ecthyma (Option A) : Deep ulcerative infection caused by Streptococcus, usually in children; heals with scarring, not necrotic. Pyoderma gangrenosum (Option C) : Painful, rapidly progressive ulcers with undermined violaceous edges, associated with systemic disease; non-infectious and not related to Pseudomonas sepsis Gram-negative folliculitis

(Option D) : Tender pustular lesions from Pseudomonas, usually self-limited, not necrotic.

References:

Rook’s Textbook of Dermatology, 9th Edition, Page 26.51

↑ *Back to this question in Part A*

@Neet_pg_bot

Q10: A 9-year-old girl has painful ulcers on her lower legs. Lesions started as pustules on a red base, developed thick crusts, and new lesions appeared nearby. What is the most likely diagnosis? (Q887135)

A. Impetigo

B. Ecthyma

C. Pyoderma gangrenosum

D. Ecthyma gangrenosum

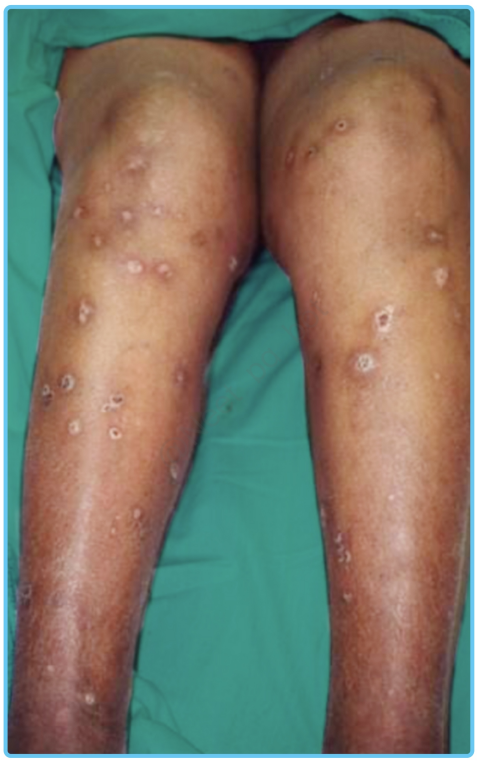

Correct Answer: B. Ecthyma

Explanation: Ecthyma is a deeper infection than impetigo, forming thick crusts over purulent ulcers, often on the legs. Ecthyma: Deeper pyogenic skin infection with adherent crusts and ulcers; heals with scarring. Commonly caused by Group A Streptococcus such as S. pyogenes, Pseudomonas aeruginosa and Staphylococcus aureus. Epidemiology: Extremes of age, immunocompromised, and diabetics Warm, humid environments, poor hygiene, and overcrowding Pathophysiology: Infection penetrates epidermis and dermis → ulceration Predisposing: trauma, dermatitis, pharyngeal carriers Causative organisms: S. pyogenes, S. aureus, P. aeruginosa Clinical features: Bullae/pustules → thick crust → purulent ulcer Common sites: buttocks, thighs, legs Autoinoculation possible Complications: Scarring, multiple lesions Management: First-line: Topical fusidic acid/mupirocin; oral flucloxacillin Second-line: Topical sulconazole/miconazole; oral erythromycin/doxycycline Third-line/severe: Oral clindamycin; IV piperacillin, gentamicin, amikacin, ciprofloxacin, ofloxacin Impetigo (Option A) : Superficial infection; crusts are thinner, and lesions rarely ulcerate. Pyoderma gangrenosum (Option C) : Rapidly enlarging, painful ulcers with undermined edges; often associated with systemic disease. Ecthyma gangrenosum (Option D) : Usually occurs in immunocompromised patients with Pseudomonas bacteremia; lesions are often necrotic and associated with sepsis.

References:

Rook’s Textbook of Dermatology, 9th Edition, Pages 26.16, 26.17

↑ *Back to this question in Part A*

@Neet_pg_bot

Q11: Which of the following conditions is caused by Corynebacterium minutissimum? (Q887131)

A. Tinea cruris

B. Erythrasma

C. Pityriasis versicolor

D. Intertrigo

Correct Answer: B. Erythrasma

Explanation: Erythrasma is caused by Corynebacterium minutissimum. Erythrasma: Epidemiology: Adults > children; warm, humid climates; may indicate diabetes ; obesity predisposes to extensive lesions. Clinical features: Sites: Toe webs, groins, axillae, submammary/intergluteal folds. Appearance: Sharply marginated reddish-brown patches; smooth → scaly. Symptoms: Usually mild itching; chronic course. Diagnosis: Coral-red fluorescence on Wood’s lamp ; scrapings show Gram-positive filaments. Management: First-line: Topical azoles 2 weeks; oral erythromycin for extensive lesions. Relapse: Antiseptics, drying powders. Second-line: Photodynamic therapy (limited). Tinea cruris (Option A) : Fungal infection by dermatophytes; lesions show scaling and inflammation, no coral-red fluorescence. Pityriasis versicolor (Option C) : Caused by Malassezia species; lesions are small, hypopigmented or hyperpigmented, mainly on the upper trunk. Intertrigo (Option D) : Non-specific inflammation in skin folds, often due to friction or secondary infection, not specifically C. minutissimum.



References:

Rook’s Textbook of Dermatology, 9th Edition, Pages 26.39 - 26.41

↑ *Back to this question in Part A*

@Neet_pg_bot

Q12: A 7-year-old child presents with findings as shown. Culture from the lesion grows Streptococcus pyogenes. Which of the following complications are associated with this condition? Post-streptococcal acute glomerulonephritis Acute rheumatic fever Scarlet fever Erythema multiforme Chorea (Q887083)

A. 1, 3 and 4 only

B. 1 and 2 only

C. 2, 3 and 5 only

D. 1, 2, 3 and 4



Correct Answer: A. 1, 3 and 4 only

Explanation: Streptococcal impetigo, usually caused by Streptococcus pyogenes, can be followed by both immune-mediated and toxin-mediated complications. A well-known and important complication is post-streptococcal acute glomerulonephritis (PSGN) , which typically develops after a latent period of about 2-3 weeks following streptococcal skin infection. The risk depends on the nephritogenic potential of the infecting strain , and this condition may have long-term renal implications . In addition, toxin-mediated and hypersensitivity reactions may occur after streptococcal impetigo. These include scarlet fever (due to erythrogenic toxin production) and erythema multiforme (a hypersensitivity reaction triggered by infection). In contrast, acute rheumatic fever does not follow streptococcal skin infections ; it is a sequela of streptococcal pharyngitis . Since Sydenham's chorea is a manifestation of acute rheumatic fever, it likewise does not occur after impetigo .

References:

Rook's Textbook of Dermatology, 9th Edition, Page 26.13

↑ *Back to this question in Part A*

@Neet_pg_bot

Q13: The image shows a 2-year-old boy brought to the clinic with complaints of rashes on his face. On examination, he has plaques covered with honey-coloured crust. There is no history of fever or any constitutional symptoms. Which is the best stain to confirm the diagnosis? (Q841811)

A. Tzanck smear

B. Gram stain

C. KOH stain

D. Von Kossa stains

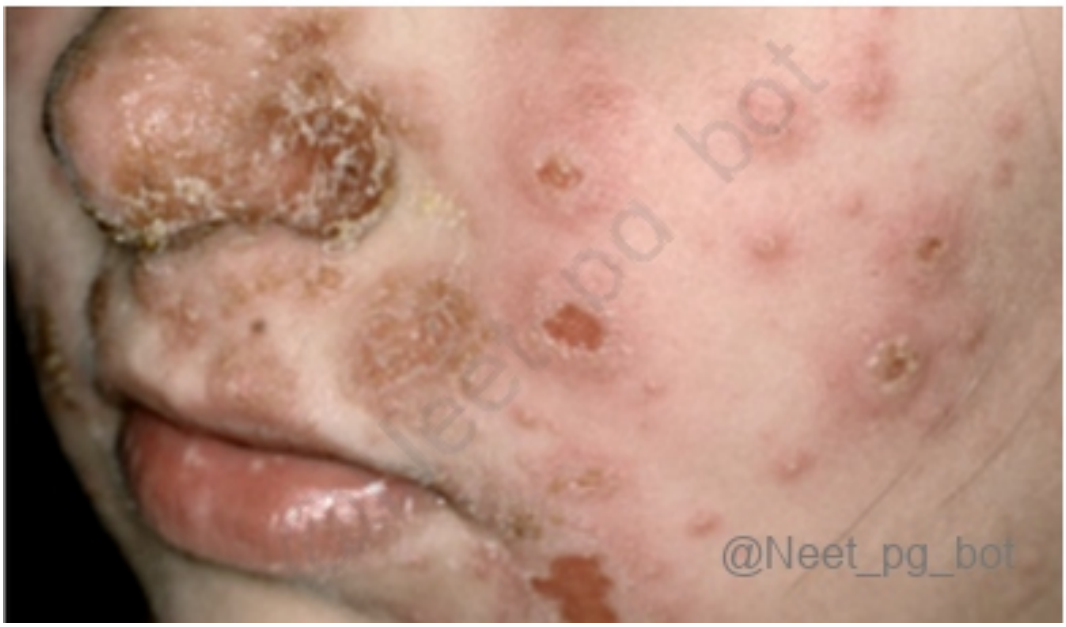

Correct Answer: B. Gram stain

■ *Listen (English)*

■ *Listen (Hindi)*

Explanation: The child has a superficial bacterial infection of the skin known as impetigo. It is most commonly seen in children. Clinical features: It has two clinical variants Bullous impetigo {{caption_text}} Non-bullous impetigo/Impetigo contagiosa {{caption_text}} Age group Newborns Preschoolers/toddlers Organism Staphylococcus aureus Both streptococcus and staphylococcus Staphylococcus is more commonly seen in developed nations. Streptococcus is more commonly seen in developing nations. Type of crust Varnish crust Crusted erosions covered by honey-coloured crust. Lesion Superficial bullae - MC Site Trunk Face (predilection towards peri-oral and peri-nasal areas) Complication Staphylococcal scalded skin syndrome (SSSS) Poststreptococcal glomerulonephritis (PSGN) {{caption_text}} Diagnosis: Gram stain/ culture is done to ascertain the causative organism. Gram's stain shows gram-positive cocci arranged in grape-like clusters Management: Clean lesion, remove crusts, apply topical antibiotic. Add systemic antibiotics if extensive. 1st: Flucloxacillin/Cloxacillin 2nd: Macrolides 3rd: Trimethoprim/Tetracyclines Tzanck smear (Option A) : Performed to diagnose the Pemphigus disorders (see image). Also used in the diagnosis of herpes {{caption_text}} KOH stain (Option C): Used in fungal infections (Candida, dermatophytes) {{caption_text}} Von Kossa stain (Option D): Used to stain calcium deposits. Ex. Calcinosis cutis in Scleroderma {{caption_text}}


@Neet_pg_bot


@Neet_pg_bot

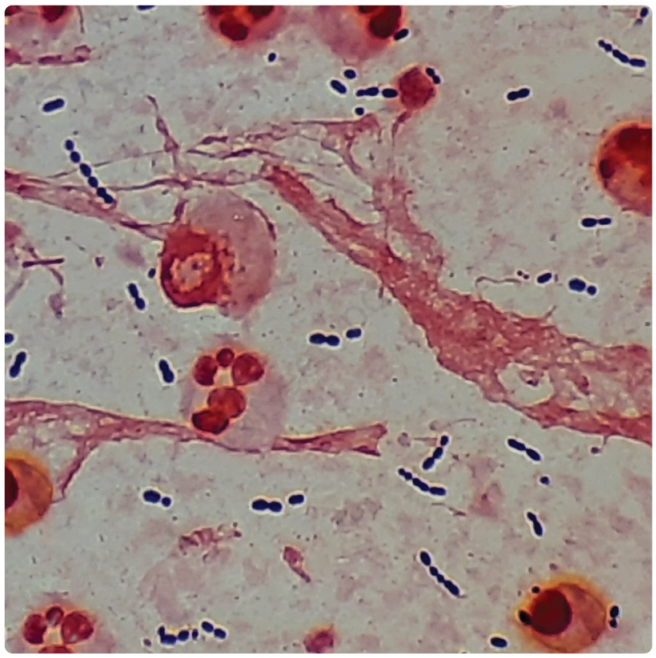

@Neet_pg_bot

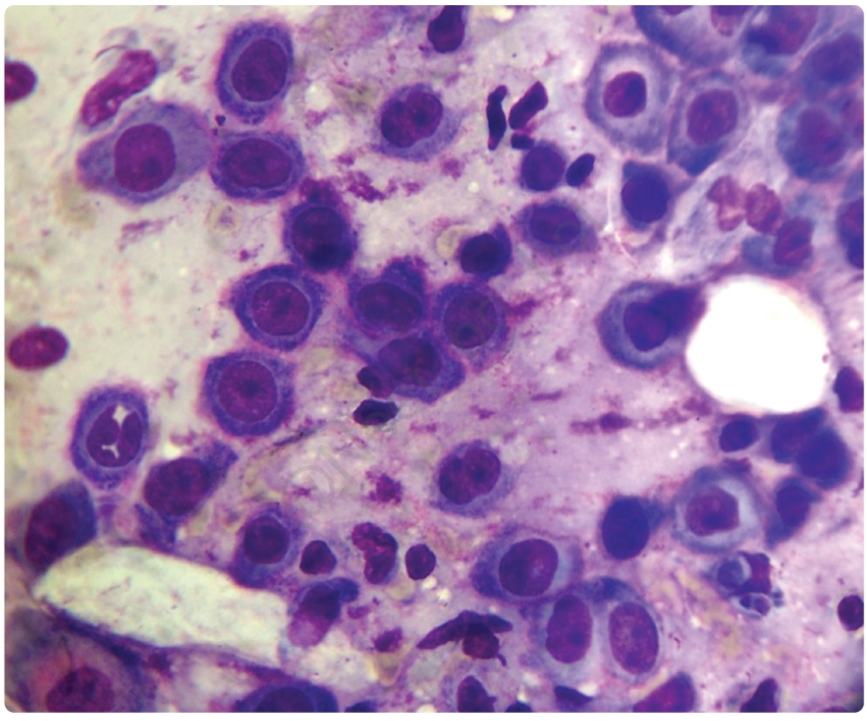

@Neet_pg_bot

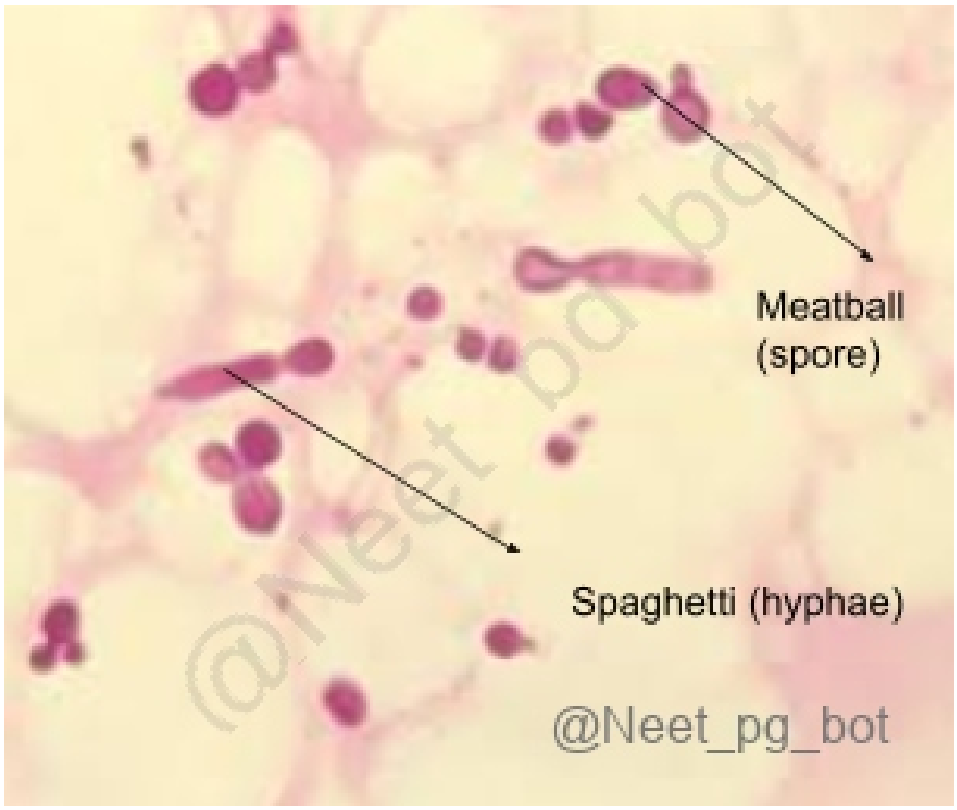

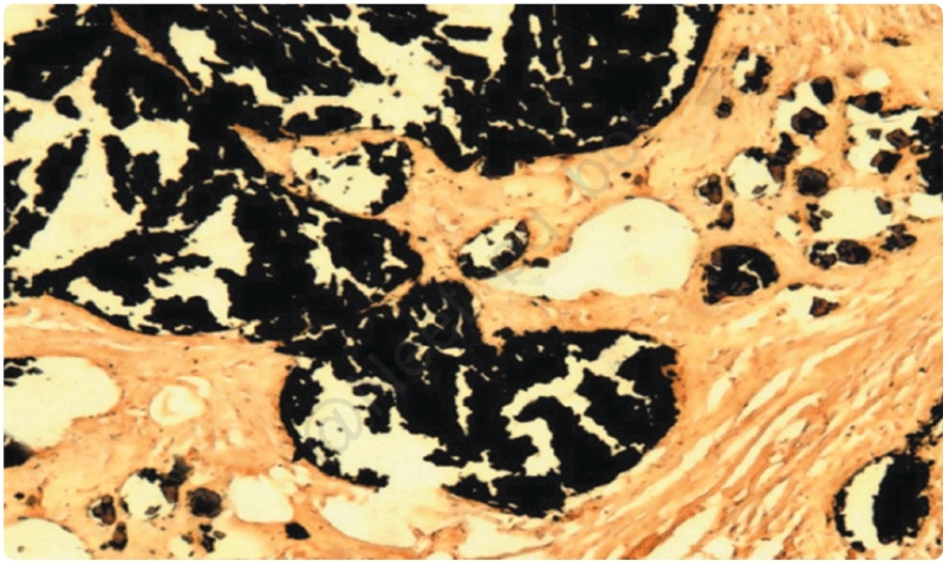

References:

Chapter 26: Bacterial infections. In: Rook's Textbook of Dermatology. 9th ed. Blackwell; 2016. p. 26.13-26.16

↑ *Back to this question in Part A*

@Neet_pg_bot

Q14: A 3-year-old child presents with a 2-day history of fever, irritability, and erythema starting around the perioral region, which quickly spreads to the face, trunk, and extremities. The child develops large, fragile bullae that rupture easily, leaving a moist, erythematous base. A positive Nikolsky sign is noted. There is no mucosal involvement, and the child has no recent history of medication use. What is the most likely diagnosis? {{caption_text}} (Q841820)

A. Staphylococcal scalded skin syndrome

B. Stevens-Johnson syndrome

C. Toxic epidermal necrolysis

D. Epidermolysis bullosa

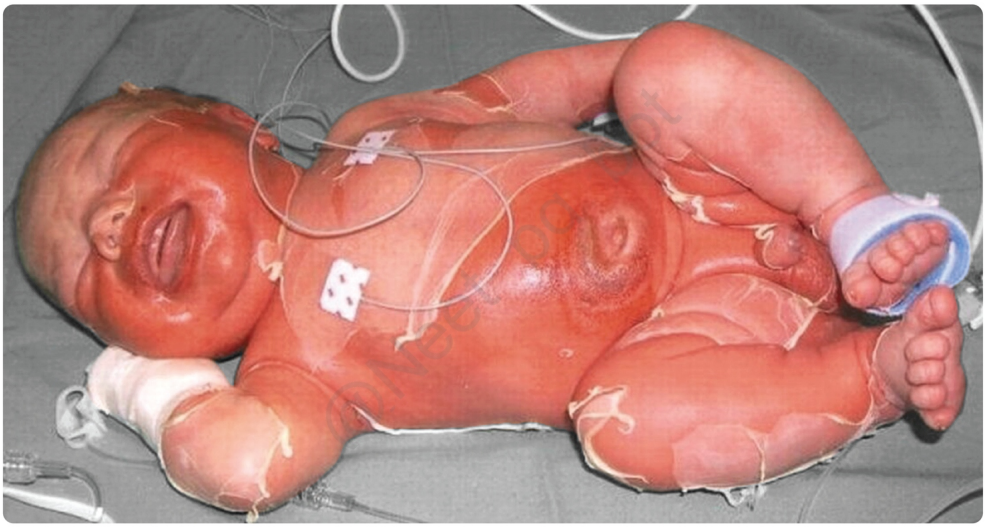

Correct Answer: A. Staphylococcal scalded skin syndrome

■ *Listen to Audio 1*

Explanation: The presence of a positive Nikolsky sign and the characteristic clinical features of severe blistering skin condition, suggests the diagnosis of Staphylococcal Scalded Skin Syndrome (SSSS). In this condition, exfoliative toxin 1 produced by Staphylococcus aureus binds to Desmoglein-1, leading to a subcorneal (intraepidermal) split. {{caption_text}} Clinical features: Tender erythema progressing to flaccid bullae Perioral crusting ("dry oatmeal" appearance) Positive Nikolsky sign No mucosal involvement Diagnosis: Usually clinical; biopsy (if needed) shows intraepidermal separation due to exfoliative toxins. Treatment: Hospitalization, IV antistaphylococcal antibiotics, and supportive care. Stevens-Johnson syndrome (Option B): Trigger: Typically a hypersensitivity reaction to medications (e.g., sulfonamides, anticonvulsants). The patient had no recent

medication use. Mucosal Involvement: SJS is characterized by severe involvement of mucous membranes (mouth, eyes, genitals). The prompt explicitly states there was no mucosal involvement. Extent: Involves less than 10% of the total body surface area. Toxic epidermal necrolysis (TEN) (Option C) : Trigger & Mucosa: Like SJS, TEN is drug-induced and involves extensive mucosal sloughing . The lack of drug history and mucosal sparing in this child rules it out. Severity: This is the most severe form of the spectrum, involving >30% of the body surface area with full-thickness epidermal necrosis. Epidermolysis bullosa (Option D): Nature: This is a genetic/hereditary structural defect in the skin, not an acute infection or toxemia. Onset: Usually presents at birth or early infancy with blisters triggered by minor mechanical friction or trauma. Clinical Context: It does not present as an acute, 2-day febrile illness with perioral redness.

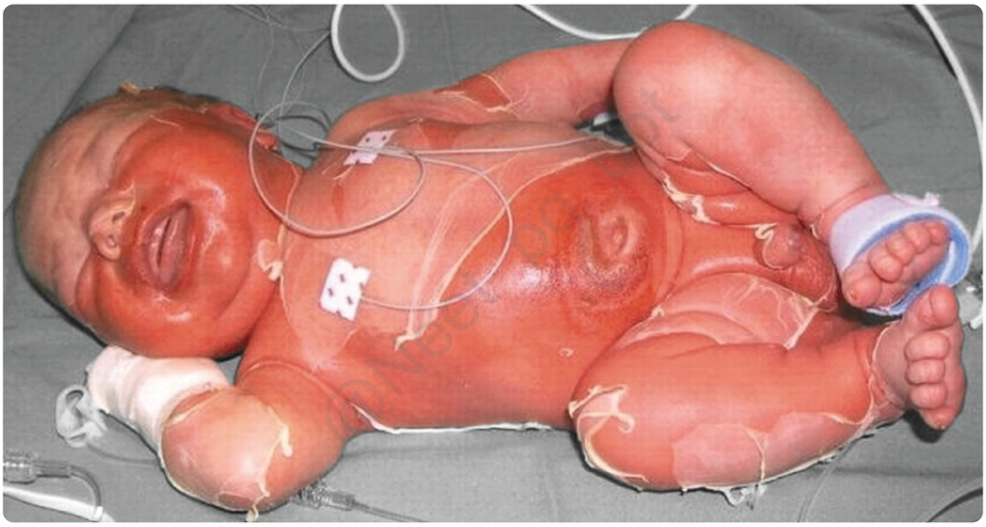

References:

Chapter 26: Bacterial infections. In: Rook's Textbook of Dermatology. 9th ed. Page 119.21,22

↑ *Back to this question in Part A*

@Neet_pg_bot

Q15: A 35-year-old woman presents with nail discoloration, as shown in the image. She has a history of recurrent nail infections but has never noticed changes like these before. Which of the following diseases could be caused by the responsible pathogen? {{caption_text}} (Q841819)

A. Ecthyma gangrenosum

B. Hot tub folliculitis

C. Malignant external otitis

D. All the above



Correct Answer: D. All the above

■ *Listen (English)*

■ *Listen (Hindi)*

Explanation: The given clinical scenario and the image suggest the diagnosis of Green nail syndrome caused by Pseudomonas aeroginosa (Gram-negative bacilli). Skin infections caused by Pseudomonas aeruginosa can result from either direct contact or as secondary seeding from bloodstream infections. These infections include, Green nail syndrome Toe web infection Hot tub folliculitis Malignant external otitis Ecthyma gangrenosum P. aeruginosa subcutaneous nodules Necrotizing skin and soft tissue infections Burn wound infections Infection Description Green nail syndrome {{caption_text}} It is characterised by onycholysis and greenish discolouration of the nail bed. The green colour is due to pyocyanin, a green pigment produced by bacteria. Ecthyma gangrenosum (Option A) {{caption_text}} It is classically associated with P. aeruginosa sepsis and bacteremia in immunocompromised patients. It typically presents as painful, erythematous papules that progress to necrotic ulcers with surrounding erythema. The lesions can rapidly evolve into deep ulcers with black eschars. Hot tub folliculitis/ Pseudomonas folliculitis (Option B) {{caption_text}} Caused by Pseudomonas aeruginosa, which thrives in warm, moist environments like hot tubs and swimming pools with inadequate chlorine levels. It presents as itchy, red monomorphic papules or pustules around the hair follicles of the trunk. Malignant external otitis (Option C) Typically affects immunocompromised individuals. Symptoms include severe ear pain, purulent discharge, and potential cranial nerve involvement. Toe web infection/ Tropical immersion foot It presents as sharply demarcated areas of maceration and tender itchy erosions, sometimes tinged with green. Management: Superficial lesions: 1% acetic acid compression, potassium permanganate soaks, or silver sulfadiazine cream. Burns: Extensive debridement and application of silver sulfadiazine. Septicaemia/severe infections: IV antibiotics (ceftazidime, gentamicin, piperacillin, azlocillin, tobramycin, amikacin) based on sensitivity tests.


@Neet_pg_bot


@Neet_pg_bot



@Neet_pg_bot



References:

Rook's Textbook of Dermatology. 9th ed. Pg. 26.50 to 26.52

↑ *Back to this question in Part A*

@Neet_pg_bot

Q16: A young man presents with coarse axillary hair, foul-smelling sweat, and yellow, waxy nodules on the hair shafts that can be easily scraped off, with no pain or itching. What is the likely diagnosis? {{caption_text}} (Q841818)

A. Pediculosis

B. Pseudonits

C. Trichomycosis nodosa

D. None of the above



Correct Answer: C. Trichomycosis nodosa

■ *Listen (English)*

■ *Listen (Hindi)*

Explanation: Trichomycosis axillaris (AKA Trichomycosis nodosa) is a superficial bacterial infection of the hair shafts caused by Corynebacterium spp (Most commonly C. flavescens) It presents as sheath-like nodules over the hair shafts, which may appear red, yellow, or black, predominantly observed in axillary hair. Sweaty and malodorous axillae are common symptoms, with no pain and itching. Pubic infection can also occur (Trichomycosis pubis). Investigations typically reveal narrow bacillary organisms on KOH mount, Gram-positive

coccobacillary structures on Gram stain, and yellow-white or yellow-green fluorescence under Wood's lamp. Treatment involves the use of Aluminium chloride as an antiperspirant.

References:

Rook’s Textbook of Dermatology. 9th ed. p. 26.41-26.42, 34.16, 32.15, 89.50

↑ *Back to this question in Part A*

@Neet_pg_bot

Q17: A 40-year-old male presents to his dermatologist with complaints of foul odor and discomfort on the soles of his feet when wearing closed shoes for prolonged periods. Upon examination, small, shallow pits on the heels and the balls of the feet are present. Which of the following features is not associated with this condition? {{caption_text}} (Q841816)

A. Associated with reduced or no sweat production

B. Occurs in weight-bearing areas

C. Common in swimmers

D. It is a superficial bacterial infection



@Neet_pg_bot

Correct Answer: A. Associated with reduced or no sweat production

■ *Listen (English)*

■ *Listen (Hindi)*

Explanation: Pitted keratolysis is a superficial bacterial infection (Option D) of the stratum corneum, commonly caused by Corynebacterium species. Risk factors include Warm and moist environments (hyperhidrosis, swimmers, wet work) (Option C) Most commonly affects the weight-bearing areas of the foot. (Option B) Conspicuous, discrete, shallow, circular lesions with a punched■out appearance coalesce in places to produce irregular erosions. There is occasionally green or brown discolouration of the horny layer. Hyperhidrosis is often associated, sometimes with maceration, stickiness and a foul odour. Management: First line: Topical antibiotics (Fusidic acid) +/- Benzoyl peroxide Botulinum toxin for hyperhidrosis Aluminium chloride

References:

Chapter 26: Bacterial infections. In: Rook's Textbook of Dermatology. 9th ed. Blackwell; 2016. p. 26.42-26.43

Barankin B. 2023. Pitted keratolysis. UpToDate

↑ *Back to this question in Part A*

@Neet_pg_bot

Q18: Which of the following best describes the typical progression of folliculitis? (Q841815)

A. Carbuncle, furuncle, folliculitis

B. Furuncle, folliculitis, carbuncle

C. Folliculitis, furuncle, carbuncle

D. Folliculitis, carbuncle, furuncle

Correct Answer: C. Folliculitis, furuncle, carbuncle

Explanation: Folliculitis is a superficial infection of the hair follicle, commonly caused by Staphylococcus aureus and presents as inflamed follicular papules and/ or pustules. Furuncle : Perifollicular abscess typically has an erythematous, indurated, tender nodule with a pus point. Carbuncle: Carbuncles are composed of two or more furuncles, and they classically have multiple pustules, or "heads," originating from the underlying abscess. Treatment: Flucloxacillin or another penicillinase■resistant antibiotic should be given. Incision and drainage or saucerization under local anaesthetic may be required.





References:

Rook’s Textbook of Dermatology. 9th Edition, Pages 26.21-26.26

↑ *Back to this question in Part A*

@Neet_pg_bot

Q19: A 27-year-old woman presents with complaints of severely itchy rashes all over her body that developed after she had used the hot tub in a hotel. On examination, she has multiple, monomorphic, erythematous papules and pinhead pustules over hair follicles, predominantly over her trunk and buttocks. Which of the following is the most likely causative organism? (Q841814)

A. Staphylococcus aureus

B. Streptococcus pyogenes

C. Corynebacterium minutissimum

D. Pseudomonas aeruginosa

Correct Answer: D. Pseudomonas aeruginosa

■ *Listen (English)*

■ *Listen (Hindi)*

Explanation: Based on the given clinical scenario, the patient has pseudomonas folliculitis or hot tub folliculitis, an infection of the skin commonly associated with swimming pool and hot tub use. Risk factors include changes to cutaneous flora, female gender, length of exposure, and skin trauma. Within 48 hours of exposure, it presents as pruritic papules and papulopustules ranging from two to ten millimetres in diameter. It most often presents on the flanks, axillae, buttocks, and ears. Management can vary with the severity of the infection. In most cases, lesions are self-limited and resolve without management in one to two weeks. In severe cases, antipseudomonal agents like ticarcillin and piperacillin can be given.

References:

Jackson J D. 2023. Infectious folliculitis. UpToDate

https://www.ncbi.nlm.nih.gov/pmc/articles/PMC7584313/

↑ *Back to this question in Part A*

@Neet_pg_bot

Q20: A 30-year-old man presents with a painful, erythematous skin rash over his leg that started two days ago and has been consistently increasing with a history of fever for the past two days. On examination, a tender, erythematous rash with ill-defined margins is visible. The local rise in temperature is present. There are no fluctuant

nodules. Which is the most common causative organism for the infection? (Q841813)

A. Candida albicans

B. Pseudomonas aeruginosa

C. Beta-hemolytic streptococci

D. Clostridium perfringens



Correct Answer: C. Beta-hemolytic streptococci

■ *Listen (English)*

■ *Listen (Hindi)*

Explanation: Cellulitis is an acute bacterial infection involving the deeper dermis and subcutaneous tissue of the skin. It occurs when bacteria enter through a breach in the skin barrier. Present as a warm, tender, erythematous rash with oedema. Margins are ill-defined, unlike erysipelas. There are no fluctuant nodules Treatment: First line Flucloxacillin/ Clarithromycin/Benzylpenicillin; Second line: Roxithromycin Prophylaxis for recurrent infections: Long-term penicillin/ erythromycin. Candida albicans (Option A): The most common cutaneous manifestation is inflammation of the skin folds, such as intertrigo. It does not lead to acute, progressive cellulitis. Pseudomonas aeruginosa (Option C): The causative organism for ‘hot tub’ folliculitis, characterized by monomorphic perifollicular rashes following prolonged exposure to contaminated water. It is associated with cellulitis only in neutropenic patients. {{caption_text}} Clostridium perfringens (Option D): It causes Clostridial myonecrosis, a severe, rapidly progressing infection characterized by sudden onset, bullous lesions, tense skin, and severe tenderness. Signs of significant systemic toxicity are also present.





References:

Chapter 26: Bacterial infections. In: Rook's Textbook of Dermatology. 9th ed. Blackwell; 2016. p. 26.19

↑ *Back to this question in Part A*

@Neet_pg_bot

Q21: A 43-year-old man presents with a fever (100.4°F) and a skin lesion on the right leg that appeared 2 days ago. He also complains of redness over his ear since yesterday. He sustained a minor laceration in the same location 1 week ago when he fell into his rose bushes while gardening. What is the probable diagnosis? (Q841812)

A. Cellulitis

B. Erysipelas

C. Ecthyma

D. Impetigo



Correct Answer: B. Erysipelas

■ *Listen (English)*

■ *Listen (Hindi)*

Explanation: Erysipelas is a skin infection that usually affects the upper half of the dermis but may also extend to the superficial cutaneous lymphatics. It occurs due to the entry of bacteria through a breach in the skin barrier. Erysipelas is most commonly caused by beta-hemolytic streptococci. Clinical features: It manifests as an area of erythema that is well-demarcated and raised around the edges. Acute-onset constitutional symptoms like fever, chills, and malaise are also present. O/E erythematous lesions with sharply demarcated borders and raised edges

along with tenderness were present. Milian's ear sign: Involvement of the ear is characteristic of erysipelas as the ear does not have a deeper dermis layer. Milian ear sign is used to distinguish between cellulitis and erysipelas as pinna does not have deep subcutaneous layer which is involved in cellulitis {{caption_text}} Treatment: First line: Flucloxacillin/ Clarithromycin Second line: Roxithromycin Prophylaxis for recurrent infections: Long-term penicillin/ erythromycin Cellulitis (Option A) Infection of lower dermis and subcutaneous tissue by Strep. pyogenes or S. aureus ; usually on legs; presents as red, tender, ill-defined plaques . Ecthyma (Option C): It is a deeper ulcerative variant of impetigo caused by group A streptococci. Lesions are hard, adherent chocolate brown crust; on removing the crust, a purulent irregular ulcer is seen. {{caption_text}} Impetigo (Option D) is characterized by honey-colored crusts rather than the sharply demarcated, raised erythematous lesions seen in erysipelas.



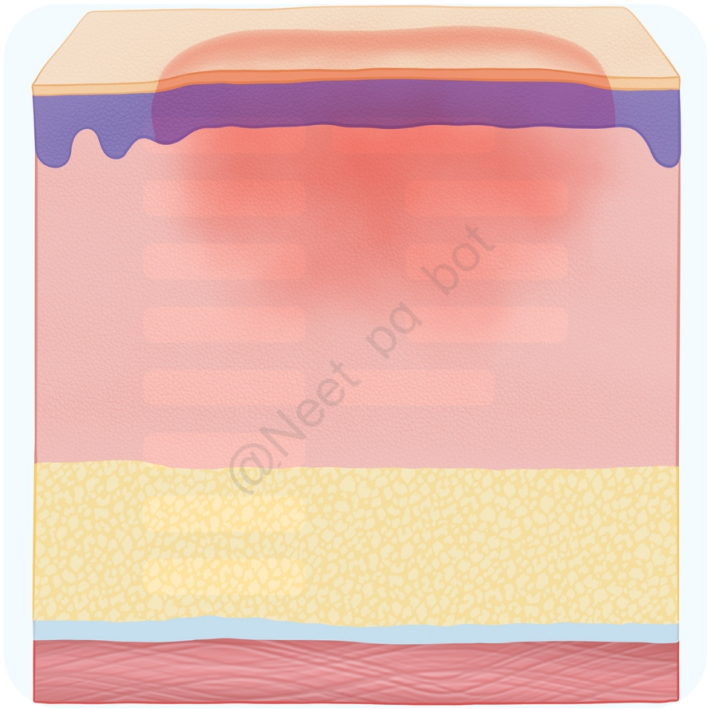

@Neet_pg_bot



@Neet_pg_bot





References:

1. Rook’s Textbook of Dermatology, 9th Edition, Chapter 26, Page 26.17-26.21. 2. Spellman D. 2023. Cellulitis and skin abscess: Epidemiology, microbiology, clinical manifestations, and diagnosis. UpToDate

↑ *Back to this question in Part A*

@Neet_pg_bot

• [15_Bacterial Infections] 030 Previous Year Questions

« Back to Folder Directory

[15_Bacterial Infections] 030 Previous Year Questions — Quick Jump

Q1 (p. 1304) *Q2 (p. 1307)* *Q3 (p. 1309)* *Q4 (p. 1310)* *Q5 (p. 1312)*

Q1: Identify the given condition and its treatment. (Q866858)

A. Staphylococcal scalded syndrome with Inj cephalexin

B. Epidermolysis bullosa with bandaging

C. Impetigo bullosa with antibiotics

D. Erythema multiforme with steroids



Correct Answer: A. Staphylococcal scalded syndrome with Inj cephalexin

Explanation: The image shows a child with widespread erythema and superficial desquamation (peeling of the skin). This is the hallmark of Staphylococcal Scalded Skin Syndrome (SSSS). Pathophysiology: SSSS is caused by an exfoliative toxin produced by Staphylococcus aureus . This toxin causes the top layer of the epidermis to

detach, leading to the characteristic blistering and peeling of the skin, making it look "scalded." Treatment: As it is a serious systemic infection, the treatment involves intravenous (IV) antistaphylococcal antibiotics to target the underlying bacterial cause. The skin itself is treated with supportive care, similar to that for a burn patient. The provided answer, while mentioning cephalexin (an oral antibiotic), likely refers to the class of antistaphylococcal antibiotics required. Incorrect Options: Epidermolysis bullosa (Option B) is a group of rare genetic disorders that cause the skin to be fragile and blister easily. It is not an infectious condition and is managed with supportive care, but it is not the primary diagnosis here. Impetigo bullosa (Option C) is a localized form of staphylococcal skin infection that presents with large blisters (bullae). It does not typically cause the widespread erythema and peeling seen in SSSS. Erythema multiforme (Option D) is a hypersensitivity reaction that presents with characteristic "target lesions" and is often managed with steroids, but the clinical picture does not fit the widespread peeling of SSSS.







References:

.

↑ *Back to this question in Part A*

Q2: What skin condition is characterized by the presence of coral red fluorescence under a woods lamp? (Q860607)

A. Erythrasma

B. Acanthosis nigricans

C. Allergic contact dermatitis

D. Cutaneous candidiasis



Correct Answer: A. Erythrasma

Explanation: Erythrasma is a superficial bacterial infection caused by Corynebacterium minutissimum. It commonly affects intertriginous areas (groin, axillae, inframammary folds, and toe webs) and presents as well-defined, reddish-brown patches with mild scaling. A key diagnostic feature is its coral red fluorescence under a Wood's lamp, which occurs due to protoporphyrin production by Corynebacterium minutissimum. Erythrasma: Erythrasma is a superficial skin infection caused by Corynebacterium minutissimum. Risk factors include diabetes mellitus, obesity, immunocompromised state, hyperhidrosis, older adults It usually presents as asymptomatic lesions in the following areas: Interdigital: Scaling, fissuring plaques, maceration Intertriginous: Hyperpigmented patches, mild scaling, wrinkling Genital/perianal: Pruritis ani Interdigital erythrasma commonly occurs with dermatophyte or candidal infections Wood's lamp examination shows coral-red fluorescence from coproporphyrin III produced by Corynebacterium minutissimum. Treatment: First line: Topical antibacterials (Fusidic acid,

Clarithromycin) or topical antifungal (Miconazole) Second line: Photodynamic therapy using porphyrin {{caption_text}} {{caption_text}} Wood's lamp examination is a diagnostic procedure used to observe fluorescence patterns in the skin under ultraviolet light. It helps identify fungal infections, bacterial infections, pigmentary disorders, and other skin conditions based on characteristic fluorescence reactions This non-invasive test is conducted in a darkened room, emitting light of wavelength 320-450nm. Disease Colour on Wood’s light Vitiligo Milky white Erythrasma Coral pink Pityriasis versicolor Yellow Tinea capitis Green Pseudomonas Green Scabies Fluorescein solution fills the burrows and is viewed with Wood’s light Porphyria Fluorescence observed in urine, teeth and blood Tuberous sclerosis Ash-leaf macules {{caption_text}} Incorrect Options: Acanthosis nigricans (Option B): Characterized by hyperpigmented, velvety plaques in intertriginous areas, associated with insulin resistance. It does not fluoresce under a Wood's lamp. Allergic Contact Dermatitis (Option C): Presents with erythema, vesicles, and pruritus after exposure to allergens. It does not fluoresce under a Wood's lamp. Cutaneous Candidiasis (Option D): Presents with erythematous, satellite pustules in moist areas but typically shows pale white or yellow fluorescence under Wood’s lamp, not coral red.







References:

Chapter 26: Bacterial infections. In: Rook's Textbook of Dermatology. 9th ed.

↑ *Back to this question in Part A*

@Neet_pg_bot

Q3: A 45-year-old patient presents with a facial appearance that is marked by thickened, coarse, and deeply furrowed skin. The skin appears to be involved in the cheeks, forehead, and nose. The patient complains of numbness and weakness in the extremities. On examination, there are hypopigmented and erythematous patches with loss of sensation. What is the medical condition characterized by the term “Leonine facies”? (Q820234)

A. Lepromatous Leprosy

B. Acromegaly

C. Myasthenia gravis

D. Bells palsy

Correct Answer: A. Lepromatous Leprosy

Explanation: Correct Option A - Lepromatous Leprosy "Leonine facies" is a term used to describe a specific facial appearance that can be seen in patients with advanced lepromatous leprosy. Lepromatous leprosy is a severe form of leprosy caused by the bacterium Mycobacterium leprae. It is characterized by the infiltration of the skin and other tissues by large numbers of bacilli, leading to significant tissue damage and deformities. The term "leonine" refers to the resemblance of the patient's facial features to those of a lion, with thickened, coarse, deeply furrowed skin. In addition to the distinct facial appearance, lepromatous leprosy can lead to peripheral nerve damage, resulting in sensory loss, muscle weakness, and other neurological symptoms. The hypopigmented and erythematous patches with loss of sensation mentioned in the patient's presentation are also characteristic of leprosy. Incorrect Options: Option B - Acromegaly: Acromegaly is a condition caused by the excessive production of growth hormone after the growth plates have closed. It leads to the enlargement of bones and tissues, resulting in enlarged hands, feet, facial features, and other body parts. While acromegaly can cause changes in facial appearance, it does not typically result in the specific "leonine facies" described in the question. Option C - Myasthenia Gravis: Myasthenia gravis is an autoimmune neuromuscular disorder characterized by muscle weakness and fatigue, particularly in the muscles that control eye and eyelid movements, facial expression, chewing, and swallowing. It does not cause the thickened, coarse, and deeply furrowed skin seen in "leonine facies." Option D - Bell's Palsy: Bell's palsy is a condition characterized by sudden weakness or paralysis of the muscles on one side of the face due to inflammation of the facial nerve. It can lead to drooping of the affected side of the face and difficulty in facial expressions, but it does not cause the specific skin changes described as "leonine facies."

↑ *Back to this question in Part A*

@Neet_pg_bot

Q4: What is the treatment of choice for a patient with paronychia, as shown in the image below? (Q855953)

A. Amoxiclav

B. Metronidazole

C. Amikacin

D. Norfloxacin



Correct Answer: A. Amoxiclav

Explanation: Clinical Presentation: The image shows paronychia , an infection around the nail fold, characterized by redness, swelling, pain, and pus collection . Most Common Cause: Acute paronychia : Staphylococcus aureus (most common), Streptococcus species. Chronic paronychia : Candida species. First-line Antibiotic: Amoxicillin-clavulanate (Amoxiclav) covers Staphylococcus aureus , Streptococcus , and anaerobes , making it the best choice. {{caption_text}} Paronychia Management Feature Acute Paronychia Chronic Paronychia Cause Bacterial (Staph aureus, Streptococci) Fungal (Candida) Onset Rapid, painful swelling Gradual, less painful Pus Formation Yes, common Rare Treatment Drainage + Amoxiclav Antifungals (topical clotrimazole) Metronidazole (Option B): Incorrect because it mainly covers anaerobes and protozoa , which are not the primary cause of paronychia. Amikacin (Option C): Incorrect because it mainly targets Gram-negative bacteria , while paronychia is mostly due to Gram-positive organisms (Staph aureus, Streptococci) . Norfloxacin (Option D): Incorrect because it is a fluoroquinolone with poor Staph aureus coverage , making it ineffective.



References:

Rook’s Dermatology, 9th Edition, Volume 1, Section 26.50- 26.52, 32

↑ *Back to this question in Part A*

@Neet_pg_bot

Q5: Which of the following organisms is most likely to be the cause of the leg lesion shown in the image below, as presented by a young man? The lesions exhibit pain, well-defined raised edges, and the patient also reports blisters on his body. Furthermore, the patient is in good health with no co-existing medical conditions. (Q859547)

A. Group B streptococcus

B. Group A streptococcus

C. Staphylococcus aureus

D. Haemophilus influenza type B



Correct Answer: B. Group A streptococcus

Explanation: From the presentation—a painful, sharply demarcated, raised-edged leg lesion (likely erysipelas) with blister formation in an otherwise healthy young individual—the most common causative organism is Group A Streptococcus (Streptococcus pyogenes). Erysipelas: Erysipelas is a skin infection that usually affects the upper half of the dermis but may also extend to the superficial cutaneous lymphatics. It occurs due to the entry of bacteria through a breach in the skin barrier. Erysipelas is most commonly caused by beta-hemolytic streptococci. Clinical features: It manifests as an area of erythema that is well-demarcated and raised around the edges. Acute onset constitutional symptoms like fever, chills and malaise are also present Milian's ear sign: Involvement of ear is characteristic of erysipelas as the ear does not have a deeper dermis layer Milian's ear sign is a distinguishing feature of erysipelas. {{caption_text}} Treatment: First line: Flucloxacillin/ Clarithromycin Second line: Roxithromycin Prophylaxis for recurrent infections: Long-term penicillin/ erythromycin Group B streptococcus (Streptococcus agalactiae) (Option A): More commonly causes neonatal sepsis, maternal infections, and certain infections in the elderly or immunocompromised. Staphylococcus aureus (Option C): Usually causes Cellulitis , which has poorly defined borders and is often associated with purulence or abscess formation. Haemophilus influenza type b (Option D): It was once a common cause of facial cellulitis in children; its incidence has plummeted due to the Hib vaccine.



References:

Chapter 26: Bacterial infections. In: Rook’s Textbook of Dermatology. 9th ed. Blackwell; 2016. p. 26.17-26.21.

Spellman D. 2023. Cellulitis and skin abscess: Epidemiology, microbiology, clinical manifestations, and diagnosis. UpToDate

Image:https://commons.wikimedia.org/wiki/File:Erysipel3.jpg

↑ *Back to this question in Part A*

@Neet_pg_bot

• [16_Viral Infections] 031 Viral Infections

« Back to Folder Directory

[16_Viral Infections] 031 Viral Infections — Quick Jump

Q1 (p. 1315)	*Q2 (p. 1316)*	*Q3 (p. 1317)*	*Q4 (p. 1318)*	*Q5 (p. 1319)*	*Q6 (p. 1320)*
Q7 (p. 1321)	*Q8 (p. 1322)*	*Q9 (p. 1323)*	*Q10 (p. 1326)*	*Q11 (p. 1329)*	*Q12 (p. 1333)*
Q13 (p. 1336)	*Q14 (p. 1338)*	*Q15 (p. 1341)*	*Q16 (p. 1343)*	*Q17 (p. 1344)*	

Q1: A 21-year-old medical student presented to the dermatology OPD with the following image on the sole and a diagnosis of warts is being made. All of the following statements are true except? {{caption_text}} (Q842031)

A. HPV 2 is the most common causative organism in Superficial plantar warts

B. Deep palmoplantar warts are also called Myrmecia warts

C. HPV 6 is the most common causative organism in Anogenital warts

D. Cryotherapy is a painless procedure



@Neet_pg_bot

Correct Answer: D. Cryotherapy is a painless procedure

■ *Listen (English)*

■ *Listen (Hindi)*

Explanation: The main disadvantage of Cryotherapy / Freezing is pain. Cryotherapy: Liquid nitrogen, carbon dioxide snow, and dimethyl ether can all cause thermal injury to the skin. Liquid nitrogen, which is frequently employed in practice, produces the coldest freeze. A cotton wool bud or cryospray is applied until a rim of iced tissue forms around the wart (visible as a white discoloration). Depending on the size and location of the wart, the freezing is maintained for 5 to 30 seconds, therefore scarring is unlikely. Cryotherapy is safer than imiquimod, podophyllin, and podofilox, which are teratogenic. Plantar warts: Verruca vulgaris (common wart) is most commonly caused by HPV types 1, 4, 27, and 57 . Plantar warts are mainly caused by HPV 1 (deep plantar) and HPV 2 (superficial plantar warts) (Option A) . Common warts typically have no symptoms and appear as firm papules with a rough, horny surface. Histologically, they exhibit acanthosis, hyperkeratosis, and papillomatosis . Deep palmoplantar warts are also called myrmecia warts (Option B). Verruca plana (flat warts) are flat-surfaced lesions, mainly caused by HPV types 3 and 10 . Anogenital warts are most commonly caused by HPV 6 and HPV 11 (Option C) .

References:

Rook's Textbook of Dermatology, 9th Edition, Page 25.43, 25.47, 25.48, 25.52

Bolognia Textbook of Dermatology, 4th Edition, Page 1214

Andrews Diseases of the Skin: Clinical Dermatology, 11th Edition, Page 401

↑ *Back to this question in Part A*

@Neet_pg_bot

Q2: A 26-year-old primigravida is living with her nephew, who has recently developed varicella. She has no history of varicella exposure or vaccination, and serological testing reveals that she is not immune to the varicella-zoster virus (VZV). Based on this information, which of the following is true? (Q842030)

A. She is susceptible to zoster

B. She is susceptible to chickenpox

C. She is immune to zoster

D. She is immune to chickenpox

Correct Answer: B. She is susceptible to chickenpox

■ *Listen (English)*

■ *Listen (Hindi)*

Explanation: The absence of antibodies against VZV indicates that the patient is susceptible to primary VZV infection, commonly known as chickenpox. VZV causes exanthematous lesions in children (chickenpox), in adults (shingles or zoster), and in pregnancy. Chickenpox in pregnancy can affect both the mother and the fetus. Mothers are at high risk of developing varicella pneumonia . The fetus can develop two types of infection, depending on the gestational period at which it acquires the infection. When maternal varicella occurs during the first half of pregnancy , the fetal infection can be asymptomatic or can manifest as congenital varicella syndrome Susceptibility to Herpes Zoster (Shingles) in Pregnancy: Though herpes zoster has a very low infectivity rate, since there are no antibodies in the mother, she is susceptible to the infection. She is susceptible to zoster (Option A): Zoster, or shingles, occurs in individuals who have had chickenpox in the past and the virus reactivates. Since the patient has never had chickenpox, she is not at risk for zoster until she has had a primary VZV infection. She is immune to zoster (Option C): Immunity to zoster implies that the patient has had a prior infection with VZV, which is not the case here as evidenced by the negative antibody test. She is immune to chickenpox (Option D): A negative varicella antibody test indicates that the patient does not have immunity to chickenpox.

References:

Rook's Textbook of dermatology, 9th Edition, Page 25.25

Bolognia Textbook of Dermatology, 4th Edition, Page 1408

www.cdc.gov/mmwr/preview/mmwrhtml/mm6228a4.htm

↑ *Back to this question in Part A*

@Neet_pg_bot

Q3: Which of the following conditions are characteristically associated with a maculopapular rash ? Measles Erythema infectiosum Varicella Rubella Urticaria (Q887253)

A. 1, 2 and 4

B. 1, 3 and 5

C. 2, 4 and 5

D. 1, 2, 3 and 4

Correct Answer: A. 1, 2 and 4

Explanation: Varicella is primarily vesicular (papules → vesicles → crusts). Urticaria produces wheals , not maculopapules. Conditions Associated with a Maculopapular Rash: Measles Rubella Erythema infectiosum (Parvovirus B19) Dengue, Chikungunya HIV (acute seroconversion) West Nile virus Zika virus Infectious mononucleosis

References:

Harrison’s Principles of Internal Medicine, 21st Edition, Pages 134-136

↑ *Back to this question in Part A*

@Neet_pg_bot

Q4: A 4-year-old child presents with a sudden onset of bright erythema over both cheeks with perioral pallor, followed 2 days later by a lace-like rash over the arms and trunk. There was no significant prodrome. What is the causative agent? (Q887249)

A. Measles virus

B. Rubella virus

C. Parvovirus B19

D. Human herpesvirus-6



Correct Answer: C. Parvovirus B19

Explanation: Parvovirus B19 causes erythema infectiosum (fifth disease), characterised by a classic “slapped cheek” rash followed by a lacy exanthem on the limbs and trunk. Erythema Infectiosum (Fifth Disease): Cause: Parvovirus B19 Clinical features: Sudden onset, minimal prodrome Children: “Slapped cheek” erythema with

perioral pallor Lace-like rash on limbs → trunk Adults: Prominent polyarthralgia, milder rash Variants: Petechial/purpuric rash Papular-purpuric gloves and socks syndrome Rare vesicular/pustular lesions Complications: Mild anemia common Aplastic crisis (rare; hemolytic disease, immunosuppression) Pregnancy: fetal hydrops or death Management: Self-limiting; supportive care Close monitoring in pregnancy and high-risk patients



References:

Rook's Textbook of Dermatology, 9th Edition, Pages 25.66,25.67

↑ *Back to this question in Part A*

@Neet_pg_bot

Q5: Imiquimod 5% cream is used in the treatment of which of the following conditions: Genital warts Superficial basal cell carcinoma Actinic keratoses Cutaneous warts Psoriasis (Q887246)

A. 1, 2 and 3 only

B. 1, 2, 3 and 4 only

C. 2, 4 and 5 only

D. 1, 3 and 5 only

Correct Answer: B. 1, 2, 3 and 4 only

Explanation: Imiquimod is a topical immunomodulator approved for genital warts, superficial basal cell carcinoma, and actinic keratoses , and it is also used for cutaneous warts . Psoriasis is not an indication for imiquimod. Imiquimod (5% cream): Topical immunomodulator Licensed indications: Genital warts Superficial basal cell carcinoma Actinic keratoses Other dermatologic uses: Cutaneous warts (including): Butchers' warts Facial filiform warts Plane warts Effective even in immunosuppressed patients Application: Poor penetration through keratinised skin May require: Twice-daily application Prolonged course (up to 24 weeks) Combination with salicylic acid Occlusion does not improve clearance Adverse effects: Local irritation and discomfort Erosion at the application site Rare vitiligo-like depigmentation

References:

Rook's Textbook of Dermatology, 9th Edition, Page 25.53

↑ *Back to this question in Part A*

@Neet_pg_bot

Q6: Which statement regarding eczema herpeticum is incorrect? (Q887244)

A. Commonly occurs in atopic eczema

B. Usually caused by HSV-1

C. Produces monomorphic vesicles with punched-out erosions

D. Does not require antiviral therapy

Correct Answer: D. Does not require antiviral therapy

Explanation: Eczema herpeticum is a potentially serious condition that requires prompt antiviral treatment (aciclovir) to prevent systemic complications. Eczema Herpeticum: (Kaposi varicelliform eruption) Widespread HSV infection in pre-existing skin disease Cause: HSV-1 (most common) (Option B) HSV-2, VZV, Coxsackie, Vaccinia (rare) Predisposition: Atopic eczema (key) (Option A) Other dermatoses, skin trauma Clinical: Sudden monomorphic vesicles → pustules (Option C) Rapid rupture → punched-out erosions Painful, erythematous skin Fever, lymphadenopathy Often widespread, the face is commonly involved Course: Fever settles in 4–5 days Heals with minimal scarring Recurrence uncommon Treatment: Oral aciclovir IV aciclovir if severe

References:

Rook's Textbook of Dermatology, 9th Edition, Pages 25.38-25.41

↑ *Back to this question in Part A*

@Neet_pg_bot

Q7: A man presents with a haemorrhagic pustular lesion on the hand developing 5–7 days after animal contact. What is the most likely diagnosis? (Q887236)

A. Pyogenic granuloma

B. Cutaneous anthrax

C. Ecthyma contagiosum

D. Herpetic whitlow



Correct Answer: C. Ecthyma contagiosum

Explanation: Ecthyma contagiosum (orf) presents as a single haemorrhagic pustule or bulla on the hands after contact with sheep or goats . It is usually self-limiting and associated with mild systemic symptoms. Ecthyma contagiosum: Agent: Parapoxvirus Source: Contact with infected sheep or goats (carcasses, sacrifice) Rare human-to-human spread Incubation: 3-10 days Clinical: Single firm papule → haemorrhagic pustule/bulla Size 2-3 cm Hands/fingers are common Mild fever, lymphadenitis, lymphangitis Complications: Giant/widespread orf (immunocompromised, atopic eczema) Erythema multiforme (2-3 weeks) Heals in 3–6 weeks , reinfection possible Management: Usually none Large lesions: excision Persistent: cryotherapy, imiquimod, cidofovir Pyogenic granuloma (Option A) : A friable, rapidly growing vascular papule that bleeds easily; not related to animal contact or viral infection. Cutaneous anthrax (Option B) : Characterised by a painless black eschar with

marked surrounding oedema; not a haemorrhagic pustule/bulla. Herpetic whitlow (Option D) : Presents with grouped vesicles and severe pain due to HSV; typically linked to oral/genital HSV exposure, not livestock contact.

References:

Rook's Textbook of Dermatology, 9th Edition, Pages 25.10,25.11

↑ *Back to this question in Part A*

@Neet_pg_bot

Q8: Which statement regarding smallpox is incorrect? (Q887235)

A. Rash spreads centrifugally from the face to the extremities

B. Lesions in the same area are at different stages

C. Palms and soles are commonly involved

D. Healing often causes permanent scarring

Correct Answer: B. Lesions in the same area are at different stages

Explanation: In smallpox, lesions are at the same stage in a given area. Lesions at different stages are characteristic of chickenpox , not smallpox. Smallpox (Variola): Eradication declared: 23rd World Health Assembly, May 1980 Incubation period: 10-14 days Clinical features: Prodrome: High fever, headache, backache, malaise Rash evolution: Macules → tense vesicles → pustules (over ~3 days) Lesions in a given area are at the same stage Distribution: Starts on the face (Option A) Spreads centrifugally Extremities > trunk Palms and soles are commonly involved (Option C) Healing: Lesions dry → scab → heal Permanent scarring common (Option D)



@Neet_pg_bot

References:

Rook’s Textbook of Dermatology, 9th Edition, Page 25.6

↑ *Back to this question in Part A*

@Neet_pg_bot

Q9: What is the causative organism of the condition shown below? (Q842034)

A. Treponema pallidum

B. Human papillomavirus 6 and 11

C. Human papillomavirus 16 and 18

D. Haemophilus ducreyi



Correct Answer: B. Human papillomavirus 6 and 11

- *Listen (English)*
- *Listen (Hindi)*

Explanation: The above shows rough finger-like, cauliflower-like growth over the vulva is suggestive of condyloma accuminata, caused by human papillomavirus (HPV 6 > HPV 11). Condyloma acuminata (anogenital warts): Benign, moist, soft, pedunculated wart found on the external genitalia and has low malignant potential. Site: They may be found in the genital area such as the penile shaft, scrotum, or labia majora of the vagina, or in the anal area. Microscopy: A branching villous structure with connective tissue stroma. Epidermis showing hyperkeratosis and acanthosis (thickening). Cytoplasmic vacuolization of the squamous cells (koilocytosis) is Characteristic. No evidence of dysplasia. The table below shows the clinical features of HPV and the types responsible for various lesions: Clinical lesion Oncogenic potential HPV types Plantar warts Benign 1 Common skin warts Benign 2, 4, 27, 57 Epidermodysplasia verrucosa Mostly benign, rarely progresses to malignancy 5, 8, 9, 12, 17 Anogenital warts Laryngeal papilloma Intraepithelial neoplasia Low malignant potential 6, 11 Palmar warts in butchers Low malignant potential 7 Carcinomas of the cervix & other genital mucosa/larynx/oesophagus High malignant potential 16, 18, 31, 33, 45, 51, 52, 56, 58, 59, 68 Treponema pallidum (Option A) causes syphilis, leading to condyloma lata during the secondary stage. These broad, moist lesions appear in areas like the genital and perianal regions, differing from HPV-induced condyloma acuminata. Human papillomavirus 16 and 18 (Option C) are associated with carcinoma of the cervix and anogenital region. Haemophilus ducreyi (Option D) causes chancroid. It presents as a painful, non-indurated ulcer with undermined edges and tender inguinal buboes . Microscopy shows a school of fish/railroad track appearance.

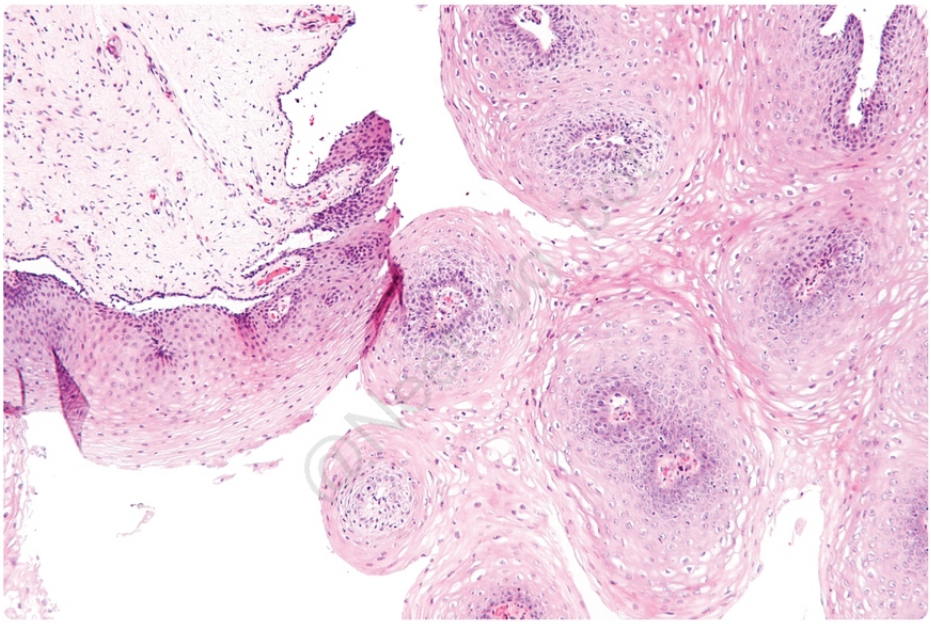

@Neet_pg_bot

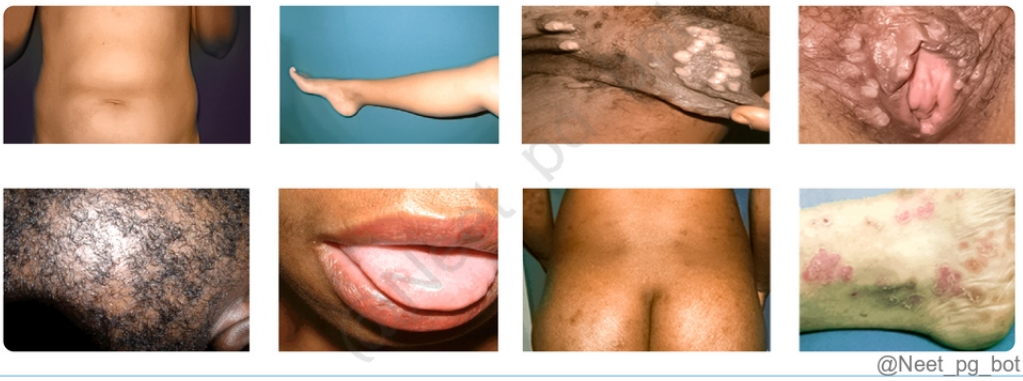

@Neet_pg_bot



@Neet_pg_bot

References:

Ananthanarayan and Paniker's Microbiology, 10th Edition, Page 557

Essentials of Medical Microbiology, 3rd Edition, Page 804

↑ *Back to this question in Part A*

@Neet_pg_bot

Q10: A 40-year-old woman presents with painful and pruritic lesions 2 days after developing a fever. She had a similar history of lesions in the past associated with fever which resolved gradually. What is the likely diagnosis? {{caption_text}} (Q842006)

A. Varicella

B. Cold sore

C. Molluscum contagiosum

D. Whitlow



Correct Answer: B. Cold sore

- *Listen (English)*
- *Listen (Hindi)*

Explanation: The given clinical scenario of a patient with painful and pruritic lesions (small, closely grouped vesicles) associated with fever in the past presenting with similar symptoms suggests herpes labialis (cold sore). Herpes labialis/cold sore: Reactivation of latent infection in trigeminal ganglion, causing asymptomatic shedding or clinically evident recurrent disease. Causative organism: HSV-1 > HSV-2 . Features: Painful and pruritic lesions. Fever is often present, which subsides in 3-5 days. The initial vesicular lesions become pustular and then crusted before healing in 7-10 days without scarring . Can be associated with itching or burning before the development of lesions. Recurrent herpetic lesions are vesicular and ulcerative and tend to occur in the same region. Treatment : Treatment Line Drugs First Line Acyclovir (topical/oral) Hydrocolloid dressing Other Drugs Topical penciclovir Prophylactic acyclovir Varicella (Option A) presents with papules and vesicles on an erythematous base with a centripetal distribution associated with systemic symptoms of fever and malaise. {{caption_text}} Molluscum contagiosum (Option C) presents with shiny, pearly white umbilicated papules. {{caption_text}} Whitlow (Option D) presents with painful swelling of the fingertips and periungual area due to herpes infection by inoculation. {{caption_text}}



@Neet_pg_bot



@Neet_pg_bot



References:

Rook's textbook of Dermatology, 9th Edition, Page 25.17-25.19

↑ *Back to this question in Part A*

@Neet_pg_bot

Q11: Three days ago, a mother brought her 1-year-old infant to the emergency room with a high fever. The infant was treated with acetaminophen. Today, the fever is gone, but the infant has developed a rash on the trunk that has spread to the limbs. The examination reveals red papules on the palate. What is the most probable diagnosis? {{caption_text}} (Q842027)

A. Rubella

B. Erythema infectiosum

C. Measles

D. Roseola infantum

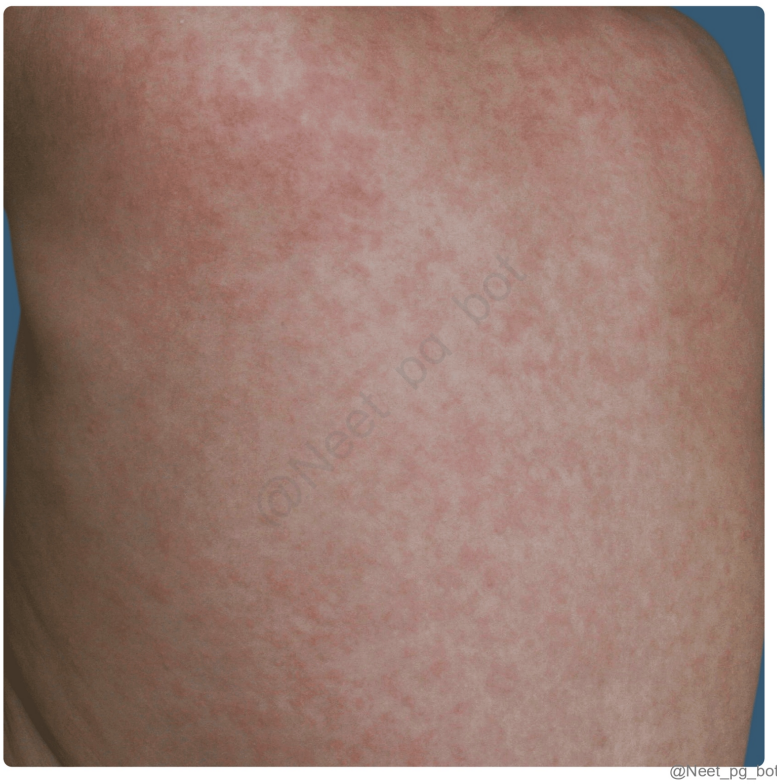



Correct Answer: D. Roseola infantum

■ *Listen (English)*

■ *Listen (Hindi)*

Explanation: Roseola infantum, caused by Human herpesvirus 6 (HHV-6) , is a common exanthematous fever in children under 2 years old. The characteristic lack of symptoms during the febrile phase followed by the appearance of a rosy rash on the trunk and neck after 3 days of high fever is suggestive of Roseola. Nagayama spots, red papules over the palate, are pathognomonic, and cervical and occipital lymph nodes are typically enlarged. Commonly confused rash-associated illnesses in children are: Rubella Roseola Measles Fever Prodrome of high fever, cough, coryza, and conjunctivitis. Abrupt onset of high fever (>39°C) without any other symptoms. Prodrome of high fever, cough, coryza, and conjunctivitis. PathognomonicFeatures Presence of posterior auricular and suboccipital lymphadenopathy Nagayama spots, red papules over the palate Koplik spots, small white lesions on the buccal mucosa, appear 1 to 2 days before the rash Rash Starts on the face and spreads downward to the trunk and extremities. The rash consists of discrete pink-red macules that may coalesce. The rash may spread to the extremities, face, and occasionally palms and soles The rash starts as erythematous macules on the face, then spreads cephalocaudally, becoming confluent. Day of onset of Rash 14-17 3-5 (after fever subsides) 3-7 {{caption_text}} Erythema infectiosum (Option B): Aka Fifth Disease; caused by parvovirus B19, while roseola is caused by HHV-6. It presents with a "slapped cheek" rash followed by a lace-like rash on the trunk, unlike roseola, which starts on the trunk after the fever subsides. Glove and stocking neuropathy Rheumatoid arthritis like illness in adults {{caption_text}}



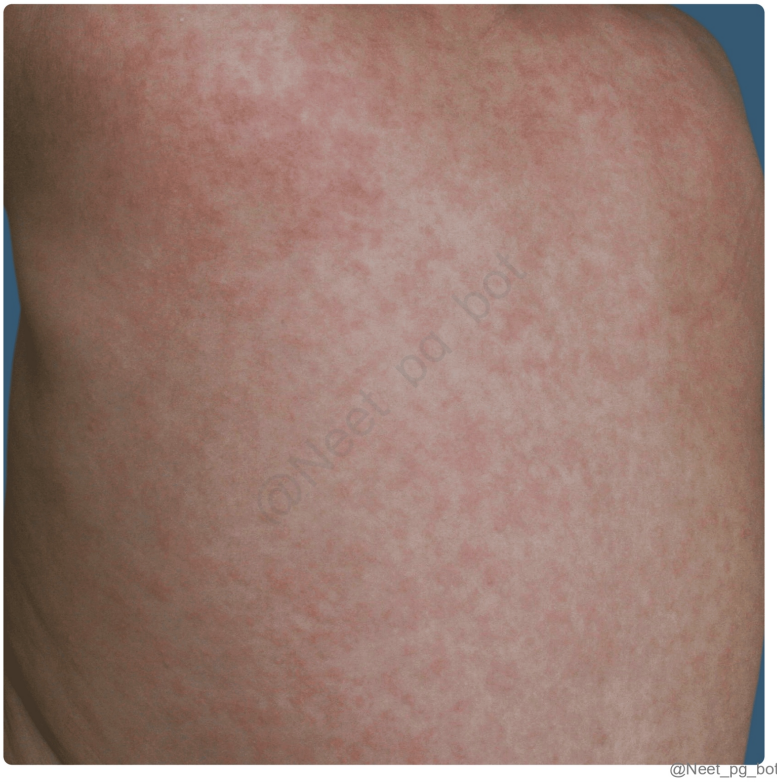
@Neet_pg_bot

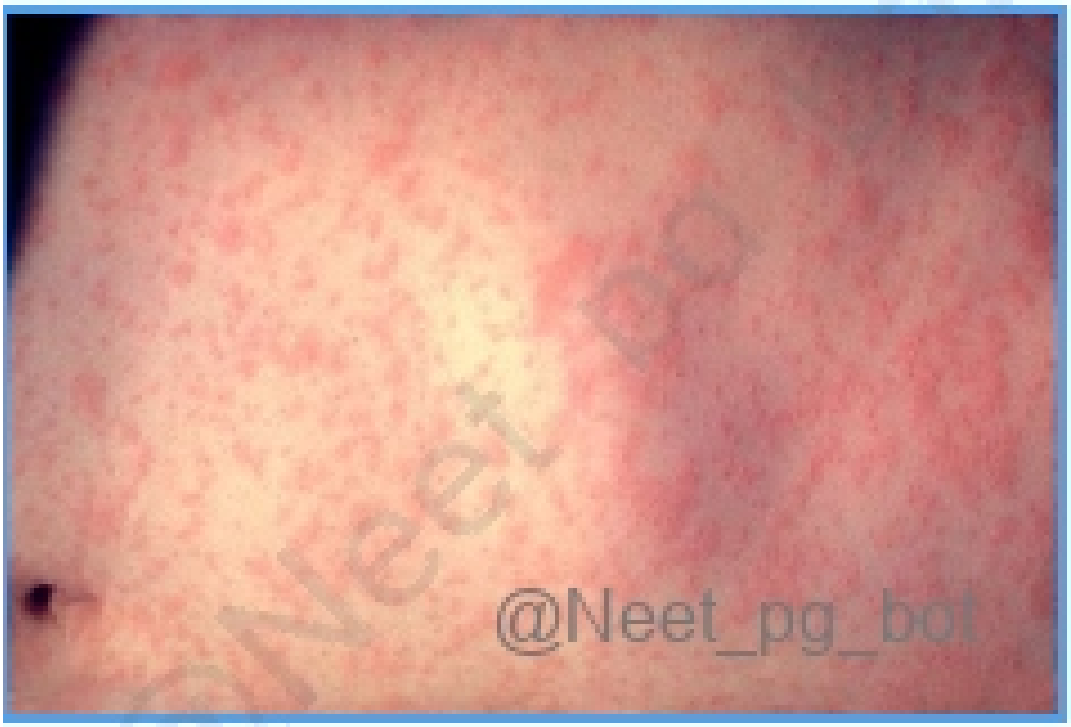
@Neet_pg_bot

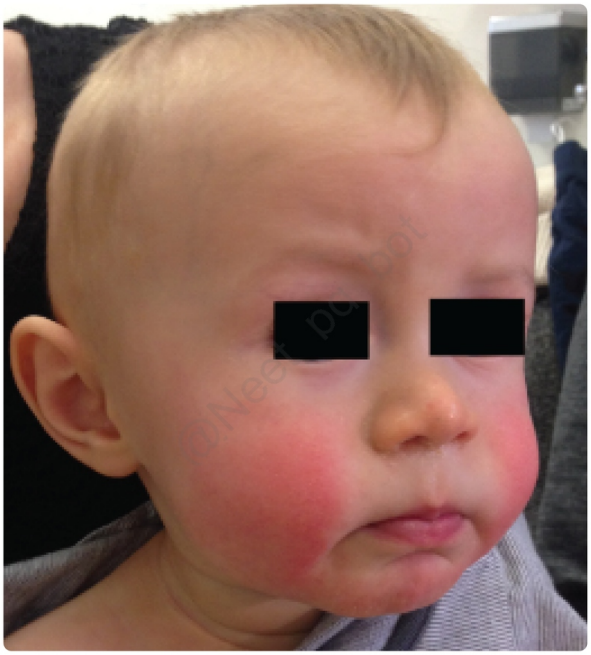

@Neet_pg_bot

References:

Rook's Textbook of Dermatology, 9th Edition, Page 25.34-25.35

Bolognia Textbook of Dermatology, 4th Edition, Page 1420

↑ *Back to this question in Part A*

@Neet_pg_bot

Q12: An immunocompromised individual presents with a corrugated white lesion on the side of the tongue as shown in the image below, which does not wipe off. The most likely causative agent is? {{caption_text}} (Q842025)

A. Candida

B. Epstein Barr Virus (EBV)

C. Human Herpes Virus (HHV7)

D. Human Herpesvirus 8 (HHV8)



Correct Answer: B. Epstein Barr Virus (EBV)

■ *Listen (English)*

■ *Listen (Hindi)*

Explanation: It is known to cause oral hairy Leukoplakia , an EBV-induced lesion typically occurring in immunocompromised individuals. The lesion appears as a white, corrugated (or hairy) patch that cannot be wiped off, which matches the presentation in the image. Disease associated with EBV Pathognomonic Findings Classic Symptoms Infectious Mononucleosis Atypical lymphocytosis, positive heterophile antibody test, elevated liver enzymes Fever Pharyngitis, Lymphadenopathy (posterior cervical) Splenomegaly Burkitt Lymphoma "Starry sky" appearance on histology Rapidly growing jaw or abdominal mass Nasopharyngeal Carcinoma Undifferentiated carcinoma with EBV DNA in tumor cells Nasal obstruction Epistaxis Hearing loss Cervical lymphadenopathy Hodgkin Lymphoma Reed-Sternberg cells on histology Painless lymphadenopathy B symptoms (fever, night sweats, weight loss), pruritus Oral Hairy Leukoplakia White, hairy patches on lateral tongue, non-scrapable Asymptomatic, common in immunocompromised individuals EBV-associated Hemophagocytic Lymphohistiocytosis (HLH) Hemophagocytosis in bone marrow/tissues Fever Hepatosplenomegaly Cytopenias Hyperferritinemia Hypertriglyceridemia Gastric Carcinoma EBV DNA in gastric carcinoma Weight loss Abdominal pain Nausea and Vomiting Candida (Option A): It typically causes oral thrush, which presents as white plaques that can be wiped off, unlike the corrugated lesion shown in the image. {{caption_text}} Candida lesions that cannot be wiped off: Chronic Hyperplastic Candidiasis Erythematous Candidiasis Human Herpes Virus (HHV6) (Option C): It is not commonly associated with oral lesions in immunocompromised patients. HHV-6 more often reactivates to cause roseola in infants or is asymptomatic in adults. Human Herpesvirus 8 (HHV8) (Option D): It is associated with Kaposi's sarcoma, not corrugated white oral lesions. Kaposi's sarcoma typically presents as red or purple lesions in the oral cavity or on the skin.

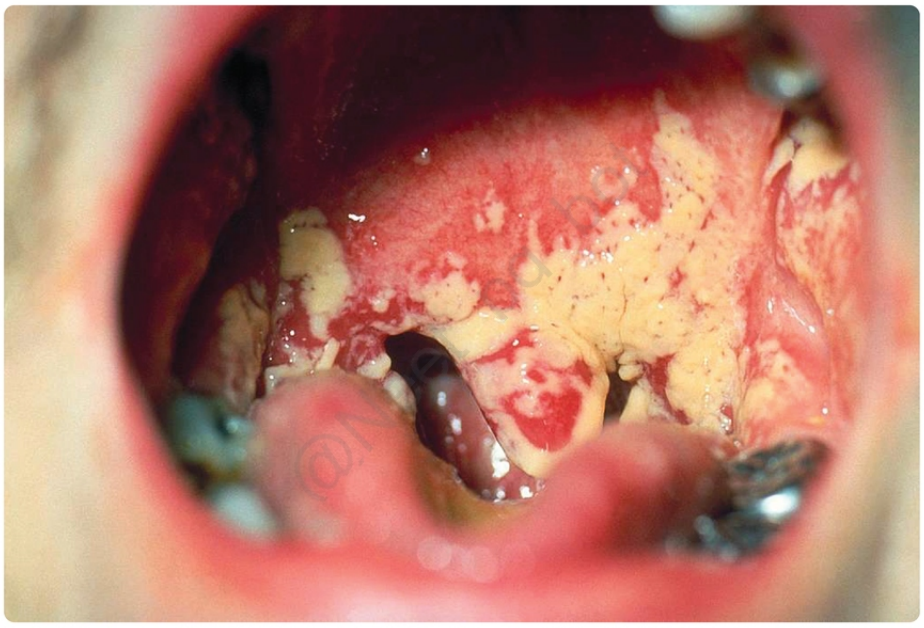



References:

Rook's textbook of Dermatology, 9th Edition, Page 33.31

Bolognia Textbook of Dermatology, 4th Edition, Page 1370

↑ *Back to this question in Part A*

Q13: Identify the incorrect statement regarding Herpes zoster (Shingles). (Q842024)

A. Varicella-zoster virus remains dormant in Dorsal root ganglion

B. A maculopapular rash is seen

C. Thoracic and lumbar dermatomes are most commonly involved

D. Mucous membranes within the affected dermatomes are involved

Correct Answer: B. A maculopapular rash is seen

■ *Listen (English)*

■ *Listen (Hindi)*

Explanation: Herpes zoster : A maculopapular rash is not seen in zoster (shingles). Herpes zoster (shingles) leads to vesicular lesions that are grouped together in a dermatomal / Segmental distribution (shown in the image mentioned below). {{caption_text}} {{caption_text}} Varicella-zoster virus (VZV) Is a human herpesvirus that causes varicella (chickenpox) as a primary infection, Infectious period: 2 days before the development of rash till all the lesions have crusted. Pleomorphic rash, distributed mainly over the trunk. Vesicles: Dew drops on rose petal appearance. It then remains in a latent form in the dorsal root ganglia (Option A) for variable periods. It can reactivate to cause herpes zoster (shingles), which leads to vesicular lesions grouped together in a dermatomal / Segmental distribution. The mucous membranes within the affected dermatomes are involved (Option D) Symptoms: The first symptom of zoster is usually pain, 1-3 days after which the lesions appear. The dermatomes of T3 to L3 spinal segments are most affected in all ages (Thoracic and lumbar dermatomes). The posterior nerve roots and ganglia show inflammatory changes. The patients are infectious, both from the virus in the lesions and nasopharynx. Treatment: Zoster is painful and carries a risk of secondary infection and post-herpetic neuralgia. All cases of herpes zoster should be treated with Acyclovir, administered at a dosage of 800 mg five times a day . It is most effective when the treatment is initiated within 72 hours of the onset of infection.

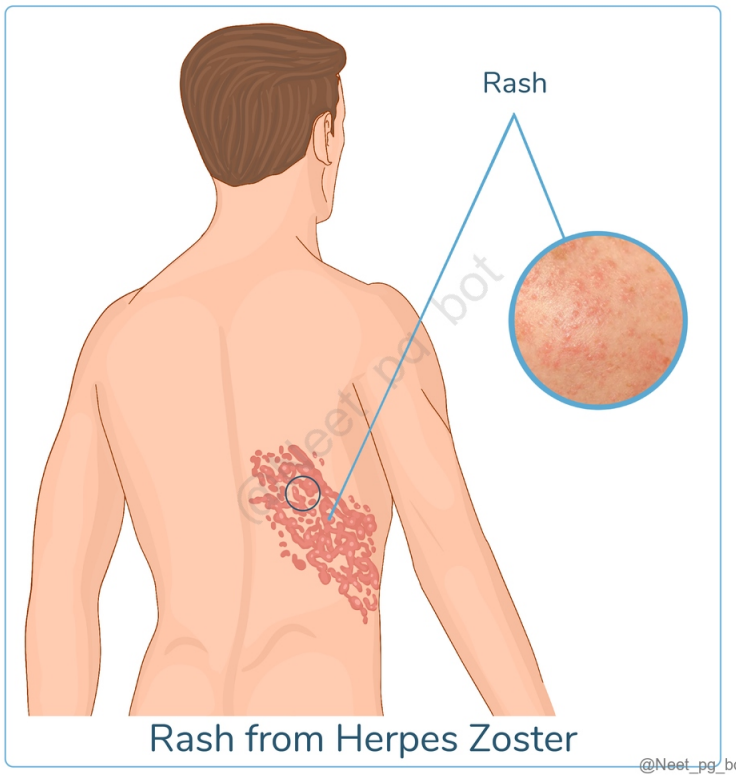



References:

Rook's Textbook of Dermatology, 9th Edition, Page 4.13, 25.27-25.28

Harrison's Principles of Internal Medicine, 21st Edition, Page 106

Bolognia Textbook of Dermatology, 4th Edition, Page 1412

↑ *Back to this question in Part A*

@Neet_pg_bot

Q14: A 4-year-old child presents with sores in the mouth and a rash on the hands and feet, as shown in the image below. What is the causative organism for this? {{caption_text}} {{caption_text}} (Q842022)

A. Coxsackievirus A16

B. Pox virus

C. Herpes virus

D. Human papillomavirus



@Neet_pg_bot



@Neet_pg_bot

Correct Answer: A. Coxsackievirus A16

- *Listen (English)*
- *Listen (Hindi)*

Explanation: The image shows vesicles on palms, soles, and oral mucosa suggestive of hand-foot-and-mouth disease. Hand-foot-mouth disease: Exanthematous fever, which mainly affects young children, is characterized by clusters of papulovesicular lesions on the skin and oral mucosa. {{caption_text}} {{caption_text}} Etiology : Coxsackievirus A16 (M/C cause) Coxsackievirus A6 (causes more severe disease) Coxsackievirus B 1-3 Enterovirus 71 Transmission: Droplets or fecal transmission. Features: Oral and pharyngeal ulcerations and a vesicular rash on palms and soles may spread to the arms, legs, oral cavity, and buttocks. Vesicles heal without crusting , which clinically differentiates them from vesicles of herpes and pox viruses. Usually a benign illness, resolving in 1-2 weeks. Complications: Aseptic meningitis Encephalitis Flaccid paralysis Pulmonary haemorrhage Pox virus (Option B) causes diseases such as smallpox (a deep-seated rash with slow evolution and centrifugal distribution) and molluscum contagiosum (which spares palms and soles). Herpes virus (Option C): While certain herpes viruses can cause oral lesions (like HSV-1) and others can cause systemic symptoms (like varicella-zoster virus), they do not typically cause the hand-foot-mouth disease pattern. Human papillomavirus (Option D) causes warts and is not typically associated with the systemic presentation of hand, foot, and mouth disease with oral sores.



@Neet_pg_bot



@Neet_pg_bot

References:

1. Rook's Textbook of Dermatology, 9th Edition, Page 117.6 2. Bolognia Textbook of Dermatology, 4th Edition, Page 1426 3. Essentials of Medical Microbiology, Apurba Sastry, 3rd Edition, Page 564 4. Ananthanarayan and Paniker’s Microbiology, 10th Edition, Page 497

↑ *Back to this question in Part A*

@Neet_pg_bot

Q15: A 10-year-old child develops round, firm, and painless bumps over the face. All of the following statements about this disease are true except? {{caption_text}} (Q842020)

A. Spread direct skin-to-skin contact with an infected person

B. RNA virus is the causative agent

C. Auto inoculation can be seen

D. Lesions are not seen in palms & Soles generally



Correct Answer: B. RNA virus is the causative agent

■ *Listen (English)*

■ *Listen (Hindi)*

Explanation: The above image shows shiny, pearly white, umbilicated papules with central umbilication which are suggestive of Molluscum contagiosum, caused by a double stranded DNA virus Virus: Molluscum contagiosum, Virus (MCV). Types of MCV: MCV-1 Children Face (Not seen over palms & soles) (Option D ruled out) MCV-2 Adults-it produces lesions over the genital area. Transmission: Spread direct skin-to-skin contact with an infected person. (Option A ruled out) Pseudo-Koebner phenomenon: New lesions develop along the line of trauma due to Autoinoculation. (Option C ruled out) Sexually transmitted molluscum contagiosum may be present over the genital area (in adults) Microscopic examination of the lesions shows eosinophilic inclusions called Henderson-Patterson bodies. (See image below) Giant (>1cm) or widespread Molluscum contagiosum are seen in immunocompromised individuals. {{caption_text}} Treatment: Usually, it is self-limiting and usually clears on its own within 6–12 months. Thus, there is no need for treatment. Destruction with cantharidin, trichloroacetic acid, diluted liquefied phenol, or surgical removal are a few options considered for severe cases. Physical Destruction (In-Office): Cryotherapy: Freezing the lesion with liquid nitrogen. Effective but can be painful. Curettage: Physically scraping the core of the lesion out with a small metal tool. Cantharidin ("Beetle Juice"): A blistering agent applied by a doctor. It’s painless during application (great for kids), but a blister forms later to "push" the virus out. Topical Medications (At-Home): Podophyllotoxin: A cream that stops cell division. Salicylic Acid or Tretinoin: Used to irritate the skin and trigger an immune response. Imiquimod: An immune-response modifier (though evidence for MC is mixed compared to its use for warts). For Immunocompromised Patients: The most effective "treatment" for MC in patients with HIV is Antiretroviral Therapy (ART) . As the CD4 count rises and the immune system recovers, the lesions typically resolve on their own.



References:

Rook's Textbook of Dermatology, 9th Edition, Page 25.12

Bolognia Textbook of Dermatology, 4th Edition, Page 1440

↑ *Back to this question in Part A*

@Neet_pg_bot

Q16: A primigravida at 38 weeks gestation presents to the emergency department in labor with symptoms of fever, headache, and genital itching. Upon examination, the cervix is found to be dilated at 7 cm, and small painful blisters with ulceration are observed around the vulva, along with inguinal lymphadenopathy. Select the incorrect statement regarding this presentation. (Q842013)

A. Cesarean section may reduce the risk of infection in the baby

B. In the case of neonatal transmission, mortality rates are typically low

C. This condition is commonly caused by HSV-2

D. Prophylactic acyclovir should be considered for her neonate.

Correct Answer: B. In the case of neonatal transmission, mortality rates are typically low

■ *Listen (English)*

■ *Listen (Hindi)*

Explanation: The above scenario is suggestive of active primary genital herpes in the mother most commonly caused by HSV 2. Neonatal herpes is transmitted from mother to newborn during childbirth or within 28 days of it Neonatal herpes has a high mortality of >60%. Features of Neonatal Herpes Localized Disease: Symptoms localized to the skin, eyes, or mouth. Infants may present with vesicular lesions, ulcerations, or erythema in these areas. Disseminated Disease: Includes hepatomegaly, splenomegaly, jaundice, respiratory distress, and coagulopathy. Disseminated disease can rapidly progress to multiorgan failure. Associated with high mortality in neonates ~85% Herpes Simplex Encephalitis: Infants may present with nonspecific symptoms such as fever, irritability, lethargy, and poor feeding, which can rapidly progress to seizures, altered consciousness, focal neurologic deficits, and coma. Most common part involved here is temporal lobe Neonatal herpes is treated with high-dose intravenous acyclovir followed by oral acyclovir for 6 months. Treatment of Herpes during pregnancy: Current Active Lesion Acyclovir 5 x 200mg for 10 days History of Active lesions in pregnancy Acyclovir from 36 weeks gestational age till delivery If active lesions present during labor LSCS Cesarean section may reduce the risk of infection in the baby (Option A): C-section is recommended to prevent neonatal herpes transmission in mothers with active genital lesions during labor. This condition is commonly caused by HSV-2 (Option C): Genital herpes is most often caused by HSV-2, though HSV-1 can also be responsible in some cases. Prophylactic acyclovir should be considered for her neonate (Option D): Neonates exposed to HSV should receive IV acyclovir promptly to reduce the risk of severe complications.

References:

Rook's textbook of dermatology, 9th Edition, Page 25.22-25.23

↑ *Back to this question in Part A*

@Neet_pg_bot

Q17: A 30-year-old male visited the outpatient department with persistent vesicular eruptions on his lips as shown in the image. Despite multiple previous treatments with oral antiviral medication, the lesions have not shown signs of improvement. Considering acyclovir-resistant recurrent herpes labialis, which of the following alternative drugs could be considered for treatment? {{caption_text}} (Q842010)

A. Lamivudine

B. Foscarnet

C. Valacyclovir

D. Ganciclovir



@Neet_pg_bot

Correct Answer: B. Foscarnet

■ *Listen (English)*

■ *Listen (Hindi)*

Explanation: Acyclovir is the cornerstone therapy for herpes infections because it is a competitive inhibitor of viral DNA polymerase. It requires phosphorylation, to be converted to its active form. Resistance occurs primarily due to Mutations in the viral thymidine kinase (TK) gene Alterations in viral DNA polymerase that diminish the ability of acyclovir to be phosphorylated into its active form Clinically, acyclovir-resistant herpes infections may manifest as persistent or recurrent lesions that do not respond to standard acyclovir therapy Alternative antiviral agents such as foscarnet, cidofovir, or brivudine may be considered for treatment. Lamivudine (Option A): Not effective against herpes viruses; primarily used for hepatitis B and HIV as a reverse transcriptase inhibitor. Valacyclovir (Option C): A prodrug of acyclovir, requiring thymidine kinase activation, and thus ineffective in acyclovir-resistant herpes. Ganciclovir (Option D): Primarily used for cytomegalovirus (CMV) infections; requires phosphorylation for activation, making it less effective against acyclovir-resistant herpes.

References:

Rooks textbook of dermatology, 9th Edition, Page 25.20

↑ *Back to this question in Part A*

@Neet_pg_bot

• [16_Viral Infections] 032 Previous Year Questions

« Back to Folder Directory

[16_Viral Infections] 032 Previous Year Questions — Quick Jump

Q1 (p. 1346) *Q2 (p. 1349)* *Q3 (p. 1351)* *Q4 (p. 1354)* *Q5 (p. 1354)* *Q6 (p. 1355)*
Q7 (p. 1358) *Q8 (p. 1359)*

Q1: A female presents with multiple small, pink, umbilicated papules on the face. What is the most likely diagnosis? (Q866857)

A. Molluscum contagiosum

B. Herpes simplex

C. HPV

D. Acne vulgaris

Correct Answer: A. Molluscum contagiosum

Explanation: The description of the skin lesions—multiple small, pink, umbilicated papules—is the classic clinical presentation of Molluscum contagiosum. Etiology: This is a common, self-limiting viral skin infection caused by a poxvirus . Lesion Characteristics: The lesions are typically flesh-colored or pink, dome-shaped papules with a characteristic central umbilication (a small indentation or dimple in the center). Affected Population: It is most common in children, particularly on the face, trunk, and extremities, but can also be seen in sexually active adults in the genital area. Herpes simplex (Option B) presents as grouped vesicles (small blisters) on an erythematous base, not umbilicated papules. Human papillomavirus (HPV) (Option C) causes warts, which are typically warty, hyperkeratotic papules and nodules, and they do not have the central umbilication seen in molluscum. Hyperkeratotic Growth Acne vulgaris (Option D) is characterized by comedones (blackheads and whiteheads), papules, pustules, and cysts. The lesions are not typically umbilicated.


@Neet_pg_bot


@Neet_pg_bot





References:

.

↑ *Back to this question in Part A*

@Neet_pg_bot

Q2: Which of the following best describes the characteristic lesion of Kaposi sarcoma? (Q866859)

A. A yellow lesion containing pus

B. A white, striated lesion that cannot be scraped off

C. A raised, purple-red lesion

D. Small, red erosions

Correct Answer: C. A raised, purple-red lesion

Explanation: The characteristic lesion of Kaposi sarcoma (KS) is a raised, purple-red lesion. Etiology: Kaposi sarcoma is a type of cancer caused by the Human Herpesvirus 8 (HHV-8) . Lesion Morphology: The lesions typically begin as flat, reddish-purple macules and progress into raised, palpable plaques and nodules . The color is a result of extravasated red blood cells and hemosiderin deposition. The violaceous (purple-red) appearance is a hallmark of this condition. Affected Population: It is most commonly seen in patients with compromised immune systems, particularly those with HIV/AIDS . Incorrect Options: A yellow lesion containing pus (Option A) would suggest a bacterial infection, like a carbuncle or abscess. A white, striated lesion that cannot be scraped off (Option B) is a classic description of oral hairy leukoplakia or lichen planus, not Kaposi sarcoma. Small, red erosions (Option D) are a non-specific finding that can be seen in many different skin conditions, such as dermatitis or candidiasis, and do not specifically describe Kaposi sarcoma.



@Neet_pg_bot



@Neet_pg_bot



References:

.

↑ *Back to this question in Part A*

@Neet_pg_bot

Q3: A child was brought with c/o multiple lesions. O/E multiple vesicular lesions are seen on the palms, soles, and oral mucosa. Which of the following is the most likely etiological agent causing the disease? (Q866863)

A. Varicella-zoster virus

B. Human-herpesvirus 6

C. Enterovirus

D. Coxsackie virus



Correct Answer: D. Coxsackie virus

Explanation: The most likely etiological agent causing multiple vesicular lesions on the palms, soles, and oral mucosa in a child is Coxsackie virus. The classic presentation described—vesicular lesions on the hands, feet, and oral mucosa—is characteristic of Hand, Foot, and Mouth Disease (HFMD). HFMD is most commonly caused by Coxsackievirus A16 and occasionally other coxsackievirus strains (like A6, A10) and Enterovirus 71. However, Coxsackievirus remains the prototypical agent linked to these clinical findings in children. Incorrect Options: Varicella-zoster virus (Option A) Causes chickenpox, which presents with a generalized vesicular rash, mostly on the trunk and face. Human herpesvirus 6 (Option B) Most known for roseola, characterized by a sudden fever followed by a maculopapular rash, not vesicular and not localized to palms/soles/oral mucosa. Enterovirus (Option C) While technically correct as a viral genus that includes both Coxsackievirus and Enterovirus 71, the most specific and most commonly implicated answer is "Coxsackie virus."







References:

.

↑ *Back to this question in Part A*

@Neet_pg_bot

Q4: A patient presents with loss of sensation on the posterior surface of the ear along with a lesion. Which structure is most likely involved? (Q852739)

A. Greater Auricular Nerve

B. Internal Jugular Vein

C. External Jugular Vein

D. External Carotid Artery

Correct Answer: A. Greater Auricular Nerve

Explanation: The Greater Auricular Nerve is a branch of the cervical plexus (C2-C3) and provides sensory innervation to: The posterior surface of the ear . The skin over the angle of the mandible and parotid gland . Part of the posterior auricular region . Lesions affecting this nerve can lead to loss of sensation in these areas. Other options: Internal Jugular Vein (Option B) : A major venous structure that drains blood from the head and neck but does not contribute to sensory innervation . External Jugular Vein (Option C) : Also a venous structure , responsible for draining superficial areas of the head, but not involved in sensation. External Carotid Artery (Option D) : A major arterial supply to the face and scalp, but it does not play a role in sensory innervation .

References:

Neena Khanna, Textbook of Dermatology, 7th Edition, Page no: 780

↑ *Back to this question in Part A*

@Neet_pg_bot

Q5: A female patient presents to the OPD with complaints of recurrent lesions on lips as shown below, which is associated with fever. Which of the following is the characteristic feature seen in Tzanck smear? (Q860094)

A. Handerson patterson bodies

B. Multinucleated giant cells

C. Owl eye appearance

D. Acantholytic cells



Correct Answer: B. Multinucleated giant cells

Explanation: The image given in the question is of Herpes labialis which is caused by Herpes simplex virus. Fever is one of the predisposing factor of Herpes labialis It is also called cold sore. It is usually present on the vermillion border of the lips. Smear is taken from the base of the vesicle Multinucleated giant cells and Acantholytic cells are present on Tzanck smear Herpes labialis/cold sore: Reactivation of latent infection in trigeminal ganglion, causing asymptomatic shedding or clinically evident recurrent disease. Causative organism: HSV-1 > HSV-2 . Features: Painful and pruritic lesions. Fever is often present, which subsides in 3-5 days. The initial vesicular lesions become pustular and then crusted before healing in 7-10 days without scarring . Can be associated with itching or burning before the development of lesions. Recurrent herpetic lesions are vesicular and ulcerative and tend to occur in the same region. Treatment : First line Acyclovir (topical/oral) Hydrocolloid dressing Topical penciclovir Second line Long-term prophylactic acyclovir Third line IV acyclovir Penciclovir Foscarnet IV cidofovir Topical imiquimod Handerson patterson bodies (Option A): Handerson patterson bodies is a histologic finding seen in Molluscum contagiosum. Owl eye appearance (Option C): refers to basophilic intranuclear inclusions surrounded by a clear halo, characteristic of Cytomegalovirus (CMV) infection. Acanthosis (Option D): Acanthosis is a histopathological finding seen in Chronic eczema.

References:

Rooks textbook of dermatology 9th ed, page no. 25.17-25.19

↑ *Back to this question in Part A*

@Neet_pg_bot

Q6: A man presents with a rash on his flank, with Itching for the past 2 weeks. The patient has tried several over-the-counter medications without any improvement. In physical examination, the rash is seen on his palms and the sole of one foot, but no oral

lesions are found. What is the Iikely diagnosis? (Q857387)

A. Urticaria

B. Viral exanthema

C. Erythema multiforme

D. Tinea manuum



Correct Answer: C. Erythema multiforme

Explanation: Erythema multiforme is usually seen as a reaction to drugs or HSV. It presents as target lesions on the palms, soles, or trunk. It shows a dusky, central area or blister, a dark red inflammatory zone surrounded by a pale ring of edema, and an erythematous halo on the extreme periphery of the lesion. Urticaria (Option A): It usually presents as wheals (erythematous, edematous, itchy, and evanescent lesions). They are small and multiple as shown below: {{caption_text}} Viral exanthem (Option B): Exanthems usually start in the trunk and spread to other parts Tinea manuum (Option D): Skin lesions caused by dermatophytes in the palms. It is a circular ring-shaped scaly lesion. {{caption_text}}


@Neet_pg_bot


@Neet_pg_bot



References:

https://www.ncbi.nlm.nih.gov/books/NBK470259/

↑ *Back to this question in Part A*

@Neet_pg_bot

Q7: A 3-year-old child is brought to the clinic with a generalized vesicular rash covering the entire body. The child's parents report that the rash started as red spots and quickly developed into fluid-filled blisters. The child also has a mild fever and is feeling irritable. What is the most likely diagnosis for this child's condition? (Q820220)

A. Varicella

B. Shingles

C. Smallpox

D. Dermatomyocytis



Correct Answer: A. Varicella

Explanation: Correct Option A – Varicella This is the most likely diagnosis based on the symptoms described. Varicella is a viral infection caused by the varicella-zoster virus (VZV). It typically presents with a generalized vesicular rash that starts as red spots and quickly develops into fluid-filled blisters. The child may also have a mild fever and feel irritable. Chickenpox is common in children and is highly contagious. The vesicles eventually crust over and heal. It's important to note that a vaccine is available for varicella, which has greatly reduced the incidence of the disease. Incorrect Options: Option B - Shingles (Herpes Zoster): Shingles is also caused by the varicella-zoster virus. However, it typically occurs in adults who had chickenpox earlier in life. Shingles presents as a painful, localized vesicular rash along a specific dermatome (nerve pathway). It is less likely in a 3-year-old child and would present differently than the generalized rash described in the scenario. Option C - Smallpox: Smallpox is a highly contagious viral infection caused by the variola virus. However, smallpox has been eradicated from the general population due to successful vaccination efforts, and it hasn't been reported since the late 1970s. The symptoms and presentation of smallpox are different from the scenario described. Option D - Dermatomyositis: Dermatomyositis is a rare inflammatory disease that affects the muscles and skin. It typically presents with muscle weakness and a characteristic skin rash, but the rash pattern and symptoms are distinct from the generalized vesicular rash described in the scenario.

References:

.

↑ *Back to this question in Part A*

@Neet_pg_bot

Q8: Which of the following does not exhibit the Koebner's phenomenon? (Q793414)

A. Vitiligo

B. Psoriasis

C. Lichen planus

D. Herpes

Correct Answer: D. Herpes

Explanation: The development of skin lesions in areas of trauma or injury is referred to as Koebner's phenomenon, also known as the isomorphic response. It is a typical finding in a few skin conditions, including psoriasis, lichen planus, vitiligo, and morphea. Koebner's peculiarity isn't found in all skin conditions, nonetheless, and one condition in which it is commonly not noticed is rosacea. Incorrect choices: Option a. Vitiligo: Vitiligo is an immune system sickness. When the immune system attacks melanocyte-containing cells in the body it results in vitiligo. These are pigment-making cells. Option b. Psoriasis: Psoriasis is a skin condition that typically manifests as a rash with itchy, scaly patches on the scalp, trunk, knees, and elbows. Psoriasis is a prevalent, chronic, and long-term condition that has no cure. Option c. Lichen planus: Lichen planus is a condition of the skin, hair, nails, mouth, and genitals. On the skin, lichen planus often appears as purple, itchy, flat bumps that develop over several weeks.

↑ *Back to this question in Part A*

@Neet_pg_bot

• [17_Fungal Infections] 033 Fungal Infections - I

« Back to Folder Directory

[17_Fungal Infections] 033 Fungal Infections - I — Quick Jump

Q1 (p. 1361) *Q2 (p. 1363)* *Q3 (p. 1366)* *Q4 (p. 1370)* *Q5 (p. 1374)* *Q6 (p. 1377)*
Q7 (p. 1381) *Q8 (p. 1384)* *Q9 (p. 1386)* *Q10 (p. 1389)* *Q11 (p. 1392)* *Q12 (p. 1396)*
Q13 (p. 1397)

Q1: During your rural service, a patient arrives at the OPD with hypopigmented lesions on his trunk and back. A Wood's lamp examination of the lesions shows yellow fluorescence, and scales become prominent when the lesion is scratched with nails. Which of the following organisms causes this infection? (Q841821)

A. Malassezia furfur

B. Microsporum audouinii

C. Trichophyton rubrum

D. Epidermophyton floccosum

Correct Answer: A. Malassezia furfur

■ *Listen (English)*

■ *Listen (Hindi)*

Explanation: The condition described is Pityriasis Versicolor, also known as Tinea Versicolor. The term "tinea" is a misnomer, as this infection is caused by the Malassezia species (including M. globosa, M. sympodialis, and M. furfur), not by dermatophytes like Microsporum or Trichophyton. Signs and Symptoms: Hypopigmented or hyperpigmented macules: Most commonly hypopigmentation due to the fungus's production of Azelaic Acid or Carboxylic Acid, found in the trunk, back, and chest. Lesions are often covered with fine “branny” scales , which are accentuated upon scraping; this sign is called the Besnier Sign or the Coup De Angle Sign. Examination Findings: Wood's Lamp Examination: It is typically yellow or gold in color , attributed to the presence of porphyrins produced by Malassezia species. {{caption_text}} KOH Preparation: "Spaghetti and meatball" aka “Banana and Grapes” appearance. {{caption_text}} Treatment: Topical Antifungal Agents such as ketoconazole cream or shampoo, selenium sulfide lotion, or ciclopirox olamine solution are used as first-line treatment. Oral Terbinafine and Griseofulvin do not help in the treatment of Tinea. Microsporum audouinii (Option B) Trichophyton rubrum (Option C) Epidermophyton floccosum (Option D) The three fungi mentioned above are dermatophytic fungi that do not cause ptyriasis versicolor; they cause tinea in various body parts.


@Neet_pg_bot

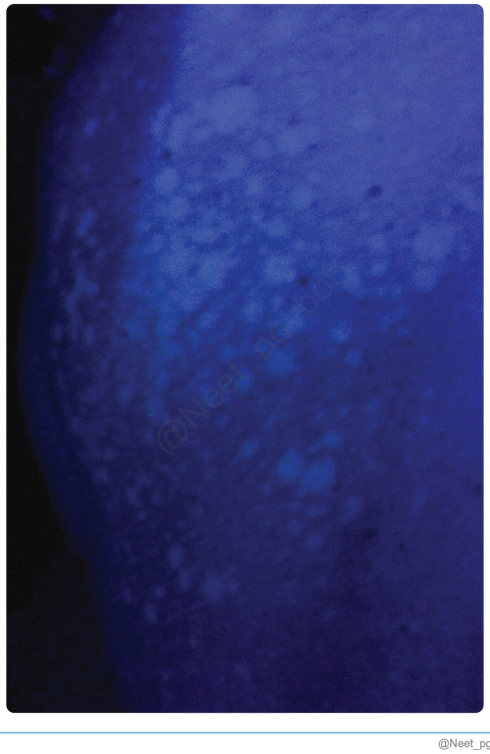
@Neet_pg_bot

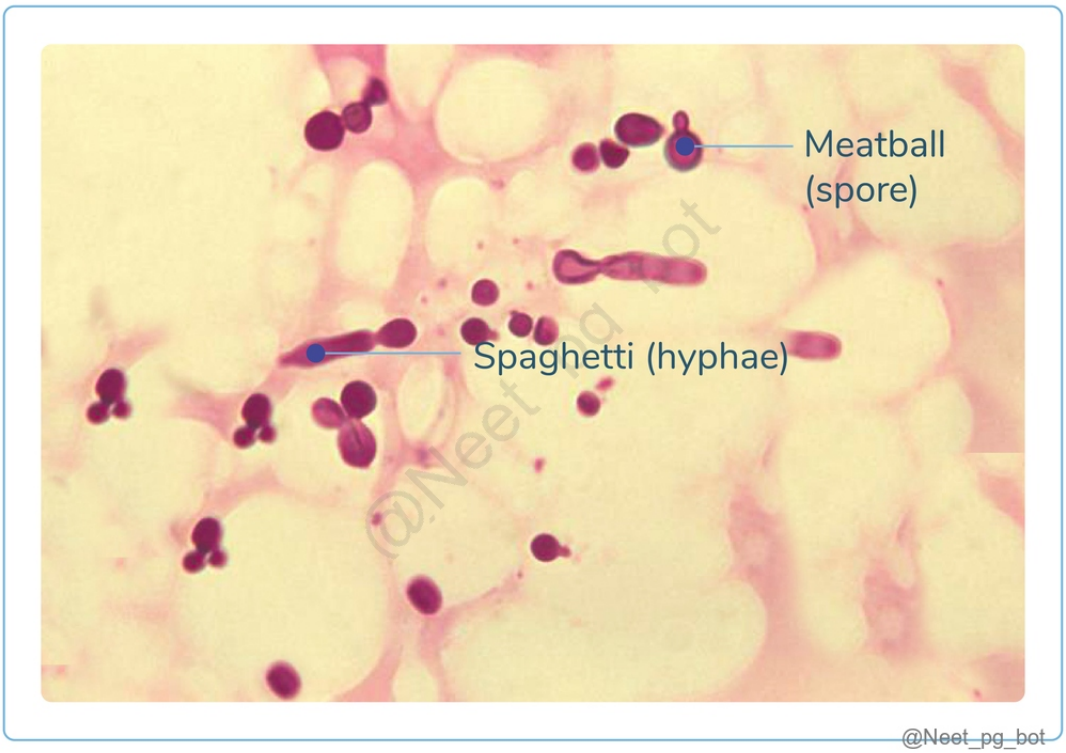

References:

Rook’s Dermatology, 9th Edition, Volume 1, Section 32

↑ *Back to this question in Part A*

@Neet_pg_bot

Q2: What would you expect to see on KOH examination of a scalp fleck from a patient with chronic dandruff? (Q841822)

A. Spaghetti and meatball appearance

B. Pilot wheel appearance

C. Conidia and conidiophores

D. Pseudohyphae

Correct Answer: A. Spaghetti and meatball appearance

Explanation: Dandruff, also known as seborrheic dermatitis of the scalp, is commonly caused by Malassezia furfur . KOH mount shows the characteristic "spaghetti and meatball" appearance, which refers to thin, branching hyphae (spaghetti) along with clusters of spores or arthroconidia (meatballs) of Malassezia yeast. The appearance is also

called the banana and grapes appearance. {{caption_text}} Pilot wheel appearance (Option B) is typically observed in paracoccidioidomycosis (thick-walled cysts with multiple, narrow-necked buds attached circumferentially - Mickey mouse appearance). {{caption_text}} Conidia and conidiophores (Option C) are structures commonly seen in cultures of Aspergillus fungi . {{caption_text}} {{caption_text}} Pseudohyphae (Option D) are chains of elongated yeast cells that lack septa , also commonly observed in Candida infections . {{caption_text}}

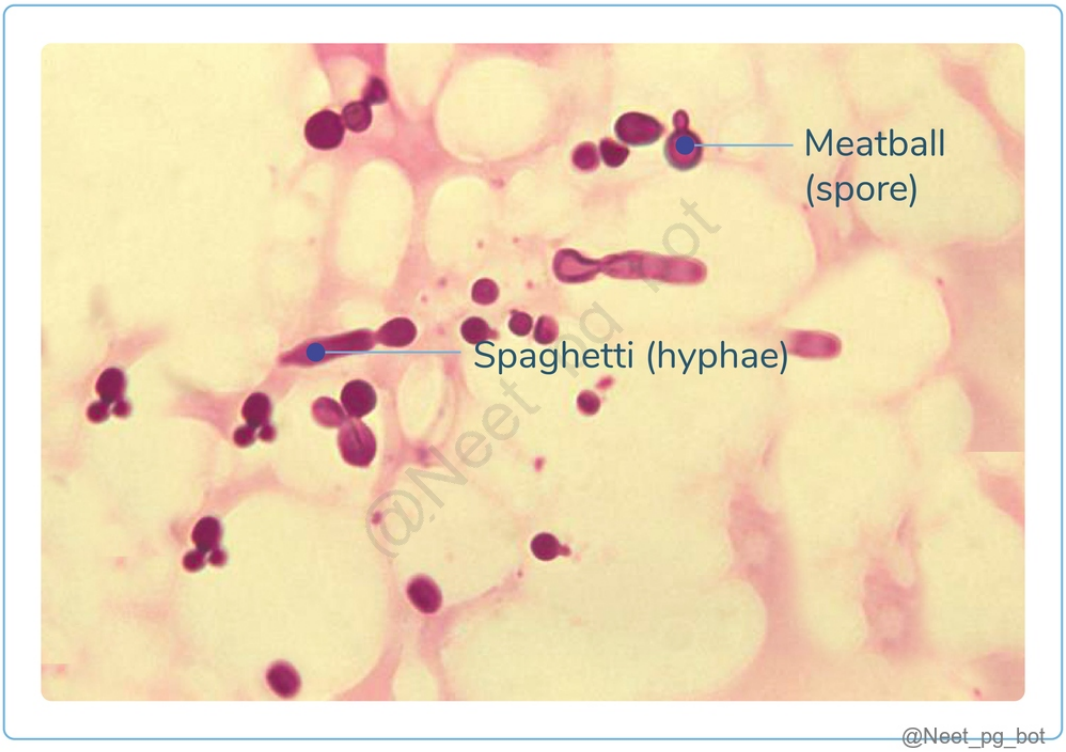



@Neet_pg_bot

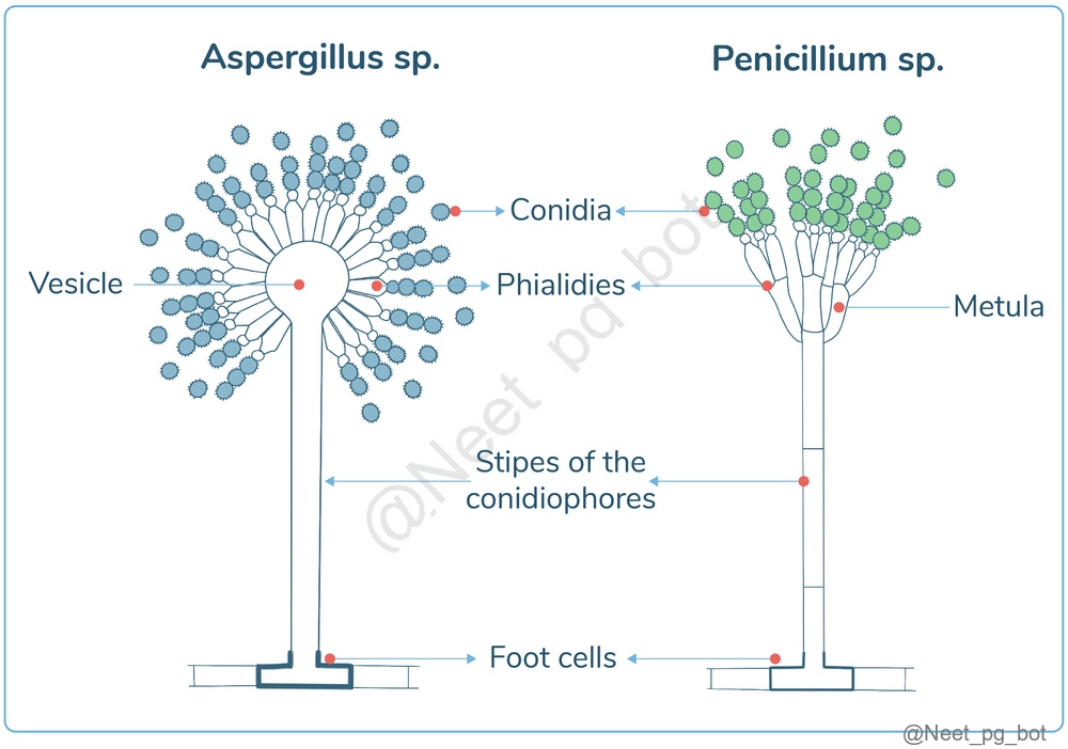

@Neet_pg_bot



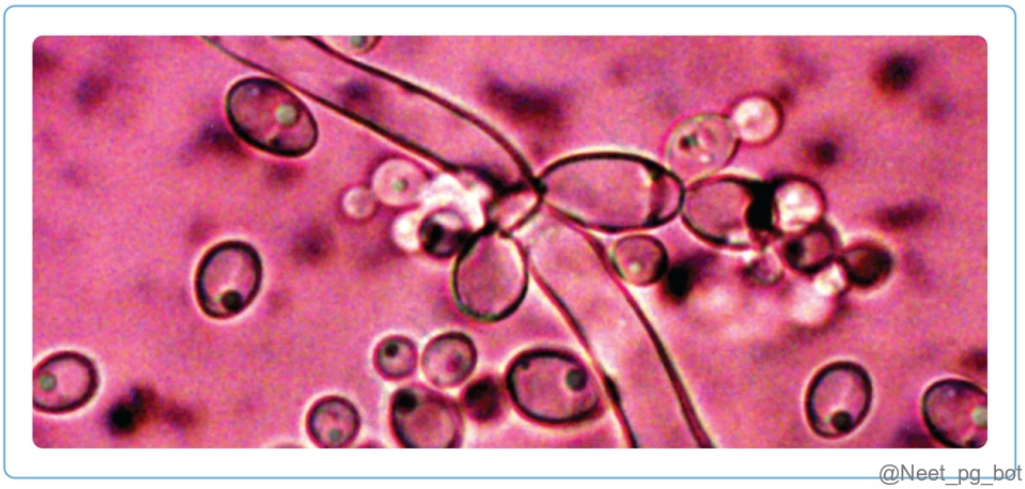

References:

Rook’s Dermatology, 9th Edition, Volume 1, Section 32

↑ *Back to this question in Part A*

@Neet_pg_bot

Q3: A 67-year-old actress, diagnosed with HIV 20 years ago, presents to your OPD with complaints of itching and flaking on her eyelids and scalp. The examination findings are shown in the image below. Which of the following conditions is not caused by the organism responsible for this patient's symptoms? (Q841823)

A. Folliculitis

B. Dandruff

C. Confluent Reticulate Papillomatosis

D. Piedra



@Neet_pg_bot

Correct Answer: D. Piedra

■ *Listen (English)*

■ *Listen (Hindi)*

Explanation: The given clinical scenario describes Seborrheic Dermatitis caused by the Malessezia (globosa [Most common] and furfur species) fungus . It is characterised by erythematous, greasy, and scaly lesions, often accompanied by itching and discomfort, in immunocompromised patients, as described in the image above. Primarily affects areas rich in sebaceous glands, such as the scalp, face, and upper trunk . Seborrheic dermatitis is also associated with other conditions, such as Parkinson's disease and immunosuppression . Treatment involves topical antifungal agents, such as ketoconazole or ciclopirox . Malessezia is known to cause folliculitis, Seborrheic dermatitis, dandruff, and confluent reticulate papillomatosis. On the other hand, piedra is a fungal infection of the hair shaft caused by fungi of the genus Trichosporon (white piedra) and piedra (black piedra). Folliculitis (Option

A): Malassezia can lead to folliculitis, particularly pityrosporum folliculitis . It typically presents with erythematous papules or pustules centred around hair follicles, which may be tender or pruritic. {{caption_text}} Dandruff (Option B) also known as pityriasis capitis or seborrheic dermatitis of the scalp , is commonly associated with Malassezia spp., the same organism implicated in the patient's symptoms. {{caption_text}} Confluent Reticulate Papillomatosis (CRP) (Option C), also known as Gougerot-Carteaud syndrome, is a rare dermatosis characterised by brown, reticulated papules typically affecting the neck and upper trunk. Malassezia spp is known to be the organism implicated in CRP. {{caption_text}}



@Neet_pg_bot





References:

Rook’s Dermatology, 9th Edition, Volume 1, Section 32

↑ *Back to this question in Part A*

@Neet_pg_bot

Q4: On your annual visit to the local orphanage in farmland to celebrate your birthday, you notice a 5-year-old boy crying due to a painful, boggy swelling on his scalp, shown in the image below. Multiple other boys in the orphanage also have areas of patchy, scaly hair loss. Which of the following is the causative organism of this patient's findings? (Q841824)

A. Tinea schoenleinii

B. Trichophyton verrucosum

C. Microsporum canis

D. Trichophyton concentricum

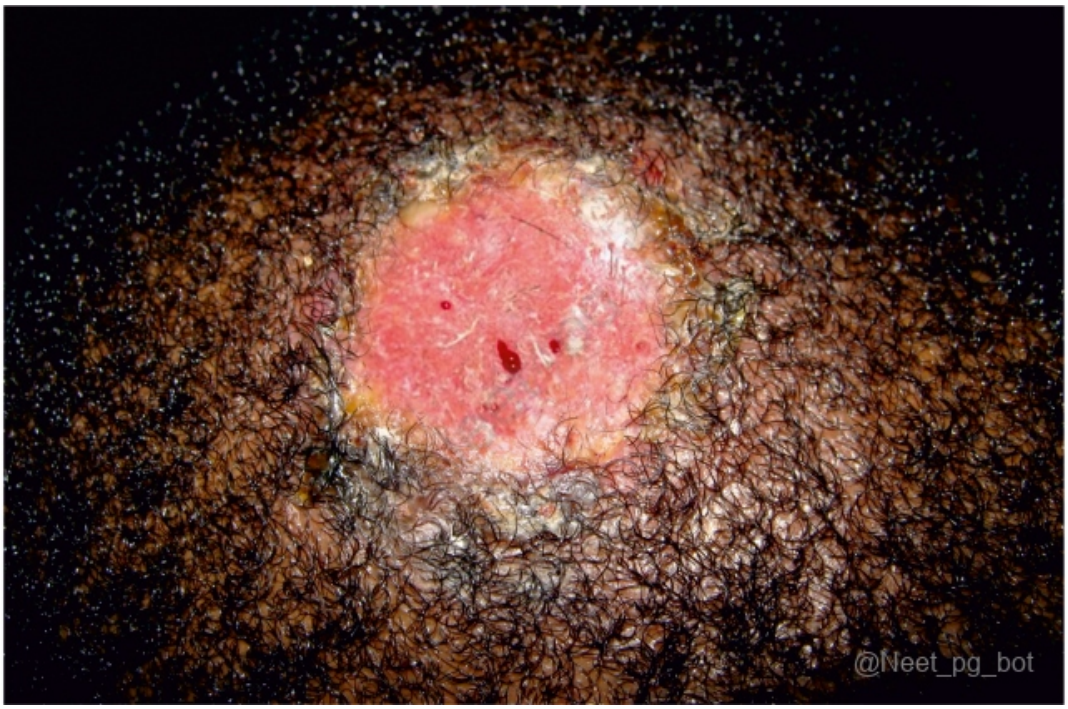

Correct Answer: B. Trichophyton verrucosum

■ *Listen (English)*

■ *Listen (Hindi)*

Explanation: The condition described is most likely a kerion, a type of inflammatory tinea capitis (scalp ringworm) caused by Trichophyton verrucosum. Tinea capitis is a fungal infection of the scalp that predominantly affects

children. Kerion presents with symptoms, including patchy hair loss, scaling, and, in some cases, a painful, boggy swelling. The characteristic feature of kerion is its inflammatory nature , with erythematous, tender nodules commonly oozing pus It is often encountered in agricultural settings where there is exposure to infected animals, particularly cattle. KOH examination: Presence of branching hyphae. {{caption_text}} Wood's lamp examination: No specific findings. The inflammatory nature of kerion distinguishes it from other fungal infections. Tinea schoenleinii (Option A), also known as favus, typically presents with thick, yellow, cup-shaped crusts known as scutula rather than painful, boggy swellings as seen in Kerion. It exhibits green fluorescence on Wood's lamp. Microsporum canis (Option C) often presents as an itchy “grey patch” associated with hair loss . Wood's lamp examination may reveal fluorescent hairs in some cases. Exophytic growth is seen in microsporium. Trichophyton concentricum (Option D) is associated with tinea corporis , a superficial fungal infection of the body. Endophytic growth is seen in trichophyton.

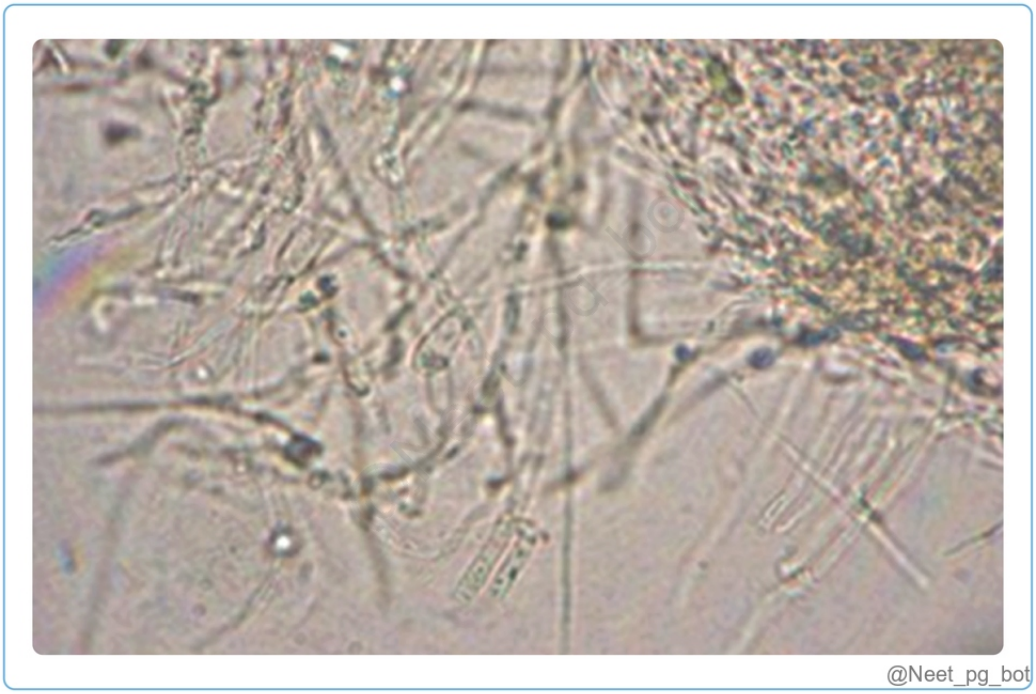

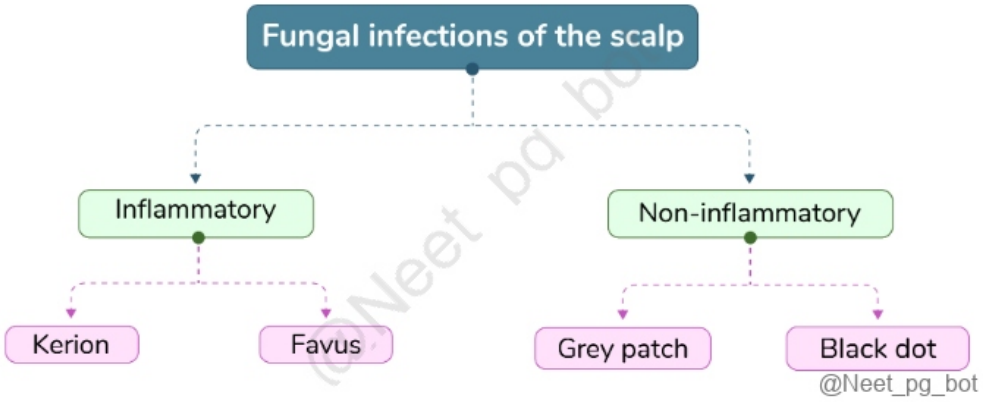

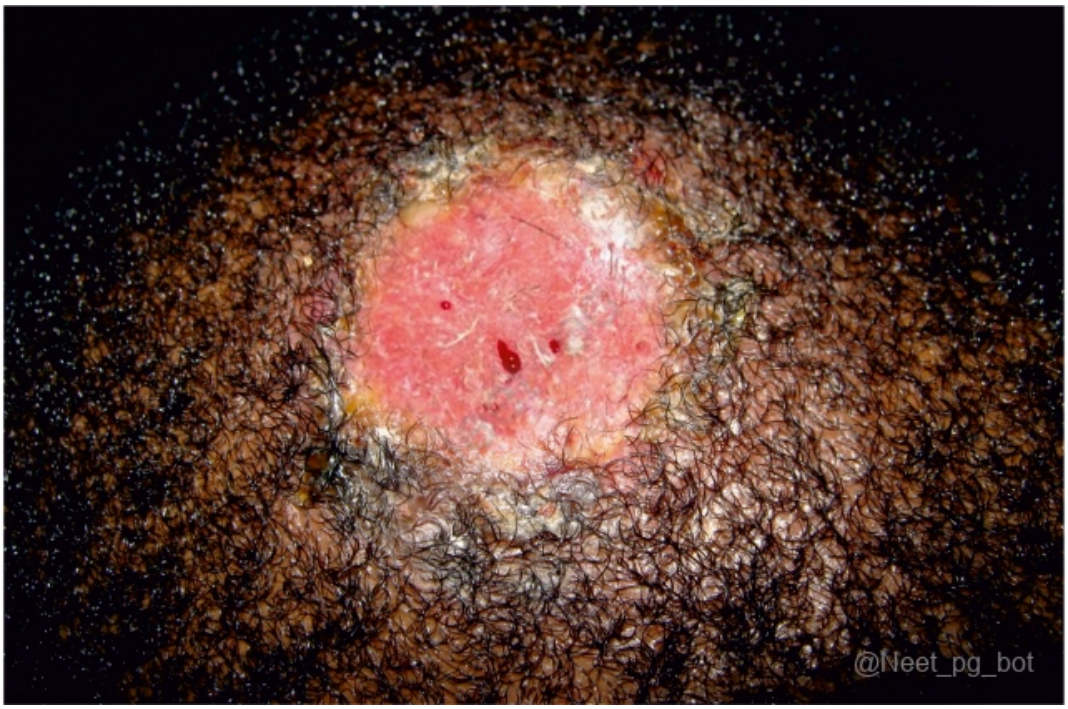
@Neet_pg_bot


@Neet_pg_bot





References:

Rook’s Dermatology, 9th Edition, Volume 1, Section 32

↑ *Back to this question in Part A*

@Neet_pg_bot

Q5: During a health check-up in a tropical coastal region, a 30-year-old patient presents with a well-demarcated, non-pruritic, dark brown macule on their palm. The lesion has gradually increased in size over the past few months. There is no associated pain or scaling. Based on the clinical findings, what is the most likely diagnosis? (Q841825)

A. Melanocytic nevus

B. Dermatofibroma

C. Tinea nigra

D. Lichen planus



Correct Answer: C. Tinea nigra

■ *Listen (English)*

■ *Listen (Hindi)*

Explanation: The given clinical scenario suggests tinea nigra. Tinea nigra is a painless, superficial fungal infection primarily affecting the palms and is characterized by darkly pigmented, flat, non-scaly patches. Tinea nigra: Superficial fungal infection of the skin caused by the fungus Hortaea werneckii (formerly known as Exophiala werneckii). Pathology: Thickening of stratum corneum (in which hyphae are present) and minimal inflammation of the dermis. Features: Asymptomatic, macular, sharply defined and non-scaly lesions. The most distinctive feature is the brown or black, resembling a silver nitrate stain. Areas affected: Palms (M/C), soles, neck, and trunk. Microscopy with a KOH mount shows pigmented filaments with conidia, abundant brown, branched, closely septate hyphae up to 5 µm in diameter, and elongated budding cells. Treatment: It is usually treated with topical antifungal agents. The most commonly used topical agents include azoles (clotrimazole or ketoconazole) or allylamines (terbinafine). Melanocytic nevus (Option A): A melanocytic nevus is a benign growth of melanocytes, typically presenting as a brown or tan mole with well-defined borders, and don’t typically show the gradual increase in size described here without other features like irregular borders or color variation. Dermatofibroma (Option B): Dermatofibromas are usually small, firm, brown or tan nodules, not macules, and they typically occur on the limbs rather than the palms. Lichen planus (Option D): Lichen planus typically presents with purplish, flat-topped papules and often involves the wrists, shins, or mucous membranes.

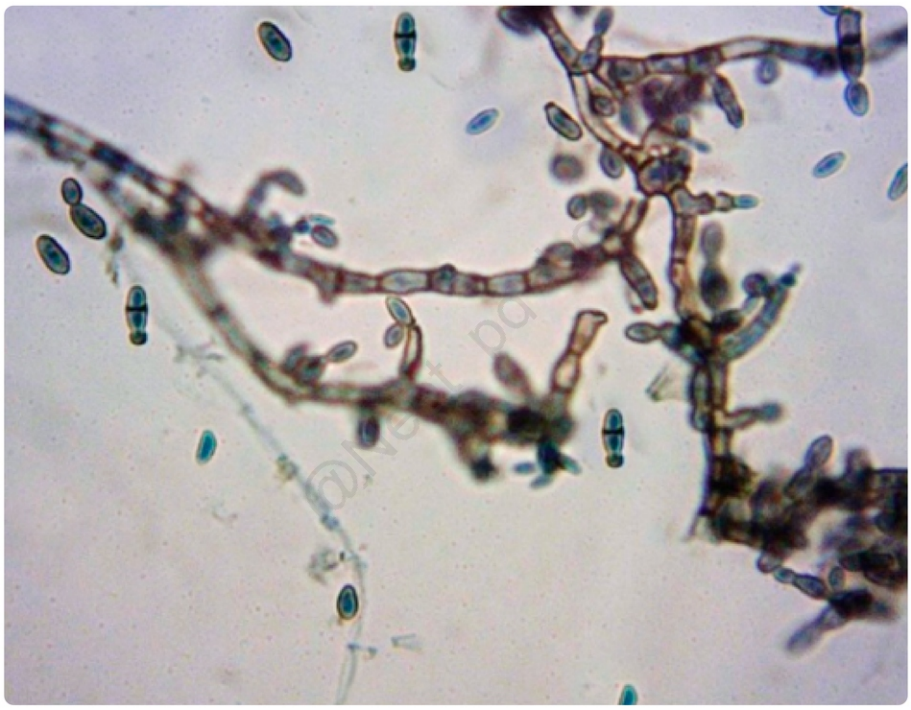


@Neet_pg_bot


@Neet_pg_bot



References:

Rook’s Dermatology, 9th Edition, Volume 1, Pages 32.14, 32.15

↑ *Back to this question in Part A*

@Neet_pg_bot

Q6: A 27-year-old boy comes to your OPD complaining of an itchy rash over his forearm for the past 8 months. He gives history of unsupervised use of over the counter creams ,but it has only gotten worse after short-lived improvements. An image of the lesion is given below. What is the most likely diagnosis ? {{caption_text}} (Q841826)

A. Tinea manuum

B. Tinea incognito

C. Tinea profunda

D. Tinea corporis



Correct Answer: B. Tinea incognito

- *Listen (English)*
- *Listen (Hindi)*

Explanation: The lesion depicted in the image shows an irregular, erythematous, scaly plaque without central clearing , lack of annularity and indistinct border of the lesions which is characteristic of tinea incognito. The prolonged use of topical corticosteroids can mask typical features of tinea, resulting in misdiagnosis and worsening of the condition. In this case, the patient's history of visiting multiple local "healing clinics" that probably used local steroid ointments and the lesion worsening after initial improvement suggest a diagnosis of tinea incognito. {{caption_text}} Causative Organisms: Trichophyton, Microsporum, and Epidermophyton species. Treatment: Stop corticosteroids. Apply topical antifungals (azoles or allylamines). Treat secondary infections if present. Educate on proper steroid use. Tinea manuum (Option A) is a dermatophyte infection of the hands, typically presenting with erythematous, scaly lesions on the palms and interdigital spaces. {{caption_text}} Tinea profunda (Option C) is a rare deep dermatophyte infection that involves invasion of the hair follicles and surrounding dermis , resulting in boggy nodules and abscess formation. {{caption_text}} Tinea corporis (Option D) is a dermatophyte infection affecting the trunk, limbs, or face, characterised by annular, erythematous lesions with central clearing and an active border. {{caption_text}}



@Neet_pg_bot



@Neet_pg_bot





References:

Rook’s Dermatology, 9th Edition, Volume 1, Section 32

↑ *Back to this question in Part A*

@Neet_pg_bot

Q7: A 62-year-old man with a history of diabetes mellitus presents to the dermatology clinic with discoloured nails. The examination findings are shown in the image below. What is the likely diagnosis? (Q841827)

A. Distal Lateral Subungual Onychomycosis

B. Paronychia

C. Nail Psoriasis

D. Onychogryphosis



Correct Answer: A. Distal Lateral Subungual Onychomycosis

■ *Listen (English)*

■ *Listen (Hindi)*

Explanation: Distal Lateral Subungual Onychomycosis is the most common type of fungal infection of the toenail (Onymychosis) or Tinea Unguium . Clinically, onychomycosis presents with nail discoloration, thickening,

subungual keratin buildup, onycholysis, and nail dystrophy. Diagnosis: Typically involves microscopic examination using KOH and fungal culture of nail clippings. Treatment: Oral antifungals such as terbinafine and itraconazole are often preferred. Nail lacquers such as ciclopirox (applied daily), olamine and amirolfine (applied weekly) are also used as topical agents to treat onychomycosis. The table below describes the types of onychomycosis Distal lateral subungual onychomycosis Most common Primarily affecting the distal & lateral portions of the nail. Proximal subungual onychomycosis Seen in individuals with HIV. Affects the proximal portion of the nail plate. Superficial white onychomycosis Characterized by the presence of white, crumbly material on the surface of the nail, which can be easily scrapped off Total dystrophic onychomycosis Characterized by extensive involvement of the nail plate, leading to complete destruction & deformity of the nail {{caption_text}} Paronychia (Option B) refers to an infection of the soft tissues surrounding the nail , often presenting with erythema, swelling, and tenderness of the nail folds. {{caption_text}} Nail Psoriasis (Option C) is a chronic inflammatory condition affecting the nails, characterised by pitting, subungual hyperkeratosis, and oil drop discolouration .Absence of salmon pink sign and skin plaques can be used to differentiate from psoriasis {{caption_text}} Onychogryphosis (Option D), also known as ram's horn nails , is a condition characterised by abnormal thickening and curvature of the nails, typically affecting the toenails, most commonly caused by improper footwear, trauma, ichthyosis, psoriasis and fungal infections {{caption_text}}




@Neet_pg_bot


@Neet_pg_bot



References:

Rook’s Dermatology, 9th Edition, Volume 1, Section 32

↑ *Back to this question in Part A*

@Neet_pg_bot

Q8: A student from a hostel dormitory visits you with complaints of narrow nodules on her hair shafts. On examination, you find that these nodules are loosely attached to the surface of the hair, white in colour and soft in consistency. Which of the following organisms is the most likely cause of this condition? (Q841828)

A. Piedra horteii

B. Trichosporon beigelii

C. Trichosporon cutaneum

D. Trichophyton violaceum

Correct Answer: B. Trichosporon beigelii

■ *Listen (English)*

■ *Listen (Hindi)*

Explanation: The condition described, characterised by narrow, soft, white nodules loosely attached to the hair shafts , is consistent with a diagnosis of White Piedra caused by Trichosporon beigelii. The differences between black and white piedra are given in the table below: White Piedra Black Piedra Etiology Trichosporon beigelii Piedra horteii Consistency Soft Hard, gritty Attachment to the hair shaft Loosely attached Tightly attached Location All hair-bearing areas Over the scalp Images {{caption_text}} {{caption_text}} Piedra horteii (Option A): As described above, Piedraia hortae causes black piedra, characterised by hard, dark nodules on the hair shafts. Trichosporon cutaneum (Option C) : Associated with skin infections and other superficial infections. Trichophyton violaceum (Option D): This dermatophyte fungus causes tinea infections of the skin and nails and may rarely affect the hair shaft.



@Neet_pg_bot

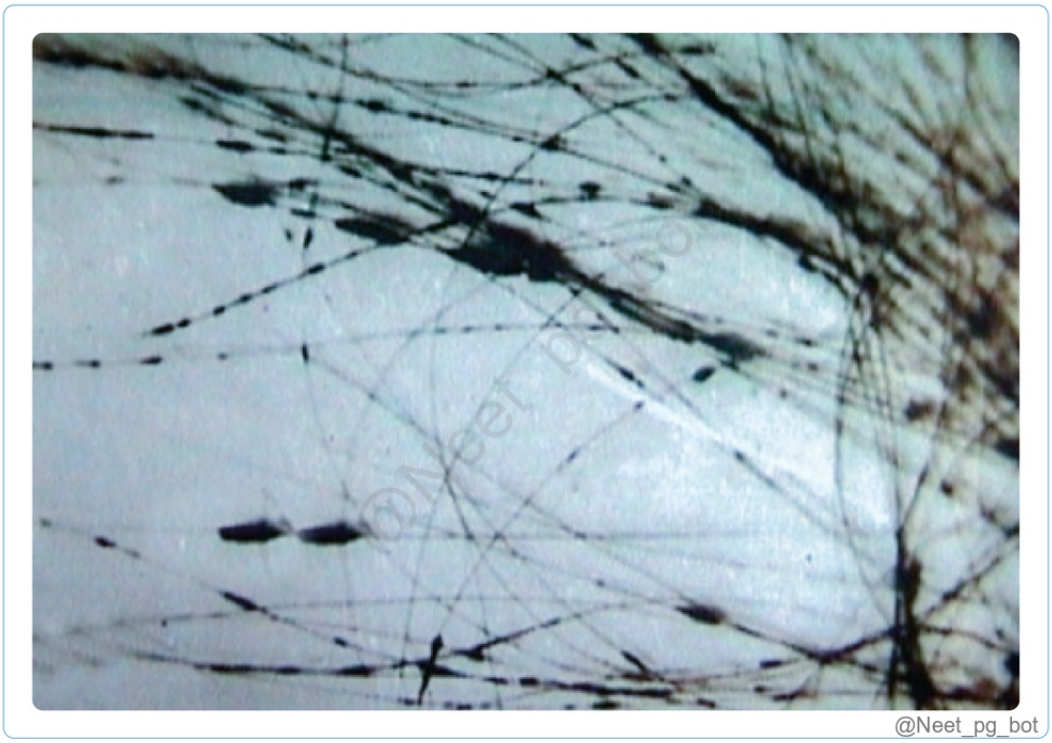

References:

Rook’s Dermatology, 9th Edition, Volume 1, Section 32

↑ *Back to this question in Part A*

@Neet_pg_bot

Q9: A 67-year-old lady with diabetes comes to your OPD complaining of itching under her breasts. On examination, you see multiple erythematous, tender patches on the inferior surface of both breasts with multiple satellite lesions as shown in the image below. What is the causative organism and the diagnosis? {{caption_text}} (Q841829)

A. Candida albicans (Intertrigo)

B. Trichophyton Circinata (Tinea)

C. Streptococcus pyogenes (Erysipelas)

D. Malassezia furfur (Ptyriasis verciolor)



Correct Answer: A. Candida albicans (Intertrigo)

■ *Listen (English)*

■ *Listen (Hindi)*

Explanation: The clinical presentation of multiple erythematous, tender patches on the inferior surface of both breasts with multiple satellite lesions is highly indicative of intertrigo , a type of cutaneous candidiasis . Candida intertrigo (Flexural candidiasis): Candida Intertrigo: Sites: Groin, buttocks, axillae, inframammary folds, umbilicus, toe/finger webs. Features: Red macerated plaques with fringed edges, satellite pustules , itching, soreness. Cause: Candida albicans (thrives in warm, moist areas). Risk factors: Diabetes, immunosuppression, obesity, antibiotics, steroids, pregnancy. Treatment: Topical clotrimazole/miconazole/nystatin; oral fluconazole or itraconazole if severe. {{caption_text}} . {{caption_text}} Trichophyton Circinata (Tinea) (Option B) causes dermatophyte infections that present as ring-shaped, circular patches on the skin. The lesions often have a clear central area with scaly, red edges. {{caption_text}} Streptococcus pyogenes (Erysipelas) (Option C): Presents with well-demarcated, erythematous, raised lesions with a fiery red appearance. It typically affects the face and extremities . Malassezia furfur (Pityriasis versicolor) (Option D): Pityriasis versicolor, caused by Malassezia furfur, presents with hypo- or hyperpigmented patches on the skin, typically on the trunk , neck , and upper arms. {{caption_text}}





@Neet_pg_bot



@Neet_pg_bot







References:

Rook's Dermatology, 9th Edition, Volume 1, Section 32

↑ *Back to this question in Part A*

@Neet_pg_bot

Q10: A 35-year-old uncircumcised male patient with a T-cell deficiency presents to your outpatient clinic. On examination, a frayed appearance and the presence of superficial pustules on the penis is noted. A KOH examination reveals the following

findings. What is the most appropriate next step in management? (Q841830)

A. Local application of nystatin gel

B. Oral fluconazole

C. Local application of terbinafine ointment

D. Oral griseofulvin

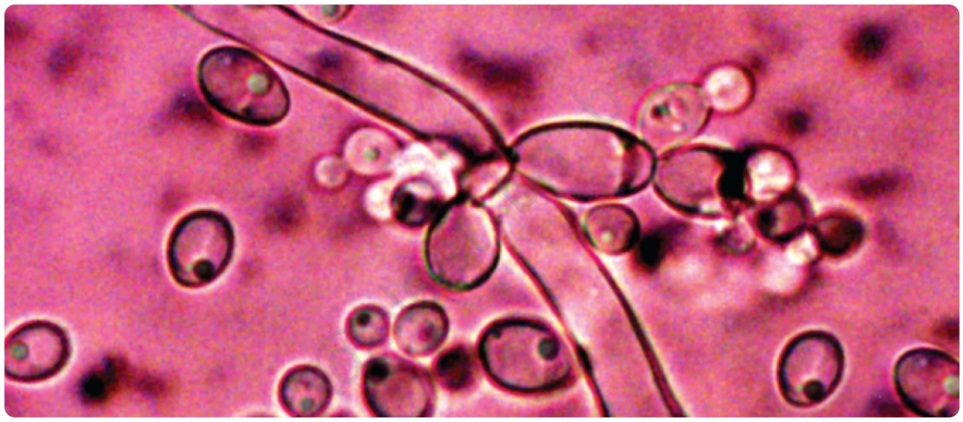

Correct Answer: B. Oral fluconazole

■ *Listen (English)*

■ *Listen (Hindi)*

Explanation: The clinical presentation of a frayed appearance, superficial pustules, and the presence of pseudohyphae on KOH examination is indicative of Balanitis due to Candida infection . Oral fluconazole is preferred for treating Candida infections involving the genital area due to its systemic action and effectiveness in eradicating the fungal infection in immunocompromised individuals. Diagnosis of Candidiasis: KOH prep: Budding yeast cells with pseudohyphae. Culture (SDA): Creamy white, smooth colonies. Germ tube test: C. albicans shows germ tube formation after serum incubation at 37°C for 2–3 hrs. Local application of nystatin gel (Option A): Nystatin is an antifungal agent effective against Candida, commonly used to treat oral thrush and vulvovaginal candidiasis. However, its local application may not be adequate for treating balanitis, particularly if the infection is extensive or involves deeper tissue layers. Local application of terbinafine ointment (Option C): Terbinafine is primarily used to treat dermatophyte infections, such as tinea corporis or tinea cruris, and is ineffective against Candida species. Oral griseofulvin (Option D) – Ineffective against Candida infections as it primarily targets dermatophyte fungi by inhibiting microtubule function.

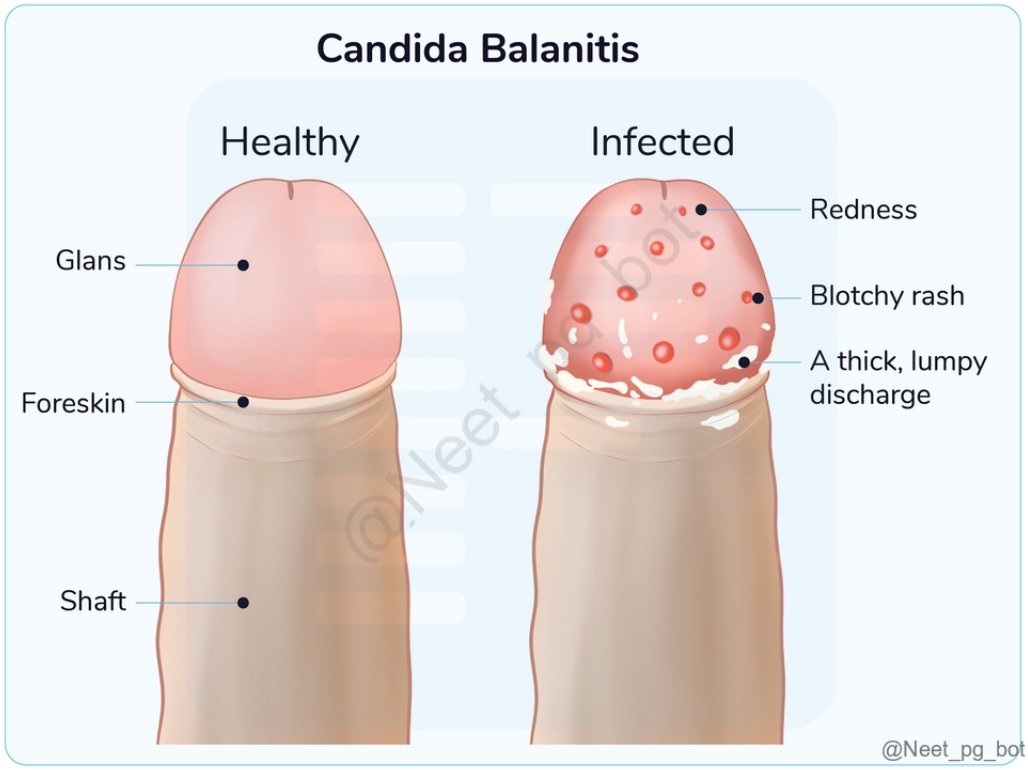
Candida Balanitis
Healthy
Infected
Glans
Foreskin
Shaft
Redness
Blotchy rash
A thick, lumpy discharge
@Neet_pg_bot

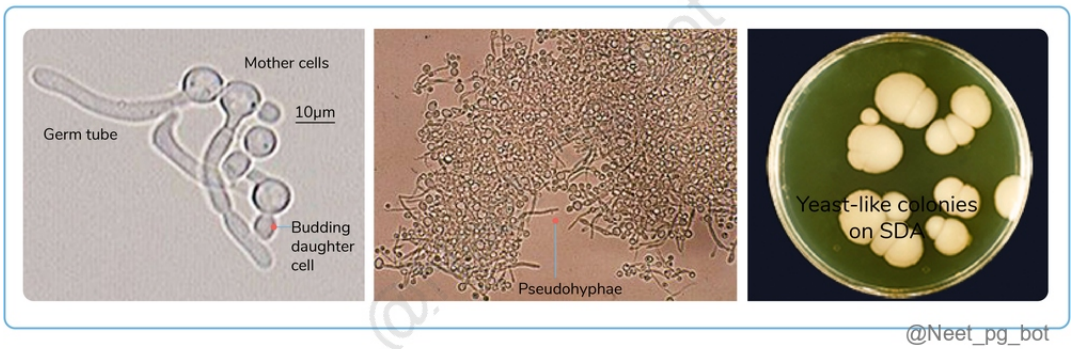
Mother cells
10µm
Germ tube
Budding daughter cell
Pseudohyphae
Yeast-like colonies on SDA
@Neet_pg_bot

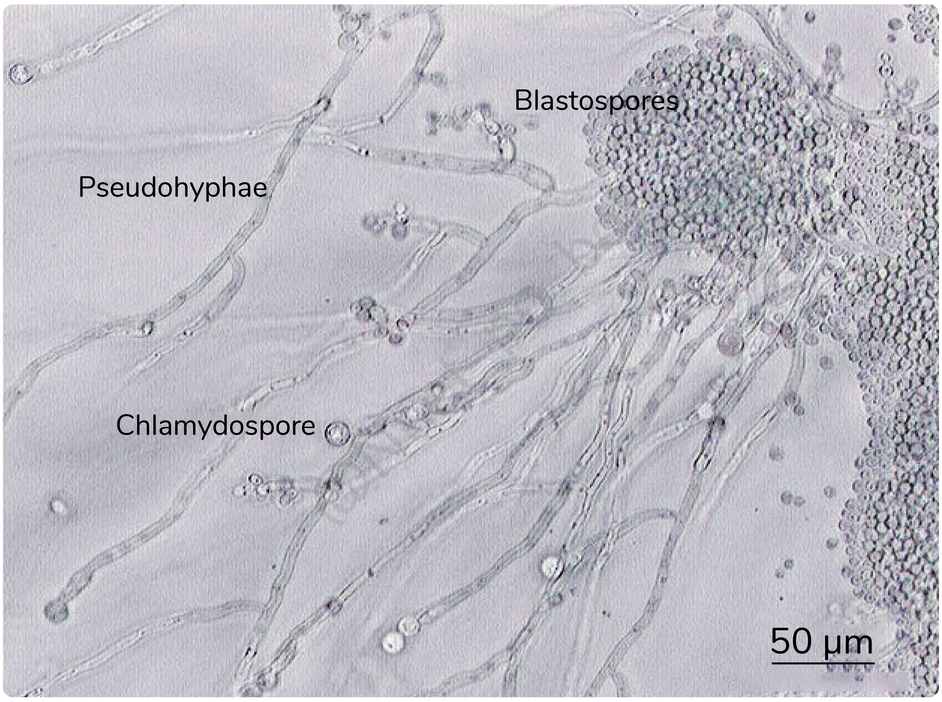

References:

Rook's Dermatology, 9th Edition, Volume 1, Section 32

↑ *Back to this question in Part A*

@Neet_pg_bot

Q11: A 40-year-old heroin and nicotine abuser with a 20-year history of untreated HIV comes to your community clinic complaining of a white patch on his tongue. You are unable to scrape the lesion off, and examination findings are given in the image below. What is the next best step of management? (Q841831)

A. Tongue biopsy

B. Nystatin gargle and Oral Fluconazole

C. Initiate Anti-Retroviral Therapy (ART)

D. Topical Corticosteroid therapy



Correct Answer: C. Initiate Anti-Retroviral Therapy (ART)

- *Listen (English)*
- *Listen (Hindi)*

Explanation: The image above describing a white plaque on the tongue, resembling cottage cheese in an immunocompromised patient, is suggestive of chronic plaque/ leukoplakia candidiasis In individuals with untreated HIV/AIDS, oral candidiasis is a common opportunistic infection. Management of HIV/AIDS involves initiating antiretroviral therapy (ART) as the primary intervention. Treatment with nystatin gargles, oral fluconazole, and oral ketoconazole- the various treatments for oral candidiasis can be initiated after ART has been started . Oral Thrush can present as: Red Lesions White Lesions Acute Lesions Antibiotic sore mouth (due to usage of antibiotics) {{caption_text}} Pseudomembranous Thrush (can be scraped off) {{caption_text}} Chronic Lesions Chronic Erythematous/ Denture Stomatitis {{caption_text}} Chronic Plaque/ leukoplakia (cannot be scraped off) {{caption_text}} Tongue biopsy (Option A): While biopsy may be considered if the diagnosis is uncertain or if premalignant lesions (submucal fibrosis, erythroleukoplakia, etc) are suspected, the priority, in this case, is to address the underlying HIV infection with ART. Nystatin gargle and Oral Fluconazole (Option B) are antifungal agents that may be used for oral candidiasis, but it is not the first-line treatment in individuals with untreated HIV/AIDS. Topical corticosteroid therapy (Option D): Corticosteroids are contraindicated in oral candidiasis as they can exacerbate fungal infections by suppressing the immune response.



@Neet_pg_bot



@Neet_pg_bot





References:

Rook’s Dermatology, 9th Edition, Volume 1, Section 32 Harrison’s Principles of Internal Medicine, 21st Edition, Chapter 216

↑ *Back to this question in Part A*

Q12: Which pattern is most likely to be observed in the hair perforation test result of Trichophyton mentagrophytes infection? (Q841832)

A. Absence of hair perforation

B. Wedge-shaped hair perforations along the hair shaft

C. Circular perforations inside the hair shaft

D. Parallel perforations on either side of the hair shaft

Correct Answer: B. Wedge-shaped hair perforations along the hair shaft

■ *Listen (English)*

■ *Listen (Hindi)*

Explanation: The hair perforation test is used to identify species of Trichophyton mentagrophytes from other dermatophytes such as Trichophyton rubrum. Trichophyton causes characteristic wedge-shaped perforations along the hair shaft , as shown in the image below; this is called a positive perforation test. {{caption_text}} Steps with hair perforation test: A strand of blonde, autoclaved hair is placed in water in a vial and incubated at room temperature. It is then inoculated with the test fungus. Individual hair is removed at intervals of up to 4 weeks and examined microscopically in lactophenol cotton blue. Isolates of T. mentagrophytes produce marked localised areas of pitting and erosion. Isolates of T. rubrum (a more common cause of tinea) do not produce marked pitting or erosion. Absence of hair perforation (Option A) – Seen in Trichophyton rubrum , which does not produce significant hair perforations, unlike T. mentagrophytes . Circular perforations inside the hair shaft (Option C) – More characteristic of Trichophyton verrucosum , which forms internal perforations instead of wedge-shaped indentations. Parallel perforations on either side of the hair shaft (Option D) – Not a recognized pattern in dermatophyte infections

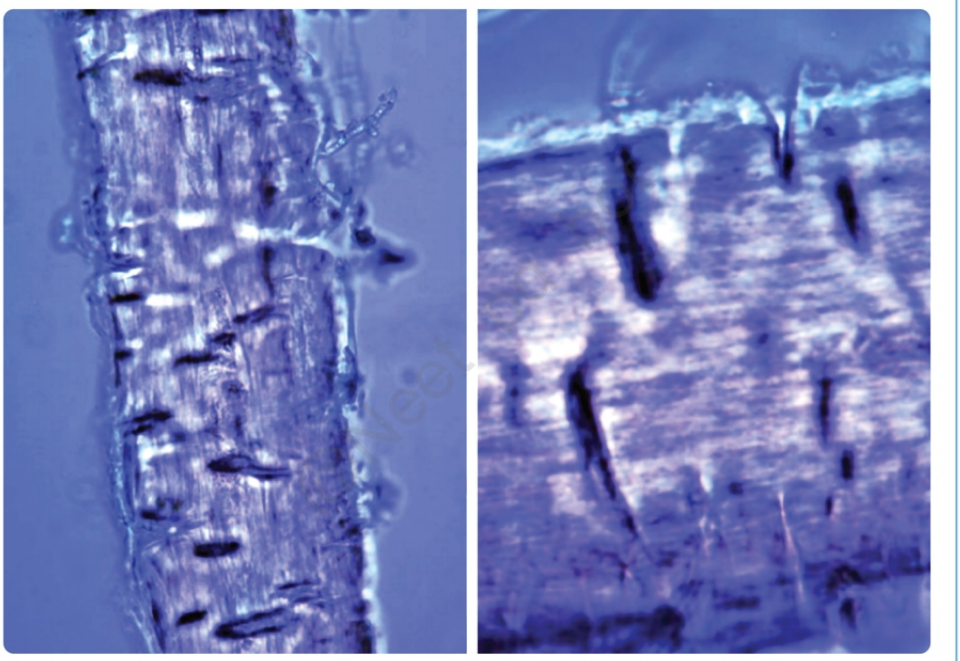

References:

Ananth Narayanan and Panniker Textbook of Microbiology, 10th Edition, Page 601

↑ *Back to this question in Part A*

@Neet_pg_bot

Q13: At your community medicine posting, a farmer arrives complaining of multiple nodules over his right leg after being pricked by a thistle. Examination findings are given in the image below. What would you expect to find on a microscopic examination of tissue from one of his lesions? {{caption_text}} (Q841833)

A. Asteroid bodies

B. Black granules

C. Muriform bodies

D. Spherules containing endospores



Correct Answer: A. Asteroid bodies

- *Listen (English)*
- *Listen (Hindi)*

Explanation: The patient’s presentation, along with the linear distribution of nodules, is suggestive of sporotrichosis/ Rose Gardner’s disease caused by Sporothrix schenckii. Sporotrichosis (Rose Gardener’s Disease): Sporotrichosis (Rose Gardener’s Disease): Cause: Sporothrix schenckii from thorn/splinter injury; spreads via lymphatics. Risk: Farmers, gardeners, barefoot walkers. Types: Lymphocutaneous (MC), fixed cutaneous, osteoarticular, pulmonary, disseminated. Diagnosis: KOH—cigar-shaped yeast; histology—asteroid bodies (Splendore-Hoeppli); culture—definitive. Treatment: Itraconazole (DOC); Amphotericin B for disseminated; potassium iodide alternative. The image below shows the culture of S. schenckii: {{caption_text}} The image below shows the asteroid body and Splendour Hoeppli phenomenon: {{caption_text}} Black Granules (Option B) Seen in mycetoma (Madura foot) caused by M. mycetomatis ; Actinomycetoma shows yellow “sulphur” granules with discharging sinuses. Madura foot: {{caption_text}} {{caption_text}} Histopathology of Actinomycotic mycetoma: {{caption_text}} Muriform bodies (Option C) Seen in chromoblastomycosis —slow-growing, verrucous lesions in farmers after thorn injury; shows sclerotic (Medlar) cells . Spherules containing endospores (Option D) are characteristic of coccidioidomycosis , a systemic fungal infection. {{caption_text}} {{caption_text}}

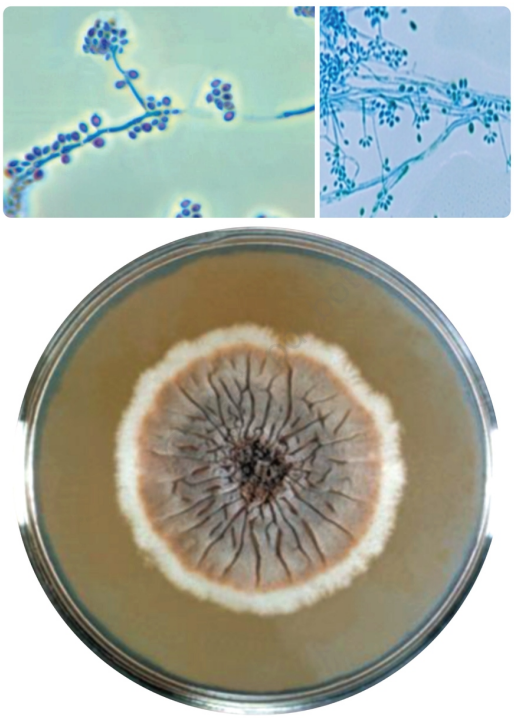

@Neet_pg_bot

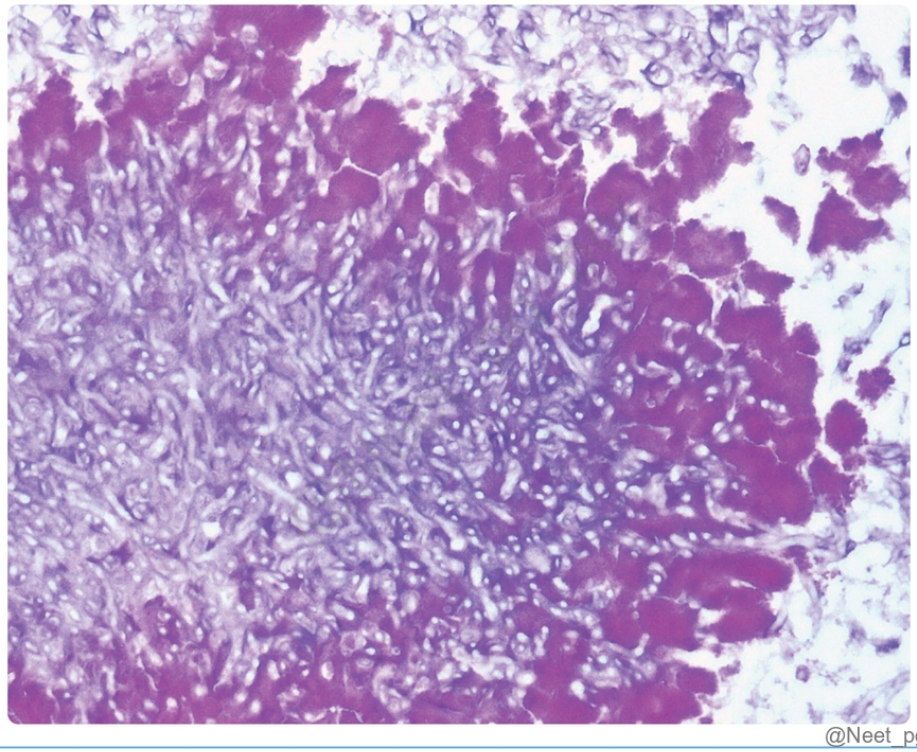

@Neet_pg_bot

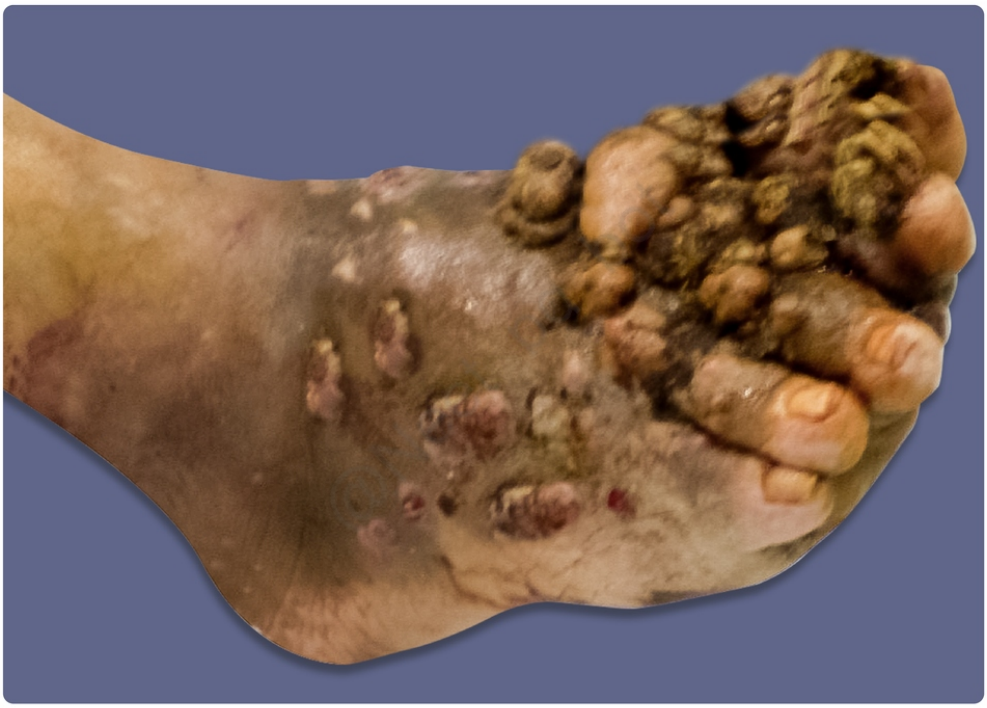

@Neet_pg_bot



@Neet_pg_bot

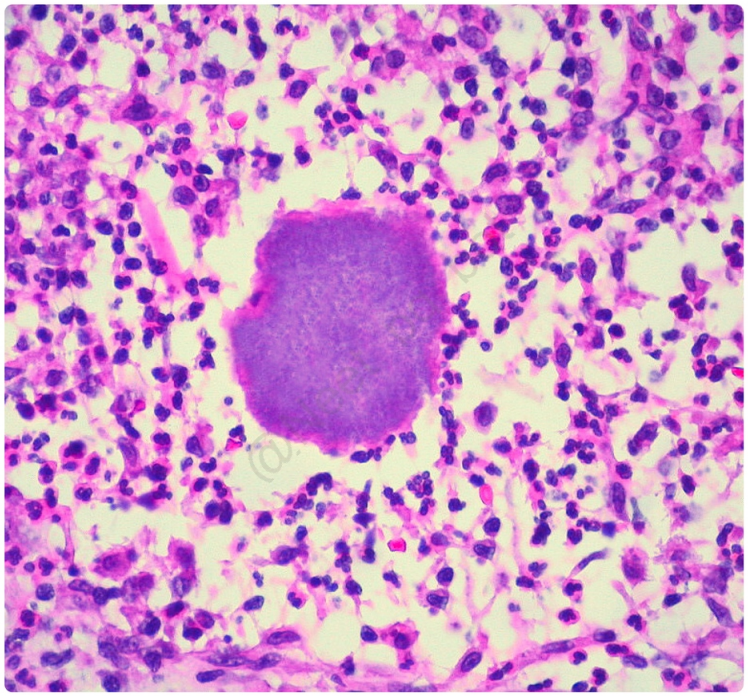

@Neet_pg_bot



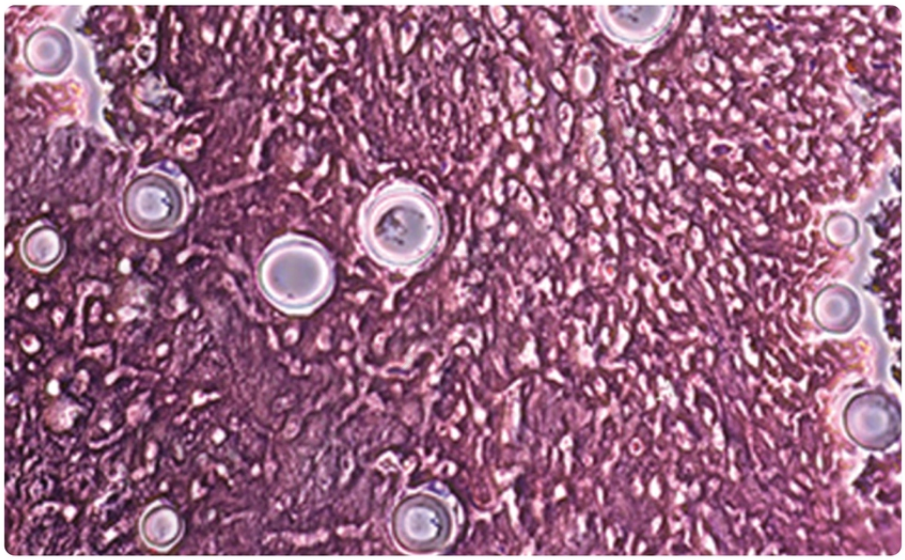

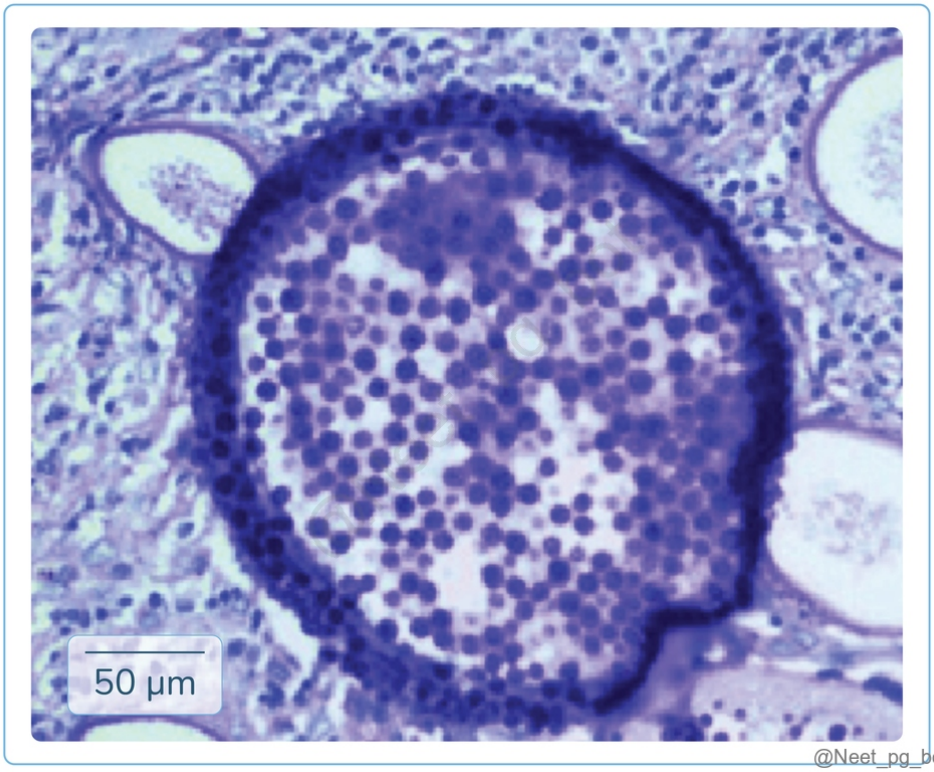

References:

Rook’s Dermatology, 9th Edition, Volume 1, Section 32

Essentials of Medical Microbiology, Apurba Sastry, 3rd edition, page 580-1

↑ *Back to this question in Part A*

@Neet_pg_bot

• [17_Fungal Infections] 034 Previous Year Questions

« Back to Folder Directory

[17_Fungal Infections] 034 Previous Year Questions — Quick Jump

Q1 (p. 1404) *Q2 (p. 1405)* *Q3 (p. 1406)* *Q4 (p. 1407)* *Q5 (p. 1409)* *Q6 (p. 1412)*

Q1: A patient presents with irregular swelling over the foot, multiple discharging sinuses, and black granules. A KOH mount is performed on the discharge. What is the most likely observation? (Q866553)

A. Arthrospores

B. Slender dematiaceous fungi

C. Yeast

D. Septate hyphae 4-5 µm



Correct Answer: D. Septate hyphae 4-5 µm

Explanation: The presentation is typical of eumycetoma (fungal mycetoma). Black granules indicate a dematiaceous (pigmented) fungus. On KOH mount, it appears as septate, pigmented hyphae. Hyphae are 4–5 µm

wide, distinguishing them from bacterial filaments. This is the definitive KOH finding confirming eumycetoma. Incorrect Answers: Option A) Arthrospores: Found in actinomycetoma (bacterial mycetoma) , thin and non-pigmented. Option B) Slender dematiaceous fungi: While the fungi are dematiaceous and slender, "septate hyphae 4–5 µm" is a more specific and accurate description of the structures observed in a KOH mount. Option C) Yeast: Unicellular , lacks hyphae; inconsistent with black granules and filamentous morphology.

References:

.

↑ *Back to this question in Part A*

@Neet_pg_bot

Q2: A 60-year-old female with a great toe infection. She had a significant discoloration with a subungual hyperkeratosis that caused surface changes. She was suspected of onychomycosis. Which is the topical drug given in toenail onychomycosis? (Q853198)

A. Itraconazole

B. Tavaborole

C. Griseofulvin

D. Caspofungin

Correct Answer: B. Tavaborole

Explanation: Tavaborole is a topical oxaborole antifungal specifically approved for onychomycosis of the toenails. It inhibits fungal leucyl-tRNA synthetase, disrupting protein synthesis. Onychomycosis is the fungal infection of the toenail (Onymychosis) or Tinea Unguium . Clinically , onychomycosis presents with various manifestations, including Discoloration of the nails (yellow, brown, or white), Thickening of the nail plate, Subungual hyperkeratosis (build-up of keratin debris under the nail), Onycholysis (separation of the nail plate from the nail bed), Nail dystrophy (deformation of the nail) Diagnosis: typically involves microscopic examination using KOH and fungal culture of nail clippings. Treatment: Oral antifungals such as terbinafine and itraconazole are often preferred. Nail lacquers such as ciclopirox (applied daily) olamine and amirolfine (applied weekly) are also used as topical agents to treat onychomycosis. The table below describes the types of onychomycosis Distal lateral subungual onychomycosis Most common Primarily affecting the distal & lateral portions of the nail Proximal subungual onychomycosis Seen in individuals with HIV The proximal portion of the nail plate Superficial white onychomycosis Characterized by the presence of white, crumbly material on the surface of the nail, which can be easily scrapped off Total dystrophic onychomycosis Characterized by extensive involvement of the nail plate, leading to complete destruction & deformity of the nail {{caption_text}} Itraconazole (Option A): Oral antifungal – Used for onychomycosis but given systemically, not topically. Griseofulvin (Option C): Oral antifungal – Primarily used for dermatophytosis; less effective for toenail infections. Caspofungin (Option D): Echinocandin antifungal – Used for systemic fungal infections like invasive candidiasis, not for onychomycosis.



References:

https://www.healthline.com/health/onychogryphosis

↑ *Back to this question in Part A*

@Neet_pg_bot

Q3: A 35-year-old patient presents to the OPD with a history of prolonged use of steroids for a skin condition. The patient complains of an expanding rash that has become less red and itchy since using the steroids. On examination, there are well-defined, slightly raised, erythematous plaques with central clearing and a scaly border on various parts of the body. What is the most likely diagnosis for this patient's condition? (Q820216)

A. Tinea incognito

B. Tinea corporis

C. Tinea cruris

D. Tinea pedis

Correct Answer: A. Tinea incognito

Explanation: Tinea incognito is a term used to describe fungal infections, specifically tinea (ringworm), that have been modified or worsened due to the inappropriate use of topical steroids . In this case, the patient's history of prolonged steroid use has likely led to the modification of the typical clinical appearance of the fungal infection. The expanding rash, reduced redness and itchiness, well-defined slightly raised plaques with central clearing, and scaly border all point to tinea incognito. The use of steroids can mask the inflammatory response and alter the clinical presentation, making it challenging to recognize the underlying fungal infection. Tinea corporis (Option B): Tinea corporis, also known as ringworm, is a fungal infection of the skin characterized by red, itchy, circular, or oval lesions with an active border and central clearing. While the patient's presentation does involve some elements seen in tinea corporis (such as well-defined plaques and central clearing), the fact that the patient has been using steroids and the alteration of the typical symptoms makes tinea incognito a more appropriate diagnosis in this case. Tinea cruris (Option C): Tinea cruris, commonly referred to as jock itch, is a fungal infection that affects the groin and inner thighs. It typically presents as red, scaly, and sometimes itchy lesions with well-defined borders. The patient's symptoms are not limited to the groin area, and the modification of symptoms due to steroid use suggests a different diagnosis. Tinea pedis (Option D): Tinea pedis, also known as athlete's foot, is a fungal infection affecting the feet. It can cause redness, itching, and scaling between the toes and on the soles of the feet. The patient's presentation involves lesions on various parts of the body and the modification of symptoms due to steroid use, which makes tinea incognito a more suitable diagnosis.

References:

.

↑ *Back to this question in Part A*

@Neet_pg_bot

Q4: A 10-year-old boy, presented with a mild painful swelling over the scalp since 3 months, as depicted below. Additionally, the patient confirms having a pet dog in his household. What is the most appropriate diagnosis of this condition? (Q855926)

A. Furuncle

B. Epidermoid cyst

C. Kerion

D. Folliculitis



Correct Answer: C. Kerion

Explanation: Clinical Presentation: Painful inflammatory swelling on the scalp . Chronic duration (3 months). Associated with a pet dog , suggesting a zoophilic fungal infection . Classic Appearance: Boggy, pustular mass with crusting and hair loss . Purulent discharge . Seen in tinea capitis (Trichophyton species, Microsporum canis - from pets) . Most Likely Diagnosis: Kerion (inflammatory tinea capitis) {{caption_text}} Kerion and Tinea Capitis Variants Feature Kerion (Inflammatory Tinea Capitis) Non-inflammatory Tinea Capitis Cause Zoophilic fungi (Microsporum canis, Trichophyton mentagrophytes) Anthropophilic fungi (Trichophyton tonsurans) Appearance Boggy, pustular , inflammatory swelling Dry, scaly patches with black dots Hair loss Yes, scarring alopecia if untreated Yes, but non-scarring Pain/Discharge Painful , pus-filled lesions Painless, no pus Diagnosis KOH mount, Wood’s lamp (fluoresces with Microsporum) KOH mount, culture Treatment Oral griseofulvin or terbinafine , topical antifungals Oral antifungals , ketoconazole shampoo Furuncle (Option A): Incorrect because it is a bacterial infection (S. aureus) and lacks hair loss . Epidermoid cyst (Option B): Incorrect because cysts are non-inflammatory , firm, and do not drain pus. Folliculitis (Option D): Incorrect because it presents as multiple small pustules , not a boggy mass .



References:

Rook’s Dermatology, 9th Edition, Volume 1, Section 32

↑ *Back to this question in Part A*

@Neet_pg_bot

Q5: Which type of alopecia is commonly associated with inflammatory alopecia in a 30-year-old male patient who presents with tinea capitis infection? (Q855958)

A. Endothrix and Favus

B. Ectothrix and Endothrix

C. Favus and Kerion

D. Kerion and Endothrix

Correct Answer: C. Favus and Kerion

Explanation: Tinea capitis is a fungal infection of the scalp caused by dermatophytes (Trichophyton & Microsporum). Inflammatory variants of tinea capitis include: Kerion: Severe inflammatory reaction with pustules,

abscesses, and hair loss. Favus: Chronic infection with yellow crusts (scutula) , leading to scarring alopecia. Types of Tinea Capitis and Alopecia Patterns Type Causative Organisms Hair Involvement Clinical Features Ectothrix {{caption_text}} Microsporum species Outside hair shaft Fluoresces under Wood's lamp Endothrix {{caption_text}} Trichophyton tonsurans Inside hair shaft No fluorescence Kerion {{caption_text}} Trichophyton verrucosum Inflammatory, patchy alopecia Boggy swelling, pustules Favus {{caption_text}} Trichophyton schoenleinii Permanent scarring alopecia Honeycomb scutula Endothrix and Favus (Option A): Incorrect because Endothrix does not cause an inflammatory response like Kerion or Favus . Ectothrix and Endothrix (Option B): Incorrect because Ectothrix is non-inflammatory , and Kerion is missing . Kerion and Endothrix (Option D): Incorrect because Endothrix infections are typically non-inflammatory , whereas Favus is a classic inflammatory type .

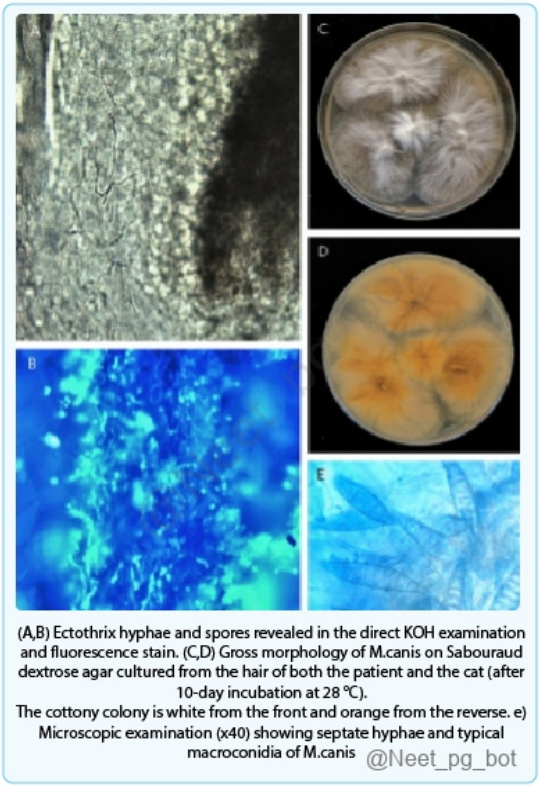

(A,B) Ectothrix hyphae and spores revealed in the direct KOH examination and fluorescence stain. (C,D) Gross morphology of M.canis on Sabouraud dextrose agar cultured from the hair of both the patient and the cat (after 10-day incubation at 28 °C).
The cottony colony is white from the front and orange from the reverse. e) Microscopic examination (x40) showing septate hyphae and typical macroconidia of M.canis @Neet_pg_bot

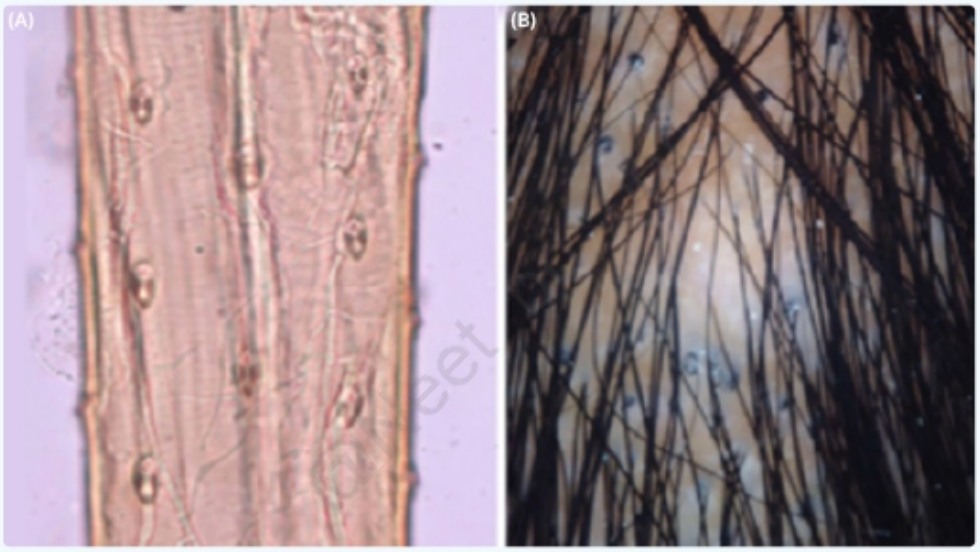

(A) KOH examination of hair shaft presented a positive endothrix result. (B) Dermoscopic examination revealed comma hair sign and large amount of corkscrew hair.

@Neet_pg_bot



@Neet_pg_bot



References:

https://pmc.ncbi.nlm.nih.gov/articles/PMC6984041/

https://pmc.ncbi.nlm.nih.gov/articles/PMC7362962/

↑ *Back to this question in Part A*

@Neet_pg_bot

Q6: A farmer presents to the outpatient department with the lesion shown. Examination of the discharge reveals black granules. What is the most likely causative organism? (Q879072)

A. Madurella mycetomatis

B. Actinomadura madurae

C. Nocardia brasiliensis

D. Streptomyces somaliensis



Correct Answer: A. Madurella mycetomatis

Explanation: Madurella mycetomatis is the commonest cause of eumycetoma producing black grains . Histopathology shows chronic inflammation with neutrophilic abscesses , giant cells, fibrosis, and black granules discharged through multiple sinuses . It is a dark-grain fungus and the grains represent microcolonies found in pus. Incorrect Options: Actinomadura madurae (Option B) produces white/yellow grains, not black; it causes actinomycetoma, not eumycetoma. Nocardia brasiliensis (Option C) is associated with pale/yellowish grains; an actinomycete, not a black-grain fungus. Streptomyces somaliensis (Option D) causes actinomycetoma with yellow/white grains, not black granules.

References:

Rook’s Textbook of Dermatology, 9th Edition., Page 992-994

↑ *Back to this question in Part A*

@Neet_pg_bot

• [18_Parasitic Infection] 035 Parasitic Infestations Of Skin

« Back to Folder Directory

[18_Parasitic Infection] 035 Parasitic Infestations Of Skin — Quick Jump

Q1 (p. 1414)	*Q2 (p. 1415)*	*Q3 (p. 1416)*	*Q4 (p. 1417)*	*Q5 (p. 1418)*	*Q6 (p. 1419)*
Q7 (p. 1421)	*Q8 (p. 1422)*	*Q9 (p. 1423)*	*Q10 (p. 1425)*	*Q11 (p. 1426)*	*Q12 (p. 1427)*
Q13 (p. 1428)	*Q14 (p. 1428)*	*Q15 (p. 1430)*	*Q16 (p. 1433)*	*Q17 (p. 1434)*	*Q18 (p. 1437)*
Q19 (p. 1439)	*Q20 (p. 1441)*	*Q21 (p. 1445)*	*Q22 (p. 1448)*	*Q23 (p. 1450)*	

Q1: A 25-year-old man presents with an intensely pruritic, rapidly progressing, serpiginous rash over the trunk and proximal limbs. The lesion is noted to migrate quickly over hours to days. Which of the following organisms is the most likely causative agent? (Q882304)

A. Strongyloides stercoralis

B. Ancylostoma braziliense

C. Cutaneous larva migrans due to hookworm species

D. Sarcoptes scabiei

Correct Answer: A. Strongyloides stercoralis

Explanation: Strongyloides stercoralis causes larva currens, a characteristic fast-moving serpiginous rash resulting from autoinfection. The rash typically migrates at a rate of several centimeters per hour, most commonly over the trunk, buttocks, and proximal thighs, which is a key distinguishing feature. Ancylostoma braziliense (Option B): Causes cutaneous larva migrans, but the rash progresses slowly (mm per day) and is usually confined to the feet or exposed skin, not rapidly moving. Cutaneous larva migrans due to hookworm species (Option C): Refers broadly to hookworm infections (Ancylostoma, Necator), which again produce slowly migrating serpiginous lesions, unlike larva currens. Sarcoptes scabiei (Option D): Causes scabies, characterized by burrows and nocturnal pruritus, not a rapidly migrating serpiginous rash.

References:

Rook's Textbook of Dermatology, 9th Edition, Page 33.17

https://mdsearchlight.com/infectious-disease/cutaneous-larva-migrans-creeping-eruption/

https://www.sciencedirect.com/topics/medicine-and-dentistry/larva-currens

↑ *Back to this question in Part A*

@Neet_pg_bot

Q2: A patient with classical scabies has thin, serpiginous burrows on the finger web spaces. Which layer of the skin does the female mite create these burrows in? (Q887368)

A. Stratum basale

B. Stratum spinosum

C. Stratum corneum

D. Dermis

Correct Answer: C. Stratum corneum

Explanation: In classical scabies, the female mite (Sarcoptes scabiei) creates characteristic serpiginous burrows within the Stratum corneum . Scabies burrow



References:

Rook’s Textbook of Dermatology, 9th Edition, Page 34.39

↑ *Back to this question in Part A*

Q3: A 24-year-old man presents with intensely pruritic, erythematous serpiginous tracks on his foot that have been slowly migrating over several days. He recently walked barefoot on a beach. What is the most likely causative organism? (Q887391)

A. Ancylostoma duodenale

B. Ancylostoma braziliense

C. Enterobius vermicularis

D. Sarcoptes scabiei



Correct Answer: B. Ancylostoma braziliense

Explanation: Cutaneous larva migrans is caused by dog and cat hookworm larvae , most commonly Ancylostoma braziliense , which migrate within the epidermis, producing creeping serpiginous lesions . Cutaneous Larva Migrans: Skin infestation caused by hookworm larvae from animals (commonly Ancylostoma braziliense and A. caninum). Larvae penetrate the skin and cause a characteristic serpiginous (snake-like) track rash. Transmission: Contact with contaminated soil/sand (e.g., barefoot walking on beaches, playgrounds). Larvae enter through intact skin . Clinical features: Pruritic, erythematous serpiginous tracks that advance slowly through the skin. Often on

feet, legs, and buttocks . May last for weeks to months if untreated Treatment: Oral albendazole or ivermectin is effective. Topical thiabendazole may be used for limited lesions. Ancylostoma duodenale (Option A) : Human hookworm causing intestinal infection and anaemia ; does not produce creeping skin lesions. Enterobius vermicularis (Option C) : Causes perianal pruritus , especially at night; no serpiginous tracks. Sarcoptes scabiei (Option D) : Causes scabies with burrows and nocturnal itching , not migrating serpiginous lesions.

References:

https://www.ncbi.nlm.nih.gov/books/NBK507706/

↑ *Back to this question in Part A*

@Neet_pg_bot

Q4: Pediculosis pubis is caused by which parasite? (Q887388)

A. Head louse

B. Body louse

C. Crab louse

D. Scabies mite

Correct Answer: C. Crab louse

Explanation: Pediculosis pubis is caused by the crab louse (Pthirus pubis) , named for its short, broad body and claw-like legs , which allow it to grasp coarse pubic hair. Pediculosis Pubis: Agent: Pthirus pubis (crab louse) Transmission: Sexual contact Sites: Pubic hair, axillae, beard, chest; eyelashes in children Features: Intense pruritus Excoriations Maculae ceruleae (blue-grey macules) Lice/nits attached to coarse hair Diagnosis: Lice or nits seen on hair shafts Treatment: Permethrin 1% / pyrethrins (repeat after 7 days) Petroleum jelly for eyelashes Treat partners; wash clothes/bedding Head louse (Option A) : Causes pediculosis capitis; infests scalp hair. Body louse (Option B) : Lives in clothing seams; causes pediculosis corporis. Scabies mite (Option D) : Sarcoptes scabiei burrows in skin; not a louse.



References:

Andrew’s Diseases of the Skin, Clinical Dermatology, 13th Edition, Page 442

↑ *Back to this question in Part A*

@Neet_pg_bot

Q5: A 28-year-old man presents with intense itching in the pubic region for 2 weeks. Examination shows excoriations and multiple blue-grey macules on the lower abdomen and thighs. Close inspection reveals findings as shown. What is the most likely diagnosis? (Q887387)

A. Pediculosis corporis

B. Scabies

C. Pediculosis pubis

D. Tinea cruris



Correct Answer: C. Pediculosis pubis

Explanation: Pediculosis pubis (crab lice) presents with pubic pruritus , nits attached to hair , and characteristic maculae ceruleae due to louse feeding. Pediculosis Pubis: Agent: Pthirus pubis (crab louse) Transmission: Sexual contact Sites: Pubic hair, axillae, beard, chest; eyelashes in children Features: Intense pruritus Excoriations Maculae ceruleae (blue-grey macules) Lice/nits attached to coarse hair Diagnosis: Lice or nits seen on hair shafts Treatment: Permethrin 1% / pyrethrins (repeat after 7 days) Petroleum jelly for eyelashes Treat partners; wash clothes/bedding Pediculosis corporis (Option A) : Lice and nits are found in clothing seams , not attached to pubic hair; causes vagabond's disease. Scabies (Option B) : Caused by mites burrowing in skin; shows burrows and nocturnal pruritus, no lice or nits on hair . Tinea cruris (Option D) : Dermatophyte infection with annular plaques and central clearing; no ectoparasites or maculae ceruleae .

References:

Andrew's Diseases of the Skin, Clinical Dermatology, 13th Edition, Page 442

↑ *Back to this question in Part A*

@Neet_pg_bot

Q6: A 60-year-old homeless man presents with findings as shown. Lice and nits are seen in clothing seams, not on the scalp. What is the most likely diagnosis? (Q887386)

A. Scabies incognito

B. Pediculosis capitis

C. Vagabond’s disease

D. Post-inflammatory hyperpigmentation

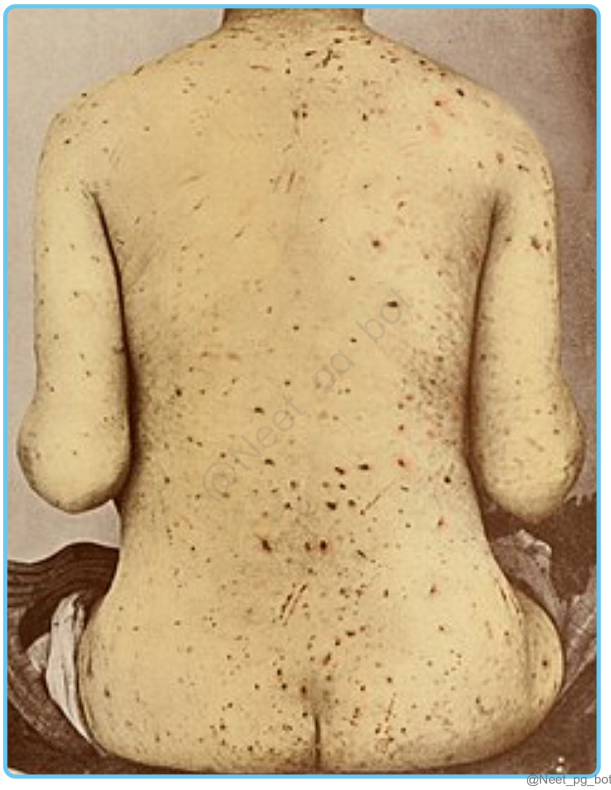

Correct Answer: C. Vagabond’s disease

Explanation: The most likely diagnosis for this patient is Vagabond’s disease . Key clues: Homeless man (poor hygiene, infrequent clothing change) Chronic pruritus Lice and nits in clothing seams (not on scalp) Diffuse hyperpigmentation and excoriations Vagabond’s disease results from chronic body lice (Pediculus corporis) infestation , seen in homeless individuals with poor hygiene. It presents with persistent pruritus, excoriations, and diffuse hyperpigmentation , and lice/nits are found in clothing seams , not on the scalp. Body / Clothing Lice (Pediculus corporis): Epidemiology: Poor hygiene, infrequent washing of clothes, is common among the homeless, refugees, and prisons Habitat: Lives in clothing seams ; visits skin only to feed; lays eggs on clothes Transmission: Close contact, shared clothing/bedding Diseases transmitted: Epidemic typhus : Rickettsia prowazekii Relapsing fever : Borrelia recurrentis Trench fever : Bartonella quintana (± endocarditis) Clinical features: Pruritus , excoriations Secondary infection Chronic cases → hyperpigmentation (vagabond’s disease) Lice/nits seen in clothes , not hair Management: Hot wash/iron clothes & bedding (kills lice and eggs) Topical pyrethroids or malathion Ivermectin for mass infestation Antibiotics if louse-borne disease present Scabies incognito (Option A) : Steroid-modified scabies with atypical lesions; mites are found in skin burrows , not in clothing. Pediculosis capitis (Option B) : Head lice infestation; nits are attached to scalp hair , not clothing seams. Post-inflammatory hyperpigmentation (Option D) : Pigmentary sequelae after inflammation; no active lice or nits present .

References:

Rook’s Textbook of Dermatology, 9th Edition, Pages 34.21, 34.22

↑ *Back to this question in Part A*

@Neet_pg_bot

Q7: A 58-year-old immunocompromised man has thick hyperkeratotic crusts on hands and feet, nail debris, minimal itching, and contact with pruritus. Skin scrapings show numerous mites. What is the diagnosis? (Q887384)

A. Nodular scabies

B. Animal scabies

C. Norwegian scabies

D. Darier disease

Correct Answer: C. Norwegian scabies

Explanation: Massive mite burden, hyperkeratotic crusts , minimal pruritus , nail involvement, and high infectivity in an immunocompromised patient are classic for crusted (Norwegian) scabies . Crusted (Norwegian) scabies: Severe, highly contagious scabies with massive mite load and hyperkeratotic crusts Pathogenesis: Impaired host immune response → uncontrolled mite proliferation Risk factors: Intellectual disability, Down syndrome , dementia, immunosuppression (HIV, HTLV-1, steroids, biologics), topical steroids; may occur in healthy individuals Clinical features: Thick warty crusts on hands, feet, palms, soles Nail dystrophy with subungual debris Erythema and scaling of scalp, face, trunk → may generalise Pruritus is minimal or absent Lymphadenopathy, eosinophilia , ↑IgE Diagnosis: Skin scrapings → numerous mites and eggs Management: Hospitalise and isolate ; treat all contacts Keratolytics + topical scabicide (repeated) Oral ivermectin (3-7 doses based on severity) Continue treatment until 2 negative scrapings Nodular scabies (Option A) : Presents with persistent pruritic nodules, usually genital or axillary, with low mite load . Animal scabies (Option B) : Causes transient pruritic papules; mites do not multiply on humans. Darier disease (Option D) : Genetic keratinisation disorder with greasy papules; no mites on scraping.



References:

Rook's Textbook of Dermatology, 9th Edition, Page 34.47

↑ *Back to this question in Part A*

@Neet_pg_bot

Q8: Which of the following statements regarding nodular scabies is incorrect? (Q887381)

A. Lesions are violaceous and intensely pruritic

B. Commonly involves the groin, axillae, and male genitalia

C. Nodules contain large numbers of live mites

D. Lesions may persist for weeks or months after treatment

Correct Answer: C. Nodules contain large numbers of live mites

Explanation: Nodular scabies represents a hypersensitivity reaction to mite antigens; live mites are usually absent in the nodules. Nodular scabies: Lesions: Few violaceous, intensely pruritic nodules (Option A ruled out) Sites:

Groin, axillae, male genitalia (Option B ruled out) Pathogenesis: Hypersensitivity reaction to mite antigens Course: May persist for weeks to months after successful treatment (Option D ruled out)



References:

Rook’s Textbook of Dermatology, 9th Edition, Page 34.42

↑ *Back to this question in Part A*

@Neet_pg_bot

Q9: A 22-year-old man presents with intense nocturnal itching and pruritic papules as shown. Two family members have similar symptoms. Which of the following tests are useful to confirm the diagnosis? Skin scraping with mineral oil microscopy. Dermoscopy Adhesive tape test Patch testing (Q887379)

A. 1, 2 and 3

B. 1 and 4

C. 2 and 4

D. 3 and 4



Correct Answer: A. 1, 2 and 3

Explanation: Based on the clinical presentation of nocturnal itching and involvement of the finger webs and wrists, the most likely diagnosis is Scabies . Skin scraping, dermoscopy, and adhesive tape test are useful for confirming this infestation; patch testing is not. Scabies - Investigations: Burrow identification or microscopy Skin scraping + mineral oil microscopy: Mites, eggs, egg shells, or scybala Negative scraping does not exclude scabies Mandatory in crusted scabies and healthcare settings Dermoscopy: Shows “jet with contrail” sign (mite in burrow) Advantages: quick, painless, screens multiple sites Limitations: cost, operator dependence Adhesive tape test: Tape applied to lesion → transferred to slide Simple; useful in severe scabies , nursing homes Low sensitivity Skin biopsy: Confirms diagnosis only if mite/parts are seen Usually nonspecific: spongiosis, eosinophil-rich infiltrate Confocal microscopy: promising but expensive; limited data Patch testing is used to diagnose allergic contact dermatitis (Type IV hypersensitivity reactions) . Suspected allergens are applied to the back under occlusive patches and left for 48 hours , with readings taken at 48-96 hours to detect delayed hypersensitivity reactions.

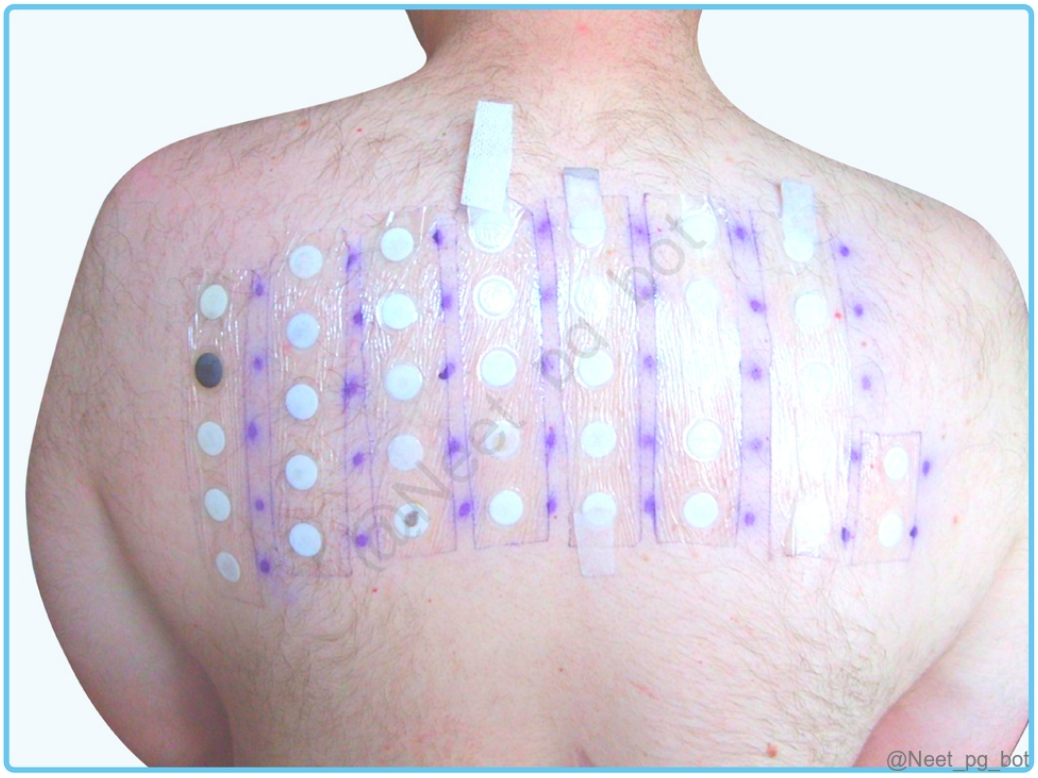

References:

Rook’s Textbook of Dermatology, 9th Edition, Page 34.43

↑ *Back to this question in Part A*

@Neet_pg_bot

Q10: A patient with nocturnal pruritus and burrows is diagnosed with scabies. Which statement regarding management is incorrect? (Q887376)

A. Treat all close contacts simultaneously

B. Apply permethrin only to visible lesions

C. Wash clothes and bedding in hot water or seal for 72 h

D. Itching may persist after treatment

Correct Answer: B. Apply permethrin only to visible lesions

Explanation: Permethrin must be applied to the entire body , not just lesions. Scabies - Management: Treat: Patient + all close contacts (even asymptomatic) (Option A ruled out) Education: Avoid close contact until all are treated

Treatment: DOC: Topical permethrin Alternatives: Benzyl benzoate, lindane, crotamiton, sulphur Oral ivermectin: 200 µg/kg (>2 yrs, >15 kg), repeat after 7-14 days Application: Apply to the entire body ; include the face in infants Do not wash your hands during treatment Environment: Wash clothes/bedding >50°C or seal 72 h (Option C ruled out) Special cases: Children: No ivermectin <15 kg Impetigo: Prefer ivermectin or add antibiotics Pregnancy: Permethrin is safe Follow-up: Itching may persist for weeks (Option D ruled out) ; reassess if >4 weeks

References:

Rook's Textbook of Dermatology, 9th Edition, Pages 34.43-34.45

↑ *Back to this question in Part A*

@Neet_pg_bot

Q11: A 6-month-old infant presents with intense itching, irritability, and a generalised papulovesicular rash. Lesions involve the scalp, face, palms, and soles. The mother also complains of nocturnal itching. Examination shows excoriations and crusted papules. What is the most likely diagnosis? (Q887374)

A. Atopic dermatitis

B. Infantile scabies

C. Impetigo

D. Papular urticaria

Correct Answer: B. Infantile scabies

Explanation: Infantile scabies characteristically involves the face, scalp, palms, and soles , with intense pruritus and household contact history, which are uncommon in classic adult scabies. Infantile Scabies: Distribution: Unlike adults, the face, scalp, palms, and soles are commonly involved Also affects the trunk and extremities Pruritus: Severe → irritability, poor feeding Lesions: Papules, vesicles, pustules, nodules Burrows may be difficult to identify History of itching in caregivers or family members Key distinction from adult scabies: Wider distribution , including head and acral areas Complications: Secondary infection due to scratching Atopic dermatitis (Option A) : Chronic, relapsing eczema; pruritus present, but no burrows and usually spares palms and soles in infants. Impetigo (Option C) : Bacterial infection with honey-colored crusts ; itching and family involvement are not typical. Papular urticaria (Option D) : Hypersensitivity to insect bites; no nocturnal pruritus or household spread.



References:

Rook's Textbook of Dermatology, 9th Edition, Pages 34.40, 34.42

↑ *Back to this question in Part A*

@Neet_pg_bot

Q12: Which of the following statements about scabies is incorrect? (Q887371)

A. Burrows are absent in animal scabies

B. Permethrin is the drug of choice for scabies

C. Crusted scabies is highly contagious

D. Animal scabies commonly causes persistent human infestation

Correct Answer: D. Animal scabies commonly causes persistent human infestation

Explanation: Animal scabies causes transient infestation in humans and does not persist , as mites cannot complete their life cycle in human skin. Animal scabies: From dogs, cats, livestock Transient pruritic papules No burrows (Option A ruled out) Resolves after animal treatment Permethrin hastens recovery Permethrin is the drug of choice for scabies (Option B) : Correct - topical 5% permethrin is first-line treatment. Crusted scabies is highly

contagious (Option C) : Correct - due to very high mite burden.

References:

Rook’s Textbook of Dermatology, 9th Edition, Page 34.40-34.47

↑ *Back to this question in Part A*

@Neet_pg_bot

Q13: A patient acquires scabies for the first time. After how long do symptoms typically begin? (Q887369)

A. Within 24-48 hours

B. 3-4 weeks

C. 6-8 weeks

D. Immediate

Correct Answer: B. 3-4 weeks

Explanation: In primary scabies, symptoms appear after 3-4 weeks due to delayed hypersensitivity to mite antigens. Reinfection causes rapid symptoms within days. In a first-time (primary) scabies infestation , symptoms are delayed because: The itching is due to a type IV (delayed) hypersensitivity reaction The body needs time to become sensitised to: Mite proteins Eggs Faecal pellets (scybala) Scabies - Clinical Features: Itching: Severe, worse at night , face spared in adults Onset: 3-4 weeks after first infection; immediate on reinfection Sites: Finger webs, wrists, elbows, axillae, buttocks, genitalia , breasts Lesions: Burrows: Brownish, tortuous tracks Papules/nodules: Very itchy, especially on the male genitalia Post-treatment: Nodules may persist for weeks Secondary lesions: Excoriations, eczema, impetigo

References:

Rook’s Textbook of Dermatology, 9th Edition, Page 34.40

↑ *Back to this question in Part A*

@Neet_pg_bot

Q14: A 25-year-old male presents with complaints of severe itching in both his hands for the last 2 weeks. He reports that the itching is significantly worse at night and disturbs his sleep. His hands show lesions characteristic of scabies. Which body site is usually not affected by this condition? {{caption_text}} (Q842037)

A. Face

B. Axilla

C. Groin/genitalia

D. Umbilicus



Correct Answer: A. Face

■ *Listen (English)*

■ *Listen (Hindi)*

Explanation: The likely diagnosis of this case is scabies, a parasitic infection of the skin caused by Sarcoptes scabiei (itch mite). Mode of spread: Scabies are highly contagious, and transmission is by skin-to-skin contact and fomites. Risk factors include poor personal hygiene. Clinical manifestation: The characteristic sign of scabies is the presence of burrows, Are thin, grayish-white or skin-colored, linear or wavy lines found in areas like the webbing between fingers, wrists, elbows, armpits, waistline, buttocks, genital area, and ankles, causing intense itching, especially at night. Examination typically reveals excoriated papules, typically over the web spaces of the fingers (as shown in the image). Other areas of the body that must be examined for lesions include: The medial aspect of the wrist The medial aspect of the forearm Umbilicus (Option D) Axilla (Option B) Nipple Genitalia/ groin (Option C) - burrows (wavy, grey tunnels) This distribution is called the circle of Hebra. The face is typically spared, due to high amounts of sebum in the facial skin but pre pubecent children lack sebaceous glands and hence their faces can be affected Circle of Hebra demonstrating the typical location of scabies lesions:

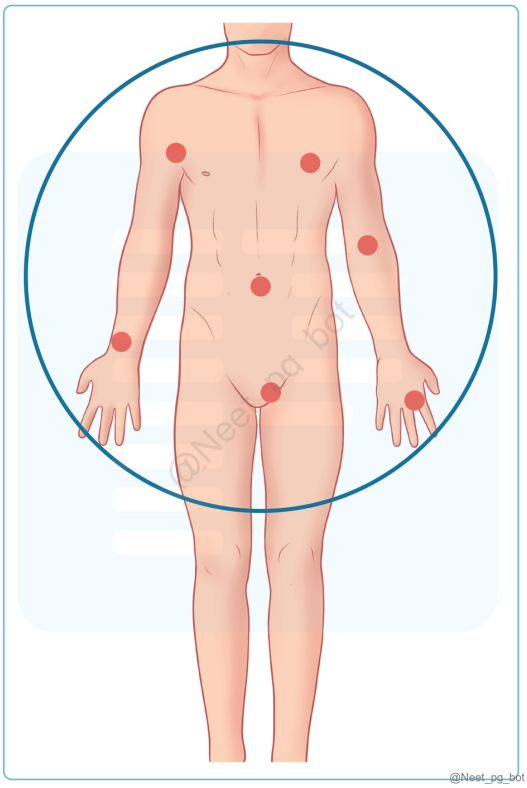

References:

Rook's Textbook of Dermatology, 9th Edition, Pages 34.1, 34.43, 34.44

www.uptodate.com/contents/scabies-epidemiology-clinical-features-and-diagnosis

↑ *Back to this question in Part A*

@Neet_pg_bot

Q15: A 22-year-old man presents with intense itching, worse at night, for 3 weeks. Examination shows multiple excoriated papules and thin serpiginous burrows as shown in the finger web spaces and flexor wrists. His roommate also has similar symptoms. What is the most likely diagnosis? (Q887364)

A. Pediculosis corporis

B. Atopic dermatitis

C. Scabies

D. Prurigo nodularis



Correct Answer: C. Scabies

Explanation: Nocturnal pruritus , involvement of the finger webs , presence of burrows , and household contact are classic findings of scabies . Scabies (Family Sarcoptidae): Cause: Sarcoptes scabiei var. Hominis Transmission: Prolonged skin-to-skin contact Mite load: ~12 mites (classical); millions in crusted scabies Life Cycle: Eggs → larvae (3-4 days) → adults Total cycle: 14-21 days Clinical features: Intense nocturnal pruritus Burrows : thin, serpiginous lines Sites: finger webs, wrists, axillae, buttocks, genitalia Face spared in adults Scabies burrows Variants Infants: Vesicles, pustules, scalp involved Elderly: Palms, soles Scabies incognito: Steroid-modified Crusted scabies: Hyperkeratotic, minimal itch, highly contagious Treatment: Treat patient + contacts DOC: Permethrin 5% topical Alternative: Benzyl benzoate Oral ivermectin: Poor compliance, outbreaks, crusted scabies Pediculosis corporis (Option A) : Causes itching from body lice, but no burrows; usually affects areas in contact with clothing seams. Atopic dermatitis (Option B) : Chronic, relapsing eczema; no burrows and not contagious. Prurigo nodularis (Option D) : Firm nodules from chronic scratching; no burrows or contagious spread.

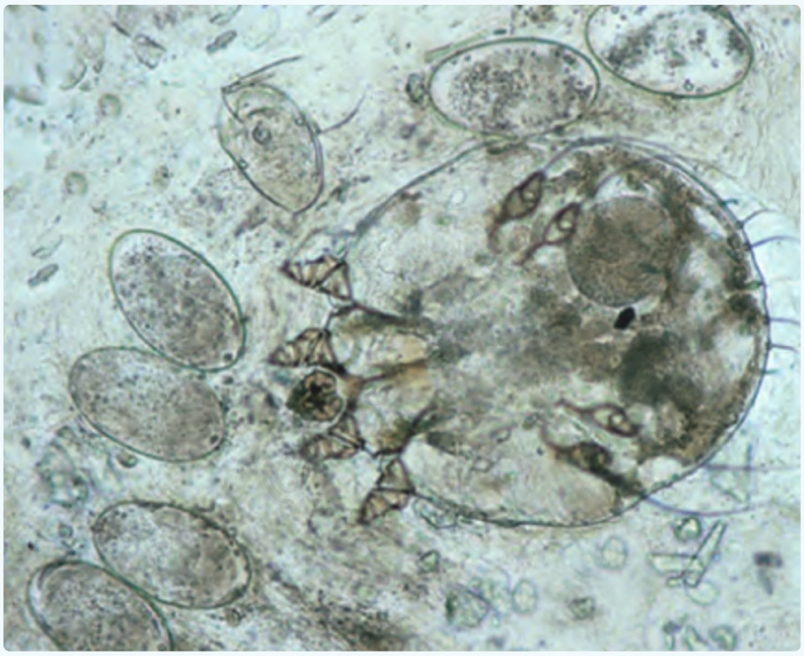

Sarcoptes scabiei, the scabies mites. Female with eggs.

@Neet_pg_bot



@Neet_pg_bot

References:

Rook’s Textbook of Dermatology, 9th Edition, Pages 34.39-34.47

↑ *Back to this question in Part A*

@Neet_pg_bot

Q16: A 50-year-old female who recently migrated from Bihar presents for evaluation of a new rash. Her history is significant for low-grade fever and fatigue over the last few months. She reports receiving some treatment at the local government hospital, but cannot recount any more details. Examination reveals hundreds of hypopigmented macules over her back and arms. She also has palpable splenomegaly. What is the likely diagnosis? (Q842063)

A. Post-kala-azar dermal leishmaniasis

B. Cutaneous leishmaniasis

C. Lepromatous leprosy

D. Pityriasis versicolor



Correct Answer: A. Post-kala-azar dermal leishmaniasis

■ *Listen (English)*

■ *Listen (Hindi)*

Explanation: This patient likely has post-kala-azar dermal leishmaniasis due to inadequately treated visceral leishmaniasis (VL). VL is transmitted by sandflies and is caused by L. donovani or L. infantum. Splenomegaly is characteristically massive. It is characterized by multiple hypopigmented macules, typically on the trunk. These may progress to papules/ nodules. Lesions may resemble those of lepromatous leprosy (Option C), but there are no associated sensorineural changes. A definitive diagnosis of VL requires the demonstration of Leishmania by smear or culture, typically using a bone marrow sample. PKDL may be diagnosed via PCR of macular scrapings. Treatment of VL involves liposomal Amphotericin B, while PKDL may be managed with Oral Miltefosin. Cutaneous leishmaniasis (Option B) is typically characterized by a pink papule that ultimately forms an indurated ulcer. There may be associated eschar (Old World) or yellow fibrin coverage (New World). Pityriasis versicolor (Option D) is a cutaneous fungal infection that may also present with multiple hypopigmented macules. However, it typically lacks systemic complaints, as seen in this patient. Condition Primary Skin Presentation Systemic Findings Key Distinguishing Features Post-Kala-Azar Dermal Leishmaniasis (PKDL) Hypopigmented macules (trunk), papules, or nodules. Massive splenomegaly; history of Visceral Leishmaniasis. Follows inadequately treated Kala-azar; diagnosed via PCR of scrapings. Lepromatous Leprosy Similar lesions to PKDL (macules/nodules). Often involves nerve thickening. Presence of sensorineural changes (unlike PKDL). Cutaneous Leishmaniasis Pink papule that evolves into an indurated ulcer. Usually localized to the skin. Presence of eschar (Old World) or yellow fibrin coverage (New World). Pityriasis Versicolor Multiple hypopigmented macules. None (purely cutaneous). Fungal infection; lacks the systemic complaints seen in Leishmaniasis.

References:

https://link.springer.com/chapter/10.1007/978-981-99-6999-9_6?

https://www.thelancet.com/journals/laninf/article/PIIS1473-3099(03)00517-6/abstract?

↑ *Back to this question in Part A*

@Neet_pg_bot

Q17: A 30-year-old male soldier who had recently been deployed to Iraq presents with a mildly itchy, raised rash on his neck. He has no other systemic complaints. Examination revealed a painless plaque with ulceration and overlying crusting associated with tender posterior lymphadenopathy. What is the likely causative organism? (Q842062)

A. Leishmania mexicana

B. Leishmania braziliensis

C. Leishmania major

D. Leishmania donovani

Correct Answer: C. Leishmania major

■ *Listen (English)*

■ *Listen (Hindi)*

Explanation: This case describes Old World Cutaneous Leishmaniasis (CL) in a soldier recently deployed to Iraq , a region endemic for Leishmania major . The clinical features (painless ulcerated plaque with crusting and lymphadenopathy) are classic for cutaneous leishmaniasis . Leishmaniasis is a vector-borne disease caused by protozoa of the genus Leishmania , transmitted by female sand flies (Phlebotomus in the Old World). The clinical spectrum ranges from cutaneous ulcers to systemic multiorgan disease (visceral leishmaniasis). Cutaneous Leishmaniasis (CL): Type Region Species Clinical Features Old World CL Middle East, Africa, Asia L. major , L. tropica Painless papule → nodule/plaque → ulcer , often with crusting and raised volcano-like margins New World CL Central and South America L. mexicana , L. braziliensis Similar lesions; L. mexicana causes Chiclero's ulcer (chronic ulcers on the ear due to multiple bites) New World CL: The ulcer may be covered with thick white-yellow fibrinous material. ‘Chiclero’s ulcer’ - multiple, small, chronic ulcers on the ear, due to multiple sandfly bites. {{caption_text}} Mucocutaneous Leishmaniasis (ML): Caused by L. braziliensis (Option B) . Involves mucosal destruction of the nasal septum, mouth, and throat . Features include nasal congestion, bleeding, pain, and eventual disfigurement . Visceral Leishmaniasis (Kala-azar): Caused by Leishmania donovani (Option D). Presents with fever, weight loss, hepatosplenomegaly, and pancytopenia . No cutaneous lesions are typical.





@Neet_pg_bot



@Neet_pg_bot

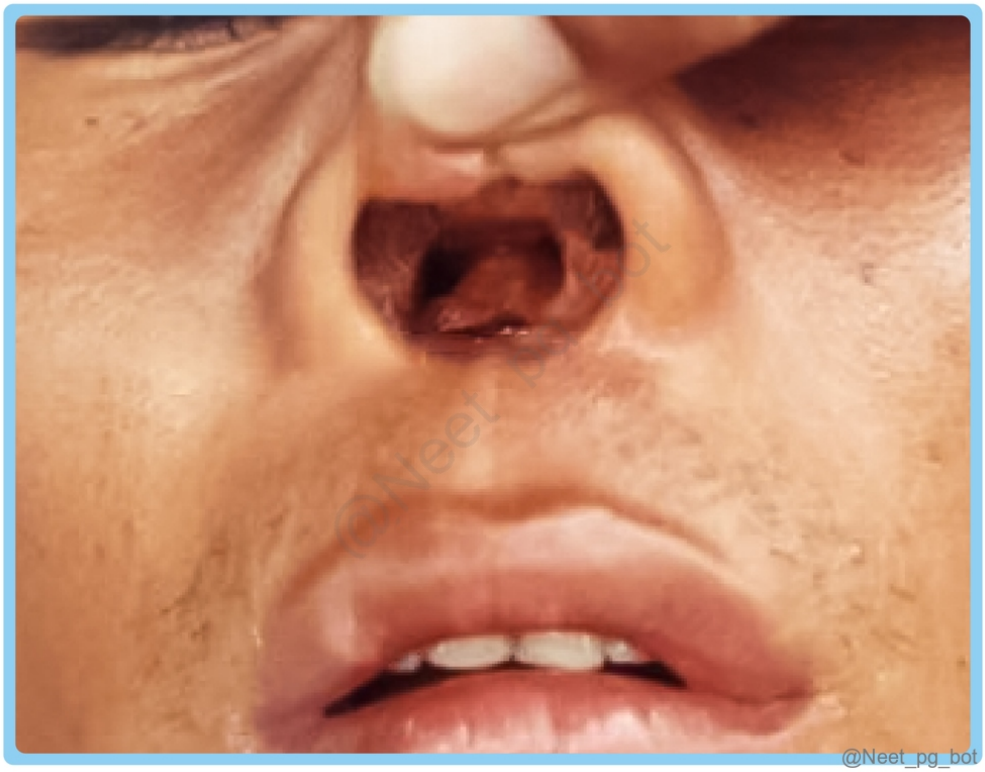

References:

www.uptodate.com/contents/cutaneous-leishmaniasis-clinical-manifestations-and-diagnosis

↑ *Back to this question in Part A*

@Neet_pg_bot

Q18: As shown in the figure, a 10-year-old boy presents with a painless swelling over his left lower eyelid. He reports visiting the Amazon forest on vacation with his family recently. If left untreated, which of the following is not a long-term risk? (Q842061)

A. Sleeping sickness

B. Heart failure

C. Megaesophagus

D. Megacolon



Correct Answer: A. Sleeping sickness

- *Listen (English)*
- *Listen (Hindi)*

Explanation: American trypanosomiasis: The given image shows Romana's sign, i.e., a swollen nodule or ‘ chagoma ’ at the site of infection, most commonly over the eyelids or near the mouth. This is an early sign of Trypanosoma cruzei infection, which is endemic to South America and is therefore called American trypanosomiasis. Trypanosoma cruzei is transmitted via the bite of the Reduviid bug , or kissing bug (named so because the bite is painless). Early symptoms are non-specific and include fever, lymphadenopathy, and the Romana sign. If untreated, it can lead to Chaga’s disease, the manifestations of which include Dilated cardiomyopathy - heart failure (Option B) , arrhythmias, sudden cardiac death. Megaesophagus and megacolon (Options C and D) - due to autonomic nerve destruction. Diagnosis of acute disease is by demonstration of T cruzi trypomastigote on blood smears. {{caption_text}} Treatment of acute disease involves Nifurtimox or Benznidazole. Chaga’s disease is incurable and requires supportive care as appropriate. Sleeping sickness: This is caused by T. brucei (rhodesiense or gambiense). It is endemic to rural Africa and is transmitted by the tse tse fly. It is also known as African trypanosomiasis. Early infection is non-specific, with fever, cervical lymphadenopathy (Winterbottom’s sign: posterior cervical triangle lymphadenopathy), Kerandl sign (delayed pain after a sharp blow or squeeze to soft tissue) and arthralgia, which lasts for varying lengths of time. Late infection is characterized by neuropsychiatric manifestations, with sleep-wake cycle disturbance prominent.

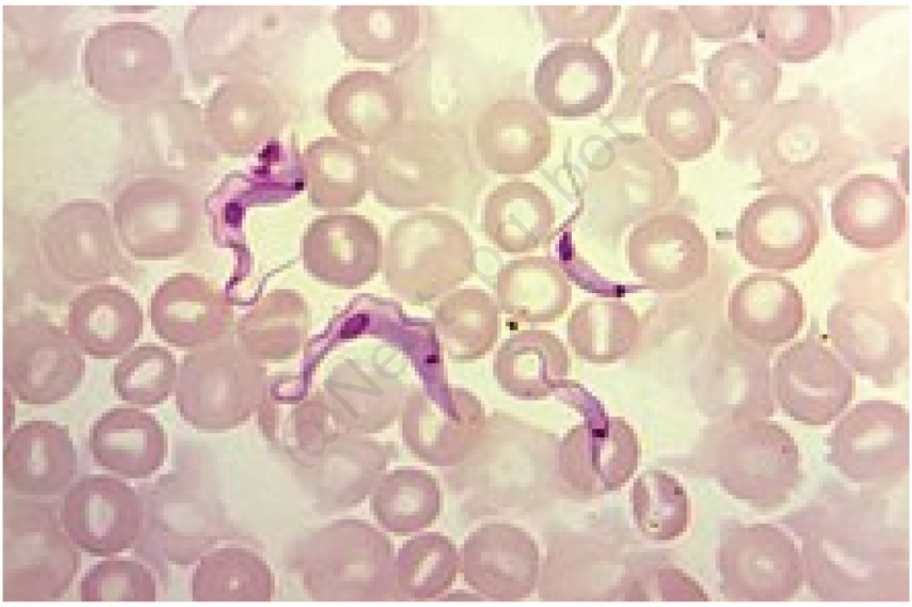

References:

www.uptodate.com/contents/human-african-trypanosomiasis-epidemiology-clinical-manifestations-and-diagnosis

www.uptodate.com/contents/chagas-disease-acute-and-congenital-trypanosoma-cruzi-infection

↑ *Back to this question in Part A*

@Neet_pg_bot

Q19: A 20-year-old female presents with an itchy lesion as shown below. She reports that it started as a small, red, itchy spot, then progressed over the next few days to its current form. She also reveals a recent beach holiday. What is the causative organism? {{caption_text}} (Q842060)

A. Loa loa

B. Ancylostoma caninus

C. Strongyloides stercoralis

D. Ascaris lumbricoides



Correct Answer: B. Ancylostoma caninus

- *Listen (English)*
- *Listen (Hindi)*

Explanation: The given case scenario describes cutaneous larva migrans. This is caused by animal hookworm larvae (Ancylostoma braziliensis/ caninum) and typically occurs due to walking barefoot on contaminated sand or soil. It classically begins with a pruritic, erythematous papule at the site of penetration, followed by intensely pruritic, serpiginous, reddish-brown skin tracks, along the path of migration of the larvae. These develop slowly over days (1-2 cm/day) The larvae cannot penetrate beyond the dermis, so systemic manifestations are uncommon. Treatment involves oral ivermectin. Loa loa (Option A) is the African eye worm. It causes Calabar swellings, painless, transient swellings over the eyelid. {{caption_text}} Strongyloides stercoralis (Option C) causes larva currens by its intradermal migration. While similar to cutaneous larva migrans, it is distinguished by more rapid migration within the skin (5-15 cm/hour), intense urticaria surrounding the path of migration, and potential perianal involvement. Ascaris lumbricoides (Option D) causes ascariasis with larvae migrating through the bloodstream to the lungs and intestines, causing primarily gastrointestinal and respiratory symptoms. Unlike hookworms, Ascaris larvae do not migrate within the skin and thus do not cause cutaneous larva migrans.



References:

https://www.uptodate.com/contents/hookworm-related-cutaneous-larva-migrans

↑ *Back to this question in Part A*

@Neet_pg_bot

Q20: A 9-year-old girl presents with complaints of an itchy scalp for the last few days. Local inspection reveals mild crusting in areas of the scalp, with multiple white nits along the hair shafts. What is the causative organism? {{caption_text}} (Q842059)

A. Pediculus humanus corporis

B. Pthirus pubis

C. Sarcopteis scabei

D. Pediculus humanus capitis



Correct Answer: D. Pediculus humanus capitis

- *Listen (English)*
- *Listen (Hindi)*

Explanation: Pediculosis capitis Pediculosis corporis Pediculosis pubis Spread Skin-to-skin contact/ fomites Skin-to-skin contact/ fomites Skin-to-skin contact sexually transmitted Causative agent Head louse (Pediculus humanus capitis) (Option D) Body louse (Pediculus humanus corporis) (Option A) Pubic louse (pthris pubis) (Option B) Classical scenario School-going children (girls - long hair) Destitute and homeless - Presentation, clinical features Itching of the scalp. Multiple lice or nits (empty eggs of the lice) May be crusting, secondary folliculitis secondary to scratching. May have regional lymphadenopathy. Morbus Errorum (body lice infestation) is characterized by excoriated itchy papules over the body and the presence of nits in the folds of clothes. Itchy papules in the groin and genital region. ‘Macula cerulea’ is a bluish dot over the affected area caused by blood extravasation secondary to anticoagulants in the louse’s saliva. Treatment 1% permethrin 1% permethrin 1% permethrin Pediculus humanus Pubic louse Sarcoptes scabiei (Option C) causes scabies, which classically presents with itchy papules over the webbed spaces of the fingers. The face and scalp are typically spared.



@Neet_pg_bot

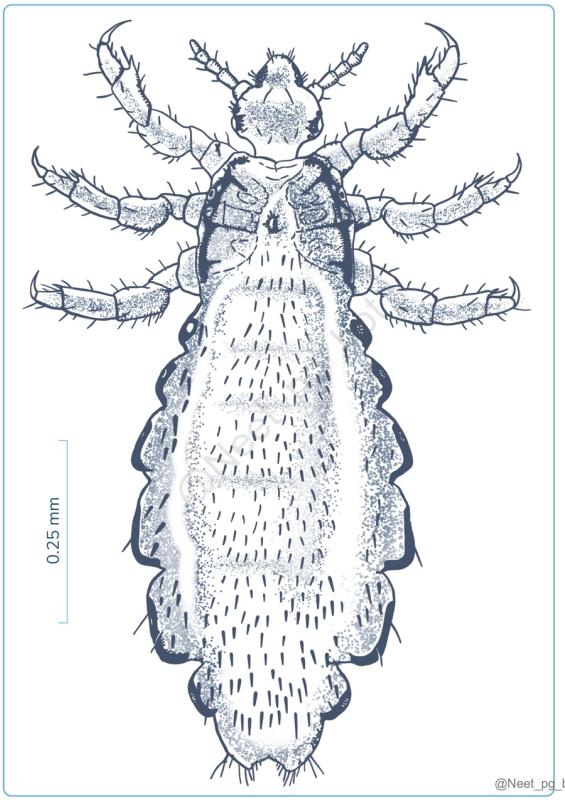



@Neet_pg_bot

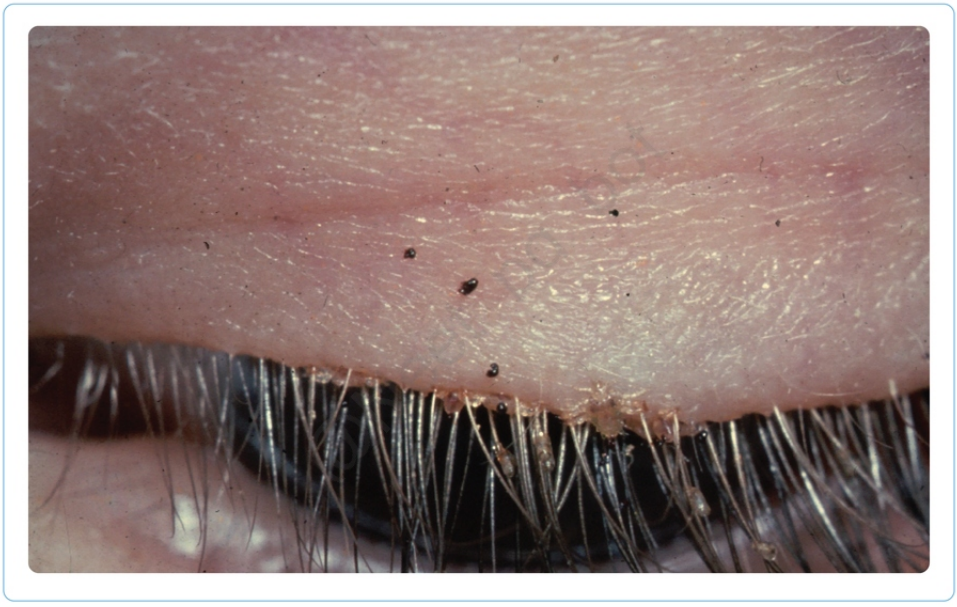

@Neet_pg_bot



References:

https://www.uptodate.com/contents/pediculosis-capitis

↑ *Back to this question in Part A*

@Neet_pg_bot

Q21: A 6-month-old girl is brought by her parents for evaluation of a rash. On examination, she appears uncomfortable, and there are multiple small red papules on her face, palms, and soles. Multiple small burrows are also seen. Microscopy of skin scrapings is shown below. What is the causative organism? (Q842058)

A. Phthiris pubis

B. Sarcoptes scabiei

C. Trichophyton

D. Staphylococcus aureus

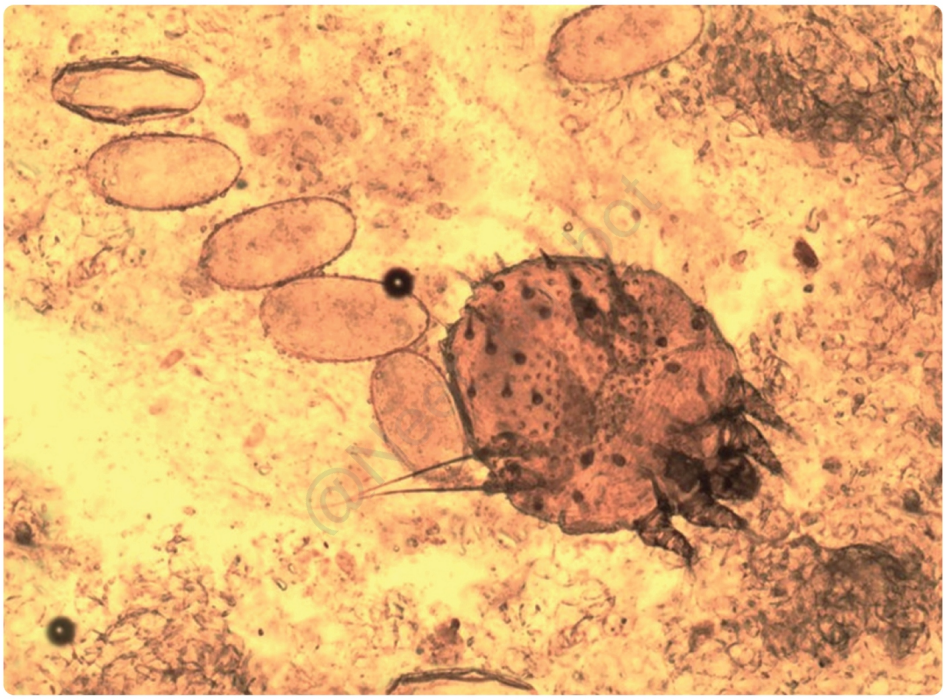

Correct Answer: B. Sarcoptes scabiei

- *Listen (English)*
- *Listen (Hindi)*

Explanation: The given clinical scenario describes infantile scabies. Infantile scabies are similar to adult scabies, except that there is more extensive involvement, including the face, palms, and soles. Examination reveals erythematous papules with burrows. Lesions may even be vesicular or bullous due to greater inflammatory response in children. {{caption_text}} Skin scraping and microscopic examination of the epidermis from the affected sites establish the diagnosis of scabies. KOH may be used to dissolve keratin debris. Microscopic evaluation will reveal mites, eggs, and feces. {{caption_text}} Mite with eggs Phthirus pubis (Option A) causes pubic lice (crab louse infestation), primarily affecting pubic hair, not associated with burrows or extensive infantile involvement. Trichophyton (Option C): A dermatophyte fungus responsible for tinea infections (e.g., ringworm), which presents with scaly patches rather than burrows or vesicles. Staphylococcus aureus (Option D) can cause impetigo and bullous skin infections but does not produce burrows, mites, or microscopic eggs in skin scrapings.



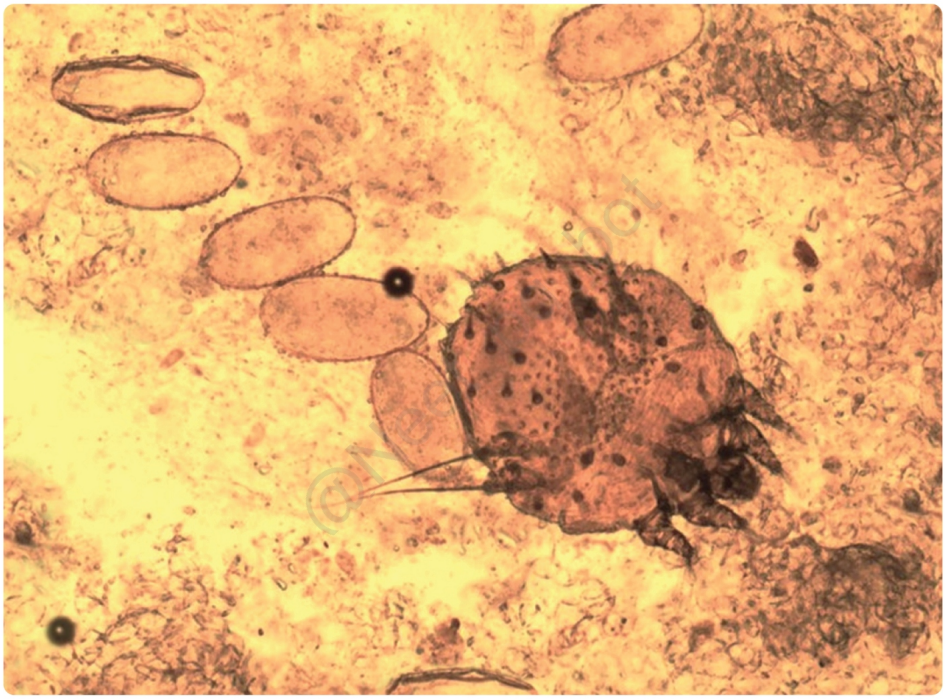

References:

https://www.aafp.org/pubs/afp/issues/2013/0415/p536.html?

https://www.uptodate.com/contents/4038

https://link.springer.com/article/10.1007/s00431-024-05535-1

↑ *Back to this question in Part A*

@Neet_pg_bot

Q22: A 30-year-old female with lymphoma on chemotherapy presents with large, crusted plaques over her entire torso, arm, and legs. She reports minimal itching. What is the optimal treatment regimen for this patient? (Q842057)

A. Oral ivermectin alone

B. Topical permethrin alone

C. Ivermectin + Permethrin

D. Topical steroids



@Neet_pg_bot

Correct Answer: C. Ivermectin + Permethrin

■ *Listen (English)*

■ *Listen (Hindi)*

Explanation: This patient likely has crusted scabies or Norwegian scabies (NS). This is a severe form of scabies due to massive infestation of the itch mite. Risk factors include: Immunocompromise (HIV, malignancy, etc) Old age Neurologic disease NS is characterized by large, hyperkeratotic plaques that may cover up to 90% of the body's surface. Due to diminished immunity, pruritus is typically absent, contributing to the accumulation of crusts. These crusts can contain millions of mites and their eggs. {{caption_text}} Treatment involves both oral ivermectin and topical permethrin. Additionally, a keratolytic agent may be used to help the penetration of permethrin. Monotherapy (Options A & B): While oral ivermectin or topical permethrin alone are used for classic scabies, they often fail when used alone for the NS due to the sheer number of mites and the protective barrier formed by the crusts. Topical steroids (Option D): Topical steroids are the treatment of choice for nodular scabies, a special form of scabies caused by a hypersensitivity response to the mites. The lesions are typically pruritic, with firm nodules/ papules over the axilla and groin. {{caption_text}} Nodules in the axilla of a patient with nodular scabies





References:

www.cdc.gov/parasites/scabies/health_professionals/

www.uptodate.com/contents/scabies-epidemiology-clinical-features-and-diagnosis

↑ *Back to this question in Part A*

@Neet_pg_bot

Q23: A 10-year-old boy is diagnosed with scabies after presenting with severe itching lesions, predominantly over his wrists and hands. What is the first-line treatment for his condition? (Q842040)

A. 5 % Permethrin

B. Gamma benzene hexachloride (GBHC)

C. Precipitated sulfur

D. Ivermectin

Correct Answer: A. 5 % Permethrin

■ *Listen (English)*

■ *Listen (Hindi)*

Explanation: 5% Permethrin is the drug of choice for scabies. It is given in addition to general measures: Anti-histamines for pruritus Wash clothes, and bedding with hot water Examine and treat family members MOA: Blocks sodium channels of the itch mite, causing paralysis. Application: Apply below the neck for 8-12 hours at a time (overnight); it is typically applied twice, one week apart. It is safe and can be used in all patients older than 2 months. 1% Permethrinis used for pediculosis GBHC (Option B): An older chloride-channel blocker that is rarely used. It is also not safe in pregnancy, in those with neurologic disorders, and in children. Precipitated sulfur (Option C) : While safe and effective, this is not the first choice, as its odour can make it unpleasant to use, But can be used in infants <2 months old. Ivermectin (Option D): Given orally (200mc/kg—two doses). It is typically reserved for patients with scabies who do not respond to permethrin, atypical scabies, and those who cannot comply with or tolerate topical alternatives. Briefly, other drugs include- Crotamiton (not safe in children), Malathion, Benzyl Benzoate, and Lindane (not safe in children, pregnancy).

References:

Rook's Textbook of Dermatology, 9th Edition, Pages 34.43, 34.44

www.cdc.gov/parasites/scabies/health_professionals/

↑ *Back to this question in Part A*

@Neet_pg_bot

• [18_Parasitic Infection] 036 Previous Year Questions

« Back to Folder Directory

[18_Parasitic Infection] 036 Previous Year Questions — Quick Jump

Q1 (p. 1452) *Q2 (p. 1452)* *Q3 (p. 1454)* *Q4 (p. 1455)* *Q5 (p. 1457)*

Q1: Which of the following treatments are appropriate for scabies in infants? a. 5% Permethrin cream b. 10% Crotamitron c. Ivermectin d. 25% Benzyl benzoate lotion (Q865457)

A. a, b, c

B. a, b, d

C. a, c, d

D. b, c, d

Correct Answer: B. a, b, d

Explanation: Ivermectin is contraindicated in children under 5 years of age; however, all the other mentioned drugs can be safely used to treat scabies in infants. Drugs for scabies Permethrin (1st line) (Option a) A highly effective pyrethroid insecticide, with nearly 100% cure rates in scabies after a single application. Lindane (2nd line) A broad-spectrum insecticide, but less effective than permethrin and has a higher risk of systemic toxicity, particularly in children. Benzyl Benzoate (2nd line) (Option d) Minimally absorbed through the skin and has low systemic toxicity but can cause neurological symptoms in children. Crotamiton (2nd line) (Option b) Less prone to cause skin irritation and has low systemic toxicity but has produced lower cure rates in scabies. Sulfur The oldest scabicide but has several disadvantages, including messy application, unpleasant odour, and the need for repeated applications. Dicophane (DDT) Can be absorbed through the skin and cause systemic toxicity, rarely used due to potential side effects and safer alternatives. Ivermectin An oral medication that is highly effective in treating scabies. Not to be given to children <5 yrs old, pregnant, or breastfeeding women. (Option c ruled out)

References:

K D Tripathi, Essentials of Medical Pharmacology, 8th Edition, Page 961-963.

↑ *Back to this question in Part A*

@Neet_pg_bot

Q2: A pregnant woman presents with lymph node swelling. She has a history of toxoplasmosis infection 5 years ago and is IgG positive. What should be the next step? (Q866558)

A. Congenital anomalies risk is high

B. Reassurance, continue pregnancy

C. Do amniotic sampling to find if fetus is infected or not

D. Start treatment

Correct Answer: B. Reassurance, continue pregnancy

Explanation: Toxoplasma IgG positivity with past infection (several years ago) indicates immunity and no active infection . Once infected, the risk of congenital transmission is only present during the acute phase of maternal infection. Chronic/past infection does not pose a risk to the fetus and requires no intervention. Therefore, reassurance and routine antenatal care are appropriate. Toxoplasmosis in pregnancy Mother Usually asymptomatic but can transmit the disease to the infant. Infective form Trophozoite crosses the placenta to infect the neonate. Risk of transplacental infection based on time of infection of the mother Transplacental infection can occur at any tim e during the pregnancy, but the gestational age influences the risk of transmission. As the gestational age increases, the risk of transmission increases, but the severity of neonatal disease decreases. Pre-pregnancy Very low chance of transmission (immunocompromised mother) First trimester Minimal risk of transmission. If transmitted, it results in more severe fetal complications. Third trimester Maximum risk of transmission. If transmitted, it is usually asymptomatic in newborns. Diagnosis of Toxoplasmosis Antenatal USG Done at 20-24 weeks of gestation and repeated every 2-4 weeks It helps detect lesions of congenital infection, such as Hydrocephalus Cerebral calcifications Ascites Serology ELISA (Enzyme-Linked Immunosorbent Assay) or IFA (Immunofluorescence Assay) is done using maternal serum to detect IgM and IgG PCR Amniotic fluid can be used to detect Toxoplasma DNA, which can confirm the diagnosis. It is not done routinely as it is invasive and expensive, and other safer options are available. Postnatal diagnosis Serology Newborn Sera and maternal sera are both used to detect IgG >= 1000: Possible infection IgM >= 1:4 after 2 weeks of age: Indicates probable diagnosis IgA : Disappears within 10 days of birth; thus, persistence indicates postnatal infection Sabin-Feldman test - Complement fixation test Other tests Animal inoculation (no longer done for clinical diagnosis) Skin test of Frenkel Microscopy of samples to detect tachyzoites using Giemsa or PAS Congenital anomalies risk is high (Option A): Risk is only high with acute infection during pregnancy, not with past resolved infection. Do amniotic sampling to find if fetus is infected or not (Option C): Unnecessary since there is no evidence of recent infection; IgM would be positive in acute infection. Start treatment (Option D): Antiparasitic treatment is indicated only in acute infection during pregnancy to reduce fetal risk, not in past infection.

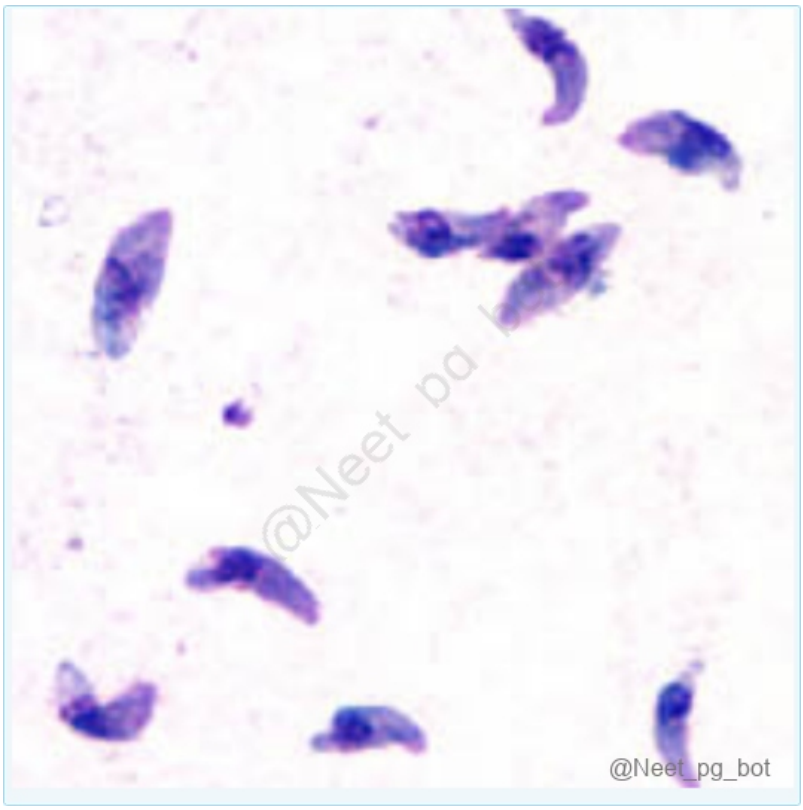

↑ *Back to this question in Part A*

@Neet_pg_bot

Q3: A young boy came to the OPD with complaints of severe itching at night. On examination, burrows are seen over intertriginous areas, axillae, umbilicus, and between digits. Which ofthe following transmits the condition described in the scenario? (Q860618)

A. Louse

B. Tick

C. Mite

D. Flea

Correct Answer: C. Mite

Explanation: The child's symptoms of severe nocturnal itching and the presence of burrows in intertriginous areas, axillae, umbilicus, and between the fingers are characteristic of scabies, which is caused by Sarcoptes scabiei (a mite). Scabies: Parasitic infection of the skin caused by Sarcoptes scabiei (itch mite). Mode of spread: Scabies are

highly contagious, and transmission is by skin-to-skin contact and fomites. Risk factors include poor personal hygiene. Clinical manifestation: The characteristic sign of scabies is the presence of burrows, Are thin, grayish-white or skin-colored, linear or wavy lines found in areas like the webbing between fingers, wrists, elbows, armpits, waistline, buttocks, genital area, and ankles, causing intense itching, especially at night. Examination typically reveals excoriated papules, typically over the web spaces of the fingers (as shown in the image). Other areas of the body that must be examined for lesions include: The medial aspect of the wrist The medial aspect of the forearm Umbilicus Axilla Nipple Genitalia/ groin- burrows (wavy, grey tunnels) This distribution is called the circle of Hebra. The face is typically spared, due to high amounts of sebum in the facial skin. Circle of Hebra demonstrating the typical location of scabies lesions Incorrect Options: Louse (Option A): Lice (Pediculus humanus capitis, Pediculus humanus corporis, Pthirus pubis) cause pediculosis (head/body/pubic lice) , which presents with itching and nits attached to hair shafts , not burrows in the skin. Tick (Option B): Ticks are blood-feeding arachnids that transmit diseases like Lyme disease, Rocky Mountain spotted fever, and babesiosis . They do not burrow into the skin or cause widespread itching. Flea (Option D): Fleas (Pulex irritans) cause pruritic papules , often in a clustered pattern ("breakfast, lunch, and dinner" sign) , but they do not form burrows in the skin.

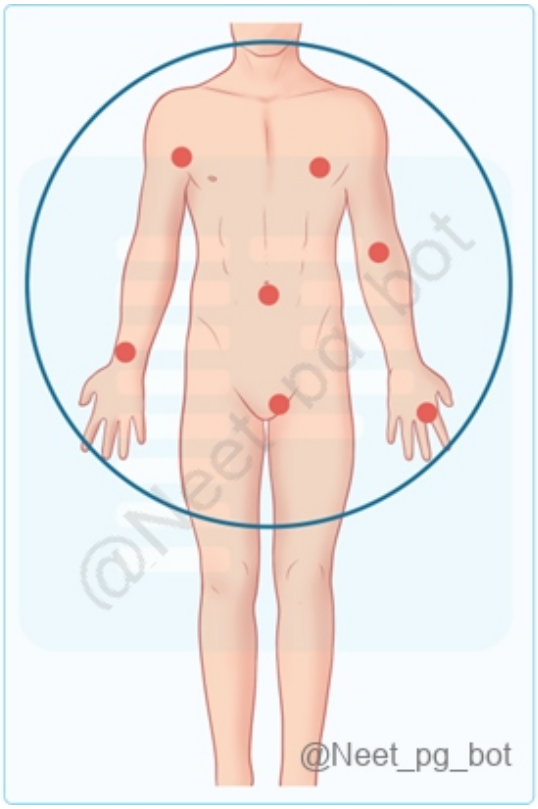

References:

https://www.uptodate.com/contents/scabies-epidemiology-clinical-features-and-diagnosis

↑ *Back to this question in Part A*

@Neet_pg_bot

Q4: The involvement of which of the following results in the given condition below? (Q820238)

A. Arteries

B. Vein

C. Lymphatics

D. DVT



Correct Answer: C. Lymphatics

Explanation: Correct Option C - Lymphatics The correct answer is lymphatics. Filariasis is a disease caused by parasitic worms, specifically Wuchereria bancrofti, Brugia malayi, and Brugia timori. These worms primarily inhabit the lymphatic system, causing inflammation and obstruction of lymphatic vessels. This leads to the clinical manifestations of filariasis, such as lymphedema (swelling), elephantiasis (severe swelling), and other related complications. Incorrect Options: Option A- Arteries: Arteries are blood vessels that carry oxygenated blood away from the heart to various parts of the body. They do not play a direct role in filariasis. Filariasis is a parasitic infection caused by thread-like filarial worms, typically transmitted through mosquito bites. The worms primarily affect the lymphatic system, not the arteries. Option B - Vein: Veins are blood vessels that carry deoxygenated blood back to the heart. Similar to arteries, veins do not have a direct role in filariasis. The infection mainly targets the lymphatic system, leading to the characteristic swelling of body parts due to impaired lymph flow. Option D - DVT (Deep Vein Thrombosis): DVT is a condition where a blood clot forms in a deep vein, usually in the legs. While DVT involves veins, it is unrelated to filariasis. DVT results from the formation of blood clots within veins, often due to factors like prolonged immobility, certain medical conditions, or genetic predisposition.

↑ *Back to this question in Part A*

@Neet_pg_bot

Q5: Identify the disease shown in the image below (Q859897)

A. Syphilis

B. Leprosy

C. Elephantiasis

D. Leishmaniasis



Correct Answer: C. Elephantiasis

Explanation: Elephantiasis is a condition characterized by massive swelling and thickening of the skin and underlying tissues, most commonly affecting the limbs and genitalia. It results from lymphatic obstruction, leading to chronic lymphedema and progressive fibrosis. Elephantiasis: Cause: Delayed sequel of repeated lymphangitis, obstruction, and lymphedema. Pathophysiology: Persistent lymph leakage into tissues → chronic lymphedema → elephantiasis. Clinical Features: Nonpitting brawny edema (firm swelling). Thickened skin, cracks, and fissures. Growth of new adventitious tissue. Increased risk of secondary bacterial and fungal infections. Commonly Affected Areas: Legs (most common), but other body parts can also be involved. Causes of Elephantiasis: Lymphatic Filariasis (most common cause) Caused by parasitic nematodes like Wuchereria bancrofti , Brugia malayi , and Brugia timori Transmitted by mosquito bites Leads to chronic lymphatic obstruction and severe swelling Non-Filarial Elephantiasis (Podoconiosis) Caused by chronic exposure to volcanic soil with high silica

content Seen in tropical regions like Africa and South America Other Causes: Repeated bacterial infections (e.g., streptococcal cellulitis) Tumors obstructing lymphatics Milroy's disease (congenital primary lymphedema) Filariasis: Agent: Wucheria bancrofti: Lymphatic filariasis Brugia malayi: Brugian/Malayan filariasis Endemic areas: Bihar, Jharkhand , Uttar Pradesh, Kerala, Gujarat Host: Definitive: Man Secondary/ intermediate: Culex quinquefasciatus or fatigans Mode of Transmission: Bite of the mosquito (vector) W. bancrofti: Culex quinquefasciatus or fatigans (polluted water) B. malayi: Mansonia (ponds, lakes) Incubation period: 8-16 months. Transmission: Cyclodevelopmental Clinical features: Asymptomatic amicrofilariae : No symptoms, smear-negative Asymptomatic microfilariae: No symptoms, smear-positive Acute stage (few months) : Fever, lymphadenitis , epididymo-orchitis. Chronic Obstructive stage (>10 years) : Hydrocele, chyluria, elephantiasis Occult stage: Tropical pulmonary eosinophilia (hypersensitivity reaction) with absent microfilariae Syphilis (Option A): Syphilis (Treponema pallidum infection) causes painless ulcers (chancre), maculopapular rash, and systemic involvement, but does not lead to massive lymphedema. Leprosy (Option B): Leprosy (Mycobacterium leprae) leads to skin lesions, nerve damage, and deformities, but does not cause gross limb swelling like elephantiasis. Leishmaniasis (Option D): Cutaneous leishmaniasis presents with ulcerative skin lesions, while visceral leishmaniasis causes hepatosplenomegaly and fever. Neither form causes lymphatic obstruction and massive swelling.

References:

https://www.sciencedirect.com/science/article/pii/S0001706X21000978#:~:tex

Park's Textbook of Preventive and Social Medicine 27th Edition Pg: 315-317

↑ *Back to this question in Part A*

@Neet_pg_bot

• [19_Skin Tumours] 037 Skin Tumors

« Back to Folder Directory

[19_Skin Tumours] 037 Skin Tumors — Quick Jump

Q1 (p. 1459)	*Q2 (p. 1462)*	*Q3 (p. 1462)*	*Q4 (p. 1465)*	*Q5 (p. 1465)*	*Q6 (p. 1467)*
Q7 (p. 1472)	*Q8 (p. 1473)*	*Q9 (p. 1474)*	*Q10 (p. 1475)*	*Q11 (p. 1477)*	*Q12 (p. 1477)*
Q13 (p. 1478)	*Q14 (p. 1480)*	*Q15 (p. 1481)*	*Q16 (p. 1482)*	*Q17 (p. 1483)*	*Q18 (p. 1485)*
Q19 (p. 1486)	*Q20 (p. 1488)*	*Q21 (p. 1489)*	*Q22 (p. 1492)*	*Q23 (p. 1493)*	*Q24 (p. 1495)*
Q25 (p. 1497)	*Q26 (p. 1501)*	*Q27 (p. 1502)*	*Q28 (p. 1503)*	*Q29 (p. 1504)*	*Q30 (p. 1506)*
Q31 (p. 1510)					

Q1: Which of the following is NOT a cutaneous marker of underlying internal malignancy? (Q841734)

A. Necrolytic migratory erythema

B. Acanthosis nigricans

C. Erythroderma

D. Erythema chronicum migrans

Correct Answer: D. Erythema chronicum migrans

■ *Listen (English)*

■ *Listen (Hindi)*

Explanation: Erythema chronicum migrans (ECM) is not typically a marker of internal malignancy. It is the characteristic rash of early Lyme disease , caused by the tick-borne spirochete Borrelia burgdorferi . Erythema Chronicum Migrans (ECM): Seen in ~90% at tick bite site, 1–36 days post-bite. Expanding ring-shaped lesion with central clearing (“target” look). May itch or burn; sometimes scaly. Fades in weeks without treatment; may have lymphadenopathy or mild systemic symptoms. Necrolytic migratory erythema (Option A):Associated with : Glucagonoma (a rare pancreatic islet cell tumor). Acanthosis nigricans (Option B): Can be a cutaneous marker of internal malignancy, most commonly gastric adenocarcinoma . Also associated with insulin resistance and diabetes mellitus . Erythroderma (Option C): Defined as inflammation affecting >90% of the body surface area . Also linked to internal malignancies , especially lymphomas



@Neet_pg_bot

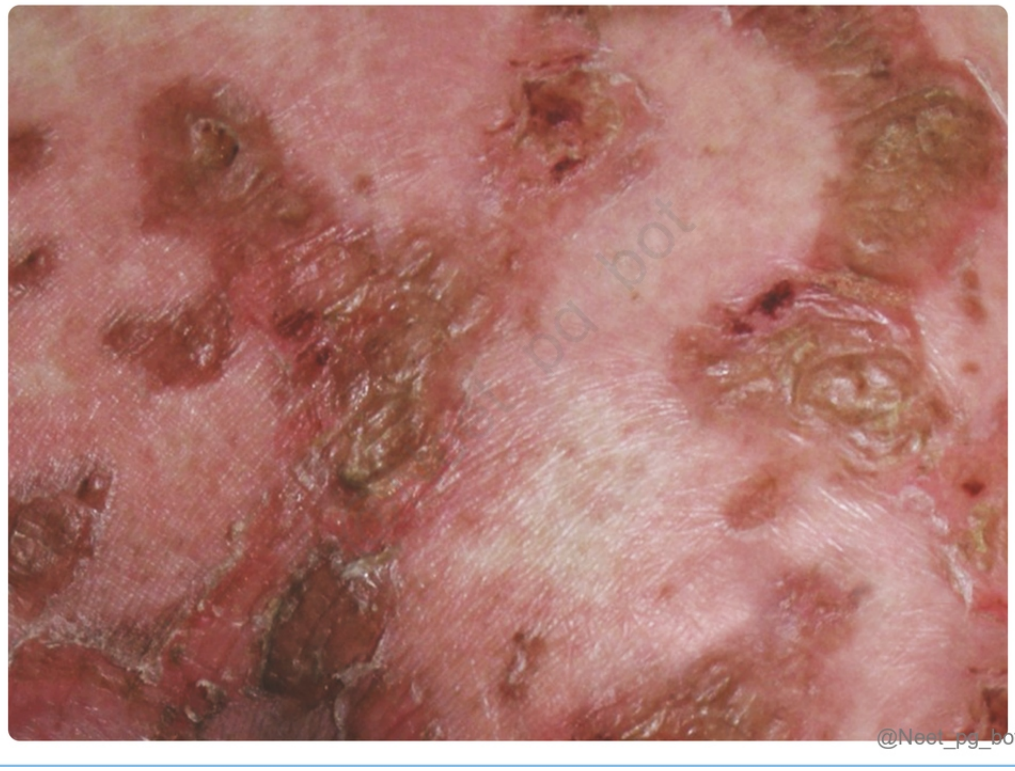

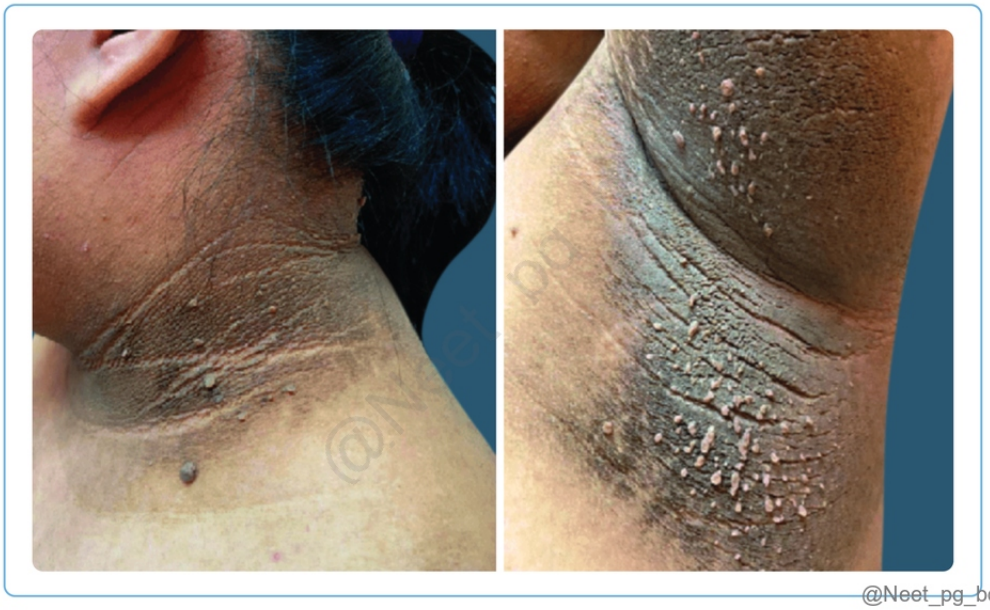



References:

Rooks Textbook of Dermatology, 9th Edition, Page 39.31, 147.1

↑ *Back to this question in Part A*

@Neet_pg_bot

Q2: Which of the following is not included in the clinical triad of sezary syndrome? (Q841730)

A. Erythroderma

B. Peripheral lymphadenopathy

C. Atypical mononuclear cells >20% of total lymphocytes

D. Follicular Mucinosis

Correct Answer: D. Follicular Mucinosis

■ *Listen (English)*

■ *Listen (Hindi)*

Explanation: Follicular mucinosis is not a part of the clinical triad of sezary syndrome. It is a type of cutaneous T-cell lymphoma presenting with boggy plaques and mucinous degeneration of hair follicles. THE TRIAD CONSISTS OF: Erythroderma: This refers to diffuse redness affecting more than 80% of the body surface area. The skin appears eczematous and may be associated with variable scaling. Sézary syndrome often presents with rapid-onset itching and erythroderma. It can occur without prior signs of another type of CTCL called mycosis fungoides. (Option A ruled out) Lymphadenopathy: Generalized enlargement of lymph nodes is a common feature. These swollen lymph nodes are often palpable and can be detected during physical examination. (Option B ruled out) Atypical Malignant (Sézary Cells): These abnormal T-cells are found in the skin, blood, and lymph nodes, comprising >20% of total lymphocyte count or total sezary count of >1000x10 9 /L. (Option C ruled out)

References:

Rooks textbook of dermatology 9th ed, page no. 140.18

↑ *Back to this question in Part A*

@Neet_pg_bot

Q3: A 50-year-old construction worker presents to the dermatology OPD with a black mole over his back as shown in the image. Which of the following investigations is the gold standard for diagnosis of this condition? (Q841722)

A. Dermoscopy

B. Clinical examination

C. Biopsy

D. CT



Correct Answer: C. Biopsy

■ *Listen (English)*

■ *Listen (Hindi)*

Explanation: The given clinical scenario along with the image showing a lesion with irregular borders , asymmetry , and uneven distribution of colors in the lesion is suggestive of malignant melanoma . The gold standard investigation for diagnosis of melanoma is histopathological examination by a biopsy. Biopsy findings in malignant melanoma: Melanoma cells: larger than normal melanocytes or nevus cells. Nuclei: enlarged, irregular, peripheral chromatin clumping, eosinophilic nucleoli. Radial phase: horizontal spread in epidermis/superficial dermis. Vertical phase: deep dermal invasion as expansile mass. The given image below shows the histology of superficial spreading melanoma (M/C type). Dermoscopy(.Option A) : noninvasive lesion exam using polarized/nonpolarized light; initial test for suspected melanoma, confirmed by biopsy.■■■■■■■ Clinical examination (Option B) detects melanoma in 80–90% using the ABCDE checklist but lacks specificity; biopsy confirms diagnosis.The ABCDE features include: Asymmetry: Irregular shapes. Border: Irregular. Colour: Various colours present or uneven distribution. Diameter: > 6 mm. Evolution: Changes in lesion over time (size, shape, itching, or bleeding). CT scan (Option D) is not used for diagnosis of malignant melanoma; rather it can be used for follow-up of patients after surgical excision.

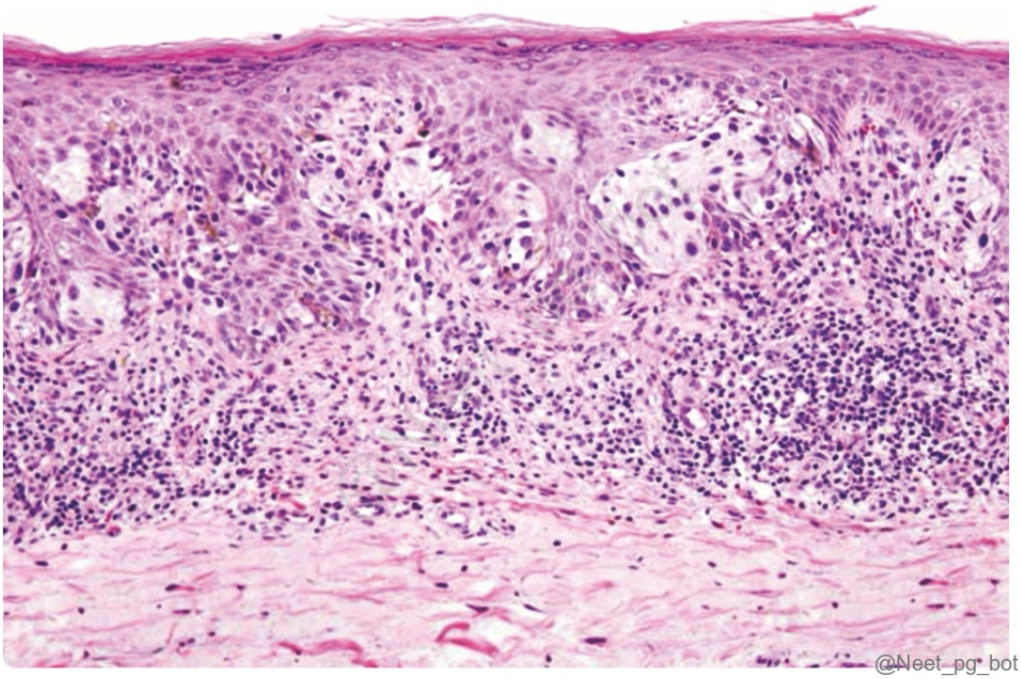

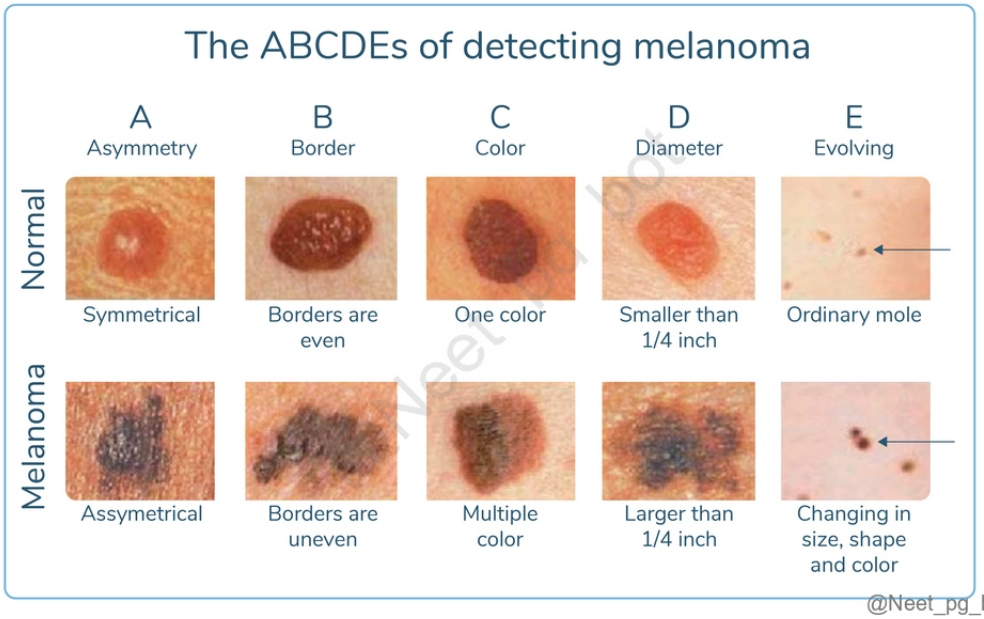

References:

Rooks Textbook of Dermatology, 9th Edition, Page 143.8-143.20

Fitzpatrick Textbook of Dermatology, 9th Edition, Page 1991, 1992

Robbins and Cotran, Pathologic Basis of Disease, 10th Edition, Page 1141

↑ *Back to this question in Part A*

@Neet_pg_bot

Q4: Extracorporeal photopheresis is most useful in which of the following conditions? (Q887632)

A. Plaque psoriasis

B. Sezary syndrome

C. Atopic dermatitis

D. Vitiligo

Correct Answer: B. Sezary syndrome

Explanation: Extracorporeal photopheresis (ECP) is an immunomodulatory therapy used primarily in erythrodermic cutaneous T-cell lymphoma (CTCL) , especially Sézary syndrome and erythrodermic mycosis fungoides. Mechanism: Leukapheresis is performed to collect the buffy coat (mononuclear cells). Psoralen (8-MOP) is added to the collected cells. The cells are exposed ex vivo to UVA light , which induces apoptosis of malignant T lymphocytes . The treated cells are then reinfused into the patient. Immunologic Effects: Induces apoptosis of tumour lymphocytes Enhances antigen presentation and dendritic cell activation Generates an anti-tumour immune response (often described as “ transimmunization ”) The overall effect is immunomodulatory rather than directly cytotoxic Treatment Schedule: Typically performed on 2 consecutive days per cycle , repeated every 2-4 weeks (monthly or fortnightly depending on protocol and response). Indications: FDA-approved for CTCL , especially erythrodermic MF / Sézary syndrome Often used in combination therapy (e.g., ECP + Interferon-α ± bexarotene) in advanced disease, with improved responses reported in case series. Plaque psoriasis (Option A): This is a chronic inflammatory papulosquamous disease primarily treated with topical therapy, phototherapy (UVB/PUVA), systemic agents, and biologics. Atopic dermatitis (Option C): This is a chronic inflammatory, IgE-mediated eczematous disorder treated with topical steroids, calcineurin inhibitors, systemic immunosuppressants, and biologics. Vitiligo (Option D): This is a depigmenting disorder due to loss of melanocytes , managed with topical agents, phototherapy, and other immunomodulators.

References:

Rook’s Textbook of Dermatology, 9th Edition, Page 140.26

https://pubmed.ncbi.nlm.nih.gov/1430395/

↑ *Back to this question in Part A*

@Neet_pg_bot

Q5: A 32-year-old man with untreated HIV infection presents with findings as shown over the hard palate and lower limbs. Biopsy shows spindle cell proliferation with

slit-like vascular spaces and extravasated erythrocytes. Which of the following statements regarding this condition is incorrect? (Q887593)

A. It is caused by Human Herpesvirus-8 infection

B. The gastrointestinal tract is a common site of visceral involvement

C. It is poorly responsive to radiotherapy

D. Risk markedly increases in immunocompromised individuals

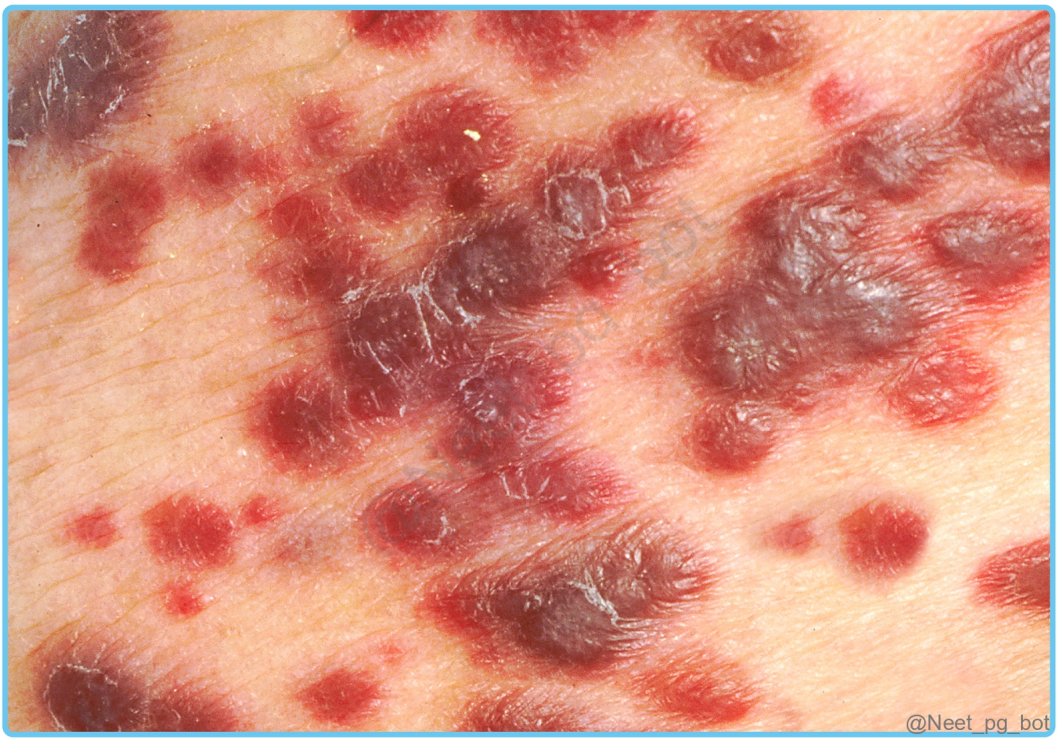

Correct Answer: C. It is poorly responsive to radiotherapy

Explanation: Kaposi sarcoma is highly radiosensitive , with high response rates in localised disease. Kaposi Sarcoma (KS): Multifocal endothelial tumour caused by HHV-8 (Option A) , usually in immunocompromised patients. Types: Classic - Elderly Mediterranean men, slow, lower limbs Endemic (African) - May be aggressive; children → lymphadenopathic Iatrogenic - Post-transplant, may regress if immunosuppression is reduced AIDS-associated - Rapid, mucocutaneous + visceral involvement Risk factors: HIV (strongest) (Option D) Organ transplantation & immunosuppressive drugs IHC markers: CD31, CD34, D2-40, Factor VIII, HHV-8 Clinical features: Violaceous patches/plaques/nodules Common on feet May cause lymphedema GI tract = most common visceral site (Option B) Complications: GI bleeding & pulmonary involvement Associated with Castleman disease & primary effusion lymphoma Treatment: HAART (AIDS-KS) Radiotherapy (very sensitive) Liposomal doxorubicin (1st line advanced) Reduce immunosuppression (iatrogenic)

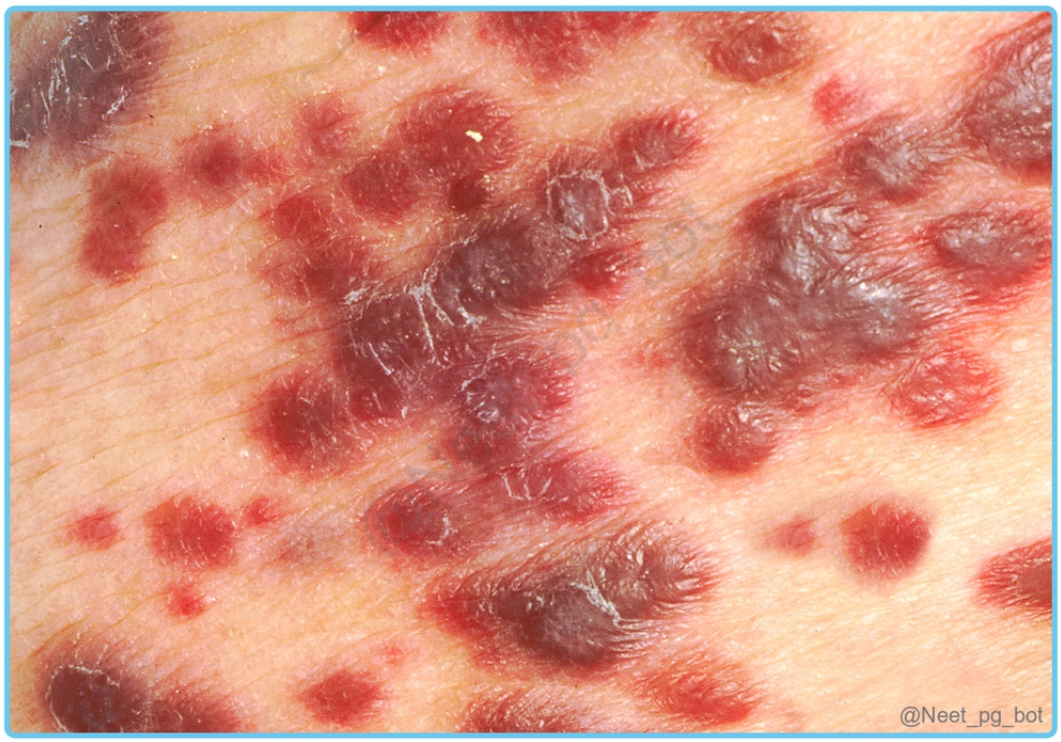

References:

Rook’s Textbook of Dermatology, 9th Edition, Pages 139.1-139.6

↑ *Back to this question in Part A*

@Neet_pg_bot

Q6: What is the most likely diagnosis based on the histopathology slide? ■ ■■ (Q887635)

A. Squamous cell carcinoma

B. Melanoma

C. Basal cell carcinoma

D. Keratoacanthoma

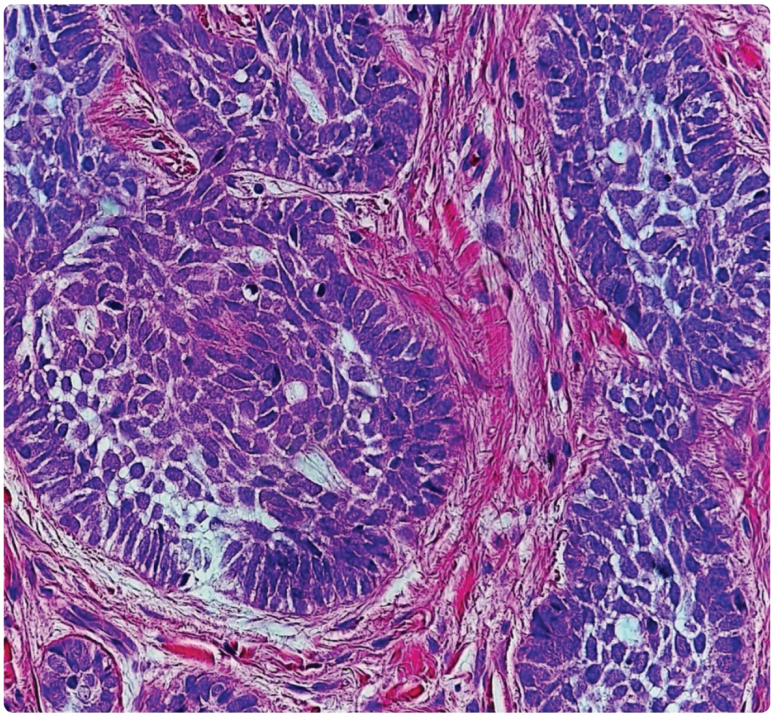



Correct Answer: C. Basal cell carcinoma

Explanation: Basaloid tumour nests, peripheral palisading, mucinous stroma, and retraction artefact (clefting) are classic diagnostic features of Basal cell carcinoma. Basal Cell Carcinoma (BCC / Rodent ulcer): Slow-growing, locally invasive, rarely metastasises; arises from basal epidermal or follicular cells. Sites: Face, around eyes, nose. Features: Scaly plaque → noduloulcerative lesion with rolled margin, telangiectasia, bleeds easily. Histology: Basaloid cells with hyperchromatic nuclei Peripheral palisading Retraction artefact (cleft between tumour & stroma) Mucinous stroma Rare keratinization Treatment: Surgical excision or Mohs micrographic surgery (first-line, especially for high-risk lesions), with topical agents like imiquimod or 5-FU for selected superficial lesions, and vismodegib for advanced or inoperable cases. ■ ■ Squamous cell carcinoma (Option A) shows keratin pearls and intercellular bridges , not basaloid palisading islands with stromal retraction. ■ ■■ Melanoma (Option B) demonstrates atypical melanocytes, pagetoid spread, and pleomorphism , not uniform basaloid nests with clefting artifact. ■ ■■ Keratoacanthoma (Option D) is characterised by a central keratin-filled crater and well-differentiated squamous epithelium , lacking peripheral palisading and retraction artefact.

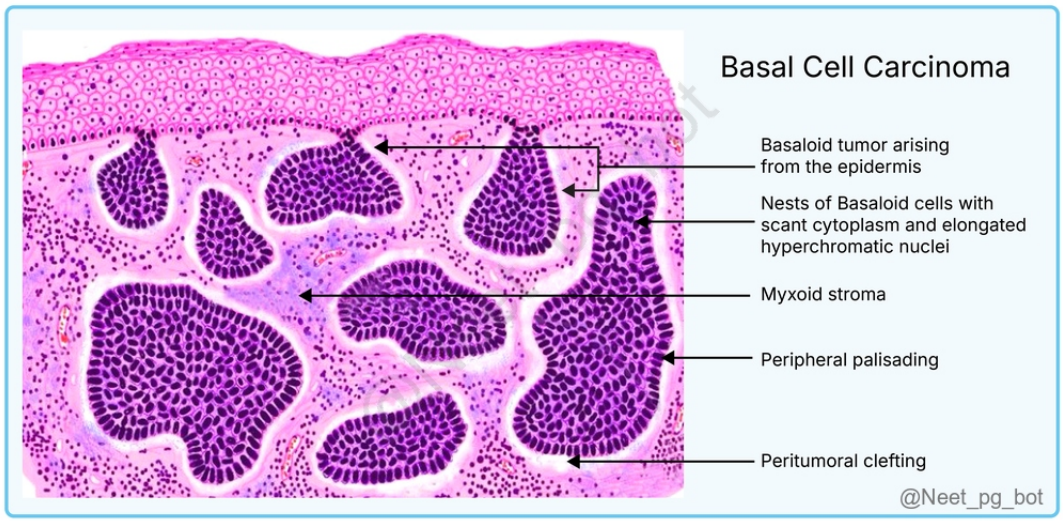



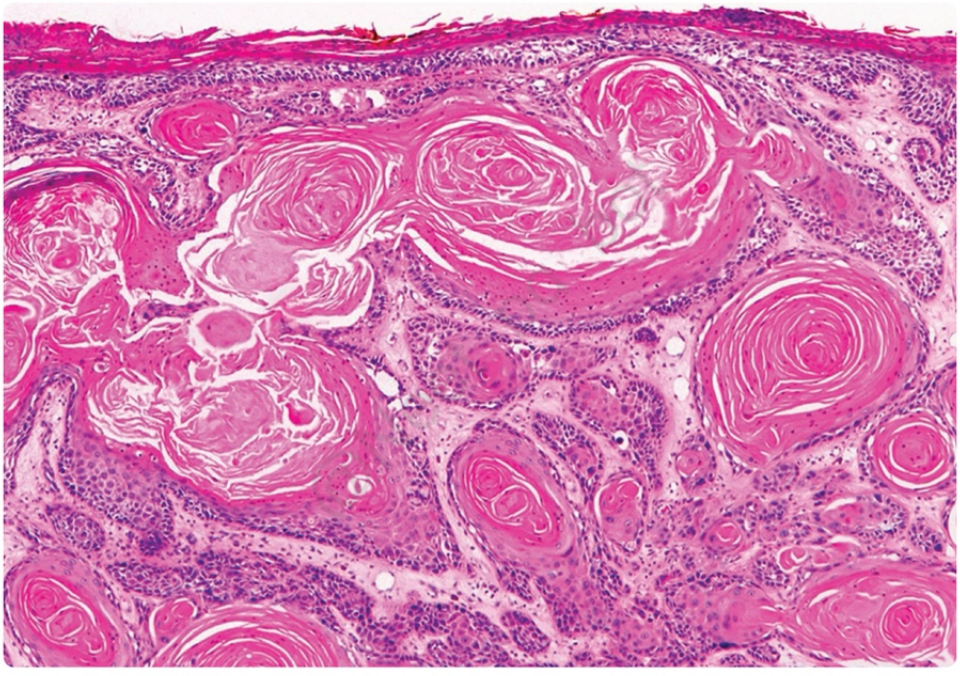

@Neet_pg_bot



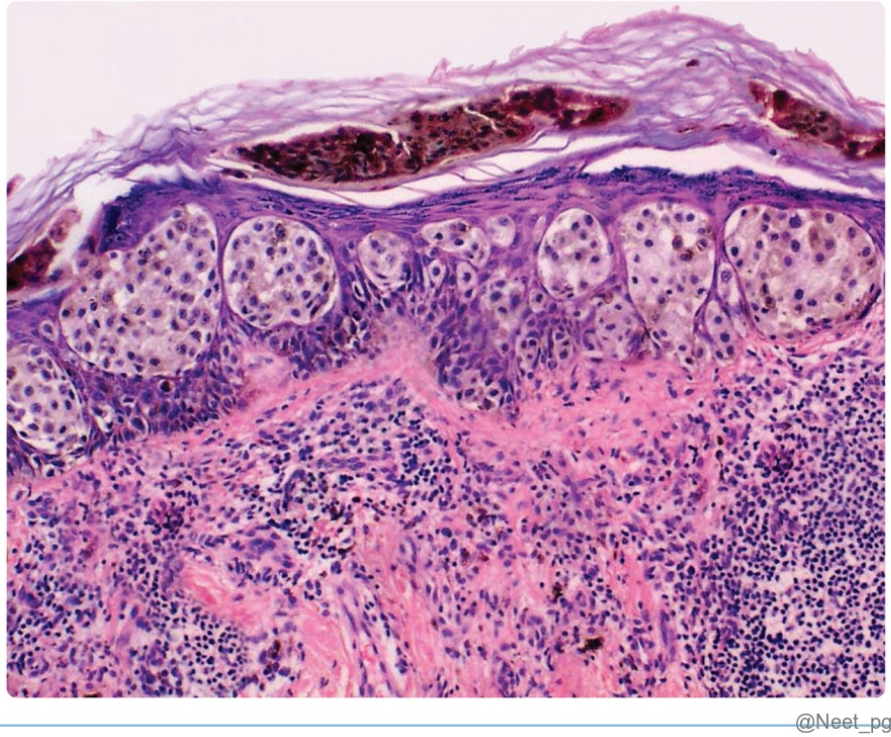

@Neet_pg_bot



References:

Rook’s Textbook of Dermatology, 9th Edition, Pages 141.4-141.8

↑ *Back to this question in Part A*

@Neet_pg_bot

Q7: A 72-year-old man presents with a slowly enlarging lesion on the lateral nose. It appears as a pearly papule with surface telangiectasia and occasional central ulceration. A biopsy confirms a diagnosis of basal cell carcinoma. Which of the following is the most common histological subtype of basal cell carcinoma? (Q887639)

A. Superficial

B. Morpheaform

C. Nodular

D. Infiltrative

Correct Answer: C. Nodular

Explanation: The nodular subtype is the most common form of basal cell carcinoma (BCC) , accounting for the majority of cases. Clinically, it typically presents as a pearly, translucent papule or nodule with surface telangiectasia and may show central ulceration (“rodent ulcer”), especially on sun-exposed areas of the face such as the nose, periocular region, and cheeks . Histologically, nodular BCC shows: Nests of basaloid cells Peripheral palisading of nuclei Retraction clefts between tumour nests and stroma Mucinous stroma Histological Variants of BCC Nodular : Most common Superficial (Option A) : Common, often on trunk Morpheaform (sclerosing/desmoplastic) (Option B) : More aggressive, ill-defined margins Infiltrative (Option D) : Aggressive growth pattern, higher recurrence risk Micronodular : Multiple small nodules, higher risk of subclinical spread Pigmented : Contains melanin, more common in darker skin types

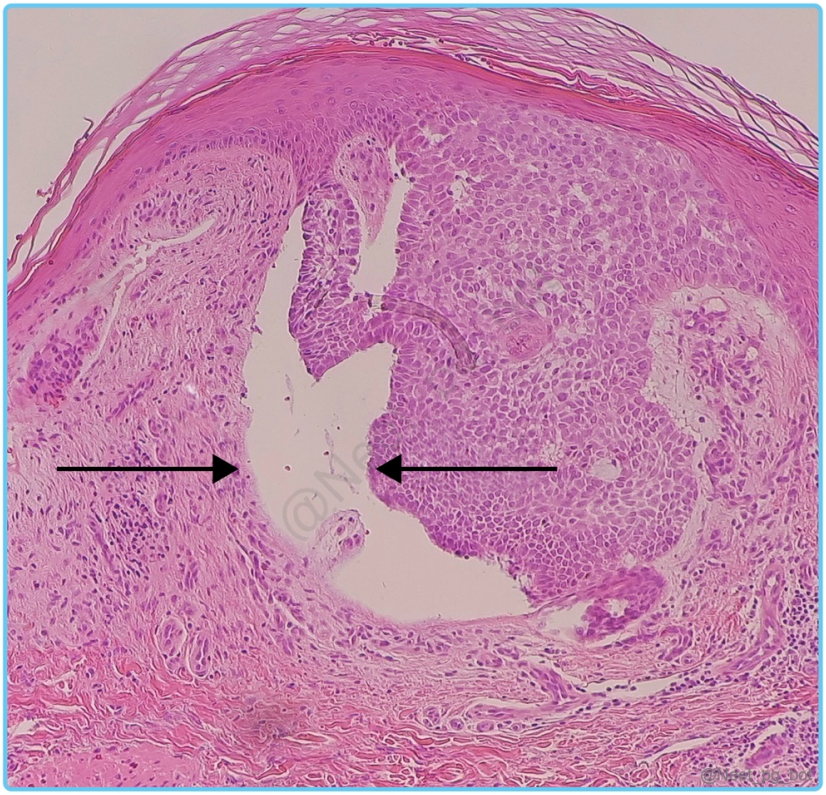

References:

Rook’s Textbook of Dermatology, 9th Edition, Pages 141.6, 141.8

↑ *Back to this question in Part A*

@Neet_pg_bot

Q8: Which of the following is not a recognised risk factor for basal cell carcinoma? (Q887640)

A. Fitzpatrick skin type I-II

B. Chronic arsenic exposure

C. Immunosuppression

D. Chronic mechanical friction

Correct Answer: D. Chronic mechanical friction

Explanation: Chronic mechanical friction is not an established risk factor for basal cell carcinoma. While trauma may occasionally draw attention to lesions, it is not causative. BCC-Risk Factors: UV Exposure (Most Important) UVB → pyrimidine dimers (direct DNA damage) UVA → ROS-mediated damage Intermittent childhood exposure more important than cumulative dose Genetic Predisposition: Nevoid basal cell carcinoma syndrome (Gorlin syndrome) Mutation in PTCH1 (Hedgehog pathway) Multiple BCC, odontogenic cysts, and palmoplantar pits p53 mutation (~50%) MC1R variants (fair skin, red hair) Fitzpatrick I-II skin (Option A) Immunosuppression (transplant, HIV, CLL) (Option C) Arsenic exposure (Option B) Ionizing radiation PUVA / UVB therapy

References:

Rook's Textbook of Dermatology, 9th Edition, Page 141.2

↑ *Back to this question in Part A*

@Neet_pg_bot

Q9: A 72-year-old woman presents with findings as shown for 10 months. It is asymptomatic. Biopsy shows atypical keratinocytes involving the entire thickness of the epidermis with an intact basement membrane. Which of the following statements regarding this condition is correct? (Q887642)

A. It is more common in males

B. It is typically a rapidly enlarging lesion

C. There is a risk of progression to invasive SCC

D. It is not associated with prior radiation exposure



Correct Answer: C. There is a risk of progression to invasive SCC

Explanation: Based on the clinical and histopathological findings described, the diagnosis is Bowen's disease (also known as Squamous Cell Carcinoma (SCC) in situ). It is characterised by full-thickness epidermal dysplasia without dermal invasion. The lifetime risk of progression to invasive SCC is about 3-5% . Bowen Disease (SCC in situ): Intraepidermal squamous cell carcinoma presenting as a persistent, well-demarcated, erythematous scaly/crusted plaque. Epidemiology: Elderly (>60 yrs), peak 7th decade Female predominance (Option A) Fair-skinned; UV exposure Risk factors: Chronic UV radiation Arsenic exposure Immunosuppression (transplant, CLL, HIV) HPV (16, 18 - genital; 16 - periungual) Radiation (Option D) , chronic inflammation Pathology: Full-thickness epidermal dysplasia Loss of polarity, atypical mitoses Intact basement membrane Clinical features: Slowly enlarging (Option B) , red scaly plaque Well-defined, slightly raised edge Usually asymptomatic Ulceration → suspect invasive SCC Common sites: Lower legs, head/neck, perianal, periungual

References:

Rook's Textbook of Dermatology, 9th Edition, Pages 142.16-142.21

↑ *Back to this question in Part A*

@Neet_pg_bot

Q10: A 58-year-old man presents with a slowly enlarging lesion on the plantar surface of his foot for 2 years. It is painless but progressively increasing in size with no regional lymphadenopathy. What is the most likely diagnosis? (Q887643)

A. Keratoacanthoma

B. Verrucous carcinoma

C. Conventional invasive squamous cell carcinoma

D. Viral wart (verruca vulgaris)



Correct Answer: B. Verrucous carcinoma

Explanation: Based on the clinical presentation and the image provided, the most likely diagnosis is Verrucous carcinoma (Epithelioma cuniculatum) . Verrucous carcinoma is a low-grade, well-differentiated variant of squamous cell carcinoma. It presents as a slow-growing, exophytic, cauliflower-like mass , commonly on the plantar surface. Histology shows minimal atypia with pushing borders rather than infiltrative growth. Metastasis is rare. May be associated with HPV, especially low-risk types (e.g., 6, 11), though the association is variable. Keratoacanthoma (Option A): This is a rapidly growing, dome-shaped keratinising tumour that typically enlarges over weeks and may spontaneously regress . Conventional invasive squamous cell carcinoma (Option C): This is a more aggressive malignancy with infiltrative growth , greater cytologic atypia, and a higher risk of metastasis . It often presents with ulceration, pain, or lymphadenopathy , unlike the slow-growing, exophytic, low-grade behaviour described. Viral wart (verruca vulgaris) (Option D): This is a benign HPV-induced lesion , usually small, multiple, and stable or slowly changing , more common in younger individuals.

References:

Rook’s Textbook of Dermatology, 9th Edition, Page 142.28

↑ *Back to this question in Part A*

@Neet_pg_bot

Q11: A 48-year-old man presents with multiple yellowish papules and nodules on the face and trunk for 3 years. Histopathology of one lesion shows a sebaceous adenoma. He also has a history of right-sided colon carcinoma diagnosed at age 45. His father died of colorectal cancer. What is the most likely diagnosis? (Q887644)

A. Gardner syndrome

B. Turcot syndrome

C. Muir-Torre syndrome

D. Cowden syndrome

Correct Answer: C. Muir-Torre syndrome

Explanation: Muir-Torre syndrome is an autosomal dominant variant of Lynch syndrome characterized by sebaceous neoplasms (adenoma, epithelioma, carcinoma) along with visceral malignancy , most commonly colorectal carcinoma. Muir-Torre Syndrome (MTS): Autosomal dominant cancer syndrome, considered a variant of Lynch syndrome (HNPCC) . Characterised by: ≥1 sebaceous neoplasm (adenoma, epithelioma, carcinoma) ± keratoacanthoma ≥1 visceral malignancy (most commonly colorectal carcinoma) Genetics: DNA mismatch repair (MMR) defect MSH2 most common MLH1, rarely MSH6, PMS2 Gardner syndrome (Option A) : Associated with FAP, osteomas, epidermoid cysts, and multiple colon polyps-not sebaceous tumors. Turcot syndrome (Option B) : Colon cancer with CNS tumors (e.g., medulloblastoma, glioma), not sebaceous neoplasms. Cowden syndrome (Option D) : Associated with trichilemmomas, oral papillomas, breast and thyroid cancers (PTEN mutation).

References:

Rook’s Textbook of Dermatology, 9th Edition, Pages 142.38-142.40

↑ *Back to this question in Part A*

@Neet_pg_bot

Q12: Which gene mutation is most commonly associated with Gorlin syndrome? (Q887646)

A. PTCH1

B. PTEN

C. MLH1

D. TP53

Correct Answer: A. PTCH1

Explanation: Gorlin syndrome (Nevoid Basal Cell Carcinoma Syndrome) is caused by germline mutations in the PTCH1 , a tumour suppressor gene located on chromosome 9q22.3 that regulates the Hedgehog signalling pathway. Nevoid Basal Cell Carcinoma Syndrome (NBCCS): Autosomal dominant disorder with multiple early-onset BCCs + characteristic skeletal, craniofacial, and neurological anomalies. Mutation in PTCH1 (Chr 9q22.3) Clinical features: Skin: Numerous BCCs (face, chest, back; sun & non-sun areas) Palmoplantar pits (diagnostic clue) Milia, epidermoid cysts Craniofacial: Frontal bossing, hypertelorism & macrocephaly Skeletal: Bifid ribs, spina bifida occulta & scoliosis Odontogenic jaw cysts, calcified falx cerebri (early), & ↑ Risk of medulloblastoma Management: Avoid radiotherapy Regular skin surveillance Excision/cryotherapy / PDT Hedgehog inhibitor: Vismodegib PTEN (Option B) : Causes Cowden syndrome, characterised by hamartomas, trichilemmomas, and increased risk of breast and thyroid cancers - not multiple early BCCs with jaw cysts. MLH1 (Option C) : DNA mismatch repair gene mutated in Lynch syndrome (hereditary nonpolyposis colorectal cancer), not associated with NBCCS features. TP53 (Option D) : Mutated in Li-Fraumeni syndrome, which predisposes to sarcomas, breast cancer, brain tumours, and adrenal carcinoma - not classic Gorlin features.

References:

Rook’s Textbook of Dermatology, 9th Edition, Pages 141.18-141.21

↑ *Back to this question in Part A*

@Neet_pg_bot

Q13: A 50-year-old man presents with a progressively widening dark streak on his thumbnail. Examination shows longitudinal melanonychia with brown-black pigmentation extending onto the proximal nail fold, visible to the naked eye. What is this sign called? (Q887647)

A. Pseudo-Hutchinson sign

B. Micro-Hutchinson sign

C. Hutchinson sign

D. Parallel ridge pattern



Correct Answer: C. Hutchinson sign

Explanation: Hutchinson sign is defined as true periungual spread of brown-black pigment from a longitudinal melanonychia onto the proximal and/or lateral nail fold , visible to the naked eye . It represents invasion or radial spread of melanocytic tumor cells beyond the nail matrix and is highly suggestive of nail unit (subungual) melanoma . Often associated with other warning features: Irregular borders of the pigmented band Color variegation (brown/black/gray) Nail plate dystrophy or splitting Should prompt urgent biopsy of the nail matrix/bed . Pseudo-Hutchinson sign (Option A) : Pigment appears visible through a translucent cuticle due to underlying nail matrix pigmentation, but there is no true periungual skin involvement. It has no diagnostic significance. Micro-Hutchinson sign (Option B) : Pigmentation of the proximal nail fold that is visible only with dermoscopy, not to the naked eye. Parallel ridge pattern (Option D) : A dermoscopic pattern seen in acral melanoma involving pigmentation along the ridges of acral skin, not specifically referring to nail fold extension.



References:

Rook’s Textbook of Dermatology, 9th Edition, Pages 144.8,144.10

↑ *Back to this question in Part A*

@Neet_pg_bot

Q14: Which of the following statements regarding risk factors of the most probable condition depicted in the image below is incorrect? (Q887648)

A. Intermittent sun exposure and sunburns increase melanoma risk.

B. Having ≥5 atypical/dysplastic naevi significantly increases melanoma risk.

C. Most cutaneous melanomas arise from pre-existing naevi.

D. Red hair independently confers increased melanoma risk.

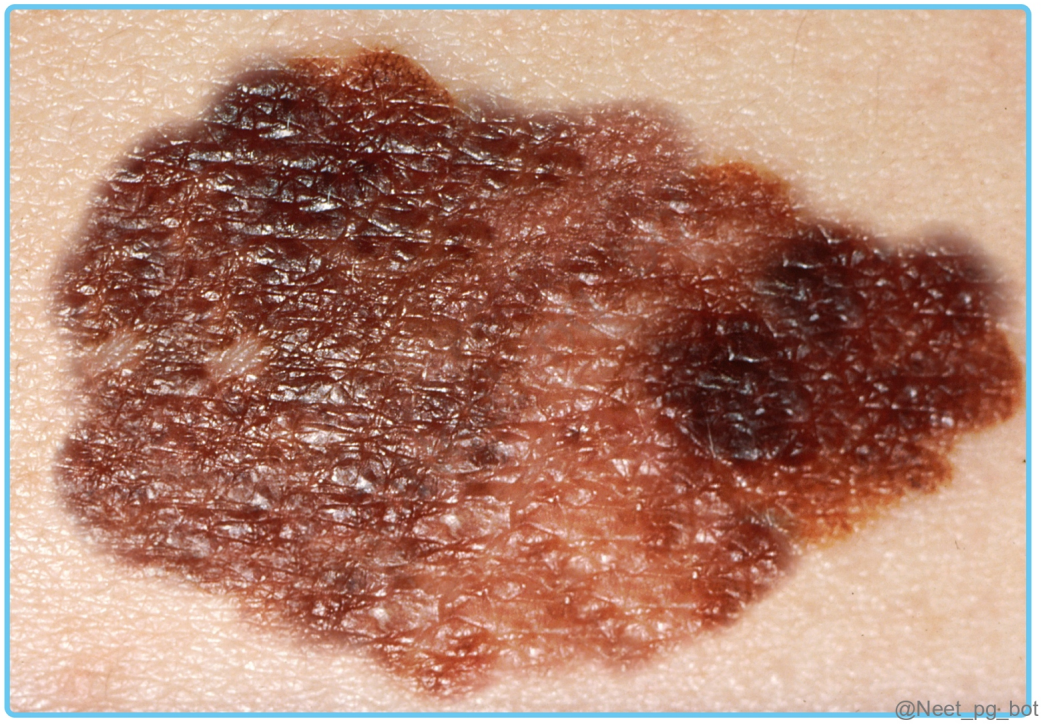

Correct Answer: C. Most cutaneous melanomas arise from pre-existing naevi.

Explanation: Most melanomas (~75-80%) arise de novo from normal skin , not from pre-existing naevi. Melanoma: Origin: 75-80% arise de novo (normal skin) 20-25% arise from a naevus Naevi & Risk: Congenital Melanocytic Naevi (CMN): Large (>20 cm) → lifetime risk ~2-3% Higher risk: truncal, >40 cm, satellites Transformation often occurs in childhood Common Acquired Naevi: Risk increases with total naevus count Atypical/Dysplastic Naevi: ≥5 atypical naevi → markedly ↑ melanoma risk (Option B) Genetic Risk: CDKN2A (most important) → familial melanoma, pancreatic cancer Phenotypic risk: Fitzpatrick I > IV Red hair (Option D) Blue eyes Freckles ≥100 naevi UV Radiation (Only Established Environmental Factor) Intermittent sun exposure & sunburn → strongest association (Option A)

References:

Rook's Textbook of Dermatology, 9th Edition, Pages 143.2-143.6

↑ *Back to this question in Part A*

@Neet_pg_bot

Q15: Which of the following genes is the most important high-penetrance susceptibility gene for familial melanoma? (Q887649)

A. CDKN2A

B. CDK4

C. MC1R

D. BAP1

Correct Answer: A. CDKN2A

Explanation: CDKN2A (9p21) is the most established high-penetrance gene for familial melanoma. Familial Melanoma: Family history → ~2× increased risk High-Penetrance Genes: CDKN2A (9p21) - Most Important Encodes: p16 (Rb pathway) & p14 (p53 pathway) Found in ~40% familial melanoma Associated with: Multiple melanomas & pancreatic cancer CDK4 (Option B) : Rare (~2% familial cases) Mutation prevents p16 inhibition → unchecked cell cycle Moderate/Low-Penetrance Genes: MC1R: (Option C) Pigmentation gene (chromosome 16) ~2× melanoma risk Red hair variants are at high risk Modifies CDKN2A penetrance MITF (E318K variant): Associated with: Multiple primary melanomas & renal cell carcinoma BAP1 (Option D) : Tumour suppressor Associated with: Uveal & cutaneous melanoma, mesothelioma & RCC

References:

Rook's Textbook of Dermatology, 9th Edition, Page 143.4

↑ *Back to this question in Part A*

@Neet_pg_bot

Q16: Which of the following is the most important prognostic factor for predicting melanoma recurrence and overall survival? (Q887650)

A. Size of the melanoma

B. Breslow thickness

C. Mitotic rate

D. Colour of lesion

Correct Answer: B. Breslow thickness

Explanation: Breslow thickness is the single most important prognostic factor in primary melanoma. Thicker tumors have a higher risk of metastasis and lower overall survival. Melanoma - Prognostic Factors: Metastasis: Can spread to any organ ; initially, often skin/subcutaneous tissue Common distant sites: lung, brain, liver, bone Sentinel node positivity → worse prognosis Breslow thickness (tumour depth) - High: Strongest predictor Measured from the top of the granular layer (or base of ulcer) to deepest invasive cell Sentinel lymph node status - High Ulceration - Moderate Negative marker for prognosis. Indicates aggressive biological subtype. Mitotic rate - Moderate Particularly relevant in thin melanomas. Higher mitotic activity → worse prognosis Low Prognostic Factors: Regression - may underestimate Breslow thickness. Age - older patients have a worse prognosis. Sex - males have slightly worse outcomes. Tumour location - head and neck melanomas have poorer prognosis.

References:

Rook’s Textbook of Dermatology, 9th Edition, Pages 143.19, 143.20

↑ *Back to this question in Part A*

@Neet_pg_bot

Q17: A 28-year-old woman has multiple firm, pink nodules on her scalp. Family history is positive. Histology shows lobules in a “jigsaw-puzzle” pattern with a hyaline basal membrane. What is the most likely diagnosis? (Q887651)

A. Trichoepithelioma

B. Cylindroma

C. Basal cell carcinoma

D. Trichilemmal cyst

Correct Answer: B. Cylindroma

Explanation: Cylindroma is a rare, usually familial adnexal (sweat gland-type) tumour , classically occurring on the scalp and head-neck region. When multiple, it is often inherited in an autosomal dominant pattern due to CYLD gene mutations and may produce the so-called “turban tumour.” Cylindroma: Pathology: Lobules with jigsaw-puzzle pattern , two cell types, hyaline basal membrane; may coexist with spiradenomas . Clinical: Multiple or solitary firm nodules, slow-growing, scalp > face/neck ; occasionally painful. Prognosis: Benign , malignant transformation is very rare. Management: Surgical excision ; grafting for large scalp lesions; topical salicylic acid is sometimes used. Trichoepithelioma (Option A) : Usually smaller facial lesions; histology shows follicular differentiation, not jigsaw pattern. Basal cell carcinoma (Option C) : Typically solitary, ulcerated, locally invasive; histology shows basaloid nests with peripheral palisading. Trichilemmal cyst (Option D) : Smooth, mobile nodules; usually solitary, no characteristic lobular histology.

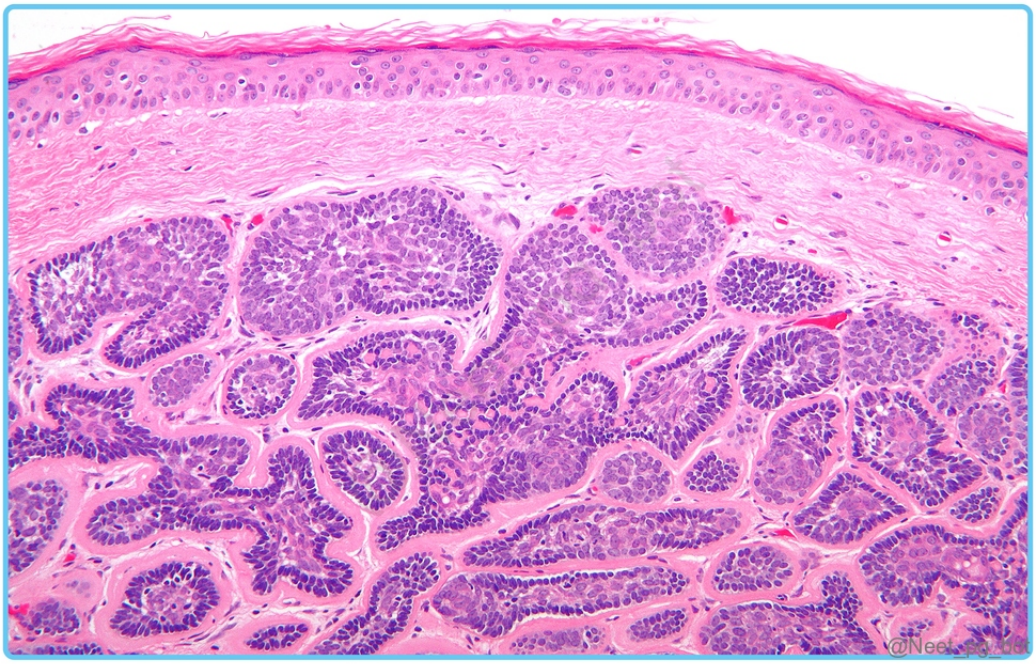



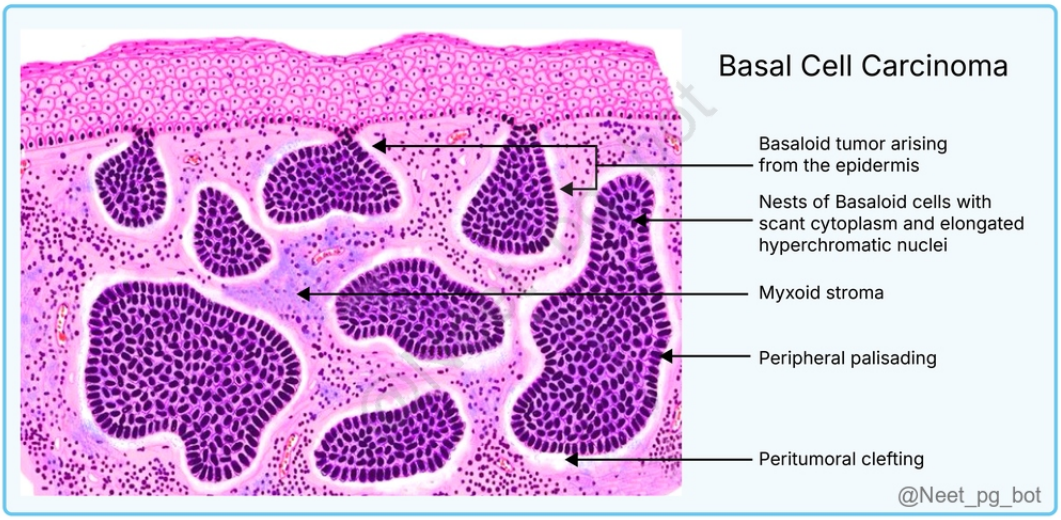

References:

Rook's Textbook of Dermatology, 9th Edition, Page 138.30

↑ *Back to this question in Part A*

@Neet_pg_bot

Q18: A 60-year-old man has chronic pruritic patches over the trunk progressing to plaques. Skin biopsy shows epidermotropism and findings as shown. What is the diagnosis? (Q887627)

A. Sézary syndrome

B. Mycosis fungoides

C. Pagetoid reticulosis

D. Adult T-cell leukaemia/lymphoma

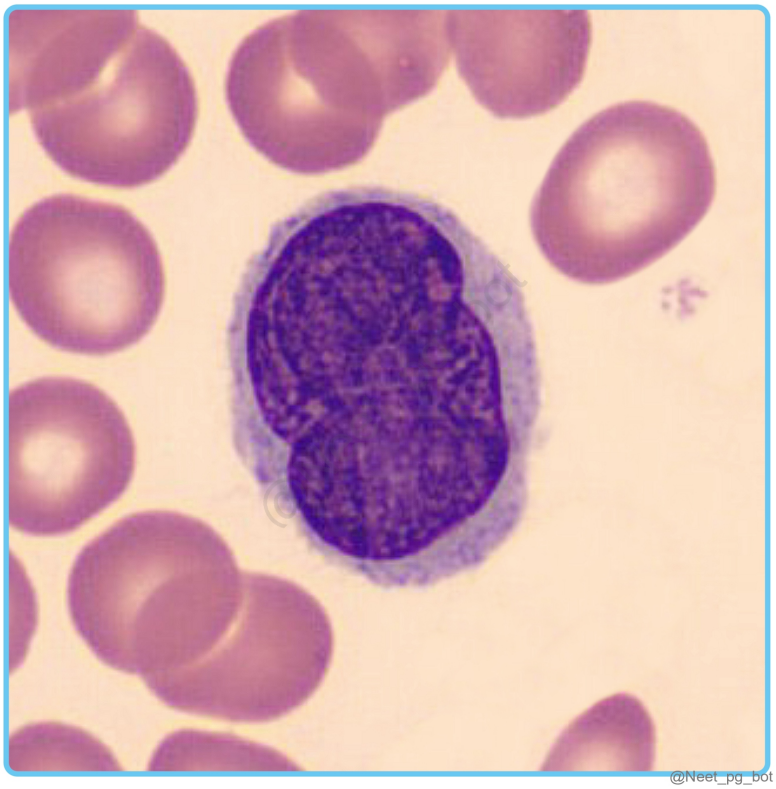

Correct Answer: B. Mycosis fungoides

Explanation: Based on the clinical presentation and the histopathological findings, the correct diagnosis is Mycosis fungoides . The image shows a Sézary cell (a T-lymphocyte with a characteristic cerebriform nucleus , meaning it looks folded like a brain). Mycosis fungoides: Most common cutaneous T-cell lymphoma (CTCL) Derived from skin-resident CD4+ memory T cells Immunophenotype: CD3+, CD4+, CD45RO+, CD7- Clinical Progression: Patches → Plaques → Tumours → Erythroderma (Common on trunk, buttocks) Histological hallmarks: Epidermotropism Pautrier microabscesses Cerebriform lymphocytes Poor prognostic factors: Age >60 Tumor stage Blood involvement Large-cell transformation Folliculotropic variant Sézary syndrome (Option A) : This is the leukemic (systemic) phase of CTCL. While it shares the cerebriform cells, it is characterised by generalised erythroderma (total body redness) and significant blood involvement, rather than the localised patch/plaque progression described here. Pagetoid reticulosis (Option C) : A rare localised variant of MF, typically presenting as a single slow-growing plaque on an extremity, which doesn't fit the "patches over the trunk" description. Adult T-cell leukemia/lymphoma (ATLL) (Option D) : Linked to the HTLV-1 virus, this typically presents more aggressively with "flower cells" (highly lobulated nuclei) rather than cerebriform cells, and often includes hypercalcemia and bone lesions.

References:

Rook’s Textbook of Dermatology, 9th Edition, Pages 140.1-140.10

↑ *Back to this question in Part A*

@Neet_pg_bot

Q19: Which of the following is the most common cutaneous T-cell lymphoma (CTCL)? (Q887597)

A. Sézary syndrome

B. Mycosis fungoides

C. Pagetoid reticulosis

D. Follicular mucinosis

Correct Answer: B. Mycosis fungoides

Explanation: Mycosis fungoides (MF) is the most common form of cutaneous T-cell lymphoma (CTCL) , accounting for the majority of primary CTCL cases . It is a primary cutaneous lymphoma of mature CD4■ T cells . Clinical Course: Patch stage →Plaque stage → Tumour stage (slow, indolent progression over years) Lesions are often erythematous to violaceous , may be pruritic , and commonly involve sun-protected areas (e.g., trunk, buttocks, thighs) Immunophenotype: CD3+, CD4+, CD45RO+, CD7- Histological hallmarks: Epidermotropism Pautrier microabscesses Cerebriform lymphocytes Sézary syndrome (Option A): This is an aggressive leukemic variant of CTCL , characterised by erythroderma, lymphadenopathy, and circulating Sézary cells . It is far less common than mycosis fungoides and therefore not the most common CTCL. Pagetoid reticulosis (Option C): This is a rare, localized variant of CTCL (also called Woringer-Kolopp disease), usually presenting as a solitary plaque with marked epidermotropism. It is uncommon compared to mycosis fungoides. Follicular mucinosis (Option D): This is a reaction pattern characterised by mucin deposition in hair follicles . It may be associated with CTCL (especially folliculotropic mycosis fungoides), but it is not itself the most common CTCL .



References:

Rook’s Textbook of Dermatology, 9th Edition, Page 140.1

↑ *Back to this question in Part A*

@Neet_pg_bot

Q20: A 50-year-old female presented with sudden eruption of asymptomatic lesions as shown in the image below. The lesions have a stuck-on appearance suggestive of a diagnosis of Seborrheic keratosis. Which of the following malignancies is commonly suspected in the given scenario? (Q841710)

A. Gastric

B. Intestinal

C. Pulmonary

D. Cardiac

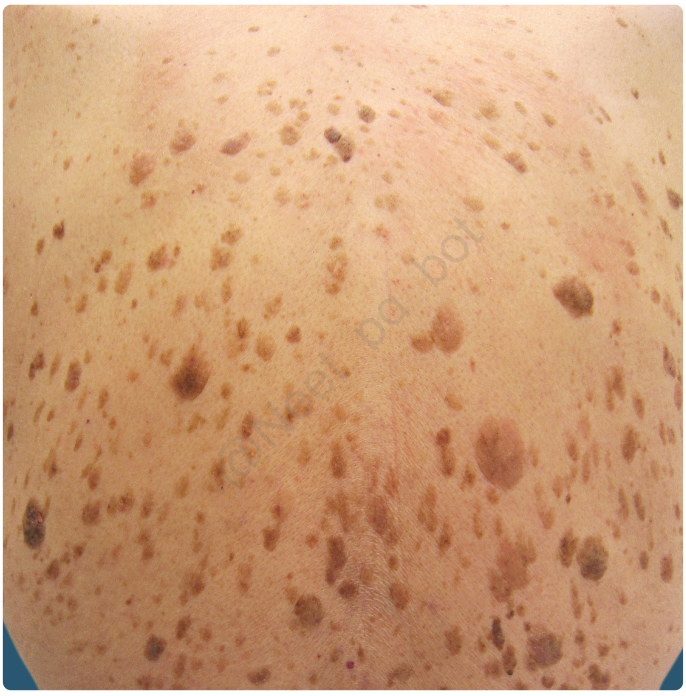

@Neet_pg_bot

Correct Answer: A. Gastric

■ *Listen (English)*

■ *Listen (Hindi)*

Explanation: A sudden eruption of multiple seborrheic keratosis lesions is known as the sign of Leser-Trelat. It can be a symptom of paraneoplastic syndrome typically associated with gastric adenocarcinoma. However, it can also be associated with other internal malignancies. Seborrheic Keratoses (SK): Benign proliferation of keratocytes Usually seen in older age groups. Appearance - Hyperkeratotic plaques with a stuck-on appearance. Follicular plugs Sign of Leser-Trelat: The sudden appearance of seborrheic keratosis on the body reveals that there is an association with underlying GI malignancy. Treatment: Treatment is usually done only for cosmetic purposes. Intestinal cancer and Lung cancer can sometimes present with this sign, but gastric adenocarcinoma has the most common association.(Options B and C ruled out) There is no established association between cardiac malignancies and signs of Leser-Trelat. Cardiac malignancies do not generally present with paraneoplastic syndromes.(Option D ruled out)

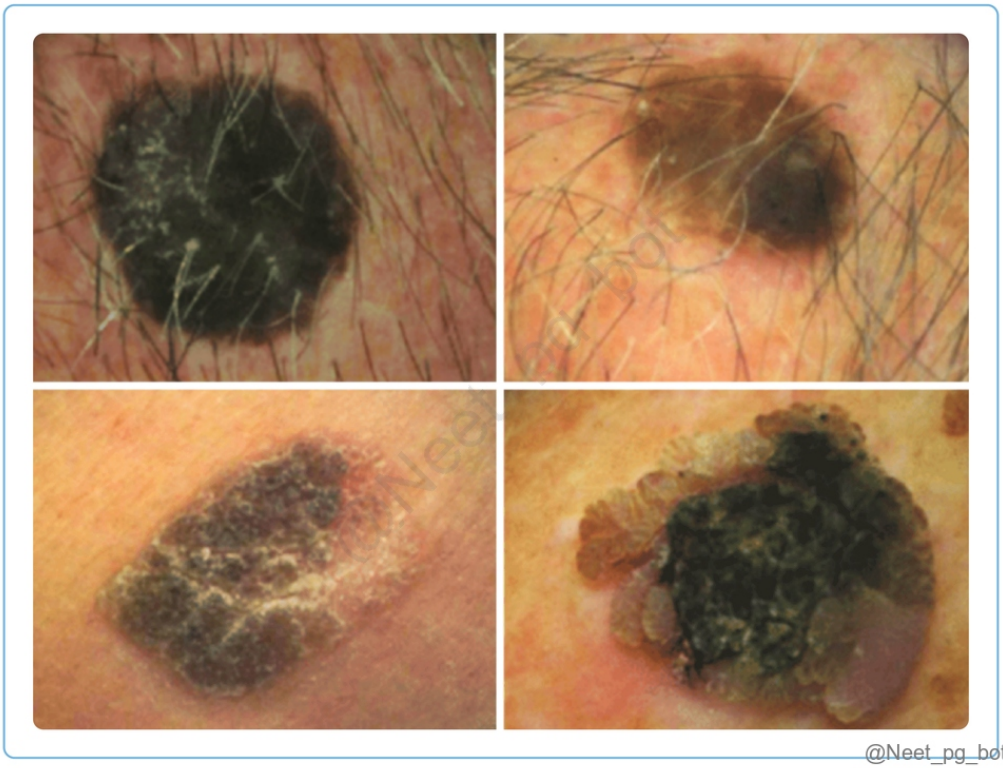

References:

Rooks textbook of dermatology 9th ed, page no. 133.2

↑ *Back to this question in Part A*

@Neet_pg_bot

Q21: A 25-year-old homosexual male presents with the following lesion on his legs which have progressed in size. Which of the following is the most common organism

associated with this condition? (Q841732)

A. HHV-4

B. HHV-6

C. HHV-8

D. HHV-5

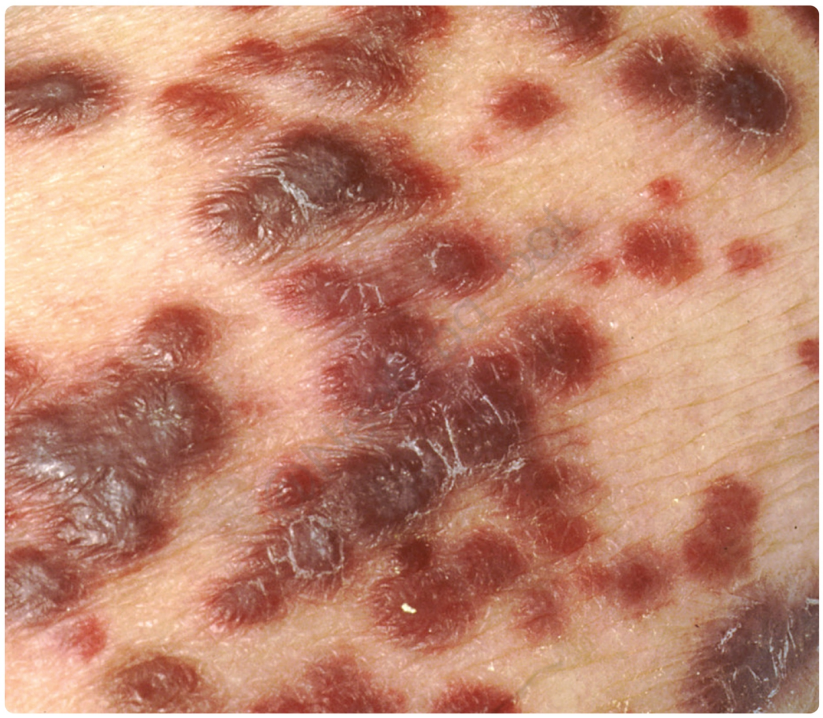

Correct Answer: C. HHV-8

■ *Listen (English)*

■ *Listen (Hindi)*

Explanation: The above image shows multiple red to purple plaque-like lesions coalescing with each other, which is suggestive of Kaposi sarcoma . Kaposi sarcoma is a vascular neoplasm. It is the most common cancer seen in HIV patients. Kaposi sarcoma caused by HHV-8 stimulates VEGF and inhibits p53 leading to malignancy. All forms of Kaposi sarcoma are associated with HHV-8 infection as an etiological agent. Types of Kaposi sarcoma: Classic (Meditteranean) Endemic African (HIV negative) Transplant associated AIDS-associated Epidemic KS HHV8 associated diseases: Kaposi’s Sarcoma: Primary Effusion Lymphoma (PEL) : PEL is a type of non-Hodgkin lymphoma characterized by the accumulation of fluid in body cavities. Multicentric Castleman Disease (MCD) : MCD is a rare lymphoproliferative disorder. Kaposi's Sarcoma of mouth due to HHV8:

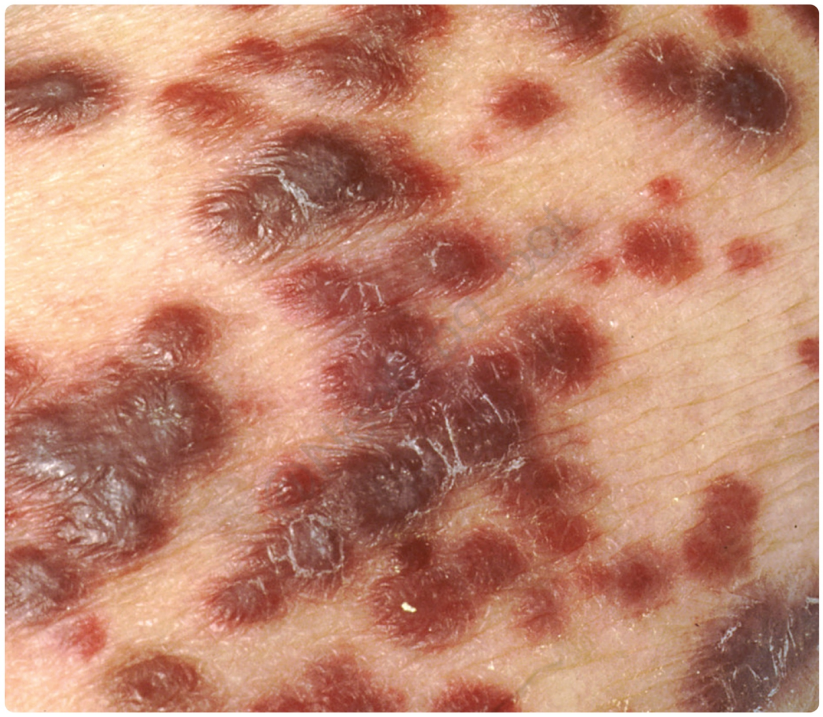

@Neet_pg_bot



@Neet_pg_bot

References:

Rooks textbook of dermatology, 9th edition, chapter 139 page no.139.1

↑ *Back to this question in Part A*

Q22: A 52-year-old male has a slow-growing, scaly, reddish patch on his lower back that has become a thickened plaque over several months. He reports no itching, pain, or discomfort. Examination reveals similar plaques on his abdomen. A biopsy shows a monoclonal proliferation of CD4+/CD45R0+ helper T cells. Which of the following is the most likely diagnosis for this patient? (Q841728)

A. Sezary syndrome

B. Psoriasis

C. Basal Cell Carcinoma

D. Mycosis Fungoides

Correct Answer: D. Mycosis Fungoides

■ *Listen (English)*

■ *Listen (Hindi)*

Explanation: The most common type of primary cutaneous T-cell lymphoma is Mycosis Fungoides. Mycosis Fungoides Cutaneous T-cell lymphoma (CD4+/CD45R0+); slow-growing, may metastasize. Site: Girdle area (abdomen, back). Clinical progression: Patch → Plaque → Tumor → Erythroderma. Histology: Epidermotropism with Pautrier's microabscesses (T-cell clusters). Treatment: Patch: Topical steroids, nitrogen mustard, PUVA/UVB. Plaque: Total skin electron therapy, interferon-α, retinoids. Advanced: CHOP regimen, extracorporeal photopheresis. Progression of mycosis fungoides: Patch stage ---------->Plaque stage---------->Tumor stage Sézary syndrome(Option A) – aggressive cutaneous T-cell lymphoma with erythroderma, lymphadenopathy, and Sézary cells ; lacks macule-plaque-tumor progression. Psoriasis (Option B) – well-defined scaly plaques on extensor surfaces; no polymorphic progression. BCC (Option C) – pearly nodular lesion with rolled border ; not progressive or erythrodermic.



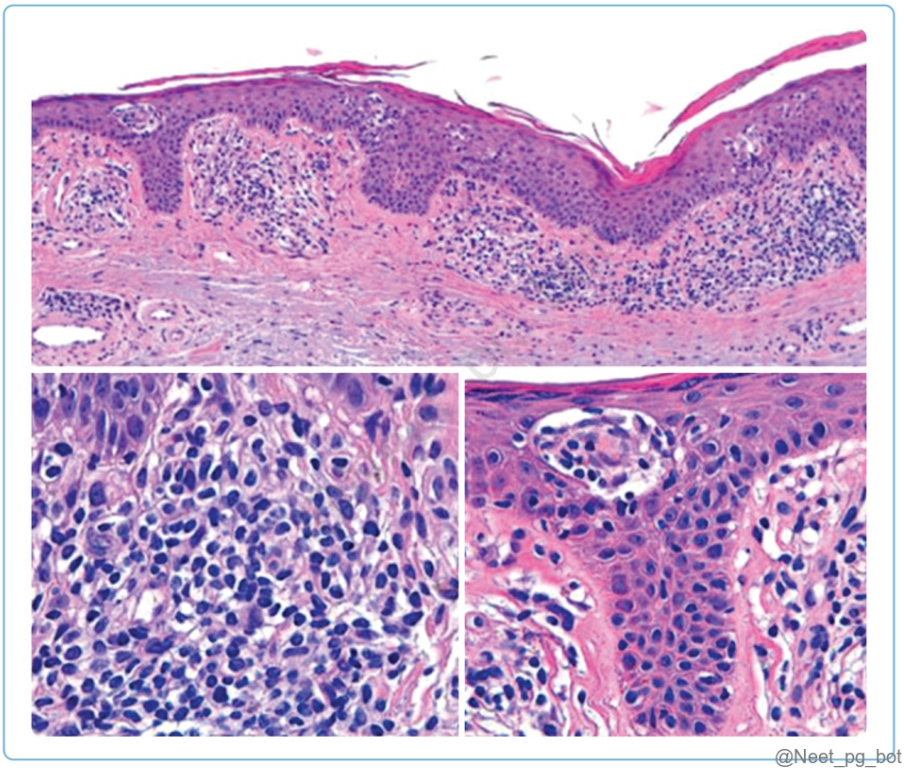

References:

Rooks textbook of dermatology 9th edition-chapter 140, page no. 140.1

↑ *Back to this question in Part A*

@Neet_pg_bot

Q23: A 45-year-old male presents with a slow-growing lesion on the face as shown in the image. What is the best indicator for the prognosis of this condition? (Q841727)

A. Tumor thickness

B. Tumor size

C. Regularity of margins

D. Symmetry of tumour



@Neet_pg_bot

Correct Answer: A. Tumor thickness

- *Listen (English)*
- *Listen (Hindi)*

Explanation: Tumor thickness or Breslow index is the best prognostic factor for melanoma. It is the distance in millimetres (mm) between the epidermal granular layer and the primary lesion's deepest level of invasion. Thicker tumours have a higher metastatic potential. The prognosis of primary melanoma depends on several factors: Tumour thickness (Breslow Depth) : Thicker tumours are associated with poor prognosis. Ulceration : It is another important independent poor prognostic factor. Even in locally advanced melanoma, primary tumour ulceration retains its significance. Mitotic Rate: Higher mitotic rates are associated with a worse prognosis. Sentinel Lymph Node Status: Lymph node involvement indicates a higher risk of metastasis and poorer outcome. Other Clinicopathologic Factors: LDH levels, tumor location, and genetic mutations

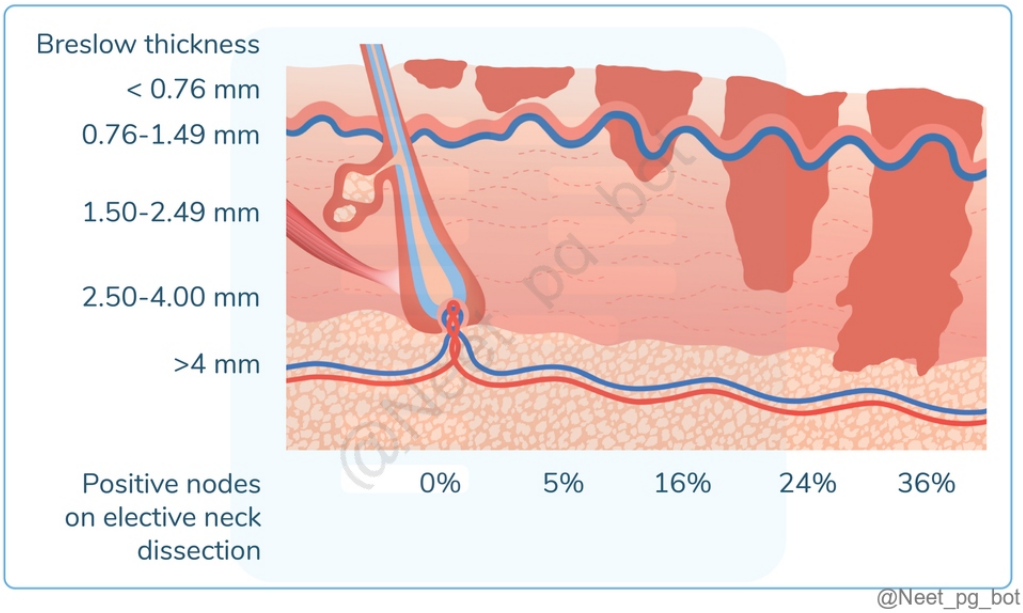

References:

Rooks textbook of dermatology 9th ed, page no. 143.19 and 143.20

https://commons.wikimedia.org/wiki/File:Melanoma_Growth_over_14_Months.jpg

↑ *Back to this question in Part A*

@Neet_pg_bot

Q24: A 65-year-old woman with fair skin and a history of teenage sunburns presents with a mole on her upper back that has become larger and darker over the past few months. The lesion is pigmented with irregular borders, color variation, asymmetry, slight elevation, and measures 1.5 cm in diameter. She reports occasional itching and tenderness but denies bleeding or ulceration. Identify the true statements regarding this condition. The most common type is nodular melanoma. CDKN2A mutation is most commonly involved in sporadic melanoma. Depth > 6 mm is suggestive of melanoma. Clark's classification is used in malignant melanoma. Interferon-5ü can be used for the prevention of metastasis. (Q841725)

A. 1,2

B. 4,5

C. 3,4

D. 1,3,5

Correct Answer: B. 4,5

■ *Listen (English)*

■ *Listen (Hindi)*

Explanation: 1. Nodular melanoma (False): Superficial spreading is the most common type. 2. CDKN2A (False): BRAF mutation is more common in sporadic melanoma. 3. Depth >6 mm (False): >6 mm size raises suspicion, but Breslow depth is for staging. 4. Clark's classification (True): Used for assessing melanoma invasion depth. 5. Interferon-α (True): Used as adjuvant therapy to prevent metastasis in high-risk melanoma. Types of Melanoma: Superficial spreading (MC): Upper back, lower legs; multicolored with raised border. Lentigo maligna: Sun-exposed face; flat brown/tan with grey or dark nodules. Acral lentiginous: Palms, soles, nail bed; dark brown to black lesions. Nodular: Any site; uniform or mixed dark hues, rapidly growing. Investigations: Clinical exam, dermoscopy, biopsy, genetics (BRAF, NRAS, NF1), IHC (S-100, HMB-45, Melan-A, MITF), CT scan. Management: Wide local excision (margin by Breslow depth), sentinel node biopsy if >1 mm; advanced cases—immunotherapy, targeted therapy, chemotherapy; interferon-α as adjuvant.

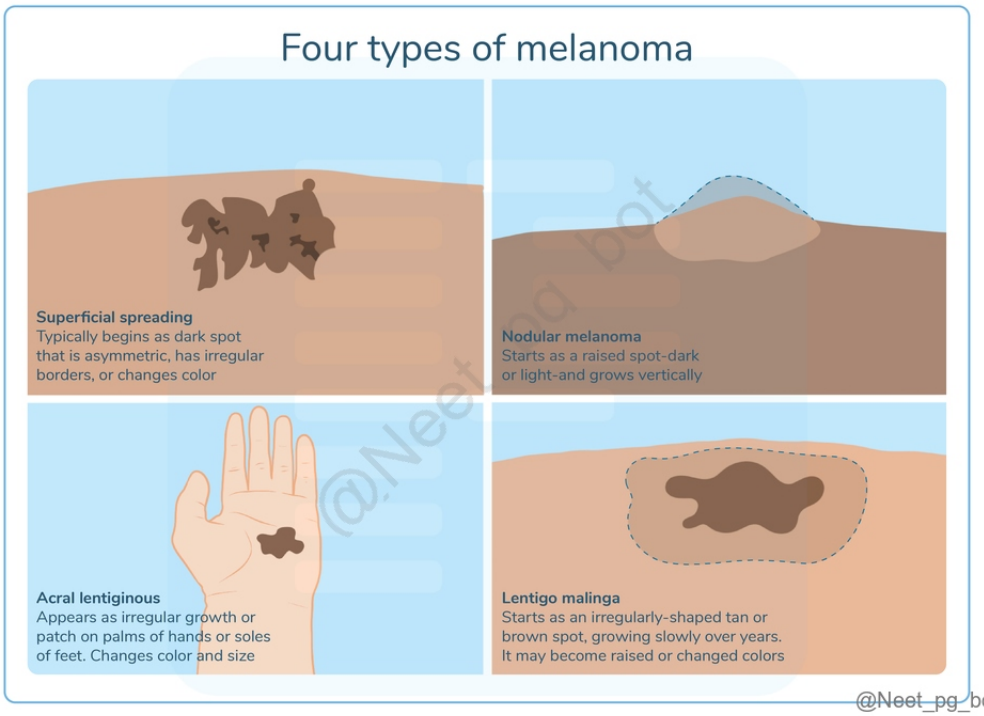



References:

Rook’s Textbook of Dermatology, 9th edition, page no. 143.7-143.28

Harrison’s Principles of Internal Medicine, 21st edition, page no. 587

↑ *Back to this question in Part A*

@Neet_pg_bot

Q25: A 38-year-old female presents with an increasing size of a mole. A lesion with irregular borders and variegated colours is noted, histopathologically confirmed as atypical melanocytes invading the dermis. Which nevus type is most commonly associated with malignant transformation to melanoma? (Q841720)

A. Dermal nevus

B. Compound nevus

C. Large congenital melanocytic nevus

D. Beckers nevus

Correct Answer: C. Large congenital melanocytic nevus

■ *Listen (English)*

■ *Listen (Hindi)*

Explanation: Large congenital melanocytic nevus, especially those over 20cm (giant congenital melanocytic nevus), have a much higher risk of developing melanoma over the individual's lifetime, particularly if they are larger or have a nodular component. Option A: Dermal nevus are typically benign and are less likely to transform into melanoma compared to congenital melanocytic nevi. Option B: Compound nevus have Nevus cells in both dermis and epidermis. They have a slight risk of malignant transformation but are not as high as in large congenital melanocytic nevus. Option D: Becker's nevus is a benign cutaneous hamartoma that is usually not associated with malignant transformation. Types of Nevi:



@Neet_pg_bot

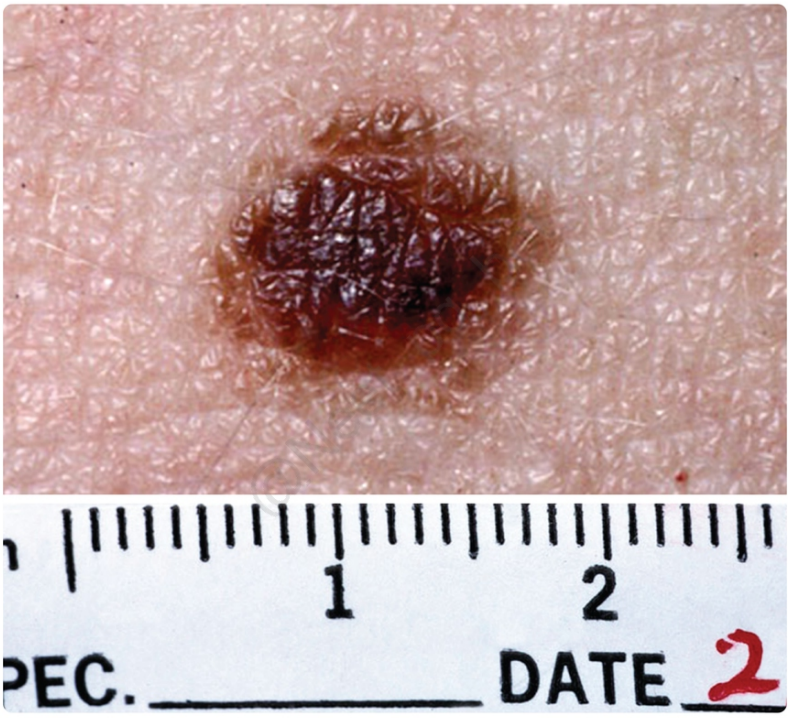

@Neet_pg_bot



@Neet_pg_bot



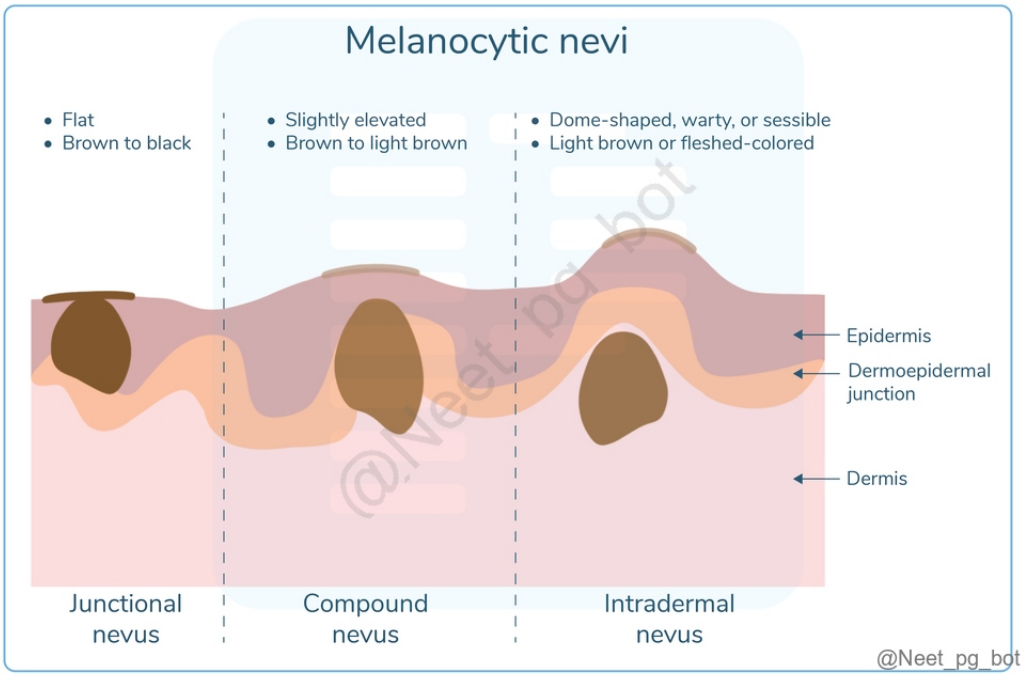

References:

Rooks textbook of dermatology 9th ed, page no. 143.2,143.16

↑ *Back to this question in Part A*

Q26: A 65-year-old female presented with a slow-growing, painless lesion on her face that has been present for several months. Physical examination reveals an ulcerated lesion with rolled borders and telangiectasias. The lesion is non-tender. What is the most likely diagnosis? (Q841719)

A. Squamous cell carcinoma

B. Basal cell carcinoma

C. Malignant melanoma

D. Dermatofibroma



Correct Answer: B. Basal cell carcinoma

■ *Listen (English)*

■ *Listen (Hindi)*

Explanation: Basal cell carcinoma Basal Cell Carcinoma (BCC / Rodent ulcer): Slow-growing, locally invasive, rarely metastasizes; arises from basal epidermal or follicular cells. Sites: Face, around eyes, nose. Features: Scaly plaque → noduloulcerative lesion with rolled margin, telangiectasia, bleeds easily. Histology: Peripheral palisading of basaloid cells with organized stroma. Treatment: Imiquimod, 5-FU, interferon α-2b, vismodegib;

surgery/Mohs for recurrence.

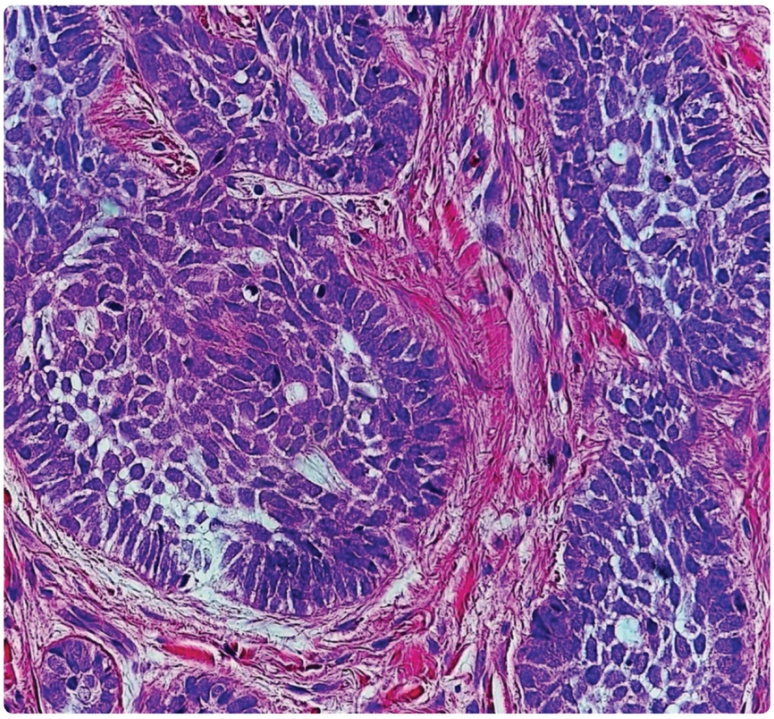

References:

Rook's Textbook of Dermatology, 9th Edition, Page 141.4-141.6

↑ *Back to this question in Part A*

@Neet_pg_bot

Q27: Which among the following is false regarding Marjolin’s Ulcer? (Q841717)

A. It has a tendency to convert into SCC and BCC.

B. It doesn’t commonly have lymphatic spread.

C. It has cauliflower-like edges.

D. It occurs within a few days of surgery.

Correct Answer: D. It occurs within a few days of surgery.

■ *Listen (English)*

■ *Listen (Hindi)*

Explanation: Meleney's ulcer occurs within a few days of surgery, while Marjolin's ulcer, which develops from a scar, takes a long time to form. Marjolin's ulcer: Marjolin's ulcer commonly develops in burn scars, venous ulcers, and osteomyelitis sinuses. SCC > BCC conversion .(Option A) Appearance: Raised everted cauliflower-like edges are seen over the scar .(Option C) Lymphatic spread is rarely seen due to scarring and poor blood supply .(Option B) Treatment: Wide local excision.



References:

Rooks textbook of dermatology 9th ed, page no.124.5

↑ *Back to this question in Part A*

@Neet_pg_bot

Q28: A 65-year-old female came with complaints of a painless nodule on the right palm for the past 3 weeks. She gave a history of sustaining a thorn prick injury to the palm 4 weeks ago. On examination, the lesions appear as shown below. What is the most likely diagnosis? (Q841716)

A. Keratoacanthoma

B. Bowens disease

C. Mycosis fungoides

D. Actinic keratosis



Correct Answer: A. Keratoacanthoma

■ *Listen to Audio 1*

Explanation: The given image showing an exophytic nodule with the central keratinous debris is suggestive of Keratoacanthoma. Keratoacanthoma is a low-grade squamous cell cancer. It presents as a proliferating dome-shaped keratin-filled crater. Patients usually give a prior history of minor trauma. M/C Site- Face > hands Phases of growth- Growth, Maturation, Resolution phase It starts as a papule. Develops to a dome-shaped nodule with a central keratin plug. Outer epidermal lining everts to surrounding skin Plug falls off. Lesion disappears. The treatment of choice is an excisional procedure with 4mm margins.

References:

Devita-cancer principles and practice of oncology,10th edition-page no. 1325

↑ *Back to this question in Part A*

@Neet_pg_bot

Q29: Identify the FALSE statement among the following regarding SCC? (Q841714)

A. It arises from keratinocytes.

B. It occurs in sun-exposed and also over sun-protected sites including mucosa.

C. It is most common in transplant recipients.

D. It has pearly rolled-out edges.

Correct Answer: D. It has pearly rolled-out edges.

■ *Listen (English)*

■ *Listen (Hindi)*

Explanation: The description of pearly rolled-out edges typically refers to BCC and not SCC. SCC often presents as a scaly or crusted lesion with potential ulceration and an everted edge. Crusting and scaling are potential signs of photodamage. Squamous cell carcinoma: SCC arises from keratinocytes or its appendages.(Option A) SCC occurs in sun-exposed sites including mucosa. SCC can occur on sun-exposed skin such as the head, neck, and arms.(Option B) Predisposing factors include UV exposure Immunocompromised individuals Xeroderma pigmentosum (XP) Albinism, LP(Lichen Planus), DLE (Discoid lupus erythematosus) SCC is most common dermatological malignancy in transplant recipients due to immunosuppression. Overall, BCC is the most common skin malignancy and SCC is the second most common.(Option C) Basal cell carcinoma: Aka Basilioma, rodent ulcer Most common human cancer Arises from basal layer of epidermis / follicular structures Slow growing , locally invasive Rarely metastasizes Clinical features: No premalignant stage Slow progressive with peripheral extension Site: Face (around eyes & nose) Presentation: Papule/ raised nodule with central ulceration Thready margin and telangiectasia (periphery) Bleeds to touch Association: Xeroderma pigmentosum (XP) Albinism Naevoid BCC syndrome/Gorlin syndrome Treatment: ■■■■■■■Medical: Low■ Risk superficial and small nodular BCC Imiquimod, 5-FU PDT Intralesional interferon α-2b Hedgehog pathway inhibitors (e.g., Vismodegib) for locally advanced/metastatic cases Surgical: ■■■■■■■■■■■■■■■■ Excision with predetermined margins → 4–5 mm surgical margin Mohs micrographic surgery Others: Cryotherapy, Electron beam radiotherapy





@Neet_pg_bot

References:

Rooks textbook of dermatology 9th ed, page no. 141.8,142.25

↑ *Back to this question in Part A*

@Neet_pg_bot

Q30: A 60-year-old male presents with a slowly growing lesion on his left forearm, occasionally bleeding post-trauma, and had a lot of sun exposure throughout his life. The biopsy of the lesion is shown below. What is the likely diagnosis? (Q841713)

A. Actinic keratosis

B. Basal cell carcinoma

C. Cutaneous squamous cell carcinoma

D. Melanoma

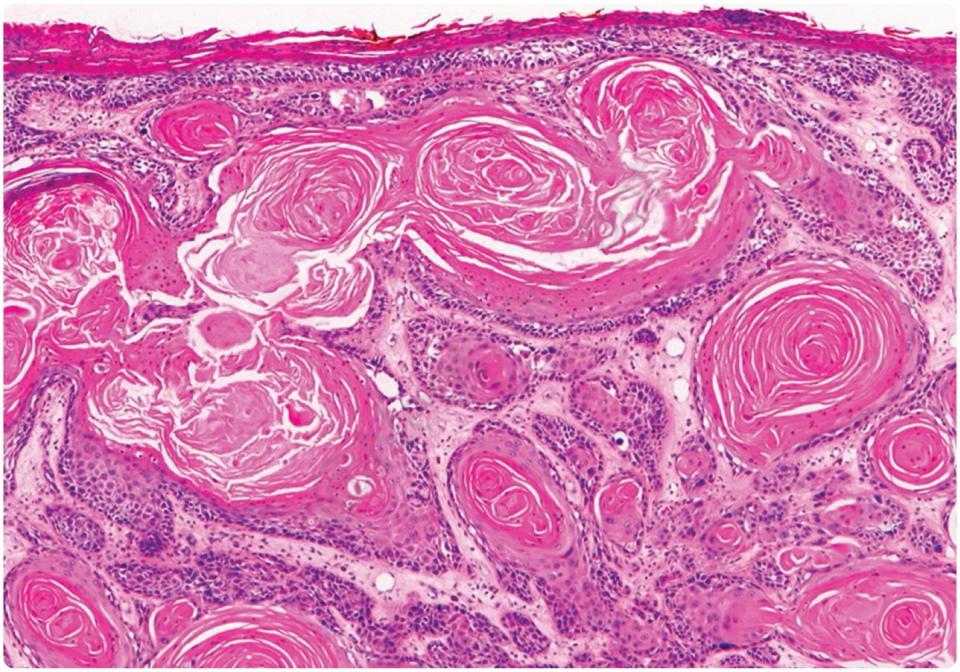

@Neet_pg_bot

Correct Answer: C. Cutaneous squamous cell carcinoma

■ *Listen (English)*

■ *Listen (Hindi)*

Explanation: Cutaneous squamous cell carcinoma (SCC): Malignant tumor of epidermal keratinocytes, common in immunocompromised (HIV, transplant). Risk factors: UV exposure, immunosuppression, xeroderma pigmentosum, albinism, LP, DLE. Presents as indurated papules, nodules, or plaques with crusting/scaling. Histology: keratin pearls. Treatment: wide excision or Mohs surgery; advanced cases—radiation/chemotherapy. Actinic keratosis (Option A) typically presents as rough, scaly erythematous lesions with epidermal dysplasia, no dermal invasion. Basal cell carcinoma (Option B): presents as pearly papules with rolled edges and telangiectasias; arises from basal cells, usually non-invasive. Melanoma (Option D) presents as asymmetric, variegated pigmented lesions with irregular borders.Histologically, melanoma arises from melanocytes and may show invasion into the dermis. However, the clinical and histological features described in the scenario are more consistent with SCC rather than melanoma.

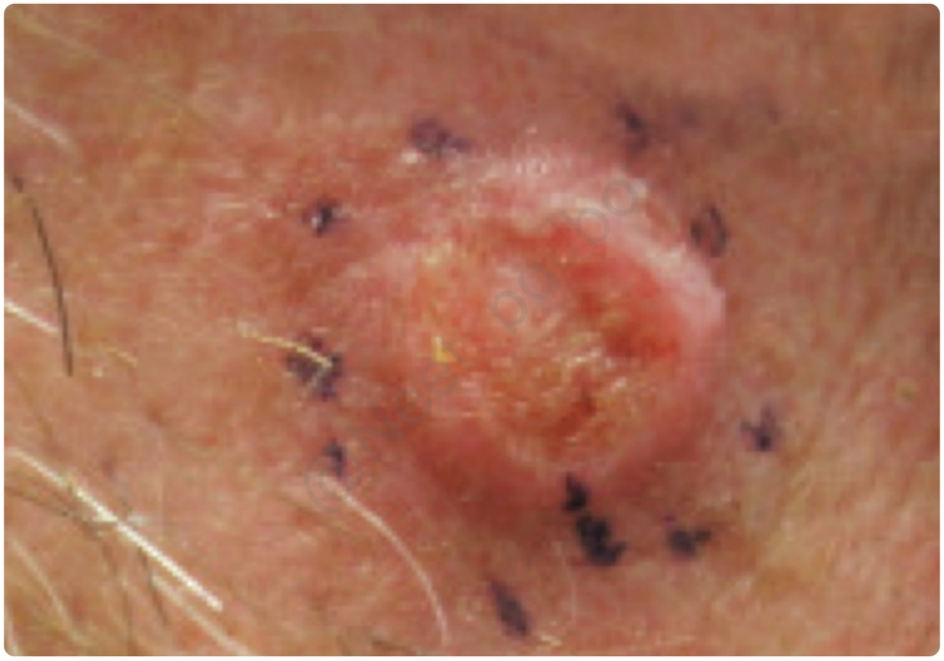

@Neet_pg_bot

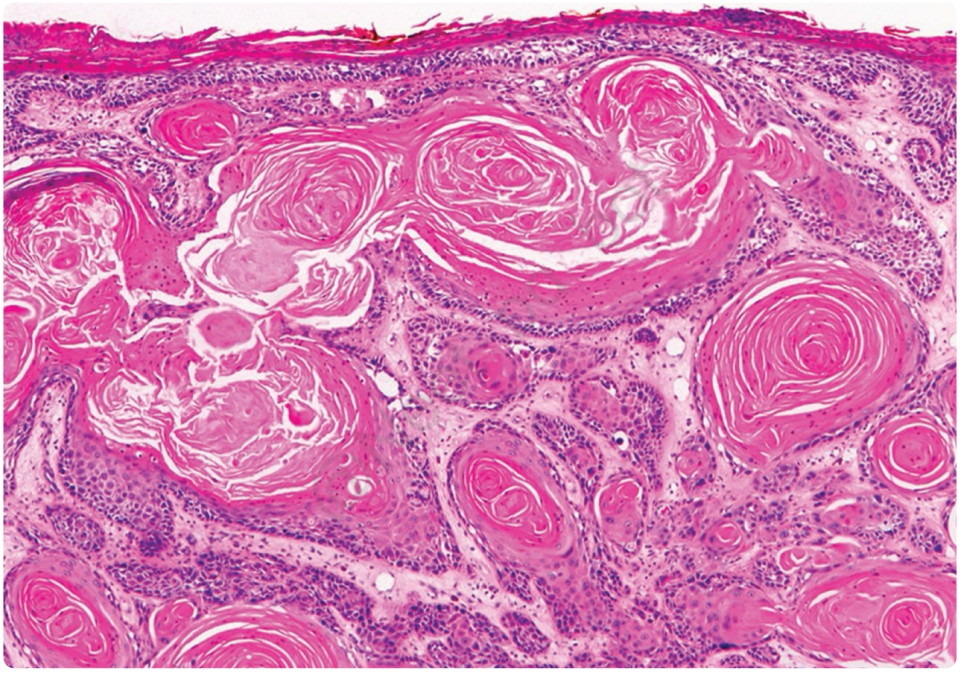

@Neet_pg_bot

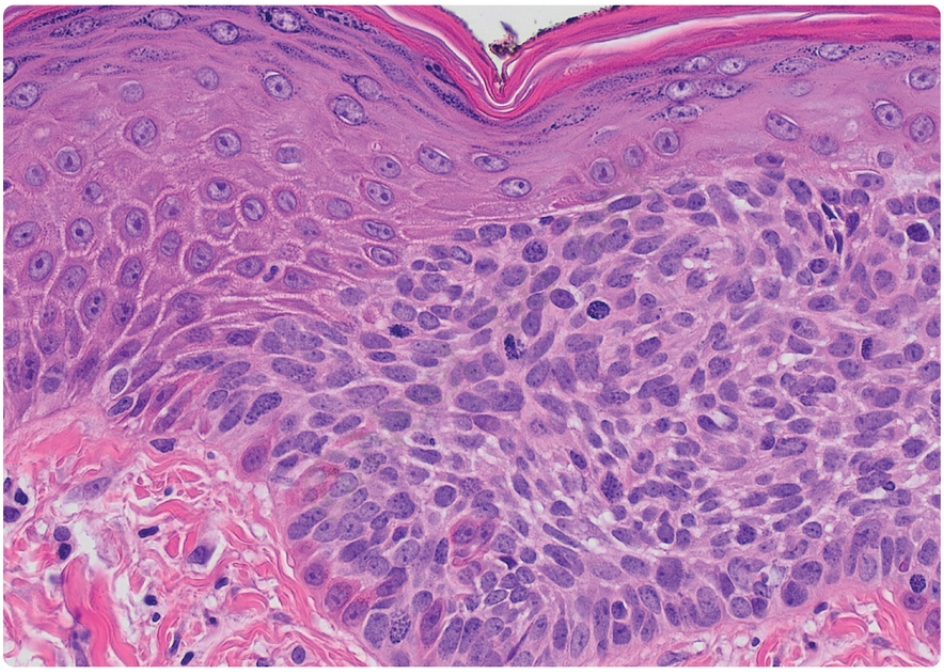

@Neet_pg_bot

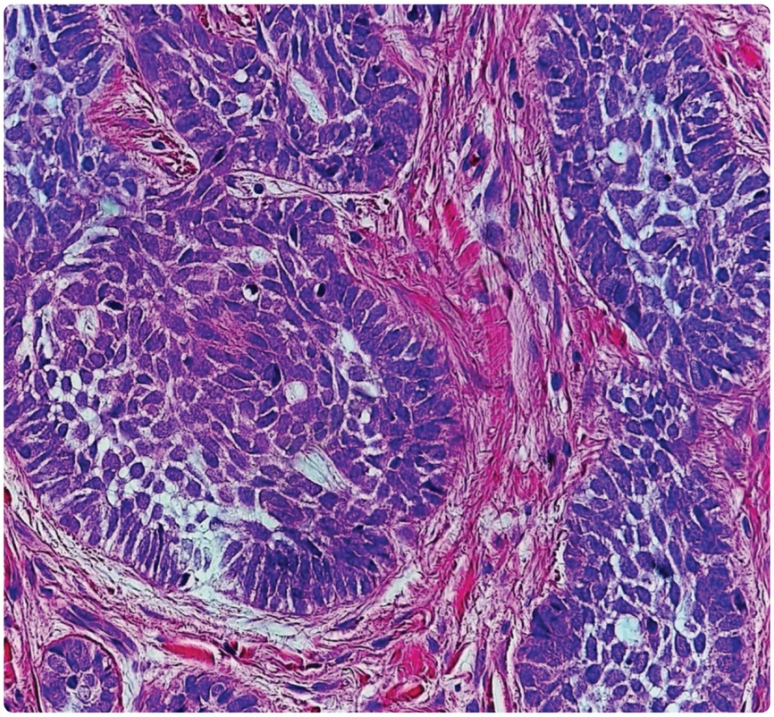

@Neet_pg_bot

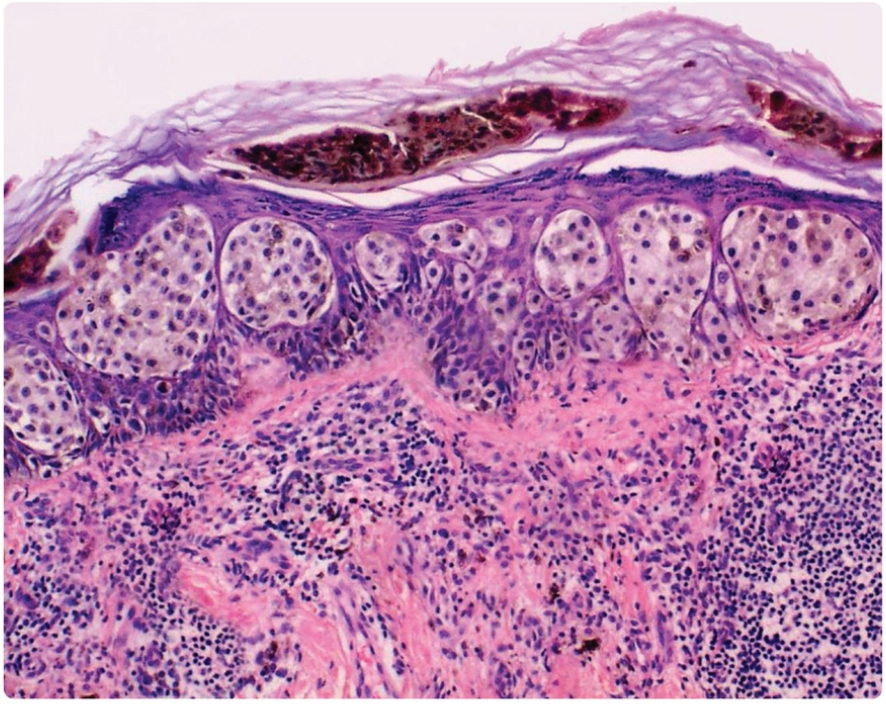

References:

Rooks Textbook of Dermatology, 9th Edition, Page 142.10

↑ *Back to this question in Part A*

@Neet_pg_bot

Q31: A 65-year-old woman presents to the dermatology clinic with a persistent, non-elevated, red, scaly plaque on her lower leg. The lesion has been slowly enlarging over the past several months. She reports no pain or bleeding from the lesion. Her medical history includes a solid-organ transplant five years ago, for which she is on immunosuppressive therapy.Which statement about this condition is NOT true? (Q841711)

A. Intraepidermal squamous cell carcinoma

B. HPV16 and HPV18 are commonly implicated, especially in genital lesions.

C. High potential for invasive malignancy

D. Occasionally it may undergo spontaneous partial resolution

Correct Answer: C. High potential for invasive malignancy

■ *Listen (English)*

■ *Listen (Hindi)*

Explanation: The clinical presentation described, including the presence of a scaly , erythematous plaque confined to the epidermis and a history of chronic sun exposure, is consistent with Bowen's disease , also known as squamous cell carcinoma in situ. The incorrect statement is that it has a high potential for invasive malignancy. Bowen's disease/Squamous cell carcinoma in situ: It is an intra-epidermal squamous cell carcinoma characterized by a persistent, non-elevated, red, scaly, or crusted plaque with a low potential for invasive malignancy .(Option A) Risk factors: Arsenic exposure. Immunosuppression (organ transplant, HIV). Chronic lymphocytic leukemia. Human papilloma virus- HPV16 and HPV18 are commonly found in Bowen disease lesions, especially in anogenital areas .(Option B) It usually grows progressively but sometimes undergoes spontaneous partial resolution .(Option D) It can occur anywhere, but more in the head and neck region. Pathology: Full-thickness epidermal dysplasia & disordered differentiation with loss of epithelial polarity. The intraepidermal portion of cutaneous adnexae is generally affected. Parakeratosis and acanthosis are usually present, and keratinocytes show variable pleomorphism, nuclear hyperchromasia, and nuclear enlargement. The dermal-epidermal junction remains distinct . HPV■associated viral cytopathic changes are frequently seen particularly, but not exclusively, in lesions from genital skin. The image shows Bowen's disease- Red, erythematous plaque:



References:

Rooks textbook of dermatology 9th ed, page no.142.16-142.17 Image : https://commons.wikimedia.org/wiki/File:Bowen%27s_disease_%28crop%29.jpg

↑ *Back to this question in Part A*

• [19_Skin Tumours] 038 Previous Year Questions

« Back to Folder Directory

[19_Skin Tumours] 038 Previous Year Questions — Quick Jump

Q1 (p. 1513) *Q2 (p. 1514)* *Q3 (p. 1515)* *Q4 (p. 1516)* *Q5 (p. 1520)* *Q6 (p. 1524)* *Q7 (p. 1527)*

Q1: A patient is diagnosed with squamous cell carcinoma at the base of the tongue. What is the most common causative agent? (Q866556)

A. EBV

B. HPV

C. HCV

D. CMV

Correct Answer: B. HPV

Explanation: Squamous cell carcinoma (SCC) of the oropharynx , particularly the base of the tongue and tonsillar region , is strongly linked to high-risk HPV infection , most commonly HPV-16 . HPV-related SCC has a better prognosis than tobacco/alcohol-related SCC. Transmission is often via orogenital contact, and the tumor shows p16 overexpression on immunohistochemistry. EBV (Option A): Associated with nasopharyngeal carcinoma, not SCC of the base of the tongue. HCV (Option C): Primarily linked to hepatocellular carcinoma and some lymphomas, not oral/oropharyngeal SCC. CMV (Option D): Typically causes disease in immunocompromised individuals (retinitis, colitis), not implicated in oral/oropharyngeal cancers.



References:

.

↑ *Back to this question in Part A*

@Neet_pg_bot

Q2: A 60-year-old person presented with an ulcer on the medial canthus. The ulcer has rolled-out, beaded margins. Histopathology shows nesting cells with peripheral palisading patterns. What is the most likely diagnosis? (Q852712)

A. Squamous Cell Carcinoma (SCC)

B. Nevus

C. Basal Cell Carcinoma (BCC)

D. Melanoma

Correct Answer: C. Basal Cell Carcinoma (BCC)

Explanation: Basal Cell Carcinoma (BCC) is the most common skin cancer and typically occurs in sun-exposed areas such as the face, particularly around the medial canthus of the eye . The classic clinical description includes: Ulceration with rolled-out, beaded margins . A pearly or translucent appearance with visible telangiectasia. Histopathology findings include: Nesting of basaloid cells . Peripheral palisading of nuclei. Clefting artifact between tumor cells and surrounding stroma. Other Options: Squamous Cell Carcinoma (SCC) (Option A) : Typically presents with a scaly, keratinized lesion that may ulcerate but lacks the rolled, pearly margins and palisading pattern seen in BCC. Nevus (Option B) : A benign lesion that does not typically ulcerate or have invasive histological features. Melanoma (Option D) : Usually presents with irregular pigmentation, asymmetry, and rapid growth , rather than a rolled-margin ulcer.

References:

Neena Khanna, Textbook of Dermatology, 5th Edition, Page no: 388-390
https://pubmed.ncbi.nlm.nih.gov/29494046/

↑ *Back to this question in Part A*

@Neet_pg_bot

Q3: Which carcinoma is the possible diagnosis in the image given below? (Q820214)

A. Basal cell carcinoma

B. Squamous cell carcinoma

C. Malignant melanoma

D. Hepatocellular carcinoma



Correct Answer: C. Malignant melanoma

Explanation: Correct option C - Malignant melanoma It presents as an irregularly shaped, dark-colored lesion with uneven borders. Malignant melanoma has a higher potential to metastasize if not detected and treated early. It is crucial to catch it at an early stage for a better prognosis. Incorrect options: Option A - Basal cell carcinoma: It appears as a flesh-colored or pinkish bump with a central depression and raised edges. It is slow-growing and rarely metastasizes. It is common in areas exposed to the sun. Option B - Squamous cell carcinoma: It is also linked to sun exposure. It presents as a firm, red nodule or a scaly, crusted lesion. It has a higher potential to metastasize if left untreated. Option D - Hepatocellular carcinoma: Hepatocellular carcinoma is a type of liver cancer that originates from hepatocytes.

↑ *Back to this question in Part A*

@Neet_pg_bot

Q4: A 60-year-old diabetic patient presents with a lesion on the nose as shown in the image below. The lesion bleeds on the touch. What is the diagnosis? (Q854645)

A. Squamous cell carcinoma

B. Basal cell carcinoma

C. Melanoma

D. Discoid lupus erythematosus



Correct Answer: B. Basal cell carcinoma

Explanation: Basal cell carcinoma (BCC), aka rodent ulcer is a slow-growing, locally invasive tumor and it rarely metastasizes. It arises from pluripotent cells within the basal layer of the epidermis or follicular structures. Clinical Features It presents initially small, scaly plaque Slow progressive course of peripheral extension Develops into nodular-ulcerative lesions, it has a thread-like margin, telangiectasia and it bleeds on touch. Site: Face, Around eyes, Nose Histopathology: peripheral palisading of tumour cells (shown in the image), the cells resemble cells of stratum basale that have grown into the dermis. This cluster of cells is surrounded at the periphery by perpendicularly arranged cells . It also has a well-organized stroma surrounding it. {{caption_text}} Treatment Medical: Imiquimod, 5-FU,Intralesional interferon α-2b Hedgehog pathway inhibitors:(Vismodegib) Surgical: Mohs micrographic surgery, Done in recurrent BCCs. Squamous cell carcinoma (Option A): Clinical Features: There is a presence of a papule, nodule, or plaque with induration, accompanied by signs of photodamage such as crusting and scaling. Histopathology: Keratin pearls. {{caption_text}} {{caption_text}} Melanoma (Option C): The image presented above doesn't meet the diagnostic criteria of malignant melanoma (ABCDE) Asymmetry: Irregular shapes. Border: Irregular. Colour: Various colours present or uneven distribution. Diameter: > 6 mm. Evolution: Changes in lesion over time (size, shape, itching, or bleeding). {{caption_text}} Discoid lupus erythematosus (Option D): This is a chronic inflammatory skin condition characterized by red, scaly, and atrophic lesions, typically without a tendency to bleed. Discoid lupus has distinct features like a well-demarcated, scaly plaque, and it usually lacks the ulcerative appearance seen in this case.


@Neet_pg_bot

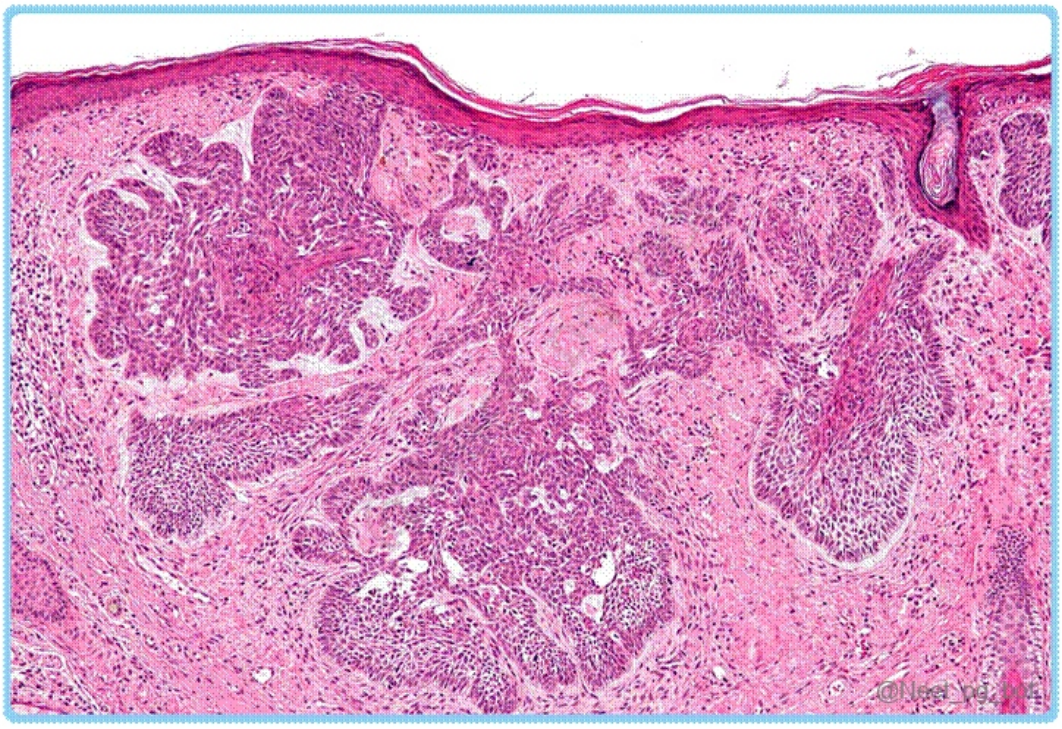

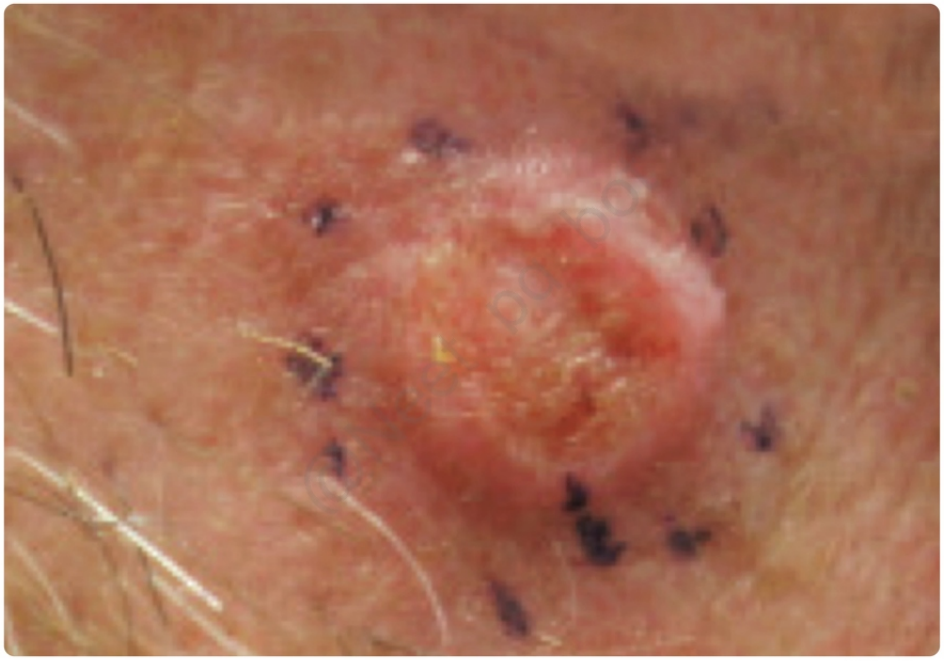

@Neet_pg_bot

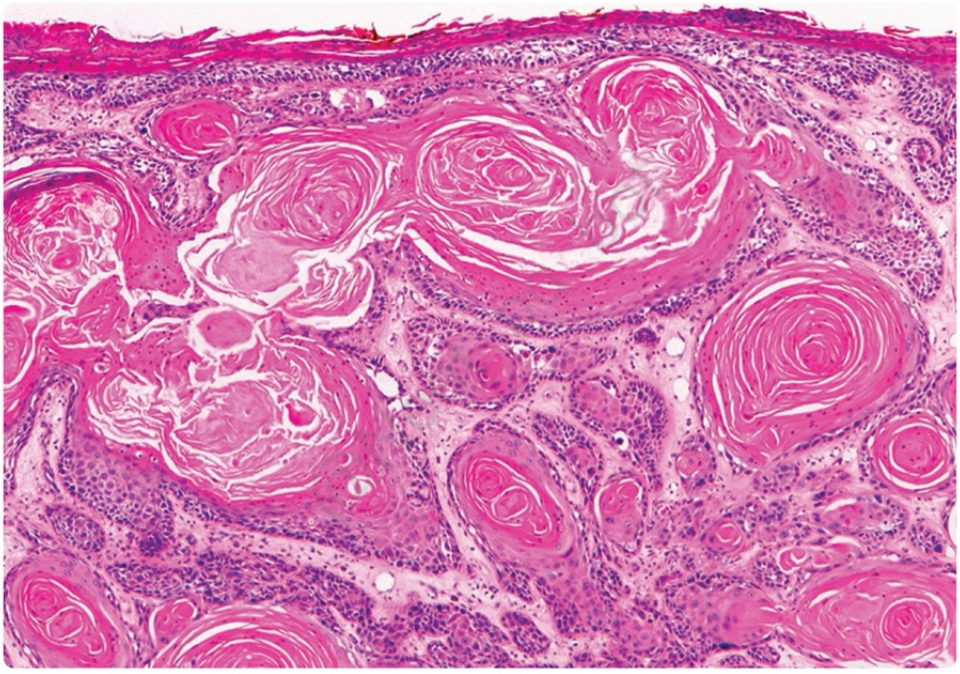

@Neet_pg_bot



References:

Rooks textbook of dermatology, 9th edition page no.141.4-141.6

↑ *Back to this question in Part A*

@Neet_pg_bot

Q5: Which of the following is associated with the clinical condition shown in the image? (Q855295)

A. Condylomata lata

B. Mole

C. Malignant melanoma

D. Basal cell carcinoma



Correct Answer: C. Malignant melanoma

Explanation: The image showing a lesion with irregular borders, asymmetry, and uneven distribution of colors , strongly suggests malignant melanoma . This is a malignant tumor arising from melanocytes located at the epidermal-dermal junction. Though rare, melanoma is highly aggressive with a significant risk of metastasis if not diagnosed early. Key Diagnostic Features of Malignant Melanoma ABCDE criteria : A symmetry. B order irregularity. C olor variation (brown, black, red, white, or blue). D iameter >6 mm. E volving lesion (changes in size, shape, or symptoms like bleeding or itching). Biopsy Findings: Large melanoma cells with enlarged nuclei , irregular contours, and clumped chromatin. Prominent eosinophilic nucleoli . Similar cellular appearance in both radial and vertical growth phases: Radial phase : Horizontal spread of melanoma within the epidermis and superficial dermis. Vertical phase : Deep invasion into dermal layers, forming an expansile mass. Risk Factors: Fair skin and history of sunburns . Family history or genetic mutations (e.g., CDKN2A mutation on chromosome 9p21). UV exposure and pre-existing nevi (e.g., dysplastic or congenital nevi). Types of Melanoma: Type Site Description Image Superficial spreading (M/C type) Any (more common on the upper back and, in women, lower legs) Brown mixed with bluish-red, bluish-black, reddish brown, and often whitish pink. The lesion border is often visibly and/or palpably raised {{caption_text}} Lentigo maligna Sun-exposed surfaces, particularly malar region and temple In flat portions, brown and tan predominate, but whitish grey sometimes present; in nodules, reddish brown, bluish grey, bluish-black. {{caption_text}} Acral lentiginous Palm, sole, nail bed, mucous membrane In flat portions, dark brown; in raised lesions (plaques), brown-black or blue-black. {{caption_text}} Nodular Any Reddish blue, purple, or bluish-black; can be uniform or mixed with brown and black. {{caption_text}} Staging and Classification: Breslow thickness : Measures depth of tumor invasion. Clark level : Describes the anatomical level of invasion. Stage Classification Clarke Breslow I Involvement of epidermis ≤ 0.75 mm II Involvement of epidermis + dermis 0.76-1.5 mm III Involvement of dermal papillae 1.5-4 mm IV Involvement of reticular dermis >4 mm V Involvement of subcutaneous tissue - Management: Early detection and histopathological confirmation via biopsy are critical for improving outcomes. Wide local excision : Margins depend on Breslow thickness. Sentinel lymph node biopsy : Indicated for lesions >1 mm in thickness. Advanced cases : Immunotherapy (e.g.,

immune checkpoint inhibitors). Targeted therapy (BRAF/MEK inhibitors for BRAF-mutant melanoma). Interferon-α : Prevents metastasis in high-risk cases. Incorrect Options: Option A) Condylomata lata: Associated with secondary syphilis, these are smooth, moist, flat-topped, and highly contagious warty lesions, typically found in the anogenital region or mucous membranes. They lack the asymmetry, irregular borders, and color variations seen in malignant melanoma. Option B) Mole: Moles (benign melanocytic nevi) are symmetric lesions with uniform color, smooth borders, and no significant changes over time. They do not exhibit the irregular and evolving features of malignant melanoma. Option D) Basal cell carcinoma: This is the most common skin cancer, presenting as a pearly or translucent papule with telangiectasias, often on sun-exposed areas. It rarely shows pigmentation or the asymmetry and color variation seen in malignant melanoma.



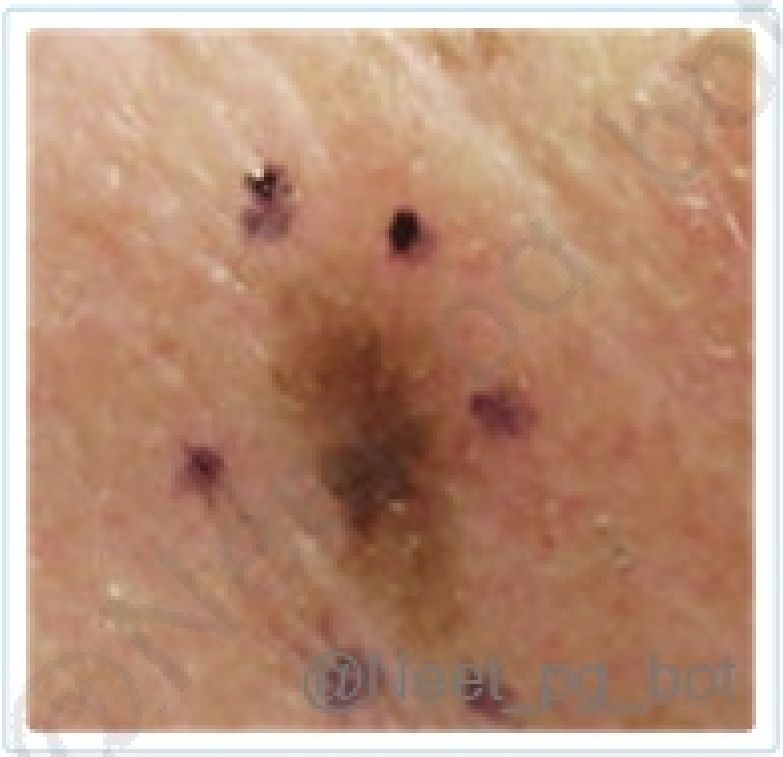
@Neet_pg_bot


@Neet_pg_bot



References:

Rook’s Textbook of Dermatology, 9th edition, page no. 143.7-143.28

Harrison’s Principles of Internal Medicine, 21st edition, page no. 587

↑ *Back to this question in Part A*

@Neet_pg_bot

Q6: A baby presents to the OPD; the image below shows the findings. What is the probable diagnosis? (Q857968)

A. Portwine stain

B. Cavernous hemangioma

C. Naevus simplex

D. Capillary hemangioma



Correct Answer: D. Capillary hemangioma

Explanation: Answer D - Capillary Hemangioma: The images show a bright red, raised, well-demarcated lesion commonly seen in infants. Capillary hemangiomas (strawberry hemangiomas) are benign vascular tumors that typically appear after birth, grow rapidly, and regress spontaneously . They are superficial hemangiomas composed of proliferating endothelial cells . Commonly occur on the face, scalp, trunk, or extremities . Most resolve by 5–7 years of age without treatment. Infantile Hemangioma (Capillary Hemangioma) Feature Capillary Hemangioma Cause Proliferation of immature endothelial cells Appearance Bright red, raised lesion with a well-demarcated border Onset Appears within first few weeks after birth Growth Pattern Rapid growth for months, then gradual involution Resolution 90% regress by 5–7 years of age Treatment Observation, propranolol (if complications occur) {{caption_text}} {{caption_text}} Portwine stain (Option A): Incorrect because port-wine stains (nevus flammeus) are flat, non-proliferative vascular malformations that do not regress . Cavernous hemangioma (Option B): Incorrect because cavernous hemangiomas are deeper, bluish, and less well-defined . Naevus simplex (Option C): Incorrect because naevus simplex ("salmon patch") is a flat, pink-red blanching lesion commonly seen on the forehead and nape of the neck .



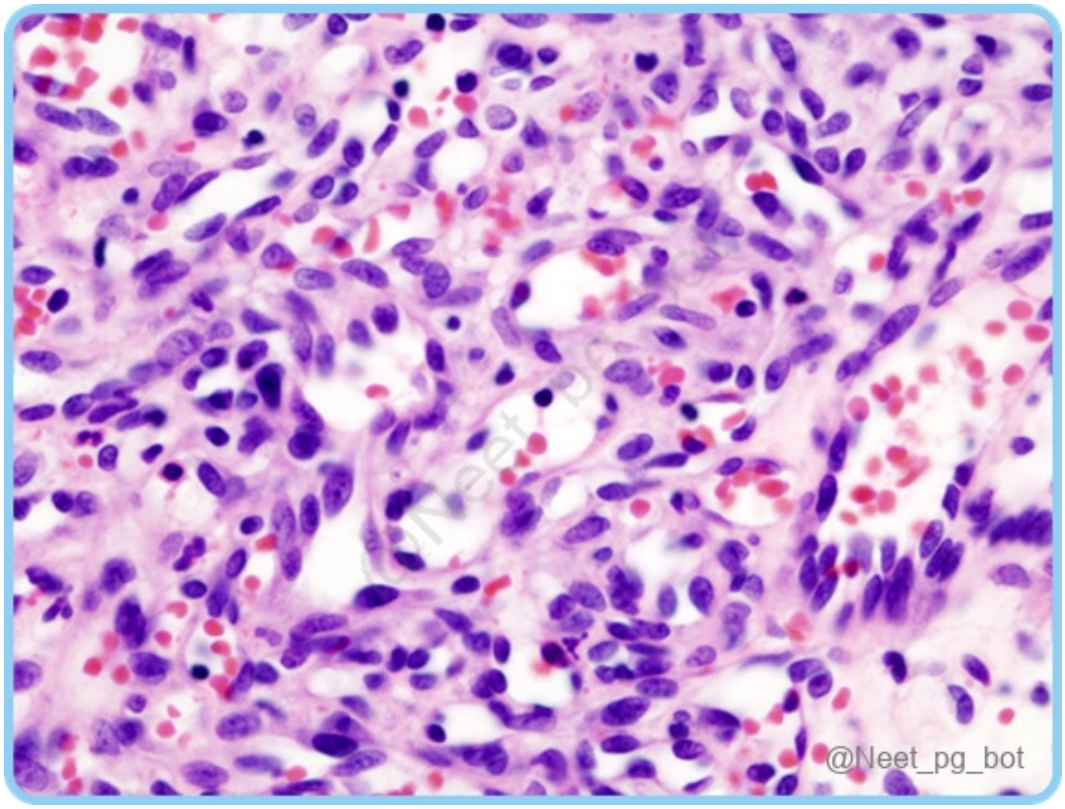

References:

Robbins Pathology 10th edition, Pg 519, 520

↑ *Back to this question in Part A*

@Neet_pg_bot

Q7: Identify the given disorder. (Q857048)

A. Melanoma

B. Hyperpigmentation

C. Basal cell carcinoma

D. Squamous cell carcinoma



Correct Answer: A. Melanoma

Explanation: The given image showing a lesion with irregular borders , asymmetry , and uneven distribution of colors in the lesion is suggestive of malignant melanoma . Malignant melanoma: Melanoma is a malignant tumour arising from melanocytes at the epidermal-dermal junction. Though it is a rare skin cancer, it has a high mortality rate. It presents as a pigmented lesion that enlarges, ulcerates, or bleeds. Risk factors: Positive family history. Fair skin. Genetics: CDKN2A (chromosome 9p21), MC1R, and TYR genes. Nevus: Congenital melanocytic nevi. Junctional nevi. Atypical nevi. Dysplastic nevi. Fitzpatrick Type 1 skin. UV light. Types of Melanoma: Type Site Description Image Superficial spreading (M/C type) Any (more common on the upper back and, in women, lower legs) Brown mixed with bluish-red, bluish-black, reddish brown, and often whitish pink. The lesion border is often visibly and/or palpably raised {{caption_text}} Lentigo maligna Sun-exposed surfaces, particularly malar region

and temple In flat portions, brown and tan predominate, but whitish grey sometimes present; in nodules, reddish brown, bluish grey, bluish-black. {{caption_text}} Acral lentiginous Palm, sole, nail bed, mucous membrane In flat portions, dark brown; in raised lesions (plaques), brown-black or blue-black. {{caption_text}} Nodular Any Reddish blue, purple, or bluish-black; can be uniform or mixed with brown and black. {{caption_text}} Investigations: Clinical examination. Dermoscopy. Biopsy. Immunohistochemistry: The markers are S-100, HMB-45 (the most specific), Melan-A (MART-1), and MITF. CT scan. Breslow's and Clarke's Classifications of Malignant Melanoma: Stage Classification Clarke Breslow I Involvement of epidermis ≤ 0.75 mm II Involvement of epidermis + dermis 0.76-1.5 mm III Involvement of dermal papillae 1.5-4 mm IV Involvement of reticular dermis >4 mm V Involvement of subcutaneous tissue - Management: Wide local excision (with margins measured before excision and determined by Breslow depth, sentinel lymph node biopsy indicated for tumours with a depth of >1.0 mm). If the tumour is aggressive: Immunotherapy. Chemotherapy. Targeted therapy. Interferon-■ is the only adjuvant treatment that has documented beneficial effects on overall survival. Incorrect Options: Hyperpigmentation (Option B): Generalized or localized increased skin pigmentation due to conditions like melasma, Addison's disease, or post-inflammatory hyperpigmentation. Does not present with an irregular, evolving lesion. Basal Cell Carcinoma (Option C): Pearly, translucent nodule with telangiectasia. Slow-growing and rarely metastasizes. May have central ulceration ("rodent ulcer"). Squamous Cell Carcinoma (Option D): Scaly, erythematous plaque or ulcer with crusting. Often seen in chronically sun-exposed areas. More locally invasive, with some potential for metastasis.

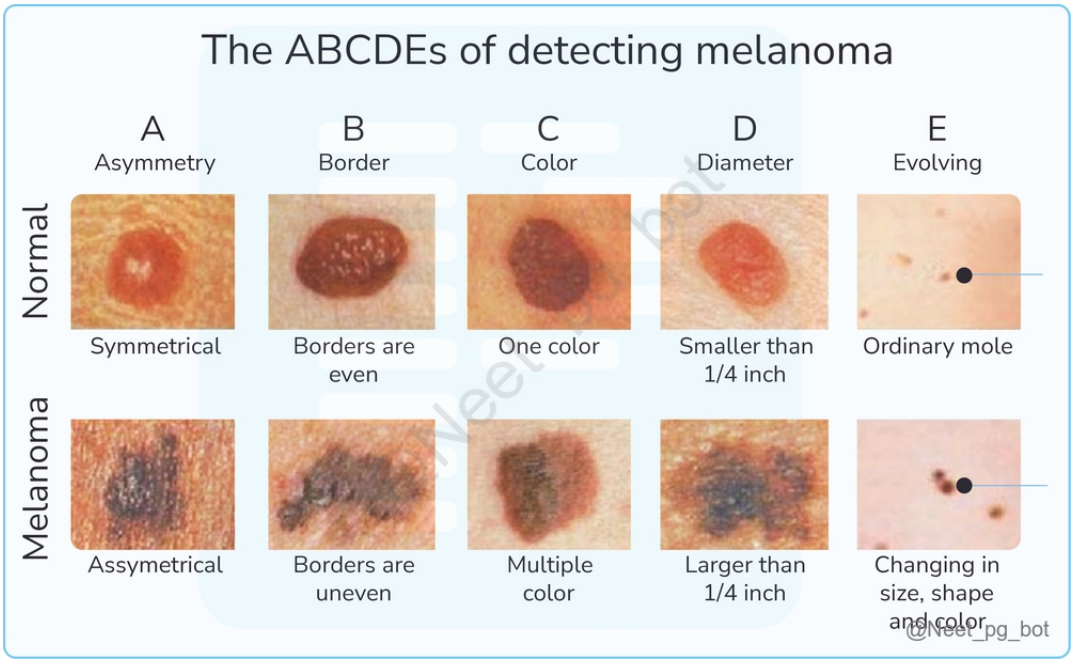


@Neet_pg_bot

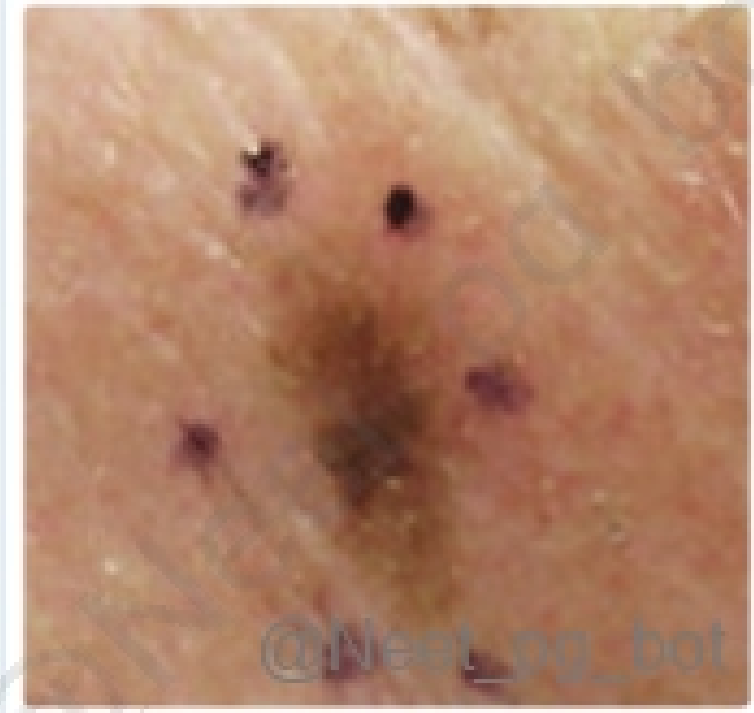
@Neet_pg_bot





References:

Rook’s Textbook of Dermatology, 9th edition, page no. 143.7-143.28

Harrison’s Principles of Internal Medicine, 21st edition, page no. 587

↑ *Back to this question in Part A*

@Neet_pg_bot