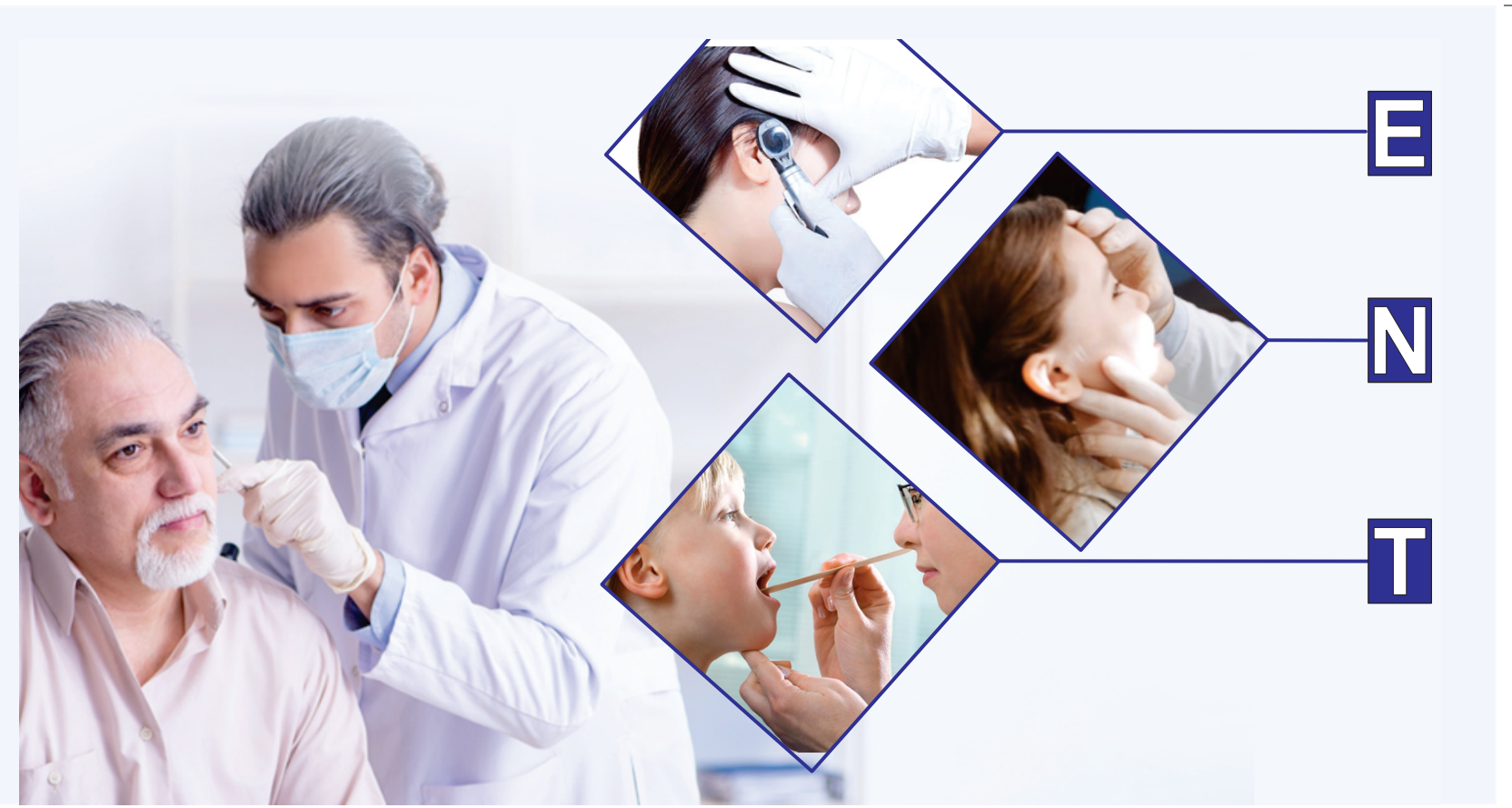

OneShot 4.0

ENT

DBMCI · 2026



ENT

| Sl. No. | CHAPTER | Page No. |
|---------|--------------------------------------|----------|
| 1. | <i>Ear Anatomy</i> | 333 |
| 2. | <i>Labyrinth</i> | 337 |
| 3. | <i>Infective Diseases of Ear</i> | 343 |
| 4. | <i>Non Infective Diseases of Ear</i> | 349 |
| 5. | <i>Throat Anatomy</i> | 355 |
| 6. | <i>Diseases of Throat</i> | 357 |
| 7. | <i>Diseases of Larynx</i> | 363 |
| 8. | <i>Carcinomas</i> | 367 |
| 9. | <i>Nose and Sinuses</i> | 371 |
| 10. | <i>Diseases of Nose and Sinuses</i> | 375 |
| 11. | <i>Multiple Choice Questions</i> | 383 |

“

**Persistent
hard work can
beat a bad
start, luck, and
intelligence.**

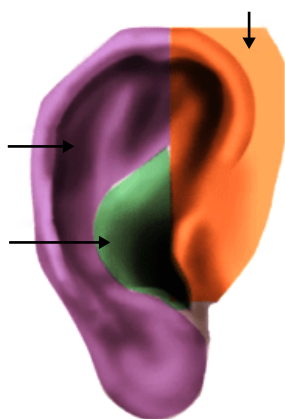
- Dr. Sanjay Agarwal

”



EAR ANATOMY

Ear Anatomy

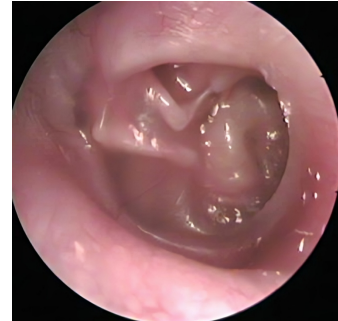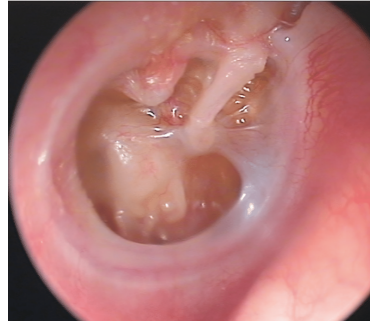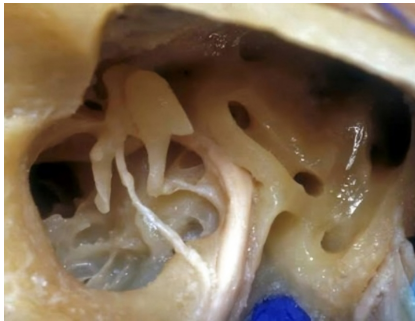


- Arnold's nerve*
- Auriculotemporal nerve*
- Auricle/Sensory branch of facial nerve*
- Lesser occipital nerve*
- Greater auricular nerve*

Middle Ear Anatomy with Facial Nerve

| <i>Eustachian Tube</i> | <i>Stapedius Muscle</i> |
|--|--|
| <p><i>36 mm long</i></p> <p><i>Child- straighter</i></p> <p><i>Function- Balance pressure & Drainage</i></p> <p><i>Investigation: Tympanometry</i></p> | <p><i>Function: Dampens loud sound</i></p> <p><u><i>Acoustic Reflex</i></u></p> <p style="padding-left: 40px;"><i>Afferent Nerve-VIII</i></p> <p style="padding-left: 40px;"><i>Efferent Nerve - VII</i></p> <p><i>Absent reflex: Hyperacusis</i></p> |

| <i>Prussack's Space</i> | <i>Facial Recess</i> |
|--|-----------------------|
| <i>Sup: Lateral Malleal fold</i> | <i>Facial Nerve</i> |
| <i>Med: Neck of malleus</i> | <i>Chorda Tympani</i> |
| <i>Lat: Pars flaccida & Scutum</i> | <i>Fossa Incudis</i> |





NOTES



ENT

NOTES

LABYRINTH

Labyrinth

| Cochlea | | Vestibule | Semi circular canals |
|------------------|-------------------------|-----------|----------------------|
| Inner Hair cells | Outer hair cells | | |
| X | Produces OAE | | |
| X | Easily damaged | | |

Investigation of Ear Diseases

| Hearing test | Vestibular function Test |
|------------------|---|
| Tuning Fork Test | Caloric test |
| Audiometry | Fistula test |
| Tympanometry | HINT |
| BERA | VEMP-Vestibular Evoked Myogenic Potential |
| OAE | |

Tuning Fork Tests (512Hz)

1. Rinne test

2. Weber test

3. ABC test/Schwabach's test

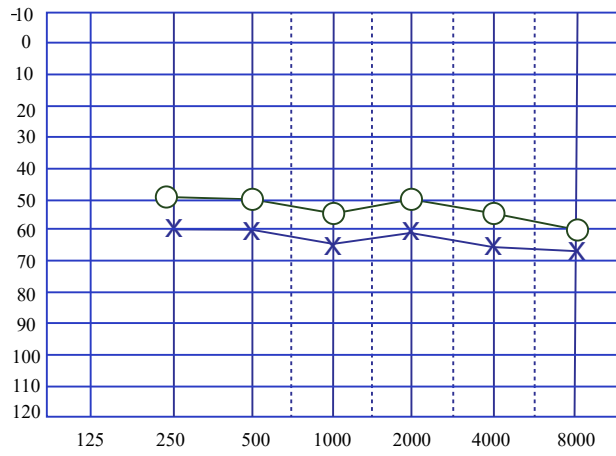
4. Bing test

5. Gelle test

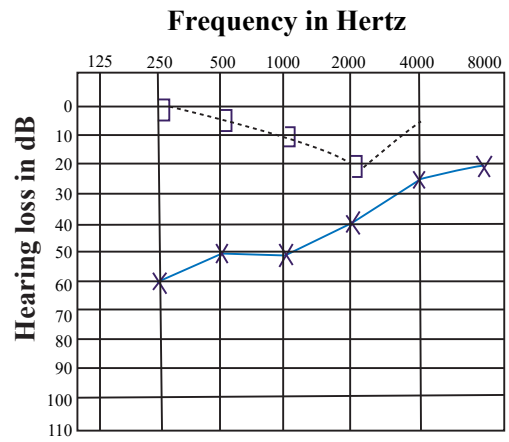
| 256Hz | 512Hz | 1024Hz | Hearing loss |
|-------|-------|--------|--------------|
| -ve | +ve | +ve | 15-30db |
| -ve | -ve | +ve | 30-45dB |
| -ve | -ve | -ve | 45-60dB |

Audiometry

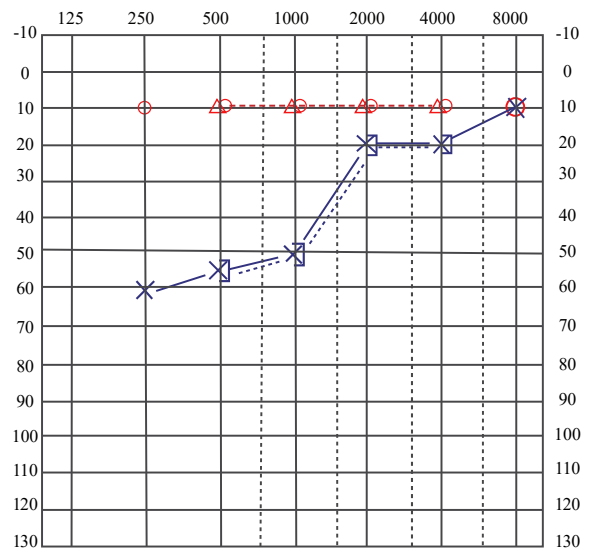
Bilateral congenital hearing loss



Carhart's notch in otosclerosis



Meniere's Disease in Left ear



B/L BC > AC, Webers to left side

B/L AC > BC; Webers to Right side

Tympanometry types:

A-----

As-----

Ad-----

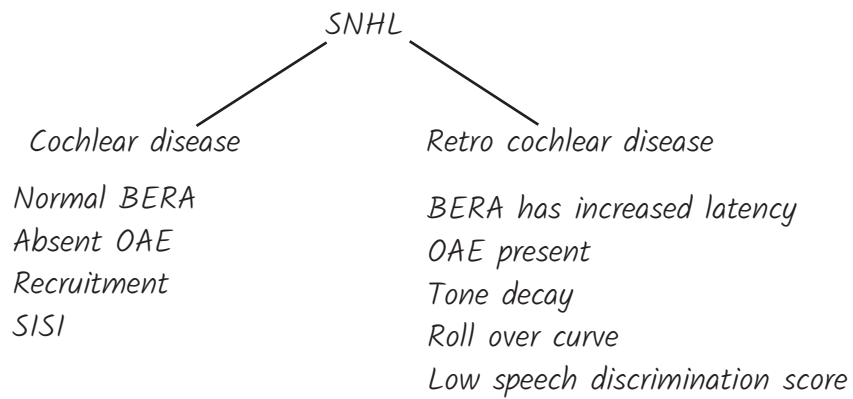
B/Flat-----

C/Negative-

BERA & OAE

Children:

Adult (if SNHL):

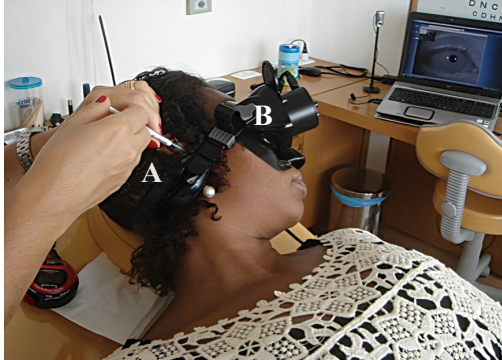

Caloric Test

C O W S

Hypoactive labyrinth: Nystagmus will be on opposite side but eyeball moves toward same side

Hyperactive labyrinth: Nystagmus on same side but eye ball moves towards opposite side



True (+) ve Fistula test

1. Labyrinthine fistula, or CSOM
2. Fenestration surgery or
Type V tympanoplasty
3. Post stapedectomy
4. Perilymph fistula

False (+) ve FT (Hennebert's sign)

Meniere's disease



Siegle's speculum

Head Impulse test

In vestibular neuronitis: On tilting the head on the side of the lesion, Saccadic movement will be seen on the opposite side



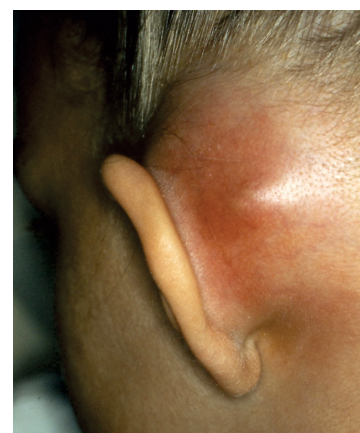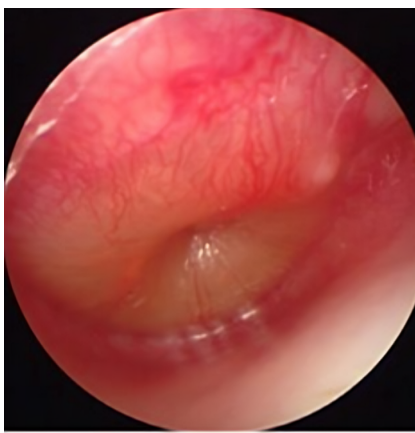
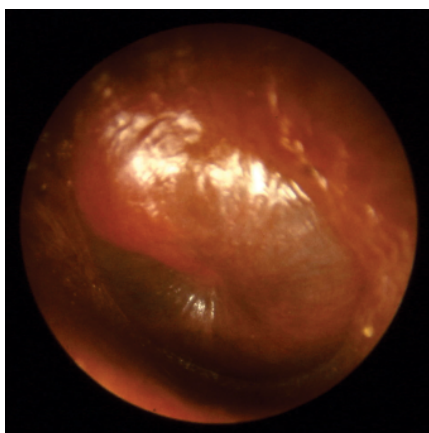
ENT

NOTES

INFECTIVE DISEASES OF EAR

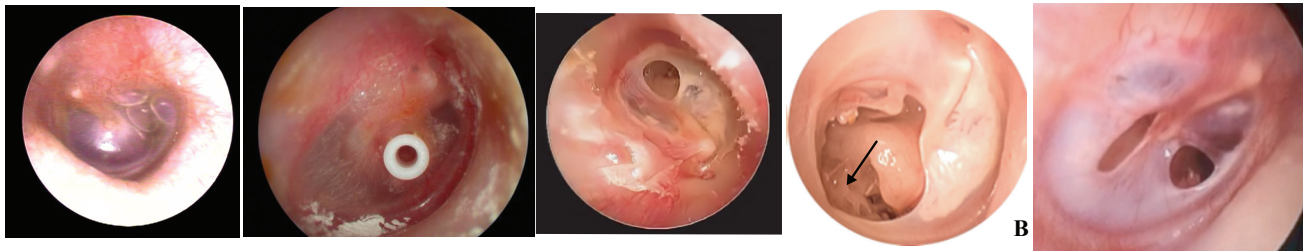
Acute Infections

| Malignant Otitis Externa | ASOM | Acute Mastoiditis |
|------------------------------------|--------------------------------------|---|
| <i>Pseudomonas</i> | <i>Streptococcus pneumoniae</i> | <i>Streptococcus pyogenes</i> |
| <i>Diabetic</i> | <i>H. influenza</i> | |
| <i>Nocturnal pain</i> | <i>Moraxella</i> | <i>Ironed out mastoid</i> |
| <i>Osteitis & facial palsy</i> | | <i>Pinna: antero-inferiorly</i> |
| | <i>Red, bulging TM</i> | <i>Light house sign</i> |
| | <i>Cart wheel</i> | <i>Reservoir sign</i> |
| | <i>Fluid level</i> | |
| | <i>Light house sign</i> | <i>Bezold's abscess- SCM</i> |
| | <i>Reservoir sign</i> | <i>Citelli's abscess- Digastric</i> |
| | | <i>Luc's abscess- Superior canal wall</i> |
| | <i>Nasal decongestants & AMB</i> | |
| | <i>Myringotomy</i> | |



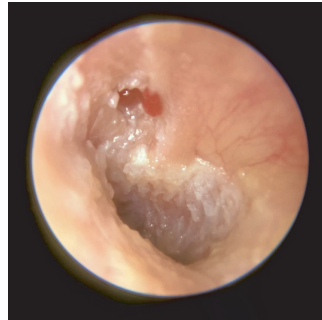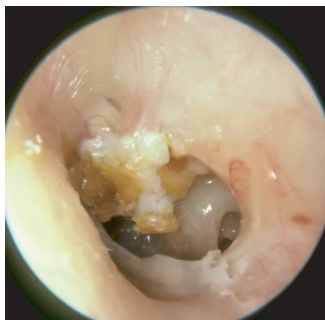
Chronic Infections

| SOM/Glue ear | Safe CSOM | Unsafe CSOM | Tuberculosis |
|---|---|--|--|
| <p>No Pathogen</p> <p>Child: Adenoid hypertrophy</p> <p>Adult: Nasopharyngoscopy</p> <p>M/C/C of HL in child</p> <p>Retracted TM</p> <p>Air bubbles</p> <p>Tympanogram: Type B</p> <p>Myringotomy+ grommet+ Adenoidectomy</p> | <p><i>Pseudomonas</i></p> <p>Copius discharge</p> <p>Central perforation</p> <p>Myringoplasty</p> | <p><i>Pseudomonas</i></p> <p>Foul smelling, scanty d/s</p> <p>Retraction pocket</p> <p>Cholesteotoma</p> <p>Marginal perforation</p> <p>Attic perforation</p> <p>MRM</p> | <p>Painless</p> <p>Watery discharge</p> <p>Multiple perforation</p> <p>Pale granulations</p> |



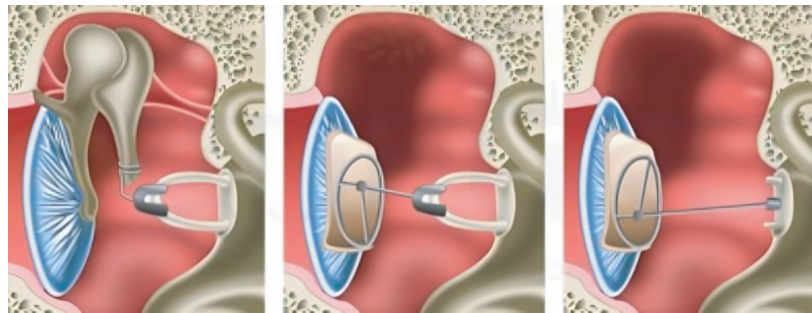
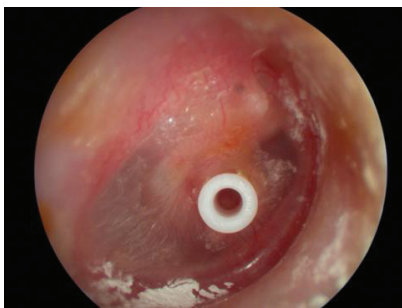Complications

| Cholesteotoma | Gradenigo's syndrome | Labyrinthine fistula | Lateral sinus thrombosis | Brain abscess |
|--|---|--|---|--|
| Prussak's space Keratin squamous epithelium Wittmack's theory MRM | 3 D's Discharge Diplopia Deep pain | Bulge of LSCC Vertigo Nystagmus True +ve FT | Picket fence fever Gresinger's sign Delta sign Crow beck sign Tobey ayer sign | Fever & headache Aphasia convulsions |



Surgeries:

| Myringotomy + Grommet | Myringoplasty | Tympanoplasty | Mastoidectomy |
|---|---|---|---|
| <p>ASOM: Posterior-inferior</p> <p>Glue ear: Antero-inferior with grommet</p> | <p>Safe CSOM</p> <p>Temporalis fascia has low BMR</p> | <p>Types:</p> <p>I: Malleus-Myringoplasty</p> <p>II: Incus</p> <p>III: Stapes head- Columella</p> <p>IV: Round window & ET</p> <p>V: Fistula on LSCC- Fenestration</p> | <p>Simple: Ac mastoiditis</p> <p>MRM: unsafe CSOM</p> <p>Radical has 3 steps:</p> <p>Exteriorization</p> <p>Retain footplate</p> <p>Block ET</p> |



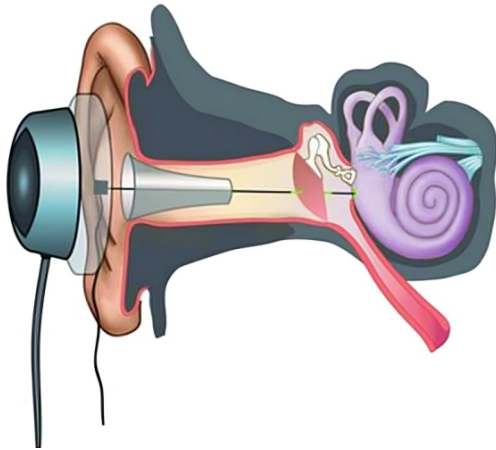
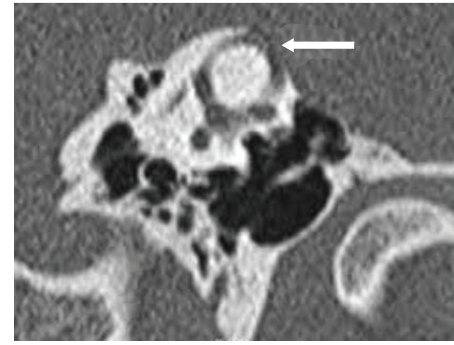
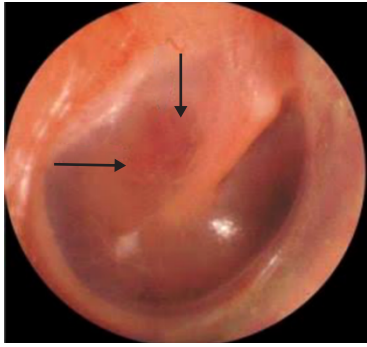


NOTES

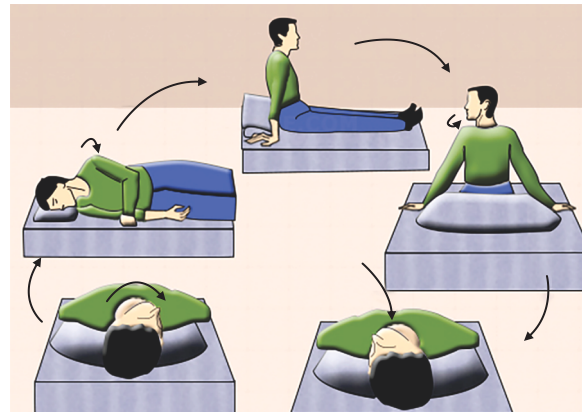


ENT

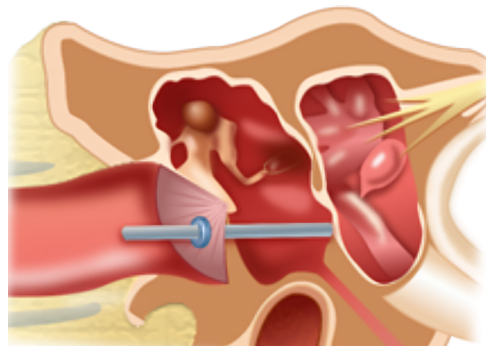
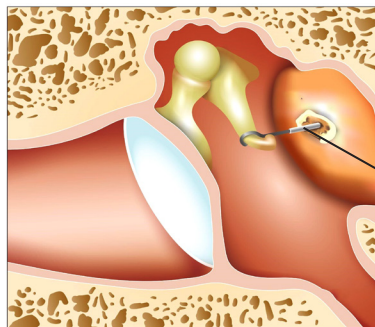
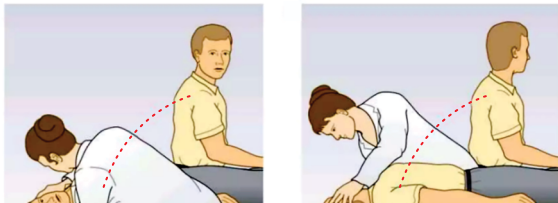
NOTES



Epley's Maneuver

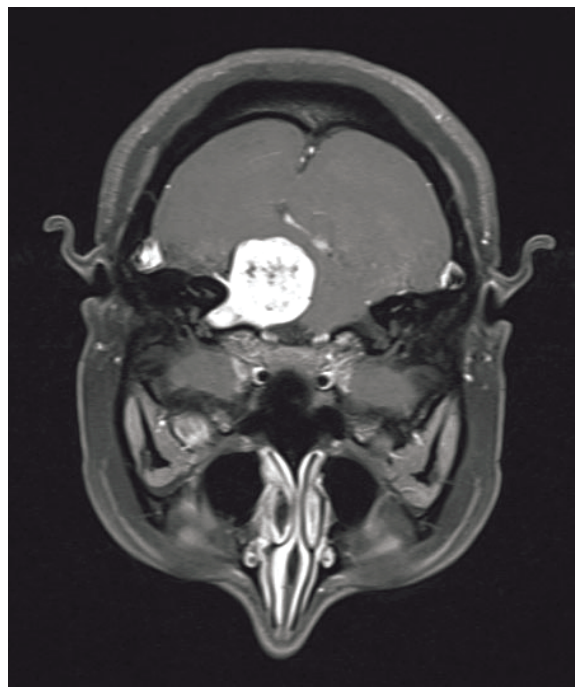
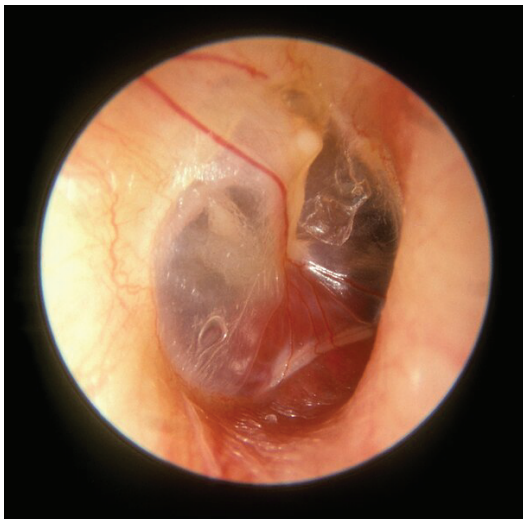


Dix hallpike maneuver



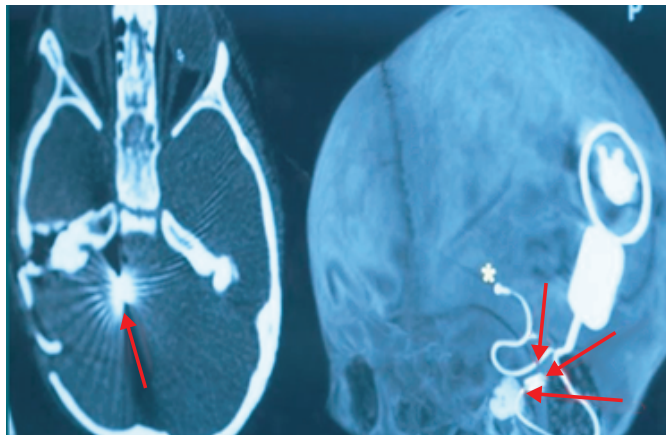
Tumours:

| Glomus Tumour | Acoustic Neuroma |
|---|--|
| <p><i>Is a Paraganglioma</i></p> <p><i>Presentation:</i></p> <p><i>Pulsatile tinnitus</i></p> <p><i>Rising sun sign</i></p> <p><i>Brown's sign</i></p> <p><i>Phelp's sign</i></p> <p><i>Aquino sign</i></p> | <p><i>Arises from Inferior vestibular nerve</i></p> <p><i>Site is C-P angle</i></p> <p><i>M/C manifestation: loss of corneal reflex</i></p> <p><i>Histelberger's sign</i></p> <p><i>Gold std inv: Gadolinium MRI</i></p> <p><i>Gamma knife stereotactic RT</i></p> |



Assistive device for Hearing

| Hearing aid | Cochlear implant | Brainstem implant |
|--|--|--|
| <p>Is an amplifier</p> <p>Used in any type of hearing loss</p> | <p>Used in B/L severe HL due to cochlear disease</p> <p>Electrodes are implanted:</p> <ol style="list-style-type: none"> 1. Through round window 2. Into scala tympani | <p>Used in B/L severe HL due to retro-cochlear diseases</p> <p>Implanted into recess of IV ventricle</p> |





NOTES



ENT

NOTES

THROAT ANATOMY

Throat:

Arteries of Tonsil:

1. Main : Tonsillar or facial artery
2. Ascending Pharyngeal
3. Ascending Palatine
4. Descending palatine
5. Dorsal Lingual

Muscles of larynx & movement of vocal cord

| Abduction | Adduction | Tension |
|--|---|--|
| <i>Helps in Breathing</i> | <i>Helps in Voice production</i> | <i>Helps in High pitch voice</i> |
| <i>Posterior cricothyroid muscle</i> | <i>Lateral cricothyroid muscle</i> <i>Inter-arytenoid muscle</i> <i>Thyroarytenoid muscle</i> <i>Cricothyroid muscle</i> | <i>Cricothyroid muscle</i> <i>Thyroarytenoid muscle</i> |
| <i>Supplied by recurrent laryngeal nerve</i> | | <i>External laryngeal nerve</i> |

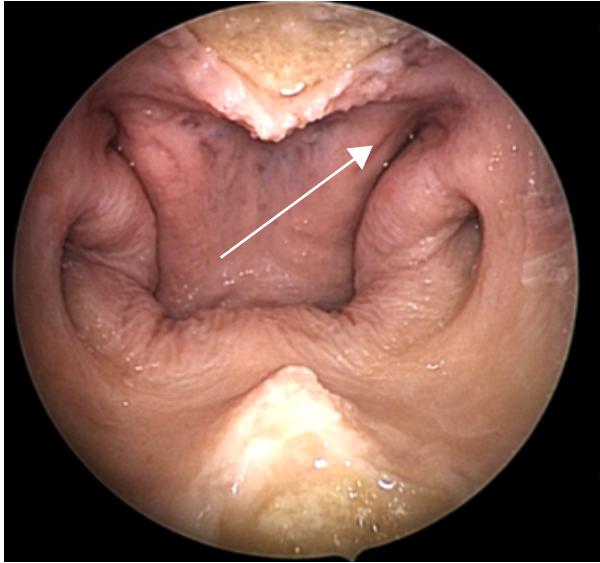


ENT

NOTES

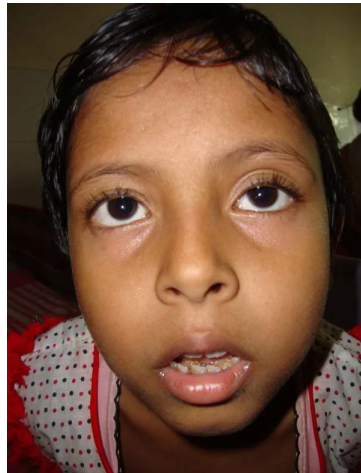DISEASES OF THROAT

Nasopharyngeal image & diseases



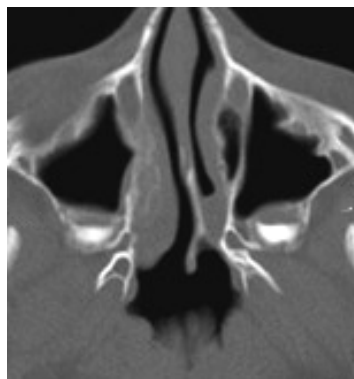
Features of Adenoid facies

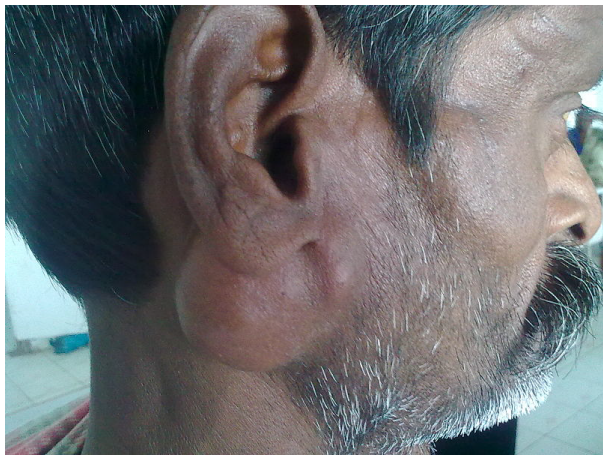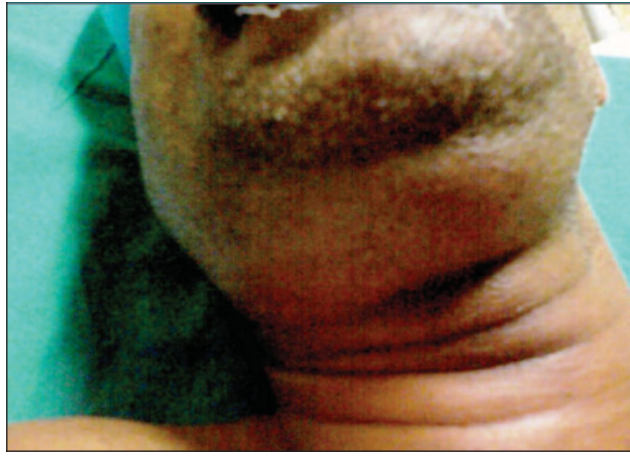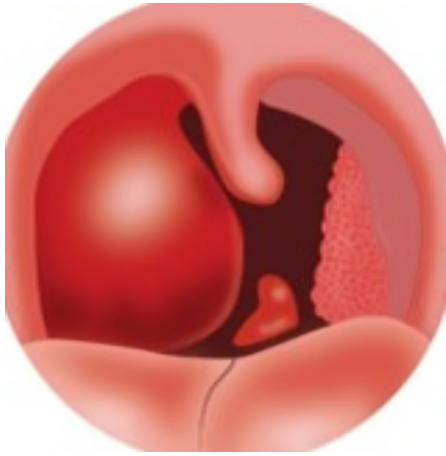High arched palate
Crowded upper teeth
Collapsed ala
Hypoplastic maxilla
Dull expression

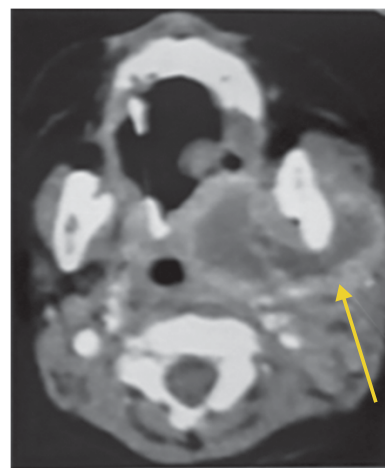
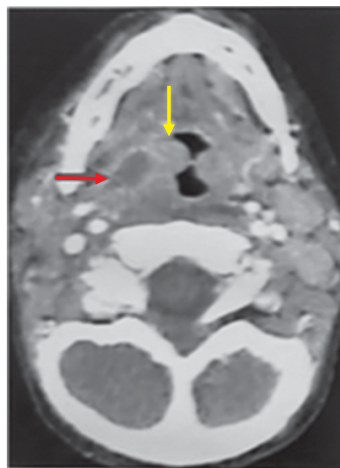
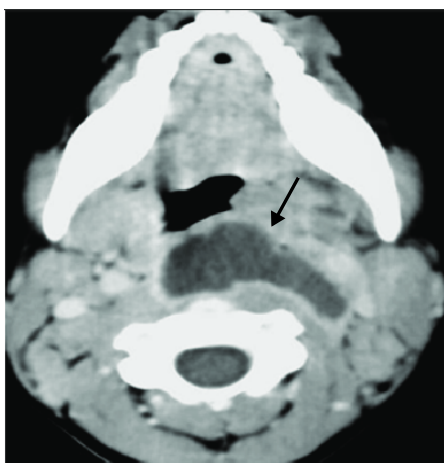
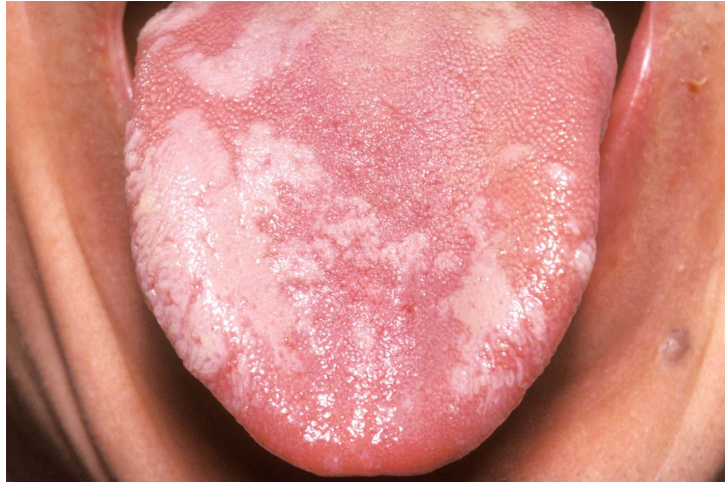
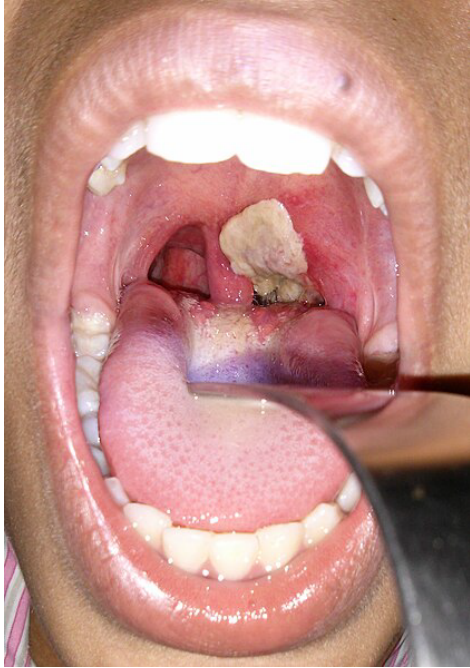
Choanal Atresia

Caused by Bucco-nasal membrane
McGovern's technique

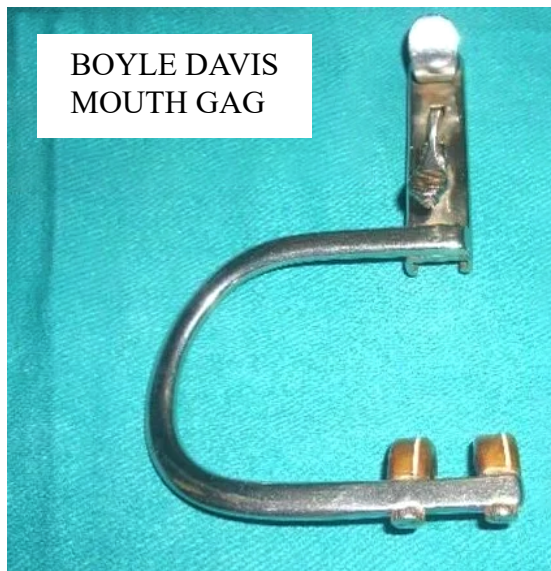






Tonsillectomy

| Indications | Contraindications |
|---|--|
| <i>Recurrent tonsillitis</i> <i>Chronic tonsillitis</i> <i>Quincy</i> <i>Eagle's disease</i> | <i>Acute tonsillitis</i> <i>Bleeding disorders</i> <i>Cleft palate</i> |



Complications of tonsillectomy

1. Bleeding

| <i>Primary bleeding</i> | <i>Reactionary bleeding</i> | <i>Secondary bleeding</i> |
|-------------------------|---|--|
| <i>Caused by veins</i> | <i>Within 24 hrs after surgery</i> <i>Caused by arteries</i> <i>Immediate re-ligation in GA</i> | <i>5-8 day</i> <i>Infection is cause</i> <i>Antibiotic + re-ligation</i> |

Other complications

2. *Grisel's syndrome*

3. *Hyper-nasal voice/rhinolalia aperta*



ENT

NOTES

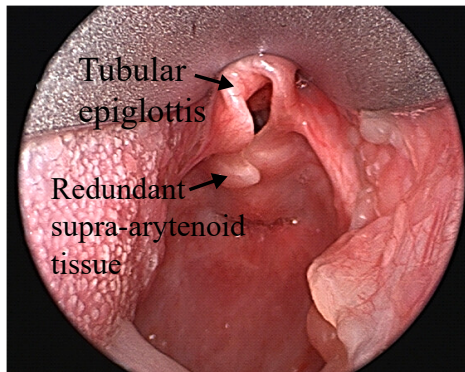
DISEASES OF LARYNX

Congenital Diseases of Larynx

Laryngomalacia: is the m/c congenital disease of larynx

Presents: a newborn with inspiratory stridor

Omega shaped epiglottis



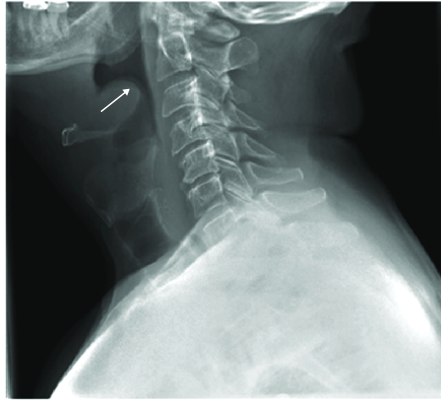
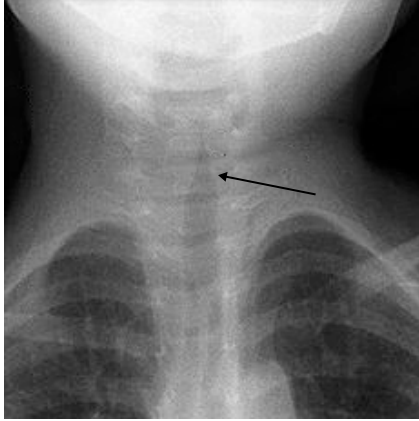
Treatment: *Reassurance*

Subglottic stenosis: *May cause expiratory or Biphasic stridor*

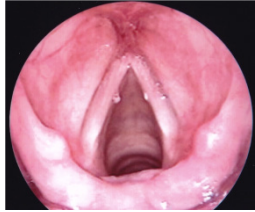

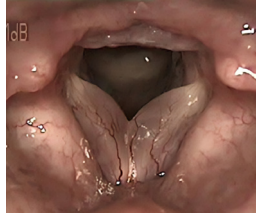

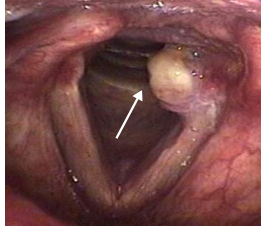
It is graded into 4 grades by 'Myer & Cotton'

Topical Mitamycin-C may be beneficial

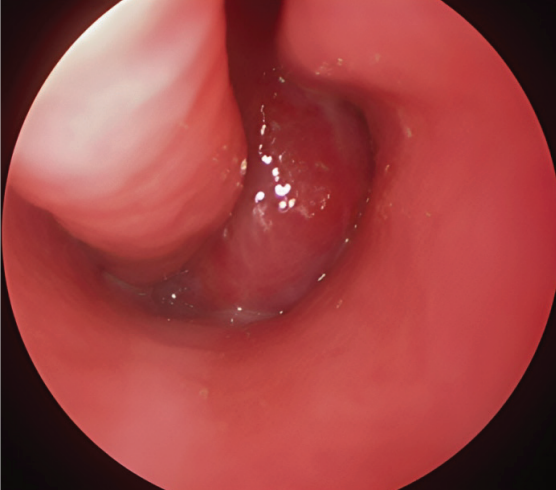

Laryngitis:

| Acute epiglottitis | CROUP | Tuberculosis |
|---|---|---|
| <p><i>Streptococcus pyogenes</i></p> <p>Child in Tripod position</p> <p>Fever, Dyspnea, Dysphagia</p> <p>X-ray: Thumb sign</p> <p>DOC: Cephalosporin</p> | <p><i>Parainfluenza virus</i></p> <p>Child lying on mother's lap</p> <p>Dyspnea, voice change</p> <p>X-Ray: Steeple sign</p> <p>Treatment:</p> <ol style="list-style-type: none"> 1. Steroid 2. Nebulisation 3. Antibiotics | <p>Site: Inter-arytenoid area</p> <p>Hoarseness & Pain</p> <p>Cobble stone appearance</p> <p>Mouse nibbled appearance</p> <p>Turban epiglottitis</p> |
|  |  | |

Non Neoplastic growth

| VC Nodule | VC Polyp | Rienke's edema | Laryngocele | Granuloma |
|--|---|--|---|---|
| <p>Misuse of voice</p> <p>Site: junction of 1/3 & 2/3</p> <p>TOC: Voice rest</p> | <p>Misuse</p> <p>Site: same</p> <p>TOC: MLS + PPI</p> | <p>Hypothyroidism</p> <p>TOC: Conservative</p> <p>-Microflap technique</p> | <p>Dilation of sac-cule in trumpet blower</p> <p>-Conservative</p> | <p>Intubation</p> <p>Posterior 1/3</p> <p>CO2 laser</p> <p>+ botox</p> <p>+ mitamycin C</p> |
|  |  |  |  |  |

Benign growths of throat

| Juvenile nasopharyngeal Angiofibroma | Laryngeal papilloma |
|--|--|
| <p>Site: Sphenopalatine foramen</p> <p>Presents: Juvenil male with Epistaxis</p> <p>Signs: Antral sign & frog face</p> <p>IOC: CECT</p> <p>Treatment: Embolization & Excision</p> | <p>Site: M/C Glottis</p> <p>Etiology: HPV 6 & HPV 11</p> <p>Presents: A child with hoarseness</p> <p>Microdebridement + intralesional cidofovir</p> |
|  |  |



ENT

NOTES

CARCINOMAS

Carcinomas

| Nasopharyngeal carcinoma | Laryngeal carcinoma |
|---|--|
| <p>Site: Fossa of Rosenmuller</p> <p>Etiology: EBV & Nitrosamine</p> <p>M/C presents: Lymphadenopathy</p> <p>Trotter's triad</p> <ol style="list-style-type: none"> 1. Soft palate palsy 2. Facial pain 3. Hearing loss <p>Treatment: chemoradiation</p> | <p>Site: Glottis</p> <p>Etiology: Smoking & Alcohol</p> <p>Presents: Hoarseness & Dyspnea</p> <p>I/L: proliferative growth</p> <p>Treatment:</p> <p>Stages I & II: transoral laser Microsurgery</p> <p>Stage III & IV: concurrent Chemoradiation</p> |

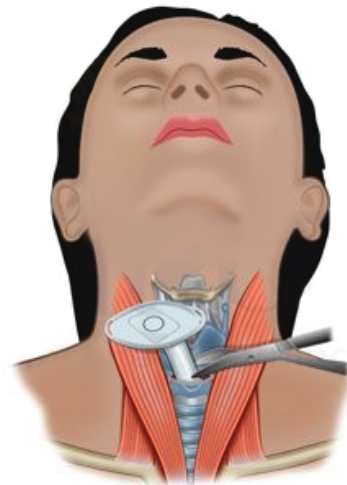
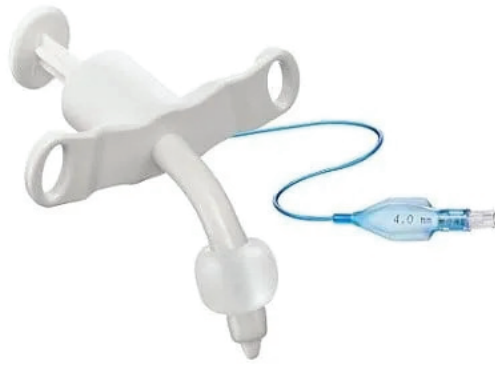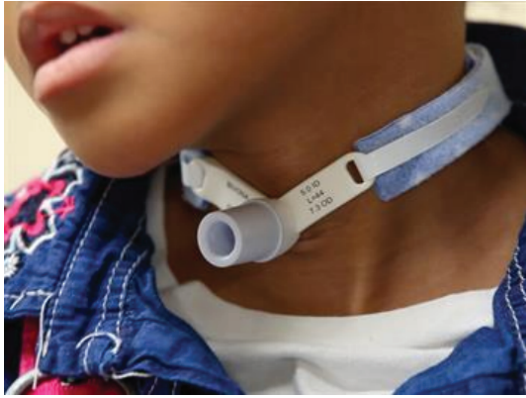Tracheostomy: M/C indication: laryngeal block due to laryngeal carcinoma

Site: Tracheal ring 2 & 3

High tracheostomy: done in ring 1

Mini-tracheostomy is also called '**cricothyroidotomy**'

M/C complication: Dislodgment of tube & bleeding



Speech rehabilitation

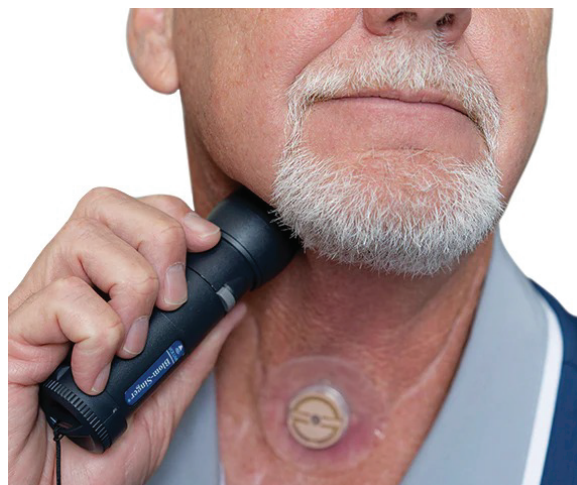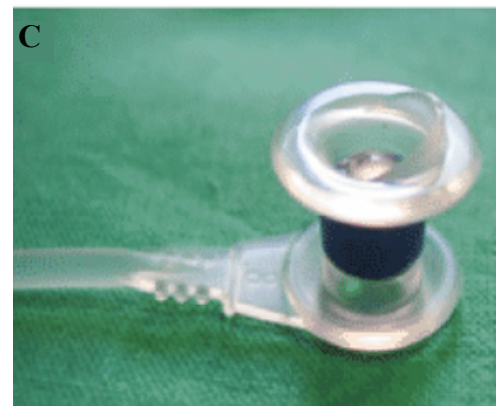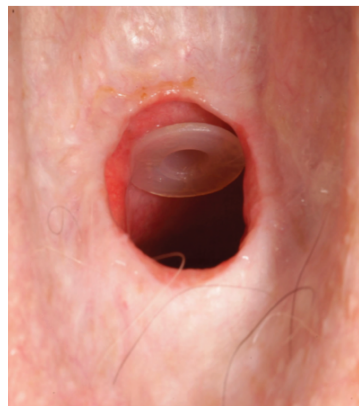
Tracheostomy:

Fenestrated tube + Muir passay valve



Laryngectomy:

1. Trachea-esophageal speech
2. Electrolarynx





ENT

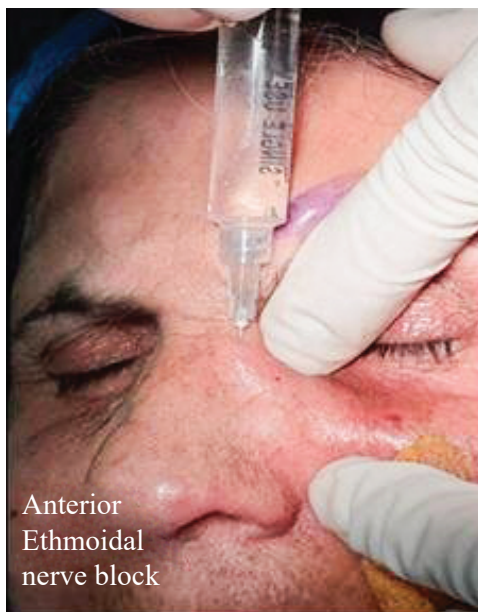
NOTES

NOSE AND SINUSES

Nose & Sinus




Anatomy

| <i>Nasal septal arteries</i> | <i>Lateral wall</i> |
|-----------------------------------|---|
| <i>Sphenopalatine artery</i> | <i>Spheno-ethmoidal recess: Sphenoid ostia</i> |
| <i>Greater palatine artery</i> | <i>Superior meatus: Posterior ethmoid ostia</i> |
| <i>Superior Labial artery</i> | <i>Middle meatus: Maxilla, Frontal & Anterior ethmoid ostia</i> |
| <i>Anterior ethmoidal artery</i> | <i>Inferior meatus: Naso-lacrimal duct</i> |
| <i>Posterior ethmoidal artery</i> | |



Anterior Ethmoidal nerve block

X-Ray of Sinuses

| Water's view | Pierre's view | Caldwell's view |
|--|--|--|
| <p>M/C view done</p> <p>Best view to see maxilla</p> <p>Sphenoid is NOT seen, at all</p> | <p>M/C view</p> <p>Best for Maxilla & Sphenoid</p> | <p>Done for Frontal sinus</p> |
|  |  |  |



NOTES



ENT

NOTES

DISEASES OF NOSE AND SINUSES

Septal diseases

Epistaxis

M/C site: Little's area/Kiesselbach's plexus

Artery of epistaxis: Sphenopalatine artery

M/C cause: Nose picking & Idiopathic

Treatment: Nose pinching, Cautery with silver nitrate, Nasal packing, Ligation of vessels

Ligation: TESPAL



Anterior Ethmoidal ligation

Deviated Nasal Septum (DNS)

M/C presents as:

1. Nasal Block- mainly on the same side
2. Sometimes, on opposite side: **Compensatory HT of Inferior turbinate**

Headache: called **Sluder's neuralgia/Anterior Ethmoidal syndrome**

Boundaries of Nasal Valve

1. Anterior end of inferior turbinate
2. Lower end of upper lateral cartilage
3. Septum

Treatment:

| Septoplasty | Sub mucosal resection |
|---|---|
| <i>Free's incision/ Hemitransfixation</i> <i>Preferred after 16-17 years</i> | <i>Killian's incision</i> <i>Bleeding is the m/c complication</i> <i>Dane after 16-17 years</i> |

Nasal polyps:**Features:**

1. *Pale in colour*
2. *Poor blood supply*
3. *Poor nerve supply*

Cause: m/c is allergy

May be seen in syndromes, like

| Samter's Triad | Kartegener's syndrome | Young's syndrome |
|----------------------------|------------------------------|-------------------------|
| <i>Polyps</i> | <i>Polyps</i> | <i>Polyps</i> |
| <i>Asthma</i> | <i>Bronchiectasis</i> | <i>Bronchiectasis</i> |
| <i>Aspirin sensitivity</i> | <i>Situs inversus</i> | <i>Azoospermia</i> |

| Maxillary/Antro-choanal polyp | Ethmoidal polyp |
|--------------------------------------|--|
| <i>M/c in children</i> | <i>M/C in adults</i> |
| <i>U/L & single</i> | <i>B/L & Multiple: 'Bunch of Grapes'</i> |
| <i>Not Recurrent</i> | <i>Is recurrent</i> |
| <i>Rx: Antibiotic & FESS</i> | <i>Rx: Steroid & FESS</i> |
| | <i>If recurrence → Ethmoidectomy</i> |


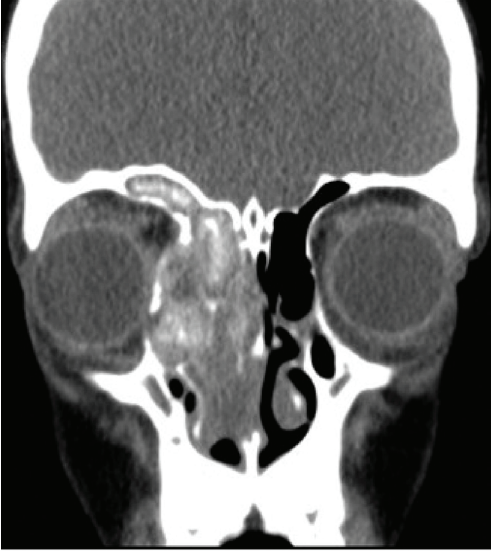





Rhinosinusitis

Non-Infective rhinosinusitis

| Allergic rhinitis | Vasomotor rhinitis | Atrophic rhinitis |
|--|--|---|
| <p>Allergic shiners Allergic salute Denis Morgan lines</p> | <p>Increased Parasympathetic Rx: Vidian Neurectomy</p> | <p>M/C/C decreased Estrogen Features Roomy cavity & Dry Crust- -----Causes Block Foul smell } Anosmia } Merciful Anosmia Alkaline nasal douche Sodium bicarbonate Sodium baborate Sodium chloride Sx: Young's surgery Lautenslager's Sx</p> |


Fungal rhinosinusitis

| Aspergillosis | Mucormycosis Rhino-Orbito-Cerebral fungus | Allergic fungal sinusitis | | | | | | | | | | | | | | | |
|---|---|---|--|-----------------------|-----------------------|---|-----------|--------------------|----------------------------|-------------------------------|------------------------------|-----------------------|-------------------|--------------------------|----------------------------|--|-----------------------|
| <p>Is M/C type A fumigatus Aspergilloma</p> | <p>Is called 'Black fungus' Seen in Diabetic Caused by Rhizopus Is angio-invasive Causes necrosis (black fungus) DOC: Lyposomal amphotericin B</p>  <p>Black fungus</p> | <p>Bent & Kuhn criteria</p> <table border="1" data-bbox="866 475 1509 772"> <thead> <tr> <th data-bbox="866 475 1197 526">Major criteria</th> <th data-bbox="1197 475 1509 526">Minor criteria</th> </tr> </thead> <tbody> <tr> <td data-bbox="866 526 1197 604">1. Evidence of type I IgE-mediated hypersensitivity</td> <td data-bbox="1197 526 1509 570">1. Asthma</td> </tr> <tr> <td data-bbox="866 604 1197 635">2. Nasal polyposis</td> <td data-bbox="1197 570 1509 613">2. Unilateral predominance</td> </tr> <tr> <td data-bbox="866 635 1197 667">3. Characteristic CT findings</td> <td data-bbox="1197 613 1509 657">3. Radiographic bone erosion</td> </tr> <tr> <td data-bbox="866 667 1197 699">4. Eosinophilic mucus</td> <td data-bbox="1197 657 1509 701">4. Fungal culture</td> </tr> <tr> <td data-bbox="866 699 1197 730">5. Positive fungal smear</td> <td data-bbox="1197 701 1509 745">5. Charcot-Leyden crystals</td> </tr> <tr> <td></td> <td data-bbox="1197 745 1509 772">6. Serum eosinophilia</td> </tr> </tbody> </table>  <p>Double density scan</p> | | Major criteria | Minor criteria | 1. Evidence of type I IgE-mediated hypersensitivity | 1. Asthma | 2. Nasal polyposis | 2. Unilateral predominance | 3. Characteristic CT findings | 3. Radiographic bone erosion | 4. Eosinophilic mucus | 4. Fungal culture | 5. Positive fungal smear | 5. Charcot-Leyden crystals | | 6. Serum eosinophilia |
| Major criteria | Minor criteria | | | | | | | | | | | | | | | | |
| 1. Evidence of type I IgE-mediated hypersensitivity | 1. Asthma | | | | | | | | | | | | | | | | |
| 2. Nasal polyposis | 2. Unilateral predominance | | | | | | | | | | | | | | | | |
| 3. Characteristic CT findings | 3. Radiographic bone erosion | | | | | | | | | | | | | | | | |
| 4. Eosinophilic mucus | 4. Fungal culture | | | | | | | | | | | | | | | | |
| 5. Positive fungal smear | 5. Charcot-Leyden crystals | | | | | | | | | | | | | | | | |
| | 6. Serum eosinophilia | | | | | | | | | | | | | | | | |

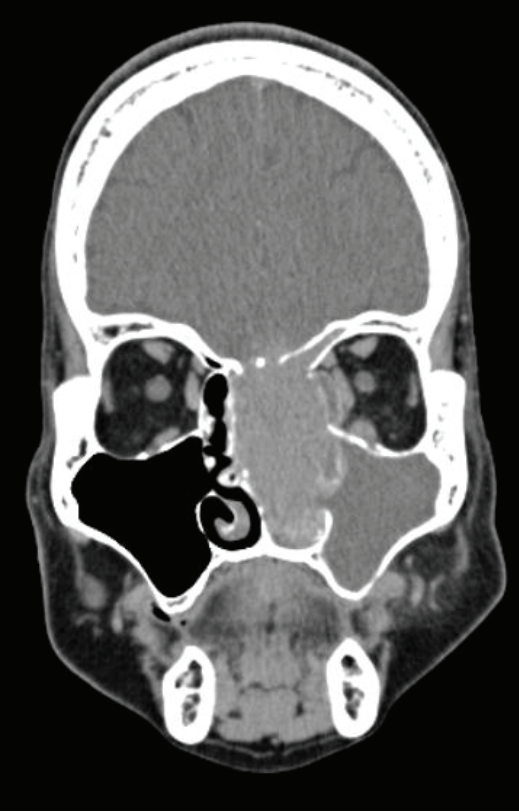
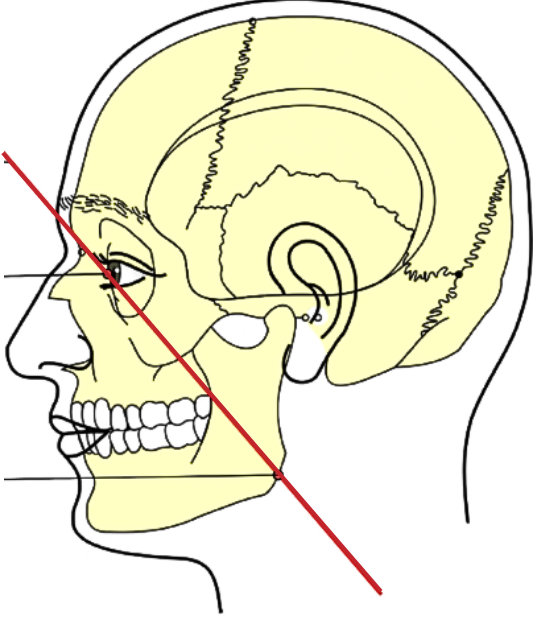
| Rhinophyma | Rhinoscleroma | Rhinosporidiosis |
|--|---|--|
| <p>Is called 'Potato Nose'</p> <p>Due to HT of sebaceous gland</p> | <p>Is called 'Woody nose'</p> <p><i>Klebsiella Rhinoscleromatis</i></p> <p>Also called Frisch bacilli</p> <p>HPE: Mikulicz cell & Russell body</p> <p>DOC: Streptomycin</p> | <p><i>Rhinosporidium seeberi</i></p> <p>Aquatic protozoa</p> <p>'Strawberry polyp'</p> <p>HPE: sporangia with endospores</p> <p>DOC: Dapsone</p> |
|  |  |  |

Fractures of facial bones

M/C facial bone to fracture is facial bone

| Septum fracture | Maxilla/Le Fort fracture | CSF Rhinorrhea |
|---|--|---|
| <p>Vertical: Chevallet fracture Horizontal: Jarjavay fracture</p> <p>Rx: Closed reduction</p>  <p>Ash's forcep</p> | <p>LF I: Horizontal fracture LF II: Pyramidal fracture LF III: cranio-facial dysjunction</p> | <p>M/C/C: cribriform plate fracture</p> <p>Features:</p> <p>Halo sign/Target sign Glucose > 30gm B2 transferrin</p> <p>Rx: Conservative</p> |

Tumours of Nose & Sinuses

| Inverted Papilloma/Ringertz tumour | Sinonasal carcinoma |
|--|--|
| <p data-bbox="243 372 784 409">Is a benign tumour with malignant potential</p> <p data-bbox="243 428 843 465">Rx: Excision & wide margin/ Medial maxillectomy</p>  | <p data-bbox="934 372 1455 409">M/C site is Maxilla: has squamous cell CA</p> <p data-bbox="934 428 1377 465">2nd: ethmoids; has adenocarcinoma</p> <p data-bbox="934 484 1192 521">m/c in woodworkers</p> <p data-bbox="934 594 1495 672">Ohngrens's line helps know the prognosis of maxillary carcinoma</p>  |

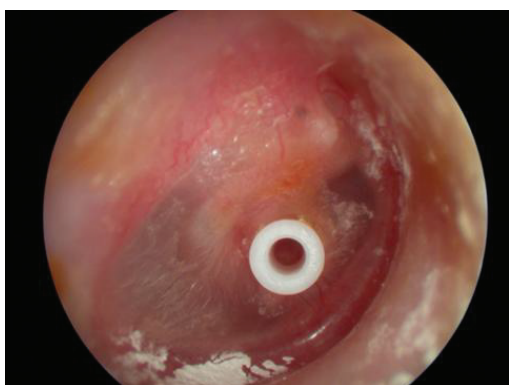

ENT

NOTES

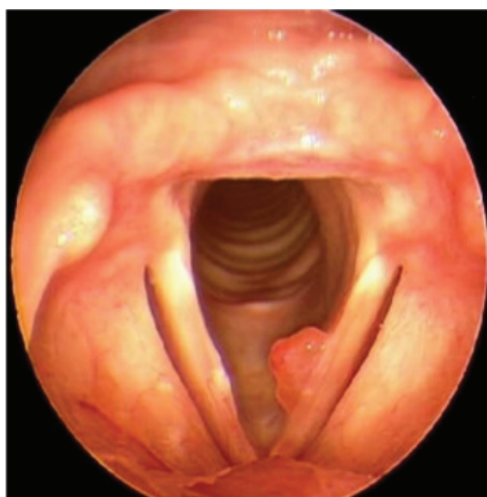MULTIPLE CHOICE QUESTIONS

1. A 8 years old child presented with hearing loss and the following surgery was done in this child.



Which of the following could be true in this child?

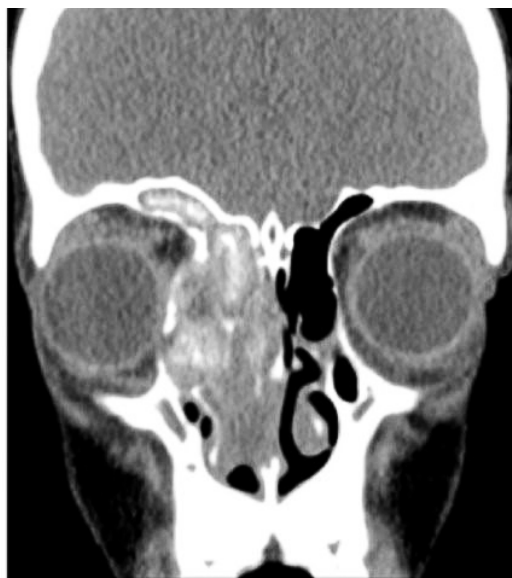- a. May have tonsillectomy along with this
 - b. if we culture the fluid of ear will be sterile
 - c. This is done in the anteroinferior quadrant
 - d. All are true
2. This is the image of a teacher who presented with hoarseness of voice.



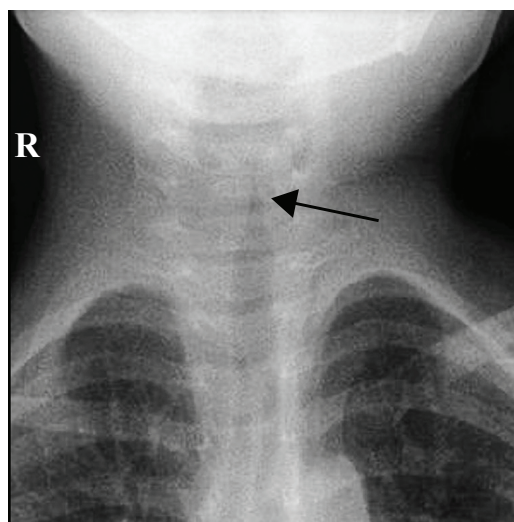
Pick the correct statement in this patient:

- a. This condition is usually unilateral
- b. It is due to fibrosis of the vocal cord
- c. Voice rest with proton pump inhibitor is the TOC
- d. All are true

3. A 35 years old lady presented with nasal obstruction & anosmia for few weeks. The CT Scan of PNS of this lady is shown. Which of the following is NOT a major criteria by 'Bent & Kuhn'?

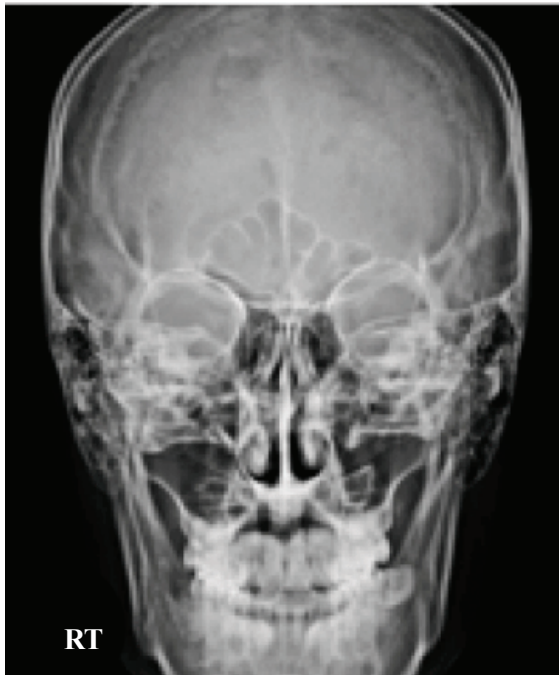

- a. The finding is described as 'double density scan'
 - b. Nasal polyp is a common finding
 - c. Fungal culture will be positive for fungus
 - d. Nasal mucin will have eosinophilia
4. A 3 years old child had fever for 2-3 days. Today she has difficulty in breathing and looked cyanosed. X-ray done is shown below. True in this case is?



- a. This is a case of CROUP
- b. The X-ray is showing 'steeple sign'
- c. Steroid with nebulization with adrenalin could be beneficial
- d. All are true

5. The X-ray of PNS shown below is done for which sinus?



- a. Maxillary sinus
- b. Frontal sinus
- c. Ethmoidal sinus
- d. Sphenoidal sinus

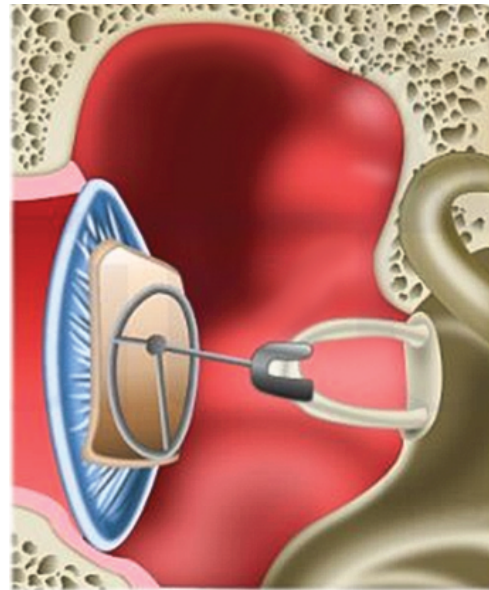
6. A patient has come to ENT OPD and was being examined for some ENT complaint. The following instrument was being used.



Which of the following could be the primary complaint (most likely) of this patient?

- a. Hoarseness of voice
- b. Hearing loss
- c. Nasal obstruction
- d. Feeling of lump in throat

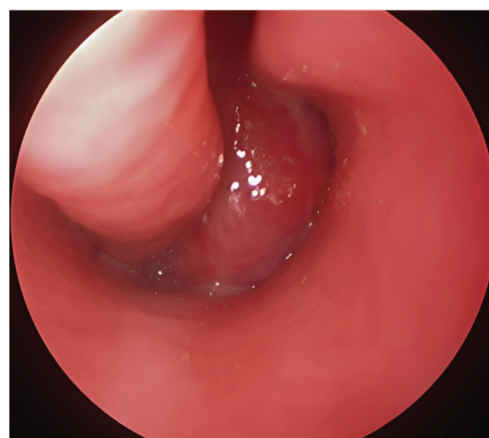7. A patient presented with hearing loss & otorrhea. He was operated for this ailment. The image of the surgery is shown



Which of the following is true in this patient?

- a. This is 'Columella surgery'
- b. Most likely diagnosis was serous otitis media
- c. The prosthesis shown is 'Total ossicular replacement prosthesis'
- d. All are true

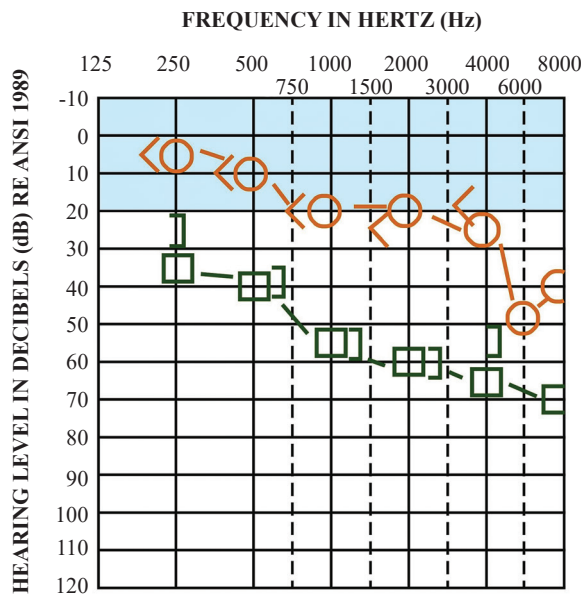
8. A 13 years old school going male child has sudden episode of epistaxis in school. He was immediately brought to emergency. His bleeding had stopped when he reached the hospital. Nasal endoscopy was done few days later and the image is shown. Which of these is true?



- a. The contractile layers in the blood vessels of this tumour are absent
- b. May have antral sign

- c. M/C site is 'sphenopalatine foramen'
- d. All are true

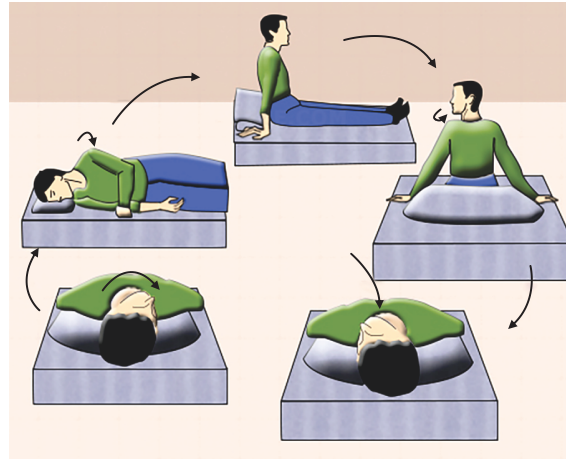
9. A driver presented with hearing loss. The audiogram is shown.



If tuning fork tests are done in this patient, which of these could be the finding?

- a. B/L positive Rinne's with Weber's lateralized to right side
- b. B/L positive Rinne's with Weber's lateralised to left side
- c. B/L negative Rinne's with Weber's lateralised to left side
- d. Right side positive Rinne's & left side negative Rinne's

10. Looking at the image of the procedure and pick the correct statement:



- a. This is canalith repositioning maneuver
- b. It is done in a patient who has continuous vertigo for few days
- c. Labyrinthectomy is the alternate treatment in this case
- d. All are true



ENT

NOTES