

# 1. Which is not a tumor suppressor gene ?

a) WT-1

b) Rb

c) p53

d) RAS

Correct Answer - D

RAS [Ref. Robbins 7<sup>th</sup>/e p 295]

*RAS is not a tumour suppressor gene, it is an oncogene.*

Normal growth and cell division is under the control of two types of genes:

(i) Protooncogenes

(ii) Tumour suppressor genes

- Protooncogenes are the genes that normally control how often a cell divides and the degree to which it differentiates. They allow cell division at a controlled rate.
  - When a protooncogene mutates into, an oncogene it becomes permanently "turned on" or activated even when it is not supposed to be. When this occurs, *cell divides too quickly which causes cancer.*
  - Tumour suppressor genes are normal genes that *slow* cell division.
  - A tumour suppressor gene is like the brake pedal on a car, it normally keeps the cell from dividing too quickly just as a brake keeps a car from going too fast.
  - When it mutates, cell division can get out of control.
- Functions of tumour suppressor gene:-
- *Repression* of genes that is essential for the continuing of the cell cycle.
  - An important function of tumour suppression gene is *repairing DNA*



esophageal cancers

- BRCA 1 and Unknown
- BRCA 2
- KLF 6          Prostate

## 2. Michaelis Gutmann bodies are seen in

a) >Xanthogranulomatous

b) >pyelonephritis

c) >Malakoplakia

d) Nail patella syndrome

Correct Answer - C

Malakoplakia [Ref. Robbins 7<sup>th</sup>/e p 1027-1028]

- Malakoplakia is a *variant of cystitis*, it is related to chronic bacterial infection mostly by *E.coli* or occasionally by *proteus* species.
- *It is characterized by unusual appearing macrophages and giant phagosomes.*
- *It points to defect in phagocytic or degradative function of macrophage.*
- *It is a peculiar pattern of vesical inflammatory reaction characterized microscopically by soft, yellow, slightly raised mucosal plaques 3-4 cm in diameter.*
- *Histologically it is characterized by infiltration with large foamy macrophages with occasional multinucleate giant cells and interspersed lymphocytes. "*
- *The macrophages have an abundant granular cytoplasm and the granularity is PAS positive.*
- *In addition to these histological changes, malakoplakia is also characterized by Michaelis Guttman bodies. - Michaelis Guttman bodies are Laminated mineralized concretions resulting from deposition of calcium in enlarged lysosomes.*
  - They are typically present both within the macrophages and between cells.
  - They demonstrate positive results using PAS stain and are diastase resistant.

diastase resistance.

- They stain with Kossa, stain for calcium and perls Prussian blue stain for iron.

- Immunohistochemical studies demonstrates positive results for CD68 antibodies.

- Malakoplakia occurs with increased frequency in *immunosuppressed transplant recipients*.

### 3. D.I.C. is seen in :

a) >Acute promyelocytic leukemia

b) >Acute myelomonocytic leukemia

c) >CMC

d) >Autoimmune hemolytic anemia

Correct Answer - A

Acute promyelocytic leukemia [Ref. Harrison 16<sup>11</sup>/e p 636]

- *Disseminated intravascular coagulation is associated with promyelocytic leukemia*
  - *Acute promyelocytic leukemia (AML-M<sub>3</sub>) constitutes 5-10% of all cases of AML*
  - *The leukemic cells of these type of anemia are hypergranular.*
  - *Granules of these leukemic cells (promyelocytes) contain thromboplastin like material resulting in widespread disseminated intravascular coagulation.*
- Also know
- *Majority of M<sub>3</sub> cases demonstrate a reciprocal translocation involving chromosome 15 and 17, t (15 ; 17)*

#### 4. Interleukin responsible for Pyrexia is:

a) IL1

b) IL3

c) IL4

d) IL8

Correct Answer - A  
IL1

## 5. Liquefactive necrosis is seen in:

a) Heart

b) Brain

c) Lungs

d) Spleen

Correct Answer - B  
Brain

**6.** Process of migration of leukocytes through the endothelium is through:

a) Phagocytosis

b) Pinocytosis

c) Diapedesis

d) Apoptosis

**Correct Answer - C**

The next step in the process of leukocyte recruitment is migration of the leukocytes through the endothelium, called **transmigration** or **diapedesis**.

**Transmigration of leukocytes occurs mainly in post-capillary venules.**

Chemokines act on the adherent leukocytes and stimulate the cells to migrate through interendothelial spaces toward the chemical concentration gradient, that is, toward the site of injury or infection where the chemokines are being produced.

**Ref:** Robbins 8th edition, Chapter 2.

7. Bridging necrosis is characteristically seen in:

a) Acute hepatitis

b) Chronic hepatitis

c) Both of the above

d) None of the above

Correct Answer - C

**Ans: C. Both of the above**

Bridging necrosis is a more severe form of hepatocellular injury in acute viral hepatitis and may progress to fulminant hepatitis or chronic hepatitis. Bridging necrosis is characterized by bands of necrosis linking portal tracts to central hepatic veins, one central hepatic vein to another, or a portal tract to another tract.

In severe cases of acute hepatitis, confluent necrosis of hepatocytes may lead to bridging necrosis connecting portal-to-portal, central-to-central, or portal-to-central regions of adjacent lobules.

Hepatocyte swelling and regeneration compress sinusoids, and the more or less radial array of hepatocyte plates around terminal hepatic veins are lost.

Bridging fibrosis is an important component of severe examples of chronic viral hepatitis and steatohepatitis.

8. Which of the following would be the best morphological feature to distinguish ulcerative colitis from Crohn's disease?

a) Diffuse distributions of pseudopolyps

b) Mucosal edema

c) Crypt abscesses

d) Lymphoid aggregates in the mucosa

Correct Answer - A

**Pseudopolyps are more commonly found in ulcerative colitis than Crohn's disease.**

These are discrete areas resulting from surviving islands of mucosa or heaped up granulation tissue.

Since in ulcerative colitis there is diffuse mucosal inflammation these pseudopolyps are diffusely distributed.

**Distinguishing features between Ulcerative colitis and Crohn's disease:**

	Ulcerative colitis	Crohn's disease
<b>Rectal involvement</b>	Yes	Variable
<b>Distribution</b>	Diffuse	Segmental or diffuse
<b>Terminal ileum</b>	Backwash ileitis	Thickened and stenosis
<b>Serosa</b>	Normal	Creeping fat
<b>Mucosa</b>	Hemorrhagic	Cobblestone and linear ulcers
<b>Pseudopolyps</b>	Frequent	Less common
<b>Strictures</b>	No	Common
<b>Fistulas</b>	No	Common
<b>Lymphoid hyperplasia</b>	Infrequent	Common
<b>Crypt abscess</b>	Extensive	Focal

**Ref:** Pediatric Inflammatory Bowel Disease By Petar Mamula page 227.

9. Autosomal recessive polycystic kidney disease is characterised by the altered expression of:

a) Polycystin

b) Nephrocystin

c) Uromodulin

d) Fibrocystin

Correct Answer - D

*Fibrocystin (polyductin) gene mutation is seen in autosomal recessive polycystic kidney disease.*

**Note:**

- **Polycystin mutation** is associated with autosomal dominant polycystic kidney disease.
- **Nephrocystin** is related to nephronophthisis.
- **Uromodulin mutation** is seen in medullary cystic kidney disease.

**Ref:** Harrisons principles of internal medicine, 18th edition, Page: 2356.

**10.** More than 90% patients of CREST syndrome with the limited cutaneous form of this disorder make which of the following autoantibodies?

a) Anti-centromere

b) Anti-DNA topoisomerase I

c) Anti-double-stranded DNA

d) Anti-Golgi

### Correct Answer - A

All forms of scleroderma are thought to have a strong autoimmune component, and glucocorticoids and azathioprine are used to suppress the inflammatory complications of scleroderma.

(Other drugs that can be used in therapy include penicillamine, which inhibits collagen cross-linking, NSAIDs for pain, and ACE inhibitors to protect the kidney if hypertension or renal damage occurs).

**The anti-centromere antibody is quite specific for CREST syndrome (96% of cases),** and is only seen in a minority of patients with diffuse scleroderma (mainly those with Raynaud's phenomenon) and rarely in systemic lupus erythematosus and mixed connective tissue disease.

#### **Also know:**

- **Anti-DNA topoisomerase I**, also called anti-Scl-70 occurs commonly (64-75%) in diffuse scleroderma, but only rarely in CREST syndrome.
- **Anti-double-stranded DNA** is fairly specific for systemic lupus erythematosus, although it only occurs in 50-60% of lupus cases.
- **Anti-Golgi antibodies** are seen most often in systemic lupus erythematosus and Sjögren syndrome.

**Ref:** Hellmann D.B., Imboden Jr. J.B. (2013). Chapter 20. Musculoskeletal & Immunologic Disorders. In M.A. Papadakis, S.J. McPhee, M.W. Rabow (Eds), CURRENT Medical Diagnosis & Treatment 2013.

**11.** 1 to 2 mm haemorrhages in skin are known as:

a) Micro bleed

b) Petechiae

c) Purpura

d) None of the above

**Correct Answer - B**

Minute 1- to 2-mm hemorrhages into skin, mucous membranes, or serosal surfaces are called **petechiae**.

These are most commonly associated with locally increased intravascular pressure, low platelet counts (thrombocytopenia), or defective platelet function (as in uremia).

**Ref:** Robbins 8th edition Chapter 4.

**12. 'Flare' in Triple response is mediated by :**

a) Axon reflex

b) Arteriolar dilation

c) Histamine release

d) Local hormones

Correct Answer - A  
A i.e. Axon reflex

### 13. Medial calcification is seen in -

a) Atherosclerosis

b) Arteriolosclerosis

c) Monckebergs sclerosis

d) Dissecting aneurysm

Correct Answer - C

Ans. is 'c' i.e., Monckebergs sclerosis

First see types of arteries

Based on their size and structural features, arteries are divided into three types.

#### **Large or Elastic arteries**

##### **Aorta**

- Its large branches, eg. - Innominate, Subclavian, common carotid, iliac.
- Pulmonary arteries.

#### **Medium sized or muscular arteries**

- Small branches of aorta → Coronary, Renal
- Small arteries and arterioles
- Within substance of the tissue
- Now see their affection ?

#### **Arteriosclerosis**

- Dont get confuse with atherosclerosis.
- Arteriosclerosis means hardening of arteries by thickening and loss of elasticity of arterial wall. o There are three patterns of arteriosclerosis.

#### **Atherosclerosis**

- Characterized by intimal lesions, i.e. atheromas, which project into vascular lumen and may obstruct it. o This is the most common

pattern of arteriosclerosis.

- It involves elastic arteries, and large & medium size muscular arteries.

### **Arteriolosclerosis**

- Seen in arterioles of patients with hypertension and diabetes.
- Two anatomic variants are common —> hyaline and hyperplastic arteriolosclerosis.

### **Monckeberg medial calcific sclerosis**

- It is seen in small and medium sized muscular arteries.
- It is a degenerative and apparently non-inflammatory disease.
- Media of these arteries becomes calcified.
- It occurs in patients older than 50 years.

## 14. Changes seen in atherosclerotic plaque at the time of rupture are all except -

a) Thin fibrosis cap

b) Multiple foam cap

c) Smooth muscle cell hypertrophy

d) Cell debris

Correct Answer - C

Ans. is 'c' i.e., Smooth muscle cell hypertrophy

- Rupture occurs in advanced atherosclerotic lesion.
- In advanced atheroma, smooth muscle cells undergo apoptosis and advanced atheromatous plaque often have mostly fibrous character with *lack of smooth muscle cells* that are seen in less advanced lesion.

## 15. Atheromatous changes of blood vessels affects early in -

a) Kidney

b) Heart

c) Liver

d) Spleen

Correct Answer - B

Ans. is 'b' i.e., Heart

### **Sites of Atherosclerosis**

Atherosclerotic plaques develop primarily in elastic arteries (e.g., aorta, carotid and iliac arteries), and large & medium sized muscular arteries (e.g., coronary artery and popliteal arteries).

In descending order, the vessels most commonly involved are -

- Abdominal aorta (most common) → Causing aneurysm
- Coronary arteries (heart) → Causing MI
- Popliteal arteries → Causing ischemic gangrene of lower limbs.
- Internal carotid arteries → Causing stroke a Circle of willis
- Vessels usually spared are
- Vessels of upper extremities
- Mesentric and renal vessels, except at their ostia.

**16. Which of the following is a non-modifiable risk factor for CHD -**

a) Diabetes

b) Smoking

c) Hypertension

d) Old age

Correct Answer - D

Ans. is 'd' i.e., Old age

- 1. Old age is a non-modifiable risk factor for atherosclerosis and coronary heart disease (CHD).
- 2. Other three (given in question) are modifiable risk factors.

**17. Most common cause of dissecting hematoma is because of -**

a) Hypertension

b) Marfan's

c) Iatrogenic

d) Kawasaki

Correct Answer - A

Ans. is 'a' i.e., Hypertension

More than 90% of dissections occur in men between the ages of 40 and 60 with antecedent hypertension.

## 18. Cystic medial necrosis is seen in-

a) Marfans syndrome

b) Friedrichs ataxia Pattern

c) Downs syndrome

d) Kawasaki disease

Correct Answer - A

Ans. is 'a' i.e., Marfan's syndrome

- Cystic medial necrosis (CMN) is a disorder of large arteries, characterized by an accumulation of a basophilic ground substance in the media with cyst-like lesions.
- It is known to occur in certain connective tissue diseases such as Marfan syndrome, Ehlers-Danlos syndrome, and annuloaortic ectasia, which usually result from degenerative changes in the aortic wall.
- The relationships between CMN and congenital heart defects as well as other disorders have been evidenced. The mechanisms are still controversial, even though many molecular studies have been conducted
- it is characterized by elastic tissue fragmentation and separation of the elastic and fibromuscular elements of the tunica media by small cleft like spaces where the normal elastic tissue is lost; these areas are filled with the amorphous extracellular matrix of connective tissue and resemble but are not truly cysts.

## 19. Small vessel vasculitis are -

a) Classical PAN

b) Wegner's granulomatosis

c) Giant cell arteritis

d) All

Correct Answer - B

Ans. is `b' i.e., Wegner's granulomatosis

- Inflammation of vessel wall is called vasculitis.
    - o Of these systemic necrotizing vasculitis, several types affect the aorta and medium sized vessels, but most affect small vessels, such as arterioles, venules, and capillaries → small vessel vasculitis.
- |                         |                         |                |
|-------------------------|-------------------------|----------------|
| Large vessel vasculitis | Medium vessel           |                |
| vasculitis              | Small vessel vasculitis |                |
| o Giant cell arteritis  | o Polyarteritis nodosa  | ANACA          |
| positive                | ANCA negative           |                |
| (Temporal arteritis)    | o Kawasaki disease      | o              |
| Wegner's granulomatosis | o Bechet's syndrome     |                |
| o Takayasu arteritis    | o Buerger's disease     | o              |
| Microscopic polyangitis | o Hypersensitivity      |                |
| o Cogan syndrome        |                         | o              |
| Churg strauss syndrome  | o Urticarial vasculitis | o Drug induced |
- Following information have been added in Pie of Robbins
- o Following are *small vessels vasculitis* and are immune-complex mediated :
- |                                    |                         |
|------------------------------------|-------------------------|
| 1. SLE                             | 3) Cryoglobulinemia     |
| 2. <i>Henoch schonlein purpura</i> | 4) Good-pasture disease |
- o Following *small vessel vasculitis* are pauci-immune, i.e. there is paucity of immune complexes:

1. Microscopic polyangitis syndrome
2. Wegener granulomatosis

3. Chrug-strauss

**20. All is true about Giant cell arteritis except ?**

a) Involves large to small sized areteries

b) Granulomatous inflammation

c) Most commonly involved artery is abdominal aorta

d) Segmental nature of the involvement

Correct Answer - C

Ans. is 'c' i.e., Most commonly involved artery is abdominal aorta  
It is the most common form of systemic vasculitis in adults, is an acute and chronic, often granulomatous, inflammation of arteries of large to small size.

It affects principally the arteries in the head—especially the temporal arteries— but also the vertebral and ophthalmic arteries and the aorta, where it may cause thoracic aortic aneurysm

**21. Raynaud's phenomenon what change is seen in vessels initial stage -**

a) No change (Fibrinoid, Thrombosis)

b) Thrombosis

c) Fibrinoid necrosis

d) Hyaline sclerosis

Correct Answer - A

Ans. is 'a' i.e., No change

*Structural changes in the arterial walls are absent except late in the course, when intimal thickening can appear.*

## 22. The tissue of origin of the Kaposi's sarcoma is ?

a) Lymphoid

b) Vascular

c) Neural

d) Muscular

Correct Answer - B

Ans is 'b' i.e., Vascular

Kaposi Sarcoma

- Kaposi sarcoma is an intermediate grade, multicentric *vascular, tumour*
  - \* The pathogenesis of kaposi sarcoma is complex, fundamentally it is *an angioproliferative disease* that is not a true neoplastic sarcoma.
- It is a manifestation of excessive proliferation of spindle cells that are believed to be of vascular origin and have features in common with endothelial and smooth muscle cells.
  - \* Grossly-Three stages of the disease can be identified
    - Patch (1st stage)
    - Plaque (intermediate stage)
    - LI Nodule (last stage)
  - \* Histologically-The changes are nonspecific in the early patch stage and more characteristic in the nodular stage which show sheets of plump proliferating spindle cells and endothelial in the dermis or subcutaneous tissue

### 23. Concentric hypertrophy of left ventricle is seen in -

a) Cong. bicuspid aortic valve

b) MS

c) AR

d) HOCM

Correct Answer - A

Ans. is 'a' i.e., Cong-Bicuspid aortic valve

Aortic stenosis causes pressure overload that results in concentric hypertrophy.

o Congenital bicuspid aortic valve causes valvular aortic stenosis.

**24. Which one of the following sets of components of cigarette smoke is a causal agent of coronary artery disease -**

a) Tar and nicotine

b) Nicotine and carbon monoxide and tar

c) Carbon monoxide and Tar

d) Carbon dioxide

Correct Answer - B

Ans. is `b' i.e., Nicotine and carbon monoxide and tar

Mechanisms for smoking-induced Coronary heart disease

Carbon monoxide induces atherogenesis.

Nicotine stimulation of adrenergic drive raising both BP and myocardial oxygen demand.

Lipid metabolism with fall in protective high-density lipoproteins.

**Note :**

- Tar is associated with carcinogenesis (not atherosclerosis). But amongst the given options option b is the best answer as it consists of both nicotine and CO.

## 25. Earliest histological change in MI -

a) Macrophage infiltration

b) Neutrophilic infiltration

c) Waviness of fibers

d) Coagulative necrosis

Correct Answer - C

Ans. is 'c' i.e., Waviness of fibers

- Variable waviness of fibres at border is the earliest histological finding (see tables of previous explanation).

## 26. 7 day old MI the most sensitive biochemical marker

a) Troponin I T

b) CPK MB

c) LDH

d) Myoglobin

Correct Answer - A

Ans. is 'a' i.e., Troponin I T

Troponin T or I is a sensitive marker and return to normal after 7-10 days (see previous explanations).

## 27. Which is not seen in Aschoff bodies -

a) Giant cells

b) Aschoff cells

c) Fibroblasts

d) Polymorphonuclear cells

Correct Answer - D

Ans. is d i.e., Polymorphonuclear cells

Aschoff bodies :

\* Aschoff bodies are focal inflammatory lesions seen during acute rheumatic fever

\* They consist of foci of swollen eosinophilic collagen surrounded by Lymphocytes (primarily T cells)

Occasional plasma cells

Aschoff giant cells (macrophages of rheumatic fever)

Antischkow cells

*(Antischkow cells are modified macrophages with abundant cytoplasm and central round to ovoid nuclei in which the chromatin is disposed in the central, slender wavy ribbon like pattern-caterpillar cells)*

Histiocytes

Fibroblasts

## 28. Vegetations in Libman-Sacks endocarditis are ?

a) Large and fragile

b) Small warty along the line of closure of valve

c) Small or medium sized on either or both sides of valve

d) Small bland vegetations

Correct Answer - C

Ans. is 'c' i.e., Small or medium sized on either or both sides of valve  
SLE, mitral and tricuspid valvulitis with small, sterile vegetations, called *Libman-Sacks endocarditis* is occasionally encountered.

The lesions are *small single or multiple, sterile, granular pink vegetations* ranging from 1 to 4 mm in diameter. The lesions may be located on the undersurfaces of the atrioventricular valves, on the valvular endocardium, on the cords, or on the mural endocardium of atria or ventricles.

An intense valvulitis may be present, characterized by fibrinoid necrosis of the valve substance that is often contiguous with the vegetation.

Subsequent fibrosis and serious deformity can result that resemble chronic RHD and require surgery.

## 29. Causes of constrictive pericarditis is/are ?

a) T.B.

b) *SLE*

c) Brucellosis

d) a and b

Correct Answer - D

**Ans. is 'a' i.e., T.B.; b' i.e., SLE**

### **Causes of constrictive pericarditis**

- \* Tuberculosis (most common cause)
- \* Pericardial malignancies (especially breast, lung)
- \* Post-viral pericarditis (especially hemorrhagic)
- \* Drugs (e.g. Hydralazine, Procainamide, minoxidil, phenytoin)
- \* Bacterial (purulent) pericarditis
- \* Trauma / post - cardiac surgery → haemopericardium
- \* Fungal pericarditis (Histoplasmosis)
- \* Connective tissue disorders (e.g. SLE, RA, Sarcoidosis)
- \* Parasitic pericarditis (toxoplasmosis, trichonosis)
- \* Dressler syndrome
- \* Mediastinal radiotherapy
- \* Renal failure

### 30. Hypertrophy is -

a) Increase in cell number

b) Increase in cell size

c) Decrease in cell number

d) Decrease in cell size

Correct Answer - B

Ans. is 'B' i.e., Increase in cell size

Hypertrophy

\* Hypertrophy refers to an *increase in the size of cells* without increase in the number, resulting in an increase in the size of tissue.

\* Hypertrophy involves cell enlargement without cell division.

\* So, hypertrophied organ has just larger cells, but no new cells (by contrast, in hyperplasia there is increase in number of new cells without increase in size).

\* Nuclei in hypertrophied cells have a higher DNA content than in normal cells because the cells arrest in the cell cycle without undergoing mitosis.

\* *Myocardium* (heart muscle) and *skeletal muscle* undergo hypertrophy.

\* The most common stimulus for hypertrophy is increased workload.

**Mechanism of hypertrophy**

\* The increase in cell size is due to *synthesis of more structural proteins*.

\* The genes that are induced during hypertrophy include those encoding transcription factors (C-fos, C-jun), growth factors (TGF- $\beta$ , TGF-1, FGF); and vasoactive agents ( $\alpha$ -agonists, endothelin-1, angiotensin II).

\* There may also be a switch of contractile proteins from adult to

fetal or neonatal forms, e.g., during myocardial hypertrophy, the  $\alpha$ -myosin heavy chain is replaced by  $\beta$ -form of the myosin heavy chain, which leads to decrease myosine ATPase activity and a slower, more energetically economical contraction.

\* In addition, some genes that are expressed only in embryonic life are re-expressed in hypertrophied myocardium, e.g., in the embryonic heart, the gene for Atrial natriuretic peptide (ANP) is expressed in both atrium and ventricle. After birth, ventricular regulation of the gene is down regulated. Myocardial hypertrophy is associated with reinduction of ANF gene expression. ANP induces salt excretion by kidney  $\rightarrow$  blood volume & pressure, decrease work load.

#### **Why do these changes occur ?**

\* As already explained, the most common stimulus for myocardial hypertrophy is increased workload.

\* All the above morphological changes that occur in hypertrophy either increase muscle activity (to handle the increased workload) or decrease the workload to heart.

### 31. Physiological hyperplasia and hypertrophy are seen simultaneously in -

a) Uterus in pregnancy

b) Skeletal muscle in atheleteas

c) Breast at puberty

d) a and c

Correct Answer - D

**Ans. is 'a > c' i.e., Uterus in pregnancy > Breast at puberty**  
**Physiological hypertrophy and hyperplasia**

\* Examples of physiologically increased growth of tissues include : -

- Skeletal muscle hypertrophy in atheletes, both in the skeletal muscle of limbs (as a response to increased muscle activity) and in left ventricle of heart (as a response to sustained outflow resistance).

- Hyperplasia of bone marrow cells producing red blood cells in individuals living at high altitude; this is stimulated by increased production of the erythropoietin.

- Hyperplasia of breast at puberty, and in pregnancy and lactation, under the influence of estrogen, progesterone, prolactin and human placental lactogen.

- Hypertrophy and hyperplasia of uterine smooth muscle in pregnancy, stimulated by estrogen.

- Thyroid hyperplasia as a consequence of the increased metabolic demand of puberty and pregnancy. For option 'c'

- "Hormonal hyperplasia is well illustrated by the proliferation of the glandular epithelium of the female breast at puberty and during pregnancy, usually accompanied by enlargement (hypertrophy) of the glandular epithelial cell" -

\* However, I am not sure about this statement of Robbin's, as no other text book has mentioned that breast at puberty undergo both hyperplasia and hypertrophy.

## 32. The sign of reversible injury in a case of alcoholic liver disease -

a) Loss of cell membrane

b) Nuclear karyolysis

c) Cytoplasmic vacuole

d) Pyknosis

Correct Answer - C

Ans. is 'c' i.e., Cytoplasmic vacuole

o Fatty changes occur in alcoholic steatosis (fatty liver). It is manifested by appearance of *lipid vacuole in the cytoplasm*, which is a sign of *reversible injury*.

o Other three options (loss of cell membrane, nuclear karyolysis and pyknosis) are signs of irreversible injury

**33. In cell death, myelin figures, are derived from-**

a) Nucleus

b) Cell membrane

c) Cytoplasm

d) Mitochondria

Correct Answer - B

Ans. is 'b' i.e., Cell membrane

- *Myeline figures are cytoplasmic bodies composed of concentric whorls of membranes, **derived from damage cell membrane.** Myelin figures appear during reversible injury but they are more pronounced in irreversible injury.*

### 34. Enzyme that protects the brain from free radical injury is -

a) Myeloperoxidase

b) Superoxide dismutase

c) MAO

d) Hydroxylase

Correct Answer - B

Ans. is 'b' i.e., Superoxide dismutase

#### Antioxidant mechanisms

Cells have multiple mechanisms to remove free radicals and thereby minimizing injury.

Several nonenzymatic and enzymatic systems contribute to the inactivation of free radical reactions.

#### A. Non-enzymatic system

o *Antioxidants (Vit 'E', Vit A, Vit C, glutathione and Cysteine)* block the initiation of free radical formation and inactivate free radicals.

o *Tissue proteins (transferrin, ferritin, lactoferrin, and ceruloplasmin).*

As already explained, iron and copper can catalyze the formation of free radicals, these transport and storage proteins decrease the reactive free iron and copper, thereby minimizing the free radical formation.

#### B. Enzymatic system

o A series of enzymes act as free radical-scavenging systems and breakdown hydrogen peroxide and superoxide anion.

##### 1. *Catalase*

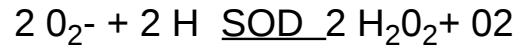o Present in *peroxisomes* and decomposes H<sub>2</sub>O<sub>2</sub>



2. *Superoxide dismutase (SOD)*


o Manganese - superoxide dismutase is present in *mitochondria*, while copper-zinc-superoxide dismutase is found in the cytosol.

o It converts superoxide to H<sub>2</sub>O<sub>2</sub>



3. *Glutathione peroxidase*

o Present in *mitochondria & cytosol*. o It catalyzes free radical breakdown.



o **The intracellular ratio of oxidized glutathione (GSSG) to reduced glutathione (GSH) is a reflection of the oxidative state of the cell.**

### 35. MI is a type of -

a) Coagulative necrosis

b) Liquefactive necrosis

c) Caseous necrosis

d) Fat necrosis

Correct Answer - A

Ans. is 'a' i.e., Coagulative necrosis

Coagulative necrosis

\* This is *most common type of necrosis*.

\* This type of necrosis is most frequently caused by sudden cessation of blood flow (ischemia) in organs such as *heart (MI), Kidney (ATN), adrenal gland, and spleen*.

**Note** : Brain is the only exception, i.e.,. It is the only solid organ in which ischemia leads to liquifactive necrosis not coagulative necrosis.

\* It is also seen with other types of injury e.g., *liver necrosis in viral hepatitis, Coagulative necrosis of skin after burns (Thermal injury)*.

\* Why there is predominant protein denaturation and no enzymatic digestion ?

*Hypoxia causes intracellular acidosis (has been explained earlier) — > .t pH results in denaturation of proteins which includes not only structural proteins hut also enzymes*

*So, there is no enzymatic digestion. o The necrotic cells retain their cellular outline for several days.*

**Liquefactive necrosis**

\* It is the necrotic degradation of tissue that rapidly undergo *softening and liquefaction* because of the *action of hydrolytic enzymes*.

\* It occurs after

It occurs after

1. *Infection i.e., suppurative inflammation* (most common).

2. *Ischemic necrosis in brain.*

Note : Brain lacks any substantial supportive stroma, so ischemic necrosis in brain is liquefactive unlike other organs where it is coagulative.

\* *Mechanism of liquefactive necrosis* —> Microbes stimulates accumulation of inflammatory cells and these cells release lysosomal enzymes.

### **Caseous necrosis**

\* It is a *variant of coagulative necrosis.*

\* It is most commonly encountered when cell death is attributable to certain organisms e.g., *mycobacterium tuberculosis (TB)* and fungi (*Histoplasma, Coccidioidomycosis*).

### **Why is it called caseous necrosis, not coagulative necrosis ?**

\* In contrast to coagulative necrosis where tissue architecture is maintained, in caseous necrosis, the tissue architecture is completely obliterated. So, it has been called caseous because of its cheesy white appearance of the area of necrosis.

### 36. Fat necrosis is common in -

a) Omentum

b) Breast

c) Retroperitoneal fat

d) All of the above

Correct Answer - D

There are 2 Types of Fat Necrosis

#### 1. Enzymatic fat necrosis

\* This is due to action of *lipase* on adipose tissue.

\* It occurs most frequently in *acute pancreatitis* due to leakage of lipase.

\* Depending on the severity of acute pancreatitis, fat necrosis may occur in :

- *Adipose tissue contiguous to pancreas, i.e., retroperitoneal fat.*
- *Adipose tissue in anterior mediastinum.*
- *Bone marrow*
- *Omental and abdominal fat*

#### 2. Nonenzymatic or Traumatic fat necrosis

\* Occurs due to trauma

\* Is seen in *subcutaneous tissue of breast, thigh, and abdomen.*

## 37. Programmed cell death is known as-

a) Cytolysis

b) Apoptosis

c) Necrosis

d) Proptosis

Correct Answer - B

Ans. is 'b' i.e., Apoptosis

\* Programmed cell death is apoptosis.

\* But remember this important fact that not all apoptosis are programmed cell death (read text below) Apoptosis

\* Apoptosis is pathway of cell death that is induced by a tightly regulated intracellular program in which cell destined to die activate enzymes that degrade the cell's own nuclear DNA, and nuclear & cytoplasmic proteins.

\* Apoptosis generally involves single cells in contrast to necrosis that usually involve a group of cells. o Apoptosis may be of two types ?

A. *Physiological (most of the time)*                      *Programmed cell death.*

B. *Pathological*    *Unprogrammed cell death.*

### **A.Physiological apoptosis**

\* Death by apoptosis is a normal phenomenon that *serves to eliminate cells that are no longer needed.* o It is important in the following physiologic situation :?

1. The programmed destruction of cells during embryogenesis, including implantation, organogenesis, and metamorphosis.
2. Hormone dependent involution in adult, e.g., endometrial cell breakdown during menstrual cycle, ovarian follicular atresia in the

menopause, the regression of lactating breast after weaning, and prostatic atrophy after castration.

3. Cell deletion in proliferating cell population in order to maintain a constant number, e.g., intestinal crypt epithelium.
4. Death of host cells that have served their useful purpose, such as neutrophils after an acute inflammatory response, and lymphocytes at the end of an immune response.
5. Elimination of potentially harmful self-reactive lymphocytes in thymus.
6. Cell death induced by cytotoxic T cells to eliminate virus infected and neoplastic cells. Same mechanism occurs in graft versus host disease.

### **B.Pathological apoptosis**

\* Apoptosis may also be pathological.

\* When cells are damaged beyond repair, especially when the damage affects the cell's DNA, the *irreparably damaged cells are eliminated* : ?

1. Cell death produced by injuries stimuli —> *Radiation* and *cytotoxic anticancer drugs* damage DNA, and if repair mechanisms cannot cope with the injury, the cell kills itself by apoptosis. In these situations, elimination of the cell may be a better alternative than risking mutations and translocations in the damaged DNA which may result in malignant transformation.
2. Cell injury in certain viral diseases, e.g., in viral hepatitis.
3. Pathologic atrophy in parenchymal after duct obstruction, such as occurs in pancreas, parotid gland.
4. Cell death in tumors.

### 38. In apoptosis, cytochrome C acts through -

a) Apaf 1

b) Bcl-2

c) FADD

d) TNF

Correct Answer - A

Ans. is 'a' i.e., Apaf 1

One of these proteins is cytochrome c, well known for its role in mitochondrial respiration. In the cytosol, *cytochrome C* binds to a protein called Apaf-1 (apoptosis activating factor-1), and the complex activates caspase-9. (Bcl-2 and Bcl-x may also directly inhibit Apaf-1 activation, and their loss from cells may permit activation of Apaf-1).

### 39. Which is activated for nuclear fragmentation in apoptosis -

a) Caspases

b) Apaf - 1

c) Oxygen free radicals

d) All

Correct Answer - A

**Ans is 'a' i.e., Caspases**

- Caspases and endonuclease cause chromatin fragmentation in apoptosis.
- They are inactive, so first they should be activated.
- Cytochrome 'c' binds with Apaf-1 and this complex activates caspases.
- Caspases cause fragmentation of chromatin and also activate endonuclease.

**About option 'b'**

- Though Apaf-1 helps in activation of caspases, it has no role in chromatin fragmentation and It does not have two separate forms active or inactive. It just forms complex with cytochrome 'C' to activate caspases.

## 40. In apoptosis which is/are involved -

a) Apaf-1

b) Bcl2

c) Caspases

d) All

Correct Answer - D

Ans. is 'a' i.e., Apaf-1; 'b' i.e., Bcl2; 'c' i.e., Caspases

- *Proapoptotic genes* : Apaf-1, Cytochrome C, Bak, Bax, Bim, AIF, P53, Caspases, TNFR1, FAS (CD95), FADD, BH3 only proteins (Bim, Bid, Bad), Smac/DIABLO.

## 41. Annexin Visa marker of

a) Apoptosis

b) Necrosis

c) Artherosclerosis

d) Inflammation

Correct Answer - A

Ans. is 'a' i.e., Apoptosis

o Annexin V assays provides simple and effective method to detect apoptosis at a very early stage.

o This assay makes advantage of the fact that phosphatidylserine (PS) is translocated from the inner (*cytoplasmic*)

leaflet of the plasma membrane to the outer (*cell surface*) leaflet soon after the induction of apoptosis and that the

annexin V protein has strong specific affinity for phosphatidyl serine.

o Phosphatidyl serine on the outer leaflet is available to bind labelled annexin V providing the basis for a simple staining assay.

o All of the annexin proteins share the property of binding calcium and phospholipids.

o Annexin V is a cause of syndrome called antiphospholipid antibody syndrome.

o Annexin V normally forms a shield around certain phospholipid molecules that blocks their entry into coagulation (clotting) reactions.

o In the antiphospholipid antibody syndrome; the formation of the shield is disrupted by the abnormal antibodies. Without the shield, there is an increased quantity of phospholipid molecules on cell membranes speeding up coagulation reactions and causing the abnormal blood clotting characteristic of antiphospholipid antibody syndrome.

---

## 42. Dystrophic calcification is seen in ?

a) Milk alkali syndrome

b) Atheromatous plaque

c) Hyperparathyroidism

d) Vitamin A intoxication

Correct Answer - B

**Ans. is 'b' i.e., Atheromatous plaque**

### **Dystrophic calcification**

\* When pathological calcification takes place *in dead, dying or degenerated tissue*, it is called dystrophic calcification. o Calcium metabolism is not altered and *serum calcium level is normal*.

Dystrophic calcification in  
dead tissues

1. In caseous necrosis of  
tuberculosis  
(most common which may be  
in lymph nodes)

2. Chronic abscess in  
liquifactive necrosis

3. Fungal granuloma

4. Infarct

5. Thrombi

6. Haematomas

7. Dead parasites-

Cystecercosis/Toxoplasma

Hydatid/Schistosoma

8. In fat necrosis of breast &  
other tissues

Dystrophic calcification in  
degenerated tissues

1. Atheromatous plaque

2. Monkeberg's sclerosis

3. Psommama bodies

4. Dens old scars

5. Senile degenerated changes such  
as in costal cartilage, tracheal,  
bronchial rings, Pineal gland in  
brain.

6. Heart valves damaged by  
rheumatic fever.

**How does calcification occurs in these site with normal serum calcium ?**

\* Calcification of dead and dying cells and tissues is a common finding in human pathologic conditions.

\* Denatured proteins in dead or irreversible damaged tissues preferentially bind phosphate ions.

\* Phosphate ions react with calcium ions to form a precipitate or calcium phosphate.

\* Thus, necrotic tissue serves as a calcium sink.

**43. Calcification of soft tissues without any disturbance of calcium metabolism is called -**

a) Ionotrophic calcification

b) Monotrophic calcification

c) Dystrophic calcification

d) Calcium induced calcification

Correct Answer - C

Ans. is 'c' i.e., Dystrophic calcification

## 44. True about gastric lymphoma -

a) Non Hodgkins lymphoma commonest variety

b) Diagnosis is made by biopsy

c) H-Pylori has direct relationship

d) All

Correct Answer - D

Ans. is 'a' i.e., Non Hodgkins lymphoma commonest variety; 'b' i.e., Diagnosis is made by biopsy; 'c' i.e., H-Pylori has direct relationship

### Gastric lymphoma

- *The stomach is the most common site for extranodal lymphoma.*
    - o Nearly all gastric lymphomas are *B-cell lymphomas of mucosa-associated lymphoid tissue (MALT lymphoma)*
    - o Majority of cases (80%) are associated with *chronic gastritis and H. Pylori infection.*
    - o The most striking evidence linking H. Pylori gastritis to MALToma is that eradication of infection by antibiotics induces durable remission with low rate of recurrence.
    - o Gastric lymphoma represents 5% of all gastric malignancies.
  - It is most prevalent in *sixth decade* of life.
    - o Like other tumors of mature B cells, MALTomas express B-cell markers *CD 19 and CD 20*. They do not express CD 5, CD 10 and CD 23.
    - o *Diagnosis is made by endoscopic biopsy.*
    - o Gastric lymphomas are *chemosensitive* and chemotherapy alone or along with surgery is used for the treatment of gastric lymphoma.
- About option 'a'
- o Most common variety of gastric lymphoma is NHL (MALToma). Very rarely, Hodgkin's lymphoma may also occur in stomach.

## 45. Most common site of GIST is -

a) Ileum

b) Esophagus

c) Colon

d) Stomach

Correct Answer - D

Ans. is 'd' i.e., Stomach

- Stomach 50-70%
- Small intestine 20-30%
- Colon & rectum 5-15%
- Esophagus < 5%

**46. Which of the following markers is specific for gastro-intestinal stomal tumor (GIST) -**

a) CD 117

b) CD 34

c) CD 23

d) S-100

Correct Answer - A

Ans. is 'a' i.e., CD 117

Immunohistochemistry

o Following markers are present in GISTs:

i) CD 117 (c kit) —>95%

ii) CD 34 —> 70%

iii) Smooth muscle actin 5%

• *CD 117 (c kit) is considered the most specific marker*

o CD 117 (c kit) immunoreactivity is the best defining feature of GISTs distinguishing them from true smooth muscle tumors (leiomyoma) and tumors arising from neural crest.

o *Although CD 117 (c kit) is considered the most specific marker for GIST, it is not pathognomonic of GIST as other tumors may also express CD 117. These tumors include mast cell tumor, germ cell tumors (seminomas), leukemias, malignant melanoma, angiolipomas, and some sarcomas.*

**47.**

## Aganglionic segment is encountered in which part of colon in case of Hirschsprung disease ?

a) Distal to dilated segment

b) In Whole colon

c) Proximal to dilated segment

d) In the dilated segment

Correct Answer - A

Ans. is 'a' i.e., Distal to dilated segment

Congenital aganglionic megacolon (Hirschsprung disease)

o Hirschsprung disease a congenital disorder characterized by aganglionosis of a portion of the intestinal tract.

o An intestinal segment **lacks both Meissner submucosal and Auerbach myenteric plexuses**. This leads to functional obstruction and intestinal dilation Proximal to the affected segment.

o Histological findings are :-

(i) *Absence of ganglion cells and ganglia in the muscle wall and submucosa of the affected segment.*

(ii) *Thickening and hypertrophy of nerve trunk.*

o *Rectum is always affected with involvement of more proximal colon to variable extent --> most cases involve the rectum and sigmoid only.*

o Proximal to the aganglionic segment, the colon undergoes progressive dilation and hypertrophy. o With time, the proximal innervated colon may become massively distended --> **megacolon**.

## 48. Multiple epidermoid cysts are seen in -

a) Turcot's syndrome

b) Gardner's syndrome

c) Peutz-Jegher syndrome

d) Familial polyposis coli

Correct Answer - B

Ans. is 'b' i.e., Gardner's syndrome

o Gardner syndrome includes adenomatous polyps of the gastrointestinal tract, desmoid tumours, osteomas, epidermoid cysts, lipomas, dental abnormalities and periampullary carcinomas.

**49. Features of Peutz-Jeghers syndrome are all except?**

a) Autosomal dominant

b) Mucocutaneous pigmentation

c) Hamartomatous polyp

d) High risk of malignancy

Correct Answer - D

Ans. is 'd' i.e., High risk of malignancy

o Malignancy is rare in hamartomatous polyps of Peutz-Jeghers syndrome.

- Other three options are correct (see previous explanation).

## 50. The features of crohns disease are all except ?

a) Lymphoid hyperplasia

b) Skin lesion

c) Transmural involvement

d) Crypt Abscess

Correct Answer - A

Ans. is 'a' i.e., Lymphoid hyperplasia

- Intermittent mild **diarrhea, fever, abdominal** pain (MC)
- **Right lower quadrant mass**, weight loss, anemia
- Sometimes **mimics appendicitis** or bowel perforation
- Anal complaints (fissure, fistula, abscess) – frequent
- Fat/vitamin malabsorption present
- Recurrence after surgery common
- Malignancy (most common cause) + with colon involvement
- String sign of Kantor is seen in Crohn's Disease.
- Creeping fat is a feature of Crohn's Disease.

**51. Female is affected, male is not. Disease is autosomal dominant, what is the chance in children?**

a) 50% affected

b) 25% affected

c) 75% affected

d) All affected

Correct Answer - A

Ans. is 'a' i.e., 50% Affected

If one of the parent (mother or father) is affected in autosomal dominant disorder, every child has 50% of chance of having the disease and 50% of chance not having the disease.

## 52. Chance of having cystic fibrosis if only one parent is affected and other is normal

-

a) 25%

b) 50%

c) 70%

d) 80%

Correct Answer - B

Ans. is 'b' i.e., 50%

Cystic fibrosis is an autosomal recessive disorder. Thus, in the given scenario (question) there are two possibilities:-1) One parent affected and the other is genotypically normal. In this condition, no child will be affected and all will be carrier.

2) One parent affected and the other is genotypically carrier (normal phenotypically). In this condition, 50% of child will be affected

### 53. True statement about inheritance of an X linked recessive trait is -

a) 50% of boys of carrier mother are affected

b) 50% of girls of diseased father are carrier

c) Father transmits disease to the son

d) Mother transmits the disease to the daughter

Correct Answer - A

Ans. is 'a' i.e., 50% of boys of carrier mother are affected

- all X-linked disorders are X-linked *recessive*.
- As male has only one X-chromosome, the male with affected gene on X-chromosome will always manifest the disease.
- On the other hand, female has 2 X-chromosomes, heterozygous female will be carrier because of expression of normal allele on the other X-chromosome.
- 50% boys of the carrier mother will be affected.
- Father will not transmit the disease to son as boys do not inherit X-chromosome from father.

**54. Normal female, whose father was color blind married a normal man. What are the chances of color blindness in son -**

a) 25%

b) 50%

c) 75%

d) No chance

Correct Answer - B

Ans. is 'b' i.e., 50%

\* Father of the female was color blind; that means she has received mutated X-chromosome from her father and she is carrier for colour blindness.

- If this female gives birth to a male child there is 50% chance that he will get the disease because the carrier female is carrying one normal X-chromosome and one mutated X-chromosome.

Note ?

\* Here I would like to mention one important fact that this question has been asked specifically for the chances of disease in a son. The question can be framed in following different ways.

- How many children will have the disease.
- What are the chances of son getting the disease.
- What are the chances of daughter getting the disease.
- How many son will have the disease.

\* Thus :?

- 25% of children will have disease.
- 50% of son (1 out of 2) will have disease.
- No daughter will have disease.

iv) Chances that son will have disease is 50% (1 out of 2 male child can get the disease).

## 55. The inheritance pattern of familial Retinoblastomas is -

a) Autosomal recessive

b) Autosomal dominant

c) X-linked dominant

d) X-linked recessive

Correct Answer - B

Ans. is 'b' i.e., Autosomal dominant

- Huntington disease
- Neurofibro-matosis
- Myotonic dys-trohy
- Tuberous scle-rosis
- Retinoblastoma

## 56. Male to male transmission is seen in -

a) Autosomal dominant diseases

b) Autosomal recessive

c) X-linked dominant

d) Mitochondrial disease

Correct Answer - A

Ans. is 'a' i.e., Autosomal dominant disease

X chromosome is not transmitted from father to son (option c is excluded) and mitochondrial disorders are always maternally inherited (option d is excluded).

Autosomal recessive disorder can be transmitted from father to son, but only if the mother is also affected or at least she is carrier. If only male is affected, autosomal recessive disorder cannot be transmitted to son.

Autosomal dominant disorder can be transmitted in any direction :-

From father to son or daughter.

From mother to son or daughter.

## 57. Single gene disorder which does not follow mendelian inheritance -

a) Sickle cell anemia

b) Down syndrome

c) Fragile X-syndrome

d) Retinoblastoma

Correct Answer - C

**Ans. is 'c' i.e., Fragile X-Synd.**

Transmission of certain single-gene disorders does not follow classical mendelian principles.

**This group of disorder can be classified into following categories ?**

1. Diseases caused by triplet - repeat mutation, e.g. fragile - X syndrome, Huntington disease, & others.
2. Disorders caused by mutation in mitochondrial genes, e.g. Leber hereditary optic neuropathy.
3. Disorder associated with genomic imprinting.
4. Disorders associated with gonadal mosaicism.

## 58. Transport of lipids from the intestine to other tissues is by -

a) Chylomicrons

b) LDL

c) HDL

d) VI DL

Correct Answer - A

Ans. is 'a' i.e., Chylomicrons

Transport of lipids

o There are two pathways of lipid transport in the body ?

### 1. Transport of dietary lipid (Exogenous pathway)

\* It is the transport of lipid from *intestine to liver*.

- *Chylomicrons transport the dietary lipid from intestine to liver.*

\* In Diet the major lipids are triglyceride and cholesterol.

\* Cholesterol is absorbed as such in proximal small intestine and is esterified to cholesteryl ester (ChE). o Triglycerides are hydrolysed by lipases to glycerol and fatty acids which are absorbed in intestine.

o Inside intestinal cells triglyceride is synthesized by fatty acids.

- *Chylomicrons* are synthesized in the small intestine that contain triglyceride, cholesteryl ester, cholesterol, phospholipids and apoprotein B-48 (apo B-48).

\* These chylomicrons are secreted in the intestinal lymph and reach the systemic circulation via thoracic duct.

- In the circulation Apo E and Apo C are transferred to chylomicrons by HDL, so now chylomicrons contain Apo B-48, Apo E, & Apo C.

\* In the circulation, Triglycerides of chylomicrons are hydrolysed

by *lipoprotein lipase (LPL)* present on endothelial cells of vessels of *skeletal muscles, adipose tissue and heart*.

\* The released fatty acids are utilized locally by these tissues.

\* The chylomicron particle progressively shrinks in size by action of LPL and, cholesterol, phospholipids and apo C are transferred to HDL, creating *chylomicron remnants* that contains more cholesterol, less triglycerides, apo E & apo B-48.

\*Chylomicron remnants are removed by liver by the *LDL receptors* that require apo E as ligand.

**Note** - Apo C-II, that is transferred from HDL to chylomicrons act as a cofactor for lipoprotein lipase. Apo A-V promotes LPL mediated triglyceride lipolysis in VLDL and chylomicrons.

## **2. Transport of Hepatic lipids (Endogenous pathway)**

\* *VLDL* is synthesized *in liver* that contains high triglyceride, ChE, cholesterol, phospholipid and Apo B-100.

\* (VLDL particles resemble chylomicrons in composition except that VLDL contains Apo B-100 instead of ApoB-48).

\* VLDL particles are secreted in the plasma and as with chylomicron, Apo E and Apo C are transferred from HDL to VLDL. Now VLDL contains Apo B-100, Apo E and Apo C.

\* In plasma, triglycerides of VLDL are hydrolysed by same lipoprotein lipase (see above) and apo C is transferred to HDL and the remnants are called *IDL*.

\* 40-60% of IDL is removed by liver via *LDL receptor* mediated endocytosis, this process require *Apo E* which acts as *ligand for LDL receptors*.

\* Remaining 1 DL is remodeled by hepatic lipase to form *LDL* that contains *maximum cholesterol*.

\* 70% of LDL is removed by liver via LDL receptor and 30% is utilized by peripheral tissues as a source of cholesterol.

## 59. Which is not a feature of Down's syndrome

a) Clinodactyly

b) Pigmented birth marks

c) Hypotonia

d) Respiratory tract Infections

Correct Answer - B

Ans. is 'b' i.e., Pigmented birth marks

- Other clinical features include :?

1) **General :- Mental retardation**, short stature

2) **Cranio-facial Brachycephaly**, epicanthic fold, protruding tongue, small ears, upward sloping palpebral fissures (**Mongoloid slant**), strabismus, nystagmus, **Brushfield spots in iris**.

3) **Limbs :- Fifth finger clinodactyly**, single palmar crease (**simian crease**), wide gap between first and second toes (sandle gap).

4) **Congenital heart disease :-** Common AV canal, **ASD (most common)**, **VSD**, PDA, fallot tetralogy.

5) **GIT :-** Anal atresia, **Duodenal atresia**, **Hirschsprung disease**, **annular pancreas**.

6) **Increased incidence of leukemia (1%)**. Leukemias common are **ALL (most common)**, **AML (M7-AML) transient myeloproliferative disorders**, and Juvenil CML.

**60. Following injury to a blood vessel, immediate haemostasis is achieved by -**

a) Fibrin deposition

b) Vasoconstriction

c) Platelet adhesion

d) Thrombosis

Correct Answer - B

Ans. is 'b' i.e., Vasoconstriction

**Hemostasis**

\* Hemostasis is a physiological process where by bleeding is halted, thus protecting the integrity of the vascular system after tissue injury.

\* It is responsible for minimizing blood loss.

\* It is commonly referred to as stoppage of bleeding.

**The hemostatic mechanisms have several functions : ?**

\* I. Maintain blood in fluid state while circulating within the vascular system.

\* Arrest bleeding at the site of injury by formation of hemostatic plug.

\* Ensure the removal of hemostatic plug when healing is complete.

The components of normal hemostasis include : ?

- Blood vessels (endothelium)
- Platelets
- Plasma coagulation factors and their inhibitors.
- Fibrinolytic system.

When a blood vessel is injured, several steps occur in hemostasis at the site of injury : ?

**Vasoconstriction**

\* After initial injury, there is a brief period arteriolar vasoconstriction, minimizing vessel diameter and slowing bleeding.

- \* This is due to reflex neurogenic mechanism and augmented by a potent endothelium derived vasoconstrictor endothelin.
- \* However this effect is transient, bleeding would resume if there will no activation of platelet and coagulation system.

### **Primary hemostasis**

- \* Endothelial injury exposes highly thrombogenic subendothelial extracellular matrix to bind (adhere) with collagen of ECM.
- \* Binding of platelets activates these cells and platelets release secretory granules.
- \* These secretory products (from secretory granules) recruit additional platelets to (platelet plug).

### **C. Secondary hemostasis**

- \* Coagulation system is activated and thrombin is generated.
- \* Thrombin converts fibrinogen to fibrin.
- \* Ultimately these events form an irreversibly fused mass of platelets, thrombin RBCs and fibrinogen —> Definitive secondary hemostatic plug.

### **D. Repair of vessels and dissolution of clot**

- \* The clot attracts and stimulates the growth of fibroblast and smooth muscle cells within the vessel wall, and begins repair process.
- \* At this stage fibrinolytic system is also activated, resulting in dissolution of the clot.

## 61. Lines of Zahn occur in -

a) Postmortem clot

b) Infarct

c) Embolus

d) Coralline thrombus

Correct Answer - D

Ans. is 'd' i.e., Coralline thrombus

*It is seen in Primary platelet thrombi.*

## 62. Anemia with reticulocytosis is seen in -

a) Hemolysis

b) Iron deficiency anemia

c) Vitamin B<sub>12</sub> deficiency

d) Aplastic anemia

Correct Answer - A

Ans. is 'a' i.e., Hemolysis

### Conditions

- Acute blood loss or hemorrhage
- Postsplenectomy
- Microangiopathic anemia
- Autoimmune hemolytic anemia
- Hemoglobinopathy (Sickle cell anemia and thalassemia)
- Post anemia treatment like folate supplementation, iron supplementation & vitamin B<sub>12</sub>, supplementation

### 63. Intravascular hemolysis occurs in -

a) Hereditary spherocytosis

b) Acute G6PD

c) Sickle cell ds

d) b and c

Correct Answer - D

Ans. is 'b' i.e., Acute G6PD; 'c' i.e., Sickle cell dis

#### **Extravascular hemolysis**

- Hereditary spherocytosis
- Thalassemia
- Sickle cell anemia
- Autoimmune hemolytic anemia 3 Drug induced immune hemolytic anemia
- G-6-PD deficiency

#### **Intravascular hemolysis**

- Paroxysmal nocturnal hemoglobinuria o G-6-PD deficiency
- Clostridial toxin
- Falciparum malaria
- Mechanical injury to red cells
- Defective cardiac valves
- Thrombin in microcirculation
- Sickle cell anemia (minor)

Note : - In G-6-PD deficiency both extravascular and intravascular hemolysis occur.

- In Sickle cell anemia, usually there is extravascular hemolysis but intravascular hemolysis can also occur.

**64. Maximum spherocytes is seen in -**

a) Autoimmune haemolytic anemia

b) Vit B12 deficiency

c) Aplastic anemia

d) None

Correct Answer - A

Ans. is 'a' i.e., Autoimmune hemolytic anemia

Most common cause of spherocytes is immunehemolytic anemia.

## 65. The primary defect which leads to sickle cell anemia is -

- a) An abnormality in porphyrin part of hemoglobin
- b) Replacement of glutamate by valine in n-chain of HbA
- c) A nonsense mutation in the I3-chain of HbA
- d) Substitution of valine by glutamate in the a-chain of HbA

Correct Answer - B

Ans. is 'b' i.e., Replacement of glutamate by valine in 13 chain of HBA

### Sickle cell anemia

- Sickle cell anemia is a hereditary hemoglobinopathy, i.e., the type of disease characterized by production of defective hemoglobin.
- Sickle cell anemia results from mutation in 13-globin gene.
- It is caused by a point mutation at the sixth position of the f3-globin chain leading to substitution of a valine residue for a glutamic acid residue resulting in sickle hemoglobin (HbS).
- Sickle cell anemia is an autosomal recessive disorder.
  - o If an individual is homozygous for the sickle cell mutation, almost all the hemoglobin in the red cell is HbS.
  - o In heterozygotes, only about 40% of the hemoglobin is HbS, the remainder being normal hemoglobins.

## 66. Which is not a feature of paroxysmal nocturnal hemoglobinuria -

a) Increased LAP score

b) Thrombosis

c) Thrombocytopenia

d) Hemolysis

Correct Answer - A

Ans. is 'a' i.e., Increased LAP score

### Clinical features of PNH

#### A. Intravascular hemolysis

\* The main feature of PNH is increased intravascular hemolysis that results in -

Hemoglobinemia	Increased urine
urobilinogen	
Hemoglobinuria	Decreased serum
haptoglobin	
Hemosiderinuria	Increased serum LDH
Increased serum bilirubin	

- *The hemolysis is paroxysmal and usually occurs in the night because during sleep the pH of blood gets slightly reduced and acidic medium leads to activation of the complement.*
- **B. Thrombosis**
- In PNH there is episodic thrombosis due to *absence of CD-59 on platelets*, this results in externalization of phosphatidylserine, a site for prothrombinase complexes and thus increase the propensity for thrombosis.
  - \* *Intrabdominal veins are the most common sites of thrombosis that may result in Budd chiary syndrome due to hepatic vein thrombosis.*

C. Other features

- *Thrombocytopenia*
- *Granulocytopenia*
  - \* *Decreased LAP score*
  - \* *Normoblastic hyperplasia of bone marrow*
  - \* *PNH patients are also at increased risk for developing acute myelogenous leukemia and aplastic anemia.*

## 67. Cold agglutinin is -

a) IgG

b) IgM

c) IgA

d) IgD

Correct Answer - B

Ans. is 'b' i.e., IgM

### **Cold agglutinin hemolytic anemia**

- This form of hemolytic anemia is caused by cold agglutinin IgM antibodies.
- Antibodies react with RBC at 0° to 4°C.
- Both intravascular and extravascular hemolysis may occur.
- IgM antibody bind to RBC and fix complement on RBC before complement mediated hemolysis occur. This transient reaction with IgM deposit C3b on RBC. C3b acts as an opsonin is that enhances the phagocytosis of RBCs in mononuclear phagocytic system of liver and spleen → extravascular hemolysis.
- However if IgM remains attached to RBC, sustained activation of complement results in formation of large amount of membrane - attack complex that destroys RBC directly --> Intravascular hemolysis.
- Causes of cold agglutinin immunohemolytic anemia : - Mycoplasma infection, I MN, CMV, Influenza, HIV, Malignant lymphoma

## 68. Response to iron in iron deficiency anemia is denoted by-

- a) Restoration of enzymes
- b) Reticulocytosis
- c) Increase in iron binding capacity
- d) Increase in hemoglobin

Correct Answer - B

Ans. is 'b' i.e., Reticulocytosis

### Response to iron therapy

- When specific iron therapy is given, *patients often show rapid subjective improvement, with disappearance or marked diminution of fatigue, lassitude, and other non-specific symptoms.* This response may occur before any improvement in anemia is observed.
- *The earliest hematological evidence of recovery is increase reticulocytes and their hemoglobin content.* The reticulocytes attain a maximal value on the 5th to 10th day after institution of therapy and thereafter gradually return to normal. The reticulocyte response may not be detectable in mild iron deficiency anemia.
- *The blood hemoglobin level is the most accurate measure of the degree of anemia in iron deficiency anemia.* During the response to therapy, the red cell count may increase temporarily to values above normal, but the hemoglobin value lags behind.
- The red cell indices may remain abnormal for some time after the normal hemoglobin level is restored. As recovery occurs, a normocytic cell population gradually replaces the microcytic population; and *one of the early signs of response to therapy is an increase in RBW from pretreatment level.*
- When treatment is fully effective, hemoglobin reaches normal levels

- by 2 months after therapy is initiated, regardless of starting values.
- Of the epithelial lesions in iron deficiency, those affecting the tongue and nails are the most responsive to treatment.

## 69. Megaloblastic anemia is seen in ?

a) ileal resection

b) Crohn's disease

c) Intestinal lymphatic ectasia

d) a and b

Correct Answer - D

Ans. is 'a' i.e., ileal resection 'b' i.e., Crohn's disease

.. Crohn's disease is a type of  
ilitis.

?. Chronic pancreatitis is a malabsorption state.

*"About 40% of patients with chronic pancreatitis have vitamin B12 malabsorption"*

## 70. The anaemia associated with leukaemia is ?

a) Iron deficiency

b) Megaloblastic type

c) Myelophthisic type

d) All of above

Correct Answer - C

Ans. is 'c' i.e., Myelophthisis type

### **Myelophthisic anemia**

- Space - occupying lesions that destroy significant amount of bone marrow or disturb the marrow architecture, depress its productive capacity. This form of anemia is referred to as myelophthisic anemia.
- Characteristically, immature erythroid and myeloid progenitors appears in the peripheral blood → Leukoerythroblastosis.
- Causes are
- Metastatic cancer (M.C. cause)
- Granulomatous disease infiltrating bone marrow.
- Myeloproliferative disorders (such as myeloid leukemia)
- Myelofibrosis

## 71. Schistocyte is/are found in -

a) TTP

b) DIC

c) Severe iron deficiency

d) All

Correct Answer - D

Ans. is all

### **Schistocytes**

- A schistocyte is defined as an irregularly shaped erythrocyte fragment caused by mechanical trauma or an intrinsic abnormality of erythrocytes.
- Schistocytes : Mechanisms and Diseases
- Shearing by fibrin strands:
- Microangiopathic hemolytic anemia
- Disseminated intravascular coagulation
- Hemangiosarcoma o Glomerulonephritis o Myelofibrosis
- Hemolytic uremic syndrome
- Hypersplenism Turbulent blood flow
- Congestive heart failure o Valvular stenosis
- Caval syndrome in heart worm disease
- Hemangiosarcoma Intrinsic abnormalities
- Chronic doxorubicin toxicosis
- Severe iron deficiency anemia
- Pyruvate kinase deficiency
- Congenital and acquired dyserythropoiesis
- Microangiopathic hemolytic anemia can occur in :- o External impact : March hemoglobinuria
- Cardiac hemolysis : Prosthetic cardiac valves

- Fibrin deposit in microvasculature: TTP, DIC, HUS

## 72. Helmet cells are characteristic of anemia of?

a) Hemolytic uremic syndrome

b) Polysplenia

c) Spherocytosis

d) Acanthocytosis

Correct Answer - A

Ans. is 'a' i.e., Hemolytic uremic syndrome

Schistocytes, helmet cells, triangle cells, burr cells are seen in microangiopathic hemolytic anemia (MAHA). Changes in erythrocyte morphology

### 73. Gamma gandy bodies are seen in all except ?

a) Cirrhosis with portal hypertension

b) Chronic myeloid leukemia

c) Sickle cell anemia

d) Thalassemia

Correct Answer - D

Ans. is 'd' i.e., Thalassemia

- **Gandy-Gamma bodies** are foci of fibrosis containing iron and calcium salts deposits on connective tissue and elastic fibres.
- **Gandy-Gamma bodies** are seen in congestive splenomegaly e.g., in sickle cell anemia, CML and liver cirrhosis.

## 74. Increased permeability in acute inflammation is due to-

a) Histamine

b) IL-2

c) TGF-P

d) FGF

Correct Answer - A

Ans. is 'a' i.e., Histamine

\* *Formation of endothelial gaps in venules, i.e. immediate transient response* is the most common mechanism causing increased vascular permeability in acute inflammation.

\* Mediators involved in this mechanism are :-

*i) Immediate (more important) : Histamine, bradykinin, leukotrienes, neuropeptide substance P. Somewhat delayed : IL-1, TNF, IFN- $\gamma$*

## 75. which of the following doesnot belong to the family of selectin?

a) P selectin

b) L selectin

c) A selectin

d) E selectin

Correct Answer - C

**Ans. is 'c' i.e., A selectin**

Leukocyte and endothelial adhesion molecules

Leukocyte adhesion and transmigration are regulated largely by binding of complementary adhesion molecules on the leukocyte & endothelial surface, and by chemical mediators.

Cytokines affect these processes by modulating the expression of adhesion molecules so that leukocytes can firmly adhere to endothelium.

There are four molecular families of adhesion receptors.

### **1. Selectin**

- Selectins function in the cell to cell interaction i.e., adhesion of leukocytes to the endothelium.
- E-selectin (CD-62 E) is present on endothelial cells and it binds to sialyl-lewis. (a sialylated form of oligosaccharide on leukocytes).
- Endothelial cell expression of E-selection is a hallmark of acute cytokine-mediated inflammation.
- P-selectin (CD-62 P) is present on endothelium and platelets and it binds to sialyl-Lewis on leukocytes.
- L-selectin (CD-62 L) is present on leukocytes and it binds to mucin-like glycoprotein G1yCAM- I on the endothelium.

### **2.Immunoglobulin family**

- Present on endothelium
- ICAM-1 (intracellular adhesion molecule-1) binds to  $\alpha_4\beta_2$ -integrins (VLA-4) of leukocytes.
- Platelet endothelial cell adhesion molecule (PECAM or CD-31) is present on both endothelium and leukocytes. It is the major adhesive molecule for diapedesis.

### **3. Integrins**

- Integrins promote cell-cell or cell-matrix interaction (in contrast to selectins that promote only cell-cell interaction) i.e., integrins help in adhesion of leukocytes to endothelium and adhesion of leukocytes to an extracellular matrix such as fibronectin, vitronectin, activated complement.

#### **Present on leukocytes**

- integrins (VLA-4) bind to VCAM-1 of the endothelium.
- $\alpha_4\beta_2$  - integrins (LFA-1 and MAC-1) bind to ICAM- 1 of the endothelium.

### **4. Mucin like glycoprotein**

- These glycoproteins are present in the extracellular matrix and on the cell surface.
- An example is Heparan sulfate, that serves as a ligand for the leukocyte adhesion molecule CD-44.

## 76. Cell-matrix adhesions are mediated by?

a) Cadherins

b) Integrins

c) Selectins

d) Calmodulin

Correct Answer - B

Ans. is 'b' i.e., Integrins

Cell-matrix adhesions, are usually mediated by intergrins

Cell-cell adhesions in Anchoring junctions are mediated by cadherins.

## 77. All are true regarding transforming growth factor- $\beta$ except-

a) Proliferation for fibroblast

b) Proliferation of endothelial cells

c) Chemotaxis of fibroblasts

d) Activation of macrophages

Correct Answer - D

Ans. is 'd' i.e., Activation of macrophages

Also see above explanation.

Growth factors and cytokines involved in regeneration and wound healing

Growth factor Epidermal growth factor

Transforming growth factor  $\alpha$

Heparin-binding EGF

Hepatocyte growth factor/scatter factor

Vascular endothelial cell growth factor (isoforms A,B,C,D)

Platelet-derived growth factor (isoforms A,B,C,D)

Fibroblast growth factor 1 (acidic), 2 (basic), and family

Transforming growth factor  $\beta$  (isoforms 1,2, 3); other members of the family are BMPs and activin

Functions

Mitogenic for keratinocytes and fibroblasts; stimulates keratinocyte migration and granulation tissue formation

Similar to EGF; stimulates replication of hepatocytes and most epithelial cells

Keratinocyte replication

Enhances proliferation of hepatocytes, epithelial cells, and endothelial cells; increases cell motility, keratinocyte replication



**78. Maximum collagen in wound healing is seen at -**

a) End of first week

b) End of second week

c) End of third week

d) End of 2 months

Correct Answer - B

Ans. is 'b' i.e., End of second week

*During second week* there is continued accumulation of collagen and proliferation of fibroblast. Maximum collagen is seen in second week.

## 79. Chemotaxis is mediated by-

a) Histamine

b) Leukotriene B4 and C5a

c) Leukotriene C4 and C3a

d) Bradykinin

Correct Answer - B

Ans. is 'b' i.e., Leukotriene B4 and C5a

- Chemotaxis is unidirectional locomotion of leukocytes towards the site of injury, oriented *along a chemical gradient*. This chemical gradient is created by substances called chemoattractants (chemotactic agents), which may be exogenous (bacterial products) or endogenous (C5a, LTB-4, IL-1, TNF, IL-8).
- C5a is the most powerful chemo-attractant (chemokine).

**80. Following injection of lymphokines, the same class of immunoglobulin are produced. This is to be referred as -**

a) Group switching

b) Clonal selection

c) Hybridisation

d) Class switching

Correct Answer - B

Ans. is 'b' i.e., Clonal selection

\* B-cells are able to make a specific antibody against a specific antigen.

\* It is due to presence of specific receptor on B-cells - B-cell receptor (BCR), that is usually an immunoglobulin Ig M or Ig D.

\* An antigen interacts with B-cell that shows best fit by virtue of its BCR.

\* The antigen binds to this receptor, and the B-cell is stimulated to divide and form a clone (clonal selection).

\* This clone of cells will become plasma cells that will secrete antibody of a particular specificity and same class.

\* Although, B-cells are the major source of antibodies (after their conversion into plasma cells), Helper - T cells are also important.

\* Helper T-cells activate B-cells by secreting *cytokines* (*lymphokines*). *In antibody formation T-cells are involved earlier than B-cells.*

Antigen exposure

Antigen presenting cells present this antigen to helper T cells  
T cells are activated

Secretion of lymphokine by T-cells

B-cells that carry BCR specific to that antigen are, stimulated (clonal selection)

B-cells proliferate and differentiate in to plasma cells

Plasma cells synthesize an immunoglobulin of same specificity as that carried by the B-cell precursors

Also know

Class switching

\* *Isotype or class switching* is a biological process that changes an antibody from one class to another. For example from Ig M (in primary response) to Ig G (in secondary response).

## 81. Most potent stimulator of Naive T-cells -

a) Mature dendritic cells

b) Follicular dendritic cells

c) Macrophages

d) B-cell

Correct Answer - A

Mature Dendritic cells

Mature B-cells and T-cells before antigenic exposure are called naive-B and T cells respectively. Sequence of events in activation of naive T cells.

- Immature dendritic cells in the epidermis are called langerhans cell.
- These immature dendritic cells (langerhans cells) capture the antigen in the epidermis.
- After capturing the antigen these cells secrete cytokines.
- These cytokines cause loss of adhesiveness of langerhans cells.
- Langerhans cells separate from each other and migrate into lymphatic vessels.
- In lymphatic vessel, maturation of langerhans cells takes place.
- Then these mature langerhans dendritic cells reach to naive T cells in the lymph nodes and present antigen to these cells and activate them.

## 82. True about MHC-class II -

a) Not involved in innate immunity

b) Cytotoxic T-cell involved

c) Present in nucleated cells

d) All

Correct Answer - A

Ans. is 'a' i.e., NOT involved in innate immunity

o MHC I and II are part of adaptive immunity. A major function of the MHC molecule is to present the antigen to T cell that is part of adaptive immunity.

Cytotoxic T cells are MHC - class I restricted.

MHC class II complex is found only on cells of the immune system (class I is found on all nucleated cells and platelets.)

The antigens binding with MHC II molecule are presented to CD4+ T cells. As discussed earlier, helper T cells/CD4 T cells are MHC II-restricted.

B cells have both MHC class I and II complexes.

### 83. Common variable hypogammaglobulinemia shows ?

a) Decreased B cell count

b) Increased B cell count

c) Compliment opsinization

d) Neutropenia

Correct Answer - C

Ans. is 'c' i.e., Normal B cells

Most patients with common variable immunodeficiency have normal or near-normal numbers of B cells in the blood and lymphoid tissues. These B cells, however, are not able to differentiate into plasma cells.

The clinical manifestations are caused by antibody deficiency. The feature common to all patients is hypogammaglobulinemia, generally affecting all the antibody classes but sometimes only IgG.

## 84. Major fibril protein in Primary Amyloidosis is -

a) AL

b) AA

c) Transthyretin

d) Procalcitonin

Correct Answer - A

Ans. is 'a' i.e., AL

### Classification of amyloidosis

o The amyloid can be classified in to following two broad groups ?

#### 1. Systemic (generalised) amyloidosis

When amyloidosis affects more than one body organ or system.

On clinical grounds, the systemic (generalised) amyloidosis is subclassified into ?

##### A. Primary

- Primary amyloidosis occurs when a specialized cell in the bone marrow (plasma cell) spontaneously produce a particular portion, (i.e. light chain) of antibody AL (*amyloid light chain*).
- It is the *most common type of amyloidosis*.

##### B. Secondary (Reactive)

- When amyloidosis occurs as a result of underlying chronic inflammatory process, i.e. AA type.
- Other systemic amyloidoses do not fall in either of these categories.

**85. Which type of Amyloidosis is caused by mutation of the transthyretin protein ?**

a) Familial Mediterranean fever

b) Familial amyloidotic polyneuropathy

c) Dialysis associated amyloidosis

d) Prion protein associated amyloidosis

Correct Answer - B

Ans. is 'b' i.e., Familial amyloidotic polyneuropathy

Transthyretin (TTR) is normal serum protein that binds and transport thyroxine and retinol.

**TTR can cause following types of amyloidosis :?**

- Mutant TTR : - *Mutation* in TTR can cause syndrome of familial *amyloidotic polyneuropathy* or *familial amyloidotic cardiomyopathy*.
- Wild (non-mutant) TTR : - There is *no mutation* of TTR and wild type TTR forms fibrils which results in *senile systemic amyloidosis (senile cardiac amyloidosis)*.

## 86. Amyloidosis is most commonly seen in ?

a) Maturity onset DM

b) Type I DM

c) Type II DM

d) HTN

Correct Answer - C

Ans. is 'c' i.e., Type II DM

The two best examples of localized amyloidosis are Alzheimer's disease and type 2 diabetes mellitus.

Localized amyloid deposition results from the production of a unique polypeptide, which contains an amyloidogenic sequence and is capable of forming a beta-pleated sheet structure necessary for these deposits to aggregate.

In type 2 diabetes it is the islet amyloid polypeptide (IAPP) also known as amylin.

In Alzheimer's the unique peptide is the beta-amyloid protein (A beta).

## 87. Serum amyloid associated protein, found in ?

a) Alzheimer's disease

b) Chronic inflammatory states

c) Chronic renal failure

d) Malignant hypertension

Correct Answer - B

Ans. is 'b' i.e., Chronic inflammatory states

a) Chronic inflammatory conditions like RA (most common), TB & leprosy, osteomyelitis, *ankylosing spondylitis*, IBD (Crohn's disease, UC), bronchiectasis.

Some tumors like Renal cell carcinoma (*hypernephroma*), Hodgkins lymphoma

## 88. Hamartoma is-

- a) Malignant tumor
- b) Metastatic tissue
- c) Development malformation
- d) Hemorrhage in vessel

Correct Answer - C

Ans. is 'c' i.e., Development malformation

### **Hamartoma**

A hamartoma is a *benign (noncancerous)* tumor-like growth consisting of a disorganized mixture of cells and tissues normally found in the area of body where the growth occurs.

\* For example, hamartoma of lung contains cartilage, blood vessels, bronchial type of structures and lymphoid tissues.

\* It is a *focal development malformation* that resembles a neoplasm in the tissue of origin.

\* But, it is *not a neoplasm* because it grows at the same rate as the surrounding tissues unlike neoplasm whose growth exceeds the growth of surrounding tissue.

### **Choristoma**

\* Choristoma is the *ectopic rest of normal tissue, i.e.*, the normal tissue is present at a different anatomical site of the body.

\* For example, presence of pancreatic tissue in mucosa of small intestine.

\* Normally arranged tissue at a different anatomical site (ectopic site) --> **Choristoma**.

\* Abnormally arranged tissue present at normal

site

-Hamartoma

## 89. Overgrowth of a skin structure at a localised region -

a) Hamartoma

b) Malignant tumor

c) Choriostoma

d) All

Correct Answer - A

Ans. is 'a' i.e., Hamartoma

Aberrant differentiation may produce a mass of disorganized but mature specialized cells or tissue indigenous to the particular site, referred to as a *hamartoma*.

An ectopic rest of normal tissue is called a *choristoma*. eg a rest of adrenal cells under the kidney capsule.

When a neoplasm, benign or malignant, produces a macroscopically visible projection above a mucosal surface and projects, it is termed a *polyp*.

## 90. Excessive fibrosis in tumor is called -

a) Anaplasia

b) Metaplasia

c) Desmoplasia

d) Dysplasia

Correct Answer - C

Ans. is 'c' i.e., Desmoplasia

- In some tumors, parenchymal cells stimulate the formation of an *abundant collagenous stroma*, referred to as desmoplasia, eg *scirrhous carcinoma of breast*.

**91. When stem cells transform to form cells characteristic of other tissues, the process is called as -**

a) De-differentiation

b) Re-differentiation

c) Trans-differentiation

d) Sub-differentiation

Correct Answer - C

Ans. is 'c' i.e., Trans-differentiation

**Transdifferentiation**

\* Transdifferentiation takes place when a non-stem cell transform into a different type of cell, or when an already differentiated stem cell creates cells outside its already established differentiation.

\* Remember very important fact that it is the non-stem cell or already differentiated stem cell (i.e. mature cell) that is transformed into other type of cell. It is not stem cell that is transforming.

\* Transdifferentiation is a type of metaplasia.

\* Then, what is the difference between transdifferentiation and metaplasia.

\* In Transdifferentiation only differentiated stem cell is transformed into other cell type, while in metaplasia any of the two, either stem cell or differentiated cell can transform into other cell type.

\* So, all transdifferentiation processes are metaplasia, but not all metaplasia are transdifferentiation. Most likely question has been wrongly framed here, there should be non-stem cell instead of stem cell in the question. Anyways answer remains the same, as no other option is related to this type of transformation.

---

**92. Carcinoma of lung, breast marker is -**

a) CEA

b) AFP

c) 11CG

d) CA-15-3

Correct Answer - A

Ans. is 'a' i.e., CEA

Carcinoembryonic antigen is a marker in cancer of colon, pancreas, *lung, breast, and ovary.*

### 93. AFP is raised in-

a) Yolk sac tumor

b) Seminoma

c) Teratoma

d) a and c

Correct Answer - D

**Ans. is 'a' i.e., Yolk sac tumor; 'c' i.e., teratoma**

AFP is a glycoprotein synthesized normally early in fetal life by yolk sac, fetal liver and fetal GIT. It is structurally and genetically related to albumin.

AFP is raised in liver cancer (hepatocellular carcinoma), lung carcinoma, pancreatic carcinoma, colon carcinoma, and non-seminoma germ cell tumor of testis/ovary (yolk sac tumor/endodermal sinus tumor, embryonal carcinoma, teratoma).

## 94. Elevated CA-125 are seen in -

a) Abdominal TB

b) Ca cervix

c) Endometriosis

d) All

Correct Answer - D

**Ans. is 'a' i.e., Abdominal TB; 'b' i.e., Ca cervix; 'c' i.e., Endometriosis**

**Elevated level of CA-125 is seen in**

\* Epithelial ovarian Cancer

\* Non ovarian tumors :- Cancers of endometrium, cervix, fallopian tubes, pancreas, breast, lung and colon.

\* Non malignant conditions:- Pregnancy, menstruation, peritonitis, endometriosis, pelvic inflammatory disease (abdominal TB) and uterine fibroids.

**95. The tumor suppressor gene P53 induces cell arrest at-**

a) M phase

b) S - G<sub>2</sub> phase

c) G<sub>1</sub> - S phase

d) G<sub>0</sub> - phase

Correct Answer - C

Ans. is 'c' i.e., G<sub>1</sub> - S phase

Factors acting at G, S point are :?

**Stimulator of cycle** : Cyclin D-CDK4 (phosphorylate RB gene); cyclin E-CDK-2.

**Inhibitors of cycle** : The Cip/kip family (p21, p27, p57); INK4a/ARF family (p16 INK4a, p14 ARF, p16, p17, p18, p19)

## 96. Major contribution to cachexia with advanced cancer?

a) Clathrin

b) Histamine

c) Interferon

d) Tumor-necrosis-factor (TNF)

Correct Answer - D

Ans. is 'd' i.e., Tumor-necrosis factor (TNF)

- Patients with cancer commonly suffer progressive loss of body fat which is accompanied by profound weakness, anorexia, and anemia. This wasting syndrome is referred to as cachexia.
  - o TNF produced by macrophages or some tumor cells is the most important mediator of cachexia.

**97. Hemolytic Uremic Syndrome is characterized by ?**

a) Microangiopathic haemolytic anaemia

b) Positive Coomb's test

c) Thrombocytopenia

d) a and c

Correct Answer - D

**Ans is 'a' i.e., Microangiopathic hemolytic anemia; 'c' i.e., Thrombocytopenia**

**Hemolytic uremic syndrome**

\* Hemolytic uremic syndrome is characterized by the triad of :

- Anemia (microangiopathic hemolytic anemia).
- Renal failure (microangiopathy of kidney involving glomerular capillaries and arterioles).
- Thrombocytopenia (due to platelet consumption).

\* Hemolytic uremic syndrome is most common in children under 2 years of age.

\* It usually follows an episode of acute gastroenteritis, often triggered by E coli.

\* The prodrome is usually of abdominal pain, diarrhoea and vomiting.

\* Shortly thereafter, signs and symptoms of acute hemolytic anemia, thrombocytopenia and acute renal failure ensue. o Sometimes neurological findings also occur. (But usually absent and differentiate HUS from TTP.) o Rarely HUS may follow respiratory tract infection.

**Etiology**

\* Gastrointestinal infection in infants with the following organism :

\* E coli, Shigella dysenteriae, Streptococcus pneumoniae

**Hematological findings in a case of microangiopathic hemolytic anemia :**

\* Presence of schistocytes (fragmented red cells). This is the hallmark of microangiopathic hemolytic anemia. o Neutrophil leukocytosis.

\* Thrombocytopenia.

\* Hemoglobinuria is mild to moderate with hemosiderinuria.

\* Blood urea and serum creatinine levels are high.

\* PT and APTT normal.

\* Elevated serum LDH

**98. All are features of haemolytic uremic syndrome, except-**

a) Hyperkalemia

b) Anaemia

c) Renal microthrombi

d) Neuro psychiatric disturbances

Correct Answer - D

Ans. is 'd' i.e., neuropsychiatric manifestations

*Hyperkalemia is seen in hemolytic uremic syndrome as a result of renal failure.*

**ABOUT NEUROPSYCHIATRIC MANIFESTATIONS**

\* *Neurological manifestations* are used to distinguish between Hemolytic uremic syndrome and Thrombotic Thrombocytopenic Purpura.

\* H.U.S. is distinguished from T.T.P by the absence of neurological symptoms and the prominence of acute renal failure.

\* Recent studies, however have tended to blur these clinical distinctions. Many adult patients with "T. T.P. lack one or more of the five criteria and patients with "HUS" have fever and neurological dysfunction.

**99. In DIC, following are seen except -**

a) Fibrinogen decreased

b) Thrombocytopenia

c) Normal APTT

d) PT elevation

Correct Answer - C  
Ans. is 'c' i.e., Normal APTT

## 100. Shelf life of blood with CPDA -

a) 2 weeks

b) 3 weeks

c) 5 weeks

d) 8 weeks

Correct Answer - C

Ans. is 'c' i.e., 5 weeks

\* Once blood is removed from the donor, it starts a sequences of in vitro changes that change its physiological properties.

\* Ensuring the blood and its products transfusion safe, their storage is a must.

\* The main aim is to minimize damage to store blood.

\* Addition of some additive solutions increases the viability of blood, particularly RBCs:

Additive	Shelf life of RBC
Acid-citrate-dextrose (ACD) days	21
Citrate phosphate dextrose (CPD) days	21
<i>Citrate phosphate dextrose-adenine (CPD-A)</i> 35 days	
Saline-adenine-Glucose-Mannitol (SAG-M) 42 days	

## 101. Not true regarding fresh frozen plasma ?

a) Supplies major coagulation factors

b) ABO match not required

c) Should be used in replacement of factors in DIC/trauma

d) To be used within 30 minutes of having trauma

Correct Answer - D

Ans. is 'd' i.e., To be used within 30 minutes of having trauma

Fresh frozen plasma contains components of *the coagulation, fibrinolytic and complement systems and other proteins.*

FFP can be *given without blood type-matched* although agglutination reactions are possible, though very rare. o There is no mention of time period within which FFP should be given after trauma.

The risks of FFP include disease transmission, anaphylactoid reactions, alloimmunization, and excessive intravascular volume, as well as transfusion related acute lung injury and an increase in infections

## 102. Starry sky appearance is seen in -

a) Burkitts lymphoma

b) CIL

c) Diffuse large B cell lymphoma

d) ALCL

Correct Answer - A

Ans. is 'a' i.e., Burkitts lymphoma

### **Burkitts lymphoma**

- It includes (1) African (endemic) Burkitt lymphoma, (2) sporadic (nonendemic) Burkitt lymphoma, and (3) a subset of aggressive lymphomas occurring in individuals infected with HIV.
- The involved tissues are effaced by a diffuse infiltrate of intermediate-sized lymphoid cells containing round or oval nuclei with coarse chromatin, several nucleoli, and a moderate amount of faintly basophilic or amphophilic cytoplasm .
- The nuclear size approximates that of benign macrophages within the tumor.
- A high mitotic index is typical, as is apoptotic tumor cell death, accounting for the presence of numerous tissue macrophages with ingested nuclear debris.
- These benign macrophages are diffusely distributed among the tumor cells and have abundant clear cytoplasm, creating a characteristic "starry sky" pattern.
- All forms of Burkitt lymphoma are associated with translocations of the c-MYC gene on chromosome 8. The partner in the translocation is usually the IgH locus (t(8;14)) but may also be the ic (t(2;8)) or y (t(8;22)) light chain locus.
- Essentially all endemic tumors are latently infected with EBV.

---

### 103. B ALL is due to -

a) T cells

b) Immature B cells

c) Immature T cells

d) Both T & B cells

Correct Answer - B

Ans. is 'b' i.e., Immature B cells

In B ALL, precursor cells are arrested at stages preceding surface expression of Ig. The leukemic blasts almost always express the pan B-cell molecules CD 19 and CD 10.

In very early pre-B cell ALL; CD 19 is the only B cell-specific marker present.

Early pre-B ALL is distinguished from late pre-B ALL by the absence of cytoplasmic IgM heavy chain in the former.

## 104. What is the chromosomal translocation in AML M3 -

a) T (18,21)

b) T (15,17)

c) T (8, 21)

d) T (9,11)

Correct Answer - B

Ans. is 'b' i.e., T(15,17)

### **Class Chromosomal abnormalities**

**M<sub>2</sub>** t (8 : 21)

**M<sub>3</sub>** t (15: 17)

**M<sub>4</sub>** inv (16)

## 105. Russell bodies are found in -

a) Multiple Myeloma

b) Gonadal tumor

c) Parkinsonism

d) Intracranial neoplasms

Correct Answer - A

Ans. is 'a' i.e., Multiple Myeloma

Plasma cell tumours are characterized by dysregulated synthesis and secretion of immunoglobulin.

This sometimes leads to intracellular accumulation of intact or partially degraded immunoglobulins. This produces certain variants of plasma cells which are :

Flame cells Characterized by presence of fiery red cytoplasm.

MOTT cells Characterized by presence of multiple blue grape like cytoplasmic droplets.

Besides these there are cells containing variety of other inclusions including.

Fibrils

Russel bodies (cytoplasmic)

Crystalline rods.

Dutcher bodies (nuclear)

## 106. CD marker of histiocytosis is -

a) CD1A

b) CD 1B

c) CD1C

d) *CD1D*

Correct Answer - A

Ans. is 'a' i.e., CD1A

o CHIA is a T cell surface antigen important in dendritic cell presentation of glycolipids and lipopeptide antigens. o It is used to diagnose Langerhans cell histiocytosis.

## 107. Dohle bodies -

a) Dilated Endoplasmic Reticulum in Neutrophils

b) Mitochondria

c) Golgi apparatus

d) Lysosomes

Correct Answer - A

Ans. is 'a' i.e., Dilated endoplasmic reticulum in neutrophils

Dohle bodies are light blue gray, basophilic inclusions in the peripheral cytoplasm of neutrophils. They are thought to be remnants of the *rough endoplasmic reticulum* containing RNA.

**108. Basophilic leucocytosis occurs in -**

a) AML

b) ALL

c) CML

d) CLL

Correct Answer - C  
Ans. is 'c' i.e., CML

## 109. Nutmeg liver is seen in -

- a) Right sided heart failure
- b) Left sided heart failure
- c) Increased pulmonary pressure
- d) Decreased pulmonary pressure

Correct Answer - A

Ans. is 'a' i.e., Right sided heart failure

o The combination of hypoperfusion and retrograde congestion (Chronic passive congestion) acts synergistically to generate centrilobular hemorrhagic necrosis. The liver takes on a variegated mottled appearance reflecting hemorrhage and necrosis in the centrilobular regions, known as nutmeg liver.

o Chronic passive congestion is seen in RHF.

## 110. Histopathology of chronic hepatitis -

a) Ball oning

b) Councilman bodies

c) Bridging necrosis

d) All

Correct Answer - C

Ans. is 'c' i.e., Bridging necrosis

. *Portal tracts show severe chronic inflammation with inflammatory cells extending into the liver lobules disrupting the limiting plate of hepatocytes.*

- *Piecemeal necrosis*

- *Portal fibrosis*

. *Bridging necrosis*

- *Interface hepatitis*

## 111. Councilman bodies are seen ill-

a) Alcoholic cirrhosis

b) Wilson's disease

c) Acute viral hepatitis

d) Autoimmune hepatitis

Correct Answer - C

Ans. is 'c' i.e., Acute viral hepatitis

### **Pathological features of acute viral hepatitis**

#### **1) Panlobular infiltration of mononuclear cells**

This mononuclear infiltration primarily consists of → *Lymphocytes, Plasma cells, Eosinophils*

Inflammatory infiltrate may spill over into the adjacent parenchyma to cause necrosis of periportal hepatocytes 4 **interface hepatitis**, can occur in both acute and chronic hepatitis.

#### **2) Hepatic cell damage - It consists of**

**a) Hepatic cell necrosis** - The necrosis is usually *focal* or *centirzonal*.

Sometimes severe necrosis such as **bridging** or **subacute** hepatic necrosis occurs.

**b) Ballooning of cells** - Damaged cells show diffuse swelling known as **ballooning degeneration**.

**c) Acidophilic degeneration of hepatocytes** - In this single necrotic liver cell has coagulated pink cytoplasm and it shows pyknosis or karyolysis. These are called councilman bodies.

**112. Pathological manifestation of chronic alcoholism include all of the following except -**

a) Piecemeal necrosis

b) Ballooning degeneration

c) Microvesicular fatty changes

d) Central hyaline sclerosis

Correct Answer - A

Ans. is 'a' i.e., Piecemeal necrosis

Steatosis (fatty liver)

- Microvesicular fatty change
- Later changes to macrovesicular fatty change

Alcoholic hepatitis

- Hepatocellular necrosis
- Ballooning degeneration
- Mallory bodies
- Neutrophilic infiltration
- Perivenular and perisinusoidal fibrosis → central hyaline

Alcoholic cirrhosis

- Nodularity
- Fibrosis

### 113. Wilson's disease is characterized by -

a) Increased serum ceruloplasmin

b) Decreased copper excretion in urine

c) Increased copper in liver

d) Autosomal dominant

Correct Answer - C

Ans. is 'c' i.e., Increased copper in liver

#### Diagnosis of Wilson disease

- *The gold standard for diagnosis is liver biopsy with quantitative copper assay --> concentration of copper in a liver biopsy sample > 200 mg/g dry weight.*  
Other tests are ?
- Serum ceruloplasmin level --> low o Urine  
copper excretion --> increased
- KF rings o DNA  
Haplotype analysis.

## 114. Klatskin tumor is -

a) Nodular type of cholangiocarcinoma

b) Fibrolamellar hepatocellular carcinoma

c) Gall bladder carcinoma

d) Hepatocellular carcinoma

Correct Answer - A

Ans. is 'a' i.e., Nodular type of cholangiocarcinoma

o According to their localization, cholangiocarcinomas are classified into

1. *Intrahepatic (10-20%)*

2. *Extrahepatic (80-90%)*

o The *extrahepatic forms* include perihilar tumors known as *Klatskin tumors*, which are located at the junction of the right and left hepatic ducts forming the common hepatic duct, and distal duct tumors.

o A subgroup of distal tumors arise in the immediate vicinity of ampulla of vater. Tumor of these region also include adenocarcinoma of duodenal mucosa and pancreatic carcinoma and are collectively referred to as *periampullary carcinomas*.

**115. Gall stones in hemolytic anaemia are -**

a) Pigment

b) Mixed

c) Cholesterol

d) Any type

Correct Answer - A  
Ans. is 'a' i.e., Pigment

## 116. Collapse of lung is called -

a) Emphysema

b) Bronchiactasis

c) Atelectasis

d) Bronchitis

Correct Answer - C

Ans. is 'c' i.e., Atelectasis

### **Atelectasis (collapse)**

#### **Atelectasis refers to:-**

- .. Incomplete expansion of lungs → Neonatal atelectasis. or
- ?. Collapse of previously inflated lung → Acquired atelectasis.
- This results in areas of relatively airless pulmonary parenchyma.
- Acquired atelectasis may be divided into

#### **Resorption (obstruction) atelectasis**

- It is consequence of complete obstruction of an airway.
- With time trapped oxygen in the affected alveoli is resorbed and collapse occurs.
- Resorption atelectasis is caused principally by obstruction due to excessive secretions (mucus plug) or exudates within small bronchioles as seen in *Bronchial asthma, chronic bronchitis, Bronchiactasis* and *foreign body aspiration*.

#### **Compression atelectasis**

- Collapse of lung occurs due to external pressure on lung.
- It is seen most commonly in patients with cardiac failure who develop pleural effusion and in patients with neoplastic pleural effusion.

#### **Contraction atelectasis**

- The collapse is due to contracture in the lung because of fibroctic

changes.

- Except for contraction atelectasis, atelectasis is a reversible disorder, i.e. collapsed lung parenchyma can be re-expanded.

## 117. Curshmann's crystals are seen in ?

a) Bronchial asthma

b) Bronchiectasis

c) Chronic bronchitis

d) Wegners granulomatosis

Correct Answer - A

Ans. is 'a' i.e., Bronchial asthma

Pathology of Asthma

*Gross ?*

- \* Lungs are overdistended because of overinflation and there may be small area of atelectasis.
- \* The most striking macroscopic finding is *occlusion* of bronchi and bronchioles by *thick tenacious mucus plugs*.

*Histology ?*

- \* Characterized by presence of numerous eosinophils and neutrophils.

*Curschntan spiral* - Whorls of shed epithelium in mucus plugs.

*Charcot -leyden crystals* - Collection of crystalloids made up of eosinophilic membrane protein.

*The other characteristic histological finding of Asthma is collectively called Airway remodelling, it includes ?*

- \* Thickening of the basement membrane of the bronchial epithelium.
- \* Edema and an inflammatory infiltrate in the bronchial walls with a prominence of eosinophils and mast cells.
- \* An increase in the size of submucosal glands.
- \* Hypertrophy of bronchial wall muscle.

The "*airway remodelling*" contributes to airflow obstruction.

---

## 118. Creola bodies are seen in -

a) Bronchial asthma

b) Chronic bronchitis

c) Emphysema

d) Bronchiectatsis

Correct Answer - A

Ans. is 'a' i.e., Bronchial asthma

Creola bodies are a histopathologic finding indicative of bronchial asthma.

Found in a patient's sputum, they are ciliated columnar cells sloughed from the bronchial mucosa of a patient with asthma.

Other common findings in the sputum of asthma patients include *Charcot-Leyden crystals*, *Curschntann's Spirals*, and *eosinophils*.

## 119. Cystic fibrosis is associated with all except ?

a) Infertility

b) Azoospermia

c) Nasal polyps

d) Renal failure

Correct Answer - D

Ans. is d i.e., Renal failure

Thick viscid plugs of mucus may also be found in the small intestine of infants. Sometimes these cause small-bowel obstruction, known as **meconium ileus**.

Chronic sinopulmonary disease manifested by : Persistent colonization/infection with typical **cystic fibrosis** pathogens, including Staphylococcus aureus, non typeable Hemophilus influenzae, mucoid and nonmucoid Pseudomonas aeruginosa, Burkholderia cepacia; Chronic cough and sputum production, nasal polyps.

**Azoospermia and infertility** are found in 95% of the males who survive to adulthood; congenital bilateral absence of the vas deferens is a frequent finding in these patients.

## 120. Anthracosis is due to inhalation of-

a) Coal dust

b) Asbestos

c) Silica dust

d) Beryllium dust

Correct Answer - A

**Ans. is 'a' i.e., Coal dust**

### **Coal worker's pneumoconiosis (Black lung)**

Black lung disease, also known as coal worker's pneumoconiosis (CWP), is caused by long exposure to coal dust. o Coal worker's pneumoconiosis has following spectrum.

#### **1. Asymptomatic anthracosis**

\* Inhaled carbon pigment is engulfed by alveolar or interstitial macrophages, which then accumulate in the connective tissue along the lymphatics.

\* Patient is completely asymptomatic.

#### **2. Simple coal worker's pneumoconiosis**

\* Characterized by coal macules (composed of carbon laden macrophages) and coal nodules (carbon laden macrophages + collagen).

\* The upper lobes and upper zones of the lower lobes are involved.

\* They are located primarily adjacent to respiratory bronchioles, the site of initial dust accumulation.

\* Centriacinar emphysema may develop.

#### **3. Complicated coal worker's pneumoconiosis**

\* Requires many years to develop.

\* Characterized by intensely blackened multiple scar larger than 2 cms. o This is also known as Progressive massive fibrosis.

**Remember**

\* In CWP and silicosis upper zones of lung are involved initially. o In asbestosis lower lung fields are involved initially.

## 121. True Statement about silicosis -

a) Produces pleural plaque

b) Associated with tuberculosis

c) Lower lobe infiltration

d) All

Correct Answer - B

**Ans. is 'b' i.e., Associated with tuberculosis**

### **Silicosis**

3 Silicosis is a lung disease caused by inhalation of crystalline silicon dioxide (silica).

\* Currently, it is the most prevalent occupational disease in the world.

\* Silicosis is a slowly progressive disease, usually presenting after decades of exposure as slowly progressive nodular fibrosing pneumoconiosis.

\* Silica occurs in both crystalline and amorphous forms but crystalline forms are much more fibrogenic. The crystalline form are quartz, cristobalite.

\* Silicosis is characterized in its early stages by nodules in the upper zones of the lung. As the disease progresses these nodules may coalesce into hard collagenous scars.

\* Fibrotic lesions occur in the hilar lymph node and pleura.

Sometimes thin sheets of calcification occur in the lymph nodes and are seen radiographically as egg shell calcification i.e. (calcium surrounding a zone lacking calcification).

\* If the disease continues to progress, expansion and coalescence of lesions produce progressive massive fibrosis. o Histologically the lesions of silicosis consists of concentric layers of hyalinized

collagen surrounded by a dense capsule of more condensed collagen.

\* Examination of the nodules by polarized microscopy reveals the birefringent silica particles.

\* Silicosis is associated with an increased susceptibility to T.B. It is postulated that silicosis results in depression of cell mediated immunity and the crystalline silica may inhibit the ability of pulmonary macrophages to kill phagocytosed mycobacteria.

\* Nodules of silicotuberculosis often display a central zone of caseation.

## 122. Pulmonary infarction occurs with all except -

- a) Saddle embolus at bifurcation
- b) Blockage of 2nd and 3rd gen end arteries
- c) Arterioles are blocked
- d) None

Correct Answer - D

Ans. is 'd' i.e., None

The morphologic consequences of embolic occlusion of the pulmonary arteries depend on the size of the embolic mass and the general state of the circulation.

Large emboli may impact in the main pulmonary artery or its major branches or lodge at the bifurcation as a saddle embolus. Sudden death often ensues, owing largely to the blockage of blood flow through the lungs. Death may also be caused by acute failure of the right side of the heart (acute cor pulmonale).

Smaller emboli can travel out into the more peripheral vessels, where they may cause infarction. In patients with adequate cardiovascular function, the bronchial arterial supply can often sustain the lung parenchyma despite obstruction to the pulmonary arterial system. Under these circumstances, hemorrhages may occur, but there is no infarction of the underlying lung parenchyma. Only about 10% of emboli actually cause infarction. Although the underlying pulmonary architecture may be obscured by the suffusion of blood, hemorrhages are distinguished by the preservation of the pulmonary alveolar architecture; in such cases, resorption of the blood permits reconstitution of the preexisting architecture.

## 123. In the stage of Grey hepatization -

a) WBC's fill the alveoli

b) RBC's fill the alveoli

c) Organisms fill the alveoli

d) Accumulation of fibrin

Correct Answer - D

Ans. is 'd' i.e., Accumulation of fibrin

### **Pathological changes of bacterial pneumonia**

#### **A.Lobar pneumonia**

- Large confluent area of the lung or entire lobes are consolidated.
- The lower lobes are affected most commonly.
- There are four stages of the inflammatory response (Laennec's stages) ?  
Stage of congestion (initial phase)
  - The affected lobe is enlarged, heavy, dark red and congested.
  - Cut surface exudes blood-stained frothy fluid.
  - There is dilatation and congestion of alveolar capillaries.
  - There are few neutrophils and numerous bacteria in the alveolar fluid.Stage of red hepatization (early consolidation)
  - The term hepatization refers to liver-like consistency of the affected lobe on cut section. o The affected lobe is red and firm.
  - The edema fluid of preceding stage is replaced by strands of fibrin.
  - There is marked cellular exudate of neutrophils with extravasation of red cells.Stage of gray hepatization (late consolidation)
  - The affected lobe is grayish brown, firm and dry.
  - The fibrin strand are dense and more numerous.

- There is progressive disintegration of red cells and neutrophils.
- The macrophages begin to appear in the exudate.
- The organisms are less numerous and appear as degenerated forms.

### **Resolution**

- The previously solid and fibrinous constituent is liquefied by enzymatic action.
- Granular and fragmented strands of fibrin in the alveolar spaces are seen due to progressive enzymatic digestion.
- There is progressive removal of fluid content as well as cellular exudate from the air spaces, resulting in restoration of normal lung parenchyma with aeration.

### **B. Bronchopneumonia**

- Patchy areas of red or grey consolidation, more often multilobar and frequently bilateral and basal (lower zones) because of tendency of secretions to gravitate into lower lobes.
- There is suppurative exudate, consisting chiefly neutrophils, filling bronchi, bronchioles and adjacent alveolar spaces.
- Alveolar septa thicken due to congested capillaries and leucocytic infiltration.

## 124. Marker of small cell cancer of lung is -

a) Chromogranin

b) Cytokeratin

c) Desmin

d) Vimentin

Correct Answer - A

Ans. is 'a' i.e., Chromogranin

Small cell carcinoma contains.

- Polypeptide hormone e.g. PTH like peptide.
- Neuroendocrine markers -4 chromogranin, Synaptophysin, Leu7

## 125. Primary pleural tumor is

a) Mesothelioma

b) Myxoma

c) Lipoma

d) All

Correct Answer - A

Ans. is 'a' i.e., Mesothelioma

Pleural tumors

\* The pleura may be involved by primary or secondary tumors.

Primary tumors

\* *Benign* --> Solitary fibrous tumor (benign fibrous mesothelioma or benign mesothelioma or *pleural fibroma*).

\* *Malignant* —> Malignant mesothelioma.

Secondary tumors

\* More common than primary tumors.

\* Most common primary sites are lung and breast.

## 126. Bronchogenic sequestration is seen in which lobe -

a) Left lower lobe

b) Right upper lobe

c) Left middle lobe

d) Left upper lobe

Correct Answer - A

Ans. is 'a' i.e., Left lower lobe

*Bronchogenic sequestration* refers to the presence of a discrete mass of lung tissue without any normal connection to the airway system.

Intralobar sequestrations are found most frequently in the *posterior basal segment of the left lower lobe*.

Blood supply to the sequestered area arises not from the pulmonary arteries but from the *aorta or its branches*.

Extralobar sequestrations are external to the lung. Found most commonly in infants as abnormal mass lesions, they may be associated with other congenital anomalies.

*Intralobar sequestrations* are found within the lung substance and are usually associated with recurrent localized infection or bronchiectasis.

## 127. Most common mediastinal tumor is?

a) Neurogenic tumor

b) Pericardial cyst

c) Hernia

d) Teratoma

Correct Answer - A

Ans. is 'a' i.e., Neurogenic tumors

*o Overall most common mediastinal masses are neurogenic tumors (20%) followed by thymomas (19%), primary cysts (18%), lymphomas (13%) and germ cell tumors (10%).*

*o Most of the mediastinal masses are located in the anterior mediastinum followed by the posterior (25%) and middle (19%).*

## 128. Podocytes are seen in -

- a) Bowman's capsule
- b) Proximal convoluted tubule
- c) Distal convoluted tubule
- d) Collecting tubule of the kidney

Correct Answer - A

Ans. is 'a' i.e., Bowman's capsule

The Bowman's capsule (capsula glomeruli/glomerular capsule) is a cup-like sac at the beginning of tubular component of a nephron.

A glomerulus is enclosed in the sac (Bowman's capsule).

Fluids from blood in the glomerulus are collected in Bowman's capsule (i.e. glomerular filtrate) and further processed along the nephron to form urine.

Outside the Bowman's capsule there are two poles.

Vascular pole → The side with afferent and efferent arterioles.

Urinary pole → The side with proximal convoluted tubule.

Inside the Bowman's capsule, the layers are as follows, from inside to outside ?

Thin layer of fenestrated endothelium

Glomerular basement membrane

Part of the glomerulus

Visceral epithelium (Podocytes)

Parietal epithelium

## 129. Most common cause of nephritic syndrome in adults?

a) Membranoproliferative glomerulonephritis

b) FSGN

c) Membranous glomerulonephritis

d) None

Correct Answer - D

Ans. is None

Most common cause of *Nephritic syndrome* is rapidly progressive glomerulonephritis (Poststreptococcal and nonstreptococcal glomerulonephritis).

Membranous glomerulonephritis is the most common cause of nephrotic syndrome (not nephritic syndrome) in adults.

Minimal change disease is the most common cause of nephrotic syndrome in children.

### Causes of Acute Nephritic Syndrome

Primary Glomerulonephritis		Systemic Disease	
1. Acute GN	1.	1. SLE	
Post-streptococcal	2.	2. Polyarteritis nodosa	
Non-streptococcal	3.	3. Wegener's granulomatosis	
2. Rapidly progressive GN	4.	4. Henoch-Schonlein purpura	
3. Membranoproliferative GN		5. Cryoglobulinaemia	
4. Focal GN			
5. IgA nephropathy			

3. IgA nephropathy

### 130. The pathogenesis of acute proliferative glomerulonephritis -

a) Cytotoxic T-cell mediated

b) Immune complex mediated

c) Antibody mediated

d) Cell-mediated (Typer IV)

Correct Answer - B

Ans. is 'b' i.e., Immune complex mediated

\* Postinfectious acute proliferative glomerulonephritis is due to immune-complex mediated (Type III) hypersensitivity.

### 131. Crescents are derived from -

a) Epithelial cells + fibrin + macrophage

b) Mesangium + fibrin + macrophage

c) Tubule + mesangium + fibrin

d) Mesangium + fibrin

Correct Answer - A

Ans. is 'a' i.e., Epithelial cells + fibrin+macrophage

#### **Renal features in RPGN**

Crescent formation - crescents are formed by ?

\* Cells → Parietal epithelial cells + WBCs (monocytes and macrophages)

\* Fibrin strands → are prominent between the cellular layers in the crescents.

- Rupture of GBM

- Subepithelial deposits in type II RPGN

- Linear deposits in the GBM in type I RPGN.

## 132. Most common cause of nephrotic syndrome in adults?

a) Membranous glomerulonephritis

b) Minimal change disease

c) Acute GN

d) Focal GN

Correct Answer - A

Ans. is 'a' i.e., Membranous glomerulonephritis

Most common cause of Nephrotic syndrome

- In adults → membranous glomerulonephritis
- In children → minimal change disease (lipoid nephrosis) Causes of Nephrotic syndrome

I. Primary Glomerulonephritis

V Malignancy

1. Minimal change disease (most common in children)

1. Carcinomas

2. Membranous GN (most common in adults)

2. Myeloma

3. Membranoproliferative GN

3. Hodgkin's disease

4. Focal segmental glomerulosclerosis

VI Pregnancy

5. Focal GN

Toxaemia of pregnancy

6. IgA nephropathy

VII Circulatory Disturbances

II Systemic diseases

1. Renal vein thrombosis

1. Diabetes mellitus

2. Constrictive pericarditis

2. Amyloidosis

3. SLE

#### M. Systemic Infections

1. Viral infections (HBV, HCV, HIV)

2. Bacterial infections (bacterial endocarditis, syphilis, leprosy)

3. Protozoa and parasites (P. falciparum malaria, filariasis)

#### IV. Hypersensitivity Reactions

1. Drugs (heavy metal compounds like gold and mercury, other drugs like penicillamine, trimethadione and tolbutamide, heroin addiction)

2. Bee stings, snake bite, poison ivy

#### VIII. Hereditary diseases

1. Alport's disease

2. Fabry's disease

3. Nail-patella syndrome

### 133. Frequency of renal involvement in HSP ?

a) 20-40%

b) >80%

c) 40-60%

d) 10%

Correct Answer - C

**Ans. is 'c' i.e., 40-60%**

The reported incidence of renal involvement in HSP varies considerably between different studies.

This may be because of the different criteria used to describe the involvement & the variability of the length used to follow up.

In different studies incidence of pediatric renal involvement *in* HSP was between 20-56% and in adults 50-78%

**134. According to WHO, membranous glomerulonephritis seen in SLE, is -**

a) Class II

b) Class III

c) Class IV

d) Class V

Correct Answer - D

Ans. is 'd' i.e., Class V

- There are several versions of WHO classification of lupus nephritis ?
  - 1) Minimal or no detectable abnormalities (class 1)
  - 2) Mesangial lupus glomerulonephritis (class II)
  - 3) Focal proliferative glomerulonephritis (class III)
  - 4) Diffuse proliferative glomerulonephritis (class IV)
  - 5) Membranous glomerulonephritis (class V)

## 135. Subepithelial deposits in kidney are seen in-

a) MPGN-1

b) GPS

c) PSGN

d) All

Correct Answer - C

Ans. is 'c' i.e., PSGN

Glomerular deposits : (i) *Subepithelial*:

o Acute GN (like PSGN)

o Membranous GN

o Heyman GN

o RPGN

(ii) *Sub endothelial* :

(iii) *Basement membrane* :

(iv) *Mesangium* :

• MPGN (Type- I)

• SLE

o Acute ON (H' 1583)

o MPGN (Type II)

o Good pasture syndrome

o IgA nephropathy, HSP

Remember

o *Anionic antigens form subendothelial deposits* o *Cationic antigens form subepithelial deposits* o *Neutral antigens form mesangial deposits*

### 136. Not true about Alport's syndrome -

a) X-linked

b) Autosomal dominant

c) Nerve deafness

d) Glomerulonephritis

Correct Answer - B

Ans. is 'b' i.e., Autosomal dominant

o Autosomal dominant form also exist, but it is very rare. Thus, among the given options, it is the best answer. o Other three options are classical features of Alport's syndrome (see previous explanations).

**137. Renal cell carcinoma is related to gene located on chromosome -**

a) 3

b) X

c) 22

d) 20

Correct Answer - A

Ans. is 'a' i.e., 3

o Clear cell carcinoma is the most common renal cell carcinoma and is associated with *3p deletion*.

### 138. Oncocytic carcinoma arises from -

a) Perivascular

b) Glomerulus

c) Loop of henle

d) Collecting duct

Correct Answer - D

Ans. is 'd' i.e., Collecting ducts

Oncocytic or Chromophobe renal carcinoma represents 5% of renal cell cancers.

It is composed of cells with prominent cell membranes and pale eosinophilic cytoplasm, usually with a halo around the nucleus.

They are, like the benign oncocytoma, thought to grow from intercalated cells of collecting ducts. o They have an excellent prognosis compared with that of the clear cell and papillary cancers.

**139. Histopathology showing large cells with plant like appearance with perinuclear halo is seen in which type of renal cell carcinoma ?**

a) Onchocytoma

b) Granular cell carcinoma

c) Angiosarcoma

d) Chromophobic

Correct Answer - D

Ans. is 'd' i.e., Chromophobic

Histopathological findings of perinuclear halo and plant cell appearance are seen in **chromophobe cell carcinoma** of RCC. Electron microscopic finding consisting of numerous 150-300 nm microvesicles is the single most distinctive and defining feature of chromophobe cell ca.

## 140. Transitional cell carcinoma bladder caused by-

a) Schistosomiasis

b) Ascariasis

c) Malaria

d) None

Correct Answer - A

Ans. is 'a' i.e., Schistosomiasis

- Transitional cell carcinoma (TCC). This is the commonest cancer of the bladder.
- More than 90% of bladder tumors arise from transitional epithelial (urothelium) lining of the bladder in continuity with the epithelial lining of the renal pelvis, ureters, and the major part of the urethra.
- **etiology:**
- Industrial occupations: Workers in industries that produce aniline dyes, rubber, plastic, textiles, and cable have a high incidence of bladder cancer.
- Schistosomiasis: There is an increased risk of bladder cancer, particularly squamous cell carcinoma, in patients having bilharzial infestation (*Schistosoma haematobium*) of the bladder.
- Dietary factors: Certain carcinogenic metabolites of tryptophan are excreted in the urine of patients with bladder cancer.
- Local lesions: Several local lesions in the bladder predispose to the development of bladder cancer. These include ectopia vesicae (atrophied bladder), vesical diverticulum, leukoplakia of the bladder mucosa and urinary diversion in the defunctionalized bladder.
- Smoking: Tobacco smoking is associated with a 2 to 3 fold increased risk of developing bladder cancer, probably due to

increased urinary excretion of carcinogenic substances.

- Drugs: Immunosuppressive therapy with cyclophosphamide and patients having analgesic-abuse (phenacetin-) nephropathy have a high risk of developing bladder cancer.

## 141. All are germ cell tumors except ?

a) Seminoma

b) Leydig cell tumor

c) Embryonal carcinoma

d) Endodermal sinus

Correct Answer - B

**Ans. is 'b' i.e., Leydig cell tumor**

**Testicular tumor**

\* Testicular tumors are divided into two major categories : ?

Germ cell tumors

\* *Seminoma* \* Embryonal carcinoma \* *Yolk sac (endodermal sinus) tumor*

- Spermatocytic seminoma
- Choriocarcinoma
- Teratoma

Sex cord tumors

- Leydig cells tumor
- Sertoli cell tumor

\* Approximately 95% of testicular tumors are germ cell tumors.

**142. Which of the following germ cell tumor is malignant ?**

a) Leydig cell tumor

b) Sertoli cell tumor

c) Seminoma

d) Dermoid cyst

Correct Answer - C

**Ans. is 'c' i.e., Seminoma**

o Among the given options only options c & d are germ cell tumors. **Seminoma is malignant** while dermoid cyst is benign.

**Germ cell tumors**

o **Malignant** - Germinoma (seminoma, dysgerminoma), embryonal carcinoma, endodermal sinus tumor (yolk sac tumor), choriocarcinoma, immature teratoma.

- **Benign** - Mature teratoma, dermoid cyst.

**143. Commonest infantile testicular tumour is ?**

a) Seminoma

b) Teratoma

c) Yolk sac tumor

d) Dysgerminoma

Correct Answer - C

Ans. is 'c' i.e., Yolk sac tumor

o Most common tumor of testis Seminoma.

o Most common tumor of testis in childhood ---> yolk sac tumor (endodermal sinus tumor or infantile embryonal carcinoma).

## 144. Tennis racket cells is seen in -

a) Sarcoma botryoides

b) Vaginal adenocarcinoma

c) Leiomyoma uterus

d) Seminoma

Correct Answer - A

Ans. is 'a' i.e., Sarcoma botryoids

• Tumor cells of sarcoma botryoids are small and have oval nuclei, with small protrusions of cytoplasm from one end, so they resemble a tennis racket.

## 145. Which is not a risk factor of endometrial carcinoma -

a) Obesity

b) Smoking

c) Infertility

d) Tamoxifen

Correct Answer - B

**Ans. is 'b' i.e., Smoking**

**Endometrial carcinoma**

- Endometrial carcinoma is the most common invasive cancer of the female genital tract and accounts for 7% of all invasive cancer in women.
- The peak incidence is in the 55- to 65-year-old woman.
- Clinicopathological studies & molecular analysis support its classification into two major broad categories.

**Type-I Carcinoma**

- Most common type.
- Majority are well differentiated & mimic proliferative endometrial glands.
- They are associated with- obesity, diabetes, hypertension, infertility and unopposed estrogen stimulation. Tamoxifen also increases the risk of endometrial cancer.
- Endometrial hyperplasia is a precursor to endometroid carcinoma.
- Mutation in PTEN tumor suppressor gene have been seen in 30-80% of endometroid carcinoma & 20% patients with endometrial hyperplasia.
- Additional molecular changes that are common are microsatellite instability & mutations in KRAS & beta catenin oncogenes.

### **Type-H Carcinoma**

- These occur in women a decade later than type I carcinoma.
- These usually arise in setting of endometrial atrophy.
- They are poorly differentiated. The most common subtype is serous carcinoma, clear cell type & malignant mixed mullerian tumor.
- The most frequent alteration described is mutation in p53 tumor suppressor gene.

## 146. Rokitanski protruberences are seen in -

a) Mucinous carcinoma

b) Teratoma

c) Epidermal cystoids adenoma

d) Papillary carcinoma

Correct Answer - B

Ans. is 'b' i.e., Teratoma

### Teratoma

o Teratomas are divided into three categories:

(1) Mature (benign):

Most benign teratomas are cystic and are known as dermoid cysts.

These neoplasms are presumably derived from the ectodermal differentiation of totipotential cells.

They are bilateral in 10% to 15% of cases.

Characteristically, they are unilocular cysts containing hair and cheesy sebaceous material. On section, they reveal a thin wall lined by an opaque, gray-white, wrinkled, apparent epidermis.

Generally, in one area of the cyst wall, a solid prominence is seen known as *Rokitansky's protuberance* where tissue elements such as tooth, bone, cartilage & various other odd tissues are present.

On histologic examination, the cyst wall is composed of stratified squamous epithelium with underlying sebaceous glands, hair shafts, and other skin adnexal structures. In most cases, *structures from other germ layers can be identified, such as cartilage, bone, thyroid tissue, and other organoid formations.*

Dermoid cysts are sometimes incorporated within the wall of a mucinous cystadenoma.

About 1% of the dermoids undergo malignant transformation of any one of the component elements ( but most commonly, squamous cell carcinoma).

### (2) Monodermal or Specialized Teratomas

The rare group of tumors, the most common of which are *struma ovarii* and *carcinoid*.

They are always unilateral, although a contralateral teratoma may be present.

*Struma ovarii* is composed entirely of mature thyroid tissue. Interestingly, these thyroidal neoplasms may hyperfunction, causing hyperthyroidism.

The ovarian carcinoid, which presumably arises from intestinal epithelium in a teratoma, might in fact be functioning, particularly in large tumors, producing 5-hydroxytryptamine and the carcinoid syndrome.

### (3) Immature Malignant Teratomas

These are rare tumors that differ from benign teratomas in that the *component tissue resembles that observed in the fetus or embryo rather than in the adult*.

The tumor is found chiefly in prepubertal adolescents and young women.

These grow rapidly and frequently penetrate the capsule with local spread or metastases.

On microscopy, there are varying amounts of immature tissue differentiating toward cartilage, glands, bone, muscle, nerve, and others.

An important risk for subsequent extraovarian spread is the histologic grade of tumor, which is based on the proportion of tissue containing immature neuroepithelium.

## 147. Proliferating breast mass is -

a) Duct ectasia

b) Fibroadenoma

c) Adenosis

d) Papilloma

Correct Answer - D

Ans. is 'd' i.e., Papilloma

Examples include atypical ductal hyperplasia, atypical lobular hyperplasia, and intraductal papillomas.

**148. Granulomatous mastitis is caused by all except -**

a) TB

b) Fungus

c) Staphylococcus

d) Antibodies to milk antigens

Correct Answer - C

Ans. is 'c' i.e., Staphylococcus

Granulomatous mastitis

- \* Granulomatous inflammation is present in less than 1% of all breast biopsy specimens.
- \* The causes include systemic granulomatous disease (e.g., Wegener granulomatosis or sarcoidosis) that occasionally involve the breast, and granulomatous infections caused by *mycobacteria* or *fungi*.
- \* Infections of this type are most common in immunocompromised patients or adjacent to foreign objects such as breast prostheses or nipple piercings.
- \* *Granulomatous lobular mastitis* is an uncommon breast-limited disease that only occurs in parous women.
- \* The granulomatous inflammation is confined to the lobules, suggesting that it is caused by a *hypersensitivity reaction to antigens expressed by lobular epithelium during lactation*.

## 149. Type of DCIS resulting in palpable abnormality?

a) Comedocarcinoma

b) Non comedo DCIS

c) Paget's disease

d) None

Correct Answer - C

Ans. is 'c' i.e., Paget's disease

*"A palpable mass is present in 50% to 60% of women with Paget disease, and almost all of these women have an underlying invasive carcinoma. In contrast, the majority of women without a palpable mass have only DCIS". — Robbin's*

\* Actually the question has been framed wrongly as Paget's disease is not a type of DCIS. It is a different lesion. But, it has been explained along with morphology of DCIS.

## 150. ER positive status in Ca Breast indicates

-

a) Prognosis

b) Etiology

c) Site

d) None

Correct Answer - A

Ans. is 'a' i.e., Prognosis

o Estrogen receptor (ER) positive breast carcinomas are generally slow growing and respond well to hormonal treatment.

o Gene expression profiling, which can measure the relative quantities of mRNA for essentially every gene, has identified five major patterns of gene expression in invasive ductal carcinoma.

Luminal A

o This is the *largest group* (40-55%) which has characteristics of normal luminal cells.

o This type is *ER positive and HER2/neu negative*.

o These cancers are generally slow growing and respond to hormonal treatment. Conversely only a small number will respond to standard chemotherapy

Luminal B

o These tumors are *ER positive, has a higher proliferative rate and overexpresses HER2/neu ---> Triple-positive cancer*.

o They compose a major group of ER-positive cancers that are more likely to have lymphnode metastases and may respond to standard chemotherapy.

Normal breast line

o These are ERpositive, *HER2/neu negative* and characterized by

the similarity of their gene expression pattern to normal tissue.

Basal line

o These are *ER negative, PR negative, HER2/neu negative Triple negative*.

o These are characterized by *expression of markers typical of myoepithelial cells (e.g., basal keratins, Pcodherins, p63, or laminin), progenitor cells, or putative stem cells (e.g. cytokeratins 5 and 6)*. o Many carcinoma arising in women with *BRAC 1 mutations are of this type*.

o These are aggressive tumors, frequent metastasis to viscera and brain can be seen ---> have poor prognosis.

HER2 positive

o These are *ER negative and overexpress HER 2/neu protein*.

## 151. Modified Bloom Richardson criteria for Carcinoma Breast includes -

a) Desmoplasia

b) Lymphovenous embolism

c) Mitotic rate

d) All

Correct Answer - C

Ans. is 'c' i.e. mitotic rate

### Grading of breast cancer

o Presently, most methods for grading use the previously cited three-tiered systems for describing tumor structure in terms of *tubule formation*, *nuclear grade* and *mitotic count*, with the latter usually expressed as the number of mitosis per 10 high- magnification field.

o Each element is scored on a scale from 1 to 3 according to criteria of the specific grading system, and the final grade is determined by the sum of mitosis.

o Totals of 3 to 5 indicate a well-differentiated or low-grade tumor; 6 to 7, a moderately differentiated or intermediate-grade tumor; and 8 to 9 , a poorly differentiated or high-grade tumor.

o This method of scoring is known as the *Nottingham combined histologic grade of Elston-Ellis modification of the Scarff-Bloom-Richardson grading system*, often reported as a *modified Scarff-Bloom-Richardson grade*.

Modified Bloom-Richarson histological grading Tubule formation

o Score 1 :- >75% of tumor has tubules

• Score 2 :- 10-75% of tumor has tubules

o Score 3 :- < 10% of tumor has tubules

Nuclear size ( nuclear polymorphism)

- o Score 1 :- tumor nuclei similar to normal duct nuclei (2-3 x RBC)
  - Score 2 :- Intermediate size nuclei
  - Score 3 :- very large nuclei, usually vesicular with prominent nucleoli
- Mitotic count
- o Score 1 :- 0-7 mitosis
  - o Score 2 :- 8-14 mitosis
  - o Score 3 :- > 15 mitosis

## 152. Most common malignant bone tumor-

a) Osteogenic sarcoma

b) Secondaries

c) Osteoma

d) Enchondroma

Correct Answer - B

Ans. is 'b' i.e., Secondaries

o Secondaries are most common malignant bone tumor.

o Osteogenic sarcoma is the most common primary malignant bone tumor.

o Osteoma is most common benign bone tumor.

### 153. Ewings sarcoma arises from -

a) G cells

b) Totipotent cells

c) Neuroectodermal cells

d) Neurons

Correct Answer - C

Ans. is c i.e., Neuroectodermal cells

o Histologically, Ewing's sarcoma has a certain resemblance to primitive neuroectodermal cells, and the tumor arises from such cells.

o It is a rare malignancy primarily affecting children and adolescents. It arises mainly in bone and less commonly in soft tissues.

o In these, there is a characteristic reciprocal chromosomal translocation, which leads to an in-frame fusion between the EWS gene and one of the ETS family gene members.

**154. Which of the following is the most common mutation in Ewing's sarcoma -**

a) Translocation X : 18

b) Translocation 11; 22

c) Activative mutation of G5<sub>a,p</sub>, surface protein

d) Missense mutation in EXT1

Correct Answer - B

**Ans. is 'b' i.e., Translocation 11; 22**

Ewing's sarcoma is typically characterized by a translocation t (11; 22) (q 24; q12) in upto 90% of patients.

**155. Tadpole cells comma shaped cells on histopathology are seen in -**

a) Trichoepithelioma

b) Spideroma

c) Rhabdomyosarcoma

d) Histiocytoma

Correct Answer - C

**Ans. is 'c' i.e., Rhabdomyosarcoma**

**Histology of rhabdomyosarcoma**

- The diagnostic cell of rhabdomyosarcoma is rhabdomyoblast.
- Rhabdomyoblast contains eccentric eosinophilic granular cytoplasm rich in thick and thin filaments. o The rhabdomyoblasts may be ?
  - i) Round**
- Elongated Tadpole or Strap cells.
- It has three variants
  - ii) Embryonal**
- Alveolar
  - iii) Pleomorphic**
- Rhabdomyoblasts are positive for *desmin*, *MYOD1* and *Myogenin*.

## 156. Perivascular lymphocytes & microglial nodules are seen in -

a) Multiple sclerosis

b) HIV encephalitis

c) CMV meningitis

d) Bacterial meningitis

Correct Answer - B

Ans. is 'b' i.e., HIV encephalitis

o Perivascular infiltrate of lymphocytes (and macrophages) with microglial nodules is seen in HIV encephalitis.

o Perivascular infiltrate of lymphocytes (and monocytes) is also seen in multiple sclerosis. But, microglial nodules are characteristic of HIV encephalitis.

**157. Regarding Dandy-Walker syndrome, all are seen except-**

a) Hydrocephalus

b) Archnoid cyst

c) Posterior fossa cyst

d) Cerebellar vermis deficiency

Correct Answer - B

Ans. is 'b' i.e., Arachnoid cyst

Dandy-walker malformation

o The Dandy-Walker malformation consists of a cystic expansion of the 4th ventricle in the posterior fossa and midline cerebellar hypoplasia.

o There is : ?

o Hydrocephalus (90% of cases)

o Agenesis of the cerebellar vermis and corpus callosum.

o Rapid increase in head size with prominent occiput.

## 158. Neurofibromatosis true all, except-

a) Autosomal recessive

b) Associated with cataract

c) Scoliosis

d) Multiple fibroma

Correct Answer - A

Ans. is 'a' i.e., Autosomal recessive

Neurofibromatosis comprises of two distinct disorders -

- \* Neurofibromatosis I

- \* Neurofibromatosis II

- \* The genes for these are located on different chromosomes.

- \* Both are inherited in an autosomal dominant pattern.

- \* The classical form of the disease with multiple neuromas is called Neurofibromatosis I and is caused by a mutation of the gene neurofibromin on chromosome 17

**159. Which of the following tumors is not derived from meninges -**

a) Hemangioblastoma

b) Meningioma

c) Fibrous tumor

d) Hemangiopericytoma

Correct Answer - A

Ans. is 'a' i.e., Haemangioblastoma

Meningeal tumors

o *Meningothelial tumor* : *Meningioma* (most common meningeal tumor).

o *Mesenchymal non-meningothelial tumors* : *Meningeal solitary fibrous tumor, hemangiopericytoma, meningeal sarcoma, fibrous histiocytoma, meningeal melanocytoma, (melanocytic tumor).*

## 160. Most common cerebellar tumor in children?

a) Astrocytoma

b) Medulloblastoma

c) Ependymoma

d) DNET

Correct Answer - A

Ans. is 'a' i.e., Astrocytoma

o The most common cerebellar tumor in adults is metastasis, whereas in children the most common tumor is an astrocytoma.

**161. Medulloblastoma most common metastasis is to ?**

a) Lung

b) CNS

c) Liver

d) Spleen

Correct Answer - B

Ans. is 'b' i.e., CNS

o Medulloblastoma spread through CSF and frequently metastasizes to different locations in the brain and spine.

o Extraneural metastasis to the rest of the body is rare.

**162. Most common site for medulloblastoma is-**

a) Cerebellum

b) Pituitary

c) Cerebrum

d) Pineal gland

Correct Answer - A

Ans. is 'a' i.e., Cerebellum

o Medulloblastoma is an infratentorial tumor and occurs exclusively in cerebellum.

## 163. Spongiform degeneration of cerebral cortex occurs in -

- a) Creutzfeldt-Jakob disease
- b) Subacute sclerosing panencephalitis
- c) Fatal familial insomnia
- d) Cerebral toxoplasmosis

Correct Answer - A

Ans. is 'a' i.e., Creutzfeldt-Jakob disease

o On microscopic examination, in *Creutzfeldt-Jakob disease* the pathognomonic finding is a spongiform transformation of the cerebral cortex and, often, deep gray matter structures (caudate, putamen); this consists of a multifocal process that results in the uneven formation of small, apparently empty, microscopic vacuoles of varying sizes within the neuropil and sometimes in the perikaryon of neurons. In advanced cases, there is severe neuronal loss, reactive gliosis, and sometimes expansion of the vacuolated areas into cystlike spaces ("status spongiosus").

o Kuru plaques are extracellular deposits of aggregated abnormal protein; they are Congo red-positive as well as PAS-positive and occur in the cerebellum in cases of *Gerstmann-Striussler-Scheinker syndrome*; they are present in abundance in the cerebral cortex in cases of variant CJD.

o In all forms of prion disease, immunohistochemical staining demonstrates the presence of proteinase-K-resistant PrP<sup>sc</sup> in tissue.

o *Fatal familial insomnia* does not show spongiform pathology. Instead, the most striking alteration is neuronal loss and reactive gliosis in the anterior ventral and dorsomedial nuclei of the thalamus;

neuronal loss is also prominent in the inferior olivary nuclei.

## 164. What is the histological appearance of brain in Creutzfeldt-Jakob disease -

a) Neuronophagia

b) Spongiform change in brain

c) Microabscesses

d) Demyelination

Correct Answer - B

Ans. is 'b' i.e., Spongiform change in brain

o The classic histologic appearance in *Creutzfeldt-Jakob disease* is *spongiform change in the gray matter* : in all six cortical layers in the cerebral cortex or with diffuse involvement of the cerebellar molecular layer. These vacuoles appear glassy or eosinophilic and may coalesce. *Neuronal loss and gliosis* are also seen.

**165. Autoimmune thyroiditis is associated with all except -**

a) *DM*

b) *Myasthenia gravis*

c) *Sly*

d) *Psoriasis*

Correct Answer - D

Ans. is 'd' i.e., *Psoriasis*

\* Autoimmune thyroiditis (Hashimoto thyroiditis) patients are at increased risk for developing other autoimmune disease :-

- i) Endocrine : Type 1 DM, autoimmune adrenalitis.*
- ii) Non-endocrine : SLE, myasthenia gravis, sjogren syndrome.*

\* These patients are also at increased risk for development of *B-cell non-Hodgkin lymphoma, especially marginal cell lymphoma of MALT lymphoma.*

**166. Orphan annie eye nuclei appearance is characteristic of -**

a) Papillary carcinoma thyroid

b) Carcinoma pituitary

c) Paraganglioma

d) Meningioma

Correct Answer - A

Ans. is 'a' i.e., Papillary carcinoma thyroid

o The nuclei of papillary carcinoma cells contain finely dispersed chromatin, which imparts an optically clear or empty appearance, giving rise to the designation ground glass or Orphan Annie eye nuclei.

**167. True about Psammoma bodies are all except ?**

a) Seen in meningioma

b) Concentric whorled appearance

c) Contains Calcium deposits

d) Seen in teratoma

Correct Answer - D

Ans. is 'd' i.e., Seen in teratoma

- o Psammoma bodies represent a process of dystrophic calcification.
- o Single necrotic cells may constitute seed crystals that become encrusted by the *mineral* deposits. The progressive acquisition of outer layers may create lamellated configurations, called psammoma bodies because of their resemblance to grains of sand.
- o Psammoma bodies are seen in : *papillary cancer of thyroid, meningioma, papillary serous cystadenocarcinoma of ovary.*

## 168. Tumor that follows rule of 10 is-

a) Pheochromocytoma

b) Oncocytoma

c) Lymphoma

d) Renal cell carcinoma

Correct Answer - A

Ans. is 'a' i.e., Pheochromocytoma

*Pheochromocytomas* usually subscribe to a convenient "rule of 10s" :-

*10% of pheochromocytomas arise in association with one of several familial syndromes.* These include the MEN-2A & MEN-2B syndromes, type I neurofibromatosis, von Hippel-Lindau syndrome & Sturge-Weber syndrome.

*10% of pheochromocytomas are extra-adrenal,* occurring in sites such as organ of Zuckerkandl & carotid body, where these chromaffin-negative tumors are usually called *paragangliomas* to distinguish them from pheochromocytomas.

*10% of nonfamilial adrenal pheochromocytomas are bilateral;* this figure may rise to 70% in cases that are associated with familial syndromes.

*10% of adrenal pheochromocytomas are biologically malignant,* although the associated hypertension represents a serious & potentially lethal complication of even "benign" tumors.

*10% of adrenal pheochromocytomas arise in childhood,* usually the familial subtypes, and with a strong male preponderance. The nonfamilial pheochromocytomas most often occur in adults between 40 & 60 years of age, with a slight female preponderance.

**169. Which of the following is most reliable feature of malignant transformation of pheochromocytoma ?**

a) Presence of mitotic figures

b) Capsular invasion

c) Vascular invasion

d) None

Correct Answer - D

Ans. is None

*"Because benign and malignant pheochromocytomas may have an identical histological appearance, the only absolute criterion of malignancy is metastasis."*

*"The diagnosis of malignant pheochromocytoma is made only when metastasis is demonstrated."*

## 170. Tertiary hyperparathyroidism is-

- a) High  $\text{PO}_4$  level with metastasis
- b) Secondary hyperparathyroidism with CRF
- c) Primary hyperparathyroidism with low  $\text{Ca}^{++}$  levels
- d) Secondary hyperparathyroidism with chief cell adenoma

Correct Answer - D

**Ans. is 'd' i.e., Secondary hyperparathyroidism with chief cell adenoma**

Davidson states "In very small proportion of cases of secondary hyperparathyroidism continuous stimulation of the parathyroid may result in adenoma formation and autonomous PTH secretion. This is known as tertiary hyperparathyroidism".

## 171. Mutation in malignant melanoma-

a) N-myc

b) CDK2A

c) RET

d) None

Correct Answer - B

Ans. is 'b' i.e., CDK2A

*"In melanoma cells, numbers of mutations and/or dysregulated expression of B-Rof N-Ras, CDK2A, MDM2, PTEN, p53 have been recognized".*

## 172. Which of the following is not true about amoebiasis?

a) ALA in 10% causes in tropics

b) Portal system efficient filter

c) Abscess due to suppuration

d) Abscess wall good for culture

Correct Answer - C

**Ans. is 'c' i.e., Abscess due to suppuration**

**Amebic liver abscess**

- Pus in *amoebic liver abscess* is not due to suppuration, but is a mixture of sloughed liver tissue and blood.
- It is chocolate brown in colour and thick in consistency (anchovy sauce pus)
- In the tropics 2-10% of the individuals infected with *Entamoeba histolytica* suffer from hepatic complications. The trophozoites are carried from the large intestine to the liver by portal vein. In the liver the capillary system acts as efficient filter and holds these parasites.
- In case of amoebic liver abscess the diagnostic aspiration is done from the abscess wall *because the trophozoites are confined to the periphery.*

### 173. Most important prognostic factor of wilms tumour -

a) Histopathology

b) Ploidy of cells

c) Age < 1 yr

d) Mutation, of clp gene

Correct Answer - A

Ans. is 'a' i.e., Histopathology

Anaplastic nuclear change is the only criterion of "unfavourable" histology in Wilm's tumor and all Wilm's tumor lacking this feature are designated as having "favourable histology".

Anaplastic nuclear change reflects extreme polypoidy & is usually apparent under low magnification.

"Anaplastic histology remains a critical determinant of adverse prognosis. Even anaplasia restricted to kidney confers an increased risk of recurrence & death, underscoring the need for correctly identifying this histologic features."

**174. Which of the following porphyrias is not inherited as an Autosomal Dominant disorder-**

a) Acute Intermittent Porphyria

b) Congenital Erythropoietic Porphyria

c) Porphyria Cutanea Tarda

d) Hereditary Coproporphyria

Correct Answer - B

Ans. is 'b' i.e., Congenital erythropoietic porphyria

Inheritance of Porphyrias

Autosomal dominant

Autosomal

Recessive

X-linked

o Acute intermittent porphyria (AIP)  
deficiency

o ALA dehydratase

o X-linked protoporphyria

o Porphyria cutanea Tarda (PCT)  
erythropoietic porphyria

o Congenital

o Hereditary coproporphyria (HCP)

o Erythropoietic

o Variegate porphyria (VP)

## 175. Glomus tumor is seen in -

a) Retroperitoneum

b) Soft tissue

c) Distal portion of digits

d) Proximal portion of digits

Correct Answer - C

Ans. is 'c' i.e., Distal portion of digits

o It is a benign but painful tumor that arises from the modified smooth muscle cells of the *glomus body*, a *specialized arteriovenous anastomosis* that is involved in thermoregulation.

o They are *most commonly found in the distal portion of the digits*, especially under the fingernails.

**176. All of the following are true about Gout, except:-**

a) Occurs due to accumulation of urate crystals in joint

b) Can be pptd by pyrazinamide

c) Birefringement crystals are present in joint

d) Occurs more in females

Correct Answer - D

Answer is D (Occurs more in females):

*Gout is more widespread in men than in women.*

*Women represent only 5-20% of patients with gout.*

*Women are seldom affected until after menopause.*

**177. First change seen in acute inflammation is:**  
***September 2009***

a) Increased permeability

b) Vasodilation

c) Neutrophil migration

d) Vasoconstriction

Correct Answer - D

Ans. **D**: Vasoconstriction

**Cardinal signs:**

- Rubor (redness) due to dilatation of arterioles
- Calor (heat)
- Dolor (pain) due to pressure on nerve endings by edema fluid and chemical mediator bradykinine
- Tumor (swelling) due to edema.
- Functio laesa (loss of function) due to inhibition of movement by pain and tissue necrosis.

**178. Portal hypertension is said to be present if portal venous pressure is more than:  
*March 2010***

a) 3-5 mm Hg

b) 5-8 mm Hg

c) 10-12 mm Hg

d) 15-20 mm Hg

Correct Answer - C

Ans. C: 10-12 mm Hg

Normal portal pressure is generally defined between 5 and 10 mm Hg.

Portal hypertension results when the portal pressure rises to 12 *mm* Hg or greater and complications can arise, such as varices and ascites.

Many conditions are associated with portal hypertension, of which cirrhosis is the most common cause

**179. Most common site of hypertensive intraparenchymal hemorrhage in brain:  
*March 2013***

a) Pons

b) Thalamus

c) Putamen

d) Cerebellum

Correct Answer - C

Ans. C i.e. Putamen

*Sites of intracerebral hemorrhage includes putamen (55%), thalamus (20-30%), cerebellum (10%), pons (5-7%) and subcortical white matter (10-15%)*

**180. Negri bodies are characteristic of:**  
***September 2008, March 2013***

a) Tetanus

b) Rabies

c) Polio

d) AIDS

Correct Answer - B

Ans. B: Rabies

Since first described by Negri in 1903, the presence of the Negri bodies are practically pathognomonic for rabies and are an important diagnostic finding.

Negri bodies are discrete, intracytoplasmic, deeply eosinophilic inclusions that measure several microns in diameter. In about 75% of cases of rabies these can be seen on hematoxylin and eosin stained sections.

They occur in neurons of the brain stem, particularly those in the hippocampus, and in the Purkinje cells of the cerebellum.

Ultrastructural studies have shown that Negri body consists of a mass of nucleocapsids surrounded by viral particles budding from intracytoplasmic membranes.

Those bodies can be seen in axons, and it is in this way that virus spreads from the central nervous system to many organs of the body.

Because Negri bodies are usually seen in intact neurons, they are found away from the inflammatory, nonspecific lesions. Rabies viral antigens can be demonstrated in infected cells by means of fluorescent antibody technique.

Antigens can be shown to be present in cells in the absence of Negri

bodies, and hence this technique is much more sensitive than the search of sections of brain for the pathognomonic cytoplasmic inclusions.

**181. Most common location of gastrinoma is:**  
***September 2007***

a) Pancreas

b) Duodenum

c) Jejunum

d) Gall bladder

Correct Answer - B

Ans. B: Duodenum

Zollinger-Ellison syndrome is a disorder where increased levels of the hormone gastrin are produced, causing the stomach to produce excess hydrochloric acid.

Often the cause is a tumor (gastrinoma) of the duodenum or pancreas producing the hormone gastrin. Gastrin then causes an excessive production of acid which can lead to peptic ulcers in almost 95% of patients.

Gastrinomas may occur as single tumors or as multiple, small tumors. About one-half to two-thirds of single gastrinomas are malignant tumors that most commonly spread to the liver and lymph nodes near the pancreas and small bowel. Nearly 25 percent of patients with gastrinomas have multiple tumors as part of a condition called multiple endocrine neoplasia type I (MEN I). MEN I patients have tumors in their pituitary gland and parathyroid glands in addition to tumors of the pancreas.

**182. Lacunar cells is seen in which type of  
Hodgkins Lymphoma:  
*September 2010***

a) Mixed cellularity type

b) Lymphocyte predominant

c) Nodular Sclerosis Type

d) All of the above

Correct Answer - C

Ans. C: Nodular Sclerosis Type

Reed-Sternberg cells (also known as lacunar histiocytes for certain types) are different giant cells found on light microscopy in biopsies from individuals with Hodgkin's lymphoma (aka Hodgkin's disease; a type of lymphoma), and certain other disorders. They are usually derived from B lymphocytes.

### 183. Following are seen in polycythemia vera except:

a) Most common cause of polycythemia

b) Increased erythropoietin

c) Erythropoietin independent growth of red cell progenitors

d) Intrinsic abnormality of hematopoietic precursors

Correct Answer - B

Polycythaemia vera (PV) is a clonal disorder characterized by increased production of all myeloid elements resulting in pancytosis (i.e increased red cells, granulocytes, platelets) in the absence of any recognizable cause.

- The term 'polycythemia vera' or 'polycythemia rubra vera' is used for primary or idiopathic polycythemia only and is the most common of all the myeloproliferative disorders.
  - Secondary polycythemia or erythrocytosis, on the other hand, may occur secondary to several causes e.g. high altitude, cardiovascular disease, a pulmonary disease with alveolar hypoventilation, heavy smoking, inappropriate increase in erythropoietin (renal cell carcinoma, hydronephrosis, hepatocellular carcinoma, cerebellar hemangioblastoma, massive uterine leiomyoma);
- clinical features:**
- headache, vertigo, tinnitus, visual alterations syncope or even coma.
  - Increased risk of thrombosis due to accelerated atherosclerosis.
  - Increased risk of hemorrhages due to increased blood volume and intrinsic platelet dysfunction e.g. epistaxis, peptic ulcer disease
  - Splenomegaly producing abdominal fullness.
  - Pruritus, especially after a bath



**184. Most common lung cancer in non-smokers is:**

a) Adenocarcinoma

b) Squamous *cell* carcinoma

c) Oat cell carcinoma

d) None of the above

Correct Answer - A

Ans. A: Adenocarcinoma

Adenocarcinoma accounts for 40% of non-small cell lung cancers. It usually originates in peripheral lung tissue. Most cases of adenocarcinoma are associated with smoking; however, among people who have never smoked ("never-smokers"), adenocarcinoma is the most common form of lung cancer.

A subtype of adenocarcinoma, the bronchioloalveolar carcinoma, is more common in female never-smokers, and may have different responses to treatment.

**185. Most common feature of sarcoidosis on chest X-ray is:**

***March 2011, March 2013***

a) Pleural effusion

b) Cavitation

c) Bilateral hilar lymphadenopathy

d) Pneumothorax

Correct Answer - C

**Ans. C: Bilateral hilar lymphadenopathy**

Sarcoidosis may be discovered unexpectedly on routine chest films as bilateral hilar lymphadenopathy

**Sarcoidosis/Sarcoid/Besnier-Boeck disease/Besnier-Boeck-Schaumann disease**

- It is a disease in which abnormal collections of chronic inflammatory cells (granulomas) form as nodules in multiple organs.
- The combination of erythema nodosum, bilateral hilar lymphadenopathy and arthralgia is called Lofgren syndrome.
- This syndrome has a relatively good prognosis
- Chest X-ray changes are divided into four stages
  1. Stage 1: Bihilar lymphadenopathy
  2. Stage 2: Bihilar lymphadenopathy and reticulonodular infiltrates
  3. Stage 3: Bilateral pulmonary infiltrates
  4. Stage 4: Fibrocystic sarcoidosis typically with upward hilar retraction, cystic and bullous changes

**186. Multiple sinuses from infection of great toe is mainly caused by:**  
***September 2007***

a) Tuberculosis

b) Actinomycetes

c) Trichosporum

d) Histoplasmosis

Correct Answer - B

Ans. B: Actinomycetes

Mycetoma is a chronic localized granulomatous inflammatory lesion common in the tropics and sub-tropics.

Multiple sinuses, soft tissue swelling and discharge of coloured granules characterize a mycetoma foot. Chronic sinuses discharging granules are caused by (1) Eumycetes (true fungi), (2) Schizomycetes, which includes

- *Actinomycosis* (aerobic higher filamentous bacteria) and
- *Botryomycosis* (bacterial infection).

- *Actinomycosis* is often caused by *Actinomadura* or *Nocardia* species wherein it gains entry after penetrating trauma (splinter, gravel or thorn prick).

Young males are commonly affected and 75% of the lesions occur in the lower limbs.

The disease slowly progresses from a nodule to multiple sinuses discharging coloured granules. Involvement of bone is late following dermal and soft tissue spread.

- *Botryomycosis* (a misnomer), a chronic suppurative infection is caused by bacteria involving skin or viscera. This rare condition mimics a deep mycotic infection and is often caused by

...mines a deep mycotic infection and is often caused by Staphylococcus or Pseudomonas species of bacteria. The feet and hands are commonly affected and penetrating trauma may be a predisposing factor. It usually presents as a nodule, sinus or ulcer, which is initially localized.

The diagnosis of actinomycosis is based on clinical findings, demonstration of characteristic granules and culture of the organism from a deep tissue biopsy.

Immunological studies (counter immuno electrophoresis and ELISA) are also used. Botryomycosis is diagnosed based on a positive gram's stain and culture; negative fungal cultures and demonstration of the characteristic botryomycotic granules at histopathology from a deep biopsy.

In endemic areas, subcutaneous swelling with sinuses should be considered as mycetoma unless proved otherwise. The differential diagnosis includes chronic osteomyelitis, tuberculosis and chronic abscesses.

**187. Barr body is NOT seen in:**  
***PGI 07; WB 08***

a) Turner syndrome

b) Klinefelter syndrome

c) Down's syndrome

d) Marfan's syndrome

Correct Answer - A

Ans. Turner syndrome

**Barr body (Sex - chromatin)**

- It is a densely staining inactivated condensed 'X' chromosome that is present in each somatic cells of female. o It is found in the *nucleus*.
- It is used as a test of genetic *femaleness* -4 it is possible to determine the genetic sex of an individual according as to whether there is a chromatin mass present on the inner surface of the nuclear membrane of cells with resting or intermitent nuclei. Remember following fact and the question will seem very easy.
- *Chromatid body (Barr body or sex chromatin) is derived from one of the two X-chromosomes which becomes inactivated.*
- *The numer of Barr bodies is thus one less than the number of X-chromosomes.*

## 188. Compensatory mechanism in acute hemorrhage?

a) Decreased myocardial contractility

b) Decreased heart rate

c) Increased heart rate

d) Increased respiratory rate

Correct Answer - C

Ans. is 'c' i.e., Increased heart rate

### **Compensatory mechanisms in acute hemorrhage**

- In acute hemorrhage there is compensatory sympathetic stimulation which causes :?
  - 1) *Generalized vasoconstriction with increased total peripheral resistance (TFR).*
  - 2) *Increased heart rate (tachycardia).*
  - 3) *Increased cardiac contractility.*
  - 4) *Increased renin release causing sodium and water retention through RAA system.*
  - 5) *Shift of fluid from intracellular and interstitial space into vascular space.*

**189. Prostaglandins are produced by ?**

a) Neutrophils

b) Endothelium

c) Macrophages

d) All of the above

Correct Answer - D  
Ans. is 'd' i.e., All of the above

## 190. Sirtuins are associated with ?

a) Antioxidant mechanism in body

b) Longevity of life span

c) Regeneration of liver after partial resection

d) Carcinogenesis in human

Correct Answer - B

Ans. is 'b' i.e., Longevity of life span

## 191. Receptor for BDNF ?

a) TrK-A

b) TrK-B

c) TrK-C

d) None

Correct Answer - B  
Ans. is 'B' i.e., TrK-B

## 192. Leukocyte migration through endothelium is induced by ?

a) Selectin

b) N CAM

c) C CAM

d) PECAM

Correct Answer - D

Ans. is 'd' i.e., PECAM

- Migration of the leukocytes through the endothelium is called transmigration or diapedesis.
- Transmigration of leukocytes occurs mainly in postcapillary venules.
- The molecules involved in transmigration are member of the immunoglobulin superfamily called CD31 or PECAM-1 (platelet endothelial cell adhesion molecule).

## 193. Large granular lymphocytes are ?

a) B cells

b) NK cells

c) T cell

d) Plasma cells

Correct Answer - B

**Ans. is 'b' NK cells**

### **Null cells (Large granular lymphocytes)**

- Null cells are called so because they lack features of surface markers of both B and T lymphocytes.
- They account for 5 to 10% of peripheral blood lymphocytes.
- They are also called "*large granular lymphocytes (LGL)*" as they contain large *azurophilic cytoplasmic granules*.
- **Members of this group are:**
  - a) Antibody dependent cytotoxic cells (ADCC)
  - b) Natural killer cells (NK Cells)

## 194. Thymic hyperplasia is seen in ?

a) Thymoma

b) Thymic lymphoma

c) Myasthenia gravis

d) Scleroderma

Correct Answer - C

**Ans. is 'c' i.e., Myasthenia gravis**

**Thymic hyperplasia**

- The term thymic hyperplasia usually applies to the appearance of B-cell germinal centers within the thymus, a finding that is referred to as *thymic follicular hyperplasia*.
- Such B-cell follicles are present in only small numbers in the normal thymus.
- It can occur in a number of chronic inflammatory and immunologic states, but it is most frequently encountered in myasthenia gravis (65% to 75% of cases).
- Similar thymic changes are sometimes encountered in Graves disease, systemic lupus erythematosus, scleroderma, rheumatoid arthritis, and other autoimmune disorders.

**195. Which one of the following statements is correct regarding chronic granulomatous disease ?**

a) It is an autosomal dominant disease

b) It is characterized by abnormal bacterial phagocytosis

c) Recurrent streptococcal infections are usual in this disease

d) Nitrobluetetrazolium test is useful for screening

Correct Answer - D

**Ans. is 'd' i.e., Nitrobluetetrazolium test is useful for screening**  
*Leukocytes from the patients of chronic granulomatous disease fail to reduce nitroblue tetrazolium (NBT) during phagocytosis. This property has been used as a screening method (NBT test) for the diagnosis of chronic granulomatous disease.*

**Chronic granulomatous disease (CGD)**

- It is a group of disorders of granulocyte and monocyte oxidative metabolism.
- Inheritance
- *X-linked* (Most common)
- *Autosomal recessive*
- Phagocytosis *is* normal but leukocytes do not undergo degranulation following phagocytosis.
- The diminished H<sub>2</sub>O<sub>2</sub> production appears to be the major reason for defective bactericidal defect.
- Mutation in the genes for the four proteins that assemble at the plasma membrane account for all patients with CGD:
- Two proteins form the heterodimer cytochrome b - 558 in the plasma membrane.

- Two other proteins interact with cytochrome after cell activation to form *NADPH oxidase* required for Hydrogen peroxide production.
- *The bacteria involved in recurrent infections are catalase positive pyogenic pathogens such as staphylococci and coliforms.* Catalase negative pathogens such as streptococci and pneumococci are handled normally.
- There is excessive inflammation with granulomas formation.

**196. Lacunar type of reed sternberg cell is seen in ?**

a) Nodular sclerosis

b) Lymphocyte predominance

c) Mixed cellularity

d) Lymphocyte depletion

Correct Answer - A  
Ans. is 'a' i.e., Nodular sclerosis

## 197. Activation of naïve B lymphocytes by protein antigens is?

a) T Cell independent

b) NK cell dependent

c) NK cell independent

d) T cell dependent

Correct Answer - D

Ans. is d i.e., T cell dependent

Upon activation, B lymphocytes proliferate and then differentiate into plasma cells that secrete different classes of antibodies with distinct functions.

Antibody responses to most protein antigens require T cell help and are said to be *T-dependent*.

Many polysaccharide and lipid antigens cannot be recognized by T cells but have multiple identical antigenic determinants (epitopes) that are able to engage many antigen receptor molecules on each B cell and initiate the process of B-cell activation; these responses are said to be *T-independent*.

## 198. Mantoux test is based on which hypersensitivity?

a) Type 1

b) Type 2

c) Type 3

d) Type 4

Correct Answer - D

**Ans. is 'd' i.e., Type 4**

**Following are the examples of type 4 hypersensitivity reactions**

**:-**

- Type 1 diabetes mellitus
- Hashimoto thyroiditis
- Crohn's disease
- Multiple sclerosis
- Contact dermatitis
- Mantoux test

## 199. Ladder tears are ?

a) Spiral tears of aortic intima

b) Vertical tears of aortic intima

c) Horizontal tears of aortic intima

d) Oblique tears of aortic intima

Correct Answer - C

Ans. is 'c' i.e., Horizontal tears of aortic intima

- *Ladder tears are the horizontal tears of intima*
- It is injury to aorta due to deceleration.
- It is so called because it resembles the rungs of a ladder.

## 200. Pendred syndrome due to mutation of ?

a) Bartillin

b) Pendrin

c) Fibrillin

d) Reticulin

Correct Answer - B

**Ans. is `b' i.e., Pendrin**

**Pendred syndrome or Pendred disease :?**

- Pendred syndrome or Pendred disease is a genetic disorder leading to congenital bilateral (both sides) sensorineural hearing loss and goitre with occasional hypothyroidism.
- It has been linked to mutations in the *PDSgene*, which codes for the *pendrin* protein (solute carrier family 26, member 4, SLC26A4). The gene is located on the long arm of chromosome 7 (7q31). It is an autosomal recessive disorder.

## 201. Which of the following is not true about idiopathic thrombocytopenic purpura?

a) Antibodies of IgM class

b) Autoantibodies to Gp IIb/ IIIa or IB IX

c) Increased megakaryocytes in bone marrow

d) Spleen is normal in size

Correct Answer - A

**Ans. is 'a' i.e., Antibodies of IgM class**

**I dopathic thrombocytopenic purpura :?**

- There are two clinical subtypes of primary I.T.P, *acute* and *chronic* both are *autoimmune disorders in which platelet destruction results from formation of antiplatelet antibodies.*

### **Pathogenesis**

- *Chronic ITP is caused by the formation of autoantibodies against platelet membrane glycoproteins most often Hb-IIIa or Ib-IX.*
- *In overwhelming majority of cases the antiplatelet antibodies are of the 'IgG' class.*
- *The mechanism of platelet destruction is similar to that seen in autoimmune hemolytic anemias. Opsonized platelets are rendered susceptible to phagocytosis by the cells of the mononuclear phagocyte system.*
- *The spleen is the major site of the destruction of platelets.*

### **Pathology**

- *The principal morphologic lesions of thrombocytopenic purpura are found in the spleen and bone marrow but they are not diagnostic.*
- *The point to stress is that despite the increased destruction of platelets in spleen, the spleen size remains normal.*

- On *histological examination* there is congestion of the sinusoids and hyperactivity and enlargement of the splenic follicles manifested by the formation of prominent germinal centres. Sometimes scattered megakaryocytes are found within the sinuses and sinusoidal walls. This represents a very *mild* form of extramedullary hematopoiesis. These splenic findings are not sufficiently distinctive to be considered diagnostic.

### **Bone Marrow**

- Bone marrow reveals a modestly increased number of megakaryocytes.
- These findings are *not specific* for autoimmune thrombocytopenic purpura, but merely reflect accelerated thrombopoiesis, being found in most forms of thrombocytopenia resulting from *increased platelet destruction*.
- *The importance of bone marrow examination is to rule out thrombocytopenias resulting from bone marrow failure.*
- A decrease in the number of megakaryocytes goes against the diagnosis of I.T.P.

## 202. Macrophage activation syndrome characterized by all except ?

a) Activation of CD 8 + T cells

b) Presence of cytokine storm

c) It is the other name for hemophagocytic lymphohistiocytosis

d) Low levels of plasma ferretin

Correct Answer - D

**Ans. is 'd' i.e., Low levels of plasma ferretin**

### **Hemophagocytic Lymphohistiocytosis**

- Hemophagocytic lymphohistiocytosis (HLH) is a reactive condition marked by cytopenias and signs and symptoms of systemic inflammation related to macrophage activation. For this reason, it is also sometimes referred to as macrophage activation syndrome.

### **Pathogenesis**

- The common feature of all forms of HLH is systemic activation of macrophages and CD8+ cytotoxic T cells.
- The activated macrophages phagocytose blood cell progenitors in the marrow and formed elements in the peripheral tissues, while the "stew" of mediators released from macrophages and lymphocytes suppress hematopoiesis and produce symptoms of systemic inflammation.
- These effects lead to cytopenias and a shock-like picture, sometimes referred to as "cytokine storm" or the systemic inflammatory response syndrome.
- Familial forms of HLH are associated with several different mutations, all of which impact the ability of cytotoxic T cells and NK to properly form or deploy cytotoxic granules.
- The most common trigger for HLH is infection, particularly with

Epstein-Barr virus (EBV).

***Clinical Features***

- Most patients present with an acute febrile illness associated with splenomegaly and hepatomegaly.
- Hemophagocytosis is usually seen on bone marrow examination, but is neither sufficient nor required to make the diagnosis.
- Laboratory studies typically reveal anemia, thrombocytopenia, and very high levels of plasma ferritin and soluble IL-2 receptor, both indicative of severe inflammation, as well as elevated liver function tests and triglyceride levels, both related to hepatitis.
- Coagulation studies may show evidence of disseminated intravascular coagulation. If untreated, this picture can progress rapidly to multiorgan failure, shock, and death.

**Treatment**

- Involves the use of immunosuppressive drugs and "mild" chemotherapy.
- Patients with germline mutations that cause HLH or who have persistent/resistant disease are candidates for hematopoietic stem cell transplantation.
- Without treatment, the prognosis is grim, particularly in those with familial forms of the disease, who typically survive for less than 2 months.

## 203. HLA associated with rheumatoid arthritis is ?

a) HLA B27

b) HLA DR 4

c) HLABI9

d) HLA DR2

Correct Answer - B

Ans. is `b' i.e. HLA DR4

Associated with the development of Rheumatoid arthritis

- HLA - DR 4
- HLA - DR 10
- HLA - DR 9

Protects against the development of Rheumatoid arthritis

- HLA - DR 5
- HLA - DR 2
- HLA - DR 3

## 204. Hepatitis B associated with ?

a) Wegener's granulomatosis

b) Systemic lupus erythmatosus

c) Polyarteritis nodosa

d) Sjogren syndrome

Correct Answer - C

Ans. is 'c' i.e., Polyarteritis nodosa

The hepatitis B surface antigen is present in 25% of patients with Polyarteritis Nodosa.

Hepatitis C antibody is present in patients with essential mixed cryoglobulinuria and rarely in patients with poly arteritis nodosa.

## 205. Normal upper limit of CA - 125 is ?

a) 25 U/ ml

b) 45 U/ ml

c) 65 U/ ml

d) 85 U/ ml

Correct Answer - A

**Ans. is 'a' i.e., 25 U/ ml**

The normal value is less than 35 U/mL

### **1) Carcinoembryonic antigen (CEA)**

- It is a glycoprotein produced by fetal gut, pancreas and liver.
- It is used as tumor marker for colorectal cancer (major use), *lung cancer, breast cancer and ovarian cancer*. It is also increased in non-neoplastic conditions like *alcoholic cirrhosis, hepatitis, IBD (CD, UC), smoking and pancreatitis*.
- In colorectal cancer it is used for screening; *response and follow up after surgery (CEA should disappear in 6 weeks after resection), prognosis (higher levels suggests high tumor burden) and to see recurrence on follow up*. CEA antigen has no correlation with hepatic metastasis.
- *CEA lacks sensitivity as well as specificity, hence cannot be used to confirm the diagnosis.*

### **2) Alpha-feto protein (AFP)**

- It is a glycoprotein synthesized normally early in fetal life by yolk sac, fetal liver and fetal GIT. *It is structurally and genetically related to albumin.*
- AFP is raised in *liver cancer (hepatocellular carcinoma), lung carcinoma, pancreatic carcinoma, colon carcinoma, and non-seminoma germ cell tumor of testis/ovary (yolk sac*

tumor/endodermal sinus tumor, *embryonal carcinoma, teratoma*).

- AFP is also raised in some non-neoplastic conditions like *cirrhosis, hepatitis, and pregnancy*.

### **3) Human chorionic gonadotropin (HCG)**

- It is a placental hormone synthesized by syncytiotrophoblasts. It is glycoprotein with two subunits (dimer) : *α-subunit and β-subunit*. But only the *β subunit of HCG is typically measured as a tumour marker because of specificity of the β subunit*. The *β* subunit of HCG has unique sequences that are not shared with other human glycoprotein hormones.
- It is detected by radioimmunoassay using antibodies to the *β* chain. *α-HCG is not used as tumour marker because α unit of the FSH, LH and TSH are identical. So there can be cross reactivity between α subunits of these hormone. That is why in case of testicular tumours the patients also undergo simultaneous assay of LH to be certain that the marker detected is β HCG.*
- HCG (*β*-HCG) is raised in *gestational trophoblastic disease (hydatidiform moles), gonadal germ cell tumor (embryonal carcinoma, choriocarcinoma), and pregnancy*.

### **4) CA-125**

- Most important cancer with elevated CA-125 is *epithelial ovarian cancer*. CA-125 is also elevated in cancers of *endometrium, cervix, fallopian tubes, pancreas, breast, lung and colon*.
- Non-neoplastic conditions causing elevation of CA-125 are *pregnancy, menstruation, endometriosis, PID, abdominal TB, peritonitis and uterine fibroid*.

### **Tumor markers for testicular/ovarian tumor**

1. *AFP (alpha-feto protein) : Teratoma, Yolk sac tumor (endodermal sinus tumor), embryonal carcinoma.*
2. *HCG (human chorionic gonadotrophin): Choriocarcinoma, embryonal carcinoma.*
3. *α<sub>1</sub>-antitrypsin : Yolk sac tumor (endodermal sinus tumor).*
4. *Placental alkaline phosphatase : Seminoma.*
5. *Other : Placental lactogen, LDH.*

**206. Which of the following interleukin is secreted by T helper 2 cells?**

a) IL 11

b) IL 7

c) IL 1

d) IL 13

Correct Answer - D

Ans. is 'd' i.e., IL 13

**A) T helper - 1 ( $T_H1$ ) secretes 4 IL-2 and interferon -  $\gamma$**

**B) T helper - 2 ( $T_H2$ ) secretes -> IL-4, IL-5, IL-6, IL-13**

## 207. Atopy in hypersensitivity is ?

a) Systemic type I hypersensitivity

b) Local type I hypersensitivity

c) Systemic type II hypersensitivity

d) Local type II hypersensitivity

Correct Answer - B

Ans. is `b' i.e., Local type I hypersensitivity

- Anaphylaxis -3 Acute, potentially fatal, systemic.
- Atopy ->Chronic, Nonfatal, Localized.

## 208. Inheritance pattern of myotonic dystrophy is ?

a) Autosomal recessive

b) Autosomal dominant

c) X linked dominant

d) X linked recessive

Correct Answer - B

**Ans. is `b' i.e., Autosomal dominant**

**Myotonic dystrophy**

- Myotonic dystrophy is an autosomal dominant multisystem disorder associated with skeletal muscle weakness, cataracts, endocrinopathy, and cardiomyopathy

**209. Gene responsible for Wilson disease is situated on which chromosome?**

a) Chromosome 11

b) Chromosome 12

c) Chromosome 13

d) Chromosome 14

Correct Answer - C

Ans. is 'c' i.e., Chromosome 13

Wilson disease is an autosomal recessive disorder caused by mutation of the ATP7B gene, resulting in impaired copper excretion into bile & failure to incorporate copper into ceruloplasmin.

The ATP 7 B gene is located on chromosome 13.

## 210. Antischkow cells are ?

a) Modified macrophages

b) Modified neutrophils

c) Modified B cells

d) Modified RBCs

Correct Answer - A

**Ans. is 'a' i.e., Modified macrophages**

### **Pathologic Features of Acute Rheumatic Fever**

Aschoff bodies focal inflammatory lesions seen in acute rheumatic fever consisting of foci of T lymphocytes, occasional plasma cells, and plump activated macrophages.

These activated macrophages called Anitschkow cells (pathognomonic for Rheumatic Fever) have abundant cytoplasm and central round-to- ovoid nuclei (occasionally binucleate) in which the chromatin condenses into a central, slender, wavy ribbon (hence also called "caterpillar cells").

Pancarditis - During acute RF, diffuse inflammation and Aschoff bodies may be found in any of the three layers of the heart, resulting in pericarditis, myocarditis, or endocarditis

Verrucae are small (1 to 2 mm) vegetations overlying necrotic foci and along the lines of closure of valves. o MacCallum plaques are irregularly thickened subendocardial lesions usually in the left atrium. o Mitral stenosis - Fish Mouth or Button - Hole stenosis.

## 211. Patient with chronic hypertension will show following changes on histology of kidney

a) Hyaline arteriosclerosis

b) Hyperplastic arteriosclerosis

c) Onion skin lesions

d) Vessel lumen dilatation

Correct Answer - A

**Ans. is 'a' i.e., Hyaline arteriosclerosis**

Hypertension is associated with two forms of *small blood vessels* disease ?

### 1. Hyaline arteriosclerosis

- There is homogenous, pink, hyaline thickening of arteriolar wall. The lumen becomes narrow. It is characteristic of benign hypertension. It may also occur in diabetes and aging.

### 2. Hyperplastic arteriosclerosis

- It is characteristic of malignant hypertension. There is concentric, laminated thickening of arteriolar wall → onion skinning. There is mucinous intimal thickening and fibrous intimal thickening.
- There may be accompanied fibrinoid deposits with necrosis of the vessels wall → fibrinoid necrosis (or necrotizing arteriolitis).
- *Favoured sites for hyperplastic arteriosclerosis are kidney, small intestine, gall bladder, peripancreatic fat, and periadrenal fat.*
- Beside these hypertension also causes :-
  - .. Atherosclerosis in large arteries.
  - ?. Degenerative changes in the walls of large and medium arteries that potentiate both aortic dissection and cerebrovascular hemorrhage.

---

## 212. NK cell shows presence of ?

a) CD 44

b) CD 16

c) CD 54

d) CD 32

Correct Answer - B

Ans. is 'b' i.e., CD 16

- These cells possess cytotoxic activity against *virus infected cells, tumor cells and transplanted foreign cells.*
- Cytotoxicity of NK cells is *neither antibody dependent nor MHC restricted.* Activity is *nonimmune* as it *does not require antigenic stimulation.*
- NK-cells are *positive for CD16 and CD56.*
- NK cells are usually *negative for CD3*, but a *subset is positive for CD3* called NK/T-cells.

## 213. Non professional antigen presenting cell is A/E ?

a) Endothelial cell

b) Epidermal cell

c) Fibroblasts

d) Red blood cells

Correct Answer - D

**Ans. is 'd' i.e., Red blood cells**

**Non-professional antigenpresenting cell**

- A non-professional APC does not constitutively express the Major Histocompatibility Complex class II (MHC class II) proteins required for interaction with naive T cells; these are expressed only upon stimulation of the non? professional APC by certain cytokines such as IFN- $\gamma$ .
- All nucleated cells express the Major Histocompatibility Complex class I necessary to be considered a nonprofessional APC.
- As erythrocytes do not have a nucleus, they are one of the few cells in the body that cannot display antigens.

## 214. Blood is stored at what temperature in blood bank?

a) -2 to -4 degrees Celsius

b) -2 to 0 degrees Celsius

c) 1 to 6 degrees Celsius

d) 6 to 12 degrees Celsius

Correct Answer - C

Ans. is 'c' i.e., 1 to 6 degrees Celsius

- *Storage temperature of blood : 1-6°C*
- *Storage temperature of packed RBCs : 40°C*
- *Storage temperature of FFP : -20°C*
- *Storage temperature of platelets: 20-24°C*

## 215. Birbeck granules in cytoplasm is seen in ?

a) Langerhans cell histiocytosis

b) Hodgkin's lymphoma

c) Non hodgkins lymphoma

d) Gastrointestinal stromal tumor

Correct Answer - A

Ans. is 'a' i.e., Langerhans cell histiocytosis

Birbeck granules are characteristic of langerhans cell histiocytosis

*Tumour cells in the langerhan's cell histiocvtosis are derived from dendritic cells and express :*

- S-100
- CD1a
- HLA-DR
- *These cells are characterized by the presence of birbeck granules in their cytoplasm unde rthe electron microscope, Birbeck granules have pentalaminar, rodlike tuular appearance and sometimes a dilated terminal end (tennis-racket appearance)*

## 216. Reticulocytes are stained by ?

a) Supravital stain

b) Purssian blue stain

c) H and E stain

d) Reticulin stain

Correct Answer - A

Ans. is 'a' i.e., Supravital stain

Usually supravital stains (methylene blue and Brilliant cresyl blue) are used for reticulocytes.

## 217. Most common type of hodgkins lymphoma is ?

a) Lymphocyte predominant

b) Lymphocyte depletion

c) Nodular sclerosis

d) Mixed cellularity

Correct Answer - C

Ans. is 'c' i.e., Nodular sclerosis

- Best Prognosis
- Worst prognosis
- Most common HL
- Most common type HL in India
- Least common type HL

Lymphocytic predominance type. —> Lymphocytic depletion type. —  
> Nodular sclerosis type.

—> Mixed cellularity type. Lymphocytic depletion type

**218. Most common site for eosinophilic granuloma is?**

a) Radius

b) Skull

c) Lumbar vertebra

d) Femur

Correct Answer - B

Ans. is 'b' i.e., Skull

The most common sites are skull bones, long bones, spinal vertebrae, mastoid and mandible.

**219. Replacement of columnar epithelium in respiratory tract to squamous epithelium is ?**

a) Hyperplasia

b) Hypoplasia

c) Metaplasia

d) None of the above

Correct Answer - C

**Ans. is `c' i.e., Metaplasia**

**Metaplasia**

- Metaplasia is a reversible change in which one differentiated cell type is replaced by another differentiated cell type.
- Metaplasia represents an adaptive substitution of cells that are sensitive to stress by cell types better able to withstand the adverse environment.

## 220. Which is the best marker of SLE ?

a) Anti Sm antibodies

b) Anti dsDNA antibodies

c) Anti histone antibodies

d) Anti Ro Antibodies

Correct Answer - B

Ans. is 'b' i.e., Anti dsDNA antibodies

*Antibodies to double - stranded DNA and the Smith (Sm) antigen are virtually diagnostic of SLE".*

**221. Most common cause of death in amyloidosis is ?**

a) Heart failure

b) Renal failure

c) Sepsis

d) None

Correct Answer - A

Ans. is 'a' i.e., Heart Failure

*'Most common cause of death is heart failure and/or abnormal cardiac rhythm' Essentials pathology*

## 222. What is true about ulcerative colitis ?

a) Involves rectum and then whole colon backwards

b) Involves only colon

c) Skip lesions seen

d) Ileum not involved

Correct Answer - A

**Ans. is- A. Involves rectum and then whole colon backwards**

**Ulcerative colitis (UC)** is a long-term condition that results in inflammation and ulcers of the colon and rectum.

## 223. Execution caspases of apoptosis are ?

a) Caspase 1 & 3

b) Caspase 3 & 5

c) Caspase 1 & 5

d) Caspase 3 & 7

Correct Answer - D  
Ans. is 'd' i.e., Caspase 3 & 7

## 224. Neurofibromatosis shows which of the following mode of inheritance ?

a) AD

b) AR

c) X linked dominant

d) X linked recessive

Correct Answer - A

**Ans. is 'a' i.e., AD**

**Neurofibromatosis shows autosomal dominant inheritance pattern**

- *Single gene disorders (Mendelian disorders) typically follow one of the three patterns of inheritance ?*

1. Autosomal dominance
2. Autosomal recessive
3. X-linked

### **Autosomal dominant disorders**

- Normally a gene pair has two alleles.
- When one allele becomes abnormal due to mutation it is called *heterozygous state*.
- When both the alleles become abnormal due to mutation it is called *homozygous state*.
- *Autosomal dominant disorders are manifested in heterozygous state, i.e. only if one allele is abnormal the disease will be manifested.*

## 225. Most common site of glomus tumor is ?

a) Under fingernails

b) Under toenails

c) Neck

d) Axilla

Correct Answer - A

Ans. is 'a' i.e., Under fingernails

Glomus tumor (Glomangioma)

- Benign tumor arising from the smooth muscle cells of the glomus body which is an arteriovenous anastomosis involved in thermoregulation.
- Most commonly present in the distal portion of the digits (under fingernails).
- Histologically, there is presence of branching vascular channels and stroma containing nests/aggregates of glomus cells arranged around vessels.

**226. Normal reticulocyte count in newborn is -**

a) 0 - 1%

b) 1 - 1.5%

c) 3 - 6%

d) 6 - 9 %

Correct Answer - C

Ans. is 'c' i.e., 3 - 6%

Normal reticulocyte count in adults is 1 - 1.5% and in newborns is 3 - 6 %

## 227. BRCA2 not associated with

a) breast cancer

b) Prostate cancer

c) Ovarian cancer

d) Vulval cancer

Correct Answer - D

Ans. is 'd' i.e., Vulval cancer

- *BRCA-1* er *BRCA-2* are commonly associated with → Carcinomas of ovary and breast.
- *Less commonly BRAC-2* is also associated with → Carcinomas of colon, prostate and pancreas.

[Ref Robbin's *Vie* p. 1076; *Clinical Surgery* by Michal M. Henry & Jeremy N. Thompson 2<sup>nd</sup>/e p. 453]

## 228. Which of the following is not a large vessel vasculitis ?

a) Takayasu arteritis

b) Cogan syndrome

c) Churg strauss syndrome

d) Giant cell arteritis

Correct Answer - C

Ans. is 'c' i.e., Churg strauss syndrome

- *Large vessel vasculitis* : Giant cell arteritis (temporal arteritis), Takayasu arteritis, Cogan syndrome.
- *Medium vessel vasculitis* : PAN (classical PAN), kawasaki disease, Buerger's disease.
- *Small vessel vasculitis* : HSP, Wegner's granulomatosis, microscopic polyangitis, churg strauss syndrome, Cryoglobulinemia, SLE, idiopathic crescentic glomerulonephritis, Bechet's syndrome, renal limited vasculitis.

## 229. Trauma to breast causes which type of necrosis ?

a) Coagulative necrosis

b) Liquefactive necrosis

c) Caseous necrosis

d) Fat necrosis

Correct Answer - D

**Ans. is 'd' i.e., Fat necrosis**

### **Fat necrosis**

Fat necrosis may be of two types : ?

### **Enzymatic fat necrosis**

- This is due to action of *lipase* on adipose tissue.
- It occurs most frequently in *acute pancreatitis* due to leakage of lipase.
- Depending on the severity of acute pancreatitis, fat necrosis may occur in : - a *Adipose tissue contiguous to pancreas, retroperitoneal fat.*
- Adipose tissue in *anterior mediastinum.*
- *Bone marrow*
- *Omental and abdominal fat*

### **Nonenzymatic or Traumatic fat necrosis**

- Occurs due to trauma
- Is seen in *subcutaneous tissue of breast, thigh, and abdomen.*

## 230. Inhibin is tumor marker for ?

a) Granulosa cell tumor

b) Malignant melanoma

c) Prolactinoma

d) Breast carcinoma

Correct Answer - A

Ans. is 'a' i.e., Granulosa cell tumor

- Granulosa cell tumor is positive for vimentin, inhibin, CD99.

## 231. Following statement is true for hemophilia patients?

a) All Females are carriers and all males are affected

b) All Males are carriers and all females are affected

c) Females are mostly carriers and all males are affected

d) Males are mostly carriers and all females are affected

Correct Answer - C

Ans. is 'c' i.e., Females are mostly carriers and all males are affected. Hemophilia is an X-linked recessive hemorrhagic disease due to mutations in the *F8* gene (hemophilia A or classic hemophilia) or *F9* gene (hemophilia B).

The disease affects 1 in 10,000 males worldwide, in all ethnic groups; hemophilia A represents 80% of all cases.

Male subjects are clinically affected; women, who carry a single mutated gene, are generally asymptomatic.

Family history of the disease is absent in 30% of cases and in these cases, 80% of the mothers are carriers of the de novo mutated allele.

## 232. Which worm causes myocarditis ?

a) Trichuris

b) Trichinella

c) Enterobius

d) Stroglyoides

Correct Answer - B

Ans. is 'b' i.e., Trichinella

- *Trichinosis is the most common helminthic disease causing myocarditis.*

### 233. Giant platelets are seen in ?

a) Bernard soulier syndrome

b) vWD

c) Polycythemia rubra vera

d) Leukemia

Correct Answer - A

Ans. is 'a' i.e., Bernard soulier syndrome

**Bernad Soulier disease** - Defect in the platelet Gplb-IX complex  
BT, mild thrombocytopenia, deficient or low levels of platelet Gplb-IX  
complex by flowcytometry  
Ristocetin aggregation test is defective

## 234. LE cell is seen in ?

a) Lupus erythmatosus

b) Lupus vulgaris

c) HNPCC

d) Medullary carcinoma of thyroid

Correct Answer - A

Ans. is 'a' i.e., Lupus erythematosus

- In SLE, antinuclear antibodies (ANPs) can not penetrate intact cells.
- However, nuclei are exposed, ANA can bind to them.
- In tissues, nuclei of damaged cells react with ANAs, lose their chromatin pattern, and become homogeneous, to produce *lupus - erythematosus (LE) bodies* or hematoxylin bodies.
- When these LE bodies are engulfed by phagocytic cells (*neutrophil or macrophage/monocyte*), the phagocytic cells are called *LE cells*.

## 235. Pelger Huet anomaly shows presence of ?

a) Hyposegmented neutrophil

b) Hypersegmented neutrophil

c) Unsegmented neutrophil

d) None of the above

Correct Answer - A

**Ans. is 'a' i.e., Hyposegmented neutrophil**

**Pelger Huet anomaly**

- It is a genetic disorder with an autosomal dominant inheritance pattern.
- It is a blood laminopathy associated with the lamin B receptor.
- It is characterized by a white blood cell type known as a neutrophil whose nucleus is hyposegmented.
- Heterozygotes are clinically normal, although their neutrophils may be mistaken for immature cells, which may cause mistreatment in a clinical setting.
- Homozygotes tend to have neutrophils with rounded nuclei that do have some functional problems.

## 236. Sentinel lymph node biopsy is used for ?

a) Melanoma

b) Basal cell carcinoma

c) Squamous cell carcinoma

d) Thyroid carcinoma

Correct Answer - A

Ans. is 'a' i.e., Melanoma

Sentinel lymph node biopsy is used for breast carcinoma and melanoma.

## 237. Interleukin 2 is produced by

a) T helper cells 1

b) T helper cells 2

c) Natural killer cells

d) Basophils

Correct Answer - A

Ans. is 'a' i.e., T helper cells 1

**A) T helper - 1 ( $T_H1$ ) secretes 4 IL-2 and interferon -  $\gamma$**

**B) T helper - 2 ( $T_H2$ ) secretes -> IL-4, IL-5, IL-6, IL-13**

**238. Popcorn cells are seen in which variety of hodgkin's disease ?**

a) Nodular sclerosis

b) Mixed cellularity

c) Lymphocyte predominant

d) Lymphocyte depletion

Correct Answer - C

Ans. is 'c' i.e., Lymphocyte predominant

Popcorn cells are found in lymphocytic predominant type of Hodgkin's Lymphoma.

### 239. Shape of birbeck granules is ?

a) Tennis racket

b) Hockey stick

c) Bat

d) Ball

Correct Answer - A

Ans. is 'a' i.e., Tennis racket

Under the electron microscope, Birbeck granules have a pentalaminar, rodlike, tubular appearance and sometimes a dilated terminal end resembling *tennis-racket appearance*.

**240. Lipid peroxidation of polyunsaturated lipids of subcellular membranes produces ?**

a) Lipofuscin

b) Hemosiderin

c) Both of above

d) None of above

Correct Answer - A

Ans. is 'a' i.e., Lipofuscin

- Lipofuscin is an insoluble pigment, also known as lipochrome or wear-and-tear pigment.
- Lipofuscin is composed of polymers of lipids and phospholipids in complex with protein, suggesting that it is derived through lipid peroxidation of polyunsaturated lipids of subcellular membranes.

**241. Paraneoplastic syndrome Hypercalcemia of malignancy, is produced due to ectopic production of which hormone by lymphomas ?**

a) PTHrP

b) 1,25 dihydroxyvitamin D

c) PGE2

d) Parathormone

Correct Answer - B

Ans. is 'b' i.e., 1, 25 dihydroxyvitamin D

Parathyroid hormone-related protein (PTHrP)

1,25 dihydroxyvitamin D

Parathyroid hormone (PTH) (rare) Prostaglandin E2 (PGE2) (rare)

## 242. HLA B51 is associated with ?

a) Behcet's disease

b) Chrug strauss syndrome

c) Microscopic polyangitis

d) Polyarteritis nodosa

Correct Answer - A

**Ans. is 'a' i.e., Behcet's disease**

**Behcet's disease :?**

- Behcet disease is a small- to medium-vessel neutrophilic vasculitis that classically presents as a clinical triad of recurrent oral aphthous ulcers, genital ulcers, and uveitis.
- There can also be gastrointestinal and pulmonary manifestations, with disease mortality related to severe neurologic involvement or rupture of vascular aneurysms. There is an association with certain HLA haplotypes (HLAB51, in particular)

## 243. PT is used to test ?

a) Extrinsic and common pathway

b) Intrinsic and common pathway

c) Intrinsic pathway

d) Extrinsic pathwa

Correct Answer - A

Ans. is 'a' i.e., Extrinsic and common pathway

Patients with hemophilia have deficiency of factor VIII that results in prolonged PTT.

**244. Which of the following is not a hereditary disease?**

a) Neurofibromatosis

b) Cretinism

c) Huntingtons disease

d) Hereditary spherocytosis

Correct Answer - B

**Ans. is 'b' i.e., Cretinism**

**Cretinism :?**

Cretinism is a condition of severely stunted physical and mental growth due to untreated congenital deficiency of thyroid hormones (congenital hypothyroidism) usually due to maternal hypothyroidism. Thus cretinism is a non hereditary condition.

**245. Point mutation in which protooncogene is responsible for the development of gastrointestinal stromal tumor**

a) KIT

b) ALK

c) RET

d) FLT3

Correct Answer - A

Ans. is 'a' i.e., KIT

- Approximately 75% to 80% of all GISTs have oncogenic, gain-of-function mutations of gene encoding the *tyrosine kinase c-KIT*.
- Approximately 8% of GISTs have mutations that activate a related tyrosine kinase, *platelet derived growth factor receptor a (PDGFRA)*.
- Constitutively active c-KIT or PDGFRA receptor tyrosine kinases activate RAS and P13K/AKT pathways and thereby promote tumor cell proliferation.

**246. Carcinoembryonic antigen is raised in which of the following non neoplastic conditions -**

a) Hepatitis

b) Pancreatitis

c) Hemolytic anemia

d) Ulcerative colitis

Correct Answer - B

Ans. is 'b' i.e., Pancreatitis

1) *Neoplastic conditions with raised CEA* → Colorectal cancer, lung cancer, breast cancer, ovarian cancer.

2) *Non-neoplastic conditions with raised CEA* → Alcoholic cirrhosis, hepatitis, IBD (UC, CD), smoking, pancreatitis and hemolytic anemia.

**247. Under Blood safety programme compulsory tests done are all except ?**

a) HIV

b) VDRL

c) Malaria

d) Hepatitis E

Correct Answer - D

**Ans. is 'd' i.e., Hepatitis E**

**Blood safety :?**

- Under Blood Safety Programme all the blood banks have to ensure that before transfusion of blood to the patient the mandatory tests for HIV, VDRL, Hepatitis B, Hepatitis C and Malaria are done.

## 248. EBV receptor mimics ?

a) CD 20

b) CD 21

c) CD 22

d) CD 23

Correct Answer - B

Ans. is 'b' i.e., CD 21

- CD 21 -> EBV receptor : Mature B cells and follicular dendritic cells.

**249. Leukocyte adhesion to endothelium is mediated by all except ?**

a) L selectin

b) E selectin

c) VCAM 1

d) VCAM 4

Correct Answer - D

Ans. is 'd' i.e., VCAM 4

**Endothelial molecule** P-selectin

E-selectin ICAM- 1 VCAM-1 Glycam-1

CD 31 (PECAM)

## 250. Boys are more likely to be affected by which genetic disorders ?

a) AD

b) AR

c) X linked dominant

d) X linked recessive

Correct Answer - D

**Ans. is 'd' i.e., X linked recessive**

### **X-linked disorders**

- Except for a few conditions, all X-linked disorders are X-linked *recessive*.
- As male has only one X-chromosome, the male with affected gene on X-chromosome will always manifest the disease.
- On the other hand, female has 2 X-chromosomes, heterozygous female will be carrier because of expression of normal allele on the other X-chromosome.
- So a boy has more probability to manifest X linked recessive as compared to girls

**251. Increased accumulation of fluid in the interstitial space is described as ?**

a) Edema

b) Effusion

c) Transudate

d) Exudate

Correct Answer - A

Ans. is 'a' i.e., Edema

Edema: accumulation of fluid in the interstitial space

Effusion: accumulation of fluid in the body cavities

## 252. Classic example of missense mutation ?

a) Thalassemia

b) Sickle cell disease

c) Sideroblastic anemia

d) Hemochromatosis

Correct Answer - B

**Ans. is 'b' i.e., Sickle cell disease**

**In sickle cell anemia there is missense type of point mutation.**

### **Mutations**

- A mutation is *apermanent change in the DNA*.
- Mutations that affect genii cells (sperm or ovum) are transmitted to progeny and may give rise to inherited disease.
- Mutations that affect somatic cells are not transmitted to progeny but are important in the genesis of cancers and congenital malformations.
- Mutations may be classified into three categories ?
  1. Gene mutations
- *The vast majority of mutations associated with hereditary disease are gene mutations.*
- These may of different types depending whether it involves complete gene or single base ?
  - (a) *Point mutation*
- A single nucleotide base is substituted by a different base.
- When a pyrimidine base is substituted by other pyrimidine base or a purine base is substituted by other purine
- *Transition.*
- When a purine is substituted by a pyrimidine or vice-versa  
Transversion.

- This may alter the code in a triplet of bases, i.e. in codon and leads to replacement of one amino acid by another in the gene product.
- Because these mutations alter the meaning of the genetic code, they are often termed *missense mutation*.
- Example is *sickle mutation* in which CTC codon in 13-chain of hemoglobin that codes for glutamic acid is changed to CAC codon that codes for valine.
- Another type of point mutation is *nonsense mutation* in which a point mutation may change an amino acid codon to a stop codon. Example is 13-thalassemia in which CAG codon in 13-chain of hemoglobin that code for glutamin is changed to stop codon UAG after point mutation.

*(b) Deletion and insertions*

- Deletion or insertion of one or two base lead to alterations in the reading frame of the DNA strand → *frame shift mutation*.
- If the number of base pairs involved is three or a multiple of three frame shift does not occur (because codon is triplet), instead an abnormal protein missing one or more amino acids is synthesized.

*(c) Trinucleotide repeat mutation*

- Normally a codon is triplet ie trinucleotide.
- In this type of mutation a codon, ie trinucleotide sequence undergoes amplification and the same codon is repeated continuously so many times in the chain.
- For example in fragile X-syndrome, CGG codon is repeated 250-4000 times, ie. there are 250-4000 tandem repeats of CGG.

2. Chromosome mutation

- Result from rearrangement of genetic material that give rise to visible structural changes in the chromosome.
- 3. Genome mutation
- Involves loss or gain of whole chromosome, e.g. *monosomy* - Turner syndrome, *trisomy* - Down syndrome.

## 253. Matrix metalloproteinases is ?

a) Cathepsin

b) Zn metalloproteinases

c) Cu metalloproteinases

d) Cd metalloproteinases

Correct Answer - A

Ans. is b i.e., Zn metalloproteinases

The outcome of the repair process of tissues is influenced by a balance between synthesis and degradation of ECM proteins. After its deposition, the connective tissue in the scar continues to be modified and remodeled.

The degradation of collagens and other ECM components is accomplished by a family of matrix *metalloproteinases (MMPs)*, so called because they are dependent on metal ions (e.g., zinc) for their activity.

MMPs include interstitial collagenases, which cleave fibrillar collagen (MMP-1, -2 and -3); gelatinases (MMP-2 and 9), which degrade amorphous collagen and fibronectin; and stromelysins (MMP-3, -10, and ,11), which degrade a variety of ECM constituents, including proteo- glycans, laminin, fibronectin, and amorphous collagen.

## 254. Tau protein seen in ?

a) Alzheimer's disease

b) Lewy body dementia

c) Pick's disease

d) Amyloidosis

Correct Answer - A

**Ans. is 'a' i.e., Alzheimer's disease**

**Alzheimer's disease :?**

- There is atrophy of frontal and temporal lobes to variable extent and severity.
- The pattern of atrophy can often be predicted in part by the clinical symptomatology.
- The atrophic regions of cortex are marked by neuronal loss, gliosis, and the presence of tau-containing neurofibrillary tangles

**255. The phenomenon by which the cancer cells are able to sustain and proliferate under adverse conditions of hypoxia is ?**

a) Warburg

b) Wanton

c) Wormian

d) Wolf

Correct Answer - A

Ans. is 'a' i.e., Warburg

Otto Warburg described the bioenergetics and metabolic features that permit cancer cells to survive under adverse conditions such as hypoxia and enable their proliferation, progression, invasiveness, and subsequent distant metastasis.

This phenomenon is thus called the growth promoting Warburg phenomenon.

## 256. Defect of glanzmann's thrombosthenia is ?

a) Gp1b-IIIa

b) GpIIIa-I Ib

c) GpIIa-IIIb

d) Gpfilb-I Ia

Correct Answer - A

Ans. is 'a' i.e., Gp1b-IIIa

- *Defect in Glanzmann's thrombosthenia* Gp IIb/IIIa
- *Defect in Bernard Soulier syndrome* Gp Ib/IX

## 257. Metastatic calcification is characterized by ?

a) Hypercalcemia

b) Hypocalcemia

c) Eucalcemia

d) None of the above

Correct Answer - A

Ans. is 'a' i.e., Hypercalcemia

Pathologic calcifications

- Dystrophic calcification: Deposition of calcium at sites of cell injury and necrosis.
- Metastatic calcification: Deposition of calcium in normal tissues, caused by hypercalcemia (usually a consequence of parathyroid hormone excess)

## 258. Most important growth factors in angiogenesis ?

a) PDGF

b) TGF alpha

c) TGF beta

d) VEGF

Correct Answer - D

Ans. is 'd i.e., VEGF

- *Two most important angiogenic factors are :*
  - Vascular endothelial growth factor (VEGF) → most important.*
  - Basic fibroblast growth factor (FGF-2).*

## 259. Necrosis with cell bodies retained as ghost cells is ?

a) Coagulative necrosis

b) Liquefactive

c) Caseous

d) None

Correct Answer - A

Ans. is 'a' i.e., Coagulative necrosis

- The microscopic anatomy of coagulative necrosis shows a lighter staining tissue containing no nuclei with very little structural damage, giving the appearance often quoted as "Ghost cells" -> outlines of cells are retained so that the cell type can still be identified but their cytoplasmic and nuclear details are lost.

## 260. Cells responsible for GVHD is ?

a) Immunocompetent T cell donor

b) Immunocompetent T Cell recipient

c) Immunocompetent B cell donor

d) Immunocompetent B cell donor

Correct Answer - A

**Ans. is 'a' i.e., Immunocompetent T-cell donor**

**Graft- versus-host disease (GVHD) :?**

GVHD occurs when immunologically competent cells (T cells) or their precursors are transplanted into immunologically crippled recipients, and the transferred cells recognize alloantigens in the host and attack host tissues.

*Most commonly involved tissues in Graft versus host disease :-*

- Liver
- Skin
- Gut

## 261. Flow cytometry is done on

a) Polycythemia

b) Thrombocytosis

c) Basophil

d) Lymphocytes

Correct Answer - D

Ans. d. Lymphocytes

"Flow cytometry can rapidly and quantitatively measure several individual cell characteristics, such as membrane antigens and the DNA content of tumor cells. Flow cytometry has also proved useful in the identification and classification of tumors arising from T and B lymphocytes and from mononuclear-phagocytic cells."- *Robbins 8/e p324*

## 262. Person having heterozygous sickle cell trait is protected from infection of:

a) *P. falciparum*

b) *P. vivax*

c) Pneumococcus

d) Salmonella

Correct Answer - A

Ans. a. *P. falciparum*

- Person having heterozygous sickle cell trait is protected from infection of *P. falciparum*.
- "People who are heterozygous for the sickle cell trait (HbS) become infected with *P. falciparum*, but they are less likely to die from infection°. The HbS trait causes the parasites to grow poorly or die because of the low oxygen concentrations°." - *Robbins 8/e p387*

### **Host Resistance to Plasmodium**

- Two general mechanisms of host resistance to Plasmodium:
- Inherited alterations in red cells make people resistant to Plasmodium°.
- Repeated or prolonged exposure to Plasmodium species stimulates an immune response that reduces the severity
- People who are heterozygous for the sickle cell trait (HbS) become infected with *P. falciparum*, but they are less likely to die from infection°.
- The HbS trait causes the parasites to grow poorly or die because of the low oxygen concentrations°.
- The geographic distribution of the HbS trait is similar to that of *P. falciparum*°, suggesting evolutionary selection of the HbS trait in people by the parasite

- HbC, another common hemoglobin mutation, also protects against severe malaria by reducing parasite proliferation°.

**Host Resistance to Plasmodium.**

- People can also be resistant to malaria due to the absence of proteins to which the parasites bind°.
- *P. vivax* enters red cells by binding to the Duffy blood group antigen°.
- Many Africans, including most Gambians, are not susceptible to infection by *P. vivax* because they do not have the Duffy antigen°.
- Antibodies and T lymphocytes specific for Plasmodium reduce disease manifestations. Cytotoxic lymphocytes may also be important in resistance to *P. falciparum*

## 263. Sequence of events in acute inflammation ?

a) Vasodilatation → Stasis → Transient vasoconstriction  
→ Increased permeability

b) Transient vasoconstriction → Stasis → Vasodilatation →  
Increased permeability

c) Transient vasoconstriction → Vasodilatation → Stasis  
→ Increased permeability

d) Transient vasoconstriction → Vasodilatation → Increased  
permeability → Stasis

Correct Answer - D

Ans. is 'd' i.e., Transient vasoconstriction → Vasodilatation  
→ Increased permeability → Stasis

1) *Changes in vascular caliber (vasodilatation)*

- *Vasodilatation is one of the earliest manifestations of acute inflammation.*
- Sometimes, it follows a *transient constriction* of arterioles, (vasoconstrictions) lasting for a few seconds -  
> *Though vasodilatation is the earliest manifestation of acute inflammation, it follows a transient period of vasoconstriction.*
- 2) *Change in vascular permeability*
- Vasodilatation is quickly followed by increased vascular permeability.
- *Increased vascular permeability is the hallmark of acute inflammation.*
- *This leads to escape of protein rich fluid (exudate) and leukocytes into extravascular space*
- 3) *Change in vascular flow (Stasis)*
- The loss of fluid results in concentration of red cells and increased

viscosity of blood - Slower blood flow - Stasis.

## 264. Gene silencing RNA ?

a) rRNA

b) tRNA

c) miRNA

d) None

Correct Answer - C

Ans. is 'c' i.e., miRNA

- According to recent studies a very large number of genes do not encode proteins. Instead, their products play important regulatory functions.
- The most recently discovered among this class of genes are that encode for gene-silencing RNAs, i.e. RNAs that do not encode proteins but instead inhibit gene expression (unlike classical RNAs which encode for proteins)

**Two gene-silencing RNAs are:**

1. Micro RNAs (miRNAs)
2. Small interfering RNAs (siRNAs)

**1. Micro RNA (miRNAs)**

- Because of their profound influence on gene regulation, miRNAs are assuming central importance in understanding normal developmental pathways, as well as pathologic conditions, such as cancer. o By current estimates there are approximately 1000 genes in humans that encode miRNAs.
- Transcription of miRNA gene produces primary miRNA transcripts, which is processed within the nucleus to form another structure, called pre-miRNA.
- Pre-miRNA is transported to cytoplasm by a transportor (Export) protein.

- Dicer (an enzyme) does the additional cutting of this pre-miRNA that are about 21-30 nucleotide in length (hence called "micro").
- At this stage mRNA is still double stranded.
- Next, the miRNA unwinds, and single strands of this duplex are incorporated into a multiprotein complex called RNA-induced silencing complex (RISC).
- Base-pairing between the miRNA strand and its target mRNA (messenger RNA) directs RISC to either cause mRNA cleavage or repress its translation.
- In this way, the gene from which the target was derived is silenced (at a post-transcription level).
- A single miRNA can silence many target genes.

## **2. Small interfering RNAs (siRNAs)**

- siRNAs work in similar manner as miRNA
- Unlike miRNA, siRNA precursors are introduced by investigators into cells.
- siRNA are becoming powerful tools for studying gene function and may in the future be used therapeutically to silence specific genes, such as oncogenes, whose products are involved in neoplastic transformation.

## 265. All are obstructive lung disease except -

a) Emphysema

b) Interstitial fibrosis

c) Asthma

d) Bronchitis

Correct Answer - B

Ans. is 'b' i.e., Interstitial fibrosis

- Diffuse pulmonary diseases are divided into two categories -  
**Obstructive disease (airway disease)**
- Obstructive disease is characterized by an increase in resistance to airflow owing to partial or complete obstruction at any level, from the trachea to the respiratory bronchioles.
- Examples are *chronic obstructive lung disease (COPD - Emphysema, bronchitis), bronchiectasis, and asthma.*
- **Restrictive disease**
- Restrictive disease is characterized by reduced expansion of lung parenchyma, with decreased total lung capacity. o It may occur due to two types of disorders -
- Chest wall disorders in the presence of Normal lungs  
Neuromuscular disorders, e.g. polio, severe obesity, pleural disease, kyphoscoliosis.
- Interstitial and infiltrative diseases of lung Pneumoconiosis, interstitial fibrosis.

**266. Centrilobular necrosis of liver may be seen with?**

a) Phosphorus

b) Arsenic

c) CCl<sub>4</sub>

d) Ethanol

Correct Answer - C

Ans. is 'c' i.e., CCl<sub>4</sub>

Zonal necrosis

. Identical regions of all liver lobules are involved. It is divided into :-

*i) Centrizonal (centrilobular) necrosis*

- Necrosis is seen around central hepatic vein. It is seen in *cardiac failure/shock, chloroform toxicity, carbon tetra chloride (ccl4) toxicity, halothane and viral hepatitis.*

*ii) Peripheral zonal (periportal) necrosis*

- Necrosis is seen around portal tracts. It is seen in *eclampsia and phosphorus poisoning.*

*iii) Midzonal necrosis*

- It is rare and is seen in yellow fever.

## 267. During angiogenesis recruitment of pericytes and periendothelial cells is due to

a) VEGF & PDGF

b) Angiopoietins, TGF & PDGF

c) TGF, VEGF & PDGF

d) VEGF, IL-6

Correct Answer - B

Ans. is 'b' i.e., Angiopoietins, TGF & PDGF

### **Angiogenesis**

- Blood vessels formation in adults is known as *angiogenesis* or *neovascularization*. It can occur by two ways:?
  - 1. Angiogenesis from pre-existing blood vessels**
    - The major steps in this process are :?
      - Vasodilatation by NO, and VEGF-induced increased permeability of the pre-existing vessel.
      - Proteolytic degradation of basement membrane by metalloproteinases (MMPs) and disruption of cell-to-cell contact between endothelial cells by plasminogen activator.
      - Migration of endothelial cells towards angiogenic stimulus.
      - Proliferation of endothelial cells, just behind the leading front of migrating cells.
      - Maturation of endothelial cells.
      - Recruitment of periendothelial cells (pericytes and vascular smooth muscle cells) to form the mature cells.
    - 2. Angiogenesis from endothelial precursor cells (EPCs)**
      - EPCs can be recruited from the bone marrow into tissues to initiate

angiogenesis.

- Growth factors involved in the process of angiogenesis
- VEGF is the most important growth factor in adult tissues undergoing angiogenesis.
- The most important receptor for VEGF is VEGFR-2, a tyrosine kinase receptor.
- VEGF induces the migration of EPCs in the bone marrow, and enhances the proliferation and differentiation of these cells at sites of angiogenesis.
- FGF 2 can also stimulate endothelial cell proliferation, differentiation and migration.
- Newly formed vessels are fragile and need to become stabilized, which requires the recruitment of pericytes and smooth muscle cells (periendothelial cells). Angiopoietin **1 and 2** (Ang **1 & 2**), PDGF and TGF- $\beta$ 3 participate in stabilization process.

**Remember**

- VEGF transcription is regulated by the transcription factor **HIF**, which is induced by hypoxia.

## 268. Heart failure cells are ?

a) Lipofuscin granules in cardiac cells

b) Pigmented alveolar macrophages

c) Pigmented pancreatic acinar cells

d) Pigment cells seen in liver

Correct Answer - B

Ans. is `B' i.e., Pigmented alveolar macrophages

- Heart failure cells (siderophages) are hemosiderin containing macrophages in alveoli that are seen in left ventricular failure and denote previous episodes of pulmonary edema.

### **Left sided heart failure**

- The major morphological and clinical effects of LVF are due increased back pressure in pulmonary circulation and the consequences of diminished peripheral blood pressure and flow.
- The extracardiac organs involved commonly are ?
  - .. Lung (most common)
  - ?. Kidney
  - }. Brain

### **Lung**

- Pressure in the pulmonary veins increases and transmitted retrogradely to capillaries and arteries.
- This results in *pulmonary congestion* and *pulmonary-edema* → *Wet lung*.
- There is perivascular and interstitial transdate, particularly in the interlobular septa responsible for kerley's `B' lines on X-rays.
- Edematous fluid accumulates in alveoli.
- Iron containing proteins and hemoglobin leak out from the capillaries, and are phagocytosed by macrophages and converted to

hemosiderin.

- Hemosiderin - containing macrophages in the alveoli (called siderophages, or heart failure cells) denote previous episodes of pulmonary edema.
- The clinical manifestations of LVF are primarily due to these changes in lungs → Dysnea, orthopnea, paroxysmal nocturnal dysnea.

### **Kidney**

- Decreased cardiac output causes a reduction in renal perfusion.
- If it is severe enough to impair the excretion of nitrogenous product (BUN, Creatinine), Prerenal ARF (Prerenal azotemia) may be precipitated.

### **Brain**

- Reduced perfusion to brain may cause hypoxic / ischemic encephalopathy.

## 269. All are true about Polycythemia vera except

a) Increased vit B<sub>12</sub>

b) Decrease LAP score

c) Leucocytosis

d) Increased platelets

Correct Answer - B

Ans. is 'b' i.e., Decrease LAP score

### **Polycythemia vera**

- Polycythemia vera is a neoplasm arising in a multipotent myeloid stem cell that is characterized by increased marrow production of erythroid, granulocytic and megakaryocytic elements.
- This leads to erythrocytosis (polycythemia), granulocytosis, and thrombocytosis in the peripheral blood.
- Polycythemia is responsible for most of the clinical symptoms of polycythemia vera.
- Polycythemia vera progenitor cells have markedly decreased requirements for erythropoietin and other hematopoietic growth factors. Accordingly serum erythropoietin levels in polycythemia vera are very low, whereas almost all other forms of absolute polycythemia are caused by elevated erythropoietin levels.

### **Clinical manifestations**

#### **1. Symptoms due to polycythemia**

- Most symptoms are related to the increased red cell mass and hematocrit, i.e., Polycythemia.
- The elevation of hematocrit is usually accompanied by increased total blood volume, and together these two promote abnormal blood

flow, particularly on the low pressure venous side of the circulation, which becomes greatly distended. That results in -

- Plethora or cyanosis owing to stagnation of deoxygenated blood in peripheral vessels.
- Headache, dizziness, hypertension and
- Diminished vision from blockade of retinal vessels.

## **2. Symptoms due to granulocytosis**

- Basophils secrete histamine that results in -
- Intense pruritis
- Peptic ulceration
- Increased vit B<sub>12</sub> binding capacity because of increase in transcobalmin I & II.

## **3. Symptoms due to Thrombocytosis**

- There is increased risk of both thrombosis and major bleeding episodes.

Thrombosis                      DVT, MI, Stroke, Budd chiari syndrome.

Bleeding                         Upper GI bleeding from peptic ulcer.

### **Laboratory features of Polycythemia vera.**

Increased Red cell count (Polycythemia)	Increased Vit B <sub>12</sub> binding capacity
Increased WBC count (Leucocytosis)	Increased blood viscosity
Increased platelet count (Thrombocytosis)	Decreased ESR
Increased Leucocyte alkaline phosphate (LAP) score	Hyperuricemia due to increased turnover of cells.
Increased hemoglobin	Increased histamine level

## 270. Intracorpuseular hemolytic anemia is seen in ?

a) Autoimmune hemolytic anemia

b) TIP

c) Thalassemia

d) Infection

Correct Answer - C

Ans. is `c' i.e., Thalassemia

- *Intracorpuseular hemolysis* : Hereditary spherocytosis, G6PD deficiency, *thalassemia*, sickle cell anemia, PNH.
- *Extracorpuseular hemolysis* : Microangiopathic hemolytic anemia (TTP, HUS, DIC), infection (malaria), prosthetic valve, *immuno-hemolytic anemia* and hyperplenism.

## 271. Gilbert syndrome, true all except ?

a) Causes cirrhosis

b) Autosomal dominant

c) Normal liver function test

d) Normal histology

Correct Answer - A

Ans. is 'a' i.e., Causes cirrhosis

Gilbert's Syndrome: ?

- o It is an autosomal dominant condition.
- o It is characterized by unconjugated hyperbilirubinemia (normally the bilirubin is transported into liver cells by intracellular proteins. In the liver bilirubin is conjugated. This conjugation is brought about by certain enzymes. In Gilbert's syndrome these enzymes are absent which cause unconjugated hyperbilirubinemia).
- The hyperbilirubinemia is usually precipitated by following conditions – Stress, Fatigue, Alcohol use, reduced calorie intake, intercurrent illness.
- The hepatic biochemical tests are normal except for elevated bilirubin level (serum bilirubin concentration are usually  $< 3\text{mg/dl}$ )  
Embryonal carcinoma The hepatic histology is normal  
There is no association with cirrhosis.

## 272. Flexner-Wintersteiner rosette is seen in-

a) Hepatoblastoma

b) Nephroblastoma

c) Neuroblastoma

d) Retinoblastoma

Correct Answer - D

Ans. is 'd' i.e., Retinoblastoma

### **Rosettes**

- Rosettes are pathological findings characterized by a halo or spoke wheel arrangement of cells surrounding a central core or hub.

### **Type of Rosette**

#### **1. Flexner - Wintersteiner Rosettes**

- A halo of cells surrounds a largely empty central hub but small cytoplasmic extension from cells project into the lumen.
- It is characteristic of retinoblastoma.
- May also be seen in → Medulloblastoma, Primitive neuroectodermal tumor, Pineoblastoma.

#### **2. Homer Wright rosettes**

- A halo of cells surrounds a central hub that contains a meshwork of fibres (neutrophil rich centre). o Homer-Wright rosettes are characteristic of neuroblastomas and medulloblastomas.
- May also be seen in → Primitive neuroectodermal tumors (PNET), Pineoblastomas, Retinoblastomas.

#### **3. True ependymal Rosette**

- A halo of cells surrounds an empty lumen.
- It is characteristic of ependymomas.

#### **4. Perivascular pseudorosettes**

- A halo of cells surrounds a blood vessel.

- The term pseudo is used because the central structure is not formed from the tumor itself, and represents a nonneoplastic element.
- May be seen in -

## 273. Band test is done in ?

a) RA

b) SLE

c) Scleroderma

d) PAN

Correct Answer - B

Ans. is 'b' i.e., SLE

### **Band test (Lupus band test)**

- Lupus band test is done upon skin biopsy, with direct immunofluorescence staining, in which, if positive, IgG and complement depositions are found at the dermoepidermal junction. This test can be helpful in distinguishing systemic lupus erythematosus (SLE) from cutaneous lupus, because in SLE the lupus band test will be positive in both involved and uninvolved skin, whereas with cutaneous lupus only the involved skin will be positive.
- The minimum criteria for positivity are:
- In sun-exposed skin : Presence of a band of deposits of IgM along the epidermal basement membrane in 50% of the biopsy, intermediate (2+) intensity or more.
- In sun protected skin : Presence of interrupted (i.e. less than 50%) deposits of IgM along the epidermal basement membrane, intermediate (2+) intensity or more.
- The presence of other immunoglobulins (especially IgA) and/or complement proteins (especially C4) increases the specificity of a positive test.

## 274. Angelman syndrome is due to -

a) Digenic inheritance

b) Inversion

c) Uniparental disomy

d) Mitochondrial disorder

Correct Answer - C

Ans. is 'c' i.e., Uniparental disomy

Prader Willi syndrome

Angelman syndrome

Paternal deletion (Paternal  
genomic imprinting)

Maternal deletion (maternal  
genomic imprinting)

Maternal uniparental disomy

Paternal uniparental disomy

## 275. Organelle where $H_2O_2$ is produced and destroyed is?

a) Peroxisome

b) Lysosome

c) Golgi body

d) Ribosome

Correct Answer - A

Ans. is 'a' i.e., Peroxisome

- Peroxisome is a membrane bound organelle found in all eukaryotic cells.
- "Peroxisomes contain a group of enzymes that oxidize a variety of substrates and thereby form hydrogen peroxide. The  $H_2O_2$  thus formed is efficiently decomposed within the organelle by catalase which is present in high concentration".
- Lysosomes can only form  $H_2O_2$  - They cannot degrade  $H_2O_2$ .

### **Remember**

- $H_2O_2$  is produced as well as destroyed in mitochondria and cytosol.
- It is produced from superoxide by enzyme SOD.
- It is destroyed by glutathione peroxidase.

## 276. Increased permeability in acute inflammation is due to?

a) Histamine

b) IL-2

c) TGF-(3

d) FGF

Correct Answer - A

Ans. is 'a' i.e., Histamine

- Formation of endothelial gaps in venules, i.e. immediate transient response is the most common mechanism causing increased vascular permeability in acute inflammation.
- Mediators involved in this mechanism are :-
- Immediate (more important) : Histamine, bradykinin, leukotrienes, neuropeptide substance P.
- Somewhat delayed: IL-1, TNF, IFN- $\gamma$

## 277. Not true about hereditary spherocytosis

a) Defect in ankyrin

b) Decreased MCV

c) Decreased MCHC

d) Reticulocytosis

Correct Answer - C

Ans. is 'c' i.e., Decreased MCHC

Laboratory findings

- *Spherocytosis* 4 Peripheral smear shows microspherocytes which are small RBCs *without central pallor* (Normally central 1/3 pallor is present in red cells).
- *MCV* with any type of hemolytic anemia.
- *MCHC* T
- *Increased unconjugate bilirubin* decreased.
- *Urine urobilinogen* T
- *Stool stercobilinogen* T
- *Reticulocytosis* -) As seen
- *Hemoglobin*
- *Serum Heptoglobin* Normal to
- *Increased osmotic fragility.*

## 278. Mantle cell lymphomas are positive for all of the following, except ?

a) CD 23

b) CD 20

c) CD 5

d) CD 43

Correct Answer - A

Ans. is 'a' i.e., **CD 23**

### **Mantle cell lymphoma**

- Mantle cell lymphoma is a type of non-Hodgkin lymphoma characterized by the presence of tumor cells that closely resemble the normal mantle zone of B-cells that surround germinal centers.
- Immunophenotype of mantle cell lymphoma
- Mantle cell lymphoma is a neoplasm of B cells.
- Therefore it expresses B cell marker: CD19, CD20
- Surface immunoglobulin heavy chain (IgM and IgD).
- Either c or X light chain.
- As the tumor cells are derived from the Mantle zone, they are positive for B cell marker of mantle zone i.e., CD-5.
- Mantle cell lymphoma is CD23 negative, this feature distinguishes it from chronic lymphocytic leukemia (CLL) which is positive for both CD5 and CD23.
- The other characteristic marker of mantle cell lymphoma is cyclin D1.

### **Cytogenetic abnormalities:**

Mantle cell lymphoma is associated with an 11: 14 translocation involving the IgH locus on chromosome 14 and the cyclin D1 locus on chromosome 11.

This leads to increased expression of cyclin D1, which promotes G1

to S phase progression during the cell cycle.

65 years old man with splenomegaly, lymphadenopathy CD-23 negative and CD-5 positive B-cell suggest the diagnosis of mantle cell lymphoma.

**Clinical features of mantle cell lymphoma:**

- It is usually present in the fifth to a sixth decade with male preponderance.
- The most common presentation is painless lymphadenopathy.
- Splenomegaly may occur.
- Occasionally, multifocal mucosal involvement of the small bowel and colon produces lymphomatoid polyposis → of all forms of NHL, mantle cell lymphoma is most likely to spread in this fashion.

## 279. Gastric carcinoma is associated with all EXCEPT ?

a) Inactivation of p53

b) Over expression of C-erb

c) Over expression of C-met

d) Activation of RAS

Correct Answer - D

Ans. is 'd' Activation of RAS

- In the course of multi-step stomach carcinogenesis, various genetic and epigenetic alterations of oncogenes, tumor-suppressor genes, DNA repair genes, cell cycle regulators and cell adhesion molecules are involved. Genetic alteration in gastric cancer include:
- Intestinal type gastric cancer: K-ras mutation, APC mutation, pS2 methylation, HMLH1 methylation, p I ema methylation, p 73 deletion and C-erb B-2 amplification.
- .. Diffuse type gastric caner: CDH I gene (E-Cadherin) mutation, K-sam amplification.
- 2. For both type: Telomerase reduction (telomerase shortening), hTERT expression, genetic instability, overexpression of the cyclin E & CDC25B & E2F I genes, p53 mutations, reduced expression, CD44 aberrabont transcripts, and amplification of the C-met Cyclin E genes.

**Coming to question:**

- All the given four genetic alterations may be associated with stomach cancer.
- However among the given options K-ras is best answer as it is associated with gastric cancer in minimum percentage (amongst given options):

Source: Textbook of mechanism of carcinogenesis and cancer prevention

K-ras mutation	-4 <10%
p53 mutation	30-60%
C-erb B-2 amplification	-->20%
C-met amplification	-->20%

## 280. Irreversible injury in myocardium occurs at ?

a) 2 minutes

b) 30 minutes

c) 2 hours

d) 5 hours

Correct Answer - B

Ans. is 'b' i.e., 30 minutes

- The metabolic rate of the heart is high, and its stores of substrate are low.
- So, heart is critically dependent on a continuous supply of oxygen and nutrients.
- Ischemia of myocardium induces profound functional, biochemical and morphological consequences.
- *Myocardial function is more sensitive to isc\_hemia* (loss of contractility occurs within 60 seconds) than myocardial structure (irreversible injury occurs in 20-40 minutes, thus myocardial necrosis begins at approximately 30 minutes after coronary occlusion).

### **Key events in ischemic cardiac myocytes**

Feature	Time
Onset of ATP depletion	Seconds
Loss of contractility	< 2 minutes
ATP reduced to 50%	10 minutes
ATP reduced to 10%	40 minutes
Irrversible injury	2040 min
Microvascular injury	> 1 hr

---

## 281. Bone marrow finding in myelofibrosis ?

a) Dry tap (hypocellular)

b) Megaloblastic cells

c) Microcytic cells

d) Thrombocytosis<sup>18</sup>

Correct Answer - A

Ans. is 'a' i.e., Dry tap (hypocellular)

### **Myelofibrosis**

- The hallmark of primary myelofibrosis is rapid development of obliterative marrow fibrosis.
- Myelofibrosis suppresses bone marrow hematopoiesis, leading to peripheral blood cytopenias.
- This results in extensive extramedullary hematopoiesis in the spleen, liver and lymphnode → Splenomegaly and hepatomegaly.
- Blood cell production from sites of extramedullary hematopoiesis is disordered and ineffective → Persistent cytopenia. Peripheral blood picture
- Leukoerythroblastosis → Presence of erythroid and granulocytic precursors in the peripheral blood.
- Tear-drop erythrocytes (dacrocytes) → Fibrotic marrow distorts and damages the membranes of erythroid progenitors.

### **Bone marrow findings**

- Initially marrow is hypercellular.
- With progression marrow becomes hypocellular and diffusely fibrotic → Bone marrow aspiration is a dry tap.
- There is increase laying down of reticulin fibril network.
- Cellularity of bone marrow is decreased, but megakaryocytes are increased and demonstrate features of dysmegakaryopoiesis.

- Dilated marrow sinusoids.

## 282. Schiller- Duval bodies is seen in

a) Choriocarcinoma

b) Embryonal cell Ca

c) Endodermal sinus tumour

d) Immature teratoma

Correct Answer - C

Ans. is 'c' i.e., Endodermal sinus tumor

- Yolk sac tumor (endodermal sinus tumor or infantile embryonal carcinoma) → Schiller - Duval bodies.
- Leydig (interstitial) cell tumor -3 Reinke crystalloids.
- Note : - Reinke crystals are also seen in the hilus cell tumor of ovary.

## 283. A/E are involved in MEN type II A ?

a) Parathyroid

b) Adrenal

c) Thyroid

d) Pituitary

Correct Answer - D

Ans. is 'd' i.e., Pituitary

### **MEN type 2A (Sipple syndrome)**

- Autosomal dominant
- It is characterised by medullary carcinoma of thyroid, pheochromocytoma and hyperparathyroidism.
- It is caused by mutation of the RET proto-oncogene in codon 634.
- Mapped to chromosome 10.
- Mutated codon- cysteine codon
- Type 2A has 3 variants-
  - a) MEN 2A with familial medullary carcinoma thyroid (1<sup>st</sup> feature of type 2A)
  - b) MEN 2A with cutaneous lichen amyloidosis
  - c) MEN 2A with Hirschsprung disease

**284. All are good prognostic factors for neuroblastoma except -**

a) Trk-A expression absent

b) Absence of 1 p loss

c) Absence of 17 p gain

d) Absence of 11 q loss

Correct Answer - A

Ans. is 'a' i.e., Trk-A expression absent

Intratumoral calcification

*DNA ploidy- Hyperdiploid or near-triploid*

*Trk-A Expression*

*CD-44 Expression*

## 285. Eosinophilia in necrosed tissue is due to

a) Coagulation of proteins

b) Denaturation of enzymes

c) Denaturation of protein

d) Mitochondrial damage

Correct Answer - C

Ans. is 'c' i.e., Denaturation of protein

- Necrotic cells show increased eosinophilia in *hematoxylin and eosin (H & E) stains*.
- It is due to -
  1. Loss of cytoplasmic RNA (or ribonucleoprotein/RNP) which binds the blue dye, hematoxylin.
  2. Denatured cytoplasmic proteins which bind the red dye, eosin.

## 286. Macrophages are converted to epithelioid cells by which cytokine ?

a) IL-2

b) IFN- $\gamma$

c) TNF- $\alpha$

d) TGF- $\beta$

Correct Answer - B

Ans. is 'b' i.e., IFN- $\gamma$

- A granuloma is a focus of chronic inflammation consisting of a microscopic aggregation of macrophages that are transformed into epithelium like cells (epithelioid cells) surrounded by a Collor of mononuclear leukocytes, principally lymphocytes and occasionally plasma cells.
- Frequently, these epithelioid cells fuse to form giant cells in the periphery or some times in the center of granuloma.

### **Pathogenesis of granuloma**

- Immune granuloma (most common type of granuloma) is a type IV hypersensitivity that involved CD-4 helper T cell.
- On-exposure to particulate antigen macrophages process and present this antigen to Helper T cells and also secretes IL-2.
- T-cells are activated on contact with this antigen and by IL-2.
- Activated T-cells (helper) produce IFN- $\gamma$ , the major cytokine of granulomatous inflammation.
- IFN- $\gamma$  has the following effects
- It is the most important activator of macrophages.
- It induce granuloma formation by conversion of activated macrophages into epithelioid cells and formation of giant cell.
- Augment the differentiation of T-cells.

- Finally there is formation of granuloma induced by IFN- $\gamma$ .
- **Remember**
- Foreign body (Nonimmune) granuloma consist almost entirely of epitheloid cells and multinucleated giant cells but no lymphocytes.
- Granulomas induced by parasites contain a large component of eosinophils.
- In lymphogranuloma venerum and Cat scratch disease granulomas have a characteristic central neutrophilic abscess surrounded by macrophages and other mononuclear cells.

## 287. The professional antigen presenting cells ?

a) B cells

b) Dendritic cells

c) T cells

d) NK cells

Correct Answer - B

Ans. is 'b' i.e., Dendritic cells

- Dendritic cells are the most potent and effective antigen presenting cells in the body - Harrison 2024 Mature B-cells and T-cells before antigenic exposure are called naive-B and T cells respectively.
- Sequence of events in activation of naive T cells.
- Immature dendritic cells in the epidermis are called langerhans cell.
- These immature dendritic cells (langerhans cells) capture the antigen in the epidermis.
- After capturing the antigen these cells secrete cytokines.
- These cytokines cause loss of adhesiveness of langerhans cells.
- Langerhans cells separate from each other and migrate into lymphatic vessels.
- In lymphatic vessel, maturation of langerhans cells takes place.
- Then these mature langerhans dendritic cells reach to naive T cells in the lymph nodes and present antigen to these cells and activate them.

**288. All are growth promoting oncogenes except ?**

a) FGF

b) TGF-a

c) TGF-p

d) PDGF

Correct Answer - C

Ans. is 'c' i.e. TGF-p

- *Growth factor genes:* SIS, HST-1, INT-2, TGFa, FGF.

## 289. Hyperplastic arteriolitis with necrotizing arteriolitis is seen in ?

a) Buerger's disease

b) Benign hypertension

c) Malignant hypertension

d) Diabetes

Correct Answer - C

Ans. is 'c' i.e., Malignant hypertension

- Hyperplastic arteriosclerosis is characteristically pathologic change seen in vessels of the patient suffering from malignant hypertension.
- Arterioles of all the organs in the body can be affected but favoured sites are
  1. Kidney
  2. Small Intestine
  3. Gall bladder
  4. Peripancreatic fat
  5. Periadrenal fat.

## 290. Fibrosis is due to ?

a) TGF-

b) TNF -

c) IL - 7

d) IL - 10

Correct Answer - A

Ans. is 'a' i.e., TGF- 13

*"TGF- $\beta$  is practically always involved as an important fibrogenic agent"* — Robbins

- Mediators involved in fibrosis :?

i) Growth factors :- TGF-( $\beta$ ), PDGF, FGF

ii) Cytokines : IL-1, IL-4, TNF, IL-13

## 291. In sickle cell anemia all are true except -

a) Sickle cells

b) Target cells

c) Howell jolly bodies

d) Ringed sideroblast

Correct Answer - D

Ans. is 'd' i.e., Ringed sideroblast

### Laboratory findings of sickle cell anemia :?

- Moderate to severe anaemia.
- Peripheral smear will show
- Sickle cells
- Target cells
- Howell-Jolly bodies because of autosplenectomy.
- A positive sickling test with a reducing substance like sodium metabisulfite.
- Sickle cell anemia is caused by replacement of normal Hemoglobin by sickled hemoglobin (HbS).
- HbS is formed by replacement of Glutamine by Valine at position 6
- This substitution replaces the polar Glutamine residue with a nonpolar Valine.
- The replacement of Glutamine by Valine generates a sticky patch on the surface of HbS.
- The sticky patch is present on both oxygenated and deoxygenated HbS
- The deoxygenated HbS also contains a complementary site for the sticky patch.
- In oxygenated hemoglobin this complementary site is masked.
- When HbS is deoxygenated the sticky patch present on its surface

binds to the complementary patch on another deoxygenated HbS molecules.

- This binding leads to polymerization of deoxyhemoglobin S forming long fibrous precipitates.
- These extend throughout the erythrocyte and mechanically distort it, causing lysis and multiple secondary clinical effect.
- So, if HbS can be maintained in an oxygenated state or if the concentration of deoxygenated HbS can be minimized, formation of these polymers will not occur and sickling can be prevented (Remember the complementary site for the sticky patch remains masked in case of Oxygenated HbS).

#### **Role of HbA in polymerization**

- Unlike HbS, HbA does not contain any sticky patch, but it does have a binding site for the sticky patch of HbS.
- Thus it can bind to HbS through its receptor site but this binding cannot extend the polymer because HbA does not contain any sticky patch to promote binding to still another hemoglobin molecule.
- So HbA interferes with the polymerisation and aggreation of HbS and reduces the intensity of sickle cell anemia.

## 292. Linitis plastica is a type of ?

a) Plastic like lining of stomach

b) Diffuse carcinoma of stomach

c) Benign ulcer

d) GIST

Correct Answer - B

Ans. is `b' i.e., Diffuse carcinoma of stomach

### **Linitis plastica**

- Involvement of a broad region of the gastric wall or entire stomach by diffuse stomach cancer cause linitis plastica.
- It is also known as Brinton's disease.
- The appearance of stomach is like leather bottle.
- The other cause of linitis plastica are
- Lye ingestion
- Metastatic infiltration of stomach
- Syphilis
- Sarcoidosis
- Non -hodgkin lymphoma of stomach

## 293. Microvesicular fatty liver is caused by ?

a) DM

b) Valproate

c) Starvation

d) IBD

Correct Answer - B

Ans. is 'b' i.e., Valproate

### **Steatosis**

- Accumulation of triglyceride fat droplets within the hepatocytes is known as steatosis or fatty liver. It may be of two types ?
- 1. Microvesicular steatosis → Multiple tiny droplets accumulate that do not displace the nucleus.
- 2. Macrovesicular steatosis → A single large droplet accumulates that displaces the nucleus.

### **Causes of steatosis**

#### **Microvesicular**

- Reye's syndrome
- Acute fatty liver of pregnancy
- Jamaican vomiting sickness
- Drugs - valproic acid, tetracycline, nucleoside analogue
- Iman's disease
- Lysosomal acid lipase deficiency
- Congenital defects of urea cycle enzymes
- Early stage of alcoholic cirrhosis
- Chronic viral hepatitis

#### **Macrovesicular**

- Alcoholic liver disease
- DM → insulin resistance

- Lipodystrophy
- PEM, starvation
- Dysbetalipoproteinemia
- TPN, Jejunioileal bypass
- Inflammatory bowel disease
- Syndrome x (obesity, DM, *hypertriglyceridemia*)
- Drugs —> CCBs, synthetic estrogens, nucleoside analogues

## 294. Localised langerhans cells histiocytosis affecting head & neck is ?

a) Letterer-siwe disease

b) Pulmonary langerhans cell histiocytosis

c) Hand-schuller-christian disease

d) Eosinophilic granuloma

Correct Answer - D

Ans. is `d i.e., Eosinophilic granuloma

### **Clinical manifestations of Langerhans cell histiocytosis (Histiocytosis-X1)**

1. Letterer Siwe disease (multifocal, multisystem LCH)

- Most frequently present *before 2 years of age*.
  - Characterized by involvement of multiple system.
  - Most common presentation is cutaneous lesions *resembling seborrheic dermatitis*.
  - Others are hepatosplenomegaly, lymphadenopathy pulmonary lesions and destructive bone lesions.
  - Extensive bone marrow infiltration leads to pancytopenia.
2. Eosinophilic granuloma (Unifocal and multifocal unisystem LCH)
- Involvement is restricted to a single system i.e., skeletal system which may be unifocal or multifocal.
  - Most commonly effected bones are skull, vertebrae, ribs, clavicle, and femur.
3. Hand-Schuller-Christian disease
- Characterized by triad of clavical bone defects, diabetes insipidus, and exophthalmos.

## 295. Which cytokine activate macrophages ?

a) IL-8

b) IFN- $\gamma$

c) PAF

d) Leukotriene B<sub>4</sub>

Correct Answer - B

Ans. is 'b' i.e., IFN- $\gamma$

### **Activated macrophages**

- Recent studies show that there are two types of activated macrophages : ?
  1. Classically activated macrophages (M1)
    - These are activated by microbial products and cytokines like IFN- $\gamma$ .
    - These cells release lysosomal enzymes, NO, IL-1, and IL-12.
    - These cells are involved in microbicidal activities and pathogenic inflammation.
  2. Alternatively activated macrophages (M2).
    - These cells are activated by microbial products and cytokines like IL-4, IL-5.
    - These cells release IL-10, TGF- $\beta$ .
    - These cells are involved in anti-inflammatory actions and wound repair.

## 296. Syphilitic aneurysm mostly involve ?

a) Arch of aorta

b) Descending aorta

c) Abdominal aorta above the renal arteries

d) Abdominal aorta below the renal arteries

Correct Answer - A

Ans. A. Arch of aorta

The ascending aorta is the segment most commonly affected (50%), followed by the arch (35%) and the descending aorta (15%)

## 297. Hurthle cell carcinoma is a variant of ?

a) Medullary carcinoma

b) Papillary carcinoma

c) Follicular carcinoma

d) Anaplastic carcinoma

Correct Answer - C

Ans. is 'c' i.e., Follicular carcinoma

### **Follicular carcinoma**

- Second most common type of thyroid cancer.
- Hurthle cells are seen.
- Differentiated from follicular adenoma by capsular and/or vascular invasion.
- Unlike in papillary carcinoma, lymphatic spread is rare, and vascular invasion is common in follicular cancers.
- Hurthle cell or oncocytic carcinoma is a variant of follicular carcinoma.

### **Papillary thyroid carcinoma**

- It is the most common type of thyroid cancer.
- Carcinoma cells have nuclei which contain finely dispersed chromatin, which imparts optically clear or empty appearance, giving rise to the ground glass or Orphan Annie eye nuclei.
- Invagination of cytoplasm may give rise to the appearance of intranuclear inclusions (Pseudoinclusions) or intranuclear grooves → the diagnosis of papillary carcinoma is based on these nuclear features.
- Psammoma bodies are present
- Lymphatic metastasis may be seen but involvement of blood vessels is rare.

- The nuclei of papillary carcinoma cells contain finely dispersed chromatin, which imparts an optically clear or empty appearance, giving rise to the designation ground glass or Orphan Annie eye nuclei.

## 298. HLA is located on ?

a) Short arm of chr-6

b) Long arm of chr-6

c) Short arm of chr-3

d) Long arm of chr-3

Correct Answer - A

Ans. is 'a' i.e., Short arm of chr- 6

- HLA complex (MHC) gene is located on the short arm of chromosome 6.
- The histocompatibility antigens (human leukocyte antigens - HLA) are cell surface antigens that induce an immune response leading to rejection of allografts.
- The principal physiologic function of the cell surface histocompatibility molecules is to bind peptide fragments of foreign proteins for presentation to antigen specific T cells.
- The histocompatibility antigens are encoded by a closely linked multiallelic cluster of genes → Major histocompatibility complex (MHC) or Human leukocyte antigens complex (HLA complex).
- HLA complex of genes is located on the short arm of chromosome 6.

**299.**

## Classification of aortic dissection depends upon?

a) Cause of dissection

b) Level of aorta affected

c) Percentage of aorta affected

d) None

Correct Answer - B

Ans. is 'b' i.e., Level of aorta affected

### **Classification of Aortic dissection**

- The risk and nature of serious complications of dissection depend strongly on the level of aorta affected, with the most serious complications occurring from the aortic valve to the arch.
- Thus aortic dissections are generally classified into two types ?  
**Proximal lesion (Type A)**
- More common and more dangerous.
- Involve either the ascending portion only or both ascending and the descending portion of aorta.
- **Distal lesion (Type B)**
- Involve only descending part distal to subclavian artery.

### 300. Thalassemia gives protection against ?

a) Filaria

b) Kala-azar

c) Malaria

d) Leptospirosis

Correct Answer - C

Ans. is 'c' i.e., Malaria

- Types of anemia that have protective effect against *P. falciparum* malaria : -
- G6PD deficiency, Sickle cell anemia, Thalassemia, HbC, Pyruvate kinase deficiency

### 301. Maltoma is positive for?

a) CD 3

b) CD 10

c) CD 23

d) CD 5

Correct Answer - C

Ans. is 'c' i.e., CD 23

Mantle cell lymphoma-

- Surface immunoglobulin heavy chain (IgM & IgD)
- CD19', CD20\*
- CD5 (+)ve & CD 23 (-)ve differentiating feature from CLL
- Cyclin D1

## 302. Terminal stage of pneumonia is

a) Congestion

b) Red hepatization

c) Gray hepatization

d) Resolution

Correct Answer - D

Ans. is 'd' i.e., Resolution

- In the usual course of pneumonia, final stage is resolution.
- However, in some neglected cases following complications may develop -  
Abscess formation    Pleural effusion, pleuritis  
Empyema                Bacteremic dissemination                Brain abscess,  
endocarditis, meningitis,  
Organization            suppurative arthritis.

### Pathological changes of bacterial pneumonia

#### **A.Lobar pneumonia**

- Large confluent area of the lung or entire lobes are consolidated.
- The lower lobes are affected most commonly.
- There are four stages of the inflammatory response (Laennec's stages) ?
  1. Stage of congestion (initial phase)
    - The affected lobe is enlarged, heavy, dark red and congested.
    - Cut surface exudes blood-stained frothy fluid.
    - There is dilatation and congestion of alveolar capillaries.
    - There are few neutrophils and *numerous bacteria* in the alveolar fluid.
  2. Stage of red hepatization (early consolidation)
    - The term hepatization refers to liver-like consistency of the affected

lobe on cut section.

- The affected lobe is *red and firm*.
- The edema fluid of preceding stage is replaced by strands of fibrin.
- There is marked cellular exudate of neutrophils with extravasation of red cells.

3. Stage of gray hepatization (late consolidation)

- The affected lobe is grayish brown, firm and dry.
- The fibrin strands are dense and more numerous.
- There is progressive disintegration of red cells and neutrophils.
- The macrophages begin to appear in the exudate.
- The organisms are less numerous and appear as degenerated forms.

4. Resolution

- The previously solid and fibrinous constituent is liquefied by enzymatic action.
- Granular and fragmented strands of fibrin in the alveolar spaces are seen due to progressive enzymatic digestion.
- There is progressive removal of fluid content as well as cellular exudate from the air spaces, resulting in restoration of normal lung parenchyma with aeration.

### **B. Bronchopneumonia**

- Patchy areas of red or grey consolidation, more often multilobar and frequently bilateral and basal (lower zones) because of tendency of secretions to gravitate into lower lobes..
- There is suppurative exudate, consisting chiefly neutrophils, filling bronchi, bronchioles and adjacent alveolar spaces.
- Alveolar septa thicken due to congested capillaries and leucocytic infiltration.

### 303. Intestinal angiodysplasia involves ?

a) AV malformation

b) Cavernous hemangioma

c) Capillary hemangioma

d) Malignant tumor

Correct Answer - A

Ans. is 'a' i.e., AV malformation

#### **Angiodysplasia**

- Angiodysplasia is characterized by malformed submucosal blood vessels (AV malformation).
- Lesions of angiodysplasia are ectatic nest of tortuous veins, venules and capillaries.
- Most common site is caecum and right colon.
- Usually occurs after 6<sup>th</sup> decade of life.
- Major presentation is bleeding (intestinal bleeding).
- Pathogenesis of angiodysplasia has been linked to mechanical and congenital factors :?

#### **1. Mechanical factor**

- Normal distension and contraction intermittently occlude submucosal veins and leads to dilatation and tortuosity of overlying vessels. Because cecum has the largest diameter, it develops the greatest wall tension. Therefore cecum is the most common site for angiodysplasia.

#### **2. Genetic (developmental) factor**

- Some data link angiodysplasia with aortic stenosis and Meckel diverticulum suggesting the possibility of a developmental component.

### 304. Perifascicular atrophy of muscle fibres is seen in?

a) Steroid myopathy

b) Dermatomyositis

c) Inclusion body myositis

d) Nemaline myopathy

Correct Answer - B

Ans. is 'b' i.e., Dermatomyositis

- Dermatomyositis is a connective-tissue disease related to polymyositis that is characterized by inflammation of the muscles and the skin.
- It is a systemic disorder that may also affect the *joints, the esophagus, the lungs, and, less commonly, the heart.*
- On the muscle biopsy, there are two classic microscopic findings of dermatomyositis. They are : *mixed B- & T-cell perivascular inflammatory infiltrate and perifascicular muscle fiber atrophy.*
- It is associated with autoantibodies, especially *anti-Jo1 antibody.*

### 305. Marker of glomus tumor?

a) CD-57

b) Cytokeratin

c) S-100

d) CD-34

Correct Answer - A

Ans. is 'a' i.e., CD-57

- Glomus tumor is a benign mesenchymal neoplasm of the subcutaneous tissue of the distal extremities and head & neck region.
- Immunohistochemistry shows smooth muscle actin, vimentin, collagen IV and CD-57, with little to no expression of neuroendocrine, endothelial or epithelial markers.
- Markers that have been proved consistently negative include cytokeratin, synaptophysin, chromogranin A, CD-31 and S-100 protein.

#### **Glomangioma (Glomuvenous malformation)**

- Glomangioma is a variant of glomus tumor
- It is characterized by multiple tumors resembling cavernous hemangioma, lined by glomus cells.
- Glomangioma is blue-red, extremely painful vascular neoplasm.
- It involves a glomeriform arteriovenous anastomosis (glomus body)
- It may be found anywhere in the skin, most often in the distal portion of fingers and toes, especially beneath the nails (subungal).
- Secondary thrombosis and phlebolith formation may occur in these lesions.

### 306. False about wound healing ?

a) Inhibited by infection

b) Inhibited by DM

c) Inhibited by hematoma

d) Inhibited by foreign body

Correct Answer - C

Ans. is 'c' i.e., Inhibited by hematoma

#### **Factors causing impairment of wound healing**

##### **A. Systemic factors**

- Poor nutrition (protein deficiency, vitamin C deficiency).
- Metabolic abnormalities (*Diabetes mellitus*).
- Poor circulatory status (Inadequate blood supply).
- Hormones, e.g. glucocorticoids.

##### **B. Local factors**

- Infection is the single most important factor.
- Mechanical factors, e.g. early mobilization.
- Foreign bodies (unnecessary sutures, fragments of steel or glass).
- Wound in poorly vascularized area, e.g. foot.

## 307. Chromosome 22 deletion syndrome is ?

a) Down syndrome

b) Di George syndrome

c) Turner syndrome

d) Klinefelter syndrome

Correct Answer - B

Ans. is 'b' i.e., Di George syndrome

### **Chromosome 22q 11.2 deletion syndrome**

- This syndrome encompasses a spectrum of disorders that result from a small deletion of *band q 11.2 on long arm of chromosome 22*. Clinical features are considered to represent two different disorders :?

#### **1 Di George syndrome**

- These patients have thymic hypoplasia with resultant T-cell immunodeficiency.
- Other features include parathyroid hypoplasia (causing hypocalcemia), cardiac malformations & facial anomalies.
- TBX-1 gene (a T-box transcription factor) is most closely associated with this syndrome. The target of TBX-1 include PAX 9, a gene that controls the development of the palate, parathyroid and thymus.

#### **2 Velo cardio facial syndrome**

- This syndrome is characterized by facial dysmorphism (prominent nose, retrognathia), cleft palate, cardiovascular anomalies, and learning disabilities.

### 308. Creatinine kinase is elevated in MI after -

a) 2 - 4 hrs.

b) 4 - 8 hrs.

c) 12 - 24 hrs

d) > 24 hrs.

Correct Answer - A

Ans. is 'a' i.e., 2 - 4 hrs

Enzyme	Initiation of rise	Peak	Return to baseline
CK-MB	2-4 hours	24 hours	48-72 hours
Troponin T and I (TnT Tnl)	2-4 hours	48 hours	7-10 days
AST/SGOT	In 12 hours	48 hours	4-5 days
LDH	24 hours	3-6 days	2 weeks

### 309. Blood when stored at 4°C can be kept for ?

a) 7 days

b) 14 days

c) 21 days

d) 28 days

Correct Answer - C

Ans. is 'c' i.e., 21 days

- The recommend temperature for storage of blood is 1-6°C.
- Actually blood can be stored for more than 21 days, depending upon the type of additive used.
- "Routine blood storage is limited to 21 days at 1-6°C when treated with acid-citrate-dextrose (ACD) or citratephosphate-dextrose (CPD); and 35 days when treated with citrate-phosposphate-dextrose-adenine (CPD-A); and 42 days when treated with saline-adenine-glucose-mannital (SAG-M)"
- So, correct answer of this question can be:
  1. 21 days (we have only this one in the options)
  2. 35 days
  3. 42 days (*This is the best answer because SAG-M is the routinely used additive these days*).
- Platelets are stored at 20-24°C for 3-5 days

### 310. AML causing Gum hypertrophy ?

a) M1

b) M2

c) M3

d) M4

Correct Answer - D

Ans. is 'd' i.e., M4

**In acute leukemias the clinical features are primarily seen because of :**

- Replacement of normal cells of bone marrow by leukemic cells resulting in anemia, thrombocytopenia, neutropenia. Infiltration of leukemic cell in various extramedullary organs causing, hepaticomegaly, splenomegaly. *Gum hypertrophy due to infiltration of gums by leukemic cells is one such feature.* It is characteristically associated with AML-M5 and AML-M4 i.e. (acute monocytic leukemia).

### 311. Type of necrosis in pancreatitis ?

a) Fibrinoid

b) Coagulative

c) Fat

d) Caseous

Correct Answer - C

Ans. is 'c' i.e., Fat

- Fat necrosis is seen most frequently in acute pancreatitis due to leakage of lipase.

#### **Fat necrosis**

- Fat necrosis may be of two types : ?
  1. Enzymatic fat necrosis
- This is due to action of lipase on adipose tissue.
- It occurs most frequently in acute pancreatitis due to leakage of lipase.
- Depending on the severity of acute pancreatitis, fat necrosis may occur in : - a Adipose tissue contiguous to pancreas, retroperitoneal fat.
- Adipose tissue in anterior mediastinum.
- Bone marrow
- Omental and abdominal fat
- 2. Nonenzymatic or Traumatic fat necrosis
- Occurs due to trauma
- Is seen in subcutaneous tissue of breast, thigh, and abdomen.

## 312. Resolution of inflammation caused by ?

a) TNF Alfa, IL-1 and CRP

b) TNF beta, IL-6 and CRP

c) TNF Alfa, IL 10 and IL 1 receptor antagonist

d) TNF gamma

Correct Answer - C

Ans. is ' c ' i.e., TNF Alfa, IL-10 and IL 1 receptor antagonist

**Actually no option is absolutely correct:**

- IL-10 is an anti-inflammatory cytokine Cause resolution of inflammation
- IL-1 is a pro-inflammatory cytokine → IL-1 receptor antagonism will cause resolution of inflammation
- TNF- $\alpha$  is an pro-inflammatory cytokine → causes inflammation
- So, in option C, two mediators are correct and one is incorrect regarding resolution of inflammation. However, among the given options only option C is the closest one.
- Proinflammatory cytokines
- Major :- *IL-1*, TNF-  $\alpha$ , *IL-6*
- Other :- *IL-2*, *IL-4*, *IL-5*, *IL-6*, *IL-8*, *IL-11*, *IL-12*, *IL-15*, *IL-21*, *IL-23*, ITN-  $\gamma$ , GM-CSF
- Anti-inflammatory cytokines
- *IL-4*, *IL-10*, *IL-13*
- Here, you can consider *IL-4* as pro-inflammatory cytokine ( as more than one options can be correct in PGIchandigarh).

### 313. Not a carcinogen for bladder cancer?

a) Benzidine

b) Isopropyl alcohol

c) Acrolein

d) Phenacetin

Correct Answer - B

Ans. is 'b' i.e., Isopropyl alcohol

#### **Risk factors for transitional cell carcinoma (TCC) of bladder ?**

- Smoking -4 Major etiological factor.
- Occupational exposure to chemicals → Nephthylamine benzidine, aniline dyes, acrolein.
- Schistosoma haematobium (Bilharziasis) → It is a risk factor for both TCC & SCC.
- Drugs —> Phenacetin
- Cyclophosphamide therapy
- Pelvic irradiations

### 314. Drug induced lupus antibodies are found in ?

a) Anti-Rho

b) Ds-DNA

c) Anti-Sm

d) Anti-histone antibody

Correct Answer - D

Ans. is 'd' i.e., Anti Histone antibody

#### **Drug induced lupus erythematosus**

- A lupus like syndrome may develop in patients receiving a variety of drugs.
- Procainamide and hydralazine are most common offenders.
- Most patients do not have symptoms of lupus erythematosus.
- Anti ds DNA antibody is rare
- There is an extremely high frequency of antihistone antibodies.
- Although multiple organs may be affected renal and CNS involvement, usually does not occur.

### 315. Donath landsteiner antibody is seen in?

a) PNH

b) Waldenstrom's macroglobulinemia

c) Paroxysmal cold hemoglobinuri

d) Malaria

Correct Answer - C

Ans. is 'c' i.e., Paroxysmal cold hemoglobinuria

#### **Paroxysmal cold hemoglobinuria (PCH)**

- PCH is characterized by intermittent massive intravascular hemolysis frequently with hemoglobinuria at low temperature.
- The autoantibodies are of IgG class, also known as Donath-Landsteiner antibody.
- These antibodies are directed against P-antigen on RBC.
- Antigen antibody complex on the red blood cell activates complement.
- As a result, large amount of membrane attack complex forms which destroys red cells directly → intravascular hemolysis.

**Causes are : -**

- Syphilis, Mycoplasma, Mumps, Measles, Flu syndrome

### 316. Cryoprecipitate is useful in?

a) Hemophilia A

b) Thrombosthenia

c) A fibrogenemi a

d) Warfarin reversal

Correct Answer - C

Ans. is 'c' i.e., Afibrogenemia

- Cryoprecipitate was originally developed for the treatment of hemophilia A. It is no longer the treatment of choice for that disorder because less infectious alternatives are available.
- At the present time, Cryoprecipitate is most often used for correction of hypofibrinogenemia in bleeding patients.

### 317. DIC is common in which AML -

a) Nonocytic (**M<sub>5</sub>**)

b) Promyelo cytic (**M<sub>3</sub>**)

c) Erythrocytic (**M<sub>6</sub>**)

d) Megakaryocytic (**M<sub>7</sub>**)

Correct Answer - B

Ans. is 'b' i.e., Promyelocytic

- Tumor cells in acute promyelocytic leukemia (M<sub>3</sub>) release procoagulant and fibrinolytic factors that cause disseminated intravascular coagulation (DIC).

### 318. Example of Apoptosis is?

a) Councilman Bodies

b) Gamma Gandy Body

c) Russell bodies

d) None

Correct Answer - A

Ans. is 'a' i.e., Councilman bodies

#### **Apoptotic body**

- One of the morphological hallmark of apoptosis is the apoptotic body which is eosinophilic and may contain some karyorrhectic nuclear debris.
- It is a result of shrinkage of cytoplasm and nuclear disruption.
- First there is surface blebbing and margination of chromatin which is followed by cell shrinkage and breakup into smaller apoptotic bodies.
- These apoptotic bodies are taken up by surrounding cells and digested.
- Since the process was seen for a long time before the mechanism was understood, apoptotic bodies in particular situations attracted specific names:
  1. Civatte bodies or colloid bodies in lichen planus.
  2. Kamino bodies in melanocytic lesions
  3. Councilman bodies in acute viral hepatitis
  4. Tingible bodies (found in macrophages) in lymphoma
  5. Sunburn cells
  6. Satellite dyskeratotic cells
  7. Eosinophilic globules

### 319. Fibrinoid necrosis with neutrophilic infiltration is seen in ?

a) PAN

b) Giant cell arteritis

c) Takayasu arteritis

d) Wegener's granulomatosis

Correct Answer - A

Ans. is 'a' i.e., PAN

- Among the given options, PAN is predominantly *necrotizing vasculitis*, characterized by **fibrinoid necrosis**.
- During acute phase of **PAN**, there is **transmural inflammation** with mixed infiltrate of **neutrophils**, eosinophils and mononuclear cells with accompanied **fibrinoid necrosis**.
- Other three options are predominantly **granulomatous vasculitis**.

### 320. Most common ocular lymphoma ?

a) T-cell lymphoma

b) Hodgkin's lymphoma

c) B-cell NHL

d) Pre T-cell lymphoma

Correct Answer - C

Ans. is 'c' i.e., B-cell NHL

non-**Hodgkin lymphoma** (NHL) is the **most common** type of **ocular lymphoma**.

### 321. Cytokine causing fever -

a) IL-6

b) IFN- $\gamma$

c) IL-18

d) IL-4

Correct Answer - A

Ans. is 'a' i.e., IL-6

#### **Pyrogenes**

- Pyrogenes are substances that cause fever.
- Pyrogens may be exogenous or endogenous
- Exogenous → Bacterial toxins
- Endogenous → IL-1, TNF- $\alpha$ , IL-6, Interferons, Ciliary's neurotropic factor
- These pyrogenes increase the level of PGE<sub>2</sub> in the hypothalamus that elevates the thermoregulatory set point and causes fever.

## 322. Normal transferrin is saturated with iron ?

a) 20%

b) 35%

c) 50%

d) 70%

Correct Answer - B

Ans. is 'b' i.e., 35%

- In normal individuals, transferrin is about one third saturated with iron, yielding serum iron levels that average 120 g/dl in men and 100 g/dl in women.

### **Serum ferritin**

- Most of the ferritin is stored in different organs (liver, spleen, bone marrow).
- Very small amounts of ferritin normally circulate in the plasma.
- Since plasma ferritin is derived largely from the storage pool of body iron, its level correlates well with body iron stores. i.e., when there is iron depletion, body store of iron is reduced that in turn leads to decrease in plasma ferritin.

### **Transferrin saturation and iron binding capacity**

- Iron is transported in the plasma by transferrin.
- Normally transferrin is 33% saturated (77% free) with iron, yield serum iron levels that average 100-120 g/dl.
- So, if serum transferrin will be 100% saturated the serum iron will be 300 g/dl. that means the total iron binding capacity of transferrin is 300 to 350 g/dl.
- When iron store is depleted e.g., in iron deficiency anemia, there is increased synthesis of transferrin that results in increased total iron

binding capacity.

- When iron store is depleted e.g., anemia of chronic disease, there is decreased synthesis of transferrin that results in decreased total iron binding capacity.

### **Serum transferrin receptors**

- Erythroid precursors have receptors for transferrin by which they receive iron from transferrin that is utilized for hemoglobin synthesis.
- When erythroid precursors mature, these receptors are shed into plasma and can be measured as serum transferrin receptors concentration.
- In iron deficiency state, there is increased erythropoiesis in bone marrow → ↑ concentration of erythroid precursor that results in increased total number of transferrin receptor → ↑ serum transferrin receptor concentration.

**323. All of the following immunohistochemical markers are positive in the neoplastic cells of granulocytic sarcoma, except ?**

a) CD45 RO

b) CD 43

c) Myeloperoxidase

d) Lysozyme

Correct Answer - A

Ans. is 'a' i.e., CD 45 RO

**Granulocytic sarcoms (Chloroma or myeloblastoma)**

- Granulocytic sarcoms or chloroma is a solid tumor composed of myeloblasts.
- A chloroma is an extramedullary manifestation of AML, i.e., it is a solid collection of leukemic cells occurring outside of the bone marrow.
- These tumors often have a green tint due to the presence of myeloperoxidase.
- Chloromas are more common in monocytic differentiation (M4 & M5 type) AML.
- Though chloromas occur most commonly in patients with AML, they may also occur in patients with : ?
- Myelodysplastic syndrome
- Myeloproliferative syndromes Myelofibrosis, CML, Polycythemia vera, Essential thrombocythosis in) Without concomitant disease, i.e., Primary chloroma.

**Chloromas are positive for : ?**

CD 68	CD 20	CD 117	Lysozyme
CD 43	CD 34	Myeloperoxidase	

**324. In glomerulus subendothelial deposits are seen in?**

a) Good pasture syndrome

b) IgA nephropathy

c) MPGN type I

d) MPGN type II

Correct Answer - C

Ans. is 'c' i.e., MPGN type I

Sub endothelial - MPGN (Type-1), SLE, Acute ON

### 325. Thromboangitis obliterans is associated with ?

a) HLA B27

b) HLA - DR4

c) HLA - B5

d) HLA - DR2

Correct Answer - C

Ans. is 'c' i.e., HLA - B5

#### **Thromboangitis obliterans (Berger disease)**

- Thromboangitis obliterans is a distinctive disease that is characterized by segmental, thrombosing acute and chronic inflammation of medium sized and small sized arteries, and sometimes secondarily extending to veins and nerves.
- Thromboangitis obliterans occurs almost exclusively among heavy-cigarette-smoking persons.
- It is more common in men but incidence is increasing in women because of increasing smoking habit in women. o Buerger disease is associated with HLA B-5 and HLA-A9.
- In thromboangitis obliterans there is acute and chronic segmental inflammation of vessels with accompanied thrombosis in the lumen.
- Typically, the thrombus contains microabscesses with a central focus of neutrophils surrounded by granulomatous inflammation.
- Later, the inflammatory process extends into contiguous veins and nerves and in time all three structures (arteries, veins and nerves) become encased in fibrous tissue, a characteristic that is very rare with other form of vasculitis.
- Clinical manifestations
- Thromboangitis obliterans affects vessels of upper and lower

extremities.

- Symptoms are due to vascular insufficiency, i.e. Ischemia of toes, feet and fingers that can lead to ulcer and frank gangrene.
- Due to neural involvement, there may be severe pain, even at rest.

**326. Which antibodies in mother with SLE is responsible for congenital heart disease in child?**

a) Anti-histone

b) Anti-Ro & Anti-LA

c) Anti ds DNA

d) Anti-centromere

Correct Answer - B

Ans. is 'b' i.e., Anti-Ro & Anti-LA

**Most sensitive**

Most specific

antibody against smith (Sm)

Associated with neonatal lupus and congenital heart block

Associated with lupus psychosis

**Antinuclear antibody (ANA)**

Antidouble stranded antibody and the

Anti Ro, AntiLA antibody

Anti P antibody

### 327. Xerostomia is seen in all except ?

a) Sjogren syndrome

b) RA

c) Sarcoidosis

d) Midline granuloma

Correct Answer - D

Ans. is 'd' i.e., Midline granuloma

#### **Sjogren syndrome**

- Sjogren syndrome is a chronic disease characterized by dry eyes (keratoconjunctivitis sicca) and dry mouth (xerostomia) resulting from immunological mediated destruction of the *lacrima and salivary glands*.
  - It occurs in two forms ?
- Primary form (SICCA SYNDROME) → Occurs as an isolated disorder.
- Secondary form When it occurs in association with other autoimmune disorder. It is *more common*.
- ◦ Autoimmune diseases associated with sjogren syndrome
- Rheumatoid arthritis
- Primary biliary cirrhosis
- Thyroiditis
- SLE
- Mixed connective tissue disease
- Sarcoidosis
- Polymyositis
- Vasculitis
- Scleroderma
- Chronic active hepatitis Amongst these, Sjogren syndrome is associated most commonly with RA.

---

### 328. True regarding fibromuscular dysplasia are all except -

a) Medium size vessels

b) OCPs predispose

c) Aneurysm may occur

d) Irregular hyperplasia

Correct Answer - B

Ans. is 'b' i.e., OCPs predispose

#### **Fibromuscular dysplasia**

- It is focal irregular thickening of the walls of medium and large muscular arteries, including renal, carotid, splanchnic, and vertebral vessels.
- Segments of vessel wall are focally thickened by a combination of irregular medial and intimal hyperplasia and fibrosis, causing luminal stenosis. In renal vessels, it may cause renovascular hypertension.
- Aneurysm may develop in the vessel segment with attenuated media, and can rupture in some cases.
- There is no association with use of oral contraceptives or sex hormone abnormalities.

### 329. Not true about Alport's syndrome ?

a) X-linked

b) Autosomal dominant

c) Nerve deafness

d) Glomerulonephritis

Correct Answer - B

Ans. is 'b' i.e., Autosomal dominant

- Autosomal dominant form also exist, but it is very rare. Thus, among the given options, it is the best answer.

- Other three options are classical features of Alport's syndrome.

#### **Alport's syndrome**

- Alport's syndrome is a type of hereditary nephritis characterized by -
- Glomerulonephritis progressing to chronic renal failure.
- Nerve deafness
- Eye defects    lenticonus, lens dislocation, posterior cataract, corneal dystrophy.
- Most commonly it is inherited as X-linked form.
- Rare autosomal - recessive and autosomal-dominant pedigrees also exist.
- Pathogenesis
- There is defective GBM synthesis because of production of abnormal collagen type IV underlies the renal lesions.
- The defect is caused by mutation in the gene encoding a  $\alpha_3$ -chain of collagen type IV.

### 330. Peliosis hepatis is caused by all except?

a) Analgesics

b) Anabolic steroids

c) OC pills

d) Danazol

Correct Answer - A

Ans. is 'a' i.e., Analgesics

- Peliosis hepatitis is a rare condition in which there is primarily sinusoidal dilatation.
- The liver contains blood filled cystic spaces, either unlined or lined with sinusoidal endothelial cells.
- Peliosis hepatitis is associated with many diseases including cancer, TB, AIDS or post transplantation immunodeficiency. It is also associated with exposure to anabolic steroids and rarely, oral contraceptives and danazol.

### 331. Pseudo-Pelger-Huet cells or seen in

a) Hairy cell leukemia

b) Multiple myeloma

c) Myelodysplastic syndrome

d) Hodgkin's lymphoma

Correct Answer - C

Ans. is 'c' i.e., Myelodysplastic syndrome

- **Peripheral blood** shows the presence of Pseudo- Pelger-Huet cells, giant platelets, macrocytes, poikilocytes and monocytosis.
- Clinical features are seen in only 50% patients including weakness, infection and hemorrhage due to pancytopenia.
- Usually patients are of an old age (mean age of onset is > 60 years). The prognosis is poor.

## 332. Acute phase reactants are all except ?

a) C-reactive protein

b) Haptoglobin

c) Endothelin

d) Fibrinogen

Correct Answer - C

Ans. is 'c' i.e., Endothelin

### Acute phase proteins (reactants)

- Acute phase reactants are a class of proteins whose plasma concentration increases or decreases in response to inflammation.
  - This response is called the acute phase reaction (acute phase response)
  - It should be noted that acute phase proteins not only increase in response to inflammation ; some decrease also
- .. Proteins which increase in response to inflammation —> Positive acute phase proteins
2. Proteins which decrease in response to inflammation Negative acute phase proteins

#### **1. Positive acute phase proteins**

C-reactive protein (3<sub>1</sub>-globulin)

$\alpha$ -1 antitrypsin

Fibrinogen, prothrombin, vWF

Ferritin

Serum amyloid A

D Plasminogen, Factor VIII

ct-2 microglobulin

Mannose binding protein

D-dimer protein

Haptoglobin

Ceruloplasmin

Complement factors

#### **2. Negative acute phase proteins**

CI Albumin & Prealbumin

Transferrin

Transcortin

Retinol binding protein

I ransthyretin

### 333. All are true about non-bacterial thrombotic endocarditis, except ?

a) Cause emboli

b) Vegetation > 5 mm

c) No inflammatory reaction

d) Locally nondestructive

Correct Answer - B

Ans. is 'b' i.e., Vegetation > 5 mm

#### **Nonbacterial thrombotic endocarditis (NBTE)**

- NBTE is characterized by the deposition of small sterile thrombi on the leaflets of the cardiac valves.
- The lesions are small, ranging from 1 mm to 5 mm.
- They occur singly or multiply along the lines of closure of leaflet or cusps.
- They are composed of bland thrombi that are loosely attached to the underlying valve.
- The vegetations are not invasive and do not elicit any inflammatory reaction. Thus, the local effect of vegetations is usually unimportant but they may be the source of systemic emboli.
- NBTE is often encountered in debilitated patients. It is seen in hypercoagulable states, e.g. cancer, promyelocytic leukemia, mucinous adenocarcinomas and increased estrogenic state.

### 334. Which one of the following stains is specific for Amyloid?

a) Periodic Acid schif (PAS)

b) Alzerian red

c) Congo red

d) Von - Kossa

Correct Answer - C

Ans. is 'c' i.e., Congo Red

- "To differentiate amyloid from other hyaline deposits (eg. Collagen and fibrin), a variety of histochemical techniques are used, of which the most widely used is Congo Red" - Robbins 7/e p. 259
- Staining for Amyloid
- Congo red : It is the most widely used specific stain for amyloid.
- Iodine staining : It is used for unfixed specimen or histological section. Amyloid stains mahogany brown and if sulfuric acid is added, it turns violet.
- Thioflavin 'T' and 'S' give secondary immunofluorescence with ultraviolet light. Thioflavin T is more useful for demonstrating juxtalomerular apparatus of the kidney.
- Metachromatic stains like crystal violet and methyl violet give rose pink appearance.
- Amyloid is PAS positive.

### 335. All are true about Fragile X syndrome except ?

a) Large head

b) Large nose

c) Large ear

d) Large testis

Correct Answer - B

Ans. is 'b' i.e., Large nose

#### **Fragile - X syndrome**

- Fragile - X syndrome is the prototype of diseases in which the mutation is characterized by a long repeating sequence of three nucleotides.
- In fragile X syndrome, trinucleotide repeat mutation involves CGG on a non-coding region.
- Clinical features of fragile - X syndrome
  - Mental retardation
  - Long face with large mandible
  - Hyperextensible joint
  - Mitral valve prolapse
  - Large everted ears
  - Large testis (macro-orchidism)
  - High arched palate
- Fragile X syndrome is the second most common cause of mental retardation, after Down's syndrome.

### 336. Concentric hypertrophy of left ventricle is seen in?

a) Mitral stenosis

b) Hypertension

c) Aortic regurgitation

d) None

Correct Answer - B

Ans. is 'b' i.e., Hypertension

- Concentric hypertrophy → In pressure overload, e.g. hypertension and aortic stenosis.
- Eccentric hypertrophy → In volume overload, e.g. in aortic regurgitation.

#### **Adaptations in heart**

- The cardiac myocyte is terminally differentiated cell that is not able to divide.
  - Myocardium cannot undergo hyperplasia, i.e. increase in the number of myocyte.
  - So, myocardium can adapt by increasing the size (i.e. hypertrophy) of the myocyte in response to stress.
  - There are two types of stresses to heart
- #### **1. Pressure overload**
- Occur in hypertension or aortic stenosis.
  - Pressure overloaded ventricles develop concentric hypertrophy of the left ventricle, with increased in wall thickness → Heart size may increase.
  - The increase in wall thickness may reduce the cavity diameter --> ratio of cavity size to wall thickness decreases.
  - There is increase in the transverse diameter (width) of myocytes, but cell length remains the same.

## **2. Volume overload**

- As occurs in aortic regurgitation
- There is dilatation of ventricular chamber along with increased thickness of ventricular wall → Eccentric hypertrophy.
- There is increase both in the transverse diameter (width) and the length of myocytes.
- It is due to deposition of the sarcomeres (functional intracellular contractile unit of cardiac muscles) in parallel to the long axis of cells.

### 337. Which does not cause sideroblastic anaemia?

a) INH

b) Chloramphenicol

c) Myelodysplastic anaemia

d) Mercury

Correct Answer - D

Ans. is 'd' i.e., Mercury

**Hereditary-** X-linked recessive sideroblastic anemia

**Acquired-**

**Hematological**

Myelofibrosis  
Myelodysplasia  
Acute leukemia  
Lymphoma  
Myeloma  
Polycythemia vera  
Hemolytic anemia

**Drugs & chemicals**

INH  
Penicillamine  
Lead  
Alcohol  
Pyridoxin deficiency  
Chloromphenicol

**Others**

RA  
Myxedema  
SLE  
Iron overload  
Porphyria

### 338. Which of the following is not a myeloproliferative disease ?

a) Polycythemia vera

b) Acute myeloid leukemia

c) Chronic myeloid leukemia

d) Essential thrombocytosis

Correct Answer - B

Ans. is 'b' i.e., Acute myeloid leukemia

#### **Chronic myeloproliferative disorders**

- The disorders in this group are ?  
Chronic myeloid leukemia      Essential thrombocytosis  
Polycythemia vera              Primary myelofibrosis
  - These diseases are characterized by neoplastic proliferation of multipotent progenitor cell that is capable of giving rise to mature erythrocytes, platelets, granulocytes, monocytes and lymphocytes.
  - An important feature of myeloproliferative disorders is that in their terminal phase they are characterized by marrow fibrosis and peripheral blood cytopenia.
  - All of them can progress over time to acute leukemia, but only CML does so invariably.
- Remember**
- CML, Polycythemia vera and essential thrombocytosis can progress to myelofibrosis in terminal stage.

### 339. All of the following are associated with carcinoma colon except ?

a) Smoking

b) Alcohol

c) Fibre diet

d) Fatty food

Correct Answer - C

Ans. is 'c' i.e., Fibre diet

- Fibre diet is protective against colon cancer (see previous explanations).

Risk factors for Colon cancer

.. Dietary factors - explained in previous question

2. Hereditary factors

- Polyposis coli
- Nonpolyposis hereditary colon cancer (also known as Lynch syndrome)

**Inflammatory bowel disease**

- Long standing IBD increases the risk
- Risk is more with ulcerative colitis than Crohn's disease.
- Risk increases with the duration and extent of colitis.
- Left sided colitis carries somewhat less risk.
- Streptococcus bovis bacteremia
- Individuals who develop endocarditis or septicemia from this bacteria, have a high incidence of occult colorectal tumors and possibly upper GI cancers also.

**Other Risk factors**

- Ureterosigmoidostomy
- Cigarette smoking - is linked to the development of colorectal

adenomas , particularly after >35 yrs of use.

- Acromegaly
- Pelvic irradiation
- Aspirin & other NSAIDs use has been found to have a protective effect (Chemoprevention)
- Other substances found to have chemopreventive action are → Oral folic acid supplementation, Oral calcium supplementation, Estrogen replacement therapy

### 340. Which of the following is labile cell ?

a) Cardiac cell

b) Liver parenchymal cell

c) Vascular endothelial cells

d) Surface epithelium

Correct Answer - D

Ans. is 'd' i.e., Surface epithelium

- When a cell proliferates, it pass through a cell cycle.

**Cell cycle has a series of phases :**

G phase → Rest phase (Presynthetic phase)

S phase → Synthetic phase in which synthesis of DNA takes place.

G<sub>2</sub>phase → Resting phase (Postsynthetic or postmitotic phase).

M phase → Mitotic phase in which mitosis takes place.

Go phase → When cell is not proliferating, it remains in quiescent phase (Go). Based on their proliferative capacity, cells are divided into S Go G,

**1. Labile cells (Continuously dividing cells) or intermitotic cells.**

- Have capacity to proliferate and regenerate.
- Have very short Go and almost always remain in cell cycle. Example are : -
- Surface epithelium (stratified squamous) of skin, oral cavity, vagina and cervix.
- Lining mucosa of all excretory ducts of glands (Salivary gland, pancreas, biliary duct).
- Columinar epithelium of GIT and uterus.
- Transitional epithelium of the urinary tract.

- Bone marrow cells and hematopoietic cells.
- Basal cells of epithelia.

## **2 . Stable or quiescent or reversible postmitotic cells.**

- Have limited capacity to proliferate and regenerate.
- Remain in G<sub>0</sub> phase of cell cycle but can enter in G<sub>1</sub> phase when stimulated i.e., they usually remain quiescent, but proliferate in response to stimuli. Example are -
- Parenchymal cells of liver, kidney and pancreas.
- Mesenchymal cells, e.g., fibroblast and smooth muscles.
- Vascular endothelium
- Osteoblast, chondroblast
- Resting lymphocytes and other leukocytes.

## **3. Permanent or nondividing or irreversible postmitotic cells.**

- Cannot divide and regenerate.
- These cells are nondividing and have left the cell cycle, i.e., they do not belong to any phase of cell cycle. Example are -
- Li Neurons
- Cardiac muscle
- Skeletal muscle

### 341. Glanzmann thrombasthenia is due to

a) Decreased Gplb

b) Decreased GpIIb/IIIa

c) Anti-GpIIb/IIIa antibodies

d) Inhibition or deficiency of ADAMTS 13

Correct Answer - B

**Ans. is. b. Decreased GpIIb/IIIa**

Glanzmann thrombasthenia is an autosomal recessive disorder. There is a failure of primary platelet aggregation with ADP or collagen due to inherited deficiency of two platelets membrane glycoproteins.

It is caused due to deficiency of glycoprotein IIb- IIIa.

### 342. Vitamin A is stored in

a) Cells of Ito

b) Hepatocyte

c) Endothelial cell

d) Kupffer cell

Correct Answer - A

#### **Answer A – Cells of Ito**

HSCs (hepatic stellate cells) (also called vitamin A-storing cells, lipocytes, interstitial cells, fat-storing cells or Ito cells) exist in the space between parenchymal cells and liver sinusoidal endothelial cells of the hepatic lobule and store 50-80% of vitamin A in the whole body as retinyl palmitate in lipid droplets in the cytoplasm.

### 343. Apoptotic gene is-

a) Bax

b) Bcl2

c) Bclx

d) Mcl

Correct Answer - B

#### **Answer-B. Bcl2**

Regulation is primarily by the Bcl-2 family of genes located on chromosome 18.

Some members of this family like bak, bid, bin, Bcl-xs (to remember, S for stimulating apoptosis) stimulate apoptosis whereas others like Bcl-2, Bcl-xl (to remember, L for lower apoptosis), etc inhibit apoptosis.

Gene families such as caspases, inhibitor of apoptosis proteins, B cell lymphoma (Bcl)-2 family of genes, tumor necrosis factor (TNF) receptor gene superfamily, or p53 gene are involved, and/or collaborate in the process of apoptosis.

### 344. Alpha one anti trypsin works by

a) inhibition of trypsin

b) inhibition of trypsinogen

c) inhibition of elastase

d) inhibition of chymotrypsin

Correct Answer - C

**Answer- C (inhibition of elastase)**

Explanation- Alpha-1 antitrypsin (A1AT) is produced in the liver, and one of its functions is to protect the lungs from neutrophil elastase, an enzyme that can disrupt connective tissue.

**345. Which one of the following is an autosomal recessive disorder?**

a) Albinism

b) Huntington's syndrome

c) Marfan's syndrome

d) Neurofibromatosis-1

Correct Answer - A

**Answer-A. Albinism**

Explanation- Albinism is caused by mutations in one of several genes, and most types are inherited in an autosomal recessive manner.

**346. Fish mouth appearance of valve in RHD is due to-**

a) Rupture of valve

b) Calcification & fibrosis

c) Hypertrophy of ventricular wall

d) None of the above

Correct Answer - B

**Answer- B. Calcification & fibrosis**

In rheumatic heart disease, an autoimmune attack on the mitral valve produces thickening of the valve leaflets. The mitral valve is often described as having a “fish-mouth” appearance.

### 347. Follicular lymphoma positivity?

a) Bcl-1

b) Bcl-6

c) Bcl- 2

d) None of the above

Correct Answer - C

**Answer-C. Bcl-2**

A translocation between chromosome 14 and 18 results in the overexpression of the bcl-2 gene. As the bcl-2 protein is normally involved in preventing apoptosis, cells with an overexpression of this protein are basically immortal. The bcl-2 gene is normally found on chromosome 18, and the translocation moves the gene near to the site of the immunoglobulin heavy chain enhancer element on chromosome 14.

### 348. what is the histological difference between them in Ulcerative colitis & Crohn's disease?

a) Diffuse distribution of pseudopolyps

b) Mucosal edema

c) Crypt abscess

d) Lymphoid aggregates in the mucosa

Correct Answer - C

differences between ulcerative colitis and Crohn's disease are as follows:

	ulcerative colitis	Crohns disease
common site	ileocolitis with rectal sparing	procolitis, rectum
protective factor	no factors	Smoking Appendicectomy
common risk factors	antibiotic during the first year of life, turner syndrome	antibiotic during the first year of life, turner syndrome
risk factor	OCP, Smoking	$\alpha$ -Methyldopa, Wiskott–Aldrich Syndrome,
T cell involved	TH1	TH2
Earliest macroscopic finding	Aphthous Ulcer	Erythematous mucosa with a fine granular surface
Wall involved	Transmural	mucosa & submucosa
Pseudopolyp	less common	most common
type of ulcer	serpentine	Collar-button ulcers
cobblestone		

appearance	present	not present
skin lesions	seen	not seen
Creeping fat	seen	not seen
Granuloma	non-caseating granuloma seen	not seen
Fistula	classical- perinatal (enterocutaneous)	not seen
strictures	common	not common
Toxic megacolon	not seen	seen
Crypt abscess and destruction	less marked	more marked
Rose thorn appearance	seen	not seen
metaplasia	Pyloric metaplasia is a clinical marker	paneth cell metaplasia
Renal calculi	calcium oxalate uveitis, migratory polyarthritis, sacroiliitis, ankylosing spondylitis, erythema nodosum, clubbing, Primary sclerosing cholangitis	not present
Extraintestinal manifestations		Similar to Crohn disease
Named criteria to assess the severity	-----	True Love Witt's criteria-UC

### 349. What is the cause of intracorpuscular defects in hemolysis?

a) Uremic syndrome

b) PCH

c) PNH

d) Portal hypertension

Correct Answer - C

**Answer-C. PNH**

#### HEMOLYTIC ANEMIA

HEMOLYSIS COULD BE:

##### 1. INTRACORPUSCULAR:

###### a. Hereditary defects

1. Defects in RBC membrane
2. Enzyme defects
3. Hemoglobinopathies
4. Thalassemia syndromes

###### b. Acquired Defects

1. PNH

##### 2. EXTRACORPUSCULAR (areas of sluggish circulation or hypo-oxygenation)

Immunhemolytic anemia, Infections, Microangiopathic, ...

**350. Type of necrosis seen in blood vessels due to immune reactions-**

a) Coagulation

b) Liquefaction

c) Fibrinoid

d) None

Correct Answer - C

**Answer- C (Fibrinoid)**

In small vessel vasculitis, fibrin plugs frequently occur in the vessel lumen, but the term fibrinoid is usually used to refer to material outside the lumen of a vessel. Fibrinoid necrosis also occurs in the walls of arterioles in malignant hypertension.

**351. In a patient with lipoprotein lipase deficiency, which of the following is increased following a fatty meal?**

a) Chylomicron

b) LDL

c) HDL

d) Apo-A

Correct Answer - A

**Answer- A. Chylomicron**

Lipoprotein lipase deficiency (Type I hyperlipoproteinemia): is a rare, autosomal recessive disorder caused by a deficiency of lipoprotein lipase. Resulting in fasting chylomicronemia and hypertriglycerolemia. There is slow clearance of chylomicrons and VLDL. Low levels of LDL and HDL. There is no increased risk of coronary disease.

**352. In Wilson's disease, there is less urinary excretion of-**

a) Phosphorus

b) Methyl- Histidine

c) Phosphotyrosine

d) Serine

Correct Answer - B

**Answer-B. Methyl- Histidine**

**Essentials of Diagnosis & Typical Features of Wilson disease:**

- Acute or chronic liver disease
- Deteriorating neurologic status
- Kayser-Fleischer rings
- Elevated liver copper
- Abnormalities in levels of ceruloplasmin and serum and urine copper.

### 353. What is the function of IL1?

a) Enhances hematopoiesis

b) Stimulates mast cells

c) Has antiviral properties

d) Endogenous pyrogen

Correct Answer - D

**Answer- D (Endogenous pyrogen)**

was formerly known as lymphocyte-activating factor (LAF).

augments the activity of many cell types, especially T cells.

is an endogenous pyrogen (EP).

induces an increase in acute phase reactants.

is a heat-stable and pH-stable peptide with a molecular weight of 17.5 kd.

occurs in two forms: IL-1 $\alpha$  and IL-1 $\beta$ .

### 354. CEAP score indicates-

a) Atrial disorders

b) Venous disorder

c) Neurological disorder

d) Trauma disorder

Correct Answer - B

**Answer- B. ( Venous disorder)**

Comprehensive Classification System for Chronic Venous Disorders (CEAP)

CEAP classification of chronic venous disease

Clinical classification

C3

Edema

C4a

Pigmentation or eczema

C4b

Lipodermatosclerosis or atrophie blanche

C5

Healed venous ulcer

### 355. IL- 1 activated by-

a) Capsase 1

b) Capsase 3

c) Capsase 8

d) Capsase 5

Correct Answer - A

#### **Answer- A (Capsase 1)**

The two inflammatory cytokines activated by Caspase-1 are excreted from the cell to further induce the inflammatory response in neighboring cells.

### 356. Parotid mass mixed consistency

a) Pleomorphic adenoma

b) Sebaceous cyst

c) Dermoid cyst

d) All

Correct Answer - A

**Answer- A (Pleomorphic adenoma)**

It is also known as “Mixed tumor, salivary gland type”, which refers to its dual origin from epithelial and myoepithelial elements as opposed to its pleomorphic appearance.

### 357. Krabbe's disease is-

a) Deficiency of Beta- galactosylcermidase

b) Deficiency of aryl sulphatase

c) Alpha galactosidase

d) Acid lipase

Correct Answer - A

**Answer- A (Deficiency of Beta- galactosylcermidase)**

Krabbe disease is caused by mutations in the GALC gene located on chromosome 14 (14q31), which is inherited in an autosomal recessive manner. Mutations in the GALC gene cause a deficiency of an enzyme called galactosylceramidase.

**358. What is the choice of treatment for idiopathic thrombocytopenia purpura (ITP)?**

a) Blood transfusion

b) Spontaneous recovery

c) IV infusion

d) Splenectomy

Correct Answer - D

**Answer- D (Splenectomy)**

Beneficial effects of splenectomy in chronic ITP are due to both removal of the major site of platelet destruction and the major source of autoantibody synthesis.

**359. Most common nephropathy associated with malignaneN is:**

a) Focal segmental glomerulosclerosis (FSGS)

b) Minimal change disease

c) IgA nephropathy

d) Membranous glomerulonephritis

Correct Answer - D

**Ans: D. Membranous glomerulonephritis**

- Most common nephropathy associated with malignancy - Membranous glomerulonephritis.
  - In 25-30% - Associated with malignancy (solid tumors of breast, lung, colon), infection (hepatitis B, malaria, Schistosomiasis), or rheumatologic disorders like lupus or rarely rheumatoid arthritis.
- Histopathology:**
- Electron-dense deposits along the epithelial side of the basement membrane with effacement of foot processes overlying deposits. (Ref Robbins 9/e p917-918; Harrison 19/e p1843).

**360. Which of the following complement factors is a marker of humoral rejection?**

a) C3d

b) C3b

c) C4d

d) C5a

Correct Answer - C

**Ans: C. C4d**

(Ref: Robbins 9/e p234)

- C4d factor is a marker for humoral rejection.
- Acute antibody-mediated rejection is manifested mainly by damage to glomeruli and small blood vessels.
- Typically, the lesions consist of inflammation of glomeruli and peritubular capillaries, associated with deposition of the complement breakdown product C4d, which is produced during activation of the complement system by the antibody- dependent classical pathway.
- Small vessels may also show focal thrombosis.

### 361. Most reactive free radical is:

a) Peroxide

b) Carboxyl

c) Hydroxyl

d) Superoxide

Correct Answer - C

**Ans: C. Hydroxyl**

(Ref Robbins 9/e p480)

- Hydroxyl radical ( $\cdot\text{OH}$ ) is the most potent reactive oxygen species.
- Most reactive oxygen-derived free radical.
- Principal ROS responsible for damaging lipids proteins & DNA.

### 362. Alpha-fetoprotein is a tumor marker for

a) Hepato cellular carcinoma

b) Multiple myeloma

c) Seminoma

d) Breast carcinoma

Correct Answer - A

Answer- A. Hepato cellular carcinoma

#### **Alpha-feto protein (AFP)**

- AFP is a well established tumor marker
- It is a glycoprotein synthesized normally early in fetal life by the yolk sac, fetal liver and fetal GIT.

#### **AFP is raised in -**

- Carcinomas > Liver Ca, Lung Ca, Colon Ca, Pancreatic Ca, Non-seminoma germ cell tumor of testis.
- Non-neoplastic conditions > Cirrhosis, Hepatitis, Pregnancy

### 363. Hypercalcemia in sarcoidosis all are true except?

a) Parathormone level is increased

b) PTHrP level is increased

c) Calcitriol level is increased

d) Oral steroids are useful

Correct Answer - A

**Answer- A. Parathormone level is increased**

- Extrarenal synthesis of calcitriol [1,25(OH)<sub>2</sub>D<sub>3</sub>] is central to the pathogenesis of abnormal calcium metabolism in sarcoidosis.
- Sarcoidosis causes an increase in 1, 25-dihydroxy vitamin D, the active metabolite of vitamin D, which is usually hydroxylated within the kidney, but in sarcoidosis patients hydroxylation of vitamin D can occur outside the kidneys, mainly inside the immune cells found in the granulomas and produces 1 alpha, 25(OH)<sub>2</sub>D<sub>3</sub>, which is the main cause for hypercalcemia in sarcoidosis.
- PTH release is inhibited by hypercalcaemia and high levels of calcitriol, so PTH level is suppressed in sarcoidosis.

### 364. Toll like receptors are seen on?

a) Macrophages

b) Natural killer cells

c) Endothelial cells

d) All of the above

Correct Answer - D

**Answer-D. All of the above**

- The Toll-like receptors are membrane proteins that recognize a variety of microbe-derived molecules and stimulate innate immune responses against the microbes.
- The Toll-like receptors are expressed on many different cell types that participate in innate immune responses including ,macrophages, dendritic cells, neutrophils, NKs cells, mucosal epithelial cells and endothelial cells.

**365. Reversible change from one cell type to other is known as -**

a) Hyperplasia

b) Hypertrophy

c) Metaplasia

d) Dysplasia

Correct Answer - C

**Ans. is 'c' i.e., Metaplasia [Ref: Robbins's 9<sup>th</sup>/e p. 376, 6<sup>th</sup> ed p 10]**

- Metaplasia is an adaptive change in which one adult (mature) cell type is replaced by another adult (mature) cell. It is completely reversible

### 366. Gaseous necrosis is seen in -

a) CMV infection

b) Staphylococcal infection

c) Treponemal infection

d) HSV infection

Correct Answer - C

**Ans. is 'c' i.e., Treponemal infection [Ref Robbin's 9<sup>th</sup> ed p. 43; Anderson's 10<sup>th</sup> ed p. 375]**

- Caseous necrosis is a feature of syphilis which is caused by treponemal infection.

#### **Gaseous necrosis**

- It is a variant of coagulative necrosis. It is most commonly encountered when cell death is attributable to certain organisms
- e.g., mycobacterium tuberculosis (TB), syphilis and fungi (Histoplasma, Coccidioidomycosis).

### 367. Substance playing a role in tumor metastasis cascade is

a) Collagenase IV

b) TNF-alpha

c) CD99

d) NM23

Correct Answer - A

**Ans is 'a' i.e. Collagenase IV**

**Various steps of metastasis and molecules involved**

1. Detachment of tumor cells - Down regulation of expression of either E-cadherins or catenins
2. Attachment to ECM (including basement membrane) - Tumor cells express integrins that helps in the attachment.
3. Degradation of ECM - proteolytic enzymes (most important proteases are metalloproteinases (MMPs) including collagenase IV).
4. Vascular dissemination and homing of tumor cells - Among adhesion molecule CD44 is of particular interest.

### 368. Rb gene is located on which chromosome?

a) 6

b) 9

c) 13

d) 21

Correct Answer - C

**Ans. is 'c' i.e.,13 [Ref Robbin's 9<sup>th</sup>Ve p. 290]**

- Retinoblastoma gene (RB gene) is located on 14 band on the long arm of chromosome 13 (13q14). RB gene is a tumor suppressor gene.
- Retinoblastoma develops when both the normal alleles of the RB genes are inactive or altered. It is typical example of Knudson's two hit hypothesis.

### 369. Absence of Ultra hepatic bile duct leads to which syndrome?

a) Von Meyenburg Complexes

b) Polycystic Liver Disease

c) Caroli Disease

d) Alagille Syndrome

Correct Answer - D

#### **Answer- D. Alagille Syndrome**

It is an autosomal recessive condition characterized by absence of bile ducts in portal tract Also called arterio hepatic dysplasia

Characteristic features:

- Genetic disorder with vascular, biliary and other anomalies.
- Absence of intrahepatic bile ducts with clinical severity ranging from severe neonatal cholestasis mimicking biliary atresia to childhood intermittent jaundice.
- Progression to cirrhosis is rare.

### 370. True about Dentigerous cyst:

a) Arises in relation to unerupted teeth

b) It most commonly encroaches maxillary antrum

c) Mandibular third molar is common site

d) Common in mandible

e) All

Correct Answer - A:C:D

**Answer- A,Arises in relation to unerupted teeth C,Mandibular third molar is common site D,Common in mandible**

- Common in lower jaw (mandible) in women 30-40 years.
- It occurs in relation to unerupted, permanent, molar tooth, most commonly the upper or lower third molar.

### 371. Vitamin A deficiency leads to metaplasia of?

a) Squamous epithelium

b) Columnar epithelium

c) Both

d) None

Correct Answer - A

#### **Answer- A. Squamous metaplasia**

- It occurs most frequently in respiratory tract as a result of chronic irritation by cigarette smoking. The columnar epithelium is replaced by squamous epithelium. This squamous metaplasia represents an attempt by the host to repair or prepare an epithelial tissue that has been damaged by environmental toxicants with a more resistant tissue.
- Squamous metaplasia is also encountered in other location such as pancreatic duct (Vit A deficiency, stones in
- pancreatic duct), gall bladder (gall stones), urinary bladder (bladder calculi, Schistosomiasis), and in endocervix.
- Though the metaplasia is reversible, if the influences that predispose to metaplasia is persistent, malignant transformation may occur in metaplastic epithelium.

### 372. Nuclei are arranged at the cell periphery in which type of cell?

a) Langhans giant cell

b) Merkel cells

c) NK cells

d) Neutrophils

Correct Answer - A

#### **Answer- A. Langhans giant cell**

- Peripheral nuclei are seen in Langhans type giant cells
- Langhans giant cells are large cells found in granulomatous conditions.
- They are formed by the fusion of epithelioid cells (macrophages) and contain nuclei arranged in a horseshoe-shaped pattern in the cell periphery.
- These cells contain 3-5 nuclei. Nuclei are arranged around the periphery in the form of a horseshoe. These cells may also act as precursors of foreign body giant cells. These cells are seen in TB & sarcoidosis.

### 373. Not true about VEGF is -

a) Highly specific for endothelium

b) Hypoxia potentiates its expression

c) Inhibits angiogenesis

d) Helps in tumor metastasis

Correct Answer - C

#### **Answer- C. Inhibits angiogenesis**

- Vascular endothelial growth factor (VEGF) is a potent angiogenic factor and was first described as an essential growth factor for vascular endothelial cells.
- VEGF is up-regulated in many tumors and its contribution to tumor angiogenesis is well defined.
- In addition to endothelial cells, VEGF receptors are expressed on numerous non-endothelial cells including tumor cells.
- Binds to endo-specific receptors Flt-1 and Flk-1 (of the tyrosine kinase family).
- Expression of VEGF potentiated by hypoxia and inactivation of p53.
- The two most important angiogenic factors in a tumor are VEGF and basic fibroblast growth factor (bFGF), thus helping in tumor metastasis.

### 374. Acute phase reactants are stimulated by

-

a) IL-6

b) IL-1

c) TNF-a

d) All of the above

Correct Answer - D

**Answer- D. All of the above**

In response to injury, local inflammatory cells (neutrophil granulocytes and macrophages) secrete a number of cytokines into the bloodstream, most notable of which are the interleukins IL6 and IL8, and TNFa. The liver responds by producing a large number of acute-phase reactants.

**375. Lymphotactin is which type of chemokine?**

a) C

b) C- C

c) C-X-C

d) C-X3-C

Correct Answer - C

**Answer- C. C-X-C**

C - chemokines :- They are specific for lymphocytes, e.g. lymphotactin.

**376. Active compound secreted by neutrophils against pathogen is known as?**

a) Major basic protein

b) Myeloperoxidase

c) Hydrolase

d) Proteoglycans

Correct Answer - B

**Answer- B. Myeloperoxidase**

The azurophilic granules of neutrophils contain the enzyme myeloperoxidase (MPO), which in the presence of a halide such as  $\text{Cl}^-$ , converts  $\text{H}_2\text{O}_2$  to hypochlorite ( $\text{HOCl}$ ).

### 377. Hydroxyl ions are destroyed in the body by?

a) Vitamin C

b) Vitamin A

c) Vitamin K

d) Vitamin D

Correct Answer - A

**Answer- A. Vitamin C**

"Vitamin C and other water soluble compounds, such as uric acid, thiols including glutathione and dihydrolipoic acid and possibly other substances such as metallothionein, serve to defend against hydroxyl radicals. Vitamin E, in contrast, is less effective in eliminating hydroxyl radicals.

**378. Most common cancer to occur in organ transplant patient is?**

a) Squamous cell carcinoma

b) Melanoma

c) Lung cancer

d) Colorectal cancer

Correct Answer - A

**Answer- A. Squamous cell carcinoma**

most common tumors after transplant

- Non melanoma skin cancer (SCC >BCC) (most common)
- NHL (2nd most common)
- Lung carcinoma
- Kaposi's sarcoma
- HCC
- Cervical carcinoma

### 379. Example of coagulative necrosis is -

a) Acute tubular necrosis

b) Stroke

c) Malignant hypertension

d) Acute pancreatitis

Correct Answer - A

**Answer- A. Acute tubular necrosis**

**The causes of coagulative necrosis are :**

1. Coagulative necrosis is most frequently caused by sudden cessation of blood flow (ischemia) in solid organs such as heart (MI), Kidney (ATN), Liver, adrenal gland, spleen. Amongst solid organs brain is the only exception, i.e., it is the only solid organ in which ischemia leads to liquefactive necrosis and not coagulative necrosis.
2. Toxic products of certain bacteria, as in calf diphtheria, necrophorus enteritis and other forms necrobacillosis.
3. Certain locally acting poisons, e.g., mercuric chloride.
4. Mild burns (thermal injury), whether produced by heat, electricity, or x-rays.
5. Zenker's degeneration necrosis of muscle. It occurs in typhoid. Rectus and diaphragm are the usual muscles affected

### 380. Trilateral retinoblastoma is?

a) Bilateral Retinoblastoma plus medulloblastoma

b) Bilateral retinoblastoma plus pineoblastoma

c) Bilateral retinoblastoma plus neuroblastoma

d) Bilateral retinoblastoma plus ependymoma

Correct Answer - B

**Answer- B. Bilateral retinoblastoma plus pineoblastoma**

- Trilateral retinoblastoma (TRb) refers to the combination of retinoblastoma (usually bilateral) and pineoblastoma. This relationship highlights the close relationship between these highly aggressive small round blue cell tumors.

### 381. What is the first sign of injury?

- a) Mitochondrial dysfunction
- b) Membrane damage
- c) Diminished ATP
- d) Release of lysosomal enzymes

Correct Answer - A

**Answer- A. Mitochondrial dysfunction**

hypoxia is the most common cause of cell injury.

Oxygen is an important requirement of mitochondria for the formation of ATP; therefore, hypoxia will result in the earliest involvement of mitochondria resulting in decreased formation of ATP.

Diminished ATP constitutes the critical mechanism of the cellular injury which leads to:

- a. Intracellular accumulation of  $Ca^{+2}$
- b. Mitochondrial dysfunction
- c. Membrane damage
- d. Release of lysosomal (hydrolytic) enzymes

## 382. Salivary scintigraphy is useful in?

a) Monomorphic adenoma

b) Pleomorphic adenoma

c) Sialidinitis

d) Sjogren syndrome

Correct Answer - D

### **Answer- D. Sjogren syndrome**

- Technitium pertechnetate scans (Salivary scintigraphy) tests the size, shape and function of the salivary glands. It is useful.
- .. To help determine the cause of salivary gland swelling (e.g. bacteria or virus).
- 2. To detect a blockage of the salivary ducts.
- 3. To detect a growth in the salivary glands (e.g. Warthin's Tumour).
- 4. To help diagnose abnormal mouth dryness as Sjogren's Syndrome.

### 383. Most common site for ectopic thyroid tissue is?

a) Ovaries

b) Lingual

c) In front of hyoid bone

d) Stomach

Correct Answer - B

**Answer- B. Lingual**

- By far the most common location is near its embryological origin at the foramen caecum, resulting in a lingual thyroid. This accounts for 90% of all cases of ectopic thyroids.

### 384. Blebs are found in which type of injury?

a) Reversible

b) Irreversible

c) Both

d) None

Correct Answer - A

**Answer- A. Reversible**

Pathological features of reversible cell injury are : Cellular swelling (earliest); loss of microvilli; cytoplasmic membrane blebs; ER swelling; Myeline figures; detachment of ribosome from ER; cytoplasmic (lipid) vacuole; clumping of chromatin.

### 385. Hydropic change is due to -

- a) Accumulation of water intracellularly
- b) Fat accumulation intracellularly
- c) Lysozyme degeneration
- d) Glycogen accumulation intracellularly

Correct Answer - A

**Answer- A> Accumulation of water intracellularly**

Hydropic change (abominoid degeneration, hydropic degeneration, parenchymatous degeneration, cloudy swelling) of a cell is degenerative change, in which the cells swell due to injury to the membrane affecting ionic transfer, causing the cytoplasm to appear cloudy and water to accumulate between the cells, with resultant Swelling of the tissue.

Cellular swelling (hydropic change) is the earliest change in cell injury (reversible).

### 386. Sphenoid dysplasia is seen in?

a) NF-1

b) Tuberous sclerosis

c) Sturge-Weber syndrome

d) Creutzfeldt-Jakob disease

Correct Answer - A

**Answer- A. NF-1**

**NF-1 is diagnosed if two of following sevens are present :**

1. Six or more cafe-au-lait macules : > 5mm in prepubertal age and > 15 mm in postpubertal age.
2. Axillary or inguinal freckling.
3. Two or more Lisch nodules (hamartomas on iris).
4. Two or more neurofibroma or one plexiform neurofibroma.
5. A distinctive osseous lesion : Sphenoid dysplasia or cortical thinning of long bones.
6. Optic glioma.
7. A first degree relative with NF-1.

### 387. Hob nail appearance is seen in

a) Clear cell carcinoma

b) Endodermal sinus tumor

c) HCC

d) Choriocarcinoma

Correct Answer - A

**Answer- A. Clear cell carcinoma**

Hobnail cell is a cell with a characteristic appearance, including a bulbous nucleus and nuclear projections into the cytoplasm. Hobnail cells are found in clear cell ovarian adenocarcinoma, collecting duct carcinoma, and in end-stage cirrhosis

### 388. Chromosome for MEN2 gene is

a) 11q13

b) 13q11

c) 10811.2

d) 11q10-2

Correct Answer - C

**Answer- C. 10811.2**

Multiple endocrine neoplasia type 1 MEN1 11813

Multiple endocrine neoplasia type 2a RET 10811.2

### 389. X-linked adrenoleukodystrophy is

- a) Fatty acid disorder
- b) Lysosomal storage disorder
- c) Mucopolysaccharidoses
- d) Glycogen defect disorder

Correct Answer - A

**Answer- A. Fatty acid disorder**

X-linked adrenoleukodystrophy(ALD/X-ALD) is a disease is caused by mutations in ABCD1, a gene located on the X chromosome, that codes for ALD, a peroxisomal membrane transporter protein.

**390. Endothelial molecule involved in rolling is -**

a) ICAM 1

b) VCAM 1

c) CD 31

d) CD 34

Correct Answer - D

**Answer- D. CD 34**

Endothelial molecule- Major Role

P-selectin- Rolling

E-selectin- Rolling and adhesion

GlyCAM- 1, CD34- Rolling

ICAM-1 (Immunoglobulin family)- Adhesion, arrest, transmigration

VCAM-1 (Immunoglobulin family)- Adhesion

PECAM-1 (CD-31)- Diapedesis (transmigration)

### 391. Stain used for tubulin is

a) Luna stain

b) Cajal stain

c) SiR stain

d) Masson's trichrome

Correct Answer - C

**Answer- C. SiR stain**

fluorescent stains (SiR-Actin and SiR-Tubulin) are cell permeable compounds which stain F-actin and microtubules, respectively.

### 392. Folding defect is associated with which disease

a) Parkinson's disease

b) Marfan syndrome

c) Acute intermittent porphyria

d) Wermer syndrome

Correct Answer - A

#### **Answer- A. Parkinson's disease**

Defective protein folding disorders (DPFDs) are a group of diverse neurological and systemic diseases in which the hallmark pathological event is the misfolding, aggregation and accumulation of a protein in different organs, inducing cellular apoptosis, tissue damage and organ dysfunction .

Includes Alzheimer's disease, transmissible spongiform encephalopathies, serpin-deficiency disorders, sickle cell anemia, Huntington's disease, diabetes type II, amyotrophic lateral sclerosis, Parkinson's disease, dialysis-related amyloidosis, spinocerebellar ataxias, secondary or reactive amyloidosis, cystic fibrosis and prion diseases.

**393. Marker for neuroblastoma among the following is?**

a) NMP 22

b) Chromogranin A

c) LDH

d) 32 microglobulin

Correct Answer - B

**Answer- B. Chromogranin A**

Neuroendocrine markers of neuroblastoma :- i) CD-56      ii)  
Chromogranin-A      iii) Synaptophysin

**394. Vasodilatation following endothelial damage is due to ?**

a) Histamine

b) IL-2

c) TGF-3

d) FGF

Correct Answer - A

**Answer- A. Histamine**

Vasodilatation :- Histamine, prostaglandins (PG D2, PGE2), prostacyclins, serotonin, Nitric oxide, bradykinin

### 395. Least desmoplastic breast carcinoma is

a) Ductal

b) Lobular

c) Tubular

d) Medullary

Correct Answer - B

**Answer- B. Lobular**

"Invasive lobular carcinoma has a tendency to spread diffusely or between the collagen fibers of the breast and produces desmoplastic response"

**396. Metastasis to thyroid comes from which primary site of malignancy?**

a) Liver

b) Testis

c) Prostate

d) Kidney

Correct Answer - D

**Answer- D. Kidney**

Most common primary sites are kidney, breast, lung, uterus, and melanoma.

### 397. Choroid metastasis is associated most commonly with?

a) Gastric carcinoma

b) Renal carcinoma

c) Brain tumor

d) Bone tumor

Correct Answer - B

**Answer- B. Renal carcinoma**

- Tumors most likely to metastasize to the choroid plexus are renal cell carcinoma and lung cancer. Other tumors with documented spread to the choroid plexus include colon, gastric, breast, thyroid, and bladder cancers, melanoma and lymphoma.

**398. All are associated with diabetic gangrene except?**

a) Wet gangrene

b) Dry gangrene

c) Gas gangrene

d) Fournier's gangrene

Correct Answer - C

**Answer- C. Gas gangrene**

It is a bacterial infection that produces gas within tissues. It can be caused by Clostridium, most commonly alpha toxin producing Clostridium perfringens, or various non-clostridial species.

### 399. Stain used for staining the nucleus is?

a) Safranin

b) Fast green

c) Hematoxylin

d) Erythrosine

Correct Answer - C

**Answer- C. Hematoxylin**

Hematoxylin stains the cell nucleus and other acidic structures (such as RNA-rich portions of the cytoplasm and the matrix of hyaline cartilage) blue, while eosin stains cytoplasm, connective tissue and other extracellular substances pink or red.

## 400. Primary granules contain which enzyme?

a) Myeloperoxidase

b) Hydrolases

c) Lactoferrin

d) Phospholipase A2

Correct Answer - A

**Answer- A. Myeloperoxidase**

Myeloperoxidase

Lysozyme

Acid hydrolases

Elastases

Nonspecific collagenase

Bacterial permeability protein

Defensin (BPI)

Cathepsin G

Phospholipase A2

**401. Peroxidase enzyme found in neutrophils is used for -**

a) Macrophage activation

b) Chemotactic agent

c) Microbial killing

d) Vasodilatation

Correct Answer - C

**Answer- C. Microbial killing**

Peroxidase (myeloperoxidase) is involved in phagocytosis (microbial killing).

## 402. Penile carcinoma is usually?

a) Squamous cell carcinoma

b) Basal cell carcinoma

c) Adenocarcinoma

d) Small cell carcinoma

Correct Answer - A

**Answer- A. Squamous cell carcinoma**

Most of penile cancers are squamous cell carcinoma and arise on glans or inner surface of prepuce.

### 403. Delayed umbilical cord detachment leukocytosis is seen in?

a) Leukocyte adhesion deficiency

b) Chronic granulomatous disease

c) Severe combined immunodeficiency

d) None of the above

Correct Answer - A

#### **Answer- A. Leukocyte adhesion deficiency**

- Leukocyte adhesion deficiency type 1 is a disorder that causes the immune system to malfunction, resulting in a form of immunodeficiency
- One of the first signs of leukocyte adhesion deficiency type 1 is a delay in the detachment of the umbilical cord stump after birth. In newborns, the stump normally falls off within the first two weeks of life; but, in infants with leukocyte adhesion deficiency type 1, this separation usually occurs three weeks or later. Also, affected infants often have inflammation of the umbilical cord stump (omphalitis) due to a bacterial infection.
- It's due to the absence of CD 18 antigen that's necessary for the formation of integrins, the substances that are responsible for the second step of leukocyte migration: adhesion. Because the leukocytes cannot efficiently reach the site of insult, they cannot engulf the offending substance, and no pus will be evident. Also, as a compensatory mechanism, there may be excessive leukocytosis.

#### 404. Collar button ulcer is found in?

a) Ulcerative colitis

b) Crohn's disease

c) Shigella

d) All of the above

Correct Answer - D

**Answer- D. All of the above**

"Collar button ulcers", a radiological sign, are manifestations of inflammatory processes within the bowel.

Collar button ulcers have also been observed in the setting of other inflammatory bowel processes, such as Crohn's disease, ischemic colitis, and shigellosis.

## 405. Phlegmonous gastritis occurs due to?

a) H. pylori

b) E. coli

c) C. jejuni

d) Cl. Tetani

Correct Answer - B

**Answer- B. E. coli**

Most cases of phlegmonous gastritis are due to alpha-hemolytic streptococci, although pneumococci, staphylococci, Escherichia coli, and rarely, Proteus Vulgaris and Clostridium welchii can be the causative organisms.

**406. Decrease in plasma osmotic pressure is cause of edema in?**

a) CHF

b) DVT

c) Nephrotic syndrome

d) None

Correct Answer - C

**Answer- C. Nephrotic syndrome**

Decreased plasma osmotic pressure of capillaries : It causes decreases in inward drivingforce. It results from Hypoproteinemia. When total plasma protein is below 5 gm/dl (normal 6-8 gm/dl) or albumin is below 2.5 gm/dl (normal 3.5-5 gm/dl) edema takes place. Conditions causing hypoproteinemia are nephrotic syndrome, liver cirrhosis, protein losing enteropathy, and PEM.

## 407. False about Patterson-Kelly-Brown syndrome is?

a) Anemia

b) Esophageal webs

c) Glossitis

d) Risk factor for adenocarcinoma

Correct Answer - D

**Answer- D. Risk factor for adenocarcinoma**

Plummer-Vinson syndrome (PVS) (Paterson-Brown-Kelly syndrome or sideropenic dysphagia), is characterized by difficulty in swallowing, iron deficiency anemia, glossitis, cheilosis, and esophageal webs.

## 408. Normal time taken for scar formation after injury is?

a) 2 weeks

b) 3 weeks

c) 4 weeks

d) 5 weeks

Correct Answer - C

### **Answer- C. 4 weeks**

Immediately after incision : Incision is filled with blood clot containing fibrin and blood cells (including ), dehydration of surface clot forms scab on surface.

Within 24 hours : Neutrophils appear at the margin of wound, which is filled with blood clot.

24-48 hours : Epithelial cells move from wound edges and fuse in the midline beneath the surface scab, producing a continuous but thin epithelium layer that closes the wound.

Day 3 : Neutrophils are replaced by macrophages, granulation tissue appears, collagen fibers are present in the margin but do not bridge the incision.

Day 5 : Abundant granulation tissue, maximum neovascularization, abundant collagen which bridges the incision, the epidermis recovers its normal thickness.

2nd week : Disappearance of leukocytes and edema, presence of fibroblasts (derived from local mesenchyme) and maximum collagen.

End of 1 month : There is scar which is made up of cellular connective tissue devoid of inflammatory infiltrate covered now by intact epidermis. There is replacement of collagen type III with

collagen type I.

**409. Vitamin deficiency associated with cystic fibrosis is**

a) K

b) B6

c) C

d) B12

Correct Answer - D

**Answer- D. B12**

Patients with cystic fibrosis (CF) are at risk of developing deficiencies of fat-soluble vitamins (A, D, E, and K) because of pancreatic insufficiency, hepatobiliary disease, or both.

**410. Which type of healing occurs in an incisional wound with infection?**

a) Primary

b) Delayed primary

c) Secondary

d) Tertiary

Correct Answer - C

**Answer- C. Secondary**

Its produced by sharp cutting instruments-  
knife,razor,blade,swords,chopper,axe etc.

Secondary healing occurs in an incisional wound with infection.

## 411. APC gene is involved in?

a) Colorectal carcinoma

b) Gastric carcinoma

c) Gastric lymphoma

d) Esophageal adenocarcinoma

Correct Answer - A

**Answer- A. Colorectal carcinoma**

The APC protein is a negative regulator that controls beta-catenin concentrations and interacts with E-cadherin, which are involved in cell adhesion.

Mutations in the *APC* gene may result in colorectal cancer

## 412. Gene for embryogenic stem cell is -

a) Oct-4

b) Nanog

c) GJA I

d) All of the above

Correct Answer - D

**Answer- D. All of the above**

A common subset of 92 genes was identified that included Nanog, GTCM-1, connexin 43 (GJA1), oct-4, and TDGF1 (cripto)."

### 413. Complement mediated hypersensitivity reaction is?

a) Type -1 hypersensitivity

b) Type -2 hypersensitivity

c) Type -4 hypersensitivity

d) None

Correct Answer - B

**Answer- B. Type -2 hypersensitivity**

Type II reactions (Antibody mediated) → Involve immunoglobulin G or Immunoglobulin M bound to cell surface antigen, with subsequent complement fixation.

## 414. T-cell mediated disease is?

a) Asthma

b) Myasthenia gravis

c) SLE

d) Sarcoidosis

Correct Answer - D

**Answer- D. Sarcoidosis**

**Type I (IgE mediated)**

- Eczema
- Hay fever
- Asthma
- Atopy
- Urticaria
- Anaphylactic shock
- Acute dermatitis
- Theobald smith phenomenon
- Prausnitz Kusnter (PK) reaction
- Casonis test
- Schultz-Dale phenomenon

**Type II (IgG, IgM and complement mediated)**

- Blood transfusion reactions
- Erythroblastosis fetalis
- Autoimmune hemolytic anemia or thrombocytopenia or agrnulocytosis<sup>4</sup>
- Pemphigus vulgaris
- Good pasture syndrome
- Bullous pemphigoid
- Pernicious anemia

- Acute rheumatic fever
- Diabetes mellitus
- Graves disease
- Myasthenia gravis
- **Type III (IgG, IgM, complement and leucocyte mediated)**
- Local-Arthus reaction
- Systemic-serum sickness
- Schick test
- Polyarteritis nodosa (PAN)
- Rheumatoid arthritis
- SLE
- Acute viral hepatitis
- Penicillamine toxicity
- Hyperacute graft rejection

**415. Type 4 hypersensitivity reaction to TB antigen is similar to which of the following?**

a) Serum sickness

b) Asthma

c) Myasthenia gravis

d) Temporal arteritis

Correct Answer - D

**Answer- D. Temporal arteritis**

**Type IV (T-Cell mediated)**

- Tuberculin test
- Lepromin test
- Sarcoidosis
- Tuberculosis
- Contact dermatitis
- Granulomatous inflammation
- Type I lepra reaction
- Patch test
- Temporal arteritis
- Jones mote reaction (cutaneous basophilic HSN)
- Graft rejection
- Fairleys test
- Frie's test

## 416. Non IgE mediated anaphylactic reaction includes -

a) Ig G

b) Ig M

c) Compliments

d) All of the above

Correct Answer - D

**Answer- D. All of the above**

Cytotoxic reactions can also cause anaphylaxis, via complement activation. Antibodies (IgG and IgM) against red blood cells, as occurs in a mismatched blood transfusion reaction, activate complement. This reaction causes agglutination and lysis of red blood cells and perturbation of mast cells resulting in anaphylaxis

## 417. Total colonic aganglionosis is a variant of?

- a) Crohn's disease
- b) Ulcerative colitis
- c) Hirschsprung's disease
- d) Tropical sprue

Correct Answer - C

### **Answer- C. Hirschsprung's disease**

Hirschsprung disease (Congenital aganglionic megacolon) is caused by defective migration of neural crest into the mesodermal layer of gut. There is aganglionosis (absence of ganglions) in a portion of intestinal tract. Intestinal segment lacks both Meissner submucosal and Auerbach myenteric plexuses.

## 418. MHC1 is involved in?

a) Tumor lysis

b) Mixed leukocyte reaction

c) Autoimmune disease susceptibility

d) All of the above

Correct Answer - A

### **Answer- A. Tumor lysis**

MHC class I molecules are present on all nucleated cells, all virus-infected cells can be detected and eliminated by CD8+Cytotoxic T lymphocytes.

MHC class I is responsible for graft rejection and cell-mediated cytolysis of viral infected or tumor cells.

## 419. Which disease is diagnosed by jejunal biopsy?

a) Celiac disease

b) Intestinal lymphoma

c) Argentaffinoma of intestine

d) Tropical sprue

Correct Answer - B

**Answer- B. Intestinal lymphoma**

**the jejunal biopsy is useful in the diagnosis of the following disorders:**

- Intestinal lymphoma
- Intestinal lymphangiectasia
- Eosinophilic gastroenteritis
- Amyloidosis
- Crohn's disease
- Infection by one or more microorganisms
- Mastocytosis
- Whipple's disease

## 420. CD4 is associated with HLA?

a) HLA 1

b) HLA 2

c) HLA 3

d) All of the above

Correct Answer - B

**Answer- B. HLA 2**

MHC-II recognizes exogenous antigen (extracellular microbes, soluble proteins) and present it to CD4 helper T cells (MHC-II restricted).

MHC class I present antigen to cytotoxic CD-8 T cells (MHC-I restricted).

## 421. All are true about Toll like receptors except?

a) Recognize microbial molecules

b) Activation of immune system

c) Regulation of calcium channel

d) Activation of transcription factors

Correct Answer - C

### **Answer- C. Regulation of calcium channel**

- Toll-like receptors (TLRs) are microbial sensors that are named for the founding member called Toll, which was discovered in *Drosophila*.
- There are ten mammalian TLRs, which recognize products of bacteria (such as endotoxin and bacterial DNA), viruses (such as double-stranded RNA), and other pathogens (Fig. 2–3, A).
- TLRs are located in plasma membranes and endosomes, so they can detect extracellular and ingested microbes.
- They are complemented by cytoplasmic and membrane molecules, from several other families, that also recognize microbial products.
- TLRs and the other receptors recognize products of different types of microbes and thus provide defense against essentially all classes of infectious pathogens.
- Recognition of microbes by these receptors activates transcription factors that stimulate the production of several secreted and membrane proteins.
- These proteins include mediators of inflammation, antiviral cytokines (interferons), and proteins that promote lymphocyte activation and even more potent immune responses.

**422. Blood group most commonly associated with gastric carcinoma is?**

a) Blood Group O

b) Blood group A

c) Blood group AB

d) Blood group B

Correct Answer - B

**Answer- B. Blood group A**

Genetic factors : Blood group A, Hereditary nonpolyposis colon cancer syndrome (HNPCC) and Familial gastric cancer syndrome (E-cadherin mutation).

**423. The most common organ to be involved in the acute phase of Graft vs host disease is?**

a) Bone marrow

b) Skin

c) Liver

d) Gut

Correct Answer - B

**Answer- B. Skin**

Acute Graft vs host disease (occurring days to weeks after transplantation) causes epithelial cell necrosis in three principal target organs: liver, skin, and gut. Destruction of small bile ducts gives rise to jaundice, and mucosal ulceration of the gut results in bloody diarrhea. Cutaneous involvement is manifested by a generalized (maculopapular) rash.

**Histological findings are-**

1. Perivascular mononuclear infiltrates.
2. Vacuolar degradation of dermo-epidermal junction.
3. Dyskeratotic cells or eosinophilic bodies in the epidermis.
4. Epidermolysis.
5. Denudation of epidermis (separation of the epidermis from the dermis).

**424. Autoimmune gastritis is associated with deficiency of vitamin?**

a) A

b) B12

c) C

d) D

Correct Answer - B

**Answer- B. B12**

In autoimmune gastritis, two important auto antibodies causing damage are anti-parietal cell antibodies (most common) and antibodies against intrinsic factor; anti-IF (most specific).

Vitamin B-12 deficiency and pernicious anemia : Due to deficiency of IF cells (secreted by parietal cells) as well as damage of IF by anti-IF antibodies.

**425. Normal value of CD4:CD8 ratio is -**

a) 0.5

b) 1

c) 1.5

d) 2

Correct Answer - D

**Answer- D. 2**

A normal CD4/CD8 ratio is 2.0, with CD4 lymphocytes equal to or greater than 400/mm<sup>3</sup> and CD8 lymphocytes equal to 200 to 800/mm<sup>3</sup>.

**426. Normally squamo-columnar junction is usually located at**

- a) Distal 2-3 cms of esophagus
- b) Proximal 2-3 cms of stomach
- c) In esophagus more than 3cms proximal to GEJ
- d) None of the above

Correct Answer - B

**Answer- A. Distal 2-3 cms of esophagus**

Proximal extension of the squamocolumnar junction beyond the distal 2-3 cms of oesophagus is abnormal and is suggestive of Barrett's esophagus.

**427. Carcinoma associated most commonly with upper one third of esophagus is**

a) Adenocarcinoma

b) Squamous cell Carcinoma

c) Adeno-squamous Carcinoma

d) Leiomyosarcoma

Correct Answer - B

**Answer- B. Squamous cell Carcinoma**

Squamous cell carcinoma is the most common type of esophageal carcinoma worldwide and in India. It usually occurs in middle 1/3rd (not common) and upper 1/3' of esophagus. Some may also arise in lower 1/3

**428. Anti Jo-1 antibodies are a feature associated with?**

a) SLE

b) Systemic sclerosis

c) Polymyositis

d) Rheumatoid arthritis

Correct Answer - C

**Answer- C. Polymyositis**

Anti-Jo-1 antibody is a myositis specific autoantibody most commonly found in patients with idiopathic inflammatory myopathies (UM).

**429. HLA marker associated with diabetes mellitus type 1 is -**

a) B 7

b) DR 4

c) DQ 3

d) DQ 4

Correct Answer - B

**Answer- B. DR 4**

HLA associated with DM1 are DR3, DR4, DR8, DQ8.

**430. The zonal necrosis most commonly affected in chronic passive hepatic congestion is?**

a) Central

b) Peripheral

c) Mid zonal

d) None

Correct Answer - A

**Answer- A. Central**

Centrilobular hemorrhagic necrosis is caused by chronic passive congestion (CPC) due to right heart failure.

### 431. What is responsible for regeneration of liver cells?

a) HGF

b) VEGF

c) TGF-13

d) IFN-y

Correct Answer - A

**Answer- A. HGF**

Hepatocyte growth factor (HGF/scatter factor) levels rise to high levels soon after partial hepatectomy. This is the only factor tested that acts by itself as a potent mitogen for isolated hepatocytes cultured in vitro. This factor is also of critical importance in development of the liver, as target deletions of its gene lead to fetal death due to hepatic insufficiency.

## 432. Expression of a gene is known as?

a) Genotype

b) Phenotype

c) Genome

d) Morphology

Correct Answer - B

### **Answer- B. Phenotype**

The genotype (The genetic makeup of an individual) of an organism is the inherited map it carries within its genetic code.

The genotype is the part (DNA sequence) of the genetic makeup of a cell. Genotype is one of three factors that determine phenotype, the other two being inherited epigenetic factors, and non-inherited environmental factors.

### 433. Group-D chromosome is?

a) Chromosome 3

b) Chromosome 6

c) Chromosome 12

d) Chromosome 15

Correct Answer - D

**Answer- D. Chromosome 15**

13-15- Six chromosomes slightly smaller than the C group with the kinetochores in a near terminal position.

**434. Acute intermittent porphyria is associated with which type of inheritance?**

a) Autosomal dominant

b) Autosomal recessive

c) X-linked dominant

d) X-linked recessive

Correct Answer - A

**Answer- A. Autosomal dominant**

Metabolic

Familial hypercholesterolemia

Acute intermittent porphyria

### 435. Strawberry gall bladder is seen in

a) Cholesterosis

b) Primary sclerosing cholangitis

c) Cholestasis

d) Primary billiary cirrhosis

Correct Answer - A

**Answer- A. Cholesterosis**

In Cholesterosis, there are deposits of cholesterol in the epithelial cells and in the submucosal macrophages. This gives appearance of multiple small yellow spots on a red hyperplastic muscosa, the straberry gallbladder.

### 436. Inheritance associated with congenital adrenal hyperplasia -

a) AR

b) AD

c) XR

d) XD

Correct Answer - A

**Answer- A. AR**

**Endocrine-**

- Congenital adrenal hyperplasia
- Albinism

### 437. True about RCC is?

a) Most common site is lower lobe of kidney

b) Most common variety is papillary type

c) Invasion of renal vein is more common than renal artery

d) Most common site of metastasis is lymph nodes

Correct Answer - C

**Answer- C. Invasion of renal vein is more common than renal artery**

Renal cell carcinoma is the most common malignant tumor of kidney. It occurs usually in 6th and 7th decade of life. There is male preponderance.

Important risk factors for RCC are smoking (most significant), obesity, hypertension, asbestos exposure, estrogen therapy, CRF, tuberous sclerosis and familial conditions (Von Hippel-Lindau syndrome).

RCC is an adenocarcinoma and most commonly arises from upper pole.

The one of the striking characteristics of RCC is to invade renal vein and is associated with poor prognosis.

### 438. Chronic bronchitis is associated with?

a) Increase in number of glands without any change in size

b) Bronchiolitis obliterans

c) Decrease in Reid index

d) Only large airways are involved

Correct Answer - B

**Answer- B. Bronchiolitis obliterans**

The earliest feature of chronic bronchitis is hypersecretion of mucus in the larger airways, associated with hypertrophy of submucosal gland of trachea and bronchi.

Later, small airways (small bronchi and bronchioles) are also involved and show goblet cell hyperplasia, and intraluminal and peribronchial fibrosis.

In most severe cases, there may be obliteration of lumen due to fibrosis → Bronchiolitis obliterans.

**439. On polarising microscopy, refractile body in the centre of granuloma is seen in?**

a) Sarcoidosis

b) Silicosis

c) Tuberculosis

d) Asbestosis

Correct Answer - B

**Answer- B. Silicosis**

Histologically the lesions of silicosis consist of concentric layers of hyalinized collagen surrounded by a dense capsule of more condensed collagen. Examination of the nodules by polarized microscopy reveals the birefringent silica particles.

**440. Most common type of pneumoconiosis, associated with TB is?**

a) Silicosis

b) Bysinosis

c) Asbestosis

d) Baggassosis

Correct Answer - A

**Answer- A. Silicosis**

Silicosis is associated with increased susceptibility to T.B.

It is postulated that silicosis results in a depression of cell-mediated immunity, and crystalline silica may inhibit the ability of pulmonary macrophages to kill phagocytosed mycobacteria.

Nodules of silicotuberculosis often contain a central zone of caseation.

## 441. Most common cause of chylothorax is?

a) Trauma

b) Lymphoma

c) Left-sided heart failure

d) Infections

Correct Answer - B

### **Answer- B. Lymphoma**

- Chylothorax is a pleural collection of a milky lymphatic fluid containing micro globules of lipid.
- It results from lymph formed in the digestive system called chyle accumulating in the pleural cavity due to either disruption or obstruction of the thoracic duct.
- The total volume of fluid may not be large, but chylothorax is always significant because it implies obstruction of the major lymph ducts, usually by intrathoracic cancer like primary or secondary mediastinal neoplasm, such as lymphoma.

## 442. Inheritance associated with fragile X-syndrome is-

a) Autosomal dominant

b) Autosomal recessive

c) X-linked dominant

d) X-linked recessive

Correct Answer - C

**Answer- C. X-linked dominant**

'None > c' i.e., X-linked dominant

The unstable triplet is transmitted in an X-linked inheritance but the probabilities of different phenotypes are far from traditional X-linked inheritance.

**443. Which type of paraneoplastic syndrome is most commonly associated with lung carcinoma?**

a) SIADH

b) Gynaecomastia

c) Acanthosis nigricans

d) Hypocalcaemia

Correct Answer - A

**Answer- A. SIADH**

SIADH is the most common paraneoplastic syndrome associated with lung carcinoma as Small cell carcinoma is the most common type of lung cancer associated with ectopic hormone production and paraneoplastic syndrome and ADH (Causing SIADH), ACTH (Causing cushingsyndrome) production are predominantly associated small cell carcinoma.

**444. Metastasis to lungs come most commonly from**

a) Breast carcinoma

b) Brain carcinoma

c) Bone carcinoma

d) Melanoma

Correct Answer - A

**Answer- A. Breast carcinoma**

Metastatic tumor to lung originate from carcinoma in the breast, colon, stomach, pancreas, kidney, prostate, liver, thyroid, adrenal, male genital tract and female genital tract.

## 445. Deficiency of p53 mutation is maximum in which lung carcinoma?

a) Small cell carcinoma

b) Squamous cell carcinoma

c) Adenocarcinoma

d) Lymphoma

Correct Answer - B

**Answer- B. Squamous cell carcinoma**

**-MYC and RB - small cell cancer**

- RAS and p16 - non-small cell cancer
- p53 - both small and non-small cell, but highest in squamous cell carcinoma
- K-RAS –adenocarcinoma

**446. In allergic bronchopulmonary aspergillosis, the location of lesions is**

a) Pleura

b) Bronchi and bronchioles

c) Alveoli

d) All of the above

Correct Answer - B

**Answer- B. Bronchi and bronchioles**

- Allergic bronchopulmonary aspergillosis (ABPA) is a condition characterized by a hypersensitivity response to the *Aspergillus* (most commonly *Aspergillus fumigatus*).
- An allergic bronchopulmonary aspergillosis is a form of lung disease that occurs in some people who are allergic to *Aspergillus*.
- With ABPA, this allergic reaction causes the immune system to overreact to *Aspergillus* leading to lung inflammation.
- ABPA causes bronchospasm (tightening of airway muscles) and mucus buildup resulting in coughing, breathing difficulty and airway obstruction.
- it also causes airway inflammation, leading to bronchiectasis—a condition marked by abnormal dilation of the bronchi and bronchioles.

## 447. HOX gene is associated with

a) Cranio-caudal development

b) Brain development

c) Teeth formation

d) All of the above

Correct Answer - A

**Answer- A. Cranio-caudal development**

HOX genes (a subset of homeotic genes) are a group of related genes that control the body plan of an embryo along the cranio-caudal (head-tail) axis.

## 448. Most common cancer found in coal mine workers

a) Anal canal

b) Testicular

c) Lung

d) Liver

Correct Answer - C

**Answer- C. Lung**

Among coal worker pneumoconiosis patients standard incidence ratio of various important carcinomas : ovary (2.0) > esophagus (1.76) Lung > (1.45) > Stomach (1.42) > Liver (1.18) > kidney (1.06) > prostate (1.02) > colorectal (1.00) > urinary bladder (0.91) > head & neck (0.87)

## 449. Chromosome for ABO gene is?

a) 9q

b) 10p

c) 11 q

d) 12p

Correct Answer - A

**Answer- A. 9q**

The ABO gene (Histo-blood group ABO system transferase enzyme) resides on chromosome 9 at the band 9q34.2.

Histo-blood group ABO system transferase is an enzyme with glycosyltransferase activity, which is encoded by the ABO gene in humans. It is ubiquitously expressed in many tissues and cell types.

## 450. Pink puffers are associated with?

a) Emphysema

b) Chronic bronchitis

c) Pneumonia

d) Bronchiectasis

Correct Answer - A

### **Answer- A. Emphysema**

A "pink puffer" is a person where emphysema is the primary underlying pathology

In emphysema, not only there is less surface area for gas exchange, there is also less vascular bed for gas exchange. . The body then has to compensate by hyperventilation (the "puffer").

Have less hypoxemia (compared to blue bloaters) and appear to have a "pink" complexion and hence "pink puffer".

## 451. Granulomatous lung disease is caused by?

a) Hypersensitivity pneumonitis

b) Sarcoma

c) Bronchogenic carcinoma

d) Bronchogenic cyst

Correct Answer - A

### **Answer- A. Hypersensitivity pneumonitis**

Granulomatous lung disease refers to a broad group of infectious and well as noninfectious conditions characterized by the formation of granulomas.

Infectious : Mycobacterial (TB & Non-TB); Fungal infection (cryptococcus, Histoplasma, Blastomycosis, Coccidioidomycosis, Aspergillosis); Parasitic Infections.

Non-infectious: Sarcoidosis; Wegner granulomatosis; Churg Strauss syndrome; Chronic granulomatous disease; Hypersensitivity pneumonitis; RA; Chronic Aspiration Pneumonitis; Langerhans Cell Histiocytosis; substances (Talc Granulomatosis, Berylliosis)

## 452. TEL-AML 1 fusion is associated with?

a) CLL

b) CML

c) ALL

d) AML

Correct Answer - C

**Answer- C. ALL**

TEL-AML 1 gene fusion is the most common genetic alteration in childhood acute lymphoblastic leukemia. It is created by balanced translocation t (12 : 21).

Cytogenetic abnormalities associated with ALL are gain of function mutation in NOTCH-1 gene in T-cell ALL.

### 453. Cag A gene is associated with

a) Hepatocellular carcinoma

b) Esophageal carcinoma

c) MALT lymphoma

d) Lung carcinoma

Correct Answer - C

**Answer- C. MALT lymphoma**

CagA, A gene that codes for an immunodominant antigen, is present only in *Helicobacter pylori* strains that are associated with severe forms of the gastroduodenal disease (type I strains).

*Helicobacter pylori* is a microaerophilic spiral-shaped lophotrichous Gram-negative bacterium that colonizes the gastric lumen of primates, including humans.

*H pylori* was identified as the cause of chronic active gastritis and peptic ulcer disease in humans and is considered to be a risk factor for the development of gastric adenocarcinoma and MALT lymphoma

## 454. Dutcher bodies are seen in?

a) Brain

b) Liver

c) Spleen

d) Bone marrow

Correct Answer - D

### **Answer- D. Bone marrow**

Dutcher bodies, which are attributed to immunoglobulin filled cytoplasm invaginating into the nucleus creating the appearance of an intranuclear inclusion.

Dutcher bodies are described as intranuclear inclusions in patients with Waldenstrom's macroglobulinemia.

The inclusions are positive on a periodic acid-Schiff reaction and were present in the cytoplasm as well as the nucleus.

They identified the inclusions as glycoprotein and postulated that they might be chemically identical to the macroglobulin in the plasma.

**455. Trinucleotide sequence associated with spino-cerebellar ataxia is?**

a) CTG

b) CUG

c) GGG

d) CAG

Correct Answer - D

**Answer- D. CAG**

Huntington's disease (CAG repeat),  
Spinocerebellar ataxia (CAG repeat),  
Friedreich ataxia (GAA repeat),  
Fragile-X-syndrome (GGG or GCC repeat),  
Dystrophia myotonica (CTG/CUG repeat)

## 456. CA-125 is?

a) Mucin glycoprotein

b) Carcinoma transmigration antigen

c) Mucopolysaccharide

d) Lipid

Correct Answer - A

### **Answer- A. Mucin glycoprotein**

\* CA-125, which stands for "Cancer Antigen 125" also known as mucin 16 or MUC16 is a protein that in humans is encoded by the MUC16 which is a member of the mucin family glycoproteins.

\* It is found in high amounts in the blood of patients with ovarian cancer.

\* CA-125 is produced on the surface of cells and is released in the bloodstream.

\* It is among the blood tests that may be ordered by a doctor if ovarian cancer is suspected.

\* CA-125 is also elevated in cancers of endometrium, cervix, fallopian tubes, pancreas, breast, lung and colon.

\* Non-neoplastic conditions causing elevation of CA-125 are pregnancy, menstruation, endometriosis, PID, abdominal TB, peritonitis and uterine fibroid.

\* reference range: CA 125 is 0-35 units/mL (0-35 kU/L).

**457. Li-fraumani syndrome occurs due to mutation in gene?**

a) p53

b) p16

c) p41

d) p12

Correct Answer - A

**Answer- A. p53**

Li-Fraumeni syndrome is due to germ line mutation in p-53 gene.

**458. Most common tumor suppressor gene involved in cancer genesis is?**

a) Rb

b) p53

c) p16

d) p73

Correct Answer - B

**Answer- B. p53**

p-53 is the most common target for genetic alteration in human tumors; A little over 50% of human tumors contain mutation in this gene.

**459. Left side shift in Arneth's count is seen in?**

a) Megaloblastic anemia

b) Septicemia

c) TB

d) Liver disease

Correct Answer - C

**Answer- C. TB**

Shift to left (hyperactive bone marrow)

Individuals who have a larger percentage of neutrophils with fewer lobes (mainly NI & N2) have a left shift which can be indicative of disease processes such as infections (pyogenic and TB), malignant tumors, hemolytic crises, myocardial infarction, acidosis, irradiation etc.

## 460. All are pre-malignant conditions except -

a) Anaplasia

b) Metaplasia

c) Hamartoma

d) Dysplasia

Correct Answer - C

A **precancerous condition** is a condition or lesion involving abnormal cells that are associated with an increased risk of developing into cancer. Clinically, precancerous conditions encompass a variety of conditions or lesions with an increased risk of developing into cancer.

**Dysplasia** is a broad term that refers to the abnormal development of cells within tissues or organs. It can lead to a wide range of conditions that involve enlarged tissue or pre-cancerous cells.

**Anaplasia** is a condition of cells with poor cellular differentiation, losing the morphological characteristics of mature cells and their orientation concerning each other and to endothelial cells. The term also refers to a group of morphological changes in a cell (nuclear pleomorphism, altered nuclear-cytoplasmic ratio, presence of nucleoli, high proliferation index) that point to a possible malignant transformation. Such loss of structural differentiation is especially seen in most, but not all, malignant neoplasms.

A hamartoma is a benign (noncancerous) tumorlike malformation made up of an abnormal mixture of cells and tissues found in areas of the body where growth occurs. It is considered a developmental error and can occur at several sites.

considering the above terms hamartoma is not a precancerous condition

---

## 461. Maximum life of transfused RBCs is

a) 110-120 days

b) 80-100 days

c) 60-80 days

d) 50-60 days

Correct Answer - B

**Answer- B. 80-100 days**

Normal average life span of red blood cells in adults is about 120 days, whereas that of transfused RBCs is about 50-60 days"

After an RBC transfusion, the mean potential life span of RBC is 85 days with a mean half life of  $43 \pm 11$  days.

## 462. Soft wood exposure leads to -

a) Nasal adenocarcinoma

b) Skin cancer

c) Liver cancer

d) Bladder cancer

Correct Answer - A

**Answer- A. Nasal adenocarcinoma**

"There is little doubt that exposure to hard wood dusts (especially that of beech 6, oak) in the furniture industry, as well as some domestic softwood outside the industry, is associated with sino-nasal cancers. Among the neoplasias, nasal adenocarcinoma is the cancer most commonly found in wood workers."

**463. Which test is used for both intrinsic and common clotting pathways?**

a) Thrombin time

b) Partial thromboplastin time

c) Ristocetin agglutination test

d) FDPs

Correct Answer - B

**Answer- B. Partial thromboplastin time**

1) Partial thromboplastin time (PTT) : It tests the intrinsic and common coagulation pathways. So, a prolonged PTT can result from deficiency of factor V, VIII (factor VIIIc, Von willebrand factor), IX, X, XI, XII, prothrombin or fibrinogen.

**464. At which cell cycle checkpoint is the cell cycle halted if the cell's DNA is damaged?**

a) G<sub>1</sub> - S

b) S - G<sub>2</sub>

c) G<sub>2</sub> - M

d) G<sub>0</sub> - G<sub>1</sub>

Correct Answer - A:C

**Answer- (A) G<sub>1</sub> - S (C) G<sub>2</sub> - M**

The S phase is the point of no return in the cell cycle, and before the cell makes the final commitment to replicate, the G<sub>1</sub>/S checkpoint checks for DNA damage. If DNA damage is present, the DNA repair machinery and mechanisms that arrest the cell cycle are put in motion. This causes delay at G<sub>1</sub>/S checkpoint.

This check point is used for the repair of the DNA which is damaged after its replication

**465. Which of the following is a pro-coagulant?**

a) Thrombomodulin

b) Protein C

c) Protein S

d) Thrombin

Correct Answer - D

**Answer- D. Thrombin**

Various factors involved in coagulation cascades are factor I (fibrinogen); factor II (prothrombin); factor III (thromboplastin or tissue factor); factor IV (calcium ions or Ca<sup>2+</sup>); factor V (labile factor); factor VI (accelerin); factor VII (stable factor or preaccelerin); factor VIII (antihemophilic factor); factor IX (christmas factor); factor X (stuart-prower factor); factor XI (plasma thromboplastin antecedent or PTA); factor XII (Hageman factor); factor XIII (fibrin stabilizing factor or Laki Lorand factor); HMWK (high molecular weight kinogen); prekallikrein; kallikrein; and platelet phospholipids.

**466. Immunohistochemical marker for sentinel node biopsy for breast carcinoma is?**

a) Cytokeratin

b) Vimentin

c) Calretinin

d) CD45

Correct Answer - A

**Answer- A. Cytokeratin**

Cytokeratin - Carcinoma

## 467. Scavenger receptors are for?

a) Oxidized LDL

b) Reduced LDL

c) HDL

d) VLDL

Correct Answer - A

**Answer- A. Oxidized LDL**

**Oxidized LDL has following effects**

1. Ingested by macrophages through the scavenger receptor, distinct from LDL receptors, thus forming foam cells.
2. Increases monocyte accumulation in lesions.
3. Stimulates release of growth factors and cytokines.
4. Is cytotoxic to smooth muscle cells and endothelial cells

## 468. Characteristic histopathological feature of rheumatic heart failure is -

a) Aschoff's nodule

b) Mc Callum patch

c) Bread & butter pericarditis

d) Shaggy vegetation

Correct Answer - A

### **Answer- A. Aschoff's nodule**

Microscopically, Aschoff bodies are areas of inflammation of the connective tissue of the heart, or focal interstitial inflammation.

Fully developed Aschoff bodies are granulomatous structures consisting of fibrinoid change, lymphocytic infiltration, occasional plasma cells, and characteristically abnormal macrophages surrounding necrotic centers.

Some of these macrophages may fuse to form multinucleated giant cells. Others may become Anitschkow cells or "caterpillar cells," so named because of the appearance of their chromatin.

Myocardium involvement results in myocarditis with Aschoff bodies. Endocardium involvement leads to the formation of small warty projections (verrucae) along the line of closure of valvular leaflets, mostly on the mitral valve.

They are pathognomic foci of fibrinoid necrosis found in many sites, most often the myocardium. Initially, they are surrounded by lymphocytes, macrophages, and a few plasma cells, but they are slowly replaced by a fibrous scar. Aschoff bodies are found in all the three layers of the heart, the least chance in the pericardium.

## 469. Not a feature of G-6PD deficiency?

a) Intravascular hemolysis

b) Oxidative stress

c) Membrane defect

d) Bite cells

Correct Answer - C

### **Answer- C. Membrane defect**

- \* Among the defects in hexose monophosphate shunt, the most common is G6PD deficiency.
- \* G6PD gene is located on the X chromosome and its deficiency is, therefore, a sex (X)-linked trait affecting males, while the females are carriers and are asymptomatic.
- \* PATHOGENESIS: Normally, red blood cells are well protected against oxidant stress because of an adequate generation of reduced glutathione via the hexose monophosphate shunt.
- \* Individuals with inherited deficiency of G6PD, an enzyme required for hexose monophosphate shunt for glucose metabolism, fail to develop adequate levels of reduced glutathione in their red cells.
- \* The clinical manifestations are those of acute hemolytic anemia within hours of exposure to oxidant stress.
- \* The hemolysis is, however, self-limiting even if the exposure to the oxidant is continued since it affects the older red cells only.

## 470. Prosthetic valves are predisposed to -

a) Thromboembolism

b) Infection

c) Hemolysis

d) All of the above

Correct Answer - D

**Answer- D. All of the above**

Thrombo- embolic events

Bleeding

Prosthetic heart valve obstruction or stenosis

Prosthetic heart valve regurgitation (valvular and paravalvular)

Infective endocarditis

Hemolytic anemia

Patient-prosthesis mismatch.

**471. Most frequent time period between myocardial infarction and subsequent myocardial rupture is -**

a) 3-4 days

b) 4-8 days

c) 1-3 weeks

d) 3-6 weeks

Correct Answer - A

**Answer- A. 3-4 days**

Myocardial rupture may occur almost anytime during 3 weeks after acute myocardial infarction, but is most common between the first and fourth days, when the infarcted wall is weakest.

## 472. Heinz bodies are removed by?

a) Macrophages

b) Lymphocytes

c) Neutrophils

d) Fibroblasts

Correct Answer - A

### **Answer- A. Macrophages**

\* The unstable hemoglobins are those hemoglobin variants that undergo denaturation and precipitation within the red cells as Heinz bodies.

\* They give rise to what is known as congenital non-spherocytic hemolytic anemia or congenital Heinz body hemolytic anemia.

\* These disorders have either autosomal dominant inheritance or develop from spontaneous mutations.

\* The unstable hemoglobins arise from either a single amino acid substitution in the globin chain or due to deletion of one or more amino acids within the  $\beta$ - globin chain so that the firm bonding of the haem group within the molecule is disturbed leading to the formation of methemoglobin and precipitation of globin chains as Heinz bodies.

\* Heinz bodies are not seen after the first one or two days since they are removed by the spleen, leading to the formation of 'bite cells' and fragmented red cells.

\* Macrophages detect the antigen and remove the damaged portions of the cell, its damaged membrane, and the denatured hemoglobin.

\* These are associated clinically with congenital hemolytic anemia, G6PD deficiency, hemolytic anemia secondary to drugs such as

phenacetin, some hemoglobinopathies (thalassemia), and after splenectomy.

### 473. Strawberry gums are seen in

a) Goodpasture's syndrome

b) Classic polyarteritis nodosa

c) Wegener's granulomatosis

d) Kawasaki syndrome

Correct Answer - C

**Answer- C. Wegener's granulomatosis**

- Strawberry gums are seen in Wegner's granulomatosis.
- Strawberry tongue is seen in Kawasaki disease.

## 474. Mutation in protein associated with restrictive cardiomyopathy?

a) Myosin regulatory proteins

b) Myosin binding protein-C

c) Troponin I

d) Tropomyosin

Correct Answer - C

### **Answer- C. Troponin I**

RCM-associated mutations have been reported in four genes that encode key sarcomeric proteins/myofilaments

1. MYH7 gene - 13-Myosin heavy chain
2. TNNI3 gene - Cardiac troponin I type 3
3. TNNT2 gene - Cardiac troponin T type 2
4. ACTC gene - a- actin

Mutations in the TNNI3 gene are one of the major causes of this condition. The TNNI3 gene provides instructions for making a protein called cardiac troponin I, which is found solely in the heart. Cardiac troponin I is one of three proteins that make up the troponin protein complex, which helps regulate tensing (contraction) and relaxation of the heart muscle.

TNNI3 gene mutations associated with familial restrictive cardiomyopathy result in the production of a defective cardiac troponin I protein.

The altered protein disrupts the function of the troponin protein complex and does not allow the heart muscle to fully relax. As a result, not enough blood enters the ventricles, leading to a buildup in the atria and lungs. The abnormal heart relaxation and blood flow is responsible for many of the signs and symptoms of familial

restrictive cardiomyopathy.

**475. In apoptosis, protein hydrolysis is due to activation of**

a) lipases

b) Transcarboxylase

c) Catalase

d) Caspases

Correct Answer - D

**Answer- D. Caspases**

**The execution phase of apoptosis**

- In this phase, initiate caspases (Caspase - 8 & 9) activate other caspases known as execution Caspases (Caspases- 3 & 7). After being activated the caspases act on many cellular components.
- In the nucleus, the target of caspase activation includes proteins involved in transcription, DNA replication, and DNA repair. Caspases activate endonucleases (DNAases) that causes double-stranded breaks in DNA.

## 476. Execution caspases of apoptosis are

a) Caspase 1 & 3

b) Caspase 3 & 5

c) Caspase 1 & 5

d) Caspase 3 & 7

Correct Answer - D

**Answer- D. Caspase 3 & 7**

Initiate caspases → Caspase - 8 & 9.

Execution caspases → Caspase - 3 & 7.

Initiate caspases are activated in initiation phase of apoptosis.

**477. Which of the following is not a free radical scavenger -**

a) Glutathione peroxidase

b) Superoxide dismutase

c) Catalase

d) Xanthine oxidase

Correct Answer - D

**Answer- D. Xanthine oxidase**

**Free radical scavgers (anti-oxidants) in body**

- 1. Non - enzymatic → Vitamins E, A & C, glutathione, cysteine, ceruloplasmin, transferrin, lactoferrin, ferritin.
- 2. Enzymes → Catalase, superoxide dismutase, glutathione peroxidase

**478. Cellular swelling with blebs and myelin figures are the changes seen in**

a) Reversible cell injury

b) Irreversible cell injury

c) Metaplasia

d) Anaplasia

Correct Answer - A

**Answer- A. Reversible cell injury**

Pathological features of reversible cell injury are : Cellular swelling (earliest); loss of microvilli; cytoplasmic membrane blebs; ER swelling; Myeline figures; detachment of ribosome from ER; cytoplasmic (lipid) vacuole; clumping of chromatin.

## 479. Endothelial molecule participating in rolling is

a) CD 34

b) CD 65

c) CD 56

d) CD 100

Correct Answer - A

**Answer- A. CD 34**

**Adhesion molecules involved in Rolling :**

- 1. Endothelial molecules : P-selectin, E-selectin, GlyCam-1, CD-34.
- 2. Leucocyte molecules : Sialyl-Lewis X-modified protein, L-selectin.

**480. What generates intracellular signals when cells are subjected to shear stress**

a) Cadherins

b) Selectins

c) Integrins

d) Focal adhesion molecules

Correct Answer - D

**Answer- D. Focal adhesion molecules**

Focal adhesion complexes are large (>100 proteins) macromolecular complexes that can be localized at hemidesmosomes, and include proteins that can generate intracellular signals when cells are subjected to increased shear stress, such as endothelium in the bloodstream, or cardiac myocytes in a failing heart.

## 481. True about wound healing with primary intention is

a) By day 5 epidermis recovers its normal thickness

b) Intense inflammatory reaction

c) Wound contraction occurs

d) Abundant granulation tissue grows

Correct Answer - A

**Answer- A. By day 5 epidermis recovers its normal thickness**  
**Healing by primary intention**

- It occurs in wounds with opposed edges, e.g., surgical incision.  
**The healing process follows a series of sequential steps : -**
- **Immediate after incision**
- Incisional space filled with blood containing fibrin and blood cells.
- Dehydration of the surface clot forms scab that covers the wound.
- **Within 24 hours**
- Neutrophils appear at the margins of wound.
- **In 24-48 hours**
- Epithelial cells move from the wound edges along the cut margin of dermis, depositing basement membrane components as they move.
- They fuse in the midline beneath the surface scab, producing a continuous but thin epithelium layer that closes the wound.
- **By day 3**
- Neutrophils are largely replaced by macrophages.
- Granulation tissue progressively invades the incision space.
- Collagen fibers now present in the margin but do not bridge the incision.
- **By day 5**
- Incisional space is largely filled with granulation tissue.

- Neovascularization is maximum.
- Collagen fibrils become more abundant and begin to bridge the incision.
- The epidermis recovers its normal thickness.

**During second week**

- Leukocytes and edema have disappeared.
- There is continued accumulation of collagen and proliferation of fibroblast.

**By the end of first month**

- Scar is made up of a cellular connective tissue devoid of inflammatory infiltrate covered now by intact epidermis.

## 482. The definition of exudate is

- a) Extravascular fluid that has a high protein concentration and contains cellular debris
- b) Extravascular fluid that has a low protein concentration
- c) Extravascular fluid with high glucose concentration
- d) Extravascular fluid with low glucose concentration

Correct Answer - A

**Answer- A. Extravascular fluid that has a high protein concentration and contains cellular debris**

Exudate is an inflammatory fluid that contains high protein content, cellular debris, and specific gravity  $>1.020$ . It occurs due to increased vascular permeability.

**483. In tuberculosis the cytokine causing fever is**

a) IL1

b) IL2

c) IL3

d) IL4

Correct Answer - A

**Answer- A. IL1**

**Pyrogenes**

- Pyrogenes are substances that cause fever.
- Pyrogens may be exogenous or endogenous
- Exogenous -4 Bacterial toxins
- Endogenous → IL-1, TNF-a, IL-6, Interferons, Ciliary's neurotropic factor

**484. Which acute phase reactant induces rouleaux formation**

a) C reactive protein

b) Fibrinogen

c) Serum amyloid A

d) IL 1

Correct Answer - B

**Answer- B. Fibrinogen**

Fibrinogen binds to red cells and causes them to form stacks (rouleaux) that sediment more rapidly at unit gravity than do individual red cells.

**485. Hyperimmune IgE syndrome is also called**

a) Jobs syndrome

b) Wiscott Aldrich syndrome

c) Chediak-Higashi syndrome

d) Digeorge syndrome

Correct Answer - A

**Answer- A. Jobs syndrome**

Job's syndrome, also called Hyper-IgE syndrome or Hyperimmunoglobulin E syndrome, is an autosomal dominant disorder due to mutations in Signal Transducer and Activator of Transcription-3 (STAT-3).

There is defect in phagocytosis. IgE levels are elevated. Other immunoglobulins are normal.

## 486. Complement C1 synthesized from -

a) Liver

b) Macrophage

c) Intestinal epithelium

d) Endothelium

Correct Answer - C

**Answer- C. Intestinal epithelium**

C1 is synthesized in intestine; C2 and C4 are synthesized by macrophages; C5 and C8 are synthesized in spleen; and C3, C6 and C9 are synthesized in liver.

[Ref: Short textbook of medical microbiology by Satish Gupte p. 92]

## 487. Perform are produced by

a) NK cell

b) Cytotoxic T cell

c) Plasma cell

d) Monocyte

Correct Answer - A

**Answer- A. NK cell**

Perforins are hole forming proteins, cause transmembrane pores through which cytotoxic factors enter the cell and destroy it by apoptosis.

Perforins are produced by:

N.K. Cells

[Ananthanarayan 126]

**488. Most common known causes of congenital anomalies in humans are**

a) Chromosomal aberrations

b) Maternal infections

c) Drugs

d) Irradiation

Correct Answer - A

**Answer- A. Chromosomal aberrations**

**Genetic**

- Chromosomal aberrations- 10-15
- Mendelian inheritance

**Environmental**

- Maternal/placental infections- 2-3
- Maternal disease states- 6-8
- Drugs and chemicals- 1
- Irradiations

Multifactorial 20-25

Unknown- 40-60

**489. Mesothelioma is positive for which intermediate filament**

a) Vimentin

b) Cytokeratin

c) GFAP

d) Desmin

Correct Answer - B

**Answer- B. Cytokeratin**

Cytokeratin- Carcinoma, mesothelioma, Non-seminoma GCT

## 490. Calretinin is used in

a) Mesothelioma

b) Hamartoma

c) Choristoma

d) Chordoma

Correct Answer - A

**Answer- A. Mesothelioma**

Calretinin and cytokeratin are positive in cases of malignant mesothelioma.

## 491. Marker of angiosarcoma is

a) CD 31

b) Cytokeratin

c) Vimentin

d) CD 55

Correct Answer - A

**Answer- A. CD 31**

The endothelial origin of these tumors can be demonstrated by immunohistochemical staining for CD31 or von Willebrand factor.

**492. Keratinization and pearl formation is characteristic of**

a) Squamous cell carcinoma

b) Basal cell carcinoma

c) Melanoma

d) Lymphoma

Correct Answer - A

**Answer- A. Squamous cell carcinoma**

Histologically, squamous cell carcinoma is characterized by the presence of keratinization and/or intercellular bridges. Keratinization may take the form of squamous pearls or individual cells with markedly eosinophilic dense cytoplasm

### 493. Grade of tumor denotes

a) Degree of differentiation

b) Degree of anaplasia

c) Stage of disease

d) Vascular invasion

Correct Answer - A

**Answer- A. Degree of differentiation**

Grading is based on the degree of differentiation of tumor cells and the number of mitosis within the tumor.

## 494. Carcinoma due to inherited mutation of p53 protooncogene

a) Li fraumeni syndrome

b) Familial adenomatous polyposis

c) Retinoblastoma

d) Osteosarcoma

Correct Answer - A

**Answer- A. Li fraumeni syndrome**

Li-Fraumeni syndrome is due to mutation in p-53 gene.

## 495. K ras mutation is seen in

a) Pancreatic carcinoma

b) Prostate carcinoma

c) Gastric carcinoma

d) Hepatic carcinoma

Correct Answer - A

**Answer- A. Pancreatic carcinoma**

K - RAS point mutation : Cancers of colon, lung and Pancreas.

H - RAS point mutation : Cancers of kidney and bladder

N - RAS point mutation : Melanoma and hematological malignancies

[Ref Robbin's 8thie p. 279 & 7h/e p. 295]

## 496. DIC is seen in all except

a) Carcinoma pancreas

b) Carcinoma prostate

c) Carcinoma lung

d) Carcinoma kidney

Correct Answer - D

**Answer- D. Carcinoma kidney**

**Cancers associated with DIC**

- Ca pancreas
- Ca lung
- Acute promyelocytic leukemia
- Ca prostate
- Ca Stomach

## 497. Histologic finding in hyperplastic arteriosclerosis

a) Concentric layer onion skin lesion

b) Mucinous intimal thickening

c) Fibrinoid atherosclerosis

d) All the above

Correct Answer - D

**Answer- D. All the above**

It is characteristic of malignant hypertension.

There is concentric, laminated thickening of arteriolar wall onion skinning.

There is mucinous intimal thickening and fibrous intimal thickening.

There may be accompanied fibrinoid deposits with necrosis of the vessels wall fibrinoid necrosis.

**498. Obliterative endarteritis of the vasa vasorum of aorta is seen in**

a) Syphilis

b) Wegener's

c) Churg Strauss

d) Cold hemoglobinuria

Correct Answer - A

**Answer- A. Syphilis**

Syphilitic aneurysm is due to obliterative endarteritis that involves vasa vasorum of aorta in the tertiary stage of syphilis.

**499. Which isoenzyme of LDH is seen in heart**

a) LDH1

b) LDH2

c) LDH3

d) LDH4

Correct Answer - A

**Answer- A. LDH1**

Most prominent isoenzyme in heart muscle is LDH-1. LDH-2 is 2nd most prominent form (after LDH 1)

## 500. MALToma is located in which layer of gastrointestinal tract

a) Lamina propria

b) Submucosa

c) Muscularispropria

d) Serosa

Correct Answer - A

### **Answer- A. Lamina propria**

Extranodal marginal zone lymphoma or mucosa-associated lymphoid tissue lymphoma (MALToma).

It is the most common form of marginal zone lymphoma. MALT lymphoma (MALToma) is divided into gastric (arising in stomach) and non-gastric (arising in small intestine, salivary gland, thyroid etc). Gastric MALToma has been associated with H.pylori infection. Immunophenotype of MALTomas shows positivity for CD 20 and CD 23. They are negative for CD 3, CD 10 and CD 5.

Histologically, MALToma takes form of a dense lymphocytic infiltrate in the lamina propria layer of GIT.

## 501. Not an irreversible injury-

a) Pyknosis

b) Pyknosis

c) Karyolysis

d) Bleb formation

Correct Answer - D

**Answer- D. Bleb formation**

**Damage to nucleus can be of three forms-**

- Pyknosis- nuclear shrinkage & chromatin condensation and clumping.
- Karyorrhexis- Nuclear fragmentation.
- Karyolysis- decreased basophilia due to dissolution of nucleus.

## 502. Hyaline degeneration is found in -

a) MI

b) Parkinson's' disease

c) Yellow fever hepatitis

d) Basophilic cell of pituitary

Correct Answer - C

**Answer- C. Yellow fever hepatitis**

1) Intracellular hyaline :Councilman bodies in yellow fever

2) Extracellular hyaline :n Corpora amylacea are round masses of hyaline seen in prostate in elderly, brain and spinal cord of old people and old infarcts of lung.

### 503. Lipofuscin is

a) Wear and tear pigment

b) Fat deposits

c) Blood pigment

d) Form of calcification

Correct Answer - A

**Answer- A. Wear and tear pigment**

- It is an insoluble pigment, also known as I and wear or tear or aging pigment. Lipofuscin is not injurious to the cell or its functions.
- Its importance lies in being the tell-tale sign of free radical injury and lipid peroxidation.

## 504. Antiapoptotic gene

a) FLIP

b) P53

c) BAX

d) BIM

Correct Answer - A

**Answer- A. FLIP**

- Proapoptotic genes : Apaf-1, Cytochrome C, Bak, Bax, Bim, AIF, P53, Caspases, TNFRI, FAS (CD95), FADD, BH3 only proteins (Bim, Bid, Bad), Smac/DIABLO.
- Antiapoptotic genes : BCL-2, BCL-X, Mcl-1, IAPs, FLIP

**505. Skin involvement along with collar stud ulceration in intestine on radiography. Diagnosis is -**

a) TB intestine

b) Ulcerative colitis

c) Intestinal Amebiasis

d) Crohn's disease

Correct Answer - B

**Answer- B. Ulcerative colitis**

Skin involvement can occur in Inflammatory bowel disease i.e. both Crohn's disease and Ulcerative colitis.

Collar stud ulceration is radiographical sign of Ulcerative colitis.

ULCERATIVE COLITIS :

**PATHOLOGY:**

Colonic mucosal inflammation; rectum almost always involved, with inflammation extending continuously (no skip areas) proximally for a variable extent; histologic features include epithelial damage, inflammation, crypt abscesses, loss of goblet cells.

**CLINICAL MANIFESTATIONS**

Bloody diarrhea, mucus, fever, abdominal pain, tenesmus, weight loss; the spectrum of severity (a majority of cases are mild, limited to rectosigmoid). In severe cases, dehydration, anemia, hypokalemia, hypoalbuminemia.

**COMPLICATIONS**

Toxic megacolon, colonic perforation; cancer risk related to extent and duration of colitis; often preceded by or coincident with dysplasia, which may be detected on surveillance colonoscopic biopsies

Diagnosis

## DIAGNOSIS

Sigmoidoscopy/colonoscopy: mucosal erythema, granularity, friability, exudate, hemorrhage, ulcers, inflammatory polyps (pseudopolyps). Barium enema: loss of haustrations, mucosal irregularity, ulcerations.

**506. Solution currently used for liver preservation for transplant is -**

a) UW solution

b) IGL solution

c) Kyoto ET solution

d) Ross Marshal Citrate solution

Correct Answer - A

**Answer- A. UW solution**

UW solution has become the gold standard liver transplantation for many years."

**507. Fibrosis associated with liver cirrhosis is mediated by -**

a) PDGF

b) IFN- $\gamma$

c) ICAM-1

d) P $\alpha$ AM-I

Correct Answer - A

**Answer- A. PDGF**

Most important mediators involved in liver fibrosis - PDGF, PAF, MMPs, TNF- $\alpha$ , TGF- $\beta$ 1, IL-1.

## 508. Not a apoptotic gene

a) P53

b) Bax

c) Mcl-1

d) n-myc

Correct Answer - D

**Answer- D. n-myc**

Proapoptotic genes : Apaf-1, Cytochrome C, Bak, Bax, Bim, AIF, P53, Caspases, TNFR1, FAS (CD95), FADD, BH3 only proteins (Bim, Bid, Bad), Smac/DIABLO.

## 509. Which of the following is false regarding carcinoid tumor ?

- a) Neuroendocrine tumor
- b) Most common site is lung
- c) Associated with serotonin production
- d) Potentially malignant tumor

Correct Answer - B

### **Answer- B. Most common site is lung**

Carcinoid tumors arise from the neuroendocrine cells (Argentaffin cells or Kulchitsky cells).

The majority are foundn GI tract, and more than 40% in small intestine (jejunum & ileum). The tracheobronchial tree and lungs are the next common sites involved.

Carcinoid tumors may rarely arise from the ovary or thymus

Carcinoid tumors are the most common malignancy of the appendix.

All carcinoids are considered to have malignant potential.

About 10% of carcinoids secrete excessive levels of a range of hormones, most notably serotonin (5-HT), leading to carcinoid syndrome. It is characterized by Flushing, Diarrhea, Wheezing, Abdominal cramping, Peripheral edema

## 510. Caseating necrosis occurs in

a) Brain

b) liver

c) kidney

d) lung

Correct Answer - D

**Answer- D. lung**

Gaseous necrosis, a variant of coagulative necrosis can be encountered in any organ where cell death is attributable to certain organisms e.g., mycobacterium tuberculosis (TB), syphilis and fungi (Histoplasma, Coccidioidomycosis).

Pulmonary tuberculosis is the most common cause of caseous necrosis. Therefore answer should be "lung".

## 511. Spread of infection causes

a) Fibrinoid necrosis

b) Fat necrosis

c) Liquefactive necrosis

d) Coagulative necrosis

Correct Answer - C

### **Answer- C. Liquefactive necrosis**

Liquefactive or colliquative necrosis occurs due to lysosomal permeability and enzymes of leukocytes digest the tissue transforming the tissue into liquid viscous mass.

Tissue architecture is lost.

Examples are- Infarct brain and abscess cavity.

## 512. COXtype 3 is a product of-

a) COX I gene

b) COX2gene

c) COX 3 gene

d) None ofthe above

Correct Answer - A

**Answer- A. COX I gene**

The COX-3 isozyme is encoded by the same gene as COX-1 (PTGS1 gene), with the difference that COX-3 retains an intron that is not retained in COX-1. It is not functional in humans.

**513. Diabetic foot is associated with following type of gangrene -**

a) Dry gangrene

b) Wet gangrene

c) Gas gangrene

d) Fournier's gangrene

Correct Answer - B

**Answer- B. Wet gangrene**

- When overlying skin of dry gangrenous tissue is devitalized, bacterial infection is superimposed and the coagulative necrosis
- is modified by liquifactive necrosis. More commonly due to venous occlusion then arterial occlusion.
- Occurs in diabetic foot and bed sores

## 514. Unfolded protein metabolism is associated with

a) Endoplasmic reticulum

b) Golgi apparatus

c) Mitochondria

d) None of the above

Correct Answer - A

**Answer- A. Endoplasmic reticulum**

The unfolded protein response (UPR) is a cellular stress response related to the endoplasmic reticulum (ER).

Diseases amenable to UPR inhibition include Creutzfeldt-Jakob disease, Alzheimer's disease, Parkinson's disease, and Huntington's disease.

## 515. Not an example of excess tissue growth

a) Granulation tissue

b) Neoplasia

c) Hyperplasia

d) Fibrosis

Correct Answer - A

**Answer- A. Granulation tissue**

Granulation tissue is a hallmark of healing. It is characterized by formation of new small blood vessels (angiogenesis or neovascularization) and proliferation of fibroblasts

**516. 1st mediator of inflammation to be released is**

a) Nitric oxide

b) PAF

c) Histamine

d) IL-1

Correct Answer - C

**Answer- C. Histamine**

- Vasoactive amines are present in preformed stores in cells and are therefore among the first mediators to be released during inflammation
- The two amines are especially important. These are :- (i) Histamine and (ii) Serotonin

## 517. Which of the following is potassium Channelopathy -

a) Hypokalemic periodic paralysis

b) Hyperkalemic periodic paralysis

c) Episodic ataxia I

d) Long QT-syndrome

Correct Answer - A

**Answer- A. Hypokalemic periodic paralysis**

Dent's disease (X linked proteinuria & Kidney stones)

Osteopetrosis (recessive or dominant)

Barter syndrome type III

Barter syndrome type IV (associated with sensorineural deafness)

Hyperkplexia (startle disease)

Juvenile myoclonus epilepsy

Epilepsy

## 518. Rolling of leucocytes on endothelial cells is mediated by

a) ICAM-1

b) (3, integrin

c) IL-8

d) P- selectin

Correct Answer - D

**Answer- D. P- selectin**

**Rolling & adhesion-**

- It is brought by- P selectin or CD 62
- PECAM- 1 involved in leucocyte migration from endothelial surface.

## 519. Perioperative shock is an example of

a) Hypovolemic shock

b) Septic shock

c) Cardiogenic shock

d) Neurogenic shock

Correct Answer - A

**Answer- A. Hypovolemic shock**

"Most common cause of hypovolemic shock is hemorrhage which may be intraoperative or postoperative."

**520.**

**Which of the following is not a part of ECM ?**

a) Lectin

b) Fibronectin

c) Laminin

d) Proteoglycans

Correct Answer - A

**Answer- A. Lectin**

Basement membrane (BM):- PAS positive amorphous structure which lie underneath epithelia of different organs and endothelial cells. Components of BM are laminin, fibronectin, tenascin, collagen type IV, enatactin (nidogen), proteoglycan & perlecan (heparan sulphate).

## 521. Calrexin and calreticulin are -

a) Glycoproteins

b) Chaperons

c) Tumor markers

d) Enzymes

Correct Answer - B

**Answer- B. Chaperons**

Calreticulin & calrexin are major  $\text{Ca}^{2+}$  binding (storage) chaperones in the endoplasmic reticulum.

**522. Which of the following is derived from fibroblast cells ?**

a) TGF-13

b) MMP2

c) Collagen

d) Angiopoietin

Correct Answer - C

**Answer- C. Collagen**

Fibroblasts produce the glycosaminoglycans, collagens, elastic fibers, reticular fibres and glycoproteins that can be seen in the extracellular matrix. They also produce cytokine TSLP.

### 523. HDL receptor is -

a) SR-BI

b) LDLR

c) HDLR

d) SR-82

Correct Answer - A

**Answer- A. SR-BI**

HDL is removed by HDL receptors scavenger receptor BI (SR-BI), which mediate the selective uptake of cholesterol from HDL.

This receptor is most abundant in liver, ovaries and adrenal glands.

## 524. Which of the following enhances acute phase response ?

a) a-2 microglobulin

b) Transferrin

c) Albumin

d) Retinal binding protein

Correct Answer - A

**Answer- A. a-2 microglobulin**

**a) Positive acute phase proteins**

- These proteins are increased during inflammation. Important examples are C-reactive protein : CRP (f31- globulin),
- a-1 antitrypsin, fibrinogen, ferritin, serum amyloid A, hepatoglobulin, ceruloplasmin, and a-2 microglobulin.

**b) Negative acute phase proteins**

- These proteins are decreased during inflammation. Important examples are albumin, prealbumin, transferrin, transcortin, transthyretin and retinal binding protein.
- Generally, positive acute phase proteins are considered as acute phase proteins.

## 525. IFN-gamma is produced by

a) Neutrophils

b) Macrophages

c) T - cells

d) B - cells

Correct Answer - C

**Answer- C. T - cells**

- Activated T-cells (helper) produce IFN- $\gamma$ , the major cytokine of granulomatous inflammation.
- IFN- $\gamma$**
- Helper T-cells are activated by IL-2 and produce IFN- $\gamma$ , the major cytokine of granulomatous inflammation
  - Finally there is formation of granuloma induced by IFN- $\gamma$ .

## 526. Homer rosette is seen in -

a) Neuroblastoma

b) Nephroblastoma

c) Hepatoma

d) Ependymoma

Correct Answer - A

**Answer- A. Neuroblastoma**

**Homer Wright rosettes**

- Homer-Wright rosettes are characteristic of neuroblastomas and medulloblastomas.
- May also be seen in -4 Primitive neuroectodermal tumors (PNET), Pineoblastomas, Retinoblastomas

## 527. Extremities are warm in which type of shock

a) Hypovolemic shock

b) Neurogenic shock

c) Anaphylactic shock

d) Cardiogenic shock

Correct Answer - B

**Answer- B. Neurogenic shock**

In hyperdynamic stage of septic shock and in neurogenic shock, extremities are warm due to vasodilatation.

**528. Lysosome with undigested particle inside is known as -**

a) Residual body

b) Phagosome

c) Phagolysosome

d) Autophagosome

Correct Answer - A

**Answer- A. Residual body**

The lysosomes that pinched off from Golgi complex are called primary lysosomes. After a primary lysosome has fused with the vacuole or vesicle containing the material to be digested, it forms the secondary lysosome. After the process of digestion has been completed, a secondary lysosome forms the residual body.

## 529. HLA-Cw6 is associated with

a) Myatshenia gravis

b) Behcet's disease

c) Pemphigus vulgaris

d) Psoriasis vulgaris

Correct Answer - D

**Answer- D. Psoriasis vulgaris**

**HLA association in psoriasis**

- Psoriasis vulgaris - Cw6, B13, B17, DRB1\*0701/2, B37
- Psoriatic arthritis - B27
- Generalized pustular psoriasis and acrodermatitis continua of Hallopeau- B27, B8
- Pustolosis of palms and soles - Aw19, Bw35

### 530. Prussian blue detects?

a) Ferric iron

b) Ferrous iron

c) Glycogen

d) Lipids

Correct Answer - A

**Answer- A. Ferric iron**

It is the classic method for demonstrating iron in tissues. The section is treated with dilute hydrochloric acid to release ferric ions from binding proteins

**531. Sezary cells show which tpe of nucleus -**

a) Pleomorphic

b) Round

c) Eosinophillic

d) Cerebriform

Correct Answer - D

**Answer- D. Cerebriform**

Sezary cells are neoplastic T-cells found in sezary syndrome (cutaneous T-cell lymphoma).

## 532. MHC-2 is present in all except

a) Cortical macrophages

b) Medullary m acrophages

c) Cortical epithelial cells

d) Medullary epithelial cells

Correct Answer - B

**Answer- B. Medullary m acrophages**

Cortical macrophages, epithelial cells and dendritic cells express high level of class II MHC molecule. Medullary macrophages express only class I MHC, while medullary epithelial cells and dendritic cells express both class I & II MHC molecules.

### 533. B cells are located in which region of lymph nodes

a) Paracortical region

b) Cortical follicles

c) Medullar sinuses

d) Subcapsular region

Correct Answer - B

**Answer- B. Cortical follicles**

**Location of immune cells in lymph node :**

- 1. T-cells : Paracortical area.
- 2. B-cells : Cortical follicles, germinal centers, medullary cords.

**534. PSGN is an example of which type of hyper sensitivity**

a) Type -1 hypersensitivity

b) Type -2 hypersensitivity

c) Type -3 hypersensitivity

d) Type -4 hypersensitivity

Correct Answer - C

**Answer- C. Type -3 hypersensitivity**

Glomerulonephritis (PSGN : Post-streptococcal GN) is a type III hypersensitivity.

### 535. Number of criteria for HLA matching are

a) 10

b) 4

c) 16

d) 22

Correct Answer - A

**Answer- A. 10**

At least 8 HLA markers for these minimum requirements: two A markers, two B markers, two C markers, and two DRB1 markers. Sometimes an additional marker, called DQ, is also matched making it 10 markers.

**536. All of the following are features of granulomatous thyroiditis except?**

a) Hyperthyroidism

b) Hypothyroidism

c) Painless

d) Giant cells on histology

Correct Answer - C

**Answer- C. Painless**

**Clinical Features-**

- Painful enlarged thyroid, fever
- Hypothyroidism
- Malaise
- Sore throat, pain referred to the jaw or ear.
- Subacute thyroiditis is a self-limited thyroid condition associated with a triphasic clinical course of hyperthyroidism, hypothyroidism, and return to normal thyroid function

### 537. Organ with least chance of rejection

a) Blood

b) Kidney

c) Heart

d) Liver

Correct Answer - D

**Answer- D. Liver**

HLA matching play a very minimal role in liver transplant therefore immune rejection is less common in liver transplant.

### 538. Mc type of graft rejection is

a) Hyperacute

b) Acute

c) Chronic

d) Acute on chronic

Correct Answer - C

**Answer- C. Chronic**

"Acute graft rejection is the most common form"

**539. In follicular carcinoma chromosomal translocation is?**

a) PAXS - PPARTI

b) RET - PTC

c) ALK - NMPI

d) IAK - TEL

Correct Answer - A

**Answer- A. PAXS - PPARTI**

Follicular - PAX8- PPAR $\alpha$  translocation

## 540. True about serum sickness is

- a) Type 2 hypersensitivity
- b) Can lead to leukocytoclastic vasculitis
- c) Hypercomplementemia
- d) Can occur due to homologous antigen

Correct Answer - B

### **Answer- B. Can lead to leukocytoclastic vasculitis**

Serum sickness is a type III hypersensitivity (immune complex mediated) reaction that results from the injection of heterologous or foreign protein or serum.

When an antiserum is given, the human immune system can mistake the proteins present for harmful antigens. The body produces antibodies, which combine with these proteins to form immune complexes. These complexes precipitate, enter the walls of blood vessels, and activate the complement cascade, initiating an inflammatory response and consuming much of the available complement component 3 (C3). The result is a leukocytoclastic vasculitis.

## 541. Most lethal combination is

a) Autosomal monosomy

b) Chromosomal monosomy

c) Autosomal trisomy

d) Chromosomal trisomy

Correct Answer - A

**Answer- A. Autosomal monosomy**

Autosomal monosomies (loss of one autosome) are incompatible with fetal development and are not found in live births. Only monosomy compatible with live birth is due to involvement of sex chromosome, i.e. Turner syndrome (45 X).

## 542. Not a feature of PSGN -

a) HTN

b) Increased urea

c) Increased creatinine

d) Normal C3 level

Correct Answer - D

**Answer- D. Normal C3 level**

Complement level is decreased in PSGN. Other options are correct.

### 543. All of the following are true about Down syndrome except

- a) Incidence of Robertsonian translocation is 1:1000
- b) Extra chromosome is of maternal origin
- c) Most common cause is trisomy 21
- d) Mosaicism 21 has no association with maternal age

Correct Answer - A

**Answer- A. Incidence of Robertsonian translocation is 1:1000**  
**Cytogenetics in Down's syndrome**

1. Trisomy 21 : It is most common (95%) cause. Extra chromosome is maternal in origin.
2. Robertson translocations (t 22:21; t 14:21; t 15:21) : This accounts for 3% (3:100) of cases.
3. Mosaicism of 21 : This accounts for 2% of cases
4. Partial trisomy : Very-very rare

## 544. Hypophosphatemic rickets is

a) AR

b) AD

c) XR

d) XD

Correct Answer - D

**Answer- D. XD**

**X-linked dominant disorders**

- Vitamine D resistant (X-linked hypophosphatemic) Rickets.
- Familial hypophosphatemia.
- Fragile X-syndrome.
- Incontinentia pigmenti.
- Rett syndrome.

**545. Irregular scarred kidney with pelvic dilatation is seen with -**

a) Chronic pyelonephritis

b) Polycystic kidney

c) Renal artery stenosis

d) Tuberculosis of kidney

Correct Answer - A

**Answer- A. Chronic pyelonephritis**

**Pathological changes of chronic pyelonephritis are :**

- 1. Irregular scarring of kidney
- 2. The hallmarks of chronic pyelonephritis are coarse corticomedullary scars overlying blunted calyces; dilated pelvis and flattening of papillae.

## 546. Structure of chromosomes is studied by?

a) C-banding

b) G-banding

c) Q-banding

d) Brd V-staining

Correct Answer - B

**Answer- B. G-banding**

**Metaphase cells are then fixed with methanol/glacial acetic acid mixture and stained by one of the several banding techniques :-**

- .. G-Banding (Giemsa banding) : It is used most commonly.
- ?. Other banding techniques : Q-Banding (Quinacrine banding), C-Banding (Constitutive banding), and R-Banding (Reverse staining Geimsa banding).

## 547. Location of gene on chromosome is identified by

a) Karyotyping

b) Genetic mapping

c) Microarray

d) Genomic imprinting

Correct Answer - B

**Answer- B. Genetic mapping**

A map of the human genome allows to understand where genes are located.

**548. Tyrosine kinase receptor is associated with proto-oncogene -**

a) RAS

b) MYC

c) RET

d) RB

Correct Answer - C

**Answer- C. RET**

It is a growth factor receptor (receptor tyrosine kinase). RET protein is a receptor for glial cell line derived neurotrophic factor. RET is normally expressed in parafollicular 'C' cells of thyroid, adrenal medulla and parathyroid cell precursors.

Point mutation in RET protooncogenes is associated with MEN-2A, MEN-2B, medullary thyroid carcinoma and Hirschsprung disease.

## 549. IgA nephropathy is not associated with?

a) Focal Mesangial proliferation

b) Gross hematuria within 1-2 days

c) On immunofluorescence deposits contain both IgA and IgG

d) Increased complement level

Correct Answer - D

**Answer- D. Increased complement level**

Complement level is normal in IgA nephropathy. It is common in children. Gross hematuria is seen in 1-2 days. It is a type of mesangioproliferative (not membranoproliferative) GN.

It is the most common type of glomerulonephritis world wide.

## 550. Characteristic feature of IgA nephropathy -

a) Serum compliment level is normal

b) More common in old age

c) It is a tFpe of membranoproliferative GN

d) Gross hematuria presents after 10 days

Correct Answer - A

**Answer- A. Serum compliment level is normal**

Compliment level is normal in IgA nephropathy. It is common in children. Gross hematuria is seen in 1-2 days. It is a type of mesangioproliferative (not membranoproliferative) GN.

It is the most common type of glomerulonephritis world wide.

**551. Which of the following has tumor promoting effect?**

a) BRAC

b) RB

c) MYC

d) p16

Correct Answer - C

**Answer- C. MYC**

RAS, Mitogen-activated protein kinase kinase, VEGF, or Akt

## 552. CEA is

a) Hormone

b) Glycoprotein

c) Enzyme

d) Tumor associated protein

Correct Answer - B

**Answer- B. Glycoprotein**

Carcinoembryonic protein (CEA) is a glycoprotein.

### 553. CEA is increased in which non-neoplastic condition

a) Hemolytic anemia

b) Pancreatitis

c) BPH

d) Pregnancy

Correct Answer - A:B

**CEA**-Carcinoembryonic antigen (CEA): CEA is also a glycoprotein normally synthesized in embryonic tissue of the gut, pancreas, and liver.

Their serum levels are high in cancers of the gastrointestinal tract, pancreas, ovarian cancer and breast.

CEA levels are also elevated in certain non-neoplastic conditions e.g. in ulcerative colitis, Crohn's disease, hepatitis, and chronic bronchitis, Alcoholic cirrhosis, smoking, pancreatitis, hemolytic anemia

**554. Most common type of renal carcinoma is**

-

a) Clear cell type

b) Chromophobe type

c) Papillary type

d) Tubular type

Correct Answer - A

**Answer- A. Clear cell type**

Clear cell carcinoma is the most common type of renal cancer accounting for about 70% to 80% of the renal cell cancer.

**555. Carcinoma originating from glands is called**

a) Basal cell carcinoma

b) Squamous cell carcinoma

c) Adenocarcinoma

d) Fibrosarcoma

Correct Answer - C

**Answer- C. Adenocarcinoma**

Benign tumor of glands → Adenoma.

Malignant tumor of gland → Adenocarcinoma.

**556. Most common histological form of lung Ca that metastasizes is -**

a) Squamous cell CA

b) Adenocarcinoma

c) Alveolar-carcinoma

d) Small cell carcinoma

Correct Answer - A

**Answer- A. Squamous cell CA**

Small cell carcinomas are the most aggressive of lung tumors, metastasize widely and are virtually incurable by surgical means.

**557. Hematological carcinoma is commonly linked to**

a) Nicotine

b) Benzene

c) Lithium

d) Alcohol

Correct Answer - B

**Answer- B. Benzene**

Benzene exposure is associated with leukemia.

**558. Elastic fibers of tunica media are secreted by**

a) Fibroblast

b) Endothelium

c) Smooth muscle

d) External lamina

Correct Answer - C

**Answer- C. Smooth muscle**

- The blood vessels are made of three layers, called from the luminal side outward, the tunica intima, the tunica media and the tunica adventitia.
- .. The tunica intima consists of an endothelium and any sub-endothelial connective tissue. It is separated from tunica media by internal elastic lamina.
- 2.. The tunica media is the layer of concentrically-arranged smooth muscle. Smooth muscle cells have secretory capabilities and the tunica media contains varying amounts of collagen fibers, elastic fibers, elastic lamellae, and proteoglycans secreted by the smooth muscle cells.

**559. Level of which of the following is not elevated in heart disease**

a) LDH

b) 5-nucleotidase

c) SGOT

d) ALP

Correct Answer - B

**Answer- B. 5-nucleotidase**

5-nucleotidase is elevated in liver disease, bone disease and pregnancy.

ALP (alkaline phosphatase) is raised in congestive heart failure

**560. Radiotherapy induced radiation pneumonitis mediated by all of the following except -**

a) TNF-c

b) PAF

c) TGF-p

d) NF-kB

Correct Answer - B

**Answer- B. PAF**

Important mediators of Radiation induced pneumonitis are TNF-a, TGF- $\beta$ 3 and Th2 cells cytokines (IL-4, IL-5, IL-6 & IL-13).  
ml response(IL-2, IFN- $\gamma$ ) is suppressed during radiation pneumonitis

**561. Which of the following does not predispose to leukemia?**

a) Genetic disorder

b) Alcohol

c) Smoking

d) Chemical exposure

Correct Answer - B

**Answer- B. Alcohol**

Etiological agents are radiation, chemicals (benzene, ethylene oxide), smoking and drugs (alkylating agents, topoisomerase II inhibitors).

## 562. Routine Rh typing includes testing?

a) A antigen

b) B antigen

c) C antigen

d) D antigen

Correct Answer - D

**Answer- D. D antigen**

After ABO, the most important antigen in transfusion practice is D. The D antigen is a member of the Rh system.

### 563. Ristocetin testing von Willebrand disease shows?

a) Increased agglutination

b) Decreased agglutination

c) Normal agglutination

d) No agglutination

Correct Answer - B

**Answer- B. Decreased agglutination**

Adding ristocetin at a final concentration of 1.25 g/l to platelet rich plasma (PRP) of a patient with von Willebrand disease (VWD) almost invariably results in a reduced agglutination of the platelets compared to a normal PRP.

**564. Osmotic fragility test is commonly used for -**

a) Iron deficiency anemia

b) Megaloblastic anemia

c) Hereditary spherocytosis

d) Aplastic anemia

Correct Answer - C

**Answer- C. Hereditary spherocytosis**

**Increased Osmotic fragility-**

- Hereditary spherocytosis
- Hemolytic anemia (acquired immune)
- Malaria
- Severe pyruvate kinase deficiency

**565. Warm antibody in AIHA is -**

a) IgE

b) IgM

c) IgG

d) IgD

Correct Answer - C

**Answer- C. IgG**

Warm antibody autoimmune hemolytic anemia is the most common form of autoimmune hemolytic anemia.

Most causative antibodies are of the IgG class, sometimes IgA antibodies are culprit.

## 566. What is true about sickle cell -

a) Sickling occurs both in heterozygous and homozygous state

b) Fetal hemoglobin facilitates Sickling

c) Sickling is reversible with oxygenation

d) Sickling Leads to decreased MCHC

Correct Answer - C

**Answer- C. Sickling is reversible with oxygenation**

Sickling of red cells is reversible initially, i.e., with oxygenation, HbS depolymerizes and cell shape normalizes.

Repeated episodes of deoxygenation and sickling, membrane damage occurs and cells become irreversibly sickled, and retain their abnormal shape even when fully oxygenated.

## 567. Distinguishing feature of reticulocyte is -

a) Constitute 10% of the red cells

b) No nucleus

c) Smaller in size than RBCs

d) Mature in lymph nodes

Correct Answer - B

**Answer- B. No nucleus**

Reticulocytes are immature red blood cells

Reticulocytes do not have a nucleus.

**568. Normal Myeloid - erythroid ratio is -**

a) 1:1

b) 2:1

c) 3:1

d) 4:1

Correct Answer - C

**Answer- C. 3:1**

Bone marrow is the major source of all hematopoietic cells (progenitor hematopoietic cells) in post-natal life. In normal adults, ratio of fat cells to hematopoietic cells is 1:1. Ratio of myeloid to erythroid is 3 : 1. Ratio of fat cells to erythroid cells is 4: 1.

## 569. hL/h blood group-

a) lacks H- antigen

b) lacks A-antigen

c) lacks B- antigen

d) All of the above

Correct Answer - D

**Answer- D. All of the above**

In Bombay blood group (h/h or Oh blood group) the precursor antigen (H antigen) is absent, consequently A and B antigens which are derived from modification of H antigen are not formed. Thus, Bombay blood group lacks H, A and B antigens.

**570. Amount of blood loss in Stage I of hemorrhagic shock is -**

a) <10%

b) <20%

c) <30%

d) <40%

Correct Answer - B

**Answer- B. <20%**

Mild hypovolemia (stage 1)(< 20% volume loss) : Only mild tachycardia is there with normal BP

Rapid loss of up to 20% of the blood volume, or slow losses of even larger amounts, may have little impact in healthy adults; greater losses, however, can cause hemorrhagic (hypovolemic) shock

**571. Which type of artery is most commonly involved in PAN?**

a) Muscular

b) Pulmonary

c) Skin

d) GIT

Correct Answer - A

**Answer- A. Muscular**

Polyarteritis nodosa or classical polyarteritis nodosa is systemic necrotizing vasculitis of medium sized muscular arteries, but does not involve small vessels i.e., arterioles, venules or capillaries.

It typically spares the pulmonary circulation.

Renal artery involvement is the major cause of death.

**572. Obliterative endarteritis in vasa vasorum is seen in -**

a) Hypertension

b) Tuberculosis

c) Syphilis

d) SLE

Correct Answer - C

**Answer- C. Syphilis**

Obliterative endarteritis that involves vasa vasorum of aorta is seen in the tertiary stage of syphilis. It may lead to syphilitic aneurysm (leuetic aneurysm).

It usually affects the proximal ascending aorta, particularly the aortic ring. Syphilitic aortitis may occasionally involve the aortic arch or descending aorta.

### 573. Heart failure cells are seen in -

a) Pulmonary edema

b) Pulmonary infarction

c) Pulmonary abscess

d) Pulmonary TB

Correct Answer - A

**Answer- A. Pulmonary edema**

Pulmonary edema & pulmonary infarction can be differentiated by the presence of heart failure cells in pulmonary edema.

Heart failure cells are Hemosiderin laden alveolar macrophages.

Heart failure cells are a manifestation of pulmonary congestion and edema (as seen in heart failure).

## 574. Heart failure cells are

a) Neutrophils

b) Macrophages

c) Lymphocytes

d) Basophils

Correct Answer - B

### **Answer- B. Macrophages**

Heart failure cells are Hemosiderin laden alveolar macrophages. Heart failure cells are a manifestation of pulmonary congestion and edema (as seen in heart failure).

Rupture of dilated and congested capillaries may result in minute intra-alveolar hemorrhages. The breakdown of erythrocytes liberates haemosiderin pigment which is taken up by alveolar macrophages, so-called heart failure cells, seen in the alveolar lumina.

## 575. Lines of Zahn are seen in -

a) Heart

b) Lung

c) Liver

d) Kidney

Correct Answer - A

**Answer- A. Heart**

Lines of Zahn → Characteristic of thrombi that is formed in heart or aorta. They have visible and microscopic laminations produced by alternating pale layer of platelets mixed with fibrin and darker layer containing red blood cells.

**576. Which protein is defective in dilated cardiomyopathy?**

a) Myosin

b) Troponin

c) Tropomyosin

d) Dystrophin

Correct Answer - D

**Answer- D. Dystrophin**

Dilated cardiomyopathy occurs due to defective cytoskeleton proteins. Most important protein involved is dystrophin. Other proteins affected are : (1) Desmin; (2) MLP Protein and (3) alphaP crystalline proteins

**577. Which of the following is seen in young's syndrome ?**

a) Azoospermia

b) Bronchiectasis

c) Infertility

d) All of the above

Correct Answer - D

**Answer- D. All of the above**

**Young's syndrome is characterized by :**

1. Bronchiectasis
2. Azoospermia & infertility
3. Sinusitis
4. Nasal polypi

## 578. Amyloidosis occurs in all except

a) Tuberculosis

b) Chronic bronchitis

c) Osteomyelitis

d) Bronchiectasis

Correct Answer - B

**Answer- B. Chronic bronchitis**

**Secondary amyloidosis**

It occurs secondary to an associated inflammatory conditions like

1. Rheumatoid arthritis (most common)
2. TB & Leprosy
3. Ankylosing spondylitis
4. Chronic osteomyelitis
5. IBD (crohn disease, ulcerative colitis)
6. Bronchiectasis

**It may also occur in some tumors**

1. Renal cell carcinoma (Hypernephroma)
2. Hodgkin lymphoma

## 579. Most common cause of death in SLE in children

a) Lupus nephritis

b) Lupus cerebritis

c) Libman Sacks endocarditis

d) Anemia and infections

Correct Answer - A

**Answer- A. Lupus nephritis**

**Major causes of death in pediatric SLE include :**

1. Renal disease (lupus nephritis)
2. Severe disease flare
3. Infections

## 580. Small posterior fossa seen in ?

a) Arnold chiari malformation

b) Dandy walker

c) Medulloblastoma

d) Schizencephaly

Correct Answer - A

**Answer- A. Arnold chiari malformation**

Small posterior fossa → arnold chiari malformation.

Large posterior fossa → dondy walker molformation

## 581. Incorrect about HIV associated nephropathy ?

a) Proteinuria

b) Shrunken kidneys

c) 15% cases show mesangial proliferation

d) Develops when CD4<200

Correct Answer - B

### **Answer- B. Shrunken kidneys**

Most common (80%) kidney lesion in AIDS is FSGS (especially collapsing variant i.e. collapsing glomerulopathy). It is termed as HIV associated nephropathy (HIVAN).

Mesangioproliferative (mesangial proliferation) GN is 2nd most kidney lesion

Other kidney lesions are diffuse proliferative GN, MPGN, IgA nephropathy, membranous GN and minimal change disease.

## 582. Pyogenic granuloma true A/E

a) Bacterial infection

b) Bleeding

c) Benign tumour

d) Capillary hemangioma

Correct Answer - A

**Answer- A. Bacterial infection**

Pyogenic granuloma (PG) or lobular capillary hemangioma is a benign vascular tumour of the skin or mucous membrane characterized by rapid growth and friable surface.

Angiogenic growth factors such as vascular endothelial growth factors (VEGF) and decorin, transcription factors, and signal transduction pathways (MAPK) are overexpressed in pyogenic granulomas

**583. Visceral aneurysm is most commonly seen in**

a) Splenic

b) Renal

c) Hepatic

d) Coronary

Correct Answer - A

**Answer- A. Splenic**

Most common visceral artery aneurysm is splenic artery aneurysm.  
2nd most common visceral artery aneurysm is hepatic artery aneurysm.

**584. All of the following provide protection against malaria except -**

a) Duffy blood group

b) Sickle cell anemia

c) Hereditary spherocytosis

d) PNH

Correct Answer - D

**Answer- D. PNH**

PNH is a hemolytic anemia caused by an acquired intrinsic defect in the cell membrane.

PNH results from acquired mutation that inhibits the synthesis of Glycosylphosphatidylinositol (GPI).

## 585. Thorium induced tumor

a) Angiosarcoma of liver

b) Renal cell carcinoma

c) Lymphoma

d) Astrocytoma

Correct Answer - A

**Answer- A. Angiosarcoma of liver**

Thorotrast (thorium dioxide) is commonly associated with liver neoplasm.

The most common liver neoplasm associated with thorium exposure

Angiosarcoma of the liver

Cholangiocarcinoma

Hepatocellular carcinoma

## 586. Most common malignancy of fallopian tube

a) SCC

b) Serous CA

c) Teratoma

d) Chorioca

Correct Answer - B

**Answer- B. Serous CA**

Serous - 49.5% - 83.3%

## 587. Warthin finkeldey cells are seen in

a) Measles

b) Rubella

c) Rabies

d) Typhoid

Correct Answer - A

**Answer: A. Measles**

**Multinucleated cells like Warthin Finkeldey are seen in Measles**

- Measles virus infects by invasion of respiratory epithelium.
- Local multiplication leads to viremia (day 2-3), then spread to RE system.
- Two types of Multinucleated giant cells in both epidermis & oral epithelium by 7-11 days.
- **Warthin Finkeldey cells of reticuloendothelial system**
- Epithelial giant cells of respiratory & other epithelia.
- **Warthin–Finkeldey cell:**
- Type of giant multinucleate cell found in hyperplastic lymph nodes early in the course of measles
- Under the light microscope, these cells consist of a large, grape-like cluster of nuclei.
- Also with HIV-infected individuals and Kimura disease .
- Rarely in neoplastic (e.g. lymphoma) & non-neoplastic lymph node disorders.
- Unknown origin; Reports of staining with markers similar to follicular dendritic cells, including CD21.

## 588. CD59 marker of which disease

a) PNH

b) PTEN

c) BRR

d) Cowden syndrome

Correct Answer - A

**Answer: A. Paroxysmal nocturnal hemoglobinuria (PNH)**

**Paroxysmal nocturnal hemoglobinuria (PNH)** is a disease, due to acquired **mutations** in "**Phosphatidylinositol GlycanComplementation Group A**" gene (**PIGA**)..

Associated with **deficiency of glycosylphosphatidylinositol (GPI)** anchor proteins along with absence of external surface membrane proteins attaching to it.

CD55 (DAF) and CD59 (MIRL) are two such complement defence proteins

**CD59 deficiency:**

- **Common finding in RBCs & WBCs of patients with chronic hemolysis suffering from PNH**

**Diagnosis:**

- The definite diagnosis based on demonstration of a substantial proportion of patient's RBC having increased susceptibility to complement (C), due to the deficiency on their surface of proteins (particularly CD59 & CD55)

## 589. Opsonin is

a) C3a

b) C3b

c) C5a

d) C6

Correct Answer - B

**Answer: B. C3b**

The process of coating a foreign particle targeting & preparing it for phagocytosis process is "Opsonization". Substances involved are opsonins.

Main opsonins from complement system is C3

**Examples of opsonins include:**

**Antibodies:**

- IgG and IgA

**Components of the complement system:**

- C3b, C4b, and iC3b

**Mannose Binding Lectin (MBL):**

- Initiates the formation of C3b
- Membrane Attack Complex (MAC)
- Includes C5b, C6, C7, C8 & polymeric C9

**Opsonization & complement proteins:**

- Mainly C3b, iC3b & C4b

**C3:**

- Most abundant protein of all complementary proteins,
  - Cleaves into C3a and C3b
- C3a -
- Binds and activates mast cells & basophils, release histamine.

**C3b -**

- Most critical component in both classical & alternative pathway
- C3b attaches to bacterial surfaces for opsonization by phagocytes

## 590. Bernard–Soulier syndrome due to deficiency of

a) Gp 2b/3a

b) Gp 1b

c) vWf

d) TNF

Correct Answer - B

**Answer: B. Gp 1b**

**Bernard–Soulier syndrome (BSS) / Hemorrhagic Purpura  
Thrombocytopenic Dystrophy**

Rare autosomal recessive coagulopathy

**Causes a deficiency of glycoprotein 1b (Gp1b), receptor for von  
Willebrand factor.**

## 591. Cowden syndrome

a) P53

b) PTEN

c) Rb

d) Ras

Correct Answer - B

**Answer: B. PTEN**

**“Phosphatase and Tensin” homolog (PTEN)**- protein in humans encoded by the **PTEN** gene. Gene mutations promotes development of cancers.

**Cowden’s disease / Multiple Hamartoma Syndrome -**

- Part of PTEN hamartoma tumor syndrome
- An autosomal dominant syndrome
- Trichilemmomas - Numerous tumors of hair follicles in face
- Multiple hamartomatous polyps in GI tract.
- Very high risk of breast & thyroid carcinoma

**Treatment:**

- B/L mastectomies recommended
- Contraindicated are mammography & other radiation exposure of breast tissue

## 592. Chromosome involved in myotonic dystrophy is

a) Chromosome 19

b) Chromosome 20

c) Chromosome 21

d) Chromosome 22

Correct Answer - A

**Answer: A - Chromosome 19**

Myotonic dystrophy is transmitted by mutation in an 'unstable trinucleotide repeat sequence' in **gene 19q 133**.

**Features:**

- An autosomal dominant disorder
- Most common adult muscular dystrophy

**Characteristics feature:**

- **Myopathy is distal** (in contrast to other myopathies - mostly proximal).
- Muscle atrophy selectively **involves type I fibres only**
- Appears by **5 years**, causes a **slow relaxation of hand grip** following a **forced voluntary closure**.

## 593. TRALI occurs within how many hours of transfusion?

a) 48 Hrs

b) 72 Hrs

c) 6 Hrs

d) 12 Hrs

Correct Answer - C

**Answer: C - 6 Hrs**

**Transfusion-Related Acute Lung Injury (TRALI) - Syndrome** characterized by **acute respiratory distress following transfusion.**

**Symptoms:**

- Typically develop **during, or within 6 hours of transfusion.**
- **Rapid onset of dyspnea & tachypnea.**
- Associated fever, cyanosis, & hypotension.

**Clinical examination:**

- Reveals **respiratory distress.**
- **Pulmonary crackles** may be present with no signs of CHF or volume overload.
- CXR - Evidence of B/L pulmonary edema unrelated to CHF (**non-cardiogenic pulmonary edema**),
- Bilateral patchy infiltrates rapidly progressing to **complete "white out"** indistinguishable from Acute Respiratory Distress Syndrome (ARDS).

## 594. Kidney responds to shock by

a) Decreases renal blood flow

b) Increases afferent arteriole resistance

c) GFR remains unaltered

d) Perfusion of kidney increases

Correct Answer - B

**Answer: B - Increases afferent arteriole resistance**

**Kidney utilizes the following mechanisms as a response to shock:**

- **Release of aldosterone** from hypoxic kidney
- **Release of ADH** due to decreased effective circulating blood volume.
- **Reduced GFR** due to **arteriole constriction**
- Tissue fluid shift into plasma due to lowered hydrostatic pressure (Hypotension)

**595. Which of the following is epithelial tumor of stomach?**

a) Carcinoid

b) Lymphoma

c) GIST

d) Gastric adenocarcinoma

Correct Answer - D

**Answer: D - Gastric adenocarcinoma**

**Malignant epithelial tumor originating from glandular epithelium of gastric mucosa.**

Aggressively invade the gastric wall.

**Lauren classification:**

- Two types of gastric adenocarcinoma are present.
- Intestinal type
- Diffuse type
- Intestinal type - Irregular tubular structures
- Diffuse type - Mucinous & colloidal "Leather-bottle stomach"

## 596. Identify an X linked disorder?

a) Color blindness

b) Thalassemia

c) Azoospermia

d) Retinitis Pigmentosa

Correct Answer - A

**Answer: A - Color blindness**

**Hereditary color blindness/ Achromatopsia**

The ability to appreciate one or more primary color is defective (**anomalous**) or absent (anopia)

**Due to mutations in X chromosome**

Red & green pigment cones coded by X chromosome; Blue coded on chromosome 7

More common in males than females

Acquired - (Optic nerve/ macular damage)

**Ishihara chart -**

- **Test red/ green color blindness - Farnsworth 100 hue test**

**Other s:**

- Azoospermia&Retinitis Pigmentosa - Y-chromosome linked disorder
- Thalassemia - Inherited (Autosomal recessive pattern) blood disorders characterized by abnormal hemoglobin production. Genes in Chromosome 11 and 16 involved.

## 597. H And L variety seen in

a) Mixed cellularity hodgkin

b) Lymphocyte depleted

c) Lymphocyte predominance

d) Nodular sclerosis

Correct Answer - C

**Answer: C - Lymphocyte predominance**

**Hodgkin lymphoma (HL) - common "Malignant Lymphomas"**

**2 entities:**

- Classical HL (cHL)
- Nodular Lymphocyte–predominant HL (NLPHL).

**Cells :**

- Classical HL - Hodgkin and Reed/Sternberg (HRS) cells
- Nodular Lymphocyte predominant HL - Lymphocytic & Histiocytic (L&H) cells

## 598. Stellate granuloma seen in

a) Sarcoidosis

b) Cat scratch disease

c) Cryptococcosis

d) Histoplasmosis

Correct Answer - B

**Answer: B - Cat scratch disease**

Bacterial infection caused by *Bartonella henselae*

Acquired infected cat/kitten scratch

**Histology:**

- Characterized by granulomatous inflammation of lymph nodes.
- Skin lesion demonstrates a circumscribed focus of necrosis
- Regional lymph nodes demonstrate **follicular hyperplasia with central stellate necrosis** with neutrophils, surrounded by palisading histiocytes (suppurative granulomas) & sinuses packed with monocytoïd B cells, usually without perifollicular and intrafollicular epithelioid cells.

## 599. Which best explains “Flipping effect”?

a) LDH 1 > LDH 2

b) LDH2 > LDH1

c) LDH 2 > LDH 3

d) LDH 3 > LDH 2

Correct Answer - A

**Answer: A - LDH 1 > LDH 2**

**Lactate dehydrogenase**, tetrameric enzyme with 4 subunits, 4 Subunits with 2 isoforms - **H isoform (Heart) & M isoform (Muscle)**

**Heart & RBCs - LDH-1 (4H);**

- Reticuloendothelial system - LDH-2 (3H1M)
- Lungs - LDH-3 (2H2M)
- Kidneys, placenta, & pancreas - LDH-4 (1H3M)
- Liver & striated muscle - LDH-5 (4M)

**Uses:**

- LDH levels are more in RBC
- Helpful in assessment of Hemolysis / Tissue breakdown

**Flipping effect:**

- Usually LDH 2 in predominant in serum & LDH 1 is predominant in heart
- Higher levels of LDH 1 than LDH 2 (Flipped pattern) is suggestive of myocardial infarction
- Damaged cardiac tissues release LDH 1 into bloodstream.

## 600. Nude mice is not resistant to xenograft due to absence of

a) B cell

b) T cell

c) Both b and t cell

d) None

Correct Answer - B

**Answer: B - T cell**

Nude mice lacks "Thymus" & cannot generate mature T lymphocytes.

Absence of T-lymphocytes makes it **unable to mount adaptive immune responses** requiring CD4, helper T cells, CD8 and cytotoxic T cells.

**Adaptive immune responses that remain unresponsive to nude mice include:**

- Antibody formation (CD4 + helper T cells)
- Cell-mediated immune responses (CD4+ and/or CD8+ T cells)
- Delayed-type hypersensitivity responses (CD4+ T cells)
- Killing of virus-infected or malignant cells (CD8 + cytotoxic T cells)
- Graft rejection (both CD4+ & CD8+ T cells)

**Uses:**

- Laboratory study animal - Insights into immune system, leukemia, solid tumors, AIDS & other immune deficiency diseases.
- Absence of functioning T cells prevents them rejecting the allografts & Xenografts.

## 601. Anaplasia is

a) Changing one type of epithelium to another

b) Nuclear chromatin

c) Lack of differentiation

d) Morphological changes

Correct Answer - C

**Answer: C - Lack of differentiation**

Refers to a lack of differentiation in neoplastic cells.

Well-differentiated tumors resemble their tissue of origin

Poorly-differentiated or undifferentiated (anaplastic) tumor cells appear primitive and lack specialization along any particular cell line.

## 602. Which level of prolactin definitely suggest prolactinoma?

a) 300 ng/ml

b) 150 ng/ml

c) 200 ng/ml

d) 100 ng/ml

Correct Answer - C

**Answer: C - 200 ng/ml**

Prolactinomas are the most common type of hyperfunctioning pituitary adenoma.

Benign tumors of pituitary gland producing prolactin.

Hyperprolactinemia causes amenorrhea, galactorrhea, loss of libido, and infertility.

Because many manifestations of hyperprolactinemia (e.g., amenorrhea) are more obvious in premenopausal women than in men or postmenopausal women, prolactinomas usually are diagnosed at an earlier stage in women of reproductive age than in other persons so affected.

Higher blood prolactin concentrations are seen.

mild elevations of serum prolactin (less than 200  $\mu\text{g/L}$ ) in a patient with a pituitary adenoma do not necessarily indicate a prolactin-secreting neoplasm.

### 603. Laxative abuse causes which of the following renal stones ?

a) Uric acid

b) Ammonium urate

c) Struvite

d) Ca oxalate

Correct Answer - B

**Answer: B - Ammonium urate**

**Based on the chemical nature two types of kidney stones:**

- Calcium oxalate (majority).
- Others include Uric acid, Struvite (Infected stones), and Cystine stones (rare hereditary metabolic disorder)

**Characteristic stone formation in laxative abuse:**

- Laxative abuse acts a factor in kidney stone formation.
- Laxative abuse causes potassium loss
- As a compensation mechanism kidney produces large amount of ammonium.
- Resulting in formation of uncommon stone type - ammonium acid urate.

**604. Which of the following can result in dactylitis**

a) Hemophilia

b) Von willebrand disease 1

c) Measles

d) Sickle Cell Anemia

Correct Answer - D

**Answer: D - Sickle Cell Anemia**

Dactylitis (Hand-Foot Syndrome) is seen in sickle cell anemia  
Severe pain affecting the bones of hands, feet, or both.  
Often 1st symptom of sickle cell anemia in babies.

## 605. Which chromosome is responsible for the production of MIF?

a) Chromosome 16

b) Chromosome 22

c) X Chromosome

d) Y chromosome

Correct Answer - D

### **Answer: D - Y Chromosome**

Anti-Mullerian Hormone (AMH) / Mullerian Inhibiting Factor (MIF); Mullerian-inhibiting Hormone (MIH) / Mullerian-inhibiting Substance (MIS).

AMH - Downstream genes regulated by SRY pathway

SRY - Gene in "Sex determining region" - short arm of Y chromosome - Testis determining factor.

Secreted by Sertoli cells of the testes.

The production of AMH is controlled by two autosomal gene loci.

Hormone code

Receptor code.

Glycoprotein hormone

Related to inhibin & activin

Member of the transforming growth factor- $\beta$  (TGF- $\beta$ )

Key roles are in growth differentiation and folliculogenesis.

**606. Which of the following condition is NOT caused by Parvovirus B19?**

a) Roseola infantum

b) Aplastic anemia in sickle cell disease

c) Fetal hydrops

d) Erythema infectiosum

Correct Answer - A

**Answer: A. Roseola infantum**

Primary infection by **parvovirus B19** often produces an acute, severe, and sometimes fatal anemia manifested as a rapid fall in red blood cell count and hemoglobin.

These patients may present initially with no clinical symptoms other than fever; this is commonly referred to as **aplastic crisis**.

**Erythema infectiosum** (also referred to as fifth disease or academy rash) is a more common disease that is clearly attributable to parvovirus B19.

Active transplacental transmission of parvovirus B19 can occur during primary infections in the first 20 weeks of pregnancy, sometimes resulting in stillbirth of fetuses that are profoundly anemic.

The progress can be so severe that hypoxic damage to the heart, liver, and other tissues leads to extensive edema (hydrops fetalis).

## 607. Which is true regarding ataxia telangiectasia:

a) Increase in AFP

b) Increases the risk of squamous cell carcinoma

c) Autosomal dominant

d) None of above

Correct Answer - A

**Answer: A - Increase in AFP**

**Increase in alpha-fetoprotein is observed in Ataxia telangiectasia**

Ataxia-telangiectasia / Ataxia-telangiectasia syndrome / **Louis-Bar syndrome**

Rare, **neurodegenerative, autosomal recessive disorder** causing severe disability.

Ataxia refers to poor coordination; Telangiectasia refers to small dilated blood vessels.

**Parts affected:**

- Cerebellum - movement & coordination difficulties
- Immune system - Predisposing to infections.
- Genetic repair system - Preventing process for repairing DNA - Cancer risk

**Features:**

- Increased incidence of **lymphoma & Leukemia**
- **Increased alpha-Fetoprotein levels**
- **Oculomotor apraxia** (difficulty in coordination between head & eye movements)
- Dysarthria

## 608. Term pathology refers to:

a) Work

b) Function

c) Details

d) Explains

Correct Answer - A

**Ans. A. Work**

**Pathology** is the medical term for the way a disease works. The science of the causes and effects of diseases, especially the branch of medicine that deals with the laboratory examination of samples of body tissue for diagnostic or forensic purposes.

**609. Leiden thrombophilia is caused by mutational deficiency of which of the following factors?**

a) Factor V

b) Factor VII

c) Factor IX

d) Factor X

Correct Answer - A

**Ans. A. Factor V**

**Factor V Leiden** thrombophilia is an inherited disorder of blood clotting. **Factor V Leiden** is the name of a specific **mutation** (genetic alteration) that results in thrombophilia, or an increased tendency to form abnormal blood clots in blood vessels. **Factor V Leiden** is the most **common** inherited form of thrombophilia.

**610. A boy presented with multiple non suppurative osteomyelitis with sickle cell anaemia. What will be the causative organism?**

a) Salmonella

b) S. aureus

c) H. influenzae

d) Enterobacter species

Correct Answer - A

**Ans. A. Salmonella**

**Following are the various micro -organism involved in osteomyelitis**

<b>Age group</b>	<b>Most common organisms</b>
Newborns (younger than 4 mo)	S. aureus, Enterobacter species, and group A and <b>B</b> Streptococcus species
Children (aged 4 mo to 4 y)	S. aureus, group A Streptococcus species, Haemophilus influenzae, and Enterobacter species
Children, adolescents (aged 4 y to adult)	S. aureus (80%), group A Streptococcus species, H. influenzae, and Enterobacter species
Adult	S. aureus and occasionally Enterobacter or Streptococcus species
Sickle cell anemia patients	Salmonella species are most common in patients with sickle cell disease

## 611. Positive acid schiff macrophages seen in ?

a) Whipples disease

b) Crohns disease

c) AIDS

d) None of the above

Correct Answer - A

**Answer : A > Whipples disease.**

The traditional laboratory diagnosis is based on light microscopy, which shows diastase-resistant, periodic acid-**Schiff** (PAS)-positive, non-**acid-fast** granules in ..... The distinction could be made by **acid-fast staining**, which is positive for patients infected with M. avium and negative for those with **Whipple's disease**.

## 612. What is the cause of myocardial shock other than MI ?

a) acute mitral regurgitation

b) ventricular septal rupture

c) isolated right ventricular shock

d) all of the above

Correct Answer - D

**Answer : D > All of the above**

**Left ventricular dysfunction (LVD)** - Most frequent cause of cardiogenic shock

**Followed by,**

- Acute mitral valve regurgitation
- Ventricular septal defect
- Isolated right ventricular shock
- Tamponade/ cardiac rupture

## 613. WHICH IS NOT CORRECT:

a) MRI needed to assess haemorrhage

b) GCS assessment helps in prognosis

c) Haematoma must be operated

d) all of the above

Correct Answer - C

### **Answer- C. Haematoma must be operated**

Treatment of hematoma depends on the location, symptoms, and the clinical situation. Some may require no treatment at all while others may be deemed a medical emergency.

Simple therapies at home may be utilized in treating superficial (under the skin) hematomas. Most injuries and bruises can be treated with resting, icing, compression, and elevating the area. This is remembered by the acronym **RICE**.

These measures usually help to reduce inflammation and diminish its symptoms.

- **Rest**
- **Ice** (Apply the ice or cold pack for 20 minutes at a time, 4 to 8 times a day.)
- **Compress** (Compression can be achieved by using elastic bandages.)
- **Elevate** (Elevation of the injured area above the level of the heart is recommended.)

### **Medical treatment for a hematoma**

- For certain small and symptom-free hematomas no medical treatment may be necessary. On the other hand, symptomatic hematomas or those located in certain locations sometimes require medical or surgical treatment.

- Even though no specific medication is available for the treatment of hematomas, management of any related symptoms can be achieved by medications. For example, pain from a hematoma can be treated with pain medications such as acetaminophen ([Tylenol](#)).
- Surgical drainage is a common method of treatment for certain hematomas.

## 614. Genital warts are caused by which virus?

a) Herpes simplex

b) Human papilloma

c) Cytomegalovirus

d) Varicella zoster

Correct Answer - B

**Ans. B. Human papilloma**

**Genital warts** are soft growths that appear on the genitals. **Genital warts** are a sexually transmitted infection (STI) caused by certain strains of the human papillomavirus (HPV). These skin growths can cause pain, discomfort, and itching.

**615. Which metal results in “Saturnine gout” formation?**

a) Cadmium

b) Lead

c) Beryllium

d) Mercury

Correct Answer - B

**Answer: B. Lead**

One manifestation of chronic lead toxicity is the rheumatologic entity known as saturnine gout.

Illicitly distilled beverages may inadvertently contain harmful toxins, like metallic lead.

Lead has been known to play a role in purine metabolism & renal insufficiency

## 616. Reed sternberg cells are found in

a) Hodgkin's disease

b) Sickle cell anaemia

c) Thalassemia

d) CML

Correct Answer - A

- Reed Sternberg cells are you derived from B lymphocytes, classically considered crippled germinal center B cells, Seen against a sea of B cells which give the tissue a moth-eaten appearance.
- They are large and are either multinucleated or have a bibbed nucleus (thus resembling an "owl's eye" appearance) with prominent eosinophilic inclusion-like nucleoli.
- They are CD30 and CD15 positive, usually negative for CD20 and CD45.
- The presence of these cells is necessary for the diagnosis of Hodgkin's lymphoma - the absence of Reed-Sternberg cells has very high negative predictive value.
- They can also be found in reactive lymphadenopathy (such as infectious mononucleosis, carbamazepine associated lymphadenopathy) and very often in other types of non-Hodgkin lymphomas.

## 617. Marked bleeding is seen in which of following conditions?

a) VMA disease

b) Haemophilia A

c) Haemophilia B

d) ALL

Correct Answer - D

**Answer: D. ALL**

Bleeding disorders can be inherited or acquired. Inherited disorders are passed down through genetics. Acquired disorders can develop or spontaneously occur later in life. Some bleeding disorders can result in severe bleeding following an accident or injury. In other disorders, heavy bleeding can happen suddenly and for no reason. There are numerous different bleeding disorders, but the following are the most common ones:

**Hemophilia A and B** are conditions that occur when there are low levels of clotting factors in your blood. It causes heavy or unusual bleeding into the joints. Though hemophilia is rare, it can have life-threatening complications.

**Factor II, V, VII, X, or XII deficiencies** are bleeding disorders related to blood clotting problems or abnormal bleeding problems. **von Willebrand's disease** is the most common inherited bleeding disorder. It develops when the blood lacks von Willebrand factor, which helps the blood to clot.

## 618. Which of the following true regarding Hemophilia A

a) Serum levels of factor VIII are decreased

b) Deficiency of factor IX

c) PT increased

d) FIT decreased

Correct Answer - A

**Answer: A. Serum levels of factor VIII are decreased**

Hemophilia is an X linked disorder of coagulation caused by the deficiency in a circulating plasma protein. Hemophilia A is caused by the deficiency of factor VIII, and hemophilia B is caused by the deficiency of factor IX.

It is PTT which is affected (increased) and not PT (unaffected).

Factor VIII is involved in the intrinsic pathway which is measured by PTT and not in extrinsic pathway which is measured as PT.

Bleeding is the common manifestation of hemophilia and the common bleeding manifestations are hemarthroses, hematomas, mucocutaneous bleeding, intracranial bleeding, hematuria and pseudotumor.

## 619. Which of the following is seen in seropositive rheumatoid arthritis?

a) Multiple joints affected

b) Symmetrical joint symptoms

c) Joint pain and swelling

d) All

Correct Answer - D

**Answer: D. All**

Positive for Rheumatoid factor in blood is seropositivity. Patients with positive rheumatoid factor usually present with symptoms like

- **Joint deformities & disability**
- **Symmetrical involvement of joints**
- **Inflammation**
- **Swelling and painful in multiple joints**, especially of hands and feet.
- Morning stiffness (short term)
- Development of firm lumps near joints - "**Rheumatoid nodules**"
- Deterioration of bone & cartilage (X- ray findings)

## 620. Which of the following is not seen in Anterior mediastinum

a) Thyroid tumour

b) Thymoma

c) Lymphoma

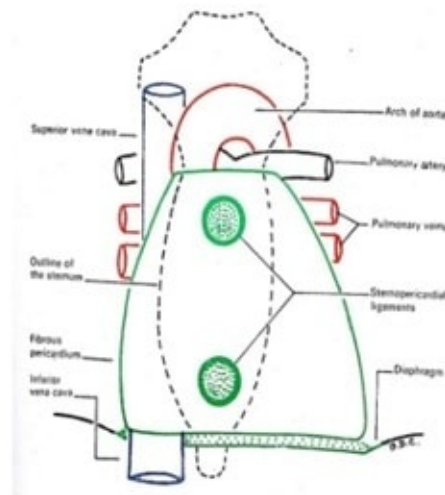
d) Neurogenic tumor

Correct Answer - D

**Answer: D. Neurogenic tumor**

### Anterior Mediastinum: Contents

- Thymus (Children)
- Sternopericardial ligaments
- Internal thoracic artery & branches
- Lymphatics & Lymph nodes



28

The anterior mediastinum is the portion of the mediastinum anterior to the pericardium and below the thoracic plane. It forms the anterior part of the inferior mediastinum and contains the thymus, lymph nodes, and may contain the portions of a retrosternal thyroid.

### **Mediastinal Tumors and Other Masses**

Superior Mediastinum	Anterior Mediastinum	Posterior Mediastinum	Middle Mediastinum
Lymphoma	Thymoma	Neurogenic tumors	Bronchogenic cyst
Thymoma	Teratoma	Lymphoma	Pericardial cyst
Thyroid lesions	Lymphoma	Gastroenteric hernia	Lymphoma
Metastatic carcinoma	Thyroid lesions		
Parathyroid tumors	Parathyroid tumors		

## 621. Struvite stone is caused by which metal?

a) Magnesium

b) Calcium

c) sodium & potassium

d) both (a) & (b)

Correct Answer - A

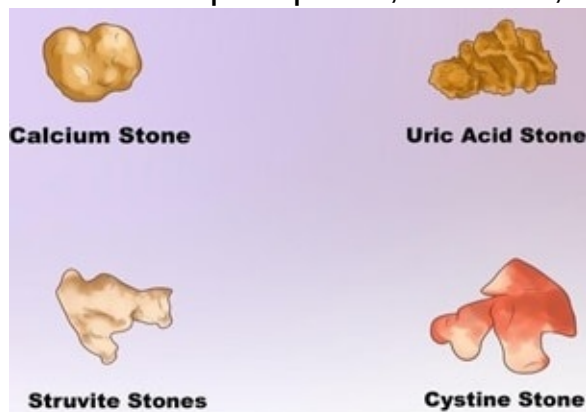
**Ans. A. Magnesium**

**Struvite, a crystalline substance is composed of magnesium ammonium phosphate ( $MgNH_4PO_4 \cdot 6H_2O$ ).**

**Struvite urinary stones have also been referred to as “infection stones” and “triple phosphate” stones.**

**Struvite stones can be caused** by alkaline urine, steroid therapy, abnormal retention of urine, a urinary tract infection, or another disorder of the urinary tract.

There are five primary types of commonly encountered urinary stones, i.e., calcium oxalate, calcium phosphate, magnesium ammonium phosphate, uric acid, and cystine.



## 622. Which of the following statements about Graves disease is false?

a) Results in hyperthyroidism

b) Autoimmune disorder

c) Common in Male

d) Referred as Toxic diffuse goitre

Correct Answer - C

**Ans. C - Common in male**

**Graves' disease:**

- **Autoimmune** system disorder
- Both men and women get affected;
- Yet, **10 times more common in women than men**
- Affects younger women < 40 years
- Results in overproduction of thyroid hormones (**hyperthyroidism**).

**Signs and symptoms:**

- Anxiety
- Irritability
- Heat sensitivity
- Increased perspiration/ warm and moist skin
- Weight loss
- **Goiter (Glandular enlargement)**
- Menstrual cycle changes
- Erectile dysfunction/ reduced libido
- Graves **Ophthalmopathy** - Bulging eyes - **Exophthalmos**
- **Graves dermopathy** - Thick, red skin on shins / top of feet.
- **Antibody for graves disease - Thyrotropin receptor antibody (TRAb) acts on the** regulatory pituitary hormone interfering the normal secretion of thyroxine.

- TRAb overrides normal regulation causing an **overproduction of thyroid hormones (hyperthyroidism)**.

## 623. Which of the following is false about Alzheimer's disease?

a) One in 10 people age 65 and older has Alzheimer's disease

b) Alzheimer's disease is curable

c) Cause dementia

d) All of the above

Correct Answer - B

**Ans. B. Alzheimer's disease is curable**

**Alzheimer's disease** Also called: **senile dementia**. A progressive disease that destroys memory and other important mental functions.

**Memory loss and confusion are the main symptoms.**

Currently, there is no **cure** for **Alzheimer's**. But drug and non-drug treatments may help with both cognitive and behavioral symptoms.

**The treatments available for Alzheimer's do not slow or stop the progression of the disease, but they may help with the symptoms for a time.**

**There are three cholinesterase inhibitors to treat Alzheimer's:**

- Donepezil (Aricept)
- Rivastigmine (Exelon)
- Galantamine (Reminyl)

**People may experience:**

- **Cognitive:** mental decline, difficulty thinking and understanding, confusion in the evening hours, delusion, disorientation, forgetfulness, making things up, mental confusion, difficulty concentrating, inability to create new memories, inability to do simple maths, or inability to recognise common things
- **Behavioural:** aggression, agitation, difficulty with self care,

irritability, meaningless repetition of own words, personality changes, restlessness, lack of restraint, or wandering and getting lost

- **Mood:** anger, apathy, general discontent, loneliness, or mood swings
  - **Psychological:** depression, hallucination, or paranoia
- Also common:** behavioral symptoms, inability to combine muscle movements, jumbled speech, or loss of appetite

## 624. Which is not included in AIDS related complex?

a) Ectopic pregnancy

b) Recurrent genital candidiasis

c) Generalised lymphadenopathy

d) Chronic diarrhea

Correct Answer - A

**Answer- A. Ectopic pregnancy**

**HIV symptoms: AIDS related complex (ARC)**

It belongs to class B of HIV symptoms. The patients at this stage have various diseases that occur because the HI virus has weakened the immune system.

**The following HIV signs may have patients with ARC:**

- Long-lasting diarrhea (over four weeks)
- Unintended heavy weight loss
- Long lasting fever
- Night sweats
- Bacterial infections caused by bacteria
- Bacterial blood poisoning (sepsis)
- Phthisis
- Herpes zoster
- Oral hairy leukoplakia (whitish changes on the lateral tongue border)
- Fungi caused by fungi
- HIV symptoms – Women: vaginal inflammation caused by fungi, malignant changes in the cervix

## 625. Which of the following are the risk factor for cutaneous lymphoma?

a) Age

b) Gender

c) Weakened immune system

d) All

Correct Answer - D

**Answer:D . All**

**Risk Factors for Lymphoma of the Skin**

**Age** Age is an important risk factor for this disease, with most cases occurring in people in their 50s and 60s. But some types of skin lymphoma can appear in younger people, even in children.

**Gender and race** Most (but not all) types of skin lymphoma are more common in men than in women. Most also tend to be more common in African-Americans than in whites. The reasons for this are not known.

**Weakened immune system** Skin lymphomas may be more common in people with acquired immunodeficiency syndrome (AIDS), who have a weakened immune system. They may also be more common in people who have had an organ transplant such as a heart, kidney or liver transplant. These people must take drugs that suppress their immune system, which may raise the risk of skin lymphoma (or lymphomas in other parts of the body).

**Infections** Infection with the human immunodeficiency virus (HIV), the virus that causes AIDS, may increase a person's risk of skin lymphoma.

**626. A 30-year-old male came with complaints of swelling around the knee joint. Histopathological examination of the swelling demonstrated many giant cells interspersed with mononuclear cells. What is the probable diagnosis**

a) Osteosarcoma

b) Ewing's sarcoma

c) Giant cell tumour

d) Chondrosarcoma

Correct Answer - C

**Correct ans: C**

GCTs are large and red-brown and often show cystic degeneration. They are composed of uniform oval mononuclear cells and scattered osteoclast-type giant cells containing 100 or more nuclei.

Mitotic figures are typically frequent.

Necrosis, hemorrhage, and reactive bone formation also are commonly present.

Ref Robbin's basics of pathology 9th edition page no.781

**627. 30 years old came with complaints of easy fatigability, exertional dyspnea, and weight loss. She also complains of frequent falls. physical examination revealed there was a bilateral decrease in vibration sense. Her hemoglobin levels were 8.2g%. She was treated with folate. Her anemia improved but neurological symptoms worsened. Which of the following is the most probable reason for her condition?**

a) Folate not absorbed

b) Unmasked pyridoxine deficiency

c) Deficiency of folate reductase in CNS

d) Folate therapy caused rapid use of Vit B12 stores aggravating symptoms

Correct Answer - D

**Ans: D. Folate therapy caused rapid use of Vit B12 stores aggravating symptoms**

Vitamin B12 is required for the recycling of tetrahydrofolate, the form of folate that is needed for DNA synthesis.

In keeping with this relationship, the anemia of vitamin B12 deficiency is reversed with the administration of folate. By contrast, folate administration does not prevent and may, in fact, worsen the

neurologic symptoms

**628. A 30-year-old woman presents with thyroid swelling. On investigations, her TSH levels are found to be elevated. Postoperative reports showed lymphocytic infiltration and hurthle cells. A most probable diagnosis is?**

a) Graves disease

b) Hashimoto's thyroiditis

c) Follicular carcinoma

d) Medullary carcinoma thyroid

Correct Answer - B

**Ans: B. Hashimoto's thyroiditis**

Hashimoto thyroiditis is the most common cause of hypothyroidism which is characterized by gradual thyroid failure secondary to the autoimmune destruction of the thyroid gland.

It is most prevalent between the ages of 45 and 65 years and is more common in women than in men, ultimately leading to a varying degree of fibrosis and thyroid enlargement.

The thyroid usually is diffusely and symmetrically enlarged. The cut surface is pale and gray-tan in appearance, and the tissue is firm and somewhat friable.

Microscopic examination reveals the widespread infiltration of the parenchyma by a **mononuclear inflammatory infiltrate** containing small lymphocytes, plasma cells, and well-developed **germinal centers**.

The thyroid follicles are atrophic and are lined in many areas by

epithelial cells distinguished by the presence of abundant eosinophilic, granular cytoplasm, termed **Hurthle**, or **oxyphil cells**.

**629. Which of the following will be seen on cardiac biopsy of a patient who had a post MI reperfusion injury?**

a) Waviness of fibres

b) Eosinophilic contraction bands

c) Neutrophils in cardiac cells

d) Swelling of cells

Correct Answer - B

**Ans: B. Eosinophilic contraction bands**

Microscopically, irreversibly damaged myocytes subject to reperfusion show contraction band necrosis;

In this pathologic process, intense eosinophilic bands of hypercontracted sarcomeres are created by an influx of calcium across plasma membranes that enhances actin-myosin interactions.

## 630. Loss of foot process is classical in case of?

a) Membranous glomerulitis

b) Segmental glomerulosclerosis

c) IgA nephropathy

d) Diabetic nephropathy

Correct Answer - B

**Ans: B. Segmental glomerulosclerosis**

Focal segmental glomerulosclerosis (FSGS) is characterized by sclerosis, hyalinosis, adhesions/synechiae formation, resulting in segmental obliteration of glomerular capillaries. On EM, foot process effacement is the predominant finding without significant basement membrane abnormalities. Immunofluorescence shows staining for IgM and C3 in sclerotic areas. Juxtamedullary nephrons are affected first and hence inadequate sampling may miss focal lesions.

<https://www.ncbi.nlm.nih.gov/books/NBK532272/>

**631. Which of the following factors play a major role in the initiation of thrombus formation?**

a) Vasoconstriction

b) Coagulation cascade activation

c) Platelets activation

d) Endothelial injury

Correct Answer - D

**Ans: D. Endothelial injury**

The three primary abnormalities that lead to thrombus formation (called Virchow's triad) are

**(1) endothelial injury,**

**(2) stasis or turbulent blood flow, and**

**(3) hypercoagulability of the blood.**

**Ref:** robbins 9th edition chapter 4

**632. A 33-year-old man presents with a 5-week history of calf pain, swelling, and low-grade fever. Serum levels of creatinine kinase are elevated. A muscle biopsy reveals numerous eosinophils also she had peripheral blood eosinophilia. Which of the following interleukins is primarily responsible for the increase in eosinophils in this patient?**

a) IL 2

b) IL 4

c) IL 1

d) IL6

Correct Answer - B

**Ans: B. IL 4**

### 633. Which of the following is true about PAN?

a) Microscopy shows fibrinoid necrosis in large arteries

b) ANCA is positive

c) 30% of people have HbsAg positive

d) Patient have hypogammaglobulinemia

Correct Answer - C


**Ans: C. 30% of people have HbsAg positive**

Polyarteritis nodosa (PAN) is a necrotizing vasculitis involving small and medium-sized muscular arteries of multiple organs and tissues. The disease occurs more commonly in adult males than females. Most commonly affected organs, in descending order of frequency of involvement, are the kidneys, heart, gastrointestinal tract, kidneys, and muscle.

The condition results from immunologic response to an identifiable antigen that may be bacteria (e.g. streptococci, staphylococci, mycobacteria), viruses (e.g. hepatitis B virus, influenza virus, CMV), malarial parasite, certain drugs, and chemicals.

There is no association with ANCA,<sup>[7]</sup> but about 30% of people with PAN have chronic hepatitis B and deposits containing HBsAg-HBsAb complexes in affected blood vessels, indicating an immune complex-mediated cause in that subset. Infection with the Hepatitis C virus and HIV are occasionally discovered in people affected by PAN.

Leukocytoclastic vasculitis, characterized by fibrinoid necrosis with neutrophilic infiltrate in the vessel wall. Many of the neutrophils are fragmented. This form is found in vasculitis caused by deposits of immune complexes.



**634. A 23-year-old male presented with a history of fatigue and tiredness. On investigation, he was found to have Hb values of 9gm%, MCV of 101 FL. peripheral smear examination showed microcytic RBC and hypersegmented neutrophils. Which is most probable etiology**

a) Lead poisoning

b) Iron deficiency anemia

c) Chronic alcoholism

d) Hemolytic anemia

Correct Answer - A

**Ans: A. Lead poisoning**

Findings

Microcytic Anemia - Iron Deficiency

Hypersegmented Neutrophils - B12 and Folic Acid Deficiency

Young & No H/o Of Alcohol Consumption [Patient came with a history of Fatigue and Tiredness] - Chronic Alcoholism can be ruled out

Hemolytic Anemia - may demonstrate red blood cell fragments called schistocytes, red blood cells that look like spheres (spherocytes), and/or red blood cells missing small pieces (bite cells). An increased number of newly made red blood cells (reticulocytes) may also be a sign of bone marrow compensation for anemia.

So Most Probable Answer would be Lead Poisoning [Tiredness & Fatigue]

**635. What is the main feature of chemotaxis as observed in white blood cells?**

a) Increased random movement of neutrophils

b) Increased adhesiveness to intima

c) Increased phagocytosis

d) Unidirectional locomotion of neutrophils

Correct Answer - D

**Ans: D. Unidirectional locomotion of neutrophils**

Chemotaxis is defined as a unidirectional movement of leukocytes up to a concentration gradient of chemotactic molecules. All granulocytes, monocytes and to a lesser extent lymphocytes respond to chemotactic stimuli with varying rates of speed.

**Chemoattractants are exogenous or endogenous. Exogenous agents are bacterial products. Endogenous mediators are:**

- Components of complement pathway C5a
- Products of lipoxygenase pathway LTB<sub>4</sub>
- Cytokines particularly those of chemokine families.

**636. Which of the following anticancer drugs are competitive inhibitors of tyrosine kinase –**

a) Imatinib and sunitinib

b) Letrozole

c) Bicalutamide

d) Fulvestrant

Correct Answer - A

**Ans. is 'a' i.e., Imatinib and sunitinib**

**Molecular targeted agents**

- Tyrosine kinase inhibitors
- Competitive inhibitors → Imatinib, Nilotinib, Sunitinib, Dasatinib, Erlotinib, Gefitinib, Lapatinib, Sorafenib (Remember all end with 'nib').
- Monoclonal antibodies → Cetuximab, panitumumab.
- HER<sub>2</sub>/neu (ERB B<sub>2</sub>) inhibitors Monoclonal antibody - Trastuzumab.
- Targeted antibody → Gemtuzumab (anti CD-33), Rituximab (anti - CD20), Alemtuzumab (anti CD-52).
- Vascular endothelial growth factor (VEGF) inhibitor → Monoclonal antibody - Bevacizumab.
- Proteasome inhibitors → Bortezomib.
- Histone deacetylase inhibitor → Vorinostat
- DNA - methyltransferase inhibitor → 5-azacytidine, 2-deoxy-5 azacytidine.
- All - trans-retinoic acid.
- Biological response modifier - Recombinant IL-2 (aldesleukin, denileukin).

\_\_\_\_\_

**637. 20 years old man presented with the complaint of swelling of the wrist for the last two years. histopathological examination showed spindle-shaped cells and verocay bodies what is the diagnosis?**

a) Lipoma

b) Dermoid cyst

c) Neuro fibroma

d) Schwannoma

Correct Answer - D

**Ans: D. Schwannoma**

spindle cells and verocay bodies are seen in schwannoma is a tumor of the tissue that covers nerves, called the nerve sheath. These tumors develop from a type of cell called a Schwann cell, which gives them their name. Schwannomas are often not cancerous (benign).

The most common type of schwannoma is vestibular schwannoma. It affects the nerve responsible for balance (also called the vestibular nerve). It can cause inner ear deafness because the hearing and balance nerve run together, and as the tumor grows it damages the hearing nerve (cochlear nerve). Because of this doctor used to call them acoustic neuromas.

Microscopically, the tumor is composed of fibrocellular bundles forming the whorled pattern.

There are areas of dense and compact cellularity (Antoni A

pattern) alternating with loose acellular areas (Antoni B pattern). Areas of Antoni A pattern show palisaded nuclei called Verocay bodies.

Nerve fibers are usually found stretched over the capsule but not within the tumor.

Areas of degeneration contain haemosiderin and lipid-laden macrophages.

Schwann cells characteristically express S-100 protein.

A schwannoma rarely ever becomes malignant.