

ॐ सर्वे भवन्तु सुखिनः । सर्वे सन्तु निरामयाः ।  
सर्वे भद्राणि पश्यन्तु । मा कश्चित् दुःख भाग्भवेत् ॥

# **NEET PG 2022 RECALL** **QUESTIONS**

● **ALL 200 MCQs** ●

《**SUBJECTWISE**  
**ARRANGED**》

जो भी एम. सी. क्यू मुझे किसी विशेष विषय के लिए उपयुक्त लगा, मैंने उसे पहले रखा है और दोबारा नहीं दोहराया है। इसलिए मेडिसिन सेक्शन में केवल 12 बहुविकल्पीय प्रश्न हैं।

Compiled and Curated by  
Dr. Anushtup Raval

<u>Pg no.</u>	<u>Subject</u>	<u>No. of Qs</u>	<u>Correct</u>	<u>Marks</u>
3	Anat	3		
3	Physio	7		
4	B'chem	15		
6	Pharm	16		
9	Path	19		
12	Micro	19		
15	FM1	10		
16	PSM	17		
19	ENT	9		
20	Ophthal	6		
21	Dermat	4		
22	Anaesthesia	2		
22	Radio	9		
23	Psychiatry	2		
24	Ortho	7		
26	Ped	7		
27	OBGY	19		
30	Surgery	17		
33	Med.	12		

---

200

---

Total → 800



6. To raise Body temp.  $\leftrightarrow$  Hypothal. temp. set point

ans: Shivering

7. Hemiballismus  $\leftrightarrow$  Subthalamic Nu.

BIOCH 1. Gaucher's -  $\beta$  Glucocerebrosidase

2. paint worker - Pb poisoning

$\downarrow$   
- Ferrochelatase

3. DNA packing - Histone

4. Complex IV  $\ominus$   $\leftrightarrow$  Cyanide

5. Cherry red  $\rightarrow$  Tay Sachs

6. McArdle  $\rightarrow$   $\downarrow$  Myophosphorylase

7. True about Warburg?  
⊗ ATP ⊗ immortal, ⊗ N<sub>2</sub> uptake.  
Aerobic glycolysis  $\bar{c}$  lactate

8. INH  $\rightarrow$  Vit B5 (PLP)

9. FAD determined by  
(Vit B2)

↓  
Glutathione Reductase

10. Mediterranean  $\rightarrow$  PQ  $\rightarrow$  hemolysis  
pathway? (G6PD $\downarrow$ )

↓  
HMP

11. Bitot spot Image.

↓  
Vit A Def.

12. Telomere / Telomerase

ans:  $\downarrow$  length of telomere  
 $\bar{c}$  aging

13. Codon  $\rightarrow$  stop

NON-SENSE mutation

14. Fatty acid transport through  
Mito Memb.

↓  
**Carnitine**

15. w/o Antidepressants → +ntc  $\bar{c}$

↓  
**VitK**

Bleeding  
Steatorrhea  
(Fat &  
Fat soluble vit  
absorp<sup>n</sup> ↓)

## PHARM

1. PCSK-9  $\ominus$  → **Evolocumab**

2. Acromegaly post  $\bar{c}$

↳ **Octreotide**

3. DOC PCM toxicity  
↓

**N-acetylcysteine**

4. Immediate relief for Migraine  
other options → prophylaxis drugs

ans: **Sumatriptan**

5. Digoxin toxicity, Immediate Mx?

Best Ans: **Digoxin Fab**

6. GH receptor Antagonist

↓  
**Pegvisomant**

7. DKA      Ketone Bodies  
RBS → 500++

next best step



**I.V. fluids  
& I.V. insulin (regular)**

8. Prolactinoma

↓  
**Bromocriptine**

9. Acute opioid poisoning

↙  
**Naloxone**

10. h/o Antidep. {TCA ↑↑} ↑QRS

↓  
**i.v. NaHCO<sub>3</sub>**      R.A.D  
Acidosis

11. Purple toe / Dermal  
Vasc. necrosis  
on 'Next' day  $\rightarrow$  Warfarin

12. Anti-parkinsons drug  
 $\downarrow$   
Selegiline

13. Aminophylline  $\rightarrow$  diuresis  
 $\swarrow$   
@ Adenosine  
receptor

14. Chemo  $\rightarrow$  Anti Emetic  
 $\downarrow$   
Dystonia  
 $\swarrow$   
dH<sub>2</sub>  
Metoclopramide

15.  $\odot$  (preg)  $\rightarrow$  Baby = tendon  
rupture  
& neuropathy  
 $\downarrow$   
FG  
 $\downarrow$   
MOA  
DNA gyrase  $\ominus$

16. least effect on pleura

↓  
Methopemins

PATH

1.

Thromboelastography

2. ↑ life span ↔ ↓ calorie intake

3. AR → cystic fibrosis

4. NET all true ↔ except

↓  
Mitochondrial DNA + mt

5. hypochromic μ-cytic {Thal} trait

↓  
HbA<sub>2</sub>

6. CML C Basophil? t{9,22}

Garden party app.

7. Michaelis Guttman body

H/P: Malakoplakia

8. Orphan Annie eye - PCT  
{ NOT true }

FNAC is NOT Acute

9. H/P: Islet cell of Langerhans

10. MCD →

LM DOES NOT show  
effacement of podocyte

11. HPE → Sertoli cell only tm  
XX testicular atrophy

12. HLA DQ2 → Celiac dz

low gluten diet

13. ↑ LDH

↑ Bilirubin

Hb'uria

Schistocytes

intravasc. →  
hemolysis

Mechanical  
2nd H.S.

14. Hemorrhoids → Bleeding → M-cytic ↓ hypochromic

15. HPE: **BCC**

{ lesion below nose &  
above angle of lips }

16. COVID-19 autopsy

↳ **acute & chronic diffuse tige.**

17. w/o sickle → repeated chest infect

HbS

↓  
**Sickle cell Anemia**

18 w/o sickle --- → septic arthritis

↓  
organisms

↓  
**Staphylococcus**

{ Salmonella is mcc of osteomyelitis  
in sickle pt. when lesion is  
@ Diaphysis } { metaphysis → knee }  
(and overall in sickle pt.)

mcc of o'myelitis @ metaphysis  
in sickle pt. is Staph aureus.

19. Muscle Biopsy → Mostly Duchenne M.D.

↓  
true statement?

↓  
die d/t heart dx.  
in 3rd decade of  
their life

MICRO

1. pencil shaped Macroconidia → Trichophyton  
red pigment → Rubrum

2. HIV pt. / fever, cough, Breathlessness /

dimorphic / Image

↓  
Talaromyces  
Marchetti

3. Acute  $\angle$  Branching → Aspergillus

4. recovered from COVID → Mucormycosis  
next best Ix?

↓  
MRI head

5. Sinus c̄ discharges → Mycetoma

↙  
Both Bacteria & Fungus

6. fever, vomiting, myalgia }  
Body louse } **Rickettsia**  
Prowazeki

7. sheathed }  
2 nuclei } **Brugia Malayi**

8. Cu penny app. → **Chromoblastomycosis**

9. HPV → genital warts c̄ 'high' of SCC

Best option → **HPV 18**

10. Botex MOA → ⊖ release (presynaptic)  
of Ach.

11. Toxres Body → Yellow fever → **17D Vaccine**

12. HbSAg +ve }  
IgM HBC +ve } → **Acute**  
**HBV infection**

13. **GDH & exotoxins** ← pseudomembranous enterocolitis

14. fever, sore throat, malaise }  
conjunctival suffusions } **Lepto-**  
scalp tenderness } **-spirochis**

15. 4 month old infant



HIV PCR

[to be done @ 6w, 6m & 18m]

16. Cholera → GM1 Ganglioside R

17. Candida species identification → CHROM agar

18. pt. on HAART → monitor viral load

19. Broad typhoe fungus → DOC  
{Mucor}

↓  
Amphotericin B

# FMT

1. **Informed consent**

2. Drunk doctor → cut major vessel → pt. dies

**criminal negligence**

3. **Thallium poisoning** → Alopecia/Madrosis  
Behavioural changes  
Mees lines

4. Image → **Defence wounds**

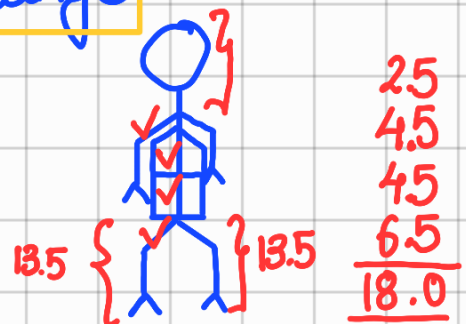
5. Image → **Septate hymen**

6.  $FeSO_4$  poisoning → **Desferrioxamine**

7. Complete ligature mark?  
transverse }  
below thyroid cartilage } → **Ligature Strangulation**

8. Image → **pistol intermediate range**  
(tattooing)

9. Burn → **15-20%**



10. Leading questions  $\leftrightarrow$  Cobb examination

PSM

1. OVP  $\rightarrow$  Use Pentavalent & discard MR

2. Case Control Study

Children exposed to chemical & have ALL

Not exposed  
No ALL  
{from hospital?}

3. Research & development of seeds  
c  $\uparrow$  nutritive property  
 $\downarrow$   
& supply to children

ans:- ???

UNICEF?

4. JSK ₹1000 to mother  
₹400 to ASHA

5. Broken vial → Puncture proof Blue Bag

6. Cu-T C/I. in Trophoblastic disease

7. Green (Triage) → Ambulatory

8. Criteria for Urban CHC

↓  
100 beds in Metro cities

9. Risk ratio = Relative Risk = 0.85

←  $\{ < 1 \}$   
Green tea is protective factor.

10. 12w primigravida → additional calories

⚡  
"throughout" preg.

11. MDR TB → INH + Rif Resistance

12. WHO stepwise {all except}

↓  
Psychological

13. Treatment done & finished } CURED  
+ 2 sample of AFB -ve }

14. Most logical & cost effective approach  
in Urban population  
↓

Remove stray dog & vaccinate dog  
population

15. 24y/o ♀ → BFinq → 18m/o baby  
heavy irregular Bleeding

↓  
Progesterone

16. Things NOT done by a MD @ PHC  
↓

announcements on loudspeakers  
& radios

17. Japanese ♀ LE = 84.3yrs

R<sub>2</sub> of cervical ca. → ↑ life/quality of life??  
by new interventions

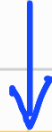Ans: QALY

# ENT

1. Image → Incus
2. Image → Parotitis
3. Image → Serous otitis Media
4. Image → INAF
5. Image oral cavity → Leukoplakia  
Alcoholic ↗

6. damage to Basilar Memb.  
high frequency H.L.

location?



@ Oval window

7. Hemlich's Maneuver

shortness of breath  
@ restaurant

8. hyperinflation of Rt. lung  
↳ Resp. difficulty

⊗ flexible ⊗ ATB ⊗ complete → Ball valve

correct → F.B.

9. Samter's triad → Aspirin  
drug?

## OPHTHAL

1. Image → Keratoconus  
Intraocular  
corneal ring

2. Image → Scleromalacia  
perforans ⊗ Staphyloma

3. Image → Pseudexfoliation Syndrome

4. penetrating trauma → Sympathetic  
ophthalmitis

↓  
pars planitis

5. diabetic pt. → pre-retinal hge  
& neovascularization at  
disc ↓

Rx: Pan Retinal Photo coagulation

6. photophobia }  
lacrimation } Trigeminal  
h'ache }

## DERMAT

1. w/o covid Sw back → Alopecia

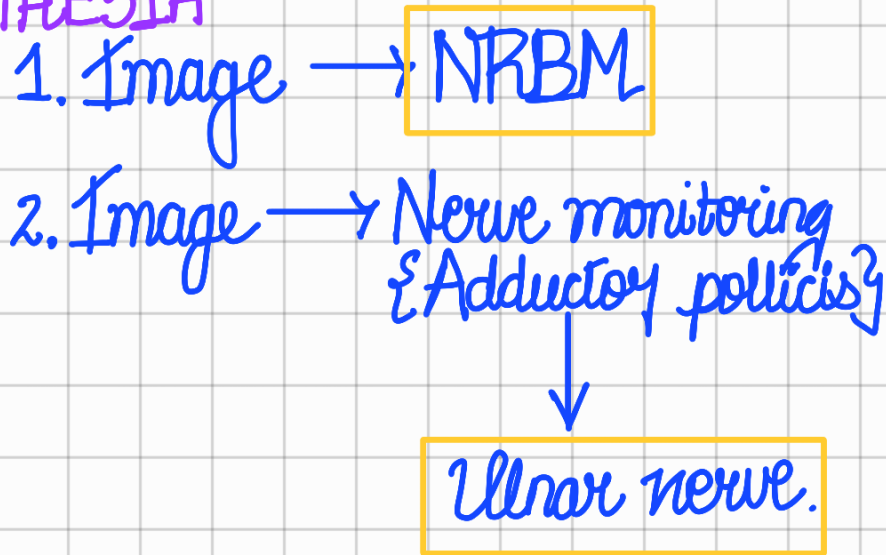
Telogen Effluvium

2. irregular pitting }  
oil drop } @ Nail → Psoriasis  
hyperkeratosis }

3. Acanthosis Nigrans → Metabolic &

4. B.I. leprosy }  
B/L cheeks } mc }  
& forehead } nerve }  
affected } → Trigeminal  
Nerve

## ANAESTHESIA



## RADIO

1. delayed IV urogram

↓

pelvic uretic jx<sup>o</sup> obstruct

2. Recurrent UTI & MCU

Vesicoureteric reflux.

3. HSG → "Septate" uterus

? Bicornuate

4. RGU → Membranous urethra

5. pincer claw → Intussuscept

6. Image → Ultrasound doppler

7. HRC → Consolidat + Air Bronchogram

8. Image → PEI-G.

9. Multiple Enchondromatosis  
Hand Xray →

## PSYCHIATRY

1. 5 day / post partum / crying /  
↓ appetite / ↓ sleeping

post partum Blues

2. ↑ urge eat → self induced vomiting  
w/ ↓ appetite suppressants / (N) BMI

Bulimia Nervosa



7. Fibular #  $\leftrightarrow$

Neurological  
+ Assessment  
+  
Analgesic  
+  
Cast

# PEDIA

1. Infantile Spasm → ACTH

2. Severe Dehydration

3. HSP → Glucocorticoids

4. IE prophylaxis →

for 5yr  
or 18y/o age

c-ever is  
latey

1.2 MU Benzathine  
Penicillin

5. Image → Bladder Exstrophy

6. no passage of urine for 24hrs

(N) 48h  
stool - 24h

↓  
Wait & Watch.

7. Child (age mentioned ~ 3y) { OR NEWBORN (?) }  
↑ TSH

↘  
Tx to assess functional status

↓  
TRAB { mostly wrong }

?  
Ectopic  
thyroid

⊗ urinary iodine

⊗ Tc

4th option ???

OG

1. Amniotic Fluid Embolism

2. Image → Mid Pelvis

3. H/O classical GS → CS @ 57w

4. primi / soft tender abdo.  
FDP position



NVD

5. Placenta removal ← 'Best' thing to do after cord gets torn

6. Ut. Aet doppler @ 14w ↓

Early onset  
pre-eclampsia

7. Trilaminar → ectopic? ?  
abortion? ? → repeat  
HCG after 48w

8. post partum day 2 ↓

1 finger below  
umbilicus

{ 1st 24h → no change in  
the size of uterus }

9. ectopic rupture @ 22 w<sup>7</sup>

Abdominal

10. Molding +++ } DTA → LSGS  
Caput +++ }

11. patellar reflex (-nt) → MgSO<sub>4</sub> toxicity

12. absolute CI of cervical cerclage → rupture of membrane.

13. PIH is d/t? → extravillous cytotrophoblast in spiral

14. Hemolysis {↑LDH} }  
↓Plt. }  
↑Liver Enzymes } → HELLP Sx

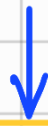15. O'n amnioc } → Renal Anomaly

16. MTP drug } → Mifepristone  
+ Misoprostol

17. At risk infant } → high order  
{all except } Birth = 3

{ ≥ 4 is grand multipara }

18. Which hormone release testosterone in ♂ fetus



HCG

Alternate Question:- ♂ ext. genitalia formed by which hormone



DHT.

19. Active phase of labour → ans:

5cm & effaced

# SURGERY

1. peau d'orange → ⊖ subdermal lymphatics

2. thyroidectomy → post op 3<sup>rd</sup> day

↓  
↓Ca<sup>2+</sup> symptoms

↓  
Tx: Ca<sup>2+</sup>, PO<sub>4</sub><sup>-2</sup> & PTH

3. Men 2b (3) { all except? }  
[M-5]

↓  
parathyroid  
adenoma

4. MC site from which Liver Abscess  
drains

↘  
Base area of Liver/  
Subdiaphragmatic

5. X-ray GrUD  
{ Gas Under Diaphragm }

↓  
Resuscitate & Laprotomy

6. Image → Fistula-in-ano  
(recurrent & multiple)

pilonidal → not multiple

7. Route of metastasis of prostate Ca to lumbar

prostatic venous plexus.

8. Image → Fournier's Gangrene

9. Leheriche & ← { claudication @ calf  
numbness @ thigh  
Impotence

ans:- Aorto iliac bifurcation

10. post op varicose → numbness @ medial aspect

Saphenous Nerve

11. Tension pneumothorax → Best Answer

Chest tube insert & drainage

① Immediate thoracotomy

② needle thoracotomy

12. Image → **Grade IV Bed Sore**

13. recurrent swelling @ one side of neck  
afraid of eating food

↓  
**Sialolithiasis**

14. erythematous pulsatile swelling

↓  
**Ix: USG.**

15. rupture of saccular aneurysm

↓  
**SAH**

16. Stab injury } → **Further Ix**  
Stable pt. }

'Next' step.

17. Mass } → **Obstructive jaundice**  
↑ALP }

# MED

1. TB meningitis  
✓ Cerebral abscess  
✓ lymphocytes

2. PMN  $600/\text{mm}^3$  → Spont. Bac. peritonitis  
{ > 250 }

3. K/C/O H1N1  
acute onset Breathlessness  
CXR - Bat wing  
pulm. edema } IV nitroglycerine

4. Irregularly Irregular pulse / pulse deficit - 20  
↓  
Atrial Fibrillation  
↓  
Absent 'a' wave

5. Stable pt.  
K/C/O CAD  
V.F. } IV amiodarone

6. 25y/o c dental caries → tooth extract  
↓  
prophylaxis of endocarditis  
NOT needed if/o.  
↓  
ASD

7.  $\text{pH} = 7.2 \downarrow$   $\text{pCO}_2 = 34 \uparrow$   $\text{HCO}_3^- = 35 \uparrow$

Resp. acidosis

8. T wave depression & U wave

hypokalemic

9. IV fluid lactate }  $\rightarrow$  P.i.L.

10. Child  $\rightarrow$  epigastric pain }  
vomiting }  
oliguria }  
lymphoblast }  
dehydrat }  
Tumour }  
Lysis }  
immediate }  
Rx }  
Hydration

11. B/L facial weakness }  
B/L hilar LN' pathy } Sarcoidosis

12. Oral ulcer }  
Hematuria }  
joint pain }  
RBC cast } Lupus Nephritis



# DISCLAIMER

**"[The author] assumes no responsibility or liability for any errors or omissions in this content. The information contained in this site is provided on an "as is" basis with no guarantees of completeness, accuracy, usefulness or timeliness..."**

Mazze karo Mitro  
Ma Ga Ma Sa